FITZPATRICK'S DERMATOLOGY

9TH EDITION

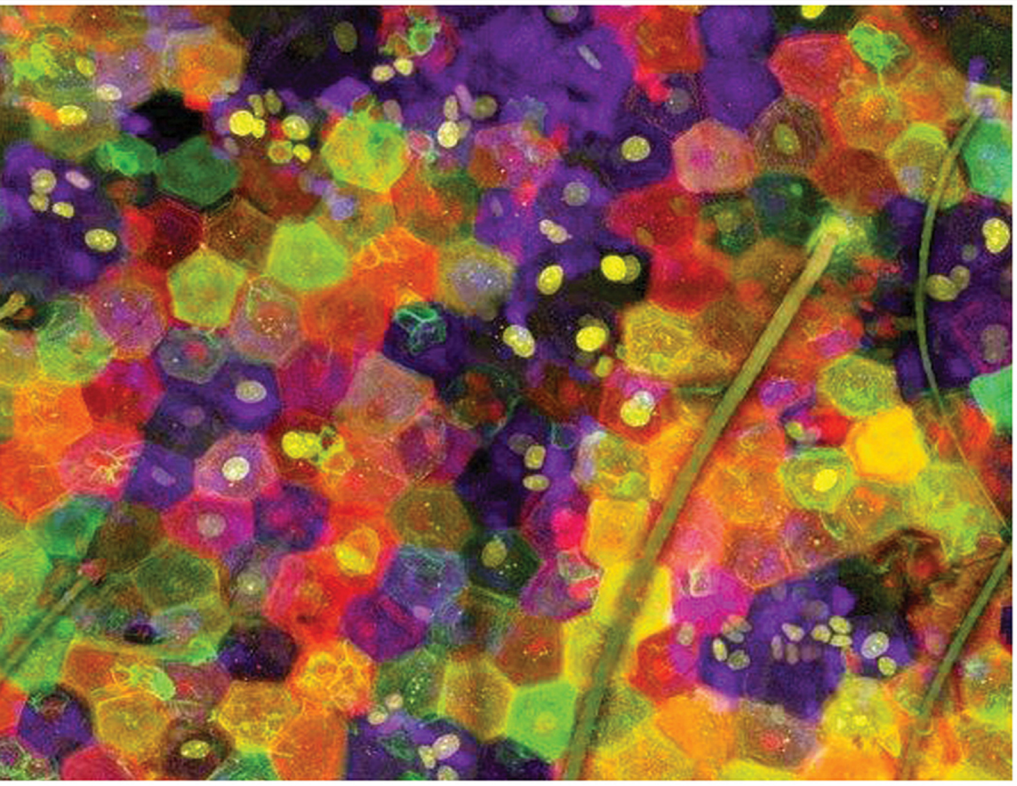

VOLUME 1

Sewon Kang
Masayuki Amagai
Anna L. Bruckner
Alexander H. Enk
David J. Margolis
Amy J. McMichael
Jeffrey S. Orringer

Mc Graw Hill Education

Fitzpatrick's Dermatology

SEWON KANG, MD, MPH
Noxell Professor and Chair
Department of Dermatology
Johns Hopkins School of Medicine
Dermatologist-in-Chief
Johns Hopkins Hospital
Baltimore, Maryland

MASAYUKI AMAGAI, MD, PhD
Professor and Chair
Department of Dermatology
Keio University School of Medicine
Tokyo, Japan

ANNA L. BRUCKNER, MD, MSCS
Associate Professor of Dermatology and Pediatrics
University of Colorado School of Medicine
Section Head, Pediatric Dermatology
Children's Hospital Colorado
Aurora, Colorado

ALEXANDER H. ENK, MD
Professor and Chair
Department of Dermatology
University of Heidelberg
Heidelberg, Germany

DAVID J. MARGOLIS, MD, PhD
Professor of Dermatology and Epidemiology
Department of Dermatology
Department of Biostatistics and Epidemiology
University of Pennsylvania Perelman School of Medicine
Philadelphia, Pennsylvania

AMY J. McMICHAEL, MD
Professor and Chair
Department of Dermatology
Wake Forest University School of Medicine
Winston-Salem, North Carolina

JEFFREY S. ORRINGER, MD
Professor and Chief
Division of Cosmetic Dermatology
Department of Dermatology
University of Michigan
Ann Arbor, Michigan

Fitzpatrick's Dermatology

Ninth Edition

EDITORS

SEWON KANG, MD, MPH

MASAYUKI AMAGAI, MD, PhD

ANNA L. BRUCKNER, MD, MSCS

ALEXANDER H. ENK, MD

DAVID J. MARGOLIS, MD, PhD

AMY J. McMICHAEL, MD

JEFFREY S. ORRINGER, MD

VOLUME I

New York Chicago San Francisco Athens London Madrid Mexico City
Milan New Delhi Singapore Sydney Toronto

Copyright © 2019 by McGraw-Hill Education. All rights reserved. Except as permitted under the United States Copyright Act of 1976, no part of this publication may be reproduced or distributed in any form or by any means, or stored in a database or retrieval system, without the prior written permission of the publisher, with the exception that the program listings may be entered, stored, and executed in a computer system, but they may not be reproduced for publication.

ISBN: 978-0-07-183783-5
MHID: 0-07-183783-3

The material in this eBook also appears in the print version of this title: ISBN: 978-0-07-183779-8,
MHID: 0-07-183779-5.

eBook conversion by codeMantra
Version 1.0

All trademarks are trademarks of their respective owners. Rather than put a trademark symbol after every occurrence of a trademarked name, we use names in an editorial fashion only, and to the benefit of the trademark owner, with no intention of infringement of the trademark. Where such designations appear in this book, they have been printed with initial caps.

McGraw-Hill Education eBooks are available at special quantity discounts to use as premiums and sales promotions or for use in corporate training programs. To contact a representative, please visit the Contact Us page at www.mhprofessional.com.

All trademarks or copyrights mentioned herein are the possession of their respective owners and McGraw-Hill Education makes no claim of ownership by the mention of products that contain these marks.

Notice

Medicine is an ever-changing science. As new research and clinical experience broaden our knowledge, changes in treatment and drug therapy are required. The author and the publisher of this work have checked with sources believed to be reliable in their efforts to provide information that is complete and generally in accord with the standards accepted at the time of publication. However, in view of the possibility of human error or changes in medical sciences, neither the author nor the publisher nor any other party who has been involved in the preparation or publication of this work warrants that the information contained herein is in every respect accurate or complete, and they disclaim all responsibility for any errors or omissions or for the results obtained from use of the information contained in this work. Readers are encouraged to confirm the information contained herein with other sources. For example and in particular, readers are advised to check the product information sheet included in the package of each drug they plan to administer to be certain that the information contained in this work is accurate and that changes have not been made in the recommended dose or in the contraindications for administration. This recommendation is of particular importance in connection with new or infrequently used drugs.

TERMS OF USE

This is a copyrighted work and McGraw-Hill Education and its licensors reserve all rights in and to the work. Use of this work is subject to these terms. Except as permitted under the Copyright Act of 1976 and the right to store and retrieve one copy of the work, you may not decompile, disassemble, reverse engineer, reproduce, modify, create derivative works based upon, transmit, distribute, disseminate, sell, publish or sublicense the work or any part of it without McGraw-Hill Education's prior consent. You may use the work for your own noncommercial and personal use; any other use of the work is strictly prohibited. Your right to use the work may be terminated if you fail to comply with these terms.

THE WORK IS PROVIDED "AS IS." McGRAW-HILL EDUCATION AND ITS LICENSORS MAKE NO GUARANTEES OR WARRANTIES AS TO THE ACCURACY, ADEQUACY OR COMPLETENESS OF OR RESULTS TO BE OBTAINED FROM USING THE WORK, INCLUDING ANY INFORMATION THAT CAN BE ACCESSED THROUGH THE WORK VIA HYPERLINK OR OTHERWISE, AND EXPRESSLY DISCLAIM ANY WARRANTY, EXPRESS OR IMPLIED, INCLUDING BUT NOT LIMITED TO IMPLIED WARRANTIES OF MERCHANTABILITY OR FITNESS FOR A PARTICULAR PURPOSE. McGraw-Hill Education and its licensors do not warrant or guarantee that the functions contained in the work will meet your requirements or that its operation will be uninterrupted or error free. Neither McGraw-Hill Education nor its licensors shall be liable to you or anyone else for any inaccuracy, error or omission, regardless of cause, in the work or for any damages resulting therefrom. McGraw-Hill Education has no responsibility for the content of any information accessed through the work. Under no circumstances shall McGraw-Hill Education and/or its licensors be liable for any indirect, incidental, special, punitive, consequential or similar damages that result from the use of or inability to use the work, even if any of them has been advised of the possibility of such damages. This limitation of liability shall apply to any claim or cause whatsoever whether such claim or cause arises in contract, tort or otherwise.

CONTENTS

Contributors xiii

Preface xxix

Acknowledgments xxxi

Volume One

PART 1 FOUNDATIONS OF CLINICAL DERMATOLOGY

1 Fundamentals of Clinical Dermatology: Morphology and Special Clinical Considerations 1
Erin H. Amerson, Susan Burgin, & Kanade Shinkai

2 Pathology of Skin Lesions 18
Rosalie Elenitsas & Emily Y. Chu

3 Epidemiology and Public Health in Dermatology 40
Junko Takeshita & David J. Margolis

PART 2 STRUCTURE AND FUNCTION OF SKIN

4 Developmental Biology of the Skin 49
Luis Garza

5 Growth and Differentiation of the Epidermis 62
Terry Lechler

6 Skin Glands: Sebaceous, Eccrine, and Apocrine Glands 70
Christos C. Zouboulis

7 Biology of Hair Follicles 89
George Cotsarelis & Vladimir Botchkarev

8 Nail 106
Krzysztof Kobielak

9 Cutaneous Vasculature 116
Peter Petzelbauer, Robert Loewe, & Jordan S. Pober

10 The Immunological Structure of the Skin 130
Georg Stingl & Marie-Charlotte Brüggen

11 Cellular Components of the Cutaneous Immune System 143
Johann E. Gudjonsson & Robert L. Modlin

12 Soluble Mediators of the Cutaneous Immune System 159
Allen W. Ho & Thomas S. Kupper

13 Basic Principles of Immunologic Diseases in Skin (Pathophysiology of Immunologic/Inflammatory Skin Diseases) 192
Keisuke Nagao & Mark C. Udey

14 Skin Barrier 206
Akiharu Kubo & Masayuki Amagai

15 Epidermal and Dermal Adhesion 232
Leena Bruckner-Tuderman & Aimee S. Payne

16 Microbiome of the Skin 253
Heidi H. Kong

17 Cutaneous Photobiology 265
Thomas M. Rünger

18 Genetics in Relation to the Skin 289
Etienne C. E. Wang, John A. McGrath, & Angela M. Christiano

19 Carcinogenesis and Skin 310
Kenneth Y. Tsai & Andrzej A. Dlugosz

20 Pigmentation and Melanocyte Biology 328
Stephen M. Ostrowski & David E. Fisher

21 Neurobiology of the Skin 351
Sonja Ständer, Manuel P. Pereira, & Thomas A. Luger

PART 3 DERMATITIS

22 Atopic Dermatitis 363
Eric L. Simpson, Donald Y. M. Leung, Lawrence F. Eichenfield, & Mark Boguniewicz

23 Nummular Eczema, Lichen Simplex Chronicus, and Prurigo Nodularis 385
Jonathan I. Silverberg

24 Allergic Contact Dermatitis 395
Jake E. Turrentine, Michael P. Sheehan, & Ponciano D. Cruz, Jr.

25 Irritant Dermatitis 414
Susan T. Nedorost

26 Seborrheic Dermatitis 428
Dae Hun Suh

27 Occupational Skin Diseases 438
Andy Chern, Casey M. Chern, & Boris D. Lushniak

PART 4 PSORIASIFORM DISORDERS

28 Psoriasis 457
Johann E. Gudjonsson & James T. Elder

29 Pityriasis Rubra Pilaris 498
Knut Schäkel

30 Parapsoriasis and Pityriasis Lichenoides 505
Stefan M. Schieke & Gary S. Wood

31 Pityriasis Rosea 518
Matthew Clark & Johann E. Gudjonsson

PART 5 LICHENOID AND GRANULOMATOUS DISORDERS

32 Lichen Planus 527
Aaron R. Mangold & Mark R. Pittelkow

33 Lichen Nitidus and Lichen Striatus 554
Aaron R. Mangold & Mark R. Pittelkow

34 Granuloma Annulare 564
Julie S. Prendiville

35 Sarcoidosis 572
Richard Marchell

PART 6 NEUTROPHILIC, EOSINOPHILIC, AND MAST CELL DISORDERS

36 Sweet Syndrome 587
Philip R. Cohen & Razelle Kurzrock

37 Pyoderma Gangrenosum 605
Natanel Jourabchi & Gerald S. Lazarus

38 Subcorneal Pustular Dermatosis (Sneddon-Wilkinson Disease) 617
Franz Trautinger & Herbert Hönigsmann

39 Autoinflammatory Disorders 621
Takashi K. Satoh & Lars E. French

40 Eosinophilic Diseases 649
Hideyuki Ujiie & Hiroshi Shimizu

41 Urticaria and Angioedema 684
Michihiro Hide, Shunsuke Takahagi, & Takaaki Hiragun

42 Mastocytosis 710
Michael D. Tharp

PART 7 REACTIVE ERYTHEMAS

43 Erythema Multiforme 723
Jean-Claude Roujeau & Maja Mockenhaupt

44 Epidermal Necrolysis (Stevens-Johnson Syndrome and Toxic Epidermal Necrolysis) 733
Maja Mockenhaupt & Jean-Claude Roujeau

45 Cutaneous Reactions to Drugs 749
Kara Heelan, Cathryn Sibbald, & Neil H. Shear

46 Erythema Annulare Centrifugum and Other Figurate Erythemas 765
Christine S. Ahn & William W. Huang

PART 8 DISORDERS OF CORNIFICATION

47 The Ichthyoses 775
Keith A. Choate & Leonard M. Milstone

48 Inherited Palmoplantar Keratodermas 816
Liat Samuelov & Eli Sprecher

49 Keratosis Pilaris and Other Follicular Keratotic Disorders 867
Anna L. Bruckner

50 Acantholytic Disorders of the Skin 877
Alain Hovnanian

51 Porokeratosis 901
Cathal O'Connor, Grainne M. O'Regan, & Alan D. Irvine

PART 9 VESICULOBULLOUS DISORDERS

52 Pemphigus 909
Aimee S. Payne & John R. Stanley

53 Paraneoplastic Pemphigus 934
Grant J. Anhalt & Daniel Mimouni

54 Bullous Pemphigoid 944
Donna A. Culton, Zhi Liu, & Luis A. Diaz

55 Mucous Membrane Pemphigoid 960
Kim B. Yancey

56 Epidermolysis Bullosa Acquisita 971
David T. Woodley & Mei Chen

57 Intercellular Immunoglobulin (Ig) A Dermatosis (IgA Pemphigus) 981
Takashi Hashimoto

58 Linear Immunoglobulin A Dermatosis and Chronic Bullous Disease of Childhood 992
Matilda W. Nicholas, Caroline L. Rao, & Russell P. Hall III

59 Dermatitis Herpetiformis 1002
Stephen I. Katz

60 Inherited Epidermolysis Bullosa 1011
M. Peter Marinkovich

PART 10 AUTOIMMUNE CONNECTIVE TISSUE AND RHEUMATOLOGIC DISORDERS

61 Lupus Erythematosus 1037
Clayton J. Sontheimer, Melissa I. Costner, & Richard D. Sontheimer

62 Dermatomyositis 1061
Matthew Lewis & David Fiorentino

63 Systemic Sclerosis 1086
Pia Moinzadeh, Christopher P. Denton, Carol M. Black, & Thomas Krieg

64 Morphea and Lichen Sclerosus 1106
Nika Cyrus & Heidi T. Jacobe

65 Psoriatic Arthritis and Reactive Arthritis 1127
Ana-Maria Orbai & John A. Flynn

66 Rheumatoid Arthritis, Juvenile Idiopathic Arthritis, Adult-Onset Still Disease, and Rheumatic Fever 1146
Warren W. Piette

67 Scleredema and Scleromyxedema 1163
Roger H. Weenig & Mark R. Pittelkow

68 Sjögren Syndrome 1170
Akiko Tanikawa

69 Relapsing Polychondritis 1186
Camille Francès

PART 11 DERMAL CONNECTIVE TISSUE DISORDERS

70 Anetoderma and Other Atrophic Disorders of the Skin 1193
Catherine Maari & Julie Powell

71 Acquired Perforating Disorders 1203
Garrett T. Desman & Raymond L. Barnhill

72 Genetic Disorders Affecting Dermal Connective Tissue 1212
Jonathan A. Dyer

PART 12 SUBCUTANEOUS TISSUE DISORDERS

73 Panniculitis 1251
Eden Pappo Lake, Sophie M. Worobec, & Iris K. Aronson

74 Lipodystrophy 1295
Abhimanyu Garg

PART 13 MELANOCYTIC DISORDERS

75 Albinism and Other Genetic Disorders of Pigmentation 1309
Masahiro Hayashi & Tamio Suzuki

76 Vitiligo 1330
Khaled Ezzedine & John E. Harris

77 Hypermelanoses 1351
Michelle Rodrigues & Amit G. Pandya

PART 14 ACNEIFORM DISORDERS

78 Acne Vulgaris 1391
Carolyn Goh, Carol Cheng, George Agak, Andrea L. Zaenglein, Emmy M. Graber, Diane M. Thiboutot, & Jenny Kim

79 Rosacea 1419
Martin Steinhoff & Jörg Buddenkotte

80 Acne Variants and Acneiform Eruptions 1448
Andrea L. Zaenglein, Emmy M. Graber, & Diane M. Thiboutot

PART 15 DISORDERS OF ECCRINE AND APOCRINE SWEAT GLANDS

81 Hyperhidrosis and Anhidrosis 1459
Anastasia O. Kurta & Dee Anna Glaser

82 Bromhidrosis and Chromhidrosis 1469
Christos C. Zouboulis

83 Fox-Fordyce Disease 1475
Powell Perng & Inbal Sander

84 Hidradenitis Suppurativa 1480
Ginette A. Okoye

PART 16 DISORDERS OF THE HAIR AND NAILS

85 Androgenetic Alopecia 1495
Ulrike Blume-Peytavi & Varvara Kanti

86 Telogen Effluvium 1507
Manabu Ohyama

87 Alopecia Areata 1517
Nina Otberg & Jerry Shapiro

88 Cicatricial Alopecias 1524
Nina Otberg & Jerry Shapiro

89 Hair Shaft Disorders 1537
Leslie Castelo-Soccio & Deepa Patel

90 Hirsutism and Hypertrichosis 1555
Thusanth Thuraisingam & Amy J. McMichael

91 Nail Disorders 1568
Eckart Haneke

PART 17 DISORDERS DUE TO THE ENVIRONMENT

92 Polymorphic Light Eruption 1611
Alexandra Gruber-Wackernagel & Peter Wolf

93 Actinic Prurigo 1628
Travis Vandergriff

94 Hydroa Vacciniforme 1634
Travis Vandergriff

95 Actinic Dermatitis 1639
Robert S. Dawe

96 Solar Urticaria 1650
Marcus Maurer, Joachim W. Fluhr, & Karsten Weller

97 Phototoxicity and Photoallergy 1657
Henry W. Lim

98 Cold Injuries 1666
Ashley N. Millard, Clayton B. Green, & Erik J. Stratman

99 Burns 1679
Benjamin Levi & Stewart Wang

PART 18 PSYCHOSOCIAL SKIN DISEASE

100 Delusional, Obsessive-Compulsive, and Factitious Skin Diseases 1693
Mio Nakamura, Josie Howard, & John Y. M. Koo

101 Drug Abuse 1705
Nicholas Frank, Cara Hennings, & Jami L. Miller

102 Physical Abuse 1717
Kelly M. MacArthur & Annie Grossberg

PART 19 SKIN CHANGES ACROSS THE SPAN OF LIFE

103 Neonatal Dermatology 1727
Raegan Hunt, Mary Wu Chang, & Kara N. Shah

104 Pediatric and Adolescent Dermatology 1750
Mary Wu Chang

105 Skin Changes and Diseases in Pregnancy 1765
Lauren E. Wiznia & Miriam Keltz Pomeranz

106 Skin Aging 1779
Michelle L. Kerns, Anna L. Chien, & Sewon Kang

107 Caring for LGBT Persons in Dermatology 1792
Howa Yeung, Matthew D. Mansh, Suephy C. Chen, & Kenneth A. Katz

PART 20 NEOPLASIA

108 Benign Epithelial Tumors, Hamartomas, and Hyperplasias 1799
Jonathan D. Cuda, Sophia Rangwala, & Janis M. Taube

109 Appendage Tumors of the Skin 1820
Ruth K. Foreman & Lyn McDivitt Duncan

110 Epithelial Precancerous Lesions 1857
Markus V. Heppt, Gabriel Schlager, & Carola Berking

111 Basal Cell Carcinoma and Basal Cell Nevus Syndrome 1884
Jean Y. Tang, Ervin H. Epstein, Jr., & Anthony E. Oro

112 Squamous Cell Carcinoma and Keratoacanthoma 1901
Anke S. Lonsdorf & Eva N. Hadaschik

113 Merkel Cell Carcinoma 1920
Aubriana McEvoy & Paul Nghiem

114 Paget's Disease 1934
Conroy Chow, Isaac M. Neuhaus, & Roy C. Grekin

115 Melanocytic Nevi 1944
Jonathan D. Cuda, Robert F. Moore, & Klaus J. Busam

116 Melanoma 1982
Jessica C. Hassel & Alexander H. Enk

117 Histiocytosis 2018
Astrid Schmieder, Sergij Goerdt, & Jochen Utikal

118 Vascular Tumors 2042
Kelly M. MacArthur & Katherine Püttgen

119 Cutaneous Lymphoma 2072
Martine Bagot & Rudolf Stadler

120 Cutaneous Pseudolymphoma 2108
Werner Kempf, Rudolf Stadler, & Martine Bagot

121 Neoplasias and Hyperplasias of Muscular and Neural Origin 2130
Hansgeorg Müller & Heinz Kutzner

122 Lipogenic Neoplasms 2172
Thomas Mentzel & Thomas Brenn

Volume Two

PART 21 METABOLIC, GENETIC, AND SYSTEMIC DISEASES

123 Cutaneous Changes in Nutritional Disease 2199
Albert C. Yan

124 The Porphyrias 2234
Eric W. Gou & Karl E. Anderson

125 Amyloidosis 2258
Peter D. Gorevic & Robert G. Phelps

126 Xanthomas and Lipoprotein Disorders 2273
Vasanth Sathiyakumar, Steven R. Jones, & Seth S. Martin

127 Fabry Disease 2292
Atul B. Mehta & Catherine H. Orteu

128 Calcium and Other Mineral Deposition Disorders 2307
Janet A. Fairley & Adam B. Aronson

129 Graft-Versus-Host Disease 2320
Kathryn J. Martires & Edward W. Cowen

130 Hereditary Disorders of Genome Instability and DNA Repair 2342
John J. DiGiovanna, Thomas M. Rünger, & Kenneth H. Kraemer

131 Ectodermal Dysplasias 2372
Elizabeth L. Nieman & Dorothy Katherine Grange

132 Genetic Immunodeficiency Diseases 2394
Ramsay L. Fuleihan & Amy S. Paller

133 Skin Manifestations of Internal Organ Disorders 2425
Amy K. Forrestel & Robert G. Micheletti

134 Cutaneous Paraneoplastic Syndromes 2441
Manasmon Chairatchaneeboon & Ellen J. Kim

135 The Neurofibromatoses 2465
Robert Listernick & Joel Charrow

136 Tuberous Sclerosis Complex 2480
Thomas N. Darling

137 Diabetes and Other Endocrine Diseases 2493
April Schachtel & Andrea Kalus

PART 22 VASCULAR DISEASES

138 Cutaneous Necrotizing Venulitis 2527
Nicholas A. Soter

139 Systemic Necrotizing Arteritis 2539
Peter A. Merkel & Paul A. Monach

140 Erythema Elevatum Diutinum 2562
Theodore J. Alkousakis & Whitney A. High

141 Adamantiades–Behçet Disease 2567
Christos C. Zouboulis

142 Kawasaki Disease 2580
Anne H. Rowley

143 Pigmented Purpuric Dermatoses 2590
Alexandra Haden & David H. Peng

144 Cryoglobulinemia and Cryofibrinogenemia 2599
Julio C. Sartori-Valinotti & Mark D. P. Davis

145 Raynaud Phenomenon 2613
Drew Kurtzman & Ruth Ann Vleugels

146 Malignant Atrophic Papulosis (Degos Disease) 2630
Dan Lipsker

147 Vascular Malformations 2636
Laurence M. Boon, Fanny Ballieux, & Miikka Vikkula

148 Cutaneous Changes in Arterial, Venous, and Lymphatic Dysfunction 2669
Sabrina A. Newman

149 Wound Healing 2700
Afsaneh Alavi & Robert S. Kirsner

PART 23 BACTERIAL DISEASES

150 Superficial Cutaneous Infections and Pyodermas 2719
Lloyd S. Miller

151 Cellulitis and Erysipelas 2746
David R. Pearson & David J. Margolis

152 Gram-Positive Infections Associated with Toxin Production 2757
Jeffrey B. Travers

153 Necrotizing Fasciitis, Necrotizing Cellulitis, and Myonecrosis 2770
Avery LaChance & Daniela Kroshinksy

154 Gram-Negative Coccal and Bacillary Infections 2782
Breanne Mordorski & Adam J. Friedman

155 The Skin in Infective Endocarditis, Sepsis, Septic Shock, and Disseminated Intravascular Coagulation 2815
Joseph C. English III & Misha Rosenbach

156 Miscellaneous Bacterial Infections with Cutaneous Manifestations 2827
Scott A. Norton & Michael A. Cardis

157 Tuberculosis and Infections with Atypical Mycobacteria 2858
Aisha Sethi

158 Actinomycosis, Nocardiosis, and Actinomycetoma 2876
Francisco G. Bravo, Roberto Arenas, & Daniel Asz Sigall

159 Leprosy 2892
Claudio Guedes Salgado, Arival Cardoso de Brito, Ubirajara Imbiriba Salgado, & John Stewart Spencer

PART 24 FUNGAL DISEASES

160 Superficial Fungal Infection 2925
Lauren N. Craddock & Stefan M. Schieke

161 Yeast Infections 2952
Iris Ahronowitz & Kieron Leslie

162 Deep Fungal Infections 2965
Roderick J. Hay

PART 25 VIRAL DISEASES

163 Exanthematous Viral Diseases 2989
Vikash S. Oza & Erin F. D. Mathes

164 Herpes Simplex 3021
Jeffrey I. Cohen

165 Varicella and Herpes Zoster 3035
Myron J. Levin, Kenneth E. Schmader, & Michael N. Oxman

166 Poxvirus Infections 3065
Ellen S. Haddock & Sheila Fallon Friedlander

167 Human Papillomavirus Infections 3095
Jane C. Sterling

168 Cutaneous Manifestations of HIV and Human T-Lymphotropic Virus 3107
Adam D. Lipworth, Esther E. Freeman, & Arturo P. Saavedra

169 Mosquito-Borne Viral Diseases 3135
Edwin J. Asturias & J. David Beckham

PART 26 SEXUALLY TRANSMITTED DISEASES

170 Syphilis 3145
Susan A. Tuddenham & Jonathan M. Zenilman

171 Endemic (Nonvenereal) Treponematoses 3173
Francisco G. Bravo, Carolina Talhari, & Khaled Ezzedine

172 Chancroid 3186
Stephan Lautenschlager & Norbert H. Brockmeyer

173 Lymphogranuloma Venereum 3193
Norbert H. Brockmeyer & Stephan Lautenschlager

174 Granuloma Inguinale 3202
Melissa B. Hoffman & Rita O. Pichardo

175 Gonorrhea, Mycoplasma, and Vaginosis 3207
Lindsay C. Strowd, Sean McGregor, & Rita O. Pichardo

PART 27 INFESTATIONS, BITES, AND STINGS

176 Leishmaniasis and Other Protozoan Infections 3223
Esther von Stebut

177 Helminthic Infections 3251
Kathryn N. Suh & Jay S. Keystone

178 Scabies, Other Mites, and Pediculosis 3274
Chikoti M. Wheat, Craig N. Burkhart, Craig G. Burkhart, & Bernard A. Cohen

179 Lyme Borreliosis. 3287
Roger Clark & Linden Hu

180 The Rickettsioses, Ehrlichioses, and Anaplasmoses 3306
Maryam Liaqat, Analisa V. Halpern, Justin J. Green, & Warren R. Heymann

181 Arthropod Bites and Stings 3324
Robert A. Schwartz & Christopher J. Steen

182 Bites and Stings of Terrestrial and Aquatic Life 3338
Camila K. Janniger, Robert A. Schwartz, Jennifer S. Daly, & Mark Jordan Scharf

PART 28 TOPICAL AND SYSTEMIC TREATMENTS

183 Principles of Topical Therapy 3363
Mohammed D. Saleem, Howard I. Maibach, & Steven R. Feldman

184 Glucocorticoids 3382
Avrom Caplan, Nicole Fett, & Victoria Werth

185 Retinoids 3395
Anna L. Chien, Anders Vahlquist, Jean-Hilaire Saurat, John J. Voorhees, & Sewon Kang

186 Systemic and Topical Antibiotics 3407
Sean C. Condon, Carlos M. Isada, & Kenneth J. Tomecki

187 Dapsone. 3423
Chee Leok Goh & Jiun Yit Pan

188 Antifungals 3436
Mahmoud Ghannoum, Iman Salem, & Luisa Christensen

189 Antihistamines 3451
Michael D. Tharp

190 Cytotoxic and Antimetabolic Agents 3463
Jeremy S. Honaker & Neil J. Korman

191 Antiviral Drugs 3493
Zeena Y. Nawas, Quynh-Giao Nguyen, Khaled S. Sanber, & Stephen K. Tyring

192 Immunosuppressive and Immunomodulatory Drugs 3517
Drew Kurtzman, Ruth Ann Vleugels, & Jeffrey Callen

193 Immunobiologics: Targeted Therapy Against Cytokines, Cytokine Receptors, and Growth Factors in Dermatology 3531
Andrew Johnston, Yoshikazu Takada, & Sam T. Hwang

194 Molecular Targeted Therapies. 3558
David Michael Miller, Bobby Y. Reddy, & Hensin Tsao

195 Antiangiogenic Agents 3590
Adilson da Costa, Michael Y. Bonner, & Jack L. Arbiser

196 Other Topical Medications. 3610
Shawn G. Kwatra & Manisha Loss

197 Photoprotection 3623
Jin Ho Chung

PART 29 PHYSICAL TREATMENTS

198 Phototherapy 3635
Tarannum Jaleel, Brian P. Pollack, & Craig A. Elmets

199 Photochemotherapy and Photodynamic Therapy 3664
Herbert Hönigsmann, Rolf-Markus Szeimies, & Robert Knobler

200 Radiotherapy 3687
Roy H. Decker & Lynn D. Wilson

PART 30 DERMATOLOGIC SURGERY

201 Cutaneous Surgical Anatomy 3697
Arif Aslam & Sumaira Z. Aasi

202 Perioperative Considerations in Dermatologic Surgery. 3706
Noah Smith, Kelly B. Cha, & Christopher Bichakjian

203 Excisional Surgery and Repair, Flaps, and Grafts 3726
Adele Haimovic, Jessica M. Sheehan, & Thomas E. Rohrer

204 Mohs Micrographic Surgery 3761
Sean R. Christensen & David J. Leffell

205 Nail Surgery 3774
Robert Baran & Olivier Cogrel

206 Cryosurgery and Electrosurgery. 3791
Justin J. Vujevich & Leonard H. Goldberg

PART 31 COSMETIC DERMATOLOGY

207 Cosmeceuticals and Skin Care in Dermatology 3803
Leslie Baumann

208 Fundamentals of Laser and Light-Based Treatments 3820
Omer Ibrahim & Jeffrey S. Dover

209 Laser Skin Resurfacing: Cosmetic and Medical Applications 3834
Bridget E. McIlwee & Tina S. Alster

210 Nonablative Laser and Light-Based Therapy: Cosmetic and Medical Indications 3846
Jeffrey S. Orringer

211 Noninvasive Body Contouring. 3857
Murad Alam

212 Treatment of Varicose Veins and Telangiectatic Lower-Extremity Vessels. 3871
Daniel P. Friedmann, Vineet Mishra, & Jeffrey T. S. Hsu

213 Chemical Peels and Dermabrasion. 3895
Gary Monheit & Bailey Tayebi

214 Liposuction Using Tumescent Local Anesthesia 3906
C. William Hanke, Cheryl J. Gustafson, William G. Stebbins, & Aimee L. Leonard

215 Soft-Tissue Augmentation 3911
Lisa M. Donofrio & Dana L. Ellis

216 Botulinum Toxin 3921
Richard G. Glogau

217 Hair Transplantation. 3931
Robin H. Unger & Walter P. Unger

Index 3951

Videos can be accessed via the following link: **mhprofessional.com/fitzderm9evideos**

Chapter Number: Title	Video Number: Title
Chapter 159: Leprosy	Video 159-1: Sensitivity Test Monofilament Video 159-2: Drop Foot Video 159-3: Walking Impairment
Chapter 205: Nail Surgery	Video 205-1: Lateral Longitudinal Biopsy Video 205-2: Biopsy of the Distal Matrix Video 205-3: Tangential Shave Excision Video 205-4: Biopsy of Onychopapilloma

CONTRIBUTORS

Sumaira Z. Aasi, MD
Clinical Professor, Dermatology, Clinical Professor (By Courtesy), Surgery–Plastic and Reconstructive Surgery, Dermatology–North Campus, Stanford University, Redwood City, California [201]

George Agak, PhD
Research Scientist, Dermatology/Medicine, David Geffen School of Medicine at UCLA, Los Angeles, California [78]

Christine S. Ahn, MD
Resident Physician, Wake Forest School of Medicine, Winston Salem, North Carolina [46]

Iris Ahronowitz, MD
Assistant Professor of Clinical Dermatology, Keck School of Medicine, University of Southern California, Los Angeles, California [161]

Murad Alam, MD, MSCI, MBA
Professor of Dermatology, Otolaryngology, and Surgery, Vice-Chair, Department of Dermatology, Chief, Section of Cutaneous and Aesthetic Surgery, Director, Micrographic Surgery and Dermatologic Oncology Fellowship, Northwestern University, Chicago, Illinois [211]

Afsaneh Alavi, MSc, MD, FRCPC
Assistant Professor of Dermatology, Women's College Hospital, University of Toronto, Toronto, Ontario, Canada [149]

Theodore J. Alkousakis, MD
Assistant Clinical Professor, University of Colorado School of Medicine, Medical Director, Adult Dermatology, Aurora, Colorado [140]

Tina S. Alster, MD
Director, Washington Institute of Dermatologic Laser Surgery, Clinical Professor of Dermatology, Georgetown University Medical Center, Washington, DC [209]

Masayuki Amagai, MD, PhD
Professor and Chair, Department of Dermatology, Keio University School of Medicine, Tokyo, Japan [14]

Erin H. Amerson, MD
Associate Professor, University of California, San Francisco, Department of Dermatology, San Francisco, California [1]

Karl E. Anderson, MD, FACP
Departments of Preventive Medicine and Community Health, and Internal Medicine (Division of Gastroenterology and Hepatology), University of Texas Medical Branch, Galveston, Texas [124]

Grant J. Anhalt, MD
Professor of Dermatology and Pathology, Department of Dermatology, Johns Hopkins Hospital, Baltimore, Maryland [53]

Jack L. Arbiser, MD, PhD
Emory University School of Medicine, Department of Dermatology, Atlanta Veterans Affairs Medical Center, Atlanta, Georgia [195]

Roberto Arenas, MD
Mycology Section, Dr. Manuel Gea Gonzalez General Hospital, Mexico City, Mexico [158]

Adam B. Aronson, MD
Resident Physician, Dermatology, University of Iowa Carver College of Medicine, Iowa City, Iowa [128]

Iris K. Aronson, MD
University of Illinois at Chicago, Chicago, Illinois [73]

Arif Aslam, MBChB, MRCP (UK), MRCGP, MRCP (Dermatology)
Consultant Dermatologist and Mohs Surgeon, St Helens and Knowsley Teachings Hospitals NHS Trust, St Helens, United Kingdom [201]

Edwin J. Asturias, MD
The Jules Amer Chair in Community Pediatrics, Children's Hospital Colorado, Associate Professor of Pediatrics and Epidemiology, Division of Pediatric Infectious Diseases, University of Colorado School of Medicine, Center for Global Health, Colorado School of Public Health, Aurora, Colorado [169]

Martine Bagot, MD, PhD
Department of Dermatology, Hôpital Saint-Louis, Paris, France [119, 120]

Fanny Ballieux, MD
Resident, Center for Vascular Anomalies, Division of Plastic Surgery, Cliniques Universitaires St Luc and University of Louvain, Brussels, Belgium [147]

Robert Baran, MD
Honorary Professor, Nail Disease Center, Cannes, France [205]

Raymond L. Barnhill, MD
Professor, Department of Pathology, Institut Curie, and University of Paris Descartes Faculty of Medicine, Paris, France, Department of Pathology, Paris, France [71]

Leslie Baumann, MD
Board Certified Dermatologist, Baumann Cosmetic and Research Institute, Miami, Florida [207]

J. David Beckham, MD
Associate Professor, Director of the Infectious Disease Fellowship Training Program, Division of Adult Infectious Diseases, University of Colorado School of Medicine, Denver, Colorado [169]

Carola Berking, MD
Department of Dermatology, University Hospital Munich, Ludwig-Maximilian University (LMU), Munich, Germany [110]

Christopher Bichakjian, MD
Department of Dermatology, University of Michigan Health System, Ann Arbor, Michigan [202]

Carol M. Black, MD, FRCP
Centre for Rheumatology and Connective Tissue Diseases, UCL Medical School, Royal Free Hospital, London, United Kingdom [63]

Ulrike Blume-Peytavi, MD
Department of Dermatology and Allergy, Charité-Universitätsmedizin, Berlin, Germany [85]

Mark Boguniewicz, MD
Professor, Division of Allergy and Immunology, Department of Pediatrics, National Jewish Health and University of Colorado School of Medicine, Denver, Colorado [22]

Michael Y. Bonner, BA
Emory University School of Medicine, Department of Dermatology, Atlanta, Georgia [195]

Laurence M. Boon, MD, PhD
Coordinator of the Center for vascular Anomalies, Division of Plastic Surgery, Cliniques Universitaires St Luc and Human Molecular Genetics, de Duve Institute, University of Louvain, Brussels, Belgium [147]

Vladimir Botchkarev, MD, PhD, FRSB
Professor and Deputy Director, Centre for Skin Sciences, University of Bradford, United Kingdom, Adjunct Professor, Department of Dermatology, Boston University School of Medicine, Boston, Massachusetts [7]

Francisco G. Bravo, MD
Associate Professor of Dermatology and Pathology, Universidad Peruana Cayetano Heredia, Lima, Peru [158, 171]

Thomas Brenn, MD, PhD
Consultant Dermatopathologist and Honorary Senior Lecturer, Department of Pathology NHS Lothian University Hospitals Trust and the University of Edinburgh, Edinburgh, United Kingdom [122]

Norbert H. Brockmeyer
Walk In Ruhr (WIR) Center for Sexual Health and Medicine, Department of Dermatology, Venerology and Allergology, Ruhr-Universität Bochum, Bochum, Germany [172, 173]

Anna L. Bruckner, MD, MSCS
Associate Professor of Dermatology and Pediatrics, University of Colorado School of Medicine, Section Head, Pediatric Dermatology, Children's Hospital Colorado, Aurora, Colorado [49]

Leena Bruckner-Tuderman, MD, PhD
Professor and Chair of Dermatology, Medical Center-University of Freiburg, Freiburg, Germany [15]

Marie-Charlotte Brüggen, MD, PhD
Department of Dermatology, University Hospital Zurich, Zurich, Switzerland [10]

Jörg Buddenkotte, MD, PhD
Academic Research Scientist, Department of Dermatology and Venereology, Hamad Medical Corporation, Doha, Qatar [79]

Susan Burgin, MD
Assistant Professor, Beth Israel Deaconness Medical Center, Harvard Medical School, Department of Dermatology, Boston, Massachusetts [1]

Craig G. Burkhart, MD
Sylvania, Ohio [178]

Craig N. Burkhart, MD
The University of North Carolina at Chapel Hill, Chapel Hill, North Carolina [178]

Klaus J. Busam, MD
Professor of Pathology and Laboratory Medicine, Weill Medical College of Cornell University, Department of Dermatopathology and Pathology, Memorial Sloan Kettering Cancer Center, New York, New York [115]

Jeffrey Callen, MD
Professor of Medicine (Dermatology), University of Louisville, Chief, Division of Dermatology, Louisville, Kentucky [192]

Avrom Caplan, MD
Department of Dermatology, Hospital of the University of Pennsylvania, Philadelphia, Pennsylvania [184]

Michael A. Cardis, MD
Department of Dermatology, Washington Hospital Center/ Georgetown University, Washington, DC [156]

Arival Cardoso de Brito, MD, PhD
Full Professor, Dermatology, Pará Federal University, Belém, Pará, Brazil [159]

Leslie Castelo-Soccio, MD, PhD
Assistant Professor of Pediatrics and Dermatology, The Children's Hospital of Philadelphia and University of Pennsylvania Perlman School of Medicine, Philadelphia, Pennsylvania [89]

Kelly B. Cha, MD, PhD
Department of Dermatology, University of Michigan Health System, Ann Arbor, Michigan [202]

Manasmon Chairatchaneeboon, MD
Clinical Instructor in Dermatology, Department of Dermatology, Faculty of Medicine Siriraj Hospital, Mahidol University, Bangkok, Thailand [134]

Mary Wu Chang, MD
Clinical Professor of Dermatology and Pediatrics, University of Connecticut School of Medicine, Farmington, Connecticut [103, 104]

Joel Charrow, MD
Professor of Pediatrics, Feinberg School of Medicine, Northwestern University, Ann and Robert H. Lurie Children's Hospital of Chicago, Division of Genetics, Birth Defects and Metabolism, Chicago, Illinois [135]

Mei Chen, PhD
Director, USC Laboratories for Investigative Dermatology, The Keck School of Medicine, University of Southern California, Los Angeles, California [56]

Suephy C. Chen, MD, MS
Vice Chair and Associate Professor of Dermatology, Emory University School of Medicine, Atlanta, Georgia [107]

Carol Cheng, MD
Assistant Clinical Professor of Dermatology/Medicine, David Geffen School of Medicine at UCLA, Los Angeles, California [78]

Andy Chern, MD, MPH
Captain, Medical Corps, United States Army, Associate Program Director, Occupational and Environmental Medicine Residency Program, Uniformed Services University of the Health Sciences, F. Edward Hébert School of Medicine, Department of Preventive Medicine and Biostatistics, Bethesda, Maryland [27]

Casey M. Chern, MD
Captain, Medical Corps, United States Army, Dermatology Resident, National Capital Consortium Dermatology Residency Program, Walter Reed National Military Medical Center, Bethesda, Maryland [27]

Anna L. Chien, MD
Assistant Professor, Department of Dermatology, Johns Hopkins School of Medicine, Baltimore, Maryland [106, 185]

Keith A. Choate, MD, PhD
Professor of Dermatology, Genetics and Pathology, Yale University School of Medicine, New Haven, Connecticut [47]

Conroy Chow, MD
Assistant Professor, Department of Dermatology, Loma Linda University, Loma Linda, California [114]

Luisa Christensen, MD
Center for Medical Mycology, University Hospitals Cleveland Medical Center, Case Western Reserve University, Cleveland, Ohio [188]

Sean R. Christensen, MD, PhD
Assistant Professor of Dermatology, Section of Dermatologic Surgery, Yale University School of Medicine, New Haven, Connecticut [204]

Angela M. Christiano, PhD
Department of Dermatology, Department of Genetics and Development, Columbia University, New York, New York [18]

Emily Y. Chu, MD, PhD
Assistant Professor of Dermatology, Hospital of the University of Pennsylvania, Perelman School of Medicine, Philadelphia, Pennsylvania [2]

Jin Ho Chung, MD, PhD
Professor and Chairman, Department of Dermatology, Seoul National University College of Medicine, Seoul, Korea [197]

Matthew Clark, MD
Dermatology Resident, University of Michigan Department of Dermatology, Ann Arbor, Michigan [31]

Roger Clark, DO
Assistant Professor of Medicine, Tufts Medical Center, Brigham and Women's Faulkner Hospital, Boston, Massachusetts [179]

Olivier Cogrel, MD
Dermatologic Surgery and Laser Unit, Dermatology Department, CHU Bordeaux, Hôpital Saint-André, Bordeaux, France [205]

Bernard A. Cohen, MD
Johns Hopkins Hospital Baltimore, Maryland [178]

Jeffrey I. Cohen, MD
Chief, Laboratory of Infectious Diseases, National Institute of Allergy and Infectious Diseases, National Institutes of Health, Bethesda, Maryland [164]

Philip R. Cohen, MD
Professor of Dermatology, University of California San Diego School of Medicine, San Diego, California [36]

Sean C. Condon, MD
Department of Dermatology, Cleveland Clinic, Cleveland, Ohio [186]

Melissa I. Costner, MD
Associate Clinical Professor, Dermatology, UT Southwestern Medical School, North Dallas Dermatology Associates, Dallas, Texas [61]

George Cotsarelis, MD
Milton B. Hartzell Professor and Chair, Department of Dermatology, Perelman School of Medicine University of Pennsylvania, Director, Program on Epithelial Regeneration and Stem Cells, University of Pennsylvania Institute for Regenerative Medicine, Philadelphia, Pennsylvania [7]

Edward W. Cowen, MD
Head, Dermatology Consultation Service, Dermatology Branch, Center for Cancer Research, National Cancer Institute, National Institutes of Health, Bethesda, Maryland [129]

Lauren N. Craddock, MD
Department of Dermatology, University of Wisconsin-Madison, Madison, Wisconsin [160]

Ponciano D. Cruz, Jr., MD
Distinguished Professor, Paul Bergstresser Endowed Chair in Dermatology, Department of Dermatology, The University of Texas, Chief of Dermatology, North Texas Veterans Affairs Medical Center, Dallas, Texas [24]

Jonathan D. Cuda, MD
Assistant Professor of Dermatology, Johns Hopkins School of Medicine, Baltimore, Maryland [108, 115]

Donna A. Culton, MD, PhD
Department of Dermatology, University of North Carolina at Chapel Hill, Chapel Hill, North Carolina [54]

Nika Cyrus, MD
Department of Dermatology, Parkland Health and Hospital System, Dallas, Texas [64]

Adilson da Costa, MD
Emory University School of Medicine, Department of Dermatology, Atlanta, Georgia [195]

Jennifer S. Daly, MD
Clinical Chief, Infectious Diseases and Immunology, Professor of Medicine, Microbiology and Physiological Systems, University of Massachusetts Medical School, Worcester, Massachusetts [182]

Thomas N. Darling, MD, PhD
Professor and Chair of Dermatology, Uniformed Services University of the Health Sciences, Bethesda, Maryland [136]

Mark D. P. Davis, MD
Professor of Dermatology, Mayo Clinic College of Medicine, Department of Dermatology, Rochester, Minnesota [144]

Robert S. Dawe, MBChB, MD(Glasg), FRCP(Edin)
Consultant Dermatologist and Honorary Reader in Dermatology, Department of Dermatology and Photobiology Unit, NHS Tayside and University of Dundee, Dundee, Scotland [95]

Roy H. Decker, MD, PhD
Associate Professor, Vice Chair and Director of Clinical Research, Department of Therapeutic Radiology, Yale School of Medicine, New Haven, Connecticut [200]

Christopher P. Denton, PhD, FRCP
Centre for Rheumatology and Connective Tissue Diseases, UCL Medical School, Royal Free Hospital, London, United Kingdom [63]

Garrett T. Desman, MD
Assistant Professor of Pathology and Dermatology, Icahn School of Medicine at Mount Sinai, New York, New York [71]

Luis A. Diaz, MD
Department of Dermatology, University of North Carolina at Chapel Hill, Chapel Hill, North Carolina [54]

John J. DiGiovanna, MD
Senior Research Physician, DNA Repair Section, Dermatology Branch, Center for Cancer Research, National Cancer Institute, National Institutes of Health, Bethesda, Maryland [130]

Andrzej A. Dlugosz, MD
Poth Professor of Cutaneous Oncology, Departments of Dermatology and Cell and Developmental Biology, University of Michigan Medical School, Ann Arbor, Michigan [19]

Lisa M. Donofrio, MD
Associate Clinical Professor, Department of Dermatology, Yale School of Medicine, Yale University, New Haven, Connecticut [215]

Jeffrey S. Dover, MD, FRCPC
SkinCare Physicians, Chestnut Hill, Massachusetts [208]

Lyn McDivitt Duncan, MD
Professor of Pathology, Harvard Medical School, Chief, Dermatopathology Unit, Department of Pathology, Massachusetts General Hospital, Boston, Massachusetts [109]

Jonathan A. Dyer, MD
Associate Professor of Dermatology and Child Health, Departments of Dermatology and Child Health, University of Missouri, Columbia, Missouri [72]

Lawrence F. Eichenfield, MD
Chief, Pediatric and Adolescent Dermatology, Professor of Dermatology and Pediatrics, Vice Chair, Department of Dermatology, University of California, San Diego School of Medicine, San Diego, California [22]

James T. Elder, MD, PhD
Kirk D. Wuepper Professor of Molecular Genetic Dermatology, Department of Dermatology, University of Michigan, Ann Arbor, Ann Arbor, Michigan [28]

Rosalie Elenitsas, MD
Professor of Dermatology, Director of Dermatopathology, Hospital of the University of Pennsylvania, Perelman School of Medicine, Philadelphia, Pennsylvania [2]

Dana L. Ellis, MD
Clinical Instructor, Department of Dermatology, Yale School of Medicine, Yale University, New Haven, Connecticut [215]

Craig A. Elmets, MD
Professor and Emeritus Chair, Department of Dermatology, University of Alabama at Birmingham, The Birmingham VA Medical Center, Birmingham, Alabama [198]

Joseph C. English III, MD
Professor of Dermatology, University of Pittsburgh, Department of Dermatology, UPMC North Hills Dermatology, Wexford, Pennsylvania [155]

Alexander H. Enk, MD
Professor and Chair, Department of Dermatology, University of Heidelberg, Heidelberg, Germany [116]

Ervin H. Epstein, Jr., MD
Children's Hospital of Oakland Research Institute, UCSF, Oakland, California [111]

Khaled Ezzedine, MD, PhD
Professor, Department of Dermatology, Hôpital Henri Mondor, EA EpiDermE (Epidémiologie en Dermatologie et Evaluation des Thérapeutiques), UPEC-Université Paris-Est Créteil, Créteil, France [76, 171]

Janet A. Fairley, MD
John S. Strauss Professor and Chair, Department of Dermatology, University of Iowa Carver College of Medicine, Iowa City, Iowa [128]

Steven R. Feldman, MD, PhD
Department of Dermatology, Wake Forest University School of Medicine, Winston-Salem, North Carolina [183]

Nicole Fett, MD, MSCE
Associate Professor of Dermatology, Department of Dermatology, Oregon Health and Science University, Portland, Oregon [184]

David Fiorentino, MD, PhD
Professor in the Department of Dermatology and the Department of Immunology and Rheumatology at Stanford University School of Medicine, Redwood City, California [62]

David E. Fisher, MD, PhD
Edward Wigglesworth Professor and Chairman, Department of Dermatology, Harvard Medical School, Director, Melanoma Program MGH Cancer Center, Director, Cutaneous Biology Research Center, Massachusetts General Hospital, Boston, Massachusetts [20]

Joachim W. Fluhr, MD
Oberarzt, Charité-Universitätsmedizin Berlin, Klinik für Dermatologie, Venerologie und Allergologie, Berlin, Germany [96]

John A. Flynn, MD, MBA, MEd
Professor and Associate Dean of Medicine, Johns Hopkins University, Baltimore, Maryland [65]

Ruth K. Foreman, MD, PhD
Instructor of Pathology, Harvard Medical School, Dermatopathology Unit, Department of Pathology, Massachusetts General Hospital, Boston, Massachusetts [109]

Amy K. Forrestel, MD
University of Pennsylvania, Department of Dermatology, Philadelphia, Pennsylvania [133]

Camille Francès, MD
AP-HP, Hôpital Tenon, Université Paris VI, Service de Dermatologie-Allergologie, Paris, France [69]

Nicholas Frank, MD
Dermatology Resident, Vanderbilt University Medical Center, Department of Internal Medicine, Division of Dermatology, Nashville, Tennessee [101]

Esther E. Freeman, MD, PhD
Assistant Professor of Dermatology, Harvard University Medical School, Director, Global Health Dermatology, Massachusetts General Hospital, Department of Dermatology, Boston, Massachusetts [168]

Lars E. French, MD
Professor and Chairman, Department of Dermatology, University of Zurich, Zurich, Switzerland [39]

Sheila Fallon Friedlander, MD
Professor of Dermatology and Pediatrics, University of California, San Diego School of Medicine, Rady Children's Hospital, San Diego, San Diego, California [166]

Adam J. Friedman, MD
Associate Professor of Dermatology, Director of Translational Research, Residency Program Director, Department of Dermatology, George Washington School of Medicine and Health Sciences, Washington, DC [154]

Daniel P. Friedmann, MD
Westlake Dermatology Clinical Research Center, Westlake Dermatology and Cosmetic Surgery, Austin, Texas [212]

Ramsay L. Fuleihan, MD
Professor of Pediatrics, Northwestern University Feinberg School of Medicine, Chicago, Illinois [132]

Abhimanyu Garg, MD
Professor of Internal Medicine, Chief, Division of Nutrition and Metabolic Diseases, Department of Internal Medicine and the Center for Human Nutrition, Distinguished Chair in Human Nutrition Research, Dallas, Texas [74]

Luis Garza, MD, PhD
Associate Professor, Department of Dermatology, Johns Hopkins School of Medicine, Baltimore, Maryland [4]

Mahmoud Ghannoum, PhD, EMBA
Center for Medical Mycology, University Hospitals Cleveland Medical Center, Case Western Reserve University, Cleveland, Ohio [188]

Dee Anna Glaser, MD
Interim Chair and Professor, Director Cosmetic and Laser Surgery, Director of Clinical Research, Department of Dermatology, Saint Louis University School of Medicine, St. Louis, Missouri [81]

Richard G. Glogau, MD
Clinical Professor of Dermatology, University of California, San Francisco, San Francisco, California [216]

Sergij Goerdt, MD
Professor of Dermatology, Chair of Dermatology, Department of Dermatology, Venereology and Allergology, University Medical Center and Medical Faculty Mannheim, University of Heidelberg, Mannheim, Germany [117]

Carolyn Goh, MD
Assistant Clinical Professor of Dermatology/Medicine, David Geffen School of Medicine at UCLA, Los Angeles, California [78]

Chee Leok Goh, MD, MBBS, M. Med (Int. Med), MRCP (UK), FRCP (Edin), Hon FACD, FAMS (Dermatology)
Clinical Professor, National Skin Centre, Singapore [187]

Leonard H. Goldberg, MD
DermSurgery Associates, Houston, Texas [206]

Peter D. Gorevic, MD
Professor of Medicine, Division of Rheumatology, Icahn School of Medicine at Mount Sinai, New York, New York [125]

Eric W. Gou, MD
Department of Internal Medicine, Division of Gastroenterology and Hepatology, University of Texas Medical Branch, Galveston, Texas [124]

Emmy M. Graber, MD, MBA
Dermatologist, The Dermatology Institute of Boston, Boston, Massachusetts [78, 80]

Dorothy Katherine Grange, MD
Professor of Pediatrics, Division of Genetics and Genomic Medicine, Department of Pediatrics, Washington University School of Medicine, St. Louis, Missouri [131]

Clayton B. Green MD, PhD
The Marshfield Clinic, Marshfield, Wisconsin [98]

Justin J. Green, MD
Division of Dermatology, Cooper Medical School of Rowan University, Camden, New Jersey [180]

Roy C. Grekin, MD
Professor of Dermatology, Director, Dermatologic Surgery and Laser Center, University of California, San Francisco, San Francisco, California [114]

Annie Grossberg, MD
Associate Director, Dermatology Residency Program, Assistant Professor, Departments of Dermatology and Pediatrics, Johns Hopkins University, Baltimore, Maryland [102]

Alexandra Gruber-Wackernagel, MD
Medical University of Graz, Research Unit for Photodermatology, Department of Dermatology, Medical University of Graz, Graz, Austria [92]

Johann E. Gudjonsson, MD, PhD
Assistant Professor, Department of Dermatology, Frances and Kenneth Eisenberg Emerging Scholar of the Taubman Medical Research Institute, University of Michigan, Ann Arbor, Michigan [11, 28, 31]

Cheryl J. Gustafson, MD
St. Vincent Carmel Medical Center, Carmel, Indiana [214]

Eva N. Hadaschik, MD
Department of Dermatology, University Hospital Heidelberg, Heidelberg, Germany [112]

Ellen S. Haddock, AB, MBA
University of California, San Diego School of Medicine, La Jolla, California [166]

Alexandra Haden, MD
Assistant Professor of Clinical Dermatology, Department of Dermatology, University of Southern California, Los Angeles, California [143]

Adele Haimovic, MD
SkinCare Physicians, Chestnut Hill, Massachusetts [203]

Russell P. Hall III, MD
J. Lamar Callaway Professor, Department of Dermatology, Duke University Medical Center, Durham, North Carolina [58]

Analisa V. Halpern, MD
Division of Dermatology, Cooper Medical School of Rowan University, Camden, New Jersey [180]

Eckart Haneke, MD, PhD
Clinical Professor (em) of Dermatology, Department of Dermatology, Inselspital, University of Berne, Bern, Switzerland [91]

C. William Hanke, MD, MPH, FACP
St. Vincent Carmel Medical Center, Carmel, Indiana [214]

John E. Harris, MD, PhD
Associate Professor, University of Massachusetts Medical School, Worcester, Massachusetts [76]

Takashi Hashimoto, MD
Professor and Director, Kurume University Institute of Cutaneous Cell Biology, Kurume, Fukuoka, Japan [57]

Jessica C. Hassel, MD
Section Head, DermatoOncology, Department of Dermatology and National Center for Tumor Diseases, University Hospital Heidelberg, Heidelberg, Germany [116]

Roderick J. Hay, DM, FRCP, FRCPath, FMedSci
Professor, Department of Dermatology, Kings College Hospital, Denmark Hill, London, United Kingdom [162]

Masahiro Hayashi, MD, PhD
Associate Professor of Dermatology, Yamagata University Faculty of Medicine, Yamagata, Japan [75]

Kara Heelan, MB BCh, BAO
Dermatology Department, University College London Hospitals, London, United Kingdom [45]

Cara Hennings, MD
University of Tennessee/Erlanger Medical Center, Chattanooga, Tennessee [101]

Markus V. Heppt, MD
Department of Dermatology, University Hospital Munich, Ludwig-Maximilian University, Munich, Germany [110]

Warren R. Heymann, MD
Division of Dermatology, Cooper Medical School of Rowan University, Camden, New Jersey [180]

Michihiro Hide, MD, PhD
Department of Dermatology, Institute of Biomedical and Health Sciences, Hiroshima University, Hiroshima, Japan [41]

Whitney A. High, MD, JD, MEng
Associate Professor of Dermatology and Pathology, University of Colorado School of Medicine, Director of Dermatopathology (Dermatology), Aurora, Colorado [140]

Takaaki Hiragun, MD, PhD
Department of Dermatology, Institute of Biomedical and Health Sciences, Hiroshima University, Hiroshima, Japan [41]

Allen W. Ho, MD, PhD
Resident Physician, Department of Dermatology, Harvard Medical School, Boston, Massachusetts [12]

Melissa B. Hoffman, MD
Resident, Dermatology, Wake Forest School of Medicine, Winston Salem, North Carolina [174]

Jeremy S. Honaker, CNP, PhD
Assistant Professor, Department of Dermatology, Case Western Reserve University, Cleveland, Ohio [190]

Herbert Hönigsmann, MD
Professor of Dermatology, Emeritus Chairman, Department of Dermatology, Medical University of Vienna, Vienna, Austria [38, 199]

Alain Hovnanian, MD, PhD
Professor of Genetics, Department of Genetics, Imagine Institute for Genetic Diseases, Necker Hospital for Sick Children, University Paris Descartes-Sorbonne Paris Cité, Paris, France [50]

Josie Howard, MD
Clinical Faculty, Departments of Psychiatry and Dermatology, University of California, San Francisco, San Francisco, California [100]

Jeffrey T. S. Hsu, MD
Clinical Assistant Professor, Department of Dermatology, University of Illinois College of Medicine at Chicago, Co-Director of Dermatologic, Laser and Cosmetic Surgery, The Dermatology Institute of DuPage Medical Group, Naperville, Illinois [212]

Linden Hu, MD
Professor of Microbiology and Medicine, Tufts University School of Medicine, Boston, Massachusetts [179]

William W. Huang, MD, MPH
Associate Professor of Dermatology, Residency Program Director, Wake Forest School of Medicine, Winston Salem, North Carolina [46]

Raegan Hunt, MD, PhD
Assistant Professor of Dermatology and Pediatrics, Texas Children's Hospital, Baylor College of Medicine, Houston, Texas [103]

Sam T. Hwang, MD, PhD
Department of Dermatology, University of California Davis School of Medicine, Sacramento, California [193]

Omer Ibrahim, MD
SkinCare Physicians, Chestnut Hill, Massachusetts [208]

Alan D. Irvine, MD, DSc
Paediatric Dermatology and National Children's Research Centre, Our Lady's Children's Hospital Crumlin, Dublin, Clinical Medicine, Trinity College, Dublin, Ireland [51]

Carlos M. Isada, MD
Department of Infectious Disease, Cleveland Clinic, Cleveland, Ohio [186]

Heidi T. Jacobe, MD, MSCS
Associate Professor, Department of Dermatology, UT Southwestern Medical Center, Dallas, Texas [64]

Tarannum Jaleel, MD
Instructor, Department of Dermatology, Duke Medical Center, Durham, North Carolina [198]

Camila K. Janniger, MD
Clinical Professor, Dermatology, Rutgers New Jersey Medical School, Englewood, New Jersey [182]

Andrew Johnston, PhD
Department of Dermatology University of Michigan School of Medicine, Ann Arbor, Michigan [193]

Steven R. Jones, MD
Ciccarone Center for the Prevention of Heart Disease, Division of Cardiology, Department of Medicine, Johns Hopkins Hospital, Baltimore Maryland [126]

Natanel Jourabchi, MD
Resident Dermatology Physician, Johns Hopkins School of Medicine, Baltimore, Maryland [37]

Andrea Kalus, MD
Associate Professor, University of Washington School of Medicine, Division of Dermatology, Seattle, Washington [137]

Sewon Kang, MD, MPH
Noxell Professor & Chair, Department of Dermatology, Johns Hopkins School of Medicine, Dermatologist-in-Chief, Johns Hopkins Hospital, Baltimore, Maryland [106, 185]

Varvara Kanti, MD
Department of Dermatology and Allergy, Charité-Universitätsmedizin, Berlin, Germany [85]

Kenneth A. Katz, MD, MSc, MSCE
Department of Dermatology, Kaiser Permanente, San Francisco, California [107]

Stephen I. Katz, MD, PhD
National Institute of Arthritis and Musculoskeletal and Skin Diseases, Bethesda, Maryland [59]

Werner Kempf, MD
Kempf and Pfaltz, Histologische Diagnostik, Department of Dermatology, University Hospital Zurich, Zurich, Switzerland [120]

Michelle L. Kerns, MD
Research Fellow, Department of Dermatology, Johns Hopkins School of Medicine, Baltimore, Maryland [106]

Jay S. Keystone, MD, MSc (CTM), FRCPC
Professor of Medicine, University of Toronto, Tropical Disease Unit, Division of Infectious Diseases, Toronto General Hospital, Toronto, Ontario, Canada [177]

Ellen J. Kim, MD
Sandra J. Lazarus Associate Professor in Dermatology, Department of Dermatology, Perelman School of Medicine at the University of Pennsylvania, Perelman Center for Advanced Medicine, Philadelphia, Pennsylvania [134]

Jenny Kim, MD, PhD
Professor of Dermatology/ Medicine/Nutrition, David Geffen School of Medicine at UCLA, Los Angeles, California [78]

Robert S. Kirsner, MD, PhD
Chairman and Harvey Blank Professor, Department of Dermatology and Cutaneous Surgery, Professor, Department of Public Health Sciences, University of Miami Miller School of Medicine, Miami, Florida [149]

Robert Knobler, MD
Associate Professor of Dermatology, Department of Dermatology, Medical University of Vienna, Vienna, Austria [199]

Krzysztof Kobielak, MD, PhD
Group Leader of Laboratory of Stem Cells, Development and Tissue Regeneration, Centre of New Technologies, University of Warsaw, Warsaw, Poland, Principal Investigator, Department of Developmental and Cell Biology, University of California, Irvine, Irvine, California [8]

Heidi H. Kong, MD, MHSc
Investigator, Dermatology Branch, Center for Cancer Research, National Cancer Institute, National Institutes of Health, Dermatology Branch Bethesda, Maryland [16]

John Y. M. Koo, MD
Professor, Psoriasis, Phototherapy, and Skin Treatment Center and Psychodermatology Clinic, Department of Dermatology, University of California San Francisco, San Francisco, California [100]

Neil J. Korman, MD, PhD
Professor, Department of Dermatology, Case Western Reserve University, Cleveland, Ohio [190]

Kenneth H. Kraemer, MD
Chief, DNA Repair Section, Dermatology Branch, Center for Cancer Research, National Cancer Institute, National Institutes of Health, Bethesda, Maryland [130]

Thomas Krieg, MD, FRCP
Department of Dermatology and Venerology, University of Cologne, Cologne, Germany [63]

Daniela Kroshinksy, MD, MPH
Associate Professor, Harvard Medical School, Director of Inpatient Dermatology, Director of Pediatric Dermatology, Massachusetts General Hospital/ MassGeneral Hospital for Children, Boston, Massachusetts [153]

Akiharu Kubo, MD, PhD
Department of Dermatology, Keio University School of Medicine, Tokyo, Japan [14]

Thomas S. Kupper, MD
Thomas B. Fitzpatrick Professor, Department of Dermatology, Brigham and Women's Hospital, Harvard Medical School, Boston, Massachusetts [12]

Anastasia O. Kurta, DO
Dermatology Resident, Department of Dermatology, Saint Louis University School of Medicine, St Louis, Missouri [81]

Drew Kurtzman, MD
Assistant Professor of Medicine (Dermatology), Director, Connective Tissue Disease Clinic, Director, Immunobullous Disease Clinic, The University of Arizona, Tucson, Arizona [145, 192]

Razelle Kurzrock, MD
Professor of Medicine and Chief, Division of Hematology and Oncology; Senior Deputy Center Director, Clinical Science; and Director, Center for Personalized Cancer Therapy and Clinical Trials Office, University of California, San Diego Moores Cancer Center, San Diego, California [36]

Heinz Kutzner, MD
Dermatopathology Friedrichshafen, Friedrichshafen, Germany [121]

Shawn G. Kwatra, MD
Department of Dermatology, Johns Hopkins School of Medicine, Baltimore, Maryland [196]

Avery LaChance, MD, MPH
Dermatology Resident, Harvard Combined Dermatology Residency Training Program, Massachusetts General Hospital, Boston, Massachusetts [153]

Eden Pappo Lake, MD
University of Illinois at Chicago, Chicago, Illinois [73]

Stephan Lautenschlager, MD
Associate Professor University of Zurich, Chairman Outpatient Clinic of Dermatology and Venereology, City Hospital Triemli, Zurich, Switzerland [172, 173]

Gerald S. Lazarus, MD
Professor of Dermatology and Medicine, Johns Hopkins School of Medicine, Baltimore, Maryland [37]

Terry Lechler, PhD
Associate Professor of Dermatology, Duke University Medical Center, Durham, North Carolina [5]

David J. Leffell, MD
David Paige Smith Professor of Dermatology and Professor of Surgery (Otolaryngology and Plastic), Section Chief of Dermatologic Surgery, Yale University School of Medicine, New Haven, Connecticut [204]

Aimee L. Leonard, MD
New England Dermatology and Laser Center, Springfield, Massachusetts [214]

Kieron Leslie, MBBS, DTM&H, FRCP
Professor of Clinical Dermatology, Dermatology Department, University of California, San Francisco, San Francisco, California [161]

Donald Y. M. Leung, MD, PhD
Department of Pediatrics, National Jewish Health, University of Colorado Denver, Denver, Colorado [22]

Benjamin Levi, MD
Director, Burn, Wound and Regenerative Medicine Laboratory, Assistant Professor of Surgery, Ann Arbor, Michigan [99]

Myron J. Levin, MD
Section of Pediatric Infectious Diseases, Department of Pediatrics, University of Colorado School of Medicine, Aurora, Colorado [165]

Matthew Lewis, MD, MPH
Clinical Assistant Professor in the Department of Dermatology at Stanford University School of Medicine, Redwood City, California [62]

Maryam Liaqat, MD
Division of Dermatology, Cooper Medical School of Rowan University, Camden, New Jersey [180]

Henry W. Lim, MD
Emeritus Chair, Department of Dermatology, Henry Ford Hospital, Senior Vice President for Academic Affairs, Henry Ford Health System, Detroit, Michigan [97]

Dan Lipsker, MD, PhD
Professor of Dermatology, Faculté de Medicine, Université de Strasbourg and Clinique Dermatologique, Hôpitaux Universitaires, Strasbourg, France [146]

Adam D. Lipworth, MD
Assistant Professor of Dermatology, Harvard University Medical School, Director, Program for Infectious Diseases of the Skin, Director of Clinical Care Redesign, Dermatology, Brigham and Women's Hospital, Boston, Massachusetts [168]

Robert Listernick, MD
Professor of Pediatrics, Feinberg School of Medicine, Northwestern University, Ann and Robert H. Lurie Children's Hospital of Chicago, Division of General Academic Pediatrics, Chicago, Illinois [135]

Zhi Liu, PhD
Department of Dermatology, University of North Carolina at Chapel Hill, Chapel Hill, North Carolina [54]

Robert Loewe, MD
Associate Professor, Department of Dermatology, Medical University Vienna, Vienna, Austria [9]

Anke S. Lonsdorf, MD
Department of Dermatology, University Hospital Heidelberg, Heidelberg, Germany [112]

Manisha Loss, MD
Department of Dermatology Johns Hopkins School of Medicine, Baltimore, Maryland [196]

Thomas A. Luger, MD
Center of Chronic Pruritus, Department of Dermatology, University of Münster, Münster, Germany [21]

Boris D. Lushniak, MD, MPH
Rear Admiral, United States Public Health Service (Retired), Professor and Chair, Preventive Medicine and Biostatistics, Uniformed Services University of the Health Sciences, F. Edward Hébert School of Medicine, Department of Preventive Medicine and Biostatistics, Bethesda, Maryland [27]

Catherine Maari, MD, FRCPC
Associate Clinical Professor, Division of Dermatology, Montreal University Health Center, University of Montreal, CHU Sainte-Justine, Montreal, Quebec, Canada [70]

Kelly M. MacArthur, MD
Chief Resident, Department of Dermatology, Johns Hopkins University, Baltimore, Maryland [102, 118]

Howard I. Maibach, MD
Department of Dermatology, University of California, San Francisco School of Medicine, San Francisco, California [183]

Aaron R. Mangold, MD
Assistant Professor of Dermatology, Mayo Clinic, Scottsdale, Arizona [32, 33]

Matthew D. Mansh, MD
Resident in Dermatology, University of Minnesota, Minneapolis, Minnesota [107]

Richard Marchell, MD
Associate Professor of Dermatology and Dermatologic Surgery, Residency Program Director, Medical University of South Carolina, Charleston, South Carolina [35]

David J. Margolis, MD, PhD
Professor of Dermatology and Epidemiology, Department of Dermatology, Department of Biostatistics and Epidemiology, University of Pennsylvania Perelman School of Medicine, Philadelphia, Pennsylvania [3, 151]

M. Peter Marinkovich, MD
Attending Physician, VA Palo Alto Health Care System, Associate Professor and Director, Blistering Disease Clinic, Department of Dermatology, Program in Epithelial Biology, Stanford University School of Medicine, Stanford, California [60]

Seth S. Martin, MD, MHS
Ciccarone Center for the Prevention of Heart Disease, Division of Cardiology, Department of Medicine, Johns Hopkins Hospital, Baltimore Maryland [126]

Kathryn J. Martires, MD
Clinical Assistant Professor, Department of Dermatology, Stanford University School of Medicine, Palo Alto, California [129]

Erin F. D. Mathes, MD
Associate Professor of Clinical Dermatology, University of California, San Francisco, San Francisco, California [163]

Marcus Maurer, MD
Charité–Universitätsmedizin Berlin, Department of Dermatology and Allergy, Berlin, Germany [96]

Aubriana McEvoy
University of Washington, Seattle, Washington [113]

John A. McGrath, MBBS, PhD
St John's Institute of Dermatology, King's College London, London, United Kingdom [18]

Sean McGregor, DO
Resident physician, Wake Forest University School of Medicine, Winston-Salem, North Carolina [175]

Bridget E. McIlwee, DO
Dermatology Resident, Division of Dermatology University of North Texas Health Science Center, Fort Worth, Texas [209]

Amy J. McMichael, MD
Professor and Chair, Department of Dermatology, Wake Forest University School of Medicine, Winston-Salem, North Carolina [90]

Atul B. Mehta, MA, MB, BChir, MD, FRCP, FRCPath
Professor, University College London, Royal Free Campus and Royal Free London NHS Foundation Trust, London, United Kingdom [127]

Thomas Mentzel, MD
Consultant Dermatopathologist and Associated Professor, Dermatopathologie Bodensee, Friedrichshafen, Germany [122]

Peter A. Merkel, MD, MPH
Chief, Division of Rheumatology, Professor of Medicine and Epidemiology, University of Pennsylvania, Philadelphia, Pennsylvania [139]

Robert G. Micheletti, MD
University of Pennsylvania, Department of Dermatology, Philadelphia, Pennsylvania [133]

Ashley N. Millard, MD
Marshfield Clinic, Marshfield, Wisconsin [98]

David Michael Miller, MD, PhD
Clinical Fellow in Medicine, Division of Hematology/Oncology, Beth Israel Deaconess Medical Center, Clinical Associate, Department of Dermatology, Massachusetts General Hospital, Boston, Massachusetts [194]

Jami L. Miller, MD
Department of Internal Medicine, Division of Dermatology, Vanderbilt University Medical Center, Nashville, Tennessee [101]

Lloyd S. Miller, MD, PhD
Associate Professor of Dermatology, Infectious Diseases and Orthopaedic Surgery, Johns Hopkins School of Medicine, Baltimore, Maryland [150]

Leonard M. Milstone, MD
Professor Emeritus of Dermatology, Yale University School of Medicine, New Haven, Connecticut [47]

Daniel Mimouni, MD
Associate Professor of Dermatology, Department of Dermatology, Beilinson Hospital, Petach Tikva, Israel, Faculty of Medicine, Tel Aviv University, Tel Aviv, Israel [53]

Vineet Mishra, MD
Assistant Clinical Professor, Division of Dermatology and Cutaneous Surgery, The University of Texas Health Science Center at San Antonio, San Antonio, Texas [212]

Maja Mockenhaupt, MD, PhD
Dokumentationszentrum schwerer Hautreaktionen (dZh), Department of Dermatology, Medical Center, University of Freiburg, Freiburg, Germany, Dokumentationszentrum schwerer Hautreaktionen (dZh), Department of Dermatology, Medical Center and Medical Faculty, University of Freiburg, Freiburg, Germany [43, 44]

Robert L. Modlin, MD, PhD
Klein Professor of Dermatology, Distinguished Professor of Medicine and Microbiology, Immunology and Molecular Genetics, Chief, Division of Dermatology, Vice Chair for Cutaneous Medicine and Dermatology Research, David Geffen School of Medicine, UCLA Med-Derm, Los Angeles, California [11]

Pia Moinzadeh, MD
Department of Dermatology and Venerology, University of Cologne, Cologne, Germany [63]

Paul A. Monach, MD, PhD
Division of Rheumatology, Immunology, and Allergy, Brigham and Women's Hospital, Chief, Rheumatology Section, VA Boston Healthcare System, Boston, Massachusetts [139]

Gary Monheit, MD
Total Skin and Beauty Dermatology, Birmingham, Alabama [213]

Robert F. Moore, MD
Resident in Anatomic Pathology, Department of Pathology, Johns Hopkins Hospital, Baltimore, Maryland [115]

Breanne Mordorski, BA
Nanodermatology Research Fellow, Department of Medicine (Division of Dermatology), Albert Einstein College of Medicine, Bronx, New York [154]

Hansgeorg Müller, MD
Dermatopathology Friedrichshafen, Friedrichshafen, Germany [121]

Keisuke Nagao, MD, PhD
Dermatology Branch, National Institutes of Health, Bethesda, Maryland [13]

Mio Nakamura, MD
Clinical Research Fellow, Psoriasis, Phototherapy, and Skin Treatment Center, Department of Dermatology, University of California, San Francisco, San Francisco, California [100]

Zeena Y. Nawas, MD
University of Texas Health Science Center, Houston, Texas [191]

Susan T. Nedorost, MD
Professor, Dermatology and Environmental Health Sciences, Case Western Reserve University, Director, Graduate Medical Education, University Hospitals Cleveland Medical Center, Cleveland, Ohio [25]

Isaac M. Neuhaus, MD
Associate Professor of Dermatology, University of California, San Francisco, San Francisco, California [114]

Sabrina A. Newman, MD
Assistant Professor of Dermatology, Director, Inpatient Dermatology, University of Colorado School of Medicine, Anschutz Medical Campus, Aurora, Colorado [148]

Paul Nghiem, MD, PhD
University of Washington, Seattle, Washington [113]

Quynh-Giao Nguyen, MD
Baylor College of Medicine, Houston, Texas [191]

Matilda W. Nicholas, MD, PhD
Assistant Professor, Department of Dermatology, Duke University Medical Center, Duke University Medical Center, Durham, North Carolina [58]

Elizabeth L. Nieman, MD
Assistant Professor of Dermatology, Division of Dermatology, Department of Medicine, Washington University School of Medicine, St. Louis, Missouri [131]

Scott A. Norton, MD, MPH, MSc
Chief of Dermatology, Children's National Medical Center, Washington, DC [156]

Cathal O'Connor, MD
Paediatric Dermatology, Our Lady's Children's Hospital, National Children's Research Centre, Our Lady's Children's Hospital Crumlin, Dublin [51]

Grainne M. O'Regan, PhD, FRCPI
Paediatric Dermatology, Our Lady's Children's Hospital, National Children's Research Centre, Our Lady's Children's Hospital Crumlin, Dublin [51]

Manabu Ohyama, MD, PhD
Professor and Chairman, Department of Dermatology, Kyorin University School of Medicine, Tokyo, Japan [86]

Ginette A. Okoye, MD
Assistant Professor of Dermatology, Johns Hopkins School of Medicine, Baltimore, Maryland [84]

Ana-Maria Orbai, MD, MHS
Assistant Professor of Medicine, Director Psoriatic Arthritis Program, Johns Hopkins Arthritis Center, Johns Hopkins School of Medicine, Division of Rheumatology, Baltimore, Maryland [65]

Anthony E. Oro, MD, PhD
Department of Dermatology, Stanford University, School of Medicine, Redwood City, California [111]

Jeffrey S. Orringer, MD
Professor and Chief, Division of Cosmetic Dermatology, Department of Dermatology, University of Michigan, Ann Arbor, Michigan [210]

Catherine H. Orteu, MBBS, BSc, MD, FRCP
University College London, Royal Free Campus and Royal Free London NHS Foundation Trust, London, United Kingdom [127]

Stephen M. Ostrowski, MD, PhD
Instructor of Dermatology, Harvard Medical School, Department of Dermatology, Cutaneous Biology Research Center, Massachusetts General Hospital, Boston, Massachusetts [20]

Nina Otberg, MD
Hair Clinic, Skin and Laser Center Potsdam, Potsdam, Germany, Otberg Medical, Hair Transplant Center Berlin–Potsdam, Berlin, Germany [87, 88]

Michael N. Oxman, MD
Division of Infectious Diseases, Department of Medicine, University of California, San Diego and Infectious Diseases Section, Medical Service, Veterans Affairs San Diego Healthcare System, San Diego, California [165]

Vikash S. Oza, MD
Assistant Professor of Dermatology and Pediatrics, The Ronald O. Perelman Department of Dermatology, New York University School of Medicine, New York, New York [163]

Amy S. Paller, MD
Walter J. Hamlin Professor and Chair, Department of Dermatology, Professor of Pediatrics, Northwestern University Feinberg School of Medicine, Chicago, Illinois [132]

Jiun Yit Pan, MBBS, MCI (NUS), GDOM (NUS), DTM&H (Lond), FRCP (Edin)
Dermatologist, National Skin Centre, Singapore [187]

Amit G. Pandya, MD
Department of Dermatology, The University of Texas, Southwestern Medical Center, Dallas, Texas [77]

Deepa Patel, BS
Clinical Research Fellow, The Children's Hospital of Philadelphia, Philadelphia, Pennsylvania [89]

Aimee S. Payne, MD, PhD
Associate Professor of Dermatology, University of Pennsylvania, Philadelphia, Pennsylvania [15, 52]

David R. Pearson, MD
Assistant Professor of Dermatology, University of Minnesota School of Medicine, Minneapolis, Minnesota [151]

David H. Peng, MD, MPH
Chair, Department of Dermatology, University of Southern California, Los Angeles, California [143]

Manuel P. Pereira, MD, PhD
Center of Chronic Pruritus, Department of Dermatology, University of Münster, Münster, Germany [21]

Powell Perng, MD
Johns Hopkins School of Medicine, Department of Dermatology, Baltimore, Maryland [83]

Peter Petzelbauer, MD
Professor of Microvascular Research, Department of Dermatology, Medical University Vienna, Vienna, Austria [9]

Robert G. Phelps, MD
Professor, Departments of Dermatology and Pathology, Icahn School of Medicine at Mount Sinai, New York, New York [125]

Rita O. Pichardo, MD
Associate Professor of Dermatology, Wake Forest University School of Medicine, Winston-Salem, North Carolina [174, 175]

Warren W. Piette, MD
Chair, Division of Dermatology, Department of Medicine, John H Stroger, Jr. Hospital of Cook County, Professor, Department of Dermatology, Rush University Medical Center, Chicago, Illinois [66]

Mark R. Pittelkow, MD
Professor of Dermatology, Mayo Clinic, Chair of Dermatology, Scottsdale, Arizona [32, 33, 67]

Jordan S. Pober, MD, PhD
Bayer Professor of Translational Medicine and Professor of Immunobiology, Pathology and Dermatology, Department of Immunobiology, Yale School of Medicine, New Haven, Connecticut [9]

Brian P. Pollack, MD, PhD
Assistant Professor, Departments of Dermatology and Pathology/Laboratory Medicine, Emory University School of Medicine, The Atlanta VA Medical Center, Atlanta, Georgia [198]

Miriam Keltz Pomeranz, MD
Associate Professor of Dermatology, The Ronald O. Perelman Department of Dermatology, New York University School of Medicine, Chief of Dermatology, NYC Health + Hospitals/Bellevue, New York, New York [105]

Julie Powell, MD, FRCPC
Clinical Professor, Dermatology and Pediatrics, University of Montreal, Director, Pediatric Dermatology, CHU Sainte-Justine, Montreal, Quebec, Canada [70]

Julie S. Prendiville, MB, FRCPC
Clinical Professor in Pediatrics, University of British Columbia, Head, Division of Pediatric Dermatology, BC Children's Hospital, Vancouver, British Columbia, Canada [34]

Katherine Püttgen, MD
Assistant Professor of Dermatology and Pediatrics, Johns Hopkins University, Baltimore, Maryland [118]

Sophia Rangwala, MD
Fellow, Dermatopathology, Johns Hopkins School of Medicine, Baltimore, Maryland [108]

Caroline L. Rao, MD
Assistant Professor, Department of Dermatology, Duke University Medical Center, Duke University Medical Center, Durham, North Carolina [58]

Bobby Y. Reddy, MD
Clinical Fellow, Department of Dermatology, Wellman Center for Photomedicine, Massachusetts General Hospital, Boston, Massachusetts [194]

Michelle Rodrigues, MBBS (Hons), FACD
Chroma Dermatology, Melbourne, Australia, Department of Dermatology, St Vincent's Hospital, Fitzroy, Victoria, Australia [77]

Thomas E. Rohrer, MD
SkinCare Physicians, Chestnut Hill, Massachusetts [203]

Misha Rosenbach, MD
Assistant Professor, Dermatology and Internal Medicine Associate Program Director, Dermatology Residency Director, Inpatient Dermatology Consult Service Director, Cutaneous Sarcoidosis Clinic, Perelman Center for Advanced Medicine, Dermatology Administration, Philadelphia, Pennsylvania [155]

Jean-Claude Roujeau MD, PhD
Emeritus Professor of Dermatology, Université Paris-Est Créteil (UPEC), Créteil, France, Department of Dermatology, Université Paris-Est Créteil, Créteil, France [43, 44]

Anne H. Rowley, MD
Professor of Pediatrics and of Microbiology/Immunology, Feinberg School of Medicine, Northwestern University Attending Physician, Division of Infectious Diseases, Ann and Robert H. Lurie Children's Hospital of Chicago, Chicago, Illinois [142]

Thomas M. Rünger, MD, PhD
Professor of Dermatology, Pathology, and Laboratory Medicine, Department of Dermatology, Boston University School of Medicine, Boston, Massachusetts [17, 130]

Arturo P. Saavedra, MD, PhD
Associate Professor of Dermatology, Harvard University Medical School, Vice-Chairman for Clinical Affairs and Medical Director, Massachusetts General Hospital, Boston, Massachusetts [168]

Mohammed D. Saleem, MD, MPH
Department of Dermatology, Wake Forest University School of Medicine, Winston-Salem, North Carolina [183]

Iman Salem, MD
Center for Medical Mycology, University Hospitals Cleveland Medical Center, Case Western Reserve University, Cleveland, Ohio [188]

Claudio Guedes Salgado, MD, PhD
Associate Professor, Pará Federal University, President of the Brazilian Leprosy Society, Marituba, Pará, Brazil [159]

Ubirajara Imbiriba Salgado, MD
Full Professor, Dermatology, Pará State University, Belém, Pará, Brazil [159]

Liat Samuelov, MD
Senior Physician, Department of Dermatology, Tel-Aviv Sourasky Medical Center, Tel-Aviv, Israel [48]

Khaled S. Sanber, MD, PhD
Baylor College of Medicine, Houston, Texas [191]

Inbal Sander, MD
Assistant Professor of Dermatology and Pathology, Johns Hopkins School of Medicine, Baltimore, Maryland [83]

Julio C. Sartori-Valinotti, MD
Assistant Professor of Medicine and Dermatology, Mayo Clinic College of Medicine, Department of Dermatology, Rochester, Minnesota [144]

Vasanth Sathiyakumar, MD
Ciccarone Center for the Prevention of Heart Disease, Division of Cardiology, Department of Medicine, Johns Hopkins Hospital, Baltimore Maryland [126]

Takashi K. Satoh, MD, PhD, MSc
Postdoctoral Research Fellow, Department of Dermatology University of Zurich, Zurich, Switzerland [39]

Jean-Hilaire Saurat, MD
Professor Emeritus, University of Geneva, Genève, Switzerland [185]

April Schachtel, MD
Dermatology Resident, University of Washington School of Medicine, Division of Dermatology, Seattle, Washington [137]

Knut Schäkel, MD
Professor and Vice Chair of Dermatology, Department of Dermatology, University Hospital, Ruprecht-Karls-University Heidelberg, Heidelberg, Germany [29]

Mark Jordan Scharf, MD
Clinical Professor of Dermatology, University of Massachusetts Medical School, Worcester, Massachusetts [182]

Stefan M. Schieke, MD
Assistant Professor, Department of Dermatology, School of Medicine and Public Health, University of Wisconsin-Madison, Medical Science Center, Madison, Wisconsin [30, 160]

Gabriel Schlager, MD
Department of Dermatology, University Hospital Munich, Ludwig-Maximilian University, Munich, Germany [110]

Kenneth E. Schmader, MD
Duke University Medical Center and Geriatric Research Education and Clinical Center (GRECC), Durham VA Medical Center. Durham, North Carolina [165]

Astrid Schmieder, MD
Senior Consultant, Section Head, Allergology, Psoriasis Competence Center, Department of Dermatology, Venereology and Allergology, University Medical Center and Medical Faculty Mannheim, University of Heidelberg, Mannheim, Germany [117]

Robert A. Schwartz, MD, MPH, DSc (Hon), FRCP Edin, FAAD
Professor and Head, Dermatology, Professor of Medicine, Professor of Pediatrics, Professor of Pathology, Rutgers New Jersey Medical School, Visiting Professor, Rutgers School of Public Affairs and Administration, Honorary Professor, China Medical University, Shenyang, China [181, 182]

Aisha Sethi, MD
Associate Professor of Dermatology, Director Yale Dermatology Global Health Program, Department of Dermatology, Yale University School of Medicine, New Haven, Connecticut [157]

Kara N. Shah, MD, PhD
Kenwood Dermatology, Cincinnati, Ohio [103]

Jerry Shapiro, MD, FRCPC
Hair Clinic, The Ronald. O. Perelman Department of Dermatology, New York University School of Medicine, New York, New York [87, 88]

Neil H. Shear, MD, PhD
Division of Dermatology, Department of Medicine, Sunnybrook Health Sciences Centre, University of Toronto, Division of Dermatology, Department of Medicine, Sunnybrook Health Sciences Centre, Toronto, Ontario, Canada [45]

Jessica M. Sheehan, MD
Derick Dermatology, Northbrook, Illinois [203]

Michael P. Sheehan, MD
Dermatology Physicians, Columbus, Indiana [24]

Hiroshi Shimizu, MD, PhD
Professor and Chairman, Department of Dermatology, Hokkaido University Graduate School of Medicine, Sapporo, Japan [40]

Kanade Shinkai, MD, PhD
Associate Professor, University of California, San Francisco, Department of Dermatology, San Francisco, California [1]

Cathryn Sibbald, BScPhm, MD
Department of Dermatology, Sunnybrook Health Sciences Centre, University of Toronto, Division of Dermatology, Department of Medicine, Sunnybrook Health Sciences Centre, Toronto, Ontario, Canada [45]

Daniel Asz Sigall, MD
Mycology Section, Dr. Manuel Gea Gonzalez General Hospital, Mexico City, Mexico [158]

Jonathan I. Silverberg, MD, PhD, MPH
Assistant Professor of Dermatology, Preventive Medicine and Medical Social Sciences, Northwestern University Feinberg School of Medicine, Director, Northwestern Medicine Multidisciplinary Eczema Center, Director, Patch Testing Clinic, Northwestern Memorial Hospital, Chicago, Illinois [23]

Eric L. Simpson, MD, MCR
Department of Dermatology, Oregon Health and Science University, Portland, Oregon [22]

Noah Smith, MD
Department of Dermatology, University of Michigan Health System, Ann Arbor, Michigan [202]

Clayton J. Sontheimer, MD
Acting Assistant Professor, Pediatric Rheumatology, University of Washington School of Medicine, Seattle Children's Hospital, Seattle, Washington [61]

Richard D. Sontheimer, MD
Professor, Dermatology, University of Utah School of Medicine, Salt Lake City, Utah [61]

Nicholas A. Soter, MD
Professor of Dermatology, New York University School of Medicine, Medical Director, Skin and Cancer Unit, Tisch Hospital, New York, New York [138]

John Stewart Spencer, PhD
Associate Professor, Microbiology, Immunology and Pathology, Colorado State University, Fort Collins, Colorado [159]

Eli Sprecher, MD, PhD
Professor and Chair, Department of Dermatology, Tel Aviv Sourasky Medical Center, Tel-Aviv, Israel and Department of Human Molecular Genetics and Biochemistry, Sackler Faculty of Medicine, Tel Aviv University, Tel Aviv, Israel, Tel Aviv, Israel [48]

Rudolf Stadler, MD, PhD
University Clinic for Dermatology, Johannes Wesling Medical Centre, University of Bochum, Minden, Germany [119, 120]

Sonja Ständer, MD
Center of Chronic Pruritus, Department of Dermatology, University of Münster, Münster, Germany [21]

John R. Stanley, MD
Professor, Department of Dermatology, Perelman School of Medicine, University of Pennsylvania, Philadelphia, Pennsylvania [52]

William G. Stebbins, MD
Vanderbilt University, Nashville, Tennessee [214]

Christopher J. Steen, MD, FAAD
Portland, Maine [181]

Martin Steinhoff, MD, PhD
Chairman, Department of Dermatology and Venereology, Hamad Medical Corporation, Doha, Qatar, Clinical Professor, Weill-Cornell University-Qatar, School of Medicine, and Qatar University, Medical School, Doha, Qatar, Professor, UCD Charles Institute for Translational Dermatology, University College Dublin, Dublin, Ireland [79]

Jane C. Sterling, MB, BChir, MA, FRCP, PhD
Cambridge University Hospitals NHS Foundation Trust, Department of Dermatology, Addenbrooke's Hospital, Cambridge University Hospitals NHS Foundation Trust, Cambridge, United Kingdom [167]

Georg Stingl, MD
Professor and Chair, Division of Immunology, Allergy and Infectious Diseases (DIAID), Department of Dermatology, Medical University of Vienna, Vienna, Austria [10]

Erik J. Stratman, MD
Clinical Professor, Department of Dermatology, University of Wisconsin School of Medicine and Public Health, Marshfield, Wisconsin [98]

Lindsay C. Strowd, MD
Assistant Professor of Dermatology, Wake Forest University School of Medicine, Winston-Salem, North Carolina [175]

Dae Hun Suh, MD, PhD
Professor, Department of Dermatology, Seoul National University College of Medicine, Acne and Rosacea Research Laboratory, Seoul National University Hospital, Seoul, South Korea [26]

Kathryn N. Suh, MD, FRCPC
Associate Professor of Medicine, University of Ottawa, Division of Infectious Diseases The Ottawa Hospital, Ottawa, Ontario, Canada [177]

Tamio Suzuki, MD, PhD
Professor and Chairman of Dermatology, Yamagata University Faculty of Medicine, Yamagata, Japan [75]

Rolf-Markus Szeimies, MD, PhD
Professor of Dermatology, Department of Dermatology and Allergology Klinikum Vest Academic Teaching Hospital Ruhr-University of Bochum, Recklinghausen, Germany [199]

Yoshikazu Takada, PhD
Department of Dermatology, University of California Davis School of Medicine, Sacramento, California [193]

Shunsuke Takahagi, MD, PhD
Department of Dermatology, Institute of Biomedical and Health Sciences, Hiroshima University, Hiroshima, Japan [41]

Junko Takeshita, MD, PhD, MSCE
Assistant Professor of Dermatology and Epidemiology, Department of Dermatology, Department of Biostatistics and Epidemiology, University of Pennsylvania Perelman School of Medicine, Philadelphia, Pennsylvania [3]

Carolina Talhari, MD
Associate Professor of Dermatology, State University of Amazonas, Manaos, Brazil [171]

Jean Y. Tang, MD, PhD
Department of Dermatology, Stanford University, School of Medicine, Redwood City, California [111]

Akiko Tanikawa, MD, PhD
Assistant Professor, Department of Dermatology, Keio University School of Medicine, Tokyo, Japan [68]

Janis M. Taube, MD
Associate Professor of Dermatology, Johns Hopkins School of Medicine, Section Head, Dermatopathology, Baltimore, Maryland [108]

Bailey Tayebi, MD, MBA
Total Skin and Beauty Dermatology, Birmingham, Alabama [213]

Michael D. Tharp, MD
The Clark W. Finnerud, MD Professor and Chair, Department of Dermatology, Rush University Medical Center, Chicago, Illinois [42, 189]

Diane M. Thiboutot, MD
Professor of Dermatology, Associate Dean of Clinical and Translational Research Education, Penn State University College of Medicine, Hershey, Pennsylvania [78, 80]

Thusanth Thuraisingam, MD, PhD
Division of Dermatology, McGill University, Montreal, Quebec, Canada [90]

Kenneth J. Tomecki, MD
Department of Dermatology, Cleveland Clinic, Cleveland, Ohio [186]

Franz Trautinger, MD
Professor of Dermatology and Venereology, Karl Landsteiner University of Health Sciences, Chairman, Department of Dermatology and Venereology, University Hospital of St. Pölten, St. Pölten, Austria [38]

Jeffrey B. Travers, MD, PhD
Chair of Pharmacology and Toxicology, Professor of Dermatology, Boonshoft School of Medicine at Wright State University, Dayton, Ohio [152]

Kenneth Y. Tsai, MD, PhD
Associate Member, Departments of Anatomic Pathology and Tumor Biology, Section Head, Non-Melanoma Skin Cancer and Treatment, Donald A. Adam Melanoma and Skin Cancer Center of Excellence, Moffitt Cancer Center, Tampa, Florida [19]

Hensin Tsao, MD, PhD
Professor of Dermatology, Head, Skin Cancer Genetics Laboratory/ Wellman Center for Photomedicine, Director, Massachusetts General Hospital Melanoma and Pigmented Lesion Center/Department of Dermatology, Director, Massachusetts General Hospital Melanoma Genetics Program/ MGH Cancer Center, Boston, Massachusetts [194]

Susan A. Tuddenham, MD, MPH
Division of Infectious Diseases, Bayview Medical Center, Johns Hopkins University, Baltimore, Maryland [170]

Jake E. Turrentine, MD
Assistant Professor, Division of Dermatology, Department of Medicine, Augusta University, Augusta, Georgia [24]

Stephen K. Tyring, MD, PhD
University of Texas Health Science Center, Houston, Texas [191]

Mark C. Udey, MD, PhD
Dermatology Branch, National Institutes of Health, Bethesda, Maryland [13]

Hideyuki Ujiie, MD, PhD
Assistant Professor, Department of Dermatology, Hokkaido University Graduate School of Medicine, Sapporo, Japan [40]

Robin H. Unger, MD
American Board of Hair Restoration Surgery, International Society of Hair Restoration Surgeons, Assistant Clinical Professor, Dermatology, Mt. Sinai School of Medicine, New York, New York [217]

Walter P. Unger, MD, FRCP (C)
American Board of Dermatology, American Board of Hair Restoration Surgery, International Society of Hair Restoration Surgeons, Clinical Professor, Dermatology, Mt. Sinai School of Medicine, New York, New York [217]

Jochen Utikal, MD
Professor of Dermatology, Section Head Dermato-Oncology, Skin Cancer Unit, German Cancer Research Center (DKFZ), Department of Dermatology, Venereology and Allergology University Medical Center and Medical Faculty Mannheim, University of Heidelberg, Mannheim, Germany [117]

Anders Vahlquist, MD
Professor, Department of Medical Sciences, Dermatology and Venereology, Uppsala University, Uppsala, Sweden [185]

Travis Vandergriff, MD
Assistant Professor of Dermatology and Pathology, Director of Dermatopathology, UT Southwestern Medical Center, Dallas, Texas [93, 94]

Miikka Vikkula, MD, PhD
Head of Laboratory of Human Molecular Genetics, de Duve Institute, University of Louvain, Brussels, Belgium [147]

Ruth Ann Vleugels, MD, MPH
Associate Professor, Harvard Medical School, Director, Autoimmune Skin Diseases Program, Director, Connective Tissue Diseases Clinic, Department of Dermatology, Brigham and Women's Hospital, Boston, Massachusetts [145, 192]

Esther von Stebut, MD
Associate Professor of Dermatology and Infectious Diseases, Department for Dermatology, University Medical Center, Johannes Gutenberg-University, Mainz, Germany [176]

John J. Voorhees, MD, FRPC
Duncan and Ella Poth Distinguished Professor and Chairman, Department of Dermatology, University of Michigan Medical School, Ann Arbor, Michigan [185]

Justin J. Vujevich, MD
Vujevich Dermatology Associates, Pittsburgh, Pennsylvania [206]

Etienne C. E. Wang, BA(Hons), MBBS, MA, MPhil
National Skin Center, Singapore, Department of Dermatology, Columbia University, New York, New York [18]

Stewart Wang, MD, PhD
Professor, Department of Surgery, Chief, Burn Surgery, Division of Plastic Surgery, Department of Surgery, University of Michigan Health Systems, Ann Arbor, Michigan [99]

Roger H. Weenig, MD
Associated Skin Care Specialists, Fridley, Minnesota [67]

Karsten Weller, MD
Department of Dermatology and Allergy, Allergie-Centrum-Charité, Charité-Universitätsmedizin Berlin, Berlin, Germany [96]

Victoria Werth, MD
Professor of Dermatology, Department of Dermatology, University of Pennsylvania School of Medicine, Philadelphia, Pennsylvania [184]

Chikoti M. Wheat, MD
Johns Hopkins School of Medicine, Baltimore, Maryland [178]

Lynn D. Wilson, MD, MPH, FASTRO
Professor, Vice Chairman and Clinical Director, Department of Therapeutic Radiology, Yale School of Medicine, New Haven, Connecticut [200]

Lauren E. Wiznia, MD
The Ronald O. Perelman Department of Dermatology, New York University School of Medicine, New York, New York [105]

Peter Wolf, MD
Professor of Dermatology and Bioimmunotherapy, Vice Chair of the Department of Dermatology, Medical University of Graz, Research Unit for Photodermatology, Department of Dermatology, Medical University of Graz, Graz, Austria [92]

Gary S. Wood, MD
Johnson Professor and Chairman, Department of Dermatology, School of Medicine and Public Health, University of Wisconsin-Madison, Madison, Wisconsin [30]

David T. Woodley, MD
Professor and Emeritus Founding Chair, Department of Dermatology, The Keck School of Medicine, University of Southern California, Los Angeles, California [56]

Sophie M. Worobec, MD
University of Illinois at Chicago, Chicago, Illinois [73]

Albert C. Yan, MD, FAAP, FAAD
Chief, Section of Pediatric Dermatology, Children's Hospital of Philadelphia, Professor, Pediatrics and Dermatology, Perelman School of Medicine at the University of Pennsylvania, Philadelphia, Pennsylvania [123]

Kim B. Yancey, MD
Professor and Chair, Department of Dermatology, University of Texas Southwestern Medical Center, Dallas, Texas [55]

Howa Yeung, MD
Chief Resident in Dermatology, Emory University School of Medicine, Atlanta, Georgia [107]

Andrea L. Zaenglein, MD
Professor of Dermatology and Pediatrics, Penn State College of Medicine, Penn State/ Hershey Medical Center, Hershey, Pennsylvania [78, 80]

Jonathan M. Zenilman, MD
Division of Infectious Diseases, Bayview Medical Center, Johns Hopkins University, Baltimore, Maryland [170]

Christos C. Zouboulis, MD, PhD
Departments of Dermatology, Venereology, Allergology and Immunology, Dessau Medical Center, Brandenburg Medical School Theodor Fontane, Dessau, Germany [6, 82, 141]

This page intentionally left blank

PREFACE

A much-treasured legacy of Dr. Thomas B. Fitzpatrick, who served as editor-in-chief for the first four editions of the book, *Fitzpatrick's Dermatology in General Medicine* (DIGM) has always aimed to be a comprehensive source of information for those interested in the clinical and basic science of dermatology. Indeed, from the very first edition of *Fitzpatrick's DIGM*, printed in 1971, this authoritative textbook has been grounded in science. We have continued this tradition in the ninth edition of the book whilst rearranging the discussion to make it more reader friendly and to minimize repetition. With coverage of subject matters expanding beyond General Medicine, we have appropriately modified the book title to *Fitzpatrick's Dermatology*. Important general basic science concepts are extensively covered in dedicated chapters appearing in an early section of the book, allowing subsequent clinical chapters to focus on relevant disease-specific pathophysiology in addition to clinical features, diagnosis, clinical course, and management.

Dermatology is a particularly visual specialty. In the preparation of this edition of the book, we have placed special emphasis on display items (in the form of clinical images, tables, and algorithmic summaries), as we strongly believe that these components are vital for the complete understanding of all readers, but particularly for those in training. What better way to optimize the visual content provided in our chapters than to seek input from trainees themselves? We had trainees review every chapter and provide feedback on additional display items they would find useful.

To further enhance the utility of this gold-standard textbook we have also improved the indexing. A good index is imperative to allow readers, including busy practicing clinicians, to easily and quickly find the particular information about a concept, condition, or therapy that they are interested in at any given time. We hope that you agree the improved indexing allows you to achieve this aim.

No modern textbook is complete without an online presence. The ninth edition is also available in the online format, and we plan to regularly post online updates to the book as new studies and/or guidelines are published. You will also have access to other useful features in the online version of *Fitzpatrick's Dermatology* on *AccessMedicine.com*.

Finally, as a completely new group of editors that is diverse in expertise and international in location of practice, we have endeavored to build on the achievements of previous editorial groups led by Drs. Thomas B. Fitzpatrick, Irwin M. Freedberg, Klaus Wolff, and Lowell A. Goldsmith, whilst providing fresh insight into the content, new thinking regarding the optimal structure of the book, and ultimately helping the book to evolve into the most relevant resource for the modern practicing or trainee dermatologist or skin biologist.

Sewon Kang
Masayuki Amagai
Anna L. Bruckner
Alexander H. Enk
David J. Margolis
Amy J. McMichael
Jeffrey S. Orringer

This page intentionally left blank

ACKNOWLEDGMENTS

We thank the many expert authors who wrote chapters for the ninth edition of *Fitzpatrick's Dermatology*. We greatly appreciate the time they dedicated to creating their masterpieces and acknowledge how difficult it must have been to fit the task in with the demands of their dermatology practice, teaching, and research. We are truly grateful. We also appreciate their patience with the editorial team while we reviewed the submissions and then reviewed them again because we wanted to carefully consider all the visual elements included in the book.

With regard to visual elements, we owe much gratitude to Noori Kim and Hester Lim who took the time to carefully read every individual chapter and provide detailed feedback on what additional display items they thought would aid the reader. With more than 200 chapters included in the book, we appreciate the sheer enormity of this task and their dedication to attention to detail.

As a completely new editorial board, we are very grateful for the engagement, advice, and encouragement afforded to us by the previous editor-in-chief Lowell A. Goldsmith. We truly appreciate the time and effort he invested to enable the smooth transition of editorial direction for the new edition of this much-loved book.

A special shout-out to Karen Edmonson, our straight-talking and very patient senior editor at McGraw-Hill Education who kept the whole editorial team motivated and helped to bring our ideas to fruition, and to our editorial project manager Bryony Mearns, who helped to coordinate submission and review of the 217 chapters, keep on top of the status of each chapter, and encourage authors and editors to progress with their book-related tasks. We also appreciate the efforts of Kim Davis and Sonam Arora who expertly coordinated everything from submission of the finalized chapters to the McGraw-Hill team through to print publication.

Finally, we are truly grateful for the understanding and patience of our families. Without their support, this textbook would never have been completed. A book like *Fitzpatrick's Dermatology* demands many evening and weekend hours that would normally be spent with loved ones, and we thank them for allowing us to dedicate many of these hours to *Fitzpatrick's Dermatology*.

Sewon Kang
Masayuki Amagai
Anna L. Bruckner
Alexander H. Enk
David J. Margolis
Amy J. McMichael
Jeffrey S. Orringer

This page intentionally left blank

Foundations of Clinical Dermatology

PART 1

Chapter 1 :: Fundamentals of Clinical Dermatology: Morphology and Special Clinical Considerations

:: Erin H. Amerson, Susan Burgin, & Kanade Shinkai

AT-A-GLANCE

- Skin diseases have characteristic morphology and distribution.
- Morphologic characteristics and reaction patterns of the skin suggest disease pathophysiology, helping focus the differential diagnosis.
- The history is indispensable in elucidating complex diagnoses.
- Knowledge and appropriate use of dermatologic terminology is essential.
- The comprehensive mucocutaneous examination, including hair and nails, should always be performed.

THE ART AND SCIENCE OF DERMATOLOGIC DIAGNOSIS

The diagnosis and treatment of cutaneous diseases requires the physician's ability to recognize the primary lesions and reaction patterns of the skin, and to put these visual clues into context with the patient's history and overall health. In this chapter, we discuss a fundamental approach to the patient presenting with a skin problem. We introduce the technical vocabulary of dermatologic description, also known as morphology. Accurately identifying morphology is an essential step in generating a differential diagnosis. Use of standard dermatologic terminology is also critical for effective clinical documentation, research, and communication with other health care providers.

The process of examining and describing skin lesions requires perception of subtle details: appreciation of a specific hue of erythema, a shape or distribution, or the presence of characteristic findings on nails or mucous membranes often hold the key to the correct diagnosis. Repeated patient encounters help to train the eye to recognize such patterns. With time and experience, the physician can associate clinical skin findings with histopathologic features, enabling a rich understanding of the pathophysiology of skin disease, as well as clinical-pathologic correlation.

APPROACH TO THE PATIENT

HISTORY

Dermatology is a visual specialty, and some skin conditions may be diagnosed at a glance. History may be crucial in complex cases, such as the patient with rash and fever, or the patient with generalized pruritus. There is therapeutic value in receiving a patient's narrative thread, as they feel heard, and they may reveal information relevant to treatment choice or invite opportunities for education and reassurance. In practice, many dermatologists take a brief history, perform a physical examination, then undertake more detailed

questioning based on the differential diagnosis that the examination suggests.

In taking a history from a patient presenting with a new skin complaint, the physician's primary goal is to establish a diagnosis, with a secondary goal of evaluating the patient as a candidate for therapy. In patients whose diagnosis is already established, the physician's goals are to reevaluate the original diagnosis, monitor disease progress and complications, and modify treatment accordingly.

Table 1-1 presents an approach to obtaining the history in a patient presenting with a skin problem. The physician may choose to customize the history depending on whether the chief complaint is a growth or an eruption, a nail or hair disorder, or another condition, and whether it is a new problem or a followup visit for an ongoing condition.

TABLE 1-1
History Taking in Dermatologic Diagnosis

Chief Complaint and History of the Present Illness

- ***Duration:*** When the condition was first noted and dates of recurrences or remissions
- ***Timing:*** Constant, intermittent, worst at night, worst in winter
- ***Evolution:*** How the condition has changed or progressed over time
- ***Location:*** Where lesions were first noted, and how they have spread, if applicable
- ***Symptoms:*** Pruritus, pain, bleeding, nonhealing, change of preexisting skin lesions, associated with fever or other systemic signs
- ***Severity:*** Ask patient to rate severity of pain or pruritus on a 10-point scale to follow severity over time
- ***Ameliorating and Exacerbating Factors:*** Sun exposure, heat, cold, trauma, exposures (such as chemicals, medications, cosmetics, perfumes, plants, or metals), relation to menses or pregnancy
- Preceding illness, new medications, new topical products, or exposures
- Therapies tried, including nonprescription or home remedies, and response to therapy
- Prior similar problems, prior diagnosis, results of biopsies or other studies performed

Medical History

- A history of all chronic illnesses, particularly those that may manifest in the skin, (diabetes, renal and hepatic disease, infection with HIV or other viruses, polycystic ovarian syndrome, lupus, thyroid disease) and those that are associated with skin disease (asthma, allergies)
- History of surgical procedures, including organ transplantation
- *Immunosuppression:* iatrogenic, infectious, or inherited
- Pregnancies
- Psychiatric disease
- History of blistering sunburns, exposure to arsenic or ionizing radiation
- ***Medication History:*** A detailed history, including prescriptions, nonprescription medications, vitamins, dietary supplements, herbal remedies, with particular attention to those medications started recently
- ***Allergies:*** To medications, foods, environmental antigens, and contactants
- ***Social History:*** Occupation, hobbies and leisure activities, alcohol and tobacco use, illicit drug use, sexual history (including high-risk activities for sexually transmitted diseases), diet, bathing habits, pets, living conditions (eg, alone, with family, homeless, in an institution), history of travel or residence in endemic areas for infectious diseases, cultural or religious practices
- ***Family History:*** Of skin disease, atopy (atopic dermatitis, asthma, hay fever) or skin cancer
- ***Review of Systems:*** May be focused or comprehensive depending on the diagnosis (asking about specific symptoms that may accompany a dermatologic condition, such as joint symptoms in psoriasis; asking a comprehensive ROS in the setting of cutaneous signs of systemic disease such as palpable purpura)

PHYSICAL EXAMINATION

SCOPE OF THE COMPLETE CUTANEOUS EXAMINATION

The complete cutaneous examination includes inspection of the entire skin surface, including often-overlooked areas such as the scalp, eyelids, ears, genitals, buttocks, perineum, and interdigital spaces; the hair; the nails; and the mucous membranes of the eyes, nose, mouth, genitals, and anus. Patients presenting with a highly focused complaint, such as a single wart or acne, may not require a comprehensive skin examination in routine clinical practice. There are many advantages to performing a complete cutaneous examination, including identification of potentially harmful lesions, such as skin cancers, providing reassurance for benign skin findings, locating additional diagnostic clues (Wickham's striae on the buccal mucosa in lichen planus, for instance), opportunities for patient education (eg, lentigines are a sign of sun damage and suggest the need for improved sun protection), and an opportunity to convey the physician's concern about the patient's skin health through a thorough examination. A thorough evaluation increases the possibility of making a diagnosis at the bedside and mitigates the risk of overlooking another diagnosis. A guide to performing the physical examination of the patient presenting with a skin problem is presented in Table 1-2.

IDEAL CONDITIONS FOR THE COMPLETE SKIN EXAMINATION

A complete skin examination is most effective when performed under ideal conditions. Excellent lighting, preferably bright, natural light, is paramount; without good lighting, subtle but important details may be missed. The patient should be fully undressed, and gowned with additional draping, if desired. Underwear, socks, shoes, makeup, and eyeglasses should be removed. The examining table should be at a comfortable height, with a head that reclines, an extendable footrest, and gynecologic stirrups. The examining room should be at a comfortable temperature for the lightly dressed patient. It should contain a sink for hand washing and disinfecting hand foam, as patients are reassured by seeing their physician wash

TABLE 1-2
Physical Examination in Dermatologic Diagnosis

General Impression of the Patient
- Well or ill
- Obese, cachectic, or normal weight
- ***Skin Color:*** Degree of pigmentation, pallor (anemia), jaundice
- ***Skin Temperature:*** Warm, cool, or clammy
- ***Skin Surface Characteristics:*** Xerosis (dryness), seborrhea (excessive oil), turgor, hyper- or hypohidrosis (excessive or decreased sweating), and texture
- ***Degree of Photoaging:*** Lentigines, actinic purpura, rhytides

Morphology
- Define the primary lesion
- Describe their color, texture
- Describe any secondary changes
- Describe their shape and configuration
- Describe the Distribution of Lesions: Localized (isolated), grouped, regional, generalized, universal, symmetrical, sun-exposed, flexural, extensor extremities, acral, intertriginous, dermatomal, follicular

Aspects of General Physical Examination That May Be Helpful
- Vital signs
- Abdominal examination for hepatosplenomegaly
- Pulses
- Lymph node examination (especially in cases of suspected infection and malignancy)

hands before the examination. If the patient and physician are of opposite genders, having a chaperone in the room may be required.

RECOMMENDED TOOLS FOR THE COMPLETE SKIN EXAMINATION

Although the physician's eyes and hands are the only essential tools for examination of the skin, the following are often useful and highly recommended:

- A magnifying tool such as a loupe, magnifying glass, and/or dermatoscope.
- A bright focused light such as a flashlight or penlight.
- Glass slides for diascopy and viral direct fluorescent antibody (DFA) testing, fungal scrapings and touch preparations, Tzanck smears, scabies prep.
- Alcohol pads to remove scale or surface oil.
- Gauze pads or tissues with water for removing makeup.
- Gloves: when any contagious condition is suspected, when contact with body fluids is possible, when examining mucous membranes and genital areas, and when performing any procedure.
- A ruler for measuring lesions.
- No. 15 and No. 11 scalpel blades for scraping and incising lesions, respectively.
- Diagnostic solutions: potassium hydroxide solution, oil, Tzanck smear, bacterial, viral, and fungal culture media.
- A camera for photographic documentation.
- A Wood lamp (365 nm) for highlighting subtle pigmentary changes.

TECHNIQUE OF THE DERMATOLOGIC PHYSICAL EXAMINATION

Consistency in a comprehensive mucocutaneous examination is essential to ensure that no areas are overlooked. One approach to the complete skin examination is presented here. First, observe the patient at a distance for general impressions (eg, asymmetry due to a stroke, cachexia, jaundice). Next, examine the patient in a systematic way, usually from head to toe, uncovering one area at a time to preserve patient modesty. Move the patient and the illumination as needed for the best view of each body area. Sometimes side lighting best reveals depth and details of skin lesion borders. Palpate lesions to determine whether they are soft, firm, tender, or fluid-filled. A magnifier worn on the head leaves both hands free for palpation of lesions. Certain lesions, especially pigmented lesions, are best examined with a dermatoscope to identify characteristic concerning features. Mucosal sites should be carefully examined with additional illumination with a penlight or flashlight. During the examination, patients may be reassured by the physician's reporting of benign lesions as they are encountered.

Special examination techniques for hair and nail disorders are discussed in Chaps. 85 through 91.

After completing the examination, it is important to document the skin findings, including the type of lesions and their locations, either descriptively or on a body map. Specific documentation using photography and triangulation based on anatomic landmarks is particularly important for lesions suspicious for skin malignancy undergoing biopsy, so that the exact location may be found and definitively treated at a later date.

INTRODUCTION TO MORPHOLOGY

Joseph Jakob von Plenck's (1738–1807) and Robert Willan's (1757–1812) work in defining basic morphologic terminology laid the foundation for the description and comparison of fundamental lesions, thereby facilitating characterization and recognition of skin disease.

The eminent dermatology professors Wolff and Johnson have asserted: to read words, one must recognize letters; to read the skin, one must recognize the basic lesions. The "letters," or elemental building blocks of morphology, are the primary lesion and secondary (epidermal) change. The skilled clinician uses macroscopic characteristics noted on examination to understand where and what types of microscopic pathologic changes are present, achieving clinical–pathologic correlation. For example, flat-topped or planar papules and plaques tend to be processes affecting the epidermis and superficial dermis, while dome-shaped or nodular lesions often exhibit deeper infiltration into

the dermis or subcutis. Scaling or crusting indicates that the epidermis is affected, while a smooth, intact surface on a palpable lesion reflects a purely dermal or subcutaneous process.

The combination of primary morphology and secondary change (or absence of secondary change) determine a diagnostic category, also known as the "reaction pattern." For example, when the primary lesion is a circumscribed papule or plaque with scale, it likely falls into the "papulosquamous" reaction pattern, which suggests a specific set of diagnostic possibilities. Once the reaction pattern has been determined, a differential diagnosis comes into focus. This differential diagnosis may be further honed by other lesional characteristics, including shape or color, and the arrangement of lesions in relationship to one another (configuration) and on the body (distribution).

It is important for the dermatologist in training to be aware that variation and ambiguity in definitions of morphologic terms exist among the dermatology community. For example, in dermatology textbooks, a papule has been described as no greater than 1 cm in size, no less than 0.5 cm, or ranging from the size of a pinhead to that of a split pea. In this chapter, the authors have selected definitions that reduce the subjectivity inherent in some morphologic frameworks.

PRIMARY MORPHOLOGY

The primary morphology describes 3 lesional characteristics: size, topography, and the character of contents (Table 1-3). The primary morphology should be the "noun" which all other "adjectives" (such as color, shape, size, texture) describe. A macule or patch is not palpable (a color change only) and raised or depressed lesions that are palpable are papules or plaques. Erosions and ulcerations may be primary or secondary.

TABLE 1-3
Primary Morphology

PRIMARY LESION	SIZE	TOPOGRAPHY	CONTENTS
Macule	<1 cm	Flat	N/A (color change only)
Patch	≥1 cm	Flat	N/A (color change only)
Papule	<1 cm	Raised/Depressed	Solid
Plaque	≥1 cm	Raised/Depressed	Solid
Nodule	≥1 cm	Raised	Solid or fluid
Vesicle	<1 cm	Raised	Fluid (serum, blood, lymph)
Bulla	≥1 cm	Raised	Fluid (serum, blood, lymph)
Pustule	<1 cm	Raised	Fluid (pus)
Erosion	Any	Depressed	N/A
Ulceration	Any	Depressed	N/A

Figure 1-1 Macule, petechiae.

FLAT (NONPALPABLE) PRIMARY LESIONS

Macule: A macule is flat, even with the surface level of surrounding skin or mucous membranes, and perceptible only as an area of color different from the surrounding skin or mucous membrane. Macules are less than 1 cm in size (Fig. 1-1).

Patch: A patch, like a macule, is a flat area of skin or mucous membranes with a different color from its surrounding. Patches are 1 cm or larger in size (Fig. 1-2).

RAISED (PALPABLE) PRIMARY LESIONS

Papule: A papule is an elevated or depressed lesion less than 1 cm in size, which may be solid or cystic. Among other characteristics, papules may be further described by their topography. Some examples include papules that are sessile, pedunculated, dome-shaped, flat-topped, filiform, mammillated, acuminate (conical), or umbilicated (Fig. 1-3).

Figure 1-2 Patch, fixed drug eruption.

Figure 1-3 Papule, lichen nitidus.

Figure 1-5 Nodule, lymphoma cutis.

Plaque: A plaque is a solid plateau-like elevation or depression that has a diameter of 1 cm or larger (Fig. 1-4).

Nodule: A nodule is a palpable lesion greater than 1 cm with a domed, spherical or ovoid shape. They may be solid or cystic. Depending on the anatomic component(s) primarily involved, nodules are of 5 main types: (1) epidermal, (2) epidermal–dermal, (3) dermal, (4) dermal–subdermal, and (5) subcutaneous. Texture is an important additional feature of nodules: firm, soft, boggy, fluctuant, etc. Similarly, different surfaces of nodules, such as smooth, keratotic, ulcerated, or fungating, also help direct diagnostic considerations (Fig. 1-5). *Tumor*, also sometimes included under the heading of nodule, may be used to describe a more irregularly shaped mass, benign or malignant.

FLUID-FILLED PRIMARY LESIONS

Vesicle and Bulla: A vesicle is a fluid-filled papule smaller than 1 cm (Fig. 1-6), whereas a bulla (blister) measures 1 cm or larger (Fig. 1-7). By definition, the wall is thin and translucent enough to visualize the contents, which may be clear, serous, or hemorrhagic. Vesicles and bullae arise from cleavage at various levels of the epidermis (intraepidermal) or the dermal–epidermal interface (subepidermal), sometimes extending into the dermis. The tenseness or flaccidity of the vesicle or bulla may help determine the depth of the split. However, reliable differentiation requires histopathologic examination of the blister edge.

Pustule: A pustule is a circumscribed, raised papule in the epidermis or infundibulum containing visible pus. The purulent exudate, composed of leukocytes with or without cellular debris, may contain organisms or may be sterile. The exudate may be white, yellow, or greenish-yellow in color. Pustules may vary in size and, in certain situations, may coalesce to form "lakes" of pus. When associated with hair follicles, pustules may appear conical and contain a hair in the center (Fig. 1-8).

Figure 1-4 Plaque, psoriasis.

Figure 1-6 Vesicle, bullous lupus erythematosus. Note brown incipient crusts marking the sites of earlier blisters now ruptured.

Figure 1-7 Vesicles and bullae, linear IgA disease.

SECONDARY CHANGE (EPIDERMAL OR SURFACE CHANGE)

Scale is a macroscopic finding indicating a change in the epidermis, usually the stratum corneum. Scale may have many different descriptive characteristics, for instance, soft, rough, gritty, bran-like, or micaceous (Table 1-4).

Crust describes dried fluid on the skin's surface due to serum, blood, pus, or a combination. When crust is round or oval, it points to the former presence of a vesicle, bulla or pustule (as seen in Fig. 1-6). Linear or angulated crusts are indicative of excoriations. Other specialized types of crust include eschar, which is dry, adherent, and dark red-purple, brown, or black in color and signals skin necrosis (Fig. 1-11), or fibrin, which is a soft, yellow crust on the surface of some ulcers.

Lichenification is a thickening and accentuation of the skin lines that results from repeated rubbing or scratching of the skin. It is found primarily in chronic eczematous processes or neurogenic processes (Fig. 1-12).

TABLE 1-4
Types of Scale

TYPE OF SCALE	DESCRIPTION
Craquelé/xerotic	Desquamation giving the appearance of dried, cracked skin. Combination of hyperkeratosis and fissuring, which appears like the cracked bed of a dry river.
Cutaneous horn	Conical projection of compact stratum corneum.
Exfoliative/ desquamative	Scales split off from the epidermis in finer scales or in sheets.
Follicular	Scales appear as keratotic plugs, spines, or filaments.
Gritty	Densely adherent scale with a sandpaper texture.
Ichthyosiform	Scales are regular, polygonal plates arranged in parallel rows or diamond patterns (fish-like, tessellated, Fig. 1-9).
Keratotic/ hyperkeratotic	Scales appear as thick, compact, adherent layers of stratum corneum.
Lamellar	Scales are thin large plates or shields attached in the middle and looser around the edges.
Pityriasiform	Scale is small and branny.
Psoriasiform (micaceous and ostraceous)	Scale is silvery and brittle and forms thin plates in several loose sheets, like mica (micaceous scale). Large scales may accumulate in heaps, giving the appearance of an oyster shell (ostraceous scale, Fig. 1-10).
Seborrheic	Scales are thick, waxy or greasy, yellow-to-brown, flakes.
Shellac-like	Scale is shiny with a sheet-like desquamating edge, like peeling paint
Wickham striae	Scale appears as a lacy white pattern overlying violaceous flat-topped papules.

Atrophy of the epidermis results in a shiny quality with "cigarette-paper" wrinkling. Atrophy of the dermis results in a depressed lesion.

A *fissure* is a linear loss of continuity of the skin's surface or mucosa that results from excessive tension

Figure 1-8 Pustule, pustular psoriasis.

Figure 1-9 Ichthyosiform scale, ichthyosis vulgaris.

Figure 1-10 Ostraceous scale, psoriasis.

Figure 1-12 Lichenification, lichen simplex chronicus.

or decreased elasticity of the involved tissue. Fissures frequently occur on the palms and soles where the thick stratum corneum is least expandable.

OTHER LESIONAL CHARACTERISTICS

In addition to primary morphology, other features of lesions can be important in narrowing a differential diagnosis; sometimes, these other characteristics are the most important determinants of the differential. For instance, the most notable feature of a rash or lesion might be its shape or distribution, which points the clinician to a specific list of possible diagnoses.

COLOR

Perhaps the most important additional feature of a lesion other than primary morphology is color. The experienced dermatologist will notice subtle variations in hue and saturation of a particular color, and can ascribe meaning to these variations. The most common types of color on the skin are variations in brown (hyperpigmentation) and red (erythema), which will be discussed in depth below. Other colors and their histopathologic correlations are described in Table 1-5.

Figure 1-11 Eschar overlying stellate purpura, calciphylaxis.

Brown: Brown color is most often representative of melanin, either within melanocytes or outside of melanocytes. Less frequently, a brown hue also may be caused by deposition of other pigments, cells, or materials in the dermis (such as deposition of hemosiderin, amyloid, or mucin; certain types of inflammation, including inflammation that is granulomatous, histiocytic, plasmacytic, or mixed). Mast cells induce melanin production in the overlying epidermis, often leading to brown color overlying the focus of mast cells in the dermis. Melanin in the epidermis, whether contained within or outside of melanocytes, appears tan to muddy brown; when it is very concentrated, as in some nevi or melanomas or heavily pigmented seborrheic keratoses, it may appear brown-black. Melanin in the dermis, either within melanocytes or extracellular, may appear brown, gray, or blue. This gray-blue color results from the "Tyndall effect," named for the 19th-century physicist John Tyndall, who described the preferential transmission of longer wavelengths (blue photospectrum) when particles are suspended in a medium (in this case, melanin or other brown pigment suspended in the dermis). Differentiation between epidermal and dermal melanin also can be aided by a Wood lamp, which accentuates epidermal but not dermal melanin.

Oxidized keratin, (within an infundibular cyst, for instance) and foreign pigmentation (such as tattoos) can also exhibit the Tyndall effect when located in the dermis.

When the epidermis is inflamed or damaged, melanin often drops to into the dermis. Therefore, many subacute, chronic, or recently resolved epidermal inflammatory diseases or injuries have a brown or gray-brown tone. The more constitutive pigment in an individual's skin, the more prominent these changes will be.

Red: Also known as "erythema," red can have infinite hues. Pale red, pink, or purple may result from

TABLE 1-5
Implications of Color Changes in Altered Skin

COLOR	PATHOLOGY	DIAGNOSTIC EXAMPLES
White	Reduced or absent melanin synthesis	Tinea versicolor, vitiligo
	Keratin	Milium
	Calcium deposit	Calcinosis cutis
	Scar	Atrophie blanche
Black	Dense melanin	Melanoma
	Intraepidermal hemorrhage	Talon noir
	Necrosis	Cutaneous anthrax
	Oxidized keratin (brown to black)	Open comedone
Brown	Melanin	Melanocytic nevus, melasma
Red-brown	Hemosiderin ("cayenne pepper")	Pigmented purpuric dermatosis
	Granulomatous inflammation ("apple jelly")	Sarcoidosis (Fig. 1-15)
	Histiocytic inflammation	Langerhans cell histiocytosis
	Mixed inflammation	Granuloma faciale
	Plasmacytic inflammation ("copper"- or "ham"-colored)	Secondary syphilis
	Mast cell inflammation	Urticaria pigmentosa
	Mucin deposition	Pretibial myxedema
	Amyloid deposition	Lichen amyloidosis
	Infiltration with smooth muscle	Cutaneous leiomyoma
	Subacute or chronic epidermal inflammation	Subacute lupus erythematosus
Red	Vascular dilation or congestion	Erysipelas
	Neutrophilic inflammation	Sweet syndrome
	Vascular neoplasm	Cherry angioma
Pink or salmon	Acute inflammation with dilation of superficial dermal vessels	Eczema, drug eruptions, urticaria, pityriasis rubra pilaris, psoriasis
Orange	Granulomatous inflammation with histiocytes having abundant cytoplasm	Juvenile xanthogranuloma
Yellow	Pus	Folliculitis
	Lipid	Xanthelasma
	Histiocytic inflammation	Necrobiosis lipoidica (Fig. 1-16)
	Elastolysis	Pseudoxanthoma elasticum
	Sebaceous glands	Sebaceous hyperplasia
	Bilirubin	Jaundice
Green	Deep hemosiderin	Ecchymosis
	Pyocyanin pigment	Pseudomonas infection
	Myeloperoxidase	Chloroma
	Tissue eosinophilia	Wells syndrome
Blue/gray	Deep dermal melanin	Blue nevus
	Deep deposition of other pigment	Argyria, tattoo
Violet to lilac	Acute lymphocytic inflammation with dilation of deep dermal blood vessels	Borders of evolving morphea, dermatomyositis, lichen planus
Plum	Vascular neoplasm	Kaposi sarcoma
	Dense lymphocytic inflammation	Lymphoma cutis
	Malignant neoplasm	Nodular amelanotic melanoma
	Hemorrhage	Ecchymosis

inflammation leading to hyperemia (subtle vascular dilation). More saturated red to purple can indicate intense hyperemia or vascular congestion (also called rubor, as seen in erysipelas); even more saturated red to purple hue can result from the either malformed or ectopic blood vessels (Fig. 1-13) or extravasated erythrocytes (petechiae or purpura, see "vascular reaction pattern" below). Variations in the hue of erythema are vast

Figure 1-13 Purple papules, Kaposi sarcoma.

and provide subtle clues to the type of inflammation present. True red is often associated with neutrophilic inflammation (as seen in cellulitis or Sweet syndrome); red-purple (violaceous erythema, Fig. 1-14) with lymphocytic inflammation (lymphoma cutis, connective tissue disease, interface reactions such as lichen planus). Granulomatous inflammation may appear red-brown (sarcoidosis, marked by the classis "apple jelly" color seen in Fig. 1-15, or a juvenile xanthogranuloma) to orange or yellow (Fig. 1-16, necrobiosis lipoidica). One major caveat is that the true hue of erythema is easiest to visualize in acute conditions affecting fair skin. Subacute or chronic conditions, particularly with epidermal involvement, will have epidermal alteration causing epidermal pigment drop-out into the dermis, making lesions appear more brown or gray. Hemorrhage can also alter the hue, making lesions appear more purple.

SHAPE AND CONFIGURATION OF LESIONS

"Shape" describes an individual macule, patch, papule, or plaque; "configuration" refers to shapes made from the arrangement of individual primary lesions in relation to one another. For example, *annular* or *linear* may be the shape of a single plaque, or a configuration of discrete papules. *Demarcation* refers to the edge of an individual lesion and whether it is sharply defined from or blends into the surrounding skin.

Figure 1-15 Apple-jelly sign, sarcoidosis.

Annular: Ring-shaped; implies that the edge of the lesion has a color and/or texture change that is more prominent on the leading edge than the center (as seen in granuloma annulare, tinea corporis, erythema annulare centrifugum) (Fig. 1-17).

Round/Nummular/Discoid: Coin-shaped; solid circle or oval; usually with uniform morphology

Figure 1-14 Violaceous Gottron papules, dermatomyositis.

Figure 1-16 Yellow, necrobiosis lipoidica diabeticorum.

Figure 1-17 Annular lesion, granuloma annulare.

Figure 1-19 Reticular eruption, livedo racemosa.

from the edges to the center (nummular eczema, plaque-type psoriasis, discoid lupus) (Fig. 1-18).

Arcuate: Arc-shaped; often a result of incomplete formation of an annular lesion (urticaria, subacute cutaneous lupus erythematosus).

Linear: Resembling a straight line; often implies an external contactant or Koebner phenomenon has occurred in response to scratching; may apply to a single lesion (such as a scabies burrow, poison ivy dermatitis, or bleomycin pigmentation) or to the arrangement of multiple lesions (as seen in lichen nitidus or lichen planus).

Geographic: A shape similar to a land mass; edges are reminiscent of a coastline

Reticular or Retiform: Net-like or lacy in appearance, with somewhat regularly spaced rings or crossing lines with sparing of intervening skin (as seen in livedo reticularis, cutis marmorata) (Fig. 1-19).

Stellate: Having multiple angulated edges, resembling a star (Fig. 1-11).

Serpiginous: Serpentine or snake-like (cutaneous larva migrans, for instance, in which the larva migrates this way and that through the skin in a wandering pattern) (Fig. 1-20).

Targetoid: Target-like, with a center darker than the periphery. *Typical targets* (eg, erythema multiforme) have 3 zones: a dark red-purple or dusky center, encircled by a paler pink zone, followed by a rim of darker erythema. *Atypical targets* have just 2 zones, a dark or dusky center with a paler pink rim. Note that both have a center darker in comparison to the outer zone; if the center is paler than the outer zone, it should be termed "annular" (Fig. 1-21).

Whorled: Like marble cake, with 2 distinct colors interspersed in a wavy pattern; usually seen in mosaic disorders in which cells of differing genotypes are interspersed (as seen in incontinentia pigmenti, hypomelanosis of Ito, linear and whorled nevoid hypermelanosis).

Figure 1-18 Nummular lesion, nummular dermatitis.

Figure 1-20 Serpiginous erythema, jellyfish sting.

Figure 1-21 Atypical targetoid lesions, Stevens-Johnson syndrome due to medication.

Grouped/Herpetiform: Lesions clustered together (a classic example is herpes simplex virus reactivation noted as grouped vesicles on an erythematous base; also seen with certain arthropod bites).

Scattered: Sparse lesions that are irregularly distributed.

Polycyclic: Formed from coalescing circles, rings, or incomplete rings (as seen in urticaria, subacute cutaneous lupus erythematosus) (Fig. 1-22).

Figure 1-22 Polycyclic eruption, pityriasis rosea.

DISTRIBUTIONS OF MULTIPLE LESIONS

Dermatomal/Zosteriform: Unilateral and lying in the distribution of a single spinal afferent nerve root; the classic example is herpes zoster (Chap. 165).

Blaschkoid: Following lines of skin cell migration during embryogenesis; generally longitudinally oriented on the limbs and circumferential on the trunk, but curvilinear rather than perfectly linear; described by Alfred Blaschko and implies a mosaic disorder (such as incontinentia pigmenti, inflammatory linear verrucous epidermal nevus).

Lymphangitic and Sporotrichoid: Lying along the distribution of a lymph vessel; implies an infectious agent that is spreading centrally from an acral site. Lymphangitic lesions are usually a red streak along a limb due to a staphylococcal or streptococcal cellulitis. When individual papules or nodules lie along the distribution of a lymphatic network, this pattern is termed "sporotrichoid" and suggests a particular infectious differential.

Sun Exposed/Photodistributed: Occurring in areas usually not covered by clothing, namely the face, dorsal hands, and a triangular area corresponding to the opening of a V-neck shirt on the upper chest (examples include photodermatitis, subacute cutaneous lupus erythematosus, polymorphous light eruption, squamous cell carcinoma). *Photo-accentuated* means the sun-exposed skin has a more dense distribution of lesions compared to non-sun-exposed skin.

Sun Protected: Occurring in areas usually covered by one or more layers of clothing; usually a dermatosis that is improved by sun exposure (such as parapsoriasis, mycosis fungoides).

Acral: Occurring in distal locations, such as on the hands, feet, wrists, ankles, ears, or penis.

Truncal: Occurring on the trunk or central body.

Extensor: Occurring over the dorsal extremities, overlying the extensor muscles, knees, or elbows (psoriasis is a classic example).

Flexor: Overlying the flexor muscles of the extremities, the antecubital and popliteal fossae (childhood atopic dermatitis, for instance).

Intertriginous: Occurring in the skin folds, where 2 skin surfaces are in contact, namely the axillae, inguinal folds, inner thighs, inframammary skin, and under an abdominal pannus; often related to moisture and heat generated in these areas.

Seborrheic: Favoring the hair-bearing locations of the skin, including scalp, eyebrows, beard, central chest, axillae, genitals. Also often favors the nasolabial and postauricular creases.

Follicular: Papules centered around hair follicles.

TABLE 1-6
A Selection of Cutaneous Diagnostic Signs[a]

CUTANEOUS SIGN	DESCRIPTION	SIGNIFICANCE
Apple-jelly sign	A yellowish hue is produced from pressure on the lesion with a glass slide	Noted in granulomatous processes (Fig. 1-15)
Asboe–Hansen sign	Lateral extension of a blister with downward pressure	Noted in blistering disorders in which the pathology is above the basement membrane zone
Auspitz sign	Pinpoint bleeding at the tops of ruptured capillaries with forcible removal of outer scales from a psoriatic plaque	Not entirely sensitive or specific for psoriasis
Buttonhole sign	A flesh-colored, soft papule feels as though it can be pushed through a "buttonhole" into the skin	Noted in a neurofibroma
Carpet tack sign	Horny plugs at the undersurface of scale removed from a lesion	Noted in lesions of chronic cutaneous lupus
Darier sign	Urticarial wheal produced in a lesion after it is firmly rubbed with a finger or the rounded end of a pen; the wheal, which is strictly confined to the borders of the lesion, may not appear for several minutes	Noted in urticaria pigmentosa and rarely with cutaneous lymphoma or histiocytosis
Dermatographism	Firmly stroking unaffected skin produces a wheal along the shape of the stroke within seconds to minutes	Symptomatic dermatographism represents a physical urticaria
Pseudo-Darier sign	Transient induration of a lesion or piloerection after rubbing	Noted in congenital smooth muscle hamartoma
Fitzpatrick (dimple) sign	Dimpling of the skin with lateral compression of the lesion with the thumb and index finger produces dimpling as a result of tethering of the epidermis to the dermal lesion	Characteristic of dermatofibroma
Nikolsky sign	Lateral pressure on unblistered skin with resulting shearing of the epidermis	Noted in blistering disorders in which the pathology is above the basement membrane zone; relevant entities include pemphigus vulgaris and toxic epidermal necrolysis

[a]Others are discussed in the chapters on diseases in which the signs occur.

Localized: Confined to a single body location.

Generalized: Widespread. A generalized eruption consisting of inflammatory (red) lesions is called an *exanthem* (rash). A macular exanthem consists of macules, a papular exanthem of papules, a vesicular exanthem of vesicles, etc.

Bilateral Symmetric: Occurring with mirror-image symmetry on both sides of the body.

Universal: Involving the entire cutaneous surface (as in erythroderma, alopecia universalis).

Table 1-6 describes some clinically relevant maneuvers that point to particular cutaneous or systemic diseases.

REACTION PATTERNS

Certain combinations of primary and secondary morphologies point the clinician to a subset of diseases. Groups of diagnoses that share similar morphologic characteristics are termed "reaction patterns," suggesting a particular list of differential diagnosis. Reaction patterns are an especially useful tool when no characteristic shape, configuration, or distribution is apparent. Determining the reaction pattern can also help guide workup (Tables 1-7 through 1-15) and initial treatment.

TABLE 1-7
Papulosquamous Reaction Pattern—Common Examples

Psoriasis
Lichen planus
Pityriasis rosea
Pityriasis rubra pilaris
Pityriasis lichenoides chronica
Syphilis (secondary)
Mycosis fungoides (MF)/parapsoriasis
Drug (lichenoid, pityriasis rosea-like)
Subacute and discoid lupus, dermatomyositis
Tinea corporis
Tinea versicolor
Seborrheic dermatitis
Nutritional deficiency
Lichenoid id reaction
Porokeratosis
Superficial basal cell carcinoma
Squamous cell carcinoma in situ

Toolbox
History
Distribution
Examine scalp, nails, mucous membranes
KOH preparation, fungal culture
Rapid plasma reagin (RPR)
Biopsy for routine histology

TABLE 1-8
Eczematous Reaction Pattern—Common Examples

Same or Similar Histology
Atopic
Irritant contact
Allergic contact
Nummular
Dyshidrosis Dishidrotic
Xerotic/asteatotic
Stasis
Photoallergic drug eruption
Actinic dermatitis/actinic prurigo
Id or "autoeczematization"
Eczematous drug eruption
Seborrheic dermatitis
Lichen simplex chronicus

Mimickers-Scraping, Biopsy May Be Helpful
Scabies
Tinea
Some blistering disorders (bullous pemphigoid, dermatitis herpetiformis)
Mycosis fungoides
Nutritional deficiency
Polymorphous light eruption

Toolbox
History
Distribution
Examine scalp, nails, mucous membranes
Patch testing
Scraping (scabies, KOH)
Biopsy for routine histology, direct immunofluorescence (DIF)
Bacterial culture, HSV culture (if superinfection suspected)

TABLE 1-9
Vesiculobullous Reaction Pattern—Common Examples

Pustules
Psoriasis
Acute generalized exanthematous pustulosis (AGEP)
Sneddon–Wilkinson/IgA pemphigus
Candida
Herpes Simplex Virus (HSV) or Varicella Zoster Virus (VZV) infections
Follicular pustules (acne/rosacea, bacterial folliculitis; Majocchi granuloma, pityrosporum folliculitis, eosinophilic folliculitis)
Impetigo
Miliaria pustulosa

Vesicles/Bullae
Acute eczematous process
Allergic contact dermatitis
Bullous arthropod
HSV/VZV
Coxsackie
Bullous tinea
Autoimmune blistering diseases
Porphyria cutanea tarda, pseudoporphyria
Polymorphous light eruption
Inherited blistering diseases
Impetigo
Miliaria crystallina
Bullous diabeticorum

Vesicles/Pustules as Secondary Processes
Infection (cellulitis, necrotizing fasciitis, deep fungal, atypical mycobacteria, leishmaniasis, scabies, nocardiosis)
Edema
Chemical/thermal/Ultraviolet burn
Necrosis
Fixed drug eruption, erythema multiforme, Stevens–Johnson syndrome, Toxic epidermal necrolysis
Neutrophilic dermatoses (leukocytoclastic vasculitis, Sweet syndrome, pyoderma gangrenosum)
Halogenodermas

Toolbox
History
Distribution
Examine scalp, nails, mucous membranes
KOH and/or fungal culture—blister roof, pustule
Bacterial culture—blister fluid, pustule
DFA, Viral culture—blister base
Biopsy for routine histology, DIF, tissue culture (bacterial, mycobacterial, fungal)

The first step to determining the reaction pattern is identifying the primary lesion. In generalized eruptions, or when mixed morphologies are present, it is useful to go to the edge of a larger lesion or group of lesions to determine the primary morphology. It is important to note that some diseases with variable morphologies may fall into more than one reaction pattern.

REACTION PATTERNS WITH SURFACE CHANGE

PAPULOSQUAMOUS

In papulosquamous eruptions, the primary lesion is a relatively thin or flat-topped papule or plaque with scale. Crust or lichenification is usually not present. Histopathologically, these processes involve the epidermis and superficial to mid-dermis. Individual papules or plaques are typically well demarcated, and there is often normal skin visible between each discrete papule or plaque (Table 1-7).

ECZEMATOUS

Eczematous eruptions consist of thin erythematous papules and plaques with epidermal change. On the surface of an acute eczematous process, there is enough epidermal spongiosis (edema between keratinocytes) to cause the formation of serous crusting, microvesicles, or sometimes frank bullae. When microvesicles collapse, they form characteristic tiny round crusts often admixed with scale and subtle or overt fissuring. When subacute to chronic, the surface is often dry, scaly, fissured, and/or lichenified from rubbing or scratching. Compared with papulosquamous eruptions, eczematous primary lesions are

TABLE 1-10
Dermal "Plus" Reaction Pattern—Common Examples

Infections
Mycobacteria: TB and atypical mycobacteria
Fungal: kerion, subcutaneous mycoses, deep fungal mycoses, mycetomas
Parasites: leishmaniasis, Chagas, nodular scabies
Bacteria: bartonella, botryomycosis, blastomycosis-like pyoderma, anthrax, gonococcus, syphilitic gumma
Viral: molluscum, disseminated VZV, verrucous HSV, poxviruses
Neoplasias: Kaposi sarcoma, SCC, BCC, Merkel cell carcinoma, amelanotic melanoma, metastases, etc.
Inflammatory: Neutrophilic (Sweet syndrome, pyoderma gangrenosum, halogenodermas), lymphoma (tumor-stage CTCL, B-cell lymphomas), sarcoidosis, polyarteritis nodosa, palisaded neutrophilic and interstitial granulomatous dermatitis

Toolbox
History
Distribution
Examine scalp, nails, mucous membranes, lymph nodes
Culture surface (viral, bacterial, fungal)
Biopsy for routine histology
Biopsy for culture (bacterial, fungal, mycobacterial)

typically ill demarcated, and individual lesions vary widely in their size and spacing. Because most eczematous eruptions share a common histology, the distribution and history are key in differentiating among them (Table 1-8).

VESICULOBULLOUS

Sometimes vesicles and bullae are quite obvious; other times, when all the blisters have ruptured, the clinician must recognize their "footprints"—clues to their recent presence. Because blisters are filled with fluid, when they collapse, they often leave behind round, oval, arcuate, or geographic erosions or crusts. When small ruptured vesicles are grouped together, as in herpes simplex, they form crust with "scalloped" edges. Other subtle clues include erosions with "mauserung" desquamation, a rumpled rim of epidermis hanging from the erosion's edge, or milia, which can result from healing of deeper blisters (Table 1-9).

Some diseases with prominent surface change defy categorization into papulosquamous, eczematous, or vesculobullous reaction patterns. The astute clinician can recognize an eruption as difficult to characterize and is aware this actually suggests a differential diagnosis in itself. Some examples include scabies, acantholytic diseases (Grover, Darier disease), some drug eruptions, some "id" reactions, and some paraneoplastic conditions.

DERMAL "PLUS"

These are dermally infiltrated papules, nodules or plaques with surface change: hyperkeratotic scale, crust, vesicles, pustules, erosion, or ulceration (Table 1-10).

TABLE 1-11
Macular Reaction Pattern—Common Examples

Pink
Vascular anomaly or neoplasm (such as nevus simplex)
Exanthems (drug, viral)
Macular granuloma annulare, interstitial granulomatous drug eruption
Tinea versicolor (can induce scale)

Red
Red to red-purple
Vascular anomaly or neoplasm (such as telangiectasia, port-wine stain)
Petechiae (due to trauma, thrombocytopenia, Rocky Mountain spotted fever, Parvovirus, scurvy)
Ecchymosis
Red to red-brown
Pigmented purpura
Telangiectasia macularis eruptive perstans (TMEP)
Erythema ab igne
Fixed drug eruption

Brown
Melasma
Lentigo
Junctional melanocytic nevus
Melanoma
Some birthmarks (Café au lait macule, nevus spilus)
Postinflammatory pigmentation
Tinea versicolor
Patch-stage KS
Flat warts
Diabetic dermopathy

White
Vitiligo
Contact leukoderma
Inherited (piebaldism, ash-leaf macule, nevus anemicus)
Postinflammatory pigmentation
Pityriasis alba
Hypopigmented MF
Tuberculoid leprosy
Guttate hypomelanosis
Flat warts
Progressive macular hypomelanosis
Bier spots

Gray/Blue
Blue nevus
Nevus of Ota
Mongolian spot
Lichen planus pigmentosa and related disorders
Drug effect (minocycline, amiodarone, hydroxychloroquine)
Deposition (ochronosis, silver)
Tattoo

Toolbox
History
Shape
Distribution
Examine mucous membranes
Wood lamp
KOH (for tinea versicolor)
Biopsy for routine histology

TABLE 1-12
Dermal Reaction Pattern—Common Examples

Inflammatory
Neutrophils (Sweet syndrome, pyoderma gangrenosum, neutrophilic eccrine hidradenitis)
Lymphocytes (tumid lupus, cutaneous lymphoid hyperplasia, morphea, lichen sclerosus)
Histiocytes (xanthomas, xanthogranulomas, granuloma annulare, sarcoidosis, Rosai-Dorfman, Multicentric Reticulohistiocytosis, palisaded neutrophilic, and interstitial granulomatous dermatitis)
Mixed (erythema elevatum diutinum, granuloma faciale)
Mastocytoma
Plasmacytoma
Well syndrome
Angiolymphoid hyperplasia with eosinophilia

Infectious
Cellulitis, Erysipelas, bartonella (Bacillary angiomatosis, cat scratch)
Mycobacteria (TB, leprosy, atypical mycobacteria)
Subcutaneous and deep fungal infection

Neoplastic
Kaposi sarcoma (plaque, tumor-stage)
Lymphomas (CTCL, B-cell)
Leukemia cutis
Adnexal neoplasms
Vascular neoplasms
BCC, SCC, nevus, melanoma, spindle cell neoplasms, Merkel cell
Cutaneous metastases
Keloid, hypertrophic scar
Dermatofibroma, Dermatofibrosarcoma protuberans

Depositional
Colloid milium
Amyloid
Mucin
Gout
Calcium

Toolbox
History
Distribution
Examine lymph nodes, mucous membranes
Biopsy for routine histology, tissue culture

REACTION PATTERNS WITHOUT SURFACE CHANGE

In the absence of surface change, the epidermis and its melanin are unaltered, often allowing color and topography to be the defining characteristics. Shape, configuration, and distribution are also helpful.

MACULAR

Macules can derive their color changes from changes in the epidermis or dermis (Table 1-11).

TABLE 1-13
Subcutaneous Reaction Pattern

Inflammatory
Erythema nodosum
Lupus and other connective tissue-related panniculitis
Subcutaneous Sweet syndrome, GA, sarcoidosis (Darier-Roussy)

Infectious
Erythema induratum
Nocardia, actinomyces

Physical
Traumatic
Cold

Other
Lipodermatosclerosis
Enzyme-mediated (pancreatic, alpha-1 antitrypsin)
Steroid and other drug injections
Subcutaneous fat necrosis of the newborn
Panniculitis-like CTCL

Toolbox
History
Distribution
Biopsy for routine histology, tissue culture

DERMAL

A dermal reaction pattern is a papule or plaque without surface change where the infiltrative process is in the dermis (Table 1-12).

SUBCUTANEOUS

Subcutaneous reaction pattern is a deeper papule or plaque, usually without surface change, though occasionally they may ulcerate and crust. The infiltrative or inflammatory process is in the subcutis (Table 1-13).

PURPURIC

Purpura are red or purple macules, patches, papules, or plaques that result from bleeding into the skin. Because blood has extravasated, they do not blanch when pressure is applied. They may range in color from true red to red-purple or magenta to red-brown ("cayenne pepper"). Purpuric macules are sometimes called "petechiae"; purpuric patches are sometimes called "ecchymoses." Ecchymosis may also overlie a plaque or nodule from dermal or subdermal hemorrhage, known as hematoma, and may appear yellow-green when a few days old. Purpuric papules, or "palpable purpura," typically represent inflammation of small vessels associated with hemorrhage, as in leukocytoclastic vasculitis, a coagulopathy affecting small vessels, as in cryoglobulinemia, or very small emboli. Purpuric plaques represent ischemia, embolism, infarction, intravascular infection, or inflammation of small-medium or medium vessels, that may lead to necrosis of the overlying epidermis. These can manifest as pink

TABLE 1-14
Purpuric Reaction Pattern—Common Examples

Vasculitis
Small vessel
Hypersensitivity vasculitis (to drug or infection)
Henoch–Schoenlein purpura (IgA vasculitis)
ANCA+
Connective-tissue disease associated
Medium vessel
Polyarteritis nodosa
Churg–Strauss
Levamisole hypersensitivity
Macular arteritis

Infectious
Meningococcemia
Purpura fulminans
Ecthyma gangrenosum
Hyperinfection strongyloidiasis
Aspergillus, mucor, and other vasculotropic fungi

Embolic
Cholesterol emboli
Septic emboli (endocarditis and others)

Vasculopathy
Calciphylaxis
Cryoglobulin, cryofibrinogen
Antiphospholipid antibody syndrome, livedoid vasculopathy, livedo racemosa
Coumadin/heparin necrosis
Levamisole hypersensitivity
Other hypercoagulable states

Other
Vascular or intravascular neoplasms (Kaposi sarcoma, angiosarcoma, intravascular lymphoma)
Cutis marmorata
Petechiae (trauma, thrombocytopenia, Rocky Mountain spotted fever, Parvovirus, scurvy)
Ecchymoses

Toolbox
History
Distribution
Other lab workup depending on morphology and history
Biopsy for routine histology
Biopsy for DIF
Biopsy for tissue culture

TABLE 1-15
Erythemas

Exanthems
Viral
Bacterial (toxic shock syndrome, scarlet fever, meningococcus, mycoplasma)
Drug (morbilliform eruption, drug-induced hypersensitivity syndrome)
Graft-vs-host disease
Kawasaki disease
Miliaria rubra

Figurate
Erythema annulare centrifugum
Deep gyrate erythemas
Erythema migrans
Erythema marginatum

Urticaria/Urticaria
Urticaria
Neutrophilic urticaria
Papular urticaria
Urticarial vasculitis
Dermal hypersensitivity reaction
Polymorphous eruption of pregnancy
Urticarial bullous pemphigoid
Acute hemorrhagic edema of childhood

Targetoid
Erythema multiforme
Mycoplasma-induced rash and mucositis
Fixed drug eruption
Urticarial vasculitis
Paraneoplastic pemphigus
Rowell-type lupus

Toolbox
History
Distribution
Examine mucous membranes
Biopsy for routine histology, DIF
Viral studies
Other lab workup depending on morphology and history

papules (usually medium vessels) or stellate dark purple plaques (Fig. 1-23), and may be accompanied by pink, red, or purple net-like ("retiform") hyperemia ("livedo"). If the overlying epidermis becomes necrotic, bullae, ulcer, and/or eschar may form at the surface (Table 1-14).

ERYTHEMAS

Erythemas are blanching red-pink macules, patches, papules, or plaques, or a combination, usually without surface change. This reaction pattern may be subdivided into *morbilliform erythemas*, *figurate erythemas*, *urticarial erythemas*, and *targetoid erythemas* (Table 1-15).

- *Morbilliform erythemas* are exanthems that are typically consist of diffuse symmetric blanching pink, red, or magenta macules and papules.
- *Figurate erythemas* are annular, arcuate, or polycyclic blanching pink to red plaques. They generally do not have surface change, with the exception of erythema annulare centrifugum, which exhibits prototypical "trailing scale."
- *Urticarial erythemas* are pink, blanching macules, papules, or plaques, often exhibiting a characteristic "wheal and flare" appearance, with blanching of the skin surrounding the primary lesion (Fig. 1-24).
- *Targetoid erythemas* have at least 2 zones of color, with a darker center compared to the periphery. The center often has a "dusky," or gray-violet, hue, owing to epidermal necrosis, or vesiculates as the necrotic epidermis detaches.

Figure 1-23 Retiform purpura with ulceration and eschar, cutaneous polyarteritis nodosa.

CONCLUSION

In the age of digital photography, the basic art and science of morphology remains paramount in dermatology to achieve accurate diagnosis and a deeper understanding of clinical–pathologic correlation. As Siemens (1891–1969) wrote, "he who studies skin diseases and fails to study the lesion first will never learn dermatology." Careful evaluation of the skin and systematic identification of primary morphology, secondary changes, and reaction pattern is essential to the art and science of dermatologic diagnosis.

Figure 1-24 Urticarial phase, bullous pemphigoid.

ACKNOWLEDGMENTS

The authors are truly grateful for the opportunity to build upon the work of Amit Garg, Nikki A. Levin, and Jeffrey D. Bernhard, authors of a previous version of this chapter. The authors thank Lindy P. Fox and Ilona J. Frieden for sharing materials and insights that informed this work.

SUGGESTED READINGS

Burgin S. *A Guidebook to Dermatologic Diagnosis*. New York, NY: McGraw-Hill. In press.

duVivier A. *Atlas of Clinical Dermatology*, 4th ed. Philadelphia, PA: Saunders; 2012.

Ghatan HEY. *Dermatological Differential Diagnosis and Pearls*, 2nd ed. Boca Raton, FL: CRC Press; 2002.

Schneiderman P, Grossman ME. *A Clinician's Guide to Dermatologic Differential Diagnosis*. Boca Raton, FL: CRC Press; 2006.

White GM, Cox NH. *Diseases of the Skin: A Color Atlas and Text*, 2nd ed. Maryland Heights, MO: Mosby; 2005.

Wolff K, Johnson R, Saavedra A, et al. *Fitzpatrick's Color Atlas and Synopsis of Clinical Dermatology*, 8th ed. New York, NY: McGraw-Hill; 2017.

Chapter 2 :: Pathology of Skin Lesions

:: Rosalie Elenitsas & Emily Y. Chu

AT-A-GLANCE

- Different tissue compartments interconnect anatomically and interact functionally. These are the reactive units of the skin.
- The superficial reaction unit comprises the epidermis, the junctional zone, and the papillary body with its vascular system.
- The reticular dermis with the deeper dermal vascular plexus is the second reactive unit.
- The third reactive unit is the subcutaneous tissue with its septal and lobular compartments.
- Hair follicles and glands are a fourth reactive unit embedded into these three units.
- Pathologic processes may involve these reactive units alone or several of them together in a concerted fashion.
- The heterogeneity and interaction of these individual cutaneous compartments explains why a few basic pathologic reactions lead to a multiplicity of clinical and pathologic reaction patterns.

INTRODUCTION TO SKIN PATHOLOGY

Skin biopsies play an important role in the care of patients with dermatologic disorders. Adequate knowledge of dermatopathology is crucial not only for interpreting the pathology report from the laboratory, but also for deciding how and where to perform the biopsy. The process of a skin biopsy is more complex than meets the eye, as it has been estimated that there are approximately 20 "handoff" steps in this process.[1] Errors can occur at any one of these steps, and accurate communication at all points is important in minimizing medical mishaps.[1,2]

CHOOSING THE TYPE OF BIOPSY

Before performing a biopsy one must review the clinical differential diagnosis, which will assist in deciding whether a shave, punch, or excisional specimen is best (Table 2-1). One must also consider the anatomical location of the biopsy, and how it will affect the cosmetic result. Shave biopsies are best for cases where most of the pathology is in the epidermis or superficial dermis. Examples include nonmelanoma skin cancer (basal cell carcinoma, squamous cell carcinoma), seborrheic keratosis, actinic keratosis, verruca vulgaris, and some melanocytic nevi. For most inflammatory dermatoses, a punch biopsy produces the best results. Excisional biopsies are used for complete removal of a cutaneous neoplasm as well as in cases of panniculitis or fasciitis where substantial deep tissue is needed. Curettage should be restricted to lesions with a known diagnosis, such as a seborrheic keratosis, verruca, or basal cell carcinoma, where histopathologic examination is less important, and mostly performed for confirmation. Curettage results in fragmented and distorted tissue making evaluation by the pathologist extremely difficult.

CHOOSING THE SITE TO BIOPSY

Although a biopsy of a cutaneous neoplasm is obvious, inflammatory dermatoses can be more challenging. Choosing the site to biopsy can be just as important as the biopsy itself. It is best to choose lesions that have not been treated, excoriated, or secondarily infected. In general, it is better to choose fully evolved lesions rather than a brand-new lesion. The exception is blistering disorders, when a new blister is ideal. In this scenario, it is important to include the edge of the blister as well as the surrounding skin that has not yet blistered. When assessing vasculitis and connective tissue disease, the age of the lesion is critical as often very early or old lesions may lack diagnostic findings. Elston[3] has eloquently reviewed important issues in biopsies of specific skin diseases. For patients with unusual or persistent dermatoses, or if cutaneous T-cell lymphoma is suspected, more than one biopsy can be beneficial. When a biopsy is performed for alopecia, two 4-mm punch biopsies are optimal: one for horizontal sections and one for vertical sections. Alternative methods, such as the HoVert technique and Tyler technique, allow for horizontal and vertical sections from one punch biopsy.[4,5]

SUBMISSION OF THE BIOPSY

All routine skin biopsies are submitted in 10% neutral buffered formalin. At the time of the biopsy, one must ensure that there is adequate formalin in the bottle (approximately 10 times the volume of the specimen), and also confirm that the specimen is

TABLE 2-1
Choosing the Type of Biopsy

SUSPECTED DIAGNOSIS	BIOPSY TYPE
Actinic keratosis	Shave
Seborrheic keratosis	Shave
Verruca	Shave
BCC, SCC	Shave most common; punch/excision
Blistering disease	Punch or deep shave edge of blister
Contact dermatitis	Punch
Connective tissue disease	Punch
Mycosis fungoides	Punch
Vasculitis	Punch
Granulomatous process	Punch
Atypical nevi	Deep shave, punch, or excision
Panniculitis	Punch (minimum 6 mm) or ellipse

BCC, basal cell carcinoma; SCC, squamous cell carcinoma.

actually in the bottle and submerged in the fluid. A double check to confirm that the skin tissue is not stuck to the punch, the shave tool, or the bottle cap can help prevent a medical mishap. In cold weather, 95% ethyl alcohol (10% of the formalin volume) must be added to the formalin to prevent freezing of the tissue and subsequent freeze artifacts, which can lead to misdiagnosis.

Direct immunofluorescence may be of benefit in some disease processes, such as autoimmune blistering diseases, discoid lupus erythematosus, and vasculitis. In this case, a separate piece of skin is submitted in Michel medium (a solution containing ammonium sulfate, *N*-ethyl maleimide, and magnesium sulfate in citrate buffer), with specific instructions to the laboratory that immunofluorescence is requested. If your laboratory is in the same building or within walking distance, the specimen can be transported on saline-soaked gauze in a sterile cup. This latter option should only be used if immediate delivery to the laboratory is possible because tissue that is not fixed in formalin or put into a holding medium such as Michel medium will begin to autolyze.

If possible, skin biopsies should be submitted to a dermatopathology laboratory. Dermatopathology laboratories are advantageous because the histotechnologists have the experience of proper embedding of small pieces of skin. Maloriented skin sections are extremely challenging to interpret even for experienced pathologists. Choosing a dermatopathology laboratory also ensures that the specimen will be interpreted by a dermatopathologist. All biopsies must be submitted with clinical information. Minimal information includes: age, sex of patient, anatomical location of the biopsy, clinical description and/or clinical diagnosis. With electronic medical records, often this can be printed directly onto the pathology form. Submitting a clinical photograph may assist in clinical pathologic correlation of both neoplastic and inflammatory disorders. Pathology reports are not always "black and white" with only one diagnosis. For inflammatory disorders, a descriptive diagnosis may result from the pathology laboratory, and the dermatologist must correlate those findings with the dermatologist's differential diagnosis. In all cases, one must always correlate the pathology findings with the clinical presentation. If the results do not make sense, one should consider either additional sampling or a discussion with the pathologist.

ASSESSMENT OF HISTOPATHOLOGY

Commonly used immunohistochemical and histochemical stains are shown in Tables 2-2 and 2-3, respectively. The skin is composed of different tissue compartments that interconnect anatomically and interact functionally. Conversely, epidermis, dermis, and subcutaneous tissue are heterogeneous in nature and an analysis of pathologic processes involving the skin, and this heterogeneity, explains how a few basic reactions lead to a multiplicity of reaction patterns within this tissue.

INFLAMMATORY REACTIONS IN THE SKIN

Pathophysiologically, the skin can be subdivided into 3 reactive units that extend beyond anatomic boundaries (Fig. 2-1); they overlap and can be divided into different subunits that respond to pathologic stimuli according to their inherent reaction capacities in a coordinated pattern: (a) superficial reactive unit, (b) reticular dermis, and (c) subcutaneous fat. Hair follicles and glands are a separate reactive unit that are predominantly in the reticular dermis.

SUPERFICIAL REACTIVE UNIT

The superficial reactive unit is composed of epidermis, the junction zone, the subjacent loose, delicate connective tissue of the papillary dermis and its capillary network, and the superficial vascular plexus (see Fig. 2-1).

EPIDERMIS

Keratinocytes represent the bulk of the epidermis. The epidermis, an ectodermal epithelium, also harbors a number of other cell populations such as melanocytes, Langerhans cells, and Merkel cells. The basal

TABLE 2-2
Commonly Used Immunohistochemical Stains

IMMUNOHISTOCHEMICAL STAIN	ASSOCIATED CONDITION(S)
Epithelial Markers	
P63	Cutaneous spindle cell squamous carcinoma
CAM5.2	Paget disease, extramammary Paget disease
CK7	Paget disease, extramammary Paget disease
CK20	Merkel cell carcinoma
Epithelial membrane antigen (EMA)	Squamous cell carcinoma
Carcinoembryonic antigen (CEA)	Sweat gland neoplasms, Paget disease, extramammary Paget disease
Mesenchymal Markers	
Desmin	Skeletal and smooth muscle tumors (leiomyoma)
Smooth muscle actin (SMA)	Glomus tumor, leiomyosarcoma
CD34	Dermatofibrosarcoma protuberans, trichoepitheliomas
Factor XIIIa	Dermatofibroma
CD31	Vascular tumors
D2-40 (podoplanin)	Lymphatic endothelial marker
GLUT1	Infantile hemangiomas
Vimentin	Sarcomas
Neuroectodermal Markers	
S100	Desmoplastic melanoma, Langerhans cell histiocytosis, granular cell tumor
HMB-45	Desmoplastic melanoma, blue nevus
Melan-A, Mart-1	Desmoplastic melanoma
Hematopoietic Markers	
CD45Ra (LCA)	Hematolymphoid proliferations
CD20	B-cell lymphomas
CD10 (CALLA)	Atypical fibroxanthomas, clear-cell hidradenoma, sebaceous tumors
CD79a	Plasma cell, B-cell marker
CD138 (syndecan-1)	Plasma cell marker
CD3	T-cell lymphomas
CD4	T-helper lymphocytic marker
CD5	Mantle cell lymphoma, chronic lymphocytic leukemia
CD7	Most commonly lost antigen in T-cell lymphoma
CD8	T-cell cytotoxic/suppressor marker
CD30	Anaplastic large cell lymphoma, lymphomatoid papulosis, chronic arthropod bites (scabies, tick)
CD1a	Langerhans cell histiocytosis
Langerin CD207)	Langerhans cells
BCL2	B-cell lymphoproliferative disorders
Infectious Diseases	
HHV8	Kaposi sarcoma

HHV8, human herpesvirus 8.
Data from Elston DM, Ferringer T. *Dermatopathology*, 2nd ed. Philadelphia: Saunders, 2013.

cells of the epidermis undergo proliferation cycles that provide for the renewal of the epidermis and, as they move toward the surface of the skin, undergo a differentiation process that results in surface keratinization. Thus, the epidermis is a dynamic tissue in which cells are constantly nonsynchronized replication and differentiation; this precisely coordinated physiologic balance between progressive keratinization as cells approach the epidermal surface to eventually undergo programed cell death and be sloughed, and their continuous replenishment by dividing basal cells, is in contrast to the relatively static minority populations of Langerhans cells, melanocytes, and Merkel cells.

TABLE 2-3
Commonly Used Histochemical Stains

HISTOCHEMICAL STAIN	FEATURE VISUALIZED
Verhoeff-Van Gieson stain	Elastic fibers (black)
Toluidine blue	Mucin (blue) Mast cell granules (metachromatic)
Masson's trichrome	Collagen (blue-green) Smooth muscle (red)
Leder stain	Mast cell cytoplasm (red)
Periodic acid–Schiff	Glycogen (red) Fungi (red)
Alcian blue	Acid mucopolysaccharides, such as mucin (blue)
Colloidal iron	Acid mucopolysaccharides (blue)
Mucicarmine	Mucopolysaccharides (pink/red)
Congo red	Amyloid (red, but apple green birefringence with polarized light)
Thioflavin T	Amyloid (yellow/yellow-green)
Crystal violet	Amyloid (red-purple metachromatically)
Prussian blue (Perls stain)	Iron (deep blue)
Fontana-Masson	Melanin (black)
Von Kossa	Calcium (black)
Alizarin red	Calcium (orange-red)
Oil red O	Lipids (red)
Sudan black	Lipids (black)
Gomori methenamine silver	Fungus (gray-black)
Ziehl-Neelsen; Fite acid-fast stain	Mycobacteria (red)
Auramine-rhodamine	Mycobacteria (red-yellow)
Warthin-starry	Spirochetes (black)
Giemsa	Myeloid cells (blue) Mast cells (blue) Leishmania, Histoplasma

Data from Elston DM, Ferringer T. *Dermatopathology*, 2nd ed. Philadelphia: Saunders, 2013.

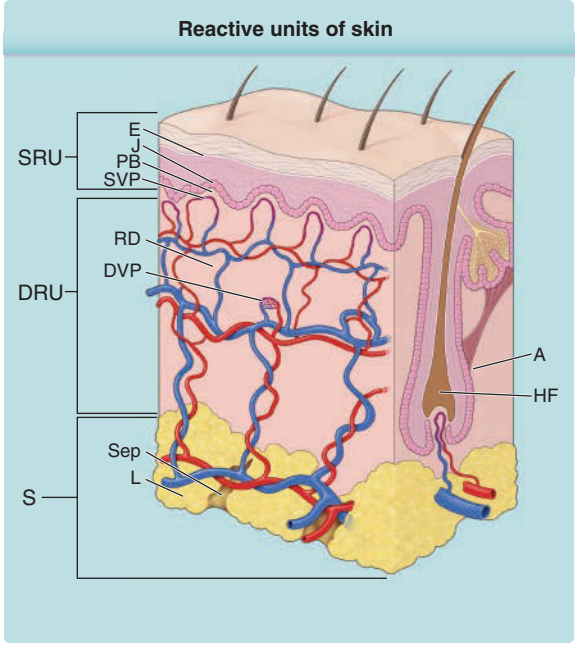

Figure 2-1 Reactive units of skin. The superficial reactive unit (*SRU*) comprises the epidermis (*E*), the junction zone (*J*), and the papillary body (*PB*, or papillary dermis) with the superficial microvascular plexus. The dermal reactive unit (*DRU*) consists of the reticular dermis (*RD*) and the deep dermal microvascular plexus (*DVP*). The subcutaneous reactive unit (*S*) consists of lobules (*L*) and septae (*Sep*). A fourth unit is the appendages (*A*; hair and sebaceous glands are the only appendages shown). *HF*, hair follicle.

Disturbances of Epidermal Cell Kinetics: Enhanced cell proliferation accompanied by an enlargement of the germinative cell pool and increased mitotic rates lead to an increase of the epidermal cell population and thus to a thickening of the epidermis (*acanthosis*, Fig. 2-2). In contrast to acanthosis is epidermal *atrophy* (thinning of epidermis, Fig. 2-3). Although there are many causes of atrophy, one primary etiology is a decrease in epidermal proliferative capacity, as may be seen with physiological aging or after the prolonged use of potent topical or systemic steroids. With atrophy, the epidermal rete ridges are initially lost, followed by progressive thinning of the epidermal layer.

Disturbances of Epidermal Cell Differentiation: A simple example of disturbed epidermal differentiation is *parakeratosis*, in which faulty and accelerated cornification leads to retention of pyknotic nuclei of epidermal cells at the epidermal surface. Instead of the normal anucleate "basket-weave" pattern, one sees retained nuclei in the stratum corneum. Parakeratosis can be the result of incomplete differentiation (eg, squamous cell carcinoma), or the result of reduced transit time, which does not permit epidermal cells to complete the entire differentiation process (eg, psoriasis).

Dyskeratosis represents altered, often premature or abnormal, keratinization, of individual keratinocytes,

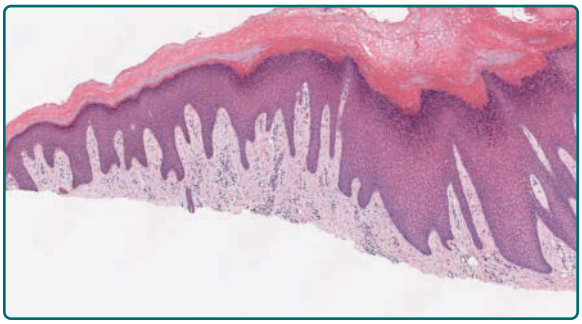

Figure 2-2 Acanthosis. The epidermis on the right side of this photomicrograph is thicker than normal because of a proliferation of keratinocytes.

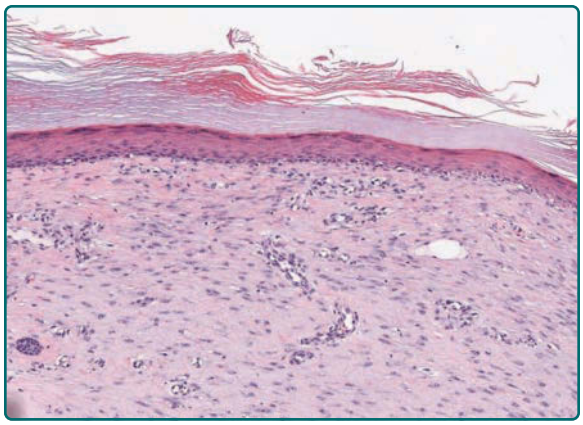

Figure 2-3 Atrophy. The epidermis is thin and there is flattening of the rete ridge architecture.

but it also refers to the morphologic presentation of apoptosis of keratinocytes. Dyskeratotic cells have an eosinophilic cytoplasm and a pyknotic nucleus and are packed with keratin filaments arranged in perinuclear aggregates. It is important to remember that although both premature or abnormal keratinization and apoptosis may produce an end-product referred to as "dyskeratosis," the early events and mechanisms responsible are different. Whereas cells early in the process of abnormal keratinization often have increased eosinophilic keratin aggregates within their cytoplasm with viable-appearing nuclei, apoptotic cells during early evolutionary stages have shrunken, pyknotic, and sometimes fragmented nuclei in the setting of normal-appearing cytoplasm.

In some diseases, dyskeratosis is the expression of a genetically programed disturbance of keratinization as is the case in Darier disease. Dyskeratosis may occur in actinic keratosis and squamous cell carcinoma. Dyskeratosis may also be caused by direct physical and chemical injuries. In the sunburn reaction, eosinophilic apoptotic cells—so-called sunburn cells—are found within the epidermis within the first 24 hours after irradiation with ultraviolet B (UVB); similar cells may occur after high-dose systemic cytotoxic treatment. Individual cell death within the epidermis is a regular phenomenon in graft-versus-host disease and in erythema multiforme.

Disturbances of Epidermal Cohesion: Epidermal cohesion is the result of intercellular attachment devices (desmosomes) and the related intercellular molecular interactions. Desmosomes dissociate and reform at new sites of intercellular contact as cells migrate through the epidermis and keratinocytes mature toward the epidermal surface. The most common result of disturbed epidermal cohesion is the intraepidermal vesicle, a small cavity filled with fluid. Table 2-4 shows a classification of blistering diseases.

Three basic morphologic patterns of intraepidermal vesicle formation are classically recognized. *Spongiosis* is an example of the *secondary* loss of cohesion between epidermal cells caused by the influx of tissue fluid into the epidermis. Serous exudate may extend from the dermis into the intercellular compartment of the epidermis; as it expands, epidermal cells remain in contact with each other only at the sites of desmosomes, acquiring a stellate appearance and giving the epidermis a sponge-like morphology (spongiosis). As the intercellular edema increases, increased white space is noted between keratinocytes (Fig. 2-4), individual cells rupture and lyse, and microcavities (spongiotic vesicles) result. Confluence of such microcavities leads to larger blisters. Leukocytes then migrate into the epidermis with spongiotic edema, which is best illustrated in acute allergic contact dermatitis. The accumulation of polymorphonuclear leukocytes within the epidermis eventually leads to the formation of a pustule.

TABLE 2-4
Classification of Blisters by Anatomic Level with Clinical Examples

Granular layer
Pemphigus foliaceus
Subcorneal pustular dermatosis
Staphylococcal scalded-skin syndrome/bullous impetigo
Spinous layer
Spongiotic dermatitis
Herpes virus infection
Friction blister
Familial benign pemphigus (Hailey-Hailey Disease)
Suprabasal
Pemphigus vulgaris
Darier disease
Subepidermal
Epidermolysis bullosa
Epidermolysis bullosa acquisita
Bullous pemphigoid
Dermatitis herpetiformis
Porphyria cutanea tarda

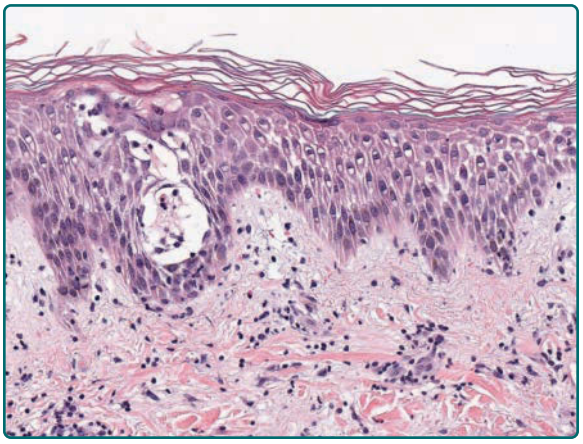

Figure 2-4 Spongiosis. Accumulation of fluid in the epidermis is manifested by white space between the keratinocytes.

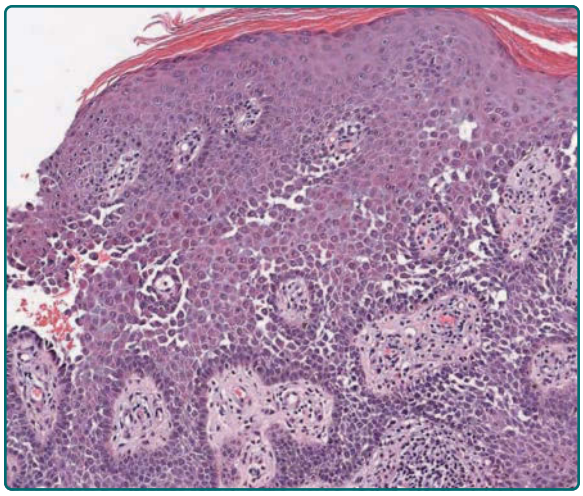

Figure 2-5 Acantholysis. Epidermal keratinocytes separate from each other and take on a rounded, rather than elongate, appearance.

Acantholysis is a *primary* loss of cohesion of epidermal cells. This is initially characterized by a widening and separation of the interdesmosomal regions of the cell membranes of keratinocytes, followed by splitting and a disappearance of desmosomes. The cells are intact but are no longer attached; they revert to their smallest possible surface and round up (Fig. 2-5). Intercellular gaps result, and the influx of fluid from the dermis leads to a cavity, which may form in a suprabasal, midepidermal, or even subcorneal location. Acantholysis occurs in a number of different pathologic processes that do not have a common etiology and pathogenesis. In the pemphigus group, acantholysis results from the interaction of autoantibodies and antigenic determinants on the keratinocyte membranes and related desmosomal adhesive proteins, and in the staphylococcal scalded-skin syndrome, it is caused by a staphylococcal exotoxin. In familial benign pemphigus, it results from the combination of a genetically determined defect of the keratinocyte cell membrane and exogenous factors. A similar phenomenon, albeit more confined to the suprabasal epidermis, occurs in Darier disease, where it is combined with dyskeratosis in the upper epidermal layers (Fig. 2-6) and a compensatory proliferation of basal cells. When acantholysis results from viral infection, it is usually combined with other cellular phenomena such as ballooning, giant cells, and nuclear moulding.

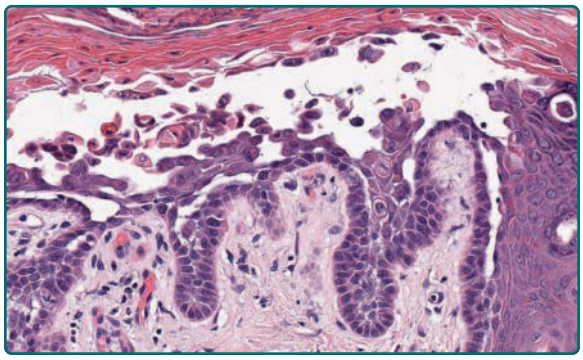

Figure 2-6 Acantholysis and dyskeratosis. This combination of features can be seen in Darier disease, warty dyskeratoma, and Grover disease.

Indeed, a loss of epidermal cohesion can also result from a primary dissolution of cells (ie, cytolysis). In the epidermolytic forms of epidermolysis bullosa, genetically defective and thus structurally compromised basal cells rupture as a result of trauma so that the cleft forms through the basal cell layer. Cytolytic phenomena in the stratum granulosum are characteristic for epidermolytic hyperkeratosis, bullous congenital ichthyosiform erythroderma, ichthyosis hystrix, and some forms of hereditary palmoplantar keratoderma.

DERMAL–EPIDERMAL JUNCTION

Epidermis and dermis are structurally interlocked by means of the epidermal rete ridges and the corresponding dermal papillae, and foot-like submicroscopic cytoplasmic microprocesses of basal cells that extend into corresponding indentations of the dermis. Dermal–epidermal attachment is enforced by hemidesmosomes that anchor basal cells onto the basal lamina; this, in turn, is attached to the dermis by means of anchoring filaments and microfibrils. These structural relationships correlate with complex molecular interactions that serve to bind the epidermis, basement membrane, and superficial dermis in a manner that promotes resistance to potentially life-threatening epidermal detachment. The basal lamina is not a rigid or impermeable structure because leukocytes, Langerhans cells, or other migratory cells pass through it without causing a permanent breach in the junction. After being destroyed by pathologic processes, the basal lamina is reconstituted; this represents an important phenomenon in wound healing and other reparative processes. Functionally, the basal lamina is part of a unit that, by light microscopy, appears as the periodic acid–Schiff–positive "basement membrane" and, in fact, represents the entire junction zone. This consists of the lamina lucida, spanned by microfilaments, and subjacent anchoring fibrils, small collagen fibers, and extracellular matrix. The junction zone is a functional complex that is primarily affected in a number of pathologic processes.

Disturbances of Dermal–Epidermal Cohesion: The destruction of the junction zone or its components usually manifests as disturbance of dermal–epidermal cohesion and leads to blister formation. In these processes, the entire epidermis forms the roof of the blister, and the floor of the blister is composed of dermis without epidermal keratinocytes. In bullous pemphigoid (Fig. 2-7), cleft formation runs through the lamina lucida of the basal membrane and is caused by autoantibodies directed against specific antigens on the cytomembrane of basal cells (*junctional blistering*). Junctional blistering also occurs in the junctional forms of epidermolysis bullosa, but here it is due to the hereditary

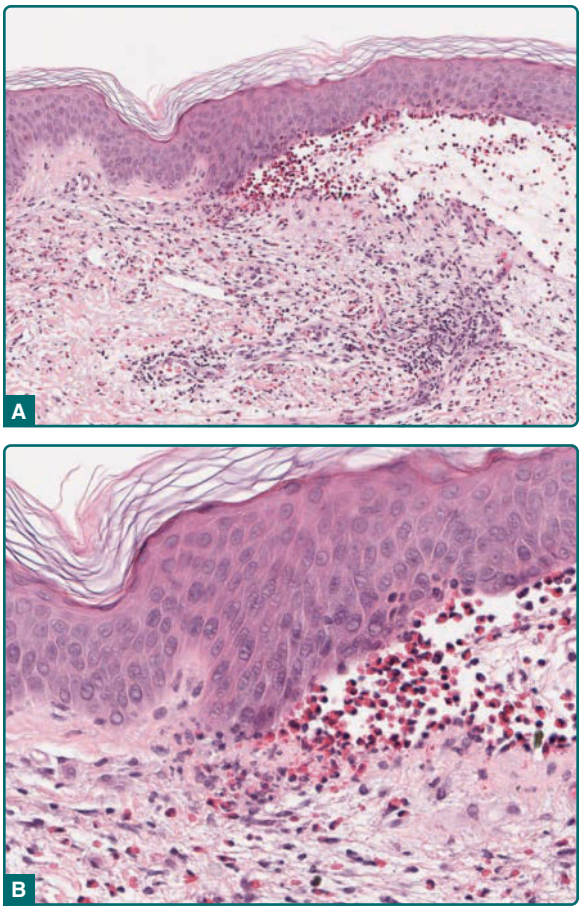

Figure 2-7 Bullous pemphigoid. **A,** There is subepidermal blister formation associated with an eosinophil-rich infiltrate. **B,** At the edge of the blister, eosinophils align at the dermal–epidermal junction.

impairment or absence of molecules important for dermal–epidermal cohesion.

In *dermolytic blistering*, the target of the pathologic process is below the basal lamina. These blisters look similar on hematoxylin and eosin (H&E) staining with the roof composed of intact epidermis. Reduced anchoring filaments and increased collagenase production result in dermolytic dermal–epidermal separation in recessive epidermolysis bullosa. Circulating autoantibodies directed against type VII collagen in anchoring fibrils are the cause of dermolytic blistering in acquired epidermolysis bullosa. Other disorders that result in dermolytic blistering include dermatitis herpetiformis, and porphyria cutanea tarda.

PATHOLOGIC REACTIONS OF THE ENTIRE SUPERFICIAL REACTIVE UNIT

Most pathologic reactions of the superficial skin involve the epidermis and the papillary dermis with the superficial microvascular plexus. This is a highly reactive tissue compartment consisting of capillaries, pre- and postcapillary vessels, mast cells, fibroblasts, macrophages, dendritic cells, and peripatetic lymphocytes, all embedded in a loose connective tissue and extracellular matrix. The prominence of involvement of one of the components over the others may lead to the development of different clinical pictures. A few examples of reaction patterns are detailed below.

Spongiotic Dermatitis: In spongiotic dermatitis such as nummular, contact, and atopic dermatitis, there is an inflammatory reaction of the papillary dermis and superficial microvascular plexus and spongiosis of the epidermis. Lymphocytes infiltrate the epidermis early in the process and aggregate around Langerhans cells, and this is followed by spongiotic vesiculation (Fig. 2-8). Parakeratosis develops as a consequence of epidermal injury and proliferative responses, and the inflammation results in acanthosis and hyperkeratosis in chronic lesions.

Psoriasis: The initial pathologic events in psoriasis appear to be the perivascular accumulation of lymphocytes within the papillary dermis and focal migration of leukocytes (often neutrophils, although T cells are also integral to pathogenesis) into the epidermis. Acanthosis caused by increased epidermal proliferation, elongation of rete ridges sometimes accompanied by an undulant epidermal surface (papillomatosis), and edema of the elongated dermal papillae together with vasodilatation of the capillary loops develop almost simultaneously (see Fig. 2-9). The disturbed differentiation of the epidermal cells results in parakeratosis, and small aggregates of neutrophils infiltrating the upper epidermis (spongiform pustules), in the parakeratotic stratum corneum (Munro microabscesses). Therefore, the composite picture characteristic of psoriasis results from a combined pathology of the papillary dermis with participation of superficial venules, the epidermis, and circulating cells. Psoriasis is an instructive example of the limited specificity of histopathologic reaction patterns within the skin because psoriasiform histologic features occur in a number of diseases unrelated to psoriasis.

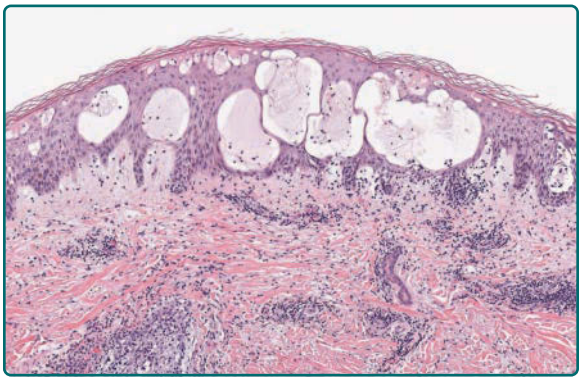

Figure 2-8 Spongiotic dermatitis. Accumulation of fluid in the epidermis leads to formation of an intraepidermal microvesicle.

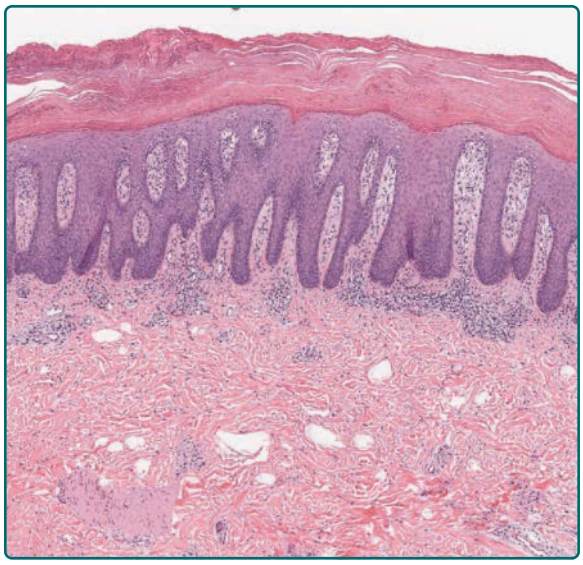

Figure 2-9 Psoriasis. There is uniform thickening of the epidermis with elongate rete ridges and a diminished granular layer.

Interface and Lichenoid Dermatitis: In both interface and lichenoid processes, lymphocytes are present along the dermal–epidermal junction associated with vacuolar alteration of basal layer keratinocytes. In an interface reaction, the infiltrate is sparse, and in lichenoid reactions, the infiltrate is dense and band-like at the dermal–epidermal junction. Subsequently there is dyskeratosis of keratinocytes, hyperkeratosis, and, occasionally, hypergranulosis (lichen planus, Fig. 2-10). Depending on the disease state, the epidermis may be thickened (lichen planus) or atrophic (lupus erythematosus).

In addition to lupus erythematosus and lichen planus, interface/lichenoid changes can be seen in dermatomyositis, erythema multiforme, secondary syphilis, fixed drug reaction, graft-versus-host disease, and lichenoid drug reactions. Differentiating these entities depends on the cellular makeup of the infiltrate (lymphocytes, eosinophils, plasma cells) and, importantly, the clinical presentation.

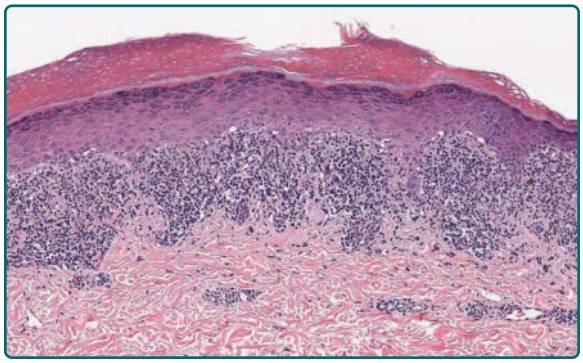

Figure 2-10 Lichen planus. An acanthotic epidermis with a band-like lymphocytic infiltrate that approximates the dermal–epidermal junction.

Subepidermal Blistering Processes: In subepidermal blistering processes, the roof of the blister is composed of full-thickness intact epidermis, and the floor of the blister is dermis without attached keratinocytes. In evaluating this group of diseases, one studies the edge of the blister and the character of the inflammatory cells. For example, in bullous pemphigoid, eosinophils align at the dermal–epidermal junction, at the edge of the blister (see Fig. 2-7). If neutrophils are seen in this area, the differential diagnosis includes dermatitis herpetiformis, linear immunoglobulin A disease, bullous lupus erythematosus, and inflammatory epidermolysis bullosa acquisita. Subepidermal blistering with little to no inflammatory cells generally indicates porphyria cutanea tarda, epidermolysis bullosa acquisita, or the cell-poor variant of pemphigoid. Direct and indirect immunofluorescence testing and/or enzyme-linked immunosorbent assay (ELISA) testing for antibodies to BP180/BP230 are often helpful in distinguishing entities in the subepidermal blister disease group.

RETICULAR DERMIS

The reticular layer of the dermis represents a second reactive unit and is composed of coarse connective tissue and the deeper dermal vascular plexus (see Fig. 2-1). The dermis represents a strong fibroelastic tissue with a network of collagen and elastic fibers embedded in an extracellular matrix with a high water-binding capacity. In contrast to the tightly interwoven fibrous components of this reticular layer of the dermis, the papillary dermis is composed of finer elastic fibers and collagen bundles that follow the structures they surround.

PATTERN EVALUATION

The dermis contains a superficial and deep vascular network. In the upper dermis, the superficial plexus supplies individual vascular districts consisting of several dermal papillae. Superficial and deep networks are connected so intimately that the entire dermal vascular system represents a single three-dimensional network. In dermal-based processes, the epidermis is relatively normal in appearance. In evaluation of pathological states, one can classify these processes into perivascular (*angiocentric*: around blood vessels), *periadnexal* (around hair follicles and/or eccrine glands), and *nodular* or diffuse inflammatory patterns. Additionally, there may be alterations of the dermal connective tissue (collagen, elastin) or deposition of material in the dermis.

***Angiocentric* Pattern (Fig. 2-11):** In the superficial microvascular system, two reaction patterns occur: (a) acute inflammatory processes in which the epidermis and junctional zone are often involved together with the vascular system, and (b) more chronic processes that often remain confined

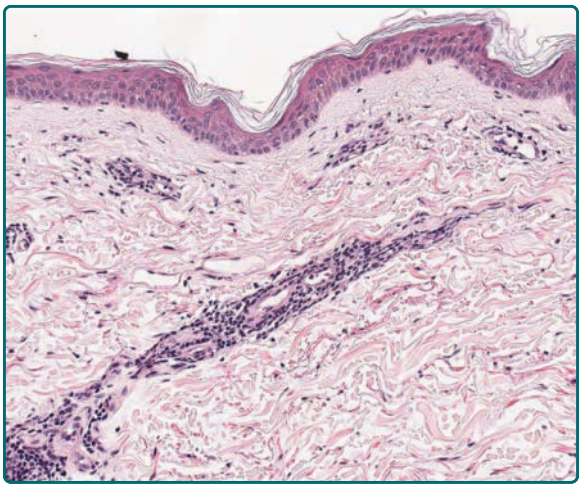

Figure 2-11 Angiocentric pattern. Inflammatory cells are seen primarily around small vessels in the dermis.

to the perivascular compartment. In this context, it should be noted that the cytologic composition of the infiltrate is important: neutrophils, eosinophils, lymphocytes, mast cells. For example, an infiltrate composed mostly of neutrophils associated with fibrin and hemorrhage is typical of small vessel or leukocytoclastic vasculitis that presents clinically as palpable purpura. In contrast, perivascular lymphocytes with hemorrhage is typical of Schamberg's pigmented purpuric dermatosis.

***Periadnexal* Pattern (Fig. 2-12):** Follicular units (hair follicle with sebaceous gland), eccrine ducts/glands, and apocrine glands constitute the skin adnexal structures. Inflammatory processes concentrated predominantly around hair follicles raise a differential diagnosis of folliculitis, acneiform processes, and infectious folliculitis by bacteria, fungus, or herpesvirus. Perieccrine inflammation is not specific, but it is often a clue that leads to a diagnosis of lupus erythematosus, neutrophilic eccrine hidradenitis, perniosis, or syringotropic mycosis fungoides. Evaluation of the character of the infiltrate is important in the pattern.

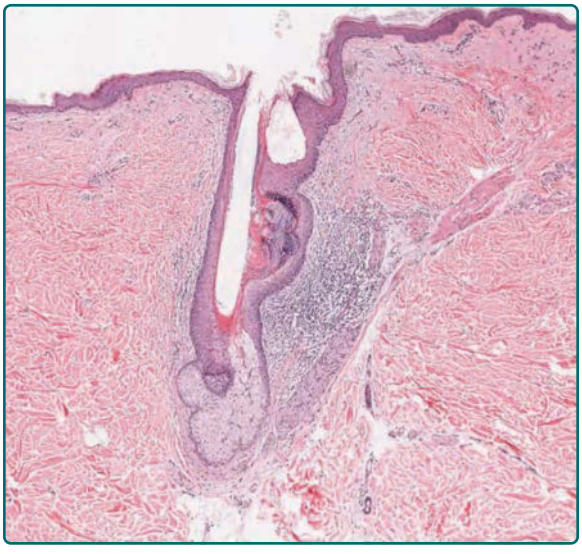

Figure 2-12 Perifollicular pattern. In this example of folliculitis, inflammatory cells surround a follicle.

***Nodular* or Diffuse Pattern (Fig. 2-13):** In this pattern of inflammation, the collections of dermal cells form larger aggregates than what is seen in the angiocentric pattern. Similar to other patterns, one must evaluate the cellular make-up of the infiltrate. Nodular collections of lymphocytes raise a differential diagnosis of cutaneous B-cell lymphoma, cutaneous lymphoid hyperplasia (pseudolymphoma), and angiolymphoid hyperplasia. In these cases, immunohistochemical staining for various T-cell and B-cell antigens is helpful in establishing the diagnosis. If neutrophils predominate in a nodular infiltrate, one considers Sweet syndrome, pyoderma gangrenosum, follicular rupture, or abscess formation associated with infection.

COMPOSITION OF THE INFILTRATE

Once a pattern is established at low magnification, one can proceed to evaluation of the specific composition of the infiltrate. Evaluation includes determining both the predominant and less prominent cell types: lymphocytes, histiocytes (with or without granulomas), neutrophils, eosinophils, plasma cells, or mast cells.

Lymphocytes: Lymphocytes have small round/oval nuclei and very little cytoplasm. Although

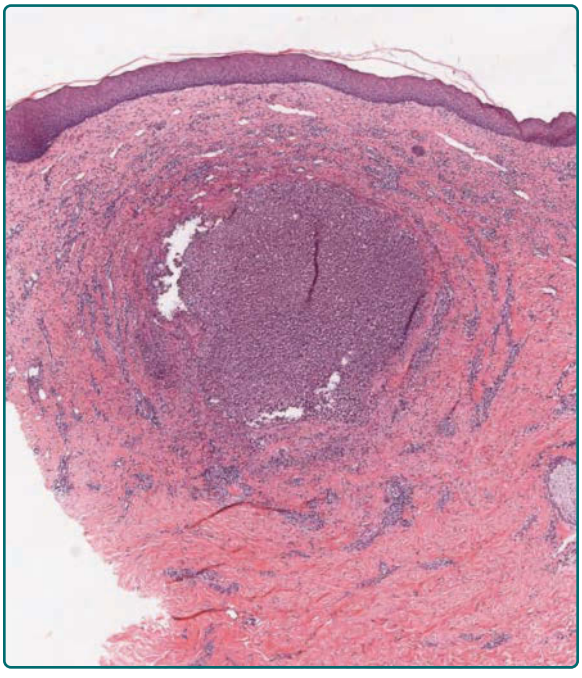

Figure 2-13 Nodular pattern. Dense aggregates of inflammatory cells are present in the dermis.

lymphocytic infiltrates occur in the majority of inflammatory dermatoses, there are a number of pathologic processes in which lymphocytes predominate, and thus determine the histologic picture. Lymphocytic infiltrates are formed in inflammatory or proliferative conditions, and in proliferative conditions, may represent a benign or malignant process.

Among the many possible reaction patterns characterized by lymphocytic infiltrates, several typical patterns can be distinguished.

- Lymphocytic cuffing of venules without involvement of the papillary dermis and the epidermis may occur in figurate erythemas, viral exanthema, and in drug eruptions. The infiltrates of chronic lymphocytic leukemia show a similar distribution pattern but are usually more pronounced.
- Perivascular lymphocytic infiltrates with a mucinous infiltration of the nonperivascular connective tissue is often a clue to a differential diagnosis of lupus erythematosus or dermatomyositis.
- Nodular lymphocytic infiltrates, often mimicking lymph node tissue, are typical of lymphocytoma cutis or cutaneous lymphoid hyperplasia. Atypical lymphocytic infiltrates involving both the superficial and deeper dermis, and cytologically characterized by pronounced pleomorphism of the cellular infiltrate, are characteristic of lymphomatoid papulosis, one of the spectrum of $CD30^+$ lymphoproliferative disorders. This condition exemplifies the problems that arise when the histopathology of a lesion is used alone to determine whether a process is benign or malignant. Without knowledge of the clinical features and the course of disease, a definitive diagnosis is extremely difficult.

Neutrophils and Eosinophils: Eosinophils are recognized by their characteristic bilobed nucleus and eosinophilic granular cytoplasm (Fig. 2-14). The presence of many eosinophils in a dermal infiltrate can be helpful in diagnosing an allergic reaction (insect bite, medication reaction, scabies), but also in the differential diagnosis of Wells syndrome (eosinophilic cellulitis), angiolymphoid hyperplasia with eosinophilia, and the prodromal stage of pemphigoid. Neutrophils have multilobed nuclei and a less-eosinophilic cytoplasm than eosinophils. Neutrophil-rich infiltrates often imply an infectious etiology especially if neutrophils aggregate in the dermis forming an abscess. In contrast, there are many noninfectious neutrophilic processes in the skin, such as Sweet syndrome, pyoderma gangrenosum, urticaria, and vasculitis.

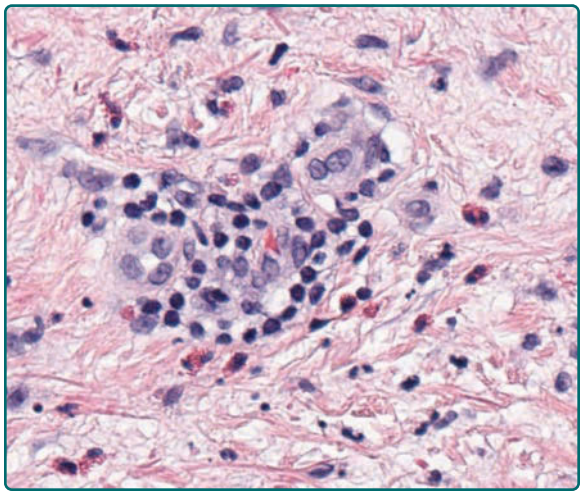

Figure 2-14 Eosinophils. The nuclei are bilobed and the cytoplasm is bright pink and granular. The lymphocytes have small dark nuclei and scant cytoplasm.

Granulomatous Reactions: Skin is an ideal tissue for granuloma formation in which histiocytes play a key role. The proliferation and focal aggregation of histiocytic cells are termed a *granuloma*. When such cells are closely clustered they resemble epithelial tissue, hence the designation *epithelioid cells*. Granulomas usually lead to destruction of preexisting tissue, particularly elastic fibers, and in such instances result in atrophy, fibrosis, or scarring. Tissue damage or destruction manifests either as necrobiosis or fibrinoid or caseous necrosis, or it may result from liquefaction and abscess formation or from replacement of preexisting tissue by fibrohistiocytic infiltrate and fibrosis.

Sarcoidal granulomas are typically characterized by nodules of epithelioid histiocytic cells, occasional Langerhans giant cells, and only a small number of lymphocytes. In addition to sarcoidosis, silica, zirconium, and beryllium granulomas, and a number of foreign-body granulomas may have such histopathologic features (Fig. 2-15).

Granulomatous reactions of the skin comprise a large spectrum of histopathologic features. Palisading granulomas surround hypocellular areas of the connective tissue with histiocytes in radial alignment (Fig. 2-16). Granuloma annulare, necrobiosis lipoidica, and rheumatoid nodules belong to this group. These reactions may have significance as signs of systemic disease.[6] Rheumatoid nodules can be associated with rheumatoid arthritis, and interstitial granulomatous dermatitis can be associated with arthritis and immune-mediated disorders.

Infectious granulomas with a sarcoidal appearance may occur in tuberculosis, syphilis, leishmaniasis, leprosy, and atypical mycobacterial or fungal infections. Necrosis can also develop within the granuloma proper, as is the case for fibrinoid necrosis in sarcoidosis, caseation in tuberculosis, or the necrosis developing in mycotic granulomas. Many of the infectious granulomas are associated with epidermal hyperplasia, often exhibiting intraepidermal abscesses. In the dermis, there is a mixture of cells, including histiocytes, epithelioid cells, eosinophils, neutrophils, and lymphocytes.

A specific form of granulomatous reaction results when the cellular infiltrate consists almost exclusively of the key granuloma cell, the *histiocyte*. One property of this cell is its capacity to store phagocytosed material. In xanthomatous reaction patterns,

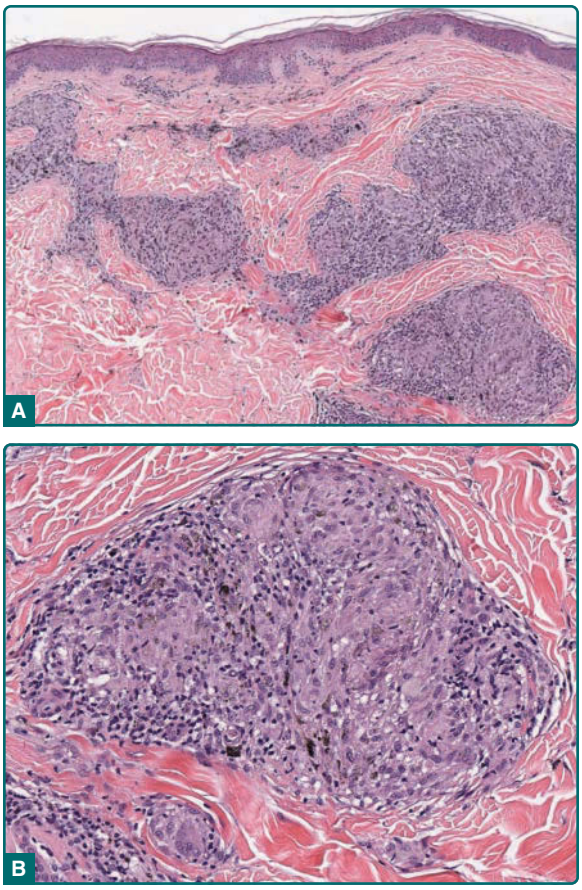

Figure 2-15 Granuloma. **A,** This foreign-body granuloma shows an aggregate of lymphocytes, histiocytes, and multinucleated giant cells forming a nodule. **B,** Higher magnification of epithelioid histiocytes and foreign material (black pigment).

histiocytes take up, store fat, and are thus transformed into foam cells (Fig. 2-17). These cells are characteristic of various types of xanthomatous processes including tuberous and eruptive xanthomas as well as xanthelasma.

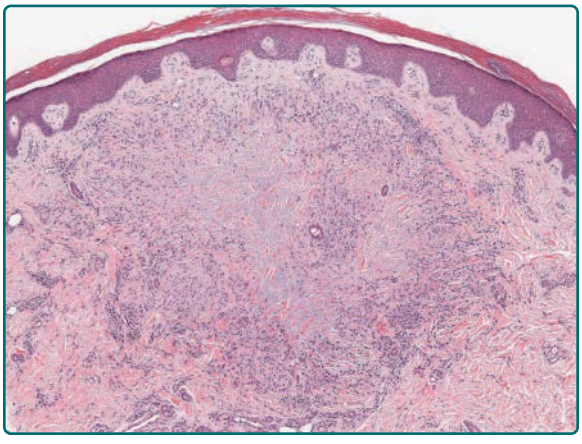

Figure 2-16 Granuloma annulare. In granuloma annulare, histiocytes and giant cells surround a zone of hypocellular collagen that shows few to no nuclei.

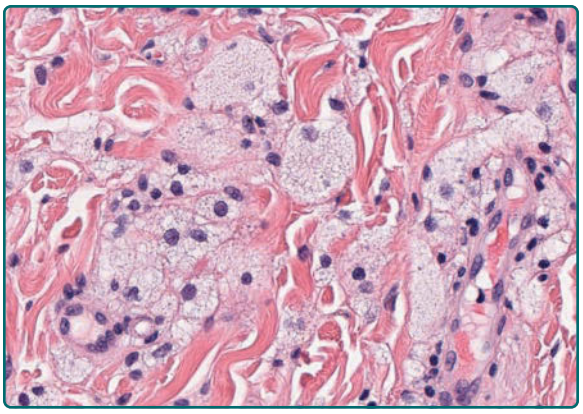

Figure 2-17 Xanthoma cells. The cytoplasm is enlarged and shows a vacuolated (bubbly) appearance.

FIBROUS DERMIS AND EXTRACELLULAR MATRIX

Sclerosing processes of the skin involve mainly the connective tissue of the dermis. The hallmark of scleroderma and morphea is the homogenization, thickening, and dense packing of the collagen bundles, and a narrowing of the interfascicular clefts within the reticular dermis. There is also a perivascular infiltrate of lymphocytes and plasma cells. Sclerodermoid changes may be found in the toxic oil syndrome and L-tryptophan disease, eosinophilic fasciitis, and mixed connective tissue disease.

Faulty synthesis or crosslinking of collagen results in a number of well-defined diseases or syndromes but leads to relatively few characteristic histopathologic changes. In the different types of the Ehlers-Danlos syndrome, the faulty collagen cannot be recognized histopathologically, and only the relative increase of elastic tissue may indicate that something abnormal has occurred in the dermis. The fragmentation and curled and clumped appearance of elastic fibers are diagnostic in pseudoxanthoma elasticum. On the other hand, in actinic elastosis, a consequence of chronic sun damage, all components of the superficial connective tissue are involved. Except for a narrow grenz zone below the epidermis, the papillary dermis, and the superficial layers of the reticular dermis are filled with clumped and curled fibers that progressively become homogenized and basophilic (Fig. 2-18). They are stained by dyes that have an affinity for elastic tissue and thus histochemically behave similar to elastic fibers.

Alterations in elastic tissue generally cannot be visualized on routine H&E staining except for actinic elastosis, and the use of special stains is necessary. Verhoeff-van Gieson staining is often used to highlight presence, absence, or alteration of elastic fibers in the dermis.

Endogenous and exogenous materials can also alter the dermis. Examples of endogenous materials include the accumulation of mucinous ground substance as one can see in pretibial myxedema, or deposits of

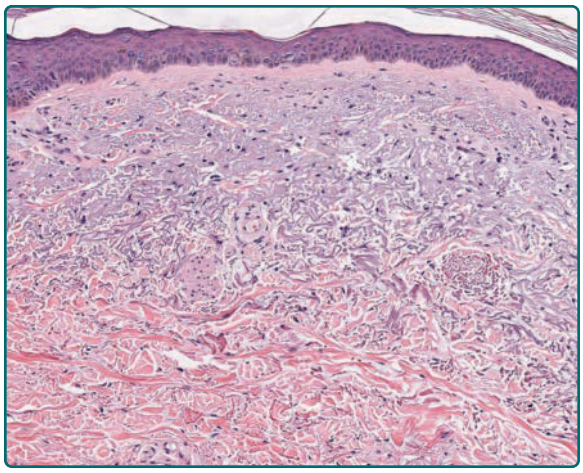

Figure 2-18 Actinic (solar) elastosis. The superficial dermis show many gray-colored elastotic fibers from chronic sun damage. In the lower portion of the photomicrograph, the collagen shows the normal pink color.

proteinaceous amyloid as nodular aggregates in the dermis or surrounding vessels and adnexal structures (systemic amyloidosis). Materials that are not produced by the body can be introduced into the dermis accidentally or in cosmetic procedures (tattoos: Fig. 2-19, filler agents).

SUBCUTANEOUS FAT

The third reactive unit, the subcutaneous tissue, is composed of lobules of adipocytes and the intervening bands of fibrous connective tissue called septa.[7]

Inflammation of subcutaneous fat reflects either an inflammatory process of the fat lobules (lobular panniculitis) or a process arising in the septum (septal panniculitis).[8,9] There may or may not be associated vasculitis. Destruction of fat, be it of a traumatic or inflammatory nature, leads to the release of fatty acids that by themselves are strong inflammatory stimuli, attracting neutrophils and scavenger histiocytes and macrophages; phagocytosis of destroyed fat usually results in lipogranuloma formation.

Septal panniculitis that follows inflammatory changes of the trabecular vessels is usually accompanied by edema, infiltration of inflammatory cells, and a histiocytic reaction. This is the classic appearance in erythema nodosum (Fig. 2-20). Recurring septal inflammation may lead to a broadening of the interlobular septa, fibrosis, and the accumulation of histiocytes and giant cells.

Lobular panniculitis refers to an inflammatory process predominantly in the subcutaneous lobules with less involvement of the septa. The lipid material derived from damaged adipocytes contains free and esterified cholesterol, neutral fats, soaps, and free fatty acids, which, in turn, exert an inflammatory stimulus.

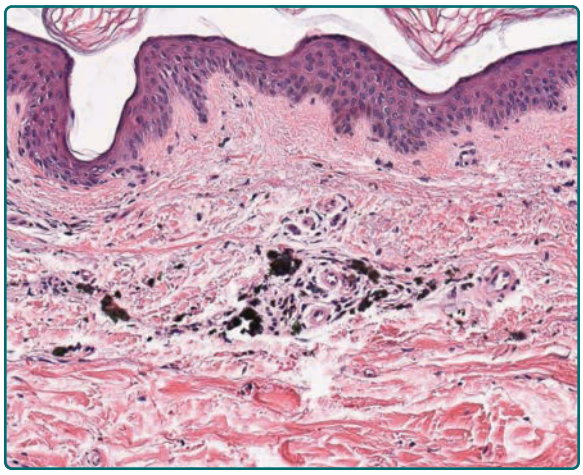

Figure 2-19 Tattoo. Foreign substances can be deposited in the dermis. Tattoo pigment is seen here as course clumps of black pigment in the superficial dermis.

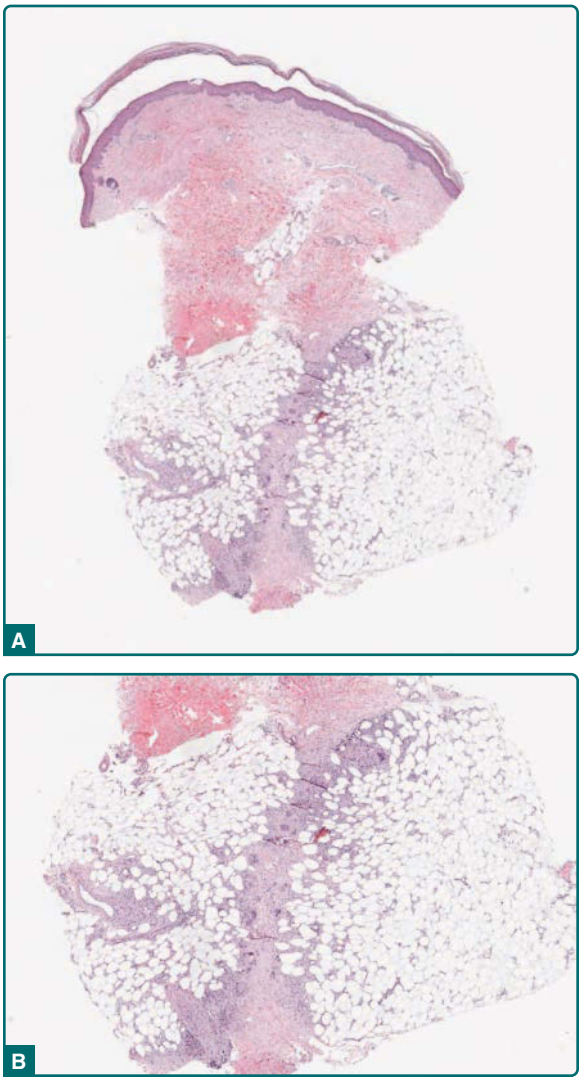

Figure 2-20 **A** and **B,** Erythema nodosum. The subcutaneous septa are thickened by fibrosis and inflammation.

Histiocytic cells migrate into the inflamed fat, and phagocytosis leads to foam cell formation.

Exogenous factors may affect the subcutaneous tissue. Traumatic panniculitis leads to necrosis of fat lobules and a reactive inflammatory and granulomatous tissue response. After the injection of oils or silicone, large cystic cavities may be formed. Oily substances may remain within the adipose tissue for long periods without causing a significant tissue reaction; oil cysts evolve that are surrounded by multiple layers of residual connective tissue, so that the tissue acquires a "Swiss cheese" appearance.

Panniculitis also occurs as a result of infectious agents (bacteria, mycobacteria, and fungal organisms) in which neutrophil-rich inflammation and/or granulomatous inflammation is characteristic.

NEOPLASTIC DISORDERS OF THE SKIN

This section discusses how to approach the evaluation of skin neoplasms based on the cell type(s) of origin, as well as features to consider in determining benignancy versus malignancy. Select neoplasms of the skin are also reviewed in greater detail, although this chapter is intended to provide only a general overview of the many skin tumors that exist.

ASSESSMENT OF SKIN TUMORS

CELL TYPES IN THE SKIN

The normal epidermis is composed of 4 cell types: keratinocytes, melanocytes, Langerhans cells, and Merkel cells. The cellular components of the normal dermis includes fibroblasts, endothelial cells lining vascular channels, smooth muscle cells, and nerve fibers. These cells types are reviewed in detail in Chap. 5.

FACTORS IN DETERMINING BENIGNANCY VERSUS MALIGNANCY OF TUMORS

The factors commonly used to assess skin tumors are (a) symmetry, (b) pattern of infiltration, (c) cytology, and (d) mitotic activity. Although specific criteria may apply for certain tumor types, benign tumors generally demonstrate reasonably good symmetry if a vertical line is drawn through the center of the tumor. Benign lesions are more likely to be well-circumscribed, whereas those with malignant potential often have a more infiltrative pattern into the surrounding tissue. Tumors that are benign tend to have cells with smaller, bland-appearing, and uniform nuclei compared to those that are malignant; in the malignant category, larger nuclei, nuclear pleomorphism, and sometimes prominent nucleoli are observed. Finally, mitotic figures can be observed in benign lesions, but are more frequently seen in malignant tumors. Atypical mitotic figures (those that are asymmetric and/or multipolar) are also more likely to appear in the setting of a malignant tumor.

TUMORS OF EPIDERMAL ORIGIN

KERATINOCYTIC TUMORS

Verruca Vulgaris: Verrucae vulgaris demonstrate marked hyperkeratosis, papillomatosis, and acanthosis (Fig. 2-21A). Verrucae vulgaris prominently feature koilocytes, cells which have structural changes secondary to human papillomavirus (HPV) infection. Koilocytes are identified by small round nuclei, perinuclear halos, and clumping of keratohyaline granules (Fig. 2-21B). They tend to be localized in the upper stratum spinosum and stratum granulosum in newer warts, and may be absent in more mature

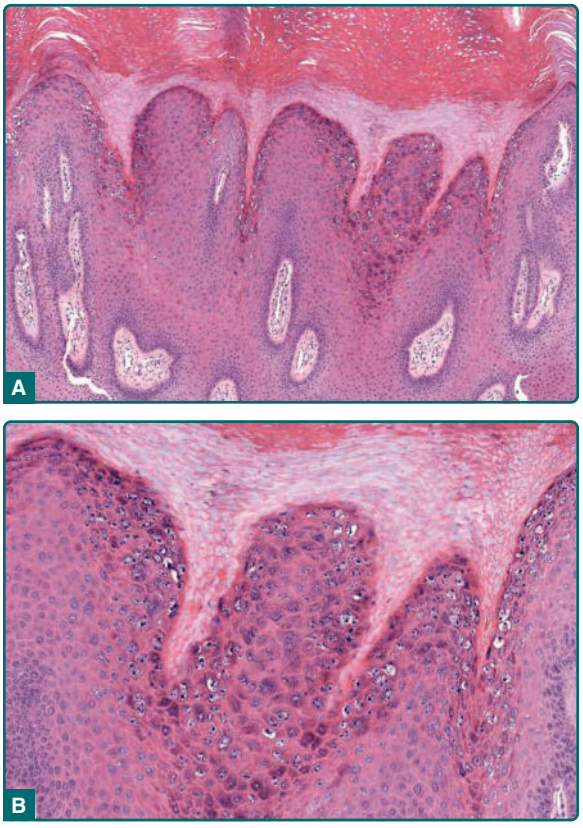

Figure 2-21 **A,** Verruca vulgaris showing hyperkeratosis, acanthosis and papillomatosis of the epidermis. **B,** Koilocytes seen in a verruca, showing clumping of keratohyaline granules and perinuclear halos.

verrucae. Parakeratosis may be seen in the stratum corneum, most often localized to the areas directly overlying koilocytes. The epidermal rete within verrucae are elongated, and the rete at the periphery of the lesions often are oriented toward the center of the warts.

Verruca Plana: Histologically, verrucae plana show hyperkeratosis and epidermal acanthosis, but lack the papillomatosis seen in verrucae vulgaris. Koilocytes are observed in the granular layer of the epidermis.

Condyloma Acuminatum: Condyloma acuminata display slight hyperkeratosis and prominent acanthosis (Fig. 2-22A). While papillomatosis is a common feature, the surface of condyloma acuminata show rounded crests (so-called knuckling) as compared to verrucae vulgaris, which demonstrate elongated, pointed spires. Compared to other types of viral warts, koilocytes are not as prominently observed in condyloma acuminata (Fig. 2-22B). HPV immunostaining may be employed to help assess for viral change within condyloma acuminata, although in our experience immunostaining is commonly negative when koilocytes are not readily observed on H&E-stained sections.

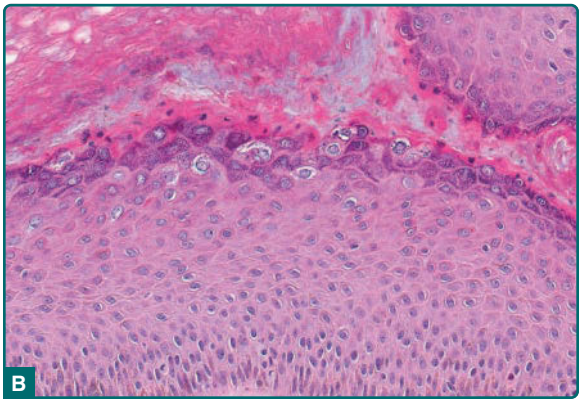

Figure 2-22 **A,** Condyloma acuminatum demonstrating hyperkeratosis and acanthosis. In contrast to verruca vulgaris, there are rounded, rather than pointed, epidermal crests. **B,** Koilocytes in condyloma acuminatum, which are frequently less prominent than those seen in verruca vulgaris.

Figure 2-23 Seborrheic keratosis with hyperkeratosis, acanthosis, and multiple pseudo horn cysts.

Seborrheic Keratosis: Seborrheic keratoses show marked hyperkeratosis, papillomatosis, and acanthosis on histology (Fig. 2-23). In some cases, thin strands of anastomosing epithelium are seen within seborrheic keratoses, resulting in a reticulated pattern. Pseudo horn cysts and horn cysts are frequently observed in the acanthotic epidermis. There is often keratinocyte pigmentation. The keratinocytes within seborrheic keratoses are usually small and bland in appearance, although when lesions are irritated or inflamed the nuclei may become enlarged. Squamous eddies, which are composed of whorls of squamous epithelial cells, are more frequently observed in inflamed or irritated seborrheic keratoses.

Inverted follicular keratoses are considered variants of seborrheic keratoses. Inverted follicular keratoses have an endophytic architecture compared to other types of seborrheic keratoses. Squamous eddies are a prominent feature in this variant.

Squamous Cell Carcinoma: When squamous cell carcinoma (SCC) is restricted only to the epidermis, it is referred to as SCC in situ. Such lesions show full-thickness atypia of the epidermis with keratinocytes that have enlarged nuclei, nuclear pleomorphism, and increased mitotic activity (Fig. 2-24). Apoptotic or dyskeratotic keratinocytes are also commonly

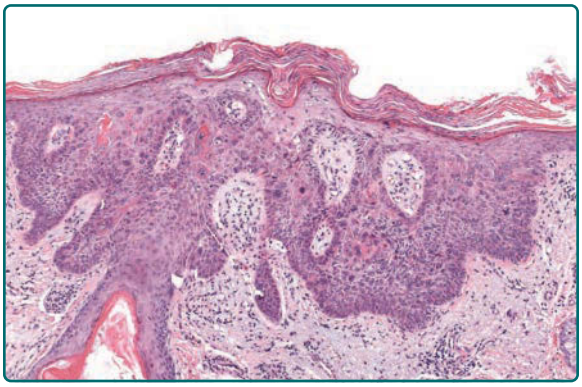

Figure 2-24 Squamous cell carcinoma in situ demonstrating full-thickness keratinocyte atypia within the epidermis. Enlarged, hyperchromatic keratinocyte nuclei are easily seen.

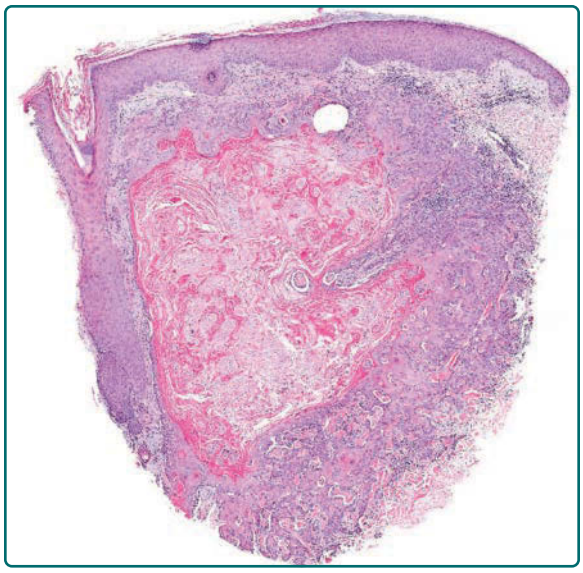

Figure 2-25 Invasive squamous cell carcinoma characterized by a nodule of atypical keratinocytes in the dermis with prominent keratinization consisting of parakeratin.

observed in SCC in situ. There is typically parakeratosis in the stratum corneum, with underlying loss of the granular layer. By definition, SCC in situ does not invade the underlying dermis, but may show extension of the atypical keratinocytes along adnexal structures including hair follicles and eccrine ducts. The term "Bowen disease" is often used interchangeably with "SCC in situ," although in our practice "Bowen disease" is reserved for SCC in situ of sun-protected anatomic sites such as the anogenital region.

Invasive SCC shows acanthosis of the epidermis, composed of atypical keratinocytes, as well as lobules of keratinocytes that have broken away from the epidermis and are embedded within the dermis (Fig. 2-25). The keratinocytes may be enlarged and glassy in appearance, with associated horn pearls composed of parakeratin. This type of pattern is seen frequently in well to moderately differentiated SCCs. More poorly differentiated tumors lack significant keratinization and often have an infiltrative pattern within the dermis. Solar elastosis is frequently observed in invasive SCCs.

Keratoacanthoma: Keratoacanthomas are very similar in appearance to well-differentiated SCCs, both clinically and histologically. However, unlike SCCs, they involute spontaneously within several months to a year after they arise. Multiple keratoacanthomas may arise spontaneously, in the context of genetic syndromes such as in Muir-Torre syndrome, or as a side effect of taking certain medications, notably the BRAF (v-raf murine sarcoma viral oncogene homolog B) inhibitors sorafenib, vemurafenib, and dabrafenib.[10,11]

Microscopically, mature keratoacanthomas show a cup-shaped epithelial proliferation, exhibiting prominent acanthosis consisting of glassy keratinocytes. There is usually a central keratin-filled crater, and the epidermis extends medially over the crater to form a "lip." The epithelial proliferation invaginates into the underlying dermis, which often displays solar elastosis. A characteristic finding of keratoacanthomas is the presence of neutrophilic microabscesses within the atypical epithelium. A lymphocyte-rich inflammatory infiltrate is frequently observed in the surrounding dermis.

Involuting keratoacanthomas show atypia of the epidermis as described above, associated with a lymphocytic infiltrate at the base of the lesion and often the presence of dyskeratotic keratinocytes. This is accompanied by fibrosis of the surrounding stroma, which eventually forms a scar.

Basal Cell Carcinoma: Histopathologically, basal cell carcinomas (BCCs) are comprised of lobules of purple or basophilic cells, which most closely resemble the cells found in the basal layer of the epidermis. The lobules display palisading of columnar cells at the periphery (Fig. 2-26A). Within the lobules, mitotic figures and apoptotic cells (often referred to as single-cell necrosis) are observed (Fig. 2-26B). The basaloid lobules typically demonstrate connection to the epidermis, and may also be seen arising from hair

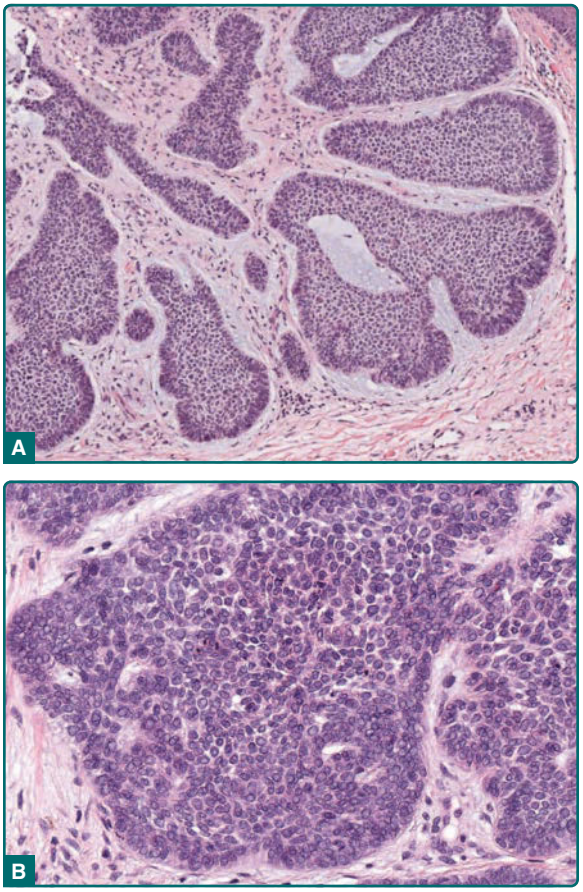

Figure 2-26 **A,** Basal cell carcinoma with lobules of purple basaloid cells exhibiting peripheral palisading in the dermis, set within a fibromyxoid stroma. **B,** Single-cell necrosis within a basaloid lobule.

follicles. In superficial BCC, the basaloid lobules are small and arise from the epidermis, without deeper involvement. In the nodular type of BCC, larger basaloid lobules with deeper dermal involvement are observed. The stroma surrounding the basaloid lobules is distinctive as it is fibromyxoid in appearance, composed of fibroblasts set within a loose mucinous matrix. Stromal retraction, or spaces between the basaloid lobules and the surrounding fibromucinous connective tissue, is commonly seen.

The infiltrative type of BCC is made up of smaller, elongated islands of basaloid cells, as compared to the tumor lobules seen in nodular BCC, and may invade deeply into the dermis. Morpheaform BCC display similarly small, elongated islands, but in association with thickened collagen bundles. These latter two histologic types, along with the micronodular type of BCC, which is composed of small tumor lobules in the dermis, represent the types of BCC at highest risk for aggressive behavior and local recurrence following surgery or other destructive treatment methods.

ADNEXAL TUMORS

This category of tumors includes those with differentiation toward various epidermal appendages including hair follicles, sweat glands (eccrine and apocrine), and sebaceous glands. Selected entities within these categories are discussed below.

Trichoepithelioma: Trichoepitheliomas demonstrate lobules of basaloid cells in embedded in the dermis, which have a cribriform or lace-like appearance (Fig. 2-27). Horn cysts are often present within the basaloid lobules. The stroma surrounding the basaloid lobules shows an increased number of fibroblasts, and lacks the mucinous ground substance typically observed in the stroma of BCCs. Papillary mesenchymal bodies are a characteristic feature of trichoepitheliomas. They form invaginations into the basaloid tumor lobules, showing many fibroblasts and strongly resembling the papillae of normal hair follicles.

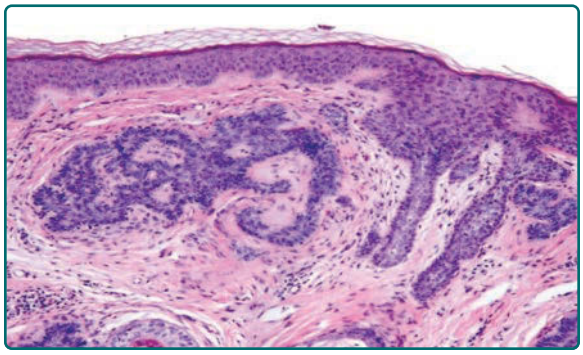

Figure 2-27 Trichoepithelioma showing cribriform basaloid lobules with a dense fibrous stroma. Papillary mesenchymal bodies are observed.

A variant of a trichoepithelioma is the desmoplastic trichoepithelioma, which classically occurs on the face of young adult women. In contrast to conventional trichoepitheliomas, desmoplastic trichoepitheliomas show elongated thin islands of basaloid cells set within a fibrotic (desmoplastic) stroma. Horn cysts are commonly seen, indicating follicular differentiation of these benign tumors. In addition, areas of calcification are frequently present.

Trichoblastoma: Trichoblastomas are benign follicular tumors, and are thought to be growths of follicular germinative cells. Trichoblastomas may be mistaken microscopically for BCCs, since they show lobules of basaloid epithelium situated in the dermis and demonstrate peripheral palisading. Unlike BCC, however, epidermal connections are not commonly observed in trichoblastomas. Another distinguishing feature compared to BCC is the stroma surrounding the basaloid islands, which is richer in fibroblasts and compacted, lacking mucinous ground substance. The stroma of trichoblastomas and trichoepitheliomas are therefore virtually identical in appearance. One variant of a trichoblastoma is the so-called trichoblastic fibroma, which shows similar epithelial and mesenchymal elements as trichoblastomas, but the basaloid islands in trichoblastic fibromas are smaller and the surrounding stroma is a more prominent feature.

Syringoma: These benign neoplasms demonstrate eccrine differentiation, and are specifically composed of collections of small eccrine ducts set with a fibrous stroma. These epithelial islands are often described as having a "tadpole-like" appearance. The individual ducts show central lumina that are lined by 2 rows of bland epithelial cells. Occasionally, the epithelial cells have a clear cell morphology, which is the result of glycogen accumulation.

Sebaceous Tumors: Sebaceous tumors may be solitary or present in multiples, particularly in the context of Muir-Torre syndrome.[12] Sebaceous tumors may be classified according to the proportion of cells within the neoplasm that exhibit sebaceous (versus basaloid) differentiation, as well as the amount of cytologic atypia observed. Given this framework, sebaceous tumors are grouped into one of the following categories: sebaceous adenoma, sebaceous epithelioma, or sebaceous carcinoma.

Sebaceous adenomas are benign tumors, which are composed of both cells with sebaceous differentiation and basaloid cells. The sebaceous cells predominate over the basaloid cells, so that most of the tumor is sebaceous in appearance. The cells are arranged in lobules and the tumor is well-circumscribed overall, lacking infiltrative growth patterns. Mitotic activity may be seen within the basaloid component of sebaceous adenomas.

In contrast to sebaceous adenomas, sebaceous epitheliomas are composed of more than 50% basaloid cells, with a smaller population of cells demonstrating sebaceous differentiation. Like sebaceous adenomas, the basaloid compartment of the tumor may exhibit

mitotic activity, and infiltrative growth is not observed. However, there may be some increased nuclear atypia compared to sebaceous adenomas.

Sebaceous carcinomas are malignant neoplasms, displaying prominent cytologic atypia in both sebaceous cell and basaloid cell types, with enlarged and pleomorphic nuclei. The tumor cells are frequently arranged in irregularly shaped lobules, and often show infiltration into the surrounding stroma. Mitoses are easily identified within the lesional cells.

MELANOCYTIC LESIONS

Common Nevi: Melanocytic nevi may involve the epidermis only, the dermis only, or both the epidermis and dermis, and accordingly are classified as being junctional, intradermal, or compound. Many nevi evolve over time, progressing from junctional to compound to primarily intradermal nevi. Common nevi are composed of nests of nevic cells, which involve in the tips of the epidermal rete in junctional and compound nevi, and the dermis in intradermal and compound nevi. Within the dermal compartment, the nevus cells show maturation, a term that refers to the distribution of larger nests of melanocytes in the superficial dermis and smaller nests, and/or single nevic cells at the base of the lesion. In common nevi, the melanocytes are typically round, with varying amounts of cytoplasm (Fig. 2-28), although nevic cells that are neurotized (resembling neural cells) are also frequently encountered.

Dysplastic Nevi: Under the microscope, dysplastic nevi exhibit architectural disorder and random (as opposed to uniform) cytologic atypia. Some of the architectural features used to render a diagnosis of a dysplastic nevus include the presence of a shoulder, bridging of melanocytic nests between adjacent epidermal rete, lamellar fibroplasia, pagetoid spread, and lentiginous growth of melanocytes along the dermal epidermal junction (Fig. 2-29). The "shoulder" refers to the junctional component of a nevus that extends at least 3 rete pegs beyond a central area of dermal nevus

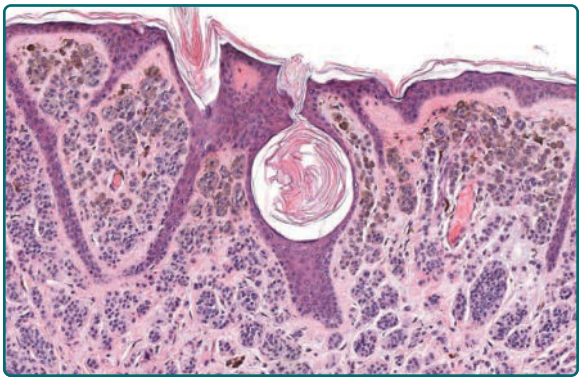

Figure 2-28 Dermal nevus. Nests of nevic cells, some showing melanin pigmentation, are present within the dermis.

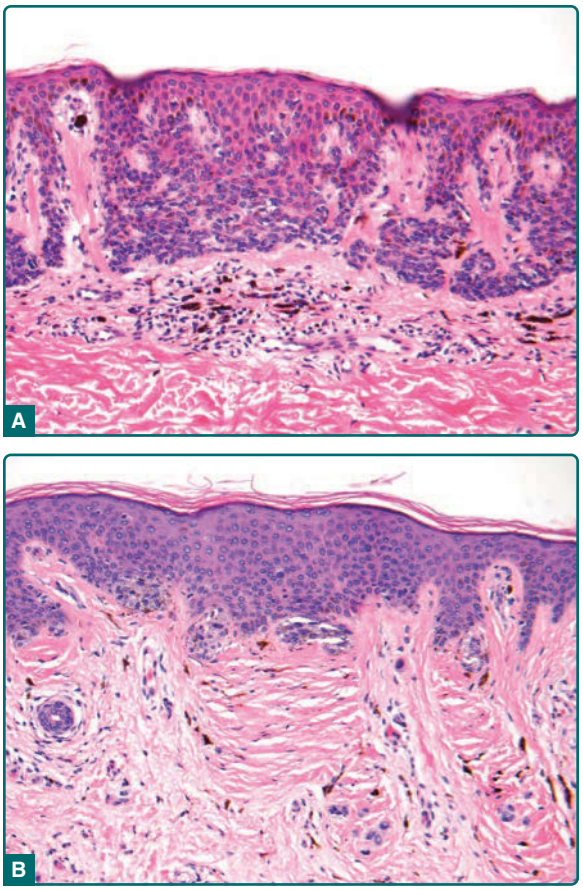

Figure 2-29 **A,** Dysplastic nevus displaying bridging of nests of melanocytes between adjacent epidermal rete pegs. **B,** Lamellar fibroplasia, a common finding in dysplastic nevi.

cells. Melanocytic bridging is a phenomenon in which nests of nevic cells from adjacent rete appear to grow toward each other and fuse. Lamellar fibroplasia is commonly observed in dysplastic nevi, and indicates fibrosis in the papillary dermis that runs in parallel to areas of bridging in the epidermis. Pagetoid spread is seen to some degree in dysplastic nevi, although not as extensively in melanomas, and denotes upward spread of melanocytes in the epidermis away from the basilar epidermis. Finally, dysplastic nevi may exhibit increased growth of single melanocytes (as opposed to merely nested growth) along the dermal–epidermal junction, a finding that is described as a lentiginous growth pattern.

Cytologic atypia is frequently observed within dysplastic nevi, and may be graded as mild, moderate, or severe. In contrast to melanomas, the cytologic atypia of dysplastic nevi is typically isolated to a subset of melanocytes (random atypia), rather than affecting nearly all the lesional melanocytes.

Spitz Nevi: Spitz nevi are melanocytic nevi that are composed of spindled and/or epithelioid melanocytes. Because of some of their architectural and cytologic features, there can be difficulty in distinguishing these lesions from melanoma. Spitz nevi typically occur in

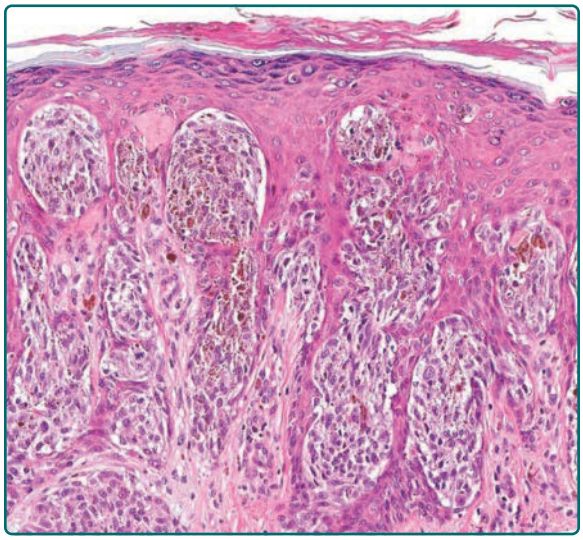

Figure 2-30 Spitz nevus with vertically oriented nests of epithelioid and spindled melanocytes. Kamino bodies are also seen.

children and young adults, although are sometimes also seen in older adults.

Spitz nevi may be compound, junctional, or intradermal. Compound lesions are most frequently observed, and demonstrate a proliferation of large nested spindled and/or epithelioid melanocytes, sometimes pigmented, along the dermal–epidermal junction, with similar nests in the underlying dermis. The epidermis is usually hyperplastic. There is often clefting around the nests of melanocytes in the epidermis (Fig. 2-30). Pagetoid spread may be seen, predominantly in the center of the lesion. Kamino bodies are a characteristic feature of Spitz nevi. These are acellular, globular eosinophilic inclusions in the epidermis, which are thought to be derived from basement membrane material. Conventional Spitz nevi show symmetry and sharp lateral circumscription. The dermal nevus cells exhibit maturation, a term that indicates the tendency of nevus cells at the base of Spitz nevi to be smaller than those in the more superficial dermis. Although dermal mitoses may be observed in Spitz nevi, the mitotic rate does not usually exceed 2 per mm^2.

Melanoma: Malignant melanomas may arise from preexisting nevi, or occur de novo. These tumors may be restricted to the epidermis only, in which case they are referred to as *melanoma in situ*. Invasive malignant melanoma usually involves the epidermis and the underlying dermis, although in a small number of cases, primary dermal melanomas are observed. Melanomas are classified as having a radial growth phase and/or vertical growth phase. Melanomas that have only a radial growth phase are those that are restricted to the epidermis, or the epidermis and the superficial dermis, in the absence of expansile tumor masses in the dermis. Vertical growth phase melanomas have dermal tumor masses that are larger than nests of melanocytes seen in the epidermis and/or have dermal mitoses.

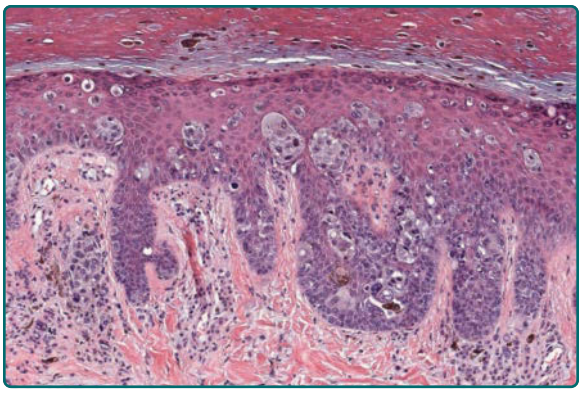

Figure 2-31 Malignant melanoma characterized by highly crowded growth of atypical melanocytes along the dermal–epidermal junction and extensive pagetoid spread. Atypical melanocytes are also present in the dermis.

While radial growth phase melanomas may be classified into several histologic types (superficial spreading, lentigo maligna, acral lentiginous, and mucosal lentiginous), a disorganized growth pattern with cytologic atypia is common to all of them (Fig. 2-31). Intraepidermal melanomas are commonly found to have confluent or near confluent growth of nested and single melanocytes along the dermal–epidermal junction. Lesions are often markedly asymmetrical. The lesional cells classically harbor uniform severe cytologic atypia. Pagetoid spread is commonly observed, to a greater extent than seen in dysplastic nevi. Solar elastosis is also frequently present, particularly in the superficial spreading and lentigo maligna types.

Superficial spreading melanomas usually display more nested growth of melanocytes compared to lentigo maligna types, and also show more extensive pagetoid spread up to the granular layer. The epidermis is thickened in superficial spreading melanoma and often atrophic in lentigo maligna melanoma. There is usually a greater degree of sun damage in the lentigo maligna type of melanoma. Acral lentiginous and mucosal lentiginous melanomas, similar to lentigo maligna melanomas, show a predominance of single melanocytes over nested growth along the dermal–epidermal junction. Pagetoid spread is seen but may not be extensive. By virtue of the sites of acral lentiginous and mucosal lentiginous melanomas, solar elastosis is minimal.

Vertical growth phase melanomas are divided into those that have a radial growth phase and those that do not. Nodular melanomas are melanomas that have only a vertical growth phase. Whereas nodular melanomas harbor an intraepidermal component, the in situ melanoma does not extend significantly beyond the lateral borders of the dermal portion of the melanoma. The vertical growth phase component of melanomas that also have a radial growth phase may be conventional, or less commonly, desmoplastic or spindle cell in morphology. Conventional vertical growth phase melanomas demonstrate dermal cells that are similar in morphology to the overlying radial growth phase. Uniform cytologic atypia and mitoses are often

found. Melanocytes in the dermis do not exhibit maturation as compared to intradermal nevi.

Desmoplastic vertical growth phase melanomas are commonly found in association with lentigo maligna or mucosal lentiginous radial growth phases. Desmoplastic melanomas feature elongated, spindled nuclei set within a fibrotic stroma rich in thickened collagen bundles. Nuclear atypia may be subtle. One helpful clue to the diagnosis of desmoplastic melanoma is the presence of nodular lymphocytic aggregates in the dermis. Of note, desmoplastic melanomas have a distinct immunohistochemical staining profile compared to conventional melanomas; they are typically MART-1 negative and positive for S-100 and SOX10 stains.

TUMORS OF DERMAL ORIGIN

Many tumors of dermal origin are derived from one of several cell types, including fibroblasts, endothelial cells, neural cells, and smooth muscle cells. These tumors may exhibit a spindle cell morphology, and certain morphologic clues are helpful in distinguishing the cell type of origin, and thus rendering an accurate diagnosis. For instance, smooth muscle cells have cigar-shaped nuclei with rounded, blunt ends that are accompanied by a perinuclear halo. Neural cells have wavy S-shaped nuclei with tapered ends. Cells that exhibit fibroblastic differentiation have elongated nuclei with tapered ends.

FIBROHISTIOCYTIC TUMORS

Dermatofibroma: Dermatofibromas exhibit fibroblastic differentiation, and are often classified as "fibrohistiocytic" because they may also display histiocytic differentiation in the form of foamy and/or giant cells. Dermatofibromas are benign lesions, which tend to have a hyperplastic epidermis and hyperpigmented, flattened rete, which are described as "dirty feet." Follicular induction is also commonly observed in the epidermis, which may closely resemble superficial BCCs. In the reticular dermis, bland-appearing spindled cells with tapered ends are observed (Fig. 2-32A), sometimes in association with round cells with foamy cytoplasm and/or giant cells. The degree of cellularity in dermatofibromas vary, as some lesions are relatively paucicellular while others are more densely cellular. "Collagen wrapping" is frequently seen, particularly at the periphery of dermatofibromas, in which spindle cells encircle collagen bundles (Fig. 2-32B). Immunohistochemical stains may be helpful in the diagnosis of dermatofibromas, as the fibrohistiocytic cells are positive for Factor XIIIa stains and negative for CD34 stains.

Dermatofibrosarcoma Protuberans: Dermatofibrosarcoma protuberans is a malignant neoplasm that is typically locally aggressive without a high incidence of metastasis. These tumors are characterized by a proliferation of bland-appearing spindle cells in the reticular dermis and subcutaneous fat. The cells intercalate between adipocytes in the subcutaneous fat, resulting in a "honeycomb" appearance (Fig. 2-33A). A storiform or whorled pattern of the cells is commonly observed in the dermal compartment (Fig. 2-33B). There is often very little cytologic atypia. The lesional cells are positive for CD34 immunohistochemical stains but negative for Factor XIIIa stains, allowing differentiation from cellular dermatofibromas.

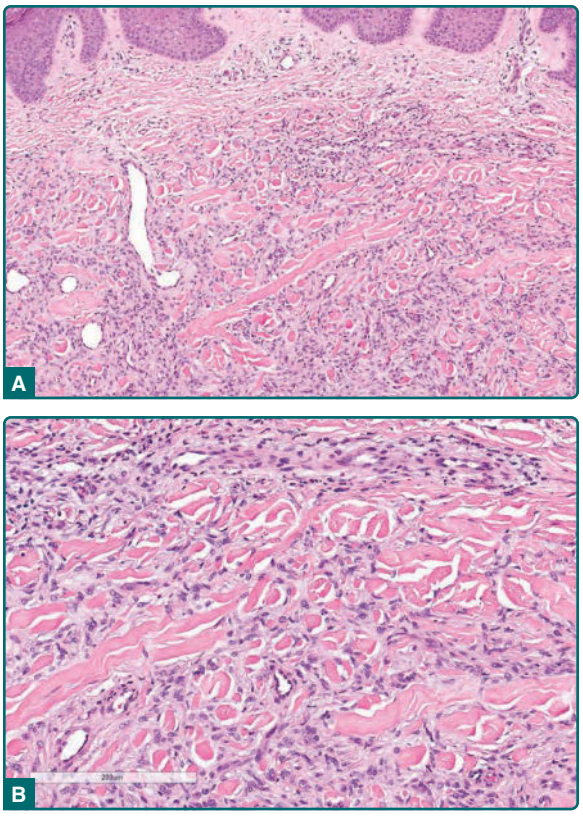

Figure 2-32 **A,** Dermatofibroma, demonstrating a proliferation of bland-appearing spindled cells in the dermis with associated collagen wrapping. **B,** Higher power view of collagen wrapping.

Atypical Fibroxanthoma: In contrast to dermatofibrosarcoma protuberans, atypical fibroxanthomas (AFXs) demonstrate marked cytologic atypia of spindled and epithelioid cells in the dermis. The lesional cells harbor markedly enlarged nuclei, nuclear pleomorphism, and mitotic figures are easily identified. Despite this prominent cytologic atypia, AFXs are readily treated with local excision and only very rarely metastasize. A panel of immunohistochemical stains including CD34, pan-cytokeratin, p63, S-100, and CD10 may be helpful in distinguishing AFX from other spindle cell tumors, including dermatofibrosarcoma protuberans, spindle-cell SCC, and spindle-cell/desmoplastic melanoma. Although CD10 is frequently positive in AFX, it is not a specific marker as it has also been reported to be positive in some carcinomas and melanomas. A biopsy of the surface of an

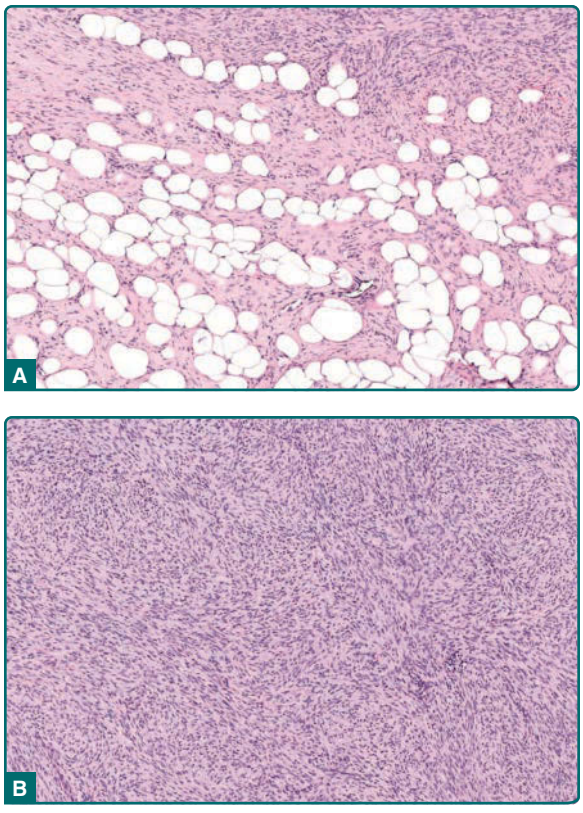

Figure 2-33 **A,** Dermatofibrosarcoma protuberans with elongated spindled cells intercalating between adipose cells in the subcutaneous fat, also known as "honeycombing." **B,** Storiform pattern of spindled cells in the dermis.

undifferentiated pleomorphic sarcoma, a lesion with potential for metastatic disease, is indistinguishable from AFX.

TUMORS OF VASCULAR ORIGIN

PYOGENIC GRANULOMA

Also known by the name *lobular capillary hemangioma*, pyogenic granuloma is a benign vascular lesion. Pyogenic granulomas are exophytic clinically, and the polypoid architecture under the microscope reflects this. Typically, there is an epidermal collarette around the dermal vascular proliferation (Fig. 2-34A). In the dermis are clusters of small capillaries lined by bland endothelial cells (Fig. 2-34B). The lobules of capillaries are set within a loose stroma containing fibroblasts.

ANGIOSARCOMA

Angiosarcomas are malignant vascular tumors. In relatively well-differentiated lesions, irregular vascular channels are seen in the dermis, which are lined by atypical endothelial cells (Fig. 2-35). The

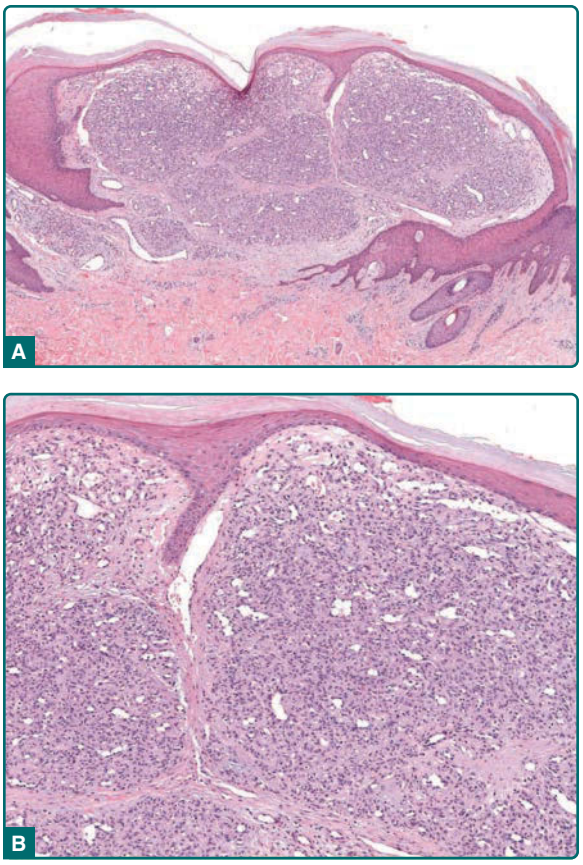

Figure 2-34 **A,** Pyogenic granuloma characterized by an epidermal collarette and clusters of capillaries in the dermis. **B,** Higher power view of lobules of capillaries in the dermis.

endothelial cells have variably enlarged nuclei and nuclear pleomorphism. The lesional cells are highlighted by endothelial cell markers, including CD31 and CD34. Poorly differentiated angiosarcomas may display increased cellularity, increased nuclear atypia, and increased number of mitoses compared to well-differentiated lesions.

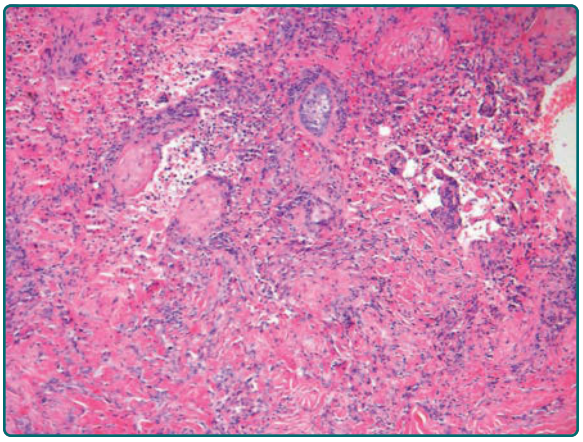

Figure 2-35 Angiosarcoma with a proliferation of atypical endothelial cells in the dermis and associated irregular vascular spaces.

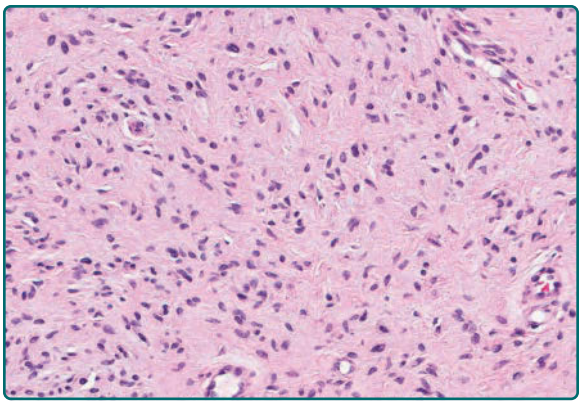

Figure 2-36 Neurofibroma showing spindled cells with wavy nuclei and characteristic pink stroma.

TUMORS OF NEURAL ORIGIN

NEUROFIBROMA

Neurofibromas are benign lesions that may occur sporadically or in the context of neurofibromatosis. They are dermal tumors that consist of small, bland neural cells with wavy, S-shaped nuclei, set within a light pink stroma (Fig. 2-36). The stroma may be myxoid. Neurofibromas tend to be well circumscribed within the dermis. Mast cells are commonly observed within neurofibromas.

SCHWANNOMAS

Also known as neurilemomas, schwannomas are as their name suggests, benign proliferations of Schwann cells. They are well-circumscribed but nonencapsulated lesions in the dermis, and are easily recognizable because there are two distinct patterns of tissue seen within them, namely Antoni A and Antoni B areas. Antoni A areas are more cellular, with areas of palisading of nuclei in parallel to one another around a relatively an acellular extracellular matrix, also referred to as *Verocay bodies*. Antoni B areas demonstrate spindled cells within a looser and often myxoid extracellular matrix.

TUMORS OF SMOOTH MUSCLE ORIGIN

LEIOMYOMA

The leiomyoma is a benign smooth muscle neoplasm, and in the skin is derived from either pilar muscle (piloleiomyoma) or from vascular smooth muscle (angioleiomyoma). In the former, there is a proliferation of smooth muscle bundles in the reticular dermis (Fig. 2-37A). The cells are pink in color and elongated,

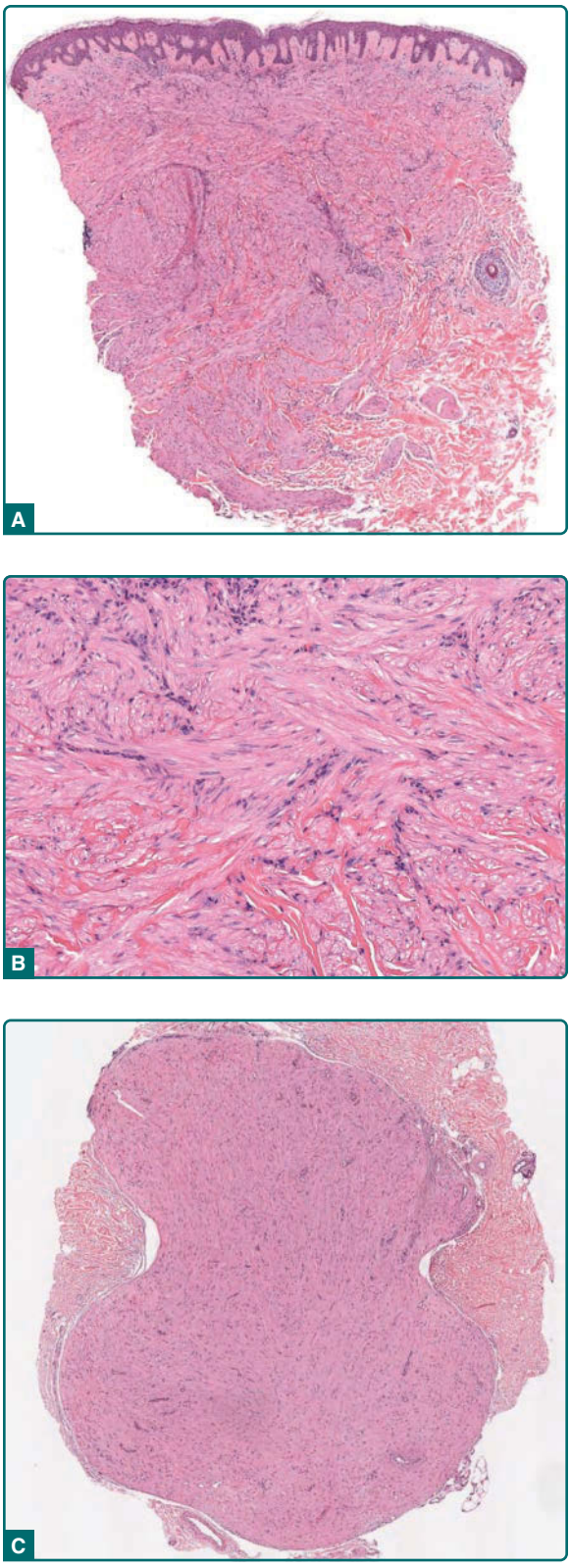

Figure 2-37 **A,** Pilar leiomyoma exhibiting fascicles of spindled cells in the reticular dermis. **B,** Higher power view of pilar leiomyoma. The spindled cells have cigar-shaped nuclei with blunt ends. **C,** Angioleiomyoma, showing characteristic deeply seated well-circumscribed nodules in the deep reticular dermis.

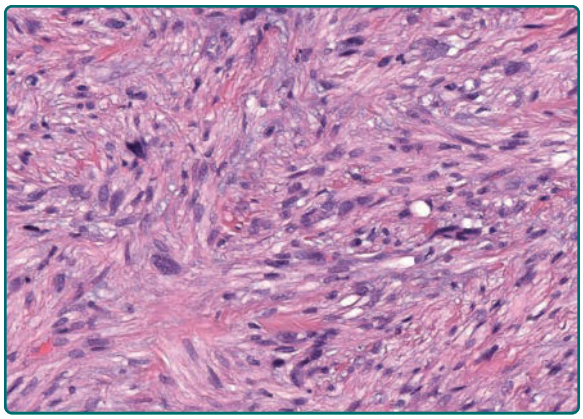

Figure 2-38 Leiomyosarcoma. The spindle cells show scattered enlarged atypical nuclei.

with cigar-shaped nuclei that have tapered ends (Fig. 2-37B). While mitoses are sometimes observed, the mitotic rate is generally very low. The typical angioleiomyoma appears as a well-circumscribed nodule in the deep reticular dermis and subcutaneous fat (Fig. 2-37C). A central vascular lumina may be seen, in addition to smaller vascular channels amid bundles of smooth muscle.

LEIOMYOSARCOMA

Similar to their benign counterparts, leiomyosarcomas may be derived from pilar muscle or vascular smooth muscle. These malignant tumors may display atypical, enlarged nuclei, increased cellularity, frequent mitoses, and/or infiltrative growth patterns (Fig. 2-38).

ACKNOWLEDGMENTS

The authors wish to acknowledge the previous authors, Drs. Martin C. Mihm, Abdul-Ghani Kibbi, George F. Murphy, and Klaus Wolff for their contributions to this chapter.

REFERENCES

1. Watson AJ, Redbord K, Taylor JS, et al. Medical error in dermatology practice: development of a classification system to drive priority setting in patient safety efforts. *J Am Acad Dermatol*. 2013;68:729-737.
2. Stratman EJ, Elston DM, Miller SJ. Skin biopsy: Identifying and overcoming errors in the skin biopsy pathway. *J Am Acad Dermatol*. 2016;74(1):19-25.
3. Elston, DM, Stratman EJ, Miller SJ. Biopsy issues in specific diseases. *J Am Acad Dermatol*. 2016;74:1-16.
4. Nguyen JV, Hudacek K, Whitten JA, et al. The HoVert technique: a novel method for the sectioning of alopecia biopsies. *J Cutan Pathol*. 2011;38(5):401-406.
5. Elston D. The "Tyler technique" for alopecia biopsies. *J Cutan Pathol*. 2012;39(2):306.
6. Magro CM, Crowson AN, Regauer S. Granuloma annulare and necrobiosis lipoidica tissue reactions as a manifestation of systemic disease. *Hum Pathol*. 27:50, 1996.
7. Requena L. Normal subcutaneous fat, necrosis of adipocytes and classification of the panniculitides. *Semin Cutan Med Surg*. 2007;26(2):66-70.
8. Requena L, Yus ES. Panniculitis. Part I. Mostly septal panniculitis. *J Am Acad Dermatol*. 2001;45(2):163-183.
9. Requena L, Sánchez Yus E. Panniculitis. Part II. Mostly lobular panniculitis. *J Am Acad Dermatol*. 2001;45(3):325-361; quiz 362-364.
10. Chu EY, Wanat KA, Miller CJ, et al. Diverse cutaneous side effects associated with BRAF inhibitor therapy: a clinicopathologic study. *J Am Acad Dermatol*. 2012;67(6):1265-1272.
11. Kong HH, Cowen EW, Azad NS, et al. Keratoacanthomas associated with sorafenib therapy. *J Am Acad Dermatol*. 2007;56(1):171-172.
12. John AM, Schwartz RA. Muir-Torre syndrome (MTS): an update and approach to diagnosis and management. *J Am Acad Dermatol*. 2016;74(3):558-566.

Chapter 3 :: Epidemiology and Public Health in Dermatology

:: Junko Takeshita & David J. Margolis

AT-A-GLANCE

- Epidemiology is the study of disease in a population.
- Epidemiologic studies may be analytic (including meta-analyses, clinical trials, and cohort and case-control studies) or descriptive.
- Most epidemiologic studies measure association; causality is difficult to establish with nonexperimental studies.
- Bias and confounding are important limitations to be aware of, especially in observational studies.

INTRODUCTION

Epidemiology is the study of disease in the population, and it includes the incidence, prevalence, distribution, cause, and natural history of disease. The study of epidemiology is concerned with the health of populations and helps to inform not only the natural history and treatment of disease but also the public health policy of a disease. Epidemiologic studies are often used to help guide evidence-based practice. Most epidemiologic studies are observational, which means that epidemiologists, in their quest to understand a disease, observe a population and how it is affected by a disease without intervening on the population. On the other hand, in experimental studies, a clinical trialist will determine how an intervention affects an individual's health by actively exposing individuals in a population to an exposure, such as a drug, of interest.

Understanding a disease includes not only identifying the cellular, genetic, and molecular causes and consequences of the illness but also assessing how the disease affects patients and the population in which they reside. Epidemiology is the basic science underpinning this exploration, and epidemiologic techniques are the foundation for nearly all clinical research. Comprehensive clinical training requires knowledge of both the basic science underlying the pathophysiology of disease as well as the epidemiology and natural history of disease. Because the techniques of an epidemiologist are often the basic science of evidence-based medicine, as a practitioner of dermatology, a good foundation in epidemiologic cutaneous science is as important as understanding the molecular basis of skin disease.

BASIC CONCEPTS

DEFINITIONS

The following are basic terms often used to describe epidemiologic studies.

Clinical trials are interventional studies that include randomized controlled trials (RCTs). These studies are considered experimental studies in that the investigator has a direct influence on the subjects in the study via an intervention and evaluates the effect of the intervention. The experimental environment is tightly controlled, allowing an investigator to determine the efficacy an intervention (ie, the effect of an intervention in an ideal setting). Although these studies provide the highest level of proof of an effect by minimizing bias (ie, internal validity), randomized clinical studies many not generalize well to all members of a population (ie, external validity).

Health services research evaluates how an individual receives health care and interacts with the health care system. These studies can include evaluations of access to care, interactions between health care providers and patients, and a patient's perception of his or her illness. Epidemiologic techniques, including clinical trials as well as techniques more common to economics, anthropology, sociology, and psychology, are often used in health services research studies.

Patient-oriented research has been defined in many different ways. At present, it most commonly refers to studies of how patients interact with their health care and disease. Outcomes of these studies are often directed by or informed by individuals with an illness of interest.

The **natural history of disease** is the course of the disease from its onset until its, or the patient's, end or resolution, the latter of which may be study outcomes of interest. It includes not just interactions with health care providers but the course of the disease within the patient's experience as well.

The **burden of disease** is a measure of how an individual is affected by an illness. Burden can include measures of how an illness changes an individual's life including economic and social costs. Burden can also be measured at the population level. For example, the prevalence of a disease can be a measure of the burden of that disease in the population.

An **outcome** is the observation of primary interest. Outcomes could include death; the onset, resolution, or change in the status of an illness; and quality of life, among others. Outcomes often have clinical relevance and should be defined before a study commences.

In many situations, the strongest association between a risk factor or intervention and an outcome is a **causal association**. In experimental studies such as a randomized clinical trial, causation is easier to establish because of the careful design of the study. When an intervention is thought to directly cause an outcome of interest, this suggests a causal association between the two. Causality can only be established with properly designed studies in which there is a clear temporal relationship between the intervention and measured outcome; the outcome is explicitly defined; the study is without noticeable bias; there is an underlying biologically plausible explanation for the relationship between the intervention and the outcome; and the measured effect between the intervention and outcome is reproducible, strong, and statistically significant. Establishing a causal association in observational studies is more difficult because of the potential for bias in these studies. Simply identifying a statistically significant association between a risk factor and an outcome is not necessarily sufficient to suggest causation. Many have opined about how to determine causation in an observational study. Sir Bradford Hill's criteria for observational studies are often cited as necessary to demonstrate causation;[1] however, not all agree. These criteria are based on the notions that a risk factor needs to occur before the outcome, the risk factor is not part of another factor's causal pathway, prior knowledge of the risk factor provides evidence that it could cause the outcome, there is a strong and dose-dependent association between the risk factor and outcome, and the association is reproducible. Although the criteria that are used to determine if an association noted in an observational study is causal are often attributed to Sir Bradford Hill, that was not his purpose when he proposed these criteria. His purpose was to begin a discussion on what might be noted in an observational study that could be used to determine causation.

An **intervention** is the application of a substance or an action to subjects in an experimental study.

A **risk factor** is an attribute that increases the likelihood of developing a disease or other outcome of interest. A risk factor could be environmental, genetic, ancestral, economic, or medication related, among others. Risk factors are important to measure, particularly in observational studies.

An **association** occurs when an attribute or other factor is found to be related to an outcome of interest. The magnitude of an association is often measured by an effect estimate, and the likelihood that the association is real is often documented by statistical significance.

Bias is a systematic error that causes the results of a study to deviate from the truth. In epidemiologic studies, bias is defined in several ways. For the purpose of this discussion, we will categorize bias into two broad categories, **selection bias** and **information bias**. **Selection bias** is a systematic error in a study caused by how subjects are selected or not selected for a study. This also applies to the selection process for an intervention or exposure to a risk factor. For example, in a cohort study evaluating whether a topical therapy used to treat psoriasis is more effective than a systemic therapy, selection bias would occur if those selected for treatment with a topical steroid had less severe disease than those selected for the systemic therapy. In a case-control study, selection bias can occur if the source population from which the cases are drawn is different from the control source population. For example, in a hypothetical case-control study evaluating the association between nonsteroidal antiinflammatory drug (NSAID) use and colon cancer, comparing cases of colon cancer drawn from patients admitted to the hospital with control participants drawn from patients with arthritis admitted to the hospital may result in a falsely low effect estimate because the control participants likely have had a high exposure to NSAIDs. **Information bias** is bias that occurs because of reporting. For example, in a case-control study evaluating the association between cigarettes and lung cancer, because of previous reports and package warnings about cigarettes, it is likely that those with cancer are more likely to recall and report a history of cigarette use than those without lung cancer. In a cohort study evaluating the risk of cancer among patients with psoriasis, information bias could be introduced if the method of information gathering (ie, psoriasis subjects answer survey questions while waiting patiently for phototherapy) elicits more detailed responses about cancer risk factors, such as cigarette use, in the psoriasis patient cohort than in the cohort of patients without psoriasis (ie, subjects without psoriasis answer survey questions while completing an office visit after a wart treatment). The ultimate problem with bias is that it cannot be measured, and as a result, it is difficult to determine the net effect of the bias on the study results.

Confounding occurs when two risk factors or exposures are associated with each other and the outcome of interest. This association often distorts the estimated effect of either risk factor on the outcome. For example, in a cohort study of the risk of malignancy in those with psoriasis, it might be important to understand the impact of cigarette use and alcohol use. This can be problematic because smoking and alcohol use has been reported to be more prevalent among patients with psoriasis than those without psoriasis, and people who smoke and drink more alcohol are more likely to develop a malignancy. When evaluating the association of any of these variables on cancer risk, it is important to assess whether the estimate is "confounded" by the other risk factors.

Efficacy is the measure of an effect in an ideal setting. Ideal settings tend to maximize the internal validity (minimize potential errors or confounding) of the study's results. For example, randomized clinical trials use precise definitions of a disease and how to use an intervention, randomization (the selection of an intervention or treatment is not based on the investigators preference but based on a prespecified numerical formula), blinding (investigators collecting data from study participants are not

aware of treatment assignment), and other specifications that ensure internal validity. These design elements maximize the likelihood that the results of the study will be unbiased. Studies that minimize bias are thought to be **internally valid**, which means that if the study was repeated using the same study design and the same study cohort, the same results would be found. Because a random sample from the population at large is not usually selected for a randomized clinical trial, these studies may not generalize to the full population. In addition, the inclusion and exclusion criteria for randomized clinical trials (eg, how a patient is determined to be eligible for enrollment) tend to be very selective and may not correspond to how a disease is defined by most health care workers. Studies that measure efficacy are called **explanatory studies**.

Effectiveness is how well an intervention works in the real world. As noted earlier, in clinical settings, the definition of a disease may lose precision, patients may not take their medications, and providers may not properly prescribe medications. Effectiveness measures allow for this loss of precision. These studies tend to be more generalizable in that they are representative of the "real" world and not the idealized world of a clinical trial. Studies that represent results that are reproducible in many other study settings are thought to be **externally valid** or generalizable.

Comparative effectiveness refers to studies that compare two or more treatments that are generally accepted to be effective. These studies use real-world treatment settings, thus allowing for imprecisions that occur in daily care. These studies are often called **pragmatic studies** in that they lack the regulatory oversight that is required by federal agencies when treatments receive initial approval, thereby allowing the study design to be more consistent with routine patient–physician interactions.

A **cohort** is a group of people. In observational studies, a cohort is often defined based on disease status or having a risk factor of interest.

STUDY DESIGNS

An understanding of epidemiologic study designs is essential to properly addressing clinical questions and interpreting published literature. Many different types of epidemiologic study designs exist, the most common of which will be reviewed here. Most studies can be divided into two basic categories: analytic and descriptive (Fig. 3-1).

ANALYTIC STUDIES

Analytic studies examine the association between an exposure and outcome. Two main types of analytic studies are experimental and observational studies.

EXPERIMENTAL STUDIES

Experimental studies are those in which subjects receive an active intervention (ie, drug or other treatment). Clinical trials are the most commonly used and recognized of the experimental studies. Clinical trials are often classified based on guidance from federal agencies such as the Food and Drug Administration (FDA). This nomenclature was created to help establish an orderly and reproducible process allowing for the evaluation of novel interventions that require federal approval before human experimentation can begin and establish a foundation for the justification for the approval of a new treatment. The FDA algorithm includes the following:

1. *Phase I studies* are the first studies performed in humans and are often designed with the notion that they are human pharmacology studies. The goal of phase I studies is to evaluate a drug's dose range, safety, tolerability, pharmacokinetics, and pharmacodynamics.

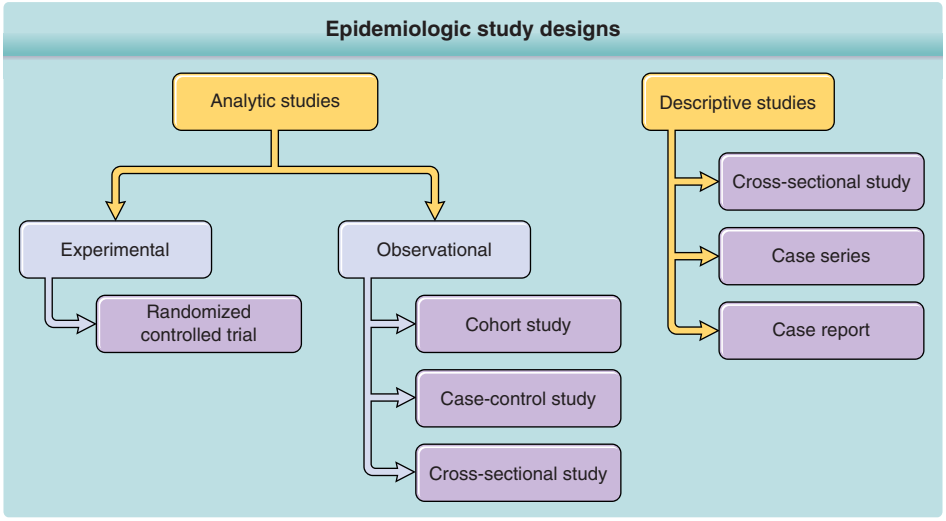

Figure 3-1 Epidemiologic study designs.

2. *Phase II studies* are also called initial efficacy studies and are conducted to initially determine the effect of an intervention on patients with the disease of interest. These studies are also conducted to obtain additional information required to properly design phase III trials.
3. *Phase III studies*, also called comparative efficacy studies, are designed to assess the efficacy of an intervention compared with that of a "control" treatment (either active treatment or placebo). Sometimes called pivotal studies, phase III studies provide the data necessary for regulatory agencies such as the FDA to decide whether or not to approve a drug. Randomization and blinding are important aspects of phase III studies that ensure their internal validity and reduce bias. These studies are often considered the best design to evaluate a new treatment.
4. *Phase IV studies*, or postmarketing studies, are usually conducted after a treatment obtains FDA approval for marketing. They may also be called effectiveness studies because of their focus on how well the approved drug works in the general population and how safe the drug is in a larger population and over a longer period of time. Sometimes phase IV studies assess the effectiveness of the intervention for uses other than the approved indication.

Given the limitations of explanatory trials, such as poor external validity or generalizability, relatively short study periods, and focus on how interventions work in the ideal setting, an increasing emphasis has been placed on studying interventions' effects in the real-world setting. As such, **pragmatic trials** have gained popularity in recent years.[2] Pragmatic trials, also known as large simple studies or Peto studies, are effectiveness studies that focus on understanding how an intervention works in the routine clinical setting. As opposed to explanatory trials, the goal of pragmatic trials is to maximize the generalizability of the results to many practice settings and minimize the scientific (with respect to internal validity), regulatory, and administrative burden common to explanatory trials. Examples of pragmatic RCTs in dermatology include a Dutch study of home versus outpatient ultraviolet B phototherapy for psoriasis (PLUTO)[3] and a UK study of prophylactic antibiotics for prevention of cellulitis (PATCH II).[4] Differences between explanatory and pragmatic trials are summarized in Table 3-1. In reality, however, few trials can be defined as purely explanatory or pragmatic and instead display a mix of explanatory and pragmatic trial characteristics. As such, tools have been developed to help classify trials as explanatory or pragmatic, including the tool by Gartlehner and coworkers[5] and the PRECIS (pragmatic-explanatory continuum indicator summary) tool by Thorpe and coworkers[6] Additionally, guidelines for quality reporting of pragmatic trials have been developed as an extension of the Consolidated Standards of Reported Trials (CONSORT) statement for RCTs.[7]

TABLE 3-1
Differences between Efficacy and Effectiveness Research

EFFICACY HOW WELL DOES THE INTERVENTION WORK IN THE IDEAL SETTING?	EFFECTIVENESS HOW WELL DOES THE INTERVENTION WORK IN THE REAL WORLD?
Stringent patient selection criteria to optimize safety	Heterogeneous patient population more susceptible to adverse events
Highly motivated patients with strict adherence to research protocol	Variations in patient motivation and ability to adhere to prescribed regimen
Highly trained investigators with expertise in the study drug	Variation in experience and knowledge of the drug by prescriber
Clinical response determined at arbitrary "short-term" time points	Clinical response determined in routine clinical visits
Maximize internal validity	Maximize external validity

OBSERVATIONAL STUDIES

Observational studies are those in which subjects are observed and exposures and outcomes are measured in routine care without any effort to intervene or otherwise influence any measured factors. The most common types of observational studies include cohort studies, case-control studies, and cross-sectional studies.

A **cohort study**, sometimes called a prospective study, follows a cohort (group of patients) over time and monitors the effect of a risk factor or exposure on the development of an outcome. For example, in an effort to answer the question of whether or not treatment of acne with isotretinoin increases the risk of developing inflammatory bowel disease (IBD), a cohort study could be designed. Individuals with acne and no prior history of IBD who are treated with isotretinoin (the exposed group) could be followed and compared with individuals who have not been treated with isotretinoin (the unexposed group) to determine if there is a difference between the two groups in risk of developing IBD. Alhusayen and coworkers performed such a study.[8] Advantages of cohort studies include the ability to evaluate for multiple outcomes in a single study and calculate incidence rates. On the other hand, cohort studies tend to be large and time consuming and are subject to bias. It is also important to recognize that many cohort studies are conducted using medical records or administrative databases, which allows for use of data that have already been collected. Thus, the data collection is retrospective. Nevertheless, the direction of observation for cohort studies using these data remains prospective in that a study start date is determined and study subjects are observed prospectively from that date for development of the outcome of interest. An example is Barbieri and coworkers' study of duration of tetracycline treatment and use of topical retinoids for treatment of acne.[9]

A **case-control study** is sometimes also called a retrospective study. These studies sample a group with a disease of interest (cases) and another that does not have the disease (controls). The study subjects are then interrogated or preceding data are examined to determine the prevalence of a risk factor. For example, Palmer and coworkers used a case-control study to identify loss-of-function variants of filaggrin that are associated with atopic dermatitis.[10] This example highlights the advantage of being able to evaluate multiple potential risk factors for a single outcome in case-control studies. An effect estimate, typically an odds ratio, is calculated based on the prevalence of exposure in the two groups. Case-control studies are often smaller than cohort studies, are particularly useful for studying rare outcomes, take much less time (subjects are not followed for the outcome to occur), and are particularly subject to selection and recall biases.

META-ANALYSIS

A **meta-analysis** is a quantitative study of studies. It is a systematic review that attempts to combine the results of multiple studies in order to create a pooled effect estimate of an outcome of interest. Meta-analyses may summarize experimental or observational studies. Because of inherent variability due to study designs, many who conduct meta-analyses favor combining only randomized clinical trials as a way to minimize bias. The outcome of interest for a meta-analysis is not always the primary outcome of the original studies that are included. By combing multiple studies, the "meta" estimates are often more precise than the individual estimates in the original studies. However, meta-analyses need to be carefully designed and interpreted because combination of results can lead to biased estimates. As a result, the analyst needs to carefully evaluate study designs, including the reproducibility and consistency between studies of the outcome of interest, as well as the heterogeneity among studies before creating the meta-estimate and providing an interpretation of results. An example meta-analysis evaluated the efficacy of oral antibiotics and oral contraceptives for the treatment of acne vulgaris.[11] Recent meta-analytic techniques called network of evidence or mixed treatment comparison have been developed to enable comparisons between treatments that were never directly compared in individual studies.

DESCRIPTIVE STUDIES

Descriptive studies are designed to report the distribution of disease or other health outcomes in a population. Descriptive studies may include **case reports** and **case series** that provide a detailed profile of single or multiple patients observed in the clinical setting. Cross-sectional studies may also be descriptive, for example, in the instance of measuring the prevalence of a particular disease or other outcome in a population.

QUALITY REPORTING AND ASSESSING EVIDENCE LEVELS

Standardized recommendations for quality reporting and levels of evidence rating scales can aid in the interpretation of epidemiologic studies and clinical recommendations or guidelines, respectively.

QUALITY REPORTING

Transparency and standardized reporting of clinical and epidemiologic studies are necessary to ensure reproducibility and allow for critical assessment and proper interpretation of study methods and results. Recommendations for quality reporting have been created with the purpose to improve study reporting. Quality reporting tools and checklists exist for systematic reviews, meta-analyses, and experimental and observational studies. Some examples include AMSTAR (A Measurement Tool to Assess Systematic Reviews),[12,13] PRISMA (Preferred Reporting Items for Systematic Reviews and Meta-Analyses),[14] and QUOROM (Quality of Reporting of Meta-Analyses) for systematic reviews or meta-analyses;[15] CONSORT (Consolidated Standards of Reporting Trials) for clinical trials;[16] and STROBE (Strengthening the Reporting of Observational Studies in Epidemiology) for observational studies,[17] among others.

LEVELS OF EVIDENCE

The ability to assess and classify evidence levels for clinical recommendations is essential for the practice of evidence-based medicine. More than 100 grading scales exist to aid in assessing levels of evidence and are used by variety of publications.[18] A few of the more commonly used scales include the SORT (Strength-of-Recommendation Taxonomy),[19] GRADE (Grading of Recommendations, Assessment, Development and Evaluation),[20] and Oxford Centre for Evidence-Based Medicine (OCEBM)[21,22] scales. The SORT scale has been adopted as the preferred grading scale by several family medicine and primary care journals, including *American Family Physician*, *Journal of the American Board of Family Practice*, and *Journal of Family Practice*, among others. The GRADE scale is the Cochrane group's recommended scale for grading quality of evidence and strength of recommendations. The OCEBM scale allows for grading of evidence for diagnostic tests, prognostic markers, and harm that many other scales do not.

MEASURES IN EPIDEMIOLOGY

Various types of measures exist in epidemiology, including descriptive, analytic, and patient-reported outcome measures. These measures are necessary for describing a population, assessing associations, and understanding the patient perspective, respectively.

DESCRIPTIVE MEASURES

Descriptive measures are used in descriptive studies and characterize an outcome of interest in a population. **Prevalence** is the frequency of a disease or other outcome of interest over a given period of time. It is measured as the number of individuals with a disease divided by the number of individuals sampled over a specified time period. Measuring prevalence is especially important and relevant for chronic diseases. Prevalence can be measured as point prevalence (ie, does an individual have the disease today), yearly prevalence (ie, does an individual have a disease during a 12-month period), lifetime prevalence, or any other given time period of interest.

Incidence is the frequency of new cases of a disease or other outcome among those who are at risk of the disease or outcome of interest within a specified period of time. The "at-risk population" refers to those who have the potential to develop the disease or other outcome of interest. For example, men would not be included in the at-risk population for a study of ovarian cancer. Generally, a new case occurs only once, and after an individual develops the disease or other outcome, he or she is removed from the population at risk. In a given time frame, incidence is measured by dividing the number of individuals who developed a disease by the number of individuals in the at-risk population.

The **duration** of a disease is how long it affects an individual. Some diseases are acute and only last for a short period of time (eg, cellulitis), and otherwise are chronic and last for a lifetime (eg, psoriasis). The magnitude of the prevalence and incidence of a disease can differ greatly because of long duration of a disease. For example, the prevalence of psoriasis in adults in the U.S. population is estimated at 2 to 4 per 100 (2% to 4%),[23,24] but the incidence is less than 1 per 1000 per person-year (0.1%).[25,26]

MEASURES OF ASSOCIATION

Many epidemiologic studies attempt to measure the impact of a risk factor on an outcome of interest. An effect estimate is a measure of this effect. A typical effect estimate is the **risk ratio** or **relative risk**, also called a **hazard ratio** in time-to-event analyses. This is a ratio of how an outcome is measured in those with a disease versus those without a disease (ie, the ratio of the incidence of the outcome in the persons exposed versus the incidence of the outcome in the group not exposed). For example, Gelfand and coworkers found the incidence of death in those with severe psoriasis is 21.3 per thousand person-years versus 12.0 per thousand person-years in those without psoriasis.[27] The overall risk ratio is 1.5, which means that those with psoriasis have a 50% increased risk of death. **Attributable risk** or **risk difference** is a variation on this measure. It is the absolute risk in the exposed persons minus the absolute risk in the nonexposed persons. Using the example above, the overall attributable risk is 6 per thousand person-years, which means that in a cohort of 1000 patients with psoriasis, 6 deaths occurred that can be associated with having psoriasis compared with not having psoriasis (Table 3-2).

Many studies use the **odds ratio** as an effect estimate. An odds ratio is the ratio of the odds that a case is exposed compared with the odds that a control is exposed. Classically, odds ratios have been associated with case-control studies. However, now odds ratios are often measured because they are easily calculated in a commonly used statistical analysis called logistic regression. When measuring risk, odds ratios and relative risks are equivalent measurements when the outcome is rare (prevalence of less than 5%), but the odds ratio overestimates the relative risk when the outcome is common. In most settings, reports of odds ratios or risk ratios are "adjusted" because study subjects rarely experience a single exposure, and thus confounding by other exposures or risk factors is of concern. Adjustment can be done by statistical manipulation and can control for confounding factors. Considering psoriasis again, those with psoriasis might be older or more likely to have cardiovascular disease than the control population. To properly estimate the risk ratio or odds ratio, it would be appropriate to remove (or adjust for) the effect of age or cardiovascular disease from the measure of the risk of death. It is important to remember that these effect estimates are measures of association and not

TABLE 3-2
Effect Estimates: An Example of Mortality Risk among Patients with Severe Psoriasis[27]

	NO PSORIASIS (*N* = 15,075)	SEVERE PSORIASIS (*N* = 3951)
Incidence rate of mortality per 1000 person-years (95% CI)	12.0 (11.3-12.8)	21.3 (19.0-23.9)
Overall hazard ratio (95% CI)	Reference	1.5 (1.3-1.7)
Overall attributable risk: number of deaths per 1000 patient-years	Reference	6.0

CI; confidence interval.



Figure 3-2 2 × 2 tables for sensitivity and specificity.

necessarily indicative of causality; other criteria need to be met to establish causal relationships.

TEST CHARACTERISTICS

In studies of diagnostic test performance, **sensitivity** and **specificity** are important test characteristics that should be reported (Fig. 3-2). The **sensitivity** of a test is the proportion of truly diseased individuals (ie, true positives and false negatives) who are defined as having the disease by a test (ie, true positives). It is also called the true positive rate. The **specificity** of a test is the proportion of individuals who truly do not have the disease (ie, false positives and true negatives) who are defined by the test as not having the disease (ie, true negatives). It is also called the true negative rate.

In clinical situations, health care providers tend to care more about the **positive** or **negative predictive value** of a test as they answer the more clinically relevant questions of how likely a patient is to have or not have a disease given a positive or negative test, respectively. The **positive predictive value** is the proportion of individuals who have a positive test that truly have the disease, and the **negative predictive value** is the proportion of individuals who have a negative test who truly do not have the disease. Whereas the sensitivity and specificity of a diagnostic test are fixed characteristics, the positive and negative predictive values of a test may vary depending on the prevalence of the disease in the population being tested. Depending on how these parameters are determined, the estimates can be influenced by disease definition and certainty of diagnosis; the prevalence, incidence, or frequency of the disease within the studied cohort; and the diagnostic criteria used to assure that the patient has the disease of interest.

PATIENT-REPORTED OUTCOME MEASURES

Our current health care and research environment places increasing importance on incorporation and consideration of the patient experience of disease and health care. As such, **patient-reported outcome measures** (PROMs), tools that assess the experience of disease and health care directly from the patient's self-report, have become a major focus of research and clinical care. PROMs vary in their focus of assessment from generic measures of overall health or quality of life (QoL) to skin-, disease-, and symptom-specific measures (Table 3-3). On a national level, the National Institutes of Health initiated the Patient-Reported Outcomes Measurement Information System (PROMIS),[28] which is a publicly available system of validated generic measures of patient-reported health

TABLE 3-3
Examples of Instruments Used to Measure Patient Reports

DOMAIN	TYPICAL INSTRUMENT(S)	COMMENT
Overall quality of life	Medical Outcomes Study Short-Form instruments (SF-36)[34] and (SF-12)[35]	36 or 12 items; commonly used in clinical research; interpretable scores
Skin-related quality of life	Dermatology Life Quality Index[36] Skindex-29,[37] Skindex-16[31]	10 items; most commonly used; focuses on functioning 29 or 16 items; focuses on emotional effects, symptoms, and functioning
Disease-specific severity	Patient-Oriented Eczema Measure (POEM),[32] Self-Administered Psoriasis Area and Severity Index (SAPASI)[38]	Correlate well with clinician measures
Symptoms: pruritus	Itch Severity Scale,[39] Pruritus-Specific Quality-of-Life Instrument,[40] ItchyQuant[33]	Demonstrate promising measurement properties
Patient satisfaction	Consumer Assessment of Healthcare Providers and Systems (CAHPS) survey[41]	Correlates with adherence, quality of life, and quality of care
Patient preferences	Utilities,[42] Willingness to Pay[43]	Correlations among different measures of preferences can be weak

status for physical, mental, and social well-being across multiple medical conditions. PROMs are particularly important in the field of dermatology in which many of the conditions that are evaluated and treated do not directly impact hard health outcomes, such as mortality, but do significantly affect patients' QoL. Several PROMs are specific to dermatology, including the skin-related QoL instruments Dermatology Life Quality Index,[29] Skindex-29,[30] and Skindex-16[31] as well as several condition-specific (eg, Patient-Oriented Eczema Measure[32]) and symptom-specific (eg, Itchy-Quant[33]) tools.

CONCLUSIONS

Epidemiology forms the basis for advancing our understanding of disease among populations. Epidemiologic, patient-oriented, and health services research is essential for furthering our knowledge of dermatologic diseases at both a population and individual level. A basic understanding of epidemiology and its study methods and measures enables the clinician to interpret primary literature and practice evidence-based medicine.

REFERENCES

1. Hill AB. The environment and disease: association or causation? *Proc R Soc Med.* 1965;58:295-300.
2. Patsopoulos NA. A pragmatic view on pragmatic trials. *Dialogues Clin Neurosci.* 2011;13(2):217-224.
3. Koek MB, Buskens E, van Weelden H, et al. Home versus outpatient ultraviolet B phototherapy for mild to severe psoriasis: pragmatic multicentre randomised controlled non-inferiority trial (PLUTO study). *BMJ.* 2009;338:b1542.
4. Thomas K, Crook A, Foster K, et al. Prophylactic antibiotics for the prevention of cellulitis (erysipelas) of the leg: results of the UK Dermatology Clinical Trials Network's PATCH II trial. *Br J Dermatol.* 2012;166(1):169-178.
5. Gartlehner G, Hansen RA, Nissman D, et al. A simple and valid tool distinguished efficacy from effectiveness studies. *J Clin Epidemiol.* 2006;59(10):1040-1048.
6. Thorpe KE, Zwarenstein M, Oxman AD, et al. A pragmatic-explanatory continuum indicator summary (PRECIS): a tool to help trial designers. *J Clin Epidemiol.* 2009;62(5):464-475.
7. Zwarenstein M, Treweek S, Gagnier JJ, et al. Improving the reporting of pragmatic trials: an extension of the CONSORT statement. *BMJ.* 2008;337:a2390.
8. Alhusayen RO, Juurlink DN, Mamdani MM et al. Isotretinoin use and the risk of inflammatory bowel disease: a population-based cohort study. *J Invest Dermatol.* 2013;133(4):907-912.
9. Barbieri JS, Hoffstad O, Margolis DJ. Duration of oral tetracycline-class antibiotic therapy and use of topical retinoids for the treatment of acne among general practitioners (GP): a retrospective cohort study. *J Am Acad Dermatol.* 2016;75(6):1142-1150 e1141.
10. Palmer CN, Irvine AD, Terron-Kwiatkowski A, et al. Common loss-of-function variants of the epidermal barrier protein filaggrin are a major predisposing factor for atopic dermatitis. *Nat Genet.* 2006;38(4):441-446.
11. Koo EB, Petersen TD, Kimball AB. Meta-analysis comparing efficacy of antibiotics versus oral contraceptives in acne vulgaris. *J Am Acad Dermatol.* 2014;71(3):450-459.
12. Shea BJ, Grimshaw JM, Wells GA, et al. Development of AMSTAR: a measurement tool to assess the methodological quality of systematic reviews. *BMC Med Res Methods.* 2007;7:10.
13. Shea BJ, Hamel C, Wells GA, et al. AMSTAR is a reliable and valid measurement tool to assess the methodological quality of systematic reviews. *J Clin Epidemiol.* 2009;62(10):1013-1020.
14. Liberati A, Altman DG, Tetzlaff J, et al. The PRISMA statement for reporting systematic reviews and meta-analyses of studies that evaluate healthcare interventions: explanation and elaboration. *BMJ.* 2009;339:b2700.
15. Moher D, Cook DJ, Eastwood S, et al. Improving the quality of reports of meta-analyses of randomised controlled trials: the QUOROM statement. Quality of Reporting of Meta-analyses. *Lancet.* 1999;354(9193):1896-1900.
16. Schulz KF, Altman DG, Moher D, et al. CONSORT 2010 statement: updated guidelines for reporting parallel group randomised trials. *BMJ.* 2010;340:c332.
17. von Elm E, Altman DG, Egger M, et al. The Strengthening the Reporting of Observational Studies in Epidemiology (STROBE) statement: guidelines for reporting observational studies. *Lancet.* 2007;370(9596):1453-1457.
18. Systems to rate the strength of scientific evidence. Evidence report/technology assessment: number 47. AHRQ publication no. 02-E015. Rockville (MD): Agency for Healthcare Research and Quality; 2002.
19. Ebell MH, Siwek J, Weiss BD, et al. Strength of recommendation taxonomy (SORT): a patient-centered approach to grading evidence in the medical literature. *Am Fam Physician.* 2004;69(3):548-556.
20. Guyatt GH, Oxman AD, Vist GE, et al. GRADE: an emerging consensus on rating quality of evidence and strength of recommendations. *BMJ.* 2008;336(7650):924-926.
21. Howick J, Chalmers I, Glasziou P, et al. The 2011 Oxford CEBM Levels of Evidence (Introductory Document). http://www.cebm.net/index.aspx?o=5653.
22. Howick J, Chalmers I, Glasziou P, et al. Explanation of the 2011 Oxford Centre for Evidence-Based Medicine (OCEBM) Levels of Evidence (Background Document). http://www.cebm.net/index.aspx?o=5653.
23. Kurd SK, Gelfand JM. The prevalence of previously diagnosed and undiagnosed psoriasis in US adults: results from NHANES 2003-2004. *J Am Acad Dermatol.* 2009;60(2):218-224.
24. Rachakonda TD, Schupp CW, Armstrong AW. Psoriasis prevalence among adults in the United States. *J Am Acad Dermatol.* 2014;70(3):512-516.
25. Bell LM, Sedlack R, Beard CM, et al. Incidence of psoriasis in Rochester, Minn, 1980-1983. *Arch Dermatol.* 1991;127(8):1184-1187.
26. Icen M, Crowson CS, McEvoy MT, et al. Trends in incidence of adult-onset psoriasis over three decades: a population-based study. *J Am Acad Dermatol.* 2009;60(3):394-401.
27. Gelfand JM, Troxel AB, Lewis JD, et al. The risk of mortality in patients with psoriasis: results from a population-based study. *Arch Dermatol.* 2007;143(12):1493-1499.
28. Cella D, Yount S, Rothrock N, et al. The Patient-Reported Outcomes Measurement Information System (PROMIS): progress of an NIH Roadmap cooperative group

during its first two years. *Med Care*. 2007;45(5 suppl 1): S3-S11.
29. Basra MK, Fenech R, Gatt RM, et al. The Dermatology Life Quality Index 1994-2007: a comprehensive review of validation data and clinical results. *Br J Dermatol*. 2008;159(5):997-1035.
30. Chren MM, Lasek RJ, Quinn LM, et al. Skindex, a quality-of-life measure for patients with skin disease: reliability, validity, and responsiveness. *J Invest Dermatol*. 1996;107(5):707-713.
31. Chren MM, Lasek RJ, Sahay AP, et al. Measurement properties of Skindex-16: a brief quality-of-life measure for patients with skin diseases. *J Cutan Med Surg*. 2001;5(2):105-110.
32. Charman CR, Venn AJ, Williams HC. The patient-oriented eczema measure: development and initial validation of a new tool for measuring atopic eczema severity from the patients' perspective. *Arch Dermatol*. 2004;140(12):1513-1519.
33. Haydek CG, Love E, Mollanazar NK, et al. Validation and Banding of the ItchyQuant: A Self-Report Itch Severity Scale. *J Invest Dermatol*. 2017;137(1):57-61.
34. Ware J. *SF-36 Health Survey Manual and Interpretation Guide*. Boston: The Health Institute, New England Medical Center; 1993.
35. Ware J Jr, Kosinski M, Keller SD. A 12-Item Short-Form Health Survey: construction of scales and preliminary tests of reliability and validity. *Med Care*. 1996;34(3):220-233.
36. Finlay AY, Khan GK. Dermatology life quality index (DLQI)—a simple practical measure for routine clinical use. *Clin Exper Dermatol*. 1994;19:210-216.
37. Chren MM et al. Improved discriminative and evaluative capability of a refined version of Skindex, a quality-of-life instrument for patients with skin diseases. *Arch Dermatol*. 1997;133(11):1433-1440.
38. Fleischer AB et al. Patient measurement of psoriasis disease severity with a structured instrument. *J Invest Dermatol*. 1994;102:967-969.
39. Majeski CJ et al. Itch Severity Scale: a self-report instrument for the measurement of pruritus severity. *Br J Dermatol*. 2007;156(4):667-673.
40. Desai NS et al. A pilot quality-of-life instrument for pruritus. *J Am Acad Dermatol*. 2008;59(2):234-244.
41. Adult Specialty Care Questionnaire 1.0: Agency for Health Care Research and Quality (AHRQ); 2010. http://www.cahps.ahrq.gov/content/products/CG/PROD_CG_CG40Products.asp?p=1021&s=213.
42. Chen SC et al. A catalog of dermatology utilities: a measure of the burden of skin diseases. *J Investig Dermatol Symp Proc*. 2004;9(2):160-168.
43. Delfino M Jr, Holt EW, Taylor CR, et al. Willingness-to-pay stated preferences for 8 health-related quality-of-life domains in psoriasis: a pilot study. *J Am Acad Dermatol*. 2008;59(3):439-447.

Structure and Function of Skin

PART 2

Chapter 4 :: Developmental Biology of the Skin

:: Luis Garza

AT-A-GLANCE

- The skin is divided into 3 layers:
  - *Epidermis:* Forms the barrier to outside world and is the locus of immune surveillance and activation to prevent and combat infections.
  - *Dermis:* Provides the main structural substance (collagen) of skin. Forms a main interface to vasculature and nervous system in the skin, and intimately interfaces with epidermis to coordinate skin function.
  - *Hypodermis:* The area beneath the collagen-rich dermis that is characterized by subcutaneous adipose tissue with a role in energy balance, as well as recently defined roles in epidermis crosstalk and immune surveillance.
- Skin development, as for other organs, occurs in the stepwise progression from more pluripotent to increasingly differentiated cells with specialized function.

How does your entire body form from a single cell? The process of development is perhaps one of the most complicated events in biology, yet occurs with startling fidelity. This chapter discusses how the skin develops as a means to introduce the reader to the structures of the skin; to create a framework to understand normal skin function; and to learn how its normal development is disrupted in a variety of inherited genetic diseases that manifest with skin symptoms.

As science and medicine increasingly converge, knowledge of normal skin development is increasingly important. For example, knowing the normal function of skin structure allows the clinician greater insight into the clinical phenotype during its disruption in the context of skin disease. This is most clearly the case for inherited skin disorders. Also, with the advent of personalized medicine and personal genome sequencing, clinicians will be responsible for interpreting how different inherited polymorphisms will affect patients. Although the field is challenged with making assumptions that findings in mice hold true for humans, the careful study of skin development is not simply an academic exercise, but a method for enhancing patient care.

TYPES OF SKIN CELLS

CELLS OF THE SKIN FORMED DURING DEVELOPMENT

- *Keratinocytes* are the central cells of the epidermis and form the intermediate filament keratins that, among other roles, provide structural resiliency to cells.
- *Fibroblasts* are the central cells of the dermis that, among other roles, secrete collagen, which provides the substance for the dermis.
- *Appendages* are organized structures of keratinocytes and fibroblasts that act together to make hair follicles, eccrine sweat glands, apocrine glands, and the nail unit.
- *Melanocytes* are cells that reside predominantly in the epidermis and synthesize melanin whose primary function is to absorb and block the sun's damaging ultraviolet light.
- *Langerhans cells* are immune cells that reside predominantly in the epidermis, and internalize and present potentially harmful antigens encountered in the environment to initiate an immune response.
- *Sensory neurons* monitor touch, pressure, temperature, and hair follicle movement.
- *Arterioles* and *venules* connect to the cardiovascular system.

- *Lymph vessels* return interstitial fluid to the circulatory system.
- *Merkel cells* live in the epidermis and sense touch.
- *Immune cells* develop elsewhere, but are important components of the skin and include T cells, B cells, dendritic cells, macrophages, neutrophils, and mast cells.

CENTRAL DEVELOPMENTAL SIGNALING PATHWAYS

- *Wnt ligands* are extracellular secreted proteins that likely have important posttranslational modifications such as palmitoylation and activate the frizzled receptors to eventually stabilize *β-catenin*, causing its nuclear translocation from cytoplasmic-associated or cytoskeletal-associated structures. β-Catenin controls epithelial differentiation, stem cell function, appendage function.
- *p63* is a transcription factor with multiple isoforms that is perhaps the central regulator of epithelial identity. Without p63, epidermis fails to stratify or fully form, which leads to failure of appendage formation.
- *Shh ligands* are extracellular secreted proteins that bind the smoothened receptor and eventually activate the *Gli* family of transcription factors. Shh is very important to hair follicle formation and function.
- *EDAR* (ectodysplasin A receptor) is a receptor for the EDA (ectodysplasin A) ligand and part of the tumor necrosis factor (TNF) receptor family. It is critically important for the development of appendages.
- The ligands Delta or Jagged bind the receptor *Notch* which initiates transcription and epidermal differentiation.
- *BMP* (bone morphogenic protein) ligands are a family of ligands that bind BMP receptors and, among other functions, regulate hair follicle cycling and growth.
- *HOX* (homeobox) transcription factor family is important in large-scale body patterning.

STRUCTURES OF THE SKIN

The structures of the skin are defined by how they support skin function, and the process of development is the acquisition of this final functional unit (Fig. 4-1). For example, because the foremost function of skin is as a barrier to prevent outside materials from entering the body, the *epidermis*, or outer layer of the skin, develops an intricate layered arrangement with the most mature surface layer being the most resistant for ingress of foreign material. Other important functions include resisting trauma, protecting from ultraviolet light, repelling infections, sensing the environment, thermoregulation, and energy metabolism. These different systems within the skin develop at different rates, and are discussed in more depth below.

As mentioned, the outermost layer of the skin is the epidermis. The cell that composes the majority of the epidermis is the *keratinocyte*, so named because the structural protein keratin is abundant in that cell. Keratinocytes are stacked in layers of increasingly more mature states until they are effectively ghosts of cells that serve only as a barrier and have little to no energy consumption. In aggregate, the epidermal layers are thicker in areas of the palms and soles, which are subjected to more pressure, and thinner in areas without such pressure, such as the eyelids. Each layer is defined by different keratins, and keratins also differ by body site. In fact, the same general arrangement of keratinocytes that mature from normal epidermis toward dead cells in the epidermis also is how teeth and hair are formed. Although in the general epidermis the dead keratinocytes are regularly released to allow for the next layer to mature and replace it, in hair and teeth those cells are retained to form the final "keratinized" structure. It is important to emphasize that many cells besides keratinocytes reside in the epidermis, including nerve cells that pierce the basal lamina, a vital scaffolding structure that separates the epidermis from the dermis, the next most internal layer of skin.

While keratins are the protein most abundant in the epidermis, collagens are the most abundant protein in the dermis. Leather used in clothing is effectively dermis and represents well the strength that collagens afford to the skin. As discussed in section "Mesenchyme/Fibroblast and Adipose Development", there are also a wide variety of unique collagens with different functions. The primary cell of the dermis is the fibroblast, which produces collagens but has a large repertoire of other functions. Within the general area of the dermis are also structures such as the invaginated epithelium of the hair follicle or the sweat gland. These invaginated areas of epithelium often become a hub for the other components of the dermis: blood vessels, lymphatic vessels, nerves, and a host of cells of hematopoietic origin.

The final layer is the *hypodermis* or the subcutaneous tissue, which transitions to the fascial layers. Although there is a greater abundance of adipocytes and much less collagen, many of the other components of the dermis are shared with the hypodermis, but, for example, with vessels and nerves of higher caliber.

GENERAL SUMMARY OF EMBRYONIC DEVELOPMENT

Human development occurs through 40 weeks of gestation, and is commonly subdivided into trimesters (Table 4-1). The week of development is typically counted beginning from the last menstrual period. The developing human is called a fetus at around 8 weeks

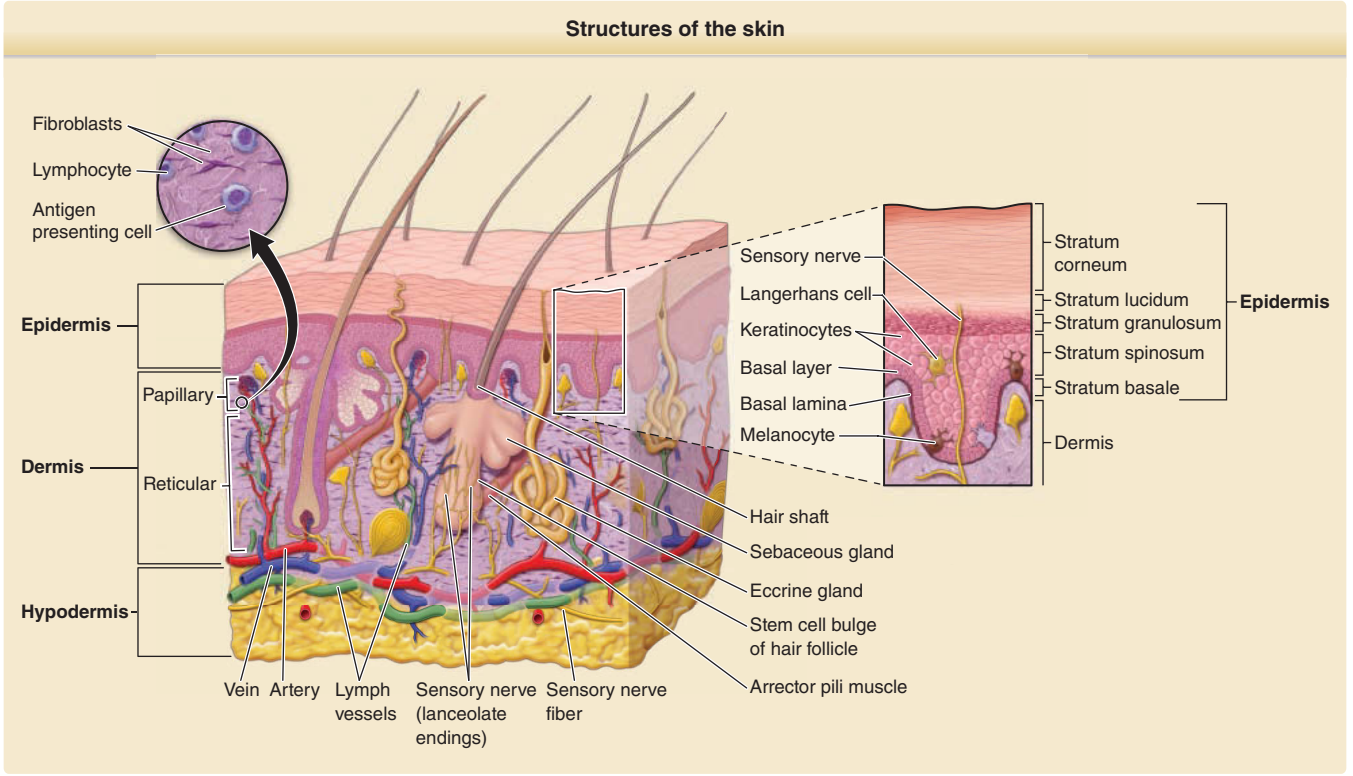

Figure 4-1 Structures of the skin. In this schematic, the general architecture of skin is depicted and makes clear the complexity required during development for formation of all elements.

TABLE 4-1
Summary of Important Developmental Stages of Skin Development

TRIMESTER	ESTIMATED GESTATIONAL AGE IN WEEKS (APPROXIMATE)	EPIDERMAL DEVELOPMENT	DERMAL DEVELOPMENT	APPENDAGEAL DEVELOPMENT
First	2	Gastrulation begins and ectoderm is formed; single-layer germinativum		
Transition from embryo to fetus:	3	Periderm forms		
	8	Intermediate layer forms		Dental placodes forming
	8	Melanocytes present	Distinct boundary between epidermis and dermis	
	9			Nail placodes form
	10	Langerhans cells present		Hair follicle placodes form
	12	Merkel cells present	Dermal–epidermal junction and basement membrane matures	Sweat gland placodes form on volar sites
Second	13		Papillary distinct from reticular dermis	
	24	Periderm sloughs	Elastic fibers visible	
Third	27			
	40	Birth		

Data from Bolognia JL, Jorizzo JL, Rapini RP, eds. *Dermatology*. New York: Mosby Elsevier; 2003.

after arms and legs have developed and show motion. This occurs during the first trimester, from weeks 0 to 12 of estimated gestational age, when organogenesis has mostly completed. The second trimester occurs from weeks 12 to 26 and is marked by continuous development, for example, the appearance of downy hair in the infant. The third trimester runs from weeks 26 to 40 and is when most development completes, including the formation of the vernix caseosa from the skin whose function is thought to lubricate for the passage through the birth canal. Interestingly, skin function is not complete even at birth as final full-barrier formation occurs afterward.

The most complicated steps of development occur at the earliest times when the skin begins to form within the first 2 weeks of development. Several canonical structures characterize early development: *morula, blastula, gastrula,* and then *somatogenesis*, and *organogenesis*. After fertilization, the initial unstructured multiplication of cells leads to the formulation of a morula. The morula divides to form a more complicated structure called a blastula, which has 2 main parts. The first is the trophoblast, which is destined to become the parts of the placenta of fetal (as opposed to maternal) origin, namely the chorion, amnion, allantois. The second is the inner cell mass (ICM), which is destined to become the actual embryo. As the ICM differentiates into 3 germ layers it becomes the gastrula, which is the first stage where skin development separates from the development of other organs.

The 3 germ layers that form during gastrulation include the *ectoderm*, the *mesoderm*, and the *endoderm*. The ectoderm forms eventually the epidermis and melanocytes, but also the nervous system. The mesoderm forms fibroblasts, blood vessels, muscles, and bone. The endoderm does not contribute to skin development. There are some exceptions to these generalities, such as some fibroblast subpopulations that actually originate from the ectoderm, as they are thought to be derived from the neural crest.

NEURAL CREST AND SOMITE DEVELOPMENT

Neural crest development is important in the skin as it contributes to structures such as melanocytes and fibroblasts, and is therefore also involved in some clinical diseases where neural crest does not mature correctly.

Neural crest development initiates during the third week of fetal life when the ectoderm forms the neural plate within it. The ectoderm is the outermost layer of the ICM and sits upon the mesoderm. A plate of cells within the ectoderm differentiates into the future central nervous system. However, at the junction between the neural plate and the ectoderm, a distinct group of cells, known as the neural crest form. During gastrulation, the neural plate forms a valley in the ectoderm, and as it does, the edges of the valley actually rise up; this raised area is the boundary between the ectoderm and the neural plate and is termed the *neural crest*, as the crest of a hill. Eventually the valley becomes so deep and narrow that top parts of the ectoderm fuse and the neural plate detaches to become the neural tube. The neural crest cells, however, are not retained in either the ectoderm or the neural tube, but instead remain free in the mesoderm. Interestingly, there are some differences

in terms of when the neural tube closes and when the neural crest cells migrate away, probably as a clue to their function. In the head, the neural crest migrate even before neural tube closure, and contribute to dermal fibroblasts in the face and anterior scalp. In the trunk, it is the last event. Neural crest cells are thought to specifically secrete the Wnt1 ligand, an important signaling molecule that activates the transcription factor and cytoskeletal protein, β-catenin.

Neural crest cells continue to migrate after neural tube morphogenesis. After detaching from the ectoderm or the neural tube, neural crests migrate either dorsally or ventrally. Persistent neural crest cells that do not complete migrations and differentiate into melanocytes are hypothesized to contribute to common blue nevi.

By the third week of human development, the mesoderm condenses into regular-spaced cuboidal segments termed *somites*, which are lateral to the neural tube. Although they mostly contribute to the axial skeleton and muscles, early somite fibroblasts are also precursors for dermal fibroblasts. Many of these fibroblasts—especially from body locations such as the back—originate from the dorsolateral portions of the somite, which is also called the *dermatomyotome*. Many diseases are associated with defects in neural crest migration, some of which affect melanocytes (see section "Melanocyte and Differentiation"). Non–melanocyte-related diseases of neural crest migration include DiGeorge syndrome where 22q11.2 deletion results in defects in cardiac, craniofacial, and endocrine organs, among others.[1]

EPIDERMIS DIFFERENTIATION

The final epidermis is a strong barrier consisting of a carefully stratified sequential layer of keratinocytes, so named because of their abundant synthesis of keratins, which are intermediate filaments with broad roles in regulating cell function even outside of their central role of providing structural support.[2] The final mature layers of the epithelium are very well defined with characteristic keratins expressed at each stage, typically with unique pairs of both a type I keratin and a type II keratin. The lack of development of some these keratins through mutations causes some blistering epidermolysis bullosa diseases, and is just one example of a family of proteins necessary for epidermal function. Understanding epithelial development (Fig. 4-2) will guide understanding of these diseases.

The development of the epidermis is unique in that it is destined to function at the air interface, but develops in the liquid environment of the amnion, and thus undergoes some unique stages that are never repeated in life. These stages are named after the layers that form such that the first is periderm formation, followed by intermediate layer formation, and, finally, full maturation.

Epidermal development begins soon after gastrulation. Although it is mostly complete in the first trimester, it is not fully complete until after birth. Skin forming begins when the ectoderm converts to a single layer known as the *germinativum*—a cuboidal, mitotically active and undifferentiated layer. It expresses the gene *p63*, which is vital for epidermal differentiation and also corrupted in the EEC syndrome. Coincident with p63 expression is conversion from the more primitive cytokeratins KRT8 and KRT18 to the more mature basal layer keratins KRT5 and KRT14.[3] At 15 days the periderm layer forms above it, which appears as flattened cells with tight junctions and polarized cytoskeletal adhesions. The periderm initially expresses the cytokeratin KRT17 and then cytokeratin KRT6. Genes that control periderm formation include *SFN*, *IRF6*, and *IKKα*, likely partially through the nuclear factor kappa B (NF-κB) pathway. Hypothesized functions for the periderm include transport of and/or protection from material from the amnion, regulation of the dermis, and contribution to epithelial maturation. Recent evidence suggests it is also a protective layer that prevents pathologic adhesions to adjacent epithelium, so that lack of periderm formation leads to the human cocoon syndrome.[4]

At around 60 days of gestation, the intermediate layer is formed between the periderm on the outside and the germinativum layer. The intermediate layer probably forms through asymmetric cell divisions in basal layer keratinocytes,[5] much as is thought to occur for suprabasal layer formation in adults. In this case, 1 daughter cell continues to function as a stem cell in the basal layer, while its asymmetric sibling cell moves upward to begin differentiation. Following the formation of these 3 layers of embryonic skin, stratification of the epidermis begins coincident with the conversion to a fetus. Barrier formation is patterned, at least in mice, initiating at the dorsum and head. From there, it moves posteriorly and toward dorsal and ventral midlines. Characteristics of low transepidermal water loss and full exclusion of dyes as tests of mature epidermis are not reached until after birth.

Defects in the establishment of the skin barrier in humans are related to the clinical ichthyosis syndromes, also called defects in cornification. A wide variety of genes are important in the establishment of the skin barrier, and disruption of any of them can, in varying degrees, cause disease. Perhaps the most common is ichthyosis vulgaris with defects in the filaggrin protein, which is present in keratohyalin granules in the upper epidermis, from which the term *granular* layer derives. But others include defects in keratins of the suprabasal layer (KRT1 and KRT10), or in enzymes that crosslink proteins to make an impermeable layer (transglutaminases), or in lipid-metabolizing enzymes whose products are important for cornification (ALOX).[6]

MESENCHYME/ FIBROBLAST AND ADIPOSE DEVELOPMENT

The dermis is formed from the mesodermal layer of the embryo; consequently, it is referred to as mesenchyme. Important structures, such as blood vessels

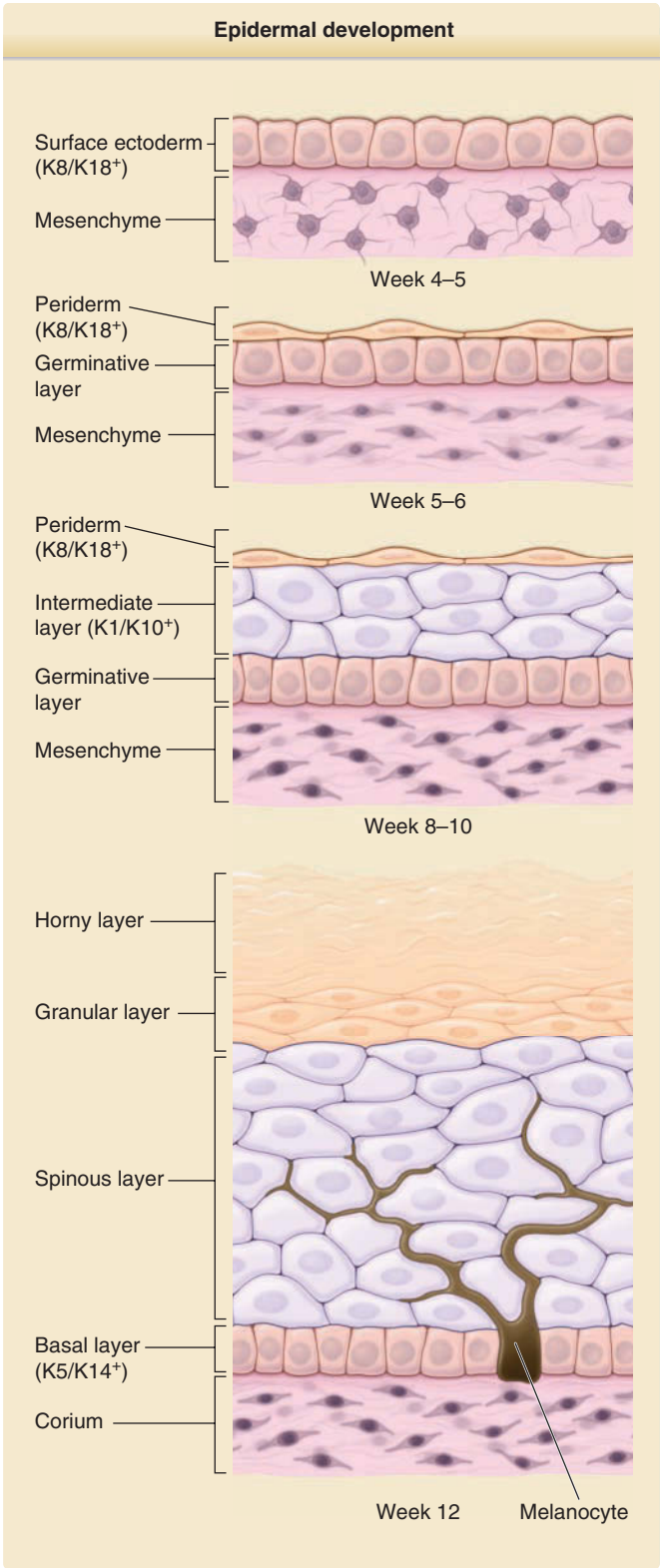

Figure 4-2 Epidermis development. Shown are the intermediate stages of skin development and acquisition of postnatal keratin expression.

and nerves, are discussed in sections "Development of the Cutaneous Nerves and Vasculature". Besides these, the primary cell type that supports the dermis is the fibroblast, which—despite a monomorphic appearance on histology—is likely a very heterogenous population. Although fibroblasts are most appreciated for their ability to abundantly secrete collagens and other extracellular matrix molecules, they are very critical even to epithelial cell function in many contexts, often depending on their location in the body and their subtype within that area of skin.[7]

The first type of fibroblast heterogeneity is the diversity of distinct lineages found at distinct body locations such as those at the distal fingertips compared to the proximal arm. Whereas fibroblasts from the ventral body are thought to derive from lateral plate mesoderm, fibroblasts from the head are thought to develop more from neural crest precursors, and those, for example, of back skin are more likely to develop from somites (and more specifically dermatomyotomes). This heterogeneity of fibroblast origin might partially explain the different features of skin in these areas, such as the high density of hair follicles in the head compared to the abdomen (see next paragraph). Even within a body part such as the limb, fibroblasts have distinct developmental origins whose signature is retained even in adulthood.[8] In particular, fibroblasts are programmed with a specific combination of *HOX* genes, which, even after culturing of fibroblasts, are retained to specify, for example, proximal to distal location with functional consequences such as the thick hairless skin on the palms and soles. This is consistent with the vital role of HOX in specifying body patterning, where mutations can lead to large-scale changes, such as legs appearing where antennae should be in Antennapedia *Drosophila* mutants.

Although the evidence is somewhat mixed, the mesenchymal cells are considered to be regulators of keratinocyte function.[9] In tissue-swapping studies where positionally mismatched epidermis and dermis layers are juxtaposed (eg, palmo-plantar dermis with haired epidermis), fibroblasts can "reprogram" keratinocyte function in some cases. Although contamination remains a theoretical concern,[10-14] this is one example suggesting that fibroblasts are not merely important for synthesis of extracellular proteins, but actually help dictate epidermal identity and function.

There is also heterogeneity of fibroblasts within a given location of skin. A common fibroblast progenitor (in mice characterized by the markers PDGFRa, Dlk1, and Irig1) gives rise to two general linages of fibroblasts, one destined for the upper dermis and one for the lower dermis. The upper dermal fibroblast progenitor (PDGFRa+, Blimp1+, Dlk−, Irig1+) become dermal papillae (a ball of fibroblasts that control hair keratinocytes), arrector pili muscle (muscle attached to hair that causes goosebumps), and the fibroblast of the upper dermis termed *papillary fibroblasts*. These fibroblasts are unique in their greater density and biased synthesis of collagens such as collagen III over collagen I. Interestingly, more detail is emerging on how these precursors differentiate and localize, such as the role of nephronectin as a maturation signal in the hair follicle stem cell compartment to induce arrector pili muscle differentiation.[15] The lower dermal fibroblast progenitor (PDGFRa+, Blimp1−, Dlk1+) give rise to not only adipocytes but to the reticular fibroblasts (lower density and biased collagen I over collagen III production). These reticular fibroblasts also differentiate to myofibroblasts during wounding, which promotes wound closure and likely also scarring. A separate group has defined another population of fibroblasts that promotes scarring in wounds and is classified by high engrailed (eng1) expression during development.[16] Although more work is needed to define the intersections of these populations and what differentially controls them, the startling heterogeneity of fibroblasts is quite clear.

One interesting developmental feature of fibroblasts is that they maintain their mesodermal capacity to transdifferentiate, for example, into bone and fat in culture, especially those from the dermal papillae, or fibroblasts surrounding the hair follicle in the hair sheath. These are classic defining features of mesenchymal stem cells derived from the bone marrow, but mesenchymal stem cells are thought to be distinct from most resident dermal fibroblasts, and not a normal component of the dermis, and do not contribute to dermis formation.[7,17] Similarly, pericytes, which are fibroblasts closely associating with blood vessels, also likely do not contribute to dermis formation.

Adipose cells have long been appreciated to have important roles in energy balance. Recently, however, a wider role has been appreciated, such as in immune surveillance[18] and coordinating hair cycling.[19] Adipocytes develop from lower dermal fibroblast progenitors. Similar to the diversity of fibroblasts, there also is an important diversity of adipocytes. Perhaps the central distinction is between white adipose cells, which function to store energy as lipid, and brown adipose, which function to burn energy through the uncoupling of oxidative phosphorylation to generate heat. In humans, brown adipose cells are thought to be located in the subcutaneous tissue at the paracervical/interscapular and supraclavicular areas.[20] Even though peroxisome-proliferator-activated receptor γ (PPARγ) is an important transcription factor for both white and brown adipose development, Prdm16 appears to be uniquely important for brown adipose development.[21] How brown adipocytes might modulate skin function in health and disease is an important area of future study.

Hallmark clinical syndromes of defects in mesenchymal development include focal dermal hypoplasia or Goltz syndrome caused by mutations in the *PORC* gene, which is important for Wnt molecule secretion. In Goltz syndrome, dermal atrophy manifests as fat herniations appearing as soft yellow to red nodules appearing in Blaschko lines and ulcers at sites of absent skin, among other symptoms. Analogous clinical syndromes for adipose tissue include the lipodystrophy syndromes such as Berardinelli-Seip where a lack of adipose development occurs from defects in the lipid synthesizing *AGPAT2* gene.[22]

MELANOCYTE DIFFERENTIATION

The dynamics of melanocyte development are clues to multiple human pigmentation inherited diseases, and perhaps even melanoma. For example, multiple hypotheses exist to explain the treatment-resistance and metastatic potential of melanomas such as their intrinsic ability to resist oxidative damage. Another posits that their considerable migration during development might be recapitulated in metastatic potential. Indeed, the great distances melanoblasts migrate beg the question on how the behavior might be different among less versus more migratory populations once the melanoblasts reach their destination. Melanocytes can be detected by the eighth week estimated gestational age (EGA)[23] in human epidermis.

Melanocytes derive from the neural crest as described in section "Neural Crest and Somite Development" migrating from the closing neural tube. Their precursor is a *SOX10*-positive progenitor, which also can differentiate into glial cells in addition to melanocytes. When differentiating into melanocytes, they begin to express the critical transcription factor MITF (microphthalmia-associated transcription factor), and also DCT and KIT proteins. These precursor cells actually can lose expression of MITF and KIT to revert to a melanoblast—the adult melanocyte stem cells—that live in the hair follicle bulge stem cell compartment. These melanoblasts differentiate through asymmetric divisions to mature melanocytes (expressing TYR [Tyrosinase]) that populate the hair follicle to give pigment to hair.[24] In addition to populating hair follicles, melanoblasts are thought to home to sweat glands where they might contribute to acral melanomas. These melanocyte stem cells supply interfollicular melanocytes as well, most dramatically during ultraviolet light therapy for patients with vitiligo.

There are a number of clinical correlates to the development of melanocytes. Melanocytes are present in the dermis more in development and less in adults. However, dermal melanocytes are thought to persist after birth in several locations, including the dorsa of the hands and feet, the sacrum/buttocks, and the scalp. These areas are clinically important because they are also common sites for blue nevi. Another example of defective melanocyte development is piebaldism where disrupted melanocyte migration secondary to defects in, for example, c-kit growth factor signaling lead to areas of albinism.

DEVELOPMENT OF THE CUTANEOUS NERVES

The skin has an extensive array of sensory neurons which during development requires careful orchestration for correct placement. Multiple types of sensory nerves can be divided based on their sensation (touch versus temperature), their location (deeper dermal Pacini pressure sensor versus hair-based touch pressure), and, most commonly, the degree of myelination (Aβ, Aδ, or C fibers).[25]

In the skin, sensory neurons develop from the trigeminal (head) or dorsal root ganglia (elsewhere). The sensory nerves of the skin begin development following motor neurons.[26] However, rather than terminating in muscles as do motor neurons, somatosensory nerves of the skin continue toward the tissue periphery. The cues for this divergence likely originate from keratinocytes, and current suggestions for the identity of these cues include heparin sulfate proteoglycans and the leukocyte-antigen–related family receptors on neurons. How they are regulated differentially in more densely innervated areas such as volar sites is an exciting question that has not been firmly resolved.

Merkel cells, which are the cause of a very malignant cutaneous neoplasm, act to tune mammalian touch receptors.[27] They develop from basal-layer keratinocytes, as proven with their absence in mice where the gene *Atoh1* is deleted in the KRT14+ keratinocytes.[28] Consistent with their function, Merkel cells are found as early as 12 weeks EGA with particular high density at volar sites, appendages, and nerves.[29] Another example of the development of epithelial sensors from keratinocytes are the taste buds of the tongue, which, consistent with a shared ectodermal heritage, are evidence of the developmental plasticity between keratinocytes and neuronal-like cells.[30]

ADNEXAL DEVELOPMENT

Adnexal structures refer to all the skin appendages, or specialized arrangements of keratinocytes for unique functional purposes such as hair, nail, or sweat production. These appendages actually have similarities in development to actual limb appendages, as seen in mice where deletions in β-catenin or p63 lead to embryos with limb deformations as well as skin appendage formation.

The best studied of these appendages is the hair follicle. The exciting analogy to development of the hair follicle is that even in the adult, the hair goes through repeating cycles of apoptosis followed by regeneration, which partially recapitulates development. During normal hair cycling, however, the bulge stem cell compartment is maintained, unlike during development where it is formed de novo. Nevertheless, it has been rediscovered that—at least in mice—adults may fully recapitulate the organogenesis of hair follicles, with even the reformation of the stem cell compartment.[31]

How does embryogenesis of a hair occur (Fig. 4-3)? One consensus is that the earliest step in hair development is initiated by the activity of β-catenin in keratinocytes rather than fibroblasts, but this opinion has shifted and it is now thought that initiation of development by β-catenin activity in keratinocytes and fibroblasts might be effectively simultaneous. These epidermal and dermal signals determine how the regular spacing of hair follicles is generated. Mathematical models of reaction–diffusion involving both activators

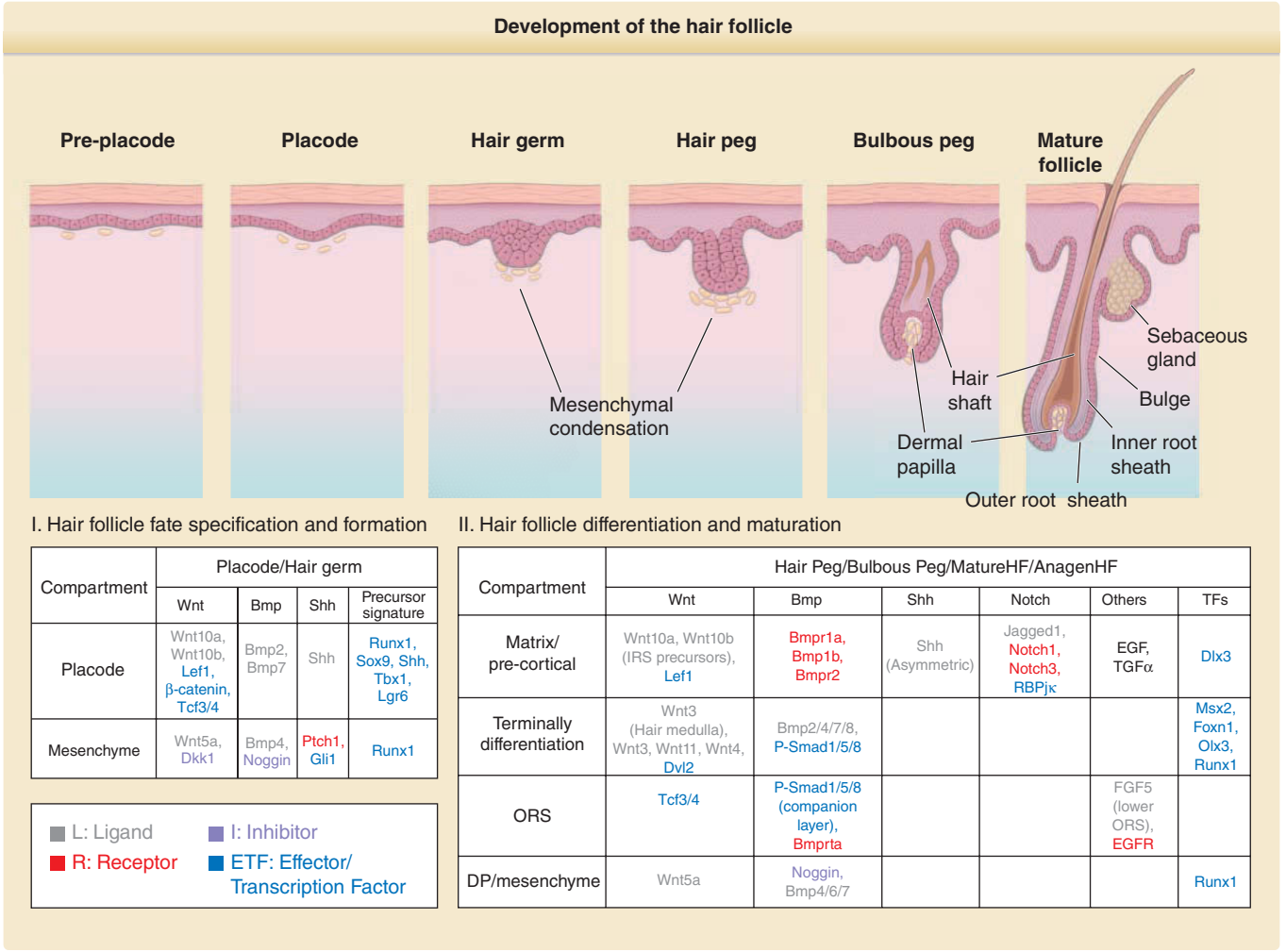

I. Hair follicle fate specification and formation

Compartment	Placode/Hair germ			
	Wnt	Bmp	Shh	Precursor signature
Placode	Wnt10a, Wnt10b, Lef1, β-catenin, Tcf3/4	Bmp2, Bmp7	Shh	Runx1, Sox9, Shh, Tbx1, Lgr6
Mesenchyme	Wnt5a, Dkk1	Bmp4, Noggin	Ptch1, Gli1	Runx1

L: Ligand
I: Inhibitor
R: Receptor
ETF: Effector/ Transcription Factor

II. Hair follicle differentiation and maturation

Compartment	Hair Peg/Bulbous Peg/MatureHF/AnagenHF					
	Wnt	Bmp	Shh	Notch	Others	TFs
Matrix/ pre-cortical	Wnt10a, Wnt10b (IRS precursors), Lef1	Bmpr1a, Bmp1b, Bmpr2	Shh (Asymmetric)	Jagged1, Notch1, Notch3, RBPjκ	EGF, TGFα	Dlx3
Terminally differentiation	Wnt3 (Hair medulla), Wnt3, Wnt11, Wnt4, Dvl2	Bmp2/4/7/8, P-Smad1/5/8				Msx2, Foxn1, Olx3, Runx1
ORS	Tcf3/4	P-Smad1/5/8 (companion layer), Bmprta			FGF5 (lower ORS), EGFR	
DP/mesenchyme	Wnt5a	Noggin, Bmp4/6/7				Runx1

Figure 4-3 Hair follicle development. Shown are the stages of hair follicle during development, with a focus on the overlapping signaling pathways between initial hair follicle morphogenesis and postnatal hair cycling. (Adapted from Lee J, Tumbar T. Hairy tale of signaling in hair follicle development and cycling. *Semin Cell Dev Biol*. 2012;23(8):906-916, with permission. Copyright © Elsevier.)

and inhibitors can effectively generate regular repeating nodes of activity, which, given the similarity to hair follicle regular arrangement, suggests that this occurs in vivo.[32] Signals involved in patterning are thought to include Wnt, but also BMP and FGF (fibroblast growth factor) signaling, among others. In this complete process, signals emanate at first broadly, and then become more localized and patterned to reflect the final tissue architecture. The broad outline of hair development shares similarities with the development of both teeth and mammary glands, among other structures.

The earliest morphologic changes are the formation of a hair placode in the epidermis, where the keratinocytes become thinner, columnar, and tightly packed. This occurs around 75 days EGA, and is accompanied by accumulations of congregated or condensed fibroblasts beneath the epidermis. The following stage is the hair germ phase (80 days EGA; sometimes referred to as hair bud), which is the more pronounced downward movement of epithelium forming a clear nubbin, followed by continued downward epithelial invasion through the peg stage (100 days EGA). During the peg stage, the epithelium begins to wrap around and encompass the associated inductive fibroblast population, which is now called the dermal papillae. Some authors include a final bulbous peg stage, by the end of which the sebaceous glands are formed. At the end of hair follicle development, the follicle is capable of creating a keratinized shaft, lanugo hair. Lanugo hair refers to the first wave of hair production and emerges around 130 days EGA. Interestingly, not all hairs develop simultaneously, and most lanugo hair is shed before birth.

The hair follicle stem cell compartment, termed *the bulge*, is so named because during development this area (located roughly between the arrector pili muscle and the sebaceous gland in the area termed *the isthmus*) is rounded out as a bulge in the otherwise straighter edge of the hair follicle.[33] In recent years, novel, distinct, stem cell populations of the hair follicle are being defined, some even outside of the bulge region, with many marked by the specific members of the LGR family of Wnt coreceptors.[34]

As mentioned above, an array of signals helps define the patterning of hair follicle development. Similarly, an orchestra of signals coordinate the final steps of morphogenesis. The activity of β-catenin is perhaps the most important for appendage development. Mice with activated versions of β-catenin in keratinocytes, for example, form supernumerary hair follicles. Downstream genes that are activated and necessary for morphogenesis include the ectodysplasin ligand (EDA) and receptor (EDAR) functions. For example, human mutations in EDAR cause syndromes where individuals are born with fewer hair follicles and sweat glands. Other genes important for hair development include the *Shh*, *BMP*, and *FGF* pathways.[35] Interestingly, different structures within the hair respond to these signals differently. For example, sebaceous gland differentiation is dependent on low activity of the β-catenin pathway, but also c-Myc, the androgen receptor, and p53, among others.[36]

Sebaceous glands develop during the bulbous peg phase from SOX9+ LRIG1+ hair follicle keratinocyte stem cells during 13th to 14th weeks of fetal life. Interestingly, while sebaceous glands have a dip in activity during childhood, they are more active during embryogenesis (in the production of the vernix caseosa) and puberty.[36] Classic sebaceous glands are always associated with hair follicles and do not exist alone, but variations of the sebaceous gland labeled as orphan sebaceous glands include the meibomian gland of the eye, the Fordyce spots of the mouth, the Tyson glands of the prepuce, and the Montgomery glands of the female areola.

Despite increased attention, less is known regarding the developmental dynamics of other appendage structures, such as the orphan sebaceous glands. Many overlaps exist, such as the primacy of epithelial–mesenchymal interactions and the involvement of the β-catenin and EDAR pathways. For example, sweat gland and nail development require EDAR, as evidenced even in small natural variants of EDAR (V370A), which confer changes in humans such as thick hair, incisor tooth shoveling, and increased eccrine sweat gland density.[37] Other similarities are that just as lanugo hair is an initial wave of keratinization, nails also have a preliminary nail that is complete and then shed in utero during the second trimester. Nail development also requires HOX programming (see HOX discussion in section "Mesenchyme/Fibroblast and Adipose Development") as is evident by patients with nail-patella with mutations in the HOX gene *LMX1b*.[21] Sweat glands in the volar skin develop around 12 to 13 weeks EGA, and the rest of the body at 20 weeks, following the same pattern of placode formation as a hair follicle.

Besides hair, nails, and sweat glands, the final appendage of the skin is the apocrine gland found in the hormonally responsive areas of the axillae and genitals. As apocrine glands are absent from most, if not all, regions of the mouse, little research has defined their developmental biology. Also, besides the above appendageal organs, there are other specialized keratinized structures, such as dermatoglyphs, the technical term for ridges responsible for characteristic fingerprints. Volar dermatoglyphics development begins around week 7 EGA when protuberances in palms and soles, called *volar pads*, appear.[38] The substance of volar pads are accumulations of grouped fibroblasts. As the volar pads involute, epidermal ridges appear as a result of local hyperproliferation of the basal layer of epidermis. There are several rounds of epidermal ridge development and also much more to learn about this process.

VASCULATURE

The vasculature are an essential development step for the continued growth and viability of the skin. The stem cells that contribute to the development of vessels are called *angioblasts*, and develop from mesoderm differentiating toward the endothelial lineage through signals such as Indian hedgehog (Ihh), FGF2, BMPs, and vascular endothelial growth factor (VEGF).[39]

The angioblasts begin as scattered cells in the mesoderm, but then coalesce and form tubes with lumens as they complete their differentiation toward endothelial cells. Following this, they arborize and sprout to extend themselves[39] to mature in reactions involving TGF-β and platelet-derived growth factor (PDGF). Angiopoietin-1 is required for the recruitment of associated cells such as pericytes.

Current models posit that cutaneous vasculature develops following cues from previously established skin peripheral sensory neurons.[40] For example, in mutants where nerve branching is misrouted, arteries follow these spurious patterns, likely through the activity of the provascular growth hormone, VEGF. This still begs the question of how veins and arteries generate a parallel alignment. This alignment is important to minimize heat loss, such that arteries warm returning venous blood along the vascular plexus. While the EphrinB2 released by arteries as a ligand for EphB4 receptor on veins is important to maintain the arteriovenous (A-V) plexus,[41] how arteries and veins are juxtaposed has only recently been elucidated. In one current model, the signaling agent Apelin is produced from arterial endothelial cells, and stimulates chemotaxis and expression of APJ, a G-protein–coupled receptor, on venous endothelial cells to promote A-V alignment.[42]

Explanations regarding the differential density of vasculature according to skin site—such as the higher density of vessels in the scalp versus the back dermis—are likely related to local cues such as from Netrins, VEGF, Slit, and Semaphorins. Contributing to this will be differences in nerve development, but also in appendageal development such as hair follicles. Given that appendageal formation often precedes full sensory neuronal development, the further elucidation of secreted factors by hair follicles or sweat glands, for example, that guide the development of nerves and vasculature is an important future area of investigation.

Lymphatic development occurs through the maturation of established venous endothelial cells that express PROX1. These cells bud and migrate off to establish lymph vessels, first in regions of VEGF-C expression in the lateral mesoderm.

There exists also a large variety of clinical syndromes with aberrant development of the vasculature. One hallmark disease is the Sturge-Weber syndrome where defects in the gene *GNAQ* cause prominent port-wine stains on the face, as well as intracranial vascular anomalies leading to seizures and mental retardation, among other symptoms, and which is more concerning than the port-wine stains.

HEMATOPOIETIC CELLS IN THE SKIN

Hematopoietic cells of the skin are of numerous types, with novel subsets often being defined, but which generally include lymphocytes and myeloid cells. Their development is varied, and, of course, the earliest development of blood cells occurs outside of the skin.[43] The yolk sac of the developing embryo is the first to contribute blood cells by supplying the nucleated red cells which supply oxygen to the developing embryo. The yolk sac also generates some important myeloid lineages, such as the skin-specific antigen presenting cells known as the Langerhans cell. Langerhans cells are detectable by 10 weeks of gestation.[44] The second wave of development of hematopoietic cells occurs in the dorsal aorta, with later contributions from the liver. Here, the hematopoietic stem cells are generated that eventually can give rise to all blood cell lineages, as well as reconstitute an entire bone marrow.

Besides Langerhans cells, how do other immune cells take residence in the skin? Recent work highlights that not all T cells simply cycle through the epidermis from the blood and lymph nodes, but that a dedicated repertoire of resident tissue memory T cells are important to maintain immunity. Resident central memory T cells, which reside in lymph nodes, likely share a common naïve T-cell precursor for these skin-specific T cells, but are developed in adults and not in embryos.[45]

Defective hematopoietic cell development can cause hallmark syndromes in the skin, including hyperimmunoglobulin E (hyper-IgE) syndrome or Job syndrome where signal transducer and activator of transcription 3 (STAT3) mutations—a vital signaling molecule in lymphocytes—leads to impaired T-helper cell 17 (TH17) development and, instead, to excessive T-helper cell 2 (TH2) profile of eosinophilia and hyper-IgE characterized by chronic eczema and recurrent skin *Staphylococcus aureus* infections.

MOSAICISM

An important developmental correlate to skin diseases is mosaicism, where an embryo acquires a novel mutation in the process of development.[48] This results in the birth of a child where a subset of cells–the daughter cell lineage from the first cell to acquire the mutation–are mutated at that DNA, while the remaining cells are comparatively healthy. The geographic pattern of disease on the individual is then a direct window on the patterns of development and expansion from the original cell. The distinct morphologies in mosaicism are varied and important, but the most classic is commonly referred to as Blaschko's lines that consists of either linear expansions, or curving patterns of the growing mutant clone that are affected by the new mutation.[48]

CONCLUSIONS

The 2012 Nobel Prize in Medicine was awarded to Shinya Yamanaka for the first defined cocktail of genes that would convert a skin fibroblast into a totipotent embryonic stem cell capable of making any tissue, the induced pluripotent stem cell (IPSC). This has ushered in a new race to understand the exact cues necessary

to engineer every cell in the body. In this way, patient-specific stem cells could be generated with simultaneous correction of genetic lesions before reimplantation into affected areas. Alternatively, unique genetic models could be made for research tools. For skin biologists, the careful understanding of skin development is a first step toward eventually harnessing the power of cellular therapy as an entirely new therapeutic domain. Although the field of developmental skin biology has been very productive, there still remain large gaps in our knowledge that are relevant to this and other avenues to improving human health.

REFERENCES

1. Menendez L, Kulik MJ, Page AT, et al. Directed differentiation of human pluripotent cells to neural crest stem cells. *Nat Protoc.* 2013;8(1):203-212.
2. Pan X, Hobbs RP, Coulombe PA. The expanding significance of keratin intermediate filaments in normal and diseased epithelia. *Curr Opin Cell Biol.* 2013;25(1):47-56.
3. Sumigray KD, Lechler T. Cell adhesion in epidermal development and barrier formation. *Curr Top Dev Biol.* 2015;112:383-414.
4. Richardson RJ, Hammond NL, Coulombe PA, et al. Periderm prevents pathological epithelial adhesions during embryogenesis. *J Clin Invest.* 2014;124(9):3891-3900.
5. Lechler T, Fuchs E. Asymmetric cell divisions promote stratification and differentiation of mammalian skin. *Nature.* 2005;437(7056):275-280.
6. Williams ML, Elias PM. Genetically transmitted, generalized disorders of cornification. The ichthyoses. *Dermatol Clin.* 1987;5(1):155-178.
7. Driskell RR, Watt FM. Understanding fibroblast heterogeneity in the skin. *Trends Cell Biol.* 2015;25(2):92-99.
8. Chang HY, Chi JT, Dudoit S, et al. Diversity, topographic differentiation, and positional memory in human fibroblasts. *Proc Natl Acad Sci U S A.* 2002;99(20):12877-12882.
9. Pearton DJ, Yang Y, Dhouailly D. Transdifferentiation of corneal epithelium into epidermis occurs by means of a multistep process triggered by dermal developmental signals. *Proc Natl Acad Sci U S A.* 2005;102(10):3714-3719.
10. Billingham RE, Silvers WK. Studies on the conservation of epidermal specificies of skin and certain mucosas in adult mammals. *J Exp Med.* 1967;125(3):429-446.
11. Doran TI, Vidrich A, Sun TT. Intrinsic and extrinsic regulation of the differentiation of skin, corneal and esophageal epithelial cells. *Cell.* 1980;22(1 Pt 1):17-25.
12. Mackenzie IC, Hill MW. Connective tissue influences on patterns of epithelial architecture and keratinization in skin and oral mucosa of the adult mouse. *Cell Tissue Res.* 1984;235(3):551-559.
13. Boukamp P, Breitkreutz D, Stark HJ, et al. Mesenchyme-mediated and endogenous regulation of growth and differentiation of human skin keratinocytes derived from different body sites. *Differentiation.* 1990;44(2):150-161.
14. Konstantinova NV, Lemak NA, Duong DM, et al. Artificial skin equivalent differentiation depends on fibroblast donor site: use of eyelid fibroblasts. *Plast Reconstr Surg.* 1998;101(2):385-391.
15. Fujiwara H, Ferreira M, Donati G, et al. The basement membrane of hair follicle stem cells is a muscle cell niche. *Cell.* 2011;144(4):577-589.
16. Rinkevich Y, Walmsley GG, Hu MS, et al. Skin fibrosis. Identification and isolation of a dermal lineage with intrinsic fibrogenic potential. *Science.* 2015;348(6232):aaa2151.
17. Higashiyama R, Nakao S, Shibusawa Y, et al. Differential contribution of dermal resident and bone marrow-derived cells to collagen production during wound healing and fibrogenesis in mice. *J Invest Dermatol.* 2011;131(2):529-536.
18. Zhang LJ, Guerrero-Juarez CF, Hata T, et al. Innate immunity. Dermal adipocytes protect against invasive *Staphylococcus aureus* skin infection. *Science.* 2015;347(6217):67-71.
19. Festa E, Fretz J, Berry R, et al. Adipocyte lineage cells contribute to the skin stem cell niche to drive hair cycling. *Cell.* 2011;146(5):761-771.
20. Virtanen KA, Lidell ME, Orava J, et al. Functional brown adipose tissue in healthy adults. *N Engl J Med.* 2009;360(15):1518-1525.
21. Harms M, Seale P. Brown and beige fat: development, function and therapeutic potential. *Nat Med.* 2013;19(10):1252-1263.
22. Nolis T. Exploring the pathophysiology behind the more common genetic and acquired lipodystrophies. *J Hum Genet.* 2014;59(1):16-23.
23. Holbrook KA, Underwood RA, Vogel AM, et al. The appearance, density and distribution of melanocytes in human embryonic and fetal skin revealed by the anti-melanoma monoclonal antibody, HMB-45. *Anat Embryol (Berl).* 1989;180(5):443-455.
24. Mort RL, Jackson IJ, Patton EE. The melanocyte lineage in development and disease. *Development.* 2015;142(7):1387.
25. Lumpkin EA, Caterina MJ. Mechanisms of sensory transduction in the skin. *Nature.* 2007;445(7130):858-865.
26. Wang F, Julien DP, Sagasti A. Journey to the skin: somatosensory peripheral axon guidance and morphogenesis. *Cell Adh Migr.* 2013;7(4):388-394.
27. Maksimovic S, Nakatani M, Baba Y, et al. Epidermal Merkel cells are mechanosensory cells that tune mammalian touch receptors. *Nature.* 2014;509(7502):617-621.
28. Morrison KM, Miesegaes GR, Lumpkin EA, et al. Mammalian Merkel cells are descended from the epidermal lineage. *Dev Biol.* 2009;336(1):76-83.
29. Moll I, Moll R, Franke WW. Formation of epidermal and dermal Merkel cells during human fetal skin development. *J Invest Dermatol.* 1986;87(6):779-787.
30. Castillo D, Seidel K, Salcedo E, et al. Induction of ectopic taste buds by SHH reveals the competency and plasticity of adult lingual epithelium. *Development.* 2014;141(15):2993-3002.
31. Ito M, Yang Z, Andl T, et al. Wnt-dependent de novo hair follicle regeneration in adult mouse skin after wounding. *Nature.* 2007;447(7142):316-320.
32. Sick S, Reinker S, Timmer J, et al. WNT and DKK determine hair follicle spacing through a reaction-diffusion mechanism. *Science.* 2006;314(5804):1447-1450.
33. Cotsarelis G, Sun TT, Lavker RM. Label-retaining cells reside in the bulge area of pilosebaceous unit: implications for follicular stem cells, hair cycle, and skin carcinogenesis. *Cell.* 1990;61(7):1329-1337.
34. Barker N, Tan S, Clevers H. Lgr proteins in epithelial stem cell biology. *Development.* 2013;140(12):2484-2494.

35. Biggs LC, Mikkola ML. Early inductive events in ectodermal appendage morphogenesis. *Semin Cell Dev Biol.* 2014;25-26:11-21.
36. Niemann C, Horsley V. Development and homeostasis of the sebaceous gland. *Semin Cell Dev Biol.* 2012;23(8):928-936.
37. Kamberov YG, Wang S, Tan J, et al. Modeling recent human evolution in mice by expression of a selected EDAR variant. *Cell.* 2013;152(4):691-702.
38. Babler WJ. Embryologic development of epidermal ridges and their configurations. *Birth Defects Orig Artic Ser.* 1991;27(2):95-112.
39. Bautch VL, Caron KM. Blood and lymphatic vessel formation. *Cold Spring Harb Perspect Biol.* 2015; 7(3):a008268.
40. Mukouyama YS, Shin D, Britsch S, et al. Sensory nerves determine the pattern of arterial differentiation and blood vessel branching in the skin. *Cell.* 2002;109(6):693-705.
41. Pasquale EB. Eph receptor signalling casts a wide net on cell behaviour. *Nat Rev Mol Cell Biol.* 2005;6(6):462-475.
42. Kidoya H, Naito H, Muramatsu F, et al. APJ regulates parallel alignment of arteries and veins in the skin. *Dev Cell.* 2015;33(3):247-259.
43. Golub R, Cumano A. Embryonic hematopoiesis. *Blood Cells Mol Dis.* 2013;51(4):226-231.
44. Fujita M, Furukawa F, Horiguchi Y, et al. Regional development of Langerhans cells and formation of Birbeck granules in human embryonic and fetal skin. *J Invest Dermatol.* 1991;97(1):65-72.
45. Gaide O, Emerson RO, Jiang X, et al. Common clonal origin of central and resident memory T cells following skin immunization. *Nat Med.* 2015;21(6):647-653.
46. Lee J, Tumbar T. Hairy tale of signaling in hair follicle development and cycling. *Semin Cell Dev Biol.* 2012;23(8):906-916.
47. Bolognia JL. *Dermatology.* New York, NY: Mosby; 2003.
48. Happle R. The categories of cutaneous mosaicism: A proposed classification. *Am J Med Genet A.* 2016 Feb;170A(2):452-459. doi: 10.1002/ajmg.a.37439. Epub 2015 Oct 22.

Chapter 5 :: Growth and Differentiation of the Epidermis

:: Terry Lechler

AT-A-GLANCE

- Epidermal homeostasis and wound healing are driven by proliferation of stem/progenitor cells in the basal layer.
- Epidermal differentiation is a tightly regulated process that is controlled by the interplay between transcription factors, chromatin modifiers, and posttranscriptional regulators.
- Terminal differentiation results in 2 barriers, tight junctions and the cornified envelopes, which protect us from the external environment.

INTRODUCTION

The epidermis must maintain a largely impenetrable barrier to the outside world over the course of a lifetime. Simultaneously, it rapidly turns over, replacing itself every 2 weeks, and retains the ability to heal wounds. To accomplish these divergent roles, the epidermis has a highly regulated proliferation/differentiation program. Progenitor cells within the basal layer of the epidermis have a very high capacity for proliferation and self-renewal, whereas the major role for differentiated cells is generation of a barrier. In this chapter, we will discuss the current understanding of the roles of stem cells in interfollicular epidermis, how proliferation is controlled in basal cells, and how multiple pathways and structures collaborate to generate an epidermal barrier. Of note, some of these findings are drawn from studies in mouse skin, which is architecturally distinct from human epidermis. However, in many cases, there are studies of cultured human cells or human disease correlates that substantiate some of the findings in mice.

EPIDERMAL GROWTH

EPIDERMAL STEM CELLS

Stem cells are progenitor cells that can both renew themselves and give rise to differentiated progeny over an extended time period. The ability of the epidermis to continually regenerate itself and to heal wounds indicates that it must contain stem cells. Further, the pioneering work of Howard Green and colleagues allowed for the growth of these epidermal stem cells in culture, which was a great boon to understanding many aspects of epidermal stem cell biology. In addition, their work allowed for the clinical use of cultured epidermal stem cells in treating burn wounds, an early example of the utility of adult stem cells in regenerative therapy.[1] Here, we will describe some current aspects of the state of knowledge of stem cells within interfollicular epidermis. Of note, however, is that this has lagged behind our understanding of stem cells of the hair follicle (discussed in Chap. 7).

When cells are cultured from the human epidermis under standard conditions, they are heterogeneous in their self-renewing ability. Some undergo only a few rounds of division and may reflect transit-amplifying cells, a highly proliferative but short-lived cell population. The cells that self-renew robustly are putative stem cells. Consistent with this difference in activity, isolated basal cells express varying levels of a number of genes, including β1 integrin, LRIG1, and CD46.[2-4] Cells with high expression of these genes have higher self-renewing capacity in vitro and tend to form clusters in intact skin. This data are consistent with the presence of a distinct stem cell pool within the basal layer. Single-cell sequencing approaches have further demonstrated that there is likely to be heterogeneity even in this enriched pool of stem cells.[4] Although it is difficult to determine the functional roles and consequences of this heterogeneity in human skin in situ, these types of studies are possible in the mouse. However, there has been continued debate about the hierarchical makeup of progenitors within the mouse epidermis. Although some studies suggest that the basal layer is composed of a single unipotent population, others have provided evidence for at least 2 types of progenitor cells that differ in proliferation dynamics and marker expression.[5-9] It is expected that in the next few years, a much clearer picture of the regulation and functions of these distinct cell types will emerge.

EPIDERMAL STEM CELL NICHE

The tissue microenvironment in which stem cells normally exist is called their niche. Niches are continually being more thoroughly defined and include factors such as direct cell-cell and cell-matrix communication, soluble secreted factors (including inflammatory,

nervous, and other tissue resident cells), and local tissue mechanical properties. The niche for stem cells in the human interfollicular epidermis is not clear. Various studies have suggested that they are located dispersed throughout the basal layer, or at either the tops or bottoms of rete ridges. Part of this may reflect regional differences in skin architecture as well as the early stages of our ability to mark and track these specific cell types. Regardless of their position, the progenitor cells in the basal layer largely produce differentiated progeny that form in columns directly above them.[10] Although progenitor cells can be lost or can expand laterally (to a limited degree) in a stochastic manner, they give rise to differentiated cells that move through the layers without significant lateral movement.[5,7,11]

EPIDERMAL PROLIFERATION

The epidermis requires continuous proliferation for both homeostatic turnover and wound healing. However, inappropriate proliferation occurs in many pathologic conditions, including cancer and psoriasis. Uncovering the underlying mechanisms regulating proliferation is therefore expected to reveal pathologic mechanisms and treatment options. It is thus important to understand the hierarchy/types of progenitor cells to determine whether there are specific kinds of cells that are amplified or hyperproliferative in response to different stimuli, whether cells are inhibited from differentiating and what molecular pathways are driving the overproliferation.

This is a complex area as many diverse external cues (chemical and mechanical) as well as genetic mutations can impact proliferation. These include endothelial signals, inflammatory signals, and extracellular matrix rigidity to name a few. Many of the major developmental signaling pathways including Wnt, Notch, Yap, and Hedgehog regulate epidermal proliferation in both physiologic and pathogenic states. Major downstream targets include the Ras-MAPK pathway and the PI3K/AKT/PTEN, which regulate growth and entry into and passage through the cell cycle.[12]

EPIDERMAL DIFFERENTIATION

BASAL CELLS

Basal progenitor cells are characterized by their mitotic activity, which is necessary for normal epidermal turnover and wound healing. These cells are most often marked by the expression of keratins 5 and 14 (Fig. 5-1). Keratins are members of the

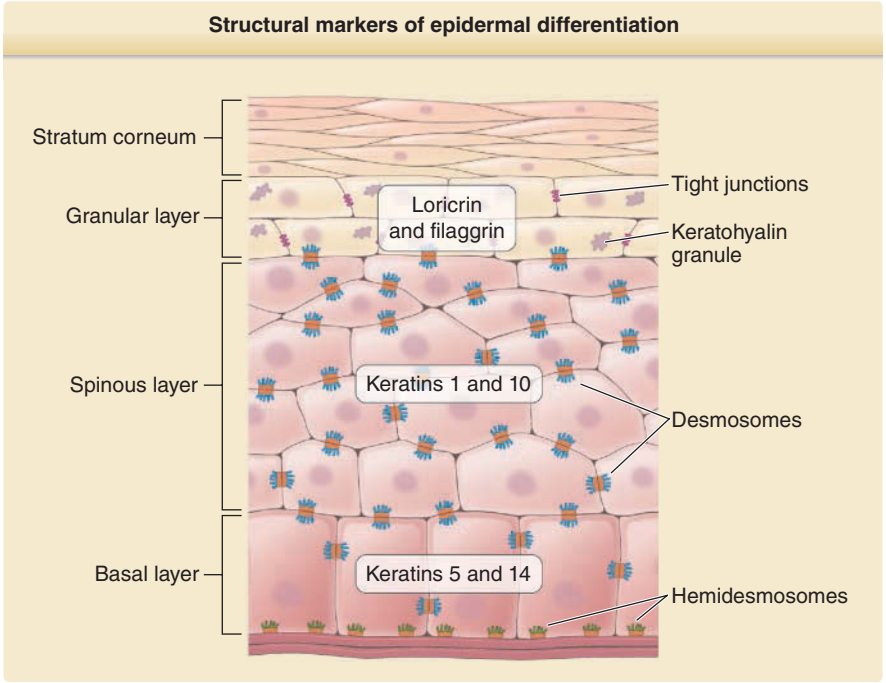

Figure 5-1 Structural markers of epidermal differentiation. Basal cells are defined by basement membrane attachment, the presence of hemidesmosomes, and the expression of keratins 5 and 14. Keratin 1 and 10, in contrast, mark all differentiated cell layers, whereas loricrin and filaggrin are expressed in upper spinous and granular cells. All cells contain desmosomes, though the makeup of desmosomes changes, with desmoglein 3 (Dsg3) and plakophilin 2 (Pkp2) being highly expressed in basal cells whereas Dsg1 and Pkp1 are highly expressed in differentiated epidermis. Tight junctions and keratohyalin granules mark the granular cells.

intermediate filament family of proteins and are obligate heterodimers that assemble to form polymers in the cell.[13] This large family of proteins shows tissue and cell type–specific expression (Table 5-1). In the epidermis, the keratin filaments stabilize both cell-cell adhesions called desmosomes and cell-substratum adhesions called hemidesmosomes. Both of these provide mechanical anchoring roles, and mutations in hemidesmosomal, desmosomal, and keratin genes result in various forms of epidermolysis bullosa (discussed in detail in Chap. 60; see Table 5-2). In addition to hemidesmosomes, basal keratinocytes are attached to the underlying substratum by focal adhesions, which bind to filamentous actin in the cell and play many roles, including promoting survival and proliferation of keratinocytes.[14] All keratinocytes, including basal keratinocytes, have cell-cell adhesions called adherens junctions, which are actin-based structures. Adherens junctions' components have diverse functions from regulating cellular architecture to growth control and inflammation.[15]

Basal keratinocytes give rise to spinous cells during epidermal homeostasis. The production of cells in the suprabasal cell layers is driven by mitotic spindle reorientation and asymmetric cell divisions during embryonic development.[16,17] However, in the adult mouse skin, delamination of basal cells from the underlying basement membrane and their subsequent migration upward appears to predominate.[7] The relative contributions of cell division orientation and delamination is not yet clear in the human epidermis. However, the pathways that control the commitment to differentiation are established in some detail. Here we will first describe characteristics of differentiated cell types followed by the intricate pathways that control differentiation.

TABLE 5-1

Keratin Family Members and Their Sites of Expression[a]

TYPE I KERATINS		TYPE II KERATINS	
NAME	MAIN SITE(S) OF EXPRESSION	NAME	MAIN SITE(S) OF EXPRESSION
K9	Epidermis (suprabasal)	K1	Epidermis (suprabasal)
K10	Epidermis (suprabasal)	K2	Epidermis (suprabasal)
K12	Cornea	K3	Cornea (suprabasal)
K13	Oral mucosa	K4	Oral mucosa (suprabasal)
K14	Complex epithelia	K5	Complex epithelia (basal layer)
K15	Complex epithelia	K6a	Epithelial appendages
K16	Epithelial appendages	K6b	Epithelial appendages
K17	Epithelial appendages	K6c	Skin (needs confirm)
K18	Simple epithelia	K7	Simple epithelia
K19	Broad distribution	K8	Simple epithelia
K20	Gut epithelium		
K23	Pancreas (needs confirm)		
K24	unknown		
K25-K28	Inner root sheath (hair follicles)	K71-K74	Inner root sheath (hair follicles)
		K75	Companion layer (hair follicles)
		K76	Oral mucosa
		K77	Sweat gland ducts
		K78	Tongue
		K79	Skin
		K80	Tongue
K31-K38	Hair shaft (hair follicles)	K81-K86	Hair shaft (hair follicles)
K39	Hair shaft (hair follicles)		
K40	Hair shaft (hair follicles)		

[a]This list was originally generated by Pierre Coulombe, John Stanley, and Tung-Tien Sun and published in the previous edition of this book.

SPINOUS CELLS

Basal to spinous differentiation is a highly regulated transition. Cells switch from a mitotic, keratin 5/14–expressing type to a postmitotic state characterized by the expression of keratins 1 and 10. There is an upregulation of desmosomes in these cells that gives them a spiny appearance in histologic sections. The composition of desmosomes also changes on differentiation. Although basal cells are high in the desmosomal cadherin, Dsg3, the levels of this protein decrease through differentiation whereas Dsg1 is upregulated.[18] Consistent with this, disruption of Dsg3-based junctions (as occurs in pemphigus vulgaris) results in disruption of cell-cell adhesion between basal cells and between the basal cells and the first layer of spinous cells. Perturbation of Dsg1 (which occurs in pemphigus foliaceus) results in blistering in more superficial layers of the epidermis.

GRANULAR CELLS

The identifying feature of these cells is keratohyalin granules. These granules are composed of keratins, profilaggrin and loricrin, and other proteins that make up the bulk of the cornified envelopes. Filaggrin and loricrin are also commonly used markers for these cell layers. Upon secretion, keratins and loricrin as well as other proteins, including small proline-rich proteins, become highly crosslinked by transglutaminase to the plasma membrane to generate cornified envelopes.

TABLE 5-2
Keratin-Based, Inherited Skin Bullous Disease Affecting Primarily the Epidermis[a]

DISEASE	RELEVANT OMIM CATALOG NUMBER(S)[a]	TARGET GENES	AFFECTED CELL TYPE	COMMENTS
Epidermolysis bullosa simplex	131800 (Koebner subtype) 131800 (Weber-Cockayne) 131760 (Dowling-Meara)	K5 or K14	Basal keratinocyte	K, WC, and DM correspond to different degrees of severity; the position/nature of the mutation in K5 or K14 is a key determinant Rare mutations in the same genes result in recessive inheritance (OMIM #60100)
Epidermolysis bullosa simplex with mottled pigmentation	131960	K5	Basal keratinocyte	A single dominant allele, K5P28L, has been found in multiple pedigrees. Typified by hyperpigmentation of healed skin blisters
Epidermolysis bullosa simplex with limb girdle muscular dystrophy	226670 (also,131950)	Plectin	Basal keratinocyte	Plectin is a cytolinker protein attaching IFs to adhesive complexes and F-actin/microtubules in keratinocytes and myocytes
Dowling-Degos disease	179850	K5 (null)	Basal keratinocyte	Inherited recessively; features multiple aberrations in skin pigmentation
Epidermolytic hyperkeratosis	113800	K1 or K10	Spinous keratinocyte	Same as bullous congenital ichthyosiform erythroderma. As for EBS, there is wide variation in severity of clinical presentation, correlating with the position and nature of the mutation affecting either K1 or K10
Ichthyosis hystrix (Curth-Macklin)	146490; 146600	K1 or K10	Spinous keratinocyte	Characteristic ridges or spikes present at the skin surface. Ultrastructurally, presence of large bundles of densely packed IFs around nucleus
Ichthyosis bullosa of Siemens palmoplantar keratodermas:	146800	K2e	Granular keratinocyte	Affects primarily flexural areas; blistering confined to the upper suprabasal layers; can be confused with mild EHK/BCIE Confined to the epidermis of palms and soles
▪ Epidermolytic	144200	K9	Spinous keratinocyte	Reflects the unique distribution of this large type I keratin
▪ Nonepidermolytic	139350 (diffuse) 600962 (focal)	K1 or K16	Spinous Keratinocyte	This is one of the rare conditions for which the Pathogenesis is not indicative of cell fragility; may reflect a nonmechanical role for keratins
▪ Striate	607654	DP, Dsg1, or K1	Spinous keratinocyte	Desmoplakin (DP) and desmoglein 1 (Dsg1) are structural components of desmosomes, to which keratin IFs are attached in epidermis

[a]Note: See the Intermediate Filament Database (*www.interfil.org*) and Online Mendelian Inheritance in Man (*www.ncbi.nlm.nih.gov/omim/*) websites for further information.

Profilaggrin is eventually metabolized into amino acids and pyrrolidone carboxylic acid and urocanic acid (sometimes referred to as natural moisturizing factor [NMF]) to provide hydration and UV protective functions.

Many of the genes required for formation of the terminal differentiated epidermis are contained in the epidermal differentiation complex, a region on chromosome 1q21. These include loricrin, involucrin, small proline-rich proteins, and late cornified envelope proteins to name a few. The transcriptional regulation of this complex is under tight control and is one of the major targets of the differentiation cascade.

It is also in the granular cells that one barrier to loss of fluids occurs. Tight junctions are cell-cell adhesions that restrict the flow of fluids and ions and act as a barrier to membrane diffusion. These structures form specifically in the granular layer, thus allowing diffusion in the intercellular spaces of live cells within the lower layers of the epidermis. At the core of tight junctions are claudins and genetic disruption of claudin 1 results in lethal barrier defects in mice and neonatal ichthyosis in humans.[19,20] The mechanisms underlying the specific formation of tight junctions in granular cells are not currently known.

The last function of granular cells is to die. The resulting cornified envelopes are not living cells, and thus nuclear and cytoplasmic contents must be eliminated. This is thought to be a modified form of programmed cell death.

STRATUM CORNEUM

Cornified envelopes are the products of terminal differentiation in the epidermis. They are acellular and anuclear structures. The core consists of keratins surrounded by highly crosslinked networks of proteins, especially loricrin. Specialized lipids surround these, rich is ceramides that are also crosslinked. The crosslinking is largely contributed by transglutaminases. Transglutaminase expression begins in the spinous layer, but it is inactive there. Both increased calcium and cofactors are thought to specifically activate transglutaminase in the upper granular layer. The crosslinking of proteins and the presence of specialized lipids result in mechanical stability and relative impermeability of the epidermis. While the stratum corneum forms an outside-in barrier, the tight junctions form an inside-out barrier and thus collaborate to form an effective barrier to the external environment.

REGULATION OF EPIDERMAL DIFFERENTIATION

As discussed above, a number of criteria are used to describe differentiation in epidermis. These include, but are not limited to, proliferation rate, expression of transcription factors, keratins and other structural proteins, and ultrastructural analyses. The structural changes that accompany differentiation are highly regulated by a cascade of pathways, including signaling pathways, transcriptional control, epigenetic factors, and posttranscriptional regulation. Though complex, we present some of the major players below that highlight the roles of these various pathways in generating the differentiated structures that are necessary for epidermal barrier formation.

TRANSCRIPTIONAL REGULATORS

p63 controls epidermal specification, but it also plays an important role in maintaining basal cell fate/proliferation and induction of differentiation.[21] Direct targets of p63 include both structural proteins and other transcription factors that regulate differentiation. One of these transcription factors, ZNF750, is in turn required for expression of another transcription factor Klf4, which plays a major role in expression of granular genes.[22] Klf4 upregulates the expression of a number of lipid-modifying enzymes and structural proteins important for cornified envelope production.[23,24] p63 also acts by controlling the epigenetic status of the genome, discussed below.

Notch signaling is a commitment factor for transition of basal cells to spinous cells.[25-27] It is absent in basal cells and activated in spinous cells. Inhibiting Notch signaling prevents many aspects of spinous cell fate, whereas activating it in basal cells is sufficient for some aspects of spinous differentiation. Although some direct targets of Notch are known, such as Hes1, a direct pathway to spinous gene expression is unclear. In some contexts, Notch collaborates with transcription factors of the AP-2 gene family to function. For example, Notch induces the expression of a transcription factor, C/EBP, in spinous cells that binds along with AP-2 factors to the promoter of keratin 10, regulating its expression.[28,29]

Transcription factors of the Grainyhead-like (GRHL) are also key promoters of epidermal differentiation. Most prominently, GRHL3 is required for efficient barrier formation, in part through regulating the expression of transglutaminase-1.[30]

Some major regulators of epidermal differentiation are highlighted in Fig. 5-2, which shows their general expression profiles and sites of action.

EPIGENETIC REGULATORS

Epigenetic regulators control the organization and/or accessibility of chromatin for transcriptional regulation. In the epidermis, differentiation is driven by coincident expression of transcription factors and chromatin states.[31]

DNA METHYLATION

Methylated DNA is usually associated with a repressive transcriptional environment. In the epidermis, this is important for suppressing expression of differentiation genes in the basal layer. Loss of the methyltransferase DNMT1 results in loss of progenitor function and premature expression of differentiation-associated genes.[32]

HISTONE MODIFICATIONS

Chromosomal DNA is organized by histones that are subject to regulatory posttranslational modifications, including methylation and acetylation, that regulate transcriptional factor occupancy. A specific methylation (lysine 27 of Histone H3) of many epidermal differentiation genes, including those from the epidermal differentiation complex, represses their expression in basal cells, whereas loss of methylation promotes differentiation.[33] Methylation also inhibits other cells' fates, such as keratinocytes giving rise to mechanosensory Merkel cells.[34] Regulated histone acetylation is also essential for epidermal differentiation. In part this is due to binding of histone deacetylases to the same gene promoters that p63 represses, highlighting the central role of the p63 axis in epidermal homeostasis.[35]

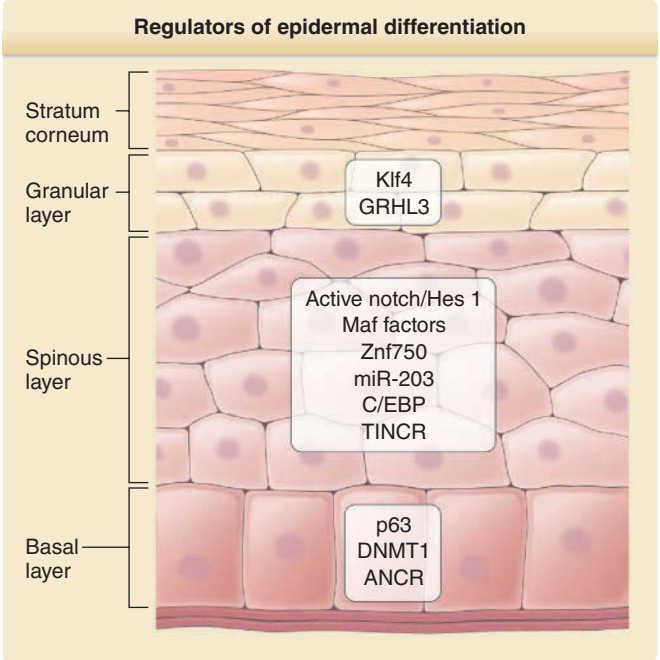

Figure 5-2 Regulators of epidermal differentiation. Transcription factors and epigenetic regulators of epidermal proliferation and differentiation are indicated. The position of the labels corresponds to the area of the epidermis where the factor is first expressed. Although direct interactions and regulations are known between some of these factors, this is both complex and incompletely understood. The text provides additional insight into cross-regulation and structural target genes.

CHROMATIN REMODELERS

This final category of epigenetic regulators is also important for proper differentiation. The SWI/SNF complex is active in differentiated cells of the epidermis, and mutations in these genes result in differentiation and barrier defects.[36] In contrast, when they are activated in basal cells, premature differentiation occurs.[37] In part, the activity of the SWI/SNF complex acts through expression of KLF4, one of the key terminal differentiation-inducing transcription factors. The physical localization of the EDC complex is also controlled by chromatin remodeling factors such as Satb and Brg1, thus exposing another layer of regulation of expression of terminal differentiation genes.[38]

POSTTRANSCRIPTIONAL REGULATION

Once transcripts are generated, there is additional control over mRNA stability and translation. This level of regulation is also key to an ordered differentiation program in the epidermis.

miRNA: miRNAs are short noncoding RNAs that generally function to modulate the levels/translation of a number of target mRNAs. One important example in the epidermis is mIR-203, which is expressed in spinous cells where it represses p63 expression, among other targets, thus ensuring proper differentiation.[39]

lncRNA: A second class of regulatory RNAs is the long noncoding (lncRNAs). In the epidermis, the 2 best characterized are ANCR and TINCR, which work to promote basal cell fate and differentiated cell fate, respectively. ANCR acts, in part, by recruiting histone methyltransferase to certain promoters. TINCR, in contrast, is upregulated in differentiated cells, where it stabilized the differentiation promoting mRNAs such as Klf4 and Grhl3.[40]

Transcript Regulation: In addition to the above pathways, recent work has highlighted roles for regulated translation/degradation of mRNAs. For example, GRHL3 is expressed at low levels in basal cells because of its mRNA being unstable. Loss of the machinery that promotes GRHL3 degradation caused increased GRHL3 expression and premature differentiation.[41] Similarly, a separate subset of mRNAs of proliferation-promoting genes is positively regulated at the translational level to maintain high levels in basal cells.[42]

CONCLUSIONS

As the epidermis needs to provide an essential barrier to the outside world and to continuously renew itself, the decisions of proliferation and differentiation are highly regulated. Pathologies resulting from dysregulation of this balance, including skin cancers, psoriasis, and ichthyosis, to name a few, are many. Further understanding of the physiologic and pathologic

control of proliferation and differentiation decisions is expected to lead to better treatments. In addition, the incredible regenerative capacity of stem/progenitor cells within the basal layer has already been clinically harnessed to treat burns and genetic skin conditions.

REFERENCES

1. De Luca M, Pellegrini G, Green H. Regeneration of squamous epithelia from stem cells of cultured grafts. *Regen Men.* 2006;1:45-57.
2. Jensen KB, Watt FM. Single-cell expression profiling of human epidermal stem and transit-amplifying cells: Lrig1 is a regulator of stem cell quiescence. *Proc Natl Acad Sci U S A.* 2006;103:11958-11963.
3. Jones PH, Watt FM. Separation of human epidermal stem cells from transit amplifying cells on the basis of differences in integrin function and expression. *Cell.* 1993;73:713-724.
4. Tan DW, Jensen KB, Trotter MW, et al. Single-cell gene expression profiling reveals functional heterogeneity of undifferentiated human epidermal cells. Development (Cambridge, England). 2013;140:1433-1444.
5. Clayton E, Doupé DP, Klein AM, et al. A single type of progenitor cell maintains normal epidermis. *Nature.* 2007;446:185-189.
6. Gomez C, Chua W, Miremadi A, et al. The interfollicular epidermis of adult mouse tail comprises two distinct cell lineages that are differentially regulated by Wnt, Edaradd, and Lrig1. *Stem Cell Reports*. 2013;1:19-27.
7. Rompolas P, Mesa KR, Kawaguchi K, et al. Spatiotemporal coordination of stem cell commitment during epidermal homeostasis. *Science.* 2016;352:1471-1474.
8. Sada A, Jacob F, Leung E, et al. Defining the cellular lineage hierarchy in the interfollicular epidermis of adult skin. *Nat Cell Biol.* 2016;18:619-631.
9. Sanchez-Danes A, Hannezo E, Larsimont JC, et al. Defining the clonal dynamics leading to mouse skin tumour initiation. *Nature.* 2016;536:298-303.
10. Ghazizadeh S, Taichman LB. Organization of stem cells and their progeny in human epidermis. *J Invest Dermatol.* 2005;124:367-372.
11. Mascre G, Dekoninck S, Drogat B, et al. Distinct contribution of stem and progenitor cells to epidermal maintenance. *Nature.* 2012;489:257-262.
12. Lopez-Pajares V, Yan K, Zarnegar BJ, et al. Genetic pathways in disorders of epidermal differentiation. *Trends Genet.* 2013;29:31-40.
13. Pan X, Hobbs RP, Coulombe PA. The expanding significance of keratin intermediate filaments in normal and diseased epithelia. *Curr Opin Cell Biol.* 2013;25:47-56.
14. Watt FM, Fujiwara H. Cell-extracellular matrix interactions in normal and diseased skin. *Cold Spring Harb Perspect Biol.* 2011;3(4). pii:a005124.
15. Sumigray KD, Lechler T. Cell adhesion in epidermal development and barrier formation. *Curr Top Dev Biol.* 2015;112:383-414.
16. Lechler T, Fuchs E. Asymmetric cell divisions promote stratification and differentiation of mammalian skin. *Nature.* 2005;437:275-280.
17. Williams SE, Beronja S, Pasolli HA, et al. Asymmetric cell divisions promote Notch-dependent epidermal differentiation. *Nature.* 2011;470:353-358.
18. Simpson CL, Patel DM, Green KJ. Deconstructing the skin: cytoarchitectural determinants of epidermal morphogenesis. *Nat Rev Mol Cell Biol.* 2011;12:565-580.
19. Furuse M, Hata M, Furuse K, et al. Claudin-based tight junctions are crucial for the mammalian epidermal barrier: a lesson from claudin-1-deficient mice. J Cell Biol. 2002;156:1099-1111.
20. Hadj-Rabia S, Baala L, Vabres P, et al. Claudin-1 gene mutations in neonatal sclerosing cholangitis associated with ichthyosis: a tight junction disease. *Gastroenterology.* 2004;127:1386-139.
21. Koster MI. p63 in skin development and ectodermal dysplasias. *J Invest Dermatol.* 2010;130:2352-2358.
22. Sen GL, Boxer LD, Webster DE, et al. ZNF750 is a p63 target gene that induces KLF4 to drive terminal epidermal differentiation. *Dev Cell.* 2012;22:669-677.
23. Patel S, Xi ZF, Seo EY, et al. Klf4 and corticosteroids activate an overlapping set of transcriptional targets to accelerate in utero epidermal barrier acquisition. *Proc Natl Acad Sci U S A.* 2006;103:18668-18673.
24. Segre JA, Bauer C, Fuchs E. Klf4 is a transcription factor required for establishing the barrier function of the skin. *Nat Genet.* 1999;22:356-360.
25. Blanpain C, Lowry WE, Pasolli HA, et al. Canonical notch signaling functions as a commitment switch in the epidermal lineage. *Genes Dev.* 2006;20:3022-3035.
26. Moriyama M, Durham AD, Moriyama H, et al. Multiple roles of Notch signaling in the regulation of epidermal development. *Dev Cell.* 2008;14:594-604.
27. Rangarajan A, Talora C, Okuyama R, et al. Notch signaling is a direct determinant of keratinocyte growth arrest and entry into differentiation. *EMBO J.* 2001;20:3427-3436.
28. Lopez RG, Garcia-Silva S, Moore SJ, et al. C/EBPalpha and beta couple interfollicular keratinocyte proliferation arrest to commitment and terminal differentiation. *Nat Cell Biol.* 2009;11:1181-1190.
29. Wang X, Pasolli HA, Williams T, et al. AP-2 factors act in concert with Notch to orchestrate terminal differentiation in skin epidermis. *J Cell Biol.* 2008;183:37-48.
30. Ting SB, Caddy J, Hislop N, et al. A homolog of Drosophila grainy head is essential for epidermal integrity in mice. *Science.* 2005;308:411-413.
31. Perdigoto CN, Valdes VJ, Bardot ES, et al. Epigenetic regulation of epidermal differentiation. *Cold Spring Harb Perspect Med.* 2014;4(2). pii:a015263.
32. Sen GL, Reuter JA, Webster DE, et al. DNMT1 maintains progenitor function in self-renewing somatic tissue. *Nature.* 2010;463:563-567.
33. Ezhkova E, Pasolli HA, Parker JS, et al. Ezh2 orchestrates gene expression for the stepwise differentiation of tissue-specific stem cells. *Cell.* 2009;136:1122-1135.
34. Bardot ES, Valdes VJ, Zhang J, et al. Polycomb subunits Ezh1 and Ezh2 regulate the Merkel cell differentiation program in skin stem cells. *EMBO J.* 2013;32:1990-2000.
35. LeBoeuf M, Terrell A, Trivedi S, et al. Hdac1 and Hdac2 act redundantly to control p63 and p53 functions in epidermal progenitor cells. *Dev Cell.* 2010;19:807-818.
36. Indra AK, Dupé V, Bornert JM, et al. Temporally controlled targeted somatic mutagenesis in embryonic surface ectoderm and fetal epidermal keratinocytes unveils two distinct developmental functions of BRG1 in limb morphogenesis and skin barrier formation. Development (Cambridge, England). 2005; 132:4533-4544.
37. Bao X, Tang J, Lopez-Pajares V, et al. ACTL6a enforces the epidermal progenitor state by suppressing

SWI/SNF-dependent induction of KLF4. *Cell Stem Cell.* 2013;12:193-203.
38. Mardaryev AN, Gdula MR, Yarker JL, et al. p63 and Brg1 control developmentally regulated higher-order chromatin remodelling at the epidermal differentiation complex locus in epidermal progenitor cells. Development (Cambridge, England). 2014;141:101-111.
39. Yi R, Poy MN, Stoffel M, et al. A skin microRNA promotes differentiation by repressing "stemness." *Nature.* 2008;452:225-229.
40. Lopez-Pajares V, Qu K, Zhang J, et al. A LncRNA-MAF:MAFB transcription factor network regulates epidermal differentiation. *Dev Cell.* 2015;32:693-706.
41. Mistry DS, Chen Y, Sen GL. Progenitor function in self-renewing human epidermis is maintained by the exosome. *Cell Stem Cell.* 2012;11:127-135.
42. Wang Y, Arribas-Layton M, Chen Y, et al. DDX6 orchestrates mammalian progenitor function through the mRNA degradation and translation pathways. *Mol Cell.* 2015;60:118-130.

Chapter 6 :: Skin Glands: Sebaceous, Eccrine, and Apocrine Glands

:: Christos C. Zouboulis

INTRODUCTION

The human skin has several types of exocrine glands (Latin, *glandulae cutis*), which release their biochemical products onto the skin surface. All skin glands consist by a secretory compartment, the gland or coil (tubulus), and an excretory part, the duct (ductus). Skin gland cells are of epithelial origin, but their secretory compartments are located at different depths in the dermis.

Three major types of skin glands are recognized according to their product, the excretory function, and the location, where the excretory ducts release their products (diseases of these glands are listed in Table 6-1). Regarding their product, skin glands are classified into glands secreting sebum (sebaceous glands) and sweat (sweat glands). Concerning their secretory function, skin glands are classified into holocrine glands, whose fully differentiated secretory cells burst and release both the cytoplasmic content and the cell membranes into their ducts, and merocrine glands, which excrete their product via exocytosis from secretory cells. Regarding the location where their ducts release their product, the ducts of sebaceous glands, in most cases, and apocrine sweat glands excrete their products into the hair follicle canal, and the eccrine sweat glands excrete directly onto the skin surface. Sebaceous glands are holocrine glands, and sweat glands (both eccrine and apocrine ones) are merocrine glands.

SEBACEOUS GLANDS

AT-A-GLANCE

- Sebaceous glands are multilobular structures that consist of acini connected to a common excretory duct and are usually associated with a hair follicle.
- Sebaceous glands vary considerably in size, even in the same individual and in the same anatomic area.
- The sebaceous glands excrete lipids by disintegration of entire cells, a process known as holocrine secretion.
- Human sebum, as it leaves the sebaceous gland, contains squalene, cholesterol, cholesterol esters, wax esters, and triglycerides.
- Sebaceous glands are regulated by several molecules, among them androgens and retinoids.

ANATOMY OF THE SEBACEOUS GLANDS

HISTOLOGY

Human sebaceous glands are multilobular structures of epithelial origin that consist of acini connected to a common excretory duct, the sebaceous duct (ductus seboglandularis) (Fig. 6-1). Sebaceous glands are composed of sebocytes, which are lipid-producing uniquely differentiated epithelial cells.[1,2] On the other hand, the sebaceous duct is lined by undifferentiated keratinocytes and is usually associated with a hair follicle which is composed of stratified squamous epithelium. The periphery of the sebaceous gland is a basal cell layer composed of small, cuboidal, nucleated, highly mitotic sebocytes.[1,3] Cells progress toward the middle of the gland and accumulate lipid droplets (LDs) as they transform into terminally differentiated cells, full of lipids.[3] The latter lack all other cellular organelles, burst, and die, excreting their entire contents to the duct in a holocrine manner (Fig. 6-2). Surrounding the glands are connective tissue capsules composed of collagen fibers that provide physical support.[4]

LOCATION

Sebaceous glands are associated with hair follicles all over the body. A sebaceous gland associated with a hair follicle is termed a *pilosebaceous unit* (see Fig. 6-1). The glands may also be found in certain nonhairy sites, including the eyelids (Meibomian glands, tarsal glands), the nipples (Montgomery glands, areolar glands), around the genitals (Tyson glands), and the mucosa (lips, gums and inner cheeks, and genitals; Fordyce spots).[1] Fordyce spots open and release their content directly to the epithelial surface. The latter are visible to the unaided eye because of their large size (up to 2 to 3 mm) and the transparency of the oral epithelium (Fig. 6-3). Only the palms and soles, which have no hair follicles, are totally devoid of sebaceous glands. In addition, the dorsal surfaces of the hand and foot have sparse sebaceous glands.[5] Sebaceous glands vary considerably in size, even within the same individual and within the same anatomic area. On the external body surface, most glands are only a fraction of a millimeter in size. The largest glands and greatest density of glands are located on the nose (1600 glands/cm^2) followed by the face and scalp (up to 400 to 900 glands/cm^2).[4] The hairs associated with these large glands are often tiny, and the total structure

TABLE 6-1
Diseases of the Major Skin Glands

Diseases of the Sebaceous Glands
Increased activity/volume
Acne vulgaris
Rosacea
(Hyper)seborrhea
Periorificial dermatitis
Hair follicle naevus
Congenital sebaceous gland hyperplasia
Senile sebaceous gland hyperplasia
Sebaceoma (sebaceous gland epithelioma)
Sebaceous carcinoma
Muir-Torre Syndrome
Decreased activity/volume
Senile xerosis cutis
Psoriasis
Lichen planopilaris
Pseudopelade Brocq
Hidradenitis suppurativa
Linear morphea
Chlor- /dioxin-induced acne
Chemotherapy-induced diffuse alopecia
Zouboulis syndrome
Diseases of the Eccrine Glands
Increased activity
Hyperhidrosis (primary and secondary)
Eccrine carcinoma
Decreased activity
Hypohidrosis/Anhidrosis
Abnormal activity/Obstruction of the eccrine duct
Neutrophilic eccrine hidradenitis
Coma bullae
Erythema multiforme
Cystic fibrosis
Miliaria (crystallina, rubra, and profunda)
Syringosquamous metaplasia)
Diseases of the Apocrine Glands
Abnormal activity
Bromhidrosis
Chromhidrosis
Fox-Fordyce disease (apocrine miliaria)
Hidradenitis suppurativa (initially considered as a disease of the apocrine glands; currently as a disease of the terminal hair follicles)

is more specifically termed *sebaceous follicles*, being a pilosebaceous unit variant, the other two being the terminal hair follicle and the vellus hair follicle.

EMBRYOGENESIS AND MORPHOGENESIS

The development of the sebaceous glands is closely related to the differentiation of hair follicles and epidermis.[6-8] At the 10th to 12th weeks of fetal life, a stratum intermedium becomes apparent, and at about the same time, developing hair germs are quite distinct. In the following weeks, the follicles extend downward into the dermis, and the rudiments of the sebaceous glands appear on the posterior surfaces of the hair pegs. By

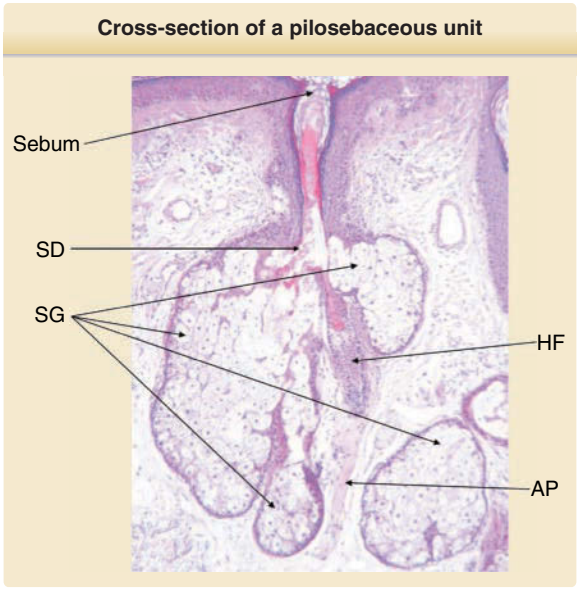

Figure 6-1 Cross-section of a pilosebaceous unit: a multiacinar sebaceous gkland associated with a hair follicle (HF). AP, arrector pili muscle (×20); SD, sebaceous duct, Sebum, sebum and keratin. (Modified with permission from: Zouboulis CC, Tsatsou F. Anatomy of the sebaceous gland. In: Zouboulis CC, Katsambas AD, Kligman AM, eds. *Pathogenesis and Treatment of Acne and Rosacea*. Berlin: Springer; 2014:27-31. Copyright © 2014.)

13 to 16 weeks, the glands are clearly distinguishable, arising in a cephalocaudal sequence from bulges (epithelial placodes) of the hair follicles. The latter contain the epidermal stem cells that generate multiple cell lineages, including epidermal and follicular keratinocytes, as well as sebaceous glands. As daughter cells migrate from the bulge region, changes in the expression patterns of numerous transcription factors determine their final cell lineage. Despite continuous differentiation of its cells, the sebaceous gland can be regenerated by the reservoir of stem cells in the hair follicle bulge. However, retroviral lineage marking has provided strong evidence that the sebaceous gland might arise and be maintained independently of the hair follicle bulge.[9]

Wnt or wingless (Wnt) and Sonic hedgehog (Shh) signaling pathways are intricately involved in embryonic patterning and cell fate decisions. Cells destined to become sebocytes have increased Shh and Myc signaling and decreased Wnt signaling (Fig. 6-4A).[10,11] In human SZ95 sebocyte and transgenic mouse models, whereas intact Wnt signaling promotes hair follicle differentiation, inhibition of Wnt signaling by preventing the Lef1–B-catenin interaction leads to sebocyte differentiation.[11,12] Loss of function and gain of function in both models demonstrated that blocking Shh signaling inhibited normal sebocyte differentiation, and constitutively activating Shh signaling increased the number and size of human sebocytes and mouse sebaceous glands in skin.

Several important molecular aspects of sebaceous gland development have been identified, mostly with the aid of genetically modified cell lines. The earliest known signal necessary for sebaceous gland

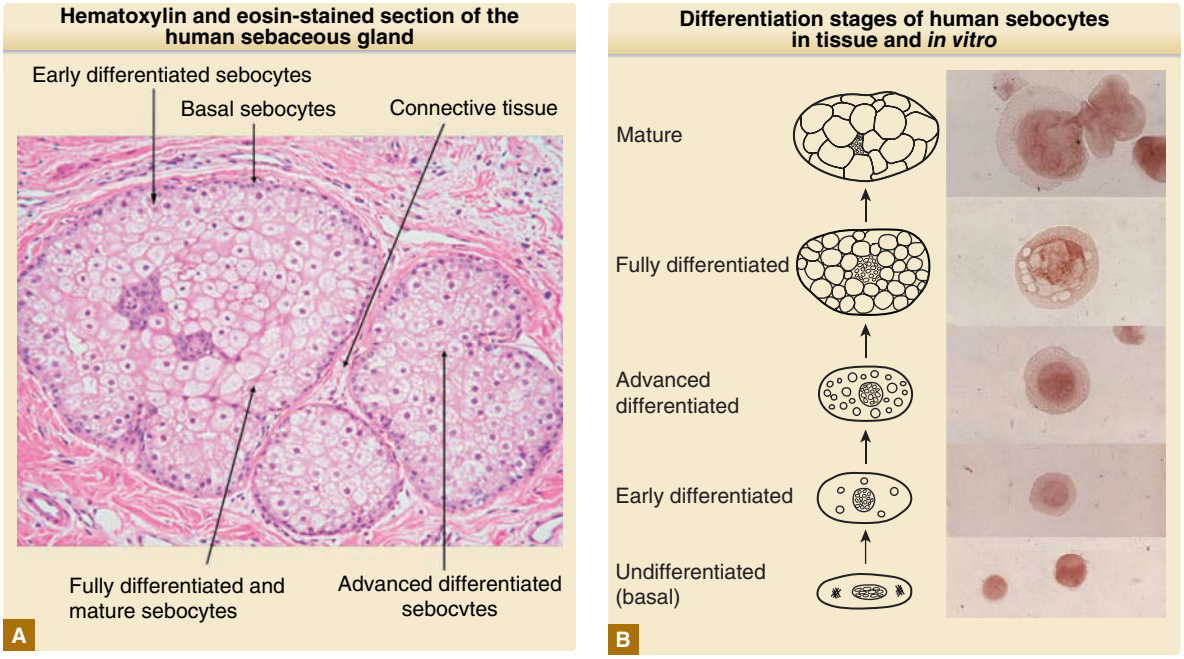

Figure 6-2 **A,** Hematoxylin and eosin–stained section of the human sebaceous gland showing the different stages of sebocyte differentiation. Cells progress toward the middle of the gland, lose their nuclei, and organelles, and accumulate lipid droplets. **B,** Differentiation stages of human sebocytes in tissue *(left)*[19] and in vitro *(right)*[3] according to Tosti17 and McEwan Jenkinson and coworkers.[18] Undifferentiated sebocytes are small cells with a high nucleocytoplasmic ratio. Early differentiated sebocytes are larger cells with a decreased nucleocyloplasmic ratio compared with the undifferentiated sebocytes and a few lipid droplets arranged in the perinuclear area. Advanced differentiated sebocytes are cells with further increases in size and decreases of the nucleocytoplasmic ratio. Multiple cytoplasmic lipid droplets are distributed inside the cytoplasm. Fully differentiated sebocytes are cells with abundant, partially large, cytoplasmic lipid droplets. Mature sebocytes are disorganized large cell with denatured nucelei; the lack of cytoplasmic lipids is caused by lysis of the cell blood cell membrane.

development is SOX9, which is in fact essential for the specification of early hair follicle stem cells and therefore for the morphogenesis of both structures (Fig. 6-5).[9] Further studies indicate that later in embryonic development, a subpopulation of these stem cells expressing PRDM1 (formerly known as BLIMP1) is established near the entrance of the sebaceous gland. PRDM1 (BLIMP-1) acts as a marker of terminal epithelial cell differentiation.[13,14] Loss of PRDM1 (BLIMP-1) results in increased gene expression of c-myc, an essential player in sebaceous gland homeostasis.[15] Overexpression of

Figure 6-3 Fordyce spots at the upper lip mucosa.

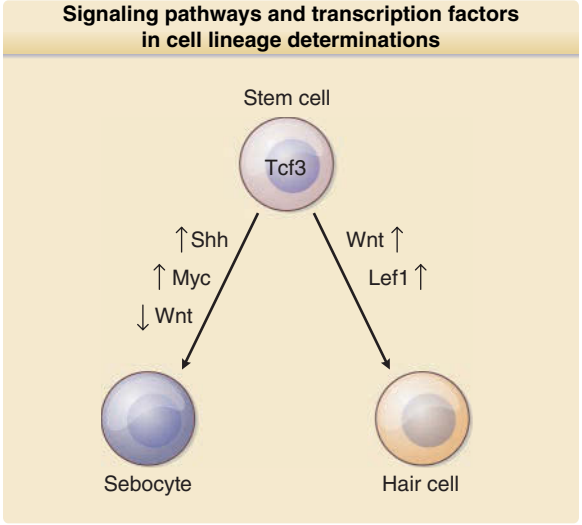

Figure 6-4 Simplified signaling pathways and transcription factors that are involved in cell lineage determinations.[9-11] As daughter cells migrate from the bulge region, changes in the expression patterns of numerous transcription factors determine their final cell lineage. Additional pathways and transcription factors play a significant role in determining each cell lineage. Lef1, lymphoid enhancer binding factor 1; Myc, myelocytomatosis oncogene; Shh, Sonic hedgehog; Tcf3, transcription factor 3; Wnt, wingless (wg)/int.

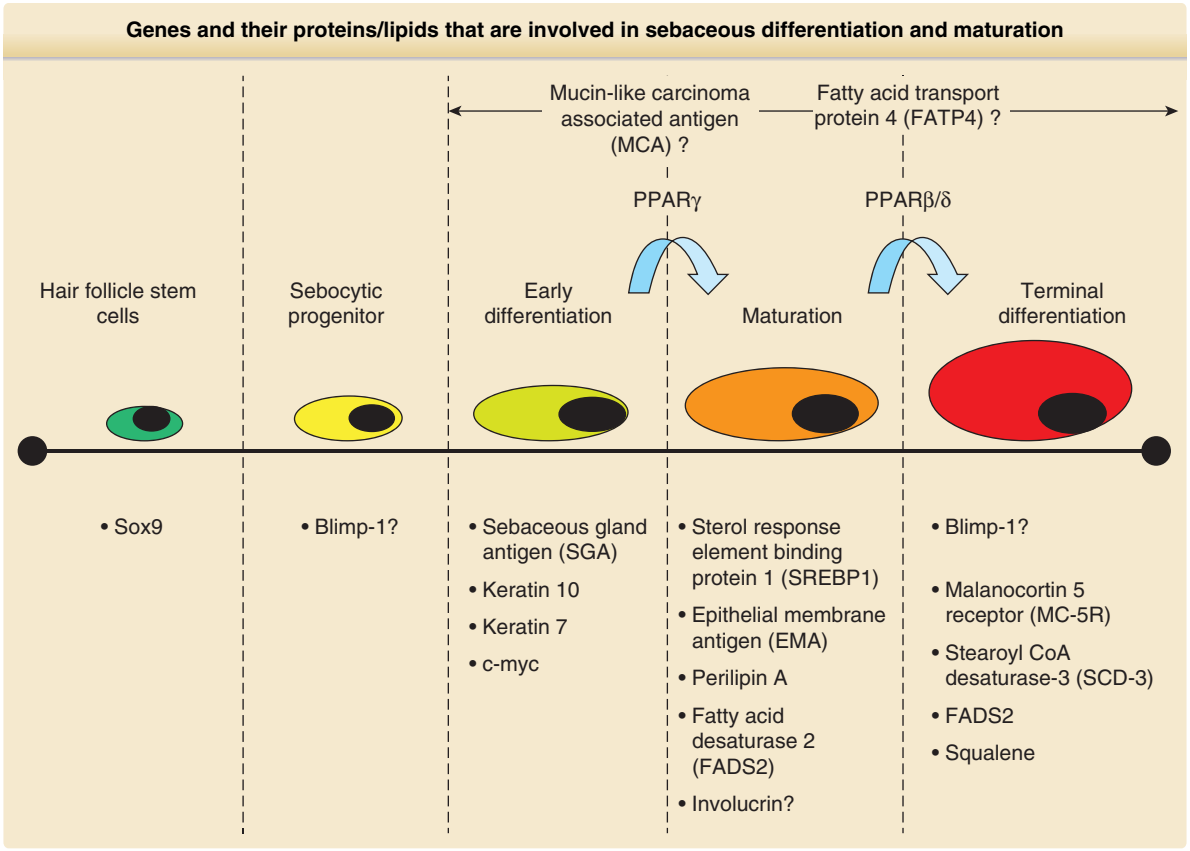

Figure 6-5 Genes and their proteins/lipids reported to be involved in sebaceous differentiation and maturation.[9] PPAR, peroxisome-proliferator-activated receptor.

c-myc in transgenic mice results in enlarged and more numerous sebaceous gland at the expense of the hair follicle lineage. Moreover, skin-specific deletion of c-myc negatively affects sebaceous gland development. In skin, c-myc and β-catenin exert opposing effects on sebocyte differentiation (see Fig. 6-4). Antagonizing Wnt–β-catenin signaling constitutes an important prerequisite for normal sebaceous differentiation in postnatal skin tissue. Stem cells expressing LRIG1, which has been suggested to be multipotent stem cells giving rise to epidermal lineages, can act under homeostatic conditions as sebocyte progenitor cells.[16]

Sebaceous gland cells at first contain glycogen. This lingers at the periphery of the gland but is quickly lost at the center, where lipid drops are visible at 17 weeks.[13,14] The future common excretory duct, around which the acini of the sebaceous gland attach, begins as a solid cord. The cells composing the cord are filled with sebum, and eventually they lose their integrity, rupture, and form a channel that establishes the first pilosebaceous canal, the duct, through which sebum flows into the follicular canal and subsequently to the skin surface. New acini result from buds on the peripheral sebaceous duct wall. The cell organization of the neonatal sebaceous acini consists of undifferentiated (basal), differentiating (early, advanced and fully differentiated), and mature sebaceous gland cells (see Fig. 6-2).[3,17-19] Undifferentiated cells arranged in a single layer facing the basal lamina, comparable to the epidermal basal layer; they represent the germinative cells of the gland, flattened or cuboidal in shape, showing round and densely basophilic nuclei.[20] These bear characteristics of stem cells because they give rise to a continual flux of proliferating and differentiating cells. The basal cells of the peripheral zone form about 40% of the gland. Growing toward the center of the gland lobules, the basal cells gradually differentiate into an early differentiated cell type, an advanced differentiated cell type, a fully differentiated cell type, and the mature sebocyte.[3,21] The maturation zone also represents about 40% of the sebaceous gland.

PHYSIOLOGY OF THE SEBACEOUS GLAND

HOLOCRINE SECRETION

The sebaceous glands exude lipids by disintegration of entire cells, a process known as *holocrine secretion*. Holocrine secretion by sebaceous gland cells does not occur mechanically via increased cell volume, as considered previously, but rather from a multistep,

cell-specific lysosomal DNase2-mediated mode of programmed cell death, which differs from apoptosis, necroptosis, and cornification.[22]

As sebaceous gland cells are displaced into the center of the gland, they begin to produce lipids, which accumulate in droplets. With approaching the sebaceous duct, they disintegrate and release their content. Only neutral lipids reach the skin surface. Proteins, nucleic acids, and the membrane phospholipids are digested and are apparently recycled during the disintegration of the cells.[2] Sebaceous gland secretion can be enhanced with increased rates of induced terminal sebocyte differentiation.

LIPID COMPOSITION OF SEBUM

Sebum production is a continuous event. The exact mechanisms underlying its regulation are not fully defined. *Complexity* and *uniqueness* are the two terms that best characterize sebaceous lipids. Δ6 desaturation, wax ester synthesis, and squalene accumulation are examples that manifest sebaceous lipid biology.[22-24] Genetic knockout animal models of lipid synthesis demonstrate dramatic changes in skin physiology and pathology, resulting from impairment of sebaceous lipid pathways.[25] Human sebum, as it leaves the sebaceous gland, contains a mixture of nonpolar (neutral) lipids, mainly triglycerides, wax esters, squalene, and smaller amounts of cholesterol and cholesterol esters (Fig. 6-6). During passage of sebum through the hair canal, bacterial enzymes hydrolyze some of the triglycerides, so that the lipid mixture reaching the skin surface contains free fatty acids and small proportions of mono- and diglycerides, in addition to the original components. Triglycerides, diglycerides, and free fatty acids form 40% to 60% of total skin surface lipids followed by wax esters (25% to 30%), squalene (12% to 15%), cholesterol esters (3% to 6%), and cholesterol (1.5% to 2.5%).[26,27] The wax esters and squalene distinguish sebum from the lipids of human internal organs, which contain no wax esters and little squalene. However, human sebaceous glands appear to be unable to transform squalene to sterols, such as cholesterol. The patterns of unsaturation of the fatty acids in the triglycerides, wax esters, and cholesterol esters also distinguish human sebum from the lipids of other organs. The "normal" mammalian pathway of desaturation involves inserting a double bond between the 9th and 10th carbons of stearic acid (18:0) to form oleic acid (18:1Δ9). However, in human sebaceous glands, the predominant pattern is the insertion of a Δ6 double bond into palmitic acid (16:0). The resulting sapienic acid (16:1Δ6) (see Fig. 6-6) is the major fatty acid of adult human sebum. Elongation of the chain by two carbons and insertion of another double bond gives sebaleic acid (18:2Δ5,8), a fatty acid thought to be unique to human sebum.[22-24]

Sebaceous fatty acids and alcohols are also distinguished by chain branching. Methyl branches can occur on the penultimate carbon of a fatty acid chain (iso branching), on the third from the last (antepenultimate) carbon (anteiso branching), or on any even-numbered carbon (internal branching). Examples of these unusual unsaturated and branched-chain moieties are included in the lipid structures in Fig. 6-6.

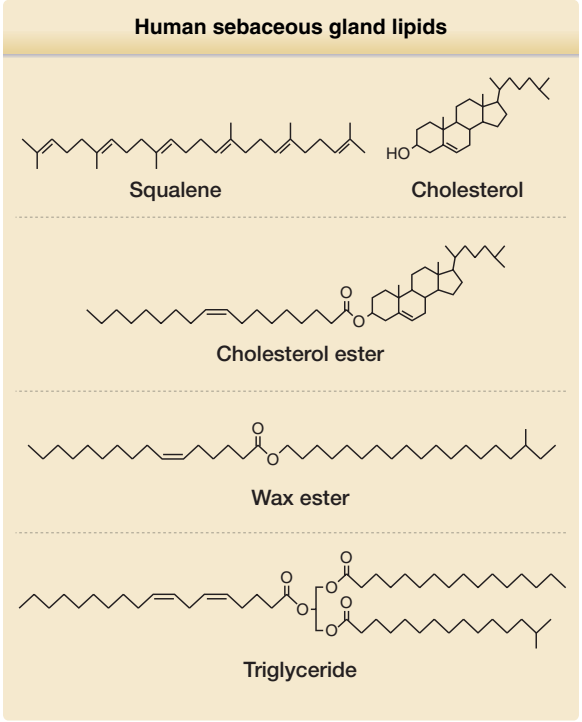

Figure 6-6 Human sebaceous gland lipids. The structures of the cholesterol ester, wax ester, and triglyceride are representative of the many species that are present. Two sebaceous-type unsaturated fatty acid moieties are shown: sapienic acid (16:1Δ6) (in the wax ester structure) and sebaleic acid (18:2Δ5,8) (in the triglyceride structure). Anteiso branching is shown in the alcohol moiety of the wax ester, and iso branching is shown in the triglyceride.

FUNCTION OF SEBUM

Sebum in humans was initially considered to solely cause acne.[28,29] Subsequently, it has been suggested that sebum reduces water loss from the skin's surface and functions to keep skin soft and smooth, although evidence for these claims in humans is minimal; however, as demonstrated in the sebaceous gland–deficient (Asebia) mouse model, glycerol derived from triglyceride hydrolysis in sebum is critical for maintaining stratum corneum hydration.[30] Sebum has later been shown to have mild antibacterial action, protecting the skin from infection by bacteria and fungi because it contains antiinflammatory lipids and immunoglobulin A, which is secreted from most exocrine glands.[31-33] Vitamin E delivery to the upper layers of the skin protects the skin and its surface lipids from oxidation. Thus, sebum flow to the surface of the skin may provide the transit mechanism necessary for vitamin E to function.[34] The current concept is that sebum is involved in the multimodal activities of the sebaceous glands (Table 6-2).

TABLE 6-2
Sebaceous Gland Functions

Embryology, Development, and Differentiation
- Expression of terminal differentiation-triggering transcription factors, including CCAAT and enhancer binding proteins and peroxisome-proliferator-activated receptors
- Partial responsibility for the three-dimensional organization of skin surface lipids and the integrity of the skin barrier
- Influence on follicular differentiation
- Highly complex acetylcholine receptor expression pattern
- Preservation of characteristics of stem-like cells despite their terminal cell differentiation program

Synthetic Activity
- Production of vernix caseosa
- Production of sebum
- Histamine-1 receptor expression and inhibition of squalene synthesis by antihistamines

Protection
- Natural photoprotective activity against ultraviolet B irradiation
- Thermoregulatory and repelling properties
- Possible involvement in wound healing

Transportation
- Delivery of antioxidants from and to the skin surface
- Sebum as vehicle of fragrance

Inflammation and Immunity
- Direct pro- and antiinflammatory properties
- Production of proinflammatory and of antiinflammatory lipids
- Toll-like receptor 2–induced upregulation of lipogenesis
- Lipid-induced innate antimicrobial activity
- Presence of antimicrobial protective immunoglobulin A and cytokine and chemokine mRNA in normal sebaceous glands
- Synthesis of antibacterial peptides and proinflammatory cytokines and chemokines in the presence of bacteria with some of the peptides being bacteriotoxic
- Expression of ectopeptidases
- Contribution to skin inflammation by promoting the differentiation of Th17 lymphocytes
- Response to lipid-mediated redox stress
- Influence of macrophage polarization and activation via sebaceous lipids

Endocrine Properties
- Regulation of the independent endocrine function of the skin
- Expression of all steroidogenic enzymes
- Regulation of local androgen synthesis
- Substantial involvement in the hormonally induced skin aging process
- Modification of lipid synthesis by combined androgens and peroxisome-proliferator-activated receptor ligands, estrogens and the insulin-like growth factor 1–insulin-like growth factor 1 complex
- Expression of vitamin D receptor and vitamin D–metabolizing enzymes
- Expression of retinoid-metabolizing cytochrome P450 enzymes
- Selective control of the action of hormones and xenobiotics on the skin
- Exhibition and affection by a regulatory neuropeptide program

INNATE IMMUNITY

Antimicrobial peptides, including cathelicidin, psoriasin, β-defensin 1, and β-defensin 2, are expressed within the sebaceous gland. Functional cathelicidin peptides have direct antimicrobial activity against *Propionibacterium acnes* but also initiate cytokine production and inflammation in the host organism.[35,36] In addition, free fatty acids in human sebum are bactericidal against gram-positive organisms as a result of its ability to increase β-defensin 2 expression.[31,36] Innate immune Toll-like receptors 2 and 4 (TLR2, TLR4) as well as CD1d and CD14 molecules are also expressed in sebaceous glands and immortalized human sebocytes.[37] With the expression of innate immune receptors and antibacterial peptides, the sebaceous gland may play an important role in pathogen recognition and protection of the skin surface.[38-41]

FACTORS REGULATING SEBACEOUS GLAND SIZE AND SEBUM PRODUCTION

Sebocytes preserve characteristics of stem-like cells despite their programming for terminal differentiation because they present a remarkable potential of bipotential differentiation.[42,43] The sebaceous gland might be maintained by unipotent stem cells that are replenished by multipotent stem cells in the hair follicle bulge.[13] However, it is an emerging view that there might be at least three distinct niches for skin stem cells: the follicle bulge, the base of the sebaceous gland, and the basal layer of the epidermis.[44]

The average transit time of sebaceous gland cells from formation to discharge, has been calculated as 7.4 days in the human gland, with 4 to 7 days in undifferentiated and 14 to 25 in differentiated lipid-producing cells.[1] Within any one glandular unit, the acini vary in differentiation and maturity. The synthesis and discharge of the lipids contained in the sebaceous cells require more than 1 week. The size of sebaceous glands increases with age. The mean size rises from 0.2 $mm^2 \pm 0.5$ mm^2 to 0.4 $mm^2 \pm 2.1$ mm^2. The sebaceous cells of prepubertal and hypogonadal boys and men are qualitatively similar to those of normal adults, even though the glands are smaller.[45] In general, whereas the number of sebaceous glands remains approximately the same throughout life, their size tends to change with age.[46] The turnover of the sebaceous glands in older adults is slowed down compared with young adults.

A variety of experimental models are used to study the factors involved in sebaceous gland regulation, including cell culture of isolated human sebaceous glands, primary sebocytes, immortalized sebocyte cell lines, and three-dimensional models, as well as mouse and hamster animal models.[47-50] Results from these investigations clearly indicate that sebaceous glands are multifactional (see Table 6-2),[51,52] regulated, among others, by ligands of sebaceous gland cell receptors (Table 6-3), such as androgen and estrogen receptors, peroxisome-proliferator-activated receptors (PPAR) and liver-X receptor (LXR), neuropeptide receptors, retinoid, and vitamin D receptors.[53-56] The ligand–receptor complexes activate pathways involving

TABLE 6-3
Hormone Receptors Expressed in Human Sebaceous Gland Cells

RECEPTORS	NATURAL LIGANDS	EFFECT ON CULTURED SEBOCYTES
Peptide Hormone and Neurotransmitter Receptors		
Serpentine (Seven-Transmembrane Domain) Receptors		
▪ Corticotropin-releasing hormone (CRH) receptors 1 and 2 (CRH-R1 > CRH-R2)	CRH, urocortin	↓ Proliferation, ↑ $\Delta^{5\text{-}4}$ 3β-hydroxysteroid dehydrogenase (CRH), ↑ lipid synthesis (CRH), ↑ IL-6 and IL-8 release (CRH)
▪ Melanocortin-1 and 5 receptors (MC-1R and MC-5R)	α-Melanocyte-stimulating hormone (α-MSH)	↓ IL-1–induced IL-8 synthesis (MC-5R), differentiation marker (MC-1R)
▪ μ-Opiate receptors (OPRs)	β-Endorphin	↓ EGF-induced proliferation, ↑ lipid synthesis
▪ VPAC receptors	Vasoactive intestinal polypeptide (VIP), receptors for neuropeptide Y and calcitonin gene-related peptide (CGRP)	Neuropeptide Y stimulates IL-6 and IL-8 release
▪ Cannabinoid receptors CR1 and CR2	Cannabinoid	
▪ Histamine receptor 1	Histamine	Regulation of squalene synthesis
Single-Transmembrane Domain Receptors with Intrinsic Tyrosine Kinase Activity		
▪ Insulin-like growth factor (IGF) I receptor	IGF-I, insulin	↑ Lipogenesis
Single-Transmembrane Domain Receptors without Intrinsic Tyrosine Kinase Activity		
▪ Growth hormone (GH) receptor	GH	↑ Differentiation, ↑ DHT effect on lipogenesis
Nuclear Receptors		
Steroid Receptors		
▪ Androgen receptor	Testosterone, 5α-dihydrotestosterone (DHT)	↑ Proliferation (with PPAR ligands ↑ lipogenesis)
▪ Progesterone receptor	Progesterone	?
Thyroid Receptors		
▪ Estrogen receptors (ER-α- and -β)	17β-Estradiol	↑ Polar lipid production
▪ Retinoic acid receptors (RAR-α and -γ)	*All-trans* retinoic acid (atRA)	↓ Proliferation
▪ Retinoid X receptors (RXR-α, > PXR-β, -γ)	9-*cis* RA	Regulate lipogenesis (?)
▪ Vitamin D receptor	Vitamin D_3	Regulates cell proliferation, cell cycle, lipid content, and IL-6 and IL-8 secretion
▪ Peroxisome proliferator-activated receptors (PPARα, PPARγ > PPARβ)	Linoleic acid (RRARβ/Δ), leukotrien-B4 (LTB4)	↑ Lipogenesis, ↑ prostaglandin E2 release, ↑ IL-6 release, ↑ COX2 synthesis
▪ Liver X receptors (LXRα and -β)	22(R)-Hydroxycholesterol	↓ Proliferation, ↑ lipogenesis, ↓ COX2 and inducible NOS

COX, cyclooxygenase; DHT, 5α-dihydrotestosterone; EGF, epidermal growth factor; IGF, insulin-like growth factor; IL, interleukin; NO, nitric oxide synthase; VPAC, vasoactive intestinal peptide receptor.

lipogenesis but also cell proliferation, differentiation, hormone metabolism, and cytokine and chemokine release.[57]

ANDROGENS

Sebaceous glands require androgenic stimulation to produce significant quantities of sebum. Individuals with a genetic deficiency of androgen receptors (complete androgen insensitivity) have no detectable sebum secretion and do not develop acne.[58] Although the most powerful androgens are testosterone and its end-organ reduction product, 5α-dihydrotestosterone (DHT), levels of testosterone do not parallel the patterns of sebaceous gland activity. For example, testosterone levels are many fold higher in males than in females, with no overlap between the sexes. However, the average rates of sebum secretion are only slightly higher in males than in females, with considerable overlap between the sexes. Also, sebum secretion starts to increase in children during adrenarche, a developmental event that precedes puberty by about 2 years.

The weak adrenal androgen, dehydroepiandrosterone sulfate (DHEAS), is probably a significant regulator of sebaceous gland activity through its conversion

to testosterone and DHT in the sebaceous gland.[59] Levels of DHEAS are high in newborns, very low in 2- to 4-year-old children, and start to rise when sebum secretion starts to increase. In adulthood, DHEAS levels show considerable individual variation but are only slightly higher in men than in women on the average. There is a decline in DHEAS levels in both sexes starting in early adulthood and continuing throughout life; this decline parallels the decline of sebum secretion. DHEAS is present in the blood in high concentration. The enzymes required to convert DHEAS to more potent androgens are present in sebaceous glands.[60] These include 3β-hydroxysteroid dehydrogenase, 17β-hydroxysteroid dehydrogenase, and 5α-reductase. Each of these enzymes exists in two or more isoforms that exhibit tissue-specific differences in their expression. The predominant isozymes in the sebaceous gland include the type 1 3β-hydroxysteroid dehydrogenase, the type 2 17β-hydroxysteroid dehydrogenase, and the type 1 5α-reductase.[61,62]

RETINOIDS

Isotretinoin (13-*cis*-retinoic acid, 13-*cis*-RA) is the most potent pharmacologic inhibitor of sebum secretion. Significant reductions in sebum production can be observed as early as 2 weeks after use.[63,64] Histologically, sebaceous glands are markedly reduced in size, and individual sebocytes appear undifferentiated lacking the characteristic cytoplasmic accumulation of sebaceous lipids.[3,65]

Isotretinoin does not interact with any of the known retinoid receptors. It may serve as a prodrug for the synthesis of all-*trans*-retinoic acid, which interacts with retinoid receptors expressed in sebaceous gland cells (retinoic acid receptors [RARs; isotypes α and γ] and retinoid X receptors [RXRs; isotypes α, β, γ]).[66] However, it has greater sebosuppressive action than do all-*trans*- or 9-*cis*-retinoic acid.[67] 13-*cis*-RA exerts pluripotent effects on human sebaceous gland cells and their lipogenesis.[63] Inhibition of androgen synthesis, cell cycle arrest, and apoptosis by 13-*cis*-RA may explain the reduction of sebaceous gland size after treatment.

PEROXISOME-PROLIFERATOR-ACTIVATED RECEPTORS

PPARs are members of the nuclear hormone receptor family and act as transcriptional regulators of a variety of genes, including those involved in lipid metabolism in adipose tissue, liver, and skin. PPARs are similar to retinoid receptors in many ways. Each of these receptors forms heterodimers with retinoid X receptors to regulate the transcription of genes involved in a variety of processes, including lipid metabolism and cellular proliferation and differentiation. PPARα, δ, and γ receptor subtypes have been detected in basal sebaceous gland cells.[54] PPARγ is also detected within differentiated cells. Pharmacologic PPAR-γ modulation regulates sebogenesis and inflammation in SZ95 human sebaceous gland cells.[68] In patients receiving fibrates (PPAR-α ligands) for hyperlipidemia or thiazolidinediones (PPAR-γ ligands) for diabetes, sebum secretion rates are increased.[69]

PPAR-γ–RXR-α and LXR–RXRα promoter interactions are of crucial importance for the regulation of key genes of lipid metabolism. Although various fatty acids, eicosanoids, and prostanoids activate PPARs, oxysterols and intermediate products of the cholesterol biosynthetic pathway activate LXRs. PPAR-α agonists and PPAR-γ antagonists may reduce sebaceous lipid synthesis and as such may be useful in the treatment of acne. On the other hand, whereas PPAR-γ agonists may be beneficial in aging skin, PPAR-δ agonists may be involved in sebaceous tumorigenesis.

LXR

LXRs, which are members of the NHR family, play a critical role in cholesterol homeostasis and lipid metabolism.[70] Treatment of SZ95 sebaceous gland cells with the LXR ligands TO901317 or 22(R)-hydroxycholesterol enhanced accumulation of LDs in the cells, which could be explained through induction of the expression of the LXRα receptor and known LXR targets, such as fatty acid synthase and sterol regulatory element–binding protein-1 (SREBP-1).[54,71]

FOXO1

FoxO1 is expressed in most lipid-metabolizing cells, including the prostate, liver, fat tissue, and skin.[72] Human sebaceous gland cells also express FoxO1. Acne and increased sebaceous lipogenesis are associated with a relative nuclear deficiency of FoxO1 caused by increased growth hormone–insulin–insulin-like growth factor 1 or fibroblast growth factor 2 signaling.

STRUCTURAL PROTEINS

During sebogenesis, lipids are stored in LDs. LDs are limited by a membrane containing phospholipids and numerous proteins and enzymes. The most relevant membrane proteins are the perilipin (PLIN) family, which possesses structural and regulatory properties. In particular, PLIN2, the major form expressed during the differentiation process, regulates the gland size in vivo and regulates sebaceous lipid accumulation.[73] Experimental downmodulation of the PLIN2 expression significantly modifies the composition of neutral lipids with a significant decrease in the unsaturated fatty acid component caused by a marked decrease in the expression of specific lipogenic enzymes. On the other hand, PLIN3 has currently been shown to modulate specific lipogenic pathways in human sebaceous gland cells.[74] Another structural protein, angiopoietin-like 4, is strongly induced during human sebocyte differentiation and regulates sebaceous lipogenesis.[75]

CONCLUSION

The regulation of sebaceous glands and human sebum production is complex. Advances are being made in this area, which may lead to alternative therapies for the reduction of sebum and improvements in acne.

SWEAT GLANDS

AT-A-GLANCE

- A human has 2 to 4 million sweat glands (200 to 400/cm^2 of skin surface).
- Up to 10 L/day of sweat is produced by acclimatized individuals.
- In humans, sweat glands are generally classified into apocrine and eccrine types.
- Hypothalamic temperature is the strongest stimulus for sweating.
- Acetylcholine is the major stimulus of eccrine sweat glands secreted by sympathetic nerves.
- Adrenergic stimulation controls apocrine gland secretion.
- Botulinum toxin inhibits sweating by preventing acetylcholine release.
- Oxidative metabolism of glucose is a major source of eccrine gland adenosine triphosphate.
- Ductal reabsorption conserves NaCl.
- Bacteria are necessary for apocrine odor.
- Odiferous precursors secretion is controlled by the MRP8 encoded by ABCC11.

Eccrine gland sweat allows the body to control its internal temperature in response to thermal stress. Apocrine gland function is more obscure but likely includes pheromone production. Although the eccrine and apocrine secretory portions of sweat glands are clearly morphologically distinctive, their ducts are histologically indistinguishable if the duct orifice cannot be detected. Immunohistological distinction can be performed by the stage-specific embryonic antigen-4 (SSEA-4), which is a marker of ductal cells of eccrine but not of apocrine sweat glands.[76]

ECCRINE SWEAT GLANDS

DEVELOPMENT OF THE ECCRINE SWEAT GLANDS

A human has approximately 2 to 4 million sweat glands (200 to 400/cm^2 of skin surface).[77] Sweat glands are found over nearly the entire body surface and are especially dense on the palms, soles, forehead, and upper limbs.[78] However, they are absent at the margins of the lips, the eardrums, and the nailbeds of fingers and toenails. Anlagen of eccrine sweat glands first appear in 3.5-month-old fetuses on the palms and soles (see Chap. 4), then develop in the axillary skin in the fifth fetal month, and finally develop over the entire body by the sixth fetal month.[78] The anlagen of the eccrine sweat gland, which develops from the epidermal ridge, is double layered and develops a lumen between the layers between the fourth and eighth fetal months. By the eighth fetal month, eccrine secretory cells resemble those of an adult; by the ninth fetal month, myoepithelial cells form around the secretory coil and the excretory duct.

ANATOMY AND FUNCTION OF THE ECCRINE SWEAT GLANDS

Two distinct segments, the secretory coil (tubulus) and the duct, form the eccrine sweat gland. The secretory coil secretes a sterile, dilute electrolyte solution with primary components of bicarbonate, potassium, sodium chloride (NaCl), and other minor components such as glucose, pyruvate, lactate, cytokines, immunoglobulins, antimicrobial peptides (eg, dermcidin,[79] β-defensin,[80] cathelicidines[81]). Relative to the plasma and extracellular fluid, the concentration of Na^+ ions is much lower in sweat (~40 mM versus ~150 mM in plasma and extracellular fluid). The eccrine excretion has a high concentration of Na^+ ions. However, Na^+ ions are partially reabsorbed via the epithelial sodium channels (ENaC) that are located on the apical membrane of the eccrine gland duct cells.[82] This reuptake of Na^+ ions reduces the loss of Na^+ during the process of perspiration.

Secretory Coil: The secretory coil contains three distinct cell types: (1) clear (secretory), (2) dark (mucoid), and (3) myoepithelial.[83] The clear and dark cells occur in approximately equal numbers but differ in their distribution. Although the dark cells border the apical (luminal) surfaces, the clear cells rest either directly on the basement membrane or on the on the myoepithelial cells. The clear cells directly access the lumen by forming intercellular canaliculi (Fig. 6-7). Spindle-shaped contractile myoepithelial cells lie on the basement membrane and abut the clear cells. An adult secretory coil is approximately 2- to 5-mm long and approximately 30 to 50 µm in diameter. Heat accumulation results in larger sweat glands and ducts, and their dimensions in turn correlate with enhanced sweat output.[84] Clear cells contain abundant mitochondria and an autofluorescent body, called the lipofuscin granule, in the cytoplasm. The clear cell plasma membrane forms many villi. The clear cell secretes water and electrolytes. Dark cells have a smooth cell surface and contain abundant dark cell granules.[83] The function of dark cells is unknown. Myoepithelial cells contain actin filaments and are contractile,[85,86] producing pulsatile sweat.

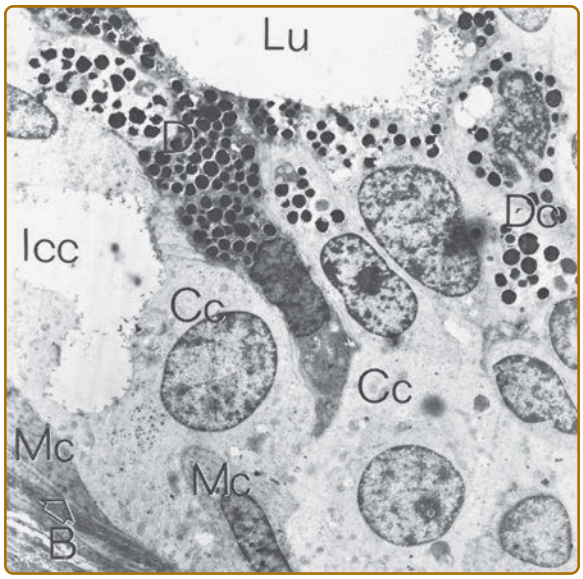

Figure 6-7 Electron micrograph of the secretory coil of a human eccrine sweat gland. B with *arrow*, basal lamina; CC, clear cell; DC, dark cell; ICC, intercellular canaliculi; Lu, lumen; MC, myoepithelial cell.

Duct: The duct of the eccrine sweat gland consists of an outer ring of peripheral or basal cells and an inner ring of luminal or cuticular cells. It seems that the proximal (coiled) duct is functionally more active than the distal straight portion in pumping Na^+ for ductal Na^+ reabsorption because Na^+, K^+-adenosine triphosphatase (ATPase) activity and the number of mitochondria are higher in the proximal portion (Fig. 6-8).[83,85,87,88] In contrast, the luminal ductal cells have fewer mitochondria, much less Na^+, K^+-ATPase activity, and a dense layer of tonofilaments near the luminal membrane, which is often referred to as the *cuticular border*. The cuticular border provides structural resilience to the ductal lumen, which may dilate whenever ductal flow of sweat is blocked. The entire structural organization of the duct is well designed for the most efficient Na^+ absorptive function. The luminal membrane serves as the absorptive surface by accommodating both Na^+ and Cl^- channels, and the basal ductal cells serve in Na^+ pumping by providing maximally expanded Na^+ pump sites and efficient energy metabolism. The lumen and the duct contain β-defensin, an antimicrobial, cysteine-rich, low-molecular-weight peptide.[80,81] In the epidermis, the duct spirals tightly upon itself.

NEURAL CONTROL OF ECCRINE SWEATING

The preoptic hypothalamic area plays an essential role in regulating body temperature: whereas local heating of the preoptic hypothalamic tissue activates generalized sweating, vasodilatation, and rapid breathing, local cooling of the preoptic area causes generalized vasoconstriction and shivering. Whereas the elevation

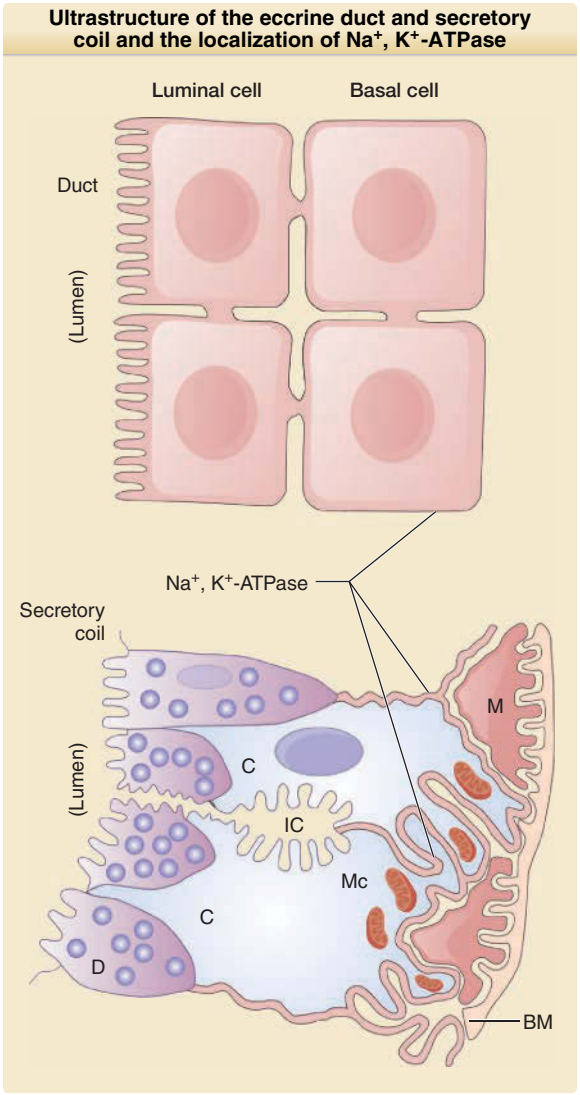

Figure 6-8 The ultrastructure of the eccrine duct and secretory coil and the localization of Na^+, K^+-adenosine triphosphatase (ATPase). The thick lines indicate the localization of Na^+, K^+-ATPase. BM, basement membrane; C, clear cell; D, dark cells; IC, intercellular canaliculi; M, myoepithelial cell; Mc, mitochondria.

of hypothalamic temperature associated with an increase in body temperature provides the strongest stimulus for thermoregulatory sweating responses, cutaneous temperature exerts a weaker influence on the rate of sweating.[84,89] On a degree-to-degree basis, an increase in internal temperature is about nine times more efficient than an increase in mean skin temperature in stimulating the sweat center. The local temperature effect is speculated to be due to increased release of periglandular neurotransmitters.

The sweating in menopausal "hot flashes" reinforces the concept of a central hypothalamic mechanism for thermal sweating but also shows that the response of individuals to the same changes in core temperature can vary. Although hormonal factors influence sweating during menopause, excessive sweating does not correlate simply with hormonal

levels. Instead, menopausal hot flashes seem to be caused by a hypersensitive brain response (particularly the hypothalamus but perhaps the insula, anterior cingulate, amygdala, and primary somatosensory cortex as well). In asymptomatic menopausal women and premenopausal women, the core temperature can change up to 0.4°C (33°F) without eliciting a response. In symptomatic postmenopausal women, changes as small as 0.1°C (32°F) trigger peripheral vasodilation and sweating. Why the brain is hypersensitive to small changes in core temperature is poorly understood, but increased levels of brain norepinephrine appear to influence the response to small changes in core temperature through their action on α_2-adrenergic receptors in the brain; higher levels of the norepinephrine metabolite 3-methoxy-4-hydroxyphenylglycol have also been found in symptomatic menopausal women compared with asymptomatic women. Decreased norepinephrine release is postulated as the mechanism by which clonidine relieves hot flashes in symptomatic women. Decreased core temperature may be the reason that women with decreased body mass index tend to have fewer symptoms even though their estrogen levels probably are lower than those in women with increased body mass index. Levels of estrogen, luteinizing hormone, and β-endorphins also were originally thought to influence hot flashes, but later studies have suggested no association.[90]

Innervation: Efferent nerve fibers originating from the hypothalamic preoptic sweat center descend through the ipsilateral brainstem and medulla and synapse in the intermediolateral cell columns of the spinal cord without crossing (although sympathetic vasomotor fibers may partially cross).[91] The myelinated axons rising from the intermediolateral horn of the spinal cord (preganglionic fibers) pass out in the anterior roots to reach (through white ramus communicans) the sympathetic chain and synapse. Unmyelinated postganglionic sympathetic class C fibers arising from sympathetic ganglia join the major peripheral nerves and end around the sweat gland. The supply to the skin of the upper limb is commonly from T2 to T8. The face and the eyelids are supplied by T1 to T4, so that resection of T2 for the treatment of palmar hyperhidrosis is likely to cause Horner syndrome. The trunk is supplied by T4 to T12 and the lower limbs by T10 to L2. Unlike the sensory innervation, a significant overlap of innervation occurs in the sympathetic dermatome because a single preganglionic fiber can synapse with several postganglionic fibers.

The major neurotransmitter released from the periglandular nerve endings is acetylcholine (Ach), an exception to the general rule of sympathetic innervation, in which noradrenaline is the peripheral neurotransmitter.[92] In addition to ACh, adenosine triphosphate (ATP), catecholamine, vasoactive intestinal peptide, atrial natriuretic peptide, calcitonin gene-related peptide, and galanin have been localized in the periglandular nerves. The significance of these peptides or neurotransmitters in relation to sweat gland function is not fully understood.

Botulinum toxin interferes with ACh release. Its heavy chain binds the neurotoxin selectively to the cholinergic terminal, and the light chain acts within the cells to prevent ACh release. Type A toxin cleaves sensory nerve action potential-25, a 25-kDa synaptosomal-associated protein; the type B light chain cleaves vesicle-associated membrane protein (also called *synaptobrevin*). Botulinum toxins are used for symptomatic relief of hyperhidrosis.[93] A more detailed description can be found in Chaps. 81 and 216.

Denervation: In humans, the sweating response to intradermal injection of nicotine or ACh disappears within a few weeks after denervation of the *postganglionic* fibers,[93,94] and the sweating response to heat ceases immediately after resection of the nerves. In contrast, after denervation of *preganglionic* fibers (caused by spinal cord injuries or neuropathies), pharmacologic responsiveness of the sweat glands is maintained from several months to 2 years, even though their thermally induced sweating is no longer present.[95]

EMOTIONAL SWEATING

Sweating induced by emotional stress (emotional sweating) can occur over the whole skin surface in some individuals, but it is usually confined to the palms, soles, axillae, and forehead. Emotional sweating on the palms and soles ceases during sleep, but thermal sweating occurs even during sleep if the body temperature rises. Because both types of sweating can be inhibited by atropine, emotional sweating is cholinergically medicated.

PHARMACOLOGY OF THE ECCRINE SWEAT GLAND AND SWEATING RATE

Sweat glands respond to cholinergic agents, α- and β-adrenergic stimulants, and other periglandular neurotransmitters, such as vasoactive intestinal peptide and ATP. Periglandular ACh is the major stimulant of sweat secretion, and its periglandular concentration determines the sweat rate in humans.[96] When dissociated clear cells are stimulated in vitro by cholinergic agents, they lose K^+ and Cl^-, increase intracellular Ca^{2+}, and shrink, mimicking actions seen in vivo. Striking individual differences exist in the degree of sweating in response to a given thermal or physical stress. In general, males perspire more profusely than females.[97] The sweat rate in a given area of the skin is determined by the number of active glands and the average sweat rate per gland. The maximal sweat rate per gland varies from 2 to 20 nL/min^2. Sweat rate increases during acclimatization, but the morphologic and pharmacologic bases of the individual and regional differences in sweating rate during acclimatization are still poorly understood (Fig. 6-9). In thermally induced sweating, the sweat rate can be mathematically related to the body and skin temperatures in a given subject only in the low sweat rate range. Cholinergic stimulation yields a 5 to 10 times higher sweating rate than does

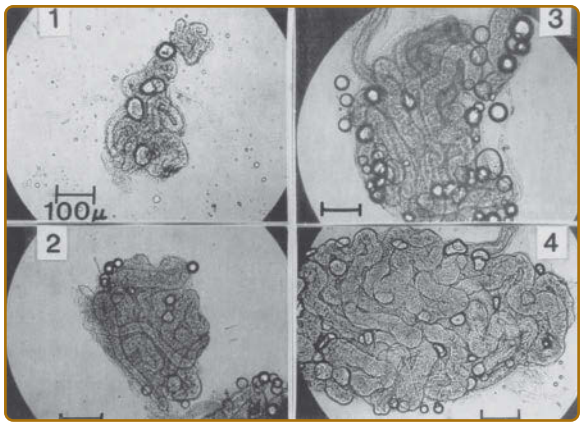

Figure 6-9 Individual variation in the size of the sweat gland in four male adults, aged 22 to 28 years. Sweat glands were isolated from skin biopsy specimens obtained from the upper back behind the axilla. Whereas subject 1 is a sedentary man who does not exercise regularly, subject 4 is a well-acclimatized athletic individual.

β-adrenergic stimulation. α-Adrenergic stimulation (by phenylephrine) is no more potent than isoproterenol (ISO) (a β-adrenergic agonist) in humans in vivo.[98] Whereas cholinergic sweating begins immediately on intradermal injection, β-adrenergic sweating requires a latent period of from 1 to 2 minutes, which suggests that the intracellular mechanism of sweat induction may be different for methacholine and for ISO. Because the sweat rate in response to adrenergic agents is rather low, it may be reasonable to surmise that adrenergic stimulation in periglandular nerves may be involved in the regulation of sweat gland function but not in the induction of sweat secretion. One consequence of dual cholinergic and adrenergic innervation is to maximize tissue accumulation of cyclic adenosine monophosphate (cAMP), which may be instrumental in stimulating the synthesis of sweat and glandular hypertrophy of the sweat gland. The possibility that periglandular catecholamine is directly involved in emotional sweating or sweating associated with pheochromocytoma[99] may be ruled out because these sweating responses can be blocked by anticholinergic agents.

PHARMACOLOGY AND FUNCTION OF ECCRINE MYOEPITHELIUM

The periodicity of sweat secretion in vivo is caused by the periodicity of central nerve impulse discharges, which occur synchronously with vasomotor tonus waves. Myoepithelial contraction occurs with cholinergic stimulation, but neither α- nor β-adrenergic agents induce tubular contraction.[100] Although the myoepithelium may contribute to sweat production via pulsatile contractions, it also seems to provide structural support for the secretory epithelium, especially under conditions in which stagnation of sweat flow (caused by ductal blockade) results in an increase in luminal hydrostatic pressure.[86]

ENERGY METABOLISM

Sweat secretion is mediated by the energy (ie, ATP)-dependent active transport of ions, so a continuous supply of metabolic energy is mandatory for sustained sweat secretion. Endogenous glycogen stored in the clear cells can sustain sweat secretion for less than 10 minutes; thus, the sweat gland must depend almost exclusively on exogenous substrates for its energy metabolism. Mannose, lactate, and pyruvate are used nearly as readily as glucose; other hexoses, fatty acids, ketone bodies, intermediates of the tricarboxylic acid cycle, and amino acids are either very poorly used or not used as substrates. The physiologic significance of lactate or pyruvate utilization by the sweat gland is not yet clear. However, because the plasma level of glucose (5.5 mM) is much higher than that of lactate (1 to 2 mM) or pyruvate (<1 mM), glucose may play a major role in sweat secretion. Oxidative metabolism of glucose is favored as the major route of ATP formation for secretory activity.[100]

COMPOSITION OF HUMAN ECCRINE SWEAT

Inorganic Ions: Sweat is formed in two steps: (1) secretion of a primary fluid containing nearly isotonic NaCl concentrations by the secretory coil and (2) reabsorption of NaCl from the primary fluid by the duct. Although a number of factors affect ductal NaCl absorption, the sweat rate (and thus the transit time of sweat) has the most important influence on final NaCl concentration. Sweat NaCl concentration increases with increasing sweat rate to plateau at around 100 mM (Fig. 6-10). Potassium (K^+) concentration in sweat is relatively constant. It ranges from 5 to 10 mM, which is slightly higher than plasma K^+ concentration. HCO_3^- concentration in the primary sweat fluid is approximately 10 mM, but that of final sweat is less than 1 mM, which indicates that HCO_3^- is reabsorbed by the duct, presumably accompanied by ductal acidification.[101] Sweat NaCl concentration is increased in individuals with cystic fibrosis.[102] Aquagenic wrinkling of the palms (whitened, wrinkling, and papillation of the palms after brief water exposure) is seen more frequently in carriers and patients with cystic fibrosis (see Chap. 81).

Lactate: The concentration of lactate in sweat usually depends on the sweat rate. At low sweat rates, lactate concentration is as high as 30 to 40 mM, but it rapidly drops to a plateau at around 10 to 15 mM as the sweat rate increases. Whereas acclimatization is known to lower sweat lactate concentrations, arterial occlusion rapidly raises sweat NaCl and lactate concentrations and reduces the sweat rate.[100] Sweat lactate is probably produced by glycolysis of glucose by the secretory cells.[103]

Urea: Urea in sweat is derived mostly from serum urea.[104] Sweat urea content is usually expressed as a sweat–plasma ratio (S/P urea). S/P urea is high (2 to 4)

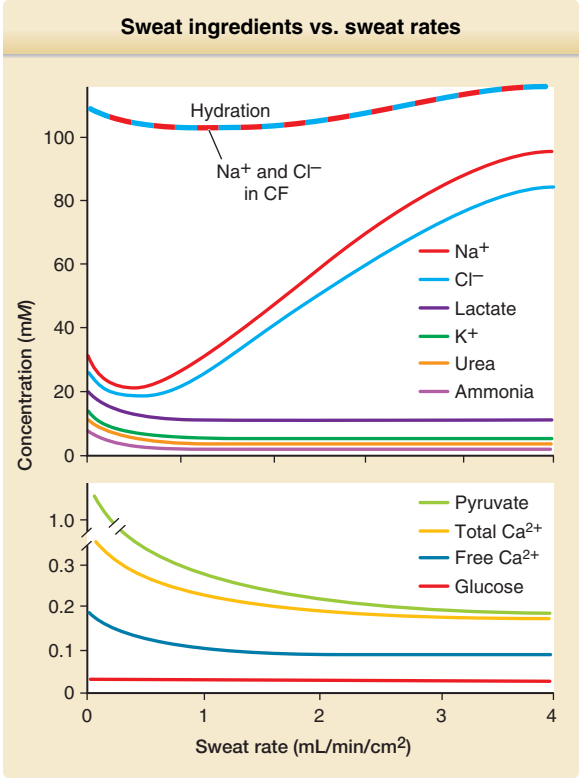

Figure 6-10 Relationship between the concentration of sweat ingredients and the sweat rate in thermally induced human sweat in normal individuals and in persons with cystic fibrosis (CF).

at a low sweat rate range but approaches a plateau at 1.2 to 1.5 as the sweat rate increases.

Ammonia and Amino Acids: The ammonia concentration in sweat is 0.5 to 8 mM,[105] which is 20 to 50 times higher than the plasma ammonia level. The concentration of sweat ammonia is inversely related to the sweat rate and sweat pH. Free amino acids are present in human sweat,[106] although it is not clear what proportion of measured amino acids derive from epidermal contamination.

Proteins Including Proteases: The concentration of sweat protein in the least contaminated, thermally induced sweat is approximately 20 mg/dL, with the major portion being low-molecular-weight proteins (ie, molecular weight <10,000). Because sweat samples collected by simple scraping (and even those collected with a plastic bag) can be massively contaminated with plasma or epidermal proteins, previous reports on the presence of α- and γ-globulins, transferrin, ceruloplasmin, orosomucoid, albumin,[106,107] and immunoglobulin E must be carefully reexamined. The sweat samples collected over an oil barrier placed on the skin (the least-contaminated sweat) contain no or trace of γ-globulin and a very small amount of albumin. Yokozeki and coworkers[108] also reported the presence of cysteine proteinases and their endogenous inhibitors in sweat and the sweat gland. Dermcidin is an antimicrobial peptide produced and secreted in sweat.[79] Other organic compounds reported to be present in sweat include histamine,[109] prostaglandin,[110] and vitamin K–like substances.[111] Sweat also contains traces of pyruvate and glucose. Sweat glucose increases concurrently with a rise in plasma glucose level. Some orally ingested drugs, including griseofulvin,[112] ketoconazole,[113] amphetamines,[114] and various chemotherapeutic agents,[115] are secreted in sweat.

MECHANISMS OF SWEAT SECRETION

Several distinct sequential processes lead to eccrine gland sweat production[116]: (1) stimulation of the eccrine sweat gland by ACh via increased intracellular Ca^{2+}; (2) Ca^{2+}-stimulated loss of cellular K^+, Cl^-, and H_2O, which leads to eccrine gland cell shrinkage; and (3) volume-activated transcellular plus paracellular fluxes of Na^+, Cl^-, and H_2O, which leads to net flux of largely isotonic NaCl solution into the glandular lumen. These processes are illustrated in Fig. 6-11.

Sweating initially is stimulated when ACh is released from periglandular cholinergic nerve endings in response to thermal or emotional stimuli. ACh binds to cholinergic receptors on the clear cell plasma membrane, stimulating intracellular Ca^{2+} release and influx, and increasing cytosolic Ca^{2+} concentrations. Increased intracellular Ca^{2+}, in turn, opens Ca^{2+}-sensitive Cl^- and K^+ channels in the clear cell basolateral membrane, which allows Cl^- and K^+ to escape. Because H_2O follows K^+ and Cl^-, to maintain cell iso-osmolarity, the cell shrinks.[116,117]

This decrease in cell volume sets off a second cascade of cell signaling events. First, decreased cell volume stimulates the NKCC1[118] class of Na/K/2Cl cotransporters, which carry Na^+, K^+, and $2Cl^-$ into the cell in an electrically neutral fashion (ie, two cations and two anions cancel out net charges). The resulting increase in cytosolic Na^+ activates the Na^+, K^+-ATPase, located in the basolateral membrane, which recycles Na^+ and K^+ across the basolateral membrane. The net movement of the negatively charged Cl^- ion across the apical membrane into the lumen in turn drives the positively charged Na^+ ion into the lumen as well, along a paracellular pathway. Therefore, the final product of glandular secretion is the net movement of Na^+, Cl^-, and H_2O into the glandular lumen to form the isotonic NaCl precursor of sweat.

ACh-induced sweating, which constitutes the bulk of sweat production, appears to be mediated by intracellular Ca^{2+}, as detailed earlier. In contrast, adrenergic-induced sweating appears to be mediated by increased intracellular cAMP.[119]

MECHANISM OF DUCTAL REABSORPTION

Because the production of large sweat volumes could lead to dangerous losses of NaCl, the sweat duct has evolved to reabsorb NaCl, which minimizes electrolyte loss, even at high sweat volumes (Fig. 6-12).

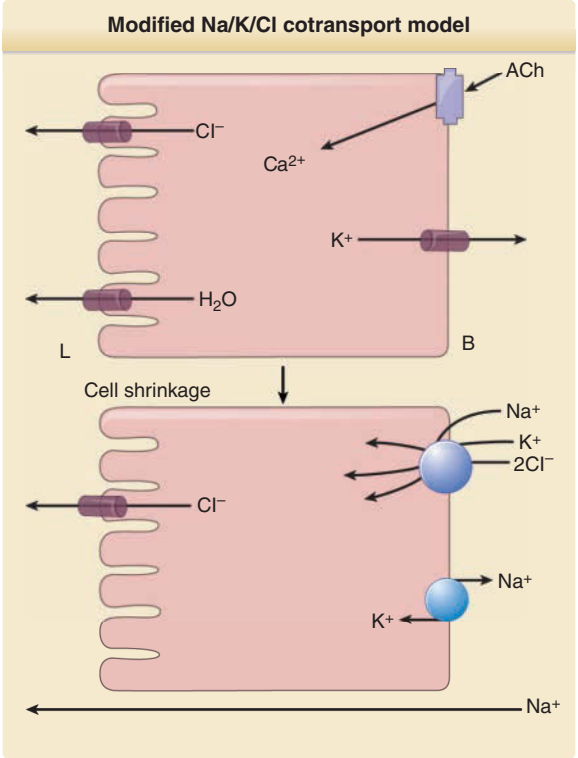

Figure 6-11 Modified Na/K/2Cl cotransport model for the ionic mechanism of cholinergic eccrine sweat secretion. Periglandular neurotransmitters, such as acetylcholine (ACh), bind to receptors on the basolateral membrane, which leads to increased intracellular Ca^{2+}; this in turn activates K^+ and Cl^- channels, mediating K^+, Cl^-, and H_2O efflux from the cell. The resulting cell shrinkage activates the basolateral $Na^+/K^+/2Cl$ antiporter, which leads to Na^+, K^+, and Cl^- influx. The Na^+ and K^+ fluxes are recycled across the basolateral membrane by the Na^+, K^+-adenosine triphosphatase. In contrast, Cl^- fluxes flow unopposed into the lumen, causing an electrical gradient that drives Na^+ exit from the tissue into the lumen via a paracellular pathway. Net fluxes: H_2O, Cl^-, and Na^+ (isotonic) flow into the lumen. pH of the secreted fluid is neutral. Paracellular Na^+ fluxes across the cell junction are indicated with an *arrow* at the bottom of the figure. B, basolateral membrane; L, luminal or apical membrane.

Ductal Na^+ reabsorption is accomplished through the coordinated activities of intracellular enzymes and plasma membrane ion channels, pumps, and exchangers. These mechanisms not only reabsorb electrolytes but also acidify the sweat, which results in a final sweat product that is hypotonic and acidic. Na^+ reenters the duct cells through the apical membrane via amiloride-sensitive[120] epithelial Na^+ channels (ENaC)[5] and is transported across the basolateral membrane by ouabain-sensitive[88] Na^+, K^+-ATPase pumps. Cl^- transport appears to be both transcellular and paracellular, with the cystic fibrosis transmembrane regulator (CFTR) Cl^- channels playing an important role in transcellular fluxes.[118] In cystic fibrosis, CFTR Cl^- channels are mutated, and eccrine duct Cl^- reabsorption is defective but not completely abolished.[27] Na^+ is increased in the duct and the sweat at the skin surface.[121] Unlike in the lung, CFTR mutations do not lead to increased ENaC-mediated Na^+ influx, which suggests that the CFTR–ENaC interactions seen in other tissues differ from that in the eccrine duct. Sweat acidification appears to be mediated via the enzyme carbonic anhydrase, the HCO_3^-/Cl and Na^+/H^+ exchangers, and the V-type H^+ ATPase. The intracellular enzyme carbonic anhydrase catalyzes HCO_3^- and H^+ production. Whereas intracellular HCO_3^- is cleared via the HCO_3^-/Cl antiporter, H^+ is pumped into the luminal sweat by the V-type H^+ ATPase.[122] The Na^+/H^+ antiporter NHE1 (Na^+/H^+ exchanger isoform 1),[123,124] found in the basolateral membrane, is important in intracellular pH regulation.

The transfer of sweat to the skin surface without leakage is important for the homeostatic regulation of skin and is impaired in atopic dermatitis; lesional skin presents a decreased claudin-3 expression in sweat glands, which is accompanied by sweat leakage.[122]

Several drugs are known to modify ductal NaCl reabsorption. When aldosterone is injected systemically or locally, the Na/K ratio in sweat begins to decrease within 6 hours, reaching a nadir at 24 hours and returning to the preinjection level in 48 to 72 hours.[121] Na^+ deprivation stimulates both renin and aldosterone secretion, but high thermal stress per se (a single 1-hour exposure of humans to a temperature of 40°C [104°F]) is a potent stimulator of renin and aldosterone secretion in either the presence or absence of sodium deprivation. In an in vitro sweat gland preparation, neither acetazolamide (a carbonic anhydrase inhibitor) nor antidiuretic hormone changed ductal or secretory function. However, more potent carbonic anhydrase inhibitors, such as topiramate,[125] have been reported to induce oligohidrosis.

APOCRINE SWEAT GLANDS

Apocrine sweat glands are found in humans, largely confined to the regions of the axillae, the perineum, and the areolae of the breast.[126] Differentiated apocrine sweat glands are present at the external auditory canal (ceruminous glands). Apocrine sweat glands do not become functional until just before puberty; thus, it is assumed that their development is associated with the hormonal changes at puberty, although the exact hormones have not been identified.

ANATOMY

Apocrine glands are coiled and localized in the subcutaneous fat near the dermis. The gland consists of a single layer of cuboidal or columnar cells. These secretory cells rest on a layer of myoepithelial cells.[127] The duct is composed of a double layer of cuboidal cells and empties into hair follicle infundibulum. Sweat and sebum are mixed in the hair follicle and arrive mixed at the epidermal surface. The apocrine sweat is cloudy, viscous, initially odorless, and at a pH of 6 to 7.5.

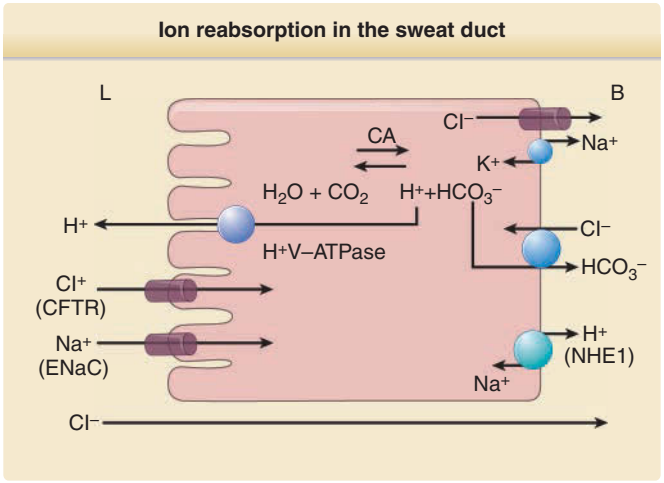

Figure 6-12 Illustration of ion reabsorption in the sweat duct. Na^+ enters the apical (luminal) membrane through epithelial Na^+ channels (ENaC) and is transported across the basolateral membrane by Na^+, K^+-adenosine triphosphatase (ATPase). Cl^- enters the cell through the cystic fibrosis transmembrane regulator Cl^- channel (CFTR) and is transported across the lumen via a paracellular pathway. H^+ generated by the enzyme carbonic anhydrase (CA) is pumped into the lumen by a V-type H^+ ATPase (H^+ V-ATPase). Intracellular pH homeostasis is maintained by parallel HCO_3^-/H^+ and Na^+/H^+ (NHE1) exchangers. The activity of these enzymes, transporters, and channels results in H^+ secretion and Na^+ and Cl^- reabsorption, which produces a final sweat that is hypotonic and acidic. Paracellular Cl^- fluxes across the cell junction are indicated with an *arrow* at the bottom of the figure. B, basolateral membrane; L, luminal or apical membrane.

The sweat of apocrine sweat glands only attains its characteristic odor upon being degraded by bacteria, which releases volatile odor molecules. More bacteria (especially corynebacteria) leads to stronger odor. The presence of axillary hair also makes the odor even more pungent because secretions, debris, keratin, and bacteria accumulate on the hair.

Like the eccrine gland, the myoepithelium fulfills dual functions in both providing structural support and pumping out preformed sweat.

β-Adrenergic receptors and purinergic receptors have been identified on apocrine glands.[94] However, nerve fibers and muscarinic receptors have not been identified, suggesting that any cholinergic stimulation acts humorally.[128]

FUNCTIONS

A number of functions have been attributed to the apocrine glands, including roles as odoriferous sexual attractants, territorial markers, and warning signals. These glands play a role in increasing frictional resistance and tactile sensibility as well as in increasing evaporative heat loss in some species. The production of pheromones by the apocrine glands of many species is well established.[129]

Because the apocrine glands of humans do not begin to function until puberty and are odor producing, it is attractive to speculate that they have some sexual function, which may now be vestigial. There are high levels of 15-lipoxygenase-2 in the secretory cells of the apocrine gland. Its product, 15-hydroxyeicosatetraenoic, a ligand for the nuclear receptor PPARγ, may function as a signaling molecule and in secretion or differentiation.[128]

COMPOSITION OF SECRETION

When it is first secreted, the apocrine sweat of humans is milky, viscid, and without odor. Apocrine sweat contains three types of precursors: fatty acids, sulfanyl alkanols, and odiferous steroids, which are converted by bacteria on axillary skin, particularly corynebacterium striatum, into odiferous substances. Secretion of amino acid and steroid precursors is controlled by an ATP-dependent efflux pump multidrug resistance protein 8 (MRP8), encoded by the gene *ABCC11*, which is expressed in apocrine sweat glands. Axillary odor is significantly reduced in Asian populations that carry a single nucleotide polymorphism in this gene, which also affects earwax characteristics.[130]

MODE OF SECRETION

Despite previous reports for apocrine (decapitation), holocrine, and merocrine types of secretion in apocrine glands, current data indicate that the secretion of apocrine glands is merocrine. Cannulation of the duct of the human apocrine sweat gland has shown that secretion is pulsatile, and it is assumed that contractions of the myoepithelial cells surrounding the secretory cells are responsible for these pulsations.[131]

CONTROL OF SECRETION

The apocrine sweat glands of humans respond to emotive stimuli only after puberty. They can be stimulated by either epinephrine or norepinephrine given locally or systemically. Studies have shown that the apocrine glands are controlled mainly by adrenergic agonists,[132] although some cholinergic control also has been

reported.[128,133] This is in contrast to the eccrine glands, which are under cholinergic control.

Although an intact nerve supply is a functional requirement of apocrine sweating, the demonstration of nerve endings or varicosities in close proximity to the glands has been difficult.[128,133] Local capillary circulation likely assists in conveying transmitter substance to the sweat gland cells, a form of neurohumoral transmission.

As would be expected, drugs that affect adrenergic systems also have an effect on apocrine sweat glands. Adrenergic neuron-blocking agents inhibit sweating, as do drugs that deplete the stores of transmitter substance in adrenergic neurons. Drugs that block specific adrenergic receptors also inhibit sweating, but the types of receptors that must be blocked differ in various species. The type of receptor that mediates the response of the apocrine glands of humans has not been elucidated.

REFERENCES

1. Zouboulis CC, Fimmel S, Ortmann J, et al. Sebaceous glands. In: Hoath SB, Maibach HI, eds. *Neonatal Skin—Structure and Function*, 2nd ed. New York: Marcel Dekker; 2003:59-88.
2. Pappas A. Sebum and sebaceous lipids. In: Zouboulis CC, Katsambas AD, Kligman AM, eds. *Pathogenesis and Treatment of Acne and Rosacea*. Berlin: Springer; 2014:33-41.
3. Zouboulis CC, Krieter A, Gollnick H, et al. Progressive differentiation of human sebocytes in vitro is characterized by increased cell size and altered antigenic expression and is regulated by culture duration and retinoids. *Exp Dermatol*. 1994;3:151-160.
4. Downie MMT, Guy R, Kealey T. Advances in sebaceous gland research: potential new approaches to acne management. *Int J Cosmet Sci*. 2004;26:291-311.
5. Benfenati A, Brillanti F. Sulla distribuzione delle ghiandole sebacee nella cute del corpo umino. *Arch Ital Dermatol*. 1939;15:33-42.
6. Montagna W. An introduction to sebaceous glands. *J Invest Dermatol*. 1974;62:120-123.
7. Thody AJ, Shuster S. Control and function of sebaceous glands. *Physiol Rev*. 1989;69:383-416.
8. Deplewski D, Rosenfield RL. Role of hormones in pilosebaceous unit development. *Endocrine Rev*. 2000; 21:363-392.
9. Zouboulis CC, Nikolakis G, Dessinioti C. Molecular aspects of sebaceous differentiation. In: Zouboulis CC, Katsambas AD, Kligman AM, eds. *Pathogenesis and Treatment of Acne and Rosacea*. Berlin: Springer; 2014:19-26.
10. Merrill B, Gat U, DasGupta R, et al. Tcf3 and Lef1 regulate lineage differentiation of multipotent stem cells in skin. *Genes Dev*. 2001;15:1688-1705.
11. Niemann C, Unden AB, Lyle S, et al. Indian hedgehog and β-catenin signaling: role in the sebaceous lineage of normal and neoplastic mammalian epidermis. *Proc Natl Acad Sci U S A*. 2003;100(suppl 1): 11873-11880.
12. Allen M, Grachtchouk M, Sheng H, et al. Hedgehog signaling regulates sebaceous gland development. *Am J Pathol*. 2003;163:2173-2178.
13. Lo Celso C, Berta MA, Braun KM, et al. Characterization of bipotent epidermal progenitors derived from human sebaceous gland: contrasting roles of c-myc and β-catenin. *Stem Cells*. 2008;26:1241-1252.
14. Magnúsdóttir E, Kalachikov S, Mizukoshi K, et al. Epidermal terminal differentiation depends on B lymphocyte-induced maturation protein-1. *Proc Natl Acad Sci U S A*. 2007;104:14988–14993.
15. Horsley V, Elder HY, Montgomery I, et al. Blimp1 defines a progenitor population that governs cellular input to the sebaceous gland. *Cell*. 2006;126: 597-609.
16. Niemann C, Horsley V. Development and homeostasis of the sebaceous gland. *Semin Cell Dev Biol*. 2012; 23:928-936.
17. Tosti A. A comparison of the histodynamics of sebaceous glands and epidermis in man: a microanatomic and morphometric study. *J Invest Dermatol*. 1974; 62:147-152.
18. Jenkinson DM, Elder HY, Montgomery I, et al. Comparative studies of the ultrastructure of the sebaceous gland. *Tissue Cell*. 1985;17:683-698.
19. Kurokawa I, Mayer-da-Silva A, Gollnick H, et al. Monoclonal antibody labeling for cytokeratins and filaggrin in the human pilosebaceous unit of normal, seborrhoeic and acne skin. *J Invest Dermatol*. 1988; 91:566-571.
20. Zouboulis CC, Tsatsou F. Anatomy of the sebaceous gland. In: Zouboulis CC, Katsambas AD, Kligman AM, eds. *Pathogenesis and Treatment of Acne and Rosacea*. Berlin: Springer; 2014:27-31.
21. Xia L, Zouboulis C, Detmar M, et al. Isolation of human sebaceous glands and cultivation of sebaceous gland-derived cells as an in vitro model. *J Invest Dermatol*. 1989; 93:315-321.
22. Fischer H, Fumicz J, Rossiter H, et al. Holocrine secretion of sebum is a unique DNase2-dependent mode of programmed cell death. *J Invest Dermatol*. 2017; 137:587-594.
23. Nicolaides N. Skin lipids: their biochemical uniqueness. *Science*. 1974;186:19-26.
24. Picardo M, Ottaviani M, Camera E, et al. Sebaceous gland lipids. *Dermatoendocrinol*. 2009;1:68-71.
25. Georgel P, Crozat K, Lauth X, et al. A TLR2-responsive lipid effector pathway protects mammals against Gram-positive bacterial skin infections. *Infect Immun*. 2005;73:4512-4521.
26. Camera E, Ludovici M, Galante M, et al. Comprehensive analysis of the major lipid classes in sebum by rapid resolution high-performance liquid chromatography and electrospray mass spectrometry. *J Lipid Res*. 2010; 51:3377-3388.
27. Nikkari T. Comparative chemistry of sebum. *J Invest Dermatol*. 1974;62:257-267.
28. Kligman AM. The uses of sebum? In. Montagna W, Ellis RA, Silver AF, eds. *Advances in Biology of Skin. Vol IV. The Sebaceous Glands*. Oxford: Pergamon Press; 1963:110-112.
29. Cunliffe WJ, Shuster S. Pathogenesis of acne. *Lancet*. 1969;1(7597):685-687.
30. Flurh JW, Mao-Qiang M, Brown BE, et al. Glycerol regulates stratum corneum hydration in sebaceous gland deficient (Asebia) mice. *J Invest Dermatol*. 2003;120:728-737.
31. Zouboulis CC, Jourdan E, Picardo M. Acne is an inflammatory disease and alterations of sebum composition initiate acne lesions. *J Eur Acad Dermatol Venereol*. 2014;28:527-532.

32. Wille JJ, Kydonieus A. Palmitoleic acid isomer (C16:1d6) is the active antimicrobial fatty acid in human skin sebum. *Skin Pharmacol Appl Skin Physiol*. 2003;16:176-187.
33. Gebhart W, Metze D, Jurecka W. Identification of secretory immunoglobulin A in human sebaceous and sweat glands. *J Invest Dermatol*. 1989;92:648.
34. Thiele JJ, Weber SU, Packer L. Sebaceous gland secretion is a major physiologic route of vitamin E delivery to skin. *J Invest Dermatol*. 1999;113:1006-1010.
35. Lee DY, Yamasaki K, Rudsil J, et al. Sebocytes express functional cathelicidin antimicrobial peptides and can act to kill propionibacterium acnes. *J Invest Dermatol*. 2008;128:1863-1866.
36. Lai Y, Gallo RL. AMPed up immunity: how antimicrobial peptides have multiple roles in immune defense. *Trends Immunol*. 2009;30:131-141.
37. Nakatsuji T, Kao MC, Zhang L, et al. Sebum free fatty acids enhance the innate immune defense of human sebocytes by upregulating beta-defensin-2 expression. *J Invest Dermatol*. 2010;130:985-984.
38. Oeff MK, Seltmann H, Hiroi N, et al. Differential regulation of Toll-like receptor and CD14 pathways by retinoids and corticosteroids in human sebocytes. *Dermatology*. 2006;213:266.
39. Lovászi M, Mattii M, Eyerich K, et al. Sebum lipids influence macrophage polarization and activation. *Br J Dermatol*. 2017;177:1671-1682.
40. Mattii M, Lovászi M, Garzorz N, et al. Sebocytes contribute to skin inflammation by promoting the differentiation of Th17 cells. *Br J Dermatol*. 2018;178(3): 722-730.
41. Lovászi M, Szegedi A, Zouboulis CC, et al. Sebaceous immunobiology is orchestrated by sebum lipids. *Dermatoendocrinol*. 2018;10:e1375636.
42. Zouboulis CC, Baron JM, Böhm M, et al. Frontiers in sebaceous gland biology and pathology. *Exp Dermatol*. 2008;17:542-551.
43. Zouboulis CC, Adjaye J, Akamatsu H, et al. Human skin stem cells and the ageing process. *Exp Gerontol*. 2008;43:986-997.
44. Fuchs E. Skin stem cells: rising to the surface. *J Cell Biol*. 2008;180:273-284.
45. Serri F, Huber WM. The development of sebaceous glands in man. In: Montagna W, Ellis RA, Silver AF, eds. *Advances in Biology of Skin. Vol. IV. Sebaceous Glands*. Oxford: Pergamon; 1963:1-18.
46. Fenske NA, Lober CW. Structural and functional changes of normal aging skin. *J Am Acad Dermatol*. 1986;15:571-585.
47. Zouboulis CC, Dessinioti C. Experimental models of the sebaceous gland. In: Zouboulis CC, Katsambas AD, Kligman AM, eds. *Pathogenesis and Treatment of Acne and Rosacea*. Berlin: Springer; 2014:43-49.
48. Zouboulis CC, Xia L, Akamatsu H, et al. The human sebocyte culture model provides new insights into development and management of seborrhoea and acne. *Dermatology*. 1998;196:21-31.
49. Zouboulis CC, Schagen S, Alestas T. The sebocyte culture—a model to study the pathophysiology of the sebaceous gland in sebostasis, seborrhoea and acne. *Arch Dermatol Res*. 2008;300:397-413.
50. Schneider M, Zouboulis CC. Primary sebocytes and sebaceous gland cell lines for studying sebaceous lipogenesis and sebaceous gland diseases. *Exp Dermatol*. 2018;27(5):484-488.
51. Nikolakis G, Stratakis CA, Kanaki T, et al. Skin steroidogenesis in health and disease. *Rev Endocr Metab Disord*. 2016;17:247-258.
52. Zouboulis CC, Picardo M, Ju Q, et al. Beyond acne: current aspects of sebaceous gland biology and function. *Rev Endocr Metab Disord*. 2017;17: 319-334.
53. Hong I, Lee MH, Na TY, et al. LXRα enhances lipid synthesis in SZ95 sebocytes. *J Invest Dermatol*. 2008; 128:1266-1272.
54. Schmuth M, Watson RE, Deplewski D, et al. Nuclear hormone receptors in human skin. *Horm Metab Res*. 2007; 39:96-105.
55. Zouboulis CC. Sebaceous cells in monolayer culture. *In Vitro Cell Dev Biol*. 1992;28A:699.
56. Zouboulis CC. Sebaceous gland in human skin—the fantastic future of a skin appendage. *J Invest Dermatol*. 2003;120:xiv-xv.
57. Alestas T, Ganceviciene R, Fimmel S, et al. Enzymes involved in the biosynthesis of leukotriene B4 and prostaglandin E2 are active in sebaceous glands. *J Mol Med*. 2006;84:75-87.
58. Imperato-McGinley J, Gautier T, Cai LQ, et al. The androgen control of sebum production. Studies of subjects with dihydrotestosterone deficiency and complete androgen insensitivity. *J Clin Endocrinol Metab*. 1993;76:524-528.
59. Chen W, Tsai SJ, Sheu HM, et al. Testosterone synthesized in cultured human SZ95 sebocytes mainly derives from dehydroepiandrosterone. *Exp Dermatol*. 2010;19:470-472.
60. Chen W, Thiboutot D, Zouboulis CC. Cutaneous androgen metabolism: basic research and clinical perspectives. *J Invest Dermatol*. 2002;119:992-1007.
61. Fritsch M, Orfanos CE, Zouboulis CC. Sebocytes are the key regulators of androgen homeostasis in human skin. *J Invest Dermatol*. 2001;116:793-800.
62. Azmahani A, Nakamura Y, Felizola SJ, et al. Steroidogenic enzymes, their related transcription factors and nuclear receptors in human sebaceous glands under normal and pathological conditions. *J Steroid Biochem Mol Biol*. 2014;144B:268-279.
63. Zouboulis CC. Isotretinoin revisited—pluripotent effects on human sebaceous gland cells. *J Invest Dermatol*. 2006;126:2154-2156.
64. Ganceviciene R, Zouboulis CC. Isotretinoin for acne vulgaris: state-of-the-art treatment for acne vulgaris. *J Dtsch Dermatol Ges*. 2010;8(suppl 1):S47-S59.
65. Zouboulis CC, Korge B, Akamatsu H, et al. Effects of 13-*cis*-retinoic acid, all-*trans*-retinoic acid and acitretin on the proliferation, lipid synthesis and keratin expression of cultured human sebocytes in vitro. *J Invest Dermatol*. 1991;96:792-797.
66. Tsukada M, Schröder M, Roos TC, et al. 13-*cis* Retinoic acid exerts its specific activity on human sebocytes through selective intracellular isomerization to all-*trans* retinoic acid and binding to retinoid acid receptors. *J Invest Dermatol*. 2000;115:321-327.
67. Hommel L, Geiger JM, Harms M, et al. Sebum excretion rate in subjects treated with oral all-*trans*-retinoic acid. *Dermatology*. 1996;193:127-130.
68. Mastrofrancesco A, Ottaviani M, Cardinali G, et al. Pharmacological PPARγ modulation regulates sebogenesis and inflammation in SZ95 human sebocytes. *Biochem Pharmacol*. 2017;138:96-106.
69. Trivedi NR, Cong Z, Nelson AM, et al. Peroxisome proliferator-activated receptors increase human sebum production. *J Invest Dermatol*. 2006;126: 2002-2009.
70. Zouboulis CC. Sebaceous gland receptors. *Dermatoendocrinol*. 2009;1:77-80.

71. Russell LE, Harrison WJ, Bahta AW, et al. Characterization of liver X receptor expression and function in human skin and the pilosebaceous unit. *Exp Dermatol*. 2007; 16:844-852.
72. Gross DN, van den Heuvel AP, Birnbaum MJ. The role of FoxO in the regulation of metabolism. *Oncogene*. 2008;27:2320-2336.
73. Dahlhoff M, Camera E, Picardo M, et al. PLIN2, the major perilipin regulated during sebocyte differentiation, controls sebaceous lipid accumulation in vitro and sebaceous gland size in vivo. *Biochim Biophys Acta Gen Subjects*. 2013;1830:4642-4649.
74. Camera E, Dahlhoff M, Ludovici M, et al. Perilipin 3 modulates specific lipogenic pathways in SZ95 sebocytes. *Exp Dermatol*. 2014;23:759-761.
75. Dahlhoff M, Camera E, Picardo M, et al. Angiopoietin-like 4, a protein strongly induced during sebocyte differentiation, regulates sebaceous lipogenesis but is dispensable for sebaceous gland function in vivo. *J Dermatol Sci*. 2014;75:148-150.
76. Borowczyk-Michalowska J, Zimolag E, Konieczny P, et al. Stage-specific embryonic antigen-4 (SSEA-4) as a distinguishing marker between eccrine and apocrine origin of ducts of sweat glands. *J Invest Dermatol*. 2017; 137(11):2437-2440.
77. Szabo G. The number of eccrine sweat glands in human skin. In: Montagna W, Ellis R, Silver A, eds. *Advances in Biology of Skin*. New York: Pergamon; 1962:1.
78. Sato K, Dobson RL. Regional and individual variations in the function of the human eccrine sweat gland. *J Invest Dermatol*. 1970;54(6):443-449.
79. Schittek B, Hipfel R, Sauer B, et al. Dermcidin: a novel human antibiotic peptide secreted by sweat glands. *Nat Immunol*. 2001;2(12):1133-1137.
80. Ali RS, Falconer A, Ikram M, et al. Expression of the peptide antibiotics human beta defensin-1 and human beta defensin-2 in normal human skin. *J Invest Dermatol*. 2001;117(1):106-111.
81. Murakami M, Lopez-Garcia B, Braff M, et al. Postsecretory processing generates multiple cathelicidins for enhanced topical antimicrobial defense. *J Immunol*. 2004;172(5):3070-3077.
82. Hanukoglu I, Boggula VR, Vaknine H, et al. Expression of epithelial sodium channel (ENaC) and CFTR in the human epidermis and epidermal appendages. *Histochem Cell Biol*. 2017;147(1):733-748.
83. Ellis R. Eccrine sweat glands: electron microscopy, cytochemistry and anatomy. In: Jadassohn J, ed. *Handbuch der Haut und Geshlechtskrankheiten*. Berlin: Springer-Verlag; 1967:223.
84. Sato F, Owen M, Matthes R, et al. Functional and morphological changes in the eccrine sweat gland with heat acclimation. *J Appl Physiol*. 1990;69(1):232-236.
85. Saga K, Sato K. Ultrastructural localization of ouabain-sensitive, K-dependent p-nitrophenyl phosphatase activity in monkey eccrine sweat gland. *J Histochem Cytochem*. 1988;36(8):1023-1030.
86. Sato K, Nishiyama A, Kobayashi M. Mechanical properties and functions of the myoepithelium in the eccrine sweat gland. *Am J Physiol*. 1979;237(3):C177-C184.
87. Hashimoto K, Gross BG, Lever WF. The ultrastructure of the skin of human embryos. I. The intraepidermal eccrine sweat duct. *J Invest Dermatol*. 1965; 45(3):139-151.
88. Sato K, Dobson RL, Mali JW. Enzymatic basis for the active transport of sodium in the eccrine sweat gland. Localization and characterization of Na-K-adenosine triphosphatase. *J Invest Dermatol*. 1971;57(1):10-16.
89. Nadel ER, Bullard RW, Stolwijk JA. Importance of skin temperature in the regulation of sweating. *J Appl Physiol*. 1971;31(1):80-87.
90. Freedman RR. Hot flashes: behavioral treatments, mechanisms, and relation to sleep. *Am J Med*. 2005;118(suppl 12B):124-130.
91. Johnson R, Spalding J. *Disorders of the Autonomic Nervous System*. Philadelphia: FA Davis; 1974.
92. Hu Y, Converse C, Lyons MC, et al. Neural control of sweat secretion: a review. *Br J Dermatol*. 2018; 178(6):1246-1256.
93. Kreyden OP, Scheidegger EP. Anatomy of the sweat glands, pharmacology of botulinum toxin, and distinctive syndromes associated with hyperhidrosis. *Clin Dermatol*. 2004;22(1):40-44.
94. Coon J, Rothman S. The sweat response to drugs with nicotine-like action. *J Pharmacol Exp Ther*. 1941;23:1.
95. Faden AI, Chan P, Mendoza E. Progressive isolated segmental anhidrosis. *Arch Neurol*. 1982;39(3):172-175.
96. Suzuki Y, Ohtsuyama M, Samman G, et al. Ionic basis of methacholine-induced shrinkage of dissociated eccrine clear cells. *J Membr Biol*. 1991;123(1):33-41.
97. Buceta JM, Bradshaw CM, Szabadi E. Hyperresponsiveness of eccrine sweat glands to carbachol in anxiety neurosis: comparison of male and female patients. *Br J Clin Pharmacol*. 1985;19(6):817-822.
98. Sato K, Sato F. Defective beta adrenergic response of cystic fibrosis sweat glands in vivo and in vitro. *J Clin Invest*. 1984;73(6):1763-1771.
99. Prout BJ, Wardell WM. Sweating and peripheral blood flow in patients with phaeochromocytoma. *Clin Sci*. 1969;36(1):109-117.
100. Sato K. The physiology, pharmacology, and biochemistry of the eccrine sweat gland. *Rev Physiol Biochem Pharmacol*. 1977;79:51-131.
101. Sato K, Sato F. Na^+, K^+, H^+, Cl^-, and Ca^{2+} concentrations in cystic fibrosis eccrine sweat in vivo and in vitro. *J Lab Clin Med*. 1990;115(4):504-511.
102. Pagaduan JV, Ali M, Dowlin M, et al. Revisiting sweat chloride test results based on recent guidelines for diagnosis of cystic fibrosis. *Pract Lab Med*. 2018;10(1):34-37.
103. Sato K, Dobson RL. Glucose metabolism of the isolated eccrine sweat gland. II. The relation between glucose metabolism and sodium transport. *J Clin Invest*. 1973;52(9):2166-2174.
104. Brusilow SW, Gordes EH. The permeability of the sweat gland to nonelectrolytes. *Am J Dis Child*. 1966;112(4):328-333.
105. Brusilow SW, Gordes EH. Ammonia secretion in sweat. *Am J Physiol*. 1968;214(3):513-517.
106. Page CO Jr, Remington JS. Immunologic studies in normal human sweat. *J Lab Clin Med*. 1967;69(4):634-650.
107. Jirka M, Blanicky P. Micro-isoelectric focusing of proteins in pilocarpine-induced sweat. *Clin Chim Acta*. 1971;31(2):329-332.
108. Yokozeki H, Hibino T, Takemura T, et al. Cysteine proteinase inhibitor in eccrine sweat is derived from sweat gland. *Am J Physiol*. 1991;260(2 Pt 2):R314-R320.
109. Garden JW. Plasma and sweat histamine concentrations after heat exposure and physical exercise. *J Appl Physiol*. 1966;21(2):631-635.
110. Forstrom L, Goldyne ME, Winkelmann RK. Prostaglandin activity in human eccrine sweat. *Prostaglandins*. 1974;7(6):459-464.
111. Seutter E, Sutorius AH. The vitamin K derivatives of some skin-mucins. 3. A route of oxygen transfer. *Int J Vitam Nutr Res*. 1971;41(4):529-536.

112. Shah VP, Epstein WL, Riegelman S. Role of sweat in accumulation of orally administered griseofulvin in skin. *J Clin Invest*. 1974;53(6):1673-1678.
113. Harris R, Jones HE, Artis WM. Orally administered ketoconazole: route of delivery to the human stratum corneum. *Antimicrob Agents Chemother*. 1983;24(6):876-882.
114. Vree TB, Muskens AT, van Rossum JM. Excretion of amphetamines in human sweat. *Arch Int Pharmacodyn Ther*. 1972;199(2):311-317.
115. Bolognia JL, Cooper DL, Glusac EJ. Toxic erythema of chemotherapy: a useful clinical term. *J Am Acad Dermatol*. 2008;59(3):524-529.
116. Sato K. The physiology and pharmacology of the eccrine sweat gland. In: Goldsmith L, ed. *Biochemistry and Physiology of the Skin*. Oxford: Oxford University Press; 1983:596.
117. Takemura T, Sato F, Saga K, et al. Intracellular ion concentrations and cell volume during cholinergic stimulation of eccrine secretory coil cells. *J Membr Biol*. 1991;119(3):211-219.
118. Reddy MM, Quinton PM. Cytosolic potassium controls CFTR deactivation in human sweat duct. *Am J Physiol Cell Physiol*. 2006;291(1):C122-C129.
119. Sato K, Sato F. Cyclic AMP accumulation in the beta adrenergic mechanism of eccrine sweat secretion. *Pflugers Arch*. 1981;390(1):49-53.
120. Garty H, Palmer LG. Epithelial sodium channels: function, structure, and regulation. *Physiol Rev*. 1997; 77(2):359-396.
121. Granger D, Marsolais M, Burry J, et al. Na^+/H^+ exchangers in the human eccrine sweat duct. *Am J Physiol Cell Physiol*. 2003;285(5):C1047-C1058.
122. Yamaga K, Murota H, Tamura A, et al. Claudin-3 loss causes leakage of sweat from the sweat gland to contribute to the pathogenesis of atopic dermatitis. *J Invest Dermatol*. 2018;138(6):1279-1287.
123. Granger D, Marsolais M, Burry J, et al. V-type H^+-ATPase in the human eccrine sweat duct: immunolocalization and functional demonstration. *Am J Physiol Cell Physiol*. 2002;282(6):C1454-C1460.
124. Nejsum LN, Praetorius J, Nielsen S. NKCC1 and NHE1 are abundantly expressed in the basolateral plasma membrane of secretory coil cells in rat, mouse, and human sweat glands. *Am J Physiol Cell Physiol*. 2005; 289(2):C333-C340.
125. de Carolis P, Magnifico F, Pierangeli G, et al. Transient hypohidrosis induced by topiramate. *Epilepsia*. 2003;44(7):974-976.
126. Shappell SB, Keeney DS, Zhang J, et al. 15-Lipoxygenase-2 expression in benign and neoplastic sebaceous glands and other cutaneous adnexa. *J Invest Dermatol*. 2001;117(1):36-43.
127. Charles A. An electron microscopic study of the human axillary apocrine gland. *J Anat*. 1959;93(2):226-232.
128. Lindsay SL, Holmes S, Corbett AD, et al. Innervation and receptor profiles of the human apocrine (epitrichial) sweat gland: routes for intervention in bromhidrosis. *Br J Dermatol.* 2008;159(3):653-660.
129. Mykytowycz R. The behavioural role of the mammalian skin glands. *Naturwissenschaften*. 1972;59(4): 133-139.
130. Martin A, Saathoff M, Kuhn F, et al. A functional ABCC11 allele is essential in the biochemical formation of human axillary odor. *J Invest Dermatol*. 2010;130(2): 529-540.
131. Sato K. Pharmacological responsiveness of the myoepithelium of the isolated human axillary apocrine sweat gland. *Br J Dermatol*. 1980;103(3):235-243.
132. Wu JM, Mamelak AJ, Nussbaum R, et al. Botulinum toxin a in the treatment of chromhidrosis. *Dermatol Surg*. 2005;31(8 Pt 1):963-965.
133. Robertshaw D. Apocrine sweat glands. In: Goldsmith L, ed. *Physiology, Biochemistry and Molecular Biology of the Skin*. Oxford: Oxford University Press; 1991:763.

Chapter 7 :: Biology of Hair Follicles

:: George Cotsarelis & Vladimir Botchkarev

AT-A-GLANCE

- The primary purpose of hair in humans is to influence social interactions.
- Hair follicle development depends on interactions between epithelial and mesenchymal cells. The genes important for this interaction are slowly being elucidated.
- Genes important for hair follicle development also play a role in hair follicle cycling.
- The hair follicle bulge possesses stem cells important for the continual regeneration of the follicle during cycling.
- Hair pigmentation depends on melanocyte stem cells and differentiated cells in the follicle. Many genes important for melanocyte behavior and hair pigmentation have been defined.

EVOLUTION AND FUNCTION OF HAIR

Hair is found only in mammals, in which during the course of evolution, its primary roles were to serve as insulation and protection from the elements. In contemporary humans, however, hair's main purpose revolves around its profound role in social interactions. Loss of hair (alopecia) and excessive hair growth in unwanted areas (hirsutism and hypertrichosis) can lead to significant psychological and emotional distress that supports a multibillion-dollar effort to reverse these conditions.

Much progress has been made in understanding hair growth, and as a result, new treatments for alopecia are on the horizon.[1,2] These advances resulted from the interest of developmental biologists and other investigators in the hair follicle as a model for a wide range of biological processes. As each hair follicle cyclically regenerates, it recapitulates its initial development. Many growth factors and receptors important during hair follicle development also regulate hair follicle cycling.[3,4] The hair follicle possesses keratinocyte and melanocyte stem cells, nerves, and vasculature that are important in healthy and diseased skin.[5-7] To appreciate this emerging information and to properly assess a patient with hair loss or excess hair (see Chaps. 85-90), an understanding of the anatomy and development of the hair follicle is essential.

EMBRYOLOGY

Morphologically, hair follicle development has been divided into eight consecutive stages, several of which are illustrated in Fig. 7-1. Each stage is characterized by unique expression patterns for growth factors and their receptors, growth factor antagonists, adhesion molecules, and intracellular signal transduction components.[8-10] Promising advances in understanding the molecular mechanisms behind hair follicle development arose through the discovery that mammalian counterparts (homologs) of genes important for normal *Drosophila* (fruit fly) development also affect hair follicle development. *Decapentaplegic (Dpp/BMP)*, *engrailed (en)*, *Homeobox (hox)*, *hedgehog/patched (hh/ptc)*, *notch*, *wingless/armadillo (wg/wnt/catenin)*, and *branchless (Fgf)* genes are all critical for hair follicle and vertebrate development in general (reviewed in [8-10]). These genes were all first discovered in *Drosophila*; thus, most of the names assigned to them describe the peculiar appearance (phenotype) of the flies carrying mutations in these genes.[11]

Follicle formation begins on the head and then moves downward to the remainder of the body in utero. The first hairs formed are lanugo hairs, which are nonpigmented, soft, and fine. Lanugo hair is typically shed between the 32nd and 36th weeks of gestation, although approximately one third of newborns still retain their lanugo hair for up to several weeks after birth.

Patterning genes, called homeobox genes, which are precisely organized in the genome so that they are expressed in strict temporal sequences and spatial patterns during development, likely are responsible for the nonrandom and symmetrical distribution of hair follicles over the body.[11,12] In adult mice, homeobox gene expression reappears in hair follicles and serves to maintain normal hair shaft production.[13] *Engrailed*, a type of homeobox gene, is responsible for dorsal-ventral patterning, and mice lacking *engrailed* develop hair follicles on their footpads.[14]

Although hair follicles and hairs all share the same basic anatomy, their growth, size, shape, pigmentation and other characteristics differ widely based on body location and variation among individuals. Many of these characteristics are established during development but are then profoundly altered by hormonal influences later in life. We are beginning to understand the genes controlling hair length, curl, and distribution because of elegant genetic studies on dogs. These studies reveal that fibroblast growth factor-5 (FGF-5), Keratin 71, and R-spondin 2 influence length, curl, and distribution, respectively.[15] In humans, thicker hair found in Asians is associated with increased activity of Edar.[16]

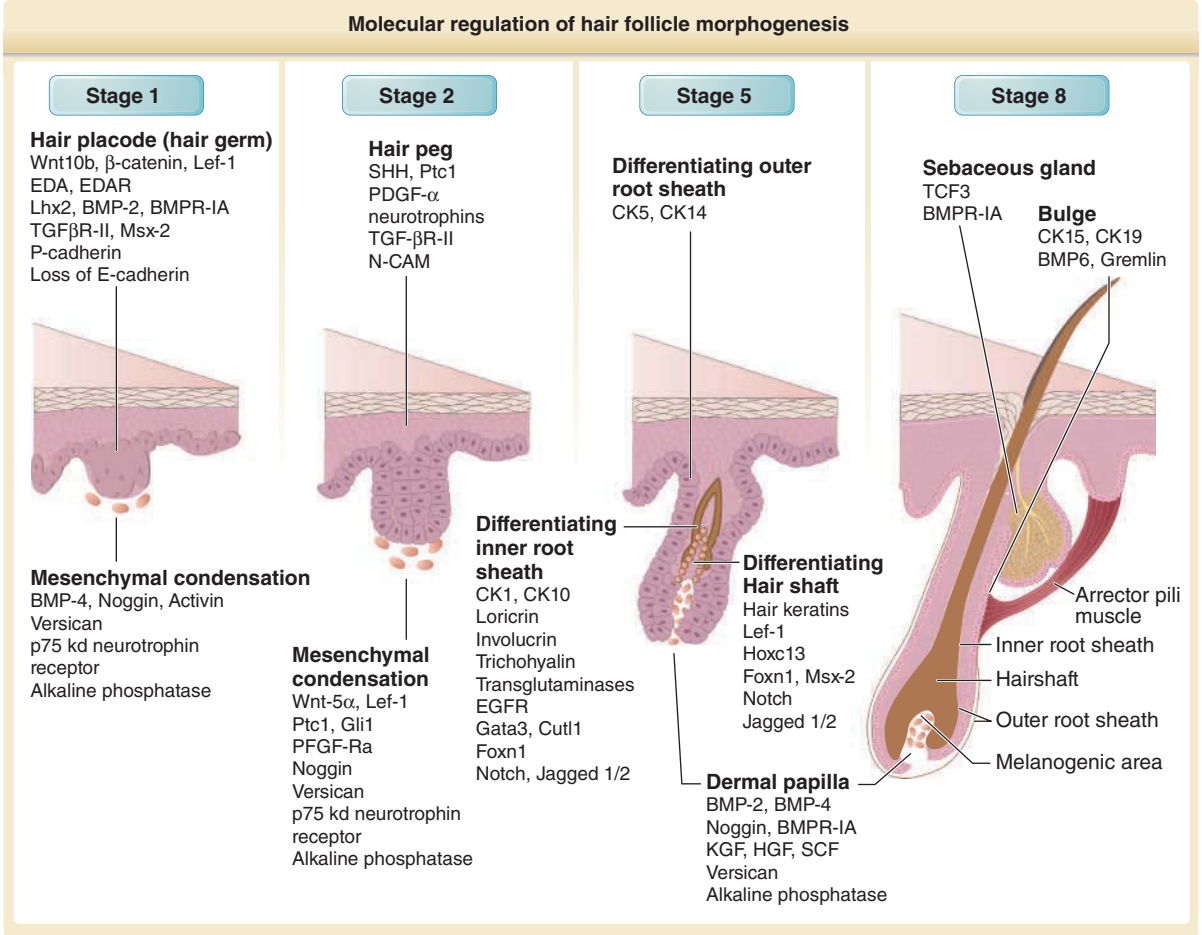

Figure 7-1 Molecular regulation of hair follicle morphogenesis. The schematic shows the expression of different growth factors, their receptors, adhesion, and cell matrix molecules; transcriptional regulators in hair follicle epithelium; and mesenchyme during distinct stages of hair follicle development. BMP, bone morphogenetic protein; BMPR-IA, bone morphogenetic protein receptor, type IA; CK, keratin 5; Cutl1, cut-like 1; E-cadherin, epithelial cadherin; EDA, ectodysplasin; EDAR, ectodysplasin receptor; EGFR, epidermal growth factor receptor; Foxn1, forkhead box N1; Gata3, GATA binding protein 3; Gli1, glioma-associated oncogene homolog 1; HGF, hepatocyte growth factor; Hoxc13, homeobox C13; KGF, keratinocyte growth factor; Lef-1, lymphoid enhancer factor 1; Lhx2, LIM homeobox 2; N-CAM, neural cell adhesion molecule; P-cadherin, placental cadherin; PDGF-α, platelet-derived growth factor α polypeptide; PFGF-Rα, platelet-derived growth factor receptor α; Ptc1, patched1; SCF, stem cell factor; Shh, sonic hedgehog; TCF3, transcription factor 3; TGF-βR-II, transforming growth factor-β receptor 2.

The size of many types of follicles changes drastically several times throughout life. For example, lanugo hair follicles, which produce hair shafts several centimeters long, convert to vellus follicles that produce small hairs that protrude only slightly from the skin surface. Later in life, vellus follicles on the male beard enlarge into terminal follicles that generate thick, long hairs. On the scalp of genetically predisposed individuals, terminal follicles miniaturize and form effete, microscopic hairs.

EPITHELIAL PLACODE OR PRIMARY HAIR GERM

In the human fetus, hair follicles develop from small collections of cells, called epithelial placodes, which corresponds to stage 1 of hair follicle development and first appear around 10 weeks of gestation (see Fig. 7-1). The epithelial placode then expands to form the "primary hair germ" whose progeny eventually generate the entire epithelial portion of the hair follicle.[17]

The hair follicle placode is formed through the centripetal migration of the basal epidermal cells and their compaction.[18] The cells of the hair placode and germ express placental cadherin and become oriented vertically, losing their desmosomes, hemidesmosomes, and epithelial cadherin, which decreases their adhesion to their neighbors.[19-21] Dermal cells beneath the hair follicle placode form a condensation, which later develops into the dermal papilla.[22] Signaling between the epithelial and mesenchymal cells during placode formation involves several signaling pathways (Wnt, Eda, Fgf, Bmp) operating via multiple feedback mechanisms[23] (see Fig. 7-1). Extensive signaling between epithelial and mesenchymal cells results in the appearance of distinct sets of lineage-specific transcription factors

(Lhx2, Sox9, Msx2, Foxi3) in the epithelial progenitor cells that promote differentiation toward a hair follicle fate. In turn, the dermal condensate beneath the hair placode expresses the extracellular matrix proteoglycan versican, p75 kD neurotrophin receptor, as well as the transcription factors Tbx18 and Sox2 (reviewed in [24-26]). These factors allow for maturation of the dermal condensate into the dermal papilla. The dermal papilla drives the growth of the fully formed follicle. These reciprocal signals pass through the intervening basement membrane, which undergoes alterations in its morphology and chemical composition that may alter its ability to sequester growth factors and binding proteins, thus possibly modulating the epithelial–mesenchymal interactions.

Many of these regulatory molecules important for the formation of the hair follicle have been defined, but how they interact to generate hair follicles in an otherwise homogeneous epithelium has yet to be determined. In one model, the spacing and size of placodes are regulated by a dermal signal, which varies in character in different body regions. The dermal signal occurs uniformly within each body region and triggers the activation of promoters and repressors of follicle fate in the epithelium that then compete with one another, resulting in the establishment of a regular array of follicles.[9,27-29] Differences in the levels of promoter and repressor activation could account for regional differences in the size and spacing of follicles. Consistent with this model, several positive and negative regulators of hair follicle fate are initially expressed uniformly in the epidermis and subsequently become localized to placodes.

One of the earliest molecular pathways that positively regulate hair follicle initiation is the WNT/β-catenin pathway. β-catenin is the downstream mediator of WNT signaling. WNT proteins bind to receptors on the cell membrane and, through a series of signals, inhibit the degradation of cytoplasmic β-catenin. β-Catenin then translocates to the nucleus, forming a complex with the LEF/TCF family of transcription factors and resulting in expression of downstream genes.[9] Activation of the β-catenin pathway appears necessary for establishing epithelial competence, a state in which the epithelial tissue has the potential to form a hair follicle. Normally, the β-catenin pathway is inactive in the adult epidermis, but by artificially activating β-catenin in epidermal basal cells of adult transgenic mice, hair follicles develop de novo.[30] This remarkable finding could eventually have therapeutic implications, although constant activation of this pathway in the hair follicle also results in pilomatricomas and trichofolliculomas, two types of relatively rare cutaneous tumors.[30,31] Whereas dermal Wnt/β-catenin signaling is also important for the survival and specification of the mesenchymal condensate cells, loss of dermal β-catenin results in arrest of hair follicle development.[32]

Ectodysplasin (*EDA*), a molecule related to tumor necrosis factor (TNF), and its receptor (*EDAR*) also are part of another major pathway that stimulate early follicle development in both mouse and human.[27,33] *EDA* gene mutations cause X-linked anhidrotic ectodermal dysplasia, a syndrome associated with decreased numbers of hair follicles, and defects of the teeth and sweat glands (see Chap. 131).[34] The *EDAR* gene is mutated in autosomal recessive and dominant hypohidrotic ectodermal dysplasias, causing identical phenotypes to those resulting from *EDA* mutations. The mouse *Edar* gene is expressed ubiquitously in the epithelium before placode formation and then becomes restricted to placodes, but the *Eda* gene is ubiquitously expressed even after placode formation.[27] Mice with mutations in these genes have the same phenotype as humans with similar mutations, and mice overexpressing Eda in the epidermis show formation of "fused" follicles because of the loss of proper spacing between neighboring hair placodes.[27,35,36] Variations in the *EDAR* gene causing higher EDAR activity are associated with thicker hair.[16]

In contrast to EDA and EDAR, which promote hair follicle development, members of the bone morphogenetic protein (BMP) family inhibit follicle formation. Whereas *Bmp2* is expressed diffusely in the ectoderm but then localizes to the early placode and underlying mesenchyme, *Bmp4* is expressed in the early dermal condensate.[37,38] BMP signaling inhibits placode formation, and neutralization of BMP activity by its antagonist Noggin promotes placode fate, at least in part via positive regulation of Lef-1 expression.[37,39-41] Mice lacking Noggin have fewer hair follicles than normal and delayed follicular development.[41] The Notch pathway also appears to play a role in determining the follicular pattern. The Notch ligand delta-1 is normally expressed in the mesenchyme underlying the placode,[42-44] and when misexpressed in a small part of the epithelium, it promotes and accelerates placode formation while suppressing placode formation in surrounding cells.[42,45]

Another secreted protein present in the follicular placode that plays a major role in epithelial-mesenchymal signaling is Sonic hedgehog (SHH).[46,47] Skin from mice lacking Shh have extremely effete hair follicles with poorly developed dermal papillae.[48-50] Patched1 (PTC1), the receptor for SHH, is expressed in the germ cells and the underlying dermal papilla, suggesting that SHH may have both autocrine and paracrine inductive properties necessary for hair germ and dermal papilla formation.[51] Patched is the gene deficient in basal cell nevus syndrome.[52]

THE BULBOUS PEG OR HAIR BUD

In the next stage of development, the bulbous peg or hair bud (or stage 2 of hair follicle development; see Fig. 7-1) is formed by elongation of the hair germ into a cord of epithelial cells. The mesenchymal cells at the sides of the peg will develop into the connective tissue sheath of the hair follicle, and those at the tip of the peg will develop into the dermal papilla. Proliferation of the epithelial cells and lateral expansion of the follicular placode are regulated by Shh, which

also promotes morphogenesis of the dermal papilla expressing the corresponding receptors.[48,49] The deepest portion of the follicle peg forms a bulbous structure surrounding the dermal papilla and goes on to form the matrix of the hair follicle, which gives rise to the hair shaft and inner root sheath. The outer root sheath forms two bulges on the side of the hair follicle farthest from the epidermis. The superficial bulge develops into the sebaceous gland. The deeper bulge serves as the future site of epithelial stem cells that generate the new lower follicle during hair follicle cycling. The arrector pili muscle usually attaches to the bulge area, and contraction of the muscle erects the hair shaft leading to "goose bumps." In the axillae, anogenital region, areolae, periumbilical region, eyelids, and external ear canals, a third bulge develops superficial to the sebaceous gland bud and gives rise to the apocrine gland.

MATURE HAIR FOLLICLE

As the hair follicle bulb appears during the bulbous peg stage, at least eight different cell layers constituting all of the components of the mature hair follicle form. Understanding which genes determine these specific cell lineages within the follicle is an important question. The inner root sheath cells express hair follicle-specific keratins Krt25-28/Krt81-86, epidermal keratins Krt1/10, components of the cornified cell envelope (loricrin, involucrin, trichohyalin, transglutaminases, and so on).[53] Differentiation of the inner root sheath is regulated by the epidermal growth factor receptor signaling and its ligand transforming growth factor (TGF-α), as well as by the enzymes involved in the TGF-α ectodomain shedding (TNF-α–converting enzyme and lysophosphatidic acid–producing enzyme PA-PLA1$_\alpha$), which prevent premature keratinization in the inner root sheath cells, leading to the formation of curly hair.[54-56] Also, BMP and Notch signaling pathways, as well as Cutl1, Dlx3, Gata-3, and Msx-2 transcription factors, are involved in the control of inner root sheath differentiation (reviewed in [57,58]).

The central lumen where the hair shaft will emerge is formed by necrosis and cornification of epithelial cells in the infundibulum. As the hair shaft is produced, several signaling pathways are involved in the control of its differentiation. Hair shaft–specific differentiation is characterized by expression of hair-specific keratins (Krt31-37, Krt81-86) and keratin-associated proteins in hair progenitor cells.[53] Wnt, Bmp, Edar, FGF, Hedgehog, IGF, and Notch signaling pathways, as well as a number of transcription factors, including Dlx3, Foxn1, Hoxc13, Krox20, and Msx2 (reviewed in [57,58]) regulate this hair shaft differentiation program. Some transcription factors, such as Foxn1, Lef1, and Hoxc13, directly regulate transcription of the hair keratin or keratin-associated protein genes.[57,58] WHN[59-61] is mutated in nude mice and rarely in humans with hair, nail, and immune defects.[62,63] Comprehensive RNAseq profiling data of the distinct cell populations in mature murine hair follicles described by Rezza and colleagues[64] reveal signaling interaction networks implicated in epithelial–mesenchymal interactions and provide a comprehensive platform linked to an interactive online database to identify and further explore the crosstalk between stem cells and their progeny in regulating hair follicle growth.

This process of hair follicle formation is repeated in several waves, with the formation of secondary follicles alongside the initial follicle. In human scalp skin, the follicles are primarily clustered into groups of three and possess an oblique orientation with a similar angle to their neighbors.

ANATOMY

HAIR TYPES

After formation of the lanugo hair that is characteristic of the prenatal period, there are two major types of hair classified according to size (Table 7-1). Terminal hairs are typically greater than 60 µm in diameter, possess a central medulla, and can grow to well over 100 cm in length. The duration of the growing stage (anagen) determines the length of the hair. The hair bulb of terminal hairs in anagen is located in the subcutaneous fat. In contrast, vellus hairs are typically less than 30 µm in diameter, do not possess a medulla, and are less than 2 cm in length. The hair bulb of vellus hairs in anagen is located in the reticular dermis. Terminal hairs are found on the scalp, eyebrows, and eyelashes at birth. Vellus hairs are found elsewhere, and, at puberty, vellus hair follicles in the genitalia, axillae, trunk, and beard area in men transform into terminal hair follicles under the influence of sex hormones. Terminal hair follicles in the scalp convert to vellus-like or miniaturized hair follicles during androgenetic alopecia (see Chap. 85).[1,65]

The curvature of the hair varies greatly among different individuals and races and ranges from straight to tightly curled. Curved hair shafts arise from curved hair follicles. The shape of the inner root sheath is thought to determine the shape of the hair. Curled hair in cross section is more elliptical or flattened in comparison with straight hair, which is rounder. Several genes influencing hair shape have been identified. Mutations in the epidermal growth factor receptor (EGFR) pathway and in insulinlike growth factor binding protein 5 result in curly hair in mice.[28,66]

TABLE 7-1
Hair Types and Characteristics

TYPE OF HAIR	ANAGEN DURATION	SIZE (DIAMETER, LENGTH)
Lanugo	1-3 months	40 µm, 1-2 cm
Vellus	1-2 weeks	<30 µm, <2 cm
Terminal	>1 year	>60 µm, 10≥100 cm
Miniaturized	<1 week	<30 µm, <2 cm

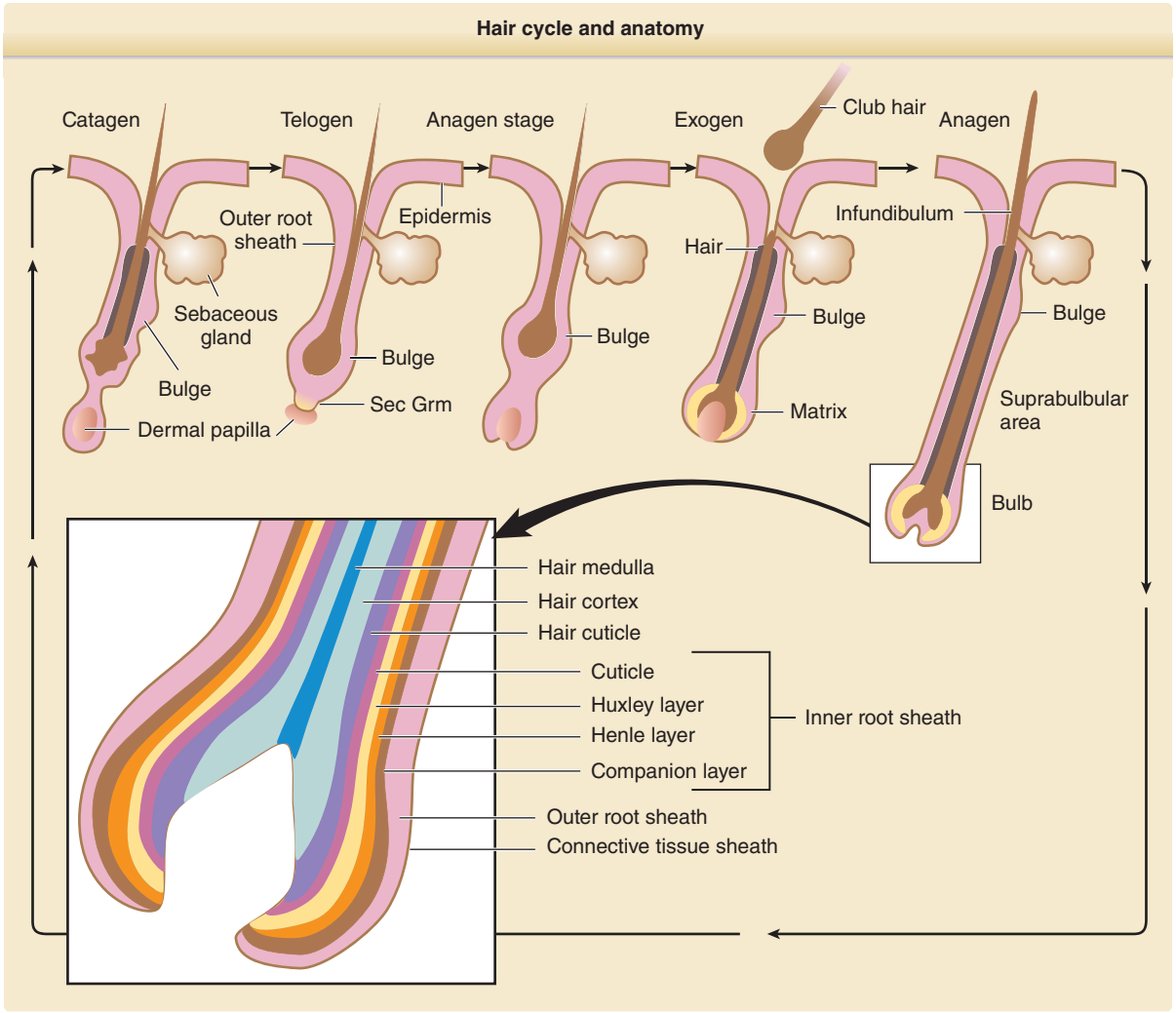

Figure 7-2 Hair cycle and anatomy. The hair follicle cycle consists of stages of rest (telogen), hair growth (anagen), follicle regression (catagen), and hair shedding (exogen). The entire lower epithelial structure is formed during anagen and regresses during catagen. The transient portion of the follicle consists of matrix cells in the bulb that generate seven different cell lineages, three in the hair shaft and four in the inner root sheath. Sec Grm, secondary germ.

MICROSCOPIC ANATOMY

The upper follicle consists of the infundibulum and the isthmus, and the lower follicle consists of the suprabulbar and the bulbar areas (Fig. 7-2).[67,68] The upper follicle is permanent, but the lower follicle regenerates with each hair follicle cycle. The major compartments of the hair from outermost to innermost include the connective tissue sheath, the outer root sheath, the inner root sheath, the cuticle, the hair shaft cortex, and the hair shaft medulla, each characterized by distinct expression of the hair follicle–specific keratins (Table 7-2).[69,70]

OUTER ROOT SHEATH

The outer root sheath is continuous with the epidermis (see Fig. 7-2) at the infundibulum and continues down to the bulb. The cells of the outer root sheath change considerably throughout the follicle. The outer root sheath in the infundibulum resembles epidermis and forms a granular layer during its keratinization. In the isthmus, the outer root sheath cells keratinize in a trichilemmal fashion, lacking a granular layer. Trichilemmal keratinization occurs where the inner root sheath begins to slough. Desmoglein expression markedly changes here as well, and trichilemmal or pilar cysts retain these characteristics.[71] Keratinocytes in the outer root sheath form the bulge at the base of the isthmus (see section "Hair Follicle Stem Cells"). These cells generally possess a higher nuclear-to-cytoplasmic ratio than other areas of the follicle. Moving downward, the outer root sheath cells become much larger and contain abundant glycogen in the suprabulbar follicle. In the bulb, the outer root sheath consists of only a single, flattened cell layer that can be traced to the base of the follicle.

TABLE 7-2
Expression of Keratin Genes in Distinct Hair Follicle (HF) Compartments

HF COMPARTMENTS	TYPE I KERATINS, NEW NOMENCLATURE (OLD NOMENCLATURE)	TYPE II KERATINS, NEW NOMENCLATURE (OLD NOMENCLATURE)
Outer root sheath	K14 (K14), K15 (K15), K16 (K16), K17 (K17), K19 (K19)	K5 (K5)
Inner root sheath, companion layer	K16 (K16), K17 (K17)	K75 (K6hf), K6 (K6)
Hair matrix or precortex	K35 (Ha5)	K85 (Hb5)
Inner root sheath, Henle layer	K25 (K25irs1), K27 (K25irs3), K28 (K25irs4)	K71 (K6irs1)
Inner root sheath, Huxley layer	K25 (K25irs1), K27 (K25irs3), K28 (K25irs4)	K71 (K6irs1), K74 (K6irs4)
Inner root sheath, cuticle	K25 (K25irs1), K26 (K25irs2), K27 (K25irs3), K28 (K25irs4)	K71 (K6irs1), K72 (K6irs2), K73 (K6irs3)
Hair, cuticle	K32 (Ha2), K35 (Ha5)	K82 (Hb2), K85 (Hb5)
Hair, mid- and upper cortex	K31 (Ha1), K33a (Ha3-I), K33b (Ha3-II), K34 (Ha4), K35 (Ha5), K36 (Ha6), K37 (Ha7), K38 (Ha8)	K81 (Hb1),[a] K83 (Hb3), K85 (Hb5), K86 (Hb6)[a]
Hair, medulla	K16 (K16), K17 (K17), K25 (K25irs1), K27 (K25irs3), K28 (K25irs4), K33 (Ha3), K34 (Ha4), K37 (Ha7)	K5 (K5), K6 (K6), K75 (K6hf), K81 (Hb1)[a]

[a]Autosomal dominant mutations of K81 and K86 lead to monilethrix (alopecia caused by increased hair fragility).
Data from Langbein L, Rogers MA, Praetzel-Wunder S, et al. K25 (k25irs1), K26 (k25irs2), k27 (k25irs3), and k28 (k25irs4) represent the type I inner root sheath keratins of the human hair follicle. *J Invest Dermatol*. 2006;126:2377; and Langbein L, Schweizer J. Keratins of the human hair follicle. *Int Rev Cytol*. 2005;243:1.

INNER ROOT SHEATH

The inner root sheath extends from the base of the bulb to the isthmus and contains four parts from outermost to innermost: the companion layer, Henle layer, Huxley layer, and inner root sheath cuticle. The companion layer (see Fig. 7-2) has been referred to as the innermost layer of the outer root sheath, but recent evidence indicates that it is more like inner root sheath than outer root sheath.[67,72], The companion layer attaches to the Henle layer and moves upward with the rest of the inner root sheath; thus, it provides a slippage plane between the outer root sheath, which is stationary, and the inner root sheath.[72] The companion layer is prominent in some follicles (eg, the beard) compared with others. The cells of the companion layer are flat compared to the cuboidal outer root sheath cells and express a type II cytokeratin, K6hf.[72] The Henle layer is one cell layer thick and is the first to develop keratohyalin granules and the first to keratinize. The Huxley layer is two to four cell layers thick and keratinizes above the Henle layer at the region known as *Adamson fringe*. Some cells within the Huxley layer protrude through the Henle layer and attach directly to the companion layer. These cells are called *Fluegelzellen* or *wing cells*.[73] The cells of the inner root sheath cuticle partially overlap, forming a "shingled roof" appearance, and they intertwine precisely with the cuticle cells of the hair shaft. This association between the two cuticles anchors the hair shaft tightly to the follicle. The inner root sheath, composed of hard keratins and associated proteins (see Table 7-2), is thought to dictate hair shape by funneling the hair shaft cells as they are produced. The transcription factor GATA-3 is critical for inner root sheath differentiation and lineage. Mice lacking this gene fail to form an inner root sheath.[74]

HAIR SHAFT

The hair shaft (and inner root sheath) arises from rapidly proliferating matrix keratinocytes in the bulb, which have one of the highest rates of proliferation in the body. The cells of the future hair shaft are positioned at the apex of the dermal papilla and form the medulla, cortex, and hair shaft cuticle (see Fig. 7-2). Immediately above the matrix cells, hair shaft cells begin to express specific hair shaft keratins in the prekeratogenous zone. The differentiation of hair shaft cells in this zone is dependent on the Lef-1 transcription factor. Lef-1 binding sites are present in most hair keratin genes. BMP receptor type 1a is also critical for matrix cell differentiation into the hair shaft because loss of this receptor prevents hair shaft differentiation.[67,75,76]

The hair shaft cuticle covers the hair, and its integrity and properties greatly impact the appearance of the hair. When the hair exits the scalp, the cuticle endures weathering, and it is often completely lost at the distal ends of long hairs. Inside the cuticle, the cortex comprises the bulk of the shaft and contains melanin. The cortex is arranged in large cable-like structures called *macrofibrils*. These, in turn, possess microfibrils that are composed of intermediate filaments. The medulla sits at the center of larger hairs, and specific keratins expressed in this layer of cells (see Table 7-2) are under the control of androgens.[68]

DERMAL PAPILLA

The dermal papilla (see Fig. 7-1) is a core of mesenchymally derived tissue enveloped by the matrix epithelium. It is comprised of fibroblasts, collagen bundles, a mucopolysaccharide-rich stroma, nerve fibers, and a single capillary loop. It is continuous with the perifollicular sheath (dermal sheath) of connective tissue that envelops the lower follicle.

Tissue recombination experiments have shown that the dermal papilla has powerful inductive properties, including the ability to induce hair follicle formation when transplanted below non–hair-bearing footpad epidermis.[77,78] This shows that the tissue patterning established during the fetal period can be altered under appropriate conditions. In human follicles, the volume of the dermal papilla correlates with the number of matrix cells and the resulting size of the hair shaft.[79] In mice, the sizes of the hair bulb and hair diameter strongly depend of the proliferative activity of the matrix keratinocytes.[80]

Many soluble growth factors that appear to act in a paracrine manner on the overlying epithelial matrix cells originate from the dermal papilla. Specifically, keratinocyte growth factor (KGF) is produced by the anagen dermal papilla, and its receptor, FGF receptor 2 (FGFR2), is found predominantly in the matrix keratinocytes. Injections of KGF into nude mice produce striking hair growth at the site of injection,[81] suggesting that KGF is perhaps necessary for hair growth and cycling. However, surprisingly, KGF knockout mice develop morphologically normal hair follicles that produce "rough" or "greasy" hair; thus, KGF's effects on hair follicle morphogenesis and cycling appear dispensable or replaceable by other growth factors with redundant functions.[82]

HAIR FOLLICLE INNERVATION

Myelinated sensory nerve fibers run parallel to hair follicles, surrounding them and forming a network (reviewed in [83]). Smaller nerve fibers form an outer circular layer, which is concentrated around the bulge of terminal follicles and the bulb of vellus follicles. Several different types of nerve endings, including free nerve endings, lanceolate nerve endings, Merkel cells, and pilo-Ruffini corpuscles are found associated with hair follicles.[84] Each nerve ending detects different forces and stimuli. Free nerve endings transmit pain, lanceolate nerve endings detect acceleration, Merkel cells sense pressure, and pilo-Ruffini structures detect tension. Perifollicular nerves contain neuromediators and neuropeptides, such as substance P and calcitonin gene-related peptide, that influence follicular keratinocytes and alter hair follicle cycling.[41,85-88] In addition to neuropeptides, nerve fibers innervating hair follicles produce Shh that signals to a population of cells in the bulge marked by the Hedgehog response gene *Gli1*.[89] The progeny of Shh-responding perineural bulge cells incorporate into healing skin wounds where, notably, they can change their lineage into epidermal stem cells. The perineural niche (including Shh) is dispensable for the follicle's contribution to wound healing but is necessary to maintain bulge cells capable of becoming epidermal stem cells.[89]

In turn, hair follicle keratinocytes produce neurotrophic factors that influence perifollicular nerves and stimulate their remodeling in a hair cycle–dependent manner.[88,90] Merkel cells, which are considered neuroendocrine cells, also produce neurotrophic factors, cytokines, or other regulatory molecules. Because Merkel cells are concentrated in the bulge area, some have postulated that these secreted factors may influence the cycling of the hair follicle.[91]

PERIFOLLICULAR SHEATH

The perifollicular sheath envelops the epithelial components of the hair follicle and consists of an inner basement membrane called the *hyaline* or *vitreous (glassy) membrane* and an outer connective tissue sheath. The basement membrane of the follicle is continuous with the interfollicular basement membrane. It is most prominent around the outer root sheath at the bulb in anagen hairs. During catagen, the basement membrane thickens and then disintegrates.

Surrounding the basement membrane is a connective tissue sheath composed primarily of type III collagen. Around the upper follicle, there is a thin connective tissue sheath continuous with the surrounding papillary dermis and arranged longitudinally. Around the lower follicle, the connective tissue sheath is more prominent, with an inner layer of collagen fibers that encircles the follicle surrounded by a layer of longitudinally arranged collagen fibers.

When transplanted under the skin, this perifollicular connective tissue has the remarkable ability to form a new dermal papilla and induce new hair follicle formation.[92] Even when the connective tissue sheath is transplanted to another individual, these follicles survive without evidence of immunologic rejection.

HAIR FOLLICLE CYCLE

Each individual hair follicle perpetually traverses through three stages: (1) growth (anagen), (2) involution (catagen), and (3) rest (telogen).[6] The length of anagen determines the final length of the hair and thus varies according to body site; catagen and telogen duration vary to a lesser extent depending on site. Scalp hair has the longest anagen of 2 years to more than 8 years. Anagen duration in young males at other sites is shorter: legs, 5 to 7 months; arms, 1.5 to 3.0 months; eyelashes, 1 to 6 months; and fingers, 1 to 3 months. In contrast to most mammals, including mice and newborn humans, in adult humans, the hairs of the scalp grow asynchronously. Approximately 90% to 93% of scalp follicles are in anagen, and the rest are primarily in telogen.[65] Applying these figures to the 100,000 to 150,000 hairs on the scalp indicates that approximately 10,000 scalp hairs are in telogen at any given time. However, because an adult loses only 50 to 100 hairs per day, this indicates that telogen is a heterogenous state. The follicles that are shedding their hair shafts are thus in "exogen," which comprises approximately 1% of the telogen hair follicles (see Fig. 7-2 and later discussion). Hair on the scalp grows at a rate of 0.37 to 0.44 mm/day or approximately 1 cm/month.

HAIR FOLLICLE STEM CELLS

Because the lower portion of the follicle cyclically regenerates, hair follicle stem cells were thought to govern this growth. Historically, hair follicle stem cells were assumed to reside exclusively in the "secondary germ" (see Fig. 7-2), which is located at the base of the telogen hair follicle. It was thought that the secondary germ moved downward to the hair bulb during anagen and provided new cells for production of the hair. At the end of anagen, the secondary germ was thought to move upward with the dermal papilla during catagen to come to rest at the base of the telogen follicle. This scenario of stem cell movement during follicle cycling was brought into question when a population of long-lived presumptive stem cells was identified in an area of the follicle surrounding the telogen club hair.[93] Subsequently, it was shown that the secondary germ is a transient structure that forms at the end of catagen from cells in the lower bulge.[94] The concept that hair follicle stem cells are permanently located in the bulge has now been confirmed using lineage analysis, which showed that the bulge cells give rise to all epithelial layers of the hair follicle.[5,95,96] In line with this, ablation of bulge cells results in destruction of the follicle.[97] These findings support the notion that loss of hair follicle stem cells in the bulge leads to permanent or cicatricial types of alopecia (see Chap. 88).

Progress has been made in defining subsets of cells within the hair follicle that serve as different stem and progenitor populations. Markers that have been shown through genetic lineage analysis to contribute to the perpetual cycling of the hair follicle include cytokeratin 15 and Lgr5.[97,98] Lgr5, although sometimes touted as an exclusive marker of secondary germ cells, also marks bulge cells. Lgr6, a gene related to Lgr5, is expressed in an area above the bulge in the upper isthmus. The cells marked by Lgr6 migrate to the epidermis during homeostasis and after wounding.[99] In addition to these markers, several others demonstrate the heterogeneity of the hair follicle epithelium.[100]

Are bulge cells the "ultimate" stem cells within the skin epithelium? For example, do they generate epidermis and sebaceous glands during homeostasis and after wounding? To answer these questions, lineage analysis and transgenic techniques were again used. As illustrated in Fig. 7-3, bulge cells do not normally move to the epidermis, but after full-thickness excision of the skin, bulge cell progeny migrate into the wound during reepithelialization.[5,97] These cells comprise approximately 30% of the cells in the regenerated epidermis. The role of bulge cells in sebaceous gland maintenance is still not clear but is under investigation.

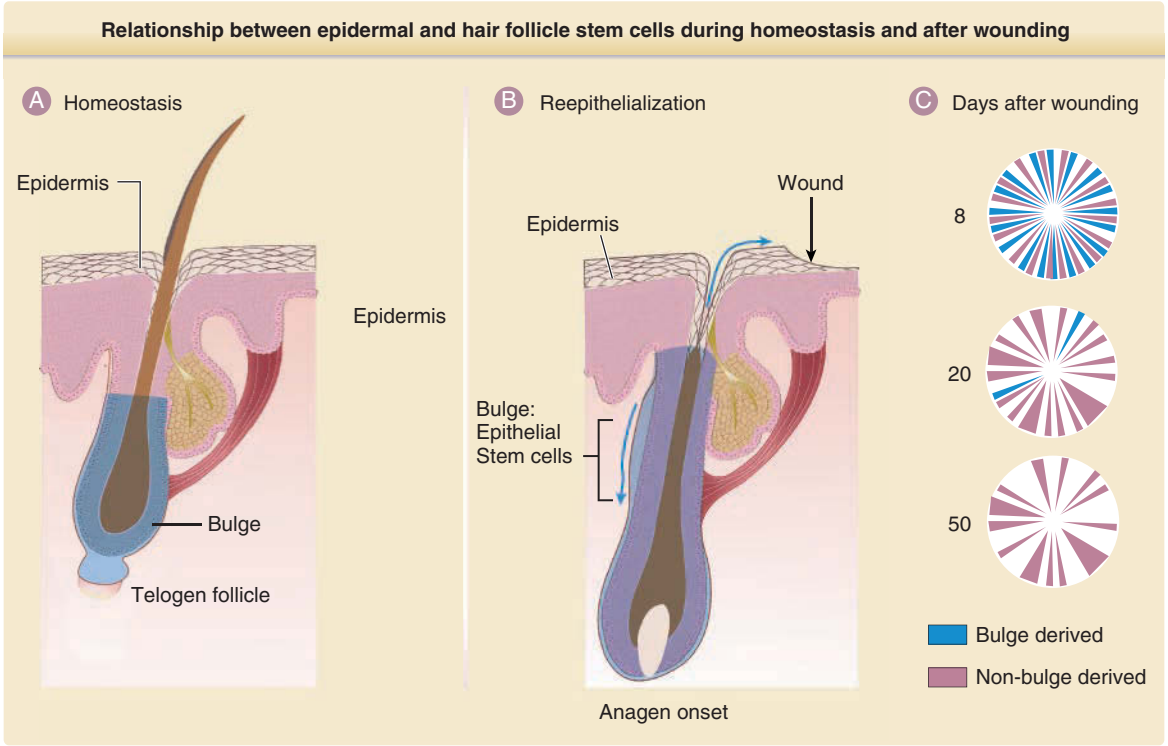

Figure 7-3 Relationship between epidermal and hair follicle stem cells during homeostasis and after wounding. **A,** During normal conditions, epidermal renewal is dependent on cell proliferation within the epidermis. Epithelial stem cells in the hair follicle bulge do not contribute to epidermal renewal. **B,** After full-thickness wounding, bulge cells contribute cells to the epidermis for immediate wound closure (*blue upward arrow*). Bulge cells also are required for hair follicle cycling (*blue downward arrow*) **C,** Over time, bulge-derived cells diminish, and non–bulge-derived cells (from the interfollicular epidermis and infundibulum) appear to predominate in the reepithelialized wound.

ANAGEN

The formation of a new lower follicle and hair at anagen onset recapitulates folliculogenesis in the fetus. Anagen can be divided into seven stages: (1) stage I—growth of the dermal papilla and onset of mitotic activity in the germlike overlying epithelium; (2) stage II—bulb matrix cells envelop the dermal papilla and begin differentiation, and the evolving bulb begins descent along the fibrous streamer; (3) stage III—bulb matrix cells show differentiation into all follicular components; (4) stage IV—matrix melanocytes reactivate; (5) stage V—hair shaft emerges and dislodges telogen hair; (6) stage VI—new hair shaft emerges from skin surface; and (7) stage VII—stable growth.[101]

During proliferation and migration of keratinocytes into the dermis to reform the new lower follicle, enzymes such as proteases and collagenases appear at the leading edge of the downgrowth, and growth factors and their receptors are upregulated similar to an epithelial wound.[6] Pathways of keratinocyte differentiation that are seen in the epidermis during wound healing, such as expression of keratin 6, are activated. Mice lacking Stat3, a regulator of cell migration in the cutaneous epithelium, show defects in wound healing and a failure of hair follicles to enter anagen,[102] thus further illustrating the similarity between wound healing and the early events of anagen. Remarkably, the dermal papilla in the midst of this degradative milieu survives and moves downward. Neurocutaneous and vascular networks are remodelled.[90,103] Melanocytes proliferate and repopulate the new hair bulb.[104] Finally, a burst of endothelial proliferation and angiogenesis in the dermal papilla marks the time point when the lower follicle is completely restored and is actively producing the new hair shaft.[105]

CATAGEN

The onset of catagen is marked by cessation of the mitotic activity of the matrix cells and by well-coordinated apoptosis in the cyclic portion of the hair follicle.[6,7] Pigment production by melanocytes ceases before matrix cell proliferation stops, thus leading to a nonpigmented proximal end in the telogen club hair (see Fig. 7-2). Melanin is often found in the surrounding dermis and papilla, where it is engulfed by macrophages. The perifollicular sheath collapses, and the vitreous or glassy membrane thickens. The lower follicle retracts upward with the dermal papilla. The perifollicular sheath forms a fibrous streamer composed of fibroblasts, small blood vessels, and collagen.[1] Eventually, the dermal papilla becomes situated immediately below the bulge at the lower portion of the isthmus.

During catagen, the largest follicles, on the scalp, for example, shorten their length from 2- to 5-mm-long structures whose deepest portion, the bulb, extends down into the subcutaneous fat to truncated 0.25- to 0.5-mm follicles in telogen. As the basement membrane around the lower follicle thickens, the dermal papilla, protected from the surrounding apoptosis and destruction (perhaps because it expresses Bcl-2, an antiapoptotic factor[6]), condenses and begins to move upward to come to rest below the bulge during telogen. The migration of the dermal papilla from the subcutaneous fat to the dermis during catagen is necessary for continued follicle cycling. This is illustrated by the syndrome of atrichia with papules.[106,107] These patients have mutations in either their hairless gene or in their vitamin D receptor gene, in which case they also have rickets. Mice with similar mutations have the hairless phenotype. We know from these mice that folliculogenesis is normal; however, when the follicles enter catagen for the first time, the lower portion of the follicle does not involute and contract properly, and the dermal papilla remains stranded in the subcutaneous fat.[93] Although bulge cells are still present, no new anagen follicles ever form, presumably because the stem cells cannot interact with the dermal papilla.[93]

The study of mouse mutants has also resulted in several key findings that have increased our understanding of the molecular events at catagen onset. Specifically, Hebert and coworkers[108] discovered that mice lacking the *Fgf5* gene have hair that is 50% longer than their wild-type littermates and that mutations in this gene are responsible for the angora phenotype that was described more than 30 years ago. Although these findings were rather unexpected, careful evaluation of *Fgf5* expression throughout the normal hair cycle demonstrated that its expression was upregulated in the outer root sheath and hair matrix cells just before the onset of catagen, suggesting that *Fgf5* may trigger catagen onset. Interestingly, the follicle still eventually entered catagen, even in the absence of FGF-5, suggesting redundancy in the FGF-5 pathway or an intrinsic finite proliferative capability of the matrix cells.[93] Further studies also demonstrated that other FGF family members and their receptors are expressed during anagen and probably also play a role in the hair follicle cycle.[109] The hair phenotype of FGF-5–deficient mice is substantially reversed by ectopic expression of the antiapoptotic gene *bcl-xL*$_x$ in the outer root sheath, suggesting that regulation of cell survival in the outer root sheath may play a role in control of the hair growth cycle.[110]

Although it has been known for many years that exogenous EGF administered to sheep results in catagen induction,[111] only through more recent transgenic and knockout studies in mice has the importance of the EGFR system in hair cycle regulation been realized.[66,112] For example, knockout mice lacking TGF-α, the major ligand for EGFR, have abnormal hair follicle development and manifest the waved hair phenotype.[55,113] When EGFR is functionally downregulated in the basal layer of the epidermis and hair follicle using a dominant negative transgenic strategy, the resulting hair is not only waved but also longer than normal.[66] Transition of the hair follicles from anagen to catagen is delayed in these mice. Hair follicles in mouse skin that completely lack EGFR also do not progress from anagen to telogen.[112] Thus, EGFR and its ligand are required for normal hair follicle development and cycling. Given the complexity of the EGFR family,

which includes four receptors (ErbB1–4) and at least six ligands, future studies are needed to clarify the role of individual family members in hair follicle cycling.

In addition to FGF-5 and EGF, neurotrophins and TGF-β1 induce premature catagen. Neurotrophin-3 and brain-derived neurotrophic factor transgenic mice show premature catagen development, and brain-derived neurotrophic factor overexpression leads to the shortening of hair length by 15%, most likely via stimulation of proapoptotic signaling through p75 kDa neurotrophin receptor,[114,115] TGF-β1 induces premature catagen in isolated human hair follicles and in mouse skin in vivo, and TGF-β1 knockout mice display delay in catagen onset.[116-118]

TELOGEN AND EXOGEN

When catagen is complete and a club hair is formed (see Fig. 7-2), the hair follicle prepares the hair for expulsion from the scalp. About 1% of telogen hairs are shed each day. Milner and colleagues[119] have proposed distinguishing hair shedding as a separate phase called *exogen*. Exogen is a highly controlled and timed event in mammals that shed on a seasonal basis. That exogen is an active stage is supported by Headington's description of one type of telogen effluvium he termed *immediate telogen release*.[120] This type of hair loss can be seen soon after starting medications, such as minoxidil, or in response to rapid fluctuations in light–dark cycles. It consists of an increase in shedding of club hairs within weeks of the precipitating event (too soon to be caused by follicles prematurely entering telogen from anagen), suggesting that club hairs that are normally retained in the follicle can be actively shed. The heterogeneity of telogen is further supported by the work of Guarrera and Rebora,[121] who followed individual hairs in situ using macrophotographs for more than 2 years and showed that several months could transpire between hair shedding and regrowth. This "lag period" is normally not present or is very short but often lasts several months in patients with androgenetic alopecia.

HAIR PIGMENTATION

Hair becomes pigmented as a result of a tightly coordinated program of melanin synthesis and transport from the hair bulb melanocytes to differentiating hair shaft keratinocytes.[122-124] This process is strictly coupled to anagen and ceases during catagen and telogen. Numerous signaling molecules, structural proteins, enzymes, cofactors, and transcriptional regulators control hair pigmentation (Figs. 7-4 and 7-5).[122,124,125]

HAIR MELANOCYTE DEVELOPMENT

Melanoblasts can be identified in the epidermis of human embryos at 50 days of estimated gestational age before the onset of hair follicle morphogenesis.[126-128] These melanocytes originate in the neural crest and migrate first to the dermis and then epidermis.[129] New data reveal that melanocytes in the skin arise from two sources: from neural crest cells migrating in the dorsolateral pathway and from Schwann cell progenitors located in cutaneous nerves.[130] Commitment of neural crest cells to the melanocyte lineage is regulated by Pax3 and microphthalmia transcription factors (Mitf), which stimulate the expression of dopachrome tautomerase (or tyrosinase-related protein 2[131]), an enzyme involved in melanin biosynthesis that also functions as an early melanoblast marker.[128] Subsequent steps of melanoblast development (migration into the dermis and epidermis) are controlled by signaling mechanisms activated through endothelin receptor type B (Ednrb) and c-kit receptor, which are mutated in humans with Hirschsprung disease and piebaldism, respectively, resulting in formation of unpigmented hairs.[129]

After entering the placode of the developing hair follicle, melanoblasts proliferate and become produce pigment synchronously with the onset of hair fiber formation.[132] Experimental and genetic data suggest that migration of melanoblasts into the hair follicle and their differentiation to pigment producing melanocytes depends on stem cell factor (SCF)/c-kit signaling. SCF is a ligand that binds to its receptor (c-kit). Pharmacologic blockade of c-kit during embryogenesis, as well as genetic ablation of SCF or c-kit in corresponding mouse mutants results in unpigmented hairs.[133-135]

HAIR FOLLICLE MELANOCYTE STEM CELLS AND PIGMENT-PRODUCING MELANOCYTES

Melanocyte stem cells located in the hair follicle bulge generate progeny that repopulate the melanocytes in the new hair bulb formed at the onset of anagen.[104,136] Melanocyte stem cells express Trp2, Bcl-2, Pax3, and other melanogenic enzymes (tyrosinase, tyrosinase-related protein 1[131]) and signaling molecules (c-kit, Ednrb, Sox10, Mitf, and Lef1)[137] are expressed at low levels. Melanocyte stem cells can be first detected in the bulge area during late stages of hair follicle morphogenesis and similar to epithelial stem cells they are quiescent.[136-138] TGF-β signaling plays an important role in controlling melanocyte stem cells entering into a noncycling (dormant) state during hair follicle morphogenesis.[139]

Maintenance of melanocyte stem cells during hair follicle cycling is controlled by TGF-β and Notch signaling pathways. Notch signaling plays a crucial role in the survival of melanocyte stem cells and immature melanoblasts by preventing apoptosis.[140] Cross-talk between the TGF-β pathway and Bcl2 is also important for maintenance of melanocyte stem cells: Bcl2

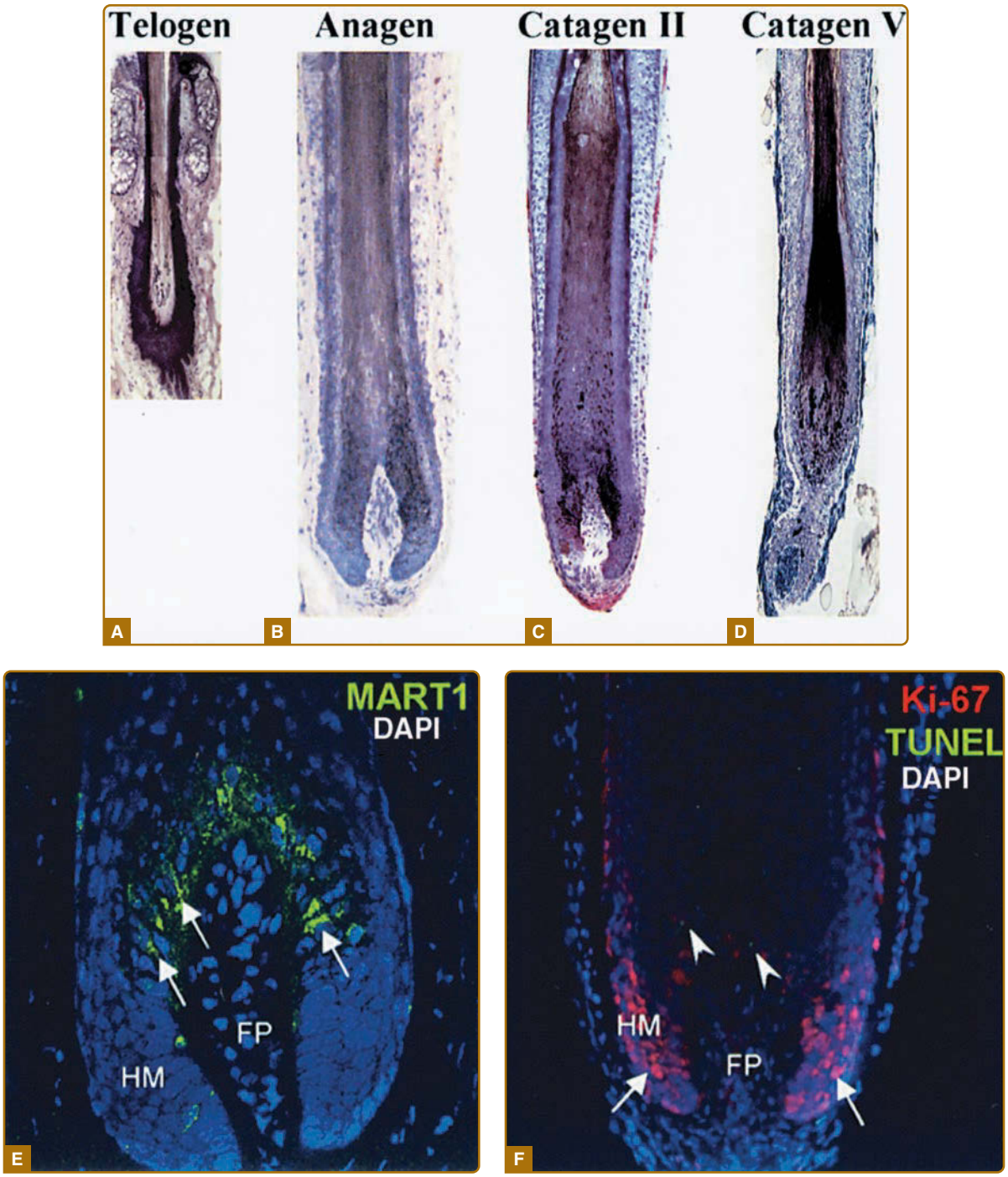

Figure 7-4 Morphology and fluorescent microscopy of human hair follicle at distinct hair cycle stages. Morphology of human hair follicle during telogen (**A**), late anagen (**B**), and early and late catagen (**C, D**). **E,** Immunofluorescent visualization of the melanocytes (*arrows*) in the hair bulb of late anagen hair follicle with antimelanoma-associated antigen recognized by T cells antibody. **F,** Immunofluorescent detection of proliferative marker Ki-67 (*arrows*) and apoptotic TUNEL+ cells (*arrowheads*) in early catagen hair follicle. FP, follicular papilla; HM, hair matrix.

plays a key role in maintenance of melanocyte stem cells, and Bcl2 knockout mice show progressive hair graying because of the depletion of melanocyte stem cells.[137-139,141,142] However, Bcl2 deficiency may be compensated by overexpression of SCF, which rescues loss of melanocyte stem cells in the hair follicle bulge of Bcl2 knockout mice.[137]

Melanocytes producing pigment are located in the hair bulb above the dermal papilla.[104,124] These cells synthesize and transport melanin to hair shaft keratinocytes and express a full set of enzymes and other proteins involved in melanin biosynthesis including tyrosinase, Trp1, Trp2 (in mice), and pMel17 (in humans).[104,137] Keratinocytes, as pigment recipient

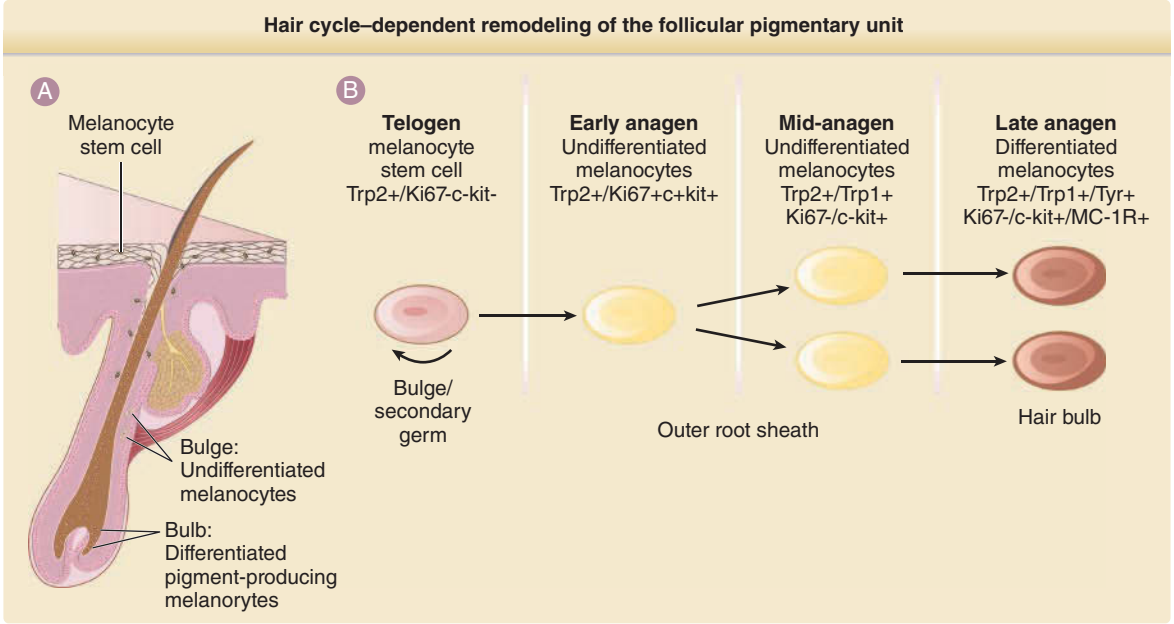

Figure 7-5 Hair cycle–dependent remodeling of the follicular pigmentary unit. **A,** Schematic illustrating localization of distinct subpopulations of melanocytes in anagen hair follicle. **B,** Dynamics of the follicular melanocytes during anagen. Expression of melanogenic markers and growth factor receptors indicated is based on the data obtained from murine hair follicles. Note that human follicular melanocytes do not express tyrosinase-related protein 2 (Trp2). c-kit, c-kit oncogene. (Data from Botchkareva NV, Khlgatian M, Longley BJ, et al. SCF/c-kit signaling is required for cyclic regeneration of the hair pigmentation unit. *FASEB J*. 2001;15:645-658.)

cells, produce Foxn1 and its target Fgf2 to identify themselves as the targets for pigment transfer.[143]

HAIR CYCLE–DEPENDENT CHANGES IN MELANOCYTES

Hair follicle melanocytes undergo substantial remodeling during hair follicle cycling.[104,124] In telogen, hair follicle melanocytes are found in the bulge, secondary hair germ, and connective tissue.[104] In humans, melanocytes in the telogen hair follicle do not express Trp1- and tyrosinase, do not proliferate, and can be visualized by expression of pMel17. Some of these cells also express c-kit receptor, and others remain c-kit-negative and represent melanocyte stem cells (MCSCs).[104,136,137] Wnt activation in MCSCs drives their differentiation into pigment-producing melanocytes.[144] TGF-β signaling is activated in melanocyte stem cells when they reenter the quiescent noncycling state during the hair cycle, and this process requires Bcl2 for cell survival.[139] After wounding or ultraviolet type B irradiation, McSCs in the hair follicle are capable of exiting the stem cell niche and migrate to the epidermis followed by their differentiation into functional epidermal melanocytes in a melanocortin 1 receptor (Mc1r)–dependent manner.[145,146]

During early anagen, resting melanocytes proliferate, differentiate, and migrate within the hair follicle synchronously with regeneration of the hair follicle bulb. Hair follicle melanocytes are maximally proliferative during early and midanagen, and their transition to melanogenic competence is accompanied by the appearance of Trp1 and tyrosinase protein.[104] However, this process is stringently controlled, and Notch signaling is necessary to prevent differentiation of melanoblasts into pigment-producing melanocytes before they reach the hair bulb, as well as for their proper positioning in the hair matrix.[147]

Similar to embryonic and early postnatal development, SCF/c-kit signaling plays a critical role in repopulation of the bulb with pigment-producing melanocytes. Whereas c-kit is expressed on proliferating, differentiating and melanocytes producing pigment, overexpression of SCF in the epidermis of transgenic mice significantly increases the number of hair follicle melanocytes and their proliferative activity.[104] Similarly, administration of the ACK45 antibody blocking c-kit signaling dramatically reduces melanocyte number in anagen hair follicles, resulting in hair depigmentation.[104] However, in the next hair cycle, the previously treated animals grow fully pigmented hairs with the normal number and distribution of melanocytes, suggesting that melanocyte stem cells are not dependent on SCF/c-kit.[104]

During catagen, melanogenic activity in the follicular melanocytes abruptly ceases. Immunohistochemical and electron microscopic data suggest that some pigment-producing melanocytes located above the follicular papilla undergo apoptosis, and others drop into the dermal papilla of the follicle.[148,149]

MOLECULAR CONTROL OF HAIR COLOR

Follicular melanocytes synthesize pigment via a cascade of enzymatic conversions of phenylalanine or tyrosine into brown-black eumelanin or yellow pheomelanin that requires melanogenic enzymes (tyrosinase, tyrosinase-related proteins 1/2, -glutamyltranspeptidase, peroxidase) and essential co-factors, such as 6-tetrahydrobiopterin.[122,148] The balance between black and yellow pigment synthesis (eumelanin and pheomelanin, respectively) is regulated by signaling through the melanocortin type 1 receptor (MC-1R) that has long been implicated in the controlling hair color.[150,151]

After binding to MC-1R, α-melanocyte stimulating hormone (α-MSH) stimulates adenylyl cyclase, resulting in elevation of intracellular cyclic adenosine monophosphate (cAMP) levels. This leads to increase of transcriptional activity of MITF that stimulates synthesis of enzymes (tyrosinase, Trp1/2) involved in eumelanin formation.[152,153] Pheomelanin synthesis in the hair follicle melanocytes of mice occurs when MC-1R signaling is inhibited by Agouti signal protein (ASP) that competes with α-MSH in binding to MC-1R.[151,152] In mice, ASP expression is positively regulated by BMP signaling, and transgenic mice overexpressing the BMP antagonist Noggin show hair darkening.[149] Although ASP is expressed in human skin, its role in human pigmentation remains unclear.[153]

Recent data also demonstrate the existence of a proopiomelanocortin (POMC)–MC-1R pathway in human hair follicles: MC-1R is expressed by hair follicle melanocytes, and its ligands α-MSH and adrenocorticotrophic hormone (ACTH) are able to promote melanocyte proliferation, dendricity, and pigment production.[154] Another POMC-derived peptide, β-endorphin, that interacts with the μ-opiate receptor expressed by hair follicle melanocytes has a similar effect.[154] However, signaling through the μ-opiate receptor may regulate hair pigmentation via modulating the activity of protein kinase C (PKC)-β, a known positive regulator of pigment production.[155]

Follicular melanocytes are sensitive to aging, which results in their premature loss and hair greying.[156] In contrast to normally pigmented hair follicles, fewer melanocytes are found in the bulb of a grey hair; however, these melanocytes still express tyrosinase and synthesize then transfer melanin to keratinocytes.[157] In addition, a population of inactive melanocytes (melanoblasts including stem cells) in the outer root sheath is markedly reduced in follicles producing grey hairs compared with ones producing pigmented hairs.[157] The fact that melanocyte stem cells are damaged in hair follicles producing grey hairs was confirmed in mice by applying ionizing radiation, which triggered premature differentiation of melanocyte stem cells in the follicular bulge into mature, pigment-producing melanocytes followed by their depletion and irreversible hair graying.[158] Deficiency of ATM-kinase, a central transducer of the DNA-damage response, sensitizes MSCs to ectopic differentiation, demonstrating its role in protecting melanocyte stem cells from their premature differentiation.[158]

CONCLUSION

A hair follicle is formed as the result of a complex interplay of signals between epithelium and mesenchyme. Many molecular pathways important in development also play roles in hair follicle formation. The product of this process is a miniature organ with distinctive vertical and concentric architecture. Both epithelial stem cells and melanocyte stem cells in the follicle are important for the constant regeneration of the follicle.

REFERENCES

1. Nieves A, Garza LA. Does prostaglandin D2 hold the cure to male pattern baldness? *Experimental Dermatology* 2014;23(4):224-227.
2. Guo H, Gao WV, Endo H & McElwee KJ. Experimental and early investigational drugs for androgenetic alopecia. *Expert Opinion on Investigational Drugs*. 2017; 26:8,917-932. doi: 10.1080/13543784.2017.1353598.
3. Fuchs E. Scratching the surface of skin development. *Nature*. 2007;445:834-842.
4. Schneider MR, Schmidt-Ullrich R, Paus R. The hair follicle as a dynamic miniorgan. *Curr Biol*. 2009;19: R132-R142.
5. Cotsarelis G. Epithelial stem cells: a folliculocentric view. *J Invest Dermatol*. 2006;126:1459-1468.
6. Stenn KS, Paus R. Controls of hair follicle cycling. *Physiol Rev*. 2001;81:449-494.
7. Botchkarev VA, Yaar M, Peters EM, et al. Neurotrophins in skin biology and pathology. *J Investig Dermatol Symp Proc*. 2006;126:1719-1727.
8. Botchkarev VA. Neurotrophins and their role in pathogenesis of alopecia areata. *J Investig Dermatol Symp Proc*. 2003;8:195-198.
9. Millar S. Molecular mechanisms regulating hair follicle development. *J Invest Dermatol*. 2002;118:216-225.
10. Schmidt-Ullrich R, Paus, R. Molecular principles of hair follicle induction and morphogenesis. *Bioessays*. 2005;27:247-261.
11. Krumlauf R. Hox genes in vertebrate development. *Cell*. 1994;7:191-201.
12. Chuong CM, Oliver G, Ting SA, et al. Gradients of homeoproteins in developing feather buds. *Development*. 1990;110:1021-1030.
13. Godwin AR, Capecchi MR. Hoxc13 mutant mice lack external hair. *Genes Dev*. 1998;12:11-20.
14. Loomis CA, Harris E, Michaud J, et al. The mouse Engrailed-1 gene and ventral limb patterning. *Nature*. 1996;382:360-363.
15. Cadieu E, Neff MW, Quignon P, et al. Coat variation in the domestic dog is governed by variants in three genes. *Science*. 2009;326:150-153.
16. Mou C, Thomason HA, Willan PM, et al. Enhanced ectodysplasin-A receptor (EDAR) signaling alters multiple fiber characteristics to produce the East Asian hair form. *Hum Mutat*. 2008;29:1405-1411.
17. Levy V, Lindon C, Harfe BD, et al. Distinct stem cell populations regenerate the follicle and interfollicular epidermis. *Dev Cell*. 2005;9:855-861.

18. Ahtiainen L, Lefebvre S, Lindfors PH, et al. Directional cell migration, but not proliferation, drives hair placode morphogenesis. *Dev Cell*. 2014;28:588-602.
19. Jamora C, DasGupta R, Kocieniewski P, et al. Links between signal transduction, transcription and adhesion in epithelial bud development. *Nature*. 2003;422: 317-322.
20. Nanba D, Hieda Y, Nakanishi Y. Remodeling of desmosomal and hemidesmosomal adhesion systems during early morphogenesis of mouse pelage hair follicles. *J Invest Dermatol*. 2000;114:171-177.
21. Rhee H, Polak L, Fuchs E. Lhx2 maintains stem cell character in hair follicles. *Science*. 2006;312:1946-1999.
22. Hardy MH. The secret life of the hair follicle. *Trends Genet*. 1992;8:55-60.
23. Sennett R, Rendl M. Mesenchymal-epithelial interactions during hair follicle morphogenesis and cycling. *Semin Cell Dev Biol*. 2012;23:917-927.
24. Botchkarev VA, Paus R. Molecular biology of hair morphogenesis: development and cycling. *J Exp Zool B Mol Dev Evol*. 2003;298:164-180.
25. Driskell RR, Clavel C, Rendl M, et al. Hair follicle dermal papilla cells at a glance. *J Cell Sci*. 2011;124:1179-1182.
26. Sennett R, Wang Z, Rezza A, et al. An integrated transcriptome atlas of embryonic hair follicle progenitors, their niche, and the developing skin. *Dev Cell*. 2015;34:577-591.
27. Bazzi H, Getz A, Mahoney MG, et al. Desmoglein 4 is expressed in highly differentiated keratinocytes and trichocytes in human epidermis and hair follicle. *Differentiation*. 2006;74:129-140.
28. Sick S, Reinker S, Timmer J, et al. WNT and DKK determine hair follicle spacing through a reaction-diffusion mechanism. *Science*. 2006;314:1447-1450.
29. Stark J, Andl T, Millar SE. Hairy math: insights into hair-follicle spacing and orientation. *Cell*. 2007;128:17-20.
30. Gat U, DasGupta R, Degenstein L, et al. De Novo hair follicle morphogenesis and hair tumors in mice expressing a truncated beta-catenin in skin. *Cell*. 1998;95:605-614.
31. Chan EF, Gat U, McNiff JM, et al. A common human skin tumour is caused by activating mutations in beta- catenin. *Nat Genet*. 1999;21:410-413.
32. Tsai SY, Sennett R, Rezza A, et al. Wnt/beta-catenin signaling in dermal condensates is required for hair follicle formation. *Dev Biol*. 2014;385:179-188.
33. Mikkola ML, Thesleff I. Ectodysplasin signaling in development. *Cytokine Growth Factor Rev*. 2003; 14:211-224.
34. Kere J, Srivastava AK, Montonen O, et al. X-linked anhidrotic (hypohidrotic) ectodermal dysplasia is caused by mutation in a novel transmembrane protein [see comments]. *Nat Genet*. 1996;13:409-416.
35. Mustonen T, Ilmonen M, Pummila M, et al. Ectodysplasin A1 promotes placodal cell fate during early morphogenesis of ectodermal appendages. *Development*. 2004;131:4907-4919.
36. Zhang M, Brancaccio A, Weiner L, et al. Ectodysplasin regulates pattern formation in the mammalian hair coat. *Genesis*. 2003;37:30-37.
37. Noramly S, Morgan BA. BMPs mediate lateral inhibition at successive stages in feather tract development. *Development*. 1998;125:3775-3787.
38. Jung HS, Francis-West PH, Widelitz RB, et al. Local inhibitory action of BMPs and their relationships with activators in feather formation: implications for periodic patterning. *Dev Biol*. 1998;196:11-23.
39. Jiang TX, Jung HS, Widelitz RB, et al. Self-organization of periodic patterns by dissociated feather mesenchymal cells and the regulation of size, number and spacing of primordia. *Development*. 1999;126: 4997-5009.
40. Patel K, Makarenkova H, Jung HS. The role of long range, local and direct signalling molecules during chick feather bud development involving the BMPs, follistatin and the Eph receptor tyrosine kinase Eph-A4. *Mech Dev*. 1999;86:51-62.
41. Botchkarev VA, Botchkareva NV, Roth W, et al. Noggin is a mesenchymally derived stimulator of hair-follicle induction. *Nat Cell Biol*. 1999;1:158-164.
42. Viallet JP, Prin F, Olivera-Martinez I, et al. Chick Delta-1 gene expression and the formation of the feather primordia. *Mech Dev*. 1998;72:159-168.
43. Crowe R, Henrique D, Ish-Horowicz D, et al. A new role for Notch and Delta in cell fate decisions: patterning the feather array. *Development*. 1998;125:767-775.
44. Powell BC, Passmore EA, Nesci A, et al. The Notch signalling pathway in hair growth. *Mech Dev*. 1998;78: 189-192.
45. Crowe R, Niswander L. Disruption of scale development by Delta-1 misexpression. *Dev Biol*. 1998;195:70-74.
46. Iseki S, Araga A, Ohuchi H, et al. Sonic hedgehog is expressed in epithelial cells during development of whisker, hair, and tooth. *Biochem Biophys Res Commun*. 1996;218:688-693.
47. Bitgood MJ, McMahon AP. Hedgehog and Bmp genes are coexpressed at many diverse sites of cell-cell interaction in the mouse embryo. *Dev Biol*. 1995;172:126-138.
48. St-Jacques B, Dassule HR, Karavanova I, et al. Sonic hedgehog signaling is essential for hair development. *Curr Biol*. 1998;8:1058-1068.
49. Chiang C, Swan RZ, Grachtchouk M, et al. Essential role for Sonic hedgehog during hair follicle morphogenesis. *Dev Biol*. 1999;205:1-9.
50. Karlsson L, Bondjers C, Betsholtz C. Roles for PDGF-A and sonic hedgehog in development of mesenchymal components of the hair follicle. *Development*. 1999;126:2611-2621.
51. Platt KA, Michaud J, Joyner AL. Expression of the mouse Gli and Ptc genes is adjacent to embryonic sources of hedgehog signals suggesting a conservation of pathways between flies and mice. *Mech Dev*. 1997;62:121-135.
52. Oro AE, Higgins KM, Hu Z, et al. Basal cell carcinomas in mice overexpressing sonic hedgehog. *Science*. 1997;276:817-821.
53. Schweizer J, Langbein L, Rogers MA, et al. Hair follicle-specific keratins and their diseases. *Exp Cell Res*. 2007;313, 2010-2020.
54. Luetteke NC, Phillips HK, Qiu TH, et al. The mouse waved-2 phenotype results from a point mutation in the EGF receptor tyrosine kinase. *Genes Dev*. 1994;8:399-413.
55. Luetteke NC, Qiu TH, Peiffer RL, et al. TGF alpha deficiency results in hair follicle and eye abnormalities in targeted and waved-1 mice. *Cell*. 1993;73:, 263-278.
56. Inoue A, Arima N, Ishiguro J, et al. LPA-producing enzyme PA-PLA(1)alpha regulates hair follicle development by modulating EGFR signalling. *EMBO J*. 2011;30:4248-4260.
57. Schneider MR, Schmidt-Ullrich R, Paus R. The hair follicle as a dynamic miniorgan. *Curr Biol*. 2009;19:R132-142.

58. Lee J, Tumbar T. Hairy tale of signaling in hair follicle development and cycling. *Semin Cell Dev Biol*. 2012;23:906-916.
59. Nehls M, Pfeifer D, Schorpp M, et al. New member of the winged-helix protein family disrupted in mouse and rat nude mutations. *Nature*. 1994;372:103-107.
60. Segre JA, Nemhauser JL, Taylor BA, et al. Positional cloning of the nude locus: genetic, physical, and transcription maps of the region and mutations in the mouse and rat. *Genomics*. 1995;28:549-559.
61. Brissette JL, Li J, Kamimura J, et al. The product of the mouse nude locus, Whn, regulates the balance between epithelial cell growth and differentiation. *Genes Dev*. 1996;10:2212-2221.
62. Meier N, Dear TN, Boehm T. Whn and mHa3 are components of the genetic hierarchy controlling hair follicle differentiation. *Mech Dev*. 1999;89:215-221.
63. Frank J, Pignata C, Panteleyev AA, et al. Exposing the human nude phenotype [letter]. *Nature*. 1999; 398:473-474.
64. Rezza A, Wang Z, Sennett R, et al. Signaling networks among stem cell precursors, transit-amplifying progenitors, and their niche in developing hair follicles. *Cell Rep*. 2016;14:3001-3018.
65. Linch CA, Whiting DA, Holland MM. Human hair histogenesis for the mitochondrial DNA forensic scientist. *J Forensic Sci*. 2001;46:844-853.
66. Murillas R, Larcher F, Conti CJ, et al. Expression of a dominant negative mutant of epidermal growth factor receptor in the epidermis of transgenic mice elicits striking alterations in hair follicle development and skin structure. *Embo J*. 1995;14:5216-5223.
67. Yuhki M, Yamada M, Kawano M, et al. BMPR1A signaling is necessary for hair follicle cycling and hair shaft differentiation in mice. *Development (Cambridge, England)*. 2004;131:1825-1833.
68. Jave-Suarez LF, Winter H, Langbein L, et al. HOXC13 is involved in the regulation of human hair keratin gene expression. *J Biol Chem*. 2002;277:3718-3726.
69. Langbein L, Schweizer J. Keratins of the human hair follicle. *Int Rev Cytol*. 2005;243:1-78.
70. Langbein L, Rogers MA, Praetzel-Wunder S, et al. K25 (K25irs1), K26 (K25irs2), K27 (K25irs3), and K28 (K25irs4) represent the type I inner root sheath keratins of the human hair follicle. *J Invest Dermatol*. 2006;126:2377-2386.
71. Wu H, Stanley JR, Cotsarelis G. Desmoglein isotype expression in the hair follicle and its cysts correlates with type of keratinization and degree of differentiation. *J Invest Dermatol*. 2003;120:1052-1057.
72. Botchkareva NV, Ahluwalia G, Shander D. Apoptosis in the hair follicle. *J Invest Dermatol*. 2006;126:258-264.
73. Langbein L, Rogers MA, Praetzel S, et al. A novel epithelial keratin, hK6irs1, is expressed differentially in all layers of the inner root sheath, including specialized huxley cells (Flugelzellen) of the human hair follicle. *J Invest Dermatol*. 2002;118:789-799.
74. Kaufman CK, Zhou P, Pasolli HA, et al. GATA-3: an unexpected regulator of cell lineage determination in skin. *Genes Dev*. 2003;17:2108-2122.
75. Andl T, Ahn K, Kairo A, et al. Epithelial Bmpr1a regulates differentiation and proliferation in postnatal hair follicles and is essential for tooth development. *Development*. 2004;131:2257-2268.
76. Kobielak K, Pasolli HA, Alonso L, et al. Defining BMP functions in the hair follicle by conditional ablation of BMP receptor IA. *J Cell Biol*. 2003;163:609-623.
77. Jahoda CA, Horne KA, Oliver RF. Induction of hair growth by implantation of cultured dermal papilla cells. *Nature*. 1984;311:560-562.
78. Reynolds AJ, Jahoda CA. Cultured dermal papilla cells induce follicle formation and hair growth by transdifferentiation of an adult epidermis. *Development*. 1992;115:587-593.
79. Elliott K, Stephenson TJ, Messenger AG. Differences in hair follicle dermal papilla volume are due to extracellular matrix volume and cell number: implications for the control of hair follicle size and androgen responses. *J Invest Dermatol*. 1999;113:873-877.
80. Sharov AA, Sharova TY, Mardaryev AN, et al. BMP signaling controls hair follicle size and modulates the expression of cell cycle-associated genes. *Proc Natl Acad Sci U S A*. 2006;103:18166-18171.
81. Danilenko DM, Ring BD, Yanagihara D, et al. Keratinocyte growth factor is an important endogenous mediator of hair follicle growth, development, and differentiation. Normalization of the nu/nu follicular differentiation defect and amelioration of chemotherapy-induced alopecia. *Am J Pathol*. 1995;147:145-154.
82. Guo L, Degenstein L, Fuchs E. Keratinocyte growth factor is required for hair development but not for wound healing. *Genes Dev*. 1996;10:165-175.
83. Paus R, Peters EM, Eichmuller S, et al. Neural mechanisms of hair growth control. [Review]. *J Investig Dermatol Symp Proc*. 1997;2:61-68.
84. Halata Z. Sensory innervation of the hairy skin (light- and electronmicroscopic study. *J Invest Dermatol*. 1993;101:75S-81S.
85. Paus R, Heinzelmann T, Schultz KD, et al. Hair-growth induction by substance-p. *Lab Invest*. 1994;0071: 134-140.
86. Hordinsky M, Ericson M, Snow D, et al. Peribulbar innervation and substance P expression following nonpermanent injury to the human scalp hair follicle. *J Investig Dermatol Symp Proc*. 1999;4:316-319.
87. Hordinsky MK, Ericson ME. Relationship between follicular nerve supply and alopecia. *Dermatol Clin*. 1996;14:651-660.
88. Peters EM, Botchkarev VA, Botchkareva NV, et al. Hair-cycle-associated remodeling of the peptidergic innervation of murine skin, and hair growth modulation by neuropeptides. *J Invest Dermatol*. 2001;116:236-245.
89. Brownell I, Guevara E, Bai CB, et al. Nerve-derived sonic hedgehog defines a niche for hair follicle stem cells capable of becoming epidermal stem cells. *Cell Stem Cell*. 2011;8:552-565.
90. Botchkarev VA, Eichmüller S, Johansson O, et al. Hair cycle-dependent plasticity of skin and hair follicle innervation in normal murine skin. *J Comp Neurol*. 1997;386:379-395.
91. Narisawa Y, Hashimoto K, Nakamura Y, et al. A high concentration of Merkel cells in the bulge prior to the attachment of the arrector pili muscle and the formation of the perifollicular nerve plexus in human fetal skin. *Arch Dermatol Res*. 1993;285:261-268.
92. Reynolds AJ, Lawrence C, Cserhalmi-Friedman PB, et al. Trans-gender induction of hair follicles. *Nature*. 1999;402, 33-34.
93. Cotsarelis G, Sun TT, Lavker RM. Label-retaining cells reside in the bulge area of pilosebaceous unit: implications for follicular stem cells, hair cycle, and skin carcinogenesis. *Cell*. 1990;61:1329-1337.
94. Ando H, Watabe H, Valencia JC, et al. Fatty acids regulate pigmentation via proteasomal degradation of

tyrosinase: a new aspect of ubiquitin-proteasome function. *J Biol Chem*. 2004;279:15427-15433.
95. Morris RJ, Liu Y, Marles L, et al. Capturing and profiling adult hair follicle stem cells. *Nat Biotechnol*. 2004;22:411-417.
96. Oshima H, Rochat A, Kedzia C, et al. Morphogenesis and renewal of hair follicles from adult multipotent stem cells. *Cell*. 2001;104:233-245.
97. Ito M, Liu Y, Yang Z, et al. Stem cells in the hair follicle bulge contribute to wound repair but not to homeostasis of the epidermis. *Nat Med*. 2005;11:1351-1354.
98. Jaks V, Barker N, Kasper M, et al. Lgr5 marks cycling, yet long-lived, hair follicle stem cells. *Nat Genet*. 2008; 40:1291-1299.
99. Snippert HJ, Haegebarth A, Kasper M, et al. Lgr6 marks stem cells in the hair follicle that generate all cell lineages of the skin. *Science*. 2010;327, 1385-1389.
100. Jaks V, Kasper M, Toftgard R. The hair follicle-a stem cell zoo. *Exp Cell Res*. 2010;316:1422-1428.
101. Müller-Röver S, Handjiski B, van der Veen C, et al. A comprehensive guide for the accurate classification of murine hair follicles in distinct hair cycle stages. *J Invest Dermatol*. 2001;117:3-15.
102. Sano S, Tarutani M, Yamaguchi Y, et al. Keratinocyte-specific ablation of stat3 exhibits impaired skin remodeling, but does not affect skin morphogenesis. *EMBO J*. 1999;18:4657-4668.
103. Mecklenburg L, Tobin DJ, Müller-Röver S, et al. Active hair growth (anagen) is associated with angiogenesis. *J Invest Dermatol*. 2000;114:909-916.
104. Botchkareva NV, Khlgatian M, Longley BJ, et al. SCF/c-kit signaling is required for cyclic regeneration of the hair pigmentation unit. *FASEB J*. 2001;15:645-658.
105. Pierard GE, de la Brassinne M. Modulation of dermal cell activity during hair growth in the rat. *J Cutan Pathol*. 1975;2:35-41.
106. Ahmad W, Faiyaz ul Haque M, Brancolini V, et al. Alopecia universalis associated with a mutation in the human hairless gene. *Science*. 1998;279:720-724.
107. Miller J, Djabali K, Chen T, et al. Atrichia caused by mutations in the vitamin D receptor gene is a phenocopy of generalized atrichia caused by mutations in the hairless gene. *J Invest Dermatol*. 2001;117:612-617.
108. Hebert JM, Rosenquist T, Gotz J, et al. FGF5 as a regulator of the hair growth cycle: evidence from targeted and spontaneous mutations. *Cell*. 1994; 78:1017-1025.
109. Rosenquist TA, Martin GR. Fibroblast growth factor signalling in the hair growth cycle: expression of the fibroblast growth factor receptor and ligand genes in the murine hair follicle. *Dev Dyn*. 1996;205:379-386.
110. Pena JC, Kelekar A, Fuchs EV, et al. Manipulation of outer root sheath cell survival perturbs the hair-growth cycle. *Embo J*. 1999;18:3596-3603.
111. Hollis DE, Chapman RE. Apoptosis in wool follicles during mouse epidermal growth factor (mEGF)-induced catagen regression. *J Invest Dermatol*. 1987;88: 455-458.
112. Hansen LA, Alexander N, Hogan ME, et al. Genetically null mice reveal a central role for epidermal growth factor receptor in the differentiation of the hair follicle and normal hair development. *Am J Pathol*. 1997;150 1959-1975.
113. Mann GB, Fowler KJ, Gabriel A, et al. Mice with a null mutation of the TGF alpha gene have abnormal skin architecture, wavy hair, and curly whiskers and often develop corneal inflammation. *Cell*. 1993;73:249-261.
114. Botchkarev VA, Botchkarev NV, Albers KM, et al. Neurotrophin-3 involvement in the regulation of hair follicle morphogenesis. *J Invest Dermatol*. 1998; 111:279-285.
115. Botchkarev VA, Botchkareva NV, Albers KM, et al. A role for p75 neurotrophin receptor in the control of apoptosis-driven hair follicle regression. *FASEB J*. 2000;14:1931-1942.
116. Foitzik K, Lindner G, Mueller-Roever S, et al. Control of murine hair follicle regression (catagen) by TGF-beta1 in vivo. *FASEB J*. 2000;14:752-760.
117. Philpott MP, Sanders D, Westgate GE, et al. Human hair growth in vitro: a model for study of hair follicle biology. *J Dermatol Sci*. 1994;7(suppl):S55-S72.
118. Blair HJ, Uwechue IC, Barsh GS, et al. An integrated genetic and man-mouse comparative map of the DXHXS674-Pdha1 region of the mouse X chromosome. *Genomics*. 1998;48:128-131.
119. Milner Y, Sudnik J, Filippi M, et al. Exogen, shedding phase of the hair growth cycle: characterization of a mouse model. *J Invest Dermatol*. 2002;119:639-644.
120. Headington JT. Telogen effluvium. New concepts and review. *Arch Dermatol*. 1993;129:356-363.
121. Guarrera M, Rebora A. Anagen hairs may fail to replace telogen hairs in early androgenic female alopecia. *Dermatology*. 1996;192:28-31.
122. Slominski A, Tobin DJ, Shibahara S, et al. Melanin pigmentation in mammalian skin and its hormonal regulation. *Physiol Rev*. 2004;84:1155-1228.
123. Magerl M, Tobin DJ, Müller-Röver S, et al. Patterns of proliferation and apoptosis during murine hair follicle morphogenesis. *J Invest Dermatol*. 2001;116:947-955.
124. Tobin DJ, Slominski A, Botchkarev V, et al. The fate of hair follicle melanocytes during the hair growth cycle. *J Invest Dermatol*. 1999;4:323-332.
125. Slominski A, Wortsman J, Plonka PM, et al. Hair follicle pigmentation. *J Invest Dermatol*. 2005;124:13-21.
126. Holbrook KA, Underwood RA, Vogel AM, et al. The appearance, density and distribution of melanocytes in human embryonic and fetal skin revealed by the anti-melanoma monoclonal antibody, HMB-45. *Anat Embryol (Berlin)*. 1989;80:443-455.
127. Jordan S, Beermann F. Nomenclature for identified pigmentation genes in the mouse. *Pigment Cell Res*. 2000; 13:70-71.
128. Yoshida H, Kunisada T, Kusakabe M, et al. Distinct stages of melanocyte differentiation revealed by anlaysis of nonuniform pigmentation patterns. *Development*. 1996; 122:1207-1214.
129. Boissy RE, Nordlund JJ. Molecular basis of congenital hypopigmentary disorders in humans: a review. *Pigment Cell Res*. 1997;10:12-24.
130. Adameyko I, Lallemend F, Aquino JB, et al. Schwann cell precursors from nerve innervation are a cellular origin of melanocytes in skin. *Cell*. 2009;139:366-379.
131. Bertolotto C, Buscà R, Abbe P, et al. Different cis-acting elements are involved in the regulation of TRP1 and TRP2 promoter activities by cyclic AMP: pivotal role of M boxes (GTCATGTGCT) and of microphthalmia. *Mol Cell Biol*. 1998;18:694-702.
132. Botchkareva NV, Botchkarev VA, Gilchrest BA. Fate of melanocytes during development of the hair follicle pigmentary unit. *J Investig Dermatol Symp Proc*. 2003;8:76-79.
133. Kunisada T, Yoshida H, Yamazaki H, et al. Transgene expression of steel factor in the basal layer of epidermis promotes survival, proliferation, differentiation

and migration of melanocyte precursors. *Development*. 1998;125:2915-2923.
134. Kunisada T, Lu SZ, Yoshida H, et al. Murine cutaneous mastocytosis and epidermal melanocytosis induced by keratinocyte expression of transgenic stem cell factor. *J Exp Med*. 1998;187:1565-1573.
135. Zsebo KM, Williams DA, Geissler EN, et al. Stem cell factor is encoded at the Sl locus of the mouse and is the ligand for the c-kit tyrosine kinase receptor. *Cell*. 1990;63:213-224.
136. McGill GG, Horstmann M, Widlund HR, et al. Bcl2 regulation by the melanocyte master regulator Mitf modulates lineage survival and melanoma cell viability. *Cell*. 2002;109:707-718.
137. Mak SS, Moriyama M, Nishioka E, et al. Indispensable role of Bcl2 in the development of the melanocyte stem cell. *Dev Biol*. 2006;291:144-153.
138. Nishimura EK, Granter SR, Fisher DE. Mechanisms of hair graying: incomplete melanocyte stem cell maintenance in the niche. *Science*. 2005;307:720-724.
139. Nishimura EK, Suzuki M, Igras V, et al. Key roles for transforming growth factor beta in melanocyte stem cell maintenance. *Cell Stem Cell* 2010;6:130-140.
140. Moriyama M, Osawa M, Mak SS, et al. Notch signaling via Hes1 transcription factor maintains survival of melanoblasts and melanocyte stem cells. *J Cell Biol*. 2006;173:333-339.
141. Veis DJ, Sorenson CM, Shutter JR, et al. Bcl-2-deficient mice demonstrate fulminant lymphoid apoptosis, polycystic kidneys, and hypopigmented hair. *Cell*. 1993;75, 229-240.
142. Yamamura K, Kamada S, Ito S, et al. Accelerated disappearance of melanocytes in bcl-2-deficient mice. *Cancer Res*. 1996;56:3546-3550.
143. Weiner L, Han R, Scicchitano BM, et al. Dedicated epithelial recipient cells determine pigmentation patterns. *Cell*. 2007;130:932-942.
144. Rabbani P, Takeo M, Chou W, et al. Coordinated activation of Wnt in epithelial and melanocyte stem cells initiates pigmented hair regeneration. *Cell*. 2011;145:941-955.
145. Chou WC, Takeo M, Rabbani P, et al. Direct migration of follicular melanocyte stem cells to the epidermis after wounding or UVB irradiation is dependent on Mc1r signaling. *Nat Med*. 2013;19:924-929.
146. Takeo M, Lee W, Rabbani P, et al. EdnrB governs regenerative response of melanocyte stem cells by crosstalk with Wnt signaling. *Cell Rep*. 2016;15:1291-1302.
147. Aubin-Houzelstein G, Djian-Zaouche J, Bernex F, et al. Melanoblasts' proper location and timed differentiation depend on Notch/RBP-J signaling in postnatal hair follicles. *J Invest Dermatol*. 2008;128:2686-2695.
148. Schallreuter KU, Beazley WD, Hibberts NA, et al. Pterins in human hair follicle cells and in the synchronized murine hair cycle. *J Invest Dermatol*. 1998;111:545-550.
149. Sharov A, Tobin DJ, Sharova TY, et al. Changes in different melanocyte populations during hair follicle involution (catagen). *J Invest Dermatol*. 2005; 125:1259-1267.
150. Abdel-Malek Z, Suzuki I, Tada A, et al. The melanocortin-1 receptor and human pigmentation. *Ann N Y Acad Sci*. 1999;885:117-133.
151. Barsh GS. What controls variation in human skin color? *PLoS Biol*. 2003;1:E27.
152. Abdel-Malek ZA. Melanocortin receptors: their functions and regulation by physiological agonists and antagonists. *Cell Mol Life Sci*. 2001;58:434-441.
153. Adan RA, Hillebrand JJ, De Rijke C, et al. Melanocortin system and eating disorders. *Ann N Y Acad Sci*. 2003;994:267-274.
154. Kauser S, Thody AJ, Schallreuter KU, et al. A fully-functional POMC/MC-1R system regulates the differentiation of human scalp hair follicle melanocytes. *Endocrinology*. 2005;146(2):532-43.
155. Cable J, Jackson IJ, Steel KP. Light (Blt), a mutation that causes melanocyte death, affects stria vascularis function in the mouse inner ear. *Pigment Cell Res*. 1993;6:215-225.
156. Tobin DJ. Human hair pigmentation—biological aspects. *Int J Cosmet Sci*. 2008;30:233-257.
157. Commo S, Gaillard O, Thibaut S, Bernard BA. Absence of TRP-2 in melanogenic melanocytes of human hair. *Pigment Cell Res*. 2004;17:488-497.
158. Inomata K, Aoto T, Binh NT, et al. Genotoxic stress abrogates renewal of melanocyte stem cells by triggering their differentiation. *Cell*. 2009;137:1088-1099.
159. Wood JM, Decker H, Hartmann H, et al. Senile hair graying: H2O2-mediated oxidative stress affects human hair color by blunting methionine sulfoxide repair. *FASEB J*. 2009;23:2065-2075.

Chapter 8 :: Nail

:: Krzysztof Kobielak

AT-A-GLANCE

The nail appendage is composed of several layers that organize the nail organ:

- The eponychium creates a border between skin epidermis and nail organ at the dorsal limit of the nail proximal fold (NPF), forming a protective seal.
- The NPF forms after skin epidermis bends inward ventrally at the eponychium's border and becomes the nail epidermis, creating the NPF, which localizes slow-cycling bifunctional nail proximal fold stem cells (NPFSCs). NPFSCs actively deliver progeny to the perinail epidermis and nail matrix along with differentiated nail plate upon nail regeneration.
- The matrix, a ventral continuation of the proximal fold after it bends dorsally and distally, is composed of actively proliferating cells called onychocytes. In the proximal nail matrix, fast-proliferating nail stem cells are located. Their differentiation is coupled directly with the ability to orchestrate digit regeneration.
- Nail matrix differentiates, forming the keratogenous zone, which finally deposit cells into the overlying nail plate.
- Hyponychium is the most distal part of the nail epithelium located peripherally to the nail bed, and beneath the nail plate at the junction between the free edge and the skin epidermis of the fingertip, it forms a seal that protects the nail bed.

INTRODUCTION

The nail organ is one of the skin appendages located on the distal phalanx of each finger and toe in human body. Interestingly, nails exhibit continuous growth under physiological conditions and can fully regenerate upon removal. This chapter covers new discoveries of nail appendage biology, its growth regulation, and the mechanism of nail differentiation. Scientists have been intensely searching for stem cells in various organs in hopes of understanding and taking advantage of their regenerative abilities. Indeed, the skin is a complex organ containing a number of different "mini-organs," skin appendages that are maintained by independent stem cell populations.

For the past several years, there have been active investigations and discussion about whether the nail organ alone possess stem cells that can regenerate the whole nail appendage or if other cells appear to contribute to nail regeneration. This chapter presents new discoveries about the coexistence of two independent populations of skin stem cells localized in the nail organ, with quite opposite cell cycle dynamics, namely a slow-cycling population of bifunctional nail proximal fold stem cells (NPFSCs) and fast-cycling nail stem cells (NSCs). In addition, their reciprocal dependence and interactions during nail organ regeneration have been discussed. Thus, nails contain a gradient of slow- to fast-cycling cells, with slow-cycling NPFCs and then more active cells in the intermediate zone (IZ) that separate them from highly proliferative stem cells in the nail proximal matrix.

We also present a new function of nail organ, specifically newly discovered NSCs in the nail proximal matrix and their adjacent progenitors in the nail distal matrix that contribute actively to nail differentiation and their surprising critical role in orchestrating digit regeneration in mammals. Moreover, stem cell isolation from nail organs and their gene expression profiling revealed their molecular characteristics, in which bone morphogenetic protein (BMP) and wingless-type MMTV integration site family (Wnt) signaling pathways were identified to be an essential in nail fate differentiation as well as in digit regeneration. Thus, current research has begun to unveil that also other skin appendages, including nails, possess their own stem cells with regenerative capacities. However, more studies are needed for further characterization of these stem cells in the nail organ that may shed some light on putative stem cell regenerative potential in human nails in the future. Therefore, because of its extraordinary regenerative potential, further studies of mechanisms regulating stem cell populations in nails and their interaction with mesenchymal cells may lead to new routes to treat various nail disorders, including amputations in humans.

NAIL ORGAN STRUCTURE (ANATOMY) AND FUNCTION

Nails belong to one of the skin appendages and are located on the distal phalanx of each finger and toe in the human body (Fig. 8-1). The nail appendage begins as an extension of the distal phalanx skin epidermis at the border called the eponychium (Fig. 8-2). At that point, the skin epidermis bends inward ventrally and becomes the nail epidermis, forming the nail proximal fold (NPF) (see Fig. 8-2). Interestingly, normal epidermal differentiation ceases just after the proximal fold folds inward at the eponychium border; thus, nail layers continuing beyond this point do not form the granular layer typically observed in normal skin epidermis. As a ventral

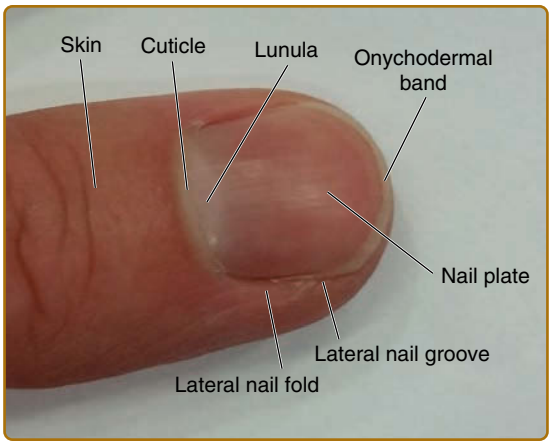

Figure 8-1 Picture of a human fingertip with the nail organ. Visible structure include the skin, cuticle, nail plate with the proximally located lunula, and the distally located onychodermal band. On the side, the nail plate is separated by the lateral nail groove and lateral nail fold.

continuation of the proximal fold after it bends dorsally and distally is the nail matrix composed of actively proliferating nail cells called onychocytes (see Figs. 8-2 and 8-3).[1] Above the matrix lies the keratogenous zone (KZ) where matrix cells differentiate, flatten out, die, and deposit into the overlying nail plate (see Figs. 8-2 and 8-3). The nail plate is a hard structure that serves as a protective covering by preventing trauma to the tips of toes and fingers; it is also used as a tool to pick up small objects, which is important for fine manipulations and subtle finger functions. Through the nail plate, the whitish crescent-shaped base is called the lunula ("small moon"), the visible part of the matrix (see Fig. 8-1). The lunula can best be seen in the thumb and may not be visible in the little finger.

Within the nail organ, the nail plate contains a hard keratinized structure composed of flattened and anucleated cells called corneocytes overlying the distal phalange (see Figs. 8-1 and 8-2). Corneocytes are formed during nail differentiation from nail cells, onychocytes. The nail plate exerts counterpressure at the fingertips for protection and enhances sensitivity. Distal to the nail matrix is the nail bed, composed of a basal layer and one or two layers of suprabasal postmitotic keratinocytes, contributing a few horn cells to the undersurface of the distal nail plate (see Fig. 8-2).[2] The nail plate is attached to the finger by interdigiting with the underlying nail bed (see Fig. 8-2). The nail cuticle extends from the edge of the proximal fold onto the nail plate, sealing the proximal end of the nail and protecting it from toxins and foreign substances (see Fig. 8-1). Laterally, the nail plate is surrounded by lateral nail grooves and lateral nail folds (see Fig. 8-1). Similarly, at the distal end border of the nail unit, the hyponychium seals the nail plate to the nail bed under the onychodermal band to prevent infection (see Figs. 8-1 and 8-2).

Comparing human nails with those of other mammals (eg, mouse nail in this example), it is apparent that the shape is very different, likely owing to differences in evolution and function. The human nail is flatter (see Figs. 8-1 and 8-3); a mammal's claw is a near conical structure with greater curvature. This shape is influenced by the underlying distal phalanx and the distribution of the matrix.[1,3]

NAIL GROWTH AND DIFFERENTIATION

So far, it is believed that the matrix is largely responsible for nail plate production. However, previously,

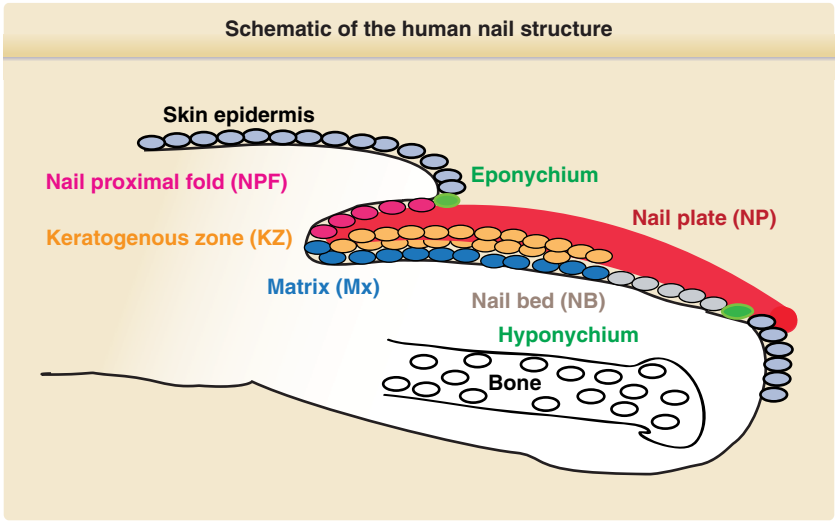

Figure 8-2 Schematic of the human nail structure (longitudinal section through the middle of nail). Different nail layers and structures with color include the nail proximal fold (*pink*), matrix (*blue*), keratogenous zone (*orange*), nail bed (*light grey*), nail plate (*red*), and flanking from both sides by eponychium and hyponychium (*green*), which separates the nail structure from the skin epidermis (*dark grey*).

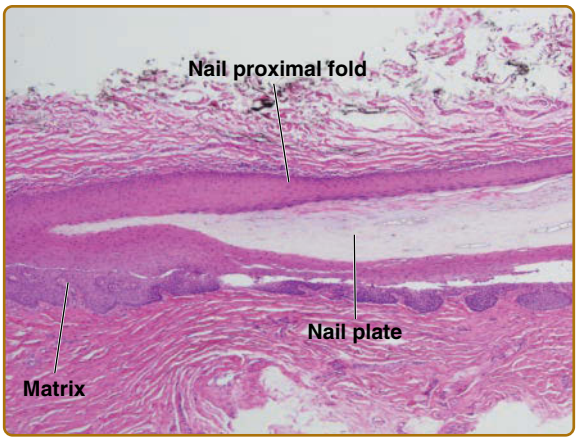

Figure 8-3 The nail apparatus. Histologic appearance of the elements that make up the nail unit (hematoxylin and eosin staining of longitudinal section through the middle of nail; original magnification ×20). Nail histologic layers are the nail proximal fold, matrix, and nail plate. (Used with permission from Dr. Sébastien de Feraudy, MD, PhD, Associate Professor & Director of Dermatopathology, UC Irvine Dermatopathology Laboratory, Irvine, CA.)

it was unclear whether the matrix is the sole source of nail differentiation or if other parts of the nail unit, such as the nail bed, also contribute to the nail plate. In the past, Lewis observed that the nail plate is composed of three different layers and proposed that they arise from three different parts of the nail unit. It was theorized that the superficial layer of the dorsal nail originates from the proximal nail fold, the intermediate nail arises from the matrix, and the deep ventral nail is produced by the nail bed.[4] About a decade later, Zaias and Alvarez used radioactive tritiated glycine to mark and follow nail cells in squirrel monkeys, demonstrating that the uptake in the label moves from the matrix into the nail plate over time.[5] Only small amounts of radioactive tritiated glycine were incorporated in the nail bed and were therefore dismissed as a source of nail production because of its inactivity. Taken together, the nail matrix was proposed to be solely responsible for nail plate formation.[5] Similar studies were also conducted on human volunteers using both tritiated thymidine (^{3}H-thymidine) and glycine in which matrix cells were proposed to migrate into the nail bed in addition to the nail plate.[6] The hypothesis that the nail is produced only by the matrix was further supported by Berker and Angus, who demonstrated that the matrix cells were highly proliferative compared with the relatively inactive nail bed.[7] In other studies, it has been proposed that although the matrix produces the bulk of the nail plate, the nail bed also contributes to the nail plate based on nail thickness and mass.[8,9] It is argued that the contribution of the nail bed to the ventral nail plate allows distal movement of the nail plate as it grows. Thus, in conclusion, there appear to be a general consensus that the nail plate is produced by matrix cells.

TWO POOLS OF STEM CELLS EXIST IN NAIL ORGAN (HOMEOSTASIS AND REGENERATION)

Whether the matrix cells are the only source of progenitor cells required for nail production or if the other layers including NPF also contribute to portion of the nail during the lifetime, meeting the criteria of being stem cells per se is evaluated in this section.

Adult stem cells found in various organs throughout the body are responsible for maintaining the normal turnover of organs as well as tissue repair in the event of an injury.[10] These are made possible by its ability to self-renew and differentiate into the different specialized cell types in its respective organs.[10] Because stem cells are required for tissue homeostasis and regeneration throughout life, they must have long-term self-renewal capacity. Moreover, it has been proposed that stem cells divide infrequently to avoid incorporation of mutations associated with cell division. In each organ, stem cells reside in specialized microenvironments called niches, which helps maintain quiescence or regulate proliferation and differentiation, which are important for tissue homeostasis and repair.[10-13]

Upon activation, these stem cells divide and leave the niche to form more differentiated transit-amplifying (TA) progenitor cells. In contrast to the relatively quiescent stem cells, TA cells rapidly proliferate and differentiate into cells needed for regeneration or repair.[10] Adult stem cells are theoretically present in all regenerative tissues, but their localization and characterization are often difficult because little is known about these organs. Therefore, scientists have used the slow-cycling property to label and identify putative stem cells in various organs. In early pulse-chase studies, animals were injected with ^{3}H-thymidine, which gets incorporated into the newly synthesized DNA of dividing cells. After efficient labeling, the animal undergoes a period of chase when dividing cells dilute out the ^{3}H-thymidine label and slow-cycling cells retain this radioactive label. This method allowed for the identification of slow-cycling label-retaining cells (LRCs).

In 1990, Cotsarelis and coworkers identified a unique population of slow-cycling LRCs in the bulge region of the hair follicle using ^{3}H-thymidine pulse chase experiments. They demonstrated that these bulge LRCs can be stimulated to proliferate upon treatment with a tumor promoter (12-O-tetradecanoylphorbol-13-acetate [TPA]) and went on to hypothesize that these LRCs are stem cells of the hair follicle.[14] Before identifying LRCs in the hair follicle bulge, Cotsarelis and coworkers also reported on LRCs in the cornea limbus using similar pulse chase experiments.[15] These limbal LRCs were also preferentially activated in response to injury and can also be stimulated by TPA.

These data support the theory that stem cells persist throughout the lifetime of an animal to contribute to the tissue during regeneration and wound repair.

Using radioactive labeling, however, researchers were unable to probe for colocalization of potential markers through immunological histology. Soon after, scientists began to use a new synthetic thymidine analog, bromodeoxyuridine (BrdU).[16] In contrast to ^{3}H-thymidine, BrdU is not radioactive. In addition, antibodies against BrdU allow for immunohistochemistry to probe for markers that colocalize with BrdU-marked LRCs.[17] Pulse-chase studies with BrdU have been widely used to identify LRCs in numerous tissues.

More recently, a new method for identifying LRCs using transgenic mice with tetracycline-induced histone 2B-green fluorescent protein (H2B-GFP) has been described.[18] With this system, a specific or ubiquitous promoter can be used to drive inducible H2B-GFP expression in the tissues of interest. One advantage of this system is that it can more efficiently label the cells before chase, but the BrdU method can only label cells that are actively dividing in the synthesis phase during pulse. Moreover, this H2B-GFP transgenic label-retaining system allows for the isolation of live LRCs for further characterization and analysis. For the first time, this method allowed the isolation of live hair follicle label-retaining stem cells for gene expression profiling to determine the molecular characteristics of these stem cells independent of any other markers such as keratin 15 (K15) or CD34.[18] Over the years, this method allowed understanding of how hair follicles and their stem cells are regulated.

SLOW-CYCLING BIFUNCTIONAL NAIL PROXIMAL FOLD STEM CELLS IN THE NAIL ORGAN

Subsequently, in addition to the hair follicle in many skin appendages, such as the cornea and sweat glands, slow-cycling stem cell characteristics were demonstrated[14,15,19-21]; however, little was known about other skin appendages such as nails.

Therefore, recent studies tried to address whether such a quiescent stem cell population also exists in continuously growing nails. First notice of existence of LRCs in the nail after BrdU pulse-chase experiments suggested the presence of LRCs in the basal layer of the nail matrix adjacent to the nail bed in the mouse nail; however, further characterization has not been performed.[22] In contrast to this localization, using immunohistochemical staining, Sellheyer and coworkers showed that the ventral proximal fold in human nails expresses hair follicle stem cell (hfSC) markers (eg, K15; keratin 19 [K19]; and pleckstrin homology-like domain, family A, member 1 protein [PHLDA1]) during embryogenesis and contains very few Ki67+ cells (a nuclear protein associated with cell proliferation), making them more quiescent similar to hfSCs, suggesting that the proximal fold may represent the human NSC niche.[23]

These discrepancies have been addressed in recent studies using H2B-GFP LRCs system in transgenic mice for the in vivo detection of quiescent, slow-cycling skin cells.[24] This method allows identifying a previously unreported population of nail LRCs within the basal layer of the NPF (Fig. 8-4).[24] Interestingly, in mice, the nail exists as a three-dimensional near-conical structure; therefore, LRCs are organized in a ringlike configuration.[24] Nail LRCs express the hfSC marker K15, and in vivo lineage tracing experiments show that K15-labeled cells, originating in the NPF, contribute to both the nail structure (see Fig. 8-4, *black arrow #2*, long term) and more predominantly to the perinail epidermis (see Fig. 8-4, *green arrow #1*), thus possessing a bifunctional stem cell characteristic. Upon nail regeneration, these K15-derived NPFSCs actively deliver progeny to the nail matrix and differentiate into the nail plate (see Fig. 8-4, *black arrow #2*). Similarly, in vivo engraftment experiments demonstrate that the nail LRCs can actively participate in functional nail regeneration. Transcriptional profiling of isolated nail LRCs revealed a requirement for BMP signaling in proper nail formation and differentiation (Fig. 8-5). Thus, BMP signaling guides NPFSCs toward nail differentiation, and without this pathway, matrix cells proliferate less, and a KZ is not observed above the matrix region (see Fig. 8-5).[24] Also, proper nail plate differentiation is compromised, and without BMP signaling, the nail adopts an epidermal fate in vivo (see Fig. 8-5). It manifests the extension of the skin epidermis granular layer throughout the nail with typical epidermal markers such as keratin 1 (K1) and loricrin expression observed in the nail plate (see Fig. 8-5). In contrast, typical differentiation nail plate marker AE13 (keratin expressed in both the hair cortex and nail plate) was undetectable (see Fig. 8-5).[24] Interestingly, a similar role of BMP signaling was observed in proper hair follicle differentiation.[25] This observation was also consistent, and the phenotype was even more severe than a phenotype of the *Msx2* and *Foxn1* double mutant; both genes previously have been showed as downstream targets of BMP signaling regulating normal nail differentiation.[26] It was also similar to *Foxn1* and *Hoxc13* single mutants, with aberrant extension of the epidermal stratum granulosum within the nail structure (see Fig. 8-5).[2,27] In addition, the role of BMP signaling is also required for maintenance of the LRC characteristic of NPFSCs (see Fig. 8-5), as previously observed in hfSCs.[28] Taken together, a novel population of bifunctional stem cells within the NPF region displays plastic homeostatic dynamics capable of responding to injury and suggests a common, coordinated mechanism of protective barrier formation that could occur between the nail and adjacent epidermis.[24]

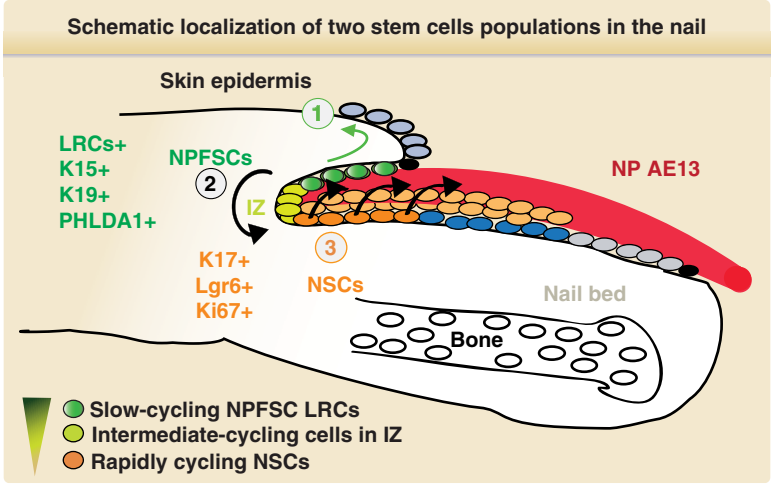

Figure 8-4 Schematic localization of two stem cells populations in the nail. Localization of nail proximal fold stem cells (NPFSCs) with slow-cycling label-retaining characteristic (LRCs) in the nail proximal fold and fast-proliferating nail stem cells (NSCs) in the proximal matrix. NPFSCs express keratin 15 (K15); keratin 19 (K19); and pleckstrin homology-like domain, family A, member 1 protein (PHLDA1). K15-marked NPFSCs contribute predominantly to the perinail epidermis (*1, green arrow*) but also to the nail matrix and nail differentiation (*2, black arrow*) during nail homeostasis. NSCs, when marked by Lgr6, participate in nail matrix structure and nail plate (NP) differentiation (*3, black arrows*). AE13, keratin that is expressed in the hair cortex and nail plate; IZ, intermediate zone; Ki67, a nuclear protein associated with cell proliferation; Lgr6, leucine-rich repeat containing G protein–coupled receptor 6.

RAPIDLY CYCLING UNIPOTENT NAIL STEM CELLS IN THE NAIL ORGAN

The nail matrix is a morphological continuation of the NPF cells that attach to each other through the IZ wrapping around the proximal end of the nail plate (see Fig. 8-4). Thus, proliferating matrix progenitor cells are found in the near vicinity of the NPF region and differentiate into cells of the KZ to form the external nail plate.

In terms of the cell proliferation dynamic, a clear distinction was observed between slow-cycling nail LRCs in the NPF and the actively dividing matrix cells after only 1 week of chase.[24] At that time point, Ki67 immunolabeling primarily is localized to proliferating

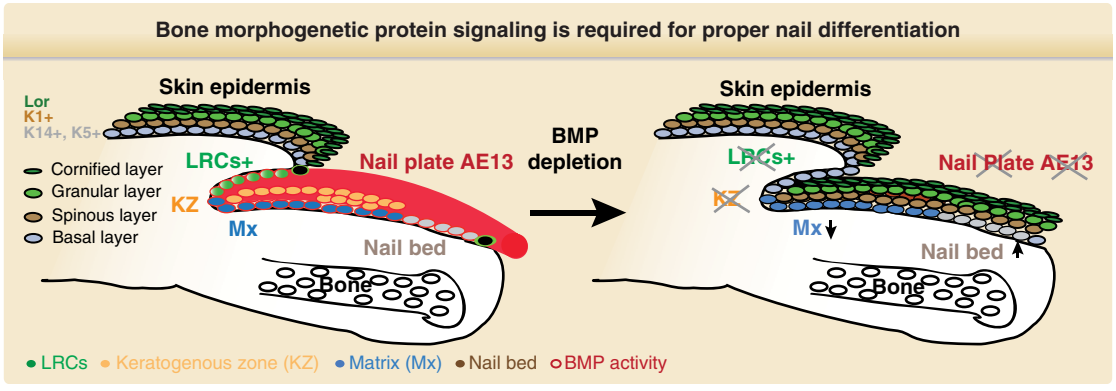

Figure 8-5 Bone morphogenetic protein (BMP) signaling is required for proper nail differentiation. Active BMP signaling is found in nail proximal fold and the nail matrix (indicated by *circles with red encasements*). BMP depletion in nails demonstrates the absence of the keratogenous zone (KZ, *orange circles*), hyperplasia of the nail bed (*grey circles*), and loss of label-retaining cells (LRCs), and an ectopic granular layer extends over the whole nail plate (layer of skin epidermis marked by *green circles*). Keratin 1 (K1) and Loricrin (Lor) epidermal markers are ectopically expressed in the absence of BMP signaling. Positive K1 staining is found in the proximal fold and ventral nail of control mice. Ectopic K1 expression (layer of skin epidermis marked by *brown circles*) is observed instead of expression of the nail plate marker AE13 (*red color*). Loricrin expression is found in the proximal fold until eponychium and is absent in the dorsal nail plate of control mice. Ectopic loricrin expression (layer of skin epidermis marked by *dark green circles*) is observed instead of expression of the nail plate marker AE13 (*red color*). The amount of proliferating cells in Mx (marked by *blue circles*) appears to be decreased, and AE13, a marker of the nail plate differentiation, is compromised without BMP signaling. Thus, the ectopic expression of epidermal markers demonstrates that BMP signaling may be required for the nail fate, and without it, the nail structure acquires an epidermal-like phenotype.

matrix cells and a minority of weakly H2B-GFP+ cells immediately adjacent to Ki67 negative strongly H2B-GFP+ proximal fold (PF) LRCs, indicating increased proliferation within the matrix in comparison with the adjacent PF region (see Fig. 8-4).

Thus, the area between both regions—the proliferating matrix and the quiescent PF IZ—has been described as containing weakly H2B-GFP+ and Ki67+ cells, which arise from H2B-GFP label dilution after cell division. The IZ gradually decreases in size with increasing periods of chase, being minimal just after a 2-week chase to completely disappearing after a 4-week chase. This indicates the existence of a gradient in cell division expanding from relatively quiescent slow-cycling LRCs in the NPF (through the IZ of more active cells) to rapidly dividing matrix cells (see Fig. 8-4).[24]

Thus, it was demonstrated that the nail matrix contains rapidly dividing progenitor cells responsible for nail differentiation. However, whether matrix cells alone possess stem cell characteristics and can generate the whole nail appendage was investigated and is addressed further later in this chapter.

To locate stem cells in nails, Takeo and coworkers used a transgenic mouse lineage tracing system. Under control of keratin 14 (K14) promoter-driven Cre recombinase–mutated estrogen receptor (Cre-ER) (K14–Cre-ER), they marked keratinocytes in the basal layer of the skin epidermis and the nail epidermis by activating LacZ expression.[29] In that system, LacZ expression was driven by the Rosa26 promoter, and its activation followed Cre-mediated removal of the floxed stop cassette. Thus, it allowed labeling genetically a small subset of K14 nail basal epidermal cells, including nail matrix cells and bed cells, using a single injection of tamoxifen and then assessing participation of LacZ-labeled cells in nail regeneration over an extended period of time. Over 5 months, the number of LacZ+ descendants of the labeled K14 nail epithelial cells extended linearly and distally, persisting as streaks that emerged only from the proximal matrix but not from the distal matrix. Proximal matrix cells possessed characteristics of undifferentiated epidermal cells expressing keratin 17 (K17) in addition to K14 with highly proliferative Ki67 marker (see Fig. 8-4). The isolated proximal matrix cells had the highest colony-forming ability in vitro, a general characteristic of epithelial stem cells. Thus, prolonged labeling results along with in vitro culture data demonstrated that the rapidly dividing proximal matrix contains self-renewing cells, meeting the criteria to be per se NSCs that sustain nail growth (see Fig. 8-4).[29]

Interestingly, a gene expression analysis between proximal matrix versus distal matrix revealed that proximal matrix cells were enriched with NSCs with downregulated Wnt signaling pathway.[29] Indeed, analyses using two different Wnt reporter mice confirmed that although the Wnt signal started from the distal part of the K17-positive NSC region and persisted into the distal matrix of K17-negative distal matrix, both signals were absent in the proximal end of the nail matrix. Consistently, Wnt signaling pathway components such as Tcf1 (also known as hepatocyte nuclear factor 1a), a nuclear mediator of Wnt signaling, and Wls (Wntless homologue) were not expressed in the proximal end of NSCs, but several keratins that contained a TCF1 and LEF1 consensus binding site were upregulated in the distal matrix, thus suggesting direct involvement of Wnt signaling in nail differentiation. This was verified by deletion of Wnt signaling activation in the nail epithelium by removing β-catenin (an essential mediator of Wnt signaling) in adult epithelium revealed by the lack of AE13, a marker for keratinized nail cells. Interestingly, without β-catenin or Wntless, the entire nail epithelium showed characteristics of the NSC region with K17-positive and highly proliferating Ki67-positive cells, thus confirming the essential role of Wnt signaling in nail differentiation.

Moreover, in a recent study, scientists identified a cell population expressing a mediator of Wnt signaling, Lgr6 (leucine-rich repeat containing G protein–coupled receptor 6), as key stem cells marker for the nail, which was localized within the nail proximal matrix, thus being consistent and confirming previous discoveries by Takeo and coworkers.[30] Indeed, Lgr6 is a molecular marker specific to the NSCs, giving rise to the nail plate and contributing to the growth of nail over time (see Fig. 8-4). Thus, these data confirmed that canonical Wnt signaling (which results in β-catenin localization to the nucleus of the nail matrix) broadly correlates with the expression of Lgr6-expressing nail matrix cells.

ROLE OF NAIL EPITHELIUM IN DIGIT REGENERATION

The tips of the digits of humans, similar to those of some mammals, including mice, are capable of complete regeneration after injury like those of amphibians.[31,32] Interestingly, this capacity is limited to the area associated with the nail, and previous studies showed that nail transplantation after amputation at the middle phalanx can induce ectopic digit bone differentiation.[31-33] Thus, this observation suggests that the nail epithelium has a special function, creating a permissive regenerative environment for digit regeneration. Recently, some cellular and molecular components of the digit regeneration process have been discovered by Takeo and associates.[29] Indeed, the process is orchestrated and depends on the presence of the overlaying nail organ and its reciprocal interaction with underlying blastema. It has been shown that nail epithelium, particularly NSCs located in the proximal nail matrix and their differentiation, is coupled directly with ability to orchestrate digit regeneration. On a molecular level in the mouse model, Wnt/β-catenin signaling from nail epithelium has been shown to be necessary for digit regeneration. The current proposed model is that NSCs in the proximal matrix give rise to distal matrix cells with Wnt activation (through Wntless), and, simultaneously, NSCs and distal matrix cells differentiate into the nail plate (Fig. 8-6). After distal

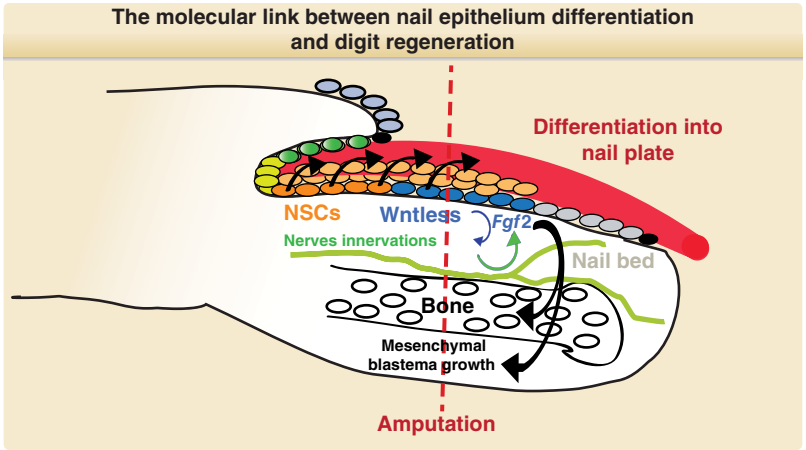

Figure 8-6 The molecular link between nail epithelium differentiation and digit regeneration. Nail stem cells (NSCs) in the proximal matrix (*dark orange circles*) give rise to distal matrix cells (*blue circles*) with Wnt activation (Wntless) under homeostatic conditions. Both proximal and distal matrix cells differentiate into the nail plate (*red color*). After distal-level amputation (*red dotted line*), the nail epithelial cells begin to regenerate the wound site along with activation Wnt signaling to differentiate into distal matrix cells and the nail plate. This Wntless activation in nail epithelium is required to promote (*blue arrow*) blastema innervations (*green*), which is necessary (*green arrow*) for Fgf2 expression in the regenerating nail epithelium (*blue circles*). Subsequently, fibroblast growth factor 2 (FGF2) promotes (*black arrow*) proliferation of Runx2-positive mesenchymal cells, ultimately leading to digit regeneration. (Adapted from Takeo M, Chou WC, Sun Q, et al. Wnt activation in nail epithelium couples nail growth to digit regeneration. *Nature*. 2013;499(7457):228-232.)

amputation at the level of the distal matrix expressing Wntless (but NSCs in proximal matrix remain intact), the wound site is covered by regenerating nail epithelial cells, which in turn activate Wnt signaling (Wntless) to differentiate into distal matrix cells and the nail plate (see Fig. 8-6). The Wnt pathway activation promotes blastema innervations through semaphorin 5a (Sema5a, an axon-guidance molecule), which is upregulated in control nail epithelium 3 weeks after amputation. Conversely, innervations are necessary for fibroblast growth factor 2 (FGF2) expression in the regenerating nail epithelium (see Fig. 8-6). Then FGF2 promotes proliferation of either Runx2-positive progenitors or Sp7 osteoblasts, ultimately leading to coupled digit regeneration (see Fig. 8-6). Interestingly, receptor for FGF2 ligand FGFR1 is expressed in mesenchymal blastema (a Runx2 progenitor); thus, the ERK pathway could be recruited to activate and maintain their proliferation (see Fig. 8-6).

Thus, nail differentiation is regulated by a WNT-dependent mechanism that is linked to digit regeneration. Indeed, Wnt deletion (in β-catenin conditional knockout [KO] mice) results in a lack of nail differentiation that manifests by absence of TopGal expression in the nail matrix (a gene reporter for WNT pathway) and AE13 expression (a marker for keratinized nail plate cells), and bone regeneration is blocked. Moreover, Runx2 progenitor cells, mesenchymal cells, and Sp7 osteoblasts underneath the nail matrix epithelium in β-catenin conditional KO mice were not stimulated to proliferate or produce BMP4. Moreover, Wnt-dependent innervation can promote digit regeneration because Sema5a is downregulated in the nail epithelium 3 weeks after amputation in β-catenin conditional KO mice. These data are in agreement that denervation (nerves removed surgically before amputation) suppresses blastema growth similar to that observed in conditional KO mice without FGF2 expression in the nail epithelium after denervation.[34,35] Interestingly, although after proximal amputation of nail matrix cells, stabilization of β-catenin induces TCF1 expression and regeneration of the distal matrix and formation of well-innervated blastema cells, β-catenin stabilization in the nail epithelium does not promote digit regeneration after amputation proximal to the NSC niche. Therefore, the remaining proximal matrix epidermis is not able to respond to β-catenin stabilization, and digit regeneration cannot be restored, which is in contrast to distal matrix function.

This results are consistent with inhibition of proper digit-tip regeneration after ablation of Lgr6, an important agonist of the Wnt pathway that marks NSCs and gives rise to the nail plate.[30] In addition, Lgr6 expression is not only limited to the nail matrix but is more broadly expressed within a subset of cells in the digit tip, namely, in the bone osteoblasts and eccrine sweat glands. Therefore, Lgr6-expressing cells not only mark NSC epithelium but also contribute to the blastema, which suggest not only direct but also a potential indirect role for Lgr6-expressing cells during digit-tip regeneration.[30] Indeed, this role has been confirmed by analysis of Lgr6-deficient mice, which have both a nail and bone regeneration defect, but it remains unclear whether the Lgr6-positive osteoblasts contribute to this phenotype. Thus, the role of these cells in normal skeletal homeostasis and digit regeneration remains to be determined in the future.

Collectively, the dual function of Wnt signaling in the NSC lineage that directs nail formation and differentiation and digit regeneration appears to be a key mechanism that coordinates the regeneration of epithelial and mesenchymal tissues in mammalian

digit-tip regeneration (see Fig. 8-6). Indeed, interestingly, some nail disorders in humans that may affect only nails include inherited anonychia and isolated congenital nail dysplasia. Affected families with inherited anonychia have severe hypoplasia of the nails in which mutations in R-spondin 4 (Rspo4), which is implicated in the Wnt signaling pathway, were identified, suggesting an important role of Rspo4 in nail development.[36]

CONCLUSIONS

Stem cells have long term self-renewal potential and are capable of differentiating into a variety of different cell types. This persistence and multipotency are crucial for the maintenance of tissue during homeostasis and repair. Because of its extraordinary regenerative potential, understanding its maintenance and regulation will prove its usefulness in tissue regeneration and treatment of various disorders.

Current discoveries unveiled the model in which stem cells in nail organs exist in two different activation mode—slow-cycling and actively proliferating ones—to fulfill the demands of continuously growing nails.[24,29] These data demonstrated that the nail organ contains a gradient of slow- to fast-cycling stem cells, with slow-cycling NPFSCs in the proximal fold, more active cells in the IZ, and finally rapidly proliferative NCSs in the nail proximal matrix regions.

Collectively, this model supports the current view about adult stem cell dynamics and potency in several organs and tissues during homeostasis and regeneration. For example, the label-retaining, NPFSCs, and rapidly proliferative NCSs present a dynamic hierarchy similar to that described in hfSCs in which some hfSCs participate in the new hair cycle and other hfSCs of the upper outer root sheath (ORS) of growing follicles reestablish the new bulge with quiescent hfSCs.[37] During this bulge activation, a gradient of slow- to fast-cycling cells is observed within the ORS extending from the bulge region toward the matrix, respectively.

Why does the nail organ possess two populations of stem cells? One answer might come from observation of similar system of two stem cell populations with different cell cycling dynamics in the intestine. In the intestine, slow-cycling LRCs stem cells have been identified in the +4 position of intestinal crypts that expressed Bmi1.[38,39] In contrast, fast-cycling stem cells were also found at the bottom of the crypts expressing Lgr5,[40] and both stem cell populations are capable of differentiating into all intestinal lineages.[39] Interestingly, recently, in the absence of rapidly proliferating Lgr5+ stem cells, Bmi1 stem cells can maintain the normal turnover of the intestines while repopulating the Lgr5+ stem cell population.[41] This suggests that Bmi1+ cells, localized where LRCs are found, act as a reserve stem cell population. Thus, a similar backup system between two populations of stem cells in nails, namely NPFSCs and NSCs, might exist to protect overall nail organ maintenance. Thus, it will be interesting to further address this in the future. Overall, this suggest that NSCs in the proximal matrix[29] integrate the adjacent neighboring proximal fold as a location of bifunctional NPFSCs.[24] Collectively, these examples underscore an inherent plasticity of the adult stem cell populations within nail epithelia, and slow-cycling NPFSCs in these highly proliferative tissues might represent a backup system for NSCs during times of stress, injury, or depletion of the stem cell population.

All these exciting discoveries about stem cell populations in the nail organ and their mutual relationships as well as reciprocal interactions between stem cells and stem cell niches help unravel new concepts in stem cell biology and have great translational potential that could considerably impact regenerative medicine. Indeed, in mouse digit-tip regeneration, it has been demonstrated that although nail epithelium with its stem cells is critical to orchestrate this process, crosstalk with other germ-layer and lineage-restricted stem/progenitor cells is essential to successfully complete this regeneration.[42] Thus, in the future, this research might potentially restore anatomical and functional structures by orchestrating full-digit regeneration, including bone, innervations, and vasculature with skin and skin appendages along with nail, therefore benefiting individuals with digit amputations.

These results have established a direct relationship between NSC differentiation and digit regeneration and suggest that NSCs may have therapeutic potential to contribute toward the development of novel treatments for amputees. This is a very important problem because many people are affected by accidental amputation of fingers or toes worldwide. Recent nail and digit regeneration data have begun to pave the way toward unveiling the underlying mechanisms required to expose this regenerative potential. Therefore, new discoveries in nail biology will very likely enhance our understanding of the fundamental mechanisms required to orchestrate digit regeneration with the potential to unlock the broad regenerative potential to reconstitute the whole limb beyond digit regeneration.

Although more studies are needed for further characterization of these stem cell population in the nail organ, these data may shed some light on putative stem cells markers for human nails in the future. Indeed, interestingly, initial observation in human of the ventral proximal fold was proposed to be the NSCs in the developing embryonic human nail based on the expression of bulge stem cell markers, K15, K19, and PHLDA1 with quiescent characteristics that might represent NPFSCs in the mouse model.[23] In contrast, the human nail matrix contains highly proliferative cells marked by Ki67, similar to the mouse nail matrix, which might be similar as NSCs highly proliferating stem cells in the proximal matrix in mice.[23] Thus, further identification, characterization, and isolation of those two distinct populations of stem cells in nail organ in humans at the ventral proximal fold and nail matrix might provide crucial understanding of nail organ biology at the molecular level, which can potentially provide insight into designing translational therapies for regrowing greater portions of the limbs and other nonregenerative tissues in the future.

Therefore, defining the regenerative potential of these NSCs and NPFSCs and the molecular mechanisms by which they are regulated in vivo (with the intent that novel therapies) may emerge toward the successful nail organ regeneration and wound healing, including treatment of amputee patients.

ACKNOWLEDGMENTS

I express my apologies to colleagues whose work could not be included in this chapter. I thank Dr. Sébastien de Feraudy, MD, PhD, associate professor and director of dermatopathology, UC Irvine Dermatopathology Laboratory (Irvine, CA), for providing the figure with hematoxylin and eosin staining of a human nail after biopsy. I thank Dr. Agnieszka Kobielak for critical reading of this manuscript and members of Dr. Krzysztof Kobielak laboratories for helpful discussions. KK is supported by the National Science Centre (NCN) Opus Grant 2015/19/B/NZ3/02948 and the National Institute of Arthritis and Musculoskeletal and Skin Diseases of the National Institutes of Health Grant R01-AR061552.

REFERENCES

1. de Berker DAR, Baran R. Science of the nail apparatus. In: Baran R, de Berker DAR, Holzberg M, Thomas L, eds. *Baran & Dawber's Diseases of the Nails and their Management*, 4th ed. Oxford, UK: Wiley-Blackwell; 2012:1-50.
2. Mecklenburg L, Paus R, Halata Z, et al. FOXN1 is critical for onycholemmal terminal differentiation in nude (Foxn1) mice. *J Invest Dermatol*. 2004;123(6):1001-1011.
3. Dawber RPR, de Berker DAR, Baran R. Science of the nail apparatus. In: Baran R, Dawber RPR, de Berker DAT, et al, eds. *Baran and Dawber's Diseases of the Nails and Their Management,* 3rd ed. Oxford, UK: Blackwell Science Ltd; 2001:1-47.
4. Lewis BL. Microscopic studies of fetal and mature nail and surrounding soft tissue. *AMA Arch Derm Syphilol*. 1954;70(6):733-747.
5. Zaias N, Alvarez J. The formation of the primate nail plate. An autoradiographic study in squirrel monkey. *J Invest Dermatol*. 1968;51(2):120-136.
6. Norton LA. Incorporation of thymidine-methyl-H3 and glycine-2-H3 in the nail matrix and bed of humans. *J Invest Dermatol*. 1971;56(1):61-68.
7. de Berker D, Angus B. Proliferative compartments in the normal nail unit. *Br J Dermatol*. 1996;135(4) 555-559.
8. Johnson M, Comaish JS, Shuster S. Nail is produced by the normal nail bed: a controversy resolved. *Br J Dermatol*. 1991;125(1):27-29.
9. Johnson M, Shuster S. Continuous formation of nail along the bed. *Br J Dermatol*. 1993;128(3):277-280.
10. Fuchs E, Tumbar T, Guasch G. Socializing with the neighbors: stem cells and their niche. *Cell*. 2004;116(6): 769-778.
11. Spradling A, Drummond-Barbosa D, Kai T. Stem cells find their niche. *Nature*. 2001;414(6859):98-104.
12. Lin H. The stem-cell niche theory: lessons from flies. *Nat Rev Genet*. 2002;3(12):931-940.
13. Watt FM, Hogan BL. Out of Eden: stem cells and their niches. *Science*. 2000;287(5457):1427-1430.
14. Cotsarelis G, Sun TT, Lavker RM. Label-retaining cells reside in the bulge area of pilosebaceous unit: implications for follicular stem cells, hair cycle, and skin carcinogenesis. *Cell*. 1990;61(7):1329-1337.
15. Cotsarelis G, Cheng SZ, Dong G, et al. Existence of slow-cycling limbal epithelial basal cells that can be preferentially stimulated to proliferate: implications on epithelial stem cells. *Cell*. 1989;57(2):201-209.
16. Albers KM, Setzer RW, Taichman LB. Heterogeneity in the replicating population of cultured human epidermal keratinocytes. *Differentiation*. 1986;31(2):134-140.
17. Bickenbach JR, Chism E. Selection and extended growth of murine epidermal stem cells in culture. *Exp Cell Res*. 1998;244(1):184-195.
18. Tumbar T, Guasch G, Greco V, et al. Defining the epithelial stem cell niche in skin. *Science*. 2004;303 (5656):359-363.
19. Leung Y, Kandyba E, Chen YB, et al. Label retaining cells (LRCs) with myoepithelial characteristic from the proximal acinar region define stem cells in the sweat gland. *PLoS One*. 2013;8(9):e74174.
20. Lu CP, Polak L, Rocha AS, et al. Identification of stem cell populations in sweat glands and ducts reveals roles in homeostasis and wound repair. *Cell*. 2012; 150(1):136-150.
21. Nakamura M, Tokura Y. The localization of label-retaining cells in eccrine glands. *J Invest Dermatol*. 2009;129(8):2077-2078.
22. Nakamura M, Ishikawa O. The localization of label-retaining cells in mouse nails. *J Invest Dermatol*. 2008; 128(3):728-730.
23. Sellheyer K, Nelson P. The ventral proximal nail fold: stem cell niche of the nail and equivalent to the follicular bulge—a study on developing human skin. *J Cutan Pathol*. 2012;39(9):835-843.
24. Leung Y, Kandyba E, Chen YB, et al. Bifunctional ectodermal stem cells around the nail display dual fate homeostasis and adaptive wounding response toward nail regeneration. *Proc Natl Acad Sci U S A*. 2014;111(42):15114-15119.
25. Kobielak K, Pasolli HA, Alonso L, et al. Defining BMP functions in the hair follicle by conditional ablation of BMP receptor IA. *J Cell Biol*. 2003;163(3):609-623.
26. Cai J, Ma L. Msx2 and Foxn1 regulate nail homeostasis. *Genesis*. 2011;49(6):449-459.
27. Godwin AR, Capecchi MR. Hoxc13 mutant mice lack external hair. *Genes Dev*. 1998;12(1):11-20.
28. Kobielak K, Stokes N, de la Cruz J, et al. Loss of a quiescent niche but not follicle stem cells in the absence of bone morphogenetic protein signaling. *Proc Natl Acad Sci U S A*. 2007;104(24):10063-10068.
29. Takeo M, Chou WC, Sun Q, et al. Wnt activation in nail epithelium couples nail growth to digit regeneration. *Nature*. 2013;499(7457):228-232.
30. Lehoczky JA, Tabin CJ. Lgr6 marks nail stem cells and is required for digit tip regeneration. *Proc Natl Acad Sci U S A*. 2015;112(43):13249-13254.
31. Borgens RB. Mice regrow the tips of their foretoes. *Science*. 1982.217(4561):747-750.
32. Mohammad KS, Day FA, Neufeld DA. Bone growth is induced by nail transplantation in amputated proximal phalanges. *Calcif Tissue Int*. 1999;65(5):408-410.
33. Zhao W, Neufeld DA. Bone regrowth in young mice stimulated by nail organ. *J Exp Zool*. 1995;271(2): 155-159.
34. Mohammad KS, Neufeld DA. Denervation retards but does not prevent toetip regeneration. *Wound Repair Regen*. 2000;8(4):277-281.

35. Brockes JP. The nerve dependence of amphibian limb regeneration. *J Exp Biol*. 1987;132:79-91.
36. Blaydon DC, Ishii Y, O'Toole EA, et al. The gene encoding R-spondin 4 (RSPO4), a secreted protein implicated in Wnt signaling, is mutated in inherited anonychia. *Nat Genet*. 2006;38(11):1245-1247.
37. Hsu YC, Pasolli HA, Fuchs E. Dynamics between stem cells, niche, and progeny in the hair follicle. *Cell*. 2011.144(1):92-105.
38. Potten CS, Owen G, Booth D. Intestinal stem cells protect their genome by selective segregation of template DNA strands. *J Cell Sci*. 2002;115(Pt 11):2381-2388.
39. Sangiorgi E, Capecchi MR. Bmi1 is expressed in vivo in intestinal stem cells. *Nat Genet*. 2008;40(7):915-920.
40. Barker N, van Es JH, Kuipers J, et al. Identification of stem cells in small intestine and colon by marker gene Lgr5. *Nature*. 2007;449(7165):1003-1007.
41. Tian H, Biehs B, Warming S, et al. A reserve stem cell population in small intestine renders Lgr5-positive cells dispensable. *Nature*. 2011;478(7368):255-259.
42. Rinkevich Y, Lindau P, Ueno H, et al. Germ-layer and lineage-restricted stem/progenitors regenerate the mouse digit tip. *Nature*. 2011;476(7361):409-413.

Chapter 9 :: Cutaneous Vasculature

:: Peter Petzelbauer, Robert Loewe, & Jordan S. Pober

AT-A-GLANCE

- The cutaneous vasculature is divided into a superficial, a deep, and a subcutaneous vascular plexus. The superficial vascular plexus is formed by parallel pairs of arterioles and venules connected via capillary loops that extend into the dermal papillae. These segments may individually or conjointly respond to exogenous or endogenous stimuli, thereby influencing skin disease expression.
- Skin microvessels are formed from an endothelial cell lining that is supported by mural cells that are pericytes in most of the microvasculature but smooth muscle cells in the larger arterioles and venules and resident perivascular leukocytes, including T cells, macrophages, mast cells, and dendritic cells.
- Skin microvessels, like other microvessels, perform three important constitutive functions: regulating fluidity of the blood, forming a barrier that separates and controls transfer of molecules and cells between circulating blood and tissue, and regulating local blood flow.
- Control of blood flow through skin microvessels have a special and critical role in thermoregulation not performed by other segments of the vasculature.
- Skin microvascular cell morphology and gene expression and function are altered by acute or chronic inflammatory skin diseases and in cancers. These processes may involve formation of new blood vessels (angiogenesis) or remodeling of preexisting vessels.
- Skin-specific microvascular responses may be influenced by keratinocyte-derived and other environmental-derived factors.

INTRODUCTION

The blood vascular system is a continuous series of hollow tubes that are lined by a one-cell-thick layer of epithelium-like mesenchymal cells, the endothelium, and are supported by various mural cells, typically pericytes (PCs) in microvessels and smooth muscle cells (SMCs) in larger caliber vessels. All vascular endothelial cells (ECs) share common features and functions and hence may be collectively described as one cell type. However, ECs from one segment of the vascular system may differ in significant ways from the ECs at other anatomic sites. Blood vessel ECs also differ from lymphatic ECs, which are not discussed in this chapter. Mural cells have distinct embryologic origins throughout the blood vasculature, but little is known about their variation with anatomic location. Consequently, these cells will be discussed as if they were homogeneous, but such descriptions should be regarded with caution.

STRUCTURE AND ORGANIZATION OF THE SKIN VASCULATURE

Approximately 3 decades ago, Irwin Braverman[1] described the organization of the vascular network of human skin. The human dermal vasculature consists of two interconnected systems, a superficial and a deep vascular plexus (DVP) with additional vascular networks surrounding sweat glands and hair follicles (Fig. 9-1).

The superficial vascular plexus (SVP) is composed of paired arterioles and venules that form an interconnected network of vessels coursing on a plane parallel to and just beneath the epidermal surface. Capillaries arise from the arterioles, extend upward within the papillary dermis at sites between the epidermal rete ridges, and then loop back down to the venules, forming arcade-like structures. Whereas the basement membrane of the arterioles appears homogeneous by electron microscopy, that of the venules is multilayered. In normal skin, most of the capillary loop is invested with a basement membrane that resembles that of the arteriole, acquiring a venule-like investiture only at the level of the deepest rete just proximal to the anastomosis with the venule of the SVP. There are no ultrastructural differences between capillary loops at different sites of the skin. The arterioles and venules of the SVP are connected by short, straight vessels to the arterioles and venules of a deeper planar network of anatomizing vessels, called the DVP (see Fig. 9-1). The plane of the DVP is parallel to that of the SVP and courses above the boundary between the reticular dermis and the underlying subcutis. The arterioles of the DVP are fed through penetrating vessels from the subcutis. The venules of DVP are drained by valve-containing veins that return to the subcutaneous fat. Capillary networks connecting the arterioles and venules of the DVP provide nourishment for the adnexal structures within the reticular dermis. The venules of the DVP serve as

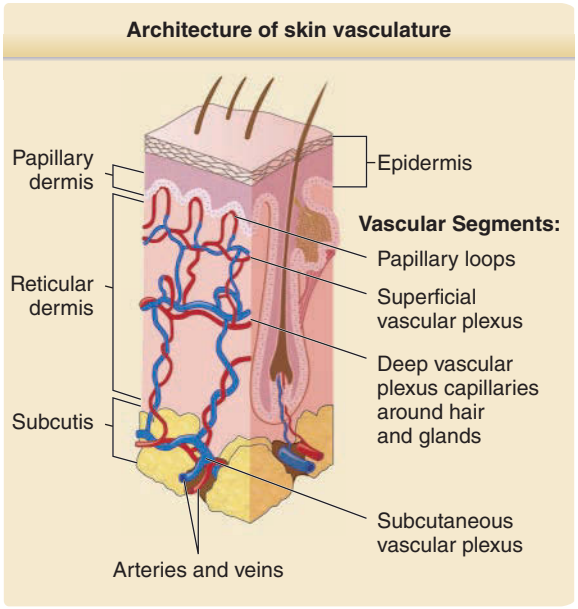

Figure 9-1 Schematic diagram of the architecture of the skin vasculature.

portals of entry for leukocytes associated with inflammation of the adnexa or for inflammation within the reticular dermis itself.

The walls of dermal arterioles are made of three layers: an intima composed of ECs, a media consisting of SMCs, and an adventitia containing some connective tissue-type cells. In the terminal arterioles, SMCs may be replaced by PCs that reside within the basement membrane of the ECs instead of in a distinct medial compartment. The walls of veins and venules have a similar structure, but compared with the corresponding arteries and arterioles, vessels of the venous circulation have a larger lumen and a thinner muscular wall and contain valves positioned at sites where the small vessels connect to larger ones. The walls of dermal capillaries and postcapillary venules consist of a monolayer of fenestrated ECs sitting on a simple basement membrane (Fig. 9-2). Capillaries are typically lined by a single file of highly curved ECs that enclose the lumen and are tightly connected to the adjacent ECs on either end, forming a tube with a lumen that is typically less than 10 μm in diameter.

Postcapillary venules are of a somewhat larger caliber, are circumferentially lined by more than one EC, have looser connections between neighboring ECs, and have a multilayered basement membrane. The fenestrae of dermal capillary ECs are formed primarily by a protein called plasmalemmal vesicle protein (PV)-1 that was previously designated as Pathologische Anatomie Leiden-endothelial (PAL-E) antigen and used as a marker of microvascular ECs. PCs that reside within the basement membrane of dermal microvessels provide structural integrity to the walls of both capillaries and postcapillary venules and contribute to basement membrane synthesis, and when it occurs, remodeling. ECs outnumber PCs in skin microvessels, and each PC contacts multiple ECs and form adherens junctions. Postcapillary venules of the SVP are also associated with various resident populations of leukocytic cells, including T cells, macrophages, dendritic cells, and mast cells. These cells, along with ECs and PCs, form the "perivascular extravasation unit"[2] of the postcapillary venules, the segment of the vasculature through which circulating leukocytes can be recruited into the dermis. These perivascular resident leukocyte populations were identified more than 20 years ago and for the most part have not been reclassified as newer understandings of leukocyte lineages and developmental programs have been elucidated. For example, it is now appreciated that memory T cells can take up long-term residence in tissues, acquiring characteristics and functions distinct from those of circulating T-cell populations.[3] The populations of perivascular T cells in noninflamed skin have not yet been categorized in comparison with circulating T cells or epidermal resident T cells with this new information in mind. Dendritic cells are now known to be quite heterogeneous with distinct developmental programs; each dendritic cell type serves different immunologic functions. Again, the types of perivascular dendritic cells have not been defined by these new criteria. Mast cells are also heterogeneous in terms of their granule contents and biosynthetic profiles, and it is unclear what human dermal perivascular mast cells may synthesize. Resident tissue macrophages are now known to originate either from more primitive embryonic origins, such as yolk sac or fetal liver, or from bone marrow–derived monocytes, and these populations also have distinct properties.[4] Finally, dermal dendrocytes, also known as veil cells, form a resident population that envelop microvessels of the SVP, associate with T cells and mast cells, and express coagulation factor XIIIa and stabilin 1 in addition to other macrophage-like markers. There has been much debate as to whether these cells are bone marrow or mesenchyme derived, and with the new appreciation of resident macrophage heterogeneity, they may in fact be neither. In general, it is proposed that all such perivascular leukocyte cell types serve as sentinels for infection or injury, but it is possible that some of these populations also have constitutive vascular functions.

Veins of the dermis form three kinds of anastomosing connections; large anastomoses of main trunks of the ascending veins, small anastomoses in the ascending sections of the small veins, and very small anastomoses from the small ascending veins reaching the papillary dermis. This anastomosing network of dermal veins is organized in polygons of various sizes, which is thought to play a role it outcomes of skin flap surgery.

PROPERTIES OF AND FUNCTIONS OF NORMAL SKIN VASCUALTURE[5]

See Table 9-1.

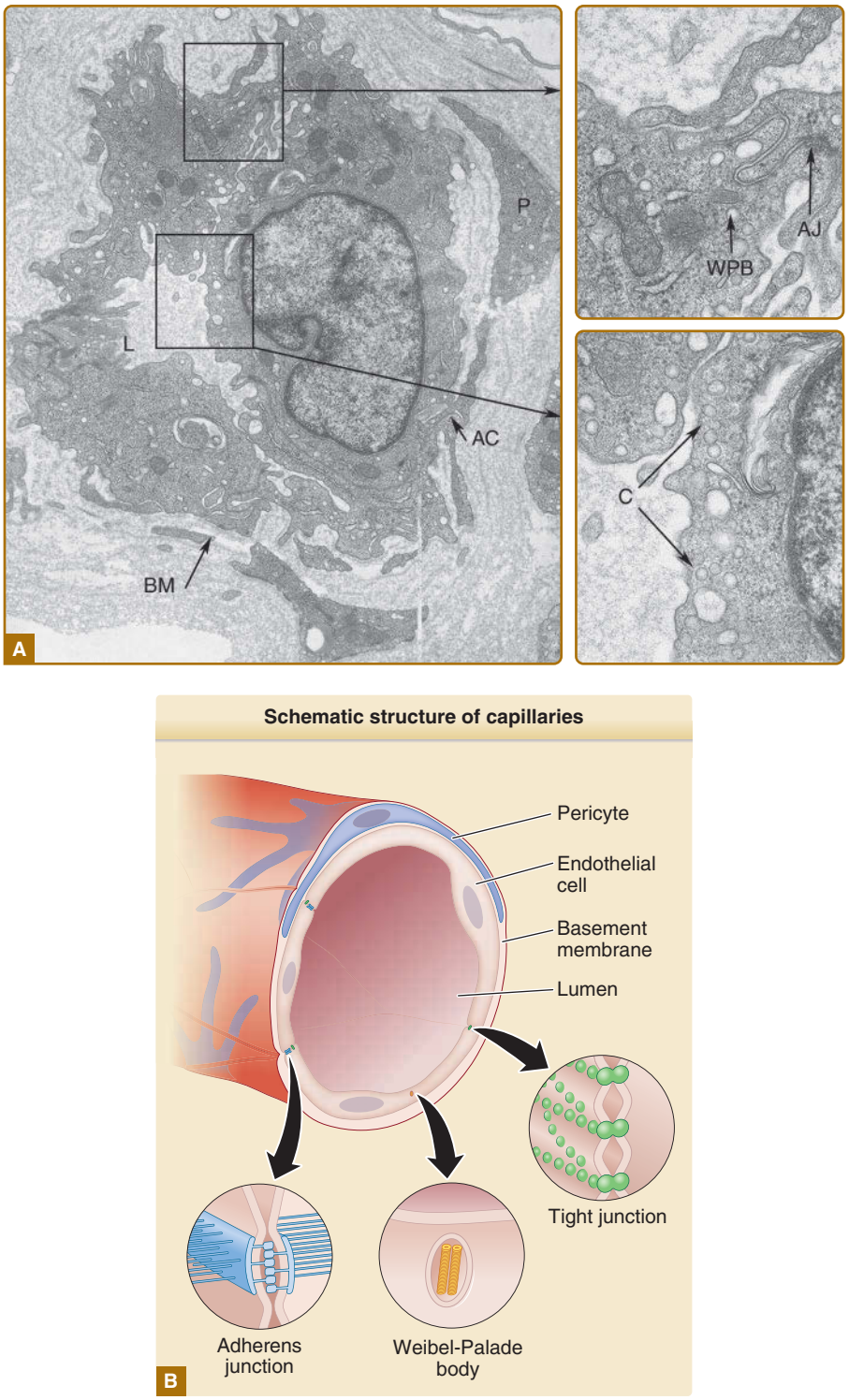

Figure 9-2 **A,** Ultrastructure of a postcapillary venule. AC, area of contact between endothelial cell and pericyte; AJ, adherens junction; BM, basement membrane; C, caveolae; L, lumen; P, pericyte; WPB, Weibel-Palade body. **B,** A schematic diagram of **A**.

HEMOSTASIS

Blood is a fluid that is poised to become a gel at sites where vessel integrity is disrupted, beneficially forming a clot to limit extravasation but typically avoiding formation of a thrombus within the vessel lumen that could occlude the vessel and limit perfusion. Vascular ECs are the principal cell responsible for maintaining blood fluidity, and they may be altered when needed to actively promote clot formation. Blood plasma contains the proteins of the coagulation system that

TABLE 9-1
Properties and Functions of Normal Skin Vasculature

1. Hemostasis
2. Permselectivity
3. Perfusion
4. Thermoregulation
5. Immune surveillance

produce fibrin gels as well as platelets that can form a primary hemostatic plug. The EC lining prevents intravascular activation both of the coagulation system and of platelets yet keeps both systems poised to respond to injury. The key inhibitors of coagulation basally expressed by ECs are tissue factor pathway inhibitor (which prevents the dramatic increases of the enzymatic activity of factor VIIa on factors IX and X that is catalyzed by tissue factor), thrombomodulin (which redirects thrombin from cleaving and thereby converting fibrinogen to fibrin to target and activate protein C instead), and anticoagulant heparan sulfates (which activate antithrombin III to function as an inhibitor of thrombin and factor Xa). ECs also basally limit platelet activation by (1) producing nitric oxide and prostacyclin (also called prostaglandin I_2), which inhibits platelet activation by elevating intracellular cyclic guanosine monophosphate and cyclic adenosine monophosphate, respectively), (2) expressing ectoenzymes that degrade platelet-activating adenosine triphosphate and adenosine diphosphate to inert adenosine monophosphate, (3) minimizing the activation of thrombin (which activates platelets by cleaving protease activated receptor 1), and (4) masking basement membrane and interstitial collagens (which can be recognized by platelet surface proteins and serve as alternative activators of platelets) (Fig. 9-3).

PERMSELECTIVITY

Dermal ECs form a barrier that permits limited passage of fluid and solutes, allowing the blood to nourish the tissues while displaying "permselectivity" for macromolecules (Fig. 9-4). ECs also basally present a virtually impenetrable barrier for blood cells (except at specialized sites of high permeability and leukocyte trafficking). In general, arterioles and capillaries are less permeable to macromolecules because ECs

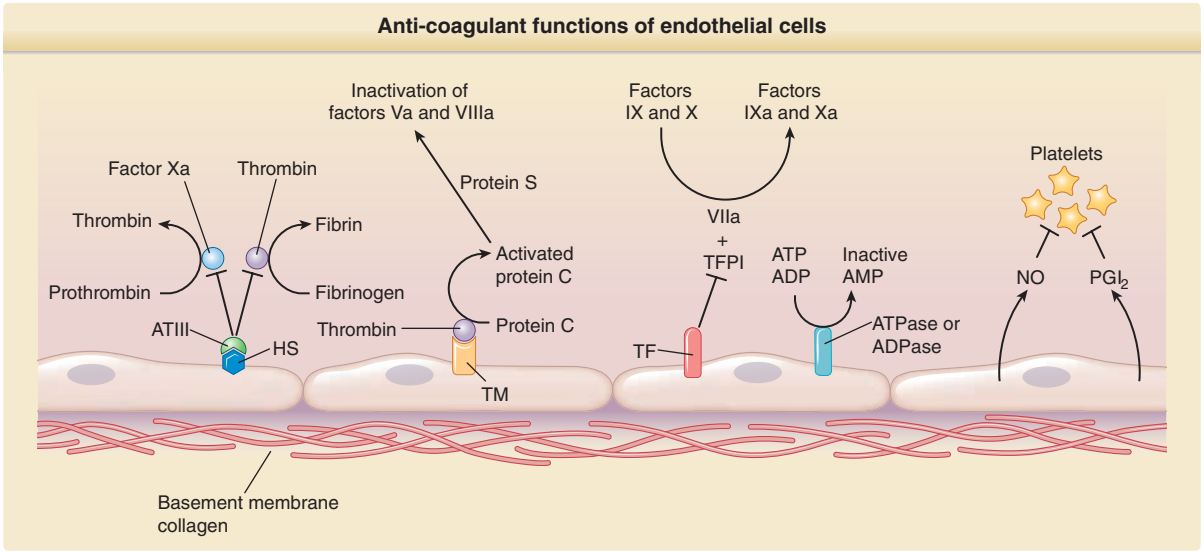

Figure 9-3 Anticoagulant and thrombotic functions of endothelial cells. To prevent coagulation, endothelial cells (1) express anticoagulant heperan sulfates (HS) that can bind and activate antithrombin III (ATIII), which then blocks the enzymatic activity of factor Xa, which converts prothrombin to thrombin, and of thrombin, which converts fibrinogen to fibrin; (2) express thrombomodulin (TM), which binds thrombin and changes it from a procoagulant enzyme that cleaves fibrinogen to fibrin into an anticoagulant enzyme that activates protein C that, in combination with protein S, then cleaves and inactivates factors V and VIII (which serve as cofactors for factors Xa and IXa, respectively); and (3) express tissue factor pathway inhibitor, which prevents tissue factor from accelerating the catalytic activity of factor VIIa, which cleaves and activates factors IX and X to factors IXa and Xa, respectively. To prevent platelet activation, endothelial cells (1) express ectoenzymes that convert extracellular adenosine triphosphate (ATP) and adenosine diphosphate (ADP), which are activators of platelets, to adenosine monophosphate (AMP), which cannot activate platelets; (2) synthesize and release inhibitors of platelet activation such as nitric oxide (NO) and prostacyclin (PGI_2); and (3) prevent platelets from coming in contact with basement membrane collagen, another activator of platelet activity. These functions are mutually reinforcing as thrombin is an activator of platelets and activated platelets provide lipid surfaces that bind coagulation factors to promote the clotting cascade.

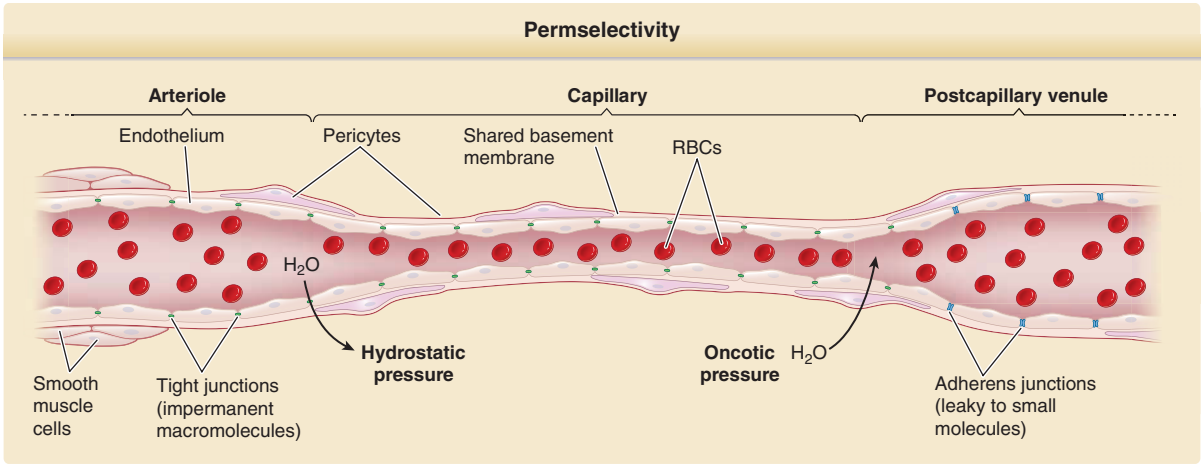

Figure 9-4 Endothelial cells establish permselective barriers. Permselectivity refers to the ability of the endothelial lining of the microvasculature to permit passage of water and solutes but not that of macromolecules. Tight junctions (TJs), which are expressed in the arterioles and capillaries, allow passage of water and solutes but prevent the passage of macromolecules and cells. Some small molecules, but not others, can pass based on size and charge. Hydrostatic pressure in the arteriolar end of the capillary forces water and solutes across the TJs and the retained macromolecules draw back water and small molecules at the venular end of the capillary through oncotic pressure. The postcapillary venules lack TJs, and their adherens junctions are dynamically regulated to allow some macromolecules to enter the tissue in the context of inflammation. RBC, red blood cell.

lining these vessels are connected to each other by tight junctions containing claudins (mostly claudin 5), junctional adhesion molecules (mostly JAM-A), and occludin (although occludin appears dispensable based on gene disruption in mice). Tight junctions prevent paracellular passage of macromolecules, limiting their crossing of the capillary EC lining to fenestrae or to vesicular transport, thereby enabling control of which molecules may pass (permselectivity). PCs may influence the barrier by stabilizing EC–EC contacts but are too sparse in skin microvessels to form a continuous surface that can directly block macromolecular transit. The capillaries, although narrower in diameter than other microvessels, have a cumulative surface area that vastly exceeds other parts of the microvasculature so that most transit takes place across this portion of the SVP. By allowing fluid and solutes to cross the EC lining by the paracellular route while preventing macromolecules to do so, dermal capillaries of the SVP allow hydrostatic pressure gradients near the arteriolar side of the capillary loop to drive fluid and solutes into the tissue and then draw them back into the bloodstream on the venular side of the capillary loop through oncotic gradients formed by the proteins retained within the vessel lumen. ECs of the postcapillary venules form few, if any, tight junctions and are instead held together primarily by adherens junctions, which are largely formed by VE-cadherin and associated catenins. (Skin arteriolar and capillary ECs also form adherence junctions, but these seem dispensable once tight junctions form.) Venules are somewhat leaky to macromolecules under basal conditions, but macromolecular escape into the tissue is limited by the relatively small (in comparison with capillary) surface area of the venular EC lining. The net result of these structural features is that dermal vascular ECs regulate rather than prevent molecular exchange between blood and tissues.

PERFUSION

ECs regulate local blood flow primarily by acting on SMCs surrounding arterioles (Fig. 9-5). These are oriented almost parallel to the vessel's circumferential or radial axis. ECs control SMC tone, which regulates the size of the vessel lumen and the resistance of the vessel to dilation. Vascular resistance along with blood pressure determines blood flow. PCs, which are also contractile, function largely to provide structural integrity to the terminal arterioles, capillaries, and postcapillary venules but may also contribute some to vascular resistance. Under normal circumstances, ECs synthesize both vasodilators, such as nitric oxide and prostacyclin, that reduce SMC tone and vasoconstrictors, such as endothelin, that increase tone. EC also express angiotensin-converting enzyme, which can generate a vasoconstrictor, angiotensin II, from angiotensin I, a circulating inert precursor. The balance between vasodilators and vasoconstrictors may be regulated by neural or hormonal signals. Importantly, inhibiting nitric oxide synthase-3 (also known as endothelial NOS) in ECs will cause vasoconstriction and increased resistance, suggesting that vasodilation is normally dominant. Recent evidence suggests that resident perivascular memory T cells specific for certain oxidized lipid adducts, can induce vasoconstriction through elaboration of cytokines such as tumor necrosis factor (TNF)-α and interleukin (IL)-17A, although it is not known if this occurs in skin.[6]

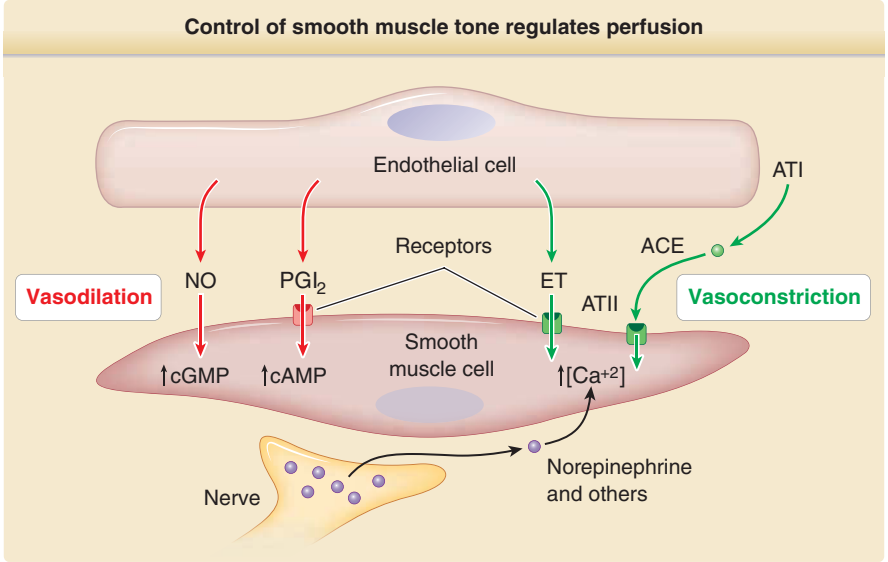

Figure 9-5 Control of perfusion by regulating smooth muscle cell tone. The active resistance of blood vessels can be modulated by altering the contractile tone mural vascular smooth muscle cells in muscular arteries and arterioles. Endothelial cells can produce vasodilators such as nitric oxide (NO) and prostacyclin (PGI_2). NO directly activates soluble guanylate cyclase to elevate cyclic guanosine monophosphate (cGMP) levels, and PGI_2 interacts with a membrane G–protein coupled receptor that activated adenylate cyclase to increase cycle adenosine monophosphate (cAMP). Both reduce the degree of actomyosin contraction. Endothelial cells can also produce vasocontrictors such as endothelin (ET) or, via the ectoenzyme angiotensin-converting enzyme (ACE), convert inactive angiotensin I (ATI) to vasoactive angiotensin II (ATII). Both ET and ATII signal through G protein–coupled receptors to increase the level of cytosolic free calcium ion, increasing the degree of actomyosin contraction. Nerves may release neurotransmitters that also bind to G protein–coupled receptors to increase cytosolic free calcium and actomyosin contraction. Increased actomyosin contraction shortens the length of the smooth muscle cells, which are arranged radially, thereby reducing the vessel lumen diameter and increasing resistance to flow.

THERMOREGULATION

The skin is the source of thermal information and is an executive organ for thermal homeostasis. Temperature is sensed through primary somatosensory afferent nerves; skin blood flow is modified through sympathetic vasodilation or vasoconstriction. To conserve heat, cutaneous vessels constrict; for convective heat transfer from the core to the periphery, cutaneous vessels dilate, and blood flow increases. The skin blood flow is normally 250 to 300 mL/min but can vary from nearly zero in cold to as much as 6 to 8 L/min, which then covers approximately 60% of the cardiac output.[7] Nonglabrous skin is subject to reflex thermoregulation by the sympathetic nervous system. The noradrenergic vasoconstrictor system is tonically active and is activated by cold exposure. Initial vasodilation to body heating is achieved by reflex removal of active vasoconstrictor tone. With further heating, the parasympathetic cholinergic nerves release predominantly acetylcholine, causing active vasodilation. Concomitantly, autonomic and sensory nerve fibers release neurotransmitters, such as substance P, calcitonin gene-related peptide, vasoactive intestinal peptide, and pituitary adenylate cyclase activating polypeptide, which directly or indirectly induce vasodilatation. Local factors such as venous congestions and increased transmural pressure also modulate skin blood flow. Glabrous skin contributes to thermoregulation through shunts from the arterial directly into the venous beds, thereby bypassing capillary loops, the thermosensitivity of the hand being significantly greater than that of soles (Table 9-2).

Dysregulation in the skin thermoregulation is seen in postmenopausal hot flushes related to changed estrogen levels. Estrogen has vasodilator function as

TABLE 9-2
Thermoregulation in Nonglabrous and Glabrous Skin

Nonglabrous Skin
-Ambient temperature
Basal activity of noradrenalic system
-Cold: vasoconstriction
Activation of noradrenalic system
-Heat: vasodilation
Shutdown of noradrenalic system
-Further heating
Parasympathetic cholinergic nerves
▪ Acetylcholine
Autonomic and sensory nerve fibers
▪ Substance P
▪ Calcitonin gene-related peptide
▪ Vasoactive intestinal peptide
▪ Pituitary adenylate cyclase activating polypeptide
Glabrous Skin
Additional thermoregulatory capacity through opening arteriovenous shunts or closing arteriovenous shunt

demonstrated in estrogen receptor knockout mice. Estrogen replacement relieves hot flashes and reduces resting body temperature in these individuals.

Individuals with Type 1 diabetes have greater skin blood flow relative to healthy control participants, potentially related to moderate vasodilation induced by a hyperinsulinemia and an impaired thermoregulatory response of skin vessels. The underlying mechanisms related to impaired heat responses remain largely unresolved. The absence of C-peptide produced in β cells or reduced nitric oxide bioavailability because of diminished NOS activity may play a role.

A pathological thermoregulatory reflex is seen in Raynaud disease; patients have an exaggerated vasospastic response to cold or emotion, resulting in ischemia of the digits. Vasospastic attacks in Raynaud disease are restricted to cutaneous arteries supplying skin sites with a rich density of arteriovenous anastomosis, a situation at glabrous sites. These sites are normally targeted by sympathetic adrenergic vasoconstrictive activity in response to cold. Patients with Raynaud disease have increased sympathetic vasoconstrictive activity, which results in increased blood flow through arteriovenous anastomosis. Of note, bosentan, antagonizing endothelin A and endothelin B receptors, which has promising clinical effects in scleroderma, does not influence vasospasm in Raynaud disease.

Patients with erythromelalgia have burning pain and vasodilation with erythema of the extremities. It is caused by mutations affecting the encoding *SCN9A* gene that leads to channelopathies. Although the primary cause of the abnormal vascular reaction is unknown, most patients have abnormal quantitative sudomotor axon reflex tests (measuring resting skin temperature, resting sweat output, and stimulated sweat output), some have abnormal adrenergic function, and others an abnormal cardiovagal function. Erythromelalgia most severely affects the palms and soles. It is therefore thought that arteriole–venule shunts are abnormally innervated or show an abnormal response. As pointed out earlier, these arteriole–venule shunts are mainly found in glabrous skin.

IMMUNE SURVEILLANCE

In addition of being a physical barrier, the skin has features of an immunologic barrier. Among resident cells housing in the skin are semiprofessional antigen-presenting cells such as keratinocytes, ECs, and macrophages and professional antigen-presenting cells such as Langerhans cells and dermal dendritic cells. In addition, the skin is populated by T cells. The majority of these cutaneous T cells are resident, largely within the epidermis, but as noted earlier, there also appear to be T cells resident in the perivascular compartment of the venules.

In addition to resident populations, there are circulating T cells with a predilection for homing to skin. More than 30 years ago, the term *skin-associated lymphoid tissues* was created (subsequently renamed the *skin immune system*), which postulated the existence of subsets of T lymphocytes displaying special affinity for the skin and that the acquisition of this affinity by T cells is determined signals received from resident cutaneous cells. After an immune response within the skin, a subset of memory T cells develops that can exit from the skin via the lymphatics to enter draining lymph nodes. These T cells may then reenter the skin upon rechallenge by the same anitigen,[8] and they may retain a preference for skin sites. The first skin-associated protein expressed on a population of memory T lymphocytes was described and termed *cutaneous lymphocyte antigen* (CLA).[9] CLA is a carbohydrate moiety on the surface of T cells closely related to sialylated Lewis X, which has homology to the core structure of P-selectin glycoprotein-1. CLA was shown to bind to E-selectin expressed on activated endothelium, but the latter is ubiquitously expressed on activated endothelium (albeit perhaps more transiently than in skin), suggesting that this is not the only mechanism regulating skin-specific leukocyte homing. A potential candidate providing additional specificity is the chemokine TARC (also called cutaneous T cell-attracting chemokine or CCL17) (Fig. 9-6), which is produced by cutaneous venules, induced in inflamed skin and absent on intestinal vessels.[10] Its receptor, CCR4, is expressed on the CLA-positive memory T cells. The interaction of TARC and CCR4 triggers E-selectin–mediated adhesion of CLA positive T cells. However, skin infiltration in CCR4-/- mice is not impaired, indicating that further regulatory pathways exist. Another candidate for skin-specific recruitment of CLA^{hi+} T cells is the chemokine CTACK (also called thymus and activation-regulated chemokine or CCL27). CTACK is constitutively expressed by basal keratinocytes and is detectable on ECs and fibroblasts of the papillary dermis.[11] It is thought that CTACK is mainly expressed and secreted by keratinocytes in the epidermis and captured and

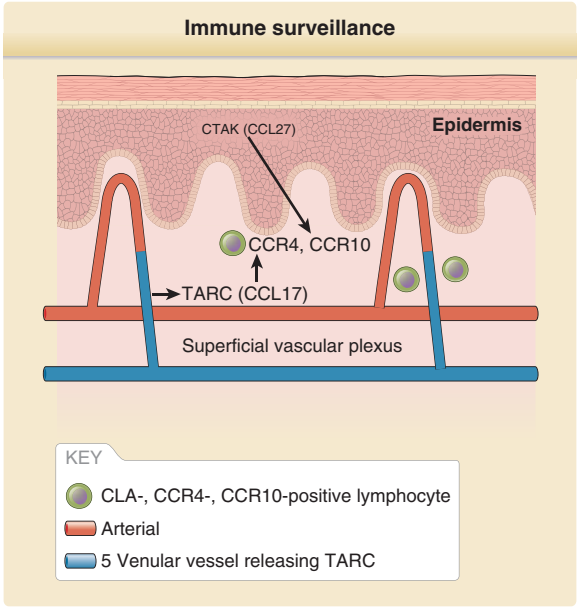

Figure 9-6 Immune surveillance.

presented by dermal cells through glycosaminoglycans or through its receptor, CCR10 (see Fig. 9-6). CCR10 is expressed on T cells and is critical for their migration into the noninflamed skin. Knockout of CCR10 changes the balance of resident regulatory T cells (Tregs) and $CD4^+$ effector T cells in the skin and causes overreactive inflammation after topical application of ovalbumin in a sensitized mouse. Using neutralizing anti-CTACK antibodies, the homing of CD4/CLA/CCR10-positive T cells is blocked.[11]

Circulating dendritic cells may also use CLA–E-selectin interactions to extravasation into the skin. A subset of B cells also may express CLA and exhibit enhanced binding to E-selectin, potentially enabling cutaneous migration. Indeed, although very rare, B cells are present in normal human skin.[12] These cells display a clonally restricted pattern, indicating recognition of a restricted antigenic repertoire—most likely against skin-associated antigens—alluding to the possibility of a skin-resident memory B-cell population. They have been shown to recirculate from the skin to regional lymph nodes by using CCR6–CCL20 interactions.

The blood also contains a population of circulating T cells, characterized as effector memory T cells that function to seek out the presence of microbial antigens to which a prior immune response had been made. These, like other T cells, detect antigen using a clonally distributed repertoire of receptors that were selected to detect microbial peptides bound to class I major histocompatibility complex (MHC) molecules (human leukocyte antigen [HLA]-A, -B, or -C of CD8+ T cells) or bound to class II MHC molecules (HLA-DR, -DP, or -DQ) but not peptides derived from self-proteins. Dermal microvascular ECs express high levels of MHC molecules of both classes under basal (noninflamed conditions) and can efficiently form peptide–MHC molecule complexes. These cells also express surface proteins, such as LFA-3, 4-1BB ligand, Ox40-ligand, and ICOS-ligand, that can provide antigen-independent enhancing signals ("costimulation") required for circulating memory T-cell activation. Recognition of antigen on the luminal surface of ECs in an infected tissue not only activates these cells but also triggers their diapedesis across the EC lining into the skin. The cell biology of this process is unique in that T-cell recognition of antigen on the EC surface causes cells to round up, rather than spread, and cross between ECs by extending a cytoplasmic protrusion containing the microtubule organizing center and cytoplasmic granules rather than these structures following the cell body and nucleus in a trailing uropod. This antigen presenting function of ECs may be redundant with presentation of antigen by perivascular dendritic cells or macrophages that also display peptide–MHC molecule complexes on extensions that protrude into the vascular lumen. Both types of signals may supplement the initiation of immunity by resident or recirculating T cells located within the perivascular unit.

DERMAL VASCULAR ALTERATIONS OF ACUTE INFLAMMATION[13]

Different segments of the microvasculature contribute in different ways to acute inflammation. Historically, much of the focus has been on changes that occur in the EC lining. Local sites of inflammation are perfused at a higher level, primarily because of a shift in the balance of vasodilatory molecules released by the EC of the arterioles and, to a lesser extent, the capillaries. The principal mediator for this change is an increase in the synthesis of prostacyclin, likely resulting from a cytokine-induced increase in the expression of cyclooxygenase (COX)-2 (also known as prostaglandin H synthase 2), which is more active than constitutively expressed COX-1. The resultant increase in blood flow results in local warming ("calor") and increased redness ("rubor") of the inflamed site. Venular EC disrupt their intracellular adherens junctions (Fig. 9-7), allowing the extravasation of large plasma

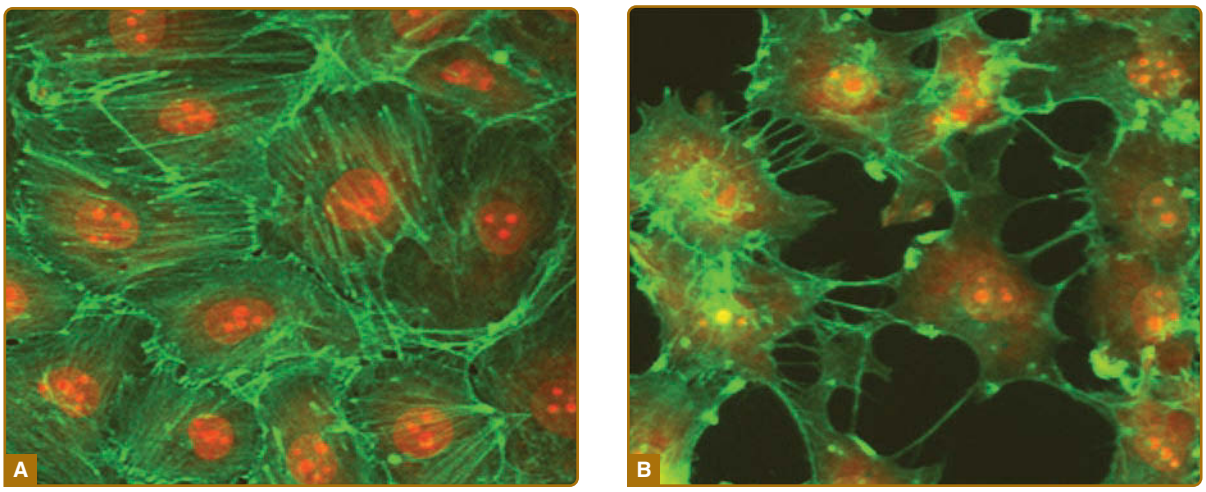

Figure 9-7 Cultured venular endothelial cells forming a continuous monolayer (**A**), thrombin-treated endothelial cells with disrupted intercellular junctions mimicking a leaky vessel (**B**). The phalloidin-staining of the actin skeleton is in *green*, and nuclei are in *red*; 1000× magnification.

proteins such as fibronectin and fibrinogen, the latter being converted to fibrin within the extravascular space, producing swelling ("tumor"). These proteins form a provisional matrix in the tissue that will allow extravasating leukocytes to attach and migrate and will serve for ultimate tissue repair. Other changes are in the display of surface molecules by the venular ECs that can serve to capture circulating leukocytes. Selectins expressed by EC cause tethering and rolling of leukocytes. Chemokines, especially IL-8 (CXCL8) for neutrophils and monocyte chemoattractant protein 1 (MCP-1, also known as CCL2), for monocytes cause spreading and firm attachment of leukocytes. Leukocyte crawling on the EC surfaces toward the extracellular junctions is mediated primarily by ICAM (intercellular adhesion molecule)-1. For mononuclear leukocytes, vascular cellular adhesion molecule (VCAM)-1 may aid in capture, rolling, and crawling. Chemokines may be made by the ECs or may be produced by sentinel cells of the perivascular unit and become displayed by attaching noncovalently to heparin sulfates on the EC luminal surface. These changes in ECs have been referred to as endothelial activation. Certain autacoids or enzymes such as thrombin may induce transient, protein synthesis–independent changes such as P-selectin translocation from intracellular storage granules (known as Weibel-Palade bodies) to the cell surface or synthesis of chemotactic lipids, such as platelet activating factor. Such changes are sometimes referred to as Type I activation, but the transient nature of such changes typically results in short-term effects, such as a wheal and flare reaction, rather than leukocyte recruitment. The latter is more dependent on new gene transcription and protein synthesis induced by inflammatory cytokines such as TNF-α, IL-1α, or IL-1β. Cytokine activation of EC can also promote coagulation by down-regulating thrombomodulin synthesis while inducing expression of tissue factor. Coagulation may be propagated by EC release of plasma membrane–derived microparticles containing tissue factor.

When leukocytes reach the intracellular junctions of postcapillary venular ECs, they engage additional proteins that contribute to extravasation. Several of these, such as platelet endothelial cell adhesion molecule (PECAM)-1, poliovirus receptor, and CD99, are stored in invaginations of the lateral border plasma membrane (known as the lateral border recycling compartment) that are brought to the cell surface to engage receptors expressed on the leukocyte. (Sometimes these molecules can line short-lived transcellular channels located near but not at the actual intercellular junction, allowing leukocytes to pass through rather than between ECs. It is not known if this distinction has any physiological significance.) After the leukocyte has passed through the EC layer, it engages basement membrane proteins and PCs that express elevated levels of ICAM-1 and chemokines in response to the same cytokines that activate ECs. The interaction with PCs may extend for 30 minutes or more as PCs contract to open gaps in the basement membrane and guide extravasating leukocytes to these areas. When outside the basement membrane, extravasated leukocytes continue to interact with PCs and perhaps with other cells of the perivascular unit, migrating along adventitial surface of the vessel.

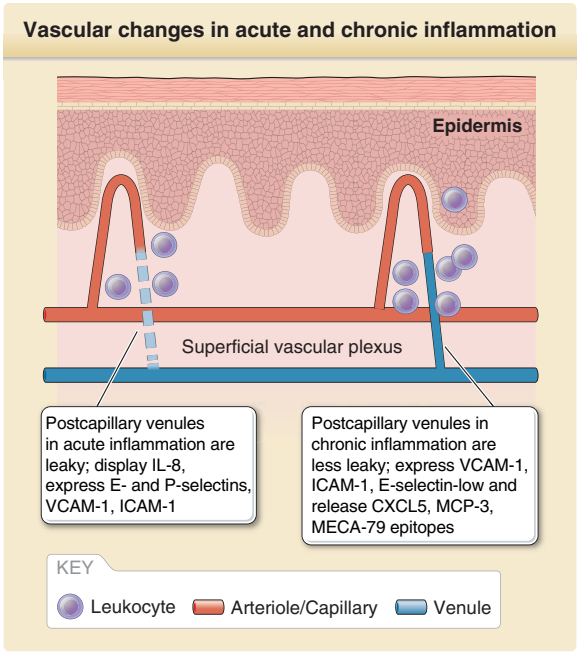

Figure 9-8 Vascular changes in acute and chronic inflammation. ICAM, intercellular adhesion molecule; IL, interleukin; MCP-3, monocyte chemoattractant protein 3; VCAM, vascular cellular adhesion molecule.

TNF-α and IL-1 induce proinflammatory changes in ECs that typically do not distinguish among different leukocyte types. However, the kinetics of induction of different adhesion molecules varies. Whereas E-selectin is made within the first 2 hours and correlates with the onset neutrophil recruitment, VCAM-1 is synthesized later (ie, in about 6 to 12 hours) and correlates with the onset of mononuclear leukocyte recruitment (Fig. 9-8). Polarizing cytokines, such as interferon (IFN)-γ or IL-4 and IL-13, favor the production of chemokines that preferentially activate T cells and effector cells mostly associated with T_H1 or T_H2-type adaptive immunity, respectively. IL-17 has little effect on ECs but instead acts on PCs to induce factors that prolong neutrophil survival (granulocyte-macrophage colony-stimulating factor and granulocyte-colony stimulating factor), favoring prolongation of neutrophilic inflammation characteristic of T_H17-type inflammation.[14]

DERMAL VASCULAR ALTERATIONS OF CHRONIC INFLAMMATION

Continuous activation of ECs is possible and results in distinct changes compared with the acute activation. Transgenic mice overexpressing TNF in an endothelium-specific manner display an inflammatory skin phenotype with epidermal hyperproliferation and

fibrosis. In culture, whereas chronic TNF-stimulated EC display a continuous and high ICAM-1 and VCAM-1 expression, E-selectin is absent and cannot be reinduced by additional TNF stimulation (ie, ECs are desensitized in regard to E-selectin expression). Interestingly, these chronic TNF-stimulated cells continuously overexpress CXCL5 and MCP-3.[15] Cultured skin ECs show sustained and higher expression of E-selectin and slower internalization and degradation of E-selectin protein compared with umbilical vein endothelium, but this may be a general property of microvascular ECs.[16] Nevertheless, sustained expression of E-selectin, although not unique to skin, is generally described as a skin-specific feature of chronic inflammation (see Fig. 9-8).

DERMAL VASCULAR CHANGES IN SPECIFIC DISEASES

ACUTE VERSUS CHRONIC SKIN INFLAMMATION: GENERAL CONSIDERATIONS

In acute dermatitis, ECs express high levels of E- and P-selectin and moderate amounts of VCAM-1 and ICAM-1. The inflammatory infiltrate consists mainly of CLA and CD45RO-positive memory T cells. In chronic skin lesions, such as psoriasis, chronic lupus erythematosus, and mycosis fungoides, ECs express moderate amounts of E-selectin and high amounts of VCAM-1. They may also undergo morphologic changes and acquire a phenotype reminiscent of high endothelial venules. This type of EC has a cuboidal appearance, different from the flat morphology of ECs lining the other vessels. High endothelial venules express sialyted, fucosylated, and sulfated carbohydrate moieties corresponding to peripheral node addressins, which are recognized by antibody MECA-79. These addressins are constitutively expressed on high endothelial venules of lymph nodes; they bind to L-selectin expressed on leukocytes and control recirculation of T cells through lymph nodes. These sialyted, fucosylated, and sulfated carbohydrate moieties may also be expressed in chronic skin lesions such as cutaneous T-cell lymphoma.[17] Also in cutaneous melanoma, blood vessels express MECA-79 moieties, and the amount of MECA-79-reactive vessels correlates with the amount of tumor infiltrating lymphocytes and with histologic signs of tumor regression.[18] In squamous cell carcinoma, numbers of MECA-79–positive vessels were found to correlate with survival.

PSORIASIS

As mentioned previously, leukocytes primarily exit the blood stream through postcapillary venules. The capillary loops within the papillary tips of the dermis have an arteriolar phenotype; hence, leukocytes can exit the bloodstream through the SVP below but not within the tips of the papillae. The situation is different in psoriasis. In this disease, the capillary loops elongate and change morphology. Whereas normal capillaries at the turnaround point sit on an arteriolar basement membrane, psoriatic capillary loops at the turnaround point touch the epidermis, a phenomenon called "kissing," and remodel the basement membrane to resemble that of the postcapillary venule. ECs within the loop proliferate, producing both elongation and an increase in diameter. (The proliferation of the ECs is sometimes misinterpreted as angiogenesis, but no new vessels are actually formed.) Furthermore, the ECs of the remodeled psoriatic loop express adhesion molecules normally associated with cytokine-activated venular ECs, supporting tethering, rolling, and extravasation of leukocytes.[19] Lymphocytes and neutrophils can now exit the vessel lumen within the tips of the papillae and migrate into the epidermis. This histologic picture of lymphocytes and neutrophils extravasation within the tips of the papillae has been termed "squirting papillae" and is a typical feature of psoriasis and contrasts findings in chronic eczema, in which leukocytes extravasate across post-capillary venules of the SVP (Fig. 9-9).

LICHEN RUBER PLANUS

Another chronic skin disease, lichen ruber planus, has an enlarged blood microcirculatory bed within the papillary dermis compared with healthy skin. Specifically, oral lichen planus has tortuous capillaries with enlarged capillary loop diameter. Intralesional bevacizumab, anti-VEGF antibody, injections induced lesion resolution without relapse during a 3-month follow-up in a small series of patients. In this setting, vascular endothelial growth factor (VEGF) not only induces angiogenesis but is also proinflammatory by inducing endothelial adhesion molecule expression which may explain effects of the anti-VEGF antibody.

SKIN VASCULATURE IN WOUND HEALING AND CANCER

ANGIOGENESIS AND VASCULOGENESIS

In healthy adults, blood vessels are stable structures with a very slow turnover of ECs. In settings of chronic inflammation, tissue injury, or tumor growth, new vessels may be formed, and existing vessels may undergo remodeling. Much of the process of vessel formation has been learned by studying the formation of the

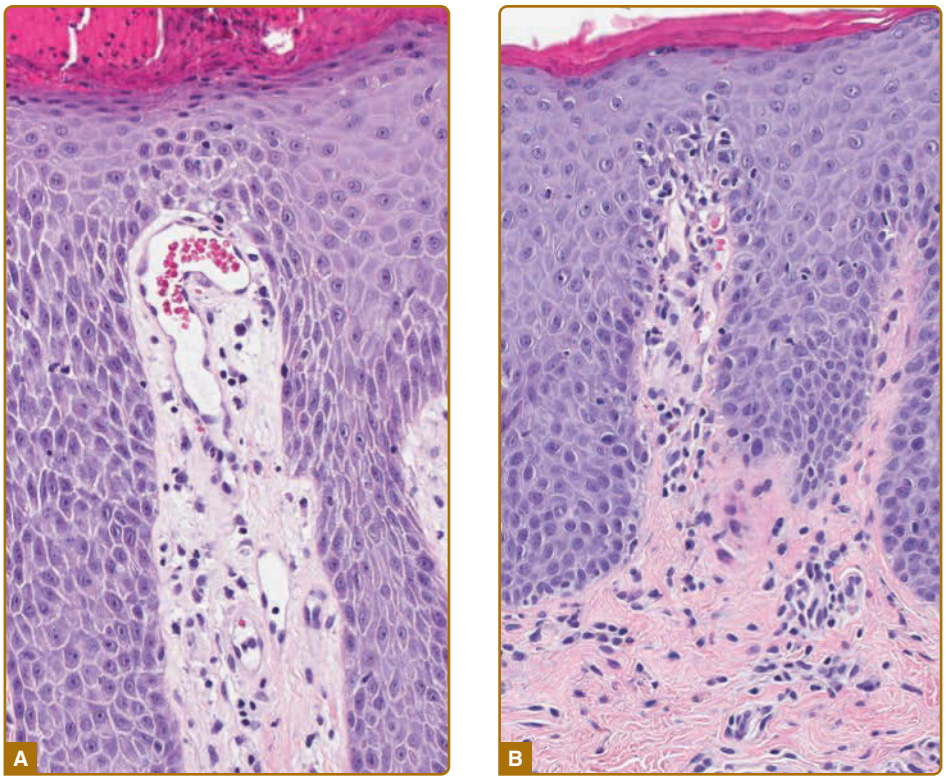

Figure 9-9 **A,** Vascular changes in psoriasis; the capillary loops within the tips of the papillae dilate, elongate, and at the turnaround point touch the epidermis, a phenomenon called "kissing." **B,** Leukocytes exit the vessel lumen within the tips of the papillae ("squirting papillae"); 20× magnification.

vascular system during embryogenesis. In embryos, ECs arise from angioblasts, which migrate to peripheral tissues and form primitive blood vessels (vasculogenesis). Subsequently, new blood vessels arise from preexisting ones (angiogenesis) (Fig. 9-10). Mesenchymal cells are then recruited into the vessel wall, where they subsequently differentiate into SMCs and PCs, a process called vascular remodeling. In adults, new blood vessels develop through angiogenesis (sprouting from preexisting blood vessels); it has been proposed that circulating endothelial progenitor cells, mesoangioblasts, and multipotent adult progenitor cells contribute to new vessel formation (adult vasculogenesis). Several investigators have proposed that these progenitors arise in the bone marrow, just as angioblasts arise in the embryonic blood island. However, it is unclear that bone marrow–derived cells give rise to stable ECs, and many such observations have now been reinterpreted to imply a role for monocytes that express EC markers, promote angiogenesis, and then disappear as the new vessels become stable. Stem cells and endothelial progenitor cells have been identified in vessel walls as resident cells. Such cells are thought to reside in a niche, awaiting appropriate stimuli such as vessel injury to take part in the repair of damaged and the formation of new blood vessels. Among such vascular wall progenitor cells are CD34+/CD31- cells that differentiate into ECs. Other resident vascular wall progenitor cells are SMC progenitors and mesenchymal stromal cells that may arise from PCs.

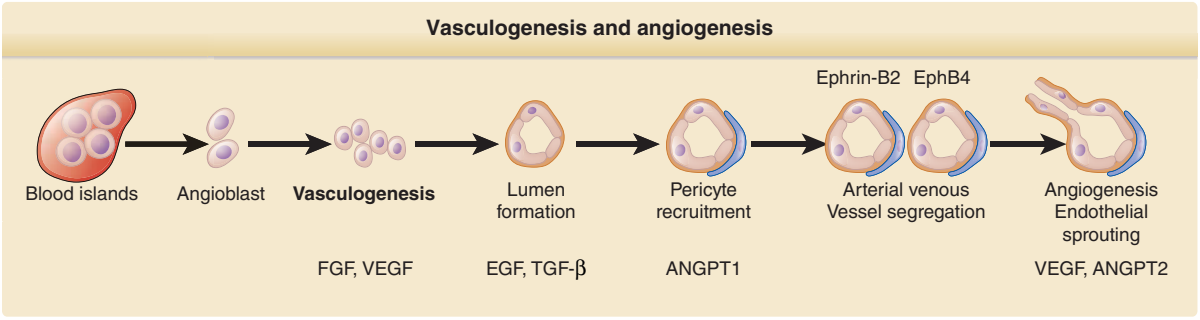

Figure 9-10 Vasculogenesis and angiogenesis. ANGPT, angiopoietin; FGF, fibroblast growth factor; TGF-β, transforming growth factor-β; VEGF, vascular endothelial growth factor.

Signals inducing new vessel formation in the skin follow the principal mechanisms given in all organs. Molecules of the VEGF family—VEGF A through E—most prominently act on ECs. Fibroblast growth factor (FGF) 1 and 2 are also potent EC mitogens but also act on SMCs, PCs, and fibroblasts. In adults, FGF-1 and FGF-2 are stored in the cytoplasms of a variety of cells and are released when cells are injured, acting as "wound hormones" to stimulate local angiogenesis and connective tissue growth. Other polypeptide factors have also been found to act on ECs in vivo and in vitro, including epidermal growth factor (EGF), heparin-binding EGF–like growth factor, and hepatocyte growth factor (HGF) or scatter factor (SF). For vascular remodeling and stabilization, tyrosine kinase receptor 1 (Tie) and 2 are required. Tie-2 mediates the dialogue between mesenchymal cells and the endothelium of the immature blood vessel through binding to angiopoietins (Fig. 9-11). The eph family of receptor tyrosine kinases and their corresponding ephrin ligands are membrane bound and appear to mediate bidirectional cell-to-cell signaling. During vascular development, ephrin-B2 marks the ECs of early arterial vessels, and ephrin-B4 marks the ECs of early veins. Platelet-derived growth factor (PDGF) and transforming growth factor (TGF)-β are secreted by ECs and promote migration of mesenchymal cells, matrix biosynthesis, and differentiation. Matrix glycoproteins such as fibronectin and laminin and receptors for matrix glycoproteins such as β_1 and β_3 integrins are also believed to play a role in vasculogenesis and angiogenesis. This seems intuitive because neither ECs nor mesenchymal cells can survive unless they interact with matrix proteins via integrin receptors.

WOUND HEALING

Full-thickness wounds heal in interconnected and overlapping stages involving coagulation, inflammation, proliferation, and remodeling. Immediately after wounding, disrupted blood vessels contract to stop bleeding. The activation of the coagulation cascade leads to platelet clot and subsequently to fibrin clot formation. At this stage, wounded vessels function as guiding structures for circulating inflammatory cells. Complement activation and the release of CXC chemokines by platelets and keratinocytes results in the recruitment of circulating neutrophils. Surrounding capillaries become leaky, resulting in further plasma and cell accumulation within wounds. The vascular leakiness gradually decreases but persists for the

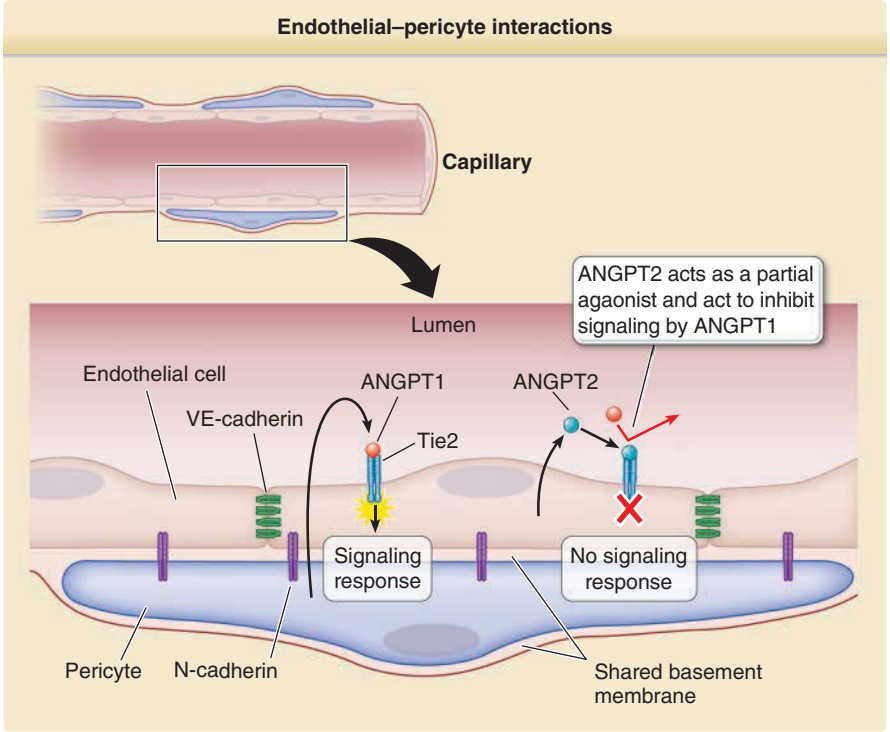

Figure 9-11 Endothelial cell (EC)–pericyte interactions. Pericytes are localized to within the basement membrane of the EC lining of microvessels and contribute to its synthesis and maintenance, and the composition and organization of the basement membrane may modify EC functions. Pericytes directly contact ECs, forming adherens junctions involving N-cadherin linkages. Pericytes also stabilize ECs by paracrine signals; the best understood of which involves pericyte secretion of angiopoietin 1 (ANGPT1), which binds to and activates the receptor tyrosine kinase Tie2 expressed on the endothelium. ANGPT1 binding prevents EC-derived ANGPT2 from binding to the same receptor. ANGPT2 acts as a partial agonist, and when its levels increase, it prevents ANGPT1-mediated signaling, leading to disruption of endothelial cell junctions associated with capillary leak, angiogenesis, or both.

next 3 to 7 days. The formation of a capillary network occurs by capillary tip extension from a parent vessel, maturation of capillary tips into capillary sprouts, anastomosis, and further branching. After this rapid formation of blood vessels during the inflammatory and proliferative stages of healing, the vascular system is remodeled, regressed, or both. The angiogenic response is mainly driven by VEGF, FGF-2, PDGF, and members of the TGF-β family (Fig. 9-12). Macrophages are the major sources of VEGF during an early healing stage; at later stages, most VEGF-expressing cells are found within the neoepithelium.[20] Under conditions of injury, hypoxia, or inflammation, keratinocytes produce and release a wide range of angiogenic factors, including members of the FGF or TGF protein family, PDGF, or VEGF. Concomitantly, VEGFR-2 is upregulated on ECs, which augments endothelial responses to VEGF. FGF-2 is derived from infiltrating macrophages but also from ECs themselves. Antibodies against FGF-2 inhibit wound angiogenesis nearly completely.

Stem cells from the skin stem cell niches and endogenous stem cells outside the niche support wound healing. These include hair follicle bulge and dermal sheath stem cells surrounding hair follicles, epidermal stem cells, and bone marrow–derived mesenchymal stem cells. Despite all preclinical wound-healing studies, translation of stem cell–based strategies in the clinical settings has had only limited success.[21] The quantitative contribution of stem cell–derived angiogenesis compared with conventional angiogenesis through local sprouting is unknown.

TUMOR ANGIOGENESIS

Skin tumors, like any other solid tumor, acquire their blood supply from the neighboring blood capillaries. Rapid tumor growth without adequate blood supply induces hypoxia. Hypoxia is augmented because of the leaky and disorganized tumor vasculature, resulting in acute fluxes in oxygen tension and in diffusion-limited regions within the tumor. Both the tumor and the stroma compartments respond to hypoxia by expressing the hypoxia-inducible factor (HIF) family of transcription factors.[22] Hypoxia stimulates tumor cells and macrophages to secrete TGF-β, PDGF, CXCL2, and endothelin, which activate fibroblasts. In fibroblasts, hypoxia stimulates extracellular matrix remodeling and the release of angiogenetic factors. Hypoxia directly effects vascular barrier function by decreasing the association between PCs and ECs. Tumors themselves may produce VEGF, FGF-2, EGF, and HGF or SF (see Fig. 9-12). Additionally, tumors may augment blood supply by intussusceptive angiogenesis (splitting of an existing blood vessel in two), vasculogenic mimicry (the formation of fluid-conducting channels by tumor cells), vessel co-option (tumor cells migrate along the preexisting vessels), and vasculogenesis.[23] Vascular mimicry appears to play a specific role in metastatic melanoma (not in primary lesions) because patients with this type of vascular channel formation have a worse 5-year survival rate.[24] Another interesting phenomenon observed in the tumor associated vasculature is endothelial-to-mesenchymal transition,

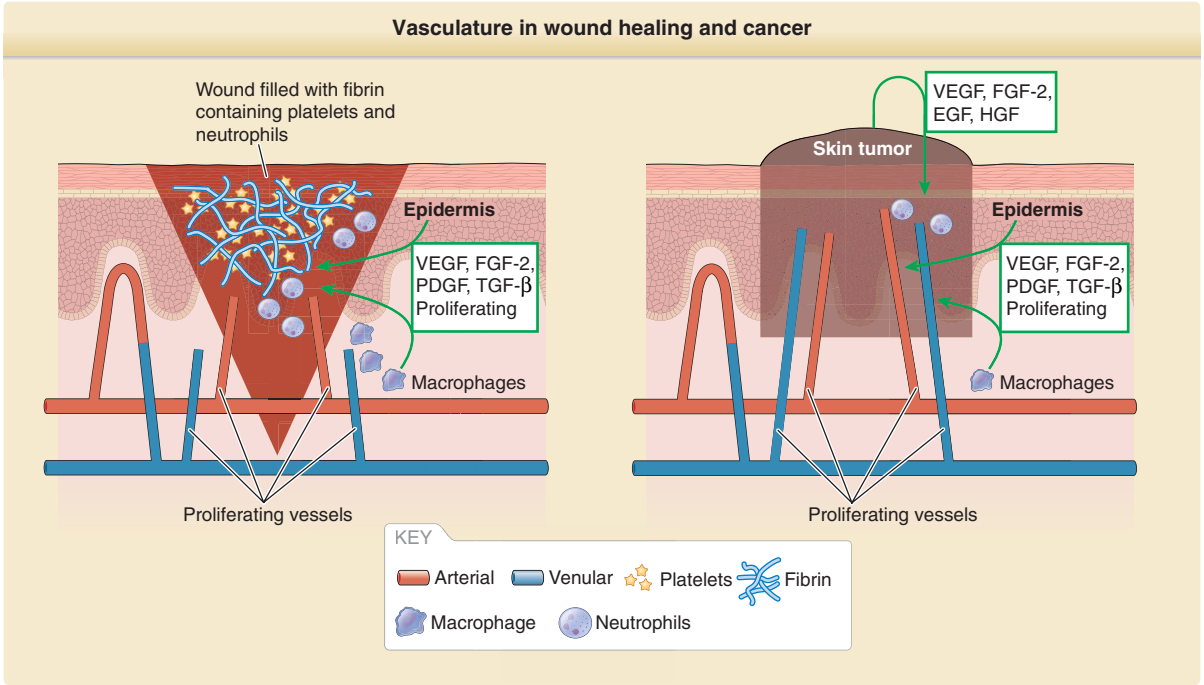

Figure 9-12 Vasculature in wound healing and cancer. EGF, endothelial growth factor; FGF, fibroblasst growth factor; HGF, hepatocyte growth factor; PDGF, platelet-derived growth factor; TGF-β, transforming growth factor-β; VEGF, vascular endothelial growth factor.

which generates cancer-associated myofibroblasts that stimulate inflammation and fibrosis and augment vascular dysfunction and as a result increase hypoxia. TGF-β is one of the driving factors of endothelial-to-mesenchymal transition.[25]

CONCLUSIONS

The skin vascular system is unique in several respects. It is organized into functionally distinct vascular segments: the loops within the tips of the papillae, the SVP, and the DVP. These segments may individually or conjointly respond to exogenous or endogenous stimuli, thereby influencing skin disease expression. Because of their proximity to the epidermis, ECs of the SVP may directly respond to keratinocyte-derived factors such as cutaneous T cell–attracting chemokine or VEGF, which results in an altered vascular architecture, phenotype, and function. Moreover, skin EC may be directly exposed to environmental antigens. In this context, the constitutive expression of HLA class II molecules by postcapillary venules implies that ECs play a role in antigen presentation, which may increase the likelihood that the antigen is recognized in a timely manner to efficiently recruit memory T cells to sites of danger.

REFERENCES

1. Braverman IM. Ultrastructure and organization of the cutaneous microvasculature in normal and pathologic states. *J Invest Dermatol*. 1989;9(suppl)3:2S-9S.
2. Weninger W, Biro M, Jain R. Leukocyte migration in the interstitial space of non-lymphoid organs. *Nat Rev Immunol*. 2014;14:232-246.
3. Fan X, Rudensky AY. Hallmarks of tissue-resident lymphocytes. *Cell*. 2016;164:1198-1211.
4. Ginhoux F, Guilliams M. Tissue-resident macrophage ontogeny and homeostasis. *Immunity* 2016;44: 439-449.
5. Pober JS, Sessa WC. Inflammation and the blood microvascular system. *Cold Spring Harb Perspect Biol*. 2015;7:a016345.
6. Wu J, Saleh MA, Kirabo A, et al. Immune activation caused by vascular oxidation promotes fibrosis and hypertension. *J Clin Invest*. 2016;126:1607.
7. Charkoudian N. Skin blood flow in adult human thermoregulation: how it works, when it does not, and why. *Mayo Clin Proc*. 2003;78:603-612.
8. Bromley SK, Yan S, Tomura M, et al. Recirculating memory T cells are a unique subset of CD4+ T cells with a distinct phenotype and migratory pattern. *J Immunol*. 2013;190:970-976.
9. Berg EL, Yoshino T, Rott LS, et al. The cutaneous lymphocyte antigen is a skin lymphocyte homing receptor for the vascular lectin endothelial cell-leukocyte adhesion molecule 1. *J Exp Med*. 1991;174:1461-1466.
10. Reiss Y, Proudfoot AE, Power CA, et al. CC chemokine receptor (CCR)4 and the CCR10 ligand cutaneous T cell-attracting che.mokine (CTACK) in lymphocyte trafficking to inflamed skin. *J Exp Med*. 2001;194:1541-1547.
11. Homey B, Alenius H, Muller A, et al. CCL27-CCR10 interactions regulate T cell-mediated skin inflammation. *Nat Med*. 2002;8:157-165.
12. Nihal M, Mikkola D, Wood GS. Detection of clonally restricted immunoglobulin heavy chain gene rearrangements in normal and lesional skin: analysis of the B cell component of the skin-associated lymphoid tissue and implications for the molecular diagnosis of cutaneous B cell lymphomas. *J Mol Diagn*. 2000;2:5-10.
13. Muller WA. Localized signals that regulate transendothelial migration. *Curr Opin Immunol*. 2016;38:24-29.
14. Lui R, Lauridsen H, Amezquita R, et al. Interleukin-17 promotes neutrophil-mediated immunity by activating microvascular pericytes and not endothelium. *J Immunol*. 2016;197(6):2400-2408.
15. Rajashekhar G, Grow M, Willuweit A, et al. Divergent and convergent effects on gene expression and function in acute versus chronic endothelial activation. *Physiol Genomics*. 2007;31:104-113.
16. Kluger MS, Johnson DR, Pober JS. Mechanism of sustained E-selectin expression in cultured human dermal microvascular endothelial cells. *J Immunol*. 1997;158: 887-896.
17. Lechleitner S, Kunstfeld R, Messeritsch-Fanta C, et al. Peripheral lymph node addressins are expressed on skin endothelial cells. *J Invest Dermatol*. 1999;113:410-414.
18. Martinet L, Le GS, Filleron T, et al. High endothelial venules (HEVs) in human melanoma lesions: major gateways for tumor-infiltrating lymphocytes. *Oncoimmunology*. 2012;1:829-839.
19. Petzelbauer P, Pober JS, Keh A, et al. Inducibility and expression of microvascular endothelial adhesion molecules in lesional, perilesional, and uninvolved skin of psoriatic patients. *J Invest Dermatol*. 1994;103:300-305.
20. Minutti CM, Knipper JA, Allen JE, et al. Tissue-specific contribution of macrophages to wound healing. *Semin Cell Dev Biol*. 2017;61:3-11.
21. Cerqueira MT, Pirraco RP, Marques AP. Stem cells in skin wound healing: are we there yet? *Adv Wound Care (New Rochelle)*. 2016;5:164-175.
22. LaGory EL, Giaccia AJ. The ever-*expanding* role of HIF in tumour and stromal biology. *Nat Cell Biol*. 2016;18: 356-365.
23. Krishna PS, Nagare RP, Sneha VS, et al. Tumour angiogenesis—origin of blood vessels. *Int J Cancer*. 2016;139:729-735.
24. Cao Z, Bao M, Miele L, et al. Stem cells in skin wound healing: are we there yet? Tumour vasculogenic mimicry is associated with poor prognosis of human cancer patients: a systemic review and meta-analysis. *Eur J Cancer*. 2013;49:3914-3923.
25. Xiao L, Kim DJ, Davis CL, et al. Tumor endothelial cells with distinct patterns of TGFbeta-driven endothelial-to-mesenchymal transition. *Cancer Res*. 2015;75:1244-1254.

Chapter 10 :: The Immunological Structure of the Skin

:: Georg Stingl & Marie-Charlotte Brüggen

AT-A-GLANCE

- Skin is a "Grenzorgan" equipped with the capacity to mount and execute immune responses.
- The cutaneous immune system disposes of an innate and adaptive arm to exert these functions.
- Molecular constituents of the cutaneous immune system include pattern recognition receptors and effector molecules.
- Tissue homeostasis requires the prevention of exaggerated responses to innocuous substances and the occurrence of host-defense reactions at a subclinical level, ie, in the absence of inflammation.
- Under pathological conditions, danger signals or other disease-eliciting/-promoting factors in the skin elicit a coordinated (host defense) reaction of its cellular and molecular elements.

The skin is a border organ ("Grenzorgan") separating the host's structural constituents from the environment and, at the same time, allowing the communication between the inside and the outside world. This dual role of the skin is commonly referred to as "skin barrier function." Its major task is to secure and maintain tissue homeostasis and, thus, to preserve host integrity. In case of a major danger signal such as the overwhelming assault of pathogenic microorganisms, it must allow for the rapid generation and mobilization of effective host defense reactions leading to the neutralization of the pathogen. To fulfill these obligations, the skin contains a variety of structural, cellular, and molecular elements, which confer physical, chemical, and immunological protection. The immunological barrier consists of the different constituents of both the innate and active immune response, which, dependent on the situation, are either productive and—at the expense of tissue destruction—protective or nonproductive and downregulating, thus preventing overreaction to an otherwise innocuous substance. This chapter describes the basic structural elements of the cutaneous innate and adaptive immune system and, based on this information, develops a concept of its functionality under physiologic and pathologic conditions.

BACKGROUND

In 1905, the pediatricians Clemens von Pirquet and Béla Schick published their monography named "Die Serumkrankheit" ("serum sickness") and meticulously described the clinical symptoms of children that had received sera of horses previously vaccinated with *Corynebacterium diphtheriae* (Fig. 10-1).[1] This serum treatment was quite successful in mitigating or even abrogating the diphtherial infection, but, as a complication, the children later developed a transitory disease attack consisting of fever, arthritis, nephritis, encephalitis, and, very notably, a skin rash. Because the intensity of the symptoms directly correlated with the amount of serum administered, Pirquet and Schick correctly speculated that serum sickness is an undesired (immunological?) host reaction against animal proteins. The validity of this assumption was not confirmed until the 1950s when investigators at the Scripps Research Institute showed that rabbits immunized with foreign proteins would develop a clinical disease complex similar to that of serum-injected children and, microscopically and serologically, characterized by the occurrence of immune complexes.[2,3] It is very likely that the skin rash in serum sickness was the first demonstration of the skin being a target of immune responses. Despite this, most dermatologists would date the actual beginning of modern immunodermatology to Beutner and Jordon's critical observations that patients with pemphigus and bullous pemphigoid exhibit pathogenic autoantibodies against desmosomal and basement membrane–associated antigens, respectively.[4,5] In this context, it is interesting that with very few exceptions, the skin, although a preferential target in several antibody-mediated diseases, is essentially devoid of B lymphocytes.

Edward Jenner's successful smallpox vaccination showed for the first time that host defense responses can also originate in the skin.[6] In this heroic experiment performed on his gardener's son, Jenner introduced, by scraping, material obtained from an infectious cowpox pustule (of a dairymaid) into the skin. Upon reinoculation with material from a fresh smallpox lesion a few weeks later, the boy was protected from the disease. Almost 100 years later, Coley's seminal observation that an ulcerated sarcoma of the breast regressed upon streptococcal superinfection implied that the (skin's) immune/defense system can also be mobilized in the combat of cancer.[7] In fact, Besredka and Gross showed in 1935 that mice that had been repeatedly immunized with homogenates of tissue sarcomas via the skin were protected against a later challenge with the wild-type cancer, whereas mice that had been vaccinated via other routes (ie, intramuscularly or intravenously) would succumb to the disease.[8] The

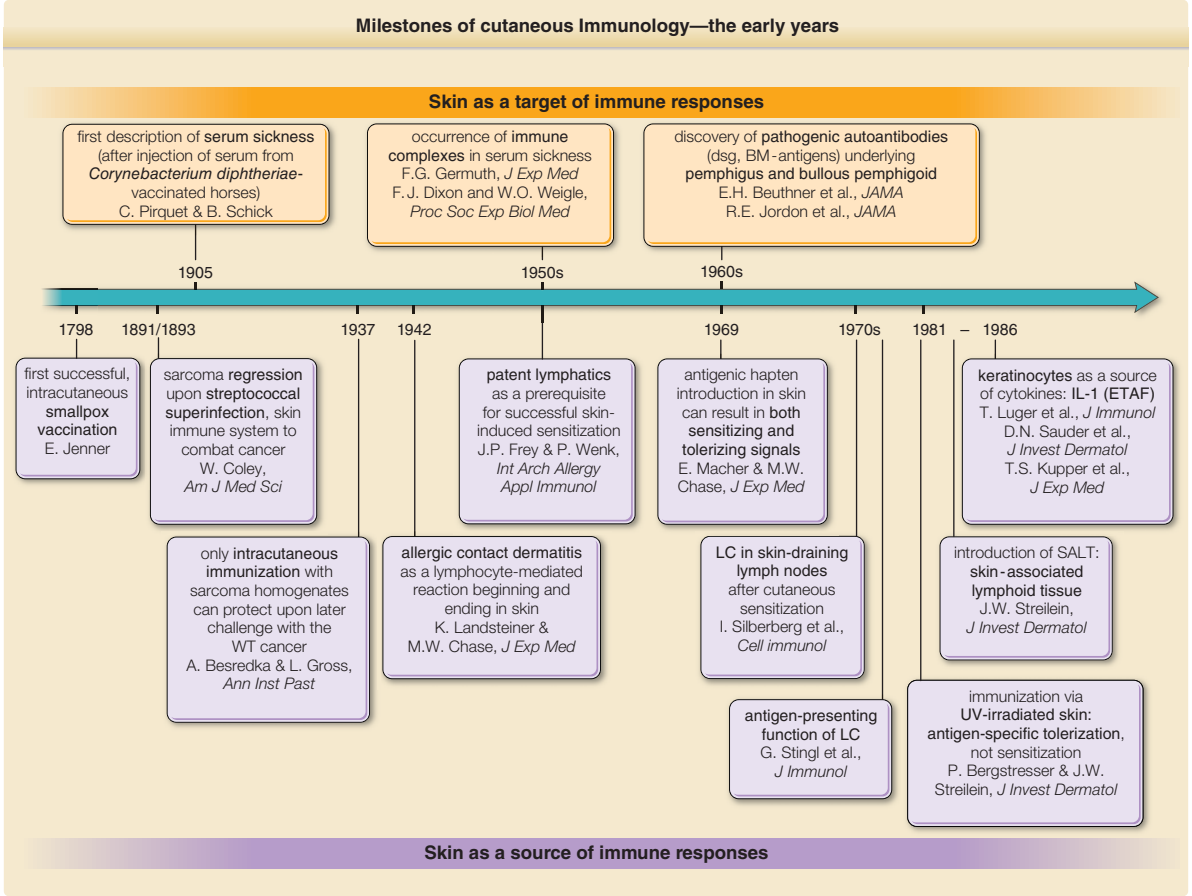

Figure 10-1 Milestones of cutaneous immunology—the early years. Major discoveries unraveling the role of the skin as a targer (upper part) and source (lower part) of immune responses.

authors speculated about the existence of a unique immunologic milieu in the skin that would preferably promote the generation of (cancer) protective immune responses. It was not until the late 1960s that we would learn more about the mechanistic details of the skin's peculiar role in the elicitation of an immune response. Based on Landsteiner's discovery[9] that allergic contact dermatitis is a lymphocyte-mediated reaction that usually begins and invariably ends in the skin, Macher and Chase, in a series of legendary experiments, came to the conclusion that in hapten-specific immune responses an antigenic depot is formed in the skin that needs to leave this organ for a successful hapten-specific sensitization to occur.[10] The finding of Frey and Wenk that patent lymphatics are a prerequisite for a successful skin-induced sensitization implied that this event would take place in the skin-draining lymph nodes.[11] Interestingly enough, Macher and Chase reported also that early removal of the cutaneous antigenic depot would result in antigen-specific unresponsiveness rather than in a null even.[12] This demonstrated clearly that introduction of an antigenic hapten in the skin can evoke not only sensitizing but also tolerizing signals. The medical relevance of this finding became obvious when it was shown that the attempt of immunization via ultraviolet (UV)-irradiated skin results in antigen-specific tolerization rather than sensitization.[13,14] Based on the original ultrastructural observation by Silberberg and Baer of the presence of Langerhans cells (LCs) in skin-draining lymph nodes after cutaneous sensitization with dinitrochlorobenzene (DNCB)[15] and the first demonstration of the antigen-presenting function of LCs,[16] the concept emerged that LCs and, later, other dendritic cells of the skin play a crucial role in capturing haptens and other exogenous antigens to induce activation of naïve T cells in skin-draining lymph nodes. Wayne Streilein coined the term *skin-associated lymphoid tissues* for this cutaneous immune circuit[17] and postulated that soluble mediators, for example, proinflammatory cytokines, produced by both leukocytes and resident skin cells such as keratinocytes,[18-20] would modulate antigen-presenting cell (APC) function and, thus, influence the outcome of the cutaneous immune response. As is shown in this review and in other chapters of this book, the skin represents an immunologic orchestra capable of generating quantitatively and qualitatively different functional voices. The enormous progress in drug discovery and development during the past decade now allows us to selectively and precisely tune the individual instruments of this network.

THE SKIN IMMUNE SYSTEM: CELLULAR AND MOLECULAR CONSTITUENTS

The skin is an organ equipped with the capacity to mount and execute immune responses. The cells and molecules needed for this exercise are summarized under the term *skin immune system*.[21] The skin immune system has an innate and an adaptive component (Table 10-1). The innate component is characterized by (a) its rapid onset, (b) its capacity to discriminate between danger and nondanger only, instead of distinguishing between individual antigenic specificities, and (c) its lack of memory. Adaptive immunity, by contrast, needs 10 to 14 days to develop, but it is characterized by an exquisite peptide specificity brought by the enormous polymorphism of human leukocyte antigens on APCs and a set of rearranged antigen receptors on B cells and T cells. Another distinguishing feature of the adaptive response is to react in an enhanced fashion to a repeated antigenic challenge (memory).[22]

Cells of the cutaneous innate response consist of both leukocytes (Table 10-1A, Fig. 10-2A) and nonleukocytes such as keratinocytes and fibroblasts. Leukocytes belonging to the innate immune system include granulocytes, mononuclear phagocytes, mast cells, innate lymphoid cells (ILCs), and two particular types of dendritic cells (DCs), namely plasmacytoid DC (pDC) and inflammatory DC. Within normal human skin (NHS), all these innate leukocytes are present in only small (mononuclear phagocytes, mast cells) or even negligible numbers (the rest).

TABLE 10-1

Cellular Constituents of the Cutaneous Immune System

CELL "FAMILY"	MEMBERS
A) Innate Immune System of the Skin	
Resident cells (nonleukocytic)	Keratinocytes Fibroblasts Sebocytes Endothelial cells Nerve cells
Granulocytes	Neutrophils (polymorphonuclear neutrophils [PMNs]) Eosinophils Basophils
Macrophages	
Mast cells	
Innate lymphoid cells (ILCs)	Cytotoxic ILCs: natural killer (NK) cells Helper ILC: ILC1 ILC2 ILC3
Dendritic cells (DC)[a]	Inflammatory DC[a] Plasmacytoid dendritic cell[a]
B) Adaptive Immune System of the Skin	
Dendritic cells	Langerhans cells CD141+ DC Dermal DC Inflammatory DC[a] pDC[a]
T lymphocytes (αβ) (details: see Fig. 10-4)	Naïve T cells Memory T cells

[a]As a consequence of their molecular and structural equipment, plasmacytoid DCs and inflammatory DCs can fulfill both innate and adaptive immune functions.

MOLECULAR CONSTITUENTS: RECEPTORS AND EFFECTORS

To do their job, both leukocytes and nonleukocytes involved in innate immunity are equipped with pattern recognition receptors (PRRs). PRR constitute a large family of either surface-bound and/or cytoplasmic receptors (eg, toll-like receptors, TLR) that are capable of rapidly sensing danger signals such as microbes and their constituents, haptens, and UV radiation (Table 10-3 lists the members of TLR familiy).[23,24] As a consequence, innate immunocytes either expand in situ or are recruited from the circulation (see Fig. 10-2B) and begin to elaborate mediators destined to neutralize and/or eliminate the pathogen (Table 10-2). These include the production of proinflammatory cytokines, chemokines, lytic molecules, proteases, complement components, and arachidonic acid metabolites, as well as a group of antimicrobial peptides (AMPs). AMPs[25] are produced in a constitutive or induced fashion and can eliminate pathogenic bacteria, viruses, fungi, and parasites, and, in addition, subserve other biologic functions such as chemotaxis or wound repair promotion.

CELLULAR CONSTITUENTS

INNATE IMMUNE SYSTEM

Granulocytes, Mast Cells: Among the leukocytes of the innate immune system, neutrophils usually act as the so-called first responders after most forms of skin injury. As an example, microbial assault results in the production/release of different types of chemotactic factors, such as chemokines, leukotrienes, and complement components. This allows neutrophils to abundantly enter the skin from the peripheral blood and migrate toward the site of injury. The main effector function of neutrophils is to eliminate microbes, either by phagocytosis (ingestion and killing) or by using their neutrophil extracellular traps,[26] which enable them to kill extracellular pathogens. Eosinophils are much less efficient phagocytes than polymorphonuclear

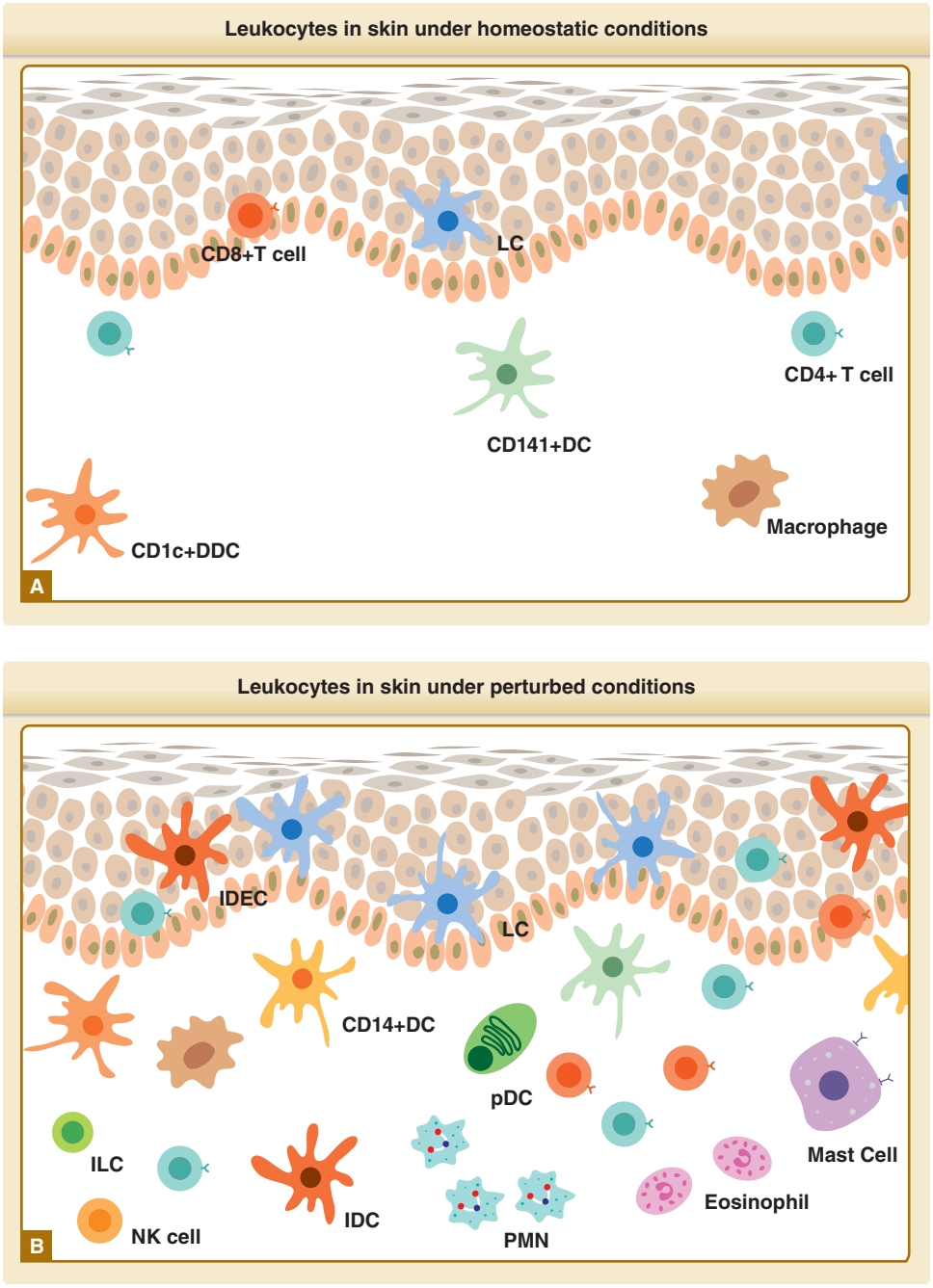

Figure 10-2 Leukocyte populations in human skin under homeostatic and inflammatory conditions. **A,** Leukocytes in skin under homeostatic conditions. Normal human skin harbors a resident T-cell population (CD4+ and CD8+) as well as various dendritic cell (DC) subsets (Langerhans cells [LC] in the epidermis; CD141+ and CD1c+ DC in the dermis). Only a few innate leukocytes are found in normal human skin, notably macrophages. **B,** Leukocytes in skin under perturbed conditions (inflammation). Under inflammatory conditions, a plethora of cells belonging to either the innate (macrophages, granulocytes, plasmacytoid dendritic cell [pDC], inflammatory DC [IDC], mast cells, innate lymphoid cell [ILC]) or adaptive immune system (CD4+ and CD8+ T cells) infiltrate the skin. IDEC, inflammatory dendritic epidermal cells; NK, natural killer; PMN, polymorphonuclear neutrophil.

neutrophils. However, by releasing preformed cationic proteins (eg, eosinophilic cationic proteins) that are toxic to several parasites, eosinophils provide efficient protection against the parasites. Basophils contain histamine-filled granules and are a rich source of cytokines such as interleukin (IL)-4 and IL-13. In this regard, basophils resemble mast cells and, similar to mast cells, play an important role in allergic tissue inflammation. Mast cells exhibit membrane-bound and cytoplasmic granules, which contain preformed mediators (eg, histamine, serotonin) and molecules synthesized upon activation (eg, tumor necrosis factor [TNF], IL-3, IL-4, IL-13), respectively. Important activation mechanisms of mast cells resulting in the release

TABLE 10-2
Overview of Effector Substances of the Innate Immune System in Skin

FAMILY OF MOLECULES	EXAMPLES
Cytokines	▪ Tumor necrosis factor (TNF), interleukin (IL)-1β, IL-6, IL-8, IL-12 ▪ IL-10, transforming growth factor (TGF)-β
Chemokines	▪ CXCL1, CXCL8, CCL3, CCL5, CCL20
Antimicrobial peptides (AMPs)	▪ Human cathelicidin LL-37 ▪ Human beta-defensins hBD-2, hBD-3 ▪ Psoriasin S100A ▪ Dermcidin ▪ Ribonuclease (RNAse) 7 ▪ Lysozyme
Complement components	▪ C3a, C5a, C3b
Arachidonic acid metabolites	▪ PGE4, LKTs, etc.
Reactive oxygen species (ROS)	
Lytic molecules	▪ Granulysin, perforin, tumor necrosis factor–related apoptosis-inducing ligand (TRAIL), granzyme B
Proteases	▪ Matric metalloproteases (MMPs) ▪ Serine proteases (eg, kallikreins)
Pattern recognition receptors (PRRs)	▪ Toll-like receptors (TLRs) ▪ Nucleotide-binding oligomerization domain (NOD)-like receptors (NLR) ▪ Retinoic acid inducible gene I (Rig1)-like receptors (RLRs) ▪ C-type lectin receptors (CLRs)

and production of molecular mediators are the interaction of complement cleavage products C3a and C5a with their respective receptors, as well as Fc-mediated binding of immunoglobulin E. In the situation of Fc-mediated binding of immunoglobulin E, immunoglobulin E crosslinking by the respective antigen results in type I hypersensitivity reactions.

Innate Lymphocytes: Much attention has focused on a family of non-T non-B lymphoid cells that includes not only cytotoxic (natural killer [NK] cells) but also so-called helper ILCs. Among the best known roles of NK cells are the recognition and killing of virally infected and neoplastic cells and the secretion of interferon (IFN)-γ, a main immunoregulatory cytokine. As opposed to CD8+ T cells, which use the recognition of major histocompatibility complex (MHC) I antigen complexes to induce killing, MHC I is recognized by inhibitory receptors on NK cells and results in the inhibition of lytic responses. On the other hand, contact with cells exhibiting altered MHC I (eg, virus-infected cells) or ligands of activating NK cell receptors at their surface induces a cytotoxic killing cascade. Helper ILCs can be subdivided into 3 subsets (ILC1, ILC2, ILC3) according to their transcription factor and cytokine profiles, which show striking similarities with T helper (Th) cell subsets. Thus both ILC1s and Th1 cells are TBET (a Th1 pathway transcription factor)-positive and produce IFN-γ; ILC2s are differentiating under the influence of GATA3 (a Th2 pathway transcription factor) and are secreting IL-5 and IL-13; and ILC3s and Th17/Th22 cells abundantly express RORC/AHR, respectively, and are a rich source of IL-17 and IL-22.[27] The exact role of helper ILCs in skin remains to be elucidated.

Macrophages: Next to polymorphonuclear neutrophils, macrophages and mononuclear phagocytes are heavily involved in the elimination of invading microbes. They accomplish this by phagocytosis and the subsequent killing of the pathogen by reactive oxygen species. Thereafter, they switch their functional program to clean up the stage and promote tissue regeneration and repair. However, we wouldn't do justice to the macrophages by simply labeling them as phagocytes given that they also exert an APC function and, by doing so, play a great role in shaping cutaneous immune responses.[28]

Dendritic Cells with Innate Immune Functions: As to DC subsets with proper innate immune functions, pDCs play a major role in antiviral defense by the massive production of type I interferons (IFN-α, IFN-β) upon activation of TLR7 and TLR9 (Table 10-3). In this context, it is noteworthy that the artificial TLR7 ligand imiquimod provides a strong activation signal for pDC, resulting not only in IFN-α production, but also in the expression of lytic molecules such as tumor necrosis factor–related apoptosis-inducing ligand.[29] This mechanism is probably responsible for the therapeutic efficacy of topical imiquimod in patients with genital warts, actinic keratosis, and basal cell carcinomas.[30] Inflammatory DCs

TABLE 10-3
Toll-Like Receptors and Ligands

TOLL-LIKE RECEPTOR (TLR)	LIGAND	
TLR1	Triacylated lipoproteins (TLR 2/1)	Gram-negative bacteria, mycobacteria
TLR2	Diacylated lipoproteins (TLR 2/6)	Gram-positive bacteria *(Propionibacterium acnes)*
TLR3	Virus-derived double-stranded RNA (dsRNA)	Viruses (dsRNA)
TLR4	Lipopolysaccharide (LPS)	Gram-negative bacteria
TLR5	Flagellin	Flagellated bacteria
TLR6	Lipopeptides	Mycobacteria
TLR7	Virus-derived single-stranded RNA (ssRNA)	Viruses (ssRNA)
TLR8	Virus-derived ssRNA	Viruses (ssRNA)
TLR9	Unmethylated DNA sequences (bacterial DNA)	Bacteria

TABLE 10-4
Main Characteristics of DC Populations in Human Skin

	LC	DDC	CD141+ DC	PDC	IDEC
Precursor	Self-maintaining? Monocytic?	Myeloid	Myeloid	Plasmacytoid	Monocytic
Markers	Langerin, CD1a, CD11c (low), CD11b, E-cadherin, DEC-205, CD39	CD1c (BDCA-1), CD1a, CD1b, CD11c, CD11b, CD33, CD172, DEC-205, CLEC6A, CLEC7A, CD206 (mannose receptor)	CD141 (BDCA-3), CD11c, DEC-205, CLEC9A	CD303 (BDCA-2), CD304 (BDCA-4), CD45RA, CD123 (IL-3R), DEC-205	CD1a, CD1c, CD11c, CD11b, CD206, CD209
Fc receptors	FcεRI, FcγRII	–	–	FcαR, FcγRIIa, FcεRI	FcεRI
TLR	TLR1, TLR2, TLR6	TLR1–8	TLR1–3, TLR6, TLR8	TLR1, TLR6, TLR7, TLR9	–
Main function	Initiation/regulation of T-cell responses	Stimulation of naïve T cells	Cross presentation	Antiviral immune response	Induction Th17-response
Cytokine production	TNF-α, IL-6, IL-8, IL-10, IL-12	TNF-α, IL-8, IL-10, IL-12, IL-23	TNF-α, (CXCL10), IFN-γ	Type-1 interferons (IFN-α)	IL-1β, TNF-α, IL-6, IL-23

All the cells listed above lack the expression of so-called lineage markers (CD3, CD14, CD19, CD20, CD56, glycophorin A) but express CD45 as well as human leukocyte antigen-D related (HLA-DR).
DC, dendritic cell; DDC, dermal dendritic cell; IFN, interferon; IL, interleukin; LC, Langerhans cell; Th, T-helper cell; TLR, toll-like receptor; TNF, tumor necrosis factor.

include various subsets (eg, tipDC [TNF-α/inducible nitric oxide synthase–producing DC], inflammatory dendritic epidermal cells)[31] and exert proinflammatory functions such as the production of TNF and inducible nitric oxide synthase[32] and the priming of Th cell responses.[33-35]

ADAPTIVE IMMUNE SYSTEM

Cells of the cutaneous adaptive response are the ones needed for the elicitation and expression of adaptive immunity. These are dendritic APC and T lymphocytes (see Table 10-1B and Fig. 10-2A).

Dendritic Cells: As outlined in Chapter 11 in greater detail, normal (unperturbed) human skin contains 3 distinct populations of antigen-presenting DCs: epidermal LCs, dermal DCs (DDCs), and CD141+ DC. They are all derived from bone marrow precursors, although for LCs there still remains some debate; Table 10-4 lists the major phenotypic features and functions of skin DC. LCs[36] express CD1a, a formalin-resistant, sulfhydryl-dependent adenosine triphosphatase/CD39, as well as surface receptors for the uptake of native and complexed antigens such as DEC-205, the FcγRII/CD32 and FcεR1. Most notably, LCs contain endocytic organelles called Birbeck granules (Fig. 10-3B),[37] whose major constituent is the C-type lectin langerin/CD207.[38] CD207 enables LCs, together with CD1a, to present nonpeptide antigens (eg, *Mycobacterium leprae*) to T cells.[39,40] MHC I and II antigens (Fig. 10-3A) are mostly located within the cytoplasm of resident LCs.[41,42] DDC are MHC II-positive, express CD1c rather than CD1a, display the mannose receptor as well as DC-SIGN (dendritic cell–specific intercellular adhesion molecule-3-grabbing nonintegrin) for antigen uptake, but are devoid of Birbeck granules/Langerin (as opposed to the situation in humans, a subpopulation of murine DDC is Langerin-positive).[43-45] Another DC subset, namely CD141 (also known as BDCA-3 or thrombomodulin)-expressing DC, was initially identified in the peripheral blood, but has been found to also constitute a very small cell population in the human dermis.[46] CD141+ DCs are characterized by the expression of CD11c and DEC-205, as well as the receptors CLEC9A, TLR3, and TLR7, which enable them to take up extracellular necrotic cells and viral nucleic acids. Functionally, the 3 different types of "resident" skin DCs exhibit the characteristic features of bone marrow–derived DCs: migration (from the skin to the draining lymph nodes during primary immune responses) and induction of helper or cytotoxic antigen-specific immune responses in naïve resting T cells.[31] In the case of CD141+ DCs, the T-cell response is usually cytotoxic in nature and directed against antigenic moieties expressed by and taken up from surrounding symbionts and then channeled in the MHC class I presentation pathway. This phenomenon is termed *cross presentation*.[47] Some evidence exists that LCs also can take up antigens from surrounding keratinocytes and present the relevant peptides to CD8+ T cells in the context of MHC I.[48] Similar to DCs from other tissues, skin DCs exhibit an antigen uptake and, at the same time, immunoinhibitory mode when located in situ.[49] Resident LCs, for instance, extend their dendrites through and beyond the tight junctions formed between keratinocytes of the stratum corneum.[50] On the other hand, LCs carry only small amounts of costimulatory molecules on their surface and produce just negligible amounts of immunostimulatory cytokines such as IL-1β, IL-6, IL-12, and IL-23. In other words, LCs display phenotypic features that favor and facilitate the activation of regulatory T cells (Tregs). In fact, when they are kept in

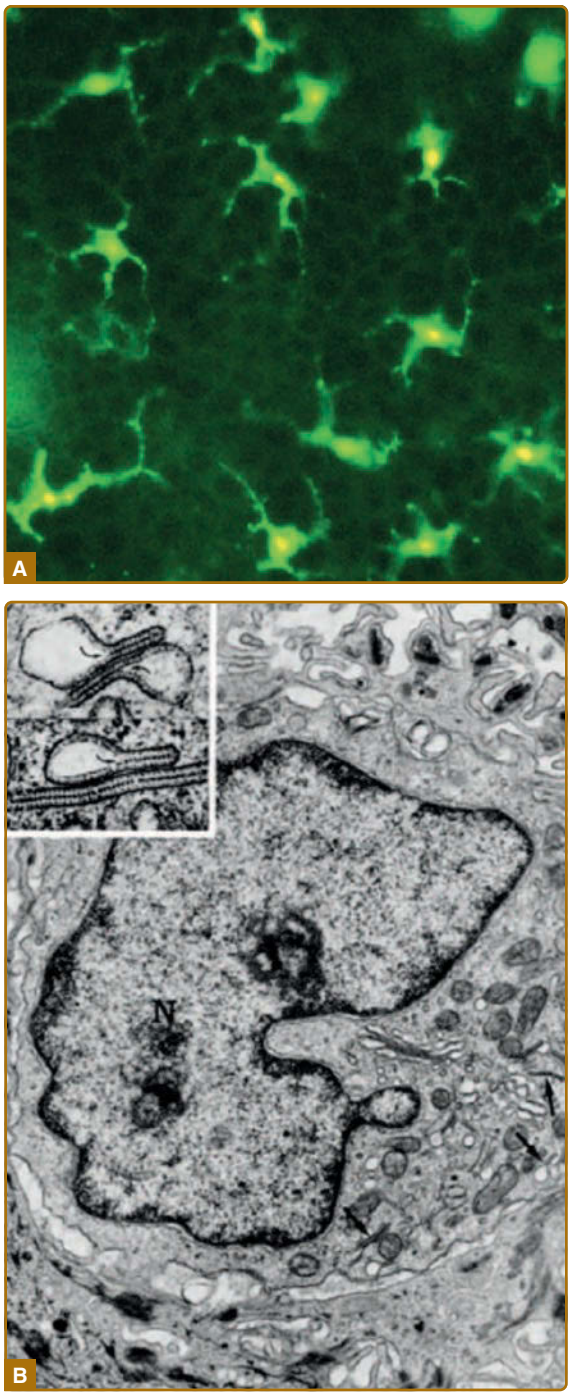

Figure 10-3 Langerhans cells (LCs). **A,** LCs in a sheet preparation of murine epidermis as revealed by anti–major histocompatibility complex class II (fluorescein isothiocyanate [FITC]) immunostaining. **B,** Electron micrograph of a LC in human epidermis. Arrows denote Birbeck granules. N, nucleus. (From Stingl G. New aspects of Langerhans cell functions. *Int J Dermatol*. 1980;19:189, with permission.) *Inset:* High-power electron micrograph of Birbeck granules. The curved arrows indicate the zipper-like fusion of the fuzzy coats of the vesicular portion of the granule. The delimiting membrane envelops 2 sheets of particles attached to it and a central lamella composed of 2 linear arrays of particles. (Copyright © 1967 Wolff. Originally published in Wolff K. The fine structure of the LC granule. *J Cell Biol*. 1967;35:468-473.)

a resting state, as by glucocorticosteroids, they preferentially promote the expansion of Treg.[51]

Upon the receipt of danger signals, LCs,[52] and probably also DDCs,[44] mature into very potent immunostimulators for both CD4+ and CD8+ naïve, as well primed, T cells. The in vivo significance of these in vitro findings is evidenced by the occurrence of similar maturation events on DC[53,54] migrating from the skin to the draining lymph nodes under danger conditions.

T Lymphocytes: In most of the older textbooks of dermatology and immunology, the skin was often referred to as "nonlymphoid tissue." If such a term refers to those tissues in which primary immune responses, that is, lymphocyte sensitization, are not or only very rarely taking place, the skin may well deserve such a designation. This, however, doesn't mean that the skin is devoid of lymphocytes. Just the opposite is true. Notwithstanding the existence of small numbers of ILCs and NK cells (see "Innate Lymphocytes" section), T lymphocytes[55] are by far the largest, and probably the most important, lymphocyte population within NHS (see Figs. 10-2A and 10-4). In fact, its size exceeds that of the T-cell population in the peripheral blood.[56] Most skin T cells are localized in the dermis and only 10% in the epidermis. T cells can be subdivided according to different criteria such as (a) antigenic experience, (b) the type of T-cell receptors (α/β vs. γ/δ), (c) type of accessory molecules expressed (CD4 vs CD8), and (d) functional differentiation (type of transcription factor; helper vs cytotoxic; cytokine secretion pattern). According to these distinguishing features, T cells of NHS, unlike skin T cells of rodents, express predominantly α/β T-cell receptors.[55] Whereas dermal T cells are mainly CD4+, epidermal T cells preferentially display the CD8+ phenotype. In their vast majority, T cells in skin express the memory (CD45RO+) rather than the naïve (CD45RA+) phenotype. According to the existing nomenclature, memory T cells are generally subdivided into central (Tcm) and effector memory (Tem) cells (Fig. 10-5).[57] Tcm cells exhibit the CCR7+/CD62L+ phenotype and are mainly found in secondary lymphoid organs such as lymph nodes and spleen. They are only sparsely scattered within NHS, but present in slightly larger numbers in chronic inflammatory (eg, eczema, psoriasis) and neoplastic (eg, cutaneous T-cell lymphoma) skin diseases.[58,59] Tem cells can be subdivided into recirculating memory T cells and tissue-resident memory T (Trm) cells. Recirculating Tem cells (CD62L-/CCR7+) constantly recirculate between nonlymphoid tissues and lymphatic organs. In contrast, Trm cells permanently reside in the skin, and, thus, can provide an extremely rapid onsite protection upon exposure to previously encountered antigens, that is, before other Tem cells are recruited from the circulation. All Trm cells are characterized by the expression of CD69 and some of them (mostly CD8+ Trm cells) by the αE integrin CD103.[57] They may have a very long life span and may thus not only be of crucial importance for the skin's immunosurveillance function, but also for the reactivation of inflammatory skin diseases

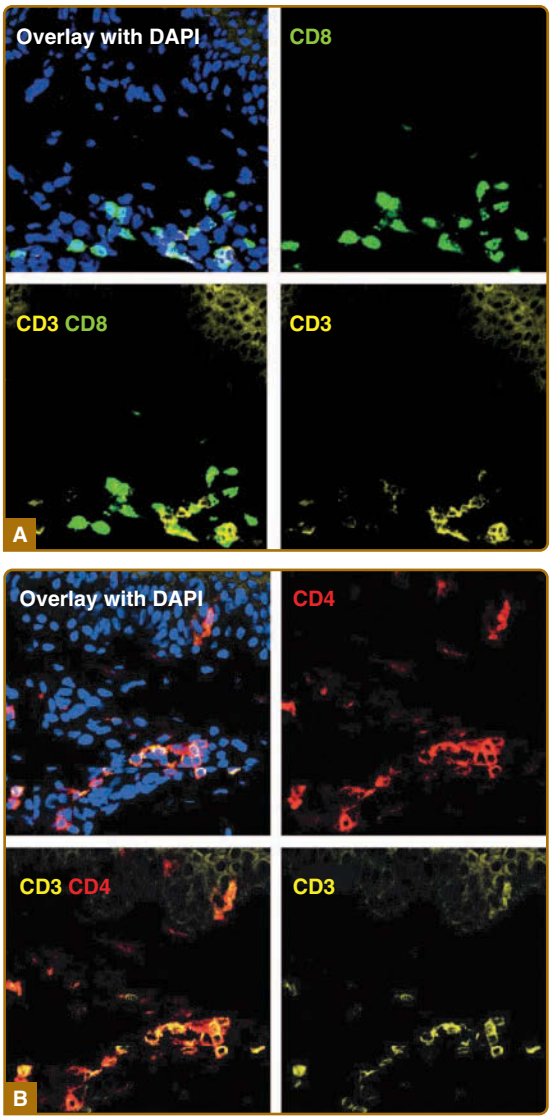

Figure 10-4 T cells in normal human skin. **A,** CD8 stained with fluorescein isothiocyanate (FITC; green); CD3 stained with APC; DAPI nuclear staining. The epidermis is located on the upper side of the images. **B,** Double immunofluorescence staining of CD4+ T cells in normal human skin (NHS): CD4 stained with tetramethylrhodamine isothiocyanate (TRITC; red); CD3 stained with allophycocyanin (APC; yellow); DAPI (4,6-diamidino-2-phenylindole) nuclear staining.

(see "The Skin Immune System under Pathologic Conditions" section).

THE SKIN IMMUNE SYSTEM UNDER HOMEOSTATIC CONDITIONS

Maintenance of cellular and tissue homeostasis requires (a) the prevention of exaggerated responses to innocuous substances (eg, human dander, plant pollen, nutrients) and (b) the occurrence of host-defense reactions at a subclinical level, that is, in the absence of

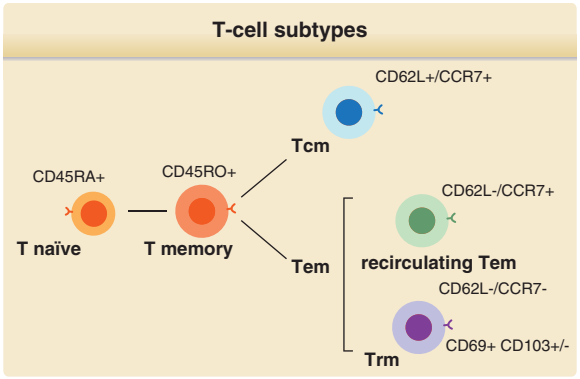

Figure 10-5 T-cell subtypes. Scheme of the different T-cell subsets as defined by their naïve/memory state. Tcm, central memory T cell; Tem, effector memory T cell; Trm, tissue-resident memory T cell.

inflammation. Concerning host-defense reactions at a subclinical level, we must assume that the overgrowth of pathogenic microorganisms in normal skin is prevented by constitutively produced mediators such as proteins with antimicrobial properties (eg, ribonucleotidases 1, 4, 5, and 7), different proteases,[60] and certain AMPs. The S100 calcium-binding protein A7 (S100A7), also known as Psoriasin, is an AMP with a baseline production by keratinocytes. Its antimicrobial effect is mainly directed against *Escherichia coli*.[61] Evidence exists that "hidden" host defense reactions are not only operative at both the innate and the adaptive levels. Commensals (eg, *Staphylococcus epidermidis*) colonizing the epidermis are capable of inducing an immune response that is dependent on the interplay between different types of DC, which interplay ultimately results in the generation of Tc17 cells. The IL-17 produced and released by these CD8+ T cells binds to IL-17 receptors on keratinocytes and triggers the production of mediators capable of preventing the overgrowth of true pathogens such as *Staphylococcus aureus*.[62]

Contrary to the original belief that antigen presentation by DCs invariably results in sensitization, it is now clear that this is luckily (!) not the case. Otherwise, every harmless environmental substance would evoke a massive tissue response. This implies that professional APCs must exist that in the absence of danger signals induce negative (ie, downregulating or tolerizing) signals. In this context, the role of LCs has been heavily debated over the years. In the older literature, LCs were generally regarded as the principal sensitizing cells in skin-derived immune responses. This theory was mainly based on the demonstration, by electron microscopy, of Birbeck granule–containing LCs in the draining lymph nodes of hapten-sensitized guinea pigs[15] and on the observation that hapten application to animal (mouse, hamster) skin with normal LC numbers would result in sensitization, whereas exposure of LC-deficient skin to the very same hapten would lead to tolerization.[14] Later, however, it became clear that LCs are dispensable for the occurrence of protective immune responses against certain microorganisms causing skin infections (eg, herpes simplex virus).[63]

The finding of migrating LCs not only under danger conditions,[64,65] but also under noninflammatory homeostatic conditions, was of crucial importance for our understanding of LC in vivo functions. In fact, LCs carrying melanosomes and/or apoptotic bodies have been detected in lymph vessels of normal skin.[66] In line with this was the demonstration of immature LCs in lymph nodes draining chronically inflamed skin.[67] Consequently, we must assume that antigen-bearing LCs and DCs are constantly trafficking between skin and lymph nodes. That the functional outcome of this event is often that of antigen-specific unresponsiveness can be deduced from the observation that most individuals without any clinical sign of nickel (Ni) allergy have circulating, Ni-specific Tregs, whereas only those suffering from contact allergy to Ni exhibit Ni-specific CD8+ cells.[68] In a similar fashion, LCs can cross-present keratinocyte-derived antigens to lymph node T cells without any clinical sign of sensitization.[69]

The important question remains whether all DC populations of the skin, dependent only on the composition of the milieu in which they reside, can evoke either sensitizing or tolerizing responses, or, alternatively, whether one given DC type is more prone to induce one or the other. An important role of the cytokine milieu DCs act in is suggested by data showing that thymic stromal lymphopoietin strongly influences DCs and LCs to skew T-cell responses toward a Th2 direction.[70,71] On the other hand, evidence exists that mice whose LC population had been depleted by genetic manipulation would develop stronger T-cell reactions to haptens or microbial antigens than would wild-type animals.[72] These findings led to the hypothesis that LCs are intrinsically destined to generate downregulating or tolerizing T-cell responses. The validity of either concept has yet to be proven.

THE SKIN IMMUNE SYSTEM UNDER PATHOLOGIC CONDITIONS

Upon the receipt of danger signals (eg, microbial invasion, exposure to irritants, sensitizing haptens and/or drugs, UV radiation, trauma, heat, cold) or the delivery of other, often ill-defined, disease-eliciting or disease-promoting factors, the skin reacts with a coordinated (host defense) reaction of its cellular and molecular elements. A major component of this tissue response is immunologic in nature. Its magnitude and quality depend on the type of danger signal involved but its usual clinical manifestation is tissue inflammation (see Fig. 10-2B). As exemplified by and probably best investigated in the kinetics of the Koebner reaction in psoriasis, the first passenger cells invading the skin or amplifying in skin are usually cells of the innate response, that is, granulocytes, monocytes, NK cells, ILCs, and pDCs. pDCs are usually detected on the (active) margins of the individual lesions.[73] ILCs of psoriatic lesions belong in their majority to the ILC3 subset and are often located in close proximity to lesional T cells.[74,75] In certain inflammatory skin diseases, infiltrating cells belong almost exclusively to the innate immune system. Examples include pustular psoriasis, pyoderma gangrenosum, acute generalized exanthematous pustulosis, Job syndrome, acne inversa, rosacea, and autoinflammatory syndromes (neutrophils), as well as eosinophilic fasciitis, eosinophilic cellulitis, and hypereosinophilic syndrome (eosinophils). It is not entirely clear whether some of these reactions have an adaptive component or not. In acne and rosacea,[76,77] for example, T cells of the Th17 lineage have been identified in lesional skin, and in the case of acne have been shown to recognize *Propionibacterium acnes*-derived peptides.[77]

In their majority, inflammatory skin diseases are characterized by a prominent, often predominating, lymphocytic infiltrate consisting mostly of T lymphocytes. B cells, interestingly enough, tend to avoid the skin, with few notable exceptions such as cutaneous *Leishmania* infection.[78,79] Now that it is possible to functionally characterize T-cell subsets in situ or freshly isolated from tissue on the basis of cytokines and transcription factors expressed,[74,80,81] many inflammatory skin diseases can now be classified according to the T-cell subset(s) involved (Table 10-5). Psoriasis, for example, is the prototype of a Th17-driven disease, whereas atopic dermatitis has a strong Th2/Th22 signature.[81] Some evidence indicates that lichen planus lesions are characterized by a Th1 pattern.[82] Allergic contact dermatitis had initially been considered as a Th1-/cytotoxic T-cell–mediated disease,[83,84] but newer evidence speaks for an important role of IL-17–producing T cells in its pathogenesis.[85-87] UV obviously favors the expansion of Treg.[88] Certain illnesses, such as graft-versus-host disease, exhibit different molecular patterns in different stages and subtypes of the disease.[89] It is not clear whether similar differences exist between the various forms (acute, subacute, and chronic) of cutaneous lupus erythematosus.

TABLE 10-5
Examples of T-Cell–Driven Skin Diseases

T-CELL PATTERN	SKIN DISEASES
Th1	Lichen planus Allergic contact dermatitis Tuberculoid leprosy Cutaneous leishmaniasis
Th2/Th22	Atopic dermatitis Acute graft-versus-host disease (GVHD) Lepromatous leprosy Diffuse leishmaniasis
Th9	To be determined (tumors?)
Th1/Th17	Chronic lichenoid GVHD
Th17	Acne vulgaris Psoriasis
Cytotoxic T cells	Allergic contact dermatitis Toxic epidermal necrolysis (?)

Some data speak for an important role of the type I IFN–Th1 axis and for a dysregulation of Treg.[90,91] The role of Th17 cells, if any, is controversially debated.[92,93] It is not unreasonable to assume that a molecular map of most (inflammatory) skin diseases will be available in the not too distant future. This will probably result in the molecular, and thus functional, subclassification of skin diseases, which on purely morphologic grounds are considered homogeneous. In psoriasis, this may be true for the small group of patients who do not or only poorly respond to the novel TNF or IL-17A antagonists. As mentioned earlier in this section, the recurrence of an inflammatory skin disease is not only caused by the influx of pathogenic leukocytes from the blood, but can also be caused by the activation of T memory cells in the skin, notably Trm. It is not entirely clear which types of APC are involved in this process. These must not necessarily be the APCs (ie, LCs and DDCs) residing in normal skin. In fact, the population of tipDCs[94] and 6-sulfo poly-*N*-acetyllactosamine DCs (slan-DCs)[95] are probably the major IL-23–producing cells in psoriatic lesions that are responsible for the differentiation of T-helper cells in Th17 cells and for their survival. In contrast, inflammatory-type DCs of myeloid origin are apparently needed for the expansion of Th2 cells in atopic dermatitis.[96] Biologic drugs now exist that allow us to interfere with the pathologic tissue response not only at the lymphocyte, but also at the APC level. In fact, the anti–IL-23p19 antibodies guselkumab, tildrakizumab, and risankizumab show excellent efficacy in the treatment of plaque psoriasis.[97-99]

A discussion of the skin immune system under pathologic conditions is incomplete without mentioning the immune contexture in human skin cancers. As already discussed earlier (see "Background"), ample evidence exists that mobilization of cells and molecules of the immune system can often result in the successful elimination of cancer cells that manifests clinically as tumor regression. This phenomenon is not infrequently seen in skin cancers such as melanoma and actinic keratoses. The cancer-destructive capacity of immune cells becomes weaker and weaker the longer the (primary) tumor persists. In other words: the cancer avoids immune destruction by slowly shifting the tumor microenvironment from a tumoricidal into a tumor-promoting mode.[100-102] All types of immune cells can be found within or around the tumor. These infiltrates are heterogeneous between different types of cancer and can be very diverse from patient to patient. It appears that the presence of high numbers of intratumoral and peritumoral granulocytes, pDCs, myeloid-derived suppressor cells, and so-called M2 macrophages, producing IL-4, IL-10, IL-13, and transforming growth factor (TGF)-β, heralds a bad prognosis, whereas large numbers of CD3+ T cells, CD8+ cytotoxic T lymphocytes, and CD45RO+ memory T cells of both the CD4 and the CD8 type are associated with a longer disease-free survival.[102] Attention is now focused on the role of IL-9–producing T cells, so-called Th9 cells, in cancer immunity.[103] In mice, they possess potent anticancer properties, especially against melanoma.[104] Studies in human (skin) cancers are urgently needed to determine the anticancer potential of Th9 cells and, thus, their possible relevance for cancer immunotherapy.

POST SCRIPTUM

In a remarkable speech delivered at the Annual Meeting of the Society of Clinical Investigation in 1981, the late immunologist Dr. William Paul predicted a golden era of clinical investigation.[105] He thought that the introduction of certain technologies (production of monoclonal antibodies and the cloning of cells and genes) would result in true accomplishment. Today, we can safely state that his prophecy was true. Technology-driven, ground-breaking discoveries at the bench are today being translated into true benefit for our patients. That dermatology is at the forefront of this development is encouraging and at the same time a challenge.

REFERENCES

1. Pirquet CP, Schick B. *Die Serumkrankheit*. Leipzig, Germany: Deuticke; 1905.
2. Germuth FG Jr. A comparative histologic and immunologic study in rabbits of induced hypersensitivity of the serum sickness type. *J Exp Med*. 1953;97(2):257-282.
3. Weigle WO, Dixon FJ. Relationship of circulating antigen-antibody complexes, antigen elimination, and complement fixation in serum sickness. *Proc Soc Exp Biol Med*. 1958;99(1):226-231.
4. Beutner EH, Lever WF, Witebsky E, et al. Autoantibodies in pemphigus vulgaris response to an intercellular substance of epidermis. *JAMA*. 1965;192:682-688.
5. Jordon RE, Beutner EH, Witebsky E, et al. Basement zone antibodies in bullous pemphigoid. *JAMA*. 1967;200(9):751-756.
6. Jenner E. *An Inquiry into the Causes and Effects of the Variolae Vaccinae, a Disease Discovered in Some of the Western Countries of England, Particularly Gloucestershire, and Known by the Name of "The Cow Pox."* London, UK: Sampson Low; 1798.
7. Coley WB. The treatment of malignant tumors by repeated inoculations of erysipelas: with a report of ten original cases. *Am J Med Sci*. 1893;105(5):487-511.
8. Besredka A, Gross L. De l'immunisation contre le sarcome de la souris par la voie intracutanée. *Ann Inst Pasteur (Paris)*. 1935;(55):491-500.
9. Landsteiner K, Chase MW. Studies on the sensitization of animals with simple chemical compounds: VI. Experiments on the sensitization of guinea pigs to poison ivy. *J Exp Med*. 1939;69(6):767-784.
10. Macher E, Chase MW. Studies on the sensitization of animals with simple chemical compounds. XI. The fate of labeled picryl chloride and dinitrochlorobenzene after sensitizing injections. *J Exp Med*. 1969;129(1):81-102.
11. Frey JR, Wenk P. Experimental studies on the pathogenesis of contact eczema in the guinea-pig. *Int Arch Allergy Appl Immunol*. 1957;11(1-2):81-100.
12. Macher E, Chase MW. Studies on the sensitization of animals with simple chemical compounds. XII. The

influence of excision of allergenic depots on onset of delayed hypersensitivity and tolerance. *J Exp Med*. 1969;129(1):103-121.
13. Kripke ML. Antigenicity of murine skin tumors induced by ultraviolet light. *J Natl Cancer Inst*. 1974;53(5): 1333-1336.
14. Streilein JW, Bergstresser PR. Langerhans cell function dictates induction of contact hypersensitivity or unresponsiveness to DNFB in Syrian hamsters. *J Invest Dermatol*. 1981;77(3):272-277.
15. Silberberg-Sinakin I, Thorbecke GJ, Baer RL, et al. Antigen-bearing Langerhans cells in skin, dermal lymphatics and in lymph nodes. *Cell Immunol*. 1976;25(2):137-151.
16. Stingl G, Katz SI, Clement L, et al. Immunologic functions of Ia-bearing epidermal Langerhans cells. *J Immunol*. 1978;121(5):2005-2013.
17. Streilein JW. Skin-associated lymphoid tissues (SALT): origins and functions. *J Invest Dermatol*. 1983;80(suppl):12s-16s.
18. Luger TA, Stadler BM, Katz SI, et al. Epidermal cell (keratinocyte)-derived thymocyte-activating factor (ETAF). *J Immunol*. 1981;127(4):1493-1498.
19. Kupper TS, Ballard DW, Chua AO, et al. Human keratinocytes contain mRNA indistinguishable from monocyte interleukin 1 alpha and beta mRNA. Keratinocyte epidermal cell-derived thymocyte-activating factor is identical to interleukin 1. *J Exp Med*. 1986;164(6):2095-2100.
20. Sauder DN, Carter CS, Katz SI, et al. Epidermal cell production of thymocyte activating factor (ETAF). *J Invest Dermatol*. 1982;79(1):34-39.
21. Bos JD, Kapsenberg ML. The skin immune system Its cellular constituents and their interactions. *Immunol Today*. 1986;7(7-8):235-240.
22. Abbas A, Lichtman AH, Pillai S. *Cellular and Molecular Immunology*. 8th ed. Philadelphia, PA: Elsevier Saunders; 2014:544.
23. De Nardo D. Toll-like receptors: activation, signalling and transcriptional modulation. *Cytokine*. 2015;74(2): 181-189.
24. Kumagai Y, Akira S. Identification and functions of pattern-recognition receptors. *J Allergy Clin Immunol*. 2010;125(5):985-992.
25. Takahashi T, Gallo RL. The critical and multifunctional roles of antimicrobial peptides in dermatology. *Dermatol Clin*. 2017;35(1):39-50.
26. Hoffmann JH, Enk AH. Neutrophil extracellular traps in dermatology: caught in the NET. *J Dermatol Sci*. 2016;84(1):3-10.
27. Klose CS, Artis D. Innate lymphoid cells as regulators of immunity, inflammation and tissue homeostasis. *Nat Immunol*. 2016;17(7):765-774.
28. Okabe Y, Medzhitov R. Tissue biology perspective on macrophages. *Nat Immunol*. 2016;17(1):9-17.
29. Stary G, Bangert C, Tauber M, et al. Tumoricidal activity of TLR7/8-activated inflammatory dendritic cells. *J Exp Med*. 2007;204(6):1441-1451.
30. Wagstaff AJ, Perry CM. Topical imiquimod: a review of its use in the management of anogenital warts, actinic keratoses, basal cell carcinoma and other skin lesions. *Drugs*. 2007;67(15):2187-2210.
31. Haniffa M, Gunawan M, Jardine L. Human skin dendritic cells in health and disease. *J Dermatol Sci*. 2015;77(2):85-92.
32. Serbina NV, Salazar-Mather TP, Biron CA, et al. TNF/iNOS-producing dendritic cells mediate innate immune defense against bacterial infection. *Immunity*. 2003;19(1):59-70.
33. Nakano H, Lin KL, Yanagita M, et al. Blood-derived inflammatory dendritic cells in lymph nodes stimulate acute T helper type 1 immune responses. *Nat Immunol*. 2009;10(4):394-402.
34. Hammad H, Lin KL, Yanagita M, et al. Inflammatory dendritic cells—not basophils—are necessary and sufficient for induction of Th2 immunity to inhaled house dust mite allergen. *J Exp Med*. 2010;207(10): 2097-2111.
35. Segura E, Touzot M, Bohineust A, et al. Human inflammatory dendritic cells induce Th17 cell differentiation. *Immunity*. 2013;38(2):336-348.
36. Romani N, Brunner PM, Stingl G. Changing views of the role of Langerhans cells. *J Invest Dermatol*. 2012;132(3, pt 2):872-881.
37. Birbeck MS, Breathnach AS, Everall JD. An electron microscope study of basal melanocytes and high-level clear cells (Langerhans cells) in vitiligo. *J Invest Dermatol*. 1961;37(1):51-64.
38. Valladeau J, Ravel O, Dezutter-Dambuyant C, et al. Langerin, a novel C-type lectin specific to Langerhans cells, is an endocytic receptor that induces the formation of Birbeck granules. *Immunity*. 2000;12(1):71-81.
39. Hunger RE, Sieling PA, Ochoa MT, et al. Langerhans cells utilize CD1a and langerin to efficiently present nonpeptide antigens to T cells. *J Clin Invest*. 2004;113(5):701-708.
40. Pena-Cruz V, Ito S, Dascher CC, et al. Epidermal Langerhans cells efficiently mediate CD1a-dependent presentation of microbial lipid antigens to T cells. *J Invest Dermatol*. 2003;121(3):517-521.
41. Vermeer BJ, Mommaas AM, Wijsman MC, et al. Ultrastructural localization of HLA-DR and HLA-DQ molecules in Langerhans cells and B cells: an immunoelectronmicroscopic study. *Reg Immunol*. 1988;1(2):85-91.
42. De Panfilis G, Manara GC, Ferrari C, et al. Simultaneous colloidal gold immunoelectronmicroscopy labeling of CD1a, HLA-DR, and CD4 surface antigens of human epidermal Langerhans cells. *J Invest Dermatol*. 1988;91(6):547-552.
43. Cerio R, Griffiths CE, Cooper KD, et al. Characterization of factor XIIIa positive dermal dendritic cells in normal and inflamed skin. *Br J Dermatol*. 1989;121(4):421-431.
44. Lenz A, Heine M, Schuler G, et al. Human and murine dermis contain dendritic cells. Isolation by means of a novel method and phenotypical and functional characterization. *J Clin Invest*. 1993;92(6):2587-2596.
45. Nestle FO, Zheng XG, Thompson CB, et al. Characterization of dermal dendritic cells obtained from normal human skin reveals phenotypic and functionally distinctive subsets. *J Immunol*. 1993;151(11): 6535-6545.
46. Haniffa M, Shin A, Bigley V, et al. Human tissues contain CD141hi cross-presenting dendritic cells with functional homology to mouse CD103+ nonlymphoid dendritic cells. *Immunity*. 2012;37(1):60-73.
47. Bevan MJ. Cross-priming for a secondary cytotoxic response to minor H antigens with H-2 congenic cells which do not cross-react in the cytotoxic assay. *J Exp Med*. 1976;143(5):1283-1288.
48. Stoitzner P, Tripp CH, Eberhart A, et al. Langerhans cells cross-present antigen derived from skin. *Proc Natl Acad Sci U S A*. 2006;103(20):7783-7788.
49. Jonuleit H, Schmitt E, Schuler G, et al. Induction of interleukin 10-producing, nonproliferating CD4(+) T cells with regulatory properties by repetitive

stimulation with allogeneic immature human dendritic cells. *J Exp Med*. 2000;192(9):1213-1222.
50. Kubo A, Nagao K, Yokouchi M, et al. External antigen uptake by Langerhans cells with reorganization of epidermal tight junction barriers. *J Exp Med*. 2009;206(13):2937-2946.
51. Stary G, Klein I, Bauer W, et al. Glucocorticosteroids modify Langerhans cells to produce TGF-beta and expand regulatory T cells. *J Immunol*. 2011;186(1):103-112.
52. Schuler G, Steinman RM. Murine epidermal Langerhans cells mature into potent immunostimulatory dendritic cells in vitro. *J Exp Med*. 1985;161(3): 526-546.
53. Romani N, Lenz A, Glassel H, et al. Cultured human Langerhans cells resemble lymphoid dendritic cells in phenotype and function. *J Invest Dermatol*. 1989;93(5):600-609.
54. van de Ven R, van den Hout MF, Lindenberg JJ, et al. Characterization of four conventional dendritic cell subsets in human skin-draining lymph nodes in relation to T-cell activation. *Blood*. 2011;118(9):2502-2510.
55. Foster CA, Yokozeki H, Rappersberger K, et al. Human epidermal T cells predominantly belong to the lineage expressing alpha/beta T cell receptor. *J Exp Med*. 1990;171(4):997-1013.
56. Clark RA, Chong BF, Mirchandani N, et al. A novel method for the isolation of skin resident T cells from normal and diseased human skin. *J Invest Dermatol*. 2006;126(5):1059-1070.
57. Watanabe R, Gehad A, Yang C, et al. Human skin is protected by four functionally and phenotypically discrete populations of resident and recirculating memory T cells. *Sci Transl Med*. 2015;7(279):279ra39.
58. Gelb AB, Smoller BR, Warnke RA, Picker LJ. Lymphocytes infiltrating primary cutaneous neoplasms selectively express the cutaneous lymphocyte-associated antigen (CLA). *Am J Pathol*. 1993;142(5): 1556-1564.
59. Akdis M, Akdis CA, Weigl L, et al. Skin-homing, CLA+ memory T cells are activated in atopic dermatitis and regulate IgE by an IL-13-dominated cytokine pattern: IgG4 counter-regulation by CLA- memory T cells. *J Immunol*. 1997;159(9):4611-4619.
60. Iwase T, Uehara Y, Shinji H, et al. *Staphylococcus epidermidis* Esp inhibits *Staphylococcus aureus* biofilm formation and nasal colonization. *Nature*. 2010;465(7296):346-349.
61. Gläser R, Meyer-Hoffert U, Harder J, et al. The antimicrobial protein Psoriasin (S100A7) is upregulated in atopic dermatitis and after experimental skin barrier disruption. *J Invest Dermatol*. 2009;129(3):641-649.
62. Naik S, Bouladoux N, Linehan JL, et al. Commensal-dendritic-cell interaction specifies a unique protective skin immune signature. *Nature*. 2015;520(7545): 104-108.
63. Allan RS, Smith CM, Belz GT, et al. Epidermal viral immunity induced by CD8alpha+ dendritic cells but not by Langerhans cells. *Science*. 2003;301(5641): 1925-1928.
64. Cumberbatch M, Illingworth I, Kimber I. Antigen-bearing dendritic cells in the draining lymph nodes of contact sensitized mice: cluster formation with lymphocytes. *Immunology*. 1991;74(1):139-145.
65. Larsen CP, Steinman RM, Witmer-Pack M, et al. Migration and maturation of Langerhans cells in skin transplants and explants. *J Exp Med*. 1990;172(5): 1483-1493.
66. Stoitzner P, Pfaller K, Stössel H, et al. A close-up view of migrating Langerhans cells in the skin. *J Invest Dermatol*. 2002;118(1):117-125.
67. Geissmann F, Dieu-Nosjean MC, Dezutter C, et al. Accumulation of immature Langerhans cells in human lymph nodes draining chronically inflamed skin. *J Exp Med*. 2002;196(4):417-430.
68. Cavani A, Nasorri F, Ottaviani C, et al. Human CD25+ regulatory T cells maintain immune tolerance to nickel in healthy, nonallergic individuals. *J Immunol*. 2003;171(11):5760-5768.
69. Holcmann M, Stoitzner P, Drobits B, et al. Skin inflammation is not sufficient to break tolerance induced against a novel antigen. *J Immunol*. 2009;183(2):1133-1143.
70. Soumelis V, Reche PA, Kanzler H, et al. Human epithelial cells trigger dendritic cell mediated allergic inflammation by producing TSLP. *Nat Immunol*. 2002. 3(7):673-680.
71. Ito T, Wang YH, Duramad O, et al. TSLP-activated dendritic cells induce an inflammatory T helper type 2 cell response through OX40 ligand. *J Exp Med*. 2005;202(9):1213-1223.
72. Kaplan DH, Jenison MC, Saeland S, et al. Epidermal Langerhans cell-deficient mice develop enhanced contact hypersensitivity. *Immunity*. 2005;23(6): 611-620.
73. Nestle FO, Conrad C, Tun-Kyi A, et al. Plasmacytoid predendritic cells initiate psoriasis through interferon-alpha production. *J Exp Med*. 2005;202(1):135-143.
74. Brüeggen MC, Bauer WM, Reininger B, et al. In situ mapping of innate lymphoid cells in human skin: evidence for remarkable differences between normal and inflamed skin. *J Invest Dermatol*. 2016;136:2396-2405.
75. Villanova F, Flutter B, Tosi I, et al. Characterization of innate lymphoid cells in human skin and blood demonstrates increase of NKp44+ ILC3 in psoriasis. *J Invest Dermatol*. 2014;134(4):984-991.
76. Buhl T, Sulk M, Nowak P, et al. Molecular and morphological characterization of inflammatory infiltrate in rosacea reveals activation of Th1/Th17 pathways. *J Invest Dermatol*. 2015;135(9):2198-2208.
77. Kistowska M, Meier B, Proust T, et al. Propionibacterium acnes promotes Th17 and Th17/Th1 responses in acne patients. *J Invest Dermatol*. 2015;135(1): 110-118.
78. Palma GI, Saravia NG. In situ characterization of the human host response to *Leishmania panamensis*. *Am J Dermatopathol*. 1997;19(6):585-590.
79. Egbuniwe IU, Karagiannis SN, Nestle FO, et al. Revisiting the role of B cells in skin immune surveillance. *Trends Immunol*. 2015;36(2):102-111.
80. Newell EW, Sigal N, Bendall SC, et al. Cytometry by time-of-flight shows combinatorial cytokine expression and virus-specific cell niches within a continuum of CD8+ T cell phenotypes. *Immunity*. 2012;36(1):142-152.
81. Nograles KE, Zaba LC, Shemer A, et al. IL-22-producing "T22" T cells account for upregulated IL-22 in atopic dermatitis despite reduced IL-17-producing TH17 T cells. *J Allergy Clin Immunol*. 2009;123(6):1244-1252 e2.
82. Terlou A, Santegoets LA, van der Meijden WI, et al. An autoimmune phenotype in vulvar lichen sclerosus and lichen planus: a Th1 response and high levels of microRNA-155. *J Invest Dermatol*. 2012;132 (3, pt 1):658-666.

83. Kehren J, Desvignes C, Krasteva M, et al. Cytotoxicity is mandatory for CD8(+) T cell-mediated contact hypersensitivity. *J Exp Med*. 1999;189(5):779-786.
84. Xu H, Dilulio NA, Fairchild RL. T cell populations primed by hapten sensitization in contact sensitivity are distinguished by polarized patterns of cytokine production: interferon gamma-producing (Tc1) effector CD8+ T cells and interleukin (Il) 4/Il-10-producing (Th2) negative regulatory CD4+ T cells. *J Exp Med*. 1996;183(3):1001-1012.
85. He D, Wu L, Kim HK, et al. CD8+ IL-17-producing T cells are important in effector functions for the elicitation of contact hypersensitivity responses. *J Immunol*. 2006;177(10):6852-6858.
86. He D, Wu L, Kim HK, et al. IL-17 and IFN-gamma mediate the elicitation of contact hypersensitivity responses by different mechanisms and both are required for optimal responses. *J Immunol*. 2009;183(2):1463-1470.
87. Kish DD, Li X, Fairchild RL. CD8 T cells producing IL-17 and IFN-gamma initiate the innate immune response required for responses to antigen skin challenge. *J Immunol*. 2009;182(10):5949-5959.
88. Schwarz A, Beissert S, Grosse-Heitmeyer K, et al. Evidence for functional relevance of CTLA-4 in ultraviolet-radiation-induced tolerance. *J Immunol*. 2000;165(4):1824-1831.
89. Brueggen MC, Klein I, Greinix H, et al. Diverse T-cell responses characterize the different manifestations of cutaneous graft-versus-host disease. *Blood*. 2014;123(2):290-299.
90. Wenzel J, Wörenkämper E, Freutel S, et al. Enhanced type I interferon signalling promotes Th1-biased inflammation in cutaneous lupus erythematosus. *J Pathol*. 2005;205(4):435-442.
91. Freutel S, Gaffal E, Zahn S, et al. Enhanced CCR5+/CCR3+ T helper cell ratio in patients with active cutaneous lupus erythematosus. *Lupus*. 2011;20(12):1300-1304.
92. Jabbari A, Suárez-Fariñas M, Fuentes-Duculan J, et al. Dominant Th1 and minimal Th17 skewing in discoid lupus revealed by transcriptomic comparison with psoriasis. *J Invest Dermatol*. 2014;134(1):87-95.
93. Stannard JN, Kahlenberg JM. Cutaneous lupus erythematosus: updates on pathogenesis and associations with systemic lupus. *Curr Opin Rheumatol*. 2016;28(5):453-459.
94. Lowes MA, Chamian F, Abello MV, et al. Increase in TNF-alpha and inducible nitric oxide synthase-expressing dendritic cells in psoriasis and reduction with efalizumab (anti-CD11a). *Proc Natl Acad Sci U S A*. 2005;102(52):19057-19062.
95. Brunner PM, Koszik F, Reininger B, et al. Infliximab induces downregulation of the IL-12/IL-23 axis in 6-sulfo-LacNac (slan)+ dendritic cells and macrophages. *J Allergy Clin Immunol*. 2013;132(5):1184-1193e8.
96. Wollenberg A, Kraft S, Hanau D, et al. Immunomorphological and ultrastructural characterization of Langerhans cells and a novel, inflammatory dendritic epidermal cell (IDEC) population in lesional skin of atopic eczema. *J Invest Dermatol*. 1996;106(3):446-453.
97. Kopp T, Riedl E, Bangert C, et al. Clinical improvement in psoriasis with specific targeting of interleukin-23. *Nature*. 2015;521(7551):222-226.
98. Blauvelt A, Papp KA, Griffiths CE, et al. Efficacy and safety of guselkumab, an anti-interleukin-23 monoclonal antibody, compared with adalimumab for the continuous treatment of patients with moderate to severe psoriasis: Results from the phase III, double-blinded, placebo- and active comparator-controlled VOYAGE 1 trial. *J Am Acad Dermatol*. 2017;76(3):405-417.
99. Gordon KB, Duffin KC, Bissonnette R, et al. A phase 2 trial of guselkumab versus adalimumab for plaque psoriasis. *N Engl J Med*. 2015;373(2):136-144.
100. Schreiber RD, Old LJ, Smyth MJ. Cancer immunoediting: integrating immunity's roles in cancer suppression and promotion. *Science*. 2011;331(6024):1565-1570.
101. Hanahan D, Weinberg RA. Hallmarks of cancer: the next generation. *Cell*. 2011;144(5):646-674.
102. Fridman WH, Pagès F, Sautès-Fridman C, et al. The immune contexture in human tumours: impact on clinical outcome. *Nat Rev Cancer*. 2012;12(4):298-306.
103. Rivera Vargas T, Humblin E, Végran F, et al. TH9 cells in anti-tumor immunity. *Semin Immunopathol*. 2017;39(1):39-46.
104. Purwar R, Schlapbach C, Xiao S, et al. Robust tumor immunity to melanoma mediated by interleukin-9-producing T cells. *Nat Med*. 2012;18(8):1248-1253.
105. Paul WE. Clinical investigation—on the threshold of a golden era? Presidential address. *J Clin Invest*. 1981;68(3):823-826.

Chapter 11 :: Cellular Components of the Cutaneous Immune System

:: Johann E. Gudjonsson & Robert L. Modlin

AT-A-GLANCE

- Human immune system consists broadly of innate vs adaptive immune responses.
- Innate immune system has multiple different cellular subsets that have in common rapid response to infection and injury but are restricted in their ability to recognize and respond to all pathogens, instead relying on germline encoded pattern recognition receptors and danger signals.
- Adaptive immune system is a slower but more adaptive arm of the immune system that can respond to near limitless range of pathogens.
- Recently identified immune cells, such as innate lymphoid cells and unconventional T cells, span the spectrum between the innate and the adaptive immune system.

INTRODUCTION

Apart from being one of the largest organs in the human body, the skin acts as a protective barrier between the internal and external environments. Although the epidermis acts as a physical and physiologic barrier to the entry of commensals and pathogens, the near constant exposure to an array of both benign and harmful microorganisms and other stressors in the skin has promoted the evolution of a complex cellular immune network, involving both the innate and adaptive parts of the immune system. This ensures adequate responses against pathogens as well as mechanisms to promote homeostasis and control excessive inflammatory response. This network in the skin has been named the skin immune system and consists of a large number of specialized skin-resident immune cells as well as circulating lymphocytes constantly recirculating between the skin, skin-draining lymph nodes, and the peripheral circulation.[1] The cellular constituents of the skin immune system involve multiple cell types, subtypes of immune cells, and often involve participation of parenchymal cells including keratinocytes, endothelial cells and fibroblasts (Fig. 11-1). The interactions between these are highly complex, with each cell type often having both specific and redundant roles in immune responses.

INNATE AND ADAPTIVE IMMUNE SYSTEM

The skin immune system includes components of both the innate and adaptive immune components (Fig. 11-2). The innate immune system recognizes specific motifs, such as proteins, lipids, nucleotides, and other metabolites, associated with broad classes of pathogens, and with the receptors for these encoded in germline DNA. In contrast, the adaptive immune system is based on the generation of near limitless antigen receptor or antibody diversity through somatic recombination, which in turn provides the foundation for immunologic memory through differentiation, expansion, and persistence of long-lived antigen-specific lymphocytes.[2] This expansion and persistence of antigen-specific lymphocytes in turn allow a more rapid and robust response in the event of subsequent immunologic challenge. In recent years, this distinction has been somewhat challenged as it has become clear that many immune cells have properties of both the innate and adaptive immune systems, and that the innate immune system can adapt to repeated challenges. Such innate immune memory response has been termed "trained immunity" and provides protection against reinfection in a T- and B-cell–independent manner.[3]

Whereas T and B cells are the primary cells of the adaptive immune system, dendritic cells and macrophages with their prominent expression of pattern-associated receptors are the key players of the innate immune system, in terms of either directly dealing with microbial infection and/or instructing the adaptive immune response. Other cell types that participate in innate immune responses include mast cells, neutrophils, and resident tissue cells such as keratinocytes, endothelial cells and fibroblasts. Several cell types have dual characteristics of the innate and adaptive immune system, including innate lymphoid cells (ILCs), and innate-like T cells, as discussed in greater detail later in this chapter.

The primary function of the innate immune system is to provide a rapid first line of defense against microbial pathogens to contain them, while the much slower but more powerful adaptive part of the immune system is being activated. The activation of the innate immune system promotes activation of the adaptive immune system and dictates what type of adaptive immune response is mounted against the invading pathogen. Therefore, these 2 systems act in synergy

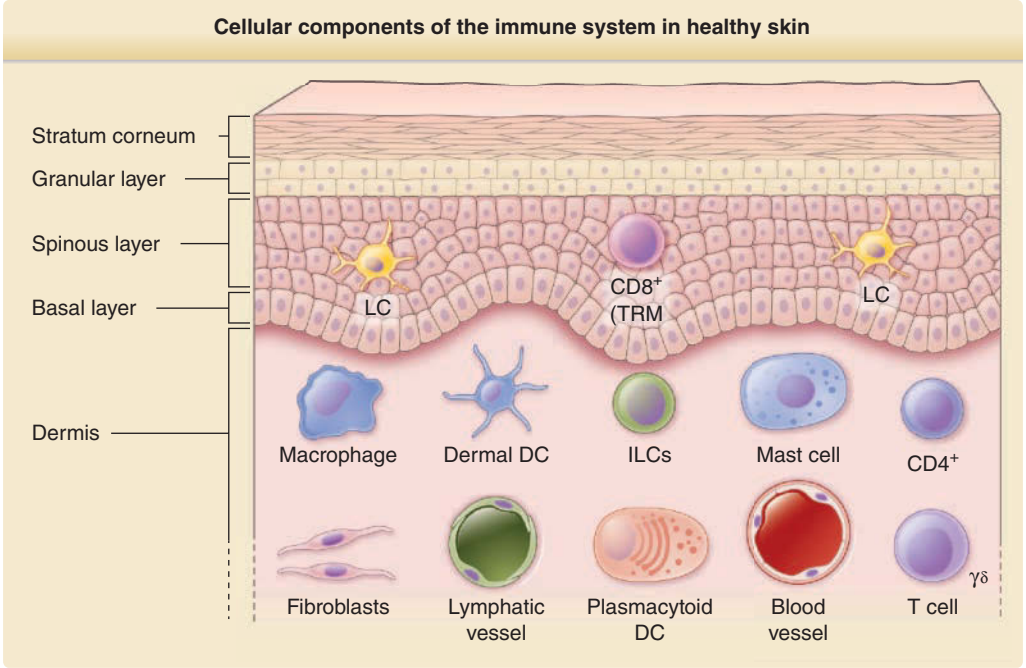

Figure 11-1 Components of the cellular immune system in healthy skin. Multiple different immune cell populations are present in healthy skin. Langerhans cells and resident memory T cells, primarily $CD8^+$, reside in the epidermal layer, whereas $CD4^+$ and γδ T cells are found in the upper dermis. Innate lymphoid cells (ILCs) are found in proximity to the dermal-epidermal junction, whereas mast cells are often in proximity to dermal blood vessels. Dermal dendritic cells and macrophages are found in the dermis. Other cells may contribute to immune responses in skin such as fibroblasts, lymphatic blood vessels, nerves (not shown), and melanocytes (not shown).

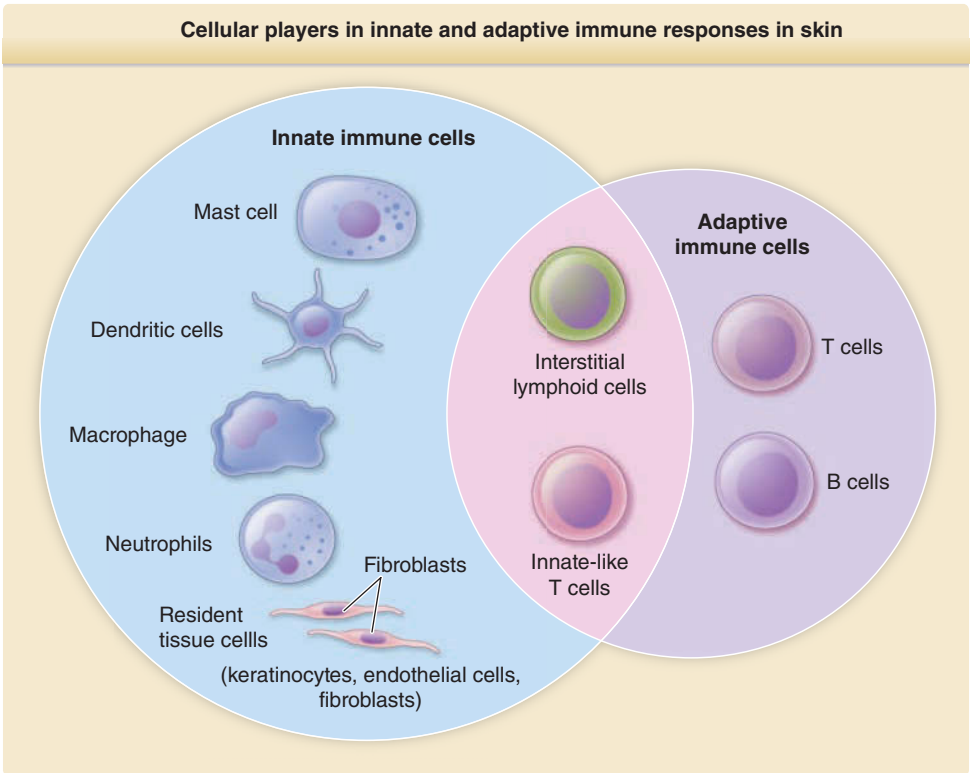

Figure 11-2 Innate and adaptive cells. Interstitial lymphoid cells and innate-like T cells have both innate and adaptive immune functions.

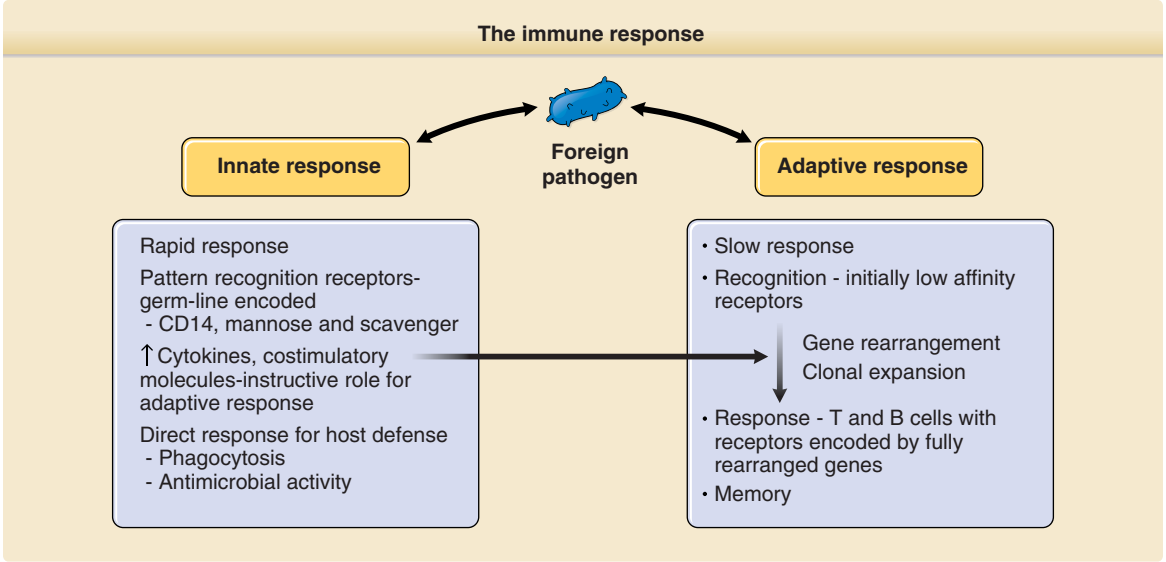

Figure 11-3 The immune system of higher vertebrates uses both innate and adaptive immune responses. These immune responses differ in the way they recognize foreign antigens and the speed with which they respond, yet they complement each other in eradicating foreign pathogens.

to defend the host, but abnormal activation of these systems can frequently lead to various inflammatory conditions and diseases (Fig. 11-3).

CELLULAR COMPONENTS OF THE IMMUNE SYSTEM

T CELLS

T cells are derived from multipotent hematopoietic stem cells in the bone marrow. Progenitor T cells migrate through the blood to the thymus, where they mature. This is the reason for the naming of these cells, where the "T" in *T cells* stands for "thymus-dependent." The majority of human T cells rearrange their alpha and beta chains on the T-cell receptor in the thymus and are termed αβ T cells, whereas a small minority of T cells in the thymus have γδ T-cell receptors. The γδ receptors have limited diversity and are considered to be part of the innate immune system. These two, αβ and γδ, are the key lineages of T cells.

T cells that have completed their primary development in the thymus, and have not yet encountered their specific antigen, are known as naïve T cells and circulate through the bloodstream to secondary lymphoid organs including lymph nodes and the spleen. Once a naïve T cell meets its specific antigen, presented to it as a peptide MHC complex on the surface of an antigen-presenting cell in secondary lymphoid organs, it is able to develop into an effector T cell and a longer-lived central memory T cells. In contrast to naïve T cells, effector T cells are able to mount a response to antigens. T cells can be either $CD4^+$ or $CD8^+$. Naive $CD8^+$ T cells recognize peptide antigens in the binding pocket of MHC class I molecules such as HLA-A, HLA-B, or HLA-C, and differentiate into cytotoxic effector T cells, which recognize and kill infected cells. Some αβ $CD8^+$ T cells with limited TCR diversity are able to respond to lipid antigens by MHC class I–like antigen-presenting molecules, including the CD1 family of proteins. $CD8^+$ effector T cells are often defined by the major cytokine that they produce, including IFN-γ, IL-4, and IL-17, as T-cytotoxic (T_C)1, T_C2, and T_C17s, respectively. Naïve $CD4^+$ T cells recognize peptide antigens in the binding pocket of MHC class II molecules such as HLA-DR, HLA-DQ, and HLA-DP on antigen-presenting cells and differentiate into effector subsets that have broader and different immunologic functions. This includes the main $CD4^+$ T-cell subsets, T helper 1 (T_H1), T_H2, T_H17, and T follicular-helper (T_{FH}), and T regulatory cells (Tregs) (Fig. 11-4).

T HELPER 1 (T_H1) CELLS

T_H1 cells are characterized by the production of the cytokines IL-2, IFN-γ, and TNF-α. T_H1 cells are the main mediators of cell-mediated immunity. These cells are characterized by the expression of the T-box transcription factor T-bet, which induces both transcriptional activation of the IFN-γ gene locus and responsiveness to the T_H1-polarizing cytokine IL-12. T_H1 cells, primarily by the release of IFN-γ, activate macrophages to kill or inhibit the growth of pathogens and trigger cytotoxic T-cell responses.

T HELPER 2 (T_H2) CELLS

T_H2 cells are characterized by the production of the cytokines IL-4, IL-5, and IL-13. The zinc-finger transcription factor GATA-3 is critical for inducing the T_H2 program in these cells. In contrast to T_H1 cells,

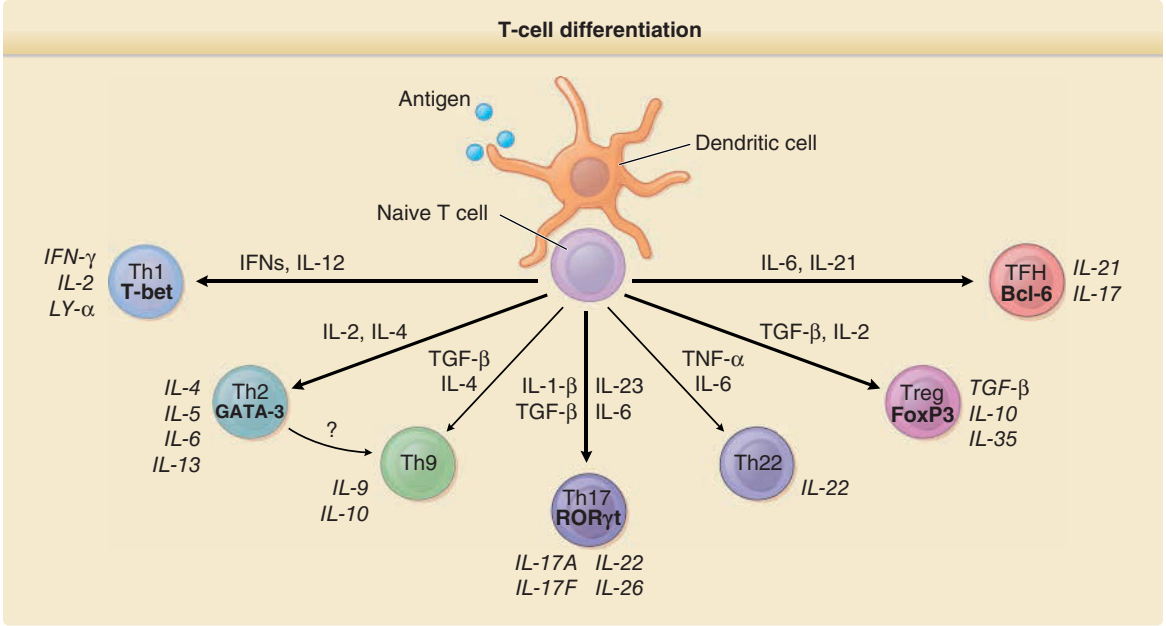

Figure 11-4 Schematic view of events governing and occurring in T-cell differentiation. Depending on the type and activation status of the antigen-presenting dendritic cells (DCs) and on the type and amounts of cytokines secreted by these and/or other cells, naïve T cells will expand and differentiate into various subsets, that is, T_H1, T_H2, T_H9, T_H17, T_H22, Treg, and T_{FH}. They exhibit different types of transcription factors and secrete different types of cytokines.

T_H2 cells facilitate humoral (antibody) responses and inhibit some cell-mediated immune responses. There is significant crossregulation between those 2 arms of the immune system. Thus, the T_H1 cytokine IFN-γ downregulates T_H2 responses, and conversely, IL-4 downregulates both Th1 responses and macrophage function.

T HELPER 9 (T_H9) CELLS

IL-9 is produced by a population of T cells, which is distinguished from other T-cell lineages such as T_H1, T_H2, and T_H17 cells. These T_H9 cells coproduce TNF-α, but unlike mouse T_H9 cells, do not produce IL-10. T_H9 cells are found primarily among the skin homing (cutaneous leukocyte antigen [CLA] positive) T-cell population and are present in healthy human skin. IL-9 promotes upregulation of other proinflammatory cytokines including IFN-γ, IL-13, and IL-17, suggesting that T_H9 activation can initiate inflammatory reactions and amplify activation and cytokine production of other T_H subsets.[4]

T HELPER 17 (T_H17) CELLS

T_H17 cells are characterized by the production of the cytokines IL-17A, IL-17F, IL-21, IL-22, and recently IL-26.[5] They depend on IL-23 for their survival and expansion,[6] and are regulated by the transcription factor RORγt. T_H17 cells are involved in antigen responses against extracellular pathogens including both bacteria and fungi. These cells have been implicated as key players in the pathogenesis of psoriasis.

T REGULATORY CELLS (TREGS)

Tregs play a key role in maintaining tolerance to self-antigens in the periphery. Loss of Tregs, as happens in IPEX (immune dysregulation, polyendocrinopathy, enteropathy, and X-linked) syndrome, results in multiorgan autoimmune disease. Tregs function by suppressing the activation, cytokine production, and proliferation of other T cells.[7] They are characterized by expression of the transcription factor FOXP3, the genetic cause of IPEX syndrome. About 5% to 10% of the T cells resident in normal human skin are FOXP3+ T regs.[8] Other populations of Tregs have been reported in humans, including IL-10 producing FOXP3-negative cells, and have been implicated in systemic lupus erythematosus.

T FOLLICULAR HELPER CELLS (T_{FH})

T_{FH} represent a distinct subset of $CD4^+$ T cells primarily found in B-cell areas of lymph nodes, spleen, and Payer patches. T_{FH} trigger the formation and maintenance of germinal centers in lymph nodes and spleen through the expression of CD40 ligand (CD40L) and the secretion of IL-21 and IL-4. These cells play a crucial role in orchestrating selection and survival of B cells that go on to differentiate into either antibody-producing plasma cells or memory B cells.

SKIN HOMING

To gain entry into the skin, T cells need to express the right surface molecules and receptors. This includes

the cutaneous lymphocyte antigen (CLA),[9] and expression of specific chemokine receptors including CCR4 and CCR10.[10] CLA is an inducible carbohydrate modification of P-selecting glycoprotein ligand-1 (PSGL-1), a known surface glycoprotein that is expressed constitutively on all human peripheral-blood T cells. This modification enables it to bind E-selectin, which is highly expressed on skin endothelial cells.[9] CCR4 binds to the chemokines CCL17 and CCL22, whereas CCR10 binds to the chemokine CCL27. CCR4 is present on essentially all skin-homing cells, whereas CCR10 is only present on a subset of skin-homing T cells.[10] This specific and highly controlled trafficking of T cells to the skin explains the greater than 100-fold enrichment of antigen-reactive T cells at the site of cutaneous inflammation compared with blood.

TISSUE RESIDENT (T_{RM}), EFFECTOR (T_{EM}), AND CENTRAL MEMORY (T_{CM}) T CELLS

Healthy human skin contains about twice as many T cells as are present in the entire blood volume, or about 20 billion. Of skin-tropic (CLA+) memory T cells, 98% are located in human skin under non-inflamed conditions and only 2% are present in the circulation.[11] These findings radically changed the long-held assumption that memory T cells continuously recirculate between peripheral organs via the blood and secondary lymphoid structures and are rapidly recruited to the site of infection when needed. Instead, a substantial number of T cells are static and reside in the skin, where they can provide rapid defense against invading pathogens. This also explains observations made from the xenotransplant model of human skin inflammation. In these studies, healthy-appearing skin of patients with psoriasis was grafted onto immunodeficient mice. After few weeks, the uninvolved skin spontaneously developed psoriasis, whereas no changes were seen for skin from nonpsoriatic healthy controls. These elegant studies demonstrated that T cells that reside in noninflamed human skin are sufficient to create an inflammatory pathology in the absence of recirculating lymphocytes.[12] These observations and others led to the naming of these T cells as "resident memory T cells," or T_{RM}.

T_{RM} cells are nonrecirculating memory T cells that are found in epithelial barrier tissues, including the GI tract, lung, skin, and reproductive tract.[13] The physiologic role of this is to provide these epithelial sites with highly protective T cells specific for the pathogens most commonly encountered through these tissues, and at the sites where they are readily available when needed[13] (Fig. 11-5). Evidence for this function of T_{RM} cells derives from vaccination studies with the live vaccinia virus through skin scarification, in which keratinocytes become infected. Vaccination via scarification generated long-term T cell–mediated immunity—characterized by increased number of skin resident memory $CD8^+$ cells—that was 100,000 times more effective than subcutaneous, intradermal, and intramuscular vaccination in protecting against reinfection of the skin.[14] Although illustrative of the function of T_{RM} cells, this study also questions the value of traditional routes of vaccination, particularly against pathogens that primarily infect the skin.[14]

T_{RM} cells have been suggested to exist as 2 phenotypically and functionally distinct populations. Both of these populations express the T_{RM} marker CD69 and are distinguished by the expression of the surface marker CD103. $CD69^+CD103^+$ T_{RM} cells are enriched in the epidermis, are predominantly $CD8^+$, and have a tendency for increased effector cytokine production, whereas $CD103^-$ T_{RM} cells are more frequently encountered in the dermis and have slightly lower but still potent effector functions when compared with recirculating T cells.[15] In contrast, $CD103^+$ T_{RM} cells have more limited proliferative capacity compared with $CD103^-$ T_{RM} cells. CD103 expression was enhanced by keratinocyte contact and is TGF-β dependent,[15] and through its binding to E-cadherin in the epidermis is responsible for retaining these cells within the epidermis.

Human skin also contains populations of recirculating memory T cells. These cells coexpress both the skin homing receptor CLA and CCR4 and the central memory markers CCR7/L-selectin (CD62L). Based on variable expression of L-selectin, these cells have been named migratory memory T cells (T_{MM}) (L-selectin negative) in contrast to central memory T cells (T_{CM}, L-selectin$^+$).[15] T_{CM} have higher sensitivity to antigenic stimulation and are less dependent on costimulation compared to naïve T cells. Following TCR triggering, T_{CM} produce mainly IL-2, but after proliferation they differentiate into effector T cells (T_{EM}), which are characterized by rapid effector function and are capable of producing large amounts of effector cytokines including IFN-γ, IL-4, and IL-17, as well as perforin in the case of $CD8^+$ T_{EM}.

Importantly, the biology of these T-cell subsets can help explain many of the clinical characteristics of various skin diseases. As T_{RM} do not migrate or recirculate, inflammatory lesions caused by these cells tend to be sharply demarcated, with abrupt cut-off from normal skin, a classic feature of skin lesions in diseases such as psoriasis. It also explains why lesions tend to persist long-term in a particular location, and often recur in the same location on discontinuation of effective therapy. Furthermore, as these cells are already on-site, they can respond to repeated antigen challenges extremely rapidly, often within hours of exposure—such as that seen in fixed drug eruptions. Finally, the biology of the T_{RM} cells can also help explain differences between types of cutaneous lymphomas, such as mycosis fungoides and Sezary syndrome, with the former being mediated by T_{RM} cells and the latter by circulating central memory T cells (T_{CM}).[15] Finally, as T_{RM} cells have a tendency to progressively accumulate in tissues with repeated antigen exposure, T_{RM}-mediated inflammatory diseases tend to worsen over time, with an increasingly rapid onset of inflammation and increasing severity of inflammation with each exposure.[13]

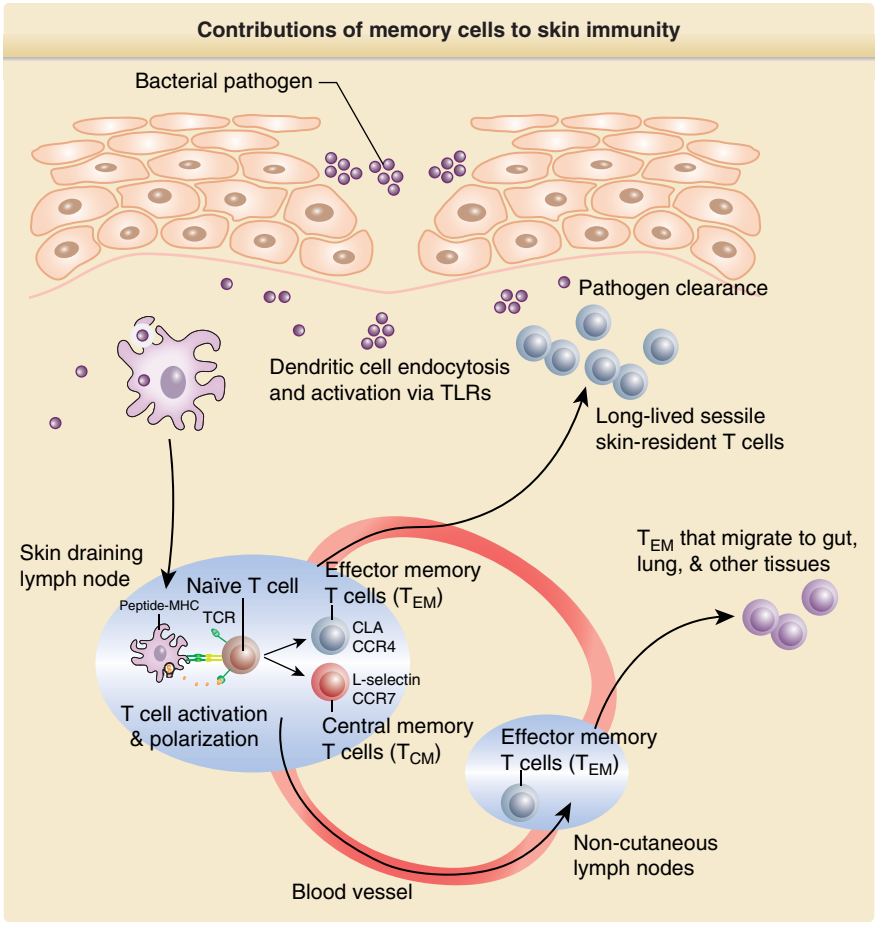

Figure 11-5 Contributions of T effector memory, central memory, and resident memory cells to skin immunity. After exposure to bacterial pathogens, resident dendritic cells in the skin become activated (ie, through activation of toll-like receptors (TLR)) and migrate to skin-draining lymph nodes. Naïve T cells recognizing bacterial peptide antigens on the surface of dendritic cells differentiate and polarize into skin homing effector memory T cells (T_{EM}) and central memory T cells (T_{CM}). Skin homing T_{EM} enter all areas of the skin but in highest number at the site of pathogen exposure. These cells will contribute to pathogen clearance, and some will become long-lived tissue-resident memory T cells (T_{RM}). T cells are also released from the skin draining lymph nodes and migrate to secondary lymphoid tissue including noncutaneous lymph nodes, giving rise to new populations of T_{EM} that home to other nonskin peripheral tissues such as the gut and lungs. (Adapted from Clark RA. *J Invest Dermatol*. 2010;130(2):362-370, with permission. Copyright © The Society for Investigative Dermatology.)

B CELLS

B cells form the humoral arm of the immune system, which is characterized by antibody production. Antibodies produced by B cells have various functions, they can bind to and neutralize pathogens by preventing their ability to enter and infect cells, and similarly they may bind and neutralize bacterial toxins. Antibodies also facilitate the uptake of pathogens by phagocytes in a process called opsonization that facilitates binding to the cell surface Fc receptor. Lastly antibodies bound to pathogens can activate proteins of the classical pathway of the complement system. As evident from the description above, the humoral immune response mainly protects extracellular spaces, blocks infection of all cells but permits uptake by phagocytes with the capacity to destroy the pathogen. B cells emigrate from the bone marrow, following which cells migrate to secondary lymphoid organs such as the spleen, peripheral lymph nodes, and gut-associated lymphoid tissue (Payer patches and mesenteric lymph nodes). B-cell activation usually requires help from T_{FH} cells. Activated B cells differentiate into either memory B cells or antibody-secreting plasma cells. Cytokines made by T_{FH} cells direct the choice of the antibody isotype in human: that is, IL-4 promotes immunoglobulin G1, G4, and E responses; IFN-γ induces immunoglobulin G3; whereas TGF-β induces immunoglobulin A responses. They also have antibody-independent roles, acting as antigen-presenting cells, and producing cytokines with potent effects on both localized and systemic immunity.

B cells are infrequently found in normal skin under homeostatic conditions and the role of B cells in cutaneous immunity remains poorly defined. For the limited number of B cells found in skin, it is unclear if they represent a specific skin-resident population or whether they are derived from circulation populations of B cells. Of note, B cells have been observed in chronic

inflammatory skin conditions such as cutaneous leishmaniasis, diffuse cutaneous sclerosis, cutaneous lupus, and atopic dermatitis, and plasma cells can similarly be found under certain inflammatory conditions such as syphilis and leprosy. IL-10-producing B cells have been found to have an anti-inflammatory effect, and have therefore been named B-regulatory cells or Bregs, but so far these findings have only been demonstrated in murine models of skin inflammation. The presence of these cells have recently been described in human skin.

UNCONVENTIONAL AND INNATE-LIKE T CELLS AND INNATE LYMPHOID CELLS (ILCs)

In recent years, a number of other nonrecirculating lymphocyte populations have been characterized. These lymphocyte populations are residents of nonlymphoid tissue and organs and include invariant natural killer T (iNKT) cells, mucosal-associated invariant T (MAIT) cells, γδ T cells, and intestinal intraepithelial lymphocytes (IELs), as well as the emerging family of ILCs. These tissue-resident lymphocytes span the continuum between the innate and adaptive immune system and share a number of features pertaining to their tissue-resident functions.[2] It is thought that these cell populations act as sensors of perturbed tissue integrity such as from infection or injury and help recruit additional immune cells from blood as well as amplifying local inflammatory responses through their effect on parenchymal cells.[2]

INNATE LYMPHOID CELLS

ILCs are defined by 3 main features: the absence of recombinant activating gene (RAG)–dependent rearranged antigen receptors; a lack of myeloid and dendritic cell phenotypical markers (negative lineage markers), and their lymphoid morphology.[16] ILCs uniformly express the IL-7 receptor alpha chain CD127 and require IL-7 for their development.[17] Keratinocytes express and secrete IL-7 and are an important source of IL-7. ILCs have striking similarities to T cells regarding their transcription factor expression and cytokine profiles. Mirroring T helper polarization of conventional $CD4^+$ T cells, ILCs can be similarly subdivided into group 1 (ILC1), 2 (ILC2), and 3 (ILC3) based on cytokine patterns.[18] ILC1s, similar to T_H1 cells, generate IFN-γ and TNF-α, have no cytotoxic molecules, and are dependent on the transcription factor T-bet. ILC2 express and produce T_H2 cytokines, including IL-4, IL-5, and IL-13, and have a high expression of the GATA-3 transcription factor. Lastly, ILC3s constitute a group of cells expressing variable levels of the transcription factors RORγt, aryl-hydrocarbon receptor (AHR), and T-bet, and release variable amounts of IFN-γ, IL-22, and IL-17[19] (Fig. 11-6).

ILCs are mainly clustered beneath the dermal-epidermal junction and exhibit a close spatial relationship to T lymphocytes.[19] This localization, and the existence of different ILC populations, suggests that these cells may have evolved to respond rapidly to pathogenic signals and to facilitate adaptive immune responses.[20] ILC respond quickly to epithelial cell–derived mediators, and respond almost exclusively by producing cytokines. This innate response is important in activating other innate immune responses in the skin, as well as initiating and orchestrating involvement of the adaptive immune system.[21,22] The outcome of this activation, depending on the ILC subset involved, and their interplay with other cell populations, is complex and may result in either amplification of the inflammatory response or its downregulation. How ILCs are regulated in the skin, the array of effector mechanisms they employ, and their potential role in maintaining skin barrier homeostasis is still incompletely understood.[20]

UNCONVENTIONAL AND INNATE-LIKE T CELLS

Unconventional or innate-like T cells express T-cell receptors of limited diversity, which recognize antigens in the context of nonclassical MHC-like molecules, or independent of MHC-related presenting molecules altogether. Lymphocytes belonging to this group include iNKT cells, MAIT cells, and γδ T cells[2] (Fig. 11-7). In addition, T cells and NKT cells have been shown to recognize nonpeptide antigens in the context of CD1 molecules.

The human cluster of differentiation 1 (CD1) gene family consists of a small number of genes that are structurally related to the MHC class I genes; however, unlike MHC class I molecules, CD1 proteins are nonpolymorphic. The CD1a, b, and c molecules are more closely homologous to one another than to CD1d,[23] and are absent in mice. In skin, CD1a and c isoforms are present on the surface of Langerhans cells, whereas, CD1a, b, and c are expressed on dermal dendritic cells.[24] CD1 molecules present a universe of lipid-based antigens to T cells and the process involves endosomal acidification, which facilitates high-affinity interaction of CD1 molecules with their cognate antigens.[25]

Autoreactive as well as CD1a-restricted T-cell responses against lepromatous leprosy and tuberculosis antigens have been reported, with the demonstration that CD1a can present a large variety of antigens including host-derived sulfatides, "headless antigens,"[26] pollen phospholipids, and mycobacterium-derived dideoxymycobactin. CD1a-autoreactive T cells home to skin, recognizing CD1a loaded with skin-derived lipids,[26] including lipids processed into free fatty acids, which allows direct interaction between the T-cell receptor and CD1a.

Langerhans cells are epidermal dendritic cells that mediate innate immune responses in skin, with phagocytic[27] and antimicrobial function, as well as a key role in antigen presentation to T cells. Langerhans cells are

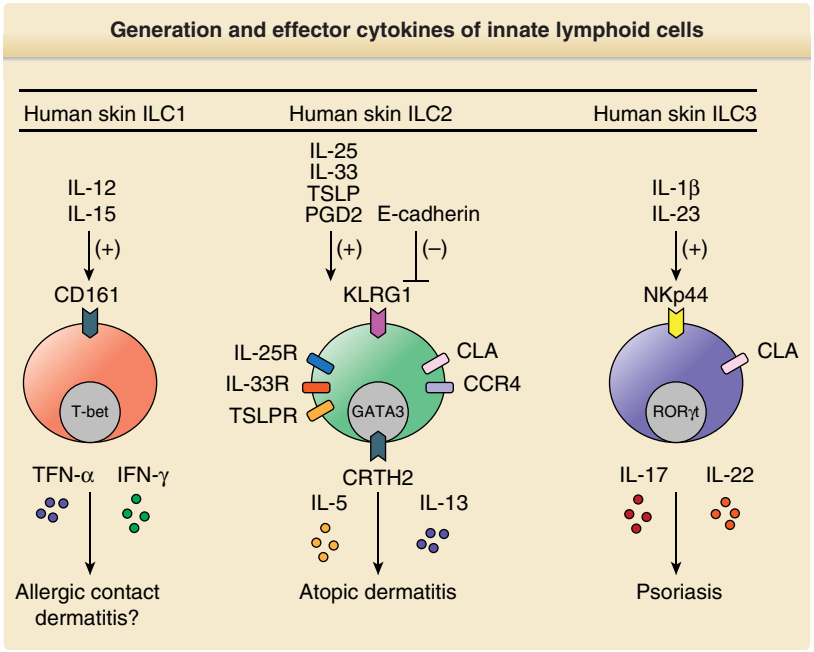

Figure 11-6 Generation and effector cytokines of innate lymphoid cells. Three populations of ILCs are found in human skin (ILC1-3). ILC1 express the surface molecule CD161 and are thought to be activated by IL-12 and IL-15. The primary cytokines produced by ILC1s are TNF-α and IFN-γ. ILC1 are implicated in the pathogenesis of allergic contact dermatitis. ILC2 are activated by the Th2 cytokines IL-25 and IL-33, TSLP, and prostaglandin PGD2. ILC2 express the receptor KLRG1 and CRTH2, CCR4, and receptors for IL-25 (IL-25R), IL-33 (IL-33R), and TSLP (TSLPR). The main effector cytokines from ILC2 include LI-5 and IL-13, and these cells have been implicated in the pathogenesis of atopic dermatitis. ILC3 are activated by IL-1 and IL-23, express the receptor NKp44, and produce IL-17 and IL-22. They are implicated in the pathogenesis of psoriasis. Each ILC subset is characterized by expression of TF factors in similar manner as Th subsets. Thus, similar to T_H1 cells, ILC1 express T-bet; ILC2 similar to T_H2 cells express GATA3 and ILC3 express RORγt similar to T_H17 cells. (Adapted from Kim BS. *J Invest Dermatol*. 2015;135(3):673-678, with permission. Copyright © The Society for Investigative Dermatology.)

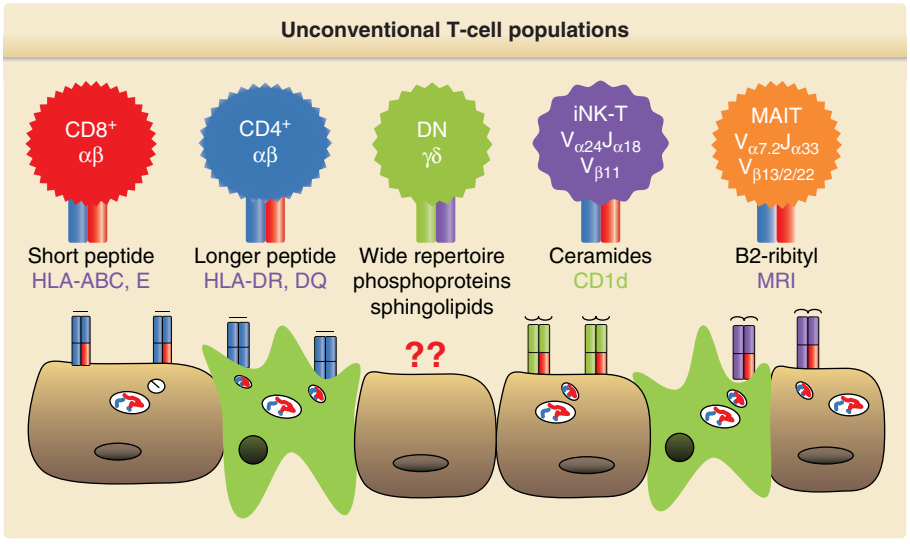

Figure 11-7 Unconventional T-cell populations. Unconventional T cells respond more quickly compared with their conventional counterparts (CD8 and CD4 αβ T cells). These cells are characterized by their limited TCR rearrangement. However, they expand the repertoire of antigens recognized by T cells. Thus, invariant natural killer (iNK) T cells are able to respond to lipid antigens presented by CD1d. Other T-cell subsets including γδ and αβ T cells are also able to recognize lipid antigens bound by members of the CD1 family of proteins (not shown). γδ T cells are able to recognize a diverse array of structures including phosphoantigens and sphingolipids apparently independent of major histocompatibility complex (MHC)-antigen presentation. Mucosal-associated invariant T (MAIT) cells recognize antigens presented in the context of an MHC-like molecule, MR1, on the surface of antigen-presenting cells or epithelia. MAIT cells respond to antigens derived from the structures of vitamins B_2 and B_9 containing a ribityl carbohydrate group. (Adapted from Johnston A, Gudjonsson JE. *J Invest Dermatol*. 2014;134(12):2864-2866, Fig. 1, with permission. Copyright © The Society for Investigative Dermatology.)

characterized by their high expression of CD1a and unique expression of langerin (CD207). Langerin is required for Birbeck granule formation, endosomal structures unique to Langerhans cells.[27] Langerin and CD1a colocalize in those endosomal structures, and CD1a is targeted to these endosomes through a Rab22-dependent pathway. Upon antigen capture, Langerhans cells mature and migrate to regional lymph nodes, where they activate T cells, which then return to the skin.

CD1-restricted T cells have a role in and contribute to host defense against microbial pathogens. Thus, group I CD1-restricted T cells secrete Th1 cytokines; are cytolytic against infected targets, as in case of mycobacterial infections; and trigger antimicrobial activity.[24] These antimicrobial T cells express perforin, granzyme B, and the antimicrobial protein granulysin in intracellular granules.[24] Granzyme B cooperates with granulysin in killing intracellular bacteria. The expression of granulysin, as has been shown in leprosy, correlates with containment of infection, and is approximately 6-fold more frequent in tuberculous leprosy than lepromatous leprosy skin lesions.[24] Furthermore, the ability of these T cells to release IFN-γ potentially leads to induction of the vitamin D–dependent antimicrobial response.[28]

INVARIANT NATURAL KILLER CELLS (iNKT CELLS)

iNKT cells are a subset of T cells that express an invariant T-cell receptor α-chain (Vα24-Jα18 in human), paired with a TCRβ of limited diversity. iNKT cells recognize glycolipid antigens presented by the MHC class I–like molecule CD1d, and can be activated by potent bacterial ligands such as cell wall sphingolipids. They can also sense changes in host lipid metabolism through recognition of less potent, transiently expressed, rare, or unstable endogenous lipids.[2] Five major distinct iNKT cell subsets express and mirror T helper cell subsets in cytokine production, including iNKT1, iNKT2, and iNKT17, analogous to the T_H1, T_H2, and T_H17, respectively. iNKT cells are dependent on the transcriptional factor PLZF for their development.

MUCOSAL-ASSOCIATED INVARIANT T (MAIT) CELLS

MAIT cells are a special subset of T cells that express a semi-variant T cell receptor combining a unique TCRα chain (Vα7.2-Jα33 in humans) with a restricted set of TCRβ chains. These cells are evolutionarily conserved and have a capacity for rapid effector function. MAIT cells are activated by bacterial riboflavin biosynthesis intermediates that are presented by the MHC class I–like molecule MR1. As mammals do not synthesize riboflavin, but instead rely on certain bacteria and yeast, MAIT cells provide a means to control certain commensal bacteria and assess and control for either overgrowth or infection by these organisms. Consistent with this scenario, only microbes with a functional biosynthetic pathway for riboflavin synthesis are able to activate MAIT cells. Distinct subsets of MAIT cells can produce IFN-γ and IL-17.[2]

γδ T-CELLS

γδ T cells are characterized by the expression of the γδ T cell receptor, and in contrast to the strict MHC restriction of αβ T-cells, several modes of antigen-recognition by γδ T cells have been described. Thus, different subsets of γδ T cells have been shown to recognize lipid-based antigens presented on the CD1 family of molecules, MHC class I–like molecules such as MICA, and even soluble ligands. As discussed here above, the CD1 gene family consists of a small number of genes that are structurally related to the MHC class I genes. However, unlike MHC class I molecules, CD1 proteins are nonpolymorphic, CD1a and c are present on the surface of Langerhans cells, whereas CD1a, b, c, and d are expressed on dermal dendritic cells. γδ T cells have an ability to self-renew in tissues independently of circulating precursors. While representing the majority of lymphocytes in mouse skin, γδ T cells only represent a small fraction (1% to 2%) of resident T cells in human skin.

NATURAL KILLER (NK) CELLS

Natural killer cells appear as large granular lymphocytes. In humans, these cells are characterized by being $CD16^+$ $CD56^+$ $CD94^+$ $CD161^+$ but negative for the T-cell markers CD3. NK cells have a role in surveying the body, looking for altered cells, either transformed or infected with viruses or parasites. The cells harboring these pathogens are killed directly via perforin/granzyme/granulysin or Fas/Fas-ligand dependent mechanisms or indirectly via the secretion of cytokines.

DENDRITIC CELLS

The main function of dendritic cells is to process antigen material and present it on the cell surface and activate T cells. Dendritic cells were first described in the late 19th century by Paul Langerhans. However, the term "dendritic cells" was first used in 1973 by Ralph Steinman and Zanvil Cohn, but Steinman was later awarded the Nobel Prize for his discovery of the central role of dendritic cells in adaptive immune response.[29]

MYELOID DENDRITIC CELLS

Dendritic cells (DCs) are a heterogenous population of cells in the immune system. Dendritic cells arise primarily from myeloid progenitors within the bone

TABLE 11-1
Dendritic Cell (DC) Subsets Found in Skin[a]

CONVENTIONAL DCs	PLASMACYTOID DC	LANGERHANS CELLS
$CD141^+$ myeloid DCs: $CD141^+$ (BDCA-3) $CLEC9A^+$, $CD11b^-$	$CD123^+$, $CD303^+$ (BDCA-2), $CD304^+$, TLR7, TLR9	$Langerin^{+++}$, $CD1a^{++}$, E-cadherin^{++}, Birbeck granules
$CD1c^+$ myeloid DCs: $TLR3^+$, $FLT3^+$, $CD11c^{low}$ $CD11c^{hi}$, $CD11b^+$, $CD1c^+$ (BDCA-1), $CD1a^+$		
Monocyte-derived DCs: $CD14^+$ $CD11b^+$, $CX3CR1^+$, $CD209^+$		

[a]Three major populations of dendritic cells (apart from inflammatory dendritic cells) are found in skin. These include $CD141^+$ and $CD1c^+$ myeloid dendritic cells and monocyte-derived DCs that are characterized by expression of CD14. Plasmacytoid dendritic cells are characterized by expression of CD123 (interleukin-3 receptor α-chain) and CD303 (BDCA-2), express TLR7 and TLR9, and are major producers of type I interferons. Langerhans cells are characterized by CD1a and langerin expression.

marrow, and migrate via the blood to tissues throughout the body, or directly to secondary lymphoid organs. There are 3 cutaneous dendritic cell populations in healthy skin: epidermal Langerhans cells, resident dermal conventional dendritic cells, and plasmacytoid dendritic cells[30] (Table 11-1). Conventional (previously called myeloid) dendritic cells are abundant at barrier tissue sites where they are in close contact with surface epithelia. During inflammation there is an additional population of myeloid dermal "inflammatory" dendritic cells.[30] Under normal homeostatic conditions, when there is no infection or tissue injury, dendritic cells are in an immature state, and in that state they efficiently take up antigens but have low levels of costimulatory molecules and not equipped to stimulate naïve T cells.

Dendritic cells are active in ingesting antigens by phagocytosis using both complement receptors and Fc receptors. Antigens taken up through these mechanisms are processed and presented in the binding pocket of MHC class II molecules for recognition by $CD4^+$ T cells. When antigen directly enters the cytosol of dendritic cells, it is processed in the proteasome, transported into the endoplasmic reticulum, and presented on the cell surface within the binding pocket of MHC class I molecules for activation of naïve $CD8^+$ T cells. Dendritic cells are also effective at cross-presentation. Cross-presentation permits the presentation of exogenous antigens, which are normally presented by MHC class II molecules, to be presented by MHC class I molecules. Cross-presentation pathways are important for immune defenses against many viruses and in elimination of autoreactive $CD8^+$ T cells.

Dermal dendritic cells are also a major source of cytokines in inflammatory conditions such as psoriasis. The inflammatory dendritic cells in psoriasis produce TNF-α and have inducible nitric oxide synthetase (iNOS) and have been termed "Tip-DCs." Pathogenicity of these cells in psoriasis is suggested by the rapid downregulation of Tip-DCs products TNF-α, IL-20, and IL-23 during treatment with effective therapies.[31] Tip-DCs can also stimulate the differentiation and activation of Th17 cells. The potential role of these DCs as sources of inflammatory mediators is in contrast to the classic role of DCs as antigen-presenting cells.[30]

PLASMACYTOID DENDRITIC CELLS

Plasmacytoid dendritic cells are a unique population of resident cutaneous dendritic cells, initially described by their morphology, which is similar to plasma cells.[32] Plasmacytoid dendritic cells are thought to act as sentinels in early defences against viral infection, particularly given their expression of Toll-like-receptors 7 and 9 (TLR7 and TLR9), and intracellular nucleic acid sensor such as RIG-1, that functions as a pattern recognition receptor for certain single stranded RNA viruses. In contrast to conventional dendritic cells, plasmacytoid dendritic cells express fewer MHC class II and co-stimulatory molecules on their surface, and the process antigens less efficiently. Given the focus of this dendritic cell subsets towards viral pathogens, their ability to produce large amounts of type 1 interferons during infections is not surprising—this has been estimated to about 10,000-fold more than any other cell type.[33] Viral RNA- and DNA-containing repeated CG nucleotides (CpG) binding to TLR7 and TLR9 are the main inducers of this type 1 interferon response. Plasmacytoid dendritic cells have been implicated in the pathogenesis of psoriasis, appearing to have a critical role in triggering the onset of psoriatic lesions, through binding of the antimicrobial peptide cathelicidin (LL37) to self-DNA and subsequent activation of TLR9.[34]

LANGERHANS CELLS

Langerhans cells are a specialized subset of dendritic cells that reside in the epidermal layer of the skin. These cells were initially described by Paul Langerhans in 1868, who described the presence of nonpigmentary dendritic cells in the epidermis and thought them to be a part of the nervous system. These cells remained an enigma for more than a century until the recognition that Langerhans cells are leukocytes derived from the bone marrow.[35] Langerhans cells account for 2% to 4% of cells in the epidermis[36] and are arranged in a dense network in between epidermal keratinocytes.[35] Langerhans cells are characterized by a unique cytoplasmic organelle, the electron-dense Birbeck granules, which have a unique "tennis-racket" shape. Langerhans cells are characterized by high expression of CD1a.[37] Langerhans cells also express CD207, also known as langerin, which is localized in the Birbeck granules and is a C-type lectin receptor, and may shuttle antigens to a nonclassical antigen-processing pathway, leading to cross-presentation of antigens on MHC class I

molecules.[27] Langerhans cells require the cytokines IL-34 and TGF-β, both derived from keratinocytes, for their development and epidermal residence.[38] The role of Langerhans cells is not yet fully clear. They can cross-prime and activate $CD8^+$ T cells' responses in an IL-15-dependent manner,[39] as well as contribute to expansion of Tregs, suggesting a role of Langerhans cells in tissue homeostasis.[40]

MACROPHAGES

Macrophages are an essential component of innate immunity and play a central role in inflammation. Macrophages reside in tissue and function as immune sentinels, where they are uniquely equipped to sense and respond to tissue invasion by infectious microorganisms and tissue injury through various scavenger, pattern recognition, and phagocytic receptors.[41] In most healthy tissues, macrophages are maintained with minimal contribution of circulating monocytes. In contrast, during injury or infection a large influx of monocytes enter injured tissues and differentiate into macrophage-like and DC-like cells.

Macrophages have been divided into 2 main populations; M1 and M2 macrophages (Table 11-2). M1 macrophages, or classically activated macrophages, are activated primarily by IFN-γ, and produce proinflammatory cytokines such as IL-1β, TNF-α, IL-12, and IL-18. They have a high expression of MHC class II molecules, and express CD68 and the costimulatory molecules CD80 and CD86. These macrophages have the ability to phagocytize large numbers of pathogens and kill intracellular bacteria. Interestingly, for efficient intracellular killing macrophages, vitamin D is required for the adaptive immune responses to overcome the ability of intracellular pathogens to avoid this killing.[28] M2 macrophages, or alternatively activated macrophages, are activated primarily by stimuli such as IL-4, IL-10, TGF-β, and IL-13. M2 macrophages are thought to play a central role in response to parasites, tissue remodeling, and allergic diseases, and may have a role in resolution of skin inflammation.[41]

TABLE 11-2
Molecules Involved in the Polarization of M1 and M2 Macrophages

	M1	M2
iNOS production	↑	—
Surface expression	MHC class II, CD40, CD68, CD80, CD86, CD25 (IL-2Rα), CD127 (IL-7Rα)[a]	MHC class II, CD206, CD209 (DC-SIGN), CD302, Dectin-1[a]
Response to stimulus	IFN-γ, LPS, GM-CSF	IL-4, IL-13, M-CSF, helminths
Arginase 1	—	↑
Cytokine production	IL-1 β, IL-6, IL-12, IL-15, IL-18, IL-23, TNF	IL-10, TGF-β
Transcription factors	IRF5	STAT6, IRF4
NFκB participation	p65	p50

[a]CD40, CD80, and CD86 are costimulatory molecules on antigen-presenting cells. CD25 and CD127 are receptors for the cytokines IL-2 and IL-7 respectively. CD206 (mannose receptor) is a pattern recognition receptor, belonging to the C-type lectin superfamily. CD302 is another C-type lectin receptor involved in cell adhesion, migration, and phagocytosis. Dectin-1 is another C-type lectin that functions as a pattern recognition receptor for a variety of glucans from fungi and plants.
Data from Chavez-Galan L et al. *Front Immunol*. 2015;6:263.

MAST CELLS

Mast cells are usually most abundant at epithelial sites, such as the skin and mucosal tissue, where they are ideally situated to act as a first line of defense against external pathogens and other environmental insults.[42] Mast cells are derived from pluripotent bone marrow precursors. After egression from the bone marrow, mast cell progenitors circulate in the blood before they enter various tissues and develop into mature mast cells. Key factors influencing the maturation of mast cells, including stem cell factor (SCF, also known as KIT ligand), which binds to the c-kit receptor (CD117), and interleukin-3 (IL-3).

Mast cells are long-lived cells that can survive in tissues for months to years and have retained the ability to proliferate in response to appropriate signals.[43] Mast cells are heterogeneous and differ in some of their properties from submucosal or connective tissue mast cells, but both can be involved in allergic reactions.

Mast cells express the receptor for immunoglobulin E (FCεRI) constitutively on their surface, and the best-known cause of mast cell activation is when antigens crosslink immunoglobulin E bound to these receptors. A relatively low level of allergen is sufficient to trigger degranulation of mast cells. Mast cells can also bind immunoglobulin G antibodies through FcγRII receptors. Mast cells can also act as sentinels of infection and are equipped with pattern recognition receptors, including various TLRs, which are activated in response to conserved pathogen-associated molecular patterns. The responses elicited to pathogens depend on the stimulus. Thus, when TLR4 is activated by lipopolysaccharide on mast cells, it leads to cytokine production in the absence of degranulation. In contrast TLR2 activation by peptidoglycans induces both degranulation and cytokine production.[43] Other factors that can induce mast cell activation besides the ones mentioned above, including complement activation (C3a and C5a), neuropeptides (substance P) and certain toxins (venom-derived, and certain bacteria-derived peptides).[42]

Mast cells have a high content of electron-dense lysosome-like secretory granules that occupy a major proportion of the cytoplasm of mature mast cells, leading to the initial nomenclature of these cells "mastung," which means "well fed" or "fattened." These

granules are filled with a plethora of preformed compounds. Histamine is probably the most well known, but other amines, such as serotonin, are also found in mast cell granules. Mast cell granules include various cytokines such as TNF-α, vascular endothelial growth factor (VEGF), various proteases, antimicrobial proteins such as cathelicidins, and chemokines. Mast cells can also produce a large number of cytokine following activation, including TNF-α, IL-3, IL-4, IL-5, and IL-6,[43] as well as lipid mediators such as leukotrienes, prostaglandins, and platelet-activating factor—these factors, when released, contribute to increased vascular permeability and edema at the site of infection or insult—the so-called wheal and flare response that occurs within minutes. As a result of these preformed mediators, which are rapidly released upon activation (in a process called degranulation), mast cells are specialized for first-line surveillance function, and regulation of the subsequent innate and adaptive immune response that follows. Thus, mast cell–derived TNF can induce upregulation of adhesions molecules on local vascular endothelium including E-selectin (which binds CLA on T cells) as well as other adhesion molecules, promoting the influx of T cells and dendritic cells. Chemokines such as CCL20 will add to this influx of inflammatory cells. Furthermore, mast cell products can directly modulate dendritic cell activation and antigen presentation by promoting antigen uptake and cross-presentation, and upregulation of costimulatory molecules required for T-cell activation. Overall, given the presence of cytokines such as IL-4, these responses are more directed toward T_H2 responses.[43] The cutaneous reactions most commonly attributed directly to mast cell activation include urticaria and anaphylaxis.

GRANULOCYTES

Basophils, neutrophils, and eosinophils are classified as granulocytes, which are characterized by the presence of lobulated nuclei and secretory granules in the cytoplasm (Table 11-3).

NEUTROPHILS

Neutrophils are the most abundant leukocytes in the blood accounting for about 35% to 70% of the peripheral blood leukocytes. Neutrophils are short-lived, with a life span somewhere between 5 and 90 hours.

TABLE 11-3
Secretory Granules

	MAST CELLS	EOSINOPHILS	BASOPHILS	NEUTROPHILS
Amines	Histamine		Histamine	
	Serotonin			
	Dopamine			
Cytokines	TNF	TNF	IL-4, 13	TNF
	IL-4, 5, 6, 15	IL-3, 4, 5, 6, 10, 12, 13		IL-1
	bFGF	VEGF		
	VEGF	TGF-β		
	TGF-β	NGF		
	NGF	TGF-α		
	SCF	GM-CSF		
Enzymes	Cathepsin B, C, L, D, E	Acid phosphatase	Neutral protease	Elastase
	Tryptase	Collagenase (MMP1)	Cathepsin G	Myeloperoxidase
	Chymase	Arylsulfatase B	Carboxypeptidase A	Collagenase (MMP1)
	Carboxypeptidase 3	Histaminase		Proteinase 3
	Cathepsin G	Phospholipase D		Cathepsin B, D, G
	MMP9	Catalase		Phospholipase A2
	ADAMTS5			Lysozyme
	Arylsulfatase A			
	Hexosaminidase			
Lipid mediators	Leukotrienes C4, B4, D4, E4	Leukotrienes C4, D4, E4	Leukotrienes C4	
	Platelet-activating factor	Thromboxane B2		
	Prostaglandin D2	Prostaglandin E1, E2		
		Platelet-activating factor		
Other	Heparanase	Major basic protein	Major basic protein	Alpha-defensins
	Cathelicidin (LL37)	Eosinophil cationic protein		
	Renin			

Generation of neutrophils is controlled by granulocyte colony-stimulating factor (G-CSF), and can reach up to 2×10^{11} cells per day. They are the hallmark cell of acute inflammation secondary to their high mobility and are usually recruited to sites of injury within minutes. They are powerful effector cells that destroy infectious threats through several different processes, including phagocytosis, degranulation, reactive oxygen species (ROS), and neutrophil extracellular traps. Neutrophils lead the first wave of host defense against infection or tissue damage.[44] Neutrophils must therefore sense, prioritize, and integrate chemotactic cues to migrate toward sites of infection or tissue damage. Neutrophils express more than 30 different receptors, including G protein–coupled, Fc, adhesion, cytokine, and pattern recognition receptors.

Once in the tissue, neutrophils contribute to the recruitment, activation, and programming of antigen-presenting cells. Neutrophils release chemokines and proinflammatory mediators that attract monocytes and dendritic cells, and influence whether macrophages differentiate to a pro- or anti-inflammatory state.[45] On a per-cell basis, neutrophils make fewer molecules of a given cytokine than macrophages or lymphocytes, but neutrophils often outnumber other leukocytes at inflammatory sites by several orders of magnitude and can therefore by important sources of proinflammatory cytokines such as TNF-α.[45] Neutrophil recruitment can be amplified exponentially in a phase termed "neutrophil swarming." This process is driven by signals from early recruited cells including neutrophils and macrophages to recruit more neutrophils both directly and indirectly through further activation of tissue and tissue resident cells.

Several different processes are critical for neutrophils to assert their destructive capabilities (Fig. 11-8). These include degranulation of preformed proinflammatory mediators, ability to mount a respiratory burst, and neutrophilic extracellular traps.

Neutrophils have several different types of granules. The first granules to be discharged on activation are peroxidase-negative. These include proteins such as lactoferrin, lipocalin, and cathelicidin (LL37) along with several metalloproteinases, which function by degrading laminin, collagen, proteoglycans, and fibronectin and therefore have an important role in facilitating neutrophil recruitment and tissue breakdown.[45] The next granules to be emptied, usually occurring as the concentration of chemoattractants increases, are peroxidase-positive, and contain the antimicrobial proteins alpha-defensins and serprocidins; serine proteases cathepsin G, neutrophil elastase, and proteinase 3; and myeloperoxidase (MPO), the iron-containing enzyme that colors pus green. Myeloperoxidase produces hypochlorous acid (HOCl) from hydrogen peroxide (H_2O_2) and chloride anion (Cl^-).[45] The serine proteases released by neutrophils have been shown to cleave the IL-36 family cytokines (IL-36α, IL-36β, and IL-36γ) into their more active forms, increasing their biologic activity approximately 500-fold.[46]

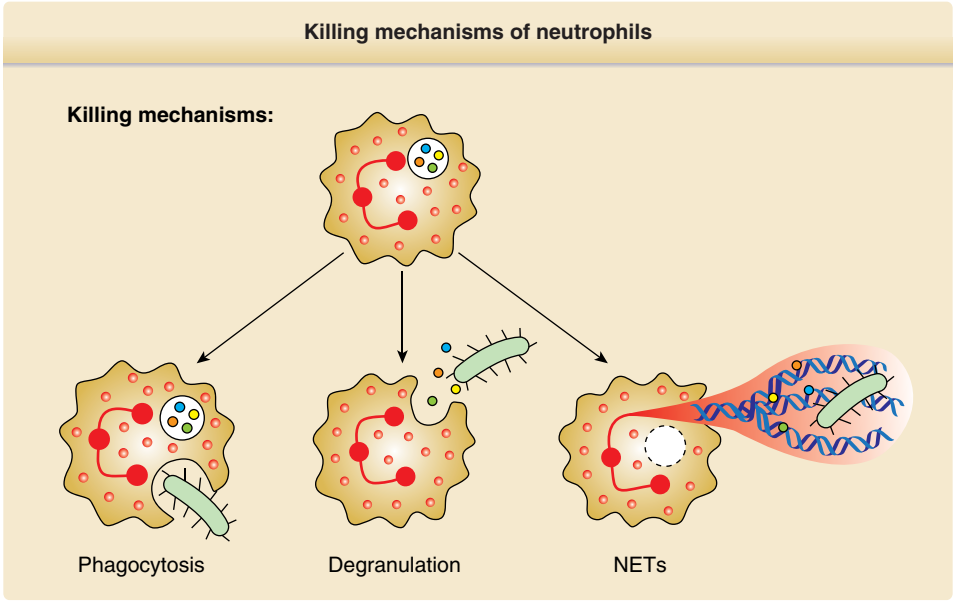

Figure 11-8 Killing mechanisms of neutrophils. Neutrophils can eliminate pathogens by multiple means, both intra- and extracellular. Neutrophils are able to ingest bacterial and other pathogens through phagocytosis and subsequently kill the pathogens using NADPH dependent mechanisms through release of reactive oxygen species or antibacterial proteins (lactoferrin, lysozymes, cathepsins, or defensins). Neutrophils have multiple cytoplasmic granules that they can release into their surroundings. Neutrophils can also eliminate extracellular microorganisms by releasing neutrophil extracellular traps (NETs). These NETs are composed of DNA to which neutrophil derived antimicrobial proteins and enzymes (myeloperoxidase, elastase) are attached to. NETs immobilize pathogens, preventing them from spreading and facilitate subsequent phagocytosis. They can also directly kill pathogens by means of proteases and antimicrobial proteins. (Adapted by permission from Springer Nature: Kolaczkowska E. *Nat Rev Immunol*. 2013;13(3):159-175; Fig. 1. Copyright © 2013.)

Interestingly, neutrophil elastase has been shown to cleave the IL-36 receptor antagonist into its highly active antagonistic form.[47] IL-36-mediated responses have been shown to be a driver of neutrophil infiltration in pustular psoriasis, and these studies show that neutrophils may both promote inflammation and help control it.

Neutrophils use respiratory burst to degrade bacteria and particles that have been ingested via their phagocytic receptors. Respiratory burst is the rapid release of reactive oxygen species (ROS) driven by the NADPH oxidase. The NADPH oxidase reaction results in a transient increase in oxygen consumption by the cells, and leads to generation of superoxide anions within the lumen of the phagolysosomes. This is converted by the enzyme superoxide dismutase (SOD) into hydrogen peroxide (H_2O_2). Further chemical and enzymatic reactions produce a range of toxic ROS including hydroxyl radial (*OH), hypochlorite (OCl^-), and hypobromite (OBr^-).

In addition to killing microbes in the phagolysosomes, neutrophils use another mechanism of destruction that is directed at extracellular pathogens. During activation, some neutrophils undergo a unique form of cell death in which the nuclear chromatin is released into the extracellular space and forms a matrix known as neutrophil extracellular traps, or NETs. NETs facilitate capturing of microorganisms, which may then be more efficiently phagocytosed by other neutrophils or macrophages.[44] NET formation requires the generation of ROS, and patients with chronic granulomatous disease, apart from having defective respiratory burst, also have reduced NET formation

Neutrophil activation can lead to substantial tissue damage, as is evident from disorders such as pyoderma gangrenosum. Therefore, it is crucial to prevent tissue damage by promoting resolution of inflammation through the removal of neutrophils from the site of injury. This clearance of neutrophils can occur through necrosis and subsequent phagocytosis by macrophages, or apoptosis. Recent studies have showed that neutrophils can also leave sites of inflammation in a process termed neutrophil reverse migration.[48]

EOSINOPHILS

Eosinophils were first described by Paul Ehrlich in 1879, who noted their capacity to be stained by acidophilic dyes. Eosin is one of these acidic dyes that bind to and form salts with basic, or eosinophilic, compounds like proteins containing amino acid residues such as arginine and lysine, staining them dark red, leading to the name eosinophils for these cells. Eosinophils are derived from pluripotent progenitors in the bone marrow and released into the peripheral blood in a mature state.

Eosinophils are readily recruited into tissues in response to appropriate stimuli such as interleukin-5 (IL-5) and the eotaxin chemokines CCL11 (eotaxin-1), CCL13, and CCL26 (eotaxin-3). Eosinophils account for somewhere between 0 and 5% of peripheral blood leukocytes. These cells can be readily distinguished from neutrophils by the virtue of their bilobed nuclei and large specific granules. The granules in eosinophils contain 4 major proteins; eosinophilic peroxidase, major basic protein, and the ribonucleases eosinophilic cationic protein and the eosinophil-derived neurotoxin. The granules also store numerous cytokines, enzymes and growth factors.[49] Eosinophils are characterized by expression of the interleukin-5-receptor subunit alpha (IL-5Rα) and the CC-chemokine receptor 3 (CCR3), which binds CCL11, CCL13, and CCL26. The cytokines IL-5 has a profound role in all aspects of eosinophil development, and can by produced by both T-cells and mast cells. The epithelial cell–derived cytokines thymic stromal lymphopoietin (TSLP), a common cytokine in atopic dermatitis, IL-25 (IL-17E), and IL-33 all promote eosinophilia by inducing IL-5 production.[49]

When eosinophils are in tissues, they are usually found in proximity to mast cells, with which they communicate extensively. The crosstalk that occurs between eosinophils and mast cells is thought to involve both physical and various soluble mediators, leading to modulation of allergic inflammation.

BASOPHILS

Basophils account for less than 1% of peripheral blood leukocytes and are the least common type of granulocyte. Since the discovery of basophils by Paul Ehrlich at the end of the 19th century, the role of this small population of cells in the blood has remained an enigma.[50] Basophils were for a long time thought to be a redundant variant of mast cells in the blood, but this does not seem to be the case as basophils differ from mast cells in many important ways. In contrast to mast cells, which mature in tissues, basophils complete their maturation in the bone marrow before they enter the peripheral blood. Basophils are short-lived, having a life span of several days in contrast to weeks to years for mast cells. Finally, basophils do not retain the ability to proliferate unlike mast cells.[50] Basophils are defined by the presence of basophilic granules in the cytoplasm, by the surface expression of the high-affinity Fc receptor for immunoglobulin E (FceRI) and by the release of chemical mediators such as histamine, after stimulation.[50] Basophils are an important source of Th2-type cytokines, and basophils secrete large quantities of IL-4, suggesting that basophils may be involved in mediating allergic diseases and immunity against parasites, and can under such conditions be recruited to peripheral tissues, although in small numbers.

KERATINOCYTES

Keratinocytes are the most abundant cell type in skin and form the epidermis. The epidermis forms a physical barrier between the "inside" and "outside," and prevents invasion of pathogens, entry of chemicals, and loss of water and other soluble mediators through the skin.

In addition, the low pH of the skin inhibits growth of bacteria, and creates optimal condition for the function and activity of skin derived antimicrobial proteins, which include human beta defensin-2 (hBD2), RNAse7, dermcidin, and cathelicidin (LL37). Keratinocytes play an active role in inflammatory responses and express multiple different Toll-like receptors including TLR1, -2, -3, -4, -5, and -10. Keratinocytes are also an important source of cytokines, either constitutively or upon induction. These cytokines include IL-1, IL-6, IL-7, IL-15, IL-20, TNF-α, TSLP, TGF-β1, IL-36, and a broad range of chemoattractants such as the S100A family of proteins, and chemokines including CXCL1, CXCL2, IL-8 (CXCL8), CCL4, CCL5, CCL17, CCL22, CXCL9, CXCL10, CCL20, which attract various inflammatory cell types, such as neutrophils (CXCL1, CXCL2, CXCL8), macrophages and dendritic cells (CCL4), Th1 cells (CXCL9, CXCL10), Th2 cells (CCL17, CCL22), and Th17 cells (CCL20). This production of antimicrobial peptides, cytokines, and chemokines by keratinocytes has multiple consequences for the migration of various subsets of inflammatory cells, influence proliferation and differentiation processes of infiltrating leukocytes, and finally affect the production of other cytokines in skin, justifying the term "cytokinocyte", which is sometimes used for keratinocytes.

REFERENCES

1. Egbuniwe IU, Karagiannis SN, Nestle FO, et al. Revisiting the role of B cells in skin immune surveillance. *Trends Immunol.* 2015;36:102-111.
2. Fan X, Rudensky AY. Hallmarks of tissue-resident lymphocytes. *Cell.* 2016;164:1198-1211.
3. Netea MG, Joosten LA, Latz E, et al. Trained immunity: a program of innate immune memory in health and disease. *Science.* 2016;352(6284):aaf1098.
4. Schlapbach C, Gehad A, Yang C, et al. Human TH9 cells are skin-tropic and have autocrine and paracrine proinflammatory capacity. *Sci Transl Med.* 2014;6(219):219-218.
5. Meller S, Di Domizio J, Voo KS, et al. T(H)17 cells promote microbial killing and innate immune sensing of DNA via interleukin 26. *Nat Immunol.* 2015;16(9):970-979.
6. Harrington LE, Hatton RD, Mangan PR, et al. Interleukin 17-producing CD4+ effector T cells develop via a lineage distinct from the T helper type 1 and 2 lineages. *Nat Immunol.* 2005;6(11):1123-1132.
7. Sakaguchi S, Sakaguchi N. Regulatory T cells in immunologic self-tolerance and autoimmune disease. *Int Rev Immunol.* 2005;24:211-226.
8. Clark RA, Huang SJ, Murphy GF, et al. Human squamous cell carcinomas evade the immune response by down-regulation of vascular E-selectin and recruitment of regulatory T cells. *J Exp Med.* 2008;205(10):2221-2234.
9. Fuhlbrigge RC, Kieffer JD, Armerding D, et al. Cutaneous lymphocyte antigen is a specialized form of PSGL-1 expressed on skin-homing T cells. *Nature.* 1997;389:978-981.
10. Soler D, Humphreys TL, Spinola SM, et al. CCR4 versus CCR10 in human cutaneous TH lymphocyte trafficking. *Blood.* 2003;101:1677-1682.
11. Clark RA, Chong B, Mirchandani N, et al. The vast majority of CLA+ T cells are resident in normal skin. *J Immunol.* 2006;176(7):4431-4439.
12. Boyman O, Hefti HP, Conrad C, et al. Spontaneous development of psoriasis in a new animal model shows an essential role for resident T cells and tumor necrosis factor-alpha. *J Exp Med.* 2004;199(5):731-736.
13. Clark RA. Resident memory T cells in human health and disease. *Sci Transl Med.* 2015;7:269rv261.
14. Liu L, Zhong Q, Tian T, et al. Epidermal injury and infection during poxvirus immunization is crucial for the generation of highly protective T cell-mediated immunity. *Nat Med.* 2010;16(2):224-227.
15. Watanabe R, Gehad A, Yang C, et al. Human skin is protected by four functionally and phenotypically discrete populations of resident and recirculating memory T cells. *Sci Transl Med.* 2015;7(279):279ra239.
16. Spits H, Artis D, Colonna M, et al. Innate lymphoid cells—a proposal for uniform nomenclature. *Nat Rev Immunol.* 2013;13(2):145-149.
17. Kang J, Coles M. IL-7: the global builder of the innate lymphoid network and beyond, one niche at a time. *Semin Immunol.* 2012;24:190-197.
18. De Obaldia ME, Bhandoola A. Transcriptional regulation of innate and adaptive lymphocyte lineages. *Annu Rev Immunol.* 2015;33:607-642.
19. Bruggen MC, Bauer WM, Reininger B, et al. In situ mapping of innate lymphoid cells in human skin: evidence for remarkable differences between normal and inflamed skin. *J Invest Dermatol.* 2016;136(12):2396-2405.
20. Kim BS. Innate lymphoid cells in the skin. *J Invest Dermatol.* 2015;135:673-678.
21. Eberl G, Colonna M, Di Santo JP, et al. Innate lymphoid cells. Innate lymphoid cells: a new paradigm in immunology. *Science.* 2015;348:aaa6566.
22. Sonnenberg GF, Artis D. Innate lymphoid cells in the initiation, regulation and resolution of inflammation. *Nat Med.* 2015;21:698-708.
23. Calabi F, Bradbury A. The CD1 system. *Tissue Antigens.* 1991;37:1-9.
24. Ochoa MT, Loncaric A, Krutzik SR, et al. "Dermal dendritic cells" comprise two distinct populations: CD1+ dendritic cells and CD209+ macrophages. *J Invest Dermatol.* 2008;128:2225-2231.
25. Niazi K, Chiu M, Mendoza R, et al. The A′ and F′ pockets of human CD1b are both required for optimal presentation of lipid antigens to T cells. *J Immunol.* 2001;166(4):2562-2570.
26. de Jong A, Cheng TY, Huang S, et al. CD1a-autoreactive T cells recognize natural skin oils that function as headless antigens. *Nat Immunol.* 2014;15(2):177-185.
27. Valladeau J, Ravel O, Dezutter-Dambuyant C, et al. Langerin, a novel C-type lectin specific to Langerhans cells, is an endocytic receptor that induces the formation of Birbeck granules. *Immunity.* 2000;12(1):71-81.
28. Fabri M, Stenger S, Shin DM, et al. Vitamin D is required for IFN-gamma-mediated antimicrobial activity of human macrophages. *Sci Transl Med.* 2011;3(104):104ra102.
29. Banchereau J, Steinman RM. Dendritic cells and the control of immunity. *Nature.* 31998;92:245-252.
30. Zaba LC, Krueger JG, Lowes MA. Resident and "inflammatory" dendritic cells in human skin. *J Invest Dermatol.* 2009;129:302-308.
31. Zaba LC, Cardinale I, Gilleaudeau P, et al. Amelioration of epidermal hyperplasia by TNF inhibition is

associated with reduced Th17 responses. *J Exp Med.* 2007;204(13):3183-3194.
32. Corcoran L, Ferrero I, Vremec D, et al. The lymphoid past of mouse plasmacytoid cells and thymic dendritic cells. *J Immunol.* 2003;170(10):4926-4932.
33. Ito T, Amakawa R, Inaba M, et al. Plasmacytoid dendritic cells regulate Th cell responses through OX40 ligand and type I IFNs. *J Immunol.* 2004;172(7):4253-4259.
34. Lande R, Gregorio J, Facchinetti V, et al. Plasmacytoid dendritic cells sense self-DNA coupled with antimicrobial peptide. *Nature.* 2007;449(7162):564-569.
35. Merad M, Ginhoux F, Collin M. Origin, homeostasis and function of Langerhans cells and other langerin-expressing dendritic cells. *Nat Rev Immunol.* 2008;8:935-947.
36. Valladeau J, Saeland S. Cutaneous dendritic cells. *Semin Immunol.* 2005;17:273-283.
37. Fithian E, Kung P, Goldstein G, et al. Reactivity of Langerhans cells with hybridoma antibody. *Proc Natl Acad Sci U S A.* 1981;78(4):2541-2544.
38. Wang Y, Szretter KJ, Vermi W, et al. IL-34 is a tissue-restricted ligand of CSF1R required for the development of Langerhans cells and microglia. *Nat Immunol.* 2012;13(8):753-760.
39. Klechevsky E, Morita R, Liu M, et al. Functional specializations of human epidermal Langerhans cells and CD14+ dermal dendritic cells. *Immunity.* 2008;29(3):497-510.
40. Seneschal J, Clark RA, Gehad A, et al. Human epidermal Langerhans cells maintain immune homeostasis in skin by activating skin resident regulatory T cells. *Immunity.* 2012;36:873-884.
41. Lavin Y, Mortha A, Rahman A, et al. Regulation of macrophage development and function in peripheral tissues. *Nat Rev Immunol.* 2015;15:731-744.
42. Wernersson S, Pejler G. Mast cell secretory granules: armed for battle. *Nat Rev Immunol.* 2014;14:478-494.
43. Abraham SN, St John AL. Mast cell-orchestrated immunity to pathogens. *Nat Rev Immunol.* 2010;10:440-452.
44. de Oliveira S, Rosowski EE, Huttenlocher A. Neutrophil migration in infection and wound repair: going forward in reverse. *Nat Rev Immunol.* 2016;16:378-391.
45. Nathan C. Neutrophils and immunity: challenges and opportunities. *Nat Rev Immunol.* 2006;6:173-182.
46. Henry CM, Sullivan GP, Clancy DM, et al. Neutrophil-derived proteases escalate inflammation through activation of IL-36 family cytokines. *Cell Rep.* 2016;14(4):708-722.
47. Macleod T, Doble R, McGonagle D, et al. Neutrophil Elastase-mediated proteolysis activates the anti-inflammatory cytokine IL-36 Receptor antagonist. *Sci Rep.* 2016;6:24880.
48. Nourshargh S, Renshaw SA, Imhof BA. Reverse migration of neutrophils: where, when, how, and why? *Trends Immunol.* 2016;37:273-286.
49. Rosenberg HF, Foster PS. Reply to eosinophil cytolysis and release of cell-free granules. *Nat Rev Immunol.* 2013;13:902.
50. Karasuyama H, Mukai K, Tsujimura Y, et al. Newly discovered roles for basophils: a neglected minority gains new respect. *Nat Rev Immunol.* 2009;9:9-13.

Chapter 12 :: Soluble Mediators of the Cutaneous Immune System

:: Allen W. Ho & Thomas S. Kupper

AT-A-GLANCE

- Cytokines are polypeptide mediators that function in communication between hematopoietic cells and other cell types.
- Cytokines often have multiple biologic activities (pleiotropism) and overlapping biologic effects (redundancy).
- Chemokines and their receptors are vital mediators of cellular trafficking.
- Chemokines are synthesized constitutively in some cells and can be induced in many other cell types.
- Cytokine and chemokine-based therapeutics now in use include recombinant cytokines, inhibitory monoclonal antibodies, fusion proteins composed of cytokine receptors and immunoglobulin chains, topical immunomodulators such as imiquimod, prevention of T-cell arrest on activated endothelium or blocking infection of T cells by human immunodeficiency virus 1 using CC chemokine receptor 5 analogs, and cytokine fusion toxins.

THE CONCEPT OF SOLUBLE MEDIATORS

When cells and tissues in complex organisms need to communicate over distances greater than one cell diameter, soluble factors must be used. A subset of these factors is most important when produced or released transiently under emergent conditions (Table 12-1). When faced with an infection- or injury-related challenge, the host must orchestrate a complex and carefully choreographed series of steps. It must mobilize certain circulating white blood cells precisely to the relevant injured area (but not elsewhere) and guide other leukocytes involved in host defense, particularly T and B cells, to specialized lymphatic tissue remote from the infectious lesion but sufficiently close to contain antigens from the relevant pathogen. After a limited period of time in this setting (ie, lymph node [LN]), antibodies produced by B cells and effector-memory T cells, can be released into the circulation and localize at the site of infection. Soluble factors produced by resident tissue cells at the site of injury, by leukocytes and platelets that are recruited to the site of injury, and by memory T cells ultimately recruited to the area, all coordinate an evolving and effective response to a challenge to host defense. Most important, the level of this response must be appropriate to the challenge, and the duration of the response must be transient, that is, long enough to decisively eliminate the pathogen but short enough to minimize damage to healthy host tissues. This chapter focuses on two major categories of soluble mediators that help regulate an effective immune response: cytokines and chemokines.

Cytokines are soluble polypeptide mediators that play pivotal roles in communication between cells of the hematopoietic system and other cells in the body.[1] Cytokines influence many aspects of leukocyte function, including differentiation, growth, activation, and migration. Although many cytokines are substantially upregulated in response to injury to allow a rapid and potent host response, cytokines also play important roles in the development of the immune system and in homeostatic control of the immune system under basal conditions. The growth and differentiation effects of cytokines are not limited to leukocytes, but we will not discuss soluble factors that principally mediate cell growth and differentiation of cells other than leukocytes in this chapter. The participation of cytokines in many aspects of immune and inflammatory responses has prompted the examination of a variety of cytokines or cytokine antagonists (primarily antibodies and fusion proteins) as agents for pharmacologic manipulation of immune-mediated diseases. Therapeutic targeting of cytokines has proven valuable in treating dermatologic disorders. Indeed, a detailed appreciation of cytokine biology sheds light onto a host of cutaneous diseases that result from immune dysfunction.

Chemokines are a large superfamily of small cytokines that are accepted as vital mediators of cellular trafficking. Since the discovery of the first *chemo*attractant cyto*kine* or chemokine in 1977, 50 additional new chemokines and 17 chemokine receptors have been discovered. Initially associated only with recruitment of leukocyte subsets to inflammatory sites,[2] it has become clear that chemokines play roles in angiogenesis, neural development, cancer metastasis, hematopoiesis, and infectious diseases. This chapter includes a review of chemokine function in inflammatory conditions but touches on the role of these molecules in other settings as well.

CYTOKINE BIOLOGY

General features of cytokines are their pleiotropism and redundancy. Before the advent of a systematic nomenclature for cytokines, most newly identified cytokines were named according to the biologic assay that was being used to isolate and characterize the

TABLE 12-1

Primary Soluble Mediators Constitutively Expressed by Human Keratinocytes

MEDIATOR	UPREGULATING STIMULI
Cytokines	
IL-1α	IL-1α, TNF-α, LPS, UVB, IFN-γ
IL-1α	IL-1α, TNF-α, LPS, UVB
IL-1RA	IL-1α, TNF-α, LPS, UVB, IFN-γ
IL-6	IL-1α, IFN-γ, IL-17, LPS
IL-18	TNF-α, UVB, LPS, dsRNA
TGF-α	TNF-α, IFN-γ
TGF-β	UVB, LPS, RA
Chemokines	
CXCL8	TNF-α, IL-1α, IFN-γ, IL-17, UVB, dsRNA, flagellin
CCL17	IFN-γ, TNF-α
CCL20	TNF-α, IL-1α, IL-1β, IFN-γ, IL-17, CD40L, dsRNA
CCL27	TNF-α, IL-1β, dsRNA

dsRNA, double-stranded RNA; IFN, interferon; IL, interleukin; LPS, lipopolysaccharide; TNF, tumor necrosis factor; UVB, ultraviolet B; RA, retinoic acid.

active molecule (eg, T-cell growth factor for the molecule that was later renamed *interleukin 2*, or IL-2). Very often, independent groups studying quite disparate bioactivities isolated the same molecule that revealed the pleiotropic effects of these cytokines. For example, before being termed *interleukin 1* (IL-1), this cytokine had been variously known as *endogenous pyrogen*, *lymphocyte-activating factor*, and *leukocytic endogenous mediator*. Many cytokines have a wide range of activities, causing multiple effects in responsive cells and a different set of effects in each type of cell capable of responding. The redundancy of cytokines typically means that in any single bioassay (eg, induction of T-cell proliferation), multiple cytokines display activity. In addition, the absence of a single cytokine (eg, in mice with targeted mutations in a cytokine gene) can often be largely or even completely compensated for by other cytokines with overlapping biologic effects.

CLASSIFICATIONS OF CYTOKINES

The first cytokines described had distinct and easily recognizable biological activities, exemplified by IL-1, IL-2, and the interferons (IFNs). The term *cytokine* was first coined by Cohen in 1975 to describe several such activities released into the supernatant of an epithelial cell line.[3] Before this, such activities had been thought to be the exclusive domain of lymphocytes (lymphokines) and monocytes (monokines) and were considered a function of the immune system. Keratinocyte cytokines were first discovered in 1981,[4] and the list of cytokines produced by this epithelial cell rivals nearly any other cell type in the body.[5,6] The number of molecules that can be legitimately termed cytokines continues to expand and has brought under the cytokine rubric molecules with a broad range of distinct biological activities. The progress in genomic approaches has led to identification of novel cytokine genes based on homologies to known cytokine genes. Making sense of this plethora of mediators is more of a challenge than ever, and strategies to simplify the analysis of the cytokine universe are sorely needed.

T-CELL SUBSETS DISTINGUISHED BY PATTERN OF CYTOKINE PRODUCTION

Another valuable concept that has withstood the test of time is the assignment of many T cell–derived cytokines into groups based on the specific helper T-cell subsets that produce them (Fig. 12-1). The original two helper T-cell subsets were termed *Th1* and *Th2*.[7] Commitment to one of these two patterns of cytokine secretion also occurs with CD8 cytotoxic T cells and γ/δ T cells. Dominance of type 1 or type 2 cytokines in a T-cell immune response has profound consequences for the outcome of immune responses to certain pathogens and extrinsic proteins capable of serving as allergens. More than 2 decades after the original description of the Th1 and Th2 subsets, strong evidence has emerged that there are other functionally significant patterns of cytokine secretion by T cells. Most prominent among these newer T-cell lineages are *Th17* cells and *regulatory T cells* (or *Treg cells* for short). The Th17 subset is distinguished by production of a high level of IL-17, but many Th17 cells also secrete IL-21 and IL-22. Th17 cells promote inflammation, and there is consistent evidence from human autoimmune diseases and mouse models of these diseases that IL-17-producing cells are critical effectors in autoimmune disease.[8] A subset of T cells known as Treg cells has emerged as a crucial subset involved in the maintenance of peripheral self-tolerance.[9] Two of the most distinctive features of Treg cells are their expression of the FoxP3 transcription factor and production of transforming growth factor-β (TGF-β), a cytokine that appears to be required for Treg cells to limit the excess activity of the proinflammatory T-cell subsets.[10] IL-10 is also a significant contributor to the suppressive activity of Treg cells, particularly at some mucosal interfaces.[11] Additional proposed helper T-cell subsets are follicular helper T (Tfh) cells that specialize in providing B cell help in germinal centers, Th9 cells distinguished by high levels of IL-9 production that function in antiparasite and antimelanoma immunity,[12] and Th22 cells associated with skin inflammation that produce IL-22 but not other Th17-associated cytokines. Not only does each of these T-cell subsets exhibit distinctive patterns of cytokine production, but cytokines

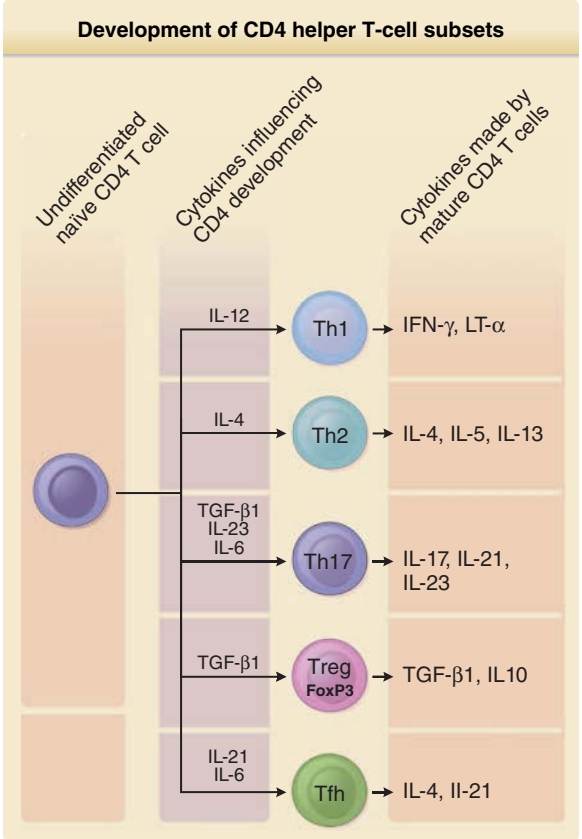

Figure 12-1 Cytokines control the development of specific CD4 helper T-cell subsets. The cytokine milieu at the time of activation of naïve undifferentiated CD4 T cells has a profound influence on the ultimate pattern of cytokine secretion adopted by fully differentiated T cells. Subsets of effector CD4 T cells with defined patterns of cytokine secretion include T helper 1 (Th1), Th2, Th17, and T follicular helper (Tfh) cells. Regulatory CD4 T cells (Treg cells) express the FoxP3 transcription factor, and their effects are mediated in part by their production of transforming growth factor-β1 (TGF-β1) and/or interleukin 10 (IL-10). IFN, interferon; LT, lymphotoxin. (Adapted from Swain SL, McKinstry KK, Strutt TM. Expanding roles for CD4+ T cells in immunity to viruses *Nat Rev Immunol*. 2012;12:136-148.)

are also key factors in influencing the differentiation of naïve T cells into these subsets. IL-12 is the key Th1-promoting factor; IL-4 is required for Th2 differentiation; and IL-6, IL-23, and TGF-β are involved in promoting Th17 development.

STRUCTURAL CLASSIFICATION OF CYTOKINES

Not all useful classifications of cytokines are based solely on analysis of cytokine function. Structural biologists, aided by improved methods of generating homogenous preparations of proteins and establishment of new analytical methods (eg, solution magnetic resonance spectroscopy) that complement the classical x-ray crystallography technique, have determined the three-dimensional structure of many cytokines. These efforts have led to the identification of groups of cytokines that fold to generate similar three-dimensional structures and bind to groups of cytokine receptors that also share similar structural features. For example, most of the cytokine ligands that bind to receptors of the hematopoietin cytokine receptor family are members of the four-helix bundle group of proteins. Four-helix bundle proteins have a shared tertiary architecture consisting of four antiparallel α-helical stretches separated by short connecting loops. The normal existence of some cytokines as oligomers rather than monomers was discovered in part as the result of structural investigations. For example, IFN-γ is a four-helix bundle cytokine that exists naturally as a noncovalent dimer. The bivalency of the dimer enables this ligand to bind and oligomerize two IFN-γ receptor complexes, thereby facilitating signal transduction. TNF-α and TNF-β are both trimers that are composed almost exclusively of β-sheets folded into a "jelly roll" structural motif. Ligand-induced trimerization of receptors in the TNF receptor family is involved in the initiation of signaling.

SIGNAL TRANSDUCTION PATHWAYS SHARED BY CYTOKINES

To accomplish their effects, cytokines must first bind with specificity and high affinity to receptors on the cell surfaces of responding cells. Many aspects of the pleiotropism and redundancy manifested by cytokines can be understood through an appreciation of shared mechanisms of signal transduction mediated by cell surface receptors for cytokines. In the early years of cytokine biology, the emphasis of most investigative work was the purification and eventual cloning of new cytokines and a description of their functional capabilities, both in vitro and in vivo. Most of the cytokine receptors have now been cloned, and many of the signaling cascades initiated by cytokines have been described in great detail. The vast majority of cytokine receptors can be classified into a relatively small number of families and superfamilies (Table 12-2), the members of which function in an approximately similar fashion. Table 12-3 lists the cytokines of particular relevance for cutaneous biology, including the major sources, responsive cells, features of interest, and clinical relevance of each cytokine. Most cytokines send signals to cells through pathways that are very similar to those used by other cytokines binding to the same class of receptors. Individual cytokines often use several downstream pathways of signal transduction, which accounts in part for the pleiotropic effects of these molecules. Nevertheless, we propose here that a few major signaling pathways account for most

TABLE 12-2
Major Families of Cytokine Receptors

RECEPTOR FAMILY	EXAMPLE	MAJOR SIGNAL TRANSDUCTION PATHWAY(S) LEADING TO BIOLOGIC EFFECTS
IL-1 receptor family	IL-1R, type 1	NF-B activation via TRAF6
TNF receptor family	TNFR1	NF-B activation involving TRAF2 and TRAF5 Apoptosis induction via "death domain" proteins
Hematopoietin receptor family (class I receptors)	IL-2R	Activation of JAK/STAT pathway
IFN/IL-10 receptor family (class II receptors)	IFN-R	Activation of JAK/STAT pathway
Immunoglobulin superfamily	M-CSF R	Activation of intrinsic tyrosine kinase
TGF-receptor family	TGF-R, types I and II	Activation of intrinsic serine/threonine kinase coupled to Smad proteins
Chemokine receptor family	CCR5	Seven transmembrane receptors coupled to G proteins
IL-17 receptor family	IL-17R	NF-B activation via Act1 and TRAF

CCR, CC chemokine receptor; IFN, interferon; IL, interleukin; JAK, Janus kinase; M-CSF, macrophage colony stimulating factor; NF-B, nuclear factor B; STAT, signal transducer and activator of transcription; TGF, transforming growth factor; TNF, tumor necrosis factor; TRAF, tumor necrosis factor receptor-associated factor.

effects attributable to cytokines. Of particularly central importance are the nuclear factor κB (NF-κB) pathway and the Janus kinase (JAK)/signal transducer and activator of transcription (STAT) pathway, described in the following sections.

NUCLEAR FACTOR κB, INHIBITOR OF κB, AND PRIMARY CYTOKINES

A major mechanism contributing to the extensive overlap between the biologic activities of the primary cytokines IL-1 and TNF is the shared use of the NF-κB signal transduction pathway. IL-1 and TNF use completely distinct cell surface receptor and proximal signaling pathways, but these pathways converge at the activation of the NF-κB transcription factor. NF-κB is of central importance in immune and inflammatory processes because a large number of genes that elicit or propagate inflammation have NF-κB recognition sites in their promoters.[13] NF-κB–regulated genes encode cytokines, chemokines, adhesion molecules, nitric oxide synthase, cyclooxygenase, and phospholipase A2.

In unstimulated cells, NF-κB heterodimers formed from p65 and p50 subunits are inactive because they are sequestered in the cytoplasm as a result of tight binding to inhibitor proteins in the IκB family (Fig. 12-2). Signal transduction pathways that activate the NF-κB system do so through the activation of an IκB kinase (IKK) complex consisting of two kinase subunits (IKKα and IKKβ) and a regulatory subunit (IKKγ). The IKK complex phosphorylates IκBα and IκBβ on specific serine residues, yielding a target for recognition by an E3 ubiquitin ligase complex. The resulting polyubiquitination marks this IκB for rapid degradation by the 26S proteasome complex in the cytoplasm. After IκB has been degraded, the free NF-κB (which contains a nuclear localization signal) is able to pass into the nucleus and induce expression of NF-κB–sensitive genes. The presence of κB recognition sites in cytokine promoters is very common. Among the genes regulated by NF-κB are *IL-1β* and *TNF-α*. This endows *IL-1β* and *TNF-α* with the capacity to establish a positive regulatory loop that favors persistent inflammation. Cytokines besides IL-1 and TNF that activate the NF-κB pathway as part of their signal transduction mechanisms include IL-17 and IL-18.

Proinflammatory cytokines are not the only stimuli that can activate the NF-κB pathway. Bacterial products (eg, lipopolysaccharide, or LPS), oxidants, activators of protein kinase C (eg, phorbol esters), viruses, and ultraviolet (UV) radiation are other stimuli that can stimulate NF-κB activity. TLR4 is a cell surface receptor for the complex of LPS, LPS-binding protein, and CD14. The cytoplasmic domain of TLR4 is similar to that of the IL-1 receptor type 1 (IL-1R1) and other IL-1R family members and is known as the *TIR* domain (for Toll/IL-1 receptor).[14] When ligand is bound to a TIR domain-containing receptor, one or more adapter proteins that also contain TIR domains are recruited to the complex. Myeloid differentiation primary response 88 (MyD88) was the first of these adapters to be identified; the other known adapters are TIRAP (TIR domain-containing adapter protein), TRIF (TIR domain-containing adapter inducing IFN-β), and TRAM (TRIF-related adapter molecule). Engagement of the adapter, in turn, activates one or more of the IL-1R-associated kinases (IRAK1 to IRAK4) that then signal through TRAF6, a member of the TRAF (TNF receptor–associated factor) family, and TAK1 (TGF-β–activated kinase) to activate the IKK complex.[15]

JAK/STAT PATHWAY

A major breakthrough in the analysis of cytokine-mediated signal transduction was the identification of a common cell surface to nucleus pathway used by the majority of cytokines. This JAK/STAT pathway was first elucidated through careful analysis of

TABLE 12-3
Cytokines of Particular Relevance for Cutaneous Biology

CYTOKINE	MAJOR SOURCES	RESPONSIVE CELLS	FEATURES OF INTEREST	CLINICAL RELEVANCE
IL-1	Epithelial cells	Infiltrating leukocytes	Active form stored in keratinocytes	IL-1Ra used to treat rheumatoid arthritis
IL-1	Myeloid cells	Infiltrating leukocytes	Caspase 1 cleavage required for activation	IL-1Ra used to treat rheumatoid arthritis
IL-2	Activated T cells	Activated T cells, Treg cells	Autocrine factor for activated T cells	IL-2 fusion toxin targets CTCL
IL-4	Activated Th2 cells, NKT cells	Lymphocytes, endothelial cells, keratinocytes	Causes B-cell class switching and Th2 differentiation	—
IL-5	Activated Th2 cells, mast cells	B cells, eosinophils	Regulates eosinophil response to parasites	Anti–IL-5 depletes eosinophils
IL-6	Activated myeloid cells, fibroblasts, endothelial cells	B cells, myeloid cells, hepatocytes	Triggers acute-phase response, promotes immunoglobulin synthesis	Anti–IL-6R used to treat rheumatoid arthritis
IL-10	T cells, NK cells	Myeloid and lymphoid cells	Inhibits innate and acquired immune responses	—
IL-12	Activated APCs	Th1 cells	Promotes TH1 differentiation, shares p40 subunit with IL-23	Anti-p40 inhibits Crohn disease and psoriasis
IL-13	Activated Th2 cells, nuocytes	Monocytes, keratinocytes, endothelial cells	Mediates tissue responses to parasites	—
IL-17	Activated Th17 cells	Multiple cell types	Mediates autoimmune diseases	Potential drug target in autoimmune disease
IL-22	Activated Th17 cells and Th22 cells	Keratinocytes	Induces cytokines and antimicrobial peptides	Contributes to psoriasis
IL-23	Activated dendritic cells	Memory T cells, Th17 cells	Directs Th17 differentiation, mediates autoimmune disease	Anti-p40 inhibits Crohn disease and psoriasis
IL-25	Activated Th2 cells, mast cells	Th17 cells	Promotes Th2 differentiation, inhibits Th17 cells	—
IL-26	Th17 cells, natural killer cells, macrophages	Epithelial cells and microorganisms	Promotes inflammation and has intrinsic anti-microbial properties	—
IL-27	Activated APCs	Th1 cells	Promotes Th1 differentiation	—
IL-31	Th2 cells, mast cells, macrophages, dendritic cells	Macrophages, epithelial cells, eosinophils	Promotes inflammation and pruritus	Potential drug target in atopic dermatitis
IL-35	Treg cells	Th17 cells and Treg cells	Inhibits Th17 cells and expands Treg cells	—
TNF-α	Activated myeloid, lymphoid, and epithelial cells	Infiltrating leukocytes	Mediates inflammation	Anti–TNF-effective in psoriasis
IFN-α and IFN-β	Plasmacytoid dendritic cells	Most cell types	Major part of innate antiviral response	Elicited by topical imiquimod application
IFN-γ	Activated Th1 cells, CD8 T cells, NK cells, dendritic cells	Macrophages, dendritic cells, naïve T cells	Macrophage activation, specific isotype switching	IFN used to treat chronic granulomatous disease
TSLP	Epithelial cells including keratinocytes	Dendritic cells, B cells, Th2 cells	Promotes Th2 differentiation	Involved in atopic diseases

APC, antigen-presenting cell; CTCL, cutaneous T-cell lymphoma; IFN, interferon; IL, interleukin; NKT, natural killer T cell; Th, T helper; TNF, tumor necrosis factor; Treg, T regulatory; TSLP, thymic stromal lymphopoietin.

signaling initiated by IFN receptors (Fig. 12-3) but was subsequently shown to play a role in signaling by all cytokines that bind to members of the hematopoietin receptor family.[16] The JAK/STAT pathway operates through the sequential action of a family of four nonreceptor tyrosine kinases (the JAKs or *Ja*nus family *k*inases) and a series of latent cytosolic transcription factors known as *STATs* (*s*ignal *t*ransducers and *a*ctivators of *t*ranscription). The cytoplasmic portions of many cytokine receptor chains are noncovalently associated with one of the four JAKs (JAK1, JAK2, JAK3, and tyrosine kinase 2 [Tyk2]).

The activity of JAK kinases is upregulated after stimulation of a cytokine receptor. Ligand binding to the cytokine receptors leads to the association of two or more distinct cytokine receptor subunits and brings the associated JAK kinases into close proximity with each other. This promotes cross-phosphorylation or

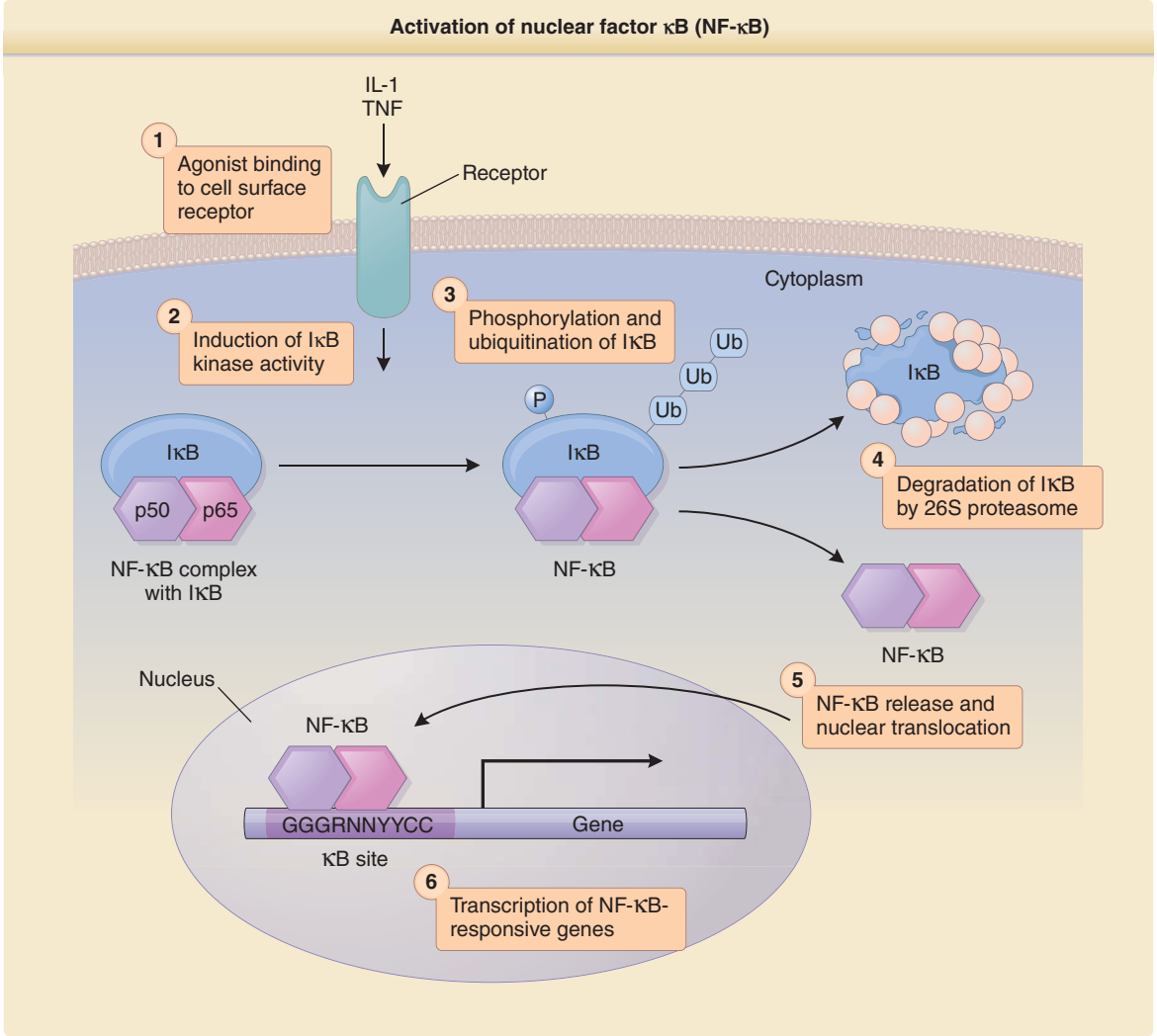

Figure 12-2 Activation of nuclear factor κB (NF-κB)–regulated genes after signaling by receptors for primary cytokines or by Toll-like receptors (TLRs) engaged by microbial products. Under resting conditions, NF-κB (a heterodimer of p50 and p65 subunits) is tightly bound to an inhibitor called IκB that sequesters NF-κB in the cytoplasm. Engagement of one of the TLRs or the signal transducing receptors for interleukin-1 (IL-1) or tumor necrosis factor (TNF) family members leads to induction of IκB kinase activity that phosphorylates IκB on critical serine residues. Phosphorylated IκB becomes a substrate for ubiquitination, which triggers degradation of IκB by the 26S proteasome. Loss of IκB results in release of NF-κB, which permits it to move to the nucleus and activate transcription of genes whose promoters contain κB recognition sites. Ub, ubiquitin.

autophosphorylation reactions that in turn fully activate the kinases. Tyrosines in the cytoplasmic tail of the cytokine receptor as well as tyrosines on other associated and newly recruited proteins are also phosphorylated. A subset of the newly phosphorylated tyrosines can then serve as docking points for attachment of additional signaling proteins bearing Src homology 2 (SH2) domains. Cytoplasmic STATs possess SH2 domains and are recruited to the phosphorylated cytokine receptors via this interaction. Homodimeric or heterodimeric STAT proteins are phosphorylated by the JAK kinases and subsequently translocate to the nucleus. In the nucleus, they bind recognition sequences in DNA and stimulate transcription of specific genes, often in cooperation with other transcription factors. The same STAT molecules can be involved in signaling by multiple different cytokines. The specificity of the response in these instances may depend on the formation of complexes involving STATs and other transcription factors that then selectively act on a specific set of genes.

Therapeutic targeting of the JAK/STAT pathway has been met with recent enthusiasm in the treatment of cutaneous autoimmune and autoinflammatory disorders. Tofacitinib is a small molecule inhibitor that targets JAK1, JAK3, and, to a lesser extent, JAK2. It has been found to be effective in the treatment of psoriasis and psoriatic arthritis, being noninferior to the anti-TNF biologic, etanercept.[17] Recent reports have also indicated efficacy in the treatment of alopecia areata.[18] Furthermore, the JAK1 and JAK2 inhibitor ruxolitinib has been beneficial in the treatment of

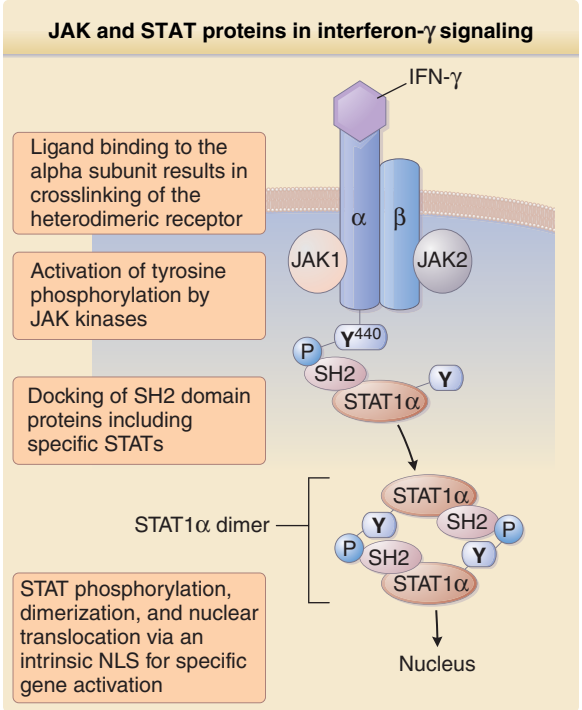

Figure 12-3 Participation of JAK (Janus kinase) and STAT (signal transducer and activator of transcription) proteins in interferon-γ (IFN-γ) signaling. Binding of human IFN-γ (a dimer) to the alpha subunit of the receptor complex results in the crosslinking of the alpha and beta subunits. The nonreceptor protein tyrosine kinases JAK1 and JAK2 are activated and phosphorylate critical tyrosine residues in the receptor such as the tyrosine at position 440 of the α chain (Y^{440}). STAT1α molecules are recruited to the IFN-γ receptor based on the affinity of their Src homology 2 (SH2) domains for the phosphopeptide sequence around Y^{440}. Receptor-associated STAT1α molecules then dimerize through reciprocal SH2-phosphotyrosine interactions. The resulting STAT1α dimers translocate to the nucleus via the nuclear localization signal (NLS) and stimulate transcription of IFN-γ–regulated genes.

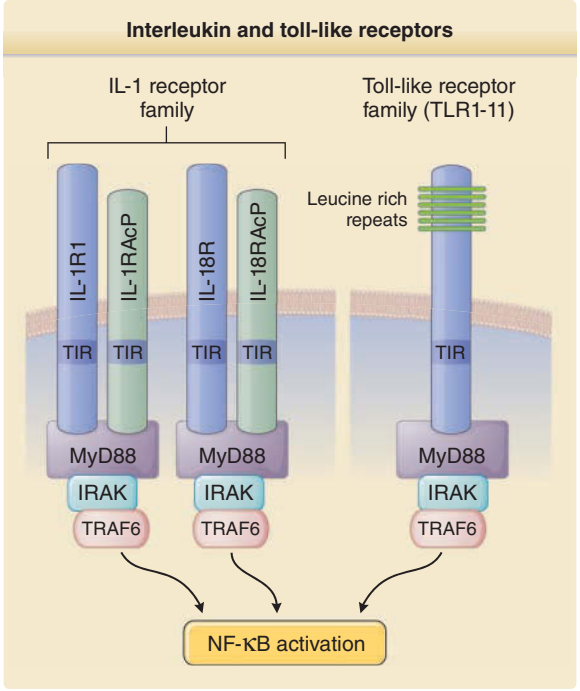

Figure 12-4 The interleukin 1 receptor (IL-1R) family and Toll-like receptors (TLRs) use a common intracellular signaling pathway. Receptors for cytokines in the IL-1 family (typified by the IL-1 and IL-18 receptors) share a common signaling domain with the TLRs (TLR1 to TLR11) called the *Toll/IL-1 receptor (TIR)* domain. The TIR domain receptors interact with TIR domain-containing adapter proteins such as MyD88 that couple ligand binding to activation of IL-1R-associated kinase (IRAK) and ultimately activation of nuclear factor κB (NF-κB). IL-1RAcP, IL-1R accessory protein; TRAF, tumor necrosis factor receptor-associated factor.

dermatomyositis,[19] with similar efficacy of tofacitinib being reported.[20] Clinical trials are currently being undertaken to evaluate the clinical efficacy of JAK inhibition in the treatment of patients with stimulator of interferon genes (STING)-associated vasculopathy with onset in infancy, an autoinflammatory disorder that targets the skin, blood vessels, and lungs. Indeed, further work must be done to fully exploit targeting the JAK/STAT pathway for maximal clinical benefit.

INTERLEUKIN-1 FAMILY OF CYTOKINES

The IL-1 family is a group of cytokines that induces a complex network of proinflammatory cytokines and regulates and initiates inflammatory responses via expression of integrins on leukocytes and endothelial cells. The IL-1 family includes a number of cytokines; however, the archetypal members, interleukins 1α and 1β along with IL-18, will be discussed further here (Fig. 12-4).

IL-1 is the prototype of a cytokine that has been discovered many times in many different biologic assays. Distinct genes encode the α and β forms of human IL-1, with only 26% homology between these proteins at the amino acid level. Both IL-1s are translated as 31-kDa molecules that lack a signal peptide, and both reside in the cytoplasm. This form of IL-1α is biologically active, but 31-kDa *IL-1β* must be activated by cleavage by caspase 1 (initially termed *interleukin-1β-converting enzyme*) in a multiprotein cytoplasmic complex called the *inflammasome* (Fig. 12-5) to generate an active molecule.[21]

In general, whereas IL-1β appears to be the dominant form of IL-1 produced by monocytes, macrophages, Langerhans cells (LCs), and dendritic cells (DCs), IL-1α predominates in epithelial cells, including keratinocytes. This is likely to relate to the fact that epithelial IL-1α is stored in the cytoplasm of cells that comprise an interface with the external environment. Such cells, when injured, release biologically active 31-kDa IL-1α and, by doing so, can initiate inflammation.[22] However, if uninjured, these cells will differentiate and ultimately release their IL-1 contents into the environment. Leukocytes, including dendritic and LCs, carry their cargo of IL-1, and its unregulated release could cause

Figure 12-5 Inflammasomes are multimeric protein complexes that assemble in the cytosol after sensing various stimuli. Although there are fundamental differences between inflammasomes depending on stimuli, canonical inflammasomes oligomerize upon activation, leading to the recruitment of the adapter ASC (apoptosis-associated speck-like protein containing a caspase activation and recruitment domain), which serves as a scaffold to recruit the inactive pro-caspase-1. Oligomerization of pro-caspase-1 proteins induces their auto-proteolytic cleavage into active caspase-1. Active caspase-1 is a cysteine-dependent protease that cleaves the precursor cytokines pro–IL-1β and pro–IL-18, generating the biologically active cytokines IL-1β and IL-18, respectively. AIM2, absent in melanoma 2; CARD, caspase activation and recruitment domain; DAMP, danger-associated molecular pattern; HIN200, hematopoietic interferon-inducible nuclear antigens with 200 amino acid repeats; LRR, leucine-rich repeat; MDP, muramyl dipeptide; NACHT, NAIP (neuronal apoptosis inhibitor protein), C2TA (MHC class 2 transcription activator), HET-E (heterokaryon incompatibility) and TP1 (telomerase-associated protein 1); PAMP, pathogen-associated molecular pattern; PYD, pyrin domain. (Adapted from Guo H, Callaway JB, Ting JP. Inflammasomes: mechanism of action, role in disease, and therapeutics. *Nat Med*. 2015;21(7):677-687.)

significant tissue damage. Thus, biologically active IL-1β release from cells is controlled at several levels: IL-1β gene transcription, *caspase 1* gene transcription, and availability of the adapter proteins that interact with caspase 1 in the inflammasome to allow the generation of mature activated IL-1β. IL-1β stimulates the egress of LCs from the epidermis during the initiation of contact hypersensitivity, a pivotal event that leads to accumulation of LCs in skin-draining LNs. Studies of mice deficient in *IL-1α* and *IL-1β* genes suggest that both molecules are important in contact hypersensitivity but that IL-1α is more critical.

Active forms of IL-1 bind to the IL-1R1 or type 1 IL-1 receptor.[14] This is the sole signal-transducing receptor for IL-1, and its cytoplasmic domain has little homology with other cytokine receptors, showing greatest homology with the *Toll* gene product identified in *Drosophila*. A second cell surface protein, the IL-1R accessory protein, or IL-1RAcP, must associate with IL-1R1 for signaling to occur. When IL-1 engages the IL-1R1–IL-1RAcP complex, recruitment of the MyD88 adapter occurs followed by interactions with one or more of the IRAKs. These kinases in turn associate with TRAF6. Stepwise activation and recruitment of additional signaling molecules culminate in the induction of IKK activity. The net result is the activation of a series of NF-κB–regulated genes.

A molecule known as the *IL-1 receptor antagonist*, or IL-1ra, can bind to IL-1R1 but does not induce signaling through the receptor. This IL-1ra exists in three alternatively spliced forms, and an isoform produced in monocytes is the only ligand for the IL-1R1 that both contains a signal peptide and is secreted from cells. Two other isoforms of IL-1ra, both lacking signal peptides, are contained within epithelial cells. The function of IL-1ra seems to be as a pure antagonist of IL-1 ligand binding to IL-1R1, and binding of IL-1ra to IL-1R1 does not induce the mobilization of IL-1RAcP. Consequently, although both IL-1α/β and IL-1ra bind with equivalent affinities to IL-1R1, the association of IL-1R1 with IL-1RAcP increases the affinity for IL-1α/β manyfold while not affecting the affinity for IL-1ra. This is consistent with the observation that a vast molar excess of IL-1ra is required to fully antagonize the effects of IL-1. The biologic role of IL-1ra is likely to be in the quenching of IL-1–mediated inflammatory responses, and mice deficient in IL-1ra show exaggerated and persistent inflammatory responses.

A second means of antagonizing IL-1 activity occurs via expression of a second receptor for IL-1, IL-1R2. This receptor has a short cytoplasmic domain and serves to bind IL-1α/β efficiently but not IL-1ra. This 68-kDa receptor can be cleaved from the cell surface by an unknown protease and released as a stable, soluble 45-kDa molecule that retains avid IL-1–binding function. By binding the functional ligands for IL-1R1, IL-1R2 serves to inhibit IL-1–mediated responses. It is likely that IL-1R2 also inhibits IL-1 activity by associating with IL-1RAcP at the cell surface and removing and sequestering it from the pool available to associate with IL-1R1. Thus, whereas soluble IL-1R2 binds to free IL-1, cell surface IL-1R2 sequesters IL-1RAcP. Expression of IL-1R2 can be upregulated by a number of stimuli, including corticosteroids and IL-4. However, IL-1R2 can also be induced by inflammatory cytokines, including IFN-γ and IL-1, probably as a compensatory signal designed to limit the scale and duration of the inflammatory response. Production of IL-1R2 serves to make the producing cell and surrounding cells resistant to IL-1-mediated activation. Interestingly, some of the most efficient IL-1–producing cells are also the best producers of the IL-1R2.

IL-18 was first identified based on its capacity to induce IFN-γ. One name initially proposed for this cytokine was IL-1γ because of its homology with IL-1α and IL-1β. Like IL-1β, it is translated as an inactive precursor molecule of 23 kDa and is cleaved to an active 18-kDa species by caspase 1. It is produced by multiple cell types in skin, including keratinocytes, LCs, and monocytes. IL-18 induces proliferation, cytotoxicity, and cytokine production by Th1 and natural killer (NK) cells, mostly synergistically with IL-12. The IL-18 receptor bears striking similarity to the IL-1 receptor.[14] The binding chain (IL-18R) is an IL-1R1 homolog, originally cloned as IL-1Rrp1. IL-18R alone is a low-affinity receptor that must recruit IL-18RAcP (a homolog of IL-1RAcP). As for IL-1, both chains of the IL-18 receptor are required for signal transduction. Although there is no IL-18 homolog of IL-1ra, a molecule known as *IL-18-binding protein* binds to soluble mature IL-18 and prevents it from binding to the IL-18R complex. More recently, it has become clear that there is a family of receptors homologous to the IL-1R1 and IL-18R molecules,[14] which have a TIR motif in common. All of these share analogous signaling pathways initiated by the MyD88 adapter molecule.

When IL-1 produced by epidermis was originally identified, it was noted that both intact epidermis and stratum corneum contained significant IL-1 activity, which led to the concept that epidermis was a shield of sequestered IL-1 surrounding the host, waiting to be released on injury. More recently, it was observed that high levels of the IL-1ra coexist within keratinocytes; however, repeated experiments show that in virtually all cases, the amount of IL-1 present is sufficient to overcome any potential for inhibition mediated by IL-1ra. Studies have now shown that mechanical stress to keratinocytes permits the release of large amounts of IL-1 in the absence of cell death. Release of IL-1 induces expression of endothelial adhesion molecules, including E-selectin, intercellular adhesion molecule-1 (ICAM-1), and vascular cell adhesion molecule-1 (VCAM-1), as well as chemotactic and activating chemokines. This attracts not only monocytes and granulocytes but also a specific subpopulation of memory T cells that bear cutaneous lymphocyte antigen on their cell surfaces. Memory T cells positive for cutaneous lymphocyte antigen are abundant in inflamed skin, comprising the majority of T cells present. Therefore, any injury to the skin, no matter how trivial, releases IL-1 and attracts this population of memory T cells. If they encounter their antigen in this microenvironment, their activation and subsequent cytokine production will amplify the inflammatory response.

This has been proposed as the basis of the clinical observation of inflammation in response to trauma, known as the *Koebner reaction*.

Several biologics that act by inhibiting IL-1 function have been developed for clinical use, including recombinant IL-1Ra (anakinra), an antibody to IL-1β (canakinumab), and an IgG Fc fusion protein that includes the ligand binding domains of the type I IL-1R and IL-1RAcP (rilonacept, also known as IL-1 Trap). All of these agents are efficacious in countering the IL-1–induced inflammation associated with a group of rare autoinflammatory diseases called the cryopyrin-associated periodic syndromes. Anakinra was initially US Food and Drug Administration (FDA) approved as a therapy for adult rheumatoid arthritis. IL-1 inhibition is also being tested as a therapy for gout, an inflammatory arthritis triggered by uric acid–mediated activation of inflammasomes that generate IL-1β.

TUMOR NECROSIS FACTOR

TNF-α is the prototype for a family of signaling molecules that mediate their biologic effects through a family of related receptor molecules. TNF-α was initially cloned on the basis of its ability to mediate two interesting biologic effects: (1) hemorrhagic necrosis of malignant tumors and (2) inflammation-associated cachexia. Although TNF-α exerts many of its biologically important effects as a soluble mediator, newly synthesized TNF-α exists as a transmembrane protein on the cell surface. A specific metalloproteinase known as *TNF-α-converting enzyme (TACE)* is responsible for most TNF-α release by T cells and myeloid cells. The closest cousin of TNF-α is TNF-β, also known as *lymphotoxin α (LT-α)*. Other related molecules in the TNF family include lymphotoxin β (LT-β) that combines with LT-α to form the LT-α1β2 heterotrimer, Fas ligand (FasL), TNF-related apoptosis-inducing ligand (TRAIL), receptor activator of NF-κB ligand (RANKL), and CD40 ligand (CD154). Although some of these other TNF family members have not been traditionally regarded as cytokines, their structures (all are type II membrane proteins with an intracellular *N*-terminus and an extracellular *C*-terminus) and signaling mechanisms are closely related to those of TNF. The soluble forms of TNF-α, LT-α, and FasL are homotrimers, and the predominant form of LT-β is the membrane-bound LT-α1β2 heterotrimer. Trimerization of TNF receptor family members by their trimeric ligands appears to be required for initiation of signaling and expression of biologic activity.

The initial characterization of TNF receptors led to the discovery of two receptor proteins capable of binding TNF-α with high affinity. The p55 receptor for TNF (TNFR1) is responsible for most biologic activities of TNF, but the p75 TNF receptor (TNFR2) is also capable of transducing signals (unlike IL-1R2, which acts solely as a biologic sink for IL-1). TNFR1 and TNFR2 have substantial stretches of close homology and are both present on most types of cells. Nevertheless, there are some notable differences between the two TNFRs.

Unlike cytokine receptors from several of the other large families, TNF signaling does not involve the JAK/STAT pathway. TNF-α evokes two types of responses in cells: (1) proinflammatory effects, and (2) induction of apoptotic cell death (Fig. 12-6). The proinflammatory effects of TNF-α, which include upregulation of adhesion molecule expression and induction of secondary cytokines and chemokines, stem in large part from activation of NF-κB and can be transduced through both TNFR1 and TNFR2. Induction of apoptosis by signaling through TNFR1 depends on a region known as a *death domain* that is absent in TNFR2, as well as interactions with additional proteins with death domains within the TNFR1 signaling complex. Signaling initiated by ligand binding to TNFR1, Fas, or other death domain–containing receptors in the TNF family eventually leads to activation of caspase 8

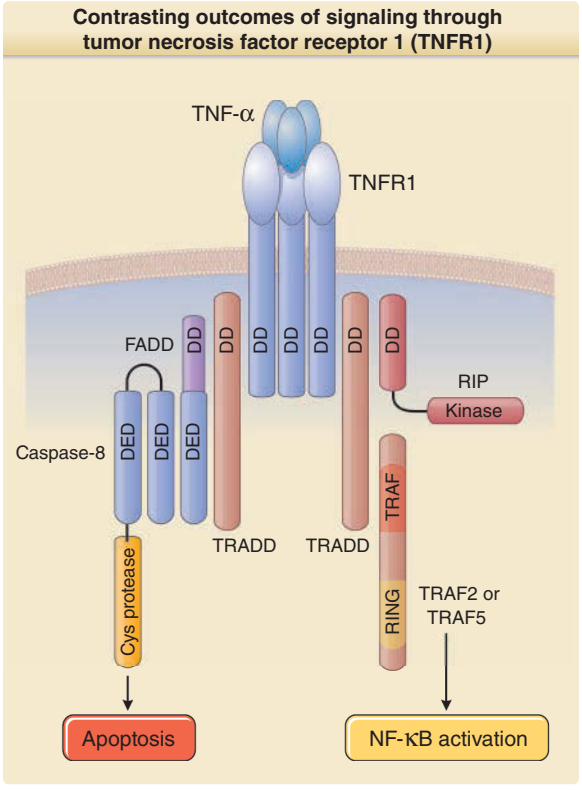

Figure 12-6 Two contrasting outcomes of signaling through tumor necrosis factor receptor 1 (TNFR1). Engagement of TNFR1 by trimeric tumor necrosis factor-α (TNF-α) can trigger apoptosis and/or nuclear factor κB (NF-κB) activation. Both processes involve the adapter protein TNFR-associated death domain (TRADD), which associates with TNFR1 via interactions between "death domains" (DD) on both proteins. For NF-κB activation, TNFR-associated factor 2 (TRAF2) and receptor-interacting protein (RIP) are required. Induction of apoptosis occurs when the death domain-containing protein Fas-associated death domain protein (FADD) associates with TRADD. FADD also contains a "death effector domain" (DED) that interacts with caspase 8 to initiate the apoptotic process. Cys, cysteine. (Adapted from Brenner D, Blaser H, Mak TW. Regulation of tumour necrosis factor signaling: live or let die. *Nat Rev Immunol*. 2015;15:362-374.)

or 10 and the nuclear changes and DNA fragmentation characteristic of apoptosis.

At least two TNFR family members (TNFR1 and the LT-β receptor) also contribute to the normal anatomic development of the lymphoid system. Mice deficient in TNF-α lack germinal centers and follicular DCs. *TNFR1* mutant mice show the same abnormalities plus an absence of Peyer patches. Mice with null mutations in *LT-α* or *LT-β* have further abnormalities in lymphoid organogenesis and fail to develop peripheral LNs.

TNF-α is an important mediator of cutaneous inflammation, and its expression is induced in the course of almost all inflammatory responses in skin. Normal human keratinocytes and keratinocyte cell lines produce substantial amounts of TNF-α after stimulation with LPS or UV light. Cutaneous inflammation stimulated by irritants and contact sensitizers is associated with strong induction of TNF-α production by keratinocytes. Exposure to TNF-α promotes LC migration to draining LNs, allowing for sensitization of naïve T cells. One molecular mechanism that may contribute to TNF-α–induced migration of LCs toward LNs is reduced expression of the E-cadherin adhesion molecule after exposure to TNF-α. Induction of CC chemokine receptor 7 (CCR7) on both epidermal and dermal antigen-presenting cells (APCs) correlates with movement into the draining lymphatics. The predominant TNFR expressed by keratinocytes is TNFR1. Autocrine signaling loops involving keratinocyte-derived TNF-α and TNFR1 lead to keratinocyte production of a variety of TNF-inducible secondary cytokines.

The central role of TNF-α in inflammatory diseases, including rheumatoid arthritis and psoriasis, has become evident from clinical studies. Clinical drugs that target the TNF pathway include the humanized anti–TNF-α antibody infliximab, the fully human anti–TNF-α antibody adalimumab, and the soluble TNF receptor etanercept. Drugs in this class are FDA approved for the treatment of several autoimmune and inflammatory diseases, including Crohn disease and rheumatoid arthritis. These three anti-TNF drugs are also FDA approved for the treatment of psoriasis and psoriatic arthritis. This class of drugs also has the potential to be valuable in the treatment of other inflammatory dermatoses. Paradoxically, they are not effective against all autoimmune diseases—multiple sclerosis appears to worsen slightly after treatment with these agents. The TNF antagonists are powerful immunomodulating drugs, and appropriate caution is required in their use. Cases of cutaneous T-cell lymphoma initially thought to represent psoriasis have rapidly progressed to fulminant disease after treatment with TNF antagonists. TNF antagonists can also allow the escape of latent mycobacterial infections from immune control, with a potentially lethal outcome for the patient.

IL-17 FAMILY OF CYTOKINES

IL-17 (also known as IL-17A) was the first described member of a family of related cytokines that now includes IL-17B through F. IL-17A and IL-17F have similar proinflammatory activities, bind to the same heterodimeric receptor composed of the IL-17RA and IL-17RC receptor chains, and act to promote recruitment of neutrophils and induce production of antimicrobial peptides. These IL-17 species normally function in immune defense against pathogenic species of extracellular bacteria and fungi. Mutations in *STAT3* associated with the hyper-IgE syndrome block the development of Th17 cells, an important cellular source of IL-17, and lead to recurrent skin infections with *Staphylococcus aureus* and *Candida albicans*.[23,24] Less is currently known about the actions of IL-17B, C, and D. IL-17E, also known as IL-25, is a product of Th2 cells and mast cells that signals through IL-17RB. A total of five receptor chains for IL-17 family cytokines have been identified, but how each of these individual receptor chains associates to form receptors for all the members of the IL-17 family remains to be elucidated. These IL-17 receptor chains are homologous to each other but display very limited regions of homology to the other major families of cytokine receptors. Recent expansion of interest in Th17 cells and the entire IL-17 family is closely linked to observations that the immunopathology of autoimmune disease in human patients and mouse models is often associated with an inappropriate expansion of Th17 cells. These findings have generated intense interest in targeting the IL-17 signaling axis in the treatment of a number of cutaneous disorders. Indeed, anti–IL-17 biologic therapies have proven tremendously successful in treating patients with psoriasis. Two human monoclonal antibodies against IL-17A, secukinumab and ixekizumab, are currently approved for use in moderate to severe chronic plaque psoriasis with a number of other therapies in clinical trials. Thus, the cytokines produced by Th17 cells and the receptors that transduce these signals may turn out to be useful targets for therapies designed to dampen autoimmunity (Fig. 12-7).

LIGANDS OF THE CLASS I (HEMATOPOIETIN RECEPTOR) FAMILY OF CYTOKINE RECEPTORS

The hematopoietin receptor family (also known as the *class I cytokine receptor family*) is the largest of the cytokine receptor families and comprises a number of structurally related type I membrane-bound glycoproteins. The cytoplasmic domains of these receptors associate with nonreceptor tyrosine kinase molecules, including the JAK kinases and Src family kinases. After ligand binding and receptor oligomerization, these associated nonreceptor tyrosine kinases phosphorylate intracellular substrates, which leads to signal transduction. Most of the multiple-chain receptors in the hematopoietin receptor family consist of a cytokine-specific α chain subunit paired with one or more shared receptor subunits. Five shared receptor subunits have been described to date: (1) the common γ chain (γ_c); (2) the common β chain shared between the IL-2 and IL-15 receptors; (3) a distinct common β chain shared between the granulocyte-macrophage

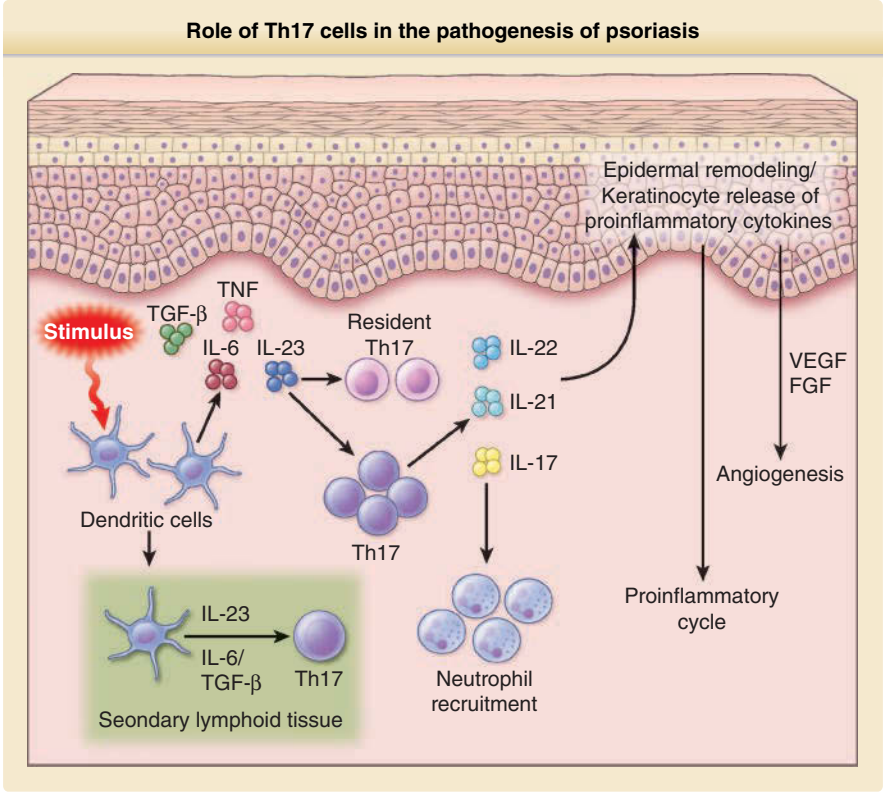

Figure 12-7 The Th17 soluble mediator axis plays a central role in the pathogenesis of psoriasis. After a stimulus such as trauma or infection in a genetically predisposed person, resident dendritic cells produce proinflammatory cytokines both at the site of injury and in the secondary lymphoid tissue, resulting in the generation of pathogenic Th17 cells. Th17 cells produce cytokines such as interleukin (IL)-17, IL-21, and IL-22. Cytokines such as IL-22 and tumor necrosis factor-α (TNF-α) induce keratinocyte hyperplasia. The cytokine milieu generated by Th17 cells also results in neutrophil recruitment and induce keratinocyte to release proangiogenic mediators and other inflammatory cytokines, leading to an inflammatory cycle of disease. FGF, fibroblast growth factor; TGF, transforming growth factor; VEGF, vascular endothelial growth factor.

colony-stimulating factor (GM-CSF), IL-3, and IL-5 receptors; (4) the IL-12Rβ2 chain shared by the IL-12 and IL-23 receptors; and (5) the glycoprotein 130 (gp130) molecule, which participates in signaling by IL-6 and related cytokines.

CYTOKINES WITH RECEPTORS THAT INCLUDE THE γ_c CHAIN

The receptor complexes using the γ_c chain are the IL-2, IL-4, IL-7, IL-9, IL-13, IL-15, and IL-21 receptors. Two of these receptors, IL-2R and IL-15R, also use the IL-2Rβ_c chain. The γ_c chain is physically associated with JAK3, and activation of JAK3 is critical to most signaling initiated through this subset of cytokine receptors.[25]

Interleukin-2 and Interleukin-15: IL-2 and IL-15 can each activate NK cells and stimulate proliferation of activated T cells. IL-2 is a product of activated T cells, and IL-2R is largely restricted to lymphoid cells. The *IL-15* gene is expressed by nonlymphoid tissues, and its transcription is induced by UVB radiation in keratinocytes and fibroblasts and by LPS in monocytes and DCs. Multiple isoforms of IL-15Rα are found in various hematopoietic and nonhematopoietic cells. The IL-2R and IL-15R complexes of lymphocytes incorporate up to three receptor chains, but most other cytokine receptor complexes have two. The affinities of IL-2R and IL-15R for their respective ligands can be regulated, and to some extent, IL-2 and IL-15 compete with each other. The highest affinity receptor complexes for each ligand (~10^{-11} M) consist of the IL-2Rβ_c and γ_c chains, as well as their respective α chains (IL-2Rα, also known as CD25, and IL-15Rα). γ_c and IL-2Rβ_c without the α chains form a functional lower affinity receptor for either ligand (10^{-8} to 10^{-10} M). Although both ligands transmit signals through the γ_c chain, these signals elicit overlapping but distinct responses in various cells. Activation of naïve CD4 T cells by T-cell receptor and costimulatory molecules induces expression of IL-2, IL-2Rα, and IL-2Rβ_c, which leads to vigorous proliferation. Prolonged stimulation of T-cell receptor and IL-2R leads to expression of FasL and activation-induced cell death. Although IL-2 signaling facilitates the death of CD4 T cells in response to sustained exposure to antigen, IL-15 inhibits IL-2–mediated activation-induced cell death as it stimulates growth. Similarly, whereas IL-15 promotes proliferation of memory CD8 T cells, IL-2 inhibits it. IL-15 is also involved in the homeostatic survival of memory CD8 T cells, NK cells, and NK T cells. These contrasting

biologic roles are illustrated by mice deficient in IL-2 or IL-2Rα that develop autoimmune disorders and mice deficient in IL-15 or IL-15Rα, which have lymphopenia and immune deficiencies. Thus, whereas IL-15 appears to have an important role in promoting effector functions of antigen-specific T cells, IL-2 is involved in reining in autoreactive T cells.[26]

Interleukin-4 and Interleukin-13: IL-4 and IL-13 are products of activated Th2 cells that share limited structural homology (~30%) and overlapping but distinct biologic activities. A specific receptor for IL-4, which does not bind IL-13, is found on T cells and NK cells. It consists of IL-4Rα (CD124) and γ_c and transmits signals via JAK1 and JAK3. A second receptor complex that can bind either IL-4 or IL-13 is found on keratinocytes, endothelial cells, and other nonhematopoietic cells. It consists of IL-13Rα1 and IL-4Rα and transmits signals via JAK1 and JAK2. These receptors are expressed at low levels in resting cells, and their expression is increased by various activating signals. Curiously, whereas exposure of monocytes to IL-4 or IL-13 suppresses expression of IL-4Rα and IL-13Rα1, the opposite effect is observed in keratinocytes. Both signal transduction pathways appear to converge with the activation of STAT6, which is both necessary and sufficient to drive Th2 differentiation. IL-13Rα2 is a cell surface receptor homologous to IL-13Rα1 that specifically binds to IL-13 but is not known to transmit any signals.[25]

The biologic effects of engagement of the IL-4 receptor vary depending on the specific cell type but most pertain to its principal role as a growth and differentiation factor for Th2 cells. Exposure of naïve T cells to IL-4 stimulates them to proliferate and differentiate into Th2 cells, which produce more IL-4, which in turn leads to autocrine stimulation that prolongs Th2 responses. Thus, the expression of IL-4 early in the immune response can initiate a cascade of Th2 cell development that results in a predominately Th2 response. The genes encoding IL-4 and IL-13 are located in a cluster with IL-5 that undergoes structural changes during Th2 differentiation that are associated with increased expression. Although naïve T cells can make low levels of IL-4 when activated, IL-4 is also produced by activated NK T cells. Mast cells and basophils also release preformed IL-4 from secretory granules in response to FcεRI-mediated signals. A prominent activity of IL-4 is the stimulation of class switching of the immunoglobulin genes of B cells. Nuocytes and natural helper cells are recently identified populations of innate immune effector cells that provide an early source of IL-13 during helminth infection. As critical factors in Th2 differentiation and effector function, IL-4 and IL-13 are mediators of atopic immunity. Indeed, therapeutic targeting of IL-4 has proven beneficial in the treatment of atopic dermatitis.[27] In addition to controlling the behavior of effector cells, they also act directly on resident tissue cells, such as in inflammatory airway reactions.[28]

Interleukin-9 and Interleukin-21: IL-9 is a product of activated Th2 cells exposed to TGF-β that acts as an autocrine growth factor as well as a mediator of inflammation.[29] It is also produced by mast cells in response to IL-10 or stem cell factor. It stimulates proliferation of T and B cells and promotes expression of immunoglobulin E by B cells. It also exerts proinflammatory effects on mast cells and eosinophils. IL-9–deficient mice exhibit deficiencies in mast cell and goblet cell differentiation. IL-9 can be grouped with IL-4 and IL-13 as cytokines that function as effectors of allergic inflammatory processes and may play an important role in asthma and allergic disorders. However, recent evidence has emerged implicating the important role that IL-9 plays in mediate antimelanoma activity.[12,30] IL-21 is also a product made by the Th2, Th17, and Tfh lineages that signals through a receptor composed of a specific α chain (IL-21R) homologous to the IL-4R α chain and γ_c.[31] Absence of an intact IL-21 receptor is associated with impaired Th2 responses.[32]

Interleukin-7 and Thymic Stromal Lymphopoietin: Mutations abrogating the function of IL-7, IL-7Rα (CD127), γ_c, or JAK3 in mice or humans cause profound immunodeficiency as a result of T- and NK-cell depletion.[25] This is principally due to the indispensable role of IL-7 in promoting the expansion of lymphocytes and regulating the rearrangement of their antigen receptor genes. IL-7 is a potent mitogen and survival factor for immature lymphocytes in the bone marrow and thymus. The second function of IL-7 is as a modifier of effector cell functions in the reactive phase of certain immune responses. IL-7 transmits activating signals to mature T cells and certain activated B cells. Like IL-2, IL-7 has been shown to stimulate proliferation of cytolytic T cells and lymphokine-activated killer cells in vitro and to enhance their activities in vivo. IL-7 is a particularly significant cytokine for lymphocytes in the skin and other epithelial tissues. It is expressed by keratinocytes in a regulated fashion, and this expression is thought to be part of a reciprocal signaling dialog between dendritic epidermal T cells and keratinocytes in murine skin. Keratinocytes release IL-7 in response to IFN-γ, and dendritic epidermal T cells secrete IFN-γ in response to IL-7.

An IL-7–related cytokine using one chain of the IL-7 receptor as part of its receptor is thymic stromal lymphopoietin (TSLP). TSLP was originally identified as a novel cytokine produced by a thymic stromal cell line that could act as a growth factor for B- and T-lineage cells. The TSLP receptor consists of the IL-7Rα and a second receptor chain (TSLPR) homologous to but distinct from the γ_c chain. TSLP has attracted interest because of its ability to prime DCs to become stronger stimulators of Th2 cells. This activity may permit TSLP to foster the development of some types of allergic diseases.[33,34]

CYTOKINES WITH RECEPTORS USING THE INTERLEUKIN-3 RECEPTOR β CHAIN

The receptors for IL-3, IL-5, and GM-CSF consist of unique cytokine-specific α chains paired with a

common β chain known as *IL-3Rβ* or β_c (CD131). Each of these factors acts on subsets of early hematopoietic cells.[35] IL-3, which was previously known as *multilineage colony-stimulating factor*, is principally a product of CD4+ T cells and causes proliferation, differentiation, and colony formation of various myeloid cells from bone marrow. IL-5 is a product of Th2 CD4+ cells and activated mast cells that conveys signals to B cells and eosinophils. IL-5 has a costimulatory effect on B cells in that it enhances their proliferation and immunoglobulin expression when they encounter their cognate antigen. In conjunction with an eosinophil-attracting chemokine known as *CC chemokine ligand 11* or *eotaxin*, IL-5 plays a central role in the accumulation of eosinophils that accompanies parasitic infections and some cutaneous inflammatory processes. IL-5 appears to be required to generate a pool of eosinophil precursors in bone marrow that can be rapidly mobilized to the blood, but eotaxin's role is focused on recruitment of these eosinophils from blood into specific tissue sites. GM-CSF is a growth factor for myeloid progenitors produced by activated T cells, phagocytes, keratinocytes, fibroblasts, and vascular endothelial cells. In addition to its role in early hematopoiesis, GM-CSF has potent effects on macrophages and DCs. In vitro culture of fresh LCs in the presence of GM-CSF promotes their transformation into mature DCs with maximal immunostimulatory potential for naïve T cells. The effects of GM-CSF on DCs probably account for the dramatic ability of GM-CSF to evoke therapeutic antitumor immunity when tumor cells are engineered to express it.[36,37]

INTERLEUKIN-6 AND OTHER CYTOKINES WITH RECEPTORS USING GLYCOPROTEIN 130

Receptors for a group of cytokines, including IL-6, IL-11, IL-27, leukemia inhibitory factor, oncostatin M, ciliary neurotrophic factor, and cardiotrophin-1, interact with a hematopoietin receptor family member, gp130, which does not appear to interact with any ligand by itself. The gp130 molecule is recruited into signaling complexes with other receptor chains when they engage their cognate ligands resulting in signal transduction.

IL-6 is the most thoroughly characterized of the cytokines that use gp130 for signaling and serves as a paradigm for discussion of the biologic effects of this family of cytokines. IL-6 is yet another example of a highly pleiotropic cytokine with multiple effects. A series of different names (including *IFN-β_2*, *B-cell stimulatory factor 2*, *plasmacytoma growth factor*, *cytotoxic T cell differentiation factor*, and *hepatocyte-stimulating factor*) were used for IL-6 before it was recognized that a single molecular species accounts for all of these activities. IL-6 acts on a wide variety of cells of hematopoietic origin. IL-6 stimulates immunoglobulin secretion by B cells and has mitogenic effects on B lineage cells and plasmacytomas. IL-6 also promotes maturation of megakaryocytes and differentiation of myeloid cells. Not only does it participate in hematopoietic development and reactive immune responses, but IL-6 is also a central mediator of the systemic acute-phase response. Increases in circulating IL-6 levels stimulate hepatocytes to synthesize and release acute-phase proteins.

There are two distinct signal transduction pathways triggered by IL-6. The first of these is mediated by the gp130 molecule when it dimerizes upon engagement by the complex of IL-6 and IL-6Rα. Homodimerization of gp130 and its associated JAK kinases (JAK1, JAK2, Tyk2) leads to activation of STAT3. A second pathway of gp130 signal transduction involves Ras and the mitogen-activated protein kinase cascade and results in phosphorylation and activation of a transcription factor originally designated *nuclear factor of IL-6*.

IL-6 is an important cytokine for skin and is subject to dysregulation in several human diseases, including some with skin manifestations. IL-6 is produced in a regulated fashion by keratinocytes, fibroblasts, and vascular endothelial cells as well as by leukocytes infiltrating the skin. IL-6 can stimulate the proliferation of human keratinocytes under some conditions. Psoriasis is one of several inflammatory skin diseases in which elevated expression of IL-6 has been described. Human herpesvirus 8 (HHV8) produces a viral homolog of IL-6 that may be involved in the pathogenesis of HHV8-associated diseases, including Kaposi sarcoma and body cavity–based lymphomas.

The other cytokines using gp130 as a signal transducer have diverse bioactivities. IL-11 inhibits production of inflammatory cytokines and has shown some therapeutic activity in patients with psoriasis. Exogenous IL-11 also stimulates platelet production and has been used to treat thrombocytopenia occurring after chemotherapy.

The IL-6 family member IL-31 has been recognized as an important mediator of cutaneous allergic diseases and atopic dermatitis, possibly through itch stimulation.[38] Major sources for IL-31 production are activated CD4+ T lymphocytes, in particular Th2 cells, mast cells, macrophages, and DCs. In contrast to all other IL-6 family members, IL-31 does not use gp130 as a receptor subunit. Rather, its cognate receptor complex is composed of the OSMRβ subunit and the IL-31RA subunit, which bears 28% sequence homology to gp130.[39] Serum IL-31 levels have been directly correlated with disease severity in atopic dermatitis, and animal models have demonstrated the role of IL-31 in the complex pathogenesis of itch symptoms in atopic dermatitis. Moreover, IL-31 acts directly to inhibit keratinocyte differentiation and filaggrin expression, thereby impairing skin barrier function in atopic dermatitis. Encouragingly, early trials of monoclonal antibodies targeting IL-31 in patients with atopic dermatitis have been efficacious in decreasing pruritus and sleeplessness. Further work on IL-31 may provide novel therapeutics for the treatment of atopic dermatitis and itch.

INTERLEUKIN-12, INTERLEUKIN 23, INTERLEUKIN-27, AND INTERLEUKIN-35: PIVOTAL CYTOKINES REGULATING T HELPER 1 AND T HELPER 17 RESPONSES

The IL-12 cytokine family includes IL-12, IL-23, IL-27, and IL-35. IL-12 is different from most other cytokines in that its active form is a heterodimer of two proteins, p35 and p40. IL-12 is principally a product of APCs such as DCs, monocytes, macrophages, and certain B cells in response to bacterial components, GM-CSF, and IFN-γ. Whereas activated keratinocytes are an additional source of IL-12 in skin. Human keratinocytes constitutively make the p35 subunit, expression of the p40 subunit can be induced by stimuli including contact allergens, phorbol esters, and UV radiation.

IL-12 is a critical immunoregulatory cytokine that is central to the initiation and maintenance of Th1 responses. Th1 responses that are dependent on IL-12 provide protective immunity to intracellular bacterial pathogens. IL-12 also has stimulatory effects on NK cells, promoting their proliferation, cytotoxic function, and the production of cytokines, including IFN-γ. IL-12 has been shown to be active in stimulating protective antitumor immunity in a number of animal models.[40]

Two chains that are part of the cell surface receptor for IL-12 have been cloned. Both are homologous to other β chains in the hematopoietin receptor family and are designated β1 and β2. The β1 chain is associated with Tyk2 and the β2 chain interacts directly with JAK2. The signaling component of the IL-12R is the β2 chain. The β2 chain is expressed in Th1 but not Th2 cells and appears to be critical for commitment of T cells to production of type 1 cytokines. IL-12 signaling induces the phosphorylation of STAT1, STAT3, and STAT4, but STAT4 is essential for induction of a Th1 response.

IL-23 is a heterodimeric cytokine in the IL-12 family that consists of the p40 chain of IL-12 in association with a distinct p19 chain. IL-23 has overlapping activities with IL-12 but also induces proliferation of memory T cells. Interest in IL-23 has been sparked by the observation that IL-23 promotes the differentiation of T cells producing IL-17 (Th17 subset). The IL-23 receptor consists of two chains: (1) the IL-12Rβ1 chain that forms part of the IL-12 receptor and (2) a specific IL-23 receptor.[41]

The third member of the IL-12 family to be discovered was IL-27. IL-27 is also a heterodimer and consists of a subunit called *p28* that is homologous to IL-12 p35 and a second subunit known as *EBI3* that is homologous to IL-12 p40. IL-27 plays a role in the early induction of the Th1 response. The IL-27 receptor consists of a receptor called *WSX-1* that associates with the shared signal-transducing molecule gp130.[41,42]

The newest member of the IL-12 family is IL-35. The IL-35 heterodimer is composed of the p35 chain of IL-12 associated with the IL-27β chain EBI3. In contrast to the other IL-12 family cytokines, IL-35 is selectively made by Treg cells, promotes the growth of Treg cells, and suppresses the activity of Th17 cells.[43]

The IL-12 family of cytokines has emerged as a promising new target for anticytokine pharmacotherapy. The approach that has been developed the furthest to date is targeting both IL-12 and IL-23 with monoclonal antibodies directed against the p40 subunit that is part of both cytokines. Ustekinumab is an antihuman p40 monoclonal antibody that has shown therapeutic activity against psoriasis comparable to that of TNF inhibitors and has received FDA approval for the treatment of psoriasis.[44] The development of anti-p40 therapies is several years behind anti-TNF-α drugs, but development of additional anti-p40 biologics for clinical use is anticipated. Novel therapies targeting p19, which would specifically block IL-23, are also in development for clinical use in psoriasis.

LIGANDS OF THE CLASS II FAMILY OF CYTOKINE RECEPTORS

A second major class of cytokine receptors with common features includes two types of receptors for IFNs, IL-10R, and the receptors for additional IL-10- related cytokines, including IL-19, IL-20, IL-22, IL-24, and IL-26.

Interferons: Prototypes of Cytokines Signaling through a JAK/STAT Pathway: IFNs were one of the first families of cytokines to be characterized in detail. The IFNs were initially subdivided into three classes: (1) IFN-α (the leukocyte IFNs), (2) IFN-β (fibroblast IFN), and (3) IFN-γ (immune IFN). The α and β IFNs are collectively called *type I IFNs*, and all of these molecules signal through the same two-chain receptor (the IFN-αβ receptor).[45] The second IFN receptor is a distinct two-chain receptor specific for IFN-γ. Both of these IFN receptors are present on many cell types within skin as well as in other tissues. Each of the chains comprising the two IFN receptors is associated with one of the JAK kinases (Tyk2 and JAK1 for the IFN-αβR, and JAK1 and JAK2 for the IFN-γR). Only in the presence of both chains and two functional JAK kinases will effective signal transduction occur after IFN binding. A new class of IFNs known as *IFN-λ* or *type III IFNs* has now been identified that has a low degree of homology with both type I IFNs and IL-10.[46] The current members of this class are IL-28A, IL-28B, and IL-29. Although the effects of these cytokines are similar to those of the type I IFNs, they are less potent. These type III IFNs use a shared receptor that consists of the β chain of the IL-10 receptor associated with an IL-28 receptor α chain.

Viruses, double-stranded RNA, and bacterial products are among the stimuli that elicit release of the type I IFNs from cells. Plasmacytoid DCs have emerged as a particularly potent cellular source of type I IFNs. Many of the effects of the type I IFNs directly or indirectly increase host resistance to the spread of viral infection. Additional effects mediated through IFN-αβR are increased expression of major histocompatibility complex (MHC)

class I molecules and stimulation of NK cell activity. Not only does it have well-known antiviral effects, but IFN-α also can modulate T-cell responses by favoring the development of a Th1 type of T-cell response. Finally, the type I IFNs also inhibit the proliferation of a variety of cell types, which provides a rationale for their use in the treatment of some types of cancer. Forms of IFN-α enjoy considerable use clinically for indications ranging from hairy cell leukemia, various cutaneous malignancies, and papillomavirus infections. Some of the same conditions that respond to therapy with type I IFNs also respond to topical immunomodulatory agents such as imiquimod. This synthetic imidazoquinoline drug is an agonist for the TLR7 receptor, whose natural ligand is single-stranded RNA. Imiquimod stimulation of cells expressing TLR7 elicits local release of large amounts of type I IFNs from plasmacytoid DCs, which can trigger clinically useful antiviral and tumor inhibitory effects against genital warts, superficial basal cell carcinoma, and actinic keratoses. Resiquimod is a related synthetic compound that activates both TLR7 and TLR8, eliciting a slightly different spectrum of cytokines.[47]

Production of IFN-γ is restricted to NK cells, CD8 T cells, and Th1 CD4 T cells. Th1 cells produce IFN-γ after engagement of the T-cell receptor, and IL-12 can provide a strong costimulatory signal for T-cell IFN-γ production. NK cells produce IFN-γ in response to cytokines released by macrophages, including TNF-γ, IL-12, and IL-18. IFN-γ has antiviral activity, but it is a less potent mediator than the type I IFNs for induction of these effects. The major physiologic role of IFN-γ is its capacity to modulate immune responses. IFN-γ induces synthesis of multiple proteins that play essential roles in antigen presentation to T cells, including MHC class I and class II glycoproteins, invariant chain, the Lmp2 and Lmp7 components of the proteasome, and the TAP1 and TAP2 intracellular peptide transporters. These changes increase the efficiency of antigen presentation to CD4 and CD8 T cells. IFN-γ is also required for activation of macrophages to their full antimicrobial potential, enabling them to eliminate microorganisms capable of intracellular growth. Similar to type I IFNs, IFN-γ also has strong antiproliferative effects on some cell types. Finally, IFN-γ is also an inducer of selected chemokines (CXC chemokine ligands 9 to 11) and an inducer of endothelial cell adhesion molecules (eg, ICAM-1 and VCAM-1). Because of the breadth of IFN-γ's activities, it comes the closest of the T-cell cytokines to behaving as a primary cytokine.

Interleukin-10: An "Antiinflammatory" Cytokine: IL-10 is one of several cytokines that primarily exert regulatory rather than stimulatory effects on immune responses. IL-10 was first identified as a cytokine produced by Th2 T cells that inhibited cytokine production after activation of T cells by antigen and APCs. IL-10 exerts its action through a cell surface receptor found on macrophages, DCs, neutrophils, B cells, T cells, and NK cells. The ligand-binding chain of the receptor is homologous to the receptors for IFN-α/β and IFN-γ, and signaling events mediated through the IL-10 receptor use a JAK/STAT pathway. IL-10 binding to its receptor activates the JAK1 and Tyk2 kinases and leads to the activation of STAT1 and STAT3. The effects of IL-10 on APCs such as monocytes, macrophages, and DCs include inhibition of expression of class II MHC and costimulatory molecules (eg, B7–1, B7–2) and decreased production of T cell-stimulating cytokines (eg, IL-1, IL-6, and IL-12). At least four viral genomes harbor viral homologs of IL-10 that transmit similar signals by binding to the IL-10R.[48]

A major source of IL-10 within skin is epidermal keratinocytes. Keratinocyte IL-10 production is upregulated after activation; one of the best-characterized activating stimuli for keratinocytes is UV irradiation. UV radiation–induced keratinocyte IL-10 production leads to local and systemic effects on immunity. Some of the well-documented immunosuppressive effects that occur after UV light exposure are the result of the liberation of keratinocyte-derived IL-10 into the systemic circulation. IL-10 also likely plays a dampening role in other types of cutaneous immune and inflammatory responses because the absence of IL-10 predisposes mice to exaggerated irritant and contact sensitivity responses.

Novel Interleukin-10–Related Cytokines: Interleukins 19, 20, 22, 24, and 26: A series of cytokines related to IL-10 have been identified and shown to engage a number of receptor complexes with shared chains.[49] IL-19, IL-20, IL-24, and IL-26 transmit signals via a complex consisting of IL-20Rα and IL-20Rβ. IL-22 signals through a receptor consisting of IL-22R and IL-10Rβ. The receptors for these IL-20 family cytokines are preferentially expressed on epithelial cells including keratinocytes. Increased expression of these cytokines and their receptors is associated with psoriasis. The IL-20 family cytokines have profound effects on the proliferation and differentiation of human keratinocytes in culture.[50] Transgenic mice overexpressing IL-20, IL-22, or IL-24 develop epidermal hyperplasia and abnormal keratinocyte differentiation.[51] All of these findings point to a significant role for these cytokines in the epidermal changes associated with cutaneous inflammation. T cells producing IL-22 that elaborate a distinct set of cytokines from Th1, Th2, and Th17 cells have been isolated from the epidermis of patients with psoriasis and other inflammatory skin disorders. The IL-22 produced by these T cells promotes keratinocyte proliferation and epidermal acanthosis.[52,53] IL-26 is produced by T cells, in particular Th17 cells, NK cells, and macrophages, and has been demonstrated to play an important role in mediating proinflammatory signals in inflammatory bowel disease and rheumatoid arthritis. However, a novel functional characteristic of IL-26 has also been established. IL-26 has structural properties uniquely reminiscent of antimicrobial peptides (AMPs). Analogous to canonical AMPs, the cationic and amphipathic nature of IL-26 allows it to kill select gram-negative bacteria, including *Pseudomonas aeruginosa*, *Klebsiella pneumoniae*, and *Escherichia coli*, as well as gram-positive *S. aureus* at

effector concentrations similar to traditional AMPs. Therefore, a more nuanced role for these cytokines is emerging.

TRANSFORMING GROWTH FACTOR-β FAMILY AND ITS RECEPTORS

TGF-β1 was first isolated as a secreted product of virally transformed tumor cells capable of inducing normal cells in vitro to show phenotypic characteristics associated with transformation. More than 30 additional members of the TGF-β family of cytokines have now been identified. They can be grouped into several families: the prototypic TGF-βs (TGF-β1 to TGF-β3), the bone morphogenetic proteins, the growth and differentiation factors, and the activins. The TGF name for this family of molecules is somewhat of a misnomer because TGF-β has antiproliferative rather than proliferative effects on most cell types. Many of the TGF-β family members play an important role in development, influencing the differentiation of uncommitted cells into specific lineages. TGF-β family members are made as precursor proteins that are biologically inactive until a large prodomain is cleaved. Monomers of the mature domain of TGF-β family members are disulfide linked to form dimers that strongly resist denaturation.

Participation of at least two cell surface receptors (type I and type II) with serine/threonine kinase activity is required for biologic effects of TGF-β.[54] Ligand binding by the type II receptor (the true ligand-binding receptor) is associated with the formation of complexes of type I and type II receptors. This allows the type II receptor to phosphorylate and activate the type I receptor, a "transducer" molecule that is responsible for downstream signal transduction. Downstream signal transmission from the membrane-bound receptors in the TGF-β receptor family to the nucleus is primarily mediated by a family of cytoplasmic Smad proteins that translocate to the nucleus and regulate transcription of target genes.

TGF-β has a profound influence on several types of immune and inflammatory processes. An immunoregulatory role for TGF-β1 was identified in part through analysis of TGF-β1 knockout mice that develop a wasting disease at 20 days of age associated with a mixed inflammatory cell infiltrate involving many internal organs. This phenotype is now appreciated to be a result in part of the compromised development of regulatory T cells when TGF-β1 is not available. Development of cells in the DC lineage is also perturbed in the TGF-β1–deficient mice, as evidenced by an absence of epidermal LCs and specific subpopulations of LN DCs. TGF-β–treated fibroblasts display enhanced production of collagen and other extracellular matrix molecules. In addition, TGF-β inhibits the production of metalloproteinases by fibroblasts and stimulates the production of inhibitors of the same metalloproteinases (tissue inhibitors of metalloproteinase, or TIMPs). TGF-β may contribute to the immunopathology of scleroderma through its profibrogenic effects.[55]

THERAPEUTIC IMPLICATIONS BASED ON CYTOKINE BIOLOGY

Cytokines and cytokine antagonists are being used therapeutically by clinicians, and development of additional agents continues, with a few specific examples described in the previous sections. Cytokine-based therapeutics may offer a more targeted approach to disrupting the underlying disease process; however, their immunosuppressive properties may increase the risk of infections and malignancy. Examples of successful therapeutic targeting of cytokines in a number of cutaneous disorders will be discussed.

TNF-α blockade has proven to be efficacious in the treatment of plaque psoriasis. Patients with active skin disease have elevated levels of TNF-α in both blood and lesional skin. More recently, the efficacy of TNF-α inhibitors in treating psoriasis has been attributed to their inhibition of Th17 cells.[56] The TNF-α antagonists approved to treat psoriasis include infliximab and adalimumab (anti–TNF-α monoclonal antibodies) and etanercept (a human TNF receptor 2 Fc fusion protein). All three agents bind to both soluble and transmembrane forms of TNF-α, interrupting TNF-α–mediated inflammatory pathways. Despite their utility clinically, these agents should be monitored closely when prescribed to patients given the risk of serious infections (eg, tuberculosis) and the potential for increased risk of malignancies or major adverse cardiovascular events.

Ustekinumab, an approved treatment for moderate to severe plaque psoriasis, is a fully human IgG1κ monoclonal antibody with high affinity and specificity for the common p40 subunit shared by IL-12 and IL-23. Increased levels of IL-23 and Th17 cytokines have been detected in human psoriatic skin, and IL-23 has been shown to induce psoriasis-like skin inflammation in mice.[57] Ustekinumab has been successful in the treatment of moderate to severe plaque psoriasis, with superior efficacy over etanercept demonstrated in the ACCEPT trial.[44] Ustekinumab has also been shown to achieve sustained clinical responses with a favorable safety profile for up to 4 years of treatment in the PHOENIX 1 and 2 trials.[58] Evidence is accumulating to suggest that IL-23 and its resulting Th17 pathway play a more important role in psoriasis than IL-12. Indeed, selective inhibition of the IL-23-specific p19 subunit improves psoriasis. Currently, there are multiple antibody-based therapeutics targeting p19 in phase III development for the treatment of psoriasis with encouraging results. Neutralization of IL-23 results in decreased numbers of skin infiltrating T cells, DCs, and neutrophils, while epidermal LCs remain unaffected.[59] Further investigation is required to fully define the role of IL-23 in the pathogenesis of

psoriasis; however, the clinical results of selective IL-23 inhibition have been, thus far, promising.

IL-17 is a key cytokine in the pathogenesis of psoriasis at the keratinocyte level.[60] As such, there is heightened interest in exploiting the IL-17 cytokine axis in the treatment of psoriasis. Secukinumab and ixekizumab are human monoclonal antibodies that target IL-17A and are approved for the treatment of moderate to severe plaque psoriasis. In two phase III clinical trials, ERASURE and FIXTURE, secukinumab was proven to be efficacious in the treatment of plaque psoriasis, with superior efficacy over etanercept demonstrated in the FIXTURE trial.[61] Two phase 3 trials, UNCOVER-2 and UNCOVER-3, showed that ixekizumab was superior to placebo and etanercept in the treatment of moderate to severe plaque psoriasis.[62] Brodalumab is a human IgG2 monoclonal antibody that binds to and blocks the IL-17 receptor and is currently undergoing the approval process for the treatment of psoriasis.

Apremilast is a novel small molecule inhibitor of phosphodiesterase 4 (PD-4) that has been recently approved for the treatment of moderate to severe plaque psoriasis and psoriatic arthritis. PD-4 is expressed predominantly in immune cells, including DCs, neutrophils, and monocytes but also in keratinocytes. Normally, PD-4 causes degradation of the secondary messenger cyclic AMP, leading to increased production of proinflammatory soluble mediators such as TNF-α, IL- 2, -12 and -23, and chemokine ligands 9 (CXCL9) and 10 (CXCL10).[63] Therefore, PD-4 inhibition by apremilast results in the reduction of proinflammatory cytokine and chemokine production. Indeed, the phase III trials, ESTEEM 1 and ESTEEM 2 demonstrated favorable efficacy and safety of apremilast compared with placebo in patients with moderate to severe plaque psoriasis.[64] Further investigation of the safety profile with long-term use is needed.

Tofacitinib, a novel oral JAK inhibitor, disrupts cytokine signaling through inhibition of JAK1 and JAK3, leading to altered lymphocyte function. There is excitement in developing tofacitinib as a viable therapeutic option for psoriasis, alopecia areata, and dermatomyositis because cytokine signaling through the JAK-STAT pathway is a major component in cutaneous inflammatory disorders. A recent phase II clinical trial demonstrated clinical improvement in psoriasis patients treated with tofacitinib compared with placebo.[65] Serendipitously, a patient with concurrent psoriasis and alopecia areata treated with tofacitinib for his psoriasis noted improvement in his alopecia as well.[66] Subsequently, a larger cohort of 90 patients with alopecia areata who were treated with tofacitinib was published, with 77% of patients achieving clinical improvement.[67] Furthermore, tofacitinib and ruxolitinib, a JAK1 and JAK2 inhibitor, respectively, have been beneficial in the treatment of dermatomyositis.[19,20] Further investigations with rigorous trials is warranted to fully evaluate the efficacy of tofacitinib in the treatment of inflammatory skin disorders.

Dupilumab is a monoclonal antibody in development for the treatment of adult patients with inadequately controlled moderate to severe atopic dermatitis. It is directed against the α-subunit of the IL-4 receptor, and through this effect blocks IL-4 and IL-13, the drivers of Th2-mediated inflammation responsible for the hallmark symptoms of atopic dermatitis. In two randomized, placebo-controlled, phase 3 trials, SOLO 1 and SOLO 2, dupilumab improved the signs and symptoms of atopic dermatitis in adult patients, including pruritus, anxiety, depression, and quality of life, compared with placebo.[27] Studies are ongoing to access the efficacy and safety of dupilumab in the pediatric population and for the treatment of asthma.

Therapeutic blockade of the IL-22–IL-22R axis has the potential to be a viable area of development in the treatment of atopic dermatitis and psoriasis. In animal models of psoriasis, IL-22 deficiency and blockade resulted in reduction of disease burden.[68] However, the initial clinical trials evaluating antihuman IL-22 antibodies have been disappointing. Therefore, the effect of inhibiting the IL-22–IL-22R pathway in psoriasis remains to be determined. In atopic dermatitis, IL-22–producing T cells appear to play a significant role in mediating disease.[69] As such, there are ongoing efforts to develop IL-22 inhibitors in the treatment of atopic dermatitis.

With certain notable exceptions, systemic cytokine therapy has been disappointing and is often accompanied by substantial morbidity. As an example, high-dose intravenous recombinant IL-2 for patients with metastatic melanoma results in low response rates (~6%) and significant morbidity occurring because of drug toxicity. Moreover, the use of high-dose IFN-α2b as adjuvant therapy for high-risk surgically resected melanoma (stage IIB or III) produced sustained improvement in relapse-free survival; however, the therapy also results in significant morbidity. More recently, however, low-dose IL-2 has proven to be beneficial in the treatment of chronic graft-versus-host disease.[70] Although current cytokine-based therapies are limited, a better understanding of cytokine biology will lead to the development and enhancement of clinical efficacious therapies.

There is increasing evidence to support the use of cytokines and cytokine antagonists for the treatment of a range of dermatologic disorders. However, this will require an understanding of the fundamental biology governing inflammatory responses at cutaneous tissues. Further investigation is needed to establish the efficacy and safety of the biological therapies currently available and to support the development of new treatments options.

CHEMOKINES: SECONDARY CYTOKINES CENTRAL TO LEUKOCYTE MOBILIZATION

Although cytokines help coordinate the different cellular mediators of an inflammatory response, chemokines, a large superfamily of small cytokines, have

two major specialized functions. First, they guide leukocytes via chemotactic gradients in tissue. Typically, this is to bring an effector cell to where its activities are required. Second, a subset of chemokines has the capacity to increase the binding of leukocytes via their integrins to ligands at the endothelial cell surface, which facilitates firm adhesion and extravasation of leukocytes in tissue. Therefore, an appreciation of chemokine biology is critical because it plays an important role in skin development, immunity, inflammation, and cancer.

An overview of the structure of chemokines and chemokine receptors will be provided that will detail the molecular signaling pathways initiated by the binding of a chemokine to its cognate receptor. Expression patterns of chemokine receptors will be highlighted because of the many types of immune cells that potentially can be recruited to skin under inflammatory conditions. Individual chemokine receptors will be highlighted in regard to biologic function, including facilitation of migration of effector T cells into the skin and the egress of APCs out of the skin. Finally, the roles of chemokines and their receptors in several cutaneous diseases—atopic dermatitis, psoriasis, cancer, and infectious disease—provide a better idea of the diversity of chemokine function in skin.

STRUCTURE OF CHEMOKINES

Chemokines are grouped into four subfamilies based on the spacing of amino acids between the first two cysteines. The CXC chemokines (also called α-chemokines) show a C–X–C motif with one nonconserved amino acid between the two cysteines. The other major subfamily of chemokines lacks the additional amino acid and is termed the CC subfamily (or β-chemokines). The two remaining subfamilies contain only one member each: the C subfamily is represented by lymphotactin, and fractalkine is the only member of the CXXXC (or CX3C) subfamily. Chemokines can also be assigned to one of two broad and, perhaps, overlapping functional groups. One group (eg, regulated upon activation, normal T cell expressed and secreted [RANTES], macrophage inflammatory protein (MIP)-1α/β liver and activation-regulated chemokine [LARC]) mediates the attraction and recruitment of immune cells to sites of active inflammation, but others (eg, secondary lymphoid-tissue chemokine (SLC) and stromal-derived factor-1 [SDF-1]) appear to play a role in constitutive or homeostatic migration pathways.[71]

The complexity and redundancy in the nomenclature of chemokines has led to the proposal for a systematic nomenclature for chemokines based on the type of chemokine (C, CXC, CX3C, or CC) and a number based on the order of discovery as proposed by Zlotnik and Yoshie.[71] For example, SDF-1, a CXC chemokine, has the systematic name CXCL12. Because both nomenclatures are still in wide use, the original names (abbreviated in most cases) as well as systematic names will be used interchangeably. Table 12-4 provides a list of chemokine receptors of interest in skin that are discussed as well as the major chemokine ligands that bind to them.

Chemokines are highly conserved and have similar secondary and tertiary structure. Based on crystallography studies, a disordered amino terminus followed by three conserved antiparallel β-pleated sheets is a common structural feature of chemokines. Fractalkine is unique in that the chemokine domain sits atop a mucin-like stalk tethered to the plasma membrane via a transmembrane domain and short cytoplasmic tail.[72] Although CXC and CC chemokines form multimeric structures under conditions required for structural studies, these associations may be relevant only when chemokines associate with cell-surface components such as glycosaminoglycans (GAGs) or proteoglycans. Because most chemokines have a net positive charge, these proteins tend to bind to negatively charged carbohydrates present on GAGs. Indeed, the ability of positively charged chemokines to bind to GAGs is thought to enable chemokines to preferentially associate with the luminal surface of blood vessels despite the presence of shear forces from the blood that would otherwise wash away the chemokines.

CHEMOKINE RECEPTORS AND SIGNAL TRANSDUCTION

Chemokine receptors are seven transmembrane spanning membrane proteins that couple to intracellular heterotrimeric G-proteins containing α, β, and γ subunits.[71] They represent a part of a large family of G protein–coupled receptors (GPCR), including rhodopsin, that have critical biologic functions. Leukocytes express several Gα protein subtypes—s, i, and q—and the β and γ subunits each have 5 and 11 known subtypes, respectively. This complexity in the formation of the heterotrimeric G protein may account for specificity in the action of certain chemokine receptors. Normally G proteins are inactive when guanosine diphosphate (GDP) is bound, but they are activated when the GDP is exchanged for guanosine triphosphate (GTP) (Fig. 12-8). After binding to a ligand, chemokine receptors rapidly associate with G-proteins, which in turn increases the exchange of GTP for GDP. Pertussis toxin is a commonly used inhibitor of GPCR that irreversibly ADP-ribosylates Gα subunits of the α_i class and subsequently prevents most chemokine receptor–mediated signaling.

Activation of G proteins leads to the dissociation of the G_α and $G_{\beta\gamma}$ subunits (see Fig. 12-6). The G_α subunit has been observed to activate protein tyrosine kinases and mitogen-activated protein kinase, leading to cytoskeletal changes and gene transcription. The G_α subunit retains GTP, which is slowly hydrolyzed

TABLE 12-4
Chemokine Receptors in Skin Biology

CHEMOKINE RECEPTOR	CHEMOKINE LIGAND	EXPRESSION PATTERN	COMMENTS
CCR1	MIP-1 (CCL3), RANTES (CCL5), MCP-3 (CCL7)	T, Mo, DC, NK, B	Migration of DCs and monocytes; strongly upregulated in T cells by IL-2
CCR2	MCP-1 (CCL2), -3, -4 (CCL13)	T, Mo	Migration of T cells to inflamed sites; replenish LC precursors in epidermis; involved in skin fibrosis via MCP-1
CCR3	Eotaxin (CCL11) > RANTES, MCP-2 (CCL8), 3,4	Eo, Ba, Th2, K	Migration of Th2 cells and "allergic" immune cells
CCR4	TARC (CCL17), MDC (CCL22)	T (benign and malignant)	Expression in Th2 > Th1 cells; highly expressed on CLA+ memory T cells; TARC expression by keratinocytes may be important in atopic dermatitis; may guide trafficking of malignant as well as benign inflammatory T cells
CCR5	RANTES, MIP-1, (CCL3,4)	T, Mo, DC	Marker for Th1 cells; migration to acutely inflamed sites; may be involved in transmigration of T cells through endothelium; major HIV-1 fusion coreceptor
CCR6	LARC (CCL20)	T, DC, B	Expressed by memory, not naïve, T cells; possibly involved in arrest of memory T cells to activated endothelium and recruitment of T cells to epidermis in psoriasis
CCR7	SLC (CCL21), ELC (CCL 19)	T, DC, B, melanoma cells	Critical for migration of naïve T cells and "central memory" T cells to secondary lymphoid organs; required for mature DCs to enter lymphatics and localize to lymph nodes; facilitates nodal metastasis
CCR9	Thymus-expressed chemokine (CCL25)	T, melanoma cells	Associated with melanoma small bowel metastases
CCR10	CTACK (CCL27)	T (benign and malignant), melanoma cells	Preferential response of CLA+ T cells to CTACK in vitro; may be involved in T cell (benign as well as malignant) homing to epidermis, where CTACK is expressed; survival of melanoma is skin
CXCR1,2	IL-8 (CXCL8), MGSA/GRO (CXCL1), ENA-78 (CXCL5)	N, NK, En, melanoma cells	Recruitment of neutrophils (eg, epidermis in psoriasis); may be involved in angiogenesis; melanoma growth factor
CXCR3	IP-10 (CXCL10), Mig (CXCL9), I-TAC (CXCL11)	T	Marker for Th1 cells and may be involved in T cell recruitment to epidermis in CTCL; includes arrest of activated T cells on stimulated endothelium
CXCR4	SDF-1, (CXCL12)	T, DC, En, melanoma cells	Major HIV-1 fusion coreceptor; involved in vascular formation; involved in melanoma metastasis to lungs
CX3CR1	Fractalkine (CX3CL1)	T, Mo, MC, NK	May be involved in adhesion on activated T cells, Mo, NK cells to activated endothelium

B, B cells; Ba, basophils; CLA, cutaneous lymphocyte-associated antigen; CTACK, cutaneous T cell attracting chemokine; DC, dendritic cells; En, endothelial cells; Eo, eosinophils; GRO, growth regulated oncogene; HIV, human immunodeficiency virus; IL-8, interleukin-8; I-TaC, interferon-inducible T-cell alpha chemoattractant; LARC, liver and activation-regulated chemokine (also known as MIP-3); MC, mast cell; MCP, monocyte chemoattractant protein; MDC, macrophage-derived chemokine; MGSA, melanoma growth stimulatory activity; Mig, monokine-induced by IFN-; MIP, macrophage inflammatory protein; Mo, monocytes; N, neutrophils; NK, natural killer cell; RANTES, regulated upon activation, normal T cell expressed and secreted; SDF, stromal-derived factor; SLC, secondary lymphoid-tissue chemokine; T, T cells; TARC, thymus and activation-regulated chemokine; Th1,2, T helper 1,2 cell.

by the GTPase activity of this subunit. This GTPase activity is both positively and negatively regulated by GTPase-activating proteins (also known as regulator of G-protein signaling [RGS] proteins). The $G_{\beta\gamma}$ dimer initiates critical signaling events in regard to chemotaxis and cell adhesion. It activates phospholipase C (PLC),[73] leading to formation of diacylglycerol (DAG) and inositol triphosphate (Ins[1,4,5]P_3). Ins(1,4,5)P_3 stimulates Ca^{2+} entry into the cytosol, which along with DAG, activates protein kinase C isoforms. Whereas the $G_{\beta\gamma}$ subunits have been shown to be critical for chemotaxis, the G_{α} subunit has no known role in chemotactic migration. There is also evidence that binding of chemokine receptors results in the activation of other intracellular effectors, including Ras and Rho, phosphatidylinositol-3-kinase (PI[3]K]).[74]

RhoA and protein kinase C appear to play a role in integrin affinity changes, and PI(3)K may be critical for changes in the avidity state of lymphocyte function-associated antigen 1 (LFA-1). Other proteins have been found that regulate the synthesis, expression, or degradation of GPCRs. For example, receptor-activity-modifying proteins (RAMPS) act as chaperones of seven transmembrane spanning receptors and regulate surface expression as well as the ligand specificity of chemokine receptors (see Fig. 12-8). Importantly, after chemokine receptors are exposed to appropriate ligands, they are frequently internalized, leading to an inability of the chemokine receptor to mediate further signaling. This downregulation of chemokine function, which has been termed "desensitization," occurs because of phosphorylation of Ser/Thr residues

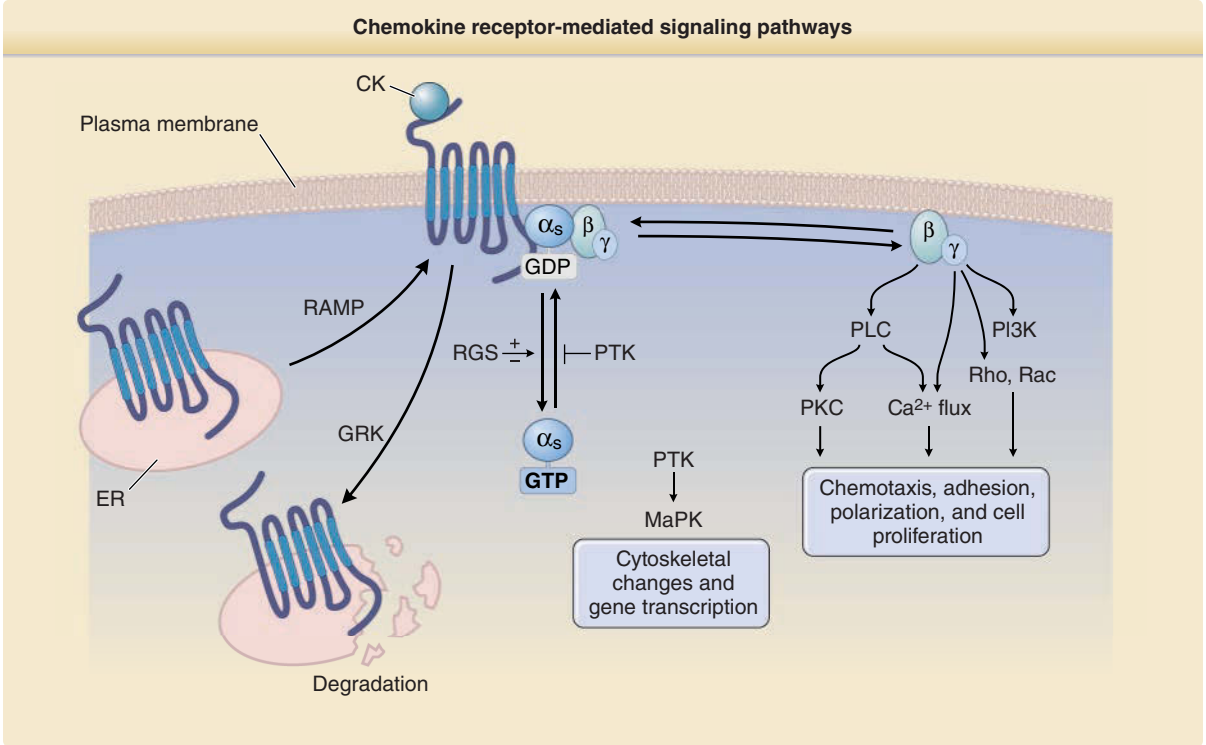

Figure 12-8 Chemokine receptor-mediated signaling pathways. CK, chemokine; DG, 1,2-diacylglycerol; ER, endoplasmic reticulum; GRK, G-protein coupled receptor kinase; IP3, inositol-1,4,5-triphosphate; MAPK, Mitogen activated protein kinase; PIP2, phosphatidylinositol-4,5-bisphosphate; PKC, protein kinase C; PLC, phospholipase C; PTK, protein tyrosine kinase(s); PTX, pertussis toxin; RAMP, receptor-activity-modifying protein; RGS, regulator of G-protein signaling.

in the C-terminal tail by proteins termed GPCR kinases and subsequent internalization of the receptor (see Fig. 12-8). Desensitization may be an important mechanism for regulating the function of chemokine receptors by inhibiting cell migration as leukocytes arrive at the primary site of inflammation.

CHEMOKINES AND CUTANEOUS LEUKOCYTE TRAFFICKING

Generally speaking, chemokines are thought to play at least three different roles in the recruitment of host defense cells, predominantly leukocytes, to sites of inflammation.[75] First, they provide the signal or signals required to cause leukocytes to come to a complete stop (ie, arrest) in blood vessels at inflamed sites such as skin. Second, chemokines have been shown to have a role in the transmigration of leukocytes from the luminal side of the blood vessel to the abluminal side. Third, chemokines attract leukocytes to sites of inflammation in the dermis or epidermis following transmigration. Keratinocytes and endothelial cells are a rich source of chemokines when stimulated by appropriate cytokines. In addition, chemokines and their receptors are known to play critical roles in the emigration of resident skin DCs (ie, LCs and dermal DCs) from the skin to draining LN via afferent lymphatic vessels, a process that is essential for the development of acquired immune responses.

This section is divided into three subsections. The first introduces basic concepts of how all leukocytes arrest in inflamed blood vessels before transmigration by introducing the multistep model of leukocyte recruitment. The second details mechanisms of T-cell migration, and the final subsection focuses on the mechanisms by which chemokines mediate the physiological migration of DCs from the skin to regional LNs.

THE MULTISTEP MODEL OF LEUKOCYTE RECRUITMENT

For leukocytes to adhere and migrate to peripheral tissues, they must overcome the pushing force of the vascular blood stream as they bind to activated endothelial cells at local sites of inflammation. According to the multistep or cascade model of leukocyte recruitment (Fig. 12-9), one set of homologous adhesion molecules termed *selectins* mediates the transient attachment of leukocytes to endothelial cells, and another set of adhesion molecules termed *integrins* and their receptors (*immunoglobulin superfamily members*) mediates stronger binding (ie, arrest) and transmigration.[76] The selectins (E-, L-, and P-selectins) are members of a larger family of carbohydrate-binding

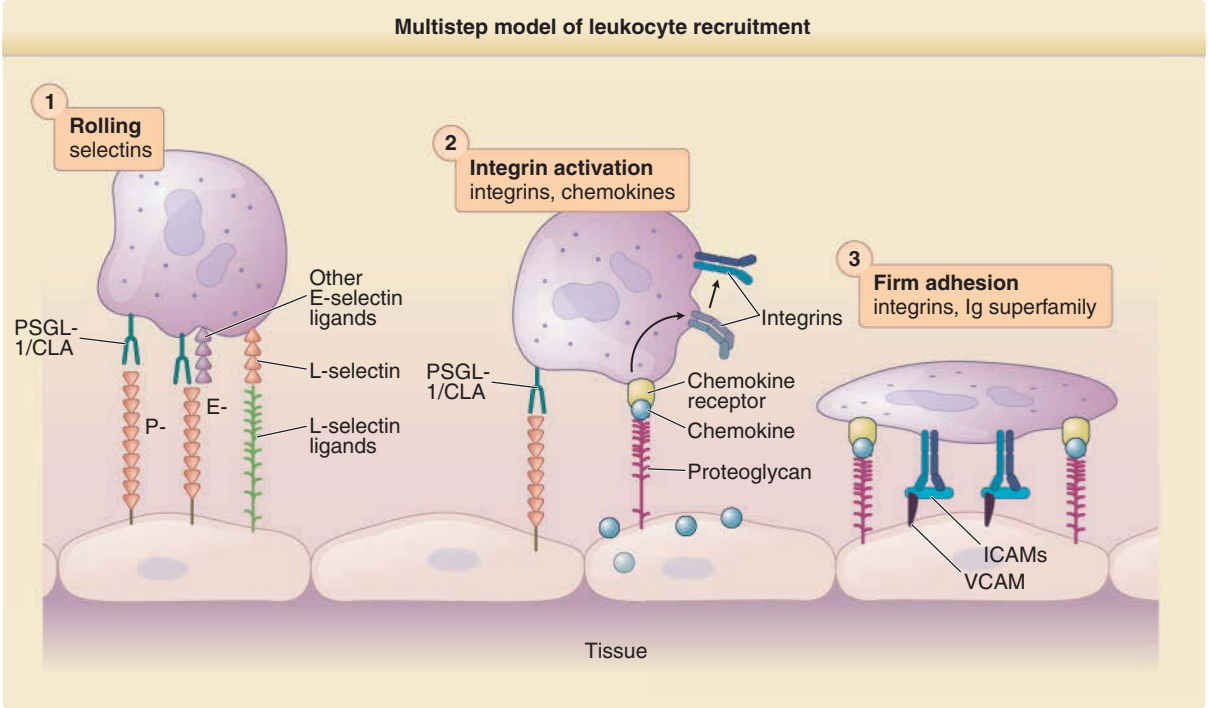

Figure 12-9 Multistep model of leukocyte recruitment. Leukocytes, pushed by the bloodstream, first transiently bind or "roll" on the surface of activated endothelial cells via rapid interactions with P-, E-, or L-selectin. Chemokines are secreted by endothelial cells and bind to proteoglycans that present the chemokine molecules to chemokine receptors on the surface of the leukocyte. After chemokine receptor ligation, intracellular signaling events lead to a change in the conformation of integrins and changes in their distribution on the plasma membrane, resulting in "integrin activation." These changes result in high-affinity and -avidity binding of integrins to endothelial cell intercellular adhesion molecules (ICAMs) and vascular cell adhesion molecule-1 (VCAM-1) in a step termed "firm adhesion," which is then followed by transmigration of the leukocyte between endothelial cells and into tissue.

proteins termed lectins. The selectins bind their respective carbohydrate ligands located on protein scaffolds and thus mediate the transient binding or "rolling" of leukocytes on endothelial cells.

The skin-associated vascular selectin known as E-selectin is upregulated on endothelial cells by inflammatory cytokines such as TNF-α and binds to sialyl Lewis x-based carbohydrates. E-selectin ligands form distinct epitopes known as the cutaneous lymphocyte-associated antigen (CLA). CLA is expressed by 10% to 40% of memory T cells and has been suggested as a marker for skin-homing T cells.[77] At least two chemokine receptors (CCR10 and CCR4) show preferential expression in CLA^+ memory T cells.[78,79] Although E-selectin is likely to be an important component of skin-selective homing, there is also evidence to suggest that L-selectin is involved in T-cell migration to skin.[80,81]

In the second phase of this model, leukocyte integrins such as those of the β_2 family must be "turned on" or activated from their resting state to bind to their counter receptors such as ICAM-1 that are expressed by endothelial cells. A vast array of data suggest that the binding of chemokines to leukocyte chemokine receptors plays a critical role in activating both β1 and β2 integrins.[74,82] Activation of chemokine receptors leads to a complex signaling cascade (see Fig. 12-9) that causes a conformational change in individual integrins that leads to increases in the affinity and avidity of individual leukocyte integrins for their ligands. Furthermore, later steps of migration (ie, transmigration or diapedesis) have been shown to be dependent on chemokines as well in specific cellular contexts.[83] In the case of neutrophils, their ability to roll on inflamed blood vessels likely depends on their expression of L-selectin and E-selectin ligands, while and arrest on activated endothelia likely depends on their expression of CXCR1 and CXCR2 as described later for wound healing. Integrin activation via chemokine-mediated signals appears to be more complex in T cells, which appear to use multiple chemokine receptors, and is described in more detail later.

CHEMOKINE-MEDIATED MIGRATION OF T CELLS

Antigen-inexperienced T cells are termed naïve and can be identified by expressing three cell surface proteins: CD45RA (an isoform of the pan-leukocyte marker), L-selectin, and the chemokine receptor CCR7. These T cells migrate efficiently to secondary LNs, where they may make contact with antigen-bearing DCs from the periphery. After being activated by DCs presenting antigen, T cells then express CD45RO, are termed

"memory" T cells, and appear to express a variety of adhesion molecules and chemokine receptors, which facilitate their extravasation from blood vessels to inflamed peripheral tissue. A specific subset of CCR7$^-$, L-selectin memory T cells has been proposed to represent an effector memory T-cell subset that is ready for rapid deployment at peripheral sites in terms of their cytotoxic activity and ability to mobilize cytokines.[84]

Although chemokines are both secreted and soluble, the net positive charge on most chemokines allows them to bind to negatively charged proteoglycans such as heparin sulfate that are present on the luminal surface of endothelial cells, thus allowing them to be presented to T cells as they roll along the luminal surface (see Fig. 12-9). After ligand binding, chemokine receptors send intracellular signals that lead to increases in the affinity and avidity of T-cell integrins such as LFA-1 and very late antigen-4 (VLA-4) for their endothelial receptors ICAM-1 and VCAM-1, respectively.[85] Only a few chemokine receptors (CXCR4, CCR7, CCR4, and CCR6) are expressed at sufficient levels on resting peripheral blood T cells to mediate this transition. With activation and IL-2 stimulation, increased numbers of chemokine receptors (eg, CXCR3) are expressed on activated T cells, making them more likely to respond to other chemokines. In several different systems, inhibition of specific chemokines produced by endothelial cells or chemokine receptors found on T cells dramatically influences T-cell arrest in vivo and in vitro.[86]

CXCR3 serves as a receptor for chemokine ligands Mig, IP-10, and I-Tac. All three of these chemokines are distinguished from other chemokines by being highly upregulated by IFN-γ. Resting T cells do not express functional levels of CXCR3 but upregulate this receptor with activation and cytokines such as IL-2. When expressed on T cells, CXCR3 is capable of mediating arrest of memory T cells on activated endothelial cells.[87] The expression of its chemokine ligands is strongly influenced by the cytokine IFN-γ, which synergistically works with proinflammatory cytokines such as TNF-α to increase expression of these ligands by activated endothelial cells[87] and epithelial cells.

In general, activation of T cells by cytokines such as IL-2 is associated with the enhanced expression of chemokine receptors CCR1, CCR2, CCR5, and CXCR3. Just as Th1 and Th2 (T cell) subsets have different functional roles, it might have been predicted that these two subsets of T cells would express different chemokine receptors. Indeed, CCR4[88-90] and CCR3[91] are associated with Th2 cells in vitro, and Th1 cells are associated with CCR5 and CXCR3.[92]

In some instances, chemokine receptors may be regarded as functional markers that characterize distinct T helper cell subsets while also promoting their recruitment to inflammatory sites characterized by "allergic" or "cell-mediated" immune responses, respectively. When T cells are activated in vitro in the presence of Th1-promoting cytokines, CXCR3 and CCR5 appear to be highly expressed, but in the presence of Th2-promoting cytokines, CCR4, CCR8, and CCR3 expression predominates. In rheumatoid arthritis, a Th1-predominant disease, many infiltrating T cells express CCR5 and CXCR3,[93] but in atopic disease, CCR4 expressing T cells may be more frequent.[88] CCR6 has recently been described as a marker for a newly characterized T-helper subset, expressing the hallmark effector cytokines IL-17 and IL-22.[94] These so-called Th17 cells play a central role in the pathogenesis of psoriasis and other chronic inflammatory autoimmune diseases.[95] However, in normal skin, the majority of skin resident T cells also co-express CCR6, suggesting that CCR6 and CCL20 interactions regulate T-cell infiltration in the skin under inflammatory as well as homeostatic conditions.[96]

Although certain chemokine receptors characterize distinct T-cell subsets, flexible regulation of their expression may increase the migratory potential of circulating T cells to diverse tissues. For example, under some conditions, both Th1 and Th2 type T cells can express CCR4.[90] Similarly, Treg and Th17 cells share chemokines receptors with other T-cell lineages but may alter their chemokine receptor expression profiles, depending on the microenvironment in which they are activated.[97]

The epidermis is a particularly rich source of chemokines, including RANTES, MIP-3α (CCL20), macrophage chemotactic protein-1 (MCP-1), IP-10, IL-8, LARC, and thymus and activation-regulated chemokine (TARC), which likely contribute to epidermal T cell migration. Keratinocytes from patients with distinctive skin diseases appear to express unique chemokine expression profiles. For instance, keratinocytes derived from patients with atopic dermatitis synthesized mRNA for RANTES at considerably earlier time points in response to IL-4 and TNF-α in comparison with cells derived from healthy individuals and psoriatic patients.[98] Keratinocytes derived from psoriatic patients synthesized higher levels of IP-10 with cytokine stimulation as well as higher constitutive levels of IL-8,[98] a chemokine known to recruit neutrophils. IL-8 may contribute to the large numbers of neutrophils that localize to the suprabasal and cornified layers of the epidermis in psoriasis. IP-10 may serve to recruit activated T cells of the Th1 helper phenotype to the epidermis and has been postulated to have a role in the recruitment of malignant T cells to the skin in cutaneous T-cell lymphomas.[99]

CTACK/CCL27 is selectively and constitutively expressed in the epidermis, and its expression is only marginally increased under inflammatory conditions.[100] Interestingly, CTACK has been reported to preferentially attract CLA$^+$ memory T cells in vitro[100] and has been demonstrated to play a role in the recruitment and function of skin-homing T cells in inflammatory disease models.[101,102]

CHEMOKINES IN THE TRAFFICKING OF DENDRITIC CELLS FROM SKIN TO REGIONAL LYMPH NODES

Antigen-presenting cells, including DCs of the skin, are critical initiators of immune responses and their

trafficking patterns are thought to influence immunological outcomes. Their mission includes taking up antigen at sites of infection or injury and bringing these antigens to regional LNs, where they both present antigen and regulate the responses of T and B cells. Skin-resident DCs are initially derived from hematopoietic bone marrow progenitors[103] and migrate to skin during the late prenatal and newborn periods of life. Under resting (steady-state) conditions, homeostatic production by keratinocytes of CXCL14 (receptor unknown) may be involved in attracting $CD14^+$ DC precursors to the basal layer of the epidermis.[104] Similarly, LCs as well as CD1c+ LC precursors are strongly chemoattracted to keratinocyte-derived CCL20.[105] Under inflammatory conditions, when skin-resident DC and LC leave the skin in large numbers, keratinocytes release a variety of chemokines, including CCL2 and CCL7 (via CCR2)[106] and CCL20 (via CCR6),[107] which may attract monocyte-like DC precursors to the epidermis to replenish the LC population.

When activated by inflammatory cytokines (eg, TNF-α and IL-1β), LPS, or injury, skin DCs, including LCs, leave the epidermis, enter afferent lymphatic vessels, and migrate to draining regional LNs, where they encounter both naive and memory T cells. Chemokines guide the DCs on this journey. Activated DC specifically upregulate expression of CCR7, which binds to secondary lymphoid tissue chemokine (SLC/CCL21), a chemokine expressed constitutively by lymphatic endothelial cells.[108,109] SLC guides DC into dermal lymphatic vessels and helps retain them in SLC-rich regional draining LN (Fig. 12-10).[110]

Interestingly, naïve T cells also strongly express CCR7 and use this receptor to arrest on high endothelial venules.[111] The importance of the CCR7 pathway is demonstrated by LCs from CCR7 knockout mouse that demonstrate poor migration from the skin to regional LN[112] and by the observation that antibodies to SLC block migration of DC from the periphery to LNs.[108] Thus, CCR7 and its ligands facilitate the recruitment of at least two different kinds of cells—naïve T cells and DCs—to the LNs through two different routes under both inflammatory[112] and resting conditions.[110]

After DCs reach the LNs, they must interact with T cells to form a so-called "immunologic synapse" that is critical for T-cell activation. Activated DCs secrete a number of chemokines, including macrophage-derived chemokine (MDC),[113] which attracts T cells to the vicinity of DCs and promotes adhesion between the two cell types.[114,115] CCR5 (via CCL3/4) has also been identified as mediating recruitment of naive CD8+ T cells to aggregates of antigen-specific $CD4^+$ T cells and DCs.[116] Therefore, chemokines orchestrate a complex series of migration patterns bringing both DCs and T cells to the confines of the LNs, where expression of chemokines by DC themselves appears to be a direct signal for binding of the T cell (see Fig. 12-10).

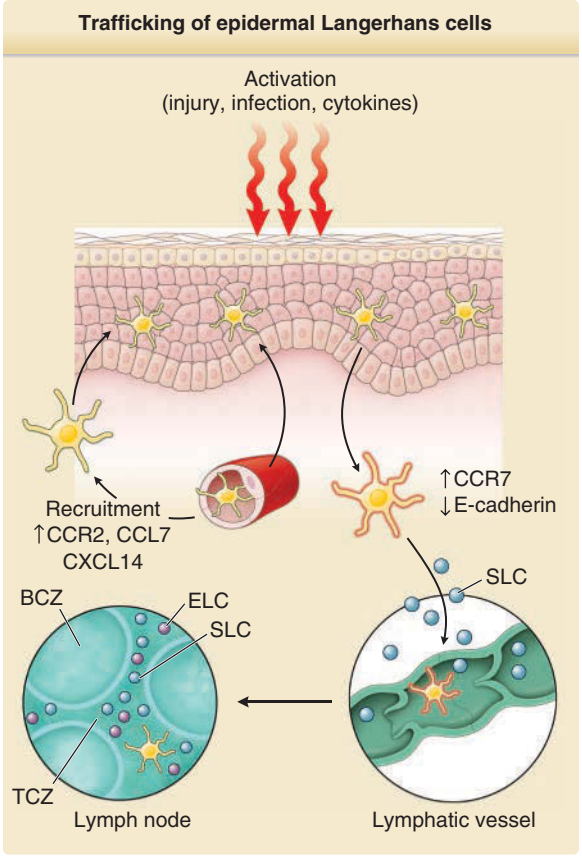

Figure 12-10 Trafficking of epidermal Langerhans cells to regional lymph nodes. Langerhans cells are activated by a variety of stimuli, including injury, infectious agents, and cytokines such as interleukin-1α (IL-1α) and tumor necrosis factor-α (TNF-α). Having sampled antigens, the activated Langerhans cells (LCs) downregulate E-cadherin and strongly upregulate CCR7. Sensing the CCR7-ligand, SLC, produced by lymphatic endothelial cells, the LCs migrate into lymphatic vessels, passively flow to the lymph nodes, and stop in the T-cell zones (TCZ) that are rich in two CCR7 ligands, SLC and EBI1 ligand chemokine (ELC). Note that chemokines also contribute to the recruitment of LC under both resting and inflammatory conditions. BCZ, B-cell zones.

CHEMOKINES IN DISEASE

ATOPIC DERMATITIS

Atopic dermatitis is a prototypical Th2-mediated, allergic skin disease with multifactorial genetic and environmental factors involved in its pathogenesis. Although multiple chemokines have been associated with the atopic phenotype, the roles of CCR4 and CCR10 in atopic dermatitis have been particularly well documented.[117] Clinical data from humans as well as experimental data in the NC/Nga mouse model of atopic dermatitis suggest that the Th2-associated chemokine receptor, CCR4, in conjunction with its ligand, TARC/CCL17, may play a role in recruiting

T cells to atopic skin. In patients with atopic dermatitis, $CLA^+CCR4^+CCR10^+$ lymphocytes were found to be increased in the peripheral blood and in lesional skin compared with control participants.[88] Moreover, serum levels of TARC/CCL17 and CTACK/CCL27 in atopic dermatitis patients were significantly higher than concentrations found in healthy or psoriatic control participants and correlated with disease severity.[118]

CCL18, whose receptor is currently unknown, has been reported to be expressed at higher levels in the skin of patients with atopic disease compared with psoriasis.[119] CCL18 is produced by APCs and attracts CLA^+ memory T cells to the skin.[120] Elevated levels of CCL18 can be found in the skin and sera of patients with atopic dermatitis but show a significant decrease after therapy.[121] Of note, CCL18 and another chemokine, CCL1 (produced by mast cells and endothelial cells), are elicited in volunteer skin after topical challenge with dust mite allergen and *Staphylococcal superantigen*.[119,122]

The recruitment of eosinophils to skin is a frequently observed finding in allergic skin diseases, including atopic dermatitis and cutaneous drug reactions, and likely is mediated by chemokines. Eotaxin/CCL11 was initially isolated from the bronchoalveolar fluid of guinea pigs after experimental allergic inflammation and binds primarily to CCR3, a receptor expressed by eosinophils,[123] basophils, and Th2 cells.[91] Injection of eotaxin into the skin promotes the recruitment of eosinophils, and antieotaxin antibodies delay the dermal recruitment of eosinophils in the late-phase allergic reaction in mouse skin.[124] Immunoreactivity and mRNA expression of eotaxin and CCR3 are both increased in lesional skin and serum of patients with atopic dermatitis but not in nonatopic controls.[125,126] Eotaxin has also been shown to increase proliferation of CCR3-expressing keratinocytes in vitro.[127] Finally, expression of eotaxin (and RANTES) by dermal endothelial cells has been correlated with the appearance of eosinophils in the dermis in patients with onchocerciasis that experience allergic reactions after treatment with ivermectin.[128] The observations above suggest that production of eotaxin and CCR3 may contribute to the recruitment of eosinophils and Th2 lymphocytes in addition to stimulating keratinocyte proliferation.

PSORIASIS

Psoriasis is characterized by hyperplasia of the epidermis (acanthosis) and a prominent dermal and epidermal inflammatory infiltrate, typically resulting in thickened, hyperkeratotic plaques. The inflammatory infiltrate of psoriatic skin is predominantly composed of Th1- and Th17-polarized memory T cells, as well as neutrophils, macrophages, and increased numbers of DCs.[129] As reviewed by others,[117] there is a growing body of evidence supporting a central role for chemokines in regulating the complex events leading to psoriatic skin inflammation. Chemokines, including CCL20[130] and CCL17,[78] mediate the arrest of effector memory T cells on endothelial cells that synthesize these chemokines.[131] In addition, both CCL17 and CCL20 can be synthesized by keratinocytes, possibly contributing to T-cell migration to the epidermis (Fig. 12-11).

Accumulating evidence strongly implicates pathogenetic Th17 cells, which strongly express CCR6, in the pathogenesis of psoriasis.[132] Th17 cells, their signature effector cytokines IL-17 and IL-22, as well as high levels of IL-23, a major growth and differentiation factor for Th17 cells, are abundant in psoriatic skin lesions.[133] Recent research suggests that CCR6 and its ligand, CCL20, are important mediators of psoriasis because both CCL20 as well as CLA^+CCR6^+ skin-homing Th17 cells are found in abundance in lesional psoriatic skin.[60,133] Moreover, CCR6-deficient mice failed to develop psoriasis-like inflammation[134] in response to intradermal IL-23 injections, a murine model for human psoriasis.[57] Interestingly, CCR6 was required for both T cell–dependent as well as T cell–independent skin inflammation in this model.[134]

Neutrophils found in the epidermis of psoriatic skin are probably attracted there by high levels of IL-8, which would act via CXCR1 and CXCR2. In addition to attracting neutrophils, IL-8 is an ELR^+ CXC chemokine that is known to be angiogenic, and it may also attract endothelial cells. This may lead to the formation of the long tortuous capillary blood vessels in the papillary dermis that are characteristic of psoriasis. Moreover, keratinocytes also express CXCR2 and thus may be autoregulated by the expression of CXCR2 ligands in the skin. Of note, an IL-8/CXCL8-producing population of memory T cells that express CCR6 has been isolated from patients with acute generalized exanthematous pustulosis (AGEP), a condition induced most commonly by drugs (eg, aminopenicillins) and characterized by small intraepidermal or subcorneal sterile pustules.[135] Similar T cells have been isolated from patients with Behçet disease and pustular psoriasis.[136] It is possible that this subpopulation of T cells contributes to neutrophil accumulation in the stratum corneum (Munro abscesses) in psoriasis and other inflammatory skin disorders characterized by neutrophil-rich infiltrates in the absence of frank infection.

CANCER

Chemokines may play a role in tumor formation and immunity in several distinct ways, including the control of angiogenesis and the induction of tumor immune responses.[137] CXC chemokines that express a three-amino-acid motif consisting of glu-leu-arg (ELR) immediately preceding the CXC signature are angiogenic, but most non–ELR CXC chemokines, except SDF-1, are angiostatic. Interestingly, it is not clear that ELR^- chemokines actually bind to chemokine receptors to reduce angiogenesis. It has been proposed that they act by displacing growth

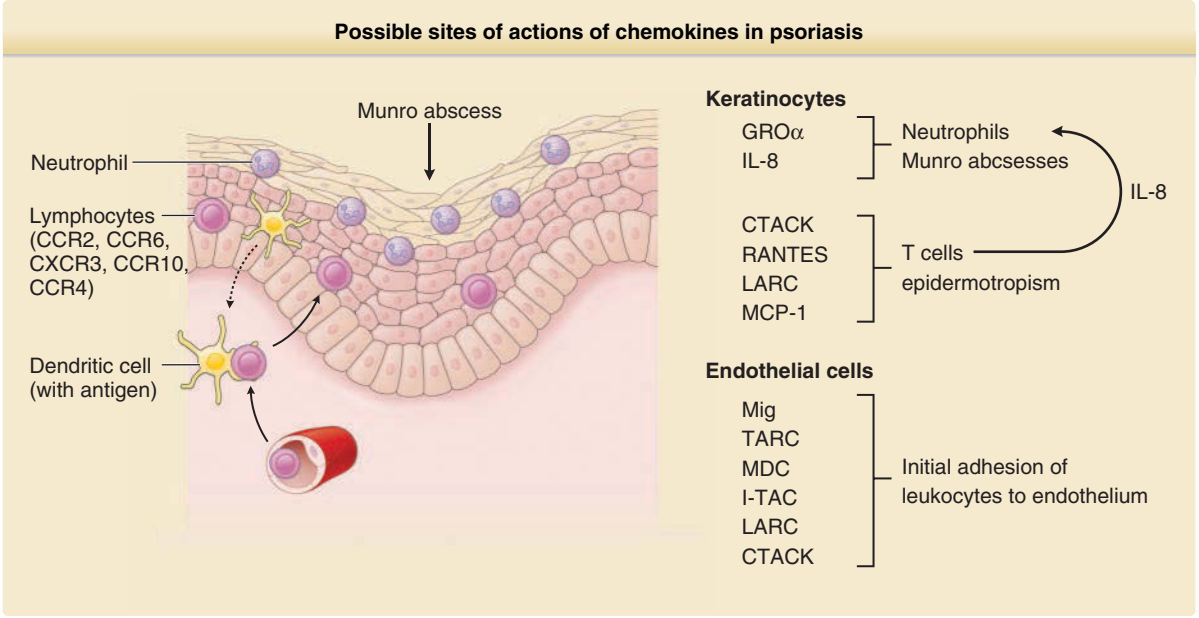

Figure 12-11 Possible sites of actions of chemokines in psoriasis. Chemokines attract both neutrophils (to form Munro abscesses) and lymphocytes via attachment to endothelial cells and then migration to the epidermis (epidermotropism). Specific chemokines tend to attract either neutrophils or lymphocytes but generally not both. A newly identified subset of T cells can secrete interleukin-8 (IL-8) and attract neutrophils in conditions such as acute generalized exanthematous pustulosis (AGEP). Dendritic cells may also secrete chemokines, attract T cells, and stimulate conjugate formation that activates T cells. Cutaneous T-cell-attracting chemokine (CTACK); growth-regulated oncogene-alpha (GRO-α); I-TAC, interferon-inducible T-cell alpha chemoattractant; LARC, liver and activation-regulated chemokine; MCP-1, macrophage chemotactic protein-1; MDC, macrophage-derived chemokine; Mig, monokine induced by gamma interferon; RANTES, regulated upon activation, normal T cell expressed and secreted; TARC, thymus and activation-regulated chemokine. (Adapted from Lonsdorf AS, Hwang ST. Chemokines. In: Goldsmith LA, Katz SI, Gilchrest BA, et al. *Fitzpatrick's Dermatology in General Medicine*, 8th ed. New York: McGraw-Hill; 2012:eFigure 12-3.1.)

factors from proteoglycans. In any event, the balance between ELR$^+$ versus ELR$^-$ chemokines is thought to contribute to the complex regulation of angiogenesis at tumor sites. IL-8, a prototypical ELR$^+$ chemokine, can be secreted by melanoma cells and has been detected in conjunction with metastatic dissemination of this cancer,[138] which may be related to its ability to attract circulating tumor cells to primary tumors and to influence leukocyte and endothelial cell recruitment.[139,140] IL-8 may also act as an autocrine growth factor for melanoma[141] as well as several other types of cancer. Although CXCR1 and CXCR2 bind IL-8 in common, several other ELR$^+$ CXC chemokines also bind to and activate CXCR2.

Tumors, including melanoma, have long been known to secrete chemokines that can attract a variety of leukocytes. The question arises as to why this is not deleterious to the tumor itself. Breast cancers, for instance, are known to secrete MCP-1, a chemokine that attracts macrophages through CCR2. Higher tissue levels of MCP-1 correlate with increasing number of macrophages within the tissue. Although chemokines secreted by tumor cells do lead to recruitment of immune cells, this does not necessarily lead to increased clearance of the tumor.[142]

Inflammatory cells such as macrophages may actually play a critical role in cancer invasion and metastasis. First, MCP-1 may increase expression of macrophage IL-4 through an autocrine feedback loop and possibly skew the immune response from Th1 to Th2. Interestingly, MCP-1–deficient mice show markedly reduced dermal fibrosis after dermal challenge with bleomycin, a finding of possible relevance to the pathogenesis of conditions such as scleroderma.[143] Second, macrophages may promote tumor invasion and metastasis.[144] The antitumor effects of specific chemokines may occur by a variety of mechanisms. ELR$^-$ CXCR3 ligands such as IP-10 are potently antiangiogenic and may act as downstream effectors of IL-12-induced, NK cell–dependent angiostasis.[145] Of note, some cancer cells can synthesize LARC, attracting immature DCs that express CCR6.[146] Experimentally, LARC has been transduced into murine tumors, where it attracts DCs in mice and suppresses tumor growth in experimental systems.[147] Last, chemokines produced by tumor cells may attract CD4$^+$CD25$^+$ Tregs that suppress host antitumor cytolytic T cells.[148]

Tumor metastasis is the most common cause of mortality and morbidity in cancer. With skin cancers such as melanoma, there is a propensity for specific sites such as brain, lung, and liver, as well as distant skin sites. Cancers may also metastasize via afferent lymphatics and eventually reach regional draining LNs. The discovery of nodal metastasis often portends a poor prognosis for the patient. In fact, the presence of

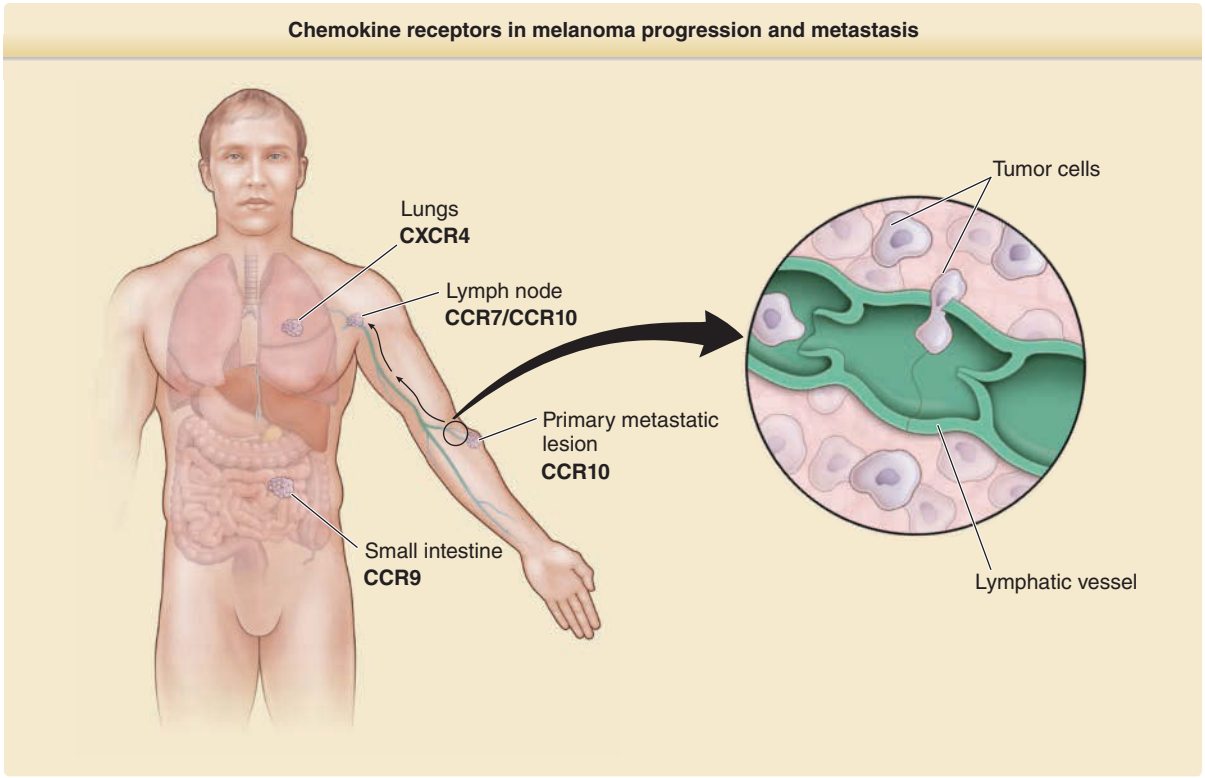

Figure 12-12 Chemokine receptors in melanoma progression and metastasis. Chemokine receptors play distinct roles in melanoma metastasis.[117] CCR10 may enhance survival of primary melanoma tumors and skin metastases. CCR7, CCR10, and, possibly CXCR4 may contribute to lymph node metastasis. CXCR4 appears to be involved in primary tumor development and metastasis at distant organ sites such as the lungs. CCR9 has been implicated in melanoma small bowel metastasis in patients.

nodal metastases is one of the most powerful negative predictors of survival in melanoma.[149]

Chemokines may play an important role in the site-specific metastases of cancers of the breast and of melanoma[150] (Fig. 12-12). Human breast cancer and melanoma lines express the chemokine receptors CXCR4 and CCR7, but normal breast epithelial cells and melanocytes do not appear to express these receptors.[151] CXCR4 is expressed in more than 23 different solid and hematopoietic cancers. Broad expression of this receptor may be due to its regulation by hypoxia, a condition common to growing tumors, via the hypoxia inducible factor-1α transcription factor.[152] Notably stromal fibroblasts within human cancers express the CXCR4 ligand, CXCL12, which stimulates tumor growth as well as angiogenesis.[153] In several different animals of breast cancer[151] and melanoma metastasis,[154] inhibition of CXCR4 with antibodies or peptides resulted in dramatically reduced metastases to distant organs. Expression of CCR7 by cancer cells, including gastric carcinoma and melanoma, appears to be critical for invasion of afferent lymphatics and LN metastasis. CCR7-transfected B16 murine melanoma cells were found to metastasize with much higher efficiency to regional LNs compared with control B16 cells after inoculation into the footpad of mice,[155] but CCR7 also directly stimulates primary B16 tumor development.[156] CCR9 may also play a role in melanoma metastasis to the small bowel, which shows high expression of the CCR9 ligand, CCL25.[157]

CCR10 is highly expressed by melanoma primary tumors[158] and is correlated with nodal metastasis in melanoma patients[159] and in experimental animal models.[158] Engagement of CCR10 by CTACK results in activation (via phosphorylation) of the phosphatidylinositol 3-kinase (PI3K) and Akt signaling pathways, leading to antiapoptotic effects in melanoma cells.[158] Because CTACK is constitutively produced by keratinocytes, it may act as a survival factor for both primary as well as secondary (metastatic) melanoma tumors that express CCR10. In fact, CCR10-activated melanoma cells become resistant to killing by melanoma antigen-specific T cells.[158] Interestingly, CCR4,[160] CXCR4,[161] and CCR10[162,163] have been implicated in the trafficking or survival of malignant T- (lymphoma) cells to skin. Thus, a limited number of specific chemokine receptors appear to play distinct, nonredundant roles in facilitating cancer progression and metastasis (summarized in Fig. 12-12).

INFECTIOUS DISEASES

Although chemokines and chemokine receptors may have evolved as a host response to infectious agents,

recent data suggest infectious organisms may have coopted chemokine- or chemokine receptor–like molecules to their own advantage in selected instances. A variety of microorganisms express chemokine receptors, including US28 by cytomegalovirus and Kaposi sarcoma herpes virus (or HHV-8) GPCR. In the case of KSHV GPCR, this receptor is able to promiscuously bind several chemokines. More importantly, it is constitutively active and may work as a growth promoter in Kaposi sarcoma.[164]

The human immunodeficiency virus (HIV)-1, the causative agent of the acquired immunodeficiency syndrome (AIDS), is an enveloped retrovirus that enters cells via receptor-dependent membrane fusion. CD4 is the primary fusion receptor for all strains of HIV-1 and binds to HIV-1 proteins, gp120 and gp41. However, different strains of HIV-1 have emerged that preferentially use CXCR4 (T-tropic) or CCR5 (M-tropic) or either chemokine receptor as a coreceptor for entry. Although other chemokine coreceptors can potentially serve as coreceptors, most clinical HIV-1 strains are primarily dual tropic for either CCR5 or CXCR4.[165]

The discovery of a 32–base pair deletion (D32) in CCR5 in some individuals that leads to low levels of *CCR5* expression in T cells and DCs and correlates with a dramatic resistance to HIV-1 infection demonstrated a clear role for CCR5 in the pathogenesis of HIV-1 infection.[166] Interestingly, the frequency of Δ32 mutations in humans is surprisingly high, and the complete absence of CCR5 in homozygotes has only been associated with a more clinically severe form of sarcoidosis. Otherwise, these individuals are healthy. In fact, there is an association of less severe autoimmune diseases in patients with these mutations.[167]

LCs reside in large numbers in the genital mucosa and may be one of the first initial targets of HIV-1 infection.[168] Because infected (activated) LCs likely enter dermal lymphatic vessels and then localize to regional LNs as described earlier, the physiologic migratory pathway of LCs may also coincidentally lead to the transmission of HIV-1 to T cells within secondary lymphoid organs. CCR5 is expressed by immature or resting LCs in the epidermis and is the target of CCR5 analogs of RANTES that block HIV infection.[169] Already, an FDA-approved small molecule inhibitor of CCR5, maraviroc, is available for use in treatment of HIV disease and may show fewer adverse effects than certain reverse transcriptase inhibitors.[170] CXCR4 antagonists may also be of clinical utility with T- or dual-tropic viruses.[171] A newly described autosomal dominant genetic syndrome composed of *w*arts (human papilloma virus [HPV] associated), *h*ypogammaglobulinemia, *i*nfections, and *m*yelokathexis (WHIM) is the result of an activating mutation in the cytoplasmic tail of the CXCR4 receptor or in yet unidentified downstream regulators of CXCR4 function.[172,173] Bacterial infections are common because myelokathexis is associated with neutropenia and abnormal neutrophil morphology. The nearly universal presence of HPV infections associated with this syndrome can involve multiple common, as well as genital, wart subtypes and suggests a critical role for normal CXCR4 function in immunologic defense against this common human pathogen.

SOLUBLE MEDIATOR NETWORK: THERAPEUTIC IMPLICATIONS AND APPLICATIONS

This chapter has attempted to bring some degree of order and logic to the analysis of a field of human biology that continues to grow at a rapid rate. An appreciation of the underlying biology governing soluble mediators sheds light on the mechanisms of cutaneous tissue homeostasis. An imbalance in this careful orchestration of cytokines and chemokines can lead to chronic disease. As highlighted in this chapter, cytokines and chemokines are currently being clinically targeted to help treat patients with a number of skin disorders. Each of the aforementioned approaches is still relatively new and open to considerable future development. An understanding of cytokines and chemokines by clinicians of the future is likely to be central to effective patient care.

REFERENCES

1. Oppenheim JJ. Cytokines: past, present, and future. *Int J Hematol*. 2001;74:3-8.
2. Charo IF, Ransohoff RM. The many roles of chemokines and chemokine receptors in inflammation. *N Engl J Med*. 2006;354:610-621.
3. Bigazzi PE, Yoshida T, Ward PA, et al. Production of lymphokine-like factors (cytokines) by simian virus 40-infected and simian virus 40-transformed cells. *Am J Pathol*. 1975;80:69-78.
4. Luger TA, Stadler BM, Katz SI, et al. Epidermal cell (keratinocyte)-derived thymocyte-activating factor (ETAF). *J Immunol*. 1981;127:1493-1498.
5. Kupper TS. The activated keratinocyte: a model for inducible cytokine production by non-bone marrow-derived cells in cutaneous inflammatory and immune responses. *J Invest Dermatol*. 1990;94:146S-150S.
6. Albanesi C, Pastore S. Pathobiology of chronic inflammatory skin diseases: interplay between keratinocytes and immune cells as a target for anti-inflammatory drugs. *Curr Drug Metab*. 2010;11:210-227.
7. Mosmann TR, Coffman RL. TH1 and TH2 cells: different patterns of lymphokine secretion lead to different functional properties. *Annu Rev Immunol*. 1989;7:145-173.
8. O'Quinn DB, Palmer MT, Lee YK, et al. Emergence of the Th17 pathway and its role in host defense. *Adv Immunol*. 2008;99: 115-163.
9. Josefowicz SZ, Rudensky A. Control of regulatory T cell lineage commitment and maintenance. *Immunity*. 2009;30:616-625.
10. Rubtsov YP, Rudensky AY. TGFbeta signalling in control of T-cell-mediated self-reactivity. *Nat Rev Immunol*. 2007;7:443-453.

11. Rubtsov YP, et al. Regulatory T cell-derived interleukin-10 limits inflammation at environmental interfaces. *Immunity*. 2008;28:546-558.
12. Purwar R, et al. Robust tumor immunity to melanoma mediated by interleukin-9-producing T cells. *Nat Med*. 2012;18:1248-1253.
13. Vallabhapurapu S, Karin M. Regulation and function of NF-kappaB transcription factors in the immune system. *Annu Rev Immunol*. 2009;27:693-733.
14. Arend WP, Palmer G, Gabay C. IL-1, IL-18, and IL-33 families of cytokines. *Immunol Rev*. 2008;223:20-38.
15. Kawai T, Akira S. The role of pattern-recognition receptors in innate immunity: update on Toll-like receptors. *Nat Immunol*. 2010;11:373-384.
16. O'Shea JJ, Murray PJ. Cytokine signaling modules in inflammatory responses. *Immunity*. 2008;28:477-487.
17. Bachelez H, et al. Tofacitinib versus etanercept or placebo in moderate-to-severe chronic plaque psoriasis: a phase 3 randomised non-inferiority trial. *Lancet*. 2015;386:552-561.
18. Kennedy Crispin M, et al. Safety and efficacy of the JAK inhibitor tofacitinib citrate in patients with alopecia areata. *JCI Insight*. 2016;1:e89776.
19. Hornung T, et al. Remission of recalcitrant dermatomyositis treated with ruxolitinib. *N Engl J Med*. 2014;371:2537-2538,.
20. Kurtzman DJ, et al. Tofacitinib citrate for refractory cutaneous dermatomyositis: an alternative treatment. *JAMA Dermatol*. 2016;152:944-945.
21. Martinon F, Mayor A, Tschopp J. The inflammasomes: guardians of the body. *Annu Rev Immunol*. 2009;27:229-265.
22. Kupper TS. Immune and inflammatory processes in cutaneous tissues. Mechanisms and speculations. *J Clin Invest*. 1990;86:1783-1789.
23. Conti HR, et al. Th17 cells and IL-17 receptor signaling are essential for mucosal host defense against oral candidiasis. *J Exp Med*. 2009;206:299-311.
24. Ho AW, Shen F, Conti HR, et al. IL-17RC is required for immune signaling via an extended SEF/IL-17R signaling domain in the cytoplasmic tail. *J Immunol*. 2010;185:1063-1070.
25. Kovanen PE, Leonard WJ. Cytokines and immunodeficiency diseases: critical roles of the gamma(c)-dependent cytokines interleukins 2, 4, 7, 9, 15, and 21, and their signaling pathways. *Immunol Rev*. 2004;202:67-83.
26. Ma A, Koka R, Burkett P. Diverse functions of IL-2, IL-15, and IL-7 in lymphoid homeostasis. *Annu Rev Immunol*. 2006;24:657-679.
27. Simpson EL, Guttman-Yassky E, Beck LA, et al. Two phase 3 trials of dupilumab versus placebo in atopic dermatitis. *N Engl J Med*. 2016;375(24):2335-2348.
28. Mentink-Kane MM, Wynn TA. Opposing roles for IL-13 and IL-13 receptor alpha 2 in health and disease. *Immunol Rev*. 2004;202:191-202.
29. Soussi-Gounni A, Kontolemos M, Hamid Q. Role of IL-9 in the pathophysiology of allergic diseases. *J Allergy Clin Immunol*. 2001;107:575-582.
30. Parrot T, Allard M, Oger R, et al. IL-9 promotes the survival and function of human melanoma-infiltrating CD4(+) CD8(+) double-positive T cells. *Eur J Immunol*. 2016;46:1770-1782.
31. Leonard WJ, Zeng R, Spolski R. Interleukin 21: a cytokine/cytokine receptor system that has come of age. *J Leukoc Biol*. 2008;84:348-356.
32. Mehta DS, Wurster AL, Grusby MJ. Biology of IL-21 and the IL-21 receptor. *Immunol Rev*. 2004;202:84-95.
33. Wang YH, Ito T, Wang YH, et al. Maintenance and polarization of human TH2 central memory T cells by thymic stromal lymphopoietin-activated dendritic cells. *Immunity*. 2006;24:827-838.
34. Ziegler SF, Artis D. Sensing the outside world: TSLP regulates barrier immunity. *Nat Immunol*. 2010;11:289-293.
35. Geijsen N, Koenderman L, Coffer PJ. Specificity in cytokine signal transduction: lessons learned from the IL-3/IL-5/GM-CSF receptor family. *Cytokine Growth Factor Rev*. 2001;12:19-25.
36. Dranoff G. GM-CSF-based cancer vaccines. *Immunol Rev*. 2002;188:147-154.
37. Eager R, Nemunaitis J. GM-CSF gene-transduced tumor vaccines. *Mol Ther*. 2005;12:18-27.
38. Sonkoly E, Muller A, Lauerma AI, et al. IL-31: a new link between T cells and pruritus in atopic skin inflammation. *J Allergy Clin Immunol*. 2006;117:411-417.
39. Diveu C, Lelièvre E, Perret D, et al. GPL, a novel cytokine receptor related to GP130 and leukemia inhibitory factor receptor. *J Biol Chem*. 2003;278:49850-49859.
40. Mach N, Dranoff G. Cytokine-secreting tumor cell vaccines. *Curr Opin Immunol*. 2000;12:571-575.
41. Kastelein RA, Hunter CA, Cua DJ. Discovery and biology of IL-23 and IL-27: related but functionally distinct regulators of inflammation. *Annu Rev Immunol*. 2007;25:221-242.
42. Yoshida H, Miyazaki Y. Regulation of immune responses by interleukin-27. *Immunol Rev*. 2008;226:234-247.
43. Collison LW, Vignali DA. Interleukin-35: odd one out or part of the family? *Immunol Rev*. 2008;226:248-262.
44. Griffiths CE, Strober BE, van de Kerkhof P, et al. Comparison of ustekinumab and etanercept for moderate-to-severe psoriasis. *N Engl J Med*. 2010;362:118-128.
45. Theofilopoulos AN, Baccala R, Beutler B, et al. Type I interferons (alpha/beta) in immunity and autoimmunity. *Annu Rev Immunol*. 2005;23:307-336.
46. Ank N, West H, Paludan SR. IFN-lambda: novel antiviral cytokines. *J Interferon Cytokine Res*. 2006;26:373-379.
47. McInturff JE, Modlin RL, Kim J. The role of toll-like receptors in the pathogenesis and treatment of dermatological disease. *J Invest Dermatol*. 2005;125:1-8.
48. Saraiva M, O'Garra A. The regulation of IL-10 production by immune cells. *Nat Rev Immunol*. 2010;10:170-181.
49. Commins S, Steinke JW, Borish L. The extended IL-10 superfamily: IL-10, IL-19, IL-20, IL-22, IL-24, IL-26, IL-28, and IL-29. *J Allergy Clin Immunol*. 2008;121:1108-1111.
50. Sa SM, Valdez PA, Wu J, et al. The effects of IL-20 subfamily cytokines on reconstituted human epidermis suggest potential roles in cutaneous innate defense and pathogenic adaptive immunity in psoriasis. *J Immunol*. 2007;178:2229-2240.
51. He M, Liang P. IL-24 transgenic mice: in vivo evidence of overlapping functions for IL-20, IL-22, and IL-24 in the epidermis. *J Immunol*. 2010;184:1793-1798.
52. Eyerich S, Eyerich K, Pennino D, et al. Th22 cells represent a distinct human T cell subset involved in epidermal immunity and remodeling. *J Clin Invest*. 2009;119:3573-3585.
53. Fujita H, Nograles KE, Kikuchi T, et al. Human Langerhans cells induce distinct IL-22-producing CD4+ T cells lacking IL-17 production. *Proc Natl Acad Sci U S A*. 2009;106:21795-21800.
54. Feng XH, Derynck R. Specificity and versatility in tgf-beta signaling through Smads. *Annu Rev Cell Dev Biol*. 2005;21:659-693.

55. Varga J, Pasche B. Transforming growth factor beta as a therapeutic target in systemic sclerosis. *Nat Rev Rheumatol*. 2009;5:200-206.
56. Zaba LC, Cardinale I, Gilleaudeau P, et al. Amelioration of epidermal hyperplasia by TNF inhibition is associated with reduced Th17 responses. *J Exp Med*. 2007;204:3183-3194.
57. Zheng Y, Danilenko DM, Valdez P, et al. Interleukin-22, a TH17 cytokine, mediates IL-23-induced dermal inflammation and acanthosis. *Nature*. 2006;445:648-651.
58. Reich K, Papp KA, Griffiths CE, et al. An update on the long-term safety experience of ustekinumab: results from the psoriasis clinical development program with up to four years of follow-up. *J Drugs Dermatol*. 2012;11:300-312.
59. Kopp T, Riedl E, Bangert C, et al. Clinical improvement in psoriasis with specific targeting of interleukin-23. *Nature*. 2015;521:222-226.
60. Nograles KE, Zaba LC, Guttman-Yassky E, et al. Th17 cytokines interleukin (IL)-17 and IL-22 modulate distinct inflammatory and keratinocyte-response pathways. *Br J Dermatol*. 2008;159(5):1092-102.
61. Langley RG, Elewski BE, Lebwohl M, et al. Secukinumab in plaque psoriasis—results of two phase 3 trials. *N Engl J Med*. 2014;371:326-338.
62. Gordon KB, Blauvelt A, Papp KA, et al. Phase 3 trials of ixekizumab in moderate-to-severe plaque psoriasis. *N Engl J Med*. 2016;375:345-356.
63. Schafer PH, Parton A, Gandhi AK, et al. Apremilast, a cAMP phosphodiesterase-4 inhibitor, demonstrates anti-inflammatory activity in vitro and in a model of psoriasis. *Br J Pharmacol*. 2010;159:842-855.
64. Papp K, et al. Apremilast, an oral phosphodiesterase 4 (PDE4) inhibitor, in patients with moderate to severe plaque psoriasis: results of a phase III, randomized, controlled trial (Efficacy and Safety Trial Evaluating the Effects of Apremilast in Psoriasis [ESTEEM] 1). *J Am Acad Dermatol*. 2015;73:37-49.
65. Papp KA, Reich K, Leonardi CL, et al. Efficacy and safety of tofacitinib, an oral Janus kinase inhibitor, in the treatment of psoriasis: a Phase 2b randomized placebo-controlled dose-ranging study. *Br J Dermatol*. 2012;167:668-677.
66. Craiglow BG, King BA. Killing two birds with one stone: oral tofacitinib reverses alopecia universalis in a patient with plaque psoriasis. *J Invest Dermatol*. 2014;134:2988-2990.
67. Liu LY, Craiglow BG, Dai F, et al. Tofacitinib for the treatment of severe alopecia areata and variants: a study of 90 patients. *J Am Acad Dermatol*. 2017;76:22-28.
68. Van Belle AB, de Heusch M, Lemaire MM, et al. IL-22 is required for imiquimod-induced psoriasiform skin inflammation in mice. *J Immunol*. 2012;188:462-469.
69. Nograles KE, Zaba LC, Shemer A, et al. IL-22-producing "T22" T cells account for upregulated IL-22 in atopic dermatitis despite reduced IL-17-producing TH17 T cells. *J Allergy Clin Immunol*. 2009;123:1244-1252 e1242.
70. Koreth J, Kim HT, Jones KT, et al. Efficacy, durability, and response predictors of low-dose interleukin-2 therapy for chronic graft-versus-host disease. *Blood*. 2016;128:130-137.
71. Zlotnik A, Yoshie O. Chemokines: a new classification system and their role in immunity. *Immunity*. 2000;12:121-127.
72. Bazan JF, Bacon KB, Hardiman G, et al. A new class of membrane-bound chemokine with a CX3C motif. *Nature*. 1997;385:640-644.
73. Jiang H, Kuang Y, Wu Y, et al. Pertussis toxin-sensitive activation of phospholipase C by the C5a and fMet-Leu-Phe receptors. *J Biol Chem*. 1996;271:13430-13434.
74. Constantin G, Majeed M, Giagulli C, et al. Chemokines trigger immediate β2 integrin affinity and mobility changes. *Immunity*. 2000;13:759-769.
75. Homey B. Chemokines and inflammatory skin diseases. *Adv Dermatol*. 2005;21:251-277.
76. Springer TA. Traffic signals for lymphocyte recirculation and leukocyte emigration: the multistep paradigm. *Cell*. 1994;76:301-314.
77. Berg EL. The cutaneous lymphocyte antigen is a skin lymphocyte homing receptor for the vascular lectin endothelial cell-leukocyte adhesion molecule 1. *J Exp Med*. 1991;174:1461-1466.
78. Campbell JJ, Haraldsen G, Pan J, et al. The chemokine receptor CCR4 in vascular recognition by cutaneous but not intestinal memory T cells. *Nature*. 1999;400:776-780.
79. Homey B, Wang W, Soto H, et al. Cutting edge: the orphan chemokine receptor G protein-coupled receptor-2 (GPR-2, CCR10) binds the skin-associated chemokine CCL27 (CTACK/ALP/ILC). *J Immunol*. 2000;164:3465-3470.
80. Lechleitner S, Kunstfeld R, Messeritsch-Fanta C, et al. Peripheral lymph node addressins are expressed on skin endothelial cells. *J Invest Dermatol*. 1999;113:410-414.
81. Hwang ST, Fitzhugh DJ. Aberrant expression of adhesion molecules by sézary cells: functional consequences under physiologic shear stress conditions. *J Invest Dermatol*. 2001;116:466-470.
82. Campbell JJ. Chemokines and the arrest of lymphocytes rolling under flow conditions. *Science*. 1998;279:381-384.
83. Kawai T, Seki M, Hiromatsu K, et al. Selective diapedesis of Th1 cells induced by endothelial cell RANTES. *J Immunol*. 1999;163:3269-3278.
84. Sallusto F, Lenig D, Förster R, et al. Two subsets of memory T lymphocytes with distinct homing potentials and effector functions. *Nature*. 1999;401:708-712.
85. Sallusto F, Mackay CR. Chemoattractants and their receptors in homeostasis and inflammation. *Curr Opin Immunol*. 2004;16:724-731.
86. Hwang ST. Mechanisms of T-cell homing to skin. *Adv Dermatol*. 2001;17:211-241.
87. Piali L, Weber C, LaRosa G, et al. The chemokine receptor CXCR3 mediates rapid and shear-resistant adhesion-induction of effector T lymphocytes by the chemokines IP10 and Mig. *Eur J Immunol*. 1998;28:961-972.
88. Vestergaard C, Bang K, Gesser B, et al. A Th2 chemokine, TARC, produced by keratinocytes may recruit CLA+CCR4+ lymphocytes into lesional atopic dermatitis skin. *J Invest Dermatol*. 2000;115:640-646.
89. Imai T. Selective recruitment of CCR4-bearing Th2 cells toward antigen-presenting cells by the CC chemokines thymus and activation-regulated chemokine and macrophage-derived chemokine. *Int Immunol*. 1999;11:81-88.
90. Andrew DP, Ruffing N, Kim CH, et al. C-C chemokine receptor 4 expression defines a major subset of circulating nonintestinal memory T cells of both Th1 and Th2 potential. *J Immunol*. 2001;166:103-111.
91. Sallusto F. Selective expression of the eotaxin receptor CCR3 by human T helper 2 cells. *Science*. 1997;277:2005-2007.
92. Bonecchi R, Bianchi G, Bordignon PP, et al. Differential expression of chemokine receptors and chemotactic

responsiveness of type 1 T helper cells (Th1s) and Th2s. *J Exp Med*. 1998;187:129-134.
93. Qin S, Rottman JB, Myers P, et al. The chemokine receptors CXCR3 and CCR5 mark subsets of T cells associated with certain inflammatory reactions. *J Clin Invest*. 1998;101:746-754.
94. Steinman L. A brief history of TH17, the first major revision in the TH1/TH2 hypothesis of T cell–mediated tissue damage. *Nat Med*. 2007;13:139-145.
95. Lowes MA, Bowcock AM, Krueger JG. Pathogenesis and therapy of psoriasis. *Nature*. 2007;445:866-873.
96. Clark RA, Chong B, Mirchandani N, et al. The vast majority of CLA+ T cells are resident in normal skin. *J Immunol*. 2006;176:4431-4439.
97. Bromley SK, Mempel TR, Luster AD. Orchestrating the orchestrators: chemokines in control of T cell traffic. *Nat Immunol*. 2008;9:970-980.
98. Giustizieri ML, Mascia F, Frezzolini A, et al. Keratinocytes from patients with atopic dermatitis and psoriasis show a distinct chemokine production profile in response to T cell–derived cytokines. *J Allergy Clin Immunol*. 2001;107:871-877.
99. Sarris AH, Daliani D, Ulmer R, et al. Interferon-inducible protein 10 as a possible factor in the pathogenesis of cutaneous T-cell lymphomas. *Clin Cancer Res*. 1997;3:169-177.
100. Morales J, Homey B, Vicari AP, Het al. CTACK, a skin-associated chemokine that preferentially attracts skin-homing memory T cells. *Proc Natl Acad Sci U S A*. 1999;96:14470-14475.
101. Reiss Y, Proudfoot AE, Power CA, et al. CC chemokine receptor (CCR)4 and the CCR10 ligand cutaneous T cell–attracting chemokine (CTACK) in lymphocyte trafficking to inflamed skin. *J Exp Med*. 2001;194:1541-1547.
102. Homey B, Alenius H, Müller A, et al. CCL27–CCR10 interactions regulate T cell–mediated skin inflammation. *Nat Med*. 2002;8:157-165.
103. Katz SI, Tamaki K, Sachs DH. Epidermal Langerhans cells are derived from cells originating in bone marrow. *Nature*. 1979;282:324-326.
104. Schaerli P, Willimann K, Ebert LM, et al. Cutaneous CXCL14 targets blood precursors to epidermal niches for Langerhans cell differentiation. *Immunity*. 2005;23:331-342.
105. Dieu-Nosjean M-C, Massacrier C, Homey B, et al. Macrophage inflammatory protein 3α is expressed at inflamed epithelial surfaces and is the most potent chemokine known in attracting Langerhans cell precursors. *J Exp Med*. 2000;192:705-718.
106. Merad M, Manz MG, Karsunky H, et al. Langerhans cells renew in the skin throughout life under steady-state conditions. *Nat Immunol*. 2002;3:1135-1141.
107. Varona R, Villares R, Carramolino L, et al. CCR6-deficient mice have impaired leukocyte homeostasis and altered contact hypersensitivity and delayed-type hypersensitivity responses. *J Clin Invest*. 2001;107:R37-R45.
108. Saeki H, Moore AM, Brown MJ, et al. Cutting edge: secondary lymphoid-tissue chemokine (SLC) and CC chemokine receptor 7 (CCR7) participate in the emigration pathway of mature dendritic cells from the skin to regional lymph nodes. *J Immunol*. 1999;162:2472-2475.
109. Gunn MD, Tangemann K, Tam C, et al. A chemokine expressed in lymphoid high endothelial venules promotes the adhesion and chemotaxis of naive T lymphocytes. *Proc Natl Acad Sci U S A*. 1998;95:258-263.
110. Ohl L, Mohaupt M, Czeloth N, et al. CCR7 governs skin dendritic cell migration under inflammatory and steady-state conditions. *Immunity*. 2004;21: 279-288.
111. Stein JV, Rot A, Luo Y, et al. The CC chemokine thymus-derived chemotactic agent 4 (Tca-4, secondary lymphoid tissue chemokine, 6ckine, exodus-2) triggers lymphocyte function–associated antigen 1–mediated arrest of rolling T lymphocytes in peripheral lymph node high endothelial venules. *J Exp Med*. 2000;191:61-76.
112. Förster R, Schubel A, Breitfeld D, et al. CCR7 coordinates the primary immune response by establishing functional microenvironments in secondary lymphoid organs. *Cell*. 1999;99:23-33.
113. Sallusto F, Palermo B, Lenig D, et al. Distinct patterns and kinetics of chemokine production regulate dendritic cell function. *Eur J Immunol*. 1999;29:1617-1625.
114. Tang HL. Chemokine up-regulation and activated T cell attraction by maturing dendritic cells. *Science*. 1999;284:819-822.
115. Wu Mt, Fang H, Hwang ST. Cutting edge: CCR4 mediates antigen-primed T cell binding to activated dendritic cells. *J Immunol*. 2001;167:4791-4795.
116. Castellino F, Huang AY, Altan-Bonnet G, et al. Chemokines enhance immunity by guiding naive CD8+ T cells to sites of CD4+ T cell–dendritic cell interaction. *Nature*. 2006;440:890-895.
117. Lonsdorf AS, Hwang ST, Enk AH. Chemokine receptors in T-cell-mediated diseases of the skin. *J Invest Dermatol*. 2009;129:2552-2566.
118. Kakinuma T, Nakamura K, Wakugawa M, et al. Thymus and activation-regulated chemokine in atopic dermatitis: serum thymus and activation-regulated chemokine level is closely related with disease activity. *J Allergy Clin Immunol*. 2001;107:535-541.
119. Pivarcsi A, Gombert M, Dieu-Nosjean MC, et al. CC chemokine ligand 18, an atopic dermatitis-associated and dendritic cell-derived chemokine, is regulated by staphylococcal products and allergen exposure. *J Immunol*. 2004;173:5810-5817.
120. Günther C1, Bello-Fernandez C, Kopp T, et al. CCL18 is expressed in atopic dermatitis and mediates skin homing of human memory T cells. *J Immunol*. 2005; 174:1723-1728.
121. Park CO, Lee HJ, Lee JH, et al. Increased expression of CC chemokine ligand 18 in extrinsic atopic dermatitis patients. *Exp Dermatol*. 2008;17(1):24-9.
122. Gombert M, et al. CCL1-CCR8 interactions: an axis mediating the recruitment of T cells and Langerhans-type dendritic cells to sites of atopic skin inflammation. *J Immunol*. 2005;174:5082-5091.
123. Combadiere C, Ahuja SK, Murphy PM. Cloning and functional expression of a human eosinophil CC chemokine receptor. *J Biol Chem*. 1995;270: 16491-16494.
124. Teixeira MM, Dieu-Nosjean MC, Winterberg F, et al. Chemokine-induced eosinophil recruitment. Evidence of a role for endogenous eotaxin in an in vivo allergy model in mouse skin. *J Clin Invest* 1997;100:1657-1666.
125. Yawalkar N, Uguccioni M, Schärer J, et al. Enhanced expression of eotaxin and CCR3 in atopic dermatitis. *J Invest Dermatol*. 1999;113:43-48.
126. Kaburagi Y, Shimada Y, Nagaoka T, et al. Enhanced production of CC-chemokines (RANTES, MCP-1, MIP-1α, MIP-1β, and eotaxin) in patients with atopic dermatitis. *Arch Dermatol Res*. 2001;293:350-355.

127. Petering H, Kluthe C, Dulkys Y, et al. Characterization of the CC chemokine receptor 3 on human keratinocytes. *J Invest Dermatol*. 2001;116:549-555.
128. Cooper PJ, Beck LA, Espinel I, et al. Eotaxin and RANTES expression by the dermal endothelium is associated with eosinophil infiltration after ivermectin treatment of onchocerciasis. *Clin Immunol*. 2000;95:51-61.
129. Prens E, Debets R, Hegmans J. T lymphocytes in psoriasis. *Clin Dermatol*. 1995;13:115-129.
130. Homey B, Dieu-Nosjean MC, Wiesenborn A, et al. Up-regulation of macrophage inflammatory protein-3 alpha/CCL20 and CC chemokine receptor 6 in psoriasis. *J Immunol*. 2000;164: 6621-6632.
131. Fitzhugh DJ, Naik S, Caughman SW, et al. Cutting edge: C-C chemokine receptor 6 is essential for arrest of a subset of memory T cells on activated dermal microvascular endothelial cells under physiologic flow conditions in vitro. *J Immunol*. 2000;165:6677-6681.
132. Singh SP, Zhang HH, Foley JF, et al. Human T cells that are able to produce IL-17 express the chemokine receptor CCR6. *J Immunol*. 2007;180:214-221.
133. Blauvelt A. T-helper 17 Cells in psoriatic plaques and additional genetic links between IL-23 and psoriasis. *J Invest Dermatol*. 2008;128:1064-1067.
134. Hedrick MN, Lonsdorf AS, Shirakawa AK, et al. CCR6 is required for IL-23–induced psoriasis-like inflammation in mice. *J Clin Invest*. 2009;119:2317-2329.
135. Schaerli P, Britschgi M, Keller M, et al. Characterization of human T cells that regulate neutrophilic skin inflammation. *J Immunol*. 2004;173:2151-2158.
136. Keller M, Spanou Z, Schaerli P, et al. T cell-regulated neutrophilic inflammation in autoinflammatory diseases. *J Immunol*. 2005;175:7678-7686.
137. Schneider G, Salcedo R, Welniak L, et al. The diverse role of chemokines in tumor progression: [rospects for intervention [review]. *Int J Mol Med*. 2001;8(3): 235-44.
138. Singh RK, Gutman M, Radinsky R, et al. Expression of interleukin 8 correlates with the metastatic potential of human melanoma cells in nude mice. *Cancer Res*. 1994;54:3242-3247.
139. Addison CL, Daniel TO, Burdick MD, et al. The CXC chemokine receptor 2, CXCR2, is the putative receptor for ELR+ CXC chemokine-induced angiogenic activity. *J Immunol*. 2000;165:5269-5277.
140. Kim M-Y, Oskarsson T, Acharyya S, et al. Tumor self-seeding by circulating cancer cells. *Cell*. 2009;139: 1315-1326.
141. Schadendorf D, Möller A, Algermissen B, et al. IL-8 produced by human malignant melanoma cells in vitro is an essential autocrine growth factor. *J Immunol*. 1993;151:2667-2675.
142. Coussens LM, Werb Z. Inflammatory cells and cancer. *J Exp Med* 2001;193:F23-F26.
143. Ferreira AM, Takagawa S, Fresco R, et al. Diminished induction of skin fibrosis in mice with MCP-1 deficiency. *J Invest Dermatol*. 2006;126:1900-1908.
144. Lin EY, Nguyen AV, Russell RG, et al. Colony-stimulating factor 1 promotes progression of mammary tumors to malignancy. *J Exp Med*. 2001;193:727-740.
145. Yao L, Sgadari C, Furuke K, et al. Contribution of natural killer cells to inhibition of angiogenesis by interleukin-12. *Blood* 1999;93:1612-1621.
146. Bell D. In breast carcinoma tissue, immature dendritic cells reside within the tumor, whereas mature dendritic cells are located in peritumoral areas. *J Exp Med.* 1999;190:1417-1426.
147. Fushimi T, Kojima A, Moore MAS, et al. Macrophage inflammatory protein 3α transgene attracts dendritic cells to established murine tumors and suppresses tumor growth. *J Clin Invest*. 2000;105:1383-1393.
148. Curiel TJ, Coukos G, Zou L, et al. Specific recruitment of regulatory T cells in ovarian carcinoma fosters immune privilege and predicts reduced survival. *Nat Med*. 2004;10:942-949.
149. Balch CM, Soong SJ, Gershenwald JE, et al. Prognostic factors analysis of 17,600 melanoma patients: validation of the American Joint Committee on Cancer melanoma staging system. *J Clin Oncol*. 2001; 19:3622-3634.
150. Kakinuma T. Chemokines, chemokine receptors, and cancer metastasis. *J Leukoc Biol*. 2006;79:639-651.
151. Muller A, Homey B, Soto H, et al. Involvement of chemokine receptors in breast cancer metastasis. *Nature* 2001;410:50-56.
152. Staller P, Sulitkova J, Lisztwan J, et al. Chemokine receptor CXCR4 downregulated by von Hippel–Lindau tumour suppressor pVHL. *Nature*. 2003;425: 307-311.
153. Orimo A, Gupta PB, Sgroi DC, et al. Stromal fibroblasts present in invasive human breast carcinomas promote tumor growth and angiogenesis through elevated SDF-1/CXCL12 secretion. *Cell*. 2005;121:335-348.
154. Murakami T, Maki W, Cardones AR, et al. Expression of CXC chemokine receptor-4 enhances the pulmonary metastatic potential of murine B16 melanoma cells. *Cancer Res*. 2002;62:7328-7334.
155. Wiley HE, Gonzalez EB, Maki W, et al. Expression of CC chemokine receptor-7 and regional lymph node metastasis of B16 murine melanoma. *JNCI J Natl Cancer Inst*. 2001;93:1638-1643.
156. Fang L, Lee VC, Cha E, et al. CCR7 regulates B16 murine melanoma cell tumorigenesis in skin. *J Leukoc Biol*. 2008;84:965-972.
157. Letsch A, Keilholz U, Schadendorf D, et al. Functional CCR9 expression is associated with small intestinal metastasis. *J Invest Dermatol*. 2004;122:685-690.
158. Murakami T, Cardones AR, Finkelstein SE, et al. Immune evasion by murine melanoma mediated through CC chemokine receptor-10. *J Exp Med*. 2003;198:1337-1347.
159. Simonetti O, Goteri G, Lucarini G, et al. Potential role of CCL27 and CCR10 expression in melanoma progression and immune escape. *Eur J Cancer*. 2006; 42:1181-1187.
160. Ferenczi K, Fuhlbrigge RC, Kupper TS, et al. Increased CCR4 expression in cutaneous T cell lymphoma. *J Invest Dermatol*. 2002;119:1405-1410.
161. Narducci MG. Skin homing of Sezary cells involves SDF-1-CXCR4 signaling and down-regulation of CD26/dipeptidylpeptidase IV. *Blood*. 2005;107: 1108-1115.
162. Notohamiprodjo M, Segerer S, Huss R, et al. CCR10 is expressed in cutaneous T-cell lymphoma. *Int J Cancer*. 2005;115:641-647.
163. Sokolowska-Wojdylo M, Wenzel J, Gaffal E, et al. Circulating clonal CLA+ and CD4+ T cells in Sezary syndrome express the skin-homing chemokine receptors CCR4 and CCR10 as well as the lymph node-homing chemokine receptor CCR7. *Br J Dermatol*. 2005;152:258-264.
164. Arvanitakis L, Geras-Raaka E, Varma A, et al. Human herpesvirus KSHV encodes a constitutively active G-protein-coupled receptor linked to cell proliferation. *Nature*. 1997;385:347-350.

165. Locati M, Murphy PM. Chemokines and chemokine receptors: biology and clinical relevance in inflammation and AIDS. *Annu Rev Med*. 1999;50: 425-440.
166. Liu R, Paxton WA, Choe S, et al. Homozygous defect in HIV-1 coreceptor accounts for resistance of some multiply-exposed individuals to HIV-1 infection. *Cell*. 1996;86:367-377.
167. Gerard C, Rollins BJ. Chemokines and disease. *Nat Immunol*. 2001;2:108-115.
168. Blauvelt A. The role of skin dendritic cells in the initiation of human immunodeficiency virus infection. *Am J Med*. 1997;102:16-20.
169. Kawamura T, Cohen SS, Borris DL, et al. Candidate microbicides block HIV-1 infection of human immature langerhans cells within epithelial tissue explants. *J Exp Med*. 2000;192:1491-1500.
170. Cooper DA, Heera J, Goodrich J, et al. Maraviroc versus efavirenz, both in combination with zidovudine-lamivudine, for the treatment of antiretroviral-naive subjects with CCR5-tropic HIV-1 infection. *J Infect Dis*. 2010;201(6):803-13.
171. Murakami T, Nakajima T, Koyanagi Y, et al. A small molecule CXCR4 inhibitor that blocks T cell line–tropic HIV-1 infection. *J Exp Med* 1997;186:1389-1393.
172. Hernandez PA, Gorlin RJ, Lukens JN, et al. Mutations in the chemokine receptor gene CXCR4 are associated with WHIM syndrome, a combined immunodeficiency disease. *Nat Genet*. 2003;34:70-74.
173. Diaz GA, Gulino AV. WHIM syndrome: a defect in CXCR4 signaling. *Curr Allergy Asthma Rep*. 2005;5:350-355.

Chapter 13 :: Basic Principles of Immunologic Diseases in Skin (Pathophysiology of Immunologic/Inflammatory Skin Diseases)

:: Keisuke Nagao & Mark C. Udey

AT A GLANCE

- Immunologic/inflammatory skin diseases result from inappropriate and frequently exaggerated responses to endogenous skin constituents or external stimuli and are orchestrated by leukocytes and nonleukocytes.
- Disease pathogenesis is often incompletely understood, but select experimental models and skin diseases have provided insight into the pathogenesis of human immunologic/inflammatory skin diseases.
- This chapter provides examples where disease pathogenesis is reasonably well understood and describes contemporary approaches that have resulted in improved understanding and, in some instances, improved therapy.

INTRODUCTION

The skin is a physical barrier that is vital for the maintenance of organismal homeostasis. It experiences, and reacts to, a constant barrage of external insults including environmental changes (heat extremes, changes in humidity, sunlight exposure, etc), allergens, toxic chemicals, and pathogenic microbes. In addition to keratinocytes, Merkel cells, melanocytes, fibroblasts, adipocytes, and vascular cells, recent studies document that skin harbors a community of resident leukocytes whose composition and activation status is tuned by commensal microbes. In aggregate, these leukocytes and nonleukocytes constitute a critically important immunologic interface between organism and other.

Immune responses involving skin are highly orchestrated. Appropriate immune responses are directed exclusively (or primarily) against external agents, they are sufficiently (but not excessively) vigorous and they are time-limited. Correspondingly, there are multiple mechanisms that promote and suppress immune and inflammatory reactions in skin. Inappropriate or dysregulated local or systemic responses against self-antigens, foreign antigens, or microbes that are associated with, or enter via, skin may result in skin diseases. Examples include allergic and inflammatory skin diseases, autoimmune diseases, and drug reactions. Selected examples of each of these disease categories will be discussed. Ultimately, detailed understanding of mechanisms that cause immunologic/inflammatory skin diseases will facilitate development of less toxic, more effective therapies.

ALLERGIC CONTACT DERMATITIS

Allergic contact dermatitis (ACD) is a common inflammatory skin condition caused by repeated exposures to haptens, typically low-molecular-weight chemicals and metals, which interact with endogenous proteins to form immunogenic (complete) antigens after entering skin. ACD can be acute or chronic, depending on the nature, dose, and frequency of allergen exposure. For example, after sensitization to urushiol (a lipid component of poison ivy sap), individuals predictably develop acute ACD after reexposure. In contrast, occupational ACD commonly results from long-term exposure to low doses of metal ions such as nickel or chromium. Topical or systemic corticosteroids are commonly prescribed for ACD, but avoiding reexposure to the relevant allergen is crucial for effective treatment. However, it is not uncommon for the offending allergen to be difficult to identify, particularly in patients with occupational ACD.

Individual susceptibility and/or familial predisposition to ACD has been observed in studies where haptens were used to sensitize human volunteers in controlled experiments. However, evidence suggesting that genetic susceptibility to ACD is important is not strong. HLA haplotype associations have been reported, but results of different studies are conflicting. Polymorphisms in genes including *ACE*, *TNFA*, and *IL16* have been described,[1-3] but the cohorts studied were small and the significance of these findings remains to be determined. A recent genomewide association studies (GWAS) performed in a Korean population with patch test–proven nickel allergy reported associations of SNPs in *Netrin-4* and *Pellino-1* with ACD.[4] Although the functional significance of these SNPs remains to be validated, the suggested involvement of Pellino-1 in ACD is interesting because Pellino-1 participates in toll-like receptor 4 (TLR4)–mediated signaling, a pathway known to be involved in nickel allergy. Possible explanations for conflicting

results in different GWASs may relate to the diversity of chemicals that cause ACD and the varying genetic compositions of the populations selected for investigation.

Rodent models of ACD (hapten-induced contact hypersensitivity [CHS] responses) have been extensively studied. These studies have provided mechanistic insights into initial responses to allergen introduction and those that occur after subsequent challenge. In the laboratory, CHS is initiated by applying haptens to shaved mouse abdominal skin. Haptens are typically dissolved in mixtures of organic solvents that penetrate stratum corneum and are mildly irritating after topical application. Although initial exposures to haptens do not cause dermatitis, the innate immune system is engaged, leading to activation of antigen-presenting cells (APCs) that acquire or express complete antigens and subsequently stimulate allergen-specific memory T cells, completing the sensitization (afferent) phase (Fig. 13-1A). When haptens are subsequently applied to mouse ear skin, T cell–mediated dermatitis results (Fig. 13-1B). The intensities of the immune responses that ensue during this elicitation phase is quantitated by measuring ear thickness (ear swelling).

Initial exposures to haptens that commonly elicit ACD in patients signal via inflammasomes and/or toll-like receptors (TLRs); 2 major pathways involved in innate immunity. In the case of urushiol, skin cells are stimulated to release ATP and other danger-associated molecular patterns (DAMPs), as well as reactive oxygen species (ROS), which generates low-molecular-weight hyaluronic acid. These events lead to inflammasome activation, resulting in release of proinflammatory chemokines and cytokines including IL-1β, IL-18, and TNF-α.[5] The human contact allergen Ni^{2+} directly binds to human, but not mouse, TLR4.[6] Ni^{2+} is not an effective sensitizer in control mice, but TLR4-deficient mice that have been genetically engineered to express human TLR4 exhibit Ni^{2+}-induced CHS. After binding to TLR4, Ni^{2+} stimulates production of interferons, IL-1β and IL-18. Cr^{2+}, another metal ion and common contact allergen, stimulates the innate immune cells by engaging both TLRs and inflammasomes.[7] TLR-signaling mediates an initial priming event to induce pro-IL-1β synthesis, and activation of the inflammasome component NLRP3 via ROS leads to processing of pro-IL-1β into bioactive cytokine.

The frequently used experimental haptens TNCB, DNFB, oxazolone, and fluorescein isothiocyanate (FITC) also activate multiple immunologically relevant signaling pathways. Activation of inflammasomes is critical because mice that are individually deficient in inflammasome components (Asc, Card9 and Nalp3 or caspase-1) each exhibit impaired CHS responses.[8-10] Deficiency of MyD88, an adaptor molecule that is required for signaling by most TLRs, and simultaneous deficiency of TLR2 and TLR4 also lead to impaired CHS responses in mice, indicating that TLRs play important roles.[11] Thus, epicutaneous application of contact sensitizers activates multiple pathways that result in an inflammatory milieu that activates APCs in skin and leads to expansion of antigen-specific T cells. These innate proinflammatory processes may

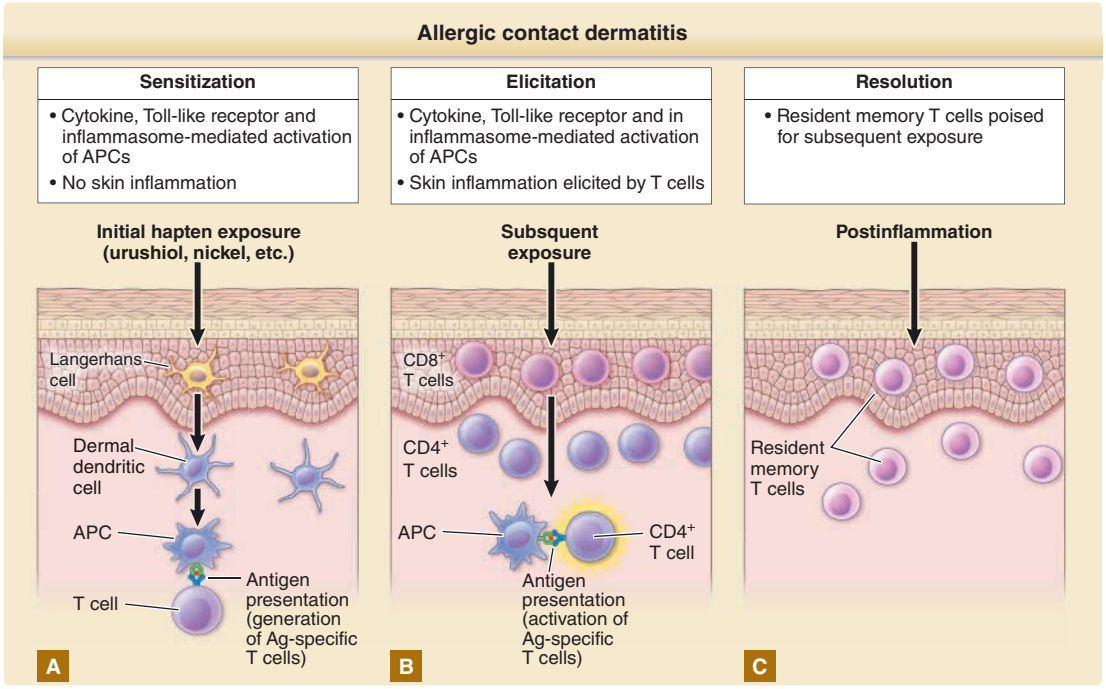

Figure 13-1 Phases of acute contact dermatitis/contact hypersensitivity. Initial exposure to haptens causes perterbations in the epidmeris, activating APCs to generate antigen-specific T cells (**A**). Subsequent exposure to the same hapten results in T cell–mediated inflammation in the skin (**B**). Resident memory T cells that are generated and distributed throughout the body surface are poised to cause inflammation on further encounters with the hapten (**C**).

originate in leukocytes and nonleukocytes, and are important upstream events that are required for contact sensitization.

Although Langerhans cells (LCs) have long been considered to be critically important APCs in CHS, evidence supporting this concept is not entirely convincing. Because haptens easily penetrate epidermis and reach the dermis, both LCs and dermal dendritic cells (DDCs) encounter contact allergens. Analysis of CHS responses in a mouse model in which LCs were constitutively depleted revealed enhanced CHS responses,[12] whereas 2 mouse models involving transient LC depletion exhibited unchanged or slightly reduced CHS responses.[13,14] Although different haptens were used in these latter studies and the timing of LC depletion also differed, none of these reports concluded that LCs were absolutely essential for CHS responses. DDCs have been demonstrated to contribute to CHS responses and may compensate for the loss of LCs in the experiments just described. Indeed, CD8α$^+$ DCs and DDCs, but not LCs, contribute to CD8$^+$ T-cell responses during antiviral responses.[15] It is possible that antigen-specific CHS responses are primarily dependent on DCs other than LCs. Another possibility is that immune responses to chemically distinct contact allergens involve different signaling pathways and/or even different leukocyte subpopulations. Recent studies propose that urushiol binds to CD1a, an MHC-related cell surface molecule that is expressed by LCs, and that CD1a-bound urushiol stimulates antigen-reactive T cells to release cytokines.[16] This may be an example in which LCs play a critical role in ACD because LCs preferentially form the complete antigen.

After activation, allergen-bearing DC migrate to skin-draining lymph nodes to initiate T-cell expansion and development of hapten-specific memory T cells (Fig. 13-1A). CD8$^+$ T cells appear to be the primary mediators of skin inflammation in ACD, but CD4$^+$ T-cell activation may be required for optimal CD8$^+$ T-cell responses (Fig. 13-1B). CD8$^+$ T cells accumulate not only in lesional and postlesional skin, but they also distribute to distant skin sites where they can persist locally as resident memory T cells (TRMs)[17] (Fig. 13-1C). After contact allergen exposure, antigen-activated naïve T cells undergo clonal expansion and differentiate into both TRM and central memory T cells.[18] TRMs mediate rapid CHS responses, whereas central memory T cells cause delayed responses. The existence of these distinct T-cell subpopulations explains why ACD can be induced in sensitized individuals after prolonged periods of time and why ACD frequently involves multiple skin sites. As is true in most T cell–mediated diseases, regulatory T cells are thought to play major roles in attenuation or termination of inflammation in CHS.

DRUG REACTIONS

Severe cutaneous adverse reactions (SCARs) are potentially life-threating conditions that are thought to be caused by aberrant immune responses that are elicited by drugs, and represent another example of immunologic/inflammatory skin diseases caused by external agents. SCARs include Stevens–Johnson syndrome (SJS), toxic epidermal necrolysis (TEN), and drug-induced hypersensitivity syndrome (DiHS) (or drug reaction eosinophilia with systemic symptoms [DRESS]).[19] Acute generalized exanthematous pustulosis is commonly included as SCAR, but is, in general, less severe than SJS/TEN and DiHS/DRESS.[19]

Prompt identification and discontinuation of offending drugs is critical for treatment of SCARs. SCARs have not been effectively modeled in experimental animals.

Evidence of genetic predisposition to SCARs and other drug eruptions has emerged in recent years. In cohorts of Han-Chinese patients, SJS/TEN that is caused by allopurinol and carbamazepine is strongly associated with the HLA haplotypes B*58:01[20] and B*15:02,[21] respectively. These studies indicate that HLA haplotypes predispose to SCARs and also demonstrate that the relationship between genotype and SJS/TEN susceptibility is drug-specific. Importantly, HLA haplotypes B*58:01 and B*15:02 are not associated with SJS/TEN in European or Japanese cohorts, indicating that genetic predispositions are dependent on ethnicity. Along these lines, dapsone hypersensitivity syndrome, a form of DiHS/DRESS, has been associated with the HLA-B*13:01 haplotype in Asians but not in Europeans and Africans.[22] The striking association of specific MHC Class I haplotypes with SCARs is consistent with the concept that T-cell receptor engagement on drug-specific CD8$^+$ T cells is causal. Although genetic predisposition to SCARs in non-Asians is also likely, this has yet to be demonstrated.

Cytotoxic T cells can be readily detected in SJS/TEN lesions, suggesting that these cells are pathogenic. In early SJS, CD8$^+$ T cells accumulate along the dermal–epidermal junction, causing interface dermatitis with keratinocyte apoptosis (Fig. 13-2) as is also observed in erythema multiforme. The involvement of CD8$^+$ T cells in SJS/TEN is consistent with the GWAS data alluded to above, because CD8$^+$ T cells recognize antigen epitopes that are associated with MHC Class I antigens. Fixed drug eruptions (FDEs) also feature CD8$^+$ T cell–mediated interface dermatitis. In FDE, discrete erythema multiforme-like lesions predictably recur in previously involved locations after systemic drug administration. This phenomenon probably reflects the existence of clones of drug-reactive CD8$^+$ resident memory T (TRM) cells that remain at sites of previous skin lesions where they are poised to respond if offending drugs are readministered. Indeed, persistence of CD8$^+$ T cells can be detected in skin long after FRD lesions have resolved.[23]

Cytotoxic T cells responses are less prominent in DiHS/DRESS. Here patients present with maculopapular or morbilliform lesions that may coalesce and become confluent. Peripheral eosinophilia is a hallmark feature of DiHS/DRESS, but the role of eosinophils in disease pathogenesis is uncertain. The presence of lymphadenopathy and appearance of atypical (activated) lymphocytes in peripheral blood suggests a

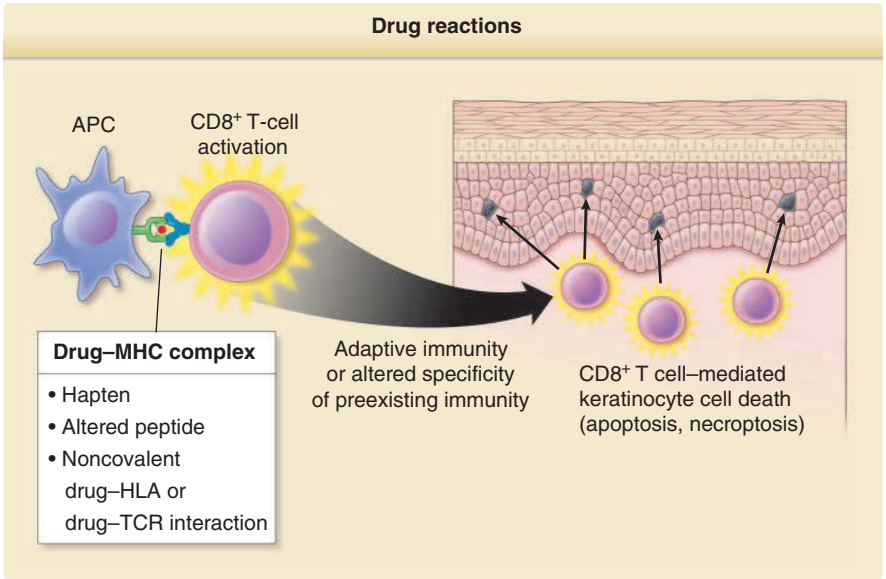

Figure 13-2 Immune-mediated mechanisms in drug hypersensitivity. Canonical or aberrant activation of T cells triggered by a culprit drug results in T cell–mediated keratinocyte cell death in severe drug reactions such as Stevens–Johnson syndrome and toxic epidermal necrolysis.

T cell–mediated pathophysiology. Expansion of regulatory T cells may result in immunocompromise in the initial stage of DiHS/DRESS,[24] allowing reactivation of herpes virus infections, including human herpes viruses 6 and 7, Epstein–Barr (EB) virus, and cytomegalovirus. EB virus–specific $CD8^+$ T cells are reported to be increased in the circulation and cause tissue damage in EB virus–infected tissues, including liver, that is typical of DiHS/DRESS.[25] B cells, which serve as a reservoir for EB virus, also may be targeted because patients frequently exhibit hypogammagloblinemia.

DiHS/DRESS patients exhibit immunologic abnormalities long after resolution of the acute phase and may develop autoimmune diseases such as Hashimoto thyroiditis, systemic lupus erythematosus, and Type I diabetes.[26] Accentuated immune responses against herpes viruses and the occurrence of autoimmune diseases suggest that breakdown of peripheral tolerance is a major contributor to DiHS/DRESS.

Drugs that cause SCARs are small molecules that are unlikely to be directly recognized by T cells. The nature of epitopes that are recognized and mechanisms that are responsible for their generation have not been delineated with certainty. Several models have been proposed[27] (Fig. 13-2). As is the case in CHS, drugs that cause SCARs may act like haptens, forming complete antigens by combining with endogenous proteins. Penicillins, for example, may bind to carrier proteins to form immunogenic neoantigens that may become targets of adaptive immunity. In abacavir hypersensitivity, the altered peptide model proposes that abacavir binds directly to the peptide-binding groove of HLA-B*57:01, thereby modifying the self-peptides that are presented, creating functionally abacavir-dependent neoantigens that can be recognized by $CD8^+$ T cells. The pharmacologic interaction with immune receptors (p-i) concept posits that drugs bypass classic antigen-processing mechanisms and trigger immune responses through direct, noncovalent interactions with human leucocyte antigen (HLA) alleles and/or T-cell receptors (TCRs) that are expressed on cell surfaces. Activation of preexisting T cells via such mechanisms could explain why drug reactions occur within hours to few days in patients after initial exposure to causative drugs.

Finally, the altered TCR repertoire model proposes that drugs bind directly to TCRs and promote inappropriate T-cell reactivity to self-antigens. Using a T-cell clone isolated from a patient with a maculopapular drug eruption, it was shown that sulfamethoxazole binds to TCR containing Vβ20-1 variable domains. TCR–drug binding could induce a conformational change in the TCR that could alter TCR specificity. TCR VB-11-ISGSY was the predominant clonotype in carbamazepine-reactive T cells (those that proliferate and produce the cytotoxic molecule granulysin) from SJS/TEN in Taiwanese patients harboring HLA B*15:02. In these studies, activation of T cells by carbamazepine was inhibited by a blocking antibody against TCR VB-11, reinforcing the importance of TCR engagement in drug hypersensitivity.

Recent human studies have improved our understanding of the pathophysiology of drug reactions (Fig. 13-2), but much remains to be learned. Development of humanized mouse models in which mechanisms can be dissected in vivo may advance the field considerably.

ATOPIC DERMATITIS

Atopic dermatitis (AD) is a common inflammatory skin disease that is characterized by dry skin and eczematous dermatitis with severe itching. Classic AD

arises in children and may be accompanied by the later onset of asthma, allergic rhinitis, and/or food allergies ("the atopic march") (Fig. 13-3). Serum levels of IgE and CCL17 (TARC), both of which are characteristic of Type 2 immune responses, are increased in AD. Other immune cells, including T helper Type 1 (Th1), Th17, and Th22 cells, likely mediate the dermatitis, however (Fig. 13-3). AD commonly remits in late childhood, but can recur later in life and persist for years thereafter. AD is routinely treated with combinations of topical steroids, immunosuppressives, and emollient creams but current therapies are inadequate. Anti-histamines are commonly prescribed, but unrelieved pruritis is a major clinical problem.

Combinations of endogenous and exogenous factors have long been suspected to be involved in AD pathogenesis but, until recently, causal factors had not been identified. The discovery that AD patients harbor loss-of-function mutations in the gene encoding the structural protein filaggrin provided compelling evidence that impairment of an epidermal structural protein contributes to AD pathogenesis.[28] GWAS have demonstrated that single-nucleotide polymorphisms (SNPs) in a number of other genes are also associated with AD.[29,30] Many of these genes are expressed in immune cells and/or pathways (eg, *IL2*, *IL6R*, *IL7RA*, and *IL18R1*), strongly suggesting that AD etiology is multifactorial. Importantly, GWASs involving genetically distinct patient cohorts have identified both overlapping and nonoverlapping gene associations, consistent with the clinical observations that AD symptoms and signs may differ depending on the patients' ethnicities, and supporting the concept that different genes may influence AD susceptibility in different patient populations.

Although GWASs identify candidate loci that may be involved in AD pathogenesis, SNPs may not result in functional alterations in gene function. Additionally, SNPs may be genetically linked to, but distinct from, genes that are actually involved in AD (linkage disequilibrium). Studies of rare genetic diseases that are caused by mutations in known genes may provide mechanistic insights if clinical features of these diseases overlap with those of AD. For example, Netherton syndrome, a disease with eczematous dermatitis as a prominent feature, is caused by mutations in the cell

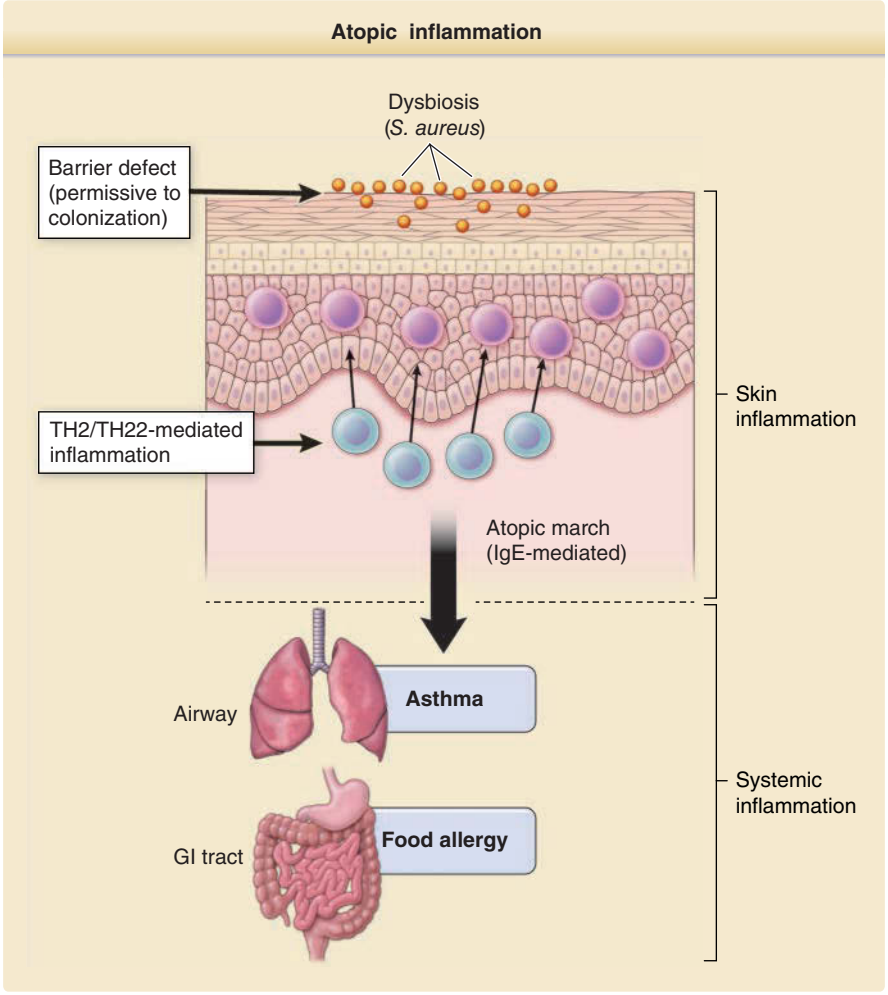

Figure 13-3 Barrier–microbiota–immune cell crosstalk in atopic dermatitis. Impaired barrier, altered microbiota, and accentuated immune responses cause local inflammation in the skin and may also lead to inflammation in distant organs.

surface protease inhibitor *SPINK5*.[31] Loss of *SPINK5* leads to increased activity of cell surface serine proteases that compromises the barrier function of the stratum corneum. Interestingly, *SPINK5* polymporphisms have been associated not with AD, but with elevated IgE levels in patients with AD.[32] Job syndrome (hyper IgE syndrome) is characterized by dermatitis and impaired Th17 responses leading to increased susceptibility to *Staphylococcus aureus* colonization or infection, and is caused by loss of function mutations in STAT3.[33] A *STAT3* SNP has been identified in classic AD,[30] suggesting that pathway dysregulation that occurs in Job syndrome might also contribute to AD. Mouse models that feature mutations of genes that are involved in genetic forms of human AD or that correspond to SNPs that are characteristic of AD could provide important mechanistic information that is relevant to patients.

Whereas asthma, allergic rhinitis, and food allergies are clearly IgE-mediated allergic diseases, the mechanisms that drive skin inflammation in AD are not well understood. Patch testing identifies allergens that cause contact dermatitis, but the utility of patch testing in AD patients is controversial, suggesting that skin inflammation that occurs in AD may not result from repetitive exposure to contact allergens. *S. aureus* commonly colonizes AD skin, but the role that this microbe plays in AD pathogenesis also has been controversial. Microbe detection and identification based on DNA sequencing has led to major advances in our understanding of the diversity of microbial communities that reside in human skin (collectively termed the "skin microbiome").[34] Using next-generation DNA sequencing, it has been determined that although only 20% to 30% of non-AD patients carry *S. aureus* as a commensal microbe, both the abundance and relative frequency of *S. aureus* representation in the skin microbiome is increased in AD patients, even when their disease is quiescent. When patients experience acute exacerbations of AD, staphylococci (primarily *S. aureus*) become predominant in the skin microbiome, indicating an intimate relationship between AD disease activity and staphylococcal dysbiosis.[35]

A mouse model that recapitulates aspects of AD and the relationship between disease activity and changes is skin microbiome composition has been established recently.[36] In this model, mice exhibited spontaneous microbial dysbiosis characterized by *S. aureus* predominance accompanied by severe eczematous dermatitis. Furthermore, cutaneous application of *S. aureus* caused eczema, whereas a commensal *Corynebacterium* species did not. Interestingly, *Corynebacterium* enhanced Th2 responses that promote IgE production and that may be relevant to the atopic march in AD patients. This suggests that AD might be effectively treated by manipulating the cutaneous microbiome. Bleach baths modify the cutaneous microbiome and thus represent a practical and cost-effective means of therapy, but mechanisms by which bleach baths control AD have yet to be characterized in detail. Because topical steroids can reverse microbial dysbiosis even in the absence of antibacterial therapy, both inflammation and microbial dysbiosis are likely to be important contributors in a vicious cycle that drives skin inflammation in AD.

The recent development of biologic agents or "biologics" allows selective targeting of mediators or cells, and the efficacy of these interventions can provide insight into the involvement of the targeted pathways in inflammatory skin diseases including AD. Omalizumab, a humanized monoclonal anti-IgE antibody, effectively treats asthma, food allergies and urticaria, but it has not been effective in AD.[37] Although this lack of efficacy may be attributed to the high serum levels of IgE in AD patients, an alternative conclusion is that skin inflammation in AD is not mediated by an IgE-dependent mechanism. Signaling pathways involving IL-4 and/or IL-13 also may be relevant in AD. Phase 3 trials document that dupilumab, which blocks IL-4 and IL-13 signaling by binding to IL-4Rα, is effective in AD.[38] The leukocytes that produce IL-4 and IL-13 in AD remain to be determined. Human and mouse Th2 cells are known to be major sources of IL-4, and murine innate lymphoid cells (lymphoid cells that lack conventional T-cell antigen receptors) have been identified as major sources of IL-13. The contribution of innate lymphoid cells to human AD will be assessed in future studies.

Small molecules that occupy the ATP-binding sites of Janus kinases (JAKs) are effective inhibitors of cytokine receptor signaling. JAK1 and JAK3 play critical roles in signaling mediated by the Th2 cytokines IL-3 and IL-13, as well as IL-7 and IL-15. These cytokines collectively support the maintenance of T lymphocytes, NK cells, and innate lymphoid cells. Tofacitinib and ruxolitinib inhibit both JAK1 and JAK3 and have activity in inflammatory diseases including rheumatoid arthritis, psoriasis and alopecia areata. In light of the efficacy of IL-4/IL-13 blockade and the association of IL-7 and IL-15 receptor polymorphisms in AD, JAK inhibitors may be useful in this patient population. Indeed, topical tofacitinib has been reported to improve Eczema Area and Severity Index (EASI) scores in a Phase IIa randomized trial in AD. Studies of newly developed targeted therapeutic agents are likely to provide additional insights into mechanisms that play important roles in AD pathogenesis.

PSORIASIS

Psoriasis is a common, recalcitrant inflammatory skin disease characterized by discrete plaques with adherent micaceous scales occurring at sites of predilection, including locations of minor skin trauma. Nail involvement is frequent, and characteristic arthritis ("psoriatic arthritis") can co-occur or occur in the absence of skin lesions. Psoriasis has not been effectively modeled in mice until recently, requiring that advances in understanding disease pathogenesis and developing effective therapies be driven by clinical research involving patients. Very recent work indicates that psoriasis is a systemic disease in which skin inflammation is dramatically evident, rather than a disease whose impact is restricted to skin.[39]

The histology of psoriatic lesions is typified by a thickened, hyperproliferative epidermis featuring markedly reduced basal keratinocyte transit times, abnormal keratinocyte differentiation, neutrophilic and lymphocytic inflammation, and prominent capillary loops that extend into the very superficial dermis. At various times, competing schools of thought espoused that psoriasis was caused by abnormalities in keratinocytes, immunocytes, and endothelial cells. The ability of antimetabolites (eg, methotrexate) and ultraviolet radiation (UVB or psoralen + UVA) to ameliorate aspects of the disease was consistent with the concept that keratinocyte growth was abnormal in psoriasis and that this might reflect intrinsic keratinocyte defects, but these interventions also have immunomodulatory properties.

The critical involvement of lymphocytes in psoriasis pathogenesis was convincingly demonstrated when increasingly selective therapies became available.[40] The calcineurin inhibitor cyclosporine is a remarkably effective antipsoriatic agent. The ability of high concentrations of cyclosporine to modulate keratinocyte growth and gene expression in vitro did not exclude keratinocytes as relevant targets in psoriatic patients with certainty, but follow-up clinical studies with the specific lymphocyte-depleting agents denileukin diftitox (an IL-2 receptor–directed cytotoxin) and alefacept (a CD2-binding LFA-3/Fc fusion protein) settled this question. Both of these agents were too toxic to be routinely administered to psoriatic patients because they have broad-spectrum antilymphocyte effects, but studies with increasingly selective immunomodulators have informed our understanding of psoriasis pathogenesis and identified effective therapeutics.

Improved treatment of psoriasis and more detailed understanding of psoriasis pathogenesis has developed in concert with the revolution in "biologic therapy." Although the anti-TNFα neutralizing antibody infliximab (one of the first widely used biologics) was first tested in patients with inflammatory bowel diseases,[41] improvement in skin lesions in patients with concurrent psoriatic led to formal testing of infliximab and demonstration of efficacy in patients with severe psoriasis vulgaris. TNFα is a primary proinflammatory cytokine with many sources, targets, and actions in skin and elsewhere, so initially it was not obvious why infliximab and other TNFα-targeting agents were particularly effective in patients with psoriasis.

The effectiveness of lymphocyte-depleting and lymphocyte-modulating agents in patients with psoriasis indicated that T cells and perturbations in cellular immunity were critical. Prior to the advent of biologics, atopic dermatitis was conceptualized as a Th2-predominant disease whereas psoriasis was thought to be Th1 mediated, with IFNγ as an important effector cytokine. Discovery of entirely new T cell subsets, especially Th17 cells that produce IL-17, opened an entirely new avenue for psoriasis research. TNFα is coproduced by dermal dendritic cells that also produce IL-23, a cytokine that is required for Th17-cell development. IL-23 is a heterodimeric protein composed of IL-23–specific p19 as well as p40, a polypeptide that is shared with the Th1-promoting cytokine IL-12. IL-17 promotes neutrophil-predominant inflammation and plays important roles in responses to microbial pathogens, in part because IL-17 modulates gene expression in keratinocytes leading to increased production of antimicrobial peptides, defensins, and other inflammatory mediators. TNFα augments the effects of IL-17 on keratinocytes.

TNFα, IL-23, and IL-17 production is elevated in lesional skin from patients with psoriasis, and effective treatment reduces the levels of these cytokines. The existence of an IL-17–dependent, TNFα-augmented feed-forward loop that amplifies inflammation in psoriatic lesions provides a construct for understanding why agents that antagonize TNFα signaling are efficacious in this disease. The relevance of the IL-23/IL-17 axis in psoriasis has been even more convincingly demonstrated in subsequent studies with increasingly selective therapeutics. Ustekinumab (anti-human p40) had dramatic effects in patients with psoriasis in pilot studies, and its efficacy has been borne out in subsequent, now long-term, Phase III studies. Because p40 is a polypeptide subunit that is shared by Th17-modulating IL-23 and Th1-modulating IL-12, effects of ustekinumab could not be definitively attributed to modulation of Th17 cells and Il-17.

The anti-IL-17A monoclonal antibodies secukiumab and ixekinumab are now FDA approved for use in patients with psoriasis because they are remarkably effective with rapid onset of action and frequently complete or almost complete responses, convincingly solidifying IL-17's critical role in psoriasis pathogenesis. Anti-IL-23 p19 monoclonal antibodies (including guselkumab) are also reported to be efficacious in psoriatic patients and may be commercially available soon. The utility of agents that target signaling of the Th17-cell product IL-22 that may cause acanthosis by acting directly on keratinocytes has yet to be demonstrated, but this approach may also have merit.

One unanswered question relates to the cellular source of IL-17 in psoriatic skin. Conventional T cells bearing antigen-specific receptors composed of α and β chains were presumed to be responsible, but the possible involvement of recently discovered innate lymphocytes must now be considered. Subsets of innate lymphocytes (termed ILC1, ILC2, and ILC3) have the capacity to produce T-cell cytokines (IFNγ, IL-5/IL-13, and IL-17, respectively) but do not recognize and are not activated by peptide antigens. These cells also do not need to proliferate to express effector function. The extent to which ILCs participate in psoriasis will require further study.

Another unanswered question relates to the aggressiveness with which psoriasis patients should be treated with biologic agents. As of this writing, studies have involved only patients with moderate to severe psoriasis. Several effective biologics have been remarkably well tolerated, but the cost of therapy is significant and cures or long-term remissions do not typically result. The discovery that patients with psoriasis have significant comorbidities, including cardiovascular disease,[42] and decreased life spans suggests

that widespread use of systemic treatments might be appropriate. It is possible that biologics may have general health-promoting activities, even in patients with mild psoriasis. Additional clinical research will be required.

From a disease pathogenesis perspective, the major unanswered question in psoriasis relates to the nature of the initial triggering event(s) and the process(es) by which the IL-23/IL-17 axis becomes engaged. Related to this, identification of the source(s) of the lynchpin cytokine IL-17 is critical (see before). Increasingly large and sophisticated GWASs have been conducted with psoriasis patients over the past several decades in an effort to obtain mechanistic insights.[43] Despite that fact that currently identified susceptibility loci explain only a minor component of the genetic predisposition in psoriasis, some conclusions can be drawn. Genetic susceptibility loci in atopic dermatitis and psoriasis are largely nonoverlapping,[44] consistent with the concept that disease-causing mechanisms are distinct in these 2 disorders. GWASs of patients with differing ethnicities yield differing results, reaffirming that psoriasis is a complex multifactorial/multigenic disorder. GWASs of psoriasis variants (including pustular psoriasis and psoriatic arthritis) also highlight different genetic loci, as might be expected in studies of patients with such distinct clinical features.[45]

Most single nucleotide polymorphisms (SNPs) that have been linked to psoriasis occur in regions of the genome that do not encode proteins. Some genetic variants may occur in important gene regulatory regions or may influence gene expression indirectly via transcription of gene regulatory noncoding RNAs. However, it is likely that at least some (and perhaps most) SNPs are actually in linkage disequilibrium with the genetic alterations that are causative. Higher-resolution studies that involve more extensive genetic characterization (whole exome or whole genome sequencing, for example) and/or even larger numbers of patients may be additionally informative.

SNPs in the MHC Class I locus confer the largest amount of genetic risk in both European and Chinese psoriasis populations.[46] Other well-established genetic risk loci include the gene encoding endoplasmic reticulum aminopeptidase 1, genes encoding components of signaling pathways that are operative in innate immunity, and genes that influence the activity of the IL-23/IL-17 axis. There are rare examples of patients with causative mutations in individual genes of interest. These genes include *IL23R*, *CARD14* (a scaffolding protein that participates in NF*k*B signaling), and *IL36RN*. It is not difficult to incorporate linkage of psoriasis to genetic alterations in genes regulating innate immunity and/or the IL-23/IL-17 axis. Strong linkage of psoriasis to genetic alterations in the MHC Class I locus suggests that adaptive immunity and conventional T cells are also very important.

Modern concepts of psoriasis pathogenesis can easily incorporate conventional T cells, but the accepted importance of Th17 cells would predict that variants of interest would occur in the MHC Class II locus, rather than the MHC Class I locus. Despite this, it has been possible to identify MHC Class I–restricted IL-17–producing $CD8^+$ T cells that react with melanocyte-derived ADAMTS-like protein 5 in some psoriatic patients.[47] In other studies, $CD4^+$ and $CD8^+$ T cells reactive with keratinocyte-derived antimicrobial peptide LL37 have been identified.[48] T cells producing IL-17 as well as IFNγ, IL-22, and IL-21 in response to LL37 are more prevalent in psoriatic patients than controls, and frequencies of antigen LL37-reactive T cells in peripheral blood correlate with disease severity. LL37 is an interesting protein antigen because it is more promiscuous with respect to MHC restriction than typical protein antigens. LL37/self DNA complexes are also potent inducers of IFNα/β production by accessory cells, so it is possible that the adjuvant properties of LL37 are also relevant to psoriasis. Undoubtedly, future studies will provide additional insights into early aspects of psoriasis pathogenesis.

ALOPECIA AREATA

Alopecia areata (AA) is an often chronic and disabling disease that is characterized by intermittent and/or long-lasting hair loss of varying severity that can occur in association with other autoimmune diseases including thyroiditis. The 3 major phenotypic variants are termed patchy, universalis (involving the entire scalp), and totalis (involving entire integument). Scalp biopsies obtained from the peripheries of expanding lesions feature lymphocyte-predominant inflammation and patients may respond to locally administered or systemic corticosteroids, both consistent with an immune-mediated etiology. Preferential association of lesional lymphocytes with anagen hair bulbs (Fig. 13-4), rather than the stem cell–containing bulge regions, is consistent with the characterization of AA as a nonscarring alopecia and the ability of skin that appears devoid of terminal hairs to "re-grow" apparently normal complements of hair in some instances.

AA is an example of a fascinating skin disease that has been studied for many years and that has only recently begun to reveal its secrets. Progress can be attributed to multidisciplinary studies of thousands of AA patients buttressed by work involving animal models. Interestingly, studies with patients and rodents have proceeded in parallel and results obtained have often been highly complementary.

Several animal models have been particularly informative.[49] One particular mouse, the C3H/HeJ mouse, develops inflammatory lesions that resemble AA with some regularity as it ages. This occurrence in mice and AA patients is thought to result from loss of "immune privilege" that is a property of normal hair follicles (HFs). The HF antigens that are targeted by lymphocytes and the mechanisms that protect HFs from immune-mediated damage under normal circumstances have not been completely characterized. Immune privilege may depend on low-level expression of MHC Class I and Class II antigens by HF keratinocytes and local production of immunosuppressive cytokines and perhaps neuropeptides. The frequency

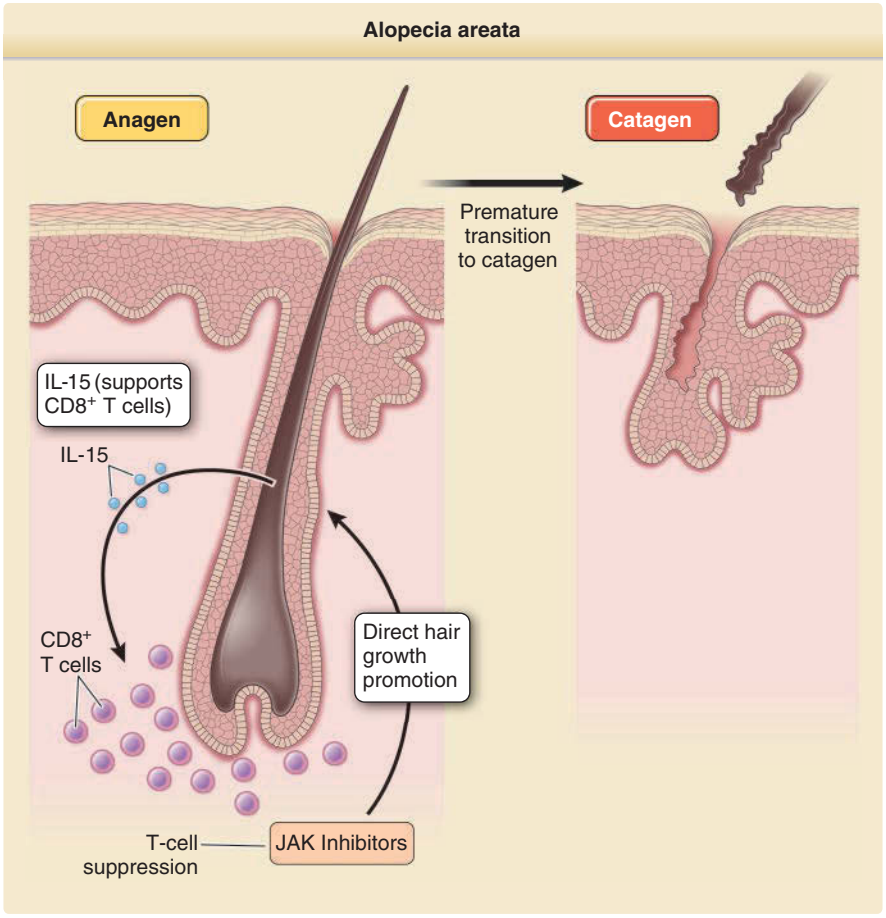

Figure 13-4 Mechanisms involved in alopecia areata. T cell–mediated inflammation in the bulb area induces premature catagen transition and leads to hair loss in alopecia areata. JAK inhibitors can reverse hair loss by suppressing inflammation and by directly acting on hair follicles to induce hair growth.

of disease development in C3H/HeJ mice can be greatly enhanced by transferring lymphocytes from affected mice into disease-free mice, documenting the importance of lymphocytes in disease pathogenesis and providing an experimental platform with which to characterize the properties of pathogenic cells, potentially dissecting mechanisms that cause HF damage and test novel therapeutic interventions.

Studies in the C3H/HeJ mouse demonstrate that $CD8^+$ (cytotoxic) T cells and IFNγ are important effectors in this model,[50] inducing HF dystrophy and premature entry into catagen via mechanisms that are incompletely characterized (Fig. 13-4). The cytokine IL-15 is known to be important for $CD8^+$ T-cell induction and/or persistence, so it is not surprising that neutralization of IL-15 also attenuates AA activity. Coadministration of $CD4^+$ $CD25^-$ (helper) T cells with $CD8^+$ T cells promotes disease progression whereas coadministration of $CD4^+$ $CD25^+$ (regulatory) T cells with $CD8^+$ T cells prevents disease induction.

The use of xenograft models that involve placement of AA patient scalp skin or normal volunteer glabrous skin onto immunocompromised SCID or SCID beige mice followed by introduction of syngeneic or allogeneic human leukocytes locally or systemically serves as a bridge between studies of the C3H/HeJ mouse model and studies of AA patients. Adoptive transfer of leukocytes results in hair loss within the xenografts, resulting in an experimental system that may facilitate delineation of pathogenic mechanisms and trials of new therapies in a relevant preclinical model. Initial studies of mice engrafted with AA scalp documented the pathogenicity of intracutaneous $CD8^+$ T cells, but logistics limited the general utility of this approach. Attempts to substitute skin and leukocytes from normal volunteers for those from AA patients demonstrated that activated lymphocytes, including NK cells, from even normal individuals could induce AA-like hair loss from syngeneic or allogeneic skin after local injection. Although this "AA" model does not allow assessment of patient-specific factors, it has been used to characterize mechanisms that can lead to hair dystrophy and to screen for agents, including phosphodiesterase inhibitors and ion channel blockers, that may have utility in AA.

There are important physiologic differences between cutaneous immune systems and hair follicles in mice and humans and, as alluded to above, xenograft studies have significant limitations. Fortunately, using contemporary approaches, in recent years it has become

possible to move from observational, correlative studies of limited scope to large-scale studies of AA patients who were initially hypothesis-generating and later hypothesis-testing. One important consequence is the identification of targeted therapies that can be expected to have a major impact on AA in the immediate future.

Initial GWASs involving >1000 AA patients and >3000 case controls identified a number of single-nucleotide polymorphisms (SNPs) that were disease-associated.[51] The location of these SNPs suggested the possible involvement of genes related to T cell–mediated immune responses (*CTLA4*, *ICOS*, *IL21*/*IL2*, *IL2RA*), NK cells (NKG2D ligand genes), as well as antigen presentation (HLA-DR/DQ genes). Subsequent GWASs and related studies have highlighted additional candidate genes that reinforce the importance of T-cell regulators and the role of HLA-DR (encoding MHC Class II antigens) as the dominant susceptibility locus.[52] In follow-up studies of the C3H/HeJ AA mouse model, the importance of $CD8^+$ $NKG2D^+$ T cells and the T-cell cytokines IFNγ, IL-2, and IL-15 was convincingly demonstrated.[50] Involvement of $CD8^+$ T cells, IFNγ and IL-15, in conjunction with studies of gene expression in lesional skin, suggested a critical role for JAKs and STAT (signal transducers and stimulators of transcription) transcription factors and the JAK/STAT pathway as a possible target for intervention. Subsequent studies indicated that selective JAK1 inhibitors have considerable activity in this model, whereas JAK3 inhibitors did not.

The best source of critical information regarding disease effector mechanisms and disease activity is involved tissue obtained from patients. Global transcriptional profiling of lesional skin is an unbiased and comprehensive way to gain insights into cells and proteins that are likely to be present at sites of disease activity. Patient- and animal model-derived samples can be subjected to analogous analyses, so results in these 2 settings can be easily compared. Recent studies of patients with patchy AA (AAP), AA universalis (AAU), and AA totalis (AAT) reinforce preexisting concepts and provide new insights as well.[53] Comparison of AA and normal cutaneous transcriptomes resulted in an AA gene expression signature with ~1000 elevated and ~1000 reduced transcripts in AA lesional skin as compared with controls. Principal components analysis indicated that the gene expression signatures of controls and AAP patients could be distinguished from those of AAU and AAT patients, while the gene expression profiles of AAU and AAT patients did not segregate. Highly represented transcripts in AA biopsies were attributable to the presence of $CD8^+$ T cells, chemokines involved in leukocyte trafficking, and IFNγ signaling (Th1-predominant inflammation). Generation of numerical scores that reflected the aggregate deviation of the gene expression signatures in AA biopsies from those of normal individuals confirmed that AAP patients could be differentiated from controls and AAU/AAT patients, and that profiles from AAU/AAT patients were more abnormal than AAP profiles. Because transcriptional profiling is a measure of ongoing physiologic activity, the latter result suggests that disease is active in AAU/AAT skin and perhaps even more active than in AAP skin. This result is not compatible with the concept that the AAU/AAT is end stage, that HFs are in irreversible catagen, and that antiinflammatory therapies cannot be of benefit in these recalcitrant AA variants.

Although the final solution of the AA puzzle is not yet available, complementary laboratory and clinical research has led to great progress. It is not yet possible to prospectively identify individuals who are at risk or to prevent disease development, but rational and effective targeted therapies are likely to be in widespread use soon. Indeed, recent Phase II studies document significant responses to JAK inhibitors in subpopulations of AA patients.[54,55] One can make the case that AA could be a "poster child" for immunologic/inflammatory skin diseases of uncertain etiology, and analogous laboratory and clinical research approaches could someday result in similar advances.

AUTOIMMUNE BLISTERING DISEASES

Autoimmune blistering diseases are chronic, debilitating diseases that manifest as blisters or erosions involving skin and/or mucous membranes. Some autoimmune blistering diseases are fatal if left untreated. Classification of these diseases is based on clinical features, including lesion distribution and gross and histologic morphology. Pemphigus and pemphigoid are the most common autoimmune blistering disorders. Pemphigus can additionally be subcategorized into pemphigus vulgaris (PV) and pemphigus foliaceous (PF). PV manifests with flaccid bullae or erosions involving mucous membranes and skin, whereas PF affects only the skin and presents with fragile blisters or superficial erosions. Bullous pemphigoid may manifest with urticarial lesions with subsequent development of tense bullae on skin and, much less commonly, erosions on mucous membranes. This stands in contradistinction to mucous membrane pemphigoid and epidermolysis bullosa acquisita, which feature primarily mucosal lesions and mucosal and cutaneous lesions, respectively.

Results from routine histology and direct or indirect immunofluorescence microscopy can provide important diagnostic information. The identification and characterization of autoantigens in blistering diseases, coupled with the demonstration that autoantibodies are pathogenic, have enabled development of novel diagnostic enzyme-linked immunosorbent assays (ELISAs) that detect circulating autoantibodies that react to corresponding autoantigens.

Pemphigus and bullous pemphigoid (BP) are the 2 most intensively studied autoimmune blistering diseases. Studies of patients' sera identified autoantibodies that react with the epidermis in the case of pemphigus patients and with the basement membrane zone in patients with bullous pemphigoid.

The demosomal protein desmoglein 3 (Dsg3) is the major autoantigen targeted initially by antibodies in pemphigus vulgaris, and desmoglein 1 (Dsg1) is the primary autoantigen in pemphigus foliaceus.[56] PV patients typically develop anti-Dsg1 autoantibodies at some point after anti-Dsg3 autoantibodies appear. Dsg3 is a major component of desmosomes that mediate cell adhesion between keratinocytes in the lower layers of the epidermis, whereas Dsg1 is a major desmosomal protein expressed by superficial epidermal keratinocytes. The distribution of Dsg3 and Dsg1 in epidermis determines the locations of blister formation in PV and PF, and the sequence of appearance of oral and cutaneous lesions in PV. Because Dsg3, but not Dsg1, is expressed in oral and esophageal mucosae, mucosal involvement is observed in PV but not in PF. Other rare forms of pemphigus include IgA pemphigus, in which IgA autoantibodies against desmocollin 1 (another component of desmosomes), Dsg1, or Dsg3 cause disease, and paraneoplastic pemphigus, which is associated with autoantibodies against multiple desmosomal proteins as well as T cells that may contribute to epidermal–dermal interface destruction.[57]

BP is caused by IgG autoantibodies that react with components of hemidesmosomes, adhesive structures that mediate adhesion of basal keratinocytes to the basement membrane. Two major antigens are targeted in BP; collagen XVII (COL17, also known as BP180 or BPAG1) and the plakin family protein BP230 (BPAG2).[58] COL17 is expressed on cell surfaces and it is considered to be the major BP autoantigen. Although anti-BP230 antibodies also can be frequently detected in patients, the pathophysiologic role of anti-BP230 antibodies is uncertain because BP230 is an intracellular protein. Related diseases include pemphigoid gestationis and pemphgoid herpetiformis. Pemphigoid gestationis exhibits clinical features and autoantibody profiles that are identical to BP and develops only in pregnant women. Mucous membrane pemphigoid has been reported in patients with circulating antibodies reactive with COL17, BP230, laminin 5, laminin 6, Type VII collagen (COL7), laminin 5, laminin 6, and β4 integrins,[59] whereas epidermolysis bullosa acquisita is caused by anti-COL7 antibodies.[60]

Injection of human PV-derived IgG causes blister development in mice.[61] Studies involving recombinant Dsg3 and Dsg1, as well as engineered molecules in which the extracellular domains were exchanged, demonstrated that the anti-Dsg3 autoantibodies that cause skin blistering target N-terminal domains of Dsg3 (extracellular domains 1 and 2).[62,63] Generation of Dsg3 knockout (KO) mice allowed development of an active disease model for PV.[64] Dsg3-reactive T and B cells are generated when Dsg3 KO mice are immunized with recombinant Dsg3. When splenocytes from Dsg3-immune Dsg3 KO mice were transferred into Dsg3-sufficient mice, recipient mice developed skin and mucosal lesions and autoantibodies reactive with Dsg3. Formation of anti-Dsg3 autoantibodies by B cells in these mice is dependent on the presence of $CD4^+$ T cells. Patients with PV and PF also harbor autoantibodies that react with antigens other than Dsg3 and Dsg1.[56,65] It is possible that these autoantibodies also contribute to pemphigus pathogenesis. Lesion formation is not thought to be complement-dependent, and anti-DSG antibodies may cause acantholysis by triggering intracellular signaling in keratinocytes.

In BP patients, the majority of anti-COL17 IgG autoantibodies target the NC16a domain.[66] In contrast to PV, passive transfer of IgG from BP patients does not cause disease in mice.[67] This may reflect varying amino acid sequences in the NC16A domains of COL17 in mice and humans. Supporting this, transgenic mice that express human COL17 do develop blisters after injection with IgG from BP patients.[68] Mechanisms that cause lesion formation in BP appear to be different from those that cause blisters in pemphigus patients. Complement (C3) deposition in the basement membrane zone is universal in BP. Passive transfer of rabbit anti-COL17 into mice causes blisters in normal mice, but not in complement-deficient mice, indicating a critical role for complement in BP lesion formation.[69] Consistent with this, passive transfer of recombinant Fab fragments of human anti-NC16a domain autoantibodies does not cause disease in human COL17-expressing transgenic mice.[66] Local complement activation in BP lesions attracts neutrophils in mice, and these cells are also thought to participate in blister formation, perhaps by producing metalloproteinases. Prominent tissue and peripheral blood eosinophilia also occurs in BP, and IgE autoantibodies can be detected in the sera and skin of a subset of BP patients, consistent with the concept that the immune mechanisms operative in BP are distinct from those in pemphigus.[66]

Autoimmune diseases develop when the immune system inappropriately attacks self-antigens. Central and peripheral tolerance, immune regulatory mechanisms acting in the thymus and peripheral organs, respectively, prevent the immune system from reacting against self in normal individuals. Mechanisms responsible for loss of tolerance in patients with autoimmune diseases have not been elucidated. However, the increased incidence of pemphigus (especially PF) in patients with thymoma suggests that impairment of central tolerance relates to the onset of pemphigus. Some patients with pemphigoid gestationis also develop autoimmune thyroiditis, suggesting that loss of tolerance may occur in these patients as well, and that both autoimmune diseases arise due to dysregulated immunity that occurs during pregnancy.

Autoimmune blistering diseases are commonly treated with systemic glucocorticoids with or without other immunosuppressive agents, including azathioprine, mycophenolate mofetil, and cyclophosphamide. The development of the monoclonal antibody rituximab has allowed targeted therapies for autoimmune bullous diseases, in particular pemphigus, that has redefined standard care of these diseases.[70,71] Rituximab binds the cell surface protein CD20 that is expressed by B cells. This leads to the depletion of both normal and autoreactive B cells in patients, and the possibility of prolonged remissions. Rituximab therapy is well tolerated, and its efficacy and safety as first line of therapy in combination with short-term corticosteroid has been recently demonstrated.[71]

A recent study reports development of an alternative approach involving chimeric autoantigen receptor (CAAR) T cells.[72] T cells are genetically modified to express Dsg3 that was engineered to activate T cells after surface crosslinking. When Dsg3-expressing CAAR T cells bind to B cells that express surface anti-Dsg3 IgG, the CAAR T cells are activated and they subsequently destroy Dsg3-reactive B cells. This strategy, or related strategies, may ultimately lead to novel antigen-specific therapies in pemphigus (and other autoantibody-mediated disorders) that are safer and more efficacious than those in use currently.

CONCLUSIONS AND FUTURE DIRECTIONS

This chapter summarizes our current understanding of the pathophysiology of several immunologic/inflammatory skin diseases. We have selected examples of diseases where our understanding is detailed. This list is short, whereas the list of immunologic/inflammatory skin diseases in which our understanding of disease pathogenesis is inadequate is long. Although studies of experimental animal models, in many cases, provide fundamental knowledge that is prerequisite for studies of humans, the efficiency with which studies of patients yield information that affects patient care is increasing. In the case of immunologic/inflammatory skin diseases, the advent of "low cost" GWAS and other genetic studies and the availability of biologic agents with exquisite specificity have been both timely and important. It seems likely that the types of approaches that have been successful in psoriasis and alopecia areata will have utility in studies of patients with other immunologic/inflammatory skin diseases if implemented with similar enthusiasm, and that improved therapies will result.

REFERENCES

1. Allen MH, Wakelin SH, Holloway D, et al. Association of TNFA gene polymorphism at position –308 with susceptibility to irritant contact dermatitis. *Immunogenetics.* 2000;51(3):201-205.
2. Nacak M, Erbagci Z, Buyukafsar K, et al. Association of angiotensin-converting enzyme gene insertion/deletion polymorphism with allergic contact dermatitis. *Basic Clin Pharmacol Toxicol.* 2007;101(2):101-103.
3. Reich K, Westphal G, König IR, et al. Association of allergic contact dermatitis with a promoter polymorphism in the IL16 gene. *J Allergy Clin Immunol.* 2003;112(6):1191-1194.
4. Kim DS, Kim DH, Lee H, et al. A genome-wide association study in Koreans identifies susceptibility loci for allergic nickel dermatitis. *Int Arch Allergy Immunol.* 2013;162(2):184-186.
5. Kaplan DH, Igyártó BZ, Gaspari AA. Early immune events in the induction of allergic contact dermatitis. *Nat Rev Immunol.* 2012;12(2):114-124.
6. Schmidt M, Raghavan B, Muller V, et al. Crucial role for human Toll-like receptor 4 in the development of contact allergy to nickel. *Nat Immunol.* 2010;11(9):814-819.
7. Adam C, Wohlfarth J, Haußmann M, et al. Allergy-inducing chromium compounds trigger potent innate immune stimulation via ROS-dependent inflammasome activation. *J Invest Dermatol.* 137(2):367-376.
8. Sutterwala FS, Ogura Y, Szczepanik M, et al. Critical role for NALP3/CIAS1/cryopyrin in innate and adaptive immunity through its regulation of caspase-1. *Immunity.* 2006;24(3):317-327.
9. Watanabe H, Gaide O, Pétrilli V, et al. Activation of the IL-1β-processing inflammasome is involved in contact hypersensitivity. *J Invest Dermatol.* 2007;127(8):1956-1963.
10. Antonopoulos C, Cumberbatch M, Dearman RJ, et al. Functional caspase-1 is required for Langerhans cell migration and optimal contact sensitization in mice. *J Immunol.* 2001;166(6):3672.
11. Martin SF, Dudda JC, Bachtanian E, et al. Toll-like receptor and IL-12 signaling control susceptibility to contact hypersensitivity. *J Exp Med.* 2008;205(9):2151.
12. Kaplan DH, Jenison MC, Saeland S, et al. Epidermal Langerhans cell-deficient mice develop enhanced contact hypersensitivity. *Immunity.* 2005;23(6):611-620.
13. Bennett CL, van Rijn E, Jung S, et al. Inducible ablation of mouse Langerhans cells diminishes but fails to abrogate contact hypersensitivity. *J Cell Biol.* 2005;169(4):569-576.
14. Kissenpfennig A, Henri S, Dubois B, et al. Dynamics and function of Langerhans cells In vivo: dermal dendritic cells colonize lymph node areas distinct from slower migrating Langerhans cells. *Immunity.* 2005;22(5):643-654.
15. Allan RS, Waithman J, Bedoui S, et al. Migratory dendritic cells transfer antigen to a lymph node-resident dendritic cell population for efficient CTL priming. *Immunity.* 2006;25(1):153-162.
16. Kim JH, Hu Y, Yongqing T, et al. CD1a on Langerhans cells controls inflammatory skin disease. *Nat Immunol.* 2016;17(10):1159-1166.
17. Jiang X, Clark RA, Liu L, et al. Skin infection generates non-migratory memory CD8+ T(RM) cells providing global skin immunity. *Nature.* 2012;483(7388):227-231.
18. Gaide O, Emerson RO, Jiang X, et al. Common clonal origin of central and resident memory T cells following skin immunization. *Nat Med.* 2015;21(6):647-653.
19. Duong TA, Valeyrie-Allanore L, Wolkenstein P, et al. Severe cutaneous adverse reactions to drugs. *Lancet.* 2017; 390(10106):1996-2011.
20. Hung S-I, Chung W-H, Liou L-B, et al. HLA-B*5801 allele as a genetic marker for severe cutaneous adverse reactions caused by allopurinol. *Proc Natl Acad Sci U S A.* 2005;102(11):4134-4139.
21. Chung W-H, Hung S-I, Hong H-S, et al. Medical genetics: a marker for Stevens-Johnson syndrome. *Nature.* 2004;428(6982):486.
22. Zhang FR, Liu H, Irwanto A, et al. HLA-B*13:01 and the dapsone hypersensitivity syndrome. *N Engl J Med.* 2013;369(17):1620-1628.
23. Shiohara T. Fixed drug eruption: pathogenesis and diagnostic tests. *Curr Opin Allergy Clin Immunol.* 2009;9(4):316-321.
24. Takahashi R, Kano Y, Yamazaki Y, et al. Defective regulatory T cells in patients with severe drug eruptions: timing of the dysfunction is associated with the pathological phenotype and outcome. *J Immunol.* 2009;182(12):8071.
25. Picard D, Janela B, Descamps V, et al. Drug reaction with eosinophilia and systemic symptoms (DRESS):

a multiorgan antiviral T cell response. *Sci Transl Med.* 2010;2(46):46ra62.
26. Kano Y, Tohyama M, Aihara M, et al. Sequelae in 145 patients with drug-induced hypersensitivity syndrome/drug reaction with eosinophilia and systemic symptoms: Survey conducted by the Asian Research Committee on Severe Cutaneous Adverse Reactions (ASCAR). *J Dermatol.* 2015;42(3):276-282.
27. Chung W-H, Wang C-W, Dao R-L. Severe cutaneous adverse drug reactions. *J Dermatol.* 2016;43(7):758-766.
28. Palmer CNA, Irvine AD, Terron-Kwiatkowski A, et al. Common loss-of-function variants of the epidermal barrier protein filaggrin are a major predisposing factor for atopic dermatitis. *Nat Genet.* 2006;38(4): 441-446.
29. Hirota T, Takahashi A, Kubo M, et al. Genome-wide association study identifies eight new susceptibility loci for atopic dermatitis in the Japanese population. *Nat Genet.* 2012;44(11):1222-1226.
30. Paternoster L, Standl M, Waage J, et al; for the EArly Genetics & Lifecourse Epidemiology (EAGLE) eczema consortium. Multi-ancestry genome-wide association study of 21,000 cases and 95,000 controls identifies new risk loci for atopic dermatitis. *Nat Genet.* 2015;47(12):1449-1456.
31. Chavanas S, Bodemer C, Rochat A, et al. Mutations in SPINK5, encoding a serine protease inhibitor, cause Netherton syndrome. *Nat Genet.* 2000;25(2):141-142.
32. Hubiche T, Ged C, Benard A, et al. Analysis of SPINK 5, KLK 7 and FLG genotypes in a French atopic dermatitis cohort. *Acta Derm Venereol.* 2007; 87:499–505.
33. Holland SM, DeLeo FR, Elloumi HZ, et al. STAT3 Mutations in the hyper-IgE syndrome. *N Engl J Med.* 2007;357(16):1608-1619.
34. Grice EA, Kong HH, Conlan S, et al. Topographical and temporal diversity of the human skin microbiome. *Science.* 2009;324(5931):1190.
35. Kong HH, Oh J, Deming C, et al. Temporal shifts in the skin microbiome associated with disease flares and treatment in children with atopic dermatitis. *Genome Res.* 2012;22(5):850-859.
36. Kobayashi T, Glatz M, Horiuchi K, et al. Dysbiosis and *Staphyloccus aureus* colonization drives inflammation in atopic dermatitis. *Immunity.* 2015;42(4):756-766.
37. Krathen RA, Hsu S. Failure of omalizumab for treatment of severe adult atopic dermatitis. *J Am Acad Dermatol.* 2005;53(2):338-340.
38. Simpson EL, Bieber T, Guttman-Yassky E, et al. Two phase 3 trials of dupilumab versus placebo in atopic dermatitis. *N Engl J Med.* 2016;375(24):2335-2348.
39. Takeshita J, Grewal S, Langan SM, et al. Psoriasis and comorbid diseases. *J Am Acad Dermatol.* 2016;76(3): 393-403.
40. Kim J, Krueger JG. Highly effective new treatments for psoriasis target the IL-23/Type 17 T cell autoimmune axis. *Annu Rev Med.* 2017;68(1):255-269.
41. Oh CJ, Das KM, Gottlieb AB. Treatment with anti-tumor necrosis factor alpha (TNF-alpha) monoclonal antibody dramatically decreases the clinical activity of psoriasis lesions. *J Am Acad Dermatol.* 2000;42(5 Pt 1): 829-830.
42. Ogdie A, Yu Y, Haynes K, et al. Risk of major cardiovascular events in patients with psoriatic arthritis, psoriasis and rheumatoid arthritis: a population-based cohort study. *Ann Rheum Dis.* 2015;74(2):326.
43. Harden JL, Krueger JG, Bowcock A. The immunogenetics of psoriasis: a comprehensive review. *J Autoimmun.* 2015;64:66-73.
44. Baurecht H, Hotze M, Brand S, et al. Genome-wide comparative analysis of atopic dermatitis and psoriasis gives insight into opposing genetic mechanisms. *Am J Hum Genet.* 2014;96(1):104-120.
45. Stuart Philip E, Nair Rajan P, Tsoi Lam C, et al. Genome-wide association analysis of psoriatic arthritis and cutaneous psoriasis reveals differences in their genetic architecture. *Am J Hum Genet.* 2015;97(6): 816-836.
46. Ray-Jones H, Eyre S, Barton A, et al. One SNP at a time: moving beyond GWAS in psoriasis. *J Invest Dermatol.* 2015;136(3):567-573.
47. Arakawa A, Siewert K, Stöhr J, et al. Melanocyte antigen triggers autoimmunity in human psoriasis. *J Exp Med.* 2015;212(13):2203.
48. Lande R, Botti E, Jandus C, et al. The antimicrobial peptide LL37 is a T-cell autoantigen in psoriasis. *Nat Commun.* 2014;5:5621.
49. Gilhar A, Schrum AG, Etzioni A, et al. Alopecia areata: animal models illuminate autoimmune pathogenesis and novel immunotherapeutic strategies. *Autoimmun Rev.* 2016;15(7):726-735.
50. Xing L, Dai Z, Jabbari A, et al. Alopecia areata is driven by cytotoxic T lymphocytes and is reversed by JAK inhibition. *Nat Med.* 2014;20(9):1043-1049.
51. Petukhova L, Duvic M, Hordinsky M, et al. Genome-wide association study in alopecia areata implicates both innate and adaptive immunity. *Nature.* 2010;466(7302):113-117.
52. Betz RC, Petukhova L, Ripke S, et al. Genome-wide meta-analysis in alopecia areata resolves HLA associations and reveals two new susceptibility loci. *Nat Commun.* 2015;6:5966.
53. Jabbari A, Cerise JE, Chen JC, et al. Molecular signatures define alopecia areata subtypes and transcriptional biomarkers. *EBioMedicine.* 2016;7:240-247.
54. Kennedy Crispin M, Ko JM, Craiglow BG, et al. Safety and efficacy of the JAK inhibitor tofacitinib citrate in patients with alopecia areata. *JCI Insight.* 2016;1(15): e89776.
55. Mackay-Wiggan J, Jabbari A, Nguyen N, et al. Oral ruxolitinib induces hair regrowth in patients with moderate-to-severe alopecia areata. *JCI Insight.* 2016;1(15): e89790.
56. Stanley JR, Amagai M. Pemphigus, bullous impetigo, and the staphylococcal scalded-skin syndrome. *N Engl J Med.* 2006;355(17):1800-1810.
57. Robinson ND, Hashimoto T, Amagai M, et al. The new pemphigus variants. *J Am Acad Dermatol.* 1999;40(5): 649-671.
58. Bağcı IS, Horváth ON, Ruzicka T, et al. Bullous pemphigoid. *Autoimmun Rev.* 2017.
59. Neff AG, Turner M, Mutasim DF. Treatment strategies in mucous membrane pemphigoid. *Ther Clin Risk Manag.* 2008;4(3):617-626.
60. Woodley DT, Burgeson RE, Lunstrum G, et al. Epidermolysis bullosa acquisita antigen is the globular carboxyl terminus of type VII procollagen. *J Clin Invest.* 1988;81(3):683-687.
61. Anhalt GJ, Labib RS, Voorhees JJ, et al. Induction of pemphigus in neonatal mice by passive transfer of IgG from patients with the disease. *N Engl J Med.* 1982;306(20):1189-1196.
62. Amagai M, Stanley JR. Desmoglein as a target in skin disease and beyond. *J Invest Dermatol.* 2012;132(3, Part 2):776-784.
63. Futei Y, Amagai M, Sekiguchi M, et al. Use of domain-swapped molecules for conformational epitope

mapping of desmoglein 3 in pemphigus vulgaris. *J Invest Dermatol.* 2000;115(5):829-834.
64. Amagai M, Tsunoda K, Suzuki H, et al. Use of autoantigen-knockout mice in developing an active autoimmune disease model for pemphigus. *J Clin Invest.* 2000;105(5):625-631.
65. Ahmed AR, Carrozzo M, Caux F, et al. Monopathogenic vs multipathogenic explanations of pemphigus pathophysiology. *Exp Dermatol.* 2016;25(11):839-846.
66. Nishie W. Update on the pathogenesis of bullous pemphigoid: An autoantibody-mediated blistering disease targeting collagen XVII. *J Dermatol Sci.* 2014;73(3):179-186.
67. Liu Z, Diaz LA, Troy JL, et al. A passive transfer model of the organ-specific autoimmune disease, bullous pemphigoid, using antibodies generated against the hemidesmosomal antigen, BP180. *J Clin Invest.* 1993;92(5):2480-2488.
68. Nishie W, Sawamura D, Goto M, et al. Humanization of autoantigen. *Nat Med.* 2007;13(3):378-383.
69. Liu Z, Giudice GJ, Swartz SJ, et al. The role of complement in experimental bullous pemphigoid. *J Clin Invest.* 1995;95(4):1539-1544.
70. Joly P, Mouquet H, Roujeau J-C, et al. A single cycle of rituximab for the treatment of severe pemphigus. *N Engl J Med.* 2007;357(6):545-552.
71. Joly P, Maho-Vaillant M, Prost-Squarcioni C, et al. First-line rituximab combined with short-term prednisone versus prednisone alone for the treatment of pemphigus (Ritux 3): a prospective, multicentre, parallel-group, open-label randomised trial. *Lancet.* 2017;389(10083):2031-2040.
72. Ellebrecht CT, Bhoj VG, Nace A, et al. Reengineering chimeric antigen receptor T cells for targeted therapy of autoimmune disease. *Science.* 2016;353(6295):179.

Chapter 14 :: Skin Barrier

:: Akiharu Kubo & Masayuki Amagai

AT-A-GLANCE

- One of the most important functions of the skin is to form a barrier between the organism and the external environment.
- The skin protects our bodies from physical damage caused by desiccation, physical stress, infection, overheating or heat loss, and ultraviolet (UV) irradiation.
- The skin is covered by the epidermis, a cornified, stratified epithelial cellular sheet that is equipped with a barrier formed by the stratum corneum and tight junctions.
- The stratum corneum is an air–liquid interface barrier on the body surface that prevents excessive water loss (inside–outside barrier) and the entry of harmful substances from the environment (outside–inside barrier).
- The stratum corneum barrier is composed of corneocytes and intercorneocyte water-impermeable lipid lamellae. Corneocytes are wrapped with cornified cell envelope and corneocyte lipid envelope and contain keratin filaments associated with filaggrin, which is degraded to natural moisturizing factors.
- The tight junctions seal the intercellular space between neighboring cells at the second layer in the stratum granulosum and form a liquid–liquid interface barrier that limits molecular movement through the paracellular pathway.
- Langerhans cells are located in the epidermis under the tight junction barrier in steady state but extend their dendrites to the outside tight junction barrier upon activation to capture external antigens at the tips of the dendrites.
- Antimicrobial peptides, lipids, the acidic pH of the stratum corneum, and continuous daily desquamation (daily detachment of dead skin cells) control the skin microbiota and protect us from infection by bacteria, yeasts, fungi, and viruses
- UV light is reflected from the stratum corneum and absorbed by urocanic acid and melanin molecules, which protect genomic DNA from UV irradiation damage.
- Sweating, blood flow control, and heat storage in subcutaneous adipose tissue protect us from cold and overheating.

INTRODUCTION

The skin is the integument of vertebrates (Table 14-1). One of the key functions of the skin is to form a protective physical barrier between the body and the external environment. The limitation of molecular movement across the skin is largely dependent on the epidermis and especially the stratum corneum in mammals. The epidermis prevents the inward and outward passage of water, electrolytes, lipids, and proteins, as well as insults from chemicals, bacteria, fungi, virus, toxins, and allergens. Defects in the formation of the epidermal barrier cause various congenital diseases (Table 14-2).

The skin protects the body from various external stresses. In protecting from heat and cold stresses, the skin maintains the internal organs at a certain constant temperature by regulating blood flow, sweat production, thermal storage in the fat layer, and thermogenesis in brown fat cells. The skin protects the body from physical stresses through coordination of the rigid surface armor of the stratum corneum; keratin cytoskeleton; and cell adhesions between keratinocytes, epidermal–dermal junctions, and dermal collagen fibers; these are discussed in Chaps. 15 and 60. Furthermore, the epidermis reflects and absorbs ultraviolet (UV) radiation from the sun to protect the genomic DNA of cells; this is particularly important in preventing carcinogenesis, which is discussed in Chaps. 19 and 20. Skin appendages, such as sweat and sebaceous glands, hairs, and nails, also have physical and chemical barrier functions; these are discussed in Chaps. 6, 7, and 8, respectively.

The skin is also equipped with immunologic barriers to the innate and acquired immune systems. Antimicrobial proteins are a diverse group of proteins that form a chemical barrier against microorganisms on the surface of the epidermis. Toll-like receptors on keratinocytes detect pathogen-associated molecular patterns such as lipoprotein and peptidoglycans that are broadly shared by bacteria but distinguishable from host molecules and control the immune responses against the microorganisms. Dendritic cells within the skin govern the acquired immunologic and allergic responses to external insults. The mechanisms of acquired immunity that protect our skin are discussed in Chaps. 10 and 11.

TABLE 14-1
Short Commentary on Jargons

Integument	The tough outer protective layer of an animal or plant that demarcates the body from the external environment
Occlusive junction	Cell–cell adhesive junction that seals the intercellular space and controls paracellular molecular movement. Invertebrates and vertebrates have different occlusive junction structures. The occlusive junction of invertebrates is called a septate junction, and that of vertebrates is called a tight junction.
Comparative Biology	Comparative biology exploits natural variation and disparities among species or taxa to understand the patterns of life by investigating phylogenies, evolution, development, physiology, and genomics
Kelvin's Tetrakaidecahedron	Fourteen-sided polyhedron composed of eight hexagons and six squares, proposed in 1887 by William Thomson (Lord Kelvin) as the best shape for packing equal-sized cells together to fill the space using the minimal surface area of each cell[142]
Transepidermal Water Loss	The loss of water that passes from inside to outside a body through the epidermis. Measurement of transepidermal water loss is useful to evaluate the stratum corneum barrier as the elevation rates of transepidermal water loss are basically in proportion to the level of barrier damage or formation.

COMPARATIVE BIOLOGY OF THE EPIDERMAL BARRIER

The lipid bilayer cell membrane provides a fundamental barrier in unicellular organisms. The cell membrane compartmentalizes the cell from the external environment. Homeostasis of the cell is maintained within the compartment demarcated by the cell membrane in an energy-dependent manner. Because the lipid bilayer membrane is highly fragile, most unicellular organisms have an additional barrier structure outside of the cell membrane (ie, the cell wall) that functions as a type of armor (Fig. 14-1).

The body's barrier to multicellular organisms is analogous to its barrier to unicellular organisms. The cell membrane of unicellular organisms corresponds to the epidermis, which is the epithelial cellular sheet that delineates the surface of multicellular organisms (see Fig. 14-1). To form a barrier with a sheet of cells, prevention of the leakage of water and solutes through intercellular spaces is crucial. Thus, the intercellular spaces are sealed by occlusive junctions, such as septate junctions in arthropods and tight junctions in vertebrates (see Table 14-1). The epidermis is composed of a single layer of cells in cephalochordates and urochordates, but multilayered (stratified) cells in vertebrates (see Fig. 14-1). Because the epidermal cells are fragile when directly exposed to harsh external environmental factors, such as hypotonic fresh water, hypertonic sea water, or dry air, the surface of the epidermis of higher organisms is covered by various external barriers. Examples of these barriers include the cuticles of arthropods, tunics of tunicates, mucous of fish and amphibians, and cornified cell layer (stratum corneum) of adult amphibians, reptiles, birds, and mammals (see Fig. 14-1).[1]

BASIC STRUCTURE OF THE EPIDERMIS

The human epidermis is a stratified epithelial cellular sheet, the uppermost part of which is cornified to form the stratum corneum. The viable (enucleated) cell layers of the epidermis consist of the stratum basale (basal cell layer), stratum spinosum (spinous cell layer), and stratum granulosum (granular cell layer) (Fig. 14-2). The stratum granulosum consists of at least three layers of flattened granular cells.[2-5] From outside to inside, the layers are named SG1, SG2, and SG3, and tight junctions seal the intercellular spaces in the SG2 layer.[3,5] The stratum corneum consists of dead cornified cells (corneocytes) and functions as an air–liquid interface barrier. The intercellular spaces of the stratum corneum are filled with water-impermeable lipid lamellae. Under the stratum corneum, cells are immersed in a water environment. The extracellular water environment of the epidermis is divided into two parts by the tight junction barrier, which is a liquid–liquid interface barrier (see Fig. 14-2). To form the stratum corneum, the SG1 cells terminally differentiate into corneocytes by filling their intercellular spaces with lipid lamellae. The multilayered structure of the epidermis is maintained, and the epidermal cells are continuously turned over. Epidermal cells proliferate only in the basal layer, differentiate with detachment from the basement membrane, move upward, become flattened at the stratum granulosum, form a tight junction at the SG2 layer, lose the tight junction at the SG1 layer, terminally differentiate into corneocytes, and detach from the top of the cornified layer as squamous scales. Continuous turnover of the epidermis enables foreign substances attached to the skin to be discarded with the daily detachment of scales.

STRATUM CORNEUM

The stratum corneum of human skin is the outermost barrier of the body's surface. The stratum corneum in humans is approximately 10 to 20 μm thick and contains about 10 to 25 layers of cornified cells.[6] The stratum corneum is directly exposed to air and protects the inner cells from damage by desiccation. It acts as a two-way barrier to prevent not only inward penetration of external molecules and microorganisms but also outward leakage of water and solutes.

TABLE 14-2

Diseases and Their Animal Models Showing Aberrant Stratum Corneum

CLASSIFICATION	GENE	PROTEIN	FUNCTION	DISEASE NAME	MIM	REFERENCES	ANIMAL MODEL
Cornified envelope formation	*LOR*	Loricrin	Major component of cornified envelope	Vohwinkel syndrome with ichthyosis	604117	24	Mouse[153]
	TGM1	Transglutaminase 1	Protein crosslinking to form cornified envelope	ARCI 1	242300	20	Mouse[16]
Cholesterol biosynthesis	*NSDHL*	NAD(P)H steroid dehydrogenase-like protein	C4 demethylase	CHILD syndrome	308050	34	Mouse[154]
	MSMO1	Methylsterol monooxygenase 1	Methylsterol monooxygenase	MCCPD	616834	33	—
Acylceramide biosynthesis	*ELOVL4*	Elongation of very-long-chain fatty acid–like 4	Elongation of very-long-chain fatty acids	ISQMR	614457	155	Mouse[156]
	CYP4F22	Cytochrome P450 4F22	γ-Hydroxylation of ultra-long-chain fatty acids	ARCI5	604777	157	—
	CERS3	Ceramide synthase 3	Catalyzing the linkage between a fatty acyl-CoA and a sphingoid base to produce ceramide	ARCI9	615023	158,159	Mouse[160]
	ABHD5	ABHD5/CGI58	ω-O-esterification of ceramide with linoleic acid	Chanarin-Dorfman syndrome	275630	161	—
	PNPLA1	Patatin-like phospholipase domain containing 1		ARCI10	615024	62	Dog[162]
	ALOX12B	Arachidonate 12-lipoxygenase type12R	Oxidation of linoleic acid in ceramide	ARCI2	242100	163	Mouse[164]
	ALOXE3	Arachidonate lipoxygenase 3		ARCI3	606545	163	Mouse[164]
Lipid transport	*ABCA12*	ATP-binding cassette A12	Lipid trafficking on the lamellar granule membrane	ARCI4A ARCI4B (Harlequin ichthyosis)	242500	26,27	Mouse[165]
Desquamation	*ST14*	Matriptase	Extracellular serine protease	ARCI11	602400	54	Mouse[166]
	SPINK5	LEKTI	Inhibitor of kallikrein proteases	Netherton syndrome	256500	55	Mouse[167,168]
Desmosomes and corneodesmosomes	*CDSN*	Corneodesmosin	Constituent of the corneodesmosome	Peeling skin syndrome 1	270300	56,57	Mouse[169]
	DSG1	Desmoglein1	Cell–cell adhesion molecule of the desmosome	SAM syndrome	615508	58	—
Filaggrin metabolism	*FLG*	Filaggrin	Bundling keratin filaments in the stratum corneum, source of natural moisturizing factors	Ichthyosis vulgaris (predisposed to atopic dermatitis)	146700	72,74	Mouse[75,170]
	CASP14	Caspase 14	Profilaggrin processing	ARCI12	617320	71	Mouse[67]
Tight junctions	*CLDN1*	Claudin-1	Cell–cell adhesion molecule of the tight junction	NISCH syndrome	607626	104	Mouse[102,103]

ABHD5, abhydrolase domain-containing 5; ARCI, autosomal recessive congenital ichthyosis; ATP, adenosine triphosphate; CGI58, comparative gene identification 58; CHILD syndrome, congenital hemidysplasia with ichthyosiform erythroderma and limb defects syndrome; CoA, coenzyme A; ISQMR, ichthyosis, spastic quadriplegia, and mental retardation; LEKTI, lymphoepithelial Kazal-type-related inhibitor; MCCPD, microcephaly, congenital cataract, and psoriasiform dermatitis; MIM, Mendelian Inheritance in Man; NISCH syndrome, neonatal ichthyosis-sclerosing cholangitis syndrome; SAM syndrome, severe dermatitis, multiple allergies and metabolic wasting syndrome.

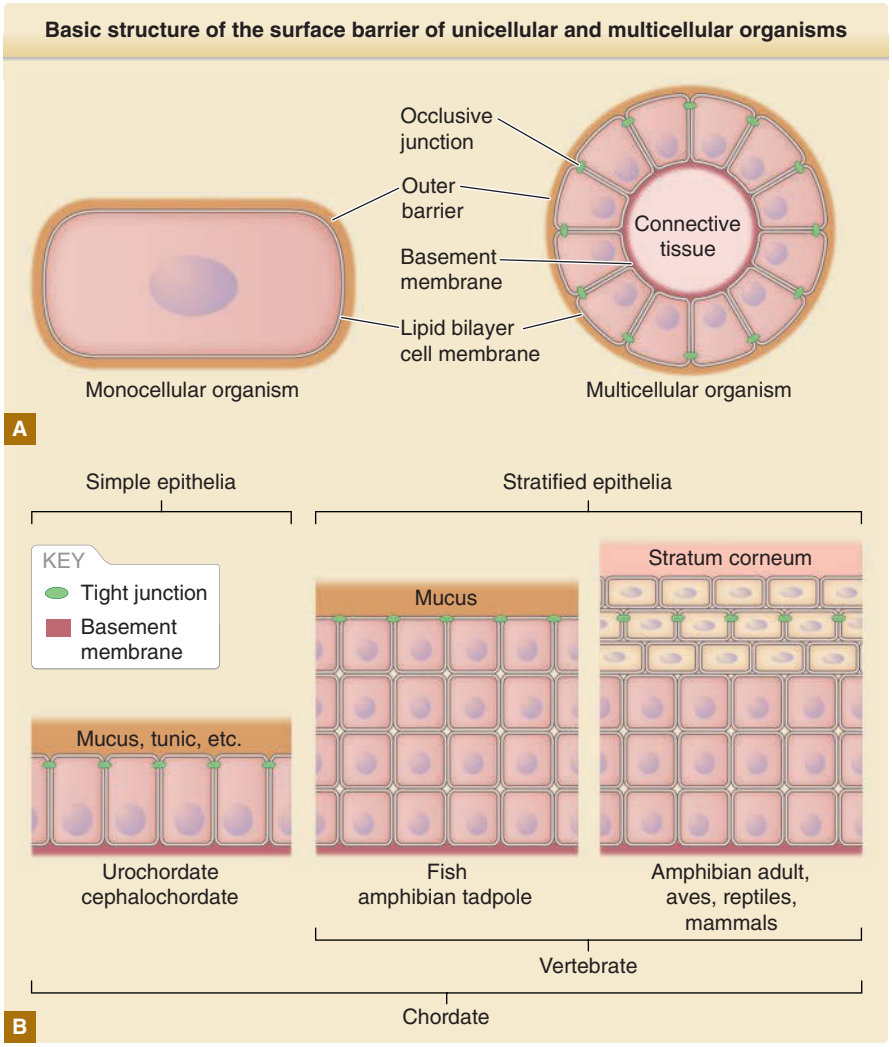

Figure 14-1 Basic structure of the surface barrier of unicellular and multicellular organisms. **A,** The lipid bilayer cell membrane is a basic diffusion barrier on the body surface of both monocellular organisms and multicellular organisms. In multicellular organisms, the intercellular spaces are sealed with occlusive junctions to limit leakage of the barrier through the paracellular pathway (see Fig. 14-9). In essence, both monocellular organisms and multicellular organisms are equipped with additional outer barriers (ie, a cell wall for monocellular organisms and mucus, cuticles, tunic matrix, or stratum corneum for multicellular organisms). **B,** Development of a stratified epithelium and stratum corneum were the two major evolutional events in vertebrate skin. Under the outer barrier, tight junctions seal the intercellular spaces in vertebrates.

BASIC STRUCTURE OF THE STRATUM CORNEUM

The stratum corneum consists of stratified corneocytes and an intercorneocyte lipid-rich matrix (Fig. 14-3). The barrier function of the stratum corneum depends on both the protein-rich materials of the corneocytes and the intercellular lipid-rich matrix. Corneocytes are terminally differentiated dead keratinocytes that adhere to one another via proteinaceous cell–cell adhesion complexes called corneodesmosomes and the adhesive force of intercellular lipid lamellae (Fig. 14-4). On routine hematoxylin and eosin staining of paraffin-embedded skin sections, the stratum corneum shows a basket-weave structure, which may cause the stratum corneum to be mistaken for a porous structure that does not have a barrier function; the basket-weave structure is, in fact, an artifact of the processing of specimens. During paraffin removal using xylene, intercorneocyte lipid is extracted, and the intercellular lipid-dependent adhesion between corneocytes becomes weakened. Because the corneodesmosomes make the lateral adhesions between corneocytes more stable than the apicobasal adhesions, the corneocyte layers detach from one another while maintaining their lateral adhesions, resulting in the formation of a basket-weave structure in paraffin-embedded sections[7,8] (Fig. 14-5). Proper fixation and staining procedures reveal the tightly packed, well-organized structure of the stratum corneum in vertical sections of the skin[2,9] (see Fig. 14-5).

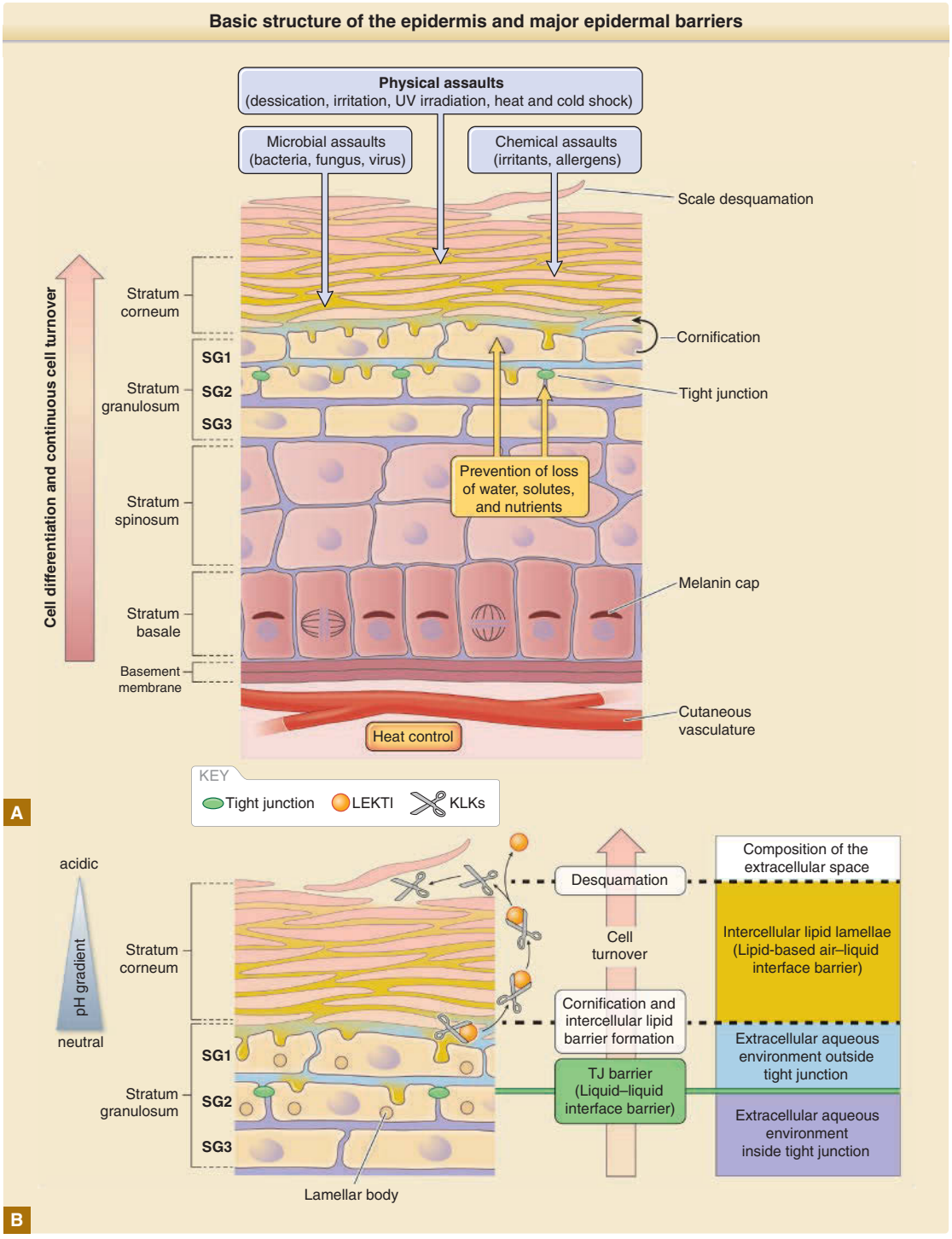

Figure 14-2 Basic structure of the epidermis and major epidermal barriers. **A,** Epidermal barriers protect the body against various outside-in physical, chemical, and microbial assaults in addition to inside-out leakage of water and solutes. Melanin caps protect the genomic DNA of basal cells from ultraviolet (UV) damage. Cells are continuously turned over to renew the epidermis and its barriers. At least three cell layers (SG1, SG2, and SG3 from outside to inside, respectively) exist in the stratum granulosum under the stratum corneum, where tight junctions (TJs) seal the intercellular spaces between the SG2 cells. **B,** Intercellular spaces are filled with lipids in, and with water under, the stratum corneum. The extracellular water environment is considered to be divided into two by the TJ barrier (extracellular space outside TJ barrier, *light blue*; extracellular space inside TJ barrier, *purple*). SG1 cells are ready to cornify at the outside TJ barrier. Contents of lamellar bodies (lipids, antimicrobial proteins, proteases, and protease inhibitors) are basically exocytosed from the apical surface of the SG2 cells to the outside TJ barrier. Kallikrein proteases (KLKs) are activated via the lower-pH-induced detachment of lymphoepithelial Kazal-type-related inhibitor (LEKTI) in the upper layers of the stratum corneum for desquamation. (Modified from Proksch E, Jensen J-M. Skin as an organ of protection. In: Goldsmith LA, Katz SI, Gilchrest BA, et al, eds. *Fitzpatrick's Dermatology in General Medicine*, 8th ed. New York: McGraw-Hill; 2012.)

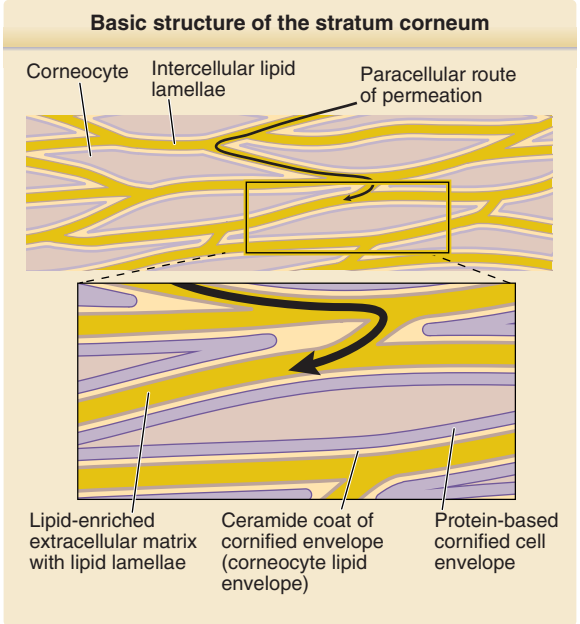

Figure 14-3 Basic structure of the stratum corneum. The stratum corneum comprises protein-based bricks (corneocytes) and lipid-based mortar (intercellular lipid lamellae). The surface of the corneocytes is coated with a thin layer of ceramide (lipid envelope). Details of how this structure is produced are shown in Fig. 14-6. (Modified from Proksch E, Jensen J-M. Skin as an organ of protection. In: Goldsmith LA, Katz SI, Gilchrest BA, et al, eds. *Fitzpatrick's Dermatology in General Medicine*, 8th ed. New York: McGraw-Hill; 2012.)

FORMATION OF A CORNIFIED CELL ENVELOPE AND CORNEOCYTE LIPID ENVELOPE

Granular layer cells terminally differentiate into corneocytes to form the stratum corneum. During cornification, a cornified cell envelope consisting of a 10-nm-thick layer of highly cross-linked insoluble proteins is formed beneath the plasma membrane,[10] and the lipid bilayer of plasma membrane is replaced by a 5-nm-thick layer of acylceramides, which is called corneocyte lipid envelope[11-13] (Fig. 14-6).

The formation of a cornified cell envelope and corneocyte lipid envelope is described as follows[14,15] (see Fig. 14-6). Envoplakin, periplakin, and involucrin expressed in granular layer cells associate with the inner surface of the plasma membrane in a calcium-dependent manner and are cross-linked to one another by transglutaminase 1.[16] Transglutaminase 1 also cross-links to other membrane-associated proteins and desmosomal proteins, fixing the cell junctions and associated cytoskeletons to the proteinaceous scaffold. The involucrin-envoplakin-periplakin–based scaffold eventually forms a monomolecular layer along the entire inner surface of the plasma membrane.[10,17-19] Defects in transglutaminase 1 are known to cause congenital ichthyosis (see Table 14-2).[20]

Before the scaffold covers the inner surface of the plasma membrane, lamellar bodies are produced from the Golgi complex and become fused to the plasma membrane. The limiting membrane of the lamellar bodies is rich in acylceramides composed of omega-hydroxylated ultra-long-chain fatty acids. The fusion of the limiting membrane with the plasma membrane gradually increases the amount of acylceramides within the lipid bilayer of the plasma membrane. The acylceramides become covalently bound to the outer surface of the scaffold of the cornified envelope by the membrane-anchored form of transglutaminase 1.[21,22] The acylceramides eventually replace the plasma membrane, which is called the corneocyte lipid envelope[11,12] (see Fig. 14-6).

The involucrin-envoplakin-periplakin–based scaffold is further reinforced in the later stage of cornification. On the inner surface of the scaffold, loricrin molecules are translocated from the cytosol and covalently cross-linked onto the scaffold to build the cornified cell envelope. Loricrin, an insoluble protein that may contribute to the water resistance of the cornified cell envelope, eventually becomes the major component of the cornified cell envelope. Varying amounts of small proline-rich proteins with minor amounts of other proteins (eg, repetin, trichohyalin, cystatin A, elafin, and late envelope proteins) are also cross-linked to the inner surface of the cornified envelope.[23] Defects in loricrin are known to cause congenital ichthyosis (see Table 14-2).[24]

FORMATION OF THE LAMELLAE OF INTERCORNEOCYTE LIPIDS

Keratinocytes of the stratum granulosum develop a specific system of lamellar bodies that allow secretion of intercorneocyte lipid lamellae.[25] Lamellar bodies are produced from the Golgi complex and stored within the cytoplasm in SG3 cells as intracellular vesicles. Lamellar bodies are enriched in polar lipids, glycosphingolipids, free sterols, and phospholipids. ABCA12 functions in cellular lipid trafficking on the limiting membrane of lamellar bodies, in which severe defects cause Harlequin ichthyosis (see Table 14-2).[26,27] The lamellar bodies may also contain proteins, such as hydrolytic enzymes to modify lipids, corneodesmosins to modify corneodesmosomes, antimicrobial peptides, and proteases and protease inhibitors to control desquamation. The contents of the lamellar bodies are delivered into the extracellular milieu through exocytosis occurring via the apical cell membrane, most probably in the SG2 cells and SG1 cells, to fill the extracellular space surrounding the SG1 cells[28] (see Fig. 14-2).

Figure 14-4 Major structures related to cornification, as seen under electron microscopy. **A,** Desmosomes (De) adhering to spinous layer cells. **B,** A lamellar body (LB) exocytosing its contents into the extracellular space at the apical surface of the SG1 cell. **C,** Contents of the lamellar body (LB) showing stripes of lipids. **D,** Corneodesmosomes (CD), cell–cell adhesion complexes between corneocytes. **E,** Intercellular lipid lamellae between corneocytes. (Images **C** and **E,** used with permission from Dr. Akemi Ishida-Yamamoto. Images **A** and **D,** used with permission from Dr. Toshihiro Nagai. Image **B** modified from Proksch E, Jensen J-M. Skin as an organ of protection. In: Goldsmith LA, Katz SI, Gilchrest BA, et al, eds. *Fitzpatrick's Dermatology in General Medicine*, 8th ed. New York: McGraw-Hill;2012.)

The lipids exocytosed from the lamellar bodies are subsequently organized into a characteristic lamellar structure that lies parallel to the cornified cell envelope during cornification of the SG1 cells (see Fig. 14-4). The covalently bound acylceramides of the corneocyte lipid envelope act as a scaffold allowing regular lamellar formation of the intercellular lipids (see Figs. 14-4 and 14-6).[22] After extrusion of the lamellar bodies into the extracellular spaces, the polar lipids are enzymatically converted into nonpolar products. Glycosphingolipids are hydrolyzed to generate ceramides, and phospholipids are converted into free fatty acids. These lipids form the intercellular lamellar component of the stratified lipid bilayer, a very dense structure packed into the interstices of corneocytes, thus forming a water-impermeable barrier.

LIPID COMPOSITION OF THE STRATUM CORNEUM

Intercellular lipids are indispensable in the formation of the permeability barrier of the stratum corneum. The major classes of lipids in the stratum corneum are cholesterol, free fatty acids, and ceramides.[29]

Cholesterol forms part of the plasma membrane in viable cell layers in the epidermis and part of the intercellular lipid lamellae in the stratum corneum. Whereas basal-layer keratinocytes are capable of resorbing cholesterol from the circulation, epidermal keratinocytes actively biosynthesize cholesterol and free fatty acids (Fig. 14-7). The majority of the cholesterol in the epidermis is synthesized

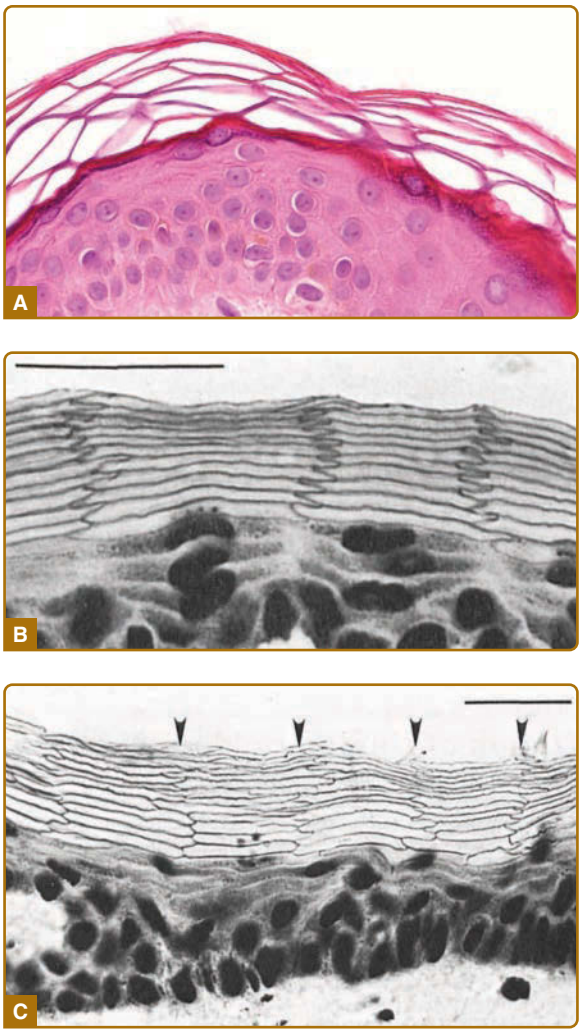

Figure 14-5 Morphology of the epidermis in cross-sections. **A,** Hematoxylin and eosin staining of paraffin-embedded section of human skin showing the basket weave–like pattern of the stratum corneum. **B,** Frozen section of hamster ear skin stained with methylene blue, expanded in an alkaline solution with a pH of 12 and showing a regular alignment of corneocytes. A remarkably ordered structure of flattened stratum granulosum cells and anucleate corneocytes can be seen. The corneocytes show a regular zigzag interdigitation pattern between cell columns. **C,** Frozen section of human abdominal skin stained with methylene blue and expanded in an alkaline solution showing partially regular alignment of corneocytes. (Image **B** from Mackenzie IC. Ordered structure of the epidermis. *J Invest Dermatol*. 1975;65:45-51, with permission; Image **C** from Mackenzie IC, Zimmerman K, Peterson L. The pattern of cellular organization of human epidermis. *J Invest Dermatol*. 1981;76:459-461, with permission. Copyright © The Society for Investigative Dermatology.)

in situ from acetyl coenzyme A (acetyl CoA).[30] The rate-limiting step in cholesterol biosynthesis is catalyzed by hydroxymethylglutaryl CoA (HMG CoA) reductase (see Fig. 14-7). Epidermal cholesterol biosynthesis is upregulated during barrier repair.[31] The cholesterol biosynthesis pathway in the epidermis is also important for the production of vitamin D.[32] The metabolic intermediate of cholesterol biosynthesis, 7-dehydrocholesterol, is converted to previtamin D in a photolytic reaction by UVB radiation; this is followed by thermal isomerization to form vitamin D_3. Deficiency in the enzymes of NSDHL and MSMO1 corresponding to cholesterol biosynthesis causes inflammatory ichthyotic skin lesions through the accumulation of toxic intermediates in CHILD (congenital hemidysplasia with ichthyosiform erythroderma and limb defects) syndrome and MSMO1 deficiency, respectively[33-35] (see Table 14-2).

The skin contains free fatty acids, as well as fatty acids bound in triglycerides, phospholipids, glycosylceramides, and ceramides. Although biosynthesis of cholesterol originates from HMG-CoA, free fatty acid synthesis originates from malonyl-CoA produced from acetyl-CoA via acetyl-CoA carboxylase (see Fig. 14-7). Saturated and monounsaturated fatty acids are synthesized in the epidermis. However, not all fatty acids can be synthesized by the epidermis or the human body. Fatty acids unable to be produced by the human body are called essential fatty acids. Essential fatty acid deficiency (EFAD), caused by unusual diets or malabsorption in humans or experimentally induced in rodents, leads to rough, scaly, and erythematous skin with severe permeability barrier defects of the epidermis.[36,37]

Ceramides consist of long-chain amino alcohols, called sphingoid bases, linked to a fatty acid via an amide bond (see Fig. 14-7). Ceramides are synthesized by serine palmitoyltransferase and hydrolysis of both glucosylceramide and sphingomyelin in the epidermis. Whereas ceramides are a minor lipid component in the mammalian body (<10% of cholesterol or phospholipids), they are a major lipid component in the stratum corneum, accounting for 30% to 40% of lipids by weight.[29] Such a high ceramide content is only observed in the stratum corneum and not in the stratum granulosum, stratum spinosum, or stratum basale. This distribution indicates that ceramide biosynthesis is spatiotemporally controlled and highly activated in the uppermost keratinocytes under terminal differentiation to corneocytes.

Among the epidermal ceramides with marked molecular heterogeneity, acylceramide is essential not only for the formation of the corneocyte lipid envelope, as described earlier, but also for the proper organization of intercorneocyte lipid lamellae and thereby the barrier function of the stratum corneum.[38-42] Acylceramide is synthesized via esterification of omega-hydroxyceramide with linoleic acid. Acylceramide is an unusual ceramide, the N-acyl chain of which is composed of omega-hydroxylated ultra-long-chain fatty acids (see Fig. 14-7). It has been suggested that the ultra-long-chain fatty acid of acylceramide spans a bilayer of lipid lamellae to link the two membranes together in the lipid lamellae and thus serves as a molecular rivet to form stratified lipid lamellae.[43] Deficiencies of the biosynthesis pathway of acylceramide cause several types of congenital ichthyosis[44] (see Table 14-2).

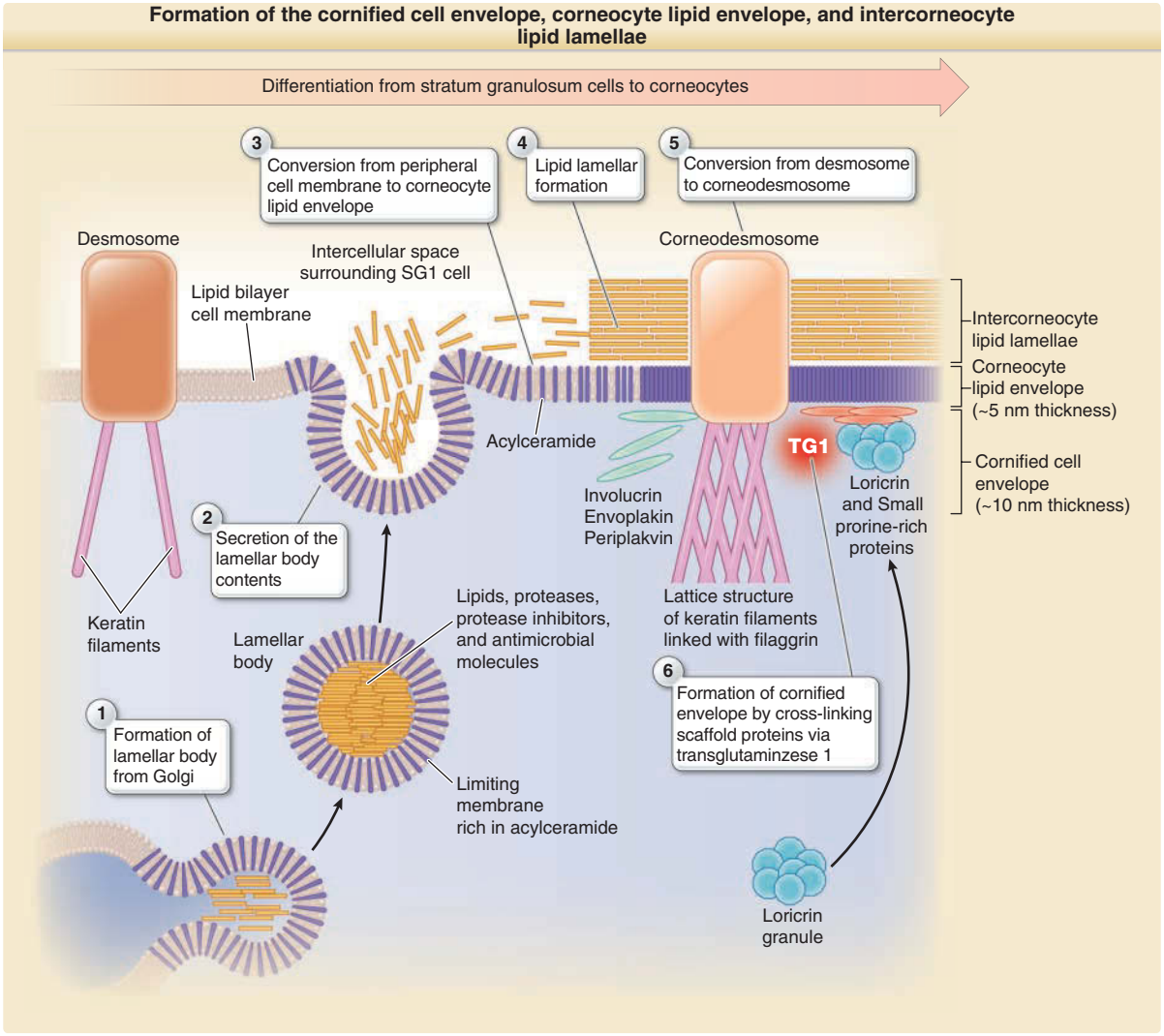

Figure 14-6 Formation of the cornified cell envelope, corneocyte lipid envelope, and intercorneocyte lipid lamellae. The time-dependent change of cornification (from SG2 cells via SG1 cells to corneocytes) is shown from left to right. A cornified cell envelope is formed beneath the lipid bilayer cell membrane via crosslinking of envoplakin, periplakin, and involucrin by transglutaminase 1 (TG1), which is further reinforced by loricrin in the later stage of cornification. Lamellar bodies exocytose their contents to the extracellular space outside tight junctions. The limiting membrane of the lamellar bodies contains a large number of acylceramides that replace the lipid bilayer cell membrane to form a corneocyte lipid envelope. As a result, the cornified cell envelope is coated by the corneocyte lipid envelope. The lipids exocytosed from lamellar bodies form the intercorneocyte lipid lamellae on the corneocyte lipid envelope to fill the intercellular space and form the water-resistant barrier of the stratum corneum. Corneodesmosin exocytosed from lamellar bodies is integrated into the desmosome, which is converted to the corneodesmosome. The lamellar bodies also exocytose proteases and protease inhibitors to control desquamation and antimicrobial proteins (see Fig. 14-12).

CORNEODESMOSOMES

Desmosomes are the major cell–cell adhesion structure in the granular, spinous, and basal cell layers. Corneodesmosin is secreted by lamellar bodies into the extracellular spaces surrounding the SG1 cells (see Figs. 14-2 and 14-6) and then integrated into the desmosomes, resulting in the formation of corneodesmosomes (ie, specific cell adhesion structures between corneocytes)[45] (see Fig. 14-4). Adhesion between corneocytes is dependent on both corneodesmosomes and intercellular lipid lamellae. Corneodesmosomes are degraded in the outer layers of the stratum corneum, and the outermost corneocytes are detached, one by one, from the top layer of the stratum corneum; this process is called desquamation.[46]

The major proteases involved in the degradation of corneodesmosomes are serine proteases belonging to the kallikrein group. Kallikreins 5, 7, and 14 are known to exist in the stratum corneum. These kallikreins are also secreted by lamellar bodies into the extracellular spaces surrounding the SG1 cells (see Fig. 14-2). Kallikreins are produced as inactive precursors and activated via proteolytic conversion by kallikreins themselves (autoactivation) or by matriptase, a transmembrane serine protease.[47,48] The protease activity

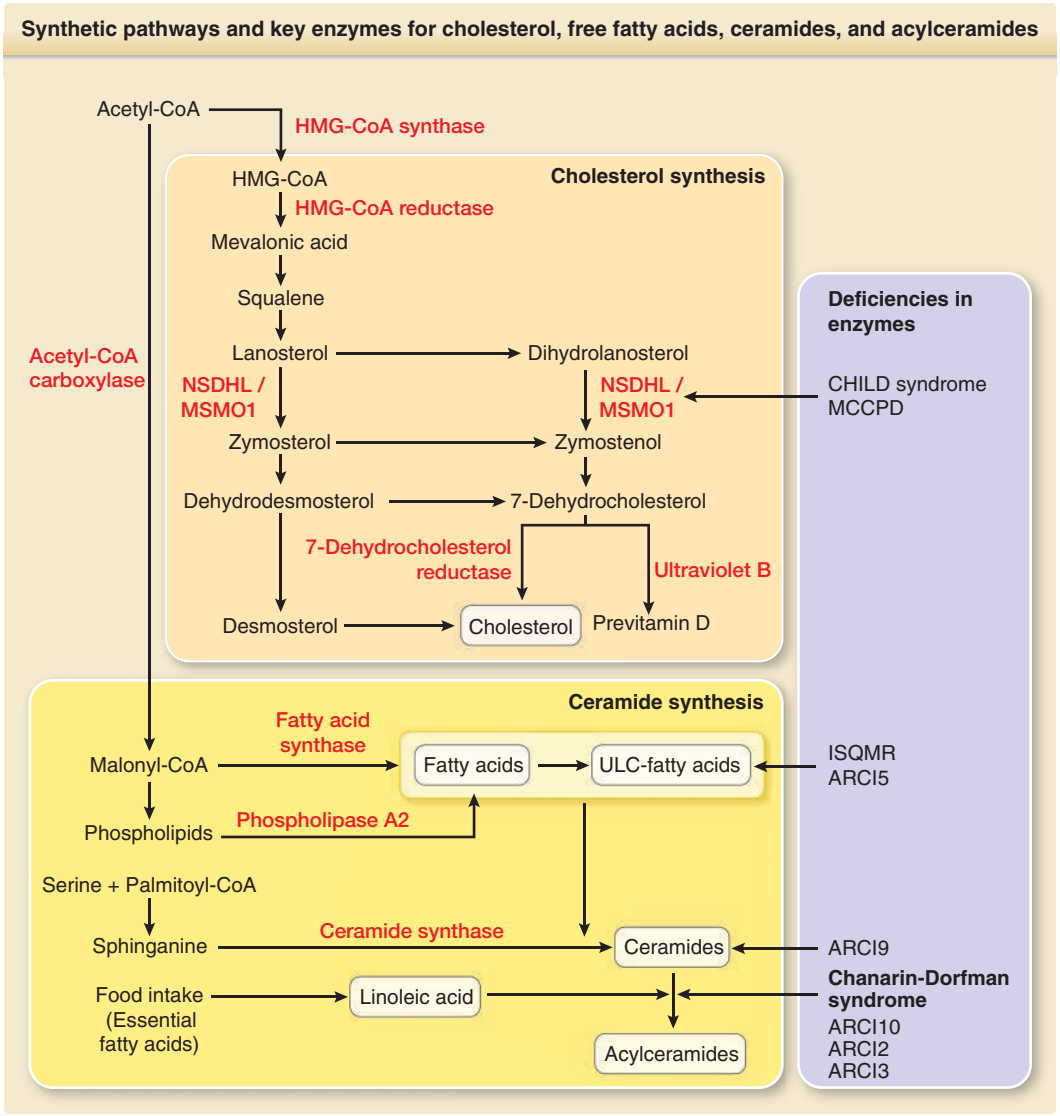

Figure 14-7 Synthetic pathways, key enzymes and deficiencies in the enzymes for cholesterol, free fatty acids, ceramides, and acylceramides. CoA, coenzyme A; HMG-CoA, hydroxymethylglutaryl CoA; CHILD syndrome, congenital hemidysplasia with ichthyosiform erythroderma and limb defects syndrome; MCCPD, microcephaly, congenital cataract, and psoriasiform dermatitis; ISQMR, ichthyosis, spastic quadriplegia, and mental retardation; ARCI, autosomal recessive congenital ichthyosis; NSDHL, NAD(P) dependent steroid dehydrogenase-like; MSMO1, methylsterol monooxygenase 1; ULC, ultra-long-chain.

of the activated kallikreins is thought to be inhibited by the direct binding of lymphoepithelial Kazal-type-related inhibitor (LEKTI), which is also secreted into the intercellular spaces via lamellar bodies.[49] The production of kallikreins as inactive precursors, and the inhibition of their protease activity by LEKTI, are considered to prohibit the degradation of corneodesmosomes in the lower layer of the stratum corneum and thus prevent premature desquamation.[50] LEKTI binding to kallikreins has been shown to be pH dependent. The lower pH of the intercellular spaces in the outer layers of the stratum corneum is thought to facilitate the dissociation of kallikreins from LEKTI and the kallikrein-dependent degradation of corneodesmosomes (see Fig. 14-2).[51-53] The outermost corneocytes eventually detach from the skin.

Congenital defects of matriptase induce congenital ichthyosis showing hyperkeratosis and impaired degradation of corneodesmosomes, probably caused by insufficient activation of kallikrein proteases.[54] In contrast, congenital defects of LEKTI induce Netherton syndrome, in which entire layers of the stratum corneum are prone to being peeled off, probably caused by the enhanced degradation of corneodesmosomes by kallikreins.[55] Such detachment of whole layers of the stratum corneum is also observed in the congenital defects of corneodesmosin or desmoglein 1[56-58] (see Table 14-2). Patients prone to total detachment of the stratum corneum are predisposed to various allergic conditions, probably via increased allergen penetration through the defective skin barrier and facilitation of percutaneous sensitization.[5,59]

KERATIN CYTOSKELETON AND FILAGGRIN

Filaggrin is the major protein of the stratum corneum. Various mutations in the filaggrin gene predispose patients to atopic eczema, allergic rhinitis, food allergies, and asthma complicated with eczema.[60-63]

In humans, filaggrin is expressed only in cornified stratified epithelia; therefore, it is expressed in skin but not in the esophagus or airways.[64] Profilaggrin is expressed in the stratum granulosum and forms intracellular aggregates known as keratohyalin granules. Under cornification, profilaggrin is processed by various proteases into mature filaggrin monomers[63] (Fig. 14-8). Filaggrin monomers bundle keratin

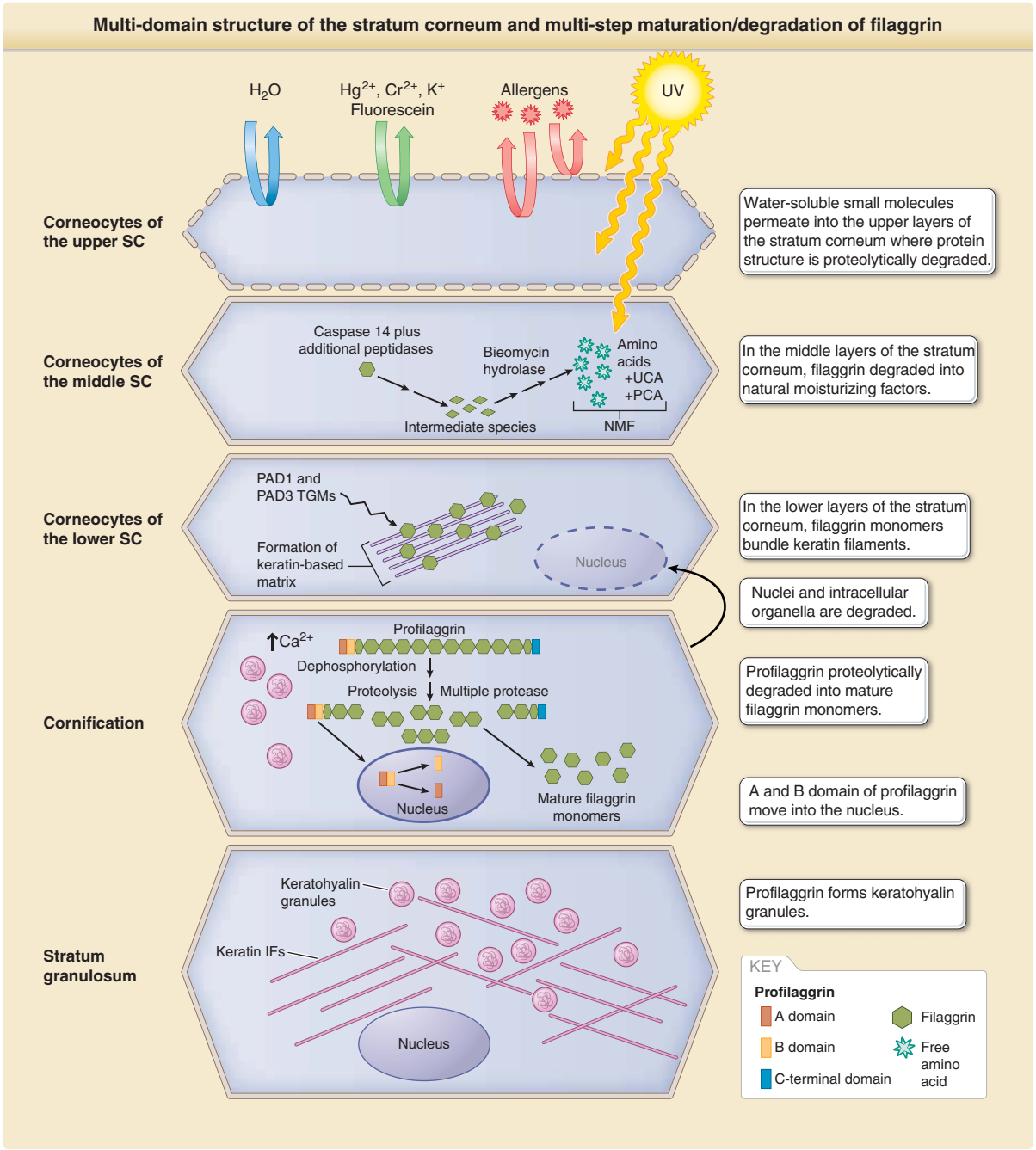

Figure 14-8 Multidomain structure of the stratum corneum and multistep maturation and degradation of filaggrin. The stratum corneum is thought to consist of at least three types of corneocytes undergoing different differentiation steps (corneocytes of the lower, middle, and upper stratum corneum). NMF, natural moisturizing factor; PAD, peptidylarginine deiminase; PCA, 2-pyrrolidone-5-carboxylic acid; IF, intermediate filament; SC, stratum corneum; TGM, transglutaminase; UCA, urocanic acid. (Modified from McAleer MA, Irvine AD. The multifunctional role of filaggrin in allergic skin disease. *J Allergy Clin Immunol*. 2013;131(2):280-291.)

intermediate filaments and may form a lattice structure in the lower layer of the stratum corneum.[65,66] The lattice structure can be observed under electron microscopy. In the later stage of cornification, keratin filaments bundled with filaggrin become cross-linked to the cornified cell envelope. The dead cornified cells lose most of their intracellular organelles and consist mostly of bundled intermediate filaments covalently attached to, and enclosed within, the cell envelope.

FILAGGRIN DEGRADATION AND NATURAL MOISTURIZING FACTORS

Filaggrin monomers bundle keratin filaments in the innermost layers of the stratum corneum. Because new corneocytes are continuously supplied at the bottom and old corneocytes are desquamated from the surface of the stratum corneum, each corneocyte gradually moves to the upper layers. During this upward movement of the corneocyte, intracellular filaggrin molecules are degraded into free amino acids and their derivatives by proteases, including caspase 14 and bleomycin hydrolase. Representative examples of the derivatives are trans-urocanic acid catalyzed from histidine by histidase and pyrrolidone carboxylic acid catalyzed from glutamine.[63,67-69] The natural moisturizing factors of the stratum corneum are composed primarily of these amino acids and their derivatives, together with lactic acid, urea, citrate, and sugars.[61,70] Deficiency of caspase 14 causes a defect in the proper degradation of filaggrin and the resultant phenotype of ichthyosis[71] (see Table 14-2).

Haploinsufficiency of filaggrin, because of various heterozygous mutations in the gene encoding filaggrin, causes ichthyosis vulgaris, a dry skin condition,[72] and predisposes patients to atopic dermatitis and various allergic diseases accompanied by eczema (eg, food allergy and asthma)[73,74] (see Table 14-2). The decrease in filaggrin induces a decrease in natural moisturizing factors, a disturbance of the lattice structure of the keratin filaments in the innermost layers of the stratum corneum, and a probable increase in the incidence of barrier breakage of the stratum corneum.[75] Such a weakness in the stratum corneum barrier may increase the chance of external allergens penetrating into the skin and the risk of percutaneous sensitization against various allergens. Most patients with severe stratum barrier defects, such as those with Netherton syndrome, have multiple allergies. In contrast, most patients who have mutations in the filaggrin gene basically develop ichthyosis vulgaris, and only some of these patients develop allergic diseases. This suggests that the barrier deficiency induced by filaggrin mutations is moderate and that the development of allergic diseases in these patients is modulated by various additional factors, such as genetic differences in immune reactions,[76] differences in the skin microbiota,[77-79] and environmental factors such as low air humidity[80] and air pollution.[81]

MULTIDOMAIN STRUCTURE OF THE STRATUM CORNEUM

Conventional cell biological analyses of the stratum corneum have been hampered by the insolubility of covalently cross-linked proteins. To overcome this difficulty, the stratum corneum has been analyzed by various special methods, such as cryoelectron microscopy, immunoelectron microscopy, Raman spectromicroscopy analysis, and time-of-flight secondary ion mass spectroscopy.[82-85] Based on the results of these analyses, the stratum corneum is considered to be divisible into several different parts with different characteristics, most likely into three parts (the upper, middle, and lower layers). For example, water-soluble small molecules soak in and out at the upper part of the stratum corneum, where the protein-based structure of the corneocytes is proteolytically degraded, and the corneocytes are thought to function as a sponge.[83,85] Further permeation of water-soluble small molecules into the middle part of the stratum corneum is rather limited, indicating that permeation barriers exist within the middle part of this structure.[83] The middle part of the stratum corneum also has a large potential to absorb and hold water, likely corresponding to the enrichment of natural moisturizing factors, which are mostly produced by the degradation of mature filaggrin.[63,82] The corneocytes of the lower part of the stratum corneum show an intracellular lattice structure of keratin filaments, integrated by mature filaggrin monomers, which is believed to contribute to the physical strength of the stratum corneum[84] (Fig. 14-9). The stratum corneum is a pile of "dead" corneocytes that lack any energy-dependent activities, such as adenosine triphosphate–dependent active transport, translation of proteins, and mRNA transcription. It is still largely unknown how the stratum corneum maintains homeostasis using the distinct features in its upper, middle, and lower layers.

PERCUTANEOUS ABSORPTION THROUGH THE STRATUM CORNEUM

Knowledge of how external molecules penetrate the epidermis is important not only for a better understanding of the pathogenesis of various skin diseases but also for the development of drug delivery for topical treatments. The paracellular route is a major pathway by which external molecules can penetrate the stratum corneum (see Fig. 14-3). Other routes of penetration into the skin are by the sebaceous glands or hair follicles, but the exact mechanisms of these pathways remain to be elucidated.[86]

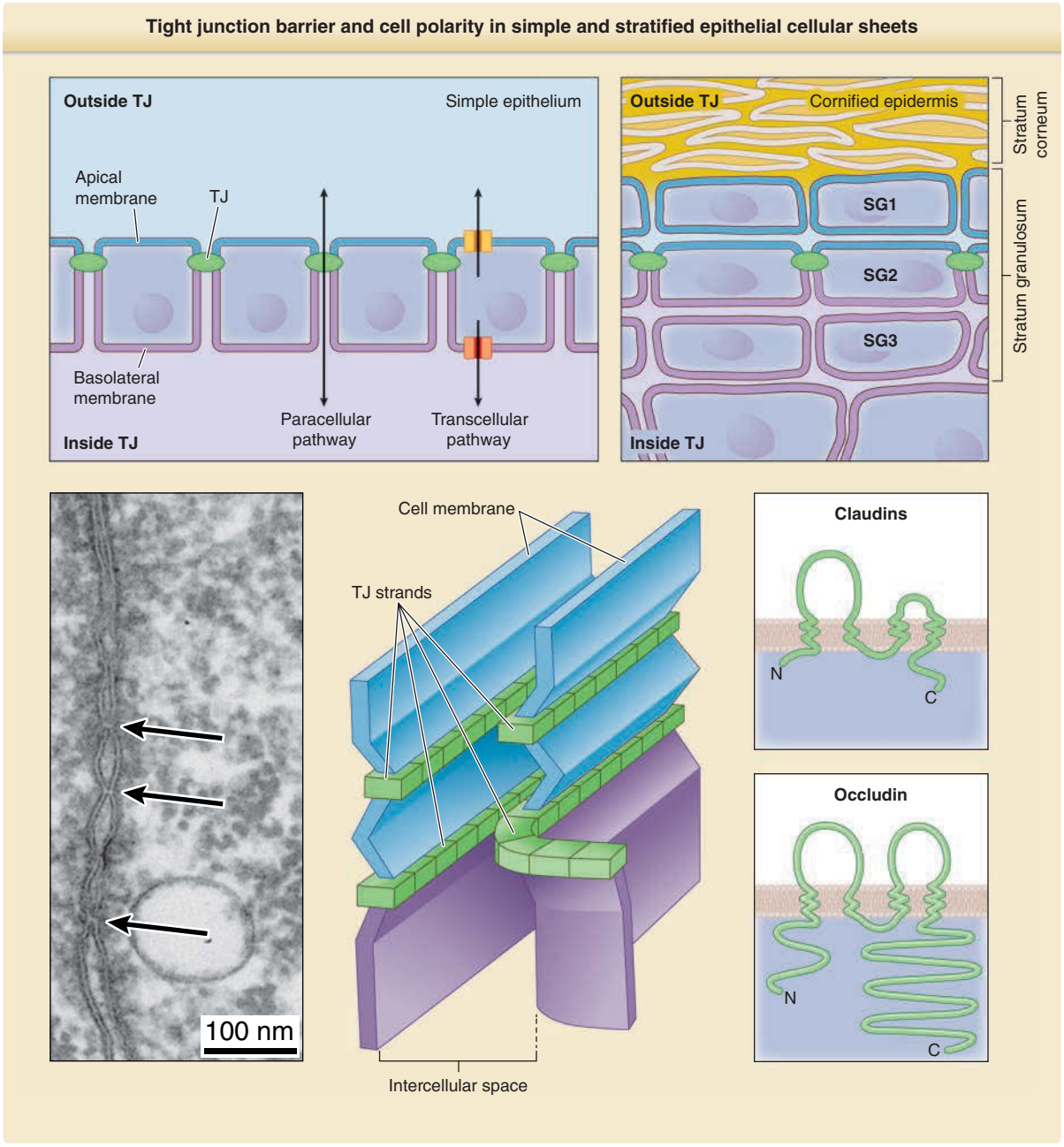

Figure 14-9 Tight junction (TJ) barrier in simple and stratified epithelial cellular sheets. The extracellular environment and plasma membrane are divided into two parts at the TJ barrier in simple epithelia. Solutes move between the two compartments via paracellular and transcellular pathways. In the epidermis, increasing evidence suggests that both the extracellular environment and plasma membrane are also divided into two parts at the TJ barrier formed between the SG2 cells, the extracellular environment outside and inside the TJ barrier, and the apical and basolateral cell membrane. In the electron micrograph (*left panel*), a TJ appears as a "kissing point" (*arrows*) where two plasma cell membranes face each other. The schematic shows the structure of TJ strands on the cell membrane and major transmembrane proteins of TJs. C, C-terminus; N, N-terminus. (Image used with permission from Dr. Hiroyuki Sasaki.)

Occlusive patches used in patch testing affect the intercorneocyte lipid lamellae and increase the permeation of solutes and solvents through the stratum corneum.[87] After passing through the stratum corneum, small molecules such as haptens can easily permeate the dermis, probably through the transcellular pathway (see Fig. 14-9). In contrast, large peptide antigens, such as the antigens of house dust mites or egg albumin, not only find it difficult to pass through the stratum corneum barrier but are also prohibited from further permeation into the skin by the tight junction barrier. Recent studies revealed that a defective stratum corneum barrier in early childhood is associated with the development of various allergic diseases, such as atopic dermatitis, allergic asthma, and food allergies, probably via enhanced antigen penetration through the stratum corneum and percutaneous sensitization.[74,88-91]

TIGHT JUNCTIONS

Multicellular organisms use epithelial cellular sheets to separate their body from the external environment or their organs from one another. Epithelia serve as selective permeability barriers to fluids that differ in chemical composition (Fig. 14-10). The occluding junctions are specialized intercellular adhesion complexes that are crucial for limiting molecular movement through the paracellular pathway (see Fig. 14-10) because they seal the intercellular spaces of the epithelial cellular sheets.[92] Tight junctions facilitate this barrier in vertebrates. In the gut of humans, for example, gut epithelia equipped with tight junction barriers separate body fluids from the fluid of the gut lumen.

STRUCTURE OF TIGHT JUNCTIONS

In simple epithelia, the tight junctions are located at the apical-most part of the apical junctional complex[93] (see Fig. 14-9). The apical junctional complex consists of tight junctions, beltlike adherens junctions, and desmosomes. The cell membrane is divided into two parts at the tight junctions—the apical cell membrane and basolateral cell membrane—both of which has a different composition of membranous proteins. Tight junctions consist of tight junction strands, which are mainly composed of four-transmembrane proteins of claudins on the plasma membrane that probably function as a zip lock to seal the adjacent plasma membrane, thereby forming a barrier against molecular movement through the paracellular pathway (see Fig. 14-9).[94,95] Other major components of tight junctions are the transmembrane proteins of occludin, junctional adhesion molecule A (JAM-A), tricellulin, and angulins, and the intracellular scaffold proteins of ZO-1, 2, and 3.[96,97] Tight junctions do not simply form an impermeable barrier but also serve as ion- and size-selective barriers that vary in tightness depending on the cell type and the composition of their structural adhesive molecules.[97-99]

FUNCTION OF TIGHT JUNCTIONS

Observations of normal human trunk skin and mouse ear, abdominal, and back skin revealed that only the single-layer cells of the SG2 layer are equipped with tight junctions and show apical and basolateral cell membrane polarity in the epidermis (see Figs. 14-2 and 14-9).[100,101] The extracellular spaces of the epidermis are divided into two parts by the tight junction barrier.[5] The SG2 and SG1 cells secret various molecules (ie, lipids and proteases) via lamellar body secretions from

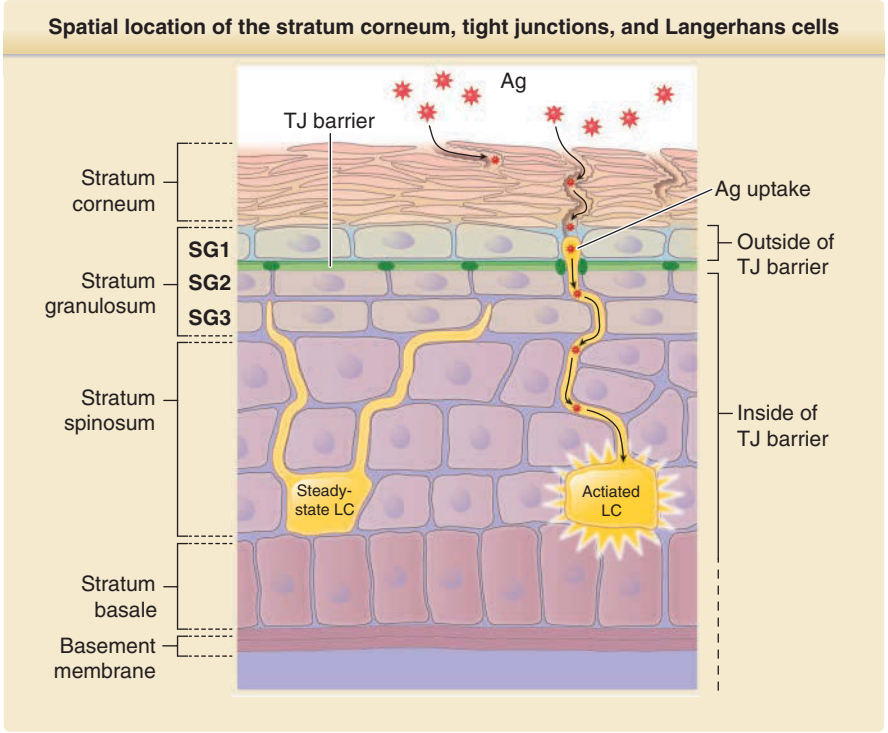

Figure 14-10 Spatial location of the stratum corneum, tight junctions (TJs), and Langerhans cells. SG2 cells form TJs (*closed circle* in *dark green*). SG1 cells are located outside the TJ barrier (*light blue*). In contrast, SG3 cells, spinous layer cells, and Langerhans cells are located inside the TJ barrier (*purple*). Dendrites of Langerhans cells in a steady state (*left yellow* cell) are located beneath the TJ but penetrate through the TJ barrier in their activated state (right *yellow* cell) to access to the outside TJ barrier. Antigen (Ag) uptake occurs from the tip of the dendrites (indicated by Ag uptake) at the outside TJ barrier.

their apical cell membrane into the extracellular spaces surrounding the SG1 cells, which are outside the tight junction barrier and are probably segregated from the environment inside the tight junction barrier (see Fig. 14-2).

A lack of claudin-1, a major claudin of the epidermis, causes leakage of the epidermal tight junction barrier and deficient formation of the stratum corneum barrier in mice, resulting in early neonatal death (probably caused by water loss from the body surface).[102] Decreased claudin-1 expression in mice induces an ichthyosis phenotype and skin inflammation.[103] A lack of claudin-1 in humans results in a very rare congenital disease called neonatal ichthyosis sclerosing cholangitis syndrome[104] (see Table 14-2). These observations indicate that a functional tight junction barrier is crucial for proper formation of the stratum corneum barrier and maintenance of epidermal homeostasis.

INTERACTION BETWEEN TIGHT JUNCTION BARRIERS AND INTRAEPIDERMAL IMMUNE-MEDIATED CELLS

Langerhans cells are antigen-presenting cells that are found in the epidermis and have multiple dendrites. They stay below the tight junction and project their dendrites upward in their steady state in both human and mice epidermis.[101,105] After activation, Langerhans cells extend their dendrites beyond the tight junction barrier and capture external antigens that penetrate through the stratum corneum (see Fig. 14-10). During this process, new tight junctions are formed between Langerhans cell dendrites and keratinocytes of the SG2 layer, enabling the uptake of external antigens without disturbing the barrier function of the tight junctions. The Langerhans cells migrate out from the epidermis, present the captured antigens to T cells in draining lymph nodes, and are considered to induce humoral immunity to the captured antigens.[101,106]

γ-δ T cells are a minor subpopulation of T cells that express T-cell receptor γ and δ. In the human epidermis, γ-δ T cells are rare; however, a large proportion of T cells are γ-δ T cells in mice epidermis.[107-110] The dendrites of γ-δ T cells have been shown to dock with the basal side of the tight junction-bearing cells in mice epidermis, forming immunologic synapses that polarize and anchor T cell projections at keratinocytes.[111]

SHAPE OF KERATINOCYTES FOR SKIN BARRIER HOMEOSTASIS

Corneocytes form according to a regular stacking structure, with regular zigzag interdigitation patterns between adjacent cell columns (see Fig. 14-5B). This regularly interdigitated stacking structure is most apparent in the skin of rodent ears but is also observed in the skin of other body regions in rodents, as well as in human skin.[112] Classic scanning electron microscopic studies of the skin surface corneocytes of the murine ear and a recent immunofluorescent microscopic study of the tight junction-bearing granular layer cells of the murine ear revealed that the basic shape of the cell is a flattened variation of Kelvin's tetrakaidecahedron (see Table 14-1) in the stratum corneum and stratum granulosum[4,113,114] (Fig. 14-11). The regular interdigitation pattern of the corneocytes is believed result from the regular interdigitated stacking of the flattened tetrakaidecahedron cells (see Figs. 14-5B and 14-11C). Computational simulation and in vivo imaging studies suggested that this regular structure is formed at the granular layer by transformation of the three-dimensional shape of cells supplied from the spinous layer, although the precise molecular mechanisms underlying the cell shape change are still unknown.[4,115-117] Only a single layer of cells (SG2 layer cells) form tight junctions at the apical edges of lateral cell–cell contacts. Therefore, tight junctions are formed at the edges of tetrakaidecahedron cells (see Fig. 14-11). When a tight junction-forming cell (an old cell) is replaced by a new cell located just beneath the old cell, the new cell first forms a new tight junction polygon beneath the old cell. Thus, each tight junction polygon becomes temporally double-edged during cell replacement (see Fig. 14-11). After that, the tight junction polygon of the old cells disappears, and eventually, the old cell is extruded to the outside of the tight junction barrier (the outside of the SG2 cell layer that forms the tight junction barrier). The temporal formation of the double-edged tight junction polygon at each cell turnover site maintains the homeostasis of the tight junction barrier.[4] The regular interdigitated stacking of the flattened tetrakaidecahedron cells enables not only the temporal formation of the double-edged tight junction polygon but also to maintain the spatial relationship between cells and desmosomal cell–cell adhesions during cell turnover that may be responsible the physical strength of the epidermis.[4] The molecular mechanisms that restrict tight junction-forming activity to the SG2 cell layer in the epidermis, the spatiotemporal regulation of cell turnover while maintaining tight junction barrier homeostasis, and the manner in which the tetrakaidecahedron cell shape is produced are currently unknown.

ANTIMICROBIAL BARRIER

ANTIMICROBIAL PROPERTY OF THE SKIN SURFACE

The skin constantly encounters microbial pathogens. Control of the skin microbiota is important to prevent bacterial and fungal infections. Continuous

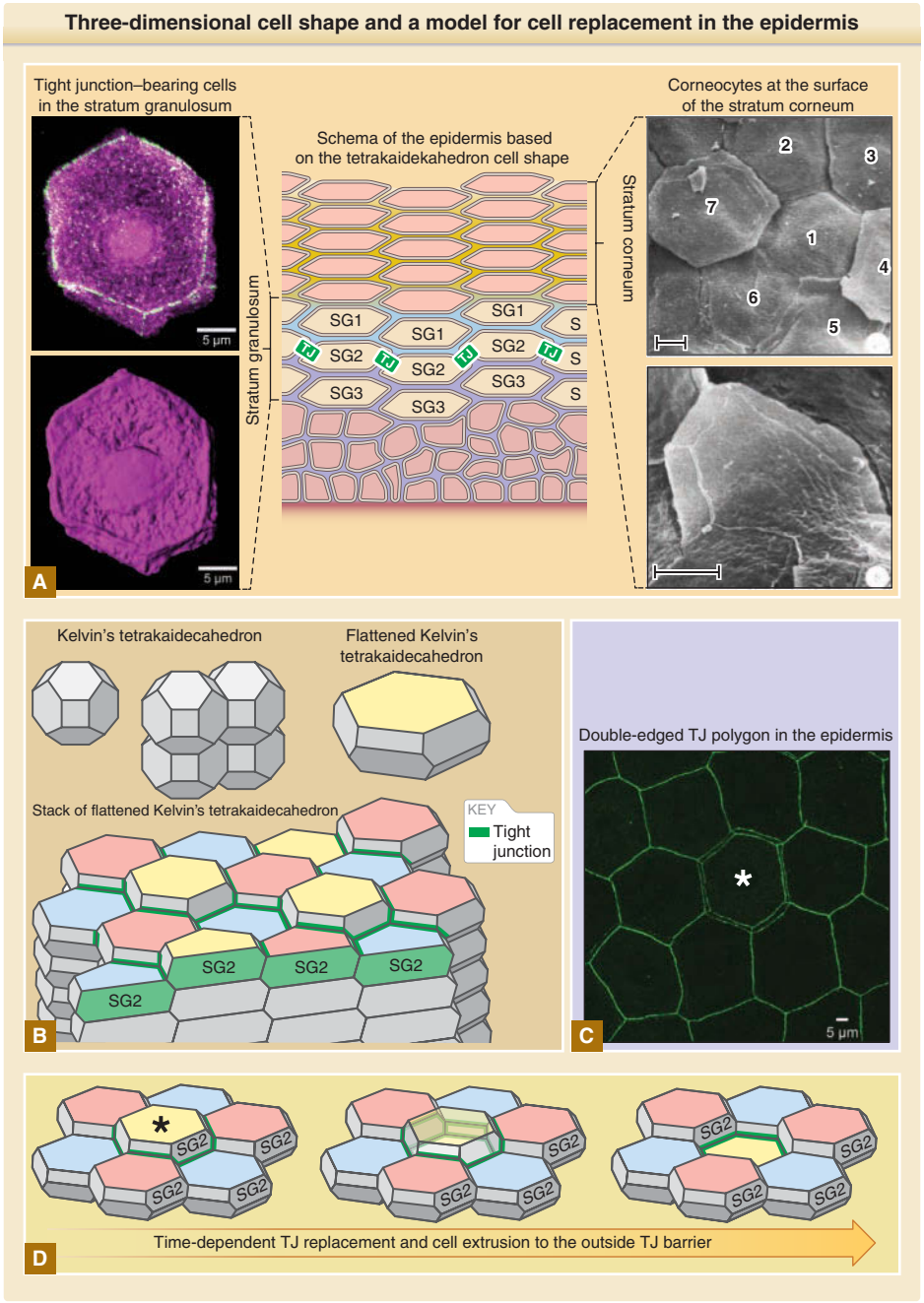

Figure 14-11 Three-dimensional cell shape of corneocytes and tight junction (TJ)–forming cells. **A,** Three-dimensional polyhedral shape of TJ-forming cells in immunofluorescent microscopic view (*left panel*) and the equivalent shape of corneocytes at the surface of the stratum corneum in scanning electron microscopic view (*right panel*) suggest that the basic shape of stratum granulosum cells and corneocytes is a flattened variation of Kelvin's tetrakaidecahedron. **B,** Kelvin's tetrakaidecahedron flattened variation of Kelvin's tetrakaidecahedron, and regular interdigitated stacks of flattened Kelvin's tetrakaidecahedron cells. SG2 cells are displayed at the top of cell columns. Three different Z-axis positions of the SG2 cells are displayed in *yellow, pink,* and *blue* on the apical surface of the cells. Tight junctions (*green* edges) located at the apical edges of the cell-cell contact between SG2 cells. **C,** En face view of the TJs (green edges stained by anti-ZO-1 antibody) in mouse ear skin. Essentially, tight junction polygons are single edged. The double-edged polygon (*asterisk*) is the site where a new TJ polygon is formed to relocate a cell from inside to outside of the TJ barrier. **D,** Conceptual model for the formation of the double-edged TJ polygon (*asterisk*) during cell turnover from inside to outside of the TJ barrier. A new TJ polygon is formed beneath the *center yellow-colored cell* (*asterisk, left panel*), resulting in the formation of a double-edged polygon (*middle panel*). Then, the outer old polygon is degraded (*right panel*). The *center yellow-colored cell* in the left panel (*asterisk*) is relocated from inside the TJ barrier (*left panel*) to outside of the TJ barrier (*right panel*) after the temporal formation of the double-edged polygon (*middle panel*). (The scanning electron microscopic picture on the right side of Image **A**, is reproduced with permission of Springer Nature from Allen TD, Potten CS. Significance of cell shape in tissue architecture. *Nature*. 1976;264:545-547.) The immunofluorescent pictures of parts A and C and schemas in B and D are from Yokouchi M, Atsugi T, Logtestijn M, et al. Epidermal cell turnover across tight junctions based on Kelvin's tetrakaidecahedron cell shape. *Elife.* 2016;5:e19593.

turnover of epidermal cells by desquamation prohibits colonization of microorganisms on the skin. The physical properties of the skin surface itself prevents bacterial growth, that is, a low carbohydrate and water content and a weakly acidic pH (a pH of 5.6 to 6.4).[118-120] The weak acidic pH is due to various substances, such as free fatty acids secreted from sebaceous glands or derived from phospholipid hydrolysis in the stratum corneum, lactic acid secreted from derived from the eccrine glands, urocanic acid mostly derived from the degradation products of filaggrin, and metabolites produced by microorganisms.[121] The epidermis is also equipped with an active antimicrobial defense system comprising antimicrobial proteins (Table 14-3).

TABLE 14-3
Antimicrobial Proteins on the Skin Surface

ANTIMICROBIAL PEPTIDES	EXPRESSION	FUNCTION
Human β-defensin 1	Epidermis	Antimicrobial activity against gram-negative bacteria Role in keratinocyte differentiation
Human β-defensin 2	Epidermis	Inducible by microbial components (*Pseudomonas aeruginosa, Staphylococcus aureus, Candida albicans*) Inducible by TNF-α IL-1 Antimicrobial activity against *Escherichia coli* and *P. aeruginosa* Weakly bacteriostatic against gram-positive bacteria
Human β-defensin 3	Epidermis	Induced by TNF-α and bacteria Bactericidal activity against Gram positive bacteria (*S. aureus and* vancomycin-resistant *Enterococcus faecium*)
Cathelicidin (LL-37)	Keratinocytes Mast cells Neutrophils Eccrine gland ductal cells	Vitamin D is a major inducer Antibacterial, antifungal, and antiviral activities Attracts mast cells and neutrophils
Psoriasin (S100A7)	Keratinocytes	Bacterial membrane permeability Bactericidal against *E. coli* Chemoattractant for CD4 cells and neutrophils
RNase 7	Stratum corneum	Broad spectrum antimicrobial activity (*S. aureus, Propionibacterium acnes, P. aeruginosa, E. coli, C. albicans*) Induced by IL-1β, IFN-γ, bacterial challenge

IFN, interferon; IL, interleukin; TNF-α, tumor necrosis factor-α.
From Modlin RL, Miller LS, Bangert C, et al. Innate and adaptive immunity in the skin. In: Goldsmith LA, Katz SI, Gilchrest BA, et al, eds. *Fitzpatrick's Dermatology in General Medicine*, 8th ed. New York: McGraw-Hill; 2012.

ANTIMICROBIAL PROTEINS ON THE SKIN SURFACE

Antimicrobial proteins are evolutionarily ancient innate immune effectors produced by almost all plants and animals.[122,123] Antimicrobial proteins show a broad antibacterial activity against both gram-positive and -negative bacteria; some even show antifungal or antiviral activity. The antimicrobial activity of most proteins occurs as a result of their unique structural characteristics, which enable disruption of the microbial membrane while leaving host cell membranes intact. These proteins also act as "alarmins" to alert host cells to react to injuries and microbial invasions.[124] Many proteins act as antimicrobial proteins/alarmins in the skin, including short proteins, such as β-defensins, cathelicidins, dermcidin, psoriasin, neuropeptides, and chemokines, and larger proteins, such as lysozymes, elastase, complement, and the S100 proteins. The variety of these antimicrobial proteins may reflect the complexity and long history of the microbial challenges at the skin surface.

The epithelial cells lining the surface of the intestine, respiratory tract, reproductive tract, and skin are the major source of antimicrobial proteins. Each epithelium has many characteristic antimicrobial proteins that are necessary for each microenvironment. Cathelicidins and β-defensins are the two major antimicrobial proteins of the skin and show a broad spectrum of antimicrobial activity in vivo.[125]

CELLS THAT PRODUCE ANTIMICROBIAL PROTEINS

Keratinocytes produce various antimicrobial proteins to defend the skin (Fig. 14-12). In particular, keratinocytes in the hair follicle constitutively produce cathelicidins and β-defensins at a higher level than the keratinocytes of the interfollicular epidermis, probably because the microenvironment of hair follicles facilitates bacterial colonization much more readily than that of the interfollicular epidermis. Secretory cells of the skin, such as those in the eccrine, apocrine, and sebaceous glands, secrete their own antimicrobial proteins and lipids and contribute to the antimicrobial activity of the skin surface. In the dermis, mast cells produce large amount of cathelicidins and store them within intracellular granules. After skin injuries, mast cells secrete cathelicidins to resist bacterial and viral infections.[126] Additionally, commensal bacteria produce their own antimicrobial proteins. For example, *Staphylococcus epidermidis*, the dominant commensal bacterium of the skin microbiota, produces several antimicrobial proteins.[127,128] These various antimicrobial proteins derived from host cells and microorganisms can modulate or regulate the composition of the skin microbiota.

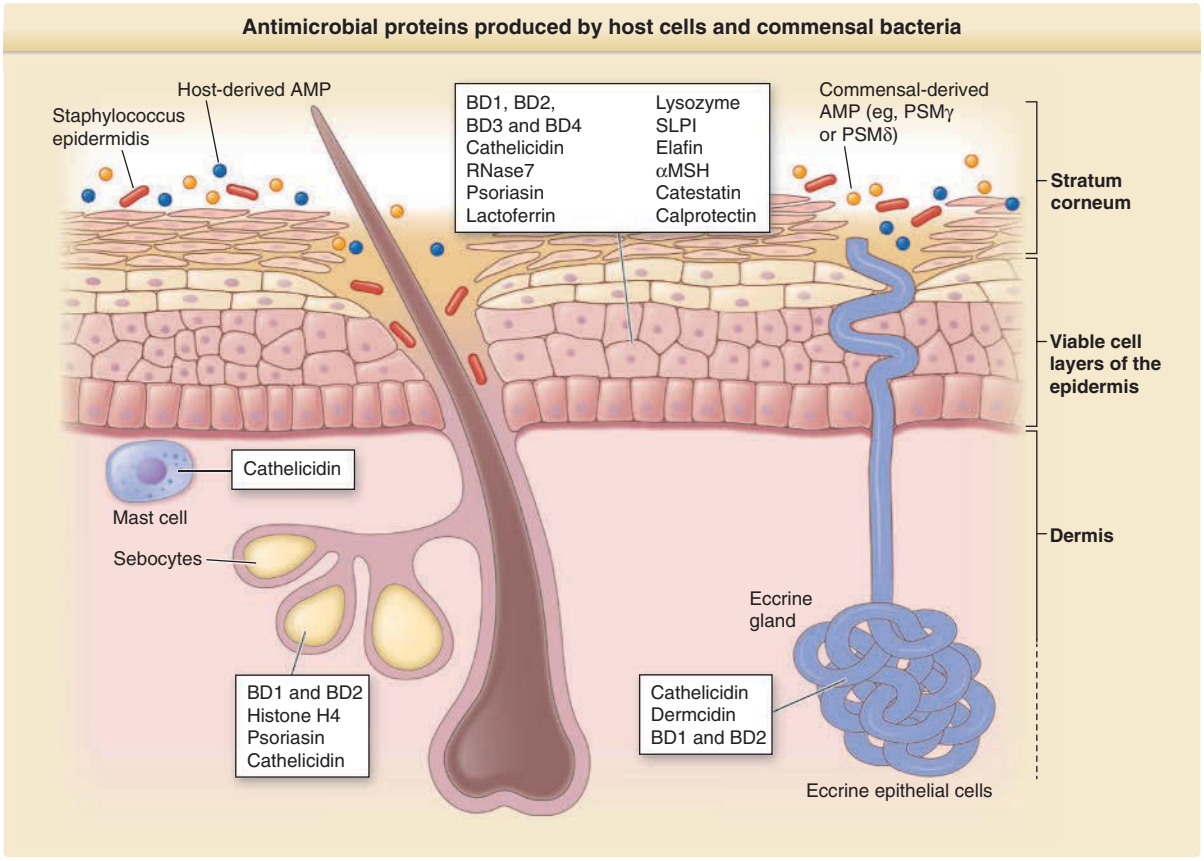

Figure 14-12 Antimicrobial proteins produced by host cells and commensal bacteria. AMP, antimicrobial proteins; BD, beta defencins; PSM, phenol soluble modulin; MSH, melanocyte-stimulating hormone; SLPI, secretory leukocyte protease inhibitor. (Adapted with permission from Springer Nature from Gallo RL, Hooper LV. Epithelial antimicrobial defence of the skin and intestine. *Nat Rev Immunol*. 2012;12:503.)

FUNCTIONS OF ANTIMICROBIAL PROTEINS

Antimicrobial proteins have various mechanisms of action[122,129,130]; many target the cell wall or cell membrane structure of microorganisms. For example, defensins and cathelicidins are usually cationic and interact with the bacterial membrane surface through electrostatic interactions. Some defensins form pores in the bacterial membrane to disrupt membrane integrity and promote bacterial lysis. Cathelicidins bind to bacterial membranes and promote membrane insertion and disruption. The mechanisms of action of several antimicrobial proteins remain unclear.

Increasing evidence indicates that some antimicrobial proteins modulate immune signaling through chemokine receptors and Toll-like receptors. Antimicrobial proteins not only stimulate chemokine and cytokine secretion from a variety of cell types but also use chemotactic activity to recruit leukocytes by direct or indirect mechanisms to modify the inflammatory response.[122,131-133] The chemotactic activities of different types of antimicrobial proteins are distinct from one another, and each recruits different types of cell. For example, LL-37, the human member of the cathelicidin family of antimicrobial peptides, recruits neutrophils, T cells, monocytes, and mast cells. LL-37 also induces keratinocytes through the mitochondrial antiviral signaling pathway to promote the production and secretion of interferon-β, which activates antiviral responses.[134] Toll-like receptors are transmembrane receptors for pattern recognition and are activated by the conserved structural pattern of microbial molecules, such as lipopolysaccharides, flagella, endotoxins, RNA, and DNA.[135] Toll-like receptor signaling is not restricted to such microbial molecules but can also be initiated by some antimicrobial proteins, allowing the immune cell responses to be modified.[136]

EPIDERMAL BARRIER OF NEWBORN SKIN

Full-term newborn babies have a well-developed and functional skin barrier at birth.[137] Although infant skin has a thinner stratum corneum with low levels of natural moisturizing factors and greater transepidermal water loss compared with adult skin, transepidermal water loss in healthy full-term newborns at birth is equal to or lower than that of adult skin (Table 14-4).[138-140]

TABLE 14-4
Similarities and Differences among Newborn, Infant, and Adult Skin

COMPOSITIONAL DIFFERENCES	PRETERM NEWBORN SKIN	FULL-TERM NEWBORN SKIN	INFANT SKIN	ADULT SKIN	REFERENCE
Epidermal surface	Lacking the stratum corneum (<24 wk of gestation) Lacking the vernix caseosa (<28 wk of gestation)	Coated by the vernix caseosa	Thin stratum corneum	Thick stratum corneum	137,140,171
Natural moisturizing factors	None or only in a few layers of the stratum corneum (<26 wk of gestation)	High in the vernix caseosa	Low in the stratum corneum	High in the stratum corneum	139,172
Surface pH	—	High	Low	Low	173-175
Sebum	—	—	Low (7-12 mo old)	High	176
Stratum corneum water content	—	—	High	Low	139
Dermal collagen fiber density	—	—	Low	High	140
Functional Differences					
Rate of water absorption	—	—	High	Low	139
Transepidermal water loss	Very high to high (depending on gestation period)	Low	High	Low	139

The stratum corneum is developed in utero under exposure to amniotic fluid, while extensive water exposure disrupts the stratum corneum barrier in adult skin. One putative mechanism for stratum corneum barrier development in utero is the formation of the fetal biofilm vernix caseosa, which coats the entire skin during the third (last) trimester.[141] The vernix caseosa is a complex mixture of water, proteins, and lipids; fetal corneocytes swollen with water are distributed throughout an amorphous mixture of lipids. The vernix protects the epidermis from amniotic fluid and facilitates formation of the stratum corneum beneath it. Vernix retention after birth, compared with vernix removal immediately after birth, has been reported to result in greater skin hydration and a lower skin surface pH at 24 hours after birth.[141] Moreover, vernix contains antimicrobial agents, including lysozyme and lactoferrin and exhibits antifungal and antibacterial activities.[142-144] This evidence implies value in retaining the vernix rather than removing it immediately after birth, as recommended by the World Health Organization.[145]

Unlike a full-term infant, a premature infant has a weak epidermal barrier and mechanically fragile dermis at birth. Babies born before 28 weeks of gestation lack the covering of the vernix. Newborns with very low birth weight have a greater risk of skin damage as a result of their insufficient skin barrier. Babies delivered at 25 weeks of gestation have only a few layers of the stratum corneum at birth and show transepidermal water loss of about 70 $g/m^2/hr$.[146] The transepidermal water loss at birth in preterm newborns gradually decreases to about 7 $g/m^2/hr$ until 35 weeks' gestation, around which time the epidermal barrier becomes well developed in utero. The epidermal barrier continues to develop after birth, but the transepidermal water loss of extremely preterm infants is significantly higher than that of full-term infants even at 1 month after delivery.[146]

BARRIER AGAINST PHYSICAL STRESSES

PHYSICAL STRUCTURE PROTECTING AGAINST MECHANICAL STRESSES

The skin, which protects our body from various mechanical physical stimuli, consists of stripes of rigid and soft tissues, that is, the rigid stratum corneum, soft layers of keratinocytes, rigid collagenous tissue of the dermis, and soft cushion of the hypodermis (which is rich in adipocytes). Deficits in the physical strength, and defects in the border, of each stripe cause various diseases that lead to physical weakness, such as epidermolytic ichthyosis; simple, junctional, and dystrophic epidermolysis bullosa; and Ehlers-Danlos syndromes (see Chaps. 15, 47, 60, and 72).

BARRIERS AGAINST ULTRAVIOLET STRESSES

Reflection at the air–skin interface, absorption by trans-urocanic acid, and diffraction via keratin filaments aligned parallel to the skin surface limit the penetration of UV radiation into the stratum corneum. In the viable cell layer of the epidermis, melanin is the major factor that absorbs UV irradiation and protects genomic DNA from UV-induced damage. Although the upper layer cells of the epidermis may undergo greater DNA damage by UV irradiation than basal

layer cells because of their location in the epidermis, the cells are tightly controlled in a nonproliferative state and are continuously eliminated from the epidermis via cell turnover, which prohibits tumorigenesis. In the proliferative basal layer cells, the damage to genomic DNA induced by UV irradiation is immediately repaired by DNA repair enzymes (see Chap. 130).

SWEATING TO PROTECT AGAINST HEAT STRESSES

The skin is a protective organ against heat and cold stress and plays an important role in controlling body temperature. In humans, cooling is mainly achieved by the evaporation of water secreted from eccrine sweat glands. Thermoplegia tends to occur in patients with congenital and acquired anhidrosis or hypohidrosis. Human skin has the highest reported density of eccrine sweat glands among all mammals.[147] Most mammals have few sweat glands but have dense hairs covering their body. Because secreted sweat does not readily evaporate under fur, it is reasonable that hairy mammals do not use sweat to cool their body. In contrast, the furless skin of humans has a high density of eccrine sweat glands and enables effective cooling via water evaporation from the body surface. Interestingly, the density of eccrine glands and hair follicles are conversely determined by one transcription factor, *En1*, in the mouse footpad.[148]

VASCULATURE AND BLOOD FLOW CONTROL AGAINST HEAT STRESSES

Cooling and maintaining heat are, in part, dependent on the control of blood flow at the skin surface and countercurrent heat exchange between arteries and veins.[149,150] When the body temperature rises, skin surface blood vessels are dilated, and the skin appears red. The blood is cooled down via sweat evaporation and radiation-induced cooling on the skin surface (Fig. 14-13). In cold

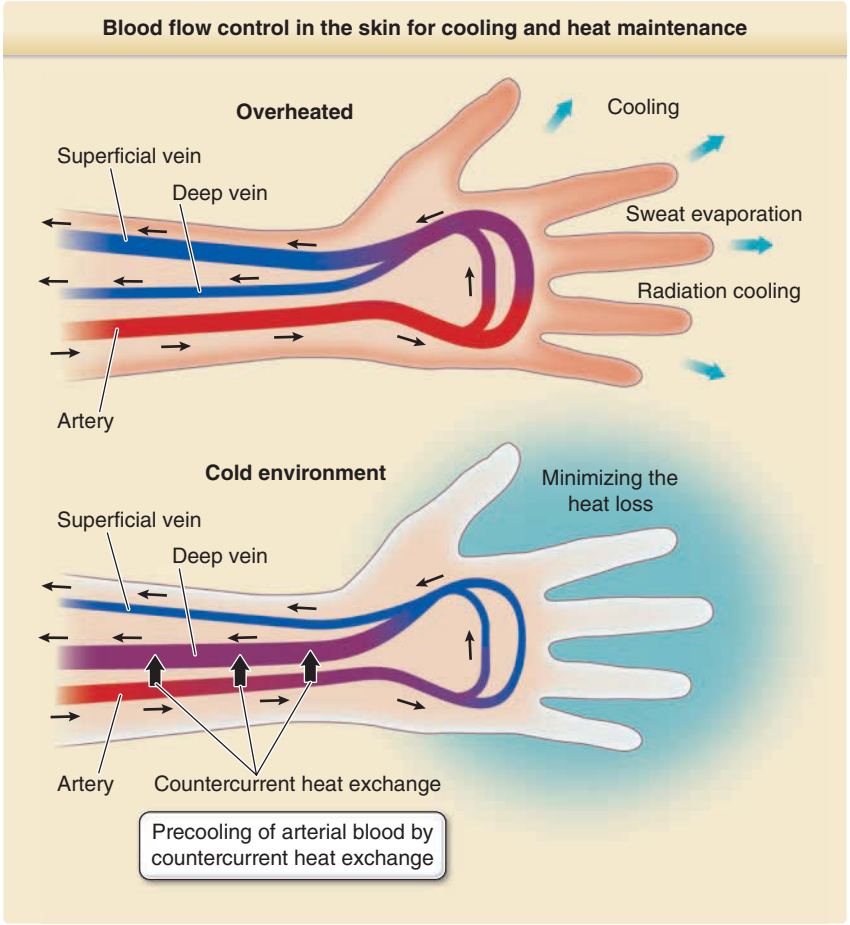

Figure 14-13 Blood flow control in the skin for cooling and heat maintenance. In a hot environment (upper panel), the superficial veins become dilated, and the blood in the superficial veins is mainly cooled via evaporation of eccrine sweat from the skin surface. In a cold environment (lower panel), the superficial veins contract, preventing heat loss from the blood. Countercurrent heat exchange between afferent arteries and dilated efferent deep veins precools the blood in the arteries before it reaches the superficial blood vessels, which also prevents heat loss from the skin surface.

air, the skin turns pale because blood vessels contract to decrease blood flow and minimize heat loss via radiation cooling. Therefore, the skin regulates blood flow at the skin surface to maintain homeostasis of the body temperature.

In the skin, arteries and veins run in close juxtaposition. Vascular countercurrent heat exchange between arteries and veins has been proposed as the mechanism by which the core body temperature is maintained under conditions of extreme cold or heat in homeothermic animals. For example, countercurrent heat exchange between afferent arteries and efferent veins in the legs of ducks prevents heat loss from the footpads, allowing ducks to paddle in icy water. In mouse skin, arteries and veins are aligned in close juxtaposition. Loss of the arteriovenous alignment in genetically engineered mice results in greater heat loss at the skin surface because warmer arterial blood reaches the skin surface without precooling via countercurrent heat exchange against the venous blood returned from the skin surface. The core body temperature decreases because of cooler venous blood returning to the body core.[151] These observations, together with measurements of the blood temperature in the arteries and veins of humans,[150] indicate that humans also use vascular countercurrent heat exchange to maintain the core body temperature under extreme conditions (see Fig. 14-13).

CONCLUSIONS

Skin, which is directly exposed to the external environment, shows species-specific adaptations, resulting in an amazing diversity among vertebrates and mammals and even among the human race and parts of the human body. It is important that dermatologists understand how human skin adapts to the external environment and how these adaptations are affected by disease. Skin is a complex superorgan consisting of the ectoderm, mesoderm, and skin microbiota. An integrated understanding of human skin, its microbiota, and the external environment that skin is exposed to is necessary for further investigation of normal skin function and of the molecular pathogenesis of various skin diseases; this will ultimately improve human health.

ACKNOWLEDGMENTS

The authors acknowledge the contributions of Ehrhardt Proksch and Jens-Michael Jensen, authors of Chap. 47, "Skin as an Organ of Protection," in the 8th edition of *Fitzpatrick's Dermatology in General Medicine*.

REFERENCES

1. Schempp C, Emde M, Wolfle U. Dermatology in the Darwin anniversary. Part 1: evolution of the integument. *J Dtsch Dermatol Ges.* 2009;7(9):750-757.
2. Mackenzie IC. Ordered structure of the epidermis. *J Invest Dermatol.* 1975;65(1):45-51.
3. Tsuruta D, Green KJ, Getsios S, et al. The barrier function of skin: how to keep a tight lid on water loss. *Trends Cell Biol.* 2002;12(8):355-357.
4. Yokouchi M, Atsugi T, Logtestijn M, et al. Epidermal cell turnover across tight junctions based on Kelvin's tetrakaidecahedron cell shape. *Elife.* 2016;5:e19593.
5. Kubo A, Nagao K, Amagai M. Epidermal barrier dysfunction and cutaneous sensitization in atopic diseases. *J Clin Invest.* 2012;122(2):440-447.
6. Potten CS. Epidermal cell production rates. *J Invest Dermatol.* 1975;65(6):488-500.
7. Haftek M, Callejon S, Sandjeu Y, et al. Compartmentalization of the human stratum corneum by persistent tight junction-like structures. *Exp Dermatol.* 2011;20(8):617-621.
8. Kitajima Y. Desmosomes and corneodesmosomes are enclosed by tight junctions at the periphery of granular cells and corneocytes, suggesting a role in generation of a peripheral distribution of corneodesmosomes in corneocytes. *J Dermatol Sci.* 2016;8(1):73-75.
9. Mackenzie JC. Ordered structure of the stratum corneum of mammalian skin. *Nature.* 1969;222(5196):881-882.
10. Rice RH, Green H. The cornified envelope of terminally differentiated human epidermal keratinocytes consists of cross-linked protein. *Cell.* 1977;11(2):417-422.
11. Elias PM, Gruber R, Crumrine D, et al. Formation and functions of the corneocyte lipid envelope (CLE). *Biochim Biophys Acta.* 2014;1841(3):314-318.
12. Swartzendruber DC, Wertz PW, Madison KC, et al. Evidence that the corneocyte has a chemically bound lipid envelope. *J Invest Dermatol.* 1987;88(6):709-713.
13. Wertz PW, Downing DT. Covalently bound omega-hydroxyacylsphingosine in the stratum corneum. *Biochim Biophys Acta.* 1987;917(1):108-111.
14. Kalinin AE, Kajava AV, Steinert PM. Epithelial barrier function: assembly and structural features of the cornified cell envelope. *Bioessays.* 2002;24(9):789-800.
15. Candi E, Schmidt R, Melino G. The cornified envelope: a model of cell death in the skin. *Nat Rev Mol Cell Biol.* 2005;6(4):328-340.
16. Matsuki M, Yamashita F, Ishida-Yamamoto A, et al. Defective stratum corneum and early neonatal death in mice lacking the gene for transglutaminase 1 (keratinocyte transglutaminase). *Proc Natl Acad Sci U S A.* 1998;95(3):1044-1049.
17. Ruhrberg C, Hajibagheri MA, Parry DA, et al. Periplakin, a novel component of cornified envelopes and desmosomes that belongs to the plakin family and forms complexes with envoplakin. *J Cell Biol.* 1997;139(7):1835-1849.
18. Ruhrberg C, Hajibagheri MA, Simon M, et al. Envoplakin, a novel precursor of the cornified envelope that has homology to desmoplakin. *J Cell Biol.* 1996;134(3):715-729.
19. Simon M, Green H. Participation of membrane-associated proteins in the formation of the cross-linked envelope of the keratinocyte. *Cell.* 1984;36(4):827-834.
20. Russell LJ, DiGiovanna JJ, Rogers GR, et al. Mutations in the gene for transglutaminase 1 in autosomal recessive lamellar ichthyosis. *Nat Genet.* 1995;9(3):279-283.
21. Marekov LN, Steinert PM. Ceramides are bound to structural proteins of the human foreskin

epidermal cornified cell envelope. *J Biol Chem.* 1998; 273(28):17763-17770.
22. Nemes Z, Marekov LN, Fesus L, et al. A novel function for transglutaminase 1: attachment of long-chain omega-hydroxyceramides to involucrin by ester bond formation. *Proc Natl Acad Sci U S A.* 1999;96(15): 8402-8407.
23. Steven AC, Steinert PM. Protein composition of cornified cell envelopes of epidermal keratinocytes. *J Cell Sci.* 1994;107(2):693-700.
24. Ishida-Yamamoto A, McGrath JA, Lam H, et al. The molecular pathology of progressive symmetric erythrokeratoderma: a frameshift mutation in the loricrin gene and perturbations in the cornified cell envelope. *Am J Hum Genet.* 1997;61(3):581-589.
25. Freinkel RK, Traczyk TN. Lipid composition and acid hydrolase content of lamellar granules of fetal rat epidermis. *J Invest Dermatol.* 1985;85(4):295-298.
26. Akiyama M, Sugiyama-Nakagiri Y, Sakai K, et al. Mutations in lipid transporter ABCA12 in harlequin ichthyosis and functional recovery by corrective gene transfer. *J Clin Invest.* 2005;115(7):1777-1784.
27. Kelsell DP, Norgett EE, Unsworth H, et al. Mutations in ABCA12 underlie the severe congenital skin disease harlequin ichthyosis. *Am J Hum Genet.* 2005;76(5):794-803.
28. Elias PM, Cullander C, Mauro T, et al. The secretory granular cell: the outermost granular cell as a specialized secretory cell. *J Investig Dermatol Symp Proc.* 1998;3(2):87-100.
29. Feingold KR. Thematic review series: skin lipids. The role of epidermal lipids in cutaneous permeability barrier homeostasis. *J Lipid Res.* 2007;48(12): 2531-2546.
30. Wertz P. Biochemistry of human stratum corneum lipids. In: Elias PM, Feingold KR, eds. *Skin Barrier,* New York: Taylor and Francis; 2006:33-42
31. Proksch E, Elias PM, Feingold KR: Regulation of 3-hydroxy-3-methylglutaryl-coenzyme A reductase activity in murine epidermis. Modulation of enzyme content and activation state by barrier requirements. *J Clin Invest.* 1990;85(3):874-882.
32. Bikle DD. Vitamin D metabolism and function in the skin. *Mol Cell Endocrinol.* 2011;347(1-2):80-89.
33. He M, Kratz LE, Michel JJ, et al. Mutations in the human SC4MOL gene encoding a methyl sterol oxidase cause psoriasiform dermatitis, microcephaly, and developmental delay. *J Clin Invest.* 2011;121(3):976-984.
34. Konig A, Happle R, Bornholdt D, et al. Mutations in the NSDHL gene, encoding a 3beta-hydroxysteroid dehydrogenase, cause CHILD syndrome. *Am J Med Genet.* 2000;90(4):339-346.
35. Paller AS, van Steensel MA, Rodriguez-Martin M, et al. Pathogenesis-based therapy reverses cutaneous abnormalities in an inherited disorder of distal cholesterol metabolism. *J Invest Dermatol.* 2011; 131(11):2242-2248.
36. Kingery FA, Kellum RE. Essential fatty acid deficiency: histochemical changes in the skin of rats. *Arch Dermatol.* 1965;91 272-279.
37. Caldwell MD, Jonsson HT, Othersen HB Jr. Essential fatty acid deficiency in an infant receiving prolonged parenteral alimentation. *J Pediatr.* 1972;81(5):894-898.
38. Rabionet M, Gorgas K, Sandhoff R. Ceramide synthesis in the epidermis. *Biochim Biophys Acta.* 2014; 1841(3):422-434.
39. Elias PM, Williams ML, Holleran WM, et al. Pathogenesis of permeability barrier abnormalities in the ichthyoses: inherited disorders of lipid metabolism. *J Lipid Res.* 2008;49(4):697-714.
40. Breiden B, Sandhoff K. The role of sphingolipid metabolism in cutaneous permeability barrier formation. *Biochim Biophys Acta.* 2014;1841(3):441-452.
41. Uchida Y, Holleran WM. Omega-O-acylceramide, a lipid essential for mammalian survival. *J Dermatol Sci.* 2008;51(2):77-87.
42. Kihara A. Synthesis and degradation pathways, functions, and pathology of ceramides and epidermal acylceramides. *Prog Lipid Res.* 2016;63:50-69.
43. Wertz PW. Lipids and barrier function of the skin. *Acta Derm Venereol Suppl (Stockh).* 2000;208:7-11.
44. Akiyama M. Corneocyte lipid envelope (CLE), the key structure for skin barrier function and ichthyosis pathogenesis. *J Dermatol Sci.* 2017;88(1):3-9.
45. Serre G, Mils V, Haftek M, et al. Identification of late differentiation antigens of human cornified epithelia, expressed in re-organized desmosomes and bound to cross-linked envelope. *J Invest Dermatol.* 1991;97(6):1061-1072.
46. Furio L, Hovnanian A. When activity requires breaking up: LEKTI proteolytic activation cascade for specific proteinase inhibition. *J Invest Dermatol.* 2011;131(11):2169-2173.
47. Sales KU, Masedunskas A, Bey AL, et al. Matriptase initiates activation of epidermal pro-kallikrein and disease onset in a mouse model of Netherton syndrome. *Nat Genet.* 2010;42(8):676-683.
48. Brattsand M, Stefansson K, Lundh C, et al. A proteolytic cascade of kallikreins in the stratum corneum. *J Invest Dermatol.* 2005;124(1):198-203.
49. Ishida-Yamamoto A, Deraison C, Bonnart C, et al. LEKTI is localized in lamellar granules, separated from KLK5 and KLK7, and is secreted in the extracellular spaces of the superficial stratum granulosum. *J Invest Dermatol.* 2005;124(2):360-366.
50. Borgono CA, Michael IP, Komatsu N, et al. A potential role for multiple tissue kallikrein serine proteases in epidermal desquamation. *J Biol Chem.* 2007;282(6):3640-3652.
51. Deraison C, Bonnart C, Lopez F, et al. LEKTI fragments specifically inhibit KLK5, KLK7, and KLK14 and control desquamation through a pH-dependent interaction. *Mol Biol Cell.* 2007;18(9):3607-3619.
52. Descargues P, Deraison C, Bonnart C, et al. Spink5-deficient mice mimic Netherton syndrome through degradation of desmoglein 1 by epidermal protease hyperactivity. *Nat Genet.* 2005;37(1):56-65.
53. Yang T, Liang D, Koch PJ, et al. Epidermal detachment, desmosomal dissociation, and destabilization of corneodesmosin in Spink5-/- mice. *Genes Dev.* 2004;18(19):2354-2358.
54. Basel-Vanagaite L, Attia R, Ishida-Yamamoto A, et al. Autosomal recessive ichthyosis with hypotrichosis caused by a mutation in ST14, encoding type II transmembrane serine protease matriptase. *Am J Hum Genet.* 2007;80(3):467-477.
55. Chavanas S, Bodemer C, Rochat A, et al. Mutations in SPINK5, encoding a serine protease inhibitor, cause Netherton syndrome. *Nat Genet.* 2000;25(2): 141-142.
56. Israeli S, Zamir H, Sarig O, et al. Inflammatory peeling skin syndrome caused by a mutation in CDSN encoding corneodesmosin. *J Invest Dermatol.* 2011;131(3):779-781.
57. Oji V, Eckl KM, Aufenvenne K, et al. Loss of corneodesmosin leads to severe skin barrier defect, pruritus,

and atopy: unraveling the peeling skin disease. *Am J Hum Genet.* 2010;87(2):274-281.
58. Samuelov L, Sarig O, Harmon RM, et al. Desmoglein 1 deficiency results in severe dermatitis, multiple allergies and metabolic wasting. *Nat Genet.* 2013;45(10):1244-1248.
59. De Benedetto A, Kubo A, Beck LA. Skin barrier disruption: a requirement for allergen sensitization? *J Invest Dermatol.* 2012;132(3 Pt 2):949-963.
60. Bieber T. Atopic dermatitis. *N Engl J Med.* 2008;358(14):1483-1494.
61. Cabanillas B, Novak N. Atopic dermatitis and filaggrin. *Curr Opin Immunol.* 2016;42:1-8.
62. Brown SJ, McLean WH. One remarkable molecule: filaggrin. *J Invest Dermatol.* 2012;132(3 Pt 2):751-762.
63. Sandilands A, Sutherland C, Irvine AD, et al. Filaggrin in the frontline: role in skin barrier function and disease. *J Cell Sci.* 2009;122(9):1285-1294.
64. De Benedetto A, Qualia CM, Baroody FM, et al. Filaggrin expression in oral, nasal, and esophageal mucosa. *J Invest Dermatol.* 2008;128(6):1594-1597.
65. Norlen L, Al-Amoudi A. Stratum corneum keratin structure, function, and formation: the cubic rod-packing and membrane templating model. *J Invest Dermatol.* 2004;123(4):715-732.
66. Norlen L. Stratum corneum keratin structure, function and formation—a comprehensive review. *Int J Cosmet Sci.* 2006;28(6):397-425.
67. Denecker G, Hoste E, Gilbert B, et al. Caspase-14 protects against epidermal UVB photodamage and water loss. *Nat Cell Biol.* 2007;9(6):666-674.
68. Denecker G, Ovaere P, Vandenabeele P, et al. Caspase-14 reveals its secrets. *J Cell Biol.* 2008;180(3):451-458.
69. Kamata Y, Taniguchi A, Yamamoto M, et al. Neutral cysteine protease bleomycin hydrolase is essential for the breakdown of deiminated filaggrin into amino acids. *J Biol Chem.* 2009;284(19):12829-12836.
70. Elias PM. Stratum corneum defensive functions: an integrated view. *J Invest Dermatol.* 2005;125(2):183-200.
71. Kirchmeier P, Zimmer A, Bouadjar B, et al. Whole-exome-sequencing reveals small deletions in CASP14 in patients with autosomal recessive inherited ichthyosis. *Acta Derm Venereol.* 2017;96(7):102-104.
72. Smith FJ, Irvine AD, Terron-Kwiatkowski A, et al. Loss-of-function mutations in the gene encoding filaggrin cause ichthyosis vulgaris. *Nat Genet.* 2006;38(3):337-342.
73. Irvine AD, McLean WH, Leung DY. Filaggrin mutations associated with skin and allergic diseases. *N Engl J Med.* 2011;365(14):1315-1327.
74. Palmer CN, Irvine AD, Terron-Kwiatkowski A, et al. Common loss-of-function variants of the epidermal barrier protein filaggrin are a major predisposing factor for atopic dermatitis. *Nat Genet.* 2006;38(4):441-446.
75. Kawasaki H, Nagao K, Kubo A, et al. Altered stratum corneum barrier and enhanced percutaneous immune responses in filaggrin-null mice. *J Allergy Clin Immunol.* 2012;129(6):1538-1546 e1536.
76. Howell MD, Kim BE, Gao P, et al. Cytokine modulation of atopic dermatitis filaggrin skin expression. *J Allergy Clin Immunol.* 2007;120(1):150-155.
77. Nakamura Y, Oscherwitz J, Cease KB, et al. Staphylococcus delta-toxin induces allergic skin disease by activating mast cells. *Nature.* 2013;503(7476):397-401.
78. Kennedy EA, Connolly J, Hourihane JO, et al. Skin microbiome before development of atopic dermatitis: early colonization with commensal staphylococci at 2 months is associated with a lower risk of atopic dermatitis at 1 year. *J Allergy Clin Immunol.* 2017;139(1):166-172.
79. Kong HH, Oh J, Deming C, et al. Temporal shifts in the skin microbiome associated with disease flares and treatment in children with atopic dermatitis. *Genome Res.* 2012;22(5):850-859.
80. Sasaki T, Furusyo N, Shiohama A, et al. Filaggrin loss-of-function mutations are not a predisposing factor for atopic dermatitis in an Ishigaki Island under subtropical climate. *J Dermatol Sci.* 2014;76(1):10-15.
81. Hidaka T, Ogawa E, Kobayashi EH, et al. The aryl hydrocarbon receptor AhR links atopic dermatitis and air pollution via induction of the neurotrophic factor artemin. *Nat Immunol.* 2017;18(1):64-73.
82. Bouwstra JA, de Graaff A, Gooris GS, et al. Water distribution and related morphology in human stratum corneum at different hydration levels. *J Invest Dermatol.* 2003;120(5):750-758.
83. Kubo A, Ishizaki I, Kubo A, et al. The stratum corneum comprises three layers with distinct metal-ion barrier properties. *Sci Rep.* 2013;3:1731.
84. Manabe M, Sanchez M, Sun TT, et al. Interaction of filaggrin with keratin filaments during advanced stages of normal human epidermal differentiation and in ichthyosis vulgaris. *Differentiation.* 1991;48(1):43-50.
85. Bodde HE, Van den Brink I, Koerten HK, et al. Visualization of in vitro percutaneous penetration of mercuric chloride; transport through intercellular space versus cellular uptake through desmosomes. *J Control Release.* 1991;15:227-236.
86. Tran TN. Cutaneous drug delivery: an update. *J Investig Dermatol Symp Proc.* 2013;16(suppl 1):S67-S69.
87. Warner RR, Boissy YL, Lilly NA, et al. Water disrupts stratum corneum lipid lamellae: damage is similar to surfactants. *J Invest Dermatol.* 1999;113(6):960-966.
88. Lack G. Epidemiologic risks for food allergy. *J Allergy Clin Immunol.* 2008;121(6):1331-1336.
89. Lack G, Fox D, Northstone K, et al. Factors associated with the development of peanut allergy in childhood. *N Engl J Med.* 2003;348(11):977-985.
90. Brough HA, Liu AH, Sicherer S, et al. Atopic dermatitis increases the effect of exposure to peanut antigen in dust on peanut sensitization and likely peanut allergy. *J Allergy Clin Immunol.* 2015;135(1):164-170.
91. Brough HA, Simpson A, Makinson K, et al. Peanut allergy: effect of environmental peanut exposure in children with filaggrin loss-of-function mutations. *J Allergy Clin Immunol.* 2014;134(4):867-875 e861.
92. Furuse M, Tsukita S. Claudins in occluding junctions of humans and flies. *Trends Cell Biol.* 2006;16(4):181-188.
93. Axelrod J, Couchman J, De Rooij J, et al. Cell junctions and the extracellular matrix. In: Alberts B, Johnson A, Lewis J, et al, eds. *Molecular Biology of the Cell*, 6th ed. New York: Garland Science; 2014.
94. Suzuki H, Nishizawa T, Tani K, et al. Crystal structure of a claudin provides insight into the architecture of tight junctions. *Science.* 2014;344(6181):304-307.
95. Krause G, Protze J, Piontek J. Assembly and function of claudins: structure-function relationships based on homology models and crystal structures. *Semin Cell Dev Biol.* 2015;42:3-12.
96. Furuse M, Izumi Y, Oda Y, et al. Molecular organization of tricellular tight junctions. *Tissue Barriers.* 2014;2:e28960.
97. Itallie CMV, Anderson JM. Architecture of tight junctions and principles of molecular composition. *Semin Cell Dev Biol.* 2014;36:157-165.

98. Tsukita S, Furuse M. Claudin-based barrier in simple and stratified cellular sheets. *Curr Opin Cell Biol.* 2002;14(5):531-536.
99. Krug SM, Schulzke JD, Fromm M. Tight junction, selective permeability, and related diseases. *Semin Cell Dev Biol.* 2014;36:166-176.
100. Yoshida K, Yokouchi M, Nagao K, et al. Functional tight junction barrier localizes in the second layer of the stratum granulosum of human epidermis. *J Dermatol Sci.* 2013;71(2):89-99.
101. Kubo A, Nagao K, Yokouchi M, et al. External antigen uptake by Langerhans cells with reorganization of epidermal tight junction barriers. *J Exp Med.* 2009;206(13):2937-2946.
102. Furuse M, Hata M, Furuse K, et al. Claudin-based tight junctions are crucial for the mammalian epidermal barrier: a lesson from claudin-1-deficient mice. *J Cell Biol.* 2002;156(6):1099-1111.
103. Tokumasu R, Yamaga K, Yamazaki Y, et al. Dose-dependent role of claudin-1 in vivo in orchestrating features of atopic dermatitis. *Proc Natl Acad Sci U S A.* 2016;113(28):E4061-4068.
104. Hadj-Rabia S, Baala L, Vabres P, et al. Claudin-1 gene mutations in neonatal sclerosing cholangitis associated with ichthyosis: a tight junction disease. *Gastroenterology.* 2004;127(5):1386-1390.
105. Yoshida K, Kubo A, Fujita H, et al. Distinct behavior of human Langerhans cells and inflammatory dendritic epidermal cells at tight junctions in patients with atopic dermatitis. *J Allergy Clin Immunol.* 2014;134(4):856-864.
106. Ouchi T, Kubo A, Yokouchi M, et al. Langerhans cell antigen capture through tight junctions confers preemptive immunity in experimental staphylococcal scalded skin syndrome. *J Exp Med.* 2011;208(13):2607-2613.
107. Bos JD, Teunissen MB, Cairo I, et al. T-cell receptor gamma delta bearing cells in normal human skin. *J Invest Dermatol.* 1990;94(1):37-42.
108. Groh V, Porcelli S, Fabbi M, et al. Human lymphocytes bearing T cell receptor gamma/delta are phenotypically diverse and evenly distributed throughout the lymphoid system. *J Exp Med.* 1989;169(4):1277-1294.
109. Stingl G, Koning F, Yamada H, et al. Thy-1+ dendritic epidermal cells express T3 antigen and the T-cell receptor gamma chain. *Proc Natl Acad Sci U S A.* 1987;84(13):4586-4590.
110. Bonyhadi M, Weiss A, Tucker PW, et al. Delta is the Cx-gene product in the gamma/delta antigen receptor of dendritic epidermal cells. *Nature.* 1987;330(6148):574-576.
111. Chodaczek G, Papanna V, Zal MA, Zal T. Body-barrier surveillance by epidermal gammadelta TCRs. *Nat Immunol.* 2012;13(3):272-282.
112. Mackenzie IC, Zimmerman K, Peterson L. The pattern of cellular organization of human epidermis. *J Invest Dermatol.* 1981;76(6):459-461.
113. Allen TD, Potten CS. Significance of cell shape in tissue architecture. *Nature.* 1976;264(5586):545-547.
114. Menton DN. A minimum-surface mechanism to account for the organization of cells into columns in the mammalian epidermis. *Am J Anat.* 1976;145(1):1-22.
115. Honda H, Morita T, Tanabe A. Establishment of epidermal cell columns in mammalian skin: computer simulation. *J Theor Biol.* 1979;81(4):745-759.
116. Honda H, Tanemura M, Imayama S. Spontaneous architectural organization of mammalian epidermis from random cell packing. *J Invest Dermatol.* 1996;106(2):312-315.
117. Rompolas P, Mesa KR, Kawaguchi K, et al. Spatiotemporal coordination of stem cell commitment during epidermal homeostasis. *Science.* 2016;352(6292):1471-1474.
118. Grice EA, Segre JA. The skin microbiome. *Nat Rev Microbiol.* 2011;9(4):244-253.
119. Korting HC, Hubner K, Greiner K, et al. Differences in the skin surface pH and bacterial microflora due to the long-term application of synthetic detergent preparations of pH 5.5 and pH 7.0. Results of a cross-over trial in healthy volunteers. *Acta Derm Venereol.* 1990;70(5):429-431.
120. Elias PM. The skin barrier as an innate immune element. *Semin Immunopathol.* 2007;29(1):3-14.
121. Ali SM, Yosipovitch G. Skin pH: from basic science to basic skin care. *Acta Derm Venereol.* 2013;93(3):261-267.
122. Gallo RL, Hooper LV. Epithelial antimicrobial defence of the skin and intestine. *Nat Rev Immunol.* 2012;12(7):503-516.
123. Schröder JM, Harder J. Antimicrobial skin peptides and proteins. *Cell Mol Life Sci.* 2006;63(4):469-486.
124. Li N, Yamasaki K, Saito R, et al. Alarmin function of cathelicidin antimicrobial peptide LL37 through IL-36γ induction in human epidermal keratinocytes. *J Immunol.* 2014;193(10):5140-5148.
125. Lai Y, Gallo RL. AMPed up immunity: how antimicrobial peptides have multiple roles in immune defense. *Trends Immunol.* 2009;30(3):131-141.
126. Di Nardo A, Yamasaki K, Dorschner RA, et al. Mast cell cathelicidin antimicrobial peptide prevents invasive group A Streptococcus infection of the skin. *J Immunol.* 2008;180(11):7565-7573.
127. Cogen AL, Yamasaki K, Muto J, et al. Staphylococcus epidermidis antimicrobial delta-toxin (phenol-soluble modulin-gamma) cooperates with host antimicrobial peptides to kill group A Streptococcus. *PLoS One.* 2010;5(1):e8557.
128. Nakatsuji T, Chen TH, Narala S, et al. Antimicrobials from human skin commensal bacteria protect against Staphylococcus aureus and are deficient in atopic dermatitis. *Sci Transl Med.* 2017;9(378):eaah4680.
129. Zhang LJ, Gallo RL. Antimicrobial peptides. *Curr Biol.* 2016;26(1):R14-R19.
130. Cullen TW, Schofield WB, Barry NA, et al. Gut microbiota. Antimicrobial peptide resistance mediates resilience of prominent gut commensals during inflammation. *Science.* 2015;347(6218):170-175.
131. Yang D, Chertov O, Oppenheim JJ. Participation of mammalian defensins and cathelicidins in antimicrobial immunity: receptors and activities of human defensins and cathelicidin (LL-37). *J Leukoc Biol.* 2001;69(5):691-697.
132. De Y, Chen Q, Schmidt AP, et al. LL-37, the neutrophil granule- and epithelial cell-derived cathelicidin, utilizes formyl peptide receptor-like 1 (FPRL1) as a receptor to chemoattract human peripheral blood neutrophils, monocytes, and T cells. *J Exp Med.* 2000;192(7):1069-1074.
133. Elssner A, Duncan M, Gavrilin M, Wewers MD. A novel P2X7 receptor activator, the human cathelicidin-derived peptide LL37, induces IL-1 beta processing and release. *J Immunol.* 2004;172(8):4987-4994.
134. Zhang LJ, Sen GL, Ward NL, et al. Antimicrobial peptide LL37 and MAVS signaling Drive interferon-beta production by epidermal keratinocytes during skin injury. *Immunity.* 2016;45(1):119-130.
135. Uematsu S, Akira S. Toll-like receptors (TLRs) and their ligands. *Handb Exp Pharmacol.* 2008;(183):1-20.

136. Funderburg N, Lederman MM, Feng Z, et al. Human-defensin-3 activates professional antigen-presenting cells via Toll-like receptors 1 and 2. *Proc Natl Acad Sci U S A*. 2007;104(47):18631-18635.
137. Visscher MO, Adam R, Brink S, et al. Newborn infant skin: physiology, development, and care. *Clin Dermatol*. 2015;33(3):271-280.
138. Kelleher MM, O'Carroll M, Gallagher A, et al. Newborn transepidermal water loss values: a reference dataset. *Pediatr Dermatol*. 2013;30(6):712-716.
139. Nikolovski J, Stamatas GN, Kollias N, et al. Barrier function and water-holding and transport properties of infant stratum corneum are different from adult and continue to develop through the first year of life. *J Invest Dermatol*. 2008;128(7):1728-1736.
140. Stamatas GN, Nikolovski J, Luedtke MA, et al. Infant skin microstructure assessed in vivo differs from adult skin in organization and at the cellular level. *Pediatr Dermatol*. 2010;27(2):125-131.
141. Visscher MO, Narendran V, Pickens WL, et al. Vernix caseosa in neonatal adaptation. *J Perinatol*. 2005;25(7):440-446.
142. Akinbi HT, Narendran V, Pass AK, et al. Host defense proteins in vernix caseosa and amniotic fluid. *Am J Obstet Gynecol*. 2004;191(6):2090-2096.
143. Tollin M, Bergsson G, Kai-Larsen Y, et al. Vernix caseosa as a multi-component defence system based on polypeptides, lipids and their interactions. *Cell Mol Life Sci*. 2005;62(19-20):2390-2399.
144. Marchini G, Lindow S, Brismar H, et al. The newborn infant is protected by an innate antimicrobial barrier: peptide antibiotics are present in the skin and vernix caseosa. *Br J Dermatol*. 2002;147(6):1127-1134.
145. World Health Organization Regional Office for the Western Pacific. *Newborn Care Until the First Week of Life: Clinical Practice Pocket Guide*. Manila, Republic of the Philippines; World Health Organization Regional Office for the Western Pacific; 2009.
146. Sedin G, Hammarlund K, Stromberg B. Transepidermal water loss in full-term and pre-term infants. *Acta Paediatr Scand Suppl*. 1983;305:27-31.
147. Lieberman DE. Human locomotion and heat loss: an evolutionary perspective. *Comprehensive Physiology*. 2015;5(1):99-117.
148. Kamberov YG, Karlsson EK, Kamberova GL, et al. A genetic basis of variation in eccrine sweat gland and hair follicle density. *Proc Natl Acad Sci U S A*. 2015;112(32):9932-9937.
149. Mitchell JW, Myers GE. An analytical model of the counter-current heat exchange phenomena. *Biophys J*. 1968;8(8):897-911.
150. Bazett H, Love L, Newton M, et al. Temperature changes in blood flowing in arteries and veins in man. *J Appl Physiol*. 1948;1(1):3-19.
151. Kidoya H, Naito H, Muramatsu F, et al. APJ regulates parallel alignment of arteries and veins in the skin. *Dev Cell*. 2015;33(3):247-259.
152. Thomson W. On the division of space with minimum partitional area. *Philos Mag*. 1887;24(151):503-514.
153. Koch PJ, de Viragh PA, Scharer E, et al. Lessons from loricrin-deficient mice: compensatory mechanisms maintaining skin barrier function in the absence of a major cornified envelope protein. *J Cell Biol*. 2000;151(2):389-400.
154. Liu XY, Dangel AW, Kelley RI, et al. The gene mutated in bare patches and striated mice encodes a novel 3beta-hydroxysteroid dehydrogenase. *Nat Genet*. 1999;22(2):182-187.
155. Aldahmesh MA, Mohamed JY, Alkuraya HS, et al. Recessive mutations in ELOVL4 cause ichthyosis, intellectual disability, and spastic quadriplegia. *Am J Hum Genet*. 2011;89(6):745-750.
156. Vasireddy V, Uchida Y, Salem N Jr, et al. Loss of functional ELOVL4 depletes very long-chain fatty acids (> or =C28) and the unique omega-O-acylceramides in skin leading to neonatal death. *Hum Mol Genet*. 2007;16(5):471-482.
157. Lefevre C, Bouadjar B, Ferrand V, et al. Mutations in a new cytochrome P450 gene in lamellar ichthyosis type 3. *Hum Mol Genet*. 2006;15(5):767-776.
158. Eckl KM, Tidhar R, Thiele H, et al. Impaired epidermal ceramide synthesis causes autosomal recessive congenital ichthyosis and reveals the importance of ceramide acyl chain length. *J Invest Dermatol*. 2013;133(9):2202-2211.
159. Radner FP, Marrakchi S, Kirchmeier P, et al. Mutations in CERS3 cause autosomal recessive congenital ichthyosis in humans. *PLoS Genet*. 2013;9(6):e1003536.
160. Rabionet M, Bayerle A, Jennemann R, et al. Male meiotic cytokinesis requires ceramide synthase 3-dependent sphingolipids with unique membrane anchors. *Hum Mol Genet*. 2015;24(17):4792-4808.
161. Lefevre C, Jobard F, Caux F, et al. Mutations in CGI-58, the gene encoding a new protein of the esterase/lipase/thioesterase subfamily, in Chanarin-Dorfman syndrome. *Am J Hum Genet*. 2001;69(5):1002-1012.
162. Grall A, Guaguere E, Planchais S, et al. PNPLA1 mutations cause autosomal recessive congenital ichthyosis in golden retriever dogs and humans. *Nat Genet*. 2012;44(2):140-147.
163. Jobard F, Lefevre C, Karaduman A, et al. Lipoxygenase-3 (ALOXE3) and 12(R)-lipoxygenase (ALOX12B) are mutated in non-bullous congenital ichthyosiform erythroderma (NCIE) linked to chromosome 17p13.1. *Hum Mol Genet*. 2002;11(1):107-113.
164. Epp N, Furstenberger G, Muller K, et al. 12R-lipoxygenase deficiency disrupts epidermal barrier function. *J Cell Biol*. 2007;177(1):173-182.
165. Yanagi T, Akiyama M, Nishihara H, et al. Harlequin ichthyosis model mouse reveals alveolar collapse and severe fetal skin barrier defects. *Hum Mol Genet*. 2008;17(19):3075-3083.
166. List K, Haudenschild CC, Szabo R, et al. Matriptase/MT-SP1 is required for postnatal survival, epidermal barrier function, hair follicle development, and thymic homeostasis. *Oncogene*. 2002;21(23):3765-3779.
167. Furio L, de Veer S, Jaillet M, et al. Transgenic kallikrein 5 mice reproduce major cutaneous and systemic hallmarks of Netherton syndrome. *J Exp Med*. 2014;211(3):499-513.
168. Hewett DR, Simons AL, Mangan NE, et al. Lethal, neonatal ichthyosis with increased proteolytic processing of filaggrin in a mouse model of Netherton syndrome. *Hum Mol Genet*. 2005;14(2):335-346.
169. Leclerc EA, Huchenq A, Mattiuzzo NR, et al. Corneodesmosin gene ablation induces lethal skin-barrier disruption and hair-follicle degeneration related to desmosome dysfunction. *J Cell Sci*. 2009;122(15):2699-2709.
170. Presland RB, Boggess D, Lewis SP, et al. Loss of normal profilaggrin and filaggrin in flaky tail (ft/ft) mice: an animal model for the filaggrin-deficient skin disease ichthyosis vulgaris. *J Invest Dermatol*. 2000;115(6):1072-1081.

171. Chiou YB, Blume-Peytavi U. Stratum corneum maturation. A review of neonatal skin function. *Skin Pharmacol Physiol.* 2004;17(2):57-66.
172. Visscher MO, Utturkar R, Pickens WL, et al. Neonatal skin maturation—vernix caseosa and free amino acids. *Pediatr Dermatol.* 2011;28(2):122-132.
173. Yosipovitch G, Maayan-Metzger A, Merlob P, et al. Skin barrier properties in different body areas in neonates. *Pediatrics.* 2000;106(1 Pt 1):105-108.
174. Hoeger PH, Enzmann CC. physiology of the neonate and young infant: a prospective study of functional skin parameters during early infancy. *Pediatr Dermatol.* 2002;19(3):256-262.
175. Giusti F, Martella A, Bertoni L, et al. Skin barrier, hydration, and pH of the skin of infants under 2 years of age. *Pediatr Dermatol.* 2001;18(2):93-96.
176. Agache P, Blanc D, Barrand C, et al. Sebum levels during the first year of life. *Br J Dermatol.* 1980;103(6): 643-649.

Chapter 15 :: Epidermal and Dermal Adhesion

:: Leena Bruckner-Tuderman & Aimee S. Payne

AT-A-GLANCE

- The adhesive structures in the skin include desmosomes, focal adhesions, hemidesmosomes, basement membranes and dermal fibril networks.
- Desmosomes are primarily responsible for epidermal adhesion.
- The major components of desmosomes are the desmosomal cadherins (desmogleins and desmocollins), plakins (desmoplakin, envoplakin, and periplakin), and armadillo family proteins (plakoglobin and plakophilins).
- Hemidesmosomes are responsible for epidermal-dermal adhesion.
- The hemidesmosomal components comprise plakin homologs, integrins, and collagenous transmembrane proteins.
- All basement membranes contain collagen IV, laminins, nidogens, heparan sulfate proteoglycans, and fibulins.
- Functional specificity of basement membranes is provided by additional tissue-specific glycoproteins.
- In addition to their structural roles, desmosomes, hemidesmosomes, and the epidermal basement membrane are biologically active in cellular signaling.
- The dermal-epidermal junction is continuous with the extracellular matrix in the papillary dermis and thus attaches the epidermis with the dermis. The pliability and tenacity of the dermis are provided by a highly organized extracellular matrix that is also biologically active in cellular signaling.
- Mutations in the genes encoding the above proteins cause hereditary skin diseases, ranging from hypotrichosis and keratoderma to epidermolysis bullosa and Kindler syndrome.
- Protein components of desmosomes, hemidesmosomes, and epidermal basement membrane are targeted in autoimmune blistering diseases of the pemphigus or pemphigoid group.

INTRODUCTION

The cell–cell and cell–basement membrane adhesion in the epidermis, and the cell-matrix adhesion in the dermis provide the skin with its resistance against environmental influences; epidermal integrity is required for protection of the entire organism against mechanical, physical, or microbial insults. The major cellular structures involved are the desmosomes at cell–cell junctions in the epidermis and the hemidesmosome–basement membrane adhesion complexes and related structures at the dermal–epidermal junction. Ultrastructurally, the hemidesmosome closely resembles one-half of the desmosome; however, at the molecular level, these 2 structures are distinct. Both represent specifically organized assemblies of intracellular and transmembrane molecules. The desmosome anchors cytoskeletal filaments to cell–cell junctions, and the hemidesmosome anchors cytoskeletal filaments of basal epithelial cells to the basement membrane. Our knowledge of the desmosomal, hemidesmosomal, and basement membrane molecules has expanded drastically in recent years as a result of the great power of both molecular genetics and proteomics. After keratinocyte transmembrane proteins were initially identified as autoantigens in pemphigus and pemphigoid, a multitude of molecules have now been characterized at both protein and gene levels, and their expression, regulation, and functions have been discerned. The antigenic epitopes in different autoimmune blistering skin diseases have been carefully mapped and, as of this writing, mutations in at least 24 different genes have been shown to underlie heritable disorders of epidermal or epidermal–dermal adhesion in humans and mice. This chapter will describe the morphologic, molecular, and functional aspects of these adhesion structures.

EPIDERMAL ADHESION

ULTRASTRUCTURE OF DESMOSOMES

The desmosome (or *macula adherens*) is the major cell adhesion junction of the epidermis, serving to anchor apposing keratinocyte cell surface membranes to the intracellular keratin intermediate filament network. Desmosomes are present in almost all epithelial tissues, including the oropharynx, gut, liver, heart, lung, bladder, kidney, prostate, thymus, cornea, and CNS, although the desmosomal protein isoforms and intermediate filament proteins vary by cell type.[1] The primary role of desmosomes in epidermal cell adhesion is evidenced by the histologic findings in epidermal spongiosis, or intercellular edema, in which adjacent keratinocytes remain attached to each other only at desmosomal

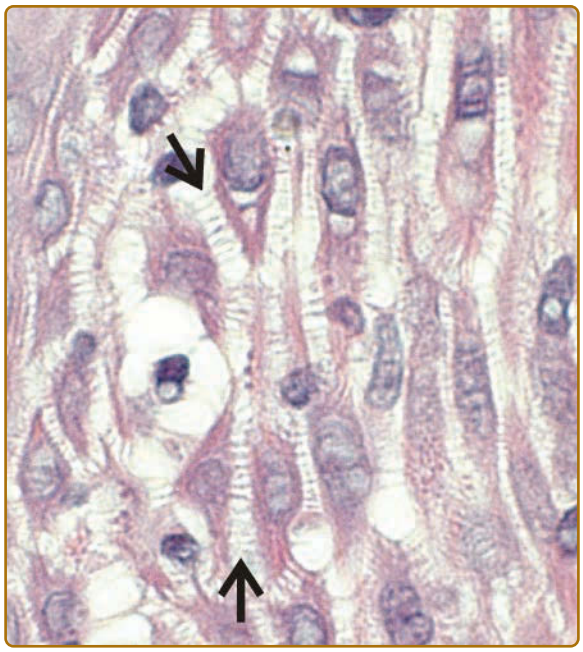

Figure 15-1 Desmosomes are the primary cell adhesion junction in the epidermis. Epidermal spongiosis, or intercellular edema due to inflammation, causes separation of keratinocytes, which remain attached by intercellular bridges representing desmosomal junctions (*arrows*). (Image used with permission from John Seykora, MD, PhD.)

junctions (Fig. 15-1). These "intercellular bridges" served as the earliest description of desmosomes in tissues, their observation made possible with the advent of light microscopy in the 19th century.[2] The development of electron microscopy techniques in the mid-20th century allowed for higher resolution micrographs that revealed the ultrastructure of these intercellular junctions. Even in the 21st century, the desmosome still remains best defined by its electron micrographic appearance, with an electron-dense midline in the intercellular space halfway between apposing plasma membranes, sandwiched by 2 pairs of electron-dense cytoplasmic plaques (Fig. 15-2A).[3] The intercellular space between plasma membranes was called the *desmoglea* (from the Greek for "desmosomal glue"), because it was presumed to provide the adhesion that kept cells together.[4]

STRUCTURE AND FUNCTION OF DESMOSOMAL PROTEINS

In anchoring the cell surface to the intermediate filament network, desmosomes create a 3-dimensional scaffolding of proteins that extend from the cell surface all the way to the nuclear envelope. This scaffolding is critical to stabilize epithelia in the face of shear stress or external trauma. Early morphologic studies led to the perception of the desmosome as a static structure, a "spot weld" functioning only to maintain intercellular adhesion.[5] Over the last 4 decades, the individual proteins comprising the desmosome have been biochemically characterized and cloned, shedding light on both the dynamic nature of the desmosome structure and the diversity of desmosomal protein function.

Desmosomal proteins fall into 3 major categories: (1) desmosomal cadherins (desmogleins and desmocollins), (2) armadillo family proteins (plakoglobin and plakophilins), and (3) plakins (desmoplakin, envoplakin, and periplakin). Additional proteins, such as corneodesmosin, kazrin, Perp, ninein, Lis1, Ndel1, and CLIP170, also have been localized to epidermal desmosomes.[6-10] Immunogold electron microscopy and cryoelectron tomography studies have further refined our understanding of how these molecular components of desmosomes are ordered within the desmosome ultrastructure[11,12] (Fig. 15-2B). The desmosomal cadherins are transmembrane proteins whose extracellular amino-terminal domains interact to form the trans-adhesive interface between cells, represented by the electron-dense midline of the desmoglea. Intracellularly, the outer dense plaque contains the desmosomal cadherin cytoplasmic tails, with plakoglobin and the desmoplakin amino-terminal domain bound approximately 20 nm from the plasma membrane, and plakophilin, approximately 10 nm from the plasma membrane. Approximately 40 to 50 nm from the plasma membrane, the desmoplakin carboxyl-terminus interacts with keratin intermediate filaments, producing the inner dense plaque. The biochemistry, expression pattern, and diseases of each desmosomal component are discussed in further detail next. Although the specific physiologic roles and pathophysiologic mechanisms affecting many of the desmosomal proteins remain under active investigation, current knowledge clearly indicates the importance of desmosomes and their components beyond just cell adhesion.

DESMOSOMAL CADHERINS

Desmogleins and desmocollins are part of the cadherin superfamily of transmembrane glycoproteins. Members of this superfamily, which includes the adherens junction protein E-cadherin, mediate calcium-dependent adhesion in a variety of epithelial tissues. In humans, there are 4 desmoglein (Dsg) isoforms and 3 desmocollin (Dsc) isoforms, each with varying expression patterns within and among epithelia.[13-15] Within normal human epidermis, Dsg1, Dsg4, and Dsc1 are expressed predominantly in the differentiated cells of the superficial epidermis, whereas Dsg2, Dsg3, Dsc2, and Dsc3 are expressed more strongly in the basal and/or suprabasal layers[16,17] (Fig. 15-3). Among different epithelial tissues, Dsg1 and Dsg3 expression

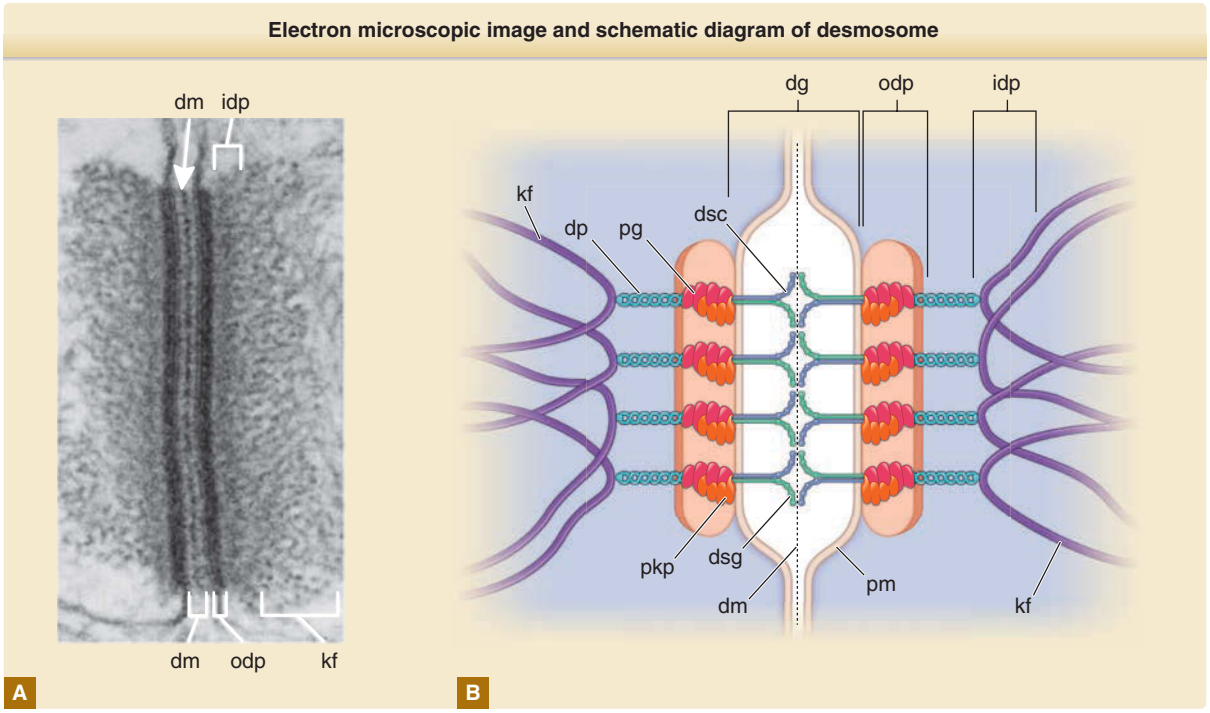

Figure 15-2 Electron microscopic image (**A**) and simplified schematic diagram (**B**) of a desmosome (drawing not to scale). Dg, desmoglea; dm, dense midline; dp, desmoplakin; dsc, desmocollin; dsg, desmoglein; idp, inner dense plaque; kf, keratin filaments; odp, outer dense plaque; pg, plakoglobin; pkp, plakophilins; pm, plasma membrane. (Electron micrograph used with permission from Kathleen Green and with permission of Elsevier, adapted from Yin T, Green KJ: Regulation of desmosome assembly and adhesion. *Semin Cell Develop Biol.* 2004;15:665.)

are largely limited to stratified squamous epithelia in the skin and oropharynx, as well as thymic epithelial cells. Dsg3 is also strongly expressed in squamous cell carcinomas and other head and neck cancers, where it has been proposed as a potential molecular target for therapy.[18] Dsg2 is the major desmoglein isoform in most simple and transitional epithelia, as well as cardiac myocytes.[19] Dsg4 is prominent in desmosomes of the hair follicle, testis, and prostate.[20,21] The expression pattern of the human desmocollins is less well characterized. In normal tissues, Dsc1 expression is largely limited to skin and oral epithelia, whereas Dsc2 is more widely expressed in most desmosome-containing epithelia and is the only desmocollin isoform in cardiac tissue.[13] Dsc3, like Dsg3, is most strongly expressed in the stratified squamous epithelia of the skin and oropharynx,[22] although UniGene data suggest weaker expression in a variety of other epithelial

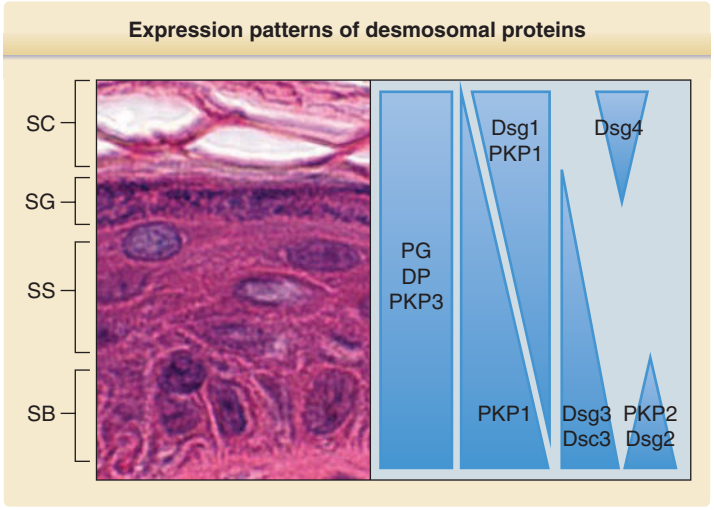

Figure 15-3 Expression patterns of desmosomal proteins in normal human epidermis. SC = stratum corneum, SG = stratum granulosum, SS = stratum spinosum, SB = stratum basale.

tissues. Desmocollin switching has been described in colorectal cancer, with downregulation of Dsc2 and upregulation of Dsc1 and Dsc3.[23]

The extracellular domains of the desmosomal cadherins consist of 4 cadherin repeats plus an extracellular anchor domain, each separated by a calcium-binding motif. All cadherins are synthesized as preproproteins, which include an amino-terminal signal sequence and propeptide. The propeptide is thought to prevent intracellular aggregation of newly synthesized cadherins within the secretory pathway of the cell. Proprotein convertases in the late Golgi network cleave the cadherin propeptide, thereby producing the mature adhesive protein.[24] Studies comparing the crystal structure of desmosomal cadherins, as well as the structure of desmosomes analyzed by cryo-electron tomography of vitreous sections compared with the solution structure of the classical cadherins, suggest common mechanisms of intercellular adhesion among the cadherin superfamily, in which a conserved amino-terminal tryptophan residue on one cadherin molecule interacts with a hydrophobic acceptor pocket in the first extracellular domain of another cadherin molecule on a neighboring cell to form the trans-adhesive interface.[25-28] Additionally, cadherins may participate in cis-adhesive interactions with cadherin molecules on the same cell through their membrane proximal domains, which may facilitate desmosome assembly. Desmosomal cadherins have been reported to engage in both homophilic (ie, Dsg–Dsg or Dsc–Dsc) and heterophilic (ie, Dsg–Dsc) interactions, although heterophilic interactions likely form the basis of epidermal intercellular adhesion.[28-31]

The cytoplasmic domains of the desmosomal cadherins are less conserved. Desmocollins have a full length "a" and a shorter "b" splice isoform. The cytoplasmic domains of desmoglein and desmocollin "a" isoforms bind plakoglobin, and some desmoglein and desmocollin isoforms may also directly bind plakophilins[32-34] (Fig. 15-2B). Increasing data suggest that desmosomal cadherins are not just adhesive molecules but may also actively regulate intracellular signaling, transcription, and other cellular processes.[1] Consistent with this, desmocollin 3-deficiency in mice causes embryonic lethality at day 2, before implantation, indicating a central role for desmocollin 3 in early tissue morphogenesis independent of its desmosomal adhesive function.[35]

In dermatology, the desmosomal cadherins are best known for their role as autoantigens in the immunobullous disease pemphigus (Chap. 52). The desmoglein 3 gene was originally discovered and cloned because it was the autoantigen in pemphigus vulgaris[36,37] (Fig. 15-4A). Since then, all of the desmosomal cadherins have been associated with human autoimmune, infectious, and/or genetic diseases (summarized below and in Table 15-1).

Desmoglein 1: Desmoglein 1 is the target of pathologic proteolytic cleavage in the infectious disorders bullous impetigo and staphylococcal scalded skin syndrome, as well as the inherited ichthyosis associated with Netherton syndrome (Chap. 47).[38,39] Cleavage of desmoglein 1 by staphylococcal exfoliative toxin occurs between extracellular domains 3 and 4.[40] Pathogenic autoantibodies to desmoglein 1 are found in pemphigus foliaceus, mucocutaneous pemphigus vulgaris, and paraneoplastic pemphigus (Chaps. 52 and 53). Most pathogenic pemphigus foliaceus autoantibodies bind the first 2 extracellular domains of desmoglein 1, overlapping sites that are critical for desmoglein intermolecular adhesion.[41-43] Desmoglein 1 is also targeted in some cases of immunoglobulin A pemphigus (intraepidermal neutrophilic-type; Chap. 57).[44] Autosomal dominant mutations causing haploinsufficiency of desmoglein 1 result in palmoplantar keratoderma (PPK; Chap. 49). The PPK is classically striate (Fig. 15-4B), occurring at sites of greatest trauma or friction, but focal and diffuse forms also have been described.[45-47]

Figure 15-4 Desmosomal proteins are pathophysiologic targets in human autoimmune and genetic diseases. **A,** Indirect immunofluorescence on monkey esophagus with pemphigus serum that contains autoantibodies to desmoglein 3. The cell surface–intercellular pattern staining is diagnostic of pemphigus. **B,** Striate palmoplantar keratoderma is associated with haploinsufficiency of desmoglein 1 or desmoplakin.

TABLE 15-1
Desmosomal Targets in Human Disease

	DESMOSOME COMPONENT	AUTOIMMUNE TARGET	GENETIC TARGET
Desmosomal cadherins	Desmoglein 1[a]	Pemphigus foliaceus, pemphigus vulgaris, IgA pemphigus (intraepidermal neutrophilic-type)	Striate PPK (AD)
	Desmoglein 2		ARVC (AD)
	Desmoglein 3	Pemphigus vulgaris, paraneoplastic pemphigus, IgA pemphigus (intraepidermal neutrophilic-type)	
	Desmoglein 4	Pemphigus foliaceus,[b] pemphigus vulgaris[b]	Hypotrichosis (AR); Monilethrix (AR)
	Desmocollin 1	IgA pemphigus (subcorneal pustular dermatosis-type)	
	Desmocollin 2		ARVC (AR and AD)
	Desmocollin 3	Pemphigus vulgaris	Hypotrichosis (AR)
Desmosomal plaque proteins	Desmoplakin I/II	Paraneoplastic pemphigus	Striate PPK (AD); Carvajal syndrome (AR): diffuse PPK, wooly hair, left ventricular cardiomyopathy; lethal acantholytic epidermolysis bullosa (AR); skin fragility–wooly hair syndrome (AR): PPK, wooly hair, nail dystrophy
	Other plakins[c]	Paraneoplastic pemphigus	
	Plakoglobin		Naxos disease: diffuse PPK, wooly hair, ARVC (AR)
	Plakophilin 1		Skin fragility and ectodermal dysplasia (AR)
	Plakophilin 2		ARVC (AD)
Stratum corneum desmosome protein	Corneodesmosin		Hypotrichosis simplex of the scalp (AD)

[a]Also targeted by exfoliative toxin in bullous impetigo and staphylococcal scalded-skin syndrome and hyperactive serine proteases in Netherton syndrome.
[b]Desmoglein 4 immunoreactivity is due to cross-reactivity with desmoglein 1 in pemphigus sera.
[c]Including envoplakin, periplakin, and bullous pemphigoid antigen 1.
AD, autosomal dominant; AR, autosomal recessive; ARVC, arrhythmogenic right ventricular cardiomyopathy; PPK, palmoplantar keratoderma.

Desmoglein 2: Desmoglein 2 has been implicated in human cardiovascular disease as a cause of autosomal dominant arrhythmogenic right ventricular cardiomyopathy (ARVC).[48] The lack of skin phenotypes in affected patients indicates that desmoglein 2 is not required for epidermal adhesion, likely due to compensatory adhesion from other more highly expressed epidermal desmosomal cadherin isoforms.

Desmoglein 3: Desmoglein 3 is the target of pathogenic autoantibodies in mucosal and mucocutaneous pemphigus vulgaris and paraneoplastic pemphigus (Chaps. 52 and 53). Most pathogenic autoantibodies in pemphigus vulgaris target the amino-terminal extracellular (EC1-2) domains of desmoglein 3, which are involved in trans- and cis-adhesion.[41,49-51] Because desmoglein 3 deficiency in mice phenotypically resembles autoimmunity to desmoglein 3 in mucosal pemphigus vulgaris with oral suprabasal erosions, pemphigus autoantibodies are thought to cause loss of desmosomal cadherin function.[52] More recent research has focused on signaling pathways activated after binding of pemphigus vulgaris autoantibodies to keratinocytes, as several biochemical inhibitors have been shown to prevent blistering in a neonatal mouse passive transfer model[53] (discussed in further detail in Chap. 52). Desmoglein 3 is also targeted in some cases of immunoglobulin A pemphigus (intraepidermal neutrophilic-type; Chap. 57).[54]

Desmoglein 4: Desmoglein 4 mutations have been described in rare autosomal recessive forms of hypotrichosis and monilethrix.[55-58] One patient demonstrated transient scalp erosions during the first 2 weeks of life. Most of the mutations in Dsg4 are frameshift or nonsense mutations that would be predicted to lead to haploinsufficiency, although missense mutations also have been reported.[59] Desmoglein 4 immunoreactivity can be observed in pemphigus vulgaris and pemphigus foliaceus sera,[58] but subsequent studies have attributed this to cross-reactivity from Dsg1 autoantibodies.[60]

Desmocollin 1: Desmocollin 1 is the target of autoantibodies in subcorneal pustular dermatosis-type immunoglobulin A pemphigus[61] (Chap. 57).

Desmocollin 2: Like desmoglein 2, desmocollin 2 is mutated in both autosomal dominant and recessive forms of ARVC, with no epidermal phenotype in affected patients.[62,63]

Desmocollin 3: Desmocollin 3 mutations were found in one Pakistani kindred with autosomal recessive hypotrichosis.[64] Autoantibodies to desmocollin 3 also have been found in pemphigus vulgaris patients, particularly those with vegetative lesions.[65-67]

PLAKOGLOBIN

Plakoglobin (also known as γ-catenin) directly binds the cytoplasmic tails of the desmogleins and desmocollin "a" isoforms, as well as E-cadherin, the major transmembrane protein of adherens junctions in epidermal keratinocytes.[68,69] It is expressed throughout all layers of the epidermis and is ubiquitously expressed in all epithelia. Plakoglobin, like plakophilin, is a member of the armadillo gene family, characterized by a conserved protein structure with head and tail domains that flank multiple homologous arm repeats.[70] Various domains of plakoglobin modulate its binding to the desmosomal cadherins.[71-73] Other domains bind to desmoplakin, thus linking desmogleins and desmocollins to desmoplakin.[74] Plakoglobin can also localize to the nucleus, where it may modulate gene transcription by TCF/LEF family members.[75,76] Although most depictions of the desmosome show both plakoglobin and plakophilin binding to desmoplakin, biochemical studies suggest that these interactions are mutually exclusive.[77] Likely, the armadillo family proteins play more dynamic roles in recruitment of desmosomal proteins to the plaque, similar to α-catenin in adherens junctions.[78,79]

Plakoglobin mutations result in Naxos disease, an autosomal recessive syndrome of diffuse PPK, wooly hair, and arrhythmogenic right ventricular cardiomyopathy, the latter of which may present in late childhood to adolescence.[80] Plakoglobin mutations also have been identified in patients with isolated cutaneous disease with normal heart development,[81] as well as in a patient with lethal congenital epidermolysis bullosa.[82]

DESMOPLAKIN

Desmoplakin exists in 2 RNA splice variants, desmoplakin I and II.[83,84] It is unknown whether different isoforms perform different cellular functions, although human disease mutations suggest that desmoplakin I is required for normal desmosomal function.[85] Desmoplakin is part of the plakin gene family,[86] which includes the hemidesmosomal proteins bullous pemphigoid antigen 1 and plectin, as well as envoplakin and periplakin. Similar to other desmosomal components, desmoplakin is a modular protein, with different modules fulfilling different functions. The central part of one desmoplakin molecule coils around the central part of another to form a rod-like center. The amino-terminal head domain binds to plakoglobin,[74] and the carboxyl-terminal tail binds to keratin.[87] Therefore, desmoplakin provides the major link between the keratin filaments and the desmosomal plaque. Desmoplakin also plays a critical role in development independent of its function in desmosomes, as desmoplakin-null mice die early in embryogenesis at E6.5, before desmosomes are formed.[88]

A broad range of desmoplakin mutations have been associated with human disease, leading to variable phenotypic combinations of PPK (striate or diffuse), dilated cardiomyopathy (left or right), wooly hair, nail abnormalities, and/or skin blisters.[59] Haploinsufficiency of desmoplakin leads to autosomal dominant striate PPK.[89] Autosomal recessive mutations in desmoplakin were described in 3 Ecuadorian families with Carvajal syndrome, consisting of diffuse PPK, wooly hair, and arrhythmogenic left ventricular cardiomyopathy.[90] A Naxos-like syndrome of PPK, wooly hair, and ARVC occurs with the p.R1267X nonsense mutation, which affects only the desmoplakin I splice isoform, indicating that desmoplakin II is not sufficient to restore normal desmosomal function in epidermis.[85] Lethal acantholytic epidermolysis bullosa (widespread epidermolysis, generalized alopecia, anonychia, and neonatal teeth) was attributed to compound heterozygous mutations in desmoplakin that caused loss of the desmoplakin tail.[91] Additionally, desmoplakin autoantibodies are observed in paraneoplastic pemphigus sera (Chap. 53).

PLAKOPHILINS

Plakophilins, like plakoglobin, can localize both to the plasma membrane as well as the nucleus, although their function outside of desmosomal adhesion is not well characterized. Plakophilins directly bind to desmoplakin, and may also directly bind keratins and some desmosomal cadherins, which is thought to aid in clustering and lateral stability of the desmosomal plaque.[32,33,77] Plakophilin 1 also associates with the eukaryotic translation initiation factor eIF4A1 in the mRNA cap complex, where it functions to regulate translation and cell proliferation.[92] Plakophilin 1 and 3 are both expressed throughout the epidermis, although plakophilin 1 is more predominant in basal compared to superficial epidermal keratinocytes, and plakophilin 2 is only expressed in the basal epidermal layer (Fig. 15-3).[93-95]

Mutations in plakophilin 1 cause ectodermal–dysplasia–skin fragility syndrome, suggesting a role for plakophilin 1 in epidermal morphogenesis as well as adhesion.[96] Plakophilin 2 mutations are the most common cause of autosomal dominant ARVC.[97,98] Currently, there are no known human diseases associated with plakophilin 3.

OTHER DESMOSOMAL PROTEINS

Envoplakin and *periplakin* are desmosomal plaque proteins expressed in the superficial layers of the epidermis. Both proteins incorporate into the corneodesmosomes of the stratum corneum. Mice deficient in envoplakin, periplakin, and involucrin do

not demonstrate adhesion defects, but instead show impaired desquamation and epidermal barrier function.[99] Envoplakin and periplakin autoantibodies are characteristic of paraneoplastic pemphigus sera (Chap. 53).

Corneodesmosin is a secreted glycoprotein that incorporates into corneodesmosomes and is also expressed in the inner root sheath of the hair follicle. Heterozygous mutations in corneodesmosin are associated with an autosomal dominant hypotrichosis simplex of the scalp.[100] Loss of cohesion in the inner root sheath and aggregates of proteolytically cleaved corneodesmosin around the hair follicle are observed in scalp biopsies of affected patients.

EPIDERMAL–DERMAL ADHESION

STRUCTURAL AND FUNCTIONAL CHARACTERISTICS OF BASEMENT MEMBRANES

Basement membranes underlie epithelial and endothelial cells and separate them from each other or from the adjacent stroma. Another form of basement membrane surrounds smooth muscle or nerve cells. The physiologic functions of basement membranes are diverse: in the various organ systems they provide support for differentiated cells, maintain tissue architecture during remodeling and repair, and, in some cases, acquire specialized functions, including the ability to serve as selective permeability barriers (eg, the glomerular basement membrane or the blood–brain barrier) or acquire strong adhesive properties, like the basement membrane at the dermal–epidermal junction, or that surrounding smooth muscle cells, which provide the tissues resistance against shearing forces.[101,102] All of these characteristics are also used during development and differentiation of multicellular organisms (Table 15-2).

Ultrastructurally, basement membranes most often appear as trilaminar structures, consisting of a central electron-dense region, known as the *lamina densa*, adjacent on either side to an apparently less-dense area, known as the *lamina lucida*. The lamina lucida directly abuts the plasma membranes of the adherent cells. The relative size of each of these regions varies in different tissues, among the basement membranes of the same tissue at different ages, and as a consequence of diseases. Basement membranes serve as substrates for the attachment of cells and fix their polarity.[103] Their continuity throughout the various organ systems stabilizes the tissue orientations and provides a template for orderly repair after injury. Major disruptions in the basement membrane result in the formation of scar tissue and the loss of function in that area.

Different basement membranes contain both common and unique components. All share a basic network structure to which specific macromolecules have been appended. These molecules are responsible for the specialized functions of different basement membranes. The basic constituents of these structures are collagen IV, laminins, nidogens, and heparan sulfate proteoglycans, although the isoforms, the polypeptide subunits, and their individual structures vary among species.[101-104]

Basement membranes provide physical separation between epithelia and their underlying extracellular matrices. This barrier is especially important in the containment of tumors. With the exception of certain cells of the immune system, nonmalignant cells seldom cross a basement membrane. In contrast, malignant cells employ multiple mechanisms to migrate through the basement membranes. Different basement membrane components and their receptors mediate the tumor-cell binding, and the basement membrane dissolution can occur by diverse mechanisms, including metalloproteases produced by the tumor cell.[105] The absence of distinguishable basement membranes in tumor biopsies is used as an indicator of malignancy. These observations underline the importance of the basal lamina as an obstacle to cell migration.

By binding biologically active signaling molecules, basement membranes regulate a multitude of biologic events. The constituent proteoglycans can bind growth factors that can be released from the complexes. Thus, the basement membranes are potent regulators of cell adhesion and migration, cytoskeleton and cell form, cell division, differentiation and polarization, and apoptosis.[103]

TABLE 15-2
Major Functions of Basement Membranes

- Scaffold for tissue organization and template for tissue repair.
- Selective permeability barriers. The renal basement membranes serve for the ultrafiltration of plasma, and other basement membranes also demonstrate selective filtration.
- Physical barriers between different types of cells or between cells and their underlying extracellular matrix.
- Firmly link an epithelium to its underlying matrix or to another cell layer and provide polarity.
- Regulate cellular functions.

ULTRASTRUCTURE OF THE DERMAL-EPIDERMAL JUNCTION

The dermal–epidermal junction is an example of a highly complex form of basement membrane,[104,106] which underlies the basal cells and extends into the upper layers of the dermis (Fig. 15-5A). This basement



Figure 15-5 **A,** Ultrastructure of the human dermal–epidermal junction as visualized by transmission electron microscopy after standard fixation and embedding protocols. af, anchoring filament; AF, anchoring fibril; AP, anchoring plaque; BM, basement membrane; Hd, hemidesmosome; Ld, lamina densa; Ll, lamina lucida. (Bar = 200 nm.) **B,** Ultrastructure of the human dermal–epidermal junction by transmission electron microscopy following protocols using high-pressure fixation and embedding techniques. Note the dense character of both the basement membrane and the subjacent papillary dermis. Anchoring filaments, anchoring fibrils, and anchoring plaques are not distinguishable. (Both images used with permission from Douglas R. Keene, MD, Shriners Hospital, Portland, Oregon.)

membrane is continuous along the epidermis and skin appendages, including sweat glands, hair follicles, and sebaceous glands. The dermal–epidermal junction can be divided into 3 distinct zones.[107] The first zone contains the keratin filament–hemidesmosome complex of the basal cells and extends through the lamina lucida to the lamina densa. The plasma membranes of the basal cells in this region contain numerous electron-dense plates known as hemidesmosomes. The intracellular architecture of the basal cells are maintained by keratin intermediate filaments, 7 to 10 nm in diameter, that course through the basal cells and insert into the desmosomes and hemidesmosomes. External to the plasma membrane is a 25- to 50-nm-wide lamina lucida that contains anchoring filaments, 2 to 8 nm in diameter, originating in the plasma membrane and inserting into the lamina densa. The anchoring filaments can be seen throughout the lamina lucida but they are concentrated in the regions of the hemidesmosomes. Thus, they appear to secure the epithelial cells to the lamina densa.

The existence of the lamina lucida in vivo has been questioned.[108] When the ultrastructure of the basement membrane is evaluated after high-pressure preservation techniques, the lamina densa appears intimately associated with the epithelial cell surface. When the dermal–epidermal junction is similarly prepared, no distinct lamina lucida is seen (Fig. 15-5B). This suggests that the lamina lucida may result from shrinkage of the cell surface away from the lamina densa due to dehydration. The appearance of anchoring filaments spanning the lamina lucida may then result from the firm attachment of constituents of the lamina densa at the hemidesmosome that is subsequently pulled from the lamina densa by shrinkage. Regardless of its actual occurrence in vivo, the evaluation of the lamina lucida by standard electron microscopy techniques has allowed identification of specific structures that would otherwise have been difficult to detect. In addition, the morphologic term *lamina lucida* remains practical in the scientific communication and continues to be used.

The second zone, the lamina densa, appears as an electron-dense amorphous structure 20 to 50 nm in width. At high magnification, it has a granular–fibrous appearance. The major molecular components of the lamina densa are collagen IV, nidogens, perlecan, and laminins, which can polymerize to networks of variable thickness.[109]

The sublamina densa contains 2 readily distinguishable microfibrillar structures. *Anchoring fibrils* appear as condensed fibrous aggregates 20 to 75 nm in diameter[110] with, at high resolution, a cross-striated banding pattern (Fig. 15-5A). The length of the anchoring fibril is difficult to measure because of its random orientation in relation to the plane of the section, but is estimated to be approximately 600 to 700 nm. The ends of the fibrils appear less tightly packed, giving a somewhat frayed appearance. The proximal end inserts into the lamina densa, and the distal end is integrated into the fibrous network of the dermis. Many of the anchoring fibrils originating at the lamina densa loop back into the lamina densa in a horseshoe-like manner. Anchoring fibrils are primarily aggregates of collagen VII.[110]

Fibrillin-containing *microfibrils*, 10 to 12 nm in diameter, are also localized in the sublamina densa region. These are elastic-related fibers, because *elastic fibers* of the dermis are formed from microfibrillar and amorphous components.[111,112] In the papillary dermis, the microfibrils insert into the basal lamina perpendicular to the basement membrane and extend into the dermis, where they gradually merge with the elastic fibers to form a plexus parallel to the dermal–epidermal junction.

In summary, the ultrastructure of the dermal–epidermal junction strongly suggests that the lamina densa functions as a structural scaffold for the attachment of the epidermal cells at one surface, secured by anchoring filaments extending from the lamina densa to the hemidesmosomes. The latter also serve as insertion points for intracellular keratin filaments that form scaffolding for the basal cells. On the opposite surface, the extracellular matrix suprastructures of the dermis are firmly attached to the lamina densa. The interaction of collagen-containing dermal fibers with the lamina densa appears to be mediated by the anchoring fibrils.

The elastic system of the dermis inserts directly into the basal lamina via the microfibrils. Thus, the dermal–epidermal junction provides a continuous series of attachments between the reticular dermis and the cytoskeleton of the basal cells. These observations suggest 4 major functions for the epidermal basement membrane: (1) a structural foundation for the secure attachment and polarity of the epidermal basal cells; (2) a barrier separating the epidermis and the dermis; (3) firm attachment of the dermis to the epidermis through a continuous system of structural elements; and (4) modification of cellular functions, such as organization of the cytoskeleton, differentiation, or rescue from apoptotic signaling via outside-in signaling mechanisms.

BIOCHEMICAL COMPOSITION OF THE BASEMENT MEMBRANE

Basement membranes contain collagenous and noncollagenous glycoproteins and proteoglycans. The collagens account for 40% to 65% of the total protein. All basement membranes contain certain isoforms of collagen IV, laminins, or nidogens, and heparan sulfate proteoglycans (Table 15-3). For example, the α3 chain of collagen IV is localized in the basement membrane of the kidney and lung, but not in those of the skin and blood vessels. In contrast, collagens VII and XVII are associated with the squamous epithelia of skin but not with the glomerular and alveolar basement membranes. In addition, many other tissue-specific components are found in basement membranes,[104,113] and the differences in macromolecular composition are responsible for morphologic and functional variance of basement membranes.

UBIQUITOUS COMPONENTS OF BASEMENT MEMBRANES

Collagen IV is a heterotrimer of 3 α chains.[113] Collagen IV molecules in different basement membranes contain genetically distinct but structurally homologous α chains. The α1 and α2 chains are ubiquitous, but the α3, α4, α5, and α6 chains show restricted distribution among tissues.[104,114] The chain organization and discriminatory interactions between the NC-1 domains govern network assembly in the basement membranes (Fig. 15-6).[114] The 6 chains of collagen IV are distributed in 3 major networks—(1) α1–α2, (2) α3–α4–α5, and (3) α1–α2–α5–α6—whose chain composition is determined by the NC-l domains. Two networks, namely, the α1–α2-containing and α3–α4–α5-containing networks, exist in the glomerular basement membrane. Smooth muscle basement membranes have an α1–α2–α5–α6-containing network in addition to the classic α1–α2 network. Within the dermal–epidermal junction, the α1–α2-containing collagen IV network dominates, but the α1–α2–α5–α6-containing network is also likely to be present.[104,114]

Mutations in the genes encoding the α1 and α2 chains cause pathologies in different organs, ranging from eye, brain, and muscle defects to small-vessel disease, which often underlies ischemic strokes and intracerebral hemorrhages and to the HANAC (hereditary angiopathy with nephropathy, aneurysms, and muscle cramps) syndrome.[104,113] Interestingly, despite the ubiquitous presence of the α1 and α2 chains of collagen IV in basement membranes, aberrations do not occur in all basement membranes, suggesting varying tissue-specific roles for collagen IV. Structural aberrations in the genes encoding the α3, α4, α5, and α6 chains cause different forms of Alport syndrome, a genetic disease characterized by nephritis and deafness.[113] The α3(IV) chain is the antigen recognized by the circulating autoantibodies in the Goodpasture syndrome.[113]

Laminins are very large glycoproteins within the lamina lucida/lamina densa of all basement membranes.[115] Three types of subunit chains have been designated α, β, and γ chains, and each laminin is a trimeric aggregate of one α, β, and γ chain. The trimers have semirigid and extended structures, which appear as an asymmetric cross in rotary shadowing electron microscopy. The long arm of the cross is approximately 125 nm in length; the short arms are variable. Each laminin molecule contains globular and rod-like domains that have been individually implicated in various functions, such as aggregation with itself and with other components of the lamina densa (Fig. 15-7), cell attachment and spreading, neurite outgrowth, or cellular differentiation.[103,115,116] The C-terminal laminin-type globular (LG) domain of the α chain, at the foot of the long arm of the laminin cross, harbors the binding site for integrins.[115]

As of this writing, 16 laminin isoforms have been identified.[115] These represent different trimeric combinations of 5 distinct α chains, 3 β chains, and 3 γ chains. Historically, laminins were named as *laminin-1* to *laminin-15*, in the order of their discovery, but this classification had grown quite impractical, with the need to memorize the numbers. The current, simplified nomenclature is based on the chain composition and the number of each α, β, and γ chain (Table 15-4). For example, the classic "prototype" laminin-1, with α chain composition α1β1γ1, is now called *laminin 111*.

TABLE 15-3

Ubiquitous Components of Basement Membranes

- Collagen IV
- Laminins
- Nidogens
- Heparan sulfate proteoglycans
- Fibulins

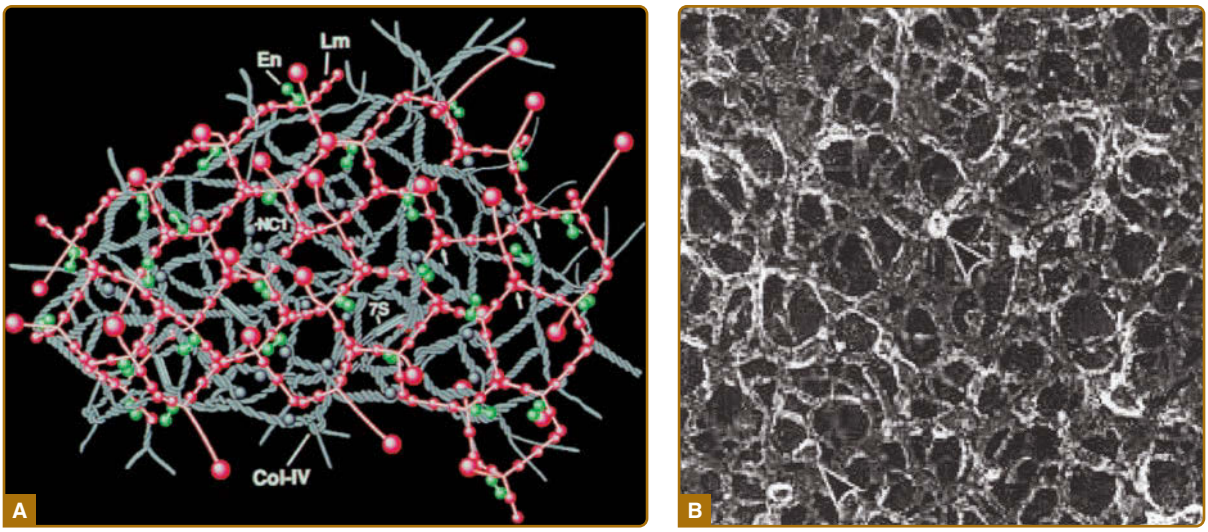

Figure 15-6 **A,** Representation of the networks formed by the ubiquitous components of the basement membranes. Monomeric collagen IV (Col-IV) self-assembles into dimers and tetramers that further aggregate into a complex lattice. Laminins self-polymerize into networks. Perlecan can oligomerize in vitro, and the glycosaminoglycan side chains interact with the Col-IV framework. Nidogen is thought to bind components of all 3 networks and also fibulins. Therefore, nidogen plays a central role as a stabilizer of the lamina densa framework. Individual molecules are not drawn to scale. (Drawing used with permission from Peter Yurchenco, MD, Robert Wood Johnson Medical School, Piscataway, NJ, USA.) **B,** Rotary shadowing image of a quick-freeze, deep-etch replica of Col-IV polymers. The replica shows an extensive, branching, and anastomosing network with occasional globular structures (*arrowhead*), which can be visualized as a model for the structure of the lamina densa. (Image B, used with permission from Toshihiko Hayashi, PhD, University of Tokyo, Japan.)

The major laminin of the epidermal basement membrane, the previous laminin-5, with α chain composition α3β3γ2, is now called *laminin 332*.[115,116] Laminin 511 is present in the basement membrane of the epidermis and the hair follicles, where it is believed to be involved in dermal–epidermal communication, developmental signaling, and stem cell functions.[116,117] The β3 chain is involved in epithelial adhesion. The γ2 chain is found only in laminin 332 in the skin. The γ3 chain, a component of laminins 423 and 523, binds nidogens and is localized in basement membrane zones of adult and embryonic brain, kidney, skin, muscle, and testis. The functions of all laminins are not yet fully understood, but by interacting with integrins and other cell surface components, laminins control cellular activities such as adhesion, migration, proliferation, and polarity in a wide variety of organs.[116]

Several human congenital diseases are caused by mutations in the laminin chains.[115,118] For example, mutations in the α3, β3, or γ2 chains underlie junctional epidermolysis bullosa, and mutations in the α2 chain cause congenital muscular dystrophy and a significant decrease in the amount of basement membrane surrounding muscle cells.[119] The absence of the basement membrane leads to progressive degeneration of the muscle due to cell death. Therefore, the prediction is that laminins, and basement membranes in general, are required to prevent apoptosis by the cell types they support.[103,115,119]

Two nidogens, nidogen 1 and 2, are distinct gene products. Both are relatively small molecules, which bind laminins at a specific site within the γ1 and the γ3 chain,[104] but also collagen IV, perlecan, and fibulins. Nidogens may act as connecting elements between the collagen IV and laminin networks and integrate other basement membrane components into this specialized extracellular matrix. Targeted ablation of nidogens in mice showed that their loss has no effect on basement membrane formation per se, but severe defects of the lung and the heart[120] that are not compatible with life. Interestingly, despite the ubiquitous presence of nidogens in basement membranes, aberrations did not occur in all basement membranes, suggesting distinct roles for nidogens in different basement membranes.[104]

Another class of ubiquitous integral basement membrane constituents are the proteoglycans. Three proteoglycans are characteristically present in vascular and epithelial basement membranes: (1) perlecan, (2) agrin, and (3) collagen XVIII.[121-123] They consist of a core protein of various lengths, and carry primarily heparan sulfate side chains. Perlecan represents a complex multidomain proteoglycan with enormous dimensions and a number of posttranslational modifications. Knockout mice lacking perlecan exhibited abnormalities in many tissues, including basement membranes, and embryonic lethality. The basement membranes deteriorated in regions under increased mechanical stress, manifesting as lethal cardiac abnormalities and skin blistering.[122] Agrin is a major heparan sulfate proteoglycan of neuromuscular junctions and renal tubular basement membranes.[122] Collagen XVIII is considered to be a hybrid collagen–proteoglycan in various organs. In collagen XVIII–deficient mice, basement membranes were altered and pathologies have been observed in different organs.[123] The proteoglycans can interact with

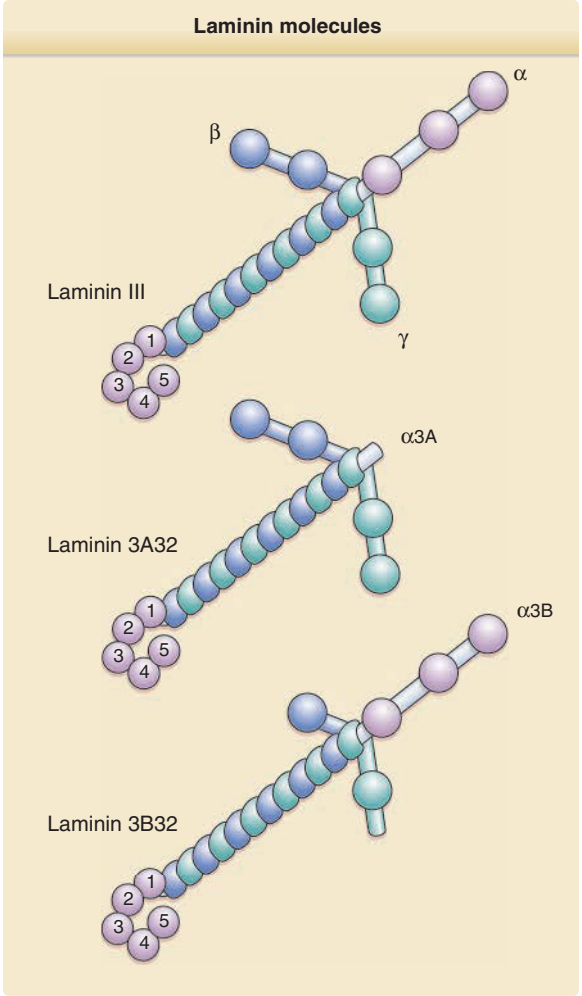

Figure 15-7 A schematic representation of laminin molecules. Each laminin is a heterotrimer of an α, a β, and a γ chain. On the top, the classic prototype laminin 111 consisting of α1β1γ1 chains is shown. The N-terminal short arm of each chain is free, the long C-termini fold to a coiled-coil and form the long arm. The distal C-terminus of the α chain contains 5 globular LG domains, which harbor the integrin-binding site. Laminin 332 exists in 2 forms, 3A32 and 3B32. These represent splice variants of the α chain, the short variant is 3A and the "full length" chain 3B. The N-termini of the β3 and γ2 chains are proteolytically processed to yield mature laminin 332.

several other molecules and are believed to contribute to the overall architecture of the basement membrane as well as provide tissue-specific functions. The high sulfate content makes them highly negatively charged and hydrophilic, and the charge density is responsible for providing the selective permeability of the glomerular basement membrane.[121]

Syndecans are transmembrane heparan sulfate proteoglycans present on most cell types, including basal keratinocytes of the epidermis. The extracellular domains have affinity for laminins and, presumably through these interactions, they engage in outside-in signaling and regulate cellular processes ranging from growth factor signaling, cell adhesion, and cytoskeletal organization, to infection of cells with microorganisms.[124]

Fibulins are a family of highly conserved, calcium-binding extracellular matrix proteins. They are located in vessel walls, basement membranes, and microfibrillar structures and they have overlapping binding sites for a variety of ligands, both basement membrane proteins and components of the interstitial connective tissues.[104] Therefore, fibulins are believed to function as intermolecular bridges that stabilize the supramolecular organization of extracellular matrix structures, such as elastic fibers and basement membranes. Genetic defects of the genes encoding fibulin 4 and 5 cause different forms of cutis laxa.

TABLE 15-4
Most Common Laminin Isoforms[a]

NAME	CHAIN COMPOSITION	TISSUE DISTRIBUTION
Laminin 111	α1β1γ1	Developing epithelia
Laminin 121	α1β2γ1	Myotendinous junction
Laminin 211	α2β1γ1	Muscle, nerves
Laminin 213	α2β1γ3	Muscle
Laminin 221	α2β2γ1	Neuromuscular junction, glomerulus
Laminin 3A11	α3β1γ1	Stratified epithelia
Laminin 3A21	α3β2γ1	Amnion, maybe other stratified epithelia
Laminin 3A32	α3β3γ2	Stratified epithelia
Laminin 3B32	α3β3γ2	Stratified epithelia, uterus, lung
Laminin 411	α4β1γ1	Endothelia, nerves, smooth muscle, adipose tissue
Laminin 421	α4β2γ1	Endothelia, neuromuscular junction, smooth muscle, glomerulus, adipose tissue
Laminin 423	α4β2γ3	Retina, CNS, kidney, testis
Laminin 511	α5β1γ1	Mature epithelia and endothelia, smooth muscle
Laminin 521	α5β2γ1	Mature epithelia and endothelia, smooth muscle, neuromuscular junction, glomerulus
Laminin 523	α5β2γ3	Retina, CNS, muscle, kidney

[a]See Durbeej M: Laminins. *Cell Tissue Res.* 2010;339:259-268.

EPIDERMAL-SPECIFIC BASEMENT MEMBRANE COMPONENTS

The dermal–epidermal junction of skin is an excellent example of specific divergence in basement membrane structure. The structural components of

hemidesmosomes, anchoring filaments, and anchoring fibrils in the basement membrane zone are quite well characterized.[104,106,107,109,110] A diagram depicting the relative locations of the proteins found at the dermal–epidermal junction is shown in Fig. 15-8. These proteins are listed in Table 15-5 and discussed in the following sections.

HEMIDESMOSOMES

Ultrastructurally, the hemidesmosome closely resembles one-half of the desmosome at cell–cell junctions in the epidermis. However, the components of these 2 structures are distinct.[125] The 230-kDa bullous pemphigoid antigen 1, or BP230 is a protein with homology to plakins, which bind intermediate filaments. It is the major component of the hemidesmosomal inner dense plaque. Ablation of BP230 is associated with epidermolysis bullosa simplex in mice and humans.[106,118] The 180-kDa bullous pemphigoid antigen 2, BP180 and the major antigen in bullous pemphigoid (Fig. 15-9), is a transmembrane collagen known as *collagen XVII*, where the collagenous domain is extracellular.[126] The intracellular ligands of collagen XVII are plectin, BP230 and β4 integrin, and the extracellular ligands α6 integrin and laminin 332.[127] The 120-kDa ectodomain of collagen XVII is shed from the cell surface by proteinases of the ADAM (a disintegrin-like and metalloproteinase-containing) family through cleavage within the juxtamembranous NC-16 domain (Fig. 15-10).[126] Mutations in collagen XVII cause junctional epidermolysis bullosa (Chap. 60), indicating that

Hypothetical relationships of molecules within the dermal–epidermal junction basement membrane

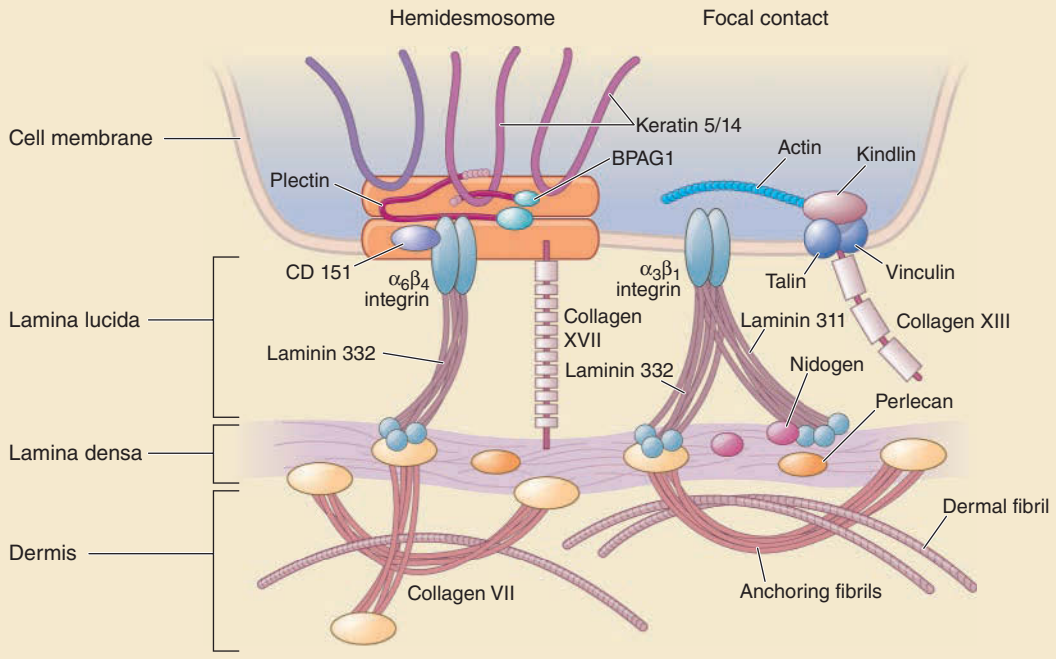

Figure 15-8 Model of the hypothetical relationships of molecules within the dermal–epidermal junction basement membrane. The illustration depicts laminin 332 as the bridge between the transmembrane hemidesmosomal integrin α6β4 and the collagen VII NC-1 domain. The tight binding of laminin 332 to α6β4 and to collagen VII provides the primary resistance to frictional forces. The transmembrane collagen XVII also participates in this stabilization, because its extracellular domain also binds laminin 332. Within the epithelial cell, the transmembrane elements bind the proteins of the hemidesmosomal dense plaque, bullous pemphigoid antigen (BPAG)1 and plectin, which then associate with the keratins. Collagen XVII binds BPAG1, integrin α6β4, and plectin, and integrin α6β4 binds plectin. The laminin 332–311 complex is shown within the basement membrane between hemidesmosomes, bound by integrin α3β1, and associated with the intracellular proteins kindlin-1, talin, and vinculin. This complex presumably maintains basement membrane stability. In vitro, integrin α3β1, kindlin-1, talin, and vinculin, and another transmembrane collagen, type XIII, are localized to the focal contacts, which may function as the link between the basement membrane and the epithelial cortical actin network. In the lamina densa, collagen IV and perlecan networks are stabilized by nidogen. Anchoring fibrils are secured to the lamina densa by the NC-1 domain of collagen VII. The fibrils project into the dermis and either terminate in anchoring plaques or loop back to the lamina densa. The anchoring fibril network binds dermal fibrils, thus securing the adhesion of the lamina densa to the papillary dermis. None of the molecules is drawn to scale.

TABLE 15-5
Hemidesmosomal and Basement Membrane Zone (Bmz) Targets in Skin Disease

	HEMIDESMOSOME/BMZ COMPONENT	AUTOIMMUNE TARGET	GENETIC TARGET
Cytoskeletal proteins	Keratin 5 and 14		EBS
Hemidesmosomal plaque proteins	Bullous pemphigoid antigen 1/BP230 Plectin	BP BP, CP	EBS EBS-MD JEB-PA
Other intracellular adhesion complex proteins	Kindlin-1		KS
Hemidesmosomal transmembrane components	Collagen XVII/BP180 α6β4 integrin CD151	BP, CP, LAD, PG BP, CP	JEB-non-Herlitz JEB-PA Pretibial EB, nephritis, deafness, β-thalassemia minor
Anchoring filament proteins	Laminin 332 Ectodomain of collagen XVII	CP LAD, BP	JEB-Herlitz JEB–non-Herlitz JEB–non-Herlitz
Anchoring fibril proteins	Collagen VII	EBA	DEB

BP, bullous pemphigoid (Chap. 54); CP, cicatricial pemphigoid (Chap. 55); DEB, dystrophic; EB (Chap. 60 for all); EB, epidermolysis bullosa; EBA, EB acquisita (Chap. 56); EBS, EB simplex; EBS–MD, EBS with muscular dystrophy; JEB, junctional EB; JEB–PA, JEB with pyloric atresia; KS, Kindler syndrome; LAD, linear immunoglobulin A dermatosis (Chap. 58); PG, pemphigoid gestationis.

it stabilizes interactions of basal keratinocytes with the basement membrane.[118] Collagen XVII is also known to regulate functions of hair follicle and melanocyte stem cells,[128] explaining why ablation of the mouse *Col17a1* gene resulted in moderate skin blistering, dental anomalies, and graying and loss of hair.[128] Plectin, another plakin homolog, is also a component of the hemidesmosome.[125] However, its tissue distribution is

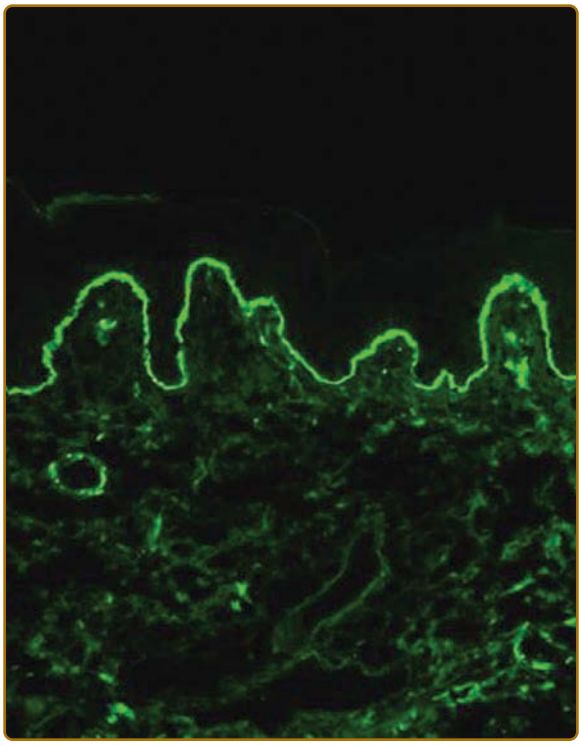

Figure 15-9 Indirect immunofluorescence staining of human skin with a pemphigoid serum that contains autoantibodies to collagen XVII.

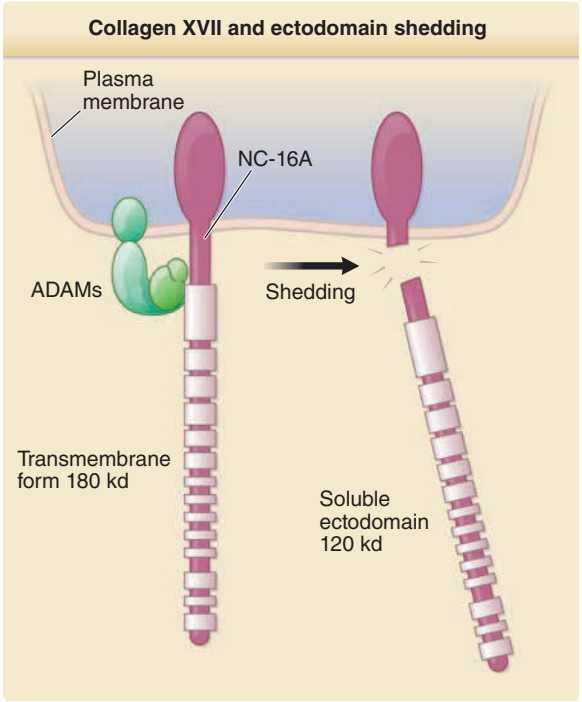

Figure 15-10 Schematic representation of collagen XVII and its ectodomain shedding. Collagen XVII is a hemidesmosomal transmembrane protein with an intracellular N-terminus. The extracellular C-terminus (ectodomain) contains several collagenous subdomains (*light pink*) and intervening noncollagenous sequences (*purple*). The ectodomain can be shed from the cell surface by proteinases of the ADAMs (a disintegrin-like and metalloproteinase-containing) family, themselves transmembrane proteins. Thus, the 180-kDa full-length molecule yields a shorter soluble ectodomain of 120 kDa. The 180-kDa full-length molecule is the classic bullous pemphigoid antigen-2, and the ectodomain is the 120-kDa linear immunoglobulin A (IgA) dermatosis antigen. Further degradation of the *C*-terminus of the ectodomain results in the 97-kDa linear IgA dermatosis antigen.

not limited to hemidesmosome-containing basement membranes. Mutations of plectin result in epidermolysis bullosa simplex with progressive muscular dystrophy and, in some cases, epidermolysis bullosa simplex with pyloric atresia,[118] indicating a role for plectin in the stability of cell–basement membrane adhesion in a variety of tissues. One key component of the hemidesmosome is the integrin α6β4.[125] It has a high affinity for laminin 332 and is essential to integration of the hemidesmosome with the underlying basement membrane. Mutations in either the α6 or β4 chains result in junctional epidermolysis bullosa associated with pyloric atresia.[118]

A member of the widely expressed cell surface transmembrane proteins of the tetraspanin family, CD151, is also a component of the hemidesmosome. It forms complexes with α3β1 and α6β4 integrins at the basolateral surface of basal keratinocytes and stabilizes their functions.[129] A very rare human genetic condition delivered indirect information on the functions of CD151. In addition to the expression of CD151 in several tissues like the kidney and the skin, its gene also encodes the MER2 blood group antigen on erythrocytes. MER2-negative patients presented with hereditary nephritis, sensorineural deafness, pretibial epidermolysis bullosa, and β-thalassemia minor.[117] These symptoms suggest that CD151 is important for the assembly of the basement membrane in the kidney, skin, and inner ear and plays a role in erythropoiesis.

OTHER EPIDERMAL–DERMAL ADHESION COMPLEXES

In addition to the hemidesmosomal components, other adhesion molecules are known to be present at the basolateral aspect of basal keratinocytes, for example, integrin α3β1, the receptor for the laminin 332–311 complex in the basement membrane between the hemidesmosomes, and another transmembrane collagen, type XIII.[118] Because these proteins are localized to focal contacts in vitro, together with vinculin and talin, they are predicted to function as the link between the basement membrane and the epithelial cortical actin network.[130] Mutations in the integrin α3 gene cause a rare systemic disorder with interstitial lung disease, nephrotic syndrome, and epidermolysis bullosa.[131] An intracellular component of this complex, kindlin-1,[132] is mutated in the Kindler syndrome,[118] a disorder with skin blistering in infancy, progressive poikiloderma, sun sensitivity, and skin cancer. In the epidermis, kindlin-1 has important functions in β1 integrin–mediated outside-in signaling that regulates cell–matrix adhesions, cell migration, and polarity.[132] Thus, kindlin-1 is necessary for the stability of the dermal–epidermal junction and that, in addition to hemidesmosomes, tethering the actin cytoskeleton to cell–matrix adhesions offers alternative means to anchor basal epithelial cells to the basement membrane.

ANCHORING FILAMENTS

The anchoring filaments contain laminin 332 and the ectodomain of collagen XVII, 2 ligands that interact with each other.[115,127] The ectodomain of collagen XVII, which protrudes from the plasma membrane into the lamina lucida, has a loop structure consistent with its role as an anchoring filament protein.[133] Laminin 332 is a disulfide-bonded complex of α3, β3, and γ2 chains. The 2 splice variants of the α3 chain, α3A and α3B, associate with the α3 and γ2 chains to form laminin 3A32 and 3B32 (Fig. 15-7).[115,116] The individual chains are considerably truncated relative to other laminin chains, and this truncation is reflected in the loss of the structures equivalent to the short arms of other laminins. Additionally, the α3 and γ2 chains are proteolytically processed after secretion from the keratinocyte, further trimming the short arms.[115] The C-terminus of the α chain, longer than that of the β and γ chains, comprises 5 globular LG modules, LG1 through LG5, which interact with cell surface receptors. The α3β1 and α6β4 integrins have affinity for the LG1-3 domains, whereas the LG4-5 tandem has affinity for syndecans and β-dystroglycan on the keratinocyte surface.[115] The LG4-5 modules are proteolytically cleaved in most laminins, a process that may modulate interactions with cell surface receptors.[115] Laminin 332 binds to laminin 311 (α3β1γ1) and to the NC-1 domain of collagen VII and to the distal ectodomain of collagen XVII.[115,116] Genetic evidence demonstrates that laminin 332 is essential in keratinocyte adhesion, as null mutations in any of its component α3, β3, or γ2 chains result in severe junctional epidermolysis bullosa[118] (Chap. 60). The severity of the laminin 332 null phenotype indirectly emphasizes its functional importance in bridging the hemidesmosomes and the anchoring fibrils.

EPITHELIAL LAMINA DENSA

The basement membrane beneath and between the hemidesmosomes contains the α1–α2-chain containing collagen IV network, probably some α1–α2–α5–α6-chain containing collagen IV network, as well as nidogen, perlecan, and α3- and α5-chain containing laminins.[104,113-115] The laminin α3 chain can associate with the β1 and γ1 chains of laminin 311, which has the unique property of forming disulfide-bonded dimers with laminin 332. The major α3-containing laminin in the lamina densa between hemidesmosomes is probably the laminin 332–311 complex.[115] As the laminin α3 chain is a ligand for integrin α3β1 present between hemidesmosomes, binding of the laminin 332–311 complex to the intracellular actin cytoskeleton is likely to be mediated by this integrin. This is consistent with observations in mice and in humans[131] in which mutations of the integrin α3 chain cause loss of the basement membrane between hemidesmosomes but not beneath them. The N-termini of laminin 332 bind to collagen VII, the main component of the anchoring fibrils in the sublamina densa that, in turn,

binds tightly to collagen I containing fibrils so that anchoring filaments and fibrils are connected to each other and to the dermis.[134] The laminin 332–311 complex and laminin 511 (α5β1γ1) contain a γ1 chain and can therefore bind nidogens and the collagen IV network.[104,115] Further, nidogen 1 and fibulin 1 and 2 are ligands for the laminin γ2 chain.[104,115] These interactions are important for the integration of laminin 332 into the extracellular matrix before the maturation of the γ2 chain, as a substantial portion of N-terminus of the γ2 chain is cleaved in human adult skin. Yet another link, which strengthens dermal–epidermal cohesion, is provided by molecular interactions between perlecan within the lamina densa and fibrillin 1 in the microfibrils.[109]

ANCHORING FIBRILS

Collagen VII is the major component of the anchoring fibrils.[110,135] The collagen VII molecule is distinguished from other collagens in that it has a very long triple-helical domain, 450 nm in length. Globular domains exist at both ends of the triple helix, the N-terminal domain NC-1 is very large. The smaller *C*-propeptide, NC-2, is believed to facilitate the formation of the antiparallel, centrosymmetric dimers, before it is removed by the metalloproteinase bone morphogenetic protein 1[135] to yield a mature collagen VII. The dimers are covalently crosslinked through disulfide bonds at the carboxyl terminus, and they aggregate laterally to form the anchoring fibrils. The fibrils are further stabilized by tissue transglutaminase, which catalyzes the formation of covalent crosslinks.[135]

The NC-1 domain of collagen VII binds to laminin 332 and collagen IV within the lamina densa.[104,115] The triple-helical domains of an antiparallel collagen VII dimer make the length of the anchoring fibril. It extends perpendicularly from the lamina densa and either loops back into the lamina densa or inserts into the dermis.[110] The anchoring fibril network forms a scaffold that entraps large numbers of dermal fibrils and binds them through covalent crosslinks between collagen VII and collagen I,[134] thus securing the lamina densa to the subjacent dermis. In the acquired form of epidermolysis bullosa, epidermolysis bullosa acquisita (Chap. 56), and in bullous systemic lupus erythematosus (Chap. 61), autoantibodies target mainly the NC-1 domain of collagen VII.

Mutations in *COL7A1*, the gene encoding collagen VII, result in dystrophic epidermolysis bullosa (Chap. 60). Almost 1000 *COL7A1* mutations have been found in both recessive and dominant forms of dystrophic epidermolysis bullosa (Fig. 15-11), and the spectrum of biologic and clinical phenotypes is very broad.[118] In mouse models, deficiency of collagen VII recapitulated the clinical and morphologic characteristics of recessive dystrophic epidermolysis bullosa in humans.[136] These mice have been useful for testing of molecular therapy strategies for dystrophic epidermolysis bullosa. Cell-, gene-, and protein-based therapy approaches all have been tested.[137,138] Recently, repositioned small molecule drugs have shown promise as disease-modifying therapies.[139]

Figure 15-11 Skin fragility and blistering in dystrophic epidermolysis bullosa. Functional deficiency of collagen VII as a result of mutations in the *COL7A1* gene leads to trauma-induced separation of the epidermis and the dermis. The blister roof is below the lamina densa, leading to scar formation on healing of the blisters.

DERMAL CELL-MATRIX ADHESION

THE EXTRACELLULAR MATRIX OF THE DERMIS

The dermal–epidermal junction is continuous with the extracellular matrix in the papillary dermis and thus attaches the epidermis with the dermis. The pliability, elasticity, and tenacity of the dermis are provided by a highly organized extracellular matrix that contains structural networks of collagens, elastin, glycoproteins, and proteoglycans with specific functional properties.[140,141] Between the networks, the space is filled by a molecularly complex amorphous matrix that binds water. Beside their structural functions, both the fibrillar and the extrafibrillar matrix are biologically active in that they bind growth factors and cytokines, interact with cells, and regulate their functions.[140,141]

Recent proteomics studies have identified a multitude of matrix molecules and extended our knowledge about their aggregate structures and functional interactions.[142-144] A particular characteristic of extracellular matrix molecules is adhesiveness, and resident skin cells, inflammatory cells, tumor cells, and even microorganisms can adhere to them.[130] Through receptor-mediated interactions, matrix suprastructures or their fragments guide cellular functions under normal skin homeostasis, growth, and regeneration, but also under pathologic conditions such as in tumors.[145] In the following, the major protein families of the dermal extracellular matrix are delineated; for more detailed information, the reader is referred to recent

reviews that provide comprehensive descriptions of the structure and functions of the extracellular matrix in the skin and other tissues.[111,112,140-144,146,147]

Collagens, a family of 28 different collagen types, are the most abundant proteins in the dermis and represent 75% of its dry weight and 20% to 30% of its volume.[140] All collagen molecules have a basic structure of 3 α-chains, which have glycine (Gly) as every third amino acid, and thus a typical sequence of (Gly-X-Y)*n*. During biosynthesis, the nascent α-chains undergo posttranslational modifications and are folded into a triple helix.[148] In a tissue-specific manner, different collagen types assemble into distinct fibrils or networks containing mixtures of several collagens and/or proteoglycans or glycoproteins that have specialized functions. In the dermis, the classic, cross-banded fibrils recognizable in the electron microscope contain collagen I, III, V, XII, and XIV. In contrast, collagen VI polymerizes into microfibrils. Other collagens are needed to provide cohesion of the epidermis or the vascular structures with the dermal extracellular matrix, for example, collagens VII, XIII, XVII, and XXIII in the epidermal basement membrane zone or collagens VIII, XV, and XVIII in the vascular basement membrane zone. Collagens have earlier been believed to be extremely stable and static structures, but it has recently become clear that collagen turnover is mediated by both control of synthesis and by an intricate catabolic network of proteinases and their inhibitors.[149]

Elastin provides dermal elasticity. Elastin molecules are rich in repetitive hydrophobic sequences and are highly crosslinked. The crosslinks between several individual molecules provide for both elasticity and insolubility of the elastic fibers. Characteristically, the fibers can be stretched by 100% or more, and still return to their original form. The main components of elastic fibers are elastin (90%) and microfibrils, which attach the fibers to the surrounding structures.[111,140] The microfibrils extend from the basement membrane into the papillary dermis, where they gradually merge with the elastic fiber plexus parallel to the dermal–epidermal junction, which appears to be continuous with the elastic fibers deep within the reticular dermis. A major component of the microfibrils is fibrillin, a family of very large glycoproteins, but they also contain or associate with other proteins, such as microfibril-associated glycoproteins (MAGPs), latent TGF-β-binding proteins (LTBPs), fibulins, EMILIN-1, and in the papillary dermis, collagen XVI.[112,150] Fibrillin 1 interacts with perlecan to attach the microfibrils to the basement membrane at the dermal–epidermal junction. Apart from guiding elastin fibril assembly and imparting tissue integrity, fibrillins and LTBPs serve as regulators of cell signaling in the dermis by controlling bioavailability of TGF-β_1. LTBPs contain multiple proteinase-sensitive sites, providing the means to solubilize the large latent complex from the dermal matrix.[112] Fibrillin can also bind to another group of signaling molecules, the bone morphogenetic proteins (BMPs). Thus, fibrillin/LTBP can target activatable TGF-β or BMPs into distinct matrix or cellular sites.

The dermal fibril networks and cells are embedded in an amorphous extrafibrillar matrix that binds water and provides the tautness of the skin. It contains proteoglycans, glycoproteins, and hyaluronic acid, which are molecularly and structurally diverse, highly organized, and biologically active.[121,140,146] Glycosaminoglycans are negatively charged polysaccharides that can bind large amounts of ions and water. They bind to different proteins to form proteoglycans with variable number, type, and length of the glycosaminoglycan chains. Four different proteoglycan-bound glycosaminoglycans are known: chondroitin sulfate, dermatan sulfate, keratan sulfate, and heparan sulfate. Versican is a major proteoglycan in the dermis, it is associated with elastic fibers and forms huge complexes with hyaluronic acid, which provides the skin with its tautness.[151] Hyaluronic acid is a ubiquitous glycosaminoglycan without protein core, a giant polysaccharide composed of *N*-acetylglucosamine/glucuronic acid disaccharides. Perlecan is the major heparan sulfate proteoglycan of basement membranes that can sequester and present growth factors to their receptors.[122] Collagen XVIII, a hybrid collagen/proteoglycan, is found in epidermal and vascular basement membranes in the skin.[123] Small leucine-rich proteoglycans, such as decorin and biglycan, have multiple functions; for example, they bind to collagen fibrils and regulate their assembly, they bind TGF-β, and are connected to immune reactions by signaling through toll-like receptors.[152] Syndecans are transmembrane and glypicans membrane–anchored heparan sulfate proteoglycans, which control cell adhesion to the matrix and interact with multiple extracellular proteins, including growth factors, and thereby regulate cell functions.[140]

CELL–MATRIX INTERACTIONS REGULATE CELLULAR FUNCTIONS

The extracellular matrix is in constant crosstalk with fibroblasts and other cell types in the dermis and guides their functions during development, aging, and regeneration, but also under pathologic conditions such as inflammation and tumorigenesis. Matrix molecules can influence a wide range of cellular events, ranging from cytoskeletal organization to cell differentiation, adhesion and migration, and apoptosis.[141,153-155] The cells in the dermis use different receptors to receive signals from the extracellular matrix, including integrins, cell surface proteoglycans, and transmembrane collagens. The family of β_1 integrins represents the most common class of matrix receptors.[130] The α-subunit of the integrin determines the ligand specificity, but the affinity and the specificity seem to vary.[145,153] The outside-in-signaling can occur via different mechanisms. Cues from the extracellular matrix

can induce receptor clustering on the cell surface and thus induce cytoplasmic complex formation between the receptors and linker molecules that bind to the cytoskeleton and thus modulate cell shape. Activation of different receptors by the extracellular matrix can also induce signaling via several signal transduction pathways, for example, the focal adhesion kinase (pp^{125}FAK)– or microtubule-associated protein (MAP) kinase-pathways that regulate transcription, cell proliferation, or differentiation.[145] Recently, it has become clear that cells also sense and react to the stiffness of the surrounding extracellular matrix. Integrins mediate the mechanosensation through binding dynamics of different integrin types, activation of stretch-activated ion channels, or unfolding of mechanosensitive proteins in focal adhesion complexes.[130] In turn, the stiffness of the dermal extracellular matrix is determined by the molecular and suprastructural composition of the collagen, elastin, and microfibrillar networks and the extrafibrillar matrix and its water content.[156,157] All these matrix–cell interactions regulate cell functions and are highly relevant not only under physiologic conditions but also in pathologically altered dermis in, for example, fibrosis or tumor stroma.[158] For detailed information on this topic, the reader is referred to excellent recent reviews.[146,147,150,153,156]

CONCLUSIONS

The epidermis and the dermal-epidermal junction are continuous with the extracellular matrix in the papillary dermis. The cell–cell and cell–basement membrane adhesion in the epidermis, and the cell–matrix adhesion in the dermis secure the attachment of the 2 skin layers and provide the skin with its resistance against environmental influences. The integrity of these adhesion structures is essential for protection of the entire organism against mechanical, physical, or microbial insults. This is indirectly demonstrated by human disorders in which cutaneous adhesion structures are targeted by either genetic mutations or by pathogenic antibodies that perturb the functions of the target proteins, such as in epidermolysis bullosa or pemphigus. Tremendous advances have recently been made in discerning the molecular and functional details of epidermal and dermal adhesion and in understanding the molecular pathology of skin fragility. This knowledge will facilitate the design of biologically valid therapeutic approaches not only for rare genetic and common autoimmune adhesion disorders but also for physiologic processes such as skin aging.

ACKNOWLEDGMENTS

The authors gratefully acknowledge the contribution of Thomas Krieg, Monique Aumailley, Manuel Koch, Mon-Li Chu, and Jouni Uitto, the authors of Chap. 63 in the 8th edition of this textbook. The contents of the chapter have been used as a basis for the section “Dermal Cell-Matrix Adhesion”.

REFERENCES

1. Getsios S, Huen AC, Green KJ. Working out the strength and flexibility of desmosomes. *Nat Rev Mol Cell Biol.* 2004;5:271-281.
2. Calkins CC, Setzer SV. Spotting desmosomes: the first 100 years. *J Invest Dermatol.* 2007;127(suppl):E2-E3.
3. Staehelin LA. Structure and function of intercellular junctions. *Int Rev Cytol.* 1974;39:191-283.
4. Gorbsky G, Steinberg MS. Isolation of the intercellular glycoproteins of desmosomes. *J Cell Biol.* 1981; 90:243-248.
5. Staehelin LA, Hull BE. Junctions between living cells. *Sci Am.* 1978;238:140-152.
6. Jonca N, Guerrin M, Hadjiolova K, et al. Corneodesmosin, a component of epidermal corneocyte desmosomes, displays homophilic adhesive properties. *J Biol Chem.* 2002;277:5024-5029.
7. Groot KR, Sevilla LM, Nishi K, et al. Kazrin, a novel periplakin-interacting protein associated with desmosomes and the keratinocyte plasma membrane. *J Cell Biol.* 2004;166:653-659.
8. Ihrie RA, Marques MR, Nguyen BT, et al. Perp is a p63-regulated gene essential for epithelial integrity. *Cell.* 2005;120:843-856.
9. Lechler T, Fuchs E. Desmoplakin: an unexpected regulator of microtubule organization in the epidermis. *J Cell Biol.* 2007;176:147-154.
10. Sumigray KD, Chen H, Lechler T. Lis1 is essential for cortical microtubule organization and desmosome stability in the epidermis. *J Cell Biol.* 2011;194: 631-642.
11. North AJ, Bardsley WG, Hyam J et al. Molecular map of the desmosomal plaque. *J Cell Sci.* 1999; 112:4325-4336.
12. Al-Amoudi A, Castano-Diez D, Devos DP, et al. The three-dimensional molecular structure of the desmosomal plaque. *Proc Natl Acad Sci U S A.* 2011;108: 6480-6485.
13. Koch PJ, Goldschmidt MD, Zimbelmann R, et al. Complexity and expression patterns of the desmosomal cadherins. *Proc Natl Acad Sci U S A.* 1992;89: 353-357.
14. Arnemann J, Sullivan KH, Magee AI, King IA, Buxton RS. Stratification-related expression of isoforms of the desmosomal cadherins in human epidermis. *J Cell Sci.* 1993;104:741-750.
15. Wu H, Stanley JR, Cotsarelis G. Desmoglein isotype expression in the hair follicle and its cysts correlates with type of keratinization and degree of differentiation. *J Invest Dermatol.* 2003;120:1052-1057.
16. Wang LH, Katube K, Jiang WW, et al. Immunohistochemical distribution patter of desmocollin 3, desmocollin 1 and desmoglein 1,2 in the pemphigus of oral mucosa and skin. *Oral Med Pathol.* 2000;5:87-94.
17. Mahoney MG, Hu Y, Brennan D, et al. Delineation of diversified desmoglein distribution in stratified squamous epitheli: implications in diseases. *Exp Dermatol.* 2006;15:101-109.
18. Chen YJ, Chang JT, Lee L, et al. DSG3 is overexpressed in head neck cancer and is a potential molecular target for inhibition of oncogenesis. *Oncogene.* 2007;26: 467-476.
19. Schafer S, Koch PJ, Franke WW. Identification of the ubiquitous human desmoglein, Dsg2, and the expression catalogue of a subfamily of desmosomal cadherins. *Exp Cell Res.* 1994;211:391-399.

20. Whittock NV, Bower C. Genetic evidence for a novel human desmosomal cadherin, desmoglein 4. *J Invest Dermatol.* 2003;120:523-530.
21. Bazzi H, Getz A, Mahoney MG, et al. Desmoglein 4 is expressed in highly differentiated keratinocytes and trichocytes in human epidermis and hair follicle. *Differentiation.* 2006;74:129-140.
22. King IA, Sullivan KH, Bennett R Jr, et al. The desmocollins of human foreskin epidermis: identification and chromosomal assignment of a third gene and expression patterns of the three isoforms. *J Invest Dermatol.* 1995;105:314-321.
23. Khan K, Hardy R, Haq A, et al. Desmocollin switching in colorectal cancer. *Br J Cancer.* 2006;95:1367-1370.
24. Posthaus H, Dubois CM, Muller E. Novel insights into cadherin processing by subtilisin-like convertases. *FEBS Lett.* 2003;536:203-208.
25. Shapiro L, Fannon AM, Kwong PD, et al. Structural basis of cell-cell adhesion by cadherins. *Nature.* 1995;374:327-337.
26. Boggon TJ, Murray J, Chappuis-Flament S, et al. C-cadherin ectodomain structure and implications for cell adhesion mechanisms. *Science.* 2002;296: 1308-1313.
27. Al-Amoudi A, Diez DC, Betts MJ, et al. The molecular architecture of cadherins in native epidermal desmosomes. *Nature.* 2007;450:832-837.
28. Harrison OJ, Brasch J, Lasso G, et al. Structural basis of adhesive binding by desmocollins and desmogleins. *Proc Natl Acad Sci U S A.* 2016;113:7160-7165.
29. Amagai M, Karpati S, Klaus-Kovtun V, et al. The extracellular domain of pemphigus vulgaris antigen (desmoglein 3) mediates weak homophilic adhesion. *J Invest Dermatol.* 1994;102:402-408.
30. Chitaev NA, Troyanovsky SM. Direct Ca2+-dependent heterophilic interaction between desmosomal cadherins, desmoglein and desmocollin, contributes to cell-cell adhesion. *J Cell Biol.* 1997;138:193-201.
31. Marcozzi C, Burdett ID, Buxton RS, et al. Coexpression of both types of desmosomal cadherin and plakoglobin confers strong intercellular adhesion. *J Cell Sci.* 1998;111:495-509.
32. Hatzfeld M, Haffner C, Schulze K, et al. The function of plakophilin 1 in desmosome assembly and actin filament organization. *J Cell Biol.* 2000;149: 209-222.
33. Bonné S, Gilbert B, Hatzfeld M, et al. Defining desmosomal plakophilin-3 interactions. *J Cell Biol.* 2003; 161:403-416.
34. Tucker DK, Stahley SN, Kowalczyk AP. Plakophilin-1 Protects Keratinocytes from Pemphigus Vulgaris IgG by Forming Calcium-Independent Desmosomes. *J Invest Dermatol.* 2014;134(4):1033-1043.
35. Den ZN, Cheng X, Merchad-Sauvage M, et al. Desmocollin 3 is required for pre-implantation development of the mouse embryo. *J Cell Sci.* 2006;119:482-489.
36. Koch PJ, Walsh MJ, Schmelz M, et al. Identification of desmoglein, a constitutive desmosomal glycoprotein, as a member of the cadherin family of cell adhesion molecules. *Eur J Cell Biol.* 1990;53:1-12.
37. Amagai M, Klaus-Kovtun V, Stanley JR. Autoantibodies against a novel epithelial cadherin in pemphigus vulgaris, a disease of cell adhesion. *Cell.* 1991; 67:869-877.
38. Amagai M, Matsuyoshi N, Wang ZH, et al. Toxin in bullous impetigo and staphylococcal scalded-skin syndrome targets desmoglein 1. *Nat Med.* 2000; 6:1275-1277.
39. Descargues P, Deraison C., Bonnart C, et al. Spink5-deficient mice mimic Netherton syndrome through degradation of desmoglein 1 by epidermal protease hyperactivity. *Nat Genet.* 2004;37:56-65.
40. Hanakawa Y, Schechter N, Lin C, et al. Molecular mechanisms of blister formation in bullous impetigo and staphylococcal scalded skin syndrome. *J Clin Invest.* 2002;110:53-60.
41. Sekiguchi M, Futei Y, Fujii Y, et al. Dominant autoimmune epitopes recognized by pemphigus antibodies map to the N-terminal adhesive region of desmogleins. *J Immunol.* 2001;167:5439-5448.
42. Li N, Aoki V, Hans-Filho G, et al. The role of intramolecular epitope spreading in the pathogenesis of endemic pemphigus foliaceus (fogo selvagem). *J Exp Med.* 2003;197:1501-1510.
43. Chan PT, Ohyama B, Nishifuji K, et al. Immune response towards the amino-terminus of desmoglein 1 prevails across different activity stages in nonendemic pemphigus foliaceus. *Br J Dermatol.* 2010;162:1242-1250.
44. Karpati S, Amagai M, Liu WL, et al. Identification of desmoglein 1 as autoantigen in a patient with intraepidermal neutrophilic IgA dermatosis type of IgA pemphigus. *Exp Dermatol.* 2000;9:224-228.
45. Rickman L, Simrak D, Stevens HP, et al. N-terminal deletion in a desmosomal cadherin causes the autosomal dominant skin disease striate palmoplantar keratoderma. *Hum Mol Genet.* 1999;8:971-976.
46. Keren H, Bergman R, Mizrachi M, et al. Diffuse nonepidermolytic palmoplantar keratoderma caused by a recurrent nonsense mutation in DSG1. *Arch Dermatol.* 2005;141:628.
47. Milingou M, Wood P, Masouye I, et al. Focal palmoplantar keratoderma caused by an autosomal dominant inherited mutation in the desmoglein 1 gene. *Dermatology.* 2006;212:117-122.
48. Pilichou K, Nava A, Basso C, et al. Mutations in desmoglein-2 gene are associated with arrhythmogenic right ventricular cardiomyopathy. *Circulation.* 2006;113:1171-1179.
49. Payne AS, Ishii K, Kacir S, et al. Genetic and functional characterization of human pemphigus vulgaris monoclonal autoantibodies isolated by phage display. *J Clin Invest.* 2005;115:888-899.
50. Di Zenzo G, Di Lullo G, Corti D, et al. Pemphigus autoantibodies generated through somatic mutations target the desmoglein-3 cis-interface. *J Clin Invest.* 2012;122:3781-3790.
51. Ohyama B, Nishifuji K, Chan PT, et al. Epitope spreading is rarely found in pemphigus vulgaris by large-scale longitudinal study using desmoglein 2-based swapped molecules. *J Invest Dermatol.* 2012; 132:1158-1168.
52. Koch PJ, Mahoney MG, Ishikawa H, et al. Targeted disruption of the pemphigus vulgaris antigen (desmoglein 3) gene in mice causes loss of keratinocyte cell adhesion with a phenotype similar to pemphigus vulgaris. *J Cell Biol.* 1997;137:1091-1102.
53. Sharma P, Mao X, Payne AS. Beyond steric hindrance: the role of adhesion signaling pathways in the pathogenesis of pemphigus. *J Dermatol Sci.* 2007;48:1-14.
54. Wang J, Kwon J, Ding X, et al. Nonsecretory IgA1 autoantibodies targeting desmosomal component desmoglein 3 in intraepidermal neutrophilic IgA dermatosis. *Am J Pathol.* 1997;150:1901-1907.
55. Schaffer JV, Bazzi H, Vitebsky A, et al. Mutations in the desmoglein 4 gene underlie localized autosomal

recessive hypotrichosis with monilethrix hairs and congenital scalp erosions. *J Invest Dermatol.* 2006;126:1286-1291.
56. Shimomura Y, Sakamoto F, Kariya N, et al. Mutations in the desmoglein 4 gene are associated with monilethrix-like congenital hypotrichosis. *J Invest Dermatol.* 2006;126:1281-1285.
57. Zlotogorski A, Marek D, Horev L, et al. An autosomal recessive form of monilethrix Is caused by mutations in DSG4: clinical overlap with localized autosomal recessive hypotrichosis. *J Invest Dermatol.* 2006;126:1292-1296.
58. Kljuic A, Bazzi H, Sundberg JP, et al. Desmoglein 4 in hair follicle differentiation and epidermal adhesion: evidence from inherited hypotrichosis and acquired pemphigus vulgaris. *Cell.* 2003;113:249-260.
59. Lai-Cheong JE, Arita K, McGrath JA. Genetic diseases of junctions. *J Invest Dermatol.* 2007;127:2713-2725.
60. Nagasaka T, Nishifuji K, Ota T, et al. Defining the pathogenic involvement of desmoglein 4 in pemphigus and staphylococcal scalded skin syndrome. *J Clin Invest.* 2004;114:1484-1492.
61. Hashimoto T, Kiyokawa C, Mori O, et al. Human desmocollin 1 (Dsc1) is an autoantigen for the subcorneal pustular dermatosis type of IgA pemphigus. *J Invest Dermatol.* 1997;109:127-131.
62. Heuser A, Plovie ER, Ellinor PT, et al. Mutant desmocollin-2 causes arrhythmogenic right ventricular cardiomyopathy. *Am J Hum Genet.* 2010;79:1081-1088.
63. Simpson MA, Mansour S, Ahnood D, et al. Homozygous mutation of desmocollin-2 in arrhythmogenic right ventricular cardiomyopathy with mild palmoplantar keratoderma and woolly hair. *Cardiology.* 2009;113:28-34.
64. Ayub M, Basit S, Jelani M, et al. A homozygous nonsense mutation in the human desmocollin-3 (DSC3) gene underlies hereditary hypotrichosis and recurrent skin vesicles. *Am J Hum Genet.* 2009;85:1-6.
65. Hisamatsu Y, Amagai M, Garrod DR, et al. The detection of IgG and IgA autoantibodies to desmocollins 1-3 by enzyme-linked immunosorbent assays using baculovirus-expressed proteins, in atypical pemphigus but not in typical pemphigus. *Br J Dermatol.* 2004;151:73-83.
66. Mao X, Nagler AR, Farber SA, et al. Autoimmunity to desmocollin 3 in pemphigus vulgaris. *Am J Pathol.* 2010;177:2724-2730.
67. Rafei D, Muller R, Ishii N, et al. IgG autoantibodies against desmocollin 3 in pemphigus sera induce loss of keratinocyte adhesion. *Am J Pathol.* 2011;178:718-723.
68. Cowin P, Kapprell HP, Franke WW, et al. Plakoglobin: a protein common to different kinds of intercellular adhering junctions. *Cell.* 1986;46:1063-1073.
69. Korman NJ, Eyre RW, Klaus-Kovtun V, et al. Demonstration of an adhering-junction molecule (plakoglobin) in the autoantigens of pemphigus foliaceus and pemphigus vulgaris. *N Engl J Med.* 1989;321:631-635.
70. Peifer M, Berg S, Reynolds AB. A repeating amino acid motif shared by proteins with diverse cellular roles. *Cell.* 1994;76:789-791.
71. Chitaev NA, Leube RE, Troyanovsky RB, et al. The binding of plakoglobin to desmosomal cadherins: patterns of binding sites and topogenic potential. *J Cell Biol.* 1996;133:359-369.
72. Wahl JK, Sacco PA, McGranahan-Sadler TM, et al. Plakoglobin domains that define its association with the desmosomal cadherins and the classical cadherins: identification of unique and shared domains. *J Cell Sci.* 1996;109(pt 5):1143-1154.
73. Witcher LL, Collins R, Puttagunta S, et al. Desmosomal cadherin binding domains of plakoglobin. *J Biol Chem.* 1996;271:10904-10909.
74. Kowalczyk AP, Bornslaeger EA, Borgwardt JE, et al. The amino-terminal domain of desmoplakin binds to plakoglobin and clusters desmosomal cadherin-plakoglobin complexes. *J Cell Biol.* 1997;139:773-784.
75. Williams BO, Barish GD, Klymkowsky MW, et al. A comparative evaluation of beta-catenin and plakoglobin signaling activity. *Oncogene.* 2000;19:5720-5728.
76. Williamson L, Raess NA, Caldelari R, et al. Pemphigus vulgaris identifies plakoglobin as key suppressor of c-Myc in the skin. *EMBO J.* 2006;25:3298-3309.
77. Bornslaeger EA, Godsel LM, Corcoran CM, et al. Plakophilin 1 interferes with plakoglobin binding to desmoplakin, yet together with plakoglobin promotes clustering of desmosomal plaque complexes at cell-cell borders. *J Cell Sci.* 2001;114:727-738.
78. Drees F, Pokutta S, Yamada S, et al. Alpha-catenin is a molecular switch that binds E-cadherin-beta-catenin and regulates actin-filament assembly. *Cell.* 2005;123:903-915.
79. Yamada S, Pokutta S, Drees F, et al. Deconstructing the cadherin-catenin-actin complex. *Cell.* 2005;123:889-901.
80. McKoy G, Protonotarios N, Crosby A, et al. Identification of a deletion in plakoglobin in arrhythmogenic right ventricular cardiomyopathy with palmoplantar keratoderma and woolly hair (Naxos disease). *Lancet.* 2000;355:2119-2124.
81. Cabral RM, Liu L, Hogan C, et al. Homozygous mutations in the 5′ region of the JUP gene result in cutaneous disease but normal heart development in children. *J Invest Dermatol.* 2010;130(6):1543-150.
82. Pigors M, Kiritsi D, Krumpelmann S, et al. Lack of plakoglobin leads to lethal congenital epidermolysis bullosa: a novel clinico-genetic entity. *Hum Mol Genet.* 2011;20:1811-1819.
83. Mueller H, Franke WW. Biochemical and immunological characterization of desmoplakins I and II, the major polypeptides of the desmosomal plaque. *J Mol Biol.* 1983;163:647-671.
84. Green KJ, Parry DAD, Steinert PS, et al. Structure of the human desmoplakins. Implications for function in the desmosomal plaque. *J Biol Chem.* 1990;265:2603-2612.
85. Uzumcu A, Norgett EE, Dindar A, et al. Loss of desmoplakin isoform I causes early onset cardiomyopathy and heart failure in a Naxos-like syndrome. *J Med Genet.* 2006;43:e05.
86. Green KJ, Virata MLA, Elgart GW, et al. Comparative structural analysis of desmoplakin, bullous pemphigoid antigen and plectin: members of a new gene family involved in organization of intermediate filments. *Int J Biol Macrobiol.* 1992;14:145-153.
87. Stappenbeck TS, Green KJ. The desmoplakin carboxyl terminus coaligns with and specifically disrupts intermediate filament networks when expressed in cultured cells. *J Cell Biol.* 1992;116:1197-1209.
88. Gallicano GI, Kouklis P, Bauer C, et al. Desmoplakin is required early in development for assembly of desmosomes and cytoskeletal linkage. *J Cell Biol.* 1998;143:2009-2022.
89. Armstrong DK, McKenna KE, Purkis PE, et al. Haploinsufficiency of desmoplakin causes a striate subtype of palmoplantar keratoderma. *Hum Mol Genet.* 1999;8:143-148.

90. Carvajal-Huerta L. Epidermolytic palmoplantar keratoderma with wooly hair and dilated cardiomyopathy. *J Am Acad Dermatol.* 1998;39:418-421.
91. Jonkman MF, Pasmooij AMG, Pasmans SGMA, et al. Loss of desmoplakin tail causes lethal acantholytic epidermolysis bullosa. *Am J Hum Genet.* 2005;77:653-660.
92. Wolf A, Krause-Gruszczynska M, Birkenmeier O, et al. Plakophilin 1 stimulates translation by promoting eIF4A1 activity. *J Cell Biol.* 2010;188:463-471.
93. Schmidt A, Langbein L, Rode M, et al. Plakophilins 1a and 1b: widespread nuclear proteins recruited in specific epithelial cells as desmosomal plaque components. *Cell Tissue Res.* 1997;290:481-499.
94. Schmidt A, Langbein L, Pratzel S, et al. Plakophilin 3—a novel cell-type-specific desmosomal plaque protein. *Differentiation.* 1999;64:291-306.
95. Mertens C, Kuhn C, Moll R, et al. Desmosomal plakophilin 2 as a differentiation marker in normal and malignant tissues. *Differentiation.* 1999;64:277-290.
96. McGrath JA, McMillan JR, Shemanko CS, et al. Mutations in the plakophilin 1 gene result in ectodermal dysplasia/skin fragility syndrome. *Nat Genet.* 1997;17:240-244.
97. Gerull B, Heuser A, Wichter T, et al. Mutations in the desmosomal protein plakophilin-2 are common in arrhythmogenic right ventricular cardiomyopathy. *Nat Genet.* 2004;36:1162-1164.
98. van Tintelen JP, Entius MM, Bhuiyan ZA, et al. Plakophilin-2 mutations are the major determinant of familial arrhythmogenic right ventricular dysplasia/cardiomyopathy. *Circulation.* 2006;113:1650-1658.
99. Sevilla LM, Nachat R, Groot KR, et al. Mice deficient in involucrin, envoplakin, and periplakin have a defective epidermal barrier. *J Cell Biol.* 2007;179:1599-1612.
100. Levy-Nissenbaum E, Betz RC, Frydman M, et al. Hypotrichosis simplex of the scalp is associated with nonsense mutations in CDSN encoding corneodesmosin. *Nat Genet.* 2003;34:151-153.
101. Timpl R. Macromolecular organization of basement membranes. *Curr Opin Cell Biol.* 1996;8(5):618-624.
102. Glentis A, Gurchenkov V, Matic Vignjevic D. Assembly, heterogeneity, and breaching of the basement membranes. *Cell Adh Migr.* 2014;8(3):236-245.
103. Yurchenco PD. Basement membranes: cell scaffoldings and signaling platforms. *Cold Spring Harb Perspect Biol.* 2011;3(2). pii: a004911.
104. van Agtmael T, BrucknerTuderman L. Basement membranes and human disease. *Cell Tissue Res.* 2010;339:167-188.
105. Kelley LC, Lohmer LL, Hagedorn EJ, et al. Traversing the basement membrane in vivo: a diversity of strategies. *J Cell Biol.* 2014;204(3):291-302.
106. Has C, Nyström A. Epidermal basement membrane in health and disease. *Curr Top Membr.* 2015;76:117-170.
107. Eady RA, McGrath JA, McMillan JR. Ultrastructural clues to genetic disorders of skin: the dermal epidermal junction. *J Invest Dermatol.* 1994;103(5 suppl):13S-18S.
108. Goldberg M, Escaig-Haye F. Is the lamina lucida of the basement membrane a fixation artifact? Eur. *J Cell Biol.* 1986;42:365-368.
109. Behrens DT, Villone D, Koch M, et al. The epidermal basement membrane is a composite of separate laminin- or collagen IV-containing networks connected by aggregated perlecan, but not by nidogens. *J Biol Chem.* 2012;287(22):18700-18709.
110. Keene DR, Sakai LY, Lunstrum GP, et al. Collagen VII forms an extended network of anchoring fibrils. *J Cell Biol.* 1987;104:611-621.
111. Baldwin AK, Simpson A, Steer R, et al. Elastic fibres in health and disease. *Expert Rev Mol Med.* 2013;15:e8.
112. Sengle G, Sakai LY. The fibrillin microfibril scaffold: a niche for growth factors and mechanosensation? *Matrix Biol.* 2015;47:3-12.
113. Mao M, Alavi MV, Labelle-Dumais C, et al. Type IV collagens and basement membrane diseases: cell biology and pathogenic mechanisms. *Curr Top Membr.* 2015;76:61-116.
114. Cummings CF, Pedchenko V, Brown KL, et al. Extracellular chloride signals collagen IV network assembly during basement membrane formation. *J Cell Biol.* 2016;213(4):479-494.
115. Yurchenco PD. Integrating activities of laminins that drive basement membrane assembly and function. *Curr Top Membr.* 2015;76:1-30.
116. Domogatskaya A, Rodin S, Tryggvason K. Functional diversity of laminins. *Annu Rev Cell Dev Biol.* 2012;28:523-553.
117. Wegner J, Loser K, Apsite G, et al. Laminin α5 in the keratinocyte basement membrane is required for epidermal-dermal intercommunication. *Matrix Biol.* 2016;56:24-41.
118. Has C, Bruckner-Tuderman L. The genetics of skin fragility. *Annu Rev Genomics Hum Genet.* 2014;15:245-268.
119. Durbeej M. Laminin-α2 chain-deficient congenital muscular dystrophy: pathophysiology and development of treatment. *Curr Top Membr.* 2015;76:31-60.
120. Bader BL, Smyth N, Nedbal S, et al. Compound genetic ablation of nidogen 1 and 2 causes basement membrane defects and perinatal lethality in mice. *Mol Cell Biol.* 2005;25:6846-6856.
121. Iozzo RV, Schaefer L. Proteoglycan form and function: a comprehensive nomenclature of proteoglycans. *Matrix Biol.* 2015;42:11-55.
122. McCarthy KJ. The basement membrane proteoglycans perlecan and agrin: something old, something new. *Curr Top Membr.* 2015;76:255-303.
123. Seppinen L, Pihlajaniemi T. The multiple functions of collagen XVIII in development and disease. *Matrix Biol.* 2011;30(2):83-92.
124. Chung H, Multhaupt HA, Oh ES, et al. Syndecans and their crucial roles during tissue regeneration. *FEBS Lett.* 2016;590(15):2408-2417.
125. Walko G, Castañón MJ, Wiche G. Molecular architecture and function of the hemidesmosome. *Cell Tissue Res.* 2015;360(3):529-544.
126. Franzke CW, Bruckner-Tuderman L, Blobel CP. Shedding of collagen XVII/BP180 in skin depends on both ADAM10 and ADAM9. *J Biol Chem.* 2009;284:23386-23396.
127. Nishie W, Kiritsi D, Nyström A, et al. Dynamic interactions of epidermal collagen XVII with the extracellular matrix: laminin 332 as a major binding partner. *Am J Pathol.* 2011;179(2):829-837.
128. Matsumura H, Mohri Y, Binh NT, et al. Hair follicle aging is driven by transepidermal elimination of stem cells via COL17A1 proteolysis. *Science.* 2016;351(6273):aad4395.
129. Karamatic Crew V, Burton N, Kagan A, et al. CD151, the first member of the tetraspanin (TM4) superfamily detected on erythrocytes, is essential for the correct assembly of human basement membranes in kidney and skin. *Blood.* 2004;104:2217-2223.

130. Heisenberg CP, Fässler R. Cell-cell adhesion and extracellular matrix: diversity counts. *Curr Opin Cell Biol.* 2012;24(5):559-561.
131. Has C, Spartà G, Kiritsi D, et al. Integrin α3 mutations with kidney, lung, and skin disease. *N Engl J Med.* 2012;366(16):1508-1514.
132. Rognoni E, Ruppert R, Fässler R. The kindlin family: functions, signaling properties and implications for human disease. *J Cell Sci.* 2016;129(1):17-27.
133. Nonaka S, Ishiko A, Masunaga T, et al. The extracellular domain of BPAG2 has a loop structure in the carboxy terminal flexible tail in vivo. *J Invest Dermatol.* 2000;115:889-892.
134. Villone D, Fritsch A, Koch M, et al. Supramolecular interactions in the dermo-epidermal junction zone: collagen VII in anchoring fibrils tightly bind to fibrillar collagen I. *J Biol Chem.* 2008;283:24506-24513.
135. Bruckner-Tuderman L. Dystrophic epidermolysis bullosa: pathogenesis and clinical features. *Dermatol Clin.* 2010;28:107-114.
136. Nyström A, Velati D, Mittapalli VR, et al. Collagen VII plays a dual role in wound healing. *J Clin Invest.* 2013;123(8):3498-3509.
137. Uitto J, Bruckner-Tuderman L, Christiano AM, et al. Progress toward treatment and cure of epidermolysis bullosa: summary of the DEBRA International research symposium EB2015. *J Invest Dermatol.* 2016;136(2):352-358.
138. Nyström A, Bornert O, Kühl T. Cell therapy for basement membrane-linked diseases. *Matrix Biol.* 2017;57-58:124-139.
139. Nyström A, Thriene K, Mittapalli V, et al. Losartan ameliorates dystrophic epidermolysis bullosa and uncovers new disease mechanisms. *EMBO Mol Med.* 2015;7(9):1211-1228.
140. Nyström A, Bruckner-Tuderman L. Biology of the extracellular matrix. In: Bolognia JL, Jorizzo JL, Schaffer JV, eds. *Dermatology.* 4th ed. Philadelphia, PA: Elsevier; 2018.
141. Mouw JK, Ou G, Weaver VM. Extracellular matrix assembly: a multiscale deconstruction. *Nat Rev Mol Cell Biol.* 2014;15(12):771-785.
142. Küttner V, Mack C, Rigbolt KT, et al. Global remodelling of cellular microenvironment due to loss of collagen VII. *Mol Syst Biol.* 2013;9:657.
143. Naba A, Clauser KR, Ding H, et al. The extracellular matrix: tools and insights for the "omics" era. *Matrix Biol.* 2016;49:10-24.
144. Randles MJ, Humphries MJ, Lennon R. Proteomic definitions of basement membrane composition in health and disease. *Matrix Biol.* 2017;57-58:12-28.
145. Eckes B, Krieg T, Wickström SA. Role of integrin signalling through integrin-linked kinase in skin physiology and pathology. *Exp Dermatol.* 2014;23(7):453-456.
146. Lee DH, Oh JH, Chung JH. Glycosaminoglycan and proteoglycan in skin aging. *J Dermatol Sci.* 2016;83(3):174-181.
147. Eckes B, Nischt R, Krieg T. Cell-matrix interactions in dermal repair and scarring. *Fibrogenesis Tissue Repair.* 2010;3:4.
148. Myllyharju J, Kivirikko KI. Collagens, modifying enzymes and their mutations in humans, flies and worms. *Trends Genet.* 2004;20:33-43.
149. Kühl T, Mezger M, Hausser I, et al. Collagen VII half-life at the dermal-epidermal junction zone: implications for mechanisms and therapy of genodermatoses. *J Invest Dermatol.* 2016;136(6):1116-1123.
150. Zeyer KA, Reinhardt DP. Fibrillin-containing microfibrils are key signal relay stations for cell function. *J Cell Commun Signal.* 2015;9(4):309-325.
151. Wight TN, Kang I, Merrilees MJ. Versican and the control of inflammation. *Matrix Biol.* 2014;35:152-161.
152. Chen S, Birk DE. The regulatory roles of small leucine-rich proteoglycans in extracellular matrix assembly. *FEBS J.* 2013;280(10):2120-2137.
153. Winograd-Katz SE, Fässler R, Geiger B, et al. The integrin adhesome: from genes and proteins to human disease. *Nat Rev Mol Cell Biol.* 2014;15(4):273-288.
154. Starke J, Wehrle-Haller B, Friedl P. Plasticity of the actin cytoskeleton in response to extracellular matrix nanostructure and dimensionality. *Biochem Soc Trans.* 2014;42(5):1356-1366.
155. Wolf K, Friedl P. Extracellular matrix determinants of proteolytic and non-proteolytic cell migration. *Trends Cell Biol.* 2011;21(12):736-744.
156. Wen JH, Vincent LG, Fuhrmann A, et al. Interplay of matrix stiffness and protein tethering in stem cell differentiation. *Nat Mater.* 2014;13(10):979-987.
157. Irianto J, Pfeifer CR, Xia Y, et al. SnapShot: mechanosensing matrix. *Cell.* 2016;165(7):1820-1820.e1.
158. Andrews JP, Marttala J, Macarak E, et al. Keloids: the paradigm of skin fibrosis-pathomechanisms and treatment. *Matrix Biol.* 2016;51:37-46.

Chapter 16 :: Microbiome of the Skin

:: Heidi H. Kong

AT-A-GLANCE

The microbes on skin are:

- Bacteria, fungi, viruses.
- Healthy vs pathogenic.

Human skin hosts a variety of commensal and pathogenic microbes, including bacteria, fungi, and viruses. The most common methods to study skin microbes are traditionally based on cultivation techniques, especially to help diagnose infections. Koch's postulates for linking a causative microbial agent to a disease represent a familiar and fundamental paradigm for understanding host–microbial interactions. Beyond the classical roles of infection-causing microbes, studies continue to examine how microbes may interact with the host as commensal symbionts and potentially contribute as pathobionts to noninfectious inflammatory diseases, such as atopic dermatitis or psoriasis, and in neoplasms, such as Merkel cell carcinoma. Ongoing research investigating host–microbial interactions increasingly uses multiple different concepts and methods to provide insights into human skin microbes.

One basic approach to exploring the symbionts and pathobionts among skin microbes is to initially determine the composition of the microbes that reside on human skin. A challenge of relying solely on cultivation methods is the difficulty in selecting the optimal culturing methods to capture the entire microbial community of human skin; some microbes may flourish under generic culture conditions, yet other microbes can require specific nutrients or special conditions. The advances in scientific methods and genomic sequencing technologies have enabled a more global culture-independent examination of the skin's complex communities of microbes.[1] Deeper study of the composition and the associated functions of the multitude of microbes residing on human skin may help uncover the roles of skin microbes in health and disease.

The constant exposure of human skin to surrounding environments presents innumerable potential interactions with such things as dust particles, humidity, clothing, emollients, other people, and pets. As a result, a rapidly growing number of studies are examining the microbiome of living organisms, the built environment, and inanimate objects that come into contact with human skin or skin debris, as well as the many potential interventions (eg, antibiotics, hygiene products, probiotics) that may alter the human skin microbiome.[2-18] This chapter introduces the concept of the skin microbiome, the major constituents of the cutaneous microbiome, and some of the interactions between skin microbes and the host, primarily highlighting culture-independent studies of the resident microbiome of human skin in healthy individuals and dermatologic disorders.

DEFINING SKIN MICROBIOME STUDIES

FROM CULTURING TO GENOMICS

Based on standard culturing methods, it is well-known that human skin harbors various microbes. Because many skin diseases are associated with microbes, the field of dermatology has been instrumental in investigating the composition of cultured bacteria and fungi on human skin and in exploring host–microbial interactions.[19-23] These culture-based studies have defined some of the basic tenets of skin microbes that continue to hold true decades later, including the presence of *Cutibacterium* (formerly *Propionibacterium*) and *Malassezia* (formerly *Pityrosporum*) on many individuals. An early example is Mary J. Marples' fundamental body of work on skin ecology including illustrations of scaled models of the body (homunculi) with relative distributions of skin microbes and physiologic features.[20] Pillsbury, Kligman, Noble, Somerville, Maibach, and many colleagues used cultivation methods to contribute significantly to the general understanding of the microbiology of skin in disease states and in healthy individuals.[19,20,24-28]

In addition to studying isolates cultivated from skin, advancements in scientific technologies have provided methods to study human skin microbes. By sequencing microbial DNA present within a sample, it is possible to eliminate initial culturing of a sample that could potentially skew the resultant findings on the composition of skin microbes. The reduced cost and increased access of sequencing have facilitated the investigations into the human microbiome. The term *microbiome* has been defined as all the microorganisms, their genomes, and the surrounding environmental conditions present in a particular ecosystem such as skin.[29] Thus, rather than studying solitary bacterial or fungal isolates, skin microbiome investigations refer to studies of the global cutaneous microbial communities. Of note, because standard microbiome studies are based on the DNA present within a sample, these methods cannot distinguish whether the DNA was from a dead or living

organism and from a resident or transient microbe. Therefore, microbiome research can complement cultivation methods to collect isolates that can be used in mechanistic studies and other -omic methods that examine the genes that are actively expressed (transcriptomics) or what proteins are present (proteomics). Additionally, existing laboratory strains of microbes are repeatedly propagated and may have different biologic properties than microbes cultivated directly from patients.

The National Institutes of Health Common Fund launched the Human Microbiome Project in 2008 to catalyze the growth in microbiome research, bringing together multidisciplinary fields to explore the skin, gut, oral, vaginal, and nasal microbiomes in patients and healthy volunteers. In addition to developing protocols for study design, sample processing, sequencing, and analysis, the Human Microbiome Project has provided a reference database of human microbiome sequences.[30-32] Advances in newer sequencing methods and other omic techniques, as well as the novel approaches to interrogate the host organism, continue to expand the abilities to examine human microbes.

GENERAL SEQUENCING METHODS OF MICROBIOME STUDIES

Based on the most established methods of microbial sequencing, which were extensively developed by environmental microbial ecologists, many of the human microbiome studies have often focused on bacteria, similar to cultivation-based investigations. Bacteria, along with cyanobacteria, are prokaryotes which have the 16S ribosomal RNA (rRNA) gene. The 16S rRNA is part of the 30S ribosomal subunit and is evolutionarily conserved because of its essential function. By focusing on the 16S rRNA gene for sequencing, investigators can target all the bacteria present within a sample without depending on the ability to cultivate these microbes.[33] There is sufficient variation among the 16S rRNA genes that enables taxonomic identification of the individual bacterial members of a given ecosystem, from soil to oceans and dental plaque to skin. With the widespread use of the 16S rRNA target gene, there are large established databases of 16S rRNA gene sequences that can be used as reference databases to taxonomically identify sequences originating from human samples. However, the nomenclature used to define a distinct bacterial entity differs between the fields of genomics and clinical microbiology. Genomic studies define a specific bacterial taxa based on the percent similarity of the genome, whereas traditional microbiology originally defined a distinct species based on morphologic, biochemical, and/or physiologic characteristics.[34] This distinction is important, particularly from a clinician's perspective, because genus- and species-level identification of a microorganism has clinical implications. Microbial genomics can provide a deeper understanding of what defines a "species" and potentially how it relates to human disease. Initial human microbiome studies used a method of sequencing (Sanger sequencing) to sequence all 9 hypervariable regions of the 16S rRNA gene, but technologic developments in sequencing methods (see Chap. 18) rely on sequencing fewer hypervariable regions of the 16S rRNA gene at a faster pace and cheaper cost, but at the expense of less-complete genomic information.

Fungi are also clinically important. Investigations about fungi have included studies regarding the roles in human infections/diseases, production of active metabolites, and influence on bacterial growth. Similar to the application of genomic sequencing of bacteria, studies have used molecular methods to study the "mycobiome". Unlike the universal use of the 16S rRNA gene as a marker gene in bacterial studies, the marker genes selected in mycobiome studies have included either a single region or combined regions targeting the 18S rRNA gene, the 28S rRNA gene, and/or the internal transcribed spacer (ITS) regions within fungal genomes.[35-39] The use of different marker genes in mycobiome studies with the resultant development of different fungal sequence reference databases, as well as the availability of relatively fewer fungal genomes than bacterial genomes, have hindered the ability to compare across studies. However, the clinical relevance of skin fungi in dermatologic disorders, and intriguing studies examining interactions between bacteria and fungi, highlight the importance of exploring the skin mycobiome.[35,37,40,41]

Studies of the human virome have been notably fewer in number than bacterial studies. The heterogeneity of viral genomes creates challenges in genomically capturing the potential breadth (ie, single-stranded and double-stranded DNA and RNA viruses) of the human virome. Genomics-based studies typically focus on DNA-only viruses or specific groups of viruses (eg, human papillomaviruses or polyomaviruses),[42-49] highlighting some of the limitations of marker gene–based studies.

Simultaneously sequencing multiple microbial kingdoms within a single skin sample requires shotgun metagenomic sequencing, which is quite complex from the processing and computational standpoints. Shotgun metagenomic sequencing is performed initially by shearing and sequencing all DNA present within a sample rather than focusing only on sequencing marker genes such as 16S or 18S rRNA genes. Thus, shotgun metagenomic sequencing can provide additional information beyond the identification of microbes within 1 kingdom (eg, bacteria), such that the functional genetic potential of the resident microbes is also sequenced and analyzed.[30,31,43,44] The limitations of shotgun metagenomic sequencing include the higher costs and the analytical challenges. The ability to sequence has outpaced the important research into the function

and biology of genes. As a result, there is incomplete knowledge of the functions of many genes, and a large proportion of resultant sequences from metagenomic sequencing studies are classified as unknown functions. Although sequencing can provide tremendous insights into human–microbial interactions, further investigations into the basic sciences to understand mechanisms of genes (and gene expression and proteins) are fundamental and critical to understanding the clinical relevance of the human skin microbiome.

SKIN MICROBIOME STUDY DESIGN

Similar to other areas of human research, study design can significantly affect the quality of the resultant findings in skin microbiome studies. Due to the sensitivity of microbiome studies related to potential confounders and contamination, with skin in particular, reviews and commentaries on important considerations for human microbiome studies have been published to emphasize the importance of careful study design (Fig. 16-1).[50-53] Studies that examine multiple body sites have demonstrated that the human microbiome varies based on the specific body site: gut, skin, oral, nares, and vaginal.[30,31,54] Of all the body sites evaluated in published studies, the skin is comprised of the most diverse communities of bacteria.[30,54] This capacity to host a relatively wide variety of microbes is likely linked to the range of microenvironments present in human skin, which have been classified in some studies based on the physiologic skin features of moist, dry, and sebaceous.[43,44,55] Similar to the body site–specificity of microbial communities observed across the gut, skin, oral, nasal, and vaginal communities, the skin microbiomes are also highly specific to the particular anatomical region of skin under investigation.

Skin samples can be collected via premoistened swab, superficial scraping, biopsy, tape strip, and/or cup scrub from defined anatomical regions.[53] Then DNA is isolated from the clinical samples. The type of DNA preparation and sequencing depends on whether the focus is on a particular kingdom of interest (ie, bacteria or fungi) or shotgun metagenomics. The sequencing reads are processed bioinformatically to enable subsequent analysis of the composition, diversity, and similarities of the microbial communities based on clinical metadata.

A major challenge in studying the microbiome of the skin is the presence of a low microbial biomass, or small amount of organic matter, leading to limited quantities of DNA. In contrast, other body regions, including the gut and oral cavity, contain large amounts of microbial DNA. The relatively low amounts of microbial DNA on skin result in samples that can be easily contaminated. For example, a small fixed amount of contaminant DNA would be a larger proportion of the microbial DNA isolated from a skin sample as compared to the microbial DNA collected from a stool sample. Because

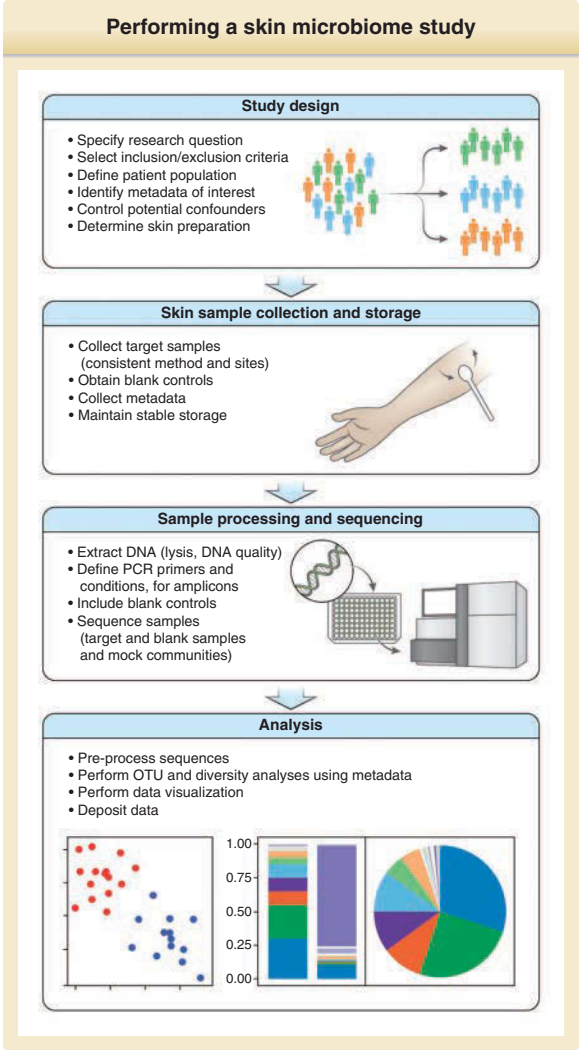

Figure 16-1 Performing a skin microbiome study. The general principles for a skin microbiome study of study design, sample collection and storage, sample processing and sequencing, and analysis with examples of data visualization are outlined. OTU, operational taxonomic unit; PCR, polymerase chain reaction. (From Kong HH, Andersson B, Clavel T, et al. Performing skin microbiome research: a method to the madness. *J Invest Dermatol*. 2017;137(3):561-568, with permission.)

of the high risk of contamination in skin microbiome studies, appropriate negative and positive controls have been recommended for sample collection, sample processing, and sequencing.[50,52,53]

With microbiome sequencing, it is difficult to quantitatively determine microbial bioburden (number of microbes). Culture-based studies use colony-counting and other methods to compare the relative bioburden of microbes present in one sample versus another. Microbiome studies typically measure results in relative proportions or percentages. Additionally, most genomic studies and analyses cannot distinguish whether microbes are dead or alive. If contamination is ruled out and microbiome sequencing identifies microbial reads (sequences), some of the microbial DNA may be from dead organisms. However, more sophisticated analyses

of metagenomic data may allow inference of whether particular microbes were proliferating at the time of sampling in comparison to other microbes.[56]

Although genomic sequencing can provide culture-independent taxonomic and metagenomic information on the microbial communities present on skin, additional studies on mechanism often require use of microbial isolates. Because two strain isolates that are classified as the same species (eg, methicillin-sensitive *Staphylococcus aureus* and methicillin-resistant *S. aureus*) can exhibit different biologic effects, collecting clinically relevant strains in parallel with microbiome studies may optimally inform subsequent functional studies.

COMPOSITION OF THE SKIN MICROBIOME

The existing knowledge of skin microbes is based on extensive work from many investigators, demonstrating the presence of both commensals and pathogens on skin including *Staphylococcus epidermidis, S. aureus, Cutibacterium acnes, Corynebacterium* spp., and *Pseudomonas aeruginosa.*[20,22,57-62] A common finding from many culture-based studies is that the skin is a diverse habitat from both macroscopic and microscopic perspectives.[63] Macroscopically, different anatomical regions (eg, forehead vs palm, flexural folds vs dorsal surfaces) are typically associated with certain bacteria and fungi. This topographical variation in skin microbes is also observed microscopically with regards to the biodiversity and localization of cutaneous microbes or microbial DNA. The surface of the skin is composed of ridges, creases, and appendageal openings and ducts. Each of these microscopic structures (eg, hair follicles, eccrine/apocrine glands, sebaceous glands) are distributed in different proportions over the skin surface, resulting in distinct microenvironments that can harbor and influence the composition of skin microbes.[63,64] For example, bacteria can break down sebum produced by sebaceous glands and the fatty substance excreted by apocrine sweat glands into byproducts. Given the microscopic topography, studies into host–cutaneous microbial interactions have examined both the different skin structures and the different layers of skin.[63,65,66]

GENOMICS STUDIES OF SKIN BACTERIAL COMMUNITIES

The early genomics-based studies focused on healthy skin and examined a single anatomical area of skin in healthy individuals, demonstrating skin microbes are more diverse than the most commonly recognized bacteria (eg, staphylococci, *Corynebacterium, Cutibacterium*) identified through culture-based studies and highlighting different methods for skin sample collection.[37,67,68] Additional studies of healthy volunteers examined multiple skin sites, including skin regions that are sites of predilection for dermatoses, including atopic dermatitis and psoriasis.[54,55] These studies showed that different skin sites harbored distinct populations of bacteria (site specificity). Even though the skin microbiome is site-specific, bacterial communities in different skin sites can share similar features based on the microenvironment of the anatomical skin site (eg, sebaceous areas, moist skin creases, dry flat surfaces).[14,43,55] Consistent with findings from culture-based studies, highly sebaceous sites (eg, forehead, retroauricular crease) were predominated by *C. acnes.* Sites that included flexural or moist folds (eg, antecubital fossa, inguinal crease) harbored bacterial species that can grow favorably in humid conditions (eg, *Corynebacterium* spp. and *Staphylococcus* spp.).[69,70] The flat surfaces of skin-hosted populations of bacteria demonstrated greater variability between study subjects as compared to sebaceous and moist skin sites. These findings highlighted the diversity and similarities of skin bacterial communities from specific anatomic regions over the human skin surface.

To further define the spatial and temporal variability of the skin microbiome, investigators studied the skin bacterial communities based on right and left symmetry, within an individual and between different individuals over time. Although the entire skin surface of a single healthy individual is comprised of multiple different skin bacterial communities, bilateral and symmetrical skin sites analyzed in healthy individuals, with the exception of hands, generally demonstrated highly similar skin microbiomes.[54,55,67,71] Because skin sites are often exposed to different surfaces and environments, potential alterations in the skin microbiome in response to specific exposures and over time have been evaluated in several studies. Examining shifts of the skin bacterial communities after exposure to bacterial communities from different skin sites (forehead and forearm) and the tongue shows that some skin sites (eg, forehead) can revert back to the originally observed bacterial communities faster than other skin sites (eg, forearm).[54] Studies have also examined the effects of hygiene practices on the skin microbiome. The elapsed time since the last handwashing affected the skin bacterial communities: some bacteria (eg, Staphylococceae, Streptococcaceae) were relatively more abundant on hands that were recently washed as compared to other bacteria (eg, Propionibacteriaceae) that were relatively more abundant with longer time intervals since the last handwashing.[71] Alteration or usage of hygiene products is associated with changes in the skin microbiome diversity in some healthy populations,[14] but not in others.[13] Studies examining the longitudinal variation in human skin bacterial communities using both 16S rRNA gene sequencing[55] and shotgun metagenomics sequencing[44,72] show that the skin bacterial communities can remain relatively stable up to 2 years after initial sampling. This stability of skin bacterial communities is specific to the particular skin site, as well specific to each individual,[44,72] and may be more likely influenced by the host environment, including global geographic location, than noncutaneous body sites.[73-76]

The largest human microbiome studies have focused on surveys of healthy young and middle-aged adults[30,31,77] with fewer studies examining the skin microbiome in children or the elderly. General changes in skin among different age groups are well-known,[78] and cultivation studies show that skin bacterial communities shift based on the age or sexual maturity of individuals.[20,22,26,79] Although the skin of neonates is considered sterile prior to birth, the skin is thought to quickly acquire skin microbes. In the skin microbiome studies of infants and young children that have been performed,[80-84] the bacterial diversity of skin has been observed to be low shortly after birth. The skin microbiome in neonates soon after delivery resembles maternal vaginal communities if born vaginally, and maternal skin communities if delivered by cesarean section.[15,82] By the second day of life, the site specificity of skin bacterial communities is observable.[83] Similar to culture-based studies, microbiome studies show that the skin bacterial communities in neonates, infants, and young children are distinct from more sexually mature children and adults, particularly at certain skin sites.[80,81,83,84] The skin microbiomes in older adults have been less frequently studied but may also demonstrate differences when comparing to younger individuals.[85] Skin physiology, including sebum production and hydration levels, may influence the composition of bacterial communities on skin.[86,87]

With the increase in skin microbiome studies, there has been an expansion of the cutaneous disorders under investigation using genomic sequencing of skin bacteria (Table 16-1). Based on common clinical observations and the considerable literature examining the link between atopic dermatitis and high frequency of *S. aureus* colonization and infections,[19,88] several genomic studies have more closely investigated the role of the microbiome in atopic dermatitis patients.[83,89-93] Questions remain whether the skin dysbiosis with increased staphylococci (*S. aureus* and, in some studies, *S. epidermidis*) observed in atopic dermatitis affects the development and/or worsening of atopic dermatitis or is a consequence of eczematous skin providing an environment conducive to staphylococcal growth. Several murine and in vitro studies suggest skin bacteria can elicit exacerbation of skin inflammation,[94-98] and one study showed topical application of *S. aureus* was associated with more-severe dermatitis.[99] However, human studies remain more challenging to study directly. If the murine studies that show that skin bacteria can modulate the developing skin immune system early in life correspond to what may occur in human skin,[100] longitudinal investigations of birth cohorts may provide a unique ability to examine skin microbes prior to the development of atopic dermatitis.[83]

Prior studies in psoriasis patients identified cocci in skin lesions,[101] isolated *S. aureus*,[28,102] and linked streptococci to psoriasis.[101,103] Consequently, microbial genomic techniques have been used to analyze the skin microbes in psoriatic skin lesions.[37,104-108] Some have identified increased relative abundances of the phylum *Proteobacteria* in psoriatic skin lesions as compared to controls.[105,108] Whereas the association between atopic dermatitis and staphylococci in microbiome studies is more consistently observed, the features of the skin microbiome in psoriasis are less defined.

In many cultivation studies, *C. acnes* frequently has been linked with acne.[109,110] As a result, several sequencing studies examined the skin microbiome in acne patients and identified different strains of *C. acnes* in individuals with acne as compared to controls.[111-115] However, the question of the role of *C. acnes* in acne causation remains unresolved[116-118] and continues to be an active area of investigation.

In addition to atopic dermatitis, psoriasis, and acne, other dermatologic conditions have been studied using microbiome methods. These studies include general atopy,[119] bacterial infections,[120,121] body odor,[122] dandruff,[39] diabetic wounds,[123-125] ichthyosis vulgaris,[126] melanoma and melanocytic nevi,[127] mycosis fungoides,[128] vitiligo,[129] and eczematous dermatitis related to primary immunodeficiency syndromes.[130,131] Distinctive patterns of skin microbiomes have been observed in several of these investigations, and further work is needed to elucidate the mechanism of the relationships between host and cutaneous microbiomes.

TABLE 16-1

Skin Microbiome Findings in Dermatologic Disorders[a]

SKIN DISEASE	SKIN MICROBIOME FINDINGS
Acne	Different strains of *Cutibacterium acnes* associated with acne patients versus controls; staphylococci are also associated with acne patients.
Atopic dermatitis	Increased relative abundances of *Staphylococcus aureus* and *Staphylococcus epidermidis* observed in flared skin; different *S. aureus* clonal strains associated with atopic dermatitis; higher fungal diversity associated with atopic dermatitis as compared to controls.
Diabetic skin and wounds	Bacterial communities in diabetic skin are less diverse; diabetic wounds associated with staphylococci and some fungi.
Primary immunodeficiency syndrome-associated dermatitis	Higher numbers of different fungi with increased *Aspergillus* and *Candida*.
Psoriasis	Lesional skin associated with decreased bacterial diversity; higher fungal diversity observed in psoriasis versus controls.

[a]Examples of microbiome findings described in patients with several dermatologic disorders.

GENOMICS STUDIES OF SKIN FUNGAL COMMUNITIES

Conditions that favor the growth of bacteria may not optimally culture fungal organisms. Cultivation studies focused on isolating fungi from healthy human skin

have isolated predominantly *Malassezia*, including *Malassezia globosa, Malassezia restricta,* and *Malassezia sympodialis*.[20,132,133] Even among the species within the genus *Malassezia*, some species grow more quickly than others.[134] As a result of the heterogeneity in optimal cultivation conditions, a comprehensive culture-based evaluation of the relative composition of skin microbes, particularly fungi, can be quite challenging. As genomics-based studies are cultivation-independent, microbiome methods can provide a global examination of microbial constituents in a given sample. Similar to culture-based studies,[20,133] genomics-based fungal studies in healthy individuals demonstrate that *Malassezia* spp. predominate in most skin sites,[35,37,41,135,136] except on feet.[35,135] Additionally, these studies show that the predominant species of *Malassezia* can vary based on the location on the skin surface.[35,135] Mycobiome studies showed *M. restricta* was predominant on the head and facial areas of healthy adult volunteers and *M. globosa* was predominant on truncal areas of skin in the same subjects. Other skin sites evaluated demonstrated mixed communities of *Malassezia.* In the studies examining fungal communities of feet, non-*Malassezia* fungi (eg, *Aspergillus, Cryptococcus, Epicoccum, Rhodotorula*) predominated.[35,135]

The topographical distribution of skin fungi likely reflects the heterogeneity of the many microenvironments of the human skin surface and the abilities of various fungal species to adapt to a particular skin region. As the predominant skin fungi, *Malassezia* isolates from skin have been studied and are known to lack the fatty synthase gene. Thus, *Malassezia* spp. are lipid-dependent and generally require lipid supplements for growth in the laboratory. Genomic differences have been identified among multiple different *Malassezia* species, particularly in the lipase and phospholipase gene content.[137] The variation in lipid profiles across different skin regions could account for the preferences of certain species of *Malassezia* found in some skin sites as compared to other sites.[138,139]

As observed in microbiome studies examining skin bacterial communities, fungal skin communities also differ depending on the age of the individual. Younger individuals are typically colonized by *Malassezia* less frequently and in lower abundances than in adults; however, colonization rates increase as individuals age during puberty and adulthood (Fig. 16-2).[134,140,141] These cultivation-based results were similar to a ITS1-based mycobiome study in which healthy preadolescent subjects between the ages of 8 and 13 years had low relative abundances of *Malassezia* and higher fungal diversity than healthy adults.[142] This has been attributed to the lipid-dependence of *Malassezia* and the increased sebaceous gland activity and sebum production in the skin of pubertal and adult individuals.[40] Additional differences are also observed in the predominant species of *Malassezia* in the skin of healthy children and more sexually mature individuals. Both culture-based and culture-independent methods show that adults have lower relative abundances of *M. globosa* and higher relative abundances of *M. restricta.* In contrast, children typically have higher relative abundances of *M. restricta* among the *Malassezia* spp. observed in their skin.[35,40,135] This distinction may be based on the variability in the lipid preferences of different *Malassezia* species.[137,142,143]

Interestingly, the high relative abundance of *Malassezia* spp. in postpubertal individuals corresponds to the higher frequency of tinea versicolor in adults, and the higher relative abundances of non-*Malassezia* fungi in the skin of prepubertal children corresponds to the higher prevalence of tinea capitis and tinea corporis in pediatric populations.[144-146] Whether mycobiome differences across different age ranges is directly linked with the predilection of dermatophyte infections in certain ages is unknown.[40] Mycobiome studies have also been performed in several dermatologic disorders, including psoriasis[37,147] and atopic dermatitis.[41] However, additional research is required to investigate whether the skin mycobiome influences dermatologic diseases.

GENOMICS STUDIES OF SKIN VIRAL COMMUNITIES

Skin viruses are of significant clinical interest because of the dermatologic diseases associated with viruses, including verruca vulgaris (human papillomaviruses), herpes labialis (herpes simplex viruses), and Merkel cell carcinoma (Merkel cell polyomavirus). Because studying cultured viruses requires use of living cells known to be infected by the viruses of interest, the application of sequencing could be used to facilitate investigations of cutaneous viruses. A major challenge of virome research is the lack of a marker gene common to all viruses, as compared to the 16S rRNA gene used for bacteria or the 18S rRNA/ITS1/28S rRNA genes used for fungi. Because DNA sequencing technology is more well-established than RNA sequencing, cutaneous virome studies have generally focused on DNA viruses and bacteriophages.

Shotgun metagenomic sequencing has been used to examine the healthy human skin virome.[42-46,49] The most common DNA viruses observed include bacteriophages, papillomaviruses, polyomaviruses, and circoviruses. The most common bacteriophages are those linked with *Cutibacterium* and *Staphylococcus*, which corresponds to the known presence of these bacterial genera in skin.[42-45] The populations of papillomaviruses observed in the microbiomes studies include both known human papillomaviruses and previously unknown papillomaviruses. With growing interest in human skin polyomaviruses after identification of the Merkel cell polyomavirus in Merkel cell carcinomas,[148] Merkel cell polyomavirus and other human polyomaviruses have been found in the skin of healthy individuals[149,150] and in some patients with skin diseases.[151-153] Unlike the site-specific predominance of bacterial and fungal communities observed in skin microbiome studies, the relative abundances of cutaneous viruses can vary widely over the skin surface

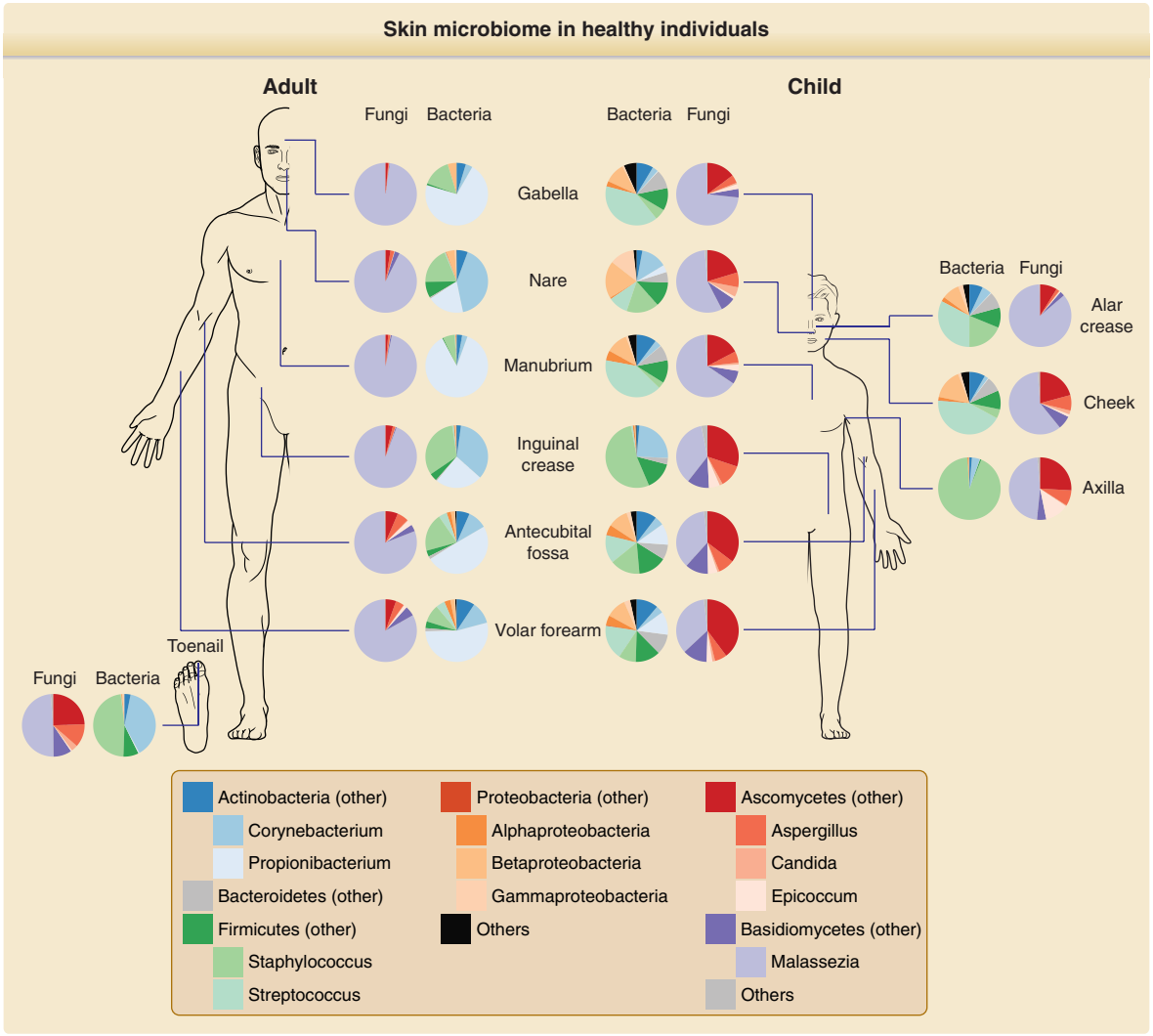

Figure 16-2 Skin microbiome in healthy individuals. The composition of skin bacterial and fungal communities from different anatomical regions in healthy adults are less diverse than in healthy children. (Figure derived from sequencing data from Jo et al.[40] and Findley et al.[35])

within and between healthy individuals. Additionally, the stability of skin viral communities can fluctuate over time within the same person.[44] The application of culture-independent sequencing technologies will improve the ability to study skin viruses and potential links to dermatologic disorders.

CONCLUSIONS

A notable driver in the increase in human microbiome studies is the interest in the gut microbiome and the research examining the potential links to human disorders such as inflammatory bowel disorders, *Clostridium difficile* colitis, diabetes, cardiovascular diseases, and cancer immunotherapies. In addition, the promising therapeutic outcomes with the use of fecal microbiota transplantation in patients with refractory and debilitating *C. difficile* colitis has spawned significant enthusiasm in gut microbiome investigations. With the relative ease in collecting sufficient microbial DNA from the high microbial biomass in stool, gut microbiome studies significantly outnumber investigations of the skin microbiome.

Although the majority of human microbiome studies have focused on single body sites (gut, oral, vaginal, nares, or skin), human diseases, including those in the realm of dermatology, can be systemic disorders such as vitiligo and other autoimmune disorders, psoriasis and the links to psoriasis arthritis and cardiovascular disorders, or pyoderma gangrenosum and inflammatory bowel disease. Thus, there may be instances in which the gut bacteria may affect skin diseases, or skin bacteria may affect distal body sites. Noncutaneous microbiome studies have been performed in patients with dermatologic conditions, including psoriasis/psoriatic arthritis[154] and atopic dermatitis.[155] These and other studies highlight the complexity of human disease and a major reason for the United States' National Institutes of Health Common Fund (the funder of the Human Microbiome Project) to bring together diverse

areas of research from clinical medicine to basic research and from microbiology,[156] biochemistry, and molecular biology to -omics[157-159] and computational and systems biology, to jointly tackle these research challenges. Collaborative efforts across research fields and advances in technologies will be critical in unraveling the complexity of these diseases and the potential relationships with the human microbiome.

Some of the goals of investigating the skin microbiome are to determine how the microbial communities influence human health and disease and to potentially develop preventive or therapeutic interventions. To date, there remain significant gaps in both what is defined as a "healthy" skin microbiome and the understanding of the possible biologic links between the presence/absence and/or relative abundances of skin microbes and human health and disease. Although the therapeutic successes of fecal microbiota transplantation for *C. difficile* colitis has generated tremendous optimism for similar therapies for dermatologic conditions, enthusiasm has been tempered by the gaps in what is known about the skin microbiome and the factors that control the balance between commensalism and pathogenicity. Additional research will be fundamental to our ability to harness the power of the human skin microbiome.

REFERENCES

1. Dekio I, Hayashi H, Sakamoto M, et al. Detection of potentially novel bacterial components of the human skin microbiota using culture-independent molecular profiling. *J Med Microbiol*. 2005;54(pt 12):1231-1238.
2. Ross AA, Neufeld JD. Microbial biogeography of a university campus. *Microbiome*. 2015;3:66.
3. Shin H, Pei Z, Martinez KA 2nd, et al. The first microbial environment of infants born by C-section: the operating room microbes. *Microbiome*. 2015;3:59.
4. Wood M, Gibbons SM, Lax S, et al. Athletic equipment microbiota are shaped by interactions with human skin. *Microbiome*. 2015;3:25.
5. Bik HM, Maritz JM, Luong A, et al. Microbial community patterns associated with automated teller machine keypads in New York City. *mSphere*. 2016;1(6):e00226.
6. Hsu T, Joice R, Vallarino J, et al. Urban transit system microbial communities differ by surface type and interaction with humans and the environment. *mSystems*. 2016;1(3):e00018.
7. Lax S, Smith DP, Hampton-Marcell J, et al. Longitudinal analysis of microbial interaction between humans and the indoor environment. *Science*. 2014;345(6200):1048-1052.
8. Fierer N, Lauber CL, Zhou N, et al. Forensic identification using skin bacterial communities. *Proc Natl Acad Sci U S A*. 2010;107(14):6477-6481.
9. Miletto M, Lindow SE. Relative and contextual contribution of different sources to the composition and abundance of indoor air bacteria in residences. *Microbiome*. 2015;3:61.
10. Song SJ, Lauber C, Costello EK, et al. Cohabiting family members share microbiota with one another and with their dogs. *Elife*. 2013;2:e00458.
11. Chase J, Fouquier J, Zare M, et al. Geography and location are the primary drivers of office microbiome composition. *mSystems*. 2016;1(2):e00022.
12. Abeles SR, Jones MB, Santiago-Rodriguez TM, et al. Microbial diversity in individuals and their household contacts following typical antibiotic courses. *Microbiome*. 2016; 4(1):39.
13. Two AM, Nakatsuji T, Kotol PF, et al. The cutaneous microbiome and aspects of skin antimicrobial defense system resist acute treatment with topical skin cleansers. *J Invest Dermatol*. 2016;136(10):1950-1954.
14. Perez Perez GI, Gao Z, Jourdain R, et al. Body site is a more determinant factor than human population diversity in the healthy skin microbiome. *PLoS One*. 2016;11(4):e0151990.
15. Dominguez-Bello MG, De Jesus-Laboy KM, Shen N, et al. Partial restoration of the microbiota of cesarean-born infants via vaginal microbial transfer. *Nat Med*. 2016;22(3):250-253.
16. Afshinnekoo EC, Meydan C, Chowdhury S, et al. Geospatial resolution of human and bacterial diversity with city-scale metagenomics. *Cell Syst*. 2015;1(1):72-87.
17. Misic AM, Davis MF, Tyldsley AS, et al. The shared microbiota of humans and companion animals as evaluated from Staphylococcus carriage sites. *Microbiome*. 2015;3:2.
18. Robertson CE, Baumgartner LK, Harris JK, et al. Culture-independent analysis of aerosol microbiology in a metropolitan subway system. *Appl Environ Microbiol*. 2013;79(11):3485-3493.
19. Leyden JJ, Marples RR, Kligman AM. *Staphylococcus aureus* in the lesions of atopic dermatitis. *Br J Dermatol*. 1974;90(5):525-530.
20. Marples M. *The Ecology of the Human Skin*. Springfield, IL: Charles C Thomas; 1965.
21. Nizet V, Ohtake T, Lauth X, et al. Innate antimicrobial peptide protects the skin from invasive bacterial infection. *Nature*. 2001;414(6862):454-457.
22. Noble WC, Somerville DA. Microbiology of human skin. In: Rook AH, ed. *Major Problems in Dermatology*. Vol 2. 2nd ed. London, UK: WB Saunders; 1974:341.
23. Sanford JA, Gallo RL. Functions of the skin microbiota in health and disease. *Semin Immunol*. 2013;25(5):370-377.
24. Pillsbury DM, Nichols AC. Bacterial flora of the normal and infected skin; an evaluation of various methods of performing skin cultures. *J Invest Dermatol*. 1946;7(6):365-373.
25. Evans CA, Smith WM, Johnston EA, et al. Bacterial flora of the normal human skin. *J Invest Dermatol*. 1950;15(4):305-324.
26. Somerville DA. The normal flora of the skin in different age groups. *Br J Dermatol*. 1969;81(4):248-258.
27. Marples RR, Downing DT, Kligman AM. Control of free fatty acids in human surface lipids by *Corynebacterium acnes*. *J Invest Dermatol*. 1971;56(2):127-131.
28. Aly R, Maibach HE, Mandel A. Bacterial flora in psoriasis. *Br J Dermatol*. 1976;95(6):603-606.
29. Marchesi JR, Ravel J. The vocabulary of microbiome research: a proposal. *Microbiome*. 2015;3:31.
30. Human Microbiome Project Consortium. Structure, function and diversity of the healthy human microbiome. *Nature*. 2012;486(7402):207-214.
31. Human Microbiome Project Consortium. A framework for human microbiome research. *Nature*. 2012;486(7402):215-221.

32. Aagaard K, Petrosino J, Keitel W, et al. The Human Microbiome Project strategy for comprehensive sampling of the human microbiome and why it matters. *FASEB J*. 2013;27(3):1012-1022.
33. Woese CR, Fox GE. Phylogenetic structure of the prokaryotic domain: the primary kingdoms. *Proc Natl Acad Sci U S A*. 1977;74(11):5088-5090.
34. Konstantinidis KT, Tiedje JM. Genomic insights that advance the species definition for prokaryotes. *Proc Natl Acad Sci U S A*. 2005;102(7):2567-2572.
35. Findley K, Oh J, Yang J, et al. Topographic diversity of fungal and bacterial communities in human skin. *Nature*. 2013;498(7454):367-370.
36. Khot PD, Ko DL, Fredricks DN. Sequencing and analysis of fungal rRNA operons for development of broad-range fungal PCR assays. *Appl Environ Microbiol*. 2009;75(6):1559-1565.
37. Paulino LC, Tseng CH, Strober BE, et al. Molecular analysis of fungal microbiota in samples from healthy human skin and psoriatic lesions. *J Clin Microbiol*. 2006;44(8):2933-2941.
38. Sugita T, Yamazaki T, Makimura K, et al. Comprehensive analysis of the skin fungal microbiota of astronauts during a half-year stay at the International Space Station. *Med Mycol*. 2016;54(3):232-239.
39. Wang L, Clavaud C, Bar-Hen A, et al. Characterization of the major bacterial-fungal populations colonizing dandruff scalps in Shanghai, China, shows microbial disequilibrium. *Exp Dermatol*. 2015;24(5):398-400.
40. Jo JH, Deming C, Kennedy EA, et al. Diverse human skin fungal communities in children converge in adulthood. *J Invest Dermatol*. 2016;136(12):2356-2363.
41. Zhang E, Tanaka T, Tajima M, et al. Characterization of the skin fungal microbiota in patients with atopic dermatitis and in healthy subjects. *Microbiol Immunol*. 2011;55(9):625-632.
42. Hannigan GD, Meisel JS, Tyldsley AS, et al. The human skin double-stranded DNA virome: topographical and temporal diversity, genetic enrichment, and dynamic associations with the host microbiome. *MBio*. 2015;6(5):e01578-15.
43. Oh J, Byrd AL, Deming C, et al. Biogeography and individuality shape function in the human skin metagenome. *Nature*. 2014;514(7520):59-64.
44. Oh J, Byrd AL, Park M, et al. Temporal stability of the human skin microbiome. *Cell*. 2016;165(4):854-866.
45. Foulongne V, Sauvage V, Hebert C, et al. Human skin microbiota: high diversity of DNA viruses identified on the human skin by high throughput sequencing. *PLoS One*. 2012;7(6):e38499.
46. Wylie KM, Mihindukulasuriya KA, Zhou Y, et al. Metagenomic analysis of double-stranded DNA viruses in healthy adults. *BMC Biol*. 2014;12:71.
47. Bzhalava D, Muhr LS, Lagheden C, et al. Deep sequencing extends the diversity of human papillomaviruses in human skin. *Sci Rep*. 2014;4:5807.
48. Deng Q, Li J, Pan Y, et al. Prevalence and associated risk factors of human papillomavirus in healthy skin specimens collected from rural Anyang, China, 2006-2008. *J Invest Dermatol*. 2016;136(6):1191-1198.
49. Ma Y, Madupu R, Karaoz U, et al. Human papillomavirus community in healthy persons, defined by metagenomics analysis of human microbiome project shotgun sequencing data sets. *J Virol*. 2014;88(9):4786-4797.
50. Goodrich JK, Di Rienzi SC, Poole AC, et al. Conducting a microbiome study. *Cell*. 2014;158(2):250-262.
51. Lauber CL, Zhou N, Gordon JI, et al. Effect of storage conditions on the assessment of bacterial community structure in soil and human-associated samples. *FEMS Microbiol Lett*. 2010;307(1):80-86.
52. Weiss S, Amir A, Hyde ER, et al. Tracking down the sources of experimental contamination in microbiome studies. *Genome Biol*. 2014;15(12):564.
53. Kong HH, Andersson B, Clavel T, et al. Performing skin microbiome research: a method to the madness. *J Invest Dermatol*. 2017;137(3):561-568.
54. Costello EK, Lauber CL, Hamady M, et al. Bacterial community variation in human body habitats across space and time. *Science*. 2009;326(5960):1694-1697.
55. Grice EA, Kong HH, Conlan S, et al. Topographical and temporal diversity of the human skin microbiome. *Science*. 2009. 324(5931):1190-1192.
56. Korem T, Zeevi D, Suez J, et al. Growth dynamics of gut microbiota in health and disease inferred from single metagenomic samples. *Science*. 2015;349(6252):1101-1106.
57. Kligman AM, Leyden JJ, McGinley KJ. Bacteriology. *J Invest Dermatol*. 1976;67(1):160-168.
58. Lai Y, Di Nardo A, Nakatsuji T, et al. Commensal bacteria regulate toll-like receptor 3-dependent inflammation after skin injury. *Nat Med*. 2009;15(12):1377-1382.
59. Leyden JJ, McGinley KJ, Nordstrom KM, et al. Skin microflora. *J Invest Dermatol*. 1987;88(3)(suppl):65s-72s.
60. Marples MJ. The normal flora of the human skin. *Br J Dermatol*. 1969;81(suppl 1):2-13.
61. Cogen AL, Nizet V, Gallo RL. Skin microbiota: a source of disease or defence? *Br J Dermatol*. 2008;158(3):442-455.
62. Chiller K, Selkin BA, Murakawa GJ. Skin microflora and bacterial infections of the skin. *J Investig Dermatol Symp Proc*. 2001;6(3):170-174.
63. Kong HH. Skin microbiome: genomics-based insights into the diversity and role of skin microbes. *Trends Mol Med*. 2011;17(6):320-328.
64. Grice EA, Segre JA. The skin microbiome. *Nat Rev Microbiol*. 2011;9(4):244-253.
65. Puhvel SM, Reisner RM, Amirian DA. Quantification of bacteria in isolated pilosebaceous follicles in normal skin. *J Invest Dermatol*. 1975;65(6):525-531.
66. Nakatsuji T, Chiang HI, Jiang SB, et al. The microbiome extends to subepidermal compartments of normal skin. *Nat Commun*. 2013;4:1431.
67. Gao Z, Tseng CH, Pei Z, et al. Molecular analysis of human forearm superficial skin bacterial biota. *Proc Natl Acad Sci U S A*. 2007;104(8):2927-2932.
68. Grice EA, Kong HH, Renaud G, et al. A diversity profile of the human skin microbiota. *Genome Res*. 2008;18(7):1043-1050.
69. Ogawa T, Katsuoka K, Kawano K, et al. Comparative study of staphylococcal flora on the skin surface of atopic dermatitis patients and healthy subjects. *J Dermatol*. 1994;21(7):453-460.
70. Hartmann AA. Effect of occlusion on resident flora, skin-moisture and skin-pH. *Arch Dermatol Res*. 1983;275(4):251-254.
71. Fierer N, Hamady M, Lauber CL, et al. The influence of sex, handedness, and washing on the diversity of hand surface bacteria. *Proc Natl Acad Sci U S A*. 2008;105(46):17994-17999.
72. Flores GE, Caporaso JG, Henley JB, et al. Temporal variability is a personalized feature of the human microbiome. *Genome Biol*. 2014;15(12):531.

73. Bashan A, Gibson TE, Friedman J, et al. Universality of human microbial dynamics. *Nature*. 2016;534(7606):259-262.
74. Clemente JC, Pehrsson EC, Blaser MJ, et al. The microbiome of uncontacted Amerindians. *Sci Adv*. 2015;1(3):e1500183.
75. Leung MH, Wilkins D, Lee PK. Insights into the pan-microbiome: skin microbial communities of Chinese individuals differ from other racial groups. *Sci Rep*. 2015;5:11845.
76. Hospodsky D, Pickering AJ, Julian TR, et al. Hand bacterial communities vary across two different human populations. *Microbiology*. 2014;160(pt 6):1144-1152.
77. Qin J, Li R, Raes J, et al. A human gut microbial gene catalogue established by metagenomic sequencing. *Nature*. 2010;464(7285):59-65.
78. Lee MM. Physical and structural age changes in human skin. *Anat Rec*. 1957;129(4):473-493.
79. Leyden JJ, McGinley KJ, Mills OH, et al. Age-related changes in the resident bacterial flora of the human face. *J Invest Dermatol*. 1975;65(4):379-381.
80. Capone KA, Dowd SE, Stamatas GN, et al. Diversity of the human skin microbiome early in life. *J Invest Dermatol*. 2011;131(10):2026-2032.
81. Costello EK, Carlisle EM, Bik EM, et al. Microbiome assembly across multiple body sites in low-birthweight infants. *MBio*. 2013;4(6):e00782-13.
82. Dominguez-Bello MG, Costello EK, Contreras M, et al. Delivery mode shapes the acquisition and structure of the initial microbiota across multiple body habitats in newborns. *Proc Natl Acad Sci U S A*. 2010;107(26):11971-11975.
83. Kennedy EA, Connolly J, Hourihane JO, et al. Skin microbiome before development of atopic dermatitis: Early colonization with commensal staphylococci at 2 months is associated with a lower risk of atopic dermatitis at 1 year. *J Allergy Clin Immunol*. 2017;139(1):166-172.
84. Oh J, Conlan S, Polley EC, et al. Shifts in human skin and nares microbiota of healthy children and adults. *Genome Med*. 2012;4(10):77.
85. Ying S, Zeng DN, Chi L, et al. The influence of age and gender on skin-associated microbial communities in urban and rural human populations. *PLoS One*. 2015;10(10):e0141842.
86. Mukherjee S, Mitra R, Maitra A, et al. Sebum and hydration levels in specific regions of human face significantly predict the nature and diversity of facial skin microbiome. *Sci Rep*. 2016;6:36062.
87. Si J, Lee S, Park JM, et al. Genetic associations and shared environmental effects on the skin microbiome of Korean twins. *BMC Genomics*. 2015;16:992.
88. Aly R, Maibach HI, Shinefield HR. Microbial flora of atopic dermatitis. *Arch Dermatol*. 1977;113(6):780-782.
89. Chng KR, Tay AS, Li C, et al. Whole metagenome profiling reveals skin microbiome-dependent susceptibility to atopic dermatitis flare. *Nat Microbiol*. 2016;1(9):16106.
90. Gonzalez ME, Schaffer JV, Orlow SJ, et al. Cutaneous microbiome effects of fluticasone propionate cream and adjunctive bleach baths in childhood atopic dermatitis. *J Am Acad Dermatol*. 2016;75(3):481-493 e8.
91. Kong HH, Oh J, Deming C, et al. Temporal shifts in the skin microbiome associated with disease flares and treatment in children with atopic dermatitis. *Genome Res*. 2012;22(5):850-859.
92. Seite S, Flores GE, Henley JB, et al. Microbiome of affected and unaffected skin of patients with atopic dermatitis before and after emollient treatment. *J Drugs Dermatol*. 2014;13(11):1365-1372.
93. Shi B, Bangayan NJ, Curd E, et al. The skin microbiome is different in pediatric versus adult atopic dermatitis. *J Allergy Clin Immunol*. 2016;138(4):1233-1236.
94. Nakatsuji T, Chen TH, Two AM, et al. *Staphylococcus aureus* exploits epidermal barrier defects in atopic dermatitis to trigger cytokine expression. *J Invest Dermatol*. 2016;136(11):2192-2200.
95. Laouini D, Kawamoto S, Yalcindag A, et al. Epicutaneous sensitization with superantigen induces allergic skin inflammation. *J Allergy Clin Immunol*. 2003;112(5):981-987.
96. Nakamura Y, Oscherwitz J, Cease KB, et al. *Staphylococcus* delta-toxin induces allergic skin disease by activating mast cells. *Nature*. 2013;503(7476):397-401.
97. Brauweiler AM, Goleva E, Leung DY. Th2 cytokines increase *Staphylococcus aureus* alpha toxin-induced keratinocyte death through the signal transducer and activator of transcription 6 (STAT6). *J Invest Dermatol*. 2014;134(8):2114-2121.
98. Kaesler S, Skabytska Y, Chen KM, et al. *Staphylococcus aureus*-derived lipoteichoic acid induces temporary T-cell paralysis independent of toll-like receptor 2. *J Allergy Clin Immunol*. 2016;138(3):780-790 e6.
99. Kobayashi T, Glatz M, Horiuchi K, et al. Dysbiosis and *Staphylococcus aureus* colonization drives inflammation in atopic dermatitis. *Immunity*. 2015;42(4):756-766.
100. Scharschmidt TC, Vasquez KS, Truong HA, et al. A wave of regulatory T cells into neonatal skin mediates tolerance to commensal microbes. *Immunity*. 2015;43(5):1011-1021.
101. Fry L, Baker BS, Powles AV, et al. Is chronic plaque psoriasis triggered by microbiota in the skin? *Br J Dermatol*. 2013;169(1):47-52.
102. Noble WC, Savin JA. Carriage of *Staphylococcus aureus* in psoriasis. *Br Med J*. 1968;1(5589):417-418.
103. Norrlind R. Psoriasis following infections with hemolytic streptococci. *Acta Derm Venereol*. 1950;30(1):64-72.
104. Martin R, Henley JB, Sarrazin P, et al. Skin microbiome in patients with psoriasis before and after balneotherapy at the Thermal Care Center of La Roche-Posay. *J Drugs Dermatol*. 2015;14(12):1400-1405.
105. Alekseyenko AV, Perez-Perez GI, De Souza A, et al. Community differentiation of the cutaneous microbiota in psoriasis. *Microbiome*. 2013;1(1):31.
106. Gao Z, Tseng CH, Strober BE, et al. Substantial alterations of the cutaneous bacterial biota in psoriatic lesions. *PLoS One*. 2008;3(7):e2719.
107. Statnikov A, Alekseyenko AV, Li Z, et al. Microbiomic signatures of psoriasis: feasibility and methodology comparison. *Sci Rep*. 2013;3:2620.
108. Fahlen A, Engstrand L, Baker BS, et al. Comparison of bacterial microbiota in skin biopsies from normal and psoriatic skin. *Arch Dermatol Res*. 2012;304(1):15-22.
109. Kirschbaum JO, Kligman AM. The pathogenic role of *Corynebacterium acnes* in acne vulgaris. *Arch Dermatol*. 1963;88:832-833.
110. Marples RR, McGinley KJ, Mills OH. Microbiology of comedones in acne vulgaris. *J Invest Dermatol*. 1973;60(2):80-83.
111. Kang D, Shi B, Erfe MC, et al. Vitamin B12 modulates the transcriptome of the skin microbiota in acne pathogenesis. *Sci Transl Med*. 2015;7(293):293ra103.
112. Liu J, Yan R, Zhong Q, et al. The diversity and host interactions of Propionibacterium acnes bacteriophages on human skin. *ISME J*. 2015;9(9):2078-2093.

113. Marinelli LJ, Fitz-Gibbon S, Hayes C, et al. *Propionibacterium acnes* bacteriophages display limited genetic diversity and broad killing activity against bacterial skin isolates. *MBio*. 2012;3(5):e00279-12.
114. Bek-Thomsen M, Lomholt HB, Kilian M. Acne is not associated with yet-uncultured bacteria. *J Clin Microbiol*. 2008;46(10):3355-3360.
115. Fitz-Gibbon S, Tomida S, Chiu BH, et al. *Propionibacterium acnes* strain populations in the human skin microbiome associated with acne. *J Invest Dermatol*. 2013;133(9):2152-2160.
116. Christensen GJ, Scholz CF, Enghild J, et al. Antagonism between *Staphylococcus epidermidis* and *Propionibacterium acnes* and its genomic basis. *BMC Genomics*. 2016;17:152.
117. Numata S, Akamatsu H, Akaza N, et al. Analysis of facial skin-resident microbiota in Japanese acne patients. *Dermatology*. 2014;228(1):86-92.
118. Yu Y, Champer J, Agak GW, et al. Different *Propionibacterium acnes* phylotypes induce distinct immune responses and express unique surface and secreted proteomes. *J Invest Dermatol*. 2016;136(11):2221-2228.
119. Hanski I, von Hertzen L, Fyhrquist N, et al. Environmental biodiversity, human microbiota, and allergy are interrelated. *Proc Natl Acad Sci U S A*. 2012;109(21):8334-8339.
120. Horton JM, Gao Z, Sullivan DM, et al. The cutaneous microbiome in outpatients presenting with acute skin abscesses. *J Infect Dis*. 2015;211(12):1895-1904.
121. van Rensburg JJ, Lin H, Gao X, et al. The human skin microbiome associates with the outcome of and is influenced by bacterial infection. *MBio*. 2015;6(5):e01315-15.
122. Troccaz M, Gaia N, Beccucci S, et al. Mapping axillary microbiota responsible for body odours using a culture-independent approach. *Microbiome*. 2015;3(1):3.
123. Gardner SE, Hillis SL, Heilmann K, et al. The neuropathic diabetic foot ulcer microbiome is associated with clinical factors. *Diabetes*. 2013;62(3):923-930.
124. Redel H, Gao Z, Li H, et al. Quantitation and composition of cutaneous microbiota in diabetic and nondiabetic men. *J Infect Dis*. 2013;207(7):1105-1114.
125. Gontcharova V, Youn E, Sun Y, et al. A comparison of bacterial composition in diabetic ulcers and contralateral intact skin. *Open Microbiol J*. 2010;4:8-19.
126. Zeeuwen PL, Ederveen TH, van der Krieken DA, et al. Gram-positive anaerobe cocci are underrepresented in the microbiome of filaggrin-deficient human skin. *J Allergy Clin Immunol*. 2017;139(4):1368-1371.
127. Salava A, Aho V, Pereira P, et al. Skin microbiome in melanomas and melanocytic nevi. *Eur J Dermatol*. 2016;26(1):49-55.
128. Dereure O, Cheval J, Du Thanh A, et al. No evidence for viral sequences in mycosis fungoides and Sezary syndrome skin lesions: a high-throughput sequencing approach. *J Invest Dermatol*. 2013;133(3):853-855.
129. Ganju P, Nagpal S, Mohammed MH, et al. Microbial community profiling shows dysbiosis in the lesional skin of vitiligo subjects. *Sci Rep*. 2016;6:18761.
130. Oh J, Freeman AF, NISC Comparative Sequencing Program, et al. The altered landscape of the human skin microbiome in patients with primary immunodeficiencies. *Genome Res*. 2013;23(12):2103-2114.
131. Smeekens SP, Huttenhower C, Riza A, et al. Skin microbiome imbalance in patients with STAT1/STAT3 defects impairs innate host defense responses. *J Innate Immun*. 2014;6(3):253-262.
132. Gueho E, Midgley G, Guillot J. The genus *Malassezia* with description of four new species. *Antonie Van Leeuwenhoek*. 1996;69(4):337-355.
133. Aspiroz C, Moreno LA, Rezusta A, et al. Differentiation of three biotypes of *Malassezia* species on human normal skin. correspondence with *M. globosa*, *M. sympodialis* and *M. restricta*. *Mycopathologia*. 1999;145(2):69-74.
134. Sugita T, Suzuki M, Goto S, et al. Quantitative analysis of the cutaneous *Malassezia* microbiota in 770 healthy Japanese by age and gender using a real-time PCR assay. *Med Mycol*. 2010;48(2):229-233.
135. Zhang E, Tanaka T, Tsuboi R, et al. Characterization of *Malassezia* microbiota in the human external auditory canal and on the sole of the foot. *Microbiol Immunol*. 2012;56(4):238-244.
136. Leung MH, Chan KC, Lee PK. Skin fungal community and its correlation with bacterial community of urban Chinese individuals. *Microbiome*. 2016:4(1):46.
137. Wu G, Zhao H, Li C, et al. Genus-wide comparative genomics of *Malassezia* delineates its phylogeny, physiology, and niche adaptation on human skin. *PLoS Genet*. 2015;11(11):e1005614.
138. Michael-Jubeli R, Bleton J, Baillet-Guffroy A. High-temperature gas chromatography-mass spectrometry for skin surface lipids profiling. *J Lipid Res*. 2011;52(1):143-151.
139. Warren R, Wertz PW, Kirkbride T, et al. Comparative analysis of skin surface lipids of the labia majora, inner thigh, and forearm. *Skin Pharmacol Physiol*. 2011;24(6):294-299.
140. Faergemann J, Fredriksson T. Age incidence of *Pityrosporum orbiculare* on human skin. *Acta Derm Venereol*. 1980;60(6):531-533.
141. Gupta AK, Kohli Y. Prevalence of *Malassezia* species on various body sites in clinically healthy subjects representing different age groups. *Med Mycol*. 2004;42(1):35-42.
142. Yamamoto A, Serizawa S, Ito M, et al. Effect of aging on sebaceous gland activity and on the fatty acid composition of wax esters. *J Invest Dermatol*. 1987;89(5):507-512.
143. Pochi PE, Strauss JS, Downing DT. Age-related changes in sebaceous gland activity. *J Invest Dermatol*. 1979;73(1):108-111.
144. Havlickova B, Czaika VA, Friedrich M. Epidemiological trends in skin mycoses worldwide. *Mycoses*. 2008;51(suppl 4):2-15.
145. Seebacher C, Bouchara JP, Mignon B. Updates on the epidemiology of dermatophyte infections. *Mycopathologia*. 2008;166(5-6):335-352.
146. Kyriakis KP, Terzoudi S, Palamaras I, et al. Pityriasis versicolor prevalence by age and gender. *Mycoses*. 2006;49(6):517-518.
147. Takemoto A, Cho O, Morohoshi Y, et al. Molecular characterization of the skin fungal microbiome in patients with psoriasis. *J Dermatol*. 2015;42(2):166-170.
148. Feng H, Shuda M, Chang Y, et al. Clonal integration of a polyomavirus in human Merkel cell carcinoma. *Science*. 2008;319(5866):1096-1100.
149. Schowalter RM, Pastrana DV, Pumphrey KA, et al. Merkel cell polyomavirus and two previously unknown polyomaviruses are chronically shed from human skin. *Cell Host Microbe*. 2010;7(6):509-515.
150. Foulongne V, Dereure O, Kluger N, et al. Merkel cell polyomavirus DNA detection in lesional and

nonlesional skin from patients with Merkel cell carcinoma or other skin diseases. *Br J Dermatol*. 2010;162(1):59-63.
151. Matthews MR, Wang RC, Reddick RL, et al. Viral-associated trichodysplasia spinulosa: a case with electron microscopic and molecular detection of the trichodysplasia spinulosa-associated human polyomavirus. *J Cutan Pathol*. 2011;38(5):420-431.
152. Nguyen KD, Lee EE, Yue Y, et al. Human polyomavirus 6 and 7 are associated with pruritic and dyskeratotic dermatoses. *J Am Acad Dermatol*. 2017;76(5):932-940.e3.
153. Stroh LJ, Gee GV, Blaum BS, et al. Trichodysplasia spinulosa-associated polyomavirus uses a displaced binding site on VP1 to engage sialylated glycolipids. *PLoS Pathog*. 2015;11(8):e1005112.
154. Scher JU, Ubeda C, Artacho A, et al. Decreased bacterial diversity characterizes the altered gut microbiota in patients with psoriatic arthritis, resembling dysbiosis in inflammatory bowel disease. *Arthritis Rheumatol*. 2015;67(1):128-139.
155. Song H, Yoo Y, Hwang J, et al. *Faecalibacterium prausnitzii* subspecies-level dysbiosis in the human gut microbiome underlying atopic dermatitis. *J Allergy Clin Immunol*. 2016;137(3):852-860.
156. Myles IA, Reckhow JD, Williams KW, et al. A method for culturing Gram-negative skin microbiota. *BMC Microbiol*. 2016;16:60.
157. Bouslimani A, Porto C, Rath CM, et al. Molecular cartography of the human skin surface in 3D. *Proc Natl Acad Sci U S A*. 2015;112(17):E2120-E2129.
158. Petras D, Nothias LF, Quinn RA, et al. Mass spectrometry-based visualization of molecules associated with human habitats. *Anal Chem*. 2016;88(22):10775-10784.
159. Arron ST, Dimon MT, Li Z, et al. High *Rhodotorula* sequences in skin transcriptome of patients with diffuse systemic sclerosis. *J Invest Dermatol*. 2014;134(8):2138-2145.

Chapter 17 :: Cutaneous Photobiology

:: Thomas M. Rünger

AT-A-GLANCE

- Radiation can only cause a photobiologic response, if it is first absorbed by a molecule (chromophore) in the skin.
- Understanding the photophysical, photochemical, and photobiologic effects of radiation exposure is helpful to understand the wavelength-dependent consequences, including burning, tanning, photodermatoses, formation of skin cancer, photoaging, and effects of phototherapy.
- Photoreactions have specific action spectra that depend on the absorption characteristics of various different intrinsic and extrinsic chromophores.
- Cutaneous vitamin D production is mediated by wavelengths within the UVB range. Optimal vitamin D blood levels are essential for good bone health and are increasingly associated with a myriad of other potential health benefits.
- Formation of DNA damage by ultraviolet radiation (UVR) mediates sunburning, tanning, and skin cancer formation.
- Skin cells are equipped with a number of damage response pathways that limit the negative impact of radiation exposure, including several different DNA repair mechanisms.
- Ultraviolet radiation–induced DNA damage can result in mutation formation. C to T and CC to TT mutations at dipyrimidine sites are highly characteristic for an induction by ultraviolet radiation and are called UV-signature mutations. Such UV-signature mutations are found in UV-induced skin cancers.
- Ultraviolet radiation has both pro- and antiinflammatory properties.
- Photoaging affects all compartments of the skin and is characterized by both clonal proliferative events and loss-of-function events.
- Photoaging is largely irreversible, possibly due in part to an UV-induced accumulation of undegradable abnormal proteins in the extra- and intracellular space.
- Exposure to visible light and infrared radiation also has photobiological consequences, including erythema, tanning, and degradation of extracellular matrix proteins.
- Rational phototherapy and photoprotection are based on these insights.

INTRODUCTION

As the outermost layer of the human body, skin is heavily exposed to damaging environmental agents, including different types of radiation (Table 17-1 and Fig. 17-1). Ionizing electromagnetic radiation, like, for example, x-rays or gamma rays, carries sufficient photon-energy to completely remove an electron from an atom or molecule (= ionization). Other types of ionizing radiation are alpha particles (2 protons and 2 neutrons) and beta particles (electrons). Alpha and beta particles are not part of the electromagnetic spectrum; they are energetic particles, as opposed to pure energy bundles (photons) of the electromagnetic radiation. Nonionizing radiation, which includes ultraviolet radiation (UVR), visible light, and infrared radiation, is able to move an electron to a higher energy state, but, in contrast to ionizing radiation, cannot remove an electron from atoms or molecules. Cutaneous photobiology is the science that studies the interaction of nonionizing radiation with skin. The term *light* is commonly reserved for wavelengths of the electromagnetic spectrum that are perceivable by the human eye: visible light.

Both ionizing and nonionizing radiation have detrimental effects on skin. Because during the development of life on earth, electromagnetic radiation has always been present, cells and organisms could only evolve with development of mechanisms that protect against the damaging effects of radiation. This chapter covers the effects of UVR, visible light, and infrared radiation on skin. Insights into the photophysical, photochemical, and photobiological processes help to understand clinical manifestations of skin exposure to these types of radiation, including sunburning, tanning, skin cancer formation, photoaging, photodermatoses, and phototherapeutic effects on skin diseases.

SOURCES OF ULTRAVIOLET AND VISIBLE RADIATION

SUNLIGHT

The shortest wavelength of solar electromagnetic radiation reaching the earth's surface is approximately 290 nm, although slightly shorter wavelengths are detected at higher altitudes. The filtering of UVC (100 to 290 nm) by the earth's atmosphere, in particular by ozone, is widely regarded a critical element in the development of life on earth, because the shorter wavelengths of UVR are highly damaging

TABLE 17-1
Divisions and Subdivisions of Electromagnetic Radiation

NAME	WAVELENGTH RANGE	SUBDIVISION	WAVELENGTH RANGE
Ionizing Radiation			
Gamma-ray	10 fm-1 pm		
X-ray	1 pm-10 nm		
Vacuum ultraviolet	10 nm-200 nm		
Nonionizing Radiation			
Ultraviolet C	100 nm-290 nm		
Ultraviolet B	290 nm-315 nm		
Ultraviolet A	315 nm-400 nm	UVA2	315 nm-340 nm
		UVA1	340 nm-400 nm
Visible light	400 nm-760 nm	Violet	400 nm-450 nm
		Blue	450 nm-500 nm
		Green	500 nm-570 nm
		Yellow	570 nm-590 nm
		Orange	590 nm-610 nm
		Red	610 nm-760 nm
Infrared	760 nm-1 mm	IR-A	760 nm-1.4 mm
		IR-B	1.4 mm-3 mm
		IR-C	3 mm-1 mm
Microwaves and radio waves	>1 mm		

to animals and plants. The subdivisions of UVR (Table 17-1 and Fig. 17-1) and of the whole spectrum of electromagnetic radiation are rather arbitrary, and it is important to recognize that photophysical properties of photons do not change abruptly between the defined ranges, but rather gradually with changing wavelength. In general, energy decreases with increasing wavelength. For example, a 300-nm UVB photon has twice the energy of a 600-nm orange photon. The most commonly used subdivision of UVR is the one defined by the Commission Internationale de l'Eclairage, CIE, and sets 315 nm as the border between UVB and UVA. Other classifications use 320 nm. The defined threshold between ultraviolet and visible radiation is based on the properties of the human eye and its ability to sense radiation. Some species, for example, birds, insects, and fish, can also see some UVA radiation.

The composition of solar radiation reaching the earth's surface varies with the time of the day because

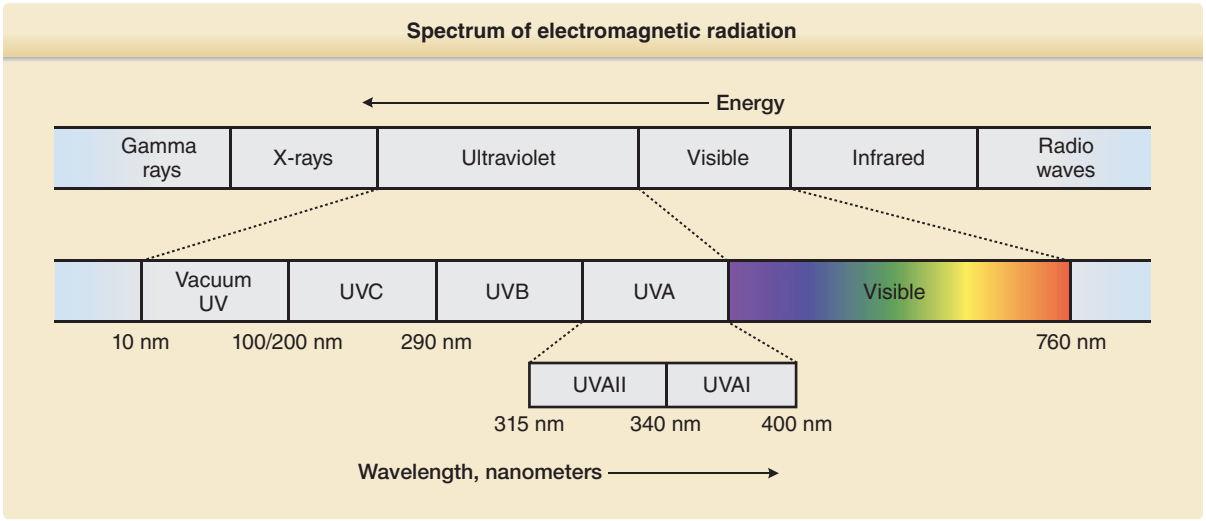

Figure 17-1 Spectrum of electromagnetic radiation divided into major wavelength regions and further subdivisions.

of changing angles of sunlight and with differences in the length solar radiation has to travel through the atmosphere. Shorter wavelengths of visible light (violet and blue) are more filtered by a longer passage through the atmosphere than longer wavelength of visible light (orange and red), resulting in redder light at sunrise and sunset, as compared to midday sunlight. Likewise, the longer wavelengths of UVR (UVA, 315 to 400 nm) penetrate matter better than UVB (280 to 315 nm). Therefore, the fraction of UVA relative to UVB increases with lower angles of solar radiation. At midday, natural sunlight contains about 50 times more UVA than UVB. Although both components are less abundant early or late in the day, the ratio between UVA and UVB increases with declining solar angles. Similarly, UVA can penetrate through window glass, but not UVB.

ARTIFICIAL SOURCES

There is a huge variety of different light sources that expose skin to visible, ultraviolet, and infrared radiation. These range from lamps used for conventional lighting purposes, for industrial applications, for phototherapy, and for tanning. Most of the light sources are designed to emit only the desired range of wavelength, for example, only visible light for lighting purposes. Nevertheless, some general lighting lamps sometimes emit small amounts of UVR, in particular fluorescent bulbs and halogen lamps. Unwanted wavelengths are often eliminated by filters. Fluorescent bulbs designed to emit UVR most often emit a broad range of wavelengths. For example, bulbs designed to emit UVA for photochemotherapy (PUVA) also emit some UVB, and those designed to emit UVB also emit some UVC. The Phillips TL01 fluorescent lamp has been a major advance in the design of UVB lamps for phototherapy, as it aligns its almost monochromatic emission at 311 to 312 nm, with therapeutic efficacy for inflammatory skin diseases, while avoiding shorter wavelengths that mostly cause sunburning, but are not effective for treatment.

PHOTOPHYSICS, PHOTOCHEMISTRY, AND PHOTOBIOLOGY: PRINCIPLES OF THE INTERACTION OF ELECTROMAGNETIC RADIATION WITH SKIN

For a photon to have biologically relevant consequences, a series of events must take place (Fig. 17-2). Optical factors of the skin and the wavelengths of the radiation determine how much and where a photon is reflected and scattered at the skin surface and within the skin. For ultraviolet and visible radiation, longer wavelengths

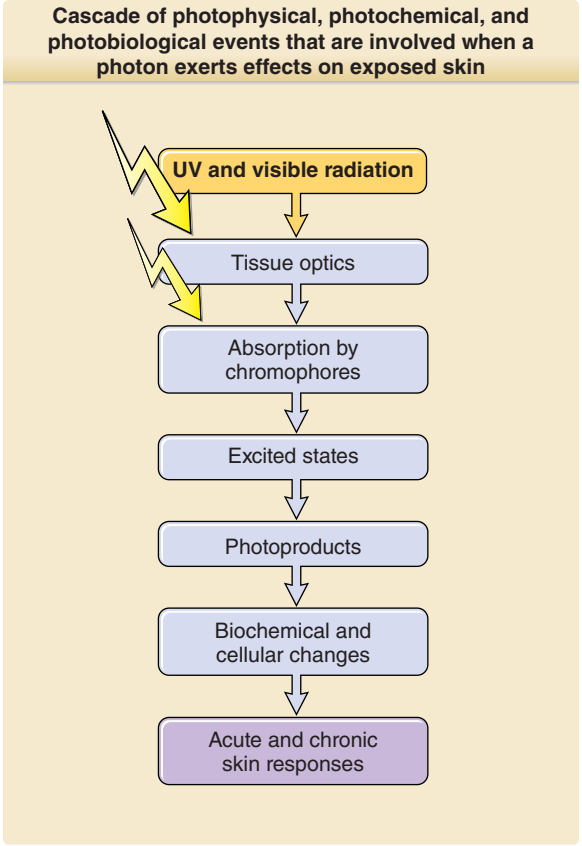

Figure 17-2 Series of photophysical, photochemical, and photobiological events that are required for a photon to have an effect on exposed skin.

penetrate matter better than shorter wavelengths. For example, UVA penetrates deeper into the dermis than UVB, of which only a small fraction penetrates deeper than the epidermis. UVC has the smallest penetration depth and in skin only reaches the stratum corneum and the upper layers of the epidermis (Fig. 17-3).

The first law of photochemistry, also known as the Grotthuß–Draper law, named after the chemists Freiherr Christian Johann Dietrich Theodor von Grotthuß and John William Draper, states that that light must first be absorbed by a chemical substance for a photochemical reaction to take place. A compound that absorbs radiation is called a chromophore. Each chromophore has a characteristic absorption spectrum, typically with one wavelength that is most likely to excite it (= absorption maximum) and a distribution of wavelengths that are less likely to do so. Well characterized chromophores in the skin are DNA (absorption maximum at 260 nm), porphyrins (absorption maximum between 400 and 410 nm), and melanin (absorption maximum in the UVC range, but also very effectively excited by UVB and UVA) (Fig. 17-4).

When a chromophore in the ground state absorbs the energy of a photon, electrons are raised to a higher orbit. If this involves no change in spin, the excited state is called singlet state. If it also undergoes a change in spin, the excited state is called a triplet state (Fig. 17-5). Upon photoexcitation, a photochemical reaction can occur to

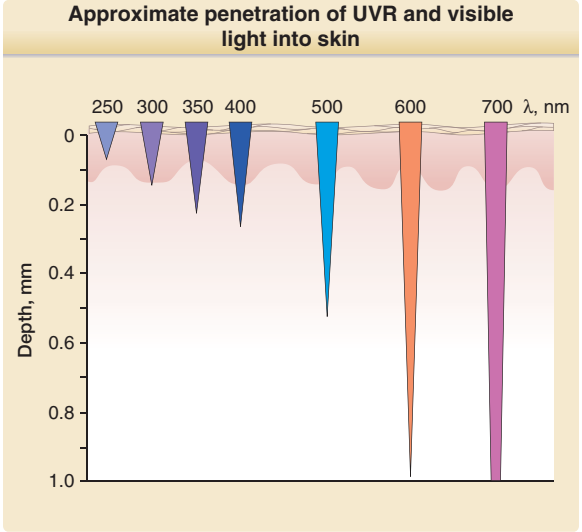

Figure 17-3 Approximate penetration of ultraviolet radiation and visible light into skin. λ = wavelength.

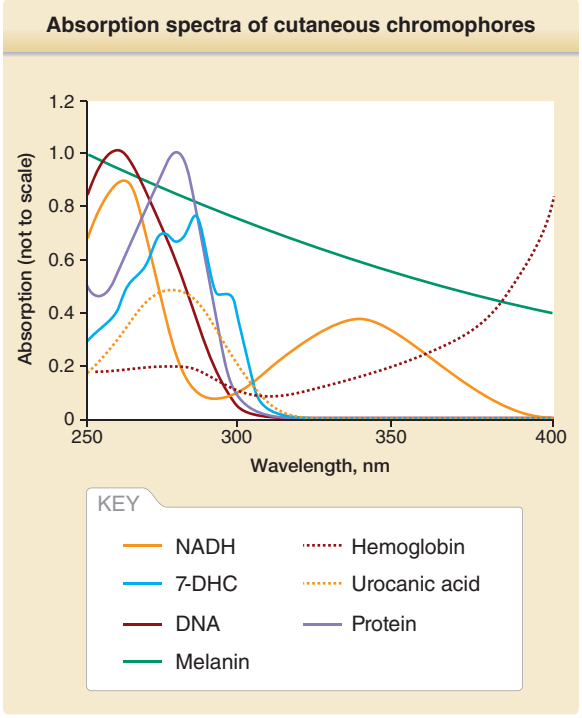

Figure 17-4 Absorption spectra of cutaneous chromophores absorbing ultraviolet radiation. Note that the relative amounts of UVR absorbed by these chromophores in skin depend on the heights of the absorption peak, the amount of each chromophore in skin, and the penetration of each wavelength into skin. For example, although the absorption maximum of naked DNA is at 260 nm, the most effective wavelengths to excite DNA in basal keratinocytes is 300 nm. This is because shorter wavelengths are absorbed and scattered in the stratum corneum and the upper layers of the epidermis and do not reach the basal keratinocytes as effectively. 7-DHC, 7-dihydrocholesterol; NADH, reduced nicotinamide adenine dinucleotide.

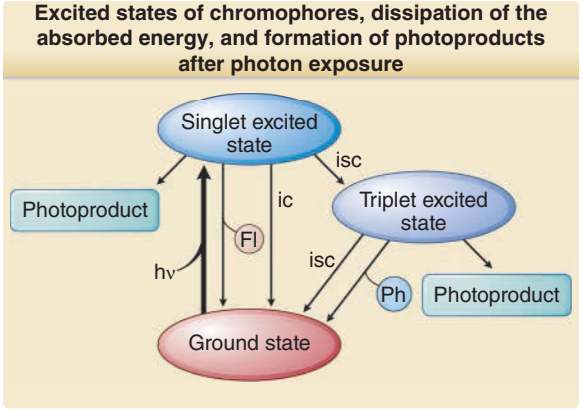

Figure 17-5 Excited states of chromophores, dissipation of the absorbed energy, and formation of photoproducts after exposure to photons of ultraviolet radiation and visible light. Fl, fluorescence; ic, internal conversion; isc, intersystem crossing; Ph, phosphorescence.

form a new, different molecule called photoproduct. For example, previtamin D3 is a photoproduct of photoexcited 7-dehydrocholesterol and the cyclobutane pyrimidine dimer the photoproduct of excited DNA. The process in which energy from an excited chromophore is transferred to another molecules is called a photosensitized reaction. A typical photobiologically relevant photosensitized reaction is energy transfer of an excited chromophore, eg, porphyrin, to oxygen with production of singlet oxygen, which in turn then reacts with other substrates, eg, guanine DNA bases. Instead of forming a photoproduct, the excited chromophore can also return to its ground state with the release of energy as heat or emission of a photon as fluorescence. The wavelengths of fluorescence is always longer (=less energetic) than the exciting wavelength (Stokes Law). For example, on excitation of protoporphyrin IX with blue light, fluorescence is red light, which has a longer wavelength than blue light and is less energetic. The excited singlet state is short-lived and the resulting fluorescence occurs in nanoseconds. Triplet states are longer-lived, as long as seconds. The photon emission from return of triplet excited states to ground states is called phosphorescence, which have longer wavelengths than fluorescence.

CUTANEOUS RESPONSES TO ULTRAVIOLET RADIATION

See Table 17-2.

VITAMIN D PHOTOBIOLOGY

FUNCTIONS OF VITAMIN D

Vitamin D regulates calcium and phosphorus metabolism. Its major role is to increase the flow of calcium into

TABLE 17-2
Comparison of Cutaneous Responses to UVA and UVB

UVA	UVB
Immediate erythema	1000 × more erythemogenic than UVA; associated with sunburn
Immediate pigment darkening (within 20 minutes after UVR exposure)	Delayed melanogenesis (peaks at 3 days)
Major role in drug induced photosensitivity; contributes to carcinogenesis	Major role in carcinogenesis
Central role in photoaging	Role in photoaging
Penetrates down to deep dermis	Penetrates no deeper than the upper dermis
Not associated with vitamin D production	Role in vitamin D production
Penetrates window glass	Does not penetrate window glass
Immunosuppression	Immunosuppression

the bloodstream, by promoting absorption of calcium and phosphorus from the intestines, and reabsorption of calcium in the kidneys, thus enabling normal mineralization of bone and muscle function.

Vitamin D deficiency results in impaired bone mineralization that leads to bone softening diseases, rickets in children and osteomalacia in adults, and possibly contributes to osteoporosis.[1-3] Deficiency can arise from inadequate intake, inadequate sunlight exposure, disorders that limit its absorption, and conditions that impair conversion of vitamin D into active metabolites, such as liver or kidney diseases. Most vulnerable to low vitamin D levels are elders, individuals living at high latitudes with long winters, obese persons, and all individuals with dark skin pigmentation living at high latitudes.[4,5] Toxicity from excess vitamin D may manifest as hypercalciuria or hypercalcemia, the latter causing muscle weakness, apathy, headache, confusion, anorexia, irritability, nausea, vomiting, and bone pain, and may lead to complications such as kidney stones and kidney failure. Chronic toxicity includes the aforementioned symptoms along with constipation, anorexia, abdominal cramps, polydipsia, polyuria, backache, and hyperlipidemia. Findings may also include calcinosis, followed by hypertension and cardiac arrhythmias (due to shortened refractory period). Although information about the effects of high doses of vitamin D is limited, 10,000 IU daily is considered a safe upper limit for adult intake. A chronic toxic dose is more than 50,000 IU/day in adults.

In addition to enhancing musculoskeletal health, vitamin D may also have an influence on the risk of a variety of other conditions, including cancer, cardiovascular disease, autoimmune disease, and infection. However, these effects remain a matter of significant controversy.[6-16]

There are 2 major sources of vitamin D, one is exogenous (diet) and the other is endogenous synthesis. When obtained from food or supplements, vitamin D is absorbed in the small intestine. Natural food sources rich in vitamin D include certain oily fish such as salmon, mackerel, tuna, herring, catfish, cod, sardines and eel, butter, margarine, yogurt, liver, liver oil, and egg yolks, but, at least in the United States, most dietary vitamin D comes from the fortification of foods like cereal, milk, and orange juice. Fortified milk, for example, typically provides 100 IU per 250-mL glass, or only a quarter of the estimated adequate daily intake for adults.

BIOCHEMICAL PATHWAY OF VITAMIN D PRODUCTION

As a result of UV exposure of the skin, provitamin D_3 (7-dehydrocholesterol, a precursor of cholesterol) is rapidly converted to previtamin D_3, which spontaneously isomerizes to vitamin D_3, entering the circulation on a binding protein and joining dietary D_2 (or ergocalciferol) and D_3 (cholecalciferol) absorbed from the gut (Fig. 17-6). Once reaching the liver, it is hydroxylated by the vitamin D 25-hydroxylase, a process that requires NADPH, O_2, and Mg^{2+}. The product 25-hydroxyvitamin D_3 (calcidiol) is stored in the hepatocytes until it is needed. On release into the plasma, it makes its way to the proximal tubules of the kidneys, where it is acted upon by 25(OH)D-1α-hydroxylase, an enzyme whose activity is increased by parathyroid hormone and low PO_4^{2-}. People with kidney disease may not be able to convert vitamin D to its active form. Following this conversion, 1,25-hydroxyvitamin D_3 (calcitriol) is released into the circulation, and by binding to a carrier protein in the plasma, vitamin D–binding protein (VDBP), it is transported to various target organs.

An action spectrum published by MacLaughlin et al. in 1982[17] shows that the most effective wavelengths to facilitate the photosynthesis of cutaneous vitamin D lie in the UVB range, with a peak at 297 nm, but the accuracy and validity of these data have been questioned more recently.[18] In tropical areas, adequate amounts of vitamin D_3 can be made in the skin with 10 to 15 minutes of biweekly sun exposure to the face, arms, and hands, or the back. Individuals with higher skin melanin content require more time in sunlight to produce the same amount of vitamin D as individuals with lower melanin content. It has been proposed that the evolutionary loss of pigment from human's African origin to the white race living in more northern, less sunny latitudes provided advantages with regard to vitamin D production and bone health in areas where the photoprotective effects of melanin were not as critical as in lower latitudes.[19] In today's lifestyles with increased indoor activity and wearing of more extensive clothing, vitamin D deficiency is often a particular problem in people of color who need more UVB exposure to produce the same amount of vitamin in the skin, as compared to more fair-skinned individuals.

It remains a matter of debate what are sufficient levels of vitamin D. These may be lower for the maintenance of bone health, and higher for the other, still controversial health benefits. Nevertheless, consistent

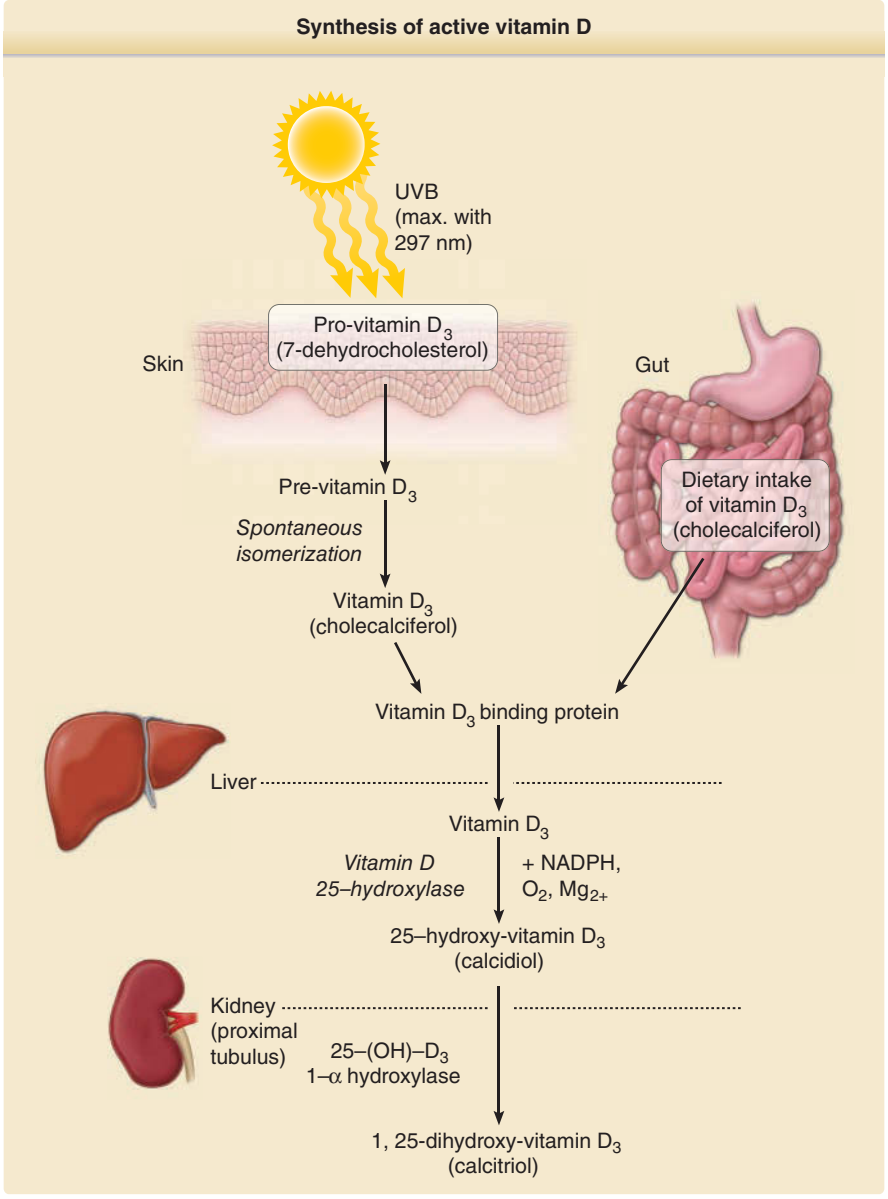

Figure 17-6 Synthesis of active vitamin D. The chromophore that absorbs UVB and initiates this pathway is 7-dehydrocholesterol. Its absorption maximum is 297 nm. The photoproduct of photoexcited 7-dehydrocholesterol is pre-vitamin D_3, which quickly isomerizes to vitamin D_3. See text for more details.

photoprotection for the prevention of the deleterious effects of UVR exposure, can undoubtedly result in vitamin D deficiency.[20,21] Combining photoprotection with vitamin D supplementation therefore appears a wise choice, as dietary sources are often insufficient to maintain appropriate vitamin D levels.

EFFECTS ON THE IMMUNE SYSTEM

Several lines of observational evidence suggest that UV radiation has both proinflammatory and antiinflammatory properties. Proinflammatory properties are supported by observations of sunburning, elucidation of inflammatory photodermatoses, induction and triggering of autoimmune connective tissue diseases, and photoaggravation of inflammatory skin diseases in some patients. Antiinflammatory/immunosuppressive effects are supported by the observations of reactivation of labial herpes simplex with UVR exposure and efficacy of UV phototherapy for the treatment of inflammatory skin diseases. UVR has profound effects on the immune system, both locally at the sites of UV exposure and systemically. Currently, the immunostimulatory effects of UV radiation are thought to be mediated by innate immunity with release of proinflammatory mediators by skin-resident and nonresident cells (eg, serotonin, prostaglandins, IL-1, IL-6, IL-8, TNF-α), induction of

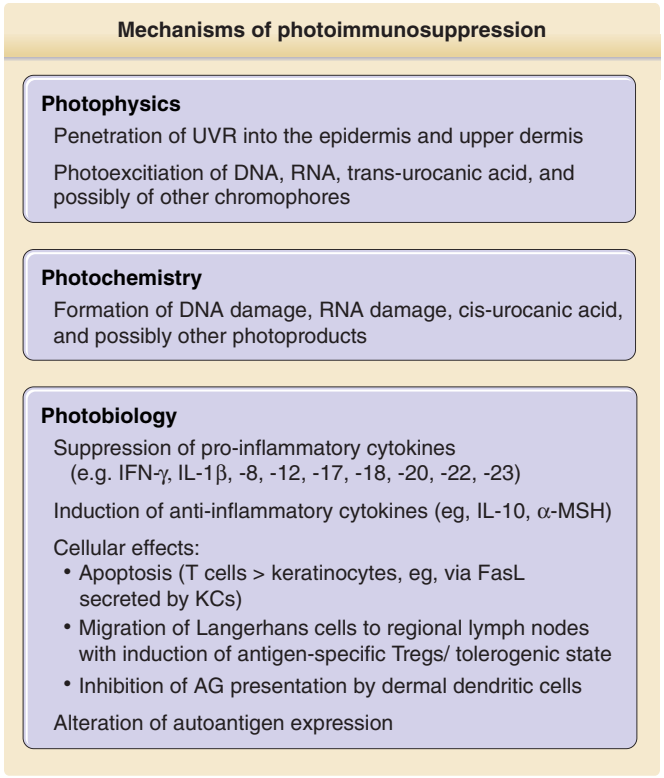

Figure 17-7 Mechanisms of photoimmunosuppression. Photoimmunosuppression is mediated by photoexcitation of chromophores, including DNA and trans-urocanic acid, formation of photoproduct (eg, cyclobutane pyrimidine dimers, cis-urocanic acid), and subsequently a range off immunologic endpoints. This cascade demonstrates a typical cascade of events following exposure of the skin to UVR, starting with photophysical responses (penetration of UVR into the skin and photoexcitation of chromophores), followed by photochemical reactions (production of photoproducts), and ultimately photobiologic consequences.

antimicrobial peptides, and recruitment of neutrophils and lymphocytes.[22] The immunosuppressive effects are thought to be mediated by migration of Langerhans cells from the epidermis to regional lymph nodes, release of antiinflammatory mediators of skin-resident and nonresident cells (eg, IL-10, α-MSH), and induction of antigen-specific regulatory T cells (Fig. 17-7). However, the view of such a pro- versus antiinflammatory dichotomy is probably overly simplistic. Instead, a variety of individual factors are likely influencing the pro- and antiinflammatory responses, resulting in different balances between these two poles. For example, for most patients with psoriasis, exposure to UV radiation results in an improvement of skin lesions, which showcases the antiinflammatory properties of UVR. A small subset of patients, however, experience worsening of their psoriasis. This demonstrates that for patients with such photoaggravated psoriasis, the net result of UVR is proinflammatory. Another example is the photodermatosis polymorphous light eruption, likely an inflammatory response to a UV-induced neoantigen. Patients with this condition have less UV-induced immunosuppression and are therefore more likely to develop this condition.[23] On the other hand, this provides them with some protection against photocarcinogenesis, likely due to a more robust immune-response to UV-induced tumor antigens.[24]

The beneficial effect of UV-induced immunosuppression is probably the prevention of autoimmune reactions against self-antigens unmasked by UV-induced cell damage. An example of a failure to prevent such autoimmune reactions is lupus erythematosus with not only aggravation of skin lesions, but also triggering of new lesions and even systemic flares after UV exposure. From animal experimentation, is has been well established that the immunosuppressive effects of UV radiation are not only local, meaning limited to UV-exposed skin, but systemic as well, affecting also nonexposed skin. These effects have been shown to be mediated by IL-10 and subsequent induction of regulatory T cells. The photoaggravation and photo-triggering of lupus erythematosus can be regarded a failure to appropriately downregulate immune reactions. The downside of photo-immunosuppression is that it prevents the recognition of UV-induced tumor antigens and with that promotes photocarcinogenesis. In addition to immunosuppression, UV radiation also induces long-lasting tolerance to antigens generated and/or unmasked following UV exposure. UV radiation can therefore be regarded a triple-edged sword for skin cancer development: it causes mutagenic DNA damage and not only inhibits the recognition of new tumor antigens but also induces tolerance against those. Chromophores of these effects on the immune

system are DNA with formation of DNA damage, RNA with formation of RNA damage, urocanic acid with UV-induced isomerization from the trans- to the cis-isoform, and porphyrins that upon photoexcitation generate reactive oxygen species and subsequently change the redox potential of membrane lipids. Although most of the immunosuppressive effects are caused by UVB, UVA also has been shown to have similar effects.[25]

SUNBURNING

Sunburning (solar erythema) is clinically characterized by erythema and a burning sensation with pain (grade 1) and can progress to blister formation (grade 2), but does not progress to grade 3, at least not with solar available doses. It typically peaks 6 to 24 hours after sun exposure, followed by tanning and desquamation. Histologically, it is characterized by epidermal edema with spongiosis, few apoptotic keratinocytes (sunburn cells), depletion of Langerhans cells, vasodilation, and a mixed inflammatory infiltrate with lymphocytes and neutrophils. Action spectra for UV-induced erythema show that erythema formation peaks at 300 nm, which is within the UVB range, but then exponentially declines with increasing wavelength into the UVA range.[26] Although very high doses of UVA can induce erythema, nonphotosensitive individuals do not develop erythema from solar available doses of UVA. UVC, albeit not present in solar radiation reaching the earth's surface, can also induce sunburning. Because the erythema action spectrum is very similar to the action spectrum for the formation of directly UV-induced pyrimidine dimer type of DNA lesions, the chromophore for the sunburning reaction is thought to be DNA.[27,28] This is further supported by the observation that many patients with defects in the repair of this type of lesions (xeroderma pigmentosum) have acute photosensitivity with a decreased UVB minimal erythema dose[29,30] and similar observations from animal experimentation, where improvement of pyrimidine dimer repair reduces photosensitivity.[31,32] Exposed skin cells with UV-induced DNA damage switch on a variety of damage response pathways, some of which result in the secretion of either preformed (eg, serotonin and TNFα) or newly synthesized inflammatory mediators (eg, prostaglandins, nitric oxide, and neuropeptides).[33]

TANNING

Darkening of the skin (tanning) is a characteristic consequence of sunburning, but also can be observed without prior burning (Fig. 17-8). It peaks approximately 3 days after UVB exposure, and is histologically characterized by an increase in basal and suprabasal melanin in the epidermis. Sensitivity for sunburning and ability to tan varies greatly among the human race and has been categorized in skin phototypes (Table 17-3), based on baseline pigmentation, sensitivity to sunburning, and ability to tan. This classification scheme was developed by Thomas B. Fitzpatrick for white skin

Figure 17-8 Tanning in a patient with nbUVB phototherapy. Note the lack of tanning in skin folds not exposed to UVR. This patient with skin phototype V did not have a sunburn prior to tanning.

in 1975[34] and has since then been extended to darker skin types. In 2015, the computing industry standard Unicode has introduced Emoji modifiers to specify skin color based on Fitzpatrick's skin phototype scale to represent diversity, which underlines the pervasiveness of skin color perception even in popular culture. An individual's sensitivity to sunburning can be measured by determining the minimal erythema dose. This is the lowest dose that causes erythema in an individual, and it correlates, albeit poorly, with the clinically determined skin phototype.[35] The skin phototypes, which are based on acute responses to UVR, are also indicators for an individual's risk for long-term effects of UVR on skin, in particular photocarcinogenesis.

The fact that the action spectrum for tanning is almost identical to the action spectrum for the formation of DNA photoproducts[36,28] indicates that DNA is the chromophore for UVR-induced tanning, very similar to erythema formation (see above), and that cellular responses to DNA damage are critical to mediate the tanning response. The increased synthesis of melanin is dependent on the UV-induced induction

TABLE 17-3
Skin Phototypes

SKIN PHOTOTYPE	BURNING AND TANNING REACTIONS UPON SUN EXPOSURE	COLOR OF UNEXPOSED SKIN
I	Always burns, never tans	Pale white
II	Always burns, then tans	White
III	Sometimes burns, can tan without prior burn	White
IV	Usually does not burn, tans easily and deeply	White to light brown
V	Rarely burns, tans easily	Brown; moderately pigmented
VI	Burns only with very high UVR doses, tans	Dark brown to black; darkly pigmented

and activation of p53, a central player in cellular DNA damage responses.[37-39] Melanin produced by melanocytes is transferred through an active process involving specialized motor-proteins to keratinocytes, where it is preferentially placed over the nuclei, forming a microparasol.[40] With this, the UV-absorbing properties of melanin shield the nuclei against the DNA-damaging effects of subsequent UV exposures. In response to the UV-induced inflammation (sunburning), the epidermal keratinocytes hyperproliferate, which results in thickening of the viable epidermis and of the stratum corneum. This thickening decreases penetration of UVR to the basal layer and with that also reduces formation of DNA damage and mutations in the skin's stem cells. These two protective mechanisms, increased pigmentation and skin thickening, together with molecular adaptations, including, for example, increased activity of DNA repair enzymes, result in a several-fold increase of the erythema threshold.[41] In addition to this delayed tanning, which is mostly induced by UVB, there is also an immediate pigment darkening, which can be observed within 20 minutes after UVR exposure. The latter is mediated by oxidation and redistribution of existing melanin, is mostly induced by UVA, and provides much less, if any, protection against subsequent exposures.

PHOTOBIOLOGIC PRINCIPLES OF PHOTODERMATOSES

The above-mentioned requirement for an excitation of a chromophore before a photobiologic reaction can occur also applies to photo-induced or photo-triggered dermatoses. For some, the chromophores are known, for others not. For example, defects in the heme biosynthesis pathways result in the accumulation of toxic pathway intermediates and cause porphyrias. Defects at an early stage of the heme biosynthesis pathway result in accumulation of nonaromatic intermediates that do not act as chromophores/photosensitizers. These porphyrias are not characterized by phototoxic reactions in the skin, but affect other organs, including, for example, the liver (eg, acute intermittent porphyria). Defects at later stages of the heme biosynthesis pathway result in the accumulation of larger, aromatic intermediates that act as chromophores. On exposure to UVR or visible light, excitation of these chromophores cause a phototoxic reaction (eg, subepidermal blisters) that is mediated by an energy transfer from the excited chromophore to oxygen (photosensitized reaction) and formation of singlet oxygen (eg, in porphyria cutanea tarda or erythropoietic protoporphyria). The absorption maximum of these intermediates, for example, uroporphyrinogen in porphyria cutanea tarda and protoporphyrin in erythropoietic protoporphyria, is between 400 and 410 nm, at the border between UVA and visible blue light. Affected patients, therefore, need to protect themselves not only against UVA but also against visible light to prevent phototoxic reactions. Different cutaneous porphyrias present with different symptoms. This is likely due to differences in water solubility and subsequent difference in tissue distribution of the accumulated intermediates. The water-soluble uroporphyrinogen diffuses freely throughout the skin and induces most of its phototoxicity closest to the light source, at the epidermal junction, entailing blister formation. In erythropoietic protoporphyria, the much more lipophilic protoporphyrin remains in the endothelial lining and causes capillary damage with subsequent dermal necrosis and pain.

In drug-induced phototoxic and photoallergic dermatitis, the chromophore is a medication or a metabolite of the medication. Such photosensitizing medications are aromatic molecules that absorb within the UVA range. Therefore, phototoxic and photoallergic drug reactions are almost exclusively induced by UVA. Photo-phytodermatitis is a phototoxic reaction mediated by plant-based chromophores, namely furocoumarins. These molecules are related to psoralens and have an absorption maximum in the UVA range. Berloque dermatitis is also a phototoxic dermatitis, in which the chromophore is the perfume ingredient bergamot oil (5-methoxy psoralen).

Polymorphous light eruption and solar urticaria are likely heterogeneous conditions with regard to involved chromophores, as eliciting wavelength vary from patient to patient, ranging from UVB, to UVA, visible light, and possibly even infrared radiation.[42-44]

Diagnostic tools for the diagnosis of photodermatoses include determination of minimal erythema dose, separated for UVA and UVB (UVA-MED and UVB-MED), photopatch testing, and search for potential chromophores, for example, elevated porphyrins in blood, urine, and stool. Identification of the wavelength that elicit photodermatoses is important in tailoring appropriate photoprotection strategies for each individual patient.

PHOTOBIOLOGIC PRINCIPLES OF PHOTOTHERAPY

Therapeutic effects of electromagnetic radiation are used to treat a variety of skin diseases, either in combination with a photosensitizer, or without. For most phototherapy centers, psoriasis is the most common indication for phototherapy. In 1981, Parrish et al.[45] published an action spectrum for the therapeutic effects of UVR for the treatment of this inflammatory skin disease. No therapeutic effect in the UVC range or with 280 or 290 nm, a maximum effect at around 300 nm, and an exponential decline of therapeutic efficacy with increasing wavelengths from 300 nm to the UVA range is similar to the erythema action spectrum described above and overlaps with the action spectrum for the formation of pyrimidine dimer type of DNA damage in the basal layer of the epidermis.[27] This suggests that the chromophore that mediates the antipsoriasis therapeutic efficacy is DNA. At a time when psoriasis was mostly understood to be a condition that is driven by epidermal hyperproliferation, it was thought that UV-induced pyrimidine dimers would block replication of

hyperproliferating keratinocytes and with that improve psoriasis. However, slowing of epidermal hyperproliferation has since then been shown to be a later effect of UVB on psoriasis lesions, not a primary therapeutic effect. Today, the therapeutic effects of UVB are thought to be mediated by the above-mentioned immunosuppressive effects. Although the exact mechanisms remain to be clarified, hyperproliferating activated T cells may be particularly prone to the cytotoxic, proapoptotic effects of UVB. Induction of immune-deviation, eg, with transformation of TH1 and TH17 lymphocytes to Tregs, may be involved.[46] Penetration of UVB is limited to the epidermis and the upper layers of the dermis, but it does not reach deeper levels of the dermis, which are often also infiltrated by immune cells in thick psoriatic plaques. It is also unclear whether skin-infiltrating lymphocytes or other immune cells are the primary target mediating efficacy of UVB phototherapy for psoriasis, or whether these are affected by signaling from UV-exposed keratinocytes.

The above-mentioned action spectrum for the therapeutic effects against psoriasis has led to the development of narrowband (nb) UVB phototherapy with bulbs that emit almost monochromatic UVB between 311 and 312 nm. This modality has been shown to be vastly more efficacious than the previously used broadband (bb) UVB phototherapy. This may be due to the avoidance of pro-erythemogenic short wavelengths of UVB (280-290 nm) that have no or only very little therapeutic efficacy and with that the ability to use significantly higher doses than with bbUVB. In addition, the higher proportion of UVB wavelengths penetrating deeper into the dermis may also facilitate a more effective reach of the target, the dermal inflammatory infiltrate. Today, nbUVB has replaced bbUVB not only for the treatment of psoriasis, but for all other UVB phototherapy indications as well, including, for example, atopic dermatitis, vitiligo, cutaneous T-cell lymphoma, etc. For these indications, the phototherapy mode of action is even less known than for psoriasis. The fact that nbUVB has been shown to be superior to bbUVB for all of these indications may suggest that the modes of action are similar to those in psoriasis. However, although the pathogenesis of these conditions is inflammatory in most of them, the exact inflammatory pathomechanisms are of course quite diverse. Much remains to learn how a single treatment modality, phototherapy with nbUVB, can improve such a diverse group of skin diseases.

Crude coal tar is a potent photosensitizer, making exposed skin very sensitive to UVR-induced erythema. At a time when bbUVB was only partially effective, the use of tar in combination with bbUVB was a common practice, for example, with the treatment regimen named of the first describer, William H. Goeckerman. Tar is a mixture of many different compounds, many of which have photosensitizing properties. With nbUVB being highly effective as a monotherapy, the use of tar as a photosensitizer has become an uncommon practice.

In contrast, photochemotherapy that combines either systemic or topical administration of psoralen with subsequent irradiation with UVA remains a common phototherapy modality, although it is much less used today than at the time before the introduction of nbUVB. Psoralens (the most commonly used one is 8-methoxy-psoralen) intercalate with DNA and on photoexcitation react with pyrimidine bases to form mono- and divalent inter- and intrastrand crosslinks. For PUVA treatment, the chromophore is 8-MOP and psoralen adducts the UVA-induced photoproducts. The absorption maxima of 8-MOP are at 248 and 301 nm, which are in the UVC and UVB range. However, the absorption curve is quite broad and UVA still effectively excites this molecule and also produces the crosslinks quite effectively. The photochemistry of 8-MOP is quite complex. Intercalated with DNA, the absorption maximum is 313 nm, and after the formation of a monoadduct, the absorption maximum shifts to 334 nm, which is in the UVA range. These crosslinks are complex DNA lesions that can only be repaired by DNA recombination, not by nucleotide excision repair, as pyrimidine dimers. Similar to the above-described earlier belief that the replication-blocking properties of UVB-induced DNA damage mediates antiproliferative and with that antipsoriatic effects, the same was suggested for PUVA-induced crosslinks.[47] As with UVB, this has since been refuted. The high efficacy of PUVA treatment may be explained by the deeper penetration of UVA into the dermis and its better reach to deeper inflammatory infiltrates. Because UVA is much less energetic and produces much less pyrimidine dimers than UVB, the addition of psoralen is likely required to bring UVA's DNA-damaging effects into the therapeutic range.

One way to circumvent the limited biologic effects of UVA is to just increase its dosing. This principle has been used for the development of high-dose UVA1 phototherapy without the use of a photosensitizer. This treatment has been shown to have some efficacy for the treatment of acute atopic dermatitis and for sclerosing conditions, for example, morphea. Chromophores that mediate this effect have not been identified, and the exact mode of action of this type of phototherapy also remains to be worked out.

Another mode of phototherapy that employs the use of a photosensitizer is photodynamic therapy (PDT). In the United States, the most commonly used agent to photosensitize skin for PDT is 5-amino-levulinic acid (5-ALA). However, 5-ALA is not the chromophore that mediates the therapeutic effects of PDT. Application of 5-ALA circumvents the rate-limiting step of 5-ALA synthesis of the heme biosynthesis pathway and results in an increase in the cellular content of protoporphyrin IX. This aromatic molecule has an absorption maximum at around 406 nm, the so-called Soret band. It is readily excited by such blue light, upon which it reacts with oxygen to form singlet oxygen. PDT with 5-ALA therefore uses blue light, and its effects are thought to be mediated by the cytotoxic effects of singlet oxygen. The destruction of premalignant and malignant skin neoplasms by PDT may be due to the complete destruction of premalignant or malignant cells, or, more likely, to the destruction of some of these cells

with unmasking of tumor-antigens and subsequent immune-mediated destruction of others. At least partial tumor selectivity may be mediated by the more effective uptake of 5-ALA by premalignant and malignant cells.

There are a number of different treatment modalities for PDT, varying by the route of application, the nature of the photosensitizer, and the wavelengths used. In either case, the wavelengths used must be carefully chosen to not only match the absorption characteristics of the photosensitizer, but also to facilitate sufficient penetration. PDT with 5-ALA and blue light is limited by the depth of penetration of blue light. In Europe, the most commonly used skin-directed PDT modality uses methyl aminolevulinic acid (MAL) in combination with red light. MAL has the advantage of better uptake into cells because of its more lipophilic properties, as compared to 5-ALA. The resulting chromophore, however, is the same as with 5-ALA. Although protoporphyrin IX is most effectively excited by blue light, its absorption curve shows a few small peaks in the green, orange, yellow, and red light range (Q-bands), which still provide sufficient photoexcitation with red light. The combination of deeper penetration of MAL, as compared to 5-ALA with the deeper penetration of red light, as compared to blue light, may make this PDT modality more effective for thicker skin lesions, for example, infiltrating skin cancers.

PDT is not limited to regular, broad-spectrum sources of visible light but can also use monochromatic radiation from a variety of different laser sources, and research on the use of lasers for PDT is currently ongoing. Other modifications of current PDT practices involve the development of other photosensitizers with different photoabsorbing properties. The elegance of the current PDT, however, is that it uses a small molecule that is easily taken up into cells and then results in an increased production of the photosensitizer within the cell. This circumvents that problem that photoabsorbing molecules are usually larger and aromatic and are therefore less likely to be internalized by cells.

PHOTOCARCINOGENESIS

Chronic exposure of the skin to ultraviolet light increases the risk for a number of different cutaneous malignancies, including basal cell carcinoma, squamous cell carcinoma, malignant melanoma, and Merkel cell carcinoma. Photocarcinogenesis is the result of a chain of photophysical, photochemical, and photobiological events in UVR-exposed skin cells (Fig. 17-9).

FORMATION OF DNA DAMAGE AND MUTATIONS BY UVR

DNA has an absorption maximum at 260 nm, which is within the UVC range. UVB is still able to strongly excite DNA and penetrates deeper into the epidermis

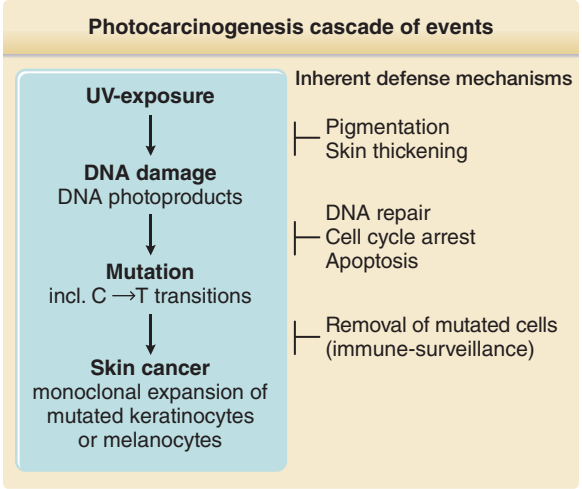

Figure 17-9 Photocarcinogenesis cascade of events. Exposure to UVR induces typical types of DNA damage, namely, cyclobutane pyrimidine dimers and 6,4-pyrimidine–pyrimidone photo-products. These often generate single and tandem base substitution mutations (C→T and CC→TT) at di-pyrimidine sites that are typical for UVR exposure and are therefore termed UV-signature mutations. With sufficient numbers of inactivating mutations in crucial genes (tumor suppressor genes), individual cells may undergo malignant transformation, clonally expand, and form skin cancers. Several inherent defense mechanisms counteract this chain of events.

than UVC and therefore induces more photochemical reactions in the basal keratinocytes and in melanocytes. A critical consequence of directly UVR-induced photoexcitation of DNA is the formation of covalent chemical bindings between 2 adjacent pyrimidine bases, thymine and cytosine. There are 2 main types of such DNA photoproducts formed by UVR, cis-syn cyclobutane pyrimidine dimers (CPDs) and pyrimidine-pyrimidone photoproducts (6-4 PPs). Both types of dimers can form between any combination of thymine and cytosine—T:T, T:C, C:T, or C:C (Fig. 17-10).

Unrepaired CPDs or 6,4-pyrimidine–pyrimidone dimers impair DNA replication and can result in mispairing if not removed prior to cells entering the S-phase of the cell cycle for DNA replication. A mispairing results in the change of the DNA sequence, a mutation. Several types of such mutations are observed after UV exposure, but by far the most common ones are C → T base exchange mutations at sites of 2 adjacent pyrimidines (dipyrimidine sites) (Fig. 17-10). This mutation is the result of misincorporation of adenine opposite cytosine during replication of the photoproduct. Without UV exposure, for example, in noncutaneous tissues or tumors, such mutations are observed only rarely, and the C → T and the C:C → T:T tandem mutations at dipyrimidine sites have therefore been named UV signature mutations.[48] Once these mutations are formed, they remain for the life span of the affected cells and are also propagated during cell division. They can be considered the memory of a cell's lifetime exposure to UVR. Some authors use the term UVB signature mutations. However, this term is

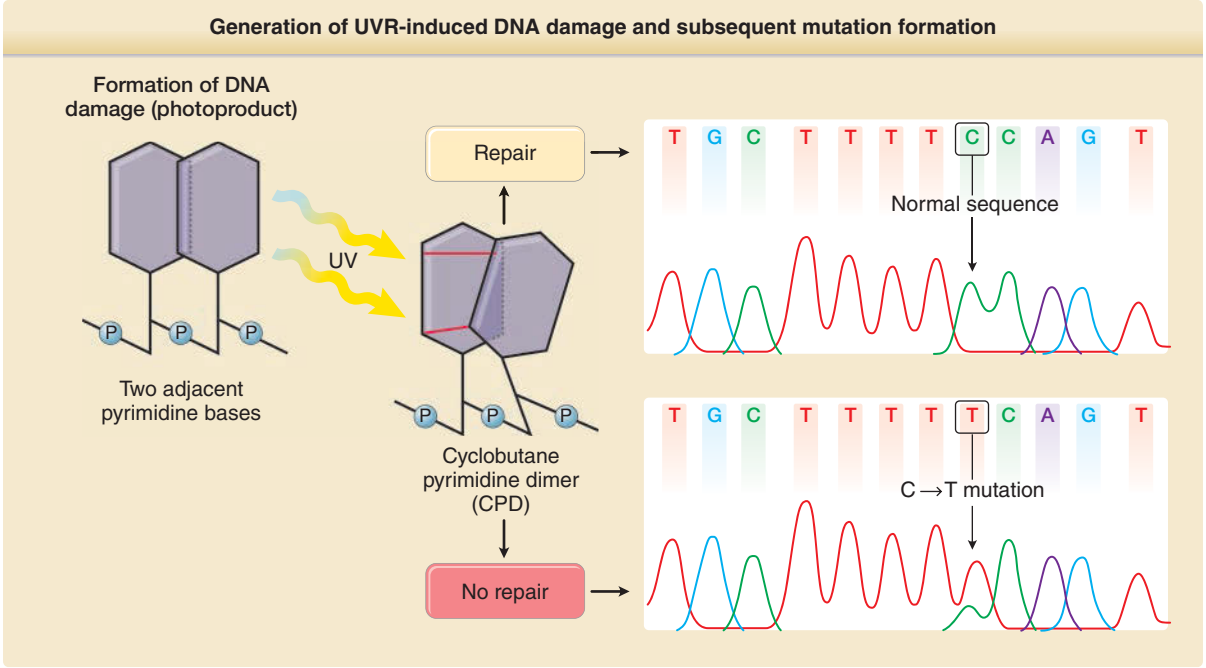

Figure 17-10 Example of UVR-induced generation of DNA damage and subsequent mutation. Upon direct excitation of the DNA molecule by UVR, adjacent pyrimidine bases (cytosine or thymine) may form covalent bonds between them, which leads to creation of pyrimidine dimers. The illustration shows an example in which 2 covalent bindings generate a tricyclic cyclobutane ring between 2 pyrimidines. Hence, this type of UV light–induced DNA damage is called a cyclobutane pyrimidine dimer, a common type of DNA photoproduct. The nucleotide excision repair DNA repair system functions to remove this damage, which results in the normal DNA sequence (upper box). If the damage is not repaired, this type of DNA photoproduct can lead to formation of a typical C→T single base substitution mutation (lower box). This is most likely to occur on replication of damaged DNA and misincorporation of adenine opposite the cytosine-containing photoproduct. An example of such a UV-signature mutation is shown on the right. Note that the mutation is located within a run of 7 pyrimidines, a common location for UV-signature mutations.

misleading, as they are also formed by UVA,[48,49] and should be avoided.

In squamous cell carcinomas and actinic keratoses, such UV signature mutations are found in the p53 gene,[48,50] in basal cell carcinomas in the genes of the sonic hedgehog signaling pathway (ptch, shh, smo) and in p53,[51] and in melanoma in the CDKN2A, PTEN, TERT promoter, and p53 genes,[52-55] demonstrating a molecular imprint of UVR as the transforming agent in tumor-specific gene mutations.

The best characterized mechanism of how UVR induces formation of pyrimidine dimers is via direct absorption of photons by DNA bases, with DNA itself acting as the chromophore (classic pathway; Fig. 17-11; left panel).

Recently, however, Premi et al.[56] (see also Brash[57]) described an alternative, melanin-dependent mechanism that likely contributes to pyrimidine dimer formation in melanocytes and in melanin-containing keratinocytes. They had observed formation of DNA photoproducts up to 3 hours after UV exposure, and then showed that the formation of these so-called "dark CPDs" is mediated by photoexcitation of melanin, in particular of pheomelanin, through formation of peroxynitrite from UV-induced nitric oxide and superoxide (melanin-dependent chemiexcitation pathway; Fig. 17-11; middle panel). With this, it appears that melanin is not only a photoprotector but may also contribute to cancer formation by increasing formation of DNA damage. This observation also provides an attractive explanation why UVA induces melanoma only in pigmented mice but not albino mice.[58]

The bystander effect describes the phenomenon that non-exposed cells in the vicinity of irradiated cells also demonstrate stress responses similar to exposed cells. UVA in particular has been shown to exert such a bystander effect in melanocytes, and long-lived UVR-induced radicals have been proposed to mediate it.[59,60] It is tempting to speculate that the long-lived peroxynitrite described by Premi et al.[56] could possibly not only generate "dark CPDs" in irradiated cells, but also in unirradiated bystander cells.

In addition to pyrimidine dimers, UVR can also induce oxidative DNA damage (oxidative pathway, Fig. 17-11; right panel), for example, through absorption of photons by other cellular chromophores and subsequent energy transfer to DNA (type I photosensitized reaction) or to molecular oxygen with formation of reactive oxygen species (ROS), which in turn react with DNA to form oxidative DNA base modifications (type II photosensitized reaction). Although UVB can generate some ROS, most of the oxidative DNA damage after exposure to natural sunlight is caused by UVA.[61,62] UVR-induced ROS are mostly singlet oxygen,

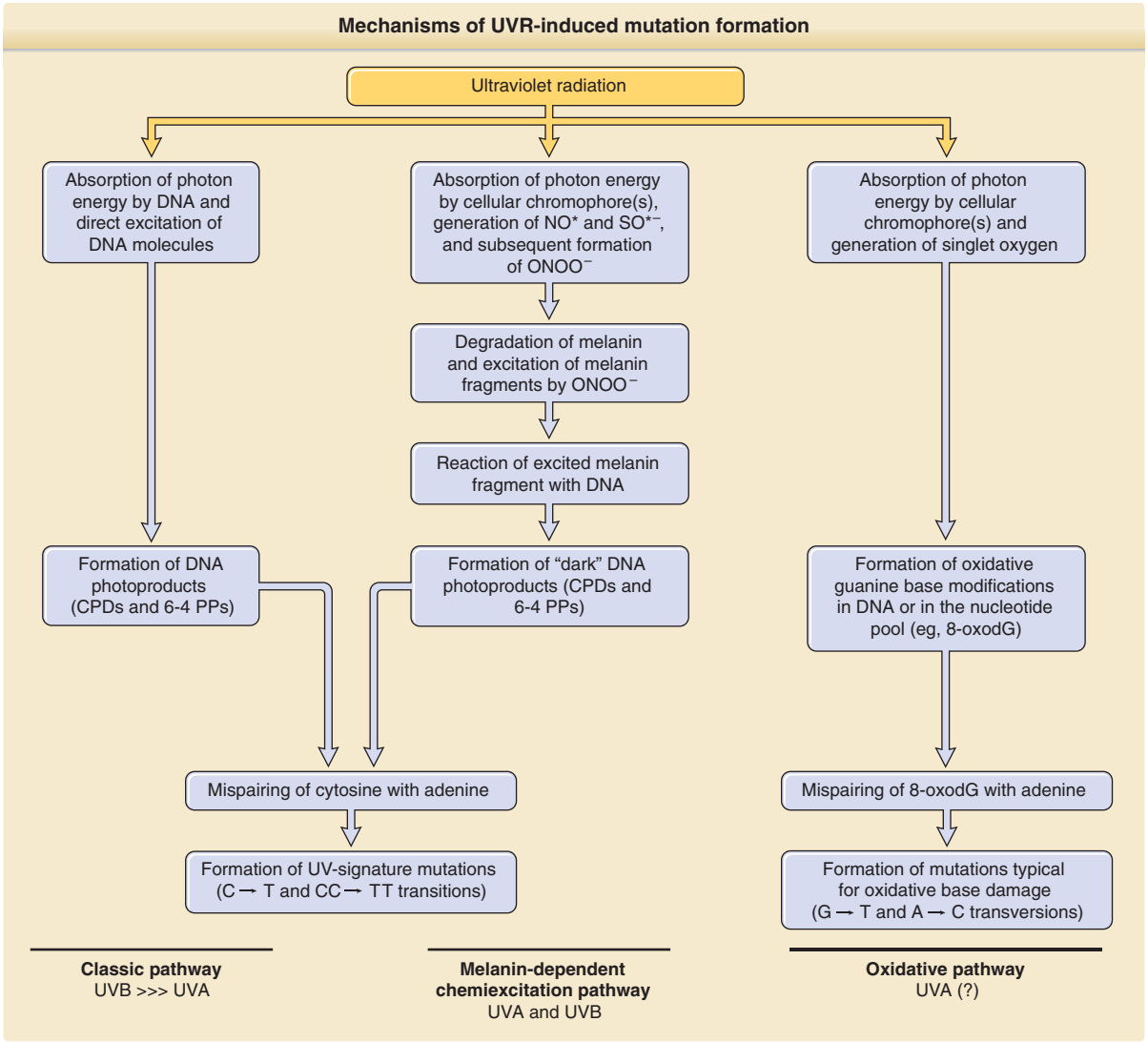

Figure 17-11 Mechanisms of UVR-induced mutation formation. In the classic pathway (left panel), adjacent pyrimidines react with each other and dimerize to form DNA photoproducts after direct excitation of DNA molecules by photons. The C → T and CC → TT UV-signature mutations may form at sites of DNA photoproducts by mispairing of cytosine(s) with adenine. Although 260 nm is the absorption maximum of DNA, UVB still strongly excites DNA and generates mutations through this pathway. UVA's ability to excite DNA is much weaker, but may still generate mutations via this mechanism. CPDs, cis-syn cyclobutane pyrimidine dimers; 6-4 PPs, pyrimidine (6-4) pyrimidone photoproducts.

The melanin-dependent chemiexcitation pathway (middle panel) was recently described by Premi et al.[56] It describes the formation of DNA photoproducts not by direct excitation of DNA, as in the classic pathway, but by energy transfer from excited melanin fragments to DNA, which involves nitric oxide (NO^*), superoxide ($SO^{*}-$), and peroxynitrite (ONOO–). This mechanism generates UV-signature mutations both after irradiation with UVA and with UVB, and contributes to mutation formation in melanocytes and melanin-containing keratinocytes.

The oxidative pathway (right panel) involves a photosensitized reaction with formation of singlet oxygen after excitation of a cellular chromophore other than DNA. Singlet oxygen then reacts with guanine either in DNA or in the nucleotide pool. A common oxidative base lesion is 8-oxo-7,8-dihydro-2′-deoxyguanosine (8-oxodG). By mispairing with adenine, G → T and A → C transversions can form. UVA has long been thought to contribute to UVR-induced mutation load through this mechanism. However, molecular evidence, in particular the low frequency of such transversions in melanomas, does not support a major role in the formation of skin cancer.

but others, for example, hydrogen peroxide, the superoxide radical, and the hydroxyl radical also may be formed, albeit in much lower numbers. ROS-induced DNA damage involves predominantly guanine bases. Several such oxidative guanine lesions have been described after UVR exposure, of which 8-dihydro-8-oxoguanosine (8-oxoG) is the best studied.

During DNA replication, 8-oxoG mispairs with adenine, giving rise to G → T transversion mutations. Similarly, oxidation of a guanosine nucleotide can result in misincorporation opposite an adenine during replication, giving rise to A → C transversions. There is no notable increase of such mutations in UVR-induced cutaneous malignancies, and it remains a matter of

debate how much oxidative DNA damage contributes to photocarcinogenesis.

An action spectrum for the formation of pyrimidine dimers and oxidative guanine base modifications in mammalian cells shows gradually changing DNA-damaging capacity with increasing wavelengths from UVC, to UVB, UVA, and visible light.[62] Few pyrimidine dimers are formed by UVA, approximately 10,000-fold less than with UVB when comparing, for example, 360 nm with 300 nm. Even when considering the much higher abundance of UVA in natural sun, UVB is most likely generating the majority of solar radiation–induced pyrimidine dimers. Nevertheless, there is mounting evidence from both in vitro and in vivo mutation spectra that pyrimidine dimers are the most important premutagenic DNA lesions not only with UVB but also with UVA, and that oxidative DNA damage plays only a minor role in mutagenesis.[49,63] One hypothesis we have brought forward to explain a higher rate of mutations at UVA-induced pyrimidine dimers, as compared to the mutation rate of the UVB-induced ones, is that UVA does not induce as robust a cellular DNA damage response as UVB, in particular with cell cycle arrest.[64] This may not be relevant for mutagenesis following exposure to broad-spectrum solar radiation, because with that the damage response can be evoked by the UVB component, which would also protect against mutagenesis at the few UVA-induced pyrimidine dimers. However, with exposures to pure UVA sources, as, for example, found with exposure to solar radiation through window glass or with use of tanning devices, UVA may be particularly mutagenic and carcinogenic.

Although oxygen radicals have been described following UVR exposure, we found no evidence that DNA double-strand breaks, a common type of DNA damage generated by such ROS, are formed by either UVB or UVA.[65,66] This is consistent with the fact that deletions or insertions, types of mutations that are commonly generated by DNA double-strand breaks, are not a common observation in UV-induced mutation spectra.

Upon accumulation of a sufficient number of mutations in specific genes (driver mutations), cells undergo malignant transformation. In this process, mutation formation is a random event. Usually, many mutations occur all over the genome of exposed cells to ultimately also accumulate the critical number of specific driver mutations. For example, the high mutagenic burden in melanoma was demonstrated by Pleasance et al.,[67] who were the first to report the full genomic sequence of a melanoma as compared to the normal sequence of a lymphoblast cell line from the same patient. Of 33,345 base substitution mutations observed in the melanoma, more than 70% were C → T UV-signature mutations. The predominance of this type of mutation that is otherwise rare in non-UV-exposed tumors is an impressive molecular account of a lifetime of sun exposure of a single melanocyte that has ultimately given rise to this melanoma. These data have since been confirmed in a large series of more than 300 melanomas, showing that a median of 77.7% of all mutations in melanoma are UV-signature mutations.[68] These data also show that the mean mutation rate in melanomas from sun-exposed sites is one of the highest of all cancers investigated in this way. This high burden of mutations with mostly C → T transitions again emphasizes the role of UVR's high mutagenic properties and its role in the pathogenesis of cutaneous melanoma.

A genetically distinct melanoma subtype presents most commonly on the face and in the elderly, but can also occur in other areas with heavily photodamaged skin. These melanomas on chronically sun-damaged skin (CSD melanomas) show an extremely high mutation burden (approx. 60 mutations/Mbase)[68,69] and often arise from an in situ melanoma termed lentigo maligna. Desmoplastic melanomas have an even higher mutation burden[70] and have a similar age and anatomic site distribution as CSD melanomas. Melanomas on sun-exposed skin without signs of chronic sun-induced damage (non-CSD melanomas) show a lower mutation burden of approximately 30 mutations/Mbase. The somatic mutations found in all of the above-mentioned melanoma subtypes show a clear UV signature, whereas mucosal and acral melanomas, which are not thought to be UVR-induced, do not. Non-CSD melanomas are most common on the lower legs in women and on the back in men.[71] At least in Western cultures, these areas tend to be photoprotected for long periods of time, for example, during winter, and are then exposed to the sun in the spring and summer, often suddenly and with subsequent sunburning. These types of melanoma therefore appear to be associated with sudden, intermittent high-dose UVR exposures of not sun-adapted skin.[72] Chronically UVR-exposed skin is characterized by an upregulation of anti-mutagenic mechanisms. The absence of such protective states in photoprotected skin, in combination with a relative inability of melanocytes to undergo apoptosis on high-dose UVR exposures has been suggested as an explanation for the induction of melanoma by intermittent UVR exposures[73] and may indicate the importance of cellular mechanisms that prevent formation of DNA damage and of mutations, and malignant transformation in chronically UVR-exposed skin (Fig. 17-9).

DNA REPAIR AND OTHER RESPONSES TO UVR-INDUCED DNA DAMAGE

DNA repair is an important cellular defense mechanism that prevents mutation formation at sites of DNA damage after UV exposure. However, it is not the only defense mechanism (Fig. 17-9). Most mutations are generated during replication of damaged DNA. Therefore, a damage-induced arrest in cell cycling, which allows more time for repair, is another important cellular damage response that prevents mutation formation.[64,74] Furthermore, programmed cell death (apoptosis) prevents the survival of cells with overwhelming DNA damage, and through that mechanism

the frequency of cells with UV-induced mutations is also reduced. Other inherent defense mechanisms against the carcinogenic properties of UVR include increased melanogenesis and thickening of the epidermis and stratum corneum, which protect from future DNA damage, as well as removal of mutated cells through host immune responses. More than 100 DNA repair genes have been identified (http://sciencepark.mdanderson.org/labs/wood/DNA_Repair_Genes.html). The nucleotide excision repair (NER) pathway acts on DNA damaged by UVR, repairing CPDs and other photoproducts, as well as on DNA damaged by certain other carcinogens (such as benzo-[a]-pyrene). In NER, the damaged nucleotide is removed and replaced with undamaged DNA. A simplified schema of the NER system describing some of the many proteins that act in concert to repair UV-induced DNA damage is shown in Fig. 17-12. Defects in these repair genes can cause human diseases including xeroderma pigmentosum (XP), Cockayne syndrome (CS), and trichothiodystrophy (TTD) (Chap. 130). For instance, XP can be caused by a defect in any one of several genes involved in NER. Based on cell fusion experiments, cells/patients with defects in the same gene are considered to be in the same complementation group, and in different complementation groups if different genes are affected. If DNA repair in the fused cell is normalized, with the wildtype gene from each cell giving rise to a functional protein that is absent in the other cell, the cells "complement" each other and are in different complementation groups. Seven such complementation groups have been identified (XP-A to XP-G), which correspond with mutations in 7 distinct genes that can cause XP.

Transcribed genes are repaired faster than the rest of the genome. In the NER pathway, the first steps

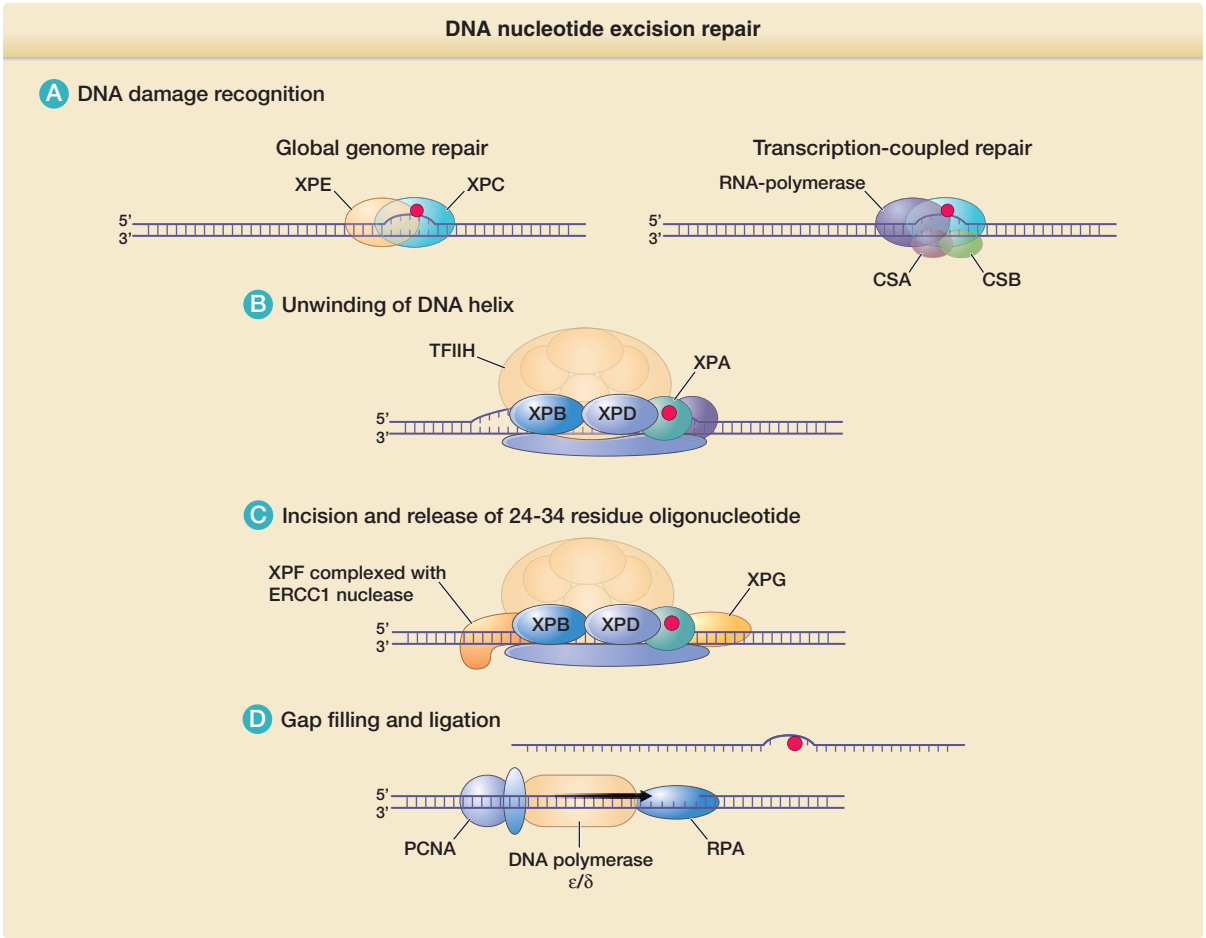

Figure 17-12 DNA nucleotide excision repair scheme. (A) Right: Damaged DNA in actively transcribed genes results in stalling of the RNA polymerase in a process that involves the CSA and CSB proteins. This serves as a signal to initiate transcription-coupled DNA repair. Left: Damaged DNA in the remainder of the genome is bound by the XPE and XPC gene products. This serves as a signal to initiate global genome repair. (B) A portion of the DNA, including the damage, is unwound by a complex of proteins including the XPB and XPD gene products. These proteins are also part of the 10-subunit basal transcription factor IIH (TFIIH). The XPA protein may stabilize the unwound DNA. (C) The XPF and XPG nucleases make single-strand cuts on either side of the damage, releasing a 24- to 34-residue segment of DNA. (D) The resulting gap is filled by DNA polymerase in a process that includes the proteins proliferating cell nuclear antigen (PCNA) and replication protein A (RPA). CSA, CSB, Cockayne syndrome complementation groups A and B; ERCC1, excision repair cross-complementing gene 1; LIG1, ligase 1; XPA, XPC, etc, xeroderma pigmentosum complementation groups A, C, etc.

involving DNA damage recognition are different in nontranscribed (global genome NER) and transcribed genes (transcription-coupled NER). In nontranscribed genes and noncoding areas, which represent most of the genome, the *XPE* and *XPC* gene products bind to UV-damaged DNA, marking it for further processing. In contrast, DNA damage in transcribed genes appears to be sensed by a stalled RNA polymerase acting in conjunction with the CSA and CSB (CS complementation groups A and B) gene products. After the DNA damage recognition steps, global genome NER and transcription-coupled NER follow the same pathway (Fig. 17-12).

In XP, pronounced NER deficiencies confer a very high risk to develop nonmelanoma skin cancer and melanoma. More subtle variations in DNA repair capacity, for example, as a consequence of polymorphisms in NER genes or of an aging-related decline, also have been linked to an increased skin cancer risk.[75-78]

Oxidative base modifications are a simpler type of DNA damage than pyrimidine dimers, as they only involve chemical changes in a single DNA base. These lesions are processed by a different DNA repair pathway, called base excision repair.

Several cellular responses to DNA damage contribute to the maintenance of genome integrity by preventing mutation formation. These include cell cycle arrest, apoptosis (programmed cell death), and DNA repair. Because these responses need to be carefully orchestrated, there are many proteins involved in the signaling of DNA damage and in the regulation of cellular DNA damage responses. Different types of DNA-damaging agents and different types of DNA damage require different DNA damage responses. A simplified version of this complex pathway is presented in Fig. 17-13. As with defects in DNA repair genes, defects in many of these DNA damage–signaling genes (boxed in Fig. 17-13) are also implicated in

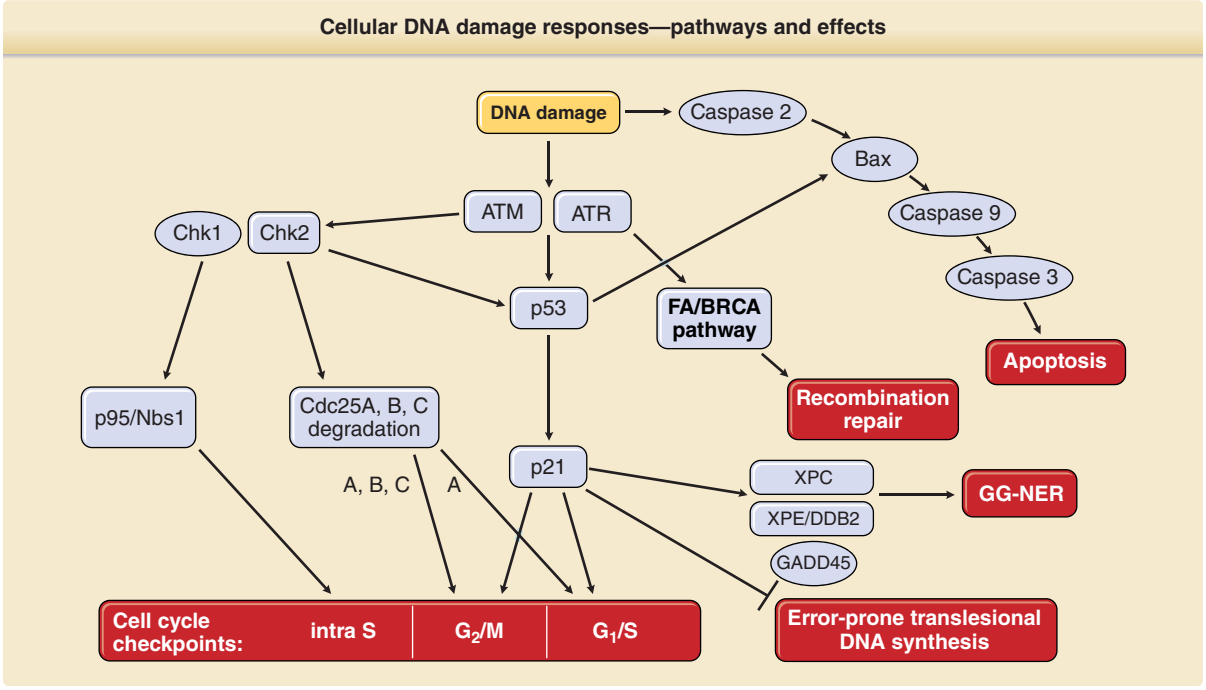

Figure 17-13 Signaling cascades that regulate apoptosis, DNA repair, translesional DNA synthesis, and activation of cell cycle checkpoints in response to UVR-induced DNA damage. This is a highly simplified diagram that depicts only the most important players in the intricate and interwoven DNA damage–signaling networks. The traditional thinking was that ATM (ataxia telangiectasia mutated gene) is activated (phosphorylated) in response to ionizing radiation (IR) and ATR (ataxia telangiectasia- and Rad3-related gene) in response to ultraviolet (UV) radiation, but newer data indicate that both are activated by IR and UV. ATM/ATR can activate (ie, phosphorylate) p53 either directly or indirectly through activation (phosphorylation) of Chk2 (an ATM target) or Chk1 (an ATR target). Through transcriptional activation of p21 and subsequent inhibition of cyclin-dependent kinases, which usually drive cells from the G1 into the S phase of the cell cycle, activated p53 activates the G1/S checkpoint (ie, arrests cells in G1). The G1/S checkpoint is also activated by Chk1/Chk2-induced phosphorylation and then degradation of Cdc25A and subsequent failure to activate cyclin-dependent kinases. Phosphorylation and subsequent degradation of Cdc25A, Cdc25B, and Cdc25C also mediate the G2/M arrest, as does p21. Intra–S phase arrest is mediated through activation (phosphorylation) of p95/Nbs1. p53 also induces global genome nucleotide excision repair (GG-NER) through transcriptional activation of XPC, XPE/p48, and GADD45. Translesional DNA synthesis has been shown to be downregulated by p53 via p21. Recombination repair is mediated through the Fanconi anemia (FA)/BRCA pathway, which in turn is dependent on ATR activation. The mitochondrial pathway of apoptosis is activated through activation of Bax by caspase 2 and p53, the initiator caspase 9, and the effector caspases 3, 6, and 7. Gene products that are defective in hereditary human diseases are boxed. DDB2, DNA damage binding protein 2; XPC, XPE, xeroderma pigmentosum complementation groups C and E.

hereditary disorders of genome instability, including, for example, ataxia telangiectasia, Fanconi anemia, familial breast cancer, Li-Fraumeni syndrome, and others (Chap. 130).

The tumor suppressor gene p53, often called the *guardian of the genome*, plays a pivotal role in regulating and orchestrating these responses and is mutated in many cancers, including cutaneous squamous cell carcinomas. Upstream regulators of p53 in the cellular DNA damage response pathway are ATM (ataxia telangiectasia mutated) and ATR (ataxia telangiectasia- and Rad3-related) genes. One of p53's several functions is the regulation of the cell cycle in response to DNA damage. After cell division (mitosis), cells have 23 pairs of chromosomes and are in the G_1 phase of the cell cycle. The chromosomes then replicate during DNA synthesis, or S phase, and as a result have twice the number of chromosomes (G_2 phase) just before mitosis (M phase). In response to damage, the cell may stop cycling (arrest) in specific cell cycle phases called *cell cycle checkpoints*. An important downstream effector in preventing cells from entering S phase (G_1/S checkpoint) is p21. p53 also induces NER by transcriptionally inducing XPC, XPE/p48, and GADD45.

If cells enter S phase with unrepaired DNA damage, or if cells are UV exposed during S phase, regular DNA polymerases stall at DNA photoproducts and detach from the DNA strand.[79] For these instances, cells are equipped with several specialized DNA polymerases for translesional DNA synthesis. DNA polymerase eta is one of these; it is specialized to bypass DNA photoproducts but may introduce mutations while doing so. It is mutated in XP variant patients, who are clinically indistinguishable from other XP patients with defects in NER (Chap. 130).[80,81] This demonstrates the importance of this second line of defense against the mutagenic and carcinogenic consequences of DNA photoproducts. p53 and p21 also downregulate the activity of this translesional DNA synthesis to maintain a low mutagenic activity at the price of reduced damage bypass.

If this translesional DNA synthesis fails, cells can use recombination repair to resolve stalled replication forks.[82] When invoked in response to damage from UV light, this third line of defense is mediated by activation of the Fanconi anemia/BRCA DNA damage response pathway.[65]

Apoptosis is a regulated physiologic process leading to cell death characterized by cell shrinkage, membrane blebbing, and DNA fragmentation. A group of cysteine proteases called *caspases* are central regulators of apoptosis. Triggers may be extrinsic or intrinsic to the cell (eg, DNA damage) and involve separate initiator caspases (eg, caspase 2 in response to DNA damage) but share the same downstream effector caspases.

Mutations in the p53 tumor suppressor gene are very commonly found in cutaneous squamous cell carcinomas and their precursors, actinic keratoses. In addition, chronically sun-exposed skin harbors many clonal proliferations of keratinocytes with p53 mutations, which are not detectable by macroscopic or microscopic abnormalities.[83] Loss of p53 function as a central regulator of antimutagenic responses entails a higher rate of mutation formation with subsequent UVR exposures. This so-called UV mutator phenotype is critical in the development of cutaneous squamous cell cancers, as it makes it much more likely that all the mutations necessary for complete malignant transformation of a single keratinocyte are accumulated with repeated UV exposures.[84]

WHICH WAVELENGTHS OF UVR CAUSE SKIN CANCER?

Although the carcinogenic properties of UVB have been well known for decades, UVA has long been considered harmless because of its inability to induce sunburning with solar available doses. However, it is now recognized that UVR is also damaging and carcinogenic in suberythemogenic doses and that UVA can induce cutaneous squamous cell carcinomas by itself in mice. Consequently, the WHO has classified UVA as an independent class I carcinogen.[85] The Utrecht-Philadelphia action spectrum for photocarcinogenesis in mice shows an exponential decline in carcinogenic efficacy in mice with increasing wavelengths from UVB to UVA.[86] Some of this decline is offset by the higher abundance of UVA in natural solar radiation. In addition, exposures to pure UVA by window glass–filtered solar radiation and in tanning parlors may significantly increase the contribution of UVA to photocarcinogenesis, as detailed above. Therefore, although it appears that UVB contributes more to photocarcinogenesis than UVA, the relative contributions of either one to a lifetime risk to develop nonmelanoma skin cancer remains unclear.

Several animal models have been used to answer the wavelengths question for melanoma. Ley[87] observed the induction of melanoma precursor lesions in the opossum with UVA, more than with UVB. However, no infiltrative melanomas could be induced. Setlow et al[88] used swordfish and observed that UVA induces melanomas more effectively than UVB. However, this observation could not be reproduced and the opposite result was reported by Mitchell et al.[89] DeFabo et al[90] used HGF/SF transgenic mice and observed melanoma induction only with UVB, but not with UVA. Later, the same group[58] observed that UVA does induce melanoma, but only in pigmented mice, not in the previously studied nonpigmented mice. With that, it appears that, at least in this mouse model, the presence of melanin is required for the induction of melanoma with UVA, but not with UVB, and that both wavelengths, UVA and UVB, can induce melanoma, but possibly via a different mechanism. It is very plausible that the recently described melanin-dependent chemiexcitation pathway for the generation of pyrimidine dimers and UV signature mutations (Fig. 17-11; middle panel) is that postulated alternative mechanism for melanomagenesis with UVA.

In addition, increases of melanoma risk with tanning parlor use provide further support for UVA being a particular risk factor for melanoma. Many studies

have shown a significantly increased risk for melanoma subsequent to sunbed/sunlamp use,[91,92] including a large prospective cohort study in 106,379 women in Sweden and Norway, showing a relative melanoma risk of 1.42 to 2.58 with use of tanning devices.[93] A melanoma epidemic in Iceland with increasing rates of melanoma between 1990 and 2006, mainly in young women, also has been associated with increased tanning bed use.[94] Melanomas at usually covered sites, for example, skin in the sacral and pubic areas, also may be attributable to UVR exposure from sunbed use.[95] When a few decades ago it was increasingly recognized that UVB (280 to 315 nm) had skin-damaging effect, but UVA (315 to 400 nm) was still considered relatively safe, the tanning industry reduced the UVB output in their devices and claimed that a UVA-induced tan would be safe. This is why the increased melanoma risk with tanning bed use may support the role of UVA as a particular risk factor for melanoma. However, tanning machines differ widely in their spectral output.[96,97] Therefore, the increased melanoma risk with sunbed use also may be due to the UVB that is still emitted by tanning devices.

The ability to generate oxidative DNA lesions increases with increasing wavelengths from UVB to UVA and it has been hypothesized that such damage, in particular when induced by UVA, could play a role in melanomagenesis.[63] When contemplating this hypothesis, it is important to recognize that at least in fibroblasts and keratinocytes, UVA has been shown to produce more pyrimidine dimers than 8-oxodG.[98] Unlike an early report of a separate UVA signature mutation observed in transformed rodent cells,[99] the majority of UVA-induced mutations has later been shown to be C → T transitions, without a particular signal for a separate UVA signature mutation or a high rate of mutations typical for oxidative base modifications, both in vitro and in vivo.[100-103]

An attractive candidate for generation of oxidative stress on exposure to UVR in melanocytes is melanin. Melanin has been described to have some photosensitizing properties, in particular, the more reddish-colored pheomelanin.[104,105] Wang et al.[106,107] reported that, on irradiation with UVA, melanocytes generate more oxidative DNA damage, have less efficient repair of oxidative DNA damage, and produce more mutations. They proposed that oxidative DNA damage is a major driver in melanomagenesis. However, they did not sequence the UVA-induced mutations and with that did not provide ultimate proof that the UVA-induced mutations are indeed the G → T or A → C transversions that are typical for oxidative DNA damage. In addition, the above-mentioned mutation data from melanomas show only a small percentage of such mutations typical for oxidative DNA damage.[67,68] Taken together, there is no proof that oxidative DNA base lesions play a major role in UVR-induced mutation formation that drives melanoma.

In summary, the evidence supports that both UVB and UVA can induce melanoma, possibly through different mechanisms. However, the relative contribution to the overall melanoma risk of UVB and UVA remain unclear.

PHOTOAGING

Photoaging describes changes observed in chronically sun-exposed skin, whereas intrinsic aging of the skin describes changes that occur with advancing age without extrinsic damage from chronic sun exposure. Skin alterations with photoaging are observed in all compartments of the skin, including the epidermis, the pigmentary system, the dermal connective tissue, the vasculature, and the subcutaneous fat (Figs. 17-14 and 17-15).[108,109] Although subtle changes of photoaging can sometimes be observed in young individuals already, manifestations of photoaging are more common in older patients, indicating that skin changes of photoaging are typically superimposed on changes of intrinsic skin aging. Many manifestations of photoaging are also observed in intrinsically aged skin. This raises the question whether photoaging is solely an acceleration of the normal aging process by chronic photodamage. Table 17-4 lists typical manifestation of cutaneous photoaging. Symptoms that involve benign, premalignant, and malignant clonal proliferations of keratinocytes and melanocytes are associated with

Figure 17-14 Pigmentary changes of photoaged skin include freckles, which are the result of clonal melanocyte proliferation events, and hypopigmentations, which are melanocyte loss-of-function events.

Figure 17-15 Deep wrinkling, in chronically photoaged skin due to actinic elastosis. Note the absence of such wrinkling in the more photoprotected areas on the lateral aspects of the chest.

aging, as cancer in general is associated with aging. They are better classified as neoplastic events, rather than aging events. They are not observed in intrinsically aged, only in photoprotected, skin. The mechanisms that drive these events are described under section "Photocarcinogenesis".

In contrast, thinning of the epidermis, hypopigmentations, loss of dermal collagen, telangiectasias (as a consequence of a diminished extracellular matrix scaffold), and loss of subcutaneous fat are loss-of-function events (Table 17-4), which are also observed with intrinsic aging. Accelerated proliferative exhaustion by chronic photodamage is a likely mechanism for these features, which is consistent with the view that photoaging represents damage-accelerated aging.

TABLE 17-4

Photoaging: Loss-of-Function Events and Clonal Proliferation Events

	LOSS OF FUNCTION	CLONAL PROLIFERATION
Epidermis		
Epidermal atrophy	✓	
Expansion of mutant clones		✓
Malignant transformation		✓
Pigmentary System		
Freckles/lentigines		✓
Hypopigmentations	✓	
Melanocytic nevi		✓
Malignant melanoma		✓
Dermal Connective Tissue		
Loss of collagen	✓	
Actinic elastosis	✓	
Vasculature		
Telangiectasias (loss of ECM scaffolding)	✓	
Subcutaneous Fat		
Loss of fat	✓	

The only nonproliferative feature of photoaged skin that is not observed in intrinsically aged skin is actinic elastosis, which is characterized by accumulation of fibrillary basophilic material in the upper and middermis. Clinically, it presents with yellowish thickening of the skin, sometimes nodular, loss of elasticity, and formation of deep wrinkles (Fig. 17-15). It is composed mainly of elastin and fibrillin, stains strongly with elastin stains, and can be degraded by elastase, but not collagenase. Elastin synthesis is upregulated following UV exposure,[110] but the UVR-induced influx of neutrophils, as seen, for example, in sunburned skin, also provides a mechanism for increased degradation via activity of elastase secreted by neutrophils. Following degradation of elastin in the extracellular space, dermal fibroblast internalize elastin fragments through receptor-mediated endocytosis to lysosomes for further degradation by the lysosomal protease cathepsin K.[111] Cathepsin K is upregulated by UVA to promote this intracellular clearing.[112] Aged fibroblasts do not upregulate cathepsin K in response to UVA, and it is hypothesized that this entails a failure to properly clear elastin fragments from the extracellular space and ultimately results in the accumulation of elastin with crosslinking to a large, abnormal macromolecule.[112] With this, actinic elastosis can be classified as a loss-of-function event. Actinic elastosis is largely irreversible, even with consistent photoprotection, which is most likely due to the fact that the large abnormal macromolecule has become undegradable. This is reminiscent of the intracellular accumulation of abnormal macromolecules and subsequent impairment of cellular function as a result of a failure to clear them from the cytoplasm via a mechanism called macroautophagy, which is an important mechanism how aged cells in general loose functions.[113]

Progerin is an abnormal splice variant of the nuclear membrane protein Lamin A. It is found in high concentrations in cells from patients with the premature aging syndrome Hutchinson Gilford progeria, but also accumulates in normally aging cells.[114,115] It interferes with many nuclear functions and ultimately results in cellular senescence and an aged cellular phenotype. This aging protein is induced by UVA via oxidative stress and induction of abnormal splicing.[116] This is yet another example how UVA in particular promotes an aging phenotype. As a result of a loss of a farnesylation site that allows degradation of lamin A, progerin is largely undegradable. This is a second example how exposure to UVA results in the accumulation of an undegradable protein that interferes with cell function. Although some of the effects of acute UVR-induced inflammation induce metabolic changes that may contribute to photoaging, for example, increased elastin synthesis, increased expression of matrix metalloproteinase (ie, collagenases), and decreased collagen synthesis, these should be reversible on cessation of UV exposure. The observation, however, is that changes of the extracellular matrix, which manifest as wrinkling and increased laxity of skin, are not reversible, may be explained by the accumulation of abnormal and undegradable proteins in the extra- and intracellular

space. Although the contribution of oxidative DNA damage to photocarcinogenesis is unproven, UVA-induced oxidative stress is likely a central mediator in these loss-of-function events in photoaging. As ROS mediate senescence, for example, via the formation of progerin,[116] they probably entail an anticancer effect that counteracts the pro-carcinogenic effects of UVR. With this, antioxidants may prevent UVR-induced loss of function events of photoaging, but may in turn also promote photocarcinogenesis.

In addition to its specific roles in inducing a cellular aging phenotype with loss of cell functions, UVA also may be a particular culprit for the changes in the dermal extracellular matrix because of its deeper penetration into the dermis, as compared to UVB. However, UVB does affect metabolism in the deep dermis even without reaching into it. For example, the induction of matrix metalloproteinases in the dermis after irradiation with UVB has been shown to be mediated by a paracrine mechanism via excretion of inflammatory mediators from keratinocytes and signaling to dermal fibroblasts.[117-119] Further signaling into the subcutaneous fat may even mediate loss of subcutaneous fat as a feature of photoaging.[120]

CUTANEOUS RESPONSES TO VISIBLE LIGHT AND INFRARED RADIATION

In comparison to UVR, the effects of other types of nonionizing radiation of the electromagnetic spectrum, namely, visible light and infrared radiation (IR), have been studied much less. However, there is increasing evidence that these also have photobiological effects on the skin.

Visible light can induce erythema and pigmentation (immediate and delayed pigment darkening, in particular in darker skin types)[121,122] and some photodermatoses can sometimes also be elicited by visible light, including, for example, solar urticaria, chronic actinic dermatitis, and cutaneous porphyrias. Potential chromophores that absorb visible light and could be mediating these effects are porphyrins, melanin, β-carotene, riboflavin, bilirubin, and hemoglobin. In addition, the action spectra for the formation of pyrimidine dimer types of DNA damage and oxidative DNA base modification extend well into the range of visible light.[62] Although the mode of action of these effects is still only very incompletely understood, these insights have led to the development of visible light–based treatment devices, including, for example, intense pulsed light (IPL), lasers, and photodynamic therapy.

IR has been implicated in photoaging and in erythema ab igne.[123,124] IRA penetrates deep into the dermis and has profound effects on the gene expression profile of dermal fibroblasts, including, for example, the induction of matrix metalloproteinase. This may contribute to the loss of collagen fiber in chronically sun-exposed skin. Although infrared radiation alone does not appear to cause skin cancer, growth behavior may be affected, for example, via prevention of apoptosis.[125]

CONCLUSIONS

The only positive effect of UVR on skin, vitamin D production, is offset by a number of serious and potentially life-threatening detrimental effects that mandate effective photoprotection for prevention. Fortunately, the negative effect of photoprotection on vitamin D metabolism can easily be addressed with oral vitamin D supplementation.

From the described effects of UVB and UVA, is it clear that photoprotection strategies must include protection against both qualities. Fortunately, the Food and Drug Administration (FDA) of the US Department of Health and Human Services issued a final role on labeling and effectiveness testing of sunscreen drug products for nonprescription human use in 2011 that addresses such broad-spectrum protection. This new standard adds an in vitro measurement for broad-spectrum protection to include UVA. It uses the critical wavelength criterion originally suggested by Diffey et al, defining broad spectrum by a wavelength of at least 370 nm at which 90% of the area under the 290- to 400-nm absorbance curve is met.[126]

The recognition that IR and visible light can damage skin has given rise in efforts to extend photoprotection to these types of radiation.[127,128] Attempts to filter visible light will probably be hampered by poor acceptability, as such filters will be visible. There may be an opportunity to filter IR, but the development of such filters has only just begun.

Systemic and topical antioxidants have been advocated to reduce UVR-, visible light-, and IR-induced oxidative damage, in particular, oxidative DNA damage.[129] However, their protective effects against any of the above-mentioned endpoints have not been well established, or are marginal at best. In addition, the evidence that oxidative DNA damage might not contribute significantly to UVA-induced mutagenesis (as was previously thought) raises the question whether antioxidants provide any protection against skin cancer. Reactive oxygen species are not only damaging but also induce cellular responses that can protect against photocarcinogenesis, including, for example, induction of senescence through generation of the aging-associated protein called progerin.[116] This suggests that antioxidants may actually be promoting photocarcinogenesis, as already suggested for other types of cancer.

In 2014, the Surgeon General and the U.S. Department of Health and Human Services published a Call to Action to Prevent Skin Cancer. Stated goals include (1) increase opportunities for sun protection in outdoor settings; (2) provide individuals with the information they need to make informed, healthy choices about UV exposure; (3) promote policies that advance the national goal of preventing skin cancer; (4) reduce harms from indoor tanning; and (5) strengthen research, surveillance, monitoring, and evaluation related to skin cancer prevention.

When thinking about public awareness campaigns, it is important to recognize that sun-seeking and tanning device–seeking behavior is, at least in some individuals, associated with a pleasurable central nervous system effect.[130-132] Such features of addiction to UVR exposure are reminiscent of the addictive nature of nicotine that has made smoking cessation programs for lung cancer prevention difficult. The fact that antismoking campaigns have been able to overcome nicotine addiction and have resulted in a decline in smoking and consequently in lung cancer deaths are encouraging for efforts to reduce rates of nonmelanoma skin cancer and melanoma by addressing addictive tanning and sun seeking. The dermatologic community has the opportunity to make a huge impact on public health by supporting the Surgeon General's Call to Action.

ACKNOWLEDGMENTS

Parts of this chapter used significant portions of Chap. 90 of the previous edition of this book, "Fundamentals of Cutaneous Photobiology and Photoimmunology," written by Irene E. Kochevar, Charles R. Taylor, and Jean Krutmann. Other parts used elements of Chap. 110, "Genome Instability, DNA Repair, and Cancer," written by Thomas M. Rünger and Kenneth H. Kraemer.

REFERENCES

1. Hudec SM, Camacho PM. Secondary causes of osteoporosis. Endocr Pract. 2013;19:120.
2. Clemens TL, Adams JS, Henderson SL, et al. Increased skin pigment reduces the capacity of skin to synthesize vitamin D3. *Lancet.* 1982;1(8263):74.
3. Holick M. Vitamin D deficiency. *N Engl J Med.* 2007;357:266.
4. Norman AW. Sunlight, season, skin pigmentation, vitamin D and 25-hydroxyvitamin: integral components of the vitamin D endocrine system. *Am J Clin Nutr.* 1998;67:1108.
5. Libon F, Cavalier E, Nikkels AF. Skin color is relevant to vitamin D synthesis. *Dermatology.* 2013;227:250.
6. Chin K, Appel LJ, Michos ED. Vitamin D, calcium, and cardiovascular disease: A"D"vantageous or "D"etrimental? An era of uncertainty. *Curr Atheroscler Rep.* 2017;19:5.
7. Unholzer S, Rothmund A, Haen E. All-rounder vitamin D? *Nervenarzt.* 2017;88(5):489.
8. Sommer I, Griebler U, Kien C, et al. Vitamin D deficiency as a risk factor for dementia: a systematic review and meta-analysis. BMC Geriatr. 2017;17:16.
9. Hoel DG, Berwick M, de Gruijl FR, et al. The risks and benefits of sun exposure 2016. *Dermatoendocrinol.* 2016;8:e1248325.
10. Libman H, Malabanan AO, Strewler GJ, et al. Should we screen for vitamin D deficiency? Grand rounds discussion from Beth Israel Deaconess medical center. *Ann Intern Med.* 2016;165:800.
11. Yakoob MY, Salam RA, Khan FR, et al. Vitamin D supplementation for preventing infections in children under five years of age. *Cochrane Database Syst Rev.* 2016;11:CD008824.
12. Kopecky SL, Bauer DC, Gulati M, et al. Lack of evidence linking calcium with or without vitamin d supplementation to cardiovascular disease in generally healthy adults: a clinical guideline from the national osteoporosis foundation and the American Society for Preventive Cardiology. *Ann Intern Med.* 2016;165:867.
13. Trummer C, Pandis M, Verheyen N, et al. Beneficial effects of UV-radiation: vitamin D and beyond. *Int J Environ Res Public Health*. 2016;13:pii: E1028.
14. Wimalawansa SJ. Non-musculoskeletal benefits of vitamin D. *J Steroid Biochem Mol Biol.* 2018;175:60.
15. Bikle DD. Extraskeletal actions of vitamin D. *Ann N Y Acad Sci.* 2016;1376:29.
16. Reddy KK, Gilchrest BA. The role of vitamin D in melanoma prevention: evidence and hyperbole. *J Am Acad Dermatol.* 2014;71:1004.
17. MacLaughlin JA, Anderson RR, Holick MF. Spectral character of sunlight modulates photosynthesis of previtamin D3 and its photoisomers in human skin. *Science.* 1982;16:1001.
18. Norval M, Björn LO, de Gruijl FR. Is the action spectrum for the UV-induced production of previtamin D3 in human skin correct? *Photochem Photobiol Sci.* 2010;9:11.
19. Beleza S, Santos AM, McEvoy B, et al. The timing of pigmentation lightening in Europeans. *Mol Biol Evol*. 2013;30:24.
20. Kuwabara A, Tsugawa N, Tanaka K, et al. High prevalence of vitamin D deficiency in patients with xeroderma pigmentosum—a under strict sun protection. *Eur J Clin Nutr.* 2015;69:693.
21. Gentzsch S, Kern JS, Loeckermann S, et al. Iatrogenic vitamin D deficiency in a patient with Gorlin syndrome: the conundrum of photoprotection. *Acta Derm Venereol.* 2014;94:459.
22. Schwarz T, Beissert S. Milestones in photoimmunology. *J Invest Dermatol.* 2013;133:E7.
23. Palmer RA, Friedmann PS. Ultraviolet radiation causes less immunosuppression in patients with polymorphic light eruption than in controls. *J Invest Dermatol.* 2004;122:291.
24. Lembo S, Fallon J, O'Kelly P, et al. Polymorphous light eruption and skin cancer prevalence: is one protective against the other? *Br J Dermatol.* 2008;159:1342.
25. Halliday GM, Byrne SN, Damian DL. Ultraviolet A radiation: its role in immunosuppression and carcinogenesis. *Semin Cutan Med Surg.* 2011;30:214.
26. Schmalwieser AW, Wallisch S, Diffey B. A library of action spectra for erythema and pigmentation. *Photochem Photobiol Sci.* 2012;11:251.
27. Young AR, Chadwick CA, Harrison GI, et al. The similarity of action spectra for thymine dimers in human epidermis and erythema suggests that DNA is the chromophore for erythema. *J Invest Dermatol.* 1998;111:982.
28. Freeman SE, Hacham H, Gange RW, et al. Wavelength dependence of pyrimidine dimer formation in DNA of human skin irradiated in situ with ultraviolet light. *Proc Natl Acad Sci U S A.* 1989;86:5605.
29. Tamura D, DiGiovanna JJ, Khan SG, et al. Living with xeroderma pigmentosum: comprehensive photoprotection for highly photosensitive patients. *Photodermatol Photoimmunol Photomed.* 2014;30:146.
30. Kraemer KH, Lee MM, Scotto J. Xeroderma pigmentosum. Cutaneous, ocular, and neurologic abnormalities in 830 published cases. *Arch Dermatol.* 1987;123:241.

31. Wolf P, Yarosh DB, Kripke ML. Effects of sunscreens and a DNA excision repair enzyme on ultraviolet radiation-induced inflammation, immune suppression, and cyclobutane pyrimidine dimer formation in mice. *J Invest Dermatol.* 1993;101:523.
32. Ley RD. Photoreactivation of UV-induced pyrimidine dimers and erythema in the marsupial *Monodelphis domestica*. *Proc Natl Acad Sci U S A.* 1985;82:2409.
33. Clydesdale GJ, Dandie GW, Muller HK. Ultraviolet light induced injury: immunological and inflammatory effects. *Immunol Cell Biol.* 2001;79:547.
34. Fitzpatrick TB. Soleil et peau. *Journal de Médecine Esthétique.* 1975;2:33.
35. Youn JI, Oh JK, Kim BK, et al. Relationship between skin phototype and MED in Korean, brown skin. *Photodermatol Photoimmunol Photomed.* 1997;13:208.
36. Parrish JA, Jaenicke KF, Anderson RR. Erythema and melanogenesis action spectra of normal human skin. *Photochem Photobiol.* 1982;36:187.
37. Nylander K, Bourdon JC, Bray SE, et al. Transcriptional activation of tyrosinase and TRP-1 by p53 links UV irradiation to the protective tanning response. *J Pathol.* 2000;190:39.
38. Khlgatian MK, Eller M, Yaar M, et al. Tyrosinase expression is regulated by p53. *J Invest Dermatol.* 1999;112:548.
39. Cui R, Widlund HR, Feige E, et al. Central role of p53 in the suntan response and pathologic hyperpigmentation. *Cell.* 2007;128:853.
40. Byers HR, Dykstra SG, Boissel SJ. Requirement of dynactin p150(Glued) subunit for the functional integrity of the keratinocyte microparasol. *J Invest Dermatol.* 2007;127:1736.
41. Hexsel CL, Mahmoud BH, Mitchell D, et al. A clinical trial and molecular study of photoadaptation in vitiligo. *Br J Dermatol.* 2009;160:534.
42. Boonstra HE, van Weelden H, Toonstra J, et al. Polymorphous light eruption: a clinical, photobiologic, and follow-up study of 110 patients. *J Am Acad Dermatol.* 2000;42:199.
43. Du-Thanh A, Debu A, Lalheve P, et al. Solar urticaria: a time-extended retrospective series of 61 patients and review of literature. *Eur J Dermatol.* 2013;23:202.
44. de Gálvez MV, Aguilera J, Sánchez-Roldán C, et al. Infrared radiation increases skin damage induced by other wavelengths in solar urticaria. *Photodermatol Photoimmunol Photomed.* 2016;32:284.
45. Parrish JA, Jaenicke KF. Action spectrum for phototherapy of psoriasis. *J Invest Dermatol.* 1981;76:359.
46. Johnson-Huang LM, Suárez-Fariñas M, Sullivan-Whalen M, et al. Effective narrow-band UVB radiation therapy suppresses the IL-23/IL-17 axis in normalized psoriasis plaques. J Invest Dermatol. 2010;130:2654.
47. Gasparro FP. Psoralen photobiology: recent advances. *Photochem Photobiol.* 1996;63:553.
48. Brash DE. UV-signature mutations. *Photochem Photobiol.* 2015;91:15.
49. Rünger TM. C → T transition mutations are not solely UVB-signature mutations, because they are also generated by UVA. *J Invest Dermatol.* 2008;128:2138.
50. Wikondahl NM, Brash DE. Ultraviolet radiation induced signature mutations in photocarcinogenesis. *J Investig Dermatol Symp Proc.* 1999;4:6.
51. Jayaraman SS, Rayhan DJ, Hazany S, et al. Mutational landscape of basal cell carcinomas by whole-exome sequencing. *J Invest Dermatol.* 2014;134:213.
52. Hocker T, Tsao H. Ultraviolet radiation and melanoma: a systematic review and analysis of reported sequence variants. *Hum Mutat.* 2007;28:578.
53. Horn S, Figl A, Rachakonda PS, et al. TERT promoter mutations in familial and sporadic melanoma. *Science.* 2013;339:959.
54. Huang FW, Hodis E, Xu MJ, et al. Highly recurrent TERT promoter mutations in human melanoma. *Science.* 2013;339:957.
55. Rünger TM. Is UV-induced mutation formation in melanocytes different from other skin cells? *Pigment Cell Melanoma Res.* 2011;24:10.
56. Premi S, Wallisch S, Mano CM, et al. Photochemistry. Chemiexcitation of melanin derivatives induces DNA photoproducts long after UV exposure. *Science.* 2015;347:842.
57. Brash DE. UV-induced melanin chemiexcitation. A new mode of melanoma pathogenesis. *Toxicologic Pathol.* 2016;44:552.
58. Noonan FP, Zaidi MR, Wolnicka-Glubisz A, et al. Melanoma induction by ultraviolet A but not ultraviolet B radiation requires melanin pigment. *Nat Commun.* 2012;3:884.
59. Nishiura H, Kumagai J, Kashino G, et al. The bystander effect is a novel mechanism of UVA-induced melanogenesis. Photochem Photobiol. 2012;88:389.
60. Redmond RW, Rajadurai A, Udayakumar D, et al. Melanocytes are selectively vulnerable to UVA-mediated bystander oxidative signaling. *J Invest Dermatol.* 2014;134:1083.
61. Kvam E, Tyrell RM. Induction of oxidative DNA base damage in human skin cells by UV and near visible radiation. *Carcinogenesis.* 1997;18:2379.
62. Kielbassa C, Roza L, Epe B. Wavelength dependence of oxidative DNA damage induced by UV and visible light. *Carcinogenesis.* 1997;18:811.
63. Rünger TM, Kappes UP. Mechanisms of mutation formation with long-wave ultraviolet light (UVA). *Photodermatol Photoimmunol Photomed.* 2008;24:2.
64. Rünger TM, Farahvash B, Hatvani Z, et al. Comparison of DNA damage responses following equimutagenic doses of UVA and UVB: a less effective cell cycle arrest with UVA may render UVA-induced pyrimidine dimers more mutagenic than UVB-induced ones. *Photochem Photobiol Sci.* 2012;11:207.
65. Dunn J, Potter M, Rees A, et al. Activation of the Fanconi anemia/BRCA pathway and recombination repair in the cellular response to solar UV. *Cancer Res.* 2006;66:11140.
66. Rizzo JL, Dunn J, Rees A, et al. No formation of DNA double-strand breaks and no activation of recombination repair with UVA. *J Invest Dermatol.* 2011;131:1139.
67. Pleasance ED, Cheetham RK, Stephens PJ, et al. A comprehensive catalogue of somatic mutations from a human cancer genome. *Nature.* 2010;463:191.
68. Cancer Genome Atlas Network. Genomic classification of cutaneous melanoma. *Cell.* 2015;161:1681.
69. Krauthammer M, Kong Y, Bacchiocchi A, et al. Exome sequencing identifies recurrent mutations in NF1 and RASopathy genes in sun-exposed melanomas. *Nat Genet.* 2015;47:996.
70. Shain AH, Garrido M, Botton T, et al. Exome sequencing of desmoplastic melanoma identifies recurrent NFKBIE promoter mutations and diverse activating mutations in the MAPK pathway. *Nat Genet.* 2015;47:1194.
71. Gordon D, Gillgren P, Eloranta S, et al. Time trends in incidence of cutaneous melanoma by detailed anatomical location and patterns of ultraviolet radiation exposure: a retrospective population-based study. *Melanoma Res.* 2015;25:348.
72. Bodekær M, Philipsen PA, Petersen B, et al. Defining "intermittent UVR exposure." *Photochem Photobiol Sci.* 2016;15:1176.

73. Gilchrest BA, Eller MS, Geller AC, et al. The pathogenesis of melanoma induced by ultraviolet radiation. *N Engl J Med.* 1999;340:1341.
74. Rünger TM. How different wavelengths of the ultraviolet spectrum contribute to skin carcinogenesis: the role of cellular damage responses. *J Invest Dermatol*. 2007;127:2103.
75. Wei Q, Lee JE, Gershenwald JE, et al. Repair of UV light-induced DNA damage and risk of cutaneous malignant melanoma. *J Natl Cancer Inst.* 2003;95:308.
76. Blankenburg S, Konig IR, Moessner R, et al. Assessment of 3 xeroderma pigmentosum group C gene polymorphisms and risk of cutaneous melanoma: a case-control study. *Carcinogenesis.* 2005;26:1085.
77. Torres S M, Luo L, Lilyquist J, et al. DNA repair variants, indoor tanning, and risk of melanoma. *Pigment Cell Melanoma Res.* 2013;26:677.
78. Wei Q. Effect of aging on DNA repair and skin carcinogenesis: a minireview of population-based studies. *J Invest Dermatol Symp Proc.* 1998;3:19.
79. Woodgate R. A plethora of lesion-replicating DNA polymerases. *Genes Dev.* 1999;13:2191.
80. Masutani C, Kusumoto R, Yamada A, et al. The XPV (xeroderma pigmentosum variant) gene encodes human DNA polymerase eta. *Nature.* 1999;399(6737):700.
81. Johnson RE, Kondratick CM, Prakash S, et al. hRAD30 mutations in the variant form of xeroderma pigmentosum. *Science.* 1999;285:263.
82. Limoli CL, Giedzinski E, Cleaver JE. Alternative recombination pathways in UV-irradiated XP variant cells. *Oncogene.* 2005;24:3708.
83. Zhang W, Remenyik E, Zelterman D, et al. Escaping the stem cell compartment: sustained UVB exposure allows p53-mutant keratinocytes to colonize adjacent epidermal proliferating units without incurring additional mutations. *Proc Natl Acad Sci U S A.* 2001;98:13948.
84. Loeb LA. Cancer cells exhibit a mutator phenotype. *Adv Cancer Res.* 1998;72:25.
85. El Ghissassi F, Baan R, Straif K, et al. A review of human carcinogens—part D: radiation. *Lancet Oncol.* 2009;10:751.
86. de Gruijl FR, Sterenborg HJ, Forbes PD, et al. Wavelength dependence of skin cancer induction by ultraviolet irradiation of albino hairless mice. *Cancer Res.* 1993;53:53.
87. Ley RD. Ultraviolet radiation A-induced precursors of cutaneous melanoma in *Monodelphis domestica*. *Cancer Res.* 1997;57:3682.
88. Setlow RB, Grist E, Thompson K, et al. Wavelengths effective in induction of malignant melanoma. *Proc Natl Acad Sci U S A.* 1993;90:6666.
89. Mitchell DL, Fernandez AA, Nairn RS, et al. Ultraviolet A does not induce melanomas in a Xiphophorus hybrid fish model. *Proc Natl Acad Sci U S A.* 2010;107:9329.
90. De Fabo EC, Noonan FP, Fears T, et al. Ultraviolet B but not ultraviolet A radiation initiates melanoma. *Cancer Res.* 2004;64:6372.
91. Boniol M, Autier P, Boyle P, et al. Cutaneous melanoma attributable to sunbed use: systematic review and meta-analysis. *BMJ.* 2012;345:e4757.
92. Gallagher RP, Spinelli JJ, Lee TK. Tanning beds, sunlamps, and risk of cutaneous malignant melanoma. *Cancer Epidemiol Biomarkers Prev.* 2005;14:562.
93. Veierød MB, Weiderpass E, Thörn M, et al. A prospective study of pigmentation, sun exposure, and risk of cutaneous malignant melanoma in women. *J Natl Cancer Inst.* 2003;95:1530.
94. Autier P, Dore JF, Eggermont A, et al. Epidemiological evidence that UVA radiation is involved in the genesis of cutaneous melanoma. *Curr Opin Oncol.* 2011;23:189.
95. Higgins EM, Du Vivier AW. Possible induction of malignant melanoma by sunbed use. *Clin Exp Dermatol.* 1992;17:357.
96. Facta S, Fusette SS, Bonino A, et al. UV emissions from artificial tanning devices and their compliance with the European technical standard. *Health Phys.* 2013;104:385.
97. Gerber B, Mathys P, Moser M, et al. Ultraviolet emission spectra of sunbeds. *Photochem Photobiol.* 2002;76:664.
98. Courdavault S, Baudouin C, Charveron M, et al. Larger yield of cyclobutane dimers than 8-oxo-7,8-dihydroguanine in the DNA of UVA-irradiated human skin cells. *Mutat Res.* 2004;556:135.
99. Drobetsky EA, Turcotte J, Châteauneuf A. A role for ultraviolet A in solar mutagenesis. *Proc Natl Acad Sci U S A.* 1995;92:2350.
100. Ikehata H, Kawai K, Komura J, et al. UVA1 genotoxicity is meditated not by oxidative damage but by cyclobutane pyrimidine dimers in normal mouse skin. *J Invest Dermatol.* 2008;128:2289.
101. Ikehata H, Higashi S, Nakamura S, et al. Action spectrum analysis of UVR genotoxicity for skin: the border wavelengths between UVA and UVB can bring serious mutation loads to skin. *J Invest Dermatol*. 2013;133:1850.
102. Rünger TM. Much remains to be learned about how UVR induces mutations. *J Invest Dermatol.* 2013;133:1717.
103. Rünger TM, Kappes UP. Mechanisms of mutation formation with long-wave ultraviolet light (UVA). *Photodermatol Photoimmunol Photomed.* 2008;24:2.
104. Kollias N, Sayre RM, Zeise L, et al. Photoprotection my melanin. *J Photochem Photobiol B.* 1991;9:135.
105. Micillo R, Panzella L, Koike K, et al. "Fifty Shades" of black and red or how carboxyl groups fine tune eumelanin and pheomelanin properties. *Int J Mol Sci.* 2016;17(5). pii: E746.
106. Wang HT, Choi BC, Tang MS. Melanocytes are deficient in repair of oxidative DNA damage and UV-induced photoproducts. *Proc Natl Acad Sci U S A.* 2010;107:12180.
107. Rünger TM. Is UV-induced mutation formation in melanocytes different from other skin cells? *Pigment Cell Melanoma Res.* 2011;24:10.
108. Poon F, Kang S, Chien A. Mechanisms and treatments of photoaging. *Photodermatol Photoimmunol Photomed.* 2014;31:65.
109. Gilchrest BA. Photoaging. *J Invest Dermatol.* 2013; 133:E2.
110. Bernstein EF, Brown DB, Urbach F, et al. Ultraviolet radiation activates the human elastin promoter in transgenic mice: a novel in vivo and in vitro model of cutaneous photoaging. *J Invest Dermatol.* 1995;105:269.
111. Gan SD, Rünger TM. Dermal fibroblasts internalize elastin to lysosomes via the elastin-binding protein of the elastin-laminin receptor. *J Dermatol Sci.* 2011;61:60.
112. Codriansky KA, Quintanilla-Dieck MJ, Gan S, et al. Intracellular degradation of elastin by cathepsin K in skin fibroblasts—a possible role in photoaging. *Photochem Photobiol.* 2009;85:1356.
113. Saftig P, Eskelinen EL. Live longer with LAMP-2. *Nat Med.* 2008;14:909.

114. Eriksson M, Brown WT, Gordon LB, et al. Recurrent de novo point mutations in lamin A cause Hutchinson-Gilford progeria syndrome. *Nature.* 2003;423:293.
115. McClintock D, Ratner D, Lokuge M, et al. The mutant form of lamin A that causes Hutchinson-Gilford progeria is a biomarker of cellular aging in human skin. *PLoS One.* 2007;2:e1269.
116. Takeuchi H, Rünger TM. Longwave UV light induces the aging-associated progerin. *J Invest Dermatol.* 2013;133:1857.
117. Fagot D, Asselineau D, Bernerd F. Matrix metalloproteinase-1 production observed after solar-simulated radiation exposure is assumed by dermal fibroblasts but involves a paracrine activation through epidermal keratinocytes. *Photochem Photobiol.* 2004;79:499.
118. Yarosh D, Dong K, Smiles K. UV-induced degradation of collagen I is mediated by soluble factors released from keratinocytes. *Photochem Photobiol.* 2008;84:67.
119. Dong KK, Damaghi N, Picart SD, et al. UV-induced DNA damage initiates release of MMP-1 in human skin. *Exp Dermatol.* 2008;17:1037.
120. Li WH, Pappas A, Zhang L, et al. IL-11, IL-1alpha, IL-6, and TNF-alpha are induced by solar radiation in vitro and may be involved in facial subcutaneous fat loss in vivo. *J Dermatol Sci.* 2013;71:58.
121. Mahmoud BH, Hexsel CL, Hamzavi IH, et al. Effects of visible light on the skin. *Photochem Photobiol.* 2008;84:450.
122. Sklar LS, Almutawa F, Lim HW, et al. Effects of ultraviolet radiation, visible light, and infrared radiation on erythema and pigmentation: a review. *Photochem Photobiol Sci.* 2013;12:54.
123. Barolet D, Christiaens F, Hamblin MR. Infrared and skin: friend or foe. *J Photochem Photobiol B.* 2016;155:78.
124. Holzer AM, Athar M, Elmets CA. The other end of the rainbow: infrared and skin. *J Invest Dermatol.* 2010;130:1496.
125. Jantschitsch C, Weichenthal M, Maeda A, et al. Infrared radiation does not enhance the frequency of ultraviolet radiation-induced skin tumors, but their growth behaviour in mice. *Exp Dermatol.* 2011;20:346.
126. Diffey BL, Tanner PR, Matts PJ, et al. In vitro assessment of the broad-spectrum ultraviolet protection of sunscreen products. *J Am Acad Dermatol.* 2000;43:1024.
127. Grether-Beck S, Marini A, Jaenicke T, et al. Photoprotection of human skin beyond ultraviolet radiation. *Photodermatol Photoimmunol Photomed.* 2014;30:167.
128. Diffey B, Cadars B. An appraisal of the need for infrared radiation protection in sunscreens. *Photochem Photobiol Sci.* 2016;15:361.
129. Lim HW, Arellano-Mendoza MI, Stengel F. Current challenges in photoprotection. *J Am Acad Dermatol.* 2017;76(3S1):S91.
130. Aubert PM, Seibyl JP, Price JL, et al. Dopamine efflux in response to ultraviolet radiation in addicted sunbed users. *Psychiatry Res.* 2016;251:7.
131. Fell GL, Robinson KC, Mao J, et al. Skin β-endorphin mediates addiction to UV light. *Cell.* 2014;157:1527.
132. Robinson KC, Fisher DE. Tanning as a substance abuse. *Commun Integr Biol.* 2014;7(5):e971579.

Chapter 18 :: Genetics in Relation to the Skin

:: Etienne C. E. Wang, John A. McGrath, & Angela M. Christiano

AT-A-GLANCE

- 25% of monogenic gene disorders with known molecular mechanisms have skin manifestations.
- Skin disease may also arise from polygenic, complex inheritance, mosaicism, and chromosomal abnormalities.
- It is crucial for dermatologists to be up-to-date with new methods of genetic diagnosis and treatment (as well as their limitations).

THE HUMAN GENOME IN DERMATOLOGY

The completion of the Human Genome Project in 2003 coincided with the dawn of the Information or Digital Age. Having sequenced more than 3 billion base pairs (bp) of DNA, with identification of most of the estimated 25,000 genes in the entire human genome, this initiative provided ourselves with a treasure trove of information to make sense of the human body and its diseases. Although a few relatively small gaps remain, the near completion of the entire sequence of the human genome is having a huge impact on both the clinical practice of genetics and the strategies used to identify disease-associated genes. Laborious positional cloning approaches and traditional functional studies are gradually being transformed by the emergence of new genomic and proteomic databases.[1] Some of the exciting challenges that clinicians and geneticists now face are determining the function of these genes, defining disease associations and, relevant to patients, correlating genotype with phenotype. Nevertheless, many discoveries are already influencing how clinical genetics is practiced throughout the world, particularly for patients and families with rare, monogenic inherited disorders. The key benefits of dissection of the genome thus far have been the documentation of new information about disease causation, improving the accuracy of diagnosis and genetic counseling, and making DNA-based prenatal testing feasible.[2] Indeed, the genetic basis of more than 2000 inherited single gene disorders has now been determined, of which about 25% have a skin phenotype. Therefore, these "genodermatoses" have direct relevance to dermatologists and their patients, and newer technologies such as whole-exome sequencing will identify even more single-gene disorders and even allow us to classify them according to their patient-specific mutations.[3]

Recently, studies in rare inherited skin disorders have also led to new insight into the pathophysiology of more common polygenic skin disorders.[4] This new information is expected to have significant implications for the development of new therapies and management strategies for patients. Therefore, understanding the basic language and principles of clinical and molecular genetics has become a vital part of day-to-day practice for clinicians. The aim of this chapter is to provide an overview of key terminology in genetics that is clinically relevant to dermatologists.

THE HUMAN GENOME

Humans have a large complex genome packaged in the form of 46 chromosomes. These consist of 22 pairs of autosomes, numbered in descending order of size from the largest (chromosome 1) to the smallest (chromosome 22), in addition to two sex chromosomes, X and Y. Whereas females possess two copies of the X chromosome, males carry one X and one Y chromosome. The haploid genome consists of about 3.3 billion bp of DNA. Of this, only about 1.5% corresponds to protein-encoding exons of genes. Apart from genes and regulatory sequences, perhaps as much as 97% of the genome is of unknown function, often referred to as "junk" DNA. However, caution should be exercised in labeling the noncoding genome as "junk" because other unknown functions may reside in these regions. Much of the noncoding DNA is in the form of repetitive sequences, pseudogenes ("dead" copies of genes lost in recent evolution), and transposable elements of uncertain relevance. Although initial estimates for the number of human genes was in the order of 100,000, current predictions, based on the essentially complete genome sequence, are in the range of 20,000 to 25,000.[5] Surprisingly, therefore, the human genome is comparable in size and complexity to that of primitive organisms such as the fruit fly. However, it is thought that the generation of multiple protein isoforms from a single gene via alternate splicing of exons, each with a discrete function, is what contributes to increased complexity in higher organisms, including humans. In addition to protein-encoding genes, there are also many genes encoding untranslated RNA molecules, including transfer RNA, ribosomal RNA, and microRNA genes. MicroRNA is thought to be involved in the control of a large number of other genes through the RNA inhibition pathway. Recently, it has emerged that tracts of the genome are transcribed at low levels in the form of exotic new RNA species, including natural antisense RNA, long interspersed noncoding

TABLE 18-1
Websites for Accessing Human Genome Data

WEBSITE	URL
University of California, Santa Cruz	http://genome.ucsc.edu
National Center for Biotechnology Information	http://www.ncbi.nlm.nih.gov
ENSEMBL	http://www.ensembl.org
Online Mendelian Inheritance in Man	http://www.ncbi.nlm.nih.gov/entrez/query.fcgi?db=omim

RNA (lncRNA), and even competing endogenous RNAs (ceRNA). These transcripts are emerging as key regulatory molecules, which add level of complexity to the epigenetic control of gene expression. Thus, a much greater proportion of the genome is actively transcribed than was previously recognized, and this trend is likely to continue in the current "postgenome" era of human genetics.

The draft sequence of the human genome was completed in 2003. Subsequently, small gaps have been filled, and the sequence has now been extensively annotated in terms of genes, repetitive elements, regulatory sequences, polymorphisms, and many other features recognizable by in silico data mining methods informed, wherever possible, by functional analysis. This annotation process will continue for some time as more features are uncovered. The human genome data, and that for an increasing number of other species, is freely available on websites (Table 18-1). Some regions of the genome, particularly near the centromeres, consist of long stretches of highly repetitive sequences that are difficult or impossible to clone or sequence. These heterochromatic regions of the genome are unlikely to be sequenced and are thought to be structural in nature, mediating the chromosomal architecture required for cell division rather than contributing to heritable characteristics.

GENETIC AND GENOMIC DATABASES

Given the size and complexity of the human genome and other genomes now available, along with the massive datasets from population-based genetic studies and gene expression studies, computing power has become increasingly central to the integration and analysis of these data. Even storage and retrieval of the sequence data associated with mammalian genome require considerable computer power and memory, and even the assembly of the raw sequence of any mammalian genome would not have been feasible without computers. Many web browsers for accessing genome data are available, and the most useful of these are listed in Table 18-1. Each of these interfaces, which are the ones that the authors find most useful and user friendly, contains a wide variety of tools for analysis and searching of sequences according to keyword, gene name, protein name, and homology to DNA or protein sequence data.

The main source of historical, clinical, molecular, and biochemical data relating to human genetic diseases is the Online Mendelian Inheritance in Man (OMIM) (see Table 18-1). All recognized genetic diseases and nonpathogenic heritable traits, including common diseases with a genetic component, as well as all known genes and proteins, are listed and reviewed by OMIM number with links to PubMed. In the spirit of the Information Age and social media, the consumer genetics company 23andMe has democratized genomic sequencing and allowed the general public to take a peek into their own genetic makeup. Their business plan, although bringing up questions about privacy and patents (out of the scope of this chapter), will provide a valuable reference dataset for pharmaceutical companies and epidemiologists in the near future.

CHROMOSOME AND GENE STRUCTURE

Human chromosomes share common structural features (Fig. 18-1). All consist of two chromosomal arms, designated as "p" and "q." If the arms are of unequal length, the short arm is always designated as the "p" arm (for *petit*, the French word for small), and the other arm is named "q" (for the subsequent letter in the alphabet). Chromosomal maps to seek abnormalities are based on the stained, banded appearance of condensed chromosomes during metaphase of mitosis. During interphase, the uncondensed chromosomes are not discernible by normal microscopy techniques. Genes can now be located with absolute precision in terms of the range of base pairs that they span within the DNA sequence for a given chromosome. The bands are numbered from the centromere outward using a system that has evolved as increasingly discriminating chromosome stains, as well as higher resolution light microscopes, became available. A typical cytogenetic chromosome band is 17q21.2, within which the type I keratin genes reside (see Fig. 18-1). Type II keratins are similarly found in a cluster on the chromosome band 12q13.

The ends of the chromosomal arms are known as *telomeres*, and these consist of multiple tandem repeats of short DNA sequences. In germ cells and certain other cellular contexts, additional repeats are added to telomeres by a protein–RNA enzyme complex known as *telomerase*. During each round of cell division in somatic cells, one of the telomere repeats is trimmed off as a consequence of the DNA replication mechanism. By measuring the length of telomeres, the "age" of somatic cells, in terms of the number of times they have divided during the lifetime of the organism, can be determined. When the telomere length falls below a certain threshold, the cell undergoes senescence. Thus, telomeres contribute to an important biological clock function that removes somatic cells that have gone through too many rounds of replication and are at a high risk of accumulating mutations that could lead to tumorigenesis or other functional aberration.[6]

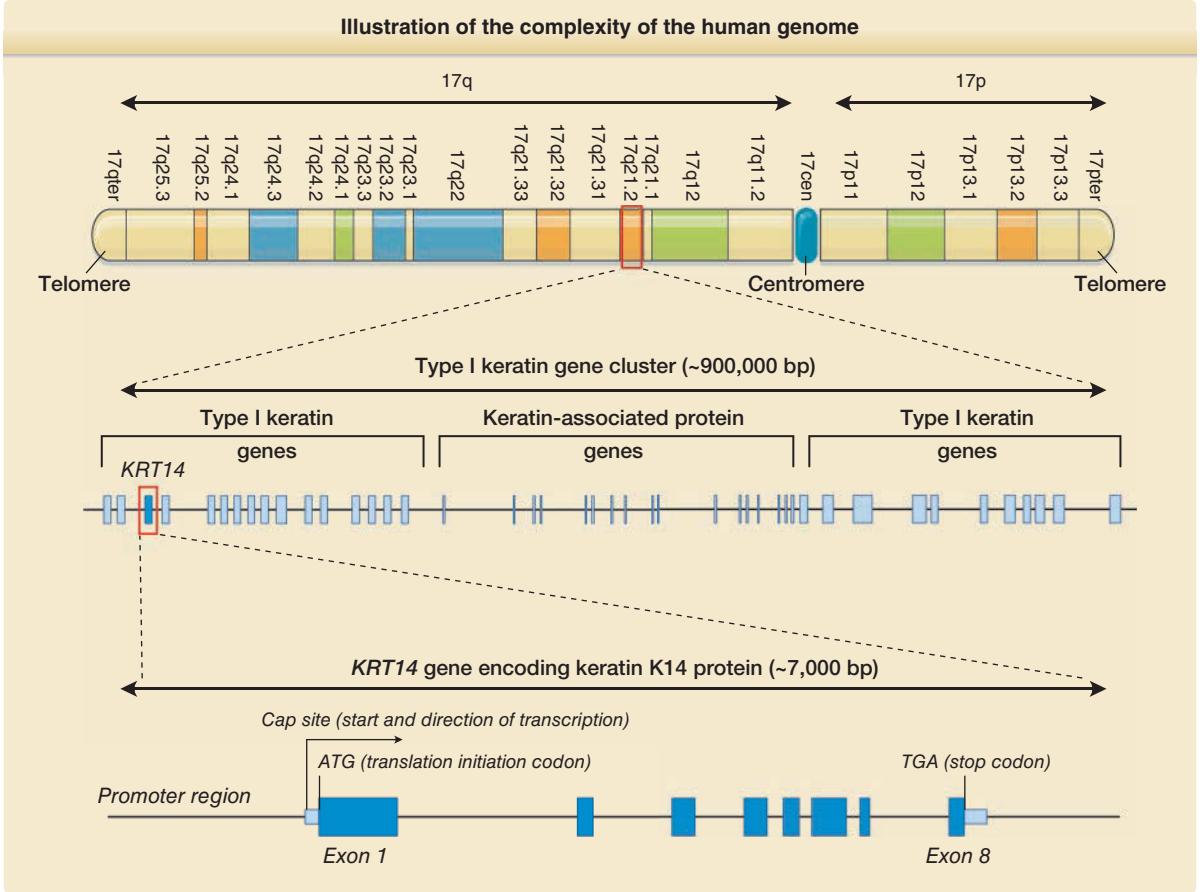

Figure 18-1 Illustration of the complexity of the human genome. At the top, the short (p) and long (q) arms of human chromosome 17 are depicted with their cytogenetic chromosome bands. One of these band regions, 17q21.2, is then highlighted to show that it is made up of approximately 900,000 base pairs (bp) and contains several genes, including 27 functional type I keratin genes. Part of this region is then further amplified to show one keratin gene, *KRT14*, encoding keratin 14, which is composed of eight exons.

The chromosome arms are separated by the centromere, which is a large stretch of highly repetitious DNA sequence. The centromere has important functions in terms of the movement and interactions of chromosomes. The centromeres of sister chromatids are where the double chromosomes align and attach during the prophase and anaphase stages of mitosis (and meiosis). The centromeres of sister chromatids are also the site of kinetochore formation. The latter is a multiprotein complex to which microtubules attach, allowing mitotic spindle formation, which ultimately results in pulling apart of the chromatids during anaphase of the cell division cycle.

The majority of chromosomal DNA contains genes interspersed with noncoding stretches of DNA of varying sizes. The density of genes varies widely across the chromosomes so that there are gene-dense regions or, alternately, large areas almost devoid of functional genes. An example of a comparatively gene-rich region of particular relevance to inherited skin diseases is the type I keratin gene cluster on chromosome band 17q21.2 (see Fig. 18-1). This figure also gives an idea of the sizes in base pairs of DNA of a typical chromosome and a typical gene located within it. This gene cluster spans about 900,000 bp of DNA and contains 27 functional type I keratin genes, several genes encoding keratin-associated proteins, and a number of pseudogenes (not shown). Because chromosome 17 is one of the smaller chromosomes, Fig. 18-1 starts to give some idea of the overall complexity and organization of the genome.

Protein-encoding genes normally consist of several exons, which collectively code for the amino acid sequence of the protein (or open reading frame). These are separated by noncoding introns. In human genes, few exons are much greater than 1000 bp in size, and introns vary from less than 100 bp to more than 1 million bp. A typical exon might be 100 to 300 bp in size. The *KRT14* gene encoding keratin 14 (K14) protein is one of the genes in which mutations lead to epidermolysis bullosa (EB) simplex (see Chap. 60) and is illustrated in Fig. 18-1. *KRT14* is contained within about 7000 bp of DNA and consists of eight modestly sized exons interspersed by seven small introns. Although all genes are present in all human cells that contain a nucleus, not every gene is expressed in all cells of tissues. For example, the *KRT14* gene is only active in basal keratinocytes of the epidermis and other

stratified epithelial tissues and is essentially silent in all other tissues. When a protein-encoding gene is expressed, the RNA polymerase II enzyme transcribes the coding strand of the gene, starting from the cap site and continuing to the end of the final exon, where various signals lead to termination of transcription. The initial RNA transcript, known as *heteronuclear RNA*, contains intronic as well as exonic sequences. This primary transcript undergoes splicing to remove the introns, resulting in the messenger RNA (mRNA) molecule.[7] In addition, the bases at the 5′ end (start) of the mRNA are chemically modified (capping) and a large number of adenosine bases are added at the 3′ end, known as the *poly-A tail*. These posttranscriptional modifications stabilize the mRNA and facilitate its transport within the cell. The mature mRNA undergoes a test round of translation, which, if successful, leads to the transport of the mRNA to the cytoplasm, where it undergoes multiple rounds of translation by the ribosomes, leading to accumulation of the encoded protein. If the mRNA contains a nonsense mutation, otherwise known as a *premature termination codon mutation*, the test round of translation fails, and the cell degrades this mRNA via the nonsense-mediated mRNA degradation pathway.[8] This is a mechanism that the cell has evolved to remove aberrant transcripts, and it may also contribute to gene regulation, particularly when very low levels of a particular protein are required within a given cell.

Splicing out of introns is a complex process. The genes of prokaryotes, such as bacteria, do not contain introns, so mRNA splicing is a process that is specific to higher organisms. In some more primitive eukaryotes, RNA molecules contain catalytic sequences known as *ribozymes*, which mediate the self-splicing out of introns without any requirement for additional factors. In mammals, splicing involves a large number of protein and RNA factors encoded by several genes. This allows another level of control over gene expression and facilitates alternative splicing of exons, so that a single gene can encode several functionally distinct variants of a protein. These isoforms are often differentially expressed in different tissues. In terms of the gene sequences important for splicing, a few base pairs at the beginning and at the end of an intron, known as the 5′ splice site (or splice donor site) and the 3′ splice site (or splice acceptor site), are crucial. A few other base pairs within the intron, such as the branch point site located 18 to 100 bp away from the 3′ end, are also critical. Mutations affecting any of the invariant residues of these splice sites lead to aberrant splicing and either complete loss of protein expression or generation of a highly abnormal protein.

The mRNA also contains two untranslated regions (UTR): (1) the 5′UTR upstream of the initiating ATG codon and (2) the 3′UTR downstream of the terminator (or stop codon, which can be TGA, TAA, or TAG). Whereas the 5′ UTR can and often does possess introns, the 3′UTR of more than 99% of mammalian genes does not contain introns. The nonsense-mediated mRNA decay pathway identifies mutant transcripts by means of assessing where the termination codon occurs in relation to introns. The natural stop codon is always followed immediately by the 3′UTR, which in turn does not normally possess any introns. If a stop codon occurs in an mRNA upstream of a site where an intron has been excised, this message is targeted for nonsense-mediated decay. The only genes that contain introns within their 3′UTR sequences are expressed at extremely low levels. This is one of the ways in which the cell can determine how much protein is made from a particular gene.

The structural complexity of genes is widely variable and not necessarily related to the size of the protein encoded. Some genes consist of only a single small exon, such as those encoding the connexin family of gap junction proteins. Such single exon genes are rapid and inexpensive to sequence routinely. In contrast, the type VII collagen gene, *COL7A1*, in which mutations lead to the dystrophic forms of EB (see Chap. 60), has 118 exons, meaning that 118 different parts of the gene need to be isolated and analyzed for molecular diagnosis of each dystrophic EB patient. The filaggrin gene (*FLG*) on chromosome 1, is the causative gene for ichthyosis vulgaris (see Chap. 47) and a susceptibility gene for atopic dermatitis (see Chap. 22) and has only three exons. However, the third exon of *FLG* is made up of repeats of a 1000-bp sequence and varies in size from 12,000 to 14,000 bp among different individuals in the population. This unusual gene structure makes routine sequencing of genes such as *COL7A1* or *FLG* difficult, time consuming, and expensive.

GENE EXPRESSION

Each specific gene is generally only actively transcribed in a subset of cells or tissues within the body. Gene expression is largely determined by the promoter elements of the gene. In general, the most important region of the promoter is the stretch of sequence immediately upstream of the cap site. This proximal promoter region contains consensus binding sites for a variety of transcription factors, some of which are general in nature and required for all gene expression, others are specific to particular tissue or cell lineage, and some are absolutely specific for a given cell type or stage of development or differentiation. The size of the promoter can vary widely according to gene family or between the individual genes themselves. For example, the keratin genes are tightly spaced within two gene clusters on chromosomes 12q and 17q, but these are exquisitely tissue specific in two different ways. First, these genes are only expressed in epithelial cells, and therefore their promoters must possess regulatory sequences that determine epithelial expression. Therefore, these regulatory elements are specific for cells of ectodermal origin. Second, these genes are expressed in very specific subsets of epithelial cells, so there must be a second level of control that specifies which epithelial cell layers express specific keratin genes. This is best illustrated in the hair follicle, where there are many different epithelial cell layers, each with a specific pattern of keratin gene expression (see Chap. 7).[9]

Transcription factors are proteins that either bind to DNA directly or indirectly by associating with other DNA-binding proteins. Binding of these factors to the promoter region of a gene leads to activation of the transcription machinery and transcription of the gene by RNA polymerase II. The transcription factor proteins are encoded by genes that are in turn controlled by promoters that are regulated by other transcription factors encoded by other genes. Thus, there are several tiers of control over gene expression in a given cell type, and the intricacies of this can be difficult to fully unravel experimentally. Nevertheless, by isolation of promoter sequences from genes of interest and placing these in front of reporter genes that can be assayed biochemically, such as firefly luciferase that can be assayed by light emission, the activity of promoters can be reproduced in cultured cells that normally express the gene. Combining such a reporter gene system with site-directed mutagenesis to make deletions or alter small numbers of base pairs within the promoter can help define the extent of the promoter and the important sequences within it that are required for gene expression. A variety of biochemical techniques, such as DNA footprinting, ribonuclease protection, electrophoretic mobility shift assays, or chromatin immunoprecipitation, can be used to determine which transcription factors bind to a particular promoter and help delineate the specific promoter sequences bound. Expression of reporter genes under the control of a cloned promoter in transgenic mice also helps shed light on the important sequences that are required to recapitulate the endogenous expression of the gene under study. Keratin promoters are unusual in that, generally, a small fragment of only 2000 to 3000 bp upstream of the gene can confer most of the tissue specificity. For this reason, keratin promoters are widely used to drive exogenous transgene expression in the various specific cellular compartments of the epidermis and its appendages for experiments to determine gene, cell, or tissue function.[10]

Some promoter or enhancer sequences act over very long distances. In some cases, sequences located millions of base pairs away, with several other genes in the intervening region, influence expression of a target gene over a distance. In some genetic diseases, mutations affecting such long-range promoter elements are now emerging. Newer techniques such as chromatin conformation capture (3C, and its next-generation iterations 4C/5C and Hi-C) allow researchers to interrogate DNA structure and regional assembly in order to identify such elements.[11,12] ATAC-seq (assay for transposase-accessible chromatin with high-throughput sequencing) is a technique that allows for distinguishing epigenetic marks in different tissues,[13,14] for example, diseased versus healthy tissues. In general, relatively few disease-causing mutations have been shown to involve promoters or enhancer elements, but this class of variation is probably greatly underrepresented because the sequences that are important for promoter activity are currently poorly characterized. Prediction of transcription factor binding sites by computer analysis is an area for further study. Pathogenic defects in microRNA or other noncoding regulatory RNA species have been postulated to contribute to autoimmunity, and their role in the pathogenesis of systemic immune disorders such as lupus erythematosus are underway.[15]

Techniques such as microarrays and RNA-sequencing have allowed researchers to study gene expression in diseased versus healthy tissues, which may have genetic, epigenetic, or environmental causes. Improvements in the accuracy, resolution, and computational analysis of these methods have allowed accurate readings down to a single cell, whereby tissue heterogeneity (whether innate or as a result of mosaicism) can be identified.

FINDING DISEASE GENES

In establishing the molecular basis of an inherited skin disease, there are two key steps. First, the gene linked to a particular disorder must be identified, and second, pathogenic mutations within that gene must be determined. Previously, diseases can be matched to genes either by genetic linkage analysis or by a candidate gene approach[16] and now additionally using whole-exome sequencing. Genetic linkage involves studying pedigrees of affected and unaffected individuals and isolating which bits of the genome are specifically associated with the disease phenotype. The goal is to identify a region of the genome that all the affected individuals—and none of the unaffected individuals—have in common; this region is likely to harbor the gene for the disorder, as well as perhaps other nonpathogenic neighboring genes that have been inherited by linkage disequilibrium. Traditionally, genome-wide linkage strategies make use of variably sized microsatellite markers scattered throughout the genome, although for recessive diseases involving consanguineous pedigrees, a more rapid approach may be to carry out homozygosity mapping using single nucleotide polymorphism (SNP) chip arrays. By contrast, the candidate gene approach involves first looking for a clue to the likely gene by finding a specific disease abnormality, perhaps in the expression (or lack thereof) of a particular protein or RNA, or from an ultrastructural or biochemical difference between the diseased and control tissues. Nevertheless, the genetic linkage and candidate gene approaches are not mutually exclusive and are often used in combination. For example, to identify the gene responsible for the autosomal recessive disorder lipoid proteinosis (see Chap. 72), genetic linkage using microsatellites was first used to establish a region of linkage on 1q21 that contained 68 genes.[17] The putative gene for this disorder, *ECM1* encoding extracellular matrix protein 1, was then identified by a candidate gene approach that searched for reduced gene expression (lack of fibroblast complementary DNA) in all these genes. A reduction in *ECM1* gene expression in lipoid proteinosis compared with control provided the clue to the candidate gene because there were no differences in any of the other patterns of gene expression. Ultrastructural

and immunohistochemical analyses can also provide clues to underlying gene pathology. For example, loss of hemidesmosomal inner plaques noted on transmission electron microscopy and a complete absence of skin immunostaining for the 230-kDA bullous pemphigoid antigen (BP230) at the dermal–epidermal junction led to the discovery of loss-of-function mutations in the dystonin (*DST*) gene, which codes for BP230, in a new form of autosomal recessive EB simplex.[18]

Having identified a putative gene for an inherited disorder, the next stage is to find the pathogenic mutation(s). This can be done by sequencing the entire gene, a feat that is becoming easier as technologic advances make automated nucleotide sequencing faster, cheaper, and more accessible. However, the large size of some genes may make comprehensive sequencing impractical, and therefore initial screening approaches to identify the region of a gene that contains the mutation may be a necessary first step. There are many mutation detection techniques available to scan for sequence changes in cellular RNA or genomic DNA, and these include denaturing gradient gel electrophoresis, chemical cleavage of mismatch, single-stranded conformation polymorphism, heteroduplex analysis, conformation sensitive gel electrophoresis, denaturing high-performance liquid chromatography, and the protein truncation test.[19]

Whichever approach is taken, having identified a difference in the patient's DNA compared with the control sample, the next stage is to determine how this segregates within a particular family and whether it is pathogenic or not. Recently, great advances have been made in DNA sequencing technology, with the emergence of "next-generation sequencing" (NGS) technologies. Currently, whole-exome sequencing has become affordable enough to be routinely used to diagnoses rare genetic disorders. Novel de novo mutations can be identified in this way, even when neither biological parent harbors the mutation. This incredible new technology is set to revolutionize human genetics again, and in particular, will facilitate identification of mutated genes in small kindreds that are not tractable by genetic linkage methods. These advances will not only have an impact on diagnosis, but it will set a foundation for precision medicine approaches such as CRISPR/Cas9 (clustered regularly interspaced short palindromic repeats) gene correction and induced pluripotent stem cell (iPSC) therapies in the future.[20,21]

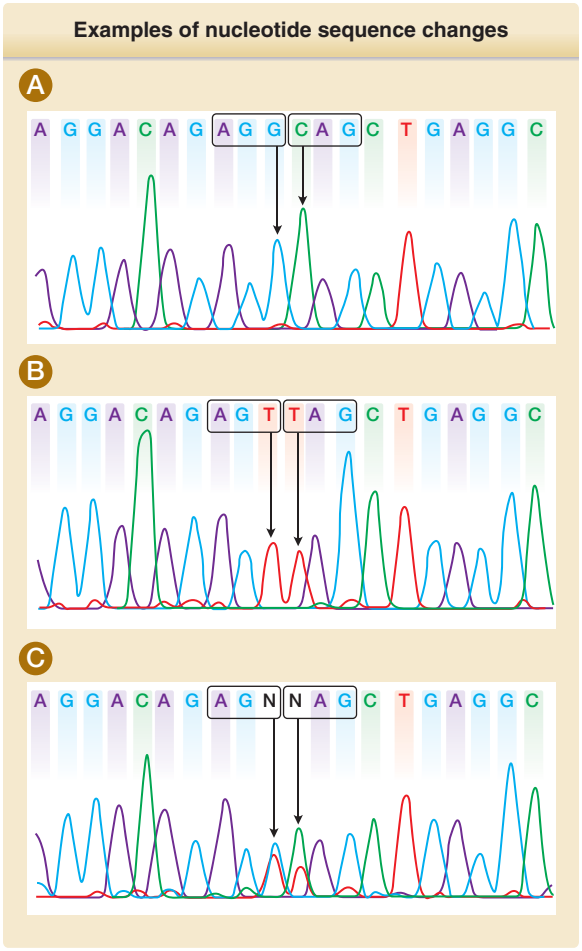

Figure 18-2 Examples of nucleotide sequence changes resulting in a polymorphism and a nonsense mutation. **A,** Two adjacent codons are highlighted. The AGG codon encodes arginine and the CAG codon encodes glutamine. **B,** The sequence shows two homozygous nucleotide substitutions. The AGG codon now reads AGT (ie, coding for serine rather than arginine). This is a common sequence variant in the normal population and is referred to as a *nonpathogenic missense polymorphism*. In contrast, the glutamine codon CAG now reads TAG, which is a stop codon. This is an example of a homozygous nonsense mutation. **C,** This sequence is from one of the parents of the subject sequenced in **B** and shows heterozygosity for both the missense polymorphism AGG > AGT and the nonsense mutation CAG > TAG, indicating that this individual is a carrier of both sequence changes.

GENE MUTATIONS AND POLYMORPHISMS

Within the human genome, the genetic code of two healthy individuals may show a number of sequence dissimilarities that have no relevance to disease or phenotypic traits. Such changes within the normal population are referred to as *polymorphisms* (Fig. 18-2). Indeed, even within the coding region of the genome, clinically irrelevant substitutions of 1 bp, known as *SNPs*, are common and occur approximately once every 250 bp.[22]

Frequently, these SNPs do not change the amino acid composition; for example, a C-to-T transition in the third position of a proline codon (CCC to CCT) still encodes for proline and is referred to as a *silent mutation*. However, some SNPs do change the nature of the amino acid; for example, a C-to-G transversion at the second position of the same proline codon (CCC to CGC) changes the residue to arginine. It then becomes necessary to determine whether a missense change such as this represents a nonpathogenic polymorphism or a pathogenic mutation. Factors favoring the latter include the sequence segregating only with

the disease phenotype in a particular family, the amino acid change occurring within an evolutionarily conserved residue, the substitution affecting the function of the encoded protein (size, charge, conformation, and so on), and the nucleotide switch not being detectable in at least 100 ethnically matched control chromosomes. Nonpathogenic polymorphisms do not always involve single nucleotide substitutions; occasionally, deletions and insertions may also be nonpathogenic.

A mutation can be defined as a change in the nucleotide sequence that leads to a change in the chemical composition of a protein. A missense mutation changes one amino acid to another. Mutations may also be insertions or deletions of bases, the consequences of which will depend on whether this disrupts the normal reading frame of a gene or not, as well as nonsense mutations, which lead to premature termination of translation (see Fig. 18-2). For example, a single nucleotide deletion within an exon causes a shift in the reading frame, which usually leads to a downstream stop codon, thus giving a truncated protein, or often an unstable mRNA that is readily degraded by the cell. However, a deletion of three nucleotides (or multiples thereof) will not significantly perturb the overall reading frame, and the consequences will depend on the nature of what has been deleted. Nonsense mutations typically occur at CpG dinucleotides, where methylation of a cytosine nucleotide often occurs. Inherent chemical instability of this modified cytosine leads to a high rate of mutation to thymine. Where this alters the codon (eg, from CGA to TGA), it will change an arginine residue to a stop codon. Nonsense mutations usually lead to a reduced or absent expression of the mutant allele at the mRNA and protein levels. In the heterozygous state, this may have no clinical effect (eg, parents of individuals with generalized severe junctional EB are typically carriers of nonsense mutations in one of the laminin 332 genes but have no skin fragility themselves; see Chap. 60), but a heterozygous nonsense mutation in the desmoplakin gene, for example, can result in the autosomal dominant skin disorder, striate palmoplantar keratoderma (see Chap. 49). This phenomenon is referred to as *haploinsufficiency* (ie, half the normal amount of protein is insufficient for function).

Apart from changes in the coding region that result in frameshift, missense, or nonsense mutations, approximately 15% of all mutations involve alterations in the gene sequence close to the boundaries between the introns and exons, referred to as *splice site mutations*. This type of mutation may abolish the usual acceptor and donor splice sites that normally splice out the introns during gene transcription. The consequences of splice site mutations are complex; sometimes they lead to skipping of the adjacent exon, and other times they result in the generation of new mRNA transcripts through utilization of cryptic splice sites within the neighboring exon or intron.

Mutations within one gene do not always lead to a single inherited disorder. For example, mutations in the *ERCC2* gene may lead to xeroderma pigmentosum (type D), trichothiodystrophy, or cerebrofacioskeletal syndrome, depending on the position and type of mutation. Other transacting factors may further modulate phenotypic expression. This situation is known as *allelic heterogeneity*. Conversely, some inherited diseases can be caused by mutations in more than one gene (eg, generalized intermediate junctional EB; see Chap. 60) and can result from mutations in the *COL17A1, LAMA3, LAMB3*, or *LAMC2* genes. This is known as *genetic* (or *locus) heterogeneity*. In addition, the same mutation in one particular gene may lead to a range of clinical severity in different individuals. This variability in phenotype produced by a given genotype is referred to as the *expressivity*. If an individual with such a genotype has no phenotypic manifestations, the disorder is said to be *nonpenetrant*. Variability in expression reflects the complex interplay between the mutation, modifying genes, epigenetic factors, and the environment and demonstrates that interpreting what a specific gene mutation does to an individual involves more than just detecting one bit of mutated DNA in a single gene.

MENDELIAN DISORDERS

There are approximately 5000 human single-gene disorders and, although the molecular basis of approximately 2000 of these has been established, understanding the pattern of inheritance is essential for counseling prospective parents about the risk of having affected children. The four main patterns of inheritance are (1) autosomal dominant, (2) autosomal recessive, (3) X-linked dominant, and (4) X-linked recessive.

For individuals with an autosomal dominant disorder (Table 18-2), one parent is affected unless there has been a de novo mutation in a parental gamete. Males and females are affected in approximately equal numbers, and the disorder can be transmitted from generation to generation; on average, half the offspring will have the condition (Fig. 18-3). It is important to counsel affected individuals that the risk of transmitting the disorder is 50% for each of their children, and that this is not influenced by the number of previously affected or unaffected offspring. Any offspring that are affected will have a 50% risk of transmitting the mutated gene to the next generation, but for any unaffected offspring, the risk of the next generation being affected is negligible, providing that the partner does not have the autosomal dominant condition. Some

TABLE 18-2
Examples of Autosomal Dominant Disorders

AUTOSOMAL DOMINANT SKIN DISORDERS	AFFECTED GENE
Ichthyosis vulgaris[a]	*FLG*
Neurofibromatosis	*NF1*
Tuberous sclerosis	*TSC1* or *TSC2*
Darier disease	*ATP2A2*
Hailey-Hailey disease	*ATP2C1*

[a]Semidominant.

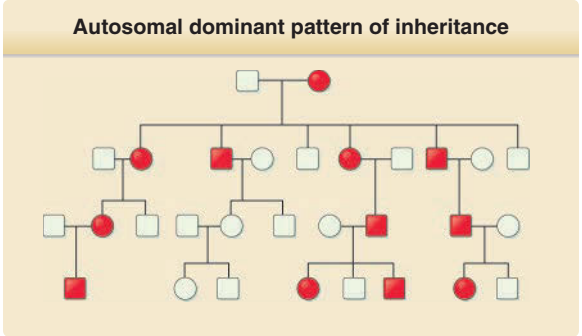

Figure 18-3 Pedigree illustration of an autosomal dominant pattern of inheritance. Key observations include the disorder affects both males and females; on average, 50% of the offspring of an affected individual will be affected; affected individuals have one normal copy and one mutated copy of the gene; and affected individuals usually have one affected parent, unless the disorder has arisen de novo. Importantly, examples of male-to-male transmission, seen here, distinguish this from X-linked dominant and are therefore the best hallmark of autosomal dominant inheritance. *Filled circles* indicate affected females; *filled squares* indicate affected males; and *unfilled circles* and *squares* represent unaffected individuals.

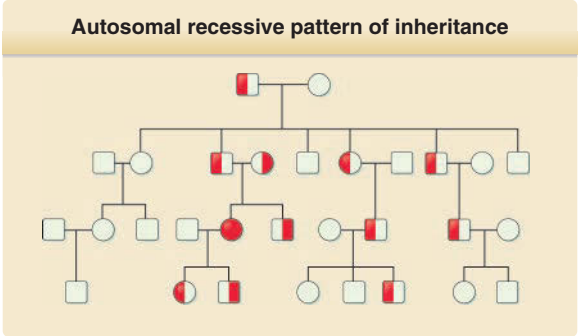

Figure 18-4 Pedigree illustration of an autosomal recessive pattern of inheritance. Key observations include the disorder affects both males and females, there are mutations on both inherited copies of the gene, the parents of an affected individual are both heterozygous carriers and are usually clinically unaffected, and autosomal recessive disorders are more common in consanguineous families. *Filled circle* indicates affected female; *half-filled circles* and *squares* represent clinically unaffected heterozygous carriers of the mutation; and *unfilled circles* and *squares* represent unaffected individuals.

dominant alleles can behave in a partially dominant fashion. The term *semidominant* is applied when the phenotype in heterozygous individuals is less than that observed for homozygous subjects. For example, ichthyosis vulgaris is a *semidominant* disorder in which the presence of one or two mutant profilaggrin gene (*FLG*) alleles can strongly influence the clinical severity of the ichthyosis.

In autosomal recessive disorders (Table 18-3), both parents are carriers of one normal and one mutated allele for the same gene, and, typically, they are phenotypically unaffected (Fig. 18-4). If both of the mutated alleles are transmitted to the offspring, this will give rise to an autosomal recessive disorder, the risk of which is 25%. If one mutated and one wild-type allele is inherited by the offspring, the child will be an unaffected carrier, similar to the parents. If both wild-type alleles are transmitted, the child will be genotypically and phenotypically normal with respect to an affected individual. If the mutations from both parents are the same, the individual is referred to as a *homozygote*, but if different parental mutations within a gene have been inherited, the individual is termed a *compound heterozygote*. For someone who has an autosomal recessive condition, be it a homozygote or compound heterozygote, all offspring will be carriers of one of the mutated alleles but will be unaffected because of inheritance of a wild-type allele from the other, clinically and genetically unaffected, parent. This assumes that the unaffected parent is not a carrier. Although this is usually the case in nonconsanguineous relationships, it may not hold true in first-cousin marriages or other circumstances when there is a familial interrelationship. For example, if the partner of an individual with an autosomal recessive disorder is also a carrier of the same mutation, albeit clinically unaffected, then there is a 50% chance of the offspring inheriting two mutant alleles and therefore also inheriting the same autosomal recessive disorder. This pattern of inheritance is referred to as *pseudodominant*.

In X-linked dominant inheritance (Table 18-4), both males and females are affected, and the pedigree pattern may resemble that of autosomal dominant inheritance (Fig. 18-5). However, there is one important difference. An affected male transmits the disorder to all his daughters and to none of his sons. X-linked dominant inheritance has been postulated as a mechanism in incontinentia pigmenti (see Chaps. 76 and 77), Conradi-Hünermann syndrome, and focal dermal hypoplasia (Goltz syndrome), conditions that are

TABLE 18-3
Examples of Autosomal Recessive Disorders

AUTOSOMAL RECESSIVE SKIN DISORDERS	AFFECTED GENE
Lamellar ichthyosis	*TGM1*
Xeroderma pigmentosum	*XP-A to XP-G*
Junctional epidermolysis bullosa	*LAMA3, LAMB3, LAMC2*
Kindler syndrome	*FERMT1*

TABLE 18-4
Examples of X-Linked Dominant Disorders

X-LINKED DOMINANT SKIN DISORDERS	AFFECTED GENE
Conradi-Hunermann-Happle syndrome	*EBP*
Incontinentia pigmenti	*NEMO*
Focal dermal hypoplasia	*PORCN*
X-linked dominant protoporphyria	*ALAS2*

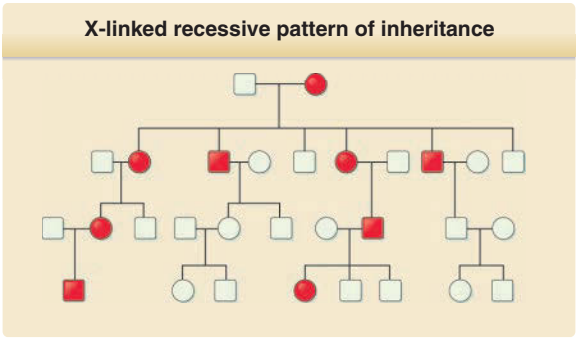

Figure 18-5 Pedigree illustration of an X-linked dominant pattern of inheritance. Key observations include affected individuals are either hemizygous males or heterozygous females, affected males will transmit the disorder to their daughters but not to their sons (no male-to-male transmission), affected females will transmit the disorder to half their daughters and half their sons, and some disorders of this type are lethal in hemizygous males and only heterozygous females survive. *Filled circles* indicate affected females; *filled squares* indicate affected males; and *unfilled circles* and *squares* represent unaffected individuals.

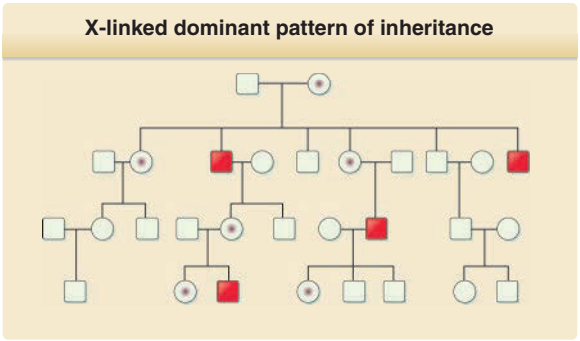

Figure 18-6 Pedigree illustration of an X-linked recessive pattern of inheritance. Key observations include usually affects only males but females can show some features because of lyonization (X-chromosome inactivation); transmitted through female carriers, with no male-to-male transmission; for affected males, all daughters will be heterozygous carriers; and female carrier will transmit the disorder to half her sons, and half her daughters will be heterozygous carriers. *Dots within circles* indicate heterozygous carrier females who may or may not display some phenotypic abnormalities; *filled squares* indicate affected males; and *unfilled circles* and *squares* represent unaffected individuals.

almost always limited to females. In most X-linked dominant disorders with cutaneous manifestations, affected males may be aborted spontaneously or die before implantation (leading to the appearance of female-to-female transmission). Most viable male patients with incontinentia pigmenti have a postzygotic mutation in *IKBKG* and no affected mother; occasionally, males with an X-linked dominant disorder have Klinefelter syndrome with an XXY genotype.

X-linked recessive conditions (Table 18-5) occur almost exclusively in males, but the gene is transmitted by carrier females, who have the mutated gene only on one X chromosome (heterozygous state). The sons of an affected male will all be normal (because their single X chromosome comes from their clinically unaffected mother) (Fig. 18-6). However, the daughters of an affected male will all be carriers (because all had to have received the single X chromosome from their father that carries the mutant copy of the gene). Some females show clinical abnormalities as evidence of the carrier state (eg, in hypohidrotic ectodermal dysplasia; see Chap. 131); the variable extent of phenotypic expression can be explained by Lyonization, the normally random process that inactivates either the wild-type or mutated X chromosome in each cell during the first weeks of gestation and all progeny cells.[23] Other carriers may not show manifestations because the affected region on the X chromosome escapes lyonization (as in recessive X-linked ichthyosis) or the selective survival disadvantage of cells in which the mutated X chromosome is activated (as in the lymphocytes and platelets of carriers of Wiskott-Aldrich syndrome; see section "Mosaicism").

TABLE 18-5
Examples of X-Linked Recessive Disorders

X-LINKED RECESSIVE SKIN DISORDERS	AFFECTED GENE
Hypohidrotic ectodermal dysplasia	*EDA, EDA1, HED*
X-linked ichthyosis	*STS*
Wiskott-Aldrich syndrome	*WAS*
Fabry disease	*GLA*
Menkes syndrome	*MNK*

CHROMOSOMAL DISORDERS

Aberrations in chromosome number or structure are common. They occur in about 6% of all conceptions, although most of these lead to miscarriage, and the frequency of chromosomal abnormalities in live births is about 0.6%. Approximately two thirds of these involve abnormalities in either the number of sex chromosomes or the number of autosomes; the remainder is chromosomal rearrangements. The number and arrangement of the chromosomes is referred to as the *karyotype*. The most common numerical abnormality is trisomy, the presence of an extra chromosome. This occurs because of nondisjunction, when pairs of homologous chromosomes fail to separate during meiosis, leading to gametes with an additional chromosome. Loss of a complete chromosome, monosomy, can affect the X chromosome but is rarely seen in autosomes because of nonviability. A number of chromosomal disorders are also associated with skin abnormalities, as detailed in Table 18-6.

Structural aberrations (fragility breaks) in chromosomes may be random, although some chromosomal regions appear more vulnerable. Loss of part of a

TABLE 18-6
Chromosomal Disorders with a Skin Phenotype

CHROMOSOMAL ABNORMALITY	SYNONYM	GENERAL FEATURES	SKIN MANIFESTATIONS
Trisomy 21	Down syndrome	Small head with flat face	1-10 year: dry skin, xerosis, lichenification
		Short and squat nose	10+ year: increased frequency of atopic dermatitis, alopecia areata, single crease in palm and fifth finger
		Ears small and misshapen	Other associations: skin infections, angular cheilitis, geographic tongue, blepharitis, red cheeks, folliculitis, seborrheic dermatitis, boils, onychomycosis, fine hypopigmented hair, vitiligo, delayed dentition and hypoplastic teeth, acrocyanosis, livedo reticularis, cutis marmorata, calcinosis cutis, palmoplantar keratoderma, pityriasis rubra pilaris, syringomas, elastosis perforans serpiginosa, anetoderma, hyperkeratotic form of psoriasis, collagenoma, eruptive dermatofibromas, urticaria pigmentosa, leukemia cutis, keratosis follicularis spinulosa decalvans
		Slanting palpebral fissures	
		Thickened eyelids	
		Eyelashes short and sparse	
		Shortened limbs, lax joints	
		Fingers short, sometimes webbed	
		Hypoplastic iris, lighter outer zone (Brushfield spots)	
Trisomy 18	Edwards syndrome	Severe mental deficiency	Cutis laxa (neck), hypertrichosis of forehead and back, superficial hemangiomas, abnormal dermatoglyphics, single palmar crease, hyperpigmentation, ankyloblepharon filiforme adnatum
		Abnormal skull shape	
		Small chin, prominent occiput	
		Low-set, malformed ears	
		"Rocker bottom" feet	
		Short sternum	
		Malformations of internal organs	
		Only 10% survive beyond first year	
Trisomy 13	Patau syndrome	Mental retardation	Vascular anomalies (especially on forehead)
		Sloping forehead because of forebrain maldevelopment (holoprosencephaly)	Hyperconvex nails
		Microphthalmia or anophthalmia	Localized scalp defects
		Cleft palate or cleft lip	Cutis laxa (neck)
		Low-set ears	Abnormal palm print (distal palmar axial triradius)
		"Rocker bottom" feet	
		Malformations of internal organs	
		Survival beyond 6 months is rare	
Chromosome 4, short arm deletion		Microcephaly	Scalp defects
		Mental retardation	
		Hypospadias	
		Cleft lip or cleft palate	
		Low-set ears, preauricular pits	

(*Continued*)

TABLE 18-6
Chromosomal Disorders with a Skin Phenotype (*Continued*)

CHROMOSOMAL ABNORMALITY	SYNONYM	GENERAL FEATURES	SKIN MANIFESTATIONS
Chromosome 5, short arm deletion		Mental retardation	Premature graying of hair
		Microcephaly	
		Cat-like cry	
		Low-set ears, preauricular skin tag	
Chromosome 18, long arm deletion		Hypoplasia of midface	Eczema in 25% of cases
		Sunken eyes	
		Prominent ear antihelix	
		Multiple skeletal and ocular abnormalities	
45 XO	Turner syndrome	Early embryonic loss; prenatal ultrasound findings of cystic hygroma, chylothorax, ascites and hydrops	Redundant neck skin and peripheral edema
		Short stature, amenorrhea	Webbed neck, low posterior hairline
		Broad chest, widely spaced nipples	Cutis laxa (neck, buttocks)
		Wide carrying angle of arms	Hypoplastic, soft upturned nails
		Low misshapen ears, high arched palate	Increased incidence of keloids
		Short fourth and fifth fingers and toes	Increased number of melanocytic nevi and halo nevi
		Skeletal abnormalities, coarctation of aorta	Failure to develop full secondary sexual characteristics
			Lymphatic hypoplasia or lymphedema
47 XXY	Klinefelter syndrome	No manifestations before puberty	May develop gynecomastia
		Small testes, poorly developed secondary sexual characteristics	Sparse body and facial hair
		Infertility	Increased risk of leg ulcers
		Tall, obese, osteoporosis	Increased incidence of systemic lupus erythematosus
48 XXYY		Similar to Klinefelter syndrome	Multiple cutaneous angiomas
			Acrocyanosis, peripheral vascular disease
47 XYY		Phenotypic males (tall)	Severe acne
		Mental retardation	
		Aggressive behavior	
49 XXXXY		Low birth weight	Hypotrichosis (variable)
		Slow mental and physical development	
		Large, low-set, malformed ears	
		Small genitalia	
Fragile X syndrome		Mental retardation	—
		Mild dysmorphism	
		Hyperextensible joints, flat feet	

chromosome is referred to as a *deletion*. If the deletion leads to loss of neighboring genes, this may result in a contiguous gene disorder, such as a deletion on the X chromosome giving rise to X-linked ichthyosis (see Chap. 47) and Kallmann syndrome. If two chromosomes break, the detached fragments may be exchanged, known as *reciprocal translocation*. If this process involves no loss of DNA, it is referred to as a *balanced translocation*. Other structural aberrations include duplication of sections of chromosomes, two breaks within one chromosome leading to inversion, and fusion of the ends of two broken chromosomal arms, leading to joining of the ends and formation of a ring chromosome. Chromosomal anomalies may be detected using standard metaphase cytogenetics but newer approaches, such as SNP arrays and comparative genomic hybridization arrays, can also be used for karyotyping. Array-based cytogenetic tools do not rely on cell division and are very sensitive in detecting unbalanced lesions as well as copy number-neutral loss of heterozygosity. These new methods have become commonplace in diagnostic genetics laboratories. A further possible chromosomal abnormality is the inheritance of both copies of a chromosome pair from just one parent (paternal or maternal), known as *uniparental disomy*.[24] Whereas *uniparental heterodisomy* refers to the presence of a pair of chromosome homologs, *uniparental isodisomy* describes two identical copies of a single homolog, and *meroisodisomy* is a mixture of the two. Uniparental disomy with homozygosity of recessive alleles is being increasingly recognized as the molecular basis for several autosomal recessive disorders, including junctional and dystrophic EB (see Chap. 60), resulting from this type of chromosomal abnormality. For certain chromosomes, uniparental disomy can also result in distinct phenotypes depending on the parental origin of the chromosomes, a phenomenon known as *genomic imprinting*.[25,26] This parent-of-origin, specific gene expression is determined by epigenetic modification of a specific gene or, more often, a group of genes, such that gene transcription is altered, and only one inherited copy of the relevant imprinted gene(s) is expressed in the embryo. This means that, during development, the parental genomes function unequally in the offspring. The most common examples of genomic imprinting are Prader-Willi (OMIM #176270) and Angelman (OMIM #105830) syndromes, which can result from maternal or paternal uniparental disomy for chromosome 15, respectively. Three phenotypic abnormalities commonly associated with uniparental disomy for chromosomes with imprinting are (1) intrauterine growth retardation, (2) developmental delay, and (3) short stature.[27]

MITOCHONDRIAL DISORDERS

In addition to the 3.3 billion bp nuclear genome, each cell contains hundreds or thousands of copies of a further 16.5-kb mitochondrial genome, which is inherited solely from an individual's mother. This closed, circular genome contains 37 genes, 13 of which encode proteins of the respiratory chain complexes; the other 24 genes generate 22 transfer RNAs and 2 ribosomal RNAs used in mitochondrial protein synthesis.[28] Mutations in mitochondrial DNA were first reported in 1988, and more than 250 pathogenic point mutations and genomic rearrangements have been shown to underlie a number of myopathic disorders and neurodegenerative diseases, some of which show skin manifestations, including lipomas, abnormal pigmentation or erythema, and hypo- or hypertrichosis.[29] Mitochondrial DNA mutations are very common in somatic mammalian cells, more than two orders of magnitude higher than the mutation frequency in nuclear DNA.[30] Mitochondrial DNA has the capacity to form a mixture of both wild-type and mutant DNA within a cell, leading to cellular dysfunction only when the ratio of mutated to wild-type DNA reaches a certain threshold. The phenomenon of having mixed mitochondrial DNA species within a cell is known as *heteroplasmy*. Mitochondrial mutations can induce or be induced by reactive oxygen species and may be found in or contribute to both chronologic aging and photoaging.[31] Somatic mutations in mitochondrial DNA have also been reported in several premalignant and malignant tumors, including malignant melanoma, although it is not yet known whether these mutations are causally linked to cancer development or simply a secondary bystander effect as a consequence of nuclear DNA instability. Conversely, adults with mitochondrial disorders have been reported to have an increased incidence of both benign (lipomas) and malignant neoplasms (eg, extramammary Paget disease, Bowen disease) of the skin,[32] suggesting a role for the mitochondrial genome in tissue and stem cell homeostasis. There is currently little understanding of the interplay between the nuclear and mitochondrial genomes in both health and disease. Nevertheless, it is evident that the genes encoded by the mitochondrial genome have multiple biologic functions linked to energy production, cell proliferation, and apoptosis.[33]

COMPLEX DISEASE GENETICS

For Mendelian disorders, identifying genes that harbor pathogenic mutations has become relatively straightforward, with hundreds of disease-associated genes being discovered through a combination of linkage, positional cloning, and candidate gene analyses. By contrast, for complex diseases, such as psoriasis and atopic dermatitis, these traditional approaches have been largely unsuccessful in mapping genes influencing the disease risk or phenotype because of low statistical power and other factors.[34,35] Complex diseases do not display simple Mendelian patterns of inheritance, although genes do have an influence, and close relatives of affected individuals may have an increased risk. To identify genes that contribute and influence

susceptibility to complex traits, several stages may be necessary, including establishing a genetic basis for the disease in one or more populations, measuring the distribution of gene effects, studying statistical power using models, and carrying out marker-based mapping studies using linkage or association. It is possible to establish quantitative genetic models to estimate the heritability of a complex trait, as well as to predict the distribution of gene effects and to test whether one or more quantitative trait loci exist. These models can predict the power of different mapping approaches but often only provide approximate predictions. Moreover, low power often limits other strategies such as transmission analyses, association studies, and family-based association tests. In addition, and relevant to several studies on psoriasis, linkage disequilibrium observed in a sample of unrelated affected and normal individuals can also be used to fine-map a disease susceptibility locus in a candidate region.

In recent years, advances in the identification of many millions of SNPs across the entire genome, as well as major advances in gene chip technology that allows up to 2 million SNPs to be typed in a given individual for a few hundred dollars, coupled with high powered computation, have led to the current era of genome-wide association studies (GWASs).[36] This has become the predominant technology for mapping complex diseases, with GWASs having already been performed for psoriasis, atopic eczema, vitiligo, and alopecia areata, and GWASs for other dermatologic complex diseases are underway. A typical GWAS design involves collecting DNA from a well-phenotyped case series of the condition of choice, preferably from an ethnically homogenous population. Normally, 2000 or more cases are required versus 3000 ethnically matched population control participants. Correct clinical ascertainment of the cases is paramount, so GWASs represent a great opportunity for close cooperation between physicians and scientists. These 5000 or more individuals are genotyped for 500,000 to 2 million SNPs, generating billions of data points. For each SNP across the genome, a statistical test is performed and a *P* value derived. If an SNP is closely linked to a disease susceptibility gene, then a particular genotype will be greatly enriched in the case series compared with the general unselected population. The *P* values are plotted along each chromosome ("Manhattan plot"), and where disease susceptibility loci exist, there are clusters of strong association. Typically, *P* values of 10^{-10} or lower are indicative of a true locus, although this generally has to be replicated in a number of other case-control sets for confirmation. Although an SNP-based GWAS is currently the method of choice in mapping complex disease genetics, it has limitations. If a causative lesion in a susceptibility locus is very heterogeneous (ie, if there are multiple mutations or other changes that cause the susceptibility), then the locus will be difficult to pinpoint by GWAS. Furthermore, across the entire field of complex disease genetics, relatively few causative genes have emerged (the role of the filaggrin gene in atopic dermatitis being a notable exception). In the majority of cases, there is currently little clue about what defect the associated SNPs are linked to that actually causes the disease susceptibility. GWASs can be very useful in uncovering new disease pathways involved in disease pathogenesis at a population level because individual variants take longer to identify.

However, recently, a conventional genetics approach has revealed fascinating new insight into the pathophysiology of one particular complex trait, namely atopic dermatitis. This finding emanated from the discovery that the disorder ichthyosis vulgaris was due to loss-of-function mutations in the gene encoding the skin barrier protein filaggrin (see Chaps. 22 and 47).[37] To dermatologists, the clinical association between this condition and atopic dermatitis is well known, and the same loss-of-function mutations in filaggrin have subsequently been shown to be a major susceptibility risk factor for atopic dermatitis, as well as asthma associated with atopic dermatitis but not asthma alone.[4] This suggests that asthma in individuals with atopic dermatitis may be secondary to allergic sensitization, which develops because of the defective epidermal barrier that allows allergens to penetrate the skin to make contact with antigen-presenting cells. Indeed, transmission–disequilibrium tests have demonstrated an association between filaggrin gene mutations and extrinsic atopic dermatitis associated with high total serum immunoglobulin E levels and concomitant allergic sensitizations.[38] These recent data on the genetics of atopic dermatitis demonstrate how the study of a "simple" genetic disorder (ichthyosis) can also provide novel insight into a complex disease (atopic dermatitis). Therefore, Mendelian disorders may be useful in the molecular dissection of more complex traits.[39]

MOSAICISM

The presence of a mixed population of cells bearing different genetic or chromosomal characteristics leading to phenotypic diversity is referred to as *mosaicism*. There are several different types of mosaicism, including single gene, chromosomal, functional, and revertant mosaicism.[40] Multiple expression patterns are recognized.[41]

Mosaicism for a single gene, referred to as *somatic mosaicism*, indicates a mutational event occurring after fertilization. The earlier this occurs, the more likely it is that there will be clinical expression of a disease phenotype as well as involvement of gonadal tissue (gonosomal mosaicism), for example, when individuals with segmental neurofibromatosis subsequently have offspring with fully penetrant neurofibromatosis (see Chap. 135). However, in general, if the mutation occurs after generation of cells committed to germline formation, then the mosaicism will not involve the gametes, and the reproductive risk of transmission is negligible. *Gonosomal mosaicism* refers to involvement of both gonads and somatic tissue, but mosaicism can occur exclusively in gonadal tissue, referred to as *gonadal mosaicism*. Clinically, this may explain recurrences among siblings of autosomal

dominant disorders such as tuberous sclerosis or neurofibromatosis, when neither parent has any clinical manifestations and gene screening using genomic DNA from peripheral blood samples yields no mutation. Segmental mosaicism for autosomal dominant disorders is thought to occur in one of two ways: either there is a postzygotic mutation with the skin outside the segment and genomic DNA being normal (type 1), or there is a heterozygous genomic mutation in all cells that is then exacerbated by loss of heterozygosity within a segment or along the lines of Blaschko (type 2). This pattern has been described in several autosomal dominant disorders, including Darier disease, Hailey-Hailey disease (see Chap. 50), superficial actinic porokeratosis (see Chap. 51), and tuberous sclerosis (see Chap. 136).

The lines of Blaschko (Fig. 18-7) were described more than 100 years ago; the pattern is attributed to the lines of migration and proliferation of epidermal cells during embryogenesis (ie, the bands of abnormal skin represent clones of cells carrying a mutation in a gene expressed in the skin).[42] Although attributed to the German dermatologist Alfred Blaschko, the literature records an almost simultaneous description of "the lines" by the American dermatologist Douglass Montgomery. Indeed, one of the clinical photographs in Montgomery's paper is illustrated as a diagram in Blaschko's work. Apart from somatic mutations (either in dominant disorders, such as epidermolytic ichthyosis [formerly called bullous congenital ichthyosiform erythroderma] leading to linear epidermolytic ichthyosis [epidermal nevus of the epidermolytic hyperkeratosis type] [see Chap. 47], or in conditions involving mutations in lethal dominant genes such as in McCune-Albright syndrome), mosaicism following Blaschko's lines is also seen in chromosomal mosaicism and functional mosaicism (random X-chromosome inactivation through Lyonization). Monoallelic expression on autosomes (with random inactivation of either the maternal or paternal allele) is also feasible and probably underdocumented.[43] Chromosomal mosaicism results from nondisjunction events that occur after fertilization. Clinically, this is found in the linear mosaic pigmentary disorders (hypomelanosis of Ito [see Chap. 77] and linear and whorled hyperpigmentation). It is important to point out that hypomelanosis of Ito is not a specific diagnosis but may occur as a consequence of several different chromosomal abnormalities that perturb various genes relevant to skin pigmentation, which has led to the term "pigmentary mosaicism" to describe this group of disorders.

Functional mosaicism relates to genes on the X chromosome because during embryonic development in females, one of the X chromosomes, either the maternal

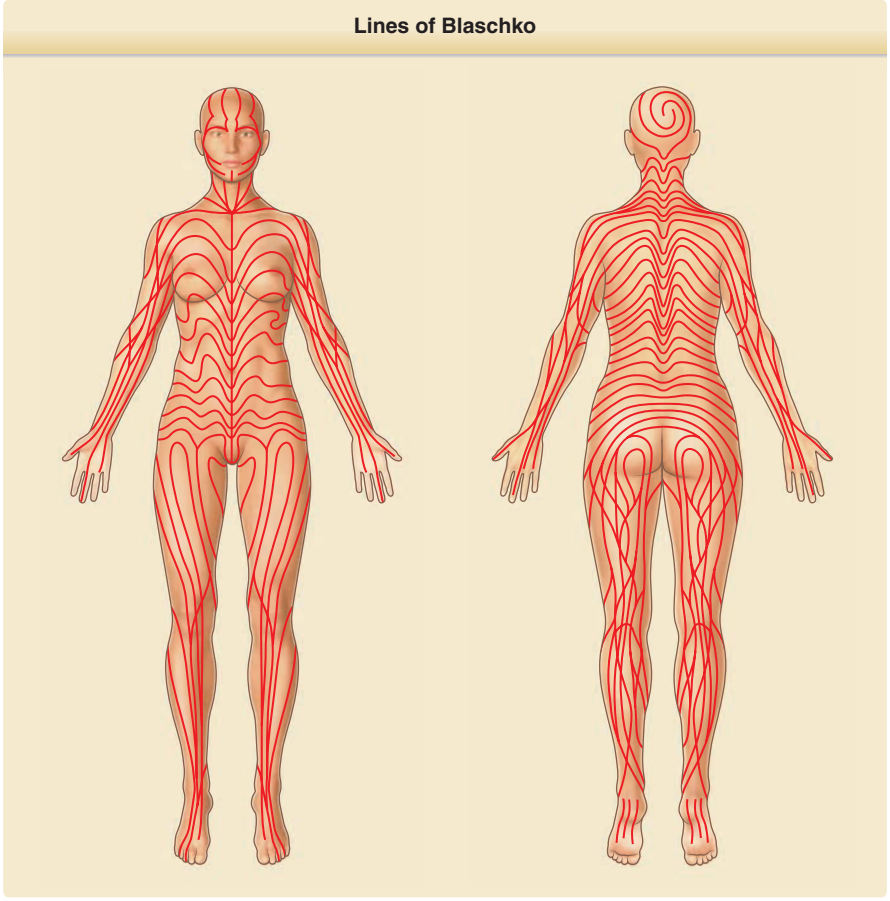

Figure 18-7 Lines of Blaschko.

or the paternal, is inactivated. For X-linked dominant disorders, such as focal dermal hypoplasia (Goltz syndrome) or incontinentia pigmenti (see Chaps. 76 and 77), females survive because of the presence of some cells in which the X chromosome without the mutation is active and able to function. For males, these X-linked dominant disorders are typically lethal unless associated with an abnormal karyotype (eg, Klinefelter syndrome; 47,XXY) or if the mutation occurs during embryonic development. For X-linked recessive conditions, such as X-linked recessive hypohidrotic ectodermal dysplasia (see Chap. 131), the clinical features are evident in hemizygous males (who have only one X chromosome), but females may show subtle abnormalities caused by mosaicism caused by X-inactivation, such as decreased sweating or reduced hair in areas of the skin in which the normal X is selectively inactivated. There are 1317 known genes on the X chromosome, and most undergo random inactivation but a small percentage (~27 genes on Xp, including the steroid sulfatase gene, and 26 genes on Xq) escape inactivation.

Revertant mosaicism, also known as *natural gene therapy*, refers to genetic correction of an abnormality by various different phenomena, including back mutations, intragenic crossovers, mitotic gene conversion, and second site mutations.[44,45] Indeed, multiple different correcting events can occur in the same patient. Such changes have been described in a few genes expressed in the skin, including the keratin 14, laminin 332, collagen XVII, collagen VII, and kindlin-1 (fermitin family homolog 1) genes in different forms of EB (Fig. 18-8; see Chap. 60) and in keratins 10 and 1 in ichthyosis with confetti (see Chap. 47). The clinical relevance of the conversion process depends on several factors, including the number of cells involved, how much reversal actually occurs, and at what stage in life the reversion takes place. Attempts have been made to culture reverted keratinocytes and graft them to unreverted sites,[46] a pioneering approach that may have therapeutic potential for some patients. Clinical success has also been reported using punch grafting of revertant mosaic skin (*LAMB3* gene correction) with sustained expression of the reversion at the grafted site.[47A] Newer protocols in provirus-mediated gene correction of keratinocyte stem cells have recently resulted in the successful replacement of significant amounts of epidermis in a severe case of junctional EB, providing further proof of concept that this is a feasible option for management of genetic skin diseases.[47B]

Figure 18-8 Revertant mosaicism in an individual with non-Herlitz junctional epidermolysis bullosa. The subject has loss-of-function mutations on both alleles of the type XVII collagen gene, *COL17A1*, but spontaneous genetic correction of the mutation in some areas has led to patches of normal-appearing skin (areas within black marker outline) that do not blister. (From Jonkman MF, Scheffer H, Stulp R, et al. Revertant mosaicism in epidermolysis bullosa caused by mitotic gene conversion. *Cell*. 1997;88:543, with permission. Copyright © Elsevier.)

Apart from mutations in nuclear DNA, mosaicism can also be influenced by environmental factors, such as viral DNA sequences (retrotransposons) that can be incorporated into nuclear DNA, replicate, and activate or silence genes through methylation or demethylation. This phenomenon is known as *epigenetic mosaicism*; such events may be implicated in tumorigenesis but have not been associated with any genetic skin disorder.

HISTOCOMPATABILITY ANTIGEN DISEASE ASSOCIATION

Human leukocyte antigen (HLA) molecules are glycoproteins that are expressed on almost all nucleated cells. The HLA region is located on the short arm of chromosome 6, at 6p21, referred to as the *MHC*. There are three classic loci at HLA class I—(1) HLA-A, (2) HLA-B, and (3) HLA-Cw—and five loci at class II—(1) HLA-DR, (2) HLA-DQ, (3) HLA-DP, (4) HLA-DM, and (5) HLA-DO. The HLA molecules are highly polymorphic, with many alleles at each individual locus. Thus, allelic variation contributes to defining a unique "fingerprint" for each person's cells, which allows an individual's immune system to define what is foreign and what is self. The clinical significance of the HLA system is highlighted in human tissue transplantation, especially in kidney and bone marrow transplantation, where efforts are made to match at the HLA-A, -B, and -DR loci. Major histocompatibility (MHC) class I molecules, complexed to certain peptides, act as substrates for $CD8^+$ T-cell activation, but MHC class II molecules on the surface of antigen-presenting cells display a range of peptides for recognition by the T-cell receptors of $CD4^+$ T helper cells (see Chap. 11). Therefore, MHC molecules are central to effective adaptive immune responses.

Conversely, however, genetic and epidemiologic data have implicated these molecules in the pathogenesis of various autoimmune and chronic inflammatory diseases. Several skin diseases, such as alopecia areata (see Chap. 87), psoriasis (see Chap. 28), psoriatic arthropathy (central and peripheral), vitiligo, dermatitis herpetiformis, pemphigus, reactive arthritis syndrome (see Chap. 65), and Behçet disease (see Chap. 141), all show an association with inheritance of certain HLA haplotypes (ie, there is a higher incidence of these conditions in individuals and families with particular HLA alleles; Table 18-7). However, the molecular mechanisms by which polymorphisms in

TABLE 18-7
Diseases and HLA Haplotype

DISEASE	HLA HAPLOTYPE
Psoriasis	HLA cw6
Alopecia areata	HLA DWB1*03; HLA DR4; HLA DQ7[a]
Psoriatic arthropathy	HLA B27; HLA B7; HLA B13, BLA B16, HLA B38, HLA B39, HLA B17, HLA cw6
Dermatitis herpetiformis	HLA DQw2[b]
Pemphigus	HLA DR4, HLA DQ1
Reactive arthritis syndrome	HLA B27
Behcet disease	HLA B51
Increased risk for carbamazepine-induced SJS and TEN	HLA-B*1502

[a]Colombe BW, Lou CD, Price VH. The genetic basis of alopecia areata: HLA associations with patchy alopecia areata versus alopecia totalis and alopecia universalis. *J Investig Dermatol Symp Proc*. 1999;4(3):216-219.
[b]Hall MA, Lanchbury JS, PJ Ciclitira, et al. HLA Association with dermatitis herpetiformis is accounted for by a cis or transassociated DQ heterodimer. *Gut*. 1991;32(5):487-490.
SJS, Stevens-Johnson syndrome; TEN, toxic epidermal necrolysis.

HLA molecules confer susceptibility to certain disorders are still unclear. This situation is further complicated by the fact that, for most diseases, it is unknown which autoantigens (presented by the disease-associated MHC molecules) are primarily involved. For many diseases, the MHC class association is the main genetic association. Nevertheless, for most of the MHC-associated diseases, it has been difficult to unequivocally determine the primary disease-risk gene(s) because of the extended linkage disequilibrium in the MHC region. However, recent genetic and functional studies support the long-held assumption that common MHC class I and II alleles themselves are responsible for many disease associations, such as the HLA cw6 allele in psoriasis. Of practical clinical importance is the strong genetic association between certain HLA alleles and the risk of adverse drug reactions. For example, in Han Chinese and some other Asian populations, HLA-B*1502 confers a greatly increased risk of carbamazepine-induced Stevens-Johnson syndrome and toxic epidermal necrolysis (60- to 80-fold increase). Therefore, screening for HLA-B*1502 before starting carbamazepine in patients from high-risk populations is recommended or required by regulatory agencies.[48]

EPIGENETICS

Disease phenotypes reflect the result of the interaction between a particular genotype and the environment, but it is evident that some variation, for example, in monozygotic twins, is attributable to neither. Additional influences at the biochemical, cellular, tissue, and organism levels occur, and these are referred to as *epigenetic phenomena*.[49] Single genes are not solely responsible for each separate function of a cell. Genes may collaborate in circuits, be mobile, exist in plasmids and cytoplasmic organelles, and can be imported by nonsexual means from other organisms or as synthetic products. Epigenetic effects reflect chemical modifications to DNA that do not alter DNA sequence but instead affect the probability or level of gene transcription. Mammalian DNA methylation machinery is made up of two components: (1) DNA methyltransferases, which establish and maintain genome-wide DNA methylation patterns, and (2) the methyl-CpG-binding proteins, which are involved in scanning and interpreting the methylation patterns. Analysis of any changes in these processes is known as *epigenomics*.[50] Examples of modifications include direct covalent modification of DNA by methylation of cytosines and alterations in proteins that bind to DNA. Such changes may affect DNA accessibility to local transcriptional complexes as well as influencing chromatin structure at regional and genome-wide levels, thus providing a link between genome structure and regulation of transcription. Indeed, epigenome analysis is now being carried out in parallel with gene expression studies (eg, microarray studies or RNA sequencing) to identify genome-wide methylation patterns and profiles of all human genes. For example, there is considerable interindividual variation in cytosine methylation of CpG dinucleotides within the MHC region genes, and hypermethylation of the HLA-C promoter has been postulated to be an epigenetic marker for psoriasis.[51]

New sensitive and quantitative methylation-specific polymerase chain reaction-based assays can identify epigenetic anomalies in cancers such as melanoma.[52] DNA hypermethylation contributes to gene silencing by preventing the binding of activating transcription factors and by attracting repressor complexes that induce the formation of inactive chromatin structures. With regard to melanoma, such changes may impact on several biologic processes, including cell cycle control, apoptosis, cell signaling, tumor cell invasion, metastasis, angiogenesis, and immune recognition. A further but as yet unresolved issue is whether there is heritability of epigenetic characteristics. Likewise, it is unclear whether environmentally induced changes in epigenetic status, and hence gene transcription and phenotype, can be transmitted through more than one generation. Such a phenomenon might account for the cancer susceptibility of grandchildren of individuals who have been exposed to diethylstilbestrol, but this has not been proved.[53] However, germ line epimutations have been identified in other human diseases, such as colorectal cancers characterized by microsatellite instability and hypermethylation of the *MLH1* DNA mismatch repair gene, although the risk of transgenerational epigenetic inheritance of cancer from such a mutation is not well established and probably small. Over the course of an individual's lifespan, epigenetic mutations (affecting DNA methylation and histone modifications) may occur more frequently than DNA mutations, and it is expected that, over the next decade, the role of epigenetic phenomena in influencing phenotypic variation will gradually become better understood.[54] High-throughput

methods of identifying differentially methylated sites in the genome has implicated epigenetics in the pathogenesis of diseases like schizophrenia,[55] obesity,[56] and type 2 diabetes mellitus.[57]

GENETIC COUNSELING

The National Society of Genetic Counselors (http://www.nsgc.org) has defined genetic counseling as "the process of helping people understand and adapt to the medical, psychological and familial implications of genetic contributions to disease." Genetic counseling should include (1) interpretation of family and medical histories to assess the chance of disease occurrence or recurrence, (2) education about inheritance, testing, management, prevention, resources, and research, and (3) counseling to promote informed choice and adaptation to the risk or condition.[58]

When the diagnosis of an inherited skin disease is established and the mode of inheritance is known, every dermatologist should be able to advise patients correctly and appropriately, although additional support from specialists in medical genetics is often necessary. Genetic counseling must be based on an understanding of genetic principles and on a familiarity with the usual behavior of hereditary and congenital abnormalities. It is also important to be familiar with the range of clinical severity of a particular disease, the social consequences of the disorder, the availability of therapy (if any), and the options for mutation detection and prenatal testing in subsequent pregnancies at risk for recurrence (one useful site is http://www.genetests.com).

A key component of genetic counseling is to help parents, patients, and families know about the risks of recurrence or transmission for a particular condition. This information is not only practical but often relieves guilt and can allay rather than increase anxiety. For example, it may not be clear to the person that he or she cannot transmit the given disorder. The unaffected brother of a patient with an X-linked recessive disorder such as Fabry disease (see Chap. 127), X-linked ichthyosis (see Chap. 47), Wiskott-Aldrich syndrome (see Chap. 132), or Menkes syndrome (see Chap. 85) need not worry about his children being affected or even carrying the abnormal allele, but he may not know this information.

Prognosis and counseling for conditions such as psoriasis in which the genetic basis is complex or still unclear is more difficult (see Chap. 28). Individuals can be advised, for example, that if both parents have psoriasis, the probability is 60% to 75% that a child will have psoriasis; if one parent and a child of that union have psoriasis, then the chance is 30% that another child will have psoriasis; and if two normal parents have produced a child with psoriasis, the probability is 15% to 20% for another child with psoriasis.[59] Ongoing discoveries in other diseases, such as melanoma, can also impact on genetic counseling. The identification of family-specific mutations in the *CDKN2A* and *CDK4* genes, as well as risk alleles in the *MC1R* and *OCA2* genes and other genetic variants allow for more accurate and informative patient and family consultations.[60]

The advent of NGS has also created new issues and dilemmas for genetic counseling. Notably, in sequencing whole exomes or genomes, the question has arisen what to do with incidental findings (ie, gene mutations not related to the phenotype that is being investigated) or variants of unknown significance. Currently, best practice guidelines dictate the need to act or pass on such collateral information only if the findings are "clinically actionable," although such policies are likely to change in the future. In addition, key governance concerns over storage and ownership of personal genomic data must be addressed.

PRENATAL DIAGNOSIS

In recent years, there has been considerable progress in developing prenatal testing for severe inherited skin disorders (Fig. 18-9). Initially, ultrastructural examination of fetal skin biopsies was established in a limited number of conditions. In the late 1970s, the first diagnostic examination of fetal skin was reported for epidermolytic hyperkeratosis (epidermolytic ichthyosis) and Herlitz (generalized severe) junctional EB (see Chap. 60).[61,62] These initial biopsies were performed with the aid of a fetoscope to visualize the fetus. However, with improvements in sonographic imaging, biopsies of fetal skin are now taken under ultrasound guidance. The fetal skin biopsy samples obtained during the early 1980s could be examined only by light microscopy and transmission electron microscopy. However, the introduction of a number of monoclonal and polyclonal antibodies to various basement membrane components during the mid-1980s led to the development of immunohistochemical tests to help complement ultrastructural analysis in establishing an accurate diagnosis, especially in cases of EB.[63] Fetal skin biopsies are taken during the midtrimester. For disorders such as EB, testing at 16 weeks' gestation is appropriate. However, for some forms of ichthyosis, the disease-defining structural pathology may not be evident at this time, and fetal skin sampling may need to be deferred until 20 to 22 weeks of development.

Nevertheless, since the early 1990s, as the molecular basis of an increasing number of genodermatoses has been elucidated, fetal skin biopsies have gradually been replaced by DNA-based diagnostic screening using fetal DNA from amniotic fluid cells or samples of chorionic villi; taken at 16 weeks' gestation for amniotic fluid and 10 to 12 weeks' for chorionic villus sampling (ie, at the end of the first trimester).[64,65] In addition, advances with in vitro fertilization and embryo micromanipulation have led to the feasibility of even earlier DNA-based assessment through preimplantation genetic diagnosis, an approach first successfully applied in 1990, for risk of recurrence of cystic fibrosis.[66] Successful preimplantation testing has also been reported for severe inherited skin disorders.[67]

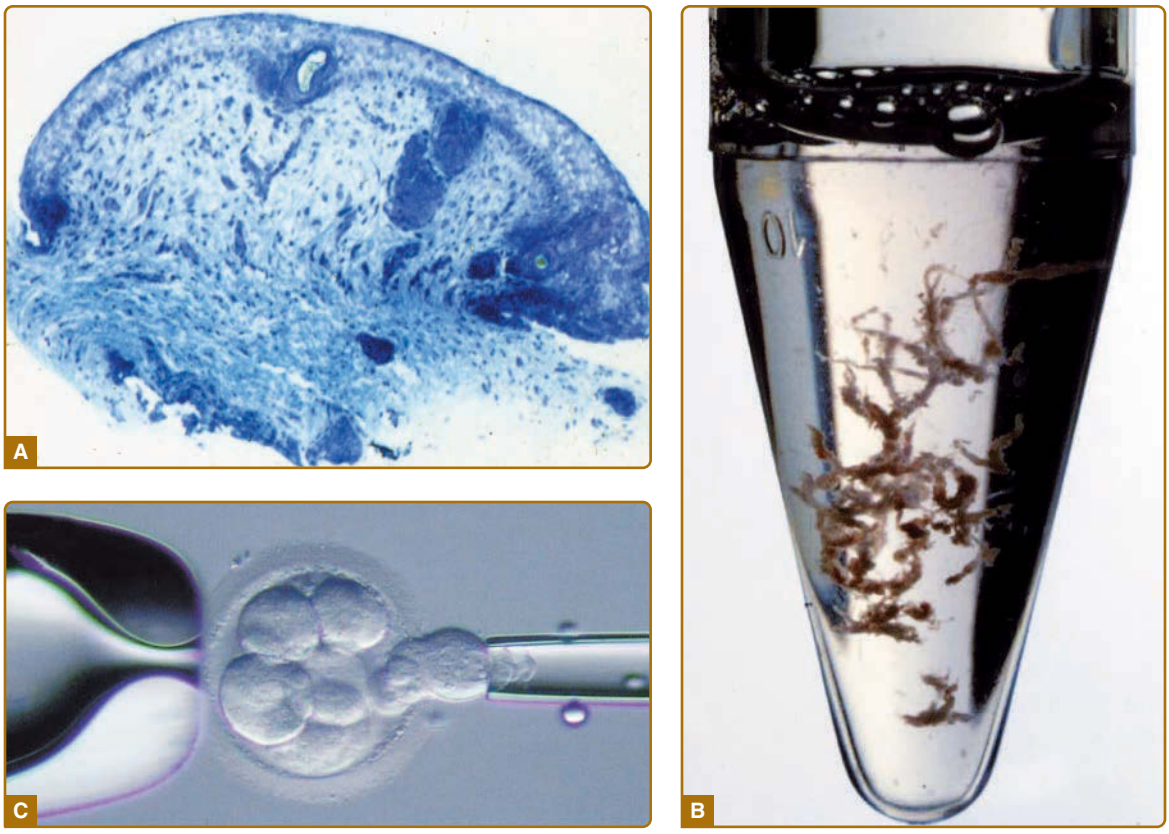

Figure 18-9 Options for prenatal testing of inherited skin diseases. **A,** Fetal skin biopsy, here shown at 18 weeks' gestation. **B,** Chorionic villi sampled at 11 weeks' gestation. **C,** Preimplantation genetic diagnosis. A single cell is being extracted from a 12-cell embryo using a suction pipette.

This is likely to become a more popular, though still technically challenging, option for some couples, in view of recent advances in amplifying the whole genome in single cells and the application of multiple linkage markers in an approach termed *preimplantation genetic haplotyping*.[68] This approach has been developed and applied successfully for generalized severe junctional EB.[69] For some disorders, alternative less invasive methods of testing are now also being developed, including analysis of fetal DNA or RNA from within the maternal circulation and the use of three-dimensional ultrasonography.

Advances in in vitro fertilization have also helped to address familial mitochondrial disorders, whereby the mothers carry mutations in the mitochondrial genome. The mother's nucleus, along with its genomic DNA, is transferred into a donated egg from another woman with healthy mitochondria, which is then fertilized by the father's sperm. This procedure, which results in three-parent families, was approved by the British Parliament in 2015 and is currently under consideration by the US Food and Drug Administration (FDA).

In the absence of effective treatment for many hereditary skin diseases at present, prenatal diagnosis can provide valuable information to couples at risk of having affected children, although detailed and supportive genetic counseling is also a vital element of all prenatal testing procedures.

GENE THERAPY AND EDITING

The field of gene therapy can be subdivided in different ways.[70] First, there are approaches aimed at treatment of recessive genetic diseases in which homozygous or compound heterozygous loss-of-function mutations lead to complete absence or complete functional ablation of a protein. These types of diseases are amenable to gene replacement therapy, and this form of gene therapy has tended to predominate because it is generally technically more feasible than treatment of dominant genetic conditions.[71] In dermatology, these include diseases such as lamellar ichthyosis (see Chap. 47), in which in most cases, there is hereditary absence of transglutaminase-1 activity in the outer epidermis, or the severe generalized form of recessive dystrophic EB, in which there is complete absence of type VII collagen expression due to recessive mutations.[72]

The second form of gene therapy, in broad terms, is aimed at treatment of dominant-negative genetic disorders and is known as *gene inhibition therapy*. Here, there is a completely different approach because these patients already carry one normal copy of the gene as well as one mutated copy. The disease occurs because an abnormal protein product produced by the mutant

allele, dominant-negative mutant protein, binds to and inhibits the function of the normal protein produced by the wild-type allele. In these cases of dominant negative inheritance, where one normal allele is sufficient for skin function, suppression of expression of the dominant negative mutant allele should be therapeutically beneficial. Recent advances in gene editing have made this therapeutic option possible. Technologies such as TALENS (transcription activator-like effector nucleases) and CRISPR/Cas9 have enabled specific targeting and manipulation of the genome and have been used to disrupt the activity of mutant alleles. For example, using iPSCs to model dystrophic dominant EB (DDEB), the mutant collagen *COL7A1* allele has been successfully edited such that the truncated mutant protein underwent proteolysis, allowing the normal allele to function in its absence.[73] This method provides proof-of-concept for ex vivo therapies, whereby keratinocytes or fibroblasts would be obtained from a skin biopsy, edited to correct the genetic mutation, and then grafted onto or injected back into the patient.

Gene therapy approaches can also be broadly subdivided according to whether they involve in vivo or ex vivo strategies.[71] Using an in vivo approach, the gene therapy agent would be delivered directly to the patient's skin or another tissue. A disadvantage of the skin as a target organ for gene therapy is that it is a barrier tissue that is fundamentally designed to prevent entry of foreign nucleic acid in the form of viruses or other pathogenic agents. This is an impediment to in vivo gene therapy development but is not insurmountable because of developments in liposome technology and other methods for cutaneous macromolecule delivery.[74] In an ex vivo approach, a skin biopsy would be taken. Keratinocytes or fibroblasts would be expanded in culture, treated with the gene therapy agent, and then grafted onto or injected back into the patient. The skin is a good organ system for both these approaches because it is very accessible for in vivo applications. In addition, the skin can be readily biopsied, and cell culture and regrafting of keratinocytes can be adapted for ex vivo gene therapy. In the future, these methods will likely be used in combination with gene editing and iPSC approaches for gene correction.

Gene replacement therapy systems have been developed for lamellar ichthyosis (see Chap. 47) and the recessive forms of EB (see Chap. 60), among other diseases. These mostly consist of expressing the normal complementary DNA encoding the gene of interest from some form of gene therapy vector adapted from viruses that can integrate their genomes stably into the human genome. Therefore, such viral vectors can lead to long-term stable expression of the replacement gene.[75] Early studies tended to use retroviral vectors or adeno-associated viral vectors, but these have a number of limitations. For example, retroviruses only transduce dividing cells and therefore fail to target stem cells; consequently, gene expression is quickly lost because of turnover of the epidermis through keratinocyte differentiation. Furthermore, there have been some safety issues in small-scale human trials for both retroviral and adeno-associated viral vectors. Lentiviral vectors, derived from short integrating sequences found in a number of immunodeficiency viruses, have the advantage of being able to stably transduce dividing and nondividing cells, with close to 100% efficiency and at low copy number. These may be the current vectors of choice, but they also have potential problems because their preferred integration sites in the human genome are currently ill defined and may lead to concerns about safety. As a proof of concept, certain serotypes of adenovirus (eg, AAV-DJ) have been shown to mediate homologous recombination efficiently and accurately ex vivo in the treatment of generalized severe junction EB without the need for drug selection. A wide variety of other vectors are under development and testing, and it should become clear in future years which vectors are effective and safe for human use. Ultimately, like all novel therapeutics, animal testing can only act as a guide because the human genome is quite different and may react differently to foreign DNA integration, so that phase I, II, and III human trials or adaptations thereof will ultimately have to be performed to determine efficacy and safety. Currently, small-scale clinical trials are ongoing for junctional and dystrophic forms of EB and are planned for a number of other genodermatoses, mainly concentrating on the more severe recessive conditions.

Treatment of dominant-negative disorders received a great deal of attention with the discovery of the RNA inhibition pathway in humans and the finding that small synthetic double-stranded RNA molecules of 19 to 21 bp, known as *short inhibitory RNA* (siRNA), can efficiently inhibit expression of human genes in a sequence-specific, user-defined manner.[76,77] There is currently a focus on development of siRNA inhibitors to selectively silence mutant alleles in dominant-negative genetic diseases, such as the keratin disorders EB simplex and pachyonychia congenita (PC). The main obstacles in developing topical siRNA therapies are their rapid degradation and poor cellular uptake. Nanospheres and liposomes are methods that increase siRNA delivery across the stratum. To enhance cellular uptake of siRNA, nonviral methods such as iontophoresis, sonophoresis, and microneedling have been attempted.

In particular, significant progress has been made in PC in recent years. Following development of reporter gene methodology to rapidly screen many different siRNA species, two siRNAs were identified that could specifically and potently silence mutant keratin K6a mRNA differing from the wild-type mRNA by only a single nucleotide (ie, these siRNAs represent allele-specific gene silencing agents). Following a battery of preclinical studies in cells and animal models to show efficacy, the K6a mutation–specific siRNA was manufactured to Good Manufacturing Practice standards and was shown to have an excellent toxicity profile in rodents, as per a small molecule drug. This facilitated FDA approval for a double-blind split body phase 1b clinical trial in a single volunteer with PC. The trial was successful, with a number of objective measures showing statistically significant clinical improvement. This study, funded by the patient advocacy organization PC Project (http://www.pachyonychia.org), was the first in human siRNA trial using a mutation-specific gene silencing approach and only the fifth siRNA trial in

humans. Together with newer gene editing technologies, this personalized medicine strategy gives hope for patients with dominant genodermatoses in which the mutant allele can be selectively targeted and future trials in EB simplex are currently in the planning stages.

PRECISION MEDICINE

We are currently at a point of convergence of the massive amounts of data obtained from population-level GWASs, patient-level whole-exome sequencing, RNA-Seq and microarray analyses, and even microbiome data, with exponential improvements in computing power and organized patient electronic health records. This gives us the opportunity to reconceptualize our dogma of diagnosis and treatment. We have entered a new era of Predictive, Preventive, Personalized and Participatory medicine, whereby each patient's diagnosis will be stratified down to the genetic and epigenetic level, and therapy will be specifically directed at this unique aberration. This new paradigm promises to allow us to understand and resolve treatment nonresponders and reorganize traditional classifications of disease, which have up till now been based on phenotype alone.

REFERENCES

1. Tsongalis GJ, Silverman LM. Molecular diagnostics: a historical perspective. *Clin Chim Acta*. 2006;369:188.
2. McGrath JA. Translational benefits from research on rare genodermatoses. *Australas J Dermatol*. 2004;45:89.
3. Takeichi T, Nanda A, Liu L, et al. Impact of next generation sequencing on diagnostics in a genetic skin disease clinic. *Exp Dermatol*. 2013;22(12): 825-831.
4. Palmer CNA, Irvine AD, Terron-Kwiatkowski A, et al. Common loss-of-function variants of the epidermal barrier protein filaggrin are a major predisposing factor for atopic dermatitis. *Nat Genet*. 2006;38:441.
5. Hsu F, Cui W, Vongsangnak W, et al. The UCSC known genes. *Bioinformatics*. 2006;22:1036.
6. Gilchrest BA, Eller MS. The tale of the telomere: implications for prevention and treatment of skin cancers. *J Investig Dermatol Symp Proc*. 2005;10:124.
7. Wessagowit V, Nalla VK, Rogan PK, et al. Normal and abnormal mechanisms of gene splicing and relevance to inherited skin diseases. *J Dermatol Sci*. 2005;40:73.
8. Amrani N, Sachs MS, Jacobson A. Early nonsense: mRNA decay solves a translational problem. *Nat Rev Mol Cell Biol*. 2006;7:415.
9. Rogers GE. Hair follicle differentiation and regulation. *Int J Dev Biol*. 2004;48:163.
10. Sinha S, Degenstein L, Copenhaver C, et al. Defining the regulatory factors required for epidermal gene expression. *Mol Cell Biol*. 2000;20:2543.
11. Barutcu AR, Fritz AJ, Zaidi SK, et al. C-ing the Genome: A Compendium of Chromosome Conformation Capture Methods to Study Higher-Order Chromatin Organization. *J Cell Physiol*. 2016;231(1):31-35.
12. Jakub JW, Grotz TE, Jordan P, et al. A pilot study of chromosomal aberrations and epigenetic changes in peripheral blood samples to identify patients with melanoma. *Melanoma Res*. 2015;25(5):406-411.
13. Buenrostro JD, Wu B, Chang HY, et al. ATAC-seq: a method for assaying chromatin accessibility genome-wide. *Curr Protoc Mol Biol*. 2015;109:21.29.1-9.
14. Bao X, Rubin AJ, Qu K, et al. A novel ATAC-seq approach reveals lineage-specific reinforcement of the open chromatin landscape via cooperation between BAF and p63. *Genome Biol*. 2015;16:284.
15. Miao CG, Yang YY, He X, et al. The emerging role of microRNAs in the pathogenesis of systemic lupus erythematosus. *Cell Signal*. 2013;25(9):1828-1836.
16. Ashton GH, McGrath JA, South AP. Strategies to identify disease genes. *Drugs Today (Barc).* 2002;38:235.
17. Hamada T, McLean WH, Ramsay M, et al. Lipoid proteinosis maps to 1q21 and is caused by mutations in the extracellular matrix protein 1 gene (ECM1). *Hum Mol Genet*. 2002;11:833.
18. Groves RW, Liu L, Dopping-Hepenstal PJ, et al. A homozygous nonsense mutation within the dystonin gene coding for the coiled-coil domain of the epithelial isoform of BPAG1 underlies a new subtype of autosomal recessive epidermolysis bullosa simplex. *J Invest Dermatol*. 2010;130(6):1551-1557.
19. Whittock NV, Ashton GH, Mohammedi R, et al. Comparative mutation detection screening of the type VII collagen gene (COL7A1) using the protein truncation test, fluorescent chemical cleavage of mismatch, and conformation sensitive gel electrophoresis. *J Invest Dermatol*. 1999;113:673.
20. Webber BR, Osborn MJ, McElroy AN, et al. CRISPR/Cas9-based genetic correction for recessive dystrophic epidermolysis bullosa. *NPJ Regen Med*. 2016;1. pii: 16014.
21. Wu W, Lu Z, Li F, et al. Efficient in vivo gene editing using ribonucleoproteins in skin stem cells of recessive dystrophic epidermolysis bullosa mouse model. *Proc Natl Acad Sci U S A*. 2017;114(7):1660-1665.
22. Gunderson KL, Kuhn KM, Steemers FJ, et al. Whole-genome genotyping of haplotype tag single nucleotide polymorphisms. *Pharmacogenomics*. 2006;7:641.
23. Happle R. X-chromosome inactivation: role in skin disease expression. *Acta Paediatr Suppl*. 2006;95:16.
24. Kotzot D, Utermann G. Uniparental disomy (UPD) other than 15: phenotypes and bibliography updated. *Am J Med Genet*. 2005;136:287.
25. Millington GW. Genomic imprinting and dermatological disease. *Clin Exp Dermatol*. 2006;31:681.
26. Pauler FM, Barlow DP. Imprinting mechanisms—it only takes two. *Genes Dev*. 2006;20:1203.
27. Fowden AL, Sibley C, Reik W, et al. Imprinted genes, placental development and fetal growth. *Horm Res*. 2006;65:50.
28. Birch-Machin MA. The role of mitochondria in ageing and carcinogenesis. *Clin Exp Dermatol*. 2006;31:548.
29. Schapira AH. Mitochondrial disease. *Lancet* 368:70, 2006.
30. Todorov IN, Todorov GI. Multifactorial nature of high frequency of mitochondrial DNA mutations in somatic mammalian cells. *Biochemistry (Mosc)*. 74:962, 2009.
31. Birch-Machin MA, Swalwell H. How mitochondria record the effects of UV exposure and oxidative stress using human skin as a model tissue. *Mutagenesis*. 2010;25:101.
32. Finsterer, J, Frank M. Prevalence of neoplasms in definite and probable mitochondrial disorders. *Mitochondrion*. 2016;29:31-34.

33. Chan DC. Mitochondria: dynamic organelles in disease, aging, and development. *Cell*. 2006;125:1241.
34. Thornton-Wells TA, Moore JH, Haines JL. Genetics, statistics and human disease: analytical retooling for complexity. *Trends Genet*. 2004;20:640.
35. Morar N, Willis-Owen SA, Moffatt MF, et al. The genetics of atopic dermatitis. *J Allergy Clin Immunol*. 2006; 118:24.
36. Manolio TA. Genomewide association studies and assessment of the risk of disease. *N Engl J Med*. 2010;363:166.
37. Smith FJD, Irvine AD, Terron-Kwiatkowski A, et al. Loss-of-function mutations in the gene encoding filaggrin cause ichthyosis vulgaris. *Nat Genet*. 2006;38:337.
38. Weidinger S, Illig T, Baurecht H. Loss-of-function variations within the filaggrin gene predispose for atopic dermatitis with allergic sensitizations. *J Allergy Clin Immunol*. 2006;118:214.
39. Antonarakis SE, Beckmann JS. Mendelian disorders deserve more attention. *Nat Rev Genet*. 2006;7:277.
40. Siegel DH, Sybert VP. Mosaicism in genetic skin disorders. *Pediatr Dermatol*. 2006;23:87.
41. Itin P, Burger B. Mosaic manifestations of monogenic skin diseases. *J Dtsch Dermatol Gen*. 2009;7:744.
42. Happle R. Transposable elements and the lines of Blaschko: a new perspective. *Dermatology*. 2002;204:4.
43. Happle R. Monoallelic expression on autosomes may explain an unusual form of pigmentary mosaicism: a historical case revisited. *Clin Exp Dermatol*. 2009;34:834.
44. Jonkman MF, Scheffer H, Stulp R, et al. Revertant mosaicism in epidermolysis bullosa caused by mitotic gene conversion. *Cell*. 1997;88:543.
45. Jonkman MF, Passmooij AM. Revertant mosaicism—patchwork in the skin. *N Engl J Med*. 2009;360:1680.
46. Gostynski A, Deviaene FC, Pasmooij AM, et al. Adhesive stripping to remove epidermis in junctional epidermolysis bullosa for revertant cell therapy. *Br J Dermatol*. 2009;161:444.
47a. Gostynski A, Pasmooij AM, Jonkman MF. Successful therapeutic transplantation of revertant skin in epidermolysis bullosa. *J Am Acad Dermatol*. 2014;70(1):98-101.
47b. Hirsch et al, *Nature*. Nov 2017. [PMID 29144448].
48. Chung WH, Hung SI, Chen YT. Genetic predisposition of life-threatening antiepileptic-induced skin reactions. *Expert Opin Drug Saf*. 2010;9:15.
49. Redei GP, Koncz C, Phillips JD. Changing images of the gene. *Adv Genet*. 2006;56:53.
50. Callinan PA, Feinberg AP. The emerging science of epigenomics. *Hum Mol Genet*. 2006;15:R95.
51. Chen M, Wang Y, Yao X, et al. Hypermethylation of HLA-C may be an epigenetic marker in psoriasis. *J Dermatol Sci*. 2016;83(1):10-16.
52. Howell PM Jr, Liu S, Ren S, et al. Epigenetics in human melanoma. *Cancer Control*. 2009;16:200.
53. Fenichel P, Brucker-Davis F, Chevalier N. The history of Distilbene(R) (Diethylstilbestrol) told to grandchildren—the transgenerational effect. *Ann Endocrinol (Paris)*. 2015;76(3):253-259.
54. Horstemke B. Epimutations in human disease. *Curr Top Microbiol Immunol*. 2006;310:45.
55. Alelu-Paz R, Carmona FJ, Sanchez-Mut JV, et al. Epigenetics in Schizophrenia: A Pilot Study of Global DNA Methylation in Different Brain Regions Associated with Higher Cognitive Functions. *Front Psychol*. 2016;7:1496.
56. Dick KJ, Nelson CP, Tsaprouni L, et al. DNA methylation and body-mass index: a genome-wide analysis. *Lancet*. 2014;383(9933):1990-1998.
57. Dayeh T, Volkov P, Salö S, et al. Genome-wide DNA methylation analysis of human pancreatic islets from type 2 diabetic and non-diabetic donors identifies candidate genes that influence insulin secretion. *PLoS Genet*. 2014;10(3):e1004160.
58. Resta RG. Defining and redefining the scope and goals of genetic counseling. *Am J Med Genet C Semin Med Genet*. 2006;142:269.
59. Capon F, Trembath RC, Barker JN. An update on the genetics of psoriasis. *Dermatol Clin*. 2004;22:339.
60. Newton-Bishop JA, Gruiss NA. Genetics: what advice for patients who present with a family history of melanoma. *Semin Oncol*. 2007;34(6):452-459.
61. Rodeck CH, Eady RA, Gosden CM. Prenatal diagnosis of epidermolysis bullosa letalis. *Lancet*. 1980;1:949.
62. Golbus MS, Sagebiel RW, Filly RA, et al. Prenatal diagnosis of congenital bullous ichthyosiform erythroderma (epidermolytic hyperkeratosis) by fetal skin biopsy. *N Engl J Med*. 1980;302:93.
63. Heagerty AH, Kennedy AR, Gunner DB, et al. Rapid prenatal diagnosis and exclusion of epidermolysis bullosa using novel antibody probes. *J Invest Dermatol*. 1986;86:603.
64. Christiano AM, Pulkkinen L, McGrath JA, et al. Mutation-based prenatal diagnosis of Herlitz junctional epidermolysis bullosa. *Prenat Diagn*. 1997;17:343.
65. Fassihi H, Eady RA, Mellerio JE, et al. Prenatal diagnosis for severe inherited skin disorders: 25 years' experience. *Br J Dermatol*. 2006;154:106.
66. Braude P, Pickering S, Flinter F, et al. Preimplantation genetic diagnosis. *Nat Rev Genet*. 2002;3:941.
67. Fassihi H, Grace J, Lashwood A, et al. Preimplantation genetic diagnosis of skin fragility-ectodermal dysplasia syndrome. *Br J Dermatol*. 2006;154:546.
68. Renwick PJ, Trussler J, Ostad-Saffari E, et al. Proof of principle and first cases using preimplantation genetic haplotyping—a paradigm shift for embryo diagnosis. *Reprod Biomed Online*. 2006;13:110.
69. Fassihi H, Liu L, Renwick PJ, et al. Development and successful clinical application of preimplantation genetic haplotyping for Herlitz junctional epidermolysis bullosa. *Br J Dermatol*. 2010;162(6):1330-1336.
70. Hengge UR. Progress and prospects of skin gene therapy: a ten year history. *Clin Dermatol*. 2005;23:107.
71. Ferrari S, Pellegrini G, Matsui T, et al. Gene therapy in combination with tissue engineering to treat epidermolysis bullosa. *Expert Opin Biol Ther*. 2006;6:367.
72. Khavari PA. Genetic correction of inherited epidermal disorders. *Hum Gene Ther*. 2000;11:2277.
73. Shinkuma S, Guo Z, Christiano AM. Site-specific genome editing for correction of induced pluripotent stem cells derived from dominant dystrophic epidermolysis bullosa. *Proc Natl Acad Sci U S A*. 2016;113(20):5676-5681.
74. Foldvari M, Kumar P, King M, et al. Gene delivery into human skin in vitro using biphasic lipid vesicles. *Curr Drug Deliv*. 2006;3:89.
75. Gagnoux-Palacios L, Hervouet C, Spirito F, et al. Assessment of optimal transduction of primary human skin keratinocytes by viral vectors. *J Gene Med*. 2005;7:1178.
76. Hickerson RP, Smith FJ, Reeves RE, et al. Single-nucleotide-specific siRNA targeting in a dominant-negative skin model. *J Invest Dermatol*. 2008; 128:59.
77. Leachman SA, Hickerson RP, Schwartz ME, et al. First-in-human mutation targeted siRNA phase Ib trial of an inherited skin disorder. *Mol Ther*. 2010;18:442.

Chapter 19 :: Carcinogenesis and Skin

:: Kenneth Y. Tsai & Andrzej A. Dlugosz

AT-A-GLANCE

- The estimated annual incidence of skin carcinomas is at least twofold higher than that of all other cancers combined, making these cancers a major burden on the U.S. health care system and a source of significant morbidity and mortality.
- Most skin cancers arise because of mutations caused by ultraviolet radiation in sunlight, with chemical carcinogens, oncogenic viruses, and other factors contributing to the development of a smaller proportion of tumors.
- The convergence of evidence from epidemiology, inherited predisposition syndromes, cancer genetics, animal models, and most recently genomics have collectively revealed unprecedented insights into the key causative events that drive the development of basal cell carcinoma (BCC) and squamous cell carcinoma (SCC).
- BCC and SCC display markedly different dependencies on specific pathways: whereas BCC is almost exclusively a Hedgehog pathway—dependent tumor, SCC appears to rely on a more varied set of gene mutations and oncogenic signaling.
- The accessibility of skin and the ability to model cancer development in animals has been highly useful in identifying the components and functions of key oncogenic signaling pathways, facilitating development of targeted therapeutics, and uncovering general principles of cancer biology.

INTRODUCTION

It was estimated that in 2017, there would be 87,110 new cases of invasive melanoma and 74,680 new cases of melanoma in situ.[1] Precise incidence data are not available for basal cell carcinoma (BCC) and cutaneous squamous cell carcinoma (SCC) because these tumors are not typically reported to cancer registries, but based on Medicare datasets, the total number of nonmelanoma skin cancers in 2006 was estimated at 4,013,890 cases (2,463,567 individuals) and in 2012 at 5,434,193 cases (affecting 3,315,554 individuals).[2] Another study, using data from the Medical Expenditure Panel Survey, estimated the number of individuals treated annually for nonmelanoma skin cancers at 3,090,442 (based on data from 2002 to 2006) and 4,301,338 (based on 2007 to 2011 data), with annual treatment costs up from $2.7 to $4.8 billion, respectively.[3] The combined incidence of BCC and SCC is thus likely to be at least twofold higher than that of all other cancers combined, which is estimated at 1,688,780 for 2017.[1] Only a small fraction of patients with BCC or SCC will die because of their cancer, but the high frequency of these malignancies nonetheless results in an estimated 2000 deaths per year, according to the American Cancer Society, and most cases are SCC. Although much less common than nonmelanoma skin cancer, melanoma has a continually rising death rate now estimated at 9730 per year.[1]

Although they are rarely lethal, nonmelanoma skin cancers cause considerable cosmetic morbidity because they frequently arise on sun-exposed sites such as the face. Understanding the etiology and pathogenesis of these malignancies is thus a significant public health goal, and development of mechanism-based, nondeforming therapies is urgently needed. The high prevalence of skin tumors, their external location, and well-defined preneoplastic lesions (for SCC and melanoma) all provide an excellent opportunities for studying the factors regulating cutaneous cancer induction in humans. Qualities that facilitate the study of human skin cancers have also been useful in establishing relevant animal models. Advances in molecular genetics, keratinocyte cell culture, and development of genetically altered mice and reconstructed human skin models have greatly facilitated the analysis of basic mechanisms of cutaneous carcinogenesis. The main focus in this chapter is on general aspects of cutaneous carcinogenesis using nonmelanoma skin cancers as illustrative examples, with more detailed discussion of specific cutaneous malignancies presented in other chapters.

CUTANEOUS CARCINOGENESIS

GENERAL PRINCIPLES

The majority of malignant tumors arise through a stepwise process marked by characteristic phenotypic changes that reflect the acquisition of multiple genetic and epigenetic alterations needed to drive tumorigenesis from its inception through to invasion and metastasis. This basic tenet of cancer biology holds true for SCC (Fig. 19-1), but the pathogenesis of BCC provides a notable exception to this rule: precursor lesions have not been identified, metastases are extremely rare, and uncontrolled activation of a single oncogenic pathway may be sufficient for BCC tumorigenesis.[4] Established cancers exhibit fundamental alterations in behavior that distinguish them from the normal tissues in which they arise. These differences include a reduced requirement for growth stimuli, impaired responses to growth

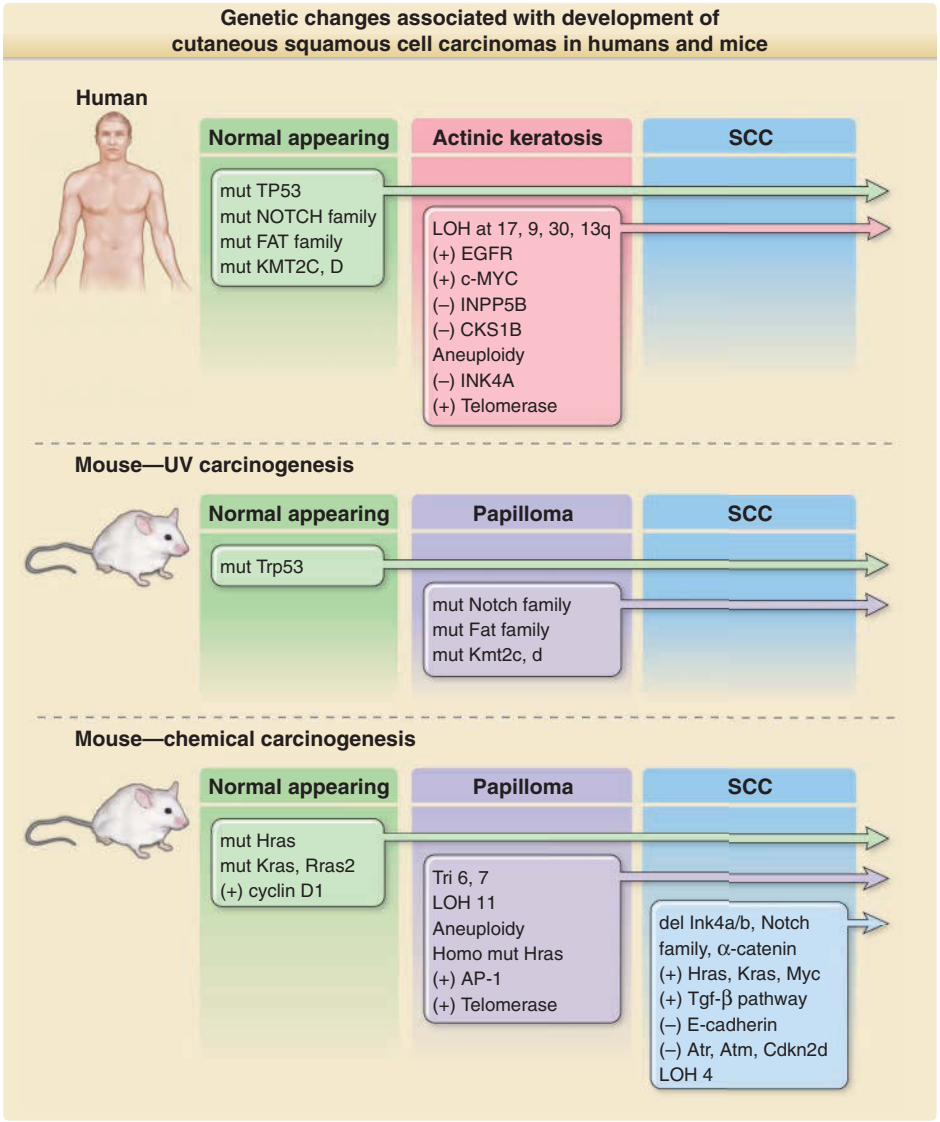

Figure 19-1 Molecular and genetic changes associated with development of cutaneous squamous cell carcinomas (SCCs) in humans and mice. The multistage evolution of cutaneous SCC in humans is depicted schematically with frequently associated genetic changes. Whereas single base mutations in early lesions frequently are characteristic of ultraviolet light-induced damage, later changes are associated with genomic instability. Increased activity of telomerase (deletion of inhibitor) or epidermal growth factor receptor (EGFR) tyrosine kinase (gene amplification) may also result from epigenetic changes. Similar changes are observed in ultraviolet (UV)-driven mouse models of cutaneous SCC.
In chemically induced mouse cutaneous SCC, the multistage evolution to invasive tumors in this model is highly ordered both temporally and genetically. Operationally defined stages include initiation, promotion, and progression. Ras mutations are characteristic of chemical mutagens used to initiate tumor formation. Early upregulation of cyclin D1 and later upregulation of transforming growth factor (TGF)-β1 occur through epigenetic mechanisms and appear to be important components of carcinogenesis. Note that most events occur early in the progression sequence in UV-induced tumors (eg, TP53 mutations), but in chemical carcinogenesis, most events occur late and often do not bear the signatures of the original mutagen. It should be noted that the data are derived from many different sources and reflect a panoply of technologies used to survey these changes.

inhibitory and differentiation signals, alterations in apoptosis, delayed or blocked senescence, angiogenesis, the capacity for invasion and metastasis, metabolic reprogramming, and the ability to evade elimination by the immune system[5] (Fig. 19-2). Although one or more of these abnormalities can be detected at different stages of tumor progression and may thus be seen in premalignant lesions, all are typically present in advanced cancers.

A driving force underlying neoplastic progression is defective DNA repair,[6] which enables the accumulation of mutations involving oncogenes and tumor suppressor genes that contribute to the observed aberrations in tumor cell function. In the past, uncovering the molecular basis of cancers relied on genetic linkage studies to identify the chromosomal locus which segregates with tumor phenotypes in cancer susceptibility syndromes or the use functional screens

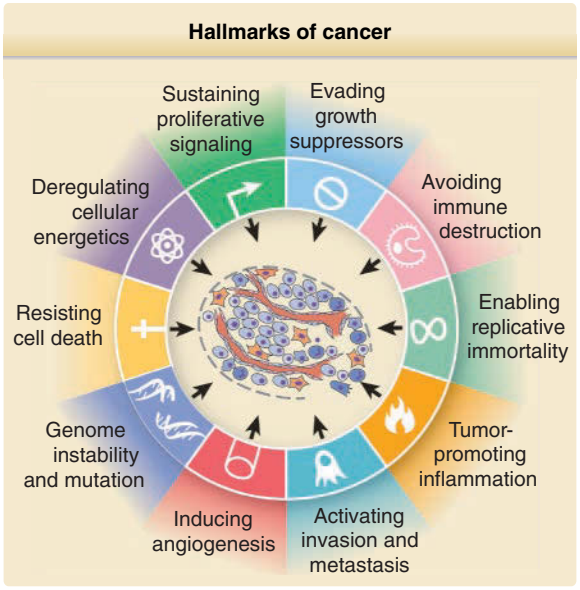

Figure 19-2 Hallmarks of cancer. Cancer cells acquire multiple properties distinguishing them from normal cells, including protection from cell death, sustained proliferation, evasion of growth inhibitory signals, the ability to invade and metastasize, immortalization, and induction of angiogenesis. More recently recognized properties important for tumorigenesis include deregulation of cellular energetics, immune evasion, genomic instability, and stimulation of inflammation. (Modified from Hanahan D, Weinberg RA. Hallmarks of cancer: the next generation. *Cell*. 2011;144(5):646-674.)

to identify genes from tumor cells that can drive neoplastic transformation in culture. However, the recent development of rapid and affordable next-generation sequencing technology, which can be used to screen for mutations in the coding portions of genes (exome sequencing) or the entire genome, has revolutionized the approach to identifying mutations that may drive cancer and serve as targets for therapeutic intervention through "personalized oncology."[7] Although some changes in cell function are cell-autonomous and can be studied in purified populations of tumor cells, others depend on various additional cell types in the tumor microenvironment that participate in the development and progression of cancer in intact organisms, including inflammatory cells, cancer-associated fibroblasts, nerves, blood vessels and lymphatics, and other components of tumor stroma.[8]

Many tumors exhibit intratumor heterogeneity,[9] which may be apparent at multiple levels. Molecular heterogeneity provides a driving force for neoplastic progression, selecting for outgrowth of cells that have acquired mutations conferring a proliferative or survival advantage and the ability to invade and metastasize. Biochemical heterogeneity occurs when subsets of tumor cells exhibit distinct oncogenic signaling properties and behavior, driven by regional differences in secreted growth factors or other microenvironmental factors.

Perhaps the most striking example of heterogeneity is the presence of a small subset of stem cell–like tumor cells, called *cancer stem cells*, in at least some tumor types. According to the cancer stem cell hypothesis, tumors contain a small number of self-renewing stem cells that produce transient-amplifying and differentiating progeny that constitute the overwhelming majority of cells in a tumor (reviewed by Nassar and coworkers[10]) (Fig. 19-3), reflecting the hierarchical organization of cell lineages in normal tissues. Cancer stem cells are also called *tumor-initiating cells* because they are functionally defined by their ability, when purified

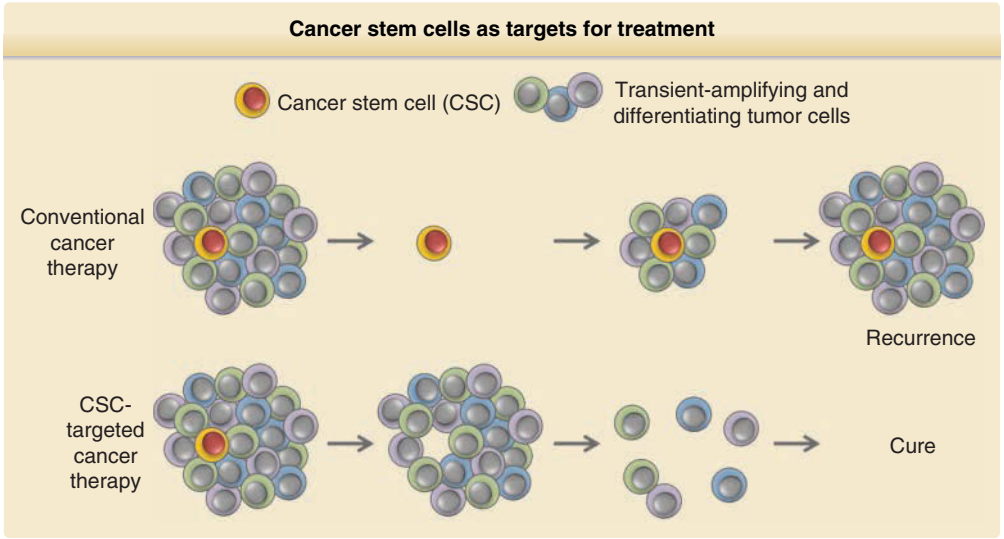

Figure 19-3 Cancer stem cells as targets for treatment. Representation of tumor mass containing a putative cancer stem cell (CSC) with its transient-amplifying and differentiating progeny that make up the bulk of the tumor. Treatment with conventional therapy may lead to rapid tumor regression, but if residual CSCs are present, tumors may recur after treatment is stopped. In contrast, CSC-targeted therapy may lead to a slower response, but after tumor cells regress, recurrence is unlikely if the CSC population has been eliminated. A hierarchical organization of CSCs and transiently amplifying progeny has been described in many, but not all, tumor types.

and tested in small numbers or even as single cells, to reform a tumor in cell transplantation experiments. Tumor cells that are not cancer stem cells, in contrast, fail to produce tumors even when tested in relatively large numbers.[10] This functional characterization generally requires that cancer stem cells possess a unique marker profile that enables them to be isolated from a heterogeneous population of tumor cells. Although the cancer stem cell concept was initially established in work centered on acute myeloid leukemia,[11] results of many subsequent studies support the existence of a hierarchical organization of tumor-initiating cells and progeny in many, but not all, solid tumors. Cancer stem cell populations have been described in SCC (reviewed by Nassar and coworkers[10]) and BCC.[12]

The cancer stem cell concept has important clinical implications because therapies that effectively kill cancer stem cells may lead to cures by eliminating the key cell population from which all remaining cells in a tumor arise. In contrast, treatments that target non–stem cells representing most of a tumor's mass may lead to striking tumor regression, but this is eventually followed by tumor recurrence because of outgrowth from remaining cancer stem cells (see Fig. 19-3). Although there are technical limitations to some of the assays used to ascertain "stemness" of isolated cancer cells, the cancer stem cell concept has been validated in multiple mouse models, and selective targeting of cancer stem cells is being pursued in an attempt to treat cancer more effectively.[13] The success of this approach will depend in part on whether transient-amplifying or differentiating tumor cells possess sufficient plasticity to revert back to a stem cell–like population after effective depletion of the original cancer stem cell pool.

An additional general property of cancers is intertumor heterogeneity. This includes phenotypic differences between tumors of the same type that are not necessarily related to malignant progression but are sufficient to justify classification into distinct morphologic categories, for example, superficial, nodular, and morpheaform subtypes of BCC. One explanation for intertumor heterogeneity is based on the notion that transformation of different cell populations produces different tumor subtypes, so a tumor's cell of origin is a key determinant of its ultimate phenotype. For example, mouse modeling suggests that oncogenic activation of the Hedgehog pathway in an epidermal basal cell may produce superficial BCC, but nodular BCCs may arise from responsive cell populations within hair follicle epithelium.[14] Experimental evidence from other tumor types supports the concept that different cells of origin give rise to distinct tumor subtypes.[15] Another example of intertumor heterogeneity is the disparate growth rates of histologically similar tumor types. This can be strikingly apparent in BCC patients, for example, in whom some nodular tumors are indolent but others grow at a much faster rate. Intertumor heterogeneity in this setting could be explained by intrinsic (genetic, epigenetic, or signaling) or extrinsic (microenvironmental) alterations that provide a growth or survival advantage to some tumors but not others.

GENETICS OF SKIN CANCER

GENERAL CONCEPTS

Studies on the molecular basis of cancer development have revealed two main classes of genes, oncogenes and tumor suppressor genes, that play a key role in the pathogenesis of cancer. An oncogene is any gene that can transform normal cells in culture and induce cancer in animals. Most oncogenes are derived from proto-oncogenes, which generally encode proteins that function as critical positive regulators of cell proliferation or inhibitors of apoptosis. Conversion to an oncogene can occur through point mutations resulting in a constitutively active protein, through DNA amplification, or through chromosomal translocations that link a highly active promoter with the proto-oncogene. The latter two mechanisms cause increased or inappropriate expression of a proto-oncogene and may alter growth regulation of a responsive normal cell. Less common mechanisms implicated in cancer entail fusion of the coding domains of two genes, producing a novel, chimeric molecule with oncogenic properties[16] or mutations in non-coding DNA that control the expression of oncogenes.[17]

Tumor suppressor genes normally function to negatively regulate cell proliferation, cause apoptosis, repair damaged DNA, or induce cellular differentiation. In contrast to oncogenes, which typically require that only one allele undergo activation via mutation, both alleles of a tumor suppressor gene must be inactivated to promote tumor development. Frequently, inactivating point mutations occur in one copy of a tumor suppressor gene, and the remaining normal copy is lost through a process of chromosomal missegregation during mitosis that leads to loss of heterozygosity. However, mutations in noncoding DNA[17] could also lead to functionally significant reductions in expression of tumor suppressor genes. In addition, altered expression of long noncoding RNAs could influence tumorigenesis by affecting signaling pathways at multiple levels.[18]

Which oncogenes and tumor suppressors contribute to development of cutaneous neoplasms? Considerable insight into the genetic basis of sporadic skin cancers has come from the identification of specific genes that underlie hereditary skin tumor syndromes.[19] The importance of DNA as a target for carcinogenesis was strongly supported by the discovery of defects in DNA repair genes in skin cancer–prone patients with xeroderma pigmentosum (see later) and several other dermatoses characterized by photosensitivity.[20] Moreover, a detailed genomic analysis of 500 metastatic tumors from various primary cancers has uncovered unanticipated germline mutations in 12.2% of cases, with 75% of them affecting DNA repair genes.[21] Taken together, these findings underscore the importance of robust DNA repair mechanisms for preventing accumulation of mutations that drive cancer development and progression.

MOLECULAR BASIS OF BASAL CELL CARCINOMA

Patients with nevoid BCC syndrome (NBCCS) are at a markedly increased risk for developing BCCs, which arise at a younger age and appear in greater numbers than in the general population. Patients with NBCCS are also predisposed to the development of a pediatric brain tumor arising in the cerebellum, medulloblastoma, as well as a variety of other defects throughout the body, including bifid ribs, calcified falx cerebri, odontogenic keratocysts, frontal bossing, palmar pits, and bifid ribs.[22] Some of these structural abnormalities must have taken place during fetal development, suggesting that the genetic alteration in NBCCS influences tissue or organ formation during embryogenesis, as well as cancer development after birth. The discovery that NBCCS is caused by germline mutations disrupting the *PTCH1* gene,[23,24] which encodes a key component of the Hedgehog signaling pathway, is in keeping with this idea. Physiologic Hedgehog signaling plays an important role in patterning and morphogenesis of various organs and tissues during development and contributes to tissue homeostasis and regeneration postnatally; in contrast, uncontrolled activation of the Hedgehog pathway (Fig. 114-1), caused by mutations affecting *PTCH1* or other Hedgehog pathway components (Table 114-1), is tightly associated with BCC development both in NBCCS patients and the general population[25-27] (see Chap. 111). Because deregulated activation of the Hedgehog pathway is detected in essentially all BCCs and pathway activation has been shown to be sufficient for BCC development and required for tumor maintenance, it was believed that pharmacologic inhibitors of this pathway may be useful in the medical management of BCC. This has proven to be the case in a significant proportion of patients with advanced or metastatic BCC treated with Hedgehog pathway inhibitors, as discussed later and in Chap. 111.

Despite the pivotal role of deregulated Hedgehog signaling in BCC development, next-generation sequencing studies have uncovered additional potential driver mutations in genes encoding MYCN, PPP6C, STK19, LATS1, PIK3CA, RAS proteins, with loss-of-function mutations and missense mutations in *PTPN14, RB1*, and *FBXW7*.[28] Additional studies will be needed to determine the functional significance of these genetic alterations and others[27] on BCC biology and treatment response.

MUTATIONS AND MOLECULAR DRIVERS IN SQUAMOUS CELL CARCINOMA

In contrast to BCC, the identification of pivotal genetic events that drive the development of cutaneous SCC has been somewhat complicated by the fact that no inherited cancer syndromes exclusively predispose to cutaneous SCC, and there is no high-frequency oncogenic driver analogous to mutant *BRAF* in melanoma. As a result, the key evidence implicating specific genetic alterations in SCC development has been pieced together through characterization of high-risk clinical scenarios, molecular analysis of animal models, genomics, and proteomics.

Three rare inherited syndromes have highlighted the importance of environmental influences, specific clinical scenarios, and pathways that drive SCC development. Xeroderma pigmentosum, characterized by extreme photosensitivity and stark acceleration in the onset of skin cancer, is associated with a nearly 10,000-fold increased risk of skin cancer before the age of 20 years.[29] The key unifying defect, caused by recessive inactivation of genes distributed across eight complementation groups, results in the lack of nucleotide excision repair, which is required for removing mutagenic DNA photoproducts caused by ultraviolet (UV) radiation. Recessive dystrophic epidermolysis bullosa is a skin fragility disorder caused by loss-of-function mutations in *COL7A1*, which results in subepidermal blistering, nonhealing wounds, and a high predisposition to SCC. The chronic scarring that results predisposes to SCC, which are clinically difficult to manage and frequently fatal.[30] Finally, heterozygous germline inactivation of transforming growth factor (TGF)-βR1 results in a susceptibility to keratoacanthomas as part of Smith-Ferguson syndrome[31] and indeed, inactivation of TGF-βR signaling more globally is associated with typical SCC development.[32] Additional genodermatoses and genes linked to SCC development are listed in Table 112-1.

By using the two-stage chemical carcinogenesis approach in mice (see later), Balmain and colleagues pioneered the molecular genetic analysis of tumor development in this classical skin cancer model and identified mutated *Hras* as the primary oncogenic driver of tumors in this model[33] 1 year after its isolation as the first human oncogene.[34] By 1991, recurrent *TP53* mutations had been identified in human SCC corresponding to hotspot sites in the DNA-binding domain and bearing characteristic C → T transitions attributed to UV exposure.[35,36]

Next-generation DNA sequencing has now provided extensive insight into the genetic lesions that may drive cutaneous SCC development. Although many of these reports are from primary tumors, some series of metastatic lesions has been reported now as well.[37-41] The mutational spectrum across the exome is, as expected, strongly dominated by C → T transitions and UV signature mutations and is overwhelmingly represented by the inactivation of tumor suppressor genes, with very few highly recurrent mutations. Taken across published exome and targeted sequencing efforts, the most frequently mutated tumor suppressor genes are *TP53*, *CDKN2A*, *NOTCH* family members, atypical cadherin *FAT* family members, the histone methyltransferases *KMT2C* and *KMT2D*, and *KNSTRN*.[37-42] The panoply of sample sources, sequencing methodologies and analysis pipelines makes direct comparisons difficult, but additional potential tumor suppressors include *CASP8*, *CREBBP*, and *CARD11*.[43] Mutant *HRAS* is observed in

up to 20% of SCC in one series.[38] Amplifications in *MYC* and *EGFR* as well as loss of *CKS1B* and *INPP*5A have also been reported in cutaneous SCC.[44-47]

Importantly, these data also show striking similarities to SCC arising in other sites. Because stratified squamous epithelia form interfaces with the environment, these tissues are frequent sites of interaction with carcinogens. *TP53* mutations occur at more than 70% frequency across all SCCs; *NOTCH* family genes are mutated in more than 70% of cutaneous SCC (cuSCC), 20% of oral head and neck SCC (HNSCC), 13% of lung SCC, and 10% of esophageal SCC, and SOX2 amplification is a common lineage-specific driver of SCC.[48] Coupled with previous results, this shows that SCCs from diverse sites share deep molecular commonalities, including alterations in global gene expression and in *TP53*, *TP63*, *NOTCH* family, and *SOX2* signaling. There is less published transcriptomic and proteomic data, although the correspondence to carcinogen-induced SCC holds prominently for HNSCC and lung SCC. Transcriptional profiling implicates transcription factors downstream of wingless-related integration site (WNT), β-catenin, and ERK (extracellular signal-regulated kinase) signaling.[37,48] Emerging literature also implicates multiple microRNAs in the development of SCC (reviewed by Konicke and coworkers[49]). Several have been implicated in multiple contexts with tumor-promoting and tumor-suppressive functions in proliferation, apoptosis, and migration.

Reverse-phase protein array-based interrogation of canonical cancer pathways showed upregulation of ERK and mTOR (mammalian target of rapamycin) pathway signaling across the progression sequence of SCC development.[50] The importance of ERK pathway signaling has also been reflected in two clinical scenarios involving drug-induced SCC: BRAF (v-raf murine sarcoma viral oncogene homolog B) inhibition used for melanoma and smoothened (SMO) inhibition used for BCC. It was observed in the initial clinical trials with the first Food and Drug Administration–approved BRAF inhibitor, vemurafenib, that approximately 22% of treated melanoma patients developed SCC or keratoacanthoma-like lesions; this adverse effect is less frequently observed with the more potent BRAF inhibitors dabrafenib and encorafenib.[51] Mechanistically, this has been attributed to both paradoxical ERK signaling resulting from the aberrant drug-induced hyperactivation of MEK (mitogen activated protein/extracellular signal-related kinase kinase)/ERK signaling in the context of wild-type *BRAF*,[52,53] often in the context of oncogenic mutant *HRAS*,[54] and to the suppression of apoptosis that occurs as a result of off-target suppression of c-Jun-N-terminal kinase (JNK) signaling.[55] Accordingly, the concomitant use of MEK with BRAF inhibitors almost completely suppresses the emergence of these SCCs.[51] Interestingly, the long-term treatment of BCCs with the SMO inhibitor vismodegib has occasionally been associated with the evolution of treated tumors to a SCC morphology that is associated with drug resistance and activation of ERK signaling.[56,57] Collectively, these data strongly implicate ERK signaling as an important pathway in SCC. This has also been validated in a UV-driven preclinical model in which MEK inhibition has potent therapeutic and chemopreventative effects.[58]

ETIOLOGY OF HUMAN SKIN CANCER

PHOTOCARCINOGENESIS

Ultraviolet radiation (UVR) in sunlight is the primary etiologic agent for all skin cancers, and thus UVR is the major carcinogen in the human environment. The powerful carcinogenic activity of UVR is attributable to its ability to damage DNA and cause mutations, its capacity to clonally expand incipient neoplastic cells whose altered signaling pathways provide a survival advantage in the face of UV-induced cytotoxicity, its ability to induce reactive oxygen species (ROS), and its activity as an immune suppressant. The association of UVR with skin cancer is so strongly supported by clinical, epidemiologic, and experimental data that it represents perhaps the most clear-cut etiologic factor in human malignancy.

UV light is a complete carcinogen and chronic exposure alone is sufficient to induce skin cancers. The process begins with carcinogen exposure, DNA damage, and the progressive acquisition of mutations. Clonal expansion occurs at least partially because of selection for these mutations, increasing the target size for further damage. The combination of these changes with key microenvironmental and immunologic consequences of UV exposure collectively drive tumor development.[59] In addition to environmental or occupational exposures, patients with various dermatoses are treated with UVR. The vast majority of experience in assessing the resulting risk for skin cancer has been in the context of psoriasis phototherapy. This risk was best established for psoralen and ultraviolet A light (PUVA) therapy in a prospective study with 20 years of follow-up initiated by Stern and colleagues, in which the risk of SCC was more than 100-fold higher and the risk of BCC was more than 11-fold higher.[60] The data on narrowband UVB has been largely confined to retrospective analyses, which suggest that there is no elevated risk of skin cancer; however, these studies are additionally limited by shorter follow-up.

ULTRAVIOLET RADIATION-INDUCED DNA DAMAGE AND REPAIR

DNA Photoproducts: The first molecular step in sunlight-induced carcinogenesis occurs when UVB photons induce DNA photoproducts (see Fig. 19-4). UVB and UVC tend to be absorbed at the 5–6 double bond of pyrimidines (thymine and cytosine). If two adjacent pyrimidines are activated, the resulting open bonds cross-react, creating a cyclobutane pyrimidine dimer (CPD). The most frequent is TT, but TC, CT, and CC cyclobutane dimers are also made. A single bond between the 6 position of one pyrimidine and the

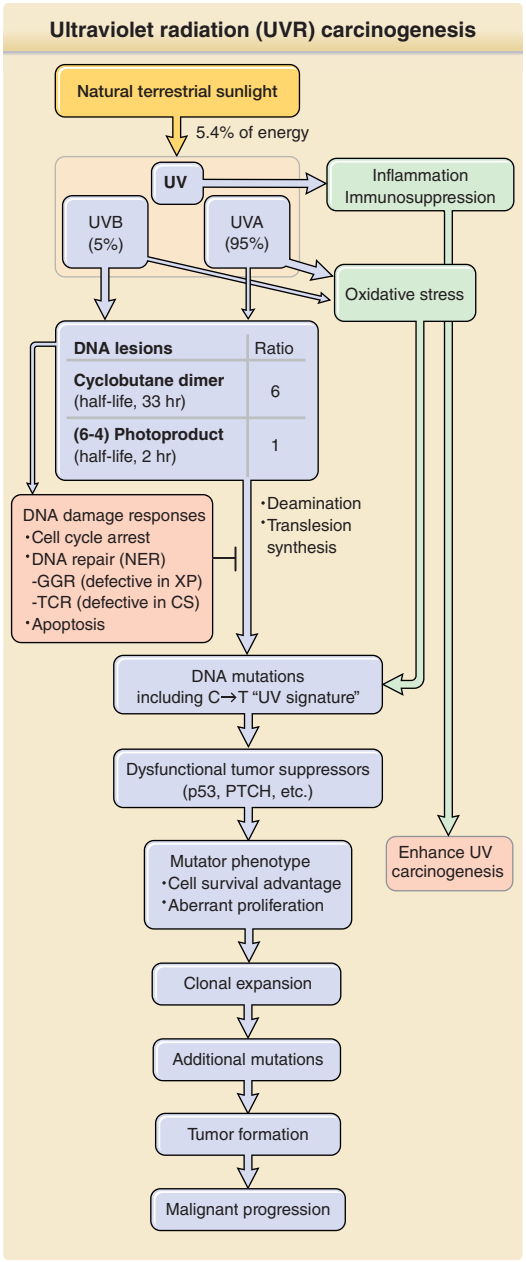

Figure 19-4 Ultraviolet radiation (UVR) carcinogenesis. UVR induces two major DNA lesions at dipyrimidine sites: cyclobutane pyrimidine dimers (CPDs) and pyrimidine (6–4) pyrimidone photoproducts [(6–4)PPs]. Ratio given [6 CPDs per 1 (6–4)PP] is that induced by simulated sunlight. UVB accounts for only 5% of UVR (~0.3% of all terrestrial sunlight energy) but produces the majority of UV-induced DNA lesions. Cells respond to UVR-induced DNA damage by activating DNA damage signaling pathways and inducing cell cycle arrest. Damaged DNA is repaired by nucleotide excision repair (NER). Unrepaired DNA lesions lead to genetic mutations through deamination or error-prone translesion synthesis. Unrepaired cytosine-containing CPDs contribute to UV signature mutation: C→T transition. Mutations in genes responsible for carcinogenesis confer a mutator phenotype including resistance to apoptosis. This expands the pool of clones susceptible to further damage and increases the potential for transformation. CS, Cockayne syndrome; GGR, global genome repair; PTCH, PATCHED1; TCR, transcription coupled repair; XP, xeroderma pigmentosum.

exocyclic group of the other instead creates a pyrimidine (6–4) pyrimidone photoproduct [(6–4)PP][61] most frequently TC. Both photoproducts distort the DNA helix and are recognized by DNA repair enzymes. Although there is 20-fold more UVA than UVB in sunlight, UVA requires up to 1000-fold greater doses for some of its biological effects such as DNA damage and minimal erythemal doses at 300 nm (UVB) and at 360 nm (UVA) for skin type II are 25 mJ/cm^2 and 32,000 mJ/cm^2, respectively.[62] UVB induces 500 photolesions per 10^6 normal bases per J/cm^2 in human skin.[63]

Ultraviolet Radiation—Induced Mutations:

A CPD can lead to a mutation in two ways (Fig. 19-5). When the lesion is copied during DNA replication, the DNA polymerase may read a damaged cytosine as a thymine and insert an adenine opposite it. At the next round of replication, the polymerase correctly inserts thymine across from adenine, resulting in a C → T substitution. Alternatively, CPDs accelerate spontaneous deamination of their cytosines to uracil, resulting in the same change. Although the TT CPD is the most common photoproduct, the addition of A across damaged T bases by DNA polymerase eta causes no mutations. If two adjacent cytosines mutate, the result is CC → TT. This distinctive pattern of mutation, C → T in which the C lies next to another pyrimidine, including CC → TT, is unique to UVR and is called the *UV signature mutation*.[64]

Signature mutations provide a tool for deducing the original carcinogen from mutations found in tumors.[64,65] Nearly all experimentally created UVB or UVC mutations are located at adjacent pyrimidines, and about two thirds are signature mutations. The remaining third, typically G → T and T → C substitutions or small insertions or deletions, are caused by UV but probably arise indirectly by ROS. G → T transversion can be caused by incorporation of adenine opposite 8-hydroxy-2′-deoxyguanosine (see Fig. 19-5), a common oxidative DNA lesion. Because this oxidative class of damage can be caused by many carcinogens, these mutations do not reveal whether their source was UVB, UVA, tobacco smoke, or intracellular oxidative phosphorylation. However, tumors carrying classic UV signature mutations must also contain UV-induced oxidative mutations. UVA weakly induces UVB signature mutations by photosensitization but generates oxidation-like mutations and T → G changes, which have been proposed to be a UVA fingerprint.[61]

Recently, a chemically distinct pathway of UV-induced CPD generation was discovered.[66] In this mechanism, UV-induced generation of the ROS peroxynitrite was found to interact with melanin, resulting in chemiexcitation of electrons in melanin to extremely high-energy states, analogous to reactions that culminate in bioluminescence. However, instead of generating light, these excited electrons can directly interact with DNA, resulting in continuous CPD formation hours after UVA or UVB exposure has ceased, so-called "dark CPDs." Importantly, these dark CPDs account for more than half of CPDs in melanocytes after UV exposure. This discovery suggests that any

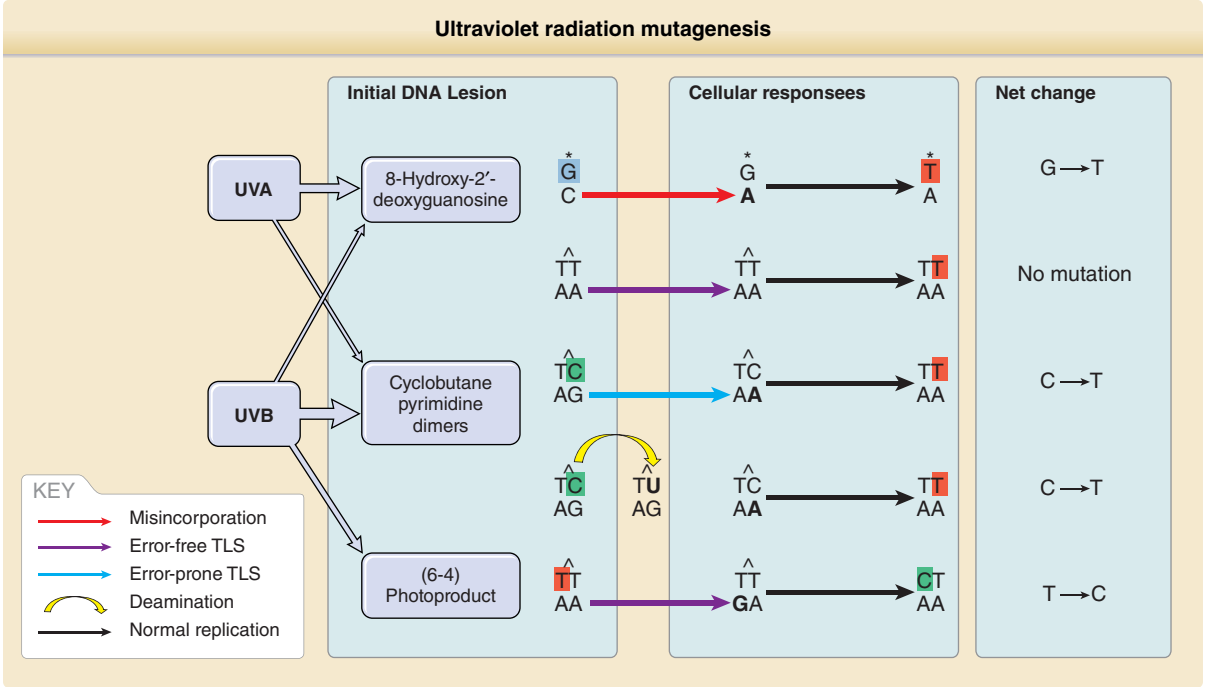

Figure 19-5 Ultraviolet radiation mutagenesis: how replication through unrepaired DNA lesions leads to DNA mutation. Cyclobutane pyrimidine dimers (CPDs) are the most relevant for ultraviolet (UV) mutagenesis and are primarily induced by UVB. Error-free translesion synthesis (TLS) adds adenines opposite CPDs, leaving thymine dimers unaffected but causing UV signature C→T transitions in cytosine dimers, which may also result from deamination. The (6–4) photoproduct induced by UVB and 8-hydroxy-2′-deoxyguanosine primarily induced by UVA are mutagenic but relatively rare.

source of ROS can potentially generate CPDs and that the kinetics of CPD generation by this mechanism may offer an opportunity for novel chemoprevention strategies beyond blocking UV exposure.[66]

MUTATION BURDEN AND CLONAL DYNAMICS IN SKIN

The repeated exposure of skin to UVR over a lifetime represents an enormous collective DNA damage burden. Indeed, initial reports dating back to 1996 showed that clones of keratinocytes aberrantly expressing stable (and therefore likely mutated) p53 could be detected in whole-mounted skin.[67,68] These *TP53*-mutant clones have also been identified in UV-exposed mouse skin.

Recently, targeted and whole-exome sequencing have shown that chronically UV-exposed clinically and histologically normal-appearing epidermis harbors about five mutations per megabase of DNA[37,69] (Fig. 19-6), a remarkably high mutational load that exceeds that of many human cancers. Indeed, skin cancers have the highest mutational loads of any human cancer reported with the possible exception of mismatch repair-deficient colon carcinomas. To be identified at all by existing DNA sequencing methodologies, there must be clones of cells bearing identical mutations of sufficient quantity to be reliably detectable at a given sequencing depth. Therefore, the extent of UV-induced mosaicism in epidermis is likely to be even greater than reported.

Although the presence of clones is interpreted as evidence of positive selection for specific mutations,[69] the frequency distribution of clone sizes suggests that clones can also spontaneously arise without the need for such selection.[70] In the case of *TP53*, it is clear that although *TP53* mutations compromise apoptosis, continued UV exposure is necessary for a selective advantage for these mutations to manifest themselves in the form of expanding clones, presumably through the inhibition or killing of surrounding normal keratinocytes. Deep sequencing of *TP53*-mutant clones in archival samples of UV-exposed human skin showed that many subclonal mutations in genes associated with SCCs are present, suggesting the widespread existence of keratinocyte patches highly predisposed to transformation.[71]

EVOLUTION OF ACTINIC KERATOSES TO SQUAMOUS CELL CARCINOMA

Estimates of the rate of progression of AK to SCC range from 0.6% at 1 year to 2.6% in 4 years.[72] At the genomic level, many of the key mutated genes observed in SCC and irradiated skin are also found in AK.[37,71] There have been no consistently identified transcriptional differences between AK and SCC. Instead, the molecular profiles of most AKs are largely indistinguishable from those of well-differentiated invasive SCC, suggesting that chemoprevention targeted to heavily mutagenized UV-exposed skin may be more effective.

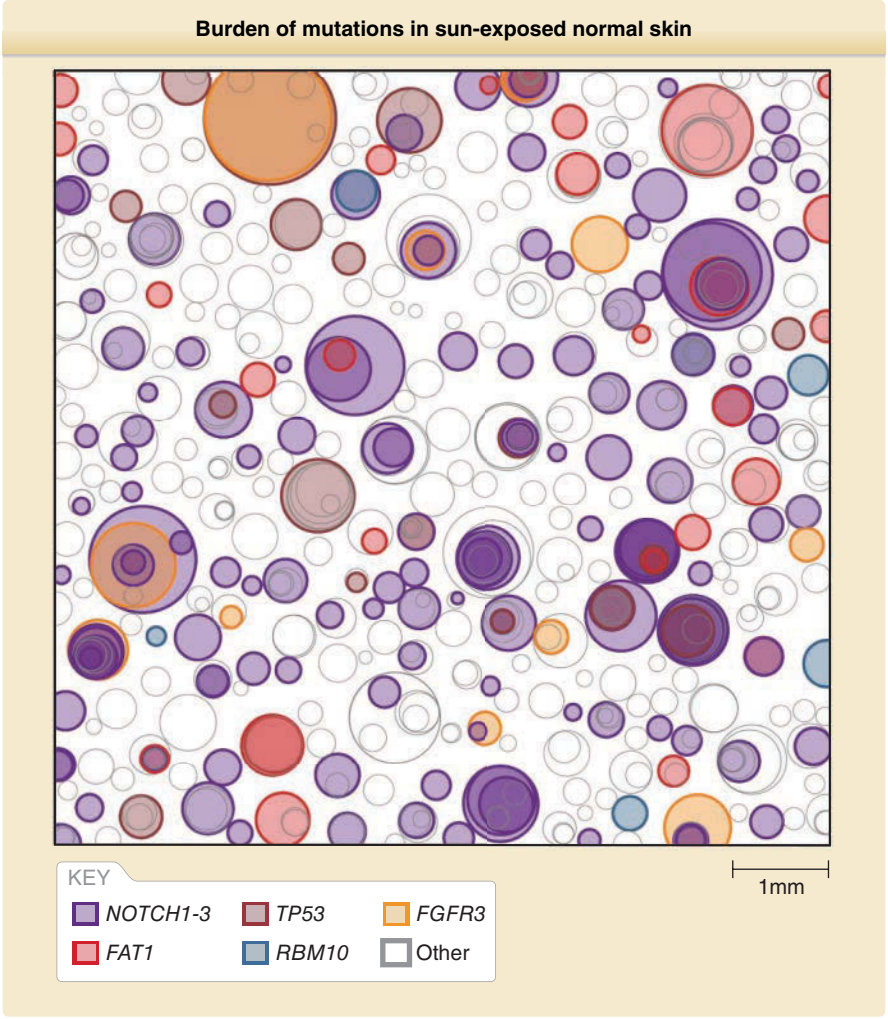

Figure 19-6 Graphical representation of mutant clone sizes in normal skin linked to specific genes implicated in SCC development. The plot represents estimated physical sizes of clones of epidermal cells based on the proportion of DNA sequences bearing a recurrent mutation and knowledge of skin biopsy sizes. Hundreds of clones bearing recurrently mutated cancer-relevant genes are found within a 1-cm^2 patch of epidermis. Some mutations are inferred to represent subclones within larger clones (overlapping circles); however, bulk sequencing precludes definitive spatial mapping. (Adapted from Martincorena I, Roshan A, Gerstung M, et al. Tumor evolution. High burden and pervasive positive selection of somatic mutations in normal human skin. *Science*. 2015;348(6237):880-886.[69] Reprinted with permission from AAAS.)

VIRAL CARCINOGENESIS

GENERAL FEATURES

Virus-associated cancers comprise up to 10% of all human malignancies, including several that arise in skin: Kaposi sarcoma; SCC (arising in epidermodysplasia verruciformis patients and a small fraction of immunosuppressed individuals); and Merkel cell carcinoma[73] (see Table 19-1). DNA viruses have evolved highly effective mechanisms, in permissive host cells, for replicating their genomes, synthesizing capsid proteins, and assembling infectious viral particles during their normal, vegetative life cycles. Because of their small size, viruses cannot produce the full complement of proteins needed for DNA replication; instead, viral "early proteins" needed during early stages of the viral life cycle hijack the host cell cycle machinery to replicate the viral genome. After primary infection, most viruses are kept in check by the host immune system with minimal evidence of productive infection. Immunosuppression can lead to viral reactivation and disease, which may reflect lysis of host cells that accumulate large numbers of viral particles.

Viral infection typically precedes cancer development by many years, and only a small subset of infected individuals develop cancer, frequently in the setting of systemic immunosuppression or impaired immune surveillance. Viral transformation is a dead end for viruses because it is usually associated with integration of viral DNA into the host cell genome in a manner that precludes viral genome replication and completion of the viral life cycle but allows for persistent expression of early viral proteins that drive cellular transformation by targeting key host cell signaling

TABLE 19-1
Virus-Induced Human Skin Tumors

VIRUS	VIRUS TYPE	SIZE	GENOME	TRANSMISSION	SKIN TUMOR TYPE (S)	OTHER TUMORS
HPV (high-risk alpha subtypes)[a]	Papillomavirus	55 nm	dsDNA (~8 kb)	Sexual contact	SCC (anogenital)	Cervical, head, and neck
KSHV (HHV8)	Herpes virus	180-200 nm	dsDNA (~165 kb)	Body fluids, tissue	Kaposi sarcoma	Primary effusion lymphoma, multicentric Castleman disease
MCPyV	Polyomavirus	45 nm	dsDNA (5.3 kb)	?	MCC	?

[a]See text for discussion of beta human papillomavirus (HPV) and cutaneous squamous cell carcinoma (SCC).
dsDNA, double-stranded DNA; HHV8, human herpesvirus-8; KSHV, Kaposi sarcoma–associated herpesvirus; MCC, Merkel cell carcinoma; MCPyV, Merkel cell polyomavirus.

proteins.[74] Thus, viral oncoproteins contribute to cancer by dysregulating many of the same proteins and pathways that are altered by exposure to UV light or other mutagens in sporadic cancers.

HUMAN PAPILLOMAVIRUSES

More than 200 types of human papillomaviruses (HPVs) have been identified and grouped into five genera, with the alpha and beta HPV types most closely linked to cancer.[75] Some alpha HPVs infect skin and cause warts, but others infect mucosal surfaces, with low-risk HPVs producing benign lesions (condylomata) and high-risk HPVs, typically HPV16 or 18, associated with malignancy (cervical cancer, most anorectal cancers, and a sizeable fraction of genital and oropharyngeal cancers). Infection by high-risk alpha HPVs is relatively common in young, sexually active individuals, but the infection is cleared via the immune system in most individuals. Beta HPVs have been linked to development of cutaneous warts and SCC in individuals with epidermodysplasia verruciformis and may play a role in the pathogenesis of cutaneous SCC in some chronically immunosuppressed individuals.[76] Nevertheless, unlike the alpha HPVs, there has been no evidence for viral transcripts in skin cancers,[37,77] indicating that beta HPVs are not required for tumor maintenance. A hit-and-run mechanism that posits a temporally and functionally restricted requirement for HPV gene transcription is still compatible with a causal role but is difficult to demonstrate definitively. The early genes E6 and E7 from high-risk alpha HPVs drive tumorigenesis by binding and degrading the tumor suppressors TP53 and RB1, respectively. In contrast, beta HPVs influence other oncogenic effectors and processes to drive cancer, leading to deficient double-strand DNA repair, impaired apoptosis, disrupted epithelial differentiation, and altered NOTCH and TGF-β signaling.[78]

HUMAN POLYOMAVIRUSES

Human polyomavirus (PyV) infections are ubiquitous. The great majority of adults harbor serologic evidence of infection by multiple human PyVs occurring at an early age followed by establishment of subclinical, persistent infection because of the presence of episomal viral DNA in the nucleus of the host cell.[79] Viral reactivation and productive infection, which requires viral genome replication and packaging into infectious virions, can occur in immunosuppressed individuals and cause clinically evident disease.[79] For example, BKPyV is associated with development of posttransplant nephropathy and hemorrhagic cystitis, and JCPyV causes progressive multifocal leukoencephalopathy.

Several PyVs have been isolated from human skin, and some are associated with distinctive skin disorders, including pruritic and dyskeratotic dermatoses (HPyV6 and HPyV7) and the hair follicle disorder trichodysplasia spinulosa (TSPyV).[80] In nearly all cases, these conditions arise in immunosuppressed hosts and are associated with productive infection, leading to accumulation of a large numbers of virions in affected cells. Merkel cell PyV (MCPyV) is also present in normal human skin but is not associated with any known skin disorders linked to productive viral infection. MCPyV is, however, detected in about 80% of Merkel cell carcinomas, which are rare but aggressive neuroendocrine malignancies that arise in skin (see Chap. 113). MCPyV viral DNA was found to be clonally integrated in MCCs,[81] strongly suggesting that this virus plays an important role at early stages of MCC development in virus-positive tumors.

Given the strong evidence pointing to a causal role for MCPyV in MCC, much effort has gone into investigating the transforming potential of the MCPyV early gene products large T and small T antigens (LTAg, sTAg). Historically, LTAg from a simian polyomavirus, SV40, has been used extensively to study fundamental aspects of cancer because of its potent ability to transform cells in cell culture and produce tumors in experimental animals.[82] The transforming properties of SV40 LTAg have been attributed largely to its ability to disrupt the functions of both TP53 and RB1, identifying these two tumor suppressors as key targets for viral oncogenesis. In contrast to LTAg, SV40 sTAg alone is not a potent oncogene, although it may contribute to LTAg-driven transformation. Intriguingly, the contribution of MCPyV TAgs to transformation appears reversed relative to that of SV40 in that sTAg appears to be the main oncogenic driver both in vitro

and in vivo.[83,84] Current studies in this area include work aimed at better defining the contributions of sTAg and LTAg to MCC development, identifying key TAg-driven changes in host cells and interacting proteins and pathways that contribute to tumorigenesis, and uncovering the MCC cell of origin.

CHEMICAL CARCINOGENESIS

Also implicated in the development of a relatively small proportion of human skin cancers are various chemicals, as a result of environmental, occupational, or medicinal exposures (Table 19-2). In 1775, Sir Percivall Pott[85] attributed the increased incidence of scrotal cancer in chimney sweeps to repeated exposure to soot. This report provided the first link between an occupational exposure and the development of cancer as well as the first example of chemical carcinogenesis. The National Toxicology Program's 14th Report on Carcinogens (http://ntp.niehs.nih.gov/go/roc14), released in 2016, lists 248 substances as either known (62 substances) or reasonably anticipated (186 substances) to be human carcinogens. Although most of these are chemicals, the list also includes physical agents (eg, ionizing and UVR) and infectious agents (eg, Kaposi sarcoma–associated herpesvirus and MCPyV), discussed earlier. Although not yet listed, the antifungal voriconazole has been linked to an increased incidence of SCCs in immunosuppressed patients.[86] Mechanisms by which chemicals cause cancer reveal striking similarities to those uncovered for UVR-induced cancer, including DNA damage, selective cytotoxicity, and immunosuppression.

OTHER CARCINOGENIC STIMULI

Ionizing radiation (IR) had been used to treat a variety of skin disorders, including acne and tinea capitus as well as malignant tumors. Interestingly the excess risk of skin cancer associated with IR exposure is almost exclusively confined to BCC and has been documented in atomic bomb survivors, radiologists, miners, and children treated for tinea capitis.[87] Childhood exposure has been associated with a significantly increased risk of BCC with a latency of over 20 years, particularly in fair-complected individuals, suggesting a strong interactions between UV and IR exposures.[88] Epidemiologically, pilots are highly exposed to cosmic IR, which is associated with a 3-fold elevated risk of BCC and 3.5-fold elevated risk of melanoma.[89]

Chronic wounds have long been recognized clinically as a risk factor for skin cancer, particularly SCC. Marjolin ulcers refer to skin cancers that arise in sites of chronic ulcers or scars, most often caused by burns[90]

TABLE 19-2
Agents Identified as Known Human Skin Carcinogens[a]

CLASS	AGENT	EXPOSURE	SKIN TUMOR TYPE(S)	OTHER TUMORS
Chemical	Arsenic	Contaminated drinking water, occupational, iatrogenic	Arsenical keratoses, SCC, BCC	Lung, digestive tract, liver, bladder, kidney, lymphatic, hematopoietic
Chemical	Azathioprine	Iatrogenic	SCC	Non-Hodgkin lymphoma, mesenchymal tumors, hepatobiliary carcinoma
Chemical	Coal tar, coal tar pitches	Occupational, iatrogenic	SCC	Lung, bladder, kidney, digestive tract, leukemia
Chemical	Coke-oven emissions	Occupational	not specified	Bladder, respiratory tract, kidney (possibly prostate, colon, and pancreas)
Chemical	Cyclosporine A	Iatrogenic	SCC	Lymphoma
Physical	Ionizing radiation	Iatrogenic, atomic bomb blast	SCC, BCC, (possibly melanoma, after childhood exposure)	Leukemia, thyroid, breast, lung, liver, salivary gland, stomach, colon, bladder, ovary, central nervous system, angiosarcoma (possibly lymphoma after childhood exposure)
Chemical	8-Methoxypsoralen	PUVA therapy	SCC, BCC, melanoma	None reported
Chemical	Mineral oils	Occupational	SCC	Gastrointestinal, sinonasal, bladder cancer (possibly lung, rectal, oral, and pharyngeal)
Chemical	Soots	Occupational	SCC	Lung, prostate, bladder, esophageal, lymphatic, hematopoietic (possibly liver)
Physical	Solar radiation; broad-spectrum UVR	Occupational (farmers, electric arc welders), recreational, indoor tanning	SCC, BCC, melanoma	None reported

[a]Information obtained primarily from the 14th Report on Carcinogens (2016), National Toxicology Program. Viral agents that cause human skin cancers are listed in Table 19-1.

BCC, basal cell carcinoma; PUVA, psoralen and ultraviolet A light; SCC, squamous cell carcinoma; UVR, ultraviolet radiation.

and most often occurring on the lower extremities and scalp. Several series detailing long-term follow-up conclude that more than 77% of these cancers are associated with burns, almost 90% of tumors are SCC, and the average interval from initial injury to tumor development was 37 years.[91,92] These SCCs are highly aggressive, resulting in nodal involvement in more than 30% of cases and distant metastases in more than 11%.[93]

ANIMAL MODELS OF HUMAN SKIN CANCER

GENETICALLY ENGINEERED MOUSE MODELS OF SKIN CANCER

SQUAMOUS CELL CARCINOMA MOUSE MODELS

Genetically engineered mouse models have enabled close focus on specific genetic events now known to be critical for SCC. Given the identification of activating *Hras* mutations in nearly all squamous papillomas and carcinomas arising during chemical carcinogenesis in mouse skin (see later), early transgenic mouse studies used oncogenic forms of *Hras* to establish the central role of sustained Hras-driven signaling in initiation and progression of squamous neoplasia. Expression of the *Hras* oncogene in skin led to development of either benign squamous papillomas or invasive SCC, depending on which cell populations were engineered to express the transgene. Only benign papillomas developed in mice with *Hras* expression targeted to interfollicular epidermis, and these required either wounding or treatment with a tumor promoter, but expression of the same oncogene in hair follicle epithelia that included stem cells led to spontaneous SCC development.[94,95] These types of studies established the utility of genetically engineered mouse models for studying the genetic and cellular basis of skin tumors.

With these initial models serving as a foundation, numerous subsequent studies explored the contribution of various other genes and pathways to squamous tumor development.[96-99] Skin-targeted expression of TGF-α or other growth factors or receptors that activate the Ras pathway also lead to squamous tumors. Expression of components of the cell cycle machinery, including E2F1, cyclin D1, and Cdk4, could also contribute to SCC development, progression, or both. Transgenic overexpression of protein kinase C (PKC) isozymes, which are key regulators of epidermal differentiation and other cellular processes, leads to development of squamous papillomas and carcinomas (PKC-α) or less differentiated SCCs that rapidly metastasized to regional lymph nodes (PKC-ε). Spontaneous or carcinogen-induced tumor formation in genetically modified mice has revealed genes and pathways that appear to be important in skin cancer induction but would not have been apparent from hereditary cancer syndromes or analysis of human skin cancers. Targeting of *Myc* to differentiating cells in transgenic mice permits proliferation in this normally postmitotic compartment and produces an actinic keratosis–like phenotype, and basal cell targeting of *Myc* using a Keratin 5 promoter yields spontaneous tumors. Mice carrying a deletion in *c-fos* developed *v-ras*^{Ha}–driven papillomas, but malignant progression to SCC was blocked. Multiple additional molecules and pathways have been implicated in SCC development through transgenic mouse modeling or recombinant human skin studies, including Smad2, Smad4, Stat3, PKC delta, PKC eta, Rac1, Pak1, Atf3, Sos, mTOR, TGF-β, Akt, Src, Fyn, and NF-κB (nuclear factor kappa B).[96-100]

The simultaneous inactivation of *Rb1* and *Trp53* in epidermis is sufficient to induce SCC in mice,[101] consistent with the ability of high-risk HPV E6 and E7 expression to cause SCC in skin.[102] Experiments using genetic ablation of the two most frequently mutated genes in SCC, *Notch1* and *Trp53*, have implicated important pathways in tumor suppression, differentiation, proliferation, and stromal interactions. Removal of *Trp53* in mice dramatically accelerates tumor induction in both chemical and UV carcinogenesis models.[96] Epidermis-specific removal of *Notch1* dramatically enhances carcinogenesis in the DMBA (7,12-dimethylbenz[a]-anthracene)/TPA (12-*O*-tetradecanoylphorbol-13-acetate) model resulting in both BCC and SCC induction.[103] When removed in mosaic fashion, it was subsequently shown that *Notch1* inactivation in skin resulted in non–cell-autonomous effects, resulting in an inflammatory woundlike phenotype, specifically acting in tumor promotion.[104] The most dramatic example of this was seen in mice lacking the *CSL* gene, a vital component of Notch signaling, solely in mesenchymal cells, including dermal fibroblasts. Remarkably, these mice spontaneously developed multifocal SCC without the need for any initiating or promoting agent,[105] demonstrating how simply disrupting Notch signaling between the mesenchyme and overlying epithelia is sufficient for tumorigenesis.

BASAL CELL CARCINOMA MOUSE MODELS

The discovery of *PTCH1* mutations in NBCCS patients and either *PTCH1* or *SMO* mutations in sporadic BCCs set the stage for studies directly testing the involvement of the Hedgehog pathway in BCC tumorigenesis. Skin-targeted mouse models developed to either express Hedgehog signaling activators (SHH, SMO, GLI1, GLI2), or delete Hedgehog signaling repressors (PTCH1, SUFU) reliably produce BCCs or BCC-like tumors in genetically engineered mice (reviewed in [4,106]) (see Chap. 111). In addition to providing in vivo evidence strongly supporting a central role for deregulated Hedgehog signaling in BCC development, these models have yielded valuable insights into the requirement for sustained Hedgehog signaling in tumor maintenance; established the importance of tissue and cellular

context, as well as Hedgehog signaling levels, during BCC tumorigenesis; uncovered functionally significant interactions with other signaling pathways; and have provided powerful models for preclinical studies.

Cellular Origins of Skin Cancer: Historically, the cell of origin of human skin tumors was inferred from histopathology and the phenotypic characteristics of tumor cells. The undifferentiated appearance of BCC tumor cells pointed to a potential origin from the epidermal basal layer or hair follicle outer root sheath. In addition, the resemblance of early-stage BCCs to embryonic hair germs and consistent expression of the outer root sheath marker keratin 17, coupled with the absence of typical BCCs on palmar and plantar skin that is devoid of pilosebaceous units, were taken as evidence supporting a hair follicle origin for BCC. SCCs, on the other hand, harbor cells that undergo terminal differentiation to form squames resembling cells in the cornified layer of epidermis, leading to the assertion that SCCs are more likely to be derived from epidermis than hair follicles. Although these observations provide a useful starting point, they assume that the phenotype of a tumor cell faithfully reflects the cell type from which it originated.

Experimental studies in mice have yielded insight into cell populations within skin that can give rise to nonmelanoma skin cancers. These studies are frequently performed by activating expression of a putative oncogene or deleting a tumor suppressor gene in specific cell populations and assessing tumor development over time. This approach typically requires breeding at least two different genetically engineered mouse models to generate bitransgenic mice carrying (1) a Cre recombinase–inducible oncogene or Cre-excisable tumor suppressor gene and (2) a hormone-activatable form of Cre recombinase expressed in specific cell types.[107] Treating these bitransgenic mouse models with hormone activates Cre recombinase in defined cell types at a specific time, leading to activation of the dormant oncogene or excision of the tumor suppressor gene. For modeling SCC, inducible expression of oncogenic *Hras* or *Kras* is frequently combined with deletion of the *Trp53* tumor suppressor gene; for modeling BCC, Hedgehog pathway oncogenes are activated or tumor suppressor genes are deleted. By combining different mouse models to target specific cell types, investigators have examined the tumorigenic potential of oncogenic drivers in hair follicle stem cells, transient-amplifying hair follicle and other progenitor cells, or interfollicular epidermal basal cells.[106-108]

From these types of experiments, several general conclusions can be drawn regarding the potential cells of origin of SCC and BCC and the importance of cellular and tissue context in tumorigenesis. Hair follicle stem cells appear to be uniquely sensitive to invasive SCC development driven by oncogenic *Kras* combined with *Trp53* deletion, with tumors progressing to advanced stages of development with a spindle cell morphology. Using the same set of oncogenic drivers, transiently amplifying hair matrix cells are completely resistant to tumor development, and interfollicular epidermal cells form either benign squamous papillomas or SCC, depending on the targeting strategy.[107,108] These studies also showed that although SCCs readily develop from follicle stem cells during the transition from the resting phase of the hair cycle (telogen) to active growth (anagen), they are largely resistant to SCC development when quiescent, in telogen.

Genetic-based models have also provided insight into the potential cell of origin of BCC but have yielded some conflicting results. [106,107,109] Initial studies showed that BCCs preferentially arose from interfollicular epidermis or from hair follicle stem cells that migrated into epidermis after wounding, but subsequent studies using a different oncogenic driver showed that BCCs could arise from follicle stem cells as well as several progenitor populations, with superficial BCCs arising from interfollicular epidermis and nodular tumors from hair follicle epithelia. Similar to *Kras+/Trp53*-deficient SCC, development of nodular BCCs was potentiated by activation of the hair cycle, establishing the importance of tissue context in driving tumorigenesis. Moreover, the magnitude of Hedgehog signaling activity was a critical determinant of tumor phenotype, with low-level signaling producing basaloid hamartomas and high-level signaling yielding nodular tumors. Taken together, these studies underscore the importance of a tumor's cell of origin in defining whether or not a tumor will develop, and if it does, its specific phenotype.

CHEMICALLY INDUCED SKIN CANCER IN RODENTS

The classical model of chemical carcinogenesis in skin has been studied for over 70 years and has proven to be a profoundly useful model for studying separable steps of tumor initiation, progression, and metastasis.[97] In the most commonly used incarnation of the model, the carcinogen DMBA is applied initially, metabolized into a potent mutagen, and causes activating *Hras* mutations, most often at Q61 with over 90% frequency. Subsequent repeated application of tumor promoters, most commonly the phorbol ester TPA, results in highly reproducible tumor induction in terms of latency, multiplicity, incidence, and progression. Other tumor promoters can be used, including UVR, okadaic acid, and physical wounding.[97] The dominant driver of these tumors is mutant *Hras*, which can undergo subsequent amplification. In this regard, one important contrast with human SCC is the early requirement for *ras* mutation as enforced by DMBA exposure, with the emergence of *Trp53* mutations later.[110] In humans, *TP53* mutations occur very early and *RAS* mutations are detected less commonly.[37-41] Nevertheless, the literature associated with this model mirrors the rise of the genetic paradigm of cancer because nearly every major cancer-related pathway has been investigated using this platform, particularly in conjunction with genetically engineered mouse models. These include the TP53, INK4A-RB1-E2F, TGF-β, PI3K/AKT, STAT3, mTOR,

and COX2 pathways, as well as multiple receptor tyrosine kinases, including EGFR (epidermal growth factor receptor) family members.[96,97] In addition, the model has been critically important in elucidating important downstream effectors of RAS in cancer.[96]

ULTRAVIOLET LIGHT–INDUCED RODENT SKIN CANCER

The most frequently used rodent model for UV-induced skin cancers has been the immunocompetent Hairless mouse, an outbred strain that lacks a functional Hairless (*Hr*) gene. These mice undergo one round of anagen soon after birth, after which point follicles degenerate into cystic structures.[111] The lack of hair obviates the need to shave the mice repeatedly and allows for consistent UV exposure over time. Although *Hr* gene function is implicated in NF-κB signaling[112] and adipogenesis,[113] the function of *Hr* in cancer is not completely understood. In terms of acquired mutations in the tumors, this model is significantly more faithful to the human condition than the DMBA/TPA model.[114] UV irradiation has also been used in more common strains such as C57BL/6 with varying degrees of susceptibility to carcinoma, the SENCAR strain being among the most sensitive. Although highly informative, UV-driven mouse models have suffered somewhat from a lack of uniformity in the spectra, dose, and irradiances used across groups and strains. Some of this is unavoidable and caused by technical limitations in reproducing spectra across different light sources.

Nevertheless, many important conclusions have been drawn from experiments with UV-driven models. *Trp53* mutations occur early, and as in chronically irradiated human skin, *Trp53* mutant clones are observed.[115] Tumors exhibit very high mutational burdens with a median of 155 mutations per megabase in a series of 18 SCCs.[114] Other mutations observed in tumors include *Notch* family members, *Ink4a*, and relatively rare mutations in *ras* and recurrent chromosomal alterations are seen that map to corresponding syntenic regions on human 3p, 11p, and 9q.[114,116-121]

As with the chemical carcinogenesis approach, many studies have focused on specific pathways, combining UV exposure with transgenic mouse models. Bypassing UV-induced apoptosis, as regulated by *Trp53*, *Survivin*, *Bcl2*, and *E2f-1*, has been shown to be necessary for full tumor susceptibility.[122-126] Some of the same regulators implicated in chemical carcinogenesis are also known to be important in UV-driven models, including the COX-2, mTOR, AKT, and ERK pathways.[127-131] Cross-species analysis with human SCC has also been performed using UV-driven models implicating WNT, β-catenin, and ERK pathways, as well as several microRNAs, including miR-21 and miR-31.[37]

TREATMENT AND PREVENTION OF SKIN CANCER

The most effective approach to reducing cancer-associated morbidity and mortality is prevention, and given the central role of UV-driven mutagenesis in skin cancer development, efforts aimed at effectively limiting exposure to sunlight and other UV sources, such as tanning beds, are likely to have a major impact on overall skin tumor development. Federal legislation restricting use of tanning beds by minors in nearly all US states is thus predicted to have a major beneficial effect at reducing skin cancer incidence in the future.[132] Various approaches to chemoprevention may also play an important role in reducing the number of SCCs,[133,134] with encouraging results presented for nicotinamide in a randomized phase 3 trial in high-risk patients, which showed a 20% and 30% reduction of BCC and SCC, respectively, at 3 months, and 11% fewer actinic keratoses.[135]

Although most skin cancers can be effectively treated with surgery, a deeper understanding of the molecular basis of these cancers may provide unique opportunities for targeting key oncogenic drivers for prevention or nonsurgical treatment. For example, because nearly all BCCs appear to be caused by unrestrained Hedgehog signaling, systemic Hedgehog pathway inhibition can be effective in treating patients with locally advanced or metastatic BCC, although side effects are common, drug resistance can develop, and tumors may recur after stopping therapy.[136] In addition to causing regression of preexisting tumors, systemic Hedgehog pathway inhibitors effectively block development of new BCCs in patients with Gorlin syndrome.[137] These findings suggest that regular use of a topical inhibitor, if effective at blocking oncogenic Hedgehog signaling, may be useful for BCC prevention in high-risk patients. Although this is an exciting possibility for patients with BCC, it seems unlikely that a single targeted therapeutic could be similarly useful for prevention of SCC tumors because multiple oncogenic alterations are engaged to variable degrees in SCC development.

CONCLUSIONS

Extensive clinical and experimental study of skin cancers has yielded important insights into the molecular and cellular basis of both BCC and SCC; led to the development of mechanism-based, targeted therapy for BCC; uncovered key molecular similarities between SCCs arising in skin and several other organs; provided powerful platforms for studying multistep cancer development using highly tractable mouse models of chemical and UV-driven carcinogenesis, as well as genetically engineered models; and shed light on fundamental aspects of tumor genetics and cancer biology that are relevant to understanding tumorigenesis in other organs. Continued progress in understanding

the pathogenesis of BCC and SCC is likely to lead to new approaches to preventing and treating these extremely common malignancies.

ACKNOWLEDGMENTS

We regret not being able to include citations to all relevant articles, given the space restrictions. We appreciate previous authors' contributions to some of the material included in the current chapter, including Drs. Masaoki Kawasumi, Paul Nghiem, Timothy Heffernan, Douglas Brash, Adam Glick, and Stuart Yuspa.

REFERENCES

1. Siegel RL, Miller KD, Jemal A. Cancer Statistics, 2017. *CA Cancer J Clin*. 2017;67(1):7-30.
2. Rogers HW, Weinstock MA, Feldman SR, et al. Incidence estimate of nonmelanoma skin cancer (keratinocyte carcinomas) in the US population, 2012. *JAMA Dermatol*. 2015;151(10):1081-1086.
3. Guy GP Jr, Machlin SR, Ekwueme DU, et al. Prevalence and costs of skin cancer treatment in the U.S., 2002-2006 and 2007-2011. *Am J Prev Med*. 2015;48(2):183-187.
4. Wong SY, Dlugosz AA. Basal cell carcinoma, Hedgehog signaling, and targeted therapeutics: the long and winding road. *J Invest Dermatol*. 2014;134(e1):E18-22.
5. Hanahan D, Weinberg RA. Hallmarks of cancer: the next generation. *Cell*. 2011;144(5):646-674.
6. Jeggo PA, Pearl LH, Carr AM. DNA repair, genome stability and cancer: a historical perspective. *Nat Rev Cancer*. 2016;16(1):35-42.
7. Roychowdhury S, Chinnaiyan AM. Translating cancer genomes and transcriptomes for precision oncology. *CA Cancer J Clin*. 2016;66(1):75-88.
8. Quail DF, Joyce JA. Microenvironmental regulation of tumor progression and metastasis. *Nat Med*. 2013;19(11):1423-1437.
9. McGranahan N, Swanton C. Clonal heterogeneity and tumor evolution: past, present, and the future. *Cell*. 2017;168(4):613-628.
10. Nassar D, Blanpain C. Cancer stem cells: basic concepts and therapeutic implications. *Ann Rev Pathol*. 2016;11:47-76.
11. Lapidot T, Sirard C, Vormoor J, et al. A cell initiating human acute myeloid leukaemia after transplantation into SCID mice. *Nature*. 1994;367(6464):645-648.
12. Colmont CS, Benketah A, Reed SH, et al. CD200-expressing human basal cell carcinoma cells initiate tumor growth. *Proc Natl Acad Sci U S A*. 2013;110(4):1434-1439.
13. Batlle E, Clevers H. Cancer stem cells revisited. *Nat Med*. 2017;23(10):1124-1134.
14. Grachtchouk M, Pero J, Yang SH, et al. Basal cell carcinomas in mice arise from hair follicle stem cells and multiple epithelial progenitor populations. *J Clin Invest*. 2011;121(5):1768-1781.
15. Sutherland KD, Visvader JE. Cellular mechanisms underlying intertumoral heterogeneity. *Trends Cancer*. 2015;1(1):15-23.
16. Kumar-Sinha C, Kalyana-Sundaram S, Chinnaiyan AM. Landscape of gene fusions in epithelial cancers: seq and ye shall find. *Genome Med*. 2015;7:129.
17. Piraino SW, Furney SJ. Beyond the exome: the role of non-coding somatic mutations in cancer. *Ann Oncol*. 2016;27(2):240-248.
18. Lin C, Yang L. Long Noncoding RNA in cancer: wiring signaling circuitry. *Trends Cell Biol*. 2018 Apr;28(4):287-301. doi: 10.1016/j.tcb.2017.11.008. Epub 2017 Dec 20.
19. Jaju PD, Ransohoff KJ, Tang JY, et al. Familial skin cancer syndromes: increased risk of nonmelanotic skin cancers and extracutaneous tumors. 2016 Mar;74(3):437-451; quiz 452-4. doi: 10.1016/j.jaad.2015.08.073.
20. Giordano CN, Yew YW, Spivak G, et al. Understanding photodermatoses associated with defective DNA repair: syndromes with cancer predisposition. *J Am Acad Dermatol*. 2016;75(5):855-870.
21. Robinson DR, Wu YM, Lonigro RJ, et al. Integrative clinical genomics of metastatic cancer. *Nature*. 2017;548(7667):297-303.
22. Kimonis VE, Goldstein AM, Pastakia B, et al. Clinical manifestations in 105 persons with nevoid basal cell carcinoma syndrome. *Am J Med Genet*. 1997;69(3):299-308.
23. Hahn H, Wicking C, Zaphiropoulous PG, et al. Mutations of the human homolog of Drosophila patched in the nevoid basal cell carcinoma syndrome. *Cell*. 1996;85(6):841-851.
24. Johnson RL, Rothman AL, Xie J, et al. Human homolog of patched, a candidate gene for the basal cell nevus syndrome. *Science*. 1996;272(5268):1668-1671.
25. Barakat MT, Humke EW, Scott MP. Learning from Jekyll to control Hyde: Hedgehog signaling in development and cancer. *Trends Mol Med*. 2010;16(8):337-348.
26. Petrova R, Joyner AL. Roles for Hedgehog signaling in adult organ homeostasis and repair. *Development*. 2014;141(18):3445-3457.
27. Pellegrini C, Maturo MG, Di Nardo L, et al. Understanding the molecular genetics of basal cell carcinoma. *Int J Mol Sci*. 2017 Nov; 18(11):2485.
28. Bonilla X, Parmentier L, King B, et al. Genomic analysis identifies new drivers and progression pathways in skin basal cell carcinoma. *Nat Genet*. 2016;48(4):398-406.
29. DiGiovanna JJ, Kraemer KH. Shining a light on xeroderma pigmentosum. *J Invest Dermatol*. 2012;132 (3 Pt 2):785-796.
30. Kim M, Murrell DF. Update on the pathogenesis of squamous cell carcinoma development in recessive dystrophic epidermolysis bullosa. *Eur J Dermatol*. 2015;25(suppl 1):30-32.
31. Goudie DR, D'Alessandro M, Merriman B, et al. Multiple self-healing squamous epithelioma is caused by a disease-specific spectrum of mutations in TGFBR1. *Nat Genet*. 2011;43(4):365-369.
32. Cammareri P, Rose AM, Vincent DF, et al. Inactivation of TGFbeta receptors in stem cells drives cutaneous squamous cell carcinoma. *Nat Commun*. 2016;7:12493.
33. Balmain A, Pragnell IB. Mouse skin carcinomas induced in vivo by chemical carcinogens have a transforming Harvey ras oncogene. *Nature*. 1983;303:72-74.
34. Parada LF, Tabin CJ, Shih C, et al. *Human* EJ bladder carcinoma oncogene is homologue of Harvey sarcoma virus ras gene. *Nature*. 1982;297(5866):474-478.
35. Brash DE, Rudolph JA, Simon JA, et al. A role for sunlight in skin cancer: UV-induced p53 mutations in squamous cell carcinoma. *Proc Natl Acad Sci U S A*. 1991;88(22):10124-10128.
36. Pierceall WE, Mukhopadhyay T, Goldberg LH, et al. Mutations in the p53 tumor suppressor gene in human cutaneous squamous cell carcinomas. *Mol Carcinog*. 1991;4(6):445-449.

37. Chitsazzadeh V, Coarfa C, Drummond JA, et al. Cross-species identification of genomic drivers of squamous cell carcinoma development across preneoplastic intermediates. *Nat Commun*. 2016;7:12601.
38. Pickering CR, Zhou JH, Lee JJ, et al. Mutational landscape of aggressive cutaneous squamous cell carcinoma. *Clin Cancer Res*. 2014;20(24):6582-6592.
39. Li YY, Hanna GJ, Laga AC, et al. Genomic analysis of metastatic cutaneous squamous cell carcinoma. *Clin Cancer Res*. 2015;21(6):1447-1456.
40. Wang NJ, Sanborn Z, Arnett KL, et al. Loss-of-function mutations in Notch receptors in cutaneous and lung squamous cell carcinoma. *Proc Natl Acad Sci U S A*. 2011;108(43):17761-17766.
41. South AP, Purdie KJ, Watt SA, et al. NOTCH1 mutations occur early during cutaneous squamous cell carcinogenesis. *J Invest Dermatol*. 2014;134(10):2630-2638.
42. Lee CS, Bhaduri A, Mah A, et al. Recurrent point mutations in the kinetochore gene KNSTRN in cutaneous squamous cell carcinoma. *Nat Genet*. 2014;46(10):1060-1062.
43. Watt SA, Purdie KJ, den Breems NY, et al. Novel CARD11 Mutations in human cutaneous squamous cell carcinoma lead to aberrant NF-kappaB regulation. *Am J Pathol*. 2015;185(9):2354-2363.
44. Salgado R, Toll A, Alameda F, et al. CKS1B amplification is a frequent event in cutaneous squamous cell carcinoma with aggressive clinical behaviour. *Genes Chromosomes Cancer*. 2010;49(11):1054-1061.
45. Sekulic A, Kim SY, Hostetter G, et al. Loss of inositol polyphosphate 5-phosphatase is an early event in development of cutaneous squamous cell carcinoma. *Cancer Prev Res (Phila)*. 2010;3(10):1277-1283.
46. Toll A, Salgado R, Yebenes M, et al. MYC gene numerical aberrations in actinic keratosis and cutaneous squamous cell carcinoma. *Br J Dermatol*. 2009;161(5):1112-1118.
47. Toll A, Salgado R, Yebenes M, et al. Epidermal growth factor receptor gene numerical aberrations are frequent events in actinic keratoses and invasive cutaneous squamous cell carcinomas. *Exp Dermatol*. 2010;19(2):151-153.
48. Dotto GP, Rustgi AK. Squamous cell cancers: a unified perspective on biology and genetics. *Cancer Cell*. 2016;29(5):622-637.
49. Konicke K, Lopez-Luna A, Munoz-Carrillo JL, et al. The microRNA landscape of cutaneous squamous cell carcinoma. *Drug Discovery Today*. 2018 Apr;23(4):864-870. doi: 10.1016/j.drudis.2018.01.023. Epub 2018 Jan 6.
50. Einspahr JG, Calvert V, Alberts DS, et al. Functional protein pathway activation mapping of the progression of normal skin to squamous cell carcinoma. *Cancer Prev Res (Phila)*. 2012;5(3):403-413.
51. Menzies AM, Kefford RF, Long GV. Paradoxical oncogenesis: are all BRAF inhibitors equal? *Pigment Cell Melanoma Res*. 2013;26(5):611-615.
52. Hatzivassiliou G, Song K, Yen I, et al. RAF inhibitors prime wild-type RAF to activate the MAPK pathway and enhance growth. *Nature*. 2010; 464(7287):431-435.
53. Poulikakos PI, Zhang C, Bollag G, et al. RAF inhibitors transactivate RAF dimers and ERK signalling in cells with wild-type BRAF. *Nature*. 2010;464(7287):427-430.
54. Su F, Viros A, Milagre C, et al. RAS mutations in cutaneous squamous-cell carcinomas in patients treated with BRAF inhibitors. *N Engl J Med*. 2012;366(3):207-215.
55. Vin H, Ojeda SS, Ching G, et al. BRAF inhibitors suppress apoptosis through off-target inhibition of JNK signaling. *eLife*. 2013;2:e00969.
56. Ransohoff KJ, Tang JY, Sarin KY. Squamous Change in Basal-Cell Carcinoma with Drug Resistance. *N Engl J Med*. 2015;373(11):1079-1082.
57. Zhao X, Ponomaryov T, Ornell KJ, et al. RAS/MAPK Activation drives resistance to Smo inhibition, metastasis, and tumor evolution in Shh pathway-dependent tumors. *Cancer Res*. 2015;75(17):3623-3635.
58. Adelmann CH, Truong KA, Liang RJ, et al. MEK Is a therapeutic and chemopreventative target in squamous cell carcinoma. *J Invest Dermatol*. 2016;136(9): 1920-1924.
59. Valejo Coelho MM, Matos TR, Apetato M. The dark side of the light: mechanisms of photocarcinogenesis. *Clin Dermatol*. 2016;34(5):563-570.
60. Archier E, Devaux S, Castela E, et al. Carcinogenic risks of psoralen UV-A therapy and narrowband UV-B therapy in chronic plaque psoriasis: a systematic literature review. *J Eur Acad Dermatol Venereol*. 2012;26(suppl 3):22-31.
61. Cadet J, Mouret S, Ravanat JL, et al. Photoinduced damage to cellular DNA: direct and photosensitized reactions. *Photochem Photobiol*. 2012;88(5):1048-1065.
62. Young AR, Chadwick CA, Harrison GI, et al. The similarity of action spectra for thymine dimers in human epidermis and erythema suggests that DNA is the chromophore for erythema. *J Invest Dermatol*. 1998;111(6):982-988.
63. Mouret S, Baudouin C, Charveron M, et al. Cyclobutane pyrimidine dimers are predominant DNA lesions in whole human skin exposed to UVA radiation. *Proc Natl Acad Sci U S A*. 2006;103(37):13765-13770.
64. Brash DE. UV signature mutations. *Photochem Photobiol*. 2015;91(1):15-26.
65. Alexandrov LB, Nik-Zainal S, Wedge DC, et al. Signatures of mutational processes in human cancer. *Nature*. 2013;500(7463):415-421.
66. Premi S, Wallisch S, Mano CM, et al. Photochemistry. Chemiexcitation of melanin derivatives induces DNA photoproducts long after UV exposure. *Science*. 2015;347(6224):842-847.
67. Ziegler A, Jonason AS, Leffell DJ, et al. Sunburn and p53 in the onset of skin cancer. *Nature*. 1994; 372(6508):773-776.
68. Jonason AS, Kunala S, Price GJ, et al. Frequent clones of p53-mutated keratinocytes in normal human skin. *Proc Natl Acad Sci. U S A*. 1996;93(24):14025-14029.
69. Martincorena I, Roshan A, Gerstung M, et al. Tumor evolution. High burden and pervasive positive selection of somatic mutations in normal human skin. *Science*. 2015;348(6237):880-886.
70. Simons BD. Deep sequencing as a probe of normal stem cell fate and preneoplasia in human epidermis. *Proc Natl Acad Sci U S A*. 2016;113(1):128-133.
71. Albibas AA, Rose-Zerilli MJJ, Lai C, et al. Subclonal evolution of cancer-related gene mutations in p53 immunopositive patches in human skin. *J Invest Dermatol*. 2018;138(1):189-198.
72. Criscione VD, Weinstock MA, Naylor MF, et al. Actinic keratoses: natural history and risk of malignant transformation in the Veterans Affairs Topical Tretinoin Chemoprevention Trial. *Cancer*. 2009;115(11):2523-2530.
73. Schiller JT, Lowy DR. Virus infection and human cancer: an overview. *Recent Results Cancer Res*. 2014; 193:1-10.
74. Mesri EA, Feitelson MA, Munger K. Human viral oncogenesis: a cancer hallmarks analysis. *Cell Host Microbe*. 2014;15(3):266-282.

75. Schiffman M, Doorbar J, Wentzensen N, et al. Carcinogenic human papillomavirus infection. *Nat Rev Dis Primers*. 2016;2:16086.
76. Meyers JM, Munger K. The viral etiology of skin cancer. *J Invest Dermatol*. 2014;134(e1):E29-E32.
77. Arron ST, Ruby JG, Dybbro E, et al. Transcriptome sequencing demonstrates that human papillomavirus is not active in cutaneous squamous cell carcinoma. *J Invest Dermatol*. 2011;131(8):1745-1753.
78. Galloway DA, Laimins LA. Human papillomaviruses: shared and distinct pathways for pathogenesis. *Curr Opin Virol*. 2015;14:87-92.
79. Imperiale MJ, Jiang M. Polyomavirus persistence. *Ann Rev Virol*. 2016;3(1):517-532.
80. Moens U, Krumbholz A, Ehlers B, et al. Biology, evolution, and medical importance of polyomaviruses: an update. *Infect Genet Evol*. 2017;54:18-38.
81. Feng H, Shuda M, Chang Y, et al. Clonal integration of a polyomavirus in human Merkel cell carcinoma. *Science*. 2008;319(5866):1096-1100.
82. Atkin SJ, Griffin BE, Dilworth SM. Polyoma virus and simian virus 40 as cancer models: history and perspectives. *Semin Cancer Biol*. 2009;19(4):211-217.
83. Wendzicki JA, Moore PS, Chang Y. Large T and small T antigens of Merkel cell polyomavirus. *Curr Opin Virol*. 2015;11:38-43.
84. Liu W, MacDonald M, You J. Merkel cell polyomavirus infection and Merkel cell carcinoma. *Curr Opin Virol*. 2016;20:20-27.
85. Pott P. Cancer scrotic. In: *Chirurgical Observations Relative to the Cataract, the Polypus of the Nose, the Cancer of the Scrotum, the Different Kinds of Ruptures, and the Mortification of the Toes and Feet*. London: Hawes, Clarke, and Collins; 1775:63.
86. Williams K, Mansh M, Chin-Hong P, et al. Voriconazole-associated cutaneous malignancy: a literature review on photocarcinogenesis in organ transplant recipients. *Clin Infect Dis*. 2014;58(7):997-1002.
87. Li C, Athar M. Ionizing radiation exposure and basal cell carcinoma pathogenesis. *Radiat Res*. 2016; 185(3):217-228.
88. Kleinerman RA. Cancer risks following diagnostic and therapeutic radiation exposure in children. *Pediatr Radiol*. 2006;36(suppl 2):121-125.
89. Gudmundsdottir EM, Hrafnkelsson J, Rafnsson V. Incidence of cancer among licenced commercial pilots flying North Atlantic routes. *Environ Health*. 2017;16(1):86.
90. Bazalinski D, Przybek-Mita J, Baranska B, et al. Marjolin's ulcer in chronic wounds - review of available literature. *Contemp Oncol (Pozn)*. 2017;21(3):197-202.
91. Karasoy Yesilada A, Zeynep Sevim K, Ozgur Sucu D, et al. Marjolin ulcer: clinical experience with 34 patients over 15 years. *J Cutan Med Surg*. 2013;17(6):404-409.
92. Oruc M, Kankaya Y, Sungur N, et al. Clinicopathological evaluation of Marjolin ulcers over two decades. *Kaohsiung J Med Sci*. 2017;33(7):327-333.
93. Shen R, Zhang J, Zhang F, et al. Clinical characteristics and therapeutic analysis of 51 patients with Marjolin's ulcers. *Exp Ther Med*. 2015;10(4):1364-1374.
94. Brown K, Strathdee D, Bryson S, et al. The malignant capacity of skin tumours induced by expression of a mutant H-ras transgene depends on the cell type targeted. *Curr Biol*. 1998;8:516-524.
95. Bailleul B, Surani MA, White S, et al. Skin hyperkeratosis and papilloma formation in transgenic mice expressing a ras oncogene from a suprabasal keratin promoter. *Cell*. 1990;62:697-708.
96. Huang PY, Balmain A. Modeling cutaneous squamous carcinoma development in the mouse. *Cold Spring Harbor Perspect Med*. 2014;4(9):a013623.
97. Abel EL, Angel JM, Kiguchi K, et al. Multi-stage chemical carcinogenesis in mouse skin: fundamentals and applications. *Nat Protoc*. 2009;4(9):1350-1362.
98. Ratushny V, Gober MD, Hick R, et al. From keratinocyte to cancer: the pathogenesis and modeling of cutaneous squamous cell carcinoma. *J Clin Invest*. 2012; 122(2):464-472.
99. Amberg N, Holcmann M, Glitzner E, et al. Mouse models of nonmelanoma skin cancer. *Methods Mol Biol*. 2015;1267:217-250.
100. Khavari PA. Modelling cancer in human skin tissue. *Nat Rev Cancer*. 2006;6(4):270-280.
101. Martinez-Cruz AB, Santos M, Lara MF, et al. Spontaneous squamous cell carcinoma induced by the somatic inactivation of retinoblastoma and Trp53 tumor suppressors. *Cancer Res*. 2008;68(3):683-692.
102. Lambert PF, Pan H, Pitot HC, et al. Epidermal cancer associated with expression of human papillomavirus type 16 E6 and E7 oncogenes in the skin of transgenic mice. *Proc Natl Acad Sci U S A*. 1993;90(12):5583-5587.
103. Nicolas M, Wolfer A, Raj K, et al. Notch1 functions as a tumor suppressor in mouse skin. *Nat. Genet*. 2003;33(3):416-421.
104. Demehri S, Turkoz A, Kopan R. Epidermal Notch1 loss promotes skin tumorigenesis by impacting the stromal microenvironment. *Cancer Cell*. 2009;16(1):55-66.
105. Hu B, Castillo E, Harewood L, et al. Multifocal epithelial tumors and field cancerization from loss of mesenchymal CSL signaling. *Cell*. 2012;149(6):1207-1220.
106. Kasper M, Jaks V, Hohl D, et al. Basal cell carcinoma—molecular biology and potential new therapies. *J Clin Invest*. 2012;122(2):455-463.
107. Blanpain C. Tracing the cellular origin of cancer. *Nat Cell Biol*. 2013;15(2):126-134.
108. Lowry WE, Flores A, White AC. Exploiting mouse models to study Ras-induced cutaneous squamous cell carcinoma. *J Invest Dermatol*. 2016;136(8):1543-1548.
109. White AC, Lowry WE. Refining the role for adult stem cells as *Cancer Cells* of origin. *Trends Cell Biol*. 2015;25(1):11-20.
110. Nassar D, Latil M, Boeckx B, et al. Genomic landscape of carcinogen-induced and genetically induced mouse skin squamous cell carcinoma. *Nat Med*. 2015;21(8):946-954.
111. Benavides F, Oberyszyn TM, VanBuskirk AM, et al. The hairless mouse in skin research. *J Dermatol Sci*. 2009;53(1):10-18.
112. Kim H, Casta A, Tang X, et al. Loss of hairless confers susceptibility to UVB-induced tumorigenesis via disruption of NF-kappaB signaling. *PLoS One*. 2012;7(6):e39691.
113. Kumpf S, Mihlan M, Goginashvili A, et al. Hairless promotes PPARgamma expression and is required for white adipogenesis. *EMBO Rep*. 2012;13(11):1012-1020.
114. Knatko EV, Praslicka B, Higgins M, et al. Whole-exome sequencing validates a preclinical mouse model for the prevention and treatment of cutaneous squamous cell carcinoma. *Cancer Prev Res (Phila)*. 2017;10(1):67-75.
115. Remenyik E, Wikonkal NM, Zhang W, et al. Antigen-specific immunity does not mediate acute regression of UVB-induced p53-mutant clones. *Oncogene*. 2003;22(41):6369-6376.
116. Ashton KJ, Weinstein SR, Maguire DJ, et al. Chromosomal aberrations in squamous cell carcinoma

and solar keratoses revealed by comparative genomic hybridization. *Arch Dermatol*. 2003;139(7): 876-882.
117. Dworkin AM, Tober KL, Duncan FJ, et al. Chromosomal aberrations in UVB-induced tumors of immunosuppressed mice. *Genes Chromosomes Cancer*. 2009;48(6):490-501.
118. Khan SG, Mohan RR, Katiyar SK, et al. Mutations in ras oncogenes: rare events in ultraviolet B radiation-induced mouse skin tumorigenesis. *Mol Carcinog*. 1996;15(2):96-103.
119. Popp S, Waltering S, Holtgreve-Grez H, et al. Genetic characterization of a human skin carcinoma progression model: from primary tumor to metastasis. *J Invest Dermatol*. 2000;115(6):1095-1103.
120. Soufir N, Queille S, Mollier K, et al. INK4a-ARF mutations in skin carcinomas from UV irradiated hairless mice. *Mol Carcinog*. 2004;39(4):195-198.
121. van Kranen HJ, de Gruijl FR, de Vries A, et al. Frequent p53 alterations but low incidence of ras mutations in UV-B-induced skin tumors of hairless mice. *Carcinogenesis*. 1995;16(5):1141-1147.
122. Brash DE. Roles of the transcription factor p53 in keratinocyte carcinomas. *Br J Dermatol*. 2006;154(suppl 1): 8-10.
123. Grossman D, Kim PJ, Blanc-Brude OP, et al. Transgenic expression of survivin in keratinocytes counteracts UVB-induced apoptosis and cooperates with loss of p53. *J Clin Invest*. 2001;108(7):991-999.
124. Knezevic D, Zhang W, Rochette PJ, et al. Bcl-2 is the target of a UV-inducible apoptosis switch and a node for UV signaling. *Proc Natl Acad Sci U S A*. 2007;104(27):11286-11291.
125. Raj D, Brash DE, Grossman D. Keratinocyte apoptosis in epidermal development and disease. *J Invest Dermatol*. 2006;126(2):243-257.
126. Wikonkal NM, Remenyik E, Knezevic D, et al. Inactivating E2f1 reverts apoptosis resistance and cancer sensitivity in Trp53-deficient mice. *Nat Cell Biol*. 2003;5(7):655-660.
127. Bermudez Y, Stratton SP, Curiel-Lewandrowski C, et al. Activation of the PI3K/Akt/mTOR and MAPK signaling pathways in response to acute solar-simulated light exposure of human skin. *Cancer Prev Res (Phila)*. 2015;8(8):720-728.
128. Dickinson SE, Janda J, Criswell J, et al. Inhibition of Akt enhances the chemopreventive effects of topical rapamycin in mouse skin. *Cancer Prev Res (Phila)*. 2016;9(3):215-224.
129. Einspahr JG, Bowden GT, Alberts DS, et al. Cross-validation of murine UV signal transduction pathways in human skin. *Photochem Photobiol*. 2008; 84(2):463-476.
130. Kim JE, Roh E, Lee MH, et al. Fyn is a redox sensor involved in solar ultraviolet light-induced signal transduction in skin carcinogenesis. *Oncogene*. 2016;35(31): 4091-4101.
131. Lee MH, Lim DY, Kim MO, et al. Genetic ablation of caspase-7 promotes solar-simulated light-induced mouse skin carcinogenesis: the involvement of keratin-17. *Carcinogenesis*. 2015;36(11):1372-1380.
132. Madigan LM, Lim HW. Tanning beds: impact on health, and recent regulations. *Clin Dermatol*. 2016; 34(5):640-648.
133. Soltani-Arabshahi R, Tristani-Firouzi P. Chemoprevention of nonmelanoma skin cancer. *Facial Plast Surg*. 2013;29(5):373-383.
134. Chen AC, Halliday GM, Damian DL. Non-melanoma skin cancer: carcinogenesis and chemoprevention. *Pathology*. 2013;45(3):331-341.
135. Chen AC, Martin AJ, Choy B, et al. A phase 3 randomized trial of nicotinamide for skin-cancer chemoprevention. *N Engl J Med*. 2015;373(17):1618-1626.
136. Basset-Seguin N, Sharpe HJ, de Sauvage FJ. Efficacy of Hedgehog pathway inhibitors in Basal cell carcinoma. *Mol Cancer Ther*. 2015;14(3):633-641.
137. Tang JY, Mackay-Wiggan JM, Aszterbaum M, et al. Inhibiting the hedgehog pathway in patients with the basal-cell nevus syndrome. *N Engl J Med*. 2012;366(23):2180-2188.

Chapter 20 :: Pigmentation and Melanocyte Biology

:: Stephen M. Ostrowski & David E. Fisher

AT-A-GLANCE

- Development of Melanocytes
  - Melanocytes are derived from neural crest lineage
  - Transcription factors (MITF, SOX10, PAX3) and signaling pathways (KIT, EDNRB) that are important for development, migration, and survival of melanocytes also play key roles in melanoma
- Function of melanocytes
  - Key function of melanocytes is to synthesize melanin and transfer to surrounding keratinocytes
  - Melanocytes can produce brown/black melanin (eumelanin) or orange/yellow melanin (pheomelanin)
  - The melanosome, a specialized lysosome-related organelle, is the site of melanin synthesis and storage
- Regulation of human pigmentation
  - Common human variants in melanocortin 1 receptor (MC1R) lead to the "red hair phenotype"—red hair, fair skin, inability to tan, and increased melanoma risk
  - MC1R signals to the MITF transcription factor to regulate pigmentation and sun-tanning

INTRODUCTION

Melanocytes are specialized cells of the epidermis and hair follicle whose primary function is to synthesize and transfer melanin to adjacent keratinocytes. Melanin synthesis occurs in a specialized organelle, the melanosome; proper melanosome biogenesis and trafficking are required for normal pigmentation. Melanocyte numbers are similar in individuals of different racial backgrounds, and instead differences of pigmentation are a result of the amount and quality of melanin in the skin, in large part driven by variability in the number, size, distribution, and function of melanosomes within keratinocytes.[1,2] Analysis of mutations in mice and humans (Table 20-1) that cause pigmentation defects have allowed the identification of key regulators of melanocyte development, survival, and function. Many of these same genes play critical roles in the pathogenesis of melanoma.

ANATOMY, ULTRASTRUCTURE, AND DISTRIBUTION OF MELANOCYTES IN HUMAN SKIN

HISTOLOGY

Melanocytes are melanin-synthesizing cells of dendritic morphology located within the basal layer of the epidermis, the hair bulb, and the outer root sheath of hair follicles. The dendritic morphology of melanocytes is not appreciable by light microscopy, but can be appreciated by immunohistochemistry (Fig. 20-1). Melanocytes contain oval nuclei slightly smaller than that of surrounding keratinocytes. Processing artifact often leaves a clear halo of cytoplasm when hematoxylin and eosin (H&E)–stained sections are viewed.

Melanocytes exist admixed with keratinocytes in the basal layer of the epidermis (Fig. 20-1). Within the epidermis, melanocytes are present at about 1/10th the number of keratinocytes.[3] On H&E-stained sections, there are very few visible melanin granules in the basal layer of light-skinned individuals. However, in persons with darker skin types, melanin granules are visible throughout all layers of the epidermis, including the stratum corneum. Special stains can be used to better visualize melanin. Silver stains such as the Fontana-Mason and Warthin-Starry stains rely on the ability of melanin to become impregnated with silver, causing intensely black precipitate in the tissue on reduction.[4,5] It has been reported that silver stains react with melanocytes from eumelanotic, but not pheomelanotic, skin tissue.[6] The oxidation of the substrate dopa to insoluble, black melanin (dopa reaction), reflects tyrosinase activity occurring in melanosomes.[7]

Immunohistologic identification of melanocytes using antibodies directed against tyrosinase, MITF, and Melan-A/Mart1 allows identification of melanocytes in paraffin-embedded tissues as well as melanoma.[8,9]

TABLE 20-1

Genetic Hypopigmentation and Hyperpigmentation Disorders Caused by Mutations in Genes Important for Melanocyte Development and Biology

DISORDER	GENE MUTATION	CLINICAL FEATURES
Hypopigmentation disorders		
Ocular albinism (OA1)	*GPR143*	Reduced pigmentation of iris and retina; photosensitivity; decreased visual acuity; nystagmus; strabismus; misrouting of optic nerve
Oculocutaneous albinism		Cutaneous albinism (pigmentary dilution of skin and hair) Ocular albinism (see above)
▪ OCA1	*TYR*	OCA1A: tyrosinase-negative (severe) albinism (complete loss of tyrosinase function) OCA1B: tyrosinase-positive (mild to moderate) albinism
▪ OCA2	*OCA2*	"Brown" albinism
▪ OCA3	*TYRP1*	"Rufous" albinism
▪ OCA4	*SLC45A2/MATP*	Variable degrees of albinism
Waardenburg Syndrome		Piebaldism, congenital deafness, heterochromia irides, synophrys, broad nasal root, dystopia canthorum
▪ WS1	*PAX3*	Classic type
▪ WS2	*MITF* *SNAI2*	Lacks dystopia canthorum
▪ WS3	*PAX3*	Limb abnormalities (hypoplasia, syndactyly)
▪ WS4	*SOX10* *EDN3* *EDNRB*	Hirschsprung disease
Tietz syndrome	*MITF*	Tyrosinase-positive cutaneous albinism; deafness; eyebrow hypoplasia
Piebaldism	*cKIT*	Depigmented forelock and abdominal skin
Hermansky-Pudlak syndrome (HPS)		Tyrosinase-positive oculocutaneous albinism (melanosome dysfunction) Bleeding diathesis (platelet granule dysfunction) Interstitial pulmonary fibrosis (HPS 1,2,4), granulomatous colitis (HPS 1,4), renal failure (rare), cardiomyopathy (rare) (caused by ceroidal lipofuscin accumulation in lysosomes) Neutropenia and cytotoxic T-cell dysfunction (HPS2)
▪ HPS1	*HPS1* (BLOC-3)	
▪ HPS2	*AP3B1* (AP-3)	
▪ HPS3	*HPS3* (BLOC-2)	
▪ HPS4	*HPS4* (BLOC-3)	
▪ HPS5	*HPS5* (BLOC-2)	
▪ HPS6	*HPS6* (BLOC-2)	
▪ HPS7	*DTNBP1* (BLOC-2)	
▪ HPS8	*BLOC1S3* (BLOC-1)	
▪ HPS9	*BLOC1S6* (BLOC-1)	
Chediak-Higashi syndrome	*LYST*	Tyrosinase-positive oculocutaneous albinism (melanosome dysfunction) Bleeding diathesis (platelet granule dysfunction) Progressive neurologic dysfunction (mechanism unknown) Severe immunodeficiency (NK cell, cytotoxic T cell, neutrophil dysfunction) Lymphomalike syndrome (overwhelming infiltration of organs by defective white blood cells) Giant lysosome-related organelles (these large granules are visible within leukocytes in peripheral blood smear)
Griscelli Syndrome		Pigmentary dilution of skin and hair (clumping of melanin within melanocytes) Neurologic abnormalities (GS1) Immunodeficiency (GS2)
▪ GS1	*MYO5A*	
▪ GS2	*RAB27A*	
▪ GS3	*MLPH*	
Hyperpigmentation disorders		
Familial progressive hyperpigmentation (FPH)	*KITLG*	Generalized patches of hyperpigmentation of skin and mucous membranes without systemic symptoms
Familial progressive hyper- and hypopigmentation (FPPH)	*KITLG*	Diffuse hyperpigmented and hypopigmented patches without systemic symptoms. Variable penetrance

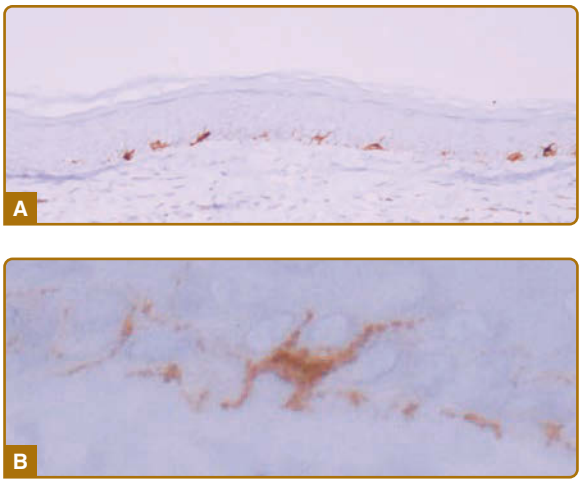

Figure 20-1 Melan-A/Mart1 immunostaining of melanocytes. **A,** Immunohistochemistry using antibody directed against Melan-A identifies melanocytes admixed with keratinocytes in the basal layer of epidermis. **B,** Higher-power magnification demonstrates the dendritic morphology of melanocytes. (Images used with permission from Dr. Roberto Novoa, Stanford University.)

Although less specific for the melanocyte lineage, antibodies directed against S100 protein have long been used with great sensitivity to detect melanocytes and melanomas.[10] Immunostaining with antibody HMB-45 (directed against gp100/PMEL17) is negative in normal adult melanocytes but offers additional specificity for examination of melanocytic neoplasms.[11] MITF protein is a transcription factor that was shown to regulate the expression of several immunohistochemical markers, including tyrosinase, Melan-A/Mart1, and HMB-45/gp100/PMEL17.[12]

ULTRASTRUCTURE

Unlike keratinocytes, melanocytes do not possess desmosomes or tonofilaments. Where they adjoin the basement membrane, melanocytes demonstrate structures resembling the hemidesmosomes of basal keratinocytes.[13] The key ultrastructural feature of the melanocyte is the melanosome, a round to oval-shaped membrane-enveloped organelle. Melanosomes containing primarily eumelanin (eumelanosomes) can be classified into 4 stages based on morphology, correlating to increasing stages of melanosome maturation (stage I to IV)[14-16] (Fig. 20-2). Stage I melanosomes are round, approximately 0.3 µm in diameter, and contain small intraluminal vesicles reminiscent of multivesicular bodies of the early endosomal compartment. Stage II melanosomes are oval in shape and are approximately 0.5 µm in diameter and exhibit deposition of a parallel fibrillar matrix. Stage I and stage II melanosomes are not melanized. Stage III melanosomes demonstrate deposition of pigment along the filaments, whereas stage IV melanosomes are fully melanized, with the electron-dense melanin completely obscuring the underlying structures (Fig. 20-2). Overall, melanosomes containing primarily pheomelanin (pheomelanosomes) exhibit similar ultrastructural stages of maturation with late stage III and IV pheomelanosomes exhibiting melanization obscuring underlying structures. However, pheomelanosomes are smaller, retain a rounded morphology at all stages, and contain a disorganized and less dense filament network.[16-18]

DISTRIBUTION OF MELANOCYTES

INTERFOLLICULAR MELANOCYTES AND THE EPIDERMAL MELANIN UNIT

In human interfollicular skin (defined as epidermal locations between hair follicles), melanocytes are admixed with keratinocytes at the basal layer of the epidermis. Cutaneous interfollicular melanocytes are present at highest density in the facial and genital skin, and at lower density in the skin of the trunk and extremities.[1,19] Chronic, sun-exposed skin contains up to a 2-fold higher number and an increase in the size and activity of the melanocytes as compared to adjacent sun-protected skin.[20,21] Thus, the differences in pigmentation following sun-induced hyperpigmentation (tanning) are predominantly due to altered pigment synthesis per melanocyte, rather than major alterations in melanocyte numbers. Similarly, there is little variation in melanocyte numbers between individuals of different skin phototypes. The key determinant of skin pigmentation is not melanocyte density but instead the increased ability of melanocytes from darker-skinned persons to synthesize and transfer brown-black eumelanin.[1]

Melanin synthesis by melanocytes and subsequent transfer of melanin to adjacent keratinocytes is required for normal pigmentation. The term "epidermal melanin unit" was first coined by Fitzpatrick to

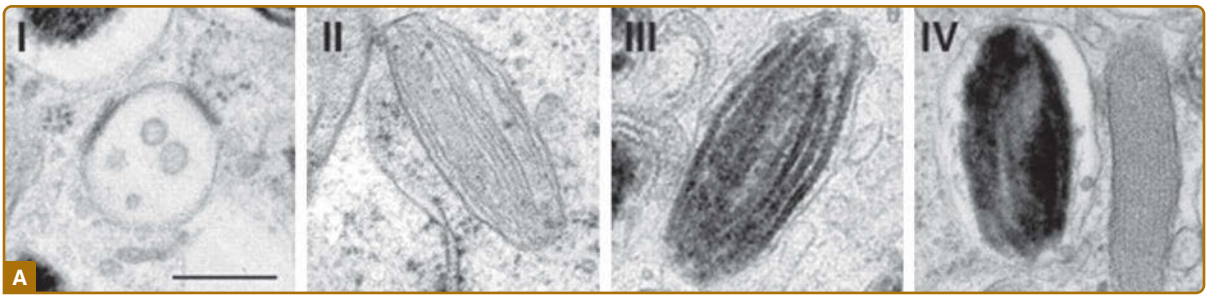

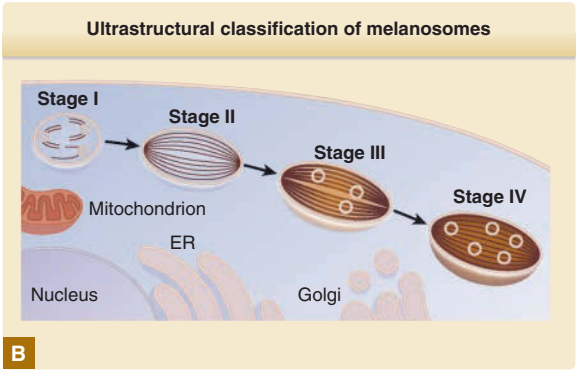

Figure 20-2 Ultrastructural classification of melanosomes. **A,** Selected images of stage I, II, III, and IV melanosomes from MNT-1 melanoma cells. High-pressure freezing of cells and freeze substitution was utilized by these authors to optimize ultrastructural preservation. (Scale bars: 200 nm.) (Used with permission from Hurbain I, et al. Electron tomography of early melanosomes: implications for melanogenesis and the generation of fibrillar amyloid sheets. *Proc Natl Acad Sci* 105(50):19726-31. Copyright (2008) National Academy of Sciences, U.S.A.) **B,** Schematic versions of the electron microscopy images.

describe this fundamental multicellular interaction.[22] Histologically, the epidermal melanin unit is characterized by a melanocyte and each of the keratinocytes that it physically contacts. Each melanocyte contacts and delivers melanin to approximately 40 keratinocytes, irrespective of anatomical location, via direct contacts with the melanocyte's protruding dendrites.

It has long been known that epidermal repigmentation during vitiligo occurs around hair follicles, suggesting that epidermal melanocytes can be regenerated from a "reservoir" of melanocyte stem cells (McSCs) of the hair follicle.[23,24] After depletion of interfollicular melanocytes in a transgenic mouse model, melanocytes were seen to be repopulated by hair follicle–derived McSCs.[25] Recent studies from mouse models have demonstrated that after wounding or UVB irradiation, hair follicle McSCs migrate before proliferation to populate the interfollicular epidermis.[26] However, the signaling pathways that guide the differentiation, survival, quiescence, and migration of McSCs to the epidermis are only beginning to emerge, and include Wnt, Endrb, transforming growth factor beta (TGFβ), and MC1R signaling.[26-29] Although most epidermal melanocytes are derived from hair follicle–resident McSCs, some epidermal melanocytes may have other origins. Recent studies in zebrafish and mice have shown that differentiated epidermal melanocytes retain the ability to proliferate in vivo.[30,31] Under the pathologic circumstance of nerve injury, Schwann cells may undergo dedifferentiation to generate ectopic melanocytes.[32]

FOLLICULAR MELANOCYTES

Within the hair follicle, the melanocyte population varies by the stage of the hair cycle. Similar to epithelial stem cells, melanocyte stem cells (McSCs) reside within the permanent bulge/secondary hair germ (sHG) area of the hair follicle and maintain a quiescent state during telogen.[25] During the anagen phase of the hair cycle, the McSCs become activated via Wnt signaling, proliferate, and give rise to differentiated melanocytes.[33] These melanocytes migrate to the bulb of the hair follicle and undergo maturation by early to mid-anagen. Differentiated melanocytes then produce and transfer melanin to the surrounding keratinocytes throughout anagen, ultimately resulting in pigmentation of the hairs. Differentiated melanocytes of the hair bulb undergo apoptosis during late catagen in step with the degenerating lower hair follicle, while the McSC population persists through each hair cycle.[34] Gradual loss of McSCs occurs with age, suggesting that age-dependent hair graying seen in humans and mice is the result of incomplete maintenance of the hair follicle McSC cell pool.[35] The demise of these follicular McSCs appears to involve their "inappropriate" differentiation and pigmentation within the stem cell niche (bulge region)—a phenomenon that temporally precedes their apoptotic cell death. Follow-up studies have shown that triggers of DNA damage such as ionizing radiation can accelerate this process of aberrant McSC differentiation and hair graying.[36]

ACRAL MELANOCYTES

Melanocytes also exist in the hairless acral surfaces of palms and soles. Recently, the lower permanent portion of the eccrine gland has been demonstrated as a niche for McSCs of the acral epidermis.[37] It has been hypothesized that acral melanoma is derived from this McSC population. Correspondingly, acral melanomas are diagnosed with high sensitivity and specificity as a result of their preferential pigmentation of the eccrine-rich ridges of the dermatoglyphs.[38]

EXTRACUTANEOUS MELANOCYTES

Neural crest–derived melanocytes exist in other areas of the body including the mucosa, cochlea, uvea, leptomeninges, and heart. Of note, retinal pigment epithelium cells synthesize melanin and form melanosomes, but these cells are derived from neuroectoderm and are developmentally unrelated to the neural crest/melanocyte lineage. The roles of melanocytes in extracutaneous sites are diverse. In addition to contributing to pigment variation of the iris, ocular melanin protects against UV radiation, and darker eye pigmentation is associated with decreased incidence of age-related macular degeneration.[39] The role of melanocytes in the CNS is unclear, but autoimmunity directed against melanocytes in Vogt–Koyanagi–Harada syndrome can lead to severe CNS inflammation. In the cochlea of the ear, melanocytes are located in and required for the normal development and function of the stria vascularis layer, a nonsensory structure required for normal hearing. Defects of the stria vascularis explain the sensorineural deafness that is found, in addition to pigmentation defects, in human patients with Waardenburg and Tietz syndromes.[40,41] Dysfunction of cardiac melanocytes predispose to arrhythmias in a mouse model.[42] Mouse studies have suggested that different signaling pathways govern the development of cutaneous versus extracutaneous melanocytes.[43] Similarly, activation of distinct biologic pathways drive the pathogenesis of ocular, cutaneous, and acral lentiginous subtypes of melanomas.[44]

FORMATION, MIGRATION, AND SURVIVAL OF THE MELANOCYTE

Melanocytes are derived from the neural crest lineage. Although traditionally melanocytes were thought to migrate only along the dorsolateral migration pathway, recent evidence has demonstrated the importance of a second wave of melanocytes derived from Schwann cell precursors that migrate along developing nerves in the ventromedial migratory pathway.[32] Evidence from mouse coat color mutants and human patients with pigmentation syndromes (Table 20-1) has allowed identification of many genes required for melanocyte formation, migration, and survival. Many of these same factors play pivotal roles in the pathogenesis of melanoma.

DIFFERENTIATION AND MIGRATION OF MELANOCYTES FROM THE NEURAL CREST

Melanocytes are exclusively derived from the highly migratory and multipotent neural crest population, as first demonstrated by seminal xenotransplantation experiments in chick embryos.[45,46] The neural crest is a transient cell population that forms at the margin of the early forming neural tube. Neural crest cells migrate along one of 2 defined migratory pathways, a dorsolateral pathway between the somites and the ectoderm and a ventromedial pathway. Neural crest cells migrate to their target sites and give rise to multiple cell types including melanocytes, craniofacial cartilage and bone, secretory endocrine cells, smooth muscles of heart and great vessels, peripheral sensory and autonomic neurons, enteric neurons, and peripheral glia.

Decades of experimental evidence supported a model in which melanocyte precursors, termed melanoblasts, delaminate from the neural tube and follow the dorsolateral pathway between the ectoderm and the somites to reach the skin, whereas the ventrolateral pathway was thought to be used only by neural crest cells specified to the neuronal and glial lineages.[47] However, a recent study has demonstrated that a significant percentage of skin melanocytes are derived from Schwann cell precursors that travel the ventromedial pathway along the developing nerve sheath. The ventromedial-derived melanocytes then detach from the nerve before migrating to the epidermis (Fig. 20-3).[32]

The development and specification of melanoblasts along the dorsolateral pathway has been well characterized in mice. Melanoblasts appear to become specified prior to or early after delamination from the neural tube. The master melanocyte transcription factor, MITF, is first expressed in melanoblasts shortly after exit from the neural tube at embryonic day 10.5-11 (E10.5-11). Immediately after delamination from the neural tube, melanoblasts move to the migration staging area (MSA) (E11.5), a structure between the neural tube and somites where melanoblasts pause before traveling upon the dorsolateral migration pathway (E12.5).[48] Other markers of melanoblast specification such as the melanogenic enzymes Dct and TYRP1 are expressed at this stage.[49] Melanoblasts then migrate laterally through the dermis, and at E12.5-13.5 melanoblasts enter the epidermis in a synchronous wave.[50] The mechanisms underlying homing and migration of melanocytes to the epidermis are incompletely understood. At around E15.5, clusters of epidermal melanoblasts migrate and populate the hair follicles. Melanocytes express the key melanogenic enzyme

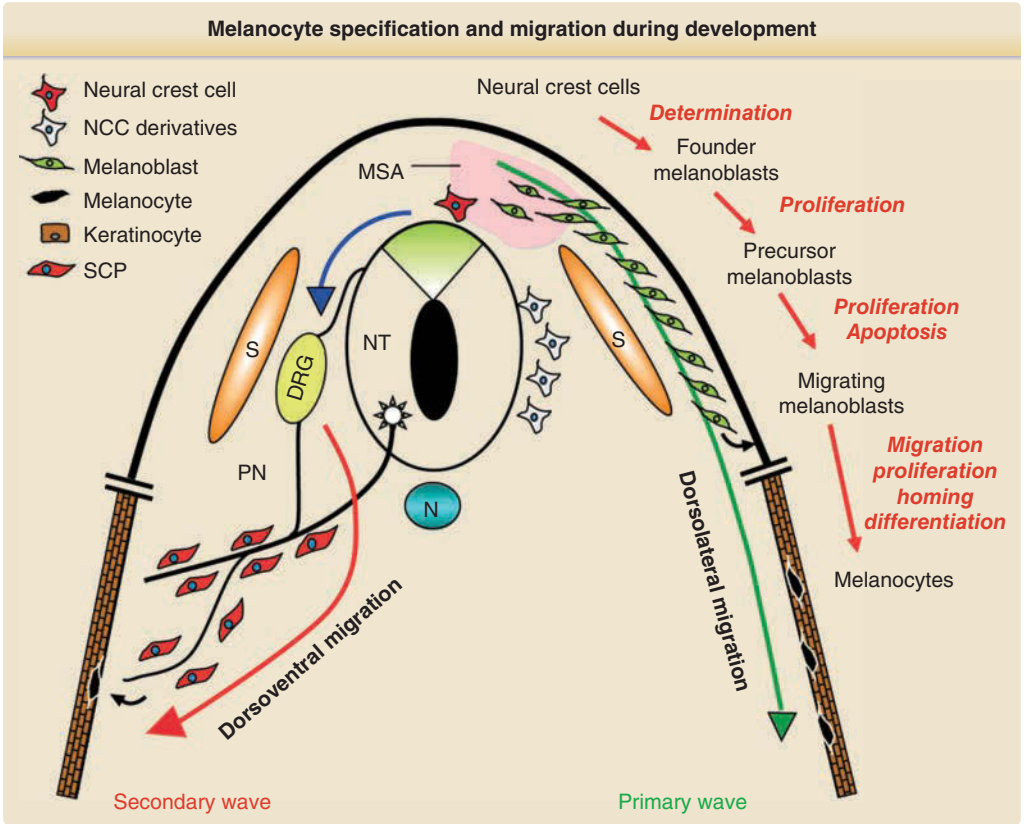

Figure 20-3 Melanocyte specification and migration during development. Upon exiting the neural tube, melanoblast precursors stall in the migration staging area (MSA), then move between the somites (S) and the ectoderm to migrate along the dorsolateral pathway (*green arrow*). Schwann cell precursors (SCPs) move through the dorsoventral pathway (*blue arrow*) in between the somites (S) and the neural tube (NT). A second wave of melanocytes (*red arrow*) arises from the SCPs. (From Bonaventure J, Domingues MJ, Larue L. Cellular and molecular mechanisms controlling the migration of melanocytes and melanoma cells. *Pigment Cell Melanoma Res*. 26(3):316-25, with permission. Copyright © 2013 John Wiley & Sons.)

tyrosinase by E14.5 and display pigmentation by E16.5. In mice, interfollicular epidermal melanocytes disappear during early postnatal life, while this population persists in humans.[51]

Though there is evidence of melanoblast specification at early developmental stages, there is controversy over whether neural crest cells and more specified precursors, such as melanoblasts, retain multipotency and give rise to multiple cell types. In vitro evidence suggests that migratory neural crest cells can give rise to multiple neural crest cell derivatives.[52,53] Similarly, melanoblasts and differentiated melanocytes isolated from the skin can exhibit multipotency when placed in culture.[54,55] Although the in vivo multipotency of neural crest cells has long been subject of debate, recent genetic lineage–tracing studies have provided exciting evidence that in vivo most premigratory and migratory neural crest cells give rise to multiple cell types, demonstrating that neural crest cells previously thought to be specified to a certain fate likely retain developmental plasticity.[56,57] This same plasticity may play an important role in the development of melanoma. In a zebrafish model, melanocytes reactivate markers of neural crest progenitors at the earliest stages of cancerous transformation.[58]

FACTORS THAT REGULATE MELANOCYTE DEVELOPMENT, SURVIVAL, AND MIGRATION

Characterization of mutations causative of mouse and human genetic pigmentary disorders (Table 20-1) has allowed the identification of networks of genes that are important for melanocyte formation, migration, and survival. Transcription factors have been shown to play a key role in directing the specification of neural crest precursors to the melanocyte fate. Receptors expressed by melanoblasts and melanocytes and their cognate growth factor ligands also are important for establishment and maintenance of the melanocyte fate. Many of these different factors also play key roles in the pathogenesis of melanoma.

TRANSCRIPTION FACTORS

MITF: Microphthalmia-associated transcription factor (MITF) is a basic helix-loop-helix leucine-zipper

(bHLHzip) transcription factor first identified as the gene mutated in *microphthalmia* mice, which, in addition to defects in retinal pigment epithelium, osteoclasts, and mast cells, exhibit loss of melanocytes of the skin and inner ear.[59] Soon after, germline mutations in MITF were identified in humans with Waardenburg syndrome type 2a, characterized by pigmentation defects and hearing loss.[60] The molecular characterization of MITF revealed a gene encoding multiple isoforms, each with a variable first exon spliced to common downstream exons 2-9.[61] The melanocyte-specific isoform (m-MITF) is downstream of promoter elements that specify transcription only in melanocytes, whereas other isoforms are generally more ubiquitously expressed.[62] The regulation of the promoter of m-MITF has been well characterized and MITF is positively regulated by other transcription factors important for neural crest development including SOX10 and PAX3 (Fig. 20-4). The developmental roles of these factors are vividly illustrated by the phenotypic consequences of their germline disruption, as occurs in the sensorineural deafness and pigmentation syndromes known as Waardenburg syndrome types 1 through 4. Of these factors, MITF (in particular the melanocyte-specific isoform m-MITF) is most lineage selective in specifying melanocyte differentiation, whereas SOX10 and PAX3 regulate expression of other lineages, including certain muscle groups and enteric ganglia/neurons. Correspondingly, mutation of MITF results in prominent pigment cell–related phenotypes whereas mutations of SOX10 and PAX3 produce pigment cell defects as well as certain nonpigmentary phenotypes (such as megacolon for SOX10).

MITF has been shown to be required for the survival, proliferation and differentiation of melanocytes. At the molecular level, MITF binds to specific E-box sequences containing the core hexanucleotide consensus element CA[C/T]GTG which is present in promoters or enhancers of numerous pigmentation-related genes.[63] Through recognition of this element, MITF drives expression of genes regulating melanin synthesis and melanosome biogenesis, including tyrosinase, TYRP1, DCT, PMEL17/silver, MLANA, and Rab27a, proliferation genes such as Cyclin-Dependent Kinase 2 (CDK2), whose genomic location is so close to PMEL17 that both are uniquely coregulated by MITF in the melanocyte lineage, and survival genes such as the antiapoptotic factors B-cell lymphoma 2 (BCL2) and BCL2a1.[64-66] MITF acts as an oncogene and is amplified in a subset of melanoma.[67] It is also subject to recurrent activating germline or sporadic mutation.[68] Activity of MITF is regulated posttranslationally by phosphorylation, ubiquitination, and sumoylation (Fig. 20-4). Sumoylation of MITF mildly reduces its transcriptional activity at genes containing multiple MITF-binding sites.[69] The E318K MITF polymorphism found at low frequency in European, North American, and Australian populations is associated with significantly increased melanoma risk, an effect likely mediated by disruption of a consensus MITF sumoylation site.[68]

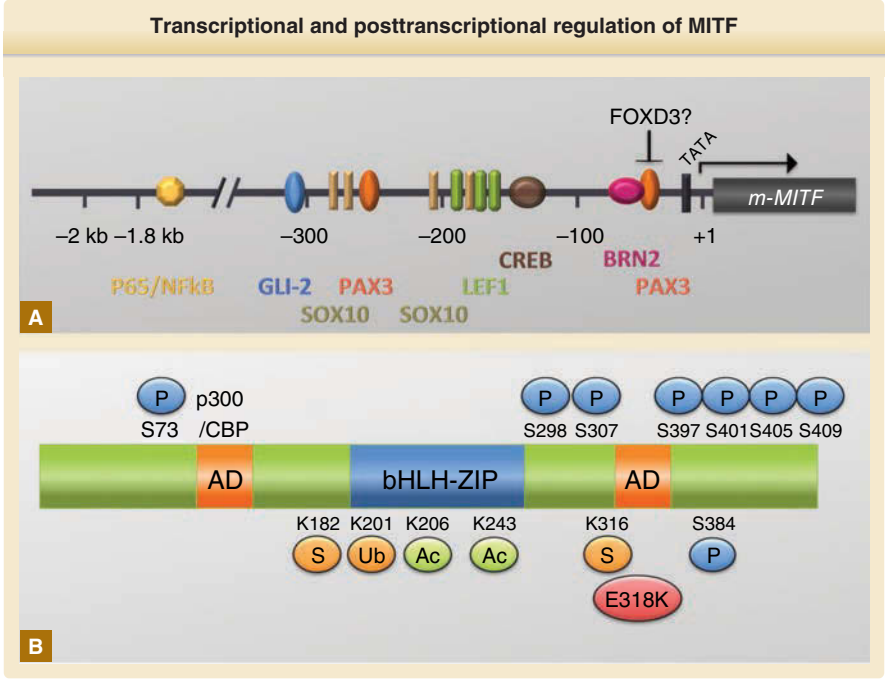

Figure 20-4 Transcriptional and posttranscriptional regulation of MITF. **A,** The proximal melanocyte-specific MITF (m-MITF) promoter contains binding sites for transcription factors, including SOX10, PAX3, CREB, and LEF1. Negative regulators of the m-MITF promoter include Brn2 and FOXD3. **B,** MITF is posttranslationally modified by several mechanisms, including phosphorylation (P), sumoylation (S), and ubiquitination (Ub). Kit signals via ERK to phosphorylate MITF at Serine 73 to positively regulate MITF activity. Sumoylation of K316 negatively regulates MITF; K316 sumoylation site is disrupted by E318K mutation. (Adapted from Wellbrock C, Arozarena I. Microphthalmia-associated transcription factor in melanoma development and MAP-kinase pathway targeted therapy. *Pigment Cell Melanoma Res*. 2015;28(4):390-406.)

PAX3: Paired Box 3 (PAX3) is a transcription factor critical for development of the neural tube.[70] PAX3 is one of the earliest markers of the neural crest, and PAX3 mutation in mice, in addition to pigmentation defects, results in abnormalities of neural crest derivatives of the sensory and sympathetic ganglia, Schwann cells, and cardiac neural crest.[71] PAX3 was subsequently found to be mutated in human Waardenburg syndrome types 1 and 3 (hearing loss, pigmentation defect, arm and hand developmental defects).[72] Pigmentation defects caused by mutation of PAX3 may be explained by a defect in melanoblast proliferation during development.[73] PAX3 has been shown to be a positive regulator of the MITF promoter in melanocytes and melanoma.[74,75]

SOX10: SRY-Box 10 (SOX10) is a transcription factor first identified as being mutated in Waardenburg type IV (Waardenburg plus megacolon) and is required for development of neural, glial, and melanocyte neural crest lineages.[76,77] SOX10 is first expressed in premigratory neural crest cells, and loss of SOX10 during development leads to complete absence of melanoblasts.[78] Recent studies using transgenic mouse models and human melanoma cell lines have demonstrated that SOX10 function is required for survival of postnatal melanocytes, melanocyte stem cells, nevi, and melanoma.[79,80] SOX10 likely mediates many of its effects on melanocyte and melanoma survival through regulation of MITF expression.[81]

SOX2: The transcription factor SOX2 plays key roles in stem cell maintenance and is one of 4 transcriptions factors required for reprogramming of somatic cells to induced pluripotent stem cells.[82] SOX2 has recently been shown play a role in specifying the melanocyte lineage during development. SOX2 binds and represses the MITF promoter. Gradual downregulation of SOX2 in Schwann cell precursors allows increased expression of MITF and emergence of the melanocyte population.[83] SOX2 also has been shown to downregulate MITF in cultured human melanocytes and human melanoma.[84]

FoxD3: Forkhead Box D3 (FoxD3) is a transcription factor that is upregulated early during neural crest development and is important for establishing the neural crest lineage. Loss of FoxD3 early in development leads to the loss of most neural crest–derived structures.[85] During later stages of neural crest development, FoxD3 acts to modulate specification of neural crest derivatives. FoxD3 actively represses MITF to favor the Schwann cell fate whereas downregulation of FoxD3 favors the melanocyte fate.[86]

GROWTH FACTOR SIGNALING

Ednrb: Endothelin receptor type B (Ednrb) is a G-protein–coupled receptor that activates several signaling pathways, including include protein kinase C (PKC), mitogen-activated protein kinase (MAPK) and cAMP/PKA. Ednrb agonists, the endothelins, are encoded by 3 genes: Endothelin 1 (Edn1), Edn2, and Edn3. Although all 3 endothelins can bind Ednrb with similar efficiency, and Edn1 has been shown to initiate melanogenesis in cultured melanocytes, Edn3 seems to be the important ligand during melanocyte development. In humans, Ednrb mutation results in Hirschsprung disease, whereas Edn3 mutation results in Waardenburg plus megacolon, suggesting roles in the development of melanocytes as well as other neural crest derivatives.[87,88] Although it does not seem to be required for the initial specification of melanoblasts, Ednrb has been shown to be required mainly for proper melanoblast migration.[89,90] Activation of Endothelin signaling also has been shown to induce melanocyte proliferation and skin pigmentation.[91,92]

c-Kit: The receptor tyrosine kinase c-Kit and the cognate Kit ligand (KITLG) (also known as Steel factor or stem cell factor/SCF) play important roles during melanocyte development. KITLG exists in transmembrane and soluble forms and in the skin is produced by endothelial cells and keratinocytes.[93] In humans, the heterozygous mutation of c-Kit results in piebaldism, which is characterized by a depigmentation of the forelock and abdominal skin.[94] Mutation of c-Kit or KITLG in mice results in loss of melanocytes.[95,96] Although c-Kit signaling does not appear to be necessary for the specification of melanoblasts, on c-Kit deficiency, the melanoblasts soon disappear after migration from the neural tube.[97]

c-Kit also plays important roles in regulating survival and differentiation/pigmentation of mature melanocytes. Blocking antibodies to c-Kit in human skin explants or adult mouse skin results in loss of melanocytes.[98,99] Conversely, KITLG injection to human skin explants increased the number, dendricity, and melanogenesis of melanocytes. Recently, polymorphism in KITLG has been shown to cause familial progressive pigmentation (FPH) and familial progressive hyper- and hypopigmentation (FPPH), 2 conditions that share the feature of enlarging hyperpigmented patches corresponding to increased melanization without change in melanocyte number.[100,101] Activating mutations and amplification of c-Kit drive the progression of a subset of acral lentiginous, mucosal, and lentigo maligna melanomas.[102] Whereas c-KIT signaling has been shown to cause MAPK-dependent phosphorylation and activation of MITF, additional mechanisms by which KIT signaling affects melanocyte survival and differentiation are poorly understood.[103]

Wnt/β-Catenin: β-Catenin is an evolutionarily conserved protein that plays key roles in developmental signaling. The multiprotein membrane destruction complex, consisting of APC, Axin1/2, and GSK3β, target β-catenin for phosphorylation and ubiquitin-dependent degradation. Canonical Wnt signaling involves binding of a Wnt family ligand to a Frizzled family receptor, which signals through Dishevelled to inhibit the membrane destruction complex, allowing for β-catenin to enter the nucleus and interact with LEF/TCF family transcription factors to activate gene transcription. Experimental evidence supports that

activating β-catenin, at least during a certain window of melanoblast migration, leads to increased proliferation and differentiation of melanocytes.[104,105] Mechanistically, β-catenin-LEF/TCF complexes have been shown to transcriptionally regulate MITF in cultured melanocytes and melanoma cells.[106] β-Catenin pathway activation also potentiates melanoma formation and metastasis in mouse models.[107,108]

Neuregulin/ErbB2/ErbB3: It has recently been reported that some melanocytes are derived from Schwann cell precursors that travel along the ventral migratory pathway.[32] The ErbB2/ErbB3 heterodimer tyrosine kinase receptor controls Schwann cell proliferation, migration, and myelination. The ligand for this receptor, neuregulin, promotes the Schwann cell fate and represses the melanocyte fate. Loss of ErbB3 or neuregulin during development decreases the number of Schwann cells and increases the number of ventrally migrated melanocytes.[32] Other signals that regulate the formation of Schwann cell–derived melanocytes during embryonic development remain to be identified.

REGULATION OF MELANOCYTE MOTILITY AND MIGRATION

Rac1: Rac1 belongs to the Rho superfamily of GTPases. Similar to other Rho GTPases, Rac1 exhibits an active conformation when bound to GTP and has well known roles in cellular migration through regulation of the actin cytoskeleton.[109] When Rac1 is deleted from melanoblasts during mouse development, melanoblasts migrate less efficiently as a result of impairment of Scar/WAVE and Arp2/3 actin regulatory complexes.[110] However, Rac1-deficient melanoblasts are still able to cross the dermal–epidermal junction and home normally to hair follicles. Recurrent activating mutations in Rac1 have been found in 9% of sun-exposed melanomas.[111] Mutation of PREX2, a guanine nucleotide exchange factor (GEF), occurs frequently in human melanomas, and these mutations may promote melanoma through activation of Rac1.[112] Loss of function of PREX1, another Rac-specific GEF, impairs melanoblast migration and melanoma metastasis in a mouse model.[113]

MELANIN AND THE MELANOSOME

There are 2 forms of melanin, eumelanin and pheomelanin, that are both derived from the precursor tyrosine. Tyrosinase converts tyrosine to dopaquinone and is a key enzyme regulating both eumelanogenesis and pheomelanogenesis. Melanin synthesis occurs in the melanosome, a specialized lysosome-related organelle. Human skin pigmentation requires both the biogenesis of melanosomes and delivery of melanogenic proteins and enzymes to the melanosome, as well as proper trafficking of the melanosome to the keratinocyte.

STRUCTURE AND FUNCTION OF MELANIN

Eumelanin (brown/black) and pheomelanin (yellow/orange) represent the 2 main forms of melanin in humans and other mammals. Eumelanin is a macromolecule composed of polymers of 5,6-dihydroxyindole (DHI; insoluble in strong alkali, black) and the carboxylate form 5,6-dihydroxyindole-2-carboxylic acid (DHICA; partially soluble in strong alkali, lighter black/brown).[114] Pheomelanin is a complex macromolecule formed by oxidation and polymerization of sulfur-containing cysteinyldopa. Pheomelanin is highly soluble in alkali.[114] The solubility of melanin may be clinically relevant, as it has been suggested that melanin degradation products can escape the melanosome and enter the nucleus to contribute to DNA damage.[115]

Pigmentation of human skin offers protection against UV-induced sunburn and DNA damage.[116-118] Skin pigmentation also protects against UV-induced skin cancer in humans, as evidenced by increased risk of nonmelanoma skin cancer in patients with albinism and lighter/fair-skinned individuals, and decreased skin cancer risk in human populations of darker skin types.[117,119] Similarly, skin pigmentation inhibits UV-induced carcinogenesis in animal models.[120,121] Melanin, and in particular eumelanin, can shield against UV radiation, though it has been demonstrated that pigmented skin or dispersed melanosomes offer only a relatively low sun protection factor (SPF).[122] Thus, melanin may have other functions in protecting against UV-induced damage. In line with this, eumelanin has been shown to scavenge UV-induced reactive oxygen species (ROS) to minimize UV damage.[123]

Pheomelanin, on the other hand, not only has decreased shielding property against UV radiation, but evidence also suggests that pheomelanin may act as a pro-oxidant. Several studies have shown that UVA reacts with purified pheomelanin to generate free radicals.[124,125] It also has been demonstrated that ROS generated by UVA interacts with pheomelanin, and to a lesser extent eumelanin, leading to melanin degradation products that induce cyclobutane pyrimidine dimer (CPD) formation long after UV exposure has ended—the so-called dark CPD. CPDs were previously thought to only be caused by immediate and direct photochemical interaction of UV with DNA, and this new mechanism could explain melanocyte-specific CPD formation that is exacerbated by the presence of pheomelanin.[115] In addition, a recent study demonstrated that in a melanoma-prone BRAF (V600E) genetically engineered mouse model, the presence of Mc1r dysfunction (the "red hair, fair skin" phenotype) was associated with significantly increased risk of melanoma in the *absence* of UV, and correlated with increased ROS in the skin of pheomelanotic mice. This effect was abrogated by introduction of a tyrosinase loss-of-function mutation (albino-redheads), suggesting that elevated melanoma risk in the red-haired background was indeed traceable to the pheomelanin synthesis pathway. These data suggest the existence of both UV-mediated and

UV-independent mechanisms through which pheomelanin contributes to melanoma formation, presumably via ROS-mediated DNA damage, to promote melanoma.[126] Recent data in humans have corroborated the murine findings, showing that melanoma risk is higher in red-haired/fair-skinned individuals even after normalization/correction for UV exposure, as defined by a set of UV damage indicators.[127,128]

MELANIN SYNTHESIS

TYROSINASE AND OTHER MELANOGENIC ENZYMES

The first step in the synthesis of both eumelanin and pheomelanin is oxidation of tyrosine to dopaquinone by the enzyme tyrosinase. Tyrosinase was first isolated from mushroom in 1895, and tyrosinase activity was first demonstrated in normal human skin by Fitzpatrick et al in 1950.[129] Tyrosinase requires binding of copper for proper function, and delivery of copper to the melanosome by ATP7A transporter is required for normal tyrosinase function.[130]

Two tyrosine-related proteins (TYRP), TYRP1 and TYRP2/Dopachrome tautomerase (DCT), show significant homology to tyrosinase and play key roles in melanogenesis. As discussed below, these proteins have distinct catalytic functions in eumelanin synthesis downstream of tyrosinase. In addition, TYRP1 and DCT complex with tyrosinase and have been shown to be important for proper trafficking and stabilization of tyrosinase.[131] Defects of tyrosinase, TYRP1, and DCT cause oculocutaneous albinism in humans. Two other genes mutated in human albinism, *OCA2* (P-protein) and *SCL45a2* (MATP, AIM, "underwhite" mutant) encode transporters whose functions are not clearly determined, but seem to be important for proper tyrosinase trafficking and melanosome maturation.[132-135]

EUMELANOGENESIS

Dopaquinone spontaneously undergoes intramolecular cyclization to form cyclodopa. Cyclodopa then undergoes redox exchange with a second molecule of dopaquinone to form dopachrome and dopa.[136] Dopachrome spontaneously decarboxylates to form DHI (less soluble, black) and DHICA (more soluble, lighter black/brown). Although the uncatalyzed reaction favors DHI formation, the presence of the (DCT) protein favors production of DHICA.[137] DHI and DHICA are then oxidized and polymerized to form eumelanin. TYRP1 exhibits DHICA-oxidase activity, promoting incorporation of DHICA into eumelanin (Fig. 20-5).[138]

PHEOMELANOGENESIS

Nonenzymatic addition of sulfhydryl groups to dopaquinone results in the formation of 5-*S*-cysteinaldopa and 2-*S*-cysteinaldopa. Cysteine serves as a major source of sulfhydryl groups, with the other source being glutathione. It has been shown that cysteinaldopa synthesis predominates in the presence of cysteine, whereas in cultured cells high tyrosine and/or low cysteine favor eumelagenesis.[139-141] Cysteinaldopa then undergoes redox exchange with dopaquinone to produce cysteinaldopaquinones. Oxidation and cyclization of cysteinaldopaquinones is followed by dehydration, rearrangement, and decarboxylation to form benzothiazole intermediates. The benzothiazole intermediates then polymerize to form pheomelanin (Fig. 20-5).

THE MELANOSOME

Melanosomes are lysosome-related organelles that exist only in melanocytes and retinal pigment epithelium. They are the main sites of synthesis and storage of melanin. Mutations in human disease syndromes that result in melanosome dysfunction, causing hypopigmentation in addition to dysfunction of other lysosome-related organelles, have resulted in identification of pathways involved in melanosome biogenesis.

STRUCTURE OF THE MELANOSOME

As described above, melanosomes have been classified by electron microscopy into morphologic stages that correspond to degree of maturation. As melanosomes mature, the key ultrastructural feature is the appearance of the parallel fibrillar network; PMEL (also known as gp100 or silver) is a pigment cell–specific protein that has been shown to be the main component of these structures. The intraluminal vesicles of stage I melanosomes have been shown to be the first site of PMEL deposition. The transmembrane PMEL protein is cleaved within the stage I and II melanosomes by the beta-site APP-cleaving enzyme 1 (BACE1) to release intraluminal amyloidogenic fragments with the capability to oligomerize.[142] The PMEL protein represents a remarkable setting in which protein aggregation, mediated by amyloid-related interactions, participate in a physiologic process: organization and deposition of melanin pigments within the melanosome organelles. Stage II melanosomes are identified by increased organization of PMEL amyloid into visible proteinaceous fibrils, which push the intraluminal vesicles outward to fuse with the melanosome membrane. 3D electron microscopy has shown that the fibrils visible on EM sections actually represent parallel sheets.[143,144] Stage III melanosomes become increasingly pigmented as melanogenic enzymes are delivered and melanin synthesis proceeds. Stage IV melanosomes are fully pigmented, and tyrosinase activity and melanin synthesis has ceased. Pheomelanosomes also have been characterized ultrastructurally in humans and other mammals, and are smaller, spherical in shape, with a granular and microvesicular, rather than fibrillar, matrix, and with microgranular and spotty melanization.[16,18] Although it is tempting to contrast pheomelanotic melanosomes

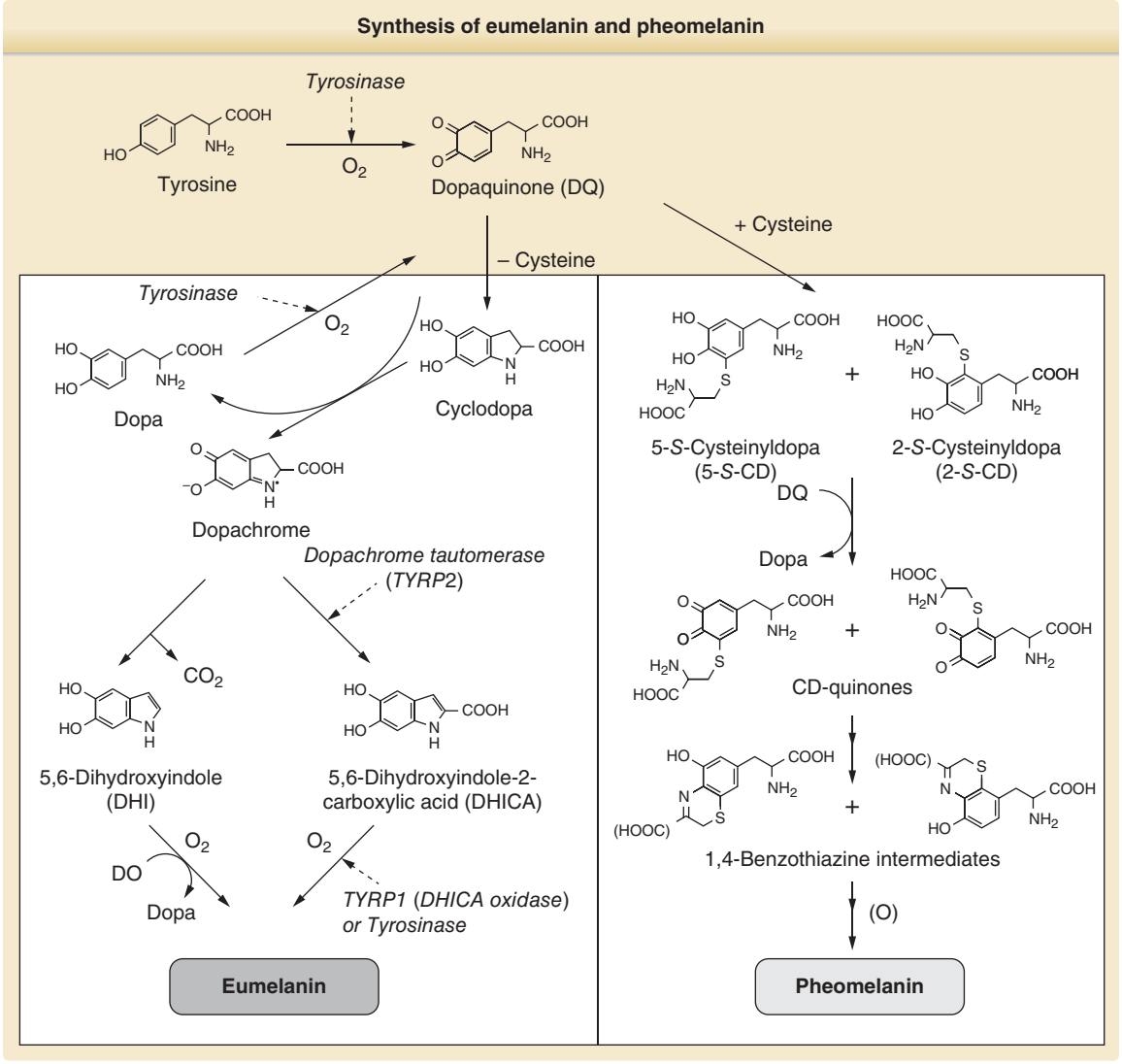

Figure 20-5 Synthesis of eumelanin and pheomelanin. Tyrosinase (TYR) is needed to generate dopaquinone (DQ) from tyrosine. DQ is the common precursor of eumelanin and pheomelanin. The enzymes tyrosinase-related protein1 (TYRP1) and TYRP2/dopachrome tautomerase are also involved in eumelanin synthesis. (From Ito S, Wakamatsu K. Chemistry of mixed melanogenesis-pivotal roles of dopaquinone. *Photochem Photobiol.* 84(3):582-92, with permission. Copyright © 2007 John Wiley & Sons.)

as differing primarily in the specific melanin species (pheomelanin vs eumelanin), it is important to recall that other melanosomal constituents also differ in the setting of MC1R variants associated with red hair, because MITF resides downstream of MC1R and regulates the expression of pigment enzymes as well as numerous melanosomal factors including PMEL, tyrosinase, TRP1, and DCT.[145]

MELANOSOME BIOGENESIS AND TRAFFICKING

Although melanosomes express some lysosomal proteins and derive from the endosomal pathway, they require unique sorting and trafficking pathways for their formation.[146] Newly synthesized PMEL traffics to the plasma membrane, and then is transferred via the endosomal pathway to the early melanosome compartment.[147] However, the exact membrane trafficking events that allow specification of the early melanosome as a distinct compartment are not well understood. Stage I melanosomes, though they are accessible to endocytosis tracing compounds and morphologically resemble early multivesicular bodies derived from the endosomal pathway, seem to form independently of the endosomal sorting complex required for transport (ESCRT) machinery needed for the classical multivesicular body pathway.[148]

Melanogenic enzymes are delivered to stage II melanosomes after the fibrillar PMEL network has been deposited, allowing melanin synthesis to begin. It has been recently shown that the recycling endosome compartment plays a key role in delivery of cargoes (tyrosinase, TYRP1, DCT) to the maturing melanosome. The recycling endosome compartment

is composed of interconnected and functionally distinct tubular networks that originate from early endosomes, and transport cargoes along microtubule tracks.[149] Mutations of any of the 10 genes encoding components of the BLOC-1, BLOC-2, BLOC-3, and AP-3 protein complexes have been long known to be responsible for Hermansky-Pudlak syndrome, a heterogeneous group of disorders characterized by hypopigmentation due to melanosome dysfunction in addition to platelet dysfunction, immunodeficiency, and lung fibrosis due to abnormalities of other lysosome-related organelles. Although the mechanism by which BLOC and AP3 complexes act in melanosome- and lysosome-related organelle biogenesis has long been unclear, they have recently been shown to play critical roles in the delivery of melanosomal cargoes in recycling endosomes.

Dysfunction of BLOC complexes cause accumulation of TYRP1 and other melanogenic enzymes within the endosomal compartment, leading to pigmentary abnormalities.[150] Recently, it has been shown that BLOC1 coordinates the action of microtubule- and actin-dependent machineries to allow proper formation and stabilization of recycling endosomal tubules required for transfer of cargoes to melanosomes.[149,151] BLOC-2 acts to properly direct recycling endosomal tubular transport intermediates to maturing melanosomes to promote melanogenic cargo deliery.[152] AP-3 is also important for sorting cargo proteins bound for melanosomes, and in different scenarios can act in concert with or independently of BLOC complexes.[153,154]

The final step in the delivery of cargo to melanosomes is the fusion of cargo-containing vesicle and tubules with the developing melanosome. This process has been shown to involve SNARE proteins that are required for membrane fusion. It has been recently shown that VAMP7 is the SNARE responsible for BLOC-1-dependent delivery of TYRP1 to the melanosome.[155] BLOC-3 is required for the subsequent recycling of VAMP7 after delivery of cargo to the melanosome, suggesting a novel mechanism by which BLOC-3 dysfunction causes pigmentation deficits[155] (Fig. 20-6).

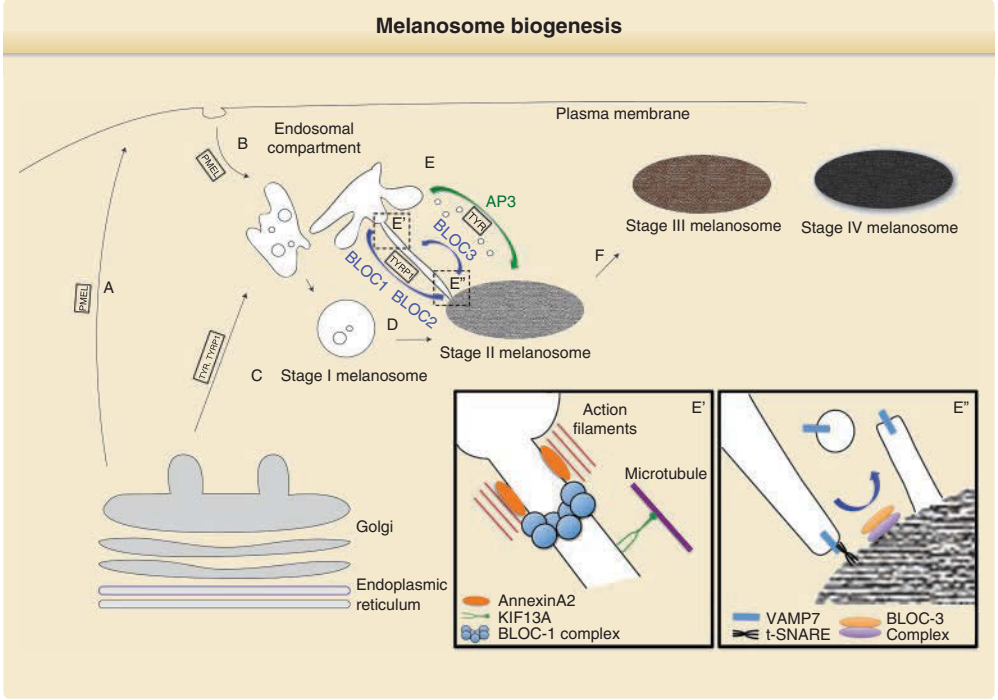

Figure 20-6 Melanosome biogenesis. The endosomal compartment plays a key role in melanosome biogenesis. (A) PMEL protein is largely delivered to the plasma membrane followed by (B) endocytosis to the endosomal compartment and then to early melanosomes. PMEL processing leads to fibril formation within the melanosome. (C) Other melanogenic enzymes such as TYR and TYRP1 are delivered to the endosomal compartment via the Golgi network. (D) Early stage I melanosomes resemble early endosomes but through unknown mechanisms are specified as a distinct compartment. These melanosomes then undergo maturation through stages II to IV. (E) Melanogenic cargoes such as TYR and TYRP1 are transferred from the early endosome/sorting endosomal compartment to stage II/III melanosomes (TYR) via an AP-3-dependent/BLOC-independent vesicular pathway or (TYRP1) via BLOC-dependent transport through recycling endosome tubules. Inset E′ BLOC-1 is required for early elongation of recycling endosome tubules on the actin cytoskeleton and for KIF13A-dependent sustained elongation along microtubules. BLOC-2 then targets these carriers specifically to the melanosome. Inset E″ VAMP7 is the t-SNARE required for fusion of the recycling endosome with the melanosome, allowing delivery of TYRP1 and other melanogenic cargoes. BLOC-3 is required for recycling of VAMP7 back to the recycling endosome.z. (F) After melanogenic cargo has been delivered, melanin synthesis takes place, leading to further maturation of melanosomes.

TRANSFER OF MELANOSOMES TO KERATINOCYTES

Stage IV melanosomes are first transferred to the dendrite tips by kinesin-mediated microtubule-dependent anterograde transport.[156,157] Dynein-mediated retrograde transport of melanosomes away from the melanocyte dendrites has been reported, and the balance of anterograde/retrograde transport may modulate melanosomal distribution after UV expsoure.[157,158] Once the melanosomes reach the actin-rich peripheral dendrite tips, the melanosome is "captured" by a receptor complex to promote peripheral accumulation and eventual transfer to the keratinocyte.[157] The GTPase Rab27a is incorporated into the melanosome membrane by a hydrophobic geranylgeranyl tail. Although Rab membrane association is intimately linked to GTP/GDP cycling, the mechanisms underlying specific targeting of Rab27a to the melanosome membrane are unknown.[159] The adapter protein melanophilin (Mlph) binds Rab27a and serves as a linker to the actin-binding motor protein MyosinVa (MyoVa), allowing transport and retention of melanosomes on the actin cytoskeleton.[160] Disruption of any component of this receptor complex leads to inefficient transfer of melanosomes to surrounding keratinocytes, and mutations in Rab27a, Mlph, and MyoVa have been identified in human patients with Griscelli syndrome (partial albinism and immunodeficiency)[161-163] (Fig. 20-7).

Once accumulated at the dendrite tips, the melanosomes can be transferred to neighboring keratinocytes. Several models have been proposed to mediate this transfer and are supported in varying degrees by experimental evidence. These models include cytophagocytosis, membrane channel, shedding-phagocytosis, and exocytosis models (Fig. 20-8). Several recent papers have given stronger support to the shedding-phagocytosis model, whereby the melanocyte sheds small plasma membrane–bound vesicles containing groups of melanosomes, which are then phagocytosed by the neighboring keratinocyte.[164,165]

Interestingly, activation of some keratinocyte-signaling pathways increases melanosome transfer. Keratinocyte growth factor (KGF), a fibroblast growth factor family member, promotes phagocytosis and transfer of melanosomes from melanocytes to keratinocytes.[166] Protease-activated receptor-2 (PAR2) activation increases phagocytosis and melanosome uptake by keratinocytes.[167] Interestingly, PAR2 expression and activity are highest in keratinocytes derived from those with darker skin type, suggesting a role in regulation of human pigmentation variation.[168]

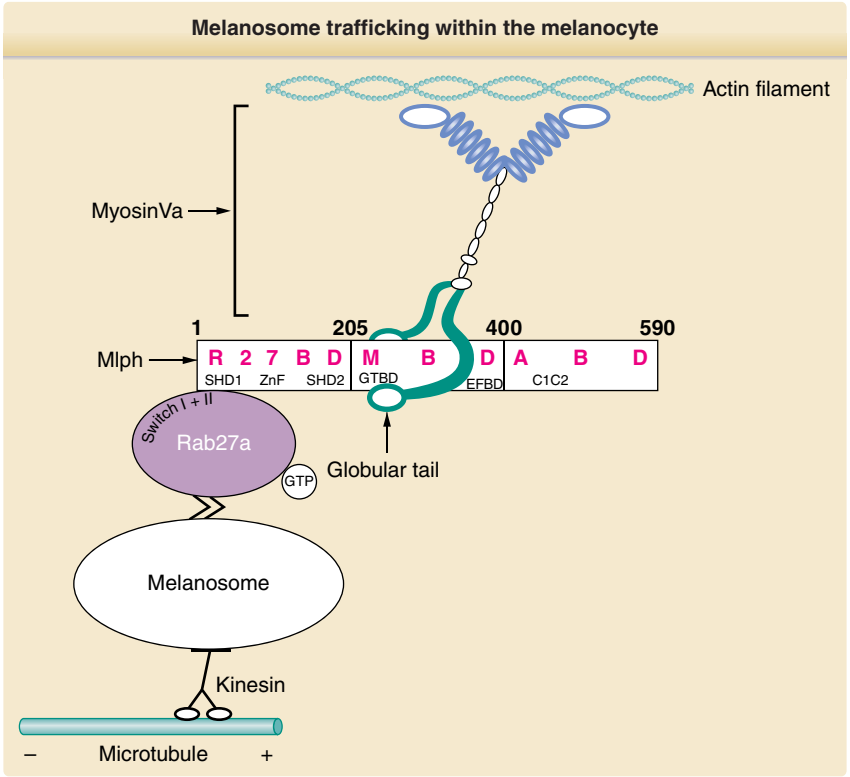

Figure 20-7 Melanosome trafficking within the melanocyte. In melanocytes, activated Rab27a localizes to the surface of mature melanosomes that have been delivered to the cell periphery on microtubules via the motor protein kinesin. On arrival to the cell periphery, melanophilin binds directly to Rab27a. Finally, MyoVa is recruited to the Rab27a–Mlph complex through a direct interaction between the MyoVa globular tail and Mlph. The stable Rab27a–Mlph–MyosinVa complex captures the melanosomes in the actin-rich dendritic tips, a necessary step for retention of the melanosome in the periphery before transfer of melanosomes to the surrounding keratinocytes. (Adapted from Van Gele M, Dynoodt P, Lambert J. Griscelli syndrome: a model system to study vesicular trafficking. *Pigment Cell Melanoma Res*. 2009;22(3):268-82, with permission. Copyright © 2009 John Wiley & Sons.)

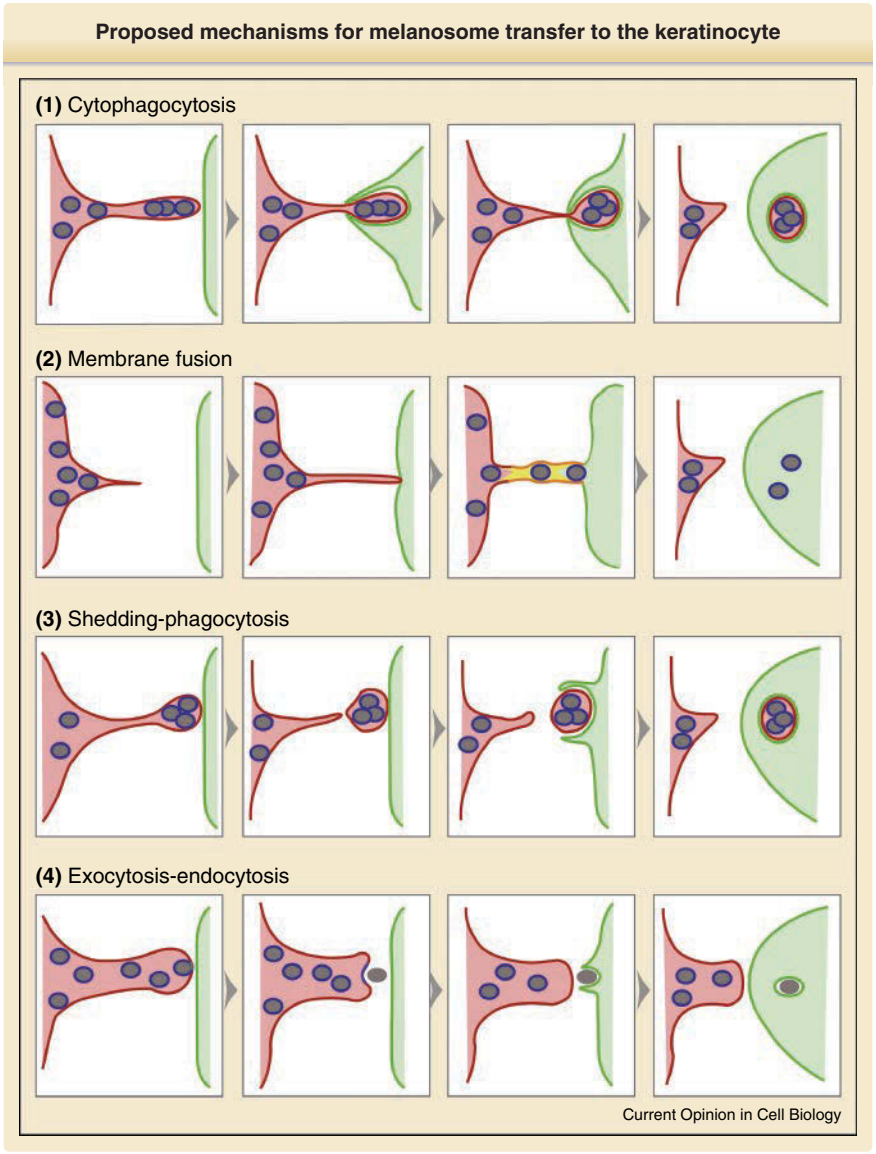

Figure 20-8 Proposed mechanisms for melanosome transfer to the keratinocyte. Cytophagocytosis model—the dendrite tip containing melanosomes is directly phagocytosed by the keratinocyte (KC) membrane. Membrane fusion model—the dendrite tip fuses with the KC membrane forming a channel through which melanosomes are trafficked. Shedding-phagocytosis model—the dendrite tip containing melanosomes buds off and is then engulfed by the KC. Exocytosis-endocytosis—individual melanosomes are exocytosed and then endocytosed by the KC. The limiting membrane of the melanosome (*blue*), the plasma membrane of the melanocyte (*red*), and the plasma membrane of the keratinocyte (*green*). (From Wu X, Hammer JA. Melanosome transfer: it is best to give and receive. *Curr Opin Cell Biol*. 2014;29:1-7, with permission. Copyright © Elsevier.)

TRAFFICKING AND DEGRADATION OF MELANOSOMES WITHIN THE KERATINOCYTE

After transfer to the keratinocyte, melanosomes are transferred by dynein-mediated retrograde transport to a perinuclear location ("nuclear capping") to protect basal keratinocytes from UV-induced DNA damage.[169] It has long been known that although the number of melanocytes does not differ between individuals of different skin types, the number, size, and distribution of melanosomes within keratinocytes shows marked racial variability.[2,170,171] Although melanosomes are primarily situated over the nucleus in all skin types, in light-skinned individuals, melanosomes are smaller, and are grouped in membrane-enclosed clusters of 4 to 8 melanosomes, whereas in darker-skinned individuals, melanosomes are larger, more numerous, and are distributed individually.[2,172] In cell culture, the skin type of the donor keratinocytes regulates the distribution of phagocytosed melanosomes.[173,174]

After localization over the nucleus of basal keratinocytes, melanosomes are thought to be degraded during the keratinocyte terminal differentiation process, as in corneocytes melanosome structures

are only rarely identified, even in individuals of the darkest skin types.[175] Several recent studies have demonstrated that keratinocytes derived from darker-skinned individuals degrade melanosomes more slowly, possibly through impairment of autophagy mediated degradation[176,177]

REGULATION OF HUMAN PIGMENTATION VARIATION

In humans and mice, there are genetic variants that favor eumelanogenesis over pheomelanogenesis. In addition, pigmentation can be induced by UV radiation. It has been shown that both the eumelanin/pheomelanin "switch" and UV-induced tanning are regulated by the MSH-MC1R-MITF pathway. The MC1R pathway also regulates other important functions of melanocytes. Other factors that regulate variations in pigmentation of human populations have been recently identified.

MSH-MC1R-MITF PATHWAY

MC1R SIGNALING

Melanocortin 1 receptor (MC1R) is a G-protein–coupled receptor (GPCR) expressed primarily by melanocytes. Similar to other GPCRs, MC1R is composed of 7 alpha-helical transmembrane domains. MC1R signaling has been shown to play a critical role in determining if a melanocyte produces predominantly eumelanin or pheomelanin. It was first discovered that inactivating mutation of *MC1R* was responsible for the reddish coat color phenotype in mice with mutation at the *extension* locus.[178] Soon after, Valverde and colleagues demonstrated that *MC1R* is highly polymorphic in human populations, and that common loss-of-function variants of *MC1R* are associated with the "red hair phenotype" characterized by red hair, fair skin, and inability to tan.[179] Activating mutations that cause constitutive activation of MC1R lead to darkening of coat color in mice.[178]

MC1R signaling is highly regulated by extracellular ligands. The canonical agonist for MC1R is α-melanocyte stimulating hormone (α-MSH). α-MSH is a key regulator of vertebrate pigmentation that was first shown by Lerner and Fitzpatrick to induce pigmentation when injected into human skin.[180] α-MSH is derived from proteolytic processing of its precursor proopiomelanocortin (POMC) (Fig. 20-9). Cleavage of POMC also generates other important signaling ligands, including β-endorphin and ACTH. Human patients with *POMC* gene mutation, in addition to endocrine dysfunction mediated by loss of action of MSH/POMC at MC4R, display the red hair phenotype, mediated by decreased signaling at MC1R.[181] Agouti protein acts as an antagonist (formally described as a "reverse agonist" that can suppress even ligand-independent activity) of MC1R signaling. Activating mutations of agouti leads to increased pheomelanin production and red-blond hair in the mouse.[182,183] Although a role for the homologous human protein agouti signal protein (ASIP) in regulating human pigmentation long remained unidentified, recent studies have linked variants in *ASIP* to skin sensitivity to sun, freckling and red hair, and skin cancer in human populations.[184,185]

As a G coupled protein receptor, it has been demonstrated that MC1R is coupled to the heterotrimeric G protein. Upon activation of MC1R, the Gαs subunit

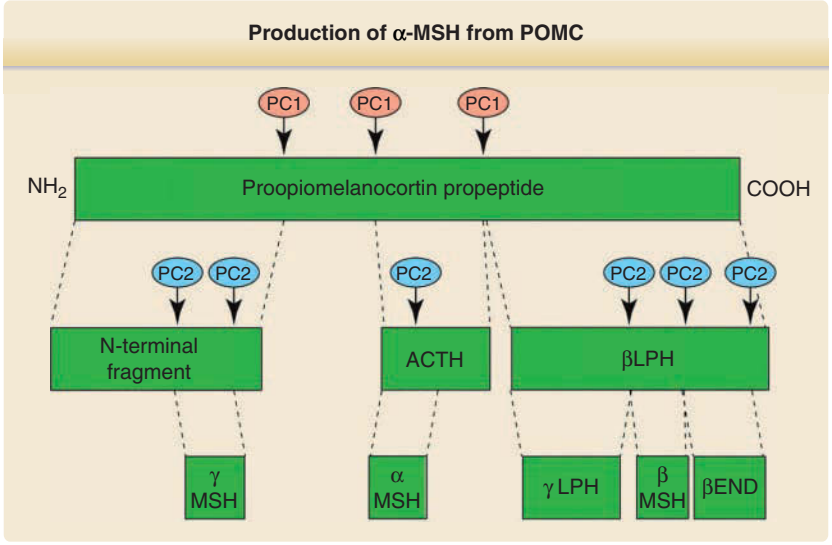

Figure 20-9 Production of α-MSH from POMC. Proopiomelanocortin (POMC) protein is cleaved into by a pair of serine protease pro-protein convertases, PC1 and PC2. PC1 cleaves POMC into 4 subunits, including an N-terminal region from which γ-MSH is derived, adrenocorticotropic hormone (ACTH), and β-lipotropin (β-LPH). α-MSH overlaps with the first 13 amino acids of ACTH and is generated by PC2 cleavage. (From Wolf Horrell EM, Boulanger MC, D'Orazio JA. Melanocortin 1 receptor: structure, function, and regulation. *Front Genet*. 2016 May 31;7:95, with permission.)

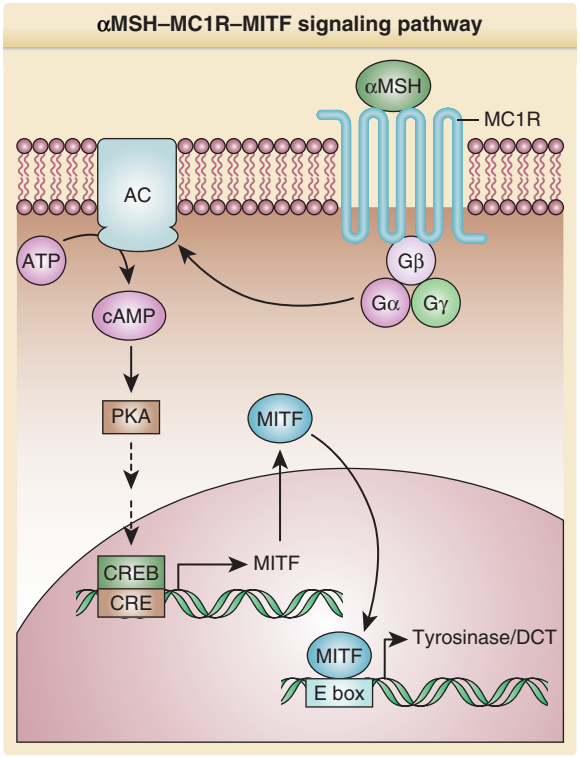

Figure 20-10 αMSH–MC1R–MITF signaling pathway. αMSH binds the melanocortin-1 receptor (MC1R), leading to G-protein activation of adenylyl cyclase. Adenylyl cyclase catalyzes the conversion of cytoplasmic ATP to cyclic AMP (cAMP). Increased intracellular cAMP activates protein kinase A (PKA), which then translocates to the nucleus to phosphorylate the CREB (cAMP-responsive-element binding protein) family of transcription factors. Phosphorylated CREB proteins induce expression of genes, including MITF. MITF binds to the conserved E boxes to induce activation of the expression of pigmentation genes such as tyrosinase and DCT. (Adapted by permission from Springer Nature: Chin L. The genetics of malignant melanoma: lessons from mouse and man. *Nat Rev Cancer*. 3(8)559-70. Copyright © 2003.)

dissociates and stimulates adenylyl cyclase activity, resulting in formation of the second messenger cyclic AMP (cAMP) from ATP (Fig. 20-10). cAMP binds to and activates protein kinase A (PKA). PKA phosphorylates and activates the transcription factor CREB. CREB binds to target DNA sequences, including those in the m-MITF promoter, increasing transcription of MITF and ultimately resulting in upregulation of MITF target genes related to melanogenesis (Fig. 20-10). Stimulation of MITF by other pathways also has been shown to increase melanogenesis. Phosphodiesterase D4 (PDED4) is transcriptionally activated by MITF in melanocytes and serves as a negative feedback regulator that degrades cAMP. Inhibition of PDED4 activates MITF expression and stimulates pigmentation in red-haired mice, toward dark brown/black melanin.[186] PPAR-gamma coactivator (PGC)-1alpha and PGC-1beta are transcriptional coactivators primarily involved in oxidative metabolism that have been shown to stimulate melanogenesis through upregulation of MITF.[187]

UV-INDUCED TANNING AND THE MC1R PATHWAY

Human pigmentation is categorized into constitutive and inducible responses. Inducible pigmentation after UV exposure (sun tanning) has 2 components that are wavelength dependent. Immediate tanning occurs within minutes to hours after sun exposure, and is mainly a response to UVA radiation. It is most noticeable in darker-skinned individuals and is mediated by oxidation and redistribution of existing melanin. Delayed tanning is mainly a response to UVB and shorter-wavelength UVA radiation and peaks at about 3 days to 1 week after sun exposure. Histologically, delayed tanning is characterized by a modest increase in the number of epidermal melanocytes, increased melanocyte dendricity and transfer of melanosome to keratinocytes, and greater melanization of individual melanosomes.[188] Overall, these factors make delayed tanning much more protective against subsequent sun exposure than immediate tanning.[189]

The inability of individuals with MC1R variants to tan after UV exposure, and the well-known ability of MSH to stimulate pigmentation long suggested a role of the MSH/MC1R pathway in regulation of UV-induced tanning. Studies in mouse models have helped to elucidate the exact nature of this interaction.[121,190] UV radiation of keratinocytes stimulates expression of POMC in a p53 dependent manner (Fig. 20-11). This leads to increased production of α-MSH from the keratinocyte, stimulation of MC1R signaling on the melanocyte, and activation of MITF and melanogenesis (Fig. 20-11). Importantly, in mice with MC1R receptor mutation that have red hair and inability to tan, stimulation of the downstream cAMP/PKA/MITF pathway by application of topical forskolin leads to increased epidermal pigmentation and protection against UV-induced carcinogenesis.[121] This suggests that the pigmentary pathways downstream of a defective MC1R remain intact, providing an opportunity for features of the "red hair phenotype," such as risk of sunburn and melanoma, to be pharmacologically reversed with development of appropriate topical agents.

Another mechanism involved in UV-induced tanning involves the TGFβ pathway. TGFβ1 produced by keratinocytes negatively regulates MITF. UV radiation of keratinocytes decreases TGFβ1 production, ultimately resulting in increased MITF pathway stimulation and increased melanogenesis.[75]

ROLE OF MC1R IN MELANOMAGENESIS

Hypomorphic MC1R variants, in addition to promoting red hair, are strong risk factors for development of human melanoma, leading to a 2- to 4-fold increased melanoma risk. MC1R variants promote pheomelanogenesis and fair skin, suggesting that decreased UV shielding may be responsible for increased melanoma risk.[191,192] However, melanoma risk is enhanced

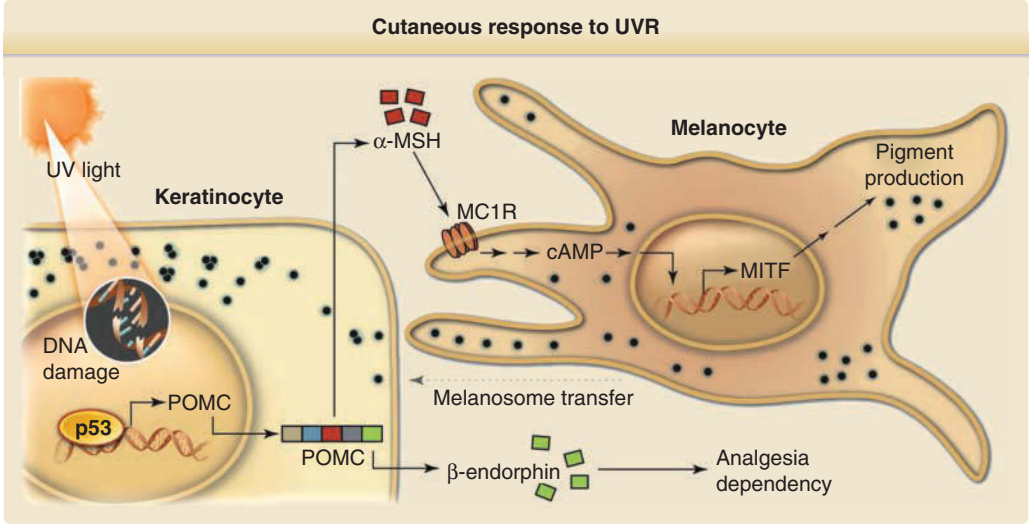

Figure 20-11 Cutaneous response to UVR. Tanning involves p53 activation in keratinocytes in response to UVR-induced DNA damage, leading to p53-mediated upregulation of proopiomelanocortin (POMC). Posttranslational cleavage of POMC produces β-endorphin and α-MSH. Secreted α-MSH stimulates MC1R on adjacent melanocytes, resulting in melanin synthesis and eventual transfer of melanin-containing vesicles (melanosomes) to keratinocytes. Chronic UVR results in elevated circulating β-endorphin levels, leading to analgesia and physical dependence. (Reprinted with permission from AAAS: Lo JA, Fisher DE. The melanoma revolution: from UV carcinogenesis to a new era in therapeutics. *Science*. 2014;346(6212):945-9.)

by MC1R variants even when controlling for degree of skin pigmentation, and missense variants of M1CR less strongly associated to the red hair phenotype still increase melanoma risk, suggesting that other mechanisms must play a role in the increased melanoma risk.[179,193] As discussed above, pheomelanin itself may play an important role in increasing melanoma risk through generation of ROS via UV-dependent and/or UV-independent mechanisms.

Recently, several other cancer-related pathways regulated by MC1R have been identified. MC1R signaling promotes the DNA nucleotide excision repair (NER) pathway, and defective NER may be a cause of the increased risk of melanoma in MC1R variant populations.[194] In support of this hypothesis, melanomas derived from patients with MC1R polymorphism harbor increased numbers of mutations.[195] Wildtype MC1R also protects the tumor suppressor PTEN from UVB-induced degradation. A recent study supports a mechanism whereby increased UVB-mediated PTEN degradation in MC1R-deficient melanocytes promotes melanoma formation.[196]

OTHER FACTORS REGULATING HUMAN PIGMENTATION

In recent years, population genetics studies have identified genetic variants that are associated with variation of skin pigmentation, hair color, and eye color in human populations. Many of these genes, such as *MC1R*, *ASIP*, and *KITLG*, play known roles in melanocyte signaling, and others such as *TYR*, *TYRP1*, *SLC45A2*, and *OCA2* encode genes known to be critical for melanin synthesis.[197,198] However, many novel genes also have been identified. A variant of *SLC24A5* is nearly ubiquitous in European populations and correlates with lighter skin color in other populations.[199,200] *SLC24A5* encodes a putative cation exchanger that is essential for normal pigmentation in cell culture and animal models.[156,201] *TPCN2* variants are associated with hair color variation, and *TPCN2* encodes a cation channel thought to regulate pigmentation through regulating melanosome pH and size.[184,202] Variants of the *Interferon Regulatory Factor 4* (*IRF4*) gene play a key role in regulating human pigmentation, and IRF4 has been shown to act with MITF to stimulate the transcription of tyrosinase.[203,204] Several studies have linked the transcription factor basonuclin 2, a transcription factor known to regulate pigmentation in zebrafish, to human pigmentation variation (BNC2).[205-207]

CONCLUSIONS

Melanocytes are neural crest derived cells that comprise a minority of epidermal cells, but impose major phenotypic changes to the appearance and functionality of skin. They synthesize pigment both constitutively and in response to environmental triggers, and participate in extensive intercellular signaling pathways that regulate production of pigment and often the final disposition of pigment in keratinocytes or the hair matrix. UV protection that is provided by melanocytes is mostly attributable to eumelanin species, whereas pheomelanin and its synthetic pathway not only lack strong UV protection but even contribute to elevated oxidative stress and measurably increased carcinogenicity. Future studies will hopefully identify opportunities to improve on strategies for skin cancer prevention—both for melanoma and non-melanoma skin cancers. Strategies exist which can effectively

shield UV species (as in broad spectrum UV filters in sunscreens). Other approaches may attempt to rescue eumelanin synthesis either through use of MSH peptides (or their analogs), or through small molecules that rescue eumelanogenesis downstream of MC1R, in skin from individuals with MC1R variants (ie light skin). Given the fact that skin cancers are among the few human malignancies for which a key carcinogen has been identified, it is hoped that these mechanistic insights may lead to improvements in prevention of skin cancer as well as general photodamage in humans.

REFERENCES

1. Staricco RJ, Pinkus H. Quantitative and qualitative data on the pigment cells of adult human epidermis. *J Invest Dermatol.* 1957;28(1):33-45.
2. Szabo G, Gerald AB, Pathak MA, et al. Racial differences in the fate of melanosomes in human epidermis. *Nature.* 1969;222(5198):1081-1082.
3. Cochran AJ. The incidence of melanocytes in normal human skin. *J Invest Dermatol.* 1970;55(1):65-70.
4. Warkel RL, Luna LG, Helwig EB. A modified Warthin-Starry procedure at low pH for melanin. *Am J Clin Pathol.* 1980;73(6):812-815.
5. Barbosa AJ, Castro LP, Margarida A, et al. A simple and economical modification of the Masson-Fontana method for staining melanin granules and enterochromaffin cells. *Stain Technol.* 1984;59(4):193-196.
6. Cleffmann G. Agouti pigment cells in situ and in vitro. *Ann N Y Acad Sci.* 1963;100:749-761.
7. Bloch B. Das problem der pigmentbildung in der Haut. *Arch Derm Syphilol.* 1917;124:129-208.
8. Jungbluth AA, Iversen K, Coplan K, et al. T311—an anti-tyrosinase monoclonal antibody for the detection of melanocytic lesions in paraffin embedded tissues. *Pathol Res Pract.* 2000;196(4):235-242.
9. King R, Weilbaecher KN, McGill G, et al. Microphthalmia transcription factor. A sensitive and specific melanocyte marker for MelanomaDiagnosis. *Am J Pathol.* 1999;155(3):731-738.
10. Nakajima T, Watanabe S, Sato Y, et al. Immunohistochemical demonstration of S100 protein in malignant melanoma and pigmented nevus, and its diagnostic application. *Cancer.* 1982;50(5):912-918.
11. Gown AM, Vogel AM, Hoak D, et al. Monoclonal antibodies specific for melanocytic tumors distinguish subpopulations of melanocytes. *Am J Pathol.* 1986;123(2):195-203.
12. Du J, Miller AJ, Widlund HR, et al. MLANA/MART1 and SILV/PMEL17/GP100 are transcriptionally regulated by MITF in melanocytes and melanoma. *Am J Pathol.* 2003;163(1):333-343.
13. Tarnowski WM. Ultrastructure of the epidermal melanocyte dense plate. *J Invest Dermatol.* 1970;55(4):265-268.
14. Moyer FH. In: Smelser GK, ed. *The Structure of the Eye.* New York: Academic Press Inc; 1961.
15. Toshima S, Moore GE, Sandberg AA. Ultrastructure of human melanoma in cell culture. Electron microscopy studies. *Cancer.* 1968;21(2):202-216.
16. Moyer FH. Genetic variations in the fine structure and ontogeny of mouse melanin granules. *Am Zool.* 1966;6(1):43-66.
17. Slominski A, Tobin DJ, Shibahara S, et al. Melanin pigmentation in mammalian skin and its hormonal regulation. *Physiol Rev.* 2004;84(4):1155-1228.
18. Jimbow K, Ishida O, Ito S, et al. Combined chemical and electron microscopic studies of pheomelanosomes in human red hair. *J Invest Dermatol.* 1983;81(6):506-511.
19. Szabo G. The number of melanocytes in human epidermis. *Br Med J.* 1954;1(4869):1016-1017.
20. Gilchrest BA, Blog FB, Szabo G. Effects of aging and chronic sun exposure on melanocytes in human skin. *J Invest Dermatol.* 1979;73(2):141-143.
21. Hendi A, Brodland DG, Zitelli JA. Melanocytes in long-standing sun-exposed skin: quantitative analysis using the MART-1 immunostain. *Arch Dermatol.* 2006;142(7):871-876.
22. Fitzpatrick TB, Breathnach AS. The Epidermal Melanin Unit System [in German]. *Dermatol Wochenschr.* 1963;147:481-489.
23. Ortonne JP, MacDonald DM, Micoud A, et al. PUVA-induced repigmentation of vitiligo: a histochemical (split-DOPA) and ultrastructural study. *Br J Dermatol.* 1979;101(1):1-12.
24. Ortonne JP, Schmitt D, Thivolet J. PUVA-induced repigmentation of vitiligo: scanning electron microscopy of hair follicles. *J Invest Dermatol.* 1980;74(1):40-42.
25. Nishimura EK, Jordan SA, Oshima H, et al. Dominant role of the niche in melanocyte stem-cell fate determination. *Nature.* 2002;416(6883):854-860.
26. Chou WC, Takeo M, Rabbani P, et al. Direct migration of follicular melanocyte stem cells to the epidermis after wounding or UVB irradiation is dependent on Mc1r signaling. *Nat Med.* 2013;19(7):924-929.
27. Yamada T, Hasegawa S, Inoue Y, et al. Wnt/beta-catenin and kit signaling sequentially regulate melanocyte stem cell differentiation in UVB-induced epidermal pigmentation. *J Invest Dermatol.* 2013;133(12):2753-2762.
28. Takeo M, Lee W, Rabbani P, et al. EdnrB governs regenerative response of melanocyte stem cells by crosstalk with Wnt signaling. *Cell Rep.* 2016;15(6):1291-1302.
29. Nishimura EK, Suzuki M, Igras V, et al. Key roles for transforming growth factor beta in melanocyte stem cell maintenance. *Cell Stem Cell.* 2010;6(2):130-140.
30. Taylor KL, Lister JA, Zeng Z, et al. Differentiated melanocyte cell division occurs in vivo and is promoted by mutations in Mitf. *Development.* 2011;138(16):3579-3589.
31. Glover JD, Knolle S, Wells KL, et al. Maintenance of distinct melanocyte populations in the interfollicular epidermis. *Pigment Cell Melanoma Res.* 2015;28(4):476-480.
32. Adameyko I, Lallemend F, Aquino JB, et al. Schwann cell precursors from nerve innervation are a cellular origin of melanocytes in skin. *Cell.* 2009;139(2):366-379.
33. Rabbani P, Takeo M, Chou W, et al. Coordinated activation of Wnt in epithelial and melanocyte stem cells initiates pigmented hair regeneration. *Cell.* 2011;145(6):941-955.
34. Sharov A, Tobin DJ, Sharova TY, et al. Changes in different melanocyte populations during hair follicle involution (catagen). *J Invest Dermatol.* 2005;125(6):1259-1267.
35. Nishimura EK, Granter SR, Fisher DE. Mechanisms of hair graying: incomplete melanocyte stem cell maintenance in the niche. *Science.* 2005;307(5710):720-724.
36. Inomata K, Aoto T, Binh NT, et al. Genotoxic stress abrogates renewal of melanocyte stem cells by triggering their differentiation. *Cell.* 2009;137(6):1088-1099.

37. Okamoto N, Aoto T, Uhara H, et al. A melanocyte–melanoma precursor niche in sweat glands of volar skin. *Pigment Cell Melanoma Res.* 2014;27(6):1039-1050.
38. Oguchi S, Saida T, Koganehira Y, et al. Characteristic epiluminescent microscopic features of early malignant melanoma on glabrous skin. A videomicroscopic analysis. *Arch Dermatol.* 1998;134(5):563-568.
39. Mitchell P, Wang JJ, Foran S, et al. Five-year incidence of age-related maculopathy lesions: the Blue Mountains Eye Study. *Ophthalmology.* 2002;109(6):1092-1097.
40. Ni C, Zhang D, Beyer LA, et al. Hearing dysfunction in heterozygous Mitf(Mi-wh)/+ mice, a model for Waardenburg syndrome type 2 and Tietz syndrome. *Pigment Cell Melanoma Res.* 2013;26(1):78-87.
41. Shibata S, Miwa T, Wu HH, et al. Hepatocyte growth factor-c-MET signaling mediates the development of nonsensory structures of the mammalian cochlea and hearing. *J Neurosci.* 2016;36(31):8200-8209.
42. Levin MD, Lu MM, Petrenko NB, et al. Melanocyte-like cells in the heart and pulmonary veins contribute to atrial arrhythmia triggers. *J Clin Invest.* 2009;119(11):3420-3436.
43. Aoki H, Yamada Y, Hara A, et al. Two distinct types of mouse melanocyte: differential signaling requirement for the maintenance of non-cutaneous and dermal versus epidermal melanocytes. *Development.* 2009;136(15):2511-2521.
44. Curtin JA, Fridlyand J, Kageshita T, et al. Distinct sets of genetic alterations in melanoma. *N Engl J Med.* 2005;353(20):2135-2147.
45. Rawles ME. Origin of pigment cells from the neural crest in the mouse embryo. *Physiol Zool.* 1947;20(3):248-266.
46. Dorris F. The production of pigment by chick neural crest in grafts to the 3-day limb bud. *J Exp Zool.* 1939;80(2):315-345.
47. Serbedzija GN, Fraser SE, Bronner-Fraser M. Pathways of trunk neural crest cell migration in the mouse embryo as revealed by vital dye labelling. *Development.* 1990;108(4):605-612.
48. Weston JA. Sequential segregation and fate of developmentally restricted intermediate cell populations in the neural crest lineage. *Curr Top Dev Biol.* 1991;25:133-153.
49. Opdecamp K, Nakayama A, Nguyen MT, et al. Melanocyte development in vivo and in neural crest cell cultures: crucial dependence on the Mitf basic-helix-loop-helix-zipper transcription factor. *Development.* 1997;124(12):2377-2386.
50. Yoshida H, Kunisada T, Kusakabe M, et al. Distinct stages of melanocyte differentiation revealed by anlaysis of nonuniform pigmentation patterns. *Development.* 1996;122(4):1207-1214.
51. Hirobe T. Histochemical survey of the distribution of the epidermal melanoblasts and melanocytes in the mouse during fetal and postnatal periods. *Anat Rec (Hoboken).* 1984;208(4):589-594.
52. Stemple DL, Anderson DJ. Isolation of a stem cell for neurons and glia from the mammalian neural crest. *Cell.* 1992;71(6):973-985.
53. Baroffio A, Dupin E, Le Douarin NM. Clone-forming ability and differentiation potential of migratory neural crest cells. *Proc Natl Acad Sci U S A.* 1988;85(14):5325-5329.
54. Dupin E, Glavieux C, Vaigot P, et al. Endothelin 3 induces the reversion of melanocytes to glia through a neural crest-derived glial-melanocytic progenitor. *Proc Natl Acad Sci U S A.* 2000;97(14):7882-7887.
55. Motohashi T, Yamanaka K, Chiba K, et al. Unexpected multipotency of melanoblasts isolated from murine skin. *Stem Cells.* 2009;27(4):888-897.
56. Baggiolini A, Varum S, Mateos JM, et al. Premigratory and migratory neural crest cells are multipotent in vivo. *Cell Stem Cell.* 2015;16(3):314-322.
57. Singh AP, Dinwiddie A, Mahalwar P, et al. Pigment cell progenitors in zebrafish remain multipotent through metamorphosis. *Dev Cell.* 2016;38(3):316-330.
58. Kaufman CK, Mosimann C, Fan ZP, et al. A zebrafish melanoma model reveals emergence of neural crest identity during melanoma initiation. *Science.* 2016;351(6272):aad2197.
59. Hodgkinson CA, Moore KJ, Nakayama A, et al. Mutations at the mouse microphthalmia locus are associated with defects in a gene encoding a novel basic-helix-loop-helix-zipper protein. *Cell.* 1993;74(2):395-404.
60. Tassabehji M, Newton VE, Read AP. Waardenburg syndrome type 2 caused by mutations in the human microphthalmia (MITF) gene. *Nat Genet.* 1994;8(3):251-255.
61. Yasumoto K, Amae S, Udono T, et al. A big gene linked to small eyes encodes multiple Mitf isoforms: many promoters make light work. *Pigment Cell Res.* 1998;11(6):329-336.
62. Fuse N, Yasumoto K, Suzuki H, et al. Identification of a melanocyte-type promoter of the microphthalmia-associated transcription factor gene. *Biochem Biophys Res Commun.* 1996;219(3):702-707.
63. Aksan I, Goding CR. Targeting the microphthalmia basic helix-loop-helix-leucine zipper transcription factor to a subset of E-box elements in vitro and in vivo. *Mol Cell Biol.* 1998;18(12):6930-6938.
64. McGill GG, Horstmann M, Widlund HR, et al. Bcl2 regulation by the melanocyte master regulator Mitf modulates lineage survival and melanoma cell viability. *Cell.* 2002;109(6):707-718.
65. Haq R, Yokoyama S, Hawryluk EB, et al. *BCL2A1* is a lineage-specific antiapoptotic melanoma oncogene that confers resistance to *BRAF* inhibition. *Proc Natl Acad Sci U S A.* 2013;110(11):4321-4326.
66. Du J, Widlund HR, Horstmann MA, et al. Critical role of CDK2 for melanoma growth linked to its melanocyte-specific transcriptional regulation by MITF. *Cancer Cell.* 2004;6(6):565-576.
67. Garraway LA, Widlund HR, Rubin MA, et al. Integrative genomic analyses identify MITF as a lineage survival oncogene amplified in malignant melanoma. *Nature.* 2005;436(7047):117-122.
68. Yokoyama S, Woods SL, Boyle GM, et al. A novel recurrent mutation in MITF predisposes to familial and sporadic melanoma. *Nature.* 2011;480(7375):99-103.
69. Miller AJ, Levy C, Davis IJ, et al. Sumoylation of MITF and its related family members TFE3 and TFEB. *J Biol Chem.* 2005;280(1):146-155.
70. Epstein DJ, Vekemans M, Gros P. Splotch (Sp2H), a mutation affecting development of the mouse neural tube, shows a deletion within the paired homeodomain of Pax-3. *Cell.* 1991;67(4):767-774.
71. Conway SJ, Henderson DJ, Copp AJ. PAX3 is required for cardiac neural crest migration in the mouse: evidence from the splotch (Sp2H) mutant. *Development.* 1997;124(2):505-514.
72. Tassabehji M, Read AP, Newton VE, et al. Waardenburg's syndrome patients have mutations in the human homologue of the Pax-3 paired box gene. *Nature.* 1992;355(6361):635-636.

73. Hornyak TJ, Hayes DJ, Chiu LY, et al. Transcription factors in melanocyte development: distinct roles for Pax-3 and Mitf. *Mech Dev.* 2001;101(1-2):47-59.
74. Smith MP, Brunton H, Rowling EJ, et al. Inhibiting drivers of non-mutational drug tolerance is a salvage strategy for targeted melanoma therapy. *Cancer Cell.* 2016;29(3):270-284.
75. Yang G, Li Y, Nishimura EK, et al. Inhibition of PAX3 by TGF-beta modulates melanocyte viability. *Mol Cell.* 2008;32(4):554-563.
76. Pingault V, Bondurand N, Kuhlbrodt K, et al. SOX10 mutations in patients with Waardenburg-Hirschsprung disease. *Nat Genet.* 1998;18(2):171-173.
77. Britsch S, Goerich DE, Riethmacher D, et al. The transcription factor SOX10 is a key regulator of peripheral glial development. *Genes Dev.* 2001;15(1):66-78.
78. Potterf SB, Mollaaghababa R, Hou L, et al. Analysis of SOX10 function in neural crest-derived melanocyte development: SOX10-dependent transcriptional control of dopachrome tautomerase. *Dev Biol.* 2001;237(2): 245-257.
79. Shakhova O, Zingg D, Schaefer SM, et al. SOX10 promotes the formation and maintenance of giant congenital naevi and melanoma. *Nat Cell Biol.* 2012;14(8): 882-890.
80. Harris ML, Buac K, Shakhova O, et al. A dual role for SOX10 in the maintenance of the postnatal melanocyte lineage and the differentiation of melanocyte stem cell progenitors. *PLoS Genet.* 2013;9(7):e1003644.
81. Verastegui C, Bille K, Ortonne JP, et al. Regulation of the microphthalmia-associated transcription factor gene by the Waardenburg syndrome type 4 gene, SOX10. *J Biol Chem.* 2000;275(40):30757-30760.
82. Yu J, Vodyanik MA, Smuga-Otto K, et al. Induced pluripotent stem cell lines derived from human somatic cells. *Science.* 2007;318(5858):1917-1920.
83. Adameyko I, Lallemend F, Furlan A, et al. SOX2 and Mitf cross-regulatory interactions consolidate progenitor and melanocyte lineages in the cranial neural crest. *Development.* 2012;139(2):397-410.
84. Cimadamore F, Shah M, Amador-Arjona A, et al. SOX2 modulates levels of MITF in normal human melanocytes, and melanoma lines in vitro. *Pigment Cell Melanoma Res.* 2012;25(4):533-536.
85. Teng L, Mundell NA, Frist AY, et al. Requirement for Foxd3 in the maintenance of neural crest progenitors. *Development.* 2008;135(9):1615-1624.
86. Nitzan E, Pfaltzgraff ER, Labosky PA, et al. Neural crest and Schwann cell progenitor-derived melanocytes are two spatially segregated populations similarly regulated by Foxd3. *Proc Natl Acad Sci U S A.* 2013;110(31):12709-12714.
87. Edery P, Attie T, Amiel J, et al. Mutation of the endothelin-3 gene in the Waardenburg-Hirschsprung disease (Shah-Waardenburg syndrome). *Nat Genet.* 1996;12(4):442-444.
88. Puffenberger EG, Hosoda K, Washington SS, et al. A missense mutation of the endothelin-B receptor gene in multigenic Hirschsprung's disease. *Cell.* 1994;79(7):1257-1266.
89. Shin MK, Levorse JM, Ingram RS, et al. The temporal requirement for endothelin receptor-B signalling during neural crest development. *Nature.* 1999;402(6761):496-501.
90. Lee HO, Levorse JM, Shin MK. The endothelin receptor-B is required for the migration of neural crest-derived melanocyte and enteric neuron precursors. *Dev Biol.* 2003;259(1):162-175.
91. Yada Y, Higuchi K, Imokawa G. Effects of endothelins on signal transduction and proliferation in human melanocytes. *J Biol Chem.* 1991;266(27):18352-18357.
92. Garcia RJ, Ittah A, Mirabal S, et al. Endothelin 3 induces skin pigmentation in a keratin-driven inducible mouse model. *J Invest Dermatol.* 2008;128(1):131-142.
93. Grabbe J, Welker P, Dippel E, et al. Stem cell factor, a novel cutaneous growth factor for mast cells and melanocytes. *Arch Dermatol Res.* 1994;287(1):78-84.
94. Giebel LB, Spritz RA. Mutation of the KIT (mast/stem cell growth factor receptor) protooncogene in human piebaldism. *Proc Natl Acad Sci U S A.* 1991;88(19):8696-8699.
95. Geissler EN, Ryan MA, Housman DE. The dominant-white spotting (W) locus of the mouse encodes the c-kit proto-oncogene. *Cell.* 1988;55(1):185-192.
96. Matsui Y, Zsebo KM, Hogan BL. Embryonic expression of a haematopoietic growth factor encoded by the Sl locus and the ligand for c-kit. *Nature.* 1990;347(6294):667-669.
97. Hou L, Panthier JJ, Arnheiter H. Signaling and transcriptional regulation in the neural crest-derived melanocyte lineage: interactions between KIT and MITF. *Development.* 2000;127(24):5379-5389.
98. Okura M, Maeda H, Nishikawa S, et al. Effects of monoclonal anti-c-kit antibody (ACK2) on melanocytes in newborn mice. *J Invest Dermatol.* 1995;105(3):322-328.
99. Grichnik JM, Burch JA, Burchette J, et al. The SCF/KIT pathway plays a critical role in the control of normal human melanocyte homeostasis. *J Invest Dermatol.* 1998;111(2):233-238.
100. Wang ZQ, Si L, Tang Q, et al. Gain-of-function mutation of KIT ligand on melanin synthesis causes familial progressive hyperpigmentation. *Am J Hum Genet.* 2009;84(5):672-677.
101. Amyere M, Vogt T, Hoo J, et al. KITLG mutations cause familial progressive hyper- and hypopigmentation. *J Invest Dermatol.* 2011;131(6):1234-1239.
102. Curtin JA, Busam K, Pinkel D, et al. Somatic activation of KIT in distinct subtypes of melanoma. *J Clin Oncol.* 2006;24(26):4340-4346.
103. Hemesath TJ, Price ER, Takemoto C, et al. MAP kinase links the transcription factor Microphthalmia to c-Kit signalling in melanocytes. *Nature.* 1998;391(6664):298-301.
104. Dunn KJ, Williams BO, Li Y, et al. Neural crest-directed gene transfer demonstrates Wnt1 role in melanocyte expansion and differentiation during mouse development. *Proc Natl Acad Sci U S A.* 2000;97(18):10050-10055.
105. Hari L, Miescher I, Shakhova O, et al. Temporal control of neural crest lineage generation by Wnt/beta-catenin signaling. *Development.* 2012; 139(12):2107-2117.
106. Widlund HR, Horstmann MA, Price ER, et al. Beta-catenin-induced melanoma growth requires the downstream target Microphthalmia-associated transcription factor. *J Cell Biol.* 2002;158(6):1079-1087.
107. Delmas V, Beermann F, Martinozzi S, et al. Beta-catenin induces immortalization of melanocytes by suppressing p16INK4a expression and cooperates with N-Ras in melanoma development. *Genes Dev.* 2007;21(22):2923-2935.
108. Damsky WE, Curley DP, Santhanakrishnan M, et al. beta-catenin signaling controls metastasis in Braf-activated Pten-deficient melanomas. *Cancer Cell.* 2011;20(6):741-754.

109. Ridley AJ. Rho GTPase signalling in cell migration. *Curr Opin Cell Biol.* 2015;36:103-112.
110. Li A, Ma Y, Yu X, et al. Rac1 drives melanoblast organization during mouse development by orchestrating pseudopod-driven motility and cell-cycle progression. *Dev Cell.* 2011;21(4):722-734.
111. Krauthammer M, Kong Y, Ha BH, et al. Exome sequencing identifies recurrent somatic RAC1 mutations in melanoma. *Nat Genet.* 2012;44(9):1006-1014.
112. Lissanu Deribe Y, Shi Y, Rai K, et al. Truncating PREX2 mutations activate its GEF activity and alter gene expression regulation in NRAS-mutant melanoma. *Proc Natl Acad Sci U S A.* 2016;113(9): E1296-E1305.
113. Lindsay CR, Lawn S, Campbell AD, et al. P-Rex1 is required for efficient melanoblast migration and melanoma metastasis. *Nat Commun.* 2011;2:555.
114. Ozeki H, Ito S, Wakamatsu K, et al. Chemical characterization of hair melanins in various coat-color mutants of mice. *J Invest Dermatol.* 1995;105(3):361-366.
115. Premi S, Wallisch S, Mano CM, et al. Photochemistry. Chemiexcitation of melanin derivatives induces DNA photoproducts long after UV exposure. *Science.* 2015;347(6224):842-847.
116. Tadokoro T, Kobayashi N, Zmudzka BZ, et al. UV-induced DNA damage and melanin content in human skin differing in racial/ethnic origin. *FASEB J.* 2003;17(9):1177-1179.
117. Fleming ID, Barnawell JR, Burlison PE, et al. Skin cancer in black patients. *Cancer.* 1975;35(3):600-605.
118. Bykov VJ, Marcusson JA, Hemminki K. Effect of constitutional pigmentation on ultraviolet B-induced DNA damage in fair-skinned people. *J Invest Dermatol.* 2000;114(1):40-43.
119. Shapiro MP, Keen P, Cohen L, et al. Skin cancer in the South African Bantu. *Br J Cancer.* 1953;7(1):45-57.
120. Yamazaki F, Okamoto H, Miyauchi-Hashimoto H, et al. XPA gene-deficient, SCF-transgenic mice with epidermal melanin are resistant to UV-induced carcinogenesis. *J Invest Dermatol.* 2004;123(1):220-228.
121. D'Orazio JA, Nobuhisa T, Cui R, et al. Topical drug rescue strategy and skin protection based on the role of Mc1r in UV-induced tanning. *Nature.* 2006;443(7109):340-344.
122. Kaidbey KH, Agin PP, Sayre RM, et al. Photoprotection by melanin—a comparison of black and Caucasian skin. *J Am Acad Dermatol.* 1979;1(3):249-260.
123. Wang A, Marino AR, Gasyna Z, et al. Photoprotection by porcine eumelanin against singlet oxygen production. *Photochem Photobiol.* 2008;84(3):679-682.
124. Wenczl E, Van der Schans GP, Roza L, et al. (Pheo) melanin photosensitizes UVA-induced DNA damage in cultured human melanocytes. *J Invest Dermatol.* 1998;111(4):678-682.
125. Panzella L, Szewczyk G, d'Ischia M, et al. Zinc-induced structural effects enhance oxygen consumption and superoxide generation in synthetic pheomelanins on UVA/visible light irradiation. *Photochem Photobiol.* 2010;86(4):757-764.
126. dMitra D, Luo X, Morgan A, et al. An ultraviolet-radiation-independent pathway to melanoma carcinogenesis in the red hair/fair skin background. *Nature.* 2012;491(7424):449-453.
127. Wendt J, Rauscher S, Burgstaller-Muehlbacher S, et al. Human determinants and the role of melanocortin-1 receptor variants in melanoma risk independent of UV radiation exposure. *JAMA Dermatol.* 2016;152(7):776-782.
128. Roider EM, Fisher DE. Red hair, light skin, and UV-independent risk for melanoma development in humans. *JAMA Dermatol.* 2016;152(7):751-753.
129. Fitzpatrick TB, Becker SW Jr, Lerner AB, et al. Tyrosinase in human skin: demonstration of its presence and of its role in human melanin formation. *Science.* 1950;112(2904):223-225.
130. Setty SR, Tenza D, Sviderskaya EV, et al. Cell-specific ATP7A transport sustains copper-dependent tyrosinase activity in melanosomes. *Nature.* 2008;454(7208):1142-1146.
131. Kobayashi T, Hearing VJ. Direct interaction of tyrosinase with Tyrp1 to form heterodimeric complexes in vivo. *J Cell Sci.* 2007;120(pt 24):4261-4268.
132. Potterf SB, Furumura M, Sviderskaya EV, et al. Normal tyrosine transport and abnormal tyrosinase routing in pink-eyed dilution melanocytes. *Exp Cell Res.* 1998;244(1):319-326.
133. Costin GE, Valencia JC, Vieira WD, et al. Tyrosinase processing and intracellular trafficking is disrupted in mouse primary melanocytes carrying the underwhite (uw) mutation. A model for oculocutaneous albinism (OCA) type 4. *J Cell Sci.* 2003;116(pt 15): 3203-3212.
134. Du J, Fisher DE. Identification of Aim-1 as the underwhite mouse mutant and its transcriptional regulation by MITF. *J Biol Chem.* 2002;277(1):402-406.
135. Newton JM, Cohen-Barak O, Hagiwara N, et al. Mutations in the human orthologue of the mouse underwhite gene (uw) underlie a new form of oculocutaneous albinism, OCA4. *Am J Hum Genet.* 2001;69(5):981-988.
136. Riley PA. The great DOPA mystery: the source and significance of DOPA in phase I melanogenesis. *Cell Mol Biol (Noisy-le-grand).* 1999;45(7):951-960.
137. Tsukamoto K, Jackson IJ, Urabe K, et al. A second tyrosinase-related protein, TRP-2, is a melanogenic enzyme termed DOPAchrome tautomerase. *EMBO J.* 1992;11(2):519-526.
138. Jimenez-Cervantes C, Solano F, Kobayashi T, et al. A new enzymatic function in the melanogenic pathway. The 5,6-dihydroxyindole-2-carboxylic acid oxidase activity of tyrosinase-related protein-1 (TRP1). *J Biol Chem.* 1994;269(27):17993-18000.
139. Land EJ, Riley PA. Spontaneous redox reactions of dopaquinone and the balance between the eumelanic and phaeomelanic pathways. *Pigment Cell Res.* 2000;13(4):273-277.
140. del Marmol V, Ito S, Bouchard B, et al. Cysteine deprivation promotes eumelanogenesis in human melanoma cells. *J Invest Dermatol.* 1996;107(5):698-702.
141. van Nieuwpoort F, Smit NP, Kolb R, et al. Tyrosine-induced melanogenesis shows differences in morphologic and melanogenic preferences of melanosomes from light and dark skin types. *J Invest Dermatol.* 2004;122(5):1251-1255.
142. Rochin L, Hurbain I, Serneels L, et al. BACE2 processes PMEL to form the melanosome amyloid matrix in pigment cells. *Proc Natl Acad Sci U S A.* 2013;110(26):10658-10663.
143. Berson JF, Harper DC, Tenza D, et al. Pmel17 initiates premelanosome morphogenesis within multivesicular bodies. *Mol Biol Cell.* 2001;12(11):3451-3464.
144. Hurbain I, Geerts WJ, Boudier T, et al. Electron tomography of early melanosomes: implications for melanogenesis and the generation of fibrillar amyloid sheets. *Proc Natl Acad Sci U S A.* 2008;105(50):19726-19731.

145. Jimbow K, Hua C, Gomez PF, et al. Intracellular vesicular trafficking of tyrosinase gene family protein in eu- and pheomelanosome biogenesis. *Pigment Cell Res.* 2000;13(suppl 8):110-117.
146. Raposo G, Tenza D, Murphy DM, et al. Distinct protein sorting and localization to premelanosomes, melanosomes, and lysosomes in pigmented melanocytic cells. *J Cell Biol.* 2001;152(4):809-824.
147. Theos AC, Berson JF, Theos SC, et al. Dual loss of ER export and endocytic signals with altered melanosome morphology in the silver mutation of Pmel17. *Mol Biol Cell.* 2006;17(8):3598-3612.
148. Theos AC, Truschel ST, Tenza D, et al. A lumenal domain-dependent pathway for sorting to intralumenal vesicles of multivesicular endosomes involved in organelle morphogenesis. *Dev Cell.* 2006;10(3):343-354.
149. Delevoye C, Heiligenstein X, Ripoll L, et al. BLOC-1 brings together the actin and microtubule cytoskeletons to generate recycling endosomes. *Curr Biol.* 2016;26(1):1-13.
150. Di Pietro SM, Falcon-Perez JM, Tenza D, et al. BLOC-1 interacts with BLOC-2 and the AP-3 complex to facilitate protein trafficking on endosomes. *Mol Biol Cell.* 2006;17(9):4027-4038.
151. Delevoye C, Hurbain I, Tenza D, et al. AP-1 and KIF13A coordinate endosomal sorting and positioning during melanosome biogenesis. *J Cell Biol.* 2009;187(2):247-264.
152. Dennis MK, Mantegazza AR, Snir OL, et al. BLOC-2 targets recycling endosomal tubules to melanosomes for cargo delivery. *J Cell Biol.* 2015;209(4):563-577.
153. Theos AC, Tenza D, Martina JA, et al. Functions of adaptor protein (AP)-3 and AP-1 in tyrosinase sorting from endosomes to melanosomes. *Mol Biol Cell.* 2005;16(11):5356-5372.
154. Sitaram A, Dennis MK, Chaudhuri R, et al. Differential recognition of a dileucine-based sorting signal by AP-1 and AP-3 reveals a requirement for both BLOC-1 and AP-3 in delivery of OCA2 to melanosomes. *Mol Biol Cell.* 2012;23(16):3178-3192.
155. Dennis MK, Delevoye C, Acosta-Ruiz A, et al. BLOC-1 and BLOC-3 regulate VAMP7 cycling to and from melanosomes via distinct tubular transport carriers. *J Cell Biol.* 2016;214(3):293-308.
156. Hara M, Yaar M, Byers HR, et al. Kinesin participates in melanosomal movement along melanocyte dendrites. *J Invest Dermatol.* 2000;114(3):438-443.
157. Wu X, Bowers B, Rao K, et al. Visualization of melanosome dynamics within wild-type and dilute melanocytes suggests a paradigm for myosin V function In vivo. *J Cell Biol.* 1998;143(7):1899-1918.
158. Byers HR, Yaar M, Eller MS, et al. Role of cytoplasmic dynein in melanosome transport in human melanocytes. *J Invest Dermatol.* 2000;114(5):990-997.
159. Pylypenko O, Goud B. Posttranslational modifications of Rab GTPases help their insertion into membranes. *Proc Natl Acad Sci U S A.* 2012;109(15):5555-5556.
160. Wu XS, Rao K, Zhang H, et al. Identification of an organelle receptor for myosin-Va. *Nat Cell Biol.* 2002;4(4):271-278.
161. Menasche G, Pastural E, Feldmann J, et al. Mutations in RAB27A cause Griscelli syndrome associated with haemophagocytic syndrome. *Nat Genet.* 2000;25(2):173-176.
162. Pastural E, Barrat FJ, Dufourcq-Lagelouse R, et al. Griscelli disease maps to chromosome 15q21 and is associated with mutations in the myosin-Va gene. *Nat Genet.* 1997;16(3):289-292.
163. Menasche G, Ho CH, Sanal O, et al. Griscelli syndrome restricted to hypopigmentation results from a melanophilin defect (GS3) or a MYO5A F-exon deletion (GS1). *J Clin Invest.* 2003;112(3):450-456.
164. Wu XS, Masedunskas A, Weigert R, et al. Melanoregulin regulates a shedding mechanism that drives melanosome transfer from melanocytes to keratinocytes. *Proc Natl Acad Sci U S A.* 2012;109(31):E2101-E2109.
165. Ando H, Niki Y, Ito M, et al. Melanosomes are transferred from melanocytes to keratinocytes through the processes of packaging, release, uptake, and dispersion. *J Invest Dermatol.* 2012;132(4):1222-1229.
166. Cardinali G, Ceccarelli S, Kovacs D, et al. Keratinocyte growth factor promotes melanosome transfer to keratinocytes. *J Invest Dermatol.* 2005;125(6):1190-1199.
167. Sharlow ER, Paine CS, Babiarz L, et al. The protease-activated receptor-2 upregulates keratinocyte phagocytosis. *J Cell Sci.* 2000;113 (pt 17):3093-3101.
168. Babiarz-Magee L, Chen N, Seiberg M, et al. The expression and activation of protease-activated receptor-2 correlate with skin color. *Pigment Cell Res.* 2004;17(3):241-251.
169. Byers HR, Maheshwary S, Amodeo DM, et al. Role of cytoplasmic dynein in perinuclear aggregation of phagocytosed melanosomes and supranuclear melanin cap formation in human keratinocytes. *J Invest Dermatol.* 2003;121(4):813-820.
170. Konrad K, Wolff K. Hyperpigmentation, melanosome size, and distribution patterns of melanosomes. *Arch Dermatol.* 1973;107(6):853-860.
171. Alaluf S, Atkins D, Barrett K, et al. Ethnic variation in melanin content and composition in photoexposed and photoprotected human skin. *Pigment Cell Res.* 2002;15(2):112-118.
172. Thong HY, Jee SH, Sun CC, et al. The patterns of melanosome distribution in keratinocytes of human skin as one determining factor of skin colour. *Br J Dermatol.* 2003;149(3):498-505.
173. Minwalla L, Zhao Y, Le Poole IC, et al. Keratinocytes play a role in regulating distribution patterns of recipient melanosomes in vitro. *J Invest Dermatol.* 2001;117(2):341-347.
174. Yoshida Y, Hachiya A, Sriwiriyanont P, et al. Functional analysis of keratinocytes in skin color using a human skin substitute model composed of cells derived from different skin pigmentation types. *FASEB J.* 2007;21(11):2829-2839.
175. Goldschmidt H, Raymond JZ. Quantitative analysis of skin color from melanin content of superficial skin cells. *J Forensic Sci.* 1972;17(1):124-131.
176. Ebanks JP, Koshoffer A, Wickett RR, et al. Epidermal keratinocytes from light vs. dark skin exhibit differential degradation of melanosomes. *J Invest Dermatol.* 2011;131(6):1226-1233.
177. Murase D, Hachiya A, Takano K, et al. Autophagy has a significant role in determining skin color by regulating melanosome degradation in keratinocytes. *J Invest Dermatol.* 2013;133(10):2416-2424.
178. Robbins LS, Nadeau JH, Johnson KR, et al. Pigmentation phenotypes of variant extension locus alleles result from point mutations that alter MSH receptor function. *Cell.* 1993;72(6):827-834.
179. Valverde P, Healy E, Jackson I, et al. Variants of the melanocyte-stimulating hormone receptor gene are associated with red hair and fair skin in humans. *Nat Genet.* 1995;11(3):328-330.

180. Lerner AB, McGuire JS. Effect of alpha- and betamelanocyte stimulating hormones on the skin colour of man. *Nature.* 1961;189:176-179.
181. Krude H, Biebermann H, Luck W, et al. Severe early-onset obesity, adrenal insufficiency and red hair pigmentation caused by POMC mutations in humans. *Nat Genet.* 1998;19(2):155-157.
182. Duhl DM, Vrieling H, Miller KA, et al. Neomorphic agouti mutations in obese yellow mice. *Nat Genet.* 1994;8(1):59-65.
183. Voisey J, van Daal A. Agouti: from mouse to man, from skin to fat. *Pigment cell Res.* 2002;15(1):10-18.
184. Sulem P, Gudbjartsson DF, Stacey SN, et al. Two newly identified genetic determinants of pigmentation in Europeans. *Nat Genet.* 2008;40(7):835-837.
185. Gudbjartsson DF, Sulem P, Stacey SN, et al. ASIP and TYR pigmentation variants associate with cutaneous melanoma and basal cell carcinoma. *Nat Genet.* 2008;40(7):886-891.
186. Khaled M, Levy C, Fisher DE. Control of melanocyte differentiation by a MITF-PDE4D3 homeostatic circuit. *Genes Dev.* 2010;24(20):2276-2281.
187. Shoag J, Haq R, Zhang M, et al. PGC-1 coactivators regulate MITF and the tanning response. *Mol Cell.* 2013;49(1):145-157.
188. Tadokoro T, Yamaguchi Y, Batzer J, et al. Mechanisms of skin tanning in different racial/ethnic groups in response to ultraviolet radiation. *J Invest Dermatol.* 2005;124(6):1326-1332.
189. Coelho SG, Yin L, Smuda C, et al. Photobiological implications of melanin photoprotection after UVB-induced tanning of human skin but not UVA-induced tanning. *Pigment Cell Melanoma Res.* 2015;28(2):210-216.
190. Cui R, Widlund HR, Feige E, et al. Central role of p53 in the suntan response and pathologic hyperpigmentation. *Cell.* 2007;128(5):853-864.
191. Peles DN, Simon JD. The ultraviolet absorption coefficient of melanosomes decreases with increasing pheomelanin content. *J Phys Chem B.* 2010;114(29):9677-9683.
192. Peles DN, Simon JD. The UV-absorption spectrum of human iridal melanosomes: a new perspective on the relative absorption of eumelanin and pheomelanin and its consequences. *Photochem Photobiol.* 2012;88(6):1378-1384.
193. Raimondi S, Sera F, Gandini S, et al. MC1R variants, melanoma and red hair color phenotype: a meta-analysis. *Int J Cancer.* 2008;122(12):2753-2760.
194. Jarrett SG, Wolf Horrell EM, Christian PA, et al. PKA-mediated phosphorylation of ATR promotes recruitment of XPA to UV-induced DNA damage. *Mol Cell.* 2014;54(6):999-1011.
195. Robles-Espinoza CD, Roberts ND, Chen S, et al. Germline MC1R status influences somatic mutation burden in melanoma. *Nat Commun.* 2016;7:12064.
196. Cao J, Wan L, Hacker E, et al. MC1R is a potent regulator of PTEN after UV exposure in melanocytes. *Mol Cell.* 2013;51(4):409-422.
197. Kenny EE, Timpson NJ, Sikora M, et al. Melanesian blond hair is caused by an amino acid change in TYRP1. *Science.* 2012;336(6081):554.
198. Anno S, Abe T, Yamamoto T. Interactions between SNP alleles at multiple loci contribute to skin color differences between caucasoid and mongoloid subjects. *Int J Biol Sci.* 2008;4(2):81-86.
199. Lamason RL, Mohideen MA, Mest JR, et al. SLC24A5, a putative cation exchanger, affects pigmentation in zebrafish and humans. *Science.* 2005;310(5755):1782-1786.
200. Basu Mallick C, Iliescu FM, Mols M, et al. The light skin allele of SLC24A5 in South Asians and Europeans shares identity by descent. *PLoS Genet.* 2013;9(11):e1003912.
201. Ginger RS, Askew SE, Ogborne RM, et al. SLC24A5 encodes a trans-Golgi network protein with potassium-dependent sodium-calcium exchange activity that regulates human epidermal melanogenesis. *J Biol Chem.* 2008;283(9):5486-5495.
202. Ambrosio AL, Boyle JA, Aradi AE, et al. TPC2 controls pigmentation by regulating melanosome pH and size. *Proc Natl Acad Sci U S A.* 2016;113(20):5622-5627.
203. Han J, Kraft P, Nan H, et al. A genome-wide association study identifies novel alleles associated with hair color and skin pigmentation. *PLoS Genet.* 2008;4(5):e1000074.
204. Praetorius C, Grill C, Stacey SN, et al. A polymorphism in IRF4 affects human pigmentation through a tyrosinase-dependent MITF/TFAP2A pathway. *Cell.* 2013;155(5):1022-1033.
205. Visser M, Palstra RJ, Kayser M. Human skin color is influenced by an intergenic DNA polymorphism regulating transcription of the nearby BNC2 pigmentation gene. *Hum Mol Genet.* 2014;23(21):5750-5762.
206. Jacobs LC, Wollstein A, Lao O, et al. Comprehensive candidate gene study highlights UGT1A and BNC2 as new genes determining continuous skin color variation in Europeans. *Hum Genet.* 2013;132(2):147-158.
207. Lang MR, Patterson LB, Gordon TN, et al. Basonuclin-2 requirements for zebrafish adult pigment pattern development and female fertility. *PLoS Genet.* 2009;5(11):e1000744.

Chapter 21 :: Neurobiology of the Skin

:: Sonja Ständer, Manuel P. Pereira, & Thomas A. Luger

AT-A-GLANCE

- The nervous system of the skin has multiple functions:
  - Collecting and transmitting environmental information on touch, pain, pruritus and temperature to the brain.
  - Reacting to ligands that induce nerve activation by the antidromic release of neuropeptides and initiation of vascular and inflammatory reactions.
  - Communication with various skin cells, including those in the immune and endocrine systems.
  - Because of these, it also has a role in maintaining skin homeostasis and processes including thermoregulation, cell growth, inflammation, host defense mechanisms, apoptosis, and wound healing.
  - In pathological conditions, the nervous system is involved in the maintenance of pruritus, pain, and inflammatory skin diseases (eg, psoriasis vulgaris, atopic dermatitis).

INTRODUCTION

The skin has a dense sensory network enabling human beings to sense different ranges and qualities of pain, pruritus, mechanical stimuli (eg, touch and vibration), and temperature. These senses have a role in the nonverbal communication among humans and also serve as protective mechanisms as they organize sensations taken from the environment that are sent to the brain. The brain not only plays a critical role in the perception of these sensations but also in their interpretation as pleasant, unpleasant, dangerous, or harmless. The skin contains a dense cutaneous sensory and autonomic network designed to sense these stimuli that also communicates with surrounding skin cells and has a bidirectional communication network within the central nervous system (CNS). This complex network is known to play a central role in the development of chronic pain and, as recently discovered, also in chronic pruritus. The latter constitutes a novel research area and is a major focus of this chapter.

THE CUTANEOUS NERVOUS SYSTEM

ANATOMY OF CUTANEOUS NERVES

Barring the stratum corneum, the entirety of the human skin is innervated. The nerves that innervate the skin, apart from the face, consist of cutaneous branches of musculocutaneous nerves that segmentally arise from the spinal nerves. Branches of trigeminal nerves in the facial tissue are responsible for its innervation. At the dermal subcutaneous junction, the primary nerve trunks enter the subcutaneous fat tissue and divide, forming a branching network. This nerve plexus supplies the vasculature, adnexal structures, and encapsulated sensory nerves (eg, Pacinian corpuscles). The nerve fibers subsequently rearrange into small nerve bundles, which, together with the blood and lymphatic vessels, form a network of interlaced nerves both beneath and within the epidermis (Fig. 21-1).[1,2] Sensory and autonomic nerve fibers constitute cutaneous nerve fibers. Afferent impulses are conducted from the periphery of sensory nerves to cell bodies in the dorsal root ganglia (DRG) and to the trigeminal ganglion in the face. Because of their unipolar nature, one branch of a cutaneous sensory neuron's single axon extends from their cell body towards the periphery, and the other extends toward the CNS. Sensory innervation is arranged into well-defined segments called dermatomes; however, an overlapping innervation can possibly occur. The skin is innervated by autonomic nerves in a dissimilar manner: a sequential two-neuron pathway is built between preganglionic fibers of spinal nerves that synapse with postganglionic fibers before innervating the target organ such as skin glands, blood vessels, and arrector pili muscles.[3]

The free nerve endings of sensory nerve fibers are found in the epidermis and papillary dermis (Fig. 21-2). Region-specific differences concerning the nerve fiber innervation density and specificity can be observed from the proximal to distal parts of the body. Specific structures (eg, the hair disk ie, an epithelial thickening around hair follicles) and encapsulated endings, such as the Ruffini and Pacinian corpuscles, as well as Meissner and Krause corpuscles, are equipped with sensory nerves and are able to sense different types

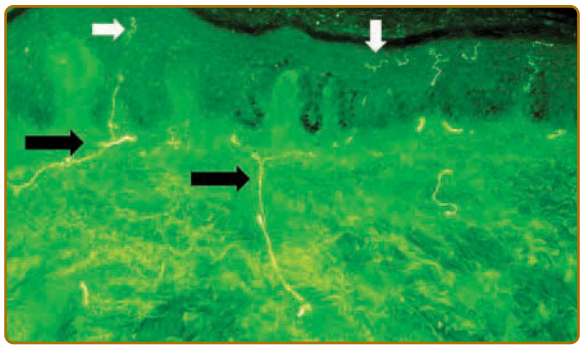

Figure 21-1 Skin nerve fibers (immunostaining with protein gene product 9.5). Dermal nerves (*black arrows*) are myelinated and thicker than intraepidermal nerves (*white arrows*). Dermal nerves from branches enter the epidermis and innervate all vital epidermal layers except the stratum corneum.

of mechanical stimuli (vibration, pressure, and so on). Sensory nerves in the epidermis are in close vicinity to keratinocytes, melanocytes, Langerhans cells, and Merkel cells. Electron and confocal microscopy have demonstrated that intraepidermal neurons are in contact with keratinocytes due to their slight invagination into keratinocyte cytoplasm. The keratinocytes' adjacent plasma membranes have been found to be slightly thickened, similar to postsynaptic membrane specializations in nervous tissues.[4,5] Autonomic nerves, in contrast to sensory nerves, do not innervate the mammalian epidermis.

FUNCTIONAL SUBGROUPS OF SENSORY NERVES

An array of physiological and pathophysiological functions in the skin is influenced by both sensory and autonomic nerves, including embryogenesis, vessel function regulation (vasoconstriction, vasodilation), body temperature and subsidiary mechanisms (eccrine and apocrine gland and erector pili activity), the perception of physical, chemical and biological stimuli on the skin's surface, epidermal barrier

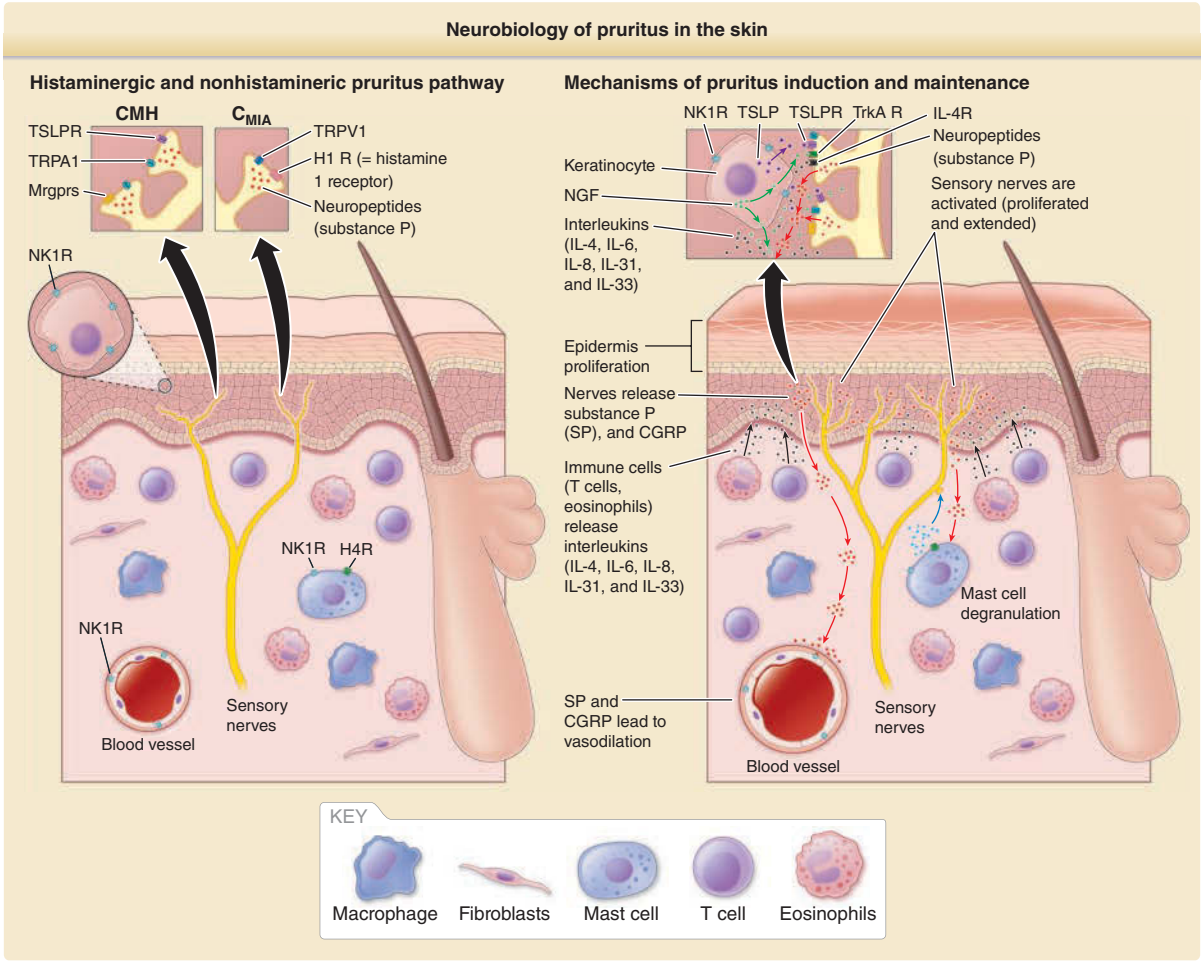

Figure 21-2 Cutaneous nerve system in normal and diseased skin. **A,** Normal skin. **B,** Pruritus. CGRP, calcitonin gene-related peptide; CMH, C mechano-heat sensitive; C_{MIA}, C mechano-insensitive afferences; H4R, Histamine 4 Receptor; IL, interleukin; Mrgprs, Mas-related G-protein coupled receptors; NGF, nerve growth factor; NK1R, neurokinin-1 receptor; TrkA, Tropomyosin receptor kinase A; TRPA1, Transient receptor potential ankyrin 1; TRPV1, transient receptor potential vanilloid 1; TSLP, thymic stromal lymphopoietin; TSLPR, thymic stromal lymphopoietin receptor.

function modulation, nerve development, inflammation, immune defenses, and wound healing. Cutaneous nerves perform said functions with the assistance of afferent (pruritus detection, pain, touch, temperature, and so on) and efferent (neuropeptide release in the skin) mechanisms. The epidermis and peripheral nervous system serve as the skin's sensory forefront. Cutaneous nerves transmit essential information to the CNS following contact or injury by parasites and their toxins, allergens, chemicals, ultraviolet radiation, pH alterations, and stress. These are considered to be the skin's natural protective mechanisms and are normally accompanied by a reaction such as an increased focus on the affected skin area, as well as scratching or the need to restrain oneself. The transmitted information can, at various CNS levels, be modulated to include the brain, spinal cord, autonomic neurons, and DRG..[6,7]

Cutaneous nerves and their respective mediators impact normal cutaneous biological processes such as postnatal skin homeostasis and prenatal skin development. The pathophysiology of a variety of systemic and skin diseases, ranging from chronic pruritus to chronic pain syndromes, are additionally affected by cutaneous nerves. It is suspected that interactions between the peripheral nervous system and CNS are involved in thermoregulation and the pathophysiology of various skin diseases, including psoriasis, atopic dermatitis and acne, wound healing, and hair loss and regrowth.

As a stress response to external or endogenous stimuli, pathophysiological and physiological processes are modulated by autonomic nerves, forming an essential communicative link with the endocrine, immune, and vascular systems.

Contingent upon the extent of their myelination, the function of cutaneous sensory nerves can be assigned to various groups, including conduction velocity, response to trophic stimuli (eg, glial cell line–derived neurotrophic factor and nerve growth factor), and neuropeptide and neuroreceptor expression: (1) Aβ sensory fibers, myelinated to a moderate degree (6 to 12 µm nerve fiber diameter) and able to stimulate touch receptors; (2) Aδ fibers, which have a thin myelin coating (1 to 5 µm diameter) and exhibit an intermediate conduction velocity (4 to 30 m/sec), as well as mediate cold and quick pain sensations and pressure; and (3) unmyelinated, thin (0.2 to 1.5 µm diameter), slow-conducting C fibers (0.5 to 2.0 m/sec). The receptor distribution of these diverse sensory nerve subtypes is evidently important for the performance of various thermal, chemical, and mechanical functions and sensations such as burning, pruritus, pain, prickling, and stinging. The $Na_v1.8$ (SNS/PN3) and $Na_v1.9$ (SNS/SNS2) sodium channels, for example, are expressed by peptidergic neurons and are closely associated with certain pain subtypes. The transient receptor potential vanilloid 1 (TRPV1) ion channel is expressed by C and Aδ nerve fiber classes.[8] TRPV1 belongs to a group of thermosensors that are expressed on keratinocytes and sensory nerves. These thermosensors perceive diverse ranges of temperature, ranging from cold (TRPA1 and TRPM8) to warmth and heat (TRPV1 to TRPV4). Furthermore, heat, pain, and pruritus are also able to be mediated by TRPV1 activation. The CNS can thus discern the quality and localization of incoming signals transmitted by different neurons thanks to this complex system.

ROLE OF CUTANEOUS C AND A FIBERS IN PRURITUS

Burning, pain, pruritus, warmth, and touch are transmitted by C fibers, which are organized into different subgroups. These polymodal nociceptors can respond to chemical, mechanical, and thermal stimuli,[9] although not all subgroups are able to sense the full range of said stimuli. Two subgroups of C fibers that perform as pruriceptors mediate pruritus, of which one subgroup responds to histamine signaling through phospholipase-β3 (PLCβ3) and the ion channel TRPV1. This same subgroup, called C_{MIA} (C mechano-insensitive afferences), is insensitive to mechanical stimuli. The second C fiber subgroup is responsive to pruritic stimuli such as cowhage. They are named CMH (C mechano-heat sensitive) because of their responsiveness to heat and mechanical stimuli. Recent studies suggest that Ad fibers can, upon activation of several pruritogens, also transmit pruritus (Fig. 21-3). Although these subgroups of pruritus-transmitting cutaneous nerves have been validated in humans, other molecular signatures of pruritus-transmitting subpopulations of nerves have been identified in animals, and mostly on the spinal level, such as with the recent discovery of gastrin-releasing peptide (GRP)/GRP receptor and natriuretic polypeptide B (Nppb), and its corresponding receptor, natriuretic peptide receptor A (Npra), as well as somatostatin and neurons expressing the receptor tyrosine kinase Ret.[10,11]

EFFERENT FUNCTION OF CUTANEOUS SENSORY NERVES

More than 20 neuropeptides, among them substance P (SP), neurotensin, neurokinin A (NKA), vasoactive intestinal peptide (VIP), calcitonin gene-related peptide (CGRP), pituitary adenylate cyclase-activating polypeptide (PACAP), peptide histidine isoleucine amide, neuropeptide Y (NPY), somatostatin (SST), dynorphin, β-endorphin, encephalin, secretoneurin, thyroid-stimulating hormone (TSH), melanocyte-stimulating hormone (MSH), and corticotropin-releasing hormone (CRH), have been identified in the skin, either in sensory nerves or other cells such as keratinocytes. Cytoplasmic vesicles store neuropeptides in unstimulated cutaneous sensory nerves. The antidromic activation of the peptidergic C_{MIA} fibers can, upon stimulation, generate the release of vasoactive neuropeptides (eg, SP and CGRP). Their release can, as

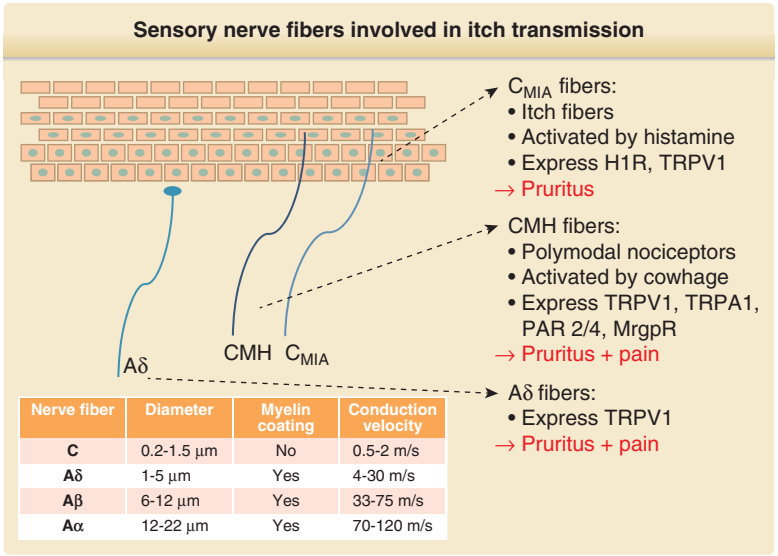

Nerve fiber	Diameter	Myelin coating	Conduction velocity
C	0.2-1.5 μm	No	0.5-2 m/s
Aδ	1-5 μm	Yes	4-30 m/s
Aβ	6-12 μm	Yes	33-75 m/s
Aα	12-22 μm	Yes	70-120 m/s

Figure 21-3 Sensory nerve fibers involved in itch transmission. C and Aδ fibers are responsible for peripheral itch transmission. Two subgroups of C fibers have been identified. Intraepidermal mechano-insensitive afferences (C_{MIA}) are activated by histamine via the TRPV1 ion channel, and mechano-heat sensitive C-fibers (CMH) respond to cowhage and express TRPV1, TRPA1, PAR2 2/4, and Mas-related G protein–coupled receptors (Mrgprs). CMH fibers also act as polymodal nociceptors. Recently, the role of Aδ fibers, which also express TRPV1, has been acknowledged in itch transmission. Properties of peripheral nerve fibers are shown in the table. (Table from Chuquilin M, Alghalith Y, Fernandez KH. Neurocutaneous disease: Cutaneous neuroanatomy and mechanisms of itch and pain. *J Am Acad Dermatol*. 2016;74:197-212, with permission. Copyright © American Academy of Dermatology.)

a result of autocrine and paracrine signaling, produce neurogenic inflammation by initiating vasodilation and mast cell degranulation. Nerve fibers are thus capable of influencing epidermal growth, cytokine expression, and keratinocyte proliferation because of this efferent effect.[12] It has been established that unmyelinated nerve fibers and mast cells have a direct connection and communication via these neuropeptides in the papillary dermis. Experimental studies have established that intradermal injections of SP cause the release of histamine through binding to its receptor on mast cells, thereby inducing a pruritogenic effect. However, it remains controversial as to whether this same connection is applicable to healthy human skin.[13] G protein–coupled receptors (GPCRs), ion channels, and particular cytokine receptors constitute a variety of neuropeptide receptors that are expressed in different cutaneous cells and are thus targets of released neuropeptides. In addition, keratinocytes, Merkel cells, microvascular endothelial cells, leukocytes, and fibroblasts are cutaneous cells that release neuropeptides under certain physiological and pathophysiological circumstances. Endopeptidases (ie, neutral endopeptidase, endothelin converting enzyme, and angiotensin-converting enzyme) are widely expressed in the skin, degrade the neuropeptides, and terminate neuropeptide-induced inflammatory and immune responses.

Neuropeptides and their high affinity receptors are essential for retaining and restoring tissue integrity, as well as regulating the skin's pathophysiological conditions. As a result, it has become apparent that a greater understanding of the skin and nervous systems' complex interactions can provide improved therapeutic approaches to skin diseases in the future. Current information demonstrates that the skin's neuronal network has a vital role in influencing a diverse range of physiological and pathophysiological functions, including host defense, inflammation, pruritus, pain, burning, wound healing, and perhaps cancer (eg, by means of modulating angiogenesis).

AUTONOMIC NERVES

Autonomic nerves, compared to sensory nerves, represent a smaller fraction of cutaneous nerve fibers. Autonomic nerve fibers in human skin are seldom derived from parasympathetic neurons but are instead nearly entirely composed of sympathetic neurons. These nerve fibers innervate arteriovenous anastomoses, blood vessels, apocrine glands, lymphatic vessels, erector pili muscles, eccrine glands, and hair follicles and are strictly distributed throughout the dermis. Autonomic nerves induce their effects primarily through releasing classic neurotransmitters (eg, acetylcholine and noradrenaline) and, to a lesser extent, certain neuropeptides, including VIP, NPY, and atrial natriuretic peptide.

The cutaneous autonomic nervous system influences the function of sweat glands and thus regulates body temperature, water modulation, and the maintenance of electrolyte balance in many organs. Noradrenaline, NPY, or both is released by sympathetic nerve fibers to innervate arteriovenous anastomoses, arterioles, and venous sinusoids, resulting in vasoconstriction. Parasympathetic nerve fibers, in contrast, mediate vasodilation via activation of the

venous sinusoids. The release of acetylcholine and VIP or peptide histidine methionine assists in this process. Sensory and autonomic nerve fibers are closely associated with dermal blood vessels. These vessels not only synthesize neuropeptides but also express receptors for neuropeptides. The seemingly most innervated regions consist of arterial sections of the arteriovenous anastomoses, arteries, capillaries, metarterioles, and precapillary sphincters. Considerable increases in the skin's blood flow provide the necessary quantity of convective heat loss during heat illness and physical activity. Reflex cutaneous vasoconstriction is necessary to hinder excessive heat dispersion during exposure to cold temperatures. Sensory nerves are essential for vasodilation. Oppositely, neuropeptides composed of sympathetic neurons (eg, NPY) mediate vasoconstriction, thus adopting a key role in several processes, including thermoregulation, the control of blood flow during inflammation and tumorigenesis, and endothelial and smooth muscle cell activation. Both cell types have been found to be responsive to both neuronal modulation in inflammatory diseases (eg, atopic dermatitis) and host defense mechanisms, neovascularization, and wound healing. The function of the apocrine, sebaceous, and sweat glands, as well as the pilosebaceous unit, is modulated by the sensory and autonomic nerves. Autonomic nerves are, under certain pathophysiological conditions, implicated in hyperhidrosis and hypohidrosis and play a pathological role in congenital diseases (eg, progressive segmental hypohidrosis and congenital sensory neuropathy type IV) and a host of other conditions, including diabetic neuropathy, complex regional pain syndrome, syringomyelia, and dysfunction after sympathectomy. It is important to note that through upregulation of the corresponding receptors during trauma or inflammation, Ciber nociceptors have the potential to develop responsiveness to adrenergic neurotransmitters. The sensory and autonomic nervous systems are thus proven to communicate and interact with diseases on a molecular level.

SPINAL CORD

Ascending afferent and descending inhibitory neurons, as well as interneurons, constitute the complex neuroanatomy of the spinal cord and, principally, the circuitry transmitting pruritus and pain signals. Pruritus transmission has been primarily studied in animal models and through clinical observations of affected patients. Both methods have provided valuable information on pruritus mechanisms in humans. The spinal cord's spinothalamic tract and other common ascending sensory pathways are shared in both pruritus and pain.[6] Many functions in pruritus and pain processing differ, although both symptoms share several mechanisms and their neuroanatomy.[14] κ-opioids are known to be analgesic and antipruritic. Although μ-opioids (eg, morphine) are also analgesic, they can potentially induce pruritus. Recent studies have used animal models to discover more about the neurotransmitters involved in spinal and trigeminal pruritus transmission. These studies have put particular emphasis on the gastrin-releasing peptide receptor (GRPR) and neurokinin-1 receptor (SP receptor; NK1R).[6] It was found that GRPR and MOR1D, a μ-opioid receptor isoform, are considerably colocalized in the superficial spinal cord and that the GRPR antagonist eradicated morphine-induced scratching. These findings were established with experiments on mice and suggest that there is a specific spinal pathway reserved for pruritus. Other substances currently under evaluation include glutamate and its effects on the AMPA/kainate receptor, natriuretic polypeptide B (Nppb) and its receptor Npra, and somatostatin and the receptor tyrosine kinase Ret. Interestingly, it is speculated that Nppb is released from primary afferent pruriceptors to excite second-order spinal interneurons. Thus, a chain of spinal neurons and interneurons may possibly play a role in cascading pruritus transmission or inhibition, depending on the discharged mediators. The correct knowledge of this process would permit the establishment of novel therapeutic targets for those with pruritus. Although this information requires adaptation for humans with chronic pruritus, these experimental data are promising and represent the first step toward better understanding the complex physiological mechanisms of pruritus. The mechanisms behind scratching are also of great importance. While a patient scratches her or his pruritus, the pruritus is relieved. It is thus speculated whether scratching triggers interneurons modulating pain, which have the potential to inhibit systems conducting pruritus transmission. μ-opioid and κ-opioid receptors are both believed to be expressed and involved with interneurons mediating pruritus. Systemic treatments with μ-antagonists (eg, naltrexone and naloxone) and κ-agonists (nalfurafine) may control various forms of chronic pruritus, including cholestatic and uremic pruritus.

NEUROBIOLOGY OF PRURITUS

To better identify environmental stimuli, cutaneous nerve fibers come equipped with several different receptor classes. Primarily GPCRs, transient receptor potential (TRP) channels, and cytokine and toll-like receptors (TLRs) are those found primarily on pruriceptors. GPCR does not directly result in the production of an action potential but is conjoined to TRP channels via intracellular signaling pathways. The activation of TRP channels, with a sufficient ion influx, allows for the generation of action potentials.[15,16] Histamine, for example, activates H1 receptors on the C_{MIA}, beginning activation of phospholipase Cβ3 (PLCβ3) and an intracellular signal cascade (Table 21-1). This results in TRPV1 activation and allows for an influx of ions, therefore producing an action potential.[15] Many of these signaling cascades have recently been detected in pruriceptors and are relevant for pruritus research. Mas-related GPCRs (Mrgprs) share a connection to

thymic stromal lymphopoietin (TSLP) receptors and have been identified amongst the mechanisms of chloroquine-induced and atopic pruritus. Mrgprs are known to induce pruritus via the cold sensory receptor TRPA1 in CMH fibers. These fibers can be selectively activated with cowhage, a cysteine protease appearing in spicules of the plant *Mucuna pruriens*.

Nowadays, cowhage and histamine are often adopted for use in experimental pruritus studies on humans. Cowhage is thought to act via protease-activated receptors (PARs) 2 and 4 located in CMH fibers. Recent studies have suggested that a functional overlapping of the PARs and Mrgprs is likely and propose that Mrgprs activation is related to the effects of cowhage.[17] The human cysteine protease cathepsin S and cowhage are highly homologous. Under certain pathological conditions, cathepsin S is induced in keratinocytes by γ interferon. It also has a role in the pruritus associated with atopic dermatitis and seborrheic dermatitis[18,19] and binds to PAR and Mrgprs. The responses to pruritus, however, share a greater link with Mrgprs in mice. TSLP, which is released by keratinocytes in atopic dermatitis, is upregulated through activation of PARs in keratinocytes. In summary, the functions of PARs and Mrgprs remain unclear, although both appear to have a role in pruritus induction.[17]

Research efforts to learn more about these have proven fruitful within the past few years. Several different pruritogens have recently been identified, and experts' knowledge on the molecular mechanisms of pruritus is continuously growing. Endothelin, cytokines (eg, interleukins [ILs] 6, 8, 31, and 33), leukotrienes, neuropeptides (SP, CGRP), serotonin, and prostaglandins are examples of mediators that are known to cause pruritus either directly via neuroreceptor activation or indirectly via upregulation of ligands targeting nerves and nerve fiber sensitization (see Table 21-1). IL-31 is a protein that has received a moderate amount of attention for its elevated levels in both the lesioned skin and serum of patients with atopic dermatitis and is also known to activate the IL-31 receptor (IL-31R). An IL-31RA subunit and oncostatin M receptor subunit constitute the heterodimeric IL-31 receptor (IL-31R). Its corresponding antibody was found to quickly diminish pruritus in affected patients.[20,21] Furthermore, IL-31 is released by inflammatory cells (eg, T cells, including Th2 cells in atopic dermatitis and eosinophils). It is suspected that a line of communication between eosinophils and keratinocytes exists in pruritic inflammatory skin diseases. TLR3, TLR4 and TLR7 are TLRs that serve as innate sensors in the immune system and thought to have a role in pruritus. They are expressed in DRGs, peripheral sensory nerves, spinal glial cells, and superficial dorsal horn neurons and are colocalized with GRP, ion channels, and Mrgprs. Experiments conducted with knockout

TABLE 21-1
Neurobiology of Pruritus: Mediators, Corresponding Receptors, and Assumed Clinical Role

MEDIATOR	NEURORECEPTOR	GENERATION OF ACTION POTENTIAL ON C FIBERS VIA	ASSUMED CLINICAL ROLE IN PRURITUS
Histamine	Histamin1 receptor	TRPV1	Urticaria
	Histamine 4 receptor on Th2 cells: increased production of IL-31	—	Atopic dermatitis
Cathepsin S	Mas-related G protein–coupled receptors (Mrgprs)	TRPA1	Atopic dermatitis, seborrheic dermatitis
Thymic stromal lymphopoietin (TSLP)	TSLP receptor (heterodimeric receptor composed of TSLP receptor chain and IL-7 receptor alpha chain)	TRPA1	Atopic dermatitis, allergic asthma
Serotonin	5-HT7	TRPA1	Atopic dermatitis, prurigo nodularis? (increased serum levels), cholestatic pruritus?, uremic pruritus?
	5-HT2	TRPV4	
Endothelin	Endothelin-1 receptor	TRPA1	Atopic dermatitis, prurigo nodularis
Substance P	Neurokinin-1 receptor (NK1R) on keratinocytes, mast cells, endothelia cells; release of pruritogenic mediators	—	Atopic dermatitis, eczema, prurigo nodularis, psoriasis vulgaris
Interleukin-31 (IL-31)	IL-31 receptor (IL-31R) (heterodimeric receptor of IL-31RA subunit and oncostatin M receptor subunit)		Atopic dermatitis, prurigo nodularis, cutaneous T-cell lymphoma, familial primary localized cutaneous amyloidosis, urticaria (serum), mastocytosis (serum)
Unknown	Toll-like receptors (TLRs) on sensory nerves, dorsal root ganglia, spinal glia cells	TRPV1	Dry skin
Autotaxin/ lysophosphatidic acid (LPA)	LPA receptor	TRPV1 (A fibers)	Cholestatic pruritus
Bile acids	TGR5 receptor	TRPA1	Cholestatic pruritus

mice have demonstrated that TLRs promote pruritus transmission[22,23] caused by multiple pruritogens such as chloroquine, endothelin-1, imiquimod, and Mrgpr agonists; however, they do not directly induce pruritus. TLR3 in the DRG, for example, intensifies TRPV1 activity and thereby boosts histamine-induced pruritus signal transduction.

The pathophysiology of chronic pruritus in humans remains unclear; however, the mechanisms of acute pruritus are much more evident. It can be assumed that complex mechanisms in the skin and CNS contribute to the development of chronic pruritus and lead to a peripheral sensitization of cutaneous nerves, central sensitization, impaired interneuron function, and descending inhibitory neurons at the spinal level. In summary, recent experimental animal models of certain diseases suggest a clinical role of certain pruritogens in inflammatory skin diseases and systemic pruritus. In most cases, however, this remains to be clinically validated in humans.

Keratinocytes, mast cells, and inflammatory cells play important roles in the induction and maintenance of pruritus. Interestingly, the cutaneous neuroanatomy is also altered in pruritic diseases. Researchers discovered that overexpression of IL-31 in transgenic mice caused pruritic skin. IL-31 was found to influence the cutaneous nerve anatomy and induce dermal nerve elongation and branching. It might also be a factor contributing to the cutaneous hyperinnervation attributed to atopic dermatitis. In humans, this might be due to disproportionate nerve elongation (eg, nerve growth factor [NGF]) and nerve repulsion factors (eg, semaphorin 3A) produced by keratinocytes.[24] The hyperinnervation of dermal nerves has been confirmed for chronic pruritus and prurigo nodularis. The intraepidermal nerves penetrating the basal membrane are reduced in numbers, which might be caused by scratching.[25] This neuroanatomical imbalance of intraepidermal nerves (caused by scratching) and dermal nerves (caused by pruritic mediators released by keratinocytes and inflammatory cells) thus clearly carries significance for the function and induction of pruritus.

ROLE OF THE NERVOUS SYSTEM IN SKIN DISEASES

Atopic dermatitis, prurigo nodularis, psoriasis vulgaris, rosacea, herpes zoster, urticaria, and wound healing represent a small number of several dermatoses with a vital neurogenic component (besides pruritus induction). Although the peripheral nervous system modulates inflammatory responses, neuronal mediators assist in the wound healing process by managing fibroblast and keratinocyte production, as well as angiogenesis. It has been known for several years that neuropeptides possess the ability to stimulate human mast cells and induce urticaria. Chronic spontaneous urticaria and, to a lesser extent, pressure urticaria exhibit increased SP levels and CGRP-induced wheal and flare reactions. Sensory nerves and mast cells express TRP ion channels that can be triggered by factors such as warmth, cold, and food allergens resulting in urticaria.

A subset of sensory neurons expressing the TRPV1 and Nav1.8 affirmed the neurogenic components involved in the pathophysiology of psoriasis and are crucial for facilitating the psoriatic inflammatory response. IL-23–producing dermal dendritic cells have been found to be in close connection to these TRPV1/Nav 1.8 positive nociceptors. Upon selective pharmacological or genetic ablation of the nociceptors, the dermal dendritic cells failed to produce IL-23 and thereby to initiate the psoriasiform skin inflammation.[26] This link seems to be clinically relevant because topical capsaicin application (depleting neuropeptides from sensory nerves and destroying superficial sensory nerves) can lead to significant improvement of psoriasis.[27] Novel topical formulations with liposomes containing capsaicin were recently developed for this indication.[28]

The skin's nervous system plays an important part in various processes, including wound healing. Several neuropeptides secreted by sensory and autonomic nerve fibers are essential to the different phases of wound healing,[29] including neurotrophin-3 (eg, nerve regeneration), CGRP (eg, angiogenesis), brain-derived neurotrophic factor (BDNF; eg, wound contraction and epithelialization), NGF (eg, nerve regeneration and fibroblast differentiation into myofibroblasts), and SP (eg, collagen maturation and remodeling).

PRURITUS

CLASSIFICATION AND CLINICAL MANIFESTATION

Pruritus, the most common symptom in dermatology, is listed by the World Health Organization's Global Burden of Disease study as one of the 50 most frequent interdisciplinary symptoms.[30,31] If present for longer than 6 weeks, pruritus is considered chronic. It is estimated that one-fifth of the global population has chronic pruritus, with a substantial number of these affected individuals having a highly impaired quality of life.[32]

The distinction between acute and chronic pruritus is not merely academic. Although the cause of acute pruritus is often easy to identify (eg, a reaction to an allergen or an episode of urticaria) and easily treated, this is not the case for chronic pruritus.[33] Complex processes, including peripheral and central sensitization involving a plethora of neuromodulators and receptors at all levels of the nervous system, are believed to take place, explaining the persistence of pruritus even after the original cause has been eliminated.[34]

Because pruritus is a highly complex symptom potentially arising from many different clinical diseases, a systematic diagnostic approach is decisive for its clinical management. A clinical classification system developed by the International Forum for the Study of Itch (IFSI) divides chronic pruritus

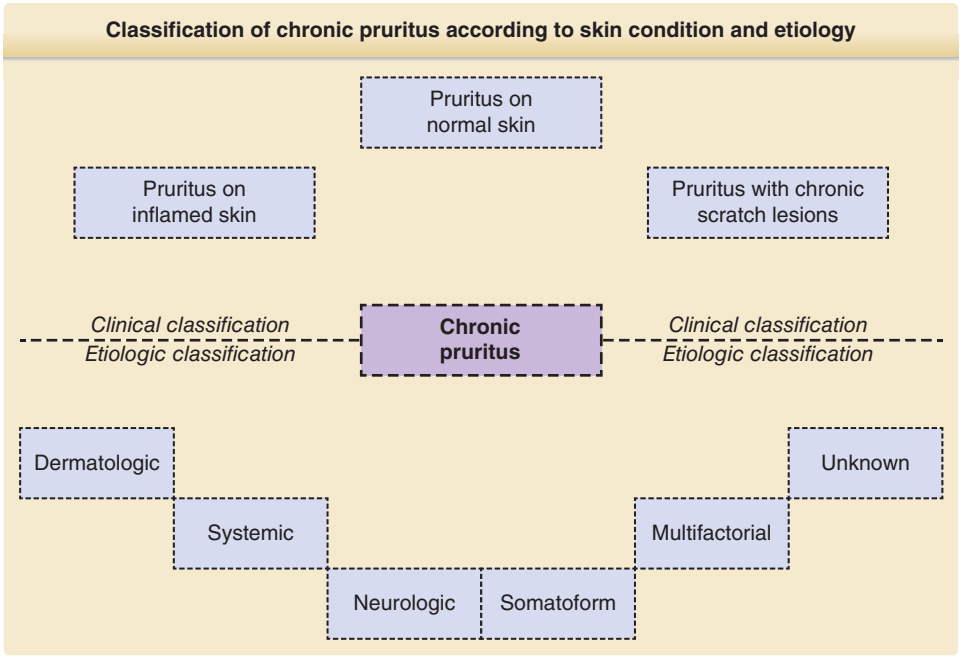

Figure 21-4 Classification of chronic pruritus according to skin condition and etiology by the International Forum for the Study of Itch.

patients into groups according to their skin condition (Fig. 21-4).[33] Patients may present with pruritus on inflamed skin (IFSI group I), on seemingly normal skin (IFSI group II), or accompanied by chronic scratch lesions (IFSI group III) (Fig. 21-5). This classification system has diagnostic relevance. For instance, although skin biopsies for histological examinations may be useful in further characterizing possible dermatoses in patients with inflamed skin or those with chronic scratch lesions, laboratory workups to investigate possible systemic or neurologic conditions gain relevance in patients with pruritus on normal skin or with chronic scratch lesions (Fig. 21-4).[33]

It is useful to group the patient into an etiological category upon taking their medical history and performing a physical, laboratory and radiological examination. This greatly aids in planning a therapeutic strategy. The IFSI has proposed a classification of chronic pruritus into categories composed of skin diseases and systemic, neurological, or somatoform conditions as causative entities for chronic pruritus (see Fig. 21-4). Noteworthy multiple causes may be present in the same patient (multifactorial pruritus), or no cause may be identifiable (pruritus of unknown origin).[33]

THERAPEUTIC APPROACH

A step-by-step approach is recommended for the treatment of chronic pruritus (Fig. 21-6). Elementary measures such as the consequent use of emollients to prevent xerosis or the avoidance of allergens and potentially irritating substances should be adopted regardless of the cause for the pruritus. Ointments containing antipruritic compounds, such as urea, menthol, and polidocanol should be recommended to patients. Additionally, antihistamines have proven symptom relief for various pruritic diseases and may be prescribed even before the etiology is discovered.[35]

If the origin of the pruritus can be determined, the physician should prepare a targeted therapy, for instance, immunosuppressive drugs (eg, cyclosporine) for atopic dermatitis, gabapentinoids for neuropathic pruritus, and antidepressants (eg, paroxetine) for paraneoplastic pruritus.

If the etiology remains unknown or the targeted therapy is unsuccessful, a symptomatic topical or systemic therapy (or both) is recommended. The topical use of calcineurin inhibitors may be useful when dealing with inflammatory conditions, and capsaicin has shown efficacy in many disorders such as neuropathic and aquagenic pruritus. Local anesthetics can be used for notalgia paraesthetica. Antidepressants are systemic agents useful for pruritus of various origins, and naltrexone may help against cholestatic and nephrogenic pruritus. Many other drugs have been used in the treatment of pruritus of various origins and can be consulted in the available guidelines.[36]

Chronic pruritus frequently leads to accompanying disorders, including sleep disturbances, depression, and anxiety. These should be treated from an early stage to mitigate a decrease in quality of life and prevent their development into a chronic condition. The use of hypnotic substances, sedating antidepressant drugs, and relaxation techniques should be discussed with the patient. Consultation with a psychosomatic specialist should be encouraged in case of mental factors.

Figure 21-5 Clinical presentation of chronic pruritus. Patients with chronic pruritus may present with inflamed skin (**A**), normal-appearing skin (**B**), or chronic scratch lesions (**C**). **A,** A 58-year-old man with atopic dermatitis. **B,** A 45-year-old man with cholestatic pruritus after liver transplant. **C,** A 60-year-old man with chronic prurigo with underlying advanced renal insufficiency.

If the mechanisms have become chronic, the pruritus may persist even after elimination of the original cause. Peripheral and central processes in the nervous system are believed to be responsible for this phenomenon.[34,37] Therapeutically, centrally acting drugs may be necessary in blocking these pathophysiological mechanisms. Another aspect to consider is the itch-scratch cycle that may develop after a prolonged period with a pruritic condition. Patients feel the urge to scratch and display an automatic scratching behavior even though the

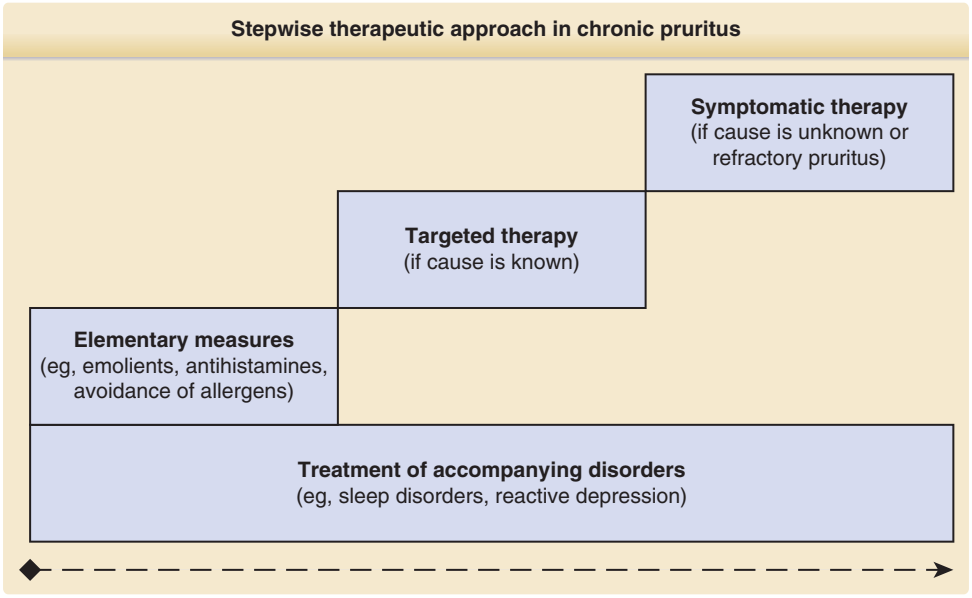

Figure 21-6 Stepwise therapeutic approach in chronic pruritus.

pruritus is no longer present. Behavioral therapies are useful in these cases and should be discussed with the patients.

NEW DRUGS

As described earlier in this chapter, new mediators, receptors, and pathways have been identified in recent years, leading to novel antipruritic compounds.

In inflammatory conditions (eg, atopic dermatitis), NK1R antagonists led to a significant reduction of scratching behavior in a mouse model of atopic dermatitis,[38] and off-label use in patients with chronic pruritus has shown promising symptomatic improvement.[39] Phase II clinical trials testing both topical and systemic NK1R antagonist compounds are underway, targeting not only inflammatory dermatoses but also prurigo nodularis, cutaneous T-cell lymphoma, and epidermolysis bullosa. Another drug class of interest targeting inflammatory dermatoses is the antibody blocking the IL-31 receptor. IL-31 receptor antagonists showed promising findings in studies on atopic dermatitis and are currently being tested in further clinical trials.[40] Topical agents targeting TRPV1 and the tyrosine receptor kinase A, a nerve growth factor receptor, are also being developed.

For pruritus arising from systemic diseases, κ-opioid receptor agonists have shown antipruritic efficacy in patients with uremic pruritus,[41,42] and bile acid transporter inhibitors are promising drugs in the treatment of cholestatic pruritus.

Randomized controlled trials are thus greatly needed for the rapid approval of promising new antipruritic agents.

SUMMARY AND PERSPECTIVES

The nervous system alters cutaneous functions in many ways. Under certain physiological conditions, it can also lead to the control of skin homeostasis; however, neuromodulators can both aggravate (proinflammatory) or mitigate (antiinflammatory) disease development under pathophysiological conditions. The skin's bidirectional capability within the peripheral nervous system and CNS is vital for skin homeostasis and disease states, as observed in inflammation, pain, and pruritus. Recent findings have enhanced our knowledge of the molecular mechanisms that regulate the functions of neuromodulators, their receptors, and controlling enzymes. Proteomics, genomics, metabolics, and the molecular imaging of neuronal structures are modern techniques that provide intriguing insights into this complex network comprised of the skin, nerves, and immune system during inflammation, chronic pain, pruritus, and tumorigenesis. Chronic pruritus is highly prevalent and can considerably impair one's quality of life. A systematic diagnostic approach is necessary because of its abundance of possible etiologies. In addition to adopting basic therapeutic measures consisting of emollient application to prevent xerosis and avoiding allergies, it is recommended to implement a targeted therapy of the underlying disease, if possible. Novel agents are currently in development in clinical and preclinical trials. Neurokinin-1 receptor antagonists, IL-31 receptor antagonists, and other agents targeting the TRPV1 constitute a group of interesting new agents for treatment of inflammatory dermatoses. κ-opioid receptor agonists, partly with μ-opioid receptor antagonist properties, are presently undergoing tests for use against uremic pruritus, and bile acid transporter inhibitors show great promise for cholestatic pruritus.

REFERENCES

1. Chuquilin M, Alghalith Y, Fernandez KH. Neurocutaneous disease: cutaneous neuroanatomy and mechanisms of itch and pain. *J Am Acad Dermatol*. 2016; 74(2):197-212.
2. Lloyd DM, McGlone FP, Yosipovitch G. Somatosensory pleasure circuit: from skin to brain and back. *Exp Dermatol*. 2015;24(5):321-324.
3. Wang N, Gibbons CH. Skin biopsies in the assessment of the autonomic nervous system. *Handb Clin Neurol*. 2013;117:371-378.
4. Chateau Y, Misery L. Connections between nerve endings and epidermal cells: are they synapses? *Exp Dermatol*. 2004;13(1):2-4.
5. Schwendinger-Schreck J, Wilson SR, Bautista DM. Interactions between keratinocytes and somatosensory neurons in itch. *Handb Exp Pharmacol*. 2015;226:177-190.
6. Akiyama T, Carstens E. Neural processing of itch. *Neuroscience*. 2013;250:697-714.
7. Boulais N, Misery L. The epidermis: a sensory tissue. *Eur J Dermatol*. 2008;18(2):119-127.
8. Wilson SR, Bautista DM. Frontiers in neuroscience: role of transient receptor potential channels in acute and chronic itch. In: Carstens E, Akiyama T, eds. *Itch: Mechanisms and Treatment*. Boca Raton, FL: CRC Press/Taylor & Francis Group; 2014.
9. Ringkamp M, Meyer R. Frontiers in neuroscience: pruriceptors. In: Carstens E, Akiyama T, eds. *Itch: Mechanisms and Treatment*. Boca Raton, FL: CRC Press/Taylor & Francis Group; 2014.
10. Stantcheva KK, Iovino L, Dhandapani R, et al. A subpopulation of itch-sensing neurons marked by Ret and somatostatin expression. *EMBO Rep*. 2016;17(4): 585-600.
11. Akiyama T, Carstens E. Frontiers in neuroscience: spinal coding of itch and pain. In: Carstens E, Akiyama T, eds. *Itch: Mechanisms and Treatment*. Boca Raton, FL: CRC Press/Taylor & Francis Group; 2014.
12. Hsieh ST, Lin WM. Modulation of keratinocyte proliferation by skin innervation. *J Invest Dermatol*. 1999;113(4):579-586.
13. Weidner C, Klede M, Rukwied R, et al. Acute effects of substance P and calcitonin gene-related peptide in human skin—a microdialysis study. *J Invest Dermatol*. 2000;115(6):1015-1020.
14. Stander S, Schmelz M. Chronic itch and pain—similarities and differences. *Eur J Pain*. 2006;10(5):473-478.

15. Garibyan L, Rheingold CG, Lerner EA. Understanding the pathophysiology of itch. *Dermatol Ther*. 2013; 26(2):84-91.
16. Bautista DM, Wilson SR, Hoon MA. Why we scratch an itch: the molecules, cells and circuits of itch. *Nat Neurosci*. 2014;17(2):175-182.
17. Reddy VB, Sun S, Azimi E, et al. Redefining the concept of protease-activated receptors: cathepsin S evokes itch via activation of Mrgprs. *Nat Commun*. 2015;6:7864.
18. Viode C, Lejeune O, Turlier V, et al. Cathepsin S, a new pruritus biomarker in clinical dandruff/seborrhoeic dermatitis evaluation. *Exp Dermatol*. 2014;23(4):274-275.
19. Kim N, Bae KB, Kim MO, et al. Overexpression of cathepsin S induces chronic atopic dermatitis in mice. *J Invest Dermatol*. 2012;132(4):1169-1176.
20. Nemoto O, Furue M, Nakagawa H, et al. The first trial of CIM331, a humanized anti-human IL-31 receptor A antibody, for healthy volunteers and patients with atopic dermatitis to evaluate safety, tolerability and pharmacokinetics of a single dose in a randomised, double-blind, placebo-controlled study. *Br J Dermatol*. 2016;174(2):296-304.
21. Feld M, Garcia R, Buddenkotte J, et al. The pruritus- and TH2-associated cytokine IL-31 promotes growth of sensory nerves. *J Allergy Clin Immunol*. 2016;138(2): 500-8.e24.
22. Taves S, Ji RR. Itch control by Toll-like receptors. *Handb Exp Pharmacol*. 2015;226:135-150.
23. Liu T, Xu ZZ, Park CK, et al. Toll-like receptor 7 mediates pruritus. *Nat Neurosci*. 2010;13(12):1460-1462.
24. Tominaga M, Takamori K. Frontiers in neuroscience: sensitization of itch signaling: itch sensitization-nerve growth factor, semaphorins. In: Carstens E, Akiyama T, eds. *Itch: Mechanisms and Treatment*. Boca Raton, FL: CRC Press/Taylor & Francis Group; 2014.
25. Haas S, Capellino S, Phan NQ, et al. Low density of sympathetic nerve fibers relative to substance P-positive nerve fibers in lesional skin of chronic pruritus and prurigo nodularis. *J Dermatol Sci*. 2010;58(3):193-197.
26. Riol-Blanco L, Ordovas-Montanes J, Perro M, et al. Nociceptive sensory neurons drive interleukin-23-mediated psoriasiform skin inflammation. *Nature*. 2014;510(7503): 157-161.
27. Boyd K, Shea SM, Patterson JW. The role of capsaicin in dermatology. *Prog Drug Res*. 2014;68:293-306.
28. Gupta R, Gupta M, Mangal S, et al. Capsaicin-loaded vesicular systems designed for enhancing localized delivery for psoriasis therapy. *Artif Cells Nanomed Biotechnol*. 2016;44(3):825-834.
29. Ashrafi M, Baguneid M, Bayat A. The role of neuromediators and innervation in cutaneous wound healing. *Acta Derm Venereol*. 2016;96(5):587-594.
30. Kopyciok ME, Stander HF, Osada N, et al. prevalence and characteristics of pruritus: a one-week cross-sectional study in a German dermatology practice. *Acta Derm Venereol*. 2016;96(1):50-55.
31. Hay RJ, Johns NE, Williams HC, et al. The global burden of skin disease in 2010: an analysis of the prevalence and impact of skin conditions. *J Invest Dermatol*. 2014;134(6):1527-1534.
32. Stander S, Schafer I, Phan NQ, et al. Prevalence of chronic pruritus in Germany: results of a cross-sectional study in a sample working population of 11,730. *Dermatology*. 2010;221(3):229-235.
33. Stander S, Weisshaar E, Mettang T, et al. Clinical classification of itch: a position paper of the International Forum for the Study of Itch. *Acta Derm Venereol*. 2007;87(4): 291-294.
34. Ikoma A, Steinhoff M, Stander S, et al. The neurobiology of itch. *Nat Rev Neurosci*. 2006;7(7):535-547.
35. Yosipovitch G, Bernhard JD. Clinical practice. Chronic pruritus. *N Engl J Med*. 2013;368(17):1625-1634.
36. Weisshaar E, Szepietowski JC, Darsow U, et al. European guideline on chronic pruritus. *Acta Derm Venereol*. 2012;92(5):563-581.
37. Stander S, Weisshaar E, Luger TA. Neurophysiological and neurochemical basis of modern pruritus treatment. *Exp Dermatol*. 2008;17(3):161-169.
38. Ohmura T, Hayashi T, Satoh Y, et al. Involvement of substance P in scratching behaviour in an atopic dermatitis model. *Eur J Pharmacol*. 2004;491(2-3):191-194.
39. Stander S, Siepmann D, Herrgott I, et al. Targeting the neurokinin receptor 1 with aprepitant: a novel antipruritic strategy. *PLoS One*. 2010;5(6):e10968.
40. Kasutani K, Fujii E, Ohyama S, et al. Anti-IL-31 receptor antibody is shown to be a potential therapeutic option for treating itch and dermatitis in mice. *Br J Pharmacol*. 2014;171(22):5049-5058.
41. Inui S. Nalfurafine hydrochloride to treat pruritus: a review. *Clin Cosmet Investig Dermatol*. 2015;8:249-255.
42. Wikstrom B, Gellert R, Ladefoged SD, et al. Kappa-opioid system in uremic pruritus: multicenter, randomized, double-blind, placebo-controlled clinical studies. *J Am Soc Nephrol*. 2005;16(12):3742-3747.

This page intentionally left blank

Dermatitis

PART 3

Chapter 22 :: Atopic Dermatitis

:: Eric L. Simpson, Donald Y. M. Leung, Lawrence F. Eichenfield, & Mark Boguniewicz

AT-A-GLANCE

- Atopic dermatitis (AD) has a prevalence peak of 15% to 20% in early childhood in industrialized countries.
- AD has variable rates of remission, with many patients continuing or recurring with symptoms into adulthood.
- AD is a chronic or chronically relapsing disorder with major features of:
  - Pruritus
  - Eczematous dermatitis (acute, subacute, or chronic) with typical morphology and age-specific patterns
  - Facial and extensor involvement in infancy
  - Flexural eczema or lichenification in children and adults
  - Commonly associated with the following:
    - Personal or family history of atopy (allergic rhinitis, asthma, atopic dermatitis)
    - Xerosis or skin barrier dysfunction
    - Immunoglobulin E reactivity
- Pathogenesis driven by skin barrier defects (most importantly in the *FLG* gene), environmental effects and alterations in immunologic responses in T cells, antigen processing, inflammatory cytokines, host defense proteins, allergen sensitivity, and infection.

INTRODUCTION

Atopic dermatitis (atopic eczema, AD) is a chronic inflammatory skin disease primarily beginning in childhood with a variable natural course. Itch is the hallmark symptom of the disease, often unrelenting in severe cases, and leads to sleep disturbance and excoriated, infection-prone skin. Patients with AD often additionally have atopic comorbidities such as allergic asthma and allergic rhinitis and experience a significantly impaired quality of life.

DEFINITIONS AND HISTORICAL PERSPECTIVE

NOMENCLATURE

The term *atopic dermatitis* was first coined in 1933 by Sulzberger and Wise and replaced early terms corresponding to probable AD such as tinea *muquese, porrigo larvalis,* and *Hebra's prurigo*. The term *atopy* was first introduced by Coca and Cooke in 1923 to describe the tendency toward developing allergic hypersensitivity manifested by asthma and hayfever.[1] The term *atopi* is derived from the Greek word *atopos* meaning "without place," reflecting the mysterious pathogenic underpinnings of allergic hypersensitivity disease. Wise and Sulzberger coined the term *atopic dermatitis* in 1933 to describe recurring eczematous skin disease found in patients with a family history of atopic disease.[2]

Importantly, they noted that patients with AD may not have a personal history of other atopic disease. Since this seminal paper, several groups attempted to rename the disease primarily to differentiate AD that has concomitant immunoglobulin E (IgE) sensitization from AD without sensitization, such as *atopiform dermatitis* and *nonatopic eczema*. A recent systematic review reveals *atopic dermatitis* to be the most commonly used name for the disease and proposed the universal use of this term for AD.[3] The authors of that paper discourage the use of less specific terms such as *eczema*, which is a morphological term and includes contact and other eczematous conditions.

DIAGNOSTIC CRITERIA

Significant advancement of our understanding of the disease could not be made without a proper disease definition. Early work by luminaries in AD, such as Rajka, Lobitz, and Hanifin, paved the way for the first comprehensive diagnostic criteria for AD—the Hanifin-Rajka criteria.[4] The major criteria have been validated and remain the gold standard for AD diagnosis. Similar to AD nomenclature, numerous attempts have been made to refine and shorten the original criteria to make them more useful in clinical practice. The UK Working Party Criteria were developed using modern statistical methods and represent a distilled set of the original criteria useful for population-based epidemiologic study.[5] The American Academy of Dermatology consensus diagnostic criteria for pediatric AD are a useful and clinician-friendly guide to AD diagnosis, although no formal validation studies have been published.[6]

EPIDEMIOLOGY

Since the 1960s, there has been a more than threefold increase in the prevalence of AD.[2] AD is a major public health problem worldwide, with a prevalence in children of 10% to 20% in the United States, Northern and Western Europe, urban Africa, Japan, Australia, and other industrialized countries.[3] The Global Disease Burden project ranks "dermatitis," which includes AD, as the highest ranking skin disease in regards to total global disability burden.[7] The prevalence of AD in adults is less clear, but recent studies estimate the prevalence to be between 3% to 7% in the United States, Germany, and Japan.[8-10] The International Study of Asthma and Allergies in Childhood (ISAAC) Phase Three study confirmed that AD is a disease with high prevalence worldwide, affecting patients in both developed and developing countries.[4] There is also an observed female preponderance for AD, with an overall female-to-male ratio of 1.3 to 1.0. Racial and ethnic differences in prevalence also exist with African Americans having a higher prevalence of the disease in the United States.[11]

Wide variations in prevalence have been observed within countries inhabited by similar ethnic groups, suggesting that environmental factors are critical in determining disease expression. Several studies reveal lower prevalence rates in rural settings compared with urban centers within the same country.[12] Other risk factors reported to be associated with AD include exposure to airborne pollution, use of hard water, increased income and education both in whites and blacks, obesity, and increased use of antibiotics.[13-17] Climate may also play a role in disease expression with lower humidity and lower ultraviolet (UV) areas displaying higher prevalence rates.[18] Climatic factors and pollution levels may also influence symptoms and flares of the disease.[19]

CLINICAL FEATURES

CUTANEOUS FINDINGS

Acute eczematous lesions are characterized by erythematous papulovesicles, often with pinpoint crusting or frank weeping. More subacute to chronic lesions often display scale, excoriation, and lichenification. Patients with AD may present with only one stage of eczematous lesions, but most often patients have a mixture of both acute and chronic lesions in multiple areas of the body simultaneously or even in the same lesion. Individual eczematous lesions of AD cannot be readily distinguished clinically or histologically from lesions found in other eczematous conditions such as allergic contact dermatitis or nummular dermatitis. Patients with darker skin tones often present with follicular accentuation, flat-topped papules in lichenified areas, and a tendency toward hyperpigmentation in inflamed areas, which can be very distressing for patients. Rarely, patients may also experience a vitiligo-like depigmentation in involved areas that is difficult to distinguish from topical steroid-induced pigment loss.

The distribution of eczematous lesions vary according to the patient's age (Fig. 22-1) and disease activity. During infancy, the AD is generally more acute and primarily involves the face (Fig. 22-2), the scalp, and the extensor surfaces of the extremities (Fig. 22-3).[20] The diaper area is usually spared. In older children and in those who have long-standing skin disease, the patient develops the chronic form of AD with lichenification and localization of the rash to the flexural folds of the extremities (Fig. 22-4). AD may subside as the patient grows older, leaving an adult with skin that is prone to itching and inflammation when exposed to exogenous irritants. Chronic hand eczema may be the primary manifestation of AD in many adults (Fig. 22-5). At least one third of patients will have clinical features of filaggrin deficiency such as ichthyosis vulgaris, keratosis pilaris, and hyperlinear palms. These clinical features are associated with genetic defects encoding the filaggrin protein and can identify patients who have a more severe disease course and allergic comorbidities.[21] Other less specific but common associated features of AD are listed in Table 22-1. Other specific skin conditions associated with AD include vitiligo and alopecia areata.[22]

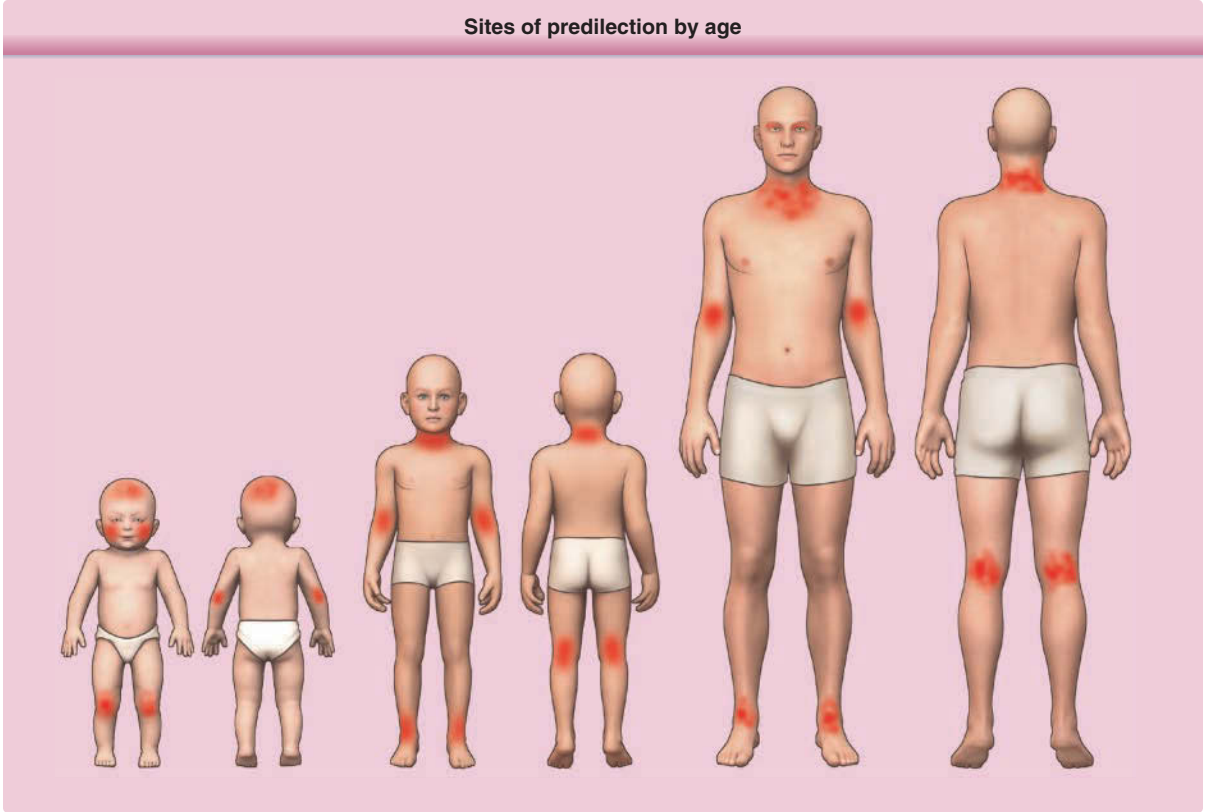

Figure 22-1 Atopic dermatitis progression and distribution: infancy, older childhood, and adulthood.

NONCUTANEOUS FINDINGS

ATOPIC COMORBIDITIES

There is growing recognition that patients with AD carry a large burden of comorbid conditions. Patients with AD often show signs of T helper 2 (Th2) immune activation, including high levels of total and specific serum IgE, eosinophilia, and a predisposition toward allergic comorbidities. Large population-based studies reveal patients with AD have a higher prevalence of

Figure 22-2 Edematous, erythematous eyelids with lichenification and hyperpigmentation in an adolescent with atopic dermatitis. Note the infraocular (Dennie-Morgan) folds.

Figure 22-3 Itching infant with atopic dermatitis. (Used with permission from Oholm Larsen, MD.)

Figure 22-4 Childhood atopic dermatitis with lichenification of antecubital fossae and generalized severely pruritic eczematous plaques.

food allergy, asthma, and allergic rhinitis. The severity of the skin disease correlates with both the risk and severity of the comorbidity.[23] AD is often the first atopic disease to develop, but the diseases can occur in any order and in any combination.[24] For example, allergic sensitization may occur before or after AD development[25] but does develop in up to 80% of patients. Large collaborative efforts to integrate clinical cohort and "omics" data are underway and suggest Th2-driven pathobiological pathways underlie the multimorbidity seen in AD.[26] There are no studies as of yet demonstrating treatment of the skin alone has a positive impact on allergic comorbidities or whether prevention of AD can halt the development of other atopic diseases ("atopic march").

PSYCHOSOCIAL IMPACT

Numerous studies in pediatric populations and adults reveal AD, especially moderate to severe disease, profoundly impacts the emotional and psychological well-being of a patient. Children with AD display more emotional and behavioral problems compared with normal control participants.[27] Population-based studies also find a higher prevalence of attention-deficit hyperactivity disorder (ADHD), anxiety, conduct disorder, and autism in children with AD compared with children without AD.[28] Children with more severe disease appear to be particularly at risk. The risk of ADHD in both children and adults appears to be mediated by sleep disturbance, a common consequence of pruritus in AD.[29]

Anxiety and depression are commonly found comorbidities in adult patients with AD. Between 43% and 57% of patients met thresholds on the Hospital Anxiety and Depression Scale for probable anxiety or depression in phase 3 clinical trials for AD.[30] Effective antiinflammatory therapy appeared to alleviate both anxiety and depression symptoms in a significant proportion of adults during these trials.

Figure 22-5 Typical papules, vesicles, and erosions seen in atopic hand dermatitis.

TABLE 22-1
Features of Atopic Dermatitis

Major Features
Pruritus
Rash on face, extensors, or both in infants and young children
Lichenification in flexural areas in older children
Tendency toward chronic or chronically relapsing dermatitis
Personal or family history of atopic disease: asthma, allergic rhinitis, atopic dermatitis
Other Common Findings
Dryness
Dennie-Morgan folds (accentuated lines or grooves below the margin of the lower eyelid)
Allergic shiners (darkening beneath the eyes)
Facial pallor
Pityriasis alba
Keratosis pilaris
Ichthyosis vulgaris
Hyperlinearity of palms and soles
White dermatographism (white line appears on skin within 1 minute of being stroked with a blunt instrument)
Conjunctivitis
Keratoconus
Anterior subcapsular cataracts
Elevated serum immunoglobulin E
Immediate skin test reactivity

COMPLICATIONS

BACTERIAL INFECTION

Superficial *Staphylococcus aureus* infections are by far the most common infection found in AD. *S. aureus* colonizes skin lesions in more than 70% of patients with AD with more severe AD having higher rates of colonization.[31,32] Studies conflict regarding the prevalence of methicillin-resistant *S. aureus* (MRSA) in this population but does not appear to be higher than

background colonization rates. Few studies address the rate of true infection from *S. aureus*, in contrast to colonization. One study from Japan found almost a twofold increase in impetigo in children with AD compared with non-AD control participants.[33] The rate of serious infections from *S. aureus* is also not well characterized in patients with AD, but there are reports in the literature of endocarditis, osteomyelitis, and septicemia.[34]

Both skin barrier and immune deficits found in AD may explain the propensity to colonization and infection. Inflamed skin increases the expression of fibronectin and fibrinogen, which are *S. aureus* binding sites.[35] The elevated pH and disrupted barrier from excoriation seen in AD skin promotes *S. aureus* growth. Antimicrobial peptide expression is also blunted in these patients, thought to be secondary to the inhibitory effect of type 2 cytokines.[36,37] Type 2 cytokines also augment the killing effect of *S. aureus* toxins on keratinocytes.[38] Blockade of type 2 cytokines in AD appears to reduce skin infections in AD.[39]

S. aureus colonization likely contributes to skin inflammation; *S. aureus* toxins activate antigen presenting cells and increase T-cell cutaneous lymphocyte antigen (CLA) expression. Flares of AD correspond to shifts in the microbiome toward larger proportions of *S. aureus* representation.[40] Antibiotic treatment of clinically uninfected skin, however, has not been found to reduce AD severity.[41] The use of dilute sodium hypochlorite baths (bleach baths) appears to improve AD severity, but it is uncertain if this is through antiinflammatory and barrier effects rather than antimicrobial ones.[42]

The decision to treat a *S. aureus* infection is not straightforward. It is often difficult to distinguish acute crusted AD or excoriation from *S. aureus* impetiginization, and culturing of lesions does not help in distinguishing between colonization and infection. Culturing is recommended, however, to help guide antibiotic therapy and identify MRSA strains. MRSA has become an increasingly important pathogen in patients with AD.[43] Erosive plaques, honey-colored crusting, folliculitis, and persistent or multiple tender pustules are indicators of clinically relevant secondary bacterial skin infection in which antibiotic use would be indicated. Interestingly, topical steroids alone reduce *S. aureus* counts illustrating the role inflammation plays in *S. aureus* susceptibility.

VIRAL INFECTION

Patients with AD display an increased susceptibility to common warts and exaggerated clinical presentations to other viral infections such molluscum contagiosum. The most serious virally mediated complication is eczema herpeticum (EH). After an incubation period of 5 to 12 days, multiple itchy, vesiculopustular lesions erupt in a disseminated pattern; vesicular lesions are umbilicated, tend to cluster, and often become hemorrhagic and crusted (Fig. 22-6). Punched-out and extremely painful erosions result. These lesions may coalesce to large, denuded, and bleeding areas that can extend over the entire body and be fatal in some cases.

Figure 22-6 Eczema herpeticum. Typical vesicles and crusting in a patient with disseminated disease.

Defects in interferon pathways may explain why some patients develop this potentially devastating complication.[44]

Although smallpox infections have been eradicated worldwide since the late 1970s, threats of bioterrorism (with smallpox and other infectious agents) have forced nations to reconsider their policies toward initiating vaccination programs. In AD patients, smallpox vaccination (or even exposure to vaccinated individuals) (see Chap. 166) may cause a severe widespread eruption (eczema vaccinatum) that appears very similar to EH. Thus, in patients with AD, vaccination is contraindicated unless there is a clear risk of smallpox. In addition, decisions regarding vaccination of family members should take into consideration the potential of eczema vaccinatum in household contacts.

Exaggerated responses to coxsackie virus have also been reported in patients with AD that may resemble EH and has been termed eczema coxsackium.[45] Children present with hand and foot vesicles or papules that resemble typical hand, foot, and mouth disease, but lesions tend to be more severe and hemorrhagic and involve additional areas involved with eczema. Despite the sometimes dramatic presentation, the skin rash resolves with no negative sequelae.

FUNGAL INFECTION

It is unclear whether superficial fungal infections are more common in atopic individuals. There has been particular interest in the role of *Malassezia sympodialis* (*Pityrosporum ovale* or *Pityrosporum orbiculare*) in AD. *M. sympodialis* is a lipophilic yeast (see Chaps. 160 and 161) commonly present in the seborrheic areas of the skin. IgE antibodies against *Malassezia furfur* are commonly found in AD patients and most frequently in patients with head and neck dermatitis.[46] Although there are some case reports of improvement of head and neck AD with antifungal therapy, controlled trials are needed to determine the efficacy of targeting fungi in AD in this subset of patients.

OCULAR PROBLEMS

Eye complications associated with severe AD can lead to significant morbidity. Eyelid dermatitis and chronic

blepharitis are commonly associated with AD and may result in visual impairment from corneal scarring. Atopic keratoconjunctivitis is usually bilateral and can have disabling symptoms that include itching, burning, tearing, and copious mucoid discharge. Vernal conjunctivitis is a severe bilateral recurrent chronic inflammatory process associated with papillary hypertrophy or cobblestoning of the upper eyelid conjunctiva. It usually occurs in younger patients and has a marked seasonal incidence, often in the spring. The associated intense pruritus is exacerbated by exposure to irritants, light, or sweating. Keratoconus is a conical deformity of the cornea believed to result from chronic rubbing of the eyes in patients with AD and allergic rhinoconjunctivitis. Cataracts were reported in the early literature to occur in up to 21% of patients with severe AD. However, it is unclear whether this was a primary manifestation of AD or the result of the extensive use of systemic and topical glucocorticoids, particularly around the eyes. Indeed, more recent studies suggest that routine screening for cataracts in patients with AD may not be productive unless there is concern about potential side effects from steroid therapy.

HAND DERMATITIS

Patients with AD often develop nonspecific, irritant hand dermatitis. It is frequently aggravated by repeated wetting and by washing of the hands with harsh soaps, detergents, and disinfectants. Atopic individuals with occupations involving wet work are prone to develop an intractable hand dermatitis in the occupational setting, which is a common cause of occupational disability. Less frequently, patients with AD may also develop a recurring chronic palmar or palmoplantar vesicular dermatitis.

EXFOLIATIVE DERMATITIS

Patients with extensive skin involvement may develop exfoliative dermatitis (see Chap. 21). This is associated with generalized redness, scaling, weeping, crusting, systemic toxicity, lymphadenopathy, and fever. Although this complication is rare, it is potentially life threatening. It is usually caused by superinfection, for example, with toxin-producing *S. aureus* or herpes simplex infection, continued irritation of the skin, or inappropriate therapy. In some cases, the withdrawal of topical or systemic glucocorticoids used to control severe AD may be a precipitating factor for exfoliative erythroderma.

ETIOLOGY AND PATHOGENESIS

OVERVIEW

Atopic dermatitis is a complex familial transmitted skin disease caused by interactions among genetic, immune, and environmental risk factors.[47] The interindividual variation of these factors compound the heterogeneity of mechanisms leading to AD. AD often occurs in association with asthma, allergic rhinitis, and food allergy. As such, AD may be considered part of a systemic disorder. Genetic and mechanistic studies suggest that two major biologic pathways are responsible for AD: epidermal dysfunction and altered innate or adaptive immune responses to microbes, allergens, stress, and irritants. Discovery of key pathogenic pathways and their associated biomarkers represents an active area of investigation required for the discovery of novel drugs or biologics that will effectively treat severe AD unresponsive to standard medications.

DECREASED SKIN BARRIER FUNCTION

Atopic dermatitis is associated with decreased in skin barrier function caused by the downregulation of cornified envelope genes (eg, keratin, filaggrin, and loricrin), reduced ceramide levels, increased endogenous proteolytic enzyme activity, and enhanced transepidermal water loss.[48] Addition of soap and detergents to the skin raises its pH, thereby increasing activity of endogenous proteases, leading to further breakdown of epidermal barrier function. The epidermal barrier may also be damaged by scratching, exposure to exogenous proteases from house dust mites, and *S. aureus*. This is worsened by the lack of certain endogenous protease inhibitors in atopic skin. These epidermal changes likely contribute to increased allergen absorption into the skin and microbial colonization. Because epicutaneous sensitization to allergen results in higher level allergic immune responses, decreased skin barrier function could act as a site for allergen sensitization and predispose such children to the development of food allergy and respiratory allergy.

GENETICS

More than 80 genes have been associated with AD.[43,49] Of these genes, loss-of-function mutations involving the epidermal barrier protein filaggrin have been most consistently replicated to be a major predisposing factor for AD in European whites and Asians. Of note, the filaggrin gene is found on chromosome 1q21, which contains genes (including involucrin, loricrin, and S100 calcium binding proteins) in the epidermal differentiation complex (EDC), known to be expressed during terminal differentiation of the epidermis. Gene profiling studies have demonstrated downregulation of genes encoding proteins involved in epidermal differentiation, including multiple skin barrier proteins and antimicrobial peptides required for host defense in AD.[50] Candidate gene approaches have also implicated

variants in the *SPINK5* gene, which is expressed in the uppermost epidermis, where its product, LEKT1, inhibits two serine proteases involved in desquamation and inflammation (stratum corneum tryptic enzyme and stratum corneum chymotryptic enzyme). Stratum corneum tryptic enzyme and stratum corneum tryptic enzyme expression is increased in AD, suggesting that an imbalance of protease versus protease inhibitor activity may contribute to atopic skin inflammation. Other skin barrier genes that have been implicated in AD include LAMA3, TMEM79, filaggrin-2 (FLG2), Late Cornified Envelope-like Proline-rich 1 (LELP1), and claudin-1 (CLDN1). The relative importance of different skin barrier genes and immune responses may vary by race.[51] It is interesting, for example, that FLG mutations have currently not been consistently found in African populations; however, loss-of-function mutations in FLG2 are associated with increased risk in African Americans.[49]

These observations establish a key role for impaired skin barrier function in the pathogenesis of AD because impaired skin barrier formation allows increased transepidermal water loss, and importantly, increased attachment and entry of allergens and chemicals from the environment, resulting in skin inflammatory responses.[47] It is important to note that filaggrin mutations and likely other mutations affecting the skin barrier can occur in normal healthy individuals, patients with ichthyosis vulgaris who do not have significant skin inflammation, and only a minority of individuals with AD have filaggrin gene mutations. This suggests that factors other than skin barrier gene mutations are also required for the development of AD.

Atopic dermatitis has also been associated with variation of genes involved in innate and adaptive immunity, interleukin-1 (IL-1) family signaling, regulatory T cells, vitamin D pathway, and nerve growth factor pathway.[43] Thus, a combination of various genetic factors may influence the development of different AD phenotypes. Patients with filaggrin null mutations often have early onset of AD, severe eczema, and high-level allergen sensitization and develop asthma later in childhood (ie, the so-called atopic march).[48,49] In patients with AD susceptible to EH (ADEH+), filaggrin mutations occur in combination with transcriptomic signatures in peripheral blood mononuclear cells (PBMCs) that are distinct from AD without a history of AD (ADEH-). In a recent report, it was demonstrated that unstimulated ADEH+ and ADEH- PBMC had similar transcriptomes.[52] However, after stimulation with herpes simplex virus (HSV), PBMCs from ADEH+ had distinct transcriptomic profiles compared with ADEH-, with striking downregulation of antiviral cytokines, including both type I and type III INFs. These results are indicative of defective innate immune responses in ADEH+ subjects.

Atopic dermatitis is a complex trait that involves interactions between multiple gene products requiring environmental factors and the immune response, leading to a final clinical phenotype. Chromosome 5q31-33 contains a clustered family of functionally related cytokine genes—IL-3, IL-4, IL-5, IL-13, and granulocyte macrophage colony-stimulating factor involved in generation of IgE, eosinophilia, and allergic inflammation. Gain-of-function mutations in the alpha subunit of the IL-4 receptor, IL-4, and IL-13 has been significantly associated with AD, providing a rationale for the use of biologicals that interfere with the IL-4 receptor signaling pathway.[30] A significant association has also been observed between *TSLP* gene polymorphisms and AD supporting further evidence for the importance of Th2 polarization in this disease.[53]

IMMUNOPATHOLOGY OF ATOPIC DERMATITIS

Based on clinical appearance and duration of illness, AD skin can be characterized as nonlesional AD, acute AD lesions (3 or fewer days after onset), and chronic skin lesions (>3 days' duration). Nonlesional AD skin may not be normal but characterized by mild epidermal hyperplasia and a sparse perivascular T-cell infiltrate. Dendritic antigen-presenting cells (eg, Langerhans cells (LCs), inflammatory dendritic epidermal cells [IDECs], macrophages) in lesional and, to a lesser extent, in nonlesional skin of AD exhibit surface-bound immunoglobulin E molecules. In acute lesions, there is epidermal spongiosis with an increased infiltration of activated memory T cells bearing the skin-homing CLA. Eosinophils, basophils, and neutrophils are rare. Mast cells are in various stages of degranulation.

Chronic lichenified lesions are characterized by a hyperplastic epidermis with elongation of the rete ridges, prominent hyperkeratosis, and minimal spongiosis. There is an increased number of IgE-bearing LCs and in the epidermis, and macrophages dominate the dermal mononuclear cell infiltrate. Mast cells are increased in number but are fully granulated. Neutrophils are absent in AD skin lesions even in the setting of increased *S. aureus* colonization and infection. Increased numbers of eosinophils are observed in chronic AD skin lesions. Eosinophils are thought to contribute to allergic inflammation by the secretion of cytokines and mediators that augment allergic inflammation and induce tissue injury in AD through the production of reactive oxygen intermediates and release of toxic granule proteins.

CYTOKINE-DRIVEN ATOPIC DERMATITIS SKIN INFLAMMATION

Atopic skin inflammation is orchestrated by the local expression of proinflammatory cytokines.[47] A key difference between epidermal keratinocytes found in AD, as compared with normal, skin is the presence of thymic stromal lymphopoietin (TSLP) and IL-33 in AD epidermis. TSLP, along with IL-33, are key cytokines secreted by epithelial cells that induce dendritic

cells to drive Th0 cells into the Th2 cell differentiation pathway. Nonlesional AD and acute AD skin lesions are predominantly associated with expression of IL-4, IL-5, IL-13, IL-25, IL-31, and IL-33 expression. These type 2 cytokines are present in all stages of AD and can be secreted by multiple cell types, including innate lymphoid type 2 cells, mast cells, and basophils, present in AD skin lesions. This contributes to substantial redundancy in allergic inflammation. As such, cytokine targeting, as opposed to cell targeting, is considered a more effective approach in the treatment of AD. The importance role of type 2 cytokines is that, in animal models, they can recapitulate elevated IgE responses, eosinophilia, skin barrier dysfunction, allergic skin inflammation, and itching observed in clinical AD.

Aside from Th2, other cytokine pathways are also activated during the evolution of AD. The IL-22–IL-17 pathway is of particular interest because it, along with IL-4 and IL-13, can inhibit terminal keratinocyte differentiation, including filaggrin expression. Because dendritic cell–derived, IL-23, enhances IL-22–IL-17 cell differentiation, all of these cytokines are being closely examined for their potential role in AD. It is interesting that IL-4 and IL-13 can enhance IL-23 production by dendritic cells. Furthermore, blockade of IL-4 and IL-13 pathway, leading to improvement in AD, is also associated with reduced IL-23 and IL-17 expression in AD skin.[54]

When acute AD become chronic AD skin lesions, there is an increase in Th1 cytokines such as INF-γ, which potentiates AD skin inflammation. It is noteworthy that experimental studies demonstrate pretreatment with IL-4 and IL-13 dampens responses to interferons and IL-17, suggesting that when the early AD lesion is exposed to IL-4 and IL-13, there is a long-lasting, persistent effect. A recent birth cohort study, however, demonstrated that TSLP could be detected in at-risk infants before the onset of AD, suggesting that the TSLP–Th2-ILC2 pathway plays a critical role in initiation of AD.[55] In chronic AD, there is an increased in IL-5, which is involved in eosinophil development and survival.

The skin-specific chemokine, cutaneous T cell–attracting chemokine (CTACK; CC chemokine ligand 27 [CCL27]), is highly upregulated in AD and preferentially attracts skin homing cutaneous lymphoid antigen $(CLA)^+$ CC chemokine receptor 10^+ $(CCR10^+)$ T cells into the skin. CCR4 expressed on skin homing CLA^+ T cells can also bind to CCL17 on the vascular endothelium of cutaneous venules. Selective recruitment of CCR4-expressing Th2 cells is mediated by macrophage-derived chemokine and thymus and activation-regulated cytokine, both of which are increased in AD. The severity of AD has been linked to the magnitude of thymus and activation-regulated cytokine levels. In addition, chemokines such as fractalkine, IFN-γ–inducible protein 10, and monokine induced by IFN-γ are strongly upregulated in keratinocytes and result in Th1-cell migration toward epidermis, particularly in chronic AD. Increased expression of the CC chemokines, macrophage chemoattractant protein-4, eotaxin, and RANTES (regulated on activation normal T-cell expressed and secreted) contribute to infiltration of macrophages, eosinophils, and T cells into both acute and chronic AD skin lesions.

IMMUNE EFFECTS ON EPITHELIAL DIFFERENTIATION COMPLEX

The dry skin and increased transepidermal water loss in individuals with AD reflect the underlying skin barrier dysfunction and loss of natural moisturizing factors that play an important role in the pathogenesis of AD.[47] Only a minority of patients, however, have FLG null mutations. Other genetic variants in the EDC and tight junctions are even rarer. The majority of patients with AD likely have immune-mediated reduction in epidermal terminal differentiation, leading to decreased generation of various epidermal structural proteins, filaggrin breakdown products, epidermal lipids, and antimicrobial peptides. TSLP, IL-4, and IL-13 are the most potent cytokines downregulating filaggrin expression by keratinocytes. IL-17, IL-22, IL-25, and IL-33 can act synergistically with IL-4 and IL-13 to further downregulate expression of epidermal proteins and lipids. This combination of events along with activation of proteases and lipases creates defective epidermal barrier function and alters epidermal acidification and loss of moisturization in AD, thereby contributing to enhanced allergen and microbial penetration met by the host immune response and clinical appearance of AD. The critical role for immune activation in driving AD pathogenesis is supported by the observation that cyclosporin is highly effective in controlling severe AD and reverses the epidermal pathology.[56] Clinical studies demonstrating that blockade of IL-4 and IL-13 immune pathways is highly effective in reversing severe AD provides definitive data that in the majority of patients, cytokine activation drives atopic inflammation. Recent studies showing AD immune activation may differ in various races and according to age group suggests the importance of more precise stratification of immune responses with clinical AD subsets.[51]

BASIS OF PRURITUS IN ATOPIC DERMATITIS

Pruritus is a prominent feature of AD, manifested as cutaneous hyperreactivity and scratching after exposure to allergens, changes in humidity, excessive sweating, and low concentrations of irritants. Control of pruritus is important because mechanical injury from scratching can induce proinflammatory cytokine and chemokine release, leading to a vicious scratch–itch cycle, perpetuating the AD skin rash. The mechanisms of pruritus in AD are poorly understood. Allergen-induced release of histamine from skin mast cells is not an exclusive cause of pruritus in AD because H_1 antihistamines do not appear to control the

itch of AD.[57,58] Recent studies demonstrating a potential role for H_4 receptors in skin pathobiology, however, suggests that histamine may play a contributory role. The observation, however, that treatment with topical corticosteroids (TCs) and calcineurin inhibitors is effective at reducing pruritus suggests that the inflammatory cells play an important role in pruritus. Molecules that have been implicated in pruritus include T cell–derived cytokines such as IL-31, stress-induced neuropeptides, proteases such as proteases that can act on protease-activated receptors, eicosanoids, and eosinophil-derived proteins.

DIAGNOSIS

The diagnosis of AD is based on a clinical assessment and guided by the criteria discussed previously. A diagnosis of AD is made only after other conditions such as psoriasis, scabies infestation, seborrheic dermatitis, or contact dermatitis have been considered and ruled out, if necessary, with additional testing. AD not responding to routine skin care or topical antiinflammatory therapy or skin lesions that are atypical in morphology or distribution should prompt the clinician to consider additional diagnoses such as T-cell lymphoma, nutritional deficiencies, or metabolic syndromes. Patients with a history of sinopulmonary infections, severe skin infections, erythroderma, or failure to thrive should be evaluated for immunodeficiency syndromes.

SUPPORTIVE STUDIES

LABORATORY TESTING

Routine potassium hydroxide microscopic evaluation can be used to rule out cutaneous fungal infections that may mimic AD. Mineral oil examination for scabies is warranted if burrows are present or vesicles are present on the palms and soles in infants. If the clinical picture suggests allergic contact dermatitis may be present (eg, atypical distribution, refractory disease), patch testing is warranted.

Atopic dermatitis guidelines of care from the American Academy of Dermatology do not recommend routine allergy testing for AD because many patients with AD have detectable antigen-specific IgE to foods and airborne and environmental allergens, especially those with severe disease.[59] History-directed skin prick testing or serum-specific IgE antibody testing may be performed to confirm a true type I food allergy if a patient reports a history of immediate-type hypersensitivity symptoms (eg, urticaria, lip swelling, abdominal pain). The Food Allergy Expert Panel sponsored by the National Institute of Allergy and Infectious Disease defined allergy as an "adverse health event"; thus, patients should not be labeled as "allergic" solely based on sensitization alone.[60] In patients with AD, positive allergy test results (in the absence of controlled food challenges) poorly predict true type I allergic responses.[61] There remains limited evidence that removal of allergens from the diet or environment improves AD outcomes.[62,63] Thompson and Hanifin noted that proper AD control with routine therapy reduces parental concern regarding diet as a contributory factor in AD.[64] The Food Allergy Expert Panel suggests that children younger than 5 years old with moderate to severe AD be considered for food allergy evaluation for milk, egg, peanut, wheat, and soy if at least one of the following conditions is met: (1) the child has persistent AD despite optimized management and topical therapy or (2) the child has a reliable history of an immediate reaction after ingestion of a specific food.[60]

Laboratory studies to rule out immunodeficiency associated with eczema include a complete blood count with differential for white blood cell count; lymphocyte phenotyping for T cells, B cells, and natural killer cells; and lymphocyte proliferation assays as well as genomic DNA analysis for pathogenic variants in genes resulting in severe combined deficiency (eg, *IL2RG, ADA, IL7R*), Omenn syndrome (hypomorphic mutations in *RAG1/RAG2* genes) or hyper-IgE (HIE) syndrome (eg, *STAT3, DOCK8, SPINK5, TYK2*). Small platelets seen on peripheral blood smear are characteristic of Wiskott-Aldrich syndrome. Both elevated serum IgE levels and elevated circulating blood eosinophils can be seen in a number of diseases besides AD, including HIE syndrome but also some immunodeficiencies. Zinc levels to rule out zinc deficiency should be obtained on fasting morning blood and corrected for any concomitant low albumin level.

PATHOLOGY

Biopsy of AD lesions with hematoxylin and eosin staining (Table 22-2) will not allow differentiation among various eczematous processes such as nummular dermatitis or allergic contact dermatitis because all eczematous processes show spongiotic dermatitis on histopathology. Biopsy is helpful to rule out cutaneous T-cell lymphomas (see Chap. 119) and should reveal epidermotropic neoplastic T cells with hyperconvoluted cerebriform nuclei and intraepidermal Pautrier microabscess formation. T-cell receptor gene rearrangement studies will demonstrate clonal rearrangement. Biopsies may not be diagnostic for Sézary syndrome, and diagnostic criteria include an absolute Sezary cell count of 1000 cells/mm^3 or greater in peripheral blood, increased CD4/CD8 ratio greater than 10 on flow cytometry analysis, or circulating T-cell clone detected by cytogenetic methods. Histopathology of psoriasis shows characteristic changes that depend on the stage of evolving lesion—initial, developing, or mature (see Chap. 28).

IMAGING

Imaging is not recommended in AD diagnosis except when ruling out specific immunodeficiencies. Chest radiographs will reveal an absent thymus in most forms of severe combined immunodeficiency as well as pulmonary infiltrates from infectious complications.

TABLE 22-2

Histopathology Comparison for Nonlesional Atopic Dermatitis, Acute Atopic Dermatitis, and Chronic Atopic Dermatitis

NONLESIONAL ATOPIC DERMATITIS	ACUTE ATOPIC DERMATITIS (<3 DAYS)	CHRONIC SKIN LESIONS (>3 DAYS)
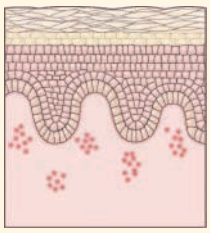	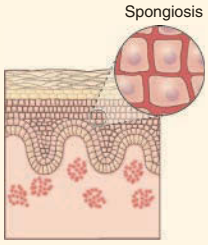	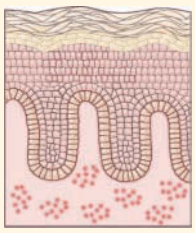
Mild epidermal hyperplasia, sparse perivascular infiltrate	Epidermal spongiosis, increased inflammatory infiltrate	Hyperplastic epidermis with elongated rete ridges, prominent hyperkeratosis, minimal spongiosis
Langerhans cells, inflammatory dendritic epidermal cells, macrophages	Mast cells (degranulating); rare eosinophils, basophils, and neutrophils	Langerhans cells, mast cells (fully granulated), neutrophils absent, increased eosinophils

Chest radiographs or computed tomography scans may reveal extensive infiltrates, cyst-forming pneumonias, and occasionally fungal lesions in HIE syndrome.

DIFFERENTIAL DIAGNOSIS

Because AD is currently not defined by a unique diagnostic biomarker, a number of inflammatory skin diseases, immunodeficiencies, skin malignancies, genetic disorders, infectious diseases, and infestations may share symptoms and signs with AD (Table 22-3). These should be considered in the initial evaluation of a patient presenting with an eczematous rash but also if a patient with a diagnosis of AD is not responding to appropriate therapy. Infants presenting in the first year of life with failure to thrive, diarrhea, a generalized scaling erythematous rash, and recurrent cutaneous or systemic infections should be evaluated for severe combined immunodeficiency syndrome. Omenn syndrome, caused by mutations in *RAG1* and *RAG2* as well as several other genes, is an autosomal recessive severe combined immunodeficiency that can present with an erythrodermic rash, as well as elevated IgE, eosinophilia, diarrhea, lymphadenopathy, hepatosplenomegaly, and susceptibility to infections.[65] The dermatitis can be eczematous though with pachydermia. Other immunodeficiency with eczematous rash includes immune dysregulation, polyendocrinopathy, enteropathy X-linked (IPEX) syndrome.[66] IPEX results from mutations of *Foxp3*, a gene located on the X chromosome that encodes a DNA-binding protein required for development of regulatory T cells. Besides dermatitis, patients typically present with a recalcitrant enteropathy, as well as autoimmune features such as type 1 diabetes, thyroiditis, hemolytic anemia, or thrombocytopenia. Wiskott-Aldrich syndrome is an X-linked recessive disorder characterized by an eczematous rash associated with thrombocytopenia along with variable abnormalities in humoral and cellular immunity and severe bacterial infections.

Hyper-IgE syndrome caused by *STAT3* mutations is an autosomal dominant multisystem disorder characterized by recurrent deep-seated bacterial infections, including cutaneous cold abscesses and pneumonias with pneumatocele formation due to *S. aureus*.[67] Although *S. aureus* is an important pathogen in this disorder, infection with other bacteria, including gram-negative species (eg, *Pseudomonas aeruginosa*) and nontuberculous mycobacteria and fungi (eg, *Aspergillus*) may occur, including invasive disease. STAT3 is an essential transcription factor for Th17 T-cell development, and because Th17 T cells play an essential role in protecting against *Candida* spp., patients with mutations in *STAT3* are susceptible to chronic mucocutaneus candidiasis. In infancy, patients may present with a papulopustular eruption of the face and scalp. Other features of HIE syndrome include skeletal abnormalities with coarse facial features and prominent frontal bossing, dental anomalies with retained primary teeth, bone fractures, and osteoporosis. Despite elevated serum IgE levels, patients usually are not atopic. Patients with mutations in the gene encoding dedicator of cytokinesis 8 protein (*DOCK8*) have an immunodeficiency that accounts for most cases of autosomal recessive HIE.[68] These patients have an eczematous dermatitis with recurrent viral infections, including some with central nevous system involvement. Patients may present with recalcitrant warts secondary to human papilloma virus, disseminated molluscum or recurrent herpes simplex infections. Malignancies, including squamous cell carcinomas and lymphomas, are an important cause of death in patients starting in the second decade of life. Another unique feature in patients with DOCK8 is that many have associated food allergies. Patients with tyrosine kinase 2 deficiency can also present with an eczematous rash with high serum IgE and recurrent cutaneous staphylococcal infections.[69]

TABLE 22-3
Differential Diagnosis of Atopic Dermatitis

Most Likely
Contact dermatitis (allergic and irritant)
Seborrheic dermatitis
Scabies
Psoriasis
Ichthyosis vulgaris
Keratosis pilaris
Dermatophytosis
Consider
Asteatotic eczema
Lichen simplex chronicus
Nummular dermatitis
Juvenile palmar-plantar dermatosis
Impetigo
Drug eruptions
Perioral dermatitis
Pityriasis alba
Photosensitivity disorders (hydroa vacciniforme, polymorphous light eruption, porphyrias)
Molluscum dermatitis
Less Common or Rare Disorders Predominant in Adolescents and Adults
Cutaneous T-cell lymphoma (mycosis fungoides or Sézary syndrome)
Human immunodeficiency virus–associated dermatosis
Lupus erythematosus
Dermatomyositis
Graft-versus-host disease
Pemphigus foliaceus
Dermatitis herpetiformis
Photosensitivity disorders (hydroa vacciniforme, polymorphous light eruption, porphyrias)
Less Common or Rare Disorders Predominant in Infants and Children
Metabolic* or *Nutritional
Phenylketonuria
Prolidase deficiency
Multiple carboxylase deficiency
Zinc deficiency (acrodermatitis enteropathica, prematurity, deficient breast milk zinc, cystic fibrosis)
Others: biotin, essential fatty acids, organic acidurias
Primary Immunodeficiency Disorders

Other diseases to consider in the differential diagnosis of AD include cutaneous T-cell lymphoma, especially in adults without a history of childhood eczema and without other atopic features.[70] Mycosis fungoides (discussed in Chap. 119) is the most common form of CTCL, Sézary syndrome is characterized by generalized erythroderma with lymphadenopathy and circulating malignant T cells (Sézary cells). Although contact dermatitis should be considered in the differential diagnosis of AD (see Chap. 24), contact allergy can also complicate AD, especially in patients whose AD appears to worsen with therapy, typically with TCs.[71] Allergic contact dermatitis complicating AD may appear as an acute flare of the underlying disease. Eczematous dermatitis has been also reported with human immunodeficiency virus infection as well as with a variety of infestations such as scabies. Other diseases that can be confused with AD include psoriasis, ichthyoses, and seborrheic dermatitis. Although psoriasis can typically be distinguished from AD based on characteristic clinical features (see Chap. 28), inverse (flexural) psoriasis or erythrodermic psoriasis may at times present more of a diagnostic challenge. Zinc deficiency can result from dietary deficiency; excessive losses with diarrhea; or chronic disease, including renal or hepatic as well as inadequate absorption associated with an inherited deficiency of the zinc carrier protein ZIP4 and can present with an eczematous rash with a perioral, acral, or perineal distribution.[72]

CLINICAL COURSE AND PROGNOSIS

Most AD starting in childhood is mild in severity, and a review of birth cohort studies found that 80% of cases remitted, at least temporarily, by 10 years of age.[73] Symptoms of AD, however, may persist or reemerge in adulthood. One primarily pediatric AD cohort found that more than 80% of patients prescribed calcineurin inhibitors reported persistent symptoms into adulthood.[74] Risk factors reported to be predictive of a persistent disease course include disease severity, later onset disease, genetic mutations in *FLG* or *FLG-2* genes, and early allergic sensitization.[75,76] It is not known whether early or aggressive treatment of AD alters the natural course. For occupational counseling, adults whose childhood AD has been in remission for a number of years may present with hand dermatitis, especially if daily activities require repeated hand wetting.

MANAGEMENT

OVERVIEW

Successful treatment of AD requires a systematic, multipronged approach that incorporates education about the disease state, skin hydration, pharmacologic therapy, and the identification and elimination of flare factors such as irritants, allergens, infectious agents, and emotional stressors (Fig. 22-7). Many factors lead to the symptom complex characterizing AD. Thus, treatment plans should be individualized to address each patient's skin disease reaction pattern, including the acuity of the rash, and the trigger factors that are unique to the particular patient. In patients refractory to conventional forms of therapy, alternative antiinflammatory and immunomodulatory agents may be necessary.

EDUCATION AS INTERVENTION

Education may be considered as a therapeutic intervention for the management of atopic dermatitis.[77]

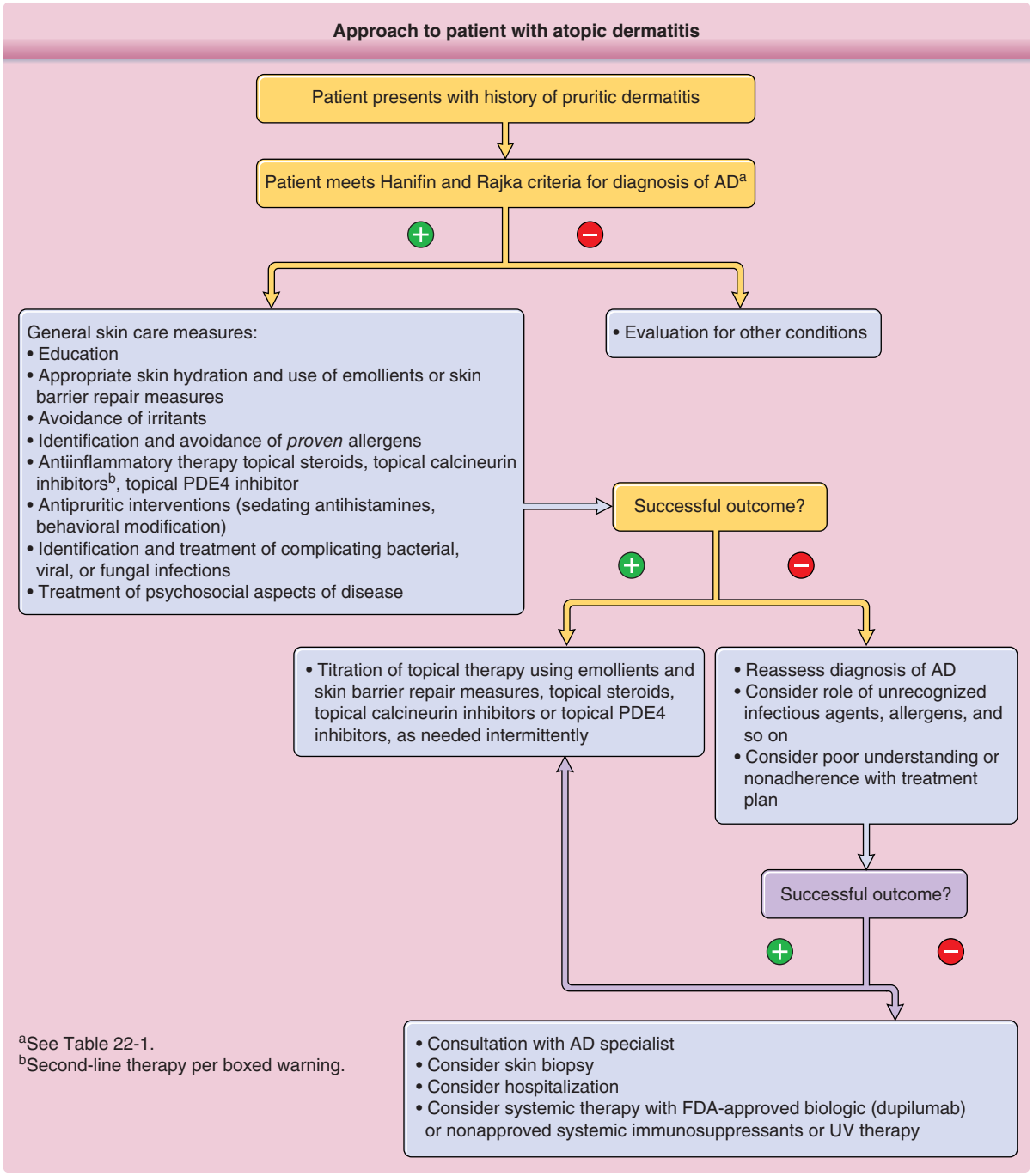

Figure 22-7 Approach to patient with atopic dermatitis (AD). FDA, Food and Drug Administration; PDE, phosphodiesterase; UV, ultraviolet.

Intensive disease education has been shown in randomized, controlled trials to improve subjective quality-of-life and objective eczema severity scores.[78] Intensive education may include comprehensive "center-based" patient/family teaching, written "handouts" and care plans, patient and family support groups, and internet-accessed media. Several resources available online are listed in Table 22-4.

IDENTIFICATION AND ELIMINATION OF TRIGGERS

GENERAL CONSIDERATIONS

Patients with AD are more susceptible to irritants than are unaffected individuals. Thus, it is important to identify and eliminate aggravating factors that trigger

TABLE 22-4
Online Resources for Patients with Atopic Dermatitis and Their Families

Coping Strategies and Support Groups
National Eczema Association (www.nationaleczema.org)
Under My Skin: A Kid's Guide to Atopic Dermatitis (www.undermyskin.com)

Specialized Atopic Dermatitis Care
American Academy of Dermatology EczemaNet (www.skincarephysicians.com/eczemanet/index.html)
The Eczema Center at Rady Children's Hospital (www.eczemacenter.org)
National Jewish Health (www.njc.org)
Northwestern University Eczema Care and Education Center (www.eczemacarecenter.com)

Information on Allergic Triggers
American Academy of Allergy, Asthma & Immunology (www.aaaai.org)
Food Allergy & Anaphylaxis Network (www.foodallergy.org)

the itch–scratch cycle. These include soaps or detergents, contact with chemicals, smoke, abrasive clothing, and exposure to extremes of temperature and humidity. Alcohol and astringents found in toiletries are drying. When soaps are used, they should have minimal defatting activity and a neutral pH or slightly acidic pH. New clothing may be laundered before wearing to decrease levels of formaldehyde and other added chemicals. Residual laundry detergent in clothing may be irritating. Using a liquid rather than powder detergent and adding a second rinse cycle facilitate removal of the detergent.

Recommendations regarding environmental living conditions should include temperature and humidity control to avoid problems related to heat, humidity, and perspiration. Every attempt should be made to allow children to be as normally active as possible. Certain sports, such as swimming, may be better tolerated than other sports involving intense perspiration, physical contact, or heavy clothing and equipment. Although UV light may be beneficial to some patients with AD, sunscreens should be used to avoid sunburn. However, because sunscreens can be irritants or allergens, care should be used to identify a nonirritating product.

SPECIFIC ALLERGENS

Foods and aeroallergens such as dust mites, animal danders, molds, and pollens have been demonstrated to exacerbate AD in some patients. In patients not responding to routine skin care and topical antiinflammatory therapies, potential allergens can be identified by taking a careful history, looking for immediate or anaphylactic clinical reactions that may trigger the itch–scratch cycle, and carrying out selective skin-prick tests or specific serum IgE levels. Negative skin test results or serum test results for allergen-specific IgE have a high predictive value for ruling out suspected allergens. Positive allergy testing results, on the other hand, poorly predicts adverse clinical reactions. Fleischer and colleagues performed food challenges on 125 children with AD who were labeled as having food allergy by allergy testing.[61] After oral food challenge, 84% to 93% of the foods being avoided were returned to the children's diet, when no immediate reactions were observed.

Elimination diets, which in some cases can be nutritionally deficient, are rarely, if ever, required. Even in patients with multiple positive skin test results, the majority of patients react to three or fewer foods on controlled challenge. In dust mite–allergic patients with AD, prolonged avoidance of dust mites has not been consistently found to result in improvement of their skin disease.[63] Avoidance measures include use of dust mite–proof encasings on pillows, mattresses, and box springs; washing bedding in hot water weekly; removing bedroom carpeting; and decreasing indoor humidity levels with air conditioning. Because there are many triggers contributing to the flares of AD, attention should be focused on identifying and controlling the flare factors that are important to the individual patient. Whereas infants and young children are more likely to have food allergies, older children and adults are more likely to be sensitive to environmental aeroallergens. Contact allergens have been increasingly recognized in AD. One study found that of children with relevant positive reactions, 34% had a diagnosis of AD.[77]

EMOTIONAL STRESSORS

Although emotional stress does not cause AD, patients often report it exacerbates the illness. AD patients often respond to frustration, embarrassment, or other stressful events with increased pruritus and scratching. Psychological evaluation or counseling should be considered in patients who have difficulty with emotional triggers or concomitant metal health conditions or symptoms contributing to difficulty in managing their disease. It may be especially useful in adolescents and young adults who consider their skin disease disfiguring. Relaxation, behavioral modification, or biofeedback may be helpful in patients with habitual scratching.[58]

INFECTIOUS AGENTS

Antistaphylococcal antibiotics are often needed in the treatment of patients who are infected with *S. aureus*. Cephalosporins or penicillinase-resistant penicillins (dicloxacillin, oxacillin, or cloxacillin) are usually beneficial for patients who are not colonized with resistant *S. aureus* strains. Because erythromycin-resistant *Staphylococci* are common, erythromycin and newer macrolide antibiotics are usually of limited utility. Topical antimicrobials such as mupirocin, fusidic acid, or more recently retapamulin offers some utility in the treatment of impetiginized lesions. A Cochrane analysis of interventions for impetigo found that topical

mupirocin and topical fusidic acid are equal to or more effective than oral treatment for patients with limited disease and that fusidic acid and mupirocin are of similar efficacy.[79] Patients should be cautioned against using topical antibiotics in an "as-needed" manner that can lead to resistant organisms.

Use of neomycin topically can result in development of allergic contact dermatitis because neomycin is among the more common allergens causing contact dermatitis. In patients with extensive superinfection, a course of systemic antibiotics is most practical. MRSA may require culture and sensitivity testing to assist in appropriate antibiotic selection. Baths with dilute sodium hypochlorite (bleach) may also benefit AD patients with superinfected eczema, especially those with recurrent MRSA, although they can occasionally be irritating. Of note, a controlled study of twice-weekly bleach baths for 3 months showed clinical benefit, although skin colonization by *S. aureus* did not disappear even when combined with intranasal mupirocin 5 days each month.[80] Bleach baths may exert their beneficial effect on AD via antiinflammatory mechanisms rather than antimicrobial ones.[81]

Herpes simplex can provoke recurrent dermatitis and may be misdiagnosed as *S. aureus* infection or severe eczema. The presence of punched-out erosions, vesicles, or infected skin lesions that do not respond to oral antibiotics should initiate a search for herpes simplex. This can be diagnosed by polymerase chain reaction identification of herpes genetic material, Giemsa-stained Tzanck smear, or direct immunofluorescence of cells scraped from the vesicle base or viral culture. Antiviral treatment for cutaneous herpes simplex infections is of critical importance in the patient with widespread AD because life-threatening dissemination has been reported (EH). Acyclovir, 400 mg three times daily for 10 days or 200 mg four times daily for 10 days by oral administration (or an equivalent dosage of one of the newer antiherpetic medications), is useful in adults with herpes simplex confined to the skin. Intravenous treatment may be necessary for severe disseminated EH. The dosage should be adjusted according to weight in children.

Dermatophyte infections can complicate AD and may contribute to exacerbation of disease activity. Patients with dermatophyte infection or IgE antibodies to *Malassezia* spp. may benefit from a trial of topical or systemic antifungal therapy, although high-quality controlled studies are lacking.

PRURITUS

The treatment of pruritus in AD should be directed primarily at the underlying causes. Reduction of skin inflammation and dryness with topical glucocorticoids or nonsteroidal antiinflammatory drugs (NSAIDs) and skin hydration, respectively, often symptomatically reduce pruritus. Inhaled and ingested allergens should be eliminated if documented to cause an urticarial skin rash in controlled challenges. Systemic antihistamines act primarily by blocking the H_1 receptors in the dermis, thereby ameliorating histamine-induced pruritus. However, histamine is not the primary mediator of itch in AD skin, thus the relative lack of convincing evidence that antihistamines improve pruritus in AD.[80] Some antihistamines are also mild anxiolytics and may offer symptomatic relief through tranquilizing and sedative effects. Studies of newer, nonsedating antihistamines show variable results in the effectiveness of controlling pruritus in AD, although they may be useful in the subset of AD patients with concomitant urticaria or concurrent allergic rhinitis.

Because pruritus is usually worse at night, the sedating antihistamines, for example, hydroxyzine or diphenhydramine, may offer an advantage with their soporific side effects when used at bedtime. Doxepin hydrochloride has both tricyclic antidepressant and H_1- and H_2-histamine receptor-blocking effects. It can be used in doses of 10 to 75 mg orally at night or up to 75 mg twice daily in adult patients. If nocturnal pruritus remains severe, short-term use of a sedative or melatonin to allow adequate rest may be appropriate for some patients.[82] Treatment of AD with topical antihistamines is generally not recommended because of potential cutaneous sensitization. However, short-term (1-week) application of topical 5% doxepin cream has been reported to reduce pruritus without sensitization. Of note, sedation is a side effect of widespread application of doxepin cream, and allergic contact dermatitis has been reported.

TOPICAL THERAPY

EMOLLIENTS

Emollients represent the cornerstone of treatment for mild AD and serve as an important flare preventive therapy for all levels of disease severity. Patients with AD have abnormal skin barrier function with increased transepidermal water loss and decreased water content and dry skin (xerosis) contributing to disease morbidity by the development of microfissures and cracks in the skin. These microfissures may serve as portals of entry for skin pathogens, irritants, and allergens. *FLG* gene mutations or acquired filaggrin protein deficiencies caused by inflammation have also been shown to result in decreased epidermal levels of natural moisturizing factor.[83] AD xerosis can become aggravated during the dry winter months and in certain work environments.

The daily use of an effective emollient helps to restore and preserve the stratum corneum barrier, decreases the need for topical glucocorticoids and NSAIDs and improves outcomes. Moisturizers are available in the form of lotions, creams, or ointments. Some lotions and creams may be irritating because of added preservatives, solubilizers, and fragrances. Lotions with high water content may be drying because of an evaporative effect and provide few lipids to the skin. Thicker, bland emollients with high lipid content are preferred but are

sometimes not well tolerated because of interference with the function of the eccrine sweat ducts and the induction of folliculitis or itching. In these patients, less occlusive agents should be used. Plain petrolatum is a common lipid base for effective emollients. Petrolatum intercalates into the stratum corneum and appears to upregulate skin barrier and antimicrobial peptide gene expression thought to be beneficial in AD.[84] The benefit of emollients with special additives, such as ceramides, is not clear, although one study found the use of a urea-containing moisturizer provided better clinical results than a standard emollient.[85]

Hydration, by baths or wet dressings, promotes transepidermal penetration of topical glucocorticoids. The optimal bathing regimen for patients with AD is not known, however, and recommendations vary by specialty. Kohn and colleagues found no differences in outcomes in patients applying TCs to wet skin compared with dry skin,[86] but the "soak and smear" method is often used in recalcitrant disease.[87] Wet dressings or "wet wraps" are recommended for use on severely affected or chronically involved areas of dermatitis refractory to therapy. However, overuse of wet dressings may result in maceration of the skin complicated by secondary infection. Wet dressings or baths also have the potential to promote drying and fissuring of the skin if not followed by topical emollient use. Thus, wet dressing therapy is reserved for poorly controlled AD and should be closely monitored by a physician.

TOPICAL ANTIINFLAMMATORY THERAPY

Topical Corticosteroids: According to AD treatment guidelines, TCs are the cornerstone of anti-inflammatory treatment in AD.[88] Because of potential side effects, many health care practitioners use topical glucocorticoids only to control acute exacerbations of AD. However, studies suggest that after control of AD is achieved with a daily regimen of topical glucocorticoid, long-term control can be maintained in a subset of patients with scheduled intermittent applications of TCs, such as twice-weekly fluticasone, to areas that have healed but are prone to developing eczema.[89]

Patients should be carefully instructed in the use of topical glucocorticoids to avoid potential side effects. The potent fluorinated glucocorticoids should be avoided on the face, the genitalia, and the intertriginous areas. A low-potency glucocorticoid preparation is generally recommended for these areas and only used intermittently for long-term use. Patients should be instructed to apply topical glucocorticoids to their skin lesions and to use emollients on uninvolved skin. Failure of a patient to respond to topical glucocorticoids is sometimes partly caused by an inadequate supply or inadequate quantity of use. It is important to remember that it takes approximately 30 g of cream or ointment to cover the entire skin surface of an adult once. To treat the entire body twice daily for 2 weeks requires approximately 840 g (2 lb) of topical glucocorticoids.

There are seven classes of topical glucocorticoids, ranked according to their potency based on vasoconstrictor assays. Because of their potential side effects, the ultrahigh-potency glucocorticoids should be used daily or twice daily only for very short periods of time (usually 2 weeks) and in areas that are lichenified but not on the face or intertriginous areas. Midpotency glucocorticoids can be used for longer periods of time to treat chronic AD involving the trunk and extremities. Newer formulations of topical steroids include gel formulations without alcohol bases that moisturize skin, and solutions, oils, foams, and shampoos that may be useful on hair-bearing surfaces.

Factors that influence topical glucocorticoid potency and the risk of side effects include the molecular structure of the compound, the vehicle, the amount of medication applied, the duration of application, and occlusion, as well as host factors, including age, body surface area and weight, skin inflammation, anatomic location of treated skin, and individual differences in cutaneous or systemic metabolism. Side effects from topical glucocorticoids are directly related to the potency ranking of the compound and the length and frequency of use, so it is incumbent on the clinician to balance the need for a more potent steroid with the potential for side effects. In addition, ointments have a greater potential to occlude the epidermis, resulting in enhanced systemic absorption when compared with creams.

Side effects from topical glucocorticoids can be divided into local side effects and systemic side effects resulting from suppression of the hypothalamic–pituitary–adrenal axis. Local side effects include the development of striae, skin atrophy, perioral dermatitis, and acne rosacea. Prolonged daily use of TCs, especially on the face, can also lead to steroid withdrawal syndrome, a condition characterized by severe erythema, swelling, and burning upon TC discontinuation.[90] The potential for potent topical glucocorticoid to cause adrenal suppression is greatest in infants and young children. Several topical steroid formulations have been specifically tested for safety and received specific U.S. Federal Drug Administration (FDA) approval for use in younger children such as desonide hydrogel and nonethanolic foam, fluocinolone acetonide oil, and fluticasone 0.05% cream. Mometasone cream and ointment are approved for children aged 2 years and older.

Because normal-appearing skin in AD shows evidence of immunologic dysregulation and inflammation, the use of TCs as maintenance therapy to normal-appearing skin has been reported in several controlled studies.[91] After control of AD with a once-daily regimen was achieved, long-term control could be maintained with twice-weekly application of fluticasone to previously involved areas. Given recent insights into skin barrier and immunologic abnormalities and colonization of normal-appearing skin in AD by *S. aureus*, it is important to appreciate that "proactive therapy" is an attempt to control residual disease, not just application of an active drug to unaffected skin.

Topical Calcineurin Inhibitors: Topical tacrolimus and pimecrolimus have been developed as nonsteroidal immunomodulators.[68] Tacrolimus ointment 0.03% has been approved for intermittent treatment of moderate to severe AD in children aged 2 years and older, with tacrolimus ointment 0.1% approved for use in adults and children 16 years and older; pimecrolimus cream 1% is approved for treatment of patients aged 2 years and older with mild to moderate AD. Both drugs have proven to be effective with a good safety profile for treatment up to 4 years with tacrolimus ointment and up to 2 years with pimecrolimus cream. A frequently observed side effect with topical calcineurin inhibitors (TCIs) is a transient burning sensation of the skin. Importantly, treatment with TCIs is not associated with skin atrophy; thus, they are particularly useful for the treatment of areas such as the face and intertriginous regions. Three-times-weekly "proactive" maintenance therapy using tacrolimus ointment has also been reported in both adults and children with AD.[92]

Ongoing surveillance and recent reports have not shown a trend for increased frequency of viral superinfections, especially EH. TCIs carry an FDA black box warning for rare cases of skin malignancy and lymphoma have been reported with topical tacrolimus, although a systematic literature review showed a slightly higher risk of lymphoma in patients with AD, with severity appearing to be a risk factor but concluding that TCIs are unlikely to be a significant factor.[93] Importantly, a case-control study of a large database that identified a cohort of 293,253 patients with AD found no increased risk of lymphoma with the use of TCIs.[93] Margolis and colleagues found no increase in malignancy incidence rates with pimecrolimus cream in a study evaluating more than 26,000 person-years.[94]

Crisaborole: Crisaborole is a boron-based topical phosphodiesterase 4 (PDE4) inhibitor recently approved for the treatment of mild to moderate AD in patients older than the age of 2 years. PDE4 inhibition is thought to decrease proinflammatory cytokine production by key immune cells that drive chronic inflammatory skin disease. Two identically designed pivotal phase 3 trials revealed crisaborole 2% ointment resulted in clear or almost clear disease (plus a two-step improvement) in 31.4% to 32.8% in the active group compared with 18.0% to 25.4% in the vehicle control groups with these differences being statistically significant.[95] No significant adverse events emerged with 4% of patients experiencing burning. Crisaborole represents a safe and efficacious novel nonsteroidal option for the treatment of mild-moderate AD.

Tar Preparations: Coal tar preparations may have antipruritic and antiinflammatory effects on the skin, although not as pronounced as those of topical glucocorticoids. Newer coal tar products have been developed that are more acceptable with respect to odor and staining of clothes than some older products. Tar shampoos can be beneficial for scalp dermatitis and are often helpful in reducing the concentration and frequency of topical glucocorticoid applications. Tar preparations should not be used on acutely inflamed skin because this often results in skin irritation. Side effects associated with tars include folliculitis and photosensitivity. There is a theoretic risk of tar being a carcinogen based on observational studies of workers using tar components in their occupations; however, epidemiologic studies do not confirm similar outcomes when used topically.[83]

PHOTOTHERAPY

Natural sunlight is frequently beneficial to patients with AD. However, if the sunlight occurs in the setting of high heat or humidity, thereby triggering sweating and pruritus, it may be deleterious to patients. Broadband UVB, broadband UVA, narrowband UVB (311 nm), UVA-1 (340 to 400 nm), and combined UVAB phototherapy can be useful adjuncts in the treatment of AD. Investigation of the photoimmunologic mechanisms responsible for therapeutic effectiveness indicates that epidermal LCs and eosinophils may be targets of UVA phototherapy, with and without psoralen, but UVB exerts immunosuppressive effects via blocking of function of antigen-presenting LCs and altered keratinocyte cytokine production. Photochemotherapy with psoralen and UVA light may be indicated in patients with severe, widespread AD, although studies comparing it with other modes of phototherapy are limited. Short-term adverse effects with phototherapy may include erythema, skin pain, pruritus, and pigmentation. Long-term adverse effects include premature skin aging and cutaneous malignancies (see Chaps. 198 and 199 for detailed discussion of phototherapy and photochemotherapy, respectively).

HOSPITALIZATION

Patients with AD who appear erythrodermic or who have widespread severe skin disease resistant to outpatient therapy should be considered for hospitalization. In many cases, removing the patient from environmental allergens or emotional stresses, intense patient education, and assurance of compliance with therapy results in a sustained improvement in their AD. Clearing of the patient's skin during hospitalization also allows the patient to undergo patch testing or allergen skin testing and appropriately controlled provocative challenges to correctly identify or rule out exacerbating factors.

SYSTEMIC THERAPY

The decision to initiate systemic therapies should be based on overall disease severity, response to

topical therapy, adherence to previous topical regimens, impact of the disease on the patient's quality of life, and understanding the patient's comorbidities and preferences. Before initiating systemic therapy, other diagnoses should be considered that can mimic or exacerbate AD such as cutaneous T-cell lymphoma, allergic contact dermatitis, scabies, or immunodeficiency syndrome. A biopsy or additional laboratory testing may be needed. What follows are discussions of oral and injectable medications previously studied or commonly used as systemic therapy in AD.[96] There are no specific guidelines or comparative effectiveness data to inform guidelines regarding the optimal first-line systemic treatment in AD nor is there a definitive algorithm for treatment.

DUPILUMAB

Dupilumab is a fully human monoclonal antibody targeting the IL-4 receptor alpha subunit. The IL-4 and IL-13 receptors share this subunit; thus, dupilumab blocks cytokine signaling through both of these receptors. Except for oral corticosteroids, dupilumab is the only FDA-approved systemic agent for the treatment of AD at this time. Dupilumab is dosed every other week and delivered as a subcutaneous injection. It is indicated for the treatment of adult patients with moderate to severe AD whose disease is not adequately controlled with topical prescription therapies or when those therapies are not advisable. In two identically designed phase 3 studies named SOLO 1 and SOLO 2, dupilumab resulted in 36% to 38% of patients reaching clear or almost clear skin after 16 weeks of treatment compared with 9% to 10% in the placebo, group which were statistically significant differences.[30] Signs of the disease as measured by the Eczema and Area Severity Index (EASI) reduced by 67% to 72%. Dupilumab treatment led to significant improvement in pruritus, quality of life, and clinically meaningful reductions in anxiety and depressive symptoms. SOLO 1 and 2 were designed as monotherapy, that is, without the concomitant use of TCs. A recent study evaluating the effects of dupilumab in combination with TCs found the addition of TCs to dupilumab to be safe and provides modest increased benefit over monotherapy.[97] This combination study named CHRONOS also evaluated outcomes with 1 year of continuous therapy showing a maintenance of benefit with longer term use.

To date, there appear to be few adverse effects of dupilumab therapy. Dupilumab does not appear to suppress normal immune responses. A recent analysis found skin infections are reduced with dupilumab treatment.[39] Vaccine responses to both T cell–dependent and T cell–independent vaccines were unchanged with treatment.[98] Injection site reactions (eg, pain on injection) and conjunctivitis are the most common drug-related adverse effects. The cause of the conjunctivitis is unclear, but it does not appear to be infectious, is usually mild to moderate in severity, and can improve with topical lubricants or antiinflammatory therapy and may spontaneously resolve.

SYSTEMIC GLUCOCORTICOIDS

The use of systemic glucocorticoids, such as oral prednisone, is rarely indicated in the treatment of patients with chronic AD but is commonly used by providers. Some patients and physicians prefer the use of systemic glucocorticoids to avoid the time-consuming skin care involving hydration and topical therapy. However, the dramatic clinical improvement that may occur with systemic glucocorticoids is frequently associated with a severe rebound flare of AD after the discontinuation of systemic glucocorticoids. Short courses of oral glucocorticoids may be appropriate for an acute exacerbation of AD while other treatment measures are being instituted. If a short course of oral glucocorticoids is given, it is important to taper the dosage and to begin intensified skin care, particularly with topical glucocorticoids and frequent bathing followed by application of emollients to prevent rebound flaring of AD.

CYCLOSPORINE

Cyclosporine is a potent immunosuppressive drug that acts primarily on T cells by suppressing cytokine transcription. The drug binds to cyclophilin, an intracellular protein, and this complex, in turn, inhibits calcineurin, a molecule required for initiation of cytokine gene transcription. Multiple studies demonstrate that both children and adults with severe AD, refractory to conventional treatment, can benefit from short-term cyclosporine treatment. Various oral dosing regimens have been recommended: whereas 5 mg/kg has generally been used with success in short- and long-term (1 year) use, some authorities advocate body weight–independent daily dosing of adults with 150 mg (low dose) or 300 mg (high dose) daily of cyclosporine microemulsion. Treatment with cyclosporine is associated with reduced skin disease and an improved quality of life (see Chap. 192 for further discussion). Discontinuation of treatment may result in rapid relapse of skin disease, although some patients may have sustained remission. Elevated serum creatinine or more significant renal impairment, hypertension, and drug–drug interactions are specific side effects of concern with cyclosporine use.

ANTIMETABOLITES

Methotrexate (MTX) is an antimetabolite with potent inhibitory effects on inflammatory cytokine synthesis and cell chemotaxis. MTX has been studied for both pediatric and adult AD patients with recalcitrant disease. One controlled study found MTX to provide an approximate 42% reduction in disease severity scores in adult patients, similar to the active comparator azathioprine.[99] A trial in children showed similar responses.[100] Side effects of MTX include hematologic

abnormalities and hepatic toxicity. The long-term risk of occult hepatic toxicity with continued use of MTX is not known, and no guidelines exist regarding the role of liver biopsy or imaging in this patient population.

Mycophenolate mofetil is a purine biosynthesis inhibitor used as an immunosuppressant in organ transplantation, which has been used for treatment of refractory inflammatory skin disorders (see Chap. 192). Open-label studies report that short-term oral mycophenolate mofetil, 2 g/day, as monotherapy results in clearing of skin lesions in adults with AD resistant to other treatment, including topical and oral steroids and psoralen and UVA light. Similar results were previously reported in another open study of ten patients with a mean reduction in the SCORAD (SCORing Atopic Dermatitis) index of 68% in all 10 patients.[101] The drug was also found to be a reasonably useful flare prevention therapy after induction with cyclosporine.[102]

The drug has generally been well tolerated with the exception of one patient developing herpes retinitis that may have been secondary to this immunosuppressive agent. Hematologic toxicity has also been observed as have cases of progressive multifocal encephalopathy. The use of the drug during pregnancy has also been associated with pregnancy loss and congenital malformations.

Azathioprine is a purine analog with antiinflammatory and antiproliferative effects. It has been used for severe AD, and several controlled trials have been reported in adults and children with modest efficacy. Myelosuppression is a significant adverse effect. Thiopurine methyl transferase levels may predict individuals at risk.

OTHER THERAPIES

Interferon-γ: IFN-γ is known to suppress IgE responses and downregulate Th2 cell proliferation and function. Several studies of patients with AD, including a multicenter, double-blind, placebo-controlled trial and two long-term open trials, have demonstrated that treatment with recombinant human IFN-γ results in clinical improvement.[103] Reduction in clinical severity of AD correlated with the ability of IFN-γ to decrease total circulating eosinophil counts. Influenza-like symptoms are commonly observed side effects early in the treatment course.

Omalizumab: Omalizumab is a monoclonal antibody targeting IgE and is approved for allergic asthma and chronic urticarial. Even though elevated IgE is present in nearly all patients with AD, case reports of omalizumab's effect in AD were conflicting. A randomized controlled trial found no clinical effects of omalizumab on AD.[104] This study suggest IgE does not play a direct role in AD pathogenesis.

Allergen Immunotherapy: Unlike allergic rhinitis and extrinsic asthma, immunotherapy with aeroallergens has not proven to be efficacious in the treatment of AD. There are anecdotal reports of both disease exacerbation and improvement. A Cochrane review of 12 studies found limited evidence supporting their use in AD, although studies were of low quality.[105] Well-controlled studies are still required to determine the role for immunotherapy with this disease.

Extracorporeal Photopheresis: Extracorporeal photopheresis consists of the passage of psoralen-treated leukocytes through an extracorporeal UVA light system. Clinical improvement in skin lesions associated with reduced IgE levels has been reported in a few patients with severe, resistant AD who were treated with extracorporeal photopheresis and topical glucocorticoids. One study found the treatment to be comparable to daily 3 mg/kg cyclosporine.[106]

Probiotics: Several studies have shown perinatal administration of probiotics, especially *Lactobacillus rhamnosus* strain GG to prevent AD in at-risk children during the first 2 years of life. The efficacy of probiotics to treat AD is less clear. Probiotics are purported to deliver beneficial microbes to the gut of patients, establishing a bacterial milieu that reduces systemic inflammatory responses. A systematic review evaluating 12 trials including 781 participants of probiotic supplementation for AD found little beneficial effect.[107] A meta-analysis of seven trials showed no significant difference in eczema severity between probiotic and placebo groups. For both treatment and prevention, more research into subgroups of responders, length of treatment, strain of *Lactobacillus*, and mechanisms involved is clearly needed.

Chinese Herbal Medications: Several placebo-controlled clinical trials have suggested that patients with severe AD may benefit from treatment with traditional Chinese herbal therapy. However, the beneficial response of Chinese herbal therapy is often temporary, and effectiveness may wear off despite continued treatment. The possibility of hepatic toxicity, cardiac side effects, or idiosyncratic reactions remains a concern. The specific ingredients of the herbs also remain to be elucidated and some topical preparations have been found to be contaminated with corticosteroids. At present, Chinese herbal therapy for AD is considered investigational.

Oral Vitamin D: Vitamin D is thought to normalize immune responses and increase antimicrobial peptide expression in AD. A pilot randomized, double-blind, placebo-controlled study looked at the benefit of oral vitamin D supplementation in children with AD from February to March in Boston.[108] Eleven pediatric patients primarily with mild AD were treated with either vitamin D (1000 IU ergocalciferol) or placebo once daily for 1 month. Investigator Global Assessment (IGA) score improved in four of six subjects in the vitamin D group (80%) compared with one of five participants in the placebo group (P = .04). In addition, there was a greater reduction in EASI score in the vitamin D compared with the placebo group, although the difference was not statistically significant. In another small controlled study, 14 healthy participants and 14 participants

with AD were supplemented with 4000 IU/day of oral vitamin D_3 (cholecalciferol) for 3 weeks.[109] Expression of the antimicrobial peptide cathelicidin was significantly increased in the skin biopsies of AD lesions compared with those in healthy skin or uninvolved AD skin, suggesting a role for oral vitamin D in improving innate immune responses in patients with AD.

Since these promising early observations, two larger controlled trials have been performed. A study of 107 Mongolian children with winter-exacerbated AD confirmed previous findings and found a significant improvement in the supplemented children.[110] In contrast, a study in 60 adults found no clinical effect of vitamin D supplementation on epidermal antimicrobial expression or clinical scores measured by EASI.[111]

PREVENTION

Given the high prevalence and morbidity associated with AD, disease prevention represents the holy grail of AD research. For decades, allergen avoidance remained the primary approach to AD prevention with middling or conflicting results. Food avoidance in pregnant or lactating mothers proved dangerous and food avoidance in infancy likely promoted the development of food allergy. The Learning Early About Peanut Allergy study found early exposure of peanut, rather than delayed exposure, dramatically reduced peanut allergy at age 5 years.[112] The 2017 NIAID Expert Panel Addendum Guidelines on prevention of peanut allergy recommend that for children with severe eczema, egg allergy, or both, introduction of solid foods begins at 4 to 6 months of age, starting with solid food other than peanuts, so that the child can demonstrate the ability to consume solid food without evidence of nonspecific signs and symptoms that could be confused with IgE-mediated food allergy.[113] A practical consideration for applying this guideline at 4 to 6 months of age is that that infants visit their health care providers for well-child evaluations and infant immunizations at this time. This provides an opportunity for eczema evaluation and, if needed, referral to a specialist for peanut allergy evaluation. Allergy testing in children with severe eczema or egg allergy should be strongly considered before the first peanut protein feeding. The use of hydrolyzed formula for AD prevention has shown a positive effect in studies, including persistence of effect in the German Infant and Nutrition study. A recent Cochrane review, however, concluded that there was no convincing evidence of hydrolyzed formula for the prevention of AD in high-risk infants.[114] Probiotics supplements appear to have a protective effect on AD development when delivered both pre- and postnatally.[115] The exact strains, dosing, and timing of the intervention is not standardized, nor is the mechanism of action understood. Protecting the skin barrier with emollients early in life in high-risk infants also appears to be promising and reduced the incidence of AD by up to 50% in two small studies.[116,117] Larger studies of this approach to AD prevention are ongoing.

REFERENCES

1. Coca AF, Cooke RA. On the classification of the phenomena of hypersensitiveness. *J Immunol.* 1923;8(3):163-182.
2. Wise F, Sulzberger MB. Footnote on problem of eczema, neurodermatitis and lichenification. In: Wise F, Sulzberger MB, eds. *The 1933 Year Book of Dermatology and Syphilogy.* Chicago: The Year Book Publishers; 1933:38-39.
3. Kantor R, Thyssen J, Paller A, et al. Atopic dermatitis, atopic eczema, or eczema? A systematic review, meta-analysis, and recommendation for uniform use of "atopic dermatitis." *Allergy.* 2016;71(10):1480-1485.
4. Hanifin JM, Rajka G. Diagnostic features of atopic dermatitis. *Acta Derm Venereol (Stockh).* 1980;92:44-47.
5. Williams HC, Burney PG, Pembroke AC, et al. The U.K. Working Party's Diagnostic Criteria for Atopic Dermatitis. III. Independent hospital validation. *Br J Dermatol.* 1994;131(3):406-416.
6. Eichenfield LF, Hanifin JM, Luger TA, et al. Consensus conference on pediatric atopic dermatitis. *J Am Acad Dermatol.* 2003;49(6):1088-1095.
7. Karimkhani C, Dellavalle RP, Coffeng LE, et al. Global Skin Disease Morbidity and Mortality: An Update From the Global Burden of Disease Study 2013. *JAMA Dermatol.* 2017;153(5):406-412.
8. Bergmann K-C, Heinrich J, Niemann H. Current status of allergy prevalence in Germany. *Allergo J Int.* 2016;25(1):6-10.
9. Saeki H, Tsunemi Y, Fujita H, et al. Prevalence of atopic dermatitis determined by clinical examination in Japanese adults. *J Dermatol.* 2006;33(11):817-819.
10. Silverberg JI, Hanifin JM. Adult eczema prevalence and associations with asthma and other health and demographic factors: a US population–based study. *J Allergy Clin Immunol.* 2013;132(5):1132-1138.
11. Shaw TE, Currie GP, Koudelka CW, et al. Eczema prevalence in the United States: data from the 2003 National Survey of Children's Health. *J Invest Dermatol.* 2011;131(1):67-73.
12. Schram ME, Tedja AM, Spijker R, et al. Is there a rural/urban gradient in the prevalence of eczema? A systematic review. *Br J Dermatol.* 2010;162(5):964-973.
13. Tsakok T, McKeever TM, Yeo L, et al. Does early life exposure to antibiotics increase the risk of eczema? A systematic review. *Br J Dermatol.* 2013;169(5):983-991.
14. Kabashima K, Otsuka A, Nomura T. Linking air pollution to atopic dermatitis. *Nat Immunol.* 2016;18(1):5-6.
15. Engebretsen KA, Bager P, Wohlfahrt J, et al. Prevalence of atopic dermatitis in infants by domestic water hardness and season of birth: cohort study. *J Allergy Clin Immunol.* 2017;139(5):1568-1574.e1561.
16. Uphoff E, Cabieses B, Pinart M, et al. A systematic review of socioeconomic position in relation to asthma and allergic diseases. *Eur Respir J.* 2015;46(2):364-374.
17. Zhang A, Silverberg JI. Association of atopic dermatitis with being overweight and obese: a systematic review and metaanalysis. *J Am Acad Dermatol.* 2015;72(4):606-616.e604.
18. Silverberg JI, Hanifin J, Simpson EL. Climatic factors are associated with childhood eczema prevalence in US. *J Invest Dermatol.* 2013;133(7):1752-1759.
19. Kim YM, Kim J, Han Y, et al. Short-term effects of weather and air pollution on atopic dermatitis symptoms in children: a panel study in Korea. *PLoS One.* 2017;12(4):e0175229.

20. Halkjaer LB, Loland L, Buchvald FF, et al. Development of atopic dermatitis during the first 3 years of life: the Copenhagen prospective study on asthma in childhood cohort study in high-risk children. *Arch Dermatol*. 2006;142(5):561-566.
21. Bremmer SF, Hanifin JM, Simpson EL. Clinical detection of ichthyosis vulgaris in an atopic dermatitis clinic: implications for allergic respiratory disease and prognosis. *J Am Acad Dermatol*. 2008;59(1):72-78.
22. Drucker AM, Thompson JM, Li WQ, et al. Incident alopecia areata and vitiligo in adult women with atopic dermatitis: Nurses' Health Study 2. *Allergy*. 2017;72(5):831-834.
23. Silverberg JI, Simpson EL. Association between severe eczema in children and multiple comorbid conditions and increased healthcare utilization. *Pediatr Allergy Immunol*. 2013;24(5):476-486.
24. Belgrave DC, Granell R, Simpson A, et al. Developmental profiles of eczema, wheeze, and rhinitis: two population-based birth cohort studies. *PLoS Med*. 2014;11(10):e1001748.
25. Lowe AJ, Abramson MJ, Hosking CS, et al. The temporal sequence of allergic sensitization and onset of infantile eczema. *Clin Exp Allergy*. 2007;37(4):536-542.
26. Anto JM, Bousquet J, Akdis M, et al. Mechanisms of the Development of Allergy (MeDALL): introducing novel concepts in allergy phenotypes. *J Allergy Clin Immunol*. 2017;139(2):388-399.
27. Chamlin SL. The psychosocial burden of childhood atopic dermatitis. *Dermatol Ther*. 2006;19(2):104-107.
28. Yaghmaie P, Koudelka CW, Simpson EL. Mental health comorbidity in patients with atopic dermatitis. *J Allergy Clin Immunol*. 2013;131(2):428-433.
29. Strom MA, Fishbein AB, Paller AS, et al. Association between atopic dermatitis and attention deficit hyperactivity disorder in U.S. children and adults. *Br J Dermatol*. 2016;175(5):920-929.
30. Simpson EL, Bieber T, Guttman-Yassky E, et al. Two phase 3 trials of dupilumab versus placebo in atopic dermatitis. *N Engl J Med*. 2016;375(24):2335-2348.
31. Tauber M, Balica S, Hsu CY, et al. Staphylococcus aureus density on lesional and nonlesional skin is strongly associated with disease severity in atopic dermatitis. *J Allergy Clin Immunol*. 2016;137(4):1272-1274.e1271-1273.
32. Totte JE, van der Feltz WT, Hennekam M, et al. Prevalence and odds of Staphylococcus aureus carriage in atopic dermatitis: a systematic review and meta-analysis. *Br J Dermatol*. 2016;175(4):687-695.
33. Hayashida S, Furusho N, Uchi H, et al. Are lifetime prevalence of impetigo, molluscum and herpes infection really increased in children having atopic dermatitis? *J Dermatol Sci*. 2010;60(3):173-178.
34. Patel D, Jahnke MN. Serious Complications from Staphylococcal aureus in atopic dermatitis. *Pediatr Dermatol*. 2015;32(6):792-796.
35. Cho SH, Strickland I, Boguniewicz M, et al. Fibronectin and fibrinogen contribute to the enhanced binding of Staphylococcus aureus to atopic skin. *J Allergy Clin Immunol*. 2001;108(2):269-274.
36. Howell MD, Boguniewicz M, Pastore S, et al. Mechanism of HBD-3 deficiency in atopic dermatitis. *Clin Immunol*. 2006;121(3):332-338.
37. Ong PY, Ohtake T, Brandt C, et al. Endogenous antimicrobial peptides and skin infections in atopic dermatitis. *N Engl J Med*. 2002;347(15):1151-1160.
38. Brauweiler AM, Goleva E, Leung DY. Th2 cytokines increase Staphylococcus aureus alpha toxin-induced keratinocyte death through the signal transducer and activator of transcription 6 (STAT6). *J Invest Dermatol*. 2014;134(8):2114-2121.
39. Drucker A, Fleming P. 282 Risk of skin infections with dupilumab for atopic dermatitis: systematic review and meta-analysis of randomized controlled trials. *J Invest Dermatol*. 2017;137(5):S48.
40. Kong HH, Oh J, Deming C, et al. Temporal shifts in the skin microbiome associated with disease flares and treatment in children with atopic dermatitis. *Genome Res*. 2012;22(5):850-859.
41. Bath-Hextall FJ, Birnie AJ, Ravenscroft JC, et al. Interventions to reduce Staphylococcus aureus in the management of atopic eczema: an updated Cochrane review. *Br J Dermatol*. 2010;163(1):12-26.
42. Knowlden S, Yoshida T, Perez-Nazario N, et al. 296 Bleach baths promote early induction of inflammatory pathway genes with no effect on skin bacterial dysbiosis in AD subjects. *J Invest Dermatol*. 2017;137(5):S50.
43. Paternoster L, Standl M, Waage J, et al. Multi-ancestry genome-wide association study of 21,000 cases and 95,000 controls identifies new risk loci for atopic dermatitis. *Nat Genet*. 2015;47(12):1449-1456.
44. Leung DY, Gao PS, Grigoryev DN, et al. Human atopic dermatitis complicated by eczema herpeticum is associated with abnormalities in IFN-gamma response. *J Allergy Clin Immunol*. 2011;127(4):965-973.e961-965.
45. Mathes EF, Oza V, Frieden IJ, et al. "Eczema coxsackium" and unusual cutaneous findings in an enterovirus outbreak. *Pediatrics*. 2013;132(1):e149-e157.
46. Bayrou O, Pecquet C, Flahault A, et al. Head and neck atopic dermatitis and malassezia-furfur-specific IgE antibodies. *Dermatology (Basel, Switzerland)*. 2005;211(2):107-113.
47. Leung DY, Guttman-Yassky E. Deciphering the complexities of atopic dermatitis: shifting paradigms in treatment approaches. *J Allergy Clin Immunol*. 2014;134(4):769-779.
48. Leung DY. Clinical implications of new mechanistic insights into atopic dermatitis. *Curr Opin Pediatr*. 2016;28(4):456-462.
49. Irvine AD, McLean WH, Leung DY. Filaggrin mutations associated with skin and allergic diseases. *N Engl J Med*. 2011;365(14):1315-1327.
50. Leung DY. New insights into atopic dermatitis: role of skin barrier and immune dysregulation. *Allergol Int*. 2013;62(2):151-161.
51. Leung DY. Atopic dermatitis: age and race do matter! *J Allergy Clin Immunol*. 2015;136(5):1265-1267.
52. Bin L, Edwards MG, Heiser R, et al. Identification of novel gene signatures in patients with atopic dermatitis complicated by eczema herpeticum. *J Allergy Clin Immunol*. 2014;134(4):848-855.
53. Wang IJ, Wu LS, Lockett GA, et al. TSLP polymorphisms, allergen exposures, and the risk of atopic disorders in children. *Ann Allergy Asthma Immunol*. 2016;116(2):139-145.e131.
54. Hamilton JD, Suarez-Farinas M, Dhingra N, et al. Dupilumab improves the molecular signature in skin of patients with moderate-to-severe atopic dermatitis. *J Allergy Clin Immunol*. 2014;134(6):1293-1300.
55. Kim J, Kim BE, Lee J, et al. Epidermal thymic stromal lymphopoietin predicts the development of atopic dermatitis during infancy. *J Allergy Clin Immunol*. 2016;137(4):1282-1285.e1281-1284.

56. Khattri S, Shemer A, Rozenblit M, et al. Cyclosporine in patients with atopic dermatitis modulates activated inflammatory pathways and reverses epidermal pathology. *J Allergy Clin Immunol*. 2014;133(6):1626-1634.
57. Klein PA, Clark RA. An evidence-based review of the efficacy of antihistamines in relieving pruritus in atopic dermatitis. *Arch Dermatol.* 1999;135(12): 1522-1525.
58. van Zuuren EJ, Apfelbacher CJ, Fedorowicz Z, et al. No high level evidence to support the use of oral H1 antihistamines as monotherapy for eczema: a summary of a Cochrane systematic review. *Syst Rev*. 2014;3(1):25.
59. Sidbury R, Tom WL, Bergman JN, et al. Guidelines of care for the management of atopic dermatitis: section 4. Prevention of disease flares and use of adjunctive therapies and approaches. *J Am Acad Dermatol*. 2014;71(6):1218-1233.
60. Boyce JA, Assa'ad A, Burks AW, et al. Guidelines for the diagnosis and management of food allergy in the United States: report of the NIAID-sponsored expert panel. *J Allergy Clin Immunol*. 2010;126(6 suppl):S1-58.
61. Fleischer DM, Bock SA, Spears GC, et al. Oral food challenges in children with a diagnosis of food allergy. *J Pediatr.* 2011;158(4):578-583.e571.
62. Bath-Hextall F, Delamere FM, Williams HC. Dietary exclusions for established atopic eczema. *Cochrane Database Syst Rev.* 2008(1):Cd005203.
63. Nankervis H, Pynn EV, Boyle RJ, et al. House dust mite reduction and avoidance measures for treating eczema. *Cochrane Database Syst Rev.* 2015;1:Cd008426.
64. Thompson MM, Hanifin JM. Effective therapy of childhood atopic dermatitis allays food allergy concerns. *J Am Acad Dermatol*. 2005;53(2 Suppl 2):S214-219.
65. Fuchs S, Rensing-Ehl A, Pannicke U, et al. Omenn syndrome associated with a functional reversion due to a somatic second-site mutation in CARD11 deficiency. *Blood.* 2015;126(14):1658-1669.
66. Bin Dhuban K, Piccirillo CA. The immunological and genetic basis of immune dysregulation, polyendocrinopathy, enteropathy, X-linked syndrome. *Curr Opin Allergy Clin Immunol.* 2015;15(6):525-532.
67. Odio CD, Milligan KL, McGowan K, et al. Endemic mycoses in patients with STAT3-mutated hyper-IgE (Job) syndrome. *J Allergy Clin Immunol*. 2015;136(5): 1411-1413.e1411-1412.
68. Aydin SE, Kilic SS, Aytekin C, et al. DOCK8 deficiency: clinical and immunological phenotype and treatment options—a review of 136 patients. *J Clin Immunol*. 2015;35(2):189-198.
69. Casanova JL, Holland SM, Notarangelo LD. Inborn errors of human JAKs and STATs. *Immunity.* 2012;36(4): 515-528.
70. Jawed SI, Myskowski PL, Horwitz S, et al. Primary cutaneous T-cell lymphoma (mycosis fungoides and Sezary syndrome): part I. Diagnosis: clinical and histopathologic features and new molecular and biologic markers. *J Am Acad Dermatol*. 2014;70(2):205. e201-216; quiz 221-202.
71. Chen JK, Jacob SE, Nedorost ST, et al. A Pragmatic Approach to Patch Testing Atopic Dermatitis Patients: Clinical Recommendations Based on Expert Consensus Opinion. *Dermatitis.* 2016;27(4):186-192.
72. Corbo MD, Lam J. Zinc deficiency and its management in the pediatric population: a literature review and proposed etiologic classification. *J Am Acad Dermatol*. 2013;69(4):616-624.e611.
73. Kim JP, Chao LX, Simpson EL, et al. Persistence of atopic dermatitis (AD): a systematic review and meta-analysis. *J Am Acad Dermatol*. 2016;75(4): 681-687.e611.
74. Margolis JS, Abuabara K, Bilker W, et al. Persistence of mild to moderate atopic dermatitis. *JAMA Dermatol.* 2014;150(6):593-600.
75. Margolis DJ, Apter AJ, Gupta J, et al. The persistence of atopic dermatitis and filaggrin (FLG) mutations in a US longitudinal cohort. *J Allergy Clin Immunol*. 2012;130(4):912-917.
76. Margolis DJ, Gupta J, Apter AJ, et al. Filaggrin-2 variation is associated with more persistent atopic dermatitis in African American subjects. *J Allergy Clin Immunol*. 2014;133(3):784-9.
77. Ahrens B, Staab D. Extended implementation of educational programs for atopic dermatitis in childhood. *Pediatr Allergy Immunol.* 2015;26(3):190-196.
78. Mason JM, Carr J, Buckley C, et al. Improved emollient use reduces atopic eczema symptoms and is cost neutral in infants: before-and-after evaluation of a multifaceted educational support programme. *BMC Dermatol.* 2013;13:7-5945-5913-5947.
79. Koning S, van der Sande R, Verhagen AP, et al. Interventions for impetigo. *Cochrane Database Syst Rev.* 2012;1:Cd003261.
80. Nankervis H, Thomas KS, Delamere FM, et al. Programme grants for applied research. In: *Scoping Systematic Review of Treatments for Eczema*. Southampton, United Kingdom: NIHR Journals Library, 2016.
81. Leung TH, Zhang LF, Wang J, et al. Topical hypochlorite ameliorates NF-kappaB-mediated skin diseases in mice. *J Clin Invest.* 2013;123(12):5361-5370.
82. Chang YS, Lin MH, Lee JH, et al. Melatonin supplementation for children with atopic dermatitis and sleep disturbance: a randomized clinical trial. *JAMA Pediatr.* 2016;170(1):35-42.
83. Mlitz V, Latreille J, Gardinier S, et al. Impact of filaggrin mutations on Raman spectra and biophysical properties of the stratum corneum in mild to moderate atopic dermatitis. *J Eur Acad Dermatol Venereol.* 2012;26(8):983-990.
84. Czarnowicki T, Malajian D, Khattri S, et al. Petrolatum: barrier repair and antimicrobial responses underlying this "inert" moisturizer. *J Allergy Clin Immunol*. 2015.
85. Akerstrom U, Reitamo S, Langeland T, et al. Comparison of moisturizing creams for the prevention of atopic dermatitis relapse: a randomized double-blind controlled multicentre clinical trial. *Acta Derm Venereol.* 2015;95(5):587-592.
86. Kohn LL, Kang Y, Antaya RJ. A randomized, controlled trial comparing topical steroid application to wet versus dry skin in children with atopic dermatitis (AD). *J Am Acad Dermatol*.2016;75(2):306-311.
87. Hajar T, Hanifin JM, Tofte SJ, et al. Prehydration is effective for rapid control of recalcitrant atopic dermatitis. *Dermatitis.* 2014;25(2):56-59.
88. Eichenfield LF, Tom WL, Berger TG, et al. Guidelines of care for the management of atopic dermatitis: section 2. Management and treatment of atopic dermatitis with topical therapies. *J Am Acad Dermatol*. 2014;71(1):116-132.
89. Hanifin J, Gupta AK, Rajagopalan R. Intermittent dosing of fluticasone propionate cream for reducing the risk of relapse in atopic dermatitis patients. *Br J Dermatol.* 2002;147(3):528-537.

90. Hajar T, Leshem YA, Hanifin JM, et al. A systematic review of topical corticosteroid withdrawal ("steroid addiction") in patients with atopic dermatitis and other dermatoses. *J Am Acad Dermatol*. 2015;72(3):541-549. e542.
91. Schmitt J, von Kobyletzki L, Svensson A, et al. Efficacy and tolerability of proactive treatment with topical corticosteroids and calcineurin inhibitors for atopic eczema: systematic review and meta-analysis of randomized controlled trials. *Br J Dermatol*. 2011;164(2):415-428.
92. Paller AS, Eichenfield LF, Kirsner RS, et al. Three times weekly tacrolimus ointment reduces relapse in stabilized atopic dermatitis: a new paradigm for use. *Pediatrics*. 2008;122(6):e1210-1218.
93. Arellano FM, Wentworth CE, Arana A, et al. Risk of lymphoma following exposure to calcineurin inhibitors and topical steroids in patients with atopic dermatitis. *J Invest Dermatol*. 2007;127(4):808-816.
94. Margolis DJ, Abuabara K, Hoffstad OJ, et al. Association between malignancy and topical use of pimecrolimus. *JAMA Dermatol*. 2015;151(6):594-599.
95. Paller AS, Tom WL, Lebwohl MG, et al. Efficacy and safety of crisaborole ointment, a novel, nonsteroidal phosphodiesterase 4 (PDE4) inhibitor for the topical treatment of atopic dermatitis (AD) in children and adults. *J Am Acad Dermatol*. 2016;75(3):494-503. e494.
96. Roekevisch E, Spuls PI, Kuester D, et al. Efficacy and safety of systemic treatments for moderate-to-severe atopic dermatitis: a systematic review. *J Allergy Clin Immunol*. 2014;133(2):429-438.
97. Blauvelt A, de Bruin-Weller M, Gooderham M, et al. Long-term management of moderate-to-severe atopic dermatitis with dupilumab and concomitant topical corticosteroids (LIBERTY AD CHRONOS): a 1-year, randomised, double-blinded, placebo-controlled, phase 3 trial. *Lancet*. 2017 Jun 10;389(10086):2287-2303. doi: 10.1016/S0140-6736(17)31191-1. Epub 2017 May 4. PubMed PMID: 28478972.
98. Blauvelt A, Simpson EL, Tyring SK, et al. Dupilumab does not affect correlates of vaccine-induced immunity: a randomized, placebo-controlled trial in adults with moderate-to-severe atopic dermatitis. *J Am Acad Dermatol*. 2018 Aug 6. pii: S0190-9622(18)32351-X. doi: 10.1016/j.jaad.2018.07.048. [Epub ahead of print] PubMed PMID: 30092324.
99. Schram ME, Roekevisch E, Leeflang MM, et al. A randomized trial of methotrexate versus azathioprine for severe atopic eczema. *J Allergy Clin Immunol*. 2011;128(2):353-359.
100. El-Khalawany MA, Hassan H, Shaaban D, et al. Methotrexate versus cyclosporine in the treatment of severe atopic dermatitis in children: a multicenter experience from Egypt. *Eur J Pediatr*. 2013;172(3): 351-356.
101. Neuber K, Schwartz I, Itschert G, Dieck AT. Treatment of atopic eczema with oral mycophenolate mofetil. *Br J Dermatol*. 2000;143(2):385-391.
102. Haeck IM, Knol MJ, Ten Berge O, et al. Enteric-coated mycophenolate sodium versus cyclosporin A as long-term treatment in adult patients with severe atopic dermatitis: a randomized controlled trial. *J Am Acad Dermatol*. 2011;64(6):1074-1084.
103. Chang TT, Stevens SR. Atopic dermatitis: the role of recombinant interferon-gamma therapy. *Am J Clin Dermatol*. 2002;3(3):175-183.
104. Heil PM, Maurer D, Klein B, et al. Omalizumab therapy in atopic dermatitis: depletion of IgE does not improve the clinical course–a randomized, placebo-controlled and double blind pilot study. *J Dtsch Dermatol Ges*. 2010;8(12):990-998.
105. Tam H, Calderon MA, Manikam L, et al. Specific allergen immunotherapy for the treatment of atopic eczema. *Cochrane Database Syst Rev*. 2016;2:Cd008774.
106. Koppelhus U, Poulsen J, Grunnet N, et al. Cyclosporine and extracorporeal photopheresis are equipotent in treating severe atopic dermatitis: a randomized cross-over study comparing two efficient treatment modalities. *Front Med (Lausanne)*. 2014;1:33.
107. Boyle RJ, Bath-Hextall FJ, Leonardi-Bee J, et al. Probiotics for treating eczema. *Cochrane Database Syst Rev*. 2008(4):Cd006135.
108. Sidbury R, Sullivan AF, Thadhani RI, et al. Randomized controlled trial of vitamin D supplementation for winter-related atopic dermatitis in Boston: a pilot study. *Br J Dermatol*. 2008;159(1):245-247.
109. Hata TR, Kotol P, Jackson M, et al. Administration of oral vitamin D induces cathelicidin production in atopic individuals. *J Allergy Clin Immunol*. 2008;122(4):829-831.
110. Camargo CA Jr, Ganmaa D, Sidbury R, et al. Randomized trial of vitamin D supplementation for winter-related atopic dermatitis in children. *J Allergy Clin Immunol*. 2014;134(4):831-835.e831.
111. Hata TR, Audish D, Kotol P, et al. A randomized controlled double-blind investigation of the effects of vitamin D dietary supplementation in subjects with atopic dermatitis. *J Eur Acad Dermatol Venereol*. 2014;28(6):781-789.
112. Du Toit G, Roberts G, Sayre PH, et al. Randomized trial of peanut consumption in infants at risk for peanut allergy. *N Engl J Med*. 2015;372(9):803-813.
113. Togias A, Cooper SF, Acebal ML, et al. Addendum guidelines for the prevention of peanut allergy in the United States: report of the National Institute of Allergy and Infectious Diseases-sponsored expert panel. *J Allergy Clin Immunol*. 2017;139(1):29-44.
114. Osborn DA, Sinn JK, Jones LJ. Infant formulas containing hydrolysed protein for prevention of allergic disease and food allergy. *Cochrane Database Syst Rev*. 2017;3:Cd003664.
115. Panduru M, Panduru NM, Salavastru CM, et al. Probiotics and primary prevention of atopic dermatitis: a meta-analysis of randomized controlled studies. *J Eur Acad Dermatol Venereol*. 2015;29(2):232-242.
116. Horimukai K, Morita K, Narita M, et al. Application of moisturizer to neonates prevents development of atopic dermatitis. *J Allergy Clin Immunol*. 2014;134(4):824-830.e826.
117. Simpson EL, Chalmers JR, Hanifin JM, et al. Emollient enhancement of the skin barrier from birth offers effective atopic dermatitis prevention. *J Allergy Clin Immunol*. 2014;134(4):818-823.

Chapter 23 :: Nummular Eczema, Lichen Simplex Chronicus, and Prurigo Nodularis

:: Jonathan I. Silverberg

AT-A-GLANCE

Nummular eczema:

- Also known as nummular dermatitis and discoid eczema.
- A chronic inflammatory skin disorder of unknown etiology.
- Papules and papulovesicles coalesce to form nummular plaques with oozing, crust, and scale.
- Most common sites of involvement are upper extremities in men and women, particularly the dorsal hands in women, and the lower extremities in men.
- Pathology may show acute, subacute, or chronic eczema.

Lichen simplex chronicus

- A chronic, severely pruritic disorder characterized by one or more lichenified plaques.
- Most common sites of involvement are scalp, nape of neck, extensor aspects of extremities, ankles, and anogenital area.
- Pathology consists of hyperkeratosis, hypergranulosis, psoriasiform epidermal hyperplasia, and thickened papillary dermal collagen.

Prurigo nodularis

- Also known as prurigo, picker's nodules, or nodular prurigo of Hyde.
- A pruritic disorder that runs a chronic course.
- Hyperkeratotic firm nodules vary in size from 0.5 to 3.0 cm and may be excoriated.
- Associations include atopic dermatitis and systemic causes of pruritus.
- Pathology consists of hyperkeratosis, hypergranulosis, psoriasiform epidermal hyperplasia, thickened papillary dermal collagen, and characteristic neural hypertrophy.

This chapter discusses the evaluation and management of *nummular dermatitis*, *lichen simplex chronicus*, and *prurigo nodularis*. These disorders are each associated with intense itch and characteristic morphologic findings. Each of these disorders may present in patients with atopic and contact dermatitis. However, these disorders often present in the absence of atopic disease and may be associated with underlying systemic disease.

NUMMULAR ECZEMA

Nummular eczema or *discoid eczema* is a morphologic term to describe coin-shaped plaques that may have multiple etiologies. The term was first coined by Devergie in 1857.[1] Nummular lesions are commonly observed in atopic dermatitis (AD), and may have a predilection for school-age children with AD[2,3] and adult-onset AD.[4] A large proportion of patients with nummular eczema have underlying allergic contact dermatitis.[5,6]

However, some use this term to describe a specific diagnosis, which excludes other common dermatoses presenting with nummular lesions.[7] The epidemiology of nummular eczema is not well-defined, in part owing to the different definitions used in studies. Prevalence estimates for nummular eczema were found to be 1 to 2 per 1000 population in studies of the populations of the U.S. in 1978[8] and Sweden in 1969.[7] Nummular eczema was encountered in 2.2% of dermatologic visits in Turkey in 2011-2012.[9] Nummular eczema is more common in adults, with multiple observed peak ages-of-onset at 15-25,[7,8,10] 50-59,[7,10] and 65-74 years.[7,8] Previous studies found conflicting results about whether nummular eczema is more common in adult males[7] or adult females.[8] No racial or ethnic predilection for nummular eczema has been demonstrated.

ETIOLOGY AND PATHOGENESIS

The pathogenesis of nummular eczema appears to be multifactorial. Many of the proposed triggers of nummular eczema overlap with those of AD, including atopy, xerosis, exogenous insult by irritants and/or allergens, microbiome, and infection. Nummular eczema does not appear to be consistently associated with atopy. Most studies found low or normal rates of personal (1.5% to 11%) and/or family history of atopy (2.5% to 15%).[7,11] However, a Thai study found high rates of personal (50%) and/or family history of atopy (38%).[10] One study found that patients with

nummular eczema were less likely to have elevated immunoglobulin E (IgE) levels.[12]

Similar to AD, nummular eczema in elderly patients is associated with xerosis clinically and lower hydration of the stratum corneum.[13] Moreover, epidermal and dermal inflammation occurring in nummular eczema was found to be predominated by T cells with even higher T-cell counts compared to AD.[14] However, in contrast with AD, the water-barrier function of stratum corneum in nummular eczema appears to be normal.[13] Nummular eczema has been reported to be triggered by exposure to irritants[10,15-17] and environmental factors[10,18] and most commonly flares in the wintertime.[7,10,19] A role for environmental allergens, such as the house dust mite and *Candida albicans* has also been touted.[13]

A large subset of nummular eczema may be related to allergic contact dermatitis. Retrospective studies of patch testing results for patients with nummular eczema found that 32.5% to 50% had at least one positive allergen,[5,6,20] of which 12% to 67% were felt to be clinically relevant.[6,10,20] Patients may develop nummular eczema-like reactions to their topical medicaments.[21] Generalized nummular eczema may be caused by oral and/or topical exposures to allergens.[22]

Microbial colonization and/or infection may play a role in nummular eczema. Nummular eczema lesions have been repeatedly shown to be sterile.[23-25] However, patients with nummular eczema may have higher rates of colonization with *Staphylococcus aureus* and methicillin-resistant *S. aureus* in the nares and subungual space.[26] Extracutaneous foci of infection, including teeth, upper respiratory tract, and lower respiratory tract, were found in 68% of patients in one study.[15] A case series found that infections were present in 39% of nummular eczema patients, with dental caries and upper respiratory tract infections being most common.[10] However, no control groups were examined in these studies. One study compared the frequency of infections in patients with nummular eczema to a matched group of patients with psoriasis and chronic urticaria.[7] Nummular eczema was associated with higher rates of dental abscesses and paradental diseases than psoriasis, but not with pulmonary or nasal infections or elevated antistreptolysin titers.[7] In a series of 13 patients with generalized nummular eczema (without a history of atopic eczema), the skin disease completely improved after odontogenic infections were treated.[27]

Nummular eczema has been reported during therapy with medications, including isotretinoin,[28] gold,[29] combination therapy with interferon α-2b and ribavirin for hepatitis C,[30,31] and infliximab.[32] Mercury amalgam was implicated as a cause of nummular eczema in two patients.[33]

Emotional stress may be a common and clinically relevant trigger of nummular eczema.[10]

CLINICAL FINDINGS

Well-demarcated, coin-shaped plaques form from coalescing papules and papulovesicles. Often, studded or satellite papulovesicles appear at the periphery of an expanding central plaque and should not be confused with the satellitosis present in fungal or yeast infections. Pinpoint oozing and crusting eventuate, and are distinctive (Figs. 23-1 and 23-2). Crust may, however, cover the entire surface (Fig. 23-3). Plaques range from 1 to >3 cm in size. The surrounding skin is generally

Figure 23-1 Nummular eczema. Coin-shaped plaques with pinpoint erosions and excoriations. (Image from Division of Dermatology, University of the Witwatersrand, Johannesburg, South Africa, with permission, from Professor D. Modi.)

Figure 23-2 Nummular eczema. Single plaque showing pinpoint erosions and crusting.

Figure 23-3 Nummular eczema in a child. Crusted plaques. (Used by permission of P. Lio, MD, Northwestern University's Feinberg School of Medicine, Chicago, IL.)

normal, but may be xerotic and/or have asteatotic eczema lesions. Pruritus varies from minimal to severe and may be worse in the evening and during periods of relaxation. Central resolution may occur, leading to annular forms. Chronic plaques are dry, scaly, and lichenified. The classic distribution of lesions is the extensor aspects of the extremities, particularly the lower extremities.[7,10] Onset of nummular eczema peaks in the winter and troughs in the summer.[7,10]

LABORATORY TESTS

Nummular eczema is not consistently associated with atopy and serum IgE levels are not useful. Nummular eczema lesions are sterile and lesional bacterial cultures are not indicated, unless there is suspicion for a superimposed infection. Antistreptolysin-O titers are not useful.

SPECIAL TESTS

Patch testing is indicated in chronic recalcitrant cases to rule out underlying contact dermatitis. Previous studies found a variety of relevant positive allergens in patch testing, including nickel, chromates, and other metals; rubber; fragrances, formaldehyde, and other preservatives commonly found in cosmetics and personal care products; neomycin and other topical medicaments; and colophony.[6,10,20]

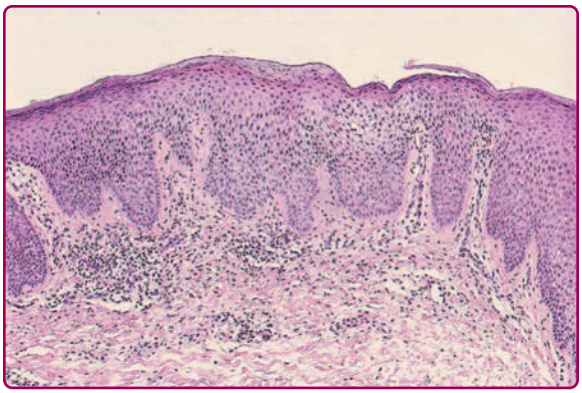

Figure 23-4 Histopathology of nummular eczema. Parakeratosis containing plasma and neutrophils (scale crust) and psoriasiform epidermal hyperplasia with spongiosis are present, with a superficial dermal perivascular infiltrate of lymphocytes, macrophages, and eosinophils.

Skin biopsy and histopathologic examination may be needed to rule out other clinical entities, such as autoimmune blistering disorders and cutaneous T-cell lymphoma. Histopathologic changes are reflective of the stage at which the biopsy is performed. Acutely, there is spongiosis, with or without spongiotic microvesicles. In subacute plaques, there is parakeratosis, scale crust, epidermal hyperplasia, and spongiosis of the epidermis (Fig. 23-4). There is a mixed cell infiltrate in the dermis. Chronic lesions may resemble lichen simplex chronicus microscopically.

DIFFERENTIAL DIAGNOSIS

Table 23-1 outlines the differential diagnosis of nummular eczema.

TABLE 23-1
Differential Diagnosis of Nummular Eczema

Most Likely
- Allergic contact dermatitis
- Stasis dermatitis
- Atopic dermatitis
- Tinea corporis

Consider
- Impetigo
- Psoriasis (longstanding plaques)
- Mycosis fungoides (longstanding plaques)
- Paget disease, when there is unilateral involvement of nipple/areola
- Bullous pemphigoid
- Pemphigus vulgaris
- Other nummular dermatoses:
  - Fixed-drug eruption
  - Pityriasis rotunda

Always Rule Out
- Tinea corporis

COMPLICATIONS

Nummular eczema may be complicated by profound sleep disturbance owing to intense itch and secondary bacterial infection.

PROGNOSIS AND CLINICAL COURSE

Nummular eczema is associated with considerable quality-of-life impairment, particularly in more extensive disease.[10] Nummular eczema is often chronic, with either an intermittent or persistent course. One study found that nummular eczema persisted for up to 30 years, with a mean duration of 3.8 years; only 44% of patients were ever free of lesions.[10] Another study found that only 22% of nummular eczema patients were disease-free, 25% had some intermittent disease, and 53% were never free of lesions after 2 years of follow-up.[19] Recurrence at prior sites of involvement is a feature of the disease.[15]

TREATMENT

Topical corticosteroids are the mainstay of treatment. Lesions are often refractory to mid-potency topical corticosteroids and require superpotent topical corticosteroids. Topical calcineurin inhibitors, such as tacrolimus and pimecrolimus, and tar preparations also may be effective. Emollients can be added adjunctively if there is accompanying xerosis. Home humidifiers may be useful for patients with winter flares; however, there is no evidence to support this recommendation. Oral sedating antihistamines are useful to improve sleep when pruritus is severe. Oral antibiotics are indicated when secondary infection is present. For widespread involvement or lesions refractory to topical treatments, phototherapy with broadband or narrowband ultraviolet B or systemic treatment with corticosteroids, cyclosporine, methotrexate[34], and the like may be beneficial.

LICHEN SIMPLEX CHRONICUS/PRURIGO NODULARIS

EPIDEMIOLOGY

Lichen simplex chronicus (LSC) and prurigo nodularis (PN) are phenotypes that are caused by repeated itching, scratching, and rubbing of the skin. They can be associated with multiple etiologies of dermatologic and/or systemic disease.[35] However, some use these terms (LSC and PN) to describe a specific diagnosis, which excludes other dermatologic disorders that present with these lesions, such as AD (ie, *nodular prurigo of Hyde*).[36,37] The epidemiology of LSC and PN is not well-defined, owing to scant studies and the different definitions used in the studies. Little is known about the descriptive epidemiology of PN. A retrospective population-based study in Taiwan found the incidence of LSC to be 25 to 28 versus 17.8 per 10,000 person-years in those with versus those without a history of anxiety disorders.[38] A cross-sectional study found that LSC and PN were encountered in 3% and 2.1% of dermatology visits, respectively.[9] PN more commonly occurs in adults, but can occasionally affect children.[9,39,40] Patients with PN in the setting of AD have been found to have an earlier age of onset as compared to those without AD.[41] LSC may be more common in patients of Asian descent for reasons unknown.[42]

ETIOLOGY AND PATHOGENESIS

LSC is induced by rubbing and scratching, whereas prurigo nodules are induced by picking and scratching secondary to itch. Some authors suggest that PN is a form of LSC.[43,44] These two disorders may represent a spectrum of manifestations secondary to chronic itch.

Various factors incite itch in both disorders and not all are well understood. Both types of lesions are commonly found in patients with AD along with xerosis and other signs and symptoms of AD. Some studies found that patients with LSC and PN have high rates of atopic disease and/or a history of AD.[39,41,45,46] "Besnier prurigo" refers to the prurigo nodules seen in AD. Prurigo nodules may also occur in other dermatoses, such as contact dermatitis[47] and pemphigoid nodularis, a rare variant of bullous pemphigoid.[48,49] LSC may develop superimposed on other dermatoses, including contact dermatitis,[50-52] psoriasis, *Candida*, and tinea infections.[53]

There may be underlying systemic causes of pruritus in patients with PN and LSC without AD. These causes include renal insufficiency, hyper- or hypothyroidism, liver failure, hepatitides B and C viruses even without liver failure, HIV disease, *Helicobacter*, mycobacterial or parasitic infection, or an underlying hematologic or solid-organ malignancy, including Hodgkin disease, and gastric and bladder cancers.[54-59] PN also has been reported to occur in the setting of celiac disease and/or dermatitis herpetiformis.[60,61] A relationship between LSC, neuropathy, and radiculopathy has been suggested in a subset of patients.[35,62]

PN and LSC appear to have a bidirectional relationship with emotional and psychological factors. A retrospective population-based study in Taiwan found that persons with anxiety disorders had significantly higher risk of subsequently developing LSC.[38] On the other hand, patients with LSC and PN have higher rates of depression, anxiety, obsessive-compulsive disorder, and other psychological disorders.[39,63-67] One

study found that 72% of patients thought that psychosocial problems were of relevance.[39]

The higher rates of psychological disorders may be partly a result of the detrimental effects of the chronic itchiness and sequelae of their skin disease.

Several pathways have been postulated for heightened perception to touch and itch in patients with LSC and PN. These include cellular and neurochemical changes at the level of cutaneous nerves in lesions, the spinal cord, and the central nervous system. PN lesions were found to have increased cutaneous nerve fibers (neural hyperplasia) and increased staining for the neuropeptides calcitonin gene-related peptide (CGRP) and substance P, but not tyrosine hydroxylase, vasoactive intestinal polypeptide, and the C-flanking region of neuropeptide Y.[68] Nerve growth factor is overexpressed in PN lesions and is implicated in the pathogenesis of cutaneous neural hyperplasia and upregulated expression of neuropeptides, such as CGRP and substance P.[69] CGRP and substance P may be modulators of itch and upregulate secretion of proinflammatory cytokines, including tumor necrosis factor alpha, interleukin (IL)-1 and IL-8 within lesional skin of PN.[68] Keratinocytes also express transient receptor potential cation channel subfamily V member 1 (TRPV1) channels, which play important roles in sensation of itch, heat and pain. TRPV1 receptors are greatly upregulated in PN.[70] IL-31 is produced by T cells and may be a direct inflammatory mediator of itch.[71] One study found that IL-31 levels were dramatically increased in PN lesions of atopic skin disease.[72] Neurotransmitters that affect mood, such as dopamine, serotonin, or opioid peptides, modulate perception of itch via descending spinal pathways.[73] Finally, environmental factors, such as heat, sweat, and irritation have been implicated in inducing itch in anogenital LSC.[53]

CLINICAL FINDINGS

HISTORY

Severe itching is the hallmark of LSC and PN. Itching may be paroxysmal, continuous, or sporadic, localized or diffuse. Itching may be described by patients as burning, stinging, or a creepy-crawly sensation akin to formication. Patients may not be aware of itching and scratching that occurs during sleep time. Patients may also develop habitual scratching or picking of lesions, even when they are not itchy. Itch is often triggered by sweating, heat, friction, extreme humidity or dryness, irritation from personal care products or clothing, and/or times of psychological distress.[53,54] LSC and PN are associated with moderate to severe quality-of-life impairment[74-77] and sexual dysfunction.[78]

CUTANEOUS LESIONS

In LSC, repeated rubbing and scratching gives rise to lichenified, dry, and scaly plaques with or without excoriations. Hyperpigmentation and hypopigmentation can be seen, particularly in patients with skin of color. The most common sites of involvement are the scalp, the nape of the neck, the ankles, the extensor aspects of the extremities, and the anogenital and vulvar regions.[79] The labia majora in women and the scrotum in men (Fig. 23-5) are the most common sites of genital involvement.[45] The upper inner thighs, groin, nipple, and areola also may be affected.[79]

Figure 23-5 Lichen simplex chronicus of the scrotum: lichenification, hyperpigmentation, and hypopigmentation with excoriation. (Image from Division of Dermatology, University of the Witwatersrand, Johannesburg, South Africa, with permission, from Professor D. Modi.)

Prurigo nodules are firm to hard on palpation, varying in size from 0.5 cm to >3.0 cm, and numbering from few to hundreds. The surface may be hyperkeratotic or crateriform. There is often overlying excoriation. Pruritus is usually severe. Limbs are affected in most cases, especially the extensor aspects (Fig. 23-6). The abdomen and sacrum were the next most common sites of involvement in one study.[39] Face and palms are rarely involved. Nodules may occur on any site that can be reached by the patient. There can be a characteristic "butterfly sign" with lesional sparing on the upper back. However, some patients may even develop nodules on hard-to-reach areas secondary to using backscratchers, knives, forks, brushes, or other instruments to scratch. Nodules may persist for months to years and resolve with postinflammatory hyperpigmentation or hypopigmentation and scarring.

Figure 23-6 Prurigo nodularis. (Used by permission of Professor D. Modi, Division of Dermatology, University of the Witwatersrand, Johannesburg, South Africa.)

RELATED PHYSICAL FINDINGS

In patients with AD, the intervening skin is often lichenified and xerotic, and patients may have other signs of atopy, such as Dennie-Morgan fold or palmar hyperlinearity. In nonatopic patients, cutaneous signs of underlying systemic disease or lymphadenopathy, signifying lymphoma, may be present.

LABORATORY TESTS

In patients with LSC or PN in whom an underlying systemic cause of pruritus is suspected, a complete blood count with differential and renal, liver, and thyroid function tests may be ordered. Testing for HIV, diabetes (fasting glucose and/or hemoglobin A1C) may be indicated.[35] A chest radiograph may be obtained to screen for lymphoma. The need for a more extensive evaluation should be individualized based on patient history and results of the aforementioned tests.

Additional testing for iron deficiency, erythrocyte sedimentation rate, gliadin antibody, zinc, cobalamin, total porphyrins, and stool examination for *Strongyloides stercoralis* may also be indicated. Ultrasound of the abdomen or lymph nodes may be indicated to rule out liver or kidney disease or lymphoma. Breath test for *Helicobacter*, lactose, and sorbitol intolerance may be indicated. Magnetic resonance imaging of the cervical spinal column is called for if the patient has localized LSC or PN (eg, brachioradial distribution).

SPECIAL TESTS

On histopathologic sections, LSC shows varying degrees of hyperkeratosis with parakeratosis and orthokeratosis, hypergranulosis, and psoriasiform epidermal hyperplasia. The papillary dermis shows thickening of collagen with coarse collagen bundles and vertical streaks. There is a variable inflammatory infiltrate around the superficial vascular plexus with lymphocytes, histiocytes, and eosinophils. A biopsy may also reveal a primary pruritic disorder, such as psoriasis, that has led to secondary lichenification. Direct immunofluorescence may be needed to rule out autoimmune skin disease, such as bullous pemphigoid or dermatitis herpetiformis. Polymerase chain reaction testing for mycobacteria may be needed if histological investigation finds granulomatous inflammatory infiltrate.

The epidermal findings in PN are similar to LSC. The lesion is more papular with bulbous epidermal hyperplasia. Papillary dermal changes also resemble LSC. There may be cutaneous neural hypertrophy with thickened nerve bundles and an increase in nerve fibers by S-100 staining. This finding may not be seen in all cases.[80]

DIFFERENTIAL DIAGNOSIS

Tables 23-2 and 23-3 outline the differential diagnoses for LSC and PN, respectively.

COMPLICATIONS

Sleep studies show that disturbances in the sleep cycle in LSC are present. Non-rapid eye movement

TABLE 23-2
Differential Diagnosis of Lichen Simplex Chronicus

Most Likely
- Lichenified atopic eczema
- Lichenified psoriasis
- Hypertrophic lichen planus

Consider
- Genital: extramammary Paget disease

Always Rule Out
- Vulva, perianally: underlying lichen sclerosus, human papillomavirus, or tinea cruris
- Scrotum: underlying human papillomavirus or tinea cruris

TABLE 23-3
Differential Diagnosis of Prurigo Nodularis

Most Likely
- Perforating disease
- Hypertrophic lichen planus
- Pemphigoid nodularis (bullous pemphigoid)
- Actinic prurigo
- Multiple keratoacanthomas
- Dermatitis herpetiformis

Consider
Nodular scabies
Dermatitis herpetiformis

sleep is disturbed and patients have an increased arousal index (brief awakenings from sleep) caused by scratching.[81]

Patients with LSC and PN have higher rates of depression, anxiety, obsessive-compulsive disorder, and other psychological disorders.[39,63-67]

A retrospective population-based cohort study found that patients with LSC had higher baseline rates of diabetes, hypertension, hyperlipidemia, cardiovascular disease, peripheral arterial disease, chronic kidney disease, depression, and anxiety, and an increased risk of developing erectile dysfunction.[78]

PROGNOSIS AND CLINICAL COURSE

Both diseases run a chronic course with persistence or recurrence of lesions. The mean duration of PN was found to be 77.5 months,[35] whereas that of anogenital LSC was found to be 30.6 months.[82] LSC and PN in association with systemic disease may have a more prolonged course than other etiologies.[35] The presence of PN in patients with renal pruritus is associated with more prolonged itch.[83] Exacerbations can occur in response to emotional stress and exogenous stimuli.

TREATMENT

Figure 23-7 outlines the stepwise management of LSC and PN. Treatment is aimed at interrupting the itch–scratch cycle. Both components should be addressed. Systemic causes of itch should be identified and addressed. In both conditions, first-line measures to control itch include potent topical corticosteroids as well as nonsteroidal antipruritic preparations such as menthol, phenol, or pramoxine. Emollients are an important adjunct, particularly for those patients with AD. Intralesional steroids, such as triamcinolone acetonide, given in varying concentrations according to the thickness of the plaque or nodule are beneficial. Topical tacrolimus has been successfully employed as a steroid-sparing agent, but may require application under occlusion to improve transcutaneous absorption. Sedating antihistamines, such as hydroxyzine, or tricyclic antidepressants, such as doxepin, may be used to abolish nighttime itch in both conditions. An open-label study of 9 patients with conventional therapy-resistant PN found that daily montelukast and fexofenadine was effective at reducing itch in 75% of patients.[84] Selective serotonin reuptake inhibitors have been recommended for relief of daytime pruritus or in patients with comorbid obsessive-compulsive disorder.[53]

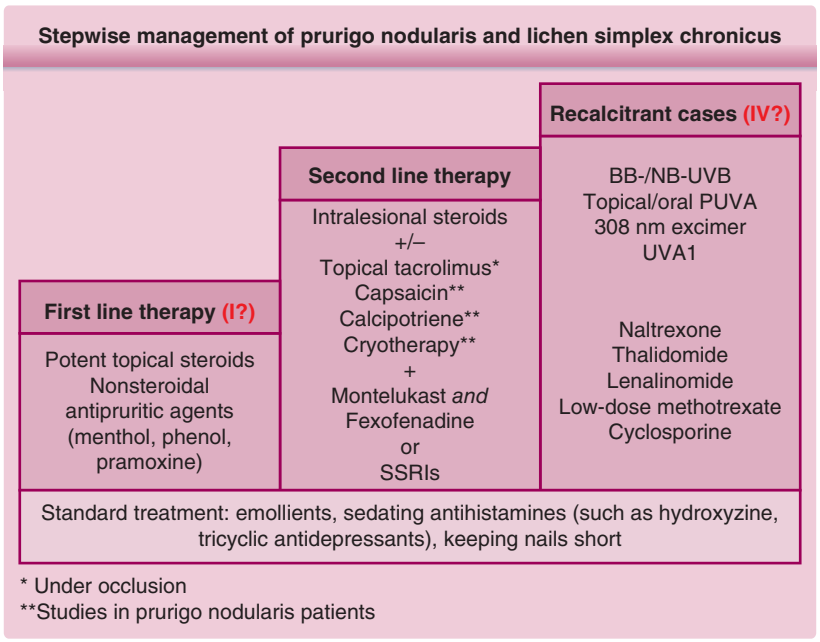

Figure 23-7 Stepwise management of prurigo nodularis and lichen simplex chronicus. BB, broadband; NB, narrowband; PUVA, psoralen and ultraviolet A; UVA, ultraviolet A; UVB, ultraviolet B.

Capsaicin, calcipotriene, and cryotherapy, with or without intralesional steroid injections, have all been successfully used in PN. Both broadband and narrowband ultraviolet B, as well as topical or oral psoralen and ultraviolet A (PUVA) show efficacy and are indicated in widespread cases. The 308-nm excimer monochromatic light, UVA1 phototherapy, and naltrexone were all effective in small series.[85-87] Thalidomide and lenalinomide,[88] low-dose methotrexate,[89] and cyclosporine[90] also are beneficial, albeit with some adverse effects reported.

The importance of avoiding scratching should be addressed with the patient. Nails should be kept short and mittens can be used to prevent scratching. Occlusive measures, such as plastic films, topical steroid impregnated tape, or Unna boots may be needed in widespread or refractory cases.

REFERENCES

1. Gross P. Nummular eczema: its clinical picture and successful therapy. *Arch Derm Syphilol*. 1941;44:1060-1077.
2. Julian-Gonzalez RE, Orozco-Covarrubias L, Duran-McKinster C, et al. Less common clinical manifestations of atopic dermatitis: prevalence by age. *Pediatr Dermatol*. 2012;29(5):580-583.
3. Krol A, Krafchik B. The differential diagnosis of atopic dermatitis in childhood. *Dermatol Ther*. 2006;19(2):73-82.
4. Kulthanan K, Boochangkool K, Tuchinda P, et al. Clinical features of the extrinsic and intrinsic types of adult-onset atopic dermatitis. *Asia Pac Allergy*. 2011;1(2):80-86.
5. Bonamonte D, Foti C, Vestita M, et al. Nummular eczema and contact allergy: a retrospective study. *Dermatitis*. 2012;23(4):153-157.
6. Krupa Shankar DS, Shrestha S. Relevance of patch testing in patients with nummular dermatitis. *Indian J Dermatol Venereol Leprol*. 2005;71(6):406-408.
7. Hellgren L, Mobacken H. Nummular eczema—clinical and statistical data. *Acta Derm Venereol*. 1969;49(2):189-196.
8. Johnson MT, Roberts J. Skin conditions and related need for medical care among persons 1-74 years. United States, 1971-1974. *Vital Health Stat 11*. 1978(212):i-v, 1-72.
9. Bilgili ME, Yildiz H, Sarici G. Prevalence of skin diseases in a dermatology outpatient clinic in Turkey. A cross-sectional, retrospective study. *J Dermatol Case Rep*. 2013;7(4):108-112.
10. Jiamton S, Tangjaturonrusamee C, Kulthanan K. Clinical features and aggravating factors in nummular eczema in Thais. *Asian Pac J Allergy Immunol*. 2013;31(1):36-42.
11. Carr RD, Berke M, Becker SW. Incidence of atopy in the general population. *Arch Dermatol*. 1964;89:27-32.
12. Krueger GG, Kahn G, Weston WL, et al. IgE levels in nummular eczema and ichthyosis. *Arch Dermatol*. 1973;107(1):56-58.
13. Aoyama H, Tanaka M, Hara M, et al. Nummular eczema: an addition of senile xerosis and unique cutaneous reactivities to environmental aeroallergens. *Dermatology*. 1999;199(2):135-139.
14. Bos JD, Hagenaars C, Das PK, et al. Predominance of "memory" T cells (CD4+, CDw29+) over "naive" T cells (CD4+, CD45R+) in both normal and diseased human skin. *Arch Dermatol Res*. 1989;281(1):24-30.
15. Krogh HK. Nummular eczema. Its relationship to internal foci of infection. A survey of 84 case records. *Acta Derm Venereol*. 1960;40:114-126.
16. Denig NI, Hoke AW, Maibach HI. Irritant contact dermatitis. Clues to causes, clinical characteristics, and control. *Postgrad Med*. 1998;103(5):199-200, 207-198, 212-193.
17. Wilkinson DS. Discoid eczema as a consequence of contact with irritants. *Contact Dermatitis*. 1979;5(2):118-119.
18. Shenoi SD, Seth M. Environmental influence, atopy and contact sensitivity in nummular dermatitis. *Indian J Dermatol Venereol Leprol*. 1999;65(5):245.
19. Cowan MA. Nummular eczema. A review, follow-up and analysis of a series of 325 cases. *Acta Derm Venereol*. 1961;41:453-460.
20. Fleming C, Parry E, Forsyth A, et al. Patch testing in discoid eczema. *Contact Dermatitis*. 1997;36(5):261-264.
21. Caraffini S, Lisi P. Nummular dermatitis-like eruption from ethylenediamine hydrochloride in 2 children. *Contact Dermatitis*. 1987;17(5):313-314.
22. Morrow DM, Rapaport MJ, Strick RA. Hypersensitivity to aloe. *Arch Dermatol*. 1980;116(9):1064-1065.
23. Jadassohn J. *Dermatologie*. Wien, Austria: Verl. f. Medizin, Weidmann & Co.; 1938.
24. Rockl H. Studies on clinical manifestations and pathogenesis of microbial eczema. I [in German]. *Hautarzt*. 1955;6(12):532-537.
25. Török L. Über das Verhältnis des Ekzems zur artefiziellen Hautentzündung und zur Impetigo. *Dermatol Wochenschr*. 1923;76:273.
26. Kim WJ, Ko HC, Kim MB, et al. Features of *Staphylococcus aureus* colonization in patients with nummular eczema. *Br J Dermatol*. 2013;168(3):658-660.
27. Tanaka T, Satoh T, Yokozeki H. Dental infection associated with nummular eczema as an overlooked focal infection. *J Dermatol*. 2009;36(8):462-465.
28. Bettoli V, Tosti A, Varotti C. Nummular eczema during isotretinoin treatment. *J Am Acad Dermatol*. 1987;16(3, pt 1):617.
29. Wilkinson SM, Smith AG, Davis MJ, et al. Pityriasis rosea and discoid eczema: dose related reactions to treatment with gold. *Ann Rheum Dis*. 1992;51(7):881-884.
30. Shen Y, Pielop J, Hsu S. Generalized nummular eczema secondary to peginterferon alfa-2b and ribavirin combination therapy for hepatitis C infection. *Arch Dermatol*. 2005;141(1):102-103.
31. Moore MM, Elpern DJ, Carter DJ. Severe, generalized nummular eczema secondary to interferon alfa-2b plus ribavirin combination therapy in a patient with chronic hepatitis C virus infection. *Arch Dermatol*. 2004;140(2):215-217.
32. Delle Sedie A, Bazzichi L, Bombardieri S, et al. Psoriasis, erythema nodosum, and nummular eczema onset in an ankylosing spondylitis patient treated with infliximab. *Scand J Rheumatol*. 2007;36(5):403-404.
33. Adachi A, Horikawa T, Takashima T, et al. Mercury-induced nummular dermatitis. *J Am Acad Dermatol*. 2000;43(2, pt 2):383-385.
34. Roberts H, Orchard D. Methotrexate is a safe and effective treatment for paediatric discoid (nummular) eczema: a case series of 25 children. *Australas J Dermatol*. 2010;51(2):128-130.
35. Iking A, Grundmann S, Chatzigeorgakidis E, et al. Prurigo as a symptom of atopic and non-atopic diseases: aetiological survey in a consecutive cohort of 108

patients. *J Eur Acad Dermatol Venereol*. 2013;27(5):550-557.
36. Lezcano L, Di Martino Ortiz B, Rodriguez Masi M, et al. Prurigo nodularis [in Spanish]. *Arch Argent Pediatr*. 2008;106(5):446-449.
37. Vaidya DC, Schwartz RA. Prurigo nodularis: a benign dermatosis derived from a persistent pruritus. *Acta Dermatovenerol Croat*. 2008;16(1):38-44.
38. Liao YH, Lin CC, Tsai PP, et al. Increased risk of lichen simplex chronicus in people with anxiety disorder: a nationwide population-based retrospective cohort study. *Br J Dermatol*. 2014;170(4):890-894.
39. Rowland Payne CM, Wilkinson JD, McKee PH, et al. Nodular prurigo—a clinicopathological study of 46 patients. *Br J Dermatol*. 1985;113(4):431-439.
40. Doyle JA, Connolly SM, Hunziker N, et al. Prurigo nodularis: a reappraisal of the clinical and histologic features. *J Cutan Pathol*. 1979;6(5):392-403.
41. Tanaka M, Aiba S, Matsumura N, et al. Prurigo nodularis consists of two distinct forms: early-onset atopic and late-onset non-atopic. *Dermatology*. 1995;190(4):269-276.
42. Rein CR, Snider BL. Lichen simplex chronicus in Orientals. *AMA Arch Derm Syphilol*. 1952;66(5):612-617.
43. Besselmann A. Zur Kenntnis der Prurigo nodularis. *Arch Derm Syphilol*. 1932;166:212-225.
44. Shaffer B, Beerman H. Lichen simplex chronicus and its variants; a discussion of certain psychodynamic mechanisms and clinical and histopathologic correlations. *AMA Arch Derm Syphilol*. 1951;64(3):340-351.
45. Singh G. Atopy in lichen simplex (neurodermatitis circumscripta). *Br J Dermatol*. 1973;89(6):625-627.
46. Miyachi Y, Okamoto H, Furukawa F, et al. Prurigo nodularis. A possible relationship to atopy. *J Dermatol*. 1980;7(4):281-283.
47. Zelickson BD, McEvoy MT, Fransway AF. Patch testing in prurigo nodularis. *Contact Dermatitis*. 1989;20(5):321-325.
48. Dangel B, Kofler L, Metzler G. Nodular subtype of bullous pemphigoid. *J Cutan Med Surg*. 2016;20(6):570-572.
49. Al-Salhi W, Alharithy R. Pemphigoid nodularis. *J Cutan Med Surg*. 2015;19(2):153-155.
50. Chey WY, Kim KL, Yoo TY, et al. Allergic contact dermatitis from hair dye and development of lichen simplex chronicus. *Contact Dermatitis*. 2004;51(1):5-8.
51. Virgili A, Bacilieri S, Corazza M. Evaluation of contact sensitization in vulvar lichen simplex chronicus. A proposal for a battery of selected allergens. *J Reprod Med*. 2003;48(1):33-36.
52. Virgili A, Bacilieri S, Corazza M. Managing vulvar lichen simplex chronicus. *J Reprod Med*. 2001;46(4):343-346.
53. Lynch PJ. Lichen simplex chronicus (atopic/neurodermatitis) of the anogenital region. *Dermatol Ther*. 2004;17(1):8-19.
54. Lee MR, Shumack S. Prurigo nodularis: a review. *Australas J Dermatol*. 2005;46(4):211-218; quiz 219-220.
55. Seshadri P, Rajan SJ, George IA, et al. A sinister itch: prurigo nodularis in Hodgkin lymphoma. *J Assoc Physicians India*. 2009;57:715-716.
56. Lin JT, Wang WH, Yen CC, et al. Prurigo nodularis as initial presentation of metastatic transitional cell carcinoma of the bladder. *J Urol*. 2002;168(2):631-632.
57. Callen JP, Bernardi DM, Clark RA, et al. Adult-onset recalcitrant eczema: a marker of noncutaneous lymphoma or leukemia. *J Am Acad Dermatol*. 2000;43(2, pt 1):207-210.
58. Neri S, Raciti C, D'Angelo G, et al. Hyde's prurigo nodularis and chronic HCV hepatitis. *J Hepatol*. 1998;28(1):161-164.
59. Shelnitz LS, Paller AS. Hodgkin's disease manifesting as prurigo nodularis. *Pediatr Dermatol*. 1990;7(2):136-139.
60. Delfino M, Nino M, Delfino G, et al. Dermatitis herpetiformis and gluten-sensitive enteropathy in a patient with nodular prurigo. *J Eur Acad Dermatol Venereol*. 2002;16(1):88-89.
61. Francesco Stefanini G, Resta F, Marsigli L, et al. Prurigo nodularis (Hyde's prurigo) disclosing celiac disease. *Hepatogastroenterology*. 1999;46(28):2281-2284.
62. Solak O, Kulac M, Yaman M, et al. Lichen simplex chronicus as a symptom of neuropathy. *Clin Exp Dermatol*. 2009;34(4):476-480.
63. Konuk N, Koca R, Atik L, et al. Psychopathology, depression and dissociative experiences in patients with lichen simplex chronicus. *Gen Hosp Psychiatry*. 2007;29(3):232-235.
64. Bhatia MS, Gautam RK, Bedi GK. Psychiatric profile of patients with neurodermatitis. *J Indian Med Assoc*. 1996;94(12):445-446, 454.
65. Sanjana VD, Fernandez RJ. Lichen simplex chronicus—a psychocutaneous disorder? *Indian J Dermatol Venereol Leprol*. 1995;61(6):336-338.
66. Attah Johnson FY, Mostaghimi H. Co-morbidity between dermatologic diseases and psychiatric disorders in Papua New Guinea. *Int J Dermatol*. 1995;34(4):244-248.
67. Fried RG, Fried S. Picking apart the picker: a clinician's guide for management of the patient presenting with excoriations. *Cutis*. 2003;71(4):291-298.
68. Abadia Molina F, Burrows NP, Jones RR, et al. Increased sensory neuropeptides in nodular prurigo: a quantitative immunohistochemical analysis. *Br J Dermatol*. 1992;127(4):344-351.
69. Johansson O, Liang Y, Emtestam L. Increased nerve growth factor- and tyrosine kinase A-like immunoreactivities in prurigo nodularis skin—an exploration of the cause of neurohyperplasia. *Arch Dermatol Res*. 2002;293(12):614-619.
70. Stander S, Moormann C, Schumacher M, et al. Expression of vanilloid receptor subtype 1 in cutaneous sensory nerve fibers, mast cells, and epithelial cells of appendage structures. *Exp Dermatol*. 2004;13(3):129-139.
71. Stott B, Lavender P, Lehmann S, et al. Human IL-31 is induced by IL-4 and promotes TH2-driven inflammation. *J Allergy Clin Immunol*. 2013;132(2):446-454, e445.
72. Sonkoly E, Muller A, Lauerma AI, et al. IL-31: a new link between T cells and pruritus in atopic skin inflammation. *J Allergy Clin Immunol*. 2006;117(2):411-417.
73. Wallengren J. Prurigo: diagnosis and management. *Am J Clin Dermatol*. 2004;5(2):85-95.
74. Kouris A, Christodoulou C, Efstathiou V, et al. Comparative study of quality of life and obsessive-compulsive tendencies in patients with chronic hand eczema and lichen simplex chronicus. *Dermatitis*. 2016;27(3):127-130.
75. An JG, Liu YT, Xiao SX, et al. Quality of life of patients with neurodermatitis. *Int J Med Sci*. 2013;10(5):593-598.
76. Murota H, Kitaba S, Tani M, et al. Impact of sedative and non-sedative antihistamines on the impaired productivity and quality of life in patients with pruritic skin diseases. *Allergol Int*. 2010;59(4):345-354.
77. Kantor R, Dalal P, Cella D, et al. Impact of pruritus on quality of life: a systematic review. *J Am Acad Dermatol*. 2016;75(5):885-886.e4.
78. Juan CK, Chen HJ, Shen JL, et al. Lichen simplex chronicus associated with erectile dysfunction: a

population-based retrospective cohort study. *PLoS One*. 2015;10(6):e0128869.
79. Novick NL. Unilateral, circumscribed, chronic dermatitis of the papillary-areolar complex: case report and review of the literature. *Mt Sinai J Med*. 2001;68(4-5): 321-325.
80. Weigelt N, Metze D, Stander S. Prurigo nodularis: systematic analysis of 58 histological criteria in 136 patients. *J Cutan Pathol*. 2010;37(5):578-586.
81. Koca R, Altin R, Konuk N, et al. Sleep disturbance in patients with lichen simplex chronicus and its relationship to nocturnal scratching: a case control study. *South Med J*. 2006;99(5):482-485.
82. Rajalakshmi R, Thappa DM, Jaisankar TJ, et al. Lichen simplex chronicus of anogenital region: a clinicoetiological study. *Indian J Dermatol Venereol Leprol*. 2011;77(1):28-36.
83. Bohme T, Heitkemper T, Mettang T, et al. Clinical features and prurigo nodularis in nephrogenic pruritus [in German]. *Hautarzt*. 2014;65(8):714-720.
84. Shintani T, Ohata C, Koga H, et al. Combination therapy of fexofenadine and montelukast is effective in prurigo nodularis and pemphigoid nodularis. *Dermatol Ther*. 2014;27(3):135-139.
85. Saraceno R, Nistico SP, Capriotti E, et al. Monochromatic excimer light (308 nm) in the treatment of prurigo nodularis. *Photodermatol Photoimmunol Photomed*. 2008;24(1):43-45.
86. Rombold S, Lobisch K, Katzer K, et al. Efficacy of UVA1 phototherapy in 230 patients with various skin diseases. *Photodermatol Photoimmunol Photomed*. 2008;24(1):19-23.
87. Metze D, Reimann S, Beissert S, et al. Efficacy and safety of naltrexone, an oral opiate receptor antagonist, in the treatment of pruritus in internal and dermatological diseases. *J Am Acad Dermatol*. 1999;41(4):533-539.
88. Lim VM, Maranda EL, Patel V, et al. A review of the efficacy of thalidomide and lenalidomide in the treatment of refractory prurigo nodularis. *Dermatol Ther (Heidelb)*. 2016;6(3):397-411.
89. Spring P, Gschwind I, Gilliet M. Prurigo nodularis: retrospective study of 13 cases managed with methotrexate. *Clin Exp Dermatol*. 2014;39(4):468-473.
90. Siepmann D, Luger TA, Stander S. Antipruritic effect of cyclosporine microemulsion in prurigo nodularis: results of a case series. *J Dtsch Dermatol Ges*. 2008;6(11):941-946.

Chapter 24 :: Allergic Contact Dermatitis

:: Jake E. Turrentine, Michael P. Sheehan, & Ponciano D. Cruz, Jr.

AT-A-GLANCE

- Allergic contact dermatitis (ACD) is a cell-mediated (type IV), delayed type, hypersensitivity reaction caused by skin contact with an environmental allergen.
- Prior sensitization is required for allergy to develop.
- The clinical manifestation of ACD is an eczematous dermatitis. The acute phase is characterized by pruritus, erythema, edema, and vesicles, usually confined to the area of direct exposure. Recurrent contact to the causative allergen may lead to chronic disease, characterized by lichenified erythematous plaques with variable hyperkeratosis, fissuring, and pigmentary changes that may spread beyond the areas of direct exposure.
- Itch and swelling are key components of the history and may be clues to allergy.
- Patch testing is the diagnostic test of choice to identify causal allergens and is indicated for patients with persistent or recurrent dermatitis in whom ACD is suspected.
- Allergen avoidance is the mainstay of ACD treatment. Educating patients about avoiding the allergen and related substances, and providing suitable alternatives, are crucial to a good outcome.

The skin is a complex and dynamic organ that serves many purposes, among which is maintenance of a physical and immunologic barrier to the environment. Therefore, the skin is the first line of defense after exposure to a variety of chemicals. Allergic contact dermatitis (ACD) accounts for approximately 20% of new incident cases of *contact dermatitis* (irritant contact dermatitis accounts for the remainder).[1] ACD, as the name implies, is an adverse cutaneous inflammatory reaction caused by contact with a specific exogenous allergen to which a person was previously sensitized. More than 3700 chemicals are implicated as causal agents of ACD in humans.[2] Following contact with an allergen, the skin reacts immunologically so that in allergic individuals, such contact produces eczematous inflammation, which can range from a mild, short-lived condition to a severe, persistent, chronic disease, depending on the specific allergen and the amount, extent, and frequency of exposure. Appropriate allergen identification through proper epicutaneous patch testing improves quality of life as measured by standard tools,[3] as it allows for avoidance of the inciting allergen and possibly sustained remission from the potentially debilitating condition. Recognition of the presenting signs and symptoms, and appropriate patch testing, are crucial in the evaluation of a patient with suspected ACD.

EPIDEMIOLOGY

Several studies have investigated the prevalence of contact allergy in the general population and in unselected subgroups of the general population. In 2007, Thyssen and colleagues[4] performed a retrospective study that reviewed the main findings from previously published epidemiologic studies on contact allergy in unselected populations of all age groups and from publishing countries (mainly North America and Western Europe). Based on these heterogeneous published data collected between 1966 and 2007, the median prevalence of contact allergy to at least 1 allergen in the general population was 21.2%. Additionally, the study found that the most prevalent contact allergens in the general population were nickel, thimerosal, and fragrance mix. The prevalence of contact allergy to specific allergens differs among various countries[5-7] and the prevalence to specific allergens is not necessarily static, as prevalence is influenced by regional changes and developments, exposure patterns, regulatory standards, and societal customs and values.

AGE

Multiple studies have recognized contact dermatitis as an important and common cause of childhood dermatitis. Although ACD is equally as likely to develop in childhood as in adulthood,[8,9] the most common allergens identified differ between the age groups. While fragrance was an important sensitizer in all ages, certain studies, such as the 2001 Augsburg study based on adults 28 to 75 years of age, showed a significant increase in fragrance allergy with increasing age.[10] Similarly, a recent Danish study demonstrated the

prevalence allergy to preservatives to be higher among those 41 to 60 years of age.[11]

GENDER

Because very few studies have looked at the induction of allergic contact sensitization in men and women under controlled circumstances, gender differences in the development of ACD are largely unknown. When the human repeat-insult patch-testing method was used to assess induction rates for 10 common allergens, women were more often sensitized to 7 of the 10 allergens studied.[12] With regard to frequency, Thyssen and colleagues found that the median prevalence of contact allergy among the general population was 21.8% in women versus 12% in men. Looking specifically at nickel sensitivity, the same study showed the prevalence to be much higher among women than men (17.1% in women vs 3% in men). This may be because pierced ears are a significant risk factor for development of nickel allergy,[13-17] and there was a higher prevalence of pierced ears in women in comparison with men (81.5% vs 12%) in the population studied.

RACE/ETHNICITY

The role of race, if any, in the development of ACD remains controversial. In one study examining North American Contact Dermatitis Group (NACDG) patch test results of 9624 patients (8610 [89.5%] white and 1014 [10.5%] black) between 1992 and 1998, there were no differences in the overall response rate to allergens. Although there were no differences in the overall response rates, white and black patients differed in the frequency of ACD to specific allergens. Although possibly related to genetic factors, ethnicity also may have determined exposure patterns and, therefore, influenced the difference in frequencies in the study.

CLINICAL FEATURES

CUTANEOUS FINDINGS

The classic presentation of ACD is a pruritic, eczematous dermatitis initially localized to the primary site of allergen exposure. Geometric, linear, or focal patterns of involvement are suggestive of an exogenous etiology. For example, ACD from plants such as poison ivy, poison oak, or poison sumac, typically presents as a linear or streaky array of erythematous papules and vesicles. Occasionally, the sensitizing substance in these plants, an oleoresin named *urushiol* may be aerosolized when the plants are burned, leading to a more generalized and severe eruption on exposed areas. Transfer of the resin from sources other than directly from the plant (such as clothes, pets, or hands) may result in rashes on unexpected sites (eg, genital involvement in a patient with poison ivy). Because the mechanism of allergen exposure influences the clinical presentation, relevant historic data gathered from thoughtful questioning may prove as useful as the distribution of the lesions.

Importantly, ACD will vary morphologically depending on the stage of the disease and severity of reaction. During the acute phase, lesions are marked by edema, erythema, and vesicle formation. Stronger allergens often result in vesicle formation, whereas weaker allergens often lead to papular lesion morphology, with surrounding erythema and edema. In the subacute phase, vesicular rupture leads to oozing, and scaly juicy papules associated with weeping and crusting dominate the clinical picture. Finally, the chronic phase is characterized by scaling, fissuring, and lichenification. A key symptom for ACD is pruritus, which seems to occur more typically than a symptom of a burning sensation.

Moreover, there are some noneczematous clinical variants of ACD (Table 24-1) that are infrequently observed.[18,19] *Erythema multiforme-like ACD* has been linked primarily to exotic woods, topical medicaments, and numerous miscellaneous chemicals. In contrast to true erythema multiforme, which typically presents on acral sites, lesions of erythema

TABLE 24-1
Noneczematous Variants of Allergic Contact Dermatitis

	SITES/APPEARANCE	COMMON CAUSES
Erythema multiforme-like allergic contact dermatitis (ACD)	Occur at periphery of allergen application; systemic symptoms of erythema multiforme are absent.	Exotic woods, medicaments
Purpuric ACD	Lower legs	Rubber, textile dyes
Lichenoid ACD	Commonly oral mucosa	Color developers, metallic dyes in tattoos; dental amalgams (oral lichenoid ACD)
Pigmented ACD	Clothed portions of body, face may be involved (Riehl melanosis)	Textile dyes, cosmetics, and fragrances
Lymphomatoid ACD	Histologic criteria only	Metals, *para*-phenylenediamine, dimethylfumarate, *para*-tert-butylphenol resin

multiforme-like ACD are typically at the periphery site of contact with the allergen, fever is usually absent, and mucosal involvement is rare. *Purpuric ACD* is mainly observed on the lower legs and/or feet and has been reported with a wide variety of allergens, including rubber and textile dyes. *Lichenoid ACD* is considered a rare variant that can mimic lichen planus; it is associated with color developers and metallic dyes in tattoos. Also, oral lichenoid ACD from dental amalgams can resemble typical oral lichen planus. *Pigmented ACD* has been mainly described in Asian-ethnicity populations. It is linked to textile dyes, cosmetics, and fragrances. *Lymphomatoid ACD* is based only on histopathologic criteria (presence of significant dermal infiltrate displaying features of pseudolymphoma). Nonspecific clinical signs include erythematous plaques, sometimes very infiltrated, at the site of application of the contact allergen. Allergens implicated in lymphomatoid ACD include metals (nickel and gold), *para*-phenylenediamine (hair dye), *para*-tert-butylphenol resin (glue), and dimethylfumarate (a mold inhibitor found in sachets within some furniture implicated in causing a previously severe epidemic of ACD).

ETIOLOGY AND PATHOGENESIS

ACD represents a classic cell-mediated (type IV), delayed hypersensitivity reaction. Type IV hypersensitivity reactions result from exposure and sensitization of a genetically susceptible host to an environmental allergen, followed by subsequent reexposure that triggers a complex inflammatory reaction. The resulting clinical picture is that of erythema, edema, and papulovesiculation, usually in the distribution of contact with the instigating allergen, and with pruritus as a major symptom.[20] To mount such a reaction, the individual must have sufficient contact with a sensitizing chemical, develop immunologic memory, and then have repeated contact with that substance later to elicit the immune response. This is an important distinction from irritant contact dermatitis in which sensitization is not required, and in which the intensity of the irritant inflammatory reaction is proportional to the dose (concentration and amount) of the irritant. By contrast, in ACD, even minute quantities of an allergen can elicit overt allergic reactions in a sensitized individual. There are two distinct phases in the development of ACD: the sensitization phase and the elicitation phase.[21]

SENSITIZATION PHASE

Unprocessed allergens are more correctly called haptens, which are typically small, lipophilic molecules with a low molecular weight (<500 daltons). Once a hapten penetrates the skin, it binds with epidermal carrier proteins to form a hapten–protein complex, which produces a complete antigen. Simultaneously, innate immunity is activated by keratinocyte release of several cytokines including interleukins 1, 8, and 18, tumor necrosis factor-α, and granulocyte-macrophage colony-stimulating factor.[22] Next, the antigen-presenting cells of the skin (Langerhans cells [LCs] and/or dermal dendritic cells), take up the hapten–protein complex ("the antigen") and express it on the cell surface on an human leukocyte antigen molecule. The antigen-presenting cell then migrates via lymphatics to regional lymph nodes where it presents the human leukocyte antigen complex to naïve antigen-specific T cells. These naïve T cells are then primed and differentiate into memory (effector) T cells, which expand clonally, acquire skin-specific homing antigens, and immigrate into circulation where they can act as effectors on target cells presenting the same antigen in the future.[23,24] The sensitization phase generally lasts 10 to 15 days and often is asymptomatic.[25] Subsequent exposure to the antigen (called *rechallenge*) leads to the elicitation phase and can occur via multiple routes, including transepidermal, subcutaneous, intravenous, intramuscular, inhalation, and oral ingestion.[26]

Of note, LCs have long been assumed to be the antigen-presenting cell responsible for inducing T cells in ACD, because of their abundance in the epidermis, easy accessibility to haptens, and strong antigen-presentation ability in vitro. However, recent studies reveal that depletion of LCs during the sensitization phase does not completely impair contact hypersensitivity responses.[27,28] Interestingly, it seems that CD1a+/CD141+ dermal dendritic cells may be the primary cells responsible for contact sensitization, although LCs may still play a role in some sitations.[22,27,29] Furthermore, it is important to note that sensitization can stimulate both helper (Th) and cytotoxic (Tc) T cells. While the most important population of cells in allergic sensitization is the Th1/Tc1 subset (interferon-γ producing), induction of Th2 and Th17/Tc17 subsets has been described and may play a role in the sensitization phase of ACD.[28]

ELICITATION PHASE

During this phase, subsequent exposure to an allergen to which the patient is already sensitized leads to clinical disease. First, hapten exposure leads to low-grade nonspecific inflammation through cellular stress as well as activation of toll-like receptors and nucleotide-binding oligomerization domain-like receptors, leading to neutrophil recruitment and, subsequently, effector T-cell recruitment.[28] Once antigen-specific effector T cells are recruited into skin containing their target antigen, they interact with antigen-presenting cells (LCs and dermal dendritic cells) in a cluster around postcapillary venules. This cluster of immune cells previously was considered the *skin-associated lymphoid tissue* but is now called *inducible skin-associated lymphoid tissue* because the clusters of immune cells only appear when they are induced by inflammation, rather than

in the steady state.[28,30] In response, the antigen-specific T cells amplify the specific immune response, releasing cytokines, including interferon-γ and tumor necrosis factor-α, which, in turn, recruit other inflammatory cells while stimulating macrophages and keratinocytes to release more cytokines.[31,32] An inflammatory response occurs as monocytes migrate into the affected area, mature into macrophages, and attract more T cells. The inflammatory response elicited typically lasts several weeks, and if allowed to run its natural course, it is thought that regulatory T cells are involved in suppression of the response. Interestingly, LCs may be involved in promoting the development of regulatory T cells that subsequently suppress the immune response in ACD, although the exact mechanisms are not yet clear.[22,28]

DIAGNOSIS

Any patient who presents with an eczematous dermatitis should be regarded as possibly having ACD. Additionally, one must consider contact allergy in patients with other types of dermatitis (eg, atopic) that is persistent and recalcitrant despite appropriate standard therapies, as well as in patients with erythroderma, or scattered generalized dermatitis.[33] Finally, it is important to avoid some commonly held misconceptions about ACD that can alter a physician's ability to recognize contact dermatitis. These were described by Marks and DeLeo[33] and include the following:

- ACD is not always bilateral even when the antigen exposure is bilateral (eg, shoe or glove allergy).
- Even when exposure to an allergen is uniform (eg, contact allergy to an ingredient of a cream that is applied on the entire face), eczematous manifestations are very often patchy.
- ACD can and does affect the palms and the soles.

The first step in the diagnosis of ACD is a careful medical and environmental exposure history. History taking should begin with a discussion of the present illness, focusing on the site(s) of onset and the topical agents used to treat the problem (including over-the-counter and prescription medications). A history of skin disease, atopy, and general health should be investigated routinely and followed by details of the usage of personal care products (soap, shampoo, conditioner, deodorant, lotions, creams, medications, hair styling products, etc.) and investigation of the patient's avocations or hobbies. The patient's occupation should be ascertained as well, and if it appears contributory, or there are potential allergenic exposures, then a thorough occupational history should be taken. Occupations requiring frequent hand washing, glove use, or chemical exposure should be prime suspects.

SUPPORTIVE STUDIES

Typically, ACD is diagnosed based on history, clinical examination, and patch test results. Occasionally, prior to determining that a dermatitis is of the allergic contact type, workup may include laboratory studies or skin biopsy. In these cases, a complete blood count may demonstrate eosinophilia or may be normal. Histologically, the presence of eosinophilic spongiosis and multinucleate dermal dendritic fibrohistiocytic cells is especially suggestive of ACD, when encountered in the presence of acanthosis, a lymphocytic infiltrate, dermal eosinophils, and hyperkeratosis.[34]

DIAGNOSTIC ALGORITHM

Independent of patch testing (discussed in "Patch-Testing Mechanics" below), the causative allergen(s) can rarely be identified by skillful analysis of the patient's exposure history and distribution of dermatitis. Most of the time, an exact cause cannot be identified based on history and examination alone, so one must develop a clinical approach that will guide patch testing. In the opinion of the authors, the two most useful approaches are a topographic approach (based on the distribution of dermatitis on the patient's skin) and an allergen-specific approach (based on knowledge of trends in dermatitis to specific allergens). Each of these approaches is reviewed in this section.

TOPOGRAPHIC APPROACH

Figure 24-1 identifies the allergens to consider based on skin lesion topography. Dermatitis distribution is often the single most important clue to the diagnosis of ACD. Typically, the area of greatest eczematous dermatitis is the area of greatest contact with the offending allergen(s). Location, in fact, can be one of the most valuable clues as to which chemical might be the culprit of a patient's ACD. For instance, an eczematous dermatitis in the periumbilical or infraumbilical area suggests contact allergy to metal snaps in jeans and belt buckles, whereas eczema distributed around the hairline and behind the ears suggests contact allergy to an ingredient(s) in hair products (hair dyes, shampoo, conditioners, styling products) (Fig. 24-2). Using the same rationale, eczema on the dorsum of the feet suggests contact allergy to products used to make shoe uppers—like leather, rubber, or dyes—whereas eczematous dermatitis on the weight-bearing surfaces of the feet suggests contact allergy to products used to make insoles/soles—like rubber and adhesive materials. Notably, facial, eyelid, lip, and neck patterns of dermatitis should always raise suspicion of a cosmetic-related contact allergy. However, for all these presentations, correct identification of the culprit chemical(s) will still require patch testing, as even the most astute and experienced clinician is, for the most part, unable to properly surmise the positive allergen(s) prior to testing. The pattern of dermatitis should be mainly used to determine whether or not to patch test, and which allergens and screening series to test.

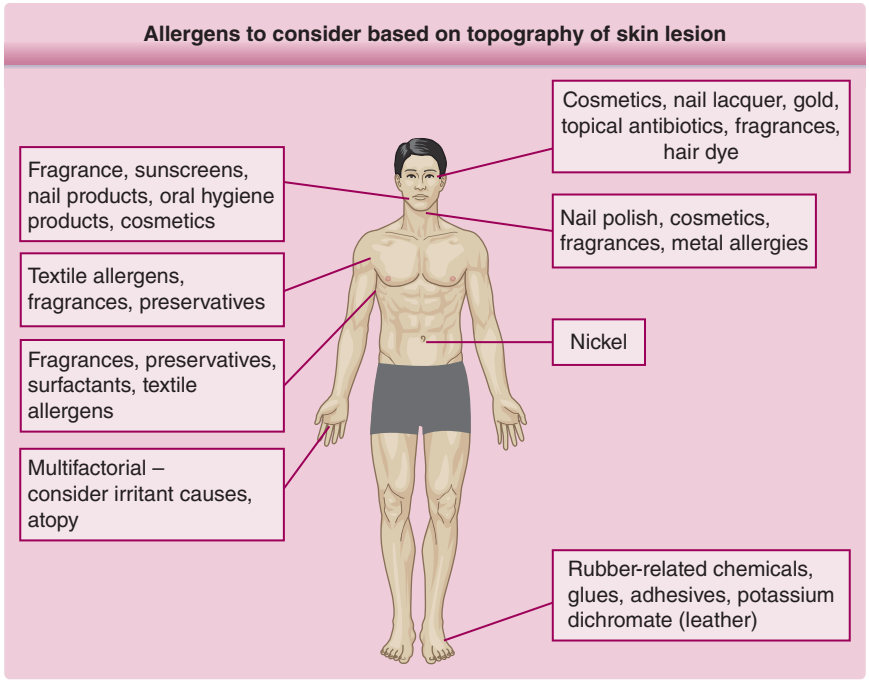

Figure 24-1 Allergens to consider based on topography of skin lesions.

Figure 24-2 Allergic contact dermatitis to *para*-phenylenediamine. **A,** Notice the eczema on the distribution of the hairline and behind the ears. **B,** Dermatitis on the forehead where the bangs came in contact with the skin of the same patient. **C,** *para*-Phenylenediamine, the most frequent relevant allergen in hair dye, is a strong sensitizer.

Occasionally, the topographic approach does not hold, and the distribution can actually be misleading. This mainly refers to cases of ectopic ACD or airborne ACD. Ectopic ACD can follow 2 circumstances: *auto transfer,* in which the allergen is inconspicuously transferred to other body sites by the fingers, the classical example being nail lacquer dermatitis located on the eyelids or lateral aspects of the neck; and *heterotransfer,* in which the offending allergen is transferred to the patient by someone else (spouse, parent, etc.); this is described in the literature as connubial or consort ACD.

A discussion of allergens in the context of common patterns of presentation is briefly detailed below.

FACE

The face is a common site for ACD. Among patients with facial dermatitis, women are more commonly affected than men, particularly by cosmetic-associated allergens such as fragrances, *para*-phenylenediamine (PPD), preservatives, and lanolin alcohols.[35] Allergens can be applied to the face directly, or inadvertently contacted from airborne or hand-to-face exposure. In addition to allergens found as ingredients in cosmetics, products used to apply them, such as cosmetic sponges, are also reported to produce facial dermatitis in rubber-sensitive patients.[36] A similar situation can be seen with nickel-plated objects such as eyelash curlers, tweezers, and bobby pins. Cellphones and accessories may also result in facial ACD. The prototypical presentation is that of a preauricular facial dermatitis in a nickel-allergic patient.[37]

SCALP

Scalp-applied allergens paradoxically show a predilection for causing dermatitis on nonscalp sites. Downstream anatomical sites, such as the face, eyelids, ears, neck, and hands, may show ACD while the scalp remains relatively uninvolved. This is likely secondary to regional differences affording the scalp a greater degree of epidermal barrier protection to potential allergens.[38] Nevertheless, patients exquisitely sensitive to certain chemicals in hair products, such as PPD or glyceryl monothioglycolate (GMT), may show a marked scalp reaction with edema and crusting. PPD is one of the most potent sensitizers known and is widely used as an ingredient in hair dyes. In general, PPD sensitization manifests on the face and scalp of female adult patients who had contact with a hair dye.[39-42] GMT is a chemical substance used in permanent wave solutions. Allergic sensitivity to GMT can manifest as intense scalp pruritus with scaling, edema, and crusting.[43]

EYELIDS

The eyelids are one of the most sensitive skin areas and are highly susceptible to irritants and allergens. This is likely a consequence of the thinness of the eyelid skin, as compared with other skin, and perhaps because the offending chemical may accumulate in eyelid folds. Transfer of small amounts of allergens used on the scalp, face, or hands can be enough to cause an eczematous reaction of the eyelids, while the primary sites of contact remain unaltered. Similarly, volatile agents may affect the eyelids first and exclusively, causing airborne eyelid contact dermatitis. Sources of contact dermatitis of the eyelids include cosmetics such as mascara, eyeliner and eye shadow, adhesive in fake eyelashes, and nickel and rubber in eyelash curlers. Furthermore, marked edema of the eyelids is often a feature of hair-dye dermatitis.[44] As mentioned earlier, eyelids are also known for being a typical site for "ectopic contact dermatitis" caused by ingredients found in nail lacquer, such as tosylamide formaldehyde resin, the chemical added to nail varnish to facilitate adhesion of the varnish to the nail and epoxy resin, also added to some nail polishes. Topical antibiotics (like bacitracin and neomycin) and certain metals (such as gold[45]) can also cause eyelid contact dermatitis. In fact, in the 2007 NACDG analysis of contact allergens associated with eyelid dermatitis,[46] gold was the most common allergen, accounting for isolated eyelid dermatitis. Notably, it has been observed that upon contact with hard particles such as titanium dioxide (used to opacify facial cosmetics, and in sunscreens as a physical blocker of ultraviolet light), gold found in jewelry may abrade, resulting in the release of gold particles that can then make contact with facial and eyelid skin, causing dermatitis.[47] Aside from gold, fragrances and preservatives are the main cosmetic allergens to cause isolated eyelid dermatitis.[48] ACD caused by allergens found in ophthalmic medicaments should also be considered. The most frequent allergens in ophthalmic preparations are the preservative phenylmercuric acetate and antibiotics.[49] Benzalkonium chloride is another preservative that is frequently used in ophthalmic preparations, and a potential irritant and allergen.[50]

LIPS

According to a NACDG study, approximately one-third of patients with isolated cheilitis—without other areas of dermatitis—are typically found to have an allergen as a contributing factor.[51,52] Allergic contact cheilitis has been reported to result from the use of a wide array of products, including cosmetics such as lip balms, lipsticks, lip glosses, moisturizers, sunscreens, nail products, and oral hygiene products (mouthwashes, toothpastes, dental floss; Fig. 24-3).[53-55] Allergic contact cheilitis has a marked female predominance, with most studies reporting a range of 70.7% to 90% female patients.[56] This is likely explained by the assumption that women wear more cosmetics and lip products than men. Most studies have reported fragrance allergens (such as fragrance mix and *Myroxylon pereirae* [balsam of Peru]) as the most common cause of contact allergy in patch-tested patients with cheilitis.[57] Of note, some uncommonly reported allergens,

Figure 24-3 Allergic contact cheilitis. Fragrances and flavorings are among the most common causes of contact allergy in patch-tested patients with cheilitis.

namely, benzophenone-3 and gallates, may be relevant to a dermatitis localized to the lips. Benzophenone-3 (oxybenzone), a major constituent of many sunscreens, is also a common ingredient in many lip products and is increasingly reported as a culprit for allergic contact cheilitis.[58,59] Gallates are antioxidants used in waxy or oily products such as lip balms, lipsticks, and lip glosses.[60] Patch testing directly to the patient's lip cosmetics can be of particular usefulness in the evaluation of isolated cheilitis. It is also important to consider wind instruments as a cause of perioral ACD in musicians.

NECK

The neck is also a highly reactive site for ACD. Cosmetics applied to the face, scalp, or hair often initially affect the neck. Nail polish ingredients (tosylamide formaldehyde resin and epoxy resin) are common culprits in this region.[61] Furthermore, as a cultural practice, perfumes are typically sprayed on the neck. In a fragrance-sensitized individual, the practice of repeated application of fragrances to the anterior neck may result in the appearance of a dermatitic plaque on the neck, which has been coined the *atomizer sign*.[62] Also, in this topographic area, metal allergy can manifest as chronic eczematous dermatitis from exposure to necklaces and jewelry clasps that contain nickel and/or cobalt.

TORSO

The differential diagnosis of an eczematous dermatitis affecting the torso can be broad. There is a multitude of potentially allergenic chemical exposures to consider if the diagnosis of ACD is entertained. The torso is typically exposed to fragrances, preservatives, surfactants, and other chemicals daily with the use of personal care products. Textile-associated chemicals may also provide a source of sensitization and elicitation of ACD. The primary potential textile allergens are disperse dyes and formaldehyde textile resins. In the past, formaldehyde textile resins contained large amounts of free formaldehyde, which led to many cases of ACD to clothing in the 1950s and 1960s.

Today, most textile finishes use modified dimethyloldihydroxyethylene urea. Blended fabrics labeled "wrinkle resistant" or "permanent press" are most likely to contain formaldehyde textile resins. Recent studies suggest that the amount of free formaldehyde in most garments today is likely below the threshold for the elicitation of dermatitis for all but the most sensitive patients.[63]

AXILLAE

Textile-associated allergens are implicated in causing ACD of the axillae. Heat, humidity, and friction may contribute to the leaching of textile resins and dyes. The prototypical presentation is an eczematous dermatitis affecting the axillary folds with relative sparing of the axillary vault.[64] The axillary region is also uniquely exposed to deodorants and antiperspirants. These products may contain high concentrations of fragrances[65] in addition to preservatives (eg, formaldehyde releasers, parabens).

HANDS AND FEET

Hand dermatitis is common and accounts for up to 80% of occupational skin disease. Certain occupations are at an increased risk for hand dermatitis, including health care workers, food handlers, and hairdressers. Hand dermatitis is most often multifactorial (eg, irritant exposure, atopy, pompholyx or chronic vesicular hand eczema, psoriasis, dermatophyte infection) adding to the complexity of both diagnosing and treating these patients. Clinical clues to an underlying component of ACD include pruritus, vesicular dermatitis affecting the finger tips, and destabilization of chronic dermatitis. Destabilization of chronic dermatitis refers to a change in treatment response, symptoms, or extent of a preexisting chronic dermatitis, and is a clue to the development of ACD. Chronic hand dermatitis in and of itself is an indication for patch testing. Similarly, the evaluation of foot dermatitis should include patch testing. The most common class of allergens to cause ACD of the feet are rubber-related chemicals (such as mercaptobenzothiazole, carbamates, thiurams, black rubber mix, and mixed dialkyl thioureas). Other allergens that need to be considered are glues and adhesives such as *p*-tert-butylphenol formaldehyde resin and potassium dichromate found in tanned leather. Footwear, such as socks and shoes, may also serve to retain topical medicaments (antibiotics, corticosteroids, antifungals) used on the feet and provide continued skin exposure over time.

MUCOUS MEMBRANES

ACD of the oral mucosa may present with contact stomatitis from dental metals, and ACD of the perianal

area may be caused by sensitizing chemicals in proctologic preparations such as benzocaine.

SCATTERED GENERALIZED DISTRIBUTION

Patients with dermatitis in a scattered generalized distribution (SGD) can present a difficult diagnostic and therapeutic challenge. SGD is defined as involvement of more than 3 body sites or involvement of 3 body sites if the sites are trunk, arms, and legs. Patch testing is often an important part of the workup in refractory cases of SGD dermatitis. In 2008, Zug and NACDG colleagues[66] examined the yield of patch testing as well as the relevant allergens in patients with SGD rashes referred for patch testing. Of 10,061 patients studied during a period of 4 years, 14.9% were categorized as SGD. Interestingly, a higher incidence of SGD was seen in males and patients with a history of atopic dermatitis. Of the patients presenting with SGD rashes, 49% had at least 1 relevant positive patch test reaction. Preservatives, fragrances, propylene glycol, cocamidopropyl betaine, ethyleneurea melamine formaldehyde, and corticosteroids were among the more frequently relevant positive allergens.

SYSTEMIC CONTACT DERMATITIS

Systemic exposure to an allergen in a sensitized patient with the subsequent development of a cutaneous delayed hypersensitivity reaction is termed *systemic contact dermatitis* (SCD).[67] Sensitization typically occurs with cutaneous exposure as with other forms of ACD. There are multiple routes of exposure for the elicitation of SCD—subcutaneous, intravenous, intramuscular, inhalation, and oral ingestion. By definition, there is no occurrence of topical skin contact to the allergen in SCD.

The clinical presentation of SCD can be complex with a high degree of variability. The simplest presentation seen is a localized recall reaction where the dermatitis occurs at the site of prior topical sensitization. The other end of the spectrum would be erythrodermic SCD. The term "baboon syndrome" was introduced in 1984 to describe a specific dermatologic response to a systemic contact allergen in which erythema of the buttocks and upper inner thighs was seen resembling the red rump of baboons.[68] Mercury, nickel, and ampicillin were the first described causative agents.[69] Over time use of the term *baboon syndrome* has broadened to include cases of drug-induced erythema of the buttocks and upper inner thighs in which previous cutaneous sensitization has not occurred. This is a deviation from the strict definition of SCD, and some have advocated for a change in nomenclature to *drug-related baboon syndrome* with or without previous cutaneous exposure to reflect the difference in pathogenic mechanisms.[69] Others have suggested the term *symmetrical drug-related intertriginous and flexural exanthema* as a more precise term which by definition denotes a specific cutaneous adverse drug reaction in which previous cutaneous sensitization is not a necessary condition. Table 24-2 shows the diagnostic criteria for symmetrical drug-related intertriginous and flexural exanthema.[69] The term *allergic contact dermatitis syndrome* has been proposed to encompass all cutaneous reactions that share the commonality of sensitization occurring through cutaneous exposure. These reactions can be further delineated based on the extent of dermatitis and route of exposure driving the elicitation phase (Table 24-3).[18] Table 24-4 lists some known oral or IV medications which may cause systemic reactivation of ACD in patients previously sensitized to related allergens by direct skin contact.[70-73]

TABLE 24-2
Diagnostic Criteria for SDRIFE

1. Exposure to a systemically administered drug either at the first or repeated dose.
2. Sharply demarcated erythema of the gluteal/perianal area and/or V-shaped erythema of the inguinal/perigenital area.
3. Involvement of at least one other intertriginous/flexural localization.
4. Symmetry of affected areas.
5. Absence of systemic signs or symptoms.

SDRIFE, symmetrical drug-related intertriginous and flexural exanthema. From Hausermann P, Harr TH, Bircher AJ. Baboon syndrome resulting from systemic drugs: is there strife between SDRIFE and allergic contact dermatitis syndrome? *Contact Dermatitis* 2004;51:297-310, with permission. Copyright © 2004 John Wiley & Sons.

A few specific examples of SCD are worth noting. Dietary nickel and balsam of Peru are associated with dyshidrosiform hand eczema.[74] The major constituents of balsam of Peru (cinnamic acid, cinnamyl cinnamate, benzyl benzoate, benzoic acid, benzyl alcohol, and esterified polymers of coniferyl alcohol) are naturally derived and have a significant number of natural cross-reactors. Tomatoes, citrus peel/zest, chocolate, ice cream, wine, beer, dark-colored sodas, and spices such as cinnamon, cloves, curry, and vanilla are potential cross-reactors with balsam of Peru.[75] Consumption of these foods may result in a systemic reactivation of ACD in some patients allergic to balsam of Peru. Salam and Fowler drew attention to the potential for dietary triggers to induce SCD in patients sensitive to balsam of Peru. In their study, almost half of the participants with a positive patch test to balsam of Peru noted clinical improvement in their dermatitis on a balsam of Peru elimination diet.

TABLE 24-3
Allergic Contact Dermatitis Syndrome

Stage 1: Localized allergic contact dermatitis
Stage 2: Regional dissemination of allergic contact dermatitis
Stage 3A: Generalized or distant involvement of allergic contact dermatitis
Stage 3B: Systemic exposure resulting in systemic contact dermatitis

Data from Lachapelle JM. The spectrum of diseases for which patch testing is recommended. Patients who should be investigated. In: Lachapelle JM, Maibach HI, eds. *Patch Testing/Prick Testing. A Practical Guide.* Berlin, Germany: Springer Verlag; 2003:11.

TABLE 24-4
Systemic Drugs That Can Cause Systemic Reactivation of Allergic Contact Dermatitis

CONTACT ALLERGEN[a]	RELATED DRUG WITH POTENTIAL TO CAUSE SYSTEMIC REACTIVATION OF ALLERGIC CONTACT DERMATITIS
Ethylenediamine dihydrochloride (stabilizer infrequently found in skin care products)	Aminophylline Piperazine antihistamines: hydroxyzine, cetirizine, levocetirizine and meclizine
Thiuram (rubber antioxidant)	Tetraethyl thiuram disulfide (generic name: disulfiram)
Thimerosal (mercury-derived preservative)	Piroxicam

[a]To which a patient had previously become sensitized by direct, topical application of the contact allergen to the skin.

ALLERGEN-SPECIFIC APPROACH

Optimal management of ACD requires knowledge of specific allergens, their sources, and the mechanisms by which individuals are exposed to the allergens. What follows are brief descriptions of the most commonly positive and important patch test allergens in North America.

METALS

Metals are a common cause of ACD. Nickel is the most frequently patch test-positive allergen worldwide, with sensitization rates that hover mostly in the range of 18% to 30%.[76]

Nickel: Nickel is an ubiquitous metal found in a variety of objects that get in contact with the skin, including costume jewelry, suspenders, zippers, button snaps, belt buckles, eyeglasses frames, cell phones, nickel-containing coins, and keys.[77] High rates of sensitization to nickel have been ascribed in women to ear piercing at an early age and in both men and women to the rising trend in piercings of other body parts.[77] Classic nickel dermatitis presents as an eruption on the earlobes, the neckline, the wrist, or the periumbilical area, which are commonly exposed to nickel-containing jewelry and to button snaps, zippers, and belt buckles. Facial dermatitis caused by nickel has also been reported to musical instruments and to cell phones.[37]

Nickel and other metals in implantable medical devices are implicated as a source of sensitization and cause of complications from local and systemic inflammation resulting from such allergy in metal-sensitive individuals. While fully confirmed cases of joint replacement failure associated with nickel or other metal sensitivity are rare, and arthroplasty prostheses uncommonly cause problems in nickel-sensitive patients, the true relevance of metal allergy in the failure of metal orthopedic implants and cardiovascular devices has yet to be fully elucidated.[78] Existing publications have largely been retrospective and can thus only suggest a possible association of metal allergy with implant failure rather than determine causation.[79] Moreover, eczematous reactions related temporally to joint replacements, stents, pacemakers, or other implants continue to be reported, albeit infrequently. With sustained use of metal implants as medical devices, we are likely to see a rise in cases referred for patch testing to help adjudicate the relevance of metal allergy. Preoperatively, patch testing may guide the choice of implants based on allergy to ingredients; postoperatively, it may help diagnose the cause of complications.[80]

To prevent development of nickel sensitivity, the European Union, in 1994, regulated the amount of nickel that may be released from objects with direct and prolonged skin contact to ≤0.5 µg nickel/cm^2/week; in 2014 this restriction was strengthened to ≤0.2 µg nickel/cm^2/week for items inserted as pierced body parts. Among Danish women, the prevalence of nickel allergy decreased from 28% in 1985 to 17% in 2007.[81] The American Academy of Dermatology and the American Contact Dermatitis Society favor enacting similar legislation in the United States.

Spot tests containing dimethylgloxime are available commercially to detect the presence of nickel, with nickel concentrations >1:10,000 (or >0.44 µg/cm^2) producing a pink precipitate on a white cotton swab and the intensity of this color read-out increasing with nickel concentration.

Cobalt: Cobalt is often added to other metals to increase the overall strength of an alloy. Cobalt is a common contaminant in nickel ores and thus frequently found in nickel compounds.[82] As with nickel, most sensitization exposures result from contact with jewelry, clothing snaps, buckles, coins, keys, and other metal objects. Like nickel, cobalt can be found in prosthetic joint replacements and dental alloys. Cobalt is also often used in ceramics, paints, and tattoos to impart a blue color. On jewelry, this blue color confers a darker appearance to alloys containing cobalt.[83] Cobalt is an ingredient of multivitamins containing vitamin B_{12} or cyanocobalamine.[84]

Cobalt often produces a pseudopurpuric appearance on patch testing in the absence of erythema or edema. This is not a positive patch test reaction, but rather an irritant effect from deposition of cobalt within eccrine glands.[78] Concomitant patch test positivity to nickel and cobalt is a common occurrence, most likely from cosensitization to both allergens. Avoidance of nickel-plated objects is a practical way of managing ACD to cobalt.

Similar to the dimethylgloxime test for nickel, a spot test using 2-nitroso-1-naphthol-4-sulfonic acid was created to detect cobalt. In contrast to the pink readout from the dimethylgloxime test for nickel, the spot test for cobalt yields a yellow-orange color in the presence of cobalt.[83]

Other Metals: Chromium (potassium chromate in patch tests) has been long-considered the classic marker for allergy to leather goods and to wet cement. However, cobalt is also a relevant marker for allergy to both leather and cement.[83] Gold is a controversial allergen as it can often give produce a positive patch test but fail to meet standards for relevance. Conversely, gold frequently manifests extremely delayed hypersensitivity that runs the risk of being interpreted as negative in patch tests that are only read less than 96 hours after application.

PRESERVATIVES

Preservative allergens include formaldehyde (and its releasers) as well as non-formaldehyde-releasing preservatives.

Formaldehyde and Formaldehyde Releasers: Formaldehyde is a colorless gas with preservative and disinfectant properties. Even though formaldehyde and formaldehyde-like agents have a broad range of uses as glues, biocides, and photographic developing agents, these chemicals are now rarely used in personal care products because of their potent sensitization capacity.[85] Instead manufacturers have replaced formaldehyde with other preservatives to prolong the microbe-free shelf life of their products. These substitutes for formaldehyde can be sorted into agents that can release formaldehyde (formaldehyde releasers) and those that do not. Formaldehyde-releasing preservatives include 2-bromo-2-nitropropane-1,3-diol (bronopol), diazolidinyl urea (Germall II), DMDM hydantoin (Glydant), imidazolidinyl urea (Germall I), quaternium-15, and tris-nitromethane (Tris Nitro).[86] Of these preservatives, quaternium-15 is the most common cosmetic allergen.[87-89]

Note that formaldehyde-containing resins are linked to 2 other forms of ACD. The first form involves the glues, toluene sulfonamide formaldehyde resin or tosylamide (used in artificial nails) and *p*-tert butylphenol formaldehyde resin (used in shoes and other garments). The second form involves use of formaldehyde derivatives to make wrinkle-free or permanent-press fabrics and clothing.

Nonreleasers of Formaldehyde: The 2 major preservatives in this category are methyldibromoglutaronitrile/phenoxyethanol (MDGN/PE) also known as *Euxyl K400* and methylchloroisothiazolinone/methylisothiazolinone (MCI/MI) also known as *Kathon CG*. Because of their high propensity for causing ACD, both of these preservatives have been banned from use in cosmetics in Europe.[90] However cosmetics produced outside the European Union and toiletries sold elsewhere may contain them. Most allergic reactions to these preservatives originate from personal care products such as creams, lotions, wet wipes, liquid soaps, and medicated tissue and toilet paper containing the allergens. Also note that, because of peculiarities related to concentrations of allergens, optimal testing may require assaying both the combined allergen pairs (*Euxyl K400* and *Kathon CG*) as well as their individual components (MDGN or PE; MCI or MI), as patch tests to only the former can miss reactions to specific allergens.

FRAGRANCES

Fragrances are aromatic compounds that impart a scent. Fragrances can be natural (from botanical or animal products) or synthetic in origin. Up to 4% of the general population are allergic to fragrances,[91,92] making these chemicals among the top causes of ACD to personal care products, with typical sites of involvement including the face and hands, behind the ears, and the neck and axillae, yielding a scattered but generalized distribution of eczematous dermatitis.[93,94] Among the main substances used by most patch test groups for screening are *M. pereirae*, *fragrance mix I* (mixture of 8 fragrance allergens), and *fragrance mix II* (6 additional allergens).[95] It is estimated that *M. pereirae* can identify up to 50% of fragrance-allergic individuals.[96] Fragrance allergens are found in many cosmetics, perfumes, pharmaceutical preparations, toothpastes, and mouthwashes, as well as in scents and flavorings for foods and drinks. Fragrance allergens can be included in skin-care products without being labeled as fragrances if they are not used primarily as fragrances but as neutralizers of unwanted scents within the merchandise.[95]

TOPICAL ANTIBIOTICS

Although there are several topical antibiotics, the 2 most commonly implicated in ACD are neomycin and bacitracin.

Neomycin: Neomycin is a member of the aminoglycoside family of antibiotics commonly used in topical formulations to prevent and treat skin, ear, and eye infections. At least 1% of the general population is allergic to neomycin, with sensitization rates as high as 10% in North America.[97] This latter high rate is most likely a result of the presence of neomycin in numerous over-the-counter preparations, especially in combination with polymyxin and bacitracin as a "triple antibiotic" cream or ointment.[98] Patients at higher risk include those with stasis dermatitis and leg ulcers, anogenital dermatitis, and otitis externa. Because antibiotic preparations are applied to already damaged skin, ACD to neomycin is not always easily recognized as it often presents as persistence or worsening of a preexisting dermatitis.[99] It may also mimic cellulitis, for which the clue for ACD is itching rather than pain. Occupational dermatitis involving the hands can occur in nurses, physicians, pharmacists, dentists, and veterinarians.[100]

Bacitracin: Like neomycin, bacitracin is a topical antibiotic frequently used for postoperative and general wound care by both the medical profession and the general public as it is readily available in over-the-counter preparations. Not only can bacitracin cause ACD, but it has been reported in association with

urticarial reactions and even, rarely, anaphylaxis.[101] Despite its high prevalence as an allergen, bacitracin is not included in the currently available T.R.U.E. (thin-layer rapid-use epicutaneous) test series. Interestingly, many patients show simultaneous sensitivity to bacitracin and neomycin, although the 2 substances are not chemically related, thereby indicating cosensitization (rather than coreactivity) to both substances.[102]

PARA-PHENYLENEDIAMINE

PPD is an oxidizing agent used as a permanent hair dye. Both consumers and hairdressers are at risk for sensitization. Interestingly, ACD to PPD often spares the scalp, while presenting as dermatitis on thinner skin of the face, eyelids, and neck.[103] Once oxidized, PPD is no longer allergenic, so that dyed hair itself does not pose further risk of allergic stimulation. This is in contrast to permed or waved hair, in which the allergen, GMT, persists in its ability to cause ACD in a sensitized individual long after the allergen has been exposed to the air (eg, from contaminated sites in a hair salon). Table 24-5 lists other allergens commonly associated with hair care. PPD can cross-react with other *para*-amino–group chemicals such as *para*-aminobenzoic acid, sulfonylureas, hydrochlorothiazide, benzocaine, procainamide, and certain azo and aniline dyes.[104,105] Additionally, PPD has gained notoriety as an adulterant added to natural henna for temporary tattoos; it darkens the henna tattoo.[106,107]

RUBBER

Rubber allergens can be classified into chemicals associated with processing of natural latex derived from the proteinaceous sap of the rubber tree (*Hevea brasiliensis*) and synthetic rubber that is unrelated to latex. Latex is a common cause of immediate-type hypersensitivity mediated by latex protein-specific immunoglobulin E. Rarely, latex itself can also cause ACD, but it is the accelerator and vulcanizing chemicals (carbamates, mercaptobenzothiazole, thiuram) and dyes (PPD) used to convert latex into commercial products (gloves, condoms, automobile tires) that are the principal causes of ACD to rubber. From a general perspective, individuals allergic to either the rubber accelerator/vulcanizer chemicals (or to latex itself) can safely use Vicryl gloves, which are safer than nitrile gloves (in lieu of latex gloves). From an epidemiologic perspective, ACD to synthetic rubber is a lesser but growing problem, with these new forms of rubber (dialkyl thioureas, neoprene, polyurethane) being incorporated into athletic clothing and equipment as well as daily wear.

TABLE 24-5
Hair Product Allergens

Hair dyes	*p*-Phenylenediamine *p*-Toluenediamine sulfate Azo dyes
Bleaching agents	Ammonium persulfate
Waving agents	Glyceryl thioglycolate
Relaxer/Straightening agents	Sodium hydroxide
Shampoos and conditioners	Fragrances Preservatives

TOPICAL STEROIDS

ACD to topical steroids is uncommon but important to consider, especially in patients whose dermatitis is unimproved or worsens despite treatment with topical steroids. On the other hand, allergy to a steroid-containing preparation is frequently due to components other than the steroid (eg, propylene glycol or preservatives). In the absence of real evidence from patch testing, desoximethasone ointment is the safest topical steroid from an allergic standpoint. The currently available T.R.U.E. Test series includes 3 markers for topical steroid allergy, namely tixocortol pivalate, budesonide, and hydrocortisone-17-butyrate. Table 24-6 lists the 5 classes of steroids based on chemical structure, the patch test allergen marker for each class, and cross reactions. The least-allergenic steroids belong to class C, as exemplified by desoximethasone.

PATCH-TESTING MECHANICS

ALLERGEN SELECTION AND PLACEMENT

Patch testing remains the gold standard for identification of the allergen or allergens causing ACD. The T.R.U.E. Test (SmartPractice, Hillerod Denmark) was introduced in 1995 and is an epicutaneous patch test system that is approved by the U.S. Food and Drug Administration for use in the diagnosis of ACD in persons 18 years of age and older. The T.R.U.E. test originally contained 23 allergens and 1 control; today, it consists of 3 panels with a total of 35 allergens plus 1 blank control. Expanded patch testing with other commercially available allergens, patch testing with patient items, and patch testing in pediatric patients remains off-label but is considered standard practice in the diagnosis of ACD. Among the 30 most frequently positive allergens found by the NACDG the T.R.U.E. test is missing the following 9 allergens: fragrance mix II, lanolin, iodopropynyl butylcarbamate, cinnamal, carmine, propylene glycol, oleamidopropyl betaine, 2-hydroxyethyl methacrylate, compositae, propolis.[76] It is challenging to quantify the sensitivity of the T.R.U.E. test system, but there is consensus that patch testing with a greater number of allergens increases the sensitivity.[108-112] A previous study noted that less than one-third of patch test patients would have all their allergens completely identified if only a

TABLE 24-6
Steroid Allergens

STRUCTURAL CLASS	PATCH-TEST ALLERGEN	CROSS-REACTIONS	MEMBERS
A	Tixocortol-21-pivalate	D2	Hydrocortisone valerate Cloprednol Fludrocortisone Prednisone
B	Budesonide	D2 (budesonide specifically)	Triamcinolone Amcinonide Desonide Fluocinolone Halcinonide Procinonide
C	—	—	Desoximethasone Betamethasone Clocortolone Dexamethasone Fluocortolone pivalate Rimexolone
D1	Clobetasol	? D2	Clobetasol Alclometasone Betamethasone valerate Diflorasone Fluocortolone hexanoate Mometasone
D2	Hydrocortisone-17-butyrate	A & budesonide	Hydrocortisone-17-butyrate Prednicarbate

standard series of 28 allergens was used,[113] thus highlighting the need for expanded patch testing in many patients.

Patch testing with the T.R.U.E. test, commercially available standardized allergens, or a patient's personal care products generally follows a standard closed-test protocol. With this protocol the allergens are placed on the back under occlusion, removed at 48 hours, and a final delayed read is performed at 72 or 96 hours. Many patch testers will perform a preliminary or early read at the 48-hour visit, but it is important to allow time after patch test removal for tape irritation to subside prior to performing a read. An interval of 20 minutes is usually sufficient. Certain situations call for an extended reading time up to 7 to 10 days out. Metals, antibiotics, and corticosteroids are notable allergens which may produce a delayed reaction. This protocol differs from the repeat open application test or use test in which a substance is applied to the cubital fossa twice a day for 1 to 3 weeks to simulate real life use. The repeat open application test can be useful for testing leave-on personal care products. A semiopen patch test protocol can be useful if testing to liquid products with irritant potential. Here the test substance or dilutions of the test substance are applied to the skin surface covering a 1 cm^2 area. The liquid is allowed to evaporate and dry. Excess material can be removed with a cotton swab. The completely dry skin is then covered with hypoallergenic tape and readings are performed at standard time intervals as noted above.

GRADING AND INTERPRETING RESULTS

At each test reading, it is traditional to note the results as positive, negative, questionable, or irritant. Positive results are also given a grade based on the strength of the reaction. The International Contact Dermatitis Research Group recommends using the grading scale for positive patch test reactions outlined by Wilkinson and colleagues,[114] which is a + to +++ scoring system, where + represents a weak nonvesicular reaction but with palpable erythema, ++ represents a strong (edematous or vesicular) reaction, and +++ represents an extreme (bullous or ulcerative) reaction (Fig. 24-4). Very weak or questionable reactions where there is only faint or macular (nonpalpable) erythema are recorded by a question mark (which is +/– in the Wilkinson system), and irritant reactions are recorded as "IR." Irritant patch test reactions have varied findings that are related to the nature and the concentration of the irritant[115] and are classically described as (a) erythematous reactions limited to the site of application of the chemical, with sharp, well-delineated margins; discretely scaly (may look "chapped") and usually not edematous. Among the patch test allergens, fragrance mix, cocamidopropyl betaine, iodopropynyl butylcarbamate, glutaraldehyde, and thiuram mix are identified as the most common allergens to produce such marginal irritant reactions. (b) Purpuric

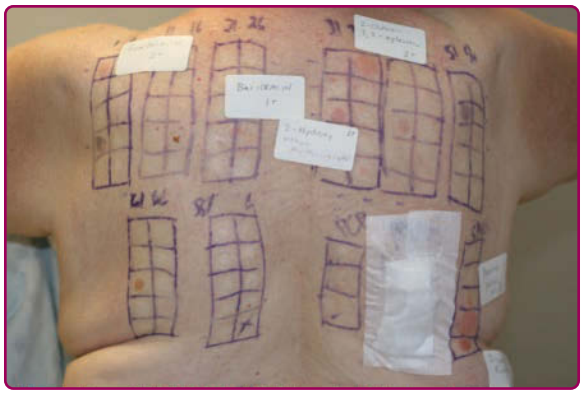

Figure 24-4 Patch-test grading. This patient had multiple relevant positive patch tests. Bacitracin, chloroxylenol, and 2-hydroxyethyl methacrylate are relevant to this patient's severe dermatitis, but are not allergens on the currently available commercial screening series.

reactions with petechial hemorrhage, which are seen in approximately 5% of patients tested to cobalt chloride. This is sometimes referred as *punctate purpura of cobalt* and should always be interpreted as an irritant reaction. Pustular reactions indicate an irritant reaction and are most commonly encountered with metallic salts such as potassium dichromate, cobalt, nickel, gold, and copper. Individuals with an atopic diathesis may show pustular irritant reactions more frequently. Other allergens in which marginal reactions should be interpreted with caution given their mild irritant potential include the preservatives formaldehyde, benzalkonium chloride, and iodopropynyl butylcarbamate; the rubber allergen carba mix, fragrance chemicals such as fragrance mix I and propolis (bee glue); the foaming agent cocamidopropyl betaine; and the emulsifiers oleamidopropyl dimethylamine and triethanolamine. It is important to mention that even paying close attention to the aforementioned morphologic features, irritant reactions are still difficult to interpret, and the morphology of the patch test response can still be a confusing guide to whether the response is allergic or irritant. When morphology is not enough, it is advisable to keep in mind that in general when the patch test reaction is sufficiently strong, an irritant reaction will be early appearing (during the first reading), and promptly resolving (often times the reaction is not as strong or sometimes not even present during the second reading). In contrast, a strong allergic reaction usually spreads, is more slowly disappearing, and is more clearly eczematous. The irritant pattern is often described as *decrescendo*, while the allergic pattern is *crescendo*.

Of note, the evaluation of positive reactions may be slightly more difficult in darker skin types (Fitzpatrick types V and VI), as erythema may not be as obvious, posing the risk of overlooking a mild positive allergic reaction. However, the edema and papules/vesicles are usually obvious and palpable; consequently, palpation of the patch test site can help detect allergic reactions in patients with darker skin types. Additionally, the darker the skin type, the more difficult it is to mark the patch test site after removal. For very dark skin, a florescent marking ink is probably best (such as a yellow highlighter), and the markings can subsequently be located by a Wood light in a darkened room at the time of patch test reading.[116]

ASSIGNING CLINICAL RELEVANCE

A positive patch test indicates a state of cutaneous sensitization to a particular allergen but does not equate to the diagnosis of ACD. A good example of this point is thimerosal. This mercuric preservative is unique in the sense that it commonly causes positive patch test reactions but very seldom does thimerosal allergy account for the patient's dermatitis. Most allergic patients presumably have been sensitized to the thimerosal present in vaccines, but have no clinical disease associated with this allergen.[117] Establishing the relevance of a positive patch test result is a critical and challenging part of patch testing. Often preliminary relevance is assigned at the time of the final patch test reading with final relevance given *retrospectively* at a later followup visit when the dermatitis has cleared after avoidance measures were implemented. Relevance is deemed to be definitive if a use test with a suspected item is positive or a patch test of a suspected object or product is positive. Current relevance is possible if the allergen is among the chemicals a patient is exposed to and can be upgraded to probable if the distribution of the dermatitis is consistent with exposure to that particular allergen. Past relevance is designated if there is a history of dermatitis in association with previous exposure to the particular allergen but to which the patient is no longer exposed. An example is a patient who is patch test-positive to neomycin who reports a rash with prior use of over-the-counter antibiotic ointments but has had no further difficulties following avoidance of products containing neomycin. Doubtful relevance is designated when there is no identifiable exposure source or if the clinical history and presentation do not fit with exposure to a particular allergen.

COMPLICATIONS OF PATCH TESTING

Patch testing is considered a safe diagnostic procedure and unwanted effects are seldom encountered. The most common side effects are expected, such as itching at the site of a positive test reaction, and irritation or pruritus from tape application. Less commonly described effects include postinflammatory pigmentary changes, infections, scarring, persistent patch test reactions, induction of flares of dermatitis, sensitization to the tested allergen, and, rarely, anaphylaxis.[118] Postinflammatory hypopigmentation

or hyperpigmentation can occur, with hyperpigmentation being more likely in darkly pigmented persons; it typically fades with time and the use of topical corticosteroids. Exposure to sunlight or artificial ultraviolet light immediately following removal of patch tests, especially to fragrance materials, can lead to hyperpigmentation of the patch test site in relation to allergen-related photosensitivity. Infection is typically mild impetiginization of the patch test site with *Staphylococcus aureus*, although other infections can occur. Scarring is most likely when patients develop bullous reactions; patients who are prone to keloids can develop keloids at these sites. Patch test reactions that persist for more than 1 month (>30 days) are considered persistent patch test reactions; this occurs most commonly from gold salts in a gold-sensitive patient (Fig. 24-5). Induction of a dermatitis flareup at the original site of an existing or preexisting dermatitis (that was caused by the positive patch test allergen) can also occur. This can be minimized by testing patients free of any current active dermatitis, if possible. Also, a positive patch test reaction in a patient who has active psoriasis or lichen planus may reproduce these dermatoses at the patch test sites (as a *Koebner phenomenon*), during the weeks following patch testing.[119] Although the risk of active sensitization during patch testing is low, it is most common to strong sensitizers, such as PPD. It typically presents as a "new reaction" noticed by the patient 10 to 21 days after patch testing, when initial patch test readings are negative at 48- and 96-hour readings.[118,120] Sometimes this can be difficult to distinguish from a delayed reaction (such as with gold or topical steroids). Anaphylaxis is an exceedingly rare side effect of patch testing that may occur with allergens known to cause a type I (immediate) hypersensitivity reaction, such as bacitracin, neomycin, ammonium persulfate (most often reported), latex, formaldehyde, and penicillin.[118]

Figure 24-5 Persistent patch test reaction to gold. This patient demonstrated sensitivity to gold during patch testing, and presented back to the clinic 3 months later stating that the patch test reaction had not resolved. The patient was treated with intralesional triamcinolone.

COMPLICATIONS FROM FAILURE TO PATCH TEST

The greatest hazard is failure to patch test appropriate patients with dermatitis. Such omission potentially dooms the patient to repeated episodes of avoidable contact dermatitis. In 2004, the American Academy of Dermatology and the Society of Investigative Dermatology studied the burden of skin disease and estimated that 72 million people in the United States suffer from ACD.[121] It is the third most common reason for patients to seek consultation with a dermatologist, accounting for 9.2 million visits in 2004 alone. Likewise, in that same year, primary care physicians received 5 million visits for unexplained dermatitis or eczema.[122] Although many of these patients will respond readily to standard treatments, others will demonstrate recalcitrant eczema. It has been estimated that approximately 16% of all chronic eczema patients would benefit from patch testing,[123] and clinical experience suggests this number may be much larger. Based on the figures above, it could be estimated that approximately 2.2 million patients each year in the United States would benefit from patch testing.

PATCH TESTING AND SYSTEMIC IMMUNOSUPPRESSIVE AGENTS

Because systemic drugs that suppress T-cell responses will suppress patch test responses, it is ideal for patch testing to be performed on patients who are not under the influence of these medications (like prednisone and cyclosporine). However, there may be circumstances when it is not possible to stop the immunosuppressive drug. In such cases, the next best option is to reduce the dose of the potentially confounding medication to a minimum to avoid false-negative patch test results.

DIFFERENTIAL DIAGNOSIS

The differential diagnosis of ACD includes a wide range of inflammatory skin disorders (Table 24-7).[124,125]

CLINICAL COURSE AND PROGNOSIS

It is difficult to assess the actual prognosis of ACD because there is no standardized instrument for such evaluation. The disruption of work, ability to return to work, and improvement of dermatitis with time are

TABLE 24-7
Differential Diagnosis of Allergic Contact Dermatitis

DIAGNOSIS	DIAGNOSTIC CLUES
Irritant contact dermatitis (ICD)	Physical findings can be indistinguishable clinically; in general, there is an absence of vesiculation (only very strong irritants produce vesicles) and burning exceeds itching. Does not spread beyond the area of contact with continued exposure.
Atopic dermatitis	Distribution of skin findings can be helpful; atopic patients can and do develop contact allergies. Worsening disease can indicate new contact allergy development.
Nummular dermatitis (ND)	Widespread ACD can assume this pattern in certain patients; nonetheless, the classical morphology of coin-shaped, well-demarcated plaques on the legs, dorsal hands, and extensor surfaces favors ND.
Seborrheic dermatitis	Greasy and scaly papulosquamous plaques usually located in the hair-bearing regions, glabella, and nasolabial folds.
Asteatotic eczema	Parchment-like patches with no edema or vesiculation on the lower legs. May have appearance of dry river bed.
Stasis dermatitis	Papulosquamous plaques with dyschromia located on the shins and medial surfaces of the lower legs, with presence of concomitant varicosities.
Pompholyx and/or dyshidrotic eczema psoriasis	Deep-seated vesicles on palms, soles, sides of the fingers, and volar edges. When it presents in its classic form, diagnosis can be straightforward, however, when the lesions are few and limited to the hands and/or feet differentiation can be more difficult. Classical location and predominance in areas of trauma (Koebnerization) can be helpful as well as the presence (if any) of concomitant arthritis.
Mycosis fungoides (MF) (patch/plaque stage cutaneous T-cell lymphoma)	The well-demarcated, atrophic, poikilodermatous, scaly patches and plaques of MF are usually found in non–sun-exposed areas of the skin, such as the trunk, breasts, hips, and buttocks (bathing suit distribution).

among outcome measures that have been studied in patients with ACD. Newer study designs have aimed to capture the increasingly important outcome measure of health-related quality of life.[126] When different quality-of-life assessment tools have been applied to populations of patients with ACD, it has been demonstrated that ACD negatively impacts quality of life significantly. Holness and colleagues[127] found that pain, itching, embarrassment, work interference, and sleep difficulties were the most significant effects in quality of life of their patch test population. Kadyk and colleagues[128] found the greatest impact on emotions, followed by symptoms, functioning, and occupational impact. Similarly, Woo and colleagues[129] reported that patients with the final diagnosis of ACD had a mean baseline quality of life equal to that of patients experiencing hair loss and psoriasis. Zug and colleagues[130] found that patients referred for patch testing were severely affected by frustration, reported feeling annoyed, and had a great concern about the persistence of their skin problem. Notably, hand involvement is strongly predictive of a negative impact on quality of life. Similarly, the extent of the disease[131] and the duration of symptoms before diagnosis are both correlated with a poor prognosis and recalcitrant disease.[132] Some studies, however, have associated increased patient knowledge with an improved prognosis.[133,134] Much of this information is extrapolated from data regarding occupational contact dermatitis.

MANAGEMENT

Identification of the offending allergen and its avoidance are the goals of diagnosis and treatment of ACD.[135] These goals can be achieved by a thorough history and physical examination that lead to patch testing of the appropriate allergens, relevant counseling tailored to the individual patient's circumstances, and effort by the patient to avoid the causative agent(s). Currently, there are 2 databases that can help patients avoid their allergens by providing lists of alternative products; these are the Contact Allergen Management Program (CAMP)[136] and the Contact Allergen Replacement Database (CARD).[137]

For a localized acute flare of ACD resulting from unintentional or inadvertent allergen exposure, topical corticosteroids are the first-line treatment and are typically required for 2 to 3 weeks of use to prevent rebound. In cases of severe or widespread eruptions, a 3-week taper of oral prednisone is usually needed; the typical oral-dosing regimen is 1 mg/kg/day for 1 week, followed by tapering weekly, for a total of 3 to 4 weeks.

ACKNOWLEDGMENTS

We thank the prior authors, Mari Paz Castanedo-Tardan, MD, and Kathryn A. Zug, MD, for providing us the framework for revising and updating this chapter.

REFERENCES

1. Mark BJ, Slavin RG. Allergic contact dermatitis. *Med Clin North Am*. 2006;90(1):169-185.
2. Cohen D, Moore M. Occupational skin disease. In: Rom WM, Markowitz S, eds. *Environmental and Occupational Medicine*. 4th ed. Philadelphia, PA: Lippincott-Williams & Wilkins; 2007:617.

3. Rajagopalan R, Anderson R. Impact of patch testing on dermatology-specific quality of life in patients with allergic contact dermatitis. *Am J Contact Dermat*. 1997;8(4):215-221.
4. Thyssen JP, Linneberg A, Menné T, et al. The epidemiology of contact allergy in the general population–prevalence and main findings. *Contact Dermatitis*. 2007;57(5):287-299.
5. Mirshahpanah P, Maibach HI. Relationship of patch test positivity in a general versus an eczema population. *Contact Dermatitis*. 2007;56(3):125-130.
6. Schnuch A, Uter W, Geier J, et al. Epidemiology of contact allergy: an estimation of morbidity employing the clinical epidemiology and drug-utilization research (CE-DUR) approach. *Contact Dermatitis*. 2002;47(1): 32-39.
7. Uter W, Gefeller O, Giménez-Arnau A, et al. Characteristics of patients patch tested in the European Surveillance System on Contact Allergies (ESSCA) network, 2009-2012. *Contact Dermatitis*. 2015;73(2):82-90.
8. Fernandez Vozmediano JM, Armario Hita JC. Allergic contact dermatitis in children. *J Eur Acad Dermatol Venereol*. 2005;19(1):42-46.
9. Zug KA, McGinley-Smith D, Warshaw EM, et al. Contact allergy in children referred for patch testing: North American Contact Dermatitis Group data, 2001-2004. *Arch Dermatol*. 2008;144(10):1329-1336.
10. Schäfer T, Böhler E, Ruhdorfer S, et al. Epidemiology of contact allergy in adults. *Allergy*. 2001;56(12): 1192-1196.
11. Thyssen JP, Engkilde K, Lundov MD, et al. Temporal trends of preservative allergy in Denmark (1985-2008). *Contact Dermatitis*. 2010;62(2):102-108.
12. Jordan WP, King SE. The development of allergic contact dermatitis in females during the comparison of two predictive patch tests. *Contact Dermatitis*. 1977;3(1):19-26.
13. Larsson-Stymne B, Widström L. Ear piercing—a cause of nickel allergy in schoolgirls? *Contact Dermatitis*. 1985;13(5):289-293.
14. Dotterud LK, Falk ES. Metal allergy in north Norwegian schoolchildren and its relationship with ear piercing and atopy. *Contact Dermatitis*. 1994;31(5):308-313.
15. Mattila L, Kilpelainen M, Terho EO, et al. Prevalence of nickel allergy among Finnish university students in 1995. *Contact Dermatitis*. 2001;44(4):218-223.
16. Jensen CS, Lisby S, Baadsgaard O, et al. Decrease in nickel sensitization in a Danish schoolgirl population with ears pierced after implementation of a nickel-exposure regulation. *Br J Dermatol*. 2002;146(4): 636-642.
17. Dotterud LK, Smith-Sivertsen T. Allergic contact sensitization in the general adult population: a population-based study from Northern Norway. *Contact Dermatitis*. 2007;56(1):10-15.
18. Lachapelle J-M, Maibach HI. *Patch Testing and Prick Testing*. Springer Science + Business Media; 2003.
19. Bonamonte D, Foti C, Vestita M, et al. Noneczematous contact dermatitis. *ISRN Allergy*. 2013;2013:361746.
20. De Groot AC. Allergic contact dermatitis. In: Marks R, ed. *Eczema*. London, UK: Martin Dunitz; 1992:104.
21. Mozzanica N. Pathogenetic aspects of allergic and irritant contact dermatitis. *Clin Dermatol*. 1992;10(2): 115-121.
22. Mowad CM, Anderson B, Scheinman P, et al. Allergic contact dermatitis: patient diagnosis and evaluation. *J Am Acad Dermatol*. 2016;74(6):1029-1040.
23. Riemann H, Schwarz T, Grabbe S. Pathomechanisms of the elicitation phase of allergic contact dermatitis [in German]. *J Dtsch Dermatol Ges*. 2003;1(8):613-619.
24. Janeway CE, Travers P, Walport M, et al. *Immunobiology: The Immune System in Health and Disease*. 6th ed. New York, NY: Garland Science Publishing; 2005.
25. Saint-Mezard P, Krasteva M, Berard F, et al. Allergic contact dermatitis. In: Bos JD, ed, *Cutaneous Immunology and Clinical Immunodermatology*. 3rd ed. Informa UK Limited; 2004:593-613.
26. Veien NK. Ingested food in systemic allergic contact dermatitis. *Clin Dermatol*. 1997;15(4):547-555.
27. Bennett CL, van Rijn E, Jung S, et al. Inducible ablation of mouse Langerhans cells diminishes but fails to abrogate contact hypersensitivity. *J Cell Biol*. 2005;169(4):569-576.
28. Honda T, Kabashima K. Novel concept of iSALT (inducible skin-associated lymphoid tissue) in the elicitation of allergic contact dermatitis. *Proc Jpn Acad Ser B Phys Biol Sci*. 2016;92(1):20-28.
29. Wang L, Bursch LS, Kissenpfennig A, et al. Langerin expressing cells promote skin immune responses under defined conditions. *J Immunol*. 2008;180(7): 4722-4727.
30. Streilein JW. Skin-associated lymphoid tissues (SALT): origins and functions. *J Invest Dermatol*. 1983;80(suppl): 12s-16s.
31. Saint-Mezard P, Berard F, Dubois B, et al. The role of CD4+ and CD8+ T cells in contact hypersensitivity and allergic contact dermatitis. *Eur J Dermatol*. 2004;14(3): 131-138.
32. Elsaie ML, Olasz E, Jacob SE. Cytokines and Langerhans cells in allergic contact dermatitis. *G Ital Dermatol Venereol*. 2008;143:195.
33. Marks, James G., DeLeo VA. *Contact and Occupational Dermatology*. St Louis, MO: Mosby-Year Book; 1992.
34. Wildemore JK, Junkins-Hopkins JM, James WD. Evaluation of the histologic characteristics of patch test confirmed allergic contact dermatitis. *J Am Acad Dermatol*. 2003;49(2):243-248.
35. Schnuch A, Szliska C, Uter W, et al. Facial allergic contact dermatitis. Data from the IVDK and review of the literature [in German]. *Hautarzt*. 2009;60(1): 13-21.
36. Furman D, Fisher AA, Leider M. Allergic eczematous contact-type dermatitis caused by rubber sponges used for the application of cosmetics. *J Invest Dermatol*. 1950;15(3):223-231.
37. Corazza M, Minghetti S, Bertoldi AM, et al. Modern electronic devices: an increasingly common cause of skin disorders in consumers. *Dermatitis*. 2016;27(3):82-89.
38. O'Goshi K, Iguchi M, Tagami H. Functional analysis of the stratum corneum of scalp skin: studies in patients with alopecia areata and androgenetic alopecia. *Arch Dermatol Res*. 2000;292(12):605-611.
39. Chan Y-C, Ng S-K, Goh C-L. Positive patch-test reactions to *para*-phenylenediamine, their clinical relevance and the concept of clinical tolerance. *Contact Dermatitis*. 2001;45(4):217-220.
40. Katugampola RP, Statham BN, English JSC, et al. A multicentre review of the hairdressing allergens tested in the UK. *Contact Dermatitis*. 2005;53(3):130-132.
41. Patel S, Basketter DA, Jefferies D, et al. Patch test frequency to *p*-phenylenediamine: follow up over the last 6 years. *Contact Dermatitis*. 2007;56(1): 35-37.

42. Duarte I, Fusaro M, Lazzarini R. Etiology of *para*-phenylenediamine sensitization: hair dye and other products. *Dermatitis*. 2008;19(6):342.
43. Parsons LM. Glyceryl monothioglycolate. *Dermatitis*. 2008;19(6):E51-E52.
44. Castanedo-Tardan MP, Zug KA. Patterns of cosmetic contact allergy. *Dermatol Clin*. 2009;27(3):265-280.
45. Fowler J. Gold allergy in North America. *Am J Contact Dermat*. 2001;12(1):3-5.
46. Rietschel RL, Warshaw EM, Sasseville D, et al. Common contact allergens associated with eyelid dermatitis: Data from the North American Contact Dermatitis Group 2003-2004 study period. *Dermatitis*. 2007;18(2):78-81.
47. Nedorost S, Wagman A. Positive patch-test reactions to gold: patients' perception of relevance and the role of titanium dioxide in cosmetics. *Dermatitis*. 2005;16(02):067.
48. Guin JD. Eyelid dermatitis: experience in 203 cases. *J Am Acad Dermatol*. 2002;47(5):755-765.
49. Landeck L, John SM, Geier J. Periorbital dermatitis in 4779 patients-patch test results during a 10-year period. *Contact Dermatitis*. 2013;70(4):205-212.
50. Wentworth AB, Yiannias JA, Davis MD, et al. Benzalkonium chloride: a known irritant and novel allergen. *Dermatitis*. 2016;27(1):14-20.
51. Lim SW, Goh CL. Epidemiology of eczematous cheilitis at a tertiary dermatological referral centre in Singapore. *Contact Dermatitis*. 2000;43(6):322-326.
52. Zoli V, Silvani S, Vincenzi C, et al. Allergic contact cheilitis. *Contact Dermatitis*. 2006;54(5):296-297.
53. Fisher AA. Contact stomatitis, glossitis and cheilitis. *Otolaryngol Clin North Am*. 1974;7(3):827-843.
54. Ophaswongse S, Maibach HI. Allergic contact cheilitis. *Contact Dermatitis*. 1995;33(6):365-370.
55. Francalanci S, Sertoli A, Giorgini S, et al. Multicentre study of allergic contact cheilitis from toothpastes. *Contact Dermatitis*. 2000;43(4):216-222.
56. Freeman S, Stephens R. Cheilitis: analysis of 75 cases referred to a contact dermatitis clinic. *Dermatitis*. 1999;10(4):198-200.
57. Strauss RM, Orton DI. Allergic contact cheilitis in the United Kingdom: a retrospective study. *Dermatitis*. 2003;14(2):75-77.
58. Aguirre A, Izu R, Gardeazahal J, et al. Allergic contact cheilitis from a lipstick containing oxybenzone. *Contact Dermatitis*. 1992;27(4):267-267.
59. Schram SE, Glesne LA, Warshaw EM. Allergic contact cheilitis from benzophenone-3 in lip balm and fragrance/flavorings. *Dermatitis*. 2007;18(4):221-224.
60. Serra-Baldrich E, Puig LL, Arnau AG, et al. Lipstick allergic contact dermatitis from gallates. *Contact Dermatitis*. 1995;32(6):359-360.
61. Lazzarini R, Duarte I, de Farias DC, et al. Frequency and main sites of allergic contact dermatitis by nail varnish. *Dermatitis*. 2008;19(6):319-322.
62. Jacob SE, Castanedo-Tardan MP. A diagnostic pearl in allergic contact dermatitis to fragrances: the atomizer sign. *Cutis*. 2008;82(5):317-318.
63. De Groot AC, Le Coz CJ, Lensen GJ, et al. Formaldehyde-releasers: relationship to formaldehyde contact allergy. Part 2. Formaldehyde-releasers in clothes: durable press chemical finishes. *Contact Dermatitis*. 2010;63(1):1-9.
64. Cohen D, Hatch KL, Maibach H, et al. Clothes make the (wo)man: diagnosis and management of clothing dermatitis. *Dermatitis*. 2001;12(4):229-231.
65. Heisterberg MV, Menné T, Andersen KE, et al. Deodorants are the leading cause of allergic contact dermatitis to fragrance ingredients. *Contact Dermatitis*. 2011;64(5):258-264.
66. Zug KA, Rietschel RL, Warshaw EM, et al. The value of patch testing patients with a scattered generalized distribution of dermatitis: retrospective cross-sectional analyses of North American Contact Dermatitis Group data, 2001 to 2004. *J Am Acad Dermatol*. 2008;59(3):426-431.
67. Jacob SE, Zapolanski T. Systemic contact dermatitis. *Dermatitis*. 2008;19(1):9-15.
68. Andersen KE, Hjorth N, Menné T. The baboon syndrome: systemically-induced allergic contact dermatitis. *Contact Dermatitis*. 1984;10(2):97-100.
69. Hausermann P, Harr T, Bircher AJ. Baboon syndrome resulting from systemic drugs: is there strife between SDRIFE and allergic contact dermatitis syndrome? *Contact Dermatitis*. 2004;51(5-6):297-310.
70. Kitamura K, Osawa J, Ikezawa Z, et al. Cross-reactivity between sensitivity to thimerosal and photosensitivity to piroxicam in guinea pigs. *Contact Dermatitis*. 1991;25(1):30-34.
71. Walker SL, Ferguson JE. Systemic allergic contact dermatitis due to ethylenediamine following administration of oral aminophylline. *Br J Dermatol*. 2004;150(3):594-594.
72. Cusano F, Ferrara G, Crisman G, et al. Clinicopathologic features of systemic contact dermatitis from ethylenediamine in cetirizine and levocetirizine. *Dermatology*. 2006;213(4):353-355.
73. Lerbaek A, Menné T, Knudsen B. Cross-reactivity between thiurams. *Contact Dermatitis*. 2006;54(3):165-168.
74. Veien NK, Hattel T, Justesen O, et al. Oral challenge with metal salts (II). Various types of eczema. *Contact Dermatitis*. 1983;9(5):407-410.
75. Salam TN, Fowler JF. Balsam-related systemic contact dermatitis. *J Am Acad Dermatol*. 2001;45(3):377-381.
76. Warshaw EM, Maibach HI, Taylor JS, et al. North American Contact Dermatitis Group patch test results. *Dermatitis*. 2015;26(1):49-59.
77. Goldenberg A, Vassantachart J, Lin EJ, et al. Nickel allergy in adults in the US. *Dermatitis*. 2015;26(5):216-223.
78. Basko-Plluska JT, Thyssen JP, Schalock, PC. Cutaneous and systemic hypersensitivity reactions to metallic implants. *Dermatitis*. 2011;22(2):65-79.
79. Schram SE, Warshaw EM, Laumann A. Nickel hypersensitivity: a clinical review and call to action. *Int J Dermatol*. 2010;49(2):115-125.
80. Schalock PC, Thyssen JP. Patch testers' opinions regarding diagnostic criteria for metal hypersensitivity reactions to metallic implants. *Dermatitis*. 2013;24(4):183-185.
81. Thyssen JP, Johansen JD, Carlsen BC, et al. Prevalence of nickel and cobalt allergy among female patients with dermatitis before and after Danish government regulation: a 23-year retrospective study. *J Am Acad Dermatol*. 2009;61(5):799-805.
82. Brant WT. *The Metallic Alloys: A Practical Guide for the Manufacture of All Kinds of Alloys, Amalgams, and Solders, Used by Metal-workers: Together with Their Chemical and Physical Properties and Their Application in the Arts and Industries*. London, UK: Henry Cary Baird; 1896.
83. Fowler JF. Cobalt. *Dermatitis*. 2016;27(1):3-8.

84. Marks JG, Elsner P, Deleo VA. Standard allergens. *Contact & Occupational Dermatology*. Elsevier BV St. Louis, MO; 2002:65-139.
85. Biebl KA, Warshaw EM. Allergic contact dermatitis to cosmetics. *Dermatol Clin*. 2006;24(2):215-232.
86. Sasseville D. Hypersensitivity to preservatives. *Dermatol Ther*. 2004;17(3):251-263.
87. Eiermann HJ, Larsen W, Maibach HI, et al. Prospective study of cosmetic reactions: 1977-1980. *J Am Acad Dermatol*. 1982;6(5):909-917.
88. Adams RM, Maibach HI, Adams RM, et al. A five-year study of cosmetic reactions. *J Am Acad Dermatol*. 1985;13(6):1062-1069.
89. de Groot AC. Contact allergy to cosmetics: causative ingredients. *Contact Dermatitis*. 1987;17(1):26-34.
90. Johansen JD, Veien N, Laurberg G, et al. Decreasing trends in methyldibromo glutaronitrile contact allergy–following regulatory intervention. *Contact Dermatitis*. 2008;59(1):48-51.
91. Larsen WG. How to test for fragrance allergy. *Cutis*. 2000;65(1):39-41.
92. Schnuch A, Uter W, Geier J, et al. Contact allergy to farnesol in 2021 consecutively patch tested patients. Results of the IVDK. *Contact Dermatitis*. 2004;50(3):117-121.
93. de Groot AC, Frosch PJ. Adverse reactions to fragrances. *Contact Dermatitis*. 1997;36(2):57-86.
94. Tomar J, Jain VK, Aggarwal K, et al. Contact allergies to cosmetics: testing with 52 cosmetic ingredients and personal products. *J Dermatol*. 2005;32(12): 951-955.
95. Cheng J, Zug KA. Fragrance allergic contact dermatitis. *Dermatitis*. 2014;25(5):232-245.
96. Larsen WG. Perfume dermatitis. *J Am Acad Dermatol*. 1985;12(1):1-9.
97. Zug KA, Warshaw EM, Fowler JF Jr, et al. Patch-test results of the North American Contact Dermatitis Group 2005-2006. *Dermatitis*. 2009;20(3):149-160.
98. Sasseville D. Neomycin. *Dermatitis*. 2010;21(1):3-7.
99. Andersen KE, White IR, Goossens A. Allergens from the standard series. In: Frosch PJ, Menne T, Lepoittevin JP, eds. *Contact Dermatitis*. Berlin, Germany: Springer; 2006:453.
100. Phillips, DK. Neomycin sulfate. In: Guin JD, ed. *Practical Contact Dermatitis*. New York, NY: McGraw-Hill; 1995: 167.
101. Katz BE, Fisher AA. Bacitracin: a unique topical antibiotic sensitizer. *J Am Acad Dermatol*. 1987;17(6): 1016-1024.
102. Sood A, Taylor JS. Bacitracin: Allergen of the year. *Am J Contact Dermat*. 2003;14(1):3-4.
103. Zapolanski T; Jacob SE. para-Phenylenediamine. *Dermatitis*. 2008;19(3):E20-E21.
104. Arroyo MP. Black henna tattoo reaction in a person with sulfonamide and benzocaine drug allergies. *J Am Acad Dermatol*. 2003;48(2):301-302.
105. Sornin de Leysat C, Boone M, Blondeel A, et al. Two cases of cross-sensitivity in subjects allergic to paraphenylenediamine following ingestion of Polaronil. *Dermatology*. 2003;206(4):379-380.
106. Chung W-H, Chang Y-C, Yang L-J, et al. Clinicopathologic features of skin reactions to temporary tattoos and analysis of possible causes. *Arch Dermatol*. 2002;138(1):88-92.
107. Neri I, Guareschi E, Savoia F, et al. Childhood allergic contact dermatitis from henna tattoo. *Pediatr Dermatol*. 2002;19(6):503-505.
108. Belsito DV. Patch testing with a standard allergen ("screening") tray: rewards and risks. *Dermatol Ther*. 2004;17(3):231-239.
109. Cohen DE, Brancaccio R, Andersen D, et al. Utility of a standard allergen series alone in the evaluation of allergic contact dermatitis: a retrospective study of 732 patients. *J Am Acad Dermatol*. 1997;36(6):914-918.
110. Larkin A. The utility of patch tests using larger screening series of allergens. *Am J Contact Dermat*. 1998;9(3):142-145.
111. Katsarma G, Gawkrodger DJ. Suspected fragrance allergy requires extended patch testing to individual fragrance allergens. *Contact Dermatitis*. 1999;41(4): 193-197.
112. Hoeck UL. More T.R.U.E Test allergens are needed. *J Am Acad Dermatol*. 2005;52(3):538.
113. Patel D, Belsito DV. The detection of clinically relevant contact allergens with a standard screening tray of 28 allergens. *Contact Dermatitis*. 2012;66(3):154-158.
114. Wilkinson DS, Fregert S, Magnusson B, et al. Terminology of contact dermatitis. *Acta Derm Venereol*. 1970;50(4):287-292.
115. Foussereau J, Benezra C, Maibach HI. *Occupational Contact Dermatitis: Clinical and Chemical Aspects*. Copenhagen, Denmark: Munkgaard; 1982.
116. Cronin E. *Contact Dermatitis*. Edinburgh, UK: Churchill Livingston; 1980.
117. Suneja T, Belsito DV. Thimerosal in the detection of clinically relevant allergic contact reactions. *J Am Acad Dermatol*. 2001;45(1):23-27.
118. Mowad CM, Anderson B, Scheinman P, et al. Allergic contact dermatitis: patient management and education. *J Am Acad Dermatol*. 2016;74(6):1043-1054.
119. Weiss G, Shemer A, Trau H. The Koebner phenomenon: review of the literature. *J Eur Acad Dermatol Venereol*. 2002;16(3):241-248.
120. Jensen CD, Paulsen E, Andersen KE. Retrospective evaluation of the consequence of alleged patch test sensitization. *Contact Dermatitis*. 2006;55(1):30-35.
121. Bickers DR, Lim HW, Margolis D, et al. The burden of skin diseases: 2004. *J Am Acad Dermatol*. 2006;55(3):490-500.
122. Stern RS. Dermatologists and office-based care of dermatologic disease in the 21st century. *J Investig Dermatol Symp Proc*. 2004;9(2):126-130.
123. Rietschel RL. Is patch testing cost-effective? *J Am Acad Dermatol*. 1989;21(4):885-887.
124. Freedman S. Diagnosis and differential diagnosis. In: Adams RM, ed. *Adams: Occupational Skin Disease*. 3rd ed. Philadelphia, PA: W.B. Saunders; 1999:189.
125. Rietschel RL. Clues to an accurate diagnosis of contact dermatitis. *Dermatol Ther*. 2004;17(3):224-230.
126. Skoet R, Zachariae R, Agner T. Contact dermatitis and quality of life: a structured review of the literature. *Br J Dermatol*. 2003;149(3):452-456.
127. Linn Holness D. Results of a quality of life questionnaire in a patch test clinic population. *Contact Dermatitis*. 2001;44(2):80-84.
128. Kadyk DL, Hall S, Belsito DV. Quality of life of patients with allergic contact dermatitis: an exploratory analysis by gender, ethnicity, age, and occupation. *Dermatitis*. 2004;15(03):117.
129. Woo PN, Hay IC, Ormerod AD. An audit of the value of patch testing and its effect on quality of life. *Contact Dermatitis*. 2003;48(5):244-247.
130. Zug KA, Aaron DM, Mackenzie T. Baseline quality of life as measured by Skindex-16+5 in patients

presenting to a referral center for patch testing. *Dermatitis*. 2009;20(1):21-28.
131. Veien NK, Hattel T, Laurberg G. Hand eczema: causes, course, and prognosis II. *Contact Dermatitis*. 2008;58(6):335-339.
132. Adisesh A, Meyer JD, Cherry NM. Prognosis and work absence due to occupational contact dermatitis. *Contact Dermatitis*. 2002;46(5):273-279.
133. Holness DL, Nethercott JR. Is a worker's understanding of their diagnosis an important determinant of outcome in occupational contact dermatitis? *Contact Dermatitis*. 1991;25(5):296-301.
134. Kalimo K, Kautiainen H, Niskanen T, et al. "Eczema school" to improve compliance in an occupational dermatology clinic. *Contact Dermatitis*. 1999;41(6):315-319.
135. Jacob SE, Castanedo-Tardan MP. Pharmacotherapy for allergic contact dermatitis. *Expert Opin Pharmacother*. 2007;8(16):2757-2774.
136. American Contact Dermatitis Society. Contact Allergen Management Program. http://acdscamp.org/. Accessed June 19, 2016.
137. Contact Allergen Replacement Database (CARD). 2008. http://contactallergy.com/index.html. Accessed June 29, 2016.

Chapter 25 :: Irritant Dermatitis

:: Susan T. Nedorost

AT-A-GLANCE

- Irritant dermatitis from wet-to-dry cycling is common in cold seasons.
- Decreasing the duration and frequency of contact with irritants may improve symptoms of irritant contact dermatitis (as opposed to allergic contact dermatitis which requires complete avoidance to clear).
- Innate immune signals from irritant dermatitis predispose to allergic dermatitis (allergic contact and atopic dermatitis).
- Emollients accelerate recovery and may help prevent the complication of allergic dermatitis in infants.
- Emollients used on normal skin over long intervals may predispose to irritant dermatitis.
- Hardening, or disappearance of symptoms, often occurs with continued irritant exposure without any treatment.
- Future understanding of ways to promote hardening could reduce the impact of allergic contact dermatitis and atopic disease which complicate irritant dermatitis.

INTRODUCTION

Irritant contact dermatitis is sometimes encountered as a primary diagnosis, but it is most important for its critical role in predisposing to atopic and allergic contact dermatitis.

When acute irritant dermatitis is the sole diagnosis, patients are often able to self-diagnose. There is obvious temporal relationship because irritant dermatitis manifests within hours of the causative exposure, and resolves within days of cessation of exposure. In contrast, allergic contact dermatitis may manifest days after exposure and persist for weeks. Consequently, accurate self-diagnosis of contact dermatitis is more common with irritant contact dermatitis than allergic contact dermatitis. The combination of straightforward self-diagnosis and shorter duration makes the presentation of irritant dermatitis for dermatologic consultation less common than that of allergic contact dermatitis.

T cells produce the inflammation of atopic and allergic contact dermatitis as part of the adaptive immune response. The adaptive response is influenced by upstream innate immune response. Irritant dermatitis provides the innate immune signals that predispose to allergic contact and atopic dermatitis. Therefore, the importance of irritant contact dermatitis is less recognition and treatment as a primary diagnosis, but its role in downstream dermatitis mediated by the adaptive immune response. Study of barrier disruption and the resulting innate immune signals should help us develop strategies to prevent irritant dermatitis so as to prevent more severe and disabling allergic and atopic dermatitis.

DEFINITIONS

Dermatitis is an inflammatory disruption of the epidermis related to physical or immunologic provocation. Dermatitis and eczema are often used interchangeably.[1] Dermatitis appears as spongiosis histologically. There is impairment of the barrier functions of the skin, which results in increased transepidermal water loss.

As Fig. 25-1 illustrates, dermatitis is usually multifactorial. Irritant dermatitis results in barrier disruption which may predispose to higher concentrations of bacteria and yeast, and these microorganisms may stimulate immune response.[2-4] Immune signals from barrier disruption also predispose to allergic contact dermatitis to chemical antigens,[5] as discussed later in "Complications."

Irritant dermatitis begins with damage to keratinocytes, which then release danger signals that promote recruitment of inflammatory cells. In severe cases, necrotic keratinocytes are evident.

Irritant dermatitis is caused by physical damage to the epidermis and is temporally more immediate after provocation than the delayed hypersensitivity response leading to allergic contact dermatitis. Many variables influence expression of irritant dermatitis including climate and season, occlusion, frequency of exposure to the irritant, and concentration of the irritant.

Dermal injury producing scarring can result from corrosive chemicals that coagulate protein and cause cutaneous scars. Corrosive chemicals are not further discussed in this chapter. Irritant chemicals by definition do not cause scarring when in contact with the skin for less than 4 hours.[6] Rarely, scarring can result from secondary infection of dermatitis, but not from uncomplicated dermatitis.

Hand dermatitis is a common site for irritant contact dermatitis. Repeated wetting and drying of the skin causes fissuring, especially if drying is rapid because of low ambient humidity.

Contact with an allergen often results in allergic contact hand dermatitis complicating irritant contact dermatitis. Consequently, the definition of pure irritant contact dermatitis is one of exclusion. Irritant hand dermatitis has been defined as "A documented exposure of the hands to an irritant, which is quantitatively

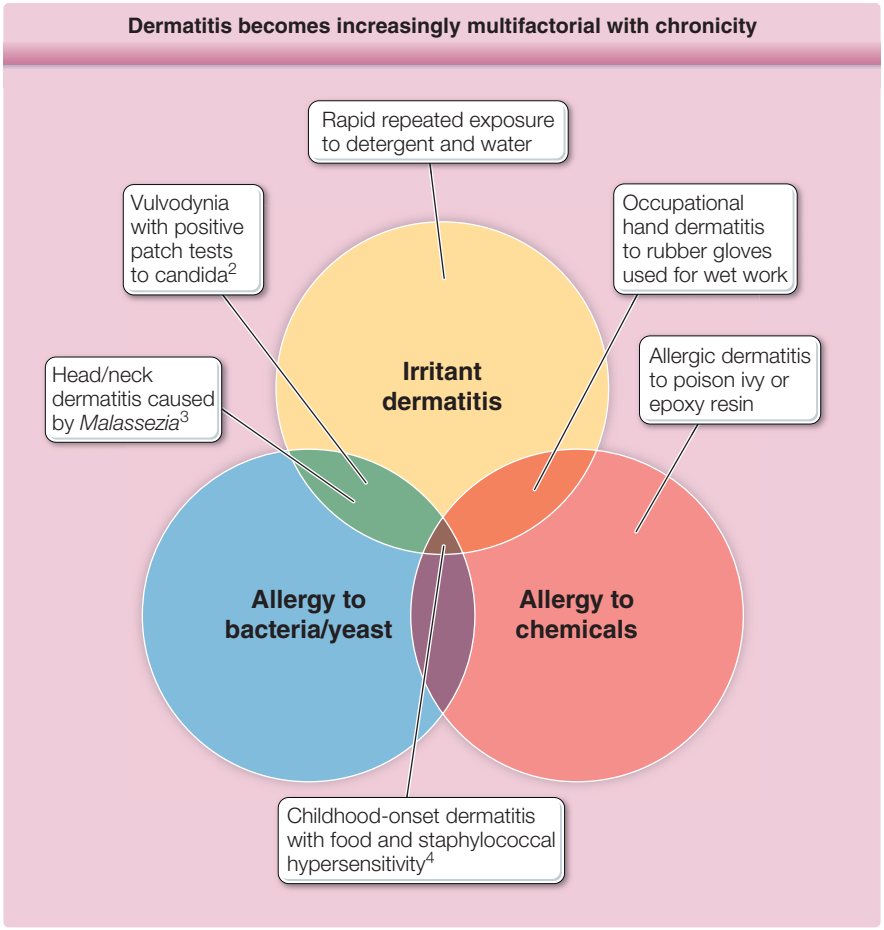

Figure 25-1 Irritant dermatitis leads to barrier disruption that promotes immune response to bacteria and yeast, as well as to chemicals in contact with the skin. Dermatitis often results from a combination of causative factors. Examples are shown here for various combinations of causative factors.

likely to cause contact dermatitis. No relevant contact allergy (no current exposure to allergens to which the patient has reacted positive in patch test)."[7]

HISTORICAL PERSPECTIVE

In the past, homemakers did more wet work, such as washing dishes by hand, and were often diagnosed with "dishpan hands." Today, irritant dermatitis in its pure form is commonly described as "chapping" or rough, cracked, sore skin. Compared to prior decades, this more commonly occurs from frequent hand hygiene as required for health care workers, or from exposure to wind and cold during outdoor sports and exercise.

Patient history is very helpful when distinguishing acute irritant dermatitis from acute allergic contact dermatitis. When chronic, irritant and allergic contact dermatitis cannot reliably be differentiated clinically or histologically. A detailed clinical history and often patch testing are required to diagnosis allergic contact dermatitis (Table 25-1).

The classification of hand dermatitis as purely irritant may depend on the absence of relevant positive patch tests to indicate allergic contact dermatitis. The percentage of cases identified as irritant varies between clinics as the number of patch tests used varies. Many cases are classified as irritant hand dermatitis with allergic or atopic hand dermatitis.[7]

The lack of a diagnostic test for irritant dermatitis makes it very difficult to comment on prevalence over time.[8] Irritant contact dermatitis in its pure form is probably a less-common reason for presentation to a dermatologist now than in the past. This may be because of decreased prevalence resulting from technology reducing the amount of wet work required for homemaking, or improved patient access to medical information, and/or improved formulations of products such as emollients and diapers.

EPIDEMIOLOGY

CLIMATE

Climate influences the rapidity of wet-to-dry cycles. In low ambient humidity, water evaporates rapidly causing uneven surface change, whereas slow drying in

TABLE 25-1
Comparison of the Symptoms of Allergic Contact Dermatitis and Irritant Contact Dermatitis

		IRRITANT CONTACT DERMATITIS	ALLERGIC CONTACT DERMATITIS
Margination and site	Acute	**Sharp, strictly confined to the site of exposure**	Spreading from site of exposure to **the periphery; usually tiny papules; may become generalized**
	Chronic	Ill-defined	Ill-defined, spreads
Evolution	Acute	**Rapid** (few hours after exposure)	**Not so rapid** (12-72 hours after exposure)
Causative agents		**Dependent on concentration of agent and state of skin barrier; occurs only above threshold level**	**Relatively independent of amount applied, usually very low concentrations sufficient, but depends on degree of sensitization**
Incidence		**May occur in practically everyone**	**Occurs only in the sensitized**

From Wolff K, Johnson R, Saavedra AP, Roh EK. *Fitzpatrick's Color Atlas and Synopsis of Clinical Dermatology*, 8th ed. New York, NY: McGraw-Hill; 2017, Table 2-3, p. 29, with permission.

higher humidity conditions results in a smoother surface. Irritant contact dermatitis can occur from cumulative irritancy from wet-to-dry cycles with or without exposure to irritant chemicals, including detergents and solvents. Wet-to-dry cycles are a common cause of irritant dermatitis in the setting of genetic predisposition to impaired barrier, as in atopic dermatitis where perioral chapping occurs in infants from drooling. Occupational hand dermatitis in the setting of wet work is more common in cold seasons when humidity indoors is low.[9]

GENDER

Women are more likely than men to have hand dermatitis, presumably because of greater wet work exposure. Occupational hand dermatitis is often multifactorial, with both an irritant and an allergic contact component, for example, in hairdressers and machinists.[10] Women reported more itching compared to men in one large study where the severity of hand dermatitis was similar in men and women.[11]

Frequency of hand washing is a risk factor for irritant hand dermatitis. Women are more likely than men to perform higher-risk wet tasks such as hairdressing, and are more likely to wash their hands frequently when away from work.[11] Irritant hand dermatitis increased coincident with campaigns to improve hand hygiene in health care workers to decrease hospital-acquired infections.[12]

ATOPIC DERMATITIS

Some people with atopic dermatitis have a genetic barrier defect. In some racial cohorts, this is caused by a mutation leading to defective filaggrin, which weakens the protein milieu that binds corneocytes together in the stratum corneum and decreases natural moisturizing factor.[13] In a study comparing patients with atopic dermatitis to healthy controls, the atopic dermatitis patients had greater reactivity to the irritant detergent sodium lauryl sulfate,[14] and in a prospective study of workers evaluated for irritant contact dermatitis, atopic patients were more likely to discontinue work.[15]

In contrast, in a population of health care workers with no history of dermatitis severe enough to warrant physician evaluation, a history of childhood flexural dermatitis did not predispose to lower the irritancy threshold to various concentrations of sodium lauryl sulfate, although irritant response to sodium lauryl sulfate did correlate with development of wintertime irritant hand dermatitis.[16] The latter observation suggests that there are individual risk factors for irritant hand dermatitis in addition to atopic dermatitis in a population of healthy hospital workers.

SPECIFIC EXPOSURES

OCCUPATIONAL EXPOSURES

In the setting of dermatologic consultation for occupational hand dermatitis, allergic contact dermatitis may be more commonly diagnosed than irritant contact dermatitis.[17] Irritant contact dermatitis is more commonly diagnosed than allergic contact dermatitis[10] in studies where larger numbers of workers are assessed. The greater prevalence of irritant dermatitis in the working population compared to the dermatologic consultation cohort may reflect the relative ease of self-diagnosing irritant contact dermatitis, and its comparative lesser severity compared to allergic contact dermatitis, such that many workers do not seek medical consultative care for irritant contact dermatitis.

Table 25-2 lists common irritants by occupation. These are rarely important diagnostically, as patients self-identify and avoid most irritants. Water—from wet work, drooling, and sweating—is the most important irritant that provokes irritant dermatitis leading to allergic contact and atopic dermatitis because it is difficult to avoid.

Oil dermatitis occurs in workers whose hands and forearms have prolonged contact with oil and who

TABLE 25-2
Irritants Encountered in Various Occupations

CONDITION	IRRITANT
Agriculture workers	Artificial fertilizers, disinfectants, pesticides, cleaners, gasoline, diesel oil, plants, and grains
Artists	Solvents, clay, plaster
Automobile and aircraft industry workers	Solvents, cutting oils, paints, hand cleansers
Bakers and confectioners	Flour, detergents
Bartenders	Detergents, wet work
Bookbinders	Solvents, glues
Butchers	Detergents, meat, waste
Cabinet makers and carpenters	Glues, detergents, thinners, solvents, wood preservatives
Cleaners	Detergents, solvents, wet work
Coal miners	Dust (coal, stone), wet conditions
Construction workers	Cement
Cooks and caterers	Detergents, vegetable juices, wet work
Dentists and dental technicians	Detergents, hand cleansers, wet work
Dry cleaners	Solvents
Electricians	Soldering fluxes
Electroplaters	Acids, alkalis
Floor-layers	Solvents
Florists and gardeners	Manure, artificial fertilizers, pesticides, wet work
Hairdressers	Permanent wave solutions, shampoos, bleaching agents, wet work
Hospital workers	Detergents, disinfectants, foods, wet work
Homemakers	Detergents, cleansers, foods, wet work
Jewelers	Detergents, solvents
Mechanics	Oils, greases, gasoline, diesel fuel, cleaners, solvents
Metal workers	Cutting oils, solvents, hand cleansers
Nurses	Disinfectants, detergents, wet work
Office workers	Solvents (photocopiers, adhesives)
Painters	Solvents, thinners, wallpaper adhesives, hand cleansers
Photography industry workers	Solvents, wet work
Plastics workers	Solvents, acids, styrene, oxidizing agents
Printers	Solvents
Rubber workers	Solvents, talc, zinc stearate, uncured rubber
Shoemakers	Solvents
Tannery workers	Acids, alkalis, reducing and oxidizing agents, wet work
Textile workers	Fibers, bleaching agents, solvents
Veterinarians and slaughterhouse workers	Disinfectants, wet work, animal entrails and secretions

Wet work (water or water plus detergent) is the most common occupational irritant.

From What occupations are at risk? OSH Answers, Canadian Centre for Occupational Health and Safety (CCOHS), October 15, 2008. https://www.ccohs.ca/oshanswers/diseases/dermatitis.html. Reproduced with the permission of CCOHS, 2016.

may develop a type of irritant dermatitis characterized by perifollicular papules and pustules.[18] Workers exposed to oil often use solvents to remove oil from the skin that further aggravates the irritant dermatitis.

Plants and *insects* less commonly cause irritant dermatitis, but when they do cause irritant dermatitis, it may appear in areas other than the hands. An example is an outbreak of irritant dermatitis from blister beetles in Thai military recruits.[19]

Fiberglass dermatitis can cause irritant contact or airborne irritant dermatitis. Airborne irritant dermatitis is characterized by eyelid and other flexural involvement of exposed skin.[20]

NONOCCUPATIONAL EXPOSURES

Table 25-3 shows common irritants encountered outside of work. *Medicaments* may cause irritation, which

TABLE 25-3
Common Irritants

Solvents including water
Detergents
Disinfectants
Anti-wrinkle medicaments

is commonly seen with the use of retinoids and benzoyl peroxide.

Diaper rash is another common example of irritant dermatitis that can occur with wet-to-dry cycles and irritation from stool. Irritant diaper dermatitis has decreased with use of superabsorbent and less-occlusive disposable diapers.[21]

EXPOSURE TO RUBBING OR STRETCHING THE SKIN

Friction from sporting equipment, such as shin guards, rubbing against skin can cause irritant dermatitis. The friction is worsened by perspiration, and the resulting dermatitis may be complicated by allergic contact dermatitis to rubber chemicals or textile dyes in the shin guard. Athletes may also develop contact dermatitis from dye in clothing that reaches skin as a result of liberation from the fabric by perspiration and friction. Testing to materials obtained from the patient's own sporting equipment in addition to relevant commercial patch test series increases the sensitivity of patch testing for allergic contact dermatitis caused by sporting equipment.[22,23] Irritant dermatitis may be mitigated by use of powder that absorbs perspiration and reduces friction.

Friction blisters are an acute skin injury that can be occupational or avocational, such as from raking leaves.

Stasis dermatitis occurs when swollen lower legs experience barrier disruption caused by stretching. Lymphatic obstruction accentuates inflammation in mice when challenged with the irritant croton oil. When challenged with the sensitizer dinitrofluorobenzene, mice with lymphatic obstruction had more swelling than those without, but also had lower levels of the inflammatory signals interferon-γ, tumor necrosis factor-α, and the chemokines CXCL9 and CXCL10 than did mice without lymphatic obstruction, suggesting that the increased swelling is a consequence of fluid retention rather than accentuated allergic contact dermatitis.[24]

CLINICAL FEATURES

CUTANEOUS FINDINGS

Epidermal disruption is the primary finding in irritant dermatitis, as opposed to allergic contact dermatitis which displays proportionately more dermal inflammatory infiltrate. Irritant contact dermatitis is characterized by redness, fissuring, oozing, and pain. Figure 25-2 shows chronic irritant contact dermatitis with epidermal thickening and pigment change. Figure 25-3 shows an irritant patch test created by applying sodium lauryl sulfate 2.5% under occlusion. Note that there is scorched appearing skin surface without much induration. Irritant dermatitis, like this patch test, usually demonstrates more epidermal than dermal inflammation. As Fig. 25-4 shows, severe acute irritant dermatitis can also produce blisters.

Figure 25-2 Thickened skin with pigment changes in areas of chronic friction on the dorsal hands caused by occupation. This is an exception to the usual finding of accentuation in flexural areas, because the frictional exposure was to the dorsal surface of the hands only.

Allergic contact dermatitis can occur with irritant dermatitis and is more likely to present with the symptoms of itch and more likely to demonstrate induration. Figure 25-5 shows an allergic patch test result. Note that there is more induration than epidermal change.

FLEXURAL ACCENTUATION

Flexural accentuation is an important sign of irritant dermatitis. Common areas for irritant dermatitis are folds in the eyelid, neck, antecubital fossae, volar wrist, and intertriginous regions.

In the cases of irritant hand dermatitis and of diaper rash, irritant dermatitis is more apparent in finger webs and creases (Fig. 25-6) and intertriginous folds,

Figure 25-3 Irritant dermatitis from a patch test with sodium lauryl sulfate. Note the scorched appearance of the skin with more surface change than papules.

Figure 25-4 Bullous irritant patch test response with blister but no surrounding induration.

Figure 25-5 Allergic dermatitis from a patch test to gold; there are multiple papules and an indurated base.

Figure 25-6 Mild wintertime irritant dermatitis in a health care worker. Note the accentuation of the chapping in the flexural areas.

Figure 25-7 Acute irritant dermatitis in a patient who mistook a body wash for an emollient and applied the body wash at bedtime. The patient awoke with inflammation primarily in the flexural areas despite application to the entire leg.

respectively, where irritants concentrate, and is worsened by increased pH from soaps and feces, respectively. Irritant cleansers cause predominantly flexural dermatitis where the concentration of irritant is highest because of occlusion.[25] Figure 25-7 shows flexural accentuation of acute dermatitis in a patient who inadvertently applied a cleanser, mistaking it for an emollient, to the entire surface of both legs.

Retinoid dermatitis also preferentially involves folds such as the nasolabial fold. This is often noted several days after starting cutaneous application, as retinoids produce a delayed irritant reaction.[26] Figure 25-8 shows irritant dermatitis on the neck in a patient who began applying tretinoin daily to the neck after tolerating long-term use on the face.

Figure 25-8 Topical retinoid-induced irritant dermatitis on the neck.

NONCUTANEOUS FINDINGS

Hand dermatitis, which always has an irritant component, is associated with anxiety and obsessive-compulsive traits, but not with depression, compared to healthy controls.[27] Contact dermatitis leads to substantial costs and lower work productivity in adults, which may lead to financial harm.[28]

ETIOLOGY AND PATHOGENESIS

RISK FACTORS

WET WORK, DETERGENTS, AND GLOVES

Occupational hand dermatitis is common in wet workers. Irritation from water is synergistic with irritation from detergent. Solvent exposure is also synergistic with detergent exposure.[29]

Glove use can protect skin from water and detergents, but perspiration or leakage of moisture around the cuff can occlude moisture under the glove causing maceration from perspiration. Rapid drying of the retained moisture when the glove is removed causes even more damage to the epidermis. Figure 25-9 shows a patient with underlying hand dermatitis who aggravated the dermatitis by wearing occlusive gloves.

In healthy human controls with no history of atopic dermatitis who were exposed to repeated half-hour intervals of water occlusion over 4 days, the detergent sodium lauryl sulfate and the alcohol *n*-propanol both caused more irritation at the test sites than they did on previously unoccluded skin. The detergent was more irritating than the alcohol solution by visual inspection of the skin, measure of transepidermal water loss, and measured decrease in natural moisturizing factor levels.[30] A review of the effects of glove occlusion similarly concluded that using waterproof gloves predisposed the skin to more-severe irritation from detergents used for hand hygiene.[31]

Figure 25-9 Irritant macerated dermatitis from wearing a wet cotton glove under an occlusive glove.

ATOPIC DERMATITIS

Filaggrin mutations are associated with early-onset dermatitis,[32] which is often considered to be "atopic dermatitis." As children become more active, flexural areas develop frictional irritant dermatitis, which leads to allergic contact dermatitis in many cases. Patch testing should be considered in cases of chronic flexural dermatitis.[33]

PATHOGENESIS

STEP 1: EPIDERMAL INSULT

The barrier function of the epidermis can be diminished by solvents that remove lipids from the upper epidermal layers, or by desiccation of the stratum corneum from repeated rapid drying. Genetic factors, such as filaggrin mutations, lower the threshold for epidermal damage to include even minor friction.

STEP 2: DANGER SIGNALS

Damaged keratinocytes release danger signals termed *alarmins* that are analogous to pathogen associated molecular patterns that defend against infections. Examples of candidate alarmins include defensins and uric acid, which may be operative in psoriasis and other inflammatory skin diseases in addition to dermatitis. In fact, the signals from epidermal trauma that drive koebnerization in psoriasis may be different than those in dermatitis and may explain the differences in downstream cytokines that explain the inverse relationship between psoriasis and autoimmune disease and allergic dermatitis.[34]

These danger signals can bind toll-like receptors and promote inflammatory pathways such as nuclear factor-κB that link to the adaptive immune response leading to allergic dermatitis.[35]

STEP 3: POTENTIAL FOR ALLERGIC SENSITIZATION

Chemical allergens and microorganisms stimulate the innate immune system, and toll-like receptors play an important role in mediating both irritant and subsequent allergic contact dermatitis.[36]

Irritant dermatitis predisposes to allergic sensitization to antigens that would not normally cause allergic contact dermatitis on noninflamed skin.

Potent sensitizers that can cause allergy on previously noninflamed skin are dependent on their inherent irritant properties. Athymic mice, as an example of intact innate response without adaptive response, mount a neutrophil response and some diminished T-helper (Th)1/Th2 cell response to the sensitizer oxazolone, while FcγR knockout mice, as an example of intact adaptive response without innate response, have a greatly diminished response when sensitized and rechallenged with oxazolone.[37]

COMPLICATIONS

ALLERGIC CONTACT DERMATITIS

Allergic contact dermatitis is dependent on irritant dermatitis either in the context of previously inflamed skin or the inherent irritant properties of the sensitizer. Toll-like receptors in a mouse model trigger an innate response that begins the education of the adaptive immune response[36] and are well-positioned to initiate an inflammatory response to microorganisms on the skin.

IMMUNE RESPONSE TO LESS-POTENT ALLERGENS, INCLUDING THE MICROBIOME

Childhood-onset dermatitis, also known as atopic dermatitis, is associated with inflammatory responses to common organisms such as *Staphylococcus aureus*, *Malassezia sympodialis*, and *Alternaria.* These organisms may exist as part of a biofilm that concentrates microorganisms and their antigens and may lead to an allergic-like immunologic response to these organisms.[38] Figure 25-10 shows a positive patch test to *M. sympodialis* yeast in a patient with adult-onset dermatitis of the neck and upper torso (Fig. 25-11).

The immune response to microbial allergens is distinct from allergic contact dermatitis to potent conventional sensitizers that function as their own irritants on normal-appearing skin. Weakly potent antigens such as propylene glycol, defined as negative in the guinea pig local lymph node assay,[39] are more likely to cause contact allergy in patients with barrier disruption triggering "danger signals." In general, patients with ongoing innate immune signals from either genetic barrier dysfunction or wet work become sensitized to less potent allergens as measured by the local lymph node assay.[40]

Figure 25-10 Positive patch test to *Malassezia sympodialis* yeast in an adult patient with dermatitis of the anterior axillary line and neck.

Figure 25-11 Distribution of dermatitis seen in patients with sensitivity to *Malassezia sympodialis.*

Patients without preexisting irritant dermatitis are more likely to become sensitized to potent antigens that likely create their own innate signal, such as poison ivy. Innate signal from disrupted skin barrier, together with the irritant signal of a potent antigen, may drive dendritic cells into the dermis and promote immunologic tolerance.[41] This is consistent with the observation that patients with atopic dermatitis are less likely to exhibit dermatitis to the potent allergen in poison ivy that is also a strong irritant.

FOOD ALLERGY

Infants with irritant dermatitis around the mouth from drooling are at risk for allergic contact sensitization from food contact with the inflamed skin. Foods are generally weak allergens and do not sensitize noninflamed skin. If initial food exposure is on mucosa, tolerance develops.[42] This likely explains the higher incidence of peanut allergy in the Unites States where initial peanut exposure is often by self-feeding peanut butter as opposed to the 10-fold lower incidence Israel where initial exposure is to soft baked peanut bambas, which are placed into the mouth directly.

Figure 25-12 Infantile dermatitis that likely began as irritant dermatitis from drooling and in this case was complicated by allergic contact dermatitis to an emollient cream confirmed by patch testing.

Patients with atopic dermatitis often, but not always, have only a transient Th1 response to cutaneous contact sensitization. This might explain the tendency for atopic dermatitis to improve as children get older. These patients also develop a more persistent Th2 skewed response[43] that might contribute to the atopic march. Figure 25-12 shows the typical perioral inflammation seen with infantile dermatitis that can be complicated by contact sensitization and food allergy with delayed and immediate type hypersensitivity (the atopic march).

Although there is no prospective study to confirm the recommendation, new foods should logically be introduced when there is no perioral irritant dermatitis and fed with an infant feeding spoon directly into the mouth rather than being self-fed, which results in substantially more skin contact.

DIAGNOSIS

SUPPORTIVE STUDIES

PATCH TESTING

Patch testing is needed to exclude a component of allergic contact dermatitis. Sensitivity of patch testing is dependent on obtaining a detailed history of personal and occupational exposures and then testing to all potential allergens based on this history. Occupational exposures almost always require specialty patch test series tailored to occupation, and often require dilution of the worker's own products to an appropriate patch test concentration and vehicle.

LABORATORY TESTING

Transepidermal water loss (TEWL) is a measure of the ability of the skin to maintain homeostasis of fluids in the body. In addition to the stratum corneum, tight junctions between living keratinocytes contribute to skin barrier function and provide defense between microbial pathogens and their ligands including toll-like receptors.[44] TEWL is a measure of barrier function and increased TEWL indicates increased permeability to antigens.[45] TEWL is not routinely tested in clinical practice but is used in research studies of irritant contact dermatitis.

PATHOLOGY

All forms of dermatitis show intercellular edema, or spongiosis, of the epidermis. In the acute phase, there is more fluid which correlates with the clinical presence of vesicles, bullae, and crusting. With chronicity, the stratum corneum exhibits hyperkeratosis, and there is less spongiosis. Figure 25-13 shows the features of subacute dermatitis. In very chronic dermatitis, there is even less spongiosis, no crusting, and elongation of the rete ridges in the epidermis and dermal fibrosis.

IMAGING

Confocal microscopy has been studied to help differentiate irritant from allergic contact dermatitis in vivo, but this is not currently used in practice.[46]

DIAGNOSTIC ALGORITHM

Diagnosis of irritant dermatitis begins with a detailed history of potential irritants, temporal course of symptoms, and examination for evidence of flexural accentuation. In patients with severe inflammation and itch, allergic contact dermatitis needs to be investigated with appropriate testing.

An example is shown in Table 25-4 for a patient with complaint of itching and redness of the hands

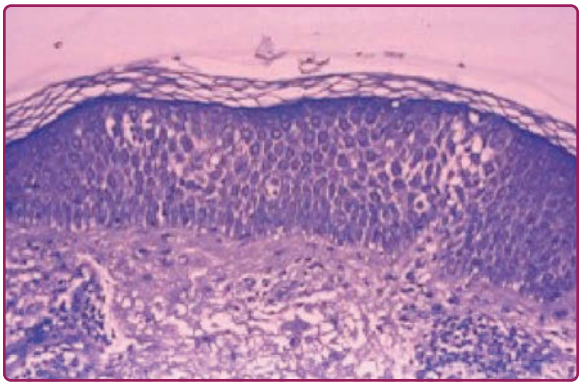

Figure 25-13 Subacute spongiotic dermatitis as seen in irritant and in allergic contact dermatitis.

TABLE 25-4
Example of Differential Diagnosis Including Irritant Dermatitis Caused by Gloves

	TIMING	TEST	COUNSELING
Contact urticaria	Itchy hives begin within minutes of exposure and resolves within hours; when chronic, skin findings may resemble dermatitis	Skin prick to latex glove or antigen specific immunoglobulin E (sensitivity 50%-90%); if negative, 15-minute wear test of latex finger cot[47]	Avoid latex if positive
Allergic contact dermatitis to rubber[a]	Itchy dermatitis begins hours to days after exposure and resolves over weeks	Patch test to a series including rubber accelerators and antioxidants, and to pieces of glove as is	Avoid natural and synthetic rubber gloves containing allergens; use vinyl or allergen-free chemically resistant gloves depending on exposure needs
Irritant contact dermatitis exacerbated by occlusive gloves	Inflammation begins within hours and resolves within days of glove avoidance; becomes more chronic over time	If patch tests are negative, proceed with counseling for irritant dermatitis, but consider the possibility of an allergen not patch tested	Wear cotton under occlusive gloves; change gloves frequently; reduce exposure to hand washing

[a]Irritant dermatitis is often the precursor of allergic dermatitis, such that counseling for irritant dermatitis is usually appropriate in addition to counseling for confirmed allergic dermatitis.

after wearing rubber gloves for wet work where irritant contact dermatitis, contact urticaria, and allergic contact dermatitis are considered. Contact urticaria to latex is an example of a contact allergen that is more common in atopic patients and where the allergic contact sensitization has a more persistent Th2 than Th1 response.

DIFFERENTIAL DIAGNOSIS

Irritant dermatitis occasionally mimics other inflammatory dermatoses such as the "mechanic's hands" sign seen in dermatomyositis (see Chap. 62).

The more common clinical dilemma is differentiating irritant dermatitis as the sole explanation for cutaneous inflammation as opposed to irritant dermatitis complicated by allergic disorder. The allergens that cause sensitization depend on the type and degree of irritant dermatitis that is present at the time of sensitization. More research in this area is needed to develop appropriate patch test series. Table 25-5 demonstrates the concept.

The likelihood of sensitization to a moderate to highly potent antigen may be greater in patients with a subclinically decreased irritancy threshold as detected by response to a low concentration patch test to sodium lauryl sulfate.[48] Wet workers are more likely to be sensitized to moderately potent allergens such as rubber accelerators.[40] The prevalence of eczema and food allergy is higher in children born in autumn or winter months,[49] supporting the relationship between climate and irritant dermatitis caused by drooling and sensitization to food on inflamed skin. However, maternal immune factors related to season may also contribute to prevalence of eczema based on immune markers in cord blood that vary by season.[50]

Patch test series are currently grouped by commonality of exposure rather than skin condition at time of sensitization, which is often not known. As discussed in the section "Immune Response to Less Potent Allergens", strong sensitizers function as their own irritant and can sensitize noninflamed skin. Most allergens on standard screening series are strong or medium potency allergens and therefore fail to detect the weaker potency allergens

TABLE 25-5
Examples of Allergens Speculated to Be Most Likely to Cause Sensitization Based on the Type and Severity of Preexisting Irritant Contact Dermatitis

TYPE OF PREEXISTING IRRITATION	EXAMPLE	POTENCY OF ALLERGEN	EXAMPLE OF ALLERGENS
Normal skin or subclinical decreased irritancy threshold	Positive patch test to low concentration sodium lauryl sulfate[48]	Strong	Poison ivy; epoxy resin
Moderate	Irritant hand dermatitis from wet work[40]	Medium	Rubber chemicals; formaldehyde-releasing preservatives
Severe	Infantile perioral dermatitis from drooling in cold season[49]	Weak	Foods; vitamin E; propylene glycol

that sensitize patients with preexisting severe irritant contact dermatitis. As a result, allergic contact dermatitis caused by weakly potent allergens in the setting of irritant contact dermatitis is not well studied and the prevalence as well as recommendations for type and frequency of patch testing are not established.

CLINICAL COURSE AND PROGNOSIS

HARDENING

Irritant dermatitis often resolves despite continued exposure to the irritant; this is known as *hardening*. The process is incompletely understood, which makes it difficult to know which patients will go on to develop chronic irritant hand dermatitis.[51] In a prospective experiment, participants challenged with repeated higher concentrations of sodium lauryl sulfate were more likely to harden than those challenged with lower concentrations or distilled water. Only about half of all participants hardened. Those who hardened and those who did not had similar measurements of hyperkeratosis and ceramide content of the stratum corneum.[52]

This area represents a tremendous knowledge gap. Hardening is the ideal response to unavoidable chronic irritant exposure. Understanding how to promote hardening could reduce the impact of allergic complications of irritant dermatitis including allergic contact dermatitis and atopic diseases.

MANAGEMENT

INTERVENTIONS

TOPICAL PREWORK PRODUCTS

British standards for occupational contact dermatitis suggest that the term *prework cream* replace *barrier cream* to avoid the suggestion that creams can replace more effective barrier equipment such as protective gloves.[53] These creams, designed for application prior to irritant exposure, may be modestly effective in some circumstances. A systematic review of barrier creams revealed considerable variation in methodology. The reviewers point out that participants were often tested on the forearm or back, rather than the hand, which is the most frequently affected site. Friction and multiple flexures on the hands may increase the risk of irritation at this site.[54] Barrier creams may not be applied in the same quantity in the workplace as in the studies. Barrier creams were more effective for preventing irritation from the detergent sodium lauryl sulfate and the alkaline sodium hydroxide than against the solvent toluene.[55]

MEDICATIONS

Given the weak evidence for the most commonly used treatments, avoidance of irritants is the best treatment option.

Although not clearly effective for prevention of hand dermatitis, use of emollients is recommended for treatment of hand dermatitis, even though some emollients appear to increase the penetration of allergen and irritants, and it is not clear which emollients are best in specific settings.[56] Only some emollients, usually with high lipid content, including petrolatum, accelerate barrier repair in experimentally induced irritant and allergic contact dermatitis.[57]

Topical corticosteroids are frequently used, but chronic use may impair barrier function by thinning the epidermis.[26] Topical immunomodulators may be of some benefit but are not consistently more effective than vehicle alone.[26]

Although rarely needed for purely irritant dermatitis, phototherapy and systemic immunosuppressive medications are often used for multifactorial dermatitis, such as hand dermatitis. Alitretinoin is considered second-line therapy for chronic hand dermatitis in Europe,[56] but is not available in the United States as of 2018.

COUNSELING

There is weak evidence that nurse-led counseling improves disease severity, but not quality of life, in patients with contact dermatitis of the hands.[58] Patients may increasingly prefer technology-assisted counseling, such as by telemedicine, as opposed to travel to a clinic, although traveling to a clinic is still needed for diagnostic testing, including patch testing.

Decreasing the frequency of exposure may allow a worker to continue with their job.[59] Alcohol-based hand sanitizers should substitute for hand washing whenever allowed, especially in cold seasons when indoor heating lowers ambient humidity.[56]

Gloves: Avoidance of irritants, including use of water-resistant gloves for wet work, is the best strategy to prevent and treat irritant dermatitis. In people without other irritant factors, that is, no history of childhood onset dermatitis to suggest genetically impaired barrier function, no use of irritant chemicals at work, infrequent wet work, occlusive gloves are well tolerated. However, occlusion alone can cause inflammation in skin that is already irritated.[60] Figure 25-14 shows a patient with atopic dermatitis where polyethylene film alone applied to the skin for 24 hours caused visible inflammation as did the adjacent 3 patch tests to sodium lauryl sulfate.

Occlusive gloves should be used for wet work but only worn for the shortest time possible. In persons with preexisting irritant dermatitis, cotton gloves are recommended under occlusive gloves if the duration of glove usage is longer than 10 minutes.[56]

People who itch with occlusion often also report itching with perspiration. The same factors that contribute

Figure 25-14 Inflammation from a rectangular piece of polyethylene film applied to atopic skin for 24 hours and compared to 3 round chambers containing sodium lauryl sulfate applied to the same subject for 24 hours.

to irritant dermatitis under gloves also cause irritation under bandages that mimic allergic contact dermatitis to adhesive.[61]

Patients who itch with occlusion generally prefer foam, lotion, or cream vehicles for topical products as they find ointments to cause itching.

TREATMENT ALGORITHM

Dermatitis should be treated as soon as it is recognized, as chronic dermatitis has a worse prognosis than acute dermatitis. All irritants should be avoided for weeks beyond visual recovery. There was lowered irritancy threshold lasting longer than 10 weeks after visual recovery from experimentally induced dermatitis from sodium lauryl sulfate applied 15 times to forearm skin over 3 weeks.[62]

The British guidelines for occupational contact dermatitis suggest referral to a dermatologist knowledgeable about patch testing for occupational contact dermatitis if there is no improvement 3 months after initial evaluation for dermatitis and if there is suspicion for allergic contact dermatitis or changes to job duties are contemplated.[53]

PREVENTION OF IRRITANT DERMATITIS

A systematic review published in 2010 found no significant evidence to prove efficacy of gloves, barrier creams, emollients, or worker education programs in preventing occupational irritant hand dermatitis.[63]

Barrier creams were discussed in the section "Topical Pre-Work Products" earlier. There are studies that show some emollients may provide some degree of prevention when used prior to developing dermatitis rather than as intervention for dermatitis. A study of normal volunteers who washed their hands 15 times daily with an antiseptic soap to mimic hand hygiene in health care workers found that 3 of 5 emollients decreased visible irritation and TEWL compared to no emollient.[64]

Duration of application prior to exposure may influence the degree to which it provides protection from an irritant. An emollient applied 15 minutes prior to exposure to sodium lauryl sulfate (SLS) prevented irritation as measured by TEWL, but daily use of the same emollient increased irritation after sodium lauryl sulfate exposure. This suggests that hydrated skin may be more susceptible to irritants and that prolonged use of emollients may actually increase the risk of irritant contact dermatitis.[65]

PREVENTION OF COMPLICATIONS

In regard to prevention of atopic dermatitis as a complication of irritant dermatitis resulting from genetic barrier deficits, a randomized controlled trial of daily application of emollients in infants from 3 weeks to 6 months of age showed a significant benefit in favor or emollients compared to no emollients. Thirteen percent of the control group used emollients despite randomization to the nonemollient group, and the authors did not comment on seasonal comparability of the control groups during this year-long study in cities in Oregon and the United Kingdom. Cream-based emollients were favored by parents in this study over oil- and ointment-based emollients.[66]

Another study of daily versus occasional application of petroleum jelly to infants from birth to 32 weeks of age showed lower incidence of dermatitis in the daily application group, but no significant decrease in sensitization to egg white as measured by antigen-specific immunoglobulin E to egg at 32 weeks of life.[67]

Prevention of both irritant contact dermatitis and its complications is understudied as discussed in the section "Clinical Course and Prognosis" on hardening. We do not know the components of emollients least likely to cause allergic contact dermatitis in various populations, the ideal pH of emollients, or the effect of various types of emollients on potentially inflammatory components of the microbiome.

SCREENING

Screening with a questionnaire to assess risk factors and visual assessment of health care worker's hands in Toronto revealed a 72% prevalence of mostly mild and some moderate hand dermatitis. Risk factors included handwashing frequency and duration of wearing gloves, but not age or gender.[68]

Screening may help identify early cases of irritant hand dermatitis, which is important because there is a delay in obtaining diagnostic patch testing from onset of symptoms ranging from 2 to 5 years. The delay is attributable to patient factors including hope that the condition will go away and anxiety over obtaining care, and to access, with most patients seeing a primary care physician first and then waiting for an

appointment with dermatologist and then again after referral to a patch test expert.[69]

Given the association between chronicity and poor prognosis, screening may reduce societal burden of disease. However, reduced burden of disease will occur only with advances in treatment and improved understanding of ways to prevent complications.

REFERENCES

1. Smith SM, Nedorost ST. "Dermatitis" defined. *Dermatitis*. 2010;21(5):248-250.
2. Ramirez De Knott HM, McCormick TS, Offertory S, et al. Cutaneous hypersensitivity to *Candida albicans* in idiopathic vulvodynia. *Contact Dermatitis*. 2005;53(4): 214-218.
3. Ramirez de Knott HM, McCormick TS, Kalka K, et al. Cutaneous hypersensitivity to *Malassezia sympodialis* and dust mite in adult atopic dermatitis with a textile pattern. *Contact Dermatitis*. 2006;54(2):92-99.
4. Nakamura Y, Oscherwitz J, Cease KB, et al. *Staphylococcus* δ-toxin induces allergic skin disease by activating mast cells. *Nature*. 2013;503(7476):397-401.
5. McFadden JP. Inflammatory skin diseases and "danger" signalling: time to take centre stage? *Br J Dermatol*. 2014;171(1):7-8.
6. Tovar R, Leikin JB. Irritants and corrosives. *Emerg Med Clin North Am*. 2015;33(1):117-131.
7. Agner T, Aalto-Korte K, Andersen KE, et al; European Environmental and Contact Dermatitis Research Group. Classification of hand eczema. *J Eur Acad Dermatol Venereol*. 2015;29(12):2417-2422.
8. Friis UF, Menné T, Schwensen JF, et al. Occupational irritant contact dermatitis diagnosed by analysis of contact irritants and allergens in the work environment. *Contact Dermatitis*. 2014;71(6):364-370.
9. Tupker R, Pinnagoda J, Coenraads P, et al. Susceptibility to irritants: a role of barrier function, skin dryness, and history of atopic dermatitis. *Br J Dermatol*. 1990;123(2):199-205.
10. Cahill JL, Williams JD, Matheson MC, et al. Occupational skin disease in Victoria, Australia. *Australas J Dermatol*. 2016;57(2):108-114.
11. Mollerup A, Veien NK, Johansen JD. An analysis of gender differences in patients with hand eczema—everyday exposures, severity, and consequences. *Contact Dermatitis*. 2014;71(1):21-30.
12. Stocks SJ, McNamee R, Turner S, et al. The impact of national-level interventions to improve hygiene on the incidence of irritant contact dermatitis in healthcare workers: changes in incidence from 1996 to 2012 and interrupted times series analysis. *Br J Dermatol*. 2015;173(1):165-171.
13. Kezic S, Kemperman PM, Koster ES, et al. Loss-of-function mutations in the filaggrin gene lead to reduced level of natural moisturizing factor in the stratum corneum. *J Invest Dermatol*. 2008;128(8): 2117-2119.
14. Bandier J, Carlsen BC, Rasmussen MA, et al. Skin reaction and regeneration after single sodium lauryl sulfate exposure stratified by filaggrin genotype and atopic dermatitis phenotype. *Br J Dermatol*. 2015; 172(6):1519-1529.
15. Landeck L, Visser M, Skudlik C, et al. Clinical course of occupational irritant contact dermatitis of the hands in relation to filaggrin genotype status and atopy. *Br J Dermatol*. 2012;167(6):1302-1309.
16. Callahan A, Baron E, Fekedulegn D, et al. Winter season, frequent hand washing, and irritant patch test reactions to detergents are associated with hand dermatitis in health care workers. *Dermatitis*. 2013;24(4):170-175.
17. Coman G, Zinsmeister C, Norris P. Occupational contact dermatitis: workers' compensation patch test results of Portland, Oregon, 2005-2014. *Dermatitis*. 2015; 26(6):276-283.
18. Chew A, Maibach H. Occupational issues of irritant contact dermatitis. *Int Arch Occup Environ Health*. 2003;76(5):339-346.
19. Suwannahitatorn P, Jatapai A, Rangsin R. An outbreak of *Paederus* dermatitis in Thai military personnel. *J Med Assoc Thai*. 2014;97(suppl 2):S96-S100.
20. Lárraga-Piñones G, Heras-Mendaza F, Conde-Salazar L. Occupational contact dermatitis in the wind energy industry. *Actas Dermosifiliogr*. 2012;103(10): 905-909.
21. Tüzün Y, Wolf R, Bağlam S, et al. Diaper (napkin) dermatitis: a fold (intertriginous) dermatosis. *Clin Dermatol*. 2015;33(4):477-482.
22. Marzario B, Burrows D, Skotnicki S. Contact dermatitis to personal sporting equipment in youth. *J Cutan Med Surg*. 2016;20(4):323-326.
23. Powell D, Ahmed S. Soccer shin guard reactions: allergic and irritant reactions. *Dermatitis*. 2010;21(3): 162-166.
24. Sugaya M, Kuwano Y, Suga H, et al. Lymphatic dysfunction impairs antigen-specific immunization, but augments tissue swelling following contact with allergens. *J Invest Dermatol*. 2012;132(3, pt 1):667-676.
25. Segal R, Eskin-Schwartz M, Trattner A, et al. Recurrent flexural pellagroid dermatitis: an unusual variant of irritant contact dermatitis. *Acta Derm Venereol*. 2015;95(1):116-117.
26. Ale IS, Maibach HI. Irritant contact dermatitis. *Rev Environ Health*. 2014;29(3):195-206.
27. Kouris A, Armyra K, Christodoulou C, et al. Quality of life, anxiety, depression and obsessive-compulsive tendencies in patients with chronic hand eczema. *Contact Dermatitis*. 2015;72(6):367-370.
28. Saetterstrøm B, Olsen J, Johansen JD. Cost-of-illness of patients with contact dermatitis in Denmark. *Contact Dermatitis*. 2014;71(3):154-161.
29. Schliemann S, Schmidt C, Elsner P. Tandem repeated application of organic solvents and sodium lauryl sulphate enhances cumulative skin irritation. *Skin Pharmacol Physiol*. 2014;27(3):158-163.
30. Angelova-Fischer I, Stilla TR, Kezic S, et al. Barrier function and natural moisturizing factor levels after cumulative exposure to short-chain aliphatic alcohols and detergents: results of occlusion-modified tandem repeated irritation test. *Acta Derm Venereol*. 2016;96(7):880-884.
31. Tiedemann D, Clausen ML, John SM, et al. Effect of glove occlusion on the skin barrier. *Contact Dermatitis*. 2016;74(1):2-10.
32. Rupnik H, Rijavec M, Korošec P. Filaggrin loss-of-function mutations are not associated with atopic dermatitis that develops in late childhood or adulthood. *Br J Dermatol*. 2015;172(2):455-461.
33. Jacob SE, Goldenberg A, Nedorost S et al Flexural eczema versus atopic dermatitis. *Dermatitis*. 2015;26(3):109-115.
34. Engebretsen KA, Thyssen JP. Skin barrier function and allergens. *Curr Probl Dermatol*. 2016;49:90-102.

35. Bianchi ME. DAMPs, PAMPs and alarmins: all we need to know about danger. *J Leukoc Biol*. 2007;81(1):1-5.
36. Nakamura N, Tamagawa-Mineoka R, Ueta M, et al. Toll-like receptor 3 increases allergic and irritant contact dermatitis. *J Invest Dermatol*. 2015;135(2):411-417.
37. Zhang L, Tinkle SS. Chemical activation of innate and specific immunity in contact dermatitis. *J Invest Dermatol*. 2000;115(2):168-176.
38. Hammond MI, Chandra J, Retuerto M, et al. "Skin Microbiome in Atopic Dermatitis: Interactions Between Bacteria (*Staphylococcus*) and Fungi (*Alternaria*)" poster. Society for Investigative Dermatology Annual Meeting; Scottsdale, AZ; 2016 (manuscript in submission).
39. Gerberick GF, Robinson MK, Ryan CA, et al. Contact allergenic potency: correlation of human and local lymph node assay data. *Am J Contact Dermat*. 2001;12(3):156-161.
40. Kohli N, Nedorost S. Inflamed skin predisposes to sensitization to less potent allergens. *J Am Acad Dermatol*. 2016;75(2):312-317.e1.
41. Lee HY, Stieger M, Yawalkar N, et al. Cytokines and chemokines in irritant contact dermatitis. *Mediators Inflamm*. 2013;2013:916497.
42. Wennergren G. What if it is the other way around? Early introduction of peanut and fish seems to be better than avoidance. *Acta Paediatr*. 2009;98(7):1085-1087.
43. Newell L, Polak ME, Perera J, et al. Sensitization via healthy skin programs Th2 responses in individuals with atopic dermatitis. *J Invest Dermatol*. 2013;133(10):2372-2380.
44. Brandner JM, Zorn-Kruppa M, Yoshida T, et al. Epidermal tight junctions in health and disease. *Tissue Barriers*. 2015;3(1-2):e974451.
45. Kasemsarn P, Bosco J, Nixon RL. The role of the skin barrier in occupational skin diseases. *Curr Probl Dermatol*. 2016;49:135-143.
46. Bohaty B, Fricker C, Gonzalez S, et al. Visual and confocal microscopic interpretation of patch tests to benzethonium chloride and benzalkonium chloride. *Skin Res Technol*. 2012;18:272-277.
47. Burkhart C, Schloemer J, Zirwas M. Differentiation of latex allergy from irritant contact dermatitis. *Cutis*. 2015;96(6):369-371, 401.
48. Schwitulla J, Brasch J, Löffler H, et al. Skin irritability to sodium lauryl sulfate is associated with increased positive patch test reactions. *Br J Dermatol*. 2014;171(1):115-123.
49. Tanaka K, Matsui T, Sato A, et al. The relationship between the season of birth and early-onset food allergies in children. *Pediatr Allergy Immunol*. 2015;26(7):607-613.
50. Thysen AH, Rasmussen MA, Kreiner-Møller E, et al. Season of birth shapes neonatal immune function. *J Allergy Clin Immunol*. 2016;137(4):1238-1246.
51. Watkins SA, Maibach HI. The hardening phenomenon in irritant contact dermatitis: an interpretative update. *Contact Dermatitis*. 2009;60(3):123-130.
52. Park SY, Kim JH, Cho SI, et al. Induction of a hardening phenomenon and quantitative changes of ceramides in stratum corneum. *Ann Dermatol*. 2014;26(1):35-42.
53. Adisesh A, Robinson E, Nicholson PJ, et al; Standards of Care Working Group. U.K. standards of care for occupational contact dermatitis and occupational contact urticaria. *Br J Dermatol*. 2013;168(6):1167-1175.
54. Mostosi C, Simonart T. Effectiveness of barrier creams against irritant contact dermatitis. *Dermatology*. 2016; 232(3):353-362.
55. Schliemann S, Petri M, Elsner P. Preventing irritant contact dermatitis with protective creams: influence of the application dose. *Contact Dermatitis*. 2014;70(1):19-26.
56. Diepgen TL, Andersen KE, Chosidow O, et al. Guidelines for diagnosis, prevention and treatment of hand eczema—short version. *J Dtsch Dermatol Ges*. 2015;13(1):77-85.
57. Held E, Lund H, Agner T. Effect of different moisturizers on SLS-irritated human skin. *Contact Dermatitis*. 2001;44(4):229-234.
58. Mollerup A, Veien NK, Johansen JD. Effectiveness of the healthy skin clinic—a randomized clinical trial of nurse-led patient counselling in hand eczema. *Contact Dermatitis*. 2014;71(4):202-214.
59. Lurati AR. Occupational risk assessment and irritant contact dermatitis. *Workplace Health Saf*. 2015;63(2): 81-87.
60. Fartasch M. Wet work and barrier function. *Curr Probl Dermatol*. 2016;49:144-151.
61. Smith SM, Zirwas MJ. Nonallergic reactions to medical tapes. *Dermatitis*. 2015;26(1):38-43.
62. Choi JM, Lee JY, Cho BK. Chronic irritant contact dermatitis: recovery time in man. *Contact Dermatitis*. 2000;42(5):264-269.
63. Bauer A, Schmitt J, Bennett C, et al. Interventions for preventing occupational irritant hand dermatitis. *Cochrane Database Syst Rev*. 2010;(6):CD004414.
64. Williams C, Wilkinson SM, McShane P, et al. A double-blind, randomized study to assess the effectiveness of different moisturizers in preventing dermatitis induced by hand washing to simulate healthcare use. *Br J Dermatol*. 2010;162(5):1088-1092.
65. Held E, Sveinsdóttir S, Agner T. Effect of long-term use of moisturizer on skin hydration, barrier function and susceptibility to irritants. *Acta Derm Venereol*. 1999;79(1):49-51.
66. Simpson EL, Chalmers JR, Hanifin JM, et al. Emollient enhancement of the skin barrier from birth offers effective atopic dermatitis prevention. *J Allergy Clin Immunol*. 2014;134(4):818-823.
67. Horimukai K, Morita K, Narita M, et al. Application of moisturizer to neonates prevents development of atopic dermatitis. *J Allergy Clin Immunol*. 2014; 134(4):824-830.e6.
68. Nichol K, Copes R, Spielmann S, et al. Workplace screening for hand dermatitis: a pilot study. *Occup Med (Lond)*. 2016;66(1):46-49.
69. Nurmohamed S, Bodley T, Thompson A, et al. Health care utilization characteristics in patch test patients. *Dermatitis*. 2014;25(5):268-272.

Chapter 26 :: Seborrheic Dermatitis

:: Dae Hun Suh

AT-A-GLANCE

- Seborrheic dermatitis is a common inflammatory skin disease affecting various age groups.
- Erythematous, greasy, scaling patches and plaques appear on scalp, face, ears, chest, and intertriginous areas.
- Severe forms, like generalized erythroderma, rarely occur.
- Etiology is unclear but may be related to abnormal immune mechanism, *Malassezia*, sebaceous glands, and individual susceptibility.
- Treatment is based on symptomatic control.

Seborrheic dermatitis (SD) is clinically characterized by erythematous, scaly patches on sebaceous gland–rich sites, including scalp, face, upper trunk, and intertriginous areas.[1] The affected areas present as various appearances from mild pinkish and sometimes greasy scaling to solid adherent crusts. Patients with this condition complain of discomfort, with symptoms of itching and burning, and also have some serious cosmetic problems, leading to psychosocial distress that has a negative impact on their quality of life.[2] SD arises in all races and ethnic groups and has a worldwide distribution, but a higher incidence and more-severe forms are observed in AIDS patients and individuals with certain neurologic conditions, such as Parkinson disease.[3]

CLINICAL FEATURES

GENERAL FEATURES

SD usually appears as a chronic and relapsing pattern in adolescents and young adults when the activity of sebaceous glands increases from hormonal effects, with the incidence increasing in patients with older than 50 years of age.[4] SD can also affect babies as young as age 2 weeks with peak incidence at 3 months of age, which is called *infantile seborrheic dermatitis* (ISD; Fig. 26-1). The overall prevalence of SD in general population is between 2.35% and 11.30%, depending on the study.[5] A male predominance is observed in all ages without any racial or regional predilection. SD is often influenced by a seasonal impact. It becomes more common and severe in the cold and dry climates, whereas it may be mitigated by sun exposure. However, several cases induced by treatment of psoralen plus ultraviolet A (PUVA) therapy have been reported.[6]

The symptoms of SD are mainly chronic, persistent, and recurrent. The red, flaking, and greasy lesions of scalp and face are easily observed, particularly on nasolabial folds (Fig. 26-2); eyebrows, upper eyelid, forehead, postauricular areas (Fig. 26-3); external auditory canal and auricle (Fig. 26-4), with generally symmetrical distribution. SD can appear in other sites, such as occiput and neck. When the sternal area on the chest (Fig. 26-5), upper back (Fig. 26-6), and umbilicus are involved, petaloid or arcuate lesions with fine pink scale can be seen. In contrast, intertriginous areas, including inguinal and axillary regions, show less scale, making SD easily confusable with intertrigo. However, variations of these clinical appearances are common. Scalp involvement is more common in the male patient, in the patient with long disease duration, and in the patient with a history of acne.[1] The severity of SD varies from mild erythema and pruritus to severe, oily, thick scale with a burning or tingling sensation. Some patients with SD also may present with *Pityrosporum* folliculitis and blepharitis. *Pityrosporum* folliculitis typically manifests as a diffuse papulopustular eruption with peripheral erythema on the trunk and arises more in immunocompromised patients. Seborrheic blepharitis usually appears as a type of anterior blepharitis, inducing flaking and scaling on the eyelids and creating uncomfortable, irritating problems.

Characteristically, ISD has a relatively different feature in contrast with SD in older ages. The nonpruritic skin eruption generally affects the frontal or vertex areas (or both areas) of the scalp and the central areas of the face with dry, thick, adherent, and flaking scale, and may be accompanied by erythematous rash on intertriginous folds of the trunk and extremities (Fig. 26-7). The extensive involvement of the scalp, commonly called "cradle cap," is one of the typical appearances observed in ISD. ISD normally resolves spontaneously within the first 6 to 12 months of life. Extensive and serious conditions should be differentiated from immunosuppressed status.

LEINER DISEASE

The term *Leiner disease* was first introduced by Carl Leiner in 1908, to describe infants with desquamative erythroderma, sparse hair, frequent loose stools, and failure to thrive.[7] Later, Miller reported other patients with similar clinical features who had generalized SD. Miller also found a lack of opsonization by the serum of the patients.[8] Since Miller's findings it has become

Figure 26-1 Cradle cap or infantile seborrheic dermatitis. (Photo contributed by University of North Carolina Department of Dermatology. From Tintinalli JE, et al. Rashes in infants and children. In Tintinalli JE, et al. *Tintinalli's Emergency Medicine: A Comprehensive Study Guide*. 8th ed. New York, NY: McGraw-Hill Education; 2016:934-952, Fig. 141-30.)

clear that Leiner disease is an umbrella phenotype rather than a single-disease entity, and a variety of immunologic defects have been identified.[9] Congenital or acquired deficiencies of C3, C5, and phagocytic activity results in defective opsonization of yeast and bacteria. Association of Leiner disease and Netherton syndrome was also suggested.[9] Secondary bacterial infection can bring death to a Leiner disease patient, so appropriate treatment, such as IV hydration, temperature regulation, and antibiotics, is essential. Infusion of fresh-frozen plasma or whole blood can be beneficial in supplementing the deficient factors in a hereditary form of Leiner's disease.[8] The prognosis of Leiner disease depends on the nature of the underlying immunologic abnormality of the patients.

PITYRIASIS AMIANTACEA

Asbestos-like scalp, called pityriasis amiantacea, was first described by Alibert in 1832. Pityriasis amiantacea is also called tinea asbestina, tinea amiantacea, keratosis follicularis amiantacea, and porrigo amiantacea. Pityriasis amiantacea is an inflammatory

Figure 26-2 Seborrheic dermatitis with involvement of (**A**) nasolabial folds, cheeks, eyebrows, and nose in white person and (**B**) nasolabial folds in a person of Asian descent.

Figure 26-3 Seborrheic dermatitis of the postauricular area.

condition of the scalp that is characterized by large plates of thick, silvering scale firmly adherent to both the scalp and hair tufts (Fig. 26-8). This can be a localized or diffuse condition, and is attributed to diffuse hyperkeratosis and parakeratosis with follicular keratosis surrounding each hair with a sheath of corneocytes and debris. It is more common in females and it may occur at any age, often without evident causes. Alopecia, which is generally reversible but is sometimes cicatricial, is a common feature of pityriasis amiantacea.[10] Concomitant secondary bacterial infection, mostly *Staphylococcus aureus*, may result in scarring alopecia, so early and appropriate treatment is necessary. The most frequent skin diseases associated with pityriasis amiantacea are psoriasis (35%) and eczematous conditions like SD and atopic dermatitis (34%). Of pediatric patients with pityriasis amiantacea, lesions in 2% to 15% develop into typical psoriasis.[11] Pityriasis amiantacea may also manifest as a complication of lichen planus,

Figure 26-4 Seborrheic dermatitis of the ear: external canal, concha bowl, and auricle.

Figure 26-5 Seborrheic dermatitis of the chest.

lichen simplex chronicus, superficial fungal, or pyogenic infection, or as an adverse effect of molecularly targeted therapy such as vemurafenib.[12,13] In these cases, therapy should be directed toward the underlying etiology.

Figure 26-6 Seborrheic dermatitis of the upper back.

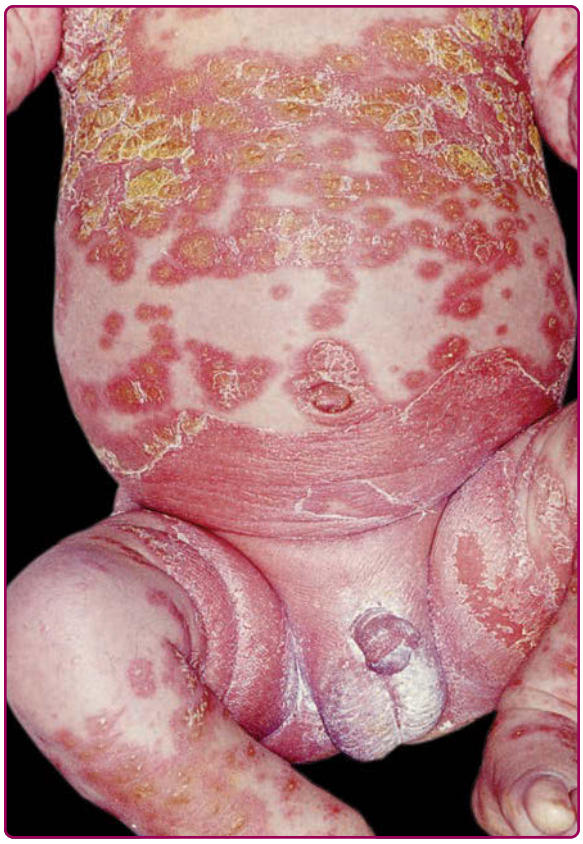

Figure 26-7 Seborrheic dermatitis in an infant. Widespread pattern of seborrheic dermatitis with psoriasiform lesions on the trunk and groin.

Figure 26-8 Pityriasis amiantacea. Masses of sticky silvery scales adhere to the scalp and cause matting of hairs they surround.

ASSOCIATIONS OF HIV AND AIDS

SD arises in more extensive and refractory patterns in up to 83% of HIV-seropositive and AIDS patients (Fig. 26-9).[4] The initial clinical symptom may appear as a butterfly-like rash seen in systemic lupus erythematosus. SD is associated with reduction of T-cell function, and gets worse as the CD4+ lymphocyte count decreases, making SD an indicator for evaluating the progression of AIDS.[14]

ETIOLOGY AND PATHOGENESIS

Many studies to uncover the pathogenesis of SD in adult and adolescent patients have been conducted, but the etiology has not been clearly identified yet.

Figure 26-9 Wide spread unusual distribution pattern of seborrheic dermatitis in a patient with AIDS. **A,** Moist patches on the centrofacial region, beard, and scalp. **B,** Moist lesions on the chest. In patients with AIDS, seborrheic dermatitis responds poorly to conventional therapy.

Multifactorial causes, including several endogenous and exogenous predisposing factors, are associated with SD. The role of sebaceous glands in pathogenesis of SD is notable considering time and lesional distribution of SD. The immunologic status of patients or the susceptibility to SD can be an important factor because SD is much more seen in those with certain underlying diseases such as AIDS and Parkinson disease. *Malassezia* may also be one of the causes of SD as antifungal medications are effective. The relationship of the SD lesions with seasonal fluctuations or sun exposure implies that multiple exogenous factors can contribute to the development of SD.

IMMUNE RESPONSE AND INFLAMMATION

The immune component may be important in the pathogenesis of SD because SD is much more common in immunosuppressed patients. The DBA/2 2C TCR transgenic mouse, which has a defect in expression of CD4+ and CD8+ cells owing to the lack of T-cell progenitor thymocytes, exhibited SD-like eruptions.[15] Several studies have focused on the cellular immunity and humoral immunity in SD, but there are some controversies. One study showed a normal CD4+-to-CD8+ ratio, whereas another study demonstrated a decreased CD4+-to-CD8+ ratio in 68% of patients.[16] A decrease in the number of B cells in 28% of patients and a rise of the number of natural killer cells in 48% of patients were reported. In addition, 60% of patients showed an increase in CD8+ cells and 70% of patients showed a diminished CD4+-to-CD8+ ratio. Also, it was stated that SD patients had an increased production of immunoglobulin (Ig) A and IgG antibodies in serum.[16] However, there was no change in the total amount of antibodies against *Malassezia* in SD, suggesting that changes to the antibodies are not likely linked with *Malassezia*.[17] The alteration of inflammatory cytokines in patients with SD has been demonstrated by immunohistochemical studies. The production of interleukin (IL)-1α, IL-1β, IL-4, IL-12, tumor necrosis factor-α, and interferon (IFN)-γ was increased in the lesions compared with the normal skin.[18] Significantly increased IL-1RA–to–IL-1α and IL-1RA–to–IL-8 ratios, as well as overproduction of histamine, were also shown to occur in SD when compared with healthy controls.[19] An investigation of gene expression by DNA microarrays in 15 patients with dandruff showed the reciprocal expression of induced inflammatory genes and repressed lipid metabolism genes compared with nondandruff individuals.[20] The expression of induced inflammatory genes was distinctly observed in uninvolved skin of the patients as well, indicating the presence of predisposing factors related to inflammation in patients with SD. Furthermore, inflammation induced by oxidative stress through reactive oxygen species may have a potential role in the pathogenesis of SD.[21]

MICROBIAL EFFECTS

Malassezia, normal flora that inhabits human skin, is suggested to be important in SD. This opinion is based on the evidences that the common lesions of SD are related to the distribution of sebaceous glands where *Malassezia* preferentially colonizes, and that antifungal medications have therapeutic effects on SD. A decline in the number of *Malassezia* by use of antifungal agents corresponds with the relief of the symptoms.[4] Moreover, pityriasis versicolor and *Pityrosporum* folliculitis, induced by *Malassezia*, are commonly accompanied by SD. However, there is a lack of difference in *Malassezia* counts between patients with SD and healthy individuals. In addition, a mycelial form of *Malassezia*, a pathogenic form observed in pityriasis versicolor, has not been detected in SD.[17] These facts propose a complex causative role of *Malassezia* for SD. The prevalence and types of the most predominant *Malassezia* species found on SD lesions differ among studies, countries, or parts of body, but *Malassezia globosa* and *Malassezia restricta* are considered to be the most important of the 14 *Malassezia* species identified.[4,22] The complete genome sequences of *M. globosa* and *M. restricta* have been determined and these genomes encode lipase and phospholipase, making the species lipophilic or lipid-dependent.[23] The primary role of these enzymes is to metabolize lipid into fatty acids to produce fungal cell walls responsible for virulence, including invasion and dissemination.[24] Not all *M. globosa* or *M. restricta* strains were found in SD, implying that there may exist specific strains capable of causing the disease.[25] Also, an increased amount of *Malassezia furfur* was observed in patients with SD versus healthy controls.[26] The high concentration of *M. furfur* can disturb protective skin barriers and induce inflammation. *Malassezin*, generated by *M. furfur* or *M. restricta*, can serve as agonists to aryl hydrocarbon receptor, which is involved in the differentiation of T-helper 17 cells and the mediation of contact sensitivity.[27]

LIPID AND HOST SUSCEPTIBILITY FACTORS

Several analyses of skin surface lipids in patients with SD or dandruff have shown alterations in those irrespective of HIV status.[28] These findings were not consistent with one another, but they introduced the causative relationship between SD and the composition of skin surface lipids. Specifically, irritating free fatty acids, such as oleic acid produced by lipase of *M. globosa*, could mediate dandruff-like flaking in the dandruff-susceptible individuals with SD but not in nonsusceptible individuals.[29] Individual susceptibility is considered to be associated with a disrupted epidermal barrier that allows penetration of the irritating metabolites. The process for *Malassezia* to reach the aryl hydrocarbon receptor in the granular and spinous

layers also may depend on such defective skin character. This host susceptibility factor could explain the lack of a positive correlation between the number of *Malassezia* and the severity of dandruff.

EPIDERMAL HYPERPROLIFERATION

Increased epidermal turnover in SD, which is also shown in psoriasis, implicates SD in a disorder of hyperproliferation, and *Malassezia* can be considered as one of the incidental outcomes derived from the phenomenon. SD resembles psoriasis in many aspects, both clinically and histologically, and it is sometimes difficult to differentiate the two diseases even after a skin biopsy. There are case reports that keratolytics and antiinflammatory medications were successful in the treatment of the patients with SD whose treatment with amphotericin B had failed.[30] This alteration of epidermis may be related with the increased activity of calmodulin and explains the basis of use of cytostatic medications such as azelaic acid.[31]

NEUROTRANSMITTER ABNORMALITIES

SD expressed in Parkinson disease has been thought to result from the elevated levels of sebum allowing the proliferation of *Malassezia*. Bilateral seborrhea observed in unilateral parkinsonism suggests the changes of sebum levels are presumably triggered by endocrine effects rather than neurotrophic effects. It may be associated with an increased circulating α-melanocyte–stimulating hormone in Parkinson disease.[32] Because the severity of SD in Parkinson disease does not correlate with the sebum excretion rate, the sebum accumulation by facial immobility may play a key role. Administration of levodopa can clinically improve the skin symptoms by reducing the sebum production or secretion by restoring the production of melanocyte-stimulating hormone-inhibiting factor. The prevalence of SD is also increased in patients with other neurologic disorders, including mood disorder, Alzheimer disease, syringomyelia, epilepsy, cerebrovascular infarcts, postencephalitis, mental retardation, poliomyelitis, quadriplegia, trigeminal nerve injury, and alcoholism. Indoor lifestyle with less sunlight exposure and hygiene status of the patients may function in this association.[4]

OTHER FACTORS

Low humidity and cold temperatures worsen SD, especially in the winter and early spring. Facial trauma (eg, scratching) and PUVA therapy also are aggravating factors.[6] Multiple drugs can lead to SD-like eruptions, including griseofulvin, cimetidine, lithium, methyldopa, arsenic, gold, auranofin, aurothioglucose, buspirone, chlorpromazine, ethionamide, haloperidol, IFN-α, phenothiazines, stanozolol, thiothixene, psoralen, methoxsalen, and trioxsalen. The SD-like dermatitis also appears in patients with zinc deficiency (acrodermatitis enteropathica and acrodermatitis enteropathica–like conditions) or biotin deficiency, but the skin eruptions do not respond to zinc or biotin supplementation.[33] It is noted that the familial form of SD was reported in an Israeli Jewish family of Moroccan descent, which was caused by autosomal dominant genetic mutation (ZNF750) encoding a zinc finger protein (C2H2).[34]

DIAGNOSIS

The diagnosis of SD remains a clinical one, based on SD's characteristic morphology and patterns. Dermoscopy enables the detailed identification of morphologic structures, which is especially helpful in diagnosing SD of the scalp. The typical magnified vascular patterns observed by dermoscopy are twisted loop, red dots and globules, and glomerular vessels in scalp psoriasis, but arborizing vessels and atypical red vessels in SD.[35] A skin biopsy is not routinely required, but may be useful when the diagnosis is unclear. The various histopathologic features can be observed depending on the different stages of the disease: acute, subacute, and chronic. Acute and subacute SD may exhibit slight to moderate spongiotic dermatitis with mild psoriasiform hyperplasia, folliculocentric crust containing scattered neutrophils at the tips of the follicular opening, orthokeratosis with focal parakeratosis, and superficial perivascular lymphohistiocytic infiltration. Chronic SD shows a more intense pattern of the foregoing features with minimal spongiosis and markedly dilated superficial vessels. However, the histopathologic picture in chronic cases is sometimes similar to those of psoriasis, and careful attention should be paid to the histopathology reading. HIV-associated SD is histologically distinctive from the ordinary SD, showing very severe patterns such as extensive parakeratosis, leukoexocytosis, necrosis of keratinocytes, and superficial perivascular infiltrate of plasma cells (Table 26-1).[36] Lesion scraping for a potassium hydroxide preparation can be beneficial to confirm the diagnosis of accompanied *Pityrosporum* folliculitis. It should be kept in mind that SD can simultaneously occur with other dermatoses. When SD occurs in infants, the classic diagnostic criteria suggested by Beare and Rook can be used in diagnosing ISD. It is composed of early onset (before 6 months of age); erythematous and scaling rash distributed in the scalp, diaper, or flexural areas; and the relative absence of pruritus.[37] Involvement of the diaper area alone is considered as a characteristic sign favoring a psoriasiform type of ISD. Above all, the clinician should remember that there is not a characteristic pathognomonic feature or laboratory test to establish the accurate diagnosis of SD.

TABLE 26-1

Histopathologic Differences between Classic Seborrheic Dermatitis and AIDS-Associated Seborrheic Dermatitis

CLASSIC SEBORRHEIC DERMATITIS	AIDS-ASSOCIATED SEBORRHEIC DERMATITIS
Epidermis	
Limited parakeratosis Rare necrotic keratinocytes No interface obliteration Prominent spongiosis	Widespread parakeratosis Many necrotic keratinocytes Focal interface obliteration with clusters of lymphocytes Sparse spongiosis
Dermis	
Thin-walled vessels Rare plasma cells No leukocytoclasis	Many thick-walled vessels Increased plasma cells Focal leukocytoclasis

From Soeprono FF, Schinella RA, Cockerell CJ, Comite SL. Seborrheic-like dermatitis of acquired immunodeficiency syndrome. A clinicopathologic study. *J Am Acad Dermatol.* 1986;14(2):242-248, with permission.

DIFFERENTIAL DIAGNOSIS

Several diseases should be considered in the differential diagnosis of SD (Tables 26-2 and 26-3), especially as ISD is easily confused with atopic dermatitis, psoriasis, histiocytosis, and scabies; sometimes it is impossible to distinguish among these diseases in infants younger than 3 months of age. Checking family history and pruritus and taking certain laboratory tests including serum IgE levels and multiple allergen stimulation tests may give a clue to whether it is atopic dermatitis or ISD. When the skin eruption arises solely on the scalp, an involvement of frontal hair lines is a distinctive feature for scalp psoriasis.[38] Langerhans cell histiocytosis, previously called Letterer-Siwe disease has more generally purpuric lesions and tends to desquamate on the scalp and ulcerate on the folds and the mucosal areas. Severe itching that includes the palms and soles suggests scabies. Intertrigo, contact dermatitis, neonatal erythroderma, and multiple carboxylase deficiency should also be excluded in infants.[39]

CLINICAL COURSE AND PROGNOSIS

Generally SD in adolescents or adults has a chronic and recurrent relapsing course. Consequently, the primary goal of treatment should be control of symptoms like pruritus, erythema, and scales, rather than cure of disease. Also, patients should be informed that they need to prepare for a future re-outbreak and avoid aggravating factors of SD. However, ISD has a benign, self-limited course; ISD spontaneously disappears by 6 to 12 months of age. Severe exacerbation with exfoliating dermatitis may occur, albeit rarely, but its prognosis is usually favorable. ISD does not progress to adulthood.

TABLE 26-2

Site-Specific Differential Diagnosis of Seborrheic Dermatitis

Scalp[a]	Psoriasis, atopic dermatitis, impetigo, tinea capitis[a] (mimics dandruff in children)
Face	Psoriasis, rosacea, contact dermatitis, impetigo, discoid lupus, sarcoid (petaloid type in African Americans), drug-induced photosensitivity
Ear canal	Psoriasis, contact dermatitis
Eyelids	Atopic dermatitis, psoriasis, *Demodex folliculorum* infestation
Chest, back	Pityriasis rosea, tinea versicolor, subacute cutaneous lupus, psoriasis vulgaris
Groin, buttock	Intertrigo (fungal, *Candida*, erythrasma), glucagonoma, extramammary Paget disease, zinc deficiency
Intertriginous	Inverse psoriasis, candidiasis, erythrasma, contact dermatitis, tinea intertrigo, Langerhans cell histiocytosis (Letterer-Siwe disease in infants)
Generalized[b]	Scabies, secondary syphilis, pemphigus foliaceus, pemphigus erythematosus, Leiner disease (infants), drug eruption
Erythrodermic[c]	Psoriasis, contact dermatitis, pityriasis rubra pilaris, drug eruption, mycosis fungoides (Sézary syndrome), lichen planus, chronic actinic dermatitis, HIV, Hodgkin disease, paraneoplastic syndrome, leukemia cutis

[a]Diffuse scalp dermatitis or inflammatory alopecia in children warrants fungal culture, potassium hydroxide preparation.
[b]Widespread truncal types warrant scabies prep and rapid plasma reagin to rule out syphilis.
[c]Erythrodermic type should be biopsied.

MANAGEMENT

Basically, using emollients (eg, mineral oil, vegetable oil, or petroleum jelly) can help improve symptoms such as scales. Soft rubbing with a brush or comb aids removing thick, adherent scales, but aggressive scraping should be avoided because it can induce further inflammation. The main recommendations for the first-line treatment of SD are topical medications, including corticosteroids, calcineurin inhibitors, antifungal drugs, and keratolytics. In the case of topical corticosteroids, mild-potency formulations are recommended to be used first because of their cutaneous adverse effects and frequent rebound phenomena. Treatment with corticosteroids is highly effective for reducing erythema, scaling, and pruritus rapidly, resulting in total clearance more often than placebo.[40] Topical calcineurin inhibitors (tacrolimus and pimecrolimus) manifest good effects on SD by blocking calcineurin, thus preventing both inflammatory cytokines and a signaling pathway in T-lymphocyte cells. No difference between topical calcineurin inhibitors and topical corticosteroids in total clearance was identified in short-term trials.[40] There is no risk of telangiectasia and skin atrophy, so topical calcineurin inhibitors are recommended

TABLE 26-3
Comparison of Infantile Seborrheic Dermatitis with Differential Diagnoses

INFANTILE SEBORRHEIC DERMATITIS	"NAPKIN" PSORIASIS	ATOPIC DERMATITIS	LETTERER-SIWE DISEASE
Occurs in the first few weeks to 3 months	Onset at 3 months	Onset within first 2 months of life, most within the first year	Occurs in newborns; other types of Langerhans cell histiocytosis (LCH) may occur between 1 and 3 years of age
Self-limited, regresses spontaneously	Self-limited	Severity decreases with age	Fatal if untreated; other variants of LCH have differing prognoses
Vertex scalp most commonly affected	Diaper commonly affected; scalp and face may be affected	Face primarily involved	Trunk and scalp involved
Adherent, yellow-brown, greasy scale	Macerated, shiny erythema on diaper region	Intensely pruritic, erythematous papules with excoriation, vesicles and serous exudate; skin appears dry	Slightly raised, rose-yellow papules on trunk that may crust and ulcerate
Face, neck, trunk, and extremities may be affected with intertriginous sites affected (axillae, groin); isolated diaper lesions more suggestive of seborrheic dermatitis	Similarly extensive involvement, but less scaling on intertriginous sites; diaper region primarily affected	Forearms and shins (extensors) often affected, axillae are spared; diaper area usually spared	Extensive involvement with moist erythematous plaques and petechial lesions on intertriginous areas; scalp involvement similar to seborrheic dermatitis

for application to the susceptible regions instead of topical corticosteroids. There are no studies comparing the efficacy of tacrolimus with pimecrolimus in SD. Maintenance therapy with topical calcineurin inhibitors may be useful in preventing the relapse or exacerbation, but their long-term safety has not been verified. Based on the presumed etiologic roles of *Malassezia*, ketoconazole has been the most heavily investigated topical agent for SD. Several randomized studies have demonstrated that 1% to 2% ketoconazole significantly lowers and improves the severity of SD versus placebo, achieving an equal remission rate with corticosteroids, with nearly 44% fewer adverse events.[41] The use of 1% ciclopirox also improved skin symptoms. In single studies for evaluating the short-term efficacy of clotrimazole and miconazole, those had almost equivalent impacts on SD compared with corticosteroids.[41] Other topical antifungal agents, such as bifonazole, terbinafine, fluconazole, and zinc pyrithione, are also likely to be useful.[4] Dandruff or pityriasis simplex capillitii may be treated by shampoos containing zinc pyrithione, selenium sulfide, ketoconazole, salicylic acid, ciclopirox, and coal tar. Lithium seems to have an antiinflammatory role inhibiting the release of arachidonic acid and restricting availability of free fatty acids essential for the growth of *Malassezia*.[42] Topical lithium has shown good results in total clearance both in HIV-negative patients and in AIDS-associated SD. Topical sulfur, propylene glycol, metronidazole, and benzoyl peroxide wash have also been used. Seborrheic blepharitis should be managed by long-term eyelid hygiene with warm compresses, followed by proper topical antibiotics and topical corticosteroid to reduce the bacterial load and marked inflammation, respectively.[43] Aluminum acetate solution can be used to decrease the symptoms of seborrheic otitis externa. In cases refractory to topical treatment, systemic therapies can be prescribed for uncontrolled multiple widespread lesions and severe cases. Low doses of systemic glucocorticoids may be used for a short period. Patients should know that SD can be controlled but not eradicated. SD patients treated by glucocorticoids should be informed of the side effects and rebound flares that occur after discontinuation of glucocorticoids. Oral antifungals may be tried for severe and refractory cases. Itraconazole, fluconazole, and pramiconazole have been used with various regimens.[44] For example, itraconazole 200 mg/day for the first 7 days of the month for several months is a regimen used to get clinical improvement. The daily administration of isotretinoin 0.1 to 0.5 mg/kg also may be effective in severe cases.

The basic principle of treatment is the same for infants. When ISD involves the diaper areas, the use of superabsorbent disposable diapers with frequent changes prevents the aggravation of the symptoms.[45] Soap and alcohol-containing compounds are not recommended in cleaning the diaper lesions. Topical medications having antifungal and antiinflammatory activities are effective choices that have a high clinical cure rate. A mild-potency steroid, such as 1% hydrocortisone, is preferred but used with caution because of its adverse effects. In more refractory cases, a mid-potency topical steroid, such as 0.1% betamethasone valerate, may be required but usable only for a short time. Keratolytic agents, including salicylic acid and selenium sulfide are dangerous to neonates because of the possibility of its percutaneous absorption. Lotion containing 0.025% licochalcone, an extract from *Glycyrrhiza inflata*, was shown to have a similar

effect compared to 1% hydrocortisone.[46] If secondary infection with fungi or bacteria is accompanied, appropriate systemic drugs should be prescribed. Dietary controls and vitamin supplementation are not beneficial in ISD.

Many researchers have proposed various alternative methods to treat SD as well, in preparation for the antifungal resistance and the adverse effects of existing therapies. Homogeneous mixture of biodegradable elements, such as urea, propylene glycol, and lactic acid, was shown to be highly effective in treatment of SD of the scalp.[47] Tea tree oil, derived from nature, was found to be of benefit in improving severity, pruritus, and greasiness in a randomized single-blind study. The antifungal property of tee tree oil, mostly to *M. furfur*, was established in an in vitro study.[48] Narrowband ultraviolet B phototherapy was confirmed as an additional choice and to be both safe and effective in an open-label prospective study. Its role in SD may be associated with its immunomodulatory and antiinflammatory function.[49]

ACKNOWLEDGMENTS

The author acknowledges the contributions of Chris D. Collins, MD, FAAD, and Chad Hivnor, MD, the former authors of this chapter, and thanks Jungyoon Moon, MD, for his devoted assistance.

REFERENCES

1. Park SY, Kwon HH, Min S, Yoon JY, et al. Clinical manifestation and associated factors of seborrheic dermatitis in Korea. *Eur J Dermatol*. 2016;26(2):173-176.
2. Szepietowski JC, Reich A, Wesołowska-Szepietowska E, et al. Quality of life in patients suffering from seborrheic dermatitis: influence of age, gender and education level. *Mycoses*. 2009;52(4):357-363.
3. Arsic Arsenijevic VS, Milobratovic D, Barac AM, et al. A laboratory-based study on patients with Parkinson's disease and seborrheic dermatitis: the presence and density of Malassezia yeasts, their different species and enzymes production. *BMC Dermatol*. 2014;14:5.
4. Gupta A, Bluhm R. Seborrheic dermatitis. *J Eur Acad Dermatol Venereol*. 2004;18(1):13-26.
5. Misery L, Rahhali N, Duhamel A, et al. Epidemiology of dandruff, scalp pruritus and associated symptoms. *Acta Derm Venereol*. 2013;93(1):80-81.
6. Naldi L, Rebora A. Clinical practice. Seborrheic dermatitis. *N Engl J Med*. 2009;360(4):387-396.
7. Dhar S, Banerjee R, Malakar R. Neonatal erythroderma: diagnostic and therapeutic challenges. *Indian J Dermatol*. 2012;57(6):475-478.
8. Schwartz RA, Janusz CA, Janniger CK. Seborrheic dermatitis: an overview. *Am Fam Physician*. 2006; 74(1):125-130.
9. Ong C, O'Toole EA, Ghali L, et al. LEKTI demonstrable by immunohistochemistry of the skin: a potential diagnostic skin test for Netherton syndrome. *Br J Dermatol*. 2004;151(6):1253-1257.
10. Verardino GC, Azulay-Abulafia L, Macedo PM, et al. Pityriasis amiantacea: clinical-dermatoscopic features and microscopy of hair tufts. *An Bras Dermatol*. 2012; 87(1):142-145.
11. Abdel-Hamid IA, Agha SA, Moustafa YM, et al. Pityriasis amiantacea: a clinical and etiopathologic study of 85 patients. *Int J Dermatol*. 2003;42(4):260-264.
12. Lacouture ME, Duvic M, Hauschild A, et al. Analysis of dermatologic events in vemurafenib-treated patients with melanoma. *Oncologist*. 2013;18(3):314-322.
13. Belum VR, Rosen AC, Jaimes N, et al. Clinico-morphological features of BRAF inhibition–induced proliferative skin lesions in cancer patients. *Cancer*. 2015;121(1):60-68.
14. Nnoruka EN, Chukwuka JC, Anisuiba B. Correlation of mucocutaneous manifestations of HIV/AIDS infection with CD4 counts and disease progression. *Int J Dermatol*. 2007;46(s2):14-18.
15. Oble DA, Collett E, Hsieh M, et al. A novel T cell receptor transgenic animal model of seborrheic dermatitis-like skin disease. *J Invest Dermatol*. 2005;124(1): 151-159.
16. Dessinioti C, Katsambas A. Seborrheic dermatitis: etiology, risk factors, and treatments: facts and controversies. *Clin Dermatol*. 2013;31(4):343-351.
17. Sandström Falk MH, Tengvall Linder M, Johansson C. The prevalence of *Malassezia* yeasts in patients with atopic dermatitis, seborrhoeic dermatitis and healthy controls. *Acta Derm Venereol*. 2005;85(1):17-23.
18. Faergemann J, Bergbrant IM, Dohse M, et al. Seborrhoeic dermatitis and *Pityrosporum (Malassezia)* folliculitis: characterization of inflammatory cells and mediators in the skin by immunohistochemistry. *Br J Dermatol*. 2001;144(3):549-556.
19. Kerr K, Schwartz JR, Filloon T, et al. Scalp stratum corneum histamine levels: novel sampling method reveals association with itch resolution in dandruff/seborrhoeic dermatitis treatment. *Acta Derm Venereol*. 2011;91(4):404-408.
20. Mills KJ, Hu P, Henry J, et al. Dandruff/seborrhoeic dermatitis is characterized by an inflammatory genomic signature and possible immune dysfunction. *Br J Dermatol*. 2012;166(Suppl2):33-40.
21. Emre S, Metin A, Demirseren DD, et al. The association of oxidative stress and disease activity in seborrheic dermatitis. *Arch Dermatol Res*. 2012;304(9):683-687.
22. Tanaka A, Cho O, Saito M, et al. Molecular characterization of the skin fungal microbiota in patients with seborrheic dermatitis. *J Clin Exp Dermatol Res*. 2014;5(6):239.
23. Xu J, Saunders CW, Hu P, et al. Dandruff-associated *Malassezia* genomes reveal convergent and divergent virulence traits shared with plant and human fungal pathogens. *Proc Natl Acad Sci U S A*. 2007;104(47): 18730-18735.
24. Patino-Uzcategui A, Amado Y, Cepero de Garcia M, et al. Virulence gene expression in *Malassezia* spp from individuals with seborrheic dermatitis. *J Invest Dermatol*. 2011;131(10):2134-2136.
25. Hiruma M, Cho O, Hiruma M, et al. Genotype analyses of human commensal scalp fungi, *Malassezia globosa*, and *Malassezia restricta* on the scalps of patients with dandruff and healthy subjects. *Mycopathologia*. 2014;177(5-6):263-269.
26. Tajima M, Sugita T, Nishikawa A, et al. Molecular analysis of *Malassezia* microflora in seborrheic dermatitis patients: comparison with other diseases and healthy subjects. *J Invest Dermatol*. 2008;128(2):345-351.
27. Gaitanis G, Magiatis P, Stathopoulou K, et al. AhR ligands, malassezin, and indolo[3,2-b]carbazole are

selectively produced by *Malassezia furfur* strains isolated from seborrheic dermatitis. *J Invest Dermatol*. 2008;128(7):1620-1625.
28. De Luca C, Valacchi G. Surface lipids as multifunctional mediators of skin responses to environmental stimuli. *Mediators Inflamm*. 2010;2010:321494.
29. DeAngelis YM, Gemmer CM, Kaczvinsky JR, et al. Three etiologic facets of dandruff and seborrheic dermatitis: *Malassezia* fungi, sebaceous lipids, and individual sensitivity. *J Invest Dermatol Proc.* 2005;10(3):295-297.
30. Hay RJ. *Malassezia*, dandruff and seborrhoeic dermatitis: an overview. *Br J Dermatol*. 2011;165(suppl 2):2-8.
31. Donovan M, Ambach A, Thomas-Collignon A, et al. Calmodulin-like skin protein level increases in the differentiated epidermal layers in atopic dermatitis. *Exp Dermatol*. 2013;22(12):836-837.
32. Mastrolonardo M, Diaferio A, Logroscino G. Seborrheic dermatitis, increased sebum excretion, and Parkinson's disease: a survey of (im)possible links. *Med Hypotheses*. 2003;60(6):907-911.
33. Trüeb RM. Serum biotin levels in women complaining of hair loss. *Int J Trichology*. 2016;8(2):73.
34. Birnbaum RY, Zvulunov A, Hallel-Halevy D, et al. Seborrhea-like dermatitis with psoriasiform elements caused by a mutation in ZNF750, encoding a putative C2H2 zinc finger protein. *Nat Genet*. 2006;38(7):749-751.
35. Kim GW, Jung HJ, Ko HC, et al. Dermoscopy can be useful in differentiating scalp psoriasis from seborrhoeic dermatitis. *Br J Dermatol*. 2011;164(3):652-656.
36. Soeprono FF, Schinella RA, Cockerell CJ, et al. Seborrheic-like dermatitis of acquired immunodeficiency syndrome. A clinicopathologic study. *J Am Acad Dermatol*. 1986;14(2):242-248.
37. Alexopoulos A, Kakourou T, Orfanou I, et al. Retrospective analysis of the relationship between infantile seborrheic dermatitis and atopic dermatitis. *Pediatr Dermatol*. 2014;31(2):125-130.
38. Kibar M, Aktan Ş, Bilgin M. Dermoscopic findings in scalp psoriasis and seborrheic dermatitis; two new signs; signet ring vessel and hidden hair. *Indian J Dermatol*. 2015;60(1):41.
39. Carlo G, Ramon G. Infantile seborrhoeic dermatitis. In: Alan I, Peter H, Albert Y. *Harper's Textbook of Pediatric Dermatology*. 3rd ed. Oxford, UK: Wiley-Blackwell; 2011:35.1-35.8.
40. Kastarinen H, Oksanen T, Okokon EO, et al. Topical anti-inflammatory agents for seborrhoeic dermatitis of the face or scalp. *Cochrane Database Syst Rev*. 2011;(5):CD009446.
41. Okokon EO, Verbeek JH, Ruotsalainen JH, et al. Topical antifungals for seborrhoeic dermatitis. *Cochrane Database Syst Rev*. 2015;(5):CD008138.
42. Mayser P, Schulz S. Precipitation of free fatty acids generated by *Malassezia*—a possible explanation for the positive effects of lithium succinate in seborrhoeic dermatitis. *J Eur Acad Dermatol Venereol*. 2016;30(8):1384-1389.
43. Pflugfelder SC, Karpecki PM, Perez VL. Treatment of blepharitis: recent clinical trials. *Ocul Surf*. 2014;12(4):273-284.
44. Gupta AK, Richardson M, Paquet M. Systematic review of oral treatments for seborrheic dermatitis. *J Eur Acad Dermatol Venereol*. 2014;28(1):16-26.
45. Tüzün Y, Wolf R, Bağlam S, et al. Diaper (napkin) dermatitis: a fold (intertriginous) dermatosis. *Clin Dermatol*. 2015;33(4):477-482.
46. Wananukul S, Chatproedprai S, Charutragulchai W. Randomized, double-blind, split-side comparison study of moisturizer containing licochalcone vs. 1% hydrocortisone in the treatment of infantile seborrhoeic dermatitis. *J Eur Acad Dermatol Venereol*. 2012; 26(7):894-897.
47. Emtestam L, Svensson Å, Rensfeldt K. Treatment of seborrhoeic dermatitis of the scalp with a topical solution of urea, lactic acid, and propylene glycol (K301): results of two double-blind, randomised, placebo-controlled studies. *Mycoses*. 2012;55(5):393-403.
48. Pazyar N, Yaghoobi R, Bagherani N, et al. A review of applications of tea tree oil in dermatology. *Int J Dermatol*. 2013;52(7):784-790.
49. Gambichler T, Breuckmann F, Boms S, et al. Narrowband UVB phototherapy in skin conditions beyond psoriasis. *J Am Acad Dermatol*. 2005;52(4):660-670.

Chapter 27 :: Occupational Skin Diseases*

:: Andy Chern, Casey M. Chern, & Boris D. Lushniak

AT-A-GLANCE

- Occupational skin diseases are the second most common occupational illness accounting for approximately 15% of occupational illnesses.
- The vast majority of occupational skin diseases are occupational contact dermatoses (irritant contact dermatitis and allergic contact dermatitis), with approximately 80% of cases occurring on the hands.
- Workers in the natural resources and mining, manufacturing, and education and health services have the highest rates of reported skin diseases and disorders.
- Occupational exposures (ultraviolet radiation and chemical carcinogens) can have a significant role in skin cancer development, which is a major public health concern.
- Personal protective equipment should be the last consideration in addressing occupational skin hazards.

INTRODUCTION

BACKGROUND

Occupational skin diseases (OSDs) are a category of skin conditions caused or aggravated primarily by workplace factors. Occupational skin diseases are common and also contribute to significant economic costs. An estimate as high as $1 billion is associated with the burden of workplace skin diseases in the US annually.[1,2] In addition, OSDs may have unique implications. Federal agencies such as the Occupational Safety and Health Administration (OSHA) have mandated criteria for recording occupationally related injuries and illnesses by the employer, and the determination of work-relatedness may result in the involvement of a workers' compensation system. Thus, a thorough knowledge of contributing factors to OSDs is vital for the timely treatment and prevention of these skin conditions to return patients and employees back to work.

HISTORICAL PERSPECTIVE

Occupational skin diseases have existed throughout history. Even in antiquity, the Roman poet Virgil (70-19 BCE) described the cutaneous manifestations of *Bacillus anthracis* exposure in sheepmen.[3] However, it was centuries later that the Italian physician Bernardino Ramazzini (1633-1714), recognized as "the Father of Occupational Medicine," would document his pioneering observations of various occupational diseases in *De Morbis Artificum Diatriba* (Diseases of Workers). In regard to OSDs, Ramazzini observed leg ulcers in fishermen, fissures and inflammation of the hands in laundrywomen, and skin eruptions in grain workers among others.[4] Although Ramazzini described associations between occupation and disease, further work identifying the causal relationship between the 2 has been the impetus for labor laws and reform. One classic example was the identification of scrotal cancer in chimney sweepers by Sir Percivall Pott (1714-1788), a British surgeon. Pott recognized that chronic exposure to soot (polycyclic aromatic hydrocarbons) lodged in the rugae led to scrotal cancer; and, in 1788, Pott's work led to the first of many Chimney Sweeps Acts passed in Britain.[5]

EXPOSURE CLASSIFICATION

The etiology of occupational injuries and illnesses, including OSDs, can be classified by the following exposures:

- Chemical: organic and inorganic compounds, elemental substances
- Mechanical: friction, pressure, vibration
- Physical: ionizing and nonionizing radiation, thermal stress
- Biologic: bacteria, viruses, fungi, parasites, insects, plants, animals

The vast majority of OSDs are attributed to chemical agents; however, mechanical, physical, and biologic exposures must be considered in the differential diagnoses as multiple concurrent exposures can often occur in the workplace.

*Disclaimer: The contents of this publication are the sole responsibility of the authors and do not necessarily reflect the views, opinions or policies of the Uniformed Services University of the Health Sciences (USUHS), the Department of Defense (DoD), or the Departments of the Army, Navy, or Air Force. Mention of trade names, commercial products, or organizations does not imply endorsement by the U.S. Government.

OCCUPATIONAL DISEASE SPECTRUM

Of all the work-related dermatologic diseases, occupational contact dermatitis (OCD) comprises 90% to 95% of OSDs.[6] The remaining 5% to 10% of OSD cases consist of a wide variety of diseases. Some of these include immunologic and nonimmunologic contact urticaria, occupational skin cancers, vibration white finger, and infections. Table 27-1 lists common categories of OSDs.

EPIDEMIOLOGY

In the United States, the Bureau of Labor Statistics (BLS) publishes annual data on occupational injuries and illnesses. Among private industry, nonfatal occupational injuries and illnesses accounted for nearly 3 million cases in 2014. Nonfatal occupational illnesses only consisted of 4.9% of the total cases, but of these, 15.2% were skin diseases.[7] The distribution of nonfatal occupational illness cases is depicted in Fig. 27-1.

Additionally, the rate of reported OSDs declined in 2014 among all industries from the previous year from 3.2 to 2.6 cases per 10,000 full-time workers.[7] However, limitations in BLS epidemiologic data may considerably underestimate the true incidence of OSDs by as much as 10 to 50 times.[2,8] Moreover, BLS categorizes wounds and bruises separately under injuries, which is not reflected in the aforementioned rates. In comparison, several studies of European countries including those with active nationwide notification programs for OCD reported incidence rates between 5 and 19 cases per 10,000 full-time workers per year for OCD alone.[9-13]

When comparing OSD among industries in the United States, education and health services accounted for the highest total skin disease cases (6100) followed by the manufacturing industry (4400) in 2014.[7] However, the highest incidence rate occurred in the natural resources and mining industries. With only 1000 total cases, natural resources and mining had an incidence rate of 5.5 cases per 10,000 full-time workers, with education and health services following behind with 4 cases per 10,000 full-time workers.[7] The total distribution of OSDs by industry is demonstrated in Fig. 27-2.

The total cases of OSD has declined over the last decade, and a corresponding decline in the incidence of OSD cases involving days away from work also has been observed, potentially reflecting not only better prevention measures but improved early management.[14] In 2014, among all OSDs, skin infections resulted in the longest duration away from work (median = 6 days) while wounds and bruises had the highest incidence rate involving days away from work (9.1 cases per 10,000 full-time workers).[7]

OCCUPATIONAL CONTACT DERMATITIS

Occupational contact dermatitis refers to any irritation of the skin arising from direct exposure to an exogenous agent and can be further divided into 2 general categories based on exposure, etiology, and pathophysiology of the resulting skin disease. These are irritant contact dermatitis (ICD) and allergic contact dermatitis (ACD). Occupations at increased risk for OCD are listed in Table 27-2.

Specifically, ICD results from a nonimmunologic reaction to a chemical, physical, or mechanical irritation of the skin causing cutaneous inflammation via a direct cytotoxic effect from an agent. Anyone may develop an ICD, and those with compromised skin barrier such as atopic dermatitis, xerosis, or light colored skin are at higher risk.[15]

In contrast, ACD is a reaction to a substance by a type IV, delayed hypersensitivity reaction. This cell-mediated, immune reaction requires prior sensitization to an allergen, which is usually a low-molecular weight chemical that acts as a hapten. Only a small percentage of people will develop ACD after contact from various haptens. For perspective, more than 57,000 chemicals have been known to cause skin irritation (ICD), whereas only about 3700 chemicals have been identified as true skin allergens.[16] Table 27-3 provides a comparison of ICD and ACD characteristics. As would be expected, the vast proportion of OCD occur on the hands (80%).[16]

IRRITANT CONTACT DERMATITIS

BACKGROUND

Irritant contact dermatitis occurs when the normal epidermal barrier is disrupted by an irritant and is often concentration or duration dependent, with no previous substance exposure necessary to elicit an effect. Effects may be visible within minutes to a few hours. Wet work tasks have been identified as the most common occupational exposure leading to contact dermatitis though other frequent causes include exposure to soaps, petroleum products, cutting oils, coolants, and solvents (Fig. 27-3).[21] The exposed hands are the most commonly involved sites for ICD given their interaction with the environment and opportunities for irritant exposure. Though there is no readily available diagnostic test for ICD, a careful history in addition to the patient's clinical presentation are usually sufficient in making the diagnosis.

CLINICAL FEATURES

Irritant contact dermatitis, unlike ACD, is not a distinct clinical entity. The clinical pictures of ICD is

TABLE 27-1
Common Occupational Skin Diseases

	ORGANISM	OCCUPATION	TREATMENT
Bacterial Infections			
Impetigo, cellulitis, furuncles, and abscesses	*Staphylococcus* sp., *Streptococcus* sp.	Meat packers, construction workers, farm workers, nurses, athletes, hairdressers, manicurists	Topical: mupirocin 2%, retapamulin 1%, fusidic acid 1% Systemic agents: dicloxacillin, cephalexin, erythromycin, clindamycin, TMP-SMX[a]
Anthrax	*Bacillus anthracis*	Workers in contact with goat hair, wool, hides	Penicillin, doxycycline (naturally occurring anthrax); Fluoroquinolone (suspected weaponized anthrax)
Fish tank granuloma	*Mycobacterium marinum*	Fisherman, fish market worker	Doxycycline, ethambutol, minocycline, rifampicin
Erysipeloid	*Erysipelothrix rhusiopathiae*	Fishermen, butchers, farmers, veterinary surgeons, poultry dressers	Penicillin, ampicillin, ceftriaxone, fluoroquinolone
Pitted keratolysis	*Corynebacterium* sp.	Barefooted laborers, soldiers, miners	Prophylactic measures; benzoyl peroxide cleanser; topical clindamycin, erythromycin solutions, miconazole, fusidic acid
Brucellosis	*Brucella* sp.	Slaughterhouse workers, farmers, veterinarians, meat packers, livestock breeders, laboratory workers.	Doxycycline combined with streptomycin OR gentamicin OR rifampin
Tularemia	*Francisella tularensis*	Laboratory workers, farmers, veterinarians, sheep workers, hunters, cooks, meat handlers, landscapers	Aminoglycoside, fluoroquinolone, doxycycline
Fungal and Yeast Infections[b]			
Tinea pedis	*Trichophyton rubrum; E. floccosum, T. mentagrophytes/ interdigitale*	Miners, military personnel, athletes, laborers	Topical: allylamines, imidazoles; Systemic agents: terbinafine, itraconazole, fluconazole
Candida, other yeast infections	*Candida albicans*	Waitresses, bartenders, food handlers	Topical: imidazoles, nystatin; Systemic agents: fluconazole
Other superficial mycoses	*Trichophyton verrucosum*	Exposure to cattle, farm buildings, and straw	Topical: allylamines, imidazoles; Systemic agents: terbinafine, itraconazole, fluconazole)
	Trichophyton mentagrophytes/ interdigitale	Cattle, domestic animal exposure	Topical: allylamines, imidazoles; Systemic agents: terbinafine, itraconazole, fluconazole
	Microsporum canis	Domestic animals, esp. cats	Systemic agents: terbinafine, itraconazole, fluconazole
	Microsporum nanum	Pigs	Topical: imidazoles[c]
	Sporothrix schenckii	Gardeners, forestry workers, nursery workers, miners, farmers	Systemic agents: itraconazole, terbinafine
Deep mycoses	*Histoplasma capsulatum*	Workers with exposure to demolition, excavation activities	Systemic agents: itraconazole; amphotericin B
	Chromoblastomycosis	Farmers, outdoor workers	Systemic agents: itraconazole, terbinafine, amphotericin B
	Phaeohyphomycosis	Farmers, outdoor workers	Surgical excision
	Eumycetoma	Farmers, outdoor workers	Itraconazole, voriconazole
Viral Infections			
Herpetic whitlow	*Herpes simplex virus*	Dental workers	Acyclovir, valacyclovir, famciclovir
Orf/ecthyma contagiosum	*Parapoxvirus*	Veterinarians, sheep herders, farmers	Supportive care, antibiotic coverage if secondary infection is suspected
Pseudocowpox/ milker's nodule	*Paravaccinia virus*	Farmers, veterinarians, fresh meat handlers	Symptomatic treatment; surgical curettage for large lesions
Human papilloma virus	*Human papilloma virus (HPV)-7*	Butchers	Destructive modalities (cryotherapy, curettage, electrodessication), podophyllotoxin, topical 5-fluorouracil, cantharidin, caustics and acids, imiquimod

[a]Dose and duration, as well as antibiotic option dependent on clinical manifestation of the infection, sites affected, and methicillin-sensitivity of the causative organism.

[b]Dose and duration of treatment are dependent on the clinical manifestation of the infection, as well as the sites affected.

[c]Roller JA, Westblom TU. Microsporum nanum infection in hog farmers. *J Am Acad Dermatol.* 1986;15(5 Pt 1):935-939.

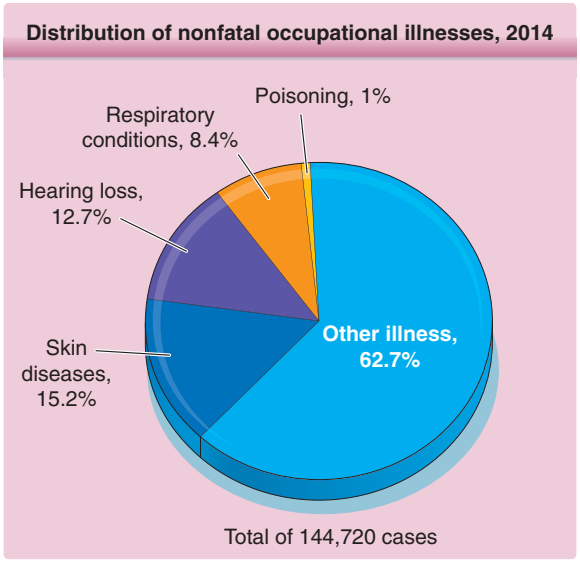

Figure 27-1 Distribution of nonfatal occupational illnesses. Distribution of nonfatal occupational illness cases by category of illness; private industry; 2014. Less than 5% of injury and illness cases reported among the private industry establishments in 2014 were illnesses. More than 60% of illness cases were categorized as "all other illnesses," which includes such things as repetitive motion cases and other systemic diseases and disorders. (Data from U.S. Bureau of Labor Statistics: 2014 Survey of Occupational Injuries & Illnesses.)

dependent on time-effect and dose relationship.[22] For instance, a severe acute response to a strong noxious irritant may present with necrosis or ulceration, whereas chronic lesions often present with lichenification, scaling, hyperpigmentation, or fissuring.

ICD presentations may be categorized as follows, although no standard case definition exists for the spectrum of ICD[16,23]:

- Acute
- Irritant reaction
- Cumulative
- Traumatic
- Asteatotic dermatitis
- Pustular and acneiform
- Subjective

Even with these categories, it is important to recognize that ICD and ACD can both have similar clinical manifestations as acute, subacute, and chronic skin conditions.

Acute Irritant Contact Dermatitis: Acute ICD manifests when the skin is exposed to a potent irritant or caustic chemical from an accident at work. The irritant reaction quickly reaches a peak, then starts to heal; this is called a *decrescendo phenomenon*. Because of the short lag time (minutes to hours after exposure) and the clear association between exposure and skin symptoms, the diagnosis can be easily made. However, it may be difficult when the patient is unaware of an exposure, and consequently, an acute ACD should be considered in the differential diagnosis. Because acute ACD is a delayed sensitization reaction, it is characterized by the *crescendo phenomenon* that is a transient increase of symptom intensity despite removal of the allergen.

Symptoms of acute ICD include burning, soreness, and stinging of the skin. These lesions are restricted to

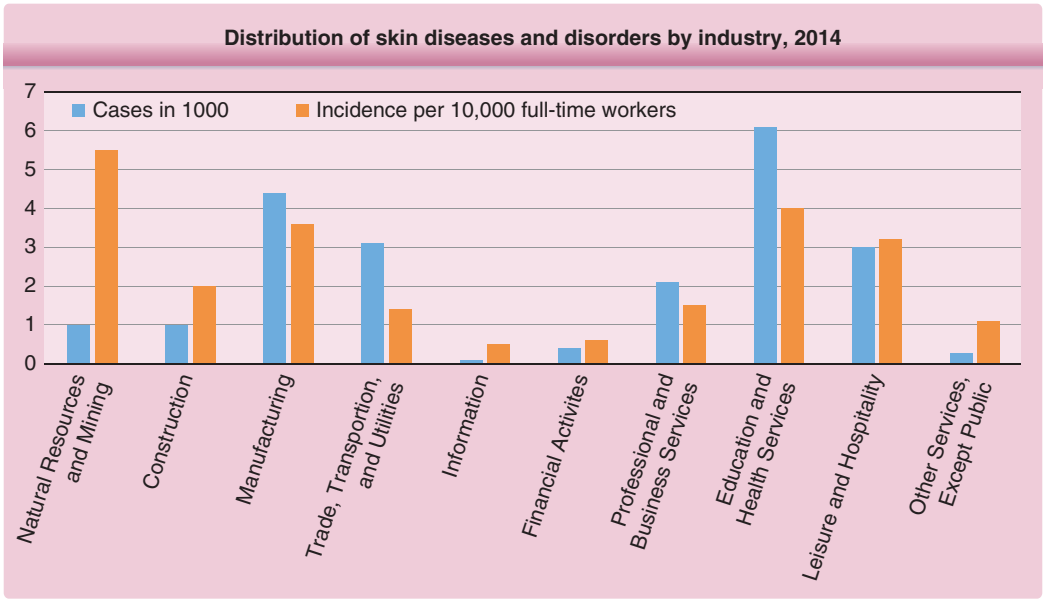

Figure 27-2 Distribution of skin diseases and disorders by industry. Distribution of skin diseases or disorders by private industry; 2014. Natural resources and mining excludes farms with fewer than 11 employees. Data for mining include establishments not governed by the Mine Safety and Health Administration rules and reporting, such as those in Oil and Gas Extraction and related support activities. (Data from U.S. Bureau of Labor Statistics: 2014 Employer-Reported Workplace Injuries & Illnesses.)

TABLE 27-2
Occupations at Increased Risk for Irritant and Allergic Contact Dermatitis

OCCUPATION	IRRITANTS	ALLERGENS
Agricultural workers	Fertilizers, germicides, dust, diesel, gasoline, oils, pesticides, plants, solvents, wet-work	Pesticides, animal feeds, barley and oats, fungicides, germicidal products, cement, plants, veterinary medications, wood dust, preservatives, wool
Bakers	Acids, flour, spices, soaps and detergents, oven cleaners, essential oils, yeast, enzymes	Ammonium persulfate; benzoyl peroxide; dyes; essential oils; enzymes; flavors; flour; some fruits
Construction workers	Acids, fibrous glass, concrete, solvents, hand cleaners	Cement, chromium, chromium compounds, cobalt, epoxy resins, nickel, resins, rubber allergens, wood dust
Cooks	Wet work, soaps and detergents, vegetable and fruit juices, raw meat and fish, spices, sugar and flour, heat	Flavors and spices, formaldehyde, garlic, sodium metabisulfite (antioxidant for vegetables)
Cosmetologists	Soaps and detergents, bleaches, solvents, permanent wave solutions, shampoos, wet-work	Dyes, amine-based products including parphenylene diamine, glyceryl monothioglycolate (perming solution), rosin, preservatives, rubber allergens, ethylmethacrylate, methylmethacrylate
Dentists and dental technicians	Wet work, adhesives (epoxy and cyanoacrylates), essential oils, orthodontic plasters, amalgam mixtures, solvents	Dental impression material, eugenol, anesthetics, mercury, disinfectants, methacrylates, latex, rubber accelerators
Florists	Wet work, soaps and detergents, fertilizers, herbicides, pesticides, mechanical and chemical plant irritants	Plants, pesticides, insecticides
Health care workers	Wet work, soaps and detergents, alcohol, ethylene oxide, medications	Latex gloves, anesthetics, antibiotics and antiseptics, phenothiazines, formaldehyde, glutaraldehyde, chloroxylenol
Housekeepers	Wet work, soaps and detergents, cleaners, polishes, oven cleaners, disinfectants	Potassium dichromate, preservatives, rubber accelerators, latex
Machinists	Solvents, coolants, cutting oils, degreasers, acids, corrosion inhibitors, heat, soaps and detergents, metal filings and swarf	Additives/preservatives in cutting fluids, chromium, nickel
Automobile mechanics	Abrasive skin cleaners, diesel, gasoline, greases, oils, solvent, transmission fluid, motor oils	Chromium, cobalt, epoxy resin; nickel
Painters	Paints, solvents, adhesives, paint removers, paintbrush cleaners, soaps and detergents	Turpentine, thinners, chromium, formaldehyde, epoxy products, polyester resins

the areas where the irritant damages the skin, which may result in erythema, edema, bullae, or necrosis with sharply demarcated borders. An asymmetric pattern may hint at an exogenous cause.

Acute ICD has a good prognosis with appropriate and symptomatic management. Acids and alkaline are the most frequent potent culprits giving rise to an acute ICD. A common example can be seen in construction workers developing chemical burns when alkaline concrete fluid spills into work boots or soaks through garments.[24] Also, several agents causing chemical burns warrant brief mention as they require

TABLE 27-3
Comparison of ICD and ACD

	IRRITANT	ALLERGIC
Onset	Within minutes for strong irritants, up to days/weeks with weak irritants	Within 24-96 h in sensitized individuals
Resolution	Improves after 3-6 weeks away from exposure	May improve within days after exposure; some cases persist
Histology	Spongiotic dermatitis	Spongiotic dermatitis
Mechanism	Nonimmune, sensitization not required; epidermal barrier disruption, epidermal cellular damage, pro-inflammatory mediators released from keratinocytes[17-19]	Immune-mediated, sensitization required; Antigen-activated primed T cells; sensitization phase typically takes 10-14 d[20]
Agent	Concentration dependent	Not concentration dependent
Atopy	Predisposition	Variable
Diagnosis	Clinical	Patch testing

Modified from Belsito DV. Occupational contact dermatitis: etiology, prevalence, and resultant impairment/disability. *J Am Acad Dermatol.* 2005;53:303-313.

Figure 27-3 Acute irritant contact dermatitis on the hand caused by an industrial solvent. There is massive blistering on the palm.

more specific therapies. These agents are summarized in Table 27-4.

Irritant Reaction Contact Dermatitis: Irritant reaction contact dermatitis is a subclinical irritant dermatitis in workers whose hands are excessively wet, including hairdressers, bartenders, and metal workers. On the hands, scaling and erythema are first identified under rings before spreading over fingers to hands and forearms. The thinner skin of the dorsum of the hand is usually affected, though irritants can also cause vesiculation resembling pompholyx. Frequently, irritant reaction contact dermatitis heals spontaneously with hardening of the skin, but may progress to cumulative irritant dermatitis.

Cumulative Irritant Contact Dermatitis: Cumulative ICD is a consequence of multiple subthreshold insults to the skin with insufficient time between insults to allow complete restoration of the skin barrier function.[28] It may result from the frequent repetition of one agitating factor but is more commonly the result of a variety of stimuli, each beginning before recovery from the foregoing stimulant. Clinical symptoms develop only when the damage exceeds an individually determined *manifestation threshold*. Patients with sensitive skin (ie, atopics) have a decreased irritant threshold or a prolonged restoration time, leading to earlier development of cumulative ICD. The threshold is not a fixed value for an individual but may decrease with disease progression. Therefore, in patients with cumulative ICD, even limited irritant exposure may sustain the condition. Cumulative ICD is associated with weak irritants rather than potent irritants with exposures occurring not only at work but also at home. The link between exposure and disease is frequently not obvious to the patient, and therefore, the diagnosis may be considerably delayed. These patients often complain of pruritus and pain due to fissuring of the hyperkeratotic skin with notable lichenification and chapping. In contrast to acute irritant dermatitis, the lesions are less sharply demarcated (Fig. 27-4).

TABLE 27-4
Selected Chemical Burns That Require Unique Therapies

CHEMICAL	TREATMENT BASICS (THEN TRANSPORT TO HOSPITAL EMERGENCY DEPARTMENT FOR FURTHER EVALUATION AND TREATMENT)
Burning metal fragments of sodium, potassium, and lithium	Extinguish with Class D fire extinguisher (containing sodium chloride, sodium carbonate or graphite base) or with sand; cover with mineral oil; extract metal particles mechanically[a]
Hydrofluoric acid	Flush with running water; then administer calcium gluconate gel (2.5%) followed by intralesional injection, if needed
White phosphorus	Remove particles mechanically; wash with soap and water; then apply copper ($CuSO_4$) sulfate in water for several minutes, remove black copper phosphide, and wash with water. Vigorous water irrigation and removal of phosphorus particles mechanically; the use of a Wood lamp (ultraviolet light) results in the fluorescing of the white phosphorus and may facilitate its removal. A brief rinse with 1% copper sulfate solution may be helpful. Copper sulfate combines with phosphorus to form a dark-copper phosphide coating on the particles that makes them easier to see and debride, and also impedes further oxidation. However, copper sulfate can cause hemolysis and hemoglobinuria, and should be used with caution.[25] More recently Kaushik and Bird recommend vigorous water washing rather than using copper sulfate.[26]
Phenolic compounds	Decontaminate with undiluted 200- to 400-Da molecular weight polyethylene glycol (PEG), which can be located in the chemical section of hospital pharmacies, followed by copious water irrigation. Isopropanol or glycerol may be substituted if PEG is not available.[27] Initial soap and water washing followed by treatment with polyethylene glycol 300 or 400 or ethanol (10%) in water.
Bromine or iodine	Wash frequently with soap and water followed by treatment with 5% sodium thiosulfate.

[a]Use of water to extinguish burning metal fragments is contraindicated because of the formation of highly alkaline hydroxides.

Figure 27-4 Irritant contact dermatitis in a construction worker who works with cement. Note the hyperkeratosis, scaling, and fissuring. There is also minimal postulation. Note that right (dominant working) hand is more severely affected than left hand.

Traumatic Irritant Contact Dermatitis: Traumatic ICD may arise after acute skin trauma, such as lacerations, burns, or acute ICD. The latter is seen frequently after use of harsh cleansers, and inquiring if patients have cleansed their skin with strong soaps or detergents is warranted. The syndrome is characterized by eczematous lesions and delayed healing. Continued use of the irritant may cause the condition to persist, and full resolution may not occur for many months after discontinuation of exposure. When warranted, harsh soaps should be replaced by an appropriate soap. Soap is used to emulsify an unwanted material on the skin. Typically, a specific cleanser for the substance that is to be removed can be identified and should be "harmless" yet effective.

Asteatotic Dermatitis: Also known as exsiccation eczematid ICD, asteatotic eczema, winter dermatitis, or eczema craquelé, asteotic dermatitis is a unique variant seen predominantly in elderly individuals with a history of extensive usage of soaps and cleansing products.[29] This leads to dry-appearing skin with ichthyosiform scaling, and patients experiencing intense pruritus. It is a condition mainly occurring in low-humidity, winter months.[30]

Pustular and Acneiform Irritant Contact Dermatitis: Pustular and acneiform ICD result from exposure to specific irritants such as croton oil, mineral oils, tars, greases, and naphthalenes. This syndrome should always be considered when acneiform lesions develop in postadolescent patients who never had teenage acne. The pustules are sterile and transient.

Subjective Irritant Contact Dermatitis: Although not well understood, subjective ICD is characterized by the lack of objective clinical signs as individuals complain of a sensation of burning or stinging (sensory irritation) after contact with certain chemicals.[31] Though no visible cutaneous irritation is generally observed, these reactions are usually dose-related and have been observed with chemicals such as lactic acid, which can be found in cosmetic products.[32]

ALLERGIC CONTACT DERMATITIS

BACKGROUND

Although it has been widely reported that 80% of all OCD cases are caused by ICD, there is broad variation in the distribution of ACD versus ICD among reports of OCD in the literature.[16,33] For instance, the North American Contact Dermatitis Group (NACDG) reported significantly more occupational ACD (60%) than ICD (32%).[34] A myriad of reasons may contribute to the disparate rates and include differences in the types of industries being studied in a geographical area, the age and sex distribution of evaluated patients, selection biases inherent among patients referred to tertiary dermatologic centers, the ability of the health care provider to fully assess the worker by patch testing, and existing national regulations and notification systems.[35]

CLINICAL FEATURES

Clinically, both ICD and ACD can have similar manifestations of pruritus, pain, erythema, swelling, xerosis, formation of wheals or blisters as well as lichenification. They both can manifest as an acute, subacute, or chronic condition. Health care workers are reported to be one of the most commonly affected professions with identified allergens, including glutaraldehyde, formaldehyde, quaternium-15, and thiuram mix.[36] Other professions frequently affected include machinists, construction workers, homemakers/house cleaners, food handlers, custodians, stock handlers, cosmetologists, and laboratory technicians (Fig. 27-5).[35] Major occupational contact allergens are listed in Table 27-5.

CONTACT URTICARIA AND IMMEDIATE CONTACT REACTIONS

Contact urticaria (CU) is a transient wheal and flare reaction from direct contact with a chemical or protein agent. Lesions appear within minutes to an hour and resolve within hours after exposure. Contact urticaria is categorized as either nonimmune-mediated or immune-mediated.[38] Additionally, CU of uncertain mechanism also has been recognized

Figure 27-5 Hand dermatitis due to mercaptobenzothiazole in corrosion inhibitors at work and subsequent use of nitrile gloves containing mercaptobenzothiazole.

and demonstrates features of both nonimmune and immune-mediated CU.

NONIMMUNOLOGIC CONTACT URTICARIA

BACKGROUND AND CLINICAL FEATURES

Nonimmunologic contact urticaria (NICU), though less well understood in regard to pathogenesis, is caused by a wide array of agents in exposed individuals who develop a reaction without previous sensitization. Nonimmunologic contact urticaria is the most common type of contact urticaria, remains localized, and is less severe than immunologic contact urticaria (ICU) reactions. Additionally, in contrast to ICU, NICU reactions are not inhibited by H-1 antihistamines, but oral or topical nonsteroidal anti-inflammatory medications are effective, suggesting a role of prostaglandins in the pathogenesis of these lesions.[39] Classification of NICU agents are reviewed in Table 27-6.[40]

TABLE 27-5
Most Frequently Reported Occupational Skin Allergens[37]

Cobalt
Chromate
Cosmetics and fragrances
Epoxies
Nickel
Plants
Preservatives
Resins
Acrylics

TABLE 27-6
Classification of Nonimmunologic Contact Urticaria Exposures

CATEGORIES	EXAMPLES
Animals	Caterpillars, arthropods, corals
Foods	Pepper, mustard, thyme
Fragrances and flavorings	Cinnamic aldehyde, balsam of Peru, cinnamic acid
Medicaments	Witch hazel, benzocaine, camphor
Metals	Cobalt
Plants	Nettles, seaweed
Preservatives and disinfectants	Benzoic acid, formaldehyde, sorbic acid
Miscellaneous	Butyric acid, pine oil, turpentine

Data from Basketter D, Lahti A. Immediate contact reactions. In: Johansen DJ, Frosch JP, Lepoittevin JP, eds. *Contact Dermatitis*. 5th ed. Berlin: Springer; 2011:137-153.

IMMUNOLOGIC CONTACT URTICARIA

BACKGROUND AND CLINICAL FEATURES

Immunologic contact urticaria (ICU) is a type I hypersensitivity reaction mediated by allergen-specific immunoglobulin E (IgE) and seen in individuals previously exposed to the specific agent. Atopic individuals are particularly at risk. ICU can spread beyond the cutaneous localized contact point and the level of spread is categorized in a staging system presented in Table 27-7.[41]

Contact urticaria from latex gloves is the prototypical example of ICU. Beginning in the early 1980s, a combination of factors including the use of latex gloves for universal precautions in light of the increasing prevalence of HIV and viral hepatitis contributed to an alarming number of individuals with type I

TABLE 27-7
Staging System for Immunologic Contact Urticaria

STAGING SYSTEM	
Stage 1	Localized urticaria, dermatitis, or nonspecific symptoms (itching, tingling, burning, etc.)
Stage 2	Generalized urticaria
Stage 3	Urticaria *and* rhinoconjunctivitis, asthma, or GI symptoms
Stage 4	Anaphylaxis

Adapted from Wang CY, Maibach HI. Immunologic contact urticaria—the human touch. *Cutan Ocul Toxicol*. 2013;32:154-160.

hypersensitivity from latex rubber.[42] As the natural rubber latex (NRL) allergy epidemic was identified in the United States and Europe, various organizations and agencies recommended several prevention strategies, including reduction of protein content in gloves (to reduce allergenicity) and providing latex-free alternatives, which helped reduce the incidence of latex allergies.[43,44] Apart from health care workers, occupations commonly affected by ICU from NRL include kitchen workers, cleaners, others who wear NRL, as well as those with occupations involved in manufacturing rubber bands, surgical gloves, and latex dolls. It is important to note that NRL can also cause a type IV hypersensitivity reaction (ie, ACD), which accounts for the majority of allergic reactions (>80%) to NRL.[45,46]

Furthermore, virtually any food is capable of eliciting an ICU response and is the second most common cause of ICU. Foods such as potato, carrot, apple, tomato, shellfish, seafood, and meats are well documented, and recent literature has highlighted the problem of wheat allergens among bakers.[41] Additional causes include preservatives, fragrances, disinfectants, antibiotics, topical medicaments, epoxy resin hardeners, formaldehyde in clothing, several woods, and birch pollen.

CONTACT URTICARIA OF UNCERTAIN MECHANISM

BACKGROUND AND CLINICAL FEATURES

This type of reaction may occur with substances that produce a CU and a generalized histamine-type reaction but lacks a direct or immunologic basis for the reaction. It is most commonly caused by ammonium persulfate in bleaching hair boosters and typically has a sudden onset characterized by erythema, edema, severe pruritus, urticaria, and occasionally syncope with wheezing and dyspnea.

OTHER OCCUPATIONAL SKIN DISEASES BY EXPOSURE CATEGORIES

CHEMICAL EXPOSURES

A significant proportion of chemical exposures result in OCD. However, there are also several exposures that lead to unique skin manifestations such as acne.

ACNE

Background and Clinical Features: Different forms of acne have been observed in several work settings associated with certain chemical exposures. Machinists with skin exposed to industrial or cutting oils can develop oil acne not only in oil-soaked clothing regions but in other areas exposed to potential airborne oil mists.[47] Additionally, coal tar plant workers, roofers, and road and construction workers exposed to coal tar oils, creosote, and pitch can develop comedonal acne particularly on the face and malar regions.[48] These compounds also contain polycyclic aromatic hydrocarbons (PAH), which are carcinogenic as well.

Exposures to certain dioxins, naphthalenes, biphenyls, dibenzofurans, azobenzenes, and azoxybenzenes also have been associated with one of the more notable forms of acne, chloracne.[49] Chloracne from these chemical exposures are typically characterized by multiple closed comedones and straw-colored cysts primarily over the malar crescents and retroauricular folds that may also involve the neck, trunk extremities, buttocks, scrotum, and penis. Specifically, a potent inducer of chloracne includes 2,3,7,8-tetrachlorodibenzo-*p*-dioxin (TCDD), which was a contaminant in some batches of Agent Orange used during the Vietnam War as well as a by-product in other industrial processes.

MECHANICAL EXPOSURES

The skin is exposed to various forms of mechanical insults on a daily basis, and numerous occupations involving repetitive tasks may lead to mechanical trauma of the skin. Friction, pressure, pounding, and vibration of the skin may create changes ranging from calluses and blisters to myositis, tenosynovitis, osseous injury, nerve damage, lacerations, shearing of tissue, or abrasions. Lacerations, abrasions, tissue disruption, and blisters additionally pave the way for secondary infection by bacteria, or less often, fungi, parasites, and viruses. Though the skin is well adapted to cope with such insults, the time allowed for adaptation determines the reaction of the skin. The effects on the skin manifestations induced by the trauma are modified by age, gender, humidity, sweating, nutritional status, infection, preexisting skin disease, as well as genetic and racial factors.[50]

Certain occupations are prone to having distinct mechanically induced skin dermatoses. For instance, musicians may develop lesions in areas of chronic rubbing specific to the instrument being played (harpist's finger, fiddler's neck, guitar nipple, cellist's chest, flautist's chin). Athletes who experience repetitive trauma while running or shearing forces from quick changes in directional movements may develop black heel or *talon noir* as well as blisters and jogger's toe. A relatively new group of skin disorders has been described with prolonged computer use with either repetitive trauma (mousing callus) or prolonged pressure (computer palms).[51] Fiberglass may cause a mechanical irritation by penetration into the skin in those who work with the man-made fibers, often causing a pruritic eruption that may resemble scabies. Plants may also induce mechanical irritant dermatitis from delicate hairs (trichromes) or hairs with

barbs (glochids). The irritation is caused by both the mechanical action of the oxalate crystal and subsequent penetration of plant toxin or enzyme into the skin.[52] Onycholysis has been reported from repetitive pressure leading to total or partial anoxia of the distal finger tips in housewives and slaughter house workers who skin cattle.[53,54]

The use of vibration-producing tools can induce painful vascular spasms in the fingers and hands known as white finger or vibration-induced white finger (VWF), which is a secondary type of Raynaud phenomenon.[55] In addition to neurovascular, soft tissue, fibrous, and bone injury to the hands and forearms, workers who use pneumatic riveters, chippers, chainsaws, drills, and hammers are at greater risk of suffering from VWF, especially in cold climates. Vibration frequencies between 30 and 300 Hz are most strongly associated with VWF and smoking is a known risk factor. Continued improvements in design of modern equipment has helped to reduce vibration and decrease the prevalence of these symptoms.

In today's society with increasing automation, less frequent manual operation of tools, and better protective gear, mechanically induced occupational skin lesions have greatly decreased in prevalence.[30]

PHYSICAL EXPOSURES

Physical agents such as extremes in temperatures, ionizing, and nonionizing radiation are well-known causes of occupational skin disease.

THERMAL STRESS

Background and Clinical Features: Heat may cause burns, hyperhidrosis, erythema, and telangiectasias. Workers in hot environments such as farmers and construction workers may develop miliaria in areas of chronic rubbing with clothing, leading to symptoms of pruritus, papule formation, and even a small risk of heat exhaustion due to an inability to maintain normal homeostasis through sweating. Relief may be obtained with wearing loose clothing and cooling the skin. Erythema ab igne also has been observed in repeated, prolonged exposure to heat and in those using laptops on their laps for extensive periods of time. In addition, preexisting skin conditions and diseases may be aggravated by heat exposure, such as rosacea, herpes simplex, and acne vulgaris.

Work-related burn injuries often result in hospitalizations with extensive treatment. Hot grease burns may be seen in kitchen workers, roofers may incur hot tar burns, and flammable and explosive liquids are known to cause most industry-related burns. Specific occupations are associated with higher rates of burn injuries, with welders having the highest incidence rates for all burn injuries.[56] Cooks, laborers, food service workers, mechanics, and nurse aides are also occupations at higher risk. One report noted that almost one third of all hospitalized burn injuries were work-related, highlighting the impact of this occupational hazard.[57]

Cold exposure may lead to Raynaud phenomenon. Frostbite is another common cold injury that may be seen affecting acral body surface areas such as the nose, ears, fingers, and toes of firemen, construction workers, postal workers, and military personnel. Individuals engaged in winter sports, refrigeration workers, icemakers, liquefied gas makers, ski patrolmen, and mountain rescue workers are also at risk.

IONIZING AND NONIONIZING RADIATION

Background and Clinical Features: Occupational skin cancers are more common than generally recognized, although it is difficult to obtain an accurate estimate of their prevalence. Ultraviolet radiation (UV), both natural and artificial, is the most important cause for all types of skin cancer to include melanoma, squamous cell carcinoma, and basal cell carcinoma.[58] It is estimated that avoiding this risk factor alone could prevent more than 3 million cases of skin cancer each year.[59]

Occupational skin cancer is characterized by long induction periods, often decades, with the first manifestations often not seen until many years after the occupational exposure.[60] Outdoor workers, loosely defined as individuals who work outdoors for 3 or more hours on a typical workday, are at high risk of harmful UV exposure and development of skin cancer.[61] These may include workers in industries such as agriculture, building and construction, fishing, transport, and landscaping as well as physical education teachers and police officers.

Other professions at risk include pilots and cabin attendants. A meta-analysis identified twice the rate of melanoma in pilots and cabin crew compared with the general population.[62] Because UV radiation is recognized to increase by 10% to 12% for every 1000 m in elevation, airline crews have the potential for increased UV exposure by as much as 2 to 3 times at cruising altitude.[63] One study identified that pilots and cabin crew flying for approximately 56 minutes at cruising altitude receive the same amount of UV-A as that from a 20-minute tanning bed session.[64]

As 90% of squamous cell carcinoma and basal cell carcinoma and two-thirds of melanomas may be attributed to excessive UV radiation exposure, the aim of primary skin cancer prevention is to limit UV radiation exposure.[60] Three measures successful in the prevention of skin cancer in outdoor workers include regular use of sunscreen, protection from direct UV radiation by suitable clothing, and changes in behavior with awareness of health and diseases resulting from exposure to UV radiation. Even with recommended strategies to use protective measures such as wide-brimmed hats, long-sleeve shirts and pants, sunscreen, and avoiding peak UV times (10 AM to 3 PM), many studies have shown inadequate use of sun protection measures by outdoor

Figure 27-6 Finger injury from overexposure to an industrial gamma radiation source. (From Sahin C, Cesur C, Sever C, Eren F. Finger injury from over-exposure to an industrial gamma radiation source. *Burns*. 2015;41:e8-e10, with permission. Copyright © Elsevier.)

workers.[65] An Australian study of construction workers discovered that only 10% of workers were using adequate sun protective measures.[66] This highlights the continued need for an increase in skin cancer awareness and safe sun practices in individuals with high levels of work-related UV radiation exposure.

To determine the role of the workplace in the development of skin cancer and actinic skin damage, one must take into consideration not only detailed occupational history with job descriptions from earliest worker employment but also nonoccupational activities, hobbies, and outdoor recreational pursuits from a worker's past.

Ionizing radiation, such as X-rays, can also cause skin cancer, primarily squamous cell carcinoma and less often basal cell carcinoma. High levels of acute exposure may lead to acute radiation dermatitis observed as erythema, itching, and cutaneous inflammation. Higher doses may manifest as skin blisters, hemorrhage, and even necrosis (Fig. 27-6). Delayed sequelae from exposure may result in chronic radiation dermatitis with skin atrophy, abnormal pigmentation, keratinization disorders, increasing sclerosis, telangiectasias, hair loss, and xerosis due to loss of sebaceous glands. Ionizing radiation sources may be found in a wide range of occupational settings, and examples include health care facilities, nuclear weapon production facilities, nuclear reactors and their support facilities, and various manufacturing settings.[67]

BIOLOGIC EXPOSURES

BACKGROUND

A number of infectious agents are responsible for occupational skin disease, especially in occupations that involve contact with animals. With greater awareness and implementation of public health measures, many historically prominent infections have greatly diminished in the general population. However, certain infectious agents are still observed in at-risk occupational groups such as health care workers, military personnel, farmers, and forestry workers. These infections, in turn, may affect the productivity of a worker and ultimately the employer when conditions favor disease transmission.

BACTERIAL INFECTIONS

Staphylococcus and Streptococcus: Staphylococci and streptococci are gram-positive bacteria that can contaminate minor lacerations, burns, puncture wounds, or abrasions leading to impetigo, cellulitis, furuncles, and abscesses. Though all occupations may be at risk, they are prevalent in meat packers, construction workers, farm workers, and those working in close contact with other infected individuals, for example, nurses, athletes, hairdressers, and manicurists. Epidemics of methicillin-resistant *Staphylococcus aureus* infections that have been difficult to control have been documented in professional football players in the United States.[68]

Anthrax: Anthrax, though endemic in parts of Africa and Asia, is rare in the United States and predominantly a cutaneous infection (Woolsorter disease) found in occupations in which workers handle imported goat hair, wool, and hides contaminated with the spores from the bacterium *Bacillus anthracis*.[69] Only 49 anthrax-related epidemiologic investigations were conducted by the U.S. Centers for Disease Control and Prevention between 1950 and 2001, with most involving agricultural settings or textile mills.[70] Because of the highly infectious nature of its spores and recent world events including the 2001 bioterrorism anthrax attacks in the United States, *Bacillus anthracis* is also considered a high-priority pathogen by several U.S. government agencies for its potential as a bioterrorist agent.

Fish Tank Granuloma: *Mycobacterium marinum* is an acid-fast, nontuberculous mycobacterium that was first isolated in 1926 from salt water fish carcasses in the Philadelphia aquarium.[71] It is responsible for fish tank granuloma (also known as swimming pool granuloma), a distinct infection presenting as a warty nodule or plaque usually at a point of trauma, often 6 weeks after exposure. Individuals with fish- or water-based occupations and hobbies are most at risk. Vectors of the infection include fresh or salt water fish, shellfish, snails, water fleas, or dolphins.[72,73]

Erysipeloid (Fish-Handler Disease): The gram-positive bacterium *Erysipelothrix rhusiopathiae* is responsible for the acute infection of erysipeloid, which is almost always an occupational disease. Human infection is associated with handling of decaying animal products such as fish, shellfish, mammals, and poultry. Infection occurs when a worker has a predisposing insult to the skin, such as an abrasion or cut that allows entry of the bacteria. A localized sharply

demarcated bright red to violaceous infection, often involving the hands, then ensues. Occupations at risk include fisherman, butchers, farmers, veterinary surgeons, and poultry dressers.[74]

Pitted Keratolysis: Pitted keratolysis is a rather common dermatologic condition caused by gram-positive bacterium (usually *Corynebacterium* species) that infects the stratum corneum of the plantar skin, leading to malodor, hyperhidrosis, and sliminess of the skin. Though well documented among bare-footed laborers, such as paddy farmers in the tropics, it is also observed in soldiers, miners, and laborers as a result of occlusive, protective shoe-wear that creates a warm and moist environment for the bacteria. Because of pain while marching and walking, the condition may cause reduced operational deployability when observed in military personnel.[75] A study of 144 US Marine volunteers in combat in Vietnam during monsoon months discovered that 49% of soldiers were affected with this condition.[76]

Brucellosis: Brucellosis is a worldwide zoonosis caused by gram-negative bacterium of the genus *Brucella* that is primarily a disease of animals in which humans are an accidental host.[77] Occupationally, the disease is contracted through inhalation of contaminated aerosols, contact with conjunctival mucosa, or entry of bacteria through cuts in the skin as a result of contact with infected animals or their products.[78] Occupations at highest risk include slaughterhouse workers, farmers, veterinarians, meat packers, livestock breeders, and laboratory workers. Nonoccupational sources of exposure include ingestion of infected milk or milk products. Brucellosis is a multisystem disease that presents with symptoms such as fevers, night sweats, myalgia, weight loss, and arthralgia but has a propensity for more serious chronicity. Skin manifestations are generally infrequent and have been reported to affect anywhere from 1% to 14% of those infected.[79] Cutaneous findings of brucellosis are often nonspecific, and findings include disseminated papular and nodular eruptions, nodosum-like erythema, extensive purpura, diffuse macular and papular rash, chronic ulcerations, and abscesses.[80]

Tularemia: Tularemia is a potentially severe zoonosis caused by *Francisella tularensis,* a gram-negative bacterium transmitted by ticks, fleas, deerflies, as well as by ingestion, inhalation, or direct contact with infected tissues. The most common presentation of tularemia is the ulceroglandular form, where an ulcer arises at the site of inoculation and regional lymphadenopathy develops. The more severe, though less common, pneumonic form may develop after inhalation of the bacteria. Historically, tularemia has been reported among laboratory workers, farmers, veterinarians, sheep workers, hunters, cooks, and meat handlers; however, recent literature supports an increased risk in landscapers, particularly for the pneumonic form of the disease. Health care workers in tularemia-endemic areas should consider a diagnosis of tularemia in landscapers who have fever or pneumonia.[81]

FUNGAL AND YEAST INFECTIONS

A wide variety of mycoses may be responsible for occupational dermatoses including most kinds of dermatophytoses, candidiasis, and even deep mycoses. Tinea pedis is a common infection of the general population but certain workers are at even greater risk of infection as a result of humid, occlusive footwear such as miners, military personnel, athletes, and laborers.[25] Zoophilic dermatophytes such as *Trichophyton verrucosum* are associated with cattle, farm buildings, and straw; *Trichophyton mentagrophytes* may be transmitted by cattle and domestic animals; *Microsporum canis* is identified in domestic animals, especially cats; and, *Microsporum nanum* may be found in pigs.[26,27,82] Thus, occupations at risk for these zoophilic dermatophytes include slaughterhouse workers, veterinarians, farmers, and pet shop workers.

Bartenders, waitresses, and food handlers are prone to developing candida skin infections as a result of their wet work, which provides a favorable environment for the yeast in macerated skin near the nails and between the digits. Prevention is key through proper drying of the skin and wearing protective gloves.

Inoculation of *Sporothrix schenckii* via puncture wounds from thorns, splinters, sticks, and sphagnum moss can lead to sporotrichosis. Those at risk include gardeners, forestry workers, nursery workers, miners, and farmers. Since the late 1990s, there has been an epidemic of sporotrichosis associated with transmission by cats in Rio de Janeiro, Brazil, thus adding veterinarians as an at-risk occupation.[83]

Other subcutaneous and deep mycoses known to be responsible for OSDs include histoplasmosis, with at-risk occupations being construction workers and farmers who participate in demolition, soil-disrupting activities, and excavation in endemic areas. Chromoblastomycosis, phaeohyphomycosis, and eumycetoma (Madura foot) are subcutaneous mycoses that are all acquired as a result of penetrating trauma to the skin.[84] Farmers and outdoor workers are most at risk for these chronic and challenging mycoses.

VIRAL INFECTIONS

Herpes Simplex Virus: The high prevalence and infectious nature of herpes simplex virus (HSV) makes it an occupational hazard among health care workers, particularly for dental practices, where HSV can be easily spread by direct (lip) or indirect (finger) contact, especially when a lesion is present in the patient.[85]

Orf (Ecthyma Contagiosum): Orf, or ecthyma contagiosum, is a zoonotic infection caused by a parapoxvirus that commonly infects sheep and goats and is transmitted to humans through contact with infected animals or fomites. Veterinarians, sheep herders, and farmers are most at risk, though it has been reported in children after visiting petting zoos and livestock fairs.[86]

Pseudocowpox (Milker Nodule): Milker nodule, also known as pseudocowpox, is an occupational

viral infection transmitted by direct contact from infected cows' udders to farmers, veterinarians, and also fresh meat handlers. Painful nodules similar to orf develop on exposed sites, become crusted, and then spontaneously resolve. Prevention consists of treating the cows' mastitis as well as using preventive measures such as gloves, soap, water, and disinfectants before and after handling these animals.[87]

Human Papilloma Virus: Viral warts causes by human papilloma virus (HPV) have been well documented in butchers and meat and fish handlers. Though these warts may be due to many different serotypes of HPV, HPV-7 (Butcher wart virus) is almost exclusive to this group of workers.[88] Recent innovations in dermatology as well as other medical specialties in the treatment of HPV-induced diseases have brought up questions regarding the controversial nature of the risk of nasopharyngeal HPV in health care personnel. However, a recent study supports a low HPV transmission risk of oral and nasal HPV in employees performing CO_2-laser evaporation of genital warts or loop electrode excision procedure (LEEP) of cervical dysplasia by gynecologists, though more studies are likely needed to further assess this relatively new occupational risk.[89]

Bloodborne Pathogens: The 3 bloodborne viruses that are known to pose a serious occupational threat to health care workers include hepatitis B virus (HBV), hepatitis C virus (HCV), and HIV. Although infections by these bloodborne pathogens generally do not exhibit acute skin findings, untreated and prolonged viral burden may have skin manifestations as well as other systemic dysfunctions. Acquisition of infection from body fluids and accidental puncture wounds are known routes of risk to health care personnel. Though safer needle devices for performing procedures and universal infection control precautions are in place, they will not completely eliminate the risk, and prophylactic treatment will remain an important component of prevention efforts.[90]

DIAGNOSIS OF OCCUPATIONAL SKIN DISEASES

PATCH TESTING AND ALLERGIC CONTACT DERMATITIS

Patch testing is the gold standard in diagnosing ACD and is pivotal in helping to determine the etiology of OSDs when assessing contact dermatitis. Early evaluation and diagnosis of ACD has been associated with decreased health care costs and improved disease course and quality of life of the patient.[91] Taking a careful exposure and occupational history is pivotal in guiding appropriate selection of allergens to be tested. Testing is performed using commercially prepared allergens, which are mixed in petrolatum or water and sold in individual syringes or vials. Allergens are grouped in series, such as the rubber, metals, glues and adhesives series, or by profession, such as the dental, hairdressers', or bakers' series. The TRUE Test® is a prepackaged, ready-to-apply kit that now consists of 3 adhesive panels of 35 allergens and allergen mixes that are reported to be responsible for the majority of cases of ACD. The North American Contact Dermatitis Group (NACDG) standard screening tray includes a greater range of allergens and is also widely used among other commercially available series.

It may be necessary to test products from the workplace, as not all allergens may be included in the panel used. However, a basic principle is to never test an unknown substance or test with known irritants such as solvents, cements, and soaps. Patch testing should be performed by a trained provider, who has access to a wide range of allergens for testing purposes and experience in interpreting results. The successful management of ACD requires a meticulous and dedicated physician who is able to not only recognize and treat the skin disease but also has an understanding of the ramifications of the results in regard to the patient's occupation and potential legal aspects of workers' compensation boards.

SKIN PRICK TESTING AND CONTACT URTICARIA

In contrast to patch testing, skin prick testing (SPT) is an allergy test used for the identification of IgE-mediated immediate hypersensitivity reactions (eg, immunologic contact urticaria). The skin prick introduces a small amount of allergen into the epidermis eliciting a localized response in the form of a wheal and erythema at the site of testing when positive. In regard to OCD, the test is used to help make a diagnosis when contact urticaria is suspected. Conventionally, it is also used for diagnosing other type I immediate hypersensitivity reactions in patients with rhinoconjunctivitis, asthma, atopic eczema, and food allergy. Specifically for ICU, a diagnostic algorithm is illustrated in Fig. 27-7. Of note, alternatives similar to SPT include scratch testing and scratch-chamber testing, which may be used for nonstandardized allergens because routine use in place of SPT is not recommended.[92]

RADIOALLERGOSORBENT TESTING AND CONTACT URTICARIA

Blood tests may be used to help measure the amount of allergen-specific antibodies present in the blood and guide the diagnosis in regards to an allergy. For

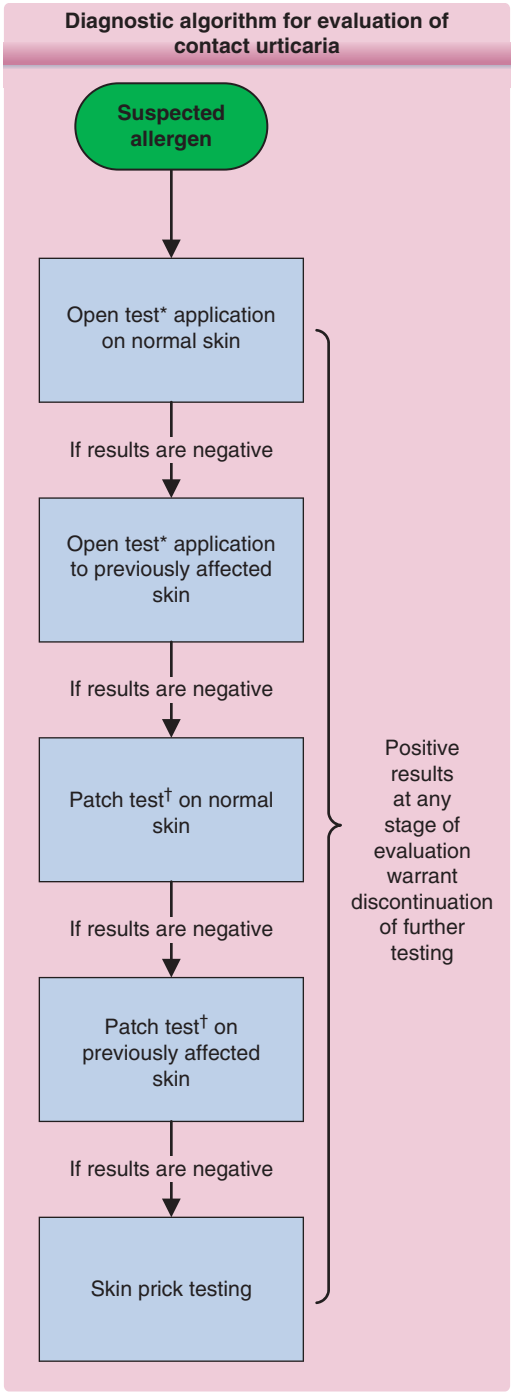

Figure 27-7 Diagnostic algorithm for evaluation of contact urticaria.[92,93,94] *Open test: application of the substance in a vehicle (petrolatum, ethanol, water) is applied over a 3 × 3-cm area and usually read at 20-, 40-, and 60-min intervals. Immunologic contact urticaria usually presents earlier (15-20 min), whereas nonimmunologic contact urticaria may be delayed (45-60 min) after application. †Patch should be removed after 15-20 min after application and interpreted at similar intervals to the open test.[38] Appropriate resuscitation equipment and medications should be readily available when testing for contact urticaria.

instance, the radioallergosorbent test (RAST) measures serum-specific IgE, though it has become outdated and is now often replaced with the more sensitive enzyme-linked immunosorbent assay (ELISA) tests that do not require radioactivity. In 2010 the United States National Institute of Allergy and Infectious Diseases recommended that the RAST measurements of specific IgE for the diagnosis of allergy be abandoned in favor of testing with more sensitive fluorescence enzyme-labeled assays.[95]

OTHER DIAGNOSTIC TESTING

Depending on the potential exposure based on occupational history and clinical examination, other diagnostic modalities may be used to make a definitive diagnosis. Common procedures in non-occupational settings such as skin scraping with potassium hydroxide (KOH) preparation and skin biopsies can similarly be utilized in the occupational setting.

In addition, several other biomonitoring methods may be employed particularly for certain occupational exposures. For example, exposure to arsenic can be detected in the blood, hair, nails, and urine; however, measuring arsenic in the urine provides the most reliable indicator of exposure. In addition, when measuring arsenic in the urine, it is important to request speciation to determine the specific amounts of organic versus inorganic arsenic. Inorganic arsenic, elemental arsenic, and arsine gas are the toxic forms leading to adverse health effects. Organic arsenic (eg, arsenobetaine), on the other hand, is relatively benign and can be found in seafood, which can significantly elevate total arsenic levels up to 72 hours after ingesting a seafood meal.

Furthermore, although beryllium sensitization can be detected through patch testing, laboratory testing of the blood is also commonly used in the occupational setting. The beryllium lymphocyte proliferation test (Be-LPT) exposes the separated white blood cells drawn from a venipuncture to a beryllium solution and measures the proliferation of these white blood cells. In one large study of more than 12,000 individuals, the sensitivity and specificity of the Be-LPT were 68.3% and 96.9%, respectively.[96] Identifying sensitization to beryllium is paramount because sensitized workers can develop chronic beryllium disease (CBD), a permanent and potentially progressive granulomatous restrictive lung disease. Observational studies suggest that early treatment of clinically apparent CBD is associated with improved pulmonary function, radiographic findings, respiratory symptoms, and functional status.[97] When beryllium sensitization is initially suspected, additional testing in conjunction with temporary or permanent work restriction may be recommended.

MANAGEMENT

Treatment of OSDs is dependent on the initial cause and is practically the same as that for skin diseases of nonoccupational origin. Identifying the specific cause(s) of the patient's disease and outlining the appropriate steps to avoid exposure and recurrences is an important role to be played by the provider. As most occupational skin disorders are preventable, patients should be educated on the appropriate preventive measures. Employers should work with their employees to mitigate hazards through the hierarchy of controls (Fig. 27-8), with the last resort for prevention being protective clothing and topical barriers, if practical. Ideally, medical providers and occupationally related disciplines including industrial hygiene should work with employers to eliminate or substitute known hazards. However, if elimination or substitution is unrealistic, engineering controls should be considered that protect workers through physically isolating hazardous processes. Other methods to help reduce exposure include administrative controls, which include alterations in work cycles to decrease exposure time to hazards.

RISK FACTORS

Understanding risk factors for OSDs is important for potential prevention of disease. Risk factors may be endogenous and beyond the control of the individual, such as age, gender, race and genetics. Or, risk factors may be exogenous and potentially modifiable, including specific occupations and duties, work practices and environment, experience level of the worker, and protective measures used.

In regard to age, reports have indicated that older individuals have reduced reactivity to irritants.[98] However, research on age and development of ACD is less clear, with studies showing mixed results.[99] Several studies have also shown that occupational ICD is seen more commonly in females. At the same time, many epidemiologic assessments may be biased by chemical exposure patterns and specific gender-related occupations, which may give a perception that females are more reactive to irritants than males, and this difference is not necessarily supported by direct comparative testing.[98] Females may be more predisposed to developing ACD, but again, this is likely related to exposure patterns and not to intrinsic skin characteristics.[100] Racial differences in dermatologic response to chemical agents also have been described, with some evidence that Asian skin may be more reactive and black skin less reactive than white skin.[101]

Increasing research on genetic factors has found genetic susceptibility markers associated with ICD and ACD. For ICD and ACD, alterations in production of pro-inflammatory cytokines interleukin (IL)-1alpha, IL-1beta, IL-8, tumor necrosis factor (TNF-alpha), and anti-inflammatory IL-1 have been associated with increased risk.[102] Additionally, mutations in the filaggrin gene have been shown to affect skin barrier functions and contribute to the development of atopic dermatitis and potential susceptibility towards contact dermatitis. Maceration and other skin disease that disrupt the skin barrier can enhance penetration of both irritants and allergens. Atopic dermatitis is known to increase the susceptibility of skin to irritants but not to allergens.[102] Consequently, workers with atopic skin disease are more likely to develop OSDs when also exposed to wet work conditions (defined as exposure of skin to liquid for more than 2 hours per day, use of occlusive gloves for more than 2 hours per day, or frequent handwashing).[103] And studies of polymorphisms in genes encoding for metabolic enzymes, such as *N*-acetyltransferases, suggest a role in developing ACD.[102]

Certain industries and occupations also appear to pose a higher risk of developing occupational dermatoses. Based on the 2010 *Occupational Health Supplement* of the National Health Interview Survey (NHIS) that sampled 17,524 adults who had worked in the preceding 12 months, the period prevalence of occupational dermatitis was highest in arts, entertainment, and recreation (12.6%) followed by health care and social assistance (12.5%) and accommodation and food services (12.4%) industries after adjusting for age, sex, and race/ethnicity.[104] Similarly, occupational categories (defined by the Standard Occupational Classification) identified with the highest prevalence of reported dermatitis included life, physical, and social sciences (18.2%) and art, design, entertainment, sports, and media (15.1%).[104] In contrast, the overall prevalence rate among the surveyed current/recent workers for dermatitis was 9.8%.

Other exogenous risk factors beyond industry and occupation may include chemical concentration, exposure duration, and use of personal protective equipment (PPE). The use of PPE, including gloves

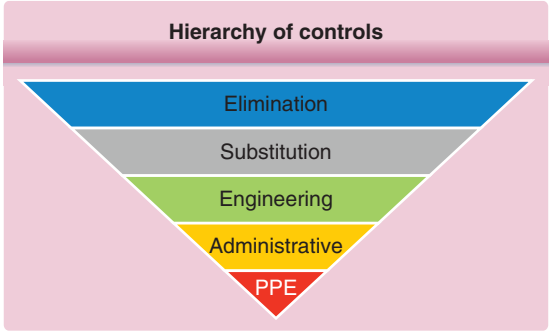

Figure 27-8 Hierarchy of controls. The hierarchy of controls highlights the major categories of mitigating hazards. The most protective to least protective are (1) complete elimination of the hazard, (2) substitution to a nonhazardous or lesser hazardous substance, (3) engineering controls to prevent exposure to the employee, (4) administrative controls to limit the duration of potential exposure, and (5) donning personal protective equipment (PPE).

and clothing, can often limit hazardous exposures; however, if used improperly, it may actually increase permeation and penetration of irritants and allergens. Furthermore, the PPE itself may directly irritate the skin or contain allergens (eg, latex gloves), so correct use of PPE is paramount. Although handwashing is generally encouraged, excessive hygiene measures and use of soaps and detergents can lead to ICD.

HEALTH RISK ASSESSMENT

Although occupational dermatologic hazards exist in many workplaces, the risks to workers are often variable and depend on a multitude of factors. In the occupational environment, this probability is evaluated through a methodical approach known as a health risk assessment. Health risk assessments encompass 4 main components: (1) hazard identification, (2) dose-response relationship, (3) exposure assessment, and (4) risk characterization.

HAZARD IDENTIFICATION

The initial step to identify workplace hazards should incorporate knowledge from industries involving similar work practices and recognize potential injuries and illnesses that can result from related exposures. Hazardous chemicals, in particular, legally require Safety Data Sheets (SDSs, formerly known as Material Safety Data Sheets [MSDSs]), which display not only chemical properties but also adverse health effects, protective equipment necessary for safe handling, and first aid measures for acute exposure treatment among others.[105] Employers must have SDSs readily available to employees for all hazardous chemicals in the workplace.

DOSE-RESPONSE RELATIONSHIP

The dose-response assessment helps delineate relative threshold concentrations of an exposure that results in adverse health effects. For many OCDs, the adverse effects are often dose-dependent with exposure. However, it is important to recognize health conditions (eg, atopic dermatitis) that can contribute to adverse health effects (eg, ICD) at lower exposure doses.

EXPOSURE ASSESSMENT

Because not all OCDs are purely from direct dermal exposures, careful assessment should be taken to determine the potential routes of exposure in the particular workplace. The work task duration and frequency should also be noted as adverse health effects can not only be dose-dependent but time-dependent as well. Furthermore, monitoring is often performed since certain toxic substances have legal permissible exposure limits (PELs) enforced by OSHA. One important caveat is that PELs do not necessarily represent safe limits. The National Institute for Occupational Safety and Health (NIOSH) and American Conference of Governmental Industrial Hygienists (ACGIH) provide recommended exposure limits that are based on adverse health effects.

RISK CHARACTERIZATION

By analyzing the collected data from hazard identification, dose-response assessments, and exposure evaluations, an overall level of risk can be assigned to the evaluated hazards. Some assessors use a risk matrix incorporating toxicity and probability of exposure to determine risk level, but regardless of the method, a safe margin of error should be in place to buffer a higher risk hazard misclassified in a lower risk category.

Ultimately, risk characterization also allows recommendations on control measures, if necessary, which may include substitution of chemicals, changes in ventilation, addition of local exhaust, alterations in work cycles, and donning of PPE.

REFERENCES

1. Kalia S, Haiducu ML. The burden of skin disease in the United States and Canada. *Dermatol Clin.* 2012;30(1):5-18, vii.
2. Mathias CG. The cost of occupational skin disease. *Arch Dermatol.* 1985;121(3):332-334.
3. Sternbach G. The history of anthrax. *J Emerg Med.* 2003;24(4):463-467.
4. Martin C, Meachen GN, Martin SC. *The Urologic and Cutaneous Review: Technical Supplement.* Vol 3. St. Louis, MO: Philmar Company; 1915.
5. Herr HW. Percivall Pott, the environment and cancer. *BJU Int.* 2011;108(4):479-481.
6. Lushniak BD. Occupational contact dermatitis. *Dermatol Ther (Heidelb).* 2004;17(3):272-277.
7. Bureau of Labor Statistics (BLS). Nonfatal Occupational Injuries and Illnesses. http://www.bls.gov/iif/.
8. Lushniak BD. The importance of occupational skin diseases in the United States. *Int Arch Occup Environ Health.* 2003;76(5):325-330.
9. Dickel H, Kuss O, Blesius CR, et al. Occupational skin diseases in Northern Bavaria between 1990 and 1999: a population-based study. *Br J Dermatol.* 2001;145(3):453-462.
10. Diepgen TL, Coenraads PJ. The epidemiology of occupational contact dermatitis. *Int Arch Occup Environ Health.* 1999;72(8):496-506.
11. Halkier-Sorensen L. Occupational skin diseases. *Contact Dermatitis.* 1996;35(1)(suppl):1-120.
12. Mathias CG, Sinks TH, Seligman PJ, et al. Surveillance of occupational skin diseases: a method utilizing workers' compensation claims. *Am J Ind Med.* 1990;17(3):363-370.

13. Meyer JD, Chen Y, Holt DL, et al. Occupational contact dermatitis in the UK: a surveillance report from EPIDERM and OPRA. *Occup Med (Lond).* 2000;50(4):265-273.
14. Emmett EA. Occupational contact dermatitis, I: incidence and return to work pressures. *Am J Contact Dermat.* 2002;13(1):30.
15. Agner T. An experimental study of irritant effects of urea in different vehicles. *Acta Derm Venereol Suppl.* 1992;177:44-46.
16. Belsito DV. Occupational contact dermatitis: etiology, prevalence, and resultant impairment/disability. *J Am Acad Dermatol.* 2005;53(2):303-313.
17. Smith HR, Basketter DA, McFadden JP. Irritant dermatitis, irritancy and its role in allergic contact dermatitis. *Clin Exp Dermatol.* 2002;27(2):138-146.
18. Weltfriend S, Ramon M, Maibach HI. *Dermatotoxicology*. 6th ed. Boca Raton, FL: CRC Press; 2004.
19. Wigger-Alberti W, Elsner P. Contact dermatitis due to irritation. *Handbook of Occupational Dermatology*. Berlin: Springer; 2000:99-110.
20. Tan CH, Rasool S, Johnston GA. Contact dermatitis: allergic and irritant. *Clin Dermatol.* 2014;32(1):116-124.
21. Caroe TK, Ebbehoj N, Agner T. A survey of exposures related to recognized occupational contact dermatitis in Denmark in 2010. *Contact Dermatitis.* 2014;70(1):56-62.
22. Patil S, Maibach HI. Effect of age and sex on the elicitation of irritant contact dermatitis. *Contact Dermatitis.* 1994;30(5):257-264.
23. Iliev D, Elsner P. Clinical irritant contact dermatitis syndromes. *Immunol Allergy Clin North Am.* 1997;17(3):365-375.
24. Skogstad M, Levy F. Occupational irritant contact dermatitis and fungal infection in construction workers. *Contact Dermatitis.* 1994;31(1):28-30.
25. Kamihama T, Kimura T, Hosokawa JI, et al. Tinea pedis outbreak in swimming pools in Japan. *Public Health.* 1997;111(4):249-253.
26. Agnetti F, Righi C, Scoccia E, et al. *Trichophyton verrucosum* infection in cattle farms of Umbria (Central Italy) and transmission to humans. *Mycoses.* 2014; 57(7):400-405.
27. Khosravi AR, Mahmoudi M. Dermatophytes isolated from domestic animals in Iran. *Mycoses.* 2003; 46(5-6):222-225.
28. Malten KE. Thoughts on irritant contact dermatitis. *Contact Dermatitis.* 1981;7(5):238-247.
29. Seyfarth F, Schliemann S, Antonov D, et al. Dry skin, barrier function, and irritant contact dermatitis in the elderly. *Clin Dermatol.* 2011;29(1):31-36.
30. Kanerva L, Elsner P, Wahlberg J, et al. *Handbook of Occupational Dermatology*. New York: Springer Science & Business Media; 2013.
31. Green BG. Measurement of sensory irritation of the skin. *Am J Contact Derm.* 2000;11(3):170-180.
32. Robinson MK, Perkins MA. Evaluation of a quantitative clinical method for assessment of sensory skin irritation. *Contact Dermatitis.* 2001;45(4):205-213.
33. Holness DL. Characteristic features of occupational dermatitis: epidemiologic studies of occupational skin disease reported by contact dermatitis clinics. *Occup Med.* 1994;9(1):45-52.
34. Rietschel RL, Mathias CG, Fowler JF Jr, et al. Relationship of occupation to contact dermatitis: evaluation in patients tested from 1998 to 2000. *Am J Contact Derm.* 2002;13(4):170-176.
35. Kucenic MJ, Belsito DV. Occupational allergic contact dermatitis is more prevalent than irritant contact dermatitis: a 5-year study. *J Am Acad Dermatol.* 2002;46(5):695-699.
36. Suneja T, Belsito DV. Occupational dermatoses in health care workers evaluated for suspected allergic contact dermatitis. *Contact Dermatitis.* 2008;58 (5):285-290.
37. Nicholson PJ, Llewellyn D, English JS. Evidence-based guidelines for the prevention, identification and management of occupational contact dermatitis and urticaria. *Contact Dermatitis.* 2010;63(4):177-186.
38. McFadden J. Immunologic contact urticaria. *Immunol Allergy Clin North Am.* 2014;34(1):157-167.
39. Lahti A. Non-immunologic contact urticaria. *Acta Derm Venereol Suppl.* 1980;60:1-49.
40. Basketter D, Lahti A. Immediate contact reactions. In: Johansen DJ, Frosch JP, Lepoittevin JP, eds. *Contact Dermatitis*. 5th ed. Berlin: Springer; 2011:137-153.
41. Wang CY, Maibach HI. Immunologic contact urticaria—the human touch. *Cutan Ocul Toxicol.* 2013;32(2): 154-160.
42. Christopher CN. Latex allergy: a real problem. *Med J Aust.* 1996;165(8):460.
43. Cohen DE, Scheman A, Stewart L, et al. American Academy of Dermatology's position paper on latex allergy. *J Am Acad Dermatol.* 1998;39(1):98-106.
44. Kahn SL, Podjasek JO, Dimitropoulos VA, et al. Natural rubber latex allergy. *Dis Mon.* 2016;62(1):5-17.
45. Heese A, van Hintzenstern J, Peters KP, et al. Allergic and irritant reactions to rubber gloves in medical health services. Spectrum, diagnostic approach, and therapy. *J Am Acad Dermatol.* 1991;25(5, pt 1): 831-839.
46. von Hintzenstern J, Heese A, Koch HU, et al. Frequency, spectrum and occupational relevance of type IV allergies to rubber chemicals. *Contact Dermatitis.* 1991;24(4):244-252.
47. Bjorkner BE. Industrial airborne dermatoses. *Dermatol Clin.* 1994;12(3):501-509.
48. Adams BB, Chetty VB, Mutasim DF. Periorbital comedones and their relationship to pitch tar: a cross-sectional analysis and a review of the literature. *J Am Acad Dermatol.* 2000;42(4):624-627.
49. Taylor JS. Environmental chloracne: update and overview. *Ann N Y Acad Sci.* 1979;320:295-307.
50. Kligman AM. The chronic effects of repeated mechanical trauma to the skin. *Am J Ind Med.* 1985;8(4-5): 257-264.
51. Goksugur N, Cakici H. A new computer-associated occupational skin disorder: Mousing callus. *J Am Acad Dermatol.* 2006;55(2):358-359.
52. Epstein W. House and garden plants. In: Jackson E, Goldner R, eds. *Irritant Contact Dermatitis*. New York: Marcel Dekker; 1990:127-165.
53. Menne T, Roed-Petersen J, Hjorth N. Pressure onycholysis in slaugtherhouse workers. *Acta Derm Venereol Suppl (Stockh).* 1985;120:88-89.
54. Sharquie IK, Al-Faham M, Karhoot JM, et al. Housewife onycholysis. *Saudi Med J.* 2005;26(9):1439-1441.
55. Olsen N. Diagnostic aspects of vibration-induced white finger. *Int Arch Occup Environ Health.* 2002; 75(1-2):6-13.
56. Islam SS, Nambiar AM, Doyle EJ, et al. Epidemiology of work-related burn injuries: experience of a state-managed workers' compensation system. *J Trauma.* 2000;49(6):1045-1051.
57. Rossignol AM, Locke JA, Boyle CM, et al. Epidemiology of work-related burn injuries in Massachusetts requiring hospitalization. *J Trauma.* 1986;26(12):1097-1101.

58. American Cancer Society. Cancer Facts & Figures 2016. http://www.cancer.org/research/cancerfactsstatistics/cancerfactsfigures2016/. Published 2016.
59. American Cancer Society. Cancer Facts & Figures 2014. http://www.cancer.org/acs/groups/content/@research/documents/webcontent/acspc-042151.pdf. Published 2014.
60. Diepgen TL, Fartasch M, Drexler H, et al. Occupational skin cancer induced by ultraviolet radiation and its prevention. *Br J Dermatol.* 2012;167(suppl 2):76-84.
61. Horsham C, Auster J, Sendall MC, et al. Interventions to decrease skin cancer risk in outdoor workers: update to a 2007 systematic review. *BMC Res Notes.* 2014;7:10.
62. Sanlorenzo M, Wehner MR, Linos E, et al. The risk of melanoma in airline pilots and cabin crew: a meta-analysis. *JAMA Dermatol.* 2015;151(1):51-58.
63. Blumthaler M, Ambach W, Ellinger R. Increase in solar UV radiation with altitude. *J Photochem Photobiol B.* 1997;39(2):130-134.
64. Sanlorenzo M, Vujic I, Posch C, et al. The risk of melanoma in pilots and cabin crew: UV measurements in flying airplanes. *JAMA Dermatol.* 2015;151(4):450-452.
65. Kutting B, Drexler H. UV-induced skin cancer at workplace and evidence-based prevention. *Int Arch Occup Environ Health.* 2010;83(8):843-854.
66. Gies P, Wright J. Measured solar ultraviolet radiation exposures of outdoor workers in Queensland in the building and construction industry. *Photochem Photobiol.* 2003;78(4):342-348.
67. Occupational Safety and Health Administration. Safety and health topics: ionizing radiation. https://www.osha.gov/SLTC/radiationionizing/. Published 2016.
68. Kazakova SV, Hageman JC, Matava M, et al. A clone of methicillin-resistant *Staphylococcus aureus* among professional football players. *N Engl J Med.* 2005;352(5):468-475.
69. Marks JG Jr, Elsner P, Deleo VA. *Contact & Occupational Dermatology*. 3rd ed. St. Louis, MO: Mosby; 2002.
70. Bales ME, Dannenberg AL, Brachman PS, et al. Epidemiologic response to anthrax outbreaks: field investigations, 1950-2001. *Emerg Infect Dis.* 2002;8(10):1163-1174.
71. Ang P, Rattana-Apiromyakij N, Goh CL. Retrospective study of *Mycobacterium marinum* skin infections. *Int J Dermatol.* 2000;39(5):343-347.
72. Bonamonte D, De Vito D, Vestita M, et al. Aquarium-borne *Mycobacterium marinum* skin infection. Report of 15 cases and review of the literature. *Eur J Dermatol.* 2013;23(4):510-516.
73. Huminer D, Pitlik SD, Block C, et al. Aquarium-borne *Mycobacterium marinum* skin infection. Report of a case and review of the literature. *Arch Dermatol.* 1986;122(6):698-703.
74. Fidalgo SG, Wang Q, Riley TV. Comparison of methods for detection of *Erysipelothrix* spp. and their distribution in some Australasian seafoods. *Appl Environ Microbiol.* 2000;66(5):2066-2070.
75. van der Snoek EM, Ekkelenkamp MB, Suykerbuyk JC. Pitted keratolysis; physicians' treatment and their perceptions in Dutch army personnel. *J Eur Acad Dermatol Venereol.* 2013;27(9):1120-1126.
76. Gill KA Jr, Buckels LJ. Pitted keratolysis. *Arch Dermatol.* 1968;98(1):7-11.
77. American Academy of Pediatrics. Brucellosis. In: Kimberlin D, Brady M, Jackson M, Long S, eds. *Red Book: 2015 Report of the Committee on Infectious Diseases*. Elk Grove Village, IL: American Academy of Pediatrics; 2015:268-270.
78. Cutler SJ, Whatmore AM, Commander NJ. Brucellosis—new aspects of an old disease. *J Appl Microbiol.* 2005;98(6):1270-1281.
79. Metin A, Akdeniz H, Buzgan T, et al. Cutaneous findings encountered in brucellosis and review of the literature. *Int J Dermatol.* 2001;40(7):434-438.
80. Milionis H, Christou L, Elisaf M. Cutaneous manifestations in brucellosis: case report and review of the literature. *Infection.* 2000;28(2):124-126.
81. Feldman KA, Stiles-Enos D, Julian K, et al. Tularemia on Martha's Vineyard: seroprevalence and occupational risk. *Emerg Infect Dis.* 2003;9(3):350-354.
82. Roller JA, Westblom TU. Microsporum nanum infection in hog farmers. *J Am Acad Dermatol.* 1986;15(5, pt 1):935-939.
83. Barros MB, de Almeida Paes R, Schubach AO. *Sporothrix schenckii* and Sporotrichosis. *Clin Microbiol Rev.* 2011;24(4):633-654.
84. Garnica M, Nucci M, Queiroz-Telles F. Difficult mycoses of the skin: advances in the epidemiology and management of eumycetoma, phaeohyphomycosis and chromoblastomycosis. *Curr Opin Infect Dis.* 2009;22(6):559-563.
85. Lewis MA. Herpes simplex virus: an occupational hazard in dentistry. *Int Dent J.* 2004;54(2):103-111.
86. Human orf virus infection from household exposures—United States, 2009-2011. *MMWR Morb Mortal Wkly Rep.* 2012;61(14):245-248.
87. Leavell UW Jr, Phillips IA. Milker's nodules. Pathogenesis, tissue culture, electron microscopy, and calf inoculation. *Arch Dermatol.* 1975;111(10):1307-1311.
88. Orth G, Jablonska S, Favre M, et al. Identification of papillomaviruses in butchers' warts. *J Invest Dermatol.* 1981;76(2):97-102.
89. Kofoed K, Norrbom C, Forslund O, et al. Low prevalence of oral and nasal human papillomavirus in employees performing CO_2-laser evaporation of genital warts or loop electrode excision procedure of cervical dysplasia. *Acta Derm Venereol.* 2015;95(2):173-176.
90. Gerberding JL. Management of occupational exposures to blood-borne viruses. *N Engl J Med.* 1995;332(7):444-451.
91. Kadyk DL, McCarter K, Achen F, et al. Quality of life in patients with allergic contact dermatitis. *J Am Acad Dermatol.* 2003;49(6):1037-1048.
92. Kim E, Maibach H. Changing paradigms in dermatology: science and art of diagnostic patch and contact urticaria testing. *Clin Dermatol.* 2003;21(5):346-352.
93. Nijhawan RI, Jacob SE. The role of patch testing in contact urticaria. *J Am Acad Dermatol.* 2008;59(2):354-355.
94. von Krogh G, Maibach HI. The contact urticaria syndrome—an updated review. *J Am Acad Dermatol.* 1981;5(3):328-342.
95. Boyce JA, Assa'ad A, Burks AW, et al. Guidelines for the diagnosis and management of food allergy in the United States: report of the NIAID-sponsored expert panel. *J Allergy Clin Immunol.* 2010;126(6)(suppl):S1-S58.
96. Stange AW, Joseph Furman F, Hilmas DE. The beryllium lymphocyte proliferation test: Relevant issues in beryllium health surveillance. *Am J Ind Med.* 2004;46(5):453-462.
97. Balmes JR, Abraham JL, Dweik RA, et al. An official American Thoracic Society statement: diagnosis and management of beryllium sensitivity and chronic

beryllium disease. *Am J Respir Crit Care Med.* 2014; 190(10):e34-e59.
98. Robinson MK. Population differences in acute skin irritation responses. Race, sex, age, sensitive skin and repeat subject comparisons. *Contact Dermatitis.* 2002;46(2):86-93.
99. Zhai H, Meier-Davis SR, Cayme B, et al. Allergic contact dermatitis: effect of age. *Cutan Ocul Toxicol.* 2012;31(1):20-25.
100. Modjtahedi BS, Modjtahedi SP, Maibach HI. The sex of the individual as a factor in allergic contact dermatitis. *Contact Dermatitis.* 2004;50(2):53-59.
101. Modjtahedi SP, Maibach HI. Ethnicity as a possible endogenous factor in irritant contact dermatitis: comparing the irritant response among Caucasians, blacks, and Asians. *Contact Dermatitis.* 2002;47(5):272-278.
102. Kezic S, Visser MJ, Verberk MM. Individual susceptibility to occupational contact dermatitis. *Ind Health.* 2009;47(5):469-478.
103. Chew AL, Maibach HI. Occupational issues of irritant contact dermatitis. *Int Arch Occup Environ Health.* 2003;76(5):339-346.
104. Luckhaupt SE, Dahlhamer JM, Ward BW, et al. Prevalence of dermatitis in the working population, united states, 2010 National Health Interview Survey. *Am J Ind Med.* 2013;56(6):625-634.
105. Occupational Safety and Health Administration. Hazard Communication. 29 CFR 1910.1200(g). Washington, DC: Occupational Safety and Health Administration; 2012.

Psoriasiform Disorders

PART 4

Chapter 28 :: Psoriasis

:: Johann E. Gudjonsson & James T. Elder

AT-A-GLANCE

- Worldwide occurrence; affects 2% to 3% of Americans; prevalence ranges from 0.1% to 3% in various populations.
- A chronic disorder with polygenic predisposition combined with triggering environmental factors such as trauma, infection, or medication.
- Erythematous scaly papules and plaques; pustular and erythrodermic eruptions occur.
- Most common sites of involvement are the scalp, elbows, knees, hands, feet, trunk, and nails.
- Psoriatic arthritis occurs in 10% to 25% of patients; pustular and erythrodermic forms may be associated with fever.
- Pathology of fully developed lesions is characterized by uniform elongation of the rete ridges, with dilated blood vessels, thinning of the suprapapillary plate, and intermittent parakeratosis. Epidermal and perivascular dermal infiltrates of lymphocytes, with neutrophils occasionally in aggregates in the epidermis.

INTRODUCTION

DEFINITION

Psoriasis is a common, immunologically mediated, inflammatory disease characterized by skin inflammation, epidermal hyperplasia, and increased risk of a painful and destructive arthritis as well as cardiovascular morbidity and psychosocial challenges. The economic and health burden of this constellation of pathologies is very substantial, yet its cause remains unknown.

HISTORICAL PERSPECTIVE

More than 2000 years ago, Hippocrates used the terms *psora* and *lepra* for conditions that can be recognized as psoriasis. Later, Celsus (ca. 25 BC) described a form of impetigo that was interpreted by Robert Willan (1757–1812) as being psoriasis. Willan separated two diseases as psoriasiform entities, a discoid lepra Graecorum and a polycyclic confluent psora leprosa, which later was called *psoriasis*. In 1841, the Viennese dermatologist Ferdinand von Hebra (1816–1880) unequivocally showed that Willan's lepra Graecorum and psora leprosa were one disease that had caused much confusion because of differences in the size, distribution, growth, and involution of lesions.

EPIDEMIOLOGY

PREVALENCE

Psoriasis is universal in occurrence. However, its reported prevalence in different populations varies considerably, from 0.91% in the United States to 8.5% in Norway.[1] The prevalence of psoriasis is lower in Asians, and in an examination of more than 25,000 Andean Indians, not a single case was seen.[2] Psoriasis appears to be equally common in males and females.

AGE OF ONSET

Psoriasis may begin at any age, but it is uncommon before the age of 10 years. It is most likely to appear between the ages of 15 and 30 years. Possession of certain human leukocyte antigen (HLA) class I antigens, particularly HLA-Cw6, is associated with an earlier age of onset and with a positive family history.

This finding led Henseler and Christophers[3] to propose that two different forms of psoriasis exist: type I, with age of onset before 40 years and HLA associated, and type II, with age of onset after 40 years, although many patients do not fit into this classification.

GENETIC EPIDEMIOLOGY

The concordance rate for psoriasis in monozygotic twins ranges from 35% to 73%.[4] This variability and the fact that these rates do not approach 100% support a role for environmental factors. Thus, the mode of inheritance for psoriasis is best described as multifactorial (ie, polygenic plus environmental factors). Interestingly, the overall prevalence of psoriasis,[1] and the concordance of psoriasis in both monozygotic and dizygotic twins decreases with decreasing distance from the equator. These observations suggest that ultraviolet (UV) light exposure may be a major environmental factor interacting with genetic factors in psoriasis.

CLINICAL FEATURES

CUTANEOUS FINDINGS

PLAQUE-TYPE PSORIASIS

The classic lesion of psoriasis is a well-demarcated, raised, red plaque with a white scaly surface (Fig. 28-1). Lesions can vary in size from pinpoint papules to plaques that cover large areas of the body. Under the scale, the skin has a glossy homogeneous erythema, and bleeding points appear when the scale is removed, traumatizing the dilated capillaries below (the Auspitz sign) (Fig. 28-2). Psoriasis tends to be a symmetric eruption, and symmetry is a helpful feature in establishing a diagnosis. Unilateral involvement can occur, however. The psoriatic phenotype may present a changing spectrum of disease expression even within the same patient.

The Koebner phenomenon (also known as the *isomorphic response*) is the traumatic induction of psoriasis on nonlesional skin; it occurs more frequently during

Figure 28-1 **A–F.** Chronic plaque psoriasis located at typical sites. Note the marked symmetry of the lesions. (Used with permission from Dr. Johann Gudjonsson and Mr. Harrold Carter.)

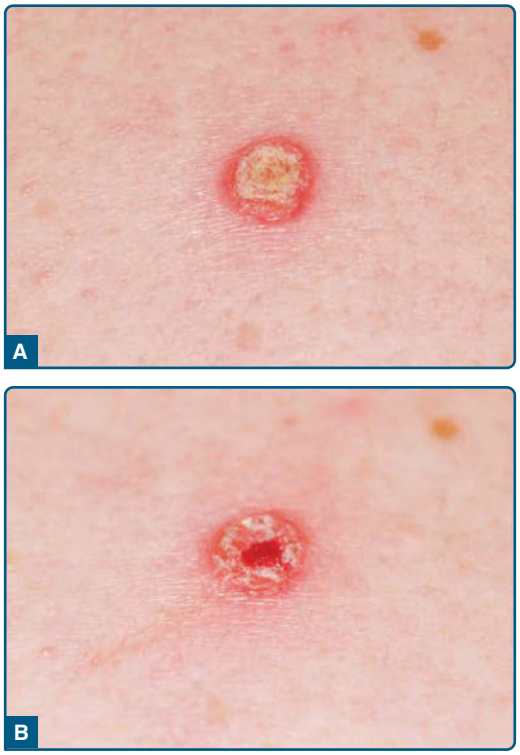

Figure 28-2 **A,** Auspitz sign. **B,** Note the point of bleeding after the scale is removed. (Used with permission from Dr. Johann Gudjonsson and Ms. Laura Vangoor.)

Figure 28-3 Koebner phenomenon. **A,** Psoriasis appearing in keratome biopsy sites 4 weeks after biopsy. **B,** Flare of psoriasis on the back after a sunburn. Note sparing of sun-protected areas. (Image **A,** used with permission from Mr. Harrold Carter. Image **B,** used with permission from Dr. James Rasmussen.)

flares of disease and is an all-or-none phenomenon (ie, if psoriasis occurs at one site of injury, it will occur at all sites of injury) (Fig. 28-3). The Koebner reaction usually occurs 7 to 14 days after injury, and from 25% to 75% of patients may develop trauma-related Koebner phenomenon at some point during their disease.

Psoriasis vulgaris is the most common form of psoriasis, seen in approximately 90% of patients. Red, scaly, symmetrically distributed plaques are characteristically localized to the extensor aspects of the extremities; particularly the elbows and knees, along with scalp, lower lumbosacral, buttocks, and genital involvement (see Fig. 28-1). Other sites of predilection include the umbilicus and the intergluteal cleft. The extent of involvement varies widely from patient to patient. Lesions may extend laterally and become circinate because of the confluence of several plaques (psoriasis gyrata). Occasionally, there is partial central clearing, resulting in ringlike lesions (annular psoriasis) (Fig. 28-4). This is usually associated with lesional clearing and portends a good prognosis. Other clinical variants of plaque psoriasis have been described depending on the morphology of the lesions, particularly those associated with gross hyperkeratosis (see Fig. 28-4). *Rupioid psoriasis* refers to lesions in the shape of a cone or limpet. *Ostraceous psoriasis*, an infrequently used term, refers to a ringlike, hyperkeratotic concave lesion, resembling an oyster shell. Finally, *elephantine psoriasis* is an uncommon form characterized by thickly scaling, large plaques, usually on the lower extremities. A hypopigmented ring (Woronoff ring) surrounding individual psoriatic lesions may occasionally be seen and is usually associated with treatment, most commonly UV radiation or topical corticosteroids (see Fig. 28-4). The pathogenesis of the Woronoff ring is not well understood but may result from inhibition of prostaglandin synthesis.

GUTTATE (ERUPTIVE) PSORIASIS

Guttate psoriasis (from the Latin *gutta*, meaning "a drop") is characterized by eruption of small (0.5–1.5 cm in diameter) papules over the upper trunk and proximal extremities (Fig. 28-5). It typically manifests at an

Figure 28-4 Unusual forms of plaque-type psoriasis. **A,** Annular psoriasis on the flank. **B,** Rupioid psoriasis in an infant. Note the cone-shaped lesions. **C,** Psoriatic patient undergoing modified Goeckerman therapy (ultraviolet B light, coal tar, and topical steroid), demonstrating Woronoff rings. **D,** Elephantine psoriasis of the lower extremities. Note psoriatic involvement of toenails. (Used with permission from Dr. Johann Gudjonsson, Mr. Harrold Carter, and Ms. Laura Vangoor.)

Figure 28-5 Guttate psoriasis, involving the thigh (**A**), hands (**B**), and back (**C** and **D**). The patient in **D** went on to develop chronic plaque psoriasis. (Used with permission from Drs. Johann Gudjonsson and Trilokraj Tejasvi, Mr. Harrold Carter, and Ms. Laura Vangoor.)

early age and as such is found frequently in young adults. This form of psoriasis has the strongest association to HLA-Cw6,[5] and streptococcal throat infection frequently precedes or is concomitant with the onset or flare of guttate psoriasis.[6] However, antibiotic treatment has not been shown to be beneficial or to shorten the disease course.[7] Patients with a history of chronic plaque psoriasis may develop guttate lesions, with or without worsening of their chronic plaques.

SMALL PLAQUE PSORIASIS

Small plaque psoriasis resembles guttate psoriasis clinically but can be distinguished by its onset in older patients, by its chronicity, and by having somewhat larger lesions (typically 1–2 cm) that are thicker and scalier than in guttate disease. It is said to be a common adult-onset presentation of psoriasis in Korea and other Asian countries.[8]

INVERSE PSORIASIS

Psoriasis lesions may be localized in the major skin folds, such as the axillae, the genitocrural region, and the neck. Scaling is usually minimal or absent, and the lesions show a glossy sharply demarcated erythema, which is often localized to areas of skin-to-skin contact (Fig. 28-6). Sweating is impaired in affected areas.

ERYTHRODERMIC PSORIASIS

Psoriatic erythroderma affects all body sites, including the face, hands, feet, nails, trunk, and extremities (Fig. 28-7). Although all the symptoms of psoriasis are present, erythema is the most prominent feature, and scaling is different compared with chronic stationary psoriasis. Instead of thick, adherent, white scale, there is superficial scaling. Patients with erythrodermic psoriasis lose excessive heat because of generalized vasodilatation, and this may cause hypothermia. Patients may shiver in an attempt to raise their body temperature. Psoriatic skin is often hypohidrotic because of occlusion of the sweat ducts, and there is an attendant risk of hyperthermia in warm climates. Lower extremity edema is common secondary to vasodilation and loss of protein from the blood vessels into the tissues. High-output cardiac failure and impaired hepatic and renal function may also occur. Psoriatic erythroderma has a variable presentation, but two forms are thought to exist. In the first form, chronic plaque psoriasis may worsen to involve most or all of the skin surface, and patients remain relative responsive to therapy. In the second form, generalized erythroderma may present suddenly and unexpectedly or result from nontolerated external treatment (eg, UVB, anthralin), thus representing a generalized Koebner reaction. Generalized pustular psoriasis (see later) may revert to erythroderma with diminished or absent pustule formation. Occasional diagnostic problems may arise in differentiating psoriatic erythroderma from other causes.

PUSTULAR PSORIASIS

Several clinical variants of pustular psoriasis exist: generalized pustular psoriasis (von Zumbusch type), annular pustular psoriasis, impetigo herpetiformis, and two variants of localized pustular psoriasis—pustulosis palmaris et plantaris and acrodermatitis continua of Hallopeau. In children, pustular psoriasis can be complicated by sterile, lytic lesions of bones and can be a manifestation of the SAPHO syndrome (synovitis, acne, pustulosis, hyperostosis, osteitis).

Generalized Pustular Psoriasis (von Zumbusch): This is a distinctive acute variant of psoriasis that is usually preceded by other forms of the disease. Attacks are characterized by fever that lasts several days and a sudden generalized eruption of sterile pustules 2 to 3 mm in diameter (Fig. 28-8). The pustules are disseminated over the trunk and extremities, including the nail beds, palms, and soles.

Figure 28-6 Flexural psoriasis. **A,** Well-demarcated, beefy-red, shiny plaques. **B,** Infant with "napkin psoriasis." (Used with permission from Dr. Johann Gudjonsson and Mr. Harrold Carter.)

Figure 28-7 Erythrodermic psoriasis. **A,** This patient rapidly developed near-complete involvement and complained of fatigue and malaise. Note the islands of sparing. **B** and **C,** This patient had total-body involvement with marked hyperkeratosis and desquamation. (Used with permission from Mr. Harrold Carter and Dr. Johann Gudjonsson.)

The pustules usually arise on highly erythematous skin, first as patches (see Fig. 28-8) and then become confluent as the disease becomes more severe. With prolonged disease, the fingertips may become atrophic. The erythema that surrounds the pustules often spreads and becomes confluent, leading to erythroderma. Characteristically, the disease occurs in waves of fevers and pustules. The cause of generalized psoriasis von Zumbusch type is unknown. Various provoking agents include infections, irritating topical treatment (Koebner phenomenon), and withdrawal of oral corticosteroids.[9] This form of psoriasis is usually associated with prominent systemic signs and can potentially have life-threatening complications such as hypocalcemia, bacterial superinfection, sepsis, and dehydration. Severe pustular psoriasis can be difficult to control and requires a potent treatment regimen with rapid onset of action to avoid life-threatening complications.

Exanthematic Pustular Psoriasis: Exanthematic pustular psoriasis tends to occur after a viral infection and consists of widespread pustules with generalized plaque psoriasis. However, unlike the von Zumbusch pattern, there are no constitutional symptoms, and the disorder tends not to recur. There is an overlap between this form of pustular psoriasis and acute generalized exanthematous pustulosis, a type of drug eruption.

Annular Pustular Psoriasis: Annular pustular psoriasis is a rare variant of pustular psoriasis. It usually presents in an annular or circinate form. Lesions may appear at the onset of pustular psoriasis, with a tendency to spread and form enlarged rings, or they may develop during the course of generalized pustular psoriasis. The characteristic features are pustules on a ringlike erythema that sometimes resembles erythema annulare centrifugum. Identical lesions are found in patients with impetigo herpetiformis, an entity defined by some as a variant of pustular psoriasis occurring in pregnancy. Onset in pregnancy is usually early in the third trimester and persists until delivery. It tends to develop earlier in subsequent pregnancies. Impetigo herpetiformis is often associated with hypocalcemia.[9] There is usually no personal or family history of psoriasis.

Pustulosis Palmaris et Plantaris: Palmoplantar pustular psoriasis (PPPP) is a rare variant of pustular psoriasis that is localized to the palms and soles. It may coexist with chronic plaque psoriasis with approximately 27% of patients having concomitant chronic plaque psoriasis.[10] It differs from chronic plaque psoriasis both in terms of genetic predisposition[11] and transcriptional changes.[12] Therefore, many authors make a distinction between palmoplantar pustulosis (PPP) and PPPP, in which chronic plaque psoriasis is present, although the lesions of PPPP and PPP

Figure 28-8 Pustular psoriasis. **A** and **B,** von Zumbusch-type generalized pustular psoriasis. Note the tiny pustules, 1 to 2 mm in diameter, on erythematous skin. **C** and **D,** localized pustular psoriasis of the leg and foot, respectively. **E,** Resolving pustular psoriasis. Note the extensive areas of desquamation. (**C–E** used with permission from Dr. Johann Gudjonsson, Dr. Trilokraj Tejasvi, and Neena Khanna.)

are indistinguishable by themselves both clinically and transcriptionally.[12] Pustulosis palmaris et plantaris is more common in females (about 78%) with a median age of onset of 47 years.[10] Psoriatic arthritis (PsA) can be seen with pustulosis palmaris et plantaris, with a prevalence of 13% to 25%.[10] Smoking is strongly associated with pustulosis palmaris et plantaris, and about 80% of patients are tobacco smokers at the time of presentation.[10]

Acrodermatitis Continua of Hallopeau: Acrodermatitis continua of Hallopeau, also known as dermatitis repens, is an extremely rare localized sterile pustular eruption of the fingers and toes.[13] It typically involves the distal portions of the fingers and toes and may occur after minor trauma or infection. Pustules often coalesce to form lakes of pus and nail loss is common. Over time, sclerosis of the underlying soft tissues and osteolysis of the distal phalanges may occur. Similar to pustulosis palmaris et plantaris, it is more common in middle-aged women. Evolution of acrodermatitis continua into generalized pustular psoriasis has been described.[13]

SEBOPSORIASIS

A common clinical entity, sebopsoriasis presents with erythematous plaques with greasy scales localized to seborrheic areas (scalp, glabella, nasolabial folds,

perioral and presternal areas, and intertriginous areas). In the absence of typical findings of psoriasis elsewhere, distinction from seborrheic dermatitis is difficult. Sebopsoriasis may represent a modification of seborrheic dermatitis by the genetic background of psoriasis and is relatively resistant to treatment. Although an etiologic role of *Pityrosporum* remains unproven, antifungal agents may be useful.

NAPKIN PSORIASIS

Napkin psoriasis usually begins between the ages of 3 and 6 months and first appears in the diaper (napkin) areas as a confluent red area with appearance a few days later of small red papules on the trunk that may also involve the limbs. These papules have the typical white scales of psoriasis. The face may also be involved with red scaly eruption. Unlike other forms of psoriasis, the rash responds readily to treatment and tends to disappear after the age of 1 year.

LINEAR PSORIASIS

Linear psoriasis is quite rare. The psoriatic lesion presents as linear lesion most commonly on the limbs but may also be limited to a dermatome on the trunk. This may be an underlying nevus, possibly an inflammatory linear verrucous epidermal nevus (ILVEN) because these lesions resemble linear psoriasis both clinically and histologically. The existence of a linear form of psoriasis distinct from ILVEN is controversial.

NAIL CHANGES

Nail changes are frequent in psoriasis, being found in up to 40% of patients,[14] and are rare in the absence of skin disease elsewhere. Nail involvement increases with age, with duration and extent of disease, and with the presence of PsA. Several distinct changes have been described and can be grouped according to the portion of the nail that is affected (Table 28-1). Nail pitting is one of the commonest features of psoriasis, involving the fingers more often than the toes (Fig. 28-9). Pits range from 0.5 to 2.0 mm in size and can be single or multiple. The proximal nail matrix forms the dorsal (superficial) portion of the nail plate, and psoriatic involvement of this region results in pitting caused by defective keratinization. Other alterations in the nail matrix resulting in deformity of the nail plate (onychodystrophy) include leukonychia, crumbling nail, and red spots in the lunula. Onychodystrophy has a stronger association with PsA than other nail changes.[14] Oil spots and salmon patches are translucent, yellow-red discolorations observed beneath the nail plate often extending distally toward the hyponychium caused by psoriasiform hyperplasia, parakeratosis, microvascular changes, and trapping of neutrophils in the nail bed.[15] Unlike pitting, which is also seen in alopecia areata and other disorders, oil spotting is considered to be nearly specific for psoriasis. Splinter hemorrhages result from capillary bleeding underneath the thin suprapapillary plate of the psoriatic nail bed. Subungual hyperkeratosis is caused by hyperkeratosis of the nail bed and is often accompanied by onycholysis (separation of the nail plate from the nail bed), which usually involves the distal aspect of the nail. Anonychia is total loss of the nail plate. Although nail changes are rarely seen in the localized pustular variant of pustulosis palmaris et plantaris, anonychia can be seen in other forms of pustular psoriasis.

TABLE 28-1
Nail Changes in Psoriasis

NAIL SEGMENT INVOLVED	CLINICAL SIGN
Proximal matrix	Pitting, onychorrhexis, Beau's lines
Intermediate matrix	Leukonychia
Distal matrix	Focal onycholysis, thinned nail plate, erythema of the lunula
Nail bed	"Oil drop" sign or "salmon patch," subungual hyperkeratosis, onycholysis, splinter hemorrhages
Hyponychium	Subungual hyperkeratosis, onycholysis
Nail plate	Crumbling and destruction plus other changes secondary to the specific site
Proximal and lateral nail folds	Cutaneous psoriasis

Modified from Del Rosso JQ, et al. Dermatologic diseases of the nail unit. In: Scher RK, Daniel CR, eds. *Nails: Therapy, Diagnosis, Surgery*, 2nd ed. Philadelphia: WB Saunders; 1997; with permission. Copyright © Elsevier.

HAIR AND SEBACEOUS GLANDS

Alopecia is not a common observation in scalp psoriasis clinically; however, both scarring and non-scarring forms of scalp alopecia have been reported (reviewed by Rittie and coworkers[16]). A recent study of nonscalp psoriasis demonstrated that psoriasis plaques have markedly fewer visible hairs than adjacent uninvolved or normal skin, without loss of hair shafts, and suggested that this might be related to sebaceous gland atrophy, which is profound in psoriasis.[16]

NONCUTANEOUS FINDINGS

GEOGRAPHIC TONGUE

Geographic tongue, also known as *benign migratory glossitis* or *glossitis areata migrans*, is an idiopathic inflammatory disorder resulting in the local loss of filiform papillae. The condition usually presents as asymptomatic erythematous patches with serpiginous borders, resembling a map. These lesions characteristically have a migratory nature. Geographic tongue has been postulated to be an oral variant of psoriasis because these lesions show several histologic features of psoriasis, including acanthosis, clubbing of the rete

Figure 28-9 Nail psoriasis. **A,** Distal onycholysis and oil drop spotting. **B,** Nail pitting. **C,** Subungual hyperkeratosis. **D,** Onychodystrophy and loss of nails in a patient with psoriatic arthritis. (Used with permission from Dr. Johann Gudjonsson, Dr. Allen Bruce, and Mr. Harrold Carter.)

ridges, focal parakeratosis, and neutrophilic infiltrate. Although the prevalence of geographic tongue is increased in psoriatic patients, this is a relatively common condition that is seen in many nonpsoriatic individuals, so its relationship to psoriasis needs further clarification.

PSORIATIC ARTHRITIS

Arthritis is a common extracutaneous manifestation of psoriasis seen in up to 40% of patients. It has a strong genetic component, and several overlapping subtypes exist. This condition is discussed in Chap. 65.

COMPLICATIONS

CARDIOVASCULAR MORBIDITY

Patients with psoriasis have an increased morbidity and mortality from cardiovascular events, particularly those with severe and long duration of psoriasis skin disease.[17] Risk of myocardial infarction is particularly elevated in younger patients with severe psoriasis,[18] and vascular inflammation as detected by ^{18}F-fluorodeoxyglucose–positron emission tomography computed tomography (PET/CT) correlates directly with the extent of cutaneous involvement.[19] In a recent study of 1.3 million German health care recipients, metabolic syndrome was 2.9-fold more frequent among patients with psoriasis, and the most common diagnoses were hypertension (35.6% in psoriasis vs 20.6% in control participants) and hyperlipidemia (29.9% vs 17.1%).[20] Patients with psoriasis have also been shown to be at increased risk for rheumatoid arthritis (RA), Crohn's disease, and ulcerative colitis[20] as well as Hodgkin's lymphoma and cutaneous T-cell lymphoma.[21]

PSYCHOSOCIAL RAMIFICATIONS

Psoriasis is emotionally disabling, carrying with it significant psychosocial difficulties. Emotional difficulties arise from concerns about appearance, resulting in lowered self-esteem, social rejection, guilt, embarrassment, emptiness, sexual problems, and impairment of professional ability.[22] The presence of pruritus and pain can aggravate these symptoms. Psychological aspects can modify the course of illness; in particular, feeling stigmatized can lead to treatment noncompliance and worsening of psoriasis. Likewise, psychological stress

can also lead to depression and anxiety. The prevalence of suicidal ideation and depression in patients with psoriasis is higher than that reported in people with other medical conditions and the general population. A comparative study reported reduction in physical and mental functioning comparable with that seen in cancer, arthritis, hypertension, heart disease, diabetes, and depression.[23] According to one survey, 79% of patients with severe psoriasis reported a negative impact on their lives.[24]

ETIOLOGY AND PATHOGENESIS

DEVELOPMENT OF LESIONS

Detailed light, electron microscopic, immunohistochemical, and molecular studies of involved and uninvolved skin of newly appearing and established psoriatic lesions provide a useful framework for relating the many cellular events that take place in a psoriatic lesion. They are illustrated schematically in Fig. 28-10 and with actual photomicrographs in Fig. 28-11. The normal-appearing skin of psoriatic patients has long been known to manifest subclinical morphologic and biochemical changes, particularly involving lipid biosynthesis.[25] In the initial pinhead-sized macular lesions, there is marked edema, and mononuclear cell infiltrates are found in the upper dermis,[26] usually confined to the area of one or two papillae. The overlying epidermis soon becomes spongiotic, with focal loss of the granular layer. The venules in the upper dermis dilate and become surrounded by a mononuclear cell infiltrate. Similar findings have been described in early macules and papules of psoriasis and in the uninvolved skin of guttate psoriasis.[27] The clinical margins of somewhat larger lesions (0.5–1.0 cm) manifest doubling of epidermal thickness, increased metabolic activity of epidermal cells, and increased mast cells and dermal macrophages with increased mast cell degranulation, as well as increased dermal T cells and dendritic cells (DCs). Toward the center of these evolving lesions, there are increasing bandlike epidermal thickness, parakeratosis, and capillary elongation, as well as perivascular infiltration of lymphocytes and macrophages without exudation into the epidermis. Squamous cells manifest enlarged extracellular spaces with only a few desmosomal connections, and parakeratosis is typically mounded or spotty. More mature lesions of psoriasis manifest uniform elongation of rete ridges, with thinning of the epidermis overlying the dermal papillae.[25] Epidermal mass is increased three to five times, and many more mitoses are observed, frequently above the basal layer. About 10% of basal keratinocytes are cycling in normal skin, but this value rises to 100% in lesional psoriatic skin.[28] Widening of the extracellular spaces between keratinocytes persists but is less prominent than in developing lesions and is more uniform than the typical spongiosis of eczematous skin lesions. The tips of the rete ridges are often clubbed or fused with adjacent ones, with thin, elongated, edematous papillae containing dilated, tortuous capillaries. Parakeratosis, with accompanying loss of the granular layer, is often horizontally confluent but may alternate with orthokeratosis. The inflammatory infiltrate around the blood vessels in the papillary dermis becomes more intense but still consists of lymphocytes, macrophages, DCs, and mast cells. Unlike the initial lesion and the transitional zone, lymphocytes are observed in the epidermis of the mature lesion. Neutrophils exit from the tips of a subset of dermal capillaries (the "squirting papillae"), leading to their accumulation in the overlying parakeratotic stratum corneum (Munro's microabscesses) and, less frequently, in the spinous layer (spongiform pustules of Kogoj). Collections of serum can also be seen in the epidermis and stratum corneum.[25]

IMMUNOPATHOGENESIS OF PSORIASIS

LYMPHOCYTES

T cells play an essential role in psoriasis as demonstrated in 1996, when it was shown that psoriasis could be induced by injecting activated autologous T cells into uninvolved psoriatic skin transplanted onto severe combined immunodeficient mice.[29] Early studies suggested that at least some T-cell responses are antigen specific because oligoclonal expansions of both $CD4^+$ and $CD8^+$ T cells have repeatedly been identified in psoriatic lesions.[30] However, more recent studies using deep T-cell receptor (TCR) sequencing indicate most of the T cells in normal, uninvolved and lesional psoriatic skin are polyclonal with approximately equal diversity[31] and thus may accumulate in response to the cytokine environment of the lesion. There is virtually no evidence for B-cell involvement or antibody-mediated processes in psoriasis. The best-characterized T cells are the $CD4^+$ and $CD8^+$ subsets. Predominantly of the memory phenotype ($CD45RO^+$), these cells express the cutaneous lymphocyte antigen, a ligand for E-selectin, which is selectively expressed on skin capillaries and therefore provides them with access to the skin.[32] Whereas $CD8^+$ T cells are predominantly located in the epidermis, $CD4^+$ T cells are predominantly located in the upper dermis. Epidermal T cells, particularly $CD8^+$ cells, appear to have a critical role in development of psoriatic plaques as either blocking the entry of these cells into the epidermis,[33] or neutralization of $CD8^+$ T cells[34] prevents development of psoriasis in a xenograft model.

The cytokine profile of psoriatic lesions is rich in interferon (IFN)-γ, indicative of T helper 1 (Th1) polarization of $CD4^+$ cells, and T cytotoxic 1 (Tc1) polarization of $CD8^+$ cells (Fig. 28-12). Two other subsets of $CD4^+$ T cells, stimulated by interleukin (IL)-23 and

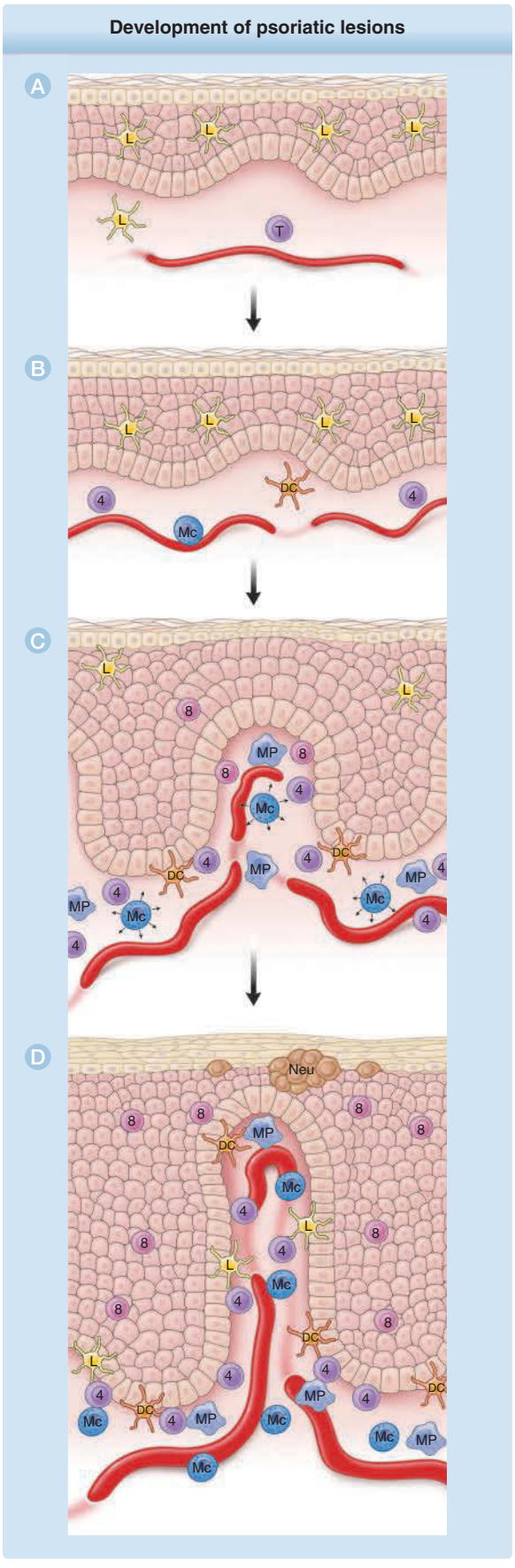

Figure 28-10 Development of psoriatic lesions. Normal skin from a healthy individual (**A**) contains epidermal Langerhans cells, scattered immature dendritic cells (D), and skin-homing memory T cells (T) in the dermis. Normal-appearing skin from a psoriatic individual (**B**) manifests slight capillary dilatation and curvature and a slight increase in the numbers of dermal mononuclear cells and mast cells (Mcs). A slight increase in epidermal thickness may be present. The transition zone of a developing lesion (**C**) is characterized by progressive increases in capillary dilatation and tortuosity, numbers of mast cells, macrophages (MPs), and T cells and mast cell degranulation (*arrowheads*). In the epidermis, there are increasing thickness with increasingly prominent rete pegs, widening of the extracellular spaces, transient dyskeratosis, spotty loss of the granular layer, and parakeratosis. Langerhans cells (L) begin to exit the epidermis, and inflammatory dendritic epidermal cells (I) and $CD8^+$ T cells (8) begin to enter the epidermis. The fully developed lesion (**D**) is characterized by fully developed capillary dilatation and tortuosity with a 10-fold increase in blood flow, numerous macrophages underlying the basement membrane, and increased numbers of dermal T cells (mainly $CD4^+$) making contact with maturing dermal dendritic cells (D). The epidermis of the mature lesion manifests markedly increased (~10-fold) keratinocyte hyperproliferation extending to the lower suprabasal layers, marked but not necessarily uniform loss of the granular layer with overlying compaction of the stratum corneum and parakeratosis, increased numbers of $CD8^+$ T cells, and accumulation of neutrophils in the stratum corneum (Munro's microabscesses).

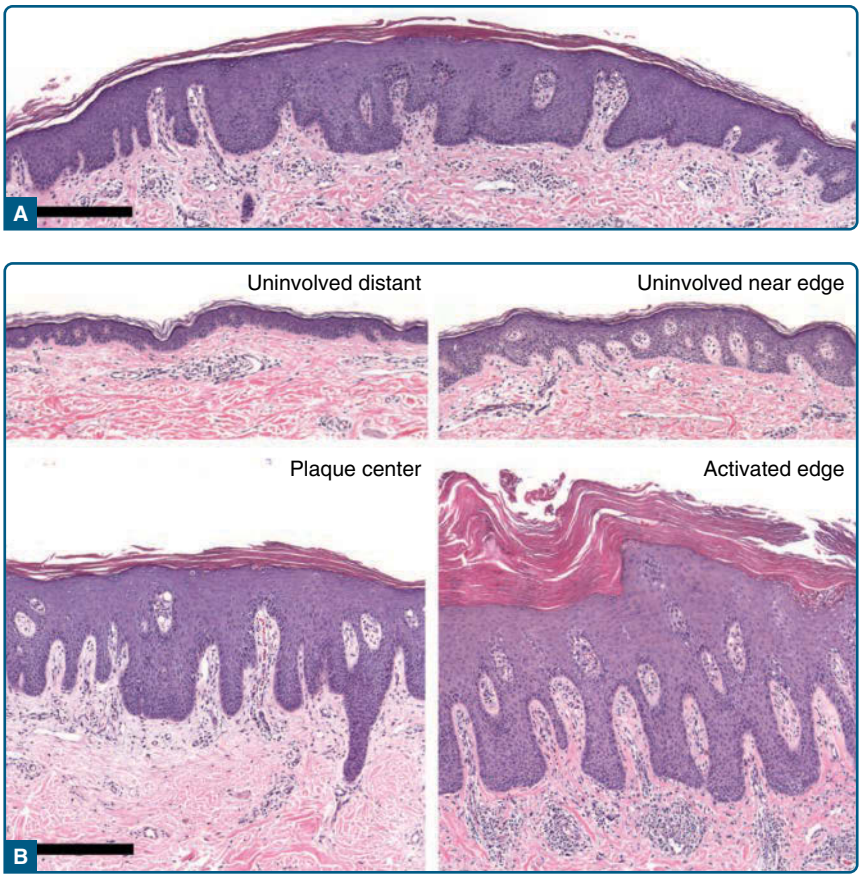

Figure 28-11 Histopathology of psoriasis. **A,** Pinpoint papule of psoriasis. In the transition from the edges to the center of the lesion, note progressive thickening of epidermis with elongation of rete pegs, increasing dilation and tortuosity of vessels, and increasing mononuclear cell infiltrate. Also note the transition from basket-weave to compact stratum corneum with loss of granular layer in the center of the lesion. (Four-mm punch biopsy, hematoxylin and eosin, scale bar, 100 μM.) **B,** Comparison of uninvolved versus involved skin. Four 4-mm biopsies were taken from the same individual sampled in *A* on the same day. "Uninvolved distant" skin was taken from the upper back 30 cm from the nearest visible lesion of psoriasis. The "uninvolved near edge" skin was taken 0.5 cm from the edge of a 20-cm plaque, which had been present for several years, according to the patient. "Center plaque" skin was taken from a relatively inactive (less red and scaly) area in the center of this plaque. "Involved edge" skin was taken from an active (more red and scaly) area about 1 cm inside the edge of the same plaque. In comparing "uninvolved distant" with "uninvolved near-edge" skin, note that the latter manifests increased thickness and early elongation of the rete pegs, dilation and early tortuosity of blood vessels, and increased numbers of mononuclear cells in the upper dermis, many of which are in a perivascular location. In this patient, "uninvolved near-edge" skin also manifests an increased frequency of dyskeratotic keratinocytes, a finding that has been noted previously at the periphery of psoriatic lesions.[53] In comparing less active with more active areas of the plaque, note that the more active area manifests increased dermal mononuclear infiltrate, increased hyperkeratosis and parakeratosis, and Munro microabscesses. (Four-mm punch biopsies, hematoxylin and eosin, scale bar, 100 μM.)

characterized by production of IL-17 (Th17, ~20% of T cells) or IL-22 (Th22, ~15% of T cells), have been shown to play a major role in maintaining chronic inflammation in psoriasis[35] (Fig. 28-13) as well as other autoinflammatory conditions. In addition to IFN-γ–producing Tc1 cells, $CD8^+$ T-cells producing IL-17 (Tc17) and IL-22 (Tc22) are found in psoriasis, most of which localize to the epidermis. These T-cell subsets have considerable functional plasticity and conversions of Tc17 to Tc1 and Th17 to Th1 have been described. Regulatory T cells (Tregs) suppress immune responses in an antigen-specific fashion and are responsible not only for downregulating successful responses to pathogens but also for the maintenance of immunologic tolerance. Several different populations of Tregs exist, but the best characterized one is the $CD4^+$ $CD25^+$ subset.[36] Tregs manifest impaired inhibitory function and failure to suppress effector T-cell proliferation in psoriasis.[37] Other "unconventional" lymphocytes implicated in the pathogenesis of psoriasis include natural killer (NK) cells, NK-T cells, γδ T-cells, mucosal-associated invariant T (MAIT) cells, and innate lymphoid cells (ILCs). These populations also represent important sources of IL-17, IFN-γ, tumor necrosis factor (TNF), and other cytokines.[38,39]

MYELOID CELLS

T cells in psoriatic lesions are in constant communication with DCs, which have a role in both the priming of

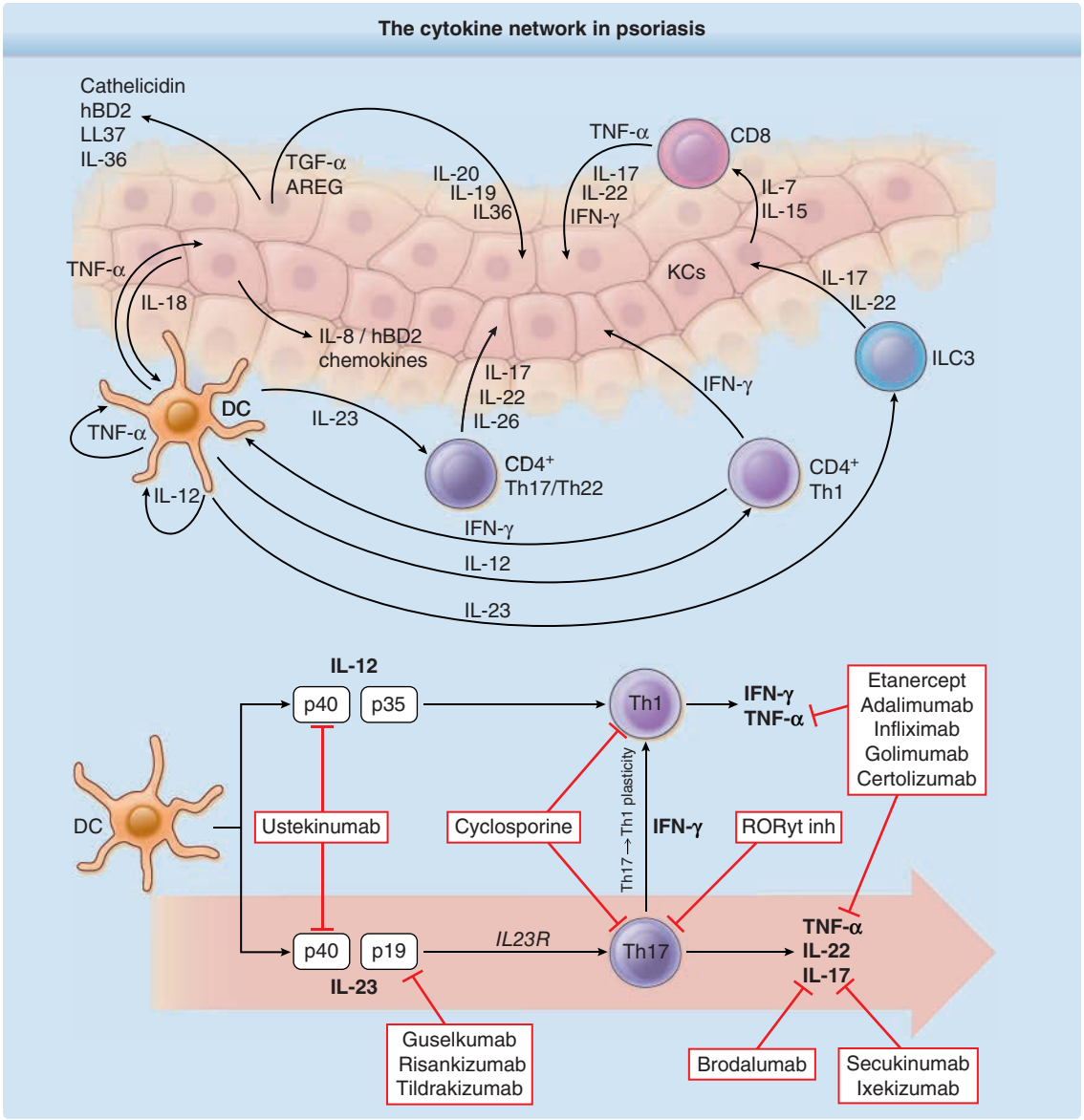

Figure 28-12 The cytokine network in psoriasis. Interferon (IFN)-γ is produced by T helper (Th) 1 cells and tumor necrosis factor (TNF)-α is produced by activated T cells and dendritic cells (DCs). IFN-γ amplifies the production of interleukin (IL)-23 by DC. In turn, IL-23 maintains and expands subsets of $CD4^+$ T cells, called Th 17 and Th22 cells, which are characterized by production of IL-17 and IL-22, respectively. ILC3 also contribute to IL-17 in psoriatic skin. $CD8^+$ T cells are predominantly found in the epidermis, and their entry into the epidermis is necessary for lesion development. IL-17, TNF-α, IFN-γ, and IL-22 synergistically promote activation of the innate keratinocyte defense response involving secretion of antimicrobial peptides such as human-β-defensin 2 (hBD-2), cathelicidin (LL37), IL-8 and other chemokines, and growth factors such as transforming growth factor (TGF)-α, amphiregulin (AREG), IL-19, and IL-20. Keratinocytes also produce IL-7 and IL-15, which influence the survival and turnover of $CD8^+$ T cells; IL-18, which via IL-12 causes DCs to further increase the production of IFN-γ by T-cells; and IL-36 family cytokines, which attracts leukocytes, including neutrophils. Notably, the majority of available systemic therapeutic agents that have shown high therapeutic efficacy in psoriasis target the IL-12–Th1 and IL-23–Th17 axes.

adaptive immune responses and the induction of self-tolerance (see Chap. 11; Fig. 28-13). Several subsets of DCs have been defined, and many of these are found in markedly increased numbers within psoriatic lesions.[40] However, the specific role of each subset is still somewhat unclear. As noted earlier, macrophages are prominent in developing psoriasis lesions, with neutrophils appearing somewhat later. Studies in a mouse model that was used to implicate macrophages suggested that neutrophils may be unnecessary for lesional development.[41] However, neutrophils are likely to play a major role in pustular psoriasis by amplifying the local inflammatory reaction through secretion of proteases such as cathepsin G, elastase, and proteinase-3. These proteases are capable of processing inactive IL-36 family cytokines (IL-36α, IL-36β, and IL-36γ) secreted by keratinocytes into their active forms. When activated, IL-36 cytokines are strong activators of keratinocytes,

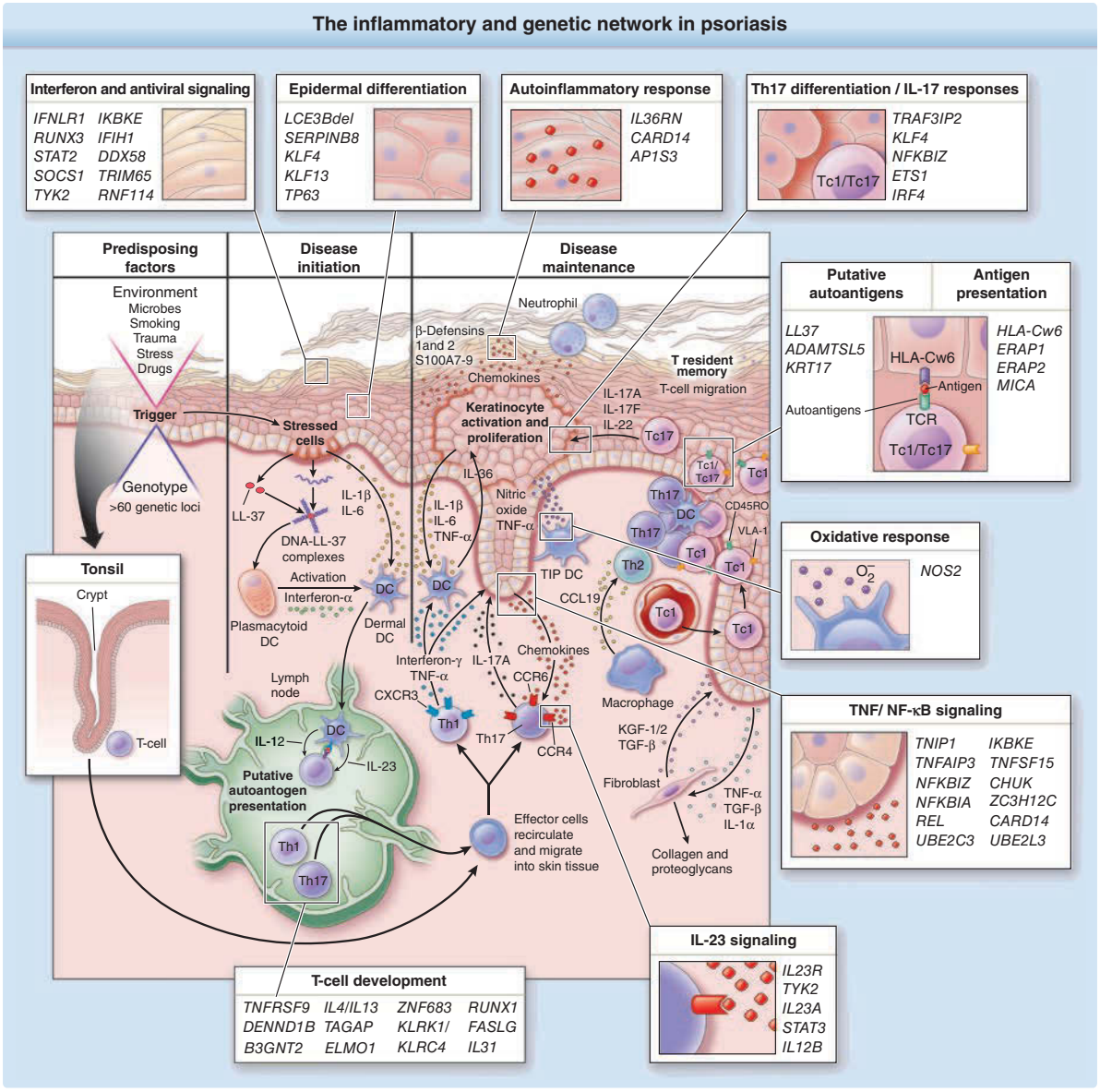

Figure 28-13 The inflammatory and genetic network in psoriasis. Psoriasis is initiated and maintained by interactions between intrinsic genetic susceptibility factors and external environmental factors, with the cutaneous immune system playing a central role. Initiation (triggering) of psoriasis lesions can occur in the skin (Koebnerization) or in the tonsils (streptococcal pharyngitis). In the context of environmental challenge, dendritic cells (DCs) are activated by "danger signals" released by damaged keratinocytes such as nucleic acids, S100 proteins, cathelicidins, and β-defensins; microbial products such as bacterial lipopolysaccharide; and proinflammatory cytokines such as interleukin (IL)-1, IL-36, and IL-8 induced in damaged keratinocytes. Through secretion of the key cytokines IL-12 and IL-23, activated DCs drive polarization and expansion of "T1" (T helper [Th] 1 and Tc1), "T17" (Th17 and Tc17) lymphocytes, which acquire skin-homing properties. Activated T1 and T17 cells secrete pro-inflammatory mediators including interferon (IFN)-γ, tumor necrosis factor (TNF)-α, IL-22, and IL-17, which act in a synergistic manner to amplify keratinocyte responses in the vicinity of the initial insult. To this end, keratinocytes increase their production of inflammatory mediators, including IL-1, IL-36, and a large number of chemokines, including IL-8 (CXCL8), CXCL9, and CXCL10. Cytokine-activated keratinocytes also release larger amounts of the various "danger signals" such as S100 proteins, cathelicidins, and β-defensins, many of which also have antimicrobial and chemotactic properties. This amplified inflammatory circuit recruits in chemotaxis and recruitment other inflammatory cells, including macrophages, DC, neutrophils, and other T-cell subsets, which act in synergy to maintain the disease process. Injured keratinocytes also produce growth factors such as TGF-α, amphiregulin (AREG), fibroblast growth factor (FGF), and nerve growth factor (NGF) to promote structural integrity, as well as T-cell growth factors, including IL-7 and IL-15. Key aspects of this process, which continue to be topics of active investigation, include the role of specific antigens in initiation versus maintenance of psoriasis and the mechanism of psoriatic epidermal hyperplasia. As indicated in the highlighted boxes, genetic variation influences multiple steps in this process, including INF and antiviral signaling, epidermal response, IL-23 signaling, cellular responses to IL-17 and TNF via NF-κB and other intracellular signaling pathways, autoinflammatory response, oxidative responses, and antigen presentation, T-cell development. Details on the role of specific candidate genes in this process can be found in Table 28-2.

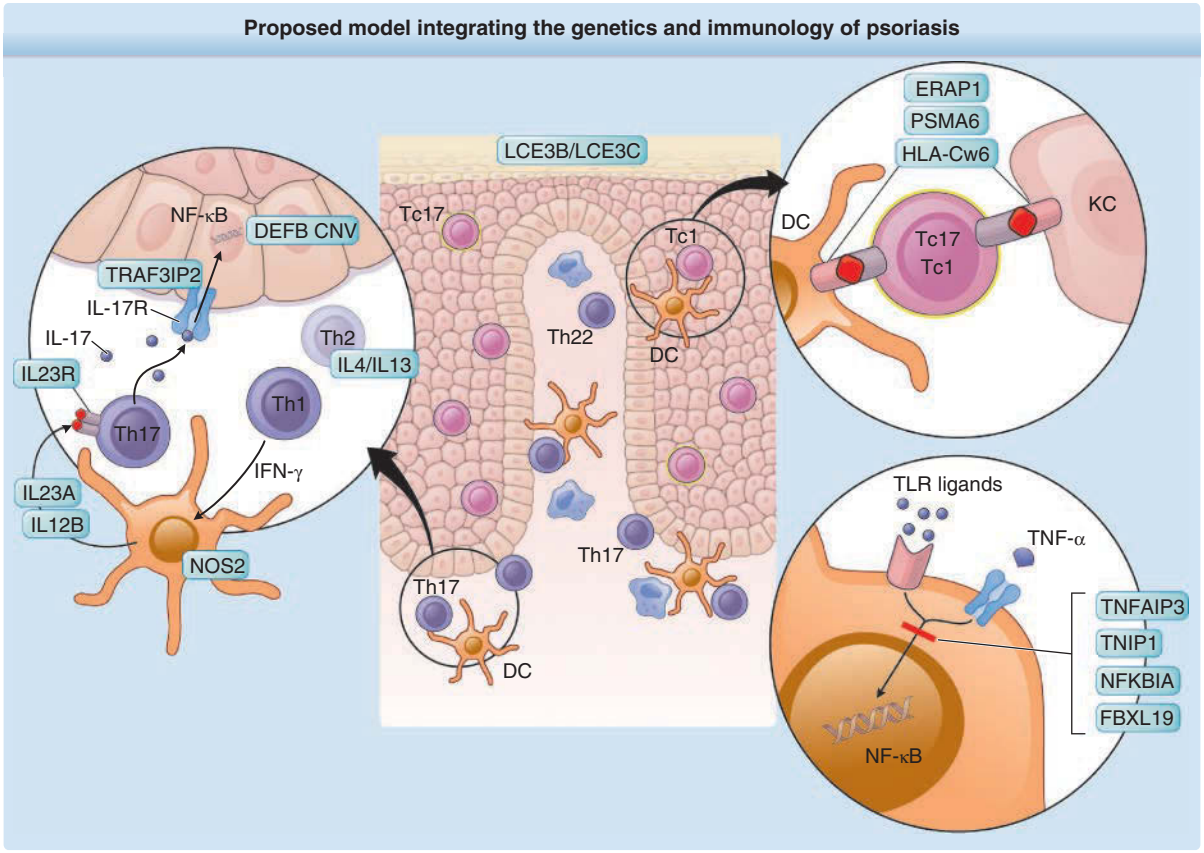

Figure 28-14 Proposed model integrating the genetics and immunology of psoriasis. Whereas the majority of the $CD8^+$ T-cells (*green*) are located in the epidermis, CD4+ T cells (*purple*) predominate in the dermis along with antigen-presenting cells and dendritic cells (DCs) (*blue*) and macrophages (Mϕs) (*orange*). Confirmed association signals are indicated by the likely candidate genes they contain. Not all known psoriasis loci are depicted in this figure; please see text and Table 28-2 for additional details. Th, T helper; TLR, toll-like receptor. (Adapted from Nair RP et al. Psoriasis bench to bedside: genetics meets immunology. *Arch Dermatol*. 2009;145(4):462-464, with permission. Copyright © 2009 American Medical Association. All rights reserved.)

leading to secretion of chemotactic proteins, particularly neutrophil chemokines, thereby amplifying and sustaining the inflammatory process.

KERATINOCYTES

Comprising the bulk of the epidermis and its appendages, keratinocytes are a major producer of proinflammatory cytokines, chemokines, and growth factors, as well as other inflammatory mediators such as eicosanoids and mediators of innate immunity such as cathelicidins, defensins, and S100 proteins. Psoriatic keratinocytes are engaged in an alternative pathway of keratinocyte differentiation called *regenerative maturation*.[42] Regenerative maturation is activated in response to immunologic stimulation. Besides keratinocytes, other skin-resident cell types, such as endothelial cells and fibroblasts, are also likely participants in the pathogenic process.[40]

GENETICS OF PSORIASIS

In recent years, many genetic variants contributing to psoriasis susceptibility have been identified, initially through linkage studies and more recently through genome-wide association studies (GWAS). An overview of the major genetically-implicated pathways in psoriasis is provided in Fig. 28-14, and a list of genetic loci identified to date is provided in Table 28-2.

MAJOR HISTOCOMPATIBILITY COMPLEX GENES

Overall, the major histocompatibility complex (MHC) accounts for the bulk of the overall genetic risk for psoriasis. Thus, although 63 currently known European-origin signals explain 28% of the genetic heritability of psoriasis, MHC signals alone contribute 11.2% of the 28%, or about 40% of the detectable heritability.[43] The major genetic signal for psoriasis in the MHC is *HLAC*0602*, which encodes HLA-Cw6 protein.[44,45] HLA-Cw6 presents antigens to $CD8^+$ T cells, which are MHC class I restricted and comprise about 80% of the T cells in the epidermis of psoriatic lesions (Fig. 28-15). $CD8^+$ T cells selectively traffic to the epidermis because they express integrin α1β1, which binds to Type IV basement membrane collagen[33] as well as integrin αEβ7, which binds to keratinocyte E-cadherin.[46]

TABLE 28-2
Genetic Susceptibility Loci in Psoriasis

CANDIDATE GENE(S)	CHROMOSOME REGION	EUROPEAN ORIGIN	CHINESE ORIGIN	PMID	FUNCTION
TNFRSF9	1p36.23	•		23143594, 26626624	Inhibits proliferation of activated T lymphocytes and induces programmed cell death
MTHFR	1p36.22		•	25854761	Required for homocysteine remethylation to methionine
IFNLR1	1p36.11	•	•	23143594, 23897274	Forms a receptor complex with IL-10 receptor β; interacts with IFN-λ family members IL28A, IL28B, and IL29
RUNX3	1p36.11	•		23143594	TF required for development of IFN-γ–producing pathogenic Th17 cells through binding with T-bet
ZNF683	1p36.11		•	25854761	TF expressed in quiescent and long-lived effector-type CD8+ T cells. Its function in human T cells seems adapted to lifelong, periodic pathogen challenges.
IL23R	1p31.3	•	•	19169254, 25854761	Subunit of the IL-23 receptor that pairs with IL12Rβ1 to initiate IL-23 signaling; associates with TYK2 and JAK2 and binds to STAT3 in a ligand-dependent manner
LRRC7	1p31.1	•		25939698	Brain-expressed leucine-rich repeat protein found in the postsynaptic density; contains a PDZ domain near its C-terminus
FUBP1	1p31.1	•		28301294	Encodes a single-stranded DNA-binding protein that binds to multiple DNA elements and has 3′-5′ helicase activity
PTPN22	1p13.2	•		25923216	Encodes a lymphoid-specific intracellular phosphatase regulating CBL function in the TCR signaling pathway; also associated with T1D, RA, SLE, vitiligo, and Graves disease
LCE3A-D	1q21.3	•	•	19169253, 19169255, 20953190	*LCE* genes are expressed in differentiated keratinocytes. *LCE3* genes are upregulated in psoriatic skin and after skin injury.
AIM2	1q23.1		•	25854761	Encodes a cytoplasmic sensor that recognizes dsDNA of microbial or host origin and assembles inflammasomes, which cleave the proinflammatory cytokines pro–IL-1β and pro–IL-18α
FASLG	1q24.3	•		28537254	Encodes Fas ligand (CD95), a transmembrane protein of the TNF family. Fas ligand–receptor interactions regulate inflammation via apoptosis and promotion of inflammatory responses.
DENND1B	1q31.3	•		25651891	Guanine nucleotide exchange factor for the endosomal small GTPase RAB35, linking RAB35 with the clathrin machinery
IKBKE	1q32.1	•		28537254	Encodes IKKε, essential for regulation of antiviral signaling. Activated downstream of cytosolic RNA/DNA sensors and mediates activation of TFs, including IRF3, IRF7, and NF-κB.
REL	2p16.1	•		20953190, 22170493	Encodes c-Rel, a member of the NF-κB family with an important role in B-cell survival and proliferation. Mice lacking both REL and RELA in KC develop a psoriasiform dermatitis.
B3GNT2	2p15	•		23143594	Encodes a member of the β-1,3-N-acetylglucosaminyl transferase family. Deficiency results in hyperactivation of lymphocytes.
IL1RL1	2q12.1		•	25854761	Encodes a member of the IL1 receptor family induced by proinflammatory stimuli and involved in helper T cell function; associated with atopic dermatitis in Oriental populations

IFIH1	2q24.2	•	•	20953190, 23143594, 25006012	Encodes a DEAD box protein upregulated in response to treatment with IFN-β; variation in *IFIH1* is associated with type 1 diabetes, vitiligo, SLE, and UC
PLCL2	3p24.3	•		25939698	Encodes a phospholipase C-like protein; associated with primary biliary cirrhosis, MS, and RA
NFKBIZ	3q12.3	•		25939698	NFKBIZ: encodes IκBz, which is an TRAF3IP2-dependent IL-17 target gene in mice and humans
CASR	3q21.1		•	25854761	Encodes a GPCR expressed in the parathyroid gland, which senses calcium concentration and modifies PTH secretion; plays a key role in mineral homeostasis and KC differentiation
GPR160	3q26.2		•	25854761	Associated with stroke in Japanese population
TP63	3q28	•		25903422	Encodes a member of the p53 family of TFs; essential for epidermal development in mice; mutations associated with ectodermal dysplasia, cleft lip or palate, and others; epidermal overexpression results in an AD-like phenotype
NFKB1	4q24		•	25006012	Encodes a 105-kD Rel-specific transcription inhibitor that is processed to a 50-kD DNA binding subunit of NF-κB; activated by cytokines, oxidants, UV light, and bacterial or viral products
CARD6	5p13.1	•		25939698	Encodes a microtubule-associated protein that interacts with RIPKs and modulates signaling pathways converging on NF-kB
ZFYVE16	5q14.1		•	25854761	Encodes an endosomal protein that regulates membrane trafficking; scaffold protein in the TGF-β pathway
ERAP1, LNPEP	5q15	•	•	20953187, 20953190, 23143594	Both genes encode endoplasmic reticulum aminopeptidases involved in trimming HLA class I-binding peptide precursors for antigen presentation. ERAP1 acts as a monomer or ERAP1/2 heterodimer. Epistasis with HLA class I in AS and Behçet disease.
IL13, IL4	5q31.1	•		19169254, 25903422	Cytokines with overlapping functions produced by Th2 cells. *IL3*, *IL5*, *IL4*, and *CSF2* form a gene cluster on chromosome 5q.
TNIP1	5q33.1	•	•	19169254, 20953187	Encodes an A20-binding protein involved in autoimmunity and tissue homeostasis through regulation of NF-κB activation; associated with myasthenia gravis, systemic sclerosis, and SLE
IL12B	5q33.3	•	•	17236132, 19169254, 19169255, 20953186, 20953190	Encodes the p40 a subunit of IL-12, a cytokine that acts on T and NK cells; expressed by DCs and activated macrophages, IL-12 is an essential inducer of Th1 development that protects against intracellular pathogens; associated with MS, CD, UC, and AS
PTTG1	5q33.3		•	20953187	Encodes an APC substrate involved in sister chromatid separation
IRF4	6p25.3	•		23143594	Encodes a TF that regulates IL17A promoter activity and Th17-mediated colitis in vivo; stabilizes the Th17 phenotype through IL-21; associated with pigmentation, RA, lymphoma, leukemia, and schizophrenia
CDKAL1	6p22.3	•		26626624	Encodes a member of the methylthiotransferase family of unknown function; variation associated with T2D, BMI, and CD
HLA-C, HLA-B, HLA-A, HLA-DR	6p21.33	•	•	19169254, 19169255, 19680446, 20953190, 25087609	HLA-B and HLA-C present antigens to $CD8^+$ T cells. HLA-C is a ligand for KIRs on NK cells. Conditional analysis demonstrates associations with multiple HLA loci. Amino acid 45 at HLA-B distinguishes between PsC and PsA.
TRAF3IP2	6q21	•		20953186, 20953188, 20953190	Interacts with TRAF proteins and I-κB kinase and MAPK to activate NF-κB TFs that mediate innate immunity

(*Continued*)

TABLE 28-2
Genetic Susceptibility Loci in Psoriasis (*Continued*)

CANDIDATE GENE(S)	CHROMOSOME REGION	EUROPEAN ORIGIN	CHINESE ORIGIN	PMID	FUNCTION
TNFAIP3	6q23.3	•		19169254, 23143594	Rapidly induced by TNF; encodes an ubiquitin-editing enzyme involved in cytokine-regulated responses; inhibits NF-κB activation and TNF-induced apoptosis
TAGAP	6q25.3	•		23143594	Encodes a protein activating a Rho GTPase for T-cell activation; mutations are associated with RA, celiac disease, and MS
CCDC129	7p14.3		•	25854761	Encodes coiled-coil domain containing protein 129 involved in receptor binding
ELMO1	7p14.1	•		23143594	An engulfment and cell motility protein that promotes phagocytosis and cell migration; associated with glioma cell invasion and diabetic nephropathy
CSMD1	8p23.2		•	20953187	A postulated tumor suppressor of squamous cell carcinomas
DDX58	9p21.1	•		23143594	Encodes a protein with a caspase recruitment domain and RNA helicase motif; recognizes dsRNA; controls immune responses
KLF4	9q31.2	•		23143594	A transcription factor that regulates p53 in G1-to-S phase transition after DNA damage; necessary for skin barrier function
TNFSF15	9q32	•		28973304	Induced by TNF and IL-1α; its product activates NF-κB and MAPKs; induces apoptosis; inhibits endothelial cell proliferation
ZNF365	10q21.2	•			Zinc finger protein; mutations are associated with uric acid–induced nephrolithiasis
CAMK2G	10q22.2	•		25939698	Encodes the γ chain of a serine/threonine, Ca(2+)/calmodulin-dependent protein kinase
ZMIZ1	10q22.3	•		22482804	Regulates transcription factors, such as androgen receptor, Smad3/4, and p53
PTEN, KLLN	10q23.31	•		28537254	*PTEN*: tumor suppressor that negatively regulates the AKT/PKB signaling pathway *KLLN*: nuclear protein that increases S phase arrest and apoptosis and is upregulated by p53
CHUK	10q24.31	•		28537254	A serine/threonine protein kinase that activates NF-κB via degradation of its inhibitor IκBα
ZNF143	11p15.4		•	25854761	Zinc finger protein transcriptional activator that initiates RNA polymerase activity
RPS6KA4, PRDX5	11q13.1	•		22482804	*RPS6KA4*: serine/threonine kinase that phosphorylates CREB1, ATF1, and histone H3 to regulate genes involved in inflammation *PRDX5*: a protective antioxidant enzyme
FOSL1	11q13.1	•	•	25854761	Regulates cell proliferation and differentiation via interactions with other AP-1 family members
ZC3H12C	11q22.3	•		23143594	Encodes a protein that inhibits TNF-induced endothelial cell activation
ETS1	11q24.3	•		23143594	TF with activator and repressor activity; plays a role in stem cell development, cell aging, and tumorigenesis
CD27	12p13.3		•	25006012	Encodes a member of the TNF receptor superfamily required for T-cell immunity; *LAG3* encodes a ligand for MHC class II receptors that is related to CD4
KLRK1, KLRC4	12p13.2	•		28537254	Transmembrane receptors that can activate NK and T cells; targeted in immune disorder and cancer treatment

IL23A, STAT2	12q13.3	•		19169254	*IL23A*: encodes p19 subunit of IL-23, which acts on memory $CD4^+$ T cells to induce STAT4 and IFN-γ *STAT2*: transcriptional activator; complexes with STAT1 in response to IFN
BRAP, MAPKAPK5	12q24.12	•		29553248	*BRAP*: sequesters BRCA1 to the cytoplasm *MAPKAPK5*: tumor suppressor activated by MAPKs in response to cell stress and inflammatory cytokines; phosphorylates HSP27
IL31	12q24.31	•		29046191	Produced by Th2 T cells; acts on keratinocyte and epithelial cells; may regulate allergic dermatoses and other allergic diseases
GJB2	13q12.11		•	20953187	A gap junction protein, also known as a connexin 26; mutations of this gene account for more than half of recessive deafness cases
COG6	13q14.11	•		25903422	Encodes a subunit of the conserved oligomeric Golgi complex
LINC00330	13q14.2	•		25903422	Long intergenic noncoding RNA 330; function unknown
UBAC2	13q32.3	•			*UBA* domain-containing 2, implicated in Behçet disease
NFKBIA, PSMA6	14q13.2	•	•	20953189, 20953190, 24070858	*NFKBIA:* moves between cytoplasm and nucleus to inhibit NF-κB; mutations associated with ectodermal dysplasia with T-cell immunodeficiency *PSMA6:* encodes a proteasomal subunit involved in cleavage of MHC class I peptides
SYNE2	14q23.2		•	25854761	A nuclear outer membrane protein that binds cytoplasmic F-actin to secure the nucleus to the cytoskeleton and maintain its structural integrity
RP11-61O1.1	14q32.2	•			Noncoding gene of unknown function
KLF13	15q13.3	•		27041562	A transcription factor containing three zinc finger DNA-binding domains[71]; regulates HPV life cycle in keratinocytes
SOCS1	16p13.13	•		23143594	A cytokine-induced negative feedback inhibitor of STAT signaling
FBXL19, PRSS53,	16p11.2	•		20953189	*FBXL19:* an E3 ubiquitin ligase that ubiquitinates IL1RL1 for degradation *PRSS53:* encodes a protein with serine-type endopeptidase activity
NOS2	17q11.2	•		20953189	Encodes an iNOS that is markedly overexpressed in psoriasis lesions
IKZF3	17q12		•	25006012	Encodes a TF in the Ikaros family; controls proliferation and differentiation of B cells; functions in chromatin remodeling
STAT3, STAT5A/B	17q21.2	•		23143594	*STAT3, STAT5A, STAT5B:* transcription factors involved in cell growth, apoptosis, and immunoregulation
TRIM65	17q25.1	•		28031478	*TRIM65:* tripartite motif containing 65; deactivates p53 through ubiquitination and is upregulated in lung carcinoma; essential for MDA5-mediated innate immunity
TMC6	17q25.3		•	25854761	An integral membrane protein of the endoplasmic reticulum; one of two genes causing epidermodysplasia verruciformis, a disease with increased susceptibility to HPV and SCC
CARD14	17q25.3	•	•	23143594, 24212883	A caspase recruitment domain-containing protein of the MAGUK family, members of which act as scaffold proteins in cell adhesion, cell polarity, and signal transduction; interacts with BCL10 to activate NF-κB and promote apoptosis

(*Continued*)

TABLE 28-2
Genetic Susceptibility Loci in Psoriasis (*Continued*)

CANDIDATE GENE(S)	CHROMOSOME REGION	EUROPEAN ORIGIN	CHINESE ORIGIN	PMID	FUNCTION
PTPN2	18p11.21	•		18923449	Encodes a protein tyrosine phosphatase with a highly conserved catalytic motif; serves as a signaling molecule to regulate cell growth, differentiation, mitosis, and oncogenesis
POLI, STARD6, MBD2	18q21.2	•		23143594	*POLI:* DNA polymerase involved in DNA repair and in mutation of immunoglobulin genes *STARD6*: homologous to STAR proteins involved in sterol transport *MBD2*: methyl-CpG binding protein that can repress or activate transcription
SERPINB8	18q22.1		•	20953187	Protease inhibitor-8, a member of the ov-serpin subfamily; serpins play a role in complement activation, fibrinolysis, coagulation, migration, apoptosis, and tumor suppression
TYK2	19p13.2	•		20953190, 23143594	Belongs to the JAK family of tyrosine kinases that propagate inflammatory signals; functions in IFN-mediated antiviral immunity; linked to hyper-IgE syndrome
ILF3,CARM1	19p13.2	•		23143594	*ILF3:* A dsRNA binding protein that regulates gene expression via mRNA stabilization *CARM1:* A arginine methyltransferase that acts on histones to regulate gene expression
FUT2	19q13.33	•		22482804	Encodes the galactoside 2-L-fucosyltransferase enzyme involved in production of H antigen precursor for the ABO blood group
ZNF816	19q13.41		•	20953187	Encodes a zinc finger protein with TF activity
RNF114, SNAI1	20q13.13	•		18364390, 23143594	*RNF114*: ubiquitin-protein ligase that degrades the inhibitor of CDKN1A to induce G1-to-S phase transition *SNAI1*: zinc finger transcriptional repressor involved in mesodermal development
IFNGR2	21q22.11		•	25854761	Non–ligand-binding β chain of IFN-γ receptor; mutations result in susceptibility to mycobacterial disease
RUNX1	21q22.12	•		25903422	The α subunit of core binding factor, which plays a role in hematopoietic development; leads to leukemia via chromosomal translocation
YDJC, UBE2L3	22q11.21	•		22482804, 23143594	*YDJC:* deacetylates carbohydrates in the breakdown of oligosaccharide *UBE2L3*: ubiquitin-conjugating enzyme that ubiquitinates p53, c-FOS, and p105.

AD, atopic dermatitis; AKT, serine/threonine kinase 1; AP-1, activator protein-1; APC, anaphase-promoting complex; AS, ankylosing spondylitis; ATF1, activating transcription factor-1; BMI, body mass index; CBL, Casitas B-lineage Lymphoma; CD, Crohn's disease; CREB1, cAMP responsive element binding protein 1; DC, dendritic cell; dsDNA, double-stranded DNA; GPCR, G-protein coupled receptor; HLA, human leukocyte antigen; HPV, human papillomavirus; IKKε, I-κB kinase epsilon; IL, interleukin; IFN, interferon; iNOS, inducible nitric oxide synthase; JAK, Janus kinase; KC, keratinocyte; KIR, killer immunoglobulin-like receptor; LCE, late cornified envelope; MAGUK, membrane-associated guanylate kinase; MAPK, mitogen-activated protein kinase; MHC, major histocompatibility complex; MS, multiple sclerosis; NF-κB, nuclear factor kappa B; NK, natural killer; PDZ, post-synaptic density, Dlg1, and ZO-1 protein; PKB, protein kinase B; PsA, psoriatic arthritis; PsC, purely cutaneous psoriasis; RA, rheumatoid arthritis; REL, proto-oncogene c-REL; RELA, proto-oncogene, NF-κB subunit; RIP, receptor-interacting kinase; SCC, squamous cell carcinoma; SLE, systemic lupus erythematosus; STAT, signal transducer and activator of transcription; T1D, type 1 diabetes; T2D, type 2 diabetes; TCR, T-cell receptor; TF, transcription factor; TGF, transforming growth factor; Th, T helper; TNF, tumor necrosis factor; TRAF, TNF receptor-associated factor; TYK2, tyrosine kinase 2; UC, ulcerative colitis; UV, ultraviolet; RIPKs, receptor-interacting protein kinase.

Functionally, epidermal invasion by CD8+ T cells correlates with lesional development in a xenograft model of psoraisis.[47] Further emphasizing the importance of MHC class I antigen presentation, several other MHC class I risk variants are associated with psoriasis independently of HLA-Cw6 in both European-origin[45] and Chinese populations.[48] The fact that oligoclonal T-cell expansions are found in CD8+ T-cells in psoriatic skin[30] suggests that in the epidermis, CD8+ T cells "interrogate" peptides bound to HLA-Cw6 on the surface of dendritic antigen-presenting cells (APCs) and expand in response to one or more specific antigens (see Figs. 28-14 and 28-15).

The nature of these antigens remains a topic of active investigation. Besides candidate antigens described in previous editions of this chapter, three recent publications have implicated additional candidate autoantigens in psoriasis, including the antimicrobial protein LL37,[49] neolipid antigens generated by mast cell phospholipase and presented by the MHC -like class I antigen-presenting protein CD1a,[50] and the melanocyte antigen ADAMTSL5. Of these, the ADAMTSL5 antigen is of genetic interest because it is presented specifically by HLA-Cw6.[51] Of note, recent immunohistochemical data suggest that expression of ADAMTSL5 may not be limited to melanocytes.[52] Although much remains to be learned about specific autoantigens, the observations that multiple HLA alleles are implicated genetically and that expanded TCR rearrangements are usually oligoclonal in nature suggest that multiple autoantigens may be involved in the pathogenesis of psoriasis.

CD4+ T cells predominate in the dermis of psoriasis lesions and are also clonally expanded in psoriasis. CD4+ T cells are also required for the development of psoriasis lesions from uninvolved skin in a xenograft model.[53] This is consistent with the identification of genetic signals in the MHC class II region in both European-origin[45] and Chinese[48] populations. Although CD4+ and CD8+ memory T cells can traffic among the skin, lymph nodes, and blood, increasing evidence indicates that when initially activated in the cutaneous environment, they spend most of their time

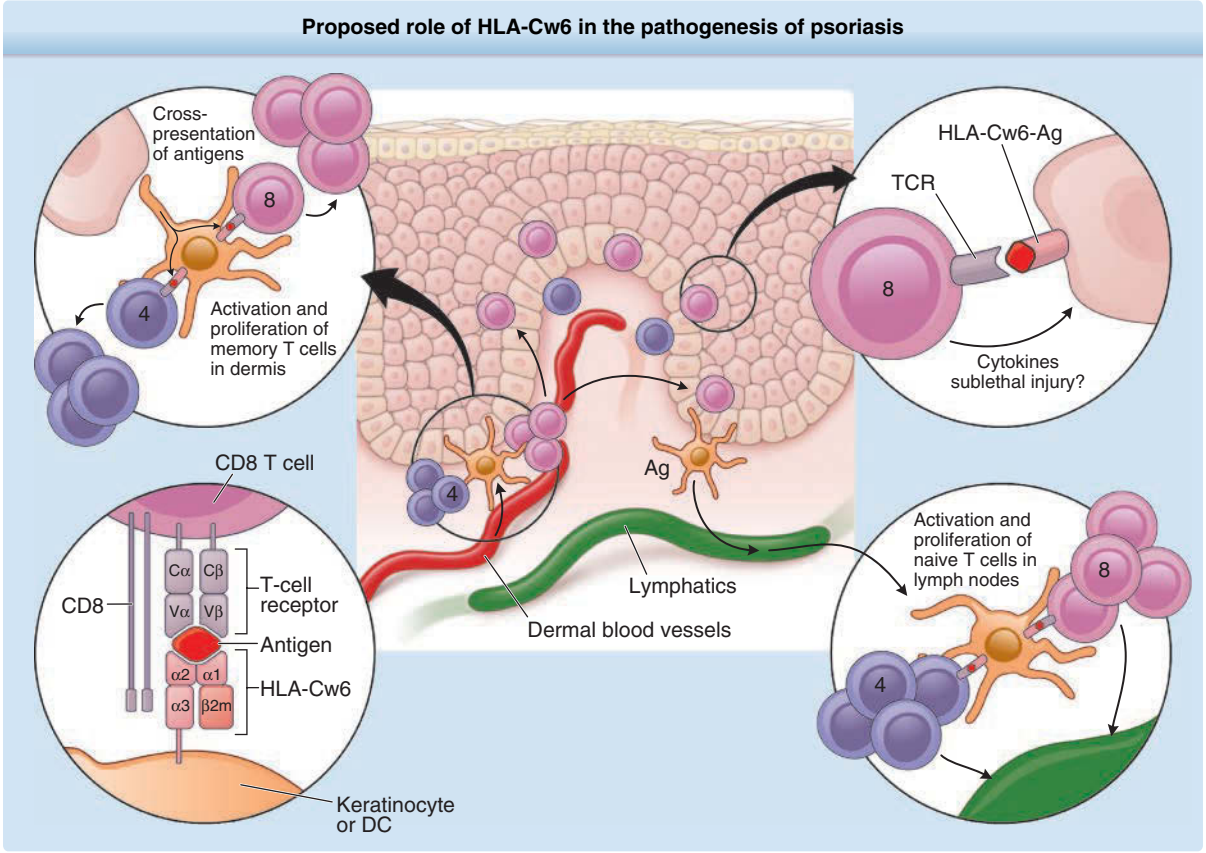

Figure 28-15 Proposed role of HLA-Cw6 in the pathogenesis of psoriasis. Antigen (Ag) in the binding pocket of human leukocyte antigen (HLA)-Cw6 interacts with a T-cell receptor (TCR). The role of HLA-Cw6 in psoriasis is likely to be twofold. HLA-Cw6 is active in cross-presenting peptides on the surface of dendritic cells (DCs), allowing activation and clonal expansion of antigen-specific CD8+ T cells. This process is dependent on CD4+ T-cell help for cross-presentation of intracellular antigens and is likely to happen both in the dermis (activation of resident memory T cells) and local lymph nodes (activation of naïve T cells). Subsequently, the activated CD8+ T cells are able to migrate into the epidermis, where they encounter HLA-Cw6 on the surface of DCs or keratinocytes presenting those same pathogenic peptides. Because these T cells express perforin, they may directly damage keratinocytes in the traditional cytotoxic manner. Activated CD8+ T cells may also trigger the local release soluble factors, including cytokines, chemokines, eicosanoids, and innate immune mediators, which could further increase local inflammation and stimulate keratinocyte proliferation.

in the skin site at which they were activated, as resident memory T cells.[32] This would be consistent with the behavior of psoriatic plaques, which tend to recur in the same body sites after therapeutic or spontaneous improvement.

NON-MAJOR HISTOCOMPATIBILITY COMPLEX GENES

Over the past decade, GWAS have identified 86 genomic regions that are associated with psoriasis at genome-wide significance (see Table 28-2). Eleven of the 86 known psoriasis risk loci are shared by European and Chinese populations, 55 loci have been established for Europeans only, and 20 loci have been established for Chinese only. Sixteen loci have also been established as susceptibility loci for PsA and 12 for purely cutaneous psoriasis.[45,54,55] Perhaps surprisingly, most of the genetic signals identified in psoriasis thus far do not affect the structure of a protein and instead are regulatory in nature.[43] Moreover, because of topologic looping of DNA in chromatin, the regulatory signals affected by genetic variation may lie at a substantial distance from the causal gene being regulated. Thus, the "candidate genes" listed in Table 28-2 cannot simply be assumed to be the causal genes underlying the observed associations. However, there is strong bioinformatic evidence indicating that the genes underlying these psoriasis genetic signals are disproportionately involved in immunity and host defense, including functions such as lymphocyte differentiation and regulation, type I IFN and pattern recognition, nuclear factor kappa B (NF-κB) signaling, and response to viruses and bacteria.[43] Correspondingly, psoriasis signals are enriched in regulatory elements active in several T-cell subsets, including $CD8^+$ T cells, and $CD4^+$ T-cell subsets, including T_h0, T_h1, and T_h17.[43] Thus, there can be little doubt that "psoriasis genes" are involved in various aspects of immunity and host defense even if many of them remain to be formally identified. Most of the non-MHC associations identified thus far fall into several interconnected functional axes: IL-23–IL-17 signaling, interferon signaling, NF-κB signaling, DC–macrophage function, and keratinocyte responses (see Fig. 28-14 and Table 28-2).

IL-23–IL-17 Signaling: Three strong regions of association map near genes involved in IL-23 signaling: *IL12B* (encoding the p40 subunit of IL-23 and IL-12), *IL23A* (encoding the p19 subunit of IL-23), and *IL23R* (encoding a subunit of the IL-23 receptor). These associations are further supported by the impressive efficacy of biologics targeting the p40 subunit common to IL-12 and IL-23[56] as well as the p19 subunit,[57] which is unique to IL-23. IL-23 signaling promotes the survival and expansion of IL-17–expressing T-cells, which protect epithelia against microbial pathogens.[58] Ankylosing spondylitis (AS) is another HLA class I–associated autoimmune disorder that is clinically associated with inflammatory bowel disease[59] and genetically associated with *IL23R*.[60] PsA shares a number of clinical similarities with AS, and is genetically associated with *IL12B*, *IL23A*, and *IL23R* (see Chap. 65). Other candidate genes relevant to this signaling axis include *TRAF3IP2* encoding Act1; a ubiquitin ligase coupling IL-17 receptors to downstream signaling pathways; *RUNX3*, which encodes a transcription factor (TF) required for development of Th17 cells; *NFKBIZ*, a TF whose expression is stimulated by IL-17 via Act1[61]; and *IRF4*, encoding a TF that regulates *IL-17A* promoter activity.

Interferon Signaling: Although the *IFNG* gene does not itself map to a psoriasis susceptibility region, its product IFN-γ is secreted by activated Th1 cells and stimulates DC to produce IL-23.[62] This may explain why Th1 and Th17 cells are co-localized in psoriasis lesions and many other sites of inflammation.[62] Another psoriasis susceptibility region contains the *IL4* and *IL13* genes. In addition to biasing T-cell differentiation away from Th1 and toward Th2, IL-4 inhibits Th17 cell development.[63] Moreover, treatment of psoriasis with IL-4 resulted in significant clinical improvement by selective silencing of IL-23 in APCs.[64] Other psoriasis genetic signals suggest involvement of Type I IFN signaling in disease pathogenesis, including associations with *DDX58* encoding RIG-I and *IFIH1* encoding MDA5. Each of these proteins bind viral nucleic acids and activate the mitochondrial antiviral signaling protein (MAVS), leading ultimately to activation of type I IFNs and IFN-stimulated genes as well as NF-κB.[65] *TYK2* encodes Tyk2, which also prominently involved in downstream type I IFN signaling and mediates responses to several other cytokines.[66]

NF-κB Signaling: Several psoriasis-associated genomic regions contain genes involved with controlling signaling through the TF NF-κB. TNF-α is a major activator of NF-κB signaling, and these associations are clinically reinforced by the dramatic therapeutic response of psoriasis to anti-TNF biologicals (see Treatment). *TNFAIP3* and *TNIP1*, respectively, encode A20 and ABIN-1, which interact with each other to regulate the ubiquitin-mediated destruction of IKKγ/NEMO, a central nexus of NF-κB signaling.[67] *TNFAIP3* is genetically associated with RA, and both *TNFAIP3* and *TNIP1* are associated with systemic lupus erythematosus (SLE). The polymorphisms implicated in RA and SLE show no association with psoriasis, suggesting that each of these diseases is driven by different variants of the *TNFAIP3* gene. *CHUK* encodes IKK-α, which activates NF-κB via degradation of IκBα, and *NFKBIA* encodes IκBα, which inhibits NF-κB signaling by sequestering it in the cytoplasm. Other notable candidate genes in this category include *FASLG* encoding Fas ligand (CD95), a transmembrane protein of the TNF family; *REL* and *NFKB1*, both of which encode members of the NF-κB family; *TNFSF15* encoding TL1, a TNF-inducible cytokine that activates NF-κB; *IKBKE* encoding IKK-ε, which functions downstream of viral sensors to activate NF-κB; and *CARD14* encoding CARMA2, which activates NF-κB via interactions with BCL10. Notably, *CARD14* has been identified as the causative gene in the *PSORS2* locus, initially identified in a large pedigree by linkage analysis.[68]

Dendritic Cell and Macrophage Function: Besides the MHC, two other regions of association contain genes whose products function in antigen presentation: *PSMA6*, which encodes a proteasomal subunit involved in MHC class I antigen processing, and *ERAP1*, an IFN-γ–inducible aminopeptidase that trims peptides for optimal binding to the MHC class I peptide groove. Macrophages and inflammatory DCs are major sources of IL-23, TNF-α and inducible nitric oxide synthetase (iNOS). Psoriasis risk variants are present in *NOS2* (encoding iNOS) and *ZC3H12C* encoding the zinc-finger protein MCPIP3, both of which are important for macrophage function.

Keratinocyte Responses: Although the TNF-α and IL-23–Th17 axes described above converge strongly at a physiological level to stimulate production of innate inflammatory mediators such as hBD2 by keratinocytes,[69] relatively few psoriasis-associated regions contain genes that are thought to function primarily in keratinocytes. The most well-established association is an insertion-deletion (indel) polymorphism of the late cornified envelope genes *LCE3B* and *LCE3C*, which was independently discovered in European-origin[70] and Chinese[71] populations. Located in the epidermal differentiation complex (EDC), these genes are expressed very late in keratinocyte terminal differentiation and are markedly overexpressed in psoriasis, wound healing, and epidermal stress.[72] Notably, the *LCE3B/3C* indel is associated with cutaneous psoriasis but not with PsA.[54] Another psoriasis risk variant resides near the *KLF4* gene, which is a TF required for establishment of skin barrier function. *TRAF3IP2*- and *NFKBIZ* –encoded proteins are known to function in IL-17 responses of epidermal cells, and several genes implicated in the pathogenesis of generalized or PPPP are primarily expressed in the epidermis, including *IL36RN*, *AP1S3*, and *CARD14*.

OTHER RISK FACTORS

OBESITY

It has been demonstrated that obese individuals are more likely to present with severe psoriasis. However, obesity does not appear to have a role in defining the onset of psoriasis.[73]

SMOKING

Heavy smoking (>20 cigarettes daily) has been associated with more than a twofold increased risk of severe psoriasis.[74] Unlike obesity, smoking appears to have a role in the onset of psoriasis.[73]

INFECTIONS

An association between streptococcal throat infection and guttate psoriasis has been repeatedly confirmed. Streptococcal throat infections have also been demonstrated to exacerbate preexisting chronic plaque psoriasis,[75] and tonsillectomy has been shown to lead to long-term improvement in psoriasis,[76] particularly in HLA-Cw6 carriers.[77] Severe exacerbation of psoriasis can be a manifestation of HIV infection. The prevalence of psoriasis in HIV infection is no higher than in the general population, indicating that this infection is not a trigger for psoriasis but rather a modifying agent. Psoriasis is increasingly more severe with progression of immunodeficiency but can remit in the terminal phase. This paradoxical exacerbation of psoriasis may be caused by loss of Tregs and increased activity of the CD8 T-cell subset.[78] Psoriasis exacerbation in HIV disease may be effectively treated with antiretroviral therapy. Psoriasis has also been associated with hepatitis C infection.

DRUGS

Medications that exacerbate psoriasis include antimalarials, β blockers, lithium, nonsteroidal antiinflammatory drugs (NSAIDs), IFNs-α and -γ, imiquimod, angiotensin-converting enzyme inhibitors, and gemfibrozil. Imiquimod acts on plasmacytoid dendritic cells (pDCs) and stimulates IFN-α production, which then strengthens both innate and Th1 immune responses.[79] Exacerbations and onset of psoriasis have been described in patients receiving TNF inhibitor therapy. The majority of these patients have PPP, but about one third develop chronic plaque psoriasis.[80] New-onset psoriasis has also been described after the anti-IL-6 treatment tocilizumab. Lithium has been proposed to cause exacerbation by interfering with calcium release within keratinocytes, whereas β blockers are thought to interfere with intracellular cyclic adenosine monophosphate levels.[81] The mechanisms by which the remaining medications exacerbate psoriasis are largely unknown.

DIAGNOSIS

An algorithm for the diagnosis and treatment of psoriasis is presented in Fig. 28-16.

PATHOLOGY

Although histopathologic examination is rarely necessary to make the diagnosis of psoriasis, it can be helpful in difficult cases. The histopathologic manifestations of guttate and chronic plaque psoriasis have already been described (see Development of Lesions).

LABORATORY TESTING

Laboratory abnormalities in psoriasis are usually not specific and may not be performed in all patients.

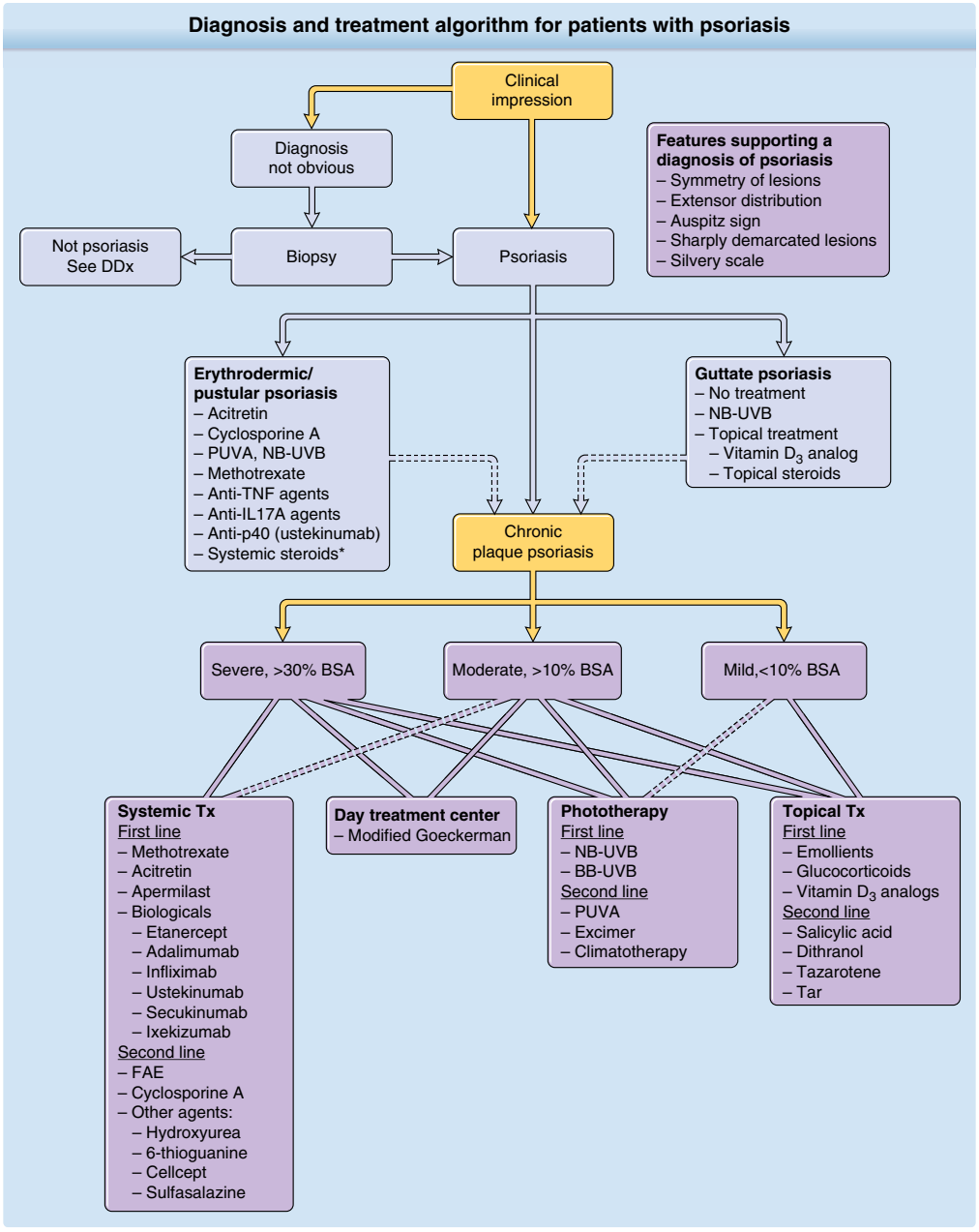

Figure 28-16 Diagnosis and treatment algorithm for patients with psoriasis. The diagnosis of psoriasis is usually based on clinical features. In the few cases in which clinical history and examination is not diagnostic, biopsy is indicated to establish the correct diagnosis. The majority of psoriasis cases fall into three major categories; guttate, erythrodermic/pustular, and chronic plaque, of which the latter is by far the most common. Guttate psoriasis is often a self-limited disease with spontaneous resolution within 6 to 12 weeks. In mild cases of guttate psoriasis, treatment may not be needed, but with widespread disease, ultraviolet B (UVB) phototherapy in association with topical therapy is very effective. Erythrodermic/pustular psoriasis is often associated with systemic symptoms and necessitates treatment with fast-acting systemic medications. The most commonly used drug for erythrodermic and pustular psoriasis is acitretin. In occasional cases of pustular psoriasis, systemic steroids may be indicated (*asterisk*). *Dotted arrows* indicate that guttate, erythrodermic, and pustular forms often evolve into chronic plaque psoriasis. Therapeutic choices for chronic plaque psoriasis are typically based on the extent of the disease. Among the main treatment regimens (topical treatment, phototherapy, day treatment centers, and systemic treatments), first- and second-line modalities are indicated by the *solid* and *dashed lines*, respectively. Individuals with conditions that limit their activities, including painful palmoplantar involvement and psoriatic arthritis, may require more potent treatments irrespective of the extent of affected body surface area. Likewise, psychological issues and the impact on quality of life should be taken into consideration. Within each treatment regimen, first-line and second-line choices are grouped. Cyclosporin A is not considered a first-line long-term systemic treatment because of its side effects, but short-term treatment can be helpful for induction of remission. If patients have incomplete response to or are unable to tolerate individual first-line systemic medications, combination regimens, rotational treatments, or use of biologic therapies should be considered. BB-UVB, broadband UVB; BSA, body surface area; DDx, differential diagnosis; FAE, fumaric acid ester; NB-UVB, narrowband UVB; PUVA, psoralen and ultraviolet A light; tx, therapy.

In severe psoriasis vulgaris, generalized pustular psoriasis, and erythroderma, a negative nitrogen balance can be detected, manifested by a decrease of serum albumin. Patients with psoriasis manifest altered lipid profiles, even at the onset of their skin disease.[82] Whether these differences in lipid profile can explain or are contributing to an increased incidence of cardiovascular events in psoriasis remains to be seen. The serum uric acid is elevated in up to 50% of patients and is mainly correlated with the extent of lesions and the activity of disease. There is an increased risk of developing gouty arthritis. Serum uric acid levels usually normalize after therapy. Markers of systemic inflammation, including C-reactive protein, α_2-macroglobulin, and erythrocyte sedimentation rate, can be increased. However, such elevations are rare in chronic plaque psoriasis uncomplicated by arthritis. Increased serum immunoglobulin (Ig) A levels and IgA immune complexes, as well as secondary amyloidosis, have also been observed in psoriasis, and the latter carries a poor prognosis.

DIFFERENTIAL DIAGNOSIS

A schema for the differential diagnosis of psoriasis is presented in Table 28-3.

CLINICAL COURSE AND PROGNOSIS

NATURAL HISTORY

It is useful to determine the age at onset and the presence or absence of a family history of psoriasis because a younger age of onset and positive family history have been associated with more widespread and recurrent disease.[3,14] In addition, the physician should inquire about the prior course of the disease because major differences exist between "acute" and "chronic" disease. In the latter form, lesions may persist unchanged for months or even years, but acute disease shows sudden outbreak of lesions within a short time (days). Likewise, patients have great variability in regard to relapses. Some patients have frequent relapses occurring weekly or monthly, but others have more stable disease with only occasional recurrence. The frequently relapsing patients tend to develop more severe disease with rapidly enlarging lesions covering significant portions of the body surface[83] and may require more rigorous treatment than those with more stable disease. The physician should also inquire about joint complaints. Although osteoarthritis is extremely common and can coexist with psoriasis, a history of onset of joint symptoms

TABLE 28-3
Differential Diagnosis of Psoriasis

PSORIASIS VULGARIS	GUTTATE	ERYTHRODERMIC	PUSTULAR
Most Likely ▪ Discoid/nummular eczema ▪ Cutaneous T-cell lymphoma (CTCL) ▪ Tinea corporis **Consider** ▪ Pityriasis rubra pilaris ▪ Seborrheic dermatitis ▪ Subacute cutaneous lupus erythematosus ▪ Erythrokeratoderma (the fixed plaques of keratoderma variabilis or progressive symmetric erythrokeratoderma ▪ Inflammatory linear verrucous epidermal nevus ▪ Hypertrophic lichen planus ▪ Lichen simplex chronicus ▪ Contact dermatitis ▪ Chronic cutaneous lupus erythematosus/discoid lupus erythematosus ▪ Hailey-Hailey disease (flexural) ▪ Intertrigo (flexural) ▪ *Candida* infection (flexural) **Always Rule Out** ▪ Bowen disease or squamous cell carcinoma in situ ▪ Extramammary Paget disease	**Most Likely** ▪ Pityriasis rosea ▪ Pityriasis lichenoides chronica ▪ Lichen planus **Consider** ▪ Small plaque parapsoriasis ▪ Pityriasis lichenoides et varioliformis acuta ▪ Lichen planus ▪ Drug eruption **Always Rule Out** ▪ Secondary syphilis	**Most Likely** ▪ Drug-induced erythroderma ▪ Eczema ▪ CTCL or Sézary syndrome ▪ Pityriasis rubra pilaris	**Most Likely** ▪ Impetigo ▪ Superficial candidiasis ▪ Reactive arthritis syndrome ▪ Superficial folliculitis **Consider** ▪ Pemphigus foliaceus ▪ Immunoglobulin A pemphigus ▪ Sneddon-Wilkinson disease (subcorneal pustular dermatosis) ▪ Migratory necrolytic erythema ▪ Transient neonatal pustular melanosis ▪ Acropustulosis of infancy ▪ Acute generalized exanthematous pustulosis

before the fourth decade or a history of warm, swollen joints should raise the suspicion of PsA (see Chap. 65). Guttate psoriasis is often a self-limited disease, lasting from 12 to 16 weeks without treatment. It has been estimated that one third to two thirds of these patients later develop the chronic plaque type of psoriasis.[84] In contrast, chronic plaque psoriasis is in most cases a lifelong disease, manifesting at unpredictable intervals. Spontaneous remissions, lasting for variable periods of time, may occur in the course of psoriasis in up to 50% of patients. The duration of remission ranges from 1 year to several decades. Erythrodermic and generalized pustular psoriasis have a poorer prognosis, with the disease tending to be severe and persistent.

MANAGEMENT

GENERAL CONSIDERATIONS

Figure 28-16 is an algorithm showing recommended treatments for various forms of psoriasis.

A broad spectrum of antipsoriatic treatments, both topical and systemic, is available for the management of psoriasis. As detailed in Tables 28-4 to 28-7, it is notable that most, if not all, of these treatments are immunomodulatory. When choosing a treatment regimen (see Fig. 28-16), it is important to reconcile the extent and the measurable severity of the disease with the patient's own perception of his or her

TABLE 28-4
Topical Treatments for Psoriasis[83]

	TOPICAL STEROIDS	VITAMIN D ANALOGUES	TAZAROTENE	CALCINEURIN INHIBITORS
Mechanism of action	Bind to glucocorticoid receptors, inhibiting the transcription of many different AP-1– and NF-κB–dependent genes, including IL-1 and TNF-α	Bind to vitamin D receptors, influencing the expression of many genes; promote keratinocyte differentiation	Metabolized to tazarotenic acid, its active metabolite, which binds to retinoic acid receptors; normalizes epidermal differentiation, exhibits a potent antiproliferative effect, and decreases epidermal proliferation	Bind to FKBP and inhibit calcineurin, decreasing the activation of the transcription factor, NF-AT, with resultant decrease in cytokine transcription, including IL-2
Dosing	10,000-fold range of potency; high-potency steroids are applied to affected areas twice daily for 2–4 wk and then intermittently (weekends)	Calcipotriene, 0.005%, to affected areas twice daily; often used alternating with topical steroids (ie, vitamin D analogues on weekdays; topical steroids on weekends)	Available in 0.05% and 0.1% formulations, both as cream and gels; apply every night to affected area	Application to affected areas twice daily
Efficacy	Very effective as short-term treatment	Efficacy is increased by combination with topical steroids; can be combined with various other therapies	Efficacy is increased by combination with topical steroids	Effective for treatment of facial and flexural psoriasis but minimally for chronic plaque psoriasis
Safety	Suppression of the hypothalamic–pituitary–adrenal axis (higher risk in children); atrophy of the epidermis and dermis; formation of striae; tachyphylaxis	Development of irritation at the site of application is common; isolated reports of hypercalcemia in patients who applied excessive quantities	When used as monotherapy, significant proportion of patients develop irritation at the site of application	Burning sensation at the site of application; case reports of development of lymphoma
Contraindications	Hypersensitivity to the steroid, active skin infection	Hypercalcemia, vitamin D toxicity	Pregnancy, hypersensitivity to tazarotene	Use only with caution for treatment of children younger than 2 yr of age
Remarks and long-term use	Long-term use increases risk of side effects	Calcipotriol is well tolerated and continues to be clinically effective with minimum of adverse effects in long-term use	Combination of steroid with tazarotene may reduce atrophy seen with superpotent topical steroids; if added during phototherapy, the UV doses should be reduced by one third	Because of anecdotal reports of association with malignancy, this class of medications recently received a black-box warning by the FDA
Pregnancy Category	C	C	X	C

AP, activator protein; FDA, Food and Drug Administration; FKBP, FK506-binding protein; IL, interleukin; NF-AT, nuclear factor of activated T cells; NF-κB , nuclear factor kappa B; UV, ultraviolet.

TABLE 28-5
Phototherapy of Psoriasis[87]

	NARROWBAND UVB (NB-UVB; 310–331 NM)	BROADBAND UVB (BB-UVB)	PSORALEN AND UVA LIGHT (PUVA)	EXCIMER LASER (308 NM)
Dosing	Dosage based on either the Fitzpatrick skin type or MED; determine MED; initial treatment at 50% of MED followed by three to five treatments weekly; lubricate before treatment Treatments 1–20: increase by 10% of initial MED Treatments ≥21: increase as ordered by physician Maintenance therapy after >95% clearance: once a week for 4 wk; keep dose the same once every two weeks for 4 weeks; decrease dose by 25% once every 4 weeks, 50% of highest dose	The dosage may be administered according to the Fitzpatrick skin type; initial treatment at 50% of MED followed by three to five treatments weekly Treatments 1–10: increase dose by 25% of initial MED Treatments 11–20: increase by 10% of initial MED Treatments ≥21: increase as ordered by physician	Dose based on MPD is recommended; if MPD testing is impractical, a regimen based on skin type may be used Initial dose: 0.5–2.0 J/cm^2, depending on skin type (or MPD) Treat twice weekly, increments of 40% per week until erythema, and then maximum 20% per week No further increments when 15 J/cm^2 is reached	The dose of energy delivered is guided by the patient's skin type and thickness of plaque; further doses are adjusted based on response to treatment or development of side effects; treatment usually given twice weekly
Efficacy	>70% improvement in a split-body study after 4 wk of treatment; 9 of 11 patients showed clearance; more effective than BB-UVB	47% improvement in a split-body study after 4 wk; only 1 of 11 patients showed clearance	Induces remission in 70%–90% of patients; less convenient than NB-UVB but may be more effective	High response rates In one study, 85% of patients showed ≥90% improvement in PASI after an average 7.2 wk of treatment; another study showed >75% improvement in 72% of patients in an average of 6.2 treatments
Safety	Photodamage, polymorphic light eruption, increased risk of skin aging and skin cancers but lower than that for PUVA	Photodamage, polymorphic light eruption, increased risk of skin aging and skin cancers	Photodamage, premature skin aging, increased risk of melanoma and nonmelanoma skin cancers, ocular damage; eye protection required with oral psoralens	Erythema, blisters, hyperpigmentation, and erosions; long-term side effects not yet clear but likely similar to NB-UVB
Contraindications	Absolute: photosensitivity disorders Relative: photosensitizing medications, melanoma, and nonmelanoma skin cancers	Absolute: photosensitivity disorders Relative: photosensitizing medications, melanoma, and nonmelanoma skin cancers	Absolute: light-sensitizing disorder, lactation, melanoma Relative: age <10 yr, pregnancy, photosensitizing medications, nonmelanoma skin cancers, severe organ dysfunction	Absolute: photosensitivity disorders Relative: photosensitizing medications, melanoma, and nonmelanoma skin cancers
Remarks	Effective as a monotherapy, but coal tar (Goeckerman regimen), anthralin (Ingram regimen), or systemic therapies may increase effectiveness in resistant cases	Coal tar (Goeckerman regimen), anthralin (Ingram regimen), or systemic therapies may increase effectiveness in resistant cases	<200 total treatments (or <2000 J/ cm^2 UVA) are recommended; combination with oral retinoids can reduce cumulative UVA exposure	Normal skin is spared from unnecessary radiation exposure because therapy is selectively directed toward lesional skin.

MED, minimal erythema dose; MPD, minimal phototoxic dose; PASI, Psoriasis Area and Severity Index; UVA, ultraviolet A; UVB, ultraviolet B.

disease. One study found that 40% of patients felt frustrated with the ineffectiveness of their current therapies, and 32% reported that treatment was not aggressive enough.[24] As psoriasis is a chronic condition, it is important to know the safety of a treatment during long-term use. In most treatments, the duration of a treatment is restricted because of the cumulative toxicity potential of an individual treatment, and in some instances, treatment efficacy may diminish with time (tachyphylaxis). Some treatments,

TABLE 28-6

Systemic Treatments for Psoriasis[96-98]

	CYCLOSPORIN A	METHOTREXATE	ACITRETIN	FUMARIC ACID ESTERS
Mechanism of action	Binds cyclophilin, and the resulting complex blocks calcineurin, reducing the effect of the NF-AT in T cells, resulting in inhibition of IL-2 and other cytokines	Blocks dihydrofolate reductase, leading to inhibition of purine and pyrimidine synthesis; also blocks AICAR transformylase, leading to accumulation of antiinflammatory adenosine	Binds to retinoic acid receptors; may contribute to improvement by normalizing keratinization and proliferation of the epidermis	Interferes with intracellular redox regulation, inhibiting NF-κB translocation; skews the T-cell response toward a Th2-like pattern
Dosing	High-dose approach: 5 mg/kg/day; then tapered Low-dose approach: 2.5 mg/kg/day; increased every 2–4 wk up to 5 mg/kg/day; tapering is recommended on discontinuation	Start with a test dose of 2.5 mg and then gradually increase dose until a therapeutic level is achieved (average range, 10–15 mg weekly; maximum, 25–30 mg weekly)	Initiate at 25–50 mg/day and escalate and titrate to response	Initiate at low dose and escalate dose weekly; after treatment response is achieved, the dose should be individually adjusted; maximum dose, 1.2 g/day
Efficacy	Very effective; ≤90% of patients achieve clearance or marked improvement	May reduce the severity of psoriasis by at least 50% in >75% of patients	Modestly effective as monotherapy	80% mean reduction in PASI
Safety	Nephrotoxicity, HTN, immunosuppression; increased risk of malignancy if before PUVA	Hepatotoxicity; chronic use may lead to hepatic fibrosis; fetal abnormalities or death, myelosuppression, pulmonary fibrosis, severe skin reactions; rarely, severe opportunistic infections	Hepatotoxicity, lipid abnormalities, fetal abnormalities or death, alopecia, mucocutaneous toxicity, hyperostosis	GI symptoms, including diarrhea; flushing ± headaches; lymphopenia, acute renal failure
Monitoring	BP; obtain baseline CBC, CMP, magnesium, uric acid, lipids, UA; repeat tests every 2–4 wk; then every month along with BP	Baseline CBC and LFTs; monitor CBC and LFTs weekly until target dose is achieved; then every 4–8 wk[96]; liver biopsy every 1.5 g (high risk) to every 3.5–4.0 g (low risk) of cumulative dose or use procollagen III assay	Baseline LFTs, CBC, lipids, pregnancy test; repeat LFTs, CBC, lipids every week for 1 mo and then every 4 wk; pregnancy test every month for women; spinal radiography if symptoms	Baseline CBC, CMP, UA; repeat tests every month for the first 6 mo and bimonthly thereafter
Contraindications	Absolute: uncontrolled HTN, abnormal renal function, history or current malignancy	Absolute: pregnancy, lactation, bone marrow dysfunction, alcohol abuse Relative: hepatic dysfunction, hepatitis, renal insufficiency, severe infections, reduced lung function	Absolute: pregnancy during or within 3 years after termination of acitretin, breastfeeding	Absolute: patients with chronic disease of the GI tract or renal disease; pregnant or lactating women; malignancy (or history of)
Remarks and long-term use	Intermittent short-course treatments appear to be safer than chronic long-term use	With appropriate monitoring, long-term use appears to be safe	Retinoids have been combined with PUVA and occasionally with UVB in an attempt to minimize the side effects and to improve therapeutic response	Not approved by the FDA for psoriasis but widely used in Europe; new formulations may reduce risk of GI symptoms
Pregnancy Category	C	X	X	C

	HYDROXYUREA	6-THIOGUANINE	MYCOPHENOLATE MOFETIL	SULFASALAZINE
Mechanism of action	Inhibits ribonucleotide diphosphate reductase, which converts ribonucleotides to deoxyribonucleotides, thus selectively inhibiting DNA synthesis in proliferating cells	Purine analog that interferes with purine biosynthesis, thereby inducing cell cycle arrest and apoptosis	A noncompetitive inhibitor of inosine monophosphate dehydrogenase, blocking de novo purine biosynthesis; selectively cytotoxic for cells that rely on de novo purine synthesis (ie, lymphocytes)	Antiinflammatory agent; inhibits 5-lipoxygenase, molecular mechanism unclear
Dosing	500 mg/day; increased to 1.0–1.5 g/day based on response and tolerance	Starting dose is 80 mg twice weekly, with 20-mg increments every 2–4 weeks; maximum dose, 160 mg three times weekly	Doses often initiated at 500– 750 mg twice a day and then increased to 1.0–1.5 g twice a day	Starting dose: 500 mg three times a day. If tolerated after 3 days, increase dose to 1 g three times a day. If tolerated after 6 wk, increase dose to 1 g four times a day.
Efficacy	In a study of 85 patients with extensive chronic plaque psoriasis, 61% had satisfactory remission	A small retrospective cohort study demonstrated >90% improvement in ≤80% of patients	Appears to be only moderately effective for treatment of psoriasis	Appears to be moderately effective treatment for severe psoriasis
Safety	Bone marrow suppression, macrocytosis; teratogenicity and mutagenicity; dermatologic side effects: lichen planus–like eruptions, exacerbation of postirradiation erythema, leg ulcers, and dermatomyositis changes	Bone marrow suppression; GI complaints, including nausea and diarrhea; hepatic dysfunction; instances of hepatovenous-occlusive disease have been reported	GI, including constipation, diarrhea, nausea and vomiting, bleeding; myelosuppression, leukopenia; headaches, HTN, peripheral edema; infectious disease, lymphoma	Headache, nausea and vomiting, which occur in approximately one third of patients; rashes, pruritus, and hemolytic anemia (associated with G6PD deficiency)
Monitoring	Baseline CBC, CMP, LFTs; repeat baseline tests weekly for 4 wk; then every 2–4 wk for at least 12 wk; then repeat tests every 3 mo; hold dosage if WBC count $<2.5 \times 10^9$/L, platelet count is $<100 \times 10^9$/L, or severe anemia	Baseline CBC, CMP, LFTs; repeat baseline tests weekly during dose escalation and then every 2 wk; hold if WBC count $\leq 4.0 \times 10^9$/L, platelet count is $<125 \times 10^9$/L, or hemoglobin <110 g/L	Baseline CBC and CMP; repeat laboratory tests weekly × 6 wk, then every 2 wk × 2 mo, and then monthly; monitor BP	Baseline CBC, CMP, and G6PD; repeat CBC and CMP weekly for 1 mo, then every 2 wk for 1 mo, then monthly for 3 mo, and then every 3 mo
Contraindications	Absolute: prior bone marrow depression (leukopenia, thrombocytopenia, anemia), pregnancy, lactation Relative: renal abnormalities	Absolute: patients with inherited deficiency of thiopurine methyltransferase enzyme have increased risk of myelosuppression; liver toxicity; pregnancy	Absolute: patients with severe infections, malignancy	Absolute: hypersensitivity to sulfasalazine, sulfa drugs, salicylates, intestinal or urinary obstruction, porphyria; precaution in patients with G6PD deficiency
Remarks and long-term use	Limited experience with long-term treatment	Patients have been effectively maintained on treatment for ≤33 mo	Limited experience with long-term treatment	Limited experience with long-term treatment
Pregnancy Category	D	D	C	B

(*Continued*)

TABLE 28-6
Systemic Treatments for Psoriasis[91-93] (*Continued*)

	APREMILAST	TOFACITINIB		
Mechanism of action	Inhibits PDE4	Inhibit the tyrosine kinases JAK1 and JAK3, with lesser inhibitory effect on JAK2		
Dosing	Dose escalation from 10 mg to 30 mg twice a day in the first week and then 30 mg twice a day thereafter	5 mg twice-a-day dosing; 10 mg twice-a-day dosing is currently being assessed in clinical trials		
Efficacy	In a study of 274 treated patients, 28.8% and 55.5% of patients achieved PASI-75 and PASI-50 response at week 16, respectively	In a study of 1861 patients, 5 mg twice-a-day dosing led to approximately 55% and 30% PASI-75 and PASI-90 response, respectively, and 10 mg twice-a-day dosing had approximately 70% and 45% PASI-75 and PASI-90 responses, respectively (week 28)		
Safety	Worsening depression; nausea, diarrhea; mild weight loss (5%–10%) has been described	Bone marrow suppression; infections, particularly upper respiratory tract infections and nasopharyngitis; diarrhea		
Monitoring	No laboratory monitoring is required	Baseline CBC, CMP, LFTs, lipids; repeat baseline tests monthly; lymphocyte count <500 cell/mm^3, ANC <500 cells/mm^3, discontinue drug; if ANC between 500 and1000 cells/mm^3 or Hgb decrease >2 g/dL or <8 g/dL interrupt dosing until ANC >1000 cell/mm^3 or Hgb has normalized		
Contraindications	Absolute: known hypersensitivity to apremilast Relative: depression	Absolute: do not initiate in patients with lymphocyte count <500 cell/mm^3, ANC <1000 cells/mm^3, or Hgb <9g/dL Relative: infections, risk of GI perforations, history of malignancy and lymphoproliferative disease		
Remarks and long-term use		FDA approval for psoriasis and PsA pending		
Pregnancy Category	C	C		

AICAR, 5-Aminoimidazole-4-carboxamide ribonucleotide; ANC, absolute neutrophil count; BP, blood pressure; CBC, complete blood cell count; CMP, comprehensive metabolic panel; FDA, Food and Drug Administration; G6PD, glucose-6-phosphate dehydrogenase; GI, gastrointestinal; HTN, hypertension; IL, interleukin; JAK, Janus kinase; LFTs, liver function tests; NF-AT, nuclear factor of activated T cells; NF-κB, nuclear factor kappa B; PDE, phosphodiesterase; PUVA, psoralen and ultraviolet A light; Th, T helper; UA, urinalysis; UV, ultraviolet; WBC, white blood cell.

TABLE 28-7

Biologic Treatments for Psoriasis

	USTEKINUMAB	ETANERCEPT	INFLIXIMAB	ADALIMUMAB	SECUKINUMAB	IXEKIZUMAB
Mechanism	Binds p40 (the common subunit of IL-12 and IL-23); blocks Th1 and Th17 differentiation and proliferation	Human recombinant, soluble TNF-α receptor; binds TNF-α and neutralizes its activity	Chimeric monoclonal antibody that has high specificity, affinity, and avidity for TNF-α	Fully human recombinant monoclonal antibody that specifically targets TNF-α	Fully human recombinant monoclonal antibody that specifically targets IL-17A	Humanized monoclonal antibody that specifically targets IL-17A
Dosing	SC injections; weight-based dosing Individuals weighing <100 kg (220 lb): 45 mg Individuals weighing >100 kg: 90 mg Injections at wk 0 and 4 and then every 12 wk	25- to 50-mg injections SC twice weekly; commonly given as 50 mg twice weekly for 12 wk followed by 50 mg weekly For pediatric patients, recommended dosing is 0.8 mg/kg weekly with a maximum of 50 mg per week	IV infusions over 2 hr; 5–10 mg/kg at weeks 0, 2, and 6	Initial dose of 80 mg followed by 40 mg given every other week starting 1 week after the initial dose	150- to 300-mg injections at weeks 0, 1, 2, 3, and 4 (loading dose) followed by injections every 4 wk	160-mg injection at week 0 followed by 80 mg at weeks 2, 4, 6, 8, 10, and 12; then 80 mg every 4 wk
Efficacy	PASI-75 at 12 wk, 67%; 71%–78% at wk 28	PASI-75 at 12 wk, 34% and at 24 wk, 44% for the 25-mg twice-weekly vs 49% and 59% for 50-mg twice-weekly dosing	PASI-75 at 10 wk, 82% (5 mg/kg) and 91% (10 mg/kg); at wk 26 (after a single course), 57% of patients maintained PASI-50, and 50% maintained PASI-75	PASI-75 at 16 wk, 71%	PASI-75 at week 12 in the range of 77%–82% PASI-90 52%–59% and PASI-100 24%–29% for 300-mg dosing	PASI-75 at week 12 achieved in 87% of patients; PASI-90 in 68% and PASI-100 in 38% of patients
Safety	Serious infections, increased risk of malignancy, reversible posterior leukoencephalopathy syndrome; live vaccinations not recommended	Serious infections, exacerbation of MS, pancytopenia, malignancy, worsening congestive heart failure; lupus-like symptoms (anti-dsDNA positive); live vaccinations should not be given	Infusion-related reactions, infections, worsening of MS, malignancy, or lymphoproliferative disease, worsening heart failure; lupus-like symptoms (anti-dsDNA positive); live vaccinations should not be given	Injection site reactions, infections, lupus-like syndrome, worsening heart failure, cytopenias, neurologic events; live vaccinations should not be given	Infections, particularly nasopharyngitis; exacerbation of IBD; hypersensitivity reactions; patients should not receive live vaccines while on treatment	Infections; hypersensitivity reactions; exacerbation of IBD
Monitoring	Baseline PPD/QuantiFERON-TB Gold	Baseline PPD/QuantiFERON-TB Gold	Baseline PPD/QuantiFERON-TB Gold	Baseline PPD/QuantiFERON-TB Gold	Baseline PPD/QuantiFERON-TB Gold	Baseline PPD/QuantiFERON-TB Gold
Long-term administration	Clinical trials have established safety up to 76wk; appears to be similar to TNF-α inhibitors	PASI response continues to increase to wk 24; large databases in patients with other immunologic diseases indicate safety	As intermittent therapy; large databases in patients with other immunologic diseases indicate relative safety	Similar to other TNF-α inhibitors	Clinical trials have shown maintenance of efficacy beyond 52 wk of treatment	Clinical trials have shown maintenance of efficacy beyond 60 wk of treatment
Pregnancy Category	B	B	B	B	B	B

dsDNA, double-stranded DNA; IBD, inflammatory bowel disease; IL, interleukin; IV, intravenous; LFA, lymphocyte function–associated antigen; MS, multiple sclerosis; PASI-50, 50% improvement in Psoriasis Area and Severity Index; PASI-75, 75% improvement in Psoriasis Area and Severity Index; PPD, purified protein derivative (of tuberculin); SC, subcutaneous; TNF, tumor necrosis factor.

TABLE 28-8

Treatment of Women of Childbearing Potential and During Pregnancy

- Special caution needs to be exercised when treating women of childbearing potential and during pregnancy.
- Medications such as methotrexate and oral retinoids should be avoided or used with extreme caution and then only along with appropriate contraception.
- In selected cases, isotretinoin rather than acitretin may be the preferred agent because of its much shorter half-life.
- Because methotrexate is fetotoxic and an abortifacient and retinoids are potent teratotoxins, the use of these agents is absolutely contraindicated in pregnancy.
- Many women experience improvement or remission during periods of pregnancy, thus decreasing the need for the more potent agents.
- If treatment is needed, emollients and other topical agents are first-line agents, often in association with ultraviolet B phototherapy.
- Many of the topical agents, such as topical steroids and calcipotriene, are Pregnancy Category C agents, and caution should be exercised with their use.
- Several of the biologic agents are Pregnancy Category B and can be used in pregnancy. Likewise, cyclosporin A may be considered because it is Pregnancy Category C and is nonteratogenic.
- Systemic psoralen and ultraviolet A light has been used on occasion in selected cases and appears to be safe.

such as calcipotriol, methotrexate (MTX), and acitretin, can be regarded as appropriate for continuous use.[85] These treatments maintain efficacy and have low cumulative toxicity potential. In contrast, topical corticosteroids, dithranol, tar, photo(chemo) therapy, and cyclosporin are not indicated for continuous chronic use, and combinatorial or rotational treatments[85] are suggested. However, patients with stable chronic plaque psoriasis who respond well to local treatments may not require a change of treatment.[85] In cases of itchy or pruritic psoriasis, treatments with an irritative potential, such as dithranol, vitamin D_3 analogues, and photo(chemo) therapy, should be used cautiously; treatments with potent antiinflammatory effects, such as topical corticosteroids, are more appropriate.[85] In patients with erythrodermic and pustular psoriasis, treatments with an irritant potential should be avoided, and acitretin, MTX, or short-course cyclosporin are the treatments of first choice.[85] See Table 28-8 for special considerations in the treatment of women of childbearing potential.

TOPICAL TREATMENTS

See Table 28-4.

Most cases of psoriasis are treated topically.[86] Because topical treatments are often cosmetically unacceptable and time consuming to use, noncompliance is on the order of 40%.[87] In most cases, ointment formulations are more effective than creams but are less cosmetically acceptable. For many patients, it is worth prescribing both cream and ointment formulations—cream for use in the morning and ointment for nighttime. Topical agents are also used adjunctively for resistant lesions in patients with more extensive psoriasis and who are concurrently being treated with either UV light or systemic agents.[88] It is worth noting that around 400 g of a topical agent is required to cover the entire body surface of an average-sized adult when used twice daily for 1 week.

CORTICOSTEROIDS

Glucocorticoids exert many, if not all, of their myriad effects by stabilizing and causing nuclear translocation of glucocorticoid receptors, which are members of the nuclear hormone receptor superfamily. Topical glucocorticoids are commonly first-line therapy in mild to moderate psoriasis and in sites such as the flexures and genitalia, where other topical treatments can induce irritation. Improvement is usually achieved within 2 to 4 weeks, with maintenance treatment consisting of intermittent applications (often restricted to the weekends). Tachyphylaxis to treatment with topical corticosteroids is a well-established phenomenon in psoriasis. Long-term topical corticosteroids may cause skin atrophy, telangiectasia, striae (Fig. 28-17), and adrenal suppression. Another concern is that when topical steroids are discontinued, patients may reflare, sometimes worse than it was before treatment.[88] This class of agents is discussed in detail in Chap. 184.

VITAMIN D_3 AND ANALOGUES

Vitamin D exerts its actions by binding to the vitamin D receptor, another member of the nuclear hormone receptor superfamily. Vitamin D_3 acts to regulate cell growth, differentiation, and immune function, as well as calcium and phosphorous metabolism. Vitamin D has been shown to inhibit the proliferation of keratinocytes in culture and to modulate epidermal differentiation. Furthermore, vitamin D inhibits production of several proinflammatory cytokines by psoriatic T-cell clones, including IL-2 and IFN-γ. Analogues of vitamin D that have been used for the treatment of skin diseases are calcipotriene, (calcipotriol), tacalcitol, and maxacalcitol. In short-term studies, potent topical corticosteroids were found to be superior to calcipotriene. When compared with short-contact anthralin or 15% coal tar, calcipotriene was the more effective agent. The efficacy of calcipotriene is not reduced with long-term treatment. Calcipotriene applied twice daily is more effective than once-daily use. Hypercalcemia is the only major concern with the use of topical vitamin D preparations. When the amount used does not exceed the recommended 100 g/week, calcipotriene can be used with a great margin of safety. Vitamin D analogues are often used in combination with or in rotation with topical corticosteroids in an effort to maximize therapeutic effectiveness while minimizing steroid-related skin atrophy.

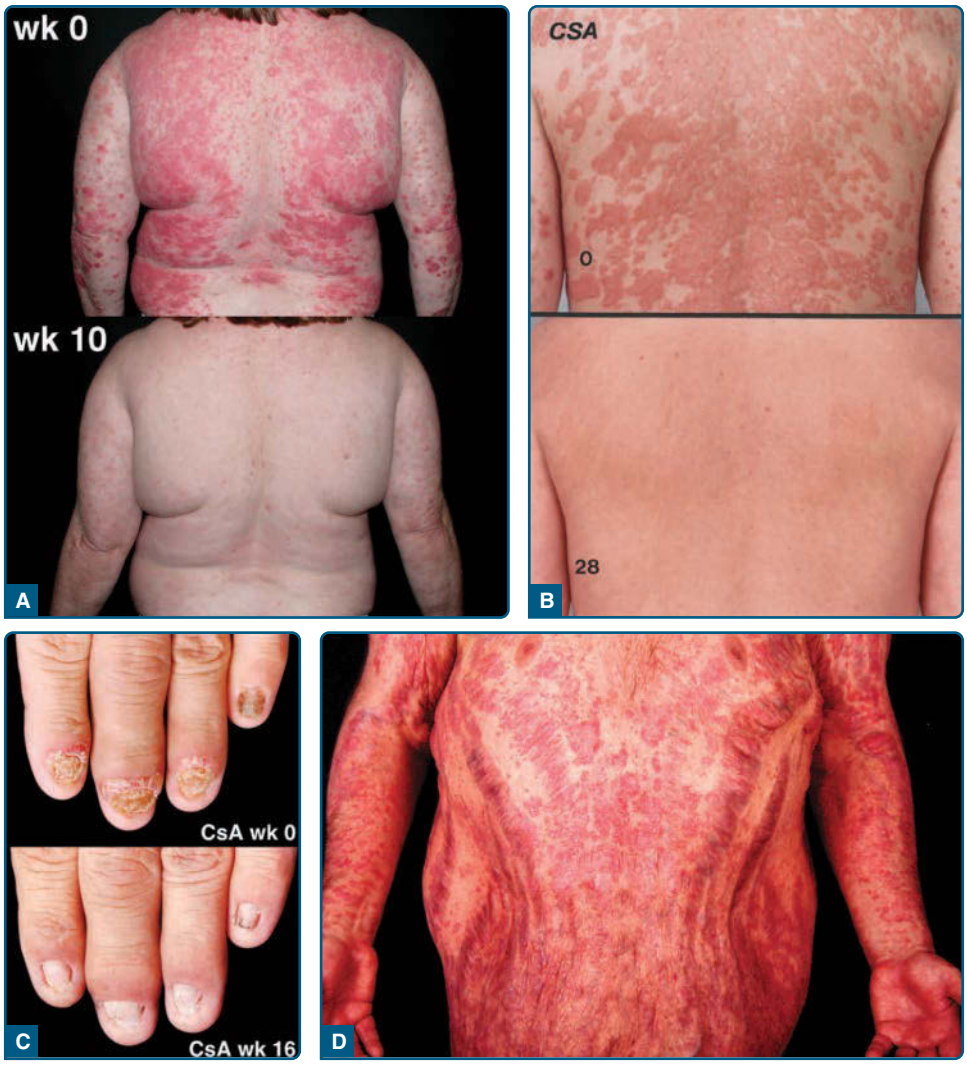

Figure 28-17 Positive and negative outcomes of psoriasis treatment. **A,** Near-complete improvement of psoriasis after 10 weeks of infliximab therapy. **B,** Marked improvement after 28 days of oral cyclosporin A (CsA) treatment. **C,** Marked reduction in nail dystrophy after 16 weeks of CsA treatment. **D,** Severe atrophy with striae distensae after several years of treatment with potent topical steroid creams. (Images used with permission from Mr. Harrold Carter.)

ANTHRALIN (DITHRANOL)

Dithranol (1,8-dihydroxy-9-anthrone) is a naturally occurring substance found in the bark of the araroba tree in South America. It can also be synthesized from anthrone. Dithranol is made up in a cream, ointment, or paste. Dithranol is approved for the treatment of chronic plaque psoriasis. Its most common use has been in the treatment of psoriasis, particularly on plaques resistant to other therapies. It can be combined with UVB phototherapy with good results (the Ingram regimen). Most common side effects are irritant contact dermatitis and staining of clothing, skin, hair, and nails. Anthralin possesses antiproliferative activity on human keratinocytes along with potent antiinflammatory effects. Classic anthralin therapy starts with low concentrations (0.05%–0.1%) incorporated in petrolatum or zinc paste and given once daily. To prevent auto-oxidation, salicylic acid (1% to 2%) should be added. The concentration is increased weekly in individually adjusted increments up to 4% until the lesions resolve. Scalp psoriasis should be treated with great caution as anthralin can stain hair purple to green.

COAL TAR

The use of tar to treat skin diseases dates back nearly 2000 years. In 1925, Goeckerman introduced the use of crude coal tar and UV light for the treatment of psoriasis. Its mode of action is not understood, and because of its inherent chemical complexity, tar is not pharmacologically standardized. It was recently suggested that carbazole, a coal-derived chemical, is the main active ingredient in tar.[89] Coal tar can be compounded in creams, ointments, and pastes at concentrations of 5% to 20%. It is often combined with salicylic acid (2%–5%), which by its keratolytic action

leads to better absorption of the coal tar. Occasionally, patients become sensitized, and a folliculitis may occur. Furthermore, it has an unwelcome smell and appearance and can stain clothing. Coal tar is carcinogenic.

TAZAROTENE

Tazarotene is a third-generation retinoid for topical use that reduces mainly scaling and plaque thickness, with limited effectiveness on erythema. It is thought to act by binding to retinoic acid receptors. It is available in 0.05% and 0.1% gels, and a cream formulation has been developed. When this drug is used as a monotherapy, a significant proportion of patients develop local irritation. Efficacy of this drug can be enhanced by combination with mid- to high-potency glucocorticoids or UVB phototherapy. When used in combination with phototherapy, it lowers the minimal erythema dose (MED) for both UVB and UVA. It has been recommended that UV doses be reduced by at least one third if tazarotene is added to phototherapy.

TOPICAL CALCINEURIN INHIBITORS

See Chap. 192.

Tacrolimus (FK-506) is a macrolide antibiotic, derived from the bacteria *Streptomyces tsukubaensis*, which, by binding to immunophilin (FK506 binding protein), creates a complex that inhibits calcineurin, thus blocking both T-lymphocyte signal transduction and IL-2 transcription. Pimecrolimus is also a calcineurin inhibitor and works in a manner similar to tacrolimus. In a study of 70 patients with chronic plaque psoriasis treated with topical tacrolimus, there was no improvement beyond that seen for placebo. However, for treatment of inverse and facial psoriasis, these agents appear to provide effective treatment.[90] The main side effect of these medications is a burning sensation at application site. Anecdotal reports of lymph node or skin malignancy require further evaluation in controlled studies, and these drugs currently carry a U.S. Food and Drug Administration (FDA) "black box warning."

SALICYLIC ACID

Salicylic acid is a topical keratolytic agent. Its mechanism of action includes reduction of keratinocyte adhesion and lowering the pH of the stratum corneum, which results in reduced scaling and softening of the plaques, thereby enhancing absorption of other agents. Therefore, salicylic acid is often combined with other topical therapies such as corticosteroids and coal tar. Topical salicylic acid decreases the efficacy of UVB phototherapy,[88] and systemic absorption can occur, particularly in patients with abnormal hepatic or renal function and when applied to more than 20% of the body surface area. No placebo-controlled studies have been performed to verify the efficacy and safety of salicylic acid as a monotherapy.

BLAND EMOLLIENTS

Between treatment periods, skin care with emollients should be performed to avoid dryness. Emollients reduce scaling, may limit painful fissuring, and can help control pruritus. They are best applied immediately after bathing or showering. The addition of urea (up to 10%) is helpful to improve hydration of the skin and remove scaling of early lesions. The use of liberal bland emollients over a thin layer of topical prescription treatments improves hydration while minimizing treatment costs.

PHOTOTHERAPY

See Table 28-5 and Chap. 198.

Phototherapy of psoriasis with artificial light sources dates back to 1925 when Goeckerman introduced a combination of topical crude coal tar and subsequent UV irradiation. In the 1970s, it was shown that broadband UVB radiation alone, if given in doses that produce a faint erythematous reaction, could clear the milder clinical forms of psoriasis. Major steps forward were the introduction of photochemotherapy with psoralen and UVA light (PUVA) in the 1970s and narrowband UVB (311–313 nm) in the 1980s.[91]

The mechanism of action of phototherapy appears to involve selective depletion of T cells, predominantly those that reside in the epidermis.[78] The mechanism of depletion may involve apoptosis, accompanied by a shift from a Th1 to a Th2 response in lesional skin.

ULTRAVIOLET B LIGHT

Ultraviolet B (UVB) light is in the range of 290-320 nm. The initial therapeutic UVB dose lies at 50% to 75% of the MED. Treatments are given two to five times per week. Because peak UVB erythema appears within 24 hours of exposure, increments can be performed at each successive treatment. The objective is to maintain a minimally perceptible erythema as a clinical indicator of optimal dosing. Treatments are given until total remission is reached or until no further improvement can be obtained with continued treatment.[92] The main side effects of UVB phototherapy are summarized in Chap. 198.

Narrowband (312 nm) UVB (NB-UVB) phototherapy is superior to conventional broadband UVB with respect to both clearing and remission times. Although early studies found NB-UVB to be as effective as PUVA, a controlled trial found that PUVA was more effective, albeit less convenient.[93] On clearing, treatment is either discontinued, or patients are subjected to maintenance therapy for 1 or 2 months. During this period, the frequency of UVB treatments is reduced while maintaining the last dose given at the time of clearing.[91,92] Systemic drugs, such as retinoids, increase the efficacy of UVB light, particularly in patients with chronic and hyperkeratotic plaque–type psoriasis.

PSORALEN AND ULTRAVIOLET A LIGHT

PUVA is the combined use of psoralens (P) and long-wave UVA radiation. The combination of drug and radiation results in a therapeutic effect, which is not achieved by the single component alone. Remission is induced by repeated controlled phototoxic reactions. A detailed account of PUVA therapy and its short- and long-term side effects is to be found in Chap. 199.

EXCIMER LASER

See Chap. 208.

Supraerythemogenic fluences of UVB and PUVA are known to result in faster clearing of psoriasis; however, the limiting factor for the use of such high fluences lies with the intolerance of the uninvolved surrounding skin as psoriatic lesions can often withstand much higher UV exposures. The monochromatic 308-nm excimer laser can deliver such supraerythemogenic doses of light (up to 6 MED, usually in the range of 2–6 MEDs) focally to lesional skin. The dosing is guided by the patients' skin type and thickness of the plaque with subsequent doses based on the response to therapy or development of side effects.[92] In a study on 124 patients, 72% of study participants achieved at least 75% clearing in an average of 6.2 treatments delivered twice weekly.[94] This treatment is commonly used for patients with stable recalcitrant plaques, particularly of the elbows and knees.

CLIMATIC THERAPY

It is well known that going to a sunny climate can improve psoriasis, although a small proportion of patients actually deteriorate. Patients should be warned not to overexpose themselves in the first few days because sunburn may progress to psoriasis (Koebner phenomenon). The best-studied effects are from the Dead Sea area,[95] and the therapeutic effects may be attributed, at least partially, to its unique climate. Because it is situated 400 m below sea level, the evaporation of the sea forms an aerosol that stays in the atmosphere above the sea and surrounding beaches. This aerosol screens out the majority of the UVB rays but not the UVA. This mixture of UV light appears to be sufficient to clear psoriasis but without sunburn. Thus, patients can stay on the shores of the Dead Sea for long periods of time with a greatly reduced risk of sunburn. This treatment is carried out over a period of 3 to 4 weeks, and improvements comparable to NB-UVB or PUVA treatments are observed. The main disadvantages are time and expense.

SYSTEMIC ORAL AGENTS[96-98]

See Table 28-6.

METHOTREXATE

Methotrexate is highly effective for chronic plaque psoriasis and is also indicated for the long-term management of severe forms of psoriasis, including psoriatic erythroderma and pustular psoriasis.[96] For mechanisms of action, see Chap. 190. When first used for the treatment of psoriasis, MTX was thought to act directly to inhibit epidermal hyperproliferation via inhibition of dihydrofolate reductase (DHFR). However, it was found to be effective at much lower doses (0.1–0.3 mg/kg/wk) in the management of psoriasis, PsA, and other inflammatory conditions such as RA. At these concentrations, MTX inhibits the in vitro proliferation of lymphocytes but not proliferation of keratinocytes. It is now thought that the main mechanism of antiinflammatory action of MTX is inhibition of (AICAR [5-aminoimidazole-4-carboxamide ribonucleotide] transformylase), an enzyme involved in purine metabolism. This leads to accumulation of extracellular adenosine, which has potent anti-inflammatory activities.[99] Consistent with a DHFR-independent mechanism of action, concomitant administration of folic acid (1–5 mg/day) reduces certain side effects, such as nausea and megaloblastic anemia, without diminishing the efficacy of anti-psoriatic treatment. The very long half-life of MTX may account for its efficacy after weekly administration and may help to explain why its onset of action is rather slow (therapeutic effects usually require 4–8 weeks to become evident). MTX is renally excreted and should therefore not be administered to patients with impairment in renal function because MTX side effects are generally dose related. Short-term toxicity and long-term concerns are discussed in Chap. 190. Recent guidelines[98] suggest that patients be divided into two separate groups based on their risk factors for liver injury: The low risk patients follow the American College of Rheumatology guidelines and are not asked to undergo liver biopsy until they have reached a cumulative MTX dose of 3.5 to 4.0 g. In contrast, patients with one or more risk factors continue to follow the previous, more stringent guidelines requiring baseline liver biopsy either before treatment or after 2 to 6 months of treatment and then at each cumulative MTX dose of 1.0 to 1.5 g.[98] The risk factors include current or past alcohol consumption, persistent abnormalities of liver function enzymes, personal, or family history of liver disease, exposure to hepatotoxic drugs or chemicals, diabetes mellitus, hyperlipidemia, and obesity. Some groups have recommended the use of amino terminal type III procollagen peptide assay for screening of liver fibrosis. Another well-known side effect of MTX is myelosuppression, especially pancytopenia, which usually occurs in the setting of folate deficiency. Leucovorin calcium (folinic acid) is the only antidote for the hematologic toxicity of MTX. When an overdose is suspected, an immediate leucovorin dose of 20 mg should be given parenterally or orally, and subsequent doses should be given every 6 hours. Pneumonitis can develop, and mucosal and skin ulcerations have also been reported in patients treated with MTX.

Discontinuation of MTX treatment is required in the event of hepatotoxicity, hematopoietic suppression, active infections, nausea, and pneumonitis. MTX is also teratogenic and should therefore not be prescribed for women who are pregnant or breastfeeding. Several classes of drugs, including NSAIDs and sulfonamides, may interact with MTX to increase toxicity.

ACITRETIN

Acitretin is a second-generation, systemic retinoid that has been approved for the treatment of psoriasis since 1997 and is discussed in Chap. 185. The clinical forms most responsive to etretinate or acitretin as monotherapy include generalized pustular and erythrodermic psoriasis.[100] Acitretin induces clearance of psoriasis in a dose-dependent fashion. Overall, higher starting doses appeared to clear psoriasis faster. The mechanism of action of retinoids for psoriasis is not fully understood. The optimal initial dose of acitretin for psoriasis is reported at 25 mg/day, with a maintenance dose of 20 to 50 mg/day. Adverse effects, such as hair loss and paronychia, occur more frequently with higher initial dose (ie, ≥50 mg/day). Most patients relapse within 2 months after discontinuing etretinate or acitretin. Acitretin should be discontinued if liver dysfunction, hyperlipidemia, or diffuse idiopathic hyperostosis develops.

APREMILAST

Apremilast is a small-molecule inhibitor of phosphodiesterase (PDE)-4, which degrades cyclic adenosine monophosphate (cAMP) intracellularly. The inhibition of PDE4 increases intracellular levels of cAMP resulting in increased activity of the TF CREB (cAMP response element-binding protein), while inhibiting NF-κB signaling. To reduce risk of gastrointestinal (GI) symptoms the drug is titrated over a period of 1 week, starting at 10-mg dosing at day 1 and ending in 30-mg twice-a-day dosing on day 6, which is maintained for the duration of treatment. Adverse effects include GI symptoms such as diarrhea, nausea, and headaches. Worsening of depression has been described, and the drug should be used with caution in individuals with history of depression or suicidal thoughts or behaviors.

TOFACITINIB

Tofacitinib is an oral Janus kinase (JAK) inhibitor. Janus kinases are a family of four tyrosine kinases (JAK1, JAK2, JAK3, and TYK2) and have a role in downstream signaling of multiple proinflammatory cytokines, including IL-2, IL-4, IL-9, IL-13, IL-21, type I and II IFN signaling, IL-6, and to a lesser extent IL-12 and IL-23.[101] At the time of this writing, tofacitinib is only approved for RA, but several clinical trials in psoriasis have been completed using either 5 mg twice a day or 10 mg twice a day.[102,103] Patients should be screened for tuberculosis before initiation, and patients need to be monitored for changes in hemoglobin, leukopenias, or lipid abnormalities. Increased incidences of viral infections, particularly herpes zoster, have been reported in patients with RA taking tofacitinib.

CYCLOSPORIN A

Cyclosporin A (CsA) is a neutral cyclic undecapeptide derived from the fungus *Tolypocladium inflatum gams*. Its mechanism of action and side effects are discussed in Chap. 192. The only formulation approved for treatment of psoriasis is available as an oral solution or in capsules. It is highly effective for cutaneous psoriasis and can also be effective for nail psoriasis (see Fig. 28-9). CsA is particularly useful in patients who present with widespread, intensely inflammatory, or frankly erythrodermic psoriasis. The dosage ranges from 2 to 5 mg/kg/day. Because the nephrotoxic effects of CsA are largely irreversible, CsA treatment should be discontinued if kidney dysfunction or hypertension occurs. CsA-induced hypertension may be treated with calcium antagonists such as nifedipine. The most common adverse effects noted in patients using CsA for short periods of time are neurologic, including tremors, headache, paresthesia, or hyperesthesia. Long-term treatment of psoriasis with low-dose CsA was found to increase risk of nonmelanoma skin cancers. However, unlike organ transplant patients treated with higher doses of CsA, there is little or no increased risk of lymphoma.

FUMARIC ACID ESTERS

Fumaric acid was first reported in 1959 to be beneficial in the systemic treatment of psoriasis[104] and is licensed in Germany for the treatment of psoriasis. Because fumaric acid itself is poorly absorbed after oral intake, esters are used for treatment. The esters are almost completely absorbed in the small intestine, and dimethylfumarate is rapidly hydrolyzed by esterases to monomethylfumarate, which is regarded as the active metabolite. The mode of action in psoriasis is not fully understood.[104] Patients with severe concomitant disease, chronic disease of the GI tract, chronic kidney disease, or with bone marrow disease leading to leukocytopenias or leukocyte dysfunction should not be treated. Likewise, pregnant or lactating women and patients with malignant disease (including positive history of malignancy) should be excluded from treatment. Prolonged therapy (up to 2 years) to prevent relapse in psoriasis patients with high disease activity is possible. Another therapeutic option is short-course intermittent therapy. Fumaric acid esters (FAEs) are given until a major improvement is achieved and are then withdrawn. If a patient remains lesion-free during prolonged treatment, the FAE dose should be gradually decreased to reach the individual's threshold.[104] Therapy with FAEs can be stopped abruptly because rebound phenomena have not been observed.

SULFASALAZINE

Sulfasalazine is an uncommonly used systemic agent in the management of psoriasis. In the only prospective double-blind study on the efficacy of sulfasalazine in psoriasis, moderate effects were seen, with 41% of the patients showing marked improvement, 41% with moderate improvement, and 18% with minimal improvement after 8 weeks of treatment.[105]

SYSTEMIC STEROIDS

See Chap. 184

In general, systemic steroids should not be used in the routine care of psoriasis. When systemic steroids are used, clearance of psoriasis is rapid, but the disease usually breaks through, requiring progressively higher doses to control symptoms. If withdrawal is attempted, the disease tends to relapse promptly and may rebound in the form of erythrodermic and pustular psoriasis. However, systemic steroids may have a role in the management of persistent, otherwise uncontrollable, erythroderma and in fulminant generalized pustular psoriasis (von Zumbusch type) if other drugs are ineffective.

MYCOPHENOLATE MOFETIL

See Chap.192

Mycophenolate mofetil is a prodrug of mycophenolic acid, an inhibitor of inosine-5′-monophosphate dehydrogenase. Mycophenolic acid depletes guanosine nucleotides preferentially in T and B lymphocytes and inhibits their proliferation, thereby suppressing cell-mediated immune responses and antibody formation. The drug is usually well tolerated with few side effects. Few studies have been done on this medication for psoriasis, but in a prospective open-label trial on 23 patients with dosage between 2 to 3 g/day, a 24% reduction of the Psoriasis Area and Severity Index (PASI) was seen after 6 weeks, with 47% improvement at 12 weeks.

6-THIOGUANINE

6-Thioguanine is a purine analog that has been highly effective for psoriasis. Apart from bone marrow suppression, GI complaints, including nausea and diarrhea, can occur, and elevation of liver function test results is common.[96] Isolated instances of hepatic venoocclusive disease have been reported.

HYDROXYUREA

Hydroxyurea is an antimetabolite that has been shown to be effective as monotherapy, but nearly 50% of patients who achieve marked improvement develop bone marrow toxicity with leukopenia or thrombocytopenia. Megaloblastic anemia is also common but rarely requires treatment.[96] Cutaneous reactions affect most patients treated with hydroxyurea, including leg ulcers, which are the most troublesome.[106]

BIOLOGIC TREATMENTS

See Table 28-7 and Chap. 193.

Based on the continuous progress in psoriasis research and advances in molecular biology, a new class of agents—targeted biologic therapies—has emerged. These agents are designed to block specific molecular steps important in the pathogenesis of psoriasis or have been transferred to the psoriasis arena after being developed for other inflammatory diseases. Currently, three types of biologics are approved or are in development for psoriasis: (1) recombinant human cytokines, (2) fusion proteins, and (3) monoclonal antibodies, which may be fully human, humanized or chimeric. Because of the risk of the development of antibodies to mouse sequences, humanized or fully human antibodies are preferred for clinical use.

Using internationally acknowledged safety and efficacy endpoints, the overall utility and benefit of biologics have been demonstrated based on the percentage of patients achieving at least a 50% improvement in PASI (PASI-50), a 75% improvement in PASI (PASI-75), the impact of treatment on quality of life, and safety and tolerability. Many of these agents have antipsoriatic activity roughly comparable to that of MTX and lack its risk of hepatotoxicity. However, they are far more expensive and carry risks of immunosuppression, infusion reactions, and antibody formation, and their long-term safety remains to be evaluated. In the opinion of the authors, use of biologic agents should be reserved for treatment of moderate to severe psoriasis that is either unresponsive to MTX or in patients for whom the use of MTX is contraindicated.

TUMOR NECROSIS FACTOR-α ANTAGONISTS

The clinical application of TNF antagonists in inflammatory diseases has exploded on the clinical realm in a manner reminiscent of the discovery of the activity of corticosteroids. TNF-α is a homotrimeric protein that exists in both transmembrane and soluble forms, the latter resulting from proteolytic cleavage and release. It is still unclear which form is more important in mediating its proinflammatory activities or the relative importance of the two p55- and p75-kd TNF-α–binding receptors. Currently, five anti-TNF biologics are available in the United States. Infliximab is a chimeric monoclonal antibody that has high specificity, affinity, and avidity for TNF-α. An example of an excellent treatment outcome with infliximab is shown in Fig. 28-17. Etanercept is a human recombinant, soluble, TNF-α receptor-Fc IgG fusion protein that binds TNF-α and neutralizes its activity. Adalimumab and golimumab are fully human recombinant IgG1 monoclonal antibodies and

specifically targets TNF-α. Certolizumab pegol is a polyethylene glycol (PEG) Fab' fragment of a humanized TNF inhibitor monoclonal antibody. The pegylation is thought to reduce immunogenicity of the drug and prolongs serum half-life without compromising activity. Currently, golimumab and certolizumab pegol are only FDA approved for PsA. Clinical trials have shown that each of these agents is well tolerated and appears suitable for long-term use in chronic plaque psoriasis. However, like all the targeted biologic therapies, they carry risks of immunosuppression.

Clinical studies have found infliximab and adalimumab to be slightly more effective than etanercept in the treatment of psoriasis. It is likely that the differential effects of these agents are associated with selectivity in their ability to perturb these receptor–ligand interactions. It is known that infliximab, adalimumab, golimumab, and etanercept bind TNF differently; whereas infliximab and adalimumab bind to both soluble and membrane-bound TNF, etanercept binds primarily to soluble TNF. Binding to membrane-bound TNF can induce a dose-dependent increase in apoptosis of T cells, but the relevance of this mechanism in psoriasis has not been evaluated. New onset of psoriasis has been described several times in patients on these agents for other conditions such as Crohn disease or RA. These paradoxical reactions are characterized by increased production of IFN-α.[107]

INTERLEUKIN-12 AND INTERLEUKIN-23 ANTAGONISTS

Ustekinumab is a human monoclonal antibody that binds the shared p40 subunit of IL-12 and IL-23 and prevents interaction with their receptors. This treatment blocks IL-12, which is critical for Th1 differentiation, but its inhibitory effect on IL-23 may be more important. As described earlier, IL-23 supports chronic inflammation mediated by Th17 and Th22 cells. Clinical studies have found ustekinumab to be slightly more effective than etanercept in the treatment of psoriasis,[108] but direct comparison with infliximab or adalimumab has not been reported.

Several agents specifically targeting the p19 subunit of IL-23 are currently in development and appear to be highly effective, consistent with a key role for IL-23 in psoriasis pathogenesis.[57,109,110]

INTERLEUKIN-17A ANTAGONISTS

Two IL-17A antagonists are currently approved for the treatment of psoriasis. Secukinumab is a fully human antibody, and ixekizumab is a humanized antibody that binds and neutralizes IL-17A. IL-17A is a critical cytokine in the pathogenesis of psoriasis, and biologics targeting IL-17A are among the most effective drugs available for the treatment of psoriasis.[111-113] Brodalumab, a fully human antibody targeting the IL-17 receptor α chain, is also highly effective[114] and has recently been FDA approved for use in psoriasis after screening for depression and suicidal ideation.

COMBINATION TREATMENTS

Combination treatment may increase efficacy and reduce side effects, so it may result in a more substantial improvement, or alternatively, may permit reduced doses to reach the same improvement as compared with monotherapy.[85] Data on combination of biologics with other systemic or topical agents are not yet widely available, but some combinations commonly used in the treatment of inflammatory arthritides, such as a combination of MTX and anti-TNF agents, may be appropriate for treatment of recalcitrant psoriatic disease.

TREATMENT OF PALMOPLANTAR PUSTULAR PSORIASIS

Palmoplantar pustular psoriasis (including PPP and PPPP) tends to be difficult to treat and is often unresponsive to treatments used for chronic plaque psoriasis. Given its rarity, randomized controlled trials are lacking. Phototherapy, cyclosporine, and topical steroids are the treatments with the most well-documented efficacy.[115] Tonsillectomy has been used to treat pustulosis palmaris et plantaris, and in a cohort of 116 Japanese patients, clinical improvement was seen in 109 (94%).[116] Notably, given its strong association with smoking, smoking cessation provides substantial clinical improvement.[117]

PREVENTION

There is no known prevention for psoriasis.

REFERENCES

1. Parisi R, Symmons DP, Griffiths CE, et al. Global epidemiology of psoriasis: a systematic review of incidence and prevalence. *J Invest Dermatol.* 2013;133(2):377-385.
2. Raychaudhuri SP, Farber EM. The prevalence of psoriasis in the world. *J Eur Acad Dermatol Venereol.* 2001;15(1):16-17.
3. Henseler T, Christophers E. Psoriasis of early and late onset: characterization of two types of psoriasis vulgaris. *J Am Acad Dermatol.* 1985;13(3):450-456.
4. Lonnberg AS, Skov L, Skytthe A, et al. Heritability of psoriasis in a large twin sample. *Br J Dermatol.* 2013;169(2):412-416.
5. Mallon E, Bunce M, Savoie H, et al. HLA-C and guttate psoriasis. *Br J Dermatol.* 2000;143(6):1177-1182.
6. Telfer NR, Chalmers RJ, Whale K, et al. The role of streptococcal infection in the initiation of guttate psoriasis. *Arch Dermatol.* 1992;128(1):39-42.

7. Chalmers RR, O'Sullivan T, Owen CC, et al. A systematic review of treatments for guttate psoriasis. *Br J Dermatol.* 2001;145(6):891-894.
8. Kim J, Oh CH, Jeon J, et al. Molecular phenotyping small (Asian) versus large (western) plaque psoriasis shows common activation of IL-17 pathway genes but different regulatory gene sets. *J Invest Dermatol.* 2016;136(1):161-172.
9. Baker H, Ryan TJ. Generalized pustular psoriasis. A clinical and epidemiological study of 104 cases. *Br J Dermatol.* 1968;80(12):771-793.
10. Becher G, Jamieson L, Leman J. Palmoplantar pustulosis—a retrospective review of comorbid conditions. *J Eur Acad Dermatol Venereol.* 2015;29(9):1854-1856.
11. Asumalahti K, Ameen M, Suomela S, et al. Genetic analysis of PSORS1 distinguishes guttate psoriasis and palmoplantar pustulosis. *J Invest Dermatol.* 2003;120(4):627-632.
12. Bissonnette R, Suarez-Farinas M, Li X, et al. Based on molecular profiling of gene expression, palmoplantar pustulosis and palmoplantar pustular psoriasis are highly related diseases that appear to be distinct from psoriasis vulgaris. *PLoS One.* 2016;11(5):e0155215.
13. Kim KH, Kim HL, Suh HY, et al. A case of acrodermatitis continua accompanying with osteolysis and atrophy of the distal phalanx that evoluted into generalized pustular psoriasis. *Ann Dermatol.* 2016;28(6):794-795.
14. Gudjonsson JE, Karason A, Runarsdottir EH, et al. Distinct clinical differences between HLA-Cw*0602 positive and negative psoriasis patients—an analysis of 1019 HLA-C- and HLA-B-typed patients. *J Invest Dermatol.* 2006;126(4):740-745.
15. Kvedar JC, Baden HP. Nail changes in cutaneous disease. *Semin Dermatol.* 1991;10(1):65-70.
16. Rittie L, Tejasvi T, Harms PW, et al. Sebaceous gland atrophy in psoriasis: an explanation for psoriatic alopecia? *J Invest Dermatol.* 2016;136(9):1792-1800.
17. Henseler T, Christophers E. Disease concomitance in psoriasis. *J Am Acad Dermatol.* 1995;32(6):982-986.
18. Gelfand JM, Neimann AL, Shin DB, et al. Risk of myocardial infarction in patients with psoriasis. *JAMA.* 2006;296(14):1735-1741.
19. Naik HB, Natarajan B, Stansky E, et al. Severity of psoriasis associates with aortic vascular inflammation detected by FDG PET/CT and neutrophil activation in a prospective observational study. *Arterioscler Thromb Vasc Biol.* 2015;35(12):2667-2676.
20. Augustin M, Reich K, Glaeske G, et al. Co-morbidity and age-related prevalence of psoriasis: analysis of health insurance data in Germany. *Acta Derm Venereol.* 2010;90(2):147-151.
21. Gelfand JM, Shin DB, Neimann AL, et al. The risk of lymphoma in patients with psoriasis. *J Invest Dermatol.* 2006;126(10):2194-2201.
22. Fortune DG, Richards HL, Griffiths CE. Psychologic factors in psoriasis: consequences, mechanisms, and interventions. *Dermatol Clin.* 2005;23(4):681-694.
23. Rapp SR, Feldman SR, Exum ML, et al. Psoriasis causes as much disability as other major medical diseases. *J Am Acad Dermatol.* 1999;41(3 Pt 1):401-407.
24. Krueger G, Koo J, Lebwohl M, et al. The impact of psoriasis on quality of life: results of a 1998 National Psoriasis Foundation patient-membership survey. *Arch Dermatol.* 2001;137(3):280-284.
25. Braun-Falco O. Dynamics of growth and regression in psoriatic lesions: alterations in the skin from normal into a psoriatic lesion, and during regression of psoriatic lesions. In: Farber EM, Cox AJ, eds. *Psoriasis: Proceedings of the International Symposium, Stanford University, 1971.* Stanford, CA: Stanford University Press; 1971:215-237.
26. Christophers E, Parzefall R, Braun-Falco O. Initial events in psoriasis: quantitative assessment. *Br J Dermatol.* 1973;89(4):327-334.
27. Brody I. Alterations of clinically normal skin in early eruptive guttate psoriasis. *J Cutan Pathol.* 1978; 5:219-233.
28. Wright NA, Camplejohn RS, eds. *Psoriasis: Cell Proliferation.* Edinburgh: Churchill Livingstone; 1983.
29. Wrone-Smith T, Nickoloff BJ. Dermal injection of immunocytes induces psoriasis. *J Clin Invest.* 1996; 98(8):1878-1887.
30. Chang JC, Smith LR, Froning KJ, et al. CD8+ T cells in psoriatic lesions preferentially use T-cell receptor V beta 3 and/or V beta 13.1 genes. *Proc Natl Acad Sci U S A.* 1994;91(20):9282-9286.
31. Harden JL, Hamm D, Gulati N, et al. Deep sequencing of the T-cell receptor repertoire demonstrates polyclonal T-cell infiltrates in psoriasis. *F1000Res.* 2015;4:460.
32. Clark RA. Resident memory T cells in human health and disease. *Sci Transl Med.* 2015;7(269):269rv261.
33. Conrad C, Boyman O, Tonel G, et al. Alpha1beta1 integrin is crucial for accumulation of epidermal T cells and the development of psoriasis. *Nat Med.* 2007;13(7):836-842.
34. Di Meglio P, Villanova F, Navarini AA, et al. Targeting CD8(+) T cells prevents psoriasis development. *J Allergy Clin Immunol.* 2016;138(1):274-276, e276.
35. Zaba LC, Cardinale I, Gilleaudeau P, et al. Amelioration of epidermal hyperplasia by TNF inhibition is associated with reduced Th17 responses. *J Exp Med.* 2007;204(13):3183-3194.
36. Beissert S, Schwarz A, Schwarz T. Regulatory T cells. *J Invest Dermatol.* 2006;126(1):15-24.
37. Sugiyama H, Gyulai R, Toichi E, et al. Dysfunctional blood and target tissue CD4+CD25high regulatory T cells in psoriasis: mechanism underlying unrestrained pathogenic effector T cell proliferation. *J Immunol.* 2005; 174(1):164-173.
38. Laggner U, Di Meglio P, Perera GK, et al. Identification of a novel proinflammatory human skin-homing Vgamma9Vdelta2 T cell subset with a potential role in psoriasis. *J Immunol.* 2011;187(5):2783-2793.
39. Teunissen MB, Munneke JM, Bernink JH, et al. Composition of innate lymphoid cell subsets in the human skin: enrichment of NCR(+) ILC3 in lesional skin and blood of psoriasis patients. *J Invest Dermatol.* 2014;134(9):2351-2360.
40. Lowes MA, Suarez-Farinas M, Krueger JG. Immunology of psoriasis. *Annu Rev Immunol.* 2014;32:227-255.
41. Stratis A, Pasparakis M, Rupec RA, et al. Pathogenic role for skin macrophages in a mouse model of keratinocyte-induced psoriasis-like skin inflammation. *J Clin Invest.* 2006;116(8):2094-2104.
42. Mansbridge JN, Knapp AM, Strefling AM. Evidence for an alternative pathway of keratinocyte maturation in psoriasis from an antigen found in psoriatic but not normal epidermis. *J Invest Dermatol.* 1984;83(4):296-301.
43. Tsoi LC, Stuart PE, Tejasvi T, et al. Large-scale meta-analysis identifies 18 novel psoriasis susceptibility loci. *Nat Commun.* 2017;8:15382.
44. Nair RP, Stuart PE, Nistor I, et al. Sequence and haplotype analysis supports HLA-C as the psoriasis susceptibility 1 gene. *Am J Hum Genet.* 2006;78(5):827-851.

45. Okada Y, Han B, Tsoi LC, et al. Fine mapping major histocompatibility complex associations in psoriasis and its clinical subtypes. *Am J Hum Genet.* 2014; 95(2):162-172.
46. Rottman JB, Smith TL, Ganley KG, et al. Potential role of the chemokine receptors CXCR3, CCR4, and the integrin alphaEbeta7 in the pathogenesis of psoriasis vulgaris. *Lab Invest.* 2001;81(3):335-347.
47. Boyman O, Hefti HP, Conrad C, et al. Spontaneous development of psoriasis in a new animal model shows an essential role for resident T cells and tumor necrosis factor-alpha. *J Exp Med.* 2004;199(5):731-736.
48. Zhou F, Cao H, Zuo X, et al. Deep sequencing of the MHC region in the Chinese population contributes to studies of complex disease. *Nat Genet.* 2016; 48(7):740-746.
49. Lande R, Botti E, Jandus C, et al. The antimicrobial peptide LL37 is a T-cell autoantigen in psoriasis. *Nat Commun.* 2014;5:5621.
50. Cheung KL, Jarrett R, Subramaniam S, et al. Psoriatic T cells recognize neolipid antigens generated by mast cell phospholipase delivered by exosomes and presented by CD1a. *J Exp Med.* 2016;213(11):2399-2412.
51. Arakawa A, Siewert K, Stohr J, et al. Melanocyte antigen triggers autoimmunity in human psoriasis. *J Exp Med.* 2015;212(13):2203-2212.
52. Bonifacio KM, Kunjravia N, Krueger JG, et al. Cutaneous expression of A disintegrin-like and metalloprotease domain containing thrombospondin type 1 motif-like 5 (ADAMTSL5) in psoriasis goes beyond melanocytes. *J Pigment Disord.* 2016;3(3).
53. Nickoloff BJ, Wrone-Smith T. Injection of pre-psoriatic skin with CD4+ T cells induces psoriasis. *Am J Pathol.* 1999;155(1):145-158.
54. Stuart PE, Nair RP, Tsoi LC, et al. Genome-wide association analysis of psoriatic arthritis and cutaneous psoriasis reveals differences in their genetic architecture. *Am J Hum Genet.* 2015;97(6):816-836.
55. Bowes J, Budu-Aggrey A, Huffmeier U, et al. Dense genotyping of immune-related susceptibility loci reveals new insights into the genetics of psoriatic arthritis. *Nat Commun.* 2015;6:6046.
56. Krueger GG, Langley RG, Leonardi C, et al. A human interleukin-12/23 monoclonal antibody for the treatment of psoriasis. *N Engl J Med.* 2007;356(6):580-592.
57. Kopp T, Riedl E, Bangert C, et al. Clinical improvement in psoriasis with specific targeting of interleukin-23. *Nature.* 2015;521(7551):222-226.
58. Bettelli E, Oukka M, Kuchroo VK. T(H)-17 cells in the circle of immunity and autoimmunity. *Nat Immunol.* 2007;8(4):345-350.
59. Thomas GP, Brown MA. Genetics and genomics of ankylosing spondylitis. *Immunol Rev.* 2010;233(1):162-180.
60. Reveille JD, Sims AM, Danoy P, et al. Genome-wide association study of ankylosing spondylitis identifies non-MHC susceptibility loci. *Nat Genet.* 2010; 42(2):123-127.
61. Johansen C, Mose M, Ommen P, et al. IkappaBzeta is a key driver in the development of psoriasis. *Proc Natl Acad Sci U S A.* 2015;112(43):e5825-5833.
62. Kryczek I, Bruce AT, Gudjonsson JE, et al. Induction of IL-17+ T cell trafficking and development by IFN-gamma: mechanism and pathological relevance in psoriasis. *J Immunol.* 2008;181(7):4733-4741.
63. Mills KH. Induction, function and regulation of IL-17-producing T cells. *Eur J Immunol.* 2008;38(10): 2636-2649.
64. Guenova E, Skabytska Y, Hoetzenecker W, et al. IL-4 abrogates T(H)17 cell-mediated inflammation by selective silencing of IL-23 in antigen-presenting cells. *Proc Natl Acad Sci U S A.* 2015;112(7):2163-2168.
65. Wu J, Chen ZJ. Innate immune sensing and signaling of cytosolic nucleic acids. *Annu Rev Immunol.* 2014;32:461-488.
66. Kreins AY, Ciancanelli MJ, Okada S, et al. Human TYK2 deficiency: mycobacterial and viral infections without hyper-IgE syndrome. *J Exp Med.* 2015; 212(10):1641-1662.
67. Mauro C, Pacifico F, Lavorgna A, et al. ABIN-1 binds to NEMO/IKKgamma and co-operates with A20 in inhibiting NF-kappaB. *J Biol Chem.* 2006;281(27): 18482-18488.
68. Jordan CT, Cao L, Roberson ED, et al. PSORS2 is due to mutations in CARD14. *Am J Hum Genet.* 2012;90(5):784-795.
69. Chiricozzi A, Nograles KE, Johnson-Huang LM, et al. IL-17 induces an expanded range of downstream genes in reconstituted human epidermis model. *PLoS One.* 2014;9(2):e90284.
70. de Cid R, Riveira-Munoz E, Zeeuwen PL, et al. Deletion of the late cornified envelope LCE3B and LCE3C genes as a susceptibility factor for psoriasis. *Nat Genet.* 2009;41(2):211-215.
71. Zhang XJ, Huang W, Yang S, et al. Psoriasis genome-wide association study identifies susceptibility variants within LCE gene cluster at 1q21. *Nat Genet.* 2009;41(2):205-210.
72. Niehues H, van Vlijmen-Willems IM, Bergboer JG, et al. Late cornified envelope (LCE) proteins: distinct expression patterns of LCE2 and LCE3 members suggest non-redundant roles in human epidermis and other epithelia. *Br J Dermatol.* 2016;174(4):795-802.
73. Herron MD, Hinckley M, Hoffman MS, et al. Impact of obesity and smoking on psoriasis presentation and management. *Arch Dermatol.* 2005;141(12): 1527-1534.
74. Fortes C, Mastroeni S, Leffondre K, et al. Relationship between smoking and the clinical severity of psoriasis. *Arch Dermatol.* 2005;141(12):1580-1584.
75. Gudjonsson JE, Thorarinsson AM, Sigurgeirsson B, et al. Streptococcal throat infections and exacerbation of chronic plaque psoriasis: a prospective study. *Br J Dermatol.* 2003;149(3):530-534.
76. Thorleifsdottir RH, Eysteinsdottir JH, Olafsson JH, et al. Throat infections are associated with exacerbation in a substantial proportion of patients with chronic plaque psoriasis. *Acta Derm Venereol.* 2016;96(6):788-791.
77. Thorleifsdottir RH, Sigurdardottir SL, Sigurgeirsson B, et al. HLA-Cw6 homozygosity in plaque psoriasis is associated with streptococcal throat infections and pronounced improvement after tonsillectomy: a prospective case series. *J Am Acad Dermatol.* 2016; 75(5):889-896.
78. Gudjonsson JE, Johnston A, Sigmundsdottir H, et al. Immunopathogenic mechanisms in psoriasis. *Clin Exp Immunol.* 2004;135(1):1-8.
79. Nestle FO, Conrad C, Tun-Kyi A, et al. Plasmacytoid predendritic cells initiate psoriasis through interferon-{alpha} production. *J Exp Med.* 2005;202(1):135-143.
80. Ko JM, Gottlieb AB, Kerbleski JF. Induction and exacerbation of psoriasis with TNF-blockade therapy: a review and analysis of 127 cases. *J Dermatolog Treat.* 2008:1-8.
81. O'Brien M, Koo J. The mechanism of lithium and beta-blocking agents in inducing and exacerbating psoriasis. *J Drugs Dermatol.* 2006;5(5):426-432.
82. Mallbris L, Granath F, Hamsten A, et al. Psoriasis is associated with lipid abnormalities at the onset of skin disease. *J Am Acad Dermatol.* 2006;54(4):614-621.

83. Christophers E. Psoriasis—epidemiology and clinical spectrum. *Clin Exp Dermatol.* 2001;26(4):314-320.
84. Martin BA, Chalmers RJ, Telfer NR. How great is the risk of further psoriasis following a single episode of acute guttate psoriasis? *Arch Dermatol.* 1996;132(6):717-718.
85. van de Kerkhof PC. Therapeutic strategies: rotational therapy and combinations. *Clin Exp Dermatol.* 2001;26(4):356-361.
86. Lebwohl M, Ali S. Treatment of psoriasis. Part 1. Topical therapy and phototherapy. *J Am Acad Dermatol.* 2001;45(4):487-498; quiz 499-502.
87. Richards HL, Fortune DG, O'Sullivan TM, et al. Patients with psoriasis and their compliance with medication. *J Am Acad Dermatol.* 1999;41(4):581-583.
88. Menter A, Korman NJ, Elmets CA, et al. Guidelines of care for the management of psoriasis and psoriatic arthritis. Section 3. Guidelines of care for the management and treatment of psoriasis with topical therapies. *J Am Acad Dermatol.* 2009;60(4):643-659.
89. Arbiser JL, Govindarajan B, Battle TE, et al. Carbazole is a naturally occurring inhibitor of angiogenesis and inflammation isolated from antipsoriatic coal tar. *J Invest Dermatol.* 2006;126(6):1396-1402.
90. Martin Ezquerra G, Sanchez Regana M, Herrera Acosta E, et al. Topical tacrolimus for the treatment of psoriasis on the face, genitalia, intertriginous areas and corporal plaques. *J Drugs Dermatol.* 2006;5(4):334-336.
91. Honigsmann H. Phototherapy for psoriasis. *Clin Exp Dermatol.* 2001;26(4):343-350.
92. Menter A, Korman NJ, Elmets CA, et al. Guidelines of care for the management of psoriasis and psoriatic arthritis: section 5. Guidelines of care for the treatment of psoriasis with phototherapy and photochemotherapy. *J Am Acad Dermatol.* 2010;62(1):114-135.
93. Yones SS, Palmer RA, Garibaldinos TT, et al. Randomized double-blind trial of the treatment of chronic plaque psoriasis: efficacy of psoralen-UV-A therapy vs narrowband UV-B therapy. *Arch Dermatol.* 2006;142(7):836-842.
94. Asawanonda P, Anderson RR, Chang Y, et al. 308-nm excimer laser for the treatment of psoriasis: a dose-response study. *Arch Dermatol.* 2000;136(5):619-624.
95. Halevy S, Sukenik S. Different modalities of spa therapy for skin diseases at the Dead Sea area. *Arch Dermatol.* 1998;134(11):1416-1420.
96. Lebwohl M, Ali S. Treatment of psoriasis. Part 2. Systemic therapies. *J Am Acad Dermatol.* 2001;45(5):649-661; quiz 662-644.
97. Pathirana D, Ormerod AD, Saiag P, et al. European S3-guidelines on the systemic treatment of psoriasis vulgaris. *J Eur Acad Dermatol Venereol.* 2009;23 (suppl 2):1-70.
98. Menter A, Korman NJ, Elmets CA, et al. Guidelines of care for the management of psoriasis and psoriatic arthritis: section 4. Guidelines of care for the management and treatment of psoriasis with traditional systemic agents. *J Am Acad Dermatol.* 2009;61(3):451-485.
99. Cronstein BN, Naime D, Ostad E. The antiinflammatory effects of methotrexate are mediated by adenosine. *Adv Exp Med Biol.* 1994;370:411-416.
100. Lee CS, Koo J. A review of acitretin, a systemic retinoid for the treatment of psoriasis. *Expert Opin Pharmacother.* 2005;6(10):1725-1734.
101. Krueger J, Clark JD, Suarez-Farinas M, et al. Tofacitinib attenuates pathologic immune pathways in patients with psoriasis: a randomized phase 2 study. *J Allergy Clin Immunol.* 2016;137(4):1079-1090.
102. Papp KA, Krueger JG, Feldman SR, et al. Tofacitinib, an oral Janus kinase inhibitor, for the treatment of chronic plaque psoriasis: long-term efficacy and safety results from 2 randomized phase-III studies and 1 open-label long-term extension study. *J Am Acad Dermatol.* 2016;74(5):841-850.
103. Bachelez H, van de Kerkhof PC, Strohal R, et al. Tofacitinib versus etanercept or placebo in moderate-to-severe chronic plaque psoriasis: a phase 3 randomised non-inferiority trial. *Lancet.* 2015;386(9993):552-561.
104. Mrowietz U, Christophers E, Altmeyer P. Treatment of severe psoriasis with fumaric acid esters: scientific background and guidelines for therapeutic use. The German Fumaric Acid Ester Consensus Conference. *Br J Dermatol.* 1999;141(3):424-429.
105. Gupta AK, Ellis CN, Siegel MT, et al. Sulfasalazine improves psoriasis. A double-blind analysis [see comments]. *Arch Dermatol.* 1990;126(4):487-493.
106. Kirby B, Gibson LE, Rogers S, et al. Dermatomyositis-like eruption and leg ulceration caused by hydroxyurea in a patient with psoriasis. *Clin Exp Dermatol.* 2000;25(3):256-257.
107. de Gannes GC, Ghoreishi M, Pope J, et al. Psoriasis and pustular dermatitis triggered by TNF-{alpha} inhibitors in patients with rheumatologic conditions. *Arch Dermatol.* 2007;143(2):223-231.
108. Griffiths CE, Strober BE, van de Kerkhof P, et al. Comparison of ustekinumab and etanercept for moderate-to-severe psoriasis. *N Engl J Med.* 2010;362(2):118-128.
109. Krueger JG, Ferris LK, Menter A, et al. Anti-IL-23A mAb BI 655066 for treatment of moderate-to-severe psoriasis: safety, efficacy, pharmacokinetics, and biomarker results of a single-rising-dose, randomized, double-blind, placebo-controlled trial. *J Allergy Clin Immunol.* 2015;136(1):116-124.
110. Gordon KB, Duffin KC, Bissonnette R, et al. A phase 2 trial of guselkumab versus adalimumab for plaque psoriasis. *N Engl J Med.* 2015;373(2):136-144.
111. Langley RG, Elewski BE, Lebwohl M, et al. Secukinumab in plaque psoriasis—results of two phase 3 trials. *N Engl J Med.* 2014;371(4):326-338.
112. Gordon KB, Blauvelt A, Papp KA, et al. Phase 3 trials of ixekizumab in moderate-to-severe plaque psoriasis. *N Engl J Med.* 2016;375(4):345-356.
113. Griffiths CE, Reich K, Lebwohl M, et al. Comparison of ixekizumab with etanercept or placebo in moderate-to-severe psoriasis (UNCOVER-2 and UNCOVER-3): results from two phase 3 randomised trials. *Lancet.* 2015;386(9993):541-551.
114. Lebwohl M, Strober B, Menter A, et al. Phase 3 studies comparing brodalumab with ustekinumab in psoriasis. *N Engl J Med.* 2015;373(14):1318-1328.
115. Sevrain M, Richard MA, Barnetche T, et al. Treatment for palmoplantar pustular psoriasis: systematic literature review, evidence-based recommendations and expert opinion. *J Eur Acad Dermatol Venereol.* 2014;28(suppl 5):13-16.
116. Takahara M. Clinical outcome of tonsillectomy for palmoplantar pustulosis and etiological relationship between palmoplantar pustulosis and tonsils. *Adv Otorhinolaryngol.* 2011;72:86-88.
117. Michaelsson G, Gustafsson K, Hagforsen E. The psoriasis variant palmoplantar pustulosis can be improved after cessation of smoking. *J Am Acad Dermatol.* 2006;54(4):737-738.

Chapter 29 :: Pityriasis Rubra Pilaris

:: Knut Schäkel

AT-A-GLANCE

- A rare inflammatory papulosquamous dermatosis, often self-limiting within a few years.
- The disease is subclassified into 6 types, including both hereditary and acquired forms.
- The hereditary form of pityriasis rubra pilaris is linked to CARD14 gain-of-function mutations, the cause of the acquired forms is unknown.
- Typical features are follicular hyperkeratotic papules that coalesce into scaly, reddish-orange–colored plaques, which may progress to erythroderma with well-demarcated islands of normal skin.
- Distinguishing pityriasis rubra pilaris from psoriasis poses a major diagnostic challenge, particularly in the early phases of the disease.
- Histopathologic examination reveals hyperkeratosis, alternating parakeratosis and orthokeratosis in a checkerboard pattern, with focal acantholytic dyskeratosis.
- The most successful treatment options are systemic retinoids, methotrexate, and photochemotherapy (psoralen and ultraviolet A). In recent years, biologics blocking tumor necrosis factor-α and interleukins-12 and -12p40 were shown to be effective.

Pityriasis rubra pilaris (PRP) is a rare, inflammatory skin disease of juvenile or adult onset with distinctive clinical features and a self-limiting or chronic evolution.

EPIDEMIOLOGY

The exact prevalence of PRP is not known. It accounts for approximately 1 in 5000 new patients presenting with skin disease in Great Britain.[1] In India this is approximately 1 in 50,000 patients (pityriasis rubra pilaris in Indians.) The disease occurs in all races with an equal male-to-female ratio.[2]

CLINICAL FEATURES

PRP comprises different entities and most cases are sporadic and have an unknown etiology. Approximately 6.5% of cases of PRP are familial[3-5] and linked to CARD14 mutations.[6] In 1980, Griffiths proposed classifying PRP into 5 types based on age of onset, clinical course, and prognosis. A sixth, HIV-associated, category was added in later years (Table 29-1).[2]

Type I (classic adult) is the most common subtype and occurs in more than 50% of all cases. Characteristically, type I PRP starts with erythematous macules forming patches and with follicular hyperkeratotic papules on the upper half of the body (Figs. 29-1A and 29-2). As the disease evolves, a yellow-orange, scaling dermatitis often spreads to a generalized erythroderma over a period of 2 to 3 months (Fig. 29-3). A diagnostic hallmark of PRP is the presence of sharply demarcated islands of unaffected skin ("nappes claires"; Fig. 29-1B). Frequently patients develop a waxy, diffuse, yellowish keratoderma of the palms and soles (Fig. 29-4).[7] Nail changes are common in these patients and include nail plate thickening, splinter hemorrhages, and subungual hyperkeratosis. In patients with uniform facial involvement, ectropion frequently develops (Fig. 29-2B).

Type II (atypical adult) PRP describes an variant, which affects 5% of PRP patients. It is characterized by its atypical morphologic picture and a long duration of more than 20 years. The clinical picture resembles ichthyosiform scaling, areas of follicular hyperkeratosis, and sparseness of the scalp hair. The cephalocaudal progression observed in type I is missing, and there is less tendency for the patients to develop erythroderma.

Type III (classic juvenile) is the clinical counterpart of type I PRP in children. It affects 10% of PRP patients, with the onset usually between the ages of 5 and 10 years.[1] The clinical course may be shorter with clearing after 1 year (Fig. 29-5).

Type IV (circumscribed juvenile) affects approximately 25% of patients. This type usually manifests in prepubertal children and young adults. It is characterized by well-demarcated hyperkeratotic erythematous plaques on the elbows and knees, resembling localized psoriasis (Fig. 29-6). These lesions do not progress to the more widespread classical type. Palmoplantar keratoderma is characteristic for type IV PRP, but may also be absent.[8] The 3-year remission rate is 32%.

Type V (atypical juvenile) PRP occurs in 5% of patients and is characterized by an early age of onset and a chronic course. Most patients of the familial PRP belong to this category. These patients were recently shown to harbor a gain-of-function mutation in the CARD14 gene encoding the *Ca*spase *R*ecruitment *D*omain family member 14 (CARD14).[6] It manifests as hyperkeratotic follicular lesions. Some patients present with scleroderma-like features affecting hands and feet.

The *type VI* (HIV-associated) variant was proposed by Miralles and colleagues.[9] These HIV-associated cases manifest with follicular papules and prominent follicular plugging. The symmetrically distributed lesions of the extensor surfaces frequently progress to erythroderma. Additional manifestations include acne conglobata, hidradenitis suppurativa, and lichen spinulosus.

TABLE 29-1
Classification Scheme of Pityriasis Rubra Pilaris[a]

TYPE	DESCRIPTION	% OF CASES	CLINICAL CHARACTERISTICS	DISTRIBUTION	COURSE
I	Classic adult	>50	Erythroderma with islands of normal skin ("nappes claires"), follicular hyperkeratosis, waxy diffuse palmoplantar keratoderma	Generalized, beginning on the head and neck, then spreading caudally	Often resolves within an average period of 3 years
II	Atypical adult	5	Combination of follicular hyperkeratosis and ichthyosiform lesions on the legs, sparse scalp hair	Generalized	Long duration (>20 years)
III	Classic juvenile	10	Similar to type I but appears in years 1 or 2 of life	Generalized	Often resolves within an average period of 1–2 years
IV	Circumscribed juvenile	25	Prepubertal children; well-demarcated scaly, erythematous plaques on the elbows and knees, resembling localized psoriasis	Localized	Uncertain, some cases clear in the late teens
V	Atypical juvenile, associated with CARD14 mutations	5	Begins in first few years, accounts for most familial cases; follicular hyperkeratosis, scleroderma-like appearance of the hands and feet	Generalized	Chronic course, improvement with retinoids but relapses when stopped
VI	HIV-associated	NA[b]	Similar to type I with variable beginning; associated with acne conglobata, hidradenitis suppurativa and lichen spinulosus	Generalized	May respond to antiretroviral triple therapy

[a]Types I to V are according to Griffiths.[2]
[b]Data not available.

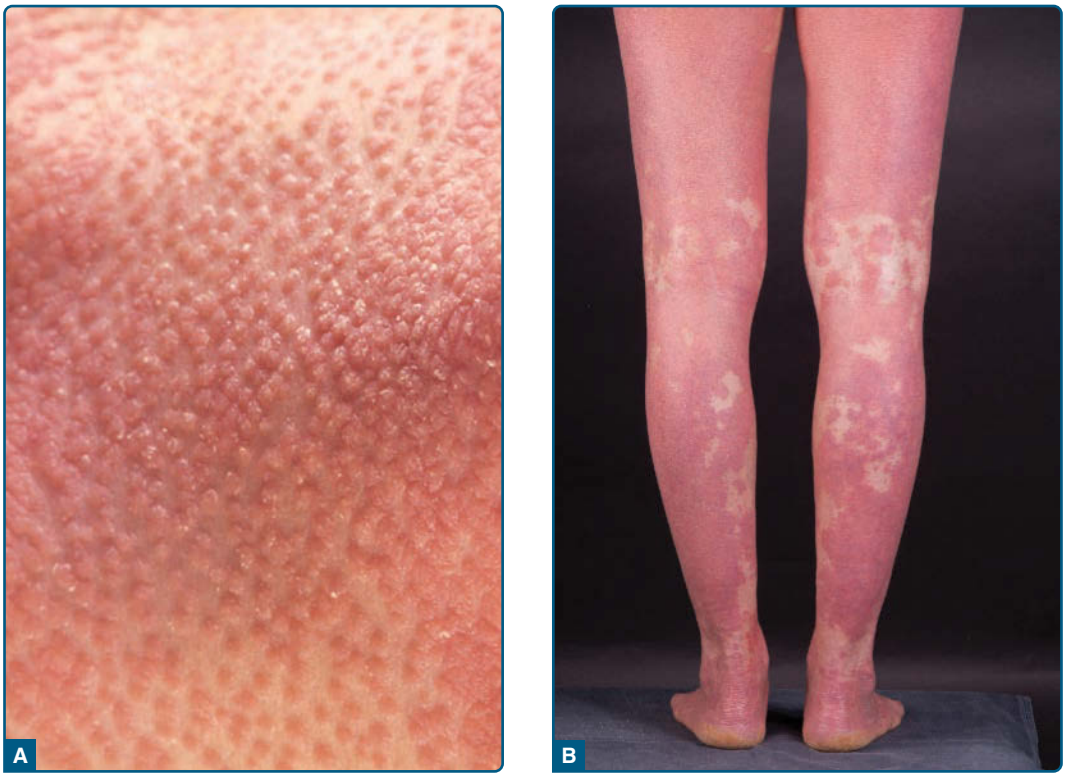

Figure 29-1 **A,** Follicular papules and **B,** islands of normal skin "nappes claires" in pityriasis rubra pilaris.

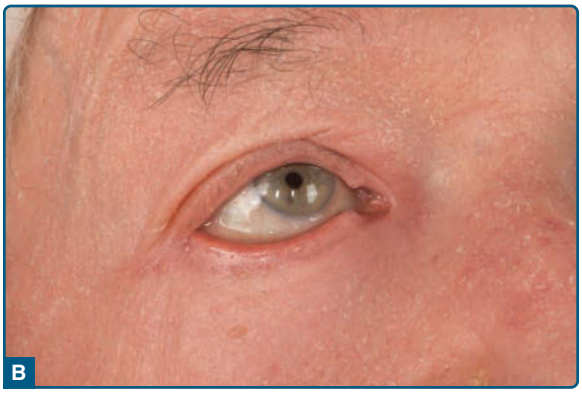

Figure 29-2 Classic adult type I pityriasis rubra pilaris presenting with monomorphic regions of affected skin, sharp margins, diffuse alopecia (**A**), and ectropion (**B**).

ASSOCIATIONS OF PITYRIASIS RUBRA PILARIS

There is an association of PRP with HIV infections, proposed as type VI PRP. In some cases, manifestation of PRP was the first sign of HIV infection,[10] and clinical responses occurred with antiretroviral therapy.[11] Multiple associations with infections, malignancies, or autoimmune diseases have been noticed, but may occur rather fortuitously.

Figure 29-3 Erythrodermic patient (classic adult type I, as in Fig. 29-2) with psoriasiform scaling (**A**) and island of normal skin (**B**).

Figure 29-4 Palmar (**A**) and plantar (**B**) "waxy" keratoderma in pityriasis rubra pilaris.

ETIOLOGY AND PATHOGENESIS

The etiology and pathogenesis of sporadic PRP remain elusive. Pathogenic mechanisms associated with infection, such as upper respiratory tract infection and HIV infection, were proposed. In type V PRP, gain-of-function mutations in the CARD14 gene linked to autosomal dominant inheritance have been identified. CARD14 is expressed in the skin and encodes the caspase recruitment domain family member 14, a known activator of nuclear factor-κB signaling. Accordingly, CARD14 levels were increased in affected individuals with PRP, and p65 was found to be activated in the skin. CARD14 mutations also have been described in familial psoriasis.[12] A study of 48 patients with PRP type I identified 12.5% of patients as having CARD14 putative mutations.[13] A second study of 61 patients with sporadic PRP did not observe CARD14

Figure 29-5 Classic juvenile pityriasis rubra pilaris type III. **A,** Confluence of lesions leads to erythroderma. **B,** Characteristic scattered islands of unaffected skin are evident.

Figure 29-6 Circumscribed juvenile pityriasis rubra pilaris type IV. Well-demarcated hyperkeratotic erythematous plaques are found on the elbows and knees mimicking psoriasis.

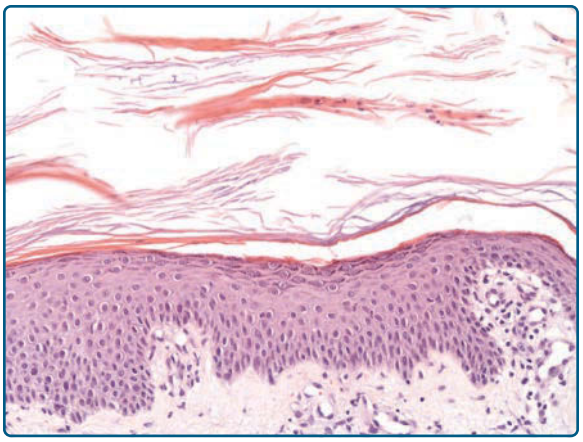

Figure 29-7 Histopathologic features of pityriasis rubra pilaris. Hyperkeratosis, alternating parakeratosis and orthokeratosis in a checkerboard pattern, with focal acantholytic dyskeratosis.

mutations.[14] Hence, CARD14 mutations may be rare in sporadic cases, and alternate mechanisms may be responsible for activation of the nuclear factor-κB signaling observed in these patients.[13]

In lesional PRP skin samples from a single patient successfully treated with the anti-IL-12/IL-23 antibody ustekinumab, upregulated expression levels were found for most proinflammatory innate cytokines, including tumor necrosis factor (TNF), IL-6, IL-12, IL-23, and IL-1β. Among adaptive T-cell cytokines, an increase of TH1 cytokines and, in particular, TH17 cytokines IL-17A, IL-17F, and IL-22 was seen.[15] Based on these findings, PRP may now be classified as a papulosquamous disease that results from abnormal activation of different inflammatory pathways. Even though PRP and psoriasis have overlapping clinical symptoms, the clinical and histopathologic features of the 2 diseases are distinct. PRP often affects the face, has the typical salmon-colored appearance, presents with classical islands of healthy skin over the trunk, distinct areas of follicular hyperkeratosis, and a waxy palmoplantar keratoderma (see Fig. 29-4). Although psoriasis-associated nail changes are missing, nail plates may be hypertrophic. The histologic picture of psoriasis with hypogranulosis, elongation of the rete ridges, vascular dilation, a high frequency of neutrophils manifesting as intraepidermal Munro microabscesses is not shared with PRP, which presents with histologic features such as alternating horizontal and vertical parakeratosis and orthokeratosis, hypergranulosis, thickening of the rete ridges, follicular hyperkeratosis, lack of neutrophilic infiltration, and limited vascular dilatation (Fig. 29-7).

Nevertheless, differentiation between PRP and psoriasis can be difficult in individual cases.

DIAGNOSIS

PRP is typically a clinical diagnosis based on the characteristic skin lesions and the age of onset. Psoriasis is an important differential diagnosis. Initial manifestations of the scalp may mimic seborrheic dermatitis. A biopsy should be taken and helps differentiating PRP from psoriasis.

DIFFERENTIAL DIAGNOSIS

Table 29-2 outlines the differential diagnosis of pityriasis rubra pilaris.

CLINICAL COURSE, PROGNOSIS MANAGEMENT

Classic adult type I PRP frequently resolves within 3 years. Reoccurrence was observed after periods of subclinical disease in up to 20% of cases. Classic juvenile type III commonly resolves within 1 to

TABLE 29-2
Differential Diagnosis of Pityriasis Rubra Pilaris

Most Likely

Localized

- Psoriasis
- Ichthyosis
- Seborrheic dermatitis of the scalp

Generalized

- Psoriasis
- Erythrokeratoderma

Consider

Localized

- Follicular eczema
- Lichen planus acuminatus
- Keratosis pilaris

Generalized

- Pityriasis lichenoides chronica
- Ichthyosiform erythroderma

Always Rule Out

- Generalized (therapy-resistant cases)
- HIV infection
- Cutaneous T-cell lymphoma

2 years. A less-favorable prognosis for remission is reported for the atypical variants types II and IV, although some cases of type IV improve in the patient's late teens. Type V PRP, which is associated with CARD14 mutations, has little or no tendency to resolve spontaneously.

PRP responds hesitantly to topical and classic systemic treatment regiments, which makes finding an effective therapy for PRP challenging. As PRP is an infrequent disease of unpredictable duration, conducting double-blind, placebo-controlled studies addressing the value of individual systemic treatment strategies are difficult. Published treatment recommendations rely on results from small case series and individual cases. From the patient's point of view, corticosteroids, and salicylic acid in combination with oral retinoids, methotrexate, and tumor necrosis factor (TNF) inhibitors were regarded as most helpful.[16] A growing number of reports demonstrate the role of biologics targeting TNF-α, interleukin (IL)-12/IL-23p40 or anti-IL-17 as a valuable second-line treatment option.

TOPICAL TREATMENT

Local treatment options for PRP regularly do not suffice to control the disease and are used as an adjunct to systemic therapy. As in psoriasis, classical keratolytic treatment is used where hyperkeratosis is the leading sign. To dampen the local inflammatory response, topical corticosteroids are often initially employed and may be followed by topical calcineurin inhibitors. Furthermore, vitamin D_3 analogs for the inhibition of various aspects of cutaneous inflammation and epidermal proliferation with enhancement of normal keratinization are successfully used for the treatment of PRP. However, percutaneous resorption of vitamin D analogs restricts treatment to no more than 30% of body surface.

SYSTEMIC TREATMENT

So far, there is no systemic therapy that works for all patients with PRP. Finding a successful therapy for the individual patient can be a challenging task. Oral retinoids generally serve as the first-line therapy in patients with PRP. They block the proliferation of keratinocytes and reduce hyperkeratosis. Acitretin and isotretinoin (1-2 mg/kg/day)[17] are effective; good responses to alitretinoin also have been reported. In a substantial proportion of patients, disease manifests at an early age. Although isotretinoin is proven to be effective in prepubertal patients, oral retinoids can induce premature closure of epiphyses or hyperostosis, and should be used with caution. Teratogenicity is another important concern in oral retinoid therapy. Teratogenicity is also a known adverse effect of methotrexate, the second most used drug for the treatment of PRP. In severe cases, methotrexate can be combined with oral retinoids.

Psoralen and ultraviolet A (PUVA) alone or in combination with oral retinoids (RE-PUVA) is another efficient treatment option. In addition, narrowband ultraviolet B (UVB) or broadband UVB can be successful. However, because PRP can be aggravated by UV light,[18-20] phototesting should be performed before initiating UV treatment.

Some authors report about beneficial effects of fumaric acid esters.[21,22] The phosphodiesterase 4-inhibitor apremilast also may be a treatment option.[23]

As an alternative treatment, anti–TNF-α, anti–IL-12/IL-23p40 (ustekinumab), and anti-IL17 have been used with good results. There are more than 30 published cases of patients with adult PRP type I successfully treated with anti-TNF.[24,25] Interestingly, ustekinumab was effective in a number of patients with PRP type I,[26-30] in a patient with a CARD14 mutation (type V),[30] but not in a patient with type IV PRP.[31] An underreporting of negative results when treatment outcomes are published as individual case reports should be considered.

In some patients with PRP, extracorporeal photopheresis has been used with success. Evidence for the use of cyclosporine, glucocorticosteroids, or azathioprine is low.

PRP associated with HIV infection has responded to triple antiretroviral therapy.[32]

Table 29-3 lists the current therapeutic options (including drug doses) for PRP used in adults and children.

TABLE 29-3
Treatment Options for Pityriasis Rubra Pilaris

First Line
Topical
▪ Emollients (water-in-oil emulsion)
▪ Keratolytics (salicylic acid, urea)
▪ Vitamin D_3 (calcipotriol)
Systemic
▪ Retinoids (0.5-0.75 mg/kg acitretin/day)
▪ Methotrexate (10-25 mg weekly or higher)
▪ Antiretroviral therapy (HIV-associated variant)
Second Line
Topical
▪ Glucocorticoids (medium to high potency)
▪ Vitamin A analogs (tazarotene)
Physical
▪ Photochemotherapy (topical or systemic PUVA)
▪ UVA1 phototherapy
▪ UVB (narrowband) phototherapy
▪ UVB phototherapy
▪ Extracorporeal photopheresis
Systemic
▪ TNF-α antagonists
▪ Anti–IL-12/IL-23p40 ustekinumab
▪ Anti-IL17
▪ Azathioprine (100-150 mg/day)
▪ Fumaric acid esters
▪ Cyclosporine (5 mg/kg/day)
▪ Apremilast

REFERENCES

1. Griffiths WA. Pityriasis rubra pilaris. *Clin Exp Dermatol.* 1980;5:105-112; Sehgal VN, Jain MK, Mathur RP. Br J Dermatol. 1989 Dec;121(6):821-822.
2. Griffiths WA. Pityriasis rubra pilaris—an historical approach. 2. Clinical features. *Clin Exp Dermatol.* 1976; 1:37-50.
3. Vasher M, Smithberger E, Lien MH, et al. Familial pityriasis rubra pilaris: report of a family and therapeutic response to etanercept. *J Drugs Dermatol.* 2010;9: 844-850.
4. Thomson MA, Moss C. Pityriasis rubra pilaris in a mother and two daughters. *Br J Dermatol.* 2007;157:202-204.
5. Sehgal VN, Srivastava G. (Juvenile) Pityriasis rubra pilaris. *Int J Dermatol.* 2006;45:438-446.
6. Fuchs-Telem D, Sarig O, van Steensel MA, et al. Familial pityriasis rubra pilaris is caused by mutations in CARD14. *Am J Hum Genet.* 2012;91:163-170.
7. Clayton BD, Jorizzo JL, Hitchcock MG, et al. Adult pityriasis rubra pilaris: a 10-year case series. *J Am Acad Dermatol.* 1997;36:959-964.
8. Caldarola G, Zampetti A, De Simone C, et al. Circumscribed pityriasis rubra pilaris type IV. *Clin Exp Dermatol.* 2007;32:471-472.
9. Miralles ES, Nunez M, De Las Heras ME, et al. Pityriasis rubra pilaris and human immunodeficiency virus infection. *Br J Dermatol.* 1995;133:990-993.
10. Sanchez-Regana M, Fuentes CG, Creus L, et al. Pityriasis rubra pilaris and HIV infection: a part of the spectrum of HIV-associated follicular syndrome. *Br J Dermatol.* 1995;133:818-819.
11. Misery I, Faure M, Claidy A. Pityriasis rubra pilaris and human immunodeficiency virus infection—type 6 pityriasis rubra pilaris? *Br J Dermatol.* 1996;135:1008-1009.
12. Jordan CT, Cao L, Roberson ED, et al. Rare and common variants in CARD14, encoding an epidermal regulator of NF-kappaB, in psoriasis. *Am J Hum Genet.* 2012;90:796-808.
13. Li Q, Jin Chung H, Ross N, et al. Analysis of CARD14 polymorphisms in pityriasis rubra pilaris: activation of NF-kappaB. *J Invest Dermatol.* 2015;135:1905-1908.
14. Eytan O, Qiaoli L, Nousbeck J, et al. Increased epidermal expression and absence of mutations in CARD14 in a series of patients with sporadic pityriasis rubra pilaris. *Br J Dermatol.* 2014;170:1196-1198.
15. Feldmeyer L, Mylonas A, Demaria O, et al. Interleukin 23-helper T cell 17 axis as a treatment target for pityriasis rubra pilaris. *JAMA Dermatol*. 2017 Apr 1;153(4): 304-308. doi: 10.1001/jamadermatol.2016.5384
16. Ross NA, Chung HJ, Li Q, et al. Epidemiologic, clinicopathologic, diagnostic, and management challenges of pityriasis rubra pilaris: a case series of 100 patients. *JAMA Dermatol.* 2016;152:670-675.
17. Borok M, Lowe NJ. Pityriasis rubra pilaris. Further observations of systemic retinoid therapy. *J Am Acad Dermatol.* 1990;22:792-795.
18. Evangelou G, Murdoch SR, Palamaras I, et al. Photoaggravated pityriasis rubra pilaris. *Photodermatol Photoimmunol Photomed.* 2005;21:272-274.
19. Iredale HE, Meggitt SJ. Photosensitive pityriasis rubra pilaris. *Clin Exp Dermatol.* 2006;31:36-38.
20. Yaniv R, Barzilai A, Trau H. Pityriasis rubra pilaris exacerbated by ultraviolet B phototherapy. *Dermatology.* 1994;189:313.
21. Klein A, Coras B, Landthaler M, et al. Off-label use of fumarate therapy for granulomatous and inflammatory skin diseases other than psoriasis vulgaris: a retrospective study. *J Eur Acad Dermatol Venereol.* 2012;26:1400-1406.
22. Coras B, Vogt TH, Ulrich H, et al. Fumaric acid esters therapy: a new treatment modality in pityriasis rubra pilaris? *Br J Dermatol.* 2005;152:388-389.
23. Krase IZ, Cavanaugh K, Curiel-Lewandrowski C. Treatment of refractory pityriasis rubra pilaris with novel phosphodiesterase 4 (PDE4) inhibitor apremilast. *JAMA Dermatol.* 2016;152:348-350.
24. Garcovich S, Di Giampetruzzi AR, Antonelli G, et al. Treatment of refractory adult-onset pityriasis rubra pilaris with TNF-alpha antagonists: a case series. *J Eur Acad Dermatol Venereol.* 2010;24:881-884.
25. Petrof G, Almaani N, Archer CB, et al. A systematic review of the literature on the treatment of pityriasis rubra pilaris type 1 with TNF-antagonists. *J Eur Acad Dermatol Venereol.* 2013;27: e131-e135.
26. Di Stefani A, Galluzzo M, Talamonti M, et al. Long-term ustekinumab treatment for refractory type I pityriasis rubra pilaris. *J Dermatol Case Rep.* 2013;7:5-9.
27. Byekova Y, Sami N. Successful response of refractory type I adult-onset pityriasis rubra pilaris with ustekinumab and acitretin combination therapy. *J Dermatol.* 2015;42:830-831.
28. Ruiz Villaverde R, Sanchez Cano D. Successful treatment of type 1 pityriasis rubra pilaris with ustekinumab therapy. *Eur J Dermatol.* 2010;20:630-631.
29. Wohlrab J, Kreft B. Treatment of pityriasis rubra pilaris with ustekinumab. *Br J Dermatol.* 2010;163:655-656.
30. Chowdhary M, Davila U, Cohen DJ. Ustekinumab as an alternative treatment option for chronic pityriasis rubra pilaris. *Case Rep Dermatol*. 2015;7:46-50.
31. Eytan O, Sarig O, Sprecher E, et al. Clinical response to ustekinumab in familial pityriasis rubra pilaris caused by a novel mutation in CARD14. *Br J Dermatol.* 2014;171:420-422.
32. Gonzalez-Lopez A, Velasco E, Pozo T, et al. HIV-associated pityriasis rubra pilaris responsive to triple antiretroviral therapy. *Br J Dermatol.* 1999;140:931-934.

Chapter 30 :: Parapsoriasis and Pityriasis Lichenoides

:: Stefan M. Schieke & Gary S. Wood

PARAPSORIASIS

AT-A-GLANCE

- Also known as parapsoriasis en plaques.
- Parapsoriasis occurs worldwide and affects mainly adults.
- Large-plaque parapsoriasis (LPP) and small-plaque parapsoriasis (SPP) are recognized.
- Large and small "plaque" lesions actually present as flat patches rather than infiltrated plaques.
- Lesions are chronic and favor non–sun-exposed skin; LPP may be poikilodermatous.
- Pathology consists of superficial, mostly $CD4^+$ T-cell infiltrate; dominant clonality is more common in LPP than in SPP.
- LPP appears to exist on a continuum with patch-stage mycosis fungoides (MF) and progresses to overt MF at a rate of approximately 10% per decade.
- SPP has minimal risk of progression to overt MF in the experience of most experts.
- Treatment options include topical corticosteroids; ultraviolet B irradiation, and psoralen and ultraviolet A irradiation; excimer laser; and topical cytotoxic drugs.

The term *parapsoriasis* was coined originally by Brocq in 1902.[1] As Table 30-1 shows, the currently accepted classification of parapsoriasis includes large- and small-plaque forms of parapsoriasis en plaques (often referred to simply as parapsoriasis) as well as acute and chronic forms of pityriasis lichenoides (known today as pityriasis lichenoides et varioliformis acuta [PLEVA] and pityriasis lichenoides chronica [PLC], respectively).[2] Pityriasis lichenoides was first described in 1894 by Neisser[3] and Jadassohn.[4] In 1899, Juliusberg delineated the chronic form and named it PLC.[5] Mucha redescribed the acute form in 1916 and distinguished it from the chronic form.[6] Habermann named the acute variant PLEVA in 1925.[7] Mucha-Habermann disease is synonymous with PLEVA. Some authors regarded lymphomatoid papulosis as a variant of pityriasis lichenoides, whereas others considered it to be a separate disease (see below). Lymphomatoid papulosis is discussed in Chap. 119 as part of the spectrum of CD30+ cutaneous lymphoproliferative disorders.

EPIDEMIOLOGY

Large-plaque parapsoriasis (LPP) and small-plaque parapsoriasis (SPP) are, in general, diseases of middle-aged and older people, with a peak incidence in the fifth decade. Occasionally, lesions arise in childhood and may be associated with pityriasis lichenoides. SPP shows a definite male predominance of approximately 3:1. LPP is probably more common in males, but the difference is not as striking as in SPP. Both occur in all racial groups and geographic regions.

CLINICAL FEATURES

CUTANEOUS FINDINGS

LPP lesions are either oval or irregularly shaped patches or very thin plaques that are asymptomatic or mildly pruritic. They are usually well marginated but may also blend imperceptibly into the surrounding skin. The size is variable, but typically most lesions are larger than 5 cm, often measuring more than 10 cm in diameter. Lesions are stable in size and may increase in number gradually. They are found mainly on the "bathing trunk" and flexural areas (Fig. 30-1). Extremities and the upper trunk, especially the breasts in women, also may be involved. They are light red-brown or salmon pink, and their surface is covered with small and scanty scales. Lesions may appear finely wrinkled—"cigarette paper" wrinkling. Such lesions exhibit varying degrees of epidermal atrophy. Telangiectasia and mottled pigmentation also are observed when the atrophy becomes prominent (Fig. 30-2). This triad of atrophy, mottled pigmentation, and telangiectasia defines the term *poikiloderma* or *poikiloderma atrophicans vasculare*, which also may be seen in other conditions (Table 30-2).

Retiform parapsoriasis refers to a rare variant of LPP that presents as an extensive eruption of scaly macules and papules in a net-like or zebra-stripe pattern that eventually becomes poikilodermatous (Fig. 30-3).

SPP, synonymously referred to as chronic superficial dermatitis, characteristically occurs as round or oval discrete patches or very thin plaques, mainly on the trunk (Fig. 30-4). The lesions measure less than 5 cm in diameter; they are asymptomatic and covered with fine, moderately adherent scales. The general health of the patient is unaffected. A distinctive variant with lesions of a finger shape, known as digitate dermatosis,[8] has

TABLE 30-1
Classification of Parapsoriasis

1. Parapsoriasis en plaques
   - A. Large-plaque parapsoriasis; variants: poikilodermatous, retiform
   - B. Small-plaque parapsoriasis; variant: digitate dermatosis
2. Pityriasis lichenoides
   - A. Pityriasis lichenoides chronica (Juliusberg)
   - B. Pityriasis lichenoides et varioliformis acuta (Mucha-Habermann)

yellowish or fawn-colored lesions (Fig. 30-5). It follows lines of cleavage of the skin and gives the appearance of a hug that left fingerprints on the trunk. The long axis of these lesions often measures greater than 5 cm. Recently, several cases of hypopigmented SPP have been described, which possibly represent a new variant of parapsoriasis.[9] Digitate lesions with a yellow hue were referred to in the past as xanthoerythrodermia perstans.[2]

COMPLICATIONS

LPP can be associated with other forms of parapsoriasis and overt cutaneous lymphomas as detailed elsewhere in this chapter. Both LPP and SPP occasionally can develop areas of impetiginization secondary to excoriation. Data from a recent Danish cohort study suggests that parapsoriasis and mycosis fungoides are associated with an increased risk for cardiovascular disease such as acute myocardial infarction and stroke, as well as increased risk for subsequent hematologic and nonhematologic malignancies and increased mortality.[10,11]

ETIOLOGY AND PATHOGENESIS

It is likely that a complete understanding of the pathogenesis of parapsoriasis will develop with our understanding of the pathogenesis of both chronic dermatitis and mycosis fungoides (MF), because parapsoriasis appears to bridge these disorders. The T cells that mediate most inflammatory skin diseases belong to the skin-associated lymphoid tissue (SALT).[12] These T cells express the cutaneous lymphocyte-associated antigen

Figure 30-1 Large-plaque parapsoriasis. Irregularly shaped patches of variable size on the arm of a 16-year-old girl.

Figure 30-2 Large-plaque parapsoriasis. Poikilodermatous variant.

and traffic between the skin and the T-cell domains of peripheral lymph nodes via the lymphatics and bloodstream. MF (see Chap. 119) is a neoplasm of SALT T cells. Sensitive polymerase chain reaction–based tumor clonality assays have underscored the SALT nature of MF tumor clones by showing that they can continue to traffic after neoplastic transformation,[13] and can even participate in delayed-type hypersensitivity reactions to contact allergens.[14] This implies that rather than being a skin lymphoma per se, MF is actually a SALT lymphoma, that is, a malignancy of a T-cell circuit rather than of one particular tissue. Trafficking of MF tumor cells has been detected even in patients with very early stage disease whose lesions were consistent clinicopathologically with LPP.[13,15] Therefore, it can be said that at least in some cases LPP is a monoclonal proliferation of SALT T cells that have the capacity to traffic between the skin and extracutaneous sites.

TABLE 30-2
Differential Diagnosis of Poikiloderma

- Large-plaque parapsoriasis
- Dermatomyositis
- Lupus erythematosus
- Chronic radiation dermatitis
- Bloom syndrome
- Rothmund-Thomson syndrome
- Dyskeratosis congenita
- Xeroderma pigmentosum

Figure 30-3 Large-plaque parapsoriasis. Retiform variant.

Figure 30-4 Small-plaque parapsoriasis. Small, discrete patches less than 5 cm in diameter.

Figure 30-5 Small-plaque parapsoriasis. Digitate dermatosis variant. Typical "fingerprint" patches on the flank. Note that their length often exceeds 5 cm.

This view is also supported by the presence of structural and numerical chromosomal abnormalities in the peripheral blood mononuclear cells of patients with LPP.[16] In this context, LPP can be regarded as the clinically benign end of the MF disease spectrum, which eventuates in transformed large cell lymphoma at its malignant extreme. To say that these diseases belong to the same disease spectrum is not to say that they are biologically equivalent disorders. To lump them all together simply as "MF" would be to ignore their distinctive clinicopathologic features, which are likely due to genetic and/or epigenetic differences, such as the *p53* gene somatic mutations observed in some cases of large-cell transformation of MF.[17] It is likely that several such differences separate these clinicopathologically defined disorders in a stepwise fashion analogous to the sequential acquisition of somatic mutations that occurs in the colon cancer disease spectrum as colonic epithelial cells progress through normal, hyperplastic, in situ carcinoma, invasive carcinoma, and metastatic carcinoma stages.

A unifying feature of the parapsoriasis group of diseases is that all of them appear to be cutaneous T-cell lymphoproliferative disorders: LPP,[12,18,19] SPP,[19] pityriasis lichenoides,[20,21] have all been shown to be monoclonal disorders in many cases. These relationships suggest that progression from LPP through the various stages of the MF disease spectrum is accompanied by an increasing gradient of dominant T-cell clonal density resulting from mutations that confer increasing growth autonomy to the neoplastic T-cell clone.[22] Interestingly, analysis of peripheral blood has demonstrated that clonal T cells are often detectable in patients with LPP/early MF[19] or SPP,[19,23] which again supports the systemic SALT nature of these "primary" skin disorders.

Dominant clonality as seen in the parapsoriasis disease group, follicular mucinosis, pagetoid reticulosis,

and certain other disorders does not equate to clinical malignancy. In fact, most patients with these diseases experience a benign clinical course, and in some cases the disease resolves completely. In addition, other types of chronic cutaneous T-cell infiltrates sometimes exhibit dominant clonality, including primary (idiopathic) erythroderma and nonspecific chronic spongiotic dermatitis. This has given rise to the concept of clonal dermatitis,[15,24] originally described in the context of clonal nonspecific chronic spongiotic dermatitis but later expanded to include other nonlymphomatous cutaneous T-cell infiltrates that harbor occult monoclonal T-cell populations. Several cases of clonal dermatitis, some of which have progressed to MF, have been identified.[15,24] We suspect that for each disease with a potential for progression to MF, the principal risk may reside in the subset showing clonal dermatitis, because this is the subset in which dysregulation has begun to occur.

Figure 30-6 depicts the postulated relationships among MF, clonal dermatitis, and selected types of chronic dermatitis. Each of the entities shown is postulated to be at risk for MF through a clonal dermatitis intermediate. In this model, MF becomes the final common pathway for the clonal evolution of neoplastic T cells emerging from the polyclonal SALT T-cell populations present in each of the various precursor diseases.

Various viruses including human herpesvirus-8 have been proposed to play a role in the pathogenesis of MF. None has been substantiated thus far.[25,26]

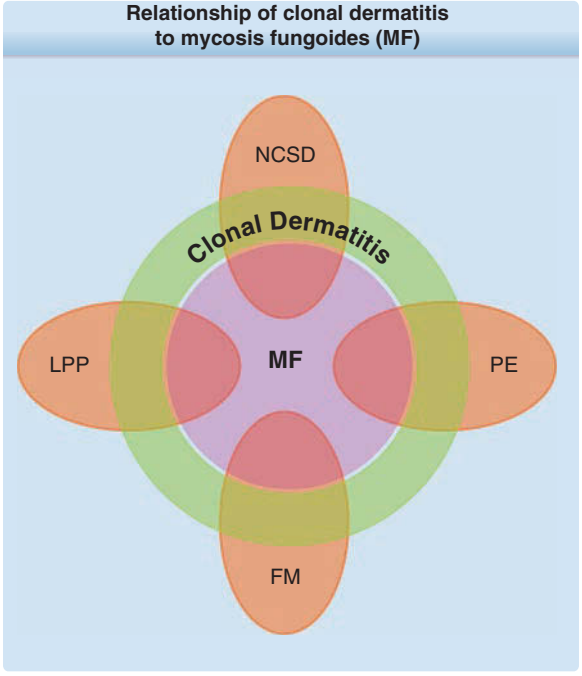

Figure 30-6 The relationship of clonal dermatitis to mycosis fungoides (MF) and various types of chronic dermatitis. The proportions of each entity that represent clonal dermatitis and MF vary with each disease and are not drawn to scale. FM, follicular mucinosis; LPP, large-plaque parapsoriasis; NCSD, nonspecific chronic spongiotic dermatitis; PE, primary erythroderma.

DIAGNOSIS

LPP is distinguished from SPP by the larger size, asymmetric distribution, and irregular shape of its lesions, which are less discrete and often poikilodermatous. LPP may be clinically and histopathologically indistinguishable from the patch stage of MF. Both LPP and SPP are readily distinguished from more advanced infiltrated plaques of MF because parapsoriasis lesions are, by definition, not thicker than patches or at most very thin plaques. This is so because the English equivalent of the French term plaques is patches, that is, lesions that are essentially flat and devoid of induration or palpable infiltration. Failure to appreciate this important distinction has led to considerable confusion and misuse of the terms LPP and SPP by some individuals. These designations more appropriately might be thought of as large-patch parapsoriasis and small-patch parapsoriasis.

The degree to which LPP is differentiated from early MF depends primarily on the histopathologic criteria used to diagnose the latter disorder. Unfortunately, there are no universally accepted minimal criteria for the diagnosis of MF; however, Table 30-3 presents one set proposed by the International Society for

TABLE 30-3
Algorithm for the Diagnosis of Patch-Stage Mycosis Fungoides (4 Points Are Required)[a]

PARAMETER	2 POINTS	1 POINT
Clinical:	Any two	Any one
Persistent, progressive patches and plaques ±		
Non–sun-exposed distribution		
Variation in size and shape		
Poikiloderma		
Histopathologic:	Both	Either
Superficial dermal T-cell infiltrate ±		
Epidermotropism		
Nuclear atypia		
Immunopathologic:	Not applicable	Any one
CD2, CD3, or CD5 <50%		
CD7 <10%		
Epidermal–dermal discordance		
Molecular biologic:	Not applicable	Present
Dominant T-cell clonality		

[a]Note: Epidermotropism implies the lack of significant spongiosis (intraepidermal lymphoid cells associated with spongiosis is termed *exocytosis* rather than *epidermotropism*). Discordance refers to differential antigen expression between the epidermis and dermis, as opposed to the biopsy specimen as a whole.

From Pimpinelli N, Olsen EA, Santucci M, et al. Defining early mycosis fungoides. *J Am Acad Dermatol.* 2005;53(6):1053-1063, with permission. Copyright © American Academy of Dermatology.

Cutaneous Lymphoma.[27] This algorithm is based on a holistic integration of clinical, histopathologic, immunopathologic, and clonality data. It differs significantly from many prior approaches because it does not rely solely on histopathologic features.[28] Assuming that histopathologic examination does not disclose features diagnostic of some other dermatosis, these criteria allow lesions to be classified as either patch-stage MF or not. For the practical purposes of clinical management, patients presenting clinically with patch lesions whose features result in a score of 4 points or more are considered to have unequivocal MF. Obviously, the more liberal the criteria, the more cases could be considered to be MF. However, there will always be some cases that fail to meet any specific set of criteria, and the designation LPP is a useful term to apply to them because it guides treatment and followup and conveys an understanding that the risk of dying from lymphoma is small.

SPP, when it presents with its distinctive digitate dermatosis lesions parallel to skin lines in a truncal distribution, stands out from other types of parapsoriasis. Individual SPP lesions may show some superficial resemblance to PLC.

Sometimes patients with MF may exhibit small patches of disease at presentation; however, these lesions typically have histopathologic features at least consistent with MF and generally are associated with larger, more classic lesions of MF elsewhere on the skin. They also may show poikilodermatous features not seen in SPP. Furthermore, the presence of well-developed, moderate to thick, small plaques, as seen in some MF patients, is incompatible with the diagnosis of SPP because the latter disorder includes only lesions that are no more than patches or very thin plaques. It is also important to recognize that partially treated or early relapsing lesions of MF may show only nonspecific features that should not be taken as evidence of a pathogenetic link to SPP or any other dermatosis.

PATHOLOGY

In early LPP lesions, the epidermis is mildly acanthotic and slightly hyperkeratotic with spotty parakeratosis. The dermal lymphocytic infiltrate tends to be perivascular and scattered (Fig. 30-7). In the more advanced lesions one observes an interface infiltrate with definite epidermotropism. These invading lymphocytes may be scattered singly or in groups, sometimes associated with mild spongiosis. In addition, the poikilodermatous lesions show atrophic epidermis, dilated blood vessels, and melanophages (Fig. 30-8). Immunohistologic studies reveal similar features in LPP and early MF, including a predominance of CD4+ T-cell subsets, frequent CD7 antigen deficiency, and widespread epidermal expression of Class II human leukocyte antigen D-related (HLA-DR).[18,29,30]

SPP exhibits mild spongiotic dermatitis with focal areas of hyperkeratosis, parakeratosis, scale crust, and exocytosis. In the dermis, there is a mild superficial perivascular lymphohistiocytic infiltrate and dermal edema (Fig. 30-9). There is no progression of the histologic features with time. Immunohistologic studies reveal a predominantly CD4+ T-cell infiltrate with nonspecific features resembling those seen in various types of dermatitides.

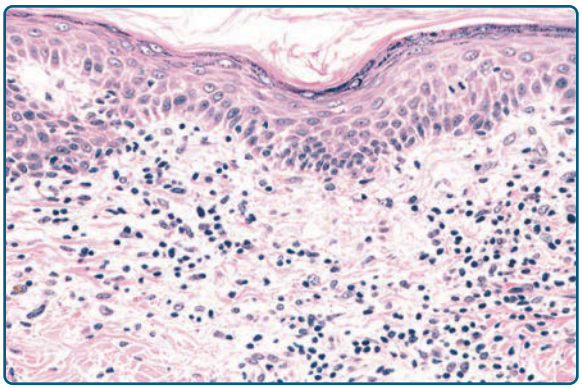

Figure 30-7 Large-plaque parapsoriasis. Mildly hyperkeratotic and focally parakeratotic epidermis with moderately dense superficial perivascular infiltrate. Lymphoid cells are mostly small, cytologically normal lymphocytes, and there is focal single-cell epidermotropism. (Used with permission from Helmut Kerl, MD.)

DIFFERENTIAL DIAGNOSIS

The clinical and/or histopathologic differential diagnosis of LPP also includes those collagen vascular diseases and genodermatoses exhibiting poikilodermatous features, lichenoid drug eruptions, secondary syphilis, chronic radiodermatitis, and occasionally several other diseases tabulated in Table 30-4. These generally can be distinguished by their associated clinical findings.

SPP is distinguished from psoriasis by the absence of the Auspitz sign (see Chap. 28), micaceous scale, nail pits, and typical psoriatic lesions involving the scalp, elbows, and knees. Histologically, its mild spongiotic dermatitis and absence of other characteristic features

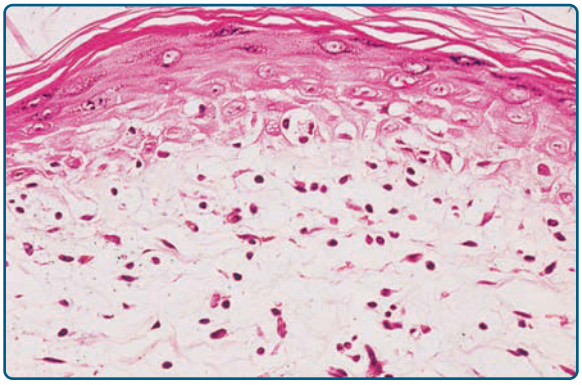

Figure 30-8 Large-plaque parapsoriasis. Atrophic variant. Sparse superficial lymphoid infiltrate with mild epidermotropism and epidermal atrophy.

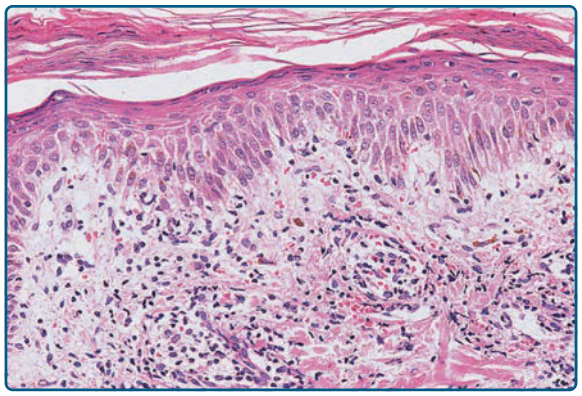

Figure 30-9 Small-plaque parapsoriasis. Superficial perivascular lymphoid infiltrate, mild spongiosis, parakeratosis, and focal scale crust.

distinguish it from PLC, psoriasis, and several of the other entities listed in Table 30-4. Clinical features are also important, such as the herald patch of pityriasis rosea and the papulovesicular coin-shaped patches favoring the lower extremities in nummular dermatitis.

TABLE 30-4
Differential Diagnosis of Large-Plaque Parapsoriasis (LPP) and Small-Plaque Parapsoriasis (SPP)

Most Likely
- LPP
  - Tinea corporis
  - Plaque-type psoriasis
  - Contact dermatitis
  - Subacute cutaneous lupus erythematosus
- SPP
  - Nummular dermatitis
  - Pityriasis rosea
  - Plaque and guttate psoriasis
  - Pigmented purpuric dermatoses
  - Pityriasis lichenoides chronica

Consider
- LPP
  - Xerotic dermatitis
  - Atopic dermatitis
  - Dermatomyositis
  - Drug eruption
  - Erythema dyschromicum perstans
  - Pigmented purpuric dermatoses
  - Early inflammatory morphea
  - Atrophoderma of Pasini–Pierini
  - Erythema annulare centrifugum
  - Pityriasis rubra pilaris
  - Genodermatoses with poikiloderma
  - Chronic radiodermatitis
- SPP
  - Tinea versicolor
  - Seborrheic dermatitis
  - Drug eruption

Always Rule Out
- LPP
  - Mycosis fungoides
  - SPP
  - Mycosis fungoides
  - Secondary syphilis

CLINICAL COURSE AND PROGNOSIS

Both LPP and SPP may persist for years to decades with little change in appearance, either clinically or histopathologically. Approximately 10% to 30% of cases of LPP progress to overt MF.[2,31,32] In this context, LPP represents the clinically benign end of the MF disease spectrum, with transformation to large cell lymphoma at the opposite extreme. The rare retiform variant is said to progress to overt MF in most cases.[2]

In contrast to LPP with its malignant potential, SPP is a clinically benign disorder in the experience of most experts. Patients with this disease as defined in this chapter rarely develop overt MF.[33] Despite this fact and what most observers consider to be its nonspecific histopathologic features, some authors favor lumping SPP within the MF disease spectrum as a very early, nonprogressive variant.[34,35] A few studies report progression from SPP to MF in approximately 10% of cases, but may have used different criteria than described in this chapter.[31-33]

MANAGEMENT

Patients with SPP should be reassured and may forego treatment. The disease may be treated with emollients, topical tar preparations, topical corticosteroids, and/or broadband or narrowband ultraviolet B (UVB) phototherapy (Table 30-5).[36] Response to therapy is variable. Patients should initially be examined every 3 to 6 months and subsequently every year to ensure that

TABLE 30-5
Treatment of Large-Plaque Parapsoriasis and Small-Plaque Parapsoriasis

First Line
- Emollients
- Topical corticosteroids
- Topical tar products
- Sunbathing
- Broadband UVB phototherapy
- Narrowband UVB phototherapy
- Low-dose ultraviolet A1 (UVA1) phototherapy

Second Line

(Mainly for large-plaque parapsoriasis cases considered to be early mycosis fungoides)
- Topical bexarotene
- Topical imiquimod
- Psoralen and UVA phototherapy
- Topical mechlorethamine
- Topical carmustine (BCNU)
- Excimer laser (308 nm)

the character of the process is stable. LPP requires more aggressive therapy: high-potency topical corticosteroids with phototherapy such as broadband UVB, narrowband UVB, low-dose ultraviolet A (UVA)1,[36] or psoralen and UVA (PUVA). The goal of treatment is to suppress the disorder to prevent possible progression to overt MF. Other methods of treatment, such as topical nitrogen mustard, have been used successfully.[37] Localized lesions may respond to excimer laser (308 nm).[38] The patient should be examined carefully every 3 months initially and every 6 months to 1 year subsequently for evidence of progression. Repeated multiple biopsies of suspicious lesions should be performed. Cases that satisfy the clinicopathologic criteria for early MF can be treated with broadband UVB, narrowband UVB, PUVA, topical nitrogen mustard, topical bexarotene gel, topical imiquimod, or topical carmustine (BCNU). Electron-beam radiation therapy generally is reserved for more advanced, infiltrated lesions of MF.

PITYRIASIS LICHENOIDES

AT-A-GLANCE

- PLEVA and PLC represent opposite ends of a disease spectrum; both entities and intermediate forms can coexist.
- All forms are characterized by spontaneously resolving, temporally overlapping crops of papules.
- PLEVA papules last for weeks and may develop crusts, vesicles, pustules, or ulcers.
- PLC papules persist for months and develop scales.
- All forms contain interface, cytotoxic T-cell infiltrates with variable epidermal destruction.
- In PLEVA, CD8+ cells predominate.
- In PLC, CD8+ or CD4+ cells predominate.
- Dominant T-cell clonality can be detected in all forms, more often in PLEVA than in PLC.
- Treatment depends on severity and ranges from topical steroids, systemic antibiotics, UV irradiation, and psoralen and UVA to systemic immunosuppressants.

EPIDEMIOLOGY

Pityriasis lichenoides affects all racial and ethnic groups in all geographic regions.[39,40] It is more common in children and young adults but can affect all ages with seasonal variation in onset favoring fall and winter. There is a male predominance of 1.5:1 to 3:1. PLC is 3 to 6 times more common than PLEVA.

CLINICAL FEATURES

CUTANEOUS FINDINGS

PLC and PLEVA exist on a clinicopathologic continuum.[2,28] Therefore, individual patients may exhibit a mixture of acute and chronic lesions sequentially or concurrently. In addition, lesions representing clinical or histopathologic intergrades between the extremes may also occur at any time.

Lesions are often asymptomatic but can be pruritic or burning, especially in the more acute cases. PLC typically presents as recurrent crops of erythematous scaly papules that spontaneously regress over several weeks to months (Fig. 30-10). PLEVA manifests as recurrent crops of erythematous papules that develop crusts, vesicles, pustules, or erosions before spontaneously regressing within a matter of weeks (Fig. 30-11). The more severe ulcerative variant is known as pityriasis lichenoides with ulceronecrosis and hyperthermia (PLUH) or febrile ulceronecrotic Mucha–Habermann disease (FUMHD). It presents as purpuric papulonodules with central ulcers up to a few centimeters in diameter (Fig. 30-12). Some researchers have proposed that this severe variant is actually an overt T-cell lymphoma.[31] Pityriasis lichenoides lesions tend to concentrate on the trunk and proximal extremities, but any region of the skin, even mucous membranes,

Figure 30-10 Pityriasis lichenoides chronica. Polymorphous appearance ranging from early erythematous papules to scaling brown-red lesions and tan-brown involuting, flat papules, and macules.

Figure 30-11 Pityriasis lichenoides et varioliformis acuta. **A,** Adolescent with multiple erythematous papules and crusted lesions in various stages of evolution. **B,** Larger papulovesicular and hemorrhagic, crusted lesions in an adult. Note varioliform scars adjacent to active lesions on posterior thigh and leg. **C,** Pustules, crusts, and necrotic-centered papules with erythematous, indurated base.

Figure 30-12 Pityriasis lichenoides, ulceronecrotic, hyperacute variant. Large necrotic eschar with halo erythema developing in febrile patient with antecedent pityriasis lichenoides et varioliformis acuta.

can be involved. Rare regional or segmental lesion distributions have been described,[41] as has rare conjunctival nodular inflammation.[42] Although there are usually numerous coexistent lesions, occasionally only a small number of lesions will be present at any one time. All forms of pityriasis lichenoides can result in postinflammatory hypopigmentation or hyperpigmentation. Chronic lesions can resolve with postinflammatory hypopigmentation, sometimes presenting as idiopathic guttate hypomelanosis. Chronic lesions rarely lead to scars. In contrast, acute lesions result in deeper dermal injury and consequently often resolve leaving varioliform (smallpox-like) scars. The presence of lesions in various stages of evolution imparts a polymorphous appearance that is characteristic of pityriasis lichenoides.

COMPLICATIONS

Secondary infection is the most common complication of pityriasis lichenoides. PLEVA may be associated with low-grade fever, malaise, headache, and arthralgia. Patients with PLUH or FUMHD can develop high fever, malaise, myalgia, arthralgia, gastrointestinal, and central nervous system symptoms which can occasionally be fatal.[43] PLC is associated uncommonly with LPP in children.[44] Despite their sometimes dominant T-cell clonal nature, PLC and PLEVA are largely considered clinically benign disorders without significant linkage to lymphomas or other malignancies, although very rare cases of progression to MF have been described.[33]

ETIOLOGY AND PATHOGENESIS

The etiology of pityriasis lichenoides is unknown. Several cases have been associated with infectious agents such as *Toxoplasma gondii*,[45] Epstein-Barr virus,[46]

cytomegalovirus,[46] varicella-zoster virus,[47] parvovirus B19,[46,48] human herpesvirus-8,[49] and HIV.[50] At least 1 case was linked with each of the following: estrogen–progesterone therapy, chemotherapy drugs, radiocontrast iodide, and influenza vaccine.[51-54] Recently, 3 cases linked to β-hydroxy-β-methylglutaryl-coenzyme A (HMG-CoA) reductase inhibitors have been described with 1 case suggestive of recurrent cutaneous eruptions upon reexposure.[55] It is uncertain whether these agents are actively involved in disease pathogenesis or merely coincidental bystanders; however, several cases associated with toxoplasmosis have cleared fairly quickly in response to specific therapy.[45] A 10-fold higher level of maternal keratinocytes have been reported in the epidermis of children with pityriasis lichenoides compared to controls.[56]

Immunohistologic studies show a reduction in CD1a+ antigen-presenting dendritic (Langerhans) cells within the central epidermis of pityriasis lichenoides lesions.[57] Keratinocytes and endothelial cells are HLA-DR+, which suggests activation by T-cell cytokines.[57] CD8+ T cells expressing the cytotoxic proteins (TIA-1) and granzyme B predominate in PLEVA, whereas CD4+ T cells predominate in PLC. Some of the T cells in PLC express FoxP3 suggestive of a regulatory T-cell phenotype.[49] Dominant T-cell clonality has been demonstrated in about half of PLEVA cases and a minority of PLC cases.[20,57,58] In aggregate, these findings raise the possibility that pityriasis lichenoides is a variably clonal cytotoxic memory T-cell lymphoproliferative response to one or more foreign antigens. Deposition of immunoglobulin M, C3, and fibrin in and around blood vessels and along the dermal–epidermal junction in early acute lesions suggests a possible concomitant humoral immune response, although this could be a secondary phenomenon.

The relationship of pityriasis lichenoides to lymphomatoid papulosis remains controversial because of overlapping clinical, histopathologic, and molecular features.[28,57,59,60] Common features include dominant T-cell clonality and spontaneous resolution of papular, predominantly lymphoid lesions. Furthermore, individual lesions with the clinicopathologic characteristics of either pityriasis lichenoides or lymphomatoid papulosis can coexist in the same patient, either concurrently or serially. It remains to be determined whether this can be explained as an artifact of sampling lymphomatoid papulosis lesions at various stages of their evolution. The presence of large CD30+ atypical lymphoid cells is the hallmark of lymphomatoid papulosis (at least types A and C). Furthermore, these cells are typically CD4+ and often lack 1 or more mature T-cell antigens, such as CD2, CD3, and CD5. These features serve to distinguish lymphomatoid papulosis from pityriasis lichenoides. Although occasional CD30+ cells can be seen in a wide variety of dermatoses, the presence of any appreciable number should favor lymphomatoid papulosis over pityriasis lichenoides as a matter of definition. It may be that the "PLC-PLEVA" and "lymphomatoid papulosis–CD30+ anaplastic large cell lymphoma" disease spectra are intersecting rather than overlapping entities; that is, although pityriasis lichenoides is a distinct cutaneous T-cell disorder, it is possible that it may sometimes serve as fertile soil for the development of the CD30+ T-cell clone characteristic of lymphomatoid papulosis.

DIAGNOSIS

Miscellaneous nonspecific abnormalities in blood test results occur but are of little practical value. Leukocytosis and a decreased CD4-to-CD8 ratio can occur.

PATHOLOGY

As with the morphology of the clinical lesions, pityriasis lichenoides can exhibit a range of histopathologic features encompassing acute, chronic, and intermediate lesional variants (Figs. 30-13 and 30-14). All cases of pityriasis lichenoides contain an interface dermatitis

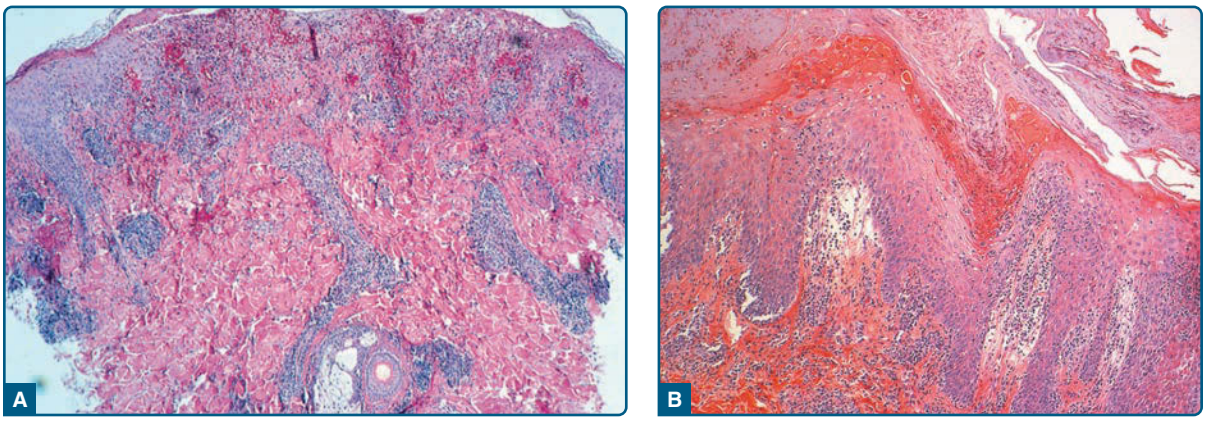

Figure 30-13 Pityriasis lichenoides et varioliformis acuta. **A,** Ulcerated papule with epidermal necrosis, hemorrhage, and superficial and deep perivascular lymphocytic infiltrate. Hematoxylin and eosin (H&E) stain. **B,** Parakeratosis and crust with marked spongiosis and epidermal necrosis. Lymphocyte exocytosis and basal hydropic changes. H&E stain.

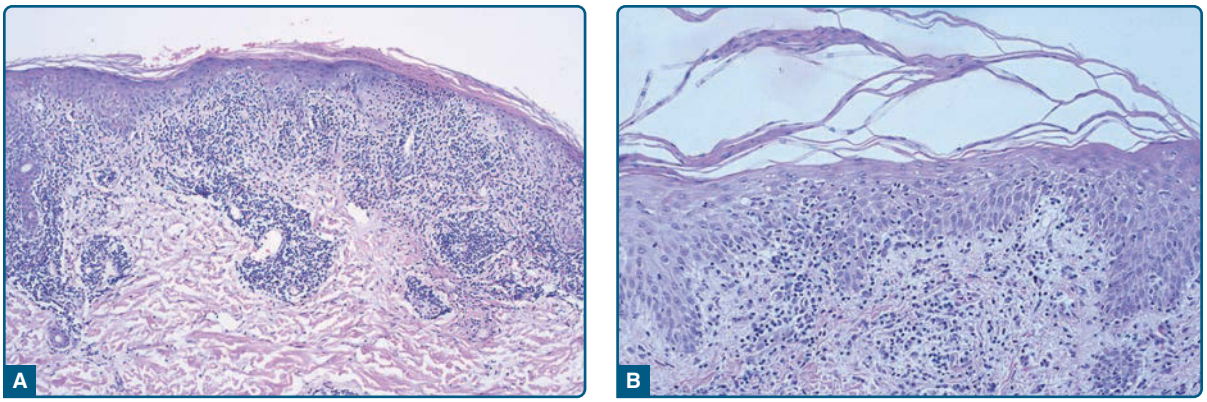

Figure 30-14 Pityriasis lichenoides] chronica. **A,** Compact parakeratosis, lymphocytic exocytosis, occasional eosinophilic necrotic keratinocytes, edema, and diffuse lymphocytic infiltrate localizing to epidermal–dermal interface and perivascular sites within the dermis. Hematoxylin and eosin (H&E) stain. **B,** Parakeratosis, spongiosis, and a predominant mononuclear cell infiltrate in the epidermis and dermis with papillary edema. H&E stain.

that is denser and more wedge shaped in the acute lesions. The infiltrate is composed mainly of lymphocytes with a variable admixture of neutrophils and histiocytes. There is exocytosis, parakeratosis, and extravasation of erythrocytes. Epidermal damage ranges from intercellular and extracellular edema in less severe cases to extensive keratinocyte necrosis, vesicles, pustules, and ulcers. The acute variants can exhibit lymphocytic vasculitis with fibrinoid degeneration of blood vessel walls.

Occasional CD30+ lymphoid cells and occasional atypical lymphoid cells may be seen as a nonspecific finding in many cutaneous lymphoid infiltrates. The presence of appreciable numbers of these cells is not consistent with classic pityriasis lichenoides and should raise concern for the lymphomatoid papulosis–CD30+ anaplastic large cell lymphoma disease spectrum. However, a recently described CD30+ variant of PLEVA illustrates the potential diagnostic confusion of some cases of pityriasis lichenoides with lymphomatoid papulosis and once more highlights the potential pathogenetic overlap between the two entities.[61] Other immunohistologic features and the clonality of pityriasis lichenoides are discussed above in "Etiology and Pathogenesis" under "Pityriasis Lichenoides."

DIFFERENTIAL DIAGNOSIS

The differential diagnosis of pityriasis lichenoides includes many papular eruptions (Table 30-6). Those that develop crusts, vesicles, pustules, or ulcers are grouped with PLEVA, whereas those that form predominantly scaly papules are grouped with PLC. Most of them can be excluded based on history and typical clinicopathologic features. A few, such as secondary syphilis and virus-associated lesions, can also be excluded based on serologic tests. Among the most challenging diseases to distinguish from pityriasis lichenoides are lymphomatoid papulosis and macular or papular variants of MF.[60] As detailed earlier, the presence of large atypical lymphoid cells (often CD30+) usually differentiates lymphomatoid papulosis from pityriasis lichenoides. Macular or papular variants of MF are rare. They exhibit classic histopathologic features of MF, including small atypical epidermotropic lymphoid cells with convoluted nuclei and a band-like superficial dermal lymphoid infiltrate.

TABLE 30-6

Differential Diagnosis of Pityriasis Lichenoides et Varioliformis Acuta (PLEVA) and Pityriasis Lichenoides Chronica (PLC)

Most Likely
- PLEVA
  - Arthropod bites, stings, infestations
  - Leukocytoclastic vasculitis
  - Viral exanthem (eg, varicella-zoster, herpes simplex)
- PLC
  - Pityriasis rosea
  - Drug eruption
  - Guttate psoriasis

Consider
- PLEVA
  - Folliculitis
  - Rickettsiosis
  - Erythema multiforme
  - Dermatitis herpetiformis
- PLC
  - Spongiotic dermatitis, papular variant
  - Small-plaque parapsoriasis
  - Lichen planus
  - Gianotti-Crosti syndrome

Always Rule Out
- PLEVA
  - Lymphomatoid papulosis
  - Secondary syphilis
- PLC
  - Lymphomatoid papulosis
  - Mycosis fungoides (papular variant)
  - Secondary syphilis

CLINICAL COURSE AND PROGNOSIS

Pityriasis lichenoides has a variable clinical course characterized by recurrent crops of lesions that spontaneously resolve. The disorder may resolve spontaneously within a few months or, less commonly, persist for years. PLEVA usually has a shorter duration than PLC. Although the conclusion was not confirmed by subsequent investigation, one report suggested that the duration of pityriasis lichenoides in children correlated better with its clinical distribution than with the relative abundance of acute and chronic lesions, which often coexisted.[62] From longest to shortest duration, the distribution of lesions ranged from peripheral (distal extremities) to central (trunk) to diffuse.

MANAGEMENT

The mainstay of traditional therapy has been a combination of topical corticosteroids and phototherapy (Table 30-7). Systemic antibiotics, such as tetracyclines, erythromycin, and azithromycin, are used primarily for their antiinflammatory rather than antibiotic effects.[63,64] Cases with minimal disease activity may not require any treatment. Photodynamic therapy has been used successfully for PLC.[65] The more acute the clinical course and the more severe the individual lesions, the more systemic therapy is indicated. Methotrexate is often effective in relatively low doses. Calcineurin inhibitors and retinoids may also be beneficial. Severe cases of PLEVA and PLUH often require systemic corticosteroids or similar drugs to gain control of systemic symptoms. Topical and systemic antibiotics may be needed to treat secondary infections complicating ulcerated skin lesions. These agents are often selected initially to cover Gram-positive pathogens, but subsequent use should be guided by culture results. Bromelain, a pineapple extract, cleared PLC lesions in 8 of 8 cases.[66]

TABLE 30-7

Treatment of Pityriasis Lichenoides et Varioliformis Acuta and Pityriasis Lichenoides Chronica

First Line

- Topical corticosteroids
- Antibiotics (erythromycin 500 mg PO 2-4 × daily[64]; tetracycline 500 mg PO 2-4 × daily,[66] minocycline 100 mg PO twice daily; azithromycin 500 mg PO on day 1 and 250 mg PO on days 2-5 bimonthly[65])
- Phototherapy (sunbathing, UVB, UVA + UVB, narrowband UVB[68,69])

Second Line

- Topical tacrolimus[70]
- Prednisone (60/40/20 mg PO taper, 5 days each)[71]
- Methotrexate (10-25 mg PO weekly)[72]
- Phototherapy (UVA1[73], psoralen + UVA[69])
- Cyclosporine (2.5-4 mg/kg/day total dose divided into twice-daily PO doses; use the minimum)[74]
- Retinoids (eg, acitretin 25-50 mg PO daily)
- Photodynamic therapy[66]
- Bromelain (pineapple extract)[67]

REFERENCES

1. Brocq L. *Les Parapsoriasis, par L. Brocq*. Paris, France: Masson; 1902.
2. Lambert WC, Everett MA. The nosology of parapsoriasis. *J Am Acad Dermatol*. 1981;5(4):373-395.
3. Neisser A. Zur Frage der lichenoiden Eruptionen. *Verh Dtsch Dermatol Ges*. 1894;4:495.
4. Jadassohn J. Uber ein eigenartiges psoriasiformes und lichenoides Exanthem. *Verh Dtsch Dermatol Ges*. 1894;4:524.
5. Juliusberg F. Uber die Pityriasis lichenoides chronica (psoriasiform lichenoides exanthem). *Arch Dermatol Syph*. 1899;50:359.
6. Mucha V. Uber einen der Parakeratosis variegata (Unna) bzw, Pityriasis lichenoides chronica nahestehenden eigentumlichen Fall. *Arch Dermatol Syph*. 1916;123:586.
7. Habermann R. Uber die akut verlaufende, nekrotisierende Unterart der Pityriasis lichenoides (Pityriasis lichenoides et varioliformis acuta). *Dermatol Ztschr*. 1925;45:42.
8. Hu CH, Winkelmann RK. Digitate dermatosis. A new look at symmetrical, small plaque parapsoriasis. *Arch Dermatol*. 1973;107(1):65-69.
9. El-Darouti MA, Fawzy MM, Hegazy RA, et al. Hypopigmented parapsoriasis en plaque, a new, overlooked member of the parapsoriasis family: a report of 34 patients and a 7-year experience. *J Am Acad Dermatol*. 2012;67(6):1182-1188.
10. Lindahl LM, Heide-Jørgensen U, Pedersen L, et al. Risk of acute myocardial infarction or stroke in patients with mycosis fungoides and parapsoriasis. *Acta Derm Venereol*. 2016;96(4):530-534.
11. Lindahl LM, Fenger-Grøn M, Iversen L. Subsequent cancers, mortality, and causes of death in patients with mycosis fungoides and parapsoriasis: a Danish nationwide, population-based cohort study. *J Am Acad Dermatol*. 2014;71(3):529-535.
12. Bos J, ed. *Skin Immune System*. Boca Raton, FL: CRC Press; 1990.
13. Veelken H, Wood GS, Sklar J. Molecular staging of cutaneous T-cell lymphoma: evidence for systemic involvement in early disease. *J Invest Dermatol*. 1995;104(6):889-894.
14. Veelken H, Sklar JL, Wood GS. Detection of low-level tumor cells in allergic contact dermatitis induced by mechlorethamine in patients with mycosis fungoides. *J Invest Dermatol*. 1996;106(4):685-688.
15. Wood GS. Analysis of clonality in cutaneous T cell lymphoma and associated diseases. *Ann N Y Acad Sci*. 2001;941:26-30.
16. Karenko L, Hyytinen E, Sarna S, et al. Chromosomal abnormalities in cutaneous T-cell lymphoma and in its premalignant conditions as detected by G-banding and interphase cytogenetic methods. *J Invest Dermatol*. 1997;108(1):22-29.
17. Li G, Chooback L, Wolfe JT, et al. Overexpression of p53 protein in cutaneous T cell lymphoma: relationship to large cell transformation and disease progression. *J Invest Dermatol*. 1998;110(5):767-770.

18. Kikuchi A, Naka W, Harada T, et al. Parapsoriasis en plaques: its potential for progression to malignant lymphoma. *J Am Acad Dermatol.* 1993;29(3):419-422.
19. Klemke CD, Dippel E, Dembinski A, et al. Clonal T cell receptor gamma-chain gene rearrangement by PCR-based GeneScan analysis in the skin and blood of patients with parapsoriasis and early-stage mycosis fungoides. *J Pathol.* 2002;197(3):348-354.
20. Shieh S, Mikkola DL, Wood GS. Differentiation and clonality of lesional lymphocytes in pityriasis lichenoides chronica. *Arch Dermatol.* 2001;137(3):305-308.
21. Dereure O, Levi E, Kadin ME. T-Cell clonality in pityriasis lichenoides et varioliformis acuta: a heteroduplex analysis of 20 cases. *Arch Dermatol.* 2000;136(12):1483-1486.
22. Wood GS. Lymphocyte activation in cutaneous T-cell lymphoma. *J Invest Dermatol.* 1995;105(suppl 1): 105S-109S.
23. Muche JM, Lukowsky A, Heim J, et al. Demonstration of frequent occurrence of clonal T cells in the peripheral blood but not in the skin of patients with small plaque parapsoriasis. *Blood.* 1999;94(4):1409-1417.
24. Siddiqui J HD, Misra M, Wood GS. Clonal dermatitis: a potential precursor of CTCL with varied clinical manifestations. *J Invest Dermatol.* 1997;108:584.
25. Amitay-Laish I, Sarid R, Ben-Amitai D, et al. Human herpesvirus 8 is not detectable in lesions of large plaque parapsoriasis, and in early-stage sporadic, familial, and juvenile cases of mycosis fungoides. *J Am Acad Dermatol.* 2012;66(1):46-50.
26. Kreuter A, Bischoff S, Skrygan M, et al. High association of human herpesvirus 8 in large-plaque parapsoriasis and mycosis fungoides. *Arch Dermatol.* 2008;144(8): 1011-1016.
27. Pimpinelli N, Olsen EA, Santucci M, et al. Defining early mycosis fungoides. *J Am Acad Dermatol.* 2005;53(6):1053-1063.
28. Wood G. *The Benign and Malignant Cutaneous Lymphoproliferative Disorders Including Mycosis Fungoides.* Baltimore, MD: Williams and Wilkins; 2001.
29. Wood GS, Michie SA, Durden F, et al. Expression of class II major histocompatibility antigens by keratinocytes in cutaneous T cell lymphoma. *Int J Dermatol.* 1994;33(5):346-350.
30. Lindae ML AE, Hoppe RT, Wood GS. Poikilodermatous mycosis fungoides and atrophic large plaque parapsoriasis exhibit similar abnormalities of T cell antigen expression. *Arch Dermatol.* 1988;124:366-372.
31. Vakeva L, Sarna S, Vaalasti A, et al. A retrospective study of the probability of the evolution of parapsoriasis en plaques into mycosis fungoides. *Acta Derm Venereol.* 2005;85(4):318-323.
32. Bernier C, Nguyen JM, Quéreux G, et al: CD13 and TCR clone: markers of early mycosis fungoides. *Acta Derm Venereol.* 2007;87(2):155-159.
33. Sibbald C, Pope E. Systematic review of cases of cutaneous T-cell lymphoma transformation in pityriasis lichenoides and small plaque parapsoriasis. *Br J Dermatol.* 2016;175(4):807-809.
34. King-Ismael D, Ackerman AB. Guttate parapsoriasis/digitate dermatosis (small plaque parapsoriasis) is mycosis fungoides. *Am J Dermatopathol.* 1992;14(6):518-530, discussion 531-515.
35. Burg G, Dummer R. Small plaque (digitate) parapsoriasis is an "abortive cutaneous T-cell lymphoma" and is not mycosis fungoides. *Arch Dermatol.* 1995;131(3):336-338.
36. Aydogan K, Yazici S, Balaban Adim S, et al. Efficacy of low-dose ultraviolet A-1 phototherapy for parapsoriasis/early-stage mycosis fungoides. *Photochem Photobiol.* 2014;90(4):873-877.
37. Lindahl LM, Fenger-Gron M, Iversen L. Topical nitrogen mustard therapy in patients with mycosis fungoides or parapsoriasis. *J Eur Acad Dermatol Venereol.* 2013;27(2):163-168.
38. Gebert S, Raulin C, Ockenfels HM, et al. Excimer-laser (308 nm) treatment of large plaque parapsoriasis and long-term follow-up. *Eur J Dermatol.* 2006;16(2):198-199.
39. Wahie S, Hiscutt E, Natarajan S, et al. Pityriasis lichenoides: the differences between children and adults. *Br J Dermatol.* 2007;157(5):941-945.
40. Bowers S, Warshaw EM. Pityriasis lichenoides and its subtypes. *J Am Acad Dermatol.* 2006;55(4):557-572, quiz 573-556.
41. Cliff S, Cook MG, Ostlere LS, et al. Segmental pityriasis lichenoides chronica. *Clin Exp Dermatol.* 1996;21(6):464-465.
42. Verhamme T, Arnaout A, Ayliffe WH. Limbal and bulbar inflammatory nodules in a patient with pityriasis lichenoides et varioliformis acuta. *Bull Soc Belge Ophtalmol.* 2008; (307):13-18.
43. Cozzio A, Hafner J, Kempf W, et al. Febrile ulceronecrotic Mucha-Habermann disease with clonality: a cutaneous T-cell lymphoma entity? *J Am Acad Dermatol.* 2004;51(6):1014-1017.
44. Samman PD. The natural history of parapsoriasis en plaques (chronic superficial dermatitis) and prereticulotic poikiloderma. *Br J Dermatol.* 1972;87(5):405-411.
45. Nassef NE, Hammam MA. The relation between toxoplasmosis and pityriasis lichenoides chronica. *J Egypt Soc Parasitol.* 1997;27(1):93-99.
46. Chuh AA. The association of pityriasis rosea with cytomegalovirus, Epstein-Barr virus and parvovirus B19 infections—a prospective case control study by polymerase chain reaction and serology. *Eur J Dermatol.* 2003;13(1):25-28.
47. Cho E, Jun HJ, Cho SH, et al. Varicella-zoster virus as a possible cause of pityriasis lichenoides et varioliformis acuta. *Pediatr Dermatol.* 2014;31(2):259-260.
48. Nanda A, Alshalfan F, Al-Otaibi M, et al. Febrile ulceronecrotic Mucha-Habermann disease (pityriasis lichenoides et varioliformis acuta fulminans) associated with parvovirus infection. *Am J Dermatopathol.* 2013;35(4): 503-506.
49. Kim JE, Yun WJ, Mun SK, et al. Pityriasis lichenoides et varioliformis acuta and pityriasis lichenoides chronica: comparison of lesional T-cell subsets and investigation of viral associations. *J Cutan Pathol.* 2011;38(8):649-656.
50. Griffiths JK. Successful long-term use of cyclosporin A in HIV-induced pityriasis lichenoides chronica. *J Acquir Immune Defic Syndr Hum Retrovirol.* 1998;18(4):396-397.
51. Wood GS, Strickler JG, Abel EA, et al. The immunohistology of pityriasis lichenoides et varioliformis acuta and pityriasis lichenoides chronica: evidence for their interrelationship with lymphomatoid papulosis. *J Am Acad Dermatol.* 1987;16:559-570.
52. Jowkar F, Namazi MR, Bahmani M, et al. Triggering of pityriasis lichenoides et varioliformis acuta by radiocontrast iodide. *J Dermatolog Treat.* 2008;19(4):249-250.
53. Kawamura K, Tsuji T, Kuwabara Y. Mucha-Habermann disease-like eruptions due to Tegafur. *J Dermatol.* 1999;26(3):164-167.
54. Castro BA, Pereira JM, Meyer RL, et al. Pityriasis lichenoides et varioliformis acuta after influenza vaccine. *An Bras Dermatol.* 2015;90(3)(suppl 1):181-184.

55. Massay RJ, Maynard AA. Pityriasis lichenoides chronica associated with use of HMG-CoA reductase inhibitors. *West Indian Med J*. 2012;61(7):743-745.
56. Khosrotehrani K, Guegan S, Fraitag S, et al. Presence of chimeric maternally derived keratinocytes in cutaneous inflammatory diseases of children: the example of pityriasis lichenoides. *J Invest Dermatol*. 2006;126(2):345-348.
57. Magro C, Crowson AN, Kovatich A, et al. Pityriasis lichenoides: a clonal T-cell lymphoproliferative disorder. *Hum Pathol*. 2002;33(8):788-795.
58. Weiss LM, Wood GS, Ellisen LW, et al. Clonal T-cell populations in pityriasis lichenoides et varioliformis acuta (Mucha-Habermann disease). *Am J Pathol*. 1987;126(3):417-421.
59. Vonderheid EC, Kadin ME, Gocke CD. Lymphomatoid papulosis followed by pityriasis lichenoides: a common pathogenesis? *Am J Dermatopathol*. 2011;33(8):835-840.
60. Vonderheid EC, Kadin ME, Telang GH. Commentary about papular mycosis fungoides, lymphomatoid papulosis and lymphomatoid pityriasis lichenoides: more similarities than differences. *J Cutan Pathol*. 2016;43(4):303-312.
61. Kempf W, Kazakov DV, Palmedo G, et al. Pityriasis lichenoides et varioliformis acuta with numerous CD30(+) cells: a variant mimicking lymphomatoid papulosis and other cutaneous lymphomas. A clinicopathologic, immunohistochemical, and molecular biological study of 13 cases. *Am J Surg Pathol*. 2012;36(7):1021-1029.
62. Rongioletti F, Rivara G, Rebora A. Pityriasis lichenoides et varioliformis acuta and acquired toxoplasmosis. *Dermatologica*. 1987;175(1):41-44.
63. Piamphongsant T. Tetracycline for the treatment of pityriasis lichenoides. *Br J Dermatol*. 1974;91(3):319-322.
64. Hapa A, Ersoy-Evans S, Karaduman A. Childhood pityriasis lichenoides and oral erythromycin. *Pediatr Dermatol*. 2012;29(6):719-724.
65. Skinner RB, Levy AL. Rapid resolution of pityriasis lichenoides et varioliformis acuta with azithromycin. *J Am Acad Dermatol*. 2008;58(3):524-525.
66. Fernandez-Guarino M, Harto A, Reguero-Callejas ME, et al. Pityriasis lichenoides chronica: good response to photodynamic therapy. *Br J Dermatol*. 2008;158(1):198-200.
67. Massimiliano R, Pietro R, Paolo S, et al. Role of bromelain in the treatment of patients with pityriasis lichenoides chronica. *J Dermatolog Treat*. 2007;18(4):219-222.
68. Brazzelli V, Carugno A, Rivetti N, et al. Narrowband UVB phototherapy for pediatric generalized pityriasis lichenoides. *Photodermatol Photoimmunol Photomed*. 2013;29(6):330-333.
69. Farnaghi F, Seirafi H, Ehsani AH, et al. Comparison of the therapeutic effects of narrow band UVB vs. PUVA in patients with pityriasis lichenoides. *J Eur Acad Dermatol Venereol*. 2011;25(8):913-916.
70. Simon D, Boudny C, Nievergelt H, et al. Successful treatment of pityriasis lichenoides with topical tacrolimus. *Br J Dermatol*. 2004;150(5):1033-1035.
71. Maekawa Y, Nakamura T, Nogami R. Febrile ulceronecrotic Mucha-Habermann's disease. *J Dermatol*. 1994;21(1):46-49.
72. Griffith-Bauer K, Leitenberger SL, Krol A. Febrile ulceronecrotic Mucha-Habermann disease: two cases with excellent response to methotrexate. *Pediatr Dermatol*. 2015;32(6):e307-e308.
73. Pinton PC, Capezzera R, Zane C, et al. Medium-dose ultraviolet A1 therapy for pityriasis lichenoides et varioliformis acuta and pityriasis lichenoides chronica. *J Am Acad Dermatol*. 2002;47(3):410-414.
74. Uzoma MA, Wilkerson MG, Carr VL, et al. Pentoxifylline and cyclosporine in the treatment of febrile ulceronecrotic Mucha-Habermann disease. *Pediatr Dermatol*. 2014;31(4):525-527.

Chapter 31 :: Pityriasis Rosea

:: Matthew Clark & Johann E. Gudjonsson

AT-A-GLANCE

- Common self-limited papulosquamous eruption typically lasting 5 to 8 weeks.
- Occurs worldwide in all races and age groups, with peak incidence between the ages of 10 and 35 years.
- Classically begins as an isolated 3- to 5-cm oval plaque on the trunk with a collarette of fine scale just inside the periphery, which plaque is called a *herald patch*.
- This is followed by a secondary eruption of similar appearing but smaller lesions on the trunk and proximal extremities, usually with their long axis along the lines of cleavage.
- Many atypical variants exist in contrast to the pattern described above.
- Pityriasis rosea can have associated systemic symptoms and pruritus, but many cases are asymptomatic.
- Etiology is unknown, but it is thought to be a viral exanthem most likely related to infection or reactivation of human herpesvirus (HHV)-6 and/or HHV-7.
- Usually only supportive treatment and reassurance is needed, but for severe cases acyclovir may hasten recovery and lessen symptoms.

In 1860, Gibert first used the term *pityriasis rosea* (PR), meaning pink (rosea) scales (pityriasis).[1] PR is most common in teenagers and young adults, and is likely a viral exanthema currently thought to be related to primary infection or reactivation of human herpesvirus (HHV)-6 (HHV-6) and/or HHV-7.[2-6] PR is fairly common, self-limited, and not associated with long-term sequelae. It classically begins as an isolated 3- to 5-cm oval plaque on the trunk with a collarette of fine scale just inside the periphery, which plaque is called a *herald patch*. This lesion is then followed by a secondary eruption of similar appearing but smaller lesions most prominently on the trunk and proximal extremities, usually with their long axis along the lines of cleavage in what is often described as a "Christmas tree" pattern. However, there are many atypical presentations of the herald patch distribution, secondary eruption morphology, and overall rash distribution. PR is commonly asymptomatic, but pruritus and systemic flu-like symptoms may be present. Often only supportive treatment and patient education are needed for management, but in cases with a widespread eruption, severe pruritus, or significant systemic symptoms acyclovir may be beneficial.

EPIDEMIOLOGY

PR has a worldwide distribution and is found in all races. One institution in the United States found the incidence to be 0.16% (~160 cases per 100,000 person-years).[7] Studies in other countries report incidences ranging from 0.75% to 1.17%.[8,9] A recent publication combined many of the PR epidemiologic studies from around the world and reported an incidence of 0.64 per 100 dermatologic patients.[10] In some studies PR was found to be more common in colder months,[7,9] but other studies show no significant seasonal variation.[2,11] Studies have demonstrated clustering of cases supporting the hypothesis of an infectious etiology.[12,13] There is a slight female preponderance at 1.39:1.[10] The peak incidence of PR occurs between the ages of 10 and 35 years, but cases have been reported ranging in age from 3 months to 83 years.[7,9,10,14] Relapse is thought to be rare, ranging from 1.8% to 3.7%.[7,15]

CLINICAL FEATURES

HISTORY

Classic PR typically begins with a solitary lesion on the trunk or less commonly an extremity known as a herald patch. This lesion typically remains isolated on average for 2 weeks in adults and 4 days in children, after which time it is followed by the onset of a secondary eruption of morphologically similar but smaller lesions on the trunk and proximal extremities. The eruption may be preceded by various prodromal symptoms such as malaise, nausea, headache, gastrointestinal, and upper respiratory symptoms. The incidence of these prodromal symptoms varies in the literature from 5% to 69%.[14,16] These symptoms can also occur during the eruption. Pruritus is severe in 25%, mild to moderate in 50%, and absent in 25% of patients.[17]

In contrast to classic PR, Drago and colleagues have reported several variants of PR, such as in pediatric patients (<10 years of age), relapsing, and a persistent form.[15,17-20] The relapsing form of PR generally consists of single episode of relapse within 1 year of the initial episode, although multiple relapses have been reported. In this variant, the secondary episodes generally lack a herald patch, are shorter lived, and consist of fewer and more localized lesions than the initial eruption. The persistent form of PR, is defined as having the eruption last for greater than 12 weeks without interruption. It commonly has a herald patch, and oral

manifestations are thought to be more common than in classic PR. When PR presents in the pediatric population it often has a different clinical course compared to classic PR. Thus, the time between the presentation of the herald patch and the secondary eruption is shorter, often lasting only 4 days, in contrast to the more typical 2-week interval. In addition, the average overall duration of the eruption tends to be shorter and on average lasts approximately 16 days.[19] Lastly, PR is reported to occur more frequently in pregnant women than in the general population, but otherwise PR during pregnancy presents in a manner similar to classic PR.

CUTANEOUS FINDINGS

The initial classic herald patch presents as a well-demarcated, thin, oval to round plaque that is usually pink, rose colored, erythematous, or, less commonly, hyperpigmented. It frequently has a slightly depressed center and fine collarette of scale within the periphery of the lesion (Figs. 31-1 and 31-2). It most commonly occurs on the trunk (50%) followed by the extremities and neck.[2] Atypical locations such as the dorsal feet, face, scalp, and genitalia have been reported. This lesion enlarges over several days usually reaching a diameter greater than 3 cm with a range of 2 to 10 cm. The incidence of the herald patch is reported to be anywhere from 12% to 94%, but is thought to be present in approximately 80% of the cases. Multiple herald patches have been observed with an incidence of 5% (Fig. 31-3). The herald patch may appear concurrently with the more generalized eruption or, less commonly, be the sole manifestation of the disease.[2,14]

The secondary eruption commonly begins approximately 2 weeks following the onset of the herald patch. However, this interval is described as ranging from a few hours to 3 months.[14] This secondary eruption is characterized by multiple, round-to-oval, 0.5- to 1.5-cm macules, papules, and plaques. These lesions are often light pink with a fine collarette of scale and resemble the herald patch in miniature. They are typically found bilaterally and symmetrically on the trunk and proximal extremities (Figs. 31-4 to 31-6). However, these lesions can extend to the distal extremities, and

Figure 31-2 A nonscaly purpuric primary plaque (herald patch) of pityriasis rosea.

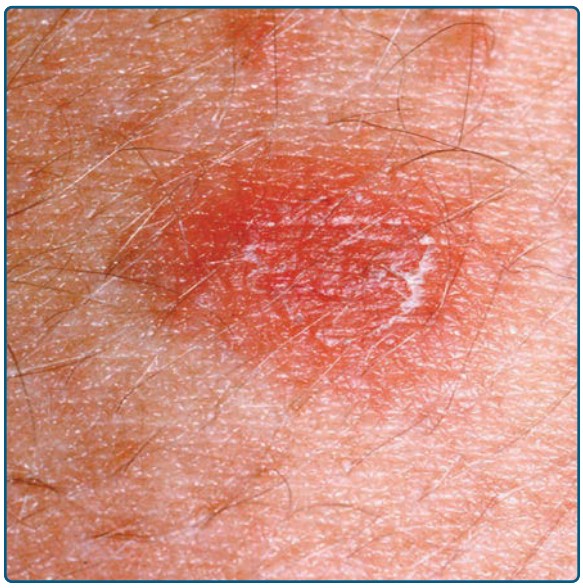

Figure 31-1 A typical primary plaque (herald patch) of pityriasis rosea, demonstrating an oval shape and fine scale inside the periphery of the plaque.

Figure 31-3 A double herald patch of pityriasis rosea.

Figure 31-4 Typical distribution of secondary plaques along the lines of cleavage on the back in a Christmas tree pattern.

Figure 31-6 Typical distribution along the lines of cleavage and morphology of the secondary eruption on the flank and abdomen of a 23-week pregnant patient. (Used with permission from Dr. Thy Thy Do and Mr. Harrold Carter.)

can been found on the palms and soles. In the classic description, these lesions are aligned with their long axis parallel to lines of cleavage giving a "Christmas tree" distribution on the upper chest and back (Fig. 31-7). This secondary eruption usually occurs in crops every few days over the course of 2 weeks, where it reaches its maximum intensity. Rarely, the secondary eruption is confined to sun-protected skin; in other cases, it is found only on sun-exposed surfaces.[14]

Many different forms of atypical secondary lesions have been described, including eczematous, papular, follicular, vesicular, urticarial, pustular, and purpuric (Figs. 31-8 and 31-9).[2,14,17] These lesions may be the only manifestation of the secondary eruption or they may

Figure 31-5 Typical distribution along the lines of cleavage and morphology of the secondary eruption on the back of a 23-week pregnant patient. (Used with permission from Dr. Thy Thy Do and Mr. Harrold Carter.)

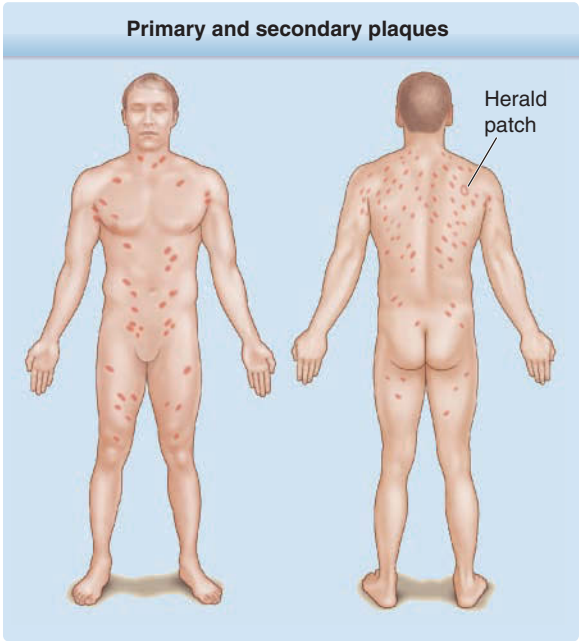

Figure 31-7 Schematic diagram of the primary plaque (herald patch) and the typical distribution of secondary plaques along the lines of cleavage on the trunk in a Christmas tree pattern.

Figure 31-8 Vesicular pityriasis rosea, showing typical primary plaque and secondary papulovesicles. Note Christmas tree distribution.

occur admixed with other morphologies, including the classic type. The vesicular lesions may be arranged in a rosette and are more common in children and young adults.[2]

Mucosal lesions can occur with PR, and although these lesions are thought to be uncommon, they have been reported in up to 16% of patients with PR.[21] The oral lesions can have varying morphologies, including punctate hemorrhagic, ulcerative, erythematous macules, plaques, bullous, and annular lesions.[22] Ulcerations are thought to be the most common form. The oral lesions typically occur along with the cutaneous eruption.[2] Lymphadenopathy can also be associated with PR particularly when patients have associated flu-like symptoms.

There are several atypical variants of PR, such as unilateral, localized, and inverse, which make up approximately 20% of cases.[14] Localized PR is often limited to 1 truncal site, whereas unilateral PR does not cross midline. Inverse PR, which is more common in children, is characterized by involvement of the body folds, face, and often distal extremities.[2,14] PR in a blaschkoid distribution or with prominent acral involvement has also been reported.[23,24]

Figure 31-9 Purpuric pityriasis rosea.

COMPLICATIONS

PR is not associated with any long-term complications in otherwise healthy individuals. Systemic symptoms, when present, are transient. PR, mostly because of the uncertain etiology, length of disease recovery, and fear of progression, can be associated with the development of anxiety and depression in 30% of cases and does negatively impact quality of life.[25] PR in pregnancy deserves special mention as it may be associated with adverse outcomes. In one study where 38 women who developed PR during pregnancy were observed, 13% had a miscarriage; it was noted, however, that the miscarriage rate of the general population is approximately 10%.[26] Perhaps of more interest was that in the 8 cases where PR began before 15 weeks of gestation, 5 (62%) resulted in abortion. Of the 33 women who bore children in this study, 9 (27%) had a premature delivery, but none of the infants had birth defects, although hypotonia, weak motility, and hyporeactivity was noted in 6 cases (18%). Based on these findings, women who develop PR during pregnancy, particularly during the first trimester, should be followed carefully for the development of adverse events.

ETIOLOGY AND PATHOGENESIS

PR has long been thought to be caused by an infectious agent. This assumption is based on the findings of case clustering, possible seasonal variation, resemblance to other known exanthems, and the presence of prodromal symptoms in some patients. Over the years there have been numerous investigations into potential causative bacterial, fungal, and viral pathogens, all with largely negative results. However, in 1997, Drago and colleagues found HHV-7 DNA in peripheral blood mononuclear cells, skin, and cell-free plasma of patients with PR suggesting an association.[6] Since 1997, multiple studies have been done that support HHV-7 and/or HHV-6 as the likely cause of PR.[5,3,27-29] These studies demonstrated the presence of HHV-7, and to a lesser extent HHV-6 DNA and messenger RNA, in both lesional and nonlesional PR skin, in peripheral blood mononuclear cells, and in plasma via real-time polymerase chain reaction, but not in controls. Furthermore serological studies using immunoglobulins M and G against HHV-7 and HHV-6 are in alignment with the findings above. All this evidence suggests PR may be related to infection with HHV-7 and, to a lesser extent, HHV-6. It is not clear if PR is caused by HHV-7 and/or HHV-6 primary infection, reactivation,

or both. The hypothesis of reactivation is supported by the finding of 7 and HHV-6 DNA in saliva which is a known reservoir of these viruses and the usual mode of transmission.[28] However, the antibody profile found by Vag and colleagues was more consistent with primary infection.[29] It should be noted that there have also been various studies with results that failed to duplicate the findings of HHV-7 and/or HHV-6 DNA in PR patients, failed to show differences in patients with PR and controls, or, in some cases, found even higher prevalence of HHV-7 and HHV-6 DNA in control individuals.[30-35] There are numerous potential reasons for these discordant results. First, HHVs have a very high prevalence in the general population, making it hard to show differences in prevalence between disease states and healthy controls without large numbers. The prevalence of HHV-6 and HHV-7 seropositivity in healthy adults has been found to be 80% to 100%[36] and >85%,[37] respectively. Also complicating analysis is that HHV-7 may influence and even cause reactivation of latent HHV-6 with subsequent disappearance of active HHV-7 replication.[2,30] This could account for the varying percentages of HHV-7 and HHV-6 in the positive studies. Lastly, the varied findings may reflect that PR like other exanthems, such as Gianotti-Crosti syndrome, can be induced by multiple pathogens.[30]

Overall the pathogenesis of PR is poorly understood and if HHV-7 and HHV-6 are the etiologic agents the mechanisms by which they lead to the clinical findings seen in PR are not known. Several studies have looked into the immunologic aspects of PR. A review of the available literature shows that cell-mediated immunity is important in the pathogenesis of PR.[38] Specifically, one study demonstrated that the inflammatory infiltrate of PR was predominantly T cells with an increased CD4-to-CD8 ratio as well as an increased proportion of Langerhans cells, which are common findings in other inflammatory skin conditions thought to be driven by cell-mediated immunity. No significant difference was found between the herald patch and fully developed PR lesions.[39] Another study looking specifically at the cytokine profile of PR found increased interleukin-17, interferon-γ, vascular endothelial growth factor, and interferon-inducible protein-10 (CXCL10). Interleukin-17 and interferon-γ in particular were mentioned as evidence that the cytokine profile in PR was not specific for, but consistent with, a viral-induced disease process.[40] Lastly, an autoimmune pathogenesis for PR has been investigated, but to date no compelling autoantigens or supporting evidence has been found.[38]

DIAGNOSIS

The diagnosis of PR is usually clinical, and in the case of classic PR fairly straightforward. The various atypical presentations, however, can pose a diagnostic challenge. A set of clinical diagnostic criteria was proposed in 2003.[41,42] In these criteria, the patient had to have 3 essential features and at least 1 of 3 optional features. The 3 essential features were discrete circular or oval lesions, scaling on most lesions, and a peripheral collarette of scale with central clearance on at least 2 lesions. The optional criteria included a truncal and proximal limb distribution with less than 10% of lesions distal to the mid-upper-arm and mid-thighs, distribution of most lesions along the ribs, and a herald patch appearing at least 2 days before the eruption. They also proposed 3 exclusion features, including multiple small vesicles at the center of 2 or more lesions, most lesions on palmar or plantar skin surfaces, and clinical or serological evidence of secondary syphilis.

LABORATORY TESTING

Routine blood tests are typically normal in PR. Although various abnormalities, including leukocytosis and an elevated erythrocyte sedimentation rate may be found, blood tests are nonspecific. As such, blood tests are not needed nor are they recommended in the diagnosis of PR.

PATHOLOGY

The histologic features of PR are nonspecific and patients with the classic presentation often do not require skin biopsy as the diagnosis can confidently be made on clinical grounds alone. The epidermal changes seen include parakeratosis which may be focal, multifocal, or confluent; orthokeratosis; mild acanthosis; a thinned granular layer; and spongiosis often with some degree of lymphocyte exocytosis (Fig. 31-10). In the dermis there is typically a superficial perivascular lymphocytic infiltrate and variable extravasated red

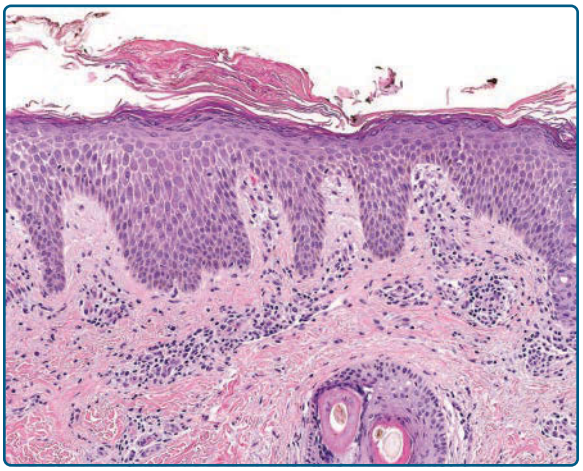

Figure 31-10 Typical epidermal changes seen in pityriasis rosea, including mounded parakeratosis with lift off, mild acanthosis, and spongiosis. (A 4-mm punch biopsy, hematoxylin and eosin stain, ×10 magnification, used with permission from Dr. Paul Harms.)

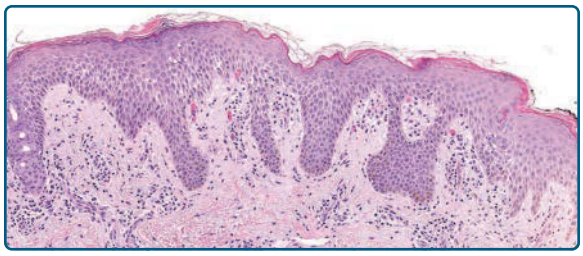

Figure 31-11 Biopsy that highlights the spongiosis, superficial perivascular lymphocytic infiltrate, and red blood cell extravasation typically seen in pityriasis rosea. (A 4-mm punch biopsy, hematoxylin and eosin stain, ×10 magnification, used with permission from Dr. Paul Harms.)

blood cells (Fig. 31-11).[39] The inflammatory infiltrate is predominantly composed of lymphocytes, neutrophils, histiocytes, and eosinophils can be seen.[2,43] There are no consistent differences in the histology of the herald patch versus the secondary lesion, but the herald patch may have a slightly deeper infiltrate with more acanthosis.[2]

DIFFERENTIAL DIAGNOSIS

Table 31-1 outlines the differential diagnosis of PR.

The differential diagnosis of PR includes various other papulosquamous disorders, including nummular eczema, guttate psoriasis, lichen planus, pityriasis lichenoides, tinea corporis, parapsoriasis, and seborrheic dermatitis. Nummular eczema generally has more round than oval lesions, typically does not follow the lines of cleavage, and has a predilection for extensor extremities. Seborrheic dermatitis can have truncal lesions similar to PR, but they generally have corresponding lesions on the scalp and/or face. Although guttate psoriasis can be very difficult to distinguish from PR, it also does not follow the lines of cleavage, lacks a larger lesion that could mimic a herald patch, and has a thicker more confluent scale typical of psoriasis. Pityriasis lichenoides has a more chronic and relapsing course, lacks a herald patch, has lesions in various stages, and involves the extremities more than classic PR. Lichen planus is usually more pruritic and chronic than PR, lacks collarette of scale, has a more violaceous color, and often prominently involves the distal extremities. Dermatophyte infection is particularly difficult to distinguish from the herald patch, especially when it presents in the folds, making mycologic investigations, such as potassium hydroxide examination, necessary to distinguish dermatophyte infection from herald patch. Skin biopsy often can help to differentiate the above conditions from PR, particularly in the atypical forms of PR.

Another entity commonly in the differential of PR that deserves special mention is secondary syphilis. The rash produced by each of these entities can be identical. Certain features that favor a diagnosis of syphilis include oral lesions, involvement of the palms and soles, and persistent lymphadenopathy. However, as noted above, all these features can be seen in PR, requiring serologic tests, starting with a rapid plasma reagin, to differentiate syphilis from PR. Because of this, some clinicians advocate checking a rapid plasma reagin in every patient suspected of having PR. In addition, one can look for other features of secondary syphilis, such as split papules, a "moth-eaten" appearing alopecia, and condyloma lata.

Many medications are also reported to cause a PR-like eruption and there is some debate over whether these cases represent a separate entity or if PR might be drug induced in some instances. Medications reported to cause such eruptions include barbiturates, captopril, clonidine, gold, metronidazole, D-penicillamine, isotretinoin, levamisole, nonsteroidal antiinflammatory agents, omeprazole, and terbinafine.[2] PR or PR-like rashes also have been described from the tyrosine kinase inhibitor imatinib and the tumor necrosis factor inhibitor adalimumab.[44-46] The development of a PR-like eruption from adalimumab is of particular interest as this medication dampens the T-helper 1 cell response, which is key in the body's defense against viral infections, and could therefore predispose to both viral infection or reactivation. The drug-induced PR-like eruptions are very similar to classic PR in appearance, but don't resolve unless the offending agent is stopped, often leaving more marked hyperpigmentation and frequently transitioning to a more lichenoid morphology.[2] The histopathology of a drug-induced PR-like eruption is also more likely to show interface dermatitis, dyskeratotic keratinocytes, and eosinophils.

TABLE 31-1
Differential Diagnosis of Pityriasis Rosea

Most Likely

- *Tinea corporis:* Scale is usually at periphery of plaques, plaques usually not oval and distributed along lines of cleavage, positive potassium hydroxide (KOH) examination.
- *Nummular dermatitis:* Plaques are usually more circular than oval, there are no collarettes of scale, and tiny vesicles are common.
- *Guttate psoriasis:* Plaques are usually smaller than pityriasis rosea (PR) lesions and do not follow lines of cleavage; scales are thick and silvery. When in doubt, perform a biopsy.

Consider

- *Pityriasis lichenoides chronica:* More chronic with persistent crops of new lesions, more confluent scale, no herald patch, and more common on extremities.
- *Lichen planus:* More pruritic, chronic, and with distal extremity involvement. Scale may show classic Wickham striae.
- *Seborrheic dermatitis:* Look for characteristic face and scalp involvement.

Always Rule Out

- *Secondary syphilis:* History of primary chancre, no herald patch, lesions typically more widespread and classically involve palms and soles. Other features of secondary syphilis, such as condyloma lata, alopecia, mucous patches, and split papules, may be present. Usually there are more severe systemic complaints and lymphadenopathy. If there is any clinical concern, perform a serologic test for syphilis (eg, a rapid plasma reagin).
- *PR-like drug eruption:* See the text for an extensive list. A drug history is needed.

CLINICAL COURSE AND PROGNOSIS

PR typically self-resolves after an average of 45 days, but ranges from 2 weeks to 5 months have been reported.[2,17] As previously stated, eruptions lasting longer than 3 months may fit into the proposed category of persistent PR. Upon resolution the only sequela is typically postinflammatory hyperpigmentation or hypopigmentation. As with other inflammatory conditions this dyspigmentation is more common in individuals with a darker skin color. There are no other significant long-term clinical outcomes from PR. As stated above, recurrence can occur, but it is very uncommon. When recurrence does happen, it is usually only once and also does not have any long-term health consequences.

MANAGEMENT

INTERVENTIONS

As discussed, PR is self-limited and therefore no treatment is necessary in many cases. Also given that many cases of PR have minimal to no symptoms the benefits of any treatment must be weighed against the potential side effects of the intervention on a case-by-case basis. Counseling patients on the natural history of PR and reassurance regarding its self-limited nature is paramount given the anxiety often associated with PR. Although there is no good data to support their use topical steroids and antihistamines are safe and may be helpful for associated pruritus. The macrolide erythromycin has been reported to hasten the clearance of PR.[16] In addition, a 2007 Cochrane review found one small, good-quality study that demonstrated benefit from erythromycin.[47] However, subsequent studies evaluating the efficacy of the macrolide antibiotics erythromycin and azithromycin failed to show any benefit when compared to placebo.[48-50] Acyclovir also has been studied as a potential therapy for PR. Drago and colleagues initially found that treatment with high-dose acyclovir (800 mg 5 times daily) for 1 week led to a 78.6% rate of complete clearance at 2 weeks compared to only a 4.4% rate of complete clearance in the placebo group, but this study was not randomized and the investigators were not blinded.[51] Several subsequent trials have all shown that acyclovir at varying doses may hasten the resolution of the rash, improve associated pruritus, and, in some cases, improve associated systemic symptoms.[52-55] Therefore, given the low cost and good safety profile of acyclovir and its derivatives, these therapeutic agents may be reasonable to consider in PR patients, particularly in those with significant pruritus, an extensive rash, or significant systemic symptoms. It should be noted that the mechanism of action of acyclovir in the treatment of PR is unclear given that acyclovir's effect is dependent on thymidine kinase, an enzyme whose gene is not expressed by HHV-7.[2] Ultraviolet B phototherapy also is reported to have some benefit in PR clearance time, although results vary on whether or not it helps with the associated pruritus.[56,57]

PREVENTION

There is currently no data available on prevention of PR.

ACKNOWLEDGMENTS

The authors acknowledge the contributions of Andrew Blauvelt, the former author of this chapter.

REFERENCES

1. Gibert CM. *Traité Pratique Des Maladies de La Peau et de La Syphilis, Volume 2*. H. Plon, Paris, France; 1860.
2. Drago F, Broccolo F, Rebora A. Pityriasis rosea: an update with a critical appraisal of its possible herpesviral etiology. *J Am Acad Dermatol*. 2009;61(2):303-318.
3. Broccolo F, Drago F, Careddu AM, et al. Additional evidence that pityriasis rosea is associated with reactivation of human herpesvirus-6 and -7. *J Invest Dermatol*. 2005;124(6):1234-1240.
4. Rebora A, Drago F, Broccolo F. Pityriasis rosea and herpesviruses: facts and controversies. *Clin Dermatol*. 2010;28(5):497-501.
5. Canpolat Kirac B, Adisen E, Bozdayi G, et al. The role of human herpesvirus 6, human herpesvirus 7, Epstein-Barr virus and cytomegalovirus in the aetiology of pityriasis rosea. *J Eur Acad Dermatol Venereol*. 2009;23(1):16-21.
6. Drago F, Ranieri E, Malaguti F, et al. Human herpesvirus 7 in patients with pityriasis rosea. *Dermatology*. 1997;195(4):374-378.
7. Chuang T-Y, Ilstrup DM, Perry H, et al. Pityriasis rosea in Rochester, Minnesota, 1969 to 1978. *J Am Acad Dermatol*. 1982;7(1):80-89.
8. Nanda A, Al-Hasawi F, Alsaleh QA. A prospective survey of pediatric dermatology clinic patients in Kuwait: an analysis of 10,000 cases. *Pediatr Dermatol*. 1999;16(1):6-11.
9. Harman M, Aytekin S, Akdeniz S, et al. An epidemiological study of pityriasis rosea in the Eastern Anatolia. *Eur J Epidemiol*. 1998;14(5):495-497.
10. Chuh A, Zawar V, Sciallis GF, et al. Pityriasis rosea, Gianotti-Crosti syndrome, asymmetric periflexural exanthem, papular-purpuric gloves and socks syndrome, eruptive pseudoangiomatosis, and eruptive hypomelanosis: do their epidemiological data substantiate infectious etiologies? *Infect Dis Rep*. 2016;8(1):6418.
11. Harvell JD, Selig DJ. Seasonal variations in dermatologic and dermatopathologic diagnoses: a retrospective 15-year analysis of dermatopathologic data. *Int J Dermatol*. 2016;55(10):1115-1118.
12. Chuh AAT, Molinari N, Sciallis G, et al. Temporal case clustering in pityriasis rosea: a regression analysis on 1379 patients in Minnesota, Kuwait, and Diyarbakir, Turkey. *Arch Dermatol*. 2005;141(6):767-771.

13. Chuh AAT, Lee A, Molinari N. Case clustering in pityriasis rosea: a multicenter epidemiologic study in primary care settings in Hong Kong. *Arch Dermatol*. 2003;139(4):489-493.
14. Gonzalez LM, Allen R, Janniger CK, et al. Pityriasis rosea: an important papulosquamous disorder. *Int J Dermatol*. 2005;44(9):757-764.
15. Drago F, Ciccarese G, Rebora A, et al. Relapsing pityriasis rosea. *Dermatology*. 2014;229(4):316-318.
16. Sharma PK, Yadav TP, Gautam RK, et al. Erythromycin in pityriasis rosea: a double-blind, placebo-controlled clinical trial. *J Am Acad Dermatol*. 2000;42(2, pt 1): 241-244.
17. Drago F, Ciccarese G, Rebora A, et al. Pityriasis rosea: a comprehensive classification. *Dermatology*. 2016;232(4):431-437.
18. Drago F, Broccolo F, Ciccarese G, et al. Persistent pityriasis rosea: an unusual form of pityriasis rosea with persistent active HHV-6 and HHV-7 infection. *Dermatology*. 2015;230(1):23-26.
19. Drago F, Ciccarese G, Broccolo F, et al. Pityriasis rosea in children: clinical features and laboratory investigations. *Dermatology*. 2015;231(1):9-14.
20. Gündüz O, Ersoy-Evans S, Karaduman A. Childhood pityriasis rosea. *Pediatr Dermatol*. 26(6):750-751.
21. Vidimos AT, Camisa C. Tongue and cheek: oral lesions in pityriasis rosea. *Cutis*. 1992;50(4):276-280.
22. Kay MH, Rapini RP, Fritz KA, et al. Oral lesions in pityriasis rosea. *Arch Dermatol*. 1985;121(11):1449.
23. Ang C-C, Tay Y-K. Blaschkoid pityriasis rosea. *J Am Acad Dermatol*. 2009;61(5):906-908.
24. Deng Y, Li H, Chen X. Palmoplantar pityriasis rosea: two case reports. *J Eur Acad Dermatol Venereol*. 2007;21(3):406-407.
25. Kaymak Y, Taner E. Anxiety and depression in patients with pityriasis rosea compared to patients with tinea versicolor. *Dermatol Nurs*. 2008;20(5):367-370, 377.
26. Drago F, Broccolo F, Zaccaria E, et al. Pregnancy outcome in patients with pityriasis rosea. *J Am Acad Dermatol*. 2008;58(5)(suppl 1):S78-S83.
27. Drago F, Malaguti F, Ranieri E, et al. Human herpes virus-like particles in pityriasis rosea lesions: an electron microscopy study. *J Cutan Pathol*. 2002;29(6): 359-361.
28. Watanabe T, Kawamura T, Jacob SE, et al. Pityriasis rosea is associated with systemic active infection with both human herpesvirus-7 and human herpesvirus-6. *J Invest Dermatol*. 2002;119(4):793-797.
29. Vág T, Sonkoly E, Kárpáti S, et al. Avidity of antibodies to human herpesvirus 7 suggests primary infection in young adults with pityriasis rosea. *J Eur Acad Dermatol Venereol*. 2004;18(6):738-740.
30. Chuh AAT, Chan HHL, Zawar V. Is human herpesvirus 7 the causative agent of pityriasis rosea?—A critical review. *Int J Dermatol*. 2004;43(12):870-875.
31. Kempf W, Adams V, Kleinhans M, et al. Pityriasis rosea is not associated with human herpesvirus 7. *Arch Dermatol*. 1999;135(9):1070-1072.
32. Kempf W, Burg G. Pityriasis rosea—a virus-induced skin disease? An update. *Arch Virol*. 2000;145(8):1509-1520.
33. Kosuge H, Tanaka-Taya K, Miyoshi H, et al. Epidemiological study of human herpesvirus-6 and human herpesvirus-7 in pityriasis rosea. *Br J Dermatol*. 2000;143(4): 795-798.
34. Wong WR, Tsai CY, Shih SR, et al. Association of pityriasis rosea with human herpesvirus-6 and human herpesvirus-7 in Taipei. *J Formos Med Assoc*. 2001;100(7): 478-483.
35. Yasukawa M, Sada E, MacHino H, et al. Reactivation of human herpesvirus 6 in pityriasis rosea. *Br J Dermatol*. 1999;140(1):169-170.
36. Levy JA, Ferro F, Greenspan D, et al. Frequent isolation of HHV-6 from saliva and high seroprevalence of the virus in the population. *Lancet*. 1990;335(8697):1047-1050.
37. Ablashi DV, Berneman ZN, Kramarsky B, et al. Human herpesvirus-7 (HHV-7): current status. *Clin Diagn Virol*. 1995;4(1):1-13.
38. Guarneri F, Cannavó SP, Minciullo PL, et al. Pityriasis rosea of Gibert: immunological aspects. *J Eur Acad Dermatol Venereol*. 2015;29(1):21-25.
39. Neoh CY, Tan AWH, Mohamed K, et al. Characterization of the inflammatory cell infiltrate in herald patches and fully developed eruptions of pityriasis rosea. *Clin Exp Dermatol*. 2010;35(3):300-304.
40. Drago F, Ciccarese G, Broccolo F, et al. The role of cytokines, chemokines, and growth factors in the pathogenesis of pityriasis rosea. *Mediators Inflamm*. 2015;2015:438963.
41. Chuh A. Diagnostic criteria for pityriasis rosea: a prospective case control study for assessment of validity. *J Eur Acad Dermatol Venereol.* 2003;17(1):101-103.
42. Zawar V, Chuh A. Applicability of proposed diagnostic criteria of pityriasis rosea: Results of a prospective case-control study in India. *Indian J Dermatol*. 2013;58(6):439.
43. Hussein MRA, Abdel-Magid WM, Saleh R, et al. Phenotypical characteristics of the immune cells in allergic contact dermatitis, atopic dermatitis and pityriasis rosea. *Pathol Oncol Res*. 2009;15(1):73-79.
44. Rajpara SN, Ormerod AD, Gallaway L. Adalimumab-induced pityriasis rosea. *J Eur Acad Dermatol Venereol*. 2007;21(9):1294-1296.
45. Cho AY, Kim DH, Im M, et al. Pityriasis rosea-like drug eruption induced by imatinib mesylate (Gleevec). *Ann Dermatol*. 2011;23(suppl 3):S360-S363.
46. Verma P, Singal A, Sharma S. Imatinib mesylate-induced cutaneous rash masquerading as pityriasis rosea of gilbert. *Indian J Dermatol*. 2014;59(3): 311-312.
47. Chuh AAT, Dofitas BL, Comisel GG, et al. Interventions for pityriasis rosea. *Cochrane Database Syst Rev.* 2007;(2):CD005068.
48. Rasi A, Tajziehchi L, Savabi-Nasab S. Oral erythromycin is ineffective in the treatment of pityriasis rosea. *J Drugs Dermatol.* 2008;7(1):35-38.
49. Pandhi D, Singal A, Verma P, et al. The efficacy of azithromycin in pityriasis rosea: a randomized, double-blind, placebo-controlled trial. *Indian J Dermatol Venereol Leprol.* 2014;80(1):36.
50. Amer A, Fischer H. Azithromycin does not cure pityriasis rosea. *Pediatrics*. 2006;117(5):1702-1705.
51. Drago F, Vecchio F, Rebora A. Use of high-dose acyclovir in pityriasis rosea. *J Am Acad Dermatol*. 2006;54(1):82-85.
52. Das A, Sil A, Das NK, et al. Acyclovir in pityriasis rosea: An observer-blind, randomized controlled trial of effectiveness, safety and tolerability. *Indian Dermatol Online J*. 2015;6(3):181-184.
53. Ganguly S. A randomized, double-blind, placebo-controlled study of efficacy of oral acyclovir in the treatment of pityriasis rosea. *J Clin Diagn Res*. 2014;8(5): YC01-YC04.
54. Noormohammadpour P, Toosi S, Hosseinpour A, et al. The comparison between the efficacy of high dose acyclovir and erythromycin on the period and signs of pityriasis rosea. *Indian J Dermatol*. 2010;55(3):246.

55. Rassai S, Feily A, Sina N, et al. Low dose of acyclovir may be an effective treatment against pityriasis rosea: a random investigator-blind clinical trial on 64 patients. *J Eur Acad Dermatol Venereol*. 2011;25(1):24-26.
56. Jairath V, Mohan M, Jindal N, et al. Narrowband UVB phototherapy in pityriasis rosea. *Indian Dermatol Online J*. 6(5):326-329.
57. Leenutaphong V, Jiamton S. UVB phototherapy for pityriasis rosea: a bilateral comparison study. *J Am Acad Dermatol*. 1995;33(6):996-999.

Lichenoid and Granulomatous Disorders

PART 5

Chapter 32 :: Lichen Planus

:: Aaron R. Mangold & Mark R. Pittelkow

AT-A-GLANCE

- Lichen planus is an idiopathic T cell–mediated process without a clear autoantigen.
- The worldwide prevalence of lichen planus is approximately 1%.
- The lesions are well-marginated, flat-topped, red-violet polygonal papules.
- The distribution is symmetrical and grouped lesions affect the flexural aspects of the arms and legs.
- Variants are based on configuration, morphology of lesion, and site of involvement.
- Histology shows basal keratinocyte damage with a lymphocyte-rich interface reaction.

INTRODUCTION

Lichen planus (Greek *leichen*, "tree moss"; Latin *planus*, "flat") is a common inflammatory condition that can affect any ectodermal-derived tissue. Both Hebra and Erasmus Wilson described a similar inflammatory papulosquamous eruption, lichen ruber and lichen planus, respectively, which likely represented the same entity.[1] Weyl and Wickham elaborated upon the morphology of lichen planus, and Gougerot and Burnier described disease involvement of mucosal sites.[2-4] Although no single feature of lichen planus is a sine qua non, classic lichen planus is typified clinically by "the four Ps"—(1) purple, (2) polygonal, (3) pruritic, and (4) papules—and histologically by a brisk lymphocytic interface reaction.

PATHOGENESIS

The pathogenesis of lichen planus is unknown. Many contributing factors are implicated and include infectious, immune, metabolic, and genetic causes. It is evident that specific immunologic mechanisms control the development of lichen planus. T cell–mediated pathologic alterations involving proinflammatory and counterregulatory mechanisms function in the pathogenesis of lichen planus. No consistent alterations in immunoglobulins have been shown in lichen planus, and humoral immunity most likely is a secondary response in immunopathogenesis. Cell-mediated immunity, on the other hand, plays a major role in lichen planus. One consistent feature of lichen planus is CD4-positive T-helper (CD4-Th) cells in the dermis despite disease chronicity and CD8-positive T-cytotoxic (CD8-Tc) cells in close proximity to damaged basal keratinocytes.[5] Based on these observations and insights from other lichenoid tissue reactions (LTRs), such as graft-versus-host-disease (GVHD), modern theories encompass three major stages: antigen recognition, lymphocyte activation, and keratinocyte apoptosis. A fourth stage, resolution, is a new and emerging facet of the disease to further understand the pathogenesis of lichen planus.

ANTIGEN RECOGNITION

The CD8-Tc cell is the effector cell of lichen planus; however, the initial antigen recognition and CD8-Tc stimulation may be driven by the initial interaction between the CD4-Th cell with the Langerhans cell (LC). The targeted antigen(s) and trigger(s) for lichen planus remains unknown. However, in other similar diseases, such as lichenoid GVHD, the target antigens are alloantigens. In oral disease, a lichen planus–specific antigen associated with major histocompatibility complex (MHC) class I on keratinocytes has been reported.[6] It is unknown if this antigen is unique to oral lichen planus and if this antigen is an autoreactive peptide or an exogenous antigen. Circulating antibodies have also been identified in multiple studies without a clear

target antigen.[7,8] A small but significant population of CD 56–positive CD 16–negative natural killer (NK) cells are observed early in the disease course of lichen planus.[9] These cells express chemokine receptor-3 (CXCR-3) and chemokine (c-c) motif ligand (CCL) -5 and -6 and release interferon-γ (IFN-γ) and tumor necrosis factor-α (TNF-α).[9] Taken together, NK cells may migrate to the site of inflammation and provide an early stimulating signal for the recruitment of CD4-Th and CD8-Tc cells.

The CD4-Th population is localized to the dermis with scattered cells in the epidermis. CD4-Th cells colocalize with the LCs. LCs are the principal antigen-presenting cells of the epidermis and they upregulate MHC class II receptors in lichenoid disease, which allows for an interaction between CD4-Th cells and keratinocytes.[10] In particular, CD4-positive LCs are seen in close approximation with the HLA-DR–positive keratinocytes.[11] In addition, the CD4-Th cells have restricted V-β gene expression, which suggests antigen-specific oligoclonal T-cell expansion.[12,13] Upon costimulation by LCs, CD4-Th cells release inflammatory cytokines, including IFN-γ, which leads to CD8-Tc activation and additional oligoclonal expansion.[14] Taken together, these findings suggest an integral role of LCs, keratinocytes, and CD4 T helper cells in antigen presentation as well as the initiation and propagation of the Th1 response via the production of IFN-γ.

The nature of antigenic stimulation is not known. Contact sensitizers such as metals could act as haptens and elicit an immunologic response. Enhanced lymphocyte reactivity to inorganic mercury, a component of dental amalgam, has been found in patients with oral LTRs. Low-grade chronic exposure to mercury, and possibly to other metals such as gold, may stimulate a lymphocytic reaction that manifests as lichen planus. A list of contact chemicals and drugs that can elicit lichenoid reactions is discussed in the section "Drug-Induced Lichen Planus." With more widespread use of biologics, specifically TNF-α inhibitors, for the treatment of various chronic inflammatory diseases, cases of TNF- α associated LTRs have been identified and implicate dysregulated cytokine production, including the upregulation of type I IFN.[15] Microbial mediators in the development of lichen planus have elicited recurring debate. Although provocative, no conclusive evidence has molecularly linked lichen planus to any of the following infections or colonization: syphilis, herpes simplex virus 2, human immunodeficiency virus (HIV), amebiasis, chronic bladder infections, hepatitis C virus (HCV), *Helicobacter pylori*, or human papillomavirus (HPV).

LYMPHOCYTE ACTIVATION

As mentioned in the prior section, following antigen recognition, CD8-Tc cells are activated and undergo oligoclonal expansion. A cascade of both pro- and antiinflammatory cytokines is released, including interleukin (IL)-2, -4, and -10; IFN-γ; TNF-α; and transforming growth factor-β1 (TGF-β1).[16,17] In lichen planus, the balance between lymphocyte activation, downregulation, and the cytokine milieu determines the disease phenotype.

IFN-γ plays a central role in lichen planus. IFN-γ induces the expression of inflammatory chemokines such as chemokine ligand (CXCL)-9, -10, and -11.[18-20] CXCR-3, their matching receptor, is predominantly expressed on the surface of IFN-γ–producing CD4-Th cells.[19-22] Peroxisome-proliferator-activated receptor γ (PPARγ) inhibits CXCL-10 and -11, and its loss may be an underlying driver result in scarring alopecia.[23,24] IFN-γ increases peripheral blood mononuclear cell (PBMC) binding to HLA-DR–positive keratinocytes.[19] Intercellular adhesion molecule 1 and vascular cell adhesion molecule expression is also enhanced by IFN-γ.[21] Therefore, IFN-γ is fundamentally involved in the upregulation of cellular adhesion molecules and subsequent migration of lymphocytes to the dermal–epidermal junction (DEJ).[25,26]

KERATINOCYTE APOPTOSIS

CD8-Tc cells are likely the terminal effector cells in lichen planus. They colocalize with apoptotic keratinocytes and have in vitro cytotoxic activity against autologous keratinocytes.[6,27] The cytotoxic effects of the CD8-Tc cells can be inhibited by blockade of the MHC class I domain.[6] The exact mechanism of apoptosis in lichen planus remains unknown. The possible mechanisms include granzyme B release, TNF-α–TNF-α R1 receptor interaction, and Fas–Fas-L interaction. Granzyme B and granulysin are expressed at 100- to 200-fold higher levels in lichen planus relative to normal skin.[28] Granzyme B, excreted by CD8-Tc cells, activates caspase-3 and promotes apoptosis.[29] TNF-α upregulates the expression of matrix metalloproteinase-9 (MMP-9) in lesional T lymphocytes of oral lichen planus and leads to disruption of the basement membrane and damage to basilar keratinocytes.[30] MMP-9 levels correlate with the phenotype, with high levels correlating with ulcerative disease.[31] Taken together, MMP-9 likely disrupts the basement membrane homeostasis, blocking normal cell survival signaling and leads to apoptosis and cell death. Fas–Fas-L expression is elevated in oral lichen planus, correlates with disease progression, and likely contributes to apoptosis of keratinocytes.[32-34]

RESOLUTION

Lichen planus tends to be a self-resolving disease; however, there is a paucity of research into the resolution phase of disease. T-regulatory cells are seen in oral lichen planus and correlate with disease subtype and activity.[35,36] Studies in acute GVHD have shown the central role of T-regulatory cells in disrupting dendritic cell (DC) and allogeneic T-cell interactions[37] and prevents disease development. DCs have a complex role in lichen planus and are involved in T-cell migration, as well as, the modulation of inflammatory signals.[38,39] Fas-L, granzyme B, and perforin can be expressed by keratinocytes, allowing for apoptosis

of lymphocytes.[40,41] Further understanding of the resolution phase of LTRs should lead to development of novel targeted therapies.

GENETIC AND EPIGENETIC REGULATION

The immune system targets various naturally occurring, but potentially deleterious, antigens (ie, viruses and bacteria, malignant cells, and exogenous contactants).[42] However, the generation of an immune response to exogenous antigens poses a risk for the development of cross-reactivity to self-antigens.[43,44] Genetic polymorphisms have been implicated in the risk of development of lichen planus, including HLA, immune signaling molecules and receptors (IFN-γ, TNF-α, TNF-α R2, IL-4, IL-6, and IL-18), oxidative stress, prostaglandin E_2 synthesis, formation of transglutaminase, thyroid hormone synthesis, prothrombin, and nuclear factor kappa B (NF-κB) as well as epigenetic regulation of genes by micro-RNA (miRNA)-146a and -155.[45] These polymorphisms may regulate the activity of proinflammatory mediators and lead to aberrant signaling. Gene expression profiling of lichen planus, identified the expression of the CXCR-3 ligand, CXCL-9, as the most specific marker for lichen planus.[46] In addition, keratinocytes were confirmed as a source of type I IFNs (-α and -β).[46]

EPIDEMIOLOGY

The exact incidence and prevalence of lichen planus are unknown. Additionally, most large, epidemiologic studies of lichen planus focus on the prevalence of oral disease or cutaneous disease and few include the ectodermal (skin, hair, nail, and mucous membranes) spectrum of lichen planus. Therefore, the 1% prevalence of lichen planus in the general population should be interpreted with caution.[47] The prevalence of lichen planus varies geographically with a range from 0.1% to 4%. Nearly two thirds of cases of lichen planus present between the ages of 30 and 60 years with a peak onset between 55 and 74 years.[48] lichen planus is less common at the extremes of age. There is no clear sexual or racial predilection in lichen planus; however, the age of onset is earlier in women.[47-49]

Childhood lichen planus accounts for only 1% to 5% of the total lichen planus cases in the general population. In Pacific Indians, childhood lichen planus is more common and accounts for nearly 20% of all cases.[50] In the United States, childhood lichen planus may be slightly more common in African Americans. Much like adult lichen planus, there is no clear sexual predilection in childhood lichen planus. The peak onset of disease is between 8 and 12 years of age.[50-53]

Fewer than 100 cases of familial lichen planus have been reported. However, a strong family history has been reported in 1.5% of adult cases and 3.8% of pediatric cases.[50,54] Familial forms are characterized by early onset, widespread and often erosive or ulcerative disease, mucosal involvement, and frequent relapses.[55,56] The atypical nature of familial lichen planus has led some to consider it a unique dermatosis. Multiple HLA haplotypes have been reported in familial lichen planus, including HLA-B27, Aw19, -B18, and -Cw8. In nonfamilial cases, HLA-A3, -A5, -A28, -B8, -B16, and Bw35 are more common.[57] HLA-B8 is more common in patients with oral lichen planus alone, and HLA-Bw35 is more common with cutaneous lichen planus alone.

CLINICAL FEATURES

Although lichen planus most commonly involves the skin and oral mucosa, any ectodermal-derived tissue may be affected, including hair, nails, internal and external genitalia, eyes, and esophagus. For this reason, a detailed history and physical examination is required to guide appropriate therapy, referrals, and monitoring. The skin lesions of lichen planus typically develop over the course of weeks. The disease duration is dependent on the location of the lesions, lesion morphology, and histologic pattern.

CUTANEOUS FINDINGS

The classic cutaneous lesions of lichen planus are well-marginated, dull red-violet, flat-topped, polygonal papules. The papules are grouped and often coalesce into plaques. Wickham striae, fine, white and adherent reticulate scale, are noted in well-developed lesions (Fig. 32-1). Wickham striae are highly characteristic in lichen planus and are more easily visualized with dermoscopy. The characteristic clinical and

Figure 32-1 Lichen planus. Flat-topped, polygonal, sharply defined papules of violaceous color, grouped and confluent. The surface is shiny and reveals fine white lines (Wickham striae). Note the hyperpigmentation of resolving lesions. (Used with permission from Mayo Foundation for Medical Education and Research, all rights reserved.)

dermoscopic features of lichen planus correlate with the characteristic histological findings of lichen planus. Wickham striae correlate with orthokeratosis, epidermal thickening, and an increased granular layer. The dull red-violet color correlates with the combination of vascular dilation and pigment incontinence. The lesions of lichen planus are often symmetrically distributed over the over the extremities. The most common areas of involvement are the flexural wrists, arms, and legs. The proximal thighs, trunk, and neck are other common sites of involvement. Involvement of the face and palms are atypical for classic lichen planus. Inverse lichen planus (discussed below) commonly involves the axillae, groin, and inframammary region.

Lichen planus tends to be extremely pruritic. The degree of pruritus appears to directly correlate with the extent of involvement with the most symptomatic disease in generalized lichen planus. One major exception is hypertrophic lichen planus, which often affects limited areas, such as the lower extremities, and is extremely pruritic.

In the acute setting, lichen planus exhibits an isomorphic (Koebner) phenomenon in which trauma induces disease (Fig. 32-2). This phenomenon is now explained by trauma-induced exposure of plasmacytoid DCs to endogenous peptides, such as cathelicidin LL-37, and endogenous antigens, such as DNA and RNA, which stimulate the release of type I IFNs (-α and -β), which propagates disease.[58] Lichen planus usually heals with postinflammatory hyperpigmentation, which is more common in darker skinned individuals. Hypopigmentation is uncommon in lichen planus, and its presence should prompt consideration of an alternative diagnosis.

Figure 32-2 Koebnerization. Linear pattern with a Koebner response adjacent to clustered papules on the flexural wrist. (Used with permission from Mayo Foundation for Medical Education and Research, all rights reserved.)

Frequent reports of childhood lichen planus have come from the Indian subcontinent.[50-52] The explanation of such a phenomenon may be multifactorial, including genetic susceptibility, infectious exposure, and social stigma associated with pigmentary changes. In support of the social implications of pigmentary changes, the largest study of childhood lichen planus in the United States found a predominance in African American children.[53] The clinical and histological features of childhood lichen planus are similar to adult lichen planus with skin and oral involvement in 42% to 60% and 17% to 30% of cases, respectively.[50-53] However, hair involvement and nail involvement is rare in 2% to 6% and 0% to 19% of cases, respectively.[50-53]

CLINICAL VARIANTS

Many variations in the clinical presentation of lichen planus have been described and are most easily categorized by the configuration of lesions, the morphologic appearance, and the site of involvement (Table 32-1). Although there may be significant variation in the presentation of specific subtypes of lichen planus, there are often morphological clues of an LTR. The underlying mechanisms driving these clinical variants are unknown; however, akin to psoriasis, these variations are likely caused by genetic polymorphisms and environmental stimuli.

CONFIGURATION

Annular Lichen Planus: Annular lesions occur in approximately 10% of lichen planus and commonly develop as an arcuate grouping of individual papules of lichen planus that coalesce to form a ring or expand centrifugally with a central clearing. Annular lesions are more common on the penis and scrotum (Fig. 32-3). Additionally, large lesions often appear annular because of central resolution and hyperpigmentation with an active, raised rim. Actinic lichen planus is seen in subtropical zones on sun-exposed, dark-skinned young adults and children, is frequently annular in shape.

Linear, Blaschkoid, and Zosteriform Lichen Planus: Papules of lichen planus may develop in a linear pattern secondary to trauma. Rarely, in fewer than 0.2% of lichen planus cases, the eruption may follow lines of Blaschko. Similar to other segmental diseases, the etiology is thought to be related to postzygotic, somatic mutations in susceptibility-associated genes.[59] Zosteriform and linear lichen planus were thought to be the same disease; however, a recent study of zosteriform lichen planus found varicella zoster antigens exclusively in zosteriform lichen planus suggesting either a viral trigger of disease or an isotopic

TABLE 32-1
Clinical Subtypes of Lichen Planus

SUBTYPES	MOST COMMON SITES OF INVOLVEMENT
Cutaneous Lichen Planus	
Actinic	Sun-exposed areas
Annular	Male genitalia, intertriginous areas
Atrophic	Predominately on lower extremities, may occur on other areas of the body
Erosive	Soles of the feet
Guttate	Trunk
Hypertrophic	Anterior legs, ankles, interphalangeal joints
Linear	Lower extremities
Follicular	Trunk and proximal extremities
Papular	Flexural surfaces
Bullous	Feet
Pigmentosus	Sun-exposed areas
Pigmentosus inversus	Intertriginous and flexural areas
Nail	Fingernails > toenails
Palmoplantar	Malleoli Palms Soles
Lichen planopilaris	Classic: vertex scalp Frontal fibrosing alopecia Graham-Little-Piccardi-Lasseur syndrome
Mucosal Lichen Planus	
Oral	
Reticular	Buccal mucosa and mucobuccal folds
Atrophic	Attached gingiva
Hypertrophic	Buccal mucosa
Erosive	Lateral and ventral tongue Buccal mucosa
Bullous	Posterior and inferior areas of the buccal mucosa
Plaque-like	Dorsum of tongue and buccal mucosa
Vulvovaginal	Vaginal introitus, clitoral hood, labia minora, labia majora, vagina
Esophageal	Proximal esophagus Proximal and distal esophagus Distal esophagus
Special Forms	
Drug induced	Sun-exposed areas, lacks oral involvement
Lichen planus–lupus erythematosus overlap	Distal extremities, sun exposed
Lichen planus pemphigoides	Extremities

Adapted with permission from Gorouhi F, Davari P, Fazel N. Cutaneous and mucosal lichen planus: a comprehensive review of clinical subtypes, risk factors, diagnosis, and prognosis. *Scientific World Journal.* 2014;2014:742826.

response related to underlying resident memory cells.[60] Therefore, the term *linear lichen planus* should only be used when dermatomal lines are not followed. It is important to differentiate linear and zosteriform lichen planus from other segmental diseases, including lichen striatus, linear epidermal nevus, inflammatory linear and verrucal epidermal nevus, linear psoriasis, and linear Darier disease.

Figure 32-3 Annular lichen planus. Violaceous, annular lesions involving the corona and body of the penis. (Used with permission from Mayo Foundation for Medical Education and Research, all rights reserved.)

MORPHOLOGY OF LESIONS

Hypertrophic Lichen Planus: Hypertrophic lichen planus occurs most commonly on the anterior shins and interphalangeal joints (Fig. 32-4). Additionally, hypertrophic lichen planus tends to be highly pruritic, refractory to treatment, and associated with relapse. The primary lesions are thickened, elevated, purple-red, hyperkeratotic plaques and nodules. Verrucal lesions may develop, which can simulate keratinocyte carcinomas, rupioid psoriasis, rupioid syphilis, reactive arthropathy, and cutaneous lupus erythematosus. The lesions of hypertrophic lichen planus may show follicular accentuation, elevation, and chalk-like scale. Chronic venous insufficiency is commonly among individuals with hypertrophic lichen planus.

Atrophic Lichen Planus: The atrophic variant of lichen planus is characterized by oligo-lesional disease with well-marginated, blue-white papules or plaques with central atrophy.[49] Early lesions are often a few millimeters in diameter but may coalesce into larger plaques. Atrophic lichen planus is most common on the proximal lower extremity and trunk. The two clinical entities in the differential diagnosis are lichen sclerosus et atrophicus and mycosis fungoides (MF). The histopathology may be subtle and has led some to believe that atrophic lichen planus occurs in late-stage resolved disease and is not a true variant of lichen planus.

Vesiculobullous Lichen Planus: Vesiculobullous lesions in lichen planus are rare. They occur secondary to an exuberant inflammatory response and an exaggerated Max-Joseph space. This is in contrast to lichen planus pemphigoides, which has classic lesions of lichen planus separated from lesions of bullous pemphigoid and positive bullous pemphigoid

Figure 32-4 Hypertrophic lichen planus. Well-marginated, acanthotic and papillomatous, dull-violet plaques are noted over the anterior shin. Areas of postinflammatory hyperpigmentation as well as superficial varicosities, signifying venous stasis, are noted. (Used with permission from Mayo Foundation for Medical Education and Research, all rights reserved.)

antibodies (BP 180 and 230) and immunofluorescence. Vesiculobullous lesions on the skin are more common on the lower extremities (Fig. 32-5) and tend to occur in acute flares of lichen planus. The disease course is similar to that of classic lichen planus. Oral vesiculobullous disease is often symptomatic and leads to erosion and ulceration.

Erosive and Ulcerative Lichen Planus: Erosive and ulcerative cutaneous disease is more common on the feet (Fig. 32-6) and oral cavity and is associated with significant pain and scarring.[61] Patients often

Figure 32-5 Vesiculobullous lichen planus. Vesicles and bullae with violaceous-erythematous papules and plaques on the foot. (Used with permission from Mayo Foundation for Medical Education and Research, all rights reserved.)

Figure 32-6 Erosive–ulcerative lichen planus. Erosions, ulcers, and granulation tissue and scarring of toes, interdigital web spaces, and soles. (Used with permission from Mayo Foundation for Medical Education and Research, all rights reserved.)

have other ectodermal involvement, which aids in the diagnosis. Scarring alopecia and loss of the toenails are common. Squamous cell carcinoma (SCC) has been described in chronic lesions of ulcerative oral lichen planus.

Follicular Lichen Planus: Follicular lichen planus may occur alone or in association with other cutaneous or mucosal forms of lichen planus.[62] Follicular lichen planus occurs most commonly on the scalp and occurs in three distinct variants, including lichen planopilaris, frontal fibrosing alopecia, and Gram-Little-Piccardi-Lassueur syndrome (GLPLS) (see the discussion of lichen planus of the scalp). Rare reported cases of lichen planus follicularis tumidus, which is characterized clinically by pruritic, red-violet pseudo-tumoral facial and posterior auricular plaques with yellow cysts.[63] Lichen planus follicularis tumidus cases often have signs of lichen planus elsewhere. The diagnosis of lichen planus follicularis tumidus should be made with caution and folliculotropic MF, and cutaneous lupus erythematosus should be considered in the differential diagnosis.

Lichen Planus Pigmentosus: Lichen planus pigmentosus is characterized by hyperpigmented, dark-brown macules in sun-exposed and flexural folds (Fig. 32-7). Lichen planus pigmentosus is more common in darker skinned individuals. Histologically, there are epidermal atrophy, a lymphocyte poor LTR, and pigment incontinence. Lichen planus pigmentosus and ashy dermatosis, or erythema dyschromicum perstans, have significant overlapping features and likely represent a phenotypic spectrum based on genetic and environmental factors.

Actinic Lichen Planus: Actinic lichen planus was first described in subtropical countries.[64] Actinic lichen planus affects young individuals of Middle Eastern descent and is most common in the spring and summer months.[65-68] There is a predilection for the face;

Figure 32-7 Lichen planus pigmentosus. Multiple, well-marginated, hyperpigmented, dark-brown macules located along the neck, with sparing of the face. The macules coalesce to form a slightly retiform pattern. This patient had involvement of the intertriginous regions and negative patch testing results. (Used with permission from Mayo Foundation for Medical Education and Research, all rights reserved.)

however, the dorsal hands, arms, and nape of the neck are also affected.[68] The primary lesions are annular well-marginated, hyperpigmented brown-violet, flat-topped, plaques with a slightly rolled border.[66] The lesions are minimally symptomatic, and more classic lesions of lichen planus may be seen in non–photo-exposed areas. The histopathology is characterized by a more brisk LTR relative to lichen planus pigmentosus, vacuolar changes, and pigment incontinence.[68]

SITE OF INVOLVEMENT

Lichen Planus of the Scalp: Lichen planopilaris, or follicular lichen planus, is a distinct clinical and histologic entity with a female predominance. There are three distinct follicular variants of lichen planus on the scalp, including lichen planopilaris, frontal fibrosing alopecia, and GLPLS. In classic lichen planopilaris, individual keratotic follicular papules form plaques on the scalp with associated scarring alopecia. Classic lichen planopilaris affects the vertex scalp and consists of diffuse erythema with perifollicular hyperkeratosis and livid erythema (Fig. 32-8A).[69] Dermoscopy can aid in the diagnosis of early scarring lichen planopilaris. Dermoscopic features of lichen planopilaris include absence of follicular opening, cicatricial white patches, peripilar casts and perifollicular scale, blue-gray dots, perifollicular erythema, and polytrichia (two or three hairs) (Fig. 32-8B).[70] Most active lesions are found within the hair-bearing areas at the edge of the alopecic patch. The scarring alopecia may be unilesional or multifocal with severe cases resulting in near-total scalp involvement. Lichen planopilaris, as well as frontal fibrosing alopecia and GLPLS, often has a significant psychological impact on affected individuals.

Frontal fibrosing alopecia was once considered an uncommon condition characterized by progressive

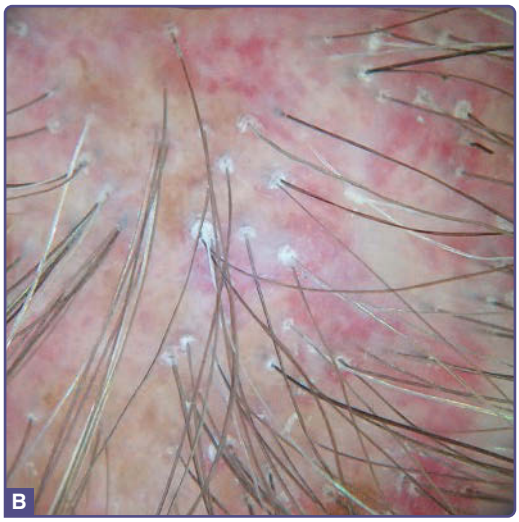

Figure 32-8 Follicular lichen planus. Lichen planopilaris. **A,** Posterior scalp scarring alopecia with perifollicular erythema and scaling. **B,** Dermoscopy showing white scarred patches, peripilar casts, perifollicular scale and erythema, and polytrichia. Frontal fibrosing alopecia. **C,** Frontal scalp with scarring alopecia, perifollicular erythema, and scaling. Note the complete loss of the eyebrows bilaterally.

frontotemporal recession caused by inflammatory destruction of the hair follicles (Fig. 32-8C). Up to 75% of women with frontal fibrosing alopecia report concomitant loss of the eyebrows, which tends to be noninflammatory.[71] The number of cases of frontal fibrosing alopecia has increased dramatically in recent years. Leave-on facial products, including sunscreen, and positive patch test results to fragrances are more common in individuals with frontal fibrosing alopecia.[72] Frontal fibrosing alopecia is more common in postmenopausal women but can occur in younger women as well. The disease is characterized by slow progression of frontal hairline recession over years.

GLPLS is a rare subtype characterized by cicatricial alopecia of the scalp, nonscarring alopecia of the axilla and groin, and follicular papules on the trunk and extremities.[73]

Pseudopelade of Brocq is a rare clinical syndrome of scarring alopecia and fibrosis, in which distinct pathologic features are absent. It is generally accepted that pseudopelade of Brocq is the end stage of follicular fibrosis caused by a primary inflammatory dermatosis such as lichen planus, lupus erythematosus, pustular scarring forms of folliculitis, fungal infections, scleroderma, and sarcoidosis.

Mucosal Lichen Planus: Lichen planus can affect any mucosal surface and most commonly involves the mouth or genitalia. Its prevalence is estimated at approximately 1% of the adult population.[47] Oral involvement occurs in approximately 60% to 70% of patients with lichen planus and may be the only manifestation in 20% to 30% of patients.[49,54,74-76] Multiple types of oral lichen planus have been described, including reticular, plaque-like, atrophic, papular, erosive or ulcerative, and bullous forms (Fig. 32-9). The reticular form of oral lichen planus is the most common and is often asymptomatic. The buccal mucosa is the most common site of involvement followed by the tongue and gingiva. Erosive and ulcerative oral lichen planus is most on the tongue, is extremely painful, and thus is commonly reported in the literature.[77] Gingival involvement may take the form of gingival stomatitis or desquamative gingivitis and is the sole manifestation in 8% of oral lichen planus. On the other hand, oral lichen planus is the most common cause of desquamative gingivitis, accounting for 75% of cases.[78]

Oral lichenoid reactions (OLRs) are similar clinically and histologically to oral lichen planus; however, with an identifiable cause. Differentiating these two entities clinically is often difficult. OLRs are usually seen on the buccal mucosa adjacent to amalgam dental fillings (Fig. 32-10).[79] Patch tests frequently show positive reactions to mercury, gold, and other metals.[80-82] Interestingly, patients with an OLR, no cutaneous lichen planus, and negative patch test results often improve with removal of amalgams.[83] This brings into question if amalgams are a bona fide hapten response or represent a special site irritant reaction, which leads to koebnerization.[84,85]

A unique lichenoid eruption has been described on the tongues of individuals with HIV. This reaction is characterized by bilateral reticular keratotic or atrophic changes of the buccal mucosa and lichenoid atrophic patches over the dorsal tongue.[86] The eruption usually follows zidovudine or ketoconazole intake and may therefore represent a unique drug hypersensitivity in the setting of immunosuppression.

Esophageal lichen planus is rare and most often affects the proximal esophagus. Esophageal lichen planus is most common in middle-aged women.[87] Nearly all cases of esophageal lichen planus have preceding or concomitant oral lichen planus.[88] Clinical clues of progressive dysphagia and odynophagia in the setting of oral lichen planus should prompt a gastroenterology referral for endoscopy. Endoscopic findings can include lacy white papules, pinpoint erosions, desquamation, pseudomembranes, and stenosis. Esophageal stricture is common and often requires multiple dilations. Histologically, esophageal lichen planus shows parakeratosis, epithelial atrophy, and lack of hypergranulosis.[87] Esophageal lichen planus often requires systemic immunosuppression with oral corticosteroids. Malignant transformation has been described; therefore, regular surveillance with gastroenterology is required.[87,89]

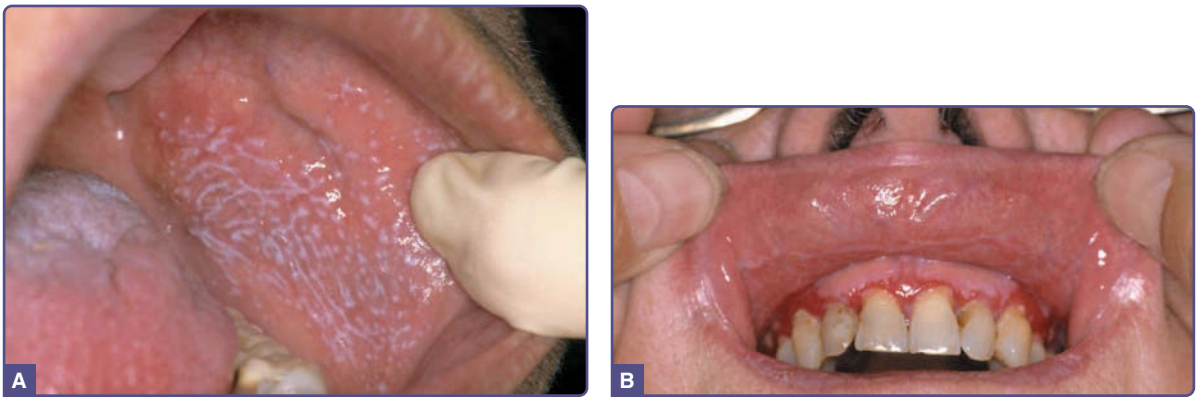

Figure 32-9 Mucosal lichen planus. **A,** Reticulate oral lichen planus with the typical lace-like, whitish reticulated pattern of oral lesions is seen on the buccal mucosa. **B,** Erosive oral lichen planus with painful erosions on the gingiva. (Used with permission from Mayo Foundation for Medical Education and Research, all rights reserved.)

Figure 32-10 Oral lichenoid tissue reaction. Reticulate oral lichenoid eruption with typical lace-like, reticulated pattern concentrated along the lower buccal mucosa and in close approximation to the underlying dental amalgams. (Used with permission from Mayo Foundation for Medical Education and Research, all rights reserved.)

Male genitalia are involved in 25% of cases of lichen planus (see Fig. 32-3). The glans penis is most commonly affected with annular lesions. Anal lesions of mucosal lichen planus present with leukokeratosis, hyperkeratosis, fissuring, and erosions (Fig. 32-11). Vulvar and vaginal lichen planus is present in 25% to 60% of patients with oral lichen planus.[74,90] Erosive and atrophic disease is most commonly reported in the literature. Clinically, the condition is often asymptomatic unless erosions develop, and then burning, itching, pain, and abnormal discharge become common.[91] Clinical examination often shows patches of leukoplakia or erythroplakia, sometimes with erosions, and occasionally, as a more generalized desquamative vaginitis. Vaginal adhesions and labial agglutination may result. Vulvovaginal gingival syndrome is a distinct triad of vulvar, vaginal, and gingival disease. Vulvovaginal gingival syndrome is characterized by erythema and erosions of the gingivae and tongue and desquamation and erosions of vulva and vagina.[92] Other cutaneous sites of involvement include skin (40%), scalp (20%), nails (13%), and esophagus (15%).[93] Vulvovaginal gingival syndrome is associated with significant long-term sequelae with nearly 90% of individuals developing fibrosis and stricture.[93] Class II HLA DBQ1*0201 allele has been found in 80% of individuals with vulvovaginal gingival syndrome with a relative risk of 3.71.[93] Given the multifocal involvement and chronic nature of vulvovaginal gingival syndrome, early institution of aggressive topical and systemic immunosuppression as well as a multidisciplinary approach is needed for optimal outcomes.

Figure 32-11 Mucosal lichen planus. Perianal leuko- and hyperkeratosis with hypertrophic, folded violaceous epithelium, fissures, and a healing biopsy site. (Used with permission from Mayo Foundation for Medical Education and Research, all rights reserved.)

Conjunctival lichen planus may manifest as cicatricial conjunctivitis. Histologically, irregular thickening with reduplication of the basement membrane is seen. Conjunctival lichen planus often a diagnostic challenge with significant overlap with cicatricial pemphigoid. In cases with severe oral and ocular disease and a lichenoid infiltrate on biopsy, one should also consider paraneoplastic autoimmune multiorgan syndrome and paraneoplastic and cicatricial pemphigoid in the differential diagnosis. Direct immunofluorescence, indirect immunofluorescence, and serologies for autoantibodies are often helpful to distinguish conjunctival lichen planus from cicatricial pemphigoid and paraneoplastic autoimmune multiorgan syndrome.[94,95] Long-term sequelae include corneal scarring, symblepharon, blindness, and lacrimal duct stenosis.[96]

Otic lichen planus is another rare manifestation of lichen planus affecting the external auditory canal and the tympanic membrane. Otic lichen planus is more common in women, often has concomitant disease at multiple body sites, and can lead to progressive hearing loss.[97] Otic lichen planus should be considered in the differential diagnosis in a patient with mucosal or cutaneous lichen planus with persistent, unexplained otorrhea or external auditory canal stenosis.

Lichen Planus of the Nails: Nail involvement occurs in 10% to 15% of lichen planus patients.[98] Lichen planus limited to the nails is uncommon and, in many cases, is followed by the development of more typical cutaneous or mucosal lesions of lichen planus. Nail involvement in children with lichen planus is rare and affects approximately 5%.[50-53] There are three major forms of nail lichen planus: classic nail lichen planus (described later) (Fig. 32-12A), 20-nail dystrophy (Fig. 32-12B), and idiopathic atrophy of the nails. The most common findings of nail lichen planus are diffuse nail involvement with thinning, longitudinal ridging, and distal nail splitting (onychoschizia). Other findings include onycholysis, longitudinal striation with a "sandpaper-like quality" (onychorrhexis), subungual hyperkeratosis, and atrophic or absent nail plates (anonychia). Dermoscopy can aid in the early diagnosis of nail lichen planus because early nail pitting may be present before the development of more classic disease.[99] Disease with prominent inflammation can result in nail loss and scarring. Pterygium or forward growth of the eponychia with adherence to the proximal nail plate is a classic finding in nail lichen planus involving the matrix. Dorsal pterygium is an irreversible process and, if present as the primary clinical findings, will likely

Figure 32-12 Nail lichen planus. **A,** Classic nail lichen planus showing longitudinal ridging and splitting of all nails (onychorrhexis) with distal splitting (onychoschizia). Additionally, the third finger shows dorsal pterygium at the lateral aspect of the nail bed with loss of the nail (anonychia). **B,** Twenty-nail dystrophy showing longitudinal ridging of all nails (trachyonychia) and atrophic nails. (Used with permission from Mayo Foundation for Medical Education and Research, all rights reserved.)

not improve with treatment. Involvement of the nail bed results in elevation of the nail plate and nail splitting. Trachyonychia, or uniform roughness of the nails, often affects all 20 nails and follows an indolent course. Idiopathic atrophy of the nails is characterized by an abrupt onset and rapidly progressive thinning of the nails with subsequent loss and scarring with or without dorsal pterygium. The latter two forms of nail lichen planus are more common in children.[100] The differential diagnosis of isolated nail lichen planus includes psoriasis, alopecia areata, atopic dermatitis, and rarely immunobullous diseases.

Inverse Lichen Planus: The inverse pattern of lichen planus is rare and is characterized by red-brown, discrete papules and flat-topped plaques. Inverse lichen planus commonly affects the flexural areas, including the axillae, inframammary region, and groin. The antecubital and popliteal areas may be rarely involved. The findings of inverse lichen planus are often isolated and involvement of other ectodermal-derived tissues is uncommon. Inverse lichen planus has been most commonly reported in whites, Asians, and recently Tunisians.[101] Unlike lichen planus pigmentosus, there is an absence of involvement in sun-exposed areas, and some prefer the term *lichen planus pigmentosus inversus*.

Palmoplantar Lichen Planus: Palmoplantar lichen planus is a rare, difficult-to-diagnose form of lichen planus. Approximately 25% of individuals with palmoplantar lichen planus have other areas of cutaneous involvement, most commonly on the anterior shin and malleoli in those with plantar disease.[102] Palmoplantar lichen planus is characterized by pruritic, red-purple, scaly plaques with or without hyperkeratosis. Because of the thickness of palmar and plantar skin, Wickham striae are absent. Four patterns of palmoplantar lichen planus are seen: plaque type, punctate, diffuse keratoderma, and ulcerated. Lesions are commonly seen on the internal plantar arch on the feet (see Fig. 32-5) and the thenar and hypothenar eminence on the hands (Fig. 32-13). Yellow, compact keratotic papules or papulonodules are seen on the lateral margins of the fingers and hand surfaces. Involvement of the fingertips is uncommon and, if present, raises the possibility of a primary or concomitant dermatitis. The lesions often appear callus-like with a faint purple hue and an inflammatory halo. The differential diagnosis includes psoriasis, warts, calluses, porokeratosis, hyperkeratotic dermatitis or eczema, tinea, or secondary syphilis.

SPECIAL FORMS

Drug-Induced Lichen Planus: Lichen planus–like or lichenoid drug eruptions are a group of cutaneous reactions identical or similar to lichen planus. Lichenoid drug eruptions have been reported after ingestion, contact, or inhalation of certain chemicals (Table 32-2).[103] They may be localized or generalized with eczematous papules and plaques. The degree of desquamation is variable. They often manifest with hyperpigmentation and alopecia. Wickham striae are rare. The eruption is often symmetrical on the trunk and extremities with less common flexural

Figure 32-13 Palmar lichen planus. Callus-like keratotic papules with a faint purple hue and an inflammatory halo are concentrated over the thenar and hypothenar eminence bilaterally. Note the relative sparing of the distal fingertips. (Used with permission from Mayo Foundation for Medical Education and Research, all rights reserved.)

TABLE 32-2
Agents Inducing Lichen Planus and Lichenoid Drug Eruptions

Most Likely
- Gold salts
- β-Blockers
- Antimalarials
- Diuretics (thiazides, furosemide, spironolactone)
- Penicillamine
- Immune checkpoint inhibitors (pembrolizumab, nivolumab, ipilimumab)

Less Likely
- Angiotensin-converting inhibitors
- Calcium channel blockers
- Sulfonylurea
- Nonsteroidal antiinflammatory drugs
- Ketoconazole
- Tetracycline
- Phenothiazine
- Sulfasalazine
- Carbamazepine
- Lithium
- Antituberculosis agents
- Iodides
- Radiocontrast media
- Radiotherapy
- Antipsoriatic therapy: etanercept, infliximab, adalimumab
- TNFα inhibitors (etanercept, infliximab, adalimumab, certolizumab)

Contact Inducers of Lichen Planus
- Color film developers
- Dental restoration materials
- Musk ambrette
- Nickel
- Gold

Photo Inducers of Lichen Planus and Lichenoid Drug Eruption
- 5-Fluorouracil
- Carbamazepine, chlorpromazine, diazoxide
- Ethambutol
- Pyritinol
- Quinine
- Quinidine
- Tetracycline
- Thiazide
- Furosemide

Inducers of Oral Lichen Planus and Lichenoid Drug Eruption
- Allopurinol
- Angiotensin-converting inhibitors
- Cyanamide
- Dental restoration materials
- Mercury, silver, gold
- Ketoconazole
- Nonsteroidal antiinflammatory drugs
- Penicillamines
- Sulphonylureas
- Interferon-α and ribavirin

involvement (Fig. 32-14). Involvement of the mucous membranes is rare and is associated with specific drugs and chemicals. A photodistributed pattern is implicated with specific drugs and chemicals as well. One new class of drugs with a high rate of lichenoid drug eruption is immune checkpoint inhibitors, ipilimumab, pembrolizumab, and nivolumab, which target

Figure 32-14 Lichenoid drug eruption. **A,** and **B,** Symmetrical, generalized, eczematous papules and plaques over the trunk and anterior shins. Wickham striae are absent, and there is sparing of the flexural surfaces. (Used with permission from Mayo Foundation for Medical Education and Research, all rights reserved.)

CTLA-4 and programmed cell death-1. Lichenoid drug eruptions are some of the most common side effects with this drug class, affecting 17% of patients.[104,105]

The latency period for the development of a lichenoid drug eruption varies from months to more than 1 year.

The time of onset depends on the dosage, host response, previous exposure, and concomitant drugs. The resolution of the lichenoid drug eruption is variable, and most resolve in 3 to 4 months. Exceptions are gold-induced lichenoid drug eruption, which can require years for resolution. For many drugs, the severity and extent of disease affect the rate of clearance. Occasionally, the lichenoid drug eruption may intermittently recur. Genetic susceptibility is likely important, especially in recurrent cases and cases involving immune-modulating drugs, such as INF-α, ipilimumab, pembrolizumab, and nivolumab.

Lichenoid contact dermatitis may result from contact with compounds such as color film developers, dental restorations, amalgams (silver, mercury, gold), and aminoglycosides (see "Mucosal Lichen Planus").[106,107] Oral lichenoid eruptions are most commonly related to dental restorations metals such as mercury, silver, and gold.[79-81,108]

Lichen Planus–Lupus Erythematosus Overlap: This rare variant of lichen planus is characterized by features of lichen planus and lupus erythematosus.[109,110] Lesions of lichen planus–lupus erythematosus overlap are red-violet, atrophic patches and plaques with hypopigmentation, telangiectasia, and minimal scale. The dorsal aspect of the extremities, specifically the hands and nails, are most commonly affected and patients often develop anonychia (Fig. 32-15). Classic features of lichen planus and lupus erythematosus are absent. Some individuals go on to develop systemic lupus erythematosus. Laboratory studies may find a weakly positive antinuclear antibody, and traditional histology and immunofluorescence show overlapping features of lichen planus and lupus erythematosus. The disease course of lichen planus–lupus erythematosus overlap is often prolonged and refractory to treatment.

Figure 32-15 Lichen planus–lupus erythematosus overlap syndrome. Lichenoid lesions over the dorsal hand and forearm. Direct immunofluorescence showed evidence of lupus erythematous. (Used with permission from Mayo Foundation for Medical Education and Research, all rights reserved.)

Lichen Planus Pemphigoides: Lichen planus pemphigoides has features of lichen planus and bullous pemphigoid (Fig. 32-16). The pathogenesis is unclear but is believed to result from the liquefactive degeneration of keratinocytes caused by a brisk LTR and the subsequent exposure of autoantigens, which result in antibody formation. Some have argued that lichen planus pemphigoides is simply lichen planus and bullous pemphigoid in coexistence. However, there are key clinical and serologic features that differentiate true lichen planus pemphigoides from concomitant lichen planus and bullous pemphigoid. First, lichen planus commonly affects individuals in the fifth to seventh decades of life and bullous pemphigoid most commonly after the seventh decade, but lichen planus pemphigoides is most common in younger individuals in the four to fifth decades of life. Additionally, lichen planus pemphigoides blisters may occur on top of lichenoid lesions as well as normal-appearing skin.

Figure 32-16 Lichen planus pemphigoides. Erythema, erosions, and bullae over the distal shin with histology showing a lichenoid tissue reaction and direct immunofluorescence showing features of bullous pemphigoid. Indirect immunofluorescence result also was positive. (Used with permission from Mayo Foundation for Medical Education and Research, all rights reserved.)

The prognosis of lichen planus pemphigoides is good and is response to conventional therapy.[111] Last, the Medical College of Wisconsin domain 4 (MCW-4) of bullous pemphigoid antigen 180 (BPAG180) appears to be unique for lichen planus pemphigoides.[112] The major consideration in the differential diagnosis is bullous lichen planus, which can be differentiated on serologies and immunofluorescence. Drug-induced lichen planus pemphigoides has been described.[113]

Keratosis Lichenoides Chronica (Nekam Disease): Keratosis lichenoides chronica (KLC), or Nekam disease, is a rare dermatosis that has distinct clinical and histologic features. Clinically, KLC is distinct from lichen planus and is characterized by lichenoid, keratotic papules and plaques in a seborrheic distribution with characteristic linear or reticulate pattern.[114] Additional sites of involvement include the palms and soles. The individual lesions tend to be folliculo- and infundibulocentric. The eruption is often asymptomatic and refractory to treatment. Histologically, KLC is characterized by a brisk LTR and often shows parakeratosis with neutrophils in the crust.[115] The diagnosis of KLC should be made with caution because other diseases such as lichen planus, lichen simplex, and lupus erthematosus (LE) may manifest a similar reaction pattern.[115]

Lichenoid Graft versus Host Disease: Chronic GVHD is traditionally considered that occurring 100 days after transplant and may manifest as a dermatitic, sclerodermoid, or lichenoid eruption, which can be indistinguishable from lichen planus. A newer consensus definition of GVHD focuses in on both clinical and chronological features, including classic acute GVHD, persist, recurrent, or late-onset acute GVHD occurring after 100 days, classic chronic GVHD, and overlap syndromes.[116] GVHD is caused by immunocompetent donor cells attacking fast dividing tissue such as the liver, gastrointestinal tract, and skin.

Although the mechanism is incompletely understood, the various forms of GVHD appear to be pathogenically distinct. Because there is a better understanding of GVHD relative to lichen planus and a clear driver of an autoantigen stimulating an allogeneic immune response, we will discuss the mechanism briefly. Whereas acute GVHD is driven by Th2 cytokine signaling, chronic GVHD is driven by Th1/Th17 signaling and increased numbers of IFN-γ– and IL-17–producing cytotoxic CD8-positive T cells.[117] Supporting this theory, mice deficient of IL-17 receptors are unable to develop GVHD.[118] Additionally, exciting new research with therapeutic potential points to the possible role of IL-17 blockade in the transdifferentiation of Th17 cells into CD4-positive T-regulatory cells.[119] Similar targets may be useful in refractory lichen planus.

Clinically, lichenoid GVHD is characterized by classic lichenoid papules with prominent follicular involvement of the head and neck as well as oral involvement.[120] Onycholysis and cicatricial alopecia may be prominent features. Histopathologically, lichenoid GVHD is often indistinguishable from lichen planus; however, satellite cell necrosis, plasma cells, and eosinophils may be subtle clues to the diagnosis.[121]

Lichenoid Keratosis: Lichenoid keratosis often consists of a single, nonpruritic, brown to red, scaling flat-topped plaque on sun-exposed skin of the extremities.[122] Lichenoid keratosis is easily differentiated clinically from lichen planus. These lesions can be histologically identical to lichen planus; however, they may have some differentiating features such as parakeratosis or a remnant lentigo, seborrheic keratosis, or actinic keratosis.

Lichenoid Dermatitis: Lichenoid dermatitis describes a reaction pattern with nonclassic lichenoid features as well as spongiosis. A study of 62 patients with lichenoid dermatitis had an alternative diagnoses with further clinical, serologic, and histopathological analysis. The differential diagnosis of lichenoid dermatitis includes dermatitis, drug eruption, lupus erythematosus, lichen planus, and cutaneous T-cell lymphoma.[123] Additional features, specifically granuloma formation, expand the differential diagnosis to include drug eruptions (including pseudolymphoma in 31%), hepatobiliary disease, endocrinopathy (diabetes mellitus and thyroiditis), rheumatoid arthritis, Crohn disease, and infection (in 28%).[124]

RELATED FINDINGS

See Table 32-3.

Lichen planus is associated with liver diseases such as autoimmune chronic active hepatitis, primary biliary cirrhosis (PBC), and postviral chronic, active hepatitis. The association of PBC is observed regardless of the use of penicillamine. Hepatitis C virus (HCV) and lichen planus are associated in certain endemic regions (East and Southeast Asia, South America, the Middle East, and Southern Europe) but not in others (North America, South Asia, and Africa).[125,126] The prevalence of HCV is 16% to 29% in

TABLE 32-3
Diseases Commonly Associated with Lichen Planus

Hepatitis C virus
Autoimmune chronic active hepatitis
Primary biliary cirrhosis
Postviral chronic, active hepatitis
Dyslipidemia
Metabolic syndrome
Hypothyroidism[a]
Lichen sclerosus et atrophicus[b]
Systemic lupus erythematosus
Sjögren disease
Dermatomyositis
Vitiligo
Alopecia areata

[a]Lichen planopilaris.
[b]Oral lichen planus.

southern European patients with lichen planus.[127,128] In patients with oral lichen planus and liver disease, there are significantly higher rates of HCV in selected populations (78% versus 3%). There is no clear association of HCV with pure cutaneous lichen planus.[129] There may be specific unidentified genetic factors contributing to this co-occurrence because large studies on HCV have not found lichen planus to be a common finding.[130] The heterogeneity of HCV and oral lichen planus may be related to the human leukocyte antigen-DR6 (HLA-DR6) haplotype, which is found in endemic regions of both diseases.[131,132] There is no strong link between hepatitis B virus (HBV) and lichen planus.[133]

Patients with lichen planus have been reported to have higher rates of dyslipidemia and to harbor more cardiac risk factors than healthy individuals.[134-136] Metabolic syndrome appears to be more common in individuals with oral lichen planus.[137] Thyroid dysfunction, most commonly hypothyroidism, is found in up to 34% of patients with lichen planopilaris.[138] Lichen sclerosus et atrophicus is seen in up to 16% of patients with oral lichen planus; however, there is no associated risk of oral lichen planus in individuals with lichen sclerosus et atrophicus.[90,139] Recent population studies have found an association between lichen planus and autoimmune diseases, including systemic lupus erythematosus, Sjögren disease, dermatomyositis, vitiligo, and alopecia areata, in the Taiwanese population.[140] Cases of lichen planus in association with internal malignancy may represent a manifestation of paraneoplastic autoimmune multiorgan syndrome.

MALIGNANT TRANSFORMATION

There has been considerable controversy as to whether oral lichen planus inherently harbors malignant potential.[77,141] It is currently believed that the risk of malignant transformation is low. Risk factors that increase the likelihood of developing oral cancer are long-standing disease, erosive or atrophic types, tobacco use, and possibly esophageal involvement. Additionally, oncogenic subtypes of HPV, including type 16, are more common in oral lichen planus and may account, in part, for the malignancy risk.[142] The reported rates of SCC development have varied: 0.8% of oral lichen planus in the United States, 1.9% in the United Kingdom, 0.6% in China, and 1% in the Swedish population.[77,143-145] The majority of these cases are in situ carcinoma or with a microinvasive pattern. The most common site for cancer is the tongue (Fig. 32-17) followed by the buccal mucosa, gingiva, and, rarely, the lip. Clinically, the lesions appear as indurated, nonhealing ulcers or exophytic lesions with a keratotic surface. Red atrophic plaques could also be seen and often correlate with in situ disease. Advanced cases may result in nodal metastases and even death. No overall increased risk of malignancy has been observed in cutaneous lichen planus.[145] There are rare case reports of cutaneous SCC arising in long-standing lesions of lichen planus. Risk factors include: hypertrophic or verrucous lichen planus, location on the lower extremity, a history of arsenic or x-ray exposure, and long-standing disease (average, 12 years).[145]

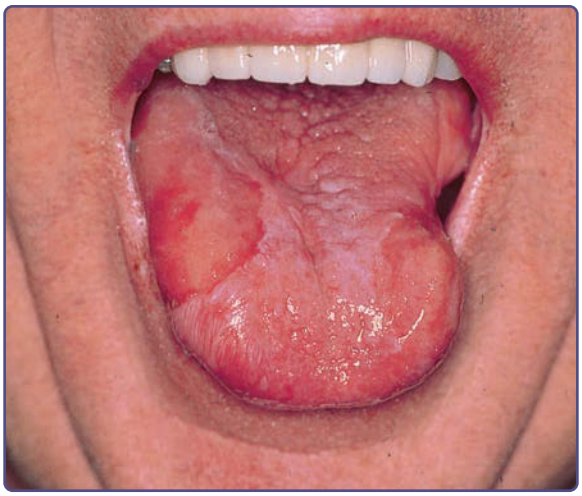

Figure 32-17 Lichen planus and squamous cell carcinoma (SCC). Long-standing oral lichen planus with scarring of the tongue. Well-circumscribed erythroplakia and erosions of the right lateral tongue was biopsied and confirmed SCC. (Used with permission from Mayo Foundation for Medical Education and Research, all rights reserved.)

DIAGNOSIS

The diagnosis of lichen planus is largely clinical. However, in cases with atypical or overlapping clinical features, a histopathologic diagnosis may be required. In cases of vesiculobullous disease or erosive disease, immunofluorescence (DIF), indirect immunofluorescence (IIF), and enzyme-linked immunosorbent assay (ELISA), may be needed to differentiate from immunobullous diseases. Laboratory testing is not required and is largely focused in upon associated morbidities and should be part of age-specific screening for risk reduction of diseases such as thyroid and cardiac disease.

SUPPORTIVE STUDIES

LABORATORY TESTING

See Table 32-4.

No specific abnormalities of laboratory analyses are seen in lichen planus. The total white blood cell count and lymphocytes may be decreased. This could be related to cytokine activation and local trafficking of cells to skin or other tissue compartments.

In cases of oral disease, allergic contact dermatitis should be ruled out because oral contact stomatitis can appear identical to lichen planus.[80,146-148] Sensitivity to mercury, gold, chromate, flavoring agents, acrylate,

TABLE 32-4
Laboratory Tests to Consider for Lichen Planus

Complete blood count
Patch testing[a]
Lipid panel
Thyroid function tests[b]
Antithyroid peroxidase antibodies
Antithyroglobulin antibodies
Hepatitis C virus testing[c]

[a]Particularly for oral lichen planus.
[b]For lichen planopilaris.
[c]For endemic areas; oral lichen planus.

and thimerosal are common sensitizers. Avoidance of these clinically relevant sensitizers results in amelioration of disease.

Dyslipidemia is more common in patients with lichen planus compared with control participants and should be tested as part of normal, preventative care.[134,135,137,149] Additionally, in cases of lichen planopilaris, one should consider testing for associated thyroid abnormalities, including thyroid-stimulating hormone, antithyroid peroxidase antibodies, and antithyroglobulin antibodies.[138]

HCV testing is controversial in lichen planus and testing should be considered in those with oral disease, risk factors for HCV (elevated liver function, intravenous drug use, a history of blood transfusion prior to 1992, and high risk sexual behaviors) as well as those in endemic areas (East and Southeast Asia, South America, the Middle East, and Southern Europe) having a prevalence of greater than 7%.[150]

PATHOLOGY

The two major pathologic findings in lichen planus are basal epidermal keratinocyte damage and a lichenoid-interface lymphocytic reaction. Classic changes are seen in established cutaneous lesions.[151] Classic lichen planus is characterized by a dense, continuous, and band-like lymphohistiocytic infiltrate at the DEJ (Fig. 32-18). The heavy infiltrate can result in effacement of the DEJ. Parakeratosis and eosinophils are absent. The epidermal changes include hyperkeratosis, wedge-shaped areas of hypergranulosis, and elongation of rete ridges that resemble a sawtooth pattern. Multiple apoptotic cells or colloid-hyaline (Civatte) bodies are seen at the DEJ. Eosinophilic colloid bodies are present in the papillary dermis. Eosinophils are absent in classic lichen planus and are seen in two thirds of lichenoid drug eruptions and are seen in significant numbers in 20.6% of cases of hypertropic lichen planus.[152-154] Melanin pigmentation is invariably present and is more pronounced in older, waning lesions in dark-skinned individuals and lichen planus pigmentosus. Separation of the epidermis in small clefts (Max Joseph cleft formation) is seen in 20% of cases.

Late disease is characterized by an atrophic epidermis, effacement of the rete ridges, occasional colloid bodies, dermal fibrosis, and melanophages. When few colloid bodies are present, distinguishing from poikiloderma may be very difficult.

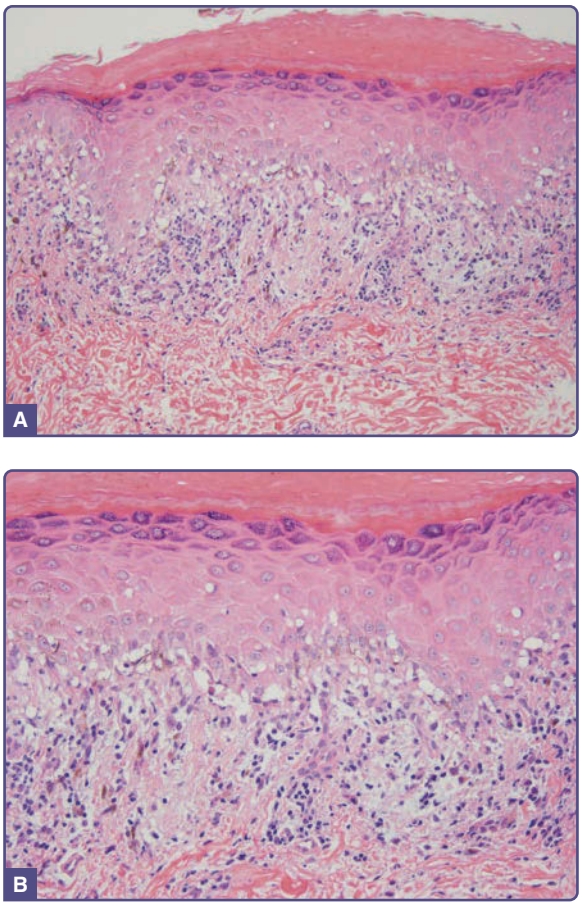

Figure 32-18 Lichen planus. **A,** The characteristic findings of lichen planus with compact orthohyperkeratosis, wedge-shaped hypergranulosis, sawtoothed rete ridges, and a lichenoid infiltrate. (Hematoxylin and eosin [H&E] × 100.) **B,** Dense, lichenoid lymphocytic infiltrate with scattered apoptotic keratinocytes and pigment incontinence. A small Max-Joseph space is noted centrally. (H&E × 200.) (Photo contributors: David J. DiCaudo, MD and Steven A. Nelson, MD. Used with permission from Mayo Foundation for Medical Education and Research, all rights reserved.)

Hypertrophic lichen planus is characterized by hyperkeratosis, acanthosis, papillomatosis, and thickened collagen bundles in the dermis (Fig. 32-19). Hypertrophic lichen planus can be mistaken for SCC; therefore, good clinical pathological correlation is needed to avoid inappropriate treatment.[155] As mentioned earlier, eosinophils are more commonly seen in hypertrophic lesions.[152]

Mucosal lesions tend to have less specific changes, and genital disease can often be inconclusive. Parakeratosis and an absent granular layer are common at mucosal sites, and plasma cells are often prominent.

Lichen planopilaris is characterized by a perifollicular, lymphohistiocytic inflammatory reaction with perifollicular fibrosis, scarring, and follicular atrophy. The initial inflammation is at the level of the isthmus and infundibulum and spares the lower segment.[156]

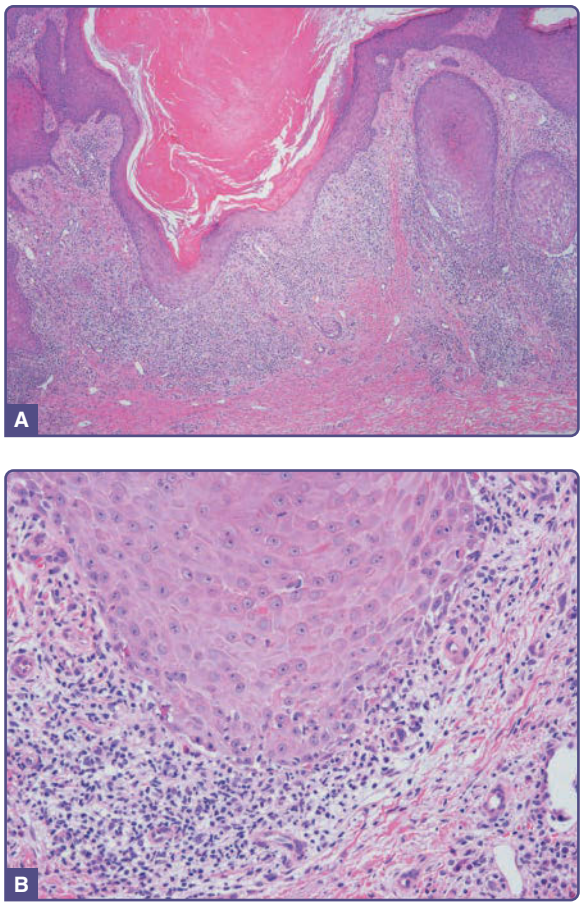

Figure 32-19 Hypertrophic lichen planus. **A,** The characteristic findings of hypertrophic lichen planus with hyperkeratosis, acanthosis, and papillomatosis. (Hematoxylin and eosin [H&E] × 40.) **B,** Dense, lichenoid lymphocytic infiltrate with scattered apoptotic keratinocytes and eosinophils. (H&E × 200.) (Photo contributors: David J. DiCaudo, MD and Steven A. Nelson, MD. Used with permission from Mayo Foundation for Medical Education and Research, all rights reserved.)

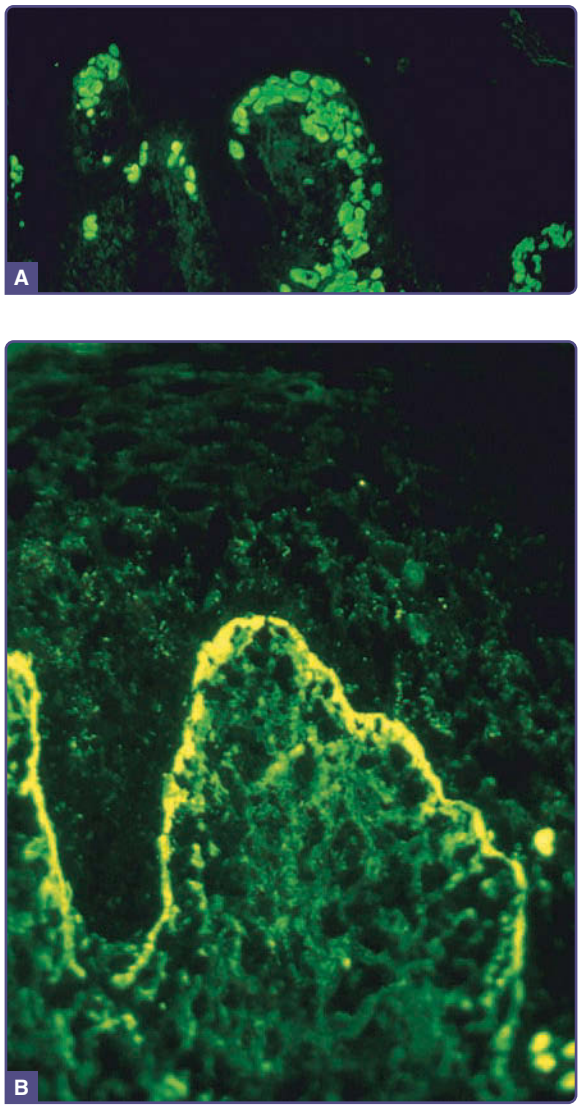

Figure 32-20 Lichen planus. Direct immunofluorescence. **A,** Fibrinogen/fibrin, shaggy pattern at the dermal–epidermal junction. **B,** Numerous immunoglobulin M-positive cytoids at the dermal–epidermal junction. (Used with permission from Mayo Foundation for Medical Education and Research, all rights reserved.)

DIF studies are focused on oral disease and show a positive finding in 62% to 75% of cases with numerous apoptotic cells at the DEJ (60%) staining with immunoglobulin M (IgM) and, occasionally, with IgG and IgA (Fig. 32-20).[157] Shaggy deposition of fibrinogen at the DEJ is seen in 55% to 70% of cases.[157,158] The criterion for lichen planus requires basement membrane zone fibrinogen and colloid bodies with one or more conjugate(s) (Mayo Clinic criteria).[157] Multiple immunoglobulin (IgG, A, and M) conjugates and granular, basilar deposition of immunoglobulins are more common in LE, and the diagnosis of lichen planus should be suspect when multiple conjugates are present.[159] DIF of oral lichen planus (sensitivity of 61% and specificity of 96%) is inferior to both hematoxylin and eosin (sensitivity of 84% and specificity of 93%) and clinical impression (sensitivity of 74% and specificity of 87%).[157] These findings emphasize the importance of clinical examination and routine histology in classic lichen planus. DIF has a role in atypical disease and is a prerequisite for the diagnosis of ulcerative and vesiculobullous lichen planus variants.

The location of the biopsy is critically important in lichen planus and varies by lichen planus subtype. The optimal location for biopsy of cutaneous lichen planus is on the proximal trunk with avoidance of the distal extremities.[158] Dermoscopic-driven biopsies of lichen planopilaris showing the key features of perifollicular erythema and scaling led to definitive diagnosis in 95% of cases.[160] Biopsies for nail disease should be guided by dermoscopy and should focus on the underlying structures involved. The presence of trachyonychia and pitting should guide a matrix biopsy, chromonychia, nail plate fragmentation, splinter hemorrhage, onycholysis, and subungual debris should guide a nail bed biopsy.[99] For DIF, the highest

sensitivity is on the mouth floor and the ventral side of the tongue. The oral biopsy specimen for DIF may be taken up to 1 cm from the lesion (including glabrous skin) without a decrease in sensitivity and should not be split.[158,161,162]

DIFFERENTIAL DIAGNOSIS

The differential diagnosis of lichen planus is quite broad. A more practical approach is to look at the age of the individual, morphology of the primary lesion, and site of involvement (Table 32-5).

CLINICAL COURSE AND PROGNOSIS

Most cutaneous lichen planus resolves within one to 2 years and may be associated with relapses. Recurrence is seen in up to 20% of cases but is more common in generalized cutaneous disease.[54,163] The duration of disease depends on the extent and site of involvement. In general, generalized disease tends to resolve more quickly. Disease duration, in ascending order, is generalized cutaneous, nongeneralized cutaneous, cutaneous and mucosal, mucosal, hypertrophic, and lichen planopilaris.[164] The mean duration of oral disease is 5 years, and hypertrophic and scalp disease are often unremitting. In higher Fitzpatrick skin types, postinflammatory changes manifest as significant, persistent pigmentary abnormalities.

TABLE 32-5
Differential Diagnosis of Lichen Planus

Morphology and Age

Classic: psoriasis, lichenoid drug eruption, lichen simplex chronicus, chronic cutaneous lupus, graft-versus-host disease, secondary syphilis, pityriasis rosea, mycosis fungoides

Annular: granuloma annulare, tinea corporis

Linear: nevus unius lateris, lichen striatus, linear epidermal nevus, psoriasis, Darier disease

Hypertrophic: lichen simplex chronicus, prurigo nodularis, lichen amyloidosis, Kaposi sarcoma, squamous cell carcinoma, psoriasis

Atrophic: lichen sclerosus, cutaneous lupus erythematosus, poikiloderma, mycosis fungoides, morphea

Vesiculobullous: lichen planus pemphigoides, epidermolysis bullosa pruriginosa, pemphigus vulgaris, bullous pemphigoid, bullous amyloidosis

Follicular: lichen nitidus, lichen spinulosa, follicular psoriasis, pityriasis rubra pilaris

Childhood: lichen nitidus, lichen striatus, pityriasis lichenoides, papular acrodermatitis of childhood, annular lichenoid dermatitis of youth, mycosis fungoides, frictional lichenoid eruption

Special Sites

Nail: psoriasis, onychomycosis, alopecia areata, atopic dermatitis

Genital: psoriasis, seborrheic dermatitis, fixed drug eruption

Palms and soles: secondary syphilis, erythema multiforme

Scalp: cicatricial alopecia, lupus erythematosus, inflammatory folliculitis, alopecia areata, cicatricial pemphigoid, keratosis follicularis spinulosa decalvans

Mucosal: pemphigus vulgaris, cicatricial pemphigoid, bullous pemphigoid, epidermolysis bullosa acquisita, paraneoplastic autoimmune multiorgan syndrome or paraneoplastic pemphigus, candidiasis, lupus erythematosus, leukokeratosis, secondary syphilis, traumatic patches, chronic ulcerative stomatitis, erythema multiforme

TREATMENT

The treatment of lichen planus is challenging and discouraging for both physicians and patients. Because of its ability to affect multiple ectodermal-derived tissues, lichen planus may require a multidisciplinary approach with dermatologists, dentists, gynecologists, and occasionally otolaryngologists, gastroenterologists, and ophthalmologists. The goal of therapy is to minimize morbidity and improve the patient's quality of life. Treatment options and the potential risks of therapy should be weighed against the extent and severity of disease. Potentially exacerbating drugs should be discontinued, trauma minimized, and microbial overgrowth reduced.

The basic concepts in the treatment of lichen planus have remained largely unchanged over the past decade. The therapies are mainly divided into skin-directed and systemic agents. The therapies for various ectodermal tissues are also similar. Nearly all of these agents act in a manner to suppress the immune response. To date, there are no disease-specific medications for lichen planus. However, Janus kinase (JAK) inhibitors target CD8-Tc cells and represent a potential, disease-specific treatment of lichenoid diseases, including lichen planus.[165] JAK inhibitors have been successful in treating refractory dermatomyositis, alopecia areata, and vitiligo.[166-168] This section provides a brief overview of the general approach to therapy for lichen planus and its variants of lichen planus.

CUTANEOUS LICHEN PLANUS

SKIN-DIRECTED THERAPIES

Topical Corticosteroids: Despite few clinical trials, high-potency topical corticosteroids are considered first-line therapy for limited cutaneous lichen planus. Occlusion may be necessary to increase penetration in cases of hypertrophic lichen planus. The sole randomized controlled trial in cutaneous lichen planus comparing calcipotriene to betamethasone valerate (twice daily for 12 weeks) found no difference between treatments.[169] If no response is observed with twice daily application for 2 to 4 weeks, changing to a higher potency corticosteroid or intralesional injections should be considered.[170]

Topical Calcineurin Inhibitors: There are no trials using topical calcineurin inhibitors in cutaneous lichen planus. However, clinical data in oral lichen

planus suggest that topical calcineurin inhibitors may be the most effective topical therapy for lichen planus. Application of tacrolimus 0.1% ointment is as effective as 0.05% clobetasol.[171] Because of cost, topical calcineurin inhibitors are a second-line topical agent and are often used in conjunction with topical steroids in refractory cases of limited cutaneous lichen planus. The combination of topical corticosteroids and calcineurin inhibitors often allows one to taper topical corticosteroids and minimize the possibility of steroid atrophy.

Intralesional Corticosteroids: Intralesional corticosteroids (5 to 10 mg/mL injected on a monthly basis) can be highly effective in resistant and hypertrophic lichen planus. However, one should use caution to prevent excessive trauma to avoid Koebnerization. Because of the risk of relapse, intralesional corticosteroids should always be combined with topical therapy or an additional corticosteroid-sparing agent.

Phototherapy: Phototherapy has been used successfully in many inflammatory diseases of the skin. Ultraviolet B (UVB) exposure of dendritic cells (DCs) impairs their interaction with T cells, alters cytokine expression, and leads to T-cell suppression and apoptosis.[172,173] UVB three times weekly until remission with taper after remission over 3 to 6 weeks has a 70% remission rate, and 85% of the patients remained in remission at 34 months.[174] A short course of oral corticosteroids in combination with UV light therapy is highly effective for generalized cutaneous lichen planus. Narrow-band UVB (311 nm) is as effective in lichen planus and has largely supplanted UVA, psoralen plus UVA (PUVA), and UVB phototherapy.[175]

SYSTEMIC THERAPIES

Systemic medications are often needed for severe, more protracted lichen planus. Oral corticosteroids are often first systemic treatments. Second-line, corticosteroid-sparing agents are sulfasalazine, metronidazole, acitretin, antimalarials (hydroxychloroquine and chloroquine), methotrexate, mycophenolate mofetil (MMF), and azathioprine (less preferred second-line agent). Because of its side effect profile, cyclosporine is considered a third-line corticosteroid-sparing agent. Within the second-line agents, particular agents are more effective for specific variants of lichen planus, which is outlined later. In general, drugs that target lymphocytes more specifically (methotrexate, MMF, and azathioprine) are of higher utility in refractory and ulcerative disease, but drugs acting indirectly on lymphocytes (sulfasalazine and metronidazole) or cellular differentiation (acitretin) are more effective for generalized disease and hypertrophic disease, respectively.

Systemic Corticosteroids: Systemic corticosteroids for cutaneous lichen planus have only been reported in one study with a 90% response rate and 32% relapse rate at 6 months.[176] Lichen planus is often responsive to 0.3 mg/kg to 1 mg/kg of oral prednisone within 4 to 6 weeks of treatment and requires a 4- to 6-week taper. In our clinical experience, systemic corticosteroids are highly effective and serve a role in attaining rapid disease control but are associated with high rates of relapse upon discontinuation. Therefore, oral should always be combined with topical therapy or an additional corticosteroid-sparing agent. Long-term monotherapy with oral corticosteroids is not recommended.

Sulfasalazine: Sulfasalazine (initial dose, 1 g/day with an increase every 3 days by 0.5 g to a maximum of 2.5 g/day) has the highest level of evidence of efficacy for lichen planus with an 83% improvement in skin lesions of generalized lichen planus and a 91% improvement in itch at 6 weeks in the therapy group.[177,178] Agranulocytosis and elevated liver function tests can occur with sulfasalazine; therefore, it is important to monitor these laboratory tests during drug initiation.

Metronidazole: An open-labeled study of oral metronidazole (250 mg three times daily for 12 weeks) showed a 74% response rate at 3 months of follow-up.[179] Alternate dosing (500 mg twice daily for 20 to 60 days) has also been reported to be successful.[180] In our experience, metronidazole is more effective in generalized cutaneous lichen planus. Because of its side effect profile, metronidazole is often considered the first-line nonimmunosuppressive systemic agent; however, one should caution patients as well as monitor for possible sensory peripheral neuropathy.[181]

Acitretin: A double-blind, placebo-controlled trial of acitretin (30 mg/day for 8 weeks) showed marked improvement in 64% of individuals.[182] Mucocutaneous side effects and hyperlipidemia were common. In our experience, acitretin is highly effective for hypertrophic lichen planus. Topical retinoids are of limited value in cutaneous lichen planus.

Antimalarials: Chloroquine has been reported effective in cutaneous lichen planus.[183,184] Hydroxychloroquine has been reported effective in oral lichen planus, lichen planopilaris, and actinic lichen planus.[185-190] However, given its favorable side effect profile, hydroxychloroquine (200 to 400 mg [up to 6.5 mg/kg ideal body weight] for 6 to 12 months) is often used as a second-line agent in cutaneous lichen planus and the first-line agent in actinic lichen planus.

Methotrexate: Methotrexate has been shown to be of benefit for more recalcitrant disease as well as in specific forms of disease, including hypertrophic lichen planus and lichen planopilaris. Recent, nonrandomized, prospective data have shown methotrexate (15 to 20 mg weekly for 4 to 24 weeks) to be highly efficacious with complete responses in 58% to 91% of cases.[191-193] Methotrexate is useful and cost effective and is a preferred second-line systemic agent.

Mycophenolate Mofetil and Azathioprine: Both oral MMF and azathioprine are used commonly in refractory cutaneous lichen planus. MMF, 2 to 3 g/day in divided doses is effective in refractory

cases; however, the clinical responses are delayed and adjuvant oral corticosteroids are often required during initiation.[194] Azathioprine has been reported effective in refractory lichen planus; however, because of its suppressive effects on T and B lymphocytes and its tolerability issues, we reserve this as a less preferred second-line agent.[195]

Cyclosporine: Cyclosporine has been reported effective at doses of 3 to 10 mg/kg/day; however, lower doses of 1.0 mg/kg/day to 2.5 mg/kg/day are likely to achieve disease remission.[196] Frequent relapses of lichen planus after discontinuation of cyclosporine, as well as its long-term side effects, limit its use in chronic lichen planus.

Other Therapies: TNF-α inhibitors, apremilast, trimethoprim–sulfamethoxazole, griseofulvin, itraconazole, terbinafine, tetracyclines, laser, IFN, alitretinoin, thalidomide, and low-dose heparin have also been reported.

ORAL LICHEN PLANUS

The cornerstone of treatment in oral lichen planus is good oral hygiene with regular professional dental cleanings.[197] Minimizing other exacerbating factors such as contact allergens, drug reactions, reducing oral microbes, and minimizing trauma can reduce disease severity as well as frequency of flares. Replacement of dental amalgams and gold dental restorations can be beneficial, even in patients with negative patch testing results.[84,85] Gingival lesions may respond less favorably. However, removal and restoration should be individualized based on the severity of disease as well as the index of suspicion of the level of involvement of the metal or prosthesis.

SKIN-DIRECTED THERAPIES

Topical Corticosteroids: Topical steroids are first-line therapy in oral lichen planus with overall clinical responses on the order of 70% to 80%. The use of occlusive materials, such as Orabase, may alleviate pain associated with ulcerative lesions. Although few direct comparisons between topical corticosteroids in lichen planus exist, the most beneficial are likely: 0.1% triamcinolone acetonide in Orabase, 0.025% to 0.05% clobetasol-17-propionate in Orabase, and 0.1% fluocinonide gel.[198,199] However, only clobetasol and fluocinonide have demonstrated a clear benefit over placebo.[200] Higher potency corticosteroids as well as more occlusive preparations lead to faster healing times.[201-203] However, the clinician and patient must weigh the benefit of an occlusive ointment or Orabase with the difficulty of application and potential for noncompliance. In general, topical corticosteroids should be applied two to six times daily based on the severity of disease. One therapeutic approach is to initiate high to ultrapotent steroid gel three times daily after meals to all affected areas followed by tacrolimus ointment twice daily. The corticosteroids are tapered every 2 to 4 weeks to a maintenance dose of two to three times weekly, and tacrolimus is continued twice daily.

The major complications of topical corticosteroids are fungal infections and, in general, higher rates of fungal infections are seen with more potent topical corticosteroids. Therefore, concomitant therapy with oral chlorohexidine gluconate mouthwash, topical anticandidal medications, or prophylactic oral fluconazole is recommended.[202,204]

Topical Calcineurin Inhibitors: Pimecrolimus 1% cream is effective in curing the erosive lesions of oral lichen planus but is ineffective at symptomatic control.[198,205] Meta-analysis has found tacrolimus 0.1% ointment one to four times daily to be more effective than clobetasol propionate ointment.[198] Cyclosporine in various preparations has been found to be less effective than both clobetasol and triamcinolone.[198,206] Because of cost, commercially available calcineurin inhibitors and increasing restrictions on compounding, we would recommend topical cyclosporine as a third-line topical agent. Transient burning with usage of topical calcineurin inhibitors is common and overlap therapy with topical corticosteroids may alleviate the burning sensation.

Retinoids: Topical tretinoin 0.05% to 0.1% gel applied twice daily may be effective in oral lichen planus; however, because of issues of irritation, this is a third-line topical agent and is often used in conjunction with topical corticosteroids.[207,208]

Intralesional Corticosteroids: Intralesional triamcinolone 0.5 mL of 40 mg/mL on a weekly basis for 4 weeks is effective in oral lichen planus.[209] More dilute concentrations, 10 mg/mL, injected every 1 to 4 weeks, in conjunction with topical corticosteroids, is highly effective. However, because of the discomfort of injection and few well-controlled studies, intralesional therapies are reserved after exhausting topical therapies.

SYSTEMIC THERAPIES

The approach to systemic therapies in oral lichen planus is similar to that of cutaneous disease. A few exceptions are the larger reported series of MMF and hydroxychloroquine in refractory oral lichen planus, the efficacy and dual benefit of oral acitretin, and the high levels of iatrogenic candida infections. In general, the hierarchy of therapy is the same; however, one should always consider the increased risk of oral SCC in erosive and refractory oral lichen planus and more heavily weigh the risks of immunosuppression against the benefits of disease control. Based on this, drugs such as acitretin, with its antiproliferative effects, and less immunosuppressive agents such as hydroxychloroquine and methotrexate are preferred.

Oral Corticosteroids: Systemic steroids are one of the most effective treatment for oral lichen planus and can provide rapid improvement in acute exacerbations.

However, there are no randomized clinical trials for systemic corticosteroids. Both clinical experience as well as prospective studies indicates that oral corticosteroids 1.5 to 2 mg/kg tapered over 3 to 6 weeks are highly effective.[210,211] Based on evidence in other erosive and blistering dermatologic diseases, doses greater than 1 mg/kg of corticosteroids add little clinical benefit and dramatically increase side effects. Studies using pulsed betamethasone, 5 mg on 2 consecutive days weekly for 3 months, showed a more rapid response but no clear long-term advantage over topicals.[212] Oral therapy should be done concomitantly with topical therapy or systemic steroid-sparing agents because patients often flare upon discontinuation. Oral candidiasis is a common complication of oral corticosteroids, and prophylaxis should be used.

Oral Retinoids: Oral acitretin is effective in oral lichen planus; one study of severe lichen planus found that 30 mg/day for 8 weeks resulted in remission in two thirds of cases.[182] Acitretin can be effective at lower doses of 25 mg 3 to 7 days per week; however, oral lichen planus often recurs after the discontinuation of therapy; therefore, adjuvant topical therapy is often necessary. In a pilot study, oral alitretinoin dosed at 30 mg/day for up to 24 weeks reduced the severity of disease by 50% in 4 of 10 patients with severe oral lichen planus.[213]

Antimalarials: Hydroxychloroquine (200 to 400 mg [up to 6.5 mg/kg ideal body weight] for 6 months) is effective as a monotherapy in oral lichen planus.[186] Despite its long half-life, improvement in erythema and pain may be seen within 1 to 2 months and reduction in erosions in 3 to 6 months.[186]

Methotrexate: Methotrexate at 2.5 to 7.5 mg weekly with adjuvant topical therapies is effective for severe, refractory oral lichen planus.[214] Based on reports in cutaneous lichen planus and in clinical practice, 10 to 15 mg weekly is more efficacious without an increase in side effects. The benefits of methotrexate can be seen within 4 to 8 weeks of initiation. Both methotrexate and MMF are first choices as a corticosteroid-sparing agent. Whereas MMF and methotrexate are preferred with erosive disease, oral retinoids are preferred with noneroded and hyperkeratotic disease. Given its low cost and relatively fast onset, methotrexate is often our preferred second-line systemic agent.

Mycophenolate Mofetil: MMF at 2 to 3 g/day in divided doses led to remission in 6 of 10 patients with severe oral lichen planus.[215] Of note, the clinical improvement of oral lichen planus using MMF can be gradual, often over 3 to 6 months, and adjuvant topical or oral corticosteroids are often necessary. Because of its tolerability and safety, MMF is considered a second-line systemic agent.

Cyclosporine: Cyclosporine has been reported effective in a report of two patients.[196] The dosages of cyclosporine are outlined in the prior section on cutaneous lichen planus therapies. Because of its long-term side effect profile and because there is no clear evidence that cyclosporine is superior to methotrexate or MMF in oral lichen planus, it is a third-line systemic agent.

Other Therapies: Additional therapies have been reported, including mesalazine, antibiotics, hydroxychloroquine, griseofulvin, thalidomide, and azathioprine, as well as parenteral alefacept, extracorporeal photopheresis, laser therapy, and PUVA therapy have all been reported as efficacious. However, these therapies often have attendant side effects or do not show clear efficacy. They are reserved as third-line corticosteroid-sparing therapies, and the risks and benefits of therapy should be considered before institution.

LICHEN PLANOPILARIS AND FRONTAL FIBROSING ALOPECIA

There are no randomized controlled trials in lichen planopilaris and only one controlled study. Therefore, many of the therapies in lichen planopilaris are based on expert opinion.[216] Lichen planopilaris has three major subtypes; however, for therapeutic purposes, they will be divided into lichen planopilaris and frontal fibrosing alopecia. These clinically distinct entities also appear to be responsive to different therapies.[217] When considering therapeutic modalities, the psychosocial effects of irreversible, scarring alopecia should be taken into account. Although the pathogenesis of lichen planopilaris is unknown, there is destruction of the bulge region, which leads to scarring. Recent studies have indicated a deficiency of PPARγ, which may lead to loss of immune privilege and scarring alopecia.[24] However, targeting of PPARγ with pioglitazone has shown mixed results with cessation of disease progression in 14% to 73% of cases.[218,219]

LICHEN PLANOPILARIS

Skin-Directed Therapies: First-line therapies for lichen planopilaris are mid to high potency topical corticosteroids with an average 53% response rate.[156,217,220] There are only limited data to determine the efficacy of topical calcineurin inhibitors, but its efficacy in cutaneous and oral lichen planus makes it common second-line topical therapy.

Systemic Therapies: Hydroxychloroquine (6.5 mg/kg of ideal body weight for 6 to 12 months) is the second most commonly used drug and showed a good response in 23% of cases.[185,217] There have been several negative studies using hydroxychloroquine, and there is good evidence that although clinical evidence of inflammation is decreased, progressive scarring of follicles continues.[216] Based on these findings, we advocate against hydroxychloroquine as a monotherapy. Oral corticosteroids at 1 mg/kg/day for 15 days with

taper over 4 months and cyclosporine 300 mg/day for 3 to 5 months are the third most commonly used drugs with a good response in 60% of cases.[156,217,220,221] However, because of its side effect profile, cyclosporine has been largely supplanted by methotrexate and MMF. Relapse is common upon discontinuation of these medicines; therefore, topicals or intralesional therapy should be used concomitantly. A commonly used combinational regimen of oral doxycycline 100 mg twice daily, MMF 2 to 3 g/day, and intralesional steroids 10 mg/mL monthly basis had marked improvement in one third of cases in 6 to 12 months.[220,222-224]

Therapeutic Approach: One approach is superpotent topical corticosteroids, clobetasol, twice daily for 1 month, daily for 3 months, and every other day for 3 months.[221] Intralesional corticosteroids, hydroxychloroquine, and doxycycline (often in combination) can be added if there is no effect at 1 to 3 months, recognizing that hydroxychloroquine monotherapy is ineffective. Other immunosuppressive agents can then be added in severe, refractory, and rapidly progressive cases, including prednisone in combination with methotrexate or MMF, and cyclosporine monotherapy may be used with the above skin-directed therapies.

FRONTAL FIBROSING ALOPECIA

Skin-Directed Therapies: High-potency topical corticosteroids have been shown to be ineffective in frontal fibrosing alopecia, for 93% of cases, but intralesional corticosteroids (10 to 20 mg/mL injected every 3 to 6 months) led to partial improvement in 60% of cases.[217,221,225,226]

Systemic Therapies: Oral 5 α-reductase inhibitors, such as finasteride (2 mg to 5 mg/day dose for 12–18 months) or dutasteride (0.5 mg every 1 to 7 days) for 12 months), are most commonly used and most effective drugs, and they result in a good response in 45% to 47% of cases.[217,225,227-230] The largest study of frontal fibrosing alopecia to date found that androgenetic alopecia (AGA) was concurrently present in 40% of the women and 67% of the men.[226] Therefore, the benefit seen with antiandrogens may be due to the component of AGA. Hydroxychloroquine has been reported effective in approximately 30% of cases; however, many of the studies had concomitant topical therapy with immune modulators and minoxidil.[71,217] Other reported therapies (eg, systemic prednisone, hormone replacement, topical calcineurin inhibitors, topical minoxidil, cyclosporine, and MMF) have only been reported in small series and have highly variable response rates.

Therapeutic Approach: Based on the above evidence, many hair experts will use as first-line therapy an oral 5-αreductase inhibitor, intralesional corticosteroids, and occasionally topical minoxidil. For severe, rapidly progressive cases, corticosteroids in combination with MMF or methotrexate and cyclosporine monotherapy may be used in conjunction with these therapies.

NAIL LICHEN PLANUS

Nail lichen planus can be extremely difficult to treat, and 20-nail dystrophy and atrophic nails are often nonresponsive. The goal of therapy should be to reduce the number of inflammatory cells within the nail and to prevent irreversible pterygium. A therapeutic approach should be very similar to cutaneous lichen planus. Ultrapotent topical and intralesional corticosteroids (5 to 10 mg/mL injected on a weekly basis) are first-line therapies. Systemic therapies should be reserved for cases manifesting significant compromise of function and causing debilitating pain. Additional therapies such as hydroxychloroquine has also been reported.[187]

ACKNOWLEDGMENTS

Steven A Nelson, MD, David J DiCaudo, and Collin Costello

REFERENCES

1. Wilson E. On leichen planus. *J Cutan Med Surg.* 1869; 3(10):117-132.
2. Weyl A. Bemerkungen zum lichen planus. *Dtsch Med Wochenschr.* 1885;11:624-626.
3. Wickham L. Sur un signe pathognomonique du lichen de Wilson (lichen plan) Stries et ponctuations grisatres. *Ann Dermatol Syphiligr (Paris).* 1895;6:517-520.
4. Gougerot H, Burnier R. Lichen plan du col uterin, accompagnant un lichen plan jugal et un lichen plan stomacal: lichen plurimuqueux sans lichen cutane. *Bull Soc Fr Dermatol Syphiligr.* 1937;44:637-640.
5. Shiohara T, Moriya N, Tanaka Y, et al. Immunopathologic study of lichenoid skin diseases: correlation between HLA-DR-positive keratinocytes or Langerhans cells and epidermotropic T cells. *J Am Acad Dermatol.* 1988; 18(1 Pt 1):67-74.
6. Sugerman PB, Satterwhite K, Bigby M. Autocytotoxic T-cell clones in lichen planus. *Br J Dermatol.* 2000; 142(3):449-456.
7. Parodi A, Cozzani E, Massone C, et al. Prevalence of stratified epithelium-specific antinuclear antibodies in 138 patients with lichen planus. *J Am Acad Dermatol.* 2007;56(6):974-978.
8. de la Faille-Kuyper EH, de la Faille HB. An immunofluorescence study of lichen planus. *Br J Dermatol.* 1974; 90(4):365-371.
9. Carbone T, Nasorri F, Pennino D, et al. CD56 highCD16-NK cell involvement in cutaneous lichen planus. *Eur J Dermatol.* 2010;20(6):724-730.
10. McCartan BE, Lamey PJ. Expression of CD1 and HLA-DR by Langerhans cells (LC) in oral lichenoid drug eruptions (LDE) and idiopathic oral lichen planus (LP). *J Oral Pathol Med.* 1997;26(4):176-180.
11. Farthing PM, Matear P, Cruchley AT. Langerhans cell distribution and keratinocyte expression of HLADR in oral lichen planus. *J Oral Pathol Med.* 1992; 21(10):451-455.
12. Kawamura E, Nakamura S, Sasaki M, et al. Accumulation of oligoclonal T cells in the infiltrating lymphocytes in oral lichen planus. *J Oral Pathol Med.* 2003;32(5):282-289.

13. Zhou XJ, Savage NW, Sugerman PB, et al. TCR V beta gene expression in lesional T lymphocyte cell lines in oral lichen planus. *Oral Dis.* 1996;2(4):295-298.
14. Fayyazi A, Schweyer S, Soruri A, et al. T lymphocytes and altered keratinocytes express interferon-gamma and interleukin 6 in lichen planus. *Arch Dermatol Res.* 1999;291(9):485-490.
15. Seneschal J, Milpied B, Vergier B, et al. Cytokine imbalance with increased production of interferon-alpha in psoriasiform eruptions associated with antitumour necrosis factor-alpha treatments. *Br J Dermatol.* 2009; 161(5):1081-1088.
16. Lodi G, Scully C, Carrozzo M, Griffiths M, et al. Current controversies in oral lichen planus: report of an international consensus meeting. Part 1. Viral infections and etiopathogenesis. *Oral Surg Oral Med Oral Pathol Oral Radiol Endod.* 2005;100(1):40-51.
17. Meller S, Gilliet M, Homey B. Chemokines in the pathogenesis of lichenoid tissue reactions. *J Invest Dermatol.* 2009;129(2):315-319.
18. Tensen CP, Flier J, Van Der Raaij-Helmer EM, et al. Human IP-9: A keratinocyte-derived high affinity CXC-chemokine ligand for the IP-10/Mig receptor (CXCR3). *J Invest Dermatol.* 1999;112(5):716-722.
19. Cole KE, Strick CA, Paradis TJ, et al. Interferon-inducible T cell alpha chemoattractant (I-TAC): a novel non-ELR CXC chemokine with potent activity on activated T cells through selective high affinity binding to CXCR3. *J Exp Med.* 1998;187(12):2009-2021.
20. Farber JM. Mig and IP-10: CXC chemokines that target lymphocytes. *J Leukoc Biol.* 1997;61(3):246-257.
21. Kim CH, Rott L, Kunkel EJ, et al. Rules of chemokine receptor association with T cell polarization in vivo. *J Clin Invest.* 2001;108(9):1331-1339.
22. Szabo SJ, Sullivan BM, Stemmann C, et al. Distinct effects of T-bet in TH1 lineage commitment and IFN-gamma production in CD4 and CD8 T cells. *Science.* 2002;295(5553):338-342.
23. Marx N, Mach F, Sauty A, et al. Peroxisome proliferator-activated receptor-gamma activators inhibit IFN-gamma-induced expression of the T cell-active CXC chemokines IP-10, Mig, and I-TAC in human endothelial cells. *J Immunol.* 2000;164(12):6503-6508.
24. Karnik P, Tekeste Z, McCormick TS, et al. Hair follicle stem cell-specific PPARgamma deletion causes scarring alopecia. *J Invest Dermatol.* 2009;129(5): 1243-1257.
25. Groves RW, Ross EL, Barker JN, et al. Vascular cell adhesion molecule-1: expression in normal and diseased skin and regulation in vivo by interferon gamma. *J Am Acad Dermatol.* 1993;29(1):67-72.
26. Bennion SD, Middleton MH, David-Bajar KM, et al. In three types of interface dermatitis, different patterns of expression of intercellular adhesion molecule-1 (ICAM-1) indicate different triggers of disease. *J Invest Dermatol.* 1995;105(1 suppl):71S-79S.
27. Khan A, Farah CS, Savage NW, et al. Th1 cytokines in oral lichen planus. *J Oral Pathol Med.* 2003;32(2):77-83.
28. Ammar M, Mokni M, Boubaker S, et al. Involvement of granzyme B and granulysin in the cytotoxic response in lichen planus. *J Cutan Pathol.* 2008;35(7):630-634.
29. Quan LT, Tewari M, O'Rourke K, et al. Proteolytic activation of the cell death protease Yama/CPP32 by granzyme B. *Proc Natl Acad Sci U S A.* 1996;93(5): 1972-1976.
30. Zhou XJ, Sugerman PB, Savage NW, et al. Matrix metalloproteinases and their inhibitors in oral lichen planus. *J Cutan Pathol.* 2001;28(2):72-82.
31. Mazzarella N, Femiano F, Gombos F, et al. Matrix metalloproteinase gene expression in oral lichen planus: erosive vs. reticular forms. *J Eur Acad Dermatol Venereol.* 2006;20(8):953-957.
32. Neppelberg E, Johannessen AC, Jonsson R. Apoptosis in oral lichen planus. *Eur J Oral Sci.* 2001;109(5): 361-364.
33. Shen LJ, Ruan P, Xie FF, et al. [Expressions of Fas/FasL and granzyme B in oral lichen planus and their significance]. *Di Yi Jun Yi Da Xue Xue Bao.* 2004;24(12): 1362-1366.
34. Dekker NP, Lozada-Nur F, Lagenaur LA, et al. Apoptosis-associated markers in oral lichen planus. *J Oral Pathol Med.* 1997;26(4):170-175.
35. Pereira JS, Monteiro BV, Nonaka CF, et al. FoxP3(+) T regulatory cells in oral lichen planus and its correlation with the distinct clinical appearance of the lesions. *Int J Exp Pathol.* 2012;93(4):287-294.
36. Tao XA, Xia J, Chen XB, et al. FOXP3 T regulatory cells in lesions of oral lichen planus correlated with disease activity. *Oral Dis.* 2010;16(1):76-82.
37. Lin KL, Fulton LM, Berginski M, et al. Intravital imaging of donor allogeneic effector and regulatory T cells with host dendritic cells during GVHD. *Blood.* 2014; 123(10):1604-1614.
38. Shiohara T, Moriya N, Saizawa KM, et al. Role of Langerhans cells in epidermotropism of T cells. *Arch Dermatol Res.* 1988;280(1):33-38.
39. Gueiros LA, Gondak R, Jorge Junior J, et al. Increased number of Langerhans cells in oral lichen planus and oral lichenoid lesions. *Oral Surg Oral Med Oral Pathol Oral Radiol.* 2012;113(5):661-666.
40. Arnold R, Seifert M, Asadullah K, et al. Crosstalk between keratinocytes and T lymphocytes via Fas/Fas ligand interaction: modulation by cytokines. *J Immunol.* 1999;162(12):7140-7147.
41. Berthou C, Michel L, Soulie A, et al. Acquisition of granzyme B and Fas ligand proteins by human keratinocytes contributes to epidermal cell defense. *J Immunol.* 1997;159(11):5293-5300.
42. Wenzel J, Tuting T. An IFN-associated cytotoxic cellular immune response against viral, self-, or tumor antigens is a common pathogenetic feature in "interface dermatitis." *J Invest Dermatol.* 2008;128(10):2392-2402.
43. Kurts C. Cross-presentation: inducing CD8T cell immunity and tolerance. *J Mol Med.* 2000;78(6):326-332.
44. Platzer B, Stout M, Fiebiger E. Antigen cross-presentation of immune complexes. *Front Immunol.* 2014;5:140.
45. Gorouhi F, Davari P, Fazel N. Cutaneous and mucosal lichen planus: a comprehensive review of clinical subtypes, risk factors, diagnosis, and prognosis. *ScientificWorldJournal.* 2014;2014:742826.
46. Wenzel J, Peters B, Zahn S, et al. Gene expression profiling of lichen planus reflects CXCL9+-mediated inflammation and distinguishes this disease from atopic dermatitis and psoriasis. *J Invest Dermatol.* 2008; 128(1):67-78.
47. McCartan BE, Healy CM. The reported prevalence of oral lichen planus: a review and critique. *J Oral Pathol Med.* 2008;37(8):447-453.
48. Axell T, Rundquist L. Oral lichen planus—a demographic study. *Community Dent Oral Epidemiol.* 1987;15(1):52-56.
49. Boyd AS, Neldner KH. Lichen planus. *J Am Acad Dermatol.* 1991;25(4):593-619.
50. Pandhi D, Singal A, Bhattacharya SN. Lichen planus in childhood: a series of 316 patients. *Pediatr Dermatol.* 2014;31(1):59-67.

51. Kanwar AJ, De D. Lichen planus in childhood: report of 100 cases. *Clin Exp Dermatol.* 2010;35(3):257-262.
52. Sharma R, Maheshwari V. Childhood lichen planus: a report of fifty cases. *Pediatr Dermatol.* 1999; 16(5):345-348.
53. Walton KE, Bowers EV, Drolet BA, et al. Childhood lichen planus: demographics of a U.S. population. *Pediatr Dermatol.* 2010;27(1):34-38.
54. Altman J, Perry HO. The variations and course of lichen planus. *Arch Dermatol.* 1961;84:179-191.
55. Singal A. Familial mucosal lichen planus in three successive generations. *Int J Dermatol.* 2005;44(1): 81-82.
56. Copeman PW, Tan RS, Timlin D, et al. Familial lichen planus. Another disease or a distinct people? *Br J Dermatol.* 1978;98(5):573-577.
57. La Nasa G, Cottoni F, Mulargia M, et al. HLA antigen distribution in different clinical subgroups demonstrates genetic heterogeneity in lichen planus. *Br J Dermatol.* 1995;132(6):897-900.
58. Wenzel J, Scheler M, Proelss J, et al. Type I interferon-associated cytotoxic inflammation in lichen planus. *J Cutan Pathol.* 2006;33(10):672-678.
59. Batra P, Wang N, Kamino H, et al. Linear lichen planus. *Dermatol Online J.* 2008;14(10):16.
60. Mizukawa Y, Horie C, Yamazaki Y, et al. Detection of varicella-zoster virus antigens in lesional skin of zosteriform lichen planus but not in that of linear lichen planus. *Dermatology.* 2012;225(1):22-26.
61. Schepis C, Siragusa M, Lentini M. Erosive lichen planus: two uncommon cases. *Acta Derm Venereol.* 2008; 88(3):268-270.
62. Gunduz K, Sacar T, Inanir I, et al. Flexural follicular lichen planus. *Clin Exp Dermatol.* 2009;34(7):e297-298.
63. Jimenez-Gallo D, Albarran-Planelles C, Linares-Barrios M, et al. Facial follicular cysts: a case of lichen planus follicularis tumidus? *J Cutan Pathol.* 2013; 40(9):818-822.
64. Katzenellenbogen I. Lichen planus actinicus (lichen planus in subtropical countries). *Dermatologica.* 1962; 124:10-20.
65. Bouassida S, Boudaya S, Turki H, et al. [Actinic lichen planus: 32 cases]. *Ann Dermatol Venereol.* 1998; 125(6-7):408-413.
66. Dammak A, Masmoudi A, Boudaya S, et al. [Childhood actinic lichen planus (6 cases)]. *Arch Pediatr.* 2008; 15(2):111-114.
67. Denguezli M, Nouira R, Jomaa B. [Actinic lichen planus. An anatomoclinical study of 10 Tunisian cases]. *Ann Dermatol Venereol.* 1994;121(8):543-546.
68. Salman SM, Kibbi AG, Zaynoun S. Actinic lichen planus. A clinicopathologic study of 16 patients. *J Am Acad Dermatol.* 1989;20(2 Pt 1):226-231.
69. Meinhard J, Stroux A, Lunnemann L, et al. Lichen planopilaris: epidemiology and prevalence of subtypes—a retrospective analysis in 104 patients. *J Dtsch Dermatol Ges.* 2014;12(3):229-235, 229-236.
70. Duque-Estrada B, Tamler C, Sodre CT, et al. Dermoscopy patterns of cicatricial alopecia resulting from discoid lupus erythematosus and lichen planopilaris. *An Bras Dermatol.* 2010;85(2):179-183.
71. Samrao A, Chew AL, Price V. Frontal fibrosing alopecia: a clinical review of 36 patients. *Br J Dermatol.* 2010;163(6):1296-1300.
72. Aldoori N, Dobson K, Holden CR, et al. Frontal fibrosing alopecia: possible association with leave-on facial skin care products and sunscreens; a questionnaire study. *Br J Dermatol.* 2016;175(4):762-767.
73. Abbas O, Chedraoui A, Ghosn S. Frontal fibrosing alopecia presenting with components of Piccardi-Lassueur-Graham-Little syndrome. *J Am Acad Dermatol.* 2007;57(2 Suppl):S15-18.
74. Eisen D. The evaluation of cutaneous, genital, scalp, nail, esophageal, and ocular involvement in patients with oral lichen planus. *Oral Surg Oral Med Oral Pathol Oral Radiol Endod.* 1999;88(4):431-436.
75. Silverman S Jr, Gorsky M, Lozada-Nur F. A prospective follow-up study of 570 patients with oral lichen planus: persistence, remission, and malignant association. *Oral Surg Oral Med Oral Pathol.* 1985;60(1):30-34.
76. Andreasen JO. Oral lichen planus. 1. A clinical evaluation of 115 cases. *Oral Surg Oral Med Oral Pathol.* 1968; 25(1):31-42.
77. Eisen D. The clinical features, malignant potential, and systemic associations of oral lichen planus: a study of 723 patients. *J Am Acad Dermatol.* 2002;46(2): 207-214.
78. Lo Russo L, Fierro G, Guiglia R, et al. Epidemiology of desquamative gingivitis: evaluation of 125 patients and review of the literature. *Int J Dermatol.* 2009; 48(10):1049-1052.
79. Cobos-Fuentes MJ, Martinez-Sahuquillo-Marquez A, Gallardo-Castillo I, et al. Oral lichenoid lesions related to contact with dental materials: a literature review. *Med Oral Patol Oral Cir Bucal.* 2009;14(10):e514-520.
80. Yiannias JA, el-Azhary RA, Hand JH, et al. Relevant contact sensitivities in patients with the diagnosis of oral lichen planus. *J Am Acad Dermatol.* 2000;42(2 Pt 1): 177-182.
81. Rogers RS 3rd, Bruce AJ. Lichenoid contact stomatitis: is inorganic mercury the culprit? *Arch Dermatol.* 2004; 140(12):1524-1525.
82. Scalf LA, Fowler JF Jr, Morgan KW, et al. Dental metal allergy in patients with oral, cutaneous, and genital lichenoid reactions. *Am J Contact Dermat.* 2001; 12(3):146-150.
83. Dunsche A, Kastel I, Terheyden H, et al. Oral lichenoid reactions associated with amalgam: improvement after amalgam removal. *Br J Dermatol.* 2003;148(1): 70-76.
84. Ibbotson SH, Speight EL, Macleod RI, et al. The relevance and effect of amalgam replacement in subjects with oral lichenoid reactions. *Br J Dermatol.* 1996; 134(3):420-423.
85. Smart ER, Macleod RI, Lawrence CM. Resolution of lichen planus following removal of amalgam restorations in patients with proven allergy to mercury salts: a pilot study. *Br Dent J.* 1995;178(3):108-112.
86. Ficarra G, Flaitz CM, Gaglioti D, et al. White lichenoid lesions of the buccal mucosa in patients with HIV infection. *Oral Surg Oral Med Oral Pathol.* 1993; 76(4):460-466.
87. Chandan VS, Murray JA, Abraham SC. Esophageal lichen planus. *Arch Pathol Lab Med.* 2008;132(6): 1026-1029.
88. Harewood GC, Murray JA, Cameron AJ. Esophageal lichen planus: the Mayo Clinic experience. *Dis Esophagus.* 1999;12(4):309-311.
89. Chryssostalis A, Gaudric M, Terris B, et al. Esophageal lichen planus: a series of eight cases including a patient with esophageal verrucous carcinoma. A case series. *Endoscopy.* 2008;40(9):764-768.
90. Belfiore P, Di Fede O, Cabibi D, et al. Prevalence of vulval lichen planus in a cohort of women with oral lichen planus: an interdisciplinary study. *Br J Dermatol.* 2006;155(5):994-998.

91. Kennedy CM, Galask RP. Erosive vulvar lichen planus: retrospective review of characteristics and outcomes in 113 patients seen in a vulvar specialty clinic. *J Reprod Med.* 2007;52(1):43-47.
92. Eisen D. The vulvovaginal-gingival syndrome of lichen planus. The clinical characteristics of 22 patients. *Arch Dermatol.* 1994;130(11):1379-1382.
93. Setterfield JF, Neill S, Shirlaw PJ, et al. The vulvovaginal gingival syndrome: a severe subgroup of lichen planus with characteristic clinical features and a novel association with the class II HLA DQB1 0201 allele. *J Am Acad Dermatol.* 2006;55(1):98-113.
94. Thorne JE, Jabs DA, Nikolskaia OV, et al. Lichen planus and cicatrizing conjunctivitis: characterization of five cases. *Am J Ophthalmol.* 2003;136(2): 239-243.
95. Hahn JM, Meisler DM, Lowder CY, et al. Cicatrizing conjunctivitis associated with paraneoplastic lichen planus. *Am J Ophthalmol.* 2000;129(1):98-99.
96. Webber NK, Setterfield JF, Lewis FM, et al. Lacrimal canalicular duct scarring in patients with lichen planus. *Arch Dermatol.* 2012;148(2):224-227.
97. Sartori-Valinotti JC, Bruce AJ, Krotova Khan Y, et al. A 10-year review of otic lichen planus: the Mayo Clinic experience. *JAMA Dermatol.* 2013;149(9): 1082-1086.
98. Tosti A, Peluso AM, Fanti PA, et al. Nail lichen planus: clinical and pathologic study of twenty-four patients. *J Am Acad Dermatol.* 1993;28(5 Pt 1): 724-730.
99. Nakamura R, Broce AA, Palencia DP, et al. Dermatoscopy of nail lichen planus. *Int J Dermatol.* 2013;52(6): 684-687.
100. Tosti A, Piraccini BM, Cambiaghi S, et al. Nail lichen planus in children: clinical features, response to treatment, and long-term follow-up. *Arch Dermatol.* 2001; 137(8):1027-1032.
101. Mohamed M, Korbi M, Hammedi F, et al. Lichen planus pigmentosus inversus: a series of 10 Tunisian patients. *Int J Dermatol.* 2016.
102. Sanchez-Perez J, Rios Buceta L, Fraga J, Garcia-Diez A. Lichen planus with lesions on the palms and/or soles: prevalence and clinicopathological study of 36 patients. *Br J Dermatol.* 2000;142(2):310-314.
103. Ellgehausen P, Elsner P, Burg G. Drug-induced lichen planus. *Clin Dermatol.* 1998;16(3):325-332.
104. Voskens CJ, Goldinger SM, Loquai C, et al. The price of tumor control: an analysis of rare side effects of anti-CTLA-4 therapy in metastatic melanoma from the ipilimumab network. *PLoS One.* 2013;8(1):e53745.
105. Hwang SJ, Carlos G, Wakade D, et al. Cutaneous adverse events (AEs) of anti-programmed cell death (PD)-1 therapy in patients with metastatic melanoma: a single-institution cohort. *J Am Acad Dermatol.* 2016; 74(3):455-461 e451.
106. Brancaccio RR, Cockerell CJ, Belsito D, et al. Allergic contact dermatitis from color film developers: clinical and histologic features. *J Am Acad Dermatol.* 1993;28(5 Pt 2): 827-830.
107. Lembo G, Balato N, Patruno C, et al. Lichenoid contact dermatitis due to aminoglycoside antibiotics. *Contact Dermatitis.* 1987;17(2):122-123.
108. Raap U, Stiesch M, Reh H, et al. Investigation of contact allergy to dental metals in 206 patients. *Contact Dermatitis.* 2009;60(6):339-343.
109. Copeman PW, Schroeter AL, Kierland RR. An unusual variant of lupus erythematosus or lichen planus. *Br J Dermatol.* 1970;83(2):269-272.
110. Romero RW, Nesbitt LT Jr, Reed RJ. Unusual variant of lupus erythematosus or lichen planus. Clinical, histopathologic, and immunofluorescent studies. *Arch Dermatol.* 1977;113(6):741-748.
111. Zaraa I, Mahfoudh A, Sellami MK, et al. Lichen planus pemphigoides: four new cases and a review of the literature. *Int J Dermatol.* 2013;52(4):406-412.
112. Zillikens D, Caux F, Mascaro JM, et al. Autoantibodies in lichen planus pemphigoides react with a novel epitope within the C-terminal NC16A domain of BP180. *J Invest Dermatol.* 1999;113(1):117-121.
113. Ben Salem C, Chenguel L, Ghariani N, et al. Captopril-induced lichen planus pemphigoides. *Pharmacoepidemiol Drug Saf.* 2008;17(7):722-724.
114. Konstantinov KN, Sondergaard J, Izuno G, et al. Keratosis lichenoides chronica. *J Am Acad Dermatol.* 1998;38(2 Pt 2):306-309.
115. Boer A. Keratosis lichenoides chronica: proposal of a concept. *Am J Dermatopathol.* 2006;28(3):260-275.
116. Filipovich AH, Weisdorf D, Pavletic S, et al. National Institutes of Health consensus development project on criteria for clinical trials in chronic graft-versus-host disease: I. Diagnosis and staging working group report. *Biol Blood Marrow Transplant.* 2005;11(12): 945-956.
117. Bruggen MC, Klein I, Greinix H, et al. Diverse T-cell responses characterize the different manifestations of cutaneous graft-versus-host disease. *Blood.* 2014; 123(2):290-299.
118. Nakae S, Komiyama Y, Nambu A, et al. Antigen-specific T cell sensitization is impaired in IL-17-deficient mice, causing suppression of allergic cellular and humoral responses. *Immunity.* 2002;17(3):375-387.
119. Gagliani N, Amezcua Vesely MC, Iseppon A, et al. Th17 cells transdifferentiate into regulatory T cells during resolution of inflammation. *Nature.* 2015; 523(7559):221-225.
120. Aractingi S, Chosidow O. Cutaneous graft-versus-host disease. *Arch Dermatol.* 1998;134(5):602-612.
121. Shulman HM, Cardona DM, Greenson JK, et al. NIH Consensus development project on criteria for clinical trials in chronic graft-versus-host disease: II. The 2014 Pathology Working Group Report. *Biol Blood Marrow Transplant.* 2015;21(4):589-603.
122. Kim HS, Park EJ, Kwon IH, et al. Clinical and histopathologic study of benign lichenoid keratosis on the face. *Am J Dermatopathol.* 2013;35(7):738-741.
123. Oliver GF, Winkelmann RK, Muller SA. Lichenoid dermatitis: a clinicopathologic and immunopathologic review of sixty-two cases. *J Am Acad Dermatol.* 1989; 21(2 Pt 1):284-292.
124. Magro CM, Crowson AN. Lichenoid and granulomatous dermatitis. *Int J Dermatol.* 2000;39(2):126-133.
125. Shengyuan L, Songpo Y, Wen W, et al. Hepatitis C virus and lichen planus: a reciprocal association determined by a meta-analysis. *Arch Dermatol.* 2009; 145(9):1040-1047.
126. Halawani M. Hepatitis C virus genotypes among patients with lichen planus in the Kingdom of Saudi Arabia. *Int J Dermatol.* 2014;53(2):171-177.
127. Imhof M, Popal H, Lee JH, et al. Prevalence of hepatitis C virus antibodies and evaluation of hepatitis C virus genotypes in patients with lichen planus. *Dermatology.* 1997;195(1):1-5.
128. Mignogna MD, Lo Muzio L, Favia G, et al. Oral lichen planus and HCV infection: a clinical evaluation of 263 cases. *Int J Dermatol.* 1998;37(8): 575-578.

129. del Olmo JA, Pascual I, Bagan JV, et al. Prevalence of hepatitis C virus in patients with lichen planus of the oral cavity and chronic liver disease. *Eur J Oral Sci.* 2000; 108(5):378-382.
130. Cheng Z, Zhou B, Shi X, et al. Extrahepatic manifestations of chronic hepatitis C virus infection: 297 cases from a tertiary medical center in Beijing, China. *Chin Med J (Engl).* 2014;127(7):1206-1210.
131. Carrozzo M, Brancatello F, Dametto E, et al. Hepatitis C virus-associated oral lichen planus: is the geographical heterogeneity related to HLA-DR6? *J Oral Pathol Med.* 2005;34(4):204-208.
132. Carrozzo M, Francia Di Celle P, Gandolfo S, et al. Increased frequency of HLA-DR6 allele in Italian patients with hepatitis C virus-associated oral lichen planus. *Br J Dermatol.* 2001;144(4):803-808.
133. Mahboob A, Haroon TS, Iqbal Z, et al. Prevalence of hepatitis B surface antigen carrier state in patients with lichen planus—report of 200 cases from Lahore, Pakistan. *J Ayub Med Coll Abbottabad.* 2007; 19(4):68-70.
134. Saleh N, Samir N, Megahed H, et al. Homocysteine and other cardiovascular risk factors in patients with lichen planus. *J Eur Acad Dermatol Venereol.* 2013.
135. Arias-Santiago S, Buendia-Eisman A, Aneiros-Fernandez J, et al. Cardiovascular risk factors in patients with lichen planus. *Am J Med.* 2011;124(6):543-548.
136. Ozlu E, Karadag AS, Toprak AE, et al. Evaluation of cardiovascular risk factors, haematological and biochemical parameters, and serum endocan levels in patients with lichen planus. *Dermatology.* 2016;232(4):438-443.
137. Baykal L, Arica DA, Yayli S, et al. Prevalence of metabolic syndrome in patients with mucosal lichen planus: a case-control study. *Am J Clin Dermatol.* 2015;16(5): 439-445.
138. Atanaskova Mesinkovska N, Brankov N, Piliang M, et al Association of lichen planopilaris with thyroid disease: a retrospective case-control study. *J Am Acad Dermatol.* 2014;70(5):889-892.
139. Saunders H, Buchanan JA, Cooper S, et al. The period prevalence of oral lichen planus in a cohort of patients with vulvar lichen sclerosus. *J Eur Acad Dermatol Venereol.* 2010;24(1):18-21.
140. Chung PI, Hwang CY, Chen YJ, et al. Autoimmune comorbid diseases associated with lichen planus: a nationwide case-control study. *J Eur Acad Dermatol Venereol.* 2015;29(8):1570-1575.
141. Mignogna MD, Lo Muzio L, Lo Russo L, et al. Clinical guidelines in early detection of oral squamous cell carcinoma arising in oral lichen planus: a 5-year experience. *Oral Oncol.* 2001;37(3):262-267.
142. Syrjanen S, Lodi G, von Bultzingslowen I, et al. Human papillomaviruses in oral carcinoma and oral potentially malignant disorders: a systematic review. *Oral Dis.* 2011;17 Suppl 1:58-72.
143. Ingafou M, Leao JC, Porter SR, et al. Oral lichen planus: a retrospective study of 690 British patients. *Oral Dis.* 2006;12(5):463-468.
144. Xue JL, Fan MW, Wang SZ, et al. A clinical study of 674 patients with oral lichen planus in China. *J Oral Pathol Med.* 2005;34(8):467-472.
145. Sigurgeirsson B, Lindelof B. Lichen planus and malignancy. An epidemiologic study of 2071 patients and a review of the literature. *Arch Dermatol.* 1991; 127(11):1684-1688.
146. Allen CM, Blozis GG. Oral mucosal reactions to cinnamon-flavored chewing gum. *J Am Dent Assoc.* 1988;116(6):664-667.
147. Gunatheesan S, Tam MM, Tate B, et al. Retrospective study of oral lichen planus and allergy to spearmint oil. *Australas J Dermatol.* 2012;53(3):224-228.
148. Lomaga MA, Polak S, Grushka M, et al. Results of patch testing in patients diagnosed with oral lichen planus. *J Cutan Med Surg.* 2009;13(2):88-95.
149. Dreiher J, Shapiro J, Cohen AD. Lichen planus and dyslipidaemia: a case-control study. *Br J Dermatol.* 2009;161(3):626-629.
150. Lapane KL, Jakiche AF, Sugano D, et al. Hepatitis C infection risk analysis: who should be screened? Comparison of multiple screening strategies based on the National Hepatitis Surveillance Program. *Am J Gastroenterol.* 1998;93(4):591-596.
151. Ellis FA. Histopathology of lichen planus based on analysis of one hundred biopsy specimens. *J Invest Dermatol.* 1967;48(2):143-148.
152. Alomari A, McNiff JM. The significance of eosinophils in hypertrophic lichen planus. *J Cutan Pathol.* 2014;41(4):347-352.
153. Lage D, Juliano PB, Metze K, et al. Lichen planus and lichenoid drug-induced eruption: a histological and immunohistochemical study. *Int J Dermatol.* 2012;51(10):1199-1205.
154. Van den Haute V, Antoine JL, Lachapelle JM. Histopathological discriminant criteria between lichenoid drug eruption and idiopathic lichen planus: retrospective study on selected samples. *Dermatologica.* 1989;179(1):10-13.
155. Tan E, Malik R, Quirk CJ. Hypertrophic lichen planus mimicking squamous cell carcinoma. *Australas J Dermatol.* 1998;39(1):45-47.
156. Mehregan DA, Van Hale HM, Muller SA. Lichen planopilaris: clinical and pathologic study of forty-five patients. *J Am Acad Dermatol.* 1992;27(6 Pt 1):935-942.
157. Helander SD, Rogers RS 3rd. The sensitivity and specificity of direct immunofluorescence testing in disorders of mucous membranes. *J Am Acad Dermatol.* 1994; 30(1):65-75.
158. Kulthanan K, Jiamton S, Varothai S, et al. Direct immunofluorescence study in patients with lichen planus. *Int J Dermatol.* 2007;46(12):1237-1241.
159. Schiodt M, Holmstrup P, Dabelsteen E, et al. Deposits of immunoglobulins, complement, and fibrinogen in oral lupus erythematosus, lichen planus, and leukoplakia. *Oral Surg Oral Med Oral Pathol.* 1981; 51(6):603-608.
160. Miteva M, Tosti A. Dermoscopy guided scalp biopsy in cicatricial alopecia. *J Eur Acad Dermatol Venereol.* 2013; 27(10):1299-1303.
161. Sano SM, Quarracino MC, Aguas SC, et al. Sensitivity of direct immunofluorescence in oral diseases. Study of 125 cases. *Med Oral Patol Oral Cir Bucal.* 2008; 13(5):E287-291.
162. Mutasim DF, Adams BB. Immunofluorescence in dermatology. *J Am Acad Dermatol.* 2001;45(6):803-822; quiz 822-804.
163. Schmidt H. Frequency, duration and localization of lichen planus. A study based on 181 patients. *Acta Derm Venereol.* 1961;41:164-167.
164. Daoud MS, Pittelkow MR. Lichen planus. In: Goldsmith L, Katz SI, Gilchrest AS, P et al, eds. *Fitzpatrick's Dermatology in General Medicine*, 8th ed. New York, NY: McGraw-Hill; 2012.
165. Okiyama N, Furumoto Y, Villarroel VA, et al. Reversal of CD8 T-cell-mediated mucocutaneous graft-versus-host-like disease by the JAK inhibitor tofacitinib. *J Invest Dermatol.* 2014;134(4):992-1000.

166. Kurtzman DJ, Wright NA, Lin J, et al. Tofacitinib citrate for refractory cutaneous dermatomyositis: an alternative treatment. *JAMA Dermatol.* 2016;152(8): 944-945.
167. Hornung T, Janzen V, Heidgen FJ, et al. Remission of recalcitrant dermatomyositis treated with ruxolitinib. *N Engl J Med.* 2014;371(26):2537-2538.
168. Harris JE, Rashighi M, Nguyen N, et al. Rapid skin repigmentation on oral ruxolitinib in a patient with coexistent vitiligo and alopecia areata (AA). *J Am Acad Dermatol.* 2016;74(2):370-371.
169. Theng CT, Tan SH, Goh CL, et al. A randomized controlled trial to compare calcipotriol with betamethasone valerate for the treatment of cutaneous lichen planus. *J Dermatol Treat.* 2004;15(3):141-145.
170. Bjornberg A, Hellgren L. Betamethasone-I7, 2I-dipropionate ointment: an effective topical preparation in lichen ruber planus. *Curr Med Res Opin.* 1976; 4(3):212-217.
171. Samycia M, Lin AN. Efficacy of topical calcineurin inhibitors in lichen planus. *J Cutan Med Surg.* 2012; 16(4):221-229.
172. Wachter T, Averbeck M, Hara H, et al. Induction of CD4+ T cell apoptosis as a consequence of impaired cytoskeletal rearrangement in UVB-irradiated dendritic cells. *J Immunol.* 2003;171(2):776-782.
173. Gibbs NK, Norval M. Photoimmunosuppression: a brief overview. *Photodermatol Photoimmunol Photomed.* 2013;29(2):57-64.
174. Pavlotsky F, Nathansohn N, Kriger G, et al. Ultraviolet-B treatment for cutaneous lichen planus: our experience with 50 patients. *Photodermatol Photoimmunol Photomed.* 2008;24(2):83-86.
175. Wackernagel A, Legat FJ, Hofer A, et al. Psoralen plus UVA vs. UVB-311 nm for the treatment of lichen planus. *Photodermatol Photoimmunol Photomed.* 2007; 23(1):15-19.
176. Pitche P, Saka B, Kombate K, et al. [Treatment of generalized cutaneous lichen planus with dipropionate and betamethasone disodium phosphate: an open study of 73 cases]. *Ann Dermatol Venereol.* 2007;134 (3 Pt 1):237-240.
177. Omidian M, Ayoobi A, Mapar MA, et al. Efficacy of sulfasalazine in the treatment of generalized lichen planus: randomized double-blinded clinical trial on 52 patients. *J Eur Acad Dermatol Venereol.* 2010; 24(9):1051-1054.
178. Bauza A, Espana A, Gil P, et al. Successful treatment of lichen planus with sulfasalazine in 20 patients. *Int J Dermatol.* 2005;44(2):158-162.
179. Rasi A, Behzadi AH, Davoudi S, et al. Efficacy of oral metronidazole in treatment of cutaneous and mucosal lichen planus. *J Drugs Dermatol.* 2010;9(10): 1186-1190.
180. Buyuk AY, Kavala M. Oral metronidazole treatment of lichen planus. *J Am Acad Dermatol.* 2000;43(2 Pt 1): 260-262.
181. Zivkovic SA, Lacomis D, Giuliani MJ. Sensory neuropathy associated with metronidazole: report of four cases and review of the literature. *J Clin Neuromuscul Dis.* 2001;3(1):8-12.
182. Laurberg G, Geiger JM, Hjorth N, et al. Treatment of lichen planus with acitretin. A double-blind, placebo-controlled study in 65 patients. *J Am Acad Dermatol.* 1991;24(3):434-437.
183. Ayres S, 3rd, Ayres S Jr. Chloroquine in treatment of lichen planus and other dermatoses. *J Am Med Assoc.* 1955;157(2):136-138.
184. Pirila V, Helanen S. Trial of chloroquine in the treatment of lichen planus. *Acta Derm Venereol.* 1958; 38(3):194-197.
185. Chiang C, Sah D, Cho BK, et al. Hydroxychloroquine and lichen planopilaris: efficacy and introduction of Lichen Planopilaris Activity Index scoring system. *J Am Acad Dermatol.* 2010;62(3):387-392.
186. Eisen D. Hydroxychloroquine sulfate (Plaquenil) improves oral lichen planus: an open trial. *J Am Acad Dermatol.* 1993;28(4):609-612.
187. Mostafa WZ. Lichen planus of the nail: treatment with antimalarials. *J Am Acad Dermatol.* 1989;20(2 Pt 1): 289-290.
188. Ramirez P, Feito M, Sendagorta E, et al. Childhood actinic lichen planus: successful treatment with antimalarials. *Australas J Dermatol.* 2012;53(1): e10-13.
189. Rivas-Tolosa N, Requena C, Llombart B, et al. Antimalarial drugs for the treatment of oral erosive lichen planus. *Dermatology.* 2016;232(1):86-90.
190. Schewach-Millet M, Skpiro D, Sofer E. Actinic lichen planus: treatment with antimalarials. *J Am Acad Dermatol.* 1990;22(2 Pt 1):325.
191. Hazra SC, Choudhury AM, Khondker L, et al. Comparative efficacy of methotrexate and mini pulse betamethasone in the treatment of lichen planus. *Mymensingh Med J.* 2013;22(4):787-797.
192. Kanwar AJ, De D. Methotrexate for treatment of lichen planus: old drug, new indication. *J Eur Acad Dermatol Venereol.* 2013;27(3):e410-413.
193. Turan H, Baskan EB, Tunali S, et al. Methotrexate for the treatment of generalized lichen planus. *J Am Acad Dermatol.* 2009;60(1):164-166.
194. Frieling U, Bonsmann G, Schwarz T, et al. Treatment of severe lichen planus with mycophenolate mofetil. *J Am Acad Dermatol.* 2003;49(6):1063-1066.
195. Verma KK, Sirka CS, Khaitan BK. Generalized severe lichen planus treated with azathioprine. *Acta Derm Venereol.* 1999;79(6):493.
196. Ho VC, Gupta AK, Ellis CN, et al. Treatment of severe lichen planus with cyclosporine. *J Am Acad Dermatol.* 1990;22(1):64-68.
197. Holmstrup P, Schiotz AW, Westergaard J. Effect of dental plaque control on gingival lichen planus. *Oral Surg Oral Med Oral Pathol.* 1990;69(5):585-590.
198. Davari P, Hsiao HH, Fazel N. Mucosal lichen planus: an evidence-based treatment update. *Am J Clin Dermatol.* 2014;15(3):181-195.
199. Ungphaiboon S, Nittayananta W, Vuddhakul V, et al. Formulation and efficacy of triamcinolone acetonide mouthwash for treating oral lichen planus. *Am J Health Syst Pharm.* 2005;62(5):485-491.
200. Voute AB, Schulten EA, Langendijk PN, et al. Fluocinonide in an adhesive base for treatment of oral lichen planus. A double-blind, placebo-controlled clinical study. *Oral Surg Oral Med Oral Pathol.* 1993; 75(2):181-185.
201. Rödström P, Hakeberg M, Jontell M, et al. Erosive oral lichen planus treated with clobetasol propionate and triamcinolone acetonide in Orabase: a double-blind clinical trial. *J Dermatol Treat* 1994;5(1): 7-10.
202. Carbone M, Conrotto D, Carrozzo M, et al. Topical corticosteroids in association with miconazole and chlorhexidine in the long-term management of atrophic-erosive oral lichen planus: a placebo-controlled and comparative study between clobetasol and fluocinonide. *Oral Dis.* 1999;5(1):44-49.

203. Lo Muzio L, della Valle A, Mignogna MD, et al. The treatment of oral aphthous ulceration or erosive lichen planus with topical clobetasol propionate in three preparations: a clinical and pilot study on 54 patients. *J Oral Pathol Med.* 2001;30(10):611-617.
204. Lodi G, Tarozzi M, Sardella A, et al. Miconazole as adjuvant therapy for oral lichen planus: a double-blind randomized controlled trial. *Br J Dermatol.* 2007; 156(6):1336-1341.
205. Lodi G, Carrozzo M, Furness S, Thongprasom K. Interventions for treating oral lichen planus: a systematic review. *Br J Dermatol.* 2012;166(5):938-947.
206. Conrotto D, Carbone M, Carrozzo M, et al. Ciclosporin vs. clobetasol in the topical management of atrophic and erosive oral lichen planus: a double-blind, randomized controlled trial. *Br J Dermatol.* 2006;154(1): 139-145.
207. Kar HK, Parsad D, Gautam RK, et al. Comparison of topical tretinoin and betamethasone in oral lichen planus. *Indian J Dermatol Venereol Leprol.* 1996;62(5): 304-305.
208. Giustina TA, Stewart JC, Ellis CN, et al. Topical application of isotretinoin gel improves oral lichen planus. A double-blind study. *Arch Dermatol.* 1986;122(5): 534-536.
209. Lee YC, Shin SY, Kim SW, et al. Intralesional injection versus mouth rinse of triamcinolone acetonide in oral lichen planus: a randomized controlled study. *Otolaryngol Head Neck Surg.* 2013;148(3):443-449.
210. Lodi G, Scully C, Carrozzo M, et al. Current controversies in oral lichen planus: report of an international consensus meeting. Part 2. Clinical management and malignant transformation. *Oral Surg Oral Med Oral Pathol Oral Radiol Endod.* 2005;100(2):164-178.
211. Carbone M, Goss E, Carrozzo M, et al. Systemic and topical corticosteroid treatment of oral lichen planus: a comparative study with long-term follow-up. *J Oral Pathol Med.* 2003;32(6):323-329.
212. Malhotra AK, Khaitan BK, Sethuraman G, et al. Betamethasone oral mini-pulse therapy compared with topical triamcinolone acetonide (0.1%) paste in oral lichen planus: a randomized comparative study. *J Am Acad Dermatol.* 2008;58(4):596-602.
213. Kunz M, Urosevic-Maiwald M, Goldinger SM, et al. Efficacy and safety of oral alitretinoin in severe oral lichen planus—results of a prospective pilot study. *J Eur Acad Dermatol Venereol.* 2016;30(2):293-298.
214. Jang N, Fischer G. Treatment of erosive vulvovaginal lichen planus with methotrexate. *Australas J Dermatol.* 2008;49(4):216-219.
215. Wee JS, Shirlaw PJ, Challacombe SJ, et al. Efficacy of mycophenolate mofetil in severe mucocutaneous lichen planus: a retrospective review of 10 patients. *Br J Dermatol.* 2012;167(1):36-43.
216. Sperling LC, Nguyen JV. Commentary: treatment of lichen planopilaris: some progress, but a long way to go. *J Am Acad Dermatol.* 2010;62(3):398-401.
217. Racz E, Gho C, Moorman PW, et al. Treatment of frontal fibrosing alopecia and lichen planopilaris: a systematic review. *J Eur Acad Dermatol Venereol.* 2013; 27(12):1461-1470.
218. Mesinkovska NA, Tellez A, Dawes D, et al. The use of oral pioglitazone in the treatment of lichen planopilaris. *J Am Acad Dermatol.* 2015;72(2):355-356.
219. Spring P, Spanou Z, de Viragh PA. Lichen planopilaris treated by the peroxisome proliferator activated receptor-gamma agonist pioglitazone: lack of lasting improvement or cure in the majority of patients. *J Am Acad Dermatol.* 2013;69(5):830-832.
220. Chieregato C, Zini A, Barba A, et al. Lichen planopilaris: report of 30 cases and review of the literature. *Int J Dermatol.* 2003;42(5):342-345.
221. Assouly P, Reygagne P. Lichen planopilaris: update on diagnosis and treatment. *Semin Cutan Med Surg.* 2009; 28(1):3-10.
222. Cho BK, Sah D, Chwalek J, et al. Efficacy and safety of mycophenolate mofetil for lichen planopilaris. *J Am Acad Dermatol.* 2010;62(3):393-397.
223. Cevasco NC, Bergfeld WF, Remzi BK, et al. A case-series of 29 patients with lichen planopilaris: the Cleveland Clinic Foundation experience on evaluation, diagnosis, and treatment. *J Am Acad Dermatol.* 2007; 57(1):47-53.
224. Spencer LA, Hawryluk EB, English JC 3rd. Lichen planopilaris: retrospective study and stepwise therapeutic approach. *Arch Dermatol.* 2009;145(3):333-334.
225. Moreno-Ramirez D, Camacho Martinez F. Frontal fibrosing alopecia: a survey in 16 patients. *J Eur Acad Dermatol Venereol.* 2005;19(6):700-705.
226. Vano-Galvan S, Molina-Ruiz AM, Serrano-Falcon C, et al. Frontal fibrosing alopecia: a multicenter review of 355 patients. *J Am Acad Dermatol.* 2014;70(4): 670-678.
227. Georgala S, Katoulis AC, Befon A, et al. Treatment of postmenopausal frontal fibrosing alopecia with oral dutasteride. *J Am Acad Dermatol.* 2009;61(1): 157-158.
228. Katoulis A, Georgala, Bozi E, et al. Frontal fibrosing alopecia: treatment with oral dutasteride and topical pimecrolimus. *J Eur Acad Dermatol Venereol.* 2009; 23(5):580-582.
229. Ladizinski B, Bazakas A, Selim MA, et al. Frontal fibrosing alopecia: a retrospective review of 19 patients seen at Duke University. *J Am Acad Dermatol.* 2013; 68(5):749-755.
230. Tosti A, Piraccini BM, Iorizzo M, et al. Frontal fibrosing alopecia in postmenopausal women. *J Am Acad Dermatol.* 2005;52(1):55-60.

Chapter 33 :: Lichen Nitidus and Lichen Striatus

:: Aaron R. Mangold & Mark R. Pittelkow

AT-A-GLANCE

- Lichen nitidus consists of small, glistening, monomorphic, flesh-colored to pink or reddish-brown papules of unknown etiology.
- On histopathology, lichen nitidus has a distinct, circumscribed infiltrate of lymphocytes, histiocytes, and giant cells in papillary dermis directly beneath a thinned epidermis.
- With lichen nitidus, there is no association with systemic disease.

LICHEN NITIDUS

EPIDEMIOLOGY

The epidemiology of lichen nitidus is unknown. Lichen nitidus does not show a clear racial or sexual predilection and is more common in children and young adults.[1] The true prevalence is unknown; however, an early clinical experience reported from the early 1900s estimated lichen nitidus to be approximately 34 cases per 100,000 African American individuals.[2] At the Mayo Clinic, the ratio of biopsies of lichen nitidus to lichen planus is 1.7 per 100. Assuming a prevalence of 1% in lichen planus and that the rates of biopsy of lichen planus and lichen nitidus are similar, this would imply a prevalence of approximately 17 cases per 100,000.

ETIOLOGY AND PATHOGENESIS

Once considered a tuberculoid reaction, lichen nitidus is currently regarded as an idiopathic lichenoid tissue reaction with distinctive clinical and histologic features.[3] The relationship between lichen nitidus and lichen planus is debated.[4] The coexistence of both diseases in some patients, the development of lichen planus after generalized lichen nitidus, and the clinical similarities to small papules of lichen planus support the view that lichen nitidus is a variant of lichen planus.[5] However, most clinicians and researchers favor the separation of these two diseases as distinct entities based on both clinical and immunologic differences and distinctive histologic changes.[6,7] Table 33-1 summarizes some of these differences and similarities. One common theory is that exogenous antigens and allergens stimulate epidermal and dermal antigen-presenting cells (eg, Langerhans cells) to activate a cell-mediated response, initiate lymphocyte accumulation, and form discrete inflammatory papules. Large numbers of Langerhans cells in the infiltrate supports this theory.[4,6] After antigen stimulation occurs, the cytokine milieu produced by the inflammatory infiltrate may lead to T-helper type 2 (Th2) cell polarization, which results in superficial dermal granulomas in the appropriate genetic background.[8] Functional impairment in cellular immunity has been reported in lichen nitidus with anergic responses to antigen stimulations and the documentation of photo-induced lichen nitidus in association with HIV.[8-10]

Interestingly, in the case of anergy, the recovery of a normal antigen response was associated with disease resolution. Similarly, the induction of allergic contact dermatitis by the topical application of dinitrochlorobenzene in a patient with lichen nitidus cleared the eruption, presumably by altering the cellular immunity, cellular infiltration, and cytokine expression.[8] Rare cases of lichen nitidus have been associated with atopic dermatitis, Crohn disease, and juvenile chronic arthritis.[11-15] A rare familial presentation of lichen nitidus has been reported, although no genetic factors of the disease have been identified.[16-18]

CLINICAL FINDINGS

Lichen nitidus is composed of multiple 1- to 2-mm, discrete, smooth, round, skin-colored papules. Individual lesions may be umbilicated with a glistening appearance (Fig. 33-1). Scale may be present and can be elicited by rubbing the surface of the papules. Occasionally, in pruritic, generalized lichen nitidus (Fig. 33-2), the papules are grouped, and an isomorphic or Koebner phenomenon (12% of cases) is observed.[19] Lesions may occur anywhere over the skin surface; however, the most frequent sites of predilection (in descending order of frequency) are the trunk (Fig. 33-3), genitalia, face, neck, hands, and lower extremities.[1] There are rare reports of linear, Blaschkoid, generalized, and actinic disease.[20-28]

Less common sites of involvement include: mucous membranes, nails, palms (Fig. 33-4), and soles.[1,29] Palmoplantar involvement is more common in older individuals, most commonly involves the central palm, and has several morphologic variants that range from pinpoint papules, pompholyx, and keratoderma.[29-34] Minute keratotic spicules, or central plugs, on the central, palmar surfaces can help distinguish palmar lichen nitidus from lichen planus. The papules may extend to the dorsa of the extremities. Nail abnormalities may be associated

TABLE 33-1
Comparison of Features between Lichen Nitidus and Lichen Planus

	LICHEN NITIDUS	LICHEN PLANUS
Incidence	Rare	Common
Lesion		
Size	Usually 1-2 mm	Variable, usually larger
Shape	Round	Polygonal
Color	Flesh, pink, red-brown	Erythematous to violaceous
Wickham striae	Absent	Present
Mucosal changes	Rare	Variably present
Pruritus	Uncommon	Usually present, marked
Histopathology		
Hyperkeratosis	Variable and focal	Usually present
Parakeratosis	Mostly present	Not found
Infiltrate	Most commonly three papillary bodies	Bandlike, extends through many rete ridges
Lymphocytes	Variable	Vast majority of cells
Histiocytes	Almost always present	Almost none
Giant cells	Occasional	None
Dyskeratotic	Occasional	Very common
Immunopathology		
Cytoids	Usually negative	Immunoglobulin M and other conjugates
Basement membrane	Usually negative	Fibrinogen, other conjugates
Immunohistochemistry		
$CD4^+$ lymphocytes	Majority of cells (less than lichen planus)	Majority of cells
$CD68^+$ cells	Common	Uncommon

Figure 33-1 Lichen nitidus. Multiple 1- to 2-mm, discrete, smooth, round, skin-colored papules over the forehead. Individual lesions have a glistening appearance. (Used with permission of Mayo Foundation for Medical Education and Research, all rights reserved.)

Figure 33-2 Lichen nitidus. **A,** Multiple, smooth flesh-colored to pink papules over the dorsal forearm showing isomorphic or Koebner phenomenon with linearly grouped papules over sites of excoriation. **B,** Similar appearing rash in a darker skinned individual. (Used with permission of Mayo Foundation for Medical Education and Research, all rights reserved.)

with palmar disease and usually manifest as longitudinal, beaded ridging, and terminal splitting with or without irregular pitting.[34] Rare clinical morphological variants include vesicular, hemorrhagic-purpuric, and spinous-follicular[35-39] (Table 33-2). The hemorrhagic-purpuric lesions are common on the palms and distal extremities.[40-42]

Actinic lichen nitidus appears most commonly in dark-skinned individuals in areas of significant sun exposure, such as the face and arms. It can recur

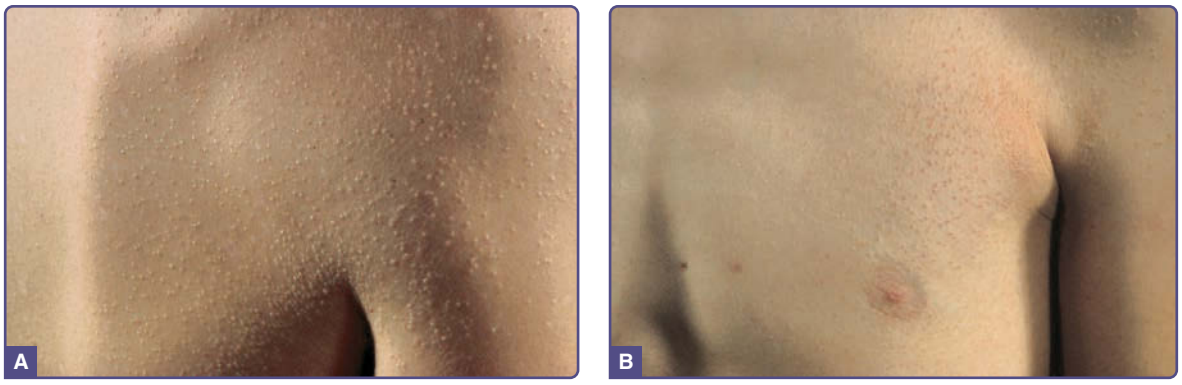

Figure 33-3 Lichen nitidus. **A,** Multiple monomorphic, dome-shaped papules over upper back, shoulder, and arm. Side lighting, as performed here, enhances visualization of the lesions. **B,** Individual papules, flesh- to pink-colored over the chest and arm and coalescing over the anterior axilla. (Used with permission of Mayo Foundation for Medical Education and Research, all rights reserved.)

with repetitive exposure to the sun and often shows a seasonal pattern.[22,23] The term *summertime lichenoid actinic eruption* is reported in the literature but is less descriptive, clinically and histologically, because it could include actinic lichen planus.[43] Cases of actinic lichen nitidus can be differentiated from other frictional lichenoid eruptions based on histology because the former should have typical histologic features of lichen nitidus, but and the latter is likely a manifestation of atopic dermatitis or polymorphous light eruption.[22,43-47]

Figure 33-4 Lichen nitidus. Extensive wrist and palmar involvement with development of hyperkeratotic lesions. (Used with permission of Mayo Foundation for Medical Education and Research, all rights reserved.)

Lichen nitidus is usually asymptomatic; however, pruritus is present in approximately 12% of cases and may be intense in fewer than 5%.[1] No constitutional symptoms or systemic abnormalities are associated with lichen nitidus.

PATHOLOGY

The histologic features of lichen nitidus are distinctive. A focused, dense infiltrate "ball" of lymphocyte, histiocytes, and foreign body or Touton-type giant cells are immediately below the epidermis with elongation of the rete ridges, expansion of the papillary dermis, and the apparent embracement by neighboring rete ridges forming the "claw" (Fig. 33-5). The classic "ball and claw" pattern, with involvement of up to three dermal papillae, is seen in 90% of cases.[1] Plasma cells and eosinophils are rare. The overlying epidermis is thinned in up to 90% of cases and demonstrates central parakeratosis without hypergranulosis in up to 56% of cases.[1] There are minimal hydropic degeneration, few dyskeratotic cells, and rare clefting and the dermal–epidermal junction (DEJ). Colloid bodies are rarely seen (10% of cases).[1,4]

Unique histologic features may be seen with clinical variants. Palmar lesions may show a deep parakeratotic plug. Perforating lesions tend to occur in areas

TABLE 33-2
Rare Forms of Lichen Nitidus

SITE OF INVOLVEMENT	CLINICAL VARIANT
Generalized	Actinic
Palmar	Vesicular
Plantar	Hemorrhagic
Linear or Blaschkoid	Spinous follicular
Nail involvement	Perforating
	Purpuric

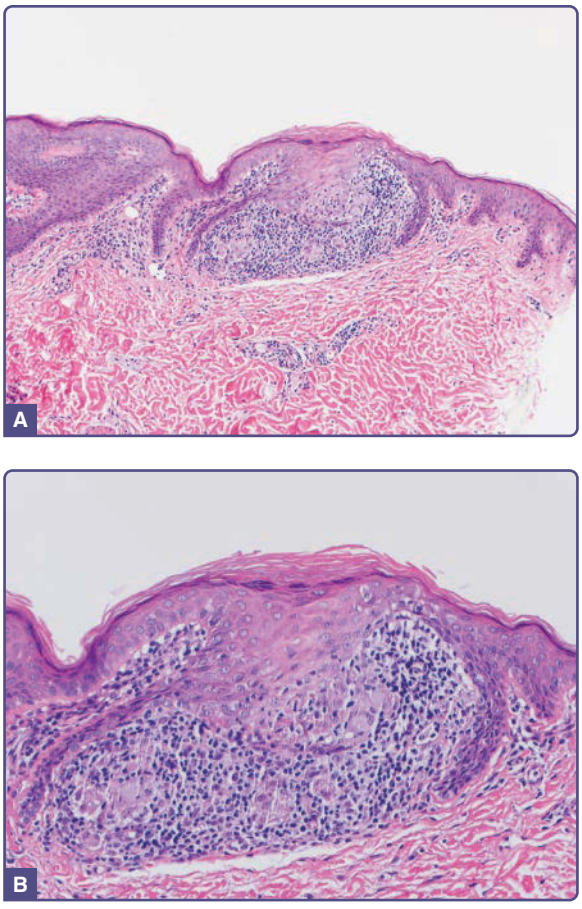

Figure 33-5 Lichen nitidus. **A,** Typical small, well-circumscribed lesion occupying only a couple of dermal papillae. Note the clawlike epidermal lateral borders. (Hematoxylin and eosin × 200.) **B,** Distinctive, circumscribed infiltrate of papillary dermis situated directly beneath thinned epidermis. Many histiocytes mingle with lymphocytes that are enveloped by bordering rete ridges. Central hyperkeratosis, epidermal thinning, and finger-like extensions of the epidermis. (Hematoxylin and eosin × 200.) (Photo contributors: David J. DiCaudo, MD and Steven A. Nelson, MD. Used with permission from Mayo Foundation for Medical Education and Research, all rights reserved.)

of friction and may have transepidermal elimination of the inflammatory infiltrate.[48,49] Purpuric or hemorrhagic lesions are associated with capillary wall degeneration and red blood cell extravasation.[41]

The majority of the cells in the infiltrate are T lymphocytes ($CD4^+$ cells predominate over $CD8^+$), Langerhans cells ($S100^+$, $CD1^+$), and macrophages-histiocytes ($CD14^+$, CD68+).[4,6,50] Results of direct immunofluorescence examination of lichen nitidus are usually negative.[7]

DIFFERENTIAL DIAGNOSIS

Differential diagnosis of lichen nitidus is summarized in Table 33-3.

PROGNOSIS

Lichen nitidus is typically a focal, asymptomatic, chronic inflammatory reaction that eventually resolves spontaneously within 1 year in two thirds of patients or, less frequently, over a few years.[1] Rarely, the eruption may persist indefinitely. Palmoplantar disease may be associated with a more chronic course.[29] New lesions may continue to develop as older lesions resolve. Lesions heal without scar formation or pigmentary abnormalities.

TABLE 33-3
Differential Diagnosis of Lichen Nitidus

Most Likely

- Lichen planus
  - Larger, polymorphic lesions located on flexural wrist, arms, and legs
  - Dermoscopy shows dotted and linear vessels with whitish lines
  - Highly pruritic
  - CD8 lymphocytes predominate
  - No granulomatous inflammation or parakeratosis
  - Direct immunofluorescence (DIF) often positive with immunoglobulin binding to cytoid bodies and shaggy deposition of fibrinogen
- Psoriasis
  - Plaques have silvery scale
  - Dermoscopy shows even dotted vessels throughout with white scale
- Verruca plana
  - Limited, asymmetric involvement
  - Variable in size
  - Verrucous surface
  - Dermoscopy shows filiform structures or red dots and globular vessels with an even colored background
- Keratosis pilaris
  - Commonly seen on the cheeks, lateral arms, and lateral hips
  - Strong atopic diathesis
  - Persistent disease
  - Dermoscopy shows perifollicular scaling with keratotic plug formation, peripilar casts, and perifollicular erythema
  - Absence of lichenoid and granulomatous infiltrate on biopsy

Consider

- Lichen spinulosus
- Papular eczema
- Follicular atopic dermatitis
- Frictional lichenoid eruption
- Molluscum contagiosum
- Lichen scrofulosorum
- Lichenoid syphilitic lesions
- Bowenoid papulosis
- Sarcoidosis
- Phrynoderma
- Lichen amyloidosis
- Papular mucinosis
- Darier disease
- Type II and IV pityriasis rubra pilaris

TREATMENT

Lichen nitidus is often asymptomatic and self-limiting, and most patients do not require treatment. However, treatment may be warranted in patients with protracted pruritus (in fewer than 5% of all cases), a generalized pattern, or lesions in cosmetically sensitive areas.[1,27,28] For most cases of lichen nitidus, topical therapies are appropriate. Mid- to high-potency topical corticosteroids are first-line topical treatments for lichen nitidus. Tacrolimus ointment is a second-line topical treatment on the body and a first-line treatment for facial and intertriginous disease.[19,51,52] Psoralen plus ultraviolet A (PUVA) has been successfully used for generalized and palmar disease; however, this has largely been supplanted by narrowband ultraviolet B, which is a safer and effective alternative.[53-56]

In cases of pruritus, oral antihistamines are a first-line systemic agent. Astemizole has been reported in the literature; however, other sedating antihistamines, such as diphenhydramine, and nonsedating antihistamines, such as fexofenadine, cetirizine, and loratadine, may be used as alternatives.[57] Systemic treatments beyond antihistamines are rarely indicated and should be reserved for more symptomatic and cosmetically disfiguring disease. In general, a therapeutic approach similar to lichen planus (see Chap. 32) with targeting of lymphocytes in aggressive and atypical disease (using prednisone or low-dose cyclosporine) and safe, less targeted therapies for specific subtypes of disease (eg, acitretin in hyperkeratotic palmar disease).[33] A short course of low-dose oral glucocorticoids (prednisone 0.3 mg/kg) may hasten resolution of more extensive, generalized, or symptomatic disease.[26] Oral corticosteroids are most successful when combined with skin-directed therapies such as topical steroids or phototherapy.

Additional systemic and skin-directed therapies have been reported and are summarized in Table 33-4. Caution is advised when considering these therapies, and the potential harm of treatment should be weighed against the relatively benign nature of lichen nitidus. When appropriate, the medications that can be considered include antituberculous medications (note: a pediatric case had a positive purified protein derivative test result),[58] low-molecular-weight heparin,[59] low-dose cyclosporine (note: concomitant atopic dermatitis),[15] and oral itraconazole (note: included lichen planus or lichen nitidus).[60] Future therapeutic modalities to consider, based on mechanistic activity, include tumor necrosis factor-α inhibitors in cases with significant granuloma formation, as well as methotrexate, mycophenolate mofetil, azathioprine, and Janus kinase inhibitors in severe, refractory cases with more marked lichenoid infiltrate.

LICHEN STRIATUS

EPIDEMIOLOGY

AT-A-GLANCE

- Lichen striatus is a rare, idiopathic, papular eruption that usually resolves in 6 to 12 months.
- Lichen striatus occurs most commonly in children aged 3 to 5 years, on the limbs, and in females.
- In lichen striatus, the eruption is characterized by the sudden onset of flat-topped, 1- to 3-mm, pink, tan, or hypopigmented papules in a linear configuration or Blaschkoid distribution.
- Lichen striatus is associated with an atopic diathesis.
- The prognosis for lichen striatus is good.

TABLE 33-4
Treatment of Lichen Nitidus

	TOPICAL	PHYSICAL	SYSTEMIC
First-line treatment	Topical steroids	Narrowband UVB (generalized)	Antihistamines (pruritus)
	Sun protection (actinic)		
Second-line treatment	Topical tacrolimus (first-line treatment on the face or intertriginous areas and second-line treatment elsewhere)	UVA and UVB (generalized)	Oral steroids, 0.3 mg/kg/day (generalized and symptomatic)
		Local PUVA (palmar)	Oral retinoids (acitretin) (palmar)
			Low-dose cyclosporine, 4 mg/kg/day (generalized and symptomatic)
Third-line treatment		PUVA (generalized)	Itraconazole (generalized)
			Antituberculous agents (isoniazid) (positive PPD result)
			Enoxaparin (generalized)

PPD, purified protein derivative; PUVA, psoralen plus ultraviolet A; UVA, ultraviolet A; UVB, ultraviolet B.

Lichen striatus was first described in 1898 by Balzer and Merier as "lichenoid trophoneurosis."[61] Lichen striatus, is a rare, idiopathic, linear dermatosis that most commonly affects individuals younger than the age of 18 years with a mean age of onset between 3 and 5 years of age.[62-64] The true incidence and prevalence of lichen striatus is unknown. This self-limited dermatosis is common in females (2–3:1) and occurs most frequently on the limbs.[63-65] Up to 60% of individuals with lichen striatus have a personal of family history of atopy.[63]

ETIOLOGY AND PATHOGENESIS

The etiology of lichen striatus is incompletely understood; however, the Blaschko-linear pattern suggests somatic mosaicism. Postzygotic, somatic mutations of keratinocytes may lead to the development of altered antigens that migrate along lines of Blaschko and can trigger an immune response. Immune tolerance develops to these endogenous autoantigens. External precipitants have been implicated in the loss of tolerance and triggering an immune response. Possible precipitating factors include environmental stressors, drugs (specifically interferon), vaccines (bacillus Calmette–Guérin), viral antigens, hypersensitivity, and skin injury.[63,64,66,67] External triggers are supported by rare cases of simultaneous onset of lichen striatus in related and unrelated siblings.[68-71] Seasonal variation, with higher onset and clustered outbreaks of lichen striatus in the spring and summer months, support an infective etiology.[64,72] Viral infections have the ability to mediate a cell-mediated responses that could act as potential triggers.[73] For example, in linear lichen planus, herpes virus DNA has been detected within lesions.[74] Similar antigenic stimuli have not been found in lichen striatus.

CLINICAL FEATURES

Lichen striatus, a type of Blaschko linear acquired inflammatory skin eruption (BLAISE), is characterized by the sudden onset (days to weeks) of flat-topped, 1- to 3-mm, pink, tan, or hypopigmented papules in a linear configuration or Blaschkoid distribution (Figs. 33-6 and 33-7).[63,75] Individual lesions may have scale. Bilateral and parallel eruptions have been reported.[63] Pruritus is present in 5% to 34% of cases and are more common in atopic individuals and adults.[62,63,65,76] The most common locations on the body are the extremities (75% to 77%) and the trunk (9% to 21%).[62,65] Less commonly, the face (3% to 13%) and nails (2.6%) can be involved.[63-65] More extensive disease is seen in adults, and these cases often appear to have concomitant dermatitis.[76] Nail involvement is uncommon and may lead to longitudinal ridging, onycholysis, splitting, fraying, and loss of the nail plate.[63,77,78] With treatment, the nail changes tend to be reversible.[77]

Figure 33-6 Lichen striatus. Multiple flat-topped, 1-t to 3-mm pink papules in a linear configuration or Blaschkoid distribution in a dark-skinned individual. (Used with permission of Mayo Foundation for Medical Education and Research, all rights reserved.)

PATHOLOGY

The histologic features of lichen striatus are variable, and biopsies are rarely performed (10% of cases).[63,64] The classic pathologic findings include hyperkeratosis, focal parakeratosis, mild spongiosis with a lichenoid tissue reaction and exocytosis, keratinocyte necrosis, and perivascular and appendageal lymphocytic infiltrate (Fig. 33-8).[62] The superficial lichenoid dermatitis and deep lymphocytic infiltrate of lichen striatus are seen in almost all cases.[62] Nonspecific findings are more common in early and late-stage disease. Histologic mimickers include lichen planus, lupus erythematosus, graft-versus-host-disease, lichen planopilaris, mycosis fungoides, syphilis, and atypical dermatitis. Langerhans cells are decreased overall; however, intraepidermal vesicles containing them along with T lymphocytes can be seen in 23% to 45% of cases.[62,79] In clinical practice, vesicles are rarely seen, indicating that atypical cases are more likely to be biopsied. Plasma cells, eosinophils, and multinucleate giant cells are seen in 22%, 19%, and 2% of cases, respectively.[62] CD8 cells are the predominant infiltrate at the DEJ, and CD4 cells are located in the dermis and perivascular area.[79,80] Dermal macrophages are common, and colloid bodies may be seen in up to half of cases.

Figure 33-7 Lichen striatus. **A,** Discrete, 1- to 3-mm pink and tan papules coalescing into larger plaques over the right scapula with a linear orientation. **B**, Pink and tan papules and plaques following the lines of Blaschko. (Used with permission of Mayo Foundation for Medical Education and Research, all rights reserved.)

DIFFERENTIAL DIAGNOSIS

The differential diagnosis of lichen striatus is summarized in Table 33-5.

PROGNOSIS AND TREATMENT

Lichen striatus is a self-limited disease with a mean duration of approximately 6 to 12 months.[63] Relapse is rare. Postinflammatory hypopigmentation is seen in up to 50% of cases but is self-limited, and lesions heal without scarring.[75] In general, treatment and laboratory testing are not necessary. For symptomatic control of pruritus, low to medium-potency topical steroids may be used as a first-line topical.[63] With facial involvement or disease refractory to topical corticosteroids, the topical calcineurin inhibitors tacrolimus and pimecrolimus are an effective alternative.[81] The use of topical calcineurin inhibitors for up to 6 weeks often results in significant improvement.[51,76] With nail involvement; topical

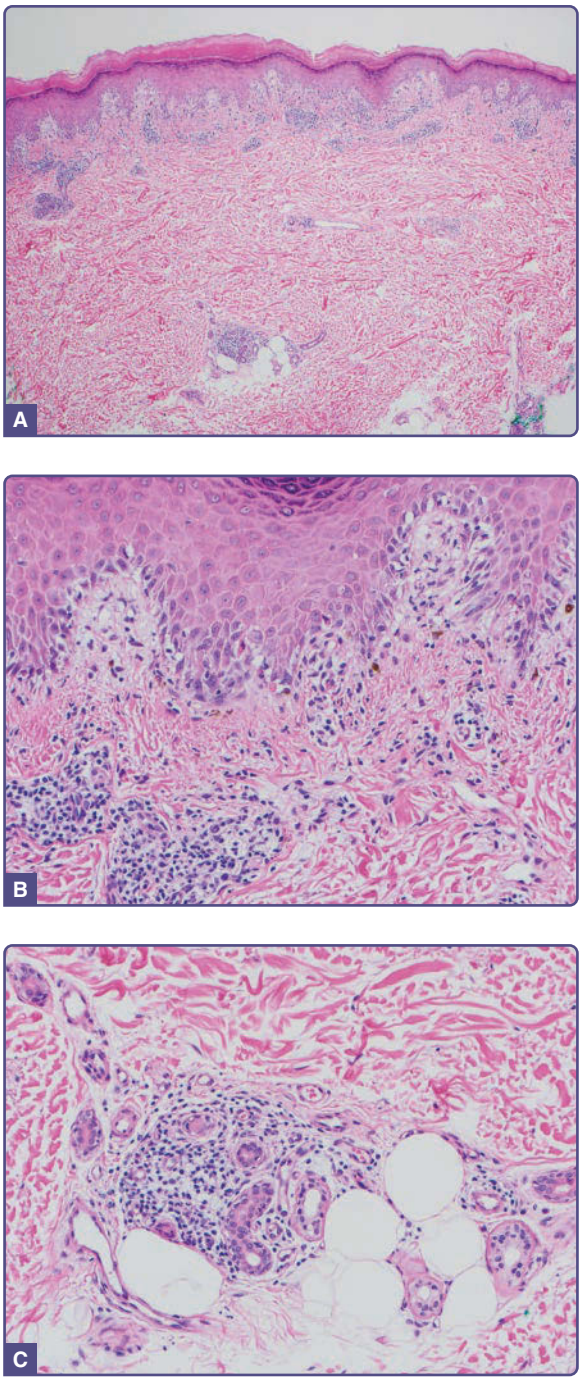

Figure 33-8 Lichen striatus. **A,** Hyperkeratosis, mild spongiosis, and lichenoid tissue reaction with perivascular and appendageal lymphocytic infiltrate. (Hematoxylin and eosin × 40.) **B,** Mild spongiosis, vacuolar lichenoid tissue reaction, clusters of necrotic keratinocytes, pigment incontinence, and perivascular lymphocytic infiltrate. (Hematoxylin and eosin × 200) **C,** Perieccrine lymphocytic infiltrate. (Hematoxylin and eosin × 200). (Photo contributors: David J. DiCaudo, MD and Steven A. Nelson, MD. Used with permission from Mayo Foundation for Medical Education and Research, all rights reserved.)

TABLE 33-5
Differential Diagnosis of Lichen Striatus

Most Likely
- Linear lichen planus
  - Patients are older
  - More violaceous primary lesion and may have other areas of involvement
  - Highly pruritic
  - Brisk lichenoid tissue reaction without periadnexal or perieccrine involvement
  - DIF often positive with Immunoglobulin binding to cytoid bodies and shaggy deposition of fibrinogen
- Inflammatory linear verrucous epidermal nevus
  - Occurs in children
  - Clinically appears psoriasis-like
  - Highly pruritic
  - Most resolve by adulthood
  - Psoriasiform changes on histopathology with alternating ortho- and parakeratosis
- Blaschkitis
  - Patients are older
  - Papular eruption, tends to be truncal, and has multiple streaks
  - Often has features of concomitant dermatitis
  - Often resolves in days to weeks
  - Relapse if common

Consider
- Linear psoriasis
- Linear Darier disease
- Linear porokeratosis
- Linear lichen nitidus
- Incontinentia pigmenti

corticosteroids and calcineurin inhibitors combined with intralesional corticosteroids (5 mg/mL of triamcinolone) improved six of seven cases.[77] Oral antihistamines may be helpful in cases of more generalized itch or in cases of sleep disruption.

ACKNOWLEDGMENTS

Steven A. Nelson, MD, David J. DiCaudo, and Collin Costello.

REFERENCES

1. Lapins NA, Willoughby C, Helwig EB. Lichen nitidus. A study of forty-three cases. *Cutis*. 1978;21(5):634-637.
2. Hazen HH. Syphilis and skin diseases in the American Negro: personal observations. *Arch Dermatol Syphilol*. 1935;31(3):316-323.
3. Barber HW. Case of lichen nitidus (pinkus) or tuberculide licheniforme et nitida (Chatellier). *Proc R Soc Med*. 1924;17(Dermatol Sect):39.
4. Smoller BR, Flynn TC. Immunohistochemical examination of lichen nitidus suggests that it is not a localized papular variant of lichen planus. *J Am Acad Dermatol*. 1992;27(2 Pt 1):232-236.
5. Di Lernia V, Piana S, Ricci C. Lichen planus appearing subsequent to generalized lichen nitidus in a child. *Pediatr Dermatol*. 2007;24(4):453-455.
6. Wright AL, McVittie E, Hunter JA. An immunophenotypic study of lichen nitidus. *Clin Exp Dermatol*. 1990;15(4):273-276.
7. Waisman M, Dundon BC, Michel B. Immunofluorescent studies in lichen nitidus. *Arch Dermatol*. 1973;107(2):200-203.
8. Kano Y, Otake Y, Shiohara T. Improvement of lichen nitidus after topical dinitrochlorobenzene application. *J Am Acad Dermatol*. 1998;39(2 Pt 2):305-308.
9. Berger TG, Dhar A. Lichenoid photoeruptions in human immunodeficiency virus infection. *Arch Dermatol*. 1994;130(5):609-613.
10. Maeda M. A case of generalized lichen nitidus with Koebner's phenomenon. *J Dermatol*. 1994;21(4):273-277.
11. Magro CM, Crowson AN. Lichenoid and granulomatous dermatitis. *Int J Dermatol*. 2000;39(2):126-133.
12. Kano Y, Shiohara T, Yagita A, et al. Erythema nodosum, lichen planus and lichen nitidus in Crohn's disease: report of a case and analysis of T cell receptor V gene expression in the cutaneous and intestinal lesions. *Dermatology*. 1995;190(1):59-63.
13. Wanat KA, Elenitsas R, Chachkin S, et al. Extensive lichen nitidus as a clue to underlying Crohn's disease. *J Am Acad Dermatol*. 2012;67(5):e218-220.
14. Bercedo A, Cabero MJ, Garcia-Consuegra J, et al. Generalized lichen nitidus and juvenile chronic arthritis: an undescribed association. *Pediatr Dermatol*. 1999;16(5):406-407.
15. Lestringant GG, Piletta P, Feldmann R, et al. Coexistence of atopic dermatitis and lichen nitidus in three patients. *Dermatology*. 1996;192(2):171-173.
16. Marks R, Jones EW. Familial lichen nitidus. The simultaneous occurrence of lichen nitidus in brothers. *Trans St Johns Hosp Dermatol Soc*. 1970;56(2):165-167.
17. Kato N. Familial lichen nitidus. *Clin Exp Dermatol*. 1995;20(4):336-338.
18. Leung AK, Ng J. Generalized lichen nitidus in identical twins. *Case Rep Dermatol Med*. 2012;2012:982084.
19. Dobbs CR, Murphy SJ. Lichen nitidus treated with topical tacrolimus. *J Drugs Dermatol*. 2004;3(6):683-684.
20. Francoeur CJ Jr, Frost M, Treadwell P. Generalized pinhead-sized papules in a child. Generalized lichen nitidus. *Arch Dermatol*. 1988;124(6):935, 938.
21. Kanwar AJ, Kaur S. Lichen nitidus actinicus. *Arch Dermatol*. 1999;135(6):714.
22. Hussain K. Summertime actinic lichenoid eruption, a distinct entity, should be termed actinic lichen nitidus. *Arch Dermatol*. 1998;134(10):1302-1303.
23. Kanwar AJ, Kaur S. Lichen nitidus actinicus. *Pediatr Dermatol*. 1991;8(1):94-95.
24. Petrozzi JW, Shmunes E. Linear lichen nitidus. *Cutis*. 1970;6(10):1109-1112.
25. Aravind M, Do TT, Cha HC, et al. Blaschkolinear acquired inflammatory skin eruption, or blaschkitis, with features of lichen nitidus. *JAAD Case Rep*. 2016;2(2):102-104.
26. Chen W, Schramm M, Zouboulis CC. Generalized lichen nitidus. *J Am Acad Dermatol*. 1997;36(4):630-631.
27. Soroush V, Gurevitch AW, Peng SK. Generalized lichen nitidus: case report and literature review. *Cutis*. 1999;64(2):135-136.
28. Rallis E, Verros C, Moussatou V, et al. Generalized purpuric lichen nitidus. Report of a case and review of the literature. *Dermatol Online J*. 2007;13(2):5.

29. Cakmak SK, Unal E, Gonul M, et al. Lichen nitidus with involvement of the palms. *Pediatr Dermatol*. 2013; 30(5):e100-101.
30. Weiss RM, Cohen AD. Lichen nitidus of the palms and soles. *Arch Dermatol*. 1971;104(5):538-540.
31. Qian G, Wang H, Wu J, et al. Different dermoscopic patterns of palmoplantar and nonpalmoplantar lichen nitidus. *J Am Acad Dermatol*. 2015;73(3):e101-103.
32. Thibaudeau A, Maillard H, Croue A, et al. [Palmoplantar lichen nitidus: a rare cause of palmoplantar hyperkeratosis]. *Ann Dermatol Venereol*. 2004;131(8-9): 822-824.
33. Park SH, Kim SW, Noh TW, et al. A case of palmar lichen nitidus presenting as a clinical feature of pompholyx. *Ann Dermatol*. 2010;22(2):235-237.
34. Munro CS, Cox NH, Marks JM, et al. Lichen nitidus presenting as palmoplantar hyperkeratosis and nail dystrophy. *Clin Exp Dermatol*. 1993;18(4): 381-383.
35. Jetton RL, Eby CS, Freeman RG. Vesicular and hemorrhagic lichen nitidus. *Arch Dermatol*. 1972; 105(3):430-431.
36. Madhok R, Winkelmann RK. Spinous, follicular lichen nitidus associated with perifollicular granulomas. *J Cutan Pathol*. 1988;15(4):245-248.
37. Summe HS, Greenlaw SM, Deng A, et al. Generalized spinous follicular lichen nitidus with perifollicular granulomas. *Pediatr Dermatol*. 2013;30(3):e20-21.
38. MacDonald AJ, Drummond A, Chui D, Holmes S. Lichen nitidus and lichen spinulosus or spinous follicular lichen nitidus? *Clin Exp Dermatol*. 2005;30(4): 452-453.
39. Park JS. Lichen nitidus and lichen spinulosus or spinous follicular lichen nitidus? A second case. *Clin Exp Dermatol*. 2011;36(5):557-558.
40. Ikenberg K, Pflugfelder A, Metzler G, et al. Thirty-year history of palmar eruptions: a quiz. Palmar purpuric lichen nitidus. *Acta Derm Venereol*. 2011;91(1): 108-109.
41. Endo M, Baba S, Suzuki H. Purpuric lichen nitidus. *Eur J Dermatol*. 1998;8(1):54-55.
42. Coulson IH, Marsden RA, Cook MG. Purpuric palmar lichen nitidus—an unusual though distinctive eruption. *Clin Exp Dermatol*. 1988;13(5):347-349.
43. Bedi TR. Summertime actinic lichenoid eruption. *Dermatologica*. 1978;157(2):115-125.
44. Isaacson D, Turner ML, Elgart ML. Summertime actinic lichenoid eruption (lichen planus actinicus). *J Am Acad Dermatol*. 1981;4(4):404-411.
45. Sardana K, Goel K, Garg VK, et al. Is frictional lichenoid dermatitis a minor variant of atopic dermatitis or a photodermatosis. Indian *J Dermatol*. 2015;60(1): 66-73.
46. Menni S, Piccinno R, Baietta S, et al. Sutton's summer prurigo: a morphologic variant of atopic dermatitis. *Pediatr Dermatol*. 1987;4(3):205-208.
47. Patrizi A, Di Lernia V, Ricci G, et al. Atopic background of a recurrent papular eruption of childhood (frictional lichenoid eruption). *Pediatr Dermatol*. 1990;7(2): 111-115.
48. Bardach H. Perforating lichen nitidus. *J Cutan Pathol*. 1981;8(2):111-116.
49. Yoon TY, Kim JW, Kim MK. Two cases of perforating lichen nitidus. *J Dermatol*. 2006;33(4):278-280.
50. Nakamizo S, Egawa G, Miyachi Y, et al. Accumulation of S-100+ CD1a+ Langerhans cells as a characteristic of lichen nitidus. *Clin Exp Dermatol*. 2011;36(7): 811-812.
51. Sorgentini C, Allevato MA, Dahbar M, et al. Lichen striatus in an adult: successful treatment with tacrolimus. *Br J Dermatol*. 2004;150(4):776-777.
52. Park J, Kim JI, Kim DW, et al. Persistent generalized lichen nitidus successfully treated with 0.03% tacrolimus ointment. *Eur J Dermatol*. 2013;23(6):918-919.
53. Do MO, Kim MJ, Kim SH, et al. Generalized lichen nitidus successfully treated with narrow-band UVB phototherapy: two cases report. *J Korean Med Sci*. 2007; 22(1):163-166.
54. Nakamizo S, Kabashima K, Matsuyoshi N, et al. Generalized lichen nitidus successfully treated with narrowband UVB phototherapy. *Eur J Dermatol*. 2010; 20(6):816-817.
55. Randle HW, Sander HM. Treatment of generalized lichen nitidus with PUVA. *Int J Dermatol*. 1986;25(5): 330-331.
56. Kim YC, Shim SD. Two cases of generalized lichen nitidus treated successfully with narrow-band UV-B phototherapy. Int *J Dermatol*. 2006;45(5):615-617.
57. Vaughn RY, Smith JG Jr. The treatment of lichen nitidus with astemizole. *J Am Acad Dermatol*. 1990;23(4 Pt 1): 757-758.
58. Kubota Y, Kiryu H, Nakayama J. Generalized lichen nitidus successfully treated with an antituberculous agent. Br *J Dermatol*. 2002;146(6):1081-1083.
59. Cholongitas E, Kokolakis G, Giannikaki E, et al. Persistent generalized lichen nitidus successfully treated with enoxaparin sodium. *Am J Clin Dermatol*. 2008;9(5): 349-350.
60. Libow LF, Coots NV. Treatment of lichen planus and lichen nitidus with itraconazole: reports of six cases. *Cutis*. 1998;62(5):247-248.
61. Balzer F, Mercier R. Trophoneurose lichenoid en bande linéare sur le trajet du nerve petit sciatique. *Ann Dermatol Syphiol.* 1898;9:258.
62. Zhang Y, McNutt NS. Lichen striatus. Histological, immunohistochemical, and ultrastructural study of 37 cases. *J Cutan Pathol*. 2001;28(2):65-71.
63. Patrizi A, Neri I, Fiorentini C, et al. Lichen striatus: clinical and laboratory features of 115 children. *Pediatr Dermatol*. 2004;21(3):197-204.
64. Kennedy D, Rogers M. Lichen striatus. *Pediatr Dermatol.* 1996;13(2):95-99.
65. Taniguchi Abagge K, Parolin Marinoni L, et al. Lichen striatus: description of 89 cases in children. *Pediatr Dermatol*. 2004;21(4):440-443.
66. Zaki SA, Sanjeev S. Lichen striatus following BCG vaccination in an infant. *Indian Pediatr*. 2011;48(2): 163-164.
67. Mask-Bull L, Vangipuram R, Carroll BJ, et al. Lichen striatus after interferon therapy. *JAAD Case Rep*. 2015; 1(5):254-256.
68. Kanegaye JT, Frieden IJ. Lichen striatus: simultaneous occurrence in siblings. Pediatrics. 1992;90(1 Pt 1): 104-106.
69. Patrizi A, Neri I, Fiorentini C, et al. Simultaneous occurrence of lichen striatus in siblings. *Pediatr Dermatol*. 1997;14(4):293-295.
70. Smith SB 3rd, Smith JB, Ellis LE, et al. Lichen striatus: simultaneous occurrence in two nonrelated siblings. *Pediatr Dermatol*. 1997;14(1):43-45.
71. Racette AJ, Adams AD, Kessler SE. Simultaneous lichen striatus in siblings along the same Blaschko line. *Pediatr Dermatol*. 2009;26(1):50-54.
72. Sittart JA, Pegas JR, Sant'Ana LA, et al. [Lichen striatus. Epidemiologic study]. *Med Cutan Ibero Lat Am*. 1989; 17(1):19-21.

73. Muller CS, Schmaltz R, Vogt T, et al. Lichen striatus and blaschkitis: reappraisal of the concept of blaschkolinear dermatoses. Br *J Dermatol*. 2011;164(2):257-262.
74. Mizukawa Y, Horie C, Yamazaki Y, et al. Detection of varicella-zoster virus antigens in lesional skin of zosteriform lichen planus but not in that of linear lichen planus. *Dermatology*. 2012;225(1):22-26.
75. Taieb A, el Youbi A, Grosshans E, et al. Lichen striatus: a Blaschko linear acquired inflammatory skin eruption. *J Am Acad Dermatol*. 1991;25(4):637-642.
76. Campanati A, Brandozzi G, Giangiacomi M, et al. Lichen striatus in adults and pimecrolimus: open, off-label clinical study. Int *J Dermatol*. 2008;47(7):732-736.
77. Kim M, Jung HY, Eun YS, et al. Nail lichen striatus: report of seven cases and review of the literature. *Int J Dermatol*. 2015;54(11):1255-1260.
78. Tosti A, Peluso AM, Misciali C, et al. Nail lichen striatus: clinical features and long-term follow-up of five patients. *J Am Acad Dermatol*. 1997;36(6 Pt 1): 908-913.
79. Gianotti R, Restano L, Grimalt R, et al. Lichen striatus—a chameleon: an histopathological and immunohistological study of forty-one cases. *J Cutan Pathol*. 1995; 22(1):18-22.
80. Zhou Y, Yu ZZ, Peng J, et al. Lichen striatus versus linear lichen planus: a comparison of clinicopathological features, immunoprofile of infiltrated cells, and epidermal proliferation and differentiation. *Int J Dermatol*. 2016; 55(4):e204-210.
81. Fujimoto N, Tajima S, Ishibashi A. Facial lichen striatus: successful treatment with tacrolimus ointment. *Br J Dermatol*. 2003;148(3):587-590.

Chapter 34 :: Granuloma Annulare

:: Julie S. Prendiville

AT-A-GLANCE

- Granuloma annulare is a relatively common disorder. The exact prevalence is unknown, but it occurs more often in children and young adults.
- A localized ring of beaded papules on the extremities is typical; generalized, subcutaneous, perforating, and patch subtypes also occur.
- The cause of granuloma annulare is unknown, and the pathogenesis is poorly understood.
- Pathologic features consist of granulomatous inflammation in a palisaded or interstitial pattern associated with varying degrees of connective tissue degeneration and mucin deposition.
- Most localized cases resolve spontaneously within 2 years.

Granuloma annulare is a benign self-limited disease that was first described by Colcott-Fox in 1895 and Radcliffe-Crocker[1] in 1902.

EPIDEMIOLOGY

Granuloma annulare is a relatively common disorder.[2] It occurs in all age groups but is rare in infancy.[2-4] The localized annular and subcutaneous forms occur more frequently in children and young adults. The generalized or disseminated variant is more common in adults. Many studies report a female preponderance,[2] but some have found a higher frequency in males.[5] Granuloma annulare does not favor a particular race or geographic area.

Most cases of granuloma annulare are sporadic. Occasional familial cases are described with occurrence in twins, siblings, and members of successive generations.[2,6,7] Attempts to identify an associated human leukocyte antigen subtype have yielded disparate results in different population groups.

CLINICAL FEATURES

HISTORY

The typical history is of one or more papules with centrifugal enlargement and central clearing. These annular lesions are often misdiagnosed as tinea corporis and treated unsuccessfully with topical antifungal agents. Subcutaneous nodules may raise suspicion about malignancy or rheumatoid disease.

Granuloma annulare is usually asymptomatic. Mild pruritus may be present, but painful lesions are rare. Nodular lesions on the feet may cause discomfort from footwear. Cosmesis is often a concern for adolescent and adult patients, particularly with generalized disease.

CUTANEOUS FINDINGS

Clinical variants of granuloma annulare include the localized, generalized, subcutaneous, perforating, and patch types. Linear granuloma annulare, a follicular pustular form, papular umbilicated lesions in children, and giant plaques have also been described. There is overlap among the different variants, and more than one morphologic type may coexist in the same patient.

LOCALIZED TYPE

The most common form of granuloma annulare is an annular or arcuate lesion. It may be skin colored, erythematous, or violaceous. It usually measures 1 to 5 cm in diameter.[2] The annular margin is firm to palpation and may be continuous or consist of discrete or coalescent papules in a complete or partial circle (Fig. 34-1). The epidermis is usually normal, but surface markings may be attenuated over individual papules. Within the annular ring, the skin may have a violaceous or pigmented appearance. Solitary firm papules or nodules may also be present. Papular lesions on the fingers may appear umbilicated.

The dorsal hands and feet, ankles, lower limbs, and wrists are the sites of predilection (see Figs. 34-1 and 34-2). Less commonly, lesions occur at other sites, including the eyelids. The palms and soles are occasionally involved. Localized annular lesions may coexist with the subcutaneous or patch forms.

GENERALIZED TYPE

The generalized form of granuloma annulare is said to comprise 8% to 15% of cases.[8] The majority of patients are adults, but it may also be seen in childhood. Unlike in localized disease, the trunk is frequently involved in addition to the neck and extremities. The face, scalp, palms, and soles may also be affected.

Generalized granuloma annulare presents as widespread papules (Fig. 34-3A), some of which coalesce to form small annular plaques or larger discolored patches with raised arcuate and serpiginous margins (see Fig. 34-3B). Lesions may be skin colored, pink, violaceous, tan, or yellow. An annular or nonannular

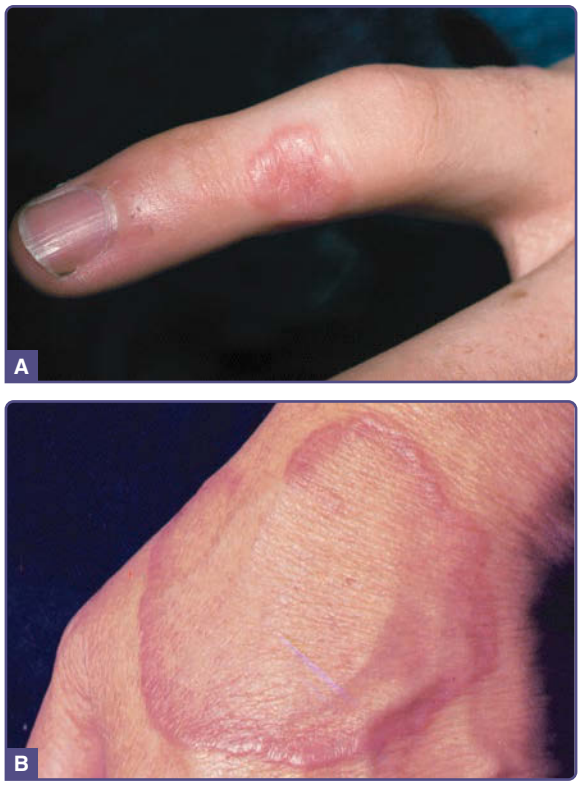

Figure 34-1 **A,** Typical annular lesion of granuloma annulare on a finger. **B,** A larger annular lesion of granuloma annulare on the dorsum of the hand.

Figure 34-3 **A,** Generalized granuloma annulare. Small papular lesions that are too small to exhibit annular configuration. **B,** Multiple annular lesions on the lower arm.

morphology may predominate. A generalized form of perforating granuloma annulare has also been described.

SUBCUTANEOUS TYPE

The subcutaneous form of granuloma annulare occurs predominantly in children[9,10] but is also described in adult patients. It is characterized by firm to hard, usually asymptomatic nodules located in the deep dermis and subcutaneous tissues. They may extend to underlying muscle, and nodules on the scalp and orbit are often adherent to the underlying periosteum.

Individual lesions measure from 6 mm to 3.5 cm in diameter. They are distributed most often on the anterior lower legs in a pretibial location. Other sites of predilection are the ankles, dorsal feet, buttocks, and hands. Nodules on the scalp, eyelids, and orbital rim may present a diagnostic challenge. Subcutaneous granuloma annulare may also be found on the penis.

Figure 34-2 Localized granuloma annulare with nodule on the hand of a child.

PERFORATING TYPE

The perforating type of granuloma annulare is a rare variant characterized by transepidermal elimination of the necrobiotic collagen. It may be localized, usually to the dorsal hands and fingers (Fig. 34-4), or generalized over the trunk and extremities. It has been described on the ears, on the scrotum, and within herpes zoster scars and tattoos. Superficial small papules develop central umbilication or crusting, and there may be discharge of a creamy fluid. Lesions heal with atrophic or hyperpigmented scars. In one series, 24% of patients complained of pruritus and 21% of pain. Papular umbilicated granuloma annulare on the hands of

Figure 34-4 Granuloma annulare on the knuckles of a dark-skinned patient. (Image used with permission from the Graham Library of Wake Forest Department of Dermatology.)

children and a generalized follicular pustular type of granuloma annulare may be clinical variants.

PATCH TYPE

Macular lesions that present as erythematous, red-brown, or violaceous patches without an annular rim are reported in adult women.[11] An arcuate dermal erythema is also observed.

NONCUTANEOUS FINDINGS

Most patients with granuloma annulare are healthy and have no other abnormal physical findings. Arthralgia is reported in association with painful lesions on the hands.[12] Granuloma annulare–like skin lesions and joint disease characterize a multisystem disorder described as interstitial granulomatous dermatitis with arthritis.[13]

Oral involvement has been observed in HIV-associated disease.[14]

ETIOLOGY AND PATHOGENESIS

The etiology of granuloma annulare is unknown, and the pathogenesis is poorly understood. Most cases occur in otherwise healthy children. A variety of predisposing events and associated systemic diseases is reported, but their significance is unclear. It is possible that granuloma annulare represents a phenotypic reaction pattern with many different initiating factors.

PREDISPOSING EVENTS

Nonspecific mild trauma is considered a possible triggering factor because of the frequent location of lesions on the distal extremities of children. An early study of subcutaneous granuloma annulare found a history of trauma in 25% of children,[2] but this observation has not been replicated. Trauma is also a suspected factor in auricular lesions. Granuloma annulare has occurred after a bee sting, a cat bite, and an octopus bite, and insect bite reactions have also been implicated.[2] There is a report of perforating granuloma annulare in long-standing tattoos. Widespread lesions have developed after waxing-induced pseudofolliculitis and erythema multiforme minor and in association with systemic sarcoidosis.[2,15] Severe uveitis without other evidence of sarcoidosis has occurred in a few patients with granuloma annulare.[16-18]

INFECTIONS AND IMMUNIZATIONS

There are several reports of the development of granuloma annulare within herpes zoster scars, sometimes many years after the active infection. It is also described after chickenpox. Generalized, localized, and perforating forms of granuloma annulare may occur in association with HIV infection. Adenovirus was isolated from a lesion in one HIV-positive patient. Epstein-Barr virus was excluded as a causative agent in these cases. However, in other instances, generalized granuloma annulare has been linked to viral infections, including Epstein-Barr virus infection, chronic hepatitis B, and hepatitis C. Vaccinations for tetanus, diphtheria toxoid, and hepatitis B vaccination have been implicated as triggering factors, although vaccination sites were spared in one case of generalized granuloma annulare.[19]

Lesions compatible with granuloma annulare may occur in patients with active tuberculosis. There are also reports of granuloma annulare after tuberculin skin tests and bacille Calmette–Guérin immunization. Evidence of *Borrelia burgdorferi* infection was detected in two reports, but this association was not confirmed in a serologic study. A case in which chronic relapsing granuloma annulare flared during scabies infestation was attributed to the Koebner phenomenon.[20]

SUN EXPOSURE

Granuloma annulare with a predilection for sun-exposed areas and seasonal recurrence has been described. Photosensitive granuloma annulare has been observed in patients with HIV infection.[14] Generalized disease after psoralen plus ultraviolet A (UVA) light therapy is reported, but it is of note that phototherapy and PUVA phototherapy have been used to treat generalized granuloma annulare.[21-23]

Actinic granuloma, also known as *annular elastolytic giant cell granuloma*, develops on photodamaged skin and is believed to represent a granulomatous reaction to actinic elastosis.[24] Its relationship to granuloma annulare is debated.

DRUGS

Granuloma annulare–like drug reactions are reported for gold therapy and treatment with allopurinol, diclofenac, quinidine, intranasal calcitonin, topiramate,

amlodipine, and thalidomide.[25] There are also reports of an association with adalimumab, infliximab, etanercept, efalizumab, and vemurafinib.[22,23,25]

An interstitial granulomatous drug reaction linked to the use of angiotensin-converting enzyme inhibitors, calcium channel blockers, and other medications is considered a distinct entity but may mimic granuloma annulare.[26,27]

PATHOGENIC MECHANISMS

The pathogenic mechanisms that result in foci of altered connective tissue surrounded by a granulomatous inflammatory infiltrate are not understood. Proposed mechanisms include (1) a primary degenerative process of connective tissue initiating granulomatous inflammation, (2) a lymphocyte-mediated immune reaction resulting in macrophage activation and cytokine-mediated degradation of connective tissue, and (3) a subtle vasculitis or other microangiopathy leading to tissue injury.[28-30]

SYSTEMIC DISORDERS AND GRANULOMA ANNULARE

DIABETES MELLITUS AND THYROID DISEASE

Development of granuloma annulare in patients with diabetes mellitus is extensively documented. Whether this is a true relationship has long been debated. The link is primarily with type 1 insulin-dependent diabetes, but cases are also reported with type 2 non–insulin-dependent disease. Localized and generalized as well as subcutaneous nodular and perforating forms of granuloma annulare have been observed. Granuloma annulare rarely predates the onset of diabetes. The histopathologic similarity between granuloma annulare and necrobiosis lipoidica diabeticorum and the coexistence of both conditions in occasional diabetic patients suggest a true association. However, most patients with granuloma annulare do not have diabetes mellitus. Studies attempting to establish a causal correlation have yielded conflicting results.[22]

Granuloma annulare has also occurred in a number of patients with thyroiditis, hypothyroidism, and thyroid adenoma.[22]

MALIGNANCY

An association between granuloma annulare and malignancy in adult patients is reported primarily with Hodgkin and non-Hodgkin lymphoma, including mycosis fungoides, Lennert lymphoma, B-cell disease, T-cell leukemia and lymphoma, and angioblastic T-cell lymphoma. It is reported less commonly with myeloid leukemias and with solid tumors, particularly of the breast. The skin lesions of cutaneous lymphoma and other hematologic malignancies can mimic granuloma annulare both clinically and histopathologically. It may be difficult to distinguish whether they represent true granuloma annulare with atypical lymphocytes or cutaneous lymphoma obscured by a granulomatous infiltrate.[31,32]

DYSLIPIDEMIA

An increased prevalence of dyslipidemia has been reported in patients with granuloma annulare.[32] This was more commonly found in generalized granuloma annulare, particularly in cases with an annular morphology.

LABORATORY TESTS

A diagnosis of localized granuloma annulare is made on clinical examination, and further evaluation is rarely indicated. Biopsy to obtain a specimen for histopathologic examination is necessary when the presentation is atypical, when lesions are symptomatic, and when the diagnosis is otherwise in doubt. Histopathologic analysis may be required to confirm a diagnosis of generalized granuloma annulare or subcutaneous nodular disease on the head and orbital region.

HISTOPATHOLOGIC FINDINGS

The diagnosis is best made at low magnification. Changes are usually observed in the upper and middle dermis, although any part of the dermis or subcutis can be involved. The characteristic histopathologic finding is a lymphohistiocytic granuloma associated with varying degrees of connective tissue degeneration and mucin deposition. The inflammatory infiltrate may have a palisaded or interstitial pattern or a mixture of both patterns.[33-35] Occasionally, a sarcoid-like pattern with large epithelioid histiocytes is seen.

The typical appearance is of single or multiple foci of inflammation with a central core of altered collagen (necrobiosis) surrounded by a wall of palisaded histiocytes (Fig. 34-5). The necrobiotic centers are usually oval, slightly basophilic, devoid of nuclei, and marked by a loss of definition of the collagen bundles and diminished or absent elastic tissue fibers. Stains for mucin and lipid often give positive results.[36]

An interstitial, nonpalisaded pattern of inflammation with histiocytes infiltrating among fragmented collagen bundles may be predominant, particularly in the generalized form. This interstitial pattern is also observed in the absence of apparent connective tissue change. Stains for mucin may be helpful in detecting connective tissue alteration within the infiltrate.

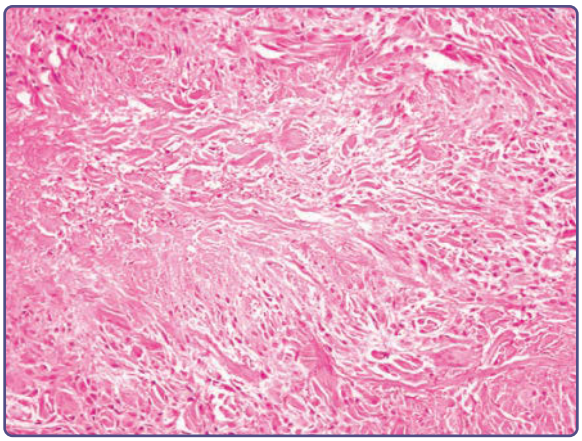

Figure 34-5 Palisading granulomatous inflammation surrounding degenerating collagen within the dermis. (Hematoxylin and eosin stain, ×200.) (Used with permission from Dr. Richard Crawford.)

Lymphocytes are admixed with histiocytes in the granuloma and in a perivascular distribution. Multinucleated giant cells may be present but are not as numerous as in actinic granuloma.[37] Neutrophils and eosinophils are occasionally seen, but plasma cells are rare. Evidence of vascular reactivity includes variable endothelial cell swelling, red cell extravasation, fibrin, leukocytoclasis, and neutrophilic infiltration in blood vessel walls. When leukocytoclastic vasculitis or nuclear debris is a prominent finding, a diagnosis of palisaded neutrophilic and granulomatous dermatitis of immune complex disease should be considered.[38]

In subcutaneous granuloma annulare (Fig. 34-6), the foci of necrobiosis are larger and lie within the deep dermis and subcutaneous fat. They may be distinguished from rheumatoid nodules by the presence of mucin in the necrobiotic zone. Central ulceration and communication between the area of necrobiosis and the surface are characteristic of perforating granuloma annulare (Fig. 34-7). Examination of serial sections may be necessary to demonstrate the necrobiotic plug. An interstitial pattern of inflammation with diffuse necrobiosis is reported in the patch type of granuloma annulare. Palisaded granulomas have also been observed in macular lesions.

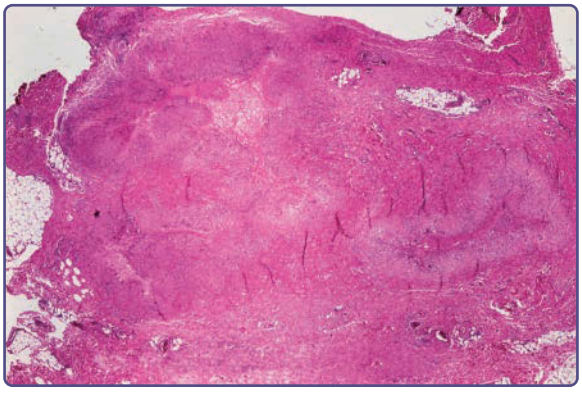

Figure 34-6 Subcutaneous granuloma annulare pathology. (Used with permission from the Graham Library of Wake Forest Department of Dermatology.)

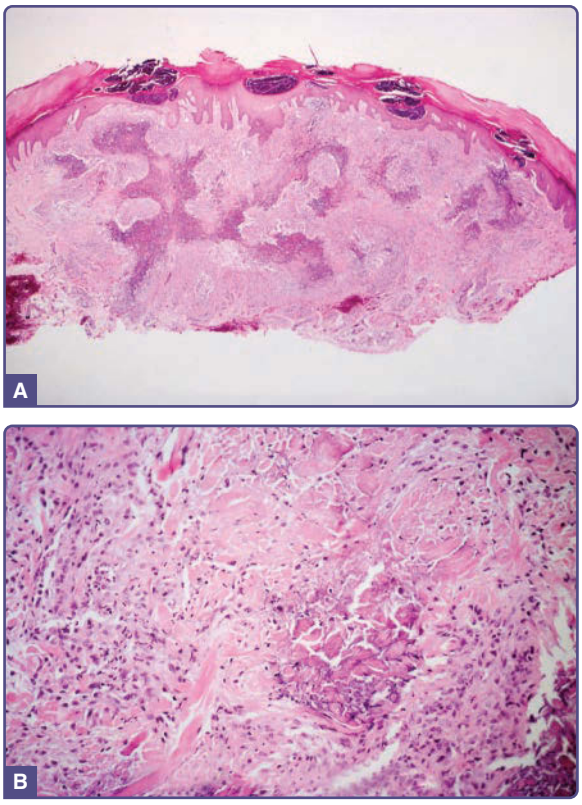

Figure 34-7 **A** and **B,** Histopathology of perforating granuloma annulare. (Used with permission from the Graham Library of Wake Forest Department of Dermatology.)

Immunofluorescence testing may show deposition of fibrin, immunoglobulin (Ig) M, and C3 as a variable finding around vessel walls or at the basement membrane zone; IgM cytoid bodies are also reported.[39] Immunohistochemistry may be useful to confirm the histiocytic nature of equivocal disease. Ultrastructural changes in the connective tissue and capillaries have been described.[40]

SPECIAL TESTS

A diagnosis of granuloma annulare is made clinically or by skin biopsy. Special investigations are usually not necessary. Further evaluation to rule out systemic disease such as infection, sarcoidosis, or malignancy may be required in atypical cases of granuloma annulare. Investigation for endocrine disease is indicated if the patient has signs or symptoms of diabetes or thyroid dysfunction. Lipid studies may be considered in the evaluation of generalized granuloma annulare.[32]

Imaging studies may be performed in subcutaneous granuloma annulare when the clinical features are not recognized or when the presentation is atypical with rapid enlargement or pain. Radiographs show a nonspecific soft tissue mass without calcification or bone involvement. Ultrasonographic examination reveals

a hypoechoic area in the subcutaneous tissues.[41,42] Magnetic resonance imaging shows a mass with indistinct margins, isointense or slightly hyperintense to muscle with T1-weighted images and with a heterogeneous but predominantly high signal intensity on T2-weighted images.[41,43]

DIFFERENTIAL DIAGNOSIS

See Table 34-1.

TREATMENT

The usual treatment options include awaiting spontaneous resolution, topical steroids, and intralesional steroids. These and various other therapies of anecdotal benefit are summarized in Table 34-2. Most

TABLE 34-1
Differential Diagnosis of Granuloma Annulare

Annular Type

Consider
- Tinea corporis
- Subacute cutaneous lupus erythematosus
- Neonatal lupus erythematosus
- Annular lichen planus
- Acute febrile neutrophilic dermatosis
- Erythema chronicum migrans
- Actinic granuloma/annular elastolytic giant cell granuloma
- Necrobiosis lipoidica diabeticorum

Rule Out
- Infections (eg, tuberculosis, atypical mycobacteria, syphilis)
- Interstitial granulomatous dermatitis with arthritis
- Interstitial granulomatous drug reaction
- Annular sarcoidosis
- Lymphoma

Generalized Type

Consider
- Lichen planus
- Lichen nitidus
- Molluscum contagiosum

Rule Out
- Lichenoid and granulomatous dermatitis of acquired immunodeficiency syndrome
- Infections (eg, tuberculosis, atypical mycobacteria, syphilis)
- Sarcoidosis
- Blau syndrome (familial granulomatous arthritis, skin eruption, and uveitis)
- Interstitial granulomatous drug reaction
- Lymphoma

Subcutaneous Type

Consider
- Erythema nodosum
- Dermoid cyst
- Rheumatoid nodules

Rule Out
- Epithelioid sarcoma
- Benign or other malignant tumors
- Deep infections

Perforating Type

Consider
- Molluscum contagiosum
- Insect bites
- Pityriasis lichenoides
- Perforating collagenosis and other perforating disorders
- Foreign body granuloma
- Papulonecrotic tuberculid
- Palisaded neutrophilic and granulomatous dermatitis of immune complex disease

Patch Type

Consider
- Morphea
- Erythema annulare centrifugum
- Parapsoriasis

Rule Out
- Lymphoma

TABLE 34-2
Treatment Options for Granuloma Annulare

- Await spontaneous resolution
- Apply topical corticosteroid with or without occlusion
- Administer intralesional triamcinolone 2.5 mg/mL

Anecdotal Reports of Benefit
- Topical
  - Tacrolimus 0.1% ointment
  - Pimecrolimus cream
  - Imiquimod 5% cream[a]
- Intralesional
  - Interferon-γ
  - Interferon-β
  - Sterile water or saline
- Systemic
  - Antimalarials
  - Retinoids
  - Antibiotics[b]
  - Corticosteroids
  - Cyclosporine
  - Zileuton with vitamin E
  - Fumaric acid esters
  - Pentoxifylline
- Hydroxyurea, chlorambucil, niacinamide, potassium iodide, dapsone
  - Etanercept[c]
  - Infliximab[c]
  - Efalizumab[c]
  - Adalimumab[c]
- Other
  - Phototherapy[d]
  - Photodynamic therapy
  - Fractional photothermolysis

  Skin biopsy
  - Cryotherapy
  - Pulsed dye, Excimer, Nd:YAG or CO_2 laser

[a]Application of 5% imiquimod cream has been reported to worsen granuloma annulare in a child.
[b]Triple antibiotic regimen (rifampicin, ofloxacin, minocycline), doxycycline, antituberculosis therapy.
[c]Development of granuloma annulare has been reported during therapy with etanercept, infliximab, and adalimumab.
[d]Narrowband ultraviolet B, ultraviolet A1, psoralen plus ultraviolet A.
Nd:YAG, neodymium-doped yttrium aluminum garnet.

treatment recommendations are based on single case reports and small cases series, and there are no controlled studies.[21-23,44-47]

CLINICAL COURSE AND PROGNOSIS

Most cases of localized granuloma annulare resolve spontaneously without sequelae. Lesions may clear within a few weeks or persist for several years. The majority disappear within 2 years. Recurrent lesions may develop months or even years later, frequently at the same site. Generalized granuloma annulare often runs a more protracted course. Perforating granuloma annulare results in scarring. There are a number of reports of anetoderma or middermal elastolysis following generalized granuloma annulare and annular elastolytic giant cell granuloma.[48,49] One case of generalized granuloma annulare in a photosensitive distribution healed with scarring and milia formation.[50]

REFERENCES

1. Radcliffe Crocker H. Granuloma annulare. *Br J Dermatol*. 1902;14:1.
2. Muhlbauer JE. Granuloma annulare. *J Am Acad Dermatol*. 1980;3:217.
3. De Aloe G, Risulo M, Sbano P, et al. Congenital subcutaneous granuloma annulare. *Pediatr Dermatol*. 2005;22:234.
4. Choi J-C, Bae J-Y, Cho S, et al. Generalized perforating granuloma annulare in an infant. *Pediatr Dermatol*. 2003;20:2.
5. Martinon-Torres F, Martinon-Sanchez JM, Martinon-Sanchez F. Localized granuloma annulare in children: a review of 42 cases. *Eur J Paediatr*. 1999;158:866.
6. Friedman SJ, Winkelmann RK. Familial granuloma annulare. *J Am Acad Dermatol*. 1987;16:600.
7. Abrusci V, Weiss E, Planas G. Familial perforating granuloma annulare. *Int J Dermatol*. 1988;27:126.
8. Dabski K, Winkelmann RK. Generalized granuloma annulare: clinical and laboratory findings in 100 patients. *J Am Acad Dermatol*. 1989;20:39.
9. Grogg KL, Nascimento AG. Subcutaneous granuloma annulare in childhood: clinicopathologic features in 34 cases. *Pediatrics*. 2001;107:e42.
10. Felner EI, Steinberg JB, Weinberg AG. Subcutaneous granuloma annulare: a review of 47 cases. *Pediatrics*. 1997;100:965.
11. Mutasim DF, Bridges AG. Patch granuloma annulare: clinicopathologic study of 6 patients. *J Am Acad Dermatol*. 2000;42:417.
12. Brey NV, Malone J, Callen JP. Acute-onset, painful acral granuloma annulare. *Arch Dermatol*. 2006;142:49.
13. Long D, Thiboutot DM, Majeski JT, et al. Interstitial granulomatous dermatitis with arthritis. *J Am Acad Dermatol*. 1996;34:957.
14. Cohen PR. Granuloma annulare: a mucocutaneous condition in human immunodeficiency virus-infected patients. *Arch Dermatol*. 1999;135:1404.
15. Ehrich EW, McGuire JL, Kim YH. Association of granuloma annulare with sarcoidosis. *Arch Dermatol*. 1992; 128:855.
16. van Kooij B, van Dijk MC, de Boer J, et al. Is granuloma annulare related to intermediate uveitis with retinal vasculitis? *Br J Ophthalmol*. 2003;87:763.
17. Brey NV, Purkiss TJ, Sehgal A, et al. Association of inflammatory eye disease with granuloma annulare? *Arch Dermatol*. 2008;144:803.
18. Arekapudi S, Whitfield K, Morrison D. Panuveitis associated with granuloma annulare in a child. *J Pediatr Ophthalmol Strabismus*. 2009;46:45.
19. Huilgol SC, Liddell K, Black MM. Generalized granuloma annulare sparing vaccination sites. *Clin Exp Dermatol*. 1995;20:51.
20. Wilsmann-Theis D, Wenzel J, Gerdsen R, et al. Granuloma annulare induced by scabies. *Acta Derm Venereol*. 2003;83:318.
21. Pavlovsky M, Samuelov L, Sprecher E, et al. NB-UVB phototherapy for generalized granuloma annulare. *Dermatol Ther*. 2016; 29:152.
22. Thornsberry LA, English JC. Etiology, diagnosis, and therapeutic management of granuloma annulare: an update. *Am J Clin Dermatol*. 2013;14:279.
23. Keimig EL. Granuloma annulare. *Dermatol Clin*. 2015; 33(3):315-29.
24. O'Brien JP, Regan W. Actinically degenerate elastic tissue is the likely antigenic basis of actinic granuloma of the skin and of temporal arteritis. *J Am Acad Dermatol*. 1999;40:214.
25. Lee SB, Weide B, Ugurel S, et al. Vemurafenib-induced granuloma annulare. *J Dtsch Dermatol Ges*. 2016;14:305.
26. Magro CM, Crowson AN, Schapiro BL. The interstitial granulomatous drug reaction. A distinctive clinical and pathological entity. *J Cutan Pathol*. 1998;25:72.
27. Perrin C, Lacour J-P, Castanet J, et al. Interstitial granulomatous drug reaction with a histological pattern of interstitial granulomatous dermatitis. *Am J Dermatopathol*. 2001;23:295.
28. Dahl MV. Speculations on the pathogenesis of granuloma annulare. *Australas J Dermatol*. 1985;26:49.
29. Mempel M, Musette P, Flaguel B, et al. T-cell receptor repertoire and cytokine pattern in granuloma annulare: defining a particular type of cutaneous granulomatous inflammation. *J Invest Dermatol*. 2002;118:957.
30. Fayyazi A, Schweyer S, Eichmeyer B, et al. Expression of IFNγ, coexpression of TNFα and matrix metalloproteinases and apoptosis of T lymphocytes and macrophages in granuloma annulare. *Arch Dermatol* Res. 2000;292:384.
31. Jouary T, Beylot-Barry M, Bergier B, et al. Mycosis fungoides mimicking granuloma annulare. *Br J Dermatol*. 2002;146:1102.
32. Wu H, Barusevicius A, Lessin SR. Granuloma annulare with mycosis fungoides-like distribution and palisaded granulomas of CD-68-positive histiocytes. *J Am Acad Dermatol*. 2004;51:39.
33. Friedmann-Birnbaum R, Weltfriend S, Munichor M, et al. A comparative histopathologic study of generalized and localized granuloma annulare. *Am J Dermatopathol*. 1989;11:144.
34. Stefanaki K, Tsivitanidou-Kakourou T, Stefanaki C, et al. Histological and immunohistochemical study of granuloma annulare and subcutaneous granuloma annulare in children. *J Cutan Pathol*. 2007;34:392.
35. Dabski K, Winkelmann RK. Generalized granuloma annulare: histopathology and immunopathology. A systematic review of 100 cases and comparison with localized granuloma annulare. *J Am Acad Dermatol*. 1989;20:28.

36. Schulman JM, LeBoit P. Adipophilin expression in necrobiosis lipoidica, granuloma annulare, and sarcoidosis. *Am J Dermatopathol*. 2015;37:203.
37. Al-Hoqail IA, Al-Ghamdi AM, Martinka M, et al. Actinic granuloma is a unique and distinct entity: a comparative study with granuloma annulare. *Am J Dermatopathol*. 2002;24:209.
38. Chu P. Connolly MK, LeBoit PE. The histopathologic spectrum of palisaded neutrophilic and granulomatous dermatitis in patients with collagen vascular disease. *Arch Dermatol*. 1994;130:1278.
39. Stefanaki K, Tsivitanidou Kakourou T, Sefananaki C, et al. Histological and immunohistochemical study of granuloma annulare and subcutaneous granuloma annulare in children. *J Cutan Pathol*. 2007;34:392.
40. Hanna WM, Moreno-Merlo F, Andrighetti L. Granuloma annulare: an elastic tissue disease? Case report and literature review. *Ultrastructural Pathol*. 1999;23:33.
41. Chung S, Frush DP, Prose NP, et al. Subcutaneous granuloma annulare: MR imaging features in six children and literature review. *Radiology*. 1999;210:845.
42. Stenzel M, Voss U, Mutze S, et al. A pretibial lump in a toddler—sonographic findings in subcutaneous granuloma annulare. *Ultraschall Med*. 2010;31:68.
43. Navarro OM, Laffan EE, Ngan B-Y. Pediatric soft-tissue tumors and pseudotumors: MR imaging features with pathologic correlation. *Radiographics*. 2009;29:887.
44. Lukacs J, Schliemann S, Elsner P. Treatment of generalized granuloma annulare—a systematic review. *J Eur Acad Dermatol Venereol*. 2015;29:1467.
45. Min MS, Lebwohl M. Treatment of recalcitrant granuloma annulare with adalimumab. *J Am Acad Dermatol*. 2016;74:127.
46. Simpson B, Foster S, Ku JH, et al. Triple antibiotic combination therapy may improve but not resolve granuloma annulare. *Dermatol Ther*. 2014;27:343.
47. Verne SH, Kennedy J, Falto-Aizpurua LA, et al. Laser treatment of granuloma annulare: a review. *Int J Dermatol*. 2016;55:376.
48. Kang HS, Paek JO, Lee MW, et al. Anetoderma developing in generalized granuloma annulare in an infant. *Ann Dermatol*. 2014;26:283.
49. Sanyal S, Hejmadi R, Taibjee SM. Granuloma annulare resolving with features of mid-dermal elastolysis. *Clin Exp Dermatol*. 2009;34:e1017.
50. Gass JK, Todd PM, Rytina E. Generalized granuloma annulare in a photosensitive distribution resolving with scarring and milia formation. *Clin Exp Dermatol*. 2009;34:e53.

Chapter 35 :: Sarcoidosis

:: Richard Marchell

AT-A-GLANCE

- Sarcoidosis is a multisystem disease characterized by granulomatous inflammation of unknown etiology commonly occurring in the lung and the skin, but any organ system can be affected.
- The type of cutaneous lesion may suggest prognosis. Lupus pernio lesions are associated with chronic disease course and scarring. Erythema nodosum lesions portend an acute self-resolving course.
- Specific lesions of sarcoidosis have a varied clinical morphology, including macules, papules, plaques, nodules, and ulcerations.
- Topical, systemic, and intralesional corticosteroids are the mainstay of therapy.
- Patients initially diagnosed with cutaneous sarcoidosis should get baseline testing to look for deleterious systemic disease, including a physical examination; neurologic review of systems; a chest radiograph; an electrocardiogram; pulmonary function tests; urine analysis; complete blood count; comprehensive metabolic panel; serum calcium level; tuberculosis screening; and an ophthalmologic examination.

Sarcoidosis is a multisystem disease characterized by granulomatous inflammation. It is theorized to be a disease of hyperactivation of the immune system, but its etiology is unknown.

HISTORICAL PERSPECTIVE

Although the lungs are the organs most commonly afflicted, sarcoidosis was actually first described in the late 1800s because of its skin manifestations. Boeck reported a case of "multiple benign sarkoid of the skin" as he believed the skin lesions resembled sarcomas but were benign.[1]

EPIDEMIOLOGY

Sarcoidosis occurs worldwide and may affect all ages and races. Disease onset is most common in the third decade of life and is slightly higher in women.[2] Sarcoidosis has a higher incidence with greater distance from the equator. The highest prevalence of sarcoidosis is found in whites in Denmark and Sweden, and in persons of African descent in the United States.[3] In the United States, the lifetime risk of sarcoidosis is 2.4% in African Americans and 0.85% in whites.[3] The incidence rate of sarcoidosis in the United States is 17.8 per 100,000 for African Americans and 8.1 per 100,000 for whites; the prevalence rate is 141.8 per 100,000 for African Americans and 49.8 per 100,000 for white individuals.[4] The highest prevalence is in African American women (178.5 per 100,000).[4] African Americans tend to have more severe symptomatic disease. African Americans are more likely to have extrapulmonary disease,[5] require treatment,[6] and have a lower rate of clinical recovery[7,8] than whites.

CLINICAL FEATURES

Table 35-1 summarizes the variable presentations of sarcoidosis.

CUTANEOUS FINDINGS

With the advent of penicillin, sarcoidosis has replaced syphilis as the great mimicker for dermatologists. The diverse variety of cutaneous sarcoidosis is bewildering. Almost all primary morphologies have been reported, including macules, papules, patches, plaques, and nodules. Alopecia occurs with scalp involvement and nail changes also occur. Epidermal changes of scaling, telangiectasia, and atrophy exist. Cutaneous lesions of sarcoidosis may occur before, coincident with, or after systemic involvement. Classically, lesions are divided into two categories: specific and nonspecific. Specific lesions have granulomatous inflammation histologically similar to the pattern seen in sarcoid lesions in other organs. Nonspecific skin findings are reactive and do not exhibit sarcoidal granulomas.

SPECIFIC CUTANEOUS LESIONS

Despite the diversity in appearance, there are several clinical presentations of specific lesions that are typical of cutaneous sarcoidosis.

Papules and Plaques: The most common presentation is the papular form (Figs. 35-1 and 35-2). These firm 1- to 5-mm papules often have a translucent red-brown or yellow-brown color. The yellow-brown coloration as reminiscent of "apple jelly" and is accentuated with the pressing of a glass slide to the skin (diascopy) (Fig. 35-3). In addition to the color change, the granulomatous lesions have a nodular quality that is appreciated with diascopy. The apple jelly appearance and nodules is not pathognomonic for sarcoidosis, as other granulomatous skin conditions,

TABLE 35-1
Variable Presentations of Sarcoidosis

	CLINICAL MANIFESTATIONS
Lupus pernio	Symmetric, violaceous, indurated plaques and nodules on nose, earlobes, cheeks, and digits
Mikulicz syndrome	Sarcoidal granulomas on mucosal surface and tongue, with bilateral enlargement of the lacrimal, parotid, sublingual, and submandibular glands
Darier-Roussy sarcoid	Presents as persistent subcutaneous nodules that may be tender or painless; occurs on extremities
Lofgren syndrome	Erythema nodosum with bilateral hilar adenopathy, arthralgia, and fever; often the presenting manifestation of sarcoidosis
Heerfordt syndrome	Fever, parotid gland enlargement, facial palsy, and anterior uveitis

including lupus vulgaris and granuloma annulare, may exhibit similar diascopic properties. However, dermoscopy may prove useful in distinguishing the cutaneous granulomas of sarcoidosis from necrobiotic granulomas. Even after therapy, dermoscopic findings of pink homogenous background, translucent orange areas, fine white scaling, and scar-like depigmentation are significantly associated with cutaneous sarcoidosis compared to necrobiosis lipoidica, granuloma annulare, and rheumatoid nodules.[9]

Epidermal changes may or may not be present (Figs. 35-4 and 35-5), but the lesions often have a waxy appearance, which reflects mild epidermal atrophy. Papular lesions occur most commonly on the face and neck, with a predilection for periorbital skin. Typically the papular lesions are asymptomatic without pain or pruritus; the most common complaint is cosmetic disfigurement.

Plaques, both annular and nonannular, and nodules may develop from papular lesions and may retain the translucent yellow-brown coloration (Fig. 35-6).

Lupus Pernio: Lupus pernio describes the relatively symmetric, violaceous, indurated plaques and nodules occurring on the nose, earlobes, cheeks, and digits (Figs. 35-7 and 35-8). The name *lupus pernio* is a misnomer preserved from the erroneous notion that these lesions might be related to lupus vulgaris and cold injury when lupus pernio was first described by Besnier in the 19th century. This distinctive clinical variant is associated with a higher incidence of systemic involvement and upper respiratory tract disease.[10] Lupus pernio lesions may directly extend into the nasal sinus, leading to epistaxis, nasal crusting, and sine bone involvement. Angiolupoid lesions are pink and violaceous papules and plaques with prominent telangiectasias that usually occur on the face; they are often considered a variant of lupus pernio.

Figure 35-2 Periorbital papular lesions.

Scar Sarcoid: Cutaneous sarcoidosis occurs preferentially within scar tissue, at traumatized skin sites, and around embedded foreign material such as silica and tattoo ink (Fig. 35-9). Scars become inflamed and infiltrated with sarcoidal granulomas. Inflammation of old scars may precede or parallel systemic disease activity. Infiltrated scars may be tender or pruritic and the only finding of a patient with significant systemic involvement. The presence of sarcoidal granulomas surrounding foreign material does not establish the diagnosis of sarcoidosis, nor does foreign material in the presence of granulomas exclude the diagnosis.

Figure 35-1 Perioral papular lesions.

Figure 35-3 Diascopy revealing "apple-jelly" coloration.

Figure 35-4 Scaling plaque. Despite being a disease that is characterized by granulomas in the dermis epidermal changes such as psoriasiform scale occur.

Subcutaneous Nodules (Darier-Roussy Sarcoid): Rarely, sarcoidosis can present as persistent subcutaneous nodules (Darier-Roussy sarcoid).[11] The nodules may be tender or painless, and preferentially occur on the extremities.

Hypopigmented Areas: Lesions appearing to be hypopigmented macules occur primarily in darkly pigmented persons (Fig. 35-10). However, upon careful palpation, induration can usually be appreciated in the areas that have granulomatous inflammation histologically. Some hypopigmented truly macular areas likely reflect postinflammatory pigment alteration as well.

Alopecia: Alopecia, both scarring and nonscarring, may occur with cutaneous lesions on hair-bearing skin such as the face and scalp. Annular plaques may have alopecia centrally. The reversibility is dependent on the degree of fibrosis and destruction of the hair follicle.

Nail Findings: Nail plate deformation and discoloration occur rarely including clubbing, subungual hyperkeratosis, and nail plate destruction. Granulomas in the nail matrix or adjacent bone lead to nail changes.

Figure 35-5 Dermal plaque. Notice there are no epidermal changes in this example of cutaneous sarcoidosis.

Figure 35-6 Plaques on neck.

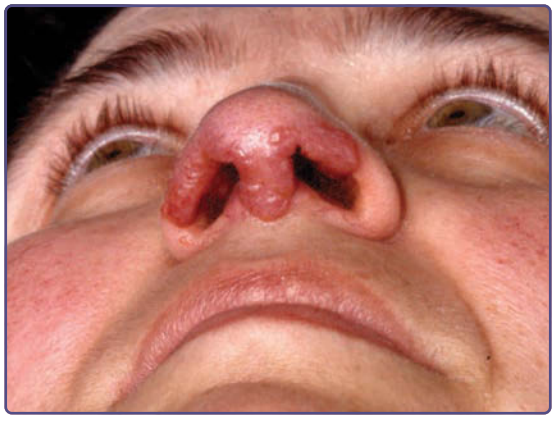

Figure 35-7 Lupus pernio along the nasal rim. This patient also had sarcoidosis of the upper respiratory tract (SURT).

Figure 35-8 Lupus pernio of the digits.

Figure 35-9 Scar sarcoid arising in an excision site.

Figure 35-11 Ulcerative lesions on the leg.

Mucous Membranes: Sarcoidal granulomas may cause papules and plaques of the mucosal surface and tongue. Infiltration of the gingiva causing "strawberry gums" mimicking Wegner granulomatosis may occur. Sarcoidosis is one cause of Mikulicz syndrome, the bilateral enlargement of the lacrimal, parotid, sublingual, and submandibular glands.

Additional Cutaneous Findings: A myriad of additional clinical presentations have also been reported. These include ichthyosis,[12] erythroderma,[13] ulcerations[14] (Fig. 35-11), morphea-form plaques,[15] lichen nitidus-like papules,[16] folliculitis-like lesions,[17] psoriasiform plaques,[18] gyrate erythema,[19] verrucous lesions,[17] faint erythema, genital lesions,[20,21] palmar erythema,[22] discoid lupus-like plaques,[23] lower-extremity edema,[24] lesions mimicking tuberculoid leprosy, areas mimicking polymorphous light eruptions,[17] and pustular lesions.[17]

NONSPECIFIC CUTANEOUS LESIONS

Erythema nodosum is the main nonspecific cutaneous manifestation of sarcoidosis. Erythema nodosum with bilateral hilar adenopathy, arthralgia, and fever is frequently the initial manifestation of sarcoidosis (Lofgren syndrome). These patients tend to have an acute form of sarcoidosis with eventual resolution.

Other nonspecific cutaneous manifestations of sarcoidosis are much less common. The neutrophilic dermatoses, Sweet disease and pyoderma gangrenosum, have been reported. Most patients with pyoderma gangrenosum have concomitant erythema nodosum.[25] Nonspecific erythematous eruptions resembling viral exanthems or drug reaction without histologic evidence of granulomas occur very rarely with acute sarcoidosis. Additionally, patients with sarcoidosis may have pruritus without granulomatous inflammation leading to prurigo nodules.[26] Erythema multiforme had been regularly cited as a nonspecific cutaneous manifestation of sarcoidosis,[17] but reports of histologically proven erythema multiforme with interface dermatitis are virtually nonexistent in the literature,[27,28] and any association is more likely coincidental. Erythroderma and nonspecific lower-extremity edema have been described as both specific and nonspecific lesions of sarcoidosis.[24,26,29,30]

Figure 35-10 Hypopigmented macules.

NONCUTANEOUS FINDINGS

Sarcoidosis is a multisystemic disease by definition and essentially all organ systems can be involved. However, symptoms are often lacking and diagnosis of systemic involvement is commonly found incidentally on routine testing, such as a chest radiograph.

PULMONARY SARCOIDOSIS

The lung is the most common organ involved with sarcoidosis. Findings on pulmonary examination are usually absent, and patients are usually asymptomatic. Dyspnea, cough, chest pain, hypoxemia, and wheezing may occur. Sarcoid lesions directly infiltrate the parenchyma of the lungs, which can lead to

pulmonary fibrosis. Fibrotic disease can lead to pulmonary hypertension and chronic *Aspergillus* infection. Additionally, lesions distort the airways and cause an obstructive lung disease. Pulmonary function tests are more likely to be abnormal when chest radiographs reveal abnormal lung parenchyma, but also may be abnormal without parenchymal findings.

OCULAR SARCOIDOSIS

The eyes are involved in at least 25% of sarcoidosis patients and involvement can be vision threatening.[31] Patients may initially be asymptomatic warranting routine ophthalmologic examination.[32] Redness, burning, itching, and dryness are the most common symptoms when present. Any portion of the eye may be involved with uveitis being most common. Lacrimal gland enlargement may occur (Fig. 35-12). Uveitis can lead to glaucoma and cataracts. Other manifestations include conjunctivitis, lacrimal gland involvement leading to keratoconjunctivitis sicca (dry eyes), and optic neuritis. Optic neuritis may rapidly lead to vision loss. Heerfordt syndrome, which includes fever, parotid gland enlargement, facial palsy, and anterior uveitis, is a classic presentation of sarcoidosis.[2]

Figure 35-12 Lacrimal gland enlargement in a patient with sarcoidosis.

CARDIAC SARCOIDOSIS

Clinical evidence of cardiac involvement is found in only 5% of sarcoidosis patients, but myocardial granulomas have been found in approximately 25% of patients at time of autopsy.[33] Most clinical problems are related to cardiac arrhythmias or left ventricular dysfunction.[34] Sudden death may occur. Congestive heart failure may result when the myocardium is massively infiltrated with granulomas. An electrocardiogram is recommended for every patient diagnosed with sarcoidosis.

NEUROSARCOIDOSIS

Any portion of the central or peripheral nervous system may be affected. Neurosarcoidosis has a predilection for the base of the brain, and cranial neuropathies are the most common manifestation.[35] The facial nerve is the most frequently involved. Mass lesions may develop in the brain or spinal cord. Aseptic meningitis and peripheral neuropathy can occur.

RENAL SARCOIDOSIS

The kidneys may be affected by direct granulomatous inflammation or by nephrolithiasis resulting from hypercalcemia. Activated sarcoidal macrophages have increased 1α-hydroxylase activity. This converts 25-hydroxyvitamin D to 1,25-dihydroxyvitamin D, the active form of the vitamin, resulting in hypercalcemia, hypercalciuria, and nephrolithiasis.[36]

HEPATIC SARCOIDOSIS

Liver involvement is common but rarely causes any clinically relevant signs or symptoms. Histologic evidence of sarcoidal granulomas is common and the liver can be a good site to biopsy to confirm the diagnosis. An increase in serum alkaline phosphatase occurs in approximately 33% of patients,[37] but does not mandate treatment. Treatment is reserved for patients with significant symptoms (hepatosplenomegaly, abdominal pain, pruritus), evidence of synthetic dysfunction, or hyperbilirubinemia. Rarely, primary biliary cirrhosis-type disease and portal hypertension may develop.[38]

OTHER ORGANS

The sinuses and upper airway are commonly involved with sarcoidosis, a condition known as sarcoidosis of the upper respiratory tract. Nasal sarcoidosis of the upper respiratory tract is often associated with lupus pernio and may cause severe epistaxis and nasal crusting. Sarcoidosis may involve the spleen, and may be associated with reduction in any blood cell line. Splenic sequestration and

bone marrow involvement may lead to leukopenia. Thrombocytopenia may result from bone marrow involvement, splenic sequestration, or from an idiopathic thrombocytopenic purpura-like syndrome related to hypergammaglobulinemia often seen in patients with sarcoidosis.[39]

ETIOLOGY AND PATHOGENESIS

Sarcoidosis is triggered by exposure to an antigen(s) with hyperactivity of the cell-mediated immune system leading to granulomatous inflammation. Presumably antigen-presenting cells, such as macrophages, recognize, process, and present the processed sarcoid-inducing antigen to CD4+ T cells of the T-helper (Th)1 subtype. The processed antigen is presented to these lymphocytes via human leukocyte antigen (HLA) class II molecules on the antigen-presenting cells that have undergone enhanced expression from exposure to the sarcoidosis antigen and possibly interferon gamma (IFN-γ).[40,41] These activated macrophages produce interleukin (IL)-12 which induces lymphocytes to shift toward a Th1 profile and causes T lymphocytes to secrete IFN-γ. These activated T cells release IL-2 and chemotactic factors that recruit monocytes and macrophages to the site of disease activity. IL-2 and other cytokines also expand various T-cell clones. IFN-γ further activates macrophages and transforms them into giant cells.[40] Tumor necrosis factor (TNF)-α, IL-2, and other cytokines may also be important in stimulating macrophages (Fig. 35-13). There is also evidence that CD4+ T cells of the Th17 subtype and Th17 cytokines also may play a role in the development of the lesions.[42] The identity of the putative antigen(s) triggering the immunologic cascade is unknown. Infectious agents and environmental antigens and have been investigated.

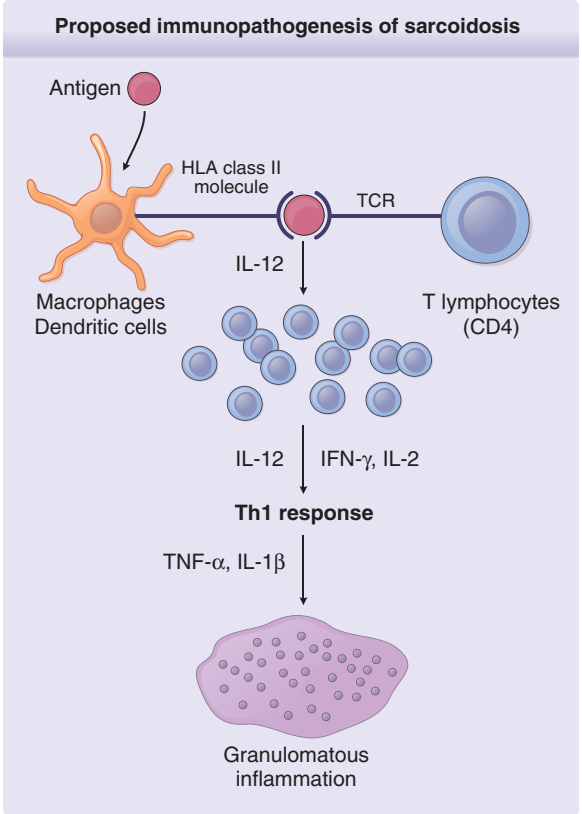

Figure 35-13 Proposed immunopathogenesis of sarcoidosis. An antigen, presently unknown, is engulfed and processed by an antigen-presenting cell (macrophage or dendritic cell). The processed antigen is presented to a T-cell receptor (TCR) of a T lymphocyte via an HLA class II molecule. Once the HLA receptor and TCR have bound the processed antigen, numerous lymphokines and cytokines of the T-helper cell subtype 1 (Th1) class are released that lead to T-cell proliferation, recruitment of monocytes, and eventual granuloma formation. A few of these lymphokines and cytokines are shown, with those released by the antigen-presenting cells on the left and those released by lymphocytes on the right. IFN, interferon; IL, interleukin; TNF, tumor necrosis factor.

RISK FACTORS

Infectious agents such as mycobacteria,[43] *Propionibacterium acnes*,[44] and *Chlamydia*[45] are associated with sarcoidosis. However, patients with sarcoidosis improve with immunosuppressive agents, which argues against a purely infectious etiology. Mineral dusts, including silica, iron,[46] and titanium,[47] are associated with sarcoidosis. Firefighters and persons with wood burning stoves are documented as having an increased risk of developing sarcoidosis.[48,49] Lifelong nonsmokers are more likely to develop the disease[50] than smokers.

Genetics play a major role in determining susceptibility to sarcoidosis. Relatives of an affected person are more likely to develop disease than is the general population.[51] Numerous studies in various ethnic groups show a relationship between HLA antigens and the development of disease, protection from disease, good prognosis, bad prognosis, acute disease, chronic disease, and various phenotypic expressions of sarcoidosis. Additionally, mutations in genes related to the immune system, including those encoding TNF, lymphotoxin α, and the IL-23 receptor, are associated with different presentations of sarcoidosis, including erythema nodosum, cardiac sarcoidosis, and uveitis.[52-55]

The interplay of antigenic and genetic risk factors suggests that there may be multiple causes of sarcoidosis. Perhaps patients have to experience a specific interaction between one or several exposures and be genetically programmed to one or several immunologic responses. Each putative antigen may be associated with a specific HLA class II molecule and T-cell receptor and/or other polymorphisms of the many molecules of the human immune system.

DIAGNOSIS

The diagnosis of sarcoidosis requires a compatible clinical picture, histologic demonstration of noncaseating granulomas, and exclusion of other diseases capable of producing similar histology or clinical features. As sarcoidosis is a diagnosis of exclusion, the diagnosis can never be confirmed with 100% certainty.[56] Often the diagnosis is assumed when the clinical presentation is typical for the disease and is not explained by an alternative cause.

The presence of noncaseating granulomas in a single organ system does not conclusively establish the diagnosis of sarcoidosis because sarcoidosis is, by definition, a systemic disease that involves multiple organs.[57] Isolated skin granulomas should not be assumed to represent sarcoidosis, and efforts must be made to exclude alternative diagnoses. Although confirmation of sarcoidosis requires proof of granulomatous involvement in at least 2 separate organs, histologic confirmation is not necessarily required in the second organ.[58]

Certain disease presentations are so specific for the diagnosis of sarcoidosis (eg, Lofgren syndrome, Heerfordt syndrome, and asymptomatic bilateral hilar adenopathy) that the diagnosis may be accepted without a tissue biopsy. For example, asymptomatic bilateral hilar lymphadenopathy noted on chest radiograph is relatively specific for sarcoidosis.

Some clinical, imaging, and laboratory tests are recommended when a diagnosis of sarcoidosis is considered. These tests screen for involvement of various organ systems (Table 35-2).

TABLE 35-2

Recommended Initial Evaluation of Patients with Sarcoidosis

- History (occupational and environmental exposure, symptoms)
- Physical examination
- Posteroanterior chest radiograph
- Pulmonary function tests: spirometry, DL_{CO}, and KL_{CO}
- Peripheral blood counts: white blood cells, red blood cells, platelets
- Serum chemistries: calcium, liver enzymes (alanine aminotransferase, aspartate aminotransferase, alkaline phosphatase), creatinine, and blood urea nitrogen
- Urine analysis
- Electrocardiogram
- Routine ophthalmologic examination
- Tuberculin skin test

DL_{CO}, diffusing capacity of lung for carbon monoxide; KL_{CO}, diffusing capacity per liter alveolar volume.

Adapted with permission of the American Thoracic Society. Copyright © 2017 American Thoracic Society. Originally from American Thoracic Society/European Respiratory Society: Statement on sarcoidosis. Joint Statement of the American Thoracic Society (ATS), the European Respiratory Society (RS) and the World Association of Sarcoidosis and Other Granulomatous Diseases (WASOG) adopted by the ATS Board of Directors and the ERS Executive Committee, February 1999. *Am J Respir Crit Care Med.* 1999;160:736. The *American Journal of Respiratory and Critical Care Medicine* is an official journal of the American Thoracic Society.

A physical examination and routine ophthalmologic examination should be performed in addition to testing. A history to assess for risk of other granulomatous diseases by occupational and environmental (eg, exposure to tuberculosis, endemic fungi, and beryllium exposure) should be performed.

LABORATORY TESTING

Recommended tests to evaluate for system disease include pulmonary function tests, complete blood count, comprehensive metabolic panel, urine analysis, electrocardiogram, and tuberculosis testing (QuantiFERON-TB gold tuberculosis assay or tuberculin skin test).

The epithelioid cell of the sarcoidal granuloma secretes angiotensin-converting enzyme.[59] Consequently, serum angiotensin-converting enzyme (SACE) levels reflect the total granuloma burden in sarcoidosis. However, elevated SACE levels are insufficiently specific for the diagnosis of sarcoidosis to rest on it alone, and insufficiently sensitive to exclude the diagnosis.[60] SACE levels are elevated in all granulomatous diseases, including infectious ones. Initial SACE levels are not different between patients who deteriorate and those who improve,[61] so they should not be used to determine treatment. Serial SACE levels may be useful for monitoring the course of sarcoidosis, but this test is not presently routinely used.

IMAGING

A posteroanterior chest radiograph is abnormal in more than 90% of patients with sarcoidosis. Staging of pulmonary radiographs is as follows:

Stage 0: normal
Stage I: bilateral hilar and/or paratracheal adenopathy
Stage II: adenopathy with pulmonary infiltrates
Stage III pulmonary infiltrates only
Stage IV: pulmonary fibrosis

Bilateral hilar adenopathy is noted in 50% to 85% of cases. Pulmonary parenchymal infiltrates are seen in 25% to 60% of cases. Asymptomatic hilar adenopathy on chest radiograph almost always represent sarcoidosis.[62] It has been suggested that histologic confirmation of sarcoidosis may not be required in asymptomatic patients provided the physical examination, complete blood count, and routine blood tests are all normal and there is no prior history of malignancy.[63] Although chest computed tomography reveals more thoracic disease than can be appreciated on chest radiography, there is insufficient evidence that computed tomography has a clinical role in the management of pulmonary sarcoidosis.[64] Characteristic round, punched out,

lytic, cystic lesions may be found in radiographs of the hands and feet.

The mechanism of gallium-67 uptake in sarcoidosis is incompletely understood. It is thought that inflammatory processes cause hyperemia and increased capillary permeability of gallium. Gallium also accumulates in macrophages and, to a lesser extent, in T lymphocytes, which are major participants in the granulomatous inflammation of sarcoidosis. Sarcoidosis may cause gallium uptake in thoracic and extrathoracic sites, although typically not in areas of skin involvement. Gallium scanning has not been found useful for monitoring the clinical course of sarcoidosis, but it may have a role in identifying organs with sarcoid involvement. The presence of panda sign (bilateral lacrimal and parotid gland uptake) and lambda sign (bilateral hilar and right paratracheal uptake) on gallium-67 scanning is highly specific for sarcoidosis and may obviate the need for invasive diagnostic procedures. However, these signs are both positive in only a small percentage of sarcoidosis patients. Organ activity has been detected by gadolinium enhancement on nuclear magnetic resonance imaging. Magnetic resonance imaging is useful in detecting neurosarcoidosis and monitoring therapeutic response. Fluorodeoxyglucose positron emission tomography scanning is more sensitive in revealing granulomatous inflammation than gallium-67 scanning and in monitoring response to treatment.[65,66]

PATHOLOGY

The epithelioid granuloma of sarcoidosis usually contains a compact collection of mononuclear phagocytes. The granulomas typically are surrounded by a paucity of lymphocytes ("naked granulomas"), but varying degrees of lymphocytic inflammation may be present (Fig. 35-14). Epithelioid cells, which are themselves transformed monocytes, are commonly present within the sarcoidal granuloma. Multinucleated giant cells of the Langerhans type result from the fusion of epithelioid cells. Although central fibrinoid necrosis is not uncommon, gross necrosis is not a characteristic feature of sarcoid granulomas and suggests an alternative diagnosis, such as tuberculosis, fungal infection, or vasculitis.[59] Mycobacterial and fungal diseases must always be considered as alternative diagnoses; therefore, stains and cultures for mycobacteria and fungi should be routinely performed. Reaction to foreign bodies such as beryllium, tattoo pigment, and paraffin can have similar histologic findings. Although there are often distinguishing features from sarcoidosis, granuloma annulare, necrobiosis lipoidica, rheumatoid nodules, cheilitis granulomatosa, and annular elastolytic giant cell granuloma may have cutaneous granulomas and are in the differential diagnosis. A clinically important aspect of the pathology of sarcoidosis involves the development of fibrosis. Dense bands of fibroblasts may encase the ball-like granulomas. This fibrotic response can produce tissue destruction and organ dysfunction that cannot be successfully reversed with therapy.

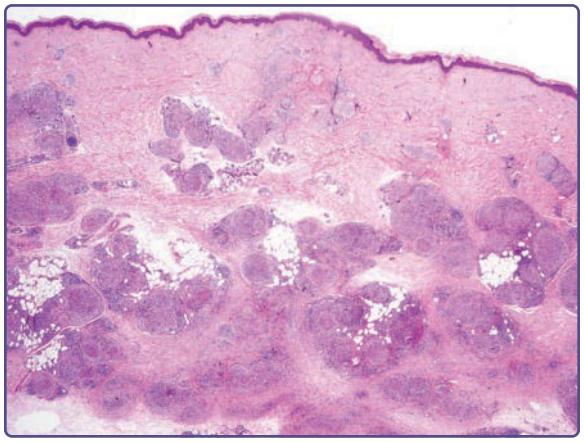

Figure 35-14 Histology of cutaneous sarcoidosis with "naked" granulomas.

DIAGNOSTIC ALGORITHM

Figure 35-15 shows an algorithm for diagnosing whether a patient has sarcoidosis.

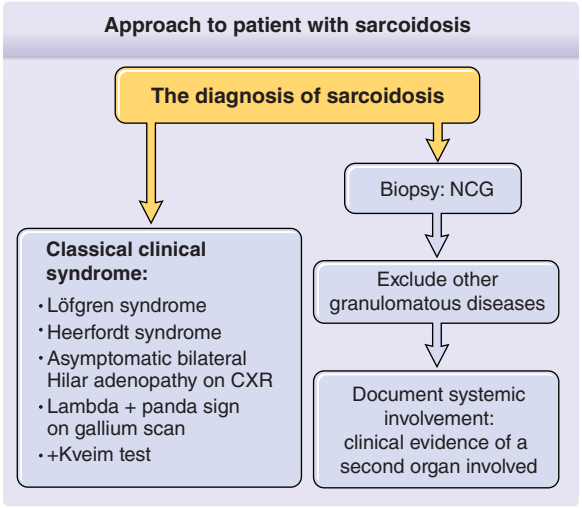

Figure 35-15 Approach to patient with sarcoidosis. Diagnostic algorithm. Usually the diagnosis is made by following the pathway on the right: A tissue biopsy demonstrates noncaseating granulomatous inflammation with a compatible clinical picture, alternative causes of granulomatous inflammation are excluded (including tuberculosis), and there is clinical evidence of systemic (multiorgan) granulomatous inflammation. On occasion, the diagnosis can be assumed without biopsy confirmation if the clinical presentation is very specific for sarcoidosis. These clinical presentations are listed on the left side of the pathway. CXR, chest radiograph; NCG, noncaseating granulomas.

TABLE 35-3
Differential Diagnosis for Cutaneous Sarcoidosis

Histologic and Clinically Similar Conditions
- Deep fungal infections can be granulomatous and clinically resemble sarcoid like blastomycosis, histoplasmosis and others
- Annular elastotic giant cell granuloma
- Granuloma annulare
- Lupus vulgaris
- Atypical mycobacterial infection
- Cheilitis granulosa
- Foreign-body reactions (eg, tattoo, soft-tissue fillers, ruptured hair follicles/cyst)
- Rheumatoid nodules
- Necrobiosis lipoidica
- Granulomatous rosacea
- Cutaneous Crohn disease
- Blau syndrome
- Granulomatous syphilis
- Granulomatous cutaneous T-cell lymphoma
- Melkersson-Rosenthal syndrome

Clinically Similar Conditions Without Similar Histologic Findings
- Amyloidosis of the skin
- Cutaneous xanthomas
- Syndromes with multiple adnexal tumors and/or dermal tumors (eg, Cowden syndrome, Brooke-Spiegler)

DIFFERENTIAL DIAGNOSIS

Granulomatous syphilis, granulomatous cutaneous T-cell lymphoma, annular elastotic giant cell granuloma, fungal infections, Blau syndrome, granuloma annulare, lupus vulgaris, atypical mycobacterial infections, foreign-body reactions (eg, tattoo, soft-tissue fillers, ruptured hair follicles/cyst), rheumatoid nodules, necrobiosis lipoidica, cheilitis granulosa, and granulomatous rosacea are in the differential diagnosis. Histologic findings are very different, but clinically, syndromes with multiple adnexal tumors, amyloidosis of the skin, and cutaneous xanthomas may resemble cutaneous sarcoidosis (Table 35-3).

CLINICAL COURSE AND PROGNOSIS

The granulomatous inflammation of sarcoidosis can remit spontaneously or with therapy. Therefore, the general prognosis of sarcoidosis is good.[57] Pulmonary sarcoidosis resolves, improves, or stabilizes in 60% to 90% of patients without treatment.[67] Remissions often occur within the first 6 months after diagnosis, although it may take 2 to 5 years.[68] The prognosis is generally favorable for liver and peripheral lymph node sarcoidosis as well. Skin lesions may resolve with or without scarring or pigmentary changes.

The development of fibrosis causes almost all significant impairment from sarcoidosis. This is probably the result of hyalinization of granulomatous inflammation. Host response and inadequate treatment may be to blame for the propensity for a brisk fibrotic response. In addition to permanent scarring of the skin from fibrosis, cutaneous lesions may ulcerate or destroy adjacent bone and cartilage. Lupus pernio lesions most commonly leave permanent scarring and destruction.

In the United States, three-fourths of the sarcoidosis deaths are related to pulmonary involvement. Sarcoidosis of the heart and central nervous system accounts for most of the remaining deaths.[69]

There is no current laboratory tests or radiologic findings that can reliably predict the outcome of sarcoidosis. Skin lesions are not a reliable indicator of prognosis, but several useful associations have been documented. Patients with cutaneous lesions area more likely to have chronic systemic sarcoidosis than patients without skin involvement.[70] Erythema nodosum with fever and arthralgia portends a good prognosis.[71] Patients with Lofgren syndrome have a more than 80% rate of spontaneous remission, generally within 4 to 6 weeks.[2] Lupus pernio indicates chronic disease and is associated with upper respiratory tract involvement, pulmonary fibrosis, and bony cysts.[2] African descent, higher stage chest radiograph (greater than stage I), age older than 40 years, splenic involvement, disease duration longer than 2 years, and forced vital capacity less than 1.5 L are associated with a worse prognosis.[57]

MANAGEMENT

Sarcoidosis often spontaneously remits, and therapy may be associated with significant side effects. Consequently, monitoring patients for development of progressive irreversible damage is a reasonable strategy. Clinicians should treat cutaneous sarcoidosis when the lesions are cosmetically unacceptable for the patient or they are scarring and infiltrative as in lupus pernio. Other appropriate reasons to initiate therapy include pulmonary symptoms, worsening pulmonary function, neurologic involvement, ocular involvement, symptomatic cardiac disease, evidence of hepatic synthetic dysfunction, and splenomegaly.

THERAPY DIRECTED AT THE SKIN

Cutaneous sarcoidosis, including lupus pernio, may be improved with prolonged application (at least 2 weeks) of class I topical steroids such as clobetasol ointment. Intralesional injections of triamcinolone (strength 3 to 10 mg/mL) are more effective. Both therapies can cause skin atrophy and hypopigmentation. Topical tacrolimus may be effective for skin disease and does not pose the same adverse effects, but is not generally as effective.[72,73]

SYSTEMIC CORTICOSTEROIDS

Systemic corticosteroids are the most reliable immediate initial therapy for sarcoidosis. Treatment of cutaneous disease is usually initiated with 40 to 60 mg/day of prednisone equivalent with tapering of therapy over a month to doses of 10 to 20 mg/day. The recommended initial dose of pulmonary sarcoidosis is 20 to 40 mg of prednisone equivalent/day.[74] Cardiac and neurologic sarcoidosis may require higher initial doses, up to 60 to 80 mg of prednisone equivalent/day.[74] The corticosteroid dosage typically is tapered 0.1 to 0.2 mg/kg over a few months.[74] It is unusual for pulmonary disease to require a maintenance dose of more than 15 mg of prednisone equivalent/day, but cutaneous, cardiac, and neurologic disease may require higher doses. An attempt should be made to taper the dose within 9 to 12 months of the initiation of therapy.[74] Life-threatening arrhythmias are an exception to this rule, and placement of an internal defibrillators may be indicated.[75-77]

If patients cannot be successfully weaned from corticosteroids, a variety of immunosuppressive medications can be used as steroid-sparing agents. Most immunosuppressive are inadequate as monotherapy. Table 35-4 lists the appropriate doses for treatment of sarcoidosis.

METHOTREXATE

Methotrexate is the most studied steroid-sparing agent. The drug requires careful monitoring of liver function tests and blood cell counts. Folic acid can

TABLE 35-4
Sarcoid Medical Therapy

AGENT	DOSE/COMMENT
Topical steroids and intralesional steroids	Localized skin lesions Class I ultrapotent steroids (eg, clobetasol 0.05% ointment) BID for 2-4 weeks then BIW Intralesional triamcinolone 2.5-10.0 mg/mL
Topical tacrolimus	Tacrolimus 0.1% ointment BID Localized skin lesions
Systemic corticosteroids	Prednisone (or equivalent) 20-40 mg/day then taper Consider higher doses for cardiac, neurologic involvement
Methotrexate	10-25 mg/week Monitor complete blood count, liver function tests >1.5 g cumulative dose consider liver biopsy or procollagen III peptide testing Consider adjunctive folate 1 mg/day
Hydroxychloroquine	200-400 mg/day Yearly ophthalmologic screening
Chloroquine	250-1000 mg/day Yearly ophthalmologic screening
Tetracycline	Minocycline 200 mg/day Doxycycline 200 mg/day Primarily for nonlupus pernio skin disease
Broad-spectrum antibiotics	CLEAR (combined levofloxacin, 500 mg/day; ethambutol, 25 mg/kg/day up to 1200 mg; azithromycin, 250 mg/day; and rifampin, 10 mg/kg/day or up to 300 mg/day) for 8 weeks
Infliximab	5 mg/kg IV q6weeks Screening/monitoring for tuberculosis Consider adjunctive low-dose methotrexate to prevent antidrug antibody formation
Adalimumab	40 mg weekly beginning at week 4 following a 160-mg dose at week 0 and an 80-mg dose at week 2
Pentoxifylline	400 mg TID
Leflunomide	100 mg/day for 3 days loading, then 10 mg/day; can increase to 20 mg/day; monitor complete blood count and liver function tests
Thalidomide	50-200 mg/day QHS dosing as sedating Peripheral neuropathy common monitoring necessary
Melatonin	20 mg/day for 1 year then 10 mg/day for 1 year QHS dosing
Cyclophosphamide	500-1000 mg IV q3-4weeks; monitor complete blood count and urinalysis; stop if hematuria develops Reserved for life-threatening disease because of carcinogenicity

be given in conjunction with methotrexate to alleviate side effects. Patients with sarcoidosis may develop cirrhosis, even if their liver function tests are normal. Liver biopsies should be considered in patients after 1 to 2 g of total therapy. Typical doses of methotrexate for cutaneous disease are 10 to 25 mg/week. Cutaneous improvement may be noted within 1 month, but maximal therapeutic benefit often does not occur until at least 6 months after the initiation of treatment.

ANTIMALARIALS HYDROXYCHLOROQUINE/ CHLOROQUINE

Antimalarial drugs are useful for sarcoidosis affecting the joints and skin, and hypercalcemia.[78,79] Antimalarial agents area not highly effective for pulmonary disease, and often take several months to be effective. Chloroquine has a higher potential of causing retinal damage than hydroxychloroquine, but patients taking either drug must have regular ophthalmologic exams. Hemolytic anemia may occur and patients with glucose-6 phosphate dehydrogenase deficiency may have a higher rate of anemia, but with usual dermatologic doses the deficiency is not an absolute contraindication for usage of hydroxychloroquine.

CYCLOPHOSPHAMIDE

Cyclophosphamide is effective for many forms of sarcoidosis. However, because of its significant side-effect profile, including carcinogenic potential, cyclophosphamide is reserved for severe or potentially life-threatening disease.

ANTIBIOTICS

Minocycline and doxycycline (doses of 100 mg twice daily) have been reported to improve skin sarcoidosis in case series. These drugs may take up to 2 years to be effective.[80] Tetracyclines modify the immune response by suppressing activity of macrophages and T lymphocytes.[81] Several months of the CLEAR (combined levofloxacin, 500 mg/day; ethambutol, 25 mg/kg/day up to 1200 mg; azithromycin, 250 mg/day; and rifampin, 10 mg/kg/day or up to 300 mg/day) regimen has also shown some effectiveness, and clinical trials are currently ongoing to better assess the usefulness of this regimen.[82]

TUMOR NECROSIS FACTOR ANTAGONISTS

TNF is a cytokine that is secreted in macrophages associated with sarcoidal granulomas.[18] Antagonists of TNF have been shown to be useful for the treatment of sarcoidosis. Pentoxifylline,[83] thalidomide,[84] infliximab,[85] and adalumimab[85] are the most studied. Infliximab appears to be particularly useful for the treatment of lupus pernio,[86] and it may be superior to the other TNF antagonists, as a study of etanercept failed to show benefit for sarcoidal uveitis.[87] Paradoxically, administration of these drugs for other conditions has been rarely associated with the development of sarcoidosis.[88]

OTHER AGENTS

Azothioprine,[89] mycophenolate mofetil,[90] leflunomide,[91] and cyclosporine[92] have been reported to be useful for the treatment of systemic sarcoidosis in small case series. Melatonin,[93] allopurinol,[94] isotretinoin,[95] and fumaric acid esters[96] have been reported to be effective for cutaneous sarcoidosis.

PROCEDURES

Phototherapy and photodynamic therapy have been used to mitigate cutaneous sarcoidosis.[97] Electrodessication, pulse-dye laser, carbon dioxide laser therapy, and reconstructive surgical procedures have all been used successfully to improve the cosmetic disfigurement of cutaneous disease.

TREATMENT ALGORITHM

Figure 35-16 presents a treatment algorithm for cutaneous sarcoidosis.

PREVENTION/SCREENING

Prevention and screening for this elusive disease are not currently practical or available.

ACKNOWLEDGMENTS

Thanks to Marc Judson, MD for his continued guidance in all things related to sarcoidosis.

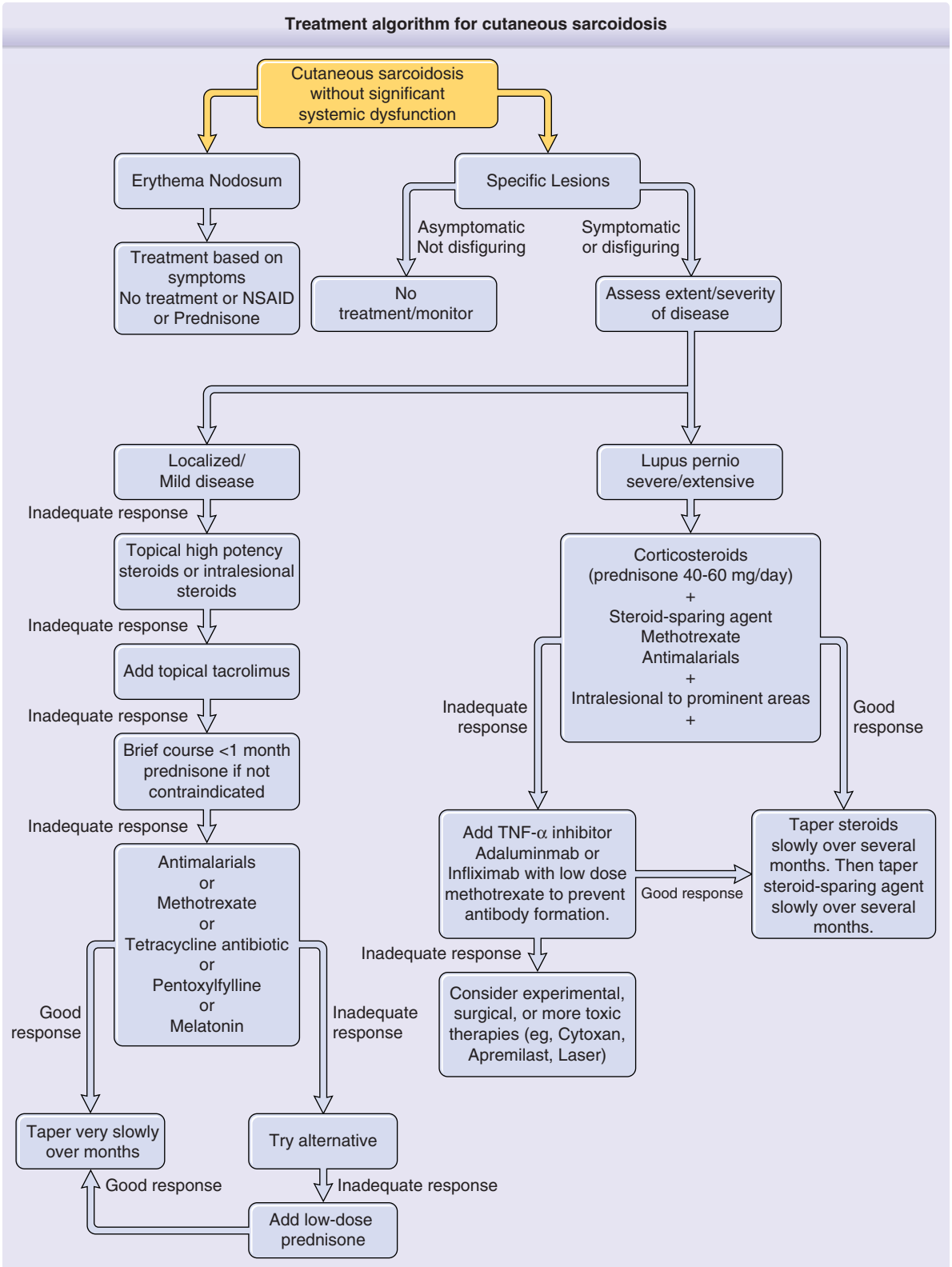

Figure 35-16 Treatment algorithm for cutaneous sarcoidosis.

REFERENCES

1. Boeck C. Multiple benign sarcoid of the skin. *J Cutan Genitourinary Dis.* 1899;17:543.
2. American Thoracic Society/European Respiratory Society: Statement on sarcoidosis. Joint Statement of the American Thoracic Society (ATS), the European Respiratory Society (RS) and the World Association of Sarcoidosis and Other Granulomatous Diseases (WASOG) adopted by the ATS Board of Directors and the ERS Executive Committee, February 1999. *Am J Respir Crit Care Med.* 1999;160:736.
3. Rybicki BA, Major M, Popovich J Jr, et al. Racial differences in sarcoidosis incidence: a 5-year study in a health maintenance organization. *Am J Epidemiol.* 1997;145(3):234-241.
4. Baughman RP, Field S, Costabel U, et al. Sarcoidosis in America. Analysis based on health care use. *Ann Am Thorac Soc.* 2016;13(8):1244-1252.
5. Baughman RP, Teirstein AS, Judson MA, et al; Case Control Etiologic Study of Sarcoidosis (ACCESS) research group. Clinical characteristics of patients in a case control study of sarcoidosis. *Am J Respir Crit Care Med.* 2001;164(10, pt 1):1885-1889.
6. Gottlieb JE, Israel HL, Steiner RM, et al. Outcome in sarcoidosis: the relationship of relapse to corticosteroid therapy. *Chest.* 1997;111(3):623-631.
7. Westney GE, Judson MA. Racial and ethnic disparities in sarcoidosis: from genetics to socioeconomics. *Clin Chest Med.* 2006;27:453.
8. Judson MA, Baughman RP, Thompson BW, et al; ACCESS Research Group. Two year prognosis of sarcoidosis: the ACCESS experience. *Sarcoidosis Vasc Diffuse Lung Dis.* 2003;20(3):204-211.
9. Ramadan S, Hossam D, Saleh MA. Dermoscopy could be useful in differentiating sarcoidosis from necrobiotic granulomas even after treatment with systemic steroids. *Dermatol Pract Concept.* 2016;6(3):17-22.
10. Spiteri MA, Matthey F, Gordon T, et al. Lupus pernio: a clinico-radiological study of thirty-five cases. *Br J Dermatol.* 1985;112(3):315-322.
11. Ando M, Miyazaki E, Hatano Y, et al. Subcutaneous sarcoidosis: a clinical analysis of nine patients. *Clin Rheumatol.* 2016;35(9):2277-2281.
12. Cather JC, Cohen PR. Ichthyosiform sarcoidosis. *J Am Acad Dermatol.* 1999;40(5, pt 2):862-865.
13. Greer KE, Harman LE Jr, Kayne AL. Unusual cutaneous manifestations of sarcoidosis. *South Med J.* 1977; 70(6):666-668.
14. Albertini JG, Tyler W, Miller OF 3rd. Ulcerative sarcoidosis case report and review of the literature. *Arch Dermatol.* 1997;133(2):215-219.
15. Burov EA, Kantor GR, Isaac M. Morpheaform sarcoidosis: report of three cases. *J Am Acad Dermatol.* 1998;39(2, pt 2):345-348.
16. Okamoto H, Horio T, Izumi T. Micropapular sarcoidosis simulating lichen nitidus. *Dermatologica.* 1985;170(5):253-255.
17. Elgart ML. Cutaneous sarcoidosis: definitions and types of lesions. *Clin Dermatol.* 1986;4:35.
18. Vega ML, Abrahams J, Keller M. Psoriasiform sarcoidosis: collision of two entities or expression of one common pathogenesis? *J Clin Aesthet Dermatol.* 2016;9(4) 55-57.
19. Altomare GF, Capella GL, Frigerio E. Sarcoidosis presenting as erythema annulare centrifugum. *Clin Exp Dermatol.* 1995;20(6):502-503.
20. McLaughlin SS, Linquist AM, Burnett JW. Cutaneous sarcoidosis of the scrotum: A rare manifestation of systemic disease. *Acta Derm Venereol.* 2002;82(3):216-217.
21. Klein PA, Appel J, Callen JP. Sarcoidosis of the vulva: a rare cutaneous manifestation. *J Am Acad Dermatol.* 1998;39(2, pt 1):281-283.
22. Cliff S, Hart Y, Knowles G, et al. Sarcoidosis presenting as palmar erythema. *Clin Exp Dermatol.* 1998;23(3):123-124.
23. Harman KE, Setterfield JF, Shirlaw PJ, et al. Clinicopathological case 1: mucous membrane pemphigoid, epidermolysis bullosa acquisita and linear immunoglobulin A disease. *Clin Exp Dermatol.* 2003;28(4): 461-462.
24. Ramanan AV, Denning DW, Baildam EM. Cutaneous childhood sarcoidosis—a rare disease refractory to treatment. *Rheumatology (Oxford)*. 2003;42(12): 1570-1571.
25. Dadban A, Hirschi S, Sanchez M, et al. Association of Sweet's syndrome and acute sarcoidosis: report of a case and review of the literature. *Clin Exp Dermatol.* 2008;34(2):189-191.
26. Callen JP. Sarcoidosis. In: Callen JP, Jorizzo JL, Bolognia J, et al, eds. *Dermatological Signs of Internal Disease,* 3rd ed. Barcelona Spain: Saunders Elsevier Science; 2003:257.
27. Beacham BE, Schuldenfrei J, Julka SS. Sarcoidosis presenting with erythema multiforme-like cutaneous lesions. *Cutis.* 1994;33(5):461-463.
28. Carswell WA. A case of sarcoidosis presenting with erythema multiforme. *Am Rev Respir Dis.* 1972;106:462.
29. Kumar S. Bilateral ankle edema with bilateral iritis. *Clin Rheumatol.* 2006;26(7):1145-1147.
30. Tomada F, Oda Y, Takata M, et al. A rare case of sarcoidosis with bilateral leg lymphedema as an initial symptom. *Am J Med Sci.* 1999;318(6):413-414.
31. Ohara K, Judson MA, Baughman RP, et al. Clinical aspects of ocular sarcoidosis. *Eur Respir J Monogr*. 2005;10:188.
32. Liu D, Birnbaum AD. Update on sarcoidosis. *Curr Opin Ophthalmol.* 2015;26(6):512-516.
33. Silverman KJ, Hutchins GM, Bulkley BH. Cardiac sarcoid: a clinicopathologic study of 84 unselected patients with systemic sarcoidosis. *Circulation.* 1978;58(6): 1204-1211.
34. Birnie DH, Nery PB, Ha AC, et al. Cardiac sarcoidosis. *J Am Coll Cardiol.* 2016;68(4):411-421.
35. Hebel R, Dubaniewicz-Wybieralska M, Dubaniewicz A. Overview of neurosarcoidosis: recent advances. *J Neurol.* 2015;262(2):258-267.
36. Singer FR. Abnormal calcium homeostasis in sarcoidosis. *N Engl J Med.* 1986;315:755.
37. Vatti R, Sharma OP. Course of asymptomatic liver involvement in sarcoidosis: the role of therapy in selected cases. *Sarcoidosis Vasc Diffuse Lung Dis.* 1997;14(1):73-76.
38. Devaney K, Goodman ZD, Epstein MS, et al. Hepatic sarcoidosis: clinicopathologic features in 100 patients. *Am J Surg Pathol.* 1993;17(12):1272-1280.
39. Sharma OP. Sarcoidosis of the upper respiratory tract: selected cases emphasizing diagnostic and therapeutic difficulties. *Sarcoidosis Vasc Diffuse Lung Dis.* 2002;19:227.
40. Costabel U. Sarcoidosis: clinical update. *Eur Respir J.* 2001;18(suppl 32):56s.
41. Newman LS, Rose CS, Maier LA. Sarcoidosis. *N Engl J Med.* 1997;336(17):1224-1234.
42. Chiarchiaro J, Chen BB, Gibson KF. New molecular targets for the treatment of sarcoidosis. *Curr Opin Pulm Med.* 2016;22(5):515-521.

43. Saboor SA, Johnson NM, McFadden J. Detection of mycobacterial DNA in sarcoidosis and tuberculosis with polymerase chain reaction. *Lancet.* 1992; 339(8800):1012-1015.
44. Ishige I, Usui Y, Takemura T, et al. Quantitative PCR of mycobacterial and propionibacterial DNA in lymph nodes of Japanese patients with sarcoidosis. *Lancet.* 1999;354(9173):120-123.
45. Gaede KI, Wilke G, Brade L, et al. Anti-Chlamydophila immunoglobulin prevalence in sarcoidosis and usual interstitial pneumoniae. *Eur Respir J.* 2002; 19(2):267-274.
46. Rybicki BA, Amend KL, Maliarik MJ, et al. Photocopier exposure and risk of sarcoidosis in African-American sibs. *Sarcoidosis Vasc Diffuse Lung Dis.* 2004;21(1): 49-55.
47. Kucera GP, Rybicki BA, Kirkey KL, et al. Occupational risk factors for sarcoidosis in African-American siblings. *Chest.* 2003;123(5):1527-1535.
48. Kajdasz DK, Lackland DT, Mohr LC, et al. A current assessment of various rurally-linked exposures as potential risk factors for sarcoidosis. *Ann Epidemiol.* 2001;11(2):111-117.
49. Presant DJ, Dhala A, Goldstein A, et al. The incidence, prevalence, and severity of sarcoidosis in New York City firefighters. *Chest.* 1999;116(5):1183-1193.
50. Newman LS, Rose CS, Bresnitz EA, et al. A case control etiologic study of sarcoidosis: Environmental and occupational risk factors. *Am J Respir Crit Care Med.* 2004;170(12):1324-1330.
51. Rybicki BA, Iannuzzi MC, Frederick MM, et al. Familial aggregation of sarcoidosis. A case-control etiologic study of sarcoidosis (ACCESS). *Am J Respir Crit Care Med.* 2001;164(11):2085-2091.
52. Gialafos E, Triposkiadis F, Kouranos V, et al. Relationship between tumor necrosis factor-α (TNFA) gene polymorphisms and cardiac sarcoidosis. *In Vivo.* 2014;28(6):1125-1129.
53. Thompson IA, Liu B, Sen HN, et al. Association of complement factor H tyrosine 402 histidine genotype with posterior involvement in sarcoid-related uveitis. *Am J Ophthalmol.* 2013;155(6):1068-1074.
54. McDougal KE, Fallin MD, Moller DR, et al; ACCESS Research Group. Variation in the lymphotoxin-alpha/ tumor necrosis factor locus modifies risk of erythema nodosum in sarcoidosis. *J Invest Dermatol.* 2009;129(8): 1921-1926.
55. Kim HS, Choi D, Lim LL, et al. Association of interleukin 23 receptor gene with sarcoidosis. *Dis Markers.* 2011;31(1):17-24.
56. Judson MA. The diagnosis of sarcoidosis. *Clin Chest Med.* 2008;29:415-427.
57. Judson MA, Baughman RP. Sarcoidosis. In: Baughman RP, DuBois RM, Lynch JP, eds. *Diffuse Lung Disease, A Practical Approach*. London, UK: Arnold Publishers; 2004:109.
58. Judson MA, Baughman RP, Teirstein AS, et al. Defining organ involvement in sarcoidosis: the ACCESS proposed instrument. ACCESS Research Group. A Case Control Etiologic Study of Sarcoidosis. *Sarcoidosis Vasc Diffuse Lung Dis.* 1999;16(1):75-86.
59. Sheffield EA. Pathology of sarcoidosis. *Clin Chest Med.* 1997;18:741.
60. Studdy PR, James DG. The specificity and sensitivity of serum angiotensin-converting enzyme in sarcoidosis and other diseases: experiences in 12 centers in six different countries. In: Chertien J, Marsac J, Saltiel JC, eds. *Sarcoidosis*. Paris, France: Pergamon Press; 1983:332.
61. Finkel R, Teirstein AS, Levine R, et al. Pulmonary function tests, serum angiotensin-converting enzyme levels, and clinical findings as prognostic indicators in sarcoidosis. *Ann N Y Acad Sci.* 1986;465:665-671.
62. Winterbauer RH, Belic N, Moores KD. A clinical interpretation of bilateral hilar adenopathy. *Ann Intern Med.* 1973;78(1):65-71.
63. Lynch JP 3rd, Kazerooni EA, Gay SE. Pulmonary sarcoidosis. *Clin Chest Med.* 1997;18(4):755-785.
64. Maña J, Teirstein AS, Mendelson DS, et al. Excessive thoracic computed tomographic scanning in sarcoidosis. *Thorax.* 1995;50(12):1264-1266.
65. Teirstein AS, Machac J, Almeida O, et al. Results of 188 whole-body fluorodeoxyglucose positron emission tomography scans in 137 patients with sarcoidosis. *Chest.* 2007;132(6):1949-1953.
66. Tavee JO, Stern BJ. Neurosarcoidosis. *Clin Chest Med.* 2015;36 (4):643-656.
67. Sones M, Israel HL. Course and prognosis of sarcoidosis. *Am J Med.* 1960;29:84-93.
68. Mañá J, Salazar A, Manresa F. Clinical factors predicting persistence of activity in sarcoidosis: A multivariate analysis of 193 cases. *Respiration.* 1994;61(4):219-225.
69. Huang CT, Heurich AE, Sutton AL, et al. Mortality in sarcoidosis: a changing pattern of the causes of death. *Eur J Respir Dis.* 1981;62(4):231-238.
70. Yanardağ H, Pamuk ON, Karayel T. Cutaneous involvement in sarcoidosis: analysis of the features in 170 patients. *Respir Med.* 2003;97(8):978-982.
71. Neville E, Walker AN, James DG. Prognostic factors predicting the outcome of sarcoidosis: an analysis of 818 patients. *Q J Med*. 1983;52(208):525-533.
72. Gutzmer R, Völker B, Kapp A, et al. Successful topical treatment of cutaneous sarcoidosis with tacrolimus [in German]. *Hautarzt*. 2003;54(12):1193-1197.
73. Katoh N, Mihara H, Yasuno H. Cutaneous sarcoidosis successfully treated with topical tacrolimus. *Br J Dermatol.* 2002;147(1):154-156.
74. Judson MA. Corticosteroids in sarcoidosis. *Rheum Dis Clin North Am.* 2016;42(1):119-135.
75. Yazaki Y, Isobe M, Hiroe M, et al; Central Japan Heart Study Group. Prognostic determinants of long-term survival in Japanese patients with cardiac sarcoidosis treated with prednisone. *Am J Cardiol.* 2001;88(9): 1006-1010.
76. Mezaki T, Chinushi M, Washizuka T, et al. Discrepancy between inducibility of ventricular tachycardia and activity of cardiac sarcoidosis—requirement of defibrillator implantation for the inactive stage of cardiac sarcoidosis. *Intern Med.* 2001;40(8):731-735.
77. Smedema J, Snoep G, van Kroonenburgh MP, et al. Cardiac involvement in patients with pulmonary sarcoidosis assessed at two university medical centers in the Netherlands. *Chest.* 2005;128(1):30-35.
78. Siltzbach LE, Teirstein AS. Chloroquine therapy in 43 patients with intrathoracic and cutaneous sarcoidosis. *Acta Med Scand Suppl.* 1964;425:302-308.
79. Adams JS, Diz MM, Sharma OP. Effective reduction in the 1,25-dihydroxyvitamin D and calcium concentration in sarcoidosis-associated hypercalcemia with short-course chloroquine therapy. *Ann Intern Med.* 1989;111(5):437-438.
80. Bachelez H, Senet P, Cadranel J, et al. The use of tetracyclines for the treatment of sarcoidosis. *Arch Dermatol.* 2001;137(1):69-73.
81. Thong YH , Ferrante A. Effect of tetracycline treatment on immunological responses in mice. *Clin Exp Immunol.* 1980;39(3):728-732.

82. Drake WP, Richmond BW, Oswald-Richter K, et al. Effects of broad-spectrum antimycobacterial therapy on chronic pulmonary sarcoidosis. *Sarcoidosis Vasc Diffuse Lung Dis.* 2013;30(3):201-211.
83. Zabel P, Entzian P, Dalhoff K, et al. Pentoxifylline in treatment of sarcoidosis. *Am J Respir Crit Care Med.* 1997;155(5):1665-1669.
84. Baughman RP, Judson MA, Teirstein AS, et al. Thalidomide for chronic sarcoidosis. *Chest.* 2002; 122(1):227-232.
85. Saketkoo LA, Baughman RP. Biologic therapies in the treatment of sarcoidosis. *Expert Rev Clin Immunol.* 2016;12(8):817-825.
86. Stagaki E, Mountford WK, Lackland DT, et al. The treatment of lupus pernio: the results of 116 treatment courses in 54 patients. *Chest.* 2009;135(2):468-476.
87. Baughman RP, Lower EE, Bradley DA, et al. Etanercept for refractory ocular sarcoidosis: Results of a double-blind randomized trial. *Chest.* 2005;128(2):1062.
88. Toussirot E, Aubin F. Paradoxical reactions under TNF-α blocking agents and other biologic agents given for chronic immune-mediate diseases: an analytical and comprehensive overview. *RMD Open.* 2016;2(2): e000239.
89. Lewis SJ, Ainslie GM, Bateman ED. Efficacy of azathioprine as second-line treatment in pulmonary sarcoidosis. *Sarcoidosis Vasc Diffuse Lung Dis.* 1999;16(1):87-92.
90. Kouba DJ, Mimouni D, Rencic A, et al. Mycophenolate mofetil may serve as a steroid-sparing agent for sarcoidosis. *Br J Dermatol.* 2003;148(1):147-148.
91. Baughman RP, Lower EE. Leflunomide for chronic sarcoidosis. *Sarcoidosis Vasc Diffuse Lung Dis.* 2004;21(1): 43-48.
92. Stern BJ, Schonfeld SA, Sewell C, et al. The treatment of neurosarcoidosis with cyclosporine. *Arch Neurol.* 1992;49(10):1065-1072.
93. Pignone AM, Rosso AD, Fiori G, et al. Melatonin is a safe and effective treatment for chronic pulmonary and extrapulmonary sarcoidosis. *J Pineal Res.* 2006;41(2) 95-100.
94. Voelter-Mahlknecht S, Benez A, Metzger S, et al. Treatment of subcutaneous sarcoidosis with allopurinol. *Arch Dermatol.* 1999;135(12):1560-1561.
95. Georgiou S, Monastirli A, Pasmatzi E, et al. Cutaneous sarcoidosis: complete remission after oral isotretinoin therapy. *Acta Derm Venereol.* 1998;78(6):457-459.
96. Breuer K, Gutzmer R, Völker B, et al. Therapy of non-infectious granulomatous skin diseases with fumaric acid esters. *Br J Dermatol.* 2005;152(6):1290-1295.
97. Karrer S, Abels C, Wimmershoff MB, et al. Successful treatment of cutaneous sarcoidosis using topical photodynamic therapy. *Arch Dermatol.* 2002;138(5): 581-584.

Neutrophilic, Eosinophilic, and Mast Cell Disorders

PART 6

Chapter 36 :: Sweet Syndrome

:: Philip R. Cohen & Razelle Kurzrock

AT-A-GLANCE

- Sweet syndrome, also referred to as acute febrile neutrophilic dermatosis, is characterized by a constellation of symptoms and findings: the acute onset of fever, neutrophilia, tender erythematous skin lesions that typically show mature neutrophils in the upper dermis, and—after initiation of systemic corticosteroids—a prompt improvement of both symptoms and lesions.
- Extracutaneous manifestations of Sweet syndrome can include cardiovascular, central nervous system, gastrointestinal, hepatic, musculoskeletal, ocular, oral, otic, pulmonary, renal, and splenic organs.
- Infection of the upper respiratory tract and/or gastrointestinal tract, inflammatory bowel disease, and pregnancy may be associated with classical Sweet syndrome.
- In individuals with previously undiagnosed or relapsing hematologic malignancies and solid tumors, malignancy-associated Sweet syndrome may occur as a cutaneous paraneoplastic syndrome.
- The onset of the dermatosis in patients following the initiation of certain medications—drug-induced Sweet syndrome—is most commonly associated with granulocyte colony-stimulating factor.
- The pathogenesis of Sweet syndrome remains to be established; cytokines—directly or indirectly—may have an important etiologic role.
- Corticosteroids, potassium iodide, and colchicine are the first-line oral systemic agents for treating Sweet syndrome.
- Indomethacin, clofazimine, cyclosporine, and dapsone are the second-line oral systemic agents for treating Sweet syndrome.
- Localized Sweet syndrome lesions may be effectively treated with the topical application of high-potency corticosteroids or intralesional corticosteroids.

DEFINITION

Sweet syndrome (also known as acute febrile neutrophilic dermatosis) is typically characterized by the acute onset of pyrexia and painful cutaneous lesions that are composed of a dense dermal inflammatory infiltrate of mature neutrophils. Neutrophilia is also frequently present. Both the condition-associated symptoms and the dermatosis-related lesions promptly resolve after initiation of treatment with systemic corticosteroids.[1]

HISTORICAL PERSPECTIVE

Dr. Robert Douglas Sweet, originally described acute febrile neutrophilic dermatosis in the August-September 1964 issue of the *British Journal of Dermatology*. He summarized the cardinal features of "a distinctive and fairly severe illness" that had been encountered in 8 women during the 15-year period from 1949 to 1964. In Dr. Sweet's department, the condition was originally referred to as the Gomm-Button disease "in eponymous honor of the first two patients" with the disease. Subsequently, this acute febrile neutrophilic dermatosis has become best known by the eponym "Sweet syndrome."[1-3]

EPIDEMIOLOGY

Numerous individuals with Sweet syndrome have been reported. There is no racial predilection and the distribution of Sweet syndrome cases is worldwide.[1] The dermatosis may present in various clinical settings: classical, malignancy-associated, and drug-induced (Tables 36-1 and 36-2).[4-7]

TABLE 36-1
Diagnostic Criteria for Classical Sweet Syndrome versus Drug-Induced Sweet Syndrome

CLASSICAL[a]	DRUG-INDUCED[b]
(1) Abrupt onset of painful erythematous plaques or nodules	(A) Abrupt onset of painful erythematous plaques or nodules
(2) Histopathologic evidence of a dense neutrophilic infiltrate without evidence of leukocytoclastic vasculitis	(B) Histopathologic evidence of a dense neutrophilic infiltrate without evidence of leukocytoclastic vasculitis
(3) Pyrexia >38°C (100.4°F)	(C) Pyrexia >38°C (100.4°F)
(4) Association with an underlying hematologic (most commonly acute myelogenous leukemia) or visceral malignancy (most commonly carcinomas of the genitourinary organs, breast, and gastrointestinal tract), inflammatory disease (Crohn disease and ulcerative colitis), or pregnancy, *or* preceded by an upper respiratory (streptococcosis) or gastrointestinal (salmonellosis and yersiniosis) infection or vaccination	(D) Temporal relationship between drug ingestion and clinical presentation, *or* temporally related recurrence after oral challenge
(5) Excellent response to treatment with systemic corticosteroids or potassium iodide	(E) Temporally related resolution of lesions after drug withdrawal or treatment with systemic corticosteroids
(6) Abnormal laboratory values at presentation (3 of 4): erythrocyte sedimentation rate >20 mm/h; positive C-reactive protein; >8000/μL leukocytes; >70% neutrophils	

[a]The presence of both major criteria (1 and 2), and 2 of the 4 minor criteria (3, 4, 5, and 6) is required to establish the diagnosis of classical Sweet syndrome; the patients with malignancy-associated Sweet syndrome are included with the patients with classical Sweet syndrome in this list of diagnostic criteria.
[b]All 5 criteria (A, B, C, D, and E) are required for the diagnosis of drug-induced Sweet syndrome.
Adapted with permission from Walker DC, Cohen PR: Trimethoprim-sulfamethoxazole-associated acute febrile neutrophilic dermatosis: case report and review of drug induced Sweet's syndrome. *J Am Acad Dermatol.* 1996;34:918-923. Copyright 1996, American Academy of Dermatology, Inc., Mosby-Year Book, Inc., St. Louis, MO.

TABLE 36-2
Medications Associated with Drug-Induced Sweet Syndrome

Abacavir
Abatacept
Aceclofenac
Acyclovir
Adalimumab
All-*trans*-retinoic acid
Amoxicillin
Amoxapine
Azacitidine
Azathioprine
Benzylthiouracil
Bortezomib
Carbamazepine
Celecoxib
Chloroquine
Ciprofloxacin
13-*Cis* retinoic acid
Citalopram
Clindamycin
Clozapine
Contraceptives
Cyclooxygenase-2 inhibitor
Diazepam
Diclofenac
Doxycycline
Efavirenz
Erythropoietin
Esomeprazole
Etanercept
Furosemide
Granulocyte colony-stimulating factor
Granulocyte-macrophage colony-stimulating factor
Hydralazine
Imatinib mesylate
Infliximab
Interferon alpha (pegylated)
Interferon beta-1b
Interleukin-2
Ipilimumab
Isotretinoin
Ketoconazole
Lamivudine
Lenalidomide
Levonorgestrel/ethinyl estradiol (Triphasil)
Levonorgestrel-releasing intrauterine system (Mirena)
Lithium
Lopinavir
Minocycline
Mitoxantrone
Nitrofurantoin
Norfloxacin
Ofloxacin
Omeprazole
Orphenadrine citrate
Pegfilgrastim
Perphenazine
Phenylbutazone
Piperacillin/tazobactam
Propylthiouracil
Quinupristin/dalfopristin
Radiocontrast agent
Riboflavin
Ritonavir
Ruxolitinib
Stavudine
Sulfa
Sulfasalazine
Ticagrelor
Topotecan
Trimethoprim-sulfamethoxazole
Triphasil
Vemurafenib
Vorinostat

CLINICAL FEATURES

HISTORY

Patients with Sweet syndrome may appear dramatically ill. Fever and leukocytosis often accompany the skin eruption. However, the skin disease can be concurrently present with the fever for the entire episode of the dermatosis or follow the fever by several days to weeks. Other Sweet syndrome associated symptoms include arthralgia, general malaise, headache, and myalgia (Table 36-3).[1]

CUTANEOUS FINDINGS

LESION MORPHOLOGY

Sweet syndrome cutaneous lesions typically appear as tender, red or purple-red, papules or nodules. The skin eruption can present as either a single lesion or multiple—often asymmetrically distributed—lesions (Fig. 36-1). The transparent, vesicle-like appearance of the lesions, described as an "illusion of vesiculation," results from the pronounced edema in the upper dermis (Fig. 36-2). Central clearing may result in annular

TABLE 36-3
Clinical Features in Patients with Sweet Syndrome

CHARACTERISTIC	CLINICAL FORM			
	CLASSICAL (%)[a]	HEMATOLOGIC MALIGNANCY (%)[a]	SOLID TUMOR (%)[a]	DRUG-INDUCED (%)[b]
Epidemiology				
Women	80	50	59	71
Prior upper respiratory tract infection	75-90	16	20	21
Recurrence[c]	30	69	41	67
Clinical Symptoms				
Fever[d]	80-90	88	79	100
Musculoskeletal involvement	12-56	26	34	21
Ocular involvement	17-72	7	15	21
Lesion Location				
Upper extremities	80	89	97	71
Head and neck	50	63	52	43
Trunk and back	30	42	33	50
Lower extremities	Infrequent	49	48	36
Oral mucous membranes	2	12	3	7
Laboratory Findings				
Neutrophilia[e]	80	47	60	38
Elevated erythrocyte sedimentation rate[f]	90	100	95	100
Anemia[g]	Infrequent	82	83	100
Abnormal platelet count[h]	Infrequent	68	50	50
Abnormal renal function[i]	11-50	15	7	0

[a]Percentages for classical, hematologic malignancy, and solid-tumor-associated Sweet syndrome adapted with permission from Cohen PR, Kurzrock R: Sweet's syndrome and cancer. *Clin Dermatol.* 1993;11:149-157. Copyright 1993, Elsevier Science Publishing Co., Inc., New York, NY.

[b]Percentages for drug-induced Sweet syndrome adapted with permission from Walker DC, Cohen PR: Trimethoprim-sulfamethoxazole-associated acute febrile neutrophilic dermatosis: case report and review of drug induced Sweet's syndrome. *J Am Acad Dermatol.* 1996;34:918-923. Copyright 1996, American Academy of Dermatology, Inc., Mosby-Year Book, Inc., St. Louis, MO.

[c]Recurrence following oral rechallenge testing in the patients with drug-induced Sweet syndrome.

[d]Temperature greater than 38°C (100.4°F).

[e]Neutrophil count greater than 6000 cells/μL.

[f]Erythrocyte sedimentation rate greater than 20 mm/h.

[g]Hemoglobin less than 13 g/dL in men and less than 12 g/dL in women.

[h]Platelet count less than 150,000/μL or greater than 500,000/μL.

[i]This includes hematuria, proteinuria, and renal insufficiency.

Figure 36-1 Unilateral lesions of Sweet syndrome around the eye and upper lip consisting of plaques and pseudovesicular papules suggesting herpes simplex.

or arcuate patterns in the later stages; indeed, these lesions can appear targetoid. In patients with malignancy-associated Sweet syndrome, the lesions may appear bullous, become ulcerated, and/or mimic the morphologic features of pyoderma gangrenosum. Over a period of days to weeks, the lesions enlarge; subsequently, they may coalesce and form irregular sharply bordered plaques (Fig. 36-3). The lesions usually resolve without scarring—either spontaneously or after treatment. In one-third to two-thirds of patients, the lesions are associated with recurrent episodes of Sweet syndrome.[1]

Figure 36-2 Multiple confluent papules and plaques of Sweet syndrome that at first sight give the illusion of vesiculation but are solid on palpation. (From Hönigsmann H, Kempter R, Wolff K. Acute febrile neurophilic dermatosis [Sweet's syndrome]—report of two cases [author's transl] [in German]. *Wien Klin Wochenschr.* 1979;91(24):842-847, with permission.)

Figure 36-3 Acute febrile neutrophilic dermatosis. Typical lesion consisting of coalescing, plaque-forming papules. **A,** Bright-red lesions on the neck. **B,** Lesion on the dorsum of the right hand exhibiting the "relief of a mountain range" feature. (From Hönigsmann H, Wolff K. Acute febrile neutrophilic dermatosis [Sweet's syndrome]. In Wolff K, Winkelmann RK, eds. *Major Problems in Dermatology*. Vol 10, Vasculitis. London, UK: Lloyd-Luke; 1980:307, with permission.)

CUTANEOUS PATHERGY AND ISOTOPIC RESPONSE

A dermatosis-associated feature of Sweet syndrome is cutaneous pathergy. This form of skin hypersensitivity occurs when Sweet syndrome skin lesions appear at sites of cutaneous trauma such as prior biopsies, injections, intravenous catheter placement, scalding, and venipuncture. They also include sites of insect bites and cat scratches, areas that have received radiation therapy, and places that have been contacted by sensitizing antigens or henna tattoo.[1,7,8]

The dermatologic eponym "Wolf's isotopic response" describes the occurrence of a new skin disorder at the site of another unrelated and already healed skin disease. Sweet syndrome has presented in this manner: lesions affecting a lymphedematous leg or postmastectomy arm and a bullous variant of Sweet syndrome on the side of the cheek and neck where a herpes zoster infection previously occurred in a 75-year-old man.[9-11]

In addition, lesions have been photodistributed or localized to the site of a prior phototoxic reaction (sunburn) in some Sweet syndrome patients.[12]

PUSTULAR DERMATOSIS

Sweet syndrome can present as a pustular dermatosis. The lesions appear as tiny pustules on the tops of the red papules or erythematous-based pustules. Some of the patients previously described as having the "pustular eruption of ulcerative colitis" are perhaps more appropriately included in this clinical variant of Sweet syndrome.[13,14]

NEUTROPHILIC DERMATOSIS OF THE DORSAL HANDS

A localized, pustular variant of Sweet syndrome, when the clinical lesions are predominantly restricted to the dorsal hands, is described as "neutrophilic dermatosis of the dorsal hands" or "pustular vasculitis of the dorsal hands." In these individuals, the lesions are similar to those of Sweet syndrome in morphology and rapid resolution after systemic corticosteroids and/or dapsone therapy was initiated. Many of patients with this form of the disease also had concurrent oral mucosa, arm, leg, back, and/or face lesions.[2,15]

SUBCUTANEOUS PANNICULITIS

Subcutaneous Sweet syndrome lesions usually present as erythematous, tender dermal nodules on the extremities. The lesions mimic erythema nodosum when they are located on the legs. One study reported findings of panniculitis in 80% of patients in which the hypodermis was affected. Therefore, even in a patient with biopsy-confirmed Sweet syndrome, tissue evaluation of one or more new dermal nodules may be necessary to establish the correct diagnosis as Sweet syndrome can present concurrently or sequentially with erythema nodosum.[3,8,15-17]

HISTIOCYTOID VARIANT

Histiocytoid Sweet syndrome was initially described by Requena et al. in 2005. The skin lesion morphology is similar to that of idiopathic Sweet syndrome. However, the dermal infiltrate is composed of mononuclear cells with a histiocytic appearance—representing immature myeloid cells.[18]

This variant of Sweet syndrome is often associated with malignancy. Drug-induced histiocytoid Sweet syndrome has also been observed in patients receiving bortezomib.[18,19]

GIANT CELLULITIS-LIKE VARIANT

A morphologically distinctive clinical variant of Sweet syndrome, characterized by relapsing widespread giant lesions, is giant cellulitis-like Sweet syndrome.

Figure 36-4 Histiocytoid giant cellulitis Sweet syndrome presenting as an erythematous plaque on the left lateral thigh of a 72-year-old woman who had an unclassified myelodysplastic syndrome/myeloproliferative disorder. (From So JK, Carlos CA, Frucht CS, et al. Histiocytoid giant cellulitis-like Sweet's syndrome: case report and review of the literature. *Dermatol Online J.* 2015;21(3):4, with permission.)

In 2013, it was originally reported in 3 morbidly obese individuals. In 2014, 2 additional patients were described, and in 2015, a sixth patient with concurrent histiocytoid Sweet syndrome was reported.[18,20-22]

Giant cellulitis-like Sweet syndrome has been observed in 5 women and 1 man, ranging in age from 48 years to 72 years (median = 61 years). The upper leg and buttocks were the most common locations of their skin lesions (Fig. 36-4). Most of the patients (66%) were obese and half of the patients had cancer.[18,20-22]

NECROTIZING VARIANT

Necrotizing Sweet syndrome is a new variant of neutrophilic dermatosis that mimics necrotizing fasciitis. It clinically presents as the rapid onset of edematous, erythematous, warm cutaneous lesions. An infectious etiology for the lesions is absent. Biopsy shows a deep-tissue neutrophilic infiltration and soft-tissue necrosis.[23]

NONCUTANEOUS FINDINGS

POTENTIAL ORGANS

The bones, central nervous system, ears, eyes, kidneys, intestines, liver, heart, lung, mouth, muscles, and spleen can be sites of extracutaneous manifestations of Sweet syndrome (Table 36-4).[1,7]

BONE INVOLVEMENT

In children, dermatosis-related sterile osteomyelitis has been reported.[1]

TABLE 36-4
Extracutaneous Manifestations of Sweet Syndrome

Bone	Acute sterile arthritis; arthralgias; focal aseptic osteitis; pigmented villonodular synovitis; sterile osteomyelitis (chronic recurrent multifocal osteomyelitis)
Central nervous system	Acute benign encephalitis; aseptic meningitis; brain single-photon emission computed tomography (SPECT) abnormalities; brainstem lesions; cerebrospinal fluid abnormalities; computerized axial tomography abnormalities; electroencephalogram abnormalities; encephalitis; Guillain-Barré syndrome; idiopathic hypertrophic cranial pachymeningitis; idiopathic progressive bilateral sensorineural hearing loss; leukoencephalopathy; magnetic resonance imaging abnormalities; neurologic symptoms; "neuro-Sweet disease"; pareses of central origin; polyneuropathy; psychiatric symptoms
Ears	Tender red nodules and pustules that coalesced to form plaques in the external auditory canal and the tympanic membrane
Eyes	Blepharitis; chemosis; conjunctival erythematous lesions with tissue biopsy showing neutrophilic inflammation; conjunctival hemorrhage; conjunctivitis; dacryoadenitis; episcleritis; glaucoma; iridocyclitis; iritis; limbal nodules; ocular congestion; periocular swelling; peripheral ulcerative keratitis; retinal vasculitis; scleritis; uveitis
Kidneys	Mesangiocapillary glomerulonephritis; urinalysis abnormalities (hematuria and proteinuria)
Intestines	Intestine with extensive and diffuse neutrophilic inflammation; neutrophilic ileal infiltrate; pancolitis (culture-negative)
Liver	Hepatic portal triad with neutrophilic inflammation; hepatic serum enzyme abnormalities; hepatomegaly
Heart	Aortic stenosis (segmental); aortitis (neutrophilic and segmental); cardiomegaly; coronary artery occlusion; heart failure; myocardial infiltration by neutrophils; vascular (aorta, brachiocephalic trunk and coronary arteries) dilatation
Lung	Bronchi (main stem) with red-bordered pustules; bronchi with neutrophilic inflammation; pleural effusion showing abundant neutrophils without microorganisms; chest roentgenogram abnormalities; corticosteroid-responsive culture-negative infiltratives; pulmonary tissue with neutrophilic inflammation
Mouth	Aphthous-like superficial lesions (buccal mucosa, tongue); bullae and vesicles (hemorrhagic: labial and gingival mucosa); gingival hyperplasia; necrotizing ulcerative periodontitis; nodules (necrotic: labial mucosa); papules (macerated: palate and tongue); pustules (individual and grouped: palate and pharynx); swelling (tongue); ulcers (buccal mucosa and palate)
Muscles	Magnetic resonance imaging (T1-weighted and T2-weighted) abnormalities: high signal intensities caused by myositis and fasciitis; myalgias (in up to half of the patients with idiopathic Sweet syndrome); myositis (neutrophilic); tendinitis; tenosynovitis
Spleen	Aseptic abscess; splenomegaly.

From Cohen PR, Kurzrock R. Sweet's syndrome revisited: a review of disease concepts. *Int J Dermatol.* 2003;42:761-778, with permission.

CARDIAC INVOLVEMENT

Sweet syndrome-associated cardiovascular involvement may occur in children. A 22-month-old white boy with Sweet syndrome developed postinflammatory elastolysis and Takayasu arteritis. Cardiovascular involvement resulting from elastolysis of the heart and aorta occurred in 3 children who were ages 17 months, 16 months, and 7 months; 2 of the patients died.[24,25]

Cardiovascular involvement, including coronary artery occlusion, occurred in a 43-year-old man with Sweet syndrome.[26]

CENTRAL NERVOUS SYSTEM INVOLVEMENT

A wide variety of neurologic symptoms have been observed in neuro-Sweet disease. This rare variant of the dermatosis, which can affect regions of the central nervous system, was originally proposed by Hisanaga et al. in 1999. Neuro-Sweet disease, in a 72-year-old man, presented with self-remitting and reversible parkinsonism. In a 49-year-old man, optic nerve involvement with panuveitis was reported. Bilateral endogenous endophthalmitis with chorioretinitis arising from nontuberculous mycobacterial infection occurred in a 47-year-old Thai woman with underlying Sweet syndrome. Radiation therapy-induced neuro-Sweet disease was described in a 67-year-old woman with oral squamous cell carcinoma.[27-30]

OCULAR INVOLVEMENT

Ocular manifestations of Sweet syndrome may be the presenting feature of the condition. In classical Sweet syndrome, the incidence of ocular involvement (such as conjunctivitis) is variable. However, in the malignancy-associated and drug-induced forms of the dermatosis it is uncommon.[1]

ORAL INVOLVEMENT

Mucosal ulcers of the mouth are uncommon in patients with classical Sweet syndrome. However, they occur more frequently in Sweet syndrome patients with hematologic disorders. The oral lesions—similar to extracutaneous manifestations of Sweet syndrome occurring at other sites—typically resolve after initiation of treatment with systemic corticosteroids.[1]

OTIC INVOLVEMENT

In a 65-year-old woman with a 10-year history of Sweet syndrome, a rapid, profound loss of hearing was reported; bilateral, progressive sensorineural hearing

loss after a severe exacerbation of Sweet syndrome had been diagnosed 7 years prior.[31]

SPLEEN INVOLVEMENT

Spleen and lymph node involvement was preceded by parvovirus B19 infection in a 45-year-old white woman with Sweet syndrome.[32]

COMPLICATIONS

Complications may occur in Sweet syndrome patients. They can either be directly related to the mucocutaneous lesions or indirectly related to the Sweet syndrome-associated conditions. Antimicrobial therapy may be necessary if the skin lesions become secondarily infected. Reappearance of the dermatosis may herald the unsuspected discovery that the cancer has recurred in patients with malignancy-associated Sweet syndrome. Disease-specific treatment may be warranted for systemic manifestations of Sweet syndrome-related conditions such as inflammatory bowel disease, sarcoidosis, and thyroid disease.[1,7]

ETIOLOGY AND PATHOGENESIS

ASSOCIATED CONDITIONS

ASSOCIATED DISEASES

Several conditions have been observed to occur either before, concurrent with, or following the diagnosis of Sweet syndrome (Table 36-5). Behçet disease, cancer, erythema nodosum, infections, inflammatory bowel disease, pregnancy, relapsing polychondritis, rheumatoid arthritis, sarcoidosis, and thyroid disease may be etiologically related to the development of Sweet syndrome. The association between Sweet syndrome and other conditions remains to be established.[1]

Sweet syndrome associated with differentiation syndrome (an inflammatory reaction with increased capillary permeability that occurs in up to 25% of patients with acute promyelocytic leukemia treated with all-*trans*-retinoic acid) was suspected in a 50-year-old man with acute promyelocytic leukemia who underwent chemotherapy with idarubicin and all-*trans*-retinoic acid.[33] The histiocytoid variant of Sweet syndrome is associated not only with medications, but also with several other conditions, including autoimmune diseases, infections and inflammation, inflammatory bowel disease, and malignancy (Table 36-6).[18] Giant cellulitis-like Sweet syndrome was associated with obesity (4 of 6 patients) and malignancy (3 of 6 patients): hematologic dyscrasia (multiple myeloma or myelodysplastic syndrome/myeloproliferative disorder) and breast cancer (Table 36-7).[18,20-22]

ASSOCIATED NEUTROPHILIC DERMATOSES

The unifying characteristic of neutrophilic dermatoses of the skin and mucosa is an inflammatory infiltrate of mature polymorphonuclear leukocytes. Concurrent or sequential occurrence either of erythema elevatum diutinum, neutrophilic eccrine hidradenitis, pyoderma gangrenosum, subcorneal pustular dermatosis, and/or vasculitis with Sweet syndrome has been observed. These conditions can display similar clinical and pathologic features; however, the location of the neutrophilic infiltrate helps differentiate them.[2,3,34,35]

CONCURRENT LEUKEMIA CUTIS

Sweet syndrome may present as either a paraneoplastic syndrome (signaling the initial discovery of an unsuspected malignancy), a drug-induced dermatosis (following treatment with either all-*trans*-retinoic acid, bortezomib, granulocyte colony-stimulating factor (G-CSF), or imatinib mesylate), or a condition whose skin lesions concurrently demonstrate leukemia cutis in patients with hematologic disorders. The most frequent hematologic dyscrasias associated with leukemia cutis (characterized by abnormal neutrophils) and Sweet syndrome (consisting of mature polymorphonuclear leukocytes) being present in the same skin lesion are acute myelocytic leukemia and acute promyelocytic leukemia. Other associated hematologic disorders that have been associated with concurrent Sweet syndrome and leukemia cutis include myelodysplastic syndrome and either chronic myelogenous leukemia or myelogenous leukemia not otherwise specified.[1,7]

One of the hypotheses to explain concurrent Sweet syndrome and leukemia cutis in the same lesion is "secondary" leukemia cutis; in patients with "secondary" leukemia cutis, the circulating immature myeloid precursor cells are innocent bystanders that have been recruited to the skin as the result of an inflammatory oncotactic phenomenon stimulated by the Sweet syndrome lesions. Another possibility is the occurrence of "primary" leukemia cutis. In patients with "primary" leukemia cutis, the leukemic cells within the skin constitute the bonified incipient presence of a specific leukemic infiltrate. Finally, in patients with "primary" leukemia cutis who were being treated with G-CSF, it is possible that the atypical cells of leukemia cutis developed into mature neutrophils of Sweet syndrome as a result of G-CSF therapy-induced differentiation of the sequestered leukemia cells.[1]

SYSTEMIC INFLAMMATORY RESPONSE SYNDROME

Sweet syndrome can occur with systemic inflammatory response syndrome. A 76-year-old man with

TABLE 36-5
Sweet Syndrome and Associated Conditions

Probably bona fide associated conditions
- Cancer: hematologic malignancies (most commonly acute myelogenous leukemia) and solid tumors (most commonly carcinomas of the genitourinary organs, breast, and gastrointestinal tract)
- Infections: most commonly of the upper respiratory tract (streptococcosis) and the gastrointestinal tract (salmonellosis and yersiniosis)
- Inflammatory bowel disease: Crohn disease and ulcerative colitis
- Medications: most commonly granulocyte colony-stimulating factor
- Pregnancy
- Vaccinations (bacille Calmette-Guérin [BCG] and influenza)

Possibly bona fide associated conditions
- Behçet disease
- Erythema nodosum
- Relapsing polychondritis
- Rheumatoid arthritis
- Sarcoidosis
- Thyroid disease: Grave disease and Hashimoto thyroiditis

Validity of associated conditions remains to be established
- α_1-Antitrypsin deficiency
- Antineutrophilic cytoplasmic antibody–associated vasculitis
- Ankylosing spondylitis
- Anti–factor VIII inhibitor
- Antiphospholipid syndrome
- Aortitis (Takayasu arteritis)
- Aplastic anemia
- Autoimmune disorders: cholangitis, dermatomyositis, lupus erythematosus (subacute and systemic), pemphigus vulgaris, and Sjögren syndrome
- Autologous stem cell transplant
- Bronchiolitis obliterans and organizing pneumonia
- Chemical fertilizer
- Chronic fatigue syndrome
- Chronic recurrent multifocal osteomyelitis
- Celiac disease
- Cirrhosis (cryptogenic)
- Common bile duct and intrahepatic duct stones
- Congenital dyserythropoietic anemia
- Congenital neutropenia (Kostmann syndrome)
- Cutis laxa (acquired, Marshall syndrome)
- Differentiation syndrome
- Dressler syndrome (postmyocardial infarction syndrome)
- End-stage renal disease
- Eosinophilic granuloma
- Familial Mediterranean fever
- Fanconi anemia
- Glycogen storage disease (type Ib)
- Granuloma annulare
- Hemophagocytic syndrome
- Immunoglobulin A nephropathy (Berger disease)
- Immunizing agent (BCG vaccination and flu)
- Immunodeficiency diseases: chronic granulomatous disease, common variable immunodeficiency, complement deficiency, HIV infection, and primary T-cell immunodeficiency disease
- Infections: *Anaplasma phagocytophilum*, bartholinitis, bronchitis, *Campylobacter* spp., *Capnocytophaga canimorsus*, *Chlamydia*, *Chlamydophila pneumoniae*, cholangitis, cholecystitis, coccidioidomycosis, cytomegalovirus, dermatophyte, *Entamoeba histolytica*, Epstein-Barr virus, *Francisella tularensis*, *Helicobacter pylori*, hepatitis (acute or chronic hepatitis B, autoimmune, cholestatic, chronic active, hepatitis C, and prior hepatitis A), herpes simplex, herpes zoster, histoplasmosis, HIV, leprosy, leptospirosis, lymphadenitis (not otherwise specified and subacute necrotizing), mycobacteria avium, chelonae, nontuberculous, and tuberculous, otitis media, pancreatitis, parvovirus B19, *Pasteurella multocida* bronchitis, *Penicillium* spp., *Pneumocystis carinii* pneumonia, pyelonephritis, sporotrichosis, *Staphylococcus aureus*, *Staphylococcus epidermidis* (methicillin-resistant), subacute bacterial endocarditis, tonsillitis, toxoplasmosis, tuberculosis, tularemias (glandular), ureaplasmosis, urinary tract, and vulvovaginitis
- Kidney transplantation
- Kikuchi disease
- Malabsorption
- Microscopic polyangiitis
- Mid-dermal elastolysis
- POEMS syndrome (*p*olyneuropathy, *o*rganomegaly, *e*ndocrinopathy, *M* protein, and *s*kin changes)
- Postoperative (pneumonectomy)
- Psoriasis vulgaris
- Rhinosinusitis
- Sialadenitis
- Still disease
- Takayasu arteritis
- Thermal injury
- Transient acantholytic dermatosis (Grover disease)
- Ureter obstruction
- Urticaria (chronic)
- Urticaria pigmentosa
- Wegner granulomatosis
- Welding burns

Sweet syndrome-associated pulmonary involvement also experienced systemic inflammatory response syndrome. Sepsis refers to systemic inflammatory response syndrome caused by infection. Yet, this man's systemic inflammatory response syndrome was attributed to Sweet syndrome because his cultures were persistently negative.[36,37]

PATHOGENESIS

The pathogenesis of Sweet syndrome remains to be definitively established and may be multifactorial.

ANIMAL MODELS

Animal models of Sweet syndrome have been described. An alteration in the gene encoding protein tyrosine phosphatase nonreceptor type 6—originally found in a mouse with clinical and histopathologic characteristics resembling Sweet syndrome—appears to be involved in the pathogenesis of certain subsets of neutrophilic dermatoses, including Sweet syndrome. In a female standard poodle dog (after treatment with the nonsteroidal antiinflammatory drug firocoxib) and in multiple dogs (temporally associated with the administration of carprofen) a condition presenting

TABLE 36-6
Conditions and Drugs Associated with Histiocytoid Sweet Syndrome

Autoimmune diseases
- Positive lupus erythematosus serologies
- Relapsing polychondritis
- Rheumatoid arthritis
- Systemic lupus erythematosus

Infections/inflammation
- Conjunctivitis
- Methicillin-resistant *Staphylococcus aureus* (pneumonia)
- Parotitis
- Sinusitis

Inflammatory bowel disease
- Crohn disease
- Ulcerative colitis

Malignancies
- Acute myelogenous leukemia
- Breast carcinoma
- Chronic lymphocytic leukemia
- Chronic monocytic leukemia
- Chronic myelogenous leukemia
- Hodgkin lymphoma
- Leukemia cutis (from acute myelomonocytic leukemia)
- Lymphoma
- Monoclonal gammopathy of undetermined significance
- Multiple myeloma
- Myelodysplastic syndrome
- Myelodysplastic syndrome/myeloproliferative disorder
- Renal carcinoma

Medications
- Azacitidine
- Azathioprine
- Bortezomib
- Cox-2 inhibitor
- Decitabine
- Trimethoprim-sulfamethoxazole

Other conditions
- Diabetes mellitus
- Erythema nodosum
- Eyelid edema
- Familial Mediterranean fever
- Glomerulonephritis
- Hypertension
- Immunosuppression
- None
- Polyarteritis nodosa
- Pregnancy

From So JK, Carlos CA, Frucht CS, et al. Histiocytoid giant cellulitis-like Sweet's syndrome: case report and review of the literature. *Dermatol Online J.* 2015;21(3):4 with permission.

as a sterile neutrophilic dermatosis, and similar to Sweet syndrome, has been observed; subsequent examination also revealed extracutaneous involvement of the esophagus, heart, lungs, and tarsus (joint space and synovium). In addition, a sterile neutrophilic dermatosis of the skin—similar to Sweet syndrome—has been described in a female Dachshund; the condition responded rapidly to corticosteroid therapy.[38-40]

BACTERIAL, VIRAL, OR TUMOR ANTIGENS

A hypersensitivity reaction to an eliciting bacterial, viral, or tumor antigen may elicit Sweet syndrome. The accompanying fever and peripheral leukocytosis suggests the possibility of a septic process. Indeed, in patients with classic Sweet syndrome, a febrile upper respiratory tract bacterial infection or tonsillitis may precede skin lesions by 1 to 3 weeks. Also, Sweet syndrome patients with *Yersinia enterocolitica* intestinal infection have improved with systemic antibiotics.[1]

FAMILIAL MEDITERRANEAN FEVER

The systemic manifestations of familial Mediterranean fever resemble those of Sweet syndrome. Indeed, the simultaneous occurrence of both conditions has been observed. In addition, the causative gene mutation for familial Mediterranean fever was detected in a patient with chronic myelogenous leukemia-associated Sweet syndrome. Hence, these conditions may have a similar pathogenesis.[7]

HUMAN LEUKOCYTE ANTIGEN SEROTYPES

A 5-week-old Japanese girl with Sweet syndrome and non-B54 types of human leukocyte antigen was reported. She is one of the youngest patients reported with the dermatosis. The potential importance of genetic background in association with Sweet syndrome is suggested by this observation.[41]

CYTOKINES

Circulating autoantibodies, dermal dendrocytes, immune complexes and leukotactic mechanisms have all been postulated to contribute to the pathogenesis of Sweet syndrome. The immunoreactivity of several cytokines (interleukin [IL]-1, IL-8, IL-17, and tumor necrosis factor-α), inflammatory cell markers (CD3, CD163, and myeloperoxidase), metalloproteinases (metalloproteinase-2 and metalloproteinase-9), and vascular endothelial growth factor have displayed significantly higher values in the lesional skin of patients with Sweet syndrome from non-Sweet syndrome individuals or patients with other neutrophilic dermatoses. The observation of a 48-year-old white woman with coexisting Sweet syndrome, Hashimoto thyroiditis, and psoriasis suggests the possibility of a CD4+ T-cell dysfunction in the pathogenesis of the dermatosis. Complement does not appear to be essential to the disease process. Antibodies to neutrophilic cytoplasmic antigens have been demonstrated in some patients; however, these are thought to represent an epiphenomenon.[1,42,43]

The development of Sweet syndrome symptoms and lesions may—directly and/or indirectly—be caused by

TABLE 36-7
Characteristics of Patients with Giant Cellulitis-Like Sweet Syndrome

AS	SYMPTOMS	WBC (cells/uL)	OTHER LABS	ASSOC DIS	TX	RESPONSE	REF
62M	Fever Malaise	10.6+	ANA– CRP+	Ob MM	Amox Pred	No effect from antibiotics; good response from oral prednisone	20 C1
48F	Fever Malaise	24+	CRP+	Ob	Pred	Good control	20 C2
54F	Fever	4.1	Creat+ TC–	Ob PBC Si	Pred	Excellent	21
60F^	Fever	10.3	TC–	–	Col Pred Dap	Response, but recurrence on colchicine and prednisone; excellent response to dapsone and prednisone	22
68F	Fever Malaise	11.3+	CRP+ TC–	Br Ob	Surg Top	Transient improvement then recurrence with topical corticosteroid; remission after surgical treatment of breast carcinoma	20 C3
72F	Fever Foot pain	73.5+	LDH+ TC–	MDS/MPD	Top	Excellent	18

The site of skin lesions and (number of patients) were: lower extremity (6 patients) [18,20 (cases 1,2, and 3), 21,22]; trunk (5 patients) [18,20 (cases 1 and 2), 21,22]; buttock (3 patients) [20 (cases 1 and 2), 21]; upper extremity (2 patients) [20 (case 2), 21]; and head and neck (1 patients).[21]

Negative; ^, patient was in her "60's"; +, elevated; Amox, amoxicillin/clavulanic acid; ANA, antinuclear antibody; AS, age (in years) and sex; Assoc dis, associated disease; Br, breast carcinoma; Col, colchicine; CR, current report; Creat, serum creatinine; CRP, C-reative protein; Dap, dapsone; F, female; LDH, lactate dehydrogenase; M, male; MDS/MPD, myelodysplastic/myeloproliferative disorder; MM, multiple myeloma; Ob, obesity; PBC, primary biliary cirrhosis; Pred, prednisone; Ref, reference; Si, sicca syndrome; Surg, surgical treatment of breast carcinoma; TC, tissue culture; Top, topical corticosteroid; Tx, treatment; WBC, white blood cell.

From So JK, Carlos CA, Frucht CS, et al. Histiocytoid giant cellulitis-like Sweet's syndrome: case report and review of the literature. *Dermatol Online J.* 2015;21(3):4 with permission.

cytokines. A patient with myelodysplastic syndrome-associated Sweet syndrome demonstrated elevated serum levels of G-CSF and IL-6; the individual was not receiving the drugs. An infant with classical Sweet syndrome had detectable levels of intraarticular synovial fluid granulocyte-macrophage colony-stimulating factor (GM-CSF). Compared to dermatosis patients with inactive Sweet syndrome, a study demonstrated that the serum G-CSF level was significantly higher in individuals with active Sweet syndrome. And, in a patient with acute myelogenous leukemia-associated Sweet syndrome and neutrophilic panniculitis, the level of endogenous G-CSF was closely associated with Sweet syndrome disease activity.[1,7,17]

IMMUNOHISTOCHEMICAL STUDIES

Significantly elevated levels of helper T-cell type 1 cytokines (IL-2 and interferon-gamma [IFN-γ]) and normal levels of a helper T-cell type 2 cytokine (IL-4) in the sera of Sweet syndrome patients have been observed in immunohistochemical studies. Serial measurements of cerebral spinal fluid IL-6, IFN-γ, IL-8, and interferon-inducible protein-10 were elevated as compared to levels in control subjects with neurologic disorders and also correlated with total cerebral spinal fluid cell counts in a patient with neuro-Sweet disease presenting with recurrent encephalomeningitis. This data suggests an important role of the helper T-cell type 1 cell (whose cytokines include IFN-γ and interferon-inducible protein-10) and IL-8 (a specific neutrophil chemoattractant) in the pathogenesis of neuro-Sweet disease. Other studies postulated that cytokine release into the dermis accounted for decreased epidermal staining for IL-1 and IL-6. In summary, G-CSF, GM-CSF, IFN-γ, IL-1, IL-3, IL-6, and IL-8 are potential cytokine candidates in the pathogenesis of Sweet syndrome.[1,7,12,17]

PHOTOSENSITIVITY

Photosensitivity may play a role in the pathogenesis of Sweet syndrome. Experimental induction of Sweet syndrome has been elicited by phototesting. Also, in a woman who was receiving trimethoprim-sulfamethoxazole, photodrug-associated Sweet syndrome developed in sun-exposed areas. Although the mechanism of pathogenesis is unknown, one hypothesis suggests an isomorphic Koebner reaction. Another postulated theory associates ultraviolet-B radiation with neutrophil activation and epidermal production of tumor necrosis factor-α and IL-8.[12,44-46]

DIAGNOSIS

DIAGNOSTIC CRITERIA

In 1986, diagnostic criteria for classical or idiopathic Sweet syndrome were proposed by Su and Liu.

They were modified in 1994 by von den Driesch (see Table 36-1). Infection (upper respiratory tract or gastrointestinal tract), inflammatory bowel disease, or pregnancy may be associated with Sweet syndrome. A seasonal preference for the onset of Sweet syndrome for either autumn or spring has been observed.[7,12,47]

Classical Sweet syndrome most commonly occurs in women; onset appears between the ages of 30 years and 60 years. Yet, classical Sweet syndrome has also been observed in younger adults and children. Brothers who developed the dermatosis at 10 and 15 days of age are the youngest Sweet syndrome patients. In the neonatal period, the appearance of Sweet syndrome in the first 6 weeks of life often heralds a serious underlying disorder, thus requiring a thorough investigation for the associated condition.[48,49]

It is appropriate to distinguish the classical form of Sweet syndrome from the malignancy-associated variant of this condition as there is a temporal association with the discovery or relapse of cancer and the onset or recurrence of many Sweet syndrome cases. A comprehensive review of 66 pediatric Sweet syndrome patients observed an associated hematologic malignancy in 44% of 30 children between 3 years and 18 years of age. In adults, malignancy-associated Sweet syndrome is most often associated with acute myelogenous leukemia and does not have a female predominance. Carcinomas of the genitourinary organs, breast, and gastrointestinal tract are the most frequently occurring cancers in Sweet syndrome patients with dermatosis-related solid tumors.[1,7,47,50]

In 1996, Walker and Cohen established the criteria for drug-induced Sweet syndrome (see Table 36-1). G-CSF is the most frequently observed agent associated with this variant of the dermatosis. However, other medications are also implicated in eliciting drug-induced Sweet syndrome (Fig. 36-5; see Table 36-2).[7,10,18,33,51-55]

SUPPORTIVE STUDIES

LABORATORY TESTING

A complete blood cell count with leukocyte differential and platelet count, evaluation of acute-phase

Figure 36-5 Distant **(A)** and closer (**B** and **C**) views of the left **(B)** and right **(C)** palms of an 86-year-old woman with proton pump inhibitor–induced Sweet syndrome. The painful erythematous-based pustules and pseudovesicular violaceous plaques on her hands appeared within 6 hours after she took an initial dose of esomeprazole. Previously, she had developed similar hand lesions on day 8 of omeprazole, which resolved after a short course of oral prednisone. (From Cohen PR. Proton pump inhibitor-induced Sweet's syndrome: report of acute febrile neutrophilic dermatosis in a woman with recurrent breast cancer. *Dermatol Pract Concept*. 2015;5:113-119, published under a Creative Commons Attribution License [http://creativecommons.org/licenses/by-nc/3.0/], with permission.)

reactants (such as the erythrocyte sedimentation rate or C-reactive protein), serum chemistries (evaluating hepatic function and renal function), and an urinalysis should be performed. As there appears to be a bona fide association between thyroid disease and Sweet syndrome, it is also reasonable to perform a serologic evaluation of thyroid function.[1]

Peripheral leukocytosis with neutrophilia and an elevated erythrocyte sedimentation rate and are the most consistent laboratory findings in Sweet syndrome. However, in patients with biopsy-confirmed Sweet syndrome, leukocytosis is not always present. For example, in some of the patients with malignancy-associated Sweet syndrome, anemia, neutropenia, and/or abnormal platelet counts may be observed.[1]

Urinalysis abnormalities (hematuria and proteinuria) and hepatic serum enzyme elevation may be observed in patients with kidney and liver involvement. Abnormalities in cerebrospinal fluid analysis may be observed in patients with central nervous system involvement.[1,7]

PATHOLOGY

When the diagnosis of Sweet syndrome is suspected, evaluation of a lesional skin biopsy is helpful. As the pathologic findings of Sweet syndrome are similar to those observed in cutaneous lesions caused by infectious agents, lesional tissue should also be submitted for bacterial, fungal, mycobacterial, and, possibly, viral cultures.[1]

Characteristically, a diffuse infiltrate of mature neutrophils is present in the papillary and upper reticular dermis (Fig. 36-6). However, the inflammatory infiltrate can also involve the epidermis or adipose tissue. In contrast to the infiltrate of mature neutrophils typically seen in Sweet syndrome, histiocytoid Sweet syndrome is characterized by a dermal infiltrate composed of immature granulocytes that are histiocytic mononuclear cells (Fig. 36-7). Morphologically, the small cells of histiocytoid Sweet syndrome appear similar to neutrophils; however, they stain for CD15, CD43, CD45 (LCA), CD68, HAM56, lysozyme, and MAC 387—thereby identifying a monocytic-histiocytic profile (Fig. 36-8).[7,18]

The inflammation in the dermis is typically dense and diffuse. However, it can also be perivascular. In addition, the dermal inflammation can demonstrate "secondary" changes of leukocytoclastic vasculitis; these changes are considered to be an epiphenomenon and not representative of a "primary" vasculitis.[2]

Exocytosis of neutrophils into the epidermis can result in neutrophilic spongiotic vesicles or subcorneal pustules. The condition is referred to as "subcutaneous Sweet syndrome" when the neutrophils are located either entirely or partially in the subcutaneous fat.[1,3]

The spectrum of pathologic changes described in cutaneous lesions of Sweet syndrome has expanded; it now includes concurrent leukemia cutis, vasculitis,

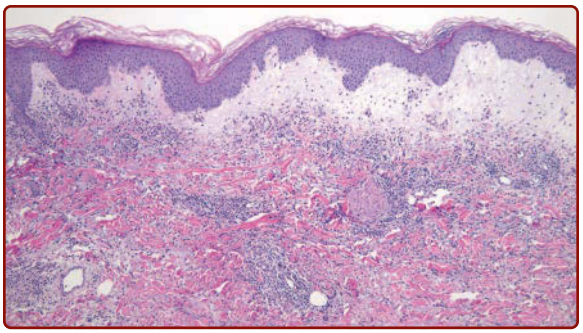

Figure 36-7 An intermediate magnification view of the histopathologic presentation of histiocytoid giant cellulitis Sweet syndrome shows prominent superficial dermal edema with a perivascular and interstitial inflammatory dermal infiltrate consisting of histiocytoid and immature granulocytic cells admixed with lymphocytes, eosinophils, and occasional neutrophils. (From So JK, Carlos CA, Frucht CS, et al. Histiocytoid giant cellulitis-like Sweet's syndrome: case report and review of the literature. *Dermatol Online J.* 2015;21(3):4, with permission.)

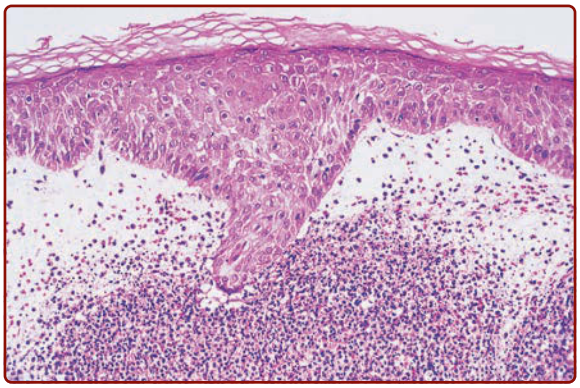

Figure 36-6 Histopathologic presentation of acute febrile neutrophilic dermatosis (Sweet syndrome) demonstrates massive edema of the papillary dermis and a dense diffuse infiltrate of mature neutrophils throughout the upper dermis (hematoxylin and eosin stain). (From Cohen PR, Holder WR, Tucker SB, et al. Sweet's syndrome in patients with solid tumors. *Cancer.* 1993;72:2723-2731, with permission. Copyright © 2006 John Wiley & Sons.)

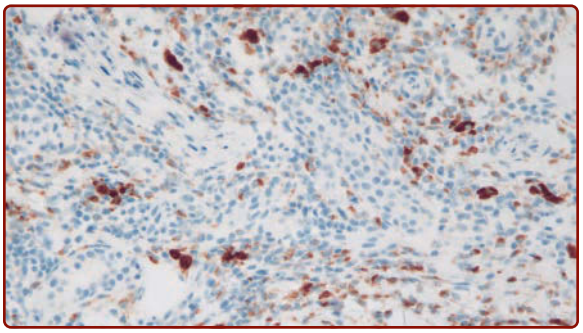

Figure 36-8 A high magnification view of the immunoperoxidase staining of the skin biopsy from the histiocytoid giant cellulitis Sweet syndrome shows positive staining of the CD68 (a histiocyte marker) cells comprising the dermal infiltrate. (From So JK, Carlos CA, Frucht CS, et al. Histiocytoid giant cellulitis-like Sweet's syndrome: case report and review of the literature. *Dermatol Online J.* 2015;21(3):4, with permission.)

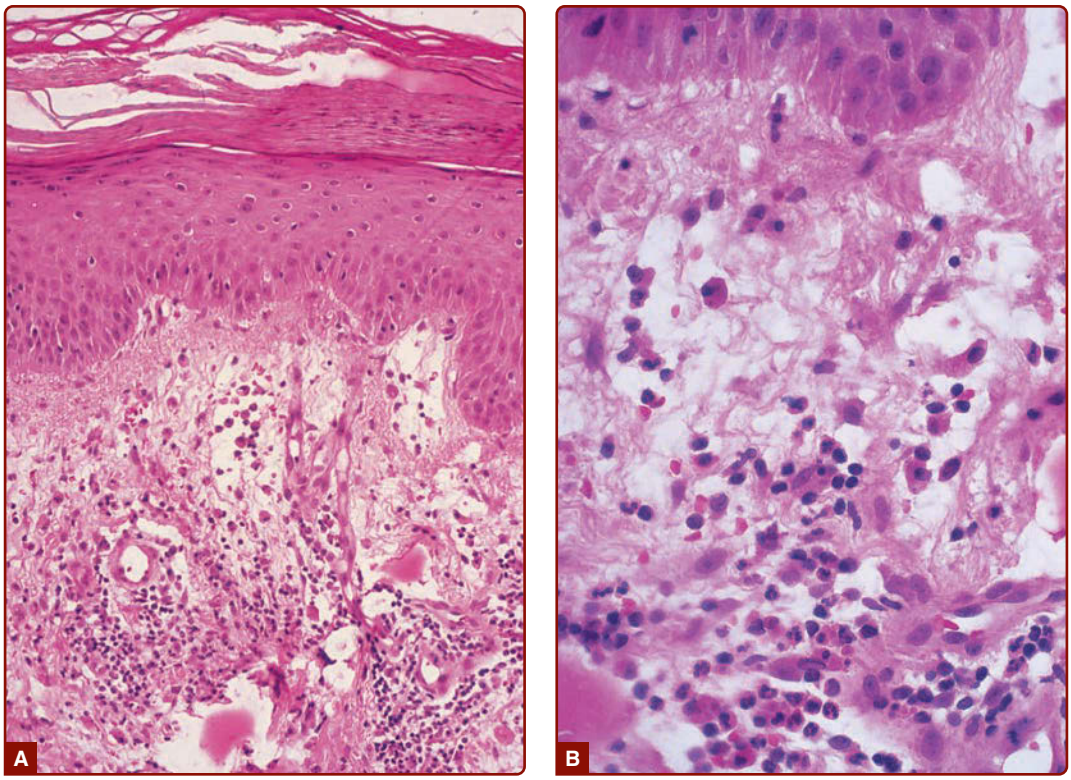

Figure 36-9 Characteristic histopathologic features of Sweet syndrome are observed at low **(A)** and high **(B)** magnification: papillary dermal edema, swollen endothelial cells, and a diffuse infiltrate of predominantly neutrophils with leukocytoclasia, yet no evidence of vasculitis (hematoxylin and eosin stain). (From Cohen PR, Holder WR, Rapini RP. Concurrent Sweet's syndrome and erythema nodosum: a report, world literature review and mechanism of pathogenesis. *J Rheumatol.* 1992;19:814-820, with permission.)

and variability of the composition or the location of the inflammatory infiltrate. Edema in the dermis, swollen endothelial cells, dilated small blood vessels, and fragmented neutrophil nuclei (referred to as karyorrhexis or leukocytoclasia) may also be present (Fig. 36-9). However, the overlying epidermis is normal and fibrin deposition or neutrophils within the vessel walls (changes of "primary" leukocytoclastic vasculitis) are usually absent.[1,2]

The inflammatory infiltrate of Sweet syndrome lesions may also contain lymphocytes or histiocytes. In some patients with either idiopathic or drug-induced or malignancy-associated Sweet syndrome, the cutaneous lesions contain eosinophils. In some of the Sweet syndrome patients with hematologic disorders, abnormal neutrophils (leukemia cutis)—in addition to mature neutrophils—comprise the dermal infiltrate.[56-58]

Extracutaneous sites can also show pathologic findings of Sweet syndrome. They often, appear as sterile neutrophilic inflammation in the involved organ. These changes have been observed in the aorta, bones, intestines, liver, lungs, and muscles of patients with Sweet syndrome.[1,7]

IMAGING

Abnormalities on brain single-photon emission computed tomography, computerized axial tomography, electroencephalograms, and magnetic resonance imaging may be observed in patients with central nervous system involvement. In a 62-year-old man with Sweet syndrome, magnetic resonance imaging findings of dermatosis-associated neutrophilic fasciitis and musculoskeletal involvement were reported. Pleural effusions and corticosteroid-responsive culture-negative infiltrates on their chest roentgenograms may be noted in patients with pulmonary involvement.[1,59]

DIFFERENTIAL DIAGNOSIS

CLINICAL DIFFERENTIAL DIAGNOSIS

The skin and mucosal lesions of Sweet syndrome mimic those of other conditions (Table 36-8). The clinical differential diagnosis of Sweet syndrome includes infectious and inflammatory disorders, neoplastic conditions, reactive erythemas, vasculitis, other cutaneous conditions, and other systemic diseases.[1,7,47]

Patients with Behçet disease, similar to those with Sweet syndrome, may develop lesions at sites of trauma. An important differentiator between Sweet syndrome and Behçet disease is human leukocyte

TABLE 36-8

Clinical Differential Diagnosis of Sweet Syndrome (Lane)

- Acral erythema
- Azathioprine hypersensitivity reaction
- Bacterial sepsis
- Behçet disease
- Bowel bypass syndrome
- Cellulitis
- Chloroma
- Chronic atypical neutrophilic dermatosis with lipodystrophy and elevated temperature (CANDLE) syndrome
- Dermatomyositis
- Drug eruptions
- Erysipelas
- Erythema elevatum diutinum
- Erythema multiforme
- Erythema nodosum
- Familial Mediterranean fever
- Gemcitabine-associated Sweet syndrome-like eruptions
- Granuloma faciale
- Halogenoderma
- Leprosy
- Leukemia cutis
- Leukocytoclastic vasculitis
- Lupus erythematosus
- Lymphangitis
- Lymphoma
- Metastatic tumor
- Neutrophilic eccrine hidradenitis
- Panniculitis
- Periarteritis nodosa
- Pyoderma gangrenosum
- Rheumatoid neutrophilic dermatitis
- Rosacea fulminans
- Schnitzler syndrome
- Syphilis
- Systemic mycosis
- Thrombophlebitis
- Tuberculosis
- Urticaria
- Viral exanthem

Adapted from Cohen PR, Kurzrock R: Sweet's syndrome and cancer. *Clin Dermatol.* 1993;11:149-157. Copyright © Elsevier.

antigen analysis. In Japan, the B51 marker is significantly higher in Behçet disease, whereas the B54 marker is more frequently associated with Sweet syndrome.[60]

Other conditions in the clinical differential diagnosis of Sweet syndrome include azathioprine hypersensitivity reaction, chronic atypical neutrophilic dermatosis with lipodystrophy and elevated temperature (CANDLE) syndrome, and gemcitabine-associated Sweet syndrome-like eruptions. In addition, not only cellulitis and other infections, but also periodic syndromes (such as familial Mediterranean fever) can be included in the differential diagnosis of giant cellulitis-like Sweet syndrome. Therefore, biopsy of the skin lesion for histology, as well as tissue cultures, should be considered in individuals for whom this variant of Sweet syndrome is suspected.[18,61-63]

HISTOLOGIC DIFFERENTIAL DIAGNOSIS

The histologic differential diagnosis of Sweet syndrome includes conditions microscopically characterized by either neutrophilic dermatosis or neutrophilic panniculitis (Table 36-9). Because the pathologic changes associated with Sweet syndrome are similar to those observed in an abscess or cellulitis, culture of lesional tissue for bacteria, fungi, and mycobacteria should be considered to rule out infection. Leukemia cutis not only mimics the dermal changes of Sweet syndrome, but can potentially occur within the same skin lesion as Sweet syndrome; however, in contrast to the mature

TABLE 36-9

Histologic Differential Diagnosis of Sweet Syndrome

- Abscess/cellulitis: Positive culture for infectious agent
- Arthropod bite reaction: History of exposure to arthropods
- Bowel (intestinal) bypass syndrome: History of jejunal-ileal bypass surgery for morbid obesity
- Erythema elevatum diutinum: Erythematous asymptomatic plaques often located on the dorsal hands and elbows; younger lesions have microscopic features of leukocytoclastic vasculitis, whereas older lesions have dermal fibrosis and mucin
- Granuloma faciale: Yellow-to-red-to-brown indurated asymptomatic facial plaques; there is a grenz zone of normal papillary dermis beneath which there is a dense diffuse inflammatory infiltrate of predominantly neutrophils (with microscopic features of leukocytoclastic vasculitis) and numerous eosinophils
- Halogenoderma: Neutrophilic dermal infiltrate with necrosis and pseudoepitheliomatous hyperplasia with intraepidermal abscesses; history of ingestion of bromides (leg lesions), iodides (facial lesions), or topical fluoride gel to teeth during tumor radiation therapy to face
- Leukemia cutis: Dermal infiltrate consists of immature neutrophils
- Leukocytoclastic vasculitis: Vessel wall destruction—extravasated erythrocytes, fibrinoid necrosis of vessel walls, karyorrhexis, and neutrophils in the vessel wall
- Lobular neutrophilic panniculitides: In addition to subcutaneous Sweet syndrome, these include α_1-antitrypsin deficiency syndrome, factitial panniculitis (secondary to the presence of iatrogenic or self-induced foreign bodies), infectious panniculitis (secondary to either a bacterial, fungal, mycobacterial, or protozoan organism), pancreatic panniculitis, rheumatoid arthritis–associated panniculitis
- Neutrophilic eccrine hidradenitis: Neutrophils around eccrine glands, often in patients with acute myelogenous leukemia receiving induction chemotherapy
- Neutrophilic urticarial dermatosis: An urticarial eruption demonstrating perivascular and interstitial neutrophilic infiltrate with intense leukocytoclasia, but without vasculitis and without dermal edema, that is often associated with a systemic disease such as Schnitzler syndrome, adult-onset Still disease, lupus erythematosus, and the hereditary autoinflammatory fever syndromes
- Pyoderma gangrenosum: Ulcer with overhanging, undermined violaceous edges
- Rheumatoid neutrophilic dermatitis: History of rheumatoid arthritis, nodules, and plaques

Adapted from Cohen PR: Paraneoplastic dermatopathology: cutaneous paraneoplastic syndromes. *Adv Dermatol.* 1995;11:215-252.

polymorphonuclear neutrophils found in Sweet syndrome, the dermal infiltrate in leukemia cutis consists of malignant immature leukocytes.[1,3,7]

The pathologic changes in the adipose tissue of subcutaneous Sweet syndrome lesions can be found either in the lobules, the septae, or both. Therefore, conditions characterized by a neutrophilic lobular panniculitis also need to always be considered and ruled out.[1,3]

The pathologic differential diagnosis of histiocytoid Sweet syndrome includes leukemia cutis and other inflammatory dermatoses histopathologically characterized by histiocytes interstitially arranged between dermal collagen bundles such as interstitial type of granuloma annulare, interstitial granulomatous dermatitis with arthritis, and methotrexate-induced rheumatoid papules.[18]

Arthropod bite reaction has also mimicked the pathologic changes observed in Sweet syndrome. Unrelated to the use of medication, the presence of eosinophils in Sweet syndrome may range from rare to abundant. Although a dense inflammatory infiltrate of neutrophils is characteristic of Sweet syndrome, sites of arthropod bites with abundant eosinophils and some neutrophils may be misinterpreted as the dermatosis.[16,64]

CLINICAL COURSE AND PROGNOSIS

In some patients with classical Sweet syndrome, the symptoms and lesions of the dermatosis eventually resolved without any therapeutic intervention. However, the lesions may persist for weeks to months. Successful management of the cancer occasionally results in clearing of the related dermatosis in patients with malignancy-associated Sweet syndrome. Similarly, spontaneous improvement and subsequent resolution of the syndrome typically follows discontinuation of the associated medication in patients with drug-induced Sweet syndrome. In some of the patients who had associated tonsillitis, solid tumors, or renal failure, surgical intervention resulted in the resolution of Sweet syndrome.[1,7,12,47]

Following either spontaneous remission or therapy-induced clinical resolution, Sweet syndrome may recur. The duration of remission between recurrent episodes of the dermatosis is variable. In cancer patients, the reappearance of dermatosis-associated symptoms and lesions may represent a paraneoplastic syndrome that is signaling the return of the previously treated malignancy. Sweet syndrome recurrences are more common in this patient population.[1,7,47]

MANAGEMENT

MEDICATIONS

FIRST-LINE TREATMENTS

The therapeutic mainstay for Sweet syndrome is systemic corticosteroids (Table 36-10). Improvement of the symptoms and resolution of the mucocutaneous lesions promptly results after initiation of therapy. In patients with refractory disease, daily pulse methylprednisolone administered intravenously may be necessary. For treating localized Sweet syndrome lesions, topical (such as 0.05% clobetasol propionate) or intralesional (such as triamcinolone acetonide at a dose

TABLE 36-10
Systemic Treatments for Sweet Syndrome

LINE	MEDICATION	DOSE
First	Prednisone	1 mg/kg/day (usually ranging from 30 mg-60 mg) as a single, oral, morning dose. Within 4-6 weeks, taper dose to 10 mg/day; however some patients may require 2-3 months of treatment or intravenous therapy.
	Methylprednisolone sodium succinate	Intravenously administered (up to 1000 mg/day) over 1 or more hours, daily for 3-5 days. This is followed by a tapering oral dose of corticosteroid or another immunosuppressant agent.
	Potassium iodide	Administered orally as 300 mg enteric-coated tablets, TID (for a daily dose of 900 mg) or as a saturated solution (1 g/mL of water) of potassium iodide (SSKI; also referred to as Lugol's solution), beginning at a dose of 3 drops TID (9 drops/day = 450 mg/day) and increasing by 1 drop TID, typically to a final dose of 21 drops/day (1050 mg) to 30 drops/day (1500 mg).[a]
	Colchicine	Administered orally at a dose of 0.5 mg TID (for a daily dose of 1.5 mg).
Second	Indomethacin	Administered at an oral daily dose of 150 mg for 7 days, and then 100 mg/day for 14 days.
	Clofazimine	Administered orally at a daily dose of 200 mg for 4 weeks, and then 100 mg/day for 4 weeks.
	Cyclosporine	Administered as monotherapy or as a second-line agent (after failure of first-line therapy or as a corticosteroid-sparing agent). Initial oral daily dose ranges from 2 mg/kg/day to 4 mg/kg/day to 10 mg/kg/day.
	Dapsone	Administered as either monotherapy or in combination therapy. Initial oral dose ranges from 100 mg/day to 200 mg/day; the latter dose is either administered as a single dose or divided into 2 equal doses.

[a]When a "standard" medicine dropper (which dispenses 20 drops per mL) is used, 1 drop = 0.05 mL (or 50 mg when the concentration of potassium iodide is 1000 mg/mL).

From Cohen PR, Kurzrock R: Sweet's syndrome revisited: a review of disease concepts. *Int J Dermatol.* 2003;42:761-778, with permission.

between 3.0 mg/cc and 10.0 mg/cc) corticosteroids may be effective.[1,7,12,17,34]

Other first-line systemic treatments for Sweet syndrome are potassium iodide and colchicine (see Table 36-10). Potential drug-induced side effects of potassium iodide include vasculitis and hypothyroidism. Gastrointestinal symptoms such as diarrhea, abdominal pain, nausea and vomiting are potential adverse effects from colchicine that may improve after lowering the daily dose of the drug.[1,7,34]

SECOND-LINE TREATMENTS

Indomethacin, clofazimine, cyclosporine, and dapsone are second-line systemic agents for Sweet syndrome (see Table 36-10). They have all been used as monotherapy after first-line therapies have failed or in the initial management of the patient. In addition, either as a corticosteroid-sparing agent or with other drugs, cyclosporine and dapsone have been used in combination therapy.[1,7,34]

ANTIBIOTICS

In some patients, Sweet syndrome lesions have improved after receiving systemic antibiotics. These patients not only include individuals with *Staphylococcus aureus* secondarily impetiginized lesions treated with an antimicrobial agent to which their bacterial strain is susceptible and patients with inflammatory bowel disease treated with metronidazole, but also persons with dermatosis-related *Yersinia* or *Chlamydia* infection treated with either doxycycline, minocycline, or tetracycline.[1,7,34]

OTHER AGENTS

In addition, predominantly in case reports, effective treatment of Sweet syndrome also has been described with other drugs, such as antineoplastic therapies (azacitidine, chlorambucil, cyclophosphamide, and rituximab), danazol, etretinate, hepatitis therapy, immunoglobulin, IFN-α, and tumor necrosis factors antagonists (adalimumab, etanercept, infliximab, and thalidomide).[7,34,51,65,66] Anakinra (an IL-1 receptor antagonist) in combination with oral prednisone was promptly effective in resolving the symptoms, and subsequently the clinical lesions, of Sweet syndrome in a patient with longstanding disease that was refractory to other therapies; it also resulted in dramatic clinical and biologic improvement in a 66-year-old man who had a 5-year history of Sweet syndrome that was refractory to various conventional treatments.[67,68] Pentoxifylline was hypothesized to be beneficial for treating Sweet syndrome; however, when used as monotherapy, it was not found to be efficacious.[2] Some of the drugs used for the treatment of Sweet syndrome, such as azacitidine, minocycline, and the tumor necrosis factor-inhibitors adalimumab, etanercept, infliximab, and lenalidomide, also have been observed to elicit the condition.[1,7,34,55]

MALIGNANCY WORKUP

In 1993, Cohen and Kurzrock proposed recommendations for the initial malignancy workup in newly diagnosed Sweet syndrome patients without a prior cancer. Their recommendations were based on the neoplasms that had concurrently been present or subsequently developed in previously cancer-free Sweet syndrome patients and the age-related recommendations of the American Cancer Society for early detection of cancer in asymptomatic persons. The recommendations included: (a) a detailed medical history; (b) a complete physical examination, including: (i) examination of the thyroid, lymph nodes, oral cavity, and skin; (ii) digital rectal examination; (iii) breast, ovary, and pelvic examination in women; and (iv) prostate and testicle examination in men; (c) laboratory evaluation: (i) carcinoembryonic antigen level; (ii) complete blood cell count with leukocyte differential and platelet count; (iii) pap test in women; (iv) serum chemistries; (v) stool guaiac slide test; (vi) urinalysis; and (vii) urine culture; and (d) other screening tests: (i) chest roentgenograms; (ii) endometrial tissue sampling in either menopausal women or women with a history of abnormal uterine bleeding, estrogen therapy, failure to ovulate, infertility, or obesity; and (iii) sigmoidoscopy in patients older than 50 years of age. Cohen and Kurzrock also suggested that it was reasonable to check a complete blood cell count with leukocyte differential and platelet count every 6 to 12 months as the initial appearance of dermatosis-related skin lesions had been reported to precede the diagnosis of a Sweet syndrome–associated hematologic malignancy by as long as 11 years.[1,47]

REFERENCES

1. Cohen PR. Sweet's syndrome—a comprehensive review of an acute febrile neutrophilic dermatosis. *Orphanet J Rare Dis.* 2007;2:34.
2. Cohen PR. Skin lesions of Sweet syndrome and its dorsal hand variant contain vasculitis: an oxymoron or an epiphenomenon? *Arch Dermatol.* 2002;138:400-403.
3. Cohen PR. Subcutaneous Sweet's syndrome: a variant of acute febrile neutrophilic dermatosis that is included in the histologic differential diagnosis of neutrophilic panniculitis. *J Am Acad Dermatol.* 2005;52:927-928.
4. Amouri M, Masmoudi A, Ammar M, et al. Sweet's syndrome: a retrospective study of 90 cases from a tertiary care center. *Int J Dermatol.* 2016;55(9):1033-1039.
5. Villarreal-Villarreal CD, Ocampo-Candiani J, Villarreal-Martinez A. Sweet syndrome: a review and update. *Actas Dermosifiliogr.* 2016;107:369-378.
6. Rochet NM, Chavan RN, Cappel MA, et al. Sweet syndrome: clinical presentation, associations, and response to treatment in 77 patients. *J Am Acad Dermatol.* 2013; 69:557-564.
7. Anzalone CL, Cohen PR. Acute febrile neutrophilic dermatosis (Sweet's syndrome). *Curr Opin Hematol.* 2013;20:26-35.
8. Qiao J, Wang Y, Bai J, et al. Concurrence of Sweet's syndrome, pathergy phenomenon and erythema

nodosum-like lesions. *An Bras Dermatol.* 2015;90: 237-239.
9. Chu CH, Cheng YP, Kao HL, et al. Lymphedema-associated neutrophilic dermatosis: two cases of localized Sweet syndrome on the lymphedematous lower limbs. *J Dermatol.* 2016;43(9):1062-1066.
10. Ainechi S, Carlson JA. Neutrophilic dermatosis limited to lipo-lymphedematous skin in a morbidly obese woman on dasatinib therapy. *Am J Dermatopathol.* 2016;38:e22-e26.
11. Endo Y, Tanioka M, Tanizaki H, et al. Bullous variant of Sweet's syndrome after herpes zoster virus infection. *Case Rep Dermatol.* 2011;3:259-262.
12. Walker DC, Cohen PR. Trimethoprim-sulfamethoxazole-associated acute febrile neutrophilic dermatosis: case report and review of drug-induced Sweet's syndrome. *J Am Acad Dermatol.* 1996;34:918-923.
13. Sommer S, Wilkinson SM, Merchant WJ, et al. Sweet's syndrome presenting as palmoplantar pustulosis. *J Am Acad Dermatol.* 2000;42:332-334.
14. Sarkany RPE, Burrows NP, Grant JW, et al. The pustular eruption of ulcerative colitis: a variant of Sweet's syndrome [letter]. *Br J Dermatol.* 1998;138:365-366.
15. Kaur S, Gupta D, Garg B, et al. Neutrophilic dermatosis of dorsal hands. *Indian Dermatol Online J.* 2015;6(1):42-45.
16. Rochael MC, Pantaleão L, Vilar EA, et al. Sweet's syndrome: study of 73 cases, emphasizing histopathological findings. *An Bras Dermatol.* 2011;86:702-707.
17. Cohen PR, Holder WR, Rapini RP. Concurrent Sweet's syndrome and erythema nodosum: a report, world literature review and mechanism of pathogenesis. *J Rheumatol.* 1992;19:814-820.
18. So JK, Carlos CA, Frucht CS, et al. Histiocytoid giant cellulitis-like Sweet's syndrome: case report and review of the literature. *Dermatol Online J.* 2015;21(3):4.
19. Ghoufi L, Ortonne N, Ingen-Housz-Oro S, et al. Histiocytoid Sweet syndrome is more frequently associated with myelodysplastic syndromes than the classical neutrophilic variant: a comparative series of 62 patients. *Medicine (Baltimore).* 2016;95:e3033.
20. Surovy AM, Pelivani N, Hegyi I, et al. Giant cellulitis-like Sweet Syndrome, a new variant of neutrophilic dermatosis. *JAMA Dermatol.* 2013;149:79-83.
21. Kaminska EC, Nwaneshiudu AI, Ruiz de Luzuriaga A, et al. Giant cellulitis-like Sweet syndrome in the setting of autoimmune disease. *J Am Acad Dermatol.* 2014;71:e94-e95.
22. Koketsu H, Ricotti C, Kerdel FA. Treatment of giant cellulitis-like Sweet syndrome with dapsone. *JAMA Dermatol.* 2014;150:457-459.
23. Kroshinsky D, Alloo A, Rothschild B, et al. Necrotizing Sweet syndrome: a new variant of neutrophilic dermatosis mimicking necrotizing fasciitis. *J Am Acad Dermatol.* 2012;67(5):945-954.
24. Ma EH, Akikusa JD, Macgregor D, et al. Sweet's syndrome with postinflammatory elastolysis and Takayasu arteritis in a child: a case report and literature review. *Pediatr Dermatol.* 2012;29(5):645-650.
25. Timmer-DE Mik L, Broekhuijsen-VAN Henten DM, Oldhoff JM, et al. Acquired cutis laxa in childhood Sweet's syndrome. *Pediatr Dermatol.* 2009;26: 358-360.
26. Acikel S, Sari M, Akdemir R. The relationship between acute coronary syndrome and inflammation: a case of acute myocardial infarction associated with coronary involvement of Sweet's syndrome. *Blood Coagul Fibrinolysis.* 2010;21:703-706.
27. Wallett A, Newland K, Foster-Smith E. Radiation therapy-induced neuro-Sweet disease in a patient with oral squamous cell carcinoma. *Australas J Dermatol.* 2017;58(2):e51-e53.
28. Niwa F, Tokuda T, Kimura M, et al. Self-remitting and reversible parkinsonism associated with neuro-Sweet disease. *Intern Med.* 2010;49:1201-1204.
29. Lobo AM, Stacy R, Cestari D, et al. Optic nerve involvement with panuveitis in Sweet syndrome. *Ocul Immunol Inflamm.* 2011;19:167-170.
30. Sinawat S, Yospaiboon Y, Sinawat S. Bilateral endogenous endophthalmitis in disseminated NTM infection: a case report. *J Med Assoc Thai.* 2011;94:632-636.
31. Cheng S, da Cruz M. Sweet's disease and profound, bilateral, sensorineural hearing loss. *J Laryngol Otol.* 2010;124:105-107.
32. Fortna RR, Toporcer M, Elder DE, et al. A case of sweet syndrome with spleen and lymph node involvement preceded by parvovirus B19 infection, and a review of the literature on extracutaneous sweet syndrome. *Am J Dermatopathol.* 2010;32:621-627.
33. Solana-Lopez G, Llamas-Velasco M, Concha-Garzon MJ, et al. Sweet syndrome and differentiation syndrome in a patient with acute promyelocytic leukemia. *World J Clin Cases.* 2015;3:196-198.
34. Cohen PR. Neutrophilic dermatoses. a review of current treatment options. *Am J Clin Dermatol.* 2009;10: 301-312.
35. Ajili F, Souissi A, Bougrine F, et al. Coexistence of pyoderma gangrenosum and sweet's syndrome in a patient with ulcerative colitis. *Pan Afr Med J.* 2015;21:151.
36. Vanourny J, Swick BL. Sweet syndrome with systemic inflammatory response syndrome. *Arch Dermatol.* 2012;148:969-970.
37. Shugarman IL, Schmit JM, Sbicca JA, et al. Easily missed extracutaneous manifestation of malignancy-associated Sweet's syndrome: systemic inflammatory response syndrome. *J Clin Oncol.* 2011;29(24): e702-e705.
38. Nesterovitch AB, Gyorfy Z, Hoffman MD, et al. Alteration in the gene encoding protein tyrosine phosphatase nonreceptor type 6 (PTPN6/SHP1) may contribute to neutrophilic dermatoses. *Am J Pathol.* 2011;178: 1434-1441.
39. Johnson CS, May ER, Myers RK, et al. Extracutaneous neutrophilic inflammation in a dog with lesions resembling Sweet's Syndrome. *Vet Dermatol.* 2009; 20:200-205.
40. Gains MJ, Morency A, Sauvé F, et al. Canine sterile neutrophilic dermatitis (resembling Sweet's syndrome) in a Dachshund. *Can Vet J.* 2010;51:1397-1399.
41. Omoya K, Naiki Y, Kato Z, et al. Sweet's syndrome in a neonate with non-B54 types of human leukocyte antigen. *World J Pediatr.* 2012;8:181-184.
42. Marzano AV, Cugno M, Trevisan V, et al. Inflammatory cells, cytokines and matrix metalloproteinases in amicrobial pustulosis of the folds and other neutrophilic dermatoses. *Int J Immunopathol Pharmacol.* 2011;24451-24460.
43. Saeed M, Brown GE, Agarwal A, et al. Autoimmune clustering: sweet syndrome, Hashimoto thyroiditis, and psoriasis. *J Clin Rheumatol.* 2011;17:76-78.
44. Pai VV, Gupta G, Athanikar S, et al. Photoinduced classic sweet syndrome presenting as hemorrhagic bullae. *Cutis.* 2014;93:E22-E24.
45. Meyer V, Schneider SW, Bonsmann G, et al. Experimentally confirmed induction of Sweet's syndrome by phototesting. *Acta Derm Venereol.* 2011;91:720-721.

46. Natkunarajah J, Gordon K, Chow J, et al. Photoaggravated Sweet's syndrome. *Clin Exp Dermatol.* 2010; 35:18-19.
47. Cohen PR, Kurzrock R. Sweet's syndrome and cancer. *Clin Dermatol.* 1993;11:149-157.
48. Parsapour K, Reep MD, Gohar K, et al. Familial Sweet's syndrome in 2 brothers, both seen in the first 2 weeks of life. *J Am Acad Dermatol.* 2003;49:132-138.
49. Gray PE, Bock V, Ziegler DS, et al. Neonatal Sweet syndrome: a potential marker of serious systemic illness. *Pediatrics.* 2012;129:e1353-e1359.
50. Kazmi SM, Pemmaraju N, Patel KP, et al. Characteristics of Sweet syndrome in patients with acute myeloid leukemia. *Clin Lymphoma Myeloma Leuk.* 2015;15:358-363.
51. Calixto R, Menezes Y, Ostronoff M, et al. Favorable outcome of severe, extensive, granulocyte colony-stimulating factor-induced, corticosteroid-resistant Sweet's syndrome treated with high-dose intravenous immunoglobulin. *J Clin Oncol.* 2014;32(5):e1-e2.
52. McNally A, Ibbetson J, Sidhu S. Azathioprine-induced Sweet's syndrome: a case series and review of the literature. *Australas J Dermatol.* 2017;58(1):53-57.
53. Cohen PR. Proton pump inhibitor-induced Sweet's syndrome: report of acute febrile neutrophilic dermatosis in a woman with recurrent breast cancer. *Dermatol Pract Concept.* 2015;5:113-119.
54. Yorio JT, Mays SR, Ciurea AM, et al. Case of vemurafenib-induced Sweet's syndrome. *J Dermatol.* 2014; 41:817-820.
55. Kalai C, Brand R, Yu L. Minocycline-induced Sweet syndrome (acute febrile neutrophilic dermatosis). *J Am Acad Dermatol.* 2012;67:e289-e291.
56. Vignon-Pennamen MD, Jullard C, Rybojad M, et al. Chronic recurrent lymphocytic Sweet's syndrome as a predictive marker of myelodysplasia: a report of 9 cases. *Arch Dermatol.* 2006;142:1170-1176.
57. Kakaletsis N, Kaiafa G, Savo[poulos C, et al. Initially lymphocytic Sweet's syndrome in male patients with myelodysplasia: a distinguished clinicopathological entity? Case report and systematic review of the literature. *Acta Haematol.* 2014;132:220-225.
58. Soon CW, Kirsch IR, Connolly AJ, et al. Eosinophilic-rich acute febrile neutrophilic dermatosis in a patient with enteropathy-associated T-cell lymphoma, type 1. *Am J Dermatopathol.* 2016;38(9):704-708.
59. Gaeta M, Mileto A, Musumeci O, et al. MRI findings of neutrophilic fasciitis in a patient with acute febrile neutrophilic dermatosis (Sweet's syndrome). *Skeletal Radiol.* 2011;40:779-782.
60. Takahama H, Kanbe T. Neutrophilic dermatosis of the dorsal hands: a case showing HLA B54, the marker of Sweet's syndrome. *Int J Dermatol.* 2010;49:1079-1080.
61. Bidinger JJ, Sky K, Battafarano DF, Henning JS. The cutaneous and systemic manifestations of azathioprine hypersensitivity syndrome. *J Am Acad Dermatol.* 2011;65:184-191.
62. Cavalcanate MF, Brunelli JB, Miranda CC, et al. CANDLE syndrome: chronic atypical neutrophilic dermatosis with lipodystrophy and elevated temperature—a rare case with a novel mutation. *Eur J Pediatr.* 2016;175:735-740.
63. Martorell-Calatayud A, Requena C, Sanmartin O, et al. Gemcitabine-associated sweet syndrome-like eruption. *J Am Acad Dermatol.* 2011;65:1236-1238.
64. Battistella M, Bourrat E, Fardet L, et al. Sweet-like reaction due to arthropod bites: a histopathologic pitfall. *Am J Dermatopathol.* 2012;34:442-445.
65. Hashemi SM, Fazeli SA, Vahedi A, et al. Rituximab for refractory subcutaneous Sweet's syndrome in chronic lymphocytic leukemia: a case report. *Mol Clin Oncol.* 2016;4:436-440.
66. Agarwal A, Barrow W, Selim MA, et al. Refractory subcutaneous Sweet syndrome treated with adalimumab. *JAMA Dermatol.* 2016;152(7):842-844.
67. Delluc A, Limal N, Puechal X, et al. Efficacy of anakinra, an IL1 receptor antagonist, in refractory Sweet syndrome. *Ann Rheum Dis.* 2008;67:278-279.
68. Kluger N, Gil-Bistes D, Guillot B, et al. Efficacy of anti-interleukin-1 receptor antagonist anakinra (Kineret) in a case of refractory Sweet's syndrome. *Dermatology.* 2011;222:123-127.

Chapter 37 :: Pyoderma Gangrenosum

:: Natanel Jourabchi & Gerald S. Lazarus

AT-A-GLANCE

- Pyoderma gangrenosum (PG) is an uncommon, neutrophilic inflammatory skin condition, which classically presents as a painful nodule, plaque, or pustule that enlarges and breaks down to form a progressively enlarging ulcer with raised, undermined, violaceous borders and a surrounding zone of erythema. Healing PG lesions develop a cribriform appearance.
- PG tends to occur and recur in areas of trauma because of the pathergic phenomenon, where trauma or irritation can induce flaring of PG.
- PG most often occurs in association with systemic inflammation, and most reported cases have an associated underlying disease (such as inflammatory bowel disease, monoclonal gammopathy, hematologic disease, inflammatory arthritis, malignancy, hidradenitis suppurativa, etc); however, PG may precede these disorders. PG has also been reported in association with genetic mutations and syndromes, such as the pyogenic arthritis, pyoderma gangrenosum, and acne (PAPA) syndrome, or without an identifiable underlying disease.
- PG most commonly presents as the classic ulcerative variant, but may also arise as bullous, pustular, or vegetative variants. Clinical features of different variants sometimes overlap in individual patients but usually one variant dominates the clinical picture.
- There is no laboratory test or investigation that establishes the diagnosis of PG with certainty. The histopathologic findings are not diagnostic but can be supportive of the diagnosis of PG in the appropriate clinical setting and are essential to rule out alternative diagnoses.
- Specified criteria (see "Diagnostic Algorithm" section) suggest the diagnosis of PG, but other conditions (particularly infection, vascular disease, and malignancy) must be excluded.
- The mainstays of management are systemic immunosuppressive agents together with appropriate local and topical therapy.
- Classic ulcerative PG is a chronic condition. Complete healing usually requires months of treatment; maintenance therapy is necessary in many and relapses are common. Significant morbidity and mortality are experienced by patients with ulcerative and bullous PG.

DEFINITIONS

Pyoderma gangrenosum (PG) is an uncommon, chronic, neutrophilic inflammatory skin condition, with the classic ulcerative variant typically presenting initially as a painful nodule, plaque, or pustule that enlarges and breaks down to form a progressively enlarging ulcer with raised, undermined, violaceous borders and a surrounding zone of erythema.[1,2] The lesions are commonly very painful, develop a cribriform appearance with healing, and tend to occur and recur in areas of trauma in up to 50% of cases.[1,2] PG is believed to occur in association with systemic inflammation, and most reported cases are associated with autoinflammatory or hematologic conditions, and typically respond to immune suppression.[1,3-5] PG most commonly presents as the classic ulcerative variant, but may also present as bullous, pustular, or vegetative variants. Unless otherwise specified, when we refer to PG in this text, we are referring to the classic ulcerative variant.

EPIDEMIOLOGY

PG is estimated to affect up to 10 cases per million people per year, and represents up to 3% of chronic leg ulcer cases, but may occur anywhere on the body. PG has been reported in people of all ages; most cases, however, present in the second to sixth decades of life, with a possible female predominance.[2,6]

DISEASE ASSOCIATIONS

Up to 70% of reported PG cases are associated with a known underlying systemic disease, such as inflammatory bowel disease (IBD), monoclonal gammopathy, hematologic disease, inflammatory arthritis, malignancy, hidradenitis suppurativa, and others, even though PG may precede these disorders. PG also has been associated with genetic mutations, as part of a genetic syndrome such as the pyogenic arthritis, PG, and acne (PAPA) syndrome, or without an identifiable underlying disorder.[7]

Nearly one-third of PG cases are associated with IBD, with similar frequency of both Crohn disease and ulcerative colitis (UC), although most of the Crohn disease cases have colonic involvement.[3,8] Paraproteinemia (monoclonal gammopathy) is seen in 10% of PG cases,[9] most commonly immunoglobulin A monoclonal gammopathy.[10] Hematologic malignancy has been seen in up to 7% of PG cases, with the most common subtype reported being acute myeloid leukemia,

and most cases of leukemia being preceded by an hematologic abnormality such as myelodysplastic syndrome.[1,11] Myeloproliferative diseases, such as polycythemia vera,[12] essential thrombocythemia,[13] and myelofibrosis (agnogenic myeloid metaplasia),[14,15] as well as leukemoid reaction,[16] also have been associated with PG. There also have been fewer reports of PG associated with Hodgkin and non-Hodgkin lymphomas, cutaneous T-cell lymphoma, and solid neoplasms originating in the breast, ovaries, bladder, prostate, colon, carcinoid, and bronchus,[9,17] although the significance of these less-frequent associations is less certain.

There also are reports of medications inducing PG, including several cases of PG associated with granulocyte colony-stimulating factor (G-CSF), which resolved after G-CSF was discontinued.[18]

CLINICAL FEATURES

CUTANEOUS FINDINGS

PG can be classified morphologically as being (a) ulcerative, (b) bullous, (c) pustular, or (d) vegetative. Although some patients may show more than 1 variant (eg, isolated pustular lesions frequently occur in patients with ulcerative PG), usually 1 variant of PG dominates the clinical picture and the patient should be classified accordingly.

Ulcerative PG is the most common and originally described variant of PG. The most common initial clinical lesion in a patient with ulcerative PG is an intensely painful erythematous papule, pustule, or nodular furuncle (these lesions are usually single but may be multiple). They erupt on apparently normal-looking skin, with the most common site being the leg. The enlarging initial lesion develops a surrounding zone of erythema that extends into the surrounding skin. As it enlarges, the center degenerates, necroses, and erodes, converting it into an eroding ulcer (Fig. 37-1), the development of which is accompanied by an alarming increase in pain. The ulcer often has a bluish/violaceous undermined edge and the base is covered with purulent necrotic material. Ulcerative PG may erode deeply with exposure of muscle or tendon in some cases.[1,2] PG can also occur at the site of trauma or surgery (Fig. 37-2), which is known as the pathergic phenomenon, where trauma or irritation can induce exaggerated flaring of PG.[1,2]

Bullous PG (sometimes called *atypical PG*) presents as a painful, rapidly expanding superficial inflammatory blister that quickly erodes. In the early acute stage, the bullous nature of the lesion is evident, but because the roof of the blister necroses rapidly, close inspection of the border of established lesions is necessary to reveal its bullous nature (Fig. 37-3). Bullous PG is commonly associated with hematologic disease and most often appears on the upper limbs.[19] This variant of PG may show clinical and histologic

Figure 37-1 **A, B,** Established lesion of classic ulcerative pyoderma gangrenosum showing well-defined ulceration, undermining, and surrounding zone of erythema.

Figure 37-2 Pathergic pyoderma gangrenosum lesions occurring along a thoracotomy scar site. Note central ulceration, violaceous borders, and peripheral rim of erythema.

Figure 37-3 Bullous pyoderma gangrenosum lesion showing collapsed roof of blister and superficial erosive quality of the subsequent ulceration.

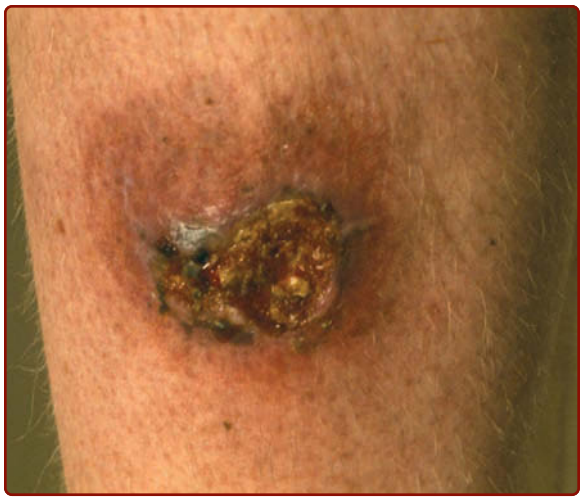

Figure 37-4 Vegetative pyoderma gangrenosum—an indolent area of chronic inflammation and ulceration that was present for months.

overlap with Sweet syndrome (one of the neutrophilic dermatoses which is itself often associated with hematologic disease).

Pustular PG (also called the *pustular eruption of IBD*) is a generalized eruption that occurs almost exclusively in the setting of an exacerbation of acute IBD (usually UC). Its onset is dramatic, with the rapid development of multiple, large, circular-to-oval, painful pustules on the trunk and, to a lesser extent, the face and limbs. Control of this eruption is difficult without controlling the bowel disease, which may require resection of diseased bowel in some cases.[1,2]

Vegetative PG (or *superficial granulomatous pyoderma*) usually presents as a single furunculoid nodule, abscess, plaque, or superficial ulcer, typically on the trunk (Fig. 37-4). In contrast to the other variants, this uncommon variant is gradual in its onset, mild in the discomfort it generates, and not usually associated with the presence of systemic disease. This form of PG is usually more responsive to localized or mild forms of systemic therapy than the other variants.[20]

Postoperative and *parastomal* PG are considered to be examples of ulcerative PG demonstrating the pathergic phenomenon.[1,2]

NONCUTANEOUS FINDINGS

As the majority of PG cases are associated with, or precede, a concurrent underlying systemic disease, a thorough history and physical examination is mandatory with a particular search for clinical and biologic markers of IBD, inflammatory arthritis, hematologic disease (monoclonal gammopathy and other dyscrasias), hematologic malignancy, and internal malignancy. Additionally, The clinician should be aware that sterile neutrophilic infiltration of internal organs (lung, bone joints, CNS, cardiovascular system, intraabdominal viscera, eye) can occur in association with or even precede the onset of cutaneous PG.[21]

COMPLICATIONS

Active or poorly controlled cutaneous PG causes significant morbidity, including severe pain, loss of mobility, anemia of chronic disease, and complications from therapeutic interventions. Many of the treatments for PG must be administered for many months and may have significant side effects. For example, corticosteroids can induce or worsen diabetes, cyclosporine can induce or worsen renal dysfunction, and immunotherapy can lead to immunocompromise, which increases risk for infection by both common and atypical microorganisms. Consequently, close monitoring and followup of patients is necessary.

Care must be taken to avoid trauma to the skin and elective surgery should be undertaken with caution because of the possibility of inducing new PG lesions through the pathergic phenomenon. Additionally, lack of recognition of the neutrophilic infiltration of internal organs in PG can lead to unnecessary surgical procedures.[1,22]

ETIOLOGY AND PATHOGENESIS

The etiology of PG is unknown, its pathogenesis is poorly understood, and the mechanisms of its pathophysiology likely differ depending on the associated underlying contributory disease. The factors predisposing to, inciting, and regulating these abnormalities are likely multifactorial, including genetic predisposition, paraimmune and/or paraneoplastic phenomena,[7] which may cause increased sensitivity to, or increased activity of, the immune response and inflammation.

Interestingly, PG occurs in association with a broad spectrum of diseases, and yet they all lead to or associate with the common phenotype of PG, lending to the hypothesis that these diseases somehow converge on inflammatory pathways leading to aberrant neutrophil activity and function.[23] Despite this similarity, there is variation in reports of the association between the disease activity of PG and that of the underlying disease state. In the setting of IBD, PG activity classically has been associated with the inflammatory process in the bowel. According to the systematic review of Agarwal et al,[8] which included 60 patients, of whom 35 (58%) had active IBD and only 9 (15%) had inactive IBD at PG diagnosis (16 (27%) with IBD activity unspecified). While some have reported no apparent association between exacerbations of bowel disease with worsening of the skin lesions,[24,25] there are multiple reports demonstrating healing of PG following therapy for the diseased bowel. Powell et al[12] reported a case series where PG lesions improved in all of 9 patients with UC following total proctocolectomy, and Talansky et al[26]

reported prompt PG skin healing within 2 months after resection of diseased bowel in 3 patients with severe ileocolitis, 1 with severe UC and 1 with moderate UC. Notably, there also has been a case of PG reported in a patient with UC 10 years after proctocolectomy,[9] which raises the question of whether there was any remaining diseased bowel.

Improvement of bullous PG has been reported after treatment and remission of acute myeloid leukemia,[27] which may be partially explained by the presence of a leukemic cell infiltrate consisting of atypical myeloblasts discovered within a PG skin sample from a patient with acute myeloid leukemia.[28] Complete recovery of PG has been reported after successful treatment of underlying hairy cell leukemia with cladribine.[29] Successful treatment of refractory PG associated with renal cell carcinoma has been reported with ustekinumab, but only after excision of the carcinoma.[30]

INFLAMMATORY MEDIATORS AND ABERRANT NEUTROPHIL ACTIVITY

T cells may be important in the development of PG through various mechanisms, including cytokine signaling and antigenic stimulus,[31] and are likely involved in some of the of the observed aberrant neutrophil activity. Marzano et al[32] looked at lesional skin biopsies from 21 patients with PG and found wound edge infiltrates of predominately CD3+ T cells and CD163+ macrophages, along with increased tumor necrosis factor-α (TNF-α), interleukin (IL)-8 (potent neutrophil chemotactic agent), IL-17 (proinflammatory cytokine; stimulates the expression of IL-8 and G-CSF), matrix metalloproteinase (MMP)-2/MMP-9 (collagenase mediating tissue damage) in the wound bed.

Based on the presence of a lymphocytic infiltrate at the active advancing border of PG lesions, it has been postulated that lymphocytic antigen activation occurs with cytokine release and neutrophil recruitment. This may take place not only in the skin but also in other tissues, such as the lung, intestine, and joints.[33] Neutrophils are thought to play a significant role in PG based on the prominent neutrophil-rich dermal infiltrate in PG pathology specimens, and PG response to antineutrophil medications like dapsone. Multiple studies have reported abnormalities in neutrophil chemotaxis, signaling, and trafficking in patients with PG.[4,34,35] These neutrophil abnormalities, and the predominance of neutrophils on histology, also give PG a place among the broader spectrum of neutrophilic dermatoses, which include Sweet syndrome (acute febrile neutrophilic dermatosis), Behçet disease, dermatitis herpetiformis, and neutrophilic eccrine hidradenitis. Besides dermal neutrophilia, other common features these conditions share include an associated underlying disorder, similarities in treatment, and a tendency for pathergy, in some more than others (PG, Sweets, Behçet, dermatitis herpetiformis).[7]

TNF-α plays an important role in production of proinflammatory cytokines, including IL-1, IL-6, IL-8, and interferon-γ, and has been shown to stimulate and enhance neutrophil degranulation and superoxide production.[36-38] TNF-α, IL-6, and soluble IL-2 receptor elevation has been reported in a patient with PG, with serum levels correlating with ulcer activity.[39] In addition to being increased in PG, IL-8 also has been shown to cause similar ulceration in human skin xenografts transfected with recombinant human IL-8.[40] Guenova et al[41] found elevated expression of IL-23 by polymerase chain reaction in a PG lesion compared with normal skin, which is significant because IL-23 plays an important role in driving inflammation associated with IL-17 production and neutrophil recruitment. Additionally, patients with the PAPA syndrome and some variants have been found to have increased production of IL-1β and IL-18.[42,43]

GENETICS

Uncovering genetic associations with PG is important as it can provide a better understanding of the pathophysiology of PG and help elucidate new targets for treatment. PG has been reported in association with systemic diseases, genetic mutations and syndromes, or in isolation. The systematic review of syndromes and genetic mutations associated with PG by DeFilippis et al[44] included 823 cases of PG, and revealed 31 (3.8%) cases of PAPA syndrome and its variants, 2 (0.2%) patients with mutations in Janus kinase (JAK) 2, 3 (0.4%) patients with mutations in methylenetetrahydrofolate reductase (MTHFR) who developed PG-like ulcerations, and 14 (1.7%) familial cases with no specific reported mutations, in addition to cases associated with IBD, polyarthritis, and hematologic disease.

The PAPA syndrome, which is an autosomal dominant disorder, has been linked to mutations in the proline-serine-threonine phosphatase interacting protein 1(*PSTPIP1*; also known as CD2 antigen-binding protein 1 [*CD2BP1*]) gene on chromosome 15q, encoding PSTPIP1, which binds to pyrin and regulates the inflammasome. Mutations in *PSTPIP1* lead to decreased inhibition of the inflammasome and increased production of IL-1β and IL-18, which can result in the inflammation seen with PAPA.[42,43]

Variations of the PAPA syndrome have been described in the literature, including PAPASH syndrome (pyogenic sterile arthritis, PG, cystic acne, and hidradenitis suppurativa), which results from an E277D missense mutation in the *PSTPIP1* gene,[45] PASH syndrome (PG, acne, and suppurative hidradenitis), which results from an increased CCTG microsatellite repeat in the promoter region of PSTPIP1,[46] as well as other variations.

JAKs are intracellular tyrosine kinases that are needed for cell differentiation, proliferation, and apoptosis. Mutations in JAKs can cause inflammatory and

myeloproliferative disorders, and also have been associated with cases of PG. Interestingly, the pathway is activated by G-CSF and TNF-α, as well as ILs and interferons.[44]

Some specific genetic loci linked to IBD susceptibility have been found to correlate with the development of PG.[47] Weizman et al[47] reviewed 5756 patients with IBD using genome-wide association data and described several genes associated with susceptibility to IBD that were significantly associated with PG, including *IL8RA* (a mediator of neutrophil migration), *MUC17*, *MMP24*, *WNK2*, *DOCK9*, *PRDM1*, and *NDIFIP1*,[22] in addition to other genetic loci associated with IBD and PG, such as *GPBAR1*, *TIMP3*, and *TRAF31P2*.[44]

HORMONAL INFLUENCES

There are reports of premenstrual flares associated with several dermatologic conditions such as hidradenitis suppurativa and acne vulgaris; the medical literature describes a positive role of estrogen and a negative role of androgens, or androgen receptor activation, in cutaneous wound healing. Jourabchi et al[48] reported a case of PG with premenstrual flares that was controlled with use of a combined oral contraceptive and antiandrogen (ethinyl estradiol/drospirenone).[48] Interestingly, hidradenitis suppurativa and acne are known to occur with PG in some patients, suggesting a related pathophysiologic mechanism. Additionally, PG, hidradenitis suppurativa, and acne have some other overlapping features, including elevated IL-17 and TNF-α in lesional skin, and positive response to TNF-α inhibitors.[22,49,50]

DIAGNOSIS

PG is currently diagnosed clinically and, very importantly, after excluding other potential causes for the skin manifestations (especially infectious causes such as atypical mycobacteria and deep fungal infections) as no specific serologic, histologic, or genetic markers have yet been found.

DIAGNOSTIC ALGORITHM

Because there are no specific diagnostic tests for PG, the following criteria are proposed to help make the diagnosis of PG, which requires the fulfillment of both major criteria and at least 2 minor criteria:[1,3,7,22]

1. Major criteria:
   a. Sudden onset of a painful lesion with the characteristic morphology described in "Cutaneous Findings" section in a patient who does not have fever, significant toxemia, or relevant drug intake.
   b. Histopathologic exclusion of significant vasculitis, malignancy, and infective organisms by special histologic studies/stains and negative tissue cultures, as well as exclusion of significant vascular stasis/occlusion by appropriate studies.
2. Minor criteria that are supportive of the diagnosis are as follows:
   a. Occurrence in an individual with systemic disease, as described in "Disease Associations" section.
   b. Classic histologic PG findings. (Note: In patients who have received systemic corticosteroids, the presence of neutrophils may be blunted and mononuclear cells may instead predominate.)
   c. Rapid reduction of pain and inflammation on initiation of high-dose systemic corticosteroid therapy and rapid ulcer healing response to high-dose systemic corticosteroid therapy with a 50% decrease in ulcer size within 1 month.
   d. History suggestive of pathergy or a clinical finding of cribriform scarring.

Providers must be aware that many patients may present months or years after initial development of skin manifestations, while taking or having tried various medications, including systemic corticosteroids or other immunosuppressants, and consequently may not present with the classic clinical findings or diagnostic criteria. Consequently, obtaining a detailed history is crucial to making the appropriate diagnosis.

SUPPORTIVE STUDIES

HISTOPATHOLOGIC STUDIES AND INFECTIOUS STAINS AND CULTURES

The histopathologic changes in the skin are not diagnostic but can be highly suggestive of PG. Pathologic changes must be considered in view of the total clinical picture. The microscopic changes that are seen depend on (a) the clinical variant of PG (ulcerative, bullous, pustular, or vegetative), (b) the timing of the biopsy, and (c) the site of the biopsy relative to the inflammatory process.

An incisional wedge skin biopsy should be taken from the edge of the PG lesion, taking care to sample a portion of normal skin progressing through the border into the area of active inflammation, to allow the various histologic patterns to be discerned. The excised tissue should then be divided with one section (fresh tissue) sent for bacterial culture, mycobacterial culture with smear, and fungal culture with microscopy, and the other portion sent in formalin for histologic evaluation requesting hematoxylin and eosin preparation with periodic acid–Schiff, Giemsa, Fite, Gram, and other stains considered relevant. If an incisional biopsy is not possible, two 4-mm punch biopsies may be performed instead. Immunofluorescence studies may show positive perivascular staining in lesional skin, which may be secondary to profound inflammation; it is not required for diagnostic purposes and can be omitted unless vasculitis is suspected in the differential diagnosis. Because PG can be complicated by secondary infection with the organisms mentioned above,

nonhealing PG or recurring PG should be rebiopsied to exclude superimposed infection.

The location of the biopsy within the lesion is particularly important as biopsies taken from the center of established lesions may have different findings from biopsies taken from peripheral skin. A marked perivascular lymphocytic infiltration may be seen in biopsies taken from the "zone" or area of erythema that surrounds active lesions of ulcerative PG. Lymphocytes may be seen to infiltrate vessel walls with intramural and intravascular fibrin deposition indicative of vascular damage (sometimes called *lymphocytic vasculitis*). Abscess formation with intense dermal neutrophilic infiltration may extend to the panniculus and areas of tissue necrosis, dominating the histologic findings in biopsies taken from central areas of ulcerative PG lesions. Leukocytoclasis is not a prominent finding and although occasionally evidence of leukocytoclastic vasculitis is seen close to the necrotic center, this is a minor feature and considered secondary to the intense inflammatory changes rather than the primary event. Histologic examination of lesional skin from a patient with bullous PG will show a subepidermal or intraepidermal bulla with overlying epidermal necrosis and marked upper dermal edema with prominence of neutrophils. Biopsy of pustular PG will show a dense dermal neutrophilic infiltration (often centered about a follicle) with subepidermal edema and infiltration of neutrophils into the epidermis with subcorneal aggregations. Vegetative PG is characterized histologically by the presence of pseudoepitheliomatous hyperplasia, sinus tract formation, and the presence of palisading granulomas in the setting of focal dermal neutrophilic abscesses.[3,7,38]

LABORATORY TESTING

All patients with PG should have these tests performed: full blood cell count with differential white cell count; complete metabolic panel; erythrocyte sedimentation rate; autoantibody screen (including antinuclear antibodies, anti-Ro/La antibodies); rheumatoid factor; antiphospholipid antibody screen; antineutrophilic cytoplasmic antibodies; serum protein electrophoresis and immunofixation studies; and chest radiography.

VASCULAR STUDIES

All patients with leg ulcers should have venous reflux studies performed to rule out significant venous insufficiency and deep venous thrombosis, in addition to ankle/toe brachial index studies to rule out ischemia as an underlying cause for the ulceration.

OTHER INVESTIGATIONS

In most patients, the following additional tests may are warranted: endoscopy (upper and/or lower gastrointestinal) to rule out often-associated IBD; careful examination of peripheral blood morphology when indicated, and if any abnormality is found, bone marrow aspirate examination should be performed; ultrasound of abdomen (including liver/spleen/aorta); and computed tomography for visualization of the thorax, abdomen, and pelvis. Figure 37-5 outlines other directed investigations.

DIFFERENTIAL DIAGNOSIS

The differential diagnosis to be considered in a patient with PG is extensive.[51] Different variants of PG (ulcerative, bullous, vegetative, pustular) suggest alternative diagnoses, and the occurrence of PG at certain cutaneous sites raises further diagnostic issues for the clinician, as shown in Table 37-1.

CLINICAL COURSE AND PROGNOSIS

The prognosis depends on the PG variant; the age and sex of the patient; presence of underlying systemic disease and other comorbid conditions; and the type, dosage, and duration of therapy required to bring the disease under control. Classic ulcerative PG is a chronic recurrent disease with a significant morbidity and mortality. Patients with this variant who are older than 65 years of age and male patients seem to have a worse prognosis. Patients with vegetative PG generally have a good prognosis, and compared to classic PG, vegetative PG lesions are more likely to heal without the use of oral corticosteroids.[20] Parastomal PG has a good prognosis, often responding to topical or intralesional steroid therapy. Patients with pustular PG often have complete remission of their cutaneous lesions if the severe IBD that usually accompanies this variant is controlled. Patients with bullous PG who have an associated hematologic disorder have a poor prognosis. The onset of bullous PG in a patient with stable polycythemia rubra vera has been reported to herald the onset of leukemic change.[30,38,52]

MANAGEMENT

APPROACH TO MANAGEMENT

Understanding the context in which PG is occurring is crucial in deciding on proper treatment approach. The unpredictable nature of PG and its variable aggressiveness in individual patients necessitate a flexible approach to treatment. Therapeutic agents must be adapted to the patient's physiologic state (pregnancy, old age, renal disease, diabetes, immunosuppressed status, etc) and also with their underlying associated disease state. Although the course of the underlying disease does not always correlate with PG flares, its treatment can result in improvement of PG. Systemic

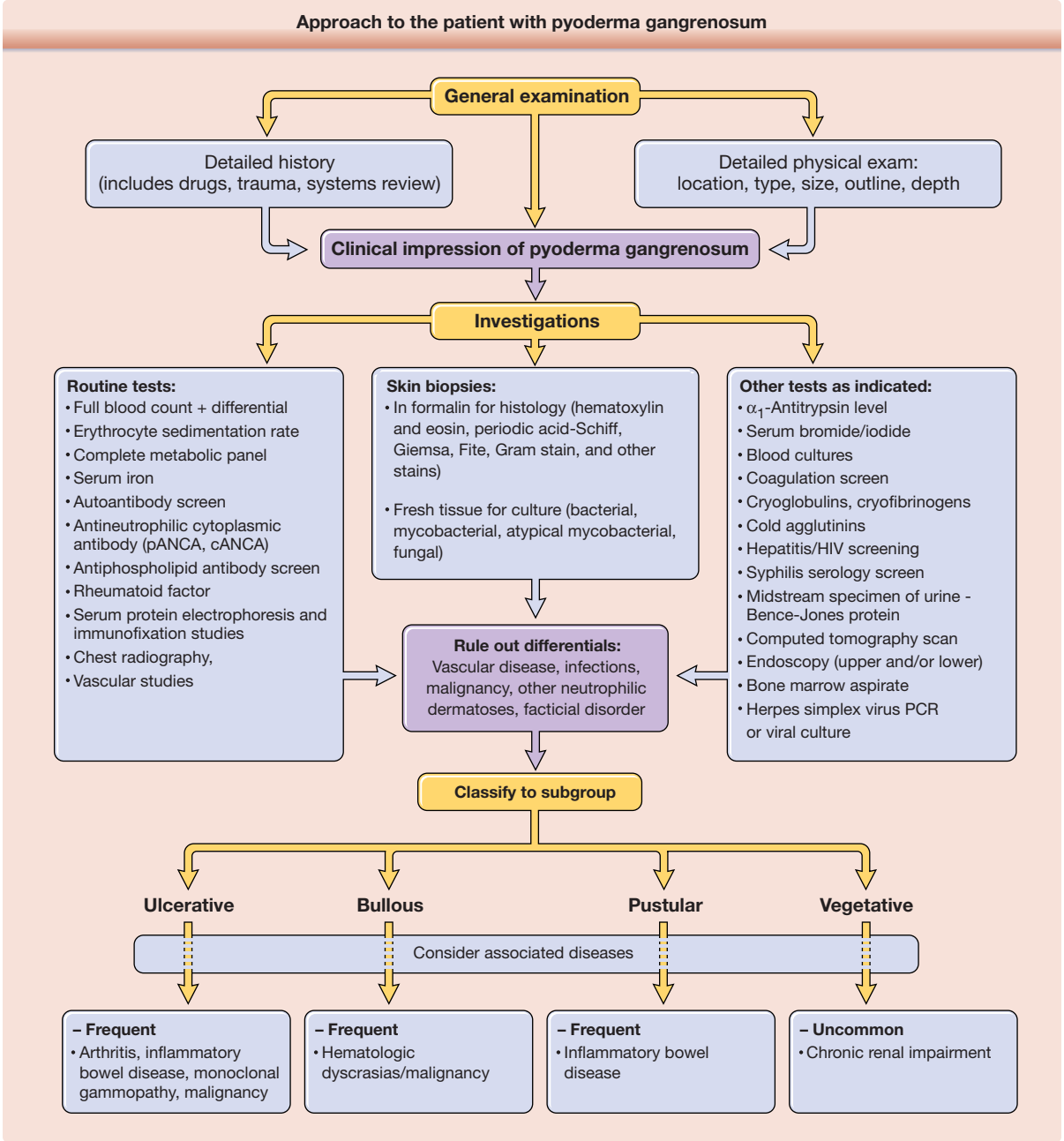

Figure 37-5 Approach to the patient with pyoderma gangrenosum. cANCA, cytoplasmic antineutrophil cytoplasmic antibody; pANCA, perinuclear antineutrophil cytoplasmic antibody; PCR, polymerase chain reaction.

steroids and/or cyclosporine may be effective in controlling PG regardless of the underlying disease state, but PG often requires combination therapy and multiple medication trials to achieve healing, and in these cases the underlying disease state should be used to help guide medication selection and treatment approach.

Adequate rest, efficient pain relief, and appropriate therapy for any comorbidities (venous stasis disease, diabetes, congestive heart failure with fluid overload, etc) that affect healing are also pivotal in the overall management strategy of a patient with PG. If other systemic illnesses are present, close collaboration with an internal medicine specialist and pertinent subspecialty physicians is needed.

MEDICATIONS

Definitive treatment guidelines for PG do not exist, partly because PG associated with different underlying diseases seems to behave differently, and also because there is a paucity of data in the literature. Approach to treatment is based on directed therapeutic immunomodulation to decrease inflammation and promote healing. Choice of treatment depends on the severity of the PG, and when possible should also attempt to

TABLE 37-1
Differential Diagnosis of Pyoderma Gangrenosum

VARIANT SPECIFIC

Ulcerative pyoderma gangrenosum (PG)

Most Likely

- Vascular
  - Venous stasis ulceration
  - Vasculopathy
  - Arterial occlusive disease
  - Vasculitis
  - Antiphospholipid–antibody syndrome
- Infection
  - Bacterial (ecthyma gangrenosum)
  - Mycobacterial/atypical mycobacterial (eg, *Mycobacterium chelonae, Mycobacterium marinum*)
  - Deep fungal infection (eg, North American blastomycosis, sporotrichosis, *Aspergillus*, *Cryptococcus*)

Consider

- Infection
  - Tertiary syphilitic ulcer
  - Amebiasis
  - Viral (herpes simplex)
- Drugs (eg, hydroxyurea, halogenoderma)
- Other
  - Dermatitis artefacta
  - Calciphylaxis
  - Necrotizing insect bite (eg, brown recluse spider)
  - Malignant rheumatoid disease (with high-titer rheumatoid factor and depressed complement levels)
  - Cutaneous involvement of malignancy process (eg, lymphoma, leukemia cutis)

Bullous PG

Most Likely

- Infection
  - Bacterial (cellulitis/impetigo)
  - Viral (especially in immunocompromised)
  - Fungal (eg, mucormycosis in persons with diabetes)
- Other
  - Sweet syndrome/Behçet disease

Consider

- Bullous dermatoses
  - Erythema multiforme
- Other
  - Insect/arthropod bite

Pustular PG

Most Likely

- Infection
  - Bacterial/viral/fungal
- Vasculitis
  - Pustular vasculitis

Consider

- Other
  - Pustular psoriasis
  - Sneddon-Wilkinson disease
  - Pustular drug eruption
  - Bowel bypass syndrome

SITE SPECIFIC[a]

Parastomal

Most Likely

- Dermatoses
  - Irritant/allergic contact dermatitis
  - Other (eg, psoriasis, eczema)
- Infection
  - Bacterial (*Staphylococcus*/*Streptococcus*)/cellulitis
  - Fungal (*Candida*)
- Other
  - Extraintestinal inflammatory
  - Bowel disease
  - Malignancy

Postsurgical Wounds

Most Likely

- Infection
  - Bacterial/cellulitis
  - Mycobacterial/atypical mycobacterial
  - Fungal (eg, mucormycosis)
- Breakdown
  - Suture allergy
  - Mechanical

Consider

- Necrotizing fasciitis
- Malignancy

Perineum

Most Likely

- Infection
  - Bacterial/viral infection (herpes simplex virus, Epstein-Barr virus, cytomegalovirus)
  - Fournier gangrene
- Other
  - Hidradenitis suppurativa
  - Extraintestinal Crohn disease
  - Squamous cell/extramammary Paget disease

Consider

- Infection
  - Syphilis
  - Lymphogranuloma venereum/granuloma inguinale
  - Leishmaniasis
- Other
  - Dermatitis artefacta
  - Behçet disease

Vegetative PG

Most Likely

- Infection
  - Bacterial/viral/fungal
  - Mycobacterial/atypical mycobacterial
  - Leishmaniasis

Consider

- Blastomycosis-like pyoderma
- Dermatitis artefacta/malignancy
- Pyoderma vegetans
- Other
  - Dermatitis artefacta

[a]The differential diagnosis of lower-limb PG is essentially that delineated for variant-specific ulcerative PG.

treat the patient's underlying condition (eg, infliximab for patients with IBD and methotrexate for patients with rheumatoid arthritis).

Mild PG with small shallow ulcers or a plaque of vegetative PG may respond to topical class I corticosteroids (clobetasol propionate 0.05%), intralesional corticosteroids, or a calcineurin inhibitor such as tacrolimus 0.1%, with twice-a-day application.

First-line therapy for more severe or extensive PG is systemic glucocorticoids. We typically begin treatment at 1 to 2 mg/kg of oral prednisone daily, with a maximum dose of 150 mg/day. For very aggressive disease, intravenous pulse methylprednisone 1 g/day for 3 to 5 days can be helpful as initial therapy, followed by daily oral glucocorticoids.[1,53,54] Response to systemic glucocorticoids is typically rapid, typically halting progression within 1 to 2 weeks. Because long-term therapy is associated with significant adverse effects, slow glucocorticoid taper should begin once progression of PG has stopped. Simultaneously beginning a steroid-sparing adjunctive agent (eg, cyclosporine, dapsone, infliximab) can help prevent flares while tapering.[1]

Oral cyclosporine is an alternative first-line treatment for patients who cannot tolerate systemic glucocorticoids and is also used as adjunctive therapy. A multicenter, parallel group, observer blind, randomized, controlled trial comparing oral prednisolone 0.75 mg/kg/day with cyclosporine 4 mg/kg/day for PG found comparable effectiveness between the 2 groups.[55] Adverse effects include renal toxicity and hypertension, which must be monitored, and recommended time course for treatment is less than 1 year.[55,56]

Systemic glucocorticoids and cyclosporine are rapid acting, which makes them ideal for initial therapy, whereas some of the other therapies can take weeks for therapeutic effect and are better suited as adjunctive or maintenance therapy, especially for severe cases. It is not uncommon for severe cases of PG to require combination therapy to control the condition while minimizing side effects from therapy. Table 37-2 outlines additional therapies. Note that most of these medications require specific baseline laboratory test results, close monitoring for adverse effects, care to prevent drug interactions, and caution for immunosuppression.

Maintenance therapy should be continued until there is complete wound healing and then slowly tapered off. In addition, patients with ulcerative PG have a significant risk of relapse, so long-term followup is required, and some patients require long-term maintenance therapy.

UNRESPONSIVE PYODERMA GANGRENOSUM AND TREATMENT CONSIDERATIONS

When PG is not responding to treatment, or if healing stalls, the provider must reassess the case:

1. Is there an uncontrolled comorbidity (eg, venous stasis, vascular ischemia, diabetes) that is inhibiting wound healing and needs to be addressed?
2. Is there a new superimposed infection that needs workup and treatment? And if so, should another biopsy be performed for pan-culture?
3. Is there a better, more directed medication that should be tried?

In patients with refractory or difficult-to-treat PG, genetic analysis can be considered and may help identify better directed therapy. DeFilippis et al[44] reviewed the published literature regarding syndromes and genetic mutations associated with PG, and found that PG responded to different treatments depending on the underlying disease process. For example, cases with the PAPA syndrome and variants with increased IL-1β improved with the anti–IL-1β monoclonal antibody canakinumab, the IL-1 receptor antagonist anakinra, and TNF-α inhibitors, whereas a case of polycythemia vera with JAK2 mutation responded to the JAK1/JAK2 inhibitor ruxolitinib, and PG-like cases with MTHFR mutations (whose pathway relies on vitamins B_6, B_9, and B_{12}) improved with B-vitamin therapy.[44]

WOUND CARE

The location, morphology, size, and depth of each lesion should be recorded (with photography) on presentation and subsequent review to help monitor course. The cutaneous lesions of PG are usually extremely tender so cleansing should be carried out daily with tepid sterile saline or a mild antiseptic solution. Silver sulfadiazine 1% cream is usually soothing when applied to the ulcerated lesions of PG and may facilitate granulation tissue formation while also inhibiting bacterial growth. A nonadhesive dressing should be applied over the lesion and held in place with a crêpe elasticized bandage wrapped firmly, but not tightly, over it. Some patients, particularly those with superficial lesions, obtain significant relief with the use of hydrocolloid dressings, which can be left on for 2 to 3 days and "melt" into the lesion. Careful instruction to the patient and nurse is important to ensure compliance and to avoid the use of irritants such as chemical desloughing agents, caustics (such as silver nitrate), or dressings such as gauze impregnated with soft paraffin and/or antibacterial agents that may adhere to the ulcer base. A variety of bacteria may be cultured from the wound surface, but these usually represent contaminants and directed antibiotic therapy is not required unless there are clinical signs of incipient cellulitis around the wound.

PROCEDURES

Debridement must not be performed aggressively and skin grafting should be avoided if possible because of pathergy and the risk of inducing new PG lesions at the donor sites. Cultured tissue allografts/autografts and the use of bovine collagen matrix have been reported to be useful in patients in whom the disease is controlled but re-epithelialization incomplete.[67]

TABLE 37-2
Treatment Options for Pyoderma Gangrenosum

MEDICATION	ADULT DOSING	LIKELY MECHANISM
Very Severe Disease		
Methylprednisolone pulse (initial treatment)	1 g/day IV for 3-5 days[a]	Blocks promoter sites of proinflammatory genes, such as IL-1α and IL-1β; inhibits synthesis of almost all known cytokines; impairs neutrophil migration; reduces circulating T cells[52,57]
Severe Disease		
Prednisone (first line)	1 mg/kg/day PO	Blocks promoter sites of proinflammatory genes, such as IL-1α and IL-1β; inhibits synthesis of almost all known cytokines; impairs neutrophil migration; reduces circulating T cells[52,57]
Cyclosporine (first line)	3-5 mg/kg/day PO	Calcineurin inhibitor on T cells, causing reduced transcriptional activation of genes for IL-2, TNF-α, IL-3, IL-4, CD40L, G-CSF, and interferon-γ[52,58,59]
Adjunctive Therapy		
Minocycline	100 mg twice daily PO	Suppresses neutrophil migration/chemotaxis, matrix metalloproteinases, and cytokine release (TNF-α, IL-6, IL-1β), and inhibits T-cell activation and proliferation[52,60]
Dapsone	50-200 mg/day PO	Inhibits neutrophil myeloperoxidase; suppresses IL-8 and TNF-α[52,61]
Mycophenolate mofetil	500 mg to 1.5 g twice daily PO	Inhibits inosine monophosphate dehydrogenase and de novo protein synthesis, thereby inhibiting T-cell and B-cell proliferation; also suppresses leukocyte recruitment[52,62]
Azathioprine	Max of 2.0-2.5 mg/kg/day PO	Synthetic purine analog derived from 6-mercaptopurine disrupts nucleic acid synthesis and interferes with T-cell activation and function[52,63]
Methotrexate	Initial test dose of 5 mg PO, gradually increasing weekly by 2.5-5.0 mg as needed, up to max dose of 30 mg/week	Folate antimetabolite that targets T cells, inhibiting dihydrofolate reductase and thymidylate synthetase, decreasing T-cell proliferation and migration, in addition to inducing adenosine release, which suppresses neutrophil oxidative activity, chemotaxis, and suppresses production of TNF-α, IL-6, IL-8, IL-12[52,64]
Biologics[b]	Infliximab: 5 mg/kg IV at weeks 0, 2, 6, followed by infusions every 6-8 weeks Etanercept: 50 mg twice weekly for 3 months, followed by 50 mg weekly Adalimumab: load with 80 mg SC, followed by 40 mg SC every 1-2 weeks Ustekinumab: weight ≤100 kg: 45 mg at 0 and 4 weeks, and then every 12 weeks weight >100 kg: 90 mg at 0 and 4 weeks, and then every 12 weeks	Infliximab: monoclonal Ab against TNF-α; binds soluble and membrane bound TNF-α and blocks its interaction with cell-surface receptors[22,52,65] Etanercept: fusion protein; binds soluble TNF-α and blocks its interaction with cell-surface receptors[22,52,65] Adalimumab: monoclonal Ab against TNF-α; binds soluble and membrane bound TNF-α and blocks its interaction with cell-surface receptors[22,52,65] Ustekinumab: IgG_1 monoclonal antibody; binds to the p40 subunit of both IL-12 and IL-23, blocking its interaction with cell-surface receptors, interfering with T-cell activation, and expression of TNF-α, IL-8, and other cytokines[52,65]
Thalidomide[c]	50-300 mg/day	Inhibits TNF-α, chemotaxis of monocytes and leucocytes, and inhibits phagocytosis by neutrophils[44,52,65]
Severe, Refractory PG, or Those With Significant Contraindications to Other Treatment Options		
Intravenous immune globulin	2 g/kg/cycle per month IV divided over 3 consecutive days	Suppression or neutralization of cytokines; blockade of leukocyte adhesion molecules; alterations in regulatory T cells and inhibition of the proinflammatory Th17 pathway[52,65,66]

[a]Followed by daily oral prednisone.
[b]Consider for severe PG in IBD (except etanercept, which is not helpful for IBD), rheumatoid arthritis, or hidradenitis suppurativa.
[c]Consider for severe PG in myelodysplastic syndrome.
Ab, antibody; G-CSF, granulocyte colony-stimulating factor; Ig, immunoglobulin; IL, interleukin; PO, per os (by mouth); SC, subcutaneously; Th, T-helper cell; TNF, tumor necrosis factor.

COUNSELING

The patient should be given realistic expectations of the speed of recovery likely in this disease. Thus, although lesions develop and evolve within days, the healing process can take weeks to months.

PREVENTION/SCREENING

A patient who has had a history of PG should be advised to avoid trauma to the skin as there is the possibility of precipitating a new lesion through

the pathergic phenomenon. If such patients have to undergo surgery, they should have close supervision by a dermatologist of their postoperative course. Patients with a history of aggressive PG may warrant a course of systemic steroids during and for a period (2 weeks or longer) postoperatively to prevent the development of new PG lesions, and subcuticular sutures should be used where possible. Patients with a history of PG and Crohn disease who are to have an ileostomy should be warned about the possible development of parastomal PG lesions, and to try to avoid irritation to the area to help prevent pathergy.

ACKNOWLEDGMENTS

We give special thanks to the authors of the prior version of this chapter, Frank C. Powell, Bridget C. Hackett, and Daniel Wallach.

REFERENCES

1. Ahronowitz I, Harp J, Shinkai K. Etiology and management of pyoderma gangrenosum: a comprehensive review. *Am J Clin Dermatol.* 2012;13:191-211.
2. Ruocco E, Sangiuliano S, Gravina AG, et al. Pyoderma gangrenosum: an updated review. *J Eur Acad Dermatol Venereol.* 2009;23:1008-1017.
3. Powell FC, Su WP, Perry HO. Pyoderma gangrenosum: classification and management. *J Am Acad Dermatol.* 1996;34:395-409.
4. Adachi Y, Kindzelskii AL, Cookingham G, et al. Aberrant neutrophil trafficking and metabolic oscillations in severe pyoderma gangrenosum. *J Invest Dermatol.* 1998;111:259-268.
5. Hickman JG, Lazarus GS. Pyoderma gangrenosum: a reappraisal of associated systemic diseases. *Br J Dermatol.* 1980;102:235-237.
6. Korber A, Klode J, Al-Benna S, et al. Etiology of chronic leg ulcers in 31,619 patients in Germany analyzed by an expert survey. *J Dtsch Dermatol Ges.* 2011;9:116-121.
7. Su WP, Davis MD, Weenig RH, et al. Pyoderma gangrenosum: clinicopathologic correlation and proposed diagnostic criteria. *Int J Dermatol.* 2004;43:790-800.
8. Agarwal A, Andrews JM. Systematic review: IBD-associated pyoderma gangrenosum in the biologic era, the response to therapy. *Aliment Pharmacol Ther.* 2013;38:563-572.
9. Cox NH, Peebles-Brown DA, MacKie RM. Pyoderma gangrenosum occurring 10 years after proctocolectomy for ulcerative colitis. *Br J Hosp Med.* 1986;36:363.
10. Powell FC, Schroeter AL, Su WP, et al. Pyoderma gangrenosum and monoclonal gammopathy. *Arch Dermatol.* 1983;119:468-472.
11. Duguid CM, O'Loughlin S, Otridge B, et al. Paraneoplastic pyoderma gangrenosum. *Australas J Dermatol.* 1993;34:17-22.
12. Powell FC, Schroeter AL, Su WP, et al. Pyoderma gangrenosum: a review of 86 patients. *Q J Med.* 1985;55:173-186.
13. Stanojevic N, Mai C. It starts with a dog scratch. *J Hosp Med.* 2010;5:494-495.
14. Callen JP, Dubin HV, Gehrke CF. Recurrent pyoderma gangrenosum and agnogenic myeloid metaplasia. *Arch Dermatol.* 1977;113:1585-1586.
15. Caughman W, Stern R, Haynes H. Neutrophilic dermatosis of myeloproliferative disorders. Atypical forms of pyoderma gangrenosum and Sweet's syndrome associated with myeloproliferative disorders. *J Am Acad Dermatol.* 1983;9:751-758.
16. Ryu J, Naik H, Yang FC, et al. Pyoderma gangrenosum presenting with leukemoid reaction: a report of 2 cases. *Arch Dermatol.* 2010;146:568-569.
17. Shahi V, Wetter DA. Pyoderma gangrenosum associated with solid organ malignancies. *Int J Dermatol.* 2015;54:e351-e357.
18. Ross HJ, Moy LA, Kaplan R, et al. Bullous pyoderma gangrenosum after granulocyte colony-stimulating factor treatment. *Cancer.* 1991;68:441-443.
19. Bennett ML, Jackson JM, Jorizzo JL, et al. Pyoderma gangrenosum. A comparison of typical and atypical forms with an emphasis on time to remission. Case review of 86 patients from 2 institutions. *Medicine (Baltimore).* 2000;79:37-46.
20. Kim RH, Lewin J, Hale CS, et al. Vegetative pyoderma gangrenosum. *Dermatol Online J.* 2014;20.
21. Field S, Powell FC, Young V, et al. Pyoderma gangrenosum manifesting as a cavitating lung lesion. *Clin Exp Dermatol.* 2008;33:418-421.
22. Braswell SF, Kostopoulos TC, Ortega-Loayza AG. Pathophysiology of pyoderma gangrenosum (PG): an updated review. *J Am Acad Dermatol.* 2015;73:691-698.
23. Butler D, Shinkai K. What do autoinflammatory syndromes teach about common cutaneous diseases such as pyoderma gangrenosum? A commentary. *Dermatol Clin.* 2013;31:427-435.
24. Vidal D, Puig L, Gilaberte M, et al. Review of 26 cases of classical pyoderma gangrenosum: clinical and therapeutic features. *J Dermatolog Treat.* 2004;15:146-152.
25. Menachem Y, Gotsman I. Clinical manifestations of pyoderma gangrenosum associated with inflammatory bowel disease. *Isr Med Assoc J.* 2004;6:88-90.
26. Talansky AL, Meyers S, Greenstein AJ, et al. Does intestinal resection heal the pyoderma gangrenosum of inflammatory bowel disease? *J Clin Gastroenterol.* 1983;5:207-210.
27. Fox LP, Geyer AS, Husain S, et al. Bullous pyoderma gangrenosum as the presenting sign of fatal acute myelogenous leukemia. *Leuk Lymphoma.* 2006;47:147-150.
28. Rafael MR, Fernandes CM, Machado JM, et al. Pyoderma gangrenosum or leukaemia cutis? *J Eur Acad Dermatol Venereol.* 2003;17:449-451.
29. Tombak A, Aygun S, Serinsoz E, et al. Complete recovery of pyoderma gangrenosum after successful treatment of underlying hairy cell leukemia with cladribine. *Korean J Intern Med.* 2015;30:739-741.
30. Cosgarea I, Lovric Z, Korber A, et al. Successful treatment of refractory pyoderma gangrenosum with ustekinumab only after excision of renal cell carcinoma. *Int Wound J.* 2016;13(5):1041-1042.
31. Brooklyn TN, Williams AM, Dunnill MG, et al. T-cell receptor repertoire in pyoderma gangrenosum: evidence for clonal expansions and trafficking. *Br J Dermatol.* 2007;157:960-966.
32. Marzano AV, Cugno M, Trevisan V, et al. Role of inflammatory cells, cytokines and matrix metalloproteinases in neutrophil-mediated skin diseases. *Clin Exp Immunol.* 2010;162:100-107.

33. Wallach D, Vignon-Pennamen MD. From acute febrile neutrophilic dermatosis to neutrophilic disease: forty years of clinical research. *J Am Acad Dermatol.* 2006;55:1066-1071.
34. Nerella P, Daniela A, Guido M, et al. Leukocyte chemotaxis and pyoderma gangrenosum. *Int J Dermatol.* 1985;24:45-47.
35. Shore RN. Pyoderma gangrenosum, defective neutrophil chemotaxis, and leukemia. *Arch Dermatol.* 1976;112:1792-1793.
36. Berkow RL, Wang D, Larrick JW, et al. Enhancement of neutrophil superoxide production by preincubation with recombinant human tumor necrosis factor. *J Immunol.* 1987;139:3783-3791.
37. Klebanoff SJ, Vadas MA, Harlan JM, et al. Stimulation of neutrophils by tumor necrosis factor. *J Immunol.* 1986;136:4220-4225.
38. Stewart RJ, Marsden PA. Biologic control of the tumor necrosis factor and interleukin-1 signaling cascade. *Am J Kidney Dis.* 1995;25:954-966.
39. Montoto S, Bosch F, Estrach T, et al. Pyoderma gangrenosum triggered by alpha2b-interferon in a patient with chronic granulocytic leukemia. *Leuk Lymphoma.* 1998;30:199-202.
40. Oka M, Berking C, Nesbit M, et al. Interleukin-8 overexpression is present in pyoderma gangrenosum ulcers and leads to ulcer formation in human skin xenografts. *Lab Invest.* 2000;80:595-604.
41. Guenova E, Teske A, Fehrenbacher B, et al. Interleukin 23 expression in pyoderma gangrenosum and targeted therapy with ustekinumab. *Arch Dermatol.* 2011;147:1203-1205.
42. Wise CA, Gillum JD, Seidman CE, et al. Mutations in CD2BP1 disrupt binding to PTP PEST and are responsible for PAPA syndrome, an autoinflammatory disorder. *Hum Mol Genet.* 2002;11:961-969.
43. Farasat S, Aksentijevich I, Toro JR. Autoinflammatory diseases: clinical and genetic advances. *Arch Dermatol.* 2008;144:392-402.
44. DeFilippis EM, Feldman SR, Huang WW. The genetics of pyoderma gangrenosum and implications for treatment: a systematic review. *Br J Dermatol.* 2015;172:1487-1497.
45. Marzano AV, Trevisan V, Gattorno M, et al. Pyogenic arthritis, pyoderma gangrenosum, acne, and hidradenitis suppurativa (PAPASH): a new autoinflammatory syndrome associated with a novel mutation of the PSTPIP1 gene. *JAMA Dermatol.* 2013;149:762-764.
46. Braun-Falco M, Kovnerystyy O, Lohse P, et al. Pyoderma gangrenosum, acne, and suppurative hidradenitis (PASH)—a new autoinflammatory syndrome distinct from PAPA syndrome. *J Am Acad Dermatol.* 2012; 66:409-415.
47. Weizman A, Huang B, Berel D, et al. Clinical, serologic, and genetic factors associated with pyoderma gangrenosum and erythema nodosum in inflammatory bowel disease patients. *Inflamm Bowel Dis.* 2014;20:525-533.
48. Jourabchi N, Rhee SM, Lazarus GS. Premenstrual flares of pyoderma gangrenosum controlled with use of a combined oral contraceptive and antiandrogen (ethinyl estradiol/drospirenone). *Br J Dermatol.* 2016;174:1096-1097.
49. Kelhala HL, Palatsi R, Fyhrquist N, et al. IL-17/Th17 pathway is activated in acne lesions. *PLoS One.* 2014; 9:e105238.
50. Schlapbach C, Hanni T, Yawalkar N, et al. Expression of the IL-23/Th17 pathway in lesions of hidradenitis suppurativa. *J Am Acad Dermatol.* 2011;65:790-798.
51. Weenig RH, Davis MD, Dahl PR, et al. Skin ulcers misdiagnosed as pyoderma gangrenosum. *N Engl J Med.* 2002;347:1412-1418.
52. Patel F, Fitzmaurice S, Duong C, et al. Effective strategies for the management of pyoderma gangrenosum: a comprehensive review. *Acta Derm Venereol.* 2015;95:525-531.
53. Prystowsky JH, Kahn SN, Lazarus GS. Present status of pyoderma gangrenosum. Review of 21 cases. *Arch Dermatol.* 1989;125:57-64.
54. Johnson RB, Lazarus GS. Pulse therapy. Therapeutic efficacy in the treatment of pyoderma gangrenosum. *Arch Dermatol.* 1982;118:76-84.
55. Ormerod AD, Thomas KS, Craig FE, et al. Comparison of the two most commonly used treatments for pyoderma gangrenosum: results of the STOP GAP randomised controlled trial. *BMJ.* 2015;350:h2958.
56. Matis WL, Ellis CN, Griffiths CE, et al. Treatment of pyoderma gangrenosum with cyclosporine. *Arch Dermatol.* 1992;128:1060-1064.
57. Oppong E, Cato AC. Effects of glucocorticoids in the immune system. *Adv Exp Med Biol.* 2015;872:217-233.
58. Kutlubay Z, Erdogan BC, Engin B, et al. Cyclosporine in dermatology. *Skinmed.* 2016;14:105-109.
59. Amor KT, Ryan C, Menter A. The use of cyclosporine in dermatology: part I. *J Am Acad Dermatol.* 2010;63:925-946; quiz 47-48.
60. Perret LJ, Tait CP. Non-antibiotic properties of tetracyclines and their clinical application in dermatology. *Australas J Dermatol.* 2014;55:111-118.
61. Wozel G, Blasum C. Dapsone in dermatology and beyond. *Arch Dermatol Res.* 2014;306:103-124.
62. Orvis AK, Wesson SK, Breza TS Jr, et al. Mycophenolate mofetil in dermatology. *J Am Acad Dermatol.* 2009;60:183-199; quiz 200-202.
63. Patel AA, Swerlick RA, McCall CO. Azathioprine in dermatology: the past, the present, and the future. *J Am Acad Dermatol.* 2006;55:369-389.
64. Chan ES, Cronstein BN. Molecular action of methotrexate in inflammatory diseases. *Arthritis Res.* 2002;4:266-273.
65. Fathi R, Armstrong AW. The role of biologic therapies in dermatology. *Med Clin North Am.* 2015;99:1183-1194.
66. Dourmishev LA, Guleva DV, Miteva LG. Intravenous Immunoglobulins: mode of action and indications in autoimmune and inflammatory dermatoses. *Int J Inflam.* 2016;2016:3523057.
67. de Imus G, Golomb C, Wilkel C, et al. Accelerated healing of pyoderma gangrenosum treated with bioengineered skin and concomitant immunosuppression. *J Am Acad Dermatol.* 2001;44:61-66.

Chapter 38 :: Subcorneal Pustular Dermatosis (Sneddon-Wilkinson Disease)

:: Franz Trautinger & Herbert Hönigsmann

AT-A-GLANCE

- A rare condition with worldwide occurrence.
- A chronic, recurrent, neutrophilic disorder with a benign course, frequently associated with various forms of immune dysfunction (most commonly immunoglobulin [Ig] A monoclonal gammopathy).
- Occurrence of intraepidermal deposits of IgA indicates a relationship with IgA pemphigus.
- Crops of flaccid, coalescing pustules; often in annular or serpiginous patterns.
- Usually distributed symmetrically in the axillae, groins, submammary, the flexor aspects of the limbs, and on the abdomen.
- Pathology: subcorneal pustules filled with polymorphonuclear leukocytes.

Subcorneal pustular dermatosis (SPD) is a rare, chronic, recurrent, pustular eruption characterized histopathologically by subcorneal pustules that contain abundant neutrophils. The condition was originally described in 1956 by Sneddon and Wilkinson,[1] who separated SPD from other previously unclassified pustular eruptions. Until 1966, when the first comprehensive review appeared, more than 130 cases had been reported, but not all fulfilled the clinical and histopathologic criteria required for this diagnosis.[2] A considerable number of additional cases have since appeared in the literature, and a subtype with intraepidermal deposits of immunoglobulin (Ig) A directed against desmocollin 1 has been recognized.[3] Today, these cases are usually classified as SPD-type IgA pemphigus, and it is a matter of debate whether the finding of epidermal IgA deposits defines a subset of SPD or a pemphigus variant that is otherwise indistinguishable from "classic" SPD.

EPIDEMIOLOGY

There is no racial predilection. Most of the reported cases have been in whites, but the disease also has been observed in Africans, Japanese, and Chinese. The condition is more common in women and in persons older than 40 years of age, but SPD may occur at any age.[2] A pustular eruption that is clinically and histologically similar to the human disease, which also responds to dapsone treatment, has been observed in dogs.[4]

ETIOLOGY AND PATHOGENESIS

The cause of SPD is unknown. Cultures of the pustules consistently do not reveal bacterial growth. The role of trigger mechanisms such as preceding or concomitant infections, although repeatedly discussed, has remained speculative. Immunologic mechanisms have been implicated in the pathogenesis and in a subset of patients, whose disease clinically resembled SPD, intraepidermal IgA deposits have been detected. Some of these patients also had circulating IgA antibodies against the same sites within the epidermis. Desmocollin 1 and in a single case also desmocollins 2 and 3 have been described as autoantigens in these cases, and the disease has been classified as a pemphigus variant (SPD-type IgA pemphigus; see Chap. 57).[3,5-7]

The occasional association of SPD with certain other diseases may represent more than a mere coincidence. Increased serum IgA has been detected in a number of patients, and the disease has been reported to occur in cases of IgA-paraproteinemia and IgA multiple myeloma.[8-12] In addition, SPD is associated with pyoderma gangrenosum,[13,14] ulcerative colitis,[15] and Crohn disease.[16] Whether or not the coexistence of these conditions reflects common pathogenetic mechanisms remain to be clarified, but an additional common denominator linking these disorders is their response to sulfone and sulfonamide therapy.

Further associations reported to date include IgG paraproteinemia,[17,18] CD30+ anaplastic large cell lymphoma,[19] marginal zone lymphoma,[20] non–small cell lung cancer,[21] apudoma,[22] rheumatoid arthritis,[23,24] systemic lupus erythematodes,[25] hyperthyroidism,[26] *Mycoplasma pneumoniae*,[27,28] and *Coccidioides immitis* infection.[29]

CLINICAL FINDINGS

The primary lesions are small, discrete, flaccid pustules, or vesicles that rapidly turn pustular and usually arise in crops within a few hours on clinically normal or slightly erythematous skin (Fig. 38-1). In dependent regions, pus characteristically accumulates in the lower half of the pustule (Fig. 38-1B); as the pustules usually have the tendency to coalesce, they often, but not always, form annular, circinate, or bizarre serpiginous patterns. After a few days, the pustules rupture and dry up to form thin, superficial scales and crusts,

Figure 38-1 Subcorneal pustular dermatosis. **A,** Typical distribution. Note accentuated involvement of groin and abdomen. Hyperpigmented macules mark previously affected areas. **B,** Close-up showing coalescence of pustules, which form annular and circinate patterns. Lesions of different developmental stages are seen side by side. At the lower right, newly formed pustule with characteristic hypopyon formation.

closely resembling impetigo. Peripheral spreading and central healing leave polycyclic, erythematous areas in which new pustules arise as others disappear (Fig. 38-1A). There is no atrophy or scarring, but an occasional brownish hyperpigmentation may mark previously affected sites. Variable intervals of quiescence, lasting from a few days to several weeks, may be followed by the sudden development of new lesions. The eruptions tend to occur symmetrically, affecting mainly the axillae, groin, abdomen, submammary areas, and the flexor aspects of the limbs. In rare cases, the face,[30] palms, and soles[31] may be involved. Scalp and mucous membranes invariably remain free of lesions. Episodic itching and burning represent subjective symptoms in a small number of patients, but there are no systemic symptoms or abnormalities in routine laboratory parameters.

HISTOPATHOLOGY

The hallmark of the disease is a strictly subcorneal pustule filled with polymorphonuclear leukocytes,[1] with only an occasional eosinophils.[2] Acantholysis is not involved in pustule formation, but a few acantholytic cells may be found in older lesions (secondary acantholysis). Surprisingly, the epidermal layers underlying the pustule exhibit little pathology, and, apart from a variable number of migrating leukocytes, there is little evidence of spongiosis or cytolytic damage to the epidermal cells. The dermis contains a perivascular infiltrate composed of neutrophils and rarely mononuclear cells and eosinophils (Fig. 38-2).

Direct immunofluorescence is usually negative. Upon detection of IgA in a pemphigus-like intercellular pattern (with or without the presence of circulating IgA antibodies directed against desmocollin 1) patients

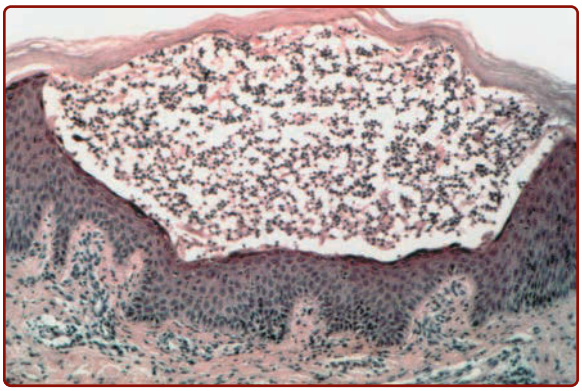

Figure 38-2 Subcorneal pustular dermatosis. Strictly subcorneal pustule filled with polymorphonuclear leukocytes, with the underlying epidermal layers exhibiting only slight edema and some migrating leukocytes. There is a mild inflammatory infiltrate around dermal blood vessels.

TABLE 38-1
Differential Diagnosis of Subcorneal Pustular Dermatosis

- Bacterial impetigo
- Dermatitis herpetiformis
- Pemphigus foliaceus
- Subcorneal pustular dermatosis-type immunoglobulin A pemphigus
- Pustular psoriasis
- Necrolytic migratory erythema
- Acute generalized exanthematous pustulosis

TABLE 38-2
Treatments for Subcorneal Pustular Dermatosis

First line	Dapsone	50-150 mg/day
	Corticosteroids	As required
Second line (anecdotally reported beneficial responses)	Retinoids, photochemotherapy, ultraviolet B, colchicine, cyclosporine, infliximab, etanercept	

should be diagnosed as SPD-type IgA pemphigus (see Ethiology and Pathogenesis earlier).

DIFFERENTIAL DIAGNOSIS

Table 38-1 outlines the differential diagnosis of SPD. An early localized eruption of SPD may be clinically and histologically indistinguishable from impetigo, but the distribution pattern of the lesions, the absence of bacteria in the pustules, and the ineffectiveness of antibiotic therapy suggest the correct diagnosis. Dermatitis herpetiformis is highly pruritic, affects primarily the extensor surfaces, and has subepidermal vesicles with granular IgA deposits in the dermal papillary tips. Pemphigus foliaceus has acantholysis and a typical immunofluorescence pattern. IgA pemphigus of the SPD-type is only distinguishable through positive findings in direct and indirect immunofluorescence. Generalized pustular psoriasis (von Zumbusch type) presents with systemic symptoms (fever, malaise, leukocytosis), and spongiform pustules within the epidermis. The necrolytic migratory eruption of glucagonoma syndrome can be differentiated by its distribution, lack of actual pustule formation, erosions of the lips and oral mucosa, and, histologically, necrobiosis of the upper epidermis. Biochemically, hyperglycemia and excess levels of glucagon are diagnostic. Acute generalized exanthematous pustulosis is widespread with an acute febrile onset and histologically exhibits spongiform subcorneal and intraepidermal pustules sometimes with leukocytoclastic vasculitis.

PROGNOSIS AND CLINICAL COURSE

SPD is a benign condition. Without treatment, attacks recur over many years and remissions are variable, lasting from a few days to several weeks. Despite the protracted course the general health of the patient is usually not impaired. However, one of our own cases who had SPD, pyoderma gangrenosum, and IgA paraproteinemia of more than 20 years' duration died of septicemia with staphylococcal abscesses in the lungs, liver, and spleen.

TREATMENT

The drug of choice is dapsone (Table 38-2) in a dose of 50 to 150 mg daily. The response is slower and less dramatic than in dermatitis herpetiformis, but complete remission is most often obtained. In some patients, the treatment may be withdrawn after several months, although in others it may have to be continued for years; the minimal effective dose to suppress disease should be determined in these patients with a chronic course. Systemic corticosteroids are less effective, although they can suppress generalized flares when given in high doses. Responses to retinoids, photochemotherapy, ultraviolet B, colchicine, cyclosporine, and topical tacalcitol (1α-24R-dihydroxyvitamin D_3) have been anecdotally reported.[32-35] More recently, anti–tumor necrosis factor-α therapy has been successfully used in single cases. Infliximab was described to induce rapid responses in 3 recalcitrant cases, with 1 patient relapsing despite continuing treatment.[25,36,37] In 2 patients, etanercept was able to induce almost complete continuing remissions for 7 and 22 months, as monotherapy or in combination with acitretin, respectively.[38] In 1 reported case of IgA myeloma-associated SPD long-lasting remission of both conditions was achieved with melphalan and autologous stem cell transplantation.[12]

REFERENCES

1. Sneddon IB, Wilkinson DS. Subcorneal pustular dermatosis. *Br J Dermatol.* 1956;68:385-394.
2. Wolff K. Ein Beitrag zur Nosologie der subcornealen pustulîsen Dermatose (Sneddon-Wilkinson). *Arch Klin Exp Dermatol.* 1966;224(3):248-267.
3. Robinson ND, Hashimoto T, Amagai M, et al. The new pemphigus variants. *J Am Acad Dermatol.* 1999;40(5):649-671.
4. Kalaher KM, Scott DW. Subcorneal pustular dermatosis in dogs and in human beings: Comparative aspects. *J Am Acad Dermatol.* 1990;22:1023-1028.
5. Hashimoto T, Kiyokawa C, Mori O, et al. Human desmocollin 1 (Dsc1) is an autoantigen for the subcorneal pustular dermatosis type of IgA pemphigus. *J Invest Dermatol.* 1997;109(2):127-131.

6. Duker I, Schaller J, Rose C, et al. Subcorneal pustular dermatosis-type IgA pemphigus with autoantibodies to desmocollins 1, 2, and 3. *Arch Dermatol.* 2009; 145(10):1159-1162.
7. Geller S, Gat A, Zeeli T, et al. The expanding spectrum of IgA pemphigus: a case report and review of the literature. *Br J Dermatol.* 2014;171(3):650-656.
8. Takata M, Inaoki M, Shodo M, et al. Subcorneal pustular dermatosis associated with IgA myeloma and intraepidermal IgA deposits. *Dermatology.* 1994;189: 111-114.
9. Vaccaro M, Cannavo SP, Guarneri B. Subcorneal pustular dermatosis and IgA lambda myeloma: a uncommon association but probably not coincidental. *Eur J Dermatol.* 1999;9(8):644-646.
10. Stone MS, Lyckholm LJ. Pyoderma gangrenosum and subcorneal pustular dermatosis: clues to underlying immunoglobulin A myeloma. *Am J Med.* 1996; 100:663-664.
11. Espana A, Gimenez-Azcarate A, Ishii N, et al. Antidesmocollin 1 autoantibody negative subcorneal pustular dermatosis-type IgA pemphigus associated with multiple myeloma. *Br J Dermatol.* 2015;172(1): 296-298.
12. von dem Borne PA, Jonkman MF, van Doorn R. Complete remission of skin lesions in a patient with subcorneal pustular dermatosis (Sneddon-Wilkinson disease) treated with anti-myeloma therapy: association with disappearance of M-protein. *Br J Dermatol.* 2017;176(5): 1341-1344.
13. Scerri L, Zaki I, Allen BR. Pyoderma gangrenosum and subcorneal pustular dermatosis, without monoclonal gammopathy. *Br J Dermatol.* 1994;130:398-399.
14. Kohl PK, Hartschuh W, Tilgen W, et al. Pyoderma gangrenosum followed by subcorneal pustular dermatosis in a patient with IgA paraproteinemia. *J Am Acad Dermatol.* 1991;24:325-328.
15. Miyakawa K, Miyamoto R, Baba S, et al. Vesiculopustular dermatosis with ulcerative colitis. Concomitant occurrence of circulating IgA anti-intercellular and anti-basement membrane zone antibodies. *Eur J Dermatol.* 1995;5:122-124.
16. Delaporte E, Colombel JF, Nguyen Mailfer C, et al. Subcorneal pustular dermatosis in a patient with Crohn's disease. *Acta Derm Venereol.* 1992;72(4):301-302.
17. Lutz ME, Daoud MS, McEvoy MT, et al. Subcorneal pustular dermatosis: a clinical study of ten patients. *Cutis.* 1998;61(4):203-208.
18. Kavala M, Karadag AS, Zindanci I, et al. A case of subcorneal pustular dermatosis with IgG monoclonal gammopathy of undetermined significance: a rare association. *Int J Dermatol.* 2015;54(12):e551-e553.
19. Guggisberg D, Hohl D. Intraepidermal IgA pustulosis preceding a CD30+ anaplastic large T-cell lymphoma. *Dermatology.* 1995;191(4):352-354.
20. Ratnarathorn M, Newman J. Subcorneal pustular dermatosis (Sneddon-Wilkinson disease) occurring in association with nodal marginal zone lymphoma: a case report. *Dermatol Online J.* 2008;14(8):6.
21. Buchet S, Humbert P, Blanc D, et al. Pustulose souscornee associee a un carcinome epidermoide du poumon. *Ann Dermatol Venereol.* 1991;118(2):125-128.
22. Villey MC, Ehrsam E, Marrakchi S, et al. Apudoma and subcorneal pustular dermatosis (Sneddon-Wilkinson disease). *Dermatology.* 1992;185(4):269-271.
23. Roger H, Thevenet JP, Souteyrand P, et al. Subcorneal pustular dermatosis associated with rheumatoid arthritis and raised IgA: simultaneous remission of skin and joint involvements with dapsone treatment. *Ann Rheum Dis.* 1990;49:190-191.
24. Butt A, Burge SM. Sneddon-Wilkinson disease in association with rheumatoid arthritis. *Br J Dermatol.* 1995;132(2):313-315.
25. Naretto C, Baldovino S, Rossi E, et al. The case of SLE associated Sneddon-Wilkinson pustular disease successfully and safely treated with infliximab. *Lupus.* 2009;18(9):856-857.
26. Taniguchi S, Tsuruta D, Kutsuna H, et al. Subcorneal pustular dermatosis in a patient with hyperthyroidism. *Dermatology.* 1995;190:64-66.
27. Winnock T, Wang J, Suys E, et al. Vesiculopustular eruption associated with *Mycoplasma pneumoniae* pneumopathy. *Dermatology.* 1996;192:73-74.
28. Bohelay G, Duong TA, Ortonne N, et al. Subcorneal pustular dermatosis triggered by *Mycoplasma pneumoniae* infection: a rare clinical association. *J Eur Acad Dermatol Venereol.* 2015;29(5):1022-1025.
29. Iyengar S, Chambers CJ, Chang S, et al. Subcorneal pustular dermatosis associated with *Coccidioides immitis*. *Dermatol Online J.* 2015;21(8).
30. Lotery HE, Eedy DJ, McCusker G. Subcorneal pustular dermatosis involving the face. *J Eur Acad Dermatol Venereol.* 1999;12(3):230-233.
31. Haber H, Wells GC. Subcorneal pustular dermatosis of the soles. *Br J Dermatol.* 1959;71:253.
32. Bauwens M, De-Coninck A, Roseeuw D. Subcorneal pustular dermatosis treated with PUVA therapy. A case report and review of the literature. *Dermatology.* 1999;198(2):203-205.
33. Marliere V, Beylot-Barry M, Beylot C, et al. Successful treatment of subcorneal pustular dermatosis (Sneddon-Wilkinson disease) by acitretin: report of a case. *Dermatology.* 1999;199(2):153-155.
34. Cameron H, Dawe RS. Subcorneal pustular dermatosis (Sneddon-Wilkinson disease) treated with narrowband (TL-01) UVB phototherapy. *Br J Dermatol.* 1997;137(1):150-151.
35. Orton DI, George SA. Subcorneal pustular dermatosis responsive to narrowband (TL-01) UVB phototherapy. *Br J Dermatol.* 1997;137(1):149-150.
36. Voigtlander C, Luftl M, Schuler G, et al. Infliximab (anti-tumor necrosis factor alpha antibody): a novel, highly effective treatment of recalcitrant subcorneal pustular dermatosis (Sneddon-Wilkinson disease). *Arch Dermatol.* 2001;137(12):1571-1574.
37. Bonifati C, Trento E, Cordiali Fei P, et al. Early but not lasting improvement of recalcitrant subcorneal pustular dermatosis (Sneddon-Wilkinson disease) after infliximab therapy: relationships with variations in cytokine levels in suction blister fluids. *Clin Exp Dermatol.* 2005;30(6):662-665.
38. Berk DR, Hurt MA, Mann C, et al. Sneddon-Wilkinson disease treated with etanercept: report of two cases. *Clin Exp Dermatol.* 2009;34(3):347-351.

Chapter 39 :: Autoinflammatory Disorders

:: Takashi K. Satoh & Lars E. French

AUTOINFLAMMATORY DISORDERS

AT-A-GLANCE

- Autoinflammatory disorders are caused by dysregulation of the innate immune system.
- Although many of the symptoms of autoinflammatory disorders, such as fever, skin lesions, and joint pain, mimic infection, the inflammation is sterile.
- Interleukin (IL)-1 plays a prominent role in a large subset of monogenic autoinflammatory disorders.
- Monogenic autoinflammatory disorders typically present in childhood but sometimes occur neonatally.
- Monogenic autoinflammatory disorders are mostly inherited in an autosomal-recessive or autosomal-dominant pattern, but there are a considerable number of sporadic cases.
- Characteristic skin eruptions are associated with a number of these disorders, including neutrophilic urticarial skin lesions, pustulosis, cellulitis-like skin lesions, erythematous and maculopapular eruptions. Skin lesions can be the sole remarkable disease manifestation in some disorders.
- Specific treatments exist, including IL-1 antagonists for cryopyrin-associated periodic syndromes (CAPS), Schnitzler syndrome, and deficiency of the interleukin (IL)-1 receptor antagonist (DIRA), and colchicine for familial Mediterranean fever (FMF). IL-1 antagonists have also been used with variable efficacy in FMF and hyperimmunoglobulinemia D with periodic fever syndrome (HIDS)/mevalonate kinase deficiency (MKD).
- An online database for autoinflammatory mutations is available at Infevers (http://fmf.igh.cnrs.fr/ISSAID/infevers/).

This chapter focuses on the clinical aspects and known pathogenesis of autoinflammatory disorders (Table 39-1). Most of these disorders present with recurrent fevers and involvement of the skin, the joints, the gastrointestinal tract, the bones, and serosal surfaces that mimic infectious disease, collagen-vascular disease, or malignant disease. Autoinflammatory disorders are, however, diseases of the innate immune system, characterized by recurrent episodes of systemic inflammation without the usual hallmarks of autoimmunity such as high autoantibody titers and the presence of antigen-specific T cells.[1,2] Although a delay in diagnosis is unfortunately common because of their rarity, the characteristic clinical features can help the clinician to make a diagnosis, which is confirmed by genetic testing.

CRYOPYRIN-ASSOCIATED PERIODIC SYNDROMES

AT-A-GLANCE

- Cryopyrin-associated periodic syndromes (CAPS) are rare autosomal dominant disorders.
- CAPS are caused by gain of function mutations in *NLRP3*, the gene encoding *NLRP3*, also known as cryopyrin.
- Gain-of-function mutations in *NLRP3* lead to inflammasome activation and subsequent abnormal interleukin (IL)-1β secretion.
- The spectrum of CAPS includes the familial cold autoinflammatory syndrome (FCAS; OMIM [Online Mendelian Inheritance in Man] #120100), Muckle-Wells syndrome (MWS; OMIM #191900), and the chronic infantile neurologic cutaneous and articular syndrome (CINCA; OMIM #607115), also known as neonatal-onset multisystem inflammatory disease (NOMID).
- The inheritance pattern in FCAS and MWS is familial whereas CINCA/NOMID cases are sporadic as a result of the severe phenotype that precludes reproduction.
- Urticarial skin lesions are a common characteristic feature in CAPS, and usually the first sign of disease.
- Clinical features include urticarial skin lesions, recurrent fever, arthralgia, conjunctivitis (FCAS, MWS, CINCA/NOMID); progressive hearing loss, amyloidosis, headache, progressive vision loss (MWS, CINCA/NOMID); and severe arthropathy, mental retardation and bone overgrowth (CINCA/NOMID).
- Histology of lesional skin reveals neutrophil-rich perivascular inflammation in the superficial dermis and mid-dermis. There is no evidence of vascular destruction or vasculitis.
- IL-1 antagonists are very effective and the standard of care in treating CAPS.

TABLE 39-1
Autoinflammatory Disorders

PATHOGENESIS	DISEASE	GENE	INHERITANCE PATTERN	PROTEIN	FLARE/FEVER PATTERN	INVOLVED ORGAN(S)
IL-1 mediated	CAPS:					
	FCAS	*NLRP3/CIAS1*	AD	NLRP3/Cryopyrin	<24 h	Skin, eyes, joints
	MWS	*NLRP3/CIAS1*	AD	NLRP3/Cryopyrin	24-48 h	Skin, eyes, joints, inner ears, meninges
	NOMID	*NLRP3/CIAS1*	AD/de novo	NLRP3/Cryopyrin	Continuous	Skin, eyes, joints, inner ears, meninges, bones
	Schnitzler syndrome	*NLRP3/CIAS1*[a]	De novo	NLRP3/Cryopyrin	Variable	Skin, bones, joints, blood (IgM gammopathy)
	DIRA	*IL1RN*	AR	IL-1 receptor antagonist	Continuous	Skin, bones, lungs (rare), vasculitis (rare)
Partially IL-1 mediated	FMF	*MEFV*	AR/AD[b]	Pyrin	1-3 days	Skin, joints, peritoneum, pleura
	HIDS/MKD	*MVK*	AR	Mevalonate kinase	3-7 days	Skin, mucosa, eyes, joints, prominent lymph nodes
	PAPA syndrome	*PSTPIP1/CD2BP1*	AD	PSTPIP1	Common	Skin, joints
	SAPHO syndrome	–	–	–	Uncommon	Skin, joints, bones
IL-36 mediated	DITRA	*IL36RN*	AR	IL-36 receptor antagonist	Common	Skin
Partially IL-36 mediated	CAMPS/PSORS2	*CARD14*	AD	CARD14	Variable	Skin
Other pathways	TRAPS	*TNFRSF1A*	AD	TNF receptor 1	1-4 weeks	Skin, eyes, joints, peritoneum, pleura
	HA20	*TNFAIP3*	AD	A20/TNFAIP3	Common	Skin, mucosa, eyes, joints, vasculitis, GI tract
	Otulipenia/ORAS	*OTULIN*	AR	OTULIN	Weeks	Skin, joints, muscles, lymph nodes, GI tract
	CANDLE/PRAAS	*PSMB8*	AR	PSMB8	Variable	Skin, joints, muscles, lymph nodes
	BS/EOS	*NOD2/CARD15*	AD/de novo	NOD2/CARD15	Uncommon	Skin, eyes, joints
	Majeed syndrome	*LPIN2*	AR	Lipin-2	Weeks-months	Skin, bones, periosteum, blood (anemia)

[a]Some patients have been shown to bear mosaicism of *NLRP3* mutations.

[b]AD is less common than AR in FMF.

AD, autosomal dominant; AR, autosomal recessive; BS, Blau syndrome; CAMPS, CARD14-mediated pustular psoriasis; CANDLE, chronic atypical neutrophilic dermatosis with lipodystrophy and elevated temperature; CAPS, cryopyrin-associated periodic syndromes; DIRA, deficiency of the IL-1 receptor antagonist; DITRA, deficiency of the IL-36 receptor antagonist; EOS, early-onset sarcoidosis; FCAS, familial cold autoinflammatory syndrome; FMF, familial Mediterranean fever; HA20, haploinsufficiency of A20; HIDS, hyperimmunoglobulinemia D with periodic fever syndrome; IgM, immunoglobulin M; IL, interleukin; MKD, mevalonate kinase deficiency; MWS, Muckle-Wells syndrome; NOMID, neonatal onset multisystem inflammatory disease; ORAS, OTULIN-related autoinflammatory syndrome; PAPA, pyogenic sterile arthritis, pyoderma gangrenosum, and acne; PRAAS, proteasome-associated autoinflammatory syndrome; PSORS2, Psoriasis 2; PSTPIP1, proline-serine-threonine phosphatase interacting protein 1; SAPHO, synovitis, acne, pustulosis, hyperostosis, and osteitis; TNF, tumor necrosis factor; TRAPS, TNF receptor-associated periodic syndrome.

EPIDEMIOLOGY

Cryopyrin-associated periodic syndromes (CAPS), also known as cryopyrinopathies, are a group of inherited inflammatory disorders caused by autosomal dominant gain-of-function mutations in *NLRP3* (the gene encoding NLRP3, also known as cryopyrin).[3,4] The spectrum of CAPS includes the familial cold autoinflammatory syndrome (FCAS; OMIM #120100),[5] Muckle-Wells syndrome (MWS; OMIM #191900),[6] and the chronic infantile neurologic cutaneous and articular syndrome (CINCA; OMIM #607115),[7] also known as neonatal-onset multisystem inflammatory disease (NOMID). Periodic fever and urticarial skin lesions are the common clinical hallmarks, but FCAS, MWS, and CINCA/NOMID have certain distinctive clinical characteristics that differentiate these CAPS within a spectrum of increasing severity: FCAS being on the mild, and CINCA/NOMID on the severe end of the spectrum (Table 39-2).

The prevalence of CAPS is estimated to be between 1 and 2 individuals per 1,000,000 people in Europe, the United States and Japan. While the inheritance pattern in FCAS and MWS is usually familial, CINCA/NOMID is sporadic owing to the severe phenotype of untreated individuals and consequent inability to reproduce.

ETIOLOGY AND PATHOGENESIS

NLRP3 belongs to the NLRs (NOD-like receptors) family of cytoplasmic pattern recognition receptors. NLRP3 can form a multiprotein complex called the *inflammasome* together with adaptor proteins, and subsequently activate caspase-1, an enzyme that cleaves pro-interleukin (IL)-1β to its active form.[8] Gain-of-function mutations in *NLRP3* associated with CAPS lead to constitutive activation of caspase-1 and subsequent abnormal IL-1β secretion.[9,10]

CLINICAL FEATURES

Urticarial skin lesions are the common characteristic features in all forms of CAPS and are usually the first sign of disease (Fig. 39-1A). They resemble common urticaria at first glance because the smooth, slightly elevated erythematous lesions (wheals) are migratory and skin returns to its normal appearance without residual pigmentation. The symptoms, however, tend to be atypical for common urticaria because lesions are usually nonpruritic or only slightly itchy and not associated with any particular sensation; some patients describe sensations of stinging, burning, and tightness. Unlike in common urticaria, urticarial skin lesions in CAPS are unresponsive to antihistamines. Histologically, the urticarial skin lesions are characterized by a neutrophilic-rich dermal perivascular inflammatory infiltrate (Fig. 39-1B).

FCAS is the mildest condition of CAPS. The main clinical features are urticarial skin lesions and low-grade fever of short duration that develop usually 1 to 2 hours after exposure to cold temperature.[11] Attacks are more common in winter and can occur upon exposure to cold outside temperatures and cold air-conditioned rooms. The ice-cube provocation test is negative for the urticaria. Systemic cold exposure is needed to trigger an intense episode. The flares tend to be brief, typically lasting less than 24 hours, and can also include arthralgia, conjunctivitis, headaches, nausea, and fatigue. The arthralgia mostly affects the hands, knees, and ankles. The attacks usually begin in infancy and early childhood.

TABLE 39-2
Clinical Characteristics of CAPS

	FCAS	MWS	CINCA/NOMID
Severity	Mild	Moderate	Severe
Duration of clinical signs	<24 h	1-2 days or subcontinuous	Continuous with variable exacerbations
Triggers	Cold induced	None	None
Fever	Recurrent	Recurrent	Continuous
Skin manifestations	Cold-induced urticarial skin lesions	Urticarial skin lesions	Urticarial skin lesions
Joint involvement	Arthralgias, stiffness	Arthralgias, arthritis	Deforming arthropathy
Neurologic involvement	None	None	Chronic aseptic meningitis
Eye involvement	Conjunctivitis	Conjunctivitis, uveitis	Conjunctivitis, uveitis, optic neuritis, papilledema
Auditory involvement	None	Sensorineural hearing loss	Sensorineural hearing loss
Amyloidosis	Rare	Frequent	Frequent

CINCA, chronic infantile neurologic cutaneous and articular syndrome; FCAS; familial cold autoinflammatory syndrome; MWS, Muckle-Wells syndrome; NOMID, neonatal onset multisystem inflammatory disease.

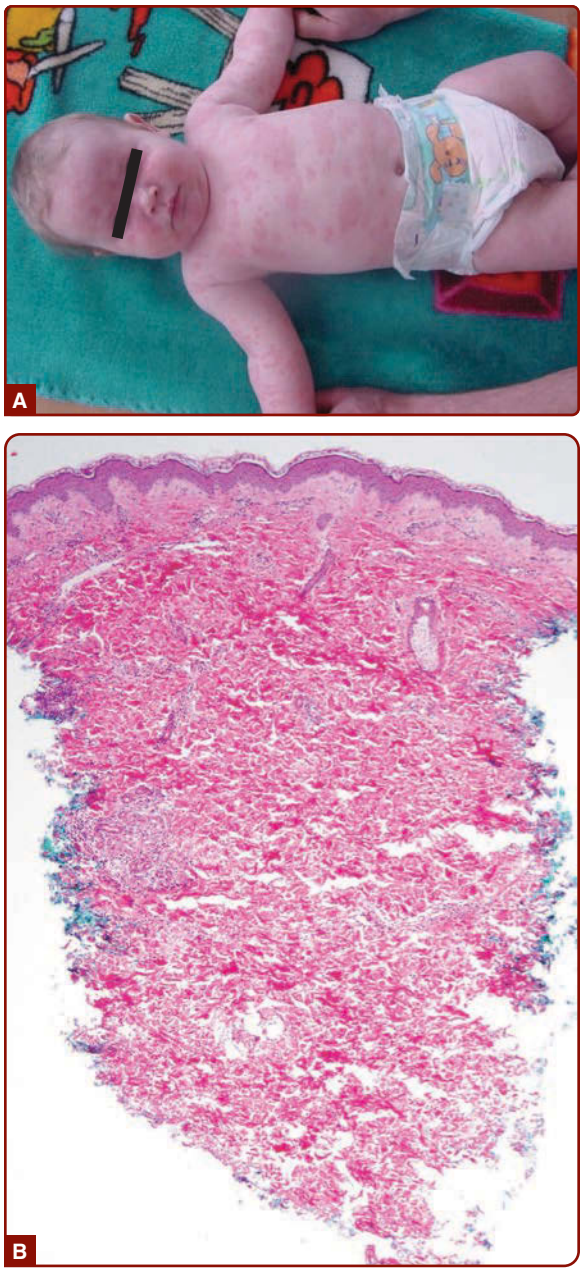

Figure 39-1 Cryopyrin-associated periodic syndromes (CAPS). **A,** Urticarial skin lesions in a 2-month-old baby with Muckle-Wells syndrome. (From Wolff K, Johnson R, Saavedra AP. *Fitzpatrick's Color Atlas and Synopsis of Clinical Dermatology*, 7th ed. New York, NY: McGraw-Hill; 2013. Used with permission from Drs. Klemens Rappersberger and Christian Posch.) **B,** Histology of the skin. Histologic examination reveals a predominant perivascular neutrophilic infiltrate without vasculitis, dilated superficial dermal capillaries, and dermal edema.

Patients with MWS or CINCA/NOMID typically present with urticarial skin lesions at birth or within hours of birth, although some patients present first symptoms later. MWS was originally described as a triad of urticaria, deafness, and amyloidosis. Inflammatory episodes in MWS can be frequent and random, and are only variably triggered by cold. Most attacks last 24 to 48 hours but can also be continuous. Patients with MWS commonly have fevers, urticarial skin lesions, arthralgia, and headache that reflects aseptic meningitis. Progressive sensory neural hearing loss often appears clinically during the second to third decade of life. Conjunctivitis and uveitis also can be present.

Patients with CINCA/NOMID tend to have persistent inflammation and, in most cases, infants have diffuse erythema and fever at birth. Chronic aseptic meningitis is common, and without treatment with IL-1 antagonists, patients typically develop progressive brain atrophy and cognitive impairment. Conjunctivitis and uveitis starts shortly after birth and elevated CNS pressure causes chronic papilledema, which can lead to serious loss of vision. Sensory neural hearing loss develops typically within the first year of life.[9] Also, patients develop characteristic long-bone epiphyseal overgrowth and short stature, and amyloidosis develops after years of chronic inflammation.[12]

DIAGNOSIS

The initial diagnosis of CAPS relies heavily on the patients' history and it should be considered in patients presenting with recurrent episodes of fever, urticarial skin lesions, joint pain, and inflammation of the eyes, without evidence of infection or autoimmune disease. Positive family history is not always evident. A delay in the diagnosis is, unfortunately, common, and initial diagnoses of viral infection or allergy are usually considered. Elevated levels of blood acute-phase reactants such as C-reactive protein (CRP), erythrocyte sedimentation rate (ESR), and serum amyloid A (SAA) are typically present, especially during attacks, but can remain elevated to some extent even between episodes although at lower levels. Marked leukocytosis, especially neutrophilia, and mild anemia are also observed. Eosinophilia can variably be present.

Skin biopsy of an urticarial skin lesion can contribute to making the diagnosis of CAPS. The histologic features are the same for FCAS, MWS, and CINCA/NOMID, and characterized by a dermal perivascular infiltration of neutrophils in the superficial dermis and mid-dermis. There is no evidence of vascular destruction or vasculitis, and the epidermis is usually intact (see Fig. 39-1B).

Careful CNS assessment is useful in CINCA/NOMID. Elevated cerebrospinal fluid pressure and leukocytosis, predominantly with neutrophils but without any evidence of infection, are present. High-resolution gadolinium-enhanced MRI can show enhancement of the leptomeninges and cochlea. Radiographs of the long bones reveal epiphyseal overgrowth that is characteristic and unique to CINCA/NOMID.[12]

Diagnostic confirmation is achieved by genetic testing for *NLRP3* mutations. Although almost all patients with FCAS and MWS are mutation-positive, not all CINCA/NOMID patients who meet the phenotypic classification have a detectable mutation. Some mutation-negative patients have *NLRP3* mosaicism, which cannot be

detected by conventional genetic analyses.[13] Consequently, a negative genetic test does not exclude the diagnosis of CAPS and it is important to consider genetic results in the context of the patient's symptoms.

DIFFERENTIAL DIAGNOSIS

FCAS may be confused with acquired cold urticaria, a more common condition. Acquired cold urticaria does not present with fever or arthralgia, and the skin lesions respond to antihistamines. Urticarial skin lesions at birth may be misdiagnosed as a benign newborn eruption. CINCA/NOMID patients can present more dramatically, mimicking neonatal sepsis or congenital "TORCH" (toxoplasmosis, other infections, rubella virus, cytomegalovirus, and herpes simplex virus) infections. Systemic juvenile idiopathic arthritis (sJIA, also called Still disease), a subtype of chronic childhood arthritis with daily fever episodes and evanescent erythematous macular skin lesions, needs to be considered in the differential diagnosis. Epiphyseal overgrowth of long bones in CINCA/NOMID can be differentially diagnosed as benign or malignant bone tumors.

CLINICAL COURSE AND PROGNOSIS

CAPS is a lifelong disease and the clinical course and prognosis greatly depends on the disease phenotype. Long-term prognosis of FCAS is good and clinical manifestations primarily affect quality of life. In MWS and CINCA/NOMID, however, early diagnosis and treatment can significantly improve the clinical course and prognosis, by reducing cumulative organ damage resulting from chronic inflammation and thus preventing severe complications. In untreated MWS individuals, the long-term prognosis is usually affected by amyloidosis, impaired renal function, and deafness. In CINCA/NOMID patients, the long-term prognosis depends on the severity of neurologic and joint involvement, as well as renal function. Hearing loss usually develops in the first decade of life, accompanied by mental retardation, progressive vision loss, and severe physical disabilities resulting from bone overgrowth and the development of joint contractures.[14]

MANAGEMENT

A large majority of patients with FCAS, MWS, and CINCA/NOMID respond dramatically to IL-1 antagonists with rapid and sustainable resolution of clinical symptoms and complete normalization of inflammatory markers such as CRP and SAA under continuous treatment. Anakinra (Kineret, a recombinant IL-1 receptor antagonist) was the first drug used to treat CAPS.[15-17] This biologic competitively inhibits the binding of IL-1α and IL-1β to the IL-1 receptor and is administered daily as a subcutaneous injection. Dosing is variable, with higher doses required to control more severe disease. Typically, 0.5 to 1.5 mg/kg/day of anakinra are sufficient to suppress disease activity in FCAS patients, but 6 to 10 mg/kg/day may be needed to treat CINCA/NOMID.[16] Anakinra can pass through the blood–brain barrier and improves aseptic meningitis and ocular and cochlear inflammation in CINCA/NOMID.

IL-1 antagonist therapy should be continued for life, and optimally started as early as possible so as to minimize irreversible neurologic complications. There are also two longer-acting IL-1 antagonists. Rilonacept (Arcalyst), also known as IL-1 Trap, is a dimeric fusion protein comprised of the extracellular domain of the human IL-1 receptor fused to the Fc domain of human immunoglobulin (Ig) G_1, that binds and neutralizes IL-1.[18] Its half-life is 8.6 days and it is administered as a weekly subcutaneous injection at 160 mg (a dose for an adult). Canakinumab (Ilaris) is a human monoclonal antibody specific for IL-1β, with a mean half-life of 26 days that is usually administered every 8 weeks at 150 mg (a dose for an adult) via subcutaneous injection.[19] Rilonacept and canakinumab have been approved by the U.S. Food and Drug Administration (FDA) for the treatment of FCAS and MWS and canakinumab by many countries including within the EU, Switzerland, and Japan, but not the United States, for CINCA/NOMID. All 3 drugs are generally well tolerated without significant limiting side effects.

SCHNITZLER SYNDROME

AT-A-GLANCE

- Schnitzler syndrome is a rare, late-onset inflammatory disease considered as a sporadic acquired autoinflammatory disorder.
- Some Schnitzler syndrome patients have been shown to have mosaicism of *NLRP3* mutations.
- Recurrent urticarial skin lesions, fever, bone pain and arthralgias are common manifestations, sharing many features with CAPS.
- Coexistence of a monoclonal IgM gammopathy is a diagnostic feature, and patients may develop a lymphoproliferative disorder.

EPIDEMIOLOGY

Schnitzler syndrome is a rare late-onset inflammatory disease characterized by recurrent fever, urticarial skin lesions, arthritis and lymphadenopathy accompanied by IgM gammopathy.[20,21] Patients present with the first symptoms typically around 50 years of age or older.

Approximately 300 cases of Schnitzler syndrome have been reported worldwide.

ETIOLOGY AND PATHOGENESIS

The exact cause of Schnitzler syndrome is still a matter of investigation but it is now considered to be a sporadic acquired autoinflammatory disorder. It has been reported that peripheral blood mononuclear cells taken from patients release increased amounts of IL-1β spontaneously and in response to lipopolysaccharide. Some Schnitzler syndrome patients have been shown to have a mosaicism of *NLRP3* mutations exclusively in the myeloid lineage.[20]

CLINICAL FEATURES

There are strong clinical similarities between Schnitzler syndrome and CAPS.[20] Recurrent urticarial skin lesions are usually the first sign of Schnitzler syndrome and can precede the other symptoms for years (Fig. 39-2A). The lesions are usually nonpruritic or only slightly itchy, resolve within 24 to 48 hours, and, invariably, antihistamines are ineffective. The frequency of urticarial skin changes ranges from daily to a few episodes per year. The histology reveals a neutrophilic infiltrate of the perivascular and interstitial dermis with intact epidermis and no signs of vasculitis, consistent with CAPS (Fig. 39-2B and C). The second most common symptom is intermittent fever, which can rise above 40°C (104°F). Many patients develop bone pain and arthralgias. Bone lesions can be observed on imaging studies. Lymphadenopathy and hepatosplenomegaly can also be seen.

Elevated CRP and ESR are typically present. Leukocytosis, usually neutrophilia, and mild anemia are also observed. Monoclonal gammopathy, mostly IgMκ light chain, is seen in 85% of Schnitzler syndrome patients, which is a characteristic feature of the syndrome and distinguishes it from CAPS.

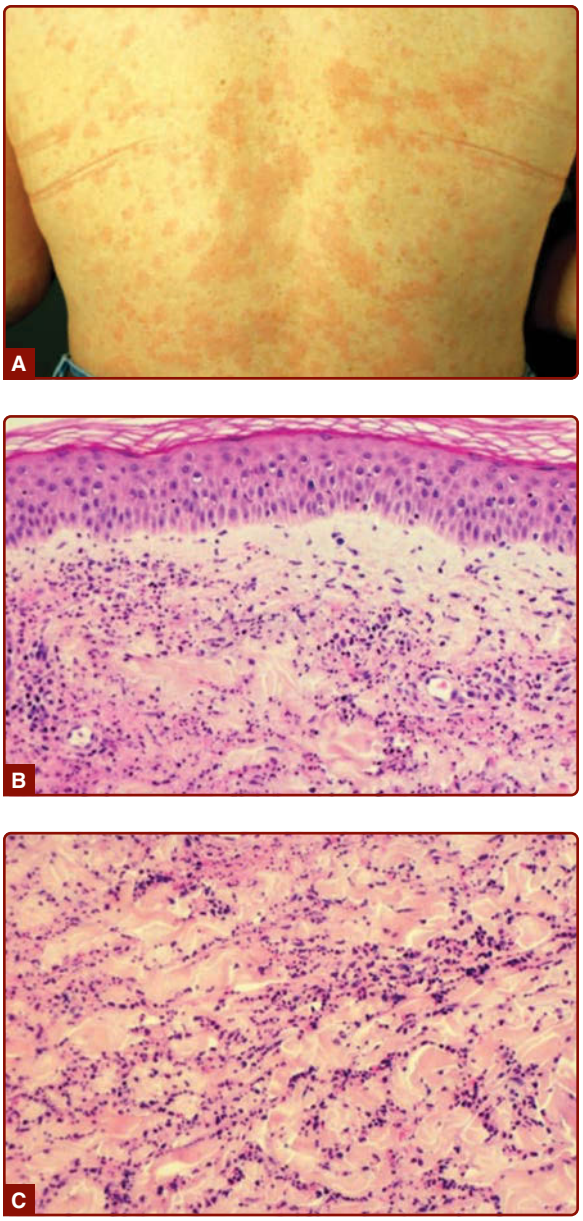

Figure 39-2 Schnitzler syndrome. **A,** Urticarial skin lesions in a patient with Schnitzler syndrome. **B,** Histology of the skin. A neutrophilic infiltrate of the dermis without vasculitis. **C,** Significant neutrophilic infiltrate with interstitial dispersion and leukocytoclasia. (From Lipsker D. The Schnitzler syndrome. *Orphanet J Rare Dis.* 2010;5:38, with permission.)

DIAGNOSIS

The diagnosis of Schnitzler syndrome relies heavily on a combination of clinical, laboratory and radiologic findings. It should be considered in patients with recurrent episodes of urticarial skin lesions, fever, and bone and joint pain without evidence of infection or autoimmune disease.

The presence of a monoclonal IgM gammopathy helps the diagnosis. Detection of mosaicism in *NLRP3* by standard Sanger sequencing is difficult and next-generation sequencing provides the opportunity for scrutinizing genetic susceptibility. An immediate and marked response to anakinra or canakinumab is supportive of the diagnosis.

DIFFERENTIAL DIAGNOSIS

Schnitzler syndrome shares many features with CAPS, notably chronic systemic inflammation, which includes urticarial skin lesions and fever. Onset age would be a distinguishing factor from CAPS but not

the absence of *NLRP3* mutation as some CAPS patients are also mutation-negative. Urticarial vasculitis should be excluded. Urticarial vasculitis usually presents with nonpruritic urticarial skin lesions persisting for more than 24 hours, arthralgia, fever, leukocytosis, and elevated CRP and ESR. Skin biopsy of urticarial vasculitis shows fibrinoid necrosis of vessel walls with fibrin extravasation, which is not observed in Schnitzler syndrome. Other differentials include cryoglobulinemia, acquired C1 inhibitor deficiency, adult-onset Still disease, and hyperimmunoglobulinemia D with periodic fever syndrome (HIDS).

CLINICAL COURSE AND PROGNOSIS

Schnitzler syndrome follows a chronic course. Amyloidosis may develop and become a serious complication. Approximately 10% to 20% of patients with Schnitzler syndrome develop a lymphoproliferative disorder such as Waldenström macroglobulinemia and B-cell lymphoma. The prevalence rate for lymphoproliferative disorders is close to that observed in patients with monoclonal IgM gammopathies of undetermined significance. The overall prognosis of Schnitzler syndrome depends on the possible evolution to lymphoproliferative disorder.

MANAGEMENT

The urticarial skin legions of Schnitzler syndrome are resistant to antihistamines. Nonsteroidal antiinflammatory drugs (NSAIDs) and corticosteroids are reported to provide variable relief from fever, bone pain, and arthralgias, but not urticarial lesions. Both anakinra and canakinumab can induce a complete remission in more than 90% of Schnitzler syndrome cases. Symptoms recur within 1 to several days upon withdrawal of anakinra.

DEFICIENCY OF THE IL-1 RECEPTOR ANTAGONIST

AT-A-GLANCE

- Deficiency of the IL-1 receptor antagonist (DIRA) is a rare autosomal recessive disorder (OMIM #612852).
- DIRA is caused by mutations in *IL1RN*, the gene coding IL-1Ra.
- Mutations in *IL1RN* lead to complete absence or dysfunction of IL-1Ra and thus to unopposed and hyperactive IL-1 signaling.
- Pustular skin eruption, oral mucosal lesions, joint swelling, and bone inflammation are common manifestations.
- Cutaneous manifestation can vary widely from normal skin with pustules to generalized severe pustulosis or ichthyosiform lesions.
- IL-1–targeted therapy with recombinant IL-1Ra is very effective.

EPIDEMIOLOGY

Deficiency of the IL-1Ra (DIRA; OMIM #612852) is a very rare autosomal recessive inherited disease caused by mutations in *IL1RN*.[22,23] The mutations in *IL1RN* are founder mutations and the carrier frequencies of identified founder mutations in Newfoundland and Puerto Rico are estimated to be 0.2% and 1.3%, respectively.[22] Reported patients so far originated from Brazil, Canada, Lebanon, Netherlands, Puerto Rico, and Turkey. Heterozygous carriers are asymptomatic.

ETIOLOGY AND PATHOGENESIS

The IL-1Ra encoded by the *IL1RN* gene functions as a negative endogenous regulator of IL-1 signaling by competitively binding to IL-1R and preventing the activities of IL-1α and IL-1β. Mutations in *IL1RN* lead to complete absence or dysfunction of IL-1Ra and thus to unopposed hyperactive IL-1 signaling.

CLINICAL FEATURES

DIRA clinically manifests as perinatal to several months of age-onset pustular skin eruption, with oral mucosal lesions, failure to gain weight and painful joint swelling. Fetal distress was present in 6 of 10 reported patients before birth. Characteristic radiographic findings include balloon-like widening of the anterior rib ends, periosteal elevation of multiple long bones, and multifocal osteolytic lesions. High fever is not a typical feature in DIRA.

Cutaneous pustulosis can range from normal skin with rare individual pustules to discrete crops of pustules, generalized severe pustulosis, or ichthyosiform lesions (Fig. 39-3A).[22-24] Oral mucosal vesicular lesions or aphthous ulcers are seen early in life in some patients, but do not seem to recur later in life. Nail changes, including onychomadesis and pits, also can be seen. Histologically, the epidermal changes in DIRA are characterized by the presence of intraepidermal neutrophils and neutrophilic pustules. Marked

Figure 39-3 Deficiency of the IL-1 receptor antagonist (DIRA). Small pustules over erythematous patches on the skin of a child with DIRA. (From Jesus AA, Osman M, Silva CA, et al. A novel mutation of IL1RN in the deficiency of interleukin-1 receptor antagonist syndrome: description of two unrelated cases from Brazil. *Arthritis Rheum.* 2011;63(12):4007-4017, with permission. Copyright © 2011 John Wiley & Sons.)

papillary dermal edema is commonly present and may be associated with subepidermal vesiculation. An intense neutrophilic inflammatory infiltrate is present throughout the dermis and may extend to involve the superficial subcutis. Changes of frank vasculitis are absent in most patients; however, vasculitis was observed in the connective and fat tissue adjacent to bone in 1 patient.

DIAGNOSIS

DIRA may be initially erroneously diagnosed as infectious osteomyelitis because of the significant bone inflammation, but the bone and blood cultures are negative and symptoms are unresponsive to antibiotics. Although DIRA and CINCA/NOMID share certain clinical similarities, patients with DIRA typically do not show urticarial skin lesions or neurologic inflammation, such as aseptic meningitis, cochlear inflammation, and mental retardation, which are seen in CINCA/NOMID. Genetic testing to identify the mutation of *IL1RN* gene confirms the diagnosis of DIRA.

CLINICAL COURSE AND PROGNOSIS

Failure to recognize the disease and treat it appropriately with recombinant IL-1Ra leads to the development of a severe inflammatory response syndrome and neonatal death from multiorgan failure.

MANAGEMENT

Treatment with recombinant IL-1Ra (anakinra, brand name Kineret), which substitutes the missing functional IL-1Ra protein, results in rapid and dramatic clinical improvement.[22,23,25] Patients with DIRA need to be treated with anakinra for life. Long-term consequences of anakinra therapy in these patients are not yet well-defined.

DEFICIENCY OF THE IL-36 RECEPTOR ANTAGONIST

AT-A-GLANCE

- Deficiency of the IL-36 receptor antagonist (DITRA) is a rare autosomal recessive disorder (OMIM #614204).
- DITRA is caused by mutations in *IL36RN*, the gene coding IL-36 receptor antagonist (IL-36Ra).
- Lack of the negative regulator IL-36Ra leads to aberrant IL-36 signaling and subsequent overproduction of IL-8, a strong neutrophil chemoattractant, in keratinocytes.
- Although DITRA was originally described in patients with familial generalized pustular psoriasis (GPP), mutations in *IL36RN* have been reported in rare cases of sporadic GPP.
- DITRA typically presents as recurrent flares of a generalized erythematopustular skin eruption of sudden onset, accompanied by high fever.
- Onset of disease is during childhood in many cases, but can occur during adulthood.
- Viral or bacterial infections, medications, menstruation, pregnancy, and withdrawal of retinoid therapy can trigger the disease.

EPIDEMIOLOGY

Deficiency of the IL-36 receptor antagonist (DITRA; OMIM #614204) is a rare autosomal recessive disorder caused by homozygous or compound heterozygous mutations in *IL36RN*.[26,27] This gene was identified as one of the causative genes of familial generalized pustular psoriasis (GPP). Mutations in *IL36RN* are also found in certain sporadic cases of GPP. DITRA is termed as a monogenic form of GPP caused by *IL36RN* mutation. The disease onset mostly commences during childhood but can occur during adulthood. Interestingly, *IL36RN* mutations are also associated with some cases of localized pustular psoriasis such as palmoplantar pustulosis (PPP) and acrodermatitis continua of Hallopeau.

ETIOLOGY AND PATHOGENESIS

IL36RN encodes the IL-36 receptor antagonist (IL-36Ra) that antagonizes all 3 proinflammatory cytokines that belong to the IL-36 family: IL-36α, IL-36β, and IL-36γ. IL-36Ra is primarily expressed in keratinocytes in the skin. Lack of the negative regulator IL-36Ra causes aberrant IL-36 signaling and subsequent IL-8 production by keratinocytes, the latter being a strong chemoattractant for neutrophils.

CLINICAL FEATURES

DITRA typically presents as recurrent and sudden onset of flares of a generalized erythematopustular skin eruption (Fig. 39-4A-D), accompanied by high fever (40-42°C [104-107.6°F]), neutrophilia, and elevated hepatic acute-phase proteins. The disease flares are thought to be triggered by viral or bacterial infections, medications (eg, amoxicillin), menstruation, pregnancy, and withdrawal of retinoid therapy. Withdrawal of systemic corticosteroids can precipitate or worsen GPP but little is known concerning this phenomenon in DITRA. The frequency of flares varies from patient to patient, and in some patients the disease manifests itself as chronic erythematous plaques without pustules. No joint involvement is observed in DITRA, but nail dystrophy can occur. DITRA can be a life-threatening disease owing to severe complications resulting from the repeated flares of prominent systemic inflammation. Skin histology demonstrates neutrophil infiltration in the upper epidermis forming spongiform pustules of Kogoj with acanthosis (Fig. 39-4E).[28]

DIAGNOSIS

DITRA is diagnosed by genetic testing revealing *IL36RN* mutation in GPP patients. GPP is often suspected clinically and confirmed by skin biopsy and laboratory tests, including neutrophilia, elevated acute-phase reactants, and absence of bacterial infection. DITRA can occur in GPP patients with or without psoriasis vulgaris, but more frequently in the absence of psoriasis vulgaris.

DIFFERENTIAL DIAGNOSIS

Differential diagnosis includes bacterial impetigo, subcorneal pustular dermatosis (Sneddon-Wilkinson disease), impetigo herpetiformis, and acute generalized exanthematous pustulosis. Acute generalized exanthematous pustulosis is a severe adverse drug reaction that is widespread with an acute febrile onset, usually not recurrent, and histologically exhibits spongiform subcorneal and intraepidermal pustules. Of note, some acute generalized exanthematous pustulosis patients also have mutations in *IL36RN*.

MANAGEMENT

The optimal treatment for DITRA has not been established yet, but IL-1 and IL-17 antagonists are reported to have efficacy. Recombinant IL-36Ra, if and when available, would be expected to be a valuable therapy.

CARD14-MEDIATED PUSTULAR PSORIASIS/ PSORIASIS 2

AT-A-GLANCE

- CARD14-mediated pustular psoriasis (CAMPS)/ psoriasis 2 (PSORS2) is a rare autosomal dominant disorder (OMIM #602723).
- CAMPS/PSORS2 is caused by gain-of-function mutations in *CARD14*.
- Gain-of-function mutations in *CARD14* lead to aberrant mitogen-activated protein kinase activity and nuclear factor-kappa B signaling, resulting in overproduction of IL-8 and IL-36γ.
- Patients with CAMPS/PSORS2 have various symptoms of psoriasis, including symptoms of plaque and pustular psoriasis.

EPIDEMIOLOGY

CARD14-mediated pustular psoriasis (CAMPS; OMIM #602723), also known as psoriasis 2 (PSORS2), is an autosomal dominant disorder caused by gain-of-function mutations in *CARD14* (also called *CARMA2*). Causative mutations in *CARD14* were described in 1 family of European decent, in 1 family of Taiwanese descent and in a Haitian child. Interestingly, some *CARD14* variants also predispose to psoriasis, and other *CARD14* mutations can cause familial pityriasis rubra pilaris (OMIM #173200).

ETIOLOGY AND PATHOGENESIS

CARD14 is primarily expressed in epidermal keratinocytes. CARD14 has multifactorial functions and activates the mitogen-activated protein kinase and

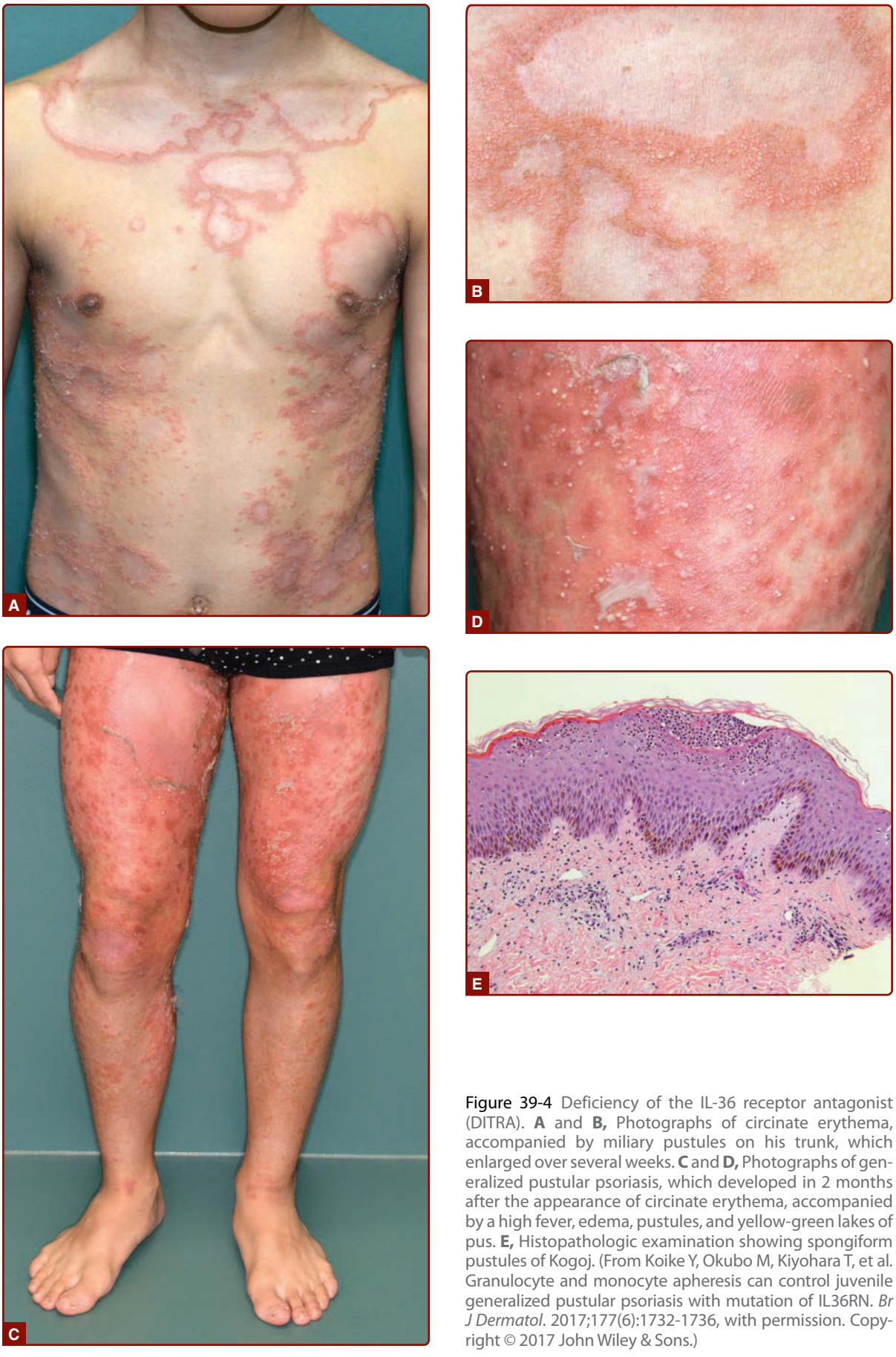

Figure 39-4 Deficiency of the IL-36 receptor antagonist (DITRA). **A** and **B,** Photographs of circinate erythema, accompanied by miliary pustules on his trunk, which enlarged over several weeks. **C** and **D,** Photographs of generalized pustular psoriasis, which developed in 2 months after the appearance of circinate erythema, accompanied by a high fever, edema, pustules, and yellow-green lakes of pus. **E,** Histopathologic examination showing spongiform pustules of Kogoj. (From Koike Y, Okubo M, Kiyohara T, et al. Granulocyte and monocyte apheresis can control juvenile generalized pustular psoriasis with mutation of IL36RN. *Br J Dermatol*. 2017;177(6):1732-1736, with permission. Copyright © 2017 John Wiley & Sons.)

nuclear factor-kappa B (NF-κB) signaling pathways. CAMPS/PSORS2-associated mutations are known to upregulate NF-κB activity.[29] This results in increased transcription of genes encoding psoriasis-associated cytokines and chemokines, including IL-8, IL-36γ, and C-C motif chemokine ligand 20 (CCL20) in keratinocytes.

CLINICAL FEATURES

Patients with CAMPS/PSORS2 can show various symptoms of common psoriasis, including plaque psoriasis and pustular psoriasis (Fig. 39-5).[30]

MANAGEMENT

Management remains to be defined, but one case of CAMPS/PSORS2 has been reported to be successfully treated with the IL-12/IL-23 antagonist ustekinumab.

FAMILIAL MEDITERRANEAN FEVER

AT-A-GLANCE

- Familial Mediterranean fever (FMF) is the most common and the first genetically characterized monogenic autoinflammatory disorder (OMIM #249100).
- FMF is caused by mutations in *MEFV*, the gene encoding pyrin.
- FMF is autosomal recessively inherited in most cases, but there is a less-common autosomal dominant form of FMF caused by mutations in *MEFV* (OMIM #134610).
- Mutations in *MEFV* lead to pyrin-inflammasome activation and subsequent abnormal IL-1β secretion.
- FMF is characterized by recurrent febrile attacks associated erysipelas-like skin lesions, peritonitis, pleuritis, and synovitis. These attacks last for 1 to 3 days.
- Erysipelas (cellulitis)-like skin lesions are a characteristic cutaneous feature of FMF.
- Histopathology of erysipelas-like skin lesions shows edema of the superficial dermis and a perivascular and interstitial neutrophilic infiltrate without vasculitis.
- Colchicine is very effective in preventing attacks and minimizing progression of amyloidosis.

EPIDEMIOLOGY

Familial Mediterranean fever (FMF; OMIM #249100) is an autosomal recessive disease characterized by recurrent attacks of fever and serosal inflammation.[31,32] FMF can affect individuals of any ethnic origin but the rates are highest in certain Mediterranean populations of Armenian, Sephardic-Jewish, Arabic, and Turkish ancestry. Of 200 people in these ethnic groups, 1 may develop the disease; 80% of cases are diagnosed before 10 years of age, and 90% before 20 years of age.

ETIOLOGY AND PATHOGENESIS

The gene responsible for FMF is the Mediterranean fever *(MEFV)* gene that encodes pyrin.[31,32] Pyrin is expressed predominantly in the cytoplasm of cells of myeloid lineage including neutrophils, along with synovial fibroblasts and dendritic cells. Pyrin can form an inflammasome together with adaptor proteins and subsequently activate caspase-1. Mutations in *MEFV* are thought to be gain-of-function mutations even though the homozygous or compound heterozygous mutations are required for inducing inflammation (gene–dosage effect is expected). Of note, there is a less-common autosomal dominant form of FMF caused by mutations in *MEFV* (OMIM #134610). Aberrant pyrin activity results in uncontrolled production of IL-1β. Pyrin is associated with microtubules and the microtubule-disrupting drug colchicine inhibits pyrin-inflammasome activation, as well as the neutrophil phagocytosis and chemotaxis.

CLINICAL FEATURES

FMF is characterized by recurrent short febrile attacks associated with peritonitis, pleuritis, synovitis and erysipelas-like skin lesions. Erysipelas-like skin lesions are well-demarcated, warm, tender, swollen, red skin lesions observed mainly on the front of the lower legs between the ankle and the knee, on the dorsum of the foot, or in the ankle region (Fig. 39-6A).[33,34] Typically, these attacks last for 1 to 3 days and occur randomly, from once per week to once in several months. Patients are completely well between the attacks. Cold exposure, fatigue, emotional stress, and menstruation may trigger an attack. Histopathology of the skin shows edema of the superficial dermis and a perivascular and interstitial neutrophilic infiltrate without vasculitis (Fig. 39-6B).

In infants, particularly children younger than age 2 years, fever alone can be the initial presenting symptom and typically progresses to include the other more specific symptoms by the age of 5 years,[35] which may

Figure 39-5 CARD14-mediated pustular psoriasis (CAMPS)/psoriasis 2 (PSORS2). The spectrum of clinical phenotypes of CAMPS/PSORS2. **A** and **B,** Generalized pustular psoriasis. **C,** Extensive plaque-type psoriasis. **D,** Mild plaque-type psoriasis involving the knees and elbows. **E,** Mild plaque-type psoriasis on the knees. (From Eskin-Schwartz M, Basel-Vanagaite L, David M, et al. Intra-familial variation in clinical phenotype of CARD14-related psoriasis. *Acta Derm Venereol.* 2016;96(7):885-887, used with permission.)

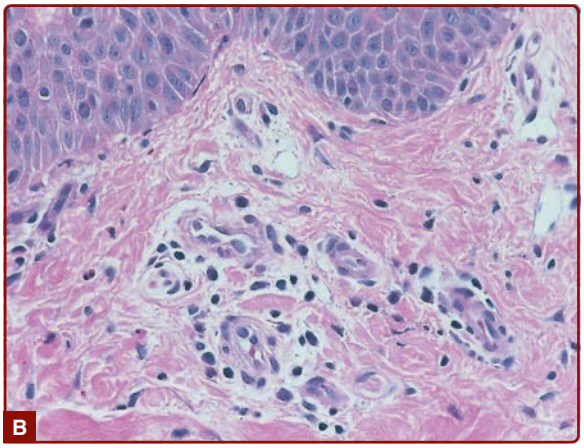

Figure 39-6 Familial Mediterranean fever (FMF). **A,** Erysipelas-like skin lesion on the right ankle showing sharply demarcated, swollen, bright erythematous skin. (From Azizi E, Fisher BK. Cutaneous manifestations of familial Mediterranean fever. *Arch Dermatol*. 1976;112(3):364-66, with permission. Copyright © 1976 American Medical Association. All rights reserved.) **B,** Histology of erysipelas-like skin lesion showing a perivascular inflammatory infiltrate in the superficial dermis.

be further complicated by the development of amyloidosis. Symptomatic pericarditis during the attacks may occur but is rare,[36,37] and echocardiography reveals small, clinically nonsignificant effusions that can be present during attacks.

DIAGNOSIS

The diagnosis of FMF relies mainly on clinical findings and it should be suspected in individuals with recurrent episodes of fever-associated erysipelas-like skin lesions and abdominal, pleural, and joint pain lasting 1 to 3 days. An increase in ESR, CRP, SAA, and fibrinogen, and low-grade neutrophilia are commonly observed during episodes.[38] Genetic testing for *MEFV* mutations provides confirmation in many patients, but not all patients bear identifiable mutations in *MEFV*. Clinicians should interpret all laboratory results in the context of the clinical situation.

DIFFERENTIAL DIAGNOSIS

The differential diagnosis varies depending on the patient's predominant clinical features. In patients with peritonitis, acute appendicitis may be suspected. In patients with joint pain and erythematous skin lesions, sJIA (Still disease) can be considered. However, sJIA has a daily fever pattern that does not resolve after several days. Spontaneous resolution of fever is a clue to the diagnosis of FMF. Erysipelas-like skin lesions can be the presenting feature of FMF and may be misdiagnosed as infectious erysipelas or cellulitis. FMF also needs to be distinguished from other familial fever syndromes including tumor necrosis factor receptor-associated periodic syndrome (TRAPS), HIDS, and CAPS.

CLINICAL COURSE AND PROGNOSIS

FMF is a lifelong disease and, as of this writing, cannot be cured. The symptoms and severity vary among affected individuals. The most-severe complication is secondary amyloidosis, which can lead to renal failure, a major cause of mortality in patients with FMF.[38] There is a poor correlation between the severity or frequency of attacks and the extent of amyloidosis. Patients can present with renal amyloidosis as the first and only manifestation of FMF. The use of colchicine markedly decreases the incidence of amyloidosis.

MANAGEMENT

Colchicine is primarily effective in preventing attacks, minimizing subclinical inflammation between attacks and preventing the development and progression of amyloidosis.[39] Colchicine is recommended in all patients regardless of the frequency and intensity of attacks. Some patients do not have improvement with colchicine and some do not tolerate the drug mainly because of its gastrointestinal side effects. Elderly patients and those with renal impairment treated with colchicine may develop myopathy or neuropathy.[40] In these cases, IL-1 antagonists, including canakinumab (human anti–IL-1β monoclonal antibody), are the second-line therapy.

HYPERIMMUNOGLOBULINEMIA D WITH PERIODIC FEVER SYNDROME/MEVALONATE KINASE DEFICIENCY

AT-A-GLANCE

- Hyperimmunoglobulinemia D with periodic fever syndrome (HIDS)/mevalonate kinase deficiency (MKD) is a rare autosomal recessive disorder (OMIM #260920).
- HIDS/MKD is caused by mutations in *MVK*, the gene coding mevalonate kinase that is involved in many cellular functions via cholesterol and isoprenoid biosynthesis.
- Mutations of *MVK* lead to reduced mevalonate kinase enzyme activity, which results in the production of IL-1β via a complex mechanism.
- Mevalonic aciduria (OMIM #610377) is a severe and fatal form of HIDS/MVK in which the enzyme activity of mevalonate kinase is below 1%.
- Attacks manifest as high, spiking fever accompanied with abdominal pain, diarrhea, vomiting, headache, joint pain, cervical lymphadenopathy, skin lesions, and in 50% of patients oral aphthous ulcers with or without genital ulceration.
- Most common skin lesions are widespread erythematous macules and papules.
- Typically, these attacks last 3 to 7 days, cease spontaneously, and recur every 4 to 8 weeks.
- Since 2016 specific therapy is available and FDA-approved for HIDS: anti–IL-1 therapy with canakinumab.

EPIDEMIOLOGY

Hyperimmunoglobulinemia D with periodic fever syndrome (HIDS; OMIM #260920)/mevalonate kinase deficiency (MKD) is an inherited disease characterized by recurrent attacks of fever, abdominal pain, and skin lesions. HIDS can affect individuals of any ethnic origin but the incidence is much higher in The Netherlands, where 1 in 350 people carry the recessive gene mutation, and the north of France.[41,42] Patients with HIDS typically present clinical initial symptoms during the first year of life.

ETIOLOGY AND PATHOGENESIS

HIDS is an autosomal recessive disorder caused by mutations in the *MVK* gene, which encodes mevalonate kinase, an enzyme involved in many cellular functions via cholesterol and isoprenoid biosynthesis.[41-43] In HIDS, the gene mutations result in reduced enzyme activity, ranging from 1% to 10% of normal levels, and subsequent overproduction of IL-1β via a complex mechanism.[44,45] Mevalonic aciduria (OMIM #610377), a more severe form of MKD with enzyme activity below 1%, is fatal at an early age.[46,47]

CLINICAL FEATURES

Attacks manifest as high, spiking fever preceded by chills accompanied by abdominal pain, diarrhea, vomiting, headache, joint pain, cervical lymphadenopathy, and skin lesions.[48] Episodes last 3 to 7 days, recover spontaneously, and recur every 4 to 8 weeks, although the interval between attacks can vary significantly even in the same patient. Onset is usually before the age of 5 years. The flares are generally triggered by immunizations, trauma including surgery or physical and emotional stress.

There is no specific cutaneous manifestation of HIDS, but more than 80% of patients have skin lesions during an acute attack.[48,49] Widespread erythematous macules and papules are the most common, followed in frequency by urticaria, annular erythema, erythematous nodules, and petechiae (Fig. 39-7). Acral lesions occur more frequently than truncal lesions. Half of patients may also have oral aphthous ulcers with or without genital ulceration. Skin biopsies typically demonstrate a nonspecific perivascular lymphocytic infiltrate with some neutrophils.

The more-severe form of MKD mevalonic aciduria is clinically characterized by periodic fever, severe neurologic impairment, severe growth retardation, and early death.

DIAGNOSIS

The diagnosis of HIDS is usually suspected clinically, but the definitive diagnosis is made by genetic testing. Laboratory investigations during attacks show elevated ESR, CRP, and neutrophilic leukocytosis. This may persist at lower levels between attacks but laboratory tests can normalize completely. The most typical finding is the consistently elevated serum IgD level, although approximately 20% of patients can

Figure 39-7 Hyperimmunoglobulinemia D with periodic fever syndrome (HIDS)/mevalonate kinase deficiency (MKD). Erythematous macules and papules distributed over both palms, arms, legs, and trunk (not shown) during an attack of HIDS/MKD. (From Takada K, Aksentijevich I, Mahadevan V, et al. Favorable preliminary experience with etanercept in two patients with the hyperimmunoglobulinemia D and periodic fever syndrome. *Arthritis Rheum.* 2003;48:2645-2651. Copyright © 2003 by the American College of Rheumatology. Reprinted with permission of Wiley-Liss, Inc., a subsidiary of John Wiley & Sons, Inc.)

have normal levels; 80% of HIDS patients present with increased IgA levels as well. Increased IgD levels alone is not specific for HIDS and can be found in other autoinflammatory diseases, including FMF and TRAPS. The presence of oral aphthous ulcers in patients with recurrent fever episodes should lead to consideration of HIDS diagnosis.

DIFFERENTIAL DIAGNOSIS

The differential diagnosis includes other causes of recurrent severe abdominal pain such as appendicitis or of periodic fever. FMF, which also presents with recurrent fever and abdominal pain, is sometimes indistinguishable. The effectiveness of colchicine in FMF can greatly help in making a correct diagnosis. Other autoinflammatory diseases, including TRAPS and MWS, should be eliminated. Oral and genital ulceration frequently seen in HIDS can lead to the misdiagnosis of Behçet disease (BD), but BD is rarely present in infants and has other diagnostic features such as uveitis and bipolar aphthosis.

CLINICAL COURSE AND PROGNOSIS

Long-term prognosis of HIDS is good and patients rarely suffer from serious physical complications of the disease, with the one exception of amyloidosis. Amyloidosis is quite rare in HIDS and all affected patients have an over 20 year-long history of attacks.

MANAGEMENT

The goal of management is to alleviate symptoms and improve quality of life. No one specific treatment for HIDS exists.[50] NSAIDs alleviate the severity and duration of fever in most patients. In patients refractory to NSAIDs, oral glucocorticoids are beneficial in reducing severity of attacks when given at the onset of an attack. Colchicine is not effective in HIDS. Anakinra (recombinant IL-1Ra) also has been successful in some cases as has the tumor necrosis factor (TNF)-α inhibitor etanercept. Canakinumab (human anti–IL-1β monoclonal antibody) has been used successfully in an increasing number of cases of HIDS. Canakinumab is longer-acting than anakinra and is administrated subcutaneously every 4 to 8 weeks. Canakinumab became the first FDA-approved biologic treatment for patients with HIDS in 2016.[51]

TUMOR NECROSIS FACTOR RECEPTOR-ASSOCIATED PERIODIC SYNDROME

AT-A-GLANCE

- TRAPS is a rare autosomal dominant disorder (OMIM #142680).
- TRAPS is caused by mutations in *TNFRSF1A*, the gene coding TNF receptor-1 (TNFR1).
- The mechanism by which the mutations in *TNFRSF1A* cause TRAPS is not well understood.
- Although attacks typically last for 3 weeks and recur every 6 weeks, duration and frequency vary greatly among individuals.
- The episodes usually occur spontaneously, but infection, minor injury, stress, or exercise may be triggers.
- Attacks are characterized by recurrent episodes of high-grade fever, myalgia, serositis, periorbital edema, conjunctivitis, and skin lesions.
- Various types of skin lesions occur, most frequently erythematous patches and plaques that can be migratory and associated with underlying myalgia.
- Histopathology of skin lesions is nonspecific, characterized by a perivascular dermal infiltrate of lymphocytes and monocytes.

EPIDEMIOLOGY

TNF receptor-associated periodic syndrome (TRAPS; OMIM #142680) is an autosomal dominant disease with episodes of recurrent fever, abdominal, chest, and muscle pain, and skin lesions that typically last for 3 weeks.[52] TRAPS was first described in a family of Irish-Scottish background and initially termed *familial Hibernian fever*. This disease has now been seen in almost all ethnic groups. TRAPS is the second most common known inherited periodic fever syndrome following FMF. More than 1000 patients have been diagnosed worldwide. About half of the patients with TRAPS have no family history. Most patients present before the age of 10 years, but approximately 10% of patients present after the age of 30 years.

ETIOLOGY AND PATHOGENESIS

TRAPS is caused by mutations of the *TNFRSF1A* gene that encodes the TNF receptor-1 (TNFR1).[52] TNFR1 is expressed on leukocytes and endothelial cells. TNFR1 is the main mediator of signaling by TNF-α and it can signal via 2 distinct pathways that lead to either apoptosis via caspase activation or to inflammation via activation of NF-κB. The pathogenic mechanism by which *TNFRSF1A* mutations lead to the autoinflammatory phenotype of TRAPS is not well understood. Several mechanisms have been proposed, including impaired TNFR shedding from the cell membrane, reduced ligand binding and defective apoptotic signaling. A murine knock-in model suggests that mutations in *TNFRSF1A* result in abnormal TNFR1 oligomerization, which sensitizes cells to stimuli such as lipopolysaccharide, resulting in enhanced activation of mitogen-activated protein kinases and increased synthesis of proinflammatory cytokines.[53]

CLINICAL FEATURES

Patients with TRAPS present recurrent episodes of high-grade fever with chills that typically last for 3 weeks. The duration and frequency of the episodes varies greatly among affected individuals. The fever can last from a few days to a few months. The frequency of recurrence can range from every 6 weeks to every few years. Occasionally, the patient may have no fevers for years. The episodes usually occur spontaneously, but infection, minor injury, stress, or exercise may be triggers. During episodes of fever, patients with TRAPS can present additional symptoms. Abdominal pain with nausea, vomiting, and diarrhea caused by sterile peritonitis are common. Most patients experience myalgia resulting from a monocytic fasciitis with a sensation of deep cramping that is migratory from the torso and the proximal limb toward the distal arms and legs. Headaches, serositis, monoarticular arthritis, and conjunctivitis are also observed.

Figure 39-8 Tumor necrosis factor receptor-associated periodic syndrome (TRAPS). Migratory erythematous eruption on the right leg of a patient with TRAPS.

Various types of skin lesions occur in TRAPS, including discrete erythematous macules and papules, erythematous patches, edematous or urticarial plaques, aphthous ulcers, and periorbital edema with conjunctivitis, some of which are migratory and associated with underlying myalgia (Fig. 39-8).[54,55] The foregoing symptoms can greatly vary both between and within individuals. Histologically, skin lesions in TRAPS are nonspecific, characterized by a perivascular dermal infiltrate of lymphocytes and monocytes.

DIAGNOSIS

The diagnosis of TRAPS relies mainly on clinical findings when recurrent long-lasting febrile attacks occur accompanied by abdominal pain and the characteristic migratory muscle pain with overlying skin lesions. Elevated levels of ESR, CRP, SAA, fibrinogen, and leukocytosis are typically present during attacks. Serum levels of soluble TNF receptor superfamily 1A may be low. The diagnosis of TRAPS is confirmed by genetic testing, but a rare mutation negative TRAPS-like phenotype also has been reported in familial and sporadic cases.

DIFFERENTIAL DIAGNOSIS

The differential diagnosis of TRAPS includes other diseases characterized by periodic fever such as FMF, HIDS, sJIA (Still disease), BD, and MWS. Fever attacks are usually longer in TRAPS than in other autoinflammatory diseases, such as FMF, HIDS, and MWS. HIDS often presents with lymphadenopathy, which is not present in TRAPS or FMF.

CLINICAL COURSE AND PROGNOSIS

With age, fever attacks may decrease in intensity and become more chronic. Approximately 10% to 15% of TRAPS cases will suffer from amyloidosis as a consequence of tissue deposition of SAA. Renal deposition of SAA leads to proteinuria and can progress to renal failure.

MANAGEMENT

NSAIDs help relieve symptoms. High-dose corticosteroids are often effective but sustained usage is associated with known side effects. The TNF-α inhibitor etanercept is an effective treatment in some patients but it can trigger severe episodes of inflammation.[56] Recent evidence suggest that anakinra (recombinant IL-1Ra) and canakinumab (human anti–IL-1β monoclonal antibody) are more effective and provide optimal control of the inflammatory manifestations over the long term.[57,58], The FDA approved canakinumab for the treatment of TRAPS in 2016.

HAPLOINSUFFICIENCY OF A20

AT-A-GLANCE

- Haploinsufficiency of A20 (HA20) is a rare autosomal dominant disorder (OMIM #616744).
- HA20 is caused by loss-of-function mutations in *TNFAIP3* gene, the gene encoding A20/TNFAIP3.
- Mutant A20/TNFAIP3 proteins act through haploinsufficiency. Mutant A20/TNFAIP3 leads to increased K63 ubiquitination and increased NF-κB–dependent proinflammatory cytokines.
- The symptoms of HA20 are indistinguishable from BD, a genetically complex disorder with early adult onset.

EPIDEMIOLOGY

Haploinsufficiency of A20 (HA20; OMIM #616744) is a rare autosomal dominant disorder characterized by features indistinguishable from BD, which is thought to result from a combination of common genetic variants with low effect. HA20 is thus considered as a part of the BD spectrum.[59-61] Reported cases so far originate from Europe, Turkey, and Japan. The percentage of BD patients that can be explained by HA20 remains to be determined.

ETIOLOGY AND PATHOGENESIS

HA20 is caused by loss-of-function mutations in *TNFAIP3* gene. TNFAIP3, also known as A20, is an ubiquitin-editing enzyme that targets K63-linked ubiquitin chains and negatively regulates both the NF-κB signaling pathway and the NLRP3-inflammasome. Mutant A20/TNFAIP3 proteins act through haploinsufficiency and increase NF-κB–dependent proinflammatory cytokines.[59,60] Interestingly, in addition to BD, *TNFAIP3* has been identified as a susceptibility locus in many chronic inflammatory disorders including rheumatoid arthritis, systemic lupus erythematosus, and inflammatory bowel disease.[60]

CLINICAL FEATURES

Symptoms of HA20 start in childhood or early adulthood. Clinical manifestations of HA20 resemble BD, presenting with fevers, bipolar ulceration of mucosal surfaces, particularly in the oral and genital areas, skin lesions, uveitis, and polyarthritis. The skin lesions include erythematous papules, pseudofolliculitis, erythema nodosum-like lesions, and pathergy (Fig. 39-9).[59-61] These patients may also develop retinal

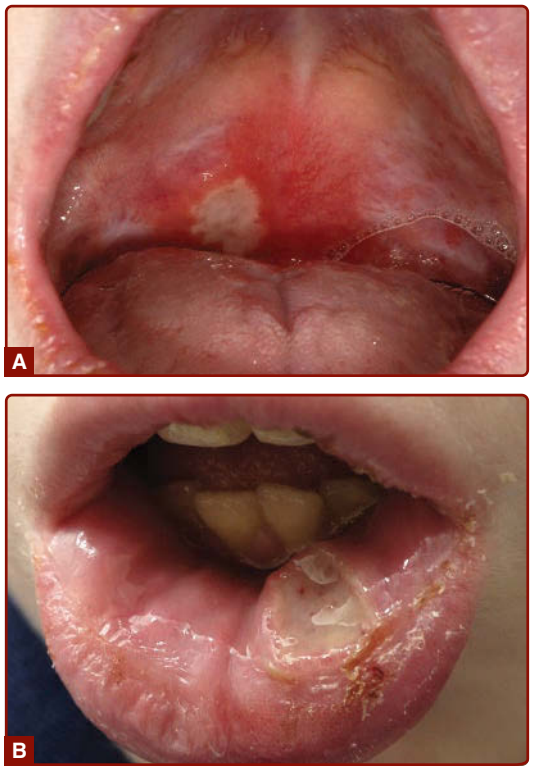

Figure 39-9 HA20. **A** and **B,** Recurrent oral ulcers. (Reprinted by permission from Springer Nature: Zhou Q, Wang H, Schwartz DM, et al. Loss-of-function mutations in TNFAIP3 leading to A20 haploinsufficiency cause an early-onset autoinflammatory disease. *Nat Genet*. 2016;48(1): 67-73. Copyright © 2016.)

vasculitis, gastrointestinal ulcers, and CNS vasculitis. Autoantibodies to nuclear antigens, ribonucleoprotein, double-stranded DNA, and the lupus anticoagulant can be found.[59]

DIAGNOSIS

The diagnosis is based on clinical findings and genetic testing for *TNFAIP3* gene mutations.

MANAGEMENT

Colchicine is effective in some patients with HA20 but not in all patients. TNF-α antagonists and IL-1R antagonists are reported to work with variable efficacy.[59-61] Future investigations are needed.

OTULIPENIA/OTULIN-RELATED AUTOINFLAMMATORY SYNDROME

AT-A-GLANCE

- Otulipenia/OTULIN-related autoinflammatory syndrome (ORAS) is a rare autosomal recessive disorder (OMIM #617099).
- Otulipenia/ORAS is caused by loss-of-function mutations in *OTULIN*.
- Mutant OTULIN leads to increased linear ubiquitination and elevated NF-κB–dependent proinflammatory transcripts.
- Patients suffer from early-onset severe systemic inflammation, including prolonged fever, rash, arthralgia, diarrhea, and progressive lipodystrophy.
- Relapsing nodular panniculitis with neutrophil infiltrate are typically observed.
- Otulipenia/ORAS can be treated with TNF-α inhibitor.

EPIDEMIOLOGY

The epidemiology of otulipenia/OTULIN-related autoinflammatory syndrome (ORAS) (OMIM #617099) is not known. Six patients have been reported and they are offspring of consanguineous relations. Two are of Turkish descent and one of Pakistani descent.[62,63]

ETIOLOGY AND PATHOGENESIS

Otulipenia/ORAS is inherited in an autosomal recessive fashion and caused by loss-of-function mutations in the *OTULIN* (also known as *GUMBY/FAM105B*) gene. OTULIN is a deubiquitinase that negatively regulates the NF-κB signaling pathway by cleaving linear ubiquitin chains, whereas A20 deubiquitinase does so by cleaving K63 ubiquitin chains. The mutant OTULIN is less stable and active, leading to activation of the NF-κB pathway and increased expression of proinflammatory transcripts in immune cells, particularly in myeloid cells.

CLINICAL FEATURES

Within days to months after birth, patients present with severe systemic inflammation, manifesting with prolonged fever, rash, arthralgia, diarrhea, progressive lipodystrophy, and developmental delay. Relapsing nodular panniculitis with neutrophil infiltrate and erythematous and pustular rash are observed in the skin. Skin biopsy demonstrates neutrophilic dermatitis and panniculitis. One patient showed septal panniculitis with vasculitis of small-sized and medium-sized blood vessels.

MANAGEMENT

Otulipenia/ORAS can be treated with TNF-α inhibitor. According to the literature, 3 patients treated with TNF-α inhibitor responded well. Variable or no efficacies have been reported with systemic steroids and anakinra (IL-1Ra). Two of 6 patients, neither of whom were treated with TNF-α inhibitor, died at the ages of 1 and 5 years old from pneumococcal septicemia, and acute renal failure and pulmonary edema, respectively.

CHRONIC ATYPICAL NEUTROPHILIC DERMATOSIS WITH LIPODYSTROPHY AND ELEVATED TEMPERATURE SYNDROME/PROTEASOME-ASSOCIATED AUTOINFLAMMATORY SYNDROME

AT-A-GLANCE

- Chronic atypical neutrophilic dermatosis with lipodystrophy and elevated temperature (CANDLE)/proteasome-associated autoinflammatory syndrome (PRAAS) is a rare autosomal recessive disorder (OMIM #256040).
- CANDLE/PRAAS is caused by homozygous or compound heterozygous mutations in *PSMB8*.
- Mutant PSMB8 results in dysregulated proteasome activity and increased interferon signaling.
- Recurrent fever, pernio-like and nodular erythema-like eruptions, long, clubbed fingers, and progressive lipodystrophy are characteristic features.

EPIDEMIOLOGY

Chronic atypical neutrophilic dermatosis with lipodystrophy and elevated temperature (CANDLE)/proteasome-associated autoinflammatory syndrome (PRAAS) is a rare inflammatory disease characterized by early-onset recurrent fever, pernio-like and nodular erythema-like eruptions, and lipomuscular atrophy.[64] This disorder was first reported in 1939 and has been described under different terms in the past, such as: Nakajo-Nishimura syndrome (OMIM #256040); joint contractures, muscle atrophy, hepatomegaly, splenomegaly, microcytic anemia, and panniculitis-induced lipodystrophy syndrome (OMIM #256040); Japanese autoinflammatory syndrome with lipodystrophy (OMIM #256040); and CANDLE syndrome (OMIM #256040). The discovery of *PSMB8* mutations in these disorders unified them within 1 spectrum of disease, also referred to as PRAAS. Approximately 60 cases have been reported in Japanese, white, Spanish, Hispanic, Jewish, and Bangladeshi families.

ETIOLOGY AND PATHOGENESIS

Autosomal recessive homozygous or compound heterozygous mutations in the proteasome subunit β8 (*PSMB8*) gene cause disorders in most cases. Of note, digenic inheritance of *PSMB8* with additional mutations of proteasome subunits including *PSMA3*, *PSMB4*, *PSMB9*, and proteasome maturation protein (*POMP*) was reported.[65] These mutations variably affect proteasome assembly and maturation, leading to an accumulation of ubiquitinated and oxidized proteins in the cell. This cell stress causes increased production of type I interferon and reactive oxygen species, resulting in a vicious cycle of increased interferon signaling.

CLINICAL FEATURES

Signs and symptoms of CANDLE/PRAAS generally develop during the first year of life. Common clinical features include recurrent fever and pernio-like and nodular erythema-like eruptions that last for a few days or weeks. Later during infancy, patients develop long, clubbed fingers and toes with joint contractures and progressive lipomuscular atrophy mainly in the face and upper limbs. (Refer to Fig. 74-2 A-E.) Other variable features include periorbital erythema and edema, myositis, short statue, lymphadenopathy, hepatosplenomegaly, and basal ganglia calcification.

DIAGNOSIS

Chronic anemia and an elevated CRP and ESR are typically present. Variable hypergammaglobulinemia and elevation of IgG, IgE, IgA, and IgM are present in the serum of CANDLE/PRAAS patients. Autoimmune features, including antinuclear antibody and other autoantibodies are also variable.

The common histologic feature of pernio-like and nodular erythema-like eruptions is a dense dermal infiltration of mononuclear cells, histiocytes, eosinophils, and neutrophils in the perivascular and interstitial areas of dermis and subcutaneous fat. There is no evidence of leukocytoclastic vasculitis.

Diagnostic confirmation is achieved by genetic testing for *PSMB8*.

CLINICAL COURSE AND PROGNOSIS

CANDLE/PRAAS is a lifelong disease with fluctuation in disease severity. Life expectancy can be reduced as a result of systemic inflammation. Quality of life

is often hampered by recurrent episodes of severe inflammation and reduced activity.

MANAGEMENT

There is no effective treatment to date for CANDLE/PRAAS. Systemic steroids can temporally improve pernio-like and nodular erythema-like eruptions, but they often return after tapering. Lipodystrophy usually remains unchanged with systemic steroids. Various antirheumatic and immunosuppressant drugs, including anakinra (IL-1Ra), tocilizumab (IL-6Ra), TNF-α inhibitor, methotrexate, hydroxychloroquine, azathioprine, cyclosporine, and tacrolimus, have no effect or result in only transient clinical improvement.

BLAU SYNDROME/ EARLY-ONSET SARCOIDOSIS

AT-A-GLANCE

- Blau syndrome (BS; OMIM #186580) is a rare autosomal dominant disorder; early-onset sarcoidosis (EOS; OMIM #609464) is a sporadic form of Blau syndrome.
- BS/EOS are caused by mutations in *NOD2*, the gene encoding NOD2.
- The mechanism by which the gain-of-function mutations in *NOD2* cause BS/EOS is unknown.
- Granulomatous dermatitis is typically the first sign of BS/EOS, occurring before 4 years of age.
- Histopathology is characterized by noncaseating granulomas composed of histiocytes and multinucleated giant cells located in the upper dermis.
- Characteristic arthritis (articular synovitis and tenosynovitis) and uveitis are common, but disease activity varies greatly among individuals.

EPIDEMIOLOGY

Blau syndrome (BS; OMIM #186580) and early-onset sarcoidosis (EOS; OMIM #609464) are rare inflammatory disorders that primarily affect the skin, joints, and eyes.[66] Although previously considered as distinct entities, BS and EOS are now recognized as familial and sporadic phenotypes of the same granulomatous disease.[67,68] BS is inherited in an autosomal dominant fashion and classically presents before the age of 4 years as a triad of granulomatous dermatitis, arthritis, and uveitis. The incidence and prevalence of BS/EOS is unknown.

ETIOLOGY AND PATHOGENESIS

BS/EOS is a monogenic disease resulting from gain-of-function mutations in *NOD2* (also known as *CARD15*). NOD2 is one of the NLRs, a family of cytoplasmic pattern recognition receptors.[69] NOD2 is mainly expressed in the cytoplasm of monocytes, macrophages, granulocytes, and dendritic cells. NOD2 recognizes muramyl dipeptide, a cell wall component of both Gram-positive and Gram-negative bacteria. This leads to activation of downstream transcriptional factors (NF-κB and mitogen-activated protein kinase) and secretion of inflammatory cytokines. The mechanism by which the gain-of-function mutations in *NOD2* induce BS/EOS is largely unknown.

CLINICAL FEATURES

Granulomatous dermatitis is typically the first sign of BS/EOS.[70,71] The skin lesions are asymptomatic, slightly scaly, discrete, yellowish to brown-red flat-topped papules on the trunk and extremities, observed in more than 90% of patients, classically children before the age of 4 years (Fig. 39-10A). Histologically, noncaseating granulomas composed of periodic acid-Schiff–positive histiocytes and multinucleated giant cells located in the upper dermis are characteristic (Fig. 39-10B). Bilateral hilar lymphadenopathy, often present in sarcoidosis, is absent in BS/EOS patients. Approximately 95% of patients have arthritis, which usually becomes clinically apparent within the first decade of life.[72] Arthritis in BS/EOS has a characteristic phenotype of chronic, symmetrical, and mostly painless polyarthritis that manifests as intraarticular synovitis and tenosynovitis (Fig. 39-10C). Joint range of motion is relatively preserved but impairment of physical function can occur. An insidious granulomatous iridocyclitis and posterior uveitis can develop into panuveitis. The usual ophthalmologic complaints are photophobia, blurred vision, and ocular pain. Eye involvement is usually bilateral and significant visual loss is observed in 20% to 30% of the affected individuals.

DIAGNOSIS

Diagnosis relies greatly on the demonstration of noncaseating granulomas in biopsies from skin, eye, and/or synovium of affected joints. Diagnostic confirmation is achieved by genetic testing for *NOD2* mutations. Familial history is a key element in defining BS. Musculoskeletal ultrasound is a useful diagnostic tool for detecting characteristically affected joints, as well as monitoring disease activity.[72]

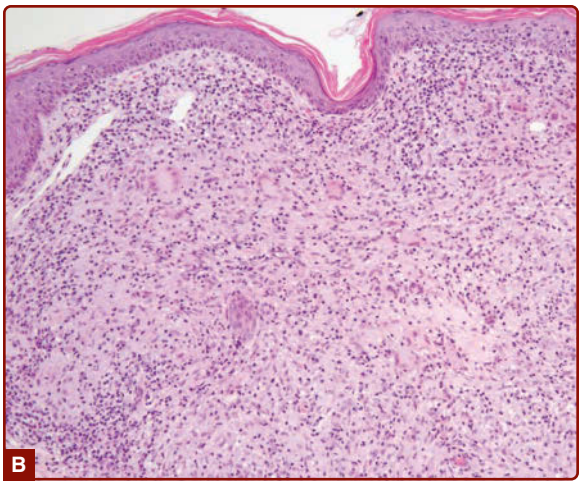

Figure 39-10 Blau syndrome (BS)/early-onset sarcoidosis (EOS). **A,** Generalized orange-brownish asymptomatic lichenoid papules at the age of 12 months. (From Stoevesandt J, Morbach H, Martin TM, et al. Sporadic Blau syndrome with onset of widespread granulomatous dermatitis in the newborn period. *Pediatr Dermatol.* 2010;27(1): 69-73, with permission. Copyright © 2010 John Wiley & Sons.) **B,** Histology of the skin. A noncaseating epithelioid granulomas in the dermis accompanied by some multinucleated giant cells. (From Kambe N, Nishikomori R, Kanazawa N. The cytosolic pattern-recognition receptor Nod2 and inflammatory granulomatous disorders. *J Dermatol Sci.* 2005;39(2):71-80, with permission. Copyright © Elsevier.) **C,** The characteristic polyarthritis involves a thick granulomatous intraarticular synovitis and tenosynovitis, causing a boggy appearance in fingers and wrists. (From Ikeda K, Kambe N, Satoh T, et al. Preferentially inflamed tendon sheaths in the swollen but not tender joints in a 5-year-old boy with Blau syndrome. *J Pediatr.* 2013;163(5):1525.e1, with permission. Copyright © Elsevier.)

DIFFERENTIAL DIAGNOSIS

Some children with BS/EOS may be misdiagnosed as sJIA (Still disease) because of similar clinical symptoms and disease course.

CLINICAL COURSE AND PROGNOSIS

BS/EOS is a chronic and progressive disease, but disease activity may fluctuate over time. A large spectrum of disease severity exists. Uveitis can be the most difficult manifestation to treat and is the main cause of long-term complications.

MANAGEMENT

Evidence concerning the optimal treatment for BS/EOS is lacking. Low-dose corticosteroid therapy is generally satisfactory during the quiescent stage. Systemic corticosteroids, immunosuppressants and biologics, mostly TNF antagonists,[73] are often combined to control both uveitis and arthritis. Methotrexate can be effective in suppressing arthritis and allowing corticosteroid tapering. IL-1 antagonists have been used with variable clinical outcomes.

PYOGENIC ARTHRITIS, PYODERMA GANGRENOSUM, AND ACNE SYNDROME

AT-A-GLANCE

- Pyogenic arthritis, pyoderma gangrenosum, and acne (PAPA) syndrome is a rare autosomal dominant disorder (OMIM #604416).
- PAPA syndrome is caused by mutations in *PSTPIP1*, the gene encoding PSTPIP1 (proline-serine-threonine phosphatase interacting protein 1).
- PSTPIP1 can interact with pyrin, mutations of which cause FMF. Although mutant PSTPIP1 has been proposed to have increased binding to pyrin and thus induce overproduction of IL-1β via the inflammasome, the exact molecular pathogenesis of PAPA syndrome remains unclear.
- Pyoderma gangrenosum, severe nodulocystic acne, and pyogenic arthritis are the clinical features.
- Cutaneous manifestations present at the time of puberty.
- Although TNF-α antagonists and IL-1Ra have shown efficacy in some patients, the treatment of PAPA syndrome remains challenging.

EPIDEMIOLOGY

Pyogenic arthritis, pyoderma gangrenosum, and acne syndrome (PAPA syndrome; OMIM #604416) is a rare pleiotropic autoinflammatory disorder characterized by early onset of recurrent sterile arthritis with neutrophilic infiltrates, with variable skin involvement including pyoderma gangrenosum and severe nodulocystic acne in adolescence and beyond.[74]

ETIOLOGY AND PATHOGENESIS

PAPA syndrome is an autosomal dominant disease caused by mutations in the *PSTPIP1* gene, previously known as *CD2BP1*.[74] Proline-serine-threonine phosphatase interacting protein 1 (PSTPIP1) is primarily expressed on hematopoietic cells and involved in the regulation of the actin cytoskeleton. PSTPIP1 has been demonstrated to interact with pyrin, the protein encoded by the *MEFV* gene, mutations of which cause FMF.[75] It is proposed that mutant PSTPIP1 has increased binding to pyrin, leading to overproduction of IL-1β via inflammasome activation. However, colchicine, which can inhibit the pyrin-inflammasome activation and is an effective remedy for FMF, is ineffective in treating PAPA syndrome. To understand the exact role of PSTPIP1 in PAPA syndrome, further studies are needed.

CLINICAL FEATURES

The clinical manifestations of this disorder include sterile pyogenic arthritis, pyoderma gangrenosum, and nodulocystic acne.[74] Arthritis begins in the first decade of life and is progressively destructive. The inflammatory episodes often begin unprovoked or after minor trauma, leading to neutrophil-rich purulent synovial inflammation. Patients with arthritis sometimes require aspiration, intraarticular corticosteroids, or drainage. During episodes of arthritis patients may present with fever. The cutaneous symptoms, pyoderma gangrenosum and severe acne, develop at the time of puberty. Pyoderma gangrenosum presents as poorly healing ulcers with typical undermined edges (Fig. 39-11). It often occurs at sites of injury and can manifest in a multifocal fashion on the entire skin surface. Severe nodulocystic acne affects most individuals with PAPA syndrome to a variable degree. Nodulocystic acne can cause scarring if untreated. Fever is rarely observed.

DIAGNOSIS

The diagnosis of PAPA syndrome should be suspected in individuals with relapsing sterile arthritis, cutaneous ulcer formation, and severe acne. Laboratory investigations during attacks show elevated acute

Figure 39-11 Pyogenic arthritis, pyoderma gangrenosum, and acne (PAPA) syndrome. Pyoderma gangrenosum of the neck in PAPA syndrome. (From Brenner M, Ruzicka T, Plewig G, et al. Targeted treatment of pyoderma gangrenosum in PAPA (pyogenic arthritis, pyoderma gangrenosum and acne) syndrome with the recombinant human interleukin-1 receptor antagonist anakinra. *Br J Dermatol.* 2009;161(5):1199-1201, with permission. Copyright © 2009 John Wiley & Sons.)

phase reactants. The diagnosis is confirmed by genetic testing for *PSTPIP1*.

DIFFERENTIAL DIAGNOSIS

sJIA (Still disease), FMF, synovitis, acne, pustulosis, hyperostosis, and osteitis (SAPHO) syndrome, and Majeed syndrome should be excluded. The autosomal dominant hereditary pattern in PAPA syndrome can help in suspecting the diagnosis.

CLINICAL COURSE AND PROGNOSIS

Typically, the symptoms get milder with age. However, the long-term prognosis is not well known because of the rarity of the disease. Joint destruction can be the main cause of long-term complications.

MANAGEMENT

The treatment of PAPA syndrome is challenging as the response to therapy varies greatly between patients. In the case of severe pyogenic arthritis, drainage of synovial fluid along with intraarticular steroid injections can help relieve pain. High-dose corticosteroids work well on arthritis and pyoderma gangrenosum, but often worsen the acne and their sustained usage can lead to cumulative side effects. TNF-α antagonist (etanercept) and IL-1Ra (anakinra) therapy have been reported to be effective in some patients with PAPA syndrome.[76,77] Further clinical evidence is, however, required.

MAJEED SYNDROME

AT-A-GLANCE

- Majeed syndrome is a rare autosomal recessive disorder (OMIM #609628).
- Majeed syndrome is caused by mutations of the *LPIN2* gene, the gene encoding lipin-2.
- The mechanism by which *LPIN2* mutation causes Majeed syndrome is not well understood.
- The symptom triad of Majeed syndrome is chronic recurrent multifocal osteomyelitis (CRMO), congenital dyserythropoietic anemia (CDA), and neutrophilic dermatosis resembling Sweet syndrome.

EPIDEMIOLOGY

Majeed syndrome (OMIM #609628) is a rare autosomal recessive disorder characterized by the triad of chronic recurrent multifocal osteomyelitis (CRMO), congenital dyserythropoietic anemia (CDA), and neutrophilic dermatosis.[78] To date, only a small number of families from the Middle East have been identified to harbor the mutation.[79]

ETIOLOGY AND PATHOGENESIS

Majeed syndrome is caused by mutations of the *LPIN2* gene that encodes lipin-2.[79] Lipin-2 is thought to be involved in glycerolipid biosynthesis, controlling inflammation and cell division, but the physiologic role of lipin-2 remains only partially understood. Mutations in the *LPIN2* gene alter the structure and function of lipin-2. Homozygotes and compound heterozygotes of nonsense and missense mutations have been identified.

CLINICAL FEATURES

CRMO begins in infancy or early childhood with recurrent episodes of pain and joint swelling. These symptoms typically persist into adulthood and can lead to short stature and joint contractures. CDA presents as hypochromic, microcytic anemia during the first year of life and ranges from mild to transfusion dependent. Most people with Majeed syndrome also develop neutrophilic dermatosis, resembling Sweet syndrome with unknown onset age and frequency. Patients can also develop erythematous plaques, psoriasis, and pustulosis. Histology of skin lesions shows dermal neutrophilic infiltration with papillary dermal edema similar to that observed in Sweet syndrome without histologic evidence of vasculitis.

DIAGNOSIS

The diagnosis is based on clinical findings and genetic testing for *LPIN2* gene mutations. Radiographs show osteolytic lesions with surrounding sclerosis. Bone biopsies are necessary to exclude infectious osteomyelitis. Bone and blood cultures are typically sterile.

DIFFERENTIAL DIAGNOSIS

The differential diagnosis includes DIRA, PAPA syndrome, SAPHO syndrome, and infectious osteomyelitis, as well as bone tumors.

CLINICAL COURSE AND PROGNOSIS

Majeed syndrome is a lifelong disease and long-term outcome is poor. The clinical course and prognosis greatly depends on the severity of clinical manifestations, particularly on the severity of anemia and disease complications, including contractures and diffuse muscle atrophy.

MANAGEMENT

CRMO can be treated with NSAIDs, or corticosteroids if nonresponsive to NSAIDs. Two Majeed syndrome patients who failed to improve with the TNF inhibitor etanercept reportedly responded dramatically to IL-1 blockade by anakinra or canakinumab.[80] CDA can be treated with red blood cell transfusion if clinically indicated. Neutrophilic dermatosis resembling Sweet syndrome can be treated by a short course of oral corticosteroids.

SYNOVITIS, ACNE, PUSTULOSIS, HYPEROSTOSIS, AND OSTEITIS SYNDROME

AT-A-GLANCE

- Synovitis, acne, pustulosis, hyperostosis, and osteitis (SAPHO) syndrome is an inflammatory disorder characterized by recurrent neutrophilic cutaneous and osteoarticular manifestations.
- PPP and severe acne are the most frequent cutaneous manifestations.
- The major osteoarticular manifestations are painful oligoarthritis and osteitis, mainly affecting the anterior chest wall.
- The treatment of SAPHO syndrome remains a challenge. Anakinra has shown promising effect in case reports.

EPIDEMIOLOGY

Synovitis, acne, pustulosis, hyperostosis, and osteitis (SAPHO) syndrome is an inflammatory disorder characterized by recurrent neutrophilic cutaneous and osteoarticular involvement. The onset of SAPHO syndrome has been often described in middle-aged adults, but it can occur at any age, including childhood. The annual prevalence is estimated at 1 in 10,000 persons in whites and 0.00144 in 100,000 persons in Japan,[81] but it may be higher as it is an an underrecognized condition with a variety of clinical presentations.

ETIOLOGY AND PATHOGENESIS

The etiology of SAPHO syndrome is considered as multifactorial, including genetic, environmental and immunologic components. Some familial cases have been reported but most cases are sporadic. IL-1 involvement in the pathogenesis of SAPHO syndrome has been proposed based on a few case reports[82,83] and needs to be defined.

CLINICAL FEATURES

SAPHO syndrome typically presents with neutrophilic skin lesions and osteoarticular manifestations, and usually these manifestations appear within 2 years of each other.[81] The most frequent skin manifestation in SAPHO syndrome is PPP, followed by severe acne, including acne conglobata, acne fulminans, or hidradenitis suppurativa.[84] Less-frequent manifestations include pustular psoriasis and psoriasis vulgaris (Fig. 39-12). The most common osteoarticular manifestations of SAPHO syndrome include oligoarthritis affecting sternocostal and sternoclavicular joints, sacroiliac joints, knees, and ankles, and osteitis affecting the anterior chest wall, such as the sternum, clavicle, and ribs, presenting with pain, tenderness, and sometimes swelling over the affected areas. Imaging with conventional radiography, ultrasonography, CT, MRI, and bone scintigraphy is useful to detect and evaluate osteoarticular involvement. Bone biopsy reveals abscesses, known as sterile osteomyelitis, progressively replaced by sclerotic bone trabeculae and marrow fibrosis in the later stages.

DIAGNOSIS

Making a diagnosis of SAPHO syndrome is challenging because not all symptoms are always present at the same time. The diagnosis is mainly based on clinical, radiologic, and histologic findings, which vary according to the duration of the disease.

DIFFERENTIAL DIAGNOSIS

During the early stage, infectious osteomyelitis and bone tumors, such as Ewing sarcoma and osteoblastoma, should be excluded. SAPHO syndrome can share several features with psoriatic arthritis, but the skin manifestation of severe acne and radiographic

Figure 39-12 Synovitis, acne, pustulosis, hyperostosis, and osteitis (SAPHO) syndrome. **A** and **B,** Well-delineated erythematous plaques with pustular component yellowish scabs on elbows and leg. **C,** Erythematous lesions with deep pustules on the soles of both feet. (From Sáez-Martín LC, Gómez-Castro S, Román-Curto C, et al. Etanercept in the treatment of SAPHO syndrome. *Int J Dermatol.* 2015;54(6):e206-e208, with permission. Copyright © 2015 John Wiley & Sons.)

signs of osteitis with hyperostosis are not typical of psoriatic arthritis. Psoriatic nail dystrophy has not been reported in patients with SAPHO syndrome. In the pediatric cases, the differential diagnosis includes Langerhans cell histiocytosis, DIRA, PAPA syndrome, and Majeed syndrome.

CLINICAL COURSE AND PROGNOSIS

The disease is usually chronic, with alternating periods of remission and relapse, except for a minority of patients with spontaneous resolution of symptoms. Although complications such as impairment of bone and joint function can develop, patients with SAPHO syndrome have a favorable prognosis in general.

MANAGEMENT

The treatment of SAPHO syndrome is mainly symptomatic. NSAIDs are generally considered as the first line of treatment. Intraarticular and systemic corticosteroids are transiently effective in the majority of patients. PPP and pustular psoriasis usually respond well to topical corticosteroids and psoralen and ultraviolet A therapy. Oral antibiotics such as doxycycline are used to treat severe acne with limited efficacy. Bisphosphonates are sometimes very effective for bone lesions because they inhibit bone resorption and turnover. For unresponsive or refractory cases, TNF-α antagonists have been used and have demonstrated a marked amelioration of bone, joint, and skin manifestations. In some cases, however, paradoxical flares and recurrence of skin lesions can be seen. Promising therapeutic effects have been shown in case reports with the IL-1Ra anakinra.[83]

ACKNOWLEDGMENTS

The authors thank Chyi-Chia Richard Lee, MD, PhD, and Raphaela Goldbach-Mansky, MD, MHS, for their contributions to this chapter in previous editions.

REFERENCES

1. Masters SL, Simon A, Aksentijevich I, et al. Horror autoinflammaticus: the molecular pathophysiology of autoinflammatory disease (*). *Annu Rev Immunol.* 2009;27:621-668.
2. Kastner DL, Aksentijevich I, Goldbach-Mansky R. Autoinflammatory disease reloaded: a clinical perspective. *Cell.* 2010;140(6):784-790.
3. Hoffman HM, Mueller JL, Broide DH, et al. Mutation of a new gene encoding a putative pyrin-like protein causes familial cold autoinflammatory syndrome and Muckle-Wells syndrome. *Nat Genet.* 2001;29(3):301-305.

4. Feldmann J, Prieur AM, Quartier P, et al. Chronic infantile neurological cutaneous and articular syndrome is caused by mutations in CIAS1, a gene highly expressed in polymorphonuclear cells and chondrocytes. *Am J Hum Genet.* 2002;71(1):198-203.
5. Kile RL and Rusk HA. A case of cold urticaria with an unusual family history. *JAMA Dermatol.* 1940;114: 1067-1068.
6. Muckle TJ. The 'Muckle-Wells' syndrome. *Br J Dermatol.* 1979;100(1):87-92.
7. Prieur AM, Griscelli C. Arthropathy with rash, chronic meningitis, eye lesions, and mental retardation. *J Pediatr.* 1981;99(1):79-83.
8. Martinon F, Burns K, Tschopp J. The inflammasome: a molecular platform triggering activation of inflammatory caspases and processing of proIL-beta. *Mol Cell.* 2002;10(2):417-426.
9. Goldbach-Mansky R, Dailey NJ, Canna SW, et al. Neonatal-onset multisystem inflammatory disease responsive to interleukin-1beta inhibition. *N Engl J Med.* 2006;355(6):581-592.
10. Gattorno M, Tassi S, Carta S, et al. Pattern of interleukin-1beta secretion in response to lipopolysaccharide and ATP before and after interleukin-1 blockade in patients with CIAS1 mutations. *Arthritis Rheum.* 2007;56(9):3138-3148.
11. Johnstone RF, Dolen WK, Hoffman HM. A large kindred with familial cold autoinflammatory syndrome. *Ann Allergy Asthma Immunol.* 2003;90(2):233-237.
12. Hill SC, Namde M, Dwyer A, et al. Arthropathy of neonatal onset multisystem inflammatory disease (NOMID/CINCA). *Pediatr Radiol.* 2007;37(2):145-152.
13. Tanaka N, Izawa K, Saito MK, et al. High incidence of NLRP3 somatic mosaicism in patients with chronic infantile neurologic, cutaneous, articular syndrome: results of an International Multicenter Collaborative Study. *Arthritis Rheum.* 2011;63(11):3625-3632.
14. Neven B, Prieur AM, Quartier dit Maire P. Cryopyrinopathies: update on pathogenesis and treatment. *Nat Clin Pract Rheumatol.* 2008;4(9):481-489.
15. Hawkins PN, Lachmann HJ, McDermott MF. Interleukin-1-receptor antagonist in the Muckle-Wells syndrome. *N Engl J Med.* 2003;348(25):2583-2584.
16. Neven B, Marvillet I, Terrada C, et al. Long-term efficacy of the interleukin-1 receptor antagonist anakinra in ten patients with neonatal-onset multisystem inflammatory disease/chronic infantile neurologic, cutaneous, articular syndrome. *Arthritis Rheum.* 2010;62(1):258-267.
17. Kullenberg T, Lofqvist M, Leinonen M, et al. Long-term safety profile of anakinra in patients with severe cryopyrin-associated periodic syndromes. *Rheumatology (Oxford).* 2016;55(8):1499-1506.
18. Hoffman HM, Throne ML, Amar NJ, et al. Efficacy and safety of rilonacept (interleukin-1 Trap) in patients with cryopyrin-associated periodic syndromes: results from two sequential placebo-controlled studies. *Arthritis Rheum.* 2008;58(8):2443-2452.
19. Lachmann HJ, Kone-Paut I, Kuemmerle-Deschner JB, et al. Use of canakinumab in the cryopyrin-associated periodic syndrome. *N Engl J Med.* 2009;360(23):2416-2425.
20. de Koning HD. Schnitzler's syndrome: lessons from 281 cases. *Clin Transl Allergy.* 2014;4:41.
21. Lipsker D. The Schnitzler syndrome. *Orphanet J Rare Dis.* 2010;5:38.
22. Aksentijevich I, Masters SL, Ferguson PJ, et al. An autoinflammatory disease with deficiency of the interleukin-1-receptor antagonist. *N Engl J Med.* 2009;360(23): 2426-2437.
23. Reddy S, Jia S, Geoffrey R, et al. An autoinflammatory disease due to homozygous deletion of the IL1RN locus. *N Engl J Med.* 2009;360(23):2438-2444.
24. Jesus AA, Osman M, Silva CA, et al. A novel mutation of IL1RN in the deficiency of interleukin-1 receptor antagonist syndrome: description of two unrelated cases from Brazil. *Arthritis Rheum.* 2011;63(12):4007-4017.
25. Schnellbacher C, Ciocca G, Menendez R, et al. Deficiency of interleukin-1 receptor antagonist responsive to anakinra. *Pediatr Dermatol.* 2013;30(6):758-760.
26. Marrakchi S, Guigue P, Renshaw BR, et al. Interleukin-36-receptor antagonist deficiency and generalized pustular psoriasis. *N Engl J Med.* 2011;365(7):620-628.
27. Onoufriadis A, Simpson MA, Pink AE, et al. Mutations in IL36RN/IL1F5 are associated with the severe episodic inflammatory skin disease known as generalized pustular psoriasis. *Am J Hum Genet.* 2011;89(3):432-437.
28. Koike Y, Okubo M, Kiyohara T, et al. Granulocyte and monocyte apheresis can control juvenile generalized pustular psoriasis with mutation of IL36RN. *Br J Dermatol.* 2017 177(6):1732-1736.
29. Jordan CT, Cao L, Roberson ED, et al. PSORS2 is due to mutations in CARD14. *Am J Hum Genet.* 2012;90(5):784-795.
30. Eskin-Schwartz M, Basel-Vanagaite L, David M, et al. Intra-familial variation in clinical phenotype of CARD14-related psoriasis. *Acta Derm Venereol.* 2016;96(7): 885-887.
31. Ancient missense mutations in a new member of the RoRet gene family are likely to cause familial Mediterranean fever. The International FMF Consortium. *Cell.* 1997;90(4):797-807.
32. French FMF Consortium. A candidate gene for familial Mediterranean fever. *Nat Genet.* 1997;17(1):25-31.
33. Azizi E, Fisher BK. Cutaneous manifestations of familial Mediterranean fever. *Arch Dermatol.* 1976;112(3):364-366.
34. Barzilai A, Langevitz P, Goldberg I, et al. Erysipelas-like erythema of familial Mediterranean fever: clinicopathologic correlation. *J Am Acad Dermatol.* 2000;42(5, pt 1): 791-795.
35. Padeh S, Livneh A, Pras E, et al. Familial Mediterranean fever in the first two years of life: a unique phenotype of disease in evolution. *J Pediatr.* 2010;156(6):985-989.
36. Zimand S, Tauber T, Hegesch T, et al. Familial Mediterranean fever presenting with massive cardiac tamponade. *Clin Exp Rheumatol.* 1994;12(1):67-69.
37. Kees S, Langevitz P, Zemer D, et al. Attacks of pericarditis as a manifestation of familial Mediterranean fever (FMF). *Q J Med.* 1997;90(10):643-647.
38. Lachmann HJ, Sengul B, Yavuzsen TU, et al. Clinical and subclinical inflammation in patients with familial Mediterranean fever and in heterozygous carriers of MEFV mutations. *Rheumatology (Oxford).* 2006;45(6): 746-750.
39. Zemer D, Revach M, Pras M, et al. A controlled trial of colchicine in preventing attacks of familial Mediterranean fever. *N Engl J Med.* 1974;291(18):932-934.
40. Kuncl RW, Duncan G, Watson D, et al. Colchicine myopathy and neuropathy. *N Engl J Med.* 1987;316(25): 1562-1568.
41. Houten SM, Kuis W, Duran M, et al. Mutations in MVK, encoding mevalonate kinase, cause hyperimmunoglobulinaemia D and periodic fever syndrome. *Nat Genet.* 1999;22(2):175-177.
42. Drenth JP, Cuisset L, Grateau G, et al. Mutations in the gene encoding mevalonate kinase cause hyper-IgD and periodic fever syndrome. International Hyper-IgD Study Group. *Nat Genet.* 1999;22(2):178-181.

43. Cuisset L, Drenth JP, Simon A, et al. Molecular analysis of MVK mutations and enzymatic activity in hyper-IgD and periodic fever syndrome. *Eur J Hum Genet.* 2001;9(4):260-266.
44. Frenkel J, Rijkers GT, Mandey SH, et al. Lack of isoprenoid products raises ex vivo interleukin-1beta secretion in hyperimmunoglobulinemia D and periodic fever syndrome. *Arthritis Rheum.* 2002;46(10):2794-2803.
45. Mandey SH, Kuijk LM, Frenkel J, et al. A role for geranylgeranylation in interleukin-1beta secretion. *Arthritis Rheum.* 2006;54(11):3690-3695.
46. Hoffmann G, Gibson KM, Brandt IK, et al. Mevalonic aciduria—an inborn error of cholesterol and nonsterol isoprene biosynthesis. *N Engl J Med.* 1986;314(25): 1610-1614.
47. Schafer BL, Bishop RW, Kratunis VJ, et al. Molecular cloning of human mevalonate kinase and identification of a missense mutation in the genetic disease mevalonic aciduria. *J Biol Chem.* 1992;267(19):13229-13238.
48. van der Hilst JC, Bodar EJ, Barron KS, et al. Long-term follow-up, clinical features, and quality of life in a series of 103 patients with hyperimmunoglobulinemia D syndrome. *Medicine (Baltimore).* 2008;87(6):301-310.
49. Drenth JP, Boom BW, Toonstra J, et al. Cutaneous manifestations and histologic findings in the hyperimmunoglobulinemia D syndrome. International Hyper IgD Study Group. *Arch Dermatol.* 1994;130(1):59-65.
50. Simon A, Drewe E, van der Meer JW, et al. Simvastatin treatment for inflammatory attacks of the hyperimmunoglobulinemia D and periodic fever syndrome. *Clin Pharmacol Ther.* 2004;75(5):476-483.
51. Kostjukovits S, Kalliokoski L, Antila K, et al. Treatment of hyperimmunoglobulinemia D syndrome with biologics in children: review of the literature and Finnish experience. *Eur J Pediatr.* 2015;174(6):707-714.
52. McDermott MF, Aksentijevich I, Galon J, et al. Germline mutations in the extracellular domains of the 55 kDa TNF receptor, TNFR1, define a family of dominantly inherited autoinflammatory syndromes. *Cell.* 1999;97(1):133-144.
53. Simon A, Park H, Maddipati R, et al. Concerted action of wild-type and mutant TNF receptors enhances inflammation in TNF receptor 1-associated periodic fever syndrome. *Proc Natl Acad Sci U S A.* 2010;107(21):9801-9806.
54. Toro JR, Aksentijevich I, Hull K, et al. Tumor necrosis factor receptor-associated periodic syndrome: a novel syndrome with cutaneous manifestations. *Arch Dermatol.* 2000;136(12):1487-1494.
55. Nakamura M, Kobayashi M, Tokura Y. A novel missense mutation in tumour necrosis factor receptor superfamily 1A (TNFRSF1A) gene found in tumour necrosis factor receptor-associated periodic syndrome (TRAPS) manifesting adult-onset Still disease-like skin eruptions: report of a case and review of the Japanese patients. *Br J Dermatol.* 2009;161(4):968-970.
56. Nedjai B, Hitman GA, Quillinan N, et al. Proinflammatory action of the antiinflammatory drug infliximab in tumor necrosis factor receptor-associated periodic syndrome. *Arthritis Rheum.* 2009;60(2):619-625.
57. Gattorno M, Pelagatti MA, Meini A, et al. Persistent efficacy of anakinra in patients with tumor necrosis factor receptor-associated periodic syndrome. *Arthritis Rheum.* 2008;58(5):1516-1520.
58. Gattorno M, Obici L, Cattalini M, et al. Canakinumab treatment for patients with active recurrent or chronic TNF receptor-associated periodic syndrome (TRAPS): an open-label, phase II study. *Ann Rheum Dis.* 2017;76(1):173-178.
59. Zhou Q, Wang H, Schwartz DM, et al. Loss-of-function mutations in TNFAIP3 leading to A20 haploinsufficiency cause an early-onset autoinflammatory disease. *Nat Genet.* 2016;48(1):67-73.
60. Shigemura T, Kaneko N, Kobayashi N, et al. Novel heterozygous C243Y A20/TNFAIP3 gene mutation is responsible for chronic inflammation in autosomal-dominant Behçet's disease. *RMD Open.* 2016;2(1):e000223.
61. Ohnishi H, Kawamoto N, Seishima M, et al. A Japanese family case with juvenile onset Behçet's disease caused by TNFAIP3 mutation. *Allergol Int.* 2017;66(1):146-148.
62. Zhou Q, Yu X, Demirkaya E, et al. Biallelic hypomorphic mutations in a linear deubiquitinase define otulipenia, an early-onset autoinflammatory disease. *Proc Natl Acad Sci U S A.* 2016;113(36):10127-10132.
63. Damgaard RB, Walker JA, Marco-Casanova P, et al. The deubiquitinase OTULIN is an essential negative regulator of inflammation and autoimmunity. *Cell.* 2016;166(5):1215-1230 e1220.
64. Kanazawa N. Nakajo-Nishimura syndrome: an autoinflammatory disorder showing pernio-like rashes and progressive partial lipodystrophy. *Allergol Int.* 2012;61(2):197-206.
65. Brehm A, Liu Y, Sheikh A, et al. Additive loss-of-function proteasome subunit mutations in CANDLE/PRAAS patients promote type I IFN production. *J Clin Invest.* 2015;125(11):4196-4211.
66. Blau EB. Familial granulomatous arthritis, iritis, and rash. *J Pediatr.* 1985;107(5):689-693.
67. Miceli-Richard C, Lesage S, Rybojad M, et al. CARD15 mutations in Blau syndrome. *Nat Genet.* 2001;29(1):19-20.
68. Kanazawa N, Okafuji I, Kambe N, et al. Early-onset sarcoidosis and CARD15 mutations with constitutive nuclear factor-kappaB activation: common genetic etiology with Blau syndrome. *Blood.* 2005;105(3):1195-1197.
69. Inohara N, Nunez G. NODs: intracellular proteins involved in inflammation and apoptosis. *Nat Rev Immunol.* 2003;3(5):371-382.
70. Schaffer JV, Chandra P, Keegan BR, et al. Widespread granulomatous dermatitis of infancy: an early sign of Blau syndrome. *Arch Dermatol.* 2007;143(3):386-391.
71. Stoevesandt J, Morbach H, Martin TM, et al. Sporadic Blau syndrome with onset of widespread granulomatous dermatitis in the newborn period. *Pediatr Dermatol.* 2010;27(1):69-73.
72. Ikeda K, Kambe N, Satoh T, et al. Preferentially inflamed tendon sheaths in the swollen but not tender joints in a 5-year-old boy with Blau syndrome. *J Pediatr.* 2013;163(5):1525 e1521.
73. Milman N, Andersen CB, Hansen A, et al. Favourable effect of TNF-alpha inhibitor (infliximab) on Blau syndrome in monozygotic twins with a de novo CARD15 mutation. *APMIS.* 2006;114(12):912-919.
74. Wise CA, Gillum JD, Seidman CE, et al. Mutations in CD2BP1 disrupt binding to PTP PEST and are responsible for PAPA syndrome, an autoinflammatory disorder. *Hum Mol Genet.* 2002;11(8):961-969.
75. Shoham NG, Centola M, Mansfield E, et al. Pyrin binds the PSTPIP1/CD2BP1 protein, defining familial Mediterranean fever and PAPA syndrome as disorders in the same pathway. *Proc Natl Acad Sci U S A.* 2003;100(23):13501-13506.
76. Stichweh DS, Punaro M, Pascual V. Dramatic improvement of pyoderma gangrenosum with infliximab in a patient with PAPA syndrome. *Pediatr Dermatol.* 2005;22(3):262-265.

77. Brenner M, Ruzicka T, Plewig G, et al. Targeted treatment of pyoderma gangrenosum in PAPA (pyogenic arthritis, pyoderma gangrenosum and acne) syndrome with the recombinant human interleukin-1 receptor antagonist anakinra. *Br J Dermatol.* 2009;161(5):1199-1201.
78. Majeed HA, Kalaawi M, Mohanty D, et al. Congenital dyserythropoietic anemia and chronic recurrent multifocal osteomyelitis in three related children and the association with Sweet syndrome in two siblings. *J Pediatr.* 1989;115(5, pt 1):730-734.
79. Ferguson PJ, Chen S, Tayeh MK, et al. Homozygous mutations in LPIN2 are responsible for the syndrome of chronic recurrent multifocal osteomyelitis and congenital dyserythropoietic anaemia (Majeed syndrome). *J Med Genet.* 2005;42(7):551-557.
80. Herlin T, Fiirgaard B, Bjerre M, et al. Efficacy of anti-IL-1 treatment in Majeed syndrome. *Ann Rheum Dis.* 2013;72(3):410-413.
81. Rukavina I. SAPHO syndrome: a review. *J Child Orthop.* 2015;9(1):19-27.
82. Colina M, Pizzirani C, Khodeir M, et al. Dysregulation of P2X7 receptor-inflammasome axis in SAPHO syndrome: successful treatment with anakinra. *Rheumatology (Oxford).* 2010;49(7):1416-1418.
83. Wendling D, Prati C, Aubin F. Anakinra treatment of SAPHO syndrome: short-term results of an open study. *Ann Rheum Dis.* 2012;71(6):1098-1100.
84. Saez-Martin LC, Gomez-Castro S, Roman-Curto C, et al. Etanercept in the treatment of SAPHO syndrome. *Int J Dermatol.* 2015;54(6):e206-e208.

Chapter 40 :: Eosinophilic Diseases

:: Hideyuki Ujiie & Hiroshi Shimizu

REGULATION OF THE PRODUCTION AND ACTIVATION OF EOSINOPHILS

AT-A-GLANCE

- Eosinophils are bone marrow–derived cells that circulate transiently and normally account for up to 6% (up to 600/mm^3) of circulating blood leukocytes.
- Eosinophils primarily are tissue-dwelling cells, but only in certain tissues in humans, with an average tissue life span of 2 to 5 days that may be increased with eosinophil survival factors for up to 14 days.
- As proinflammatory cells, the presence of eosinophils within most tissues is associated with pathologic states that include infections, allergic reactions and atopic diseases, fibrotic disorders, reactive eosinophilias, and hypereosinophilic syndromes.
- Eosinophils play a role in innate and adaptive immune responses, which may explain why they are present in normal, noninflamed tissues such as the gastrointestinal tract and lymphoid tissues.
- This section reviews the biologic actions of eosinophils with particular focus on what controls eosinophil production, activation, and tissue trafficking.
- Pharmacologic manipulation of eosinophil inflammation is possible as new, more specific strategies are emerging.

ONTOGENY AND DEVELOPMENT

Eosinophils develop in the bone marrow from multipotential, stem cell–derived CD34+ myeloid progenitor cells in response to eosinophilopoietic cytokines and growth factors (Fig. 40-1). They are released into the circulation as mature cells.[1-3] Important stimulatory cytokines and growth factors for eosinophils include interleukin (IL)-3, granulocyte-macrophage colony-stimulating factor (GM-CSF), and IL-5. Activated T cells likely are the principal sources of IL-3, GM-CSF, and IL-5 that induce eosinophil differentiation in bone marrow. However, depending on pathogenic stimuli, eosinophilopoietic cytokines may be released by other cell types, including mast cells, macrophages, natural killer cells, endothelial cells, epithelial cells, fibroblasts, and even eosinophils, themselves.[4] IL-3 and GM-CSF are pluripotent cytokines that have effects on other hematopoietic lineages. IL-5 is the most selective eosinophil-active cytokine, but it is relatively late acting. Although it is both necessary and sufficient for eosinophil differentiation, IL-5 demonstrates maximum activity on the IL-5 receptor (IL-5R)–positive eosinophil progenitor pool that first is expanded by earlier acting pluripotent cytokines such as IL-3 and GM-CSF[4]; expression of the high-affinity IL-5R is a prerequisite for eosinophil development. Exodus from the bone marrow also is regulated by IL-5. IL-3 and GM-CSF, along with IL-5, promote survival, activation, and chemotaxis of eosinophils through binding to receptors that have a common β chain (CD131) with IL-5R, and unique α chains.

INTERACTIONS OF EOSINOPHILIC FACTORS AND CYTOKINES AND INTRACELLULAR SIGNALING

The interactions of eosinophilopoietic factors with their receptors stimulate a cascade of complex biochemical events through signal transduction. Signaling events progress in 4 steps: (a) juxtamembranous signaling in which membrane-anchored tyrosine kinases and lipid kinases are activated; (b) signal interfacing which serves to transduce juxtamembranous signals to cytosolic signals; (c) mobile signaling in which cytosolic signaling molecules translocate from the receptor site to other cellular compartments including the nucleus, mitochondria, and cytoskeleton; and (d) transcription activation resulting from nuclear translocation and initiation of gene transcription. Studies show the pivotal role of IL-5 in immune responses involving eosinophils through receptor-driven signaling.[5] IL-5 binds to the α chain of the IL-5R and induces recruitment of the common β (βc) chain to IL-5R. Janus kinase (JAK) 2 tyrosine kinase is constitutively associated with IL-5Rα, and JAK1 tyrosine kinase with IL-5Rβc; both are activated with IL-5 binding as part of the juxtamembranous step. Adaptor proteins, *src* homologs and collagen (Shc), SH2-containing phosphatase-2 (SHP-2), growth factor receptor-bound protein 2 (Grb2), Vav, and lipid

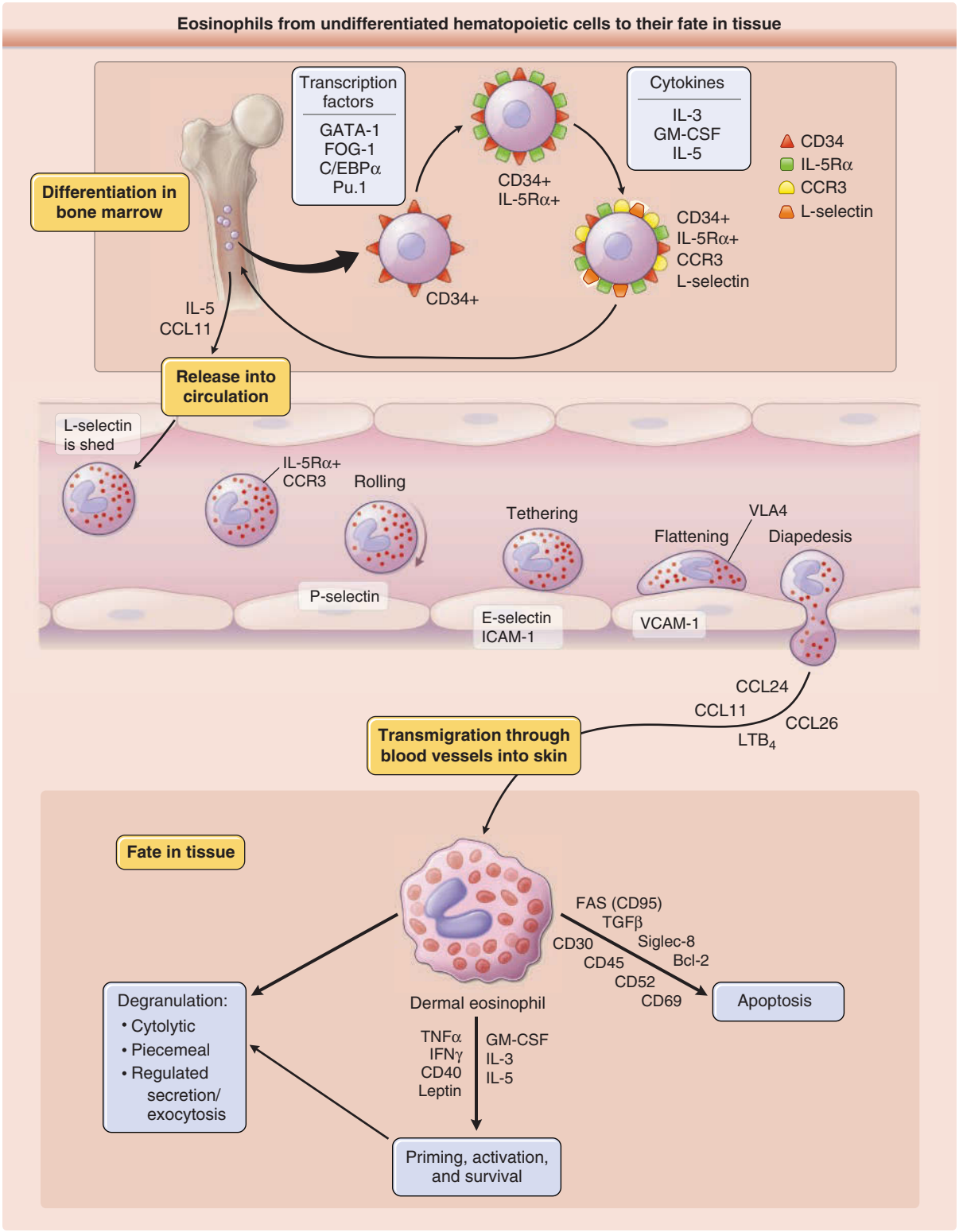

Figure 40-1 The progression of eosinophils from undifferentiated hematopoietic cells to their fate in tissue. The image depicts the eosinophil's life from differentiation in the bone marrow to vascular transmigration to its fate in tissue with key factors noted. GM-CSF, granulocyte-macrophage colony-stimulating factor; ICAM, intercellular adhesion molecule; IFN, interferon; IL, interleukin; LTB_4, leukotriene B_4; TGF, transforming growth factor; TNF, tumor necrosis factor; VCAM, vascular cell adhesion molecule.

kinases, phosphatidylinositol 3-kinase, function in the interfacing step. The activation of JAK2 and signal transducer and activator of transcription (STAT) 5 is essential for IL-5–dependent signal transduction. The Ras guanosine triphosphatase–extracellular signal-regulated kinase and also known as Ras–mitogen-activated protein kinase pathway, in addition to the JAK2-STAT5 pathway, is important in IL-5 signaling in the mobile step. The JAK-STAT and Ras–mitogen-activated protein kinase pathways converge at various levels in IL-5 signaling of eosinophils. Multiple other interactive signal transduction pathways induce and regulate gene expression for eosinophil growth, development, activation, and survival.[6]

EOSINOPHIL ULTRASTRUCTURE AND GRANULE CONTENT

Figure 40-2 shows the products of eosinophils and localization of granule proteins.

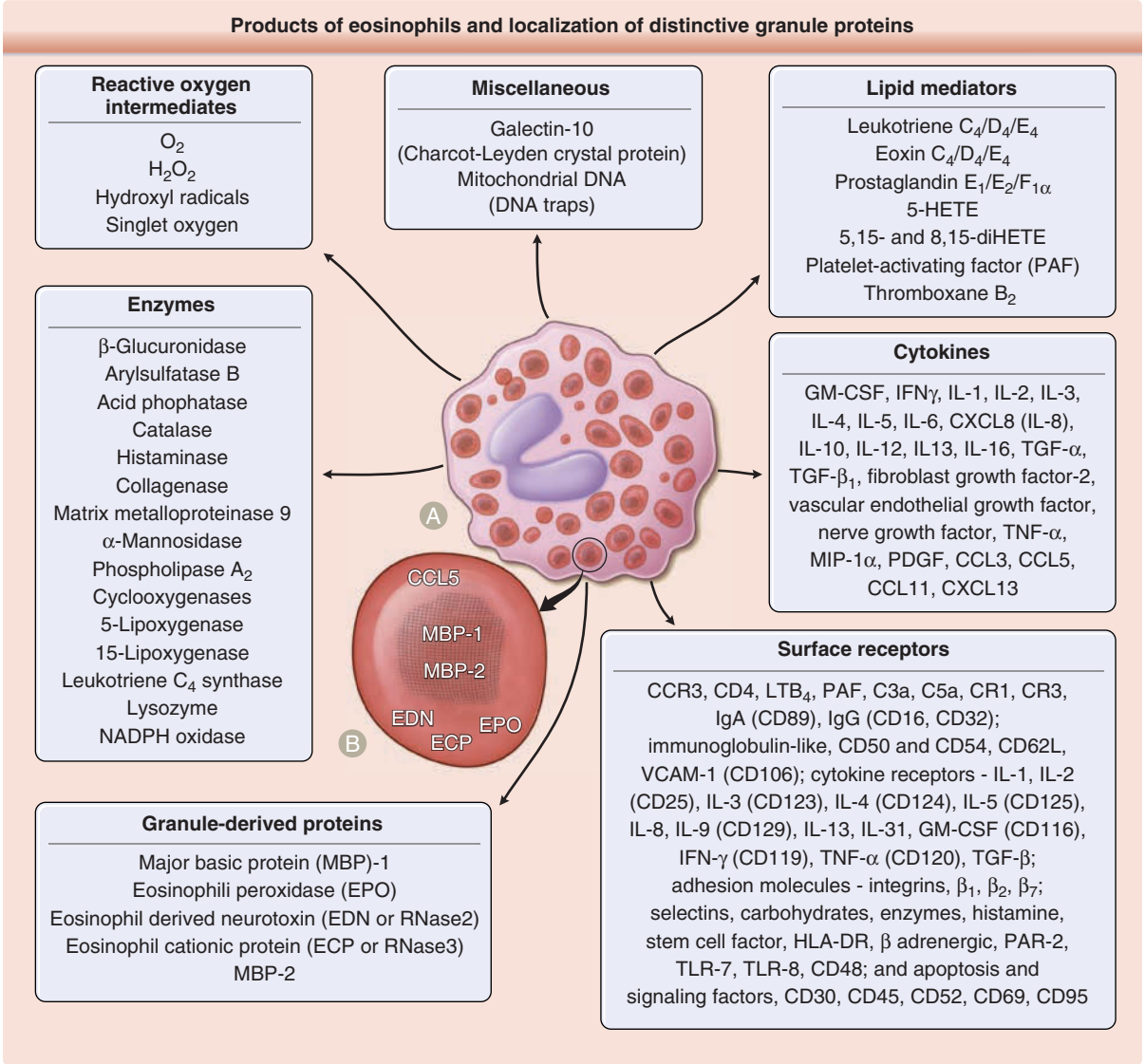

Figure 40-2 The products of eosinophils and localization of distinctive granule proteins. Eosinophils produce myriad products, including toxic granule proteins, which implicate their role in disease pathogenesis. The characteristic eosinophil granules are coarse and, as their name implies, eosinophilic upon staining with eosin. Distinctive granule proteins are localized to core and matrix portions of the specific cytoplasmic granules. **A,** An intact dermal eosinophil with its distinctive granules and typical bilobed nucleus. **B,** Characteristic specific (secondary) eosinophil granule with electron dense crystalline core and radiolucent matrix showing localization of distinctive granule proteins. GM-CSF, granulocyte-macrophage colony-stimulating factor; HETE, hydroxyeicosatetraenoic acid; HLA-DR, human leukocyte antigen-D related; IFN, interferon; Ig, immunoglobulin; IL, interleukin; MIP, macrophage inflammatory protein; NADPH, nicotinamide adenine dinucleotide phosphate; PDGF, platelet-derived growth factor; TGF, transforming growth factor; TLR, Toll-like receptor; TNF, tumor necrosis factor.

Mature eosinophils are 12 to 17 µm in diameter and, therefore, slightly larger than neutrophils. They typically have a bilobed nucleus with highly condensed peripheral chromatin. Eosinophils have distinctive cytoplasmic granules, demonstrated by their staining properties with acidic dyes such as eosin, and by their unique electron microscopy appearance. These specific or secondary granules are composed of an electron-dense core and a less-electron-dense matrix, the core being a crystalline lattice by electron microscopy. In cross section, the eosinophil contains approximately 30 of these membrane-bound, core-containing, secondary granules.[1] Five highly basic proteins are found within the granules: (a) major basic protein (MBP)-1, (b) MBP-2, (c) eosinophil-derived neurotoxin (EDN) also known as ribonuclease (RNase)2, (d) eosinophil cationic protein (ECP) also known as RNase3, and (e) eosinophil peroxidase (EPO). Several other types of proteins are found in secondary granules and include enzymes, cytokines, growth factors, and chemokines. Eosinophils contain 3 other types of cytoplasmic granules, referred to as (a) primary granules, (b) small granules, and (c) secretory vesicles. Primary granules are of variable size, round, uniformly dense, present in 1 to 3 per electron microscopy cross section, and more common in immature eosinophilic promyelocytes. These granules may contain Charcot-Leyden crystal protein (also known as galectin-10), which also can be found in neutrophils[7]; Charcot–Leyden crystals are characteristically found in asthmatic sputum and in feces from patients with helminth infections or eosinophilic gastroenteritis. Small granules contain acid phosphatase and arylsulfatase and are present at 2 to 8 per electron microscopy cross section. Secretory vesicles, also referred to as tubulovesicular structures or microgranules, are characterized by their small, dumbbell-shaped appearance and their albumin content. They are the most abundant granules in number, with approximately 160 per electron microscopy cross section. Normal eosinophils contain varying numbers of non–membrane-bound lipid bodies, which are the principal stores of arachidonic acid. Lipid bodies also contain the enzymes, cyclooxygenase, 5- and 15-lipoxygenase, which are required to synthesize prostaglandins, leukotrienes (LTs), and eoxins, and are increased in activated eosinophils.[1]

BIOLOGIC FUNCTIONS

In mammals, such as the mouse and humans, the eosinophil is released as a mature cell into the circulation from the bone marrow, but is present in the blood only transiently, ranging from 8 to 18 hours. Eosinophils comprise a small portion, normally 6% or less, of circulating leukocytes. They are primarily tissue-dwelling cells, but only in certain tissues in humans, with an average tissue life span of 2 to 5 days. This may be prolonged by cytokines that increase eosinophil survival for up to 14 days. Under normal circumstances, a balance exists between bone marrow production and release of eosinophils, their time in circulation, and their entrance into tissues. Changes in any one of the compartments causes an increase or decrease in circulating and tissue eosinophils. Eosinophilia in blood or tissue or both is associated with helminthiasis, allergic hypersensitivity, and other pathologic conditions. In humans, bone marrow, spleen, lymph node, thymus, and gastrointestinal tract from the stomach through the colon, sparing the esophagus, are the only tissues in which eosinophils normally reside.[8] Furthermore, the gastrointestinal tract is the only organ other than bone marrow in which extracellular eosinophil granule protein deposition is observed even under homeostatic conditions. Eosinophils and their granule proteins are found in the lamina propria in normal gastrointestinal tract and are not found in Peyer patches or epithelium. Eosinophils in the lamina propria are reported to be able to induce the differentiation of regulatory T cells by producing transforming growth factor (TGF)-β_1 and all-*trans* retinoic acid.[9] The recruitment of eosinophils to the gastrointestinal, thymic, uterine, and mammary tissues is under the control of the CC chemokine, CCL11.[10,11] Eosinophils can also respond to tissue-damage signals and promote tissue remodeling. One study showed that eosinophils can migrate to areas of tissue injury or necrosis though the high-mobility group box-1 protein (HMGB1) released from necrotic cells and the receptor for advanced glycation end products expressed on eosinophils.[12] Moreover, it is proposed that eosinophils may play a role in the repair of gastric mucosal tissue during *Helicobacter pylori* infection.[13]

Once eosinophils enter tissues, most do not recirculate. Several possible mechanisms exist for removal of tissue eosinophils, including shedding of the cells across mucosal surfaces into the lumen of the intestinal or respiratory tract, engulfment of apoptotic eosinophils by macrophages, and lysis or degranulation with cellular degeneration. In various inflammatory conditions, including those affecting the skin, striking numbers of free granules and/or eosinophil granule protein deposition are present in the absence of intact eosinophils.[1] Isolated eosinophil granules express extracellular domains for interferon (IFN)-γ receptor and CCR3 and, upon stimulation, respond independently as organelles by releasing ECP.[14]

ROLE OF EOSINOPHILS IN IMMUNE FUNCTION

Shortly after their discovery by Paul Ehrlich in 1879, eosinophils were observed in association with helminth infections. Theories have been promulgated that eosinophils are important for host defense against parasites spawning numerous studies.[15] For example, in vitro studies demonstrated that eosinophils are cytotoxic to large nonphagocytosable organisms, such as multicellular helminthic parasites. Eosinophils bind

to host-derived immunoglobulins and complement components on the surface of their targets (so-called antibody- or complement-) dependent cytotoxicity. They also bind to carbohydrate ligands expressed on parasites, such as the LewisX-related molecules, and cell adhesion molecules similar to selectins. Eosinophils are activated to release their granule products with deposition of these biologically active proteins in and around the parasites causing disruption of the parasite's integument and, ultimately, death of the organism. The granule proteins have different effects. ECP produces fragmentation and disruption whereas MBP-1 produces a distinctive ballooning detachment of the tegumental membrane, and EDN is active only at high concentrations, causing crinkling of the tegumental membrane.[16] However, in murine models in which blood, marrow, and tissue eosinophilia is largely abolished by neutralizing IL-5 activity, the intensities of primary or secondary parasitic infection are unchanged, indicating that eosinophils have little or no role in parasitic host defense in these models.[1] The results must be interpreted cautiously because mouse and human eosinophils have functional differences, and mice are not natural hosts of many of the parasites tested experimentally.

Eosinophils also release cytotoxic granule proteins onto the surface of fungal organisms and into the extracellular milieu in fungal infections. Eosinophils kill fungi in a contact-dependent manner. Eosinophils adhere to the fungal cell wall component, β-glucan, via a β_2-integrin surface molecule, CD11b.[17] Eosinophils do not express other common fungal receptors, such as dectin-1 and lactosylceramide, and, specifically, do not react with chitin. However, chitin, which is a polymer that confers structural rigidity to fungi, helminths, crustaceans, and insects, induces accumulation of eosinophils in tissues through production of LTB_4 in mice.[18] Eosinophils also are activated by fungal organisms that release proteases, such as *Alternaria*, through protease-activated receptors (PARs). For example, fungal aspartate protease activates eosinophils through PAR-2, thereby mediating the innate responses of eosinophils to certain fungi.[19]

As a granulocyte, the eosinophil is capable of phagocytosing and killing bacteria and other small microbes in vitro, but eosinophils cannot effectively defend against bacterial infections when neutrophil function is deficient. Nevertheless, investigations reveal that eosinophils may have a role in innate immunity against bacteria using a unique mechanism, DNA trap.[20] Eosinophils rapidly release mitochondrial DNA when exposed to bacteria, a complement component, C5a, or CCR3 ligands. The traps contain eosinophil granule proteins, ECP and MBP, and have antimicrobial effects. In the extracellular space, the granule proteins and mitochondrial DNA form structures that bind and kill bacteria both in vitro and in vitro. Eosinophils, unlike neutrophils, do not undergo cell death as part of this process. This may be an important innate immune response, particularly in mucosal epithelium.[20]

Eosinophils may have other roles in immune responses as well. Through major histocompatibility complex class II expression and IL-1α production, they can function as antigen-presenting cells for a variety of viral, parasitic, and microbial antigens, including staphylococcal superantigens, and allergens.[21,22] Eosinophils are recruited to secondary lymphoid structures to promote the proliferation of effector T cells, even though they are unable to affect naïve T cells.[23] Eosinophils, as sources of cytokines, influence T-cell–dependent responses.[1] In keeping with the prominence of eosinophils in allergic disorders, eosinophils are involved in T-cell polarization favoring T-helper (Th)2 by promoting Th1 apoptosis in addition to their influence via cytokine expression.[21,24-27]

Interestingly, it is also reported that eosinophils play a role in helminth parasite-elicited protection against autoimmunity, as observed in a mouse model of multiple sclerosis.[28]

In allograft rejection, a number of studies have demonstrated the diagnostic and prognostic value of eosinophils, especially in the acute rejection of allografts.[29,30] On the other hand, a recent study indicated that a lower eosinophil count in peripheral blood predicts adverse prognosis of allograft rejection in heart transplant patients.[31] Further investigation into these possible roles of eosinophils and their mechanisms in acute allograft rejection is warranted.

ROLE OF EOSINOPHILS IN DISEASE

The activities of eosinophil-derived products include direct cytotoxic effects on structural cells and microbes, increased vascular permeability, procoagulant effects, innate immune responses to some parasites, viruses, fungi, and tumor cells, enhancement of leukocyte migration, amplification of effector T-cell responses, and, possibly, mammary gland development. Collectively, these varied biologic actions provide the pathophysiologic basis for the signs and symptoms observed in eosinophil-associated diseases.

Eosinophils in lymph nodes and spleen are especially increased after allergen exposures or microbial insults.[32,33] In allergic inflammation, the involvement of eosinophils is promoted by the stimulation of thymic stromal lymphopoietin, a cytokine that is mainly secreted by epithelial cells in response to allergens or other environmental stimuli.[34-36] Eosinophils have been found in several cancers, particularly in lymphomas, leukemias, and colon cancer. Clinical studies indicate that certain tumors associated with tissue and/or peripheral eosinophilia have a more favorable prognosis,[37] whereas in other tumors, such as nodular sclerosing Hodgkin disease, Sézary syndrome, and gastric carcinomas, they are thought to confer a poor prognosis. In Sézary syndrome, the tumor cells produce IL-5 and, therefore, are responsible for the eosinophilia, which is a reflection of tumor burden.[38] Where eosinophilia is a good prognostic factor, eosinophils are considered to be part of an effective host response to the tumor.[39,40]

EOSINOPHIL CONSTITUENTS AND THEIR ACTIVITIES

The eosinophil contains and produces myriad factors that implicate its role in inflammation and tissue destruction and remodeling (see Fig. 40-2).[41] Products released by eosinophils include chemoattractants, colony-stimulating factors, and endothelial-activating cytokines. In addition to toxic cationic proteins from specific granules and oxidative products released into tissues following activation, these factors include arachidonic acid–derived lipids, hydrolytic enzymes, neuropeptides, colony-stimulating factors, and cytokines/chemokines that facilitate further leukocyte recruitment to sites of inflammation (see Fig. 40-2). Surface molecule expression is important in all aspects of eosinophil biology, from promoting growth and differentiation to eosinophil trafficking into tissue to activation and/or priming of the cells to senescence. Numerous membrane factors are expressed on eosinophils that further direct eosinophil biologic effects.

EOSINOPHIL GRANULE PROTEINS

Among the products of eosinophils that are most damaging to the host are the specific granule's cationic proteins. Knowledge of their biologic actions provides insight into their functions in human disease. Once deposited, the granule proteins persist in tissues for extended times—EPO for 1 week, ECP for 2 weeks, EDN for 2.5 weeks, and MBP-1 for 6 weeks.[42] Each of these proteins induces direct tissue damage to both host cells, including myocytes, endothelium, neurons, epithelium, and smooth muscle, and microbes. All 4 of the cationic granule proteins (EPO, ECP, EDN, and MBP-1) likely contribute to the edema observed in skin diseases because of their vasodilatory effects, with contribution from mast cells and basophil histamine release by MBP-1.[43] Eosinophil granule proteins stimulate various cells in addition to mast cells and basophils, including neutrophils and platelets. Nodules, eosinophilia, rheumatism, dermatitis, and swelling (NERDS), episodic angioedema with eosinophilia (Gleich syndrome), urticaria, eosinophilic cellulitis (Wells syndrome), and insect bite reactions demonstrate variable degrees of edema that are probably explained, at least in part, by this mechanism. Eosinophil granule proteins injected into skin produce lesions, including dose-dependent wheal-and-flare reactions by MBP and ulcerations by ECP and EDN.[44,45]

MAJOR BASIC PROTEIN

MBP comprises the crystalloid core of the specific eosinophil granule. It was so named because it accounts for a major portion (approximately 55% in guinea pig) of the eosinophil granule protein and has a high isoelectric point (calculated at greater than pH 11) that is so strongly basic it cannot be measured accurately. It is now known that MBP is expressed as 2 homologs, MBP-1 and MBP-2, coded by different genes on chromosome 11. MBP-1 directly damages helminths and also lethally damages mammalian cells and tissues, examples of which are its ability to cause exfoliation of bronchial epithelial cells and to kill tumor cells. MBP-1 exerts its effects by increasing cell membrane permeability through surface charge interactions leading to disruption of the cell-surface lipid bilayer. MBP-1 and MBP-2, but none of the other eosinophil granule proteins, stimulate histamine and LTC_4 release from human basophils. Furthermore, MBP-1 and MBP-2 stimulate neutrophils, inducing release of superoxide, lysozyme, and IL-8. MBP-1 and EPO are potent platelet agonists causing release of 5-hydroxytryptamine and promoting clotting.

EOSINOPHIL PEROXIDASE

EPO is highly basic, pI 10.8, localized in the matrix of the specific eosinophil granule and is a key participant in generating reactive oxidants and free radical species in activated eosinophils. EPO consists of a heavy chain and a light chain encoded with a prosequence. Although MBP is present in the highest molar concentration in eosinophil granules, EPO, by weight, is the most abundant protein constituting approximately 25% of the specific eosinophil granule's total protein mass. EPO kills numerous microorganisms in the presence of hydrogen peroxide, generated by eosinophils and other phagocytes, and halide. This combination of products also initiates mast cell secretion. EPO binding to microbes, including *Staphylococcus aureus*, greatly potentiates their killing by phagocytes. EPO-coated tumor cells are spontaneously lysed by activated macrophages.

EOSINOPHIL CATIONIC PROTEIN AND EOSINOPHIL-DERIVED NEUROTOXIN

ECP (or RNase3) and EDN (or RNase2) are homologous proteins with sequence identity in 37 of 55 amino acid residues. ECP also has neurotoxic activity. ECP and EDN play a role in viral host defense to RNA viruses.[46-48] EDN induces the migration and maturation of dendritic cells.[49] It also is an endogenous ligand of Toll-like receptor 2 (TLR2) and can activate myeloid dendritic cells by triggering the Toll-like receptor 2–myeloid differentiation factor 88 signaling pathway.[27] Based on its ability to serve as a chemoattractant and activator of dendritic cells along with enhancing antigen-specific Th2-biased immune responses, EDN functions as an alarmin, alerting the adaptive immune system to preferentially enhance antigen-specific Th2 responses.[27]

LIPID MEDIATORS

Lipid bodies in eosinophils are storage sites for arachidonic acids. Eosinophils produce several arachidonic acid metabolites, including cysteinyl LTs from the 5-lipoxygenase pathway (LTC_4, LTD_4, and LTE_4) and thromboxanes and prostaglandins (PGs) from the cyclooxygenase pathway (thromboxane B_2, PGE_2, and $PGF_1\alpha$).[50,51]

CYTOKINES

Eosinophils are a considerable source of growth factors and regulatory and proinflammatory cytokines and chemokines.[1,52] The various growth factors produced by eosinophils include TGF-α, TGF-β, fibroblast growth factor (FGF)-2, vascular endothelial growth factor, nerve growth factor, and platelet-derived growth factor (PDGF)-β. There is evidence that these growth factors induce stromal fibrosis and basement membrane thickening at sites of chronic eosinophilic inflammation including nasal polyps, asthmatic airways and, likely, in certain skin disorders, such as atopic dermatitis.[1] Another group of cytokines produced by eosinophils modulates other immune cells and includes tumor necrosis factor (TNF)-α, macrophage inflammatory protein-1α (CCL3), IL-1α, IL-2, IL-3, IL-4, IL-5, IL-6, CXCL8 (IL-8), IL-10, IL-12, IL-13, IL-16, GM-CSF, and IFN-γ.[52] Additional chemokines produced by eosinophils are CXCL13 (B-lymphocyte chemoattractant factor), CCL5 (regulated on activation, normal T cells expressed and secreted [RANTES]), and CCL11, in addition to CCL3 and CXCL8. All these cytokines are constitutively produced in low levels in resting eosinophils and induced in inflammatory conditions with activation of eosinophils by engagement of receptors with immunoglobulins, complement and cytokines, including those produced by eosinophils, themselves, in an autocrine manner. Notably, eosinophils produce the 3 principal cytokines involved in their own growth and differentiation—IL-3, IL-5, and GM-CSF—as well as CCL5 and CCL11, the chemokines important in their own chemotaxis. In summary, the eosinophil-derived cytokines may function in both an autocrine and paracrine fashion and likely have pathophysiologic relevance.

SURFACE EXPRESSION

Eosinophils express numerous receptors and other factors on their surface membranes through which they communicate with the extracellular environment, but no single surface protein is uniquely expressed on eosinophils. These receptors have been identified either by flow cytometry or by functional assays, and can be grouped as follows: chemotactic factor and complement receptors, including chemokine, LT, and platelet-activating factor (PAF); immunoglobulin supergene family member receptors, including immunoglobulins; cytokine receptors; adhesion molecule receptors; receptors involved in apoptosis; and miscellaneous receptors and surface factors. Eosinophil membrane proteins are promising targets for therapeutic modulation of eosinophil effects (see "Pharmacologic Manipulation" below).

CHEMOTACTIC FACTOR AND COMPLEMENT RECEPTORS

Chemotactic factors are important in orchestrating cellular trafficking to sites of inflammation as well as physiologic homing (eg, eosinophils to gastrointestinal tract). The eosinophil has receptors for many chemotactic agents, including LTB_4, PAF, bacterial products (*N*-formyl-methionyl-leucyl-phenylalanine), and the complement anaphylatoxins C3a and C5a. Eosinophils express complement receptor (CR)1 (CD35), a receptor for C1q that also binds C4b, C3b, and iC3b, and CR3 (Mac-1, CD11b/CD18) in addition to receptors for C3a and C5a. These are important receptors in eosinophil effector functions. The binding of chemokines to their respective receptors mediates many biologic effects, which, in addition to cell shape change and migration, includes cell activation, receptor internalization, induction of the respiratory burst with generation of toxic oxygen metabolites, and transient activation of integrin adhesiveness. The chemotaxins listed above have potent effects on eosinophils but are nonselective in that they are active on other leukocytes. Because many eosinophil-associated diseases are characterized by tissue eosinophil infiltration with little or no neutrophil infiltration, the identification of the CCR3 receptor and its ligands was an important breakthrough in discovering eosinophil-selective chemotaxins.[53] Specific members of the chemokine family are critical for the cellular trafficking of eosinophils. The major ligands of CCR3, CCL5, CCL11, CCL13 (monocyte chemotactic protein-4), CCL24 (eotaxin-2), and CCL26 (eotaxin-3) play a critical role in both the homeostatic and inflammation-induced recruitment of eosinophils to tissue sites.[54,55]

IMMUNOGLOBULIN GENE SUPERFAMILY MEMBER RECEPTORS

Many of the studies of eosinophil functions, including phagocytosis, antigen-dependent cytotoxicity, oxygen metabolism, LTC_4 production, and eosinophil survival, have been performed using immunoglobulin (Ig) G-coated targets. Among eosinophil surface receptors for the Ig family members, the most highly expressed receptor is FcγRII (CD32), which binds aggregated IgG, particularly of the subclasses IgG_1 and IgG_3. The binding of IgG to this receptor may be important in eosinophil degranulation in parasitic and allergic diseases, along with other eosinophil functions.[1] Freshly isolated eosinophils express only FcγRII (CD32) of the IgG receptors, but eosinophils can be stimulated by

cytokines, particularly IFN-γ, to express FcγRI (CD64) and FcγRIII (CD16), as well as to augment FcγRII (CD32) expression.

Intercellular adhesion molecule (ICAM)-1 (CD54) and ICAM-3 (CD50) are members of Ig superfamily expressed on eosinophils and are likely important in leukocyte–leukocyte and leukocyte–tissue cell adhesion through leukocyte function-associated antigen-1 ($\alpha_L\beta_2$; CD11a/CD18) as its counterligand (see Fig. 40-1).

CYTOKINE RECEPTORS

Cytokine receptors are present at low levels on the surfaces of eosinophils. Receptors for IL-3 (CD123), IL-5 (CD125), and GM-CSF (CD116) are readily detected and, all share a common β chain (CD132). Eosinophil activation has been observed by a variety of other cytokines through presumed and/or detected receptors. These include stem cell factor (c-kit receptor; CD117), IFN-γ (CD119), TNF-α (CD120), IL-4 (CD124), IL-9 (CD129 and CD132), IL-13 (gp65), IL-2 (CD25), IL-31, and TGF-β receptors. Many of these receptors are for cytokines that eosinophils produce, providing further evidence that they have autocrine functions.

ADHESION MOLECULE RECEPTORS

Adhesion molecule receptors are expressed on the eosinophil cell surface to mediate trafficking to and within tissues, and for general cell–cell interactions.[56] These receptors fall into three groups: (a) Ig superfamily, (b) selectins and their glycoprotein counterligands, and (3) integrins. L-selectin (CD62L) and P-selectin glycoprotein ligand-1 (PSGL-1, CD162) are expressed at high levels on eosinophils, whereas E-selectin ligands, as an example, sialyl–Lewis-X (CD15s), are expressed at very low levels. P-selectin together with PSGL-1 is the most important selectin pair in eosinophil migration into tissues.

Eosinophils express a variety of integrins (β_1, β_2, and β_7) on their surface, which facilitate their adhesion to extracellular matrix proteins, vascular cellular adhesion molecule (VCAM)-1 (CD106) on activated endothelium, or ICAM-1 present on resting or activated epithelium and activated endothelium. Integrins are composed of 2 subunits that exist as noncovalently associated heterodimers, with α and β subunits. The β_1 integrins expressed on eosinophils include $\alpha_4\beta_1$ (very late antigen [VLA]-4), which binds to VCAM-1 found on activated endothelium and the extracellular matrix protein, fibronectin. Eosinophil adhesion to fibronectin induces the autocrine production of eosinophil-activating survival cytokines, IL-3, IL-5, and GM-CSF.

RECEPTORS INVOLVED IN APOPTOSIS

Eosinophils express several "death receptors," which are involved in apoptotic pathways, such as Fas receptor (CD95), Siglec-8, CD30, CD45, Campath (CD52), and CD69, along with important intracellular regulators of eosinophil apoptosis, such as the members of the B-cell leukemia/lymphoma (Bcl)-2 and inhibitor of apoptosis families.[57] Diseases characterized by eosinophilia likely result, in part, from delayed or defective apoptotic pathways allowing accumulation and persistence of eosinophils in blood and/or tissues.

FACTORS WORKING TOGETHER

The various products elaborated by eosinophils in response to receptor activation do not necessarily function independently but often act in concert to mediate their biologic effects. For example, the release of TGF-α, TGF-β, FGF-2, vascular endothelial growth factor, matrix metalloproteinase-9, and inhibitors of matrix metalloproteinases from activated eosinophils collectively induce fibroblast proliferation and extracellular matrix protein production. Eosinophils contribute factors of their own and influence factor production from other cells; for example, eosinophil mediators induce platelet release of TGF-β. After intradermal eosinophil infiltration, there is production of extracellular proteins, including tenascin and procollagen 1, as well as myofibroblast formation.[58] Eosinophil-induced fibrosis is observed in the lungs and heart of patients with hypereosinophilic syndrome, in and around organs in other fibrosing/sclerosing disorders, and in the skin of patients with eosinophilic fasciitis (Shulman syndrome), eosinophilia–myalgia syndrome, and toxic oil syndrome.[59] Eosinophil granule proteins, MBP-1 and EDN, along with other neuroactive mediators produced by eosinophils, such as nerve growth factor, vasoactive intestinal peptide, and substance P, likely affect nerve physiology. In fact, eosinophils and eosinophil granule proteins are often observed in close proximity to nerve endings.[60,61] Eosinophil-induced nerve dysfunction is likely an important part of the gastric dysmotility observed in subjects with food allergies, the dysfunction of vagal muscarinic M2 receptors observed in patients with asthma, and may also contribute to itch along with other physiologic aberrations in atopic dermatitis and other cutaneous diseases.[61,62] Collectively, the eosinophil's response to surface factors determines its role in health and disease.

TISSUE TRAFFICKING

The selective recruitment of eosinophils into sites of inflammation results from interactions among eosinophil-activating cytokines, chemokine-inducing cytokines, and endothelial-activating cytokines (see Fig. 40-1). Similar to other leukocytes, selectin, integrin, and Ig gene superfamily members contribute

to the signaling involved in eosinophil trafficking. In particular, eosinophils constitutively express the integrin, VLA-4, which interacts with its ligand, VCAM-1, induced on endothelial cells by cytokines, especially Th2 cytokines (IL-4 and IL-13).[63] After movement through vessels, eosinophils adhere to extracellular matrix proteins. Here, surface factors, such as CD11b/CD18 (Mac-1), bind to fibrous proteins such as fibronectin, laminin, and collagen, and, not only determine where eosinophils will reside, but likely prolong their survival.[64] In this regard, the CD11b/CD18 (Mac-1) integrin is also critical for eosinophil effector functions, including degranulation.[65]

EOSINOPHIL-ACTIVATING CYTOKINES

Eosinophil-activating cytokines can be produced by many cell types in addition to T cells and mast cells, including keratinocytes, endothelial cells, and monocytes, along with eosinophils, themselves. The eosinophil-activating cytokines, IL-3, IL-5, GM-CSF, and others, enhance chemotactic responses, in addition to multiple other effects on eosinophils, such as promoting maturation, cell survival, and LT production.[66]

ENDOTHELIAL-ACTIVATING CYTOKINES

During eosinophil migration, at least 3 types of endothelial activations occur. The first is the expression of P-selectin, which occurs when Weibel-Palade bodies in endothelial cells are transported to the cell surface rapidly after exposure to histamine, LTs, and a host of other inflammatory mediators. Expression of P-selectin on the endothelial cell surface initiates leukocyte rolling, via CD162 (PSGL-1), which is the important initial step before firm adhesion and transendothelial migration. A second type of endothelial activation is that induced by nonspecific activators such as IL-1 and TNF-α. These cytokines stimulate endothelial expression of E-selectin, ICAM-1, and VCAM-1, to which eosinophils firmly adhere, or "tether." They also induce production of chemokines by endothelial cells. The third type of endothelial activation is that induced by IL-4 and IL-13. These cytokines selectively induce VCAM-1, which is centrally involved in the recruitment of VLA-4–positive cells, including eosinophils, basophils, and lymphocytes, into sites of allergic inflammation.

CHEMOKINES

The transition from rolling to firm adherence is substantially increased by CCR3 ligands, the CC chemokines. Induction of the expression of chemokines by activated endothelial cells results in higher levels of chemokines on or near the endothelial surface, which transiently affect β_1-integrin and β_2-integrin avidity, resulting in firm adhesion of the eosinophil to the endothelial cell. However, chemokines produced by structural cells such as fibroblasts, smooth muscle cells, and epithelium probably are more important in directing migration and activation of eosinophils within tissues than those expressed on endothelial cells.[67]

Tissue chemokine expression forms a gradient signal that guides eosinophils into tissue. CCL11 guides eosinophils into tissue locations in which eosinophils are normally present, thymus, uterus, mammary gland, and gastrointestinal tract.[68] In Th2 disorders, Th2 cytokines induce chemokine expression. In skin, IL-4, IL-13, and TNF-α stimulate CCL11, CCL24, and CCL26 production from mast cell and lymphocyte sources, as well as from fibroblasts (CCL11 and CCL26) and keratinocytes (CCL26).[69] As in eosinophilic esophagitis, CCL26 may be important in atopic dermatitis in which serum CCL26 levels correlate with disease activity.[70]

Arachidonic acid metabolites, particularly, the cysteinyl LTs, LTC_4, LTD_4, and LTE_4, and PGD_2, are involved in eosinophil trafficking as evidenced by the observations that LT receptor antagonists reduce blood and lung eosinophilia and that mice, depleted of LTB_4 receptors, have markedly reduced lung eosinophilia after allergen exposure. Eosinophil, basophil, and Th2 cell recruitment occurs, to some extent, through CRTH2 (CD294), the high-affinity PGD_2 type 2 receptor.

ACTIVATION OF EOSINOPHILS

Various inflammatory mediators activate eosinophils. In addition to cytokines, TNF-α, GM-CSF, IL-3, and IL-5, the inflammatory mediators include complement components, C3a and C5a, lipid mediators, LTC_4 and PAF, and chemokines, as well as engagement of IgA and IgG Fc receptors. IL-33 regulates eosinophils in the mechanisms of allergic inflammatory response. Nuclear factor κB and mitogen-activated protein kinase pathways are activated upon IL-33 ligation to receptors on eosinophils, promoting the cell surface expression of CD11b and ICAM-1 and the production of proinflammatory cytokines such as IL-6, IL-8, and IL-13.[30,71] Eosinophil differentiation from CD117+ hematopoietic progenitor cells is directly induced by IL-33 in an IL-5-dependent manner.[72]

CD11b/CD18 (Mac-1)-dependent cellular adhesion is a critical component for degranulation and superoxide production induced by GM-CSF and PAF eosinophil activation and likely is an in vitro mechanism that results from eosinophil contact with stromal cells and/or proteins.[73] Members of the CC chemokine subfamily (CCL5, CCL7 [MCP-3], CCL11, CCL13 [MCP-4], and CCL24) that bind to the chemokine receptor, CCR3, also potently activate eosinophils. Activated eosinophils develop a number of phenotypic changes, including a reduction in granules, vacuolization, and

an expansion of their cytoplasm, leading to a reduction in cell density and are referred to as *hypodense*. The number of hypodense cells predicts allergic disease severity. A cell-surface marker that distinguishes hypodense from normodense eosinophils has not been identified, but there are several surface markers with enhanced expression on in vitro or in vitro–activated or hypodense cells: α_M integrin (CD11b), α_X integrin (CD11c), FcγRIII (CD16), hyaluronic acid receptor (CD44), ICAM-1 (CD54), CD69, and HLA-DR (human leukocyte antigen-D related).[74]

Upon recruitment and activation in tissues, eosinophils have various effects as detailed in previous sections. In tissues, eosinophils release granule contents into their extracellular space via 3 mechanisms: piecemeal degranulation, regulated secretion (also referred to as regulated exocytosis), and cytolytic degranulation.

PHARMACOLOGIC MANIPULATION

Eosinophil-associated disease is a term that, strictly speaking, refers to diseases in which eosinophil numbers or eosinophil granule protein levels (or other eosinophil products) are associated with disease activity. This term encompasses multiple heterogeneous disorders, including skin diseases, in which targeting eosinophils and/or their products is a therapeutic goal. Many available treatments reduce eosinophil numbers, thereby inhibiting eosinophilic inflammation, including glucocorticoids, calcineurin inhibitors, IFN-α, IFN-γ, LT antagonists, myelosuppressive/cytotoxic drugs, and, possibly, antihistamines. However, none is specific for eosinophils. It is only in recent years that selective and direct reduction of eosinophils has been achieved, and these therapies have provided new insight into disease pathogenesis.[75]

Among the nonselective drugs for eosinophil reduction, glucocorticoids generally are very effective. The immediate (within 3 hours) reduction in circulating eosinophils observed after systemic administration of glucocorticoids likely occurs as a consequence of sequestration into extramedullary organs (liver, spleen, and lymph node), as has been shown in rodents. Glucocorticoids affect eosinophil infiltration into tissues by 4 mechanisms: sequestration into lymphoid tissues, induction of eosinophil apoptosis, reduction of eosinophil production by bone marrow, and alterations in the production of the cytokines/chemokines important in eosinophil trafficking.[76-78] Glucocorticoids suppress the production of several cytokines important for the induction of adhesion molecules on endothelial cells, including IL-1, TNF-α, IL-4, and IL-13, and the release of eosinophil-active chemokines, including CCL5, CCL7, and CCL11. Unfortunately, "steroid resistance" develops in some patients, and long-term administration of glucocorticoids is associated with limiting side effects.

Calcineurin antagonists, such as cyclosporine, tacrolimus, and pimecrolimus, broadly inhibit T-cell cytokine release, including those that specifically induce eosinophilic inflammation (IL-4, IL-5, and GM-CSF). They also decrease the expression of CCL5, CCL11, and IL-5 with associated decreased tissue eosinophilia as has been shown in atopic dermatitis.[79] Mammalian target of rapamycin (mTOR) inhibitors, including rapamycin, have direct effects on eosinophils, decreasing eosinophil granule protein release after IL-5 activation.[80] The use of these therapeutic agents are limited by their side effects, including immunosuppression, as well as other metabolic effects that may be in part genetically determined.[81]

Several myelosuppressive drugs, including hydroxyurea, vincristine sulfate, cyclophosphamide, methotrexate, 6-thioguanine, 2-chlorodeoxyadenosine and cytarabine combination therapy, pulsed chlorambucil, and etoposide, may be beneficial in eosinophil-associated disease alone or as steroid-sparing agents. Hydroxyurea has been particularly effective in decreasing circulating eosinophil numbers.

In myeloproliferative hypereosinophilic syndrome (chronic eosinophilic leukemia) with the *FIP1L1-PDGFRA* mutation that codes for a tyrosine kinase, imatinib mesylate, a tyrosine kinase inhibitor, is approved for the treatment of chronic myelogenous leukemia and the hypereosinophilic syndrome, and has produced rapid, complete or near-complete remissions.[82] Patients who have features of myeloproliferative hypereosinophilic syndrome (HES) but who lack *FIP1L1-PDGFRA* still may respond to imatinib.[83]

Alemtuzumab is a monoclonal antibody to CD52 that is used to deplete CD52+ lymphocytes in the treatment of chronic (B-cell) lymphocytic leukemia and T-cell lymphoma. Eosinophils, but not neutrophils, also express CD52, and alemtuzumab has been useful in treating patients with refractory HES, including those with abnormal T cells,[84-86] but has serious limiting side effects from cytopenias, infusion reactions and infections.

Mepolizumab is the first humanized monoclonal antibody against IL-5. It has proved effective in inhibiting eosinophilia and in reducing asthma exacerbation rates.[87]

Benralizumab is an anti–IL-5 receptor α (IL-5Rα) humanized monoclonal antibody. This therapy produced reduced eosinophilia in a dose-dependent manner in a Phase I trial on persons with asthma.[88] As other eosinophilopoietic factors may circumvent the requirement for IL-5 in some cases, targeting IL-5Rα is considered to be more effective in reducing eosinophils than therapies directed at IL-5 itself.[89]

Both IFN-α and IFN-γ may be therapeutically beneficial in eosinophil-associated disease by inhibiting eosinophil degranulation and inflammatory mediator release. IFN-α may be better tolerated than IFN-γ and is used as a steroid-sparing agent predominantly in patients with lymphocytic variant HES, but also may be useful in myeloproliferative variant HES.[90,91]

EOSINOPHILS IN CUTANEOUS DISEASES

AT-A-GLANCE

- Eosinophils may be seen in skin biopsy specimens from a broad range of cutaneous diseases but are not pathognomonic for any dermatosis.
- Eosinophils are an important component of the characteristic histologic pattern in a limited number of diseases, including the following:
  - Angiolymphoid hyperplasia with eosinophilia.
  - Eosinophilic, polymorphic, and pruritic eruption associated with radiotherapy.
  - Eosinophilic pustular folliculitis.
  - Erythema toxicum neonatorum.
  - Eosinophilic ulcer of the oral mucosa.
  - Eosinophilic vasculitis.
  - Granuloma faciale.
  - Hypereosinophilic syndromes.
  - Incontinentia pigmenti.
  - Kimura disease.
  - Pachydermatous eosinophilic dermatitis.
  - Wells syndrome (eosinophilic cellulitis).
- Clinical reaction patterns with eosinophil involvement include diseases in which eosinophils probably play a pathogenic role and are a component of the histologic pattern, but are not essential for diagnosis.
- Evidence for involvement of eosinophils in cutaneous diseases is provided by observation of intact eosinophils in lesional tissue sections and/or by immunostains for their toxic granule proteins, which are deposited in tissues.

Eosinophils have myriad inflammatory activities that implicate them in disease.[41,54,92] Peripheral blood eosinophilia and/or tissue infiltration by eosinophils occur in a variety of common and unusual diseases, including those of infectious, immunologic, and neoplastic etiologies. Organ-specific eosinophil disorders occur in the skin, lung, and gastrointestinal tract.[93-95] Eosinophils are conspicuous in tissue sections stained with hematoxylin and eosin because of their intense avidity for eosin dye. Common dermatoses associated with eosinophils in lesional tissues include arthropod bites and drug eruptions. Parasitic infections, especially those caused by ectoparasites and helminthes, typically have a marked host response with eosinophilia.[33,96] Autoimmune blistering diseases, such as bullous pemphigoid and the various forms of pemphigus, often have prominent eosinophil infiltration, including histologic presentation as eosinophilic spongiosis.[97,98] Infiltration of eosinophils in the subcutaneous tissues, so-called eosinophilic panniculitis, is not a specific diagnosis but rather is seen to a variable degree in diverse entities.[99,100] Eosinophils may be found in Langerhans cell histiocytosis,[101] cutaneous epithelial neoplasms,[102] and lymphoproliferative disorders.[103] Although eosinophils constitute one of the histologic features in numerous cutaneous diseases, eosinophil infiltration represents a criterion for histologic diagnosis in relatively few entities (Table 40-1).

TABLE 40-1
Eosinophils in Cutaneous Diseases

- Diseases characterized by tissue eosinophils
- Angiolymphoid hyperplasia with eosinophilia
- Eosinophilic, polymorphic, and pruritic eruption associated with radiotherapy
- Eosinophilic pustular folliculitis
  - Classical (Ofuji disease)
  - Infantile/neonatal
  - HIV-associated
- Erythema toxicum neonatorum
- Eosinophilic ulcer of oral mucosa
  - Granuloma faciale
  - Hypereosinophilic syndromes
  - Kimura disease
  - Pachydermatous eosinophilic dermatitis
  - Wells syndrome (eosinophilic cellulitis)
- Diseases typically associated with tissue eosinophils
  - Arthropod bites and sting reactions
  - Bullous dermatoses
    - Pemphigoid
    - Pemphigus
    - Incontinentia pigmenti
  - Dermatoses of pregnancy
  - Drug reactions
    - DRESS (drug rash with eosinophilia and systemic symptoms)/drug hypersensitivity syndrome
    - Interstitial granulomatous drug reaction
  - Histiocytic diseases
    - Langerhans cell histiocytosis
    - Juvenile xanthogranuloma
  - Parasitic diseases/infestations
  - Urticaria and angioedema
  - Eosinophilic granulomatosis with polyangiitis
- Histologic patterns defined by eosinophils
  - Eosinophilic spongiosis
    - Acute dermatitis
      - Allergic contact dermatitis
    - Arthropod bite
    - Immunobullous diseases
      - Pemphigoid
      - Pemphigus
    - Incontinentia pigmenti
  - Eosinophilic panniculitis
    - Arthropod bite
    - Erythema nodosum
    - Gnathostomiasis
    - Injection granuloma
    - Vasculitis
    - Wells syndrome
- Eosinophils of doubtful, limited, or no value in histologic diagnosis
  - Drug reaction versus graft-versus-host disease
  - Granuloma annulare
  - Interstitial granulomatous dermatitis
  - Neoplasms
    - Lymphoproliferative disorders (except hypereosinophilic syndrome types)
    - Keratoacanthoma

The absence, presence, or number of eosinophils in skin biopsy specimens is often of limited value in reliably choosing among differential diagnoses with different and potentially important implications for clinical management, such as drug reaction versus acute graft-versus-host disease.[104,105] Eosinophils play a role in certain categories of clinical reactions, particularly those characterized by edema.[43] The degree of tissue eosinophil granule protein deposition in such diseases, that exhibit relatively few or no intact eosinophils, suggests that the pathogenic influence of eosinophils may be unrelated to their numbers in tissues. The degree of cutaneous eosinophil infiltration should be taken in the context of other clinical features, other histologic features, and knowledge that its diagnostic power has limitations.[106] However, eosinophils do have potent biologic activities, particularly imparted by their distinctive granules, and eosinophils may play a pathogenic role in the absence of identifiable cells in tissues.

HYPEREOSINOPHILIC SYNDROMES

AT-A-GLANCE

- Spectrum of entities defined by criteria (Table 40-2).
- Cutaneous lesions are common and may be the presenting sign.
- Two major HES subtypes and several variants.
  - Lymphocytic HES characterized by T-cell clones that produce IL-5.
  - Variant HES subtypes may evolve into lymphocytic HES.
    - Organ-restricted.
    - Associated with specific disorders such as eosinophilic granulomatosis with polyangiitis (formerly known as Churg-Strauss syndrome).
    - Undefined with benign, complex, and episodic presentations.
  - Myeloproliferative HES associated with a deletion on chromosome 4 that produces a tyrosine kinase fusion gene *Fip1-like 1*/PDGFRα or other mutation associated with eosinophil clonality.
    - Responsive to imatinib.
    - Severely debilitating mucosal ulcers portend a grim prognosis unless HES is treated.
    - Overlap with mastocytosis.
    - Familial HES variant, family history of documented persistent eosinophilia of unknown cause.
  - Associated embolic events constitute a medical emergency.
- Eosinophilic endomyocardial disease occurs in HES and in patients with prolonged peripheral blood eosinophilia from any cause.

HES consists of a spectrum of disorders that occur worldwide and span all age groups. More than 90% of patients with myeloproliferative HES and the mutant gene are males, but lymphocytic HES shows equal gender distribution. The relative frequencies of these subtypes are unknown, although up to 25% of HES patients may have lymphocytic HES. Rare familial cases have been reported. A miniepidemic of eosinophilic esophagitis, a subtype of overlap HES with organ-restricted disease, emerged over the last decade with prevalence estimates as high as 1:2500 among children and 1:4000 among adults.[107,108]

CLINICAL FEATURES

Patients satisfying HES diagnostic criteria (see Table 40-2) present with signs and symptoms related to the organ systems infiltrated by eosinophils.[109-111] HES often presents with skin lesions that may be the only manifestations of HES.[112-114] Pruritic erythematous macules, papules, plaques, wheals, or nodules are present in more than 50% of patients.[115] CD3– CD4+ lymphocytic HES patients exhibit a particularly high prevalence of skin manifestation, as high as 94%.[116] Lesions may involve the head, trunk, and extremities. Urticaria and angioedema occur in all HES subtypes and are characteristic of certain variant subtypes. Erythema annulare centrifugum,[117] bullous pemphigoid,[118] lymphomatoid papulosis,[119] livedo reticularis, purpura and/or other signs of vasculitis,[120-123] Wells syndrome (eosinophilic cellulitis),[124,125] and multiple other mucocutaneous manifestations[126] may be found in patients with HES (Table 40-3). The complications are mostly hematologic, cardiovascular, pulmonary, and neurologic.[127]

In myeloproliferative HES, the usual presenting complex includes fever, weight loss, fatigue, malaise, skin lesions, and hepatosplenomegaly.[111,128-130] Mucosal ulcers of the oropharynx or anogenital region

TABLE 40-2
Revised Diagnostic Criteria for Hypereosinophilic Syndromes[148]

1. Blood eosinophilia >1500 eosinophils/mm^3 on at least 2 separate determinations or evidence of prominent tissue eosinophilia associated with symptoms and marked blood eosinophilia.
2. Exclusion of secondary causes of eosinophilia, such as parasitic or viral infections, allergic diseases, drug-induced or chemical-induced eosinophilia, hypoadrenalism, and neoplasms.

Original Criteria[289]

- Peripheral blood eosinophilia of at least 1500 eosinophils/mm^3.
  - Longer than 6 months; or
  - Less than 6 months with evidence of organ damage.
- Signs and symptoms of multiorgan involvement.
- No evidence of parasitic or allergic disease or other known causes of peripheral blood eosinophilia.

TABLE 40-3

Mucocutaneous Manifestations in Hypereosinophilic Syndrome

- Angioedema
- Bullae (bullous pemphigoid)
- Dermographism
- Digital gangrene
- Eczema
- Eosinophilic cellulitis (Wells syndrome)
- Erosions
- Erythema
- Erythema annulare centrifuge
- Erythroderma
- Excoriations
- Livedo reticularis
- Lymphomatoid papulosis
- Macules
- Mucosal ulcers (oral and genital)
- Nail-fold infarctions
- Necrosis
- Nodules
- Papules
- Patches
- Pruritus
- Purpura
- Raynaud phenomenon
- Splinter hemorrhages
- Ulcers
- Urticaria
- Vasculitis

Modified from Leiferman KM, Gleich GJ, Peters MS. Dermatologic manifestations of the hypereosinophilic syndromes. *Immunol Allergy Clin North Am.* 2007;27(3):415-441, and Stetson CL, Leiferman, KM. Eosinophilic dermatoses. In: Bolognia JL, Jorizzo JL, Rapini RP, et al, eds. *Dermatology*. 2nd ed. St. Louis, MO: Mosby; 2008:369-378.

(Fig. 40-3) are also seen. Cardiac disease occurs frequently.[131] Eosinophils adhere to endocardium and release granule proteins onto endothelial cells, thrombus formation follows, and, finally, subendocardial fibrosis with restrictive cardiomyopathy occurs. Mitral or tricuspid valvular insufficiency results from tethering of chordae tendineae.[131] Cardiac abnormalities that are essentially identical to those of HES but are confined to the intramural regions can occur without appreciable peripheral blood eosinophilia.[132,133] Splinter hemorrhages and/or nail-fold infarcts may herald the onset of thromboembolic disease. The central and peripheral nervous system, lungs, and, rarely, kidneys may be affected.[111] Patients with myeloproliferative HES frequently present with clinical features resembling those of chronic myelogenous leukemia and, depending on the classification, are regarded as having chronic eosinophilic leukemia. Although chromosomal abnormalities characterize this subtype and the disease may evolve into definite leukemia, the relatively mature nature of the eosinophils and lack of evidence for clonal expansion may preclude such classification.

Lymphocytic HES commonly is associated with severe pruritus, eczema, erythroderma, urticaria, and angioedema, as well as lymphadenopathy and, rarely, endomyocardial fibrosis.[134]

Eosinophilic granulomatosis with polyangiitis is a variant HES subtype. Other variant HES subtypes include Gleich syndrome,[44] in which eosinophil counts fluctuate with extreme angioedema.

ETIOLOGY AND PATHOGENESIS

Eosinophils are implicated as the cause of most end-organ damage in all HES subtypes.[41,75] Clinical improvement usually parallels a decrease in eosinophil count. Patients with lymphocytic HES have abnormal T-cell clones with unusual surface phenotypes, including CD3+ CD4– CD8– and CD3– CD4+. These T cells display activation markers, such as CD25, and secrete Th2 cytokines, including high levels of IL-5.[134,135] An 800-kilobase deletion on chromosome band 4q12 that codes for a tyrosine kinase has been found in myeloproliferative HES.[136] Patients with this *FIP1L1-PDGFRA* gene mutation form a distinct subset of HES, with cardiomyopathy and endomyocardial fibrosis, that responds to imatinib. Patients in this HES subset have elevated serum tryptase levels and increased atypical spindle-shaped mast cells in

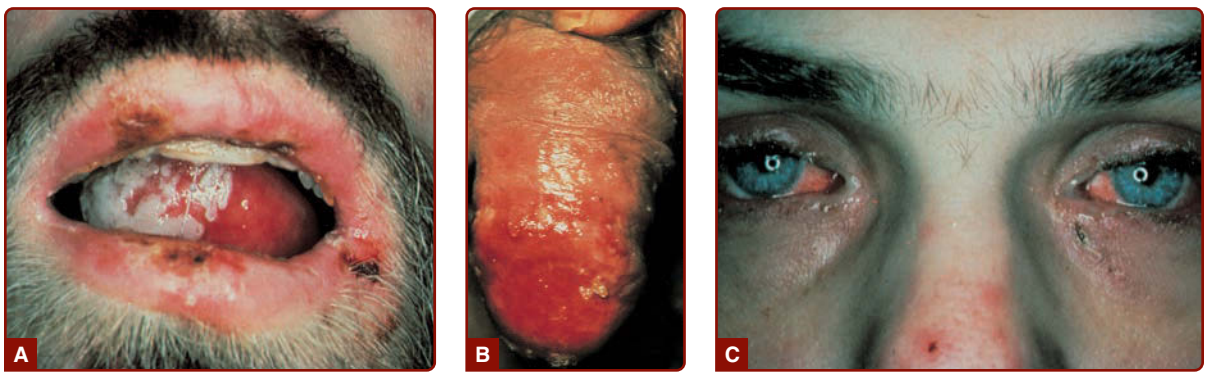

Figure 40-3 Hypereosinophilic syndrome. Mucosal erosions and ulcers of the mouth (**A**) and glans penis (**B**); conjunctival irritation (**C**).

bone marrow.[137-139] Although they do not have clinical manifestations of systemic mastocytosis or exhibit all its immunologic markers, these patients satisfy criteria for mastocytosis.[140] The *FIP1L1-PDGFRA* gene is detected in mast cells,[141] eosinophils, neutrophils, and mononuclear cells. Many HES patients also have marked neutrophilia, likely caused by the aberrant gene in the neutrophil lineage. Thus, alteration of several cell lines probably contributes to the pathogenesis of myeloproliferative HES.[142,143] Myeloproliferative HES with abnormalities of *PDGFRB* and *FGFR1*, other well-characterized variants of myeloproliferative HES, has the potential to progress to aggressive myeloid malignancies.[144] Therefore, it is recommended to assess other translocations in patients with negative *PDGFRA* screening. Multiple other chromosomal abnormalities have been identified in myeloproliferative HES, including translocations, partial and complete chromosomal deletions, and trisomies 8, 15, and 21. Myeloproliferative HES with documented mutations also is known as chronic eosinophilic leukemia. The World Health Organization has an updated 2008 classification scheme for myeloid disorders and eosinophilia.[145,146] The etiology of the other HES variants is not well understood, although patients in several HES subtypes, including with episodic angioedema and eosinophilia (Gleich syndrome)[44] and the NERDS syndrome,[147] have developed T-cell clones.[148]

DIAGNOSIS

A key criterion for diagnosis is marked peripheral blood eosinophilia (see Table 40-2).[109,149-151] Other causes of eosinophilia, including allergic and parasitic diseases, should be excluded. Tests to detect organ involvement, particularly measurement of liver enzyme levels, are important. Because eosinophilic endomyocardial disease can develop in any patient with prolonged peripheral blood eosinophilia, patients should undergo periodic echocardiography along with close observation for signs of thromboembolism. Increased serum levels of IgE are often present in lymphocytic HES, and levels of vitamin B_{12} and tryptase may be increased in myeloproliferative HES. The Chic2 fluorescent in situ hybridization assay detects the deletion that produces the *FIP1L1-PDGFRA* gene product and should be performed, because patients with this mutation respond to treatment with imatinib.[139,141] Alternatively, the mutant gene can be detected by a polymerase chain reaction assay. Both tests are available commercially. In patients who lack the fusion gene, testing for other clonal cytogenetic abnormalities or abnormal clonal T-cell populations is warranted.[137] Cytoflow of peripheral blood lymphocytes and immunophenotyping of tissue lymphocytes should be performed for the diagnosis of lymphocytic HES and repeated periodically to detect transformation from a variant HES type to lymphocytic HES or to T-cell lymphoma.[134] Table 40-4 an HES evaluation assessment scheme for patients with eosinophilia.

The cutaneous histopathologic features of HES vary with the type of lesion. Skin biopsy specimens from urticarial lesions resemble idiopathic urticaria, with generally mild, nonspecific perivascular and interstitial infiltration of lymphocytes, eosinophils, and, occasionally, neutrophils. Immunostaining reveals

TABLE 40-4
Evaluation of Patients with Eosinophilia

- History
- Attention to travel (parasite exposure)
- Ingestants (drugs, health foods, food supplements, and food allergy)
  - Close contacts with itch (ectoparasites)
- Physical examination
  - Cutaneous features (see Table 40-3)
  - Cardiovascular signs
    - Murmur of mitral insufficiency
    - Nails for splinter hemorrhage (medical emergency)
  - Hepatosplenomegaly
  - Lymphadenopathy
- Laboratory studies
  - Repeated complete blood counts with differentials
  - Cytogenetics for chromosomal abnormalities to include
    - *FIP1L1-PDGFRA* (*CHIC2* gene) deletional mutation
    - T-cell subsets for clonality by cytoflow/T-cell receptor gene rearrangement
  - B-cell clonality analyses
  - Inflammatory and immunologic markers
    - Erythrocyte sedimentation rate
    - C-reactive protein
    - Rheumatoid factor
    - Antiproteinase 3 and antimyeloperoxidase (cytoplasmic antineutrophil cytoplasmic antibody and perinuclear antineutrophil cytoplasmic antibody)
    - IgE level
    - Strongyloides IgG antibody
    - IL-5 serum level
  - Metabolic parameters
    - Liver function tests to include aspartate aminotransferase and alanine aminotransferase
    - Renal function tests to include creatinine, blood urea nitrogen and urinalysis for protein and sediment
    - Muscle enzymes to include creatine phosphokinase and aldolase
    - B_{12} serum level
    - Mast cell/basophil tryptase (protryptase) level
    - Coagulation factors
  - Troponin (before initiation of imatinib treatment)
  - Serum protein analyses
    - Serum protein electrophoresis
    - Quantitative immunoglobulins
    - Immunofixation electrophoresis for monoclonal proteins
- Imaging tests
  - Echocardiography
  - Computerized tomography of chest, abdomen, and pelvis
- Gastrointestinal endoscopy, as indicated
- Pulmonary function tests, as indicated
- Bone marrow aspirate and biopsy with staining for tryptase and reticulum (myelofibrosis)
- Tissue biopsy of skin and/or other accessible affected organs
  - Histologic examination
  - Direct immunofluorescence for immunobullous disease
  - Immunostaining for eosinophil granule proteins

Modified from Gleich GJ, Leiferman KM. The hypereosinophilic syndromes: current concepts and treatments. *Br J Haematol*. 2009;145(3):271-85, with permission. Copyright © 2009 Blackwell Publishing Ltd.

extensive deposition of eosinophil granule proteins, in the absence of intact eosinophils, in episodic angioedema with eosinophilia,[44] HES with mucosal ulcers,[45] and in synovial tissues in NERDS.[147] Other than in eosinophilic granulomatosis with polyangiitis, vasculitis only rarely is associated with HES.[120-122]

DIFFERENTIAL DIAGNOSIS

Table 40-5 outlines the differential diagnosis of HES.

Clinically, parasitic infections and infestations may closely resemble HES.[152] A history of travel to endemic areas or certain dietary exposure implicates helminthiasis. Along with eosinophilia, total serum IgE levels higher than 500 IU/mL commonly are found in helminthic infections. Examination of stool samples for ova and parasites and serologic testing for *Strongyloides* antibodies should be performed. In patients with isolated urticarial plaques with or without angioedema, the differential diagnosis includes common and persistent urticaria,[153,154] but demonstration of multiorgan involvement supports HES. HES with episodic angioedema may resemble hereditary angioedema clinically, although patients with hereditary angioedema often have a family history of the disease rarely have the markedly elevated eosinophil counts that characterize HES, and may be distinguished by complement abnormalities. Pruritic eczematous lesions of lymphocytic HES may resemble those of atopic dermatitis, contact dermatitis, drug reaction, fungal infection, and T-cell lymphoma. There are multiple diseases in the differential diagnosis of patients with orogenital ulcers,[129] including those associated with thrombosis, such as Behçet syndrome, Crohn disease, ulcerative colitis, and Reiter syndrome. Others considerations are recurrent aphthous stomatitis, immunobullous diseases, erythema multiforme, lichen planus, herpes simplex infection, and syphilis.

TABLE 40-5

Differential Diagnosis of Hypereosinophilic Syndrome

- Parasitic infection
- Ectoparasitic infestation
- Urticaria
- Hereditary angioedema
- Atopic dermatitis
- Contact dermatitis
- Drug reaction
- Fungal infection
- Mycosis fungoides
- Sézary syndrome
- Behçet syndrome
- Crohn disease
- Ulcerative colitis
- Reiter syndrome
- Recurrent aphthous stomatitis
- Erythema multiforme
- Lichen planus
- Immunobullous disease
- Herpes simplex infection
- Syphilis

CLINICAL COURSE, PROGNOSIS, AND MANAGEMENT

Myeloproliferative HES with mucosal lesions portend an aggressive clinical course; death is likely within 2 years of presentation if the disorder is untreated.[129,155] In contrast to myeloproliferative HES, lymphocytic HES generally follows a benign course, and T-cell clones can remain stable for years. Patients should be observed closely and regarded as having premalignant or malignant T-cell proliferation, because the disease may evolve into lymphoma, especially in CD3– CD4+ T-cell populations.[156]

During the decade or more after diagnosis, HES may evolve into acute leukemia and, less commonly, is associated with B-cell lymphomas. The overall 5-year survival rate for HES patients is 80%; congestive heart failure from the restrictive cardiomyopathy of eosinophilic endomyocardial disease is a major cause of death, followed by sepsis.

The goal of treatment is to relieve symptoms and improve organ function while keeping peripheral blood eosinophils at 1000 to 2000/mm^3 and minimizing treatment side effects (Fig. 40-4). Recent reviews have delineated evaluation and management of HES.[29,70-72,77,82,128,149-151] Corticosteroids are one of the most commonly used and most effective therapeutic agents in the treatment of HES.[116] They are considered the first-line therapy in patients without the gene mutation, once *Strongyloides* infection has been excluded.[157] Approximately 70% of patients will respond, with peripheral eosinophil counts returning to normal. Patients with elevated thymus and activation-regulated chemokine (TARC) and with lymphocytic HES have particularly favorable responses to steroid therapy.[89,110,158] Patients for whom glucocorticoid monotherapy fails have a worse prognosis generally; in such cases, or when long-term side effects become problematic, other treatments should be used. Myeloproliferative HES is responsive to imatinib.[159] In patients with the mutant gene *FIP1L1-PDGFRA*, administration of imatinib mesylate is indicated and usually induces hematologic remission, but endomyocardial disease may worsen during the first several days of treatment. Troponin levels should be monitored before and during imatinib therapy.[160,161] To improve cardiac function, glucocorticoids should be given before and with initiation of imatinib therapy. Imatinib resistance can develop.[162-164] Effective treatment of HES in imatinib-responsive patients results in improvement of associated conditions, including cardiac involvement with endocarditis[165] and myelofibrosis,[166] and skin disease with bullous pemphigoid.[118] Patients who have features of myeloproliferative HES but who lack *FIP1L1-PDGFRA* still may respond to imatinib.[83] IFN-α has been beneficial in treating myeloid and lymphocytic HES.[90,91] In one patient, loss of the *FIP1L1-PDGFRA* mutation after several years of IFN-α therapy was

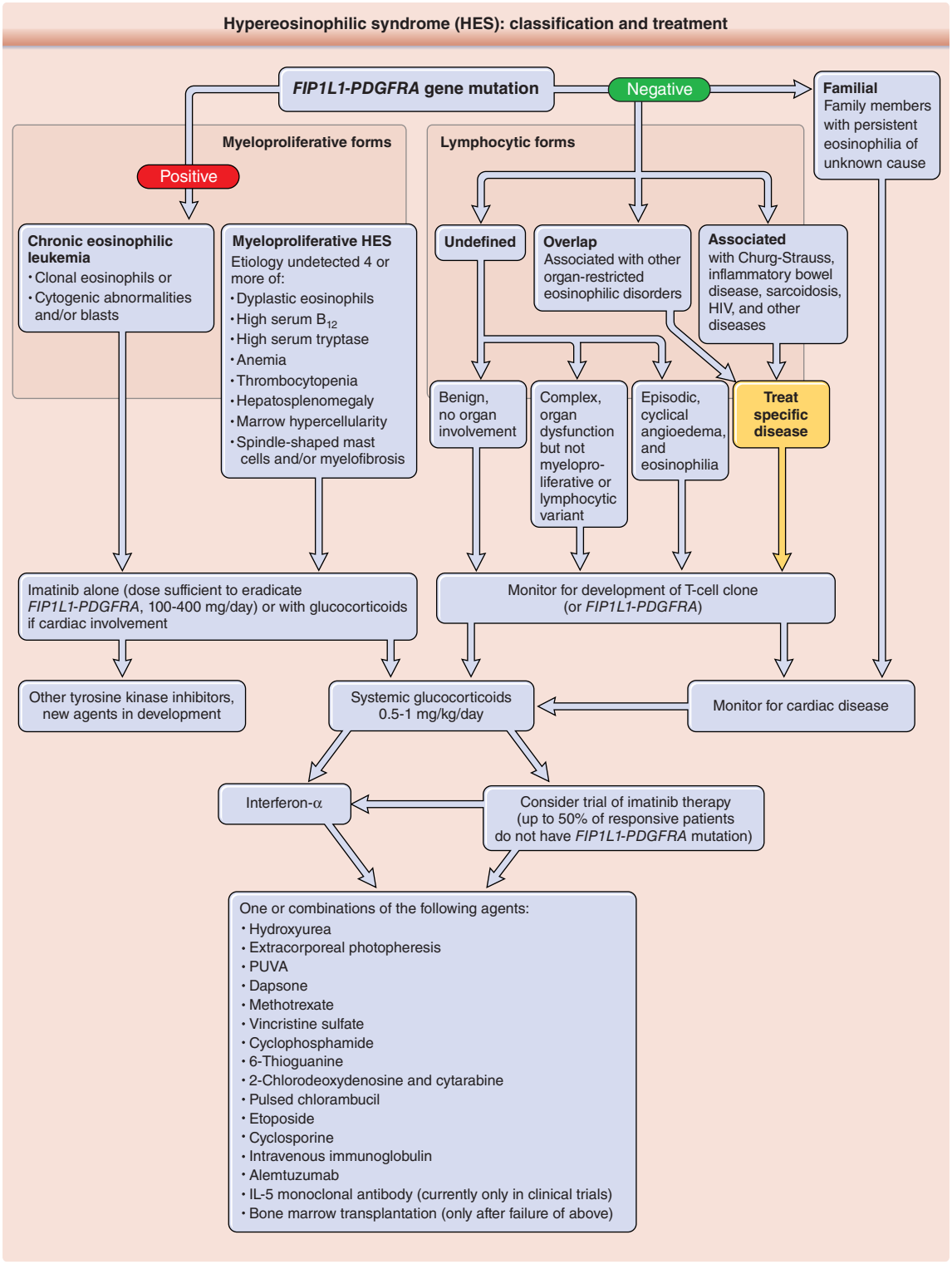

Figure 40-4 Hypereosinophilic syndrome (HES): classification and treatment. Provisional classification consists of myeloproliferative, lymphocytic and familial forms of HES. Chronic eosinophilic leukemia with clonal eosinophilia and myeloproliferative HES with features of the disease but without proof of clonality are included in the myeloproliferative forms of HES; HES with eosinophil hematopoietin-producing T cells with or without a documented T-cell clone constitute the lymphocytic forms of HES. Further HES classification refinement is expected in the near future from a multidisciplinary consensus compendium that is in preparation. *FIP1L1-PDGFRA*, Fip1-like 1 gene/platelet-derived growth factor receptor-α gene; IL-5, interleukin 5; PUVA, psoralen plus ultraviolet A phototherapy. (Information from Roufosse F, Weller PF. Practical approach to the patient with hypereosinophilia. *J Allergy Clin Immunol.* 2010;126(1):39-44; Klion AD. Approach to the therapy of hypereosinophilic syndromes. *Immunol Allergy Clin North Am.* 2007;27(3):551-556; and Stetson CL, Leiferman KM. Eosinophilic dermatoses. In: Bolognia JL, Jorizzo JL, Rapini RP, et al. *Dermatology*. 2nd ed. St. Louis, MO: Mosby; 2008:369-378.)

associated with complete remission.[167] Extracorporeal photopheresis alone or in combination with IFN-α or other therapies represent additional therapeutic options. Other treatments for HES with reported benefit include hydroxyurea, dapsone, vincristine sulfate, cyclophosphamide, methotrexate, 6-thioguanine, 2-chlorodeoxyadenosine and cytarabine combination therapy, pulsed chlorambucil, etoposide, cyclosporine, intravenous Ig, and psoralen plus ultraviolet A phototherapy.[168] Refractory disease may respond to infliximab (anti–TNF-α)[169] or alemtuzumab (anti-CD52),[84-86] as well as to bone marrow and peripheral blood stem cell allogeneic transplantation.[170,171] Two monoclonal antibodies against human IL-5 (mepolizumab and reslizumab) are associated with clinical improvement and reductions in peripheral blood and dermal eosinophils, particularly in patients with lymphocytic HES.[172-176] Treatments targeting IL-5 have provided new insights into understanding eosinophil-associated disease.[75]

WELLS SYNDROME

AT-A-GLANCE

- Single or multiple lesions commonly located on the extremities or trunk.
- Lesions may be painful or pruritic.
- Associated with general malaise but uncommonly with fever.
- Edematous and erythematous lesions evolve into plaques with violaceous borders.
- Blisters may be a prominent feature.
- Multiple recurrences.
- Peripheral blood eosinophilia common.
- Histologic pattern characterized by dermal infiltration with eosinophils, and flame figures surrounded by histiocytes.
- Systemic glucocorticoids usually therapeutic.

CLINICAL FEATURES

Cutaneous edema was the common clinical thread in the first 4 cases reported by Wells.[177] After prodromal burning or itching, lesions begin with erythema and edema (Fig. 40-5A), sometimes in the form of annular or arcuate plaques or nodules (Fig. 40-5B). Over a period of days, they evolve into large edematous plaques with violaceous borders. Bullae may develop.[178-181] Individual lesions gradually change from bright red to brown-red and then to blue-gray or greenish-gray, resembling morphea (Fig. 40-5C). Less-common clinical presentations include papules, vesicles (Fig. 40-6), and hemorrhagic bullae. The cutaneous lesions may be single or multiple and may be located at any site, but typically involve the extremities and, less often, the trunk.[182] The most frequent systemic complaint in patients with Wells syndrome is malaise; fever occurs in a minority of cases. Some patients have

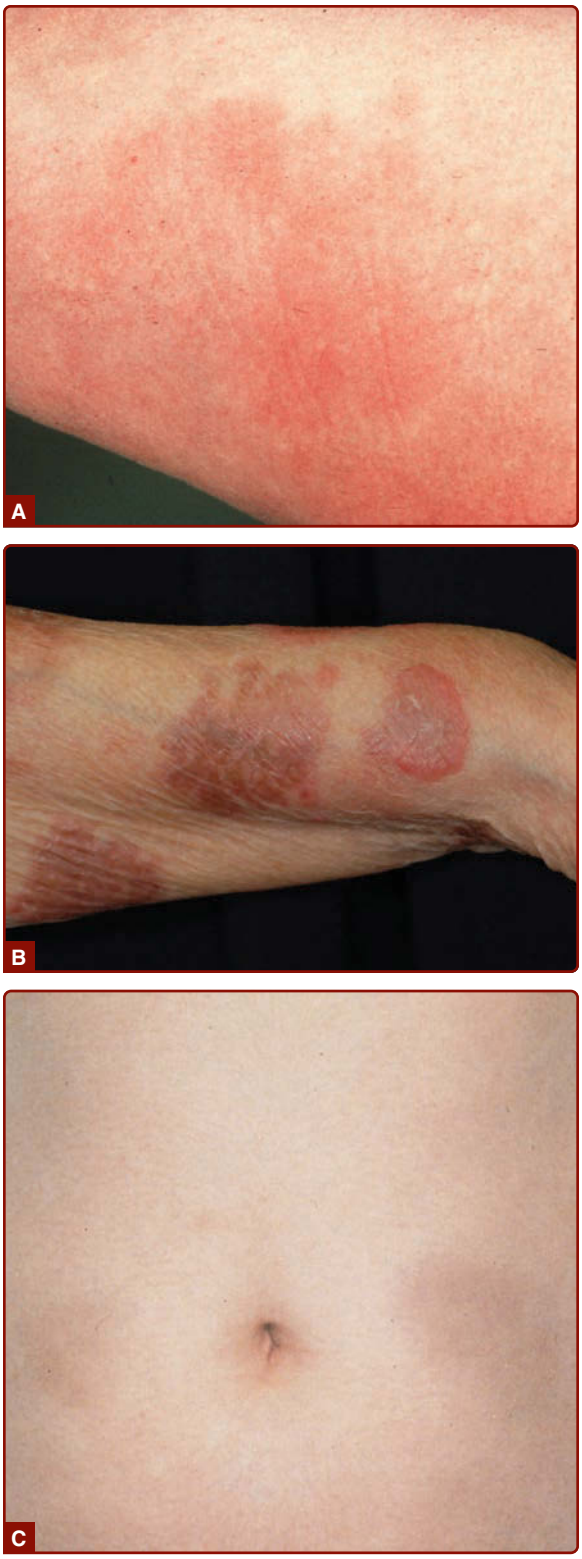

Figure 40-5 Wells syndrome. **A,** Early lesion with erythema and edema. **B,** An arcuate plaques and pigmentation. **C,** Late lesion resembling morphea.

Figure 40-6 Familial Wells syndrome. Plaques with erythema, edema, vesicles, and bullae resembling acute dermatitis or pemphigoid. (From Davis MD, Brown AC, Blackston RD, et al. Familial eosinophilic cellulitis, dysmorphic habitus, and mental retardation. *J Am Acad Dermatol.* 1998;38(6, pt 1):919-928, with permission. Copyright © American Academy of Dermatology.)

an associated underlying disorder such as hematologic or nonhematologic malignancies.

ETIOLOGY AND PATHOGENESIS

The etiology and pathogenesis of Wells syndrome is unclear. A nonspecific hypersensitivity reaction in response to exogenous and/or endogenous stimuli is regarded as the important pathomechanism.[183] Some cases appear to be idiopathic, while many others suggest a triggering event, such as insect bites, viral or bacterial infections, and drugs and vaccines. The association with an underlying disorder, such as a malignancy, also has been reported.

DIAGNOSIS

Peripheral blood eosinophilia is observed in approximately 50% of patients. Skin lesions histologically are characterized by diffuse dermal infiltration with eosinophils, histiocytes, and foci of amorphous and/or granular material associated with connective tissue fibers, which Wells termed *flame figures*.[177] In the early stages, there also is dermal edema. Later, histiocytes palisade around flame figures. Vasculitis is usually absent.[184] In addition to 8 patients with the syndrome, the 1979 report of Wells and Smith includes 9 patients with the typical histologic features of eosinophilic cellulitis but in association with a variety of clinical diagnoses, including pemphigoid, eczema, and tinea.[185] This and subsequent reports of flame figures in lesions from patients with a wide spectrum of diseases (Table 40-6) indicate that the flame figure is characteristic for, but not diagnostic of, Wells syndrome.[186] When examined for eosinophil granule MBP by immunofluorescence, flame figures show bright extracellular staining (Fig. 40-7), indicating that extensive eosinophil degranulation has occurred.[187]

DIFFERENTIAL DIAGNOSIS

Table 40-7 outlines the differential diagnosis of Wells syndrome.

TABLE 40-6
Conditions Associated with Wells Syndrome and/or Flame Figures

- Arthropod bite
- Ascariasis
- Bronchogenic carcinoma
- Eosinophilic granulomatosis with polyangiitis
- Colonic adenocarcinoma
- Dental abscess
- Dermographism
- Drug reaction
- Eczema
- Eosinophilic fasciitis
- Eosinophilic pustular folliculitis
- Herpes gestationis
- Herpes simplex infection
- HIV
- Hymenoptera sting
- Hypereosinophilic syndrome
- Immunobullous diseases
- Mastocytoma
- Molluscum contagiosum
- Myeloproliferative diseases
- Onchocerciasis
- Vaccinations
- Tinea
- Toxocariasis
- Urticaria
- Ulcerative colitis
- Varicella

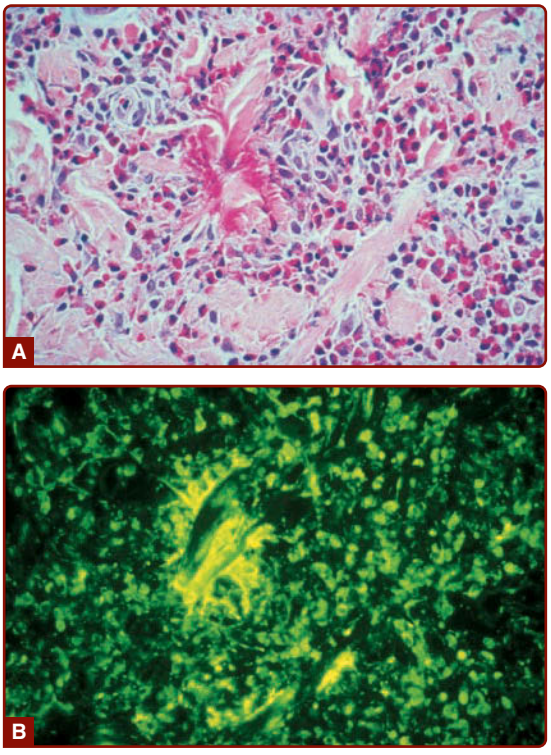

Figure 40-7 Flame figure in familial Wells syndrome. **A,** Hematoxylin and eosin–stained section. **B,** Eosinophil granule major basic protein immunostain (of serial section to **A**) shows extensive granule protein deposition localized to the flame figure. (Original magnification ×400.)

TABLE 40-7
Differential Diagnosis of Wells Syndrome

- Urticaria
- Erysipelas
- Acute cellulitis
- Pemphigoid
- Morphea

Urticaria, erysipelas, and acute cellulitis should be considered in the differential diagnosis of the early stages of Wells syndrome (see Fig. 40-5A). Later, plaques may resemble morphea (see Fig. 40-5C). The presence of blisters may suggest pemphigoid (see Fig. 40-6). Flame figures are the hallmark of Wells syndrome, but, because they have been identified in biopsy specimens from other dermatoses (see Table 40-6), they are not alone sufficient for the diagnosis. However, a diagnosis of Wells syndrome in the absence of flame figures should be met with skepticism, even in the presence of dermal infiltration with eosinophils and histiocytes.[186]

CLINICAL COURSE, PROGNOSIS, AND MANAGEMENT

Wells syndrome resolves without scarring, usually within weeks to months, but multiple recurrences are common. Lesions usually improve dramatically after administration of systemic glucocorticoids, and tapering of steroid dose over 1 month is well tolerated in most patients. Recurrences or persistent cases can be effectively maintained with low-dose (5 mg) alternate-day prednisone.[188] For patients who fail to respond, or who experience relapse often enough to raise concerns about the long-term side effects of systemic glucocorticoid therapy, other options, such as minocycline, dapsone, griseofulvin, and antihistamines, may be beneficial. Cyclosporine and IFN-α also have been used with success. For treatment of mild disease, topical glucocorticoids may be sufficient. It also can be beneficial to treat the underlying condition or triggering factor.[189-191]

ANGIOLYMPHOID HYPERPLASIA WITH EOSINOPHILIA (EPITHELIOID HEMANGIOMA)

AT-A-GLANCE

- Kimura disease (KD) occurs mainly in Asian males; angiolymphoid hyperplasia with eosinophilia (ALHE) occurs in all races, with a female predominance.
- KD is found in a younger age group than ALHE.
- Both ALHE and KD are characterized by recurrent dermal and/or subcutaneous lesions, primarily of the head and neck area.
  - ALHE lesions tend to be smaller, more superficial, and more numerous than those of KD.
  - KD tends to involve subcutaneous tissues, regional lymph nodes, and salivary glands.
- ALHE may be painful, pruritic, or pulsatile, whereas KD is generally asymptomatic.
- Peripheral blood eosinophilia present in both diseases.
- Increased IgE levels are found only in KD.
- Renal disease is associated only with KD (reported incidence of 10% to 20%).
- Histopathologic features:
  - Dominant feature of KD is lymphoid proliferation, often with germinal centers, whereas ALHE is characterized by vascular proliferation with numerous large epithelioid or histiocytoid endothelial cells.
  - Fibrosis is characteristic of KD and is limited or absent in ALHE.
  - Inconspicuous to numerous eosinophils in ALHE.
  - Eosinophil abscesses may occur in KD.

Angiolymphoid hyperplasia with eosinophilia (ALHE) occurs in both males and females, but there is a slight female predominance. Patients are generally in the third to fifth decade of life. In contrast to Kimura disease (KD), which develops mainly in Asian males at puberty, ALHE has no racial predilection.

CLINICAL FEATURES

ALHE shows a predilection for the head and neck area, including the ears,[192] and is characterized by solitary, few, or multiple, sometimes grouped, erythematous, violaceous, or brown papules, plaques, or nodules of the dermis and/or subcutaneous tissues (Fig. 40-8). Lesions may be associated with pruritus or pain, or may pulsate. Although they are confined to the skin in most patients, mucosal involvement may occur.[193]

ETIOLOGY AND PATHOGENESIS

The pathogenesis of ALHE is unknown, but it has been considered a vascular proliferation arising in response to or in association with underlying vascular malformation. There is a history of trauma in some cases. ALHE has been reported to occur in pregnancy, which implies that sex hormones may be a factor in its development.[194] ALHE also has developed in patients with T-cell clonality, which suggests that it may be an early or low-grade T-cell lymphoma and further highlights a relationship between T cells and eosinophils, particularly T cells with the Th2 phenotype.[195,196]

Figure 40-8 Angiolymphoid hyperplasia with eosinophilia. **A,** Multiple grouped brown nodules. **B,** Reddish papules.

DIAGNOSIS

Approximately 20% of patients have peripheral blood eosinophilia; IgE levels are unremarkable. There is no association with renal disease. The dominant histologic feature is a well-defined area, in the dermis and/or subcutis, of prominent vascular proliferation with large epithelioid or histiocytoid endothelial cells that contain abundant eosinophilic cytoplasm, often with cytoplasmic vacuoles. There are variable numbers of eosinophils and lymphocytes,[197] with an occasional finding of lymphoid nodules. In their report of 116 patients with ALHE, Olsen and Helwig found 53 cases in which "an arterial structure" appeared to be associated with venules or "was the area of endothelial proliferation," which provided evidence that these lesions may represent a form of arteriovenous shunt.[198] The stroma typically is myxoid, and fibrosis is minimal or absent. Mast cells may be a component of the histologic picture.

TABLE 40-8
Differential Diagnosis of Angiolymphoid Hyperplasia with Eosinophilia

- Kimura disease
- Pyogenic granuloma
- Epithelioid hemangioendothelioma
- Epithelioid angiosarcoma
- Kaposi sarcoma

DIFFERENTIAL DIAGNOSIS

Table 40-8 outlines the differential diagnosis of ALHE.

KD also develops preferentially on the head and neck area, especially around the ears. It is characterized by solitary or multiple brownish plaques or intracutaneous and/or subcutaneous masses (Fig. 40-9). The lesions are generally asymptomatic, but they can be pruritic. Atopic disease may be associated. Lesions of ALHE generally are smaller, more superficial, and more numerous than those of KD, and often are symptomatic. Patients with KD also show peripheral blood eosinophilia and increased IgE levels. The dominant histologic feature is lymphoid proliferation, often with germinal centers with prominent infiltration of eosinophils. Fibrosis is characteristic, and eosinophil abscesses may occur. Although lymphoid follicles may occur in ALHE, they represent the dominant characteristic of KD (Table 40-9), and although KD may exhibit some vascularity, it lacks the large epithelioid endothelial cells that are a key feature of ALHE (Table 40-9). ALHE should be distinguished from a variety of benign and malignant vascular proliferations, including pyogenic granuloma, epithelioid hemangioendothelioma, and

Figure 40-9 Kimura disease. Solitary brownish nodules and multiple papules.

TABLE 40-9
Comparison of Angiolymphoid Hyperplasia with Eosinophilia and Kimura Disease

	ALHE	KD
Gender	Typically middle-aged females	Predominantly young-adult Asian males
Symptoms	Pruritus, pain, pulsation	Asymptomatic
Lesion type and location	Small and superficial, with overlying erythema; head and neck region	Large, mainly subcutaneous; overlying skin normal; head and neck region; may involve regional lymph nodes and salivary glands
Lymphoid follicles	Uncommon	Prominent lymphoid follicles with germinal centers
Vascular proliferation	Prominent vascular proliferation with large epithelioid/histiocytoid endothelial cells; evidence of underlying vascular malformation may be evident	Some stromal vascularity with unremarkable endothelial cells
Fibrosis	Absent or limited	Prominent
Serum immunoglobulin E level	Normal	Increased
Nephropathy	Absent	Present in up to 20% of patients

Kaposi sarcoma—all of which lack a noticeable eosinophil infiltrate. Although it is nonspecific, the dermoscopic finding of ALHE with polymorphous vascular pattern may be helpful in differential diagnosis from other vascular tumors.[199]

CLINICAL COURSE, PROGNOSIS AND MANAGEMENT

ALHE tends to be chronic and nonremitting over months to years. Intervention is dictated in part by the number, location, size of lesions, and the patient's general health.[200] Patients with solitary or a few small lesions may benefit from excision or Mohs surgery,[201] but there may be recurrence at the surgical site (Fig. 40-10). A variety of other treatment modalities have been used with success, including systemic and intralesional glucocorticoid administration, IFN-α therapy,[202] cryotherapy,[203] laser therapy,[204] and topical application of tacrolimus.[205]

KIMURA DISEASE

Table 40-10 outlines the differential diagnosis of KD.

Figure 40-10 Angiolymphoid hyperplasia with eosinophilia. **A,** Forehead nodule. **B,** Recurrence of lesions in skin graft and adjacent sites 6 years after surgical removal of lesion in **A**.

MANAGEMENT

Surgical excision is the treatment of choice when feasible in patients with a single or a limited number of nodules, but lesions may recur.[206,207] Other therapeutic options include systemic glucocorticoids, cyclosporine, and radiation therapy.[208,209] The presence of renal disease may influence or dictate the therapeutic regimen.

TABLE 40-10
Differential Diagnosis of Kimura Disease

- Angiolymphoid hyperplasia with eosinophilia
- Lymphoma

The finding of PDGF-α and c-kit in tissues from KD patients suggests that imatinib or another tyrosine kinase inhibitor may be effective in the disease.[210]

EOSINOPHILIC PUSTULAR FOLLICULITIS

AT-A-GLANCE

- Three clinical types that are characterized by follicular papules and pustules, and may involve the head, trunk, and extremities.
- Classic eosinophilic pustular folliculitis (Ofuji disease).
  - Typically occurs in Japanese patients, who have chronic, recurrent follicular pustules, with a tendency to form circinate plaques, in a seborrheic distribution.
- Eosinophilic pustular folliculitis associated with immunosuppression.
  - Most often occurs in patients with human immunodeficiency virus infection, who have severely pruritic papules of the face and upper trunk.
- Eosinophilic pustular folliculitis of infancy/neonatal period.
  - Follicular pustules of the scalp.
- Tendency for recurrences and chronicity (except eosinophilic pustular folliculitis of infancy).
- Characterized by follicular and perifollicular eosinophil infiltration.
- Associated with peripheral blood eosinophilia.

CLINICAL FEATURES

At present, eosinophilic pustular folliculitis (EPF) is divided into 3 variants: classical EPF, immunosuppression-associated EPF, and infantile EPF.[211] Immunosuppression-associated EPF may be subdivided into an HIV-associated type and a malignancy-associated type.[212-214] Classical EPF presents as recurrent crops or clusters of follicular papules and pustules, which may form an annular pattern and usually resolve in 7 to 10 days (Fig. 40-11A). Lesions predominantly involve the face and trunk but also may affect the extremities, with involvement of the palms and soles in approximately 20% of patients.[215] In infantile type of EPF, lesions typically are located on the scalp, but also may be found on the face and extremities. In some neonates who have pustular eruptions that clinically resemble EPF and typically have peripheral blood eosinophilia, the disorder may be classified more appropriately under the term *eosinophilic pustulosis* because the cutaneous infiltrates are not folliculocentric.[216] In contrast,

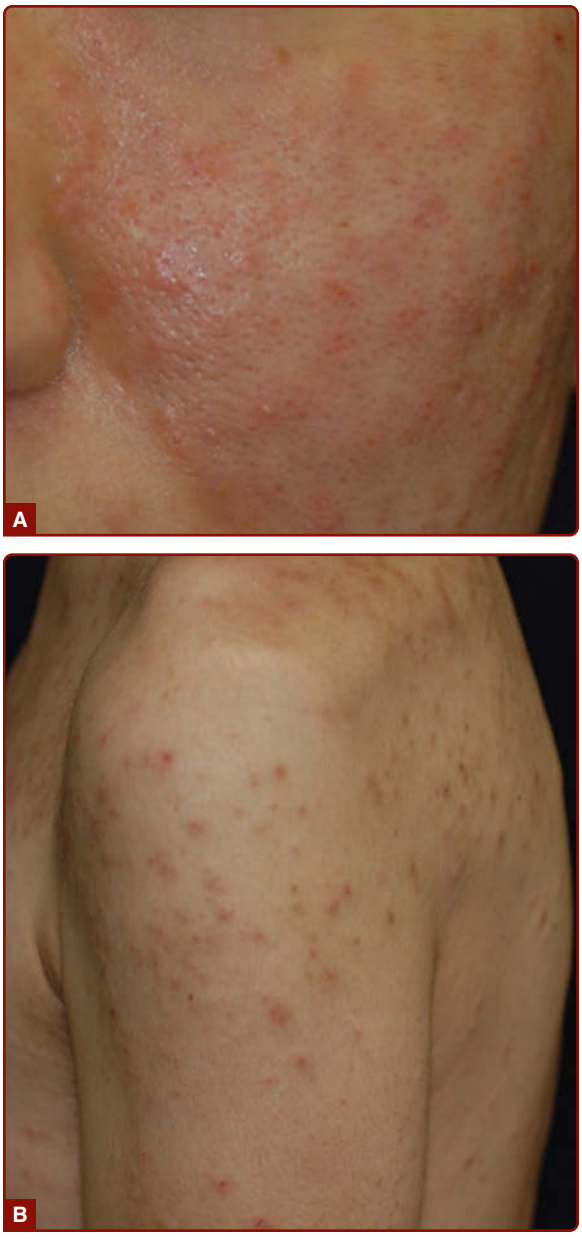

Figure 40-11 Eosinophilic pustular folliculitis. **A,** Itchy reddish papules and pustules on the cheek. **B,** An HIV-associated case with itchy red papules on the upper arm, shoulder, and back.

HIV-associated EPF tends to manifest as extremely pruritic discrete follicular papules, typically involving the head and neck and often the proximal extremities (Fig. 40-11B). Rosenthal et al emphasized the urticarial quality of such lesions.[217]

ETIOLOGY AND PATHOGENESIS

The etiology of EPF remains unknown. The occasional association with HIV infection suggests the possible contribution of immunocompromised status to the development of EPF. Interestingly, some cases of HIV-associated EPF develop lesions after starting highly active anti-retroviral therapy (HAART), indicating that

EPF may occur as a result of immune reconstruction rather than immunodeficiency in these HAART-treated cases.[218-220] Drugs,[221,222] parasitic or viral infections,[223,224] and pregnancy[225,226] are also reported as possible factors related to EPF. The higher expression of ICAM-1 and leukocyte function-associated antigen-1 on the follicular epithelium, and VCAM-1 around hair follicles in EPF lesions, suggest that these molecules are relevant to the selective migration of eosinophils and lymphocytes to the hair follicles in EPF.[227] One study demonstrated that an interaction between PGD_2 and a chemoattractant receptor-homologous molecule expressed on T-helper type 2 (CRTH2) cells may be involved in the pathogenesis of classical EPF and that indomethacin may exert its therapeutic effect by reducing CRTH2 expression, as well as by inhibiting PGD_2 synthesis.[228]

DIAGNOSIS

Patients suspected of having EPF should be evaluated for underlying immune deficiency, particularly HIV infection. Peripheral blood eosinophilia is a component of all 3 types of EPF. TARC is reported to be elevated in serum and to correlate with peripheral blood eosinophilia.[229] Although patients with classical EPF usually have eosinophilia with leukocytosis, HIV-positive patients often exhibit eosinophilia with lymphopenia. Low CD4+ T-cell counts and high IgE levels are typical of HIV-associated EPF.[217] Elevated serum IgE is uncommon in infantile EPF.[230] Histologically, the most striking feature is the infiltration of eosinophils into hair follicles and perifollicular areas, sometimes with follicular damage. The infiltrates also may contain lymphocytes and neutrophils, and may be perivascular as well as follicular.[231] Flame figures can also be observed in infantile EPF.[230] Follicular mucinosis has been noted in association with EPF[232]; however, T-cell clonality is not observed in EPF-associated follicular mucinosis.[233]

DIFFERENTIAL DIAGNOSIS

Table 40-11 outlines the differential diagnosis of EPF.

Folliculitis secondary to bacterial or fungal infection must be kept in mind, particularly in immunosuppressed patients. Based on the distribution of lesions, seborrheic dermatitis should be considered, when there is head and neck involvement, and palmar–plantar pustular psoriasis may also be included in the differential diagnosis when there is hand and foot involvement. Acneiform eruption, rosacea, and lupus miliaris disseminatus faciei may resemble EPF. Erythema toxicum neonatorum, acropustulosis, and acne neonatorum also should be considered in infants. Follicular mucinosis usually is clinically and histologically distinguishable from EPF. One of the most important differential diagnoses is cutaneous T-cell lymphoma, which can resemble EPF both clinically and histopathologically.[212]

TABLE 40-11

Differential Diagnosis of Eosinophilic Pustular Folliculitis

- Folliculitis, bacterial or fungal
- Seborrheic dermatitis
- Palmar–plantar pustular psoriasis
- Acne, including acne neonatorum
- Erythema toxicum neonatorum
- Acropustulosis
- Follicular mucinosis

CLINICAL COURSE, PROGNOSIS, AND MANAGEMENT

The infantile type of EPF has a good prognosis, whereas classical and HIV-associated EPF are characterized by recurrences. Postinflammatory pigmentation may be seen as lesions resolve, but scarring does not occur.

Topical glucocorticoids and topical calcineurin inhibitors generally are the first approach to the treatment of all types of EPF. Topical tacrolimus is helpful for facial lesions.[234] Nonsteroidal antiinflammatory drugs, particularly indomethacin, also are recommended as first-line therapy; clinical improvement may be observed within 2 weeks and is associated with a decrease in peripheral blood eosinophil counts.[235-237] Ultraviolet light therapy (ultraviolet B or psoralen and ultraviolet A) may be beneficial. Topical permethrin, systemic retinoids, systemic glucocorticoids, cyclosporine, itraconazole, metronidazole, cetirizine, minocycline, dapsone, and IFNs have been tried with success.[235,236] Antiretroviral treatment that results in increased CD4 cell counts often is associated with improvement in HIV-associated EPF. The first-line treatment of infantile EPF is observation or topical steroid therapy. Infantile EPF tends to resolve spontaneously within several years and usually shows good response to topical steroids.[230]

PAPULOERYTHRODERMA OF OFUJI

AT-A-GLANCE

- Papuloerythroderma tends to occur in elderly males.
- The lesions are usually pruritic.
- Erythroderma-like eruptions formed by confluent flat-topped, red-to-brown papules are characteristic.
- The unique sparing of the abdominal skin folds is termed *deck-chair sign*.

(Continued)

AT-A-GLANCE (*Continued*)

- Approximately 20% of cases are associated with hematologic or visceral malignancies.
- Papuloerythroderma may progress to cutaneous T-cell lymphoma.
- The majority of cases are associated with peripheral blood eosinophilia.
- Ultraviolet treatment and corticosteroids are usually effective; however, the disorder is sometimes refractory to treatment.

CLINICAL FEATURES

Papuloerythroderma of Ofuji was described as a distinctive pattern of erythroderma by Ofuji in 1984.[238] Many cases occur in elderly males, especially in the eighth or ninth decades. Itchy erythroderma-like eruptions formed by the coalescence of flat-topped, red-to-brown papules with a cobblestone appearance is characteristic (Fig. 40-12).[239] It affects the limbs and trunk; the face and flexures are usually spared. The characteristic sparing of the abdominal skin folds is called *deck-chair sign*. Mucous membranes, hair, and nails are always spared. Palmoplantar keratoderma and dermatopathic lymphadenopathy are reported in approximately 20% of patients.[239] Approximately 20% of cases with papuloerythroderma are associated with hematologic neoplasms such as non-Hodgkin lymphoma and leukemia or visceral malignancies including gastric, colon, and prostate carcinomas.[240-243]

ETIOLOGY AND PATHOGENESIS

The pathogenesis of papuloerythroderma is unknown. It remains controversial whether it is an independent clinical entity or a unique manifestation of an underlying disorder. Malignancy, atopic diathesis, infections and drug intake are reported to be possible causes of papuloerythroderma. Several findings (eosinophil infiltration of the lesional skin and occasional association of atopic diathesis) suggest a role for T lymphocytes polarized toward the Th2 phenotype in the pathogenesis of papuloerythroderma, although the target antigens of those T lymphocytes are unclear. It is reported that the percentages of circulating CCR4+ CD4+ Th2 cells are higher than those of CXCR3+ CD4+ Th1 cells in patients with drug-induced papuloerythroderma.[244] A recent study demonstrated that the percentages of IL-4–producing, IL-13–producin, and IL-22–producing CD4+ and CD8+ T cells were significantly higher in the circulations of patients with papuloerythroderma than in the circulations of healthy controls. In addition, the expression of both cutaneous lymphocyte antigen and CCR4 was markedly upregulated in those cells. These findings suggest that skin-homing Th2/Th22 cells may contribute to the pathogenesis of papuloerythroderma.[245]

Figure 40-12 Papuloerythroderma of Ofuji. Flat-topped red-to-brown papules with a cobblestone appearance on the abdomen. The sparing of the skin folds, called *deck-chair sign*, is seen.

DIAGNOSIS

Characteristic flat-topped, red-to-brown confluent papules and the deck-chair sign are highly diagnostic, although the deck-chair sign is observed in other erythrodermas, such as psoriasis and atopic dermatitis.[243,246] Peripheral eosinophilia is detected in more than 80% of patients.[239] Lymphocytopenia and increased serum IgE are sometimes observed. Histopathology shows nonspecific spongiotic dermatitis-like patterns, that is, acanthosis, spongiosis, and infiltration of lymphocytes, histiocytes, and variable amounts of eosinophils distributed in the mid-upper dermis and around microvessels, which resemble chronic dermatitis.[239]

DIFFERENTIAL DIAGNOSIS

Typical papuloerythroderma can be distinguished from other erythrodermas by its characteristic clinical appearance. Some cases show histologic findings of cutaneous T-cell lymphoma such as mycosis fungoides.[247,248] It was also reported that papuloerythroderma progressed to cutaneous T-cell lymphoma.[246] As it can be associated with atopic diathesis, malignancies, infections, and drugs,[239] underlying complications must be examined.

CLINICAL COURSE, PROGNOSIS, AND MANAGEMENT

Papuloerythroderma tends to be chronic over years and non–self-limiting. Oral prednisolone is effective in the majority of cases. Ultraviolet treatment alone or in combination with oral and topical corticosteroids is reported to be very efficient.[242] Etretinate,[249] cyclosporine,[250] and IFN[251] are also reported as effective for papuloerythroderma. However, papuloerythroderma is frequently refractory to treatment.

GRANULOMA FACIALE

AT-A-GLANCE

- Granuloma faciale is an uncommon inflammatory dermatosis characterized clinically by reddish brown papules and plaques primarily involving the face.
- The pathology shows changes of a chronic leukocytoclastic vasculitis with a mixed infiltrate containing eosinophils, extensive perivascular fibrin deposition, and dermal fibrosis.
- Etiology is unknown.

Granuloma faciale occurs predominantly in adult men and women. There is a slight male predominance, and mean age at presentation is 52 years.[252,253] Granuloma faciale can occur in individuals of any race; however, it is more common in whites.

CLINICAL FEATURES

Granuloma faciale is characterized by solitary papules, plaques, or nodules. The lesions are typically asymptomatic red, brown, or violaceous plaques that are soft, smooth, and well circumscribed, often showing follicular accentuation and telangiectasia (Figs. 40-13 and 40-14). The prominent follicular openings sometimes show a "peau d'orange" appearance. Ulceration is rare. Lesions are most common on the face. Sites of predilection include the nose, preauricular area, cheeks, forehead, eyelids, and ears.[252,254] Rarely, patients may present with multiple lesions or lesions on the trunk or extremities. Extrafacial lesions have been reported both as isolated findings and in conjunction with facial lesions. Lesions are typically asymptomatic; however, patients may complain of tenderness, burning, or pruritus.[252] Photoexacerbation of lesions has been reported.[255] It is rarely associated with systemic disease.[256]

Figure 40-13 Granuloma faciale. Raised edematous plaques on cheek showing prominent follicular ostia.

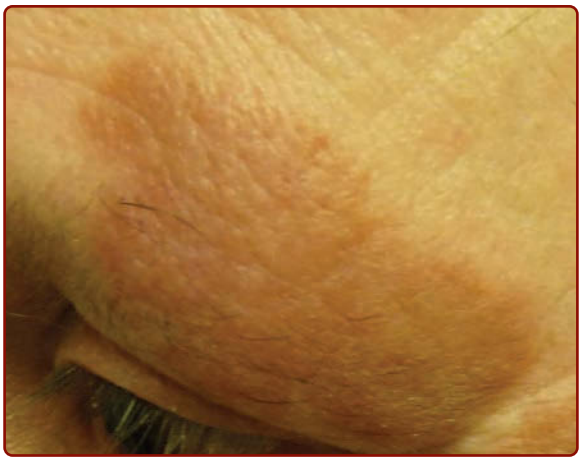

Figure 40-14 Granuloma faciale. Single plaque on the temple showing prominent follicular ostia and central dell.

ETIOLOGY AND PATHOGENESIS

The etiology of granuloma faciale is unknown. The disease can be considered a localized chronic fibrosing vasculitis.[257] Immunofluorescence studies have revealed deposition of immunoglobulins and complement factors in the vessel walls consistent with a type III immunologic response, marked by deposition of circulating immune complexes surrounding superficial and deep blood vessels.[258,259] However, other authors have described negative results with immunofluorescence.[254]

DIAGNOSIS

An extensive laboratory evaluation is not required. Peripheral blood eosinophilia is occasionally detected. The diagnosis may be established by a combination of clinical findings and confirmatory tissue biopsy results. A punch biopsy that includes the full thickness of the dermis is recommended. Histologic examination shows a normal-appearing epidermis, which may be separated from the underlying inflammatory infiltrate by a narrow grenz zone (Fig. 40-15). Within the dermis is a dense and diffuse infiltrate of lymphocytes, plasma cells, eosinophils, and neutrophils with evidence of leukocytoclasis (Fig. 40-16). The inflammatory infiltrate surrounds the blood vessels, which show evidence of fibrin deposition. In later stages, the perivascular fibrin deposition becomes extensive and dominates the histologic picture. Deposition of hemosiderin may contribute to the brown color seen clinically. Electron microscopy studies confirm the presence of an extensive eosinophilic infiltrate with Charcot–Leyden crystals and numerous histiocytes filled with lysosomal vesicles; however, cases with few

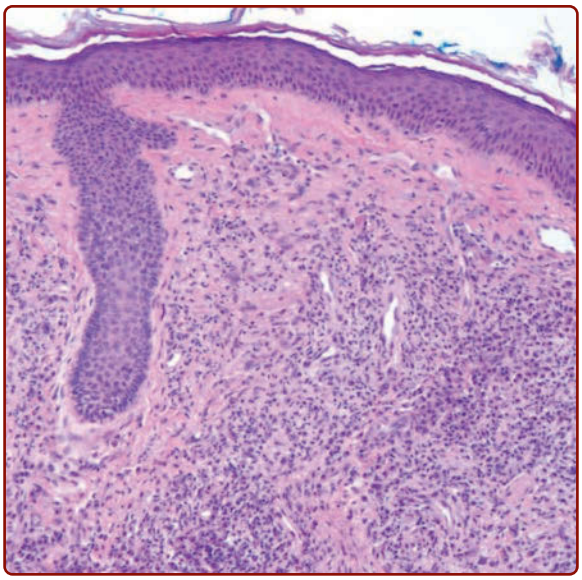

Figure 40-15 Granuloma faciale. This low-power histologic section shows a mixed infiltrate of lymphocytes, histiocytes, neutrophils, plasma cells, and eosinophils. There is sparing of a narrow grenz zone between the inflammatory infiltrate and the overlying epidermis.

eosinophils in the infiltrate have also been described.[260] Immunoglobulins, fibrin, and complement can be found deposited along the dermal–epidermal junction in a granular pattern and around blood vessels by direct immunofluorescence.[258] Recently, dermoscopy has come to be used for assisting the diagnosis. It reveals a translucent white-gray or pink background intermingled with whitish streaks and elongated telangiectasias. The finding of dilated follicular openings, which are more evident under dermoscopy, is of value in the differential diagnosis.[261]

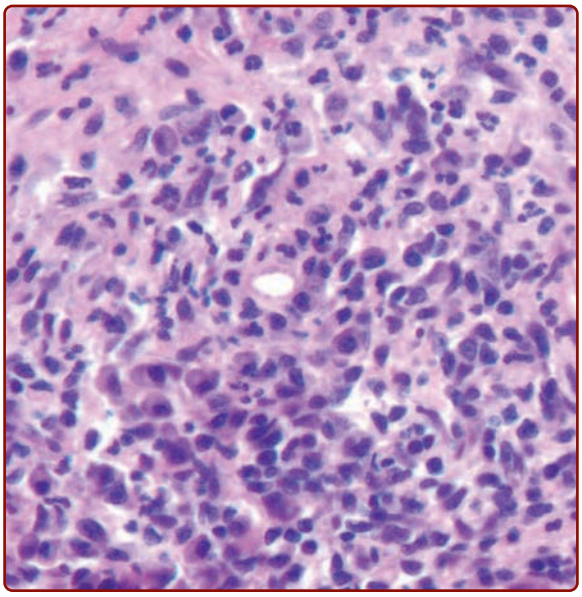

Figure 40-16 Granuloma faciale. This histologic section shows perivascular deposition of fibrin and a mixed infiltrate of lymphocytes, neutrophils, and eosinophils.

DIFFERENTIAL DIAGNOSIS

The clinical differential diagnosis for granuloma faciale includes discoid lupus erythematosus, polymorphous light eruption, fixed drug eruption, benign lymphocytic infiltrate of Jessner, lymphoma cutis, pseudolymphoma, sarcoidosis, granuloma annulare, tinea faciei, insect bite reaction, xanthogranuloma, mastocytoma, actinic keratosis, basal cell carcinoma, Langerhans cell histiocytosis, and rosacea (Table 40-12). The diagnosis can be reliably made by histologic examination. Absence of serologic evidence of lupus erythematosus helps differentiate these lesions from the lesions of discoid lupus erythematosus. The primary histologic differential diagnosis is erythema elevatum diutinum (EED). Both diseases represent chronic forms of fibrosing small vessel vasculitis and may be related. However, there are several clinical and histologic differences. EED is characterized by multiple lesions, primarily located on extensor surfaces of the extremities in a symmetric acral distribution. The trunk and face are typically spared in EED. Histologically, both show a chronic fibrosing vasculitis.[262] However, a grenz zone of normal collagen beneath the epidermis is not typical of EED. Eosinophils and plasma cells are more prominent in granuloma faciale, whereas

TABLE 40-12
Differential Diagnosis of Granuloma Faciale

Most Likely
- Face
  - Sarcoidosis
  - Benign lymphocytic infiltrate of Jessner
  - Rosacea
- Extrafacial
  - Erythema elevatum diutinum

Consider
- Face
  - Discoid lupus erythematosus
  - Lymphoma cutis
  - Angiolymphoid hyperplasia with eosinophilia
  - Tinea faciei
  - Actinic keratosis
  - Basal cell carcinoma
  - Xanthogranuloma
  - Mastocytoma
- Extrafacial
  - Granuloma annulare
  - Benign lymphocytic infiltrate of Jessner
  - Fixed drug eruption

Always Rule Out
- Face
  - Discoid lupus erythematosus
- Trunk
  - Erythema elevatum diutinum

neutrophils are more frequently found in EED. EED may be associated with systemic conditions, primarily monoclonal gammopathies, and shows an excellent response to dapsone.[263,264] The histologic and clinical differential may also include ALHE. However, the lesions of ALHE contain blood vessels with prominent "hobnail" endothelial cells that protrude into the vascular lumina rather than perivascular fibrin deposition. One case of tinea faciei caused by *Trichophyton rubrum* has been described with clinical and histologic changes consistent with granuloma faciale.[265]

CLINICAL COURSE, PROGNOSIS, AND MANAGEMENT

Granuloma faciale tends to be chronic and rarely resolves spontaneously. Lesions may be present for weeks or months. It is usually resistant to treatment and tends to relapse after treatment.

A variety of medical and surgical therapies have been used in the treatment of granuloma faciale (Table 40-13). Because of the small number of patients involved, randomized trials to evaluate these treatments are lacking. Resistance to therapy and cosmetic complications should be discussed with the patient before initiation of therapy. Topical and intralesional steroids have been administered with modest improvement.[252,266] Cryosurgery has been applied with effective results.[267,268] Because the disease is known to be a variant of chronic leukocytoclastic vasculitis, dapsone 25 to 100 mg/day has been used with benefit in a number of patients.[269,270] Topical tacrolimus ointment 0.1% also has been used with success.[271] Surgical excision may be an option for small lesions. Lesions of granuloma faciale have been treated with a variety of medical lasers. In multiple studies using pulsed-dye lasers at 585 to 595 nm, clinical improvement has been demonstrated.[272-275] A carbon dioxide laser also has been applied with varying success.[276] The use of an argon laser resulted in total resolution of the granuloma faciale with subsequent scarring. The lesions in 2 patients were reported to respond to the potassium-titanyl-phosphate 532-nm laser in combination with tacrolimus ointment 0.1%.[277] Case studies suggest a beneficial effect of tacrolimus ointment,[278,279] as well as pimecrolimus cream 1%.[279]

TABLE 40-13
Treatments for Granuloma Faciale

	TOPICAL	PHYSICAL	SYSTEMIC
First-line therapy	Topical corticosteroids	Cryotherapy Intralesional steroids Pulsed-dye laser	Dapsone, 50-100 mg/day
Second-line therapy	Topical tacrolimus ointment	Surgical excision	

CLINICAL REACTION PATTERNS WITH EOSINOPHIL INVOLVEMENT

There are a variety of diseases in which eosinophils may be present in cutaneous lesions, with or without associated peripheral blood eosinophilia, but either the histologic pattern is unremarkable or eosinophils are not critical for the histologic diagnosis of the given entity (see Table 40-1). In many of these dermatoses, the eosinophil loses its morphologic integrity after disruption through cytolysis and is not identifiable histologically.[280] However, toxic granule proteins and other inflammatory eosinophil products are deposited in skin, persist for extended periods of time, and cause tissue effects.[42,45] Clinical reaction patterns associated with eosinophil involvement include edema, chronic dermatitis/pruritus (eg, atopic dermatitis and prurigo nodularis), drug reactions, blisters (eg, pemphigoid), fibrosis, and vasculitis. Eosinophils may be observed in a variety of cutaneous and extracutaneous neoplasms.

EOSINOPHILIC FASCIITIS

Eosinophilic fasciitis usually presents with pain, erythema, edema, and induration of the extremities, as well as peripheral blood eosinophilia and hypergammaglobulinemia.[281] Contractures and rippling of the skin may develop. Groove sign is a characteristic finding of eosinophilic fasciitis, consisting of a depression along the course of the superficial veins that is more marked upon elevation of the affected limb.[282] There is infiltration of lymphocytes, plasma cells, mast cells, and eosinophils, as well as increased thickness of the fascia.

EOSINOPHILIA-MYALGIA SYNDROME

Eosinophilia-myalgia syndrome, historically related to ingestion of certain lots of L-tryptophan,[283] is characterized by marked peripheral eosinophilia, disabling generalized myalgias, pneumonitis, myocarditis, neuropathy, encephalopathy, and fibrosis,[284] a constellation of features that are similar to but distinguishable from eosinophilic fasciitis.[285,286] Cutaneous abnormalities of eosinophilia-myalgia syndrome include edema, pruritus, a faint erythematous rash, hair loss, and *peau d'orange* or morphea-like skin lesions.[287] Lungs, heart, and nervous system may be affected.[288] There is a prominent inflammatory infiltrate in the perimysium and fascia, and striking evidence of eosinophil granule protein deposition in skin and around muscle bundles.[283]

ACKNOWLEDGMENTS

The author gratefully acknowledges the following researchers for their valuable contributions: Kristin M. Leiferman, Lisa A. Beck, and Gerald J. Gleich for the section "Regulation of the Production and Activation of Eosinophils"; Kristin M. Leiferman and Margot S. Peters for the section "Eosinophils in Cutaneous Diseases" (excluding the section "Granuloma Faciale"); and David A. Mehregan and Darius R. Mehregan for parts of "Granuloma Faciale."

REFERENCES

1. Kita H, Adolphson CR, Gleich GJ: Biology of eosinophils. In: Adkinson NF Jr, Yunginger JW, Busse WW, et al, eds. *Middleton's Allergy: Principles and Practice*. 6th ed. Philadelphia, PA: Mosby; 2003:305-332.
2. Blanchard C, Rothenberg ME: Biology of the eosinophil. *Adv Immunol.* 2009;101:81-121.
3. Hogan SP, Rosenberg HF, Moqbel R, et al. Eosinophils: biological properties and role in health and disease. *Clin Exp Allergy.* 2008;38(5):709-750.
4. Ackerman SJ, Bochner BS. Mechanisms of eosinophilia in the pathogenesis of hypereosinophilic disorders. *Immunol Allergy Clin North Am.* 2007;27(3):357-375.
5. Adachi T, Alam R. The mechanism of IL-5 signal transduction. *Am J Physiol.* 1998;275(3, pt 1):C623-C633.
6. Kouro T, Takatsu K. IL-5- and eosinophil-mediated inflammation: from discovery to therapy. *Int Immunol.* 2009;21(12):1303-1309.
7. Abedin MJ, Kashio Y, Seki M, et al. Potential roles of galectins in myeloid differentiation into three different lineages. *J Leukoc Biol.* 2003;73(5):650-656.
8. Kato M, Kephart GM, Talley NJ, et al. Eosinophil infiltration and degranulation in normal human tissue. *Anat Rec.* 1998;252(3):418-425.
9. Chen HH, Sun AH, Ojcius DM, et al. Eosinophils from murine lamina propria induce differentiation of naïve T cells into regulatory T cells via TGF-β1 and retinoic acid. *PloS One.* 2015;10:e0142881.
10. Zhang J, Lathbury LJ, Salamonsen LA. Expression of the chemokine eotaxin and its receptor, CCR3, in human endometrium. *Biol Reprod.* 2000;62(2):404-411.
11. Gouon-Evans V, Pollard JW. Eotaxin is required for eosinophil homing into the stroma of the pubertal and cycling uterus. *Endocrinology.* 2001;142(10):4515-4521.
12. Lotfi R, Herzog GI, DeMarco RA, et al. Eosinophils oxidize damage-associated molecular pattern molecules derived from stressed cells. *J Immunol.* 2009;183:5023-5031.
13. Prevete N, Rossi FW, Rivellese F, et al. *Helicobacter pylori* HP (2-20) induces eosinophil activation and accumulation in superficial gastric mucosa and stimulates VEGF-alpha and TGF-beta release by interaction with formyl-peptide receptors. *Int J Immunopathol Pharmacol.* 2013;26:647-662.
14. Neves JS, Perez SA, Spencer LA, et al. Eosinophil granules function extracellularly as receptor-mediated secretory organelles. *Proc Natl Acad Sci U S A.* 2008;105(47):18478-18483.
15. Butterworth AE: The eosinophil and its role in immunity to helminth infection. *Curr Top Microbiol Immunol.* 1977;77:127-168.
16. Ackerman SJ, Gleich GJ, Loegering DA, et al. Comparative toxicity of purified human eosinophil granule cationic proteins for schistosomula of *Schistosoma mansoni*. *Am J Trop Med Hyg.* 1985;34(4):735-745.
17. Yoon J, Ponikau JU, Lawrence CB, et al. Innate antifungal immunity of human eosinophils mediated by a beta 2 integrin, CD11b. *J Immunol.* 2008;181(4):2907-2915.
18. Reese TA, Liang HE, Tager AM, et al. Chitin induces accumulation in tissue of innate immune cells associated with allergy. *Nature.* 2007;447(7140):92-96.
19. Matsuwaki Y, Wada K, White TA, et al. Recognition of fungal protease activities induces cellular activation and eosinophil-derived neurotoxin release in human eosinophils. *J Immunol.* 2009;183(10):6708-6716.
20. Yousefi S, Gold JA, Andina N, et al. Catapult-like release of mitochondrial DNA by eosinophils contributes to antibacterial defense. *Nat Med.* 2008;14(9):949-953.
21. Shi HZ, Humbles A, Gerard C, et al. Lymph node trafficking and antigen presentation by endobronchial eosinophils. *J Clin Invest.* 2000;105(7):945-953.
22. Shi HZ. Eosinophils function as antigen-presenting cells. *J Leukoc Biol.* 2004;76(3):520-527.
23. van Rijt LS, Vos N, Hijdra D, et al. Airway eosinophils accumulate in the mediastinal lymph nodes but lack antigen-presenting potential for naive T cells. *J Immunol.* 2003;171(7):3372-3378.
24. Kita H. The eosinophil: a cytokine-producing cell? *J Allergy Clin Immunol.* 1996;97(4):889-892.
25. Lacy P, Moqbel R. Eosinophil cytokines. *Chem Immunol.* 2000;76:134-155.
26. MacKenzie JR, Mattes J, Dent LA, et al. Eosinophils promote allergic disease of the lung by regulating CD4(+) Th2 lymphocyte function. *J Immunol.* 2001;167(6):3146-3155.
27. Yang D, Chen Q, Su SB, et al. Eosinophil-derived neurotoxin acts as an alarmin to activate the TLR2-MyD88 signal pathway in dendritic cells and enhances Th2 immune responses. *J Exp Med.* 2008;205(1):79-90.
28. Finlay CM, Stefanska AM, Walsh KP, et al. Helminth products protect against autoimmunity via innate type 2 cytokines IL-5 and IL-33, which promote eosinophilia. *J Immunol.* 2016;196:703-714.
29. Le Moine A, Surquin M, Demoor FX, et al. IL-5 mediates eosinophilic rejection of MHC class II-disparate skin allografts in mice. *J Immunol.* 1999;163:3778-3784.
30. Long H, Liao W, Wang L, et al. A player and coordinator: the versatile roles of eosinophils in the immune system. *Transfus Med Hemother.* 2016;43(2):96-108.
31. Arbon KS, Albers E, Kemna M, et al. Eosinophil count, allergies, and rejection in pediatric heart transplant recipients. *J Heart Lung Transplant.* 2015;34:1103-1111.
32. Adamko D, Lacy P, Moqbel R. Eosinophil function in allergic inflammation: from bone marrow to tissue response. *Curr Allergy Asthma Rep.* 2004;4(2):149-158.
33. Klion AD, Nutman TB. The role of eosinophils in host defense against helminth parasites. *J Allergy Clin Immunol.* 2004;113(1):30-37.
34. Kato A, Favoreto S Jr, Avila PC, et al. TLR3 and Th2 cytokine-dependent production of thymic stromal lymphopoietin in human airway epithelial cells. *J Immunol.* 2007;179:1080-1087.
35. Allakhverdi Z, Comeau MR, Jessup HK, et al. Thymic stromal lymphopoietin is released by human epithelial cells in response to microbes, trauma, or inflammation and potently activates mast cells. *J Exp Med.* 2007;204:2553-2558.

36. Hui CC, Rusta-Sallehy S, Asher I, et al. The effects of thymic stromal lymphopoietin and IL-3 on human eosinophil-basophil lineage commitment: relevance to atopic sensitization. *Immun Inflamm Dis.* 2014;2:44-55.
37. Ellyard JI, Simson L, Parish CR. Th2-mediated antitumour immunity: friend or foe? *Tissue Antigens.* 2007;70(1):1-11.
38. Tancrède-Bohin E, Ionescu MA, de La Salmonière P, et al. Prognostic value of blood eosinophilia in primary cutaneous T-cell lymphomas. *Arch Dermatol.* 2004;140(9):1057-1061.
39. Takanami I, Takeuchi K, Gika M. Immunohistochemical detection of eosinophilic infiltration in pulmonary adenocarcinoma. *Anticancer Res.* 2002;22(4): 2391-2396.
40. Nielsen HJ, Hansen U, Christensen IJ, et al. Independent prognostic value of eosinophil and mast cell infiltration in colorectal cancer tissue. *J Pathol.* 1999;189(4):487-495.
41. Gleich GJ. Mechanisms of eosinophil-associated inflammation. *J Allergy Clin Immunol.* 2000;105(4): 651-663.
42. Davis MD, Plager DA, George TJ, et al. Interactions of eosinophil granule proteins with skin: limits of detection, persistence, and vasopermeabilization. *J Allergy Clin Immunol.* 2003;112(5):988-994.
43. Leiferman KM, Peters MS, Gleich GJ. The eosinophil and cutaneous edema. *J Am Acad Dermatol.* 1986;15(3):513-517.
44. Gleich GJ, Schroeter AL, Marcoux JP, et al. Episodic angioedema associated with eosinophilia. *N Engl J Med.* 1984;310(25):1621-1626.
45. Plager DA, Davis MD, Andrews AG, et al. Eosinophil ribonucleases and their cutaneous lesion-forming activity. *J Immunol.* 2009;183(6):4013-4020.
46. Rosenberg HF, Domachowske JB. Eosinophils, eosinophil ribonucleases, and their role in host defense against respiratory virus pathogens. *J Leukoc Biol.* 2001;70(5):691-698.
47. Rosenberg HF, Dyer KD, Domachowske JB. Respiratory viruses and eosinophils: exploring the connections. *Antiviral Res.* 2009;83(1):1-9.
48. Rosenberg HF, Dyer KD, Domachowske JB. Eosinophils and their interactions with respiratory virus pathogens. *Immunol Res.* 2009;43(1-3):128-137.
49. Yang D, Chen Q, Rosenberg HF, et al. Human ribonuclease A superfamily members, eosinophil-derived neurotoxin and pancreatic ribonuclease, induce dendritic cell maturation and activation. *J Immunol.* 2004;173(10):6134-6142.
50. Bandeira-Melo C, Woods LJ, Phoofolo M, et al. Intracrine cysteinyl leukotriene receptor-mediated signaling of eosinophil vesicular transport-mediated interleukin-4 secretion. *J Exp Med.* 2002;196(6):841-850.
51. Bandeira-Melo C, Bozza PT, Weller PF. The cellular biology of eosinophil eicosanoid formation and function. *J Allergy Clin Immunol.* 2002;109(3):393-400.
52. Spencer LA, Szela CT, Perez SA, et al. Human eosinophils constitutively express multiple Th1, Th2, and immunoregulatory cytokines that are secreted rapidly and differentially. *J Leukoc Biol.* 2009;85(1):117-123.
53. Daugherty BL, Siciliano SJ, DeMartino JA, et al. Cloning, expression, and characterization of the human eosinophil eotaxin receptor. *J Exp Med.* 1996;183(5): 2349-2354.
54. Rothenberg ME, Hogan SP. The eosinophil. *Annu Rev Immunol.* 2006;24:147-174.
55. Oliveira SH, Lukacs NW. The role of chemokines and chemokine receptors in eosinophil activation during inflammatory allergic reactions. *Braz J Med Biol Res.* 2003;36(11):1455-1463.
56. Tachimoto H, Ebisawa M, Bochner BS. Cross-talk between integrins and chemokines that influences eosinophil adhesion and migration. *Int Arch Allergy Immunol.* 2002;128(suppl 1):18-20.
57. Simon HU. Molecules involved in the regulation of eosinophil apoptosis. *Chem Immunol Allergy.* 2006;91: 49-58.
58. Munitz A, Levi-Schaffer F. Eosinophils. "New" roles for "old" cells. *Allergy.* 2004;59(3):268-275.
59. Noguchi H, Kephart GM, Colby TV, et al. Tissue eosinophilia and eosinophil degranulation in syndromes associated with fibrosis. *Am J Pathol.* 1992;140(2):521-528.
60. Costello RW, Jacoby DB, Gleich GJ, et al. Eosinophils and airway nerves in asthma. *Histol Histopathol.* 2000; 15(3):861-868.
61. Durcan N, Costello RW, McLean WG, et al. Eosinophil-mediated cholinergic nerve remodeling. *Am J Respir Cell Mol Biol.* 2006;34(6):775-86.
62. Steinhoff M, Neisius U, Ikoma A, et al. Proteinase-activated receptor-2 mediates itch: a novel pathway for pruritus in human skin. *J Neurosci.* 2003;23(15): 6176-6180.
63. Bochner BS, Schleimer RP. The role of adhesion molecules in human eosinophil and basophil recruitment. *J Allergy Clin Immunol.* 1994;94(3, pt 1):427-438; quiz 439.
64. Pazdrak K, Young TW, Stafford S, et al. Cross-talk between ICAM-1 and granulocyte-macrophage colony-stimulating factor receptor signaling modulates eosinophil survival and activation. *J Immunol.* 2008;180(6):4182-4190.
65. Wardlaw A. Eosinophil trafficking: new answers to old questions. *Clin Exp Allergy.* 2004;34(5):676-679.
66. Rosenberg HF, Phipps S, Foster PS. Eosinophil trafficking in allergy and asthma. *J Allergy Clin Immunol.* 2007;119(6):1303-1310, quiz 1311-1312.
67. Lee SC, Brummet ME, Shahabuddin S, et al. Cutaneous injection of human subjects with macrophage inflammatory protein-1 alpha induces significant recruitment of neutrophils and monocytes. *J Immunol.* 2000;164(6):3392-3401.
68. Mishra A, Hogan SP, Lee JJ, et al. Fundamental signals that regulate eosinophil homing to the gastrointestinal tract. *J Clin Invest.* 1999;103(12):1719-1727.
69. Igawa K, Satoh T, Hirashima M, et al. Regulatory mechanisms of galectin-9 and eotaxin-3 synthesis in epidermal keratinocytes: possible involvement of galectin-9 in dermal eosinophilia of Th1-polarized skin inflammation. *Allergy.* 2006;61(12):1385-1391.
70. Kagami S, Kakinuma T, Saeki H, et al. Significant elevation of serum levels of eotaxin-3/CCL26, but not of eotaxin-2/CCL24, in patients with atopic dermatitis: serum eotaxin-3/CCL26 levels reflect the disease activity of atopic dermatitis. *Clin Exp Immunol.* 2003;134(2):309-313.
71. Suzukawa M, Koketsu R, Iikura M, et al. Interleukin-33 enhances adhesion, CD11b expression and survival in human eosinophils. *Lab Invest.* 2008;88:1245-1253.
72. Stolarski B, Kurowska-Stolarska M, Kewin P, et al. IL-33 exacerbates eosinophil-mediated airway inflammation. *J Immunol.* 2010;185:3472-3480.
73. Horie S, Kita H. CD11b/CD18 (Mac-1) is required for degranulation of human eosinophils induced

by human recombinant granulocyte-macrophage colony-stimulating factor and platelet activating factor. *J Immunol.* 1994;152(11):5457-5467.
74. Matsumoto K, Appiah-Pippim J, Schleimer RP, et al. CD44 and CD69 represent different types of cell-surface activation markers for human eosinophils. *Am J Respir Cell Mol Biol.* 1998;18(6):860-866.
75. Bochner BS, Gleich GJ. What targeting eosinophils has taught us about their role in diseases. *J Allergy Clin Immunol.* 2010;126(1):16-25, quiz 26-27.
76. Schwiebert LM, Beck LA, Stellato C, et al. Glucocorticosteroid inhibition of cytokine production: relevance to antiallergic actions. *J Allergy Clin Immunol.* 1996;97(1, pt 2):143-152.
77. Schleimer RP, Bochner BS. The effects of glucocorticoids on human eosinophils. *J Allergy Clin Immunol.* 1994;94(6, pt 2):1202-1213.
78. Umland SP, Schleimer RP, Johnston SL. Review of the molecular and cellular mechanisms of action of glucocorticoids for use in asthma. *Pulm Pharmacol Ther.* 2002;15(1):35-50.
79. Park CW, Lee BH, Han HJ, et al. Tacrolimus decreases the expression of eotaxin, CCR3, RANTES and interleukin-5 in atopic dermatitis. *Br J Dermatol.* 2005;152(6):1173-1181.
80. Meng Q, Ying S, Corrigan CJ, et al. Effects of rapamycin, cyclosporine A, and dexamethasone on interleukin 5-induced eosinophil degranulation and prolonged survival. *Allergy.* 1997;52(11):1095-1101.
81. Bai JP, Lesko LJ, Burckart GJ. Understanding the genetic basis for adverse drug effects: the calcineurin inhibitors. *Pharmacotherapy.* 2010;30(2):195-209.
82. Klion AD. Approach to the therapy of hypereosinophilic syndromes. *Immunol Allergy Clin North Am.* 2007;27(3):551-560.
83. Cools J, DeAngelo DJ, Gotlib J, et al. A tyrosine kinase created by fusion of the *PDGFRA* and *FIP1L1* genes as a therapeutic target of imatinib in idiopathic hypereosinophilic syndrome. *N Engl J Med.* 2003;348(13):1201-1214.
84. Pitini V, Teti D, Arrigo C, et al. Alemtuzumab therapy for refractory idiopathic hypereosinophilic syndrome with abnormal T cells: a case report. *Br J Haematol.* 2004;127(5):477.
85. Sefcick A, Sowter D, Dasgupta E, et al. Alemtuzumab therapy for refractory idiopathic hypereosinophilic syndrome. *Br J Haematol.* 2004;124(4):558-559.
86. Wagner LA, Speckart S, Cutter B, et al. Treatment of FIP1L1/PDGFRA-negative hypereosinophilic syndrome with alemtuzumab, an anti-CD52 antibody. *J Allergy Clin Immunol.* 2009;123(6):1407-1408.
87. Walsh G. Mepolizumab-based therapy in asthma: an update. *Curr Opin Allergy Clin Immunol.* 2015;15:392-396.
88. Wechsler ME, Fulkerson PC, Bochner BS, et al. Novel targeted therapies for eosinophilic disorders. *J Allergy Clin Immunol.* 2012;130:563-571.
89. Cogan E, Roufosse F. Clinical management of the hypereosinophilic syndromes. *Expert Rev Hematol.* 2012;5(3):275-290.
90. Butterfield JH. Interferon treatment for hypereosinophilic syndromes and systemic mastocytosis. *Acta Haematol.* 2005;114(1):26-40.
91. Butterfield JH. Treatment of hypereosinophilic syndromes with prednisone, hydroxyurea, and interferon. *Immunol Allergy Clin North Am.* 2007;27(3):493-518.
92. Leiferman KM. A current perspective on the role of eosinophils in dermatologic diseases. *J Am Acad Dermatol.* 1991;24(6, pt 2):1101-1112.
93. Simon D, Wardlaw A, Rothenberg ME. Organ-specific eosinophilic disorders of the skin, lung, and gastrointestinal tract. *J Allergy Clin Immunol.* 2010;126(1):3-13.
94. Zuo L, Rothenberg ME. Gastrointestinal eosinophilia. *Immunol Allergy Clin North Am.* 2007;27(3):443-455.
95. Wechsler ME. Pulmonary eosinophilic syndromes. *Immunol Allergy Clin North Am.* 2007;27(3):477-492.
96. Kephart GM, Andrade ZA, Gleich GJ. Localization of eosinophil major basic protein onto eggs of *Schistosoma mansoni* in human pathologic tissue. *Am J Pathol.* 1988;133(2):389-396.
97. Emmerson RW, Wilson-Jones E. Eosinophilic spongiosis in pemphigus. A report of an unusual histological change in pemphigus. *Arch Dermatol.* 1968;97(3):252-257.
98. Crotty C, Pittelkow M, Muller SA. Eosinophilic spongiosis: a clinicopathologic review of seventy-one cases. *J Am Acad Dermatol.* 1983;8(3):337-343.
99. Winkelmann RK, Frigas E. Eosinophilic panniculitis: a clinicopathologic study. *J Cutan Pathol.* 1986;13(1):1-12.
100. Adame J, Cohen PR. Eosinophilic panniculitis: diagnostic considerations and evaluation. *J Am Acad Dermatol.* 1996;34(2, pt 1):229-234.
101. Trocme SD, Baker RH, Bartley GB, et al. Extracellular deposition of eosinophil major basic protein in orbital histiocytosis X. *Ophthalmology.* 1991;98(3):353-356.
102. Quaedvlieg PJ, Creytens DH, Epping GG, et al. Histopathological characteristics of metastasizing squamous cell carcinoma of the skin and lips. *Histopathology.* 2006;49(3):256-264.
103. Butterfield JH, Kephart GM, Banks PM, et al. Extracellular deposition of eosinophil granule major basic protein in lymph nodes of patients with Hodgkin's disease. *Blood.* 1986;68(6):1250-1256.
104. Weaver J, Bergfeld WF. Quantitative analysis of eosinophils in acute graft-versus-host disease compared with drug hypersensitivity reactions. *Am J Dermatopathol.* 2010;32(1):31-34.
105. Marra DE, McKee PH, Nghiem P. Tissue eosinophils and the perils of using skin biopsy specimens to distinguish between drug hypersensitivity and cutaneous graft-versus-host disease. *J Am Acad Dermatol.* 2004;51(4):543-546.
106. Romero LS, Kantor GR. Eosinophils are not a clue to the pathogenesis of granuloma annulare. *Am J Dermatopathol.* 1998;20(1):29-34.
107. Rothenberg ME. Eosinophilic gastrointestinal disorders (EGID). *J Allergy Clin Immunol.* 2004;113(1):11-28, quiz 29.
108. Noel RJ, Putnam PE, Rothenberg ME. Eosinophilic esophagitis. *N Engl J Med.* 2004;351(9):940-941.
109. Roufosse F, Weller PF. Practical approach to the patient with hypereosinophilia. *J Allergy Clin Immunol.* 2010;126(1):39-44.
110. Ogbogu PU, Bochner BS, Butterfield JH, et al. Hypereosinophilic syndrome: a multicenter, retrospective analysis of clinical characteristics and response to therapy. *J Allergy Clin Immunol.* 2009;124(6):1319-1325.e3.
111. Sheikh J, Weller PF. Clinical overview of hypereosinophilic syndromes. *Immunol Allergy Clin North Am.* 2007;27(3):333-355.
112. Roufosse F, Simonart T, Cogan E. Skin lesions as the only manifestation of the idiopathic hypereosinophilic syndrome. *Br J Dermatol.* 2001;144(3):639.
113. Offidani A, Bernardini ML, Simonetti O, et al. Hypereosinophilic dermatosis: skin lesions as the only

manifestation of the idiopathic hypereosinophilic syndrome? *Br J Dermatol.* 2000;143(3):675-677.
114. Barna M, Kemeny L, Dobozy A. Skin lesions as the only manifestation of the hypereosinophilic syndrome. *Br J Dermatol.* 1997;136(4):646-647.
115. Kazmierowski JA, Chusid MJ, Parrillo JE, et al. Dermatologic manifestations of the hypereosinophilic syndrome. *Arch Dermatol.* 1978;114(4):531-535.
116. Curtis C, Ogbogu P. Hypereosinophilic syndrome. *Clin Rev Allergy Immunol.* 2016;50(2):240-251.
117. Miljkovic J, Bartenjev I: Hypereosinophilic dermatitis-like erythema annulare centrifugum in a patient with chronic lymphocytic leukaemia. *J Eur Acad Dermatol Venereol.* 2005;19(2):228-231.
118. Hofmann SC, Technau K, Müller AM et al. Bullous pemphigoid associated with hypereosinophilic syndrome: Simultaneous response to imatinib. *J Am Acad Dermatol.* 2007;56(suppl 5):S68-S72.
119. McPherson T, Cowen EW, McBurney E, et al. Platelet-derived growth factor receptor-alpha-associated hypereosinophilic syndrome and lymphomatoid papulosis. *Br J Dermatol.* 2006;155(4):824-826.
120. Jang KA, Lim YS, Choi JH, et al. Hypereosinophilic syndrome presenting as cutaneous necrotizing eosinophilic vasculitis and Raynaud's phenomenon complicated by digital gangrene. *Br J Dermatol.* 2000;143(3):641-644.
121. Kim SH, Kim TB, Yun YS, et al. Hypereosinophilia presenting as eosinophilic vasculitis and multiple peripheral artery occlusions without organ involvement. *J Korean Med Sci.* 2005;20(4):677-679.
122. Ito K, Hara H, Okada T, et al. Hypereosinophilic syndrome with various skin lesions and juvenile temporal arteritis. *Clin Exp Dermatol.* 2009;34(5):e192-e195.
123. Hayashi M, Kawaguchi M, Mitsuhashi Y, et al. Case of hypereosinophilic syndrome with cutaneous necrotizing vasculitis. *J Dermatol.* 2008;35(4):229-233.
124. Tsuji Y, Kawashima T, Yokota K, et al. Wells' syndrome as a manifestation of hypereosinophilic syndrome. *Br J Dermatol.* 2002;147(4):811-812.
125. Bogenrieder T, Griese DP, Schiffner R, et al. Wells' syndrome associated with idiopathic hypereosinophilic syndrome. *Br J Dermatol.* 1997;137(6):978-982.
126. Leiferman KM, Gleich GJ, Peters MS. Dermatologic manifestations of the hypereosinophilic syndromes. *Immunol Allergy Clin North Am.* 2007;27(3):415-441.
127. Weller PF, Bubley GJ. The idiopathic hypereosinophilic syndrome. *Blood.* 1994;83(10):2759-2779.
128. Klion AD, Bochner BS, Gleich GJ, et al. Approaches to the treatment of hypereosinophilic syndromes: A workshop summary report. *J Allergy Clin Immunol.* 2006;117(6):1292-1302.
129. Leiferman KM, Gleich GJ. Hypereosinophilic syndrome: case presentation and update. *J Allergy Clin Immunol.* 2004;113(1):50-58.
130. Vandenberghe P, Wlodarska I, Michaux L, et al. Clinical and molecular features of FIP1L1-PDFGRA (+) chronic eosinophilic leukemias. *Leukemia.* 2004;18(4):734-742.
131. Ogbogu PU, Rosing DR, Horne MK III. Cardiovascular manifestations of hypereosinophilic syndromes. *Immunol Allergy Clin North Am.* 2007;27(3):457-475.
132. Fuzellier JF, Chapoutot L, Torossian PF. Mitral valve repair in idiopathic hypereosinophilic syndrome. *J Heart Valve Dis.* 2004;13(3):529-531.
133. Blauwet LA, Breen JF, Edwards WD, et al. Atypical presentation of eosinophilic endomyocardial disease. *Mayo Clin Proc.* 2005;80(8):1078-1084.
134. Roufosse F, Cogan E, Goldman M. Lymphocytic variant hypereosinophilic syndromes. *Immunol Allergy Clin North Am.* 2007;27:389-413.
135. Roufosse F, Cogan E, Goldman M. Recent advances in pathogenesis and management of hypereosinophilic syndromes. *Allergy.* 2004;59(7):673-689.
136. Gotlib J, Cools J, Malone JM 3rd, et al. The FIP1L1-PDGFRalpha fusion tyrosine kinase in hypereosinophilic syndrome and chronic eosinophilic leukemia: implications for diagnosis, classification, and management. *Blood.* 2004;103(8):2879-2791.
137. Bain BJ, Fletcher SH. Chronic eosinophilic leukemias and the myeloproliferative variant of the hypereosinophilic syndrome. *Immunol Allergy Clin North Am.* 2007;27(3):377-388.
138. Gleich GJ, Leiferman KM. The hypereosinophilic syndromes: still more heterogeneity. *Curr Opin Immunol.* 2005;17(6):679-684.
139. Pardanani A, Brockman SR, Paternoster SF, et al. FIP1L1-PDGFRA fusion: prevalence and clinicopathologic correlates in 89 consecutive patients with moderate to severe eosinophilia. *Blood.* 2004;104(10):3038-3045.
140. Tefferi A, Pardanani A, Li CY. Hypereosinophilic syndrome with elevated serum tryptase versus systemic mast cell disease associated with eosinophilia: 2 distinct entities? *Blood.* 2003;102(8):3073-3074, author reply 3074.
141. Pardanani A, Ketterling RP, Brockman SR, et al. CHIC2 deletion, a surrogate for FIP1L1-PDGFRA fusion, occurs in systemic mastocytosis associated with eosinophilia and predicts response to imatinib mesylate therapy. *Blood.* 2003;102(9):3093-3096.
142. Yamada Y, Rothenberg ME, Lee AW, et al. The FIP1L1-PDGFRA fusion gene cooperates with IL-5 to induce murine hypereosinophilic syndrome (HES)/chronic eosinophilic leukemia (CEL)-like disease. *Blood.* 2006;107(10):4071-4079.
143. Yamada Y, Cancelas JA. FIP1L1/PDGFR alpha associated systemic mastocytosis. *Int Arch Allergy Immunol.* 2010;152(suppl 1):101-105.
144. Tefferi A, Gotlib J, Ardanani A. Hypereosinophilic syndrome and clonal eosinophilia: point-of-care diagnostic algorithm and treatment update. *Mayo Clin Proc.* 2010;85(2): 158-164.
145. Vardiman JW, Thiele J, Arber DA, et al. The 2008 revision of the World Health Organization (WHO) classification of myeloid neoplasms and acute leukemia: rationale and important changes. *Blood.* 2009;114(5):937-951.
146. Tefferi A, Thiele J, Vardiman JW. The 2008 World Health Organization classification system for myeloproliferative neoplasms: order out of chaos. *Cancer.* 2009;115(17):3842-3847.
147. Butterfield JH, Leiferman KM, Gleich GJ. Nodules, eosinophilia, rheumatism, dermatitis and swelling (NERDS): a novel eosinophilic disorder. *Clin Exp Allergy.* 1993;23(7):571-580.
148. Simon HU, Rothenberg ME, Bochner BS, et al. Refining the definition of hypereosinophilic syndrome. *J Allergy Clin Immunol.* 2010;126(1):45-49.
149. Klion A. Hypereosinophilic syndrome: current approach to diagnosis and treatment. *Annu Rev Med.* 2009;60:293-306.
150. Gleich GJ, Leiferman KM. The hypereosinophilic syndromes: current concepts and treatments. *Br J Haematol.* 2009;145(3):271-285.
151. Tefferi A, Gotlib J, Pardanani A. Hypereosinophilic syndrome and clonal eosinophilia: point-of-care

diagnostic algorithm and treatment update. *Mayo Clin Proc.* 2010;85(2):158-164.
152. Nutman TB. Evaluation and differential diagnosis of marked, persistent eosinophilia. *Immunol Allergy Clin North Am.* 2007;27(3):529-549.
153. Lee JS, Loh TH, Seow SC, et al. Prolonged urticaria with purpura: the spectrum of clinical and histopathologic features in a prospective series of 22 patients exhibiting the clinical features of urticarial vasculitis. *J Am Acad Dermatol.* 2007;56(6):994-1005.
154. Amano H, Nagai Y, Ishikawa O. Persistent urticaria characterized by recurrent lasting urticarial erythema with histological features of prominent perivascular eosinophilic infiltration. *Clin Exp Dermatol.* 2009;34(5):e14-e17.
155. Leiferman KM, O'Duffy JD, Perry HO, et al. Recurrent incapacitating mucosal ulcerations. A prodrome of the hypereosinophilic syndrome. *JAMA.* 1982;247(7):1018-1020.
156. Pardanani A, Ketterling RP, Li CY, et al. FIP1L1-PDGFRA in eosinophilic disorders: prevalence in routine clinical practice, long-term experience with imatinib therapy, and a critical review of the literature. *Leuk Res.* 2006;30(8): 965-970.
157. Scowden EB, Schaffner W, Stone WJ. Overwhelming strongyloidiasis: an unappreciated opportunistic infection. *Medicine (Baltimore).* 1978;57(6): 527-544.
158. de Lavareille A, Roufosse F, Schmid-Grendelmeier P, et al. High serum thymus and activation-regulated chemokine levels in the lymphocytic variant of the hypereosinophilic syndrome. *J Allergy Clin Immunol.* 2002;110:476-479.
159. Simon HU, Cools J. Novel approaches to therapy of hypereosinophilic syndromes. *Immunol Allergy Clin North Am.* 2007;27(3):519-527.
160. Pitini V, Arrigo C, Azzarello D, et al. Serum concentration of cardiac troponin T in patients with hypereosinophilic syndrome treated with imatinib is predictive of adverse outcomes. *Blood.* 2003;102(9):3456-3457, author reply 3457.
161. Sato Y, Taniguchi R, Yamada T, et al. Measurement of serum concentrations of cardiac troponin T in patients with hypereosinophilic syndrome: a sensitive non-invasive marker of cardiac disorder. *Intern Med.* 2000;39(4):350.
162. Burgess MR, Sawyers CL. Treating imatinib-resistant leukemia: the next generation targeted therapies. *ScientificWorldJournal.* 2006;6:918-930.
163. O'Hare T, Corbin AS, Druker BJ. Targeted CML therapy: controlling drug resistance, seeking cure. *Curr Opin Genet Dev.* 2006;16(1):92-99.
164. Simon D, Salemi S, Yousefi S, et al. Primary resistance to imatinib in Fip1-like 1-platelet-derived growth factor receptor alpha-positive eosinophilic leukemia. *J Allergy Clin Immunol.* 2008;121:1054-1056.
165. Rotoli B, Catalano L, Galderisi M, et al. Rapid reversion of Loeffler's endocarditis by imatinib in early stage clonal hypereosinophilic syndrome. *Leuk Lymphoma.* 2004;45(12):2503-2507.
166. Klion AD, Robyn J, Akin C, et al. Molecular remission and reversal of myelofibrosis in response to imatinib mesylate treatment in patients with the myeloproliferative variant of hypereosinophilic syndrome. *Blood.* 2004;103(2):473-478.
167. Cervetti G, Galimberti S, Carulli G, et al. Imatinib therapy in hypereosinophilic syndrome: a case of molecular remission. *Leuk Res.* 2005;29(9):1097-1098.
168. Tefferi A. Modern diagnosis and treatment of primary eosinophilia. *Acta Haematol.* 2005;114(1):52-60.
169. Taverna JA, Lerner A, Goldberg L, et al. Infliximab as a therapy for idiopathic hypereosinophilic syndrome. *Arch Dermatol.* 2007;143(9):1110-1112.
170. Halaburda K, Prejzner W, Szatkowski D, et al. Allogeneic bone marrow transplantation for hypereosinophilic syndrome: long-term follow-up with eradication of FIP1L1- PDGFRA fusion transcript. *Bone Marrow Transplant.* 2006;38(4):319-320.
171. Ueno NT, Anagnostopoulos A, Rondón G, et al. Successful non-myeloablative allogeneic transplantation for treatment of idiopathic hypereosinophilic syndrome. *Br J Haematol.* 2002;119(1):131-134.
172. Walsh GM. Reslizumab, a humanized anti-IL-5 mAb for the treatment of eosinophil-mediated inflammatory conditions. *Curr Opin Mol Ther.* 2009;11(3):329-336.
173. Klion AD, Law MA, Noel P, et al. Safety and efficacy of the monoclonal anti-interleukin-5 antibody SCH55700 in the treatment of patients with hypereosinophilic syndrome. *Blood.* 2004;103(8):2939-2941.
174. Rothenberg ME, Klion AD, Roufosse FE, et al. Treatment of patients with the hypereosinophilic syndrome with mepolizumab. *N Engl J Med.* 2008;358(12): 1215-1228.
175. Plotz SG, Simon HU, Darsow U, et al. Use of an anti-interleukin-5 antibody in the hypereosinophilic syndrome with eosinophilic dermatitis. *N Engl J Med.* 2003;349(24):2334-2339.
176. Boucher RM, Gilbert-McClain L, Chowdhury B. Hypereosinophilic syndrome and mepolizumab. *N Engl J Med.* 2008;358(26):2838-2839, author reply 2839-2840.
177. Wells GC. Recurrent granulomatous dermatitis with eosinophilia. *Trans St Johns Hosp Dermatol Soc.* 1971;57:46-56.
178. Gilliam AE, Bruckner AL, Howard RM, et al. Bullous "cellulitis" with eosinophilia: case report and review of Wells' syndrome in childhood. *Pediatrics.* 2005;116(1):e149-e155.
179. Ling TC, Antony F, Holden CA, et al. Two cases of bullous eosinophilic cellulitis. *Br J Dermatol.* 2002;146(1):160-161.
180. Utikal J, Peitsch WK, Kemmler N, et al. Bullous eosinophilic cellulitis associated with ulcerative colitis: Effective treatment with sulfasalazine and glucocorticoids. *Br J Dermatol.* 2007;156(4):764-766.
181. Katoulis AC, Bozi E, Samara M, et al. Idiopathic bullous eosinophilic cellulitis (Wells' syndrome). *Clin Exp Dermatol.* 2009;34(7):e375-e376.
182. Moossavi M, Mehregan DR. Wells' syndrome: a clinical and histopathologic review of seven cases. *Int J Dermatol.* 2003;42(1):62-67.
183. Arca E, Köse O, Karslioğlu Y, et al. Bullous eosinophilic cellulitis succession with eosinophilic pustular folliculitis without eosinophilia. *J Dermatol.* 2007;34:80-85.
184. Sinno H, Lacroix JP, Lee J, et al. Diagnosis and management of eosinophilic cellulitis (Wells' syndrome): a case series and literature review. *Can J Plast Surg.* 2012;20:91-97.
185. Wells GC, Smith NP: Eosinophilic cellulitis. *Br J Dermatol.* 1979;100(1):101-109.
186. Leiferman KM, Peters MS. Reflections on eosinophils and flame figures: where there's smoke there's not necessarily Wells syndrome. *Arch Dermatol.* 2006;142(9):1215-1218.
187. Peters MS, Schroeter AL, Gleich GJ. Immunofluorescence identification of eosinophil granule major

basic protein in the flame figures of Wells' syndrome. *Br J Dermatol.* 1983;109(2):141-148.
188. Coldiron BM, Robinson JK. Low-dose alternate-day prednisone for persistent Well's syndrome. *Arch Dermatol.* 1989;125:1625-1626.
189. Ludwig RJ, Grundmann-Kollmann M, Holtmeier W, et al. Herpes simplex virus type 2-associated eosinophilic cellulitis (Wells' syndrome). *J Am Acad Dermatol.* 2003;48(5 suppl):S60-S61.
190. Sakaria SS, Ravi A, Swerlick R, et al. Wells' syndrome associated with ulcerative colitis: a case report and literature review. *J Gastroenterol.* 2007;42:250-252.
191. Chung CL, Cusack CA. Wells syndrome: an enigmatic and therapeutically challenging disease. *J Drugs Dermatol.* 2006;5:908-911.
192. Effat KG. Angiolymphoid hyperplasia with eosinophilia of the auricle: progression of histopathological changes. *J Laryngol Otol.* 2006;120(5):411-413.
193. Suzuki H, Hatamochi A, Horie M, et al. A case of angiolymphoid hyperplasia with eosinophilia (ALHE) of the upper lip. *J Dermatol.* 2005;32(12):991-995.
194. Zarrin-Khameh N, Spoden JE, Tran RM. Angiolymphoid hyperplasia with eosinophilia associated with pregnancy: a case report and review of the literature. *Arch Pathol Lab Med.* 2005;129(9):1168-1171.
195. Gonzalez-Cuyar LF, Tavora F, Zhao XF, et al. Angiolymphoid hyperplasia with eosinophilia developing in a patient with history of peripheral T-cell lymphoma: evidence for multicentric T-cell lymphoproliferative process. *Diagn Pathol.* 2008;3:22.
196. Chen JF, Gao HW, Wu BY, et al. Angiolymphoid hyperplasia with eosinophilia affecting the scrotum: a rare case report with molecular evidence of T-cell clonality. *J Dermatol.* 2010;37(4):355-359.
197. Helander SD, Peters MS, Kuo TT, et al. Kimura's disease and angiolymphoid hyperplasia with eosinophilia: new observations from immunohistochemical studies of lymphocyte markers, endothelial antigens, and granulocyte proteins. *J Cutan Pathol.* 1995;22(4):319-326.
198. Olsen TG, Helwig EB. Angiolymphoid hyperplasia with eosinophilia. A clinicopathologic study of 116 patients. *J Am Acad Dermatol.* 1985;12(5, pt 1):781-796.
199. Rodríguez-Lomba E, Avilés-Izquierdo JA, Molina-López I, et al. Dermoscopic features in 2 cases of angiolymphoid hyperplasia with eosinophilia. *J Am Acad Dermatol.* 2016;75(1):e19-e21.
200. Cheney ML, Googe P, Bhatt S, et al. Angiolymphoid hyperplasia with eosinophilia (histiocytoid hemangioma): evaluation of treatment options. *Ann Otol Rhinol Laryngol.* 1993;102(4, pt 1):303-308.
201. Miller CJ, Ioffreda MD, Ammirati CT. Mohs micrographic surgery for angiolymphoid hyperplasia with eosinophilia. *Dermatol Surg.* 2004;30(8):1169-1173.
202. Rampini P, Semino M, Drago F, et al. Angiolymphoid hyperplasia with eosinophilia: successful treatment with interferon alpha 2b. *Dermatology.* 2001; 202(4):343.
203. Cooper SM, Dawber RP, Millard P. Angiolymphoid hyperplasia with eosinophilia treated by cryosurgery. *J Eur Acad Dermatol Venereol.* 2001;15(5):489-490.
204. Angel CA, Lewis AT, Griffin T, et al. Angiolymphoid hyperplasia successfully treated with an ultralong pulsed dye laser. *Dermatol Surg.* 2005;31(6):713-716.
205. Mashiko M, Yokota K, Yamanaka Y, et al. A case of angiolymphoid hyperplasia with eosinophilia successfully treated with tacrolimus ointment. *Br J Dermatol.* 2006;154(4):803-804.
206. Yuen HW, Goh YH, Low WK, et al. Kimura's disease: a diagnostic and therapeutic challenge. *Singapore Med J.* 2005;46(4):179-183.
207. Takeishi M, Makino Y, Nishioka H, et al. Kimura disease: diagnostic imaging findings and surgical treatment. *J Craniofac Surg.* 2007;18(5):1062-1067.
208. Wang YS, Tay YK, Tan E, et al. Treatment of Kimura's disease with cyclosporine. *J Dermatolog Treat.* 2005;16(4):242-244.
209. Abuel-Haija M, Hurford MT. Kimura disease. *Arch Pathol Lab Med.* 2007;131(4):650-651.
210. Sun QF, Xu DZ, Pan SH, et al. Kimura disease: review of the literature. *Intern Med J.* 2008;38(8):668-672.
211. Takamura S, Teraki Y. Eosinophilic pustular folliculitis associated with hematological disorders: a report of two cases and review of Japanese literature. *J Dermatol.* 2016;43(4):432-435.
212. Fujiyama T, Tokura Y. Clinical and histopathological differential diagnosis of eosinophilic pustular folliculitis. *J Dermatol.* 2013;40(6):419-423.
213. Soeprono FF, Schinella RA. Eosinophilic pustular folliculitis in patients with acquired immunodeficiency syndrome. Report of three cases. *J Am Acad Dermatol.* 1986;14(6):1020-1022.
214. Lambert J, Berneman Z, Dockx P, et al. Eosinophilic pustular folliculitis and B-cell chronic lymphatic leukaemia. *Dermatology.* 1994;189(suppl 2):58-59.
215. Takematsu H, Nakamura K, Igarashi M, et al. Eosinophilic pustular folliculitis. Report of two cases with a review of the Japanese literature. *Arch Dermatol.* 1985;121(7):917-920.
216. Asgari M, Leiferman KM, Piepkorn M, et al. Neonatal eosinophilic pustulosis. *Int J Dermatol.* 2006;45(2): 131-134.
217. Rosenthal D, LeBoit PE, Klumpp L, et al. Human immunodeficiency virus-associated eosinophilic folliculitis. A unique dermatosis associated with advanced human immunodeficiency virus infection. *Arch Dermatol.* 1991;127(2):206-209.
218. Long H, Zhang G, Wang L, et al. Eosinophilic skin diseases: a comprehensive review. *Clin Rev Allergy Immunol.* 2016;50(2):189-213.
219. Katoh M, Nomura T, Miyachi Y, et al. Eosinophilic pustular folliculitis: a review of the Japanese published works. *J Dermatol.* 2013;40:15-20.
220. Rajendran PM, Dolev JC, Heaphy MR Jr, et al. Eosinophilic folliculitis: before and after the introduction of anti-retroviral therapy. *Arch Dermatol.* 2005;141:1227-1231.
221. Mizoguchi S, Setoyama M, Higashi Y, et al. Eosinophilic pustular folliculitis induced by carbamazepine. *J Am Acad Dermatol.* 1998;38:641-643.
222. Laing ME, Laing TA, Mulligan NJ, et al. Eosinophilic pustular folliculitis induced by chemotherapy. *J Am Acad Dermatol.* 2006;54:729-730.
223. Opie KM, Heenan PJ, Delaney TA, et al. Two cases of eosinophilic pustular folliculitis associated with parasitic infestations. *Australas J Dermatol.* 2003;44:217-219.
224. Gul U, Kilic A, Demiriz M. Eosinophilic pustular folliculitis: the first case associated with hepatitis C virus. *J Dermatol.* 2007;34:397-399.
225. Kus S, Candan I, Ince U, et al. Eosinophilic pustular folliculitis (Ofuji's disease) exacerbated with pregnancies. *J Eur Acad Dermatol Venereol.* 2006;20:1347–1348.
226. Mabuchi T, Matsuyama T, Ozawa A. Case of eosinophilic pustular folliculitis associated with pregnancy. *J Dermatol.* 2011;38:1191-1193.

227. Teraki Y, Konohana I, Shiohara T, et al. Eosinophilic pustular folliculitis (Ofuji's disease). Immunohistochemical analysis. *Arch Dermatol.* 1993;129:1015-1019.
228. Satoh T, Shimura C, Miyagishi C, et al. Indomethacin-induced reduction in CRTH2 in eosinophilic pustular folliculitis (Ofuji's disease): a proposed mechanism of action. *Acta Derm Venereol.* 2010;90:18-22.
229. Murayama T, Nakamura K, Tsuchida T. Eosinophilic pustular folliculitis with extensive distribution: correlation of serum TARC levels and peripheral blood eosinophil numbers. *Int J Dermatol.* 2015;54(9): 1071-1074.
230. Hernández-Martín Á, Nuño-González A, Colmenero I, et al. Eosinophilic pustular folliculitis of infancy: a series of 15 cases and review of the literature. *J Am Acad Dermatol.* 2014;68:150-155.
231. McCalmont TH, Altemus D, Maurer T, et al. Eosinophilic folliculitis. The histologic spectrum. *Am J Dermatopathol.* 1995;17(5):439-446.
232. Buezo GF, Fraga J, Abajo P, et al. HIV-Associated eosinophilic folliculitis and follicular mucinosis. *Dermatology.* 1998;197(2):178-180.
233. Lee MW, Lee DP, Choi JH, et al. Failure to detect clonality in eosinophilic pustular folliculitis with follicular mucinosis. *Acta Derm Venereol.* 2004;84(4): 305-307.
234. Kabashima K, Sakurai T, Miyachi Y. Treatment of eosinophilic pustular folliculitis (Ofuji's disease) with tacrolimus ointment. *Br J Dermatol.* 2004;151(4):949-950.
235. Ellis E, Scheinfeld N. Eosinophilic pustular folliculitis: a comprehensive review of treatment options. *Am J Clin Dermatol.* 2004;5(3):189-197.
236. Fukamachi S, Kabashima K, Sugita K, et al. Therapeutic effectiveness of various treatments for eosinophilic pustular folliculitis. *Acta Derm Venereol.* 2009;89(2):155-159.
237. Ota T, Hata Y, Tanikawa A, et al. Eosinophilic pustular folliculitis (Ofuji's disease): indomethacin as a first choice of treatment. *Clin Exp Dermatol.* 2001;26(2):179-181.
238. Ofuji S, Furukawa F, Miyachi Y, et al. Papuloerythroderma. *Dermatologica.* 1984;169:125-130.
239. Torchia D, Miteva M, Hu S, et al. Papuloerythroderma 2009: two new cases and systematic review of the worldwide literature 25 years after its identification by Ofuji et al. *Dermatology.* 2010;220(4):311-320.
240. Ofuji S. Papuloerythroderma. *J Am Acad Dermatol.* 1990;22(4):697.
241. Schepers C, Malvehy J, Azón-Masoliver A. Papuloerythroderma of Ofuji: a report of 2 cases including the first European case associated with visceral carcinoma. *Dermatology.* 1996;193:131-135.
242. Bech-Thomsen N, Thomsen K. Ofuji's papuloerythroderma: a study of 17 cases. *Clin Exp Dermatol.* 1998;23:79-83.
243. Bettoli V, Pizzigoni S, Borghi A, et al. Ofuji papuloerythroderma: a reappraisal of the deck-chair sign. *Dermatology.* 2004;209:1-4.
244. Sugita K, Kabashima K, Nakamura M, et al. Drug-induced papuloerythroderma: Analysis of T-cell populations and a literature review. *Acta Derm Venereol.* 2009;89:618-622.
245. Teraki Y, Inoue Y. Skin-homing Th2/Th22 cells in papuloerythroderma of Ofuji. *Dermatology.* 2014;228: 326-331.
246. Pal S, Haroon TS. Erythroderma: a clinicoetiologic study of 90 cases. *Int J Dermatol.* 1998;37:104-107.
247. Shah M, Reid WA, Layton AM. Cutaneous T-cell lymphoma presenting as papuloerythroderma—a case and review of the literature. *Clin Exp Dermatol.* 1995;20:161-163.
248. Suh KS, Kim HC, Chae YS, et al. Ofuji papuloerythroderma associated with follicular mucinosis in mycosis fungoides. *J Dermatol.* 1998;25:185-189.
249. Fujii K, Kanno Y, Ohgo N. Etretinate therapy for papuloerythroderma. *Eur J Dermatol.* 1999;9:610-613.
250. Sommer S, Henderson CA. Papuloerythroderma of Ofuji responding to treatment with cyclosporin. *Clin Exp Dermatol.* 2000;25:293-295.
251. Ota M, Sato-Matsumura KC, Sawamura D, et al. Papuloerythroderma associated with hepatitis C virus infection. *J Am Acad Dermatol.* 2005;52(suppl 1): 61-62.
252. Radin DA, Mehregan DR. Granuloma faciale: distribution of the lesions and review of the literature. *Cutis.* 2003;72:213.
253. Marcoval J, Moreno A, Peyr J. Granuloma faciale: a clinicopathological study of 11 cases. *J Am Acad Dermatol.* 2004;51:269.
254. Ortonne N, Wechsler J, Bagot M, et al. Granuloma faciale: a clinicopathologic study of 66 patients. *J Am Acad Dermatol.* 2005;53(6):1002-1009.
255. Johnson WC, Higdon RS, Helwig EB. Granuloma faciale. *Arch Dermatol.* 1959;79:42.
256. Dowlati B, Firooz A, Dowlati Y. Granuloma faciale: successful treatment of nine cases with a combination of cryotherapy and intralesional corticosteroid injection. *Int J Dermatol.* 1997;36:548.
257. Carlson JA, LeBoit PE. Localized chronic fibrosing vasculitis of the skin: an inflammatory reaction that occurs in settings other than erythema elevatum diutinum and granuloma faciale. *Am J Surg Pathol.* 1997;21:698.
258. Nieboer C, Kalsbeek GL. Immunofluorescence studies in granuloma eosinophilicum faciale. *J Cutan Pathol.* 1978;5:68.
259. Barnadas MA, Curell R, Alomar A. Direct immunofluorescence in granuloma faciale: a case report and review of literature. *J Cutan Pathol.* 2006;33:508-511.
260. Schnitzler L, Verret JL, Schubert B. Granuloma faciale: ultrastructural study of three cases. *J Cutan Pathol.* 1977;4:123.
261. Teixeira DA, Estrozi B, Ianhez M. Granuloma faciale: a rare disease from a dermoscopy perspective. *An Bras Dermatol.* 2013;88(6)(suppl 1):97-100.
262. Sangueza OP, Pilcher B, Martin Sangueza J. Erythema elevatum diutinum: a clinicopathological study of eight cases. *Am J Dermatopathol.* 1997;19:214.
263. Roustan G, Sánchez Yus E, Salas C, et al. Granuloma faciale with extrafacial lesions. *Dermatology.* 1999;198(1):79-82.
264. Crowson AN, Mihm MC Jr, Magro CM. Cutaneous vasculitis: a review. *J Cutan Pathol.* 2003;30:161.
265. Frankel DH, Soltani K, Medenica MM, et al. Tinea of the face caused by *Trichophyton rubrum* with histologic changes of granuloma faciale. *J Am Acad Dermatol.* 1988;18(2, pt 2):403-406.
266. Maillard H, Grognard C, Toledano C, et al. Granuloma faciale: efficacy of cryosurgery in two cases [in French]. *Ann Dermatol Venereol.* 2000;127(1):77-79.
267. Zacarian SA. Cryosurgery effective for granuloma faciale. *J Dermatol Surg Oncol.* 1985;11:11.
268. Goldner R, Sina B. Granuloma faciale: the role of dapsone and prior irradiation on the cause of the disease. *Cutis.* 1984;33:478.
269. van de Kerkhof PC. On the efficacy of dapsone in granuloma faciale. *Acta Derm Venereol.* 1994;74:61.

270. Mitchell D. Successful treatment of granuloma faciale with tacrolimus. *Dermatol Online J.* 2004;10:23.
271. Cheung ST, Lanigan SW. Granuloma faciale treated with the pulsed dye laser: a case series. *Clin Exp Dermatol.* 2005;30:373.
272. Welsh JH, Schroeder TL, Levy, ML. Granuloma faciale in a child successfully treated with the pulsed dye laser. *J Am Acad Dermatol.* 1999;41:351.
273. Ammirati CT, Hruza GJ. Treatment of granuloma faciale with the 585-nm pulsed dye laser. *Arch Dermatol.* 1999;135:903.
274. Chatrath V, Rohrer TE. Granuloma faciale successfully treated with long-pulsed tunable dye laser. *Dermatol Surg.* 2002;28:527.
275. Elston DM. Treatment of granuloma faciale with the pulsed dye laser. *Cutis.* 2000;65:97.
276. Ludwig E, Allam JP, Bieber T, et al. New treatment modalities for granuloma faciale. *Br J Dermatol.* 2003;149(3):634-637.
277. Pérez-Robayna N, Rodríguez-García C, González-Hernández S, et al. Successful response to topical tacrolimus for a granuloma faciale in an elderly patient. *Dermatology.* 2009;219(4):359-360.
278. Patterson C, Coutts I. Granuloma faciale successfully treated with topical tacrolimus. *Australas J Dermatol.* 2009;50:217-219.
279. Ertam I, Ertekin B, Unal I, et al. Granuloma faciale: is it a new indication for pimecrolimus? A case report. *J Dermatolog Treat.* 2006;17(4):238-240.
280. Cheng JF, Ott NL, Peterson EA, et al. Dermal eosinophils in atopic dermatitis undergo cytolytic degeneration. *J Allergy Clin Immunol.* 1997;99(5):683-692.
281. Antic M, Lautenschlager S, Itin PH. Eosinophilic fasciitis 30 years after—what do we really know? Report of 11 patients and review of the literature. *Dermatology.* 2006;213(2):93-101.
282. Pinal-Fernandez I, Callejas-Moraga EL, Roade-Tato ML, et al. Groove sign in eosinophilic fasciitis. *Lancet.* 2014;384(9956):1774.
283. Hertzman PA, Blevins WL, Mayer J, et al. Association of the eosinophilia-myalgia syndrome with the ingestion of tryptophan. *N Engl J Med.* 1990;322(13):869-873.
284. Mori Y, Kahari VM, Varga J. Scleroderma-like cutaneous syndromes. *Curr Rheumatol Rep.* 2002;4(2):113-122.
285. Varga J, Griffin R, Newman JH, et al. Eosinophilic fasciitis is clinically distinguishable from the eosinophilia-myalgia syndrome and is not associated with L-tryptophan use. *J Rheumatol.* 1991;18(2):259-263.
286. Varga J, Kahari VM. Eosinophilia-myalgia syndrome, eosinophilic fasciitis, and related fibrosing disorders. *Curr Opin Rheumatol.* 1997;9(6):562-570.
287. Uitto J, Varga J, Peltonen J, et al. Eosinophilia-myalgia syndrome. *Int J Dermatol.* 1992;31(4):223-228.
288. Martin RW, Duffy J, Engel AG, et al. The clinical spectrum of the eosinophilia-myalgia syndrome associated with L-tryptophan ingestion. Clinical features in 20 patients and aspects of pathophysiology. *Ann Intern Med.* 1990;113(2):124-134.
289. Chusid MJ, Dale DC, West BC, et al. The hypereosinophilic syndrome: analysis of fourteen cases with review of the literature. *Medicine (Baltimore).* 1975;54(1):1-27.

Chapter 41 :: Urticaria and Angioedema

:: Michihiro Hide, Shunsuke Takahagi, & Takaaki Hiragun

AT-A-GLANCE

- Urticaria is defined as a skin disorder characterized by local transient skin or mucosal edema (wheal) and an area of redness (erythema) that typically accompany itchy sensations and diminish within 1 day.
- Symptoms may occur either spontaneously (spontaneous or idiopathic urticaria) or in response to specific stimuli, such as physical stimuli or sweating (the increase of body core temperature).
- Mast cells and their histamine being released either spontaneously or in response to various stimuli play a crucial role in the pathogenicity of urticaria.
- Spontaneous or idiopathic urticaria is the subtype of urticaria that most patients experience.
- Autoantibodies against immunoglobulin (Ig) E or the high-affinity IgE receptor (FcεRI) that activate mast cells and basophils and induce histamine release may be detected in up to half of patients with chronic spontaneous or idiopathic urticaria (type II autoimmunity).
- A certain population of patients may develop angioedema mediated by bradykinin rather than histamine.
- Infections, stress, fatigue, and drugs, especially nonsteroidal antiinflammatory drugs and angiotensin-converting enzyme inhibitors, may cause or aggravate urticaria or angioedema.
- However, the mechanism of mast cell activation or the exacerbation of urticaria by various factors, except for exogenous antigens and autoantibodies, remains largely unknown.
- Nonsedative second-generation antihistamines are the mainstay of pharmaceutical therapy.
- Omalizumab, anti-IgE antibody, or immunosuppressive medications may be taken for the treatment of urticaria and angioedema that is refractory to antihistamines even at high doses.

INTRODUCTION

DEFINITIONS

Urticaria is defined as a skin disorder characterized by local transient skin or mucosal edema (wheal) and an area of redness (erythema) that typically accompany itchy sensations and diminish within a day. Angioedema is a local and transient skin or mucosal edema that develops in deep tissues mostly without itching but may accompany pain or burning sensations. Both wheals and angioedema may develop together in one patient, but either one may develop exclusively in individual patients. Whereas the term *urticaria* is used as an entity of disease, *angioedema* may mean either disease or eruption. Either wheals and angioedema or both may appear as a symptom of other disease entities, such as anaphylaxis (either wheals or angioedema), autoinflammatory syndromes (wheals), mastocytosis (wheals known as Darier sign) or hereditary angioedema (HAE; angioedema). The international guidelines advocated by the European Academy of Allergy and Clinical Immunology (EAACI)/Global Allergy and Asthma European Network (GA²LEN)/European Dermatology Forum (EDF)/World Allergy Organization (WAO) (EAACI guideline) define urticaria as a disease characterized by the development of wheals (hives), angioedema, or both and distinguishes urticaria from medical conditions in which wheals, angioedema, or both can occur as a symptom, such as a skin prick test, anaphylaxis, autoinflammatory syndromes, or HAE (bradykinin-mediated angioedema).[1]

HISTORICAL PERSPECTIVE

The school of Hippocrates first described the association of urticaria with nettles and insect bites.[2] Stinging nettle (*Urtica dioica*) contains histamine-, serotonin-, and acetylcholine-containing fluids inside the spicules and causes contact urticaria-like symptoms.[3] Therefore, the name "nettles" frequently appeared in several languages until the middle of the 19th century. The word "urticaria" was first used in 1792 by Johann Peter Frank to describe the disease.[2] In 1878, Paul Ehrlich first described aniline-positive cells in connective tissues and named them "Mastzellen (well-fed cells)."[4] In 1910, Henry Dale clarified the physiological role of histamine on smooth muscle.[5] In 1913, Hans Eppinger showed that wheals, erythema, and pain developed at sites of local injections of histamine.[6] In 1937, Daniel Bovet[7] developed antihistamine, which became the mainstay of treatment for urticaria. In 1953, James F. Riley showed that mast cells are the main source of histamine in the skin.[8] In 1966, Kimishige Ishizaka identified immunoglobulin (Ig) E and clarified its role in type I hypersensitivity, the pathological mechanism of allergic urticaria.[9]

EPIDEMIOLOGY

Studies in Europe reported the lifetime prevalence (prevalence during the whole lifetime until the investigation) of urticaria as around 8% to 10%.[10-12] Hellgren found a point prevalence (prevalence at the time of the investigation) of around 0.1% in the total population of Sweden,[13] and more recently, Gaig and coworkers reported a point prevalence of 0.6% in the Spanish population.[14] The reason for such large variations in the prevalence among reports is unclear, but possible explanations include differences in the methods employed, definition of urticaria, and geographical and cultural characteristics. Many cases of urticaria that diminish within a few weeks or develop on just a single or a few occasions may be overlooked and not included in some survey results.

Chronic spontaneous urticaria (CSU) and inducible urticarias, including physical urticaria, cholinergic urticaria, and contact urticaria, that persist for more than 6 weeks can be grouped as "nonacute" or "chronic" urticaria. One study of the prevalence of CSU with the classification recommended by the EAACI guidelines found a prevalence of 0.8% in a 1-year period in Germany.[12] Statistical analysis of patients with nonacute urticaria suggests that 66% to 93% have CSU, 4% to 33% a physical urticaria, and 1% to 7% have cholinergic urticaria.[15-18] A limitation of many studies is that they give no information about how they evaluate combinations of multiple subtypes of urticaria. In fact, as many as half of patients with CSU may also have other types of urticaria.[19] In addition, CSU can be further divided into that with concomitant angioedema, that without angioedema and that with recurrent angioedema without wheals. The available data suggest that whereas 33% to 67% of all patients with CSU exhibit wheals and angioedema, 29% to 65% exhibit only wheals and 1% to 13% only angioedema.[20] Differences in prevalence by race or ethnic group are unknown, but data are scarce.[20]

Regarding sex, the majority of studies show that women have urticaria nearly twice as often as men do.[10,12,13-15,17,18,20-27] This is true not only for CSU but also for many other types of urticaria. Among patients with CSU, the prevalence of a positive autologous serum skin test (ASST) result was reported to be higher in women than in men.[28]

The peak age of CSU patients is between 20 and 40 years in most studies.[16,17,21,23,27,29] A survey of office-based practices for all types of urticaria in the United States reported a bimodal age distribution in patients aged birth to 9 years and 30 to 40 years.[30] The first peak may represent the predominance of acute spontaneous urticaria, allergic urticaria (urticarial reactions), and cholinergic urticaria in children.

Few data are available concerning the relationship between prevalence of urticaria and socioeconomic status, education, ethnic background or place of residence. A German study showed that people with a high socioeconomic status and those who live in larger cities are more likely to have urticaria.[11] However, the deviations were too small to conclude whether the results reflect true variations in prevalence or just differences in disease awareness. Other studies failed to show a difference in the prevalence of urticaria with regard to education, occupation, income, place of residence, and ethnic background.[10,12,14,31]

CLINICAL FEATURES

CUTANEOUS FINDINGS

Circumscribed, raised, usually pruritic, and evanescent areas of edema that involve the superficial portion of the dermis are known as wheals. A wheal may appear mostly reddish but could also be whitish, especially when edema is significant. Edema that extends into the deep dermis or subcutaneous and submucosal layers is known as angioedema.

Urticaria and angioedema may occur in any location together or individually. Angioedema commonly affects the face, especially the eyelids and lips, or a portion of the extremities (Fig. 41-1E). It may be painful but not pruritic and may last for several days. Involvement of the lips, cheeks, and periorbital areas is common, but angioedema also may affect the tongue, pharynx, or larynx. The individual lesions of urticaria arise suddenly, rarely persist for longer than 24 to 36 hours, and may continue to recur for indefinite periods. Most wheals, but not angioedema, are highly pruritic. The size, shape, and color of wheals are quite variable. Wheals on the eyelids and lips and those in the deep dermis in delayed pressure urticaria (DPU) may be difficult to be distinguished from angioedema. Certain subtypes of urticaria have characteristic morphologies. Spontaneous urticarias (acute and chronic) may involve large, small, flowerlike, or annular wheals, and they are usually heterogeneous (Fig. 41-2). The heterogeneity of wheals in size and shape is one of the characteristics of spontaneous urticaria. In severe cases of spontaneous urticaria, wheals may accompany purpura, lasting for a few days. In such cases, urticarial vasculitis should be excluded. In most cases of physical urticarias, wheals develop diffusely within the affected areas (Figs. 41-1A, 41-1B, and 41-1D), but wheals of cholinergic, adrenergic, and aquagenic urticaria are usually small (<5 mm) and disseminated in the provoked area of the skin (Fig. 41-1C). The duration of individual wheals is long in spontaneous urticarias and deep pressure urticaria and shorter in physical urticarias.[32] The development of angioedema is rare in physical urticaria but may be observed in cholinergic urticaria.[33-35]

NONCUTANEOUS FINDINGS

During urticarial attacks, patients often feel discomfort of the stomach and intestine. Infections of the gastrointestinal tract may induce urticaria and vice versa. Pharyngeal edema can be seen in angioedema, especially bradykinin-induced angioedema.[36] Certain kinds of

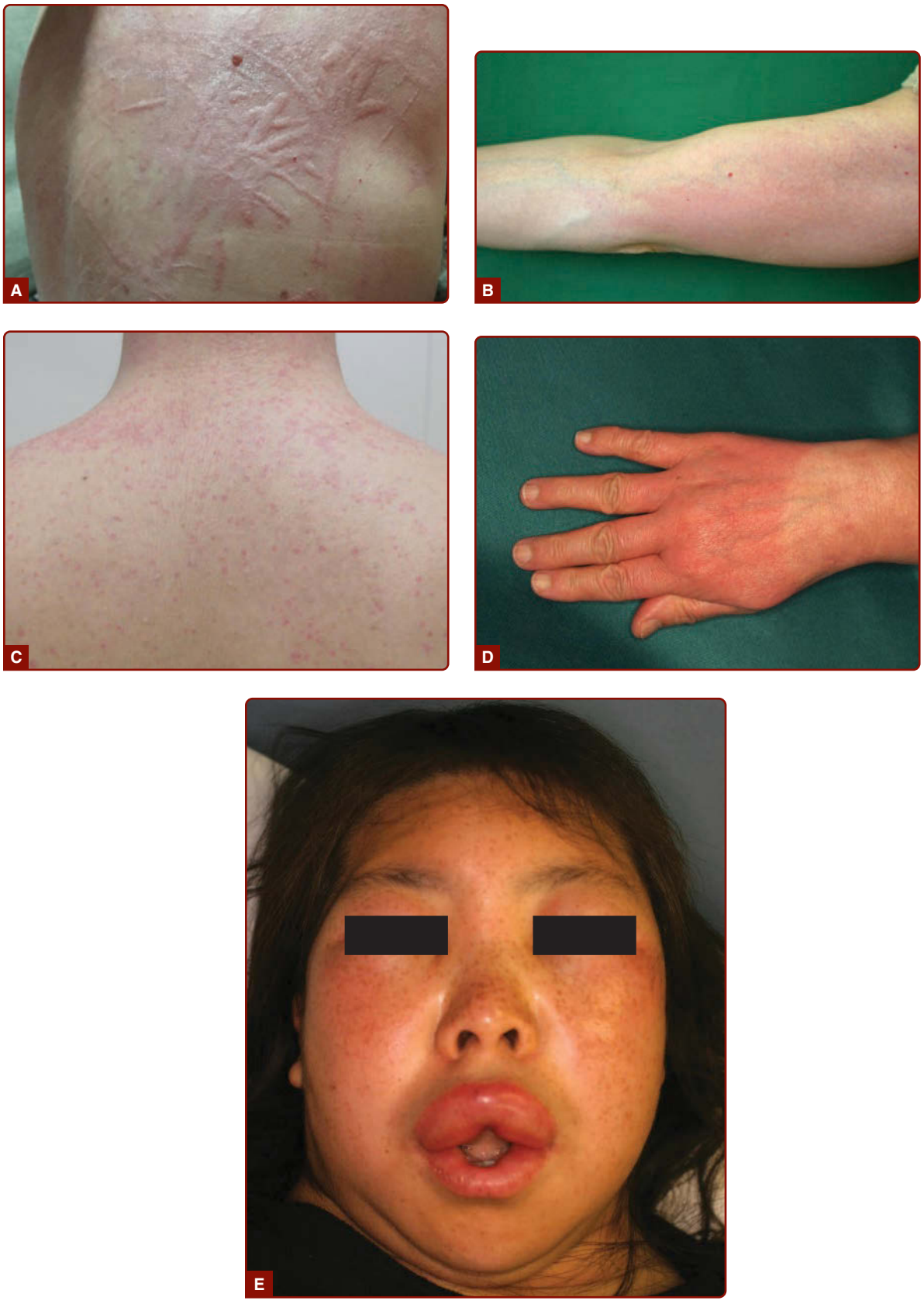

Figure 41-1 Clinical presentation of symptomatic dermographism (**A** and **B**), cholinergic urticaria evoked by exercise (**C**), local contact urticaria evoked by immersion in hot water (**D**), and hereditary angioedema (**E**).

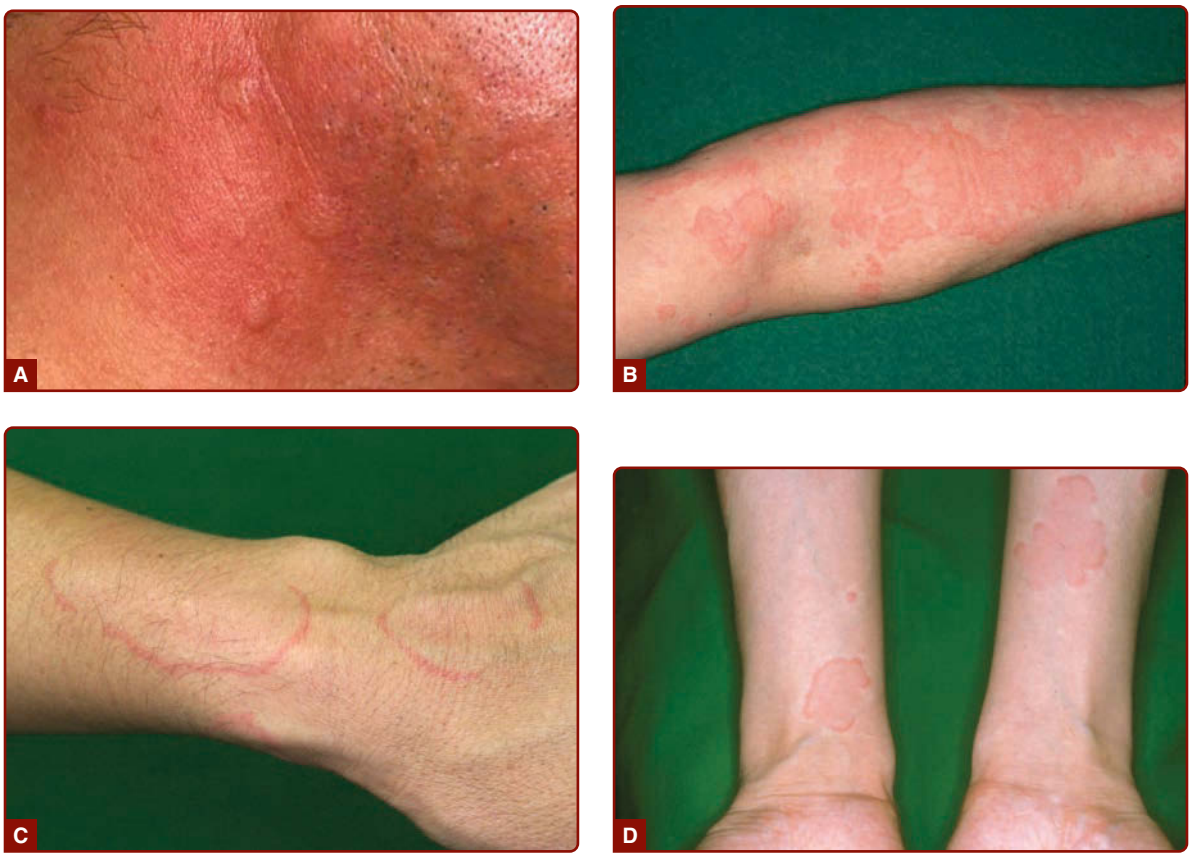

Figure 41-2 Clinical presentation of acute urticaria (**A**), chronic spontaneous urticaria (CSU) (**B**), CSU with an annular shape (**C**), and CSU with a flower shape (**D**). (Images **A, B,** and **D,** reproduced from *JDA*. 2012;122(11):2627-2634, with permission.)

urticarias, especially inducible ones such as allergic urticaria, and cholinergic urticaria, may develop into anaphylaxis. Anaphylaxis is defined as "a serious, life-threatening generalized or systemic hypersensitivity reaction" and "a serious allergic reaction that is rapid in onset and might cause death."[37] It mostly, but not always, affects the skin (urticarial rash) and respiratory (dyspnea) and circulatory systems (low blood pressure, syncope). Severe cases of physical urticaria may also include systemic symptoms such as headache, dizziness, syncope, wheezing, and nausea.

COMPLICATIONS

AUTOIMMUNE THYROID DISEASES

The association between CSU and thyroid autoimmunity has been reported in many studies. The frequency of thyroid autoantibodies in patients with CSU is significantly higher than those in control participants.[38,39] The frequency of overt and subclinical thyroid dysfunction was also significantly higher than those of a control Spanish population.[39] A subgroup of patients with CSU who possess IgE antibodies against thyroid peroxidase (TPO) might evoke autoallergic degranulation of mast cells.[40]

OTHER AUTOIMMUNE DISEASES

Patients with CSU exhibit autoimmune diseases other than thyroid autoimmunity. Especially female patients with CSU were reported to have a significantly higher incidence of rheumatoid arthritis, Sjögren syndrome, celiac disease, type I diabetes mellitus, and systemic lupus erythematosus (SLE).[41]

SUBTYPES OF URTICARIA

Because there is a large variation in features in urticaria, not only in the pathogenesis but also in terms of management, urticaria has been classified by its various aspects, such as duration, trigger and mode of induction, and underlying causes. The international consensus meeting held in 2013 for making the EAACI guidelines reached a consensus for standard classification. This classification divides urticaria into acute and chronic at 6 weeks from the onset. Chronic urticaria is further classified into spontaneous urticaria and inducible urticaria. The latter is induced by physical stimuli and includes physical urticaria (cold urticaria, DPU, heat urticaria, solar urticaria, symptomatic dermographism, vibratory angioedema), cholinergic urticaria, and contact urticaria (Table 41-1). This classification

TABLE 41-1
Recommended Diagnostic Tests in Frequent Urticarial Subtypes

TYPES	SUBTYPES	ROUTINE DIAGNOSTIC TESTS (RECOMMENDED)	EXTENDED DIAGNOSTIC PROGRAMME[a] (BASED ON HISTORY) FOR IDENTIFICATION OF UNDERLYING CAUSES OR ELICITING FACTORS AND FOR RULING OUT POSSIBLE DIFFERENTIAL DIAGNOSES IF INDICATED
Spontaneous urticaria	Acute spontaneous urticaria	None	None[b]
	CSU	Differential blood count. ESR and/or CRP	Avoidance of suspected triggers (eg, drugs); Conduction of diagnostic tests for (in no preferred order): (i) infectious diseases (eg, *Helicobacter pylori*); (ii) functional auto-antibodies (eg, autologous skin serum test); (iii) thyroid gland disorders (thyroid hormones and auto-antibodies); (iv) allergy (skin tests and/or allergen avoidance test, eg, avoidance diet); (v) concomitant CIndU, see below; (vi) severe systemic diseases (eg, tryptase); (vii) other (eg, lesional skin biopsy)
Inducible urticaria	Cold urticaria	Cold provocation and threshold test[c,d]	Differential blood count and ESR or CRP, rule out other diseases, especially infections[e]
	Delayed pressure urticaria	Pressure test and threshold test[c,d]	None
	Heat urticaria	Heat provocation and threshold test[c,d]	None
	Solar urticaria	UV and visible light of different wavelengths and threshold test[c]	Rule out other light-induced dermatoses
	Symptomatic dermographism	Elicit dermographism and threshold test[c,d]	Differential blood count, ESR or CRP
	Vibratory angioedema	Test with vibration, for example, Vortex or mixer[d]	None
	Aquagenic urticaria	Provocation testing[d]	None
	Cholinergic urticaria	Provocation and threshold testing[d]	None
	Contact urticaria	Provocation testing[d]	None

[a]Depending on suspected cause.
[b]Unless strongly suggested by patient history, for example allergy.
[c]All tests are carried out with different levels of the potential trigger to determine the threshold.
[d]For details on provocation and threshold testing, refer to Magerl M, Altrichter S, Borzova E, et al. The definition, diagnostic testing, and management of chronic inducible urticarias? The EAACI/GA2LEN/EDF/UNEV consensus recommendations 2016 update and revision.
[e]For further info, refer to Maurer M. Cold urticaria. In: Saini SS, Callen J, editors. UpToDate. Boston, MA: Wolters Kluwer Health; 2014.
ESR, erythrocyte sedimentation rate; CRP, C-reactive protein.
From Zuberbier T, Aberer W, Asero R, et al. The EAACI/GA(2) LEN/EDF/WAO Guideline for the definition, classification, diagnosis, and management of urticaria: the 2017 revision and update. *Allergy*. 2018;73:1393-1414, with permission. Copyright © 2018 EAACI and John Wiley and Sons.

has been maintained in the guideline updated in 2018.[1] In daily practice, wheals or angioedema may also develop as a reaction to certain stimuli or as a symptom of other disease entities. This chapter describes various subtypes of urticaria that require treatment or management in clinical practice even if they are not included in the EAACI guideline. Morphological characteristics of urticaria subtypes are summarized in Table 41-2.

SPONTANEOUS URTICARIA

Spontaneous urticaria is defined as urticaria that occurs spontaneously almost every day without any apparent cause or trigger. The name "idiopathic urticaria" has also been used for the same entity for a long time, but the use of "spontaneous" urticaria has been recommended by the EAACI guidelines and endorsed by many relevant societies.[1] The major skin manifestation is wheals, and they may be accompanied by angioedema in up to half of patients.[20] In some cases, only angioedema may appear. Compared with superficial wheals, angioedema occurs less frequently, such as every few days, weeks, or months, and the symptoms of angioedema last longer than a day, usually for a few days. The shape, size, and duration of individual wheals are highly variable and heterogeneous as described in the Cutaneous Findings in the section of "Clinical Features" and Fig. 41-2. Flowerlike or annular-shaped wheals are characteristic of this subtype of urticaria. Although symptoms may be very severe and disabling, they are mostly nonlethal. There is no qualitative difference between acute spontaneous urticaria and CSU, but acute forms tend to be more severe. Cutaneous manifestations of urticarial vasculitis and autoinflammatory syndromes may resemble long-lasting wheals observed in this type of urticaria.

SYMPTOMATIC DERMOGRAPHISM

Symptomatic dermographism, also called as urticaria factitia, dermographic urticaria, mechanical urticaria,

TABLE 41-2
Characteristics of Wheals Observed in Subtypes of Urticaria

	SPONTANEOUS URTICARIA TYPE (POLYMORPHIC)	ANNULAR TYPE, PRUPURIC LESION	CHOLINERGIC TYPE (SMALL (<5 MM) AND DISSEMINATED)	LINEAR TYPE	LOCALIZED PROVOKED AREA TYPE	MUCOSAL TYPE
Spontaneous urticaria	+++	++	+			none to ++[a]
Type I allergy mediated and many drug-induced urticarias	++				++	none to ++[a]
Cold, solar, heat, and deep pressure urticarias					+++	none to ±[c]
Symptomatic dermographism (mechanical urticaria)				+++	++	none to ±[c]
Cholinergic, aquagenic, and adrenergic urticarias			+++		none to ++[a]	none to +[b]
Angioedema						+++

[a]A spectrum from none to ++.
[b]A spectrum from none to +.
[c]A spectrum from non to ±.

or simply dermographism, is the most common subtype among the physical urticarias. Symptomatic dermographism is characterized by itching or burning skin sensations and the development of pruritic wheals and flare in areas exposed to shearing forces on the skin. The shape of wheals and erythema is mostly liner or consists of liner elements because of the forms of eliciting stimuli (see Fig. 41-1A). However, a widespread flare with vague margins may develop when patients extensively scratch the skin (see Fig. 41-1B). In rare and severe cases of symptomatic dermographism, erythematous lines may accompany punctate wheals characteristic of cholinergic urticaria (*cholinergic dermographism*).[42] Wheals and itch of this urticaria subtype develop shortly after the stimuli and disappear approximately within 30 minutes in most cases. In certain cases of DPU, wheals of symptomatic dermographism may return in the same site or newly develop 3 to 6 hours after stimulation and persist for up to 48 hours (*delayed dermographism*).[43] In some rare cases, wheals may be markedly augmented when the skin is chilled (*cold-dependent dermographism*).[44] There is a case report of this subtype urticaria developing in the genital region during sexual intercourse.[45]

COLD URTICARIA

Cold urticaria is a physical urticaria being characterized by the appearance of wheals and flare in response to cold. In most cases, local skin contact with a cold substance induces wheals and flare in the area of cold contact (*cold contact urticaria*). The cutaneous appearance of wheals and flare is typically flat and widely spread but may also be punctate. Itching and wheals of the skin occur within minutes and persist up to 1 hour. In severe cases, the mouth and pharynx may swell after drinking cold liquid. Patients with cold urticaria may also develop anaphylactic symptoms, including palpitations, headache, wheezing, and loss of consciousness, and drowning may occur after cold water bathing. In rare cases, erythematous edematous and deep swelling may appear 9 to 18 hours after cold challenge (*delayed cold urticaria*).[46]

In cases of *systemic cold urticaria*, widespread wheals and flare develop in response to cooling of the core body temperature, not by the local exposure to cold.[47] Systemic cold urticaria may be either idiopathic or secondary to underlying diseases. Patients with *familial cold urticaria syndrome* develop erythematous macules and infrequent wheals associated with burning and pruritus on exposure to cold; this is now classified as a subtype of *cryopyrin-associated periodic syndrome (CAPS)*, an autosomal dominant inherited disease which is associated with a genetic mutation of *NLRP3 (CIASI)*. It may include headaches, conjunctivitis, and arthralgias. The average delay between cold exposure and onset of symptoms is 2.5 hours, and the average duration of an episode is 12 hours.[48] More recently, a new mutation in *PLCG2*, encoding phospholipase $C\gamma_2$, with gain of function has been identified in families with a dominantly inherited complex of cold-induced urticaria, antibody deficiency, and susceptibility to infection and autoimmunity.[49] Patients with these hereditary disorders do not develop wheals and flare in response to the local ice-cube test (see the "Diagnosis" section).

HEAT URTICARIA

Heat urticaria is a rare subtype of physical urticaria characterized by wheals and flare that develop within minutes after local heat exposure to the skin and disappear within a few hours at the longest (see Fig. 41-1D). In contrast to cholinergic urticaria that involves small punctate eruptions in response to conditions that elicit sweating, patients with heat urticaria develop wheals and flare that spread in the area of skin exposed to heat, regardless of the core body temperature or sweating.

SOLAR URTICARIA

Solar urticaria is a rare subtype of physical urticaria characterized by wheals and flare that develop within minutes after local exposure of the skin to certain wavelengths of light. The urticarial lesions usually resolve within hours but may accompany headache, syncope, dizziness, wheezing, and nausea. The shape of skin eruptions in solar urticaria is consistent with the area exposed to the light of an eliciting wavelength. There may be widespread wheals, flare, or punctate redness but not the small wheals observed in cholinergic urticaria. The face and hands may develop fewer lesions than skin areas that are usually covered by clothes because of hardening due to chronic exposure to sunlight.

DELAYED PRESSURE URTICARIA

Delayed pressure urticaria is characterized by deep dermal wheals that appear in a continuously compressed region with a latency of 30 minutes or several hours after the release of the compression. The wheals last for several hours or up to 3 days and may be accompanied by a burning sensation or pain rather than the itching often seen with CSU.[50] DPU may develop by itself but may often be accompanied by CSU.[51]

VIBRATORY URTICARIA AND ANGIOEDEMA

Vibratory urticaria and angioedema is a rare subtype of physical urticaria characterized by cutaneous swelling developing immediately at the site of contact with vibratory stimuli, such as jogging, vigorous toweling, or using lawnmowers.[52] Recently, the missense mutation of *ADGRE2* has been reported to be associated with familial vibratory urticaria with autosomal dominant inheritance.[53]

AQUAGENIC URTICARIA

Aquagenic urticaria is a rare subtype of urticaria induced by local skin exposure to water. The eruptions are induced regardless of the temperature of the water. This characteristic of aquagenic urticaria helps differentiate it from cold urticaria and heat urticaria, which may also be induced by skin exposure to water at certain temperatures. Aquagenic urticaria is characterized by small wheals, resembling eruptions of cholinergic urticaria, but wheals in this urticaria subtype are generally fewer in number as compared with eruptions of cholinergic urticaria. They are usually surrounded by wide flares. Pruritus without a wheal and flare reaction developing after exposure to water is classified as aquagenic pruritus of a different disease entity.[54]

CHOLINERGIC URTICARIA

Cholinergic urticaria is a distinct subtype of urticaria induced by stimuli that cause sweating and distinctive for its small urticarial eruptions. Cholinergic urticaria is more common in children, adolescents, and young adults. Stimuli can be physical exercise, a hot temperature environment, or emotional or gustatory excitation. The eruptions are punctate 1- to 4-mm wheals or red spots with or without surrounding flare (see Fig. 41-1C). In severe cases, the eruptions may become confluent, generalized urticaria and even develop into anaphylaxis.[35,55,56] In rare cases, such lesions may accompany angioedema (*cholinergic angioedema*).[34,57] A case of angioedema that developed in response to exercise without punctate wheals or erythema was also reported.[58] Of note, most patients who develop angioedema are female and have an associated atopic diathesis or sweat allergy.[57,58] Cholinergic urticaria is usually pruritic but may be painful or sting, especially at the time when eruptions are developing. The wheal and flare reaction usually develops within 30 minutes and completely disappears within a few hours.

Cholinergic urticaria must be differentiated from exercise-induced urticaria and anaphylaxis, which is induced by exercise but not by passive warming. Certain cases of cholinergic urticaria may be evoked by systemic cold stimuli (*cold cholinergic urticaria*). Such cases should be differentiated from familial cold urticaria. Pruritus without wheals induced by conditions that elicit sweating has also been described (*cholinergic pruritus*).[59]

A substantial proportion of patients with cholinergic urticaria may also have atopic dermatitis and show type I hypersensitivity against human sweat.[60] The major antigen in sweat has been identified as MGL_1304, a protein produced and released by *Malassezia globosa* on human skin.[61,62] Another subset of patients with cholinergic urticaria have partial impairment of sweat production.[63] Most patients with this type of cholinergic urticaria complain of pain rather than itching, especially in winter.[35]

CONTACT URTICARIA

Contact urticaria is classified as a subtype of inducible urticaria characterized by immediate development of a wheal and flare reaction at the site of contact with specific substances. It may be either immunologic (IgE mediated) or nonimmunologic. The wheal and flare usually appears within 30 minutes and completely disappears within a few hours and may also develop into generalized urticaria and even anaphylaxis. Cold urticaria, heat urticaria, and aquagenic urticaria are also induced by contact with a substance with corresponding physical characteristics but are usually not included in this category. Cases in which oral edema and discomfort are the main symptoms, induced by contact of the oral mucosa with certain foods, are called as *oral allergy syndrome* (OAS).[64]

URTICARIAL VASCULITIS

Urticarial vasculitis is characterized by recurrent urticarial lesions that last for more than 24 hours, leaving pigmentation and demonstrating histopathologic evidence of leukocytoclastic vasculitis. Shapes of wheals

and flare observed in urticarial vasculitis are similar to those observed in spontaneous urticaria and may be indistinguishable from those of CSU with long-lasting wheals. Patients with urticarial vasculitis may also develop livedo reticularis, Raynaud phenomenon, and angioedema.[65-69]

URTICARIAL REACTIONS AND SYMPTOMS OF OTHER SYSTEMIC DISEASE ENTITIES

Wheal Developing from Skin Test: Wheals and flare may develop in response to intracutaneous injection of histamine or antigen. However, these reactions are usually not included in urticaria as a disease entity.

Hereditary Angioedema: Hereditary angioedema is a disease entity characterized by recurrent angioedema based on a hereditary etiology. Symptoms of HAE may develop anywhere in the body, especially in the skin, gastrointestinal tract and airway, and be extremely severe. This may be clinically indistinguishable from angioedema secondary to idiopathic mechanisms (see Fig. 41-1E). Importantly, those with HAE do not develop superficial wheals. Patients with HAE may be complicated with urticaria, but it is very rare.

Anaphylaxis: Wheal and flare is the most frequent sign observed in anaphylaxis. Anaphylaxis is induced by either allergic or nonallergic mechanisms and includes systemic symptoms beyond involvement of the skin.

Darier Sign: This is a wheal and flare reaction induced by scratching a lesion of mastocytosis. Nonlesional skin does not produce such a reaction.

ETIOLOGY AND PATHOGENESIS

The common feature of urticaria is a rapid and transient vasodilation and extravasation of plasma into cutaneous or mucosal tissues accompanied by itch sensory nerve activation. These reactions are mostly explained by degranulation of cutaneous mast cells, which release histamine and other vasoactive mediators, including arachidonic acid metabolites, such as prostaglandins and leukotrienes. The crucial role of mast cells in urticaria has been proven by histologic observations of mast cell degranulation in the lesional skin of wheals, the increase of local histamine concentration in skin fluid or plasma of urticarial lesions, and the clinical efficacy of antihistamines for more than half of patients with CSU.[20] Indeed, type I hypersensitivity against exogenous antigens may well explain such reactions in allergic urticaria. However, the mechanism of mast cell activation and its relationship to various underlying diseases in other types of urticaria are largely unclear.

TYPE I HYPERSENSITIVITY

Mast cells play a pivotal role in type I hypersensitivity reactions via the high-affinity IgE receptors (FcεRI) and antigen-specific IgE (Fig. 41-3). Crosslinking of FcεRI leads to the activation of numerous signaling molecules, SYK, LAT, PLCγ, and PKC, and finally results in degranulation with release of preformed mediators such as histamine and newly synthesized ones such as arachidonic acid metabolites, platelet-activating factor, and proinflammatory cytokines.[63] Patients who possess antigen-specific IgE may respond to antigens that reach cutaneous mast cells via various pathways such as ingestion, inhalation, or skin exposure. If patients are exposed daily to the causative antigen, urticaria may be chronic.[70] Otherwise, urticaria developing through this mechanism appears as episodic or acute urticaria. Certain dietary antigens that take time to be absorbed, such as poly-γ-glutamine contained in fermented soybeans and gel-fish, may cause symptoms after a few hours or even later.[71,72] However, in most cases, urticaria symptoms develop in 15 minutes to 1 hour after the antigen exposure. Many studies suggest that the population of patients who develop urticaria because of clinically apparent, classical type I allergy against exogenous antigens, such as food and drugs, is less than 10% of the whole population of patients with urticaria.[73,74]

Recently, it has been proven that approximately two thirds of patients with cholinergic urticaria are sensitized by antigens in human sweat. Such patients show positive

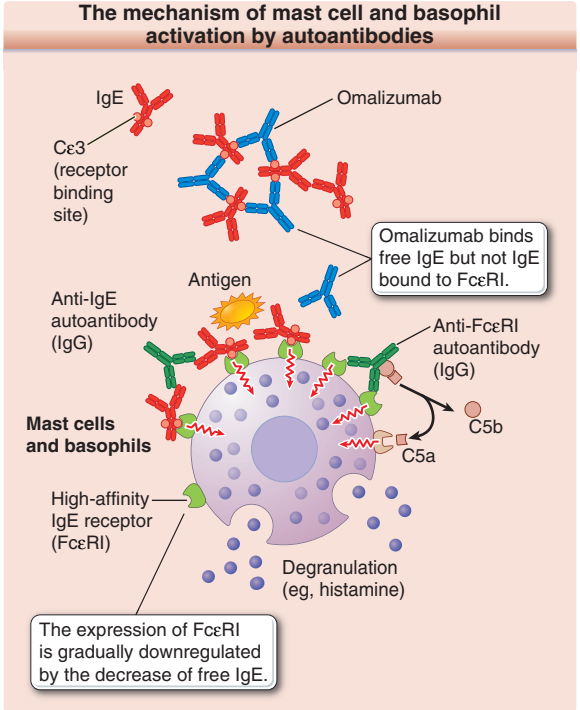

Figure 41-3 The pathogenesis of autoimmune urticaria and the proposed mechanism of action of omalizumab for autoimmune urticaria. FcεRI, the high-affinity immunoglobulin E receptor; Ig, immunoglobulin.

reactions in skin testing with autologous sweat and histamine release testing using their basophils and purified human sweat.[60,61] The major antigen of human sweat for these reactions has been identified as MGL_1304, a 17-kD protein produced and released by *M. globosa*.[62]

AUTOIMMUNE MECHANISM

An autoimmune diathesis in CSU was initially suspected because of the increased incidence of antithyroid antibodies, including antimicrosomal (peroxidase) and antithyroglobulin IgG autoantibodies, as seen in patients with Hashimoto disease.[75]

It is now known that one third to half of patients with CSU possess functional IgG autoantibodies against IgE[76] or the high-affinity IgE receptors (FcεRI)[77] that release histamine from mast cells and basophils.[78] Autoantibodies against IgE crosslink IgE together with FcεRI to which the IgE bind. In cases with autoantibodies against FcεRI, they directly bind to and crosslink FcεRI without IgE. In a certain population of patients, IgE bound to FcεRI competes with the autoantibodies against FcεRI (see Fig. 41-3). The histamine-releasing (basophil-activating) activity of the autoantibodies against FcεRI is partially, if not fully, dependent on the activation the classical complement cascade.[79,80] The presence of these autoantibodies may be screened using ASST and proven with the histamine release test using sera of the patients and basophils obtained from healthy individuals.[81]

Patients with CSU and a positive ASST result might be more intractable and reveal more severe symptoms than those with a negative ASST result.[82] A recent study revealed that the time to respond to treatment with omalizumab for patients with a positive ASST result is longer than for those with a negative ASST.[83]

The involvement of autoantigens that bind to IgE has also been suggested both in CSU and inducible urticarias.[78] Recently, the mechanism of autoimmunity involving tissue antigens recognized by IgE and that mentioned above involving IgE/FcεRI recognized by IgG have been proposed to be classified as type I and type II autoimmunities, respectively.[78] The involvement of type I autoimmunity has been suggested based on passive transfer of the sensitization using sera of patients or skin tests with human skin extracts.[84-93] In solar urticaria, there is evidence that an antigen on the skin may become evident on irradiation with light of crucial wavelengths followed by complement activation.[94-96] Histamine release from skin tissue specimens biopsied from a patient with cold urticaria in response to cooling and rewarming suggests the presence of a pathogenic molecule in the skin that is sufficient to activate mast cells.[97] However, no solid molecules have been identified to date.

Autoantibodies, either IgG or IgE against thyroid antigens, such as thyroglobulin and TPO, may be detected in patients with CSU. However, they are mostly not related to abnormalities of thyroid function, and the therapeutic effect of thyroxin on urticaria with normal thyroid functions is controversial.[98] Furthermore, the continuous presence of autoantibodies or autoantigens cannot explain diurnal and local occurrence of wheals observed in spontaneous urticaria. Thus, no autoantigens have been identified that explain the entire clinical picture of urticaria in each patient. Nevertheless, recently observed rapid effects of omalizumab, anti-IgE antibody, on both spontaneous and physical urticarias suggest the involvement of endogenous antigens that bind to IgE in the pathogenesis of various, if not all, types of urticaria.[99] Studies of some patients with physical urticaria suggested the involvement of abnormal IgE that change confirmation in response to physical stimuli and activate mast cells.[100]

In a subtype of urticarial vasculitis with hypocomplementemia, IgG autoantibody against C1q is identified (*hypocomplementemic urticarial vasculitis syndrome*).[66]

PSEUDOALLERGY

Nonallergic hypersensitivity to dietary pseudoallergens, including naturally occurring food ingredients such as salicylates and biogenous amines, food additives, and continuous use of oral or topical nonsteroidal antiinflammatory drugs (NSAIDs), may be relevant as a cause or a precipitating or aggravating factor for CSU. Because the mechanism of urticaria provoked by pseudoallergens remains unclear, strict exclusion and subsequent provocation testing with a suspected substance are necessary for the diagnosis.[32] For a diagnosis of food pseudoallergy, a 3-week pseudoallergen-free diet may be followed by well-motivated patients. The increased sensitivity of patients with CSU to histamine in the diet (histamine intolerance) has been suggested.[101] In fact, high concentrations of histamine produced in scombroid (histidine-rich fish) by bacteria-derived histidine-decarboxylase may cause anaphylactic reactions even in apparently normal individuals (scombroid poisoning).[102] Moreover, symptoms of some patients with CSU may be improved by the avoidance of pseudoallergens and histamine in the diet. However, the efficacy of such diet restriction in the management of CSU is still controversial.[103] Although many reports suggest that food additives aggravate chronic urticaria, they may be based on self-reporting[22] or on the improvement in symptoms from stringent pseudoallergen-free diets.[104] In a double-blind, placebo-controlled study, only 19% of patients responded to a provocation test with individual pseudoallergens, but the symptoms of 73% of patients ceased or were greatly reduced on the pseudoallergen-free diet. Red wines may contain vasoactive amines, including histamine, which could aggravate urticaria, but symptoms poorly correlate with histamine content.[105] Notably, pseudoallergy may not be simply diagnosed based on a patient's history.[101] Thus, dietary factors, including pseudoallergens and histamine, are likely involved in the cause of CSU to some extent, but none of them by themselves may explain the mechanisms of direct mast cell activation.

COAGULATION SYSTEM

In patients with CSU, especially those with severe symptoms, the levels of plasma coagulation markers, such as prothrombin fragment 1+2 (PF_{1+2}), fibrin degradative products (FDPs), and D-dimer, are higher than those in healthy control participants. They correlate with disease severity and return to normal levels with remission or control of symptoms by treatments.[106-110] Moreover, an increased potential for blood coagulation is also observed to correlate with disease severity in CSU.[111,112] Furthermore, massive expression of tissue factors has been demonstrated in eosinophils in the lesions of CSU.[108] Alternatively, small amounts of histamine and lipopolysaccharides may synergistically induce the expression of tissue factors, which is sufficient to trigger the coagulation cascade on endothelial cells.[113] Activated coagulation factors, such as FVIIa, FXa, and thrombin, can activate protease-activating receptors (PARs) and may thus activate skin mast cells. In fact, medications that control coagulation and the fibrinolytic system, such as warfarin, nafamostat, and the combination of heparin and tranexamic acid, have been reported to be effective for cases of CSU.[114-117] However, no direct evidence of human mast cell activation by activated coagulation factors by themselves has been reported. Moreover, no clinically apparent thrombosis is observed in patients with urticaria. Thus, it is still not clear whether abnormalities in the coagulation pathway observed in CSU are causative or epiphenomena of increased vascular permeability.

UNDERLYING DISORDERS ASSOCIATED WITH INDUCIBLE URTICARIAS

Symptoms of inducible urticarias are induced by specific stimuli, including specific physical conditions, sweat induction, and contact with specific substances corresponding to physical urticarias, cholinergic urticaria, and contact urticaria, respectively. As mentioned earlier, specific IgE may link such stimuli and mast cells, resulting in allergic reactions in response to the stimuli. The other mechanisms that make patients sensitive to certain stimuli remains largely unknown. However, in limited cases of cold urticaria, solar urticaria, and vibratory angioedema, definitive causes may be identified by serologic or genetic analyses.

COLD URTICARIA

Most cases of local cold urticaria are considered to be primary cold urticaria. In this type, no relation to underlying causes or abnormal findings upon clinical examination are observed. In rare cases, cryoproteins, such as cryoglobulin and cryofibrinogen, may be identified, either idiopathically or in association with collagen vascular disease, chronic lymphatic leukemia, myeloma, or infectious disease, including infectious mononucleosis.[86,118,119] Hereditary systemic cold urticaria may be presented as a systemic inflammatory symptom caused by genetic mutations of *NLRP3 (CIASI)* or *PLCG2* (see the "Cold Urticaria" section of Clinical Features).

SOLAR URTICARIA

The cause of solar urticaria is usually unknown, but a rare case can be diagnosed as caused by porphyrias and classified as type VI solar urticaria.[120,121]

VIBRATORY ANGIOEDEMA

Recently, a missense mutation in *ADGRE2* has been identified in patients with autosomal dominant vibratory urticaria and revealed to make mast cells sensitive to vibration in an IgE-independent manner.[53] The role of protein coded by *ADGRE2* in nonhereditary-type vibratory angioedema remains to be investigated.

NEUROLOGIC MECHANISM

It is a unique characteristic of mast cells in the skin or connective tissues that they respond to basic peptides, such as substance P, vasoactive intestinal peptide, somatostatin, neurokinin A and B, bradykinin, calcitonin gene-related peptide, and adrenocorticotropic hormone (ACTH).[122-125] They also express numerous receptors for ligands, including the above-mentioned neuropeptides and acetylcholine as well as Toll-like receptors.[63,78,126,127] Therefore, these neurotransmitters have been hypothesized to be triggers of mast cell activation in urticaria. However, the concentration required for a neuropeptide to induce histamine release is as high as 10^{-6} M,[128] and the mechanism of neuropeptide release in the skin is still unclear. Recently, excessive release of acetylcholine from the cholinergic nerve terminal to compensate for impaired sweat production by sweat glands in acquired idiopathic generalized anhidrosis was suggested as a mechanism of mast cell activation and the development of cholinergic urticaria observed in this disease.[63]

INFECTIONS

Acute infections by viruses and bacteria are known to be often associated with spontaneous urticaria, especially with the onset of acute urticaria in children and in transient aggravation of CSU.[129] Many studies have suggested chronic persistent infection by *Helicobacter pylori* as an important cause of CSU,[130] but its significance is disputed.[131,132] The relationship between many other kinds of infections and urticaria have not been substantiated.

STRESS AND FATIGUE

Many investigators have suggested a relationship between stress or fatigue and aggravation or elicitation of urticaria.[133] Patients with CSU were found to have higher levels of life event stress and perceived stress[134] and experienced stressful life events before the onset of the disease.[135-137] However, urticaria itself induces stress and impairs the quality of life (QOL) of patients. Moreover, the importance of psychological factors is difficult to scientifically evaluate. Depression and anxiety were found more frequently in patients with chronic urticaria in one study[138] but not in another.[139] Thus, it is controversial whether stress and fatigue should be included as underlying causes of urticaria. Nevertheless, with respect to QOL assessments, it is good clinical practice to ask patients with urticaria about their psychosomatic and psychiatric conditions.

OTHER ORGAN DISORDERS

In addition to infections and thyroid dysfunction, which have already been described, many other extracutaneous disorders such as collagen diseases and malignancies have been reported to underlie chronic urticaria. In some cases, the treatment of these disorders resulted in the remission of urticaria. However, reports are mostly anecdotal, and a large epidemiologic study denied the association between malignancies and chronic urticaria.[140] A retrospective population-based cohort study using data from the National Health Insurance research database in Taiwan reported an increased risk of hematologic malignancies.[141] With respect to physical urticaria, cryoglobulinemia was identified in several patients with cold contact urticaria (see the paragraph of "Cold Urticaria in Underlying Disorders Associated With Inducible Urticarias" in this section). However, in other cases, the relationship between these disorders and the pathogenesis of urticaria is largely unknown. Moreover, screening for malignant neoplasms as a routine test for urticaria is no longer recommended by the guidelines and consensus document.[1,142]

In cases of angioedema without wheals, myeloproliferative disorders and autoimmune disorders such as SLE may underlie the disease by consuming C1-hinhibitor (C1-INH) and developing autoantibodies against C1-INH, respectively, resulting in an overproduction of bradykinin[143] (Fig. 41-4).

OTHER FACTORS THAT MAY INDUCE OR AGGRAVATE URTICARIAL REACTIONS

Various factors are known to elicit or aggravate urticaria, which are mostly preexisting. They may be a cause of episodic or acute urticaria but not fundamental causes of chronic urticarias (Table 41-3). They should be carefully evaluated and avoided, if present.

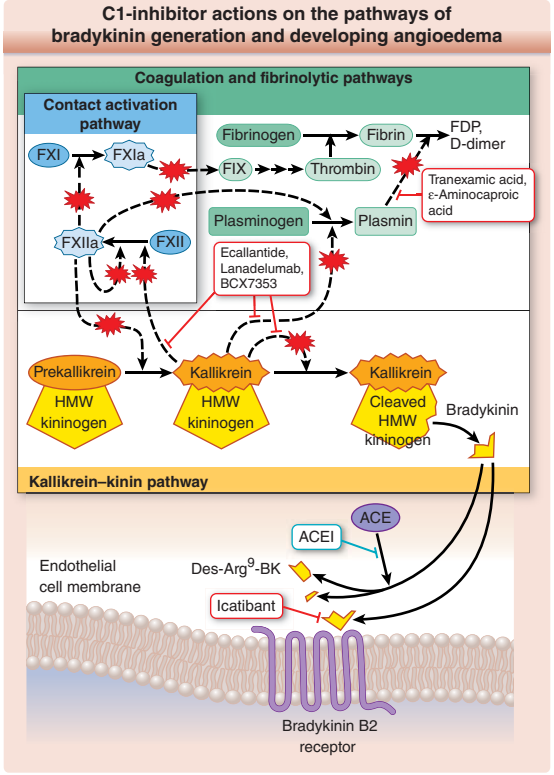

Figure 41-4 C1 inhibitor actions on pathways involved in bradykinin production. Points of inhibition by C1 inhibitor are shown by *red blasts*; other known mechanisms of pathway inhibition are also detailed. ACE, angiotensin-converting enzyme; ACEI, angiotensin-converting enzyme inhibitor; F, factor; FDP, fibrin degradative product; HMW, high molecular weight. (Information in this illustration was derived from Zuraw BL. Clinical practice. Hereditary angioedema. *N Engl J Med*. 2008;359:1027-1036.)

ASPIRIN AND OTHER NONSTEROIDAL ANTIINFLAMMATORY DRUGS

Aspirin and other NSAIDs, which inhibit cyclooxygenase (COX)-1, may induce or aggravate wheals and angioedema. These medications may also elicit respiratory symptoms (aspirin asthma). However,

TABLE 41-3
Potential Causes of Episodic or Acute Urticaria

Foods: allergens such as milk and eggs (for infants), nuts, seeds, fruits, and seafood (for adults) and pseudoallergens (food additives, salicylates, histamine, and other amines)
Drugs: antibiotics (β-lactams, vancomycin, polymyxin B), NSAIDs (oral, injection, topical), opioids, contrast media, opioids, ACE inhibitors (for angioedema)
Vaccines
Blood products: transfusions
Stings: bee, wasp venoms
Contactants: latex, chemicals
Inhalants: latex powder, chemicals

ACE, angiotensin-converting enzyme; NSAID, nonsteroidal antiinflammatory drug.

the development of skin symptoms and respiratory symptoms appears to be independent.[144,145] Food-dependent exercise-induced urticaria (FDEIA) may be aggravated or induced by aspirin or NSAIDs when administered with causative dietary elements even without exercise.[146,147] COX-2–selective NSAIDs tend to be safer than aspirin or other relatively potent COX-1 inhibitors. However, sensitivities of individual patients to NSAIDs are not necessarily correlated with their COX-1 inhibitory activities.[145]

SERUM SICKNESS

Several days to a few weeks after the administration of the offending agent, which could be not only heterologous serum, but also be certain drugs, urticaria may develop with fever, lymphadenopathy, myalgia, arthralgia, and arthritis. Symptoms are usually self-limited and last 4 to 5 days.[148,149]

BLOOD PRODUCTS

Urticaria may develop after the administration of blood products. It usually is the result of immune complex formation and complement activation.[149] Aggregated IgG may also be responsible for urticarial reactions.[149]

CONTRAST MEDIA

Contrast media may cause allergic reactions after its intravenous infusion. The prevalence of allergic reactions to iodinated contrast media (ICM) is estimated to be 0.05% to 0.1% of patients undergoing radiologic studies with ICM.[150] The application of nonionic dimeric ICM with higher physiological osmolality has decreased the number of immediate reactions occurring within 1 hour, but the prevalence of nonimmediate hypersensitivity reactions has increased in the past decade. Erythema and wheals with or without angioedema are the most common signs of immediate reactions, but delayed nonimmediate reactions may include a maculopapular rash.[150]

Most reactions are attributed to non-IgE mechanisms, but an IgE-mediated mechanism was also proven by positive skin testing or basophil activation testing in some cases.[150]

OTHER MAST CELL AND BASOPHIL ACTIVATORS

Opiate analgesics, polymyxin B, curare, D-tubocurarine, and vancomycin induce histamine release from mast cells or basophils, especially when given at high doses, and may cause urticaria or other cutaneous rashes upon the episode of administration.[149,151] On the other hand, angiotensin-converting enzyme (ACE) inhibitors do not cause release or production of mediators by themselves but inhibit degradation of bradykinin. Unlike most other medications, these may cause or aggravate angioedema after multiple administrations over a few days or longer after administration. These medications thus function as an underlying cause of angioedema rather than a direct stimulus (see Fig. 41-4).[143]

RISK FACTORS

Urticaria may occur at any age, and no difference in prevalence has been reported based on race or ethnic group. Women outnumber men by two to one with CSU. CSU may be associated with infections and autoimmune disorders, such as thyroid diseases and collagen diseases (see section "Complications in the Clinical Features"). However, the prevalence of urticaria in patients with these diseases is low, and thus they are not generally thought of as risk factors. Genetic analysis of a white population indicated a strong association between HLA-DR4 and patients with CSU with functional autoantibodies against IgE or FcεRI.[152] Cholinergic urticaria is often complicated by atopic dermatitis.[60] Urticaria mediated by an IgE mechanism, especially those caused by latex allergy and OAS, may be associated with an atopic diathesis. Health care workers, individuals with atopic dermatitis, and patients with spina bifida have a higher risk of developing latex allergy than other people.[153]

DIAGNOSIS

A characteristic feature of urticaria is the transient nature of individual eruptions. Therefore, the diagnosis of urticaria itself is not difficult. However, the diagnosis of subtypes of urticaria is necessary for proper management in individual patients. Laboratory tests and provocation tests should be performed based on careful history taking and inspection. Extensive laboratory investigations add little to making a final diagnosis.[154] The overall diagnostic algorithm recommended by the EAACI guidelines[1] is shown in Fig. 41-5.

HISTORY TAKING

A thorough and comprehensive history is essential for diagnosis and the elucidation of causative or aggravating factors. Because clinical examination findings for urticaria are highly variable and depend on the subtypes of urticaria, it is most important to narrow down the clinical diagnosis based on the history and physical examination before laboratory testing. Flares in disease activity during the evening to early morning is not specific but is a common feature of spontaneous urticaria. Wheals of inducible urticaria do not usually last for more than 4 hours, except for those of DPU. In some types of physical urticaria such as delayed dermographism[43] and delayed cold urticaria,[46] wheals may occur several hours after the stimuli, but the wheal does not last for long. Triggers; aggravating factors, if any; and the shape, size, and duration of

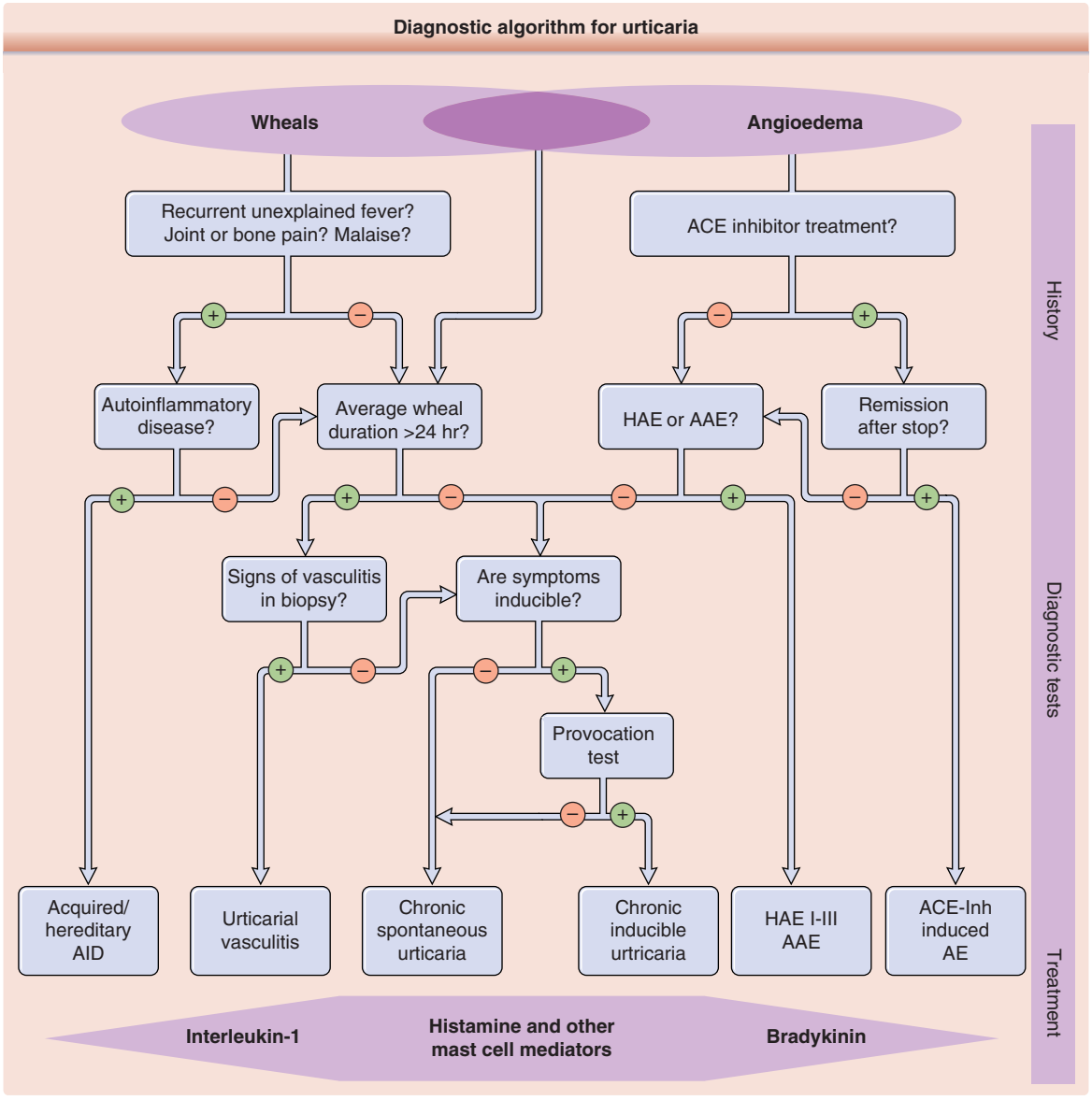

Figure 41-5 Diagnostic algorithm for urticaria. AAE, acquired angioedema due to C1-inhibitor deficiency; ACE-Inh, angiotensin-converting enzyme inhibitor; AE, angioedema; AID, auto-inflammatory disease; HAE, hereditary angioedema. (From Zuberbier T, Aberer W, Asero R, et al. The EAACI/GA(2) LEN/EDF/WAO Guideline for the definition, classification, diagnosis, and management of urticaria: the 2013 revision and update. *Allergy*. 2014;69:868-887, with permission. Copyright © 2014 John Wiley & Sons.)

individual wheals helps in diagnosing the subtype of urticaria (see section "Cutaneous Findings in the Clinical Features"). Urticarial vasculitis should be ruled out if individual wheals last for 24 hours or longer, especially with purpura. Mast cell–mediated angioedema (ie, non–bradykinin-mediated type) does not usually occur in the larynx. Bradykinin-mediated angioedema does not accompany superficial wheals.

LABORATORY TESTING

No routine laboratory testing is necessary or recommended for acute spontaneous urticaria. If a patient's history strongly suggests an allergic mechanism, prick tests and measurement of antigen-specific IgE are recommended. For CSU, a complete blood count, erythrocyte sedimentation rate, or C-reactive protein (CRP) is recommended. For further investigation, an extended diagnostic workup such as examination for *Helicobacter pylori*, Type I allergy, autoantibodies, and thyroid hormone may be undertaken. It is important, however, to note that the detection of a specific disorder may not always lead to an improvement in the symptoms of urticaria. Potential blood biomarkers in CSU to distinguish patients and control participants are D-dimer, CRP, matrix metalloproteinase-9, mean platelet volume (MPV), factor VIIa, prothrombin fragment 1+2 (PF1+2), tumor necrosis factor (TNF), dehydroepiandrosterone sulphate, and vitamin D.[155] Biomarkers reflecting disease severity in CSU are FDP, D-dimer, F1+2, CRP, interleukin-6 (IL-6), and MPV.[110,155]

Several factors, diseases, and conditions have been reported as underlying causes of urticaria. However, a systematic review of the laboratory investigations for chronic urticaria revealed that the number of diagnoses identified varied from 1% to 84% and was not related to the number of laboratory tests performed.[156] Therefore, extensive workups are not recommended for routine screening of the causes of urticarias unless suggested by the medical history or physical examination.[1] The recommended diagnostic tests corresponding to each urticaria subtype are summarized in Table 41-1.

DIAGNOSIS OF URTICARIA SUBTYPES

After thorough history taking and careful skin inspection, the following diagnostic tests should be considered based on tentative clinical diagnosis of urticaria subtype (see Table 41-1).

SPONTANEOUS URTICARIA

The diagnosis of spontaneous urticaria is made based on history and skin inspection. In addition to the spontaneous appearance of wheals of characteristic shape, diurnal variation and a long-lasting course of individual wheals may help make this diagnosis. For acute spontaneous urticaria, no routine laboratory tests are recommended, but the diseases and reactions listed in Table 41-4 should be differentiated. The presence of extracutaneous signs and symptoms and long-lasting eruptions, especially with purpura or epidermal change, such as dryness and desquamation, are important signs of different or complicated diseases. For such eruptions, a skin biopsy should help solidify the diagnosis.

The presence of IgG autoantibodies against IgE or FcεRI should be demonstrated by a histamine release assay using the patient's serum and basophils from healthy donors. This test may reveal the specificity of the autoantibodies against IgE, FcεRI, and degrees of their dependence on or competition with IgE for histamine release. However, this assay is somewhat cumbersome and requires special equipment, which has therefore limited its application. A solid phase assay, such as enzyme-linked immunosorbent assay, is relatively easy and quantitative but not specific.[79] Alternatively, skin reactions evoked by ASST[81] have been widely used as a screening test because of their relative simplicity and high sensitivity. In ASST, 0.05 mL of autologous serum is intradermally injected on the volar forearm skin along with normal saline and 10 μg/mL of histamine as the negative and positive controls, respectively.

TABLE 41-4
Differential Diagnosis of Urticaria

Wheal-like Eruption
1. Insect bites
2. Erythema multiforme
3. Erythema nodosum
4. Drug eruptions
5. Adult-onset Still disease
6. Shiitake dermatitis (resembling dermographic urticaria)
7. Maculopapular cutaneous mastocytosis (urticaria pigmentosa)
8. Urticarial vasculitis
9. Cryopyrin-associated periodic syndromes
10. Schnitzler syndrome
11. Polymorphic eruption of pregnancy

Angioedema-like Eruption
1. Insect bites
2. Cellulitis
3. Erysipelas
4. Episodic angioedema with eosinophilia
5. Bradykinin-mediated angioedema (eg, HAE)
6. Well's syndrome
7. Cheilitis granulomatosa
8. Granulomatous blepharitis

HAE, hereditary angioedema.

Data from Zuberbier T, et al. *Allergy* 2014;69:868-87; Bernstein JA, Lang DM, Khan DA, et al. The diagnosis and management of acute and chronic urticaria: 2014 update. *J Allergy Clin Immunol*. 2014;133(5):1270-1277; and Hide M, et al. *Nihon Hifukagakkai Zasshi* 2011;121:1339-88.

SYMPTOMATIC DERMOGRAPHISM (MECHANICAL URTICARIA)

For the diagnosis of symptomatic dermographism, several instruments have been developed and used to determine the threshold of individual patients. The forearm is more suitable for this test than the abdomen, back, or pretibial areas. The result is considered positive if the patient shows a wheal and reports itching at the site of provocation at 36 g/mm^2 or less. A wheal response without itching on provocation at 60 g/mm^2 or higher indicates the less clinically significant simple dermographism.[32] Reactions of this subtype of urticaria and other inducible urticarias, except for DPU, should be evaluated 5 to 10 minutes after testing.

COLD CONTACT URTICARIA

Cold provocation is performed by applying a wrapped ice cube or cold water for 5 minutes. In this way, the threshold duration of cold application can be determined. The use of a thermoelectric element (*TempTest*)[157] can be used to determine the threshold by temperature.[32] These tests induce wheal formation in cold contact urticaria but not for systemic cold urticaria, in which patients develop widespread wheals in response to cooling of the core body temperature or to cold wind.[47,49]

Systemic cold urticaria should be differentiated from cold contact urticaria because it may be a manifestation of autoinflammatory disease (familial cold urticaria; see Cold Urticaria in section "Clinical Features").

HEAT URTICARIA

Provocation of heat contact urticaria is performed by applying hot metal, water, or a glass cylinder filled with hot water at 45°C to the skin of the volar forearm.

The *TempTest*[157] used for cold contact urticaria may also be used for this type of urticaria. Cholinergic urticaria, solar urticaria, and aquagenic urticaria, which may also be associated with high temperatures or hot water, should be differentiated.

SOLAR URTICARIA

Solar urticaria should be differentiated from polymorphic light eruption. A provocation test for solar urticaria should be done on the buttock skin, but parts of the trunk that are usually covered by clothes can also be tested. The light source may be sunlight or a slide projector from a distance of 10 cm with or without filters or a monochromator (ultraviolet [UV] A or B, or visible light).[32]

DELAYED PRESSURE URTICARIA

Provocation may be performed by suspending a 7-kg weight on a 3-cm shoulder strap for 15 minutes or applying rods supported in a frame to the back, thighs, or forearm. Unlike the other inducible urticarias, the skin reaction should occur after a latent period, typically 2 to 4 hours after the pressure has been applied. Skin biopsies reveal an inflammatory infiltrate with prominent eosinophils but no vasculitis.[32]

VIBRATORY URTICARIA AND ANGIOEDEMA

The forearms are held on a flat plate placed on a vortex mixer that runs at between 780 and 1380 rpm for 10 minutes. The site of application should be assessed for swelling 10 minutes after testing.[32]

AQUAGENIC URTICARIA

Provocation is performed by attaching wet clothes at body temperature for 20 minutes. Wiping the test area with an organic solvent and challenging with saline instead of tap water may increase the reactivity.[1,32,158]

CHOLINERGIC URTICARIA

The diagnosis is established by an appropriate provocation test for the patient's age and general condition (eg, on a treadmill or stationary bicycle). To differentiate from exercise-induced anaphylaxis, a passive warming test should be done, recording core body temperature to achieve an increase of 1.0°C or more. Skin testing with intradermal injection of 0.1 mL of acetylcholine at 100 µg/mL may reinforce the diagnosis of cholinergic urticaria. The test result should be considered positive if the test site shows satellite wheals around the injection site. The specificity of this test seems to be high, but the sensitivity is approximately 30% to 50%.[32]

CONTACT URTICARIA

For the diagnosis of contact urticaria, the suspected substance is applied in its original form or as an extract on a normal looking area of the volar forearm or the upper back for 15 to 20 minutes. If this test result is negative, occlusive application is applied followed by a prick test. For patients with a history of severe symptoms, tests should be started with sufficiently diluted suspected substances. *In vitro* tests may also be used for contact urticaria from Type I allergy, such as latex allergy.[32]

URTICARIAL VASCULITIS

Urticaria-like eruptions that last for longer than 24 hours should be differentiated from urticarial vasculitis. Clinical features such as fevers, malaise, arthralgia, uveitis, diffuse glomerulonephritis, and obstructive and restrictive pulmonary disease may be diagnostically helpful, but histologic examination of a skin biopsy is essential for confirmation of the diagnosis.[67,159]

ANGIOEDEMA

Angioedema is diagnosed mostly by its clinical features, including localized mucosal or deep skin edema that is nonpitting and lasts for hours to a few days. If angioedema is induced by specific stimuli that are also known to induce superficial wheals or occurs together with wheals, it is likely mast cell mediated and is classified as a subtype of urticaria (see Table 41-1). If angioedema occurs spontaneously without wheals, a bradykinin-mediated mechanism should be carefully differentiated. Whereas mast cell–mediated spontaneous angioedema can be severe but is mostly nonlethal, bradykinin-mediated angioedema can be lethal.[143] The mechanisms of bradykinin production and degradation with related molecules are shown in Fig. 41-4.

Hereditary Angioedema: HAE is classified into three subtypes based on the condition of C1-INH.[143,160] Patients with type I lack C1-INH protein, but those with type II lack activity of C1-INH because of genetic point mutations. Type III, also called as HAE with normal C1-INH, is a rare subtype of HAE. Type III develops mostly in females, and a gain-of-function mutation of factor XII may be identified in some patients. Recently, new genetic mutations, one in an angiopoietin-1 gene and another in a plasminogen gene, were identified in families with type III HAE.[161,162] Whereas the levels of C1-INH activity and C4 are decreased in both type I and type II HAE, C1-INH protein concentration is low only in type I HAE. During attacks of HAE, coagulation markers, such as D-dimer, FDP and PF1+2 may increase.[163,164] Prodromal symptoms, such as erythema marginatum, may precede HAE attacks in up to 50% of patients.

Acquired Angioedema: Bradykinin-mediated angioedema may develop either by overconsumption of C1-INH caused by myeloproliferative diseases

or because of the presence of autoantibodies against C1-INH. In the case of overconsumption of C1-INH, the level of C1q is decreased, as well as those of C1-INH and C4.

Angiotensin-Converting Enzyme Inhibitor–Induced Angioedema: ACE is a dipeptidylcarboxypeptidase that converts angiotensin I to angiotensin II and cleaves bradykinin. Therefore, its inhibitor, ACE inhibitor, used for the treatment of hypertension, inhibits degradation of bradykinin.

AUTOINFLAMMATORY SYNDROME

Autoinflammatory diseases are a diverse group of inherited conditions characterized by systemic inflammation in the absence of infection and are accompanied by a range of organ-specific manifestations.[165] Two of them, Schnitzler syndrome and cryopyrin-associated periodical syndrome (CAPS), are known to include urticaria-like symptoms.

Schnitzler Syndrome: Schnitzler syndrome is characterized by urticaria-like eruptions and monoclonal IgM or possibly IgG gammopathy accompanied by systemic symptoms such as fever and bone and muscle pain.[166,167] Its histology resembles an urticarial vasculitis or neutrophilic urticaria.

Cryopyrin Associated Periodical Syndrome: Familial cold-autoinflammatory syndrome, Muckle-Wells syndrome, and chronic infantile neurologic cutaneous articular syndrome may include an urticaria-like eruption. The eruption may be induced by exposure to cold but may also develop spontaneously and does not usually cause pruritus. Patients may develop periodic fever, arthralgia, amyloidosis, and nerve deafness. The common and crucial cause of these syndromes has been identified as gain-of-function mutations in *NLRP3 (CIASI)*, resulting in overproduction of IL-1β.[168] Skin biopsy demonstrates neutrophil-dominant cell infiltration, but gene analysis is most definitive for making the diagnosis.

URTICARIA AND ANAPHYLAXIS INDUCED BY EXERCISE

Exercise may induce urticaria in patients with cholinergic urticaria and in patients with exercise-induced anaphylaxis. Some patients may develop urticaria and anaphylaxis regardless of food intake (exercise-induced anaphylaxis [EIA]), but others develop symptoms only when they exercise after eating certain foods (FDEIA). The demonstration of specific food allergen-reactive IgE in the serum may help but may not be sufficient for making the diagnosis of FDIEA.[146,147] The presence of anti–ω5-gliadine IgE in adults has been reported to be an exceptionally good marker for FDEIA caused by wheat in terms of both sensitivity and specificity.[169] An exercise challenge test is typically performed according to the protocol of Bruce and colleagues.[170] The sensitivity of provocation testing for FDEIA was reported to be up to 70%.[169]

EVALUATION OF DISEASE CONDITIONS

Urticaria and underlying conditions in patients with urticaria should be evaluated in both specific and comprehensive ways.

DISEASE SEVERITY

Disease severity of inducible urticarias may be evaluated according to the threshold for eliciting factors (see Table 41-1). For spontaneous urticaria and angioedema, questionnaire-based scores may be used. The urticaria activity score over 7 consecutive days (UAS7) is a unified and simple scoring system that records daily wheals and itching and has been validated in comparison with the Dermatology Life Quality Index (DLQI).[171] Disease activity of angioedema may be evaluated by a 4-week-long record of edema in terms of frequency, duration, subjective sensations, and disability of patients (Angioedema Activity Score [AAS]).[172]

For CSU, coagulation and fibrinolysis markers, such as D-dimer, FDP, PF1+2, and CRP, have been reported to reflect disease severity or activity (see Coagulation System in the section "Etiology and Pathogenesis"), but their sensitivities are low.[173] Serum levels of proinflammatory cytokines, such as IL-6, TNF, and IL-23, may also reflect disease activity in certain patients but are of doubtful usefulness.[32,174] Peripheral blood basopenia and low release of histamine from basophils may also be associated with disease activity,[175,176] but the value of these markers is at present confined to the research laboratory.[177]

QUALITY OF LIFE

CSU has a high overall impact on QOL as compared with other common dermatologic conditions,[178-180] The QOL of patients with superficial urticaria and that of patients with angioedema may be evaluated using the Chronic Urticaria Quality of Life Questionnaire (CU-Q2oL)[181] and Angioedema Quality of Life Questionnaire (AE-QoL),[182] respectively.[1]

CONTROL STATUS

The tools mentioned earlier—UAS-7, AAS, CU-Q2oL, and AE-QoL—may not adequately cover conditions of inducible urticarias and angioedema. More recently, an easy and comprehensive method of evaluation for all kinds of urticaria and angioedema has been developed. It is called the Urticaria Control Test (UCT), and it may be applied to all kinds of urticaria and angioedema.[183] The short version of the UCT asks only four retrospective questions about the patient's condition over the previous 4 weeks. These instruments have been translated and validated in many languages. The AAS, AE-QoL, and UCT are now available in various languages from Moxie GmbH, Berlin, Germany.[184]

PATHOLOGY

Pathological findings in urticaria consist of edema in the dermis and perivascular and interstitial infiltration of inflammatory cells. Inflammatory cells usually consist of lymphocytes, eosinophils, and neutrophils. Commonly, lymphocytes are dominant in the perivascular area, but eosinophils and neutrophils tend to have an interstitial distribution. A few reports revealed an increase in mast cells in perivascular areas and the interstitium of lesions,[185-187] but others did not.[188] The presence of basophils has been demonstrated with specific antibodies.[189] The degree of infiltration of these inflammatory cells varies according to subtypes of urticaria, individual variability, and the time from the onset of wheals (Figs. 41-6A to 41-6C). Detailed studies of infiltrated lymphocytes revealed that they are both Th_1 and Th_2, or Th_0 because they express IL-4, IL-5, and interferon (IFN)-γ.[190] Neutrophils and eosinophils exist in dermal capillaries, and this is considered as an early change in numerous inflammatory skin diseases, including urticarias. Infiltration of neutrophils is prominent especially in acute urticaria and physical urticarias. Urticaria or urticaria-like eruptions that persist for longer than a day and involve predominantly neutrophilic infiltration without apparent vasculitis may also be called neutrophilic urticaria, neutrophilic urticarial dermatosis, or urticaria-like neutrophilic dermatosis.[191-193] Similar changes may be observed in the skin lesions of CAPS and Schnitzler syndrome. Eosinophils may play a more important role than suggested by hematoxylin and eosin staining because extracellular eosinophil major basic protein is frequently

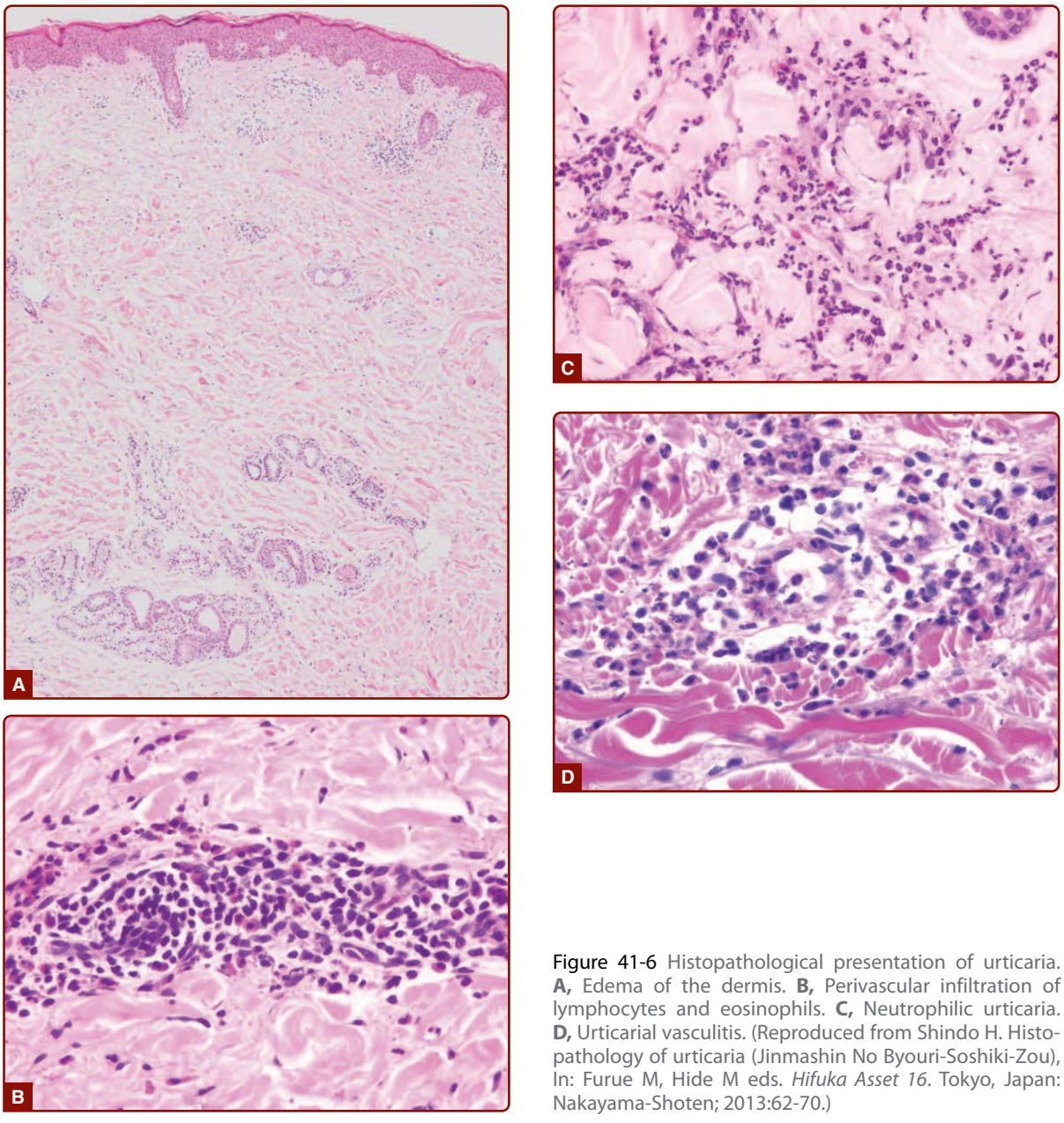

Figure 41-6 Histopathological presentation of urticaria. **A,** Edema of the dermis. **B,** Perivascular infiltration of lymphocytes and eosinophils. **C,** Neutrophilic urticaria. **D,** Urticarial vasculitis. (Reproduced from Shindo H. Histopathology of urticaria (Jinmashin No Byouri-Soshiki-Zou), In: Furue M, Hide M eds. *Hifuka Asset 16*. Tokyo, Japan: Nakayama-Shoten; 2013:62-70.)

deposited in spontaneous wheals.[194] Moderately dense infiltrates of eosinophils were observed in DPU.[51] These cellular changes correlated with moderate upregulation of the vascular endothelial adhesion molecules E-selectin, intercellular adhesion molecules 1, and vascular cell adhesion molecule 1 on perivascular cells.[195]

Urticaria with histologic evidence of vasculitis (*venulitis*) is defined as urticarial vasculitis (Fig. 41-6D). However, in clinical practice, it may sometimes be difficult to differentiate lesions of urticarial vasculitis from those of spontaneous urticaria when all histopathological features of vasculitis, including endothelial cell damage, fibrin deposition, leukocytoclasis, and erythrocyte extravasation, are not present in the skin specimen.[68] Moreover, a continuum of histologic changes between urticaria and urticarial vasculitis has been recognized in a series of patients with intermediate histologic features.[196,197] Some authors suggest that leukocytoclasis or fibrin deposition with or without erythrocyte extravasation may be sufficient for a diagnosis in difficult cases.[68]

IMAGING

Imaging examinations such as ultrasound, computed tomography (CT), or magnetic resonance imaging (MRI) are not required for ordinary urticarias. In cases of edema developing in pharyngeal and laryngeal areas or in the gastrointestinal tract, especially caused by bradykinin-mediated angioedemas, imaging tests might be useful or even essential. Patients with HAE may present with episodic swelling in various body parts, such as the face, neck, bowel, genitals, and extremities. Airway obstruction caused by edema of the larynx, oropharynx, and prevertebral soft tissue may cause suffocation, and this can be detected by endoscopy, radiographs, CT scans, and MRI examinations.[36,198] Patients may also have acute abdominal pain caused by swelling of the gastrointestinal tract. Imaging in such situations may be helpful to avoid unnecessary surgical interventions.[198]

DIAGNOSTIC ALGORITHM

A diagnosis of urticaria or angioedema (or both) should be made based on careful observation of the skin and history taking followed by clinical examination to confirm the diagnosis and evaluate disease severity. It is recommended not to perform extensive screening or workup without a known clinical diagnosis of an urticaria subtype.[1] The algorithm recommended by EAACI guidelines is shown in Fig. 41-5.

DIFFERENTIAL DIAGNOSIS

The diagnosis of urticaria is not difficult in most cases if suddenly appearing and transiently disappearing eruptions are confirmed by patient's history and clinical observations. Diseases that may manifest similar symptoms to urticaria and angioedema are listed in Table 41-4. Diseases that include wheals or angioedema should be differentiated by the presence of nonurticarial, mostly extracutaneous symptoms, such as fever and arthralgia.

CLINICAL COURSE AND PROGNOSIS

A study showed that most patients (85%) who had an acute spontaneous urticaria and began treatment within 1 week of disease onset improved shortly afterward. However, approximately 7% of this cohort continued to have symptoms for more than 1 year. Prolongation of disease activity tends to be seen among patients who required other medications in addition to a standard dose of antihistamine.[199] Other studies, albeit from specialized centers, indicate that most patients have CSU for more than 1 year.[14-18,22,200,201] Moreover, a considerable number of patients even seem to be affected for longer than 5 years. In some rare cases, urticaria may even last for up to 50 years.[200] A retrospective study using Kaplan-Meier methods of patients with CSU who visited a tertiary medical center revealed the estimated improved rates at 12 months, 24 months, and 60 months as 36.6%, 51.2%, and 66.1%, respectively.[201]

However, the reported time course is highly variable among studies. Reported remission rates at 1 year ranged from 20% to 80%. Among these studies, four factors appear to be associated with prolonged prognosis, namely, (1) initial disease severity, (2) presence of angioedema, (3) combination of CSU and physical urticaria(s), and (4) autoreactivity (positive ASST result).[20] A recent retrospective study showed that patients with CSU and positive ASST results responded more slowly to omalizumab than those with negative ASST results.[83]

MANAGEMENT

INTERVENTIONS

The treatment of urticaria and angioedema consists of two basic approaches. One is the identification and removal of the cause or factors that aggravate the condition. Another is the continuous use of antisymptomatic treatment with medications. For inducible urticaria, the avoidance of stimuli that induce symptoms is important, but in certain subtypes (solar urticaria, heat contact urticaria, cold contact urticaria, cholinergic urticaria, and urticaria induced by type I food allergy), repetitive exposure to slight stimuli may rather reduce the sensitivity of the patients (hardening or tolerance). Aggravating factors, if applicable for individual cases, should be removed to the extent possible (see section "Etiology and Pathogenesis" and Table 41-3). The algorithm of pharmaceutical treatment recommended by current guidelines[1] is essentially the same for all subtypes

of chronic urticaria, except for bradykinin-mediated angioedema. In many cases of mast cell–mediated urticaria, especially in spontaneous urticaria, symptoms can be controlled to acceptable levels without identification of the cause. On the other hand, antihistamines, corticosteroids, and adrenaline are all ineffective for bradykinin-mediated angioedema.

MEDICATIONS

Medication should be taken continuously rather than an on-demand basis for both spontaneous urticaria and inducible urticaria patients who develop symptoms daily or almost daily.[1] However, if symptoms develop only occasionally, a schedule of medication use may be determined on a case-by-case basis. For HAE, three aims of medications should be considered based on the severity and frequency of the symptoms: on-demand therapy for emerging symptoms, short-term prophylaxis, and long-term prophylaxis.[143,160]

FIRST-LINE THERAPY

The second-generation nonsedating antihistamines are the mainstay of treatment for all kinds of mast cell–mediated urticaria. Generally, first-generation sedating antihistamines are no longer recommended. Although they appear to help with sleep at night, there may be carry-over effects of sedation in the morning and may cause paradoxical excitation or possibly epilepsy in children.

SECOND-LINE THERAPY

For intractable cases resistant to standard doses of antihistamines, increased dosing of antihistamines up to fourfold is recommended in EAACI guideline[202] and practice parameters by the American Academy of Allergy, Asthma and Immunology (AAAAI) and the American College of Allergy, Asthma and Immunology (ACAAI)[142] (American consensus document). Numerous reports have demonstrated the efficacy of high-dose antihistamines. Recently, a meta-analysis of using high dose antihistamines showed that this significantly improved control of pruritus but not wheal number.[203]

THIRD- AND FOURTH-LINE THERAPY

For cases in which high-dose antihistamines fail to achieve enough improvement, several additional therapies are recommended. The guideline published by the British Society for Allergy and Clinical Immunology (BSACI)[202] and the American consensus document[142] recommend adding antileukotrienes before the use of omalizumab and cyclosporine. However, EAACI guideline published in 2018 recommend adding omalizumab first as the third line therapy.[1] Systemic corticosteroids are recommended only to be used in limited circumstances, especially for severe symptoms in acute urticaria and acute aggravation of CSU. It should be noted that continuous use of corticosteroids (longer than 10 days) is not recommended because of the risk of side effects.[1,142,203] The treatment algorithms published in EAACI guidelines[1] and the American consensus document[142] are shown in Fig. 41-7.

The efficacy and safety of omalizumab, anti-IgE antibody, for the treatment of urticaria has been well studied, and it is now approved for the treatment of CSU in many countries.[204-206] The proposed mechanism of action of omalizumab is shown in Fig. 41-3. A recent meta-analysis of randomized controlled studies showed that a dosage of 300 mg/month is recommended for intractable CSU regardless of the levels of serum total IgE.[204] In theory, omalizumab inhibits circulating IgE and consequently decreases the number of FcεRI on mast cells and basophils. Although it takes 2 months or longer for omalizumab to decrease the number of cell surface FcεRI, the clinical effect of omalizumab on CSU may become apparent within 1 week.[100] Moreover, omalizumab is effective for virtually all subtypes of urticaria mediated by mast cells, including DPU and urticarial vasculitis,[99,207] although such usage is off label. A number of possible mechanisms have been hypothesized, but none of them so far can fully explain its effect on urticaria.[100]

EXCEPTIONAL CASES AND OTHER MEDICATIONS IN THE TREATMENT OF URTICARIA

In most cases of DPU and urticarial vasculitis, antihistamines are not effective. Systemic steroids or other immunosuppressive or modulatory agents may be necessary to suppress symptoms.[208] As supplementary or alternative treatments, the following may also be used in combination with antihistamines for refractory cases: histamine H2-blockers, dapsone (diaphenylsulfone, DDS), antifibrinolytics (tranexamic acid or ε-aminocaproic acid) especially for patients with angioedema, methotrexate, tacrolimus, hydroxychloroquine, intravenous immunoglobulin therapy, plasmapheresis, and narrow-band UVB.[1,209] However, evidence supporting the use of these medications is still weak, and reports are anecdotal. Moreover, most drugs have the potential for causing serious side effects. Most important, none of the pharmaceutical treatments mentioned has been proven to modify the natural course of urticaria in terms of achieving a cure. Therefore, it is important to consider a balance between the burden of symptoms and that of treatment.

Treatment of bradykinin-mediated HAE, as recommended in various guidelines and consensus documents,[143,160] is illustrated in Fig. 41-4. Icatibant, ecallantide, and purified or recombinant C1-INH are used for acute attacks. Purified or recombinant C1-INH, lanadelumab, and BCX7653 are used or are under development for use as prophylaxis. A few studies have reported the efficacy of icatibant for acute

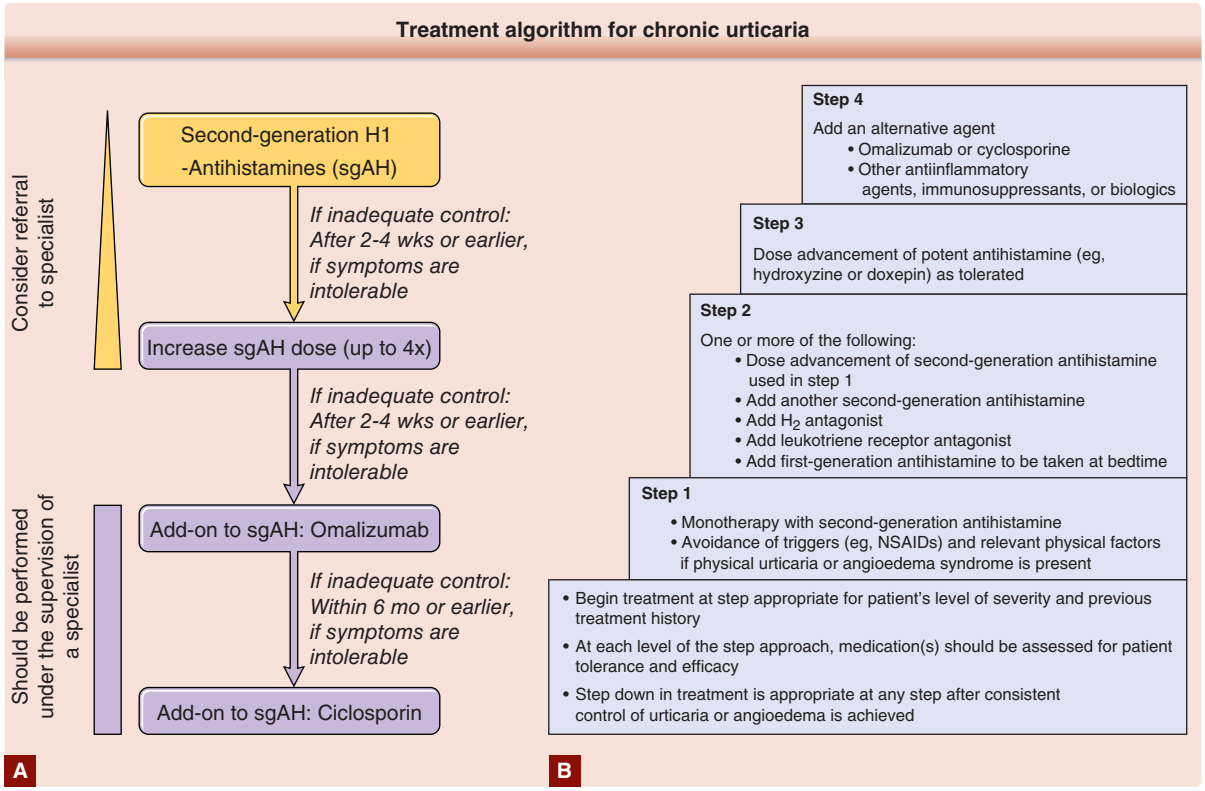

Figure 41-7 Treatment algorithm for chronic urticaria recommended by the European Academy of Allergy and Clinical Immunology/Global Allergy and Asthma European Network/European Dermatology Forum/World Allergy Organization (**A**) and that for chronic urticaria by the American Academy of Allergy, Asthma and Immunology and the American College of Allergy, Asthma and Immunology (**B**). NSAID, nonsteroidal antiinflammatory drug. (Image **A,** from Zuberbier T, Aberer W, Asero R, et al. The EAACI/GA(2) LEN/EDF/WAO Guideline for the definition, classification, diagnosis, and management of urticaria: the 2017 revision and update. *Allergy*. 2018;73:1393-1414, with permission. Copyright © 2018 EAACI and John Wiley and Sons. Image **B,** From Bernstein JA, Lang DM, Khan DA, et al. The diagnosis and management of acute and chronic urticaria: 2014 update. *J Allergy Clin Immunol*. 2014;133:1270-1277, with permission. Copyright © American Academy of Allergy, Asthma & Immunology.)

attacks of angioedema caused by ACE inhibitors,[210,211] although one study contradicted these findings.[212]

TREATMENT IN PEDIATRIC PATIENTS

The principle of treatment for children with urticaria is the same as for adults.[1] Dosing should follow the relevant manufacturer's recommendations.

TREATMENT IN PREGNANT AND LACTATING WOMEN

Use of any systemic treatment should generally be avoided in pregnant women, especially in the first trimester. Moreover, antihistamines cross the placenta. On the other hand, there is no reliable evidence that the medications listed in the algorithm of EAACI guideline are teratogenic. Thus, the same treatment principles and algorithm are suggested for both pregnant and lactating women with urticaria.[1] Among antihistamines, chlorphenamine is often chosen based on its long availability and safety record.[213] Current guidelines on urticaria support the use of cetirizine and loratadine desirably after the first trimester of pregnancy if the benefits of an antihistamine are considered to outweigh any risks of administration for an individual patient.[1,202]

COUNSELING

No particular methods have been established for urticaria, but patients with CSU may have substantial impairment of their QOL, as much as with ischemic heart disease.[214] Patients with hereditary diseases, such as HAE and autoinflammatory syndromes, should be offered qualified counseling as necessary.

TREATMENT ALGORITHM

The treatment algorithm recommended in EAACI guideline and the American consensus document are shown in Fig. 41-7.

PREVENTION AND SCREENING

There are no measures for preventing or screening for the development of urticaria. On the other hand, all family members of patients with HAE type I and type II who are older than 1 year old are

recommended to undergo screening for the diagnosis of HAE. A case of a 9-year-old boy who died from the first attack of HAE has been reported.[215] Early diagnosis and preparation for attacks should reduce the risk.

REFERENCES

1. Zuberbier T, Aberer W, Asero R, et al. The EAACI/GA(2) LEN/EDF/WAO Guideline for the definition, classification, diagnosis, and management of urticaria: the 2017 revision and update. *Allergy.* 2018;73(7):1393-1414.
2. Czarnetzki BM. History of urticaria. *Urticaria*. 1986:1-4.
3. Cummings AJ, Olsen M. Mechanism of action of stinging nettles. *Wilderness Environ Med.* 2011;22(2):136-139.
4. Beaven MA. Our perception of the mast cell from Paul Ehrlich to now. *Eur J Immunol.* 2009;39(1):11-25.
5. Dale HH, Laidlaw PP. The physiological action of β-iminazolylethylamine. *J Physiol.* 1910;41(5):318-344.
6. Eppinger H. Über eine eigentümliche Hautkrankheit, hervorgerufen durch Ergamin. *Wien Med Wschr.* 1913;63:1413-1416.
7. Bovet D. Introduction to antihistamine agents and antergan derivatives. 1950. *Ann N Y Acad Sci*. 50(9):1089-1126.
8. Riley JF, West GB. The presence of histamine in tissue mast cells. *J Physiol.* 1953;120(4):528-537.
9. Ishizaka K, Ishizaka T. Identification of IgE. *J Allergy Clin Immunol.* 2016;137(6):1646-1650.
10. Bakke P, Gulsvik A, Eide GE. Hay fever, eczema and urticaria in southwest Norway. Lifetime prevalences and association with sex, age, smoking habits, occupational airborne exposures and respiratory symptoms. *Allergy.* 1990;45(7):515-522.
11. Herrmann-Kunz E. Häufigkeit allergischer Krankheiten in Ost- und Westdeutschland. 1999;61(2):S100-S105.
12. Zuberbier T, Balke M, Worm M, et al. Epidemiology of urticaria: a representative cross-sectional population survey. *Clin Exp Dermatol.* 2010;35(8):869-873.
13. Hellgren L. The prevalence of urticaria in the total population. *Acta Allergol.* 1972;27(3):236-240.
14. Gaig P, Olona M, Munoz Lejarazu D, et al. Epidemiology of urticaria in Spain. *J Investig Allergol Clin Immunol.* 2004;14(3):214-220.
15. van der Valk PG, Moret G, Kiemeney LA. The natural history of chronic urticaria and angioedema in patients visiting a tertiary referral centre. *Br J Dermatol.* 2002;146(1):110-113.
16. Kozel MM, Mekkes JR, Bossuyt PM, et al. Natural course of physical and chronic urticaria and angioedema in 220 patients. *J Am Acad Dermatol.* 2001;45(3):387-391.
17. Kulthanan K, Jiamton S, Thumpimukvatana N, et al. Chronic idiopathic urticaria: prevalence and clinical course. *J Dermatol.* 2007;34(5):294-301.
18. Humphreys F, Hunter JA. The characteristics of urticaria in 390 patients. *Br J Dermatol.* 1998;138(4):635-638.
19. Tanaka T, Kameyoshi Y, Hide M. [Analysis of the prevalence of subtypes of urticaria and angioedema]. *Arerugi.* 2006;55(2):134-139.
20. Maurer M, Weller K, Bindslev-Jensen C, et al. Unmet clinical needs in chronic spontaneous urticaria. A GA(2)LEN task force report. *Allergy.* 2011;66(3):317-330.
21. Quaranta JH, Rohr AS, Rachelefsky CS, et al. The natural history and response to therapy of chronic urticaria and angioedema. *Ann Allergy.* 1989;62(5):421-424.
22. Juhlin L. Recurrent urticaria: clinical investigation of 330 patients. *Br J Dermatol.* 1981;104(4):369-381.
23. Steinhardt MJ. Urticaria and angioedema—statistical survey of five hundred cases. *Ann Allergy.* 1954;12(6):659-670.
24. Sabroe RA, Seed PT, Francis DM, et al. Chronic idiopathic urticaria: comparison of the clinical features of patients with and without anti-FcεRI or anti-IgE autoantibodies. *J Am Acad Dermatol.* 1999;40(3):443-450.
25. Nettis E, Dambra P, D'Oronzio L. Reactivity to autologous serum skin test and clinical features in chronic idiopathic urticaria. *Clin Exp Dermatol.* 2002;27(1):29-31.
26. Caproni M, Volpi W, Giomi B. Chronic idiopathic and chronic autoimmune urticaria: clinical and immunopathological features of 68 subjects. *Acta Derm Venereol.* 2004;84(4):288-290.
27. Giménez-Arnau AM, Ferrer M, Peter HJ, et al. Urticaria crónica: estudio etiológico prospectivo e importancia del síndrome autoinmune. *Actas Dermosifiliogr.* 2004;95(9):560-566.
28. Asero R. Sex differences in the pathogenesis of chronic urticaria. *J Allergy Clin Immunol.* 2003;111(2):425-426.
29. Champion R, Roberts S, Carpenter R, Roger J. Urticaria and angioedema: a review of 554 patients. *Br J Dermatol.* 1969;81(8):588-597.
30. Henderson RL Jr, Fleischer AB Jr, Feldman SR. Allergists and dermatologists have far more expertise in caring for patients with urticaria than other specialists. *J Am Acad Dermatol.* 2000;43(6):1084-1091.
31. Ferrer M. Epidemiology, healthcare, resources, use and clinical features of different types of urticaria. *J Investig Allergol Clin Immunol.* 2009;19(suppl 2):21-26.
32. Hide M, Hiragun M, Hiragun T. Diagnostic tests for urticaria. *Immunol Allergy Clin North Am.* 2014;34(1):53-72.
33. Miyake M, Oiso N, Ishii K, et al. Angioedema associated with excessive sweating and sweat allergy. *J Dermatol.* 2017;44(4):e58-e59.
34. Washio K, Fukunaga A, Onodera M, et al. Clinical characteristics in cholinergic urticaria with palpebral angioedema: report of 15 cases. *J Dermatol Sci.* 2017;85(2):135-137.
35. Fukunaga A, Washio K, Hatakeyama M, et al. Cholinergic urticaria: epidemiology, physiopathology, new categorization, and management. *Clin Auton Res.* 2018;28(1):103-113.
36. Shibuya M, Takahashi N, Yabe M, et al. Hereditary angioedema as the cause of death from asphyxia: postmortem computed tomography study. *Allergol Int.* 2014;63(3):493-494.
37. Simons FE, Ardusso LR, Bilo MB, et al. World allergy organization guidelines for the assessment and management of anaphylaxis. *World Allergy Organ J.* 2011;4(2):13-37.
38. Pan XF, Gu JQ, Shan ZY. The prevalence of thyroid autoimmunity in patients with urticaria: a systematic review and meta-analysis. *Endocrine.* 2015;48(3):804-810.
39. Diaz-Angulo S, Lopez-Hoyos M, Munoz Cacho P, et al. Prevalence of thyroid autoimmunity in Spanish patients with chronic idiopathic urticaria: a case-control study involving 343 subjects. *J Eur Acad Dermatol Venereol.* 2016;30(4):692-693.

40. Altrichter S, Peter HJ, Pisarevskaja D, et al. IgE mediated autoallergy against thyroid peroxidase—a novel pathomechanism of chronic spontaneous urticaria? *PLoS One*. 2011;6(4):e14794.
41. Confino-Cohen R, Chodick G, Shalev V, et al. Chronic urticaria and autoimmunity: associations found in a large population study. *J Allergy Clin Immunol.* 2012; 129(5):1307-1313.
42. Baughman RD, Jillson OF. Seven specific types of urticaria. With special reference to delayed persistent dermographism. *Ann Allergy.* 1963;21:248-255.
43. Warin RP. Clinical observations on delayed pressure urticaria. *Br J Dermatol.* 1989;121(2):225-228.
44. Kaplan AP. Unusual cold-induced disorders: cold-dependent dermatographism and systemic cold urticaria. *J Allergy Clin Immunol.* 1984;73(4):453-456.
45. Lambiris A, Greaves MW. Dyspareunia and vulvodynia are probably common manifestations of factitious urticaria. *Br J Dermatol.* 1997;136(1):140-141.
46. Back O, Larsen A. Delayed cold urticaria. *Acta Derm Venereol.* 1978;58(4):369-371.
47. Kivity S, Schwartz Y, Wolf R, et al. Systemic cold-induced urticaria—clinical and laboratory characterization. *J Allergy Clin Immunol.* 1990;85(1 Pt 1):52-54.
48. Hoffman HM, Wanderer AA, Broide DH. Familial cold autoinflammatory syndrome: phenotype and genotype of an autosomal dominant periodic fever. *J Allergy Clin Immunol.* 2001;108(4):615-620.
49. Ombrello MJ, Remmers EF, Sun G, et al. Cold urticaria, immunodeficiency, and autoimmunity related to PLCG2 deletions. *N Engl J Med.* 2012;366(4):330-338.
50. Nettis E, Colanardi MC, Soccio AL, et al. Desloratadine in combination with montelukast suppresses the dermographometer challenge test papule, and is effective in the treatment of delayed pressure urticaria: a randomized, double-blind, placebo-controlled study. *Br J Dermatol.* 2006;155(6):1279-1282.
51. Morioke S, Takahagi S, Iwamoto K, et al. Pressure challenge test and histopathological inspections for 17 Japanese cases with clinically diagnosed delayed pressure urticaria. *Arch Dermatol Res.* 2010;302(8): 613-617.
52. Lawlor F, Black AK, Breathnach AS, et al. Vibratory angioedema: lesion induction, clinical features, laboratory and ultrastructural findings and response to therapy. *Br J Dermatol.* 1989;120(1):93-99.
53. Boyden SE, Desai A, Cruse G, et al. Vibratory urticaria associated with a missense variant in ADGRE2. *N Engl J Med.* 2016;374(7):656-663.
54. Heitkemper T, Hofmann T, Phan NQ, et al. Aquagenic pruritus: associated diseases and clinical pruritus characteristics. *J Dtsch Dermatol Ges.* 2010; 8(10):797-804.
55. Kaplan AP, Natbony SF, Tawil AP, et al. Exercise-induced anaphylaxis as a manifestation of cholinergic urticaria. *J Allergy Clin Immunol.* 1981;68(4):319-324.
56. Sheffer AL, Soter NA, McFadden ER Jr, et al. Exercise-induced anaphylaxis: a distinct form of physical allergy. *J Allergy Clin Immunol.* 1983;71(3):311-316.
57. Grant RT. Observation on urticaria provoked by emotion, by exercise and by warming the body. *Clin Sci.* 1936;2:253-272.
58. Miyake M, Oiso N, Ishii K, et al. Angioedema associated with excessive sweating and sweat allergy. *J Dermatol.* 2017;44(4):e58-e59.
59. Berth-Jones J, Graham-Brown RA. Cholinergic pruritus, erythema and urticaria: a disease spectrum responding to danazol. *Br J Dermatol.* 1989;121(2):235-237.
60. Takahagi S, Tanaka T, Ishii K, et al. Sweat antigen induces histamine release from basophils of patients with cholinergic urticaria associated with atopic diathesis. *Br J Dermatol.* 2009;160(2):426-428.
61. Hiragun M, Hiragun T, Ishii K, et al. Elevated serum IgE against MGL_1304 in patients with atopic dermatitis and cholinergic urticaria. *Allergol Int.* 2014; 63(1):83-93.
62. Hiragun T, Ishii K, Hiragun M, et al. Fungal protein MGL_1304 in sweat is an allergen for atopic dermatitis patients. *J Allergy Clin Immunol.* 2013;132(3): 608-615.e604.
63. Tokura Y. New etiology of cholinergic urticaria. *Curr Probl Dermatol.* 2016;51:94-100.
64. Kashyap RR, Kashyap RS. Oral allergy syndrome: an update for stomatologists. *J Allergy (Cairo).* 2015; 2015:543928.
65. Wisnieski JJ. Urticarial vasculitis. *Curr Opin Rheumatol.* 2000;12(1):24-31.
66. Grotz W, Baba HA, Becker JU, et al. Hypocomplementemic urticarial vasculitis syndrome: an interdisciplinary challenge. *Dtsch Arztebl Int.* 2009; 106(46):756-763.
67. Zuberbier T, Maurer M. Urticarial vasculitis and Schnitzler syndrome. *Immunol Allergy Clin North Am.* 2014;34(1):141-147.
68. Monroe EW. Urticarial vasculitis: an updated review. *J Am Acad Dermatol.* 1981;5(1):88-95.
69. Black AK. Urticarial vasculitis. *Clin Dermatol.* 1999; 17(5):565-569.
70. Takahagi S, Tanaka A, Iwamoto K, et al. Contact urticaria syndrome with IgE antibody against a cefotiam-unique structure, evoked by nonapparent exposure to cefotiam. *Clin Exp Dermatol.* 2017;42(5): 527-531.
71. Inomata N, Chin K, Nagashima M, et al. Late-onset anaphylaxis due to poly (gamma-glutamic acid) in the soup of commercial cold Chinese noodles in a patient with allergy to fermented soybeans (natto). *Allergol Int.* 2011;60(3):393-396.
72. Inomata N, Chin K, Aihara M. Anaphylaxis caused by ingesting jellyfish in a subject with fermented soybean allergy: possibility of epicutaneous sensitization to poly-gamma-glutamic acid by jellyfish stings. *J Dermatol.* 2014;41(8):752-753.
73. Nettis E, Pannofino A, D'Aprile C, et al. Clinical and aetiological aspects in urticaria and angio-oedema. *Br J Dermatol.* 2003;148(3):501-506.
74. Champion RH. A practical approach to the urticarial syndromes—a dermatologist's view. *Clin Exp Allergy.* 1990;20(2):221-224.
75. Leznoff A, Sussman GL. Syndrome of idiopathic chronic urticaria and angioedema with thyroid autoimmunity: a study of 90 patients. *J Allergy Clin Immunol.* 1989;84(1):66-71.
76. Grattan CE, Francis DM, Hide M, et al. Detection of circulating histamine releasing autoantibodies with functional properties of anti-IgE in chronic urticaria. *Clin Exp Allergy.* 1991;21(6): 695-704.
77. Hide M, Francis DM, Grattan CE, et al. Autoantibodies against the high-affinity IgE receptor as a cause of histamine release in chronic urticaria. *N Engl J Med.* 1993;328(22):1599-1604.
78. Kolkhir P, Church MK, Weller K, et al. Autoimmune chronic spontaneous urticaria: what we know and what we do not know. *J Allergy Clin Immunol.* 2017;139(6):1772-1781.e1771.

79. Kikuchi Y, Kaplan AP. Mechanisms of autoimmune activation of basophils in chronic urticaria. *J Allergy Clin Immunol.* 2001;107(6):1056-1062.
80. Ferrer M, Nakazawa K, Kaplan AP. Complement dependence of histamine release in chronic urticaria. *J Allergy Clin Immunol.* 1999;104(1):169-172.
81. Konstantinou GN, Asero R, Maurer M, et al. EAACI/GA(2)LEN task force consensus report: the autologous serum skin test in urticaria. *Allergy.* 2009;64(9):1256-1268.
82. Sanchez-Borges M, Caballero-Fonseca F, Capriles-Hulett A, et al. Factors linked to disease severity and time to remission in patients with chronic spontaneous urticaria. *J Eur Acad Dermatol Venereol.* 2017;31(6):964-971.
83. Gericke J, Metz M, Ohanyan T, et al. Serum autoreactivity predicts time to response to omalizumab therapy in chronic spontaneous urticaria. *J Allergy Clin Immunol.* 2017;139(3):1059-1061.e1051.
84. Sherman WB, Seebohm PM. Passive transfer of cold urticaria. *J Allergy.* 1950;21(5):414-424.
85. Samsoe-Jensen T. Cold urticaria; report of a case: passive transfer and in vitro experiments with skin cells. *Acta Derm Venereol.* 1955;35(2):107-110.
86. Houser DD, Arbesman CE, Ito K, et al. Cold urticaria. Immunologic studies. *Am J Med.* 1970;49(1):23-33.
87. Kaplan AP, Beaven MA. In vivo studies of the pathogenesis of cold urticaria, cholinergic urticaria, and vibration-induced swelling. *J Invest Dermatol.* 1976;67(3):327-332.
88. Horio T. Photoallergic urticaria induced by visible light. Additional cases and further studies. *Arch Dermatol.* 1978;114(12):1761-1764.
89. Newcomb RW, Nelson H. Dermographia mediated by immunoglobulin E. *Am J Med.* 1973;54(2):174-180.
90. Horiko T, Aoki T. Dermographism (mechanical urticaria) mediated by IgM. *Br J Dermatol.* 1984;111(5):545-550.
91. Murphy GM, Zollman PE, Greaves MW, et al. Symptomatic dermographism (factitious urticaria)—passive transfer experiments from human to monkey. *Br J Dermatol.* 1987;116(6):801-804.
92. Czarnetzki BM, Breetholt KH, Traupe H. Evidence that water acts as a carrier for an epidermal antigen in aquagenic urticaria. *J Am Acad Dermatol.* 1986;15(4 Pt 1):623-627.
93. Illig L, Heinicke A. [Pathogenesis of cholinergic urticaria. V. The pharmacologic reactivity of the Prausnitz-Kustner reaction and the origin of the antigen]. *Arch Klin Exp Dermatol.* 1967;230(1):34-47.
94. Gigli I, Schothorst AA, Soter NA, et al. Erythropoietic protoporphyria. Photoactivation of the complement system. *J Clin Invest.* 1980;66(3):517-522.
95. Lim HW, Perez HD, Poh-Fitzpatrick M, et al. Generation of chemotactic activity in serum from patients with erythropoietic protoporphyria and porphyria cutanea tarda. *N Engl J Med.* 1981;304(4):212-216.
96. Lim HW, Poh-Fitzpatrick MB, Gigli I. Activation of the complement system in patients with porphyrias after irradiation in vivo. *J Clin Invest.* 1984;74(6):1961-1965.
97. Kaplan AP, Garofalo J, Sigler R, et al. Idiopathic cold urticaria: in vitro demonstration of histamine release upon challenge of skin biopsies. *N Engl J Med.* 1981;305(18):1074-1077.
98. Kolkhir P, Metz M, Altrichter S, et al. Comorbidity of chronic spontaneous urticaria and autoimmune thyroid diseases: a systematic review. *Allergy.* 2017:1440-1460.
99. Metz M, Ohanyan T, Church MK, et al. Omalizumab is an effective and rapidly acting therapy in difficult-to-treat chronic urticaria: a retrospective clinical analysis. *J Dermatol Sci.* 2014;73(1):57-62.
100. Kaplan AP, Gimenez-Arnau AM, Saini SS. Mechanisms of action that contribute to efficacy of omalizumab in chronic spontaneous urticaria. *Allergy.* 2017;72(4):519-533.
101. Siebenhaar F, Melde A, Magerl M, et al. Histamine intolerance in patients with chronic spontaneous urticaria. *J Eur Acad Dermatol Venereol*. 2016.
102. Hungerford JM. Scombroid poisoning: a review. *Toxicon.* 2010;56(2):231-243.
103. Wagner N, Dirk D, Peveling-Oberhag A, et al. A Popular myth—low-histamine diet improves chronic spontaneous urticaria—fact or fiction? *J Eur Acad Dermatol Venereol.* 2017;31(4):650-655.
104. Zuberbier T, Chantraine-Hess S, Hartmann K, et al. Pseudoallergen-free diet in the treatment of chronic urticaria. A prospective study. *Acta Derm Venereol.* 1995;75(6):484-487.
105. Kanny G, Gerbaux V, Olszewski A, et al. No correlation between wine intolerance and histamine content of wine. *J Allergy Clin Immunol.* 2001;107(2):375-378.
106. Asero R. Plasma D-dimer levels and clinical response to ciclosporin in severe chronic spontaneous urticaria. *J Allergy Clin Immunol.* 2015;135(5):1401-1403.
107. Cugno M, Marzano AV, Asero R, et al. Activation of blood coagulation in chronic urticaria: pathophysiological and clinical implications. *Intern Emerg Med.* 2010;5(2):97-101.
108. Asero R, Tedeschi A, Coppola R, et al. Activation of the tissue factor pathway of blood coagulation in patients with chronic urticaria. *J Allergy Clin Immunol.* 2007;119(3):705-710.
109. Tedeschi A, Kolkhir P, Asero R, et al. Chronic urticaria and coagulation: pathophysiological and clinical aspects. *Allergy.* 2014;69(6):683-691.
110. Takahagi S, Mihara S, Iwamoto K, et al. Coagulation/fibrinolysis and inflammation markers are associated with disease activity in patients with chronic urticaria. *Allergy.* 2010;65(5):649-656.
111. Sakurai Y, Morioke S, Takeda T, et al. Increased thrombin generation potential in patients with chronic spontaneous urticaria. *Allergol Int.* 2015;64(1):96-98.
112. Takeda T, Sakurai Y, Takahagi S, et al. Increase of coagulation potential in chronic spontaneous urticaria. *Allergy.* 2011;66(3):428-433.
113. Yanase Y, Morioke S, Iwamoto K, et al. Histamine and Toll-like receptor ligands synergistically induce endothelial cell gap formation by the extrinsic coagulating pathway. *J Allergy Clin Immunol.* 2018;141(3):1115-1118.e7.
114. Mahesh PA, Pudupakkam VK, Holla AD, et al. Effect of warfarin on chronic idiopathic urticaria. *Indian J Dermatol Venereol Leprol.* 2009;75(2):187-189.
115. Parslew R, Pryce D, Ashworth J, et al. Warfarin treatment of chronic idiopathic urticaria and angio-oedema. *Clin Exp Allergy.* 2000;30(8):1161-1165.
116. Takahagi S, Shindo H, Watanabe M, et al. Refractory chronic urticaria treated effectively with the protease inhibitors, nafamostat mesilate and camostat mesilate. *Acta Derm Venereol.* 2010;90(4):425-426.
117. Asero R, Tedeschi A, Cugno M. Heparin and tranexamic acid therapy may be effective in treatment-resistant chronic urticaria with elevated d-dimer: a pilot study. *Int Arch Allergy Immunol.* 2010;152(4):384-389.

118. Costanzi JJ, Coltman CA Jr. Kappa chain cold precipitable immunoglobulin G (IgG) associated with cold urticaria. I. Clinical observations. *Clin Exp Immunol.* 1967;2(2):167-178.
119. Morais-Almeida M, Marinho S, Gaspar A, et al. Cold urticaria and infectious mononucleosis in children. *Allergol Immunopathol (Madr).* 2004;32(6):368-371.
120. Palma-Carlos AG, Palma-Carlos ML. Solar urticaria and porphyrias. *Eur Ann Allergy Clin Immunol.* 2005; 37(1):17-20.
121. Goetze S, Elsner P. Solar urticaria. *J Dtsch Dermatol Ges.* 2015;13(12):1250-1253.
122. Yu Y, Blokhuis BR, Garssen J, et al. Non-IgE mediated mast cell activation. *Eur J Pharmacol.* 2016; 778:33-43.
123. Theoharides TC. Neuroendocrinology of mast cells: challenges and controversies. *Exp Dermatol.* 2017; 26(9):751-759.
124. Okabe T, Hide M, Koro O, et al. Substance P induces tumor necrosis factor-alpha release from human skin via mitogen-activated protein kinase. *Eur J Pharmacol.* 2000;398(2):309-315.
125. Okabe T, Hide M, Koro O, et al. The release of leukotriene B4 from human skin in response to substance P: evidence for the functional heterogeneity of human skin mast cells among individuals. *Clin Exp Immunol.* 2001;124(1):150-156.
126. Yu Y, Yip KH, Tam IY, et al. Differential effects of the Toll-like receptor 2 agonists, PGN and Pam3CSK4 on anti-IgE induced human mast cell activation. *PLoS One.* 2014;9(11):e112989.
127. Subramanian H, Gupta K, Ali H. Roles of Mas-related G protein-coupled receptor X2 on mast cell-mediated host defense, pseudoallergic drug reactions, and chronic inflammatory diseases. *J Allergy Clin Immunol.* 2016;138(3):700-710.
128. Weidner C, Klede M, Rukwied R, et al. Acute effects of substance P and calcitonin gene-related peptide in human skin—a microdialysis study. *J Invest Dermatol.* 2000;115(6):1015-1020.
129. Minciullo PL, Cascio A, Barberi G, et al. Urticaria and bacterial infections. *Allergy Asthma Proc.* 2014;35(4): 295-302.
130. Federman DG, Kirsner RS, Moriarty JP, et al. The effect of antibiotic therapy for patients infected with Helicobacter pylori who have chronic urticaria. *J Am Acad Dermatol.* 2003;49(5):861-864.
131. Wedi B, Raap U, Kapp A. Chronic urticaria and infections. *Curr Opin Allergy Clin Immunol.* 2004;4(5):387-396.
132. Curth HM, Dinter J, Nigemeier K, et al. Effects of Helicobacter pylori eradication in chronic spontaneous urticaria: results from a retrospective cohort study. *Am J Clin Dermatol.* 2015;16(6):553-558.
133. Koblenzer CS. Psychosomatic concepts in dermatology. A dermatologist-psychoanalyst's viewpoint. *Arch Dermatol.* 1983;119(6):501-512.
134. Chung MC, Symons C, Gilliam J, et al. Stress, psychiatric co-morbidity and coping in patients with chronic idiopathic urticaria. *Psychol Health.* 2010;25(4):477-490.
135. Fava GA, Perini GI, Santonastaso P, et al. Life events and psychological distress in dermatologic disorders: psoriasis, chronic urticaria and fungal infections. *Br J Med Psychol.* 1980;53(3):277-282.
136. Malhotra SK, Mehta V. Role of stressful life events in induction or exacerbation of psoriasis and chronic urticaria. *Indian J Dermatol Venereol Leprol.* 2008;74(6):594-599.
137. Yang HY, Sun CC, Wu YC, et al. Stress, insomnia, and chronic idiopathic urticaria—a case-control study. *J Formos Med Assoc.* 2005;104(4):254-263.
138. Hashiro M, Okumura M. Anxiety, depression, psychosomatic symptoms and autonomic nervous function in patients with chronic urticaria. *J Dermatol Sci.* 1994; 8(2):129-135.
139. Sheehan-Dare RA, Henderson MJ, Cotterill JA. Anxiety and depression in patients with chronic urticaria and generalized pruritus. *Br J Dermatol.* 1990;123(6):769-774.
140. Lindelof B, Sigurgeirsson B, Wahlgren CF, et al. Chronic urticaria and cancer: an epidemiological study of 1155 patients. *Br J Dermatol.* 1990;123(4):453-456.
141. Chen YJ, Wu CY, Shen JL, et al. Cancer risk in patients with chronic urticaria: a population-based cohort study. *Arch Dermatol.* 2012;148(1):103-108.
142. Bernstein JA, Lang DM, Khan DA, et al. The diagnosis and management of acute and chronic urticaria: 2014 update. *J Allergy Clin Immunol.* 2014; 133(5):1270-1277.
143. Lang DM, Aberer W, Bernstein JA, et al. International consensus on hereditary and acquired angioedema. *Ann Allergy Asthma Immunol.* 2012;109(6):395-402.
144. Ameisen JC, Capron A. Aspirin-sensitive asthma. *Clin Exp Allergy.* 1990;20(2):127-129.
145. Inomata N, Osuna H, Yamaguchi J, et al. Safety of selective cyclooxygenase-2 inhibitors and a basic non-steroidal anti-inflammatory drug (NSAID) in Japanese patients with NSAID-induced urticaria and/or angioedema: comparison of meloxicam, etodolac and tiaramide. *J Dermatol.* 2007;34(3):172-177.
146. Harada S, Horikawa T, Ashida M, et al. Aspirin enhances the induction of type I allergic symptoms when combined with food and exercise in patients with food-dependent exercise-induced anaphylaxis. *Br J Dermatol.* 2001;145(2):336-339.
147. Asaumi T, Yanagida N, Sato S, et al. Provocation tests for the diagnosis of food-dependent exercise-induced anaphylaxis. *Pediatr Allergy Immunol.* 2016; 27(1):44-49.
148. de Silva HA, Ryan NM, de Silva HJ. Adverse reactions to snake antivenom, and their prevention and treatment. *Br J Clin Pharmacol.* 2016;81(3):446-452.
149. Kaplan A. *Urticaria and Angioedema.* New York: McGraw-Hill Medical; 2012.
150. Rosado Ingelmo A, Dona Diaz I, Cabanas Moreno R, et al. Clinical practice guidelines for diagnosis and management of hypersensitivity reactions to contrast media. *J Investig Allergol Clin Immunol.* 2016;26(3):144-155.
151. Wood MJ. Comparative safety of teicoplanin and vancomycin. *J Chemother.* 2000;12(suppl 5):21-25.
152. O'Donnell BF, O'Neill CM, Francis DM, et al. Human leucocyte antigen class II associations in chronic idiopathic urticaria. *Br J Dermatol.* 1999;140(5):853-858.
153. Gawchik SM. Latex allergy. *Mt Sinai J Med.* 2011;78(5): 759-772.
154. Kozel MM, Mekkes JR, Bossuyt PM, et al. The effectiveness of a history-based diagnostic approach in chronic urticaria and angioedema. *Arch Dermatol.* 1998;134(12):1575-1580.
155. Kolkhir P, Andre F, Church MK, et al. Potential blood biomarkers in chronic spontaneous urticaria. *Clin Exp Allergy.* 2017;47(1):19-36.
156. Kozel MM, Bossuyt PM, Mekkes JR, Bos JD. Laboratory tests and identified diagnoses in patients with physical and chronic urticaria and angioedema: A systematic review. *J Am Acad Dermatol.* 2003;48(3):409-416.

157. Magerl M, Abajian M, Krause K, et al. An improved Peltier effect-based instrument for critical temperature threshold measurement in cold- and heat-induced urticaria. *J Eur Acad Dermatol Venereol.* 2015;29(10):2043-2045.
158. Hide M, Yamamura Y, Sanada S, et al. Aquagenic urticaria: a case report. *Acta Derm Venereol.* 2000;80(2):148-149.
159. Soter NA, Austen KF, Gigli I. Urticaria and arthralgias as manifestations of necrotizing angiitis (vasculitis). *J Invest Dermatol.* 1974;63(6):485-490.
160. Maurer M, Magerl M, Ansotegui I, et al. The international WAO/EAACI guideline for the management of hereditary angioedema-The 2017 revision and update. *Allergy.* 2018;73(8):1575-1596.
161. Bafunno V, Firinu D, D'Apolito M, et al. Mutation of the angiopoietin-1 gene (ANGPT1) associates with a new type of hereditary angioedema. *J Allergy Clin Immunol.* 2018;141(3):1009-1017.
162. Bork K, Wulff K, Steinmuller-Magin L, et al. Hereditary angioedema with a mutation in the plasminogen gene. *Allergy.* 2018;73(2):442-450.
163. Cugno M, Zanichelli A, Bellatorre AG, et al. Plasma biomarkers of acute attacks in patients with angioedema due to C1-inhibitor deficiency. *Allergy.* 2009; 64(2):254-257.
164. Iwamoto K, Morioke S, Yanase Y, et al. Tissue factor expression on the surface of monocytes from a patient with hereditary angioedema. *J Dermatol.* 2014; 41(10):929-932.
165. Aksentijevich I, Zhou Q. NF-kappaB pathway in autoinflammatory diseases: dysregulation of protein modifications by ubiquitin defines a new category of autoinflammatory diseases. *Front Immunol.* 2017;8:399.
166. Krause K, Tsianakas A, Wagner N, et al. Efficacy and safety of canakinumab in Schnitzler syndrome: a multicenter randomized placebo-controlled study. *J Allergy Clin Immunol.* 2017;139(4):1311-1320.
167. Bhattacharyya J, Mihara K, Morimoto K, et al. Elevated interleukin-18 secretion from monoclonal IgM+ B cells in a patient with Schnitzler syndrome. *J Am Acad Dermatol.* 2012;67(3):e118-120.
168. de Torre-Minguela C, Mesa Del Castillo P, Pelegrin P. The NLRP3 and pyrin inflammasomes: implications in the pathophysiology of autoinflammatory diseases. *Front Immunol.* 2017;8:43.
169. Morita E, Kunie K, Matsuo H. Food-dependent exercise-induced anaphylaxis. *J Dermatol Sci.* 2007; 47(2):109-117.
170. Bruce RA, Blackmon JR, Jones JW, et al. Exercising testing in adult normal subjects and cardiac patients. *Pediatrics.* 1963;32(suppl):742-756.
171. Mlynek A, Zalewska-Janowska A, Martus P, et al. How to assess disease activity in patients with chronic urticaria? *Allergy.* 2008;63(6):777-780.
172. Weller K, Groffik A, Magerl M, et al. Development, validation, and initial results of the Angioedema Activity Score. *Allergy.* 2013;68(9):1185-1192.
174. Rabelo-Filardi R, Daltro-Oliveira R, Campos RA. Parameters associated with chronic spontaneous urticaria duration and severity: a systematic review. *Int Arch Allergy Immunol.* 2013;161(3):197-204.
174. Metz M, Krull C, Maurer M. Histamine, TNF, C5a, IL-6, -9, -18, -31, -33, TSLP, neopterin, and VEGF are not elevated in chronic spontaneous urticaria. *J Dermatol Sci.* 2013;70(3):222-225.
175. Grattan CE, Dawn G, Gibbs S, et al. Blood basophil numbers in chronic ordinary urticaria and healthy controls: diurnal variation, influence of loratadine and prednisolone and relationship to disease activity. *Clin Exp Allergy.* 2003;33(3):337-341.
176. Eckman JA, Hamilton RG, Gober LM, et al. Basophil phenotypes in chronic idiopathic urticaria in relation to disease activity and autoantibodies. *J Invest Dermatol.* 2008;128(8):1956-1963.
177. Doong JC, Chichester K, Oliver ET, et al. Chronic idiopathic urticaria: systemic complaints and their relationship with disease and immune measures. *J Allergy Clin Immunol Pract.* 2017;5(5):1314-1318.
178. Lewis V, Finlay AY. 10 years experience of the Dermatology Life Quality Index (DLQI). *J Investig Dermatol Symp Proc.* 2004;9(2):169-180.
179. Maurer M, Staubach P, Raap U, et al. ATTENTUS, a German online survey of patients with chronic urticaria highlighting the burden of disease, unmet needs and real-life clinical practice. *Br J Dermatol.* 2016; 174(4):892-894.
180. Murota H, Kitaba S, Tani M, et al. Impact of sedative and non-sedative antihistamines on the impaired productivity and quality of life in patients with pruritic skin diseases. *Allergol Int.* 2010;59(4):345-354.
181. Baiardini I, Giardini A, Pasquali M, et al. Quality of life and patients' satisfaction in chronic urticaria and respiratory allergy. *Allergy.* 2003;58(7):621-623.
182. Weller K, Groffik A, Magerl M, et al. Development and construct validation of the angioedema quality of life questionnaire. *Allergy.* 2012;67(10):1289-1298.
183. Weller K, Groffik A, Church MK, et al. Development and validation of the Urticaria Control Test: a patient-reported outcome instrument for assessing urticaria control. *J Allergy Clin Immunol.* 2014;133(5):1365-1372, 1372.e1361-1366.
184. GmbH M. Moxie. http://moxie-gmbh.de/medical-products/.
185. Natbony SF, Phillips ME, Elias JM, et al. Histologic studies of chronic idiopathic urticaria. *J Allergy Clin Immunol.* 1983;71(2):177-183.
186. Elias J, Boss E, Kaplan AP. Studies of the cellular infiltrate of chronic idiopathic urticaria: prominence of T-lymphocytes, monocytes, and mast cells. *J Allergy Clin Immunol.* 1986;78(5 Pt 1):914-918.
187. Nettis E, Dambra P, Loria MP, et al. Mast-cell phenotype in urticaria. *Allergy.* 2001;56(9):915.
188. Smith CH, Kepley C, Schwartz LB, et al. Mast cell number and phenotype in chronic idiopathic urticaria. *J Allergy Clin Immunol.* 1995;96(3):360-364.
189. Ito Y, Satoh T, Takayama K, et al. Basophil recruitment and activation in inflammatory skin diseases. *Allergy.* 2011;66(8):1107-1113.
190. Ying S, Kikuchi Y, Meng Q, et al. TH1/TH2 cytokines and inflammatory cells in skin biopsy specimens from patients with chronic idiopathic urticaria: comparison with the allergen-induced late-phase cutaneous reaction. *J Allergy Clin Immunol.* 2002;109(4):694-700.
191. Peters MS, Winkelmann RK. Neutrophilic urticaria. *Br J Dermatol.* 1985;113(1):25-30.
192. Winkelmann RK, Wilson-Jones E, Smith NP, et al. Neutrophilic urticaria. *Acta Derm Venereol.* 1988;68(2): 129-133.
193. Levender MM, Silvers DN, Grossman ME. Urticaria-like neutrophilic dermatosis in association with IgA gammopathy: a new entity. *Br J Dermatol.* 2014;170(5): 1189-1191.
194. Peters MS, Schroeter AL, Kephart GM, et al. Localization of eosinophil granule major basic protein in chronic urticaria. *J Invest Dermatol.* 1983;81(1):39-43.

195. Barlow RJ, Ross EL, MacDonald D, et al. Adhesion molecule expression and the inflammatory cell infiltrate in delayed pressure urticaria. *Br J Dermatol.* 1994;131(3):341-347.
196. Jones RR, Bhogal B, Dash A, et al. Urticaria and vasculitis: a continuum of histological and immunopathological changes. *Br J Dermatol.* 1983;108(6): 695-703.
197. Phanuphak P, Kohler PF, Stanford RE, et al. Vasculitis in chronic urticaria. *J Allergy Clin Immunol.* 1980; 65(6):436-444.
198. Gakhal MS, Marcotte GV. Hereditary angioedema: imaging manifestations and clinical management. *Emerg Radiol.* 2015;22(1):83-90.
199. Tanaka T, Hiragun M, Hide M, et al. Analysis of primary treatment and prognosis of spontaneous urticaria. *Allergol Int.* 2017;66(3):458-462.3.
200. Toubi E, Kessel A, Avshovich N, et al. Clinical and laboratory parameters in predicting chronic urticaria duration: a prospective study of 139 patients. *Allergy.* 2004;59(8):869-873.
201. Hiragun M, Hiragun T, Mihara S, et al. Prognosis of chronic spontaneous urticaria in 117 patients not controlled by a standard dose of antihistamine. *Allergy.* 2013;68(2):229-235.
202. Powell RJ, Leech SC, Till S, et al. BSACI guideline for the management of chronic urticaria and angioedema. *Clin Exp Allergy.* 2015;45(3):547-565.
203. Guillen-Aguinaga S, Jauregui Presa I, Aguinaga-Ontoso E, et al. Updosing nonsedating antihistamines in patients with chronic spontaneous urticaria: a systematic review and meta-analysis. *Br J Dermatol.* 2016;175(6):1153-1165.
204. Zhao ZT, Ji CM, Yu WJ, et al. Omalizumab for the treatment of chronic spontaneous urticaria: a meta-analysis of randomized clinical trials. *J Allergy Clin Immunol.* 2016;137(6):1742-1750.e1744.
205. Saini SS, Bindslev-Jensen C, Maurer M, et al. Efficacy and safety of omalizumab in patients with chronic idiopathic/spontaneous urticaria who remain symptomatic on H1 antihistamines: a randomized, placebo-controlled study. *J Invest Dermatol.* 2015; 135(1):67-75.
206. Kaplan A, Ledford D, Ashby M, et al. Omalizumab in patients with symptomatic chronic idiopathic/ spontaneous urticaria despite standard combination therapy. *J Allergy Clin Immunol.* 2013;132(1):101-109.
207. Fueyo-Casado A, Campos-Munoz L, Gonzalez-Guerra E, et al. Effectiveness of omalizumab in a case of urticarial vasculitis. *Clin Exp Dermatol.* 2017.
208. Kobza-Black A. Delayed pressure urticaria. *J Investig Dermatol Symp Proc.* 2001;6(2):148-149.
209. Berroeta L, Clark C, Ibbotson SH, et al. Narrow-band (TL-01) ultraviolet B phototherapy for chronic urticaria. *Clin Exp Dermatol.* 2004;29(1):97-98.
210. Bas M, Greve J, Stelter K, et al. A randomized trial of icatibant in ACE-inhibitor-induced angioedema. *N Engl J Med.* 2015;372(5):418-425.
211. Botnaru T, Robert A, Mottillo S. Icatibant compared to steroids and antihistamines for ACE-inhibitor-induced angioedema. *CJEM.* 2017;19(2):159-162.
212. Straka BT, Ramirez CE, Byrd JB, et al. Effect of bradykinin receptor antagonism on ACE inhibitor-associated angioedema. *J Allergy Clin Immunol.* 2016.
213. Grattan CE, Humphreys F. Guidelines for evaluation and management of urticaria in adults and children. *Br J Dermatol.* 2007;157(6):1116-1123.
214. O'Donnell BF, Lawlor F, Simpson J, et al. The impact of chronic urticaria on the quality of life. *Br J Dermatol.* 1997;136(2):197-201.
215. Bork K, Hardt J, Schicketanz KH, et al. Clinical studies of sudden upper airway obstruction in patients with hereditary angioedema due to C1 esterase inhibitor deficiency. *Arch Intern Med.* 2003;163(10):1229-1235.

Chapter 42 :: Mastocytosis

:: Michael D. Tharp

AT-A-GLANCE

MASTOCYTOSIS

- The hallmark of mastocytosis is a pathologic accumulation of mast cells in tissues.
- Mastocytosis occurs at any age but children are more commonly affected.
- Cutaneous findings consist of hyperpigmented macules, papules, or nodules, or a diffuse infiltration of the dermis.
- Most children only have skin involvement, whereas adults are more likely to have systemic disease.
- Mastocytosis is usually associated with somatic activating mutations of *c-kit* with the 816 codon mutation being most common.
- Many patients have few, if any, symptoms, but some experience varying degrees of flushing, pruritus, hypotension, nausea, dyspepsia, and diarrhea.
- Most common extracutaneous tissues involved are the bone marrow, liver, spleen, and lymph nodes.
- Some patients may develop an associated myeloproliferative or myelodysplastic disorder.
- No effective cure currently exists; treatment is focused on controlling symptoms

MAST CELLS

- Mast cells are derived from pluripotent stem cells.
- Stem cell factor is the ligand for KIT and is required for mast cell proliferation and survival.
- Mast cells release both preformed and newly generated mediators.

EPIDEMIOLOGY

Mastocytosis represents a group of disorders characterized by an abnormal accumulation of mast cells in one or more organs. Although the true incidence of this disease is unknown, most cases arise in children, with approximately 70% of cases occurring by 6 months of age and more than 90% occurring within the first 2 years of life.[1-5] Congenital mastocytosis is less common, representing approximately 18% to 31% of childhood cases.[2-4] The prevalence of childhood-onset mastocytosis is reported to range from 2.0 to 5.4 cases/1000 population.[1,2] The prevalence of adult-onset systemic mastocytosis (SM) in Denmark has been reported to be approximately 1/10,000 population over a 14-year period.[6] Mastocytosis has no gender preference, and it has been reported in all races.[5]

While most mastocytosis patients have no family history, there are reports of more than 70 familial cases, including monozygotic twins, some of which were discordant for this disease.[7-9]

PATHOGENESIS

Mast cells arise from the bone marrow as agranular, undifferentiated, CD34+, KIT+ (CD117) pluripotent progenitor cells. After migrating into tissues, immature mast cells assume their typical granular morphology.[10] KIT, a Type III tyrosine kinase is the product of the protooncogene c-*kit* located on chromosome 4q12. This enzyme is expressed on mast cells, as well as melanocytes, primitive hematopoietic stem cells, primordial germ cells, and interstitial cells of Cajal and serves as the receptor for its ligand, stem cell factor (SCF). Crosslinking of KIT by SCF is essential for mast cell maturation. The gene for SCF is located on chromosome 12, and encodes a protein that localizes to the cell membrane.[10,11] Membrane-bound and a soluble forms of SCF exist, both of which are capable of inducing KIT activation. Soluble KIT is thought to arise from chymase-induced cleavage of the membrane bound form.[12] SCF is produced by bone marrow stromal cells, fibroblasts, keratinocytes, endothelial cells, as well as reproductive Sertoli and granulosa cells. Mature mast cells require SCF for survival.[11,12] Other cytokines that appear important in regulating mast cell growth and differentiation include interleukin-3 (IL-3), IL-4, IL-6, and IL-9 and interferon (IFN)-γ. IL-3 shares a number of signal transduction pathways with SCF, but has minimal direct effects on human mast cell proliferation except in early cultures. IL-4 enhances mast cell function when added to mature cultures. IL-6 increases mast cell mediator concentration[13] and IL-9 appears to increase the number of mast cells in culture.[14] In developing mast cells, IFN-γ inhibits mast cell proliferation and influences mast cell phenotype and function.[13]

Mutations in *c-kit* appear to play a central role in mastocytosis. Somatic mutations in codon 816 of *c-kit*, lead to amino acid substitutions (D816V, D816Y, D816F, D816I, and D816H), and cause constitutive activation of KIT, resulting in continued mast cell growth and development.[15,16] Mutations in this codon are most common in adults with mastocytosis, but also occur in childhood onset disease.[2,15,17] Among 50 children with this disorder, 42% had detectable mutations at codon 816 (exon 17), while another 42% had activating mutations in the extracellular and transmembrane regions of KIT (exons 8-11). The remaining 8 children reported in this study had no detectable *c-kit* mutations. There was no clear correlation between the extent of disease

TABLE 42-1
c-Kit Mutations in Mastocytosis

Activating Mutations
D816V, D816Y, D816F, D816I, D816H, S849I, D835Y, N822I, D820G, V560G, V559I, A53D, D572A, F522C, K509I, S476I, C443Y, D419Y, del417-418, ITD 501-502, ITD 502-503, ITD 505-508
Inactivating Mutations
E839K, del exon 3-13
Increased Sensitivity to Stem Cell Factor
M541L

and the presence or absence of *c-kit* mutations among these 50 patients.[17] In another report of 22 children and adults with mastocytosis, 11 adult patients and 4 children had 816 activating mutations. Four other pediatric patients with typical lesions of urticaria pigmentosa (UP) lacked changes in this codon, and in 3 other children, an inactivating *c-kit* mutation (codon E839K) was detected.[15] Less common activating c-*kit* mutations, such asV560G, also have been characterized in some adult patients with mastocytosis,[15,16] as have severely truncated, inactive KITs (Table 42-1).[18] A transgenic mouse model of mastocytosis has been reported using the human activating D816V *c-kit* mutation.[19] The clinical expression of this disorder ranged from indolent mast cell hyperplasia to invasive mast cell tumors, even though genetically identical animals expressed the same D816V mutation. These clinical and investigative observations indicate that *c-kit* activating mutations play an important role in the development of mastocytosis. However, the finding of a varied clinical expression of mastocytosis in an animal model along with the fact that some children and adults with mastocytosis have no *c-kit* mutations or have inactivating *c-kit* mutations, strongly suggests that other, yet to be defined, factors influence the full clinical expression of this disease. Indeed, mutations in addition to *c-kit* have been identified in some adults with SM. These include the tumor-suppressor gene *TET2*, was well as *ASXL1, JAK2, SRSF2, DNMT3A, RUNX1,* and *CBL*, all of which may play a role in persistent and more aggressive disease.[20,21]

CLINICAL FINDINGS

CLASSIFICATION

Mastocytosis represents a disease spectrum characterized by a diverse phenotypic expression, along with pathologic and genetic findings that affect prognosis. Table 42-2 represents the World Health Organization (WHO) classification of mastocytosis.[5] Cutaneous mastocytosis (CM) and indolent SM (ISM) represent the majority of patients with this disease. Most children have CM, which is manifested as UP (Fig. 42-1) or, less commonly, as mastocytomas (Fig. 42-2), or as diffuse CM (Fig. 42-3). SM occurs mostly in adults, and ISM is the most common form. Table 42-3 lists the criteria for SM. SM with an associated clonal hematologic non–mast-cell-lineage disease (SM-AHNMD) occurs almost uniquely in adults, and can be demonstrated, by examining the peripheral blood and bone marrow. Hematologic disorders associated with SM-AHNMD include myeloproliferative and myelodysplastic disorders, such as polycythemia rubra vera, chronic myeloid leukemia, chronic myelomonocytic leukemia, idiopathic myelofibrosis, chronic eosinophilic leukemia and the hypereosinophilic syndrome, acute and chronic lymphocytic leukemia, and non-Hodgkin

TABLE 42-2
World Health Organization Classification of Mastocytosis[a]

VARIANT TERM	ABBREVIATION	SUBVARIANTS	EXAMPLES
Cutaneous mastocytosis	CM		Urticaria pigmentosa Diffuse CM Mastocytoma of skin Telangiectasia macularis eruptiva perstans (TMEP)
Indolent systemic mastocytosis	ISM	Smoldering SM Isolated bone marrow mastocytosis	
Systemic mastocytosis with an associated clonal hematologic non–mast-cell-lineage disease	SM-AHNMD		Acute myelogenous leukemia Myelodysplastic syndrome Chronic myelomonocytic leukemia Chronic eosinophilic leukemia Non-Hodgkin lymphoma
Aggressive systemic mastocytosis	ASM	Acute vs chronic	
Mast cell leukemia	MCL		
Mast cell sarcoma	MCS		
Extracutaneous mastocytoma	ECM		

[a]For details of the WHO classification of mastocytosis, see Valent P, et al.[5]

Figure 42-1 Urticaria pigmentosa in a child.

Figure 42-2 Mastocytoma on the sole of a child.

Figure 42-3 Diffuse cutaneous mastocytosis in a child.

TABLE 42-3
Diagnostic Criteria for Systemic Mastocytosis (Major and One Minor or Three Minor Criteria Are Needed)[a]

Major
- Multifocal dense infiltrates of mast cells in bone marrow and/or other extracutaneous organs

Minor
- More than 25% of the mast cells in bone marrow aspirate smears or tissue biopsy sections are spindle shaped or display atypical morphology.
- Detection of a codon 816 *c-kit* point mutation in blood, bone marrow, or lesional tissue.
- Mast cells in bone marrow, blood, or other lesional tissue expressing CD25 or CD2.
- Baseline total tryptase level greater than 20 ng/mL.

[a]For details of the WHO classification of mastocytosis, see Valent P, et al.[5]

and Hodgkin lymphoma. Patients with aggressive SM (ASM) frequently have evidence of impaired liver function, hypersplenism, and/or malabsorption, but they do not have a distinctive hematologic disorder or mast cell leukemia (MCL). Patients with ASM have rapidly increasing mast cell numbers and are difficult to manage medically.[5,22] MCL is rare and characterized by multiorgan failure, bone marrow smears demonstrating a greater than 20% mast cell population among the nucleated cell population. In the peripheral blood, mast cells are at least 10% of nucleated cells.[5,23] Both acute and chronic forms of MCL have been described; they are differentiated based on symptoms and organ involvement.[23] Mast cell sarcomas are rare; they have localized destructive growth, but distant spread is possible. Mast cells in these tumors are highly atypical and immature. Extracutaneous mastocytomas are extremely rare, usually localized to the lung, and consist of mature mast cells.[5,22,24,25]

CUTANEOUS LESIONS

UP was originally described in children and is the most common skin manifestation of childhood-onset CM. UP lesions in children appear as tan to brown papules and, less commonly, as macules, ranging in size from 1.0 to 2.5 cm in diameter (see Fig. 42-1). These lesions may be present at birth or arise during infancy. They frequently appear on the trunk and often spare the central face, scalp, palms, and soles. Cutaneous lesions in adults, on the other hand, are much smaller (approximately 5 mm or less in diameter) reddish-brown macules and papules (Fig. 42-4). On close lesion inspection, variable hyperpigmentation and fine telangiectasias are detectable. In patients with Type I skin, these lesions may lack pigment and appear pink to red. Adult skin lesions are most numerous on the trunk and proximal extremities and appear less frequently on the face, distal extremities, or palms and soles. While adult lesions may appear and resolve

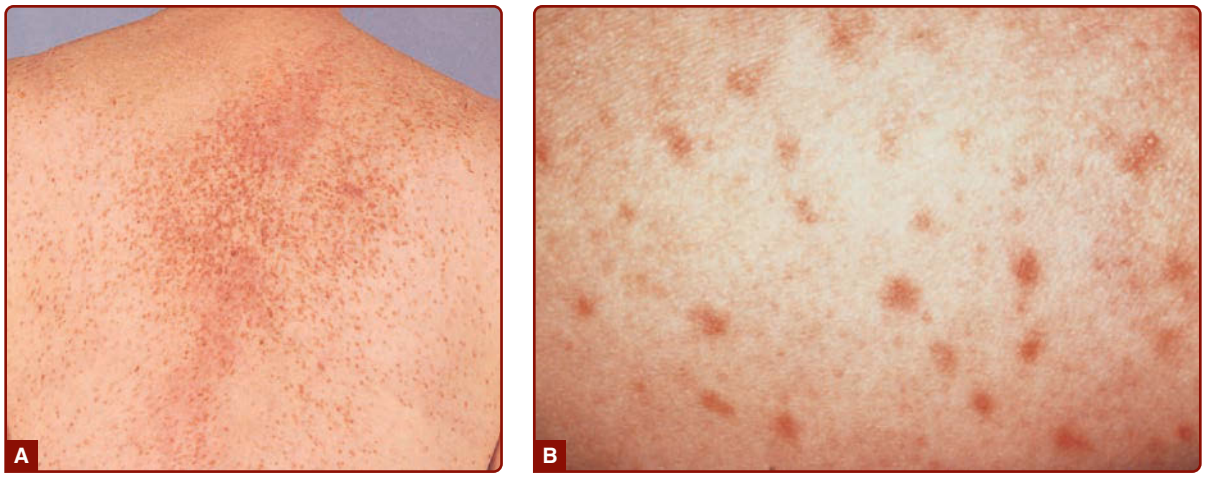

Figure 42-4 Typical red brown papules in an adult with indolent systemic mastocytosis. **A,** Hundreds of lentigo-like macules are seen on the back of this adult. If vigorously rubbed, these lesions will show urtication and become erythematous, raised, and pruritic. **B,** Close-up view of the macules.

over months in individual patients, their number usually increases over years. Most adults with ISM have cutaneous lesions, but skin involvement is less common in patients with more advanced forms of SM (SM-AHNMD, ASM, or MCL).[5,22,24,25]

Solitary mastocytomas are tan-brown nodules that occur in approximately 10% to 35% of children and frequently appear on the distal extremities (see Fig. 42-2). Their onset is generally before 6 months of age.[1-4] Scratching or rubbing skin lesions leads to urtication and erythema known as *Darier sign*. This reaction is readily demonstrated in childhood UP and mastocytomas, but often is less pronounced in adult skin lesions.[24-27] The difference in lesional skin reactivity between children and adults with CM is best explained by the observation that mast cell concentrations in mastocytomas and childhood UP are 150-fold and 40-fold greater than in normal skin, respectively, whereas the mast cell content in lesions of adult mastocytosis is only 8 times greater than normal controls.[27] Because trauma to mastocytomas is associated with systemic symptoms such as flushing and hypotension, vigorous scratching of UP lesions or mastocytomas is not advised.[1-4,24,26]

Diffuse CM (DCM) is seen almost exclusively in infants (see Fig. 42-3), although it may persist into adult life. The skin often has a peau d'orange appearance and yellowish-brown discoloration. Rarely, individual yellow-tan papules have been described; the individual yellow-tan papules are called *xanthelasmoidal mastocytosis*.[26,28] Dermographism with formation of hemorrhagic blisters can occur in the first months to years of life in children with DCM, but these blisters often resolve within several years, even though the DCM may persist (Fig. 42-5).[1-4,26] Telangiectasia macularis eruptiva perstans is rare, and is seen almost exclusively in adults. It appears as telangiectatic macules and patches without hyperpigmentation (Fig. 42-6). The Darier sign and pruritus are variable in patients with telangiectasia macularis eruptiva perstans.[24-26] Tumor-like growths also have been described in an adult mastocytosis patient in whose mast cells expressed the V560G *c-kit* mutation.[29]

RELATED CLINICAL FINDINGS

Most children with CM and adults with CM or ISM have few, if any, symptoms, but children with DCM are more likely to have skin and GI symptoms.[1,2] When symptoms occur, they are caused by the release of mast cell mediators, such as histamine, eicosanoids, and cytokines, and often involve several different organs (ie, skin and GI tract or skin and cardiovascular) (Table 42-4). Symptoms and signs of mastocytosis may include: pruritus, flushing, diarrhea, abdominal pain, nausea, bloating, vomiting, gastric reflux, palpitations, dizziness, and/or syncope. Of interest is the relative absence of pulmonary symptoms in mastocytosis patients. Complaints of fever, night sweats, malaise, weight loss, bone pain, epigastric distress, and problems with mentation (cognitive disorganization) often

Figure 42-5 Bullous eruption on the back of a child with diffuse cutaneous mastocytosis.

Figure 42-6 Telangiectasia macularis eruptive perstans.

signal the presence of SM. Symptoms of mastocytosis can be exacerbated by exercise, heat, or local trauma to skin lesions (childhood UP and mastocytomas). In addition, alcohol, narcotics, salicylates, nonsteroidal antiinflammatory drugs (NSAIDs), polymyxin B, anticholinergics, and some systemic anesthetic agents may induce mast cell mediator release.[5,23-26] It has been suggested that anaphylaxis from hymenoptera stings may be more common in mastocytosis patients, but deaths associated with extensive mast cell mediator release are rare.[2,5,30]

Extracutaneous disease is extremely uncommon in children, but when present GI symptoms are the most frequent.[1,2,4] GI symptoms in adults ranges from 25% to 70%.[5,31,32] Diarrhea is the most common symptom and may result from gastric hypersecretion, increased motility, and/or malabsorption. Increased gastric acid secretion is likely a result of elevated histamine release, which may cause gastritis and peptic ulcer disease.[33] Malabsorption with associated diarrhea is limited to a subset of patients with usually more advanced disease. While hepatic disease in adults and children with ISM is rare, liver and spleen involvement, including portal hypertension and ascites associated with liver fibrosis, may occur in patients who have SM-AHNMD or ASM.[5,24,25,34] Splenomegaly, detected either clinically or by CT scan, has been reported in 50% to 60% of adult SM patients.[26,35] However, in 2 other studies, each with more than 140 adult mastocytosis patients, splenomegaly was observed in only 8% to 9% of cases.[36,37] Increased numbers of mast cells and eosinophils are frequently observed in the spleen, as are

TABLE 42-4
Selected Mast Cell Mediators

MEDIATORS	BIOLOGIC EFFECTS	POSSIBLE CONSEQUENCES
Preformed		
Histamine	Vasodilation, increased vascular permeability, gastric hypersecretion, bronchoconstriction	Hypotension, flushing, urticaria, abdominal pain (peptic, colic), nausea, vomiting, diarrhea, malabsorption CNS symptoms
Heparin	Anticoagulant, inhibition of platelet aggregation	Prolonged bleeding time Osteoporosis/osteopenia
Tryptase	Endothelial cell activation, fibrinogen cleavage, mitogenic for smooth muscle cells	Osteoporosis/osteopenia, disruption of cascade systems (clotting, etc)
Chymase	Converts angiotensin I to II, lipoprotein degradation Cleaves membrane-bound stem cell factor	Hypertension Hyperpigmentation Skin mast cell accumulation (?)
Newly Synthesized		
Leukotrienes	Increased vascular permeability, bronchoconstriction, vasoconstriction	Bronchospasm, hypotension
Prostaglandins	Vasodilation, bronchoconstriction	Flushing, urticaria, hypotension CNS symptoms
Cytokines		
Stem cell factor	Growth and survival of mast cells, chemotaxis of KIT+ cells, melanogenesis	Mast cell hyperplasia, focal aggregates
Tumor necrosis factor-α	Activation of vascular endothelial cells, cachexia, fatigue	Weight loss, fever, fatigue
Transforming growth factor-β	Enhanced production of connective tissue components	Fibrosis
Interleukin (IL)-1	Activates fibroblasts, lymphocytes and increases neutrophils	Fibrosis, fever
IL-5	Eosinophil growth factor	Eosinophilia
IL-6	Growth and survival of mast cells	Fever, bone pain, osteoporosis/osteopenia
Granulocyte-macrophage colony-stimulating factor	Granulocyte and monocyte growth and activation	Eosinophilia

varying degrees of fibrosis and hematopoiesis. Lymph node enlargement is uncommon in most patients with ISM, but occurs in patients with more advanced disease. Among 58 SM patients, 15 (26%) had peripheral lymphadenopathy, whereas 11 (19%) had central nodal disease.[38] Anemia, leukopenia, thrombocytopenia, and eosinophilia also may occur in association with SM and suggest SM-AHNMD or ASM.[5,22,24,25]

Musculoskeletal pain affects 19% to 28% of mastocytosis patients. Skeletal lesions occur in patients with SM, but are rare in children with this disorder.[1,2,36,39,40] In one large study of 142 adults with mastocytosis, 40% had skeletal involvement.[36] Bony lesions may appear as radiopacities, radiolucencies, or a mixture of the two. The skull, spine, and pelvis are most commonly involved. In another study of 58 adult SM patients, 34 (57%) had diffuse bone involvement, whereas only 1(2%) had focal lesions.[39] In 199 ISM patients, disease-related lumbar spine osteoporosis was more frequently observed in men. The prevalence of vertebral fractures was 20% in men compared to 14% in women with mastocytosis. This observation has led to the recommendation to consider the diagnosis of mastocytosis in men with unexplained osteroporosis.[40]

Neuropsychiatric abnormalities have been reported, and include decreased attention span, memory impairment, headache, and irritability. Depression as a consequence of chronic disease or possibly mediated by mast cell mediators may occur.[41,42]

Information pertaining to pregnancy in mastocytosis is limited. However, there are numerous reports of successful, full-term deliveries in women with mast cell disease.[43,44] In a report of 45 pregnancies in 30 mastocytosis patients, 10 (22%) had worsening mast cell–related symptoms, whereas 15 (33%) experienced improved or resolved symptoms. Among the 45 newborns, only 7 were premature, had a low birthweight and/or suffered from respiratory distress. No fatal maternal or fetal outcomes were reported.[45]

LABORATORY TESTS

The diagnosis of mastocytosis is established by demonstrating increased numbers of mast cells in 1 or more organs. For patients with CM, mast cell infiltrates can be detected in a biopsy of lesional skin using special stains, such as toluidine (Fig. 42-7), Giemsa, or monoclonal antibodies that recognize mast cell tryptase or CD117 (KIT).[26,27,46] Biopsy specimens of normal-appearing skin from patients with mastocytosis have normal concentrations of mast cells as determined by morphometrics, and thus are not helpful in establishing the diagnosis.[27]

Detection of circulating mast cell mediators and/or their metabolites can offer indirect evidence of mastocytosis, and their measurement may be useful in patients without cutaneous lesions. Two forms (α and β) of mast cell tryptase have been identified. α-Tryptase is elevated in patients with SM, with or without acute symptoms, whereas increased levels of β-tryptase can be detected both in mastocytosis patients and in allergic patients experiencing anaphylactic reactions.

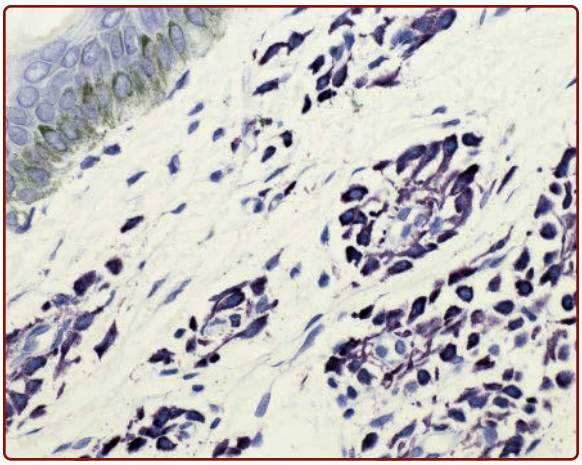

Figure 42-7 Histopathology of urticaria pigmentosa, toluidine blue stain.

Total (α + β) serum tryptase levels are most commonly measured and correlate with the extent of mast cell disease.[47,48] In children, elevated serum tryptase levels correlate with more-extensive skin involvement and a greater number and severity of symptoms.[48] Of adult mastocytosis patients with total serum tryptase levels between 20 and 75 ng/mL, 50% had evidence of SM, whereas all patients with levels >75 ng/mL had proven systemic involvement.[47] Total serum tryptase levels of >20 ng/mL are currently considered abnormal and represent one of the minor criteria for SM (see Table 42-3).[5] Total serum tryptase levels also can provide an estimate of a patient's overall mast cell burden, and thus serial measurements in adults every 6 to 12 months may prove useful in following disease progression.

Determinations of urinary histamine metabolite levels may be worthwhile as a diagnostic test in patients without cutaneous lesions and in whom the diagnosis of mastocytosis is unclear. The major urinary metabolite of histamine, 1,4-methylimidazole acetic acid is often persistently elevated in SM patients and correlates with the extent of mast cell disease. Methylhistamine is next most common urinary histamine metabolite, and can be measured if 1,4-methylimidazole acetic acid levels are not available in commercial laboratories. Certain foods high in histamine content, such as spinach, eggplant, cheeses (eg, Parmesan, Roquefort, and blue), and red wines, can artificially elevate the levels of urinary histamine and its metabolites, and thus should be avoided during the collection process.[49]

Mast cells can induce bone changes that cause radiographically detectable lesions. Skeletal lesions occur more frequently in adult patients with SM, and are rare in children with this disorder.[1,26,36,40] In one large study of 142 adults with mastocytosis, 57 (40%) had skeletal involvement.[36] The proximal long bones, skull, spine, ribs, and pelvis are most commonly affected. Skeletal scintigraphy (bone scan) is more sensitive, but less specific, than routine radiographs for detecting and locating active lesions. Thus, radiographs of the skull, spine, and pelvis serve as a reasonable preliminary

test for detecting bone involvement in mastocytosis patients.[36,40]

The bone marrow is often involved in patients with SM, and bone marrow biopsies are indicated for patients suspected of having more advanced disease (SM-AHNMD, ASM, MCL).[5,22] In a report of 71 adults with mastocytosis, 90% had increased numbers of spindle-shaped, bone marrow mast cells with focal perivascular, peritrabecular, and/or intertrabecular accumulations.[26] WHO criteria for SM have been defined and include the bone marrow findings of multifocal dense mast cell aggregates, atypical mast cell morphology, and the expression of CD2 and/or CD25 by bone marrow mast cells (see Table 42-3). A bone marrow biopsy in childhood-onset disease is not recommended unless there is evidence of systemic involvement as demonstrated by hepatosplenomegaly, lymphadenopathy, and/or unexplained peripheral blood abnormalities.[1,2,50] Mast cells in bone marrow biopsies are best identified by immunostaining with antitryptase (Fig. 42-8) or CD117 monoclonal antibodies as decalcification interferes with the effectiveness of metachromatic stains.[5,22]

Roentgenographic abnormalities of the GI tract fall into 3 major categories: (a) peptic ulcers; (b) abnormal mucosal patterns such as mucosal edema, multiple nodular lesions, coarsened mucosal folds, or multiple polyps; and (c) motility disturbances. A biopsy of the GI tract may be indicated for patients in whom the diagnosis of SM is suspected, but who lack skin lesions. Histologic sections of jejunal biopsies show moderate blunting of the villi and may show increased mast cell numbers in association with variable numbers of eosinophils.[22,26,31,51] Increased mast cells in bowel biopsies should always be correlated with other signs and symptoms of mastocytosis as these findings also have been reported in patients with irritable bowel syndrome and mast cell activation syndrome.[51]

Despite the infrequency of significant hepatic disease, liver function tests may be abnormal in up to 50% of SM patients.[26,39] Elevated serum IL-6 levels, soluble SCF receptor (CD117), and IL-2 receptor (CD25) levels are associated with SM, but their specificity is not established.[52]

The initial evaluation of a prepubertal child with mastocytosis generally does not require extensive testing if the history and physical examination do not indicate the presence of SM. In contrast, the presence of noncutaneous signs and symptoms or disease onset in adolescents or adults necessitates a complete blood count (CBC) with differential, liver function test, total serum tryptase level, and skeletal radiographs (Fig. 42-9 and see Table 42-4). While bone marrow biopsies have been recommended by some clinicians for all adult mastocytosis patients, it is the opinion of this author that this procedure is unnecessary for those with a normal CBC. Should the CBC become abnormal in an adult patient, however, then the cause of this abnormality should be investigated by examining the bone marrow.

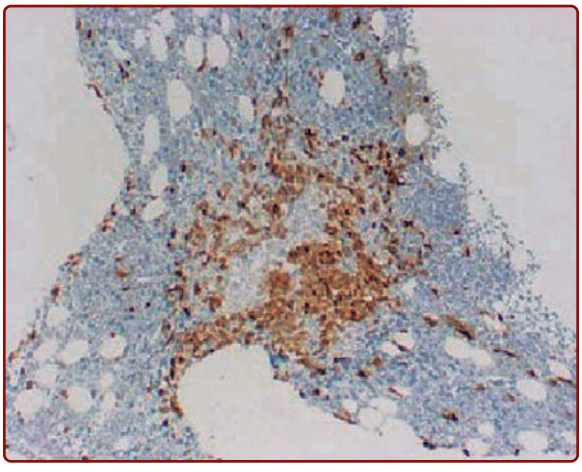

Figure 42-8 Classic mastocytosis bone marrow lesion (×100), tryptase stain.

DIFFERENTIAL DIAGNOSIS

Cutaneous lesions of childhood and adult mastocytosis are so characteristic, that they are rarely confused with other skin disorders. Because UP lesions may urticate, they could initially be mistaken for urticaria. However, individual urticaria lesions last only a few hours and lack the associated hyperpigmentation seen in UP. Rarely, nodular scabies lesions have been confused with UP. Some childhood mastocytosis patients, especially those with DCM, may develop bullae, and, thus, the differential diagnosis for blistering diseases in infants such as bullous impetigo, bullous arthropod bites, linear immunoglobulin A bullous dermatosis, bullous pemphigoid, epidermolysis bullosa, toxic epidermal necrolysis, and incontinentia pigmenti should be considered (Table 42-5). The differential diagnosis of mastocytomas in children includes juvenile xanthogranulomas, Spitz nevi, pseudolymphomas, or, rarely, in resolving lesions, a café-au-lait macule. Adult UP lesions might initially appear as lentigines or atypical melanocytic nevi; however, they usually have an associated erythema (telangiectasia) not seen in these melanocytic lesions.

Mastocytosis should be suspected in patients without skin lesions if they have symptoms suggesting mast cell mediator release, and one or more of the following: hepatomegaly, splenomegaly, lymphadenopathy, and/or peripheral blood abnormalities as well as peptic ulcer disease, malabsorption, or unexplained osteoporosis or radiographic/bone scan abnormalities (Table 42-6). In the last few years, patients with nonclonal mast cell activation syndrome have been described. This condition is characterized by symptoms of mast cell mediator release, such as flushing, abdominal cramping, diarrhea, headache, and/or memory/concentration difficulties. However, these patients lack evidence of unregulated mast cell proliferation. Nonclonal mast cell activation syndrome has been reported more frequently in women who experience urticaria/angioedema, respiratory symptoms,

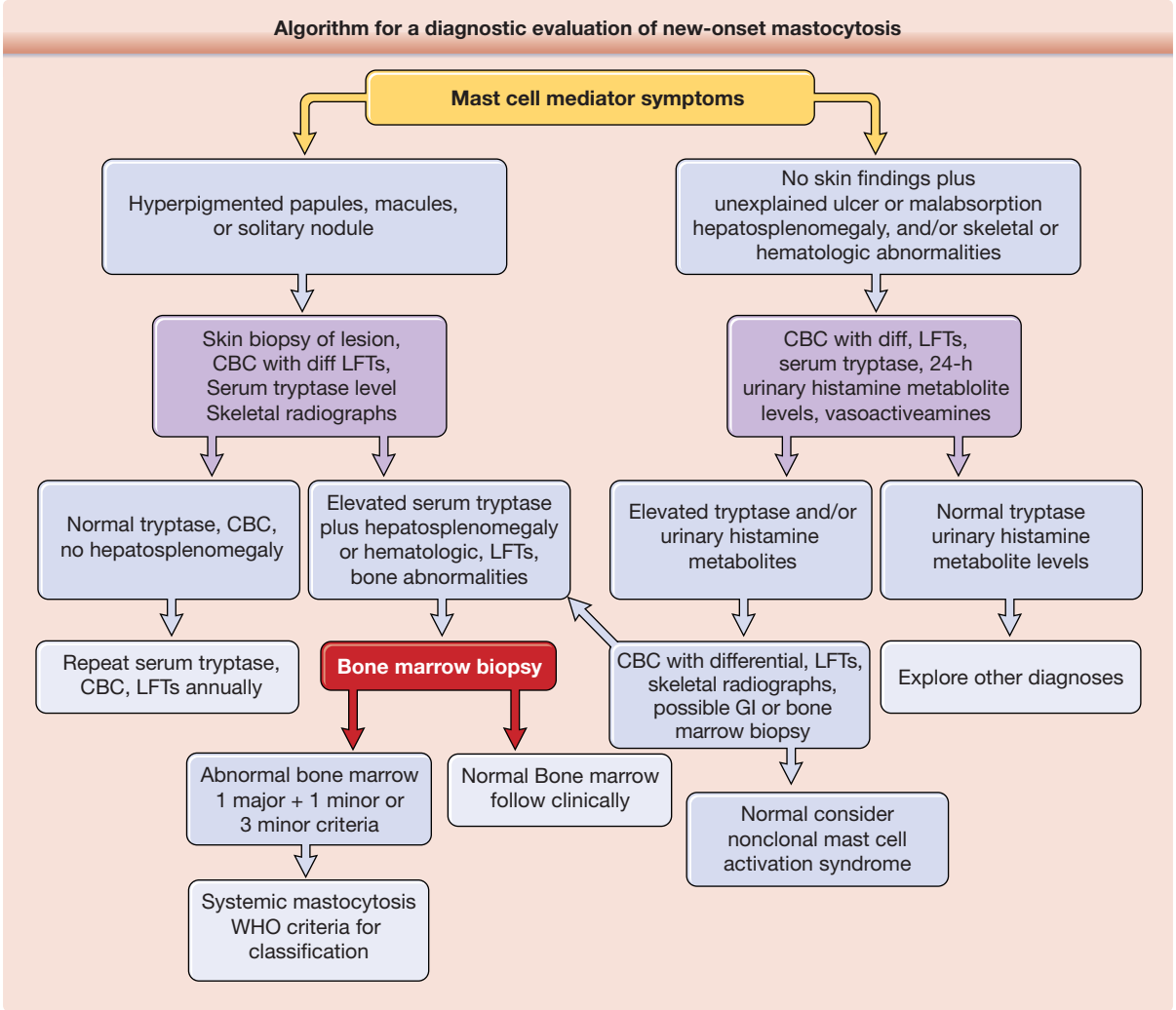

Figure 42-9 Algorithm for a diagnostic evaluation of new-onset mastocytosis (especially in adolescents and adults). CBC, complete blood cell count; LFT, liver function test; Tc, technetium; WHO, World Health Organization. For details of the WHO classification of mastocytosis, see Valent P, et al.[5]

have drugs as a trigger for their symptoms, and total serum tryptase levels <15 ng/mL.[53] In addition, these patients often respond to H_1 and H_2 antihistamines and leukotriene inhibitors.[53,54] Nonclonal mast cell activation syndrome must be differentiated from the broader term *mast cell activation disorder*, which also includes various forms of mastocytosis.[54] In patients with flushing, the diagnosis of a carcinoid tumor or pheochromocytoma should be considered. Mastocytosis patients, however, do not excrete increased amounts of 5-hydroxyindoleacetic acid, and patients with carcinoid tumor or pheochromocytoma do not have histologic evidence of mast cell proliferation or elevated serum tryptase levels.[24-26]

PROGNOSIS

Pediatric-onset cutaneous disease has a favorable prognosis with 45% to 68% of patients experiencing complete disease regression with a median followup of 15 to 20 years.[1,2] Children born of mothers with ISM reportedly are free of disease.[42,44] It has been postulated that children with activating *c-kit* mutations may represent those patients whose disease persists into adulthood; however, activating *c-kit* mutations, including D816V, have been identified in up to 84% of children with mastocytosis.[17] To date, there has been no correlation of disease severity or outcome in children who have *c-kit* mutations.[2,17] Most adults with skin lesions of mastocytosis have only CM or ISM, and rarely develop more advanced disease having a life expectancy commensurate with the general population. In a study of 145 adults with ISM, the cumulative probabilities of developing more advanced mast cell disease at 10 and 25 years were 1.7% and 8.4%, respectively.[37] Patients with ISM who have evidence of hepatosplenomegaly, lymphadenopathy and/or serum tryptase levels of >200 ng/mL have been referred to as smoldering SM. The prognosis of this group is not well defined but is believed to be less favorable than the ISM group.[5,22,37] Older patients who experience

TABLE 42-5
Differential Diagnosis of Cutaneous Mast Cell Disease

Most Likely
- Diffuse or localized red-brown papules/macules
  - Urticaria
  - Multiple nevi
  - Langerhans cell histiocytosis
  - Juvenile xanthogranulomas
  - Nodular scabies
  - Café-au-lait spots
  - Multiple cutaneous lentiginosis
- Bullous lesions
  - Linear immunoglobulin A dermatosis
  - Bullous impetigo
  - Epidermolysis bullosa
  - Arthropod bite reaction
  - Toxic epidermal necrolysis
  - Incontinentia pigmenti
- Solitary papule or nodule
  - Congenital nevus
  - Juvenile xanthogranuloma
  - Pseudolymphoma

fading of their lesions continue to exhibit bone marrow lesions typical of their diagnosis, whether ISM or SM-AHNMD.[55] Patients with SM-AHNMD have a variable course, which is dependent on the prognosis of their hematologic disorder. One study suggests that SM-AHNMD patients who express a mutation in the *ASXL1* gene have a poorer overall survival than those who express wild-type *ASXL1*.[20] In patients with ASM, the mean survival is 2 to 4 years, but the prognosis may improve with aggressive symptomatic management. The prognosis for MCL is poor, with a mean survival of less than 1 year.[23,37] Additional poor prognostic findings in adult mastocytosis patients include detectable D816V mutations in non–mast cell populations, as well as the expression of one or more non–*c-kit* gene mutations (*TETS, SRSF2, ASXLI, ASCL1, RUNXI,* and *CBL*).[20,21]

TABLE 42-6
Differential Diagnosis of Systemic Mastocytosis without Skin Lesions[a]

Gastrointestinal
- Peptic ulcer disease
- Ulcerative colitis
- Gluten-sensitive enteropathy
- Hepatitis
- Parasitic disease

Nonclonal Mast Cell Activation Syndrome
- Cardiovascular
- Idiopathic anaphylaxis
- Intrinsic cardiac disease
- Endocrine
- Adrenal tumor
- Vasoactive intestinal polypeptide tumor
- Carcinoid syndrome
- Medullary thyroid carcinoma
- Gastrinoma

Neoplastic/Oncologic
- Hypereosinophilic syndrome
- Lymphoma
- Myeloma
- Histiocytosis
- Bone tumor metastases
- Paget disease of the bone

[a]Some forms of mast cell disease may not show cutaneous manifestations. These include aggressive systemic mastocytosis, mast cell leukemia, systemic mastocytosis with an associated clonal hematologic non–mast-cell-lineage disease, and isolated bone marrow mastocytosis.

TREATMENT

The management of patients with mastocytosis includes counseling patients about the pathophysiology of their disease, avoidance of factors that provoke mast cell mediator release, and management of symptoms associated with these released mediators (Tables 42-7 and 42-8). Mastocytosis patients should be cautioned to avoid potential mast cell degranulating agents such as ingested alcohol, anticholinergic preparations, aspirin, NSAIDs, narcotics, and polymyxin B sulfate. In addition, heat and friction can induce local or systemic symptoms and should be avoided whenever possible. A number of systemic anesthetic agents, including systemic lidocaine, D-tubocurarine, metocurine, etomidate, thiopental, succinylcholine hydrochloride (suxamethonium chloride), enflurane, and isoflurane, have been directly or indirectly implicated in precipitating symptoms of mastocytosis. Recent reports indicate that fentanyl, sufentanil, remifentanil, paracetamol, midazolam, propofol, ketamine, desflurane, sevoflurane, *cis*-atracurium, pancuronium, and vecuronium bromide, are safe alternative systemic anesthetics for mastocytosis patients. It is recommended that mastocytosis patients undergoing general anesthesia be monitored postoperatively for

TABLE 42-7
Treatment of Cutaneous Mastocytosis

	TOPICAL	SYSTEMIC
First line	Topical glucocorticoids	Avoidance of triggering factors such as heat, friction, or drugs $H_1 \pm H_2$ antihistamines
Second line	Psoralen and ultraviolet A light (adults only)	Leukotriene antagonists or 5-lipoxygenase inhibitor
	Pulsed-dye laser for adult-type skin lesions and telangiectasia macularis eruptiva perstans	Oral cromolyn sodium Ketotifen
Third line	Intralesional corticosteroids Surgical excision (mastocytoma)	Omalizumab

TABLE 42-8
Treatment of Noncutaneous Mastocytosis Symptoms

	GASTROINTESTINAL	CARDIOVASCULAR	MUSCULOSKELETAL	HEMATOLOGIC
First line	H_2 antihistamines, oral cromolyn (children)	H_1 and H_2 antihistamines Subcutaneous epinephrine (anaphylaxis)	Calcium supplement ± vitamin D supplement	2-Chlorodeoxyadenosine
Second line	Proton pump inhibitors	Oral glucocorticoids (prophylaxis)	Bisphosphonates	Systemic chemotherapy appropriate for hematologic disorder
	Leukotriene antagonist		Nonsteroidal antiinflammatory drugs with caution	
	Anticholinergics			
Third line	Omalizumab Oral glucocorticoids	Omalizumab	Omalizumab Oral glucocorticoids Local radiation to bony lesions	Allogeneic stem cell transplantation

Note: Cytoreductive therapy is restricted to patients with aggressive variants of mastocytosis (systemic mastocytosis with an associated clonal hematologic non–mast-cell-lineage disease, aggressive systemic mastocytosis, and mast cell leukemia).

24 hours because delayed anaphylaxis can occur hours after surgery. In contrast to systemic anesthetics, local injections of lidocaine normally can be used safely in patients with mastocytosis unless there is a history of reaction.[56,57]

There is currently no generally recognized cure for mastocytosis, nor are there effective mast cell stabilizing drugs. Thus, treatment of milder forms of this disorder is focused, in great part, on symptomatic relief. In children and adults who are asymptomatic, no therapy is needed. Chronic administration of H_1 antihistamines is often helpful in reducing cutaneous and GI symptoms.[22,45] The second-generation H_1 antihistamines, cetirizine, loratadine, and fexofenadine, have distinct advantages over first-generation antihistamines because they have longer half-lives and have more specific activity on the H_1 receptor.[58] Higher-than-recommended doses of combined H_1 antihistamines may be required for symptom control. For example, fexofenadine 360 mg in the morning and up to 40 mg of cetirizine at night may be necessary for alleviating histamine-related symptoms. Doxepin, a tricyclic antidepressant, has potent H_1 activity and can be used when H_1 antihistamines have been ineffective. This agent, however, can cause cardiac QT interval prolongation and should be used with caution in older patients as well as those with a history of cardiac arrhythmias, renal insufficiency, or hepatic disease.[57] Both ketotifen and azelastine, antihistamines with potential mast cell–stabilizing properties, appear to be most beneficial in reliving GI symptoms associated with mastocytosis, but neither drug offers a significant advantage over a standard antihistamines.[58,59] H_2 antihistamines (cimetidine, ranitidine, famotidine, or nizatidine) may be beneficial in patients with symptoms of gastric acid hypersecretion and malabsorption, but also may assist in controlling pruritus, flushing, and wheal formation when administered with an H_1 agent.[22,45,58] If GI symptoms persist with the use of H_2 antihistamines, proton pump inhibitors may be effective secondary treatments.[45,58]

Disodium cromoglycate (cromolyn sodium) may have some efficacy in the treatment of mastocytosis, particularly in relieving GI complaints in children, but may require higher-than-recommended doses. Cromolyn sodium, however, does not lower plasma or urinary histamine levels in patients with mastocytosis.[60] Low-dose aspirin (500 mg twice daily) has been used successfully in some patients to reduce flushing, tachycardia, and syncope. However, aspirin must be used with extreme caution in patients with a history of NSAID intolerance, as it may cause vascular collapse in some patients with mastocytosis and exacerbate peptic ulcer disease.[61] Leukotriene inhibitors antagonize cysteinyl leukotriene receptors, and have been reported effective in controlling symptoms of flushing, diarrhea, abdominal cramping, and wheezing in mastocytosis patients.[62,63]

Omalizumab is a monoclonal antibody against immunoglobulin E that has proven effective in reducing or eliminating symptoms of mastocytosis in adults who are recalcitrant to antihistamines and leukotriene inhibitors. Effective doses range from 150 to 450 mg/month. Although this monthly therapy has proven effective in managing symptoms from mast cell mediator release, it requires continued administration because it does not reduce mast cell proliferation.[64-66]

Potent topical glucocorticoids applied daily under occlusion for 8 to 12 weeks reduces the number of cutaneous lesions. However, this therapy is impractical for patients with diffuse skin involvement, and lesions of mastocytosis recur with discontinuation of therapy.[67] Oral glucocorticoids may have some efficacy in patients with malabsorption, bone disease, abdominal pain, recurrent anaphylaxis, and ascites; this medication, however, should be reserved for patients with advanced disease, and tapered to the

lowest effective dose.[45,57,68] Osteoporosis should be treated with calcium and vitamin D supplementation along with bisphosphonates as needed to maintain normal bone density.[57,69]

Self-injectable epinephrine syringes should be prescribed for patients with a history of anaphylaxis. However, some experts recommend that all mastocytosis patients should carry preloaded epinephrine syringes with them regardless of their anaphylaxis history.[45,57] Patients prescribed epinephrine should be prepared to self-administer this drug, and have a plan for emergency management. If subcutaneous epinephrine is insufficient, intensive therapy for vascular collapse should be instituted in a hospital setting. Patients with recurrent episodes of anaphylaxis also should receive continuous H_1 and H_2 antihistamines to lessen the severity of attacks. Episodes of vascular collapse in mastocytosis patients may be spontaneous, but have also occurred after insect stings or after administration of iodinated contrast media. In the latter case, premedication with corticosteroids and antihistamines is recommended before such procedures.

Methoxypsoralen with ultraviolet A (PUVA) light can relieve pruritus and whealing after 1 to 2 months of treatment.[70,71] However, pruritus usually recurs within 3 to 6 months after PUVA discontinuation. Pigmentation induced by PUVA also may camouflage lesions of UP in some adult patients; however, this benefit must be weighed against the increased risk of skin cancers associated with long-term treatment.

Cytoreductive therapy should be considered in patients with SM-AHNMD, ASM, MCL, or mast cell sarcoma. The risk-to-benefit ratio must be carefully considered because of the dose-limiting toxicities of the various drugs. IFN-α may be considered for advanced SM. In 2 studies, IFN-α was most efficacious in ameliorating the signs and symptoms of mast cell disease; however, improvement was only transitory.[72,73] 2-Chlorodeoxyadenosine is efficacious in more advanced SM patients with an overall response rate of approximately 55%.[73,74] Even though this drug appears to be the treatment of choice in patients with advanced mastocytosis, myelosuppression may limit its use.[74]

Splenectomy may improve survival in patients with ASM that have a poor prognosis.[75] Radiotherapy has been used to treat refractory bone pain in advanced disease.[76]

More recently, patients with advanced SM (SM-AHNMD, ASM, and MCL) have been treated with allogeneic hematopoietic stem cell transplantation. In a retrospective review of 57 mastocytosis patients treated with allogeneic hematopoietic stem cell transplantation, 16 (28%) had a complete remission, whereas 12 (21%) had stable disease. All 38 patients with SM-AHNMD achieved complete remission for a time; however, 10 experienced a relapse and 5 died of their associated clonal hematologic non–mast-cell-lineage disease. Patients with stable disease and SM-AHNMD had a better overall survival than those with progressing mastocytosis or MCL. The overall survival at 1 and 3 years for the entire treatment group was 62% and 55%, respectively.[77]

Targeting the tyrosine kinase KIT has been another important strategy for treating patients with mastocytosis. The first-generation tyrosine kinase inhibitor, imatinib, however, has proven ineffective in patients expressing KIT D816 because it is unable to inhibit this mutated receptor.[78,79] Imatinib, however, has been reported to cure a mastocytosis patient who expressed only normal (wild-type) *c-kit*.[80] Second-generation tyrosine kinase inhibitors, dasatinib and nilotinib, inhibit the in vitro growth of D816V-expressing mast cell lines. However, these agents also have been disappointing in their ability to reduce the signs or symptoms in SM patients with the D816 mutation.[81-83] The multikinase inhibitor midostaurin, which inhibits both wild-type and mutated *c-kit*, has been used in patients with advanced SM. Among 116 advanced SM patients receiving this agent, there were no complete remissions, but 53 patients had some response to therapy. Patients with SM-AHNMD had the best response rate (75%) in contrast to MCL patients who responded the least (50%). Unfortunately, these responses were limited in duration.[84] Taken together, these observations along with the clinical heterogeneity of mastocytosis, strongly suggest that other molecular abnormalities, in addition to *c-kit* mutations, play an important role in this disease. Thus it appears that more effective future therapies will be based on the identification of additional altered genes.

REFERENCES

1. Lange M, Niedoszytko M, Renke J, et al. Clinical aspects of paediatric mastocytosis: a review of 101 cases. *J Eur Acad Dermatol Venereol.* 2013;27:97.
2. Meni C, Bruneau J, Gorgin-Lavialle S, et al. Paediatric mastocytosis: a systematic review of 1747 cases. *Br J Dermatol.* 2015;172:642.
3. Caplan RM. The natural course of urticaria pigmentosa. *Arch Dermatol.* 1963;87:146.
4. Heide R, Tank B, Oranje AP. Mastocytosis in childhood. *Pediatr Dermatol.* 2002;19:375.
5. Valent P, et al. In: Jaffe ES, Harris NL, Stein H, et al, eds. *World Health Organization Classification of Tumours: Pathology and Genetics of Tumours of the Haematopoietic and Lymphoid Tissues*. Lyon, France: IARC Press; 2001.
6. Cohen SS, Skovbo S, Vestergaard H, et al. Epidemiology of systemic mastocytosis in Denmark. *Br J Haematol.* 2014;166:521.
7. Noto G, Pravata G. Arico M. Concordant urticaria pigmentosa in a couple of identical twins. A five-year follow up. *Acta Derm Venereol.* 1995;75:499.
8. Gay MW, Noojin RO, Finely WH. Urticaria pigmentosa discordant in identical twins. *Arch Dermatol.* 1970;102:29.
9. Cainelli T, Marchesi L, Pasquali F, et al. Monozygotic twins discordant for cutaneous mastocytosis. *Arch Dermatol.* 1983;119:1021.
10. Rottem M, Okada T, Goff JP, et al. Mast cells cultured from the peripheral blood of normal donors and patients with mastocytosis originate from a CD34+/FcεRI- cell population. *Blood.* 1994;84:2489.
11. Anderson DM, Lyman SD, Baird A, et al. Molecular cloning of mast cell growth factor, a hematopoietin that

is active in both membrane bound and soluble forms. *Cell.* 1990;63:235.
12. Longley BJ, Tyrell L, Ma Y, et al. Chymase cleavage of stem cell factor yields a bioactive, soluble product. *Proc Natl Acad Sci U S A.* 1998;94:9017.
13. Kulka M, Metcalfe DD. High-resolution tracking of cell division demonstrates differential effects of TH1 and TH2 cytokines on SCF-dependent human mast cell production in vitro: correlation with apoptosis and Kit expression. *Blood.* 2005;105:592.
14. Lappalainen J, Lindstedt KA, Kovanen PT. A protocol for generating high numbers of mature and functional human mast cells from peripheral blood. *Clin Exp Allergy.* 2007;37:1404.
15. Longley BJ, Metcalfe DD, Tharp M, et al. Activating and dominant inactivating c-kit catalytic domain mutations in distinct clinical forms of human mastocytosis. *Proc Natl Acad Sci U S A.* 1999;96:1609.
16. Nagata H. kada T, Worobec A, et al. c-Kit mutation in a population of patients with mastocytosis. *Int Arch Allergy Immunol.* 1997;113:184.
17. Bodemer C, Hermine O, Pamerini F, et al. Pediatric mastocytosis is a clonal disease associated with D816V c-KIT mutations. *J Invest Dermatol.* 2010;130:804.
18. Ja CI, Tharp MD. Activating KIT mutations are not necessary for mastocytosis. *J Invest Dermatol.* 2016; 136:S64.
19. Zappulla JP, Dubreuil P, Desbois S, et al. Mastocytosis in mice expressing human Kit receptor with the activating Asp816Val mutation. *J Exp Med.* 2005;202:1635.
20. Damaj G, Joris M, Chandesris O, et al. ASXL1 but not TET2 mutations adversely impact overall survival of patients suffering systemic mastocytosis with associated clonal hematologic non mast cell diseases. *PLoS One.* 2014;9:e85362.
21. Schwaab J, Schnittger S, Sotlar K, et al. Comprehensive mutational profiling in advanced systemic mastocytosis. *Blood.* 201;122:2460.
22. Valent P, Akin C, Sperr W, et al. Mastocytosis: pathology, genetics and current options for therapy. *Leuk Lymphoma.* 2005;46:35.
23. Valent P, Sotlar K, Sperr WR, et al. Refined diagnostic criteria and classification of mast cell leukemia (MCL) and myelomastocytic leukemia (MML): a consensus proposal. *Ann Oncol.* 2014;25:1691.
24. Theoharides T, Valent P, Akin C. Mast cells, mastocytosis and related disorders. *N Engl J Med.* 2015;373:163.
25. Carter MC, Metcalfe DD, Komarow HD. Mastocytosis. *Immunol Allergy Clin North Am.* 2014;34:1.
26. Sagher F, Even-Paz Z. *Mastocytosis and the Mast Cell*. Chicago, IL: Yearbook Medical; 1967.
27. Kasper CS, Freeman R, Tharp MD. Diagnosis of mastocytosis subsets using a morphometric point counting technique. *Arch Dermatol.* 1987;123:1017.
28. Nabavi NS, Nejad MH, Feli S, et al. Adult onset xanthelasmoid mastocytosis: report of a rare entity. *Indian J Dermatol.* 2016;61:468.
29. Kasprowicz S, Chan IJ, Tharp MD. Nodular mastocytosis. *Arch Dermatol.* 2006;55:347.
30. Dubois AD. Mastocytosis and hymenoptera allergy. *Curr Opin Allergy Clin Immunol.* 2004;4:291.
31. Jensen RT. Gastrointestinal abnormalities and involvement in systemic mastocytosis. *Hematol Oncol Clin North Am.* 2000;14:579.
32. Topar G, Staudacher C, Geisen F, et al. Urticaria pigmentosa: a clinical, hematopathologic and serologic study of 30 adults. *Am J Clin Pathol.* 1998;109:279.
33. Sokol H, Georgin-Lavialle S, Canioni D, et al. Gastrointestinal manifestations in mastocytosis: a study of 83 patients. *J Allergy Clin Immunol.* 2013;132:866.
34. Mican JM, Di Bisceglie Am, Fong TL, et al. Hepatic involvement in mastocytosis: clinicopathologic correlations in 41 cases. *Hepatology.* 1995;22:1163.
35. Metcalfe DD. The liver, spleen and lymph nodes in mastocytosis. *J Invest Dermatol.* 1991;96:45S.
36. Lanternier F, Cohen-Akenine A, Palmerini F, et al. Phenotypic and genotypic characteristics of mastocytosis according to the age of onset. *PLoS One.* 2008;3(4):e1906.
37. Escribano L, Alvarez-Twose I, Sanchez-Munoz L, et al. Prognosis in adult indolent systemic mastocytosis: a long-term study of the Spanish Network on Mastocytosis in a series of 145 patients. *J Allergy Clin Immunol.* 2009;124:514.
38. Travis WD, Li C-Y. Pathology of the lymph node and spleen in systemic mast cell disease. *Mod Pathol.* 1986;1:4.
39. Travis W, Li CY, Bergstralh EJ, et al. Systemic mast cell disease. *Medicine (Baltimore).* 1988;67:345
40. Rossini M, Zanotti R, Viapiana O, et al. Bone involvement and osteoporosis in mastocytosis. *Immunol Allergy Clin North Am.* 2014;34:383.
41. Rogers MP, Bloomingdale K, Murawski BJ, et al. Mixed organic brain syndrome as a manifestation of systemic mastocytosis. *Psychosom Med.* 1986;48:437.
42. Ciach K, Niedoszytko M, Abacjew-Chmylko A, et al. Pregnancy and delivery in patients with mastocytosis treated at the Polish center of European Competence Network on Mastocytosis (ECNM). *PLoS One.* 2016;11(1):e0146924.
43. Worobec AS, Akin C, Scott LM, et al. Mastocytosis complicating pregnancy. *Obstet Gynecol.* 2000;95:391.
44. Matito A, Alvarez-Twose I, Morgado JM, et al. Clinical Impact of pregnancy in mastocytosis: a study of the Spanish Network of Mastocytosis (REMA) in 45 cases. *Int Arch Allergy Immunol.* 2011;156:104.
45. Escribano L, Akin C, Castells M, et al. Mastocytosis: current concepts in diagnosis and treatment. *Ann Hematol.* 2002;81:677.
46. Akin C, Krishenbaum AS, Semere T, et al. Analysis of the surface expression of c-kit and occurrence of the c-kit Asp816Val activating mutation in T cells, B cells, and myelomonocytic cells in patients with mastocytosis. *Exp Hematol.* 2000;28:140.
47. Schwartz LB, Sakai K, Bradford TI, et al. The alpha form of human tryptase is the predominant type present in blood at baseline in normal subjects and is elevated in those with systemic mastocytosis. *J Clin Invest.* 1995;96:2702.
48. Alvarez-Twose I, Vano-Galvan S, Sanchez-Munoz L, et al. Increased serum baseline tryptase levels and extensive skin involvement are predictors for the severity of mast cell activation in children with mastocytosis. *Allergy.* 2012;67:813.
49. Keyzer JJ, de Monchy JG, van Doormall JJ, et al. Improved diagnosis of mastocytosis by measurement of urinary histamine metabolites. *N Engl J Med.* 1983;309:1603.
50. Uzzaman A. Maric, I, Noel P, et al. Pediatric-onset mastocytosis: a long term clinical follow up and correlation with bone marrow histology. *Pediatr Blood Cancer.* 2009;53:629.
51. Doyle LA, Sepehr GJ, Hamilton MJ, et al. A clinicopathologic study of 24 cases of systemic mastocytosis

involving the gastrointestinal tract and assessment of mucosal mast cell density in irritable bowel syndrome and asymptomatic patients. *Am J Surg Pathol.* 2014;38:832.
52. Brockow K, Akin C, Huber M, et al. Levels of mast-cell growth factors in plasma and in suction skin blister fluid in adults with mastocytosis: correlation with dermal mast-cell numbers and mast-cell tryptase. *J Allergy Clin Immunol.* 2002;109:82.
53. Alvarez-Twose I, Gonzalez de Olano D, Sanchez-Munoz L, et al. Clinical, biological, and molecular characteristics of clonal mast cell disorders presenting with systemic mast cell activation symptoms. *J Allergy Clin Immunol.* 2010;125:1269.
54. Valent P. Mast cell activation syndromes: definition and classification. *Allergy.* 2013;68:417.
55. Brockow K, Scott LM, Worobec AS, et al. Regression of urticaria pigmentosa in adult patients with systemic mastocytosis: correlation with clinical patterns of disease. *Arch Dermatol.* 2002;138:785.
56. Konrad FM, Schroeder TH. Anaesthesia in patients with mastocytosis. *Acta Anaesthesiol Scand.* 2009;53;207.
57. Cardet JC, Akin C, Lee MJ, et al. Mastocytosis: update on pharmacotherapy and future directions. *Expert Opin Pharmacother.* 2013;14:2033.
58. Simons E, Akdis CA. Histamine and antihistamines. In: Busse W, Bochner B. Holgate S, et al, eds. *Middleton's Allergy: Principles and Practices*. Vol. 2. 7th ed. St. Louis, MO; Mosby; 2008:1517.
59. Kettelhut BV, Berkebile C, Bradely D, et al. A double-blind, placebo-controlled, crossover trial of ketotifen versus hydroxyzine in the treatment of pediatric mastocytosis [see comments]. *J Allergy Clin Immunol.* 1989;83:866.
60. Horan RF, Sheffer AL, Austen KF. Cromolyn sodium in the management of systemic mastocytosis. *J Allergy Clin Immunol.* 1990;85:852.
61. Butterfiedl JH. Survey of aspirin administration in systemic mastocytosis. *Prostaglandins Other Lipid Mediat.* 2009;88:122.
62. Tolar J, Tope, Neglia JP, et al. Leukotriene-receptor inhibition for the treatment of systemic mastocytosis. *N Engl J Med.* 2004;350:735.
63. Turner PJ, Kemp AS, Rogers M, et al. Refractory symptoms successfully treated with leukotriene inhibition in a child with systemic mastocytosis. *Pediatr Dermatol.* 2012;29:222.
64. Bell MC, Jackson DJ. Prevention of anaphylaxis related to mast cell activation syndrome with omalizumab. *Ann Allergy Asthma Immunol.* 2012;108:383.
65. Carter MC, Robyn JA, Bressler PB, et al. Omalizumab for the treatment of unprovoked anaphylaxis in patients with systemic mastocytosis. *J Allergy Clin Immunol.* 2007;119:1550.
66. Douglass JA, Carroll K, Voskamp A, et al. Omalizumab is effective in treating systemic mastocytosis in a non-atopic patient. *Allergy.* 2010;65:926.
67. Barton J, Lavker RM, Schechter NM, et al. Treatment of urticaria pigmentosa with corticosteroids. *Arch Dermatol.* 1985;121:1516.
68. Kurosawa M. Response to cyclosporin and low dose methylprednisone in aggressive systemic mastocytosis. *J Allergy Clin Immunol.* 1999;103:S412.
69. Lim AY, Ostor AJ, Love S, et al. Systemic mastocytosis; a rare cause of osteoporosis and its response to bisphosphonate treatment. *Ann Rheum Dis.* 2004;64:965.
70. Czarnetzki BM, Rosenbach T, Kolde G, et al. Phototherapy of urticaria pigmentosa: clinical response and changes of cutaneous reactivity, histamine and chemotactic leukotrienes. *Arch Dermatol Res.* 1985;277:105.
71. Vella Briffa D, Eady RA, James MP, et al. Photochemotherapy (PUVA) in the treatment of urticaria pigmentosa. *Br J Dermatol.* 1983;109:67.
72. Butterfield JH. Response of severe systemic mastocytosis to interferon alpha. *Br J Dermatol.* 1998;138:489.
73. Lim KH, Pardanani A, Butterfield JH, et al. Cytoreductive therapy in 108 adults with systemic mastocytosis: outcome analysis and response predication during treatment with interferon-alpha, hydroxyurea, imatinib mesylate or 2-chlorodeoxyadenosine. *Am J Hematol.* 2009;84:790.
74. Pardanani A, Hoffbrand AV, Butterfield JH, et al. Treatment of systemic mast cell disease with 2-chlorodeoxyadenosine. *Leuk Res.* 2004;28;127.
75. Friedman B, Darling G, Norton J, et al. Splenectomy in the management of systemic mast cell disease. *Surgery.* 1990;107:94.
76. Johnstone PA, Macan JM, Metcalfe DD, et al. Radiotherapy of refractory bone pain due to systemic mast cell disease. *Am J Clin Oncol.* 1994;17:328.
77. Ustun C, Reiter A, Scott BL, et al. Hematopoietic stem-cell transplantation for advanced systemic mastocytosis. *J Clin Oncol.* 2014;32:3264.
78. Akin C, Fumo G, Yavuz AS, et al. A novel form of mastocytosis associated with a transmembrane c-kit mutation and response to imatinib. *Blood.* 2004;103:3222.
79. Vega-Ruiz A, Cortes JE, Sever M, et al. Phase II study of imatinib mesylate as therapy for patients with systemic mastocytosis. *Leuk Res.* 2009;33;1481.
80. Valent P, Cerny-Reiterer S, Hoermann G, et al. Long-lasting complete response to imatinib in a patient with systemic mastocytosis exhibiting wild type KIT. *Am J Blood Res.* 2014;4:93.
81. Purtill D, Cooney J, Sinniah R, et al. Dasatinib therapy for systemic mastocytosis: four cases. *Eur J Haematol.* 2008;80;456.
82. Hochhaus A, Baccarani M, Giles FJ, et al. Nilotinib in patients with systemic mastocytosis: analysis of the phase 2, open-label, single-arm nilotinib registration study. *J Cancer Res Clin Oncol.* 2015;141:2047.
83. Verstovsek S, Tefferi, A, Cortes J, et al. Phase II study of dasatinib in Philadelphia chromosome-negative acute and chronic myeloid diseases, including systemic mastocytosis. *Clin Cancer Res.* 2008;14:3906.
84. Gotlib J, Kluin-Nelemans HC, George TI, et al. Efficacy and safety of midostaurin in advanced systemic mastocytosis. *N Engl J Med.* 2016;374:2530.

Reactive Erythemas

PART 7

Chapter 43 :: Erythema Multiforme

:: Jean-Claude Roujeau & Maja Mockenhaupt

AT-A-GLANCE

- Erythema multiforme is a rare cutaneous or mucocutaneous eruption characterized by "target" lesions, predominantly on the face and extremities.
- The highest incidence was found in male children and young adults.
- It has a benign course but frequent recurrences, possible ocular complications.
- Most cases are related to infections (herpes simplex virus [HSV] and *Mycoplasma pneumoniae*). Medications are *not* a common cause, in contrast to the spectrum of drug-induced epidermal necrolysis (see Chap. 44) that are different diseases.
- Herpes-induced recurrences can be prevented by long-term use of anti-HSV medications. Thalidomide, mycophenolate mofetil, or both may be considered in recalcitrant, recurrent cases.

INTRODUCTION

DEFINITIONS

Erythema multiforme (EM) is an acute mucocutaneous syndrome originally described by von Hebra in 1860 as *erythema exudativum multiforme*. It is defined by a distinctive clinical pattern (with consistent histopathology when done). The course is usually mild and self-limited but carries a risk of relapse. Based on the degree of mucous membrane involvement, EM is separated into EM minus (EMm, also called EM minor) if only the skin and lips are involved and EM majus (EMM, also called EM major) when mucous membranes are affected. Subtypes of EM are described in Table 43-1.

Historically, a variety of factors have contributed to a confusing nosology, especially with the concept of a so-called "EM spectrum" from EMm to Stevens-Johnson syndrome (SJS) and toxic epidermal necrolysis (TEN). The definition of EM in this chapter is based on the classification proposed 25 years ago by Bastuji-Garin and colleagues.[1] The principle of the classification was to consider SJS and TEN as severity variants of a process termed *epithelial necrolysis* (EN; see Chap. 44) and to separate them from EM. The validity of that classification has been established by several studies, especially the prospective international Severe Cutaneous Adverse Reactions study[2] and by recent series[3,4] showing that compared with SJS and TEN, EM cases have different demographic features, clinical presentation, severity, and causes.

The consensus classification was improved by German investigators by separation of EMM into *typical EMM* (typical targets on the extremities) and *atypical EMM* with more extensive distribution of atypical, larger targets, occasionally involving the skin around the mouth and the eyes, resulting in clown-like facies. The relevance of that subclassification was supported by the demonstration of younger age and more frequent association with *Mycoplasma pneumoniae* infection in cases of atypical EMM.[5]

Cases of mucosal disease with target lesions on the trunk are often diagnosed as SJS or *M. pneumoniae*–associated SJS, especially in the pediatric realm. However, we consider these cases EMM caused by *M. pneumoniae*. Other authors have proposed that mucocutaneous eruptions associated with *M. pneumoniae* are a distinct entity, termed *M. pneumoniae*-induced rash and mucositis (MIRM).[4] It is certainly true that EMM and the range of presentations of EN have to be differentiated, no matter what the cause. It is also true that typical EMM associated with herpes simplex virus (HSV) presents differently than atypical EMM

TABLE 43-1
Erythema Multiforme (EM) Subtypes

SUBTYPE	CLINICAL FEATURES	ASSOCIATED ETIOLOGY
EM minus (EMm)	Typical targets Acral skin and lip involvement No mucosal erosions	HSV, other infections
EM majus (EMM)	Typical targets Acral skin involvement Mucosal erosions	HSV, other infections
Atypical EMM	Giant targets Central distribution Prominent mucosal erosions	*Mycoplasma pneumoniae*, HSV
Mucosal EMM	No or minimal skin lesions Prominent mucosal erosions	*M. pneumoniae*
Continuous or persistent EM	Typical targets Acral skin involvement Few mucosal erosions Overlapping recurrences	HSV, idiopathic

HSV, herpes simplex virus.

associated with *M. pneumoniae*, but we do not consider atypical EMM a distinct entity.

Atypical EMM may present in a variety of forms, sometimes predominantly affecting the skin and sometimes predominantly affecting two or more mucosal sites. If only the mucous membranes are involved, making the correct diagnosis may be a challenge. In 1878, the ophthalmologist Fuchs described a patient with erosions of the eyes and mouth and a transient skin eruption. The term *Fuchs syndrome* (also called ectodermosis pluriorificialis) has been applied to such cases that share demographic and etiologic features with atypical EMM. The term *mucosal EMM*, a subset of atypical EMM, is now preferred.

Unfortunately, the International Classification of Diseases 10th Revision (ICD-10) did not incorporate these advances and uses the same code, L51.1, for SJS and bullous EM, and classifies TEN as L51.2 under the heading of EM (L51). Nonspecific codes maintain the confusion of a so-called "EM spectrum" despite the accumulation of evidence of different mechanisms, clinical presentations, severity, and causes of EM versus SJS-TEN.[2-4]

EPIDEMIOLOGY

EM is considered relatively common, but the true incidence is unknown. There is selection bias for severe cases requiring hospitalization in the medical literature; such cases are rare and occur in the range of 0.5 to 1 per million per year.[6] EMm is likely more frequent than EMM. Another obstacle to proper evaluation of incidence is the misdiagnosis of EM in patients with annular or figurate eruptions, including annular urticaria, serum sickness–like eruption, polymorphous maculopapular eruptions,[7] subacute cutaneous lupus erythematosus,[8] and even SJS or TEN.[7]

EM occurs in patients of all ages but is most prevalent in adolescents and young adults. There is a male preponderance (male:female ratio of 2 to 3:1). Recurrence happens in about 10% of patients with EMM and up to 30% in EMm, more frequently, but not exclusively, in HSV-associated cases.

There are no established associations of underlying disease with risk for EM. HIV infection and collagen vascular disorders increase the risk of SJS and TEN but not EM. Cases may occur in clusters, which supports a role for infectious agents. The incidence does not vary with ethnicity or geographic location.

Predisposing genes have been reported. A total of 66% of EM patients have HLA-DQB1*0301 allele compared with 31% of control participants.[9] However, this association has not translated into a meaningful clinical test or intervention.

CLINICAL FEATURES

HISTORY

Prodromal symptoms are absent in most cases. If present, they are usually mild, suggesting an upper respiratory infection (cough, rhinitis, low-grade fever). In EMM, fever higher than 38.5°C (101.3°F) is present in one third of cases.[2] Prior occurrences are reported in up to one third of patients and help make the correct diagnosis. The events of the preceding 3 weeks should be reviewed for clinical evidence of any precipitating agent, with a special focus on signs and symptoms of HSV and symptoms of respiratory infection or influenza-like illness.

In more than 70% of patients with recurrent EM, an episode of recurrent HSV infection precedes the skin lesions. The association with herpes labialis predominates over that with genital herpes or herpes in other locations. EM usually follows recurrent herpes but may also occur after primary HSV infection. The average interval is 7 days (range, 2–17 days). The duration of the lag period appears to be specific for individual patients. In a small number of patients, HSV recrudescence and EM may occur simultaneously. Not all episodes of EM are preceded by clinically evident HSV, and not all HSV episodes are followed by EM. Episodes of recurrent HSV infection may precede the development of HSV-related EM by years.

CUTANEOUS FEATURES

The skin eruption arises abruptly. In most patients, all lesions appear within 3 days, but in some, several crops follow each other during a single episode of EM. Often there are a limited number of lesions, but up to hundreds may form. Most occur in a symmetric, distribution on the extensor surfaces of the extremities (hands, feet, elbows, and knees), face, and neck and less frequently on the thighs, buttocks, and trunk. Lesions often first appear distally and then spread in

Figure 43-1 Mixture of typical targets and papules in a case of erythema multiforme.

a centripetal manner. Mechanical factors (Koebner phenomenon) and actinic factors (predilection for sun-exposed sites) appear to influence the distribution of lesions. Although patients occasionally report burning and itching, the eruption is usually asymptomatic.

The diversity in clinical pattern implied by the name *multiforme* is mainly related to the *features of single lesions*. Most lesions are usually very similar in a given patient at a given time. The typical target lesion is a highly regular, circular, wheal-like erythematous papule or plaque that persists for 1 week or longer (Fig. 43-1). It measures from a few millimeters to approximately 3 cm and may expand slightly over 24 to 48 hours. Although the periphery remains erythematous and edematous, the center becomes violaceous and dark; inflammatory activity may regress or relapse in the center, which gives rise to concentric rings of color (see Figs. 43-1 to 43-4). Often, the center turns

Figure 43-2 Typical target lesions on the palm.

Figure 43-3 Typical targets around the knee.

Figure 43-4 Disseminated targets on the trunk (atypical erythema multiforme majus).

Figure 43-5 Giant targets on the arm (atypical erythema multiforme majus).

purpuric or necrotic or transforms into a tense vesicle or bulla. The result is the classic target or iris lesion.

According to the current classification,[1,5] typical target lesions consist of at least three concentric components: (1) a dusky central disk or blister; (2) more peripherally, an infiltrated pale ring; and (3) an erythematous halo. Not all lesions of EM are typical; some display two rings only (raised atypical targets). However, all are infiltrated papules, in contrast to macules, which are the typical lesions in EN (SJS and TEN). In some patients with EM, most lesions are violaceous vesicles overlying a just slightly darker central portion, encircled by an erythematous margin (see Figs. 43-2 to 43-4). Larger lesions (Fig. 43-5) may have a central bulla and a marginal ring of vesicles (herpes iris of Bateman).

In most cases, EM affects well under 10% of the body surface area. In 88 hospital cases of EMM prospectively included in the Severe Cutaneous Adverse Reactions study, the median involvement was 1% of the body surface area.[2] The duration of an individual lesion is shorter than 2 weeks, but residual discoloration may remain for months. There is no scarring unless mechanical manipulation takes place.

NONCUTANEOUS FEATURES

Mucosal lesions are present in up to 70% of patients, most often limited to the oral cavity.

Predilection sites are the lips, on both the cutaneous and mucosal sides, nonattached gingivae, and the ventral side of the tongue. The hard palate is usually spared, as are the attached gingivae. On the cutaneous part of the lips, identifiable target lesions may be discernible (Fig. 43-6). In children and adolescents, lips and oral mucosa are often affected very severely both in cases caused by *M. pneumoniae* or by respiratory infections caused by unspecified infectious agents. On the mucosa proper, there are erosions with fibrinous deposits, and occasionally intact vesicles and bullae can be seen (Fig. 43-7). The process may rarely extend to the throat, larynx, and even the trachea and bronchi.

Eye involvement begins with pain and bilateral conjunctivitis in which vesicles and erosions can occur (Fig. 43-8). In children, ocular lesions appear to be more

Figure 43-6 Involvement of the lips with a target pattern in erythema multiforme majus.

frequent and more severe in *M. pneumoniae*–associated cases.[10] The nasal, urethral, and anal mucosae also may be inflamed and eroded.

RELATED PHYSICAL FINDINGS

Fever and other constitutional symptoms are usually absent in EMm, and the noncutaneous physical examination is normal. Fever higher than 38.5°C (101.3°F) is present in one third of EMM cases. Mouth erosions may be painful enough to impair alimentation. The patient may be unable to close the mouth and constantly drools blood-stained saliva. Cervical lymphadenopathy is usually present in these patients. The pain of genital erosions may lead to reflex urinary retention. Cough and hypoxia may occur in *M. pneumoniae*–related cases.

COMPLICATIONS

In contrast to SJS, in which cutaneous lesions may progress to extensive detachment of the epidermis, there is no risk of "skin failure" or visceral involvement

Figure 43-7 Oral erosions in erythema multiforme majus.

Figure 43-8 Conjunctivitis with erosions in erythema multiforme majus.

in EMM. Mouth erosions may impair oral alimentation. Reflex anuria from periurethral erosions rarely needs bladder catheterization. Severe ocular lesions leading to sequelae are rare but can occur, and ocular symptoms must be checked by an ophthalmologist in the acute phase of the disease and followed appropriately.[10]

ETIOLOGY AND PATHOGENESIS

Most cases of EM are related to infections (Table 43-2). HSV is the most common cause, principally in recurrent cases. Proof of causality of HSV is firmly established from clinical experience, epidemiology,[2] detection of HSV DNA in the lesions of EM,[11,12] and prevention of EM by suppression of HSV recurrences.[13] Clinically, a link with HSV can often be made. EM eruptions begin on average 7 days after HSV eruptions. The delay can be substantially shorter, especially with more recurrences. Not all symptomatic HSV recurrences are followed by EM, and asymptomatic ones can induce EM. Therefore, the causal link can be overlooked by both the patient and physician. HSV-1 is usually the cause, but HSV-2 can also induce EM.

M. pneumoniae is the second major cause of EM overall and the first in children.[5,14] In cases related to *M. pneumoniae*, the clinical presentation is often atypical (giant targets, clown-like facial distribution) and more severe than in cases associated with HSV. The relationship to *M. pneumoniae* is often difficult to establish. Clinical and radiologic signs of atypical pneumonia can be mild, and *M. pneumoniae* is usually not directly detected. Polymerase chain reaction (PCR) testing of throat swabs, or bronchopulmonary lavage if performed, for *M. pneumoniae* is the most sensitive technique for diagnostic confirmation. Serologic results are considered diagnostic in the presence of IgM or IgA antibodies to *M. pneumoniae* in the acute phase or a more than twofold increase in IgG antibodies in paired serum samples obtained at onset and after 2 or 3 weeks. *M. pneumoniae*–related EM can recur.

Many other infections have been reported as causes of EM in individual cases or small series, but the evidence for causality of these other agents is only circumstantial. Published reports have implicated infection with EBV, Orf virus, varicella zoster virus, parvovirus B19, hepatitis B and C viruses, and a variety of other bacterial or viral infections. Immunization has been also implicated as a cause in children, but a spurious association can be suspected.

Drugs are also a reported cause of EM, although a true association is unlikely. Most reports of drug-associated EM actually deal with imitators,[7] for example, annular urticaria (also called urticaria multiforme)[15] or disseminated maculopapular eruptions with some lesions resembling targets (Fig. 43-9). EM-like dermatitis may also result from contact sensitization. These eruptions should be viewed as imitators of EM despite some clinical and histopathologic

TABLE 43-2

Conditions Commonly Associated with Erythema Multiforme

Herpes simplex virus
Mycoplasma pneumoniae
Epstein-Barr virus
Orf
Varicella zoster virus
Parvovirus B19
Hepatitis B
Hepatitis C

Figure 43-9 Figurate erythema in a case of "drug eruption" to amoxicillin, frequently and erroneously reported as drug-induced erythema multiforme.

similarities. Literature reports of drug-associated EM also include typical cases of SJS or TEN, particularly under the moniker EMPACT syndrome (EM, phenytoin and cranial radiation therapy).[7] Such terms create more confusion on EM and minimize the potential severity of drug reactions.

Idiopathic cases are those in which neither HSV infection nor any other cause can be identified. These cases are fairly common in routine clinical circumstances. However, HSV has been found in situ by PCR in up to 40% of such presentations.[3] Some idiopathic cases respond to prophylactic antiviral treatment and are thus likely to have been triggered by asymptomatic HSV infection. Others are resistant and probably have another cause.

Another suspected variant of recurrent EMM was reported to be associated with desmoplakin I and II autoantibodies.[16] However, the presence of acantholysis in skin biopsies of such cases suggests a variant of pemphigus that clinically resembles EM. The recently reported efficacy of rituximab in such cases also supports this hypothesis.[17] Conversely, in a series of 54 cases of typical EMM, antiepidermal antibodies were not found.[18]

The underlying mechanisms of HSV-associated EM have been extensively investigated.[11,13,19,20] It is unknown whether similar mechanisms apply to EM from other causes.

Complete, infective HSV has never been isolated from lesions of HSV-associated EM, but the presence of HSV DNA in skin lesions has been reported in numerous studies using PCR assays. These studies demonstrated that keratinocytes contain viral DNA fragments that always include the viral polymerase (*Pol*) gene. HSV Pol DNA is located in basal keratinocytes and in the lower spinous cell layers, and viral Pol protein is synthesized. HSV-specific T cells, including cytotoxic cells, are recruited, and the virus-specific response is followed by a nonspecific inflammatory amplification by autoreactive T cells. The cytokines produced in these cells induce the delayed hypersensitivity–like appearance in histopathologic evaluation of biopsy sections of EM lesions.

HSV is present in the blood for a few days during an overt recurrence of herpes. If keratinocytes were infected from viremia, one would expect signs and symptoms of disseminated herpes rather than EM. Instead, HSV DNA is transported to the epidermis by monocytes, macrophages, and $CD34^+$ Langerhans cell precursors harboring the skin-homing receptor cutaneous lymphocyte antigen that engulf the virus and fragment its DNA. Upregulation of adhesion molecules greatly increases binding of HSV-containing mononuclear cells to endothelial cells and contributes to the dermal inflammatory response. Upon reaching the epidermis, the cells transmit the viral polymerase gene *Pol* to keratinocytes. Viral genes may persist for a few months, but the synthesis and expression of the Pol protein will last for only a few days. This may explain the transient character of clinical lesions that are likely induced by a specific immune response to Pol protein and amplified by autoreactive cells. Effector cells are CD4 T lymphocytes with a restricted Vβ repertoire. Incomplete fragmentation of viral DNA, increased number of circulating $CD34^+$ cells, or increased immune response to Pol protein characterize the small proportion of individuals with recurrent herpes infections who develop EM.

DIAGNOSIS

An approach to the diagnosis and management of EM is shown in Fig. 43-10. EM is usually diagnosed clinically. A skin biopsy and laboratory investigations are useful when the diagnosis is not certain. After making the diagnosis, the need for hospitalization is considered. Admission is suggested for patients with EMM with oral lesions severe enough to impair drinking and feeding, when a diagnosis of SJS is suspected, or when severe constitutional symptoms are present. Establishing the underlying cause of EM is also part of the evaluation.

SUPPORTIVE STUDIES

LABORATORY

There are no specific laboratory tests for EM. In more severe cases, an elevated erythrocyte sedimentation rate, moderate leukocytosis, increased levels of acute-phase proteins, and mildly elevated liver aminotransferase levels may occur. Antidesmoplakin antibodies are not found.[18]

HISTOPATHOLOGY

Early lesions of EM exhibit lymphocyte accumulation at the dermal–epidermal interface with exocytosis into the epidermis, lymphocytes attached to scattered necrotic keratinocytes (satellite cell necrosis), spongiosis, vacuolar degeneration of the basal cell layer, and focal junctional and subepidermal cleft formation. Acantholysis is not a feature of EM. The papillary dermis may be edematous but principally contains a moderate to dense mononuclear cell infiltrate, which is more abundant in older lesions. The vessels are ectatic with swollen endothelial cells, and there may be extravasated erythrocytes and eosinophils. In advanced lesions, subepidermal blister formation may occur, but necrosis rarely involves the entire epidermis (Fig. 43-11). In late lesions, melanophages may be prominent. Immunofluorescence findings are negative or nonspecific.

The histopathologic appearance of EM lesions differs from that of EN, in which dermal inflammation is moderate to absent and epidermal necrosis is much more pronounced (see Chap. 44). Still, the histopathologic appearances are somewhat overlapping and often do not allow the distinction of EM from EN, especially if the sample is obtained from the bullous center of the lesion. The main reason for performing

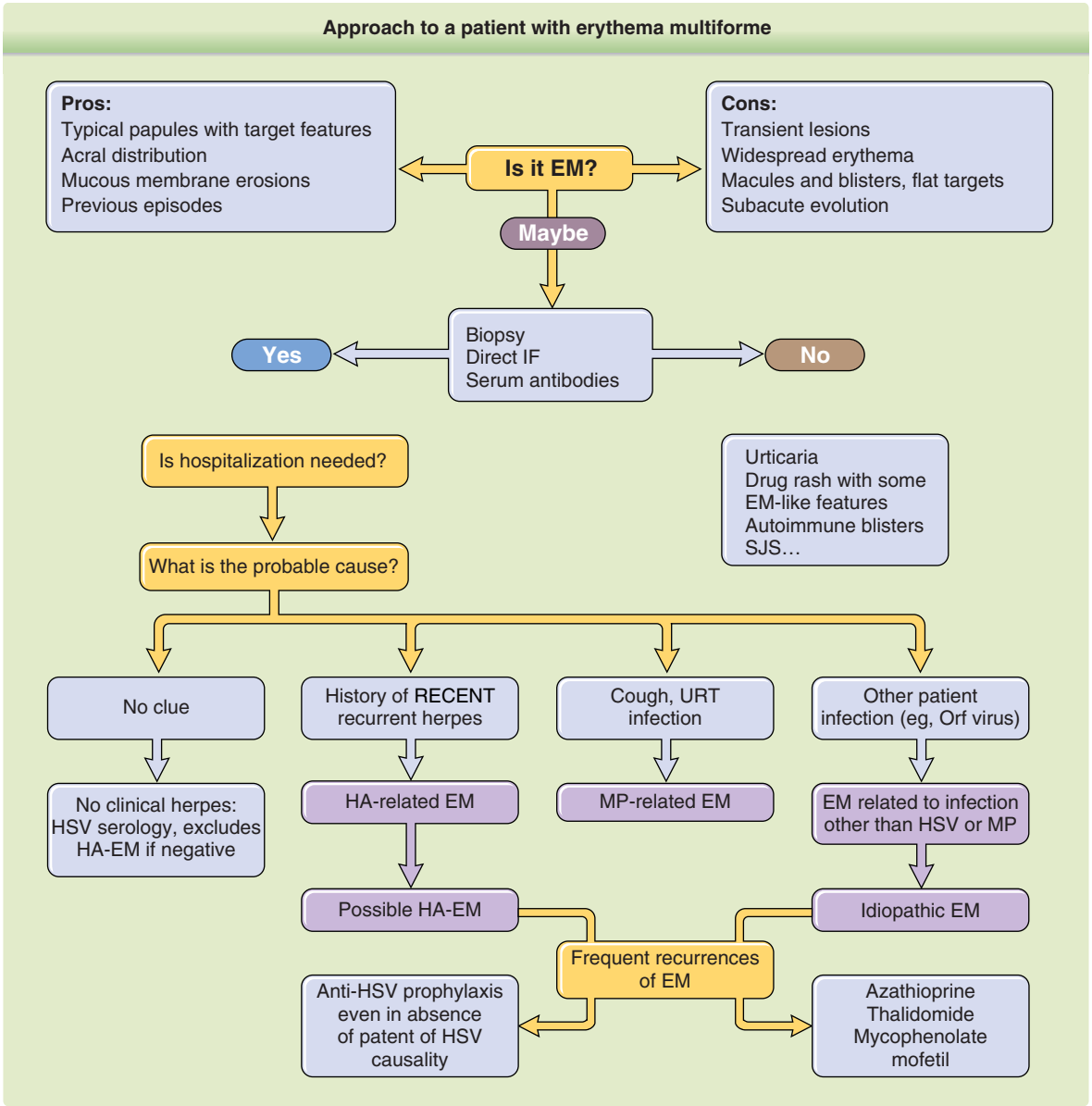

Figure 43-10 Approach to a patient with erythema multiforme (EM). ADR, adverse drug reaction; HA-EM, herpes-associated erythema multiforme; IF, immunofluorescence; MP, *Mycoplasma pneumoniae*; SJS, Stevens-Johnson syndrome; URT, upper respiratory tract.

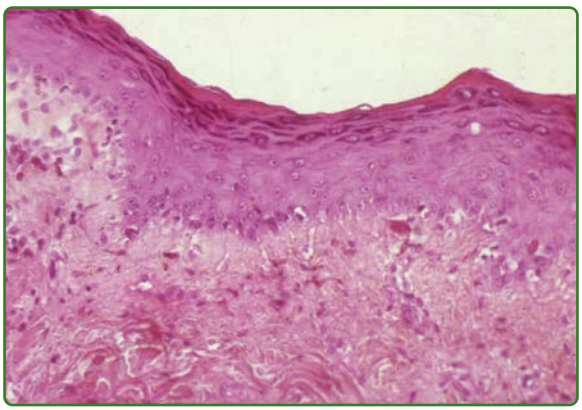

Figure 43-11 Histopathology of erythema multiforme.

a biopsy in EM is to rule out other diagnoses, such as autoimmune blistering diseases, Sweet syndrome, and vasculitis.

UNDERLYING ETIOLOGY

In the presence of respiratory symptoms, a chest radiograph is indicated to evaluate for pneumonia, and PCR assay or serologic testing may help detect *M. pneumoniae* infection. In the case of recurrent EM, a link to HSV can be confirmed by evaluating preceding lesions of herpes labialis using HSV PCR, direct fluorescent antibodies, or viral culture. However, these studies are not useful when applied to the target lesions. Amplification of HSV *Pol* gene from biopsy

samples of EM lesions is not done routinely. A negative result on serologic testing for HSV may be helpful only to exclude the possibility of herpes-association. The positive predictive value of the presence of HLA-DQB1*0301 is too low to have clinical value.

DIFFERENTIAL DIAGNOSIS

The differential diagnosis of EM is reviewed in Table 43-3.

The most important differential diagnosis, SJS, should be recognized promptly for three reasons: (1) the possibility of life-threatening complications, (2) the risk of progression to TEN, and (3) the need for urgent withdrawal of suspected causative drug(s) (see Chap. 44). Pain, constitutional symptoms, severe erosions of mucosae, rapid progression, and dusky or violaceous often confluent macules and blisters are alerting features.

In rare cases of EM affecting only mucous membranes, the diagnosis is especially difficult and often made when further bouts include a few skin lesions. The history is extremely important, especially related to infections and recurrence. Pemphigus, cicatricial pemphigoid, allergic or toxic contact stomatitis, toxic erosive stomatitis, aphthae, and lichen planus should be considered.

COURSE AND PROGNOSIS

EMm runs a mild course in most cases, and each individual attack subsides within 1 to 4 weeks. Recovery is complete, and there are usually no sequelae, except for transient skin discoloration. The ocular erosions of EMM may cause severe residual scarring of the eyes, especially in adults and in non–herpes-related cases.[21] *M. pneumoniae*–related EMM may be associated with severe erosive bronchitis that may rarely lead to sequelae.[22]

Whatever the cause of EM, recurrences are common and may characterize the majority of cases. In reports of large series of patients with recurrent EM, the mean number of attacks was 6 per year (range, 2 to 36), and the mean total duration of disease was 6 to 9 years. In 33%, the condition persisted for more than 10 years.[23] Up to 50 recurrences have been described in a single patient. The severity of episodes in patients with recurrent EM is highly variable and unpredictable. The frequency of episodes and cumulative duration of disease are not correlated with the severity of attacks. The frequency and severity of recurrent EM tends to decrease spontaneously over time (after 2 years or longer), parallel with the improvement of recurring HSV infection when associated. In a substantial proportion of recurrent cases, a cause cannot be determined.[24] A small fraction of patients experience prolonged series of overlapping attacks of EM; this has been *labeled continuous EM* or *persistent EM*.[25] Persistent EM may be related to HSV but also to other viral infections, inflammatory bowel diseases, or malignancy.

MANAGEMENT

Based on retrospective series or small controlled trials, the use of systemic corticosteroids seems to shorten the duration of fever and eruption, especially swelling and pain of the mucosae but may increase the length of hospitalization because of complications. However, the methodology of most studies was poor, with small series often mixing the various forms of idiopathic and virus-associated EM and drug-induced SJS. The use of systemic corticosteroids can neither be recommended nor blamed.[20,26]

Administering anti-HSV drugs for the treatment of an established episode of postherpetic EM is useless.[27]

When symptomatic, patients with *M. pneumoniae* infection should be treated with antibiotics (macrolides in children; macrolides or quinolones in adults). There is no evidence indicating whether it improves the evolution of the associated EM. Therefore, when asymptomatic infection is diagnosed by PCR or serologic testing, treatment is not mandatory.

Liquid antacids, topical glucocorticoids, and local anesthetics relieve symptoms of painful mouth or genital erosions. In case of eye involvement, an ocular lubricant should be administered at least three times a day, and topical steroids may be recommended by the ophthalmologist. There are no specific studies on the use of amniotic membrane in EMM cases with eye involvement. However, a number of patients considered to have SJS who were treated successfully with amniotic grafts may have actually had EMM. Because the mucosal involvement is the same in EMM and SJS, grafting of amniotic membrane in EMM cases with severe eye involvement should be helpful.

PREVENTION

Continuous therapy with oral anti-HSV drugs is effective at preventing recurrences of herpes-associated EM, including some cases without clinical evidence of precipitating HSV.[13] Topical acyclovir therapy used in a prophylactic manner does not prevent recurrent herpes-associated EM.[28]

In a series of 65 patients with recurrent EM, 11 were treated with azathioprine when all other treatments had failed. Azathioprine was beneficial in all 11 patients.[23] Mycophenolate mofetil can be also useful.

Retrospective uncontrolled analyses of thalidomide therapy have indicated that it is moderately effective for the treatment of established EM.[29] Thalidomide is probably the most effective treatment of recurrent or persistent cases when anti-HSV drugs have failed.[30,31]

In one randomized controlled trial, levamisole appeared useful. Because agranulocytosis is a severe and not exceptional adverse effect, levamisole use is permitted in only a few countries. The benefit–risk ratio is probably too low to support its use in the treatment of EM.

TABLE 43-3

Differential Diagnoses of Erythema Multiforme (EM)

	MUCOUS MEMBRANE LESIONS	SKIN LESIONS PATTERN	HISTOPATHOLOGIC FINDINGS	LABORATORY TESTING	COURSE
Urticaria	No	Annular, circinate, blanching erythema Transient lesions (individual lesions last ≤24 hr)	Edema		More acute than EM
Maculopapular drug eruption	Rare (lips)	Widespread polymorphous, targetlike lesions, macules, papules, plaques	Most often nonspecific		
Lupus erythematosus ("Rowell syndrome")	Possible (mouth)	Face and thorax Large targetlike lesions, annular plaques	Interface dermatitis Positive result of DIF ("lupus band")	Antinuclear antibodies present	Subacute
Paraneoplastic pemphigus	Always; tends to be severe	EM-like lesion plus lichenoid papules Positive Nikolsky sign	Acantholysis, positive DIF	Antibodies present (not always)	Chronic
Cicatricial pemphigoid	Constant	Circinate erythematous patches	Subepidermal blister, positive DIF	Antibodies present	Chronic
Bullous pemphigoid (BP)/IgA-linear dermatosis	Possible in BP; rare in IgA-linear dermatosis	Bullae and crusts in different stages	Subepidermal blister, positive DIF	Antibodies present	Chronic (or relapsing)
Antidesmoplakin "EM majus"	Constant	EM-like lesions	Basal acantholysis, positive DIF	Antibodies present	Acute relapsing
Stevens-Johnson syndrome	Constant	Widespread small blisters Atypical targets, typically confluent Constitutional symptoms	Interface dermatitis, epidermal necrosis		Acute
Sweet syndrome (acute febrile neutrophilic dermatosis)	Rare	Erythematous papules and succulent plaques	Spongiosis with subcorneal vesicles and pustules	Neutrophilia	Acute

DIF, direct immunofluorescence testing; IgA, immunoglobulin A.

REFERENCES

1. Bastuji-Garin S, Rzany B, Stern RS, S et al. A clinical classification of cases of toxic epidermal necrolysis, Stevens-Johnson syndrome and erythema multiforme. *Arch Dermatol*. 1993;129:92.
2. Auquier-Dunant A, Mockenhaupt M, Naldi L, et al. Correlations between clinical patterns and causes of erythema multiforme majus, Stevens-Johnson syndrome and toxic epidermal necrolysis. *Arch Dermatol*. 2002;138:1019.
3. Wetter DA, Camilleri RJ. Clinical, etiologic and histopathologic features of Stevens-Johnson syndrome during an 8-year period at Mayo Clinic. *Mayo Clin Proc*. 2010;85:131.
4. Canavan TN, Mathes EF, Frieden I, et al. Mycoplasma pneumoniae-induced rash and mucositis as a syndrome distinct from Stevens-Johnson syndrome and erythema multiforme: a systematic review. *J Am Acad Dermatol*. 2015;72:23.
5. Schröder W, Mockenhaupt M, Schlingmann J, et al. Clinical re-classification of severe skin reactions and evaluation of their etiology in a population-based registry. In: Victor N, et al, eds. *Medical Informatics, Biostatistics and Epidemiology for Efficient Health Care and Medical Research: Contributions from the 44th Annual Conference of the GMDS*. Heidelberg: Urban & Vogel; 1999:107-110.
6. Rzany B, Mockenhaupt M, Baur S, et al. Epidemiology of erythema exsudativum multiforme majus, Stevens-Johnson syndrome, and toxic epidermal necrolysis in Germany (1990-1992): structure and results of a population-based registry. *J Clin Epidemiol*. 1996;49:769.
7. Roujeau JC. Re-evaluation of "drug-induced" erythema multiforme in the medical literature. *Br J Dermatol*. 2016;175(3):650-651.
8. Bonciolini V, Antiga E, Caproni M, et al. Rowell syndrome. Does it exist? *Clin Exp Dermatol*. 2014;39:58.
9. Khalil I, Lepage V, Douay C, et al. HLA DQB1*0301 allele is involved in the susceptibility to erythema multiforme. *J Invest Dermatol*. 1991;97:697.
10. Moreau JF, Watson RS, Hartman ME, et al. Epidemiology of ophthalmologic disease associated with erythema multiforme, Stevens-Johnson syndrome, and toxic epidermal necrolysis in hospitalized children in the United States. *Pediatr Dermatol*. 2014;31:163.
11. Brice SL, Krzemien D, Weston WL, et al. Detection of simplex virus DNA in cutaneous lesions of erythema multiforme. *J Invest Dermatol*. 1989;93:183.
12. Ng PPL, Sun YJ, Tan HH, et al. Detection of Herpes simplex virus genomic DNA in various subsets of erythema multiforme by polymerase chain reaction. *Dermatology*. 2003;207:349.
13. Tatnall FM, Schofield JK, Leigh IM. A double-blind, placebo-controlled trial of continuous acyclovir therapy in recurrent erythema multiforme. *Br J Dermatol*. 1995;132:267.
14. Prindaville B, Newell BD, Nopper AJ, et al. Mycoplasma pneumoniae–associated mucocutaneous disease in children: dilemmas in classification. *Pediatr Dermatol*. 2014;6:670.
15. Starnes L, Patel T, Skinner RB. Urticaria multiforme—a case report. *Pediatr Dermatol*. 2011;28:436.
16. Foedinger D, Elbe-Bürger A, Sterniczky B, et al. Erythema multiforme associated human autoantibodies against desmoplakin I and II: biochemical characterization and passive transfer studies into newborn mice. *J Invest Dermatol*. 1998;111:503.
17. Hirsch G, Ingen-Housz-Oro S, Fite C, et al. Rituximab, a new treatment for difficult-to-treat chronic erythema multiforme major? Five cases. *J Eur Acad Dermatol Venereol*. 2016;30:1140.
18. Komorowski L, Mockenhaupt M, Sekula P, et al. Lack of a specific humoral autoreactivity in sera from patients with early erythema exsudativum multiforme majus. *J Invest Dermatol*. 2013;133:2799.
19. Kokuba H, Imafuku S, Burnett JW, et al. Longitudinal study of a patient with herpes-simplex-virus-associated erythema multiforme: viral gene expression and T cell repertoire usage. *Dermatology*. 1999;198: 233-242.
20. Ono F, Bhuvnesh K. Sharma BK, et al. CD34+ cells in the peripheral blood transport Herpes simplex virus DNA fragments to the skin of patients with erythema multiforme (HAEM). *J Invest Dermatol*. 2005;124:1215-1224.
21. Kunimi Y, Hirata Y, Aihara M, et al. Statistical analysis of Stevens-Johnson Syndrome caused by Mycoplasma pneumonia infection in Japan. *Allergol Int*. 2011;60;525-532.
22. Edwards C, Penny M, Newman J. Mycoplasma pneumoniae, Stevens-Johnson syndrome, and chronic obliterative bronchitis. *Thorax*. 1983;38:867.
23. Schofield JK, Tatnall FM, Leigh IM. Recurrent erythema multiforme: clinical features and treatment in a large series of patients *Br J Dermatol*. 1993;128:542.
24. Wetter DA, Davis MD. Recurrent erythema multiforme: Clinical characteristics, etiologic associations, and treatment in a series of 48 patients at Mayo Clinic, 2000 to 2007. *J Am Acad Dermatol*. 2010;62:45.
25. Chen CW, Tsai TF, Chen YF, et al. Persistent erythema multiforme treated with thalidomide. *Am J Clin Dermatol*. 2008;9:123.
26. Riley M, Jenner R. Towards evidence based emergency medicine: best BETs from the Manchester Royal Infirmary. Bet 2. Steroids in children with erythema multiforme. *Emerg Med J*. 2008;25:594.
27. Weston WL, Morelli JG. Herpes simplex virus-associated erythema multiforme in prepubertal children. *Arch Pediatr Adolesc Med.* 1997;151:1014.
28. Fawcett HA, Wansbrough-Jones MH, Clark AE, et al. Prophylactic topical acyclovir for frequent recurrent herpes simplex infection with and without erythema mutliforme. *BMJ*. 1983;287:798.
29. Cherouati K, Claudy A, Souteyrand P, et al. Treatment by thalidomide of chronic multiforme erythema: its recurrent and continuous variants. A retrospective study of 26 patients [in French] *Ann Dermatol Venereol*. 1996;123:375.
30. Wu JJ, Huang DB, Pang KR, et al. Thalidomide: dermatological indications, mechanisms of action and side-effects. *Br J Dermatol.* 2005;153:254.
31. Lozada F. Levamisole ion the treatment of erythema multiforme; a double-blind trial in 14 patients. *Oral Surg Med Oral Pathol*. 1982;53:28.

Chapter 44 :: Epidermal Necrolysis (Stevens-Johnson Syndrome and Toxic Epidermal Necrolysis)

:: Maja Mockenhaupt & Jean-Claude Roujeau

AT-A-GLANCE

- Epidermal necrolysis is a rare life-threatening reaction mainly induced by medication.
- Widespread apoptosis of keratinocytes is provoked by the activation of a cell-mediated cytotoxic reaction and amplified by cytokines, mainly granulysin.
- Confluent purpuric and erythematous macules evolving to flaccid blisters and epidermal detachment often start on the upper trunk and spread to the limbs associated with mucous membrane involvement.
- Histopathology shows full-thickness necrosis of epidermis associated with mild mononuclear cell infiltrate.
- A dozen "high-risk" drugs account for half of cases.
- More than 20% of cases remain idiopathic or may be caused by infection.
- Early identification and withdrawal of suspect medication in drug-induced cases are essential for good patient outcomes.
- Treatment consists mainly of supportive care, but recent evidence suggests a significant benefit of immunomodulating treatment with cyclosporine.
- The death rate is high and increases with disease severity and age of the patient. The majority of survivors have long-lasting sequelae, needing systematic follow-up examinations.

INTRODUCTION

Stevens-Johnson syndrome (SJS) and toxic epidermal necrolysis (TEN) are acute life-threatening mucocutaneous reactions characterized by extensive necrosis and detachment of the epidermis and mucosal epithelium (Table 44-1). In 1922, Stevens and Johnson first reported two cases of disseminated cutaneous eruptions associated with an erosive stomatitis and severe ocular involvement.[1] In 1956, Lyell described patients with epidermal loss secondary to necrosis and introduced the term *toxic epidermal necrolysis*.[2] Because SJS and TEN share clinical pattern, histopathologic findings, etiology, risk factors, and mechanisms, they are considered as severity variants of one disease entity that differs only in the extent of skin detachment related to the body surface area.[3-5] Therefore, it seems more appropriate to use the designation *epidermal (or epithelial) necrolysis* for both, as proposed by Ruiz-Maldonado (acute disseminated epidermal necrosis)[6] and Lyell (exanthematic necrolysis).[7]

EPIDEMIOLOGY

Epidermal necrolysis (EN) is rare. The overall incidence of SJS and TEN was estimated at 1 to 6 cases per million person-years and 0.4 to 1.2 cases per million person-years, respectively.[8-10] Whereas incidences as high as 5 or 6 cases per million per year derive from medical databases not primarily designed for epidemiologic analysis of rare diseases,[11] incidences of 1 to 2 cases per million per year were calculated using population-based prospective case registry data.[12,13]

EN can occur at any age, but the risk increases with age leading to the highest incidence in older adults after 65 years of age.[14] Women are more frequently affected, showing a sex ratio of 0.6. Patients infected with HIV and to a lesser degree patients with collagen vascular disease and cancer are at increased risk.[15,16] The overall mortality rate associated with EN is 22% to 27%, varying from approximately 10% for SJS to almost 50% for TEN.[17-19] Increasing age, significant comorbidity, and greater extent of skin detachment correlate with poor prognosis. A prognosis score (SCORTEN) has been constructed for EN,[20] and its usefulness has been confirmed by several teams[21-24] (Table 44-2).

ETIOLOGY

The exact pathophysiology of EN is still unclear; however, drugs are the most important etiologic factors. More than 100 different drugs have been implicated,[25-31] but fewer than a dozen "high-risk" medications account for about half of cases in Europe (Table 44-3), as evidenced by two multinational case-control studies.[16,27-30] These high-risk drugs are antibacterial sulfonamides, aromatic antiepileptic drugs, allopurinol, oxicam nonsteroidal antiinflammatory drugs, lamotrigine, and nevirapine.[28-30] The risk seems confined to the first 8 weeks of treatment and most inducing medications revealed the first continuous

TABLE 44-1
Consensus Definition of Stevens-Johnson Syndrome/Toxic Epidermal Necrolysis[a]

CRITERION	EM MAJUS	SJS	SJS–TEN OVERLAP	TEN WITH MACULAE	TEN ON LARGE ERYTHEMA (WITHOUT SPOTS)
Skin detachment (%)	<10	<10	10–30	>30	>10
Typical target lesions	+	–	–	–	–
Atypical target lesions	Raised	Flat	Flat	Flat	–
Maculae	–	+	+	+	–
Distribution	Mainly limbs	Widespread	Widespread	Widespread	Widespread

[a]According to Bastuji-Garin et al.[3]

EM, erythema multiforme, SJS, Stevens-Johnson syndrome, TEN, toxic epidermal necrolysis.

exposure between 4 and 28 days before reaction onset.[28] Slow dose escalation decreases the rate of mild rashes to lamotrigine and nevirapine,[32,33] but there is no evidence that it decreases the risk of EN.[28,30] Oxcarbazepine, a 10-keto derivative of carbamazepine, which was considered to carry a lower risk, seems to significantly cross-react with carbamazepine.[34] Many nonsteroidal antiinflammatory drugs were suspected to be associated with EN, but there is a substantial difference in risk for EN among them, with oxicam derivatives showing the highest risk, acetic acid derivatives such as diclofenac a moderate, and propionic acid derivatives such as ibuprofen no increased risk.[16,28,35] A significant but much lower risk has also been reported for various groups of antibiotics such as cephalosporins, quinolones, tetracyclines, and aminopenicillins.[28] Corticosteroids were significantly associated with an increased relative risk, but confounding could not be

TABLE 44-2
SCORTEN: A Prognostic Scoring System for Patients with Epidermal Necrolysis

SCORTEN	
PROGNOSTIC FACTORS	**POINTS**
Age > 40 yr	1
Heart rate > 120 beats/min	1
Cancer or hematologic malignancy	1
Body surface area involved >10%	1
Serum urea level > 10 mM	1
Serum bicarbonate level >20 mM	1
Serum glucose level > 14 mM	1
Scorten	**Mortality rate (%)**
0–1	3.2
2	12.1
3	35.8
4	58.3
5	90

Data from Bastuji-Garin S, Fouchard N, Bertocchi M, et al: SCORTEN: A severity-of-illness score for toxic epidermal necrolysis. *J Invest Dermatol*. 2000;115:149.

TABLE 44-3
Drugs and Recommendations in Stevens-Johnson Syndrome/Toxic Epidermal Necrolysis[a]

Drugs with a high risk to induce SJS/TEN

Their use should be carefully evaluated, and they should be suspected promptly.

Allopurinol

Lamotrigine

Cotrimoxazole (and other antiinfective sulfonamides and sulfasalazine)

Carbamazepine

Nevirapine

NSAIDs (oxicam type, eg, meloxicam)

Phenobarbital

Phenytoin

An interval of 4–28 days between beginning of drug use and onset of the adverse reaction is most suggestive of an association between the medication and SJS/TEN.

When patients are exposed to several medications with high expected benefits, the timing of administration is important to determine which one(s) must be stopped and if some may be continued or reintroduced.

The risks of various antibiotics to induce SJS/TEN are within the same order of magnitude but substantially lower than the risk of antiinfective sulfonamides.

Valproic acid does not seem to have an increased risk for SJS/TEN in contrast to other antiepileptics.

Diuretics and oral antidiabetics with sulfonamide structure do not appear to be risk factors for SJS/TEN.

Drugs with a moderate (significant but substantially lower) risk for SJS/TEN

Cephalosporines

Macrolides

Quinolones

Tetracyclines

NSAIDs (acetic acid type, eg, diclofenac)

Drugs with no increased risk for SJS/TEN

Beta-blockers

ACE inhibitors

Calcium channel blockers

Thiazide diuretics (with sulfonamide structure)

Sulfonylurea antidiabetics (with sulfonamide structure)

Insulin

NSAIDs (propionic acid type, eg, ibuprofen)

[a]According to Mockenhaupt et al.[28]

ACE, angiotensin-converting enzyme; NSAID, nonsteroidal antiinflammatory drug; SJS, Stevens-Johnson syndrome; TEN, toxic epidermal necrolysis.

excluded.[28] Recent analysis of systematically ascertained registry data on EN using ALDEN (algorithm for causality assessment in EN)[36] in comparison with results of two case-control studies[16,28] revealed that over a period of more than 2 decades, the proportion of validated cases that could be explained by medications with a significant (high and moderate) risk was stable (65%–68%). For roughly one third of the cases, no patent drug cause could be identified, suggesting that many more cases than previously thought have to be considered as "non–drug related" or "idiopathic."[37] The role of infectious agents in the development of EN is much less prominent than for erythema multiforme (see Chap. 43).[5] However, cases of EN associated with *Mycoplasma pneumoniae* infection, viral disease, and immunization have been reported, particularly in children.[38] In many cases a clinical infection is present, but despite extensive laboratory workup, no specific viral or bacterial agent can be detected.[39] Cases of EN have been reported after bone marrow transplantation. Some are an extreme form of acute graft-versus-host disease (GVHD; see Chap. 129); others could be drug-induced. The relationship between EN and GVHD is difficult to assess because clinical and histologic skin features are often indistinguishable.[40] Lupus erythematosus (systemic LE or subacute cutaneous LE) is associated with an increased risk of EN.[16,28] In such cases, drug causality is often doubtful and necrolysis might be an extreme phenotype of cutaneous lupus. Therefore, erosive LE has to be considered as a differential diagnosis of EN.[41,42] Finally, radiotherapy in addition to treatment with antiepileptic drugs, such as phenytoin, phenobarbital, or carbamazepine, can trigger EN with lesions localized predominantly at sites of radiation treatment.[43,44]

PATHOGENESIS

Even if the precise sequence of molecular and cellular events is incompletely understood, several studies provided important clues to the pathogenesis of EN. The immunologic pattern of early lesions suggests a cell-mediated cytotoxic reaction against keratinocytes leading to massive apoptosis.[45,46] Immunopathologic studies have demonstrated the presence of cytotoxic cells, including natural killer T cells (NKT) and drug-specific $CD8^+$ T lymphocytes in early lesions; monocytes and macrophages and granulocytes are also recruited.[47-49] CD94/NKG2C was identified as a killer effector molecule in patients with EN.[50] However, it is generally accepted that specific and nonspecific cytotoxic cells are too few within the lesions to explain full-thickness necrosis of extensive areas of the epidermis and mucous membranes. Amplification by cytokines has been suspected for years, especially for factors activating "death receptors" on cell membranes, especially antitumor necrosis factor (TNF) α and soluble Fas ligand (Fas-L).[47,51] In the past decade, it had been widely accepted that Fas-L was inducing the apoptosis of keratinocytes in EN,[51,52] despite partial evidence and discordant findings.[53-55] An important study has challenged this dogma by demonstrating the key role of granulysin in EN.[56] The cytolytic protein granulysin was present in the blister fluid of patients with EN at concentrations much higher than those of perforin, granzyme B, or Fas-L. At such concentrations, only granulysin, and to a much lesser degree perforin, were able to kill human keratinocytes in vitro; Fas-L was not. Furthermore, injection of granulysin in the dermis of normal mice resulted in clinical and histologic lesions of EN.[57] Recently, interleukin (IL)-15 could be demonstrated to be associated with severity and mortality in EN.[58] When combined, these results strongly suggest that the effector mechanisms of EN have been deciphered. Cytotoxic T cells develop and are usually specifically directed against the native form of the drug rather than against a reactive metabolite, contrarily to what has been postulated for many years. These cells kill keratinocytes directly and indirectly through the recruitment of other cells that release soluble death mediators, the principal being granulysin and probably also IL-15.[56-58]

These advances in understanding the final steps of the reaction point to inhibition of release or blockade of granulysin as major aims of therapeutic interventions.

Little is known on the initial and intermediate steps. We still do not understand why very few individuals develop a violent immune response to medications and why effector cells are especially directed to the skin and other epithelia. Actually, most drugs associated with a high risk for EN can also induce a variety of milder and more frequent reactions. Drug-specific CD8 cytotoxic T-lymphocytes were also found in milder skin like maculopapular eruption.[59] Hence, it is tempting to speculate on an abnormal regulation of immune response. Regulatory $CD4^+$ $CD25^+$ T cells have been demonstrated to be potentially important in the prevention of severe epidermal damage induced by reactive cytotoxic T lymphocytes in a mouse model of EN.[60] Similar regulatory cells may play a role in drug eruptions in humans.[61] Altered regulation of the immune response to medications in patients with EN could result from comorbidities that are frequent (eg, cancer, HIV infection, collagen vascular disease), from comedications (eg, corticosteroids), or from genetic background.

Genetic susceptibility plays an important role in the development of EN to a few "high-risk" medications. A strong association was observed in Han Chinese from Taiwan between the human leukocyte antigen HLA-B*1502 and EN induced by carbamazepine and between HLA-B*5801 and EN induced by allopurinol.[62,63] B*1502 association with carbamazepine-related cases was confirmed in several Southeast Asian countries[64,65] but not in Japan and Korea.[66,67] The association between carbamazepine-induced EN and HLA-B*1502 was not present in European patients without Asian ancestry.[68] On the other hand, HLA-B*5801 was confirmed to be associated with allopurinol-related EN in Japan[66] and Europe,[69] but the strength of association was lower than in Taiwan. A genome-wide association study on samples of European EN-patients confirmed the

involvement of genetic variants located in the HLA region. No other locus reached genome-wide statistical significance in this large sample. If some loci outside HLA play a role in EN, their effect might be very small.[70]

CLINICAL FINDINGS

Even in cases requiring immediate referral to specialized wards, the dermatologist will have a specific role in the management of patients with EN (Fig. 44-1).

HISTORY

EN clinically most often begins with unspecific prodromal symptoms such as sore throat, runny nose, cough, headache, fever, and malaise preceding the mucocutaneous lesions by 1 to 3 days. They are followed by the appearance of erythematous macules and atypical targets of the skin that may be confluent and on which blisters occur. Burning or stinging of the eyes, pain when swallowing, or urinating progressively develop, heralding mucous membrane involvement. The majority of cases begin with nonspecific symptoms followed either first by mucous membrane or by cutaneous involvement, but some cases may start with the specific lesions of skin and mucosa. Whatever the initial symptoms are, their rapid progression, the addition of new signs, severe pain, and constitutional symptoms should alert one to the onset of a severe disease.

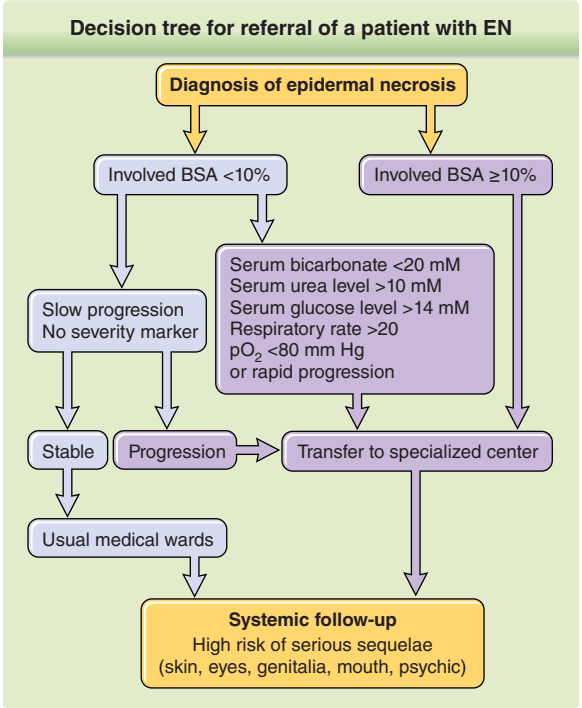

Figure 44-1 Decisional tree for referral of a patient with epidermal necrolysis. BSA, body surface area. (Adapted from Ellis MW. A case report and a proposed algorithm for the transfer of patients with Stevens-Johnson syndrome and toxic epidermal necrolysis to a burn center. *Mil Med*. 2002;167:701.)

A common problem is the fact that medications taken to treat the prodromal symptoms are often accused to have caused the reaction. This mainly concerns antipyretics, analgesics, and secretolytics, sometimes summarized as "cough and cold medicines." When looking at the use of these medications more closely, they have usually been taken and tolerated before and were started after the onset of prodromal symptoms of EN ("protopathic bias"). Neither of these patterns is typical for exposure to medications causing EN, which have not been used previously and the exposure of which is the first continuous use started 4 weeks to 4 days before reaction onset. Furthermore, these substances do not belong to the drug groups for which epidemiologic studies have estimated an increased risk to induce EN.[28,39]

CUTANEOUS LESIONS

The eruption is initially symmetrically distributed on the face, the upper trunk, and the proximal part of limbs.[71] The distal portions of the arms as well as the legs are relatively spared, but the eruption can rapidly extend to the rest of the body within a few days and even within a few hours. The initial skin lesions are characterized by erythematous, dusky red, irregularly shaped purpuric macules, which progressively coalesce. Atypical target lesions with dark centers are often observed (Fig. 44-2A). Confluence of necrotic lesions leads to extensive and diffuse erythema. Nikolsky sign, or dislodgement of the epidermis by lateral pressure, is positive on erythematous zones (Figs. 44-3 and 44-4). At this stage, the lesions evolve to flaccid blisters, which spread with pressure and break easily (see Fig. 44-2B). The necrotic epidermis is easily detached at pressure points or by frictional trauma, revealing large areas of exposed, red, sometimes oozing dermis (see Figs. 44-2C and 44-2D). In other areas, epidermis may remain.

Patients are classified into one of three groups according to the total area in which the epidermis is detached or "detachable" (positive Nikolsky): (1) SJS, less than 10% of body surface area (BSA); (2) SJS–TEN overlap, between 10% and 30%; (3) TEN, more than 30% of BSA.[3,5] Correct evaluation of the extent of detachment is difficult, especially in zones with spotty lesions. It is helpful to remember that the surface of one hand (palm and fingers) represents a little less than 1% of the BSA.

MUCOUS MEMBRANE INVOLVEMENT

Mucous membrane involvement (nearly always on at least two sites) is observed in approximately 90% of cases and can precede or follow the skin eruption. It begins with erythema followed by painful erosions of the oral, ocular, genital, nasal, anal and sometimes

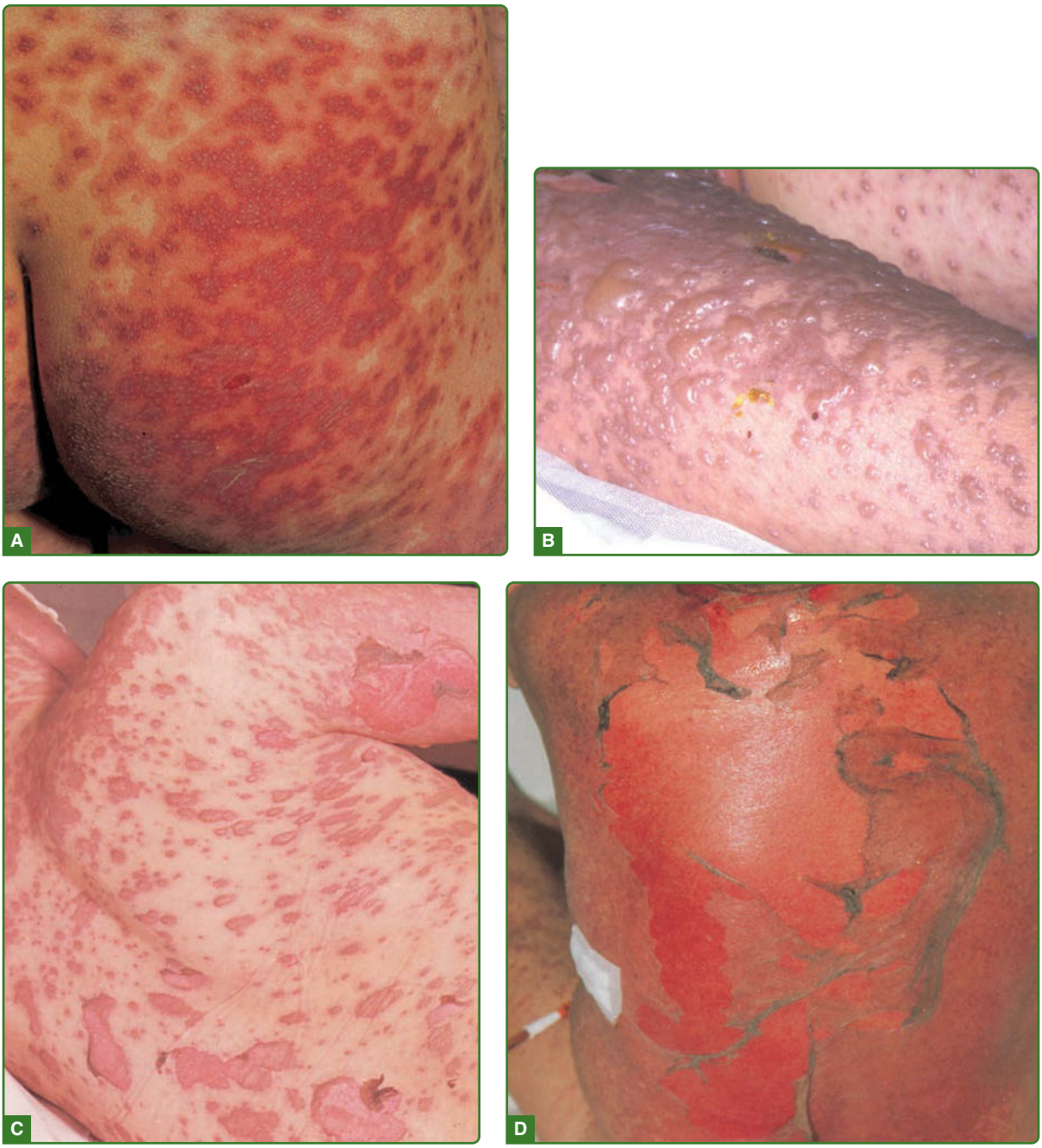

Figure 44-2 **A,** Early eruption. Erythematous dusky red macules (flat atypical target lesions) that progressively coalesce and show epidermal detachment. **B,** Early presentation with vesicles and blisters. Note the dusky color of blister roofs, strongly suggesting necrosis of the epidermis. **C,** Advanced eruption. Blisters and epidermal detachment have led to large confluent erosions. **D,** Full-blown epidermal necrolysis characterized by large erosive areas reminiscent of scalding.

tracheal or bronchial mucosa. This usually leads to impaired alimentation, photophobia, conjunctivitis, and painful micturition. The oral cavity and the vermilion border of the lips are almost invariably affected and feature painful hemorrhagic erosions coated by grayish white pseudomembranes and hemorrhagic crusts of the lips (Fig. 44-5). Approximately 80% of patients have conjunctival lesions,[72,73] mainly manifested by pain, photophobia, lacrimation, redness, and discharge. Severe forms may lead to epithelial defect and corneal ulceration, anterior uveitis, and purulent conjunctivitis. Synechiae between eyelids and conjunctiva often occur. There may be shedding of eyelashes (Fig. 44-5B). Genital erosions are frequent, often overlooked in women, and may lead to synechiae.[74,75]

SYSTEMIC INVOLVEMENT

EN is associated with high fever, pain, and weakness. Visceral involvement is also possible, particularly with

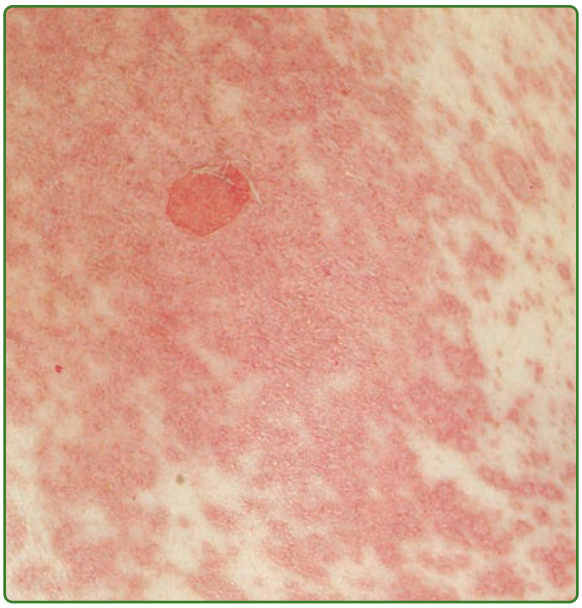

Figure 44-3 Early exanthematous phase with Nikolsky sign.

pulmonary and digestive complications. Early pulmonary complications occur in approximately 25% of patients and are essentially manifested by elevated respiratory rate and cough, which should prompt strict surveillance.[76,77] Bronchial involvement in EN is not correlated with the extent of skin lesions or with the offending agent. In most cases, chest radiographs are normal on admission but can rapidly reveal interstitial lesions that can progress to acute respiratory distress syndrome. In all reported cases, when acute respiratory failure developed rapidly after the onset of skin involvement, it was associated with poor prognosis. In the case of respiratory abnormalities, fiberoptic bronchoscopy may be useful to distinguish a specific epithelial detachment in the bronchi from an infectious pneumonitis, which has a much better prognosis.

Gastrointestinal tract involvement is less commonly observed, with epithelial necrosis of the esophagus, small bowel, or colon manifesting as profuse diarrhea with malabsorption, melena, and even colonic perforation.[78,79] Renal involvement has been reported. Proteinuria, microalbuminuria, hematuria, and azotemia are not rare. Proximal tubule damage can result from necrosis of tubule cells by the same process that destroys epidermal cells.[80] Glomerulonephritis is rare.[81]

Figure 44-4 Blisters, erosions, and large areas of positive Nikolsky sign on the back of a patient with toxic epidermal necrolysis. One aim of local treatment is to protect "detachable" epidermis from being detached by using antishear dressings.

LABORATORY TESTS

LABORATORY VALUES

There is no laboratory test to support the diagnosis of EN. Laboratory examinations are essential for evaluation of severity, prognosis, and daily management as for all life-threatening conditions in intensive care units (ICUs).

Evaluation of respiratory rate and blood oxygenation are among the first steps to take in the emergency department. Any alteration should be checked through measurement of arterial blood gas levels. Serum bicarbonate levels below 20 mM indicate a poor prognosis.[20] They usually result from respiratory alkalosis related to the specific involvement of bronchi and more rarely from metabolic acidosis.

Massive transdermal fluid loss is responsible for electrolyte imbalances, hypoalbuminemia, and hypoproteinemia, and mild and transient renal insufficiency and prerenal azotemia are common. Increased blood urea nitrogen level is one marker of severity. Anemia is common, and mild leukocytosis as well as thrombocytopenia may occur. Neutropenia is often considered to be an unfavorable prognostic factor but is too rare to have a significant impact on SCORTEN. Transient peripheral $CD4^+$ lymphopenia is nearly always seen and is associated with decreased T-cell function. Mild elevation in levels of hepatic enzymes and amylase (most probably of salivary origin) are frequent but without impact on prognosis. A hypercatabolic state is responsible for inhibition of insulin secretion or insulin resistance, which results in hyperglycemia and occasionally overt diabetes. A blood glucose level above 14 mM may be a marker of severity.[20] Other abnormalities in laboratory values may occur, indicating involvement of other organs and complications such as sepsis.

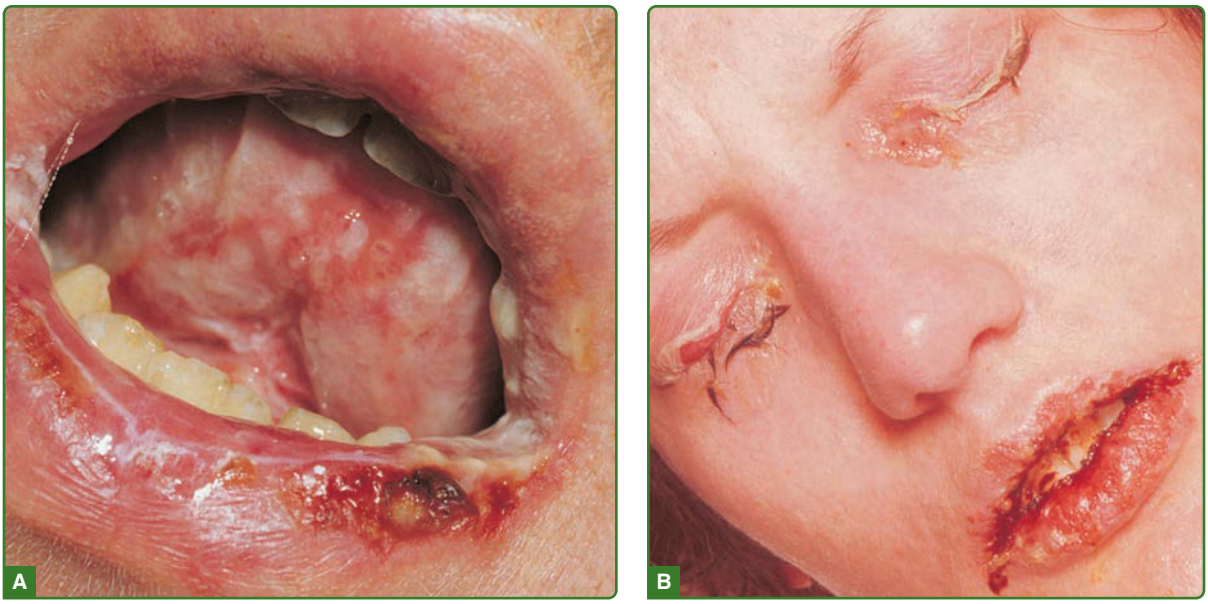

Figure 44-5 **A,** Extensive erosions and necroses of the lower lip and oral mucosa. **B,** Massive erosions covered by crusts on the lips. Note also shedding of the eyelashes.

HISTOPATHOLOGY

Skin biopsy for routine histologic and possibly immunofluorescence studies are strongly recommended, especially if there are alternative diagnoses to consider (see Fig. 44-3). The biopsy should be taken from a fresh lesion, preferably form the erythematous margin and not directly out of a blister because the latter carries the risk that epidermis and dermis are completely separated or partly lost. If similar lesions are present on the legs and elsewhere, the biopsy should preferentially not be taken from the legs below the knee. In the latter localization, changes could be superimposed by stasis dermatitis, complicating the correct histopathologic diagnosis.[82]

In the early stages, epidermal involvement is characterized by sparse apoptotic keratinocytes in the suprabasal layers (Fig. 44-6). In fully developed stages of the disease, when epidermal detachment and epidermolysis appear, in addition to the already mentioned changes subepidermal vesiculation secondary to extensive vacuolar alteration and confluent necrosis of keratinocytes develops.[82,83] Apoptosis of epithelial cells may involve sweat glands and hair follicles. A moderately dense mononuclear cell infiltrate of the papillary dermis is observed, mainly represented by lymphocytes, often $CD8^+$ and macrophages.[83,84] Occasional eosinophilic granulocytes may be found. Variable numbers of extravasated erythrocytes are present. As the process develops rapidly, usually neither melanophages nor siderophages are found in the upper part of the dermis. The cornified layer remains unchanged. Results of direct immunofluorescence test are negative. Histopathology of involved mucous membranes show a similar pattern but are rarely performed.[85]

DIFFERENTIAL DIAGNOSIS

See Table 44-4.

Milder presentations of EN must be distinguished from erythema multiforme minus (without mucous membrane involvement) and majus (with mucous membrane involvement; EMM) (see Chap. 43). Early EN cases are often initially diagnosed as varicella, especially in children. The rapid progression of skin lesions and the severity of mucous membrane involvement should lead to considering potential EN.

The absence of mucous membrane involvement or its restriction to a single site must always raise the suspicion of an alternative diagnosis: staphylococcal scalded skin syndrome in infants but also in adults with septicemia; purpura fulminans in children and young adults; and acute generalized exanthematous pustulosis, phototoxicity, tension or pressure blisters in adults. Thermal burns are occasionally an issue when a transient loss of consciousness occurs as well as in small children or older adults in nursing homes.[71]

Linear immunoglobulin (Ig) A bullous disease and paraneoplastic pemphigus present with a less acute progression. Pathologic findings and a positive result on direct immunofluorescence testing are important for these diagnoses.

In all aspects, including pathology, generalized bullous fixed drug eruption (GBFDE) resembles EN. However, the distinction is worthwhile because GBFDE has a reputation for much better prognosis, probably because of the mild involvement of mucous membranes and the absence of visceral complications. Prior events, rapid onset after drug intake, and very large, well-demarcated blisters are the hallmarks of GBFDE.[86]

Toxic destruction of epithelia, whether through contact (fumigants) or ingestion (colchicine poisoning,

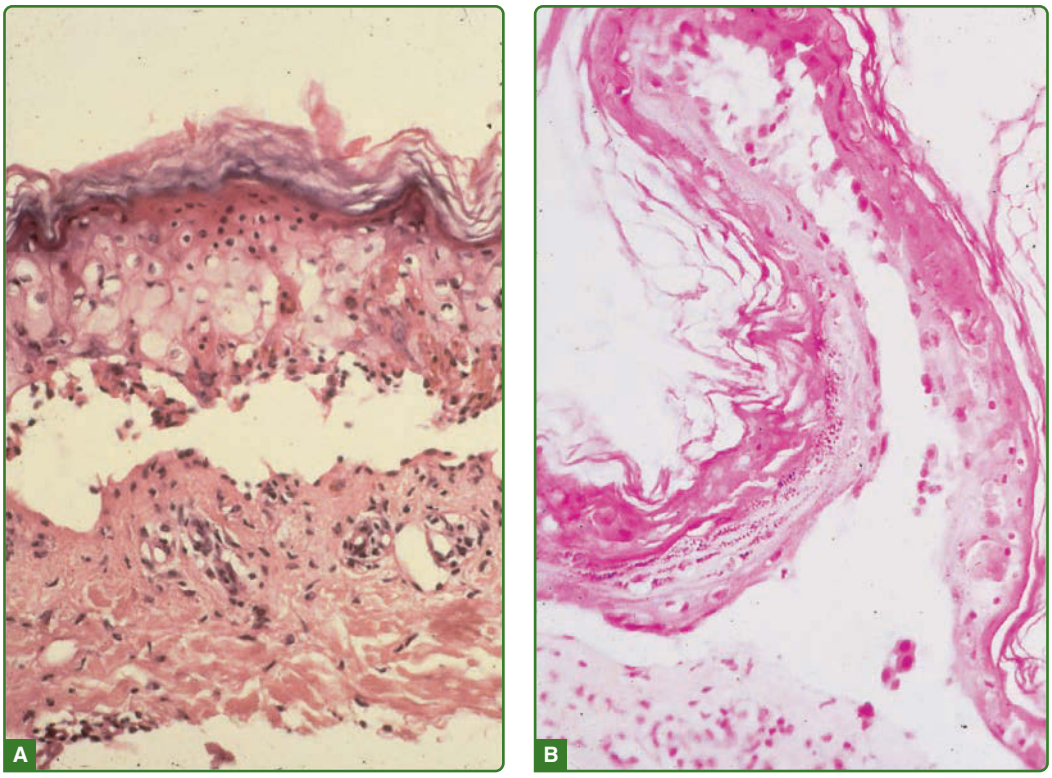

Figure 44-6 Histologic appearance of epidermal necrolysis. **A,** Eosinophilic necrosis of the epidermis in the peak stage, with little inflammatory response in the dermis. Note cleavage in the junction zone. **B,** The completely necrotic epidermis has detached from the dermis and folded like a sheet.

methotrexate overdose), may result in clinical features of EN but with skin erosions often predominating in the folds. In these rare cases, causality is generally obvious.

TABLE 44-4
Differential Diagnoses of Epidermal Necrolysis (EN)

Most Likely
- Limited EN (SJS)
  - Erythema multiforme majus
  - Varicella
- Widespread EN (SJS–TEN overlap and TEN)
  - Acute generalized exanthematous pustulosis
  - Generalized bullous fixed drug eruption

Consider
- Paraneoplastic pemphigus
- Linear IgA bullous disease
- Pressure blisters after coma
- Phototoxic reaction
- Graft-versus-host disease

Always Rule Out
- Staphylococcal scalded skin syndrome
- Thermal burns
- Skin necrosis from disseminated intravascular coagulation or purpura fulminans
- Chemical toxicity (eg, colchicine intoxication, methotrexate overdose)

IgA, immunoglobulin; EN, epidermal necrolysis; SJS, Stevens-Johnson syndrome; TEN, toxic epidermal necrolysis.

Overreporting of EN is common. It usually arises from confusion between desquamation and detachment of epidermis and between mucous membranes and periorificial skin. Because of such confusion, patients with a desquamative rash and scaly lips are not rarely diagnosed with and reported as having EN.

COMPLICATIONS AND SEQUELAE

During the acute phase, the most common complication of EN is sepsis. The epithelial loss predisposes these patients to infections, which are the main causes of mortality.[4,71] Central intravenous lines are a source for infection and should be avoided in favor of peripheral lines if possible. *Staphylococcus aureus* and *Pseudomonas* spp. are the most frequent pathogens, but about one third of positive blood cultures contain enterobacteriae not present on the skin, a finding that suggests bacterial translocation from gut lesions.[87] Multisystem organ failure and pulmonary complications are observed in more than 30% and 15% of cases, respectively.[88]

A very important advance in EN is the recent understanding that sequelae (Table 44-5) are more frequent and more severe than previously thought.[89] After the well-known risks of the acute stage, EN behaves as a chronic disease. More medical attention should be directed to that phase to better understand the

TABLE 44-5
Epidermal Necrolysis-Related Sequelae

Ophthalmic
- Chronic inflammation
- Fibrosis
- Entropion
- Trichiasis
- Symblepharon
- Alterations in vision
- Corneal ulcerations

Nails
- Dystrophy
- Permanent anonychia
- Ridging
- Pigmentary changes of the nail beds

Oral Mucosa
- Dryness
- Dysgeusia
- Late alterations of teeth

Vulvar or Vaginal
- Dyspareunia
- Vaginal dryness
- Genital adhesions

Other
- Esophageal strictures
- Intestinal strictures
- Urethral strictures
- Anal strictures
- Chronic lung disease

frequency, mechanisms, and evolution of sequelae. Adequate management and prevention of sequelae are as important as saving the patient's life during the acute phase.

A large European cohort has found that 90% of patients who survived EN had sequelae 1 year after the acute stage of the disease, with a mean of three different problems per patient and an important negative impact on the quality of life for about half of them. A 5-year follow-up revealed similar data, demonstrating that many patients never got back to their normal activities before the reaction.[90] Symptoms suggesting posttraumatic stress disorder are not rare. Psychiatric consultation and psychological support have been considered to be helpful by affected patients and should be included into supportive care protocols. Late ophthalmic complications are reported in 20% to 75% of patients with EN, with a credible figure of about 50% (Fig. 44-7).[72,73,89] The relationship between the initial severity of ocular involvement and the development of late complications seems to be well established. However, late complications have also been observed in patients whose ocular involvement was considered to be mild during the acute stage of the disease. Late ophthalmic complications are mainly caused by functional alteration of the conjunctival epithelium with dryness and abnormal lacrimal film. This leads to chronic inflammation, fibrosis, entropion, trichiasis, and symblepharon. Long-term irritation and deficiency of stem cells in the limbus may result in metaplasia of corneal

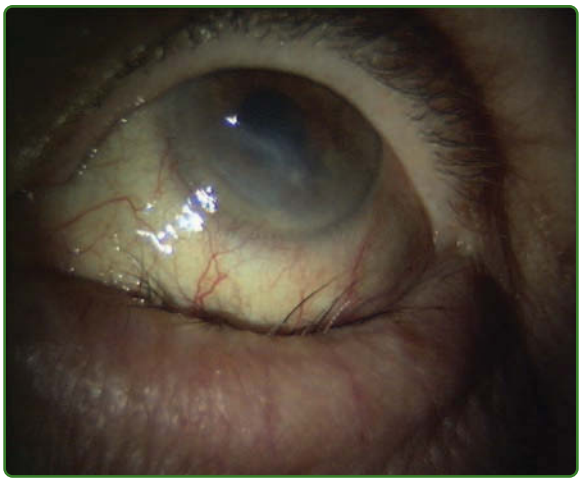

Figure 44-7 Late ocular complications of epidermal necrolysis. Note opaque corneal epithelium, neovessels, and irritating eyelashes on lower eyelids. (Used with permission from Julie Gueudry, MD, and Marc Muraine, MD, PhD, Hôpital Charles Nicolle, Rouen, France.)

epithelium with painful ulcerations, scarring, and altered vision.[72]

Hypopigmentation and hyperpigmentation of the skin are most frequent sequelae; residual hypertrophic or atrophic scars rarely occur. Nail changes, including change in pigmentation of the nail bed, ridging, dystrophic nails, and permanent anonychia, occur in more than 30% of cases (Fig. 44-8). Mouth sequelae are present in about one third of patients who complain of dryness, altered taste, and late alterations of teeth.[91]

Vulvar and vaginal complications of EN are reported by about 25% of patients.[74] Dyspareunia is not rare and is related to vaginal dryness, itching, pain, and bleeding. Genital adhesions may lead to the requirement for surgical treatment.[75] Esophageal, intestinal, urethral, and anal strictures may also develop, although rarely. Chronic lung disease can be observed after EN, often attributed to bronchiolitis obliterans, and occasionally requiring lung transplantation.[77,92] Because these late complications and sequelae may develop insidiously, it is strongly suggested that all patients surviving EN

Figure 44-8 Abnormal regrowth of nails after epidermal necrolysis.

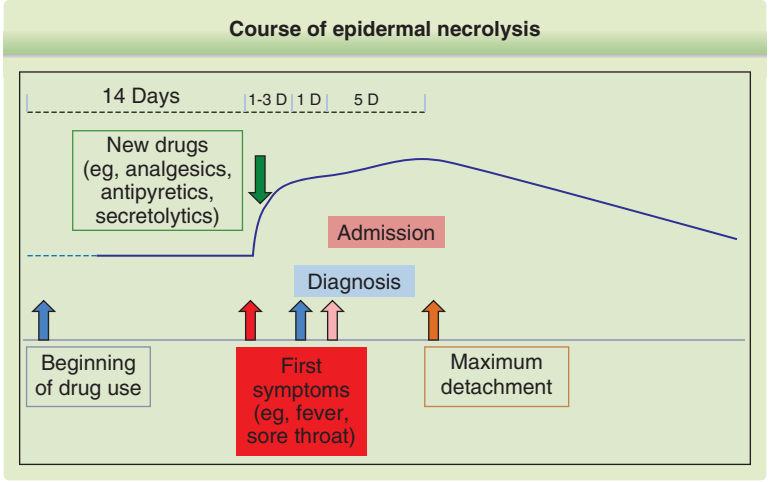

Figure 44-9 Course of epidermal necrolysis (EN). First symptoms of the reaction are unspecific like fever, sore throat, and reduced state of health (prodromal symptoms). Medications given for the prodromal symptoms are not associated with EN even if the first clear sign (mucosal involvement, macules) appears after their intake ("protopathic bias"; 1-3D). After admission the progression of EN to maximum skin detachment continues for up to 5 days (5D).

have a clinical follow-up a few weeks after discharge and 1 year later, including examination by an ophthalmologist and by other organ specialist(s) as indicated by abnormal signs and symptoms.

PROGNOSIS AND CLINICAL COURSE

The epidermal detachment progresses for 5 to 7 days (Figs. 44-9 and 44-10). Then patients enter a plateau phase, which corresponds to progressive reepithelialization. This can take a few days to a few weeks, depending on the severity of the disease and the prior general condition of the patient. During this period, life-threatening complications such as sepsis or systemic organ failure may occur. The overall mortality rate associated with EN is 22% to 27%, varying from approximately 10% for SJS to almost 50% for TEN,[17,18] but is highly dependent on the age of the patient and her or his underlying diseases. Thus, the mortality rate in children even with severe EN is very low compared with older adults. The prognosis is not affected by the cause of the reaction, whether drug or infection or unknown causality, type or dose of the responsible drug, or the presence of HIV infection (see Table 44-2).[16,20,71,88]

Prospective follow-up has shown an additional abnormally increased mortality rate in the 3-month period after hospital discharge, which seems to result from the negative impact of EN on prior severe chronic conditions, for example, malignancies (RegiSCAR, unpublished data).

TREATMENT

EN is a life-threatening disease that requires optimal management: early recognition and withdrawal of the offending drug(s) in drug-induced cases and supportive care in an appropriate hospital setting (Table 44-6).

Figure 44-10 Clinical course of epidermal necrolysis (EN). Evolution at days 3 (**A**), 8 (**B**), 3 months (**C**), and 3 years (**D**) after onset of EN.

TABLE 44-6

Therapeutic Options in the Management of Epidermal Necrolysis[a]

1. Early recognition and immediate withdrawal of offending drugs(s)
2. Supportive treatment
   - Fluid replacement (preferably with a peripheral line)
   - Correct electrolyte imbalance
   - Early nutritional support (nasogastric tube)
   - Culture for skin, blood, and urine specimens
     - (Antibiotics only if bacterial infections are suspected)
     - Prophylactic anticoagulation
3. Skin care
   - Extensive debridement not recommended
4. Early ophthalmologic evaluation and care.
   - Use of preservative-free emollients, antiseptic eye drops, vitamin A

Mechanical disruption of early synechiae

5. Antifungal or antiseptic mouth rinse
6. Systemic steroids
   - Use is controversial

Medium doses for short periods (days rather than weeks) may be beneficial

7. Cyclosporine A
   - Early administration may halt the progression of skin detachment and increase survival
   - Dose: 3 mg/kg for 10 days
8. Anti-TNF monoclonal antibodies
   - Etanercept may be of benefit
   - Extreme caution is advised

[a]Specific treatment options for the acute phase of epidermal necrolysis (EN) are underlined. Although larger trials are still needed, recent evidence based on smaller studies has suggested these may be of benefit in the management of EN.

TFN, tumor necrosis factor.

Prompt withdrawal of offending agent(s) is associated with an increased rate of survival in patients with EN induced by drugs with short elimination half-lives.[93] At the same time, it is preferable to continue every important and nonsuspected medication. This is of medical benefit for the affected patient and may furthermore avoid reluctance of the patient's physicians to prescribe them in the future. In case of doubt, all not life-sustaining drugs should be stopped when initiated and administered within the previous 8 weeks.

SYMPTOMATIC TREATMENT

Only patients with limited skin involvement, a SCORTEN score of 0 or 1, and a disease that is not rapidly progressing can be treated in nonspecialized wards. Depending on the local or national facilities, patients who do not need intensive care may remain in dermatology units or hospitals (eg, in many European countries), others should be transferred to ICUs or burn centers.[94] Although recent studies suggest that immunomodulating treatment with cyclosporine (ciclosporin) could be beneficial (see later), supportive measures are most important.[18,88,95,96] Supportive care consists of maintaining hemodynamic equilibrium and preventing life-threatening complications. The aims are similar to those for the treatment of extensive burns.

EN is associated with significant fluid loss from erosions, which results in hypovolemia and electrolyte imbalance. Fluid replacement must be started as soon as possible and adjusted daily. Volumes of infusions are usually less than for burns of similar extent of skin detachment because interstitial edema is absent. Peripheral venous lines are preferred when possible because the sites of insertion of central lines are often involved in detachment of epidermis and prone to infection. The environmental temperature should be raised to 28°C to 30°C (82.4°F to 86°F). The use of an air-fluidized bed improves patient comfort.

Early nutritional support is preferentially provided by nasogastric tube to promote healing and to decrease the risk of bacterial translocation from the gastrointestinal tract. To reduce the risk of infection, aseptic and careful handing is required. Skin, blood, and urine specimens should be cultured for bacteria and fungi at frequent intervals. Prophylactic antibiotics are not indicated. Patients should receive antibiotics when clinical infection is suspected. Prophylactic anticoagulation should be provided during hospitalization.

We do not recommend extensive and aggressive debridement of necrotic epidermis in EN because the superficial necrosis is not an obstacle to reepithelialization and might even accelerate the proliferation of stem cells due to the inflammatory cytokines. This is the single noticeable divergence between authors of this chapter and the recommendations of US burn centers.[96] A few recent series suggest that debridement is necessary neither in superficial burns[97] nor in EN.[98,99] There is no standard policy on wound dressings and the use of antiseptics. It is a matter of experience for each center. Skillfulness on the part of specialized nurses, careful manipulation, and an aggressive protocol of prevention and treatment of pain are essential.

Eyes should be examined daily by an ophthalmologist. Preservative-free emollients, antibiotic or antiseptic eye drops, and vitamin A are often used every 2 hours in the acute phase, and mechanical disruption of early synechiae is indicated. Early graft of cryopreserved amniotic membrane has been proposed as capable to decrease the rate of severe eye sequelae.[72]

The mouth should be rinsed several times a day with antiseptic or antifungal solution.

SPECIFIC TREATMENT IN ACUTE STAGE

Because of the importance of immunologic and cytotoxic mechanisms, a large number of immunosuppressive and antiinflammatory therapies have been tried to halt the progression of the disease. The low prevalence of the disease makes randomized clinical trials hard to perform, so most publications on treatment are case reports and rather small case series.

CORTICOSTEROIDS

The use of systemic corticosteroids is still controversial. Some studies found that such therapy could prevent the extension of the disease when administered during the early phase, especially as intravenous pulses for a few days.[100] Other studies concluded that steroids did not stop the progression of the disease and were even associated with increased mortality and sepsis when administered for 2 to 3 weeks. Thus, systemic corticosteroids cannot be recommended as the mainstay treatment of EN,[96] but a large cohort study has suggested a benefit quoad vitam when steroids were given in a medium dose for a few days.[101] A recent systematic review revealed a beneficial effect on corticosteroids in the treatment of SJS and TEN. Although the potential effect on the progression of skin detachment could not be analyzed by that approach, the results on outcome (death versus survival) were favorable.[102]

INTRAVENOUS IMMUNOGLOBULINS

The proposal to use high-dose intravenous immunoglobulin (IVIG) was based on the hypothesis that Fas-mediated cell death can be abrogated by the anti-Fas activity present in commercial batches of normal human Ig.[51] Benefits have been claimed by several studies, mainly case compilations with patients included in more than one study and case reports[51,103-105] but refuted by several others.[22,101,106-108] The large cohort study published in 2008 comparing the treatment in 281 patients with EN could not demonstrate a beneficial effect of IVIG.[101] Thus, IVIG could not be considered the standard of care in recent years,[96] especially after the finding that the Fas-L—Fas pathway was not, or only marginally, involved in the mechanisms of EN.[56] The recent systematic review mentioned did not find a favorable effect of IVIG, neither on the study nor on the individual patient level.[102] Taking these findings into account, we conclude that IVIG should not be used to treat patients with EN.[109]

CYCLOSPORINE A

Cyclosporine is a powerful immunosuppressive agent associated with biologic effects that are theoretically useful in the treatment of EN: activation of T helper cells and cytokines; inhibition of $CD8^+$ cytotoxic mechanisms; and antiapoptotic effect through inhibition of Fas-L, nuclear factor-κB, and TNF-α. Several case reports and series suggested the efficacy of cyclosporine A (CyA) in halting the progression of skin detachment in EN without worrisome side effects when administered early.[110,111] In the pilot study performed in the French Reference Center for EN, the initial dose of 3 mg of CyA per kilogram body weight was slowly tapered over 1 month (3 mg/kg body weight for 10 days followed by 2 mg/kg for 10 days and 1 mg/kg for 10 days).[111] However, in recent years, the protocol was modified to 3 mg/kg body weight for 10 days only, with the usual dose adjustment in cases with renal failure (personal communication). The recent systematic review of EN treatment also saw positive effects of CyA, but the number of studies and patients treated were too small to demonstrate a significant finding.[102] A recent study from Spain compared the treatments of EN in two large specialized units and concluded that the use of CyA was beneficial both in terms of halting disease progression and survival.[112]

These new studies are a real breakthrough concerning the immunomodulating treatment of EN. Because randomized double-blind, placebo-controlled trials are hardly feasible in rare and unexpectable conditions such as EN that may affect anyone at any time at any place, systematic surveillance of treatment modalities (eg, CyA use) is warranted.[109]

PLASMAPHERESIS OR HEMODIALYSIS

The rationale for using plasmapheresis or hemodialysis is to prompt the removal of the offending medication, its metabolites, or inflammatory mediators such as cytokines. A small series reported their efficacy and safety in treating EN.[113-116] However, considering the absence of evidence and the risks associated with intravascular catheters, these treatments cannot be recommended.

ANTI–TUMOR NECROSIS FACTOR AGENTS

Anti-TNF monoclonal antibodies have been successfully used to treat a few patients. Recently, a study comparing corticosteroids and etanercept reported improved clinical outcomes in patients with EN treated with the latter. Furthermore, decreased levels of TNF-α and granulysin were observed.[117] Nevertheless, because a prior randomized controlled trial of thalidomide, an anti-TNF agent, had to be interrupted because of significantly increased mortality,[118] extreme caution is suggested in the use of anti-TNF agents to treat EN.

TREATMENT OF SEQUELAE

Very promising treatments have now been developed for the ocular sequelae of EN, including gas-permeable scleral lenses[119,120] and grafting of autologous stem cells from contralateral limbus or mouth mucosa.[121,122] With the exception of ocular sequelae, the literature contains only case reports related to treating sequelae. Photoprotection and cosmetic lasers may help resolve the pigmentation changes on the skin, but specific studies do not exist. This also accounts for nail disorders caused by EN.

PREVENTION

Primary prevention is only feasible in populations where a strong association has been established between a simple genetic maker and the risk of EN.

That is the case for HLA-B*1502 and EN induced by carbamazepine in persons of Southeast Asian ancestry. The US Food and Drug Administration has issued the recommendation to test patients of Han Chinese and Thai origin for HLA-B*1502 before prescribing carbamazepine. In Taiwan, testing of HLA-B*1502 before prescription of carbamazepine has led to a substantial reduction of EN-cases.[123] In Hong Kong, however, the screening policy was associated with prevention of carbamazepine-induced EN without reducing the overall burden of EN induced by antiepileptic medication, likely because clinicians preferred drugs not requiring a genetic test but that may also induce EN.[124] In individuals of Han Chinese or Southeast Asian origin, alternative antiepileptic drugs can be carefully prescribed, although there may be an association of EN with phenytoin and HLA-B*1502 as well.[64] The present status of research on the pharmacogenetics of EN makes it rather unlikely to identify another genetic marker with such a clear and high association to be useful for primary prevention.[70]

Secondary prevention is important for patients who experienced EN and are reluctant to take any medication. The most important issue is to evaluate drug causality. In vitro tests or patch tests to medications occasionally can be useful in the exploration of drug allergy. When used in patients with EN, their sensitivity is low.[125,126] Careful inquiry into all exposures to medications in the few weeks preceding the onset of the reaction leads to the identification of a probable culprit drug in approximately 67% of cases. The most useful clinical criteria are duration of treatment before onset (typically 4 to 28 days), absence of prior intake, and use of a drug known for being associated with a high risk.[36]

The few published cases of recurrent SJS or TEN—and so-called recurrent cases of SJS that are actually cases of EMM—were always caused by inadvertent readministration of the same or a very closely related medication. Epidemiology and in vitro studies suggest that the list of possible cross-reactive medications is rather narrow, based on close chemical similarities. As an example, there is no evidence that patients who experienced EN in reaction to an antiinfective sulfonamide are at increased risk for reaction to sulfonamide-related diuretics or antidiabetic medications. Only antiinfectious sulfonamides and sulfasalazine should be contraindicated in this situation.

A list of the suspected medication(s) and molecules of the same biochemical structure must be given to the patient on a personal "allergy card" or "allergy passport." It may also be useful to provide a list of drugs of common use that cannot be suspected.

REFERENCES

1. Stevens AM, Johnson FC. A new eruptive fever associated with stomatitis and ophthalmia: report of two cases in children. *Am J Dis Child*. 1922;24:526.
2. Lyell A. Toxic epidermal necrolysis: an eruption resembling scalding of the skin. *Br J Dermatol*. 1956;68:355.
3. Bastuji-Garin S, Rzany B, Stern RS, et al. Clinical classification of cases of toxic epidermal necrolysis, Stevens-Johnson syndrome, and erythema multiforme. *Arch Dermatol*. 1993;129:92.
4. Lissia M, Mulas P, Bulla A, et al. Toxic epidermal necrolysis (Lyell's disease). *Burns*. 2010;36:152.
5. Auquier-Dunant A, Bastuji-Garin S, Revuz J, et al. Correlation between clinical patterns and causes of erythema multiforme majus, Stevens Johnson and toxic epidermal necrolysis. *Arch Dermatol*. 2002; 138:1019.
6. Ruiz-Maldonado R. Acute disseminated epidermal necrosis types 1, 2, and 3: study of sixty cases. *J Am Acad Dermatol*. 1985;13:623.
7. Lyell A. Requiem for toxic epidermal necrolysis. *Br J Dermatol*. 1990;122:837.
8. Chan HL, Stern RS, Arndt KA, et al. The incidence of erythema multiforme, Stevens-Johnson syndrome, and toxic epidermal necrolysis: a population based study with particular reference to reactions caused by drugs among outpatients. *Arch Dermatol*. 1990;126:43.
9. Roujeau JC, Guillaume JC, Fabre JP, et al. Toxic epidermal necrolysis (Lyell syndrome). Incidence and drug etiology in France (1981–1985). *Arch Dermatol*. 1990;126:37.
10. Schöpf E, Stühmer A, Rzany B, et al. Toxic epidermal necrolysis and Stevens-Johnson syndrome. An epidemiologic study from West-Germany. *Arch Dermatol*. 1991;27:839-842.
11. Frey N, Jossi J, Bodmer M, et al. The epidemiology of Stevens-Johnson syndrome and toxic epidermal necrolysis in the UK. *J Invest Dermatol*. 2017;137(6):1240-1247.
12. Rzany B, Mockenhaupt M, Baur S, et al. Epidemiology of erythema exsudativum multiforme majus, Stevens-Johnson syndrome, and toxic epidermal necrolysis in Germany (1990-1992): structure and results of a population-based registry. *J Clin Epidemiol*. 1996;49:769.
13. Nägele D, et al. Incidence of Stevens-Johnson syndrome /toxic epidermal necrolysis: results of 10 years from the German Registry. *Pharmacoepidemiol Drug Safe*. 2017.
14. Mockenhaupt M, et al. Frequency and incidence of severe cutaneous adverse reactions in different age groups. *Pharmacoepidemiol Drug Safe*. 2011; 20:34.
15. Rzany B, Mockenhaupt M, Stocker U, et al. Incidence of Stevens-Johnson syndrome and toxic epidermal necrolysis in patients with the acquired immunodeficiency syndrome in Germany. *Arch Dermatol*. 1993;129:1059.
16. Roujeau JC, Kelly JP, Naldi L, Ret al. Medication use and the risk of Stevens-Johnson syndrome or toxic epidermal necrolysis. *N Engl J Med*. 1995;333:1600.
17. Sekula P, Dunant A, Mockenhaupt M, et al. Comprehensive survival analysis of a cohort of patients with Stevens-Johnson syndrome and toxic epidermal necrolysis. *J Invest Dermatol*. 2013; 133(5):1197-1204.
18. Paulmann M, Mockenhaupt M. Severe drug hypersensitivity reactions: clinical pattern, diagnosis, etiology and therapeutic options. *Curr Pharm Des*. 2017;22:6852-6861.
19. Risser J, Lewis K, Weinstock MA. Mortality of bullous skin disorders from 1979 through 2002 in the United States. *Arch Dermatol*. 2009;145:1005.

20. Bastuji-Garin S, Fouchard N, Bertocchi M, et al. SCORTEN: a severity-of-illness score for toxic epidermal necrolysis. *J Invest Dermatol*. 2000;115:149.
21. Trent JT, Kirsner RS, Romanelli P, et al. Use of the SCORTEN to accurately predict mortality in patients with toxic epidermal necrolysis in the United States. *Arch Dermatol*. 2004;140:890.
22. Brown KM, Silver GM, Halerz M, et al. Toxic epidermal necrolysis: does immunoglobulin make a difference? *J Burn Care Rehabil*. 2004;25:81.
23. Guégan S, Bastuji-Garin S, Poszepczynska-Guigné E, et al. Performance of the SCORTEN during the first five days of hospitalisation to predict the prognosis of epidermal necrolysis. *J Invest Dermatol*. 2006;126:272.
24. Cartotto R, Mayich M, Nickerson D, et al. SCORTEN accurately predicts mortality among toxic epidermal necrolysis patients treated in a burn center. *J Burn Care Res*. 2008;29:141.
25. Lyell A. Toxic epidermal necrolysis (the scalded skin syndrome): a reappraisal. *Br J Dermatol*. 1979;100:69.
26. Roujeau JC, Stern RS. Severe adverse cutaneous reactions to drugs. *N Engl J Med*. 1994;331:1272.
27. Rzany B, Correia O, Kelly JP, et al. Risk of Stevens-Johnson syndrome and toxic epidermal necrolysis during first weeks of antiepileptic therapy: a case control study. *Lancet*. 1999;353:2190.
28. Mockenhaupt M, Viboud C, Dunant A, et al. Stevens-Johnson syndrome and toxic epidermal necrolysis: assessment of medication risks with emphasis on recently marketed drugs. The EuroSCAR-study. *J Invest Dermatol*. 2008;128:35.
29. Halevy S, Ghislain PD, Mockenhaupt M, et al. Allopurinol is the most common cause of Stevens-Johnson syndrome and toxic epidermal necrolysis in Europe and Israel. *J Am Acad Dermatol*. 2008;58:25.
30. Fagot JP, Mockenhaupt M, Bouwes-Bavinck JN, et al. Nevirapine and the risk of Stevens Johnson syndrome or toxic epidermal necrolysis. *AIDS*. 2001;15:1843.
31. Mockenhaupt M, Messenheimer J, Tennis P, et al. Risk of Stevens-Johnson and toxic epidermal necrolysis in new users of antiepileptics. *Neurology*. 2005;64:1134.
32. Ketter TA, Wang PW, Chandler RA, et al. Dermatology precautions and slower titration yield low incidence of lamotrigine treatment-emergent rash. *J Clin Psychiatry*. 2005;66:642.
33. Warnock JK, Morris DW. Adverse cutaneous reactions to mood stabilizers. *Am J Clin Dermatol*. 2003;4:21.
34. Beran RG. Cross-reactive skin eruption with both carbamazepine and oxcarbazepine. *Epilepsia*. 1993;34:163.
35. Mockenhaupt M, Kelly JP, Kaufman D, et al. The risk of Stevens-Johnson syndrome and toxic epidermal necrolysis associated with nonsteroidal antiinflammatory drugs: a multinational perspective. *J Rheumatol*. 2003;30:2234.
36. Sassolas B, Haddad C, Mockenhaupt M, et al. ALDEN, an algorithm for assessment of drug causality in Stevens-Johnson syndrome and toxic epidermal necrolysis: comparison with case-control analysis. *Clin Pharmacol Ther*. 2010;88(1):60-68.
37. Mockenhaupt M, Dunant A, Paulmann M, et al. Drug causality in Stevens-Johnson syndrome/toxic epidermal necrolysis in Europe: analysis of 10 years RegiSCAR study. *Pharmacoepidemiol Drug Safe*. 2016; 25(Supp 3):3.
38. Fournier S, Bastuji-Garin S, Mentec H, et al. Toxic epidermal necrolysis associated with Mycoplasma pneumoniae infection. *Eur J Clin Microbiol Infect Dis*. 1995;14:558.
39. Paulmann M, Mockenhaupt M. Fever in Stevens-Johnson syndrome and toxic epidermal necrolysis in pediatric cases: laboratory work-up and antibiotic therapy. *Pediatr Infect Dis J*. 2017;36:513-515.
40. Stone N, Sheerin S, Burge S. Toxic epidermal necrolysis and graft versus host disease: a clinical spectrum but a diagnostic dilemma. *Clin Exp Dermatol*. 1999;24:260.
41. Ting W, Stone MS, Racila D, et al. Toxic epidermal necrolysis-like acute cutaneous lupus erythematosus and the spectrum of the acute syndrome of apoptotic pan-epidermolysis (ASAP): a case report, concept review and proposal for new classification of lupus erythematosus vesiculobullous skin lesions. *Lupus*. 2004;13:941.
42. Ziemer M, Kardaun SH, Liss Y, et al. Stevens-Johnson syndrome and toxic epidermal necrolysis in patients with lupus erythematosus: a descriptive study of 17 cases from a national registry and review of the literature. *Br J Dermatol*. 2012;166, 575-600.
43. Fleisher AB Jr, Rosenthal DI, Bernard SA, et al. Skin reactions to radiotherapy—a spectrum resembling erythema multiforme: case report and review of the literature. *Cutis*. 1992;49:35.
44. Wöhrl S, Loewe R, Pickl WF, et al. EMPACT syndrome. *J Dtsch Dermatol Ges*. 2005;3:39.
45. Correia O, Delgado L, Ramos JP, et al. Cutaneous T-cell recruitment in toxic epidermal necrolysis: further evidence of CD8+ lymphocyte involvement. *Arch Dermatol*. 1993;129:466.
46. Paul C, Wolkenstein P, Adle H, et al. Apoptosis as a mechanism of keratinocyte death in toxic epidermal necrolysis. *Br J Dermatol*. 1996;134:710.
47. Paquet P, Nikkels A, Arrese JE, et al. Macrophages and tumor necrosis factor alpha in toxic epidermal necrolysis. *Arch Dermatol*. 1994;130:605.
48. Le Cleach L, Delaire S, Boumsell L, et al. Blister fluid T lymphocytes during toxic epidermal necrolysis are functional cytotoxic cells which express human natural killer inhibitory receptors. *Clin Exp Immunol*. 2000;119:225.
49. Nassif A, Bensussan A, Dorothée G, et al. Drug specific cytotoxic T-cells in the skin lesions of a patient with toxic epidermal necrolysis. *J Invest Dermatol*. 2002;118:728.
50. Morel E, Escamochero S, Cabañas R, et al. CD94/NKG2C is a killer effector molecule in patients with Stevens-Johnson syndrome and toxic epidermal necrolysis. *J Allergy Clin Immunol*. 2010; 25, 3:703-710.
51. Viard I, Wehrli P, Bullani R, et al. Inhibition of toxic epidermal necrolysis by blockade of CD95 with human intravenous immunoglobulin. *Science*. 1998;282:490.
52. Abe R, Shimizu T, Shibaki A, et al. Toxic epidermal necrolysis and Stevens-Johnson syndrome are induced by soluble Fas Ligand. *Am J Pathol*. 2003;162:1515.
53. Berthou C, Michel L, Soulié A, et al. Acquisition of granzyme B and Fas ligand proteins by human keratinocytes contributes to epidermal cell defence. *J Immunol*. 1997;159:5293.
54. Nassif A, Moslehi H, Le Gouvello S, et al. Evaluation of the potential role of cytokines in toxic epidermal necrolysis. *J Invest Dermatol*. 2004;123:850.
55. Stur K, Karlhofer FM, Stingl G. Soluble FAS ligand: a discriminating feature between drug-induced skin eruptions and viral exanthemas. *J Invest Dermatol*. 2007;127:802.

56. Chung WH, Hung SI, Yang JY, et al. Granulysin is a key mediator for disseminated keratinocyte death in Stevens-Johnson syndrome and toxic epidermal necrolysis. *Nat Med*. 2008;14:1343.
57. Abe R, Yoshioka N, Murata J, et al. Granulysin as a marker for early diagnosis of the Stevens-Johnson syndrome. *Ann Intern Med*. 2009;151:514.
58. Su SC, Mockenhaupt M, Wolkenstein P, et al. Interleukin-15 is associated with severity and mortality in Stevens-Johnson syndrome/toxic epidermal necrolysis. *J Invest Dermatol*. 2017;137(5):1065-1073.
59. Kuechler PC, Britschgi M, Schmid S, et al. Cytotoxic mechanisms in different forms of T-cell-mediated drug allergies. *Allergy*. 2004;59:613.
60. Azukizawa H, Sano S, Kosaka H, et al. Prevention of toxic epidermal necrolysis by regulatory cells. *Eur J Immunol*. 2005;35:1722.
61. Takahashi R, Kano Y, Yamazaki Y, et al. Defective regulatory T cells in patients with severe drug eruptions: timing of the dysfunction is associated with the pathological phenotype and outcome. *J Immunol*. 2009;182:8071.
62. Chung WH, Hung SI, Hong HS, et al. Medical genetics: a marker for Stevens Johnson syndrome. *Nature*. 2004;428:486.
63. Hung SI, Chung WH, Liou LB, et al. HLA-B*5801 allele as a genetic marker for severe cutaneous adverse reactions caused by allopurinol. *Proc Natl Acad Sci U S A*. 2005;102:4134.
64. Locharernkul C, Loplumlert J, Limotai C, et al. Carbamazepine and phenytoin induced Stevens-Johnson syndrome is associated with HLA-B*1502 allele in Thai population. *Epilepsia*. 2008;49:2087.
65. Mehta TY, Prajapati LM, Mittal B, et al. Association of HLA-B*1502 allele and carbamazepine-induced Stevens-Johnson syndrome among Indians. *Indian J Dermatol Venereol Leprol*. 2009;75:579.
66. Kaniwa N, Saito Y, Aihara M, et al. HLA-B locus in Japanese patients with anti-epileptics and allopurinol-related Stevens-Johnson syndrome and toxic epidermal necrolysis. *Pharmacogenomics*. 2008;9:1617.
67. Chung WH, Hung SI, Chen YT. Genetic predisposition of life-threatening antiepileptic-induced skin reactions. *Expert Opin Drug Saf*. 2010;9:15.
68. Lonjou C, Thomas L, Borot N, et al. A marker for Stevens-Johnson syndrome: ethnicity matters. *Pharmacogenomics J*. 2006;6:265.
69. Lonjou C, Borot N, Sekula P, et al. A European study of HLA-B in Stevens-Johnson syndrome and toxic epidermal necrolysis related to five high-risk drugs. *Pharmacogenet Genomics*. 2008;18:99.
70. Genin E, Schumacher M, Roujeau JC, et al. Genome-wide association study of Stevens-Johnson syndrome and toxic epidermal necrolysis in Europe. *Orphanet J Rare Dis*. 2011;6:52.
71. Mockenhaupt M. Severe drug-induced skin reactions: clinical pattern, diagnostics and therapy. *J Dtsch Dermatol Ges*. 2009;7:142.
72. Shay E, Kheirkhah A, Liang L, et al. Amniotic membrane transplantation as a new therapy for the acute ocular manifestations of Stevens-Johnson syndrome and toxic epidermal necrolysis. *Surv Ophthalmol*. 2009;54:686.
73. Gueudry, Roujeau JC, Binaghi M, et al. Risk factors for the development of ocular complications of Stevens-Johnson syndrome and toxic epidermal necrolysis. *Arch Dermatol*. 2009;145:157.
74. Meneux E, Wolkenstein P, Haddad B, et al. Vulvovaginal involvement in toxic epidermal necrolysis: a retrospective study of 40 cases. *Obstet Gynecol*. 1998;91:283.
75. Mockenhaupt M, Ziemer M. Erythema multiforme majus, Stevens-Johnson syndrome, toxic epidermal necrolysis and graft-versus-host disease. In: Kirtschig G, Cooper S, eds. *Gynecologic Dermatology*., London: Medical Publishers; 2016:79-88.
76. Lebargy F, Wolkenstein P, Gisselbrecht M, et al. Pulmonary complications in toxic epidermal necrolysis: prospective clinical study. *Intensive Care Med*. 1997;23:1237.
77. McIvor RA, Zaidi J, Peters WJ, et al. Acute and chronic respiratory complications of toxic epidermal necrolysis. *J Burn Care Rehabil*. 1996;17:237.
78. Michel P, Joly P, Ducrotte P, et al. Ileal involvement in toxic epidermal necrolysis (Lyell syndrome). *Dig Dis Sci*. 1993;38:1938.
79. Carter FM, Mitchell CK. Toxic epidermal necrolysis—an unusual cause of colonic perforation. Report of a case. *Dis Colon Rectum*. 1993;36:773.
80. Blum L, Chosidow O, Rostoker G, et al. Renal involvement in toxic epidermal necrolysis. *J Am Acad Dermatol*. 1996;34:1088.
81. Krumlovsky FA, Del Greco F, Herdson PB, et al. Renal disease associated with toxic epidermal necrolysis (Lyell's disease). *Am J Med*. 1974;57:817.
82. Ziemer M, Mockenhaupt M. Severe drug-induced skin reactions: clinical pattern, diagnostics and therapy. In: Khopkar U, ed. *Skin Biopsy*. InTech-Open Access Publisher. 2011. http://www.intechopen.com/articles/show/title/severe-drug-induced-skin-reactions-clinical-pattern-diagnostics-and-therapy.
83. Rzany B, Hering O, Mockenhaupt M, et al. Histopathological and epidemiological characteristics of patients with erythema multiforme majus, Stevens-Johnson syndrome and toxic epidermal necrolysis. *Br J Dermatol*. 1996;135:6.
84. Quinn AM, Brown K, Bonish BK, et al. Uncovering histologic criteria with prognostic significance in toxic epidermal necrolysis. *Arch Dermatol*. 2005;141:683.
85. Williams GP, Mudhar HS, Leyland M. Early pathological features of the cornea in toxic epidermal necrolysis. *Br J Ophthalmol*. 2007;91:1129.
86. Lipowicz S, Sekula P, Ingen-Housz-Oro S, et al. Prognosis of generalized bullous fixed drug eruption: a case control study. *Br J Dermatol*. 2013;168(4):726-732.
87. de Prost N, Ingen-Housz-Oro S, Duong Ta, et al. Bacteremia in Stevens-Johnson syndrome and toxic epidermal necrolysis: epidemiology, risk factors, and predictive value of skin cultures. *Medicine (Baltimore)*. 2010;89:28.
88. Palmieri T, Greenhalgh DG, Saffle JR, et al. A multicenter review of toxic epidermal necrolysis treated in U.S. burn centers at the end of the twentieth century. *J Burn Care Rehabil*. 2002;23:87.
89. Haber J, Hopman W, Gomez M, et al. Late outcome in adult survivors of toxic epidermal necrolysis after treatment in burn center. *J Burn Care Rehabil*. 2005;26:33.
90. Paulmann M, Mockenhaupt M, Dunant A, et al. Stevens-Johnson syndrome and toxic epidermal necrolysis: long-term sequelae based on a 5-year follow-up analysis. *Pharmacoepidem Drug Safe*. 2017; 26(Supp 2):3.
91. Gaultier F, Rochefort J, Landru MM, et al. Severe and unrecognized dental abnormalities after drug-induced epidermal necrolysis. *Arch Dermatol*. 2009;145:1332.
92. Bakirtas A, Harmanci K, Toyran M, et al. Bronchiolitis obliterans: a rare chronic pulmonary complication

associated with Stevens-Johnson syndrome. *Pediatr Dermatol*. 2007;24:E22.
93. Garcia-Doval I, LeCleach L, Bocquet H, et al. Toxic epidermal necrolysis and Stevens-Johnson syndrome. Does early withdrawal of causative drugs decrease the risk of death? *Arch Dermatol*. 2000;136:323.
94. Ellis MW. A case report and a proposed algorithm for the transfer of patients with Stevens-Johnson syndrome and toxic epidermal necrolysis to a burn center. *Mil Med*. 2002;167:701.
95. Creamer D, Walsh SA, Dziewulski P, et al. U.K. guidelines for the management of Stevens-Johnson syndrome/toxic epidermal necrolysis in adults. *Br J Dermatol*. 2016;174, 1194-1227.
96. Endorf EW, Cancio LC, Gibran NS. Toxic epidermal necrolysis clinical guidelines. *J Burn Res*. 2008;29:706.
97. Lal S, Barrow RE, Wolf SE, et al. Biobrane improves wound healing in burned children without increased risk of infection. *Shock*. 2000;14:314.
98. Boorboor P, Vogt PM, Bechara FG, et al. Toxic epidermal necrolysis: use of Biobrane or skin coverage reduces pain, improves mobilisation and decreases infection in elderly patients. *Burns*. 2008;34:487.
99. Dorafshar AH, Dickie SR, Cohn AB, et al. Antishear therapy for toxic epidermal necrolysis: an alternative treatment approach. *Plast Reconstr Surg*. 2008;122:154.
100. Kardaun SH, Jonkman MF. Dexamethasone pulse therapy for Stevens-Johnson syndrome/toxic epidermal necrolysis. *Acta Derm Venereol*. 2007;87:144.
101. Schneck J, Fagot JP, Sekula P, et al. Effects of treatments on the mortality of Stevens-Johnson syndrome and toxic epidermal necrolysis: a retrospective study on patients included in the prospective EuroSCAR Study. *J Am Acad Dermatol*. 2008;58:33.
102. Zimmermann S, Sekula P, Venhoff M, et al. Systemic immunomodulating therapies for Stevens-Johnson syndrome and toxic epidermal necrolysis: a systematic review and meta-analysis. *JAMA Dermatol*. 2017;153(6):514-522.
103. Trent JT, Kirsner RS, Romanelli P, et al. Analysis of intravenous immunoglobulin for the treatment of toxic epidermal necrolysis using SCORTEN. *Arch Dermatol*. 2003;139:39.
104. Prins C, Kerdel FA, Padilla RS, et al. Treatment of toxic epidermal necrolysis with high-dose intravenous immunoglobulins. *Arch Dermatol*. 2003;139:26.
105. Stella M, Clemente A, Bollero D, et al. Toxic epidermal necrolysis (TEN) and Stevens-Johnson syndrome (SJS): experience with high-dose intravenous immunoglobulins and topical conservative approach. A retrospective analysis. *Burns*. 2007;33:452.
106. Bachot N, Revuz J, Roujeau JC. Intravenous immunoglobulin treatment for Stevens-Johnson and toxic epidermal necrolysis. *Arch Dermatol*. 2003;139:33.
107. Shortt R, Gomez M, Mittman N, et al. Intravenous immunoglobulin does not improve outcome in toxic epidermal necrolysis. *J Burn Care Rehabil*. 2004;25:246.
108. Faye O, Roujeau JC. Treatment of epidermal necrolysis with high-dose intravenous immunoglobulins (IVIG). Clinical experience to date. *Drugs*. 2005;65(15):2085-2090.
109. Roujeau JC, Mockenhaupt M, Guillaume JC, et al. New evidence supporting cyclosporine efficacy in epidermal necrolysis. *J Invest Dermatol*. 2017; 137(10):2047-2049.
110. Arévalo JM, Lorente JA, González-Herrada C, et al. Treatment of toxic epidermal necrolysis with cyclosporine A. *J Trauma*. 2000;48:473.
111. Valeyrie-Allanore L, Wolkenstein P, Brochard L, et al. Pilot study of ciclosporin treatment for Stevens-Johnson syndrome and toxic epidermal necrolysis. *Br J Dermatol*. 2010;163(4):847-853.
112. González-Herrada C, Rodríguez-Martín S, Cachafeiro L, et al. Ciclosporin use in epidermal necrolysis is associated with an important mortality reduction: evidence from three different approaches. *J Invest Dermatol*. 2017;137(10):2092-2100.
113. Bamichas G, Natse T, Christidou F, et al. Plasma exchange in patients with toxic epidermal necrolysis. *Ther Apher*. 2002;6:225.
114. Chaidemenos GC, Chrysomallis F, Sombolos K, et al. Plasmapheresis in toxic epidermal necrolysis. *Int J Dermatol*. 1997;36:218.
115. Egan CA, Grant WJ, Morris SE, et al. Plasmapheresis as an adjunct treatment in toxic epidermal necrolysis. *J Am Acad Dermatol*. 1999;40:458.
116. Lissia M, Figus A, Rubino C. Intravenous immunoglobulins and plasmapheresis combined treatment in patients with severe toxic epidermal necrolysis: preliminary report. *Br J Plast Surg*. 2005;58:504.
117. Wang CW, Yang LY, Chen CB, et al. Randomized, controlled trial of TNF-α antagonist in CTL-mediated severe cutaneous adverse reactions. *J Clin Invest*. 2018;128(3):985-996.
118. Wolkenstein P, Latarjet J, Roujeau JC, et al. Randomised comparison of thalidomide versus placebo in toxic epidermal necrolysis. *Lancet*. 1998;352:1586.
119. Rosenthal P, Cotter J. The Boston Scleral Lens in the management of severe ocular surface disease. *Ophthalmol Clin North Am*. 2003;16:89.
120. Tougeron-Brousseau B, Delcampe A, Gueudry J, et al. Vision-related function after scleral lens fitting in ocular complications of Stevens-Johnson syndrome and toxic epidermal necrolysis. *Am J Ophthalmol*. 2009;148:852.
121. Daya SM, Ilari FA. Living related conjunctival limbal allograft for the treatment of stem cell deficiency. *Ophthalmology*. 2001;108:126.
122. Nishida K, Yamato M, Hayashida Y, et al. Corneal reconstruction with tissue engineered cell sheets composed of autologous oral epithelium. *N Engl J Med*. 2004;351:1187.
123. Chen P, Lin JJ, Lu CS, et al. Carbamazepine induced toxic effects and HLA-B*1502 screening in Taiwan. *N Engl J Med*. 2011;364:1126-1133.
124. Chen Z, Liew D, Kwan P. Effects of a HLA-B*15:02 screening policy on antiepileptic drug use and severe skin reactions. *Neurology*. 2014;83:2077-2084.
125. Barbaud A, Collet E, Milpied B. A multicentre study to determine the value and safety of drug patch tests for the three main classes of severe cutaneous adverse drug reactions. *Br J Dermatol*. 2013;3:555-562.
126. Kano Y, Hirahara K, Mitsuyama Y, et al. Utility of the lymphocyte transformation test in the diagnosis of drug sensitivity: dependence on its timing and the type of drug eruption. *Allergy*. 2007;62:1439.

Chapter 45 :: Cutaneous Reactions to Drugs

:: Kara Heelan, Cathryn Sibbald, & Neil H. Shear

AT-A-GLANCE

- Drug-induced cutaneous eruptions are common.
- They range from common nuisance rashes to rare life-threatening diseases.
- The spectrum of clinical manifestations includes exanthematous, urticarial, pustular, and bullous eruptions.
- These reactions may mimic other cutaneous diseases such as acne, porphyria, lichen planus, and lupus.
- Fixed drug eruptions are usually solitary dusky macules that recur at the same site.
- Drug reactions may be limited solely to skin or may be part of a severe systemic reaction, such as drug hypersensitivity syndrome or toxic epidermal necrolysis.

Complications of drug therapy are a major cause of patient morbidity and account for a significant number of patient deaths.[1] Drug eruptions range from common nuisance eruptions to rare or life-threatening drug-induced diseases. Drug reactions may be solely limited to the skin, or they may be part of a systemic reaction, such as drug hypersensitivity syndrome or toxic epidermal necrolysis (TEN; see Chap. 44).

Drug eruptions are often distinct disease entities and must be approached systematically, like any other cutaneous disease. A precise diagnosis of the reaction pattern can help narrow possible causes, because different drugs are more commonly associated with different types of reactions.

EPIDEMIOLOGY

The incidence of cutaneous adverse drug reactions varies across populations. A systematic review of the medical literature, encompassing 9 studies, concluded that cutaneous reaction rates varied from 0% to 8%.[2] The risk in hospitalized patients ranges from 10% to 15%.[3] In a French cohort of hospitalized patients, the most common reactions were maculopapular (56%), with severe reactions in a minority (34%).[4]

Outpatient studies of cutaneous adverse drug reactions estimate that 2.5% of children who are treated with a drug, and up to 12% of children treated with an antibiotic, will experience a cutaneous reaction.[5] Elderly patients do not appear to have an increased risk of maculopapular exanthems, and may have a lower incidence of serious reactions.[6] Populations that may have an increased risk of drug reactions in hospital include patients with HIV, connective tissue disorders (including lupus erythematosus), non-Hodgkin lymphoma, and hepatitis.[7]

CLINICAL FEATURES

MORPHOLOGIC APPROACH TO DRUG ERUPTIONS

Although there are many presentations of cutaneous drug eruptions, the morphology of many cutaneous eruptions may be exanthematous, urticarial, blistering, or pustular. The extent of the reaction is variable. For example, once the morphology of the reaction has been documented, a specific diagnosis (eg, fixed drug eruption [FDE] or acute generalized exanthematous pustulosis [AGEP]) can be made. The reaction may also present as a systemic syndrome (eg, serum sickness–like reaction or hypersensitivity syndrome reaction). Fever is generally associated with such systemic cutaneous adverse drug reactions (ADRs).

EXANTHEMATOUS ERUPTIONS

Exanthematous eruptions, sometimes referred to as *morbilliform* or *maculopapular*, are the most common form of drug eruptions, accounting for approximately 95% of skin reactions (Fig. 45-1).[2] Simple exanthems are erythematous changes in the skin without blistering, pustulation, or associated systemic signs. The eruption typically starts on the trunk and spreads peripherally in a symmetric fashion. Pruritus is almost always present. These eruptions usually occur within 1 week of initiation of therapy and may appear 1 or 2 days after drug therapy has been discontinued.[8] Resolution, usually within 7 to 14 days, occurs with a change in color from bright red to a brownish red, which may be followed by desquamation. The differential diagnosis in these patients includes an infectious exanthem (eg, viral, bacterial, or rickettsial), collagen vascular disease, and infections.

Exanthematous eruptions can be caused by many drugs, including β-lactams ("the penicillins"),

FIGURE 45-1 Exanthematous drug eruption: ampicillin. Symmetrically arranged, brightly erythematous macules and papules, which are discrete in some areas and confluent in others on the trunk and discrete on the extremities.

sulfonamide antimicrobials, nonnucleoside reverse transcriptase inhibitors (eg, nevirapine), and antiepileptic medications. Studies show that drug-specific T cells play a major role in exanthematous, bullous, and pustular drug reactions.[9] In patients who have concomitant infectious mononucleosis, the risk of developing an exanthematous eruption while being treated with an aminopenicillin (eg, ampicillin) increases from 3% to 7% to 60% to 100%.[10] A similar drug–virus interaction has been observed in 50% of patients infected with HIV who are exposed to sulfonamide antibiotics.[11]

An exanthematous eruption in conjunction with fever and internal organ inflammation (eg, liver, kidney, CNS) signifies a more serious reaction, known as the *hypersensitivity syndrome reaction* (HSR), drug-induced hypersensitivity reaction, or drug reaction with eosinophilia and systemic symptoms (Table 45-1).[12] It occurs in approximately 1 in 3000 exposures to agents such as aromatic anticonvulsants, lamotrigine, sulfonamide antimicrobials, dapsone, nitrofurantoin, nevirapine, minocycline, metronidazole, and allopurinol (Fig. 45-2). HSR occurs most frequently on first exposure to the drug, with initial symptoms starting 1 to 6 weeks after exposure. Fever and malaise are often the presenting symptoms. Atypical lymphocytosis with subsequent eosinophilia may occur during the initial phases of the reaction in some patients. Although most patients have an exanthematous eruption, more serious cutaneous manifestations may be evident (Fig. 45-3). Internal organ involvement can be asymptomatic.[13] Immune-mediated thyroid dysfunction is a possible long-term complication resulting in hyperthyroidism or hypothyroidism, and may not present until 3 to 12 months after the first symptoms appear.[14]

TABLE 45-1
Morphologic Classification

Exanthematous	
Simple	Exanthematous drug eruption
Complex	Drug-induced hypersensitivity syndrome
Urticarial	
Simple	Urticaria
Complex	Serum sickness-like reaction
Pustular	
Simple	Acneiform
Complex	Acute generalized exanthematous pustulosis
Bullous	
Simple	Pseudoporphyria Fixed drug eruption
Complex	Drug-induced pemphigus Drug-induced bullous pemphigoid Drug-induced linear immunoglobulin A disease Stevens-Johnson syndrome Toxic epidermal necrolysis
Papulosquamous	Drug-induced subcutaneous lupus Drug-induced dermatomyositis
Purpuric	Drug-induced vasculitis
Lichenoid	Drug-induced lichenoid
Miscellaneous	Pseudolymphoma Neutrophilic eccrine hidradenitis

URTICARIAL ERUPTIONS

Urticaria is characterized by pruritic red wheals of various sizes. Individual lesions generally last for less than 24 hours, although new lesions can commonly develop. When deep dermal and subcutaneous tissues are also swollen, the reaction is known as *angioedema*.

FIGURE 45-2 Drug hypersensitivity syndrome: phenytoin. Symmetric, bright red, exanthematous eruption, confluent in some sites; the patient had associated lymphadenopathy.

FIGURE 45-3 Hypersensitivity syndrome reaction, characterized by fever, a pustular eruption, and hepatitis, in a 23-year-old man after 18 days of treatment with minocycline.

Angioedema is frequently unilateral and nonpruritic and lasts for 1 to 2 hours, although it may persist for 2 to 5 days.[15]

Urticaria and angioedema, when associated with drug use, are usually indicative of an immunoglobulin (Ig) E–mediated immediate hypersensitivity reaction. This mechanism is typified by immediate reactions to penicillin and other antibiotics (see Chap. 41). Signs and symptoms of IgE-mediated allergic reactions typically include pruritus, urticaria, cutaneous flushing, angioedema, nausea, vomiting, diarrhea, abdominal pain, nasal congestion, rhinorrhea, laryngeal edema, and bronchospasm or hypotension. Urticaria and angioedema can also be caused by non–IgE-mediated reactions that result in direct and nonspecific liberation of histamine or other mediators of inflammation.[8] Drug-induced non–IgE-mediated urticaria and angioedema are usually related to nonsteroidal antiinflammatory drugs (NSAIDs) and angiotensin-converting enzyme (ACE) inhibitors.[16]

Serum sickness–like reactions (see Table 45-1) are defined by the presence of fever, rash (usually urticarial), and arthralgias 1 to 3 weeks after initiation of drug therapy. Lymphadenopathy and eosinophilia may also be present; however, in contrast to true serum sickness, immune complexes, hypocomplementemia, vasculitis, and renal lesions are absent.

Cefaclor is associated with an increased relative risk of serum sickness–like reactions. The overall incidence of cefaclor-induced serum sickness–like reactions has been estimated to be 0.024% to 0.2% per course of cefaclor prescribed. In genetically susceptible hosts, a reactive metabolite is generated during the metabolism of cefaclor that may bind with tissue proteins and elicit an inflammatory response manifesting as a serum sickness–like reaction.[12]

Other drugs that have been implicated in serum sickness–like reactions are cefprozil, bupropion, minocycline, and rituximab[17] as well as infliximab.[18] The incidence of serum sickness–like reactions caused by these drugs is unknown.

PUSTULAR AND ACNEIFORM ERUPTIONS

Acneiform eruptions are associated with the use of iodides, bromides, adrenocorticotropic hormone, glucocorticoids, isoniazid, androgens, lithium, actinomycin D, and phenytoin. Drug-induced acne may appear in atypical areas, such as on the arms and legs, and is most often monomorphous. Comedones are usually absent. That acneiform eruptions do not affect prepubertal children indicates that previous hormonal priming is a necessary prerequisite. In cases in which the offending agent cannot be discontinued, topical tretinoin may be useful.[19]

An acneiform eruption occurs in the majority of patients taking epidermal growth factor receptor inhibitors (eg, gefitinib, erlotinib, cetuximab), with an incidence as high as 81.6%.[20] The eruption is characterized by pruritic follicular papules and pustules without comedones, and presents within 1 to 2 weeks of treatment initiation.[21] Concurrent cutaneous findings include paronychia, xerosis, and skin fissures. The eruption is dose dependent, with respect to both incidence and severity, and correlates with tumor response and overall survival.[15,22] Specific treatment alternatives include tetracyclines and low-dose isotretinoin.[21] Antihistamines (cetirizine, loratadine, hydroxyzine) and doxepin are helpful in targeting the associated pruritus. There is contradictory evidence for the benefit of tetracyclines for prophylaxis.[23,24]

AGEP is an acute febrile pustular eruption that occurs 24 to 48 hours after initiation of the implicated drug. It is characterized by small monomorphous nonfollicular sterile pustules concentrated on the trunk and intertriginous regions. Systemic features include leukocytosis with neutrophilia, fever, elevated liver enzymes with steatosis or hepatomegaly, renal insufficiency, and pleural effusions with hypoxemia (Fig. 45-4; see Table 45-1).[25] Generalized desquamation occurs after approximately 2 weeks. The estimated incidence of AGEP is approximately 1 to 5 cases per million per year. It is most commonly associated with β-lactam, macrolide and quinolone, antibiotics, anticonvulsants, sulfonamides, calcium channel blockers (diltiazem), and terbinafine.[26,27] Differential diagnosis includes pustular psoriasis, HSR with pustulation, subcorneal pustular dermatosis (Sneddon-Wilkinson disease), pustular vasculitis, or, in severe cases of AGEP, TEN. The typical histopathologic analysis of AGEP lesions shows spongiform subcorneal and/or intraepidermal pustules, an often marked edema of the papillary dermis, and perivascular infiltrates with neutrophils and exocytosis of some eosinophils. Discontinuance of therapy is usually the extent of treatment necessary in most patients, although some patients may require the use of corticosteroids.

FIGURE 45-4 Acute generalized exanthematous pustulosis in a 48-year-old man who developed nonfollicular pustules and fever after 7 days of treatment with diltiazem.

BULLOUS ERUPTIONS

Table 45-2 outlines the clinical features of selected cutaneous reactions to drugs.

PSEUDOPORPHYRIA

Pseudoporphyria is a cutaneous phototoxic disorder that can resemble either porphyria cutanea tarda in adults or erythropoietic protoporphyria in children but differs from these entities by the presence of normal porphyrin levels (see Chap. 124). Pseudoporphyria of the porphyria cutanea tarda variety is characterized by skin fragility, blister formation, and scarring in photodistribution. The other clinical pattern mimics erythropoietic protoporphyria and manifests as cutaneous burning, erythema, vesiculation, angular chicken pox–like scars, and waxy thickening of the skin. The eruption may begin within 1 day of initiation of therapy or may be delayed in onset for as long as 1 year. The course is prolonged in some patients, but most reports describe symptoms that disappear several weeks to several months after the offending agent is withdrawn. Because of the risk of permanent facial scarring, the implicated drug should be discontinued if skin fragility, blistering,

TABLE 45-2
Clinical Features of Selected Cutaneous Reactions to Drugs

CLINICAL PRESENTATION	DRUG ERUPTION	TIME TO ONSET	FEVER	INTERNAL ORGAN INVOLVEMENT	ARTHRALGIA	LYMPHADENOPATHY	IMPLICATED DRUGS
Hypersensitivity syndrome reaction	Exanthem, exfoliative dermatitis, pustular eruptions, SJS-TEN	DRESS: 2-6 weeks, SJS-TEN: 1-3 weeks	Present	Present	Absent	Present	Aromatic anticonvulsants (eg, phenytoin, phenobarbital, carbamazepine), sulfonamide antibiotics, dapsone, minocycline, allopurinol, lamotrigine
Serum sickness–like reaction	Urticaria, exanthem		Present	Absent	Present	Present	Cefaclor, cefprozil, bupropion, minocycline, infliximab, rituximab
Drug-induced lupus	Usually absent		Present/absent	Present/absent	Present	Absent	Procainamide, hydralazine, isoniazid, minocycline, acebutolol
Drug-induced subacute cutaneous lupus erythematosus	Papulosquamous or annular cutaneous lesion (often photosensitive)	Variable	Absent	Absent	Absent	Absent	Thiazide diuretics, calcium channel blockers, ACE inhibitors
Acute generalized exanthematous pustulosis	Nonfollicular pustules on an edematous erythematous base	24-48 hours	Present	Present in ~20%	Absent	Absent	β Blockers, macrolide antibiotics, calcium channel blockers

Abbreviations: ACE, angiotensin-converting enzyme; DRESS, drug rash with eosinophilia and systemic symptoms; SJS, Stevens-Johnson syndrome; TEN, toxic epidermal necrolysis.

or scarring occurs.[28] In addition, the use of broad-spectrum sunscreen and protective clothing should be recommended. Drugs that have been associated with pseudoporphyria include naproxen and other NSAIDs, diuretics, antibiotics (tetracycline, ciprofloxacin, ampicillin-sulbactam/cefepime), retinoids, cyclosporine, dapsone, oral contraceptive pills, amiodarone, and voriconazole.[29]

DRUG-INDUCED LINEAR IMMUNOGLOBULIN A DISEASE

Both idiopathic and drug-induced linear IgA disease (see Chap. 58) are heterogeneous in clinical presentation. Cases of the drug-induced type have morphologies resembling erythema multiforme, bullous pemphigoid, and dermatitis herpetiformis. The drug-induced disease may differ from the idiopathic entity in that mucosal or conjunctival lesions are less common, spontaneous remission occurs once the offending agent is withdrawn, and immune deposits disappear from the skin once the lesions resolve. Drug-induced disease may present more commonly with erosions mimicking TEN, with a more severe clinical course and risk of sepsis and shock.[30] Time to onset is reported between 2 days to 4 weeks.

Biopsy specimens are necessary for diagnosis. Histologically, the 2 entities are similar. A study suggests that, as in the idiopathic variety, the target antigen is not unique in the drug-induced disease. Although 13% to 30% of patients with sporadic linear IgA have circulating basement membrane zone antibodies, these antibodies have not been reported in drug-induced cases.[31] In patients with linear IgA bullous disease proven by direct immunofluorescence, the index of suspicion of drug induction should be higher in cases with only IgA and no IgG in the basement membrane zone. Several drugs can induce linear IgA bullous dermatosis, the most frequently reported being vancomycin.[30,32]

DRUG-INDUCED PEMPHIGUS

Pemphigus may be considered as drug-induced or drug-triggered (ie, a latent disease that is unmasked by the drug exposure; see Chap. 57). Drug-induced pemphigus caused by penicillamine and other thiol-containing drugs (eg, piroxicam, captopril) tends to remit spontaneously in 35% to 50% of cases, presents as pemphigus foliaceus, has an average interval to onset of 1 year, and is associated with the presence of antinuclear antibodies in 25% of patients.

Most patients with nonthiol drug-induced pemphigus manifest clinical, histologic, immunologic, and evolutionary aspects similar to those of idiopathic pemphigus vulgaris with mucosal involvement and show a 15% rate of spontaneous recovery after drug withdrawal. Treatment of drug-induced pemphigus begins with drug cessation. Systemic glucocorticoids and other immunosuppressive drugs are often required until all symptoms of active disease disappear. Vigilant followup is required after remission to monitor the patient and the serum for autoantibodies to detect an early relapse.[16]

DRUG-INDUCED BULLOUS PEMPHIGOID

Drug-induced bullous pemphigoid (see Chap. 54) can encompass a wide variety of presentations, ranging from the classic features of large, tense bullae arising from an erythematous, urticarial base with moderate involvement of the oral cavity, through mild forms with few bullous lesions, to scarring plaques and nodules with bullae. Numerous medications have been reported to cause bullous pemphigoid, including diuretics (furosemide and spironolactone), ACE inhibitors, and antibiotics (penicillins and fluoroquinolones).[33] In contrast to patients with the idiopathic form, patients with drug-induced bullous pemphigoid are generally younger, and more commonly may have a positive Nikolsky sign, lesions on normal-appearing skin, target lesions on the palms and soles, involvement of the lower legs, and mucosal involvement.[33] In addition, the histopathologic findings are of a perivascular infiltration of lymphocytes with neutrophils and marked eosinophils, intraepidermal vesicles with foci of necrotic keratinocytes, thrombi in dermal vessels, and a possible lack of tissue-bound and circulating anti–basal membrane zone IgG.[34]

In the acute, self-limited condition, resolution occurs after the withdrawal of the culprit agent, with or without glucocorticoid therapy, and rarely recurs, unlike its idiopathic counterpart. In some patients, however, the drug may actually trigger the idiopathic form of the disease, with a more severe and persistent course.

STEVENS-JOHNSON SYNDROME AND TOXIC EPIDERMAL NECROLYSIS

(See Chap. 44)

Stevens-Johnson syndrome (SJS) and TEN or the SJS-TEN spectrum, represent variants of the same disease process. Differentiation between the 2 patterns depends on the nature of the skin lesions and the extent of body surface area involvement.

The understanding of the pathogenesis of severe cutaneous ADRs has expanded greatly. Various factors, including pharmacogenetic and immunogenic determinants, may influence the likelihood of a reaction and variability in innate and adaptive immunity may influence the clinical presentation.[35] In addition, the detection of drug-specific T-cell proliferation provides evidence that T cells are involved in severe skin rashes.[36]

FIXED DRUG ERUPTIONS

FDEs usually appear as solitary round or ovoid, erythematous, bright red or dusky red macules that may evolve into an edematous plaque; bullous-type lesions may be present. Widespread or generalized FDE may mimic TEN, but differs in its absence of systemic

FIGURE 45-5 Fixed drug eruption. (From Wolff K, Johnson R, Saavedra AP, et al. *Fitzpatrick's Color Atlas and Synopsis of Clinical Dermatology*, 8th ed. New York, NY: McGraw-Hill; 2017, with permission, Fig. 23-7.)

involvement and more marked hyperpigmentation.[37] FDEs are commonly found on the genitalia and in the perianal area, although they can occur anywhere on the skin surface (Figs. 45-5 and 45-6). A review of 59 cases suggested a sex-dependent pattern of distribution with women more commonly presenting with lesions on the hands and feet, and men on the genitalia.[38] Some patients may complain of burning or stinging,

FIGURE 45-6 Fixed drug eruption: tetracycline. A well-defined plaque on the knee, merging with 3 satellite lesions. The large plaque exhibits epidermal wrinkling, a sign of incipient blister formation. This was the second such episode after ingestion of a tetracycline. No other lesions were present.

TABLE 45-3
Drugs Implicated in Fixed Drug Eruptions

Nonsteroidal antiinflammatory agents (acetaminophen)
Antibiotics
Tetracyclines (tetracycline, minocycline, doxycycline)
Sulfonamides, other sulfa drugs
Metronidazole
Nystatin
Salicylates
Phenylbutazone, phenacetin
Barbiturates
Oral contraceptives
Quinine (including quinine in tonic water), quinidine
Phenolphthalein
Food coloring (yellow): in food or medications

and others may have fever, malaise, and abdominal symptoms. FDE can develop from 30 minutes to 8 to 16 hours after ingestion of the medication. After the initial acute phase lasting days to weeks, residual grayish or slate-colored hyperpigmentation develops. On rechallenge, not only do the lesions recur in the same location, but also new lesions often appear.

More than 100 drugs have been implicated in causing FDEs (Table 45-3). A review of 134 cases at a single site highlighted NSAIDs, acetaminophen, and antibiotics as the most frequent culprits.[39] Another commonly cited trigger is pseudoephedrine. A haplotype linkage in trimethoprim-sulfamethoxazole–induced FDE has been documented.

A challenge or provocation test with the suspected drug may be useful in establishing the diagnosis. Patch testing at the site of a previous lesion yields a positive response in up to 43% of patients. Results of prick and intradermal skin tests may be positive in 24% and 67% of patients, respectively.[40,41] Food-initiated fixed eruptions also exist and are important to consider when assessing causation.

DRUG-INDUCED HYPERPIGMENTATION

Table 45-4 summarizes the main patterns of drug-induced hyperpigmentation, Table 45-5 outlines drug-induced nail hyperpigmentation, and Table 45-6 summarizes cytotoxic drug-induced skin pigmentation distribution patterns.

DRUG-INDUCED LICHENOID ERUPTIONS

Drug-induced lichen planus produces lesions that are clinically and histologically indistinguishable from those of idiopathic lichen planus (see Chap. 32); however,

TABLE 45-4
Summary of the Main Patterns of Drug-Induced Hyperpigmentation

CAUSATIVE DRUG	DISTRIBUTION	HISTOLOGY
Nonsteroidal antiinflammatory drugs	Extremities, trunk, mucous membranes (fixed drug eruption)	Epidermal necrosis
Antimalarials	Nails, legs, head, rarely mucous membranes	Melanin, siderin deposition
Psychotropic drugs	Sun-exposed areas, sometimes blue-gray	Melanin and drug complexes within dermal macrophages
Amiodarone	Sun-exposed areas	Amiodarone and lipofuscin accumulation within dermal histiocytes
Cytotoxic drugs	Variable	Variable
Tetracyclines	Sun-exposed areas, acne scars, sites of previous inflammation, mucous membranes, internal organs	Cyclin, melanin, hemosiderin, lipofuscin accumulation
Silver	Skin (diffuse), nails, mucous membranes	Silver granule deposition within dermal histiocytes or free dermis
Gold	Sun-exposed areas, blue-gray	Deposits of gold granules within dermal histiocytes or free dermis

Adapted by permission from Springer: Dereure O. Drug-induced skin pigmentation. *Am J Clin Dermatol*. 2001;2(4):253-262. Copyright © 2001.

lichenoid drug eruptions often appear initially as eczematous with a purple hue and involve large areas of the trunk. Usually the mucous membranes and nails are not involved. Histologically, focal parakeratosis, focal interruption of the granular layer, cytoid bodies in the cornified and granular layers, the presence of eosinophils and plasma cells in the inflammatory infiltrate, and an infiltrate around the deep vessels favor a diagnosis of lichenoid drug eruption.[42] Photodistributed presentations may lack these specific features and be interchangeable with idiopathic lichen planus on histology.[43]

Many drugs, including β-blockers, penicillamine, and ACE inhibitors, especially captopril, reportedly produce this reaction. Lichen planus–like eruptions also have been reported with tumor necrosis factor (TNF)-α antagonists (infliximab, etanercept, and adalimumab) and antibodies to the immune checkpoint T-cell receptor programmed death (PD)-1 and PD-1 ligand.[44-46] The mean latent period is between 2 months and 3 years for penicillamine, approximately 1 year for β-adrenergic blocking agents, and 3 to 6 months for ACE inhibitors. For anti-TNF treatments, the time to reaction is similar, with onset occurring between 3 weeks and 62 weeks, and for PD-1 and PD-1 ligand

TABLE 45-5
Drug-Induced Nail Hyperpigmentation

CAUSATIVE DRUG	CLINICAL PATTERN OF PIGMENTATION
Antimalarials	Nail bed with transversal bands or diffuse pigmentation
Cytotoxic drugs: cisplatin, doxorubicin, idarubicin, fluorouracil, bleomycin, docetaxel, dacarbazine, and hydroxyurea (hydroxycarbamide)	Longitudinal or transverse pigmented bands or diffuse pigmentation, sometimes coexisting with leukonychia or onycholysis (docetaxel)
Silver	Longitudinal or diffuse
Phenothiazines	Diffuse
Zidovudine	Diffuse

Reprinted with permission from Springer: Dereure O. Drug-induced skin pigmentation. *Am J Clin Dermatol*. 2001;2(4):253-262. Copyright © 2001.

TABLE 45-6
Cytotoxic Drug-Induced Skin Pigmentation Distribution Patterns

CLINICAL PATTERN OF PIGMENTATION	CAUSATIVE DRUG
Diffuse	Busulfan, cyclophosphamide, methotrexate, hydroxyurea (hydroxycarbamide), procarbazine
Dorsal surfaces of extremities	Cisplatin, doxorubicin, mitoxantrone
Flexural areas, palmar and plantar surfaces	Ifosfamide, fluorouracil, tegafur, bleomycin, doxorubicin
Patchy	Cisplatin
On areas of trauma (electrocardiogram electrodes, occlusive dressing, friction)	Cyclophosphamide, fluorouracil, ifosfamide, topical carmustine, cisplatin, thiotepa, hydroxyurea (hydroxycarbamide), bleomycin, docetaxel
Serpentine supravenous pigmentation at infusion sites	Fotemustine, fluorouracil, vinorelbine, cisplatin, docetaxel, combination of cytarabine, asparaginase, mercaptopurine and cyclophosphamide
On previous tumoral areas	Mechlorethamine, cyclophosphamide, hydroxyurea
Postinflammatory	Combination of ifosfamide, cisplatin and etoposide (in intertriginous areas)
With photosensitivity	Fluorouracil, daunorubicin, doxorubicin
Flagellated	Fluorouracil, bleomycin
Reticulated	Fluorouracil

Reprinted with permission from Springer: Dereure O. Drug-induced skin pigmentation. *Am J Clin Dermatol*. 2001;2(4):253-262. Copyright © 2001.

antibodies time to onset is several months. The latent period may be shortened if the patient has been previously exposed to the drug. Resolution usually occurs within 2 to 4 months. Rechallenge with the culprit drug has been attempted in a few patients, with reactivation of symptoms within 4 to 15 days.[46]

DRUG-INDUCED CUTANEOUS PSEUDOLYMPHOMA

Pseudolymphoma is a process that simulates lymphoma but has a benign behavior and does not meet the criteria for malignant lymphoma. Drugs are a well-known cause of both B-cell and T-cell cutaneous pseudolymphomas (see Chap. 120). Other possible triggers include foreign agents, such as insect bites, infections (eg, HIV), and idiopathic causes.[47] Medications that have been implicated include anticonvulsants (carbamazepine, phenytoin, valproic acid), ACE inhibitors, allopurinol, cyclosporine, levofloxacin, antihistamines, and analgesics.[48] Fluoxetine and other antidepressants may stimulate B-cell proliferation leading to a pseudolymphoma as a response to their suppressive effects on T cells.[49]

Anticonvulsant-induced pseudolymphoma generally occurs after 1 week to 2 years of exposure to the drug. Within 7 to 14 days of drug discontinuation, the symptoms usually resolve. The eruption often manifests as single lesions but can also be widespread erythematous papules, plaques, or nodules. Most patients also have fever, marked lymphadenopathy and hepatosplenomegaly, and eosinophilia. Mycosis fungoides–like lesions are also associated with these drugs.[50]

DRUG-INDUCED LUPUS AND DERMATOMYOSITIS

(See Chap. 61)

Drug-induced lupus is characterized by frequent musculoskeletal complaints, fever, weight loss, pleuropulmonary involvement in more than half of patients, and, in rare cases, renal, neurologic, or vasculitic involvement (see Table 45-1). Many patients have no cutaneous findings of lupus erythematosus. The most common serologic abnormality is positivity for antinuclear antibodies with a homogenous pattern. Although antihistone antibodies are seen in up to 95% of drug-induced lupus, they are not specific for the syndrome and are found in 50% to 80% of patients with idiopathic lupus erythematosus. Unlike in idiopathic lupus erythematosus, antibodies against double-stranded DNA are typically absent, whereas anti–single-stranded DNA antibodies are often present.[51] Genetic factors may also play a role in the development of drug-induced lupus. Human leukocyte antigen-D related (HLA-DR)-4 is present in 73% of the patients with hydralazine-induced lupus and in 70% of patients with minocycline-induced lupus.[52] Evidence now suggests that abnormalities during T-cell selection in the thymus initiate lupus-like autoantibody induction.[53]

Many drugs have been implicated in causing drug-induced lupus syndromes, especially hydralazine, procainamide, isoniazid, methyldopa, and minocycline.[54] The identification of minocycline as a cause of drug-induced lupus makes it important for dermatologists to recognize this syndrome. Minocycline-induced lupus typically occurs after 2 years of therapy. The patient presents with a symmetric polyarthritis. Hepatitis is often detected on laboratory evaluation. Cutaneous findings include livedo reticularis, painful nodules on the legs, and nondescript eruptions. Antihistone antibodies are seldom present.

In contrast, drug-induced subacute cutaneous lupus erythematosus (SCLE) is characterized by a papulosquamous or annular cutaneous lesion, which is often photosensitive, and absent or mild systemic involvement. Although it has been suggested that some of the implicated drugs may enhance photosensitivity in predisposed individuals leading to the eruption, this theory has not been proven. The clinical morphology and histopathology are indistinguishable from subacute cutaneous lupus erythematosus that is not drug-induced.[55] Circulating anti-Ro (Sjögren syndrome A) antibodies have also been identified in many patients.

The most common drugs associated with subacute cutaneous lupus erythematosus include terbinafine, thiazide diuretics, calcium channel blockers, and ranitidine.[55] The time course to onset of the eruption appears to be drug dependent, with an average of 5 weeks for terbinafine, 3 years for calcium channel blockers, and a range of 6 months to 5 years for thiazides.[55] The rash resolves after a few weeks with discontinuation of the offending drug, but anti-Ro antibodies may remain positive indefinitely.

Drug-induced dermatomyositis can present with the classic cutaneous findings in dermatomyositis, including a pruritic photodistributed papulosquamous exanthem. The majority of drug-induced cases have the pathognomonic heliotrope rash or Gottron papules.[56] In a review of 70 cases, muscular involvement (proximal muscle weakness or elevated muscle-derived enzymes) was present in 28 (40%) patients and pulmonary involvement in 8 patients (11%).[56] Both skin findings and myositis may clear after 2 months to 1 year of discontinuing the offending drug. The most common medications implicated are hydroxyurea, penicillamine, and β-hydroxy-β-methylglutaryl-coenzyme A (HMG-CoA) reductase inhibitors.[56] There are also reports of TNF-α-inhibitor–induced dermatomyositis.[57]

PURPURIC ERUPTIONS

Drug-induced vasculitis represents approximately 10% of the acute cutaneous vasculitides and usually involves small vessels (see Chap. 138). Drugs that are associated with vasculitis include propylthiouracil, hydralazine, granulocyte colony-stimulating factor, granulocyte-macrophage colony-stimulating factor,

allopurinol, cefaclor, minocycline, penicillamine, phenytoin, isotretinoin, and anti-TNF agents, including etanercept, infliximab, and adalimumab.[45] More recent triggers have been rituximab and the cocaine adulterant levamisole.[58] The average interval from initiation of drug therapy to onset of drug-induced vasculitis is 7 to 21 days; in the case of rechallenge, lesions can occur in fewer than 3 days.[8]

The clinical hallmark of cutaneous vasculitis is palpable purpura, classically found on the lower extremities. Urticaria can be a manifestation of small-vessel vasculitis, with individual lesions remaining fixed in the same location for more than 1 day. Other features include hemorrhagic bullae, ulcers, nodules, Raynaud disease, and digital necrosis. The same vasculitic process may also affect internal organs, such as the liver, kidney, gut, and CNS, and can be potentially life threatening.[59]

Drug-induced vasculitis can be difficult to diagnose and is often a diagnosis of exclusion. In some cases, serologic testing has revealed the presence of perinuclear-staining antineutrophil cytoplasmic autoantibodies against myeloperoxidase. Unlike in antineutrophilic cytoplasmic antibody-associated vasculitides, antihistone and antiphospholipid antibodies can be seen.[60] Uniquely in levamisole-induced vasculitis, a common finding is both perinuclear and cytoplasmic antineutrophilic cytoplasmic antibody. Alternative causes for cutaneous vasculitis such as infection or autoimmune disease must be eliminated. Tissue eosinophilia may be an indicator of drug induction in cutaneous small-vessel vasculitis. Drug-induced vasculitis tends to have less progression to glomerulonephritis, better outcomes, and require less immunosuppressive treatment.[58] Most cases resolve with drug withdrawal alone, but systemic glucocorticoids may provide benefit.

ANTICOAGULANT-INDUCED SKIN NECROSIS

Anticoagulant-induced skin necrosis begins 3 to 5 days after initiation of treatment. The majority of cases of anticoagulant-induced skin necrosis (Fig. 45-7) have been attributed to coumarin congeners (bishydroxycoumarin, phenprocoumon, acenocoumarol, and warfarin). Early red, painful plaques develop in adipose-rich sites such as breasts, buttocks, and hips. These plaques may blister, ulcerate, or develop into necrotic areas. It is estimated that 1 in 10,000 persons who receive an anticoagulant is at risk of this adverse event. The incidence is 4 times higher in women, the majority of whom are obese, with a peak incidence in the sixth and seventh decades of life. Affected patients often have been given a large initial loading dose of warfarin in the absence of concomitant heparin therapy. An accompanying infection, such as pneumonia, viral infection, or erysipelas, may be seen in up to 25% of patients. An association with protein C and protein S deficiencies exists, but pretreatment screening is not warranted. An association with heterozygosity for factor V Leiden mutation has been reported.

FIGURE 45-7 Skin necrosis in a patient after 4 days of warfarin therapy.

The pathogenesis of this adverse event is the paradoxical development of occlusive thrombi in cutaneous and subcutaneous venules resulting from a transient hypercoagulable state. This results from the suppression of the natural anticoagulant protein C at a greater rate than the suppression of natural procoagulant factors.

Treatment involves the discontinuation of warfarin, administration of vitamin K, and infusion of heparin at therapeutic dosages. Fresh-frozen plasma and purified protein C concentrates have been used. Supportive measures for the skin are a mainstay of therapy. The morbidity rate is high; 60% of affected individuals require plastic surgery for remediation of full-thickness skin necrosis by skin grafting. These patients may be treated with warfarin in the future, but small dosages (2 to 5 mg daily) are recommended, with initial treatment under heparin coverage.[61,62]

NEUTROPHILIC ECCRINE HIDRADENITIS

Neutrophilic eccrine hidradenitis is a benign condition that has been described in patients with leukemia who are receiving chemotherapy (Table 45-7 identifies other chemotherapy-associated drug reactions). Cases have also been described in the absence of chemotherapy or drug triggers. It classically presents with dark erythematous to violaceous edematous plaques that can be asymptomatic or tender.[63] Lesions can occur on the face, including periorbitally, or on the trunk and extremities. It can mimic cellulitis, and is ultimately

TABLE 45-7

Newer Chemotherapeutic Agents and Their Adverse Cutaneous Drug Reactions

CLASS	AGENTS	ADVERSE CUTANEOUS DRUG REACTIONS
Spindle inhibitor	Taxanes: docetaxel, paclitaxel	Hand–foot skin reaction; combined with sensory abnormalities: erythrodysesthesia; radiation recall urticaria, exanthems, mucositis, alopecia, nail changes; scleroderma-like changes on lower extremities; subacute cutaneous lupus erythematosus (SCLE), acute generalized exanthematous pustulosis (AGEP) and fixed drug reaction (paclitaxel)
Antimetabolites	Vinca alkaloids: vincristine, vinblastine, vinorelbine	Phlebitis, alopecia, acral erythema, extravasation reactions (including necrosis)
	Fludarabine	Serpentine supravenous hyperpigmentation, macular, papular exanthem, mucositis, acral erythema, paraneoplastic pemphigus, drug-induced SCLE
	Cladribine	Exanthem, toxic epidermal necrolysis (TEN)(?)
	Capecitabine	Hand–foot skin reaction, acral hyperpigmentation, palmoplantar keratoderma, pyogenic granuloma, inflammation of actinic keratoses
	Tegafur	Hand–foot skin reaction, acral hyperpigmentation; pityriasis lichenoides et varioliformis acuta, phototoxic reactions
	Gemcitabine	Mucositis, alopecia, maculopapular exanthem, radiation recall, linear immunoglobulin (Ig) A bullous dermatosis, pseudoscleroderma, lipodermatosclerosis, erysipelas-like plaques, pseudolymphoma, lymphomatoid papulosis
	Pemetrexed	Exanthema, radiation recall, urticarial vasculitis
Genotoxic agents	Carboplatin	Alopecia, hypersensitivity reaction (erythema, facial swelling, dyspnea, tachycardia, wheezing), palmoplantar erythema, facial flushing
	Oxaliplatin	Hypersensitivity reaction (see preceding); irritant extravasation reaction; radiation recall
	Liposomal doxorubicin	Acral erythema, palmoplantar erythrodysesthesia neutrophilic eccrine hidradenitis, hyperpigmentation (blue-gray), mucositis, alopecia, exanthems, radiation recall, ultraviolet light recall
	Liposomal daunorubicin	Alopecia, mucositis, extravasation reactions
	Idarubicin	Radiation recall; alopecia, acral erythema, mucositis, nail changes (transverse pigmented bands), extravasation reactions
	Topotecan	Maculopapular exanthem, alopecia, neutrophilic hidradenitis
	Irinotecan	Mucositis, alopecia, lichenoid reactions
Signal transduction inhibitors	Epidermal growth factor receptor (EGFR) antagonists: gefitinib, cetuximab, erlotinib, panitumumab	Papulopustular eruptions in seborrheic areas, erythematous plaques, telangiectasias; xerosis, paronychia; hair abnormalities (trichomegaly, curling, fragility). Usually start a week after initiation of drug. Can treat with topical antibiotics, retinoids (topical or systemic). Can also lead to paronychia, trichomegaly, leukocytoclastic vasculitis, urticaria, anaphylaxis and necrolytic migratory erythema
	Multikinase inhibitors: imatinib	Maculopapular exanthem (face, forearms, ankles), exfoliative dermatitis, graft-versus-host reaction-like reaction, erythema nodosum, vasculitis, Stevens-Johnson syndrome (SJS), AGEP; hypopigmentation, hyperpigmentation, darkening of hair, nail hyperpigmentation, lichen planus–like eruption (skin and oral mucosa), follicular mucinosis, pityriasis rosea–like eruption, Sweet syndrome, exacerbation of psoriasis, palmoplantar hyperkeratosis, porphyria cutanea tarda, primary cutaneous Epstein-Barr virus–related B-cell lymphoma
	Dasatinib and nilotinib	Localized and generalized erythema, maculopapular exanthem, mucositis, pruritus, exfoliation, alopecia, xerosis "acne," urticaria, panniculitis, Sweet syndrome
	Sorafenib and sunitinib	Rash/desquamation, hand–foot skin reaction, pain, alopecia, mucositis, xerosis, flushing edema, seborrheic dermatitis, yellow skin coloration (sunitinib, 1 week after starting drug), subungual splinter hemorrhages, pyoderma gangrenosum, squamous cell carcinoma (SCC) (KA-type), and eruptive melanocytic lesions (sorafenib)
Proteasome inhibitor	Bortezomib	Erythematous nodules and plaques, morbilliform exanthem, ulceration, vasculitis and Sweet syndrome
Immune modulators	Ipilimumab (CTLA-4 AB)	Immune-mediated side effects: macular and papular eruption, pruritus, hepatitis, vitiligo, hypothyroidism, enterocolitis, hepatitis, SJS-TEN
	Pembrolizumab and nivolumab (PD-1 receptor antibody)	Immune-mediated side effects: macular and papular eruption, pruritus, vitiligo, hypothyroidism, enterocolitis, hepatitis, mucositis
BRAF (v-raf murine sarcoma viral oncogene homolog B) inhibitors	Vemurafenib	Rash (68%), arthralgias, photosensitivity (42%), SCC (23%, most occur in first few months)
	Dabrafenib	Pyrexia, headaches, rash

From Wolff K, Johnson R, Saavedra AP, et al. *Fitzpatrick's Color Atlas and Synopsis of Clinical Dermatology*. 8th ed. New York, NY: McGraw-Hill; 2017, Table 23-7, with permission.

diagnosed based on histopathology demonstrating a neutrophilic infiltrate of the eccrine unit and necrosis of the eccrine coils and glands with dermal edema.[63] Antineutrophilic agents have been used successfully, including colchicine as treatment and dapsone prophylactically.[64,65]

ETIOLOGY AND PATHOGENESIS

ETIOLOGY

The list of implicated medications in adverse drug eruptions is exhaustive and includes all prescription and nonprescription substances, as well as naturopathic remedies, radiocontrast dyes, and illicit drugs. For this reason, in the evaluation of a patient with a history of a suspected ADR, it is important to obtain a detailed medication history. The morphology and systemic features of a presentation, as well as the time of onset with relation to the medication history, may provide guidance identifying the more-likely culprit medications. New drugs started within the preceding 3 months, especially those within 6 weeks, are potential causative agents for most cutaneous eruptions (exceptions include drug-induced lupus, drug-induced pemphigus, and drug-induced cutaneous pseudolymphoma), as are drugs that have been used intermittently.

PATHOGENESIS OF DRUG ERUPTIONS

Most cutaneous drug eruptions occur as a result of an immune-mediated reaction to a medication, and can involve IgE or IgG or lymphocytes (Table 45-8). The multiple possible reactions result in the heterogeneous spectrum of presentations. The immune system may target the native drug, its metabolic products, altered self, or a combination of these factors.[11] The specific pathogenesis of each presentation is described under "Clinical Features" section. Predisposing factors can be divided into constitutional and acquired factors (Table 45-9).

Constitutional factors include pharmacogenetic variation in drug-metabolizing enzymes and human leukocyte antigen (HLA) associations. Acetylator phenotype alters the risk of developing drug-induced lupus caused by hydralazine, procainamide, and isoniazid.

The formation of toxic metabolites of the aromatic anticonvulsants may play a pivotal role in the development of HSR.[66] In most individuals, the chemically reactive metabolites that are produced are detoxified

TABLE 45-9
Nonimmunologic Drug Reactions

Idiosyncrasy	Reactions resulting from hereditary enzyme deficiencies
Individual idiosyncrasy to a topical or systemic drug	Mechanisms not yet known
Cumulation	Reactions are dose dependent, based on the total amount of drug ingested; pigmentation caused by gold, amiodarone, or minocycline
Reactions caused by combination of a drug with ultraviolet irradiation (photosensitivity)	Reactions have a toxic pathogenesis but can also be immunologic in nature
Irritancy/toxicity of a topically applied drug	5-Fluorouracil, imiquimod
Atrophy by topically applied drug	Glucocorticoids

From Wolff K, Johnson R, Saavedra AP, et al. *Fitzpatrick's Color Atlas and Synopsis of Clinical Dermatology*. 8th ed. New York, NY: McGraw-Hill; 2017, Table 23-2, with permission.

TABLE 45-8
Immunologic Drug Reactions

TYPE OF REACTION	PATHOGENESIS	EXAMPLES OF CAUSATIVE DRUG	CLINICAL PATTERNS
Type I	Immunoglobulin (Ig) E-mediated; immediate-type immunologic reactions	Penicillin, other antibiotics	Urticaria/angioedema of skin/mucosa, edema of other organs, and anaphylactic shock
Type II	Drug + cytotoxic antibodies cause lysis of cells such as platelets or leukocytes	Penicillin, sulfonamides, quinidine, isoniazid	Petechiae resulting from thrombocytopenic purpura, drug-induced pemphigus
Type III	IgG or IgM antibodies formed to drug; immune complexes deposited in small vessels activate complement and recruitment of granulocytes	Immunoglobulins, antibiotics, rituximab, infliximab	Vasculitis, urticaria, serum sickness
Type IV	Cell-mediated immune reaction; sensitized lymphocytes react with drug, liberating cytokines, which trigger cutaneous inflammatory response	Sulfamethoxazole, anticonvulsants, allopurinol	Morbilliform exanthematous reactions, fixed drug eruption, lichenoid eruptions, Stevens-Johnson syndrome, toxic epidermal necrolysis

From Wolff K, Johnson R, Saavedra AP, et al. *Fitzpatrick's Color Atlas and Synopsis of Clinical Dermatology*. 8th ed. New York, NY: McGraw-Hill; 2017, Table 23-7, with permission.

by epoxide hydroxylases. If detoxification is defective, however, one of the metabolites may act as a hapten and initiate an immune response, stimulate apoptosis, or cause cell necrosis directly. Approximately 70% to 75% of patients who develop anticonvulsant HSR in response to one aromatic anticonvulsant show cross-reactivity to the other aromatic anticonvulsants. In addition, in vitro testing shows that there is a pattern of inheritance of HSR induced by anticonvulsants. Thus, counseling of family members and disclosure of risk is essential.

Sulfonamide antimicrobials are both sulfonamides (contain SO_2-NH_2) and aromatic amines (contain a benzene ring-NH_2). Aromatic amines can be metabolized to toxic metabolites, namely hydroxylamines and nitroso compounds.[67] In most people, the metabolite is detoxified. However, HSRs may occur in patients who either form excess oxidative metabolites or are unable to detoxify such metabolite. Because siblings and other first-degree relatives may be at an increased risk (perhaps as high as 1 in 4) of developing a similar adverse reaction, counseling of family members is essential.

Other aromatic amine-containing drugs, such as procainamide, dapsone, and acebutolol, may also be metabolized to chemically reactive compounds. It is recommended that patients who develop symptoms compatible with a sulfonamide-induced HSR avoid these aromatic amines, because the potential exists for cross-reactivity. However, cross-reactivity is much less likely to occur between sulfonamides antimicrobials and drugs that are not aromatic amines (eg, sulfonylureas, thiazide diuretics, furosemide, celecoxib, and acetazolamide).[68]

HLA class I molecules (HLA-A, HLA-B, HLA-C) present intracellular antigens to CD8+ T cells. Carriers of specific HLA class I alleles are associated with severe drug reactions: HLA-B*1502 with carbamazepine-induced SJS-TEN and phenytoin-induced SJS in Han Chinese, HLA-B*5801 with allopurinol-induced SJS-TEN, and HLA-B*5701 with abacavir drug hypersensitivity.

HLA class II molecules (HLA-DP, HLA-DQ, HLA-DR) present extracellular antigens to CD4+ T-helper cells. HLA-DR4 is significantly more common in individuals with hydralazine-related drug-induced lupus than in those with idiopathic systemic lupus erythematosus.[69] HLA factors may also influence the risk of reactions to nevirapine, abacavir, carbamazepine, and allopurinol.[70-72]

Many drugs associated with severe idiosyncratic drug reactions are metabolized by the body to form reactive, or toxic, drug products.[73] These reactive products comprise only a small proportion of a drug's metabolites and are usually rapidly detoxified. However, patients with drug hypersensitivity syndrome, TEN, and SJS resulting from treatment with sulfonamide antibiotics and the aromatic anticonvulsants (eg, carbamazepine, phenytoin, phenobarbital, primidone, and oxcarbazepine) show greater sensitivity in in vitro assessments to the oxidative, reactive metabolites of these drugs than do control subjects.[66]

Acquired factors also alter an individual's risk of drug eruption. Active viral infection and concurrent use of other medications alter the frequency of drug-associated eruptions. Reactivation of latent viral infection with human herpesvirus 6 also appears common in drug hypersensitivity syndrome, and may be partially responsible for some of the clinical features and/or course of the disease.[13,74] Active infection or reactivation of human herpesvirus 6 has been observed in patients who develop allopurinol HSR.[75] Viral infections may act as, or generate the production of, danger signals that lead to damaging immune responses to drugs, rather than immune tolerance.

Drug–drug interactions may also alter the risk of cutaneous eruption. Valproic acid increases the risk of severe cutaneous adverse reactions to lamotrigine, another anticonvulsant.[76] The basis of these interactions and reactions is unknown, but they may represent a combination of factors, including alterations in drug metabolism, drug detoxification, antioxidant defenses, and immune reactivity.

DIAGNOSIS

The iatrogenic disorders described here are distinct disease entities, although they may closely mimic many infective or idiopathic diseases. A drug cause should be considered in the differential diagnosis of a wide spectrum of dermatologic diseases, particularly when the presentation or course is atypical.

The diagnosis of a cutaneous drug eruption involves the precise characterization of reaction type. A wide variety of cutaneous drug-associated eruptions may also warn of associated internal toxicity (Table 45-10). Even the most minor cutaneous eruption should trigger a clinical review of systems, because the severity of systemic involvement does not necessarily mirror that of the skin manifestations. Hepatic, renal, joint, respiratory, hematologic, and neurologic changes should be sought, and any systemic symptoms or signs investigated. Fever, malaise, pharyngitis, and other systemic symptoms or signs should be investigated. A usual screen would include a full blood count, liver and renal function tests, and a urine analysis.

TABLE 45-10

Clinical Features That Warn of a Potentially Severe Drug Reaction

- Systemic
  - Fever and/or other symptoms of internal organ involvement such as pharyngitis, malaise, arthralgia, cough, and meningismus
  - Lymphadenopathy
- Cutaneous
  - Evolution to erythroderma
  - Prominent facial involvement ± edema or swelling
  - Mucous membrane involvement (particularly if erosive or involving conjunctiva)
  - Skin tenderness, blistering or shedding
  - Purpura

Skin biopsy should be considered for all patients with potentially severe reactions, such as those with systemic symptoms, erythroderma, blistering, skin tenderness, purpura, or pustulation, as well as in cases in which the diagnosis is uncertain. Some cutaneous reactions, such as FDE, are almost always due to drug therapy, and approximately 40–50%% of SJS-TEN cases are also drug related.[77] Other more common eruptions, including exanthematous or urticarial eruptions, have many nondrug causes.

There is no gold standard investigation for confirmation of a drug cause. Instead, diagnosis and assessment of cause involve analysis of a constellation of features, such as timing of drug exposure and reaction onset, course of reaction with drug withdrawal or continuation, timing and nature of a recurrent eruption on rechallenge, a history of a similar response to a cross-reacting medication, and previous reports of similar reactions to the same medication. Investigations to exclude nondrug causes are similarly helpful.

Several in vitro investigations can help confirm causation in individual cases, but their exact sensitivity and specificity remain unclear. Investigations include the lymphocyte toxicity and lymphocyte transformation assays.[78] The basophil activation test has been reported to be useful to evaluate patients with possible drug allergies to β-lactam antibiotics, NSAIDs, and muscle relaxants.[11] Penicillin skin testing with major and minor determinants is useful for confirmation of an IgE-mediated immediate hypersensitivity reaction to penicillin.[11] Patch testing has been used in patients with ampicillin-induced exanthematous eruptions, AGEP reactions,[79] and abacavir-induced hypersensitivity,[80] and in the ancillary diagnosis of FDEs. Patch testing has greater sensitivity if performed over a previously involved area of skin.

DIFFERENTIAL DIAGNOSIS

Table 45-11 summarizes drug eruptions mimicry.

CLINICAL COURSE AND PROGNOSIS

The course and outcome of drug-induced disease are influenced by both host and disease factors. The vast majority of simple drug exanthems are self-limited. In complicated exanthems, there can be significant morbidity and mortality related to systemic manifestations.

SJS-TEN is associated with the highest mortality. The SCORTEN (SCORe of TEN) is a scale that was developed to help assess severity and predict mortality, and is calculated within the first 24 hours of admission. The 7 criteria include age older than 40 years, laboratory indices (urea <10 mmol/L, glucose >14 mmol/L, bicarbonate <20 mEq/L), tachycardia (heart rate >140 beats per minute), presence of malignancy, and body surface area >10% at presentation.[81] Each criteria fulfilled is given a score of 1, with associated mortality ranging from 3% (1 point) to 90% (5 points).

Patients will have recurrence if exposed to the same medication, and in more systemic eruptions, the recurrence could be more severe and fatal. The recurrence rate in SJS-TEN may be as high as 20% as reported in a series of pediatric cases.[82]

Complex exanthems can also be associated with long-term complications. In SJS-TEN, scarring can affect multiple systems with resulting sequelae in skin (hyperpigmentation, eruptive nevi, alopecia, nail dystrophy), eyes (dry eyes, photophobia, trichiasis, symblepharon), genitalia (dyspareunia, urinary retention, dryness), and lungs (chronic bronchitis,

TABLE 45-11
Drug Eruptions Mimicry

CLINICAL PRESENTATION	PATTERN AND DISTRIBUTION OF SKIN LESIONS	MUCOUS MEMBRANE INVOLVEMENT	IMPLICATED DRUGS	TREATMENT
Stevens-Johnson syndrome	Atypical targets, widespread	Present	Aromatic anticonvulsants,[a] lamotrigine, sulfonamide antibiotics, allopurinol, piroxicam, dapsone	IVIg, cyclosporine, supportive care
Toxic epidermal necrolysis	Epidermal necrosis with skin detachment	Present	As above	IVIg, cyclosporine, supportive care
Pseudoporphyria	Skin fragility, blister formation in photodistribution	Absent	Tetracycline, furosemide, naproxen	Supportive care
Linear IgA disease	Bullous dermatosis	Present/absent	Vancomycin, lithium, diclofenac, piroxicam, amiodarone	Supportive care
Pemphigus	Flaccid bullae, chest	Present/absent	Penicillamine, captopril, piroxicam, penicillin, rifampin, propranolol	Supportive care
Bullous pemphigoid	Tense bullae, widespread	Present/absent	Furosemide, penicillamine, penicillins, sulfasalazine, captopril	Supportive care

Abbreviations: IgA, immunoglobulin A; IVIg, intravenous immunoglobulin.
[a]The aromatic anticonvulsants are phenytoin, carbamazepine, phenobarbital, oxcarbazepine, and primidone.

bronchiectasis).[83] Immune-mediated thyroid disorders are a well-recognized complication of hypersensitivity syndromes and can present months after resolution of the exanthem.

MANAGEMENT

Treatment of SJS-TEN includes discontinuance of the suspected drug(s) and supportive measures, such as careful wound care, hydration, and nutritional support. The use of corticosteroids in the treatment of SJS and TEN is controversial.[84,85] Intravenous immunoglobulin (up to 4 g over 3 days) has been shown in some reports to halt progression of TEN, especially when intravenous immunoglobulin is started early. However, some studies have not found an improved outcome in patients with TEN who are treated with intravenous immunoglobulin.[35] A newer study concluded that neither corticosteroids nor intravenous immunoglobulins had any significant effect on mortality in comparison to supportive care only.[86] Other treatment modalities include cyclosporine,[87] cyclophosphamide, and plasmapheresis. Patients who have developed a severe cutaneous ADR should not be rechallenged with the drug. Desensitization therapy with the medication may also be a risk.

Cutaneous drug eruptions do not usually vary in severity with dose. Less-severe reactions may abate with continued drug therapy (eg, transient exanthematous eruptions associated with commencement of a new HIV antiretroviral regimen). However, a reaction suggestive of a potentially life-threatening situation should prompt immediate discontinuation of the drug, along with discontinuation of any interacting drugs that may slow the elimination of the suspected causative agent. Although the role of corticosteroids in the treatment of serious cutaneous reactions is controversial, most clinicians choose to start prednisone at a dosage of 1 to 2 mg/kg/day when symptoms are severe. Antihistamines, topical corticosteroids, or both can be used to alleviate symptoms.[88] Resolution of the reaction over a reasonable time frame after the drug is discontinued is consistent with a drug cause but also occurs for many infective and other causes of transient cutaneous eruptions. Drug desensitization, also known as induction of drug tolerance, has been used primarily for IgE-mediated reactions caused by drugs such as penicillin or monoclonal antibodies such as rituximab and infliximab.[11,89] Patients should not be rechallenged or desensitized if they have suffered a potentially serious reaction.

PREVENTION

Cutaneous reactions to drugs are largely idiosyncratic and unexpected; serious reactions are rare. Once a reaction has occurred, however, it is important to prevent future similar reactions in the patient with the same drug or a cross-reacting medication. For patients with severe reactions, wearing a bracelet (eg, MedicAlert, www.medicalert.org) detailing the nature of the reaction is advisable, and patient records should be appropriate labeled.

Host factors appear important in many reactions. Some of these can be inherited, which places first-degree relatives at a greater risk than the general population for a similar reaction to the same or a metabolically cross-reacting drug. This finding appears to be important in SJS, TEN, and drug hypersensitivity syndrome.

Reporting reactions to the manufacturer or regulatory authorities is important. Postmarketing voluntary reporting of rare, severe, or unusual reactions remains crucial to enhance the safe use of pharmaceutical agents.

REFERENCES

1. Lazarou J, Pomeranz B, Corey P. Incidence of adverse drug reactions in hospitalized patients: a meta-analysis of prospective studies. *JAMA.* 1998;279:1200-1205.
2. Bigby M. Rates of cutaneous reactions to drugs. *Arch Dermatol.* 2001;137:765-770.
3. Thong BY, Tan TC. Epidemiology and risk factors for drug allergy. *Br J Clin Pharmacol.* 2011;71(5):684-700.
4. Fiszenson-Albala F, Auzerie V, Mahe E, et al. A 6-month prospective survey of cutaneous drug reactions in a hospital setting. *Br J Dermatol.* 2003;149(5):1018-1022.
5. Segal A, Doherty K, Leggott J, et al. Cutaneous reactions to drugs in children. *Pediatrics.* 2007;120:e1082-e1096.
6. Heng YK, Lim YL. Cutaneous adverse drug reactions in the elderly. *Curr Opin Allergy Clin Immunol.* 2015;15(4):300-307.
7. Hernandez-Salazar A, Rosales SP, Rangel-Frausto S, et al. Epidemiology of adverse cutaneous drug reactions. A prospective study in hospitalized patients. *Arch Med Res.* 2006;37(7):899-902.
8. Valeyrie-Allanore L, Sassolas B, Roujeau J. Drug-induced skin, nail and hair disorders. *Drug Saf.* 2007;30:1011-1030.
9. Schnyder B, Pichler W. Mechanisms of drug-induced allergy. *Mayo Clin Proc.* 2009;84:268-272.
10. Kerns D, Shira J, Go S. Ampicillin rash in children. *Am J Dis Child.* 1973;125:187-190.
11. Khan D, Solensky R. Drug Allergy. *J Allergy Clin Immunol.* 2010;125:S126-S137.
12. Kearns G, Wheeler J, Childress S, et al. Serum sickness-like reactions to cefaclor: role of hepatic metabolism and individual susceptibility. *J Pediatr.* 1994;125:805-811.
13. Eshki M, Allanore L, Musette P, et al. Twelve-year analysis of severe cases of drug reaction with eosinophilia and systemic symptoms. *Arch Dermatol.* 2009;145:67-72.
14. Gupta A, Eggo M, Uetrecht J, et al. Drug-induced hypothyroidism: the thyroid as a target organ in hypersensitivity reactions to anticonvulsants and sulfonamides. *Clin Pharmacol Ther.* 1992;51:56-67.
15. Liu HB, Wu Y, Lv TF, et al. Skin rash could predict the response to EGFR tyrosine kinase inhibitor and the prognosis for patients with non-small cell lung cancer: a systematic review and meta-analysis. *PLoS One.* 2013;8(1):e55128.
16. Ruocco V, Sacerdoti G. Pemphigus and bullous pemphigoid due to drugs. *Int J Dermatol.* 1991;30:307-312.

17. Todd D, Helfgott S. Serum sickness following treatment with rituximab. *J Rheumatol.* 2007;34:430-433.
18. Gamarra R, McGraw S, Drelichman VS, et al. Serum sickness-like reactions in patients receiving intravenous infliximab. *J Emerg Med.* 2006;30:41-44.
19. Remmer H, Falk W. Successful treatment of lithium-induced acne. *J Clin Psychiatry.* 1986;47:48.
20. Su X, Lacouture M, Jia Y, et al. Risk of hig-grade skin rash in cancer patients treated with cetuximab: an antibody against epidermal growth factor receptor: systemic review and meta-analysis. *Oncology.* 2009;77:124-133.
21. Macdonald JB, Macdonald B, Golitz LE, et al. Cutaneous adverse effects of targeted therapies: part I: inhibitors of the cellular membrane. *J Am Acad Dermatol.* 2015;72(2):203-218; quiz 219-220.
22. Cowen E. Epidermal growth factor receptor inhibitors: a new era of drug reactions in a new era of cancer therapy. *J Am Acad Dermatol.* 2007;56:514-517.
23. Jatoi A, Dakhil SR, Sloan JA, et al. Prophylactic tetracycline does not diminish the severity of epidermal growth factor receptor (EGFR) inhibitor-induced rash: results from the North Central Cancer Treatment Group (Supplementary N03CB). *Support Care Cancer.* 2011;19(10):1601-1607.
24. Scope A, Agero AL, Dusza SW, et al. Randomized double-blind trial of prophylactic oral minocycline and topical tazarotene for cetuximab-associated acne-like eruption. *J Clin Oncol.* 2007;25(34):5390-5396.
25. Hotz C, Valeyrie-Allanore L, Haddad C, et al. Systemic involvement of acute generalized exanthematous pustulosis: a retrospective study on 58 patients. *Br J Dermatol.* 2013;169(6):1223-1232.
26. Sidoroff A, Dunant A, Viboud C, et al. Risk factors for acute generalized exanthematous pustulosis (AGEP)-results of a multinational case-control study (EuroSCAR). *Br J Dermatol.* 2007;157(5):989-996.
27. Guevara-Gutierrez E, Uribe-Jimenez E, Diaz-Canchola M, et al. Acute generalized exanthematous pustulosis: report of 12 cases and literature review. *Int J Dermatol.* 2009;48:253-258.
28. Lang B, Finlayson L. Naproxen-induced pseudoporphyria in patients with juvenile rheumatoid arthritis. *J Pediatr.* 1994;124:639-642.
29. Beer K, Applebaum D, Nousari C. Pseudoporphyria: discussion of etiologic agents. *J Drugs Dermatol.* 2014;13(8):990-992.
30. Chanal J, Ingen-Housz-Oro S, Ortonne N, et al. Linear IgA bullous dermatosis: comparison between the drug-induced and spontaneous forms. *Br J Dermatol.* 2013;169(5):1041-1048.
31. Primka E, Liranzo E, Bergfeld W, et al. Amiodarone-induced linear IgA disease. *J Am Acad Dermatol.* 1994;31: 809-811.
32. Panasiti V, Rossi M, Devirgiliis V, et al. Amoxicillin-clavulanic acid-induced linear immunoglobulin A bullous dermatosis: case report and review of the literature. *Int J Dermatol.* 2009;48:1006-1010.
33. Stavropoulos PG, Soura E, Antoniou C. Drug-induced pemphigoid: a review of the literature. *J Eur Acad Dermatol Venereol.* 2014;28(9):1133-1140.
34. Lee J, Downham T. Furosemide-induced bullous pemphigoid: case report and review of literature. *J Drugs Dermatol.* 2006;5:562-564.
35. Paquet P, Pierard G. New insights in toxic epidermal necrolysis (Lyell's syndrome): clinical considerationsk, pathobiology and targeted treatments revistied. *Drug Saf.* 2010;33:189-212.
36. Mockenhaupt M. Severe drug-induced skin reactions: clinical pattern, diagnostics and therapy. *J Dtsch Dermatol Ges.* 2009;7:142-160.
37. Patell RD, Dosi RV, Shah PC, et al. Widespread bullous fixed drug eruption. *BMJ Case Rep.* 2014;2014.
38. Brahimi N, Routier E, Raison-Peyron N, et al. A three-year-analysis of fixed drug eruptions in hospital settings in France. *Eur J Dermatol.* 2010;20(4):461-464.
39. Jung JW, Cho SH, Kim KH, et al. Clinical features of fixed drug eruption at a tertiary hospital in Korea. *Allergy Asthma Immunol Res.* 2014;6(5):415-420.
40. Barbaud A, Goncalo M, Bruynzeel D, et al. Guidelines for performing skin tests with drugs in the investigation of cutaneous adverse drug reactions. *Contact Dermatitis.* 2001;45:321-328.
41. Ozkaya E. Fixed drug eruption: state of the art. *J Drugs Dermatol.* 2008;6:181-188.
42. Lage D, Juliano PB, Metze K, et al. Lichen planus and lichenoid drug-induced eruption: a histological and immunohistochemical study. *Int J Dermatol.* 2012;51(10):1199-1205.
43. West AJ, Berger TG, LeBoit PE. A comparative histopathologic study of photodistributed and nonphotodistributed lichenoid drug eruptions. *J Am Acad Dermatol.* 1990;23(4, pt 1):689-693.
44. Schaberg KB, Novoa RA, Wakelee HA, et al. Immunohistochemical analysis of lichenoid reactions in patients treated with anti-PD-L1 and anti-PD-1 therapy. *J Cutan Pathol.* 2016;43(4):339-346.
45. Kerbleski J, Gottlieb A, SW. Dermatological complications and safety of anti-TNF treatments. *Gut.* 2009;58:1033-1039.
46. Halevy S, Shai A. Lichenoid drug eruptions. *J Am Acad Dermatol.* 1993;29:249-255.
47. Albrecht J, Fine L, Piette W. Drug-associated lymphoma and pseudolymphoma: recognition and management. *Dermatol Clin.* 2007;25:233-244.
48. Sarantopoulos GP, Palla B, Said J, et al. Mimics of cutaneous lymphoma: report of the 2011 Society for Hematopathology/European Association for Haematopathology workshop. *Am J Clin Pathol.* 2013;139(4): 536-551.
49. Breza TS Jr, Zheng P, Porcu P, et al. Cutaneous marginal zone B-cell lymphoma in the setting of fluoxetine therapy: a hypothesis regarding pathogenesis based on in vitro suppression of T-cell-proliferative response. *J Cutan Pathol.* 2006;33(7):522-528.
50. Scheinfeld N. Impact of phenytoin therapy on the skin and skin disease. *Expert Opin Drug Saf.* 2004;3:655-665.
51. Antonov D, Kazandjieva J, Etugov D, et al. Drug-induced lupus erythematosus. *Clin Dermatol.* 2004;22:157-166.
52. Dunphy, Oliver M, Rands A, et al. Antineutrophil cytoplasmic antibodies and HLA class II alleles in minocycline-induced lupus-like syndrome. *Br J Dermatol.* 2000;142:461-467.
53. Rubin R. Drug-induced lupus. *Toxicology.* 2005;209: 135-147.
54. Sarzi-Puttini P, Atzeni F, Capsoni F, et al. Drug-induced lupus erythematosus. *Autoimmunity.* 2005;38:507-518.
55. Lowe GC, Henderson CL, Grau RH, et al. A systematic review of drug-induced subacute cutaneous lupus erythematosus. *Br J Dermatol.* 2011;164(3):465-472.
56. Seidler AM, Gottlieb AB. Dermatomyositis induced by drug therapy: a review of case reports. *J Am Acad Dermatol.* 2008;59(5):872-880.
57. Klein R, Rosenbach M, Kim EJ, et al. Tumor necrosis factor inhibitor-associated dermatomyositis. *Arch Dermatol.* 2010;146(7):780-784.

58. Grau RG. Drug-induced vasculitis: new insights and a changing lineup of suspects. *Curr Rheumatol Rep.* 2015;17(12):71.
59. Justiniano H, Berlingeri-Ramos A, Sanchez J. Pattern analysis of drug-induced skin diseases. *Am J Dermatopathol.* 2008;30:352-369.
60. Radic M, Martinovic Kaliterna D, Radic J. Drug-induced vasculitis: a clinical and pathological review. *Neth J Med.* 2012;70(1):12-17.
61. Nazarian RM, Van Cott EM, Zembowicz A, et al. Warfarin-induced skin necrosis. *J Am Acad Dermatol.* 2009;61:325-332.
62. Bircher A, Harr T, Hohenstein L, et al. Hypersensitivity reactions to anticoagulant drugs: diagnosis and management options. *Allergy.* 2006;61:1432-1440.
63. Copaescu AM, Castilloux JF, Chababi-Atallah M, et al. A classic clinical case: neutrophilic eccrine hidradenitis. *Case Rep Dermatol.* 2013;5(3):340-346.
64. Shear NH, Knowles SR, Shapiro L, et al. Dapsone in prevention of recurrent neutrophilic eccrine hidradenitis. *J Am Acad Dermatol.* 1996;35(5, pt 2):819-822.
65. Belot V, Perrinaud A, Corven C, et al. Adult idiopathic neutrophilic eccrine hidradenitis treated with colchicine [in French]. *Presse Med.* 2006;35(10, pt 1): 1475-1478.
66. Shear N, Spielberg S. Anticonvulsant hypersensitivity syndrome, in vitro assessment of risk. *J Clin Invest.* 1988;82:1826-1832.
67. Castrejon J, Berry N, El-Ghalesh S, et al. Stimulation of human T cells with sulfonamides and sulfonamide metabolites. *J Allergy Clin Immunol.* 2010;125:411-418.
68. Knowles S, Shapiro L, Shear N. Should celecoxib be contraindicated in patients who are allergic to sulfonamides? Revisiting the meaning of "sulfa" allergy. *Drug Saf.* 2001;24:239-247.
69. Batchelor J, Welsh K, Tinoco R, et al. Hydralazine-induced systemic lupus erythematosus: influence of HLA-DR and sex on susceptibility. *Lancet.* 1980;1:1107-1109.
70. Hung S, Chung W, Jee S, et al. Genetic susceptibility to carbamazepine-induced cutaneous adverse drug reactions. *Pharmacogenet Genomics.* 2006;16:297-306.
71. Dainichi T, Uchi H, Morol Y, et al. Stevens-Johnson syndrome, drug-induced hypersensitivity syndrome and toxic epidermal necrolysis caused by allopurinol in patients with a common HLA allele: what causes the diversity. *Dermatology.* 2007;215:86-88.
72. Tozzi V. Pharmacogenetics of antiretrovirals. *Antiviral Res.* 2010;85:190-200.
73. Uetrecht J. Is it possible to more accurately predict which drug candidates will cause idiosyncratic drug reactions? *Curr Drug Metab.* 2000;1:133-141.
74. Seishima M, Yamanaka S, Fujisawa T, et al. Reactivation of human herpesvirus (HHV) family members other than HHV-6 in drug-induced hypersensitivity syndrome. *Br J Dermatol.* 2006;155:344-349.
75. Chiou C, Yang L, Hung S, et al. Clinicopathological features and prognosis of drug rash with eosinophilia and systemic symptoms: a study of 30 cases in Taiwan. *J Eur Acad Dermatol Venereol.* 2008;22:1044-1049.
76. Sullivan J, Shear N. What are some of the lessons learnt from in vitro studies of severe unpredictable drug reactions? *Br J Dermatol.* 2000;142:205.
77. Auquier-Dunant A, Mockenhaupt M, Naldi L, et al. Correlations between clinical patterns and causes of erythema multiforme major, Stevens-Johnson syndrome and toxic epidermal necrolysis. *Arch Dermatol.* 2002;138:1019-1024.
78. Neuman M, Malkiewicz I, Shear N. A novel lymphocyte toxicity assay to assess drug hypersensitivity syndromes. *Clin Biochem.* 2000;33:517-524.
79. Barbaud A. Drug patch testing in systemic cutaneous drug allergy. *Toxicology.* 2005;209:209-216.
80. Shear N, LMilpied B, Bruynzeel D, et al. A review of drug patch testing and implications for HIV clinicians. *AIDS.* 2008;22:1-9.
81. Bastuji-Garin S, et al. SCORTEN: a severity-of-illness score for toxic epidermal necrolysis. *J Invest Dermatol.* 2000;115:149.
82. Finkelstein Y, Soon GS, Acuna P, et al. Recurrence and outcomes of Stevens-Johnson syndrome and toxic epidermal necrolysis in children. *Pediatrics.* 2011;128(4):723-728.
83. Downey A, Jackson C, Harun N, et al. Toxic epidermal necrolysis: review of pathogenesis and management. *J Am Acad Dermatol.* 2012;66(6):995-1003.
84. Tripathi J, Ditto A, Grammer L, et al. Corticosteroid therapy in an additional 13 cases of Stevens-Johnson syndrome: a total series of 67 cases. *Allergy Asthma Proc.* 2000;21:101-105.
85. Murphy J, Purdue G, Hunt J. Toxic epidermal necrolysis. *J Burn Care Rehabil.* 1997;18:417-420.
86. Schneck J, Fagot J, Sekula P, et al. Effects of treatments of the mortality of Stevens-Johnson syndrome and toxic epidermal necrolysis: a retrospective study on patients included in the prospective EuroSCAR study. *J Am Acad Dermatol.* 2008;58:33-40.
87. Arevalo J, Lorente J, Gonzalez-Herrada C, et al. Treatment of toxic epidermal necrolysis with cyclosporin A. *J Trauma.* 2000;48:473-478.
88. Drake L, Dinehart S, Farmer R, et al. Guidelines of care for cutaneous adverse drug reactions. *J Am Acad Dermatol.* 1996;35:458-461.
89. Brennan P, Bouza T, Hsu F, et al. Hypersensitivity reactions to mAbs: 105 desensitizations in 23 patients, from evaluation to treatment. *J Allergy Clin Immunol.* 2009;124:1259-1266.

Chapter 46 :: Erythema Annulare Centrifugum and Other Figurate Erythemas

:: Christine S. Ahn & William W. Huang

ERYTHEMA ANNULARE CENTRIFUGUM

AT-A-GLANCE

- Uncommon inflammatory hypersensitivity reaction characterized by annular or polycyclic plaques with central clearing and peripheral scale.
- Favors the extremities and trunk.
- Chronic condition that recurs and remits.
- Two histologic variants: superficial variant consists of spongiosis, parakeratosis, hyperkeratosis or basal vacuolar changes with a perivascular infiltrate, and deep variant consists of perivascular lymphocytic infiltrate concentrated in the upper dermis without any epidermal changes.
- Treatments include topical corticosteroids, vitamin D analogs, antibiotics, and antifungals.

The figurate or reactive erythemas encompass a variety of cutaneous eruptions that are characterized by erythematous lesions with annular, polycyclic, and/or arcuate configurations. The prototype of these disorders is erythema annulare centrifugum (EAC), which was a term first used by Darier in 1916 to describe an erythematous annular or polycyclic plaque that enlarged centrifugally with a trailing scale.[1] The classification of EAC and other figurate erythemas is controversial, with some authors believing that the superficial and deep forms of EAC represent distinct clinical entities, and others considering EAC to be a clinical reaction pattern rather than a specific clinicopathologic entity.[2]

EPIDEMIOLOGY

Although there is limited epidemiologic data on the prevalence of EAC, it is thought to be an uncommon disorder. Based on 4 clinicopathologic series in the literature that includes 202 patients, EAC exhibits no sex predilection and largely occurs in adults, with a peak incidence in the third and fourth decades.[2-5] EAC also has been described in infants and children.[6,7]

CLINICAL FEATURES

EAC presents in the skin as a pink papule that expands centrifugally, forming an annular or polycyclic plaque with central clearing. In the superficial variant, lesions are slightly elevated and demonstrate desquamation at the inner margin, also referred to as a "trailing scale" (Figs. 46-1 and 46-2). The deep variant of EAC has an indurated, firm border, often without prominent scaling. The most common symptom associated with EAC is pruritus, although it is often asymptomatic. Residual scarring is uncommon, although postinflammatory hyperpigmentation may occur after lesions resolve. The most frequent sites of involvement of EAC are the buttocks, thighs, and trunk. In a series of 66 cases, the most common sites of involvement were the lower extremities (36 cases, 48%) and trunk (22 cases, 28%). Upper extremities and head and neck involvement were less common, observed in 12 cases (16%) and 6 cases (8%), respectively. When categorized by the extent of involvement, 28 patients (58%) had lesions located on only one site, 19 patients (28%) on 2 sites, and 9 patients (14%) had generalized disease with 3 or more sites.[4]

ETIOLOGY AND PATHOGENESIS

The etiology of EAC is not fully understood. Although most cases are idiopathic, it has been suggested that EAC is a hypersensitivity reaction to an antigen, and has been linked to cutaneous or systemic infections, malignancy, drugs, certain disease states, and pregnancy.

RISK FACTORS

Although largely anecdotal, EAC has been observed in the setting of infections, malignancies, medications, pregnancy, and other systemic diseases in up to 72% of cases.[4] In one study, 40% of patients with EAC had a concomitant superficial dermatophyte infection, most commonly tinea pedis, and 13% had internal malignancies, including non-Hodgkin lymphoma and acute myelogenous leukemia.[4] In a separate review of 39 patients with EAC, 13 (33%) had associated conditions, with the most common being superficial dermatophyte infection 5 (13%), pregnancy 2 (5%), thyroid cancer 2 (5%), and medication use 2 (5%).[2]

Figure 46-1 Superficial erythema annulare centrifugum. A large annular plaque with trailing scale behind the advancing erythematous edge.

Figure 46-2 Superficial erythema annulare centrifugum. Multiple lesions demonstrated epidermal changes with a trailing scale. (Used with permission from Wilfried Neuse and Thomas Ruzicka, Düsseldorf, Germany.)

Dermatophyte infections may be a risk factor for EAC. In cases associated with tinea pedis, lesions of EAC tend to resolve with treatment of the dermatophytosis.[2] In addition to dermatophytoses, EAC is associated with other cutaneous infections such as molluscum contagiosum and herpes zoster, as well as systemic infections, including Epstein-Barr virus and HIV.[8-10] Paraneoplastic erythema annulare centrifugum eruptions occur most commonly with lymphoproliferative malignancies such as lymphomas and leukemias, and often precede the diagnosis of the underlying malignancy. It is thought to occur as a result of cytokine or tumor-associated factors as the clinical course tends to parallel the activity of the neoplasm, with resolution with treatment and recurrence with relapse of the malignancy.[11,12]

A wide of range of drugs are associated with EAC, including finasteride; azacitidine; pegylated interferon-α_{2a} and ribavirin in the treatment of hepatitis C; rituximab; ustekinumab; amitriptyline; and gold sodium thiomalate.[13-18] However, no specific drugs have been reported consistently to establish a true relationship. EAC also has been reported in the setting of some disease states, such as autoimmune hepatitis and systemic lupus erythematosus. In some cases, EAC can be the presenting sign of systemic disease.[19] In pregnant women, EAC tends to occur during the second and third trimesters, and typically remits spontaneously around the time of delivery without recurrence.[20,21]

DIAGNOSIS

The diagnosis of EAC is primarily a clinical diagnosis. Histopathologic examination can help differentiate EAC from other conditions that cause annular lesions and confirm the diagnosis. Other laboratory studies do not have a role in the diagnosis of EAC.

PATHOLOGY

EAC is characterized histologically by the presence of a dense perivascular infiltrate composed of lymphocytes, histiocytes, and occasional eosinophils. As a result of the well-demarcated distribution that tightly wraps around blood vessels, the infiltrate has been described as a "coat-sleeve" pattern. There are 2 distinct histologic patterns of EAC: superficial type and deep type. In the superficial type, epidermal changes that correspond to clinical findings are observed, which include parakeratosis, hyperkeratosis, spongiosis, and/or vacuolar degeneration. The perivascular infiltrates are more prominent in the upper dermis in the superficial type (Fig. 46-3). In the deep type, epidermal changes are absent or minimal, and there can be mild edema in the papillary dermis along with perivascular infiltrates involving vascular plexuses in both the upper and lower dermis.[2]

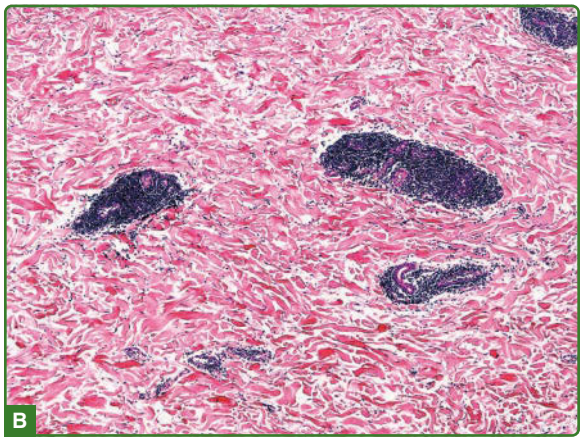

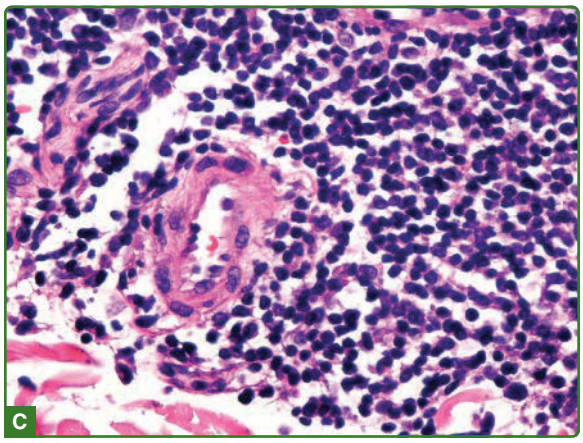

Figure 46-3 Erythema annulare centrifugum. **A,** Dense perivascular infiltrate in the superficial and med dermis. **B** and **C,** Lymphocytic infiltrate tightly wrapped around blood vessels in a "coat-sleeve" pattern.

DIFFERENTIAL DIAGNOSIS

The differential diagnosis for EAC includes other annular erythematous lesions. It is important to rule out entities such as Lyme borreliosis, lupus erythematosus, and an underlying tumor or annular metastasis. See Table 46-1.

TABLE 46-1
Differential Diagnosis for Erythema Annulare Centrifugum

Erythema chronicum migrans
Annular subacute cutaneous lupus erythematosus
Annular urticaria
Erythema multiforme
Tinea corporis
Annular psoriasis
Mycosis fungoides

CLINICAL COURSE AND PROGNOSIS

EAC is a chronic condition that tends to persist over several months to years, following a waxing and waning course. Some cases regress spontaneously, while others can be resistant to treatment. In a retrospective review of 66 patients with EAC, the duration of disease was 2.8 years.[4] Among 27 patients with follow-up data, 13 (48%) of patients had an excellent response to treatment but 5 (18.5%) had persistent skin lesions that failed to improve after 1 year of treatment. Of these cases with poor response to treatment, almost all cases were superficial-type EAC. The average duration of continuous lesions of EAC was 4.75 months; although the deep-type lesions tended to be longer lasting, the recurrence rate was higher for superficial-type lesions.[2]

MANAGEMENT

Symptomatic EAC can be treated with topical corticosteroids, topical vitamin D analogs, and antihistamines if there is associated pruritus. Systemic corticosteroids clears lesions of EAC, but cessation of therapy can lead to rebound recurrence of disease. There are reports of antifungals and antibiotics such as fluconazole, erythromycin, and metronidazole being used successfully to treat EAC.

ERYTHEMA MIGRANS

AT-A-GLANCE

- Cutaneous manifestation of early localized Lyme disease that occurs at the site of the bite of *Ixodes* species ticks infected with *Borrelia burgdorferi.*
- Characterized by annular erythema that expands to create a "bull's-eye" appearance.
- Seen in 70% to 80% of individuals with Lyme disease.

Erythema migrans is an annular erythema that represents an early cutaneous manifestation of Lyme borreliosis, which is an infection caused by the spirochete *Borrelia burgdorferi*, transmitted through the bite of species of *Ixodes* ticks (see Chap. 179). Chapter 180 discusses other tick-borne diseases.

EPIDEMIOLOGY

Erythema migrans and Lyme disease are seen worldwide, but with a higher prevalence in parts of North America, central and eastern Europe, and eastern Asia. In the United States, it is the fifth most common nationally notifiable disease, with an estimated incidence of 7.9 cases per 100,000 population in 2014.[22] The incidence of Lyme disease is more heavily concentrated in areas endemic to the white-footed mouse and white-tailed deer, the natural hosts of *Ixodes* ticks. *Ixodes scapularis* is the primary vector responsible for Lyme disease in the northeastern, mid-Atlantic, and north-central US, whereas *Ixodes pacificus* is the primary vector in the Pacific coast. Approximately 96% of confirmed Lyme disease cases were reported from 14 states concentrated in the Northeast and upper Midwest in 2014, according to the Centers for Disease Control and Prevention.[22] Most cases of Lyme disease occur during the months of June, July, and August, and there is a bimodal distribution of incidence, with peaks between the ages of 5 and 19 years, and between 55 and 69 years.[1]

CLINICAL FEATURES

CUTANEOUS FINDINGS

The 3 stages of Lyme disease are early localized disease, early disseminated disease, and chronic disease. Erythema migrans occurs at the initial site of the tick bite and is a hallmark cutaneous finding of the first stage of Lyme disease. It is characterized by an erythematous expanding annular plaque with a central area of clearing, often described as a "bull's-eye" lesion (Fig. 46-4). The most common associated symptoms include warmth, pruritus, and pain, although it can be asymptomatic. In some cases, erythema migrans can be vesicular. Primary lesions of erythema migrans occur in areas where tick bites are likely to occur and go unnoticed, such as the trunk, axillae, groin, and popliteal fossae. Lesions grow centrifugally and can grow at a rate of up to 3 cm per day.[1] At the time of presentation, the mean diameter of lesions of erythema migrans are 10 to 16 cm, depending on the site of involvement, with larger lesions found on the trunk and smaller lesions found on the lower extremities. Multiple lesions of erythema migrans can be seen in the setting of multiple tick bites or spirochetemia or lymphatic spread.

Figure 46-4 Erythema chronicum migrans. Erythematous bite site surrounded by an expanding red plaque, reminiscent of the bull's-eye of a target. (Used with permission from the collection of Dr. John L. Aeling.)

In most cases, ticks must be attached for at least 24 hours before bacteria is transmitted, and erythema migrans occurs at the site of the bite, approximately 7 to 14 days after tick detachment (range: 3 to 30 days). Approximately 70% to 80% of individuals infected with Lyme disease develop lesions of erythema migrans, and up to 45% of patients presenting with erythema migrans have spirochetemia.[1,23]

NONCUTANEOUS FINDINGS

In addition to erythema migrans, other signs and symptoms of early Lyme disease include regional lymphadenopathy, arthralgias, arthritis, myositis, pancarditis, facial palsy, conjunctivitis, and hepatitis.[1]

COMPLICATIONS

Complications of erythema migrans occur as a reflection of untreated Lyme disease. While the lesions of erythema migrans often resolve spontaneously over weeks to months, if untreated, patients can progress to the second stage of Lyme disease, which involves widespread spirochete dissemination with neurologic, rheumatologic, and cardiac involvement, and the third stage, with persistent neuroborreliosis, severe erosive arthritis, and acrodermatitis chronica atrophicans. Borrelial lymphocytoma is a benign reactive lymphoid hyperplasia that can occur in response to untreated *Borrelia* infections. Usually observed in the early disseminated stage of Lyme disease, it is rarely seen in the United States, as it is more associated with *Borrelia afzelii* and *Borrelia garinii*, which are causative organisms seen in Europe. Acrodermatitis chronica atrophicans, which is typical of chronic Lyme disease infection, is also seen more often in European populations, and is characterized by enlarging, edematous plaques on the distal extremities with a bluish-red hue that evolve into atrophic plaques.[1,23]

ETIOLOGY AND PATHOGENESIS

Erythema migrans occurs at the site of the bite of an *Ixodes* tick carrying a pathogenic strain of *B. burgdorferi*. *Ixodes* ticks acquire *B. burgdorferi* when feeding on an infected host, and the bacteria survive in a protected environment in the tick midgut epithelium because of the presence of surface lipoproteins outer-surface protein (Osp) A and OspB. Infected ticks then transmit *B. burgdorferi* to new hosts through the salivary glands. Another surface protein, OspC is involved in salivary gland invasion and plays an important role in the early colonization and infection of new hosts. OspC is thought to bind to Salp15, a tick salivary protein, which inhibits components of the host immune system.[1]

RISK FACTORS

Risk factors for erythema migrans are largely dependent on human behaviors that increase exposure to infected ticks, such as spending time outdoors in endemic areas and a lack of protective clothing. Other risk factors independent of modifiable behaviors include geographic location and seasonal patterns in tick activity.

DIAGNOSIS

The diagnosis of erythema migrans is made based on clinical presentation, signs and symptoms of Lyme disease, and a history of possible tick exposure. In some cases, laboratory tests and histopathologic examination can help confirm the diagnosis.

LABORATORY TESTING

The Centers for Disease Control and Prevention defines a 2-step process to support the diagnosis of Lyme disease. In the first step, enzyme immunoassay or indirect immunofluorescence assay is performed to detect antibodies. If positive or equivocal, a Western blot analysis is performed, which confirms the diagnosis if positive. Western blot analysis should not be performed without a positive or equivocal antibody test because of the risk for false-positive results.[22]

PATHOLOGY

The histologic features of erythema migrans are similar to those of other gyrate erythemas. Nonspecific findings of mild inflammatory infiltrates composed of lymphocytes and occasional eosinophils and plasma cells can be seen, concentrated around blood vessels. Silver stains such as the Warthin-Starry stain can be used to detect spirochetes in the skin, including *B. burgdorferi.*

DIFFERENTIAL DIAGNOSIS

The differential diagnosis for erythema migrans includes exaggerated arthropod bite reactions, cellulitis, erysipelas, and fixed drug eruptions. Another tick-borne disease, southern tick-associated rash illness, can present with a rash similar to erythema migrans.

CLINICAL COURSE AND PROGNOSIS

Erythema migrans can present with a single lesion or can progress to multiple lesions as the infection with *B. burgdorferi* becomes disseminated. The lesions of erythema migrans often resolve after weeks to months. In the absence of treatment, patients can develop signs and symptoms of early disseminated and chronic disseminated Lyme disease.

MANAGEMENT

MEDICATIONS

Treatment of erythema migrans with appropriate systemic antibiotics in the early stages of Lyme disease usually results in complete resolution. The most common antibiotics used to treat Lyme disease are doxycycline, amoxicillin, and cefuroxime. In disseminated and advanced disease with neurologic or cardiac involvement, intravenous antibiotics may be required. Empiric antibiotic treatment of individuals with tick bites is not recommended, as only 1% of individuals bitten by ticks in endemic areas develop Lyme disease.[1] Prophylaxis with a single dose of doxycycline is indicated to decrease the risk of developing Lyme disease only when the individual is from an endemic area, has been bitten by a tick identified as *I. scapularis,* has had tick attachment for longer than 36 hours, and prophylaxis can be started within 72 hours of tick removal.[22]

ERYTHEMA MARGINATUM

AT-A-GLANCE

- Cutaneous manifestation of rheumatic fever, occurring after pharyngeal infection with group A β-hemolytic streptococcus.
- One of the major criteria of acute rheumatic fever.
- Pink lesions that expand centrifugally that favor the trunk, axillae, and extremities, and spare the face.
- Clinical course is independent of the underlying disease; lesions can persist after treatment of acute rheumatic fever.

Erythema marginatum, also known as erythema marginatum rheumaticum, is an annular, erythematous eruption that was first described in patients with rheumatic fever in 1831. Only seen in a minority of patients with acute rheumatic fever, erythema marginatum is a cutaneous manifestation that is one of the major American Heart Association criteria for rheumatic fever, which include carditis, migratory polyarthritis, Sydenham chorea, erythema marginatum, and subcutaneous nodules. Minor criteria are fever, arthralgias, and abnormal laboratory findings such as elevated erythrocyte sedimentation rate, C-reactive protein, or a prolonged PR interval on echocardiogram. The diagnosis of acute rheumatic fever is made when 2 major or 1 major and 2 minor criteria are met.[24]

EPIDEMIOLOGY

Acute rheumatic fever occurs as a complication of an antecedent pharyngeal infection with group A β-hemolytic streptococcus, seen in approximately 3% of untreated infections. The incidence of erythema marginatum is higher in developing countries, with a mean incidence of 19 cases per 100,000 population. In the United States and developed countries, the incidence of acute rheumatic fever is lower, ranging from 2 to 14 cases per 100,000 population. Although part of the major criteria, erythema marginatum is seen in fewer than 10% of patients with acute rheumatic fever. It occurs more often in children than in adults, with peak age of onset between 5 and 15 years.[25]

CLINICAL FEATURES

CUTANEOUS FINDINGS

Erythema marginatum classically presents as erythematous macules that spread to become annular or polycyclic patches or plaques. As the lesions expand centrifugally, there can be a central area of clearing. The borders of the lesions are often well demarcated. There are usually no epidermal changes present and the lesions are often asymptomatic. Lesions have a predilection for the trunk, axillae, and proximal extremities, and typically spare the face. Individual lesions of erythema marginatum tend to appear and disappear (Fig. 46-5), and may be more evident with hot showers or baths.

Subcutaneous nodules are another cutaneous finding that represents one of the major criteria of acute rheumatic fever. These are small and typically occur over bony prominences such as the wrists, elbows, knees, and ankles. They are seen more in patients with chronic, longstanding disease and are usually painless.

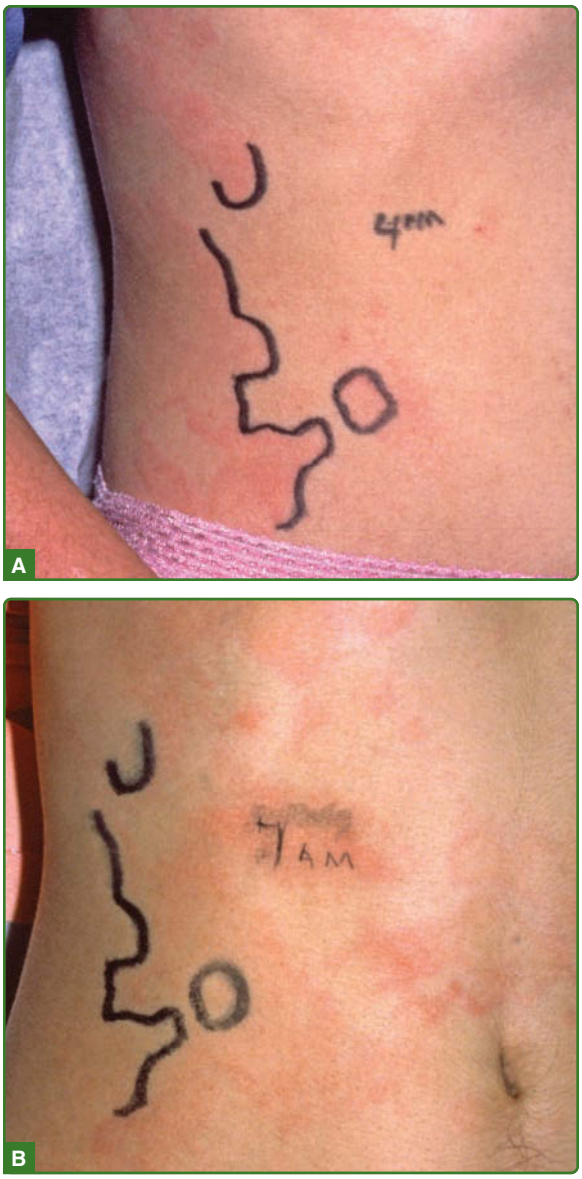

Figure 46-5 The transient nature of erythema marginatum. Polycyclic erythema that "migrated" over several hours. (Used with permission from the Fitzsimmons Army Medical Center Dermatology Archive.)

NONCUTANEOUS FINDINGS

Noncutaneous findings seen in association with erythema marginatum include migratory arthritis (usually involving the large joints), carditis, valvulitis, Sydenham chorea, fever, and arthralgias. In particular, erythema marginatum often occurs in conjunction with acute carditis.[24]

COMPLICATIONS

The complications of erythema marginatum are the sequelae of acute rheumatic fever, the most severe of which is rheumatic heart disease with valvular damage. Up to 50% of patients with carditis at the time of

initial presentation go on to develop acquired valvular disease, most often involving calcification of the mitral valve, leading to mitral stenosis. A less-common complication associated with acute rheumatic fever is Jaccoud arthropathy, which is a chronic, painless arthropathy of the hands and feet.[24,25]

ETIOLOGY AND PATHOGENESIS

The exact mechanism by which the cutaneous lesions of erythema marginatum develop in acute rheumatic fever remains unknown. However, the pathogenesis of acute rheumatic fever is multifactorial, with pathogen triggers, molecular mimicry, and host genetic factors playing a role. Epitopes in human myosin, actin, tropomyosin, and other proteins also have been observed cross-reacting with group A streptococcal antigens.[25]

DIAGNOSIS

The diagnosis of erythema marginatum is a clinical one, based on the appearance of typical cutaneous findings and a history of acute rheumatic fever. Performing supportive studies to confirm the diagnosis of acute rheumatic fever can help confirm the diagnosis of erythema marginatum. Because of the nonspecific findings seen on histopathologic examination, skin biopsies do not have much of a role in diagnosing erythema marginatum.

LABORATORY TESTING

The diagnosis of streptococcal pharyngitis can be made through a positive throat culture, positive rapid streptococcal antigen test, or the presence of antistreptococcal antibodies such as antistreptolysin O antibody, antideoxyribonuclease B, streptokinase, and antihyaluronidase. Acute-phase reactants, such as C-reactive protein and erythrocyte sedimentation rate, are usually elevated and are part of the minor diagnostic criteria of acute rheumatic fever.[25]

PATHOLOGY

The histologic findings of erythema marginatum are nonspecific. Biopsy specimens usually demonstrate a patchy interstitial and perivascular infiltrate composed of neutrophils without evidence of vasculitis. Although these findings are not specific to erythema marginatum, a skin biopsy can help differentiate erythema marginatum from other clinical entities.

DIFFERENTIAL DIAGNOSIS

In addition to other gyrate erythemas, the main differential includes annular urticaria, annular erythema of infancy, and neutrophilic figurate erythema of infancy.

CLINICAL COURSE AND PROGNOSIS

Erythema marginatum follows an indolent clinical course that is independent of acute rheumatic fever. Even after the treatment of acute rheumatic fever, lesions of erythema marginatum may persist.

MANAGEMENT

No intervention is necessary for the treatment of erythema marginatum, apart from the treatment of the underlying acute rheumatic fever. Lesions of erythema marginatum are self-limited and eventually resolve spontaneously.

ERYTHEMA GYRATUM REPENS

AT-A-GLANCE

- Usually a paraneoplastic phenomenon.
- Characteristic wood grain appearance with multiple concentric rings.
- Thought to be an immune reaction caused by cross-reaction between tumor and skin antigens.
- Remits with treatment of the underlying malignancy.

Erythema gyratum repens is a figurate erythema with a distinctive clinical appearance that was historically considered to be strictly a paraneoplastic cutaneous phenomenon. Newer studies suggest that erythema gyratum repens can also occur abruptly without cause and in the setting of medication use.

EPIDEMIOLOGY

Erythema gyratum repens is a rare condition, with an unknown incidence. Approximately 70% to 80% of cases are associated with malignancy, with the most common being lung, breast, esophagus, and stomach neoplasms.[26] It is thought to primarily affect adults because of its link to malignancies, thus its distribution in the population, age of onset, and risk factors mirror those for underlying malignancies.

Figure 46-6 Erythema gyratum repens. Multiple annular lesions on a woman with underlying malignancy. (Used with permission from the Fitzsimmons Army Medical Center Dermatology Archive.)

CLINICAL FEATURES

Erythema gyratum repens features multiple, erythematous, annular lesions that advance at a rapid rate of up to 1 cm per day (Fig. 46-6). As the lesions spread, they form concentric rings that impart a "wood-grain" pattern. The epidermis often has a superficial scale at the edges, and patients often complain of pruritus. The onset of the lesions can occur from 1 year before to 1 year after the diagnosis of malignancy. Additional associated cutaneous findings can be seen, which include acquired ichthyosis and palmoplantar keratoderma.[26]

ETIOLOGY AND PATHOGENESIS

The etiology of erythema gyratum repens is not completely known, but it is suggested that it occurs as an immune reaction caused by the cross-reaction between tumor antigens and cutaneous antigens. In some cases, similar deposits of immunoglobulin G and C3 have been identified in the basement membrane zone of the skin and in the associated neoplasm, simultaneously.[27] The responsible antigens have not been identified but studies have shown an accumulation of Langerhans cells in the epidermis in lesions of erythema gyratum repens.

DIAGNOSIS

As a consequence of its distinctive clinical appearance, erythema gyratum repens can usually be diagnosed based on clinical appearance. The presence of a known malignancy can help support clinical suspicion, whereas the new diagnosis of erythema gyratum repens without a known malignancy should prompt the clinician to perform appropriate screening for a possible underlying neoplasm.

PATHOLOGY

Histopathologic features are nonspecific. Common epidermal changes include mild spongiosis, hyperkeratosis, and parakeratosis. Similar to other figurate erythemas, there is often a perivascular infiltrate composed of lymphocytes, histiocytes, and occasional eosinophils.

DIFFERENTIAL DIAGNOSIS

Table 46-2 outlines the differential diagnosis for erythema gyratum repens.

CLINICAL COURSE AND PROGNOSIS

The clinical course and prognosis of erythema gyratum repens parallels the course of the underlying malignancy.

MANAGEMENT

Treatment (Table 46-3) can involve symptomatic relief with topical corticosteroids. Resolution of skin lesions occurs with treatment of the underlying malignancy. In cases of relapse or metastases, erythema gyratum repens can recur.

TABLE 46-2
Differential Diagnosis for Erythema Gyratum Repens

- Figurate erythemas
  - Erythema annulare centrifugum
  - Erythema marginatum
- Erythrokeratoderma variabilis
- Psoriasis
- Pityriasis rubra pilaris
- Tinea corporis
- Tinea imbricate
- Mycosis fungoides
- Bullous pemphigoid
- Linear immunoglobulin A bullous dermatosis

TABLE 46-3

Summary for Erythema Annular Centrifugum and Other Figurate Erythemas

	EPIDEMIOLOGY	CLINICAL FEATURES	ETIOLOGY	RISK FACTORS AND ASSOCIATED CONDITIONS	HISTOLOGIC FINDINGS	PROGNOSIS	MANAGEMENT
erythema annular centrifugum (EAC)	Adults in 3rd or 4th decades	Pink papule that expands centrifugally; characteristic annular/polycyclic plaque with central clearing and trailing scale. Deep variants lack prominent scaling	Idiopathic; possibly a hypersensitivity reaction	Infections (dermatophyte), malignancies (non-Hodgkin lymphoma, acute myelogenous leukemia), medications, pregnancy	Dense perivascular infiltrate in a "coat sleeve" pattern	Chronic, with waxing and waning course. May regress spontaneously. Resolution of associated conditions (fungal infection, pregnancy) may lead to improvement	Topical corticosteroids, vitamin D analogs, antihistamines; treatment of underlying fungal infection, if present
Erythema migrans	Bimodal distribution: ages 5-19 years, and 55-69 years; occurs in 70%-80% of individuals infected with Lyme disease	Occurs at initial site of tick bite, with an erythematous expanding annular plaque with central clearing; "bull's-eye" lesion. May progress to multiple lesions	*Borrelia burgdorferi;* hallmark cutaneous finding of early Lyme disease	Dependent on exposure to infected ticks	Nonspecific inflammation; mild lymphocytic infiltrate with occasional eosinophils and plasma cells; Warthin-Starry stain may detect spirochetes	Lesions resolve spontaneously. Untreated Lyme disease can progress to systemic involvement	Doxycycline, amoxicillin, or cefuroxime
Erythema marginatum (also, erythema marginatum rheumaticum)	Children more commonly affected (peaks at age 5-15 years); seen in 3% of untreated group A β-hemolytic streptococcus infections	Erythematous macules that spread to become annular or polycyclic patches or plaques with central clearing. Predilection for trunk, axillae, proximal extremities	Cutaneous manifestation of acute rheumatic fever; molecular mimicry may play a role in cutaneous signs	Group A β-hemolytic streptococcus infection	Nonspecific; patchy interstitial and perivascular infiltrate composed of neutrophils	Indolent course; cutaneous findings are independent of rheumatic heart disease treatment	Acute rheumatic fever should be treated
Erythema gyratum repens	Rare. Adults most commonly affected; 70%-80% associated with malignancies	Multiple, erythematous, annular lesions with rapid rate of growth (1 cm per day). Characteristic "wood-grain" pattern or concentric rings. May be associated with acquired ichthyosis and palmoplantar keratoderma	May be caused by an immune reaction to the cross-reaction between tumor antigens and cutaneous antigens	Malignancies of the lung, breast, esophagus, and stomach	Nonspecific; mild spongiosis, hyperkeratosis, and parakeratosis	Resolves once underlying malignancy is treated. Course parallels underlying malignancy	Topical corticosteroids may provide symptomatic relief

ACKNOWLEDGMENTS

The authors would like to acknowledge Dr. Omar P. Sangueza for the contribution of histologic images to this chapter, and the contributions of Walter H.C. Burgdorf, the former author of this chapter.

REFERENCES

1. Darier J. De l'erythème annulaire centrifuge (erythema papulocirciné migrateur et chronique) et de quelque eruptions analogues. *Ann Dermatol Syphiligr (Paris).* 1916;6:57-76.
2. Kim DH, Lee JH, Lee JY, et al. Erythema annulare centrifugum: analysis of associated diseases and clinical outcomes according to histopathologic classification. *Ann Dermatol.* 2016;28(2):257-259.
3. Weyers W, Diaz-Cascajo C, Weyers I. Erythema annulare centrifugum: results of a clinicopathologic study of 73 patients. *Am J Dermatopathol.* 2003;25(6):451-462.
4. Kim KJ, Chang SE, Choi JH, et al. Clinicopathologic analysis of 66 cases of erythema annulare centrifugum. *J Dermatol.* 2002;29(2):61-67.
5. Mahood JM. Erythema annulare centrifugum: a review of 24 cases with special reference to its association with underlying disease. *Clin Exp Dermatol.* 1983;8(4):383-387.
6. Kruse LL, Kenner-Bell BM, Mancini AJ. Pediatric erythema annulare centrifugum treated with oral fluconazole: a retrospective series. *Pediatr Dermatol.* 2016;33(5):501-506.
7. Bottoni U, Innocenzi D, Bonaccorsi P, et al. Erythema annulare centrifugum: report of a case with neonatal onset. *J Eur Acad Dermatol Venereol.* 2002; 16(5):500-503.
8. Chu CH, Tuan PK, Yang SJ. Molluscum contagiosum-induced erythema annulare centrifugum. *JAMA Dermatol.* 2015;151(12):1385-1386.
9. Ohmori S, Sugita K, Ikenouchi-Sugita A, et al. Erythema annulare centrifugum associated with herpes zoster. *J UOEH.* 2012;34(3):225-229.
10. González-Vela MC, González-López MA, Val-Bernal JF, et al. Erythema annulare centrifugum in a HIV-positive patient. *Int J Dermatol.* 2006;45(12):1423-1425.
11. Chodkiewicz HM, Cohen PR. Paraneoplastic erythema annulare centrifugum eruption: PEACE. *Am J Clin Dermatol.* 2012;13(4):239-246.
12. Mu EW, Sanchez M, Mir A, et al. Paraneoplastic erythema annulare centrifugum eruption (PEACE). *Dermatol Online J.* 2015;21(12).
13. Gönül M, Külcü Çakmak S, Ozcan N, et al. Erythema annulare centrifugum due to pegylated interferon-α-2a plus ribavirin combination therapy in a patient with chronic hepatitis C virus infection. *J Cutan Med Surg.* 2014;18(1):65-68.
14. di Meo N, Stinco G, Fadel M, et al. Erythema annulare centrifugum in the era of triple therapy with boceprevir plus pegylated interferon α-2b and ribavirin for hepatitis C virus infection. *J Cutan Med Surg.* 2015;19(3):203-204.
15. Chou WT, Tsai TF. Recurrent erythema annulare centrifugum during ustekinumab treatment in a psoriatic patient. *Acta Derm Venereol.* 2013;93(2):208-209.
16. Al Hammadi A, Asai Y, Patt ML, et al. Erythema annulare centrifugum secondary to treatment with finasteride. *J Drugs Dermatol.* 2007;6(4):460-463.
17. Mendes-Bastos P, Coelho-Macias V, Moraes-Fontes MF, et al. Erythema annulare centrifugum during rituximab treatment for autoimmune haemolytic anaemia. *J Eur Acad Dermatol Venereol.* 2014;28(8):1125-1127.
18. García-Doval I, Peteiro C, Toribio J. Amitriptyline-induced erythema annulare centrifugum. *Cutis.* 1999; 63(1):35-36.
19. Chander R, Yadav P, Singh A, et al. Systemic lupus erythematosus presenting as erythema annulare centrifugum. *Lupus.* 2014;23(11):1197-1200.
20. Chiang CH, Lai FJ. Pregnancy-associated erythema annulare centrifugum. *J Formos Med Assoc.* 2015; 114(7):670-671.
21. Senel E, Gulec AT. Erythema annulare centrifugum in pregnancy. *Indian J Dermatol.* 2010;55(1):120-121.
22. Centers for Disease Control and Prevention. *Lyme Disease: Data and Statistics.* 2015. Accessed August 22, 2016. http://www.cdc.gov/lyme/stats/.
23. Bhate C, Schwartz RA. Lyme disease: part I. Advances and perspectives. *J Am Acad Dermatol.* 2011;64(4): 619-636.
24. Mullegger RR. Dermatological manifestations of Lyme borreliosis. *Eur J Dermatol.* 2004;14(5):296-309.
25. Burke RJ, Chang C. Diagnostic criteria of acute rheumatic fever. *Autoimmun Rev.* 2014;13(4-5):503-507.
26. Chakravarty SD, Zabriskie JB, Gibofsky A. Acute rheumatic fever and streptococci: the quintessential pathogenic trigger of autoimmunity. *Clin Rheumatol.* 2014; 33(7):893-901.
27. Rongioletti F, Fausti V, Parodi A. Erythema gyratum repens is not an obligate paraneoplastic disease: a systematic review of the literature and personal experience. *J Eur Acad Dermatol Venereol.* 2014;28(1):112-115.
28. Caux F, Lebbe C, Thomine E, et al. Erythema gyratum repens. A case studied with immunofluorescence, immunoelectron microscopy and immunohistochemistry. *Br J Dermatol.* 1994;131(1):102-107.

Disorders of Cornification

PART 8

Chapter 47 :: The Ichthyoses

:: Keith A. Choate & Leonard M. Milstone

AT-A-GLANCE

- The ichthyoses are a heterogeneous group of skin diseases characterized by generalized scaling, and often areas of thickened skin.
- Most types are inherited, and these usually present at birth or appear in childhood; however, some forms are acquired.
- Scales may vary in size, color, and body site.
- The may be accompanied by erythema, abnormalities in adnexal structures, and palmoplantar keratoderma.
- The may be associated with systemic findings, such as failure to thrive, increased susceptibility to infection, atopic dermatitis, neurosensory deafness, and neurologic and other disease.
- Histopathology is usually nonspecific with few notable exceptions.
- Early genetic testing can aid in the diagnosis and anticipation of potential systemic abnormalities.

INTRODUCTION

This chapter discusses the heterogeneous group of disorders known as the ichthyoses that share the common feature of generalized scaling and most commonly arise at birth or childhood but can be acquired later in life. Ichthyoses commonly result from genetic mutations in a diverse group of genes, including membrane transporters, lipid biosynthesis enzymes, and structural proteins, among many others. Ensuing epithelial barrier compromise, hyperproliferation, and hyperkeratosis become evident as scaling. Associated systemic abnormalities are often attributable to noncutaneous functions of mutant genes.

The hallmark of ichthyosis is scale, which reflects altered differentiation of the epidermis. Because the Greek word for horn (scale) is *keras* and the Latin is *cornu*, in this chapter, the terms *epidermal differentiation*, *keratinization*, and *cornification* are used synonymously. The name *ichthyosis* is derived from the Greek *ichthys*, meaning "fish," and refers to the similarity in appearance of the skin to fish scale. Both inherited and acquired forms are found. Early reports of ichthyosis in the Indian and Chinese literature date back to several hundred years BC, and the condition was discussed by Willan in 1798.[1]

Ichthyosis can present at birth or develop later in life. It can occur as a disease limited to the skin or in association with abnormalities of other organ systems. A number of well-defined types of ichthyosis with characteristic features can be reliably diagnosed. However, because of the great clinical heterogeneity and the profound effect of the environment on scaling, a specific diagnosis can be challenging in certain patients and families without the aid of genetic testing.

CLASSSIFICATION OF THE ICHTHYOSES

Siemens introduced genetic concepts into the ichthyoses.[2] Wells and Kerr classified the heritable ichthyoses[3] and separated X-linked recessive ichthyosis from ichthyosis vulgaris (IV).[4] Gassman developed the concept of retention versus hyperproliferation hyperkeratosis.[5] Van Scott, Frost, and Weinstein subsequently proposed a classification of the ichthyoses based on differences in rates of epidermal turnover, characterizing them as either disorders of epidermal hyperproliferation or disorders of prolonged retention of the stratum corneum.[6] Subsequently, Williams and Elias proposed a classification that lists the disorders

of cornification in which clinical, genetic, or biochemical data suggest a distinct disease.[7]

Genetic investigation of the ichthyoses has revealed causative mutations in genes relevant to structural proteins, lipid biosynthesis, cell–cell communication, desquamation, and many other pathways and has, in many cases, provided insight into previously unknown determinants of epidermal homestasis.[8] The advent of whole-exome sequencing (WES) has led to phenotypic expansion, and a new classification of the ichthyoses is evolving based not only on mutant genes but also on specific mutations. Knowing which gene is mutated and what the effects of a given mutation are enables understanding of disease pathobiology. Defining these disorders on the basis of common molecular processes leads to more rational approaches to understanding their pathophysiology and treatment. Inheritance patterns and common clinical features of selected hereditary ichthyoses are shown in Tables 47-1 to 47-3. Grouping these disorders according to the function of encoded proteins (Table 47-4) facilitates understanding of the clinical phenotypes in terms of underlying mechanism. However, further work is necessary to clearly understand how specific mutations result in clinical disease and to develop targeted therapeutic interventions.

In 2009, a consensus conference proposed a revised nomenclature and classification of the ichthyoses, which has replaced commonly used but varied descriptive terms with descriptors based on inheritance and pathobiology.[9] Primary criteria for classification included whether the disorder is limited to the skin (nonsyndromic) or affects the skin and other organ systems (syndromic), its mode of inheritance, and disease pathobiology. Thus, disorders previously referred to as harlequin ichthyosis, lamellar ichthyosis (LI), and congenital ichthyosiform erythroderma became autosomal recessive congenital ichthyosis (ARCI) and bullous ichthyosis, bullous congenital ichthyosiform erythroderma (BCIE), epidermolytic hyperkeratosis, and ichthyosis exfoliativa became epidermolytic ichthyosis (EI), among other updates.[9] Although likely to be further refined in coming years, 2009 consensus nomenclature will be used throughout this chapter.

CLINICAL PRESENTATION

Several features are useful in distinguishing different forms of ichthyosis. These include age of onset, presence of collodion membrane at birth, quality of scale, presence or absence of erythroderma, abnormalities in other parts of the skin (eg, thickened palms and soles, ectropion, eclabium) and adnexal structures (eg, alopecia or hair shaft abnormalities), and involvement of other organ systems. Among distinguishing features, the appearance of the surface of the skin can aid in diagnosis. Visible scaling may be seen in some patients, which can be distinguished by size, configuration, color, and adherence of scale, and there can be thickening of the skin with or without visible scale known as keratoderma. Thickening of the stratum corneum, evident either clinically or histologically, is termed *hyperkeratosis*. Light microscopic features are usually diagnostic in EI and can be helpful in selected ichthyoses (eg, Refsum disease, neutral lipid storage disease, acquired ichthyosis of sarcoidosis, and mycosis fungoides), but histopathologic examination may not be useful to distinguish other ichthyoses.[10] In many cases, the clinical diagnosis may be clarified by genetic analysis, although mutations are not always found. The development of ichthyosis in adulthood may be a marker of systemic disease.

GENETICS

Family history and a multigeneration pedigree may indicate the mode of inheritance. However, many autosomal dominant diseases (eg, EI) have a high frequency of spontaneous (also called *de novo*) mutation. Thus, the lack of a positive family history does not rule out autosomal dominant inheritance. Alternatively, the presence of parental consanguinity may suggest autosomal recessive inheritance. Distinguishing among autosomal dominant, de novo mutation, and autosomal recessive inheritance in pedigrees without prior affected individuals presents a unique clinical challenge in many cases. The advent of WES has permitted ascertainment of inheritance patterns, genetic diagnosis, and gene discovery in many cases.[11,12]

Prenatal molecular diagnosis has become possible. Alternative methods, including fetoscopy and fetal skin biopsy, are limited to later times in pregnancy, harbor a risk of fetal mortality, and are now rarely performed.[13] When it is possible to do prenatal diagnosis by molecular analysis of a fetal sample, it is optimally performed early in pregnancy. This can be done with chorionic villous sampling in the first trimester (10 to 12 weeks after last menstrual period) or by amniocentesis in the second trimester in disorders in which the underlying genetic defect is known and the specific mutation in the family has been identified.[14] Prenatal diagnosis by mutational analysis has been accomplished in a number of the ichthyoses. Preimplantation genetic diagnosis is a reasonable alternative and has been accomplished for many inherited disorders, including ARCI and EI.[15] The procedure requires that the couple undergo in vitro fertilization to obtain embryos. The embryos are then screened by molecular methods to detect the mutation that is segregating in the family. Only embryos that screen negative for the mutation are selected and then can be used for implantation in the uterus to achieve pregnancy. Noninvasive methods of molecular diagnosis (evaluation of fetal DNA circulating in the mother's blood) offer potential for the future.[16,17] For autosomal recessive disorders in which the mutation is known, carrier detection may be performed for at-risk relatives.

TABLE 47-1

Features of Selected Ichthyoses with Dominant Inheritance[a]

DIAGNOSIS	ONSET	CHARACTERISTIC CLINICAL FEATURES	ASSOCIATED FEATURES	GENE	PROTEIN	FUNCTION
Autosomal Semidominant						
Ichthyosis vulgaris (OMIM #146700)	Infancy or childhood	Fine or centrally tacked-down scale with superficial fissuring; relative flexural sparing, worse on lower extremities; hyperlinear palms and soles	Keratosis pilaris; atopy	*FLG*	Absence of filaggrin	Uncertain—may aggregate keratin filaments and be a precursor to stratum corneum humectants
Autosomal Dominant						
Epidermolytic ichthyosis (OMIM #113800)	Birth	Heterogeneous; may have verrucous, firm, hyperkeratotic (hystrix) spines, often linearly arrayed in flexural creases; blisters; may have erythroderma and/or palmar/plantar keratoderma	Frequent skin infections; characteristic pungent odor	*KRT1*, *KRT10*	Keratin 1 or 10	Structural protein abnormality leading to keratin intermediate filament dysfunction—epidermal fragility
Superficial epidermolytic ichthyosis (OMIM #146800)	Birth	Redness and blistering at birth; later develop hyperkeratosis, accentuated over flexures; mauserung (molting): collarette-like lesion where uppermost epidermis has been lost		*KRT2*	Keratin 2, which is expressed in superficial epidermis	As above for EI
Erythrokeratodermia variabilis (OMIM #133200)						
Generalized type	Birth	Generalized hyperkeratosis and figurate, migratory red patches	Red patches move over minutes to hours; may be triggered by changes in temperature	*GJB3*, *GJB4*, *GJA*	Connexin 30.3, 31, or 43; connexins form gap junction channels between cells	Abnormal intercellular communication
Localized type	Variable	Localized hyperkeratotic plaques with figurate, migratory red patches	Hyperkeratotic plaques may be induced by trauma; considerable intrafamilial variability			
Progressive symmetric erythrokeratoderma (OMIM #602036)	Shortly after birth	Erythematous, scaly plaques, symmetrically distributed over extremities, buttocks, and face; stabilize in early childhood; trunk tends to be spared		*LOR*, *GJB4*	Loricrin, connexin 30.3	Cornified envelope precursor, gap junction protein
Keratitis–ichthyosis–deafness (KID) syndrome Recessive has been reported (OMIM #148210)	Birth/ infancy	Progressive corneal opacification; either mild generalized hyperkeratosis or discrete erythematous plaques, which may be symmetric; neurosensory deafness	Follicular hyperkeratosis, scarring alopecia, dystrophic nails, susceptibility to infection	*GJB2*	Connexin 26; connexins form gap junction channels between cells	Abnormal intercellular communication

[a]These are the predominant modes of inheritance.

EI, epidermolytic ichthyosis; OMIM, Online Mendelian Inheritance in Man.

TABLE 47-2
Features of Selected Ichthyoses with X-linked Inheritance[a]

DIAGNOSIS	ONSET	CHARACTERISTIC CLINICAL FEATURES	ASSOCIATED FEATURES	GENE	PROTEIN	FUNCTION
X-linked recessive ichthyosis (OMIM #308100)	Birth or infancy	Fine to large scales; comma-shaped corneal opacities on posterior capsule	Cryptorchidism; female carriers may have corneal opacities and delay of onset or progression of labor in affected pregnancies	*STS*	Steroid sulfatase	Lipid metabolism—abnormal cholesterol metabolism with accumulation of cholesterol sulfate
Chondrodysplasia punctata X-linked recessive (CDPX; (OMIM #302950)	Birth	May begin as erythroderma, linear or whorled atrophic areas or hyperkeratosis, alopecia, skeletal abnormalities, short stature	Cataracts, deafness	*ARSE*	Arylsulfatase E	Lipid metabolism—ill defined: failure of hydrolysis of sulfate ester bonds
X-linked dominant chondrodysplasia punctata (Conradi-Hünermann-Happle syndrome) (CDPX2) (OMIM #302960)	Birth	CIE at birth; clears and is replaced by linear hyperkeratosis, follicular atrophoderma and pigmentary abnormalities, and stippled calcifications on radiographs	Occurs almost exclusively in females; hair shaft abnormalities, short stature, cataracts	*EBP*	EBP, also known as 3β-hydroxysteroid-$\Delta^{8,7}$-isomerase	Lipid metabolism—abnormal cholesterol biosynthesis
CHILD syndrome (OMIM #308050)	Birth	Congenital hemidysplasia, ichthyosiform erythroderma, limb defects	Occurs almost exclusively in females	*NSDHL*; *EBP* reported	NSDHL (3 β-hydroxysteroid dehydrogenase); EBP reported	Lipid metabolism—postsqualene cholesterol biosynthesis

[a]These are the predominant modes of inheritance.
CHILD, *c*ongenital *h*emidysplasia with *i*chthyosiform erythroderma and *l*imb *d*efects; CIE, congenital ichthyosiform erythroderma; EBP, emopamil-binding protein; NSDHL,= *N*AD(P)H steroid *deh*ydrogenase-*l*ike protein; OMIM, Online Mendelian Inheritance in Man.

ETIOLOGY AND PATHOGENESIS

The epidermis undergoes a regular pattern of self-renewal. Its primary cell type, the keratinocyte, undergoes a regular pattern of differentiation to enable the skin to fulfil its role as a barrier to mechanical trauma and desiccation. The end product of differentiation is the stratum corneum, which is composed of terminally differentiated keratinocytes, corneocytes ("bricks"), surrounded by an intercellular matrix ("mortar") (see Chaps. 5 and 14). The corneocyte bricks are protein enriched, and the intercellular mortar is composed of hydrophobic, lipid-enriched membrane bilayers.[7]

The keratin-laden corneocytes are thought to be primarily responsible for the resilience and water retention properties of the stratum corneum, and the matrix forms most of the permeability barrier to water loss. The normal stratum corneum undergoes desquamation in an organized and invisible manner, with individual corneocytes separating from each other and shedding as single cells. Ichthyotic skin has an abnormal quality and quantity of scale, the barrier function of the stratum corneum is compromised, and there may be alterations in the kinetics of epidermal cell proliferation (see Chap. 5). The stratum corneum can be viewed as a compartment, with thickening of the stratum corneum being the result of cells entering the compartment at an increased rate, leaving (corneocyte desquamation) too slowly, or both.

The process of epidermal differentiation is complex and not completely understood. Defects in many different aspects and steps of this process can lead to a similar end result: abnormal stratum corneum and scale. Genetic investigation of inherited ichthyoses has revealed pathways central to epithelial differentiation. For example, mutations in genes that encode the suprabasal epidermal keratins, keratins 1 and 10, cause EI when they affect the highly conserved encoded rod domains necessary for polymerization of keratin intermediate filaments.[18-20] Mutations in the gene encoding transglutaminase-1, an enzyme that catalyzes the cross-linking of proteins and attachment of ceramides during the formation of corneocytes, are found in a large fraction of patients with autosomal recessive congenital ichthyosis.[21-23] Mutations in *SPINK5*, encoding a serine protease inhibitor, cause

TABLE 47-3

Features of Selected Ichthyoses with Autosomal Recessive Inheritance

DIAGNOSIS	ONSET	CHARACTERISTIC CLINICAL FEATURES	ASSOCIATED FEATURES	GENE	PROTEIN	FUNCTION OR FUNCTIONAL DEFECT
ARCI						
ARCI/LI	Birth; often collodion presentation	Large, platelike, brown scale over most of the body; accentuated on lower extremities; ectropion, eclabium, and alopecia. palmar/plantar involvement varies	Heat intolerance	See Table 47-4	See Table 47-4	See Table 47-4
ARCI/CIE		Fine, white scale; generalized erythroderma; palmar/plantar involvement varies				
Harlequin ichthyosis (OMIM #242500)	Birth	Markedly thickened skin with geometric, deep fissures; at birth survivors develop severe erythroderma	Restricted respiration, feeding; neonatal sepsis; often leads to neonatal death; failure to thrive	*ABCA12*	ATP-binding cassette, subfamily A, member 12	Lipid metabolism—membrane transport, abnormality of lipid metabolism
Ichthyosis prematurity syndrome (OMIM #608649)	Birth	Premature delivery of infants with erythrodermic, edematous, caseous scaling skin resembling excessive vernix caseosa, evolves into dry, scaly skin with follicular accentuation with signs of atopy	Respiratory distress, and transient peripheral eosinophilia; the respiratory signs resolve	*FATP4 (SLC27)*	Fatty acid transport protein 4	Lipid metabolism—fatty acid transport
Netherton syndrome (OMIM #256500)	Birth	Ichthyosis linearis circumflexa or similar to congenital ichthyosiform erythroderma; trichorrhexis invaginata	Atopy; high serum levels of IgE; may have aminoaciduria; failure to thrive	*SPINK5*	LEKTI (a serine protease inhibitor)	Protein metabolism-inhibits degradation of desmosomal proteins and perhaps filaggrin in stratum corneum.
Sjögren-Larsson syndrome (OMIM #270200)	Ichthyosis apparent at birth	Generalized fine to coarse hyperkeratosis; spastic diplegia; mental retardation; retinal glistening white dots	Short stature, seizures	*FALDH (ALDH10, ALDH3A2)*	Fatty aldehyde dehydrogenase	Lipid metabolism—fatty aldehyde metabolism

(*Continued*)

TABLE 47-3

Features of Selected Ichthyoses with Autosomal Recessive Inheritance (*Continued*)

DIAGNOSIS	ONSET	CHARACTERISTIC CLINICAL FEATURES	ASSOCIATED FEATURES	GENE	PROTEIN	FUNCTION OR FUNCTIONAL DEFECT
Refsum disease (OMIM #266500)	Ichthyosis develops years after birth	Progressive neurologic dysfunction; skeletal, cardiac, and renal abnormalities	Retinitis pigmentosa, elevated plasma phytanic acid	Most *PAHX; PEX* 7 also reported (see RCPD below)	Phytanoyl-CoA hydroxylase (PhyH)	Peroxisome abnormality—deficiency of phytanic acid catabolism; results in phytanic acid accumulation.
Trichothiodystrophy (Tay syndrome; *PIBI(D)*S, *IBI(D)*S, *BI(D)*S) (OMIM #278730, OMIM #601675, OMIM #234050)	Some have ichthyosis, which may be apparent at birth; may have collodion presentation	*B*rittle hair, *p*hotosensitivity, *s*hort stature, *i*chthyosis, *i*ntellectual impairment, microcephaly, recurrent infections	Abnormally low sulfur content of hair.	Majority have defect in *ERCC2* (XPD). A few have mutations in *ERCC3* (XPB), *GTF2H5* (TTDA), or *TTDN1*.	Most XPD. XPB, TTDA, or TTDN1 in a few	Components of transcription factor TFIIH
Chanarin–Dorfman syndrome (neutral lipid storage disease; OMIM #275630)	Birth; may have collodion membrane	Generalized scaling, resembles CIE; variable extracutaneous involvement: cataracts, decreased hearing, psychomotor delay.	Severe pruritus; neurologic abnormalities; hepatic abnormalities; lipid droplets in circulating leukocytes	*ABHD5*	Abhydrolase domain-containing protein 5	Lipid metabolism—activates adipose-triglyceride lipase for lipolysis of triglycerides
Neonatal ichthyosis–sclerosing cholangitis syndrome (OMIM #6073718)	Birth	Neonatal cholestatic jaundice, mild ichthyosis with fine, white scales.	Scarring alopecia of the scalp and eyebrows, enamel dysplasia	*CLDN1*	Claudin 1	Abnormal tight junction
Multiple sulfatase deficiency (OMIM #272200)	Birth	Ichthyosis resembling X-linked recessive	Neurologic deterioration; skeletal abnormalities; facial dysmorphism	*SUMF1*	Cα-formylglycine generating enzyme	Generates catalytic residue in active site of eukaryotic sulfatases

ARCI, autosomal recessive congenital ichthyosis; CIE, congenital ichthyosiform erythroderma; IgE, immunoglobulin E; LI, lamellar ichthyosis; OMIM, Online Mendelian Inheritance in Man.

TABLE 47-4
Selected Ichthyoses Organized by Cellular Defect

DISEASE	INHERITANCE	GENE/PROTEIN
		Cytoskeleton
Epidermolysis bullosa simplex	AD	*KRT5,14*/keratins 5,14
Dowling-Degos disease	AD	*KRT5*
Galli-Galli disease	AD	*KRT5*
Ichthyosis with confetti	AD	*KRT10/KRT1*
Epidermolytic ichthyosis	AD	*KRT1,10*/keratins 1,10
Ichthyosis bullosa of Siemens	AD	*KRT2*/keratin 2
Epidermolytic PPK	AD	*KRT9*/keratin 9
Pachyonychia congenita	AD	*KRT6A,6B,16,17*/keratins 6A,6B,16,17
Non-epidermolytic PPK	AD	*KRT1, KRT16*/keratins 1,16
Naxos	AR	*JUP*/Junctional plakoglobin
White sponge nevus	AD	*KRT4,13*/keratins 4,13
Ichthyosis vulgaris	AD	*FLG*/filaggrin
		Cornified Envelope
Lamellar ichthyosis	AR	*TGM1*/transglutaminase 1
Bathing suit ichthyosis	AR	*TGM1* temperature-sensitive mutation
Keratoderma (Camissa)	AD	*LOR*/loricrin
Generalized peeling skin disease	AR	CDSN/corneodesmosin
		Membrane Transporters
Darier disease	AD	*ATP2A2*/SERcalciumATPase
Acrokeratosis verruciformis	AD	*ATP2A2*/SERcalciumATPase
Hailey-Hailey disease	AD	*ATP2C1*
Ichthyosis with sclerosing cholangitis	AR	*CLDN1*/claudin-1
Lamellar	AR	*ABCA12*
Harlequin	AR	*ABCA12*
Ichthyosis prematurity syndrome	AR	*FATP4*
		Cell Junction Proteins
PPK with deafness (Vohwinkel)	AD	*GJB2*/Connexin 26
Erythrokeratoderma variabilis	AD	*GJB3*/Connexin 31 *GJB4*/Connexin30.3
Keratitis–ichthyosis–deafness (KID)	AD	*GBJ2*/Connexin 26
Nonepidermolytic PPK (striate)	AD	*DSP*/desmoplakin
	AR	*DSP*/desmoplakin
	AD	*DSG1*/desmoglein 1
		Snare Protein
CEDNIK (cerebral dysgenesis, neuropathy, ichthyosis, and keratoderma)	AR	*SNAP29*/synaptosome associated protein 29
ARC (arthrogryposis-renal dysfunction-cholestasis)	AR	*VSP33B*/vacuolar protein sorting homologue B
		Metabolic Enzymes
X-linked ichthyosis	X-LR	*STS*/steroid sulfatase
Tyrosinemia II (Richner-Hanhart)	AR	*TAT*/tyrosine aminotransferase
Sjögren-Larsson	AR	*ALDH3A2*/fatty aldehyde dehydrogenase
Refsum	AR	*PAXH*/phytanoyl CoA hydroxylase
Conradi-Hunermann	X-LD	*EBP*/3β-hydroxysterol δ7-isomerase
CHILD (congenital hemidysplasia, ichthyosiform erythroderma and limb defects)	X-LD	*EBP*/3β-hydroxysterol δ7-isomerase *NSDHL*/ NAD(P) dependent steroid dehydrogenase-like
Gaucher	AR	*GBA*/glucocerebrosidase B
Chanarin-Dorfman (neutral lipid storage)	AR	*ABHD5*/(CGI-58)
Neutral lipid storage with myopathy	AR	*PNPLA2*/patatin-like phospholipase domain-containing protein
Autosomal recessive congenital ichthyosis	AR	*ALOXE3*/lipoxygenase 3 *ALOX12B*/12(R)-lipoxygenase E3 *NIPAL4*/magnesium transporter NIPA4 *CYP4F22*/cytochrome P450 family 4 subfamily F member 22 *PNPLA1*/patatin like phospholipase domain containing 1, CERS3/ceramide synthase 3, SDR9C7/short chain dehydrogenase/reductase family 9C, member 7, SULT2B1/sulfotransferase family 2B member 1
Self-improving collodion ichthyosis	AR	*ALOX12B* and *ALOXE3*

(*Continued*)

TABLE 47-4
Selected Ichthyoses Organized by Cellular Defect (*Continued*)

DISEASE	INHERITANCE	GENE/PROTEIN
		Protease/Protease Inhibitors
Papillion-Lefevre keratoderma	AR	*CTSC*/cathepsin C
Ichthyosis linearis circumflexa (Netherton)	AR	*SPINK5*/serine protease inhibitor 5
Ichthyosis follicularis/ photophobia (IFAP)	X-LR	*MBTPS2*/membrane bound transcription factor peptidase, site 2
ARCI with hypotrichosis	AR	*ST14*/matriptase
		Proteasome
KLIK (keratosis linearis with ichthyosis congenita and sclerosing keratoderma)	AR	*POMP*/proteasome maturation protein
		Secreted Proteins
Mal de Meleda keratoderma	AR	*SLURP1*/secreted Ly6/UPAR related protein 1
		DNA Repair and Transcription
Trichothiodystrophy	AR	*ERCC2*/excision repair cross-complementation group 2 *GTF2H5*/general transcription factor IIH subunit 5 *GTF2E2*/general transcription factor IIE subunit 2 *ERCC3*/excision repair cross-complementation group 3

AD, autosomal dominant; AR, autosomal recessive; ARCI, autosomal recessive congenital ichthyosis; CHILD, *c*ongenital *h*emidysplasia, *i*chthyosiform erythroderma, and *l*imb *d*efects; PPK X-LD, X-linked dominant; X-LR, X-linked recessive.

Netherton syndrome and confirm a role for proteolysis and protease inhibitors in normal epidermal differentiation.[24] Finally, mutations in *FLG* result in reduced or absent filaggrin and decreased moisture binding in the stratum corneum of patients with IV.[25] These cardinal examples highlight the observation that mutations in a host of genes encoding proteins with highly divergent functions affect normal keratinocyte differentiation and cause ichthyosis. It is yet unknown how defects in diverse processes result in similar phenotypes, although studies suggest that defects in the barrier may result in inflammation and hyperproliferation.[26,27] Furthermore, our evolving understanding of these mechanisms continues to clarify the multisystem, clinical phenotypes observed in several ichthyosiform disorders.

COMMON THERAPEUTIC APPROACHES

Current therapies for the inherited ichthyoses are symptomatic and focus on hydration, lubrication, and keratolysis.[28,29] Ichthyotic skin, even if thickened, has a decreased barrier function and increased transepidermal water loss. Because pliability of the stratum corneum is a function of its water content, hydration can soften the surface of the skin. In moist, humid climates, most ichthyoses improve. Moistening the skin with, for example, long baths can hydrate it. Well-hydrated areas of hyperkeratosis can more easily be thinned with mild abrasives (eg, sponges, buff puffs, pumice stones). Addition of bath oils or application of lubricants before drying can prolong the hydration and softening. Depending on the ichthyosis and environmental conditions, individual patients may prefer specific lubricating agents, which can take the form of lotions, creams, oils, ointments, or petrolatum. In dry climates and winter months, humidifiers can be used to create a more hospitable environment.

Keratolytic agents are used to enhance corneocyte desquamation and thereby remove scale and thin hyperkeratotic stratum corneum. There are many commercially available keratolytic creams and lotions containing urea, salicylic acid, or α-hydroxy acids (eg, lactic acid, glycolic acid). Urea may function by its capacity to bind water. Propylene glycol (40%–60% in water), with or without occlusion, can also be effective in scale removal. Occlusion can effectively increase skin hydration and facilitate desquamation; it can also enhance the effect of keratolytic agents. Special care should be taken when using extensive areas of occlusion with keratolytic agents and in individuals who may be heat intolerant. The markedly impaired barrier function in ichthyosis should be considered when using topical preparations over large areas of body surface. For example, widespread use of topical salicylic acid preparations can lead to significant absorption, intoxication (eg, nausea, tinnitus, dyspnea, hallucinations), and even death.[30] Children are at greater risk because they have a greater body surface area per unit weight than adults, a situation that effectively heightens the possibility of developing systemic toxicity from topicals. Although

the use of topical retinoids in most of the ichthyoses appears to be safe,[31] the abnormal skin barrier should be considered when treating concomitant dermatoses in patients with ichthyosis. When using topical agents such as tacrolimus, pimecrolimus, or topical steroids, when increased systemic absorption has been observed, monitoring of serum levels may be necessary.[32]

Another risk to children is that in several types of ichthyosis nutritional requirements may be high, and inadequate nutrition can lead to failure to thrive. This was thought to be related to the large turnover of scale; however, recent studies suggest energy loss from impaired barrier function is the cause.[33]

Some patients with ichthyosis have decreased sweating with heat intolerance. It is important for the parents of a newborn with ichthyosis to be aware of the possibility of decreased sweating and to be attentive for signs of heat intolerance, such as flushing and lethargy, particularly during hot weather and, as the child grows, during exercise. Avoiding hot environments, carrying spray bottles with water to moisten the skin and cool it through evaporation, and cooling vests can minimize heat stress.

Systemic retinoid therapy with isotretinoin or acitretin (see Chap. 185) can induce dramatic improvement in many ichthyoses. The decision to initiate systemic retinoid therapy should be weighed carefully because after the drug is started, continued benefit usually requires chronic therapy. Retinoic acid metabolism–blocking agents, which increase endogenous retinoid levels, offer a possible alternative.[34]

Fungal infections are common, both of skin and nails, and are often undiagnosed because of the generalized scaling. A high index of suspicion can help diagnose tinea corporis, capitis, or versicolor when the only symptom may be localized pruritus (which is often intense) and the only sign a difference in the character of scale or a localized area of alopecia.

ICHTHYOSIS VULGARIS

Ichthyosis vulgaris (Online Mendelian Inheritance in Man [OMIM] #146700), the most common ichthyosis, is relatively mild. The disease was thought to be autosomal dominant, and a study of English school children found that 1 in 250 were affected.[4] Mutations in the gene encoding profilaggrin cause IV.[25] Profilaggrin contains multiple copies of filaggrin, which has various structural and biochemical functions during cornification. The inheritance pattern has been clarified to be semidominant; individuals who carry one mutated allele have a mild phenotype, but those with mutations in both profilaggrin alleles (homozygotes or compound heterozygotes for the mutations) (Fig. 47-1) manifest a severe clinical phenotype. In the Anglo-European population, the prevalence of clinical disease is as high as 1 in 80.[35,36]

CLINICAL FEATURES

Although infants usually have normal skin, the disease often manifests within the first year of life. The scale of IV is usually most prominent on the extensor surfaces of the extremities, with flexural sparing. The diaper area tends to be spared. There may be fine, white scales over large areas. Particularly on the lower extremities, which are often the most severely involved area, the scales may be centrally attached, with "cracking" (superficial fissuring through the stratum corneum) at the edges. This turning up at the edges can lead to the skin feeling rough.

ETIOLOGY AND PATHOGENESIS

Filaggrin is an epidermal protein involved in the aggregation of keratin intermediate filaments,[37] is an important component of the cornified envelope,[38] and helps retain moisture in the stratum corneum. Keratin filaments form a network, or cell matrix, that gives structural integrity to the epidermal keratinocytes. As keratinocytes mature into corneocytes, the keratin filaments collapse and are cross-linked to the cornified cell envelope. Filaggrin is synthesized as a high-molecular-weight precursor, profilaggrin, that contains multiple filaggrin molecules and is localized to keratohyalin granules. Biochemical studies of epidermis from patients with IV have shown absence of or decrease in filaggrin and its precursor, profilaggrin.[39,40] The association between IV and atopic dermatitis has been long appreciated on clinical grounds. Null mutations in the gene encoding profilaggrin (*FLG*) have now been shown to be a strong predisposing factor for atopic dermatitis in the Anglo-European population. A strong association is also found with individuals who have sensitivity to common allergens, allergic rhinitis, early-onset and persistent eczema, and asthma in the presence of atopic dermatitis.[35,41]

DIFFERENTIAL DIAGNOSIS

In some cases, it is difficult to distinguish mild IV from simple dry skin (xerosis). Evolving understanding of this very common condition is beginning to clarify how a spectrum of underlying mutations can cause the diverse clinical severity of dry skin from xerosis to severe IV. In addition, on the basis of skin findings alone, males with severe IV may be difficult to differentiate from those affected with X-linked recessive ichthyosis.[42,43] The histopathologic findings of IV are variable, and the characteristic orthohyperkeratosis and absent granular layer may only be seen in individuals with two abnormal alleles.

Figure 47-1 **A–F,** Ichthyosis vulgaris (*FLG* mutation). Small, centrally adherent scales generally spare intertriginous areas. Increased number and depth of palmar markings are usually noted.

CLINICAL COURSE, PROGNOSIS, AND MANAGEMENT

A number of other findings are commonly observed in association with IV.[42] Hyperlinear palms are usually present, and some patients may have palmar/plantar thickening approaching a keratoderma. Keratosis pilaris is common, even in individuals with mild IV, and usually involves the outside of the arms, extensor thighs, and buttocks. Even though IV is usually not considered a syndromic ichthyosis, atopy is also frequently observed and can manifest as hay fever, eczema, or asthma. These findings can confound an accurate diagnosis because hyperlinear palms and keratosis pilaris may be seen in atopic individuals who do not have IV. Rarely, individuals with IV may have hypohidrosis with heat intolerance. There is great variation in the severity of clinical manifestations among affected individuals in the same family. The condition

usually worsens in climates that are dry and cold and improves in warm, humid environments, where the disease may clear dramatically. Most patients respond well to regular application of emollients, and use of α-hydroxy acids can reduce scaling when present.

X-LINKED RECESSIVE ICHTHYOSIS

In the 1960s, *X-linked recessive ichthyosis* (OMIM #308100) was distinguished clinically from other ichthyoses.[4] X-linked recessive ichthyosis occurs in approximately 1 in 1500 to 6000 males.[5,44] Steroid sulfatase (arylsulfatase C) deficiency causes XLI;[45,46] in 90% of cases, genetic deletion of the *STS* locus is causative.[47] The remainder are point mutations in *STS*.

CLINICAL FEATURES

Scaling may begin in the newborn period and is usually most prominent on the extensor surfaces, although there is significant involvement of the flexural areas. Although the extent and degree of scaling are variable, X-linked ichthyosis can usually be distinguished from IV on clinical criteria and inheritance pattern.[5,48] The latter tends to be associated with hyperlinear palms and soles, keratosis pilaris, and a family history of atopy. X-linked ichthyosis tends to have more severe involvement with larger scale (Fig. 47-2), and comma-shaped, corneal opacities may be present in half of adult patients.[49,50] Corneal opacities do not affect vision and may be present in female carriers. Affected males have an increased risk of cryptorchidism, and independently, they are at increased risk for the development of testicular cancer.[51]

ETIOLOGY AND PATHOGENESIS

Steroid sulfatase hydrolyzes sulfate esters, which include cholesterol sulfate and sulfated steroid hormones.[52] Sulfated fetal adrenal hormones undergo desulfation to estrogens, which are excreted in maternal urine. The absence of steroid sulfatase enzyme in the fetal placenta leads to low maternal urinary estrogens, and in some pregnancies, to a failure of labor to initiate or to progress normally. In males with X-linked recessive ichthyosis, steroid sulfatase enzyme activity is decreased or absent in many tissues, including epidermis, stratum corneum, leukocytes, and in cultured fibroblasts.[53] Carrier females have been found to have leukocyte steroid sulfatase levels intermediate between those observed in normal individuals and those in affected males.

Figure 47-2 X-linked recessive ichthyosis (*STS* mutation). Small, centrally adherent, dark scales often involve sides of neck and face; they are less severe in flexures. Palms and soles show little to no involvement.

Cholesterol sulfate levels are elevated in the serum, epidermis, and scale.[54] Steroid sulfatase is one of a group of arylsulfatases located on chromosome Xp22. More than 90% of the mutations in X-linked ichthyosis are deletions that can often be detected by fluorescence in situ hybridization (FISH) or array-comparative genomic hybridization (CGH), available in many clinical laboratories. Confirmation of the diagnosis can also be made by finding an elevation in serum cholesterol sulfate levels.

In the epidermis, steroid sulfatase catalyzes the hydrolysis of cholesterol sulfate. Topical application of cholesterol sulfate in mice can induce a scaling disorder, further supporting the role of cholesterol sulfate hydrolysis in corneocyte desquamation. Cholesterol sulfate inhibits the proteases that degrade corneodesmosomes, resulting in inhibition of desquamation and a retention hyperkeratosis.[55]

DIAGNOSIS

Skin and eye findings, history of prolonged labor, and evidence of X-linked transmission enable diagnosis of XLI.[45,56] Notably, a significant fraction of patients now are recognized in utero through maternal screening that assesses levels of α-fetoprotein, human chorionic gonadotropin, and estriol. Because steroid sulfatase is necessary for placental estrogen production, triple screen results indicating low estriol are present in XLI pregnancies.[47] Because the majority of maternal urinary estrogens are derived from the fetal adrenal glands and are metabolized by the placenta, low levels can reflect fetal abnormalities or death, raising concern in parents. However, in XLI, low levels do not indicate severe fetal morbidity. Although skin biopsy is rarely done, histopathologic examination shows compact orthohyperkeratosis, acanthosis, papillomatosis, and a thickened granular layer. Many assays are available for the diagnosis of XLI, including FISH for *STS*, array-CGH, deletion and point mutation detection via next-generation sequencing, and enzymatic assays of steroid sulfatase function.

CLINICAL COURSE, PROGNOSIS, AND MANAGEMENT

Although in most cases, XLI is primarily a cutaneous disorder, genetic deletions that include *STS* and adjacent sulfatases explain the overlap syndromes involving chondrodysplasia punctata and X-linked ichthyosis.[57] The X-linked form of Kallmann syndrome, in which hypogonadotropic hypogonadism and anosmia are found, often with renal abnormalities, obesity, synkinesis (mirror image movements of the extremities), cleft palate, and spastic paraplegia, can also be seen in association with X-linked recessive ichthyosis as part of a contiguous gene deletion syndrome. Because of this and because of the association with testicular carcinoma, patients with X-linked recessive ichthyosis should be queried about anosmia and have periodic testicular examination.[44,58]

When scaling is prominent, long bathwater soaks with or without bicarbonate can aid in desquamation.[59] Emollients, including those with α-hydroxy acids or lactic acid, can aid in desquamation.

COLLODION BABY AND NEWBORN PRESENTATIONS

Most cases of ichthyosis, excluding IV and X-linked ichthyosis, present at birth with red, scaly skin. In the United States, the incidence of such cases is estimated to be 5 to 10 per 100,000 live births.[60] A fraction of these present with a collodion membrane, which is shed early in life with features of congenital ichthyosis or normal skin subsequently developing. Genotype is not the sole determinant of collodion baby presentation because many with the common genotypes associated with collodion membranes present with simply red scaly skin. No differences in the pathogenesis of these two newborn presentations of ichthyosis have been identified, and management is generally similar for both.

CLINICAL FEATURES

A *collodion baby* is born encased in a translucent, parchment-like membrane that is taut and may impair respiration and sucking. Birth can be premature, contributing to morbidity. During the first 2 weeks of life, the membrane breaks up and peels off and can leave fissures, with impairment of the barrier to infection and water loss (Fig. 47-3).

Figure 47-3 Collodion infant. The infant is 36 hours old and is covered with a macerated membrane that shows fissures; note ectropion and eclabium. The condition may develop over time into various clinical phenotypes, including autosomal recessive congenital ichthyosis and self-healing collodion baby.

TABLE 47-5
Disorders Associated with Collodion Membrane

Common
- Autosomal recessive congenital ichthyosis (lamellar ichthyosis, congenital ichthyosiform erythroderma, overlap)

Rare
- Ankyloblepharon-ectodermal dysplasia-cleft lip/palate (AEC) syndrome
- Chondrodysplasia punctata
- Gaucher disease
- Loricrin keratoderma
- Neutral lipid storage disease
- Self-healing collodion baby
- Sjögren–Larsson syndrome
- Trichothiodystrophy
- X-linked hypohidrotic ectodermal dysplasia

ETIOLOGY AND PATHOGENESIS

The in utero aqueous environment contributes to the development of the collodion presentation, which transforms into a wide spectrum of ichthyosis phenotypes as the child grows (Table 47-5). This is the usual presentation of ARCI and is less commonly seen in several other forms of ichthyosis and rarely Gaucher disease. In addition, an autosomal recessive, self-healing collodion phenotype has been described, in which the skin greatly clears within the first few weeks and transitions into mildly affected or normal skin.[61] Eleven Swedish and four Danish patients with a self-improving ichthyosis resulting in xerosis, hyperlinear palms, red cheeks, and anhidrosis were found to have mutations in *ALOX12B*, *ALOX3E*, or *TGM1*.[62]

CLINICAL COURSE, PROGNOSIS, AND MANAGEMENT

In caring for a collodion infant or other newborn with ichthyosis, consideration of a potentially increased risk of infection, difficulties in thermal regulation, and hypernatremic dehydration caused by increased transepidermal water loss is essential.[63] Newborn care should include careful monitoring for infection and of temperature, hydration, and electrolytes and measures to keep the peeling membrane soft and lubricated to facilitate flexibility and desquamation. Appropriate pain management and eye care should be used when indicated. These newborns usually benefit from a humidified incubator where the air is saturated with water; wet compresses followed by bland lubricants can be used to further hydrate the membrane and achieve maximum pliability.[64] Before spontaneous peeling of the collodion membrane, the thickened stratum corneum can dry and harden in areas such as the extremities and can constrict, leading to distal swelling, cyanosis, and rarely necrosis in some cases. Release of constricting bands via curettage or debridement can prevent complications.[65]

AUTOSOMAL RECESSIVE CONGENITAL ICHTHYOSIS

The term *autosomal recessive congenital ichthyosis* is used to describe a heterogeneous group of disorders that present at birth with generalized involvement of the skin. Autosomal recessive ichthyosis is rare and has been estimated to occur in about 1 in 300,000 persons.[5]

In older literature, *nonbullous congenital ichthyosiform erythroderma* (NCIE, also called *lamellar ichthyosis*, with autosomal recessive inheritance) was distinguished from BCIE (also called epidermolytic hyperkeratosis [EHK], with autosomal dominant inheritance) based on clinical appearance (bullae) and pattern of inheritance.[6,66] That the term LI was used interchangeably with NCIE and included a spectrum of phenotypes has led to some confusion. We also now understand that genotype alone does not determine whether the phenotype will be LI or CIE. Williams and Elias distinguished LI from NCIE (usually called *congenital ichthyosiform erythroderma*), a milder erythrodermic form, and these descriptors remain useful clinical descriptors in clinical practice.[67] In LI, one sees large, dark, platelike scales, and although infants may be red at birth, adults have little to no erythroderma (Figs. 47-4 to 47-6). In the more severe, classic presentation of LI, tautness of the facial skin leads to traction on the eyelids and lips, resulting in ectropion and eclabium. Scarring alopecia, most prominent at the periphery of the scalp, may be partly caused by traction at the hairline. In contrast, CIE has generalized redness and fine, white scales (eg, Figs. 47-7 and 47-9). Patients with classic CIE have little to no ectropion, eclabium, or alopecia. However, many patients do not fit neatly into these two clinical descriptions[68] in that they have features of both LI and CIE with a clinical phenotype intermediate between both disorders. Therefore, it can be useful to consider these two distinctive presentations as ends of a spectrum, between which lie a gradation of clinical phenotypes with variable degrees of erythema and coarseness of scale. Individual features such as collodion membrane (discussed earlier), ectropion, and alopecia can occur across the spectrum. Although attempts to refine the categorization of these disorders by biochemical and ultrastructural observations have failed to yield a consistent and replicable classification scheme, identification of the spectrum of specific molecular defects underlying these conditions may aid classification.[8] Identification of mutations has, so far, found ARCI to be caused by 10 different genes that are important for the formation of the intercellular lipid layer or the cornified envelope of keratinocytes, including *TGM1* (OMIM #191995), *ALOX12B*

Figure 47-4 Autosomal recessive congenital ichthyosis (*TGM1* mutations, classic lamellar ichthyosis, moderate). Large dark scales are often most obvious over extensor extremities and forehead. Mild to moderate erythema and palmar-plantar keratoderma are usual. The severity of scale varies widely (see Fig. 47-6).

(OMIM #603741), *ALOXE3* (OMIM #607206), *NIPAL4* (OMIM #609383), *CYP4F22* (OMIM #611495), *ABCA12* (OMIM #607800), *PNPLA1* (OMIM #612121), *CERS3* (OMIM #615276), *SDR9C7* (OMIM #609767), and *SULT2B1* (OMIM #604125).

CLINICAL FEATURES

LAMELLAR ICHTHYOSIS PHENOTYPE

The LI phenotype of ARCI is apparent at birth, and the newborn usually presents encased in a collodion membrane (see Fig. 47-3). At this time, the skin may be red. Over time, the skin develops large, platelike scales, and most are centrally attached with raised borders. The scales tend to be largest over the lower extremities, where the large, platelike scales separated by superficial fissuring can lead to an appearance similar to that of a dry riverbed. During childhood and into adulthood, the degree of erythema may vary. Involvement of the palms and soles in LI is variable and ranges from minimal hyperlinearity to severe keratoderma. This phenotype is most often associated with mutations in *TGM1*, but even mutations in one gene result in a highly variable phenotype (see Figs. 47-4 to 47-6).

The lips and mucous membranes tend to be spared in LI, but the adnexal structures may be compromised by the adherent, firm scales. Thick stratum corneum on the scalp tends to encase hairs and in conjunction with the tautness of the skin may lead to a scarring alopecia, most marked at the periphery of the scalp. Hyperkeratosis interferes with normal sweat gland function, resulting in hypohidrosis, but the degree of impairment varies between patients. Some patients have severe heat intolerance and must be vigilant to avoid overheating.

Bathing suit ichthyosis is a subtype of LI in which affected individuals develop the scaling typical of LI but limited to the bathing suit area. The distribution correlates with warmer areas of skin. Decreased transglutaminase is found in these areas, and unique, temperature-sensitive mutations in *TGM1* have been identified in affected individuals.[69-72]

CONGENITAL ICHTHYOSIFORM ERYTHRODERMA PHENOTYPE

As with LI, the CIE phenotype of ARCI is apparent at birth, and the newborn usually presents with a taut, shiny, collodion membrane. After shedding of

Figure 47-5 Autosomal recessive congenital ichthyosis (*TGM1* mutations, classic lamellar ichthyosis, mild). Large dark scales are often most obvious over extensor extremities and forehead. Mild to moderate erythema and palmar-plantar keratoderma are usual. Severity of scale varies widely (see Fig. 47-4).

the membrane, the skin of infants with CIE remains red, usually with a fine, white, generalized scale (see Figs. 47-7 and 47-8). On the lower legs, the scale may be larger and darker. In contrast to LI, the classic presentation of CIE may have little to no ectropion, eclabium, or alopecia. As in LI, there is a wide variation in the ability to sweat, and patients with CIE may have minimal sweating with severe heat intolerance. Mucous membranes are usually spared. Palm and sole involvement is variable. Nails may have ridging, but they are often spared. As with all the ichthyoses, dermatophyte infection of the skin and nails is common.

HARLEQUIN ICHTHYOSIS PHENOTYPE

A dramatic, severe, and sometimes fatal presentation of ichthyosis is that of *harlequin ichthyosis* (OMIM #242500) (Fig. 47-9). The child is often

Figure 47-6 Severity spectrum for mutations in *TGM1*. Phenotypic variability is seen across individuals with the same mutation.

Figure 47-7 Autosomal recessive congenital ichthyosis (*ALOXE3* mutations). The volar and dorsal surfaces of hands and feet show exaggerated linear markings. Scale elsewhere, when present, is fine and white and overlies mild erythema.

Figure 47-8 Autosomal recessive congenital ichthyosis (*ALOX12B* mutations). The volar and dorsal surfaces of hands and feet show increased linear markings. Scale elsewhere, when present, is fine and white and overlies mild erythema.

Figure 47-9 Harlequin infant. Harlequin ichthyosis. Note the rudimentary ears and the distorted appearance as a result of the thick "plates" of stratum corneum. This infant died a few days after birth.

premature and born with thick, shiny plates of stratum corneum separated by deep, red fissures that tend to form geometric patterns, as seen in the patched costumes of the harlequin clowns from the Italian Commedia dell'Arte dating from the 16th and 17th centuries. There are poorly developed or absent ears and marked ectropion and eclabium. The fingertips are tapered, and there is hyperconvexity of the nails. Uniformly fatal before 1980, a substantial fraction of patients with harlequin ichthyosis now survive with a persistent and severe erythroderma (Fig. 47-10).[65,73,74]

Netherton syndrome (OMIM #256500) is an autosomal recessive disorder featuring ichthyosis, a structural hair shaft abnormality, and atopy.[75] When present, a key finding is *ichthyosis linearis circumflexa* (ILC), a characteristic, polycyclic, serpiginous, migratory, double-edged scale at the margins of erythematous plaques (Fig. 47-11). Other patients, however, can present with a more severe erythroderma with or without ILC (Fig. 47-12). Histopathologic examination is not specific, but absent or thin stratum corneum is highly suggestive. Most patients have a specific hair shaft abnormality called *trichorrhexis invaginata,* in which the distal hair segment is telescoped into the proximal one, forming a ball-and-socket-like deformity on microscopic examination (Fig. 47-13). This is also known as "bamboo hair" and is caused by abnormal cornification of the internal root sheath. Hair from multiple areas should be examined because only 20% to 50% of hair may be affected; the characteristic abnormality may be more commonly observed on eyebrow hair.[76-78] The hair defects may not be detectable at birth and may disappear with age. Atopy-like diathesis may occur in these patients as atopic dermatitis, asthma, or severe food allergy (particularly to nuts) and marked elevations of serum immunoglobulin E. In some patients, generalized aminoaciduria, mild developmental delay, and impaired cellular immunity may also be present.[79]

Figure 47-10 Autosomal recessive congenital ichthyosis (*ABCA12* mutations, moderate). Large flat scales and moderate generalized erythema. All digits are tapered.

Figure 47-11 Netherton syndrome (*SPINK 5* mutation, ichthyosis linearis circumflexa predominant). Serpiginous, migrating scales peel away to reveal underling erythema. The palms and soles have mild to moderate keratoderma.

Figure 47-12 Netherton syndrome (*SPINK 5* mutation, erythroderma predominant). Small white scales cover areas of mild to severe generalized erythema. Serpiginous, peeling scales are often limited to areas around the ankles and wrists. The palms and soles have mild to moderate keratoderma.

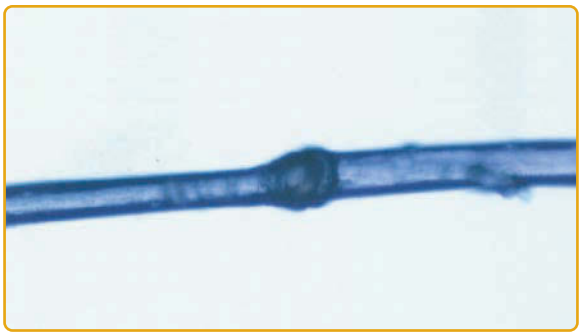

Figure 47-13 Netherton syndrome hair abnormalities. A small bamboo hair shaft shows features of trichorrhexis invaginata.

ETIOLOGY AND PATHOGENESIS

LAMELLAR ICHTHYOSIS AND CONGENITAL ICHTHYOSIFORM ERYTHRODERMA PHENOTYPES

The LI and CIE phenotypes represent a clinical spectrum, and mutations in many of the same genes underlie both phenotypes. A cardinal gene implicated in LI phenotypes is *TGM1*.[21,22] Even with this gene, there is great phenotypic variability (see Figs. 47-6 to 47-8). *TGM1* encodes transglutaminase 1; transglutaminases catalyze calcium-dependent cross-linking of proteins through the formation of ε-(γ-glutamyl)lysine isodipeptide bonds. During the formation of the stratum corneum, transglutaminase catalyzes the cross-linking of cellular proteins, including involucrin, loricrin, small proline-rich proteins, keratins, filaggrin, and others. The resulting protein complex is deposited on the inner side of the plasma membrane to form the cornified envelope. Transglutaminase also attaches ceramides secreted into the intercellular space by lamellar bodies to cornified envelope proteins, notably involucrin, and thereby is important in the formation of both the protein and lipid components of the stratum corneum.[80]

In a human skin–immunodeficient mouse xenograft model, transfer of a transglutaminase-1 gene into transglutaminase-1-deficient keratinocytes from LI patients resulted in normalization of transglutaminase expression and epidermal architecture in addition to restoration of cutaneous barrier function.[81] More recently, topical application of recombinant transglutaminase-1 in liposomes has been shown to normalize histology and function in murine xenografts.[82]

Autosomal recessive mutations in the genes encoding lipoxygenases *ALOXE3* (see Fig. 47-9) and *ALOX12B* (see Fig. 47-10) were found to cause CIE.[83] Lipoxygenases catalyze the formation of hydroperoxides from polyunsaturated fatty acids. In the skin, the products of *ALOXE3* and *ALOX12B* play a central role in the generated of oxidized ceramides, which are incorporated into the corneocyte lipid envelope.[84]

Altogether, mutations in 10 genes can cause ARCI phenotypes, and these include: *TGM1* (OMIM #190195), *ALOX12B* (OMIM #603741), *ALOXE3* (OMIM #*607206), *NIPAL4/Ichthyin6* (OMIM #609383), *CYP4F227* (OMIM #611495), *ABCA12* (OMIM #607800), *PNPLA1* (OMIM #612121), *CERS3* (OMIM #615276), *SDR9C7* (OMIM #609767), and *SULT2B1* (OMIM #604125).

HARLEQUIN ICHTHYOSIS PHENOTYPE

Harlequin ichthyosis results from autosomal recessive inheritance of mutations in *ABCA12*, which codes for an adenosine triphosphate (ATP)-binding cassette (ABC) transporter involved in lamellar granule secretion and epidermal lipid transport. Whereas premature termination, loss-of-function mutations most commonly underlie harlequin ichthyosis,[85,86] missense mutations in *ABCA12* have been identified in individuals with less severe ARCI (Fig. 47-14).[87,88] In harlequin ichthyosis, normal lamellar granules are not found; instead, there are small vesicles that lack internal structure. There is also no evidence of the lipid lamellae that form between granular and cornified cells as a result of discharge of lamellar granule contents into the intercellular space.[89]

Netherton syndrome has been found to be caused by mutations in *SPINK5,* a gene encoding LEKTI (lymphoepithelial Kazal-type related inhibitor).[24] LEKTI is a serine protease inhibitor that is predominantly expressed in epithelial and lymphoid tissues and may be important in the downregulation of inflammatory pathways. It inhibits the proteases that degrade the corneodesmosome, thus allowing premature desquamation. LEKTI polymorphisms are associated with common atopy and atopic dermatitis.[90,91] Early reports of Netherton syndrome recognized signs of reduced cellular immunity manifesting as viral warts and negative skin testing to microbial antigens. The danger of such defective cellular immunity was reinforced with the report of Folster-Holst and coworkers, who identified oncogenic human papillomavirus in a 28-year-old woman with vulvar condyloma that rapidly transformed to an aggressive squamous cell carcinoma.[92] In our experience, all adults with Netherton have papillomatous changes in intertriginous areas, but the role of papilloma viruses in the development of these lesions has not been established.

DIAGNOSIS

Clinical features and history are central to establishing a diagnosis in ARCI. Advances in genetic testing, either via research pathways (see section "Registry for Ichthyosis and Related Skin Disorders") or clinical laboratories, has allowed the rapid ascertainment of genetic diagnoses. These tests use next-generation sequencing of a panel of genes or a selected subset of genes assessed via exome sequencing. Genetic testing permits confirmation of diagnosis and counseling regarding potential disease comorbidities. Clinical features supporting phenotypes include the following:

Figure 47-14 Autosomal recessive congenital ichthyosis (*ABCA12* mutation, mild). Scales on the shins are large, but those elsewhere are small on background of mild erythema. Moderate palmar keratoderma with increased linear markings and tapered fifth digit.

LI and CIE typically presents with a collodion membrane at birth that sheds to reveal either the thick, adherent scale of LI or the erythroderma and finer scale of CIE. Histopathologic examination rarely aids in the diagnosis of LI or CIE, with both disorders showing nonspecific acanthosis and hyperkeratosis.

Harlequin ichthyosis has a classical clinical presentation, with armorlike plates of scale and deep fissures present at birth which shed to reveal severe erythroderma and scaling.

Netherton syndrome presents with hair shaft abnormalities, with or without ILC or erythroderma, in the setting of atopic features. These clinical findings provide strong support for the diagnosis of Netherton syndrome.

CLINICAL COURSE, PROGNOSIS, AND MANAGEMENT

LAMELLAR ICHTHYOSIS AND CONGENITAL ICHTHYOSIFORM ERYTHRODERMA

Treatment with oral retinoids can improve or prevent some sequelae of these phenotypes. Patients frequently notice an increase in sweating, with improved heat tolerance. Although retinoid therapy can cause blepharitis or even conjunctivitis, it is usually well tolerated by patients with LI and CIE. Moreover, the ability of systemic retinoid (and in some cases, topical retinoid) therapy to decrease thick periocular scale can decrease the tendency to develop ectropion.[93] Nevertheless, patients with severe scaling and ectropion usually require careful eye maintenance. Because of the ectropion, the eyelids may fail to close fully, particularly during sleep; hydration with liquid tears during the day and ophthalmic lubricants at night can prevent exposure keratitis. Individuals with mutations in *ALOXE3* and *ALOX12B* tend to have less scaling that those with mutations in *TGM1* and, consistent with this observation, are findings in a recent study showing that ectropion is less common (35%) in CIE than in LI (57%).[94]

HARLEQUIN ICHTHYOSIS

Advances in neonatal intensive care, together with facilitating desquamation by judicious use of systemic retinoid therapy, have led to improvements in survival and to the use of the name "harlequin baby" rather than "harlequin fetus." These children are at risk during the neonatal period. Abnormal water loss through the skin and poor temperature regulation lead to risk of fluid and electrolyte imbalance.

The infants are also at risk for infection beginning in the skin but at the same time (because of poor temperature regulation) do not show the usual signs of infection. Normal respiration may be restricted by the taut skin. Treatment with systemic retinoids during the newborn period can facilitate desquamation of the membrane and is associated with improved outcomes.[73,95] Some infants and children have had failure to thrive and require tube feeding. After shedding of harlequin scale, erythroderma is prominent. In children and adults, topical and systemic retinoids can be helpful in the management of ectropion and hyperkeratosis.

NETHERTON SYNDROME

At birth, affected children may present with generalized erythroderma, and in some individuals, erythroderma persists throughout life with a phenotype on the LI–CIE spectrum of ARCI.[96] In others, erythroderma fades, and ILC ensues. Infants and children may have feeding problems, with poor absorption and failure to thrive.[97] Pruritus can be profound, and scratching can lead to lichenification at the flexures.

Tacrolimus ointment, a topical immunomodulator (see Chap. 192), is effective in common atopic dermatitis with minimal systemic absorption. However, Netherton syndrome is complicated by an abnormal skin barrier, allowing increased percutaneous absorption and associated risk for systemic toxic effects. This should be considered when using topical agents such as tacrolimus because monitoring of serum levels may be necessary[98] and topical steroids because iatrogenic Cushing syndrome has been reported.[32] Furthermore, topical and systemic retinoids should be avoided in patients with Netherton syndrome because they can further exacerbate the condition.

KERATINOPATHIC ICHTHYOSES

Keratinopathic ichthyoses result from mutations in genes encoding keratins, components of the intermediate filament network that are central to cellular structural integrity. Phenotypes falling within the keratinopathic ichthyosis spectrum include EI, superficial epidermolytic ichthyosis (SEI, ichthyosis bullosa of Siemens), ichthyosis hysterix Curth-Macklin, annular EI, and ichthyosis with confetti (IWC).

CLINICAL FEATURES

EPIDERMOLYTIC ICHTHYOSIS

In 1902, Brocq described bullous ichthyotic erythroderma and distinguished the blistering type from the nonblistering type of CIE.[99] The original description included three unrelated patients whose clinical manifestations varied. However, this was probably the first description of EI (OMIM #113800). The disease is named for the distinctive histopathologic features of vacuolar degeneration of the epidermal keratinocyte (ie, epidermal lysis) and associated hyperkeratosis. EI is also known as EHK and BCIE, earlier descriptive names signifying characteristic histopathologic changes or the blistering, neonatal presentation with subsequent scaling and redness, respectively.

EI is transmitted as an autosomal dominant trait with a prevalence of approximately 1 in 200,000 to 300,000 persons. There is a high frequency of spontaneous mutation, and as many as half of the patients have no family history.[10] The disease usually presents at birth with blistering, redness, and peeling and can be mistaken for epidermolysis bullosa or staphylococcal scalded skin on clinical examination (Fig. 47-15A). Because there is a high frequency of new mutations, the disease may be unexpected, and the diagnosis may be unknown. The newborn may require intensive care with fluid and electrolyte monitoring.

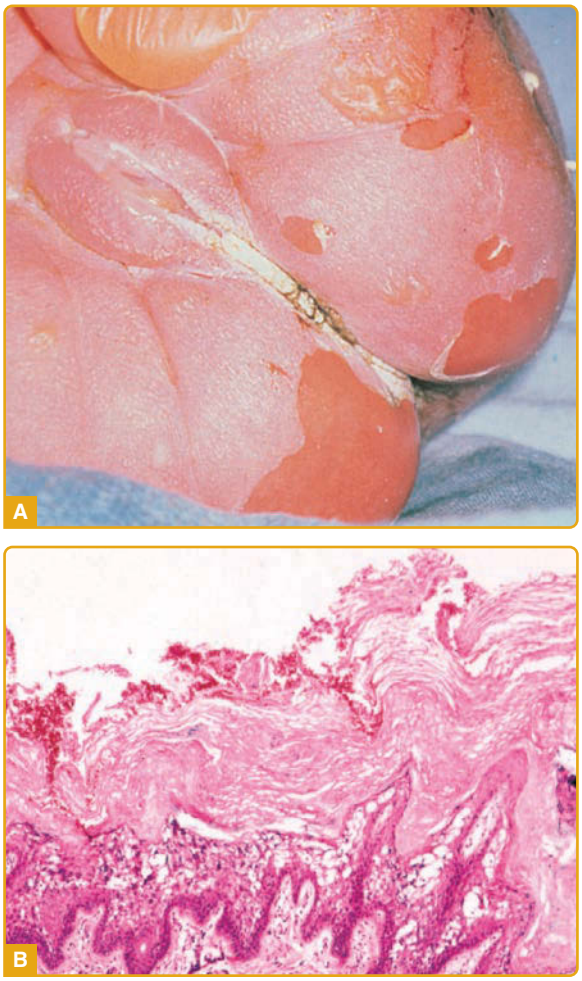

Figure 47-15 Epidermolytic ichthyosis infantile presentation. **A,** Newborn showing blistering and erosions. **B,** Epidermolytic ichthyosis histology. The stratum corneum is thickened (hyperkeratosis), and there is prominent vacuolar degeneration of suprabasilar epidermis most marked at the granular layer.

Specialized skin care can minimize blistering and enhance healing of erosions and may include lubrication to decrease friction and mechanical trauma, protective padding, and specialized wound dressings. Newborns with extensive erosions are prone to bacterial infection and sepsis, and carefully chosen topical and systemic antibiotics can minimize the extent of infection. With time, generalized hyperkeratosis may develop, which may or may not be associated with erythroderma. EI skin usually has a characteristic odor, thought to be related to superinfection by mixed flora. Histopathology shows a thickened stratum corneum and vacuolar degeneration of the upper epidermis, leading to the histologic term *EHK*. The vacuolar degeneration usually involves the upper epidermis and occasionally all of the suprabasilar keratinocytes. Granular cells exhibit dense, enlarged, irregularly shaped masses that appear to be keratohyalin granules (Fig. 47-15B).

All patients with EI have a characteristic corrugated scale that becomes accentuated in areas of body folds (Figs. 47-16 and 47-17). There is striking clinical heterogeneity in EI with phenotypes, including isolated, thick palmoplantar hyperkeratosis, generalized spiny scale, migratory patches of erythrokeratoderma, keratoderma with superficial peeling scale, and generalized exfoliative erythroderma.[100]

LINEAR ICHTHYOSIFORM ERYTHRODERMA

Linear EI, a variant of epidermal nevus, presents in a linear mosaic pattern caused by a postzygotic, spontaneous mutation during embryogenesis. Areas of hyperkeratosis alternating with normal skin are often distributed in streaks along Blaschko lines. These may be limited to a few streaks, often bounded by the midline, or there may be many stripes, with widespread, patchy involvement. Linear EI has been found to result from somatic mutations in *KRT1* and *KRT10* that are identical to those found in generalized disease.[101,102] If the mosaicism affected gonadal tissue, individuals with linear EI can transmit the mutation to offspring with resulting generalized EI.[103,104]

SUPERFICIAL EPIDERMOLYTIC ICHTHYOSIS

SIE (ichthyosis bullosa of Siemens) is a rare autosomal dominant genodermatosis. Patients are born with redness and blistering. The redness subsides over the subsequent weeks to months, and the skin develops corrugated hyperkeratosis, particularly over flexural areas (Fig. 47-18). In some areas, there may be a

Figure 47-16 Epidermolytic ichthyosis (*KRT10* mutation). Generalized coarse, columnar scales often have a corrugated pattern over flexures. Scales unevenly desquamate from the underlying epidermis to reveal mild to moderate generalized erythema. Hyperkeratosis of the palms and soles is mild to moderate, and pseudoainhum occurs.

Figure 47-17 Epidermolytic ichthyosis (*KRT1* mutation). Generalized coarse, columnar scales often have a corrugated pattern over flexures. Scales unevenly desquamate from underlying epidermis to reveal mild to moderate generalized erythema. Hyperkeratosis of the palms and soles is often severe, and pseudoainhum occurs.

Figure 47-18 Epidermolytic ichthyosis (*KRT2* mutation). Smooth, mildly corrugated scale is generally accentuated at flexures or areas of mild friction. Circular or geometric areas of stratum corneum peeling are common. Erythema is mild, and the palms and soles are spared.

lichenified appearance to the skin. As with EI, the epidermis is fragile; however, the fragility is more superficial. This can result in loss of the uppermost epidermis (predominantly the stratum corneum), yielding a characteristic, collarette-like depressed area that has been described as "mauserung" (molting). Histologically, the epidermis shows hyperkeratosis and vacuolization similar to EHK but confined to the granular layer.[10] Mutations have been found in the gene encoding keratin 2, a differentiation keratin of the suprabasilar epidermis that is expressed in the more superficial epidermal layers.[105,106]

ANNULAR EPIDERMOLYTIC ICHTHYOSIS

Annular EI is a rare autosomal dominant disorder that presents at birth or within in the first few months of life with severe, intermittent scaling and blistering that resolves during puberty.[107,108] Residual, limited plaques with corrugated scale and erythema are seen primarily in flexural and intertriginous skin (Fig. 47-19). In some cases, explosive bouts of widespread erythema with blisters and pustules are seen.[109] Patients subsequently develop widespread, migratory, polycyclic, and annular scaling plaques. Light and electron microscopy reveals findings of EI. Mutations in *KRT10* and *KRT1* have been found.[109,110]

ICHTHYOSIS WITH CONFETTI

This rare disorder is also known as *ichthyosis variegata* and *congenital reticulated ichthyosiform erythroderma*, descriptive terms that fail to capture its clinical evolution over the course of life. IWC presents with congenital erythroderma, malformation of the auricle, and tapering of the digits which leads to the frequent clinical diagnosis of CIE. In childhood, palmoplantar keratoderma develops, and the severity ranges from mild to severe.[111] Most individuals with IWC develop small islands of normal-appearing skin beginning in childhood (Fig. 47-20), although later presentation has also been reported. Normal areas of skin have been shown to arise from loss of heterozygosity on chromosome 17q or 12q via mitotic recombination of disease-causing mutations in the genes encoding keratin 10 (*KRT10*) and keratin 1 (*KRT1*).[112-114] Histopathology shows a clear transition from affected epidermis to normal skin within white spots. In individuals with IWC caused by mutations in *KRT10*, bandlike parakeratosis, psoriasiform acanthosis and vacuolated, binuclear upper epidermal keratinocytes are seen, and electron microscopy shows perinuclear filament retraction and poor investment of desmosomes with intermediate filaments.[114] In individuals with IWC caused by mutations in *KRT1*, affected skin shows psoriasiform acanthosis, prominent keratohyalin granules, perinuclear vacuolization with rare binucleate cells, and thick

Figure 47-19 Epidermolytic ichthyosis, annular with PPK (*KRT1* mutation). Circumscribed erythematous plaques with coarse scale and a corrugated pattern accentuated at flexures. The palms and soles variably involved.

Figure 47-20 Ichthyosis with confetti (*KRT10* mutation). Phylloid (leaf-like) areas of normal skin on a background of mild to severe erythema and scale increase in number and size starting in the first decade of life. Palmar and plantar erythrokeratoderma vary from mild to severe. Contractures may occur at small and large joints.

hyperkeratosis, and electron microscopy shows perinuclear filament detachment.[113]

ETIOLOGY AND PATHOGENESIS

Within keratinocytes, keratin intermediate filaments form an elaborate network that confers structural stability to the cells. In the suprabasilar, differentiating keratinocytes of interfollicular epidermis, this network is primarily formed by keratins 1 and 10, which polymerize to form intermediate filaments. In the granular layer, keratin 2 partially replaces keratin 1 in intermediate filaments.

EPIDERMOLYTIC ICHTHYOSIS

On electron microscopic examination, clumping of filaments is observed to begin in the first suprabasal layer. These aggregated filaments are clumps of keratin intermediate filaments that contain the suprabasal keratins 1 and 10.[10,115] When expressed in keratinocytes, mutant keratins in EI and SEI aggregate and clump, with collapse of the intermediate filament network and ensuing cytolysis. Aggregates are cytotoxic, and mutations in *KRT10* have been shown to disrupt epidermal differentiation and formation of the lipid permeability barrier while inducing epidermal hyperproliferation.[116,117] Mutations in genes coding keratin 1, 2, or 10 have been identified in a number of EI kindreds.[118] In many cases, severe palmar/plantar involvement implies mutations in *KRT1*; this may reflect the "redundancy" of K9 (a keratin that occurs only in the suprabasal epidermis of palmar and plantar skin) and K10 in palmar/plantar epithelium. Mutations in *KRT9* have been found in families with epidermolytic PPK (Vörner) (see Chap. 48).[119]

ICHTHYOSIS WITH CONFETTI

IWC does not feature marked skin fragility, and electron microscopy shows no evidence of filament aggregates, though perinuclear filament retraction is seen. Expression of *KRT10* mutants in cells leads to intermediate filament network collapse and intranuclear accumulation of K10 within the nucleolus, and expression of *KRT1* mutants similarly leads to intermediate filament network collapse with intranuclear accumulation of K1.[112-114] Because all revertant spots arise from mitotic recombination and spots of normal skin increase in number and size over time, IWC *KRT1* and

KRT10 mutations appear to affect homologous recombination and confer selective advantage to normal keratinocytes.

DIAGNOSIS

Diagnosis combines clinical findings, histopathology, and genetic analysis. Clinical features can inform diagnosis. For examples, the appearance of white spots of normal skin in childhood suggests IWC, but a history of blistering at birth with less frequent blistering over time and histology showing epidermolysis and hypergranulosis suggests EI or SEI. Genetic testing permits precision in diagnosis, with mutations found in *KRT1*, *KRT10*, or *KRT2*.

CLINICAL COURSE, PROGNOSIS, AND MANAGEMENT

Although the neonatal presentation of widespread blistering can be dramatic in EI and SEI, in the first few weeks of life, hyperkeratosis becomes more prominent, and blisters become more localized to areas of friction. Areas of thick hyperkeratosis, which are not pliable and have a hard, rough surface, are prone to mechanical trauma. In patients with the hystrix type of porcupine-like hyperkeratosis, the rough surface causes high traction with objects moving across the skin surface, which tend to catch on the hyperkeratotic horn and peel it off. Topical agents such as lubricants and keratolytics can reduce the thickened, rough areas and help to minimize blistering and erosion. In contrast, patients with erythroderma and peeling, who do not have the thick areas of hyperkeratotic spines, have less need for keratolytics but still need lubricants. Acute exacerbations may occur from skin infections. Bacterial infection of the skin is common, often leads to enhanced blistering, and may require frequent therapy with topical and oral antibiotics. Dilute bleach baths aid in controlling bacterial odor and colonization, and bicarbonate baths can facilitate desquamation. Topical retinoids can reduce scaling locally,[120] and systemic retinoids can markedly reduce hyperkeratosis, decreasing grooming and bathing time.[121,122] Dosing must be slowly titrated because fragility can increase with higher doses, particularly in EI. For reasons that are not well understood, blistering and infection are less of a problem for adults than for children with EI.

CONNEXIN DISORDERS

Mutations in genes encoding connexins lead to erythrokeratoderma, and phenotypes include keratitis ichthyosis deafness syndrome and erythrokeratodermia variabilis et progressiva (EKVP). There are overlapping clinical features and phenotypic variability, even within kindreds, in these disorders.[123,124]

CLINICAL FEATURES

EKVP (OMIM #133200) represents a spectrum of phenotypes initially described as progressive symmetric erythrokeratodermia (PSEK) and erythrokeratodermia variabilis (EKV) but that have been found to have a common genetic basis.[125] The progressive symmetric erythrokeratodermia phenotype was first definitively described by Darier in 1911[126] and is characterized by well-demarcated, erythematous, hyperkeratotic plaques that are symmetrically distributed over the extremities and buttocks, and often the face[127] (Fig. 47-21). The trunk tends to be spared, but the palms and soles may be involved. The plaques appear shortly after birth, progress slowly during the first few years, and then stabilize in early childhood. The plaques usually remain stable in location and appearance but may undergo partial regression at puberty. The erythrokeratodermia variabilis phenotype was described by Mendes da Costa in 1925 as a rare disorder typically presenting at birth or during the first year of life.[128] Both generalized involvement (see Fig. 47-25) characterized by persistent, red-brown hyperkeratotic plaques and accentuated skin markings and localized involvement that is limited in extent and characterized by sharply demarcated, hyperkeratotic plaques that are symmetrically arrayed and remain relatively fixed for months to years have been described. Although many features are shared with PSEK, EKV also demonstrates sharply demarcated, migratory red patches that vary in size from a few to many centimeters. These geographic, figurate red patches appear or regress over minutes to hours; some individuals complain of burning at these sites, but they are asymptomatic in others. The red patches develop independently of the hyperkeratosis. Palmoplantar hyperkeratosis may be present, but hair and mucous membranes are unaffected. Histopathologic features include hyperkeratosis, acanthosis, papillomatosis, and capillary dilatation. Epidermis involved with severe papillomatosis and suprapapillary thinning may result in a "church spire" appearance. EKVP is inherited in an autosomal dominant pattern with incomplete penetrance and variable expressivity, although rare recessive cases have been described.[129]

KERATITIS–ICHTHYOSIS–DEAFNESS SYNDROME

KID syndrome (OMIM #148210) is a rare disorder characterized by keratitis (with progressive corneal opacification), ichthyosis, and deafness (neurosensory). Involvement of multiple ectodermal tissues qualifies KID syndrome as an ectodermal dysplasia. Most cases are compatible with autosomal dominant inheritance.

Figure 47-21 Erythrokeratoderma variabilis (*GJB3; GJB4; GJA1* mutations). Corrugated coarse plaques are usually accentuated in the flexures. Palm and sole involvement may be severe. Circumscribed erythematous patches may be fixed or evanescent.

The disease is characterized by discrete erythematous plaques, and there may be mild, generalized hyperkeratosis (Fig. 47-22). The distinctive plaques may have a discrete border and a verrucous appearance with crusting and may be conspicuously figurate and symmetric on the face. Furrowing about the mouth results in characteristic facies. There may be prominent follicular hyperkeratosis, which can result in a scarring alopecia of the scalp. "Leather-like" palmar/plantar keratoderma is almost always seen.[130] Descriptions of nail changes vary from absent, delayed appearance after birth, atrophic, or brittle to thickened, with loss of or "rough" cuticles, subungual hyperkeratosis, and leukonychia. The teeth may be small. Auditory evoked potential studies allow detection of the hearing deficit in infancy. Keratitis may develop.

ETIOLOGY AND PATHOGENESIS

ERYTHROKERATODERMIA VARIABILIS ET PROGRESSIVA

Mutations in *GJB3, GJB4,* and *GJA1*, the genes encoding connexin 31, 30.3, and 43, respectively, have been identified in kindreds with EKVP.[11,124,128,131,132] Connexins are a family of proteins that aggregate to form gap junctions that are important channels for intercellular communication. This intercellular signaling system is crucial for maintaining tissue homeostasis, growth control, development, and synchronized response of cells to stimuli. In the cell, connexins oligomerize to form homotypic or heterotypic hexameric connexons in the Golgi, which are transported to the cell membrane, where they can either function as nonjunctional hemichannels or dock with connexins in neighboring cells. Mutant connexins can show impaired intercellular communication through gap junctions and leakiness of hemichannels.[124] The critical deficit in causing the pathology has not been established.

KERATITIS–ICHTHYOSIS–DEAFNESS SYNDROME

Dominant mutations in *GJB2,* the gene encoding connexin 26, have been detected in sporadic cases and familial KID syndrome.[133] Functional studies of cells expressing mutated connexin 26 demonstrated failure of a fluorescent tracer to pass through gap junction channels to neighboring cells, consistent with disruption of intercellular communication.[124,133] Mutant connexin 26

Figure 47-22 Keratitis ichthyosis deafness syndrome (*GJB2* mutation). Smooth or gritty columns of hyperkeratosis give the skin a pebbly or rough appearance and are most prominent at body folds, palms, and soles and around orifices. Erythema is usually mild. Bacterial and fungal infections are common.

also forms poor gap junctions and leaky heterotypic hemichannels with connexin 43.[134] Different mutations in the same gene (*GJB2*) encoding connexin 26 have also been found in a family with a mutilating palmoplantar keratoderma (Vohwinkel disease; see Chap. 48) and deafness (without ichthyosis).[135] The identification of mutations in the genes encoding a variety of connexin proteins has highlighted the role of connexin-mediated intercellular communication through gap junctions in the development and maintenance of ectodermal tissues. Connexins 26, 30, and 31 are expressed in the stratified epithelia of the cochlea and epidermis, and abnormalities in these proteins can cause sensorineural hearing impairment and skin disorders.[136]

CLINICAL COURSE, PROGNOSIS, AND MANAGEMENT

ERYTHROKERATODERMIA VARIABILIS ET PROGRESSIVA

Affected individuals frequently have normal skin at birth, and initial lesions present in infancy or childhood. Skin involvement can wax and wane over the course of an individual's life. Systemic retinoid treatment improves hyperkeratotic lesions and may also clear the figurate red patches when present. The hyperkeratotic skin lesions may be triggered by trauma to the skin, and the red patches may be triggered by a change in temperature.

KERATITIS ICHTHYOSIS DEAFNESS SYNDROME

Cutaneous severity can vary significantly in KID syndrome, particularly in the neonatal period. Keratitis and deafness are variably severe; when present, they may be progressive. Developmental brain defects, often asymptomatic, are common, and some recommend routine magnetic resonance imaging.[137] Affected individuals can have an increased susceptibility to bacterial, fungal, or viral infections.[138] Squamous cell carcinoma of the skin and tongue has also been reported.[139] In contrast to many other ichthyotic conditions, treatment of these patients with oral retinoids has been reported to be of little benefit and possibly to exacerbate the corneal neovascularization. The p.A88V and p.G45E mutations in *GJB2* are associated with neonatal lethality, primarily caused by respiratory failure.[140-143a]

PEELING SKIN DISORDERS

CLINICAL FEATURES

The *peeling skin syndromes* (PSSs; OMIM #270300) were initially described in case reports and were later classified into those with acral predominance, those that were generalized and noninflammatory, and those that were generalized and inflammatory. Skin peeling was often intermittent, and patients lacked the general hyperkeratosis seen in most ichthyoses. These few early cases made it clear that this was a very heterogeneous group of diseases. In the past 12 years, five recessive gene mutations have been reported from one to four families with findings described as PSSs.

The common clinical features included painless, easy peeling skin without scarring, exacerbation by friction and humidity, first appearance from the second day to mid-first decade of life. Many had itch, and some reportedly had cutaneous and systemic allergy.

ETIOLOGY AND PATHOGENESIS

Mutations in *CDSN*, which encodes corneodesmosin, cause inflammatory PSS with atopy, pruritus, and marked deficits in cutaneous barrier function, termed PSS1 (OMIM #270300).[144] Affected individuals have superficial exfoliation, ichthyosiform erythroderma, and frequent cutaneous infections in childhood. Corneodesmosin is a component of desmosomes and corneodesmosomes at the transition from cells of the stratum granulosum to the stratum corneum. Mutations in *CDSN* lead to loss of corneodesmosin expression, eliminating the adhesion between the upper epidermis and the stratum corneum and disrupting terminal differentiation. One consequence of defective differentiation is upregulation of kallikrein 5, a stratum corneum tryptic enzyme that further exacerbates the peeling skin phenotype.

Mutations in the gene coding for transglutaminase 5, a ubiquitously expressed transglutaminase with widespread expression in skin, have been identified in multiple kindreds with acral peeling skin, PSS2 (OMIM #609796).[145] Transglutaminase 5 is expressed in the granular layer of skin and is central to the formation of the cornified envelope, cross-linking structural proteins including involucrin, loricrin, filaggrin, and small proline-rich proteins. Failure to cross-link these proteins leads to shedding at the stratum corneum interface.

Autosomal recessive mutations in *CHST8*, which encodes N-acetylgalactosamine-4-O-sulfotransferase, an enzyme central to the production of sulfated glycosaminoglycans in the epidermis, have been found in a single kindred with PSS3 (OMIM #616265).[146] Affected individuals develop generalized white scaling after 5 years of age which is prominent on the extremities and peels easily. N-acetylgalactosamine-4-O-sulfotransferase functions in glycosylation of proteins central to epidermal differentiation and desquamation.

Autosomal recessive, loss of function mutations in *CSTA* which encodes cystatin A, a cysteine protease inhibitor expressed throughout the epidermis, have also been reported in kindreds with acral PSS, some with more generalized exfoliative ichthyosis, classified as PSS4 (OMIM #607936).[147-150] Cystatin A has a central role in desmosomal adhesion in basal layers of the epidermis, and peeling skin caused by *CSTA* mutations accordingly shows a deeper level of cleavage than is seen in individuals with mutations in *TGM5*.[149]

Autosomal recessive mutation in *SERPINB8*, which belongs to a large family of protease inhibitors, causes a noninflammatory PSS, PSS5 (OMIM #617115).

SYNDROMIC ICHTHYOSES

Syndromic ichthyoses feature moderate to severe extracutaneous involvement. A selection of syndromic ichthyoses will be described.

CHANARIN-DORFMAN SYNDROME

Chanarin-Dorfman syndrome (neutral lipid storage disease with ichthyosis; OMIM #275630) is an autosomal recessive disorder characterized by accumulation of triglycerides in the cytoplasm of keratinocytes, leukocytes, muscle, liver, fibroblasts, and other tissues with normal blood lipid levels. The resulting ichthyosis features generalized lamellar scales with variable erythema, and corrugated accentuation of hyperkeratosis in flexures is common (Fig. 47-23). An EKV-like presentation has been reported.[151] Presentation is often that of a collodion baby with ectropion and eclabium. Extracutaneous involvement, which is generally not as severe as in neutral lipid storage disease without ichthyosis caused by mutations in *PNPLA2*, is variable and may be mild, including cataracts, decreased hearing, hepatosplenomegaly with abnormal liver enzymes and fatty liver, psychomotor delay, myopathy with elevations in serum muscle enzymes, and neurologic abnormalities.

Histopathology of oil red O or Sudan III stains of frozen skin sections shows lipid droplets in dermal cells, in the basal layer (and to a lesser extent suprabasally), and in the acrosyringia of the eccrine ducts. Examination of peripheral blood smears shows lipid vacuoles within granulocytes, eosinophils, and monocytes, a feature that may also be present in carriers.[152] Mutations in the *ABHD5* gene have been identified.[153] ABHD5 belongs to a large family of proteins, most of which are enzymes, and appears to activate adipose-triglyceride lipase in the initial step in lipolysis of triglycerides. In the absence of ABHD5, triglycerides

Figure 47-23 Autosomal recessive congenital ichthyosis (*ABHD5* mutations, Chanarin-Dorfman disease; neutral lipid storage disease). Dark scales may vary, in the same individual, from large and flat to small and columnar. Mild to moderate erythema and exaggerated r accentuated linear markings over dorsa of hands and feet are common.

accumulate in cells[154] and in lamellar bodies where, after secretion, they interfere with lipid lamellae formation in the stratum corneum, resulting in increased transepidermal water loss.[155]

CHILD SYNDROME

CHILD syndrome (OMIM #308050) is a rare disorder consisting of *c*ongenital *h*emidysplasia, *i*chthyosiform erythroderma, and *l*imb *d*efects, which is found almost exclusively in females. It is a mosaic disorder featuring red scaly plaques intermixed with normal skin on one side of the body with minimal contralateral involvement. There may be bands of normal skin on the affected side (Fig. 47-24). Limb defects occur ipsilateral to the ichthyosis and range from digital hypoplasia to agenesis of the extremity. There may be punctate calcification of cartilage. Unilateral hypoplasia can involve the central nervous system and cardiovascular, pulmonary, renal, endocrine, and genitourinary systems. The inheritance pattern is X-linked dominant, with the condition being lethal in males. X-inactivation of the mutant allele gives rise to normal skin in affected females. Most affected individuals have loss-of-function mutations in *NSDHL* (*N*AD[P]H *s*teroid *deh*ydrogenase-*l*ike protein) encoding a 3β-hydroxysteroid dehydrogenase.[156,157] NSDHL functions in the post-squalene cholesterol biosynthetic pathway, catalyzing

Figure 47-24 CHILD (*c*ongenital *h*emidysplasia, *i*chthyosiform erythroderma, and *l*imb *d*efects) syndrome. Linear stripes of erythrokeratoderma are present on the back.

intermediate steps in the conversion of lanosterol to cholesterol.[158] The disorder is related to X-linked dominant chondrodysplasia punctata caused by mutations in emopamil-binding protein (EBP), which also has skin and skeletal abnormalities, and one individual with a CHILD phenotype has been reported with an *EBP* mutation. EPB is downstream of NSDLH in the cholesterol synthetic pathway.

Pathogenesis-based therapy ameliorates the cutaneous findings in CHILD syndrome. Defects in NSDHL lead to a failure to synthesize cholesterol and accumulation of 4-methyl and 4,4-dimethol sterols to toxic levels. Phenotypic improvement of the skin findings in CHILD syndrome was achieved by topical application of cholesterol and lovastatin. This supplies the end product of cholesterol biosynthesis while blocking the pathway at the level of HMG CoA reductase, proximal to NSDHL, thereby preventing synthesis of toxic intermediates.[159]

CHONDRODYSPLASIA PUNCTATA

Chondrodysplasia punctata is a clinically and genetically diverse group of rare diseases, first described by Conradi, that share the features of stippled calcification of the epiphyses and skeletal changes resulting from abnormal deposition of calcium in the areas of enchondral bone formation during fetal development and early infancy. Clinical severity ranges from severe dwarfism and death during infancy to a radiographic abnormality that resolves over time leaving minor skeletal changes. Several forms also include ichthyosiform changes. An autosomal recessive (rhizomelic) type, and both X-linked dominant[160] and recessive forms[161] have been described.

RHIZOMELIC CHONDRODYSPLASIA PUNCTATA

Rhizomelic chondrodysplasia punctata (RCDP; OMIM #215100) is also known as peroxisomal biogenesis disorder complementation group 11 (CG11). It is an autosomal recessive, rare, multisystem developmental disorder characterized by dwarfism caused by symmetric shortening of the proximal long bones (ie, rhizomelia), specific radiologic abnormalities (ie, the presence of stippled calcifications of cartilage, vertebral body clefting), joint contractures, congenital cataracts, ichthyosis, and severe mental retardation. Skin changes are present in approximately 25% of patients. RCDP is a disorder of peroxisomes, membrane-bound multifunctional organelles found in all nucleated cells. Their functions vary with cell type and include a variety of pathways (eg, hydrogen peroxide–based respiration, fatty acid β-oxidation, and lipid and cholesterol synthesis) involving the synthesis and degradation of various compounds. Hereditary human peroxisomal disorders are subdivided into disorders of peroxisome biogenesis, in which the organelle is not formed normally, and those involving a single peroxisomal enzyme. RCDP is caused by mutations in *PEX7*, a gene that encodes peroxin 7, a receptor required for targeting a subset of enzymes to peroxisomes.[162] Thus, it is a peroxisome biogenesis disorder characterized by loss of multiple peroxisomal metabolic functions.

X-LINKED RECESSIVE CHONDRODYSPLASIA PUNCTATA

X-linked recessive chondrodysplasia punctata (CDPX; OMIM #302950) can involve skin (linear or whorled atrophic or ichthyosiform hyperkeratosis, follicular atrophoderma, may begin as erythroderma), hair (coarse, lusterless, cicatricial alopecia), short stature and skeletal abnormalities, cataracts, and deafness. Curry and associates studied a family that had atypical ichthyosis and elevated cholesterol sulfate in two affected males and identified an X chromosomal deletion (Xp22) that included the gene for steroid sulfatase.[161] There is a cluster of arylsulfatase genes at this location. Mutations in *ARSE*, the gene encoding the enzyme arylsulfatase E, were found in five patients; however, it is possible that the disorder may also be caused by mutations in adjacent arylsulfatase genes.[163] The similarity to warfarin embryopathy suggests that warfarin embryopathy may be caused by drug-induced inhibition of the same enzyme.

X-LINKED DOMINANT CHONDRODYSPLASIA PUNCTATA

X-linked dominant chondrodysplasia punctata (CDPX2; Conradi-Hünermann-Happle syndrome, OMIM #302960) is characterized by a mosaic pattern of skin involvement along Blaschko lines caused by mosaic X-chromosome inactivation (lyonization). It occurs almost exclusively in females, with loss of the gene function hypothesized to be lethal to males.[164] Affected females have a normal life expectancy, and there may be increased disease expression in successive generations (anticipation). Occurrence in a male has been observed in association with a 47, XXY karyotype. Conradi-Hünermann-Happle syndrome presents at birth as a congenital ichthyosiform erythroderma that clears over months and is replaced by linear hyperkeratosis, follicular atrophoderma, and pigmentary abnormalities. Hair shaft abnormalities and cicatricial alopecia can also occur. Stippled calcifications are seen in radiographs of areas of endochondral bone formation during childhood but may no longer be visible after puberty. Stature may be short, with asymmetric shortening of the legs. Cataracts occur, usually asymmetrically, in about two thirds of patients. Histochemical staining for calcium may show calcifications within the epidermis, especially

within hair follicles in young children, which may not be present in older children.[165] Mutations in the gene encoding the EBP cause the syndrome. EBP was first identified as a binding target for the drug emopamil, a calcium channel blocker. It was later found to be 3β-hydroxysteroid-δ8-δ7-isomerase that catalyses an intermediate step in the conversion of lanosterol to cholesterol.[160] Although this is another ichthyosis caused by abnormality in cholesterol synthesis, the pathophysiology of how this defect causes clinical manifestations is unclear.

ICHTHYOSIS FOLLICULARIS, ALOPECIA, AND PHOTOPHOBIA SYNDROME

Noninflammatory follicular hyperkeratosis, nonscarring alopecia, photophobia, and characteristic facies are seen in the X-linked recessive ichthyosis follicularis, alopecia, and photophobia syndrome (IFAP) syndrome (OMIM #308205, see Chap. 49). Less constant features include recurrent respiratory infections, nail abnormalities, angular cheilitis, keratotic plaques on the extensor surface of the extremities, inguinal hernia, cryptorchidism, short stature, seizures, and psychomotor developmental delay.[166] Mutations in the *MBTPS2* gene cause this syndrome presumably by resulting in impaired cholesterol homeostasis and endoplasmic reticulum stress.[167]

ICHTHYOSIS PREMATURITY SYNDROME

Complications such as polyhydramnios in the second trimester of pregnancy occur in the ichthyosis prematurity syndrome (OMIM #608649), resulting in premature delivery of infants with erythrodermic, edematous, caseous scaling skin resembling excessive vernix caseosa, respiratory distress, and transient peripheral eosinophilia.[168] The respiratory signs, erythema, and skin changes resolve, leaving signs of atopy and dry, scaly skin with follicular accentuation more pronounced than is seen in keratosis pilaris. Mutations in the fatty acid transport protein 4 gene *FATP4* (*SLC27*) cause this disorder.[169,170]

MULTIPLE SULFATASE DEFICIENCY

Multiple sulfatase deficiency (OMIM #272200) is a rare autosomal recessive disorder. Clinical features include neurologic deterioration, skeletal abnormalities, facial dysmorphism, and ichthyosis resembling that seen in X-linked steroid sulfatase deficiency. The disorder is a composite of the clinical features of both metachromatic leukodystrophy and a mucopolysaccharidosis. It is characterized by a deficiency of both lysosomal (arylsulfatases A and B) and microsomal (arylsulfatase C/steroid sulfatase of X-linked ichthyosis) arylsulfatases, resulting in the accumulation of sulfatides, glycosaminoglycans, sphingolipids, and steroid sulfates in tissues and body fluids.[171] The gene coding for sulfatase modifying factor 1 (*SUMF1*), which generates a unique amino acid derivative, C_{α}-formylglycine, necessary for catalytic activity of all sulfatases, is mutated in individuals with multiple sulfatase deficiency.[172,173]

REFSUM DISEASE

Refsum disease (heredopathia atactica polyneuritiformis; OMIM #266500) is a rare, progressive, degenerative disorder of lipid metabolism resulting from the failure to break down dietary phytanic acid and its subsequent accumulation in tissues. This autosomal recessive condition affects mostly Scandinavians and populations originating from Northern Europe. Clinical manifestations include retinitis pigmentosa, peripheral neuropathy, cerebellar ataxia, cranial nerve dysfunction (neural deafness, anosmia), miosis, electrocardiographic abnormalities, cardiomyopathy, renal tubular dysfunction, and skeletal abnormalities (epiphyseal dysplasia). Ichthyosis, which is variable, generally develops after the neurologic and ophthalmologic manifestations. Often there are small white scales over the trunk and extremities resembling IV. Routine hematoxylin and eosin histologic examination shows variably sized vacuoles in the epidermal basal and suprabasilar cells, which correspond to lipid accumulation seen with lipid stains of frozen sections.[174]

Phytanic acid (a 20-carbon, branched-chain fatty acid) is derived from a variety of dietary sources including dairy products, ruminant fats, and chlorophyll-containing foods, although chlorophyll-bound phytol cannot be absorbed in humans. The disease is caused by a deficiency of PhyH, a peroxisomal protein that catalyzes the α-oxidation of phytanic acid. PhyH deficiency leads to the accumulation of phytanic acid in the serum and tissues, where it substitutes for the fatty acids normally present. Although mutations in *PAHX*, the gene encoding PhyH, are responsible for most cases of Refsum disease, there is genetic heterogeneity.[175] The Refsum phenotype has been described in patients with mutations *PEX7*, the affected gene in RCDP (see earlier). Phytanic acid and other chlorophyll metabolites bind the *retinoid X receptor* (RXR), as does its natural ligand, 9-*cis*-retinoic acid, and they may be physiologically active in coordinating cellular metabolism through RXR-dependent signaling pathways. However, the role of RXR in the pathogenesis of Refsum disease is unclear. Refsum disease is distinguished from infantile Refsum disease, a fulminant generalized peroxisomal biogenesis disorder in which young children present with severe neurologic abnormalities,

mental retardation, hepatomegaly, and dysmorphic features in addition to the other signs of adult Refsum disease.[176]

Refsum disease is a rare example of an ichthyosis whose pathophysiology was understood well enough before identification of the causative gene to make rational treatment recommendations. The diagnosis can be made by detection of elevated levels of plasma phytanic acid. In children who do not have elevated plasma levels of phytanic acid, the diagnosis may be made by measuring PhyH activity in cultured fibroblasts.[177] Treatment includes dietary restriction of foods containing phytanic acid and its precursors. In the clinical setting of a delayed onset of ichthyosis in association with neurologic impairment, this disorder should be considered because therapy can arrest progression.

SJÖGREN-LARSSON SYNDROME

In 1957, Sjögren and Larsson reported on 13 families from north Sweden with a syndrome of congenital ichthyosis, spastic paralysis, and mental retardation. Sjögren-Larsson syndrome (SLS; OMIM #270200) is a rare, autosomal recessive disorder that presents at birth with an ichthyosis that may range from fine scaling to generalized hyperkeratosis. Erythema may be present at birth but tends to gradually clear by 1 year of age. Collodion-like membranes are rarely seen. The ichthyosis manifests as fine scale, large scale, or thickening of the stratum corneum without scale. Pruritus is common. Thickened areas may be yellow to brown in color and have a lichenified appearance with accentuated skin markings (Fig. 47-25). The most involved areas are the sides and back of the neck, lower abdomen, and flexures. Hair, nails, and the ability to sweat are generally normal.[178] During the first 2 to 3 years, neurologic manifestations of spastic diplegia or tetraplegia and mental retardation develop and can be accompanied by speech defects and seizures. A characteristic ophthalmologic finding is the presence of glistening white dots in the macula of the retina. These occur after 1 year of age and may not be present in all patients.

SLS is caused by fatty alcohol:NAD oxidoreductase (FAO) deficiency. FAO is a complex enzyme with two separate proteins that sequentially catalyze the oxidation of fatty alcohol to fatty aldehyde and subsequently to fatty acid. Mutations found in the *ALDH3A2* gene confirmed the role for this enzyme in the cause of this disorder and the importance of this pathway for normal desquamation. *ALDH3A2* is a microsomal enzyme that catalyzes the oxidation of medium- and long-chain aliphatic aldehydes derived from metabolism of fatty alcohol, phytanic acid, ether glycerolipids, and

Figure 47-25 Autosomal recessive congenital ichthyosis, Sjögren-Larsson syndrome (*ALDH3A2* mutations). Generalized smooth hyperkeratosis *(keratoderma)* results in large adherent scales on extremities and accentuated linear surface markings. There is usually little erythema, but scratching produces fine white scale and erythema.

leukotriene B4.[179] The identification of decreased fibroblast FAO activity in a family with atypical cutaneous findings (lack of ichthyosis or discrete plaques rather than generalized ichthyosis) has expanded the spectrum of clinical phenotypes associated with abnormal FAO activity.[180]

TRICHOTHIODYSTROPHY

Trichothiodystrophy (TTD; OMIM #601675, also see Chap. 130) is an autosomal recessive disorder that includes a broad spectrum of clinical phenotypes linked by the characteristic features of sulfur deficient, brittle hair that exhibits alternating birefringence (tiger tail banding) when viewed under polarizing microscopy (Fig. 47-26).[181] The spectrum of clinical involvement is broad, ranging from only hair to severe multisystem abnormalities. A survey of 112 cases reported in the literature found ichthyosis (65%) as the most common skin finding followed by photosensitivity (42%). Of the patients with ichthyosis, about one third presented with a collodion membrane at birth. Erythroderma, when present at birth, usually decreases over weeks with evolution into a generalized ichthyosis, usually without erythema, which varies from small fine, scaling to large, dark yellow-brown hyperkeratosis (see Fig. 47-17B).[182,183] There may be flexural sparing and palmoplantar keratoderma. Nail findings are found in more than half of the patients and include dystrophic nails (ridging, splitting) (see Fig. 47-17A), hypoplasia, brittle nails, and koilonychia.[184] Ectropion usually does not occur. Photosensitivity can range from subtle to severe. Other common findings in TTD include intellectual impairment, short stature, microcephaly, characteristic facial features (protruding ears, micrognathia), recurrent infections, and cataracts.

A series of mnemonics have been used to describe the constellation of findings as BIDS (*b*rittle hair, *i*ntellectual impairment, *d*ecreased fertility, and *s*hort stature); patients who also have *i*chthyosis have been called IBIDS, and with the addition of *p*hotosensitivity, PIBI(D)S has been used.[185] However, these terms do not account for the other multisystem findings that are commonly present.

The majority of TTD patients with ichthyosis have a defect in the function or activity of TFIIH, a protein complex involved in DNA repair and transcription. Most mutations are in *ERCC2*. Other mutations affect *ERCC3*, *GTF2H5*, and *GTF2E2*. Two other genes causing TTD, *MPLKIP* and *RNF113A*, have not been associated with ichthyosis and their function is unknown.[186-190] Although many patients with

Figure 47-26 Autosomal recessive congenital ichthyosis, trichothiodystrophy (*ERCC2*, *ERCC3*, *GTF2H5*, *GTF2E2* mutations). Beyond the newborn period, there is usually very mild generalized hyperkeratosis and minimal erythema. Hair shows characteristic alternating birefringence in polarized light.

TTD have photosensitivity, in contrast to xeroderma pigmentosum, these photosensitive patients have not been observed to be at high risk for the development of skin cancer. Nucleotide excision repair is one normal cellular mechanism by which structural DNA damage (eg, ultraviolet-induced cyclobutane pyrimidine dimers) is removed and repaired (see Chaps. 20 and 134).

ACQUIRED ICHTHYOSIS

The development of ichthyosis in adulthood can be a manifestation of systemic disease and has been described in association with malignancies, drugs, endocrine and metabolic disease, malnutrition, HIV and other infections, and autoimmune conditions.[191-194] The granular layer is often attenuated in this disorder, and the scale often resembles to that seen in mild IV. Although Hodgkin disease is the most common malignancy reported with acquired ichthyosis, non-Hodgkin lymphomas and a variety of other malignancies have also been observed. Histology may be diagnostic in acquired ichthyosis associated with mycosis fungoides.[195] Skin involvement may follow the course of malignancy and clear with effective cancer treatment. Acquired ichthyosis is commonly seen in association with AIDS; ichthyotic or xerotic skin has been observed in up to 30% of patients with AIDS.[196] A study of HIV-1–positive intravenous drug users found acquired ichthyosis occurred only after profound helper T cell depletion, more frequently with coinfection with human T-cell leukemia or lymphoma virus type II, and suggested that it may be a marker for concomitant infection with both viruses.[197]

In acquired ichthyosis occurring in association with sarcoidosis, skin biopsy can be diagnostic, showing noncaseating granulomas in the dermis.[198] Acquired ichthyosis may be a marker of autoimmune disease, occurring with systemic lupus erythematosus, dermatomyositis, mixed connective tissue disease, and eosinophilic fasciitis.[199,200] It has been described in bone marrow transplant recipients, in whom it may be related to graft-versus-host disease.[201]

Although occurrence in association with cholesterol-lowering agents (nicotinic acid, triparanol) highlights the relationship between cholesterol metabolism and normal desquamation, acquired ichthyosis has been observed with a variety of drugs, including cimetidine, clofazimine, hydroxyurea, cholesterol-lowering agents, and others.[202,203] Kava is a psychoactive beverage made from the root of a pepper plant and used for thousands of years by Pacific Islanders. Heavy kava drinkers can acquire a reversible ichthyosiform eruption called kava dermopathy. In Western nations, kava is sold in health food stores as a relaxant.[204]

PITYRIASIS ROTUNDA

Sharply demarcated, round or oval scaly patches with hypo- or hyperpigmentation are seen in pityriasis rotunda. Although this uncommon disorder is usually acquired, occasional familial cases have been described.[205]

RETICULATED PAPILLOMATOSIS OF GOUGEROT AND CARTEAUD

Confluent and reticulated papillomatosis of Gougerot and Carteaud is an uncommon but distinctive acquired ichthyosiform dermatosis seen in young adults and characterized by persistent brown, scaly macules, papules, patches, and plaques. Lesions tend to be localized predominantly on the neck, upper trunk (intermammary and interscapular regions), and axillae, where they tend to be confluent and become reticulated towards the periphery. The lesions bear a clinical resemblance to tinea versicolor, a skin infection with *Pityrosporum* spp. A variety of treatment approaches have been reported, including topical (keratolytics, derivatives of vitamin A and D, antimicrobials) and systemic (antibiotics, retinoids) agents. Minocycline has been suggested as a first-line treatment; successful retreatment of recurrences supports the concept that this condition is an abnormal response to an infection or inflammation.[206,207]

RESOURCES

The Foundation for Ichthyosis and Related Skin Types (FIRST) (phone: 800-545-3286; http://www.firstskinfoundation.org; email: info@firstskinfoundation.org.) provides support and information for affected individuals, family members, friends, and health care provider.

The Genetic Testing Registry (https://www.ncbi.nlm.nih.gov/gtr/) provides disease reviews, genetic testing resources, and educational materials.

Online Mendelian Inheritance in Man, (http://www.ncbi.nlm.nih.gov/entrez/query.fcgi?db=OMIM) (trademark Johns Hopkins University), a catalog of human genes and genetic disorders, is a useful reference with links to additional resources.

The Registry for Ichthyosis and Related Disorders is a resource for investigators to improve diagnosis and treatment of these disorders (Yale University, Department of Dermatology, PO Box 208059, 333 Cedar Street, New Haven, CT 06510; email: ichthyosisregistry@yale.edu).

ACKNOWLEDGMENTS

The authors are grateful to Philip Fleckman and John J. DiGiovanna, who authored the prior version of this chapter and have provided text, tables, and photographs that appear here.

REFERENCES

1. Willan R. *On Cutaneous Diseases. [Pt. 1].* Brown & Merritt, London: Kimber and Conrad; 1809:1798.
2. Siemens HW. Studies on the heredity of skin diseases XI ichthyosis congenita. *Archiv Fur Dermatologie Und Syphilis.* 1929;158(1):111-127.
3. Wells RS, Kerr CB. Genetic classification of ichthyosis. *Arch Dermatol.* 1965;92(1):1-6.
4. Wells RS, Kerr CB. Clinical features of autosomal dominant and sex-linked ichthyosis in an English population. *Br Med J.* 1966;1(5493):947-950.
5. Traupe H. The Ichthyoses: A Guide to Clinical Diagnosis, Genetic Counseling, and Therapy. Berlin; New York: Springer-Verlag; 1989.
6. Frost P, Van Scott EJ. Ichthyosiform dermatoses. Classification based on anatomic and biometric observations. *Arch Dermatol.* 1966;94(2):113-126.
7. Williams ML, Elias PM. Genetically transmitted, generalized disorders of cornification. The ichthyoses. *Dermatol Clin.* 1987;5(1):155-178.
8. Marukian NV, Choate KA. Recent advances in understanding ichthyosis pathogenesis. *F1000Res.* 2016;5.
9. Oji V, Tadini G, Akiyama M, et al. Revised nomenclature and classification of inherited ichthyoses: results of the First Ichthyosis Consensus Conference in Soreze 2009. *J Am Acad Dermatol.* 2010;63(4):607-641.
10. Ross R, DiGiovanna JJ, Capaldi L, et al. Histopathologic characterization of epidermolytic hyperkeratosis: a systematic review of histology from the National Registry for Ichthyosis and Related Skin Disorders. *J Am Acad Dermatol.* 2008;59(1):86-90.
11. Boyden LM, Craiglow BG, Zhou J, et al. Dominant de novo mutations in gja1 cause erythrokeratodermia variabilis et progressiva, without features of oculodentodigital dysplasia. *J Invest Dermatol.* 2015;135(6):1540-1547.
12. Boyden LM, Kam CY, Hernandez-Martin A, et al. Dominant de novo DSP mutations cause erythrokeratodermia-cardiomyopathy syndrome. *Hum Mol Genet.* 2016;25(2):348-357.
13. Fassihi H, McGrath JA. Prenatal diagnosis of epidermolysis bullosa. *Dermatol Clin.* 2010;28(2):231-237, viii.
14. Tabor A, Alfirevic Z. Update on procedure-related risks for prenatal diagnosis techniques. *Fetal Diagn Ther.* 2010;27(1):1-7.
15. Yanagi T, Akiyama M, Sakai K, et al. DNA-based prenatal exclusion of harlequin ichthyosis. *J Am Acad Dermatol.* 2008;58(4):653-656.
16. Meredith S, Kaposy C, Miller VJ, et al. Impact of the increased adoption of prenatal cfDNA screening on non-profit patient advocacy organizations in the United States. *Prenat Diagn.* 2016;36(8):714-719.
17. Buysse K, Beulen L, Gomes I, et al. Reliable noninvasive prenatal testing by massively parallel sequencing of circulating cell-free DNA from maternal plasma processed up to 24h after venipuncture. *Clin Biochem.* 2013;46(18):1783-1786.
18. Digiovanna JJ, Bale SJ. Epidermolytic hyperkeratosis—applied molecular-genetics. *J Invest Dermatol.* 1994;102(3):390-394.
19. Meibodi NT, Nahidi Y, Javidi Z. Epidermolytic hyperkeratosis in inflammatory linear verrucous epidermal nevus. *Indian J Dermatol.* 2011;56(3):309-312.
20. Mirza H, Kumar A, Craiglow BG, et al. Mutations affecting keratin 10 surface-exposed residues highlight the structural basis of phenotypic variation in epidermolytic ichthyosis. *J Invest Dermatol.* 2015;135(12):3041-3050.
21. Huber M, Rettler I, Bernasconi K, et al. Mutations of keratinocyte transglutaminase in lamellar ichthyosis. *Science.* 1995;267(5197):525-528.
22. Russell LJ, DiGiovanna JJ, Rogers GR, et al. Mutations in the gene for transglutaminase 1 in autosomal recessive lamellar ichthyosis. *Nat Genet.* 1995;9(3):279-283.
23. Fischer J. Autosomal recessive congenital ichthyosis. *J Invest Dermatol.* 2009;129(6):1319-1321.
24. Chavanas S, Bodemer C, Rochat A, et al. Mutations in SPINK5, encoding a serine protease inhibitor, cause Netherton syndrome. *Nat Genet.* 2000;25(2):141-142.
25. Smith FJ, Irvine AD, Terron-Kwiatkowski A, et al. Loss-of-function mutations in the gene encoding filaggrin cause ichthyosis vulgaris. *Nat Genet.* 2006;38(3):337-342.
26. Paller AS, Renert-Yuval Y, Suprun M, et al. An IL-17-dominant immune profile is shared across the major orphan forms of ichthyosis. *J Allergy Clin Immunol.* 2017;139(1):152-165.
27. Duckney P, Wong HK, Serrano J, et al. The role of the skin barrier in modulating the effects of common skin microbial species on the inflammation, differentiation and proliferation status of epidermal keratinocytes. *BMC Res Notes.* 2013;6:474.
28. Traupe H. Ichthyoses and related keratinization disorders. Management, clinical features and genetics. *Hautarzt.* 2004;55(10):931-941.
29. Fleckman P. Management of the ichthyoses. *Skin Therapy Lett.* 2003;8(6):3-7.
30. Germann R, Schindera I, Kuch M, et al. Life threatening salicylate poisoning caused by percutaneous absorption in severe ichthyosis vulgaris. *Hautarzt.* 1996;47(8):624-627.
31. Nguyen V, Cunningham BB, Eichenfield LF, et al. Treatment of ichthyosiform diseases with topically applied tazarotene: risk of systemic absorption. *J Am Acad Dermatol.* 2007;57(5 suppl):S123-125.
32. Borzyskowski M, Grant DB, Wells RS. Cushing's syndrome induced by topical steroids used for the treatment of non-bullous ichthyosiform erythroderma. *Clin Exp Dermatol.* 1976;1(4):337-342.
33. Moskowitz DG, Fowler AJ, Heyman MB, et al. Pathophysiologic basis for growth failure in children with ichthyosis: an evaluation of cutaneous ultrastructure, epidermal permeability barrier function, and energy expenditure. *J Pediatr.* 2004;145(1):82-92.
34. Verfaille CJ, Vanhoutte FP, Blanchet-Bardon C, et al. Oral liarozole vs. acitretin in the treatment of ichthyosis: a phase II/III multicentre, double-blind, randomized, active-controlled study. *Br J Dermatol.* 2007;156(5):965-973.
35. Palmer CN, Irvine AD, Terron-Kwiatkowski A, et al. Common loss-of-function variants of the epidermal barrier protein filaggrin are a major predisposing factor for atopic dermatitis. *Nat Genet.* 2006;38(4):441-446.
36. Brown SJ, Relton CL, Liao H, et al. Filaggrin haploinsufficiency is highly penetrant and is associated with increased severity of eczema: further delineation of the skin phenotype in a prospective

epidemiological study of 792 school children. *Br J Dermatol.* 2009;161(4):884-889.
37. Dale BA, Holbrook KA, Steinert PM. Assembly of stratum corneum basic protein and keratin filaments in macrofibrils. *Nature.* 1978;276(5689):729-731.
38. Rice RH, Bradshaw KM, Durbin-Johnson BP, et al. Distinguishing ichthyoses by protein profiling. *PLoS One.* 2013;8(10):e75355.
39. Sybert VP, Dale BA, Holbrook KA. Ichthyosis vulgaris: identification of a defect in synthesis of filaggrin correlated with an absence of keratohyaline granules. *J Invest Dermatol.* 1985;84(3):191-194.
40. Sandilands A, Sutherland C, Irvine AD, et al. Filaggrin in the frontline: role in skin barrier function and disease. *J Cell Sci.* 2009;122(Pt 9):1285-1294.
41. van den Oord RA, Sheikh A. Filaggrin gene defects and risk of developing allergic sensitisation and allergic disorders: systematic review and meta-analysis. *BMJ.* 2009;339:b2433.
42. Mevorah B, Krayenbuhl A, Bovey EH, et al. Autosomal dominant ichthyosis and X-linked ichthyosis. Comparison of their clinical and histological phenotypes. *Acta Derm Venereol.* 1991;71(5):431-434.
43. Cuevas-Covarrubias SA, Kofman-Alfaro SH, Palencia AB, et al. Accuracy of the clinical diagnosis of recessive X-linked ichthyosis vs ichthyosis vulgaris. *J Dermatol.* 1996;23(9):594-597.
44. Hand JL, Runke CK, Hodge JC. The phenotype spectrum of X-linked ichthyosis identified by chromosomal microarray. *J Am Acad Dermatol.* 2015;72(4):617-627.
45. Marinkovic-Ilsen A, Koppe JG, Jobsis AC, et al. Enzymatic basis of typical X-linked ichthyosis. *Lancet.* 1978;2(8099):1097.
46. Shapiro LJ, Weiss R, Buxman MM, et al. Enzymatic basis of typical X-linked ichthyosis. *Lancet.* 1978;2(8093):756-757.
47. Fernandes NF, Janniger CK, Schwartz RA. X-linked ichthyosis: an oculocutaneous genodermatosis. *J Am Acad Dermatol.* 2010;62(3):480-485.
48. Merrett JD, Wells RS, Kerr CB, et al. Discriminant function analysis of phenotype variates in ichthyosis. *Am J Hum Genet.* 1967;19(4):575-585.
49. Jay B, Blach RK, Wells RS. Ocular manifestations of ichthyosis. *Br J Ophthalmol.* 1968;52(3):217-226.
50. Sever RJ, Frost P, Weinstein G. Eye changes in ichthyosis. *JAMA.* 1968;206(10):2283-2286.
51. Lykkesfeldt G, Bennett P, Lykkesfeldt AE, et al. Testis cancer. Ichthyosis constitutes a significant risk factor. *Cancer.* 1991;67(3):730-734.
52. Rose FA. Review: the mammalian sulphatases and placental sulphatase deficiency in man. *J Inherit Metab Dis.* 1982;5(3):145-152.
53. Epstein EH Jr, Williams ML, Elias PM. Steroid sulfatase, X-linked ichthyosis, and stratum corneum cell cohesion. *Arch Dermatol.* 1981;117(12):761-763.
54. Epstein EH Jr, Bonifas JM. Recessive X-linked ichthyosis: lack of immunologically detectable steroid sulfatase enzyme protein. *Hum Genet.* 1985;71(3):201-205.
55. Milstone LM. Epidermal desquamation. *J Dermatol Sci.* 2004;36(3):131-140.
56. Webster D, France JT, Shapiro LJ, et al. X-linked ichthyosis due to steroid-sulphatase deficiency. *Lancet.* 1978;1(8055):70-72.
57. Ballabio A, Zollo M, Carrozzo R, et al. Deletion of the distal short arm of the X chromosome (Xp) in a patient with short stature, chondrodysplasia punctata, and X-linked ichthyosis due to steroid sulfatase deficiency. *Am J Med Genet.* 1991;41(2):184-187.
58. Paige DG, Emilion GG, Bouloux PM, et al. A clinical and genetic study of X-linked recessive ichthyosis and contiguous gene defects. *Br J Dermatol.* 1994;131(5):622-629.
59. Milstone LM. Scaly skin and bath pH: rediscovering baking soda. *J Am Acad Dermatol.* 2010;62(5):885-886.
60. Milstone LM, Miller K, Haberman M, et al. Incidence of moderate to severe ichthyosis in the United States. *Arch Dermatol.* 2012;148(9):1080-1081.
61. Theiler M, Mann C, Weibel L. Self-healing collodion baby. *J Pediatr.* 2010;157(1):169-169;e161.
62. Vahlquist A, Bygum A, Ganemo A, et al. Genotypic and clinical spectrum of self-improving collodion ichthyosis: ALOX12B, ALOXE3, and TGM1 mutations in Scandinavian patients. *J Invest Dermatol.* 2010;130(2):438-443.
63. Ozturk A, Caksen H, Cetin N, et al. A retrospective study on 16 collodion babies. *Turk J Pediatr.* 1997;39(1):55-59.
64. Nguyen MA, Gelman A, Norton SA. Practical events in the management of a collodion baby. *JAMA Dermatol.* 2015;151(9):1031-1032.
65. Glick JB, Craiglow BG, Choate KA, et al. Improved management of harlequin ichthyosis with advances in neonatal intensive care. *Pediatrics.* 2017; 139(1).
66. Simpson JR. Congenital ichthyosiform erythrodermia. *Trans St Johns Hosp Dermatol Soc.* 1964;50:93-104.
67. Williams ML, Elias PM. Heterogeneity in autosomal recessive ichthyosis. Clinical and biochemical differentiation of lamellar ichthyosis and nonbullous congenital ichthyosiform erythroderma. *Arch Dermatol.* 1985;121(4):477-488.
68. Bernhardt M, Baden HP. Report of a family with an unusual expression of recessive ichthyosis. Review of 42 cases. *Arch Dermatol.* 1986;122(4):428-433.
69. Jacyk WK. Bathing-suit ichthyosis. A peculiar phenotype of lamellar ichthyosis in South African blacks. *Eur J Dermatol.* 2005;15(6):433-436.
70. Oji V, Hautier JM, Ahvazi B, et al. Bathing suit ichthyosis is caused by transglutaminase-1 deficiency: evidence for a temperature-sensitive phenotype. *Hum Mol Genet.* 2006;15(21):3083-3097.
71. Hackett BC, Fitzgerald D, Watson RM, et al. Genotype-phenotype correlations with TGM1: clustering of mutations in the bathing suit ichthyosis and self-healing collodion baby variants of lamellar ichthyosis. *Br J Dermatol.* 2010;162(2):448-451.
72. Marukian NV, Hu RH, Craiglow BG, et al. Expanding the Genotypic spectrum of bathing suit ichthyosis. *JAMA Dermatol.* 2017;153(6):537-543.
73. Rajpopat S, Moss C, Mellerio J, et al. Harlequin ichthyosis: a review of clinical and molecular findings in 45 cases. *Arch Dermatol.* 2011;147(6):681-686.
74. Milstone LM, Choate KA. Improving outcomes for harlequin ichthyosis. *J Am Acad Dermatol.* 2013;69(5):808-809.
75. Hurwitz S, Kirsch N, McGuire J. Reevaluation of ichthyosis and hair shaft abnormalities. *Arch Dermatol.* 1971;103(3):266-271.
76. Dev T, Raman Kumar M, Sethuraman G. Ichthyosis linearis circumflexa with bamboo hair: challenges in the diagnosis and management. *BMJ Case Rep.* 2017;2017.

77. Salodkar AD, Choudhary SV, Jadwani G, et al. Bamboo hair in Netherton's syndrome. *Int J Trichology.* 2009;1(2):143-144.
78. Ito M, Ito K, Hashimoto K. Pathogenesis in trichorrhexis invaginata (bamboo hair). *J Invest Dermatol.* 1984;83(1):1-6.
79. Renner ED, Hartl D, Rylaarsdam S, et al. Comel-Netherton syndrome defined as primary immunodeficiency. *J Allergy Clin Immunol.* 2009;124(3): 536-543.
80. Nemes Z, Marekov LN, Fesus L, et al. A novel function for transglutaminase 1: attachment of long-chain omega-hydroxyceramides to involucrin by ester bond formation. *Proc Natl Acad Sci U S A.* 1999; 96(15):8402-8407.
81. Choate KA, Medalie DA, Morgan JR, et al. Corrective gene transfer in the human skin disorder lamellar ichthyosis. *Nat Med.* 1996;2(11):1263-1267.
82. Aufenvenne K, Larcher F, Hausser I, et al. Topical enzyme-replacement therapy restores transglutaminase 1 activity and corrects architecture of transglutaminase-1-deficient skin grafts. *Am J Hum Genet.* 2013;93(4):620-630.
83. Jobard F, Lefevre C, Karaduman A, et al. Lipoxygenase-3 (ALOXE3) and 12(R)-lipoxygenase (ALOX12B) are mutated in non-bullous congenital ichthyosiform erythroderma (NCIE) linked to chromosome 17p13.1. *Hum Mol Genet.* 2002;11(1):107-113.
84. Munoz-Garcia A, Thomas CP, Keeney DS, et al. The importance of the lipoxygenase-hepoxilin pathway in the mammalian epidermal barrier. *Biochim Biophys Acta.* 2014;1841(3):401-408.
85. Akiyama M, Sugiyama-Nakagiri Y, Sakai K, et al. Mutations in lipid transporter ABCA12 in harlequin ichthyosis and functional recovery by corrective gene transfer. *J Clin Invest.* 2005;115(7):1777-1784.
86. Kelsell DP, Norgett EE, Unsworth H, et al. Mutations in ABCA12 underlie the severe congenital skin disease harlequin ichthyosis. *Am J Hum Genet.* 2005; 76(5):794-803.
87. Sakai K, Akiyama M, Yanagi T, et al. ABCA12 is a major causative gene for non-bullous congenital ichthyosiform erythroderma. *J Invest Dermatol.* 2009;129(9):2306-2309.
88. Lefevre C, Audebert S, Jobard F, et al. Mutations in the transporter ABCA12 are associated with lamellar ichthyosis type 2. *Hum Mol Genet.* 2003;12(18): 2369-2378.
89. Milner ME, O'Guin WM, Holbrook KA, Dale BA. Abnormal lamellar granules in harlequin ichthyosis. *J Invest Dermatol.* 1992;99(6):824-829.
90. Walley AJ, Chavanas S, Moffatt MF, et al. Gene polymorphism in Netherton and common atopic disease. *Nat Genet.* 2001;29(2):175-178.
91. Fortugno P, Furio L, Teson M, et al. The 420K LEKTI variant alters LEKTI proteolytic activation and results in protease deregulation: implications for atopic dermatitis. *Hum Mol Genet.* 2012;21(19):4187-4200.
92. Fölster-Holst R, Swensson O, Stockfleth E, et al. Comèl-Netherton syndrome complicated by papillomatous skin lesions containing human papillomaviruses 51 and 52 and plane warts containing human papillomavirus 16. *Br J Dermatol.* 1999;140(6):1139-1143.
93. Craiglow BG, Choate KA, Milstone LM. Topical tazarotene for the treatment of ectropion in ichthyosis. *JAMA Dermatol.* 2013;149(5):598-600.
94. Pigg MH, Bygum A, Ganemo A, et al. Spectrum of autosomal recessive congenital ichthyosis in Scandinavia: clinical characteristics and novel and recurrent mutations in 132 patients. *Acta Derm Venereol.* 2016;96(7):932-937.
95. Shibata A, Ogawa Y, Sugiura K, et al. High survival rate of harlequin ichthyosis in Japan. *J Am Acad Dermatol.* 2014;70(2):387-388.
96. Sprecher E, Tesfaye-Kedjela A, Ratajczak P, et al. Deleterious mutations in SPINK5 in a patient with congenital ichthyosiform erythroderma: molecular testing as a helpful diagnostic tool for Netherton syndrome. *Clin Exp Dermatol.* 2004;29(5): 513-517.
97. Geyer AS, Ratajczak P, Pol-Rodriguez M, et al. Netherton syndrome with extensive skin peeling and failure to thrive due to a homozygous frameshift mutation in SPINK5. *Dermatology.* 2005;210(4): 308-314.
98. Allen A, Siegfried E, Silverman R, et al. Significant absorption of topical tacrolimus in 3 patients with Netherton syndrome. *Arch Dermatol.* 2001;137(6): 747-750.
99. Brocq L. *Erythrodermie congénitale ichthyosiforme avec hyperépidermotrophie, par L. Brocq. Ann Derm Syph*. Masson; 3:1-31,1902.
100. DiGiovanna JJ, Bale SJ. Clinical heterogeneity in epidermolytic hyperkeratosis. *Arch Dermatol.* 1994;130(8):1026-1035.
101. Paller AS, Syder AJ, Chan YM, et al. Genetic and clinical mosaicism in a type of epidermal nevus. *N Engl J Med.* 1994;331(21):1408-1415.
102. Uchiyama K, Nakanishi G, Fujimoto N, et al. Localized linear epidermolytic epidermal nevus of male genitalia with a recurrent keratin 10 mutation, p.Arg156His. *Eur J Dermatol.* 2013;23(4):557-558.
103. Nazzaro V, Ermacora E, Santucci B, et al. Epidermolytic hyperkeratosis: generalized form in children from parents with systematized linear form. *Br J Dermatol.* 1990;122(3):417-422.
104. Chassaing N, Kanitakis J, Sportich S, et al. Generalized epidermolytic hyperkeratosis in two unrelated children from parents with localized linear form, and prenatal diagnosis. *J Invest Dermatol.* 2006;126(12):2715-2717.
105. Rothnagel JA, Traupe H, Wojcik S, et al. Mutations in the rod domain of keratin 2e in patients with ichthyosis bullosa of Siemens. *Nat Genet.* 1994;7(4):485-490.
106. McLean WH, Morley SM, Lane EB, et al. Ichthyosis bullosa of Siemens—a disease involving keratin 2e. *J Invest Dermatol.* 1994;103(3):277-281.
107. Sahn EE, Weimer CE Jr, Garen PD. Annular epidermolytic ichthyosis: a unique phenotype. *J Am Acad Dermatol.* 1992;27(2 Pt 2):348-355.
108. Jha A, Taneja J, Ramesh V, et al. Annular epidermolytic ichthyosis: a rare phenotypic variant of bullous congenital ichthyosiform erythroderma. *Indian J Dermatol Venereol Leprol.* 2015;81(2):194-197.
109. Sybert VP, Francis JS, Corden LD, et al. Cyclic ichthyosis with epidermolytic hyperkeratosis: a phenotype conferred by mutations in the 2B domain of keratin K1. *Am J Hum Genet.* 1999;64(3):732-738.
110. Joh GY, Traupe H, Metze D, et al. A novel dinucleotide mutation in keratin 10 in the annular epidermolytic ichthyosis variant of bullous congenital ichthyosiform erythroderma. *J Invest Dermatol.* 1997;108(3):357-361.

111. Choate KA, Milstone LM. Phenotypic expansion in ichthyosis with confetti. *JAMA Dermatol.* 2015; 151(1):15-16.
112. Lim YH, Qiu J, Saraceni C, et al. Genetic reversion via mitotic recombination in ichthyosis with confetti due to a KRT10 polyalanine frameshift mutation. *J Invest Dermatol.* 2016;136(8):1725-1728.
113. Choate KA, Lu Y, Zhou J, et al. Frequent somatic reversion of KRT1 mutations in ichthyosis with confetti. *J Clin Invest.* 2015;125(4):1703-1707.
114. Choate KA, Lu Y, Zhou J, et al. Mitotic recombination in patients with ichthyosis causes reversion of dominant mutations in KRT10. *Science.* 2010;330(6000):94-97.
115. Cheng J, Syder AJ, Yu QC, et al. The genetic basis of epidermolytic hyperkeratosis: a disorder of differentiation-specific epidermal keratin genes. *Cell.* 1992;70(5):811-819.
116. Li H, Torma H. Retinoids reduce formation of keratin aggregates in heat-stressed immortalized keratinocytes from an epidermolytic ichthyosis patient with a KRT10 mutation*. *Acta Derm Venereol.* 2013;93(1):44-49.
117. Fuchs E, Coulombe P, Cheng J, et al. Genetic bases of epidermolysis bullosa simplex and epidermolytic hyperkeratosis. *J Invest Dermatol.* 1994; 103(5 suppl):25S-30S.
118. Hotz A, Oji V, Bourrat E, et al. Expanding the clinical and genetic spectrum of KRT1, KRT2 and KRT10 mutations in keratinopathic ichthyosis. *Acta Derm Venereol.* 2016;96(4):473-478.
119. Reis A, Hennies HC, Langbein L, et al. Keratin 9 gene mutations in epidermolytic palmoplantar keratoderma (EPPK). *Nat Genet.* 1994;6(2):174-179.
120. Ogawa M, Akiyama M. Successful topical adapalene treatment for the facial lesions of an adolescent case of epidermolytic ichthyosis. *J Am Acad Dermatol.* 2014;71(3):e103-105.
121. El-Ramly M, Zachariae H. Long-term oral treatment of two pronounced ichthyotic conditions: lamellar ichthyosis and epidermolytic hyperkeratosis with the aromatic retinoid, Tigason (RO 10-9359). *Acta Derm Venereol.* 1983;63(5):452-456.
122. Digiovanna JJ, Mauro T, Milstone LM, et al. Systemic retinoids in the management of ichthyoses and related skin types. *Dermatol Ther.* 2013;26(1):26-38.
123. Rogers M. Erythrokeratodermas: a classification in a state of flux? *Australas J Dermatol.* 2005;46(3): 127-141; quiz 142.
124. Lilly E, Sellitto C, Milstone LM, et al. Connexin channels in congenital skin disorders. *Semin Cell Dev Biol.* 2016;50:4-12.
125. van Steensel MA, Oranje AP, van der Schroeff JG, et al. The missense mutation G12D in connexin30.3 can cause both erythrokeratodermia variabilis of Mendes da Costa and progressive symmetric erythrokeratodermia of Gottron. *Am J Med Genet A.* 2009;149A(4):657-661.
126. Darier MJ. Erythokeratodermia verruqueuse, symétrique et progressive. *Bull Soc Fr Dermatol Syphiligr.* 1911(22):252.
127. Ruiz-Maldonado R, Tamayo L, del Castillo V, et al. Erythrokeratodermia progressiva symmetrica: report of 10 cases. *Dermatologica.* 1982;164(2): 133-141.
128. Richard G, Brown N, Rouan F, et al. Genetic heterogeneity in erythrokeratodermia variabilis: novel mutations in the connexin gene GJB4 (Cx30.3) and genotype-phenotype correlations. *J Invest Dermatol.* 2003;120(4):601-609.
129. Gottfried I, Landau M, Glaser F, et al. A mutation in GJB3 is associated with recessive erythrokeratodermia variabilis (EKV) and leads to defective trafficking of the connexin 31 protein. *Hum Mol Genet.* 2002;11(11):1311-1316.
130. Caceres-Rios H, Tamayo-Sanchez L, Duran-Mckinster C, et al. Keratitis, ichthyosis, and deafness (KID syndrome): review of the literature and proposal of a new terminology. *Pediatr Dermatol.* 1996;13(2): 105-113.
131. Richard G, Smith LE, Bailey RA, et al. Mutations in the human connexin gene GJB3 cause erythrokeratodermia variabilis. *Nat Genet.* 1998;20(4): 366-369.
132. Macari F, Landau M, Cousin P, et al. Mutation in the gene for connexin 30.3 in a family with erythrokeratodermia variabilis. *Am J Hum Genet.* 2000; 67(5):1296-1301.
133. Richard G, Rouan F, Willoughby CE, et al. Missense mutations in GJB2 encoding connexin-26 cause the ectodermal dysplasia keratitis-ichthyosis-deafness syndrome. *Am J Hum Genet.* 2002;70(5):1341-1348.
134. Shuja Z, Li L, Gupta S, et al. Connexin26 mutations causing palmoplantar keratoderma and deafness interact with connexin43, modifying gap junction and hemichannel properties. *J Invest Dermatol.* 2016;136(1):225-235.
135. Maestrini E, Korge BP, Ocana-Sierra J, et al. A missense mutation in connexin26, D66H, causes mutilating keratoderma with sensorineural deafness (Vohwinkel's syndrome) in three unrelated families. *Hum Mol Genet.* 1999;8(7):1237-1243.
136. Richard G, Brown N, Smith LE, et al. The spectrum of mutations in erythrokeratodermias—novel and de novo mutations in GJB3. *Hum Genet.* 2000;106(3):321-329.
137. Todt I, Mazereeuw-Hautier J, Binder B, et al. Dandy-Walker malformation in patients with KID syndrome associated with a heterozygote mutation (p.Asp50Asn) in the GJB2 gene encoding connexin 26. *Clin Genet.* 2009;76(4):404-408.
138. Ma H, Liang P, Chen J, et al. Keratitis-ichthyosis-deafness syndrome accompanied by disseminated cutaneous fungal infection. *J Dermatol.* 2017.
139. Sakabe J, Yoshiki R, Sugita K, et al. Connexin 26 (GJB2) mutations in keratitis-ichthyosis-deafness syndrome presenting with squamous cell carcinoma. *J Dermatol.* 2012;39(9):814-815.
140. Esmer C, Salas-Alanis JC, Fajardo-Ramirez OR, et al. Lethal keratitis, ichthyosis, and deafness syndrome due to the A88V connexin 26 mutation. *Rev Invest Clin.* 2016;68(3):143-146.
141. Jonard L, Feldmann D, Parsy C, et al. A familial case of keratitis-ichthyosis-deafness (KID) syndrome with the GJB2 mutation G45E. *Eur J Med Genet.* 2008;51(1):35-43.
142. Huckstepp RT, Eason R, Sachdev A, et al. CO2-dependent opening of connexin 26 and related beta connexins. *J Physiol.* 2010;588(Pt 20):3921-3931.
143. Huckstepp RT, id Bihi R, Eason R, et al. Connexin hemichannel-mediated CO2-dependent release of ATP in the medulla oblongata contributes to central respiratory chemosensitivity. *J Physiol.* 2010; 588(Pt 20):3901-3920.
143a. Lilly E, Bunick CG, Maley AM, et al. More than keratitis, ichthyosis and deafness: multisystem effects

of lethal GJB2 mutations. *J Amer Acad Dermatol*, in press.
144. Oji V, Eckl KM, Aufenvenne K, et al. Loss of corneodesmosin leads to severe skin barrier defect, pruritus, and atopy: unraveling the peeling skin disease. *Am J Hum Genet.* 2010;87(2):274-281.
145. Cassidy AJ, van Steensel MA, Steijlen PM, et al. A homozygous missense mutation in TGM5 abolishes epidermal transglutaminase 5 activity and causes acral peeling skin syndrome. *Am J Hum Genet.* 2005;77(6):909-917.
146. Cabral RM, Kurban M, Wajid M, et al. Whole-exome sequencing in a single proband reveals a mutation in the CHST8 gene in autosomal recessive peeling skin syndrome. *Genomics.* 2012;99(4):202-208.
147. Blaydon DC, Nitoiu D, Eckl KM, et al. Mutations in CSTA, encoding Cystatin A, underlie exfoliative ichthyosis and reveal a role for this protease inhibitor in cell-cell adhesion. *Am J Hum Genet.* 2011;89(4):564-571.
148. Pavlovic S, Krunic AL, Bulj TK, et al. Acral peeling skin syndrome: a clinically and genetically heterogeneous disorder. *Pediatr Dermatol.* 2012;29(3): 258-263.
149. Muttardi K, Nitoiu D, Kelsell DP, et al. Acral peeling skin syndrome associated with a novel CSTA gene mutation. *Clin Exp Dermatol.* 2016;41(4):394-398.
150. Krunic AL, Stone KL, Simpson MA, et al. Acral peeling skin syndrome resulting from a homozygous nonsense mutation in the CSTA gene encoding cystatin A. *Pediatr Dermatol.* 2013;30(5):e87-88.
151. Pujol RM, Gilaberte M, Toll A, et al. Erythrokeratoderma variabilis-like ichthyosis in Chanarin-Dorfman syndrome. *Br J Dermatol.* 2005;153(4):838-841.
152. Srebrnik A, Tur E, Perluk C, et al. Dorfman-Chanarin syndrome. A case report and a review. *J Am Acad Dermatol.* 1987;17(5 Pt 1):801-808.
153. Lefevre C, Jobard F, Caux F, et al. Mutations in CGI-58, the gene encoding a new protein of the esterase/lipase/thioesterase subfamily, in Chanarin-Dorfman syndrome. *Am J Hum Genet.* 2001;69(5):1002-1012.
154. Yamaguchi T, Omatsu N, Matsushita S, et al. CGI-58 interacts with perilipin and is localized to lipid droplets. Possible involvement of CGI-58 mislocalization in Chanarin-Dorfman syndrome. *J Biol Chem.* 2004;279(29):30490-30497.
155. Demerjian M, Crumrine DA, Milstone LM, et al. Barrier dysfunction and pathogenesis of neutral lipid storage disease with ichthyosis (Chanarin-Dorfman syndrome). *J Invest Dermatol.* 2006;126(9): 2032-2038.
156. Konig A, Happle R, Bornholdt D, et al. Mutations in the NSDHL gene, encoding a 3beta-hydroxysteroid dehydrogenase, cause CHILD syndrome. *Am J Med Genet.* 2000;90(4):339-346.
157. Bornholdt D, Konig A, Happle R, et al. Mutational spectrum of NSDHL in CHILD syndrome. *J Med Genet.* 2005;42(2):e17.
158. Avgerinou GP, Asvesti AP, Katsambas AD, et al. CHILD syndrome: the NSDHL gene and its role in CHILD syndrome, a rare hereditary disorder. *J Eur Acad Dermatol Venereol.* 2010;24(6):733-736.
159. Paller AS, van Steensel MA, Rodriguez-Martin M, et al. Pathogenesis-based therapy reverses cutaneous abnormalities in an inherited disorder of distal cholesterol metabolism. *J Invest Dermatol.* 2011;131(11):2242-2248.
160. Derry JM, Gormally E, Means GD, et al. Mutations in a delta 8-delta 7 sterol isomerase in the tattered mouse and X-linked dominant chondrodysplasia punctata. jderry@immunex.com. *Nat Genet.* 1999;22(3):286-290.
161. Curry CJ, Magenis RE, Brown M, et al. Inherited chondrodysplasia punctata due to a deletion of the terminal short arm of an X chromosome. *N Engl J Med.* 1984;311(16):1010-1015.
162. Braverman N, Steel G, Obie C, et al. Human PEX7 encodes the peroxisomal PTS2 receptor and is responsible for rhizomelic chondrodysplasia punctata. *Nat Genet.* 1997;15(4):369-376.
163. Franco B, Meroni G, Parenti G, et al. A cluster of sulfatase genes on Xp22.3: mutations in chondrodysplasia punctata (CDPX) and implications for warfarin embryopathy. *Cell.* 1995;81(1):15-25.
164. Happle R. X-linked dominant chondrodysplasia punctata. Review of literature and report of a case. *Hum Genet.* 1979;53(1):65-73.
165. Kolde G, Happle R. Histologic and ultrastructural features of the ichthyotic skin in X-linked dominant chondrodysplasia punctata. *Acta Derm Venereol.* 1984;64(5):389-394.
166. Bornholdt D, Atkinson TP, Bouadjar B, et al. Genotype-phenotype correlations emerging from the identification of missense mutations in MBTPS2. *Hum Mutat.* 2013;34(4):587-594.
167. Oeffner F, Fischer G, Happle R, et al. IFAP syndrome is caused by deficiency in MBTPS2, an intramembrane zinc metalloprotease essential for cholesterol homeostasis and ER stress response. *Am J Hum Genet.* 2009;84(4):459-467.
168. Lwin SM, Hsu CK, McMillan JR, et al. Ichthyosis prematurity syndrome: from fetus to adulthood. *JAMA Dermatol.* 2016;152(9):1055-1058.
169. Klar J, Schweiger M, Zimmerman R, et al. Mutations in the fatty acid transport protein 4 gene cause the ichthyosis prematurity syndrome. *Am J Hum Genet.* 2009;85(2):248-253.
170. Sobol M, Dahl N, Klar J. FATP4 missense and nonsense mutations cause similar features in ichthyosis prematurity syndrome. *BMC Res Notes.* 2011;4:90.
171. Kepes JJ, Berry A, 3rd, Zacharias DL. Multiple sulfatase deficiency: bridge between neuronal storage diseases and leukodystrophies. *Pathology.* 1988; 20(3):285-291.
172. Dierks T, Schmidt B, Borissenko LV, et al. Multiple sulfatase deficiency is caused by mutations in the gene encoding the human C(alpha)-formylglycine generating enzyme. *Cell.* 2003;113(4):435-444.
173. Cosma MP, Pepe S, Annunziata I, et al. The multiple sulfatase deficiency gene encodes an essential and limiting factor for the activity of sulfatases. *Cell.* 2003;113(4):445-456.
174. Davies MG, Marks R, Dykes PJ, et al. Epidermal abnormalities in Refsum's disease. *Br J Dermatol.* 1977;97(4):401-406.
175. Jansen GA, Ofman R, Ferdinandusse S, et al. Refsum disease is caused by mutations in the phytanoyl-CoA hydroxylase gene. *Nat Genet.* 1997;17(2):190-193.
176. Jansen GA, Waterham HR, Wanders RJ. Molecular basis of Refsum disease: sequence variations in phytanoyl-CoA hydroxylase (PHYH) and the PTS2 receptor (PEX7). *Hum Mutat.* 2004;23(3):209-218.
177. Kitareewan S, Burka LT, Tomer KB, et al. Phytol metabolites are circulating dietary factors that

activate the nuclear receptor RXR. *Mol Biol Cell.* 1996; 7(8):1153-1166.
178. Jagell S, Liden S. Ichthyosis in the Sjogren-Larsson syndrome. *Clin Genet.* 1982;21(4):243-252.
179. Rizzo WB, Carney G. Sjogren-Larsson syndrome: diversity of mutations and polymorphisms in the fatty aldehyde dehydrogenase gene (ALDH3A2). *Hum Mutat.* 2005;26(1):1-10.
180. Nigro JF, Rizzo WB, Esterly NB. Redefining the Sjogren-Larsson syndrome: atypical findings in three siblings and implications regarding diagnosis. *J Am Acad Dermatol.* 1996;35(5 Pt 1):678-684.
181. Price VH, Odom RB, Ward WH, et al. Trichothiodystrophy: sulfur-deficient brittle hair as a marker for a neuroectodermal symptom complex. *Arch Dermatol.* 1980;116(12):1375-1384.
182. Happle R, Traupe H, Grobe H, et al. The Tay syndrome (congenital ichthyosis with trichothiodystrophy). *Eur J Pediatr.* 1984;141(3):47-152.
183. Jorizzo JL, Atherton DJ, Crounse RG, et al. Ichthyosis, brittle hair, impaired intelligence, decreased fertility and short stature (IBIDS syndrome). *Br J Dermatol.* 1982;106(6):705-710.
184. Faghri S, Tamura D, Kraemer KH, et al. Trichothiodystrophy: a systematic review of 112 published cases characterises a wide spectrum of clinical manifestations. *J Med Genet.* 2008;45(10):609-621.
185. Rebora A, Crovato F. PIBI(D)S syndrome—trichothiodystrophy with xeroderma pigmentosum (group D) mutation. *J Am Acad Dermatol.* 1987;16(5 Pt 1): 940-947.
186. Nakabayashi K, Amann D, Ren Y, et al. Identification of C7orf11 (TTDN1) gene mutations and genetic heterogeneity in nonphotosensitive trichothiodystrophy. *Am J Hum Genet.* 2005;76(3):510-516.
187. Weeda G, Eveno E, Donker I, et al. A mutation in the XPB/ERCC3 DNA repair transcription gene, associated with trichothiodystrophy. *Am J Hum Genet.* 1997;60(2):320-329.
188. Corbett MA, Dudding-Byth T, Crock PA, et al. A novel X-linked trichothiodystrophy associated with a nonsense mutation in RNF113A. *J Med Genet.* 2015;52(4):269-274.
189. Marionnet C, Benoit A, Benhamou S, et al. Characteristics of UV-induced mutation spectra in human XP-D/ERCC2 gene-mutated xeroderma pigmentosum and trichothiodystrophy cells. *J Mol Biol.* 1995;252(5):550-562.
190. Stefanini M, Lagomarsini P, Arlett CF, et al. Xeroderma pigmentosum (complementation group D) mutation is present in patients affected by trichothiodystrophy with photosensitivity. *Hum Genet.* 1986; 74(2):107-112.
191. Holzman SB, Durso SC. Nutritional deficiency and acquired ichthyosis. *J Gen Intern Med.* 2017.
192. Martin-Cascon M, Sanchez-Guirao AJ, Herranz-Marin MT. Paraneoplastic acquired ichthyosis in lung cancer. *Arch Bronconeumol.* 2015;51(11):609.
193. Sparsa A, Boulinguez S, Le Brun V, et al. Acquired ichthyosis with pravastatin. *J Eur Acad Dermatol Venereol.* 2007;21(4):549-550.
194. Patel N, Spencer LA, English JC 3rd, et al. Acquired ichthyosis. *J Am Acad Dermatol.* 2006;55(4):647-656.
195. Hodak E, Amitay I, Feinmesser M, et al. Ichthyosiform mycosis fungoides: an atypical variant of cutaneous T-cell lymphoma. *J Am Acad Dermatol.* 2004; 50(3):368-374.
196. Goodman DS, Teplitz ED, Wishner A, et al. Prevalence of cutaneous disease in patients with acquired immunodeficiency syndrome (AIDS) or AIDS-related complex. *J Am Acad Dermatol.* 1987;17(2 Pt 1): 210-220.
197. Kaplan MH, Sadick NS, McNutt NS, et al. Acquired ichthyosis in concomitant HIV-1 and HTLV-II infection: a new association with intravenous drug abuse. *J Am Acad Dermatol.* 1993;29(5 Pt 1):701-708.
198. Zhang H, Ma HJ, Liu W, et al. Sarcoidosis characterized as acquired ichthyosiform erythroderma. *Eur J Dermatol.* 2009;19(5):516-517.
199. Humbert P, Agache P. Acquired ichthyosis: a new cutaneous marker of autoimmunity. *Arch Dermatol.* 1991;127(2):263-264.
200. de la Cruz-Alvarez J, Allegue F, Oliver J. Acquired ichthyosis associated with eosinophilic fasciitis. *J Am Acad Dermatol.* 1996;34(6):1079-1080.
201. Spelman LJ, Strutton GM, Robertson IM, et al. Acquired ichthyosis in bone marrow transplant recipients. *J Am Acad Dermatol.* 1996;35(1):17-20.
202. Williams ML, Feingold KR, Grubauer G, et al. Ichthyosis induced by cholesterol-lowering drugs. Implications for epidermal cholesterol homeostasis. *Arch Dermatol.* 1987;123(11):1535-1538.
203. Kumar B, Saraswat A, Kaur I. Mucocutaneous adverse effects of hydroxyurea: a prospective study of 30 psoriasis patients. *Clin Exp Dermatol.* 2002;27(1):8-13.
204. Hannam S, Murray M, Romani L, et al. Kava dermopathy in Fiji: an acquired ichthyosis? *Int J Dermatol.* 2014;53(12):1490-1494.
205. Grimalt R, Gelmetti C, Brusasco A, et al. Pityriasis rotunda: report of a familial occurrence and review of the literature. *J Am Acad Dermatol.* 1994;31(5 Pt 2): 866-871.
206. Petit A, Evenou P, Civatte J. Confluent and reticulated papillomatosis of Gougerot and Carteaud. Treatment by minocycline. *Ann Dermatol Venereol.* 1989;116(1):29-30.
207. Bruynzeel-Koomen CA, de Wit RF. Confluent and reticulated papillomatosis successfully treated with the aromatic etretinate. *Arch Dermatol.* 1984; 120(9):1236-1237.

Chapter 48 :: Inherited Palmoplantar Keratodermas

:: Liat Samuelov & Eli Sprecher

AT-A-GLANCE

- Inherited palmoplantar keratodermas (PPKs) are a heterogeneous group of genodermatoses characterized by hyperkeratosis of the palms and soles, with or without associated features. They are usually classified according to their morphology (diffuse, focal, punctate), mode of inheritance, and the presence or absence of extracutaneous features.
- Epidermolytic PPK (EPPK) is the most common form of diffuse keratoderma. It results from heterozygous mutations in *KRT9* (most cases) or *KRT1* (the minority of cases) encoding keratin 9 and keratin 1, respectively. Epidermolytic hyperkeratosis is seen on histology. A similar but milder phenotype of diffuse PPK is evident in nonepidermolytic PPK (NEPPK) Unna-Thost type, caused by heterozygous mutations in *KRT1*.
- Diffuse NEPPK with transgrediens may be observed in Greither syndrome and PPK Bothnia type caused by missense heterozygous mutations in *KRT1* and heterozygous gain-of-function mutations in *AQP5*, respectively. PPK Bothnia type also manifests with a white, spongy appearance of the palms and soles upon exposure to water.
- Mal de Meleda is a form of autosomal recessive, progressive, diffuse, mutilating PPK with transgrediens caused by biallelic mutations in *SLURP1*.
- Nagashima-type PPK is the most common type of PPK in the Asian population and is characterized by diffuse, transgrediens, nonprogressive, nonmutilating PPK. The palmoplantar skin assumes a typical whitish spongy appearance after water immersion. This form of PPK is caused by biallelic mutations in *SERPIN7* encoding a serine protease inhibitor.
- Olmsted syndrome, caused by mutations in *TRPV3* (autosomal dominant or autosomal recessive inheritance) or *MBTPS2* (X-linked recessive inheritance), is characterized by diffuse mutilating PPK with periorificial keratotic plaques.
- Heterozygous mutations in the gene *GJB2* encoding connexin 26 result in four genodermatoses featuring PPK and hearing impairment, including Vohwinkel syndrome (mutilating honeycomb-like PPK and starfish-shaped keratotic plaques), keratosis–ichthyosis–deafness (KID) syndrome (erythrokeratoderma, grainy PPK, abnormal ectodermal features, progressive keratitis, and recurrent infections), Bart-Pumphrey syndrome (honeycomb-like PPK, knuckle pads, and leukonychia), and PPK with deafness syndrome. A form of KID syndrome associated with congenital atrichia results from mutations in *GJB6* encoding Cx30.
- Loricrin keratoderma, caused by heterozygous frameshift mutations in *LOR* encoding loricrin, is a variant of Vohwinkel syndrome not associated with hearing impairment but featuring generalized ichthyosis.
- PPK with hearing impairment can also result from point mutations in the *MTTS1* gene encoding a mitochondrial transfer RNA.
- Hidrotic ectodermal dysplasia (Clouston syndrome) is a form of ectodermal dysplasia associated with diffuse PPK and nail and hair abnormalities caused by heterozygous mutations in *GJB6* encoding connexin 30.
- Huriez syndrome, an autosomal dominant inherited PPK with unknown etiology, is characterized by diffuse PPK, scleroatrophy, sclerodactyly, and occurrence of squamous cell carcinomas within atrophic skin.
- Papillon-Lefevre syndrome is an autosomal recessive disorder caused by mutations in the gene *CTSC* encoding cathepsin C. It is characterized by diffuse PPK with transgrediens and severe progressive periodontitis.
- Naxos disease (ND) and Carvajal syndrome (CS), caused by mutations in the genes *JUP* and *DSP* encoding plakoglobin and desmoplakin, respectively, are cardiocutaneous syndromes featuring PPK (diffuse in ND and striate in CS), woolly hair, and cardiomyopathy (right ventriculopathy in ND and mainly left ventricle involvement in CS).
- Striate PPK results from heterozygous nonsense or frameshift mutations in the genes encoding desmoglein 1, desmoplakin, and to a lesser degree keratin 1.
- Pachyonychia congenita is a group of rare autosomal dominant disorders caused by mutations in one of five keratin genes, including *KRT6A, KRT6B, KRT6C, KRT16,* or *KRT17* encoding keratins 6a, 6b, 6c, 16, and 17, respectively, known to be expressed in differentiated epithelial tissues. It manifests with focal painful PPK, thick dystrophic nails with a characteristic appearance, and associated features such as oral leukokeratosis, pilosebaceous cysts, and natal teeth.

(Continued)

AT-A-GLANCE (*Continued*)

- Howel-Evans syndrome is an autosomal dominant disorder featuring focal PPK and mucosal (particularly esophageal) squamous cell carcinomas with associated findings of follicular hyperkeratosis and oral leukokeratosis caused by heterozygous mutations in *RHBDF2*, encoding iRhom2, a protein known to play a role in epidermal growth factor receptor (EGFR) signaling.
- Richner-Hanhart syndrome is an autosomal recessive disease caused by mutations in the *TAT* gene encoding tyrosine aminotransferase, a hepatic cytosolic enzyme important for tyrosine and phenylalanine metabolism. It is characterized by painful focal PPK, bilateral keratitis, and mental retardation.
- Punctate PPK (PPKP) type 1 is characterized by multiple, painful, yellow-brown hyperkeratotic papules on the palms and soles that most commonly appear during the first or second decades of life. It may result from mutations in one of two genes: *AAGAB* encoding p34 protein with resultant upregulation of EGFR or *COL14A1* encoding collagen type XIV α1. PPKP type 2 is characterized by skin-colored to yellow asymptomatic keratotic spines with histopathologic findings resembling cornoid lamella of porokeratosis. PPKP type 3 (acrokeratoelastoidosis of Costa) manifests with round to oval, white-yellow translucent papules with predilection to the thenar and hypothenar areas and pressure points with histopathologic findings of decreased elastic tissue and fragmented elastic fibers. The genes responsible for PPKP type 2 and 3 are still to be elucidated.
- Cole disease, characterized by punctate PPK, hypopigmented macules, and possible internal organs calcifications, is caused by mutations in *ENPP1* leading to impaired insulin signaling.
- Management of all forms of PPK focuses on topical treatments (mainly emollients and keratolytic agents), mechanical measures, methods to relieve pain or inhibit sweating, treatment of secondary infections, and various walking aids. Oral retinoids have been shown to be effective in several types of inherited PPK, and the development of more targeted therapeutic approaches is underway.

INTRODUCTION

The term *palmoplantar keratoderma (PPK)* refers to a group of potentially debilitating and clinically and genetically heterogeneous disorders of cornification which are clinically characterized by abnormal focal or diffuse thickening of the skin on the palms and soles. These disorders can occur as both acquired or inherited conditions. Inherited PPKs are characterized by familial occurrence and a relatively early age of onset in most cases. Genodermatoses associated with PPK are shown in Table 48-1, and several examples are presented in Fig. 48-1. This chapter focuses on inherited disorders in which PPK is a dominant feature.

Several classification systems of PPKs have been proposed. Originally, the classification was based on assessment of several clinical and histologic characteristics, including the specific morphology and pattern of palmoplantar hyperkeratosis, the extent of involvement (isolated PPK or syndromic PPK associated with ectodermal defects and/or extracutaneous manifestations), mode of inheritance (autosomal dominant, autosomal recessive, X-linked, mitochondrial), age of onset, and the presence or absence of epidermolysis on histology.[1-3] Three morphological patterns are usually distinguished: (1) diffuse PPK with uniform involvement of the entire palmoplantar surface; (2) focal PPK with localized hyperkeratosis predominantly on pressure points that is further subdivided into areata or nummular type (oval lesions, mainly on the plantar surface) and striate type (longitudinal hyperkeratotic lesions extending from the palms along the volar surface of the fingers associated with focal to diffuse thickening of the plantar skin); and (3) punctate PPK with multiple, discrete 1-mm to 1-cm round keratotic papules over the palms and soles. In addition, palmoplantar involvement may feature transgrediens (extension of hyperkeratosis onto the dorsal aspects of the fingers, toes, hands, feet, and flexor aspects of the wrists and heels) or mutilation caused by pseudoainhum (constricting bands around digits) formation.[4] With the deciphering of the pathogenesis of most forms of inherited PPKs, novel classification schemes include the etiology of the PPK in addition to morphological features.[2-6]

Elucidating the molecular disease mechanisms of PPKs has led to the discovery of new disorders and syndromes, providing new insights into the biological roles of epidermal structural components and paving the way for the development of novel, disorder-specific treatment modalities.[7-9]

EPIDEMIOLOGY

Although inherited PPKs are rare disorders when considered individually, their actual prevalence and incidence may be underestimated given the fact that mildly affected individuals do not require medical intervention or may be incorrectly diagnosed.[8,10] However, in several countries or communities in which consanguineous marriages are common, inherited PPKs may occur with high prevalence. In Northern Sweden, nonepidermolytic PPK (NEPPK) is characterized by a prevalence of 0.3% to 0.55%,[11] but in Northern Ireland, the prevalence of epidermolytic PPK (EPPK) was found to be 4.4 per 100,000 people.[12] In South India, a

TABLE 48-1
Genodermatoses with Palmoplantar Keratoderma as an Associated Feature

	ENTITY WITH ASSOCIATED PALMOPLANTAR KERATODERMA
Ichthyoses	Autosomal recessive congenital ichthyosis (ARCI)
	Epidermolytic ichthyosis (Fig. 48-10A)
	Ichthyosis Curth-Macklin
	Keratosis linearis–ichthyosis congenital–keratoderma (KLICK) syndrome
	Trichothiodystrophy
	Chanarin-Dorfman syndrome
	Sjogren-Larsson syndrome
	Conradi-Hunermann-Happle syndrome (Fig. 48-10B)
	CEDNIK syndrome
	MEDNIK syndrome
	Ichthyosis prematurity syndrome
Erythrokeratodermias	Erythrokeratodermia variabilis
	Progressive symmetric erythrokeratodermia
Epidermolysis bullosa (EB)	EB simplex (localized and generalized severe)
	Recessive dystrophic epidermolysis bullosa
	Kindler syndrome
	Ectodermal dysplasia–skin fragility syndrome
Ectodermal dysplasias	Schopf-Schulz-Passarge syndrome
	Oculodentodigital dysplasia
	Odontoonychodermal dysplasia
	Naegeli-Franceschetti-Jadassohn syndrome
	Dermatopathia pigmentosa reticularis
	Autosomal recessive ectodermal dysplasia syndrome
Rasopathies	Costello syndrome
Others	Darier disease (see Fig. 48-10C)
	Acrokeratosis verruciformis of Hopf
	Cowden syndrome
	Epidermodysplasia verruciformis
	Pityriasis rubra pilaris
	Severe dermatitis, multiple allergies and metabolic wasting (SAM) syndrome
	Dyskeratosis congenita
	Keratosis follicularis spinulosa decalvans (KFSD)
	Ichthyosis follicularis congenital atrichia and photophobia syndrome (IFAP)
	Basal cell nevus syndrome (Gorlin syndrome)

CEDNIK, cerebral dysgenesis, neuropathy, ichthyosis, and keratoderma; MEDNIK, mental retardation, enteropathy, deafness, neuropathy, ichthyosis, keratodermia.

prevalence rate of 5.2 in 10,000 was documented with Unna-Thost syndrome being the most prevalent entity seen in approximately 38% of cases.[13] In general, EPPK is the most common form of diffuse keratoderma with a worldwide incidence of 2.2 to 4.4 per 100,000 live newborns.[1,14,15]

DIAGNOSIS

As briefly mentioned already, the past years have led to significant progress in our understanding of the pathogenesis of inherited PPKs. These advances can in turn be harnessed to facilitate the diagnosis of these conditions using algorithms integrating both clinical and molecular features. Fig. 48-2 depicts one such algorithm based on the use of four sets of data: (1) cutaneous findings including PPK morphology (eg, diffuse, focal, punctate, mutilating), hair (eg, woolly hair), or nail abnormalities, as well as features associated with other genodermatoses (eg, skin fragility); (2) extracutaneous findings (eg, periodontitis, deafness); (3) mode of inheritance (eg, autosomal dominant, autosomal recessive, mitochondrial inheritance); and (4) histopathologic findings such as epidermolytic hyperkeratosis, disadhesion of keratinocytes, or parakeratosis. Using this algorithm, almost forms of PPK can be assigned to one set of genes which should be sequenced to lead to the final diagnosis.

DIFFERENTIAL DIAGNOSIS

Palmoplantar hyperkeratosis may represent a feature of both inherited and acquired conditions. Acquired conditions listed in Table 48-2 usually occur later in life and include inflammatory disorders (eg, psoriasis, lichen planus, pityriasis rubra pilaris, chronic dermatitis, reactive arthritis), paraneoplastic keratoderma, cutaneous lymphoma, chemical and drug exposure, malnutrition, metabolic disorders (eg, hypothyroidism), keratoderma climactericum, and infectious diseases (eg, dermatophytes, scabies, verruca vulgaris and syphilis).[16]

Genodermatoses that feature PPK are listed in Table 48-1. Several distinctive characteristics can be shared by some of these diseases. For example, autoamputation of digits can accompany PPK in loricrin keratoderma (LK), Vohwinkel syndrome (VS), Olmsted syndrome (OS), Sybert PPK, mal-de-Meleda (MDM), PPK-Gamborg-Nielsen, and PPK congenital alopecia syndrome 2 (PPKCA2).[17,18] Other nonhereditary diseases that may cause constricting bands with or without hyperkeratosis include leprosy, tertiary syphilis, yaws, scleroderma, Raynaud syndrome, amniotic bands, ergotamine poisoning, spinal medulla tumors, syringomyelia, and scar formation from frostbite, burns, and trauma.[19]

PPK with transgrediens may be observed in LK, Nagashima type-PPK (NPPK), Greither disease, OS, Papillon-Lefevre syndrome (PLS). PPK with sensorineural hearing loss (SNHL) should raise the differential diagnosis of VS syndrome, keratitis–ichthyosis–deafness (KID) syndrome and other *GJB2*-associated diseases, or mitochondrial inherited-PPK with deafness.

Figure 48-1 Genodermatoses with palmoplantar keratoderma as an associated feature. **A,** Diffuse palmar keratoderma with blisters in a patient with epidermolytic ichthyosis caused by *KRT1* mutation. **B,** Focal hyperkeratotic plantar plaques on weight-bearing areas in a patient with Conradi-Hunermann-Happle syndrome. **C,** Thick, yellow, hyperkeratotic plaques on plantar skin in a patient with Darier disease.

Several syndromes are characterized by PPK associated with squamous cell carcinoma (SCC) within areas of abnormal keratinization (eg, Huriez and Unna-Thost syndromes). Other genodermatoses including dyskeratosis congenita, Rothmund-Thomson syndrome, and xeroderma pigmentosum are associated with elevated absolute rates of SCC.

A few forms of PPKs feature gingival and dental anomalies (eg, OS, PLS, Haim-Munk syndrome, and Kindler syndromes).

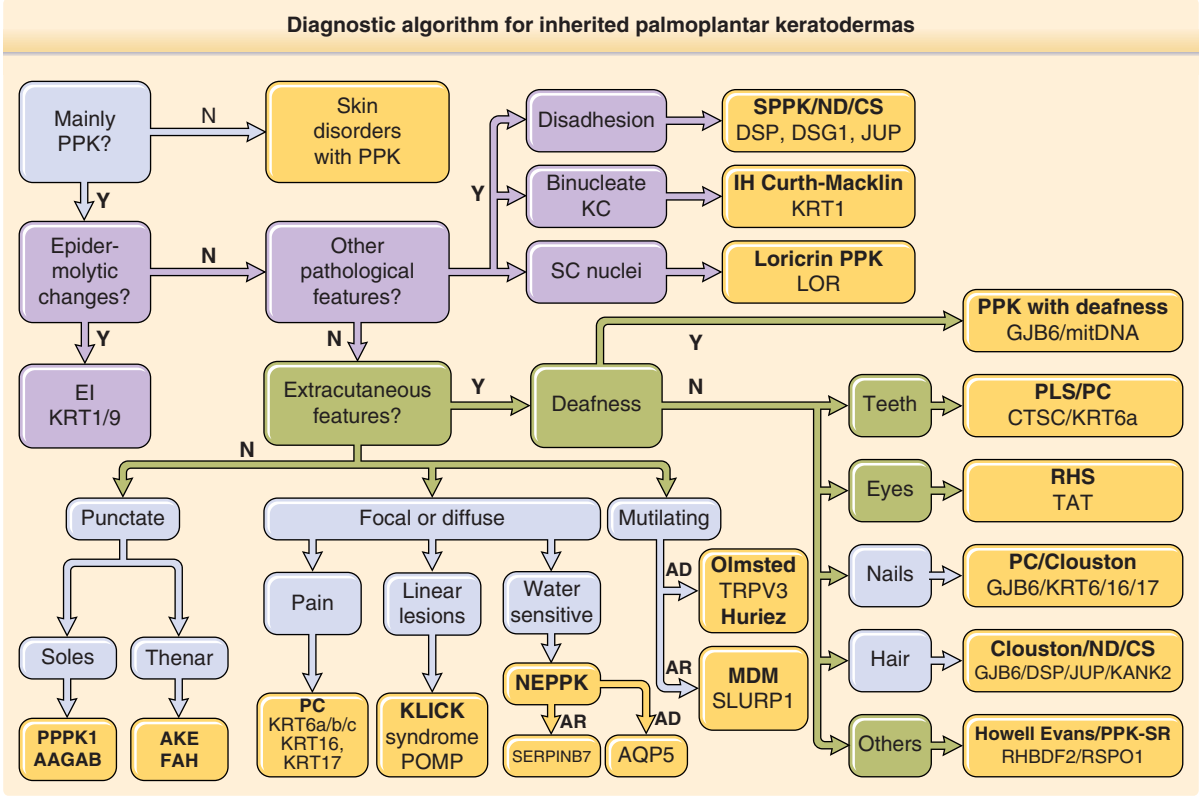

Figure 48-2 Diagnostic algorithm for inherited palmoplantar keratodermas (PPKs). Most patients with inherited PPK can be assigned to one gene based on four criteria: cutaneous findings, extracutaneous manifestations, mode of inheritance, and histopathologic findings. AAGAB, α-and γ-adaptin-binding protein P34; AKE, acrokeratoelastoidosis; AQP5, aquaporin 5; CS, Carvajal syndrome; CTSC, cathepsin C; DSG1, desmoglein 1; DSP, desmoplakin; EI, epidermolytic ichthyosis; FAH, focal acral hyperkeratosis; GJB6, gap junction protein β6; IH, ichthyosis hystrix; JUP, plakoglobin; KANK2, KN motif and ankyrin repeat domains 2; KC, keratinocytes; KLICK, Keratosis linearis–ichthyosis congenital–keratoderma; KRT, keratin; LOR, loricrin; MDM, mal de Meleda; ND, Naxos disease; NEPPK, nonepidermolytic palmoplantar keratoderma; PC, pachyonychia congenita; PLS, Papillon-Lefevre syndrome; POMP, proteasome maturation protein; PPK-SR, palmoplantar keratoderma with sex reversal; PPPK1, punctate palmoplantar keratoderma type I; RHBDF2, rhomboid 5 homolog 2; RHS, Richner-Hanhart syndrome; RSPO1, R-spondin 1; SC, stratum corneum; SERPINB7, serpin family B member 7; SLURP-1, secreted LY6/PLAUR domain containing 1; SPPK, striate palmoplantar keratoderma; TAT, tyrosine aminotransferase; TRPV3, transient receptor potential cation channel subfamily V member 3. (The authors acknowledge the contributions of Maurice van Steensel, Vinzenz Oji, Edel A. O'Toole, David Hansen, Mary Schwartz, and Frances Smith in the preparation of this figure.)

Wrinkling of palmoplantar skin may be a feature in aquagenic wrinkling of the palms with *CFTR* mutations, PPK Bothnia type with *AQP5* mutations, NPPK with *SERPINB7* mutations, and acrokeratoelastoidosis (AKE).

The differential diagnosis of punctate palmoplantar keratosis includes verruca vulgaris, corns over pressure points, porokeratosis punctate palmaris et plantaris, keratosis punctate of the palmar creases, Cole disease, Darier disease, Cowden disease, Gorlin syndrome, acrokeratosis verruciformis of Hopf, epidermodysplasia verruciformis, and arsenic exposure.[20-22]

PPK associated with sclerosis localized to dorsal hands and sclerodactyly may be a feature of Huriez syndrome, Unna-Thost syndrome (occasionally shows sclerodactyly or nail changes), PPKCA2, and palmoplantar hyperkeratosis with SCC of the skin and sex reversal. Systemic sclerosis may show similar features.

PPK with nail changes typical for pachyonychia congenita (PC) may be observed in Clouston syndrome caused by *GJB6* mutations (may show similar nail changes and painful keratoderma) or homozygous mutations in *FZD6*, encoding frizzled 6, a Wnt-signaling pathway receptor in the nail matrix, which was recently discovered as the cause of congenital nail dystrophy.[23] Dyskeratosis congenita manifest with features overlapping with PC, including nail dystrophy, PPK, hyperhidrosis, and oral leukoplakia. Onychomycosis should be excluded in cases of PPK with nail findings.

COMMON THERAPEUTIC APPROACHES

In general, the management of all forms of PPK is aimed at alleviating disease manifestations and focuses on mechanical measures, methods to relieve pain, treatment of secondary infections, and various

TABLE 48-2
Acquired Conditions Associated with Palmoplantar Hyperkeratosis and Other Features Resembling Palmoplantar Keratoderma

Inflammatory Skin Disorders
Palmoplantar psoriasis
Lichen planus
Pityriasis rubra pilaris
Chronic dermatitis
Reactive arthritis
Metabolic Disorders
Hypothyroidism, myxedema
Chronic lymphedema
Drugs and Chemical Exposures
Lithium, hydroxyurea, verapamil, bleomycin
Chemotherapeutic agents
Chlorinated hydrocarbon
Chronic arsenic exposure
Infectious Diseases
Dermatophytes
Scabies
Verruca vulgaris
Syphilis
Leprosy
Tuberculosis
Malignancies
Paraneoplastic keratoderma
Cutaneous lymphoma
Malnutrition
Miscellaneous
Keratoderma climactericum
Pitted keratolysis
Punctate porokeratosis

walking aids. Topical treatment includes the regular use of emollients and topical keratolytic formulations (eg, 10% to 20% salicylic acid or 35% to 70% propylene glycol combined with thick emollient), with occlusion if necessary. In addition, topical calcipotriol and topical tazarotene have been shown to be effective in EPPK and PLS, respectively.[24] Dermatophyte or bacterial secondary infections and hyperhidrosis should be diagnosed and treated aggressively to avoid disease aggravation. Soaking in water and mechanical removal of hyperkeratotic areas (eg, grooming and trimming) are additional therapeutic measures that may provide symptom relief. Pain can be relieved by orthotics or insoles, wicking socks, ventilated or cushioned footwear, and maintaining body weight to reduce repeated trauma to the feet and the tendency to develop callus and blisters.

ORAL RETINOIDS

Oral retinoids are usually effective. Low-dose, short-term, or intermittent therapy are sometimes recommended given the possible long-term side effects, the chronic nature of the condition, and the risk of aggravated skin fragility, which may exacerbate disease manifestation in several types of PPK. More specifically, systemic retinoids were shown to be effective in EPPK,[25] MDM,[26] VS, and LK[27-30] and in cases of OS,[31-34] Huriez syndrome,[35] punctate PPK 1,[36,37] and PLS (for both PPK and periodontopathy).[38-40] Systemic retinoids have been found to be effective in KID syndrome (for hyperkeratosis, dissecting cellulitis of the scalp, and cancer chemoprophylaxis), although some reports demonstrated only partial response and exacerbation of corneal neovascularization with isotretinoin.[28,41-46] Accordingly, a low starting dose of acitretin (0.5 mg/kg/day) or alitretinoin (10 mg/day) with gradual increase depending on response and tolerability is recommended.[47-49]

SURGICAL THERAPY

Surgical excision and grafting is an option in focal PPK and in cases associated with mutilation.[4,50] Specific surgical approaches are discussed later.

INHERITED PALMOPLANTAR KERATODERMAS

DIFFUSE PALMOPLANTAR KERATODERMAS WITHOUT EXTRACUTANEOUS FEATURES, DOMINANT INHERITANCE

EPIDERMOLYTIC PALMOPLANTAR KERATODERMA

Clinical Features: EPPK (Vörner type; Online Mendelian Inheritance in Man [OMIM] #144200), first described by Vörner in 1901, is an autosomal dominant disorder characterized by yellowish, diffuse PPK with erythematous sharp margins at the edge of the palms (Fig. 48-3A) and soles (Fig. 48-3B).[51] Most cases present at birth or during the first weeks of life, although appearance up to the third year of life has been reported. The initial presentation is palmoplantar erythema that starts at the margins of the palms and soles, extends toward the center, and subsequently becomes covered with thick scale and remains stable throughout life.[25,52] Transgrediens and hyperkeratotic lesions over the elbows, knees, and knuckle pads have been reported.[53-60] It may be complicated with painful fissures, hyperhidrosis, maceration, and secondary bacterial and fungal infections with an offending odor.[57] Digital mutilation with pseudoainhum and

Figure 48-3 Epidermolytic palmoplantar keratoderma. Yellow, diffuse palmoplantar keratoderma with erythematous sharp margins at the edge of the palms (**A**) and soles (**B**). A heterozygous mutation in *KRT9* was identified in this patient.

camptodactyly has been reported.[59-62] In most cases, PPK is an isolated finding, although the rare occurrence of EPPK in association with leg ulcers, scleroderma, familial multiple carcinomas, and Ehlers-Danlos syndrome type III has been reported.[25,63-65]

Etiology and Pathogenesis: EPPK is an autosomal dominant genodermatosis caused by heterozygous mutations in *KRT9* encoding keratin 9.[66] Mutations in *KRT1* encoding keratin 1 have also been reported in association with EPPK in a minority of cases.[67-70]

Keratin 9 is a type I intermediate filament protein whose expression is confined to the suprabasal layers of the palmoplantar epidermis. Similar to all other keratins, KRT9 comprises three major domains: the head domain; the central α-helix rod domain, which is composed of four helical subsegments (1A, 1B, 2A, and 2B) that are interrupted by three nonhelical linker domains (L1, L12, and L2); and the tail domain.[71,72] Most *KRT9* mutations identified to date are located in the 1A or 2B segments of the α-helix rod domain, which are highly conserved in all keratin proteins and are essential for the formation of the keratin heterodimer and play a pivotal role in the congregation and stabilization of keratin intermediate filaments. Most causative genetic defects are missense or frameshift (small in-frame insertion–deletion) mutations acting in a dominant-negative manner. A mutational hotspot exists at codon 163 of *KRT9* (in the central α-helix rod domain) that encodes the amino acid arginine, which is often mutated to tryptophan, glutamine, or proline. p.Arg163Trp accounts for approximately 30% of all EPPK-causing mutations across different ethnic groups.[73,74]

Keratin 1 is a type II keratin expressed at the suprabasal cells committed to terminal differentiation that forms heterodimer with keratin 9 in palmoplantar epidermis and with keratin 10 in all other skin surfaces, including hair-bearing skin and other stratified orthokeratinized squamous epithelia.[6,75-77] The reported *KRT1* mutations in families with EPPK involve larger in-frame deletions affecting the helix boundary motifs of the rod domain,[68] different from the missense mutations in the same domains reported in epidermolytic ichthyosis (EI; see Chap. 47) and from frameshift mutations in the V2 domain that have been found in striate keratoderma and in ichthyosis hystrix Curth-Macklin.[78,79] Other mutations in *KRT1* that were associated with EPPK are gain-of-function (GOF) mutations at the beginning of the helix 1B domain of the central α-helical coiled-coil rod domain and an insertion of 18 amino acids in the 2B rod domain, emphasizing that mutations located more central in the rod domain of keratin 1 do not disrupt the function of filament assembly and stability as much as those in the helix initiation and termination sequence seen in EI cases.[67,70]

Pathology: Skin biopsies show compact orthohyperkeratosis, hypergranulosis, acanthosis, and epidermolytic hyperkeratosis manifested by perinuclear vacuolization of the keratinocytes and large irregularly-shaped keratohyaline granules located in the granular layers of the epidermis. Moreover, dyskeratosis manifested by intracytoplasmic and perinuclear eosinophilic homogenizations with round-oval eosinophilic inclusions were identified in involved epidermis corresponding to the intracytoplasmic aggregates and clumps of tonofilaments seen ultrastructurally.[3,80,81] More than one biopsy may be required to demonstrate epidermolytic changes and the typical histologic alterations of epidermolytic hyperkeratosis may be noticed in the acrosyringium.[25]

Ultrastructural findings include intracytoplasmic vacuolization in the upper spinous and granular cell layers; disruption and dispersion of the cellular organelles with indistinct cellular borders; intracytoplasmic dense aggregates of tonofilaments surrounding the nuclei; dense clumps of tonofilaments; abundant glycogen and ribosomes; detachment of tonofibrils from desmosomal plaques; large keratohyalin granules present from the mid malpighian layers; "composite" keratohyalin granules consisting of a homogeneous, relatively electron-lucent core; and dense peripheral deposits.[65,80,82-86]

Specific Treatments: Inhibition of *Krt9* mutant allele expression in a mouse model of EPPK using ribonucleic acid interference (RNAi)–based therapy has been demonstrated.[73] In addition, a transgenic mouse model of EPPK was treated with a mutant-specific short hairpin RNA (shRNA) that resulted in knockdown of the mutant protein with restoration of normal morphology and function of the skin.[87]

UNNA-THOST PALMOPLANTAR KERATODERMA

Clinical Features: Diffuse nonepidermolytic PPK (NEPPK, Unna-Thost type; OMIM #600962) is an autosomal dominant genodermatosis first described by Unna and Thost in 1880. Clinical features are similar to those of diffuse EPPK, although they are often milder, with presentation in the first few months of life. Onset during the third decade of life has been reported. NEPPK is characterized by diffuse, well-demarcated, yellowish, thick hyperkeratosis with an erythematous rim overlying the palms and soles. It tends to be smoother and waxier than EPPK, which is thicker and fissured.[4] Hyperhidrosis, as well as refractory secondary dermatophyte infections and pitted keratolysis leading to maceration and desquamation, are common findings seen more frequently in NEPPK than in EPPK.[88-91] In addition, the presence of hyperkeratosis around the umbilicus and the nipple with mild thickening and dryness of the knees and elbows has been reported.[92] Cases associated with atopic dermatitis[93] and verrucous carcinoma[94] have been described. Associations with acrocyanosis of the distal third of the extremities, clinodactyly of the fifth finger, and perianal or pericrural involvement have been reported.[95-97]

In general, EPPK and NEPPK show substantial clinical overlap, and histopathologic evaluation is often required to distinguish between them.

Etiology and Pathogenesis: Originally, Unna-Thost PPK was recognized as a nonepidermolytic form of diffuse PPK clinically resembling Vörner PPK. However, Kuster and coworkers investigated the original family reported by Unna and Thost and found epidermolytic hyperkeratosis on histology and identified a mutation located in the coil-1A domain at the beginning of the central rod domain of *KRT9*. This mutations is in close proximity to the mutation found in the original family reported by Vörner, suggesting that Unna-Thost and Vörner PPKs are the same entity.[57,98]

In a single family with diffuse NEPPK, a missense mutation was identified in the terminal V1 variable subdomain (nonhelical head domain) of keratin 1. In contrast with other reported *KRT1* mutations involving central domains important for filament assembly and stability that result in epidermolysis, this mutation is likely to be important for interactions of keratin filaments with other cellular components including the desmosomes.[92] This mutation results in distortion in keratinocytes shape and prevention of efficient distribution of lamellar body lipid material with impaired barrier formation.[99]

Another missense mutation in *KRT1* resulting in a mild phenotype has been identified in the 2B rod domain, again underscoring that mutations affecting the central part of the keratin 1 rod domain do not disrupt filament assembly to the same extent as mutations located at the initiation or termination motif of the helix sequence.[100]

Diffuse NEPPK, without other clinical features of PC, has been reported with heterozygous mutations in *KRT6c* and *KRT16*. The phenotype consists of diffuse PPK on the soles and focal hyperkeratosis on the palms. In cases of NEPPK when no pathogenic mutation is identified in *KRT1*, screening for *KRT6c* and *KRT16* mutations may be valuable.[101,102]

Pathology: Diffuse NEPPK shows nonspecific histopathologic findings, including hyperkeratosis, orthokeratosis, acanthosis, and either hyper- or hypogranulosis with no evidence of epidermolytic hyperkeratosis.[92,93] Close inspection and repeated biopsies are needed to exclude small foci of epidermolytic hyperkeratosis compatible with EPPK.

GREITHER SYNDROME

Clinical Features: Transgrediens et progrediens PPK (Greither syndrome; OMIM #133200) was originally described in 1952 by Greither.[103] Greither syndrome is an autosomal dominant disease with marked intra- and interfamilial variability. It characteristically starts to develop after the second year of life (although appearance soon after birth or later in childhood and adolescence has been documented). It is characterized by diffuse, thickened, scaly, yellowish PPK with an erythematous rim and transgrediens. The involvement of the skin over the Achilles tendon and gradual extension of patchy hyperkeratotic, erythematous, and hyperpigmented papules and plaques towards the shins, knees, thighs, knuckles, wrists, elbows, and flexural areas are typical.[95,103-107] Greither PPK tends to involute after the fifth decade of life. Hyperhidrosis is a common feature, and pitted keratolysis may be an associated finding. A case presenting as neonatal blistering and erythroderma, initially diagnosed as EI, has been reported.[77] An association with atopic dermatitis has been described.[108] A case of malignant melanoma arising on the hyperkeratotic sole of a patient with Greither PPK has been documented.[109] Severe cases of PPK may be complicated by spontaneous autoamputation and digit deformities.[110] Greither syndrome has been described in association with incontinentia pigmenti, acrocyanosis, and erythrokeratoderma variabilis in isolated cases.[104,111-113]

Sybert PPK is another form of progressive, diffuse, autosomal dominant PPK with transgrediens and autoamputation, however it manifests with more severe hyperkeratosis as compared to Greither PPK.[110]

Etiology and Pathogenesis: Greither syndrome is inherited in an autosomal dominant fashion and was shown to result from a missense mutation in *KRT1* affecting the helix initiation motif at the amino terminal end of the central rod domain of keratin 1,[108] a region known to be essential for effective filament assembly.[114] The causative gene for Sybert PPK has not been identified yet.

Pathology: The characteristic findings in Greither syndrome are acanthosis, marked hyperkeratosis, and hypergranulosis. A case with striking vacuolation of the superficial keratinocytes and numerous keratohyaline granules in the granular layer consistent with epidermolytic hyperkeratosis has been reported.[108] Moreover, focal depressions of the epidermis occupied by round foci of a compact orthokeratotic horny layer have been reported.[106] The described histopathologic findings in Sybert PPK are epidermal hyperplasia with hypergranulosis, parakeratosis, and orthokeratosis, as well as a sparse lymphocytic infiltrate in the papillary dermis. Ultrastructural studies revealed normal keratin filaments with abnormal structure and distribution of keratohyaline granules.[110]

LORICRIN KERATODERMA

Clinical Features: LK (mutilating keratoderma with ichthyosis, VS Camisa type; OMIM #604117) is a rare, autosomal dominant disorder. It features honeycomb-like PPK, starfish-like hyperkeratoses, prominent knuckle pads on the dorsal aspects of the hands, and pseudoainhum leading to autoamputation of the digits. These signs, when associated with hearing impairment, are referred to as VS (see later).[115] LK is a variant of VS reported by Camisa and Rossana in 1984 with no hearing impairment but with prominent generalized ichthyosis. The two essential clinical features for establishing the diagnosis are the characteristic honeycomb-like keratoderma and generalized ichthyosis, although the phenotype of LK is truly heterogeneous. LK manifests at birth or in early childhood and progresses gradually throughout adulthood. The clinical findings include moderate, generalized ichthyosiform dermatitis with dryness and fine scales affecting the trunk and extremities and hyperkeratosis localized to body folds with no evidence of erythema. Palmoplantar involvement is characterized by diffuse, symmetrical, well-demarcated transgrediens honeycomb-like PPK with an erythematous border (Fig. 48-4A),[27,116,117] although diffuse hyperkeratosis with no evidence of a honeycomb-like pattern may be seen. Knuckle pads, hyperkeratotic plaques on the dorsal parts of the hands, and pseudoainhum have been reported in LK pedigrees in varying frequencies,[117-124] and a collodion membrane may be seen at birth in approximately 35% of cases.[120,121,125] Association of LK with vitiligo, atopic dermatitis, neurodevelopmental delay, and microcephaly has been reported.[121,123]

Etiology and Pathogenesis: LK results from heterozygous frameshift insertion or deletion mutations in *LOR* which encodes loricrin. Loricrin is synthetized in the granular layer of the epidermis and then migrates to the cell periphery, where it is located beneath the plasma membrane and is crosslinked to other cytosolic proteins including involucrin, forming the cornified cell envelope (CCE).[30,117,119-121,123,125-130] Most mutations in *LOR* implicated in LK lead to a frameshift, delayed termination, and aberrant protein elongation. Experiments in transgenic mice suggest that *LOR* mutations exert a gain of function deleterious effect. The mutant loricrin forms arginine-rich nuclear localization sequences that "tag" a protein exposed on the cell surface for import into the cell nucleus by nuclear transport. The abnormal localization of loricrin in the nucleus alters nuclear/nucleolar functions, including nonribosomal RNA processing and growth factor signal transduction, and disrupts apoptotic processes in terminally differentiated keratinocytes.[124,126,131-134]

No clear genotype–phenotype correlation has been reported and variable intrafamilial disease severity has been reported.[117,120,121]

LK skin demonstrates abnormal epidermal permeability barrier function[130,131] similar to the skin barrier defects seen in various ichthyoses, including lamellar ichthyosis with transglutaminase-1 mutations.[135] Cell lines overexpressing mutant form of *LOR* demonstrated increased proliferation rate through activation of AKT-kinase with phosphorylation of ERK1/2, epidermal growth factor receptor (EGFR), and signal

Figure 48-4 Rare forms of transgrediens palmoplantar keratoderma. **A,** A case of loricrin palmoplantar keratoderma with diffuse, well-demarcated, honeycomb-like palmoplantar keratoderma with an erythematous border. **B,** Vohwinkel syndrome with a "honeycomb-like" appearance **C,** Huriez syndrome. Diffuse, well-confined hyperkeratotic plaques over the palms. (Used with permission from Dr. Cameron Kennedy, Bristol Royal Infirmary, United Kingdom.)

transducer and activator of transcription 3 (STAT3) compared with cell lines expressing the wild-type loricrin.[136]

Pathology: Histopathologic features include hyperkeratosis, significant parakeratosis, acanthosis, hypergranulosis (although the granular later may appear normal), diffuse vacuolar changes, focal cytolytic changes, and necrotic suprabasal keratinocytes.[118] Ultrastructural findings consist of abundant keratohyaline granules, vacuolar changes and disruption of suprabasal keratinocytes, and deposition of electron-dense intranuclear inclusions within the granular layer that contain loricrin as shown by immunogold studies.[117,118]

PALMOPLANTAR KERATODERMA BOTHNIA TYPE

Clinical Features: PPK Bothnia type (PPKB; OMIM #600231) was first described in 1994 as an autosomal dominant form of diffuse NEPPK, which has a high prevalence (0.3% to 0.55%) in two provinces of the West and Northwest Gulf of Bothnia in Northern Sweden.[11] PPKB has been described also in a large pedigree of Chinese Han descent,[137] and a common founder mutation in the British population has been suggested.[138] PPKB clinically resembles Nagashima PPK (see later) and usually manifests during infancy or childhood with a diffuse, homogenous hyperkeratosis with a yellowish hue over the palms and soles that extends to the dorsal digits.[11] These patients, even with a barely detectable mild phenotype, demonstrate a typical white spongy appearance of affected areas upon exposure to water. Hyperhidrosis, maceration, and secondary fungal infections are common, as are abnormal nails (curved with ragged cuticles). In contrast to this condition, aquagenic wrinkling of the palms, which is often found in conjunction with cystic fibrosis (CF), is characterized by translucent whitish papules, excessive wrinkling, and palmar edema induced by brief exposure to water.[137,139,140]

Etiology and Pathogenesis: PPKB is an autosomal dominant disorder caused by GOF mutations in the gene *AQP5*, encoding water-channel protein aquaporin 5 (AQP5), first identified in 2013 by Blaydon and coworkers.[141]

Aquaporins are cell-membrane transporters that enable the osmotic movement of water across the cell membrane in many cell types. AQP5 is mostly found in the apical plasma membrane and is involved in the excretion of water from exocrine glands (salivary gland, lacrimal gland, and sweat gland); it is also expressed in epithelial cells of the lung and the cornea.[141] Of note, hypohidrosis in Sjogren syndrome has been associated with decreased expression of AQP5.[142] In normal palmoplantar skin, AQP5 is localized to the plasma membrane of keratinocytes of the stratum granulosum, and in PPKB lesions, AQP5 expression is retained. However, affected keratinocytes are subject to increased water uptake through the plasma membrane.[141]

It has been suggested from protein modeling studies that PPKB-causing mutations increase the diameter of the constriction point of the AQP5 water channel with a direct influence on AQP5 gating or water flow through the channel.[141] Aquagenic wrinkling of palms (transient edematous whitish plaques on the palms upon exposure to water and hyperhidrosis) has been associated with aberrant expression of AQP5 in sweat glands.[143] Activation of transient receptor potential vanilloid 4 (TRPV4) results in increased cytosolic calcium concentration essential for sweat secretion, although its overactivation in keratinocytes may result in apoptosis and hyperkeratosis as demonstrated in OS caused by *TRPV3* mutations.[144,145] Because TRPV4 and AQP5 are both expressed in eccrine sweat glands and keratinocytes,[141] it has been speculated that palmoplantar hyperhidrosis and hyperkeratosis in PPKB are a result of GOF effect of the AQP5–TRPV4 complex, indicating that PPKB is a skin channelopathy.[137] A possible disease mechanism for aquagenic wrinkling of the palms in patients with CF is dysfunction of the TRPV4 channels in keratinocytes, resulting in dysregulated water influx through eccrine ducts.[139]

Histopathology: Histopathologic findings are nonspecific and include orthohyperkeratosis and a mild lymphocytic infiltrate in the upper dermis.[137]

DIFFUSE PALMOPLANTAR KERATODERMA WITHOUT EXTRACUTANEOUS FEATURES, RECESSIVE INHERITANCE

MAL DE MELEDA

Clinical Features: MDM (OMIM #248300) is a rare autosomal recessive disorder initially described in patients native to the Croatian island of Meleda (Mljet). The diagnostic criteria for the disease were presented in 1969.[146] Since then, the disease has been described in other parts of the world, including the Middle East, Western Europe, and North Africa with higher prevalence in certain populations, mainly in the Mediterranean and Adriatic regions, because of a founder effect. A few cases have been reported in Taiwan, China, Japan, Indonesia, and India.[147-157]

The onset of the disease is during infancy or early childhood with diffuse transgressive yellowish waxy hyperkeratotic plaques outlined by a red scaly border over the palms (Fig. 48-5A) and soles

Figure 48-5 Mal de Meleda. Diffuse, yellow, waxy hyperkeratotic plaque outlined by a red, scaly border over the palms (**A**) and soles (**B**) with extension onto the dorsal surface of the hands and feet in a glove (**C**) and stocking (**D**) distribution. Involvement of the groin area (**E**), keratotic plaques over joints (**F**), nail abnormalities (**G**), and pseudoainhum (**H**) are associated findings.

(Fig. 48-5B) that are preceded by prominent and persistent erythema. The palmoplantar hyperkeratosis progresses with age and extends onto the dorsal surface of the hands and feet in a glove (Fig. 48-5C) and stocking (Fig. 48-5D) distribution, the flexor aspects of the wrists and ankles and over the Achilles tendon, forearms, elbows, and knees.[147,154] Involvement of the inguinal and groin regions (Fig. 48-5E) has been described.[147,148]

Additional features are knuckle pads, lichenoid or keratotic plaques over joints (Fig. 48-5F), perioral erythema, hyperhidrosis with superinfection, malodorous maceration and painful fissures, nail abnormalities (eg, koilonychia, clubbing, onycholysis, nail thickening, dystrophy and subungual hyperkeratosis) (Fig. 48-5G), sclerodactyly, and brachydactyly. Circumscribed hyperkeratotic plaques over the fingers and toes result in a cone-shaped appearance (Fig. 48-5H), digital constrictions, pseudoainhum, and progressive functional impairment with reduced mobility.[158-160]

Although penetrance is complete, phenotype varies with geographic origin and ethnic background. In addition, no clear genotype–phenotype correlation has been identified, and environmental factors (mechanical trauma and heat) seem to influence the disease course.[147,148,150,154] A case with no plantar involvement, a milder phenotype with slightly erythematous palmoplantar keratotic plaques, and an atypical appearance with multiple 2- to 5-mm keratolytic pits outlined by brownish red erythema over the palmoplantar surface (mainly plantar skin) have been described.[26,147,154] Cases with no evidence of transgrediens have been described.[151] Heterozygous carriers may manifest with mild diffuse PPK or smooth skin on the palms and soles with keratotic papules.[161]

Several cases of malignant melanoma (MM) arising in the hyperkeratotic lesions of patients with MDM have been described in the literature.[149,162,163] A case complicated by irregular hyperpigmented spots on palmoplantar skin and the appearance of Bowen disease on the sole in a patient have been reported.[164,165] Accordingly, periodic screening for MM and other neoplasms is warranted.

PPK Gamborg-Nielsen (PPK-GN; OMIM #244850), an autosomal recessive disorder first described in patients from the northernmost county of Sweden by Gamborg Nielsen in 1985, is considered by some as a milder form of MDM. It manifests with a similar phenotype but less severe diffuse palmoplantar hyperkeratosis and no nail deformities or distant keratosis, although knuckle pads and tapered fingers may be observed.[166-168]

Etiology and Pathogenesis: MDM is caused by biallelic mutations in the *SLURP1* gene (previously known as ARS component B), which contains three translated exons and encodes the lymphocyte antigen 6 /urokinase-type plasminogen activator receptor related protein-1 (SLURP-1), a member of the Ly-Upar superfamily of proteins that play a role in transmembrane signal transduction, cell activation, and cell adhesion.[148,169] SLURP-1 is considered a secreted epidermal neuromodulator that is likely to be essential for both epidermal homeostasis and inhibition of tumor necrosis factor (TNF)-α release by macrophages during wound healing.[170]

Genetic heterogeneity is suggested in MDM because families without a *SLURP1* mutation have been reported.[171,172]

PPK-GN has recently been shown to be an allelic variant of MDM. A homozygous mutation in *SLURP1*, c.43T>C, was identified in 14 individuals from northern Sweden, and compound heterozygous mutations, c.280T>A and c.43T>C, were identified in one individual from southern Sweden. The c.43T>C mutation had been previously reported in MDM,[168] supporting that PPK-GN is a mild variant of MDM and not a separate entity.[173]

SLURP-1 has been shown to be expressed in human skin, mainly in keratinocytes underlying the upper epidermal layers, and it has a role in maintaining the skin's physiologic and structural integrity. SLURP-1 upregulates the expression of transglutaminase 1, cytokeratin 10, and caspases 3 and 8 with resultant increased apoptotic activity which exceeds that of TNF-α. In addition, it regulates epidermal differentiation through cholinergic pathways.[174]

Moreover, SLURP-1 expression correlates with abnormal immune responses. Mutations in this gene resulted in defective T-cell activation responses,[149] and SLURP-1 increased acetylcholine synthesis in T cells and attenuated T-cell proliferation. These effects were abolished by a α7-nAChR antagonist, indicating that SLURP-1 modulates the functional development of T cells via α7-nAChR-mediated pathways.[175] Accordingly, patients with homozygous *SLURP1* mutations are prone to viral infections and to the development of MM.[176] The higher incidence of MM in patients with MDM is not only attributable to defective T-cell activation and prolonged inflammation in hyperkeratotic skin[162,163] but may also result from defective apoptotic activity[177,178] and defective regulation of TNF-α release from macrophages.[179,180]

It has been suggested that SLURP-1 deficiency influences the efficiency of triglyceride hydrolysis in keratinocytes, an essential process for the formation of acylceramides important for the epidermal barrier.[181,182] It has been hypothesized that leakage of interstitial fluids into the stratum corneum and accumulation of triglyceride droplets in *SLURP1*-deficient skin are conditions favoring microorganism growth responsible for the malodorous skin of MDM.[181]

SLURP-1 may play a role in the pathogenesis of psoriasis. Its expression was upregulated in the skin of imiquimod-induced psoriasis in mice, and *SLURP1* mRNA expression was significantly upregulated after stimulation with interleukin (IL)-22 which was completely suppressed by STAT3 inhibition. In addition, SLURP-1 significantly suppressed the growth of *Staphylococcus aureus*,[183] and it has been shown to regulate epithelialization and wound healing in both cutaneous and oral wounds.[184]

Pathology: The histologic features of MDM are hyperkeratosis, orthokeratosis, foci of parakeratosis, marked acanthosis, a more pronounced stratum lucidum, and a perivascular lymphohistiocytic infiltrate.[185] Electron microscopy findings are a less-abrupt-than-normal transition between the stratum granulosum and stratum corneum; normal intermediate filaments and corneodesmosomes; and nonspecific, irregularly shaped keratohyalin granules with a spongy appearance.[26] In palmoplantar sections from patients with MDM, as well as in their sweat, SLURP-1 was either absent or barely detectable. It has been suggested that SLURP-1 assessment in sweat collected by the standard pilocarpine procedure used for the diagnosis of CF may serve as a rapid screening test for MDM.[186]

NAGASHIMA-TYPE PALMOPLANTAR KERATODERMA

Clinical Features: Nagashima-type PPK (NPPK; OMIM #615598), is an autosomal recessive disorder first described by Nagashima in 1977. The disease was initially named Meleda-type PPK, but in 1989 the term NPPK (or keratosis palmoplantaris Nagashima) was coined to distinguish this form of PPK from true MDM, given its milder phenotype and on-progressive nature after puberty.[187,188] Most cases have been reported in Japan and China, and the estimated prevalence in those countries is 1.2 in 10,000 and 2.3 to 3.1 in 10,000, respectively,[189,190] making it the most common type of PPK in Asian populations. Several cases have been described outside East Asia with estimated prevalence rates of NPPK in non-Asian populations as low as 0.5 in 100,000,000.[189,191,192]

NPPK typically begins in the first years of life (from birth through the fourth year) and gradually progresses until puberty with no further progression thereafter. It is characterized by a diffuse, well-demarcated, erythematous palmoplantar hyperkeratosis that extends to the dorsal surfaces of the hands, feet, inner wrists, ankles, and Achilles tendon area. Involvement of the elbows and knees is common. A single case with involvement of the central lumbar area, cubital fossae, forearms, thighs, and popliteal fossae has been described.[193] Hyperkeratosis on the ears and toenail dystrophy (atrophic nail plates with fragile distal edges and spontaneous peeling) are rare features that have been reported in isolated cases.[194,195] It is frequently complicated by hyperhidrosis, superinfection by dermatophytes, a distinct odor, and maceration.[187,188,190-192] There is no evidence of constricting bands, spontaneous amputation, or flexion contractures in contrast to other more severe forms of autosomal recessive transgressive diffuse PPKs, such as MDM and PPK-GN.[188,192] In addition, patients with NPPK display a whitish spongy appearance within 10 minutes of water exposure specifically in the erythematous hyperkeratotic areas, suggesting enhanced water permeation into the stratum corneum in NPPK lesional skin.[189,190] A case of MM arising within the lesions of NPPK has been reported.[196]

Etiology and Pathogenesis: NPPK is caused by biallelic mutations in the gene *SERPINB7*, encoding serpin family B member 7 (SERPIN7), a cytoplasmic member of the serine protease inhibitor (serpin) superfamily. Most cases of NPPK are caused by loss-of-function (LOF) mutations resulting from aberrant splicing or premature stop codons with nonsense or frameshift mutations.[197] Compound heterozygosity for a missense founder mutation c.830C>T, resulting in proline to leucine in the highly conserved residue 277, resulted in NPPK phenotype with mislocalized SERPIN7 within corneocytes.[198]

A recurrent nonsense mutation in *SERPINB7*, c.796C>T, has been found to be prevalent in both Chinese and Japanese NPPK patients, probably reflecting

a founder effect. Accordingly, it has been suggested that mutation screening for c.796C>T in *SERPINB7* can serve as a diagnostic strategy in the setting of Chinese and Japanese patients with diffuse, nonmutilating PPKs.[190,193,199]

Epidermal protease inhibitors, such as LEKTI, LEKTI-2, elafin, serpins, and cystatins, play a crucial role in maintaining epidermal homeostasis by inhibiting both endogenous proteases residing in the stratum granulosum and the stratum corneum and exogenous proteases from bacteria, fungi, viruses, pollen, and house dust mites that attack the epidermis.[200,201] Mutations affecting serpins can cause symptoms either by loss of protease inhibitory activity and uncontrolled protease activity or by aggregation of mutant serpins polymers in serpin-synthesizing cells with cell death and tissue damage (the "serpinopathies").

SERPINB7 has been shown to be distributed in the epidermis, especially in the stratum granulosum and upper part of the stratum corneum, with predominant cytoplasmic expression. In NPPK skin, SERPINB7 immunoreactivity is markedly diminished.[189] Although SERPINB7 is ubiquitously expressed in human epidermis, NPPK is limited to the hands, feet, knees, and elbows, suggesting that chronic exposure to mechanical stress may have a role in the development of NPPK and that SERPINB7 might inhibit mechanical stress-induced proteases and protect keratinocytes or corneocytes from protease-mediated cellular damage.[189]

The whitish spongy change upon water exposure in NPPK, similar to PPKB with *AQP5* mutations and aquagenic keratoderma with *CFTR* mutations has been suggested to result from enhanced water permeation into the damaged stratum corneum.

Pathology: Histopathologic findings in NPPK include orthohyperkeratosis with acanthosis, hypergranulosis, and a mild to moderate perivascular lymphocytic infiltrate in the upper dermis.[191,192,199] A predominance of CD4+ T cells with barely detectable CD20+ B cells was observed in dermal infiltrates.[202]

DIFFUSE INHERITED PALMOPLANTAR KERATODERMA WITH EXTRACUTANEOUS FEATURES, DOMINANT INHERITANCE

OLMSTED SYNDROME

Clinical Features: OS (OMIM #614594), first reported in 1927 by Olmsted,[203] is a rare disorder with a prevalence of less than 1 in 1,000,000. It usually appears at birth, during the neonatal period, or in early childhood, although appearance later in childhood has been described,[204] and progressively worsen over time. Both sexes are affected, although male patients comprise 60% of reported cases.[205] It is characterized by symmetric, sharply demarcated, diffuse PPK with yellowish-brown hyperkeratosis, painful fissures, and erythematous borders in association with periorificial keratotic plaques. These plaques may be restricted to the areas around the mouth, nostrils, ear meatus, anus, and perigenital region or may extend to involve nonperiorificial sites such as the neck, upper thorax, lower abdomen, arms, elbows, knees, thighs, and inguinal folds. The PPK typically starts focally and is distributed on the pressure points. It gradually extends to most of the surface of the palms and soles with thick hyperkeratotic plaques that eventually result in flexion deformity of the fingers, pseudoainhum, and spontaneous amputation of the digits or the hands. The PPK is typically painful and disabling, interfering with walking and daily activities. Cases with more focal or punctuate keratoderma, lacking pseudoainhum or significant periorificial keratotic lesions, have been reported.[204,206-209] Additional findings are severe pruritus with sleep disturbances, onychodystrophy (ridged and rough nails, onychogryphosis, leukonychia, onycholysis, paronychia, subungual hyperkeratosis, absence of nails), abnormal dentition (absence of premolar teeth, periodontal disease with premature teeth loss),[210,211] sweating abnormalities, oral leukokeratosis, hyperhidrosis, hyperkeratotic linear streaks, follicular keratosis, cheilitis, and ichthyotic lesions.[208,212-220] Hair abnormalities are common, although rare cases have normal hair, and include alopecia (diffuse, universal or patchy); hypotrichosis; and thinning, curly, woolly, coarse, and dry or easily broken hair. Microscopic findings of affected hair include pili torti, trichorrhexis nodosa, reduced pigment, longitudinal ridges, and transverse fractures of the hair shaft.[33,205,213,217-219] Sparse and thin eyebrows and eyelashes, madarosis, as well as trichomegaly were observed in OS.[206,214,221] Secondary bacterial and candidal infections,[216,222,223] SCC (verrucous carcinoma or its variant epithelioma cuniculatum), and MM can develop within the PPK.[224-227] A case associated with cone-shaped fingers and a sclerodactyly-like appearance overlapping with clinical features of Huriez syndrome has been described.[228] Extracutaneous manifestations are uncommon and include hearing loss,[211] ocular abnormalities (corneal dystrophy, inflamed lacrimal glands or ducts or meibomian gland dysfunction, chronic blepharitis),[214,216] short stature,[218,226] primary sclerosing cholangitis,[229] mental retardation,[203,230] joint laxity, ankyloses, osteopenia, and osteolysis.[145,203-205,211,218,223,226,231,232] Erythromelalgia[206,228,233] has been reported in several cases.

Etiology and Pathogenesis: Although most cases reported to date have been sporadic, familial cases with different modes of inheritance, including autosomal dominant, autosomal recessive and X-linked inheritance, have been reported. Autosomal dominant, semidominant, and autosomal recessive OS have been shown to be cause by mutations in the gene *TRPV3* encoding transient receptor potential vanilloid 3 (TRPV3),[145,206,221,232,233] and mutations in the gene *MBTPS2* encoding the membrane-bound transcription factor protease site 2 have been identified in X-linked

recessive OS.[234] There is no clear genotype–phenotype correlation in OS.

Mutations in *TRPV3* are associated with persistence of basal keratins[208,235] and increased expression of Ki-67.[219,220] Keratinocytes expressing mutant TRPV3 are prone to cell death, and the epidermis of OS patients displays increased apoptotic cells compared with control participants.[145]

TRPV3 is highly expressed in keratinocytes and in the hair follicles (HFs), spinal cord, sensory neurons, brain, and cornea. It has an important role in epidermal barrier formation, regulation of hair growth, and modulation of pain sensation and pruritus, explaining the manifestations of OS.[236-240] TRPV3 activation increases intracellular Ca^{2+} concentration and is associated with transforming growth factor (TGF)-α/EGFR signaling, which is known to regulate epidermal differentiation.[241] The role of TRPV3 in mediating EGFR signaling in hair and skin barrier function was demonstrated using a *Trpv3* knockout mouse model that developed a wavy hair coat and curly whiskers in addition to red, dry, scaly skin at birth.[239] In addition, mice or rats carrying heterozygous mutations in *Trpv3* exhibited hair paucity and dermatitis.[242]

Mutations in *MBTPS2*, encoding a zinc metalloprotease essential for cholesterol homeostasis and endoplasmic reticulum (ER) stress response, have been reported in cases of OS with X-linked recessive inheritance.[234] Mutations in *MBTPS2* were first identified in ichthyosis follicularis atrichia photophobia (IFAP) syndrome[243] (see Chap. 49), which is allelic to X-linked recessive OS. A case with features of both OS and IFAP syndrome has been reported.[244]

There is no obvious clinical difference between OS patients carrying either *TRPV3* or *MBTPS2* mutations, and clinical variability is observed within the same family or among different patients harboring the same mutations, supporting a role for modifier genes, environmental effects, or epigenetic factors. Moreover, genetic heterogeneity is likely given the fact that some patients do not carry mutations in either *TRPV3* or *MBTPS2.*

Pathology: The histopathologic findings of OS are nonspecific and include psoriasiform epidermal hyperplasia, orthohyperkeratosis, focal parakeratosis, hypo- or hypergranulosis, acanthosis, and inflammatory infiltrates in the upper dermis, which may contain mast cells.[145,205,232] Epidermal vesicular degeneration has been reported.[228] Electron microscopy findings include large, coarse, densely packed bundles of tonofilaments in the keratinocytes of the mid Malpighian layer and increased numbers of coarse keratohyaline granules in the granular layer. Decreased number of pigment granules and absence of Langerhans cells were reported.[228]

Specific Treatments: Partial excision of palmoplantar keratosis or full-thickness excision with skin grafting has been performed with clinical improvement.[245] EGFR inhibitors have been shown to improve PPK,[246] and TRPV3 antagonists may be an effective treatment for patients harboring GOF mutations in the *TRPV3* gene.

CONNEXIN-ASSOCIATED PALMOPLANTAR KERATODERMAS: VOHWINKEL SYNDROME, KERATITIS–ICHTHYOSIS–DEAFNESS SYNDROME, BART-PUMPHREY SYNDROME, AND PALMOPLANTAR KERATODERMA WITH DEAFNESS

Clinical Features: VS (keratoderma hereditaria mutilans; OMIM #124500) was first reported in 1929 by Vohwinkel[115] and Wigley.[247] VS is characterized by a triad of diffuse, mutilating PPK with a "honeycomb-like" appearance (see Fig. 48-4B); "starfish-shaped" keratotic plaques on the dorsal hands, feet, and extensor surfaces; and fibrous constricting bands (pseudoainhum) at the interphalangeal joints of the hands and feet that result in autoamputation.[248] Most cases are also associated with high-frequency SNHL.[27,29,249-252] The disease is more common among white women. It tends to manifest in the neonatal period and progresses throughout life. Cases with PPK characterized by callosities at pressure points or striate lesions at sites of injury, suggesting an isomorphic phenomenon, have been reported.[250] The disease may be associated with generalized ichthyosis,[28] acanthosis nigricans,[253] cicatricial or nonscarring alopecia, nail anomalies, knuckle pads, bullous lesions on the soles,[249] and craniofacial anomalies (cleft lip and palate, microcephaly, and facial asymmetry).[27,29,249,250,254-257] The appearance of SCC and basal cell carcinoma (BCC) in the hyperkeratotic lesions has been reported.[28] Cases associated with deafmutism,[18] mental retardation,[258] spastic paraplegia with myopathy,[29] psychomotor developmental retardation, and epileptic seizures[259,260] have been reported.

KID syndrome (OMIM #148210; see Chap. 47) is the most severe cutaneous connexin disorder, involving epithelia of ectodermal origin (skin, appendages, nail, teeth) along with significant inner ear and cornea involvement.[261,262] Disease manifestations were first described in 1915, although the name KID syndrome was coined by Skinner and coworkers in 1981.[262,263] The disease manifests at birth or during infancy. Its cutaneous features are erythrokeratoderma with symmetrical, well-circumscribed hyperkeratotic plaques with a reticulated pattern, leather-like appearance, or diffuse furfuraceous scaling with underlying erythema and a relative predilection for the axillae and neck. Other manifestations include thickened skin with coarse-grained appearance or follicular hyperkeratosis without erythema. The characteristic PPK is diffuse and has a rough, stippled, or grainy appearance (Fig. 48-6). Chronic cheilitis and perleche are common. Associated findings are nail dystrophy, oral manifestations (leukokeratosis, deep fissures of the tongue, dental abnormalities including caries and delayed eruption of teeth, persistent oral mucosal papules), hypohidrosis, and heat intolerance. Numerous KID syndrome patients have sparse hair, and 10% to 23% have congenital atrichia.[261,264] Most patients develop

Figure 48-6 Keratitis–ichthyosis–deafness (KID) syndrome. Diffuse, hyperkeratotic, plantar keratoderma with the characteristic rough, stippled, and grainy appearance.

progressive keratitis that begins during childhood and may first manifest as photophobia. The keratitis is characterized by corneal inflammation, pain, and corneal neovascularization and may be associated with chronic blepharitis, conjunctivitis, keratoconjuctivitis sicca, and limbal defects and may cause progressive visual decline and blindness. Associated ophthalmologic features are loss of eyebrows and eyelashes, hyperkeratosis of the eyelids, trichiasis, early-onset cataract, and bilateral lacrimal punctal agenesis.[261,265-272] Conversely, cases with no evidence of ophthalmologic manifestations have been described.[273,274] In addition, patients with KID have congenital, bilateral, and severe SNHL, which is not progressive, compared with the corneal findings.[275] Patients are prone to mucocutaneous infections, mostly bacterial and candidal, which can be fatal in the neonatal period.[276,277] Viral infections (molluscum contagiosum and cytomegalovirus), recurrent pulmonary infiltrates, and recurrent otitis externa have been reported.[278,279] Patients are prone to developing benign cutaneous tumors, mainly trichilemmoma,[280-282] although isolated cases of multiple poromas and porokeratotic eccrine ostial and dermal duct nevus have been described.[283] Approximately 10% of affected individuals are reported to develop SCC of the skin (mainly acral sites and areas of chronic infection or inflammation) and tongue, apparently caused by p53 loss in the lesions.[41,261,268,269,278,280,284-287] SCCs may cause death in patients with KID given their aggressive phenotype and the tendency to develop multiple tumors.[280] In addition, single cases of an association with sebaceous carcinoma, peripheral T-cell non-Hodgkin lymphoma, malignant histiocytoma, and metastatic malignant pilar tumors have been reported.[271,281,288-290] An association between KID syndrome and hidradenitis suppurativa and dissecting cellulitis of the scalp has been described.[47,281,291,292] KID syndrome may result in death in infancy from severe infections or respiratory compromise.[276,293-295]

Bart-Pumphrey syndrome (BPS; OMIM #149200) is a rare, autosomal dominant disorder first described by Bart and Pumphrey in 1967. It is characterized by severe SNHL, PPK with a honeycomb-like appearance, knuckle pads, and leukonychia.[296-298] Hearing loss and knuckle pads are the most common findings; leukonychia and PPK are seen less frequently.[296,297,299-302] The PPK features diffuse, sharply demarcated thickening of the palmoplantar skin with a punctate, grainy surface reminiscent of VS. Striate appearance has been described as well.[302]

PPK and deafness (OMIM #148350) is an autosomal dominant condition in which PPK may be diffuse, transgrediens with fissures and underlying erythema or with a milder phenotype with skin fold accentuation over pressure points. Knuckle pads may be present. Hearing impairment may become apparent during infancy; is bilateral, prelingual, and slowly progressive; and affects high-frequency tones.[303-309]

Etiology and Pathogenesis: Gap junctions, which are formed by connexons, are intercellular junctions that facilitate and regulate the passage of water and small molecules between adjacent cells. The oligomerization of six connexins leads to the formation of a hemichannel called a connexon, and connexons of two opposing cells interact with each other through their extracellular portions to form a channel that is the basic unit of the gap junction. Connexins are expressed in a tissue and differentiation specific manner.[310-315] The epidermis, its appendages, and other ectoderm-derived epithelia of the inner ear and cornea share the expression of several connexin proteins, including Cx26, Cx30, Cx31, and Cx43. Cx43 is ubiquitously expressed in all epithelial cells of ectodermal origin, and similar to Cx26, it has been shown to play a role in wound healing.[316] The expression of Cx26 is limited to cochlear cells, corneal limbal cells, palmoplantar epidermis, around the openings of eccrine sweat glands and ducts, and in the inner and outer root sheath of human HFs. Cx26 expression is widely paralleled by the expression pattern of Cx30 (both share 76% amino acid identity).[317,318] In contrast to Cx30, which is prevalent in the upper differentiated layers of interfollicular epidermis, Cx26 is only expressed at low levels in palmoplantar epidermis but is strongly induced in response to wounding and in hyperproliferative diseases.[318-320] Cx26 is also expressed in epithelial supporting cells surrounding the sensory hair cells of the cochlea and in the fibrocytes lining the cochlear duct, where it mediates the recycling of potassium ions passing through the hair cells back to the endolymph during auditory transduction.[321,322]

GJB2 encodes Cx26. Recessive mutations producing complete loss of expression or function are the single most common cause of nonsyndromic SNHL in humans.[323] In addition, mutations in connexin genes are known to cause several inherited human disorders not associated with PPK or other dermatological abnormalities, including X-linked Charcot-Marie-Tooth disease (Cx32),[324] zonular pulverent cataract (Cx50),[325] and oculodentodigitaldysplasia (Cx43).[326] Moreover, several inherited genodermatoses result from heterozygous mutations in connexin genes (see Table 48-1 and Fig. 48-2).[250,327-329]

Connexins consist of four transmembrane domains, three cytoplasmic domains (the amino-terminus, a cytoplasmic loop and the carboxy terminus domains), and two extracellular loops. Both the N-terminal and C-terminal parts of the proteins are located in the cytoplasm. The membrane spanning and extracellular domains are highly conserved, and the main differences between connexins are found in their C-terminal tails.[311,330] Most dominant-negative *GJB2* mutations associated with hearing impairment and cutaneous involvement reported so far are located in the cytoplasmic N-terminal or in the first extracellular loop of Cx26, which is highly conserved among the connexins and is involved in the control of voltage gating, channel permeability, multimer assembly, and the interactions between connexons. Accordingly, mutations affecting the first extracellular domain may affect both protein transport and channel permeability.[311,317] In addition, different mutations in this domain result in different pathophysiological effects, such as blockage of conductance, dominant effect on wild-type Cx26, protein folding, and altered hemichannel structural stability, leading to a variable clinical phenotype. Moreover, co-oligomerization of different connexins into heteromeric connexons plays a role in the pathogenesis and in the dynamic nature of connexin-associated phenotypes, which are mostly caused by a dominant negative effect on intercellular communication.[311,331]

Most reported cases of VS result from the recurrent heterozygous missense mutation, p.Asp66His, in *GJB2* which results in an amino acid substitution from aspartic acid to histidine in a highly conserved residue of the first extracellular domain.[330] This mutation could selectively impair the ability of Cx26 to form heteromeric and homomeric connexons,[332] resulting in a change in charge or conformation of Cx26 with disruption of gating properties for certain molecules or ions.

Generalized knockout of *Gjb2* in mice is embryonic lethal (caused by placental insufficiency), but conditional *Gjb2* knockout in the mouse inner ear resulted in deafness.[333] Transgenic expression of a dominant-negative *Gjb2* mutation revealed a progressive degeneration of the sensory hair cells with the loss of the tunnel of Corti as a result of disturbed cortilymph homeostasis,[334] illustrating the essential role played by Cx26 in the auditory function in the inner ear. Transgenic mice expressing the p.Asp66His mutation exclusively in the suprabasal epidermis exhibited keratoderma with constriction bands on the tail, marked thickening of the epidermal cornified layers, and increased epidermal TUNEL staining, indicative of either excess apoptosis or premature terminal differentiation.[335] Premature keratinocyte death might induce compensatory basal cell proliferation, leading to the massive thickening of the stratum corneum.

Both autosomal dominant[41,43] and autosomal recessive[336] forms of KID syndrome have been described, although autosomal dominant inheritance is more common.[42,337] Cases with suggested parental germline mosaicism have been reported.[286,294,338] Most affected individuals harbor a recurrent missense mutation in *GJB2*, p.Asp50Asn, leading to replacement of aspartic acid in codon 50 with asparagine.[298,317,339-342] In addition, hystrix-like ichthyosis-deafness (HID) syndrome, which is allelic to KID syndrome,[343] has been reported to result from the p.Asp50Asn mutation and other *GJB2* missense mutations.[298] Asp50 is a pore-lining residue that is highly conserved among connexins and is crucial for gap junction formation and function; p.Asp50Asn results in intracellular expression of the mutant protein, suggesting altered trafficking to the plasma membrane and absence of gap junction plaques.[344,345] The mutation p.Gly45Glu has been identified in a fatal forms of KID syndrome.[294] All KID syndrome–causing mutations cluster in regions coding for the first extracellular domain and the cytoplasmic amino terminal domain of Cx26 and are predicted to alter the charge and structure of this domain, in contrast to nonsyndromic Cx26-associated mutations that are located along the protein.[314,317] Recent experiments in *Xenopus laevis* oocytes demonstrate that hemichannels formed by several Cx26 KID mutants are inhibited by mefloquine; mefloquine attenuated increased macroscopic membrane currents in primary mouse keratinocytes expressing the human Cx26 p.Gly45Glu mutation.[346]

A heterozygous mutation in *GJB6*, encoding Cx30, has been shown to result in KID syndrome as well. This mutation is predicted to alter the sequence and charge of the first transmembrane helix of Cx30 and was reported in a child with typical characteristics of KID syndrome, including follicular, spiny hyperkeratosis, congenital atrichia, and nail abnormalities.[264] A similar mutation had been implicated in Clouston syndrome (see later) without evidence for abnormal sweating, hearing, photophobia, and keratitis,[347] underscoring the profound influence of other genetic and epigenetic factors in modifying the clinical outcome of connexin disorders and emphasizing the phenotypic variability of *GJB6* mutations. It has been speculated that the unique phenotype of this patient is related to the presence of a homozygous polymorphism in *GJB2*.[264]

In BPS, two mutations involving the first extracellular domain of Cx26, p.N54K, and p.G59S have been reported, underscoring the importance of this domain in docking of connexin hemichannels and voltage gating.[299,302]

PPK with deafness results from heterozygous mutations in the *GJB2* gene clustered in or at the border of the first extracellular loop domain.[303-306] One of these dominant mutations, p.R75Q (c.224G>A), was described for the first time by Uyguner and coworkers in a Turkish family[305] and was reported in isolated deafness and in association with PPK.[348]

Pathology: Histopathologic manifestations of VS include compact hyperkeratosis; orthokeratosis; acanthosis; significant hypergranulosis with large, irregularly shaped keratohyaline granules; papillomatosis of the epidermis; and dermal fibrosis with a sparse perivascular lymphocytic infiltrate.[256,298,349] Ultrastructural findings are marked swollen mitochondria and increased numbers of desmosomes in the spinous and granular layers with corneocytes containing many membrane coating granules and lipid-like vacuoles.[349]

Skin biopsies obtain from PPK in KID syndrome may display epidermal hyperplasia, compact orthokeratotic hyperkeratosis, and focal parakeratosis. Hypogranulosis may be observed, although cases with a prominent granular layer have been reported, and swollen keratinocytes with slightly vacuolated cytoplasm are described. Keratotic plugging is a common feature. Inflammatory cells in the upper dermis may be evident, especially in cases of infection.[264,294,350]

Histopathologic findings in BPS are massive orthokeratotic hyperkeratosis, hypergranulosis, acanthosis, and papillomatosis. Epidermal gap junctions appear normal on electron microscopy.[302]

Specific Treatments: In VS, cross finger flap,[248] treatment with Z-plasty,[351] full-thickness excision of the constriction band with a full-thickness skin graft,[352] and a distant abdominal skin flap for fifth digit constriction bands[353] have been described. Reported treatments for the ocular manifestations of KID syndrome are keratolimbal allograft, keratoplasty and immunosuppression,[354] keratectomy,[43] topical corticosteroids and cyclosporine,[355] and bevacizumab has been shown to be effective in a single case.[356]

PALMOPLANTAR KERATODERMA–CONGENITAL ALOPECIA SYNDROME

Clinical Features: Two forms of PPK with congenital alopecia have been described. An autosomal dominant form has a milder phenotype (PPKCA1, Stevanovic type; OMIM #104100),[357-360] and the recessively inherited form is associated with pseudo-ainhum, sclerodactyly, contractures, and sometimes cataracts (PPKCA2, Wallis type; OMIM #212360).[257,361-363] Hair is normal or sparse at birth, and noncicatricial alopecia involving the scalp, body, or facial hair becomes apparent in early infancy. Trichorrhexis nodosa may be evident on hair microscopy. PPK develops in late infancy and is well-defined, focal or linear, nonmutilating, and transgrediens in the dominant cases. In the recessive cases, it features progressive thickening of the lateral and medial aspects of palms and soles with an erythematous rim and skin cracks that subsequently involve the dorsal fingers, resulting in contractures, pseudoainhum, and sclerodactyly. Associated findings are follicular plugging with ulerythema ophryogenes–like features; keratosis pilaris; and hyperkeratotic plaques over the ankles, elbows, and popliteal fossae, with multiple spiky, horn-like lesions reminiscent of ichthyosis hystrix and nail abnormalities (eukonychia, nail dystrophy).[364] Cataracts, meningocele, and unilateral deafness were reported in single cases.[257,358,361]

Etiology and Pathogenesis: PPKCA1 has been shown to result from a heterozygous missense mutation in the gene *GJA1*, encoding Cx43, which exerts a GOF effect on the Cx43 hemichannel. Cx43 is ubiquitously expressed in various organs, including the epidermis and HFs.[365,366]

PPKCA1 is allelic to oculodentodigital dysplasia (ODDD), which is characterized by craniofacial dysmorphism; dental, ophthalmologic, and limb abnormalities; and neurodegeneration, and is occasionally associated with PPK and hair and nail anomalies. In ODDD, most mutations result in retention of the mutant protein in the ER or decreased permeability of the channels with nonfunctional gap junctions.[326,367-369]

The responsible gene for PPKCA2 has not been identified yet.

Pathology: Hyperkeratotic plaques show orthohyperkeratosis with follicular plugging and perivascular lymphocytic infiltration in the papillary dermis.[364] Scanning electron microscopy of the hair shafts reveals multiple pits with cuticular weathering[364] or longitudinal grooves.[360]

HIDROTIC ECTODERMAL DYSPLASIA (CLOUSTON SYNDROME; SEE CHAP. 131)

Clinical Features: Hidrotic ectodermal dysplasia (HED, Clouston syndrome; OMIM #129500) was first described in 1895[370] and later by Clouston in families from Quebec.[371,372] HED is an autosomal dominant ectodermal dysplasia particularly common among the French-Canadian population because of a founder effect,[328] although it has been reported in several ethnic groups.[347,373-380] The main features of this condition include nail dystrophy, hair loss, and palmoplantar hyperkeratosis with normal sweat glands and teeth.[378,381,382]

Nail abnormalities are usually present; in nearly 30%, they are the only manifestation of the syndrome. They range from almost normal-appearing nails to short nails and anonychia.[371] Nail plate changes include thickening, brittleness, ridging, discoloration, splitting, onycholysis, and 20-nail dystrophy.[347,371,372,381] Paronychia and nail infections are common and may result in nail matrix destruction.[371,374,383] Hair abnormalities may be progressive and involve the scalp, facial, and body hair and include atrichia or hypotrichosis with brittle, fine, pale, or slow-growing hair.[384] PPK is diffuse with a velvet-like or cobblestoned appearance extending onto the fingertips and knuckles with fissures. In a large Han Chinese family, the hyperkeratosis of the palms and soles tended to worsen with time.[379] Cases of HED with nail changes resembling PC, either as a solitary finding or in association with alopecia but with no evidence of PPK have been reported.[385-387] Keratotic papules and plaques over the upper and lower extremities and discrete hyperpigmentation over digital joints have been described. Rare associations include strabismus, cataract and photophobia, hearing impairment, mental deficiency, and bone abnormalities (thickening of the skull, abnormal phalanges).[371,372,382,383,388-391]

Etiology and Pathogenesis: HED is caused by autosomal dominant heterozygous mutations in *GJB6*,

encoding Cx30.[328] Cx30 is a 261–amino acid polypeptide consisting of four transmembrane domains, two extracellular domains, and three cytoplasmic domains similar to other connexins.[392,393] Cx30 is expressed in the epidermis (middle and upper spinous layers), HFs (outer root sheath, hair matrix), nails (nail matrix and nail bed), brain, and inner ear.[328,394-399]

A mouse model for HED carrying the p.A88V mutation in *GJB6* demonstrates mild hyperkeratosis of palmoplantar skin, enlarged and hyperproliferative sebaceous glands, and altered hearing (both are not common features in HED).[400] In addition, this mutation resulted in significant apoptosis, possibly through leaky hemichannels.[401] It has been suggested that the leaky hemichannels resulting from the p.A88V mutation could stimulate proliferation through activation of Ca^{2+}-dependent kinases with altered gene expression or cell cycle reentry.[400]

Similar to other connexin disorders, HED is characterized by extensive clinical and genetic heterogeneity. A patient with clinical features of HED and ODDD and extensive hyperkeratosis of the skin was found to have an heterozygous mutation, p.V41L, in *GJA1* encoding Cx43, as well as a heterozygous sequence variant (P.R127H) in *GJB2*.[402] A Chinese patient with HED was found to carry two missense mutations, p.N14S in *GJB6* and p.F191L in GJB2,[389] and a Japanese patient with HED associated with hearing impairment and photophobia was found to harbor a heterozygous missense mutations in *GJB6* (p.Ala88Val) and a polymorphism in *GJB2* (p.Val27Ile).[390]

In contrast to *GJB2* mutations that result in skin symptoms and deafness, mutations in *GJB6* typically result in skin manifestations with no evidence of hearing impairment. It is possible that Cx26 compensates for the absence of Cx30 in the inner ear and not in the skin, but Cx30 cannot completely compensate for the loss of Cx26 at both sites because mutant Cx26 exerts a dominant negative effect on other co-expressed connexins. However, a case of KID syndrome caused by a mutation in *GJB6* and a case of HED with SNHL and photophobia have been reported; in addition, a p.T5M mutation in *GJB6* results in dominant nonsyndromic hearing loss, suggesting that functional redundancy may be dependent on additional factors such as the location and nature of the causative mutations.[264,390,403]

Pathology: Hypotrichotic skin reveals normal epidermis, a normal distribution of eccrine and sebaceous glands, and absence or remnants of HFs.[347,379,384] PPK lesions reveal hyperkeratosis with irregular and reticulated acanthosis.[389]

HURIEZ SYNDROME

Clinical Features: Huriez syndrome (sclerotylosis; OMIM #181600) was first described by Huriez and coworkers in 1969 in two families from Northern France.[404] Since then, kindred from different ethnicities have been described, including Tunisian, Indian, German, English, Italian, and Japanese families.[405-411] Most cases are inherited in an autosomal dominant fashion, and several sporadic cases have been reported.[409,412] Huriez syndrome is characterized by diffuse PPK, scleroatrophy of the hands and fingers, occurrence of SCC within atrophic skin, and sclerodactyly leading to contractures. The disease is present at birth or appears in the first years of life and persists with no further progression. The PPK manifests as diffuse, yellowish-grey, nonerythematous, well-confined hyperkeratotic plaques mainly involving the palms with extension towards the fingers and accentuation of palmar creases (Fig. 48-4C). The soles are less frequently involved and usually show accentuation over pressure sites. A porokeratotic appearance has been described. Scleroatrophic changes include a pseudosclerodermoid appearance of the hands and digits with absence of dermatoglyphs and erythematous, atrophic appearance of the dorsal aspect of the hands, fingers, and tips of the fingers and toes with no evidence of Raynaud phenomenon. Associated findings are hypohidrosis and nail changes including hypoplasia, curving, onychorrhexis, koilonychia, longitudinal ridging, and clubbing. Manifestations reported in isolated cases are poikiloderma-like changes, distinctive small nodules on the fingers, and facial telangiectasia. Malignant degeneration starts with the occurrence of skin ulcers on the atrophic skin of the hands and development of SCC by the third to fourth decade of life. The estimated risk of SCC is 13%, a greater than 100-fold higher risk. These tumors tend to show poor differentiation with high rates of metastasis and a calculated mortality rate of 5%.[35,404,406-408,413,414] Cases associated with internal malignancies (gastric carcinoma, pharyngeal carcinoma) have been described, but internal malignancies do not seem to be more frequent in Huriez syndrome than in the general population.[35,404]

Etiology and Pathogenesis: The pathogenesis of Huriez syndrome and the mechanism involved in tumor formation are unknown. Previously, a linkage between Huriez syndrome and the certain blood groups has been reported[415]; however subsequent studies failed to confirm this finding.[35,407] Lee and coworkers mapped the gene to chromosome 4q23.[416] Loss of heterozygosity of 4q has been reported in the majority of SCCs originating from head and neck and in almost 50% of cases of cervical carcinoma. However, in the former, the region involved extends distal to the locus of Huriez syndrome with possible overlap on its centromeric end.[416]

Immunohistochemical and ultrastructural studies revealed an almost complete absence of epidermal Langerhans cells within involved skin.[405,406] Moreover, positive p53 staining (indicative of abnormal function of p53) was observed in atypical keratinocytes, suggesting that *p53* mutations may be responsible for the development of actinic keratoses and SCC in Huriez syndrome.[409]

Pathology: Skin biopsies obtained from PPK skin reveal marked acanthosis and papillomatosis, hypergranulosis with increased number of keratohyaline granules, and orthokeratotic hyperkeratosis. No

abnormalities are observed in the dermis and sweat glands. In scleroatrophic regions, the epidermis shows hypergranulosis with orthokeratotic hyperkeratosis, dense collagen fibers in the reticular dermis, and thin elastic fibers. Sparse dermal mononuclear cell infiltrates may be seen.[35,405,409,412,413] A case with vacuolar degeneration of keratinocytes in the upper spinous layers has been reported.[411] Ultrastructural findings are dense bundles of tonofilaments throughout epidermal layers with abundant keratohyaline distributed in large clumps of irregular density. Areas of scleroatrophic skin show similar changes in tonofilaments and keratohyaline but with addition features of thinned oxytalan and elaunin fibers at the dermal–epidermal junction, irregular borders, and nonhomogeneous appearance of elastic fibers with evidence of elastic fibers engulfed by macrophages.[35]

DIFFUSE INHERITED PALMOPLANTAR KERATODERMA WITH EXTRACUTANEOUS FEATURES, RECESSIVE INHERITANCE

PAPILLON-LEFEVRE SYNDROME

Clinical Features: PLS (OMIM #245000) is a rare, autosomal recessive disorder characterized by palmoplantar hyperkeratosis and severe progressive periodontitis, causing loss of primary and permanent teeth with periosteal changes of the alveolar bone.[417-420] Periodontal disease severity has been shown to peak in the teens and declines with age.[421] The estimated prevalence of PLS is 1 to 4 cases per 1 million people, and the carrier rate is 2 to 4 per 1000. There is no gender predilection, but consanguinity has been observed in approximately half of cases.[422,423] PPK may appear at birth or during the first months of life, although in most cases, both PPK and periodontitis develop between the sixth month and fourth year of life, often beginning with the eruption of the first teeth.[424] Of note, there is no correlation between the severity of the cutaneous and dental manifestations.[425] The PPK is characterized by diffuse, erythematous, sharply demarcated hyperkeratotic and scaly plaques on both palms and soles with transgrediens features extending onto the dorsal aspect of the hands and feet (Fig. 48-7A). It may be associated with hyperhidrosis, foul-smelling odor, and nail abnormalities (transverse grooving and fissuring). Atypical cases with late-onset periodontitis and palmoplantar lesions or cases with isolated PPK or periodontitis have been described.[426-429] Sharply demarcated, psoriasiform, hyperkeratotic plaques can be observed on the knees, elbows, and ankles, and a more widespread distribution resembling psoriasis

Figure 48-7 Plantar keratodermas of Papillon-Lefèvre and Howel-Evans syndromes. **A,** Diffuse keratoderma in Papillon-Lefèvre syndrome caused by mutation in cathepsin C. **B,** Howell-Evans syndrome showing focal, yellow, thick plaques localized to areas of pressure on the soles. (Part A used with permission from Barts and the London NHS Trust, United Kingdom.)

has also been described.[38,423,425] Increased susceptibility to infections is typical; pyogenic skin infections as well as hepatic or cerebral abscesses and pneumonia have been reported.[423,430] PLS may be associated with intellectual disability and calcification of the dura mater. Isolated cases have been reported in association with growth retardation, infantile voice, and hypothyroidism, although these may not be directly related to the PLS phenotype.[38,420,423,431,432] An association with atopic diathesis and elevated immunoglobulin E (IgE) levels has been reported.[38,421,433,434] Acral lentiginous melanoma may be more common in PLS, at least among Japanese patients.[435]

Etiology and Pathogenesis: PLS results from LOF homozygous or compound heterozygous mutations in the gene *CTSC*, encoding cathepsin C (CTSC), also known as dipeptidyl peptidase I. More than 70 mutations have been reported from ethnically diverse populations; approximately half are homozygous missense mutations altering protein folding and function, 25% are nonsense, and nearly 25% are frameshift mutations.[38,420,436] PLS is allelic to Haim-Munk syndrome (HMS; OMIM #245010), a disorder described mostly in individuals from Cochin, India, characterized by the presence of pes planus, arachnodactyly, acroosteolysis, and onychogryphosis in addition to

PPK and periodontitis. Individuals with HMS do not have evidence of cerebral calcification and bacterial infections. Sulák and coworkers recently reported two Hungarian patients, one with PLS and one with HMS, who carry the same homozygous nonsense mutation in the *CTSC* gene,[437] supporting the notion that PLS and HMS are phenotypic variants of the same disease. PLS is also allelic to prepubertal periodontitis without skin manifestations.[438-440]

CTSC belongs to the papain superfamily of cysteine peptidases and is a tetrameric enzyme consisting of four identical subunits linked together by noncovalent bonds. It plays an important role in intracellular degradation of proteins and coordinates the zymogen activation of serine proteases in cells with immune or inflammatory function including neutrophils, mast cells, cytotoxic T cells, and natural killer cells.[441-446] The protein is expressed as a pro-proteinase in epithelial and myeloid cells, and a multistep process leads to its activation.[418,447] The *CTSC* mutations in patients with PLS are associated with loss of CTSC enzymatic protease activity; carriers of the mutations demonstrate reduced activity compared with control participants.[448] In has been shown that the absence of active CTSC in the urine serves as a strong and reliable indicator for PLS and allows screening for the disease in populations with a high frequency of consanguinity.[417]

Analysis of PLS patient neutrophils show that proteins normally found in the azurophilic granules (elastase, cathepsin G, proteinase 3) are completely absent in mature neutrophils but not in progenitor cells, indicating that *CTSC* mutations promotes protease degradation in mature immune cells. Because significant immunodeficiency is not evident in patients with PLS, neutrophil serine proteases are probably dispensable for human immunoprotection.[449]

Elevated IgE levels have been demonstrated in several cases of PLS, and the delayed resorption of the roots of primary teeth in hyper-IgE syndrome patients led to the suggestion that serum IgE may influence periodontal metabolism. This is supported by improvement in periodontal inflammation in PLS after a decline in IgE levels.[421] Moreover, a T helper (Th) 2 phenotype is evident in PLS with reduced levels of Th1 cells and interferon-γ and increased levels of IL-4.[434]

Pathology: Histopathology analysis in PLS reveal irregular hyperkeratosis, hypergranulosis, marked acanthosis, and perivascular lymphocytic and histiocytic infiltrate in the dermis.[39,428,434] Lipid-like vacuoles in corneocytes and granulocytes in addition to irregular keratohyalin granules and reduction in tonofilaments[39] are evident on electron microscopy.

NAXOS DISEASE

Clinical Features: Naxos disease (ND; OMIM #601214) is an autosomal recessive disease caused by mutations in *JUP* encoding plakoglobin (PG).[450] The disease was originally described in families from the Greek island of Naxos by Protonotarios and coworkers. Since then it has been reported in various ethnicities.[451-455]

The disease is characterized by a triad of diffuse PPK, cardiomyopathy, and woolly hair.[450,456,457] The woolly hair appears at birth and features sparse and brittle, sometimes hypopigmented hair. Hair abnormalities are seen in scalp, eyebrows, and axillary and pubic hair. PPK develops during the first year of life and is characterized by diffuse, well-demarcated, nontransgredient hyperkeratotic plaques over the palms and soles, which may be surrounded by an erythematous border. Other cutaneous features are hyperhidrosis and nail abnormalities. Arrhythmogenic right ventricular dysplasia/cardiomyopathy (ARVD/C) usually becomes symptomatic by adolescence with syncope being its first manifestation in most cases. Ventricular tachycardia and sudden death as a result of arrhythmia, which is a major cause of death in Naxos disease (one third of patients die prematurely with a mean age at death of 32 years), are common complications, and symptoms of right heart failure usually appear in the final stages. Left ventricular involvement may also be seen with further disease progression.[452,455,456,458-461]

Etiology and Pathogenesis: ND is an autosomal recessive disorder caused by biallelic mutations in *JUP* encoding PG. The most common reported mutation to date is a homozygous 2-bp deletion which results in a premature stop codon and expression of a truncated PG lacking 56 residues from the C-terminal domain of the protein.[450,454,456,462] Heterozygous carriers of that mutation usually have no skin or hair abnormalities, although woolly hair may be evident, and minor heart involvement has been documented in approximately 25% of cases.[456] Carriers of other mutations that result in residual PG expression display a milder phenotype of PPK, woolly hair, and skin fragility with no evidence of cardiomyopathy.[463] Interestingly, an autosomal dominant mutation with one amino acid insertion in the PG N-terminal domain has been described in cases of ARVC/C with no evidence of PPK or hair abnormalities.[464] Moreover, biallelic missense mutations in the *JUP* gene have been reported in association with PPK and ARVC/C similar to ND with universal alopecia instead of wooly hair.[465]

PG is a member of the armadillo protein family and a constituent protein in adherens and desmosomal junctions in many tissues, including heart muscle and epidermis. The intracellular tail of desmosomal cadherins (desmogleins and desmocollins) is connected to PG and plakophilins through armadillo repeat domains and amino-terminal head domains, respectively. These two armadillo proteins interact with desmoplakin, a plakin protein that links the desmosomal plaque to the keratin cytoskeleton.[466-471]

A Naxos-like phenotype (ARVC associated with severe left ventricular involvement, PPK, and woolly hair) is also associated with homozygous mutations in the gene *DSC2*, encoding the desmosomal cadherin desmocollin 2.[472] In addition, woolly hair and PPK similar to ND but with no evidence of cardiomyopathy are associated with a homozygous missense mutation

in *KANK2*, encoding the steroid receptor coactivator interacting protein that controls activation of steroid receptors.[473]

Pathology: Palmoplantar skin reveals findings compatible with NEPPK.[450,457]

PALMOPLANTAR HYPERKERATOSIS WITH SQUAMOUS CELL CARCINOMA OF SKIN AND SEX REVERSAL SYNDROME

Clinical Features: Palmoplantar hyperkeratosis with SCC of skin and sex reversal (OMIM #610644) is an autosomal recessive disorder described in patients from Southern Italy. It is characterized by sclerodactyly, PPK associated with multiple cutaneous SCCs, early teeth loss caused by chronic periodontal disease, nail hypoplasia with longitudinal ridging, hypogenitalism (ambiguity of external genitalia), gynecomastia, hypospadias with altered plasma sex hormone levels (low testosterone and high follicle-stimulating hormone), and sex reversal (46,XX karyotype in a male phenotype). Associated findings are hypertriglyceridemia, laryngeal cancer, nodular testicular hyperplasia, bilateral cataracts, and bilateral optic nerve coloboma.[411,474,475] A similar presentation has been described in a case of true hermaphroditism with the presence of both ovarian and testicular tissue in a 46,XX woman.[476]

Etiology and Pathogenesis: This disorder results from homozygous mutations in the gene *RSPO1,* encoding R-spondin1. R-spondins are ligands interacting with Fzd–LRP receptor complexes important for β-catenin stabilization.[477] Keratinocytes isolated from the PPK revealed fibroblast-like morphology and larger intercellular spaces with inability to form stratified epidermal layers in organotypic cultures.[478]

Pathology: Palmoplantar skin reveals orthokeratotic hyperkeratosis compatible with NEPPK.[474]

DIFFUSE INHERITED PALMOPLANTAR KERATODERMA WITH EXTRACUTANEOUS FEATURES, MITOCHONDRIAL INHERITANCE

PALMOPLANTAR KERATODERMA WITH DEAFNESS

Clinical Features: The association of PPK and SNHL with a pattern of maternal inheritance caused by a mutation in the extrachromosomal mitochondrial genome (mtDNA) has been identified in several families originating from New Zealand, Japan, France, and Portugal. PPK appears during childhood (5 to 15 years of age) and is characterized by orange-yellow diffuse, well-demarcated, palmoplantar hyperkeratotic plaques with minimal to no erythema. It predominantly involves pressure points and may progress gradually. Although less common, extension onto the dorsal aspects of the hands and feet with a honeycomb-like pattern has been reported, and keratotic plaques over the knees, elbows, and Achilles tendon may be observed. PPK may also be rather focal, resembling calluses, and may involve only plantar skin. Clearing of PPK during pregnancy has been described. Hearing impairment may start in infancy but usually appears by 5 years of age and is bilateral, mild to severe, and may be progressive. Incomplete penetrance is common and is higher for hearing loss (60%) than for skin manifestations (37%). Both sexes are equally affected.

Etiology and Pathogenesis: All affected individuals harbor a common homoplasmic point mutation (c.A7445G) in the mitochondrial transfer RNA (tRNA) encoding the *MTTS1* gene.[479-481] This mutation results in a significant decrease in serine tRNA level with abnormal processing of mitochondrial mRNA and proteins.[482]

Pathology: PPK shows orthokeratotic hyperkeratosis, focal parakeratosis, acanthosis, and focal hypogranulosis.[479-481] Ultrastructural findings are large keratohyaline granules with bundles of tonofilaments not attached to desmosomes and located at the periphery of the nucleus.[479,481]

FOCAL INHERITED PALMOPLANTAR KERATODERMA WITHOUT EXTRACUTANEOUS FEATURES, DOMINANT INHERITANCE

STRIATE PALMOPLANTAR KERATODERMA

Clinical Features: Striate palmoplantar keratoderma (SPPK) is a rare autosomal dominant disorder that may result from mutations in *DSP*, *DSG1*, or *KRT1* encoding desmoplakin, desmoglein 1, or keratin 1, respectively. SPPK is characterized by linear, thickened, hyperkeratotic plaques over the palms that extend along the volar aspect of the digits (Fig. 48-8A) and by circumscribed areas of skin thickening on the soles (Fig. 48-8B). The disease initially presents during the first or second decade of life and is typically exacerbated by manual labor. Nail abnormalities may

Figure 48-8 Focal palmoplantar keratoderma with *DSG1* mutation. Linear, thickened, hyperkeratotic plaques on the palms which extend along the volar aspect of the digits (**A**) and circumscribed areas of hyperkeratotic plaques on the soles (**B**).

rarely be observed (onycholysis, discoloration) and hyperkeratotic plaques over the knees, ankles, knuckle and toe pads, and dorsal aspect of the digits and toes have been reported.[483-486] There are no other skin, hair, or extracutaneous manifestations.[461,485,487-491]

Mutations in *DSG1* have been found to also result in diffuse and focal hyperkeratosis of the palms and soles with no evidence of striate lesions.[483,486,492]

Etiology and Pathogenesis: SPPK is caused by nonsense and frameshift heterozygous mutations in the *DSG1* or *DSP* genes, demarcating two SPPK subtypes: type I (OMIM #148700) and type II (OMIM #125647), respectively.[489,493,494] The mutations result in haploinsufficiency indicating that decreased expression of these proteins by 50% is sufficient for epidermal function in nonpalmoplantar skin but not at sites subjected to major mechanical trauma such as the palms and soles.[461,493-495]

Of note, SPPK-causing mutations in *DSG1* have recently been shown to be inherited in a semidominant, rather than dominant, fashion. Biallelic mutations in *DSG1* cause skin dermatitis, multiple allergies, and metabolic wasting (SAM) syndrome (OMIM #615508)[496] (Fig. 48-9). Thus, genetic counseling of any patient affected with SPPK should take into consideration these data.

Desmoglein 1 and desmoplakin are important components of the desmosomal plaque. Desmoglein 1, a transmembrane protein that belongs to the family of desmosomal cadherins, is expressed in the upper epidermal layers and plays a critical role in cell–cell adhesion and signal transduction pathways regulating epidermal proliferation and differentiation.[497] Loss of desmoglein 1 results in downregulation of proapoptotic signaling, promotes keratinocytes proliferation, and inhibits epidermal differentiation as a result of unopposed ERK signaling, explaining the hyperkeratotic phenotype seen in SPPK.[498-501] Moreover, it has been suggested that desmoglein 1 deficiency results in SPPK via elevated Ras activity,[502] which is supported by the high rate of PPK in disorders of the Ras–MAPK (mitogen-activated protein kinase) pathway.[501]

Similarly, loss of desmoplakin, a plaque protein that plays a crucial role in anchoring intermediate filaments to desmosomal cadherins, has been shown to result in increased cell proliferation and enhanced G1-to-S-phase entry in the cell cycle associated with elevated phospho-ERK1/2 and phospho-Akt levels.[503]

A heterozygous frameshift mutation affecting the keratin 1 tail domain was found to underlie SPPK type III (OMIM #607654).[79] This mutation leads to the partial loss of the glycine loop motif in the V2 domain and affects the function of the desmosomal plaque during cornification.[78]

Pathology: Histopathology findings in SPPK are orthohyperkeratosis, acanthosis, papillomatosis, widening of the intercellular spaces, and disadhesion of

Figure 48-9 Plantar keratoderma in a patient with skin dermatitis, multiple allergies, and metabolic wasting syndrome resulting from biallelic mutations in *DSG1*.

keratinocytes in the upper epidermal layers. Although not entirely specific or sensitive for PPK, the latter two findings serve as a clue for the diagnosis of PPK caused by mutations in genes encoding desmosomal proteins.[484,490,492,504] Immunohistochemical studies demonstrate abnormal perinuclear aggregation of keratin filaments associated with upregulation of KRT16 and abnormal involucrin expression.[493-495] Ultrastructural findings are loosening of intercellular connections and disruption of desmosome–keratin intermediate filament interactions with clumped keratin filaments in a perinuclear distribution. Diminished abnormal-appearing desmosomal structures may be observed.[495]

HEREDITARY KERATOSIS PALMOPLANTARIS VARIANT OF WACHTERS

Clinical Features: Hereditary keratosis palmoplantaris variant of Wachters (PPK varians, Brünauer-Fohs-Siemens syndrome, Siemens syndrome) is a rare autosomal dominant disease with complete penetrance, more common in males, which normally appears in the first or second decade of life. It is characterized by yellowish, nontransgredient, symmetric, nummular, hyperkeratotic plaques localized to pressure points on the soles but that may become more confluent with time. Palmar hyperkeratotic lesions are described as either linear, nummular, membranous, fissured, or periungual. Nummular hyperkeratotic plaques over the elbows, knees, and Achilles tendon were described. Palmoplantar hyperhidrosis, painful transverse fissures, and nail changes (ridging and cuticle hyperkeratosis) may be associated.[505-507] A single case of malignant melanoma arising in the hyperkeratotic lesions on the foot has been described.[508] Varied phenotypic expression with inter- and intrafamilial variability resulted in the description of distinct subtypes and led to the term *keratosis palmoplantaris varians* that was introduced by Wachters in 1963.[509]

Etiology and Pathogenesis: Hereditary keratosis palmoplantaris variant of Wachters is an autosomal dominant disorder, although sporadic cases have been reported. The causative gene is yet to be identified. Immunohistochemical studies show early expression of both filaggrin and involucrin.[505,510]

It is worth mentioning that it is not yet clear whether hereditary keratosis palmoplantaris variant of Wachters and hereditary painful callosities are legitimate distinct entities or are in fact outstanding cases of more common forms of PPK such as PC (*KRT16* mutations) or EPPK (*KRT1* mutations).

Pathology: Histopathology findings include hyperkeratosis, hypergranulosis, possible focal parakeratosis, and acanthosis with no epidermolytic changes or dermal inflammatory cell infiltrate. Ultrastructural findings are tightly packed tonofibrils and large masses of keratohyaline granules with abnormal configuration.[505,510]

FOCAL INHERITED PALMOPLANTAR KERATODERMA WITH EXTRACUTANEOUS FEATURES, DOMINANT INHERITANCE

PACHYONYCHIA CONGENITA

Clinical Features: PC (OMIM #167200 and 167210) is a group of rare autosomal dominant disorders of keratinization caused by mutations in one of five keratin genes, including *KRT6A, KRT6B, KRT6C, KRT16,* or *KRT17.* PC was first described in the beginning of the 20th century,[511,512] although the causative genes were only identified in the late 1990s.[513-515] PC prevalence in Western countries is 0.9 cases per million with a worldwide PC population estimated to be between 5000 and 10,000.[516-518] The severity of the clinical features varies among and within families as the phenotype may be influenced by modifier genes or environmental factors.[519]

Historically, PC has been divided into two subtypes: PC-1 (Jadassohn-Lewandowski), featuring oral leukokeratosis and caused by mutations in *KRT6A* or *KRT16* and PC-2 (Jackson-Lawler) caused by mutations in *KRT6B* or *KRT17* and featuring cysts and natal teeth. However, phenotypic characterization of more than 1000 mutation-verified PC patients enrolled in the International PC Research Registry showed considerable overlap between these subtypes and lead to a new classification scheme based on the mutant gene. Cases of clinically suspected PC with no identified mutation in the known PC-related genes are termed PC-U (unknown).[518,519]

The three clinical features that are reported in more than 90% of PC patients are thickened toenails, plantar keratoderma, and plantar pain. Thickened toenails, the phenotypic feature that gave its name to the condition, appear during early childhood but may occur also in the first weeks of life (especially with mutations in *KRT6A*). Pachyonychia is characterized by significant subungual hyperkeratosis and very thick nails with a characteristic inverted U or V shape that grow to full length or terminate prematurely (Fig. 48-10A). Paronychia with staphylococcal and candida superinfection may be seen. On average, 9 toenails are involved, and mutations in *KRT6A* carry the highest likelihood of having 10 toenails affected. Nail involvement is variable, even within family members carrying the same mutations. Fingernails, although reported to be involved in many patients (100% of patients with *KRT6A* mutations), may be spared, especially with mutations in *KRT6B*.[518] The most common manifestation of plantar keratoderma is focal PPK (FPPK) with calluses over weight-bearing areas (Fig. 48-10B), although diffuse keratoderma may be observed. Blistering, fissures,

Figure 48-10 Pachyonychia congenita. *KRT6A* mutation with the characteristic nail abnormalities (V-shape thick nails and subungual hyperkeratosis) (**A**) and focal palmoplantar keratoderma with calluses over weight-bearing areas (**B**). Mutations in *KRT17* are typically associated with various types of epidermal inclusion cysts (**C**).

and open sores are common. Palmar lesions are less prominent and usually occur in response to occupational mechanical trauma. The average age of onset of PPK is 4 years, although it may appear at birth or have delayed onset (30 years of age). It is very typical that FPPK starts when children begin to walk. Patients with *KRT16* and *KRT6A* mutations develop keratoderma earlier than patients with *KRT6B* and *KRT17* mutations.[518] Although PC classically causes a nontransgredient FPPK, several cases with transgrediens and involvement of the dorsal feet have been described (mostly with *KRT6A* mutations).[520] Plantar pain occurs in all subtypes, may be more severe in warmer weather, and is considered the most important and debilitating feature that affects patients' quality of life. The severe pain is secondary to blister formation deep underneath the thick callus as demonstrated by high-frequency ultrasound.[521] Approximately 60% of PC patients display neuropathic pain features with the existence of nociceptive pain in the remainder.[517]

Additional features are mucosal involvement, cyst formation, and natal teeth. Oral leukokeratosis was reported in 70% of patients. It tends to appear by 5 years of age, although onset at birth was reported in approximately half of the patients and was most characteristic with mutations in *KRT6A* or *KRT17*. It may be the first manifestation of PC in newborns, is often mistaken for candidiasis, and may alter sucking or feeding, causing failure to thrive. About 40% of patients (mostly with *KRT17* mutations) exhibit various types of epidermal inclusion cysts. Pilosebaceous cysts, such as steatocystomas (Fig. 48-10C), and vellus hair cysts are most common and normally develop during puberty, continue throughout adulthood, and may require surgical removal. The face and trunk are affected. Comedone-like cysts may be found in the axillae, mainly in children.[522] Follicular keratosis on the trunk and extremities, mostly in areas of friction such as the knees and elbows, may be observed in approximately 50% of patients and usually present by early childhood. The phenomenon of natal teeth (erupted teeth present at birth or by 1 month) was reported in 15% of patients with PC, almost exclusively with *KRT17* mutations.[518,519] Primary and secondary dentition is normal.

Less commonly associated features are palmoplantar hyperhidrosis, angular cheilitis, and corneal dystrophy.[523] Alopecia was described in two cases of homozygous, semidominant missense mutations in *KRT17*.[524] Hoarseness with life-threatening respiratory distress secondary to laryngeal leukokeratosis has been seen in infants and children with *KRT6A* mutations. Moreover, infants and children with *KRT6A* mutations may demonstrate severe pain anterior to the ear on first sucking or eating that lasts a few seconds.[525,526]

In PC resulting from mutations in *KRT16*, mild FPPK is a universal finding; however, many mutations in *KRT16* produce a less pronounced phenotype with FPPK restricted to weight-bearing areas of the soles, limited or absent nail involvement, and no evidence of oral leukokeratosis, leading to the diagnosis of focal NEPPK rather than PC.[527-531]

Mutations in *KRT6C* have been reported to be associated with a milder phenotype similar to some of the *KRT16* mutations. These cases are characterized by plantar keratoderma (FPPK over pressure sites or diffuse PPK) and callosities over the palms with absent or minor nail changes, such as hypertrophy of the fifth toenail, and plantar blisters. Leukokeratosis may be seen but with no additional clinical findings.[532,533] Key clinical features of PC with associated mutations are summarized in Table 48-3.

Etiology and Pathogenesis: PC is caused by heterozygous mutations in one of five keratin genes expressed in differentiated epithelial tissues: *KRT6A, KRT6B, KRT6C, KRT16*, and *KRT17*, encoding keratins 6a, 6b, and 6c (type II keratins) and keratins 16 and 17 (type I keratins). The expression of keratins

TABLE 48-3
Pachyonychia Congenita: Key Features

GENE	FREQUENCY (%)	COMMON MUTATION (S)	KEY CLINICAL FEATURES
KRT6A	40	p. Asn172del	Thickened toenails and fingernails since infancy Highest likelihood of having 10 toenails affected; Earlier onset of FPPK; transgrediens and involvement of the dorsal feet may occur Oral leukokeratosis Laryngeal leukokeratosis with hoarseness and life-threatening respiratory distress
KRT16	25–30	p. Arg127Cys (mild) p. Arg127Pro (severe) p. Leu128Gln (mild) p .Leu128Pro (severe)	Mild FPPK with limited or absent nail involvement Earlier onset FPPK is possible Coinheritance of *FLG* mutations aggravates the phenotype
KRT17	20	p. Asn92Ser	Delayed onset of FPPK Oral leukokeratosis Epidermal inclusion cysts (steatocystomas, vellus hair cysts) Natal teeth Alopecia[a]
KRT6B	5–9		Fingernails may be spared Delayed onset of FPPK
KRT6C	3		Mostly mild FPPK and callosities over the palms with absent or minor nail changes[b] Leukokeratosis with no additional clinical features may be seen

[a]In a single case of homozygous semidominant inheritance.
[b]A milder phenotype may be the consequence of more restricted expression of keratin 6c in palmoplantar skin and nails compared with keratins 6a and 6b. *KRT6C* mutation carriers in the general population have been reported.
FPPK, focal palmoplantar keratoderma.

6 and 16 is restricted in normal epidermis to the upper outer hair root sheath and nail bed, palmoplantar skin, and suprabasal orogenital mucosal keratinocytes.[534] In addition, wounding or inflammation induces their expression in interfollicular epidermis, and they are expressed at high levels in cultured keratinocytes from both normal and psoriatic skin.[535]

Autosomal dominant inheritance is observed in more than half of the cases; the remaining cases are caused by spontaneous dominant mutations.[536] There are a few case reports of apparent recessive PC inheritance. However, there are no such cases with confirmed genetic testing, and it is likely that most if not all of these cases represent phenocopies of PC.[537] Semidominant inheritance for *KRT17* mutations has been reported as mentioned earlier.[524] Paternal germ cell mosaicism for a *KRT6A* mutation has also been described.[538] Most mutations are missense mutations, and the remainder are small in-frame deletion, frameshift, nonsense, or splice-site mutations that are likely to exert a dominant-negative effect.[536] The majority of reported mutations to date involve the highly conserved helix boundary domains at either end of the α-helical rod domain, being vital for the elongation phase of filament assembly.[539]

Skin biopsies obtained from PC-involved skin show markedly induced expression of the PC-related genes *KRT6*, *KRT16*, and *KRT17*, which are known to be upregulated in states of stress or injury. Mechanical stress may lead to upregulation of both wild-type and mutant forms of these keratins and perturbed intermediate filament formation caused by mutant keratin incorporation, triggering the PC phenotype. This in turn has been linked to aberrant expression of additional mutant keratin as part of the wound healing response, resulting in a vicious cycle of gradual worsening.[540-542] Moreover, overexpression of genes related to cell adhesion (*DSC2*, *CDSN*, and *GJB2*), cornified cell envelope formation (involucrin and loricrin) and desquamation (kallikrein [KLK]-5; *SPINK6*, and *SERPINs*) and non–PC-related keratins (*KRT75* and *KRT85*) has been observed. Pain-associated genes are also upregulated in PC-involved skin, including *KLK10* (catalyzes the production of bradykinin) and *SPRR1A* (a structural protein in keratinocytes being expressed also by neurons), which may relate to the severe pain featured by PC patients.[542]

Pathology: Skin biopsies obtained from PPK lesions reveal features of NEPPK. Reduced granular layer and cytolysis in the outer root sheath of HFs may be seen.[513,530] Epidermolytic hyperkeratosis has been observed in a case associated with mutation in *KRT16* with striate palmar hyperkeratosis and diffuse PPK of the soles.[101] Ultrastructurally, suprabasal keratinocytes in PC are characterized by densely aggregated keratin filament bundles, predominantly in the perinuclear region and sparing the cell periphery. Reduced desmosome number with widened intercellular spaces and reduced keratohyaline granules are additional findings.[513]

Specific Treatments: Contradictory data regarding the efficacy of retinoids in PC have been published with an improvement in both PPK and nail dystrophy in some reports and no improvement in others. In addition, the treatment had to be withheld in many patients with observed improvement because

of increased pain as a result of epidermal thinning and predisposition to infections.[543-546]

In PC, the most effective approach to nail dystrophy consists of mechanical treatments (filing, grinding, cutting, or clipping) and soaking the nails. Surgical avulsion is sometimes ineffective because of regrowth of nails. Oral leukokeratosis may be improved by keeping good oral hygiene, gentle brushing, and oral antibiotics. Follicular hyperkeratosis is treated with oral and topical retinoids, keratolytic agents, and emollients. Steatocystoma multiplex and other pilosebaceous cysts can be treated by incision and drainage, excision, intralesional steroid injection, and oral antibiotics in the case of secondary infections.[544,547-550] Recently, targeted and more specific therapies have been studied in PC. Rapamycin has been shown to result in marked improvement in painful plantar calluses and in quality of life by selectively blocking translation of mRNAs, including *KRT6* mRNA. However, the use of oral rapamycin was limited by side effects, including gastrointestinal symptoms. A clinical trial with topical rapamycin is underway.[526,551] Moreover, a specific siRNA that selectively silences the expression of a specific pathogenic mutation in *KRT6A* has been shown to lead to callus regression and pain control in a phase Ib clinical trial.[552] New approaches for more efficient, safe, and practical ways to deliver siRNA into the epidermis are needed to avoid the painful injections.[548,552-557]

HOWEL-EVANS SYNDROME

Clinical Features: Howel-Evans syndrome (tylosis with esophageal cancer; OMIM #148500) is a rare autosomal dominant disorder with complete penetrance characterized by the association of PPK and mucosal SCCs, particularly of the esophagus. It was first reported by Howel-Evans and coworkers in 1958[558] and has been described in families from a range of countries.[559-565] The estimated prevalence of the disorder in the general population is less than 1 in 1,000,000.[566] The onset of PPK is usually during childhood or adolescence (between 5 and 15 years, although most cases are evident by 7 to 8 years of age). It is characterized by focal, yellowish, thick plaques localized to areas of pressure or friction on the palms and soles (see Fig. 48-7B) that may be associated with painful fissures and secondary infections. Sparing of the palms may be evident.[567] Additional findings are follicular hyperkeratosis, cutaneous horns, and oral leukokeratosis. Cases of SCC of the oropharynx have been recorded.[559-566,568,569]

Esophageal lesions present as few-millimeter, white, polypoid lesions throughout the esophagus. About 95% of patients with Howel-Evans syndrome develop carcinoma by 65 years of age, similar to the onset of sporadic cases.[566]

In patients with Howel-Evans syndrome, screening includes annual gastroscopy. Besides surveillance, diet, and lifestyle modification to reduce risk factors for esophageal carcinoma are recommended.[566]

Etiology and Pathogenesis: Howel-Evans syndrome results from GOF missense mutations in *RHBDF2*, which encodes a catalytically inactive rhomboid intramembrane serine, iRhom2. iRhom2 belongs to a family of seven transmembrane-spanning proteins, which are serine intramembrane proteases associated with EGFR signaling and mitochondrial remodeling.[570,571] RHBDF2 is an iRhom that lost its protease activity during evolution but retained key nonprotease functions (regulation of EGF and TNF-α signaling pathways).[572,753]

Skin biopsies obtained from patients with Howel-Evans syndrome demonstrate cytoplasmic localization of iRhom2 compared with the normal membrane expression seen in normal skin. Similar cytoplasmic localization is observed in biopsies obtained from Howel-Evans syndrome esophageal carcinoma and from sporadic squamous esophageal tumors, suggesting that dysregulation of iRhom2 plays a role in these malignancies.[574,575]

iRhom2 has been shown to regulate the trafficking and activation of ADAM17, a membrane bound sheddase that has been shown to play a pivotal role in the proteolytic cleavage and release of substrates from the cell surface, including TNF-α, members of the EGF family of growth factors, and desmosomes.[573,576] Epidermal keratinocytes from patients with Howel-Evans syndrome show upregulated ADAM17 activity, resulting in increased EGFR activity, increased desmosome processing, immature epidermal desmosomes, upregulated epidermal transglutaminase activity, and resistance to staphylococcal infection.[577] Moreover, these keratinocytes demonstrate features of dysregulated wound repair in vitro.[577,578]

Overexpression of EGFR has been demonstrated in sporadic esophageal SCC and several other carcinomas and correlates with reduced survival. Moreover, expression of ADAM17 has been shown to correlate with progression of esophageal carcinoma.[579-5815] Accordingly, precancerous esophageal lesions seen in Howel-Evans syndrome may be a result of dysregulated EGFR signaling.[574]

Pathology: Affected skin reveals acanthosis, orthohyperkeratosis, and hypergranulosis with no parakeratosis or spongiosis.[566,567]

FOCAL INHERITED PALMOPLANTAR KERATODERMA WITH EXTRACUTANEOUS FEATURES, RECESSIVE INHERITANCE

RICHNER-HANHART SYNDROME

Clinical Features: Richner-Hanhart Syndrome (RHS, tyrosinemia type II, oculocutaneous tyrosinosis, keratosis palmoplantaris with corneal dystrophy;

OMIM #276600) is a rare autosomal recessive disorder named after the original reports of Richner and Hanhart. Its incidence is less than 1 in 250,000, occurring in various ethnic groups, although it seems to be particularly prevalent in Mediterranean countries and in the Arab world.[582-587]

Symptoms typically appear in early childhood and include a triad of painful PPK, bilateral keratitis, and mental retardation that results from intracellular accumulation of tyrosine crystals and a secondary inflammatory response in the involved tissues.

Ocular manifestations include photophobia, pain, tearing, redness, and pseudoherpetiform keratitis with corneal ulcerations. Ocular manifestations occur in 75% of cases, present soon after birth or within the first year of life, and usually antedate the cutaneous manifestations. Skin manifestations usually begin after the first year of life and consist of well-demarcated, focal, palmoplantar, white-yellow, hyperkeratotic plaques surrounded by erythema on the weight-bearing areas of the soles. There is associated pain and often hyperhidrosis. The fingertips, hypothenar, and thenar eminences can also be affected. Sixty percent of cases, particularly untreated ones, present with neurologic manifestations, including mental retardation, nystagmus, tremor, ataxia, and convulsions.[588-591] A case with epileptic seizures, mild mental retardation, and photophobia with no other ophthalmologic or skin manifestations has been reported.[592]

Etiology and Pathogenesis: RHS is an autosomal recessive disorder caused by mutations in the *TAT* gene encoding tyrosine aminotransferase (TAT). As a consequence of TAT deficiency, tyrosine accumulates in tissues. More than 20 mutations have been identified within the *TAT* gene with alteration of the activity and stability of the tyrosine aminotransferase enzyme.[572,587,593-600] It was hypothesized that disease severity, particularly neurologic disabilities, correlates with the presence of a mutant protein but its total absence is associated with more favorable features.[601,602]

Previous reports have suggested that palmoplantar lesions in RHS result from intracellular L-tyrosine crystals that destabilize lysosomal membranes and initiate a cascade of cell injury and inflammation, resulting in the typical skin lesions. This hypothesis is consistent with the presence of crystals in tyrosine-induced lesions in the corneal epithelium of rats and in the spinous layer keratinocytes of patient epidermis.[603-606] However, later studies failed to demonstrate crystals in epidermal keratinocytes and suggested that the palmoplantar hyperkeratosis results from an excessive intracellular concentration of tyrosine that leads to noncovalent cross-links among keratins and the formation of aggregated tonofilaments.[607]

Laboratory Findings: RHS is diagnosed by a high level of serum tyrosine (with normal phenylalanine) and accumulation of tyrosine metabolites in the urine (p-hydroxyphenylpyruvate, p-phenylacetate, p-hydroxyphenylacetate).[601] A static level of urinary succinylacetone distinguishes RHS from type 1 tyrosinemia.

Pathology: Histopathologic findings in RHS include marked acanthosis, hyperkeratosis, and significant hypergranulosis. Parakeratosis, a parakeratotic column in the acrosyringium, and multinucleated keratinocytes in the spinous cell layer are possible findings. Increased mitotic activity in the suprabasal layers and thin, elongated epidermal ridges, may be seen.[586,601,608,609] Intracytoplasmic tyrosine crystals have been reported.[606] Ultrastructural findings include thickening of the granular layer and increased synthesis of tonofibrils and keratohyalin, large numbers of microtubules, and tonofibrillar masses with tubular channels or inclusions of microtubules. Multinucleated keratinocytes in the spinous layer and lipid droplets in the cornified layer may be observed.[586,607,609]

Specific Treatments: The key to the management of RHS is early diagnosis and early initiation of a diet that restricts tyrosine and phenylalanine to reduce the risk and severity of long-term complications of hypertyrosinemia, especially in the eye and skin.[601,609,610] Tandem mass spectrometry newborn screening for inborn errors of metabolism identifies RHS in the asymptomatic neonatal period.[611] Retinoids improve skin and eye lesions, but they do not prevent mental retardation and should be considered discriminately in children.[612] A case in which thigh skin was grafted onto a plantar lesion demonstrated hyperkeratosis that spared the graft area with the formation of a keratotic wall around it.[613]

CARVAJAL SYNDROME

Clinical Features: Carvajal syndrome (CS; OMIM #605676), first reported by Carvajal-Huerta in 1998, is an autosomal recessive disease caused by mutations in the *DSP* gene (encoding desmoplakkin) and characterized by a triad of woolly hair, SPPK, and cardiomyopathy. Left ventricular dilated cardiomyopathy develops during childhood; the right ventricle may also be involved.[614-616] Patients may demonstrate only skin or cardiac features or the full phenotype. Woolly hair appears at birth and may be associated with sparse eyebrows and axillary and pubic hair. SPPK develops during childhood, although cases with appearance at birth have been reported. A case featuring alopecia of the scalp, eyebrows, and eyelashes has been described.[617] Additional cutaneous features are linear lichenoid keratotic papules in the flexural folds, follicular hyperkeratosis on the elbows and knees or scattered across the abdomen and lower limbs, nail abnormalities (dystrophy, onychogryphosis, clubbing), transient pruritic vesicles, and psoriasiform plaques.[614-618] CS cases with dominant

inheritance are associated with hypo- or oligodontia and leukonychia or brittle nails.[618,619] Co-occurrence with congenital unilateral deafness, recurrent pharyngitis, and diarrhea was reported.[620] The left ventricle is severely affected by the second decade of life in more than 90% of patients, although cardiomyopathy with symptoms of progressive heart failure presenting as early as the first years of life has been reported. Congestive heart failure and ventricular arrhythmia are the most common causes of death during adolescence.[617,621]

Etiology and Pathogenesis: Desmoplakin is a central component of the desmosomes, which are cell-to-cell junctions in simple and stratified squamous epithelia and cardiac muscle that connect intermediate filaments to the desmosomal cadherins in the cytoplasmic membrane. The N-terminal plakin domain of DSP binds PG, plakophilins, and desmosomal cadherins, its C-terminal domain connects the cytoskeleton intermediate filaments, and its central coiled-coil rod domain is responsible for homodimerization.[622] DSP is expressed in all epidermal layers, in the outer root sheath, companion layer, and Henle and Huxley layers of the HF; intercalated discs are important for cardiomyocyte binding in the heart.[623-625]

The first homozygous mutation in *DSP* causing CS was described in an Ecuadorian pedigree and resulted in a truncated protein lacking the C-domain tail region responsible for intermediate filament binding.[614] Another recessive missense mutation that was associated with blisters in early childhood and ARVC during adolescence was described in Arab kindred and affected the C-terminal domain of the protein.[616] Several other homozygous mutations resulting in truncated protein involving the coiled-coil rod domain and the C-terminal domain with impaired intermediate filament binding have been described.[626]

Dominant heterozygous mutations in *DSP* have been reported in cases of tooth agenesis in addition to the common triad of CS (dilated cardiomyopathy with wooly hair, keratoderma, and tooth agenesis; DCWHKTA; OMIM #615821).[618,619,627,628] In these cases, the mutations affect the N-terminal domain of DSP and most involve exon 14, suggesting that this region serves as a hot spot and disrupts desmosome scaffolds in a dominant-negative fashion. The clinical feature of tooth agenesis is in line with studies in mice demonstrating a role of desmosomal proteins in teeth development.[629,630]

Besides DCWHKTA, heterozygous *DSP* mutations are linked to ARVD type 8 (OMIM #607450) and isolated SPPK (see earlier). Homozygous or compound heterozygous *DSP* mutations also result in lethal acantholytic epidermolysis bullosa (OMIM #609638) and skin fragility–woolly hair syndrome (OMIM #607655).[628,631,632]

Pathology: The histopathology findings in CS are hyperkeratosis, papillomatosis, spongiosis, epidermolytic hyperkeratosis, and dyskeratosis. Acantholysis may be seen in the spinous layer.[614]

PUNCTATE INHERITED PALMOPLANTAR KERATODERMA WITHOUT EXTRACUTANEOUS FEATURES, DOMINANT INHERITANCE

PUNCTATE PALMOPLANTAR KERATODERMA TYPE I

Clinical Features: Punctate palmoplantar keratoderma (PPKP) type I (PPKP1; keratosis punctate palmoplantaris type Buschke-Fischer-Brauer; OMIM #148600 [PPKP1A] and 614936 [PPKP1B]) is a rare autosomal dominant disease. The estimated incidence of PPKP1 is approximately 1 to 3 per 100,000 individuals in various populations across Europe, the Middle East, and Asia.[36,588,633-636]

The disease has its onset during the first or second decades of life, although a later onset has also been described.[589,591,633,637-640] It is characterized by multiple hyperkeratotic, centrally indented, yellow to brown papules distributed irregularly over the palmoplantar skin (Fig. 48-11). Lesions may be painful. They increase in size and number with advancing age and coalescence into more confluent plaques, particularly on pressure-bearing areas of plantar skin. A phenotype resembling human papilloma virus–induced papilloma-like lesions has been described.[641,642] Dermoscopic findings of palmoplantar lesions are well-demarcated, structureless, yellow-orange areas

Figure 48-11 Punctate palmoplantar keratoderma type I caused by mutation in *AAGAB*. Multiple hyperkeratotic, centrally indented, yellow to brown papules irregularly distributed over the palmar skin.

surrounded by a whitish halo with no evidence of dotted vessels commonly seen in verruca vulgaris.[37] Lesions reveal white fluorescence with Wood light examination.[643]

Etiology and Pathogenesis: PPKP1 is an autosomal dominant disease that results from heterozygous mutations in two genes, *AAGAB* (PPKP1A) and *COL14A1* (PPKP1B).

AAGAB encodes the α-and γ-adaptin-binding protein p34,[599.634,635,641] which contains an adaptin-binding domain and a Rab-like GTPase domain that might play an important role in clathrin-coated vesicle trafficking as a chaperone and in skin integrity.[635,641,644,645] Inter- and intrafamilial phenotypic variability is common and may be related to the effect of modifier genes or of aging and environmental factors.[36,591] Genetic anticipation (earlier disease onset in later generations) has been reported.[633,639] To date, more than 30 null variants in *AAGAB* have been identified, and haploinsufficiency was suggested as a possible disease-causing mechanism.[635]

A missense mutation in *COL14A1*, encoding collagen type XIV α1 chain, was identified in a large Chinese family with PPKP1 and incomplete penetrance.[646] The protein is mainly expressed in well-differentiated tissues and in late embryonic development, and the reported mutation involves the collagen triple helix repeat region.

Pathology: Histopathologic findings in PPPK include marked hyperkeratosis and acanthosis with epidermal invagination associated with focal parakeratosis, hyper- or hypogranulosis, and overlying orthokeratosis.[634,635,641] Transmission electron microscopy of lesional plantar skin shows an abnormal abundance of small vesicles close to the cell membrane in the basal epidermal layer and prominent dilatation of the Golgi apparatus, consistent with a defect in vesicle transport.[641]

PUNCTATE PALMOPLANTAR KERATODERMA TYPE 2

Clinical Features: PPKP type II (PPKP2; porokeratotic type; OMIM #175860) is an autosomal dominant disease characterized by multiple, firmly attached, tiny, skin-colored to yellow, asymptomatic, keratotic spines arising on the palms and soles around puberty or in the early 20s. Lesions may increase in number over the years with possible extension onto the dorsal and lateral surfaces of the fingers.[646-649] Lesions reveal white fluorescence resembling "stars under the moonlight" with Wood light examination.[650]

Facial sebaceous hypoplasia was reported in male patients.[649] Acquired cases with a similar phenotype have been described in association with internal malignancies.[651]

Etiology and Pathogenesis: The molecular etiology of PPKP2 is unknown. Most described cases are acquired; however, there are also familial cases with autosomal dominant inheritance. The pathogenesis involves enhanced epidermal proliferation of the basal layer under the columnar parakeratoses.[652]

Pathology: Histopathology findings in PPKP2 are compact vertical parakeratotic columns in the stratum corneum overlying hypogranular epidermis resembling cornoid lamellae.[648] Ultrastructural findings are numerous, variable-sized, pyknotic nuclei in the stratum corneum and reduced number of keratohyaline granules in the granular layer.[652]

PUNCTATE PALMOPLANTAR KERATODERMA TYPE 3

Clinical Features: PPKP type III (PPKP3, AKE [of Costa]; OMIM #101850) is a rare autosomal dominant disorder that usually appears during childhood or adolescence, although onset in infancy or adulthood has also been reported. There is no racial or ethnic predilection.[653] AKE is characterized by asymptomatic, round to oval, whitish to yellow and translucent papules, and more rarely nodules and plaques, with a hyperkeratotic surface or umbilication. Changes are located on the palms and soles with predilection for the thenar and hypothenar areas of the hands and pressure sites on the palms and soles. A linear pattern or "paving stones" arrangement over the radial and ulnar margins of the hands may be seen (Fig. 48-12).[654,655] In severe cases, lesions may affect the dorsal aspects of hands and feet (including knuckle pads), wrists, and ankles.[653,656] Aquagenic PPK can be associated,[657] and unilateral involvement has been described.[658,659] Nail dystrophy and hyperhidrosis may be observed.[657,660] Although AKE is usually confined to the skin, a case with reduced elasticity in medium and large arteries and an association with systemic and nodular scleroderma has been reported.[664-663]

Figure 48-12 Punctate palmoplantar keratoderma type III (acrokeratoelastoidosis). Round to oval yellow papules with central umbilication and a linear pattern of arrangement over the lateral margin of the sole.

TABLE 48-4
Summary for Palmoplantar Keratodermas

	EXTRACUTANEOUS FEATURES	INHERITANCE	FEATURES	GENE	PROTEIN
Diffuse PPK					
Epidermolytic PPK	–	AD	Most common form of diffuse keratoderma, with erythematous sharp margins at the edge of the palms and soles, with thickening and fissuring	*KRT9, KRT1*	Keratin 9, keratin 1
Unna-Thost PPK	–	AD	Diffuse, well-demarcated, yellowish, thick hyperkeratosis with an erythematous rim overlying the palms and soles; smooth and waxy texture	*KRT1*	Keratin 1
Greither syndrome	–	AD	Diffuse, thickened, scaly yellowish PPK, with transgrediens	*KRT1*	Keratin 1
Loricrin keratoderma	–	AD	Honeycomb-like PPK, starfish-like hyperkeratosis, prominent knuckle pads and pseudoainhum	*LOR*	Loricrin
PPK Bothnia type	–	AD	Diffuse, homogenous hyperkeratosis with a yellowish hue; aquagenic wrinkling of palms	*AQP5*	Aquaporin 5
Mal de Meleda	–	AR	Progressive, mutilating PPK with transgrediens; yellowish waxy hyperkeratotic plaques with a red, scaly border over palms and soles; risk for malignancies	*SLURP1*	SLURP1
Nagashima-type PPK	–	AR	Most common type in Asians; transgrediens, nonprogressive, nonmutilating; well-demarcated, erythematous palmoplantar hyperkeratosis	*SERPINB7*	SERPIN7
Olmsted syndrome	+	AD	Mutilating PPK with periorificial keratotic plaques; symmetric, sharply demarcated diffuse PPK with painful fissures and erythematous borders; hair abnormalities are common	*TRPV3* *MBTPS2* (X-linked cases)	TRPV3
Vohwinkel syndrome	+	AD	PPK with hearing impairment; mutilating honeycomb-like PPK, with starfish shaped keratotic plaques, pseudoainhum	*GJB2*	Connexin 26
Keratitis–ichthyosis–deafness syndrome	+	AD	Erythrokeratoderma, grainy PPK with a rough, stippled appearance, chronic cheilitis and perleche, abnormal ectodermal features, progressive keratitis	*GJB2*	Connexin 26
Bart-Pumphrey syndrome	+	AD	Honeycomb-like, diffuse, sharply demarcated PPK, knuckle pads, leukonychia	*GJB2*	Connexin 26
Palmoplantar Keratoderma with deafness	+	AD	Diffuse, transgrediens PPK with underlying erythema, knuckle pads, hearing impairment	*GJB2*	Connexin 26
PPK–congenital alopecia syndrome	+	AD	Well-defined, focal, nonmutilating transgrediens PPK; noncicatricial alopecia; recessive forms may have pseudoainhum and sclerodactyly	*GJB6*	Connexin 30
Hidrotic ectodermal dysplasia (Clouston) syndrome	+	AD	Diffuse, velvety or cobblestone-like PPK with fissures; nail dystrophy and hair loss	*GJB6*	Connexin 30
Huriez syndrome	+	AD	Diffuse, yellowish-grey, nonerythematous PPK, scleroatrophy, sclerodactyly, SCCs	Chromosome 4q23	
Papillon-Lefevre syndrome	+	AR	Diffuse, erythematous, sharply demarcated hyperkeratotic PPK with transgrediens; severe progressive periodontitis and loss of primary and permanent teeth	*CTSC*	Cathepsin C
Naxos disease	+	AR	Diffuse, well-demarcated, nontransgrediens PPK; wooly hair; right ventriculopathy	*JUP*	Plakoglobin

(*Continued*)

TABLE 48-4
Summary for Palmoplantar Keratodermas (*Continued*)

	EXTRACUTANEOUS FEATURES	INHERITANCE	FEATURES	GENE	PROTEIN
Palmoplantar hyperkeratosis with SCC of skin and sex reversal syndrome	+	AR	PPK with multiple SCCs and sclerodactyly; chronic periodontal disease leading to loss of teeth; hypogenitalism, altered plasma sex hormone levels, and sex reversal	*RSPO1*	R-spondin1
PPK with deafness	+	Mitochondrial	Orange-yellow, diffuse, well-demarcated PPK with minimal to no erythema over pressure points; hearing impairment	*MTTS1*	Decreased serine tRNA levels
Focal PPK					
Striate PPK	–	AD	Linear, thickened hyperkeratotic plaques over palms and volar aspects of digits; circumscribed thickening of soles	*DSG1, KRT1*	Desmoglein 1, desmoplakin, keratin 1
Hereditary keratosis palmoplantaris variant of Wachters	–	AD	Yellowish, nontransgrediens, symmetric, nummular hyperkeratotic plaques on pressure points of the soles; painful transverse fissures may be present	Unknown	
Pachyonychia congenital	+	AD	Thickened toenails, plantar keratoderma and plantar pain; oral mucosa may be involved, with cyst formation and natal teeth	*KRT6A, KRT6B, KRT6C, KRT16, KRT17*	Keratin 6a, keratin 6b, keratin 6c, keratin 16, keratin 17
Howel-Evans syndrome	+	AD	Focal yellowish thick plaques over pressure points on the palms and soles, with painful fissures; esophageal SCCs, follicular hyperkeratosis, oral leukokeratosis	*RHBDF2*	iRohm2
Richner-Hanhart syndrome	+	AR	Well-demarcated, focal, white-yellow painful PPK on pressure points, bilateral keratitis, mental retardation	*TAT*	Tyrosine aminotransferase
Carvajal syndrome	+	AR	Striate keratoderma; wooly hair, left ventriculopathy; lichenoid keratotic papules in flexural areas, nail abnormalities, unilateral deafness	*DSP*	desmoplakin
Punctate PPK					
Punctate PPPK type I	–	AD	Painful, hyperkeratotic papules with central indentation irregularly distributed on palms and soles	*AAGAB* *COL14A1*	P34 protein Collagen type XIV alpha 1
Punctate PPPK type 2	–	AD	Asymptomatic, firmly attached, yellow keratotic spines on palms and soles	unknown	
Punctate PPPK type 3 (acrokeratoelastoidosis of Costa)	–	AD	Asymptomatic, round-oval, white-yellow translucent hyperkeratotic or umbilicated papules	Chromosome 2p25-p12	
Cole disease	+	AD	Punctate PPK, irregularly shaped, hypopigmented macules over proximal trunk, with internal organ calcification	*ENPP1*	Endonucleotide pyrophosphatase/phosphodiesterase 1

AD, autosomal dominant; AR, autosomal recessive; PPK, palmoplantar keratoderma; PPPK, punctate palmoplantar keratoderma; SCC, squamous cell carcinoma.

Focal acral hyperkeratosis (FAH) is an autosomal dominant inherited disease with phenotypic resemblance to AKE, including nail abnormalities.[664] However, no elastic tissue abnormalities are observed in these cases. FAH is often considered to be a variant of AKE, although this notion is not accepted by some authors.[654,665-668]

Etiology and Pathogenesis: PPKP3 is an autosomal dominant inherited disorder, although sporadic cases have been described.[669,670] The genetic basis of the disease has yet to be elucidated, although preliminary linkage studies suggest a possible locus on 2p25-p12.[671,672]

Ultrastructural studies support AKE involves a defect in secretion of elastic material and a failure of elastic fiber synthesis rather than degeneration of elastic fibers.[673] In addition, the formation of the keratotic papules are a result of filaggrin overproduction that accumulates over the granular layer before its incorporation into the CCE.[674]

Pathology: AKE lesions show orthokeratotic hyperkeratosis, acanthosis, and hypergranulosis. Both lesional and normal-appearing skin reveal decreased elastic tissue and fragmented, thickened, or thinned elastic fibers (elastorrhexis) in the reticular dermis with sparing of the papillary dermis.[657] Ultrastructural findings are fibroblasts with dense granules at the cytoplasm periphery with reduced extracellular content of elastic fibers.[673]

PUNCTATE INHERITED PALMOPLANTAR KERATODERMA WITH EXTRACUTANEOUS FEATURES, DOMINANT INHERITANCE

COLE DISEASE

Clinical Features: Cole disease (OMIM #615522) is a rare autosomal dominant disorder that presents at birth or during early infancy and is characterized by punctate PPK and irregularly shaped, hypopigmented macules distributed over the proximal extremities or less typically over the trunk.[674-678] Calcifications in several organs (tendons, breast, and spleen) have been described.[678,680]

Etiology and Pathogenesis: Cole disease results from heterozygous mutations in the gene *ENPP1*, encoding ectonucleotide pyrophosphatase/phosphodiesterase 1, a cell surface protein that generates extracellular inorganic pyrophosphate by catalyzing the hydrolysis of adenosine triphosphate to adenosine monophosphate.[681] ENPP1 is composed of eight domains including phosphodiesterase, nuclease, and somatomedin B–like (SMB) domains.[682] Biallelic mutations affecting the phosphodiesterase domain that mediates ENPP1 catalytic activity or the nuclease domain have been shown to be associated with inherited disorders featuring abnormal calcium homeostasis or ectopic calcifications,[683-685] and mutations associated with Cole disease affect highly conserved cysteine residues clustered within the SMB domains.[678,680] Given the notion that ENPP1 has been shown to inhibit insulin signaling through the interaction between its SMB domain and insulin receptor,[684-687] it is suggested that abnormal insulin signaling plays a role in the pathogenesis of Cole disease.[688-691]

Pathology: Skin biopsies obtained from palmoplantar lesions show hyperkeratosis, orthokeratosis, hypergranulosis, and acanthosis. Calcified deposits in the dermis may be seen.[676] Hypopigmented macules demonstrate hyperkeratosis, reduced melanin content in keratinocytes, and normal or reduced number of melanocytes.[678,680,692] Ultrastructural findings of hypopigmented lesions consist of disproportionately large numbers of melanosomes within the cytoplasm and dendrites of melanocytes with paucity of melanosomes in adjacent keratinocytes, suggesting abnormal melanosome transfer as the primary pathomechanism for hypopigmentation in Cole disease.[678,680]

SUMMARY

See Table 48-4.

REFERENCES

1. Braun-Falco M. Hereditary palmoplantar keratodermas. *J Dtsch Dermatol Ges.* 2009;7(11):971-984; quiz 984-975.
2. Itin PH. Classification of autosomal dominant palmoplantar keratoderma: past-present-future. *Dermatology.* 1992;185(3):163-165.
3. Itin PH, Fistarol SK. Palmoplantar keratodermas. *Clin Dermatol.* 2005;23(1):15-22.
4. Ratnavel RC, Griffiths WA. The inherited palmoplantar keratodermas. *Br J Dermatol.* 1997;137(4):485-490.
5. Kimyai-Asadi A, Kotcher LB, Jih MH. The molecular basis of hereditary palmoplantar keratodermas. *J Am Acad Dermatol.* 2002;47(3):327-343; quiz 344-326.
6. McLean WH, Epithelial Genetics G. Genetic disorders of palm skin and nail. *J Anat.* 2003;202(1):133-141.
7. Paller AS. The molecular bases for the palmoplantar keratodermas. *Pediatr Dermatol.* 1999;16(6):483-486.
8. Has C, Technau-Hafsi K. Palmoplantar keratodermas: clinical and genetic aspects. *J Dtsch Dermatol Ges.* 2016;14(2):123-140.
9. Sakiyama T, Kubo A. Hereditary palmoplantar keratoderma "clinical and genetic differential diagnosis." *J Dermatol.* 2016;43(3):264-274.
10. Schiller S, Seebode C, Hennies HC, et al. Palmoplantar keratoderma (PPK): acquired and genetic causes of a not so rare disease. *J Dtsch Dermatol Ges.* 2014;12(9):781-788.

11. Lind L, Lundstrom A, Hofer PA, et al. The gene for diffuse palmoplantar keratoderma of the type found in northern Sweden is localized to chromosome 12q11-q13. *Hum Mol Genet.* 1994;3(10): 1789-1793.
12. Covello SP, Irvine AD, McKenna KE, et al. Mutations in keratin K9 in kindreds with epidermolytic palmoplantar keratoderma and epidemiology in Northern Ireland. *J Invest Dermatol.* 1998;111(6):1207-1209.
13. Gulati S, Thappa DM, Garg BR. Hereditary palmoplantar keratodermas in South India. *J Dermatol.* 1997;24(12):765-768.
14. Hamm H, Happle R, Butterfass T, et al. Epidermolytic palmoplantar keratoderma of Vorner: is it the most frequent type of hereditary palmoplantar keratoderma? *Dermatologica.* 1988;177(3):138-145.
15. Lopez-Valdez J, Rivera-Vega MR, Gonzalez-Huerta LM, et al. Analysis of the KRT9 gene in a Mexican family with epidermolytic palmoplantar keratoderma. *Pediatr Dermatol.* 2013;30(3):354-358.
16. Patel S, Zirwas M, English JC 3rd. Acquired palmoplantar keratoderma. *Am J Clin Dermatol.* 2007;8(1):1-11.
17. Lucker GP, Van de Kerkhof PC, Steijlen PM. The hereditary palmoplantar keratoses: an updated review and classification. *Br J Dermatol.* 1994;131(1):1-14.
18. Peris K, Salvati EF, Torlone G, et al. Keratoderma hereditarium mutilans (Vohwinkel's syndrome) associated with congenital deaf-mutism. *Br J Dermatol.* 1995;132(4):617-620.
19. Schamroth JM. Mutilating keratoderma. *Int J Dermatol.* 1986;25(4):249-251.
20. Aloi FG, Pippione M. Porokeratotic eccrine ostial and dermal duct nevus. *Arch Dermatol.* 1986;122(8): 892-895.
21. Lederman JS, Sober AJ, Lederman GS. Immunosuppression: a cause of porokeratosis? *J Am Acad Dermatol.* 1985;13(1):75-79.
22. Neumann RA, Knobler RM, Jurecka W, et al. Disseminated superficial actinic porokeratosis: experimental induction and exacerbation of skin lesions. *J Am Acad Dermatol.* 1989;21(6):1182-1188.
23. Wilson NJ, Hansen CD, Azkur D, et al. Recessive mutations in the gene encoding frizzled 6 cause twenty nail dystrophy—expanding the differential diagnosis for pachyonychia congenita. *J Dermatol Sci.* 2013;70(1):58-60.
24. Lucker GP, van de Kerkhof PC, Steijlen PM. Topical calcipotriol in the treatment of epidermolytic palmoplantar keratoderma of Vorner. *Br J Dermatol.* 1994;130(4):543-545.
25. Kanitakis J, Tsoitis G, Kanitakis C. Hereditary epidermolytic palmoplantar keratoderma (Vorner type). Report of a familial case and review of the literature. *J Am Acad Dermatol.* 1987;17(3):414-422.
26. Gruber R, Hennies HC, Romani N, et al. A novel homozygous missense mutation in SLURP1 causing Mal de Meleda with an atypical phenotype. *Arch Dermatol.* 2011;147(6):748-750.
27. Camisa C, Rossana C. Variant of keratoderma hereditaria mutilans (Vohwinkel's syndrome). Treatment with orally administered isotretinoin. *Arch Dermatol.* 1984;120(10):1323-1328.
28. Bondeson ML, Nystrom AM, Gunnarsson U, et al. Connexin 26 (GJB2) mutations in two Swedish patients with atypical Vohwinkel (mutilating keratoderma plus deafness) and KID syndrome both extensively treated with acitretin. *Acta Derm Venereol.* 2006;86(6):503-508.
29. Chang Sing Pang AF, Oranje AP, Vuzevki VD, et al. Successful treatment of keratoderma hereditaria mutilans with an aromatic retinoid. *Arch Dermatol.* 1981;117(4):225-228.
30. O'Driscoll J, Muston GC, McGrath JA, et al. A recurrent mutation in the loricrin gene underlies the ichthyotic variant of Vohwinkel syndrome. *Clin Exp Dermatol.* 2002;27(3):243-246.
31. Hausser I, Frantzmann Y, Anton-Lamprecht I, et al. [Olmsted syndrome. Successful therapy by treatment with etretinate]. *Hautarzt.* 1993;44(6):394-400.
32. Rivers JK, Duke EE, Justus DW. Etretinate: management of keratoma hereditaria mutilans in four family members. *J Am Acad Dermatol.* 1985;13(1):43-49.
33. Tang L, Zhang L, Ding H, et al. Olmsted syndrome: a new case complicated with easily broken hair and treated with oral retinoid. *J Dermatol.* 2012;39(9):816-817.
34. Ueda M, Nakagawa K, Hayashi K, et al. Partial improvement of Olmsted syndrome with etretinate. *Pediatr Dermatol.* 1993;10(4):376-381.
35. Delaporte E, N'Guyen-Mailfer C, Janin A, et al. Keratoderma with scleroatrophy of the extremities or sclerotylosis (Huriez syndrome): a reappraisal. *Br J Dermatol.* 1995;133(3):409-416.
36. Nomura T, Yoneta A, Pohler E, et al. Punctate palmoplantar keratoderma type 1: a novel AAGAB mutation and efficacy of etretinate. *Acta Derm Venereol.* 2015;95(1):110-111.
37. Nomura T, Moriuchi R, Takeda M, et al. Low-dose etretinate shows promise in management of punctate palmoplantar keratoderma type 1: case report and review of the published work. *J Dermatol.* 2015;42(9):889-892.
38. Tekin B, Yucelten D, Beleggia F, et al. Papillon-Lefevre syndrome: report of six patients and identification of a novel mutation. *Int J Dermatol.* 2016;55(8):898-902.
39. Sarma N, Ghosh C, Kar S, et al. Low-dose acitretin in Papillon-Lefevre syndrome: treatment and 1-year follow-up. *Dermatol Ther.* 2015;28(1):28-31.
40. Nazzaro V, Blanchet-Bardon C, Mimoz C, et al. Papillon-Lefevre syndrome. Ultrastructural study and successful treatment with acitretin. *Arch Dermatol.* 1988;124(4):533-539.
41. Grob JJ, Breton A, Bonafe JL, et al. Keratitis, ichthyosis, and deafness (KID) syndrome. Vertical transmission and death from multiple squamous cell carcinomas. *Arch Dermatol.* 1987;123(6):777-782.
42. Langer K, Konrad K, Wolff K. Keratitis, ichthyosis and deafness (KID)-syndrome: report of three cases and a review of the literature. *Br J Dermatol.* 1990;122(5):689-697.
43. Nazzaro V, Blanchet-Bardon C, Lorette G, et al. Familial occurrence of KID (keratitis, ichthyosis, deafness) syndrome. Case reports of a mother and daughter. *J Am Acad Dermatol.* 1990;23(2 Pt 2):385-388.
44. Patel V, Sun G, Dickman M, et al. Treatment of keratitis-ichthyosis- deafness (KID) syndrome in children: a case report and review of the literature. *Dermatol Ther.* 2015;28(2):89-93.
45. Hazen PG, Carney JM, Langston RH, et al. Corneal effect of isotretinoin: possible exacerbation of corneal neovascularization in a patient with the keratitis, ichthyosis, deafness ("KID") syndrome. *J Am Acad Dermatol.* 1986;14(1):141-142.
46. Zhang X, He Y, Zhou H, et al. Severe ichthyosis-related disorders in children: response to acitretin. *J Dermatolog Treat.* 2007;18(2):118-122.
47. Prasad SC, Bygum A. Successful treatment with alitretinoin of dissecting cellulitis of the scalp in

keratitis-ichthyosis-deafness syndrome. *Acta Derm Venereol.* 2013;93(4):473-474.
48. Werchau S, Toberer F, Enk A, et al. Keratitis-ichthyosis-deafness syndrome: response to alitretinoin and review of literature. *Arch Dermatol.* 2011;147(8): 993-995.
49. DiGiovanna JJ, Peck GL. Oral synthetic retinoid treatment in children. *Pediatr Dermatol.* 1983;1(1):77-88.
50. Xoagus E, Hudson D, Moodley S. Palmoplantar keratoderma surgical management. *J Plast Reconstr Aesthet Surg.* 2014;67(12):e316-e317.
51. Vorner H. Zur Kenntnis des Keratoma hereditarium palmare et plantare. *Arch Dermatol Syph.* 1901; 56:3-31.
52. Klaus S, Weinstein GD, Frost P. Localized epidermolytic hyperkeratosis. A form of keratoderma of the palms and soles. *Arch Dermatol.* 1970;101(3):272-275.
53. Codispoti A, Colombo E, Zocchi L, et al. Knuckle pads, in an epidermal palmoplantar keratoderma patient with Keratin 9 R163W transgrediens expression. *Eur J Dermatol.* 2009;19(2):114-118.
54. Li M, Yang LJ, Hua HK, et al. Keratin-9 gene mutation in epidermolytic palmoplantar keratoderma combined with knuckle pads in a large Chinese family. *Clin Exp Dermatol.* 2009;34(1):26-28.
55. Chiu HC, Jee SH, Sheen YS, et al. Mutation of keratin 9 (R163W) in a family with epidermolytic palmoplantar keratoderma and knuckle pads. *J Dermatol Sci.* 2007;45(1):63-65.
56. Hamada T, Ishii N, Karashima T, et al. The common KRT9 gene mutation in a Japanese patient with epidermolytic palmoplantar keratoderma and knuckle pad-like keratoses. *J Dermatol.* 2005;32(6):500-502.
57. Kuster W, Reis A, Hennies HC. Epidermolytic palmoplantar keratoderma of Vorner: re-evaluation of Vorner's original family and identification of a novel keratin 9 mutation. *Arch Dermatol Res.* 2002; 294(6):268-272.
58. Lu Y, Guo C, Liu Q, et al. A novel mutation of keratin 9 in epidermolytic palmoplantar keratoderma combined with knuckle pads. *Am J Med Genet A.* 2003 ;120A(3):345-349.
59. Du ZF, Wei W, Wang YF, et al. A novel mutation within the 2B rod domain of keratin 9 in a Chinese pedigree with epidermolytic palmoplantar keratoderma combined with knuckle pads and camptodactyly. *Eur J Dermatol.* 2011;21(5):675-679.
60. Liang YH, Liu QX, Huang L, et al. A recurrent p.M157R mutation of keratin 9 gene in a Chinese family with epidermolytic palmoplantar keratoderma and literature review. *Int J Dermatol.* 2014;53(8): e375-e379.
61. Funakushi N, Mayuzumi N, Sugimura R, et al. Epidermolytic palmoplantar keratoderma with constriction bands on bilateral fifth toes. *Arch Dermatol.* 2009;145(5):609-610.
62. Umegaki N, Nakano H, Tamai K, et al. Vorner type palmoplantar keratoderma: novel KRT9 mutation associated with knuckle pad-like lesions and recurrent mutation causing digital mutilation. *Br J Dermatol.* 2011;165(1): 199-201.
63. Mofid MZ, Costarangos C, Gruber SB, et al. Hereditary epidermolytic palmoplantar keratoderma (Vorner type) in a family with Ehlers-Danlos syndrome. *J Am Acad Dermatol.* 1998;38(5 Pt 2): 825-830.
64. Sommer G, Vakilzadeh F, Echternacht K, et al. Keratosis palmo-plantaris cum degeneratione granulosa. *Hum Genet.* 1976;33(1):85-87.
65. Chevrant-Breton J, Kerbrat P, Le Marec B, et al. Familial autosomal dominant epidermolytic palmo-plantar keratoderma and adenocarcinoma (study of 4 generations). *Ann Dermatol Venereol.* 1985;112(10):841-844.
66. Reis A, Hennies HC, Langbein L, et al. Keratin 9 gene mutations in epidermolytic palmoplantar keratoderma (EPPK). *Nat Genet.* 1994;6(2):174-179.
67. Hatsell SJ, Eady RA, Wennerstrand L, et al. Novel splice site mutation in keratin 1 underlies mild epidermolytic palmoplantar keratoderma in three kindreds. *J Invest Dermatol.* 2001;116(4):606-609.
68. Terron-Kwiatkowski A, Paller AS, Compton J, et al. Two cases of primarily palmoplantar keratoderma associated with novel mutations in keratin 1. *J Invest Dermatol.* 2002;119(4):966-971.
69. Terron-Kwiatkowski A, Terrinoni A, Didona B, et al. Atypical epidermolytic palmoplantar keratoderma presentation associated with a mutation in the keratin 1 gene. *Br J Dermatol.* 2004;150(6):1096-1103.
70. Terron-Kwiatkowski A, van Steensel MA, van Geel M, et al. Mutation S233L in the 1B domain of keratin 1 causes epidermolytic palmoplantar keratoderma with "tonotubular" keratin. *J Invest Dermatol.* 2006;126(3): 607-613.
71. Uitto J, Richard G, McGrath JA. Diseases of epidermal keratins and their linker proteins. *Exp Cell Res.* 2007;313(10):1995-2009.
72. Langbein L, Heid HW, Moll I, et al. Molecular characterization of the body site-specific human epidermal cytokeratin 9: cDNA cloning, amino acid sequence, and tissue specificity of gene expression. *Differentiation.* 1993;55(1):57-71.
73. Leslie Pedrioli DM, Fu DJ, Gonzalez-Gonzalez E, et al. Generic and personalized RNAi-based therapeutics for a dominant-negative epidermal fragility disorder. *J Invest Dermatol.* 2012;132(6):1627-1635.
74. Liu WT, Ke HP, Zhao Y, et al. The most common mutation of KRT9, c.C487T (p.R163W), in epidermolytic palmoplantar keratoderma in two large Chinese pedigrees. *Anat Rec.* 2012;295(4):604-609.
75. Moll I, Heid H, Franke WW, et al. Distribution of a special subset of keratinocytes characterized by the expression of cytokeratin 9 in adult and fetal human epidermis of various body sites. *Differentiation.* 1987;33(3):254-265.
76. Swensson O, Langbein L, McMillan JR, et al. Specialized keratin expression pattern in human ridged skin as an adaptation to high physical stress. *Br J Dermatol.* 1998;139(5):767-775.
77. Knobel M, O'Toole EA, Smith FJ. Keratins and skin disease. *Cell Tissue Res.* 2015;360(3):583-589.
78. Sprecher E, Ishida-Yamamoto A, Becker OM, et al. Evidence for novel functions of the keratin tail emerging from a mutation causing ichthyosis hystrix. *J Invest Dermatol.* 2001;116(4):511-519.
79. Whittock NV, Smith FJ, Wan H, et al. Frameshift mutation in the V2 domain of human keratin 1 results in striate palmoplantar keratoderma. *J Invest Dermatol.* 2002;118(5):838-844.
80. Bergman R, Khamaysi Z, Sprecher E. A unique pattern of dyskeratosis characterizes epidermolytic hyperkeratosis and epidermolytic palmoplantar keratoderma. *Am J Dermatopathol.* 2008;30(2):101-105.
81. Fuchs-Telem D, Padalon-Brauch G, Sarig O, et al. Epidermolytic palmoplantar keratoderma caused by activation of a cryptic splice site in KRT9. *Clin Exp Dermatol.* 2013;38(2):189-192; quiz 192.
82. Blasik LG, Dimond RL, Baughman RD. Hereditary epidermolytic palmoplantar keratoderma. *Arch Dermatol.* 1981;117(4):229-231.

83. Fritsch P, Honigsmann H, Jaschke E. Epidermolytic hereditary palmoplantar keratoderma. Report of a family and treatment with an oral aromatic retinoid. *Br J Dermatol.* 1978;99(5):561-568.
84. Haneke E. Keratosis palmaris et plantaris with Vorner's granulous degeneration. *Hautarzt.* 1982; 33(12):654-656.
85. Laurent R, Prost O, Nicollier M, et al. Composite keratohyaline granules in palmoplantar keratoderma: an ultrastructural study. *Arch Dermatol Res.* 1985;277(5):384-394.
86. Hashimoto K, Mizuguchi R, Tanaka K, et al. Palmoplantar keratoderma (Voerner) with composite keratohyalin granules: studies on keratinization parameters and ultrastructures. *J Dermatol.* 2000;27(1):1-9.
87. Lyu YS, Shi PL, Chen XL, et al. A small indel mutant mouse model of epidermolytic palmoplantar keratoderma and its application to mutant-specific shRNA therapy. *Mol Ther Nucleic Acids.* 2016;5:e299.
88. Devos SA, Delescluse J. An unusual case of palmoplantar keratoderma. *J Eur Acad Dermatol Venereol.* 2003;17(1):68-69.
89. Gamborg Nielsen P, Faergemann J. Dermatophytes and keratin in patients with hereditary palmoplantar keratoderma. A mycological study. *Acta Derm Venereol.* 1993;73(6):416-418.
90. Maruyama R, Katoh T, Nishioka K. A case of Unna-Thost disease accompanied by Epidermophyton floccosum infection. *J Dermatol.* 1999;26(1):63-66.
91. Nielsen PG. Hereditary palmoplantar keratoderma and dermatophytosis in the northernmost county of Sweden (Norrbotten). *Acta Derm Venereol Suppl.* 1994;188:1-60.
92. Kimonis V, DiGiovanna JJ, Yang JM, et al. A mutation in the V1 end domain of keratin 1 in non-epidermolytic palmar-plantar keratoderma. *J Invest Dermatol.* 1994;103(6):764-769.
93. Loh TH, Yosipovitch G, Tay YK. Palmar-plantar keratoderma of Unna Thost associated with atopic dermatitis: an underrecognized entity? *Pediatr Dermatol.* 2003;20(3):195-198.
94. Rogozinski TT, Schwartz RA, Towpik E. Verrucous carcinoma in Unna-Thost hyperkeratosis of the palms and soles. *J Am Acad Dermatol.* 1994;31(6): 1061-1062.
95. Sybert VP. *Genetic Skin Disorders.* Oxford: Oxford University Press; 2010.
96. Aguirre-Negrete MG, Hernandez A, Ramirez-Soltero S, et al. Keratosis palmaris et plantaris with clinodactyly. A distinct autosomal dominant genodermatosis. *Dermatologica.* 1981;162(4):300-303.
97. Nielsen PG. Diffuse palmoplantar keratoderma associated with acrocyanosis. A family study. *Acta Derm Venereol.* 1989;69(2):156-161.
98. Kuster W, Becker A. Indication for the identity of palmoplantar keratoderma type Unna-Thost with type Vorner. Thost's family revisited 110 years later. *Acta Derm Venereol.* 1992;72(2):120-122.
99. Candi E, Tarcsa E, Digiovanna JJ, et al. A highly conserved lysine residue on the head domain of type II keratins is essential for the attachment of keratin intermediate filaments to the cornified cell envelope through isopeptide crosslinking by transglutaminases. *Proc Natl Acad Sci U S A.* 1998;95(5):2067-2072.
100. Liu XP, Ling J, Xiong H, et al. Mutation L437P in the 2B domain of keratin 1 causes diffuse palmoplantar keratoderma in a Chinese pedigree. *J Eur Acad Dermatol Venereol.* 2009;23(9):1079-1082.
101. Almutawa F, Thusaringam T, Watters K, et al. Pachyonychia congenita (K16) with unusual features and good response to acitretin. *Case Rep Dermatol.* 2015; 7(2):220-226.
102. Akasaka E, Nakano H, Nakano A, et al. Diffuse and focal palmoplantar keratoderma can be caused by a keratin 6c mutation. *Br J Dermatol.* 2011;165(6):1290-1292.
103. Greither A. Keratosis extremitatum hereditaria progrediens mit dominanten Erbgang. *Hautarzt.* 1952;3: 198-203.
104. Beylot-Barry M, Taieb A, Surleve-Bazeille JE, et al. Inflammatory familial palmoplantar keratoderma: Greither's disease? *Dermatology.* 1992;185(3): 210-214.
105. Fluckiger R, Itin PH. Keratosis extremitatum (Greither's disease): clinical features, histology, ultrastructure. *Dermatology.* 1993;187(4):309-311.
106. Grilli R, Aguilar A, Escalonilla P, et al. Transgrediens et progrediens palmoplantar keratoderma (Greither's disease) with particular histopathologic findings. *Cutis.* 2000;65(3):141-145.
107. Tay YK. What syndrome is this? Greither syndrome. *Pediatr Dermatol.* 2003;20(3):272-275.
108. Gach JE, Munro CS, Lane EB, et al. Two families with Greither's syndrome caused by a keratin 1 mutation. *J Am Acad Dermatol.* 2005;53(5 suppl 1):S225-230.
109. Seike T, Nakanishi H, Urano Y, et al. Malignant melanoma developing in an area of palmoplantar keratoderma (Greither's disease). *J Dermatol.* 1995;22(1):55-61.
110. Sybert VP, Dale BA, Holbrook KA. Palmar-plantar keratoderma. A clinical, ultrastructural, and biochemical study. *J Am Acad Dermatol.* 1988;18(1 Pt 1):75-86.
111. Kansky A, Arzensek J. Is palmoplantar keratoderma of Greither's type a separate nosologic entity? *Dermatologica.* 1979;158(4):244-248.
112. Richard G, Lin JP, Smith L, et al. Linkage studies in erythrokeratodermias: fine mapping, genetic heterogeneity and analysis of candidate genes. *J Invest Dermatol.* 1997;109(5):666-671.
113. Wollina U, Knopf B, Schaaschmidt H, et al. [Familial coexistence of erythrokeratodermia variabilis and keratosis palmoplantaris transgrediens et progrediens]. *Hautarzt.* 1989;40(3):169-172.
114. Porter RM, Lane EB. Phenotypes, genotypes and their contribution to understanding keratin function. *Trends Genet.* 2003;19(5):278-285.
115. Vohwinkel K. Keratoderma hereditaria mutilans. *Arch Dermatol Syphil.* 1929;158:354-364.
116. Maestrini E, Monaco AP, McGrath JA, et al. A molecular defect in loricrin, the major component of the cornified cell envelope, underlies Vohwinkel's syndrome. *Nat Genet.* 1996;13(1):70-77.
117. Hotz A, Bourrat E, Hausser I, et al. Two novel mutations in the LOR gene in three families with loricrin keratoderma. *Br J Dermatol.* 2015;172(4):1158-1162.
118. Pohler E, Cunningham F, Sandilands A, et al. Novel autosomal dominant mutation in loricrin presenting as prominent ichthyosis. *Br J Dermatol.* 2015;173(5):1291-1294.
119. Matsumoto K, Muto M, Seki S, et al. Loricrin keratoderma: a cause of congenital ichthyosiform erythroderma and collodion baby. *Br J Dermatol.* 2001;145(4): 657-660.
120. Yeh JM, Yang MH, Chao SC. Collodion baby and loricrin keratoderma: a case report and mutation analysis. *Clin Exp Dermatol.* 2013;38(2):147-150.
121. Gedicke MM, Traupe H, Fischer B, et al. Towards characterization of palmoplantar keratoderma caused by gain-of-function mutation in loricrin: analysis of

a family and review of the literature. *Br J Dermatol.* 2006;154(1):167-171.
122. Armstrong DK, McKenna KE, Hughes AE. A novel insertional mutation in loricrin in Vohwinkel's keratoderma. *J Invest Dermatol.* 1998;111(4):702-704.
123. Kinsler VA, Drury S, Khan A, et al. A novel microdeletion in LOR causing autosomal dominant loricrin keratoderma. *Br J Dermatol.* 2015;172(1):262-264.
124. Song S, Shen C, Song G, et al. A novel c.545-546insG mutation in the loricrin gene correlates with a heterogeneous phenotype of loricrin keratoderma. *Br J Dermatol.* 2008;159(3):714-719.
125. Korge BP, Ishida-Yamamoto A, Punter C, et al. Loricrin mutation in Vohwinkel's keratoderma is unique to the variant with ichthyosis. *J Invest Dermatol.* 1997;109(4):604-610.
126. Ishida-Yamamoto A, Kato H, Kiyama H, et al. Mutant loricrin is not crosslinked into the cornified cell envelope but is translocated into the nucleus in loricrin keratoderma. *J Invest Dermatol.* 2000;115(6):1088-1094.
127. Drera B, Tadini G, Balbo F, et al. De novo occurrence of the 730insG recurrent mutation in an Italian family with the ichthyotic variant of Vohwinkel syndrome, loricrin keratoderma. *Clin Genet.* 2008;73(1):85-88.
128. Takahashi H, Ishida-Yamamoto A, Kishi A, et al. Loricrin gene mutation in a Japanese patient of Vohwinkel's syndrome. *J Dermatol Sci.* 1999;19(1):44-47.
129. Kalinin AE, Kajava AV, Steinert PM. Epithelial barrier function: assembly and structural features of the cornified cell envelope. *BioEssays.* 2002;24(9):789-800.
130. Schmuth M, Fluhr JW, Crumrine DC, et al. Structural and functional consequences of loricrin mutations in human loricrin keratoderma (Vohwinkel syndrome with ichthyosis). *J Invest Dermatol.* 2004;122(4):909-922.
131. Suga Y, Jarnik M, Attar PS, et al. Transgenic mice expressing a mutant form of loricrin reveal the molecular basis of the skin diseases, Vohwinkel syndrome and progressive symmetric erythrokeratoderma. *J Cell Biol.* 2000;151(2):401-412.
132. Ishida-Yamamoto A. Loricrin keratoderma: a novel disease entity characterized by nuclear accumulation of mutant loricrin. *J Dermatol Sci.* 2003;31(1):3-8.
133. Nithya S, Radhika T, Jeddy N. Loricrin—an overview. *J Oral Maxillofac Pathol.* 2015;19(1):64-68.
134. Koch PJ, de Viragh PA, Scharer E, et al. Lessons from loricrin-deficient mice: compensatory mechanisms maintaining skin barrier function in the absence of a major cornified envelope protein. *J Cell Biol.* 2000;151(2):389-400.
135. Elias PM, Schmuth M, Uchida Y, et al. Basis for the permeability barrier abnormality in lamellar ichthyosis. *Exp Dermatol.* 2002;11(3):248-256.
136. Yoneda K, Demitsu T, Nakai K, et al. Activation of vascular endothelial growth factor receptor 2 in a cellular model of loricrin keratoderma. *J Biol Chem.* 2010;285(21):16184-16194.
137. Cao X, Yin J, Wang H, et al. Mutation in AQP5, encoding aquaporin 5, causes palmoplantar keratoderma Bothnia type. *J Invest Dermatol.* 2014;134(1):284-287.
138. Abdul-Wahab A, Takeichi T, Liu L, et al. Autosomal dominant diffuse nonepidermolytic palmoplantar keratoderma due to a recurrent mutation in aquaporin-5. *Br J Dermatol.* 2016;174(2):430-432.
139. Park L, Khani C, Tamburro J. Aquagenic wrinkling of the palms and the potential role for genetic testing. *Pediatr Dermatol.* 2012;29(3):237-242.
140. Rongioletti F, Tomasini C, Crovato F, et al. Aquagenic (pseudo) keratoderma: a clinical series with new pathological insights. *Br J Dermatol.* 2012;167(3):575-582.
141. Blaydon DC, Lind LK, Plagnol V, et al. Mutations in AQP5, encoding a water-channel protein, cause autosomal-dominant diffuse nonepidermolytic palmoplantar keratoderma. *Am J Hum Genet.* 2013;93(2):330-335.
142. Iizuka T, Suzuki T, Nakano K, Sueki H. Immunolocalization of aquaporin-5 in normal human skin and hypohidrotic skin diseases. *J Dermatol.* 2012;39(4):344-349.
143. Kabashima K, Shimauchi T, Kobayashi M, et al. Aberrant aquaporin 5 expression in the sweat gland in aquagenic wrinkling of the palms. *J Am Acad Dermatol.* 2008;59(2 suppl 1):S28-32.
144. Prompt CA, Quinton PM. Functions of calcium in sweat secretion. *Nature.* 1978;272(5649):171-172.
145. Lin Z, Chen Q, Lee M, et al. Exome sequencing reveals mutations in TRPV3 as a cause of Olmsted syndrome. *Am J Hum Genet.* 2012;90(3):558-564.
146. Schnyder UW, Franceschetti AT, Ceszarovic B, et al. [Autochthonous Meleda disease]. *Ann Dermatol Syphiligr (Paris).* 1969;96(5):517-530.
147. Eckl KM, Stevens HP, Lestringant GG, et al. Mal de Meleda (MDM) caused by mutations in the gene for SLURP-1 in patients from Germany, Turkey, Palestine, and the United Arab Emirates. *Hum Genet.* 2003;112(1):50-56.
148. Fischer J, Bouadjar B, Heilig R, et al. Mutations in the gene encoding SLURP-1 in Mal de Meleda. *Hum Mol Genet.* 2001;10(8):875-880.
149. Tjiu JW, Lin PJ, Wu WH, et al. SLURP1 mutation-impaired T-cell activation in a family with mal de Meleda. *Br J Dermatol.* 2011;164(1):47-53.
150. Wajid M, Kurban M, Shimomura Y, et al. Mutations in the SLURP-1 gene underlie Mal de Meleda in three Pakistani families. *J Dermatol Sci.* 2009;56(1):27-32.
151. Sakabe J, Kabashima-Kubo R, Kubo A, et al. A Japanese case of Mal de Meleda with SLURP1 mutation. *J Dermatol.* 2014;41(8):764-765.
152. Taylor JA, Bondavalli D, Monif M, et al. Mal de Meleda in Indonesia: mutations in the SLURP1 gene appear to be ubiquitous. *Australas J Dermatol.* 2016;57(1):e11-13.
153. Nellen RG, Claessens T, Subramaniam R, et al. A novel mutation in SLURP1 in patients with mal de Meleda from the Indian subcontinent. *J Dermatol Sci.* 2015;80(1):76-78.
154. Bchetnia M, Laroussi N, Youssef M, et al. Particular Mal de Meleda phenotypes in Tunisia and mutations founder effect in the Mediterranean region. *BioMed Res Int.* 2013;2013:206803.
155. Nellen RG, Steijlen PM, Hennies HC, et al. Haplotype analysis in western European patients with mal de Meleda: founder effect for the W15R mutation in the SLURP1 gene. *Br J Dermatol.* 2013;168(6):1372-1374.
156. Zhang J, Cheng R, Ni C, et al. First Mal de Meleda report in Chinese Mainland: two families with a recurrent homozygous missense mutation in SLURP-1. *J Eur Acad Dermatol Venereol.* 2016;30(5):871-873.
157. Ward KM, Yerebakan O, Yilmaz E, et al. Identification of recurrent mutations in the ARS (component B) gene encoding SLURP-1 in two families with mal de Meleda. *J Invest Dermatol.* 2003;120(1):96-98.
158. Franceschetti AT, Reinhart V, Schnyder UW. Meleda disease. *J Genet Hum.* 1972;20(4):267-296.
159. Marrakchi S, Audebert S, Bouadjar B, et al. Novel mutations in the gene encoding secreted lymphocyte antigen-6/urokinase-type plasminogen activator receptor-related protein-1 (SLURP-1) and description of five ancestral haplotypes in patients with Mal de Meleda. *J Invest Dermatol.* 2003;120(3):351-355.

160. Bergman R, Bitterman-Deutsch O, Fartasch M, et al. Mal de Meleda keratoderma with pseudoainhum. *Br J Dermatol.* 1993;128(2):207-212.
161. Mokni M, Charfeddine C, Ben Mously R, et al. Heterozygous manifestations in female carriers of Mal de Meleda. *Clin Genet.* 2004;65(3):244-246.
162. Mozzillo N, Nunziata CA, Caraco C, et al. Malignant melanoma developing in an area of hereditary palmoplantar keratoderma (Mal de Meleda). *J Surg Oncol.* 2003;84(4):229-233.
163. Sartore L, Bordignon M, Bassetto F, et al. Melanoma in skin affected with keratoderma palmoplantaris hereditaria (Mal de Meleda): treatment with excision and grafting. *J Am Acad Dermatol.* 2009;61(1):161-163.
164. Baroni A, Piccolo V, Di Maio R, et al. Mal de Meleda with hyperpigmented spots. *Eur J Dermatol.* 2011; 21(3):459-460.
165. Tourlaki A, Bentivogli M, Boneschi V, et al. Genetically proven Mal de Meleda complicated by Bowen's disease of the sole. *Eur J Dermatol.* 2011;21(2):292-294.
166. Nielsen PG. Two different clinical and genetic forms of hereditary palmoplantar keratoderma in the northernmost county of Sweden. *Clin Genet.* 1985; 28:361-366.
167. Kastl I, Anton-Lamprecht I, Gamborg Nielsen P. Hereditary palmoplantar keratosis of the Gamborg Nielsen type. Clinical and ultrastructural characteristics of a new type of autosomal recessive palmoplantar keratosis. *Arch Dermatol Res.* 1990;282(6):363-370.
168. Zhao L, Vahlquist A, Virtanen M, et al. Palmoplantar keratoderma of the Gamborg-Nielsen type is caused by mutations in the SLURP1 gene and represents a variant of Mal de Meleda. *Acta Derm Venereol.* 2014;94(6):707-710.
169. Bickmore WA, Longbottom D, Oghene K, et al. Colocalization of the human CD59 gene to 11p13 with the MIC11 cell surface antigen. *Genomics.* 1993;17(1):129-135.
170. Chimienti F, Hogg RC, Plantard L, et al. Identification of SLURP-1 as an epidermal neuromodulator explains the clinical phenotype of Mal de Meleda. *Hum Mol Genet.* 2003;12(22):3017-3024.
171. van Steensel MA, van Geel MV, Steijlen PM. Mal de Meleda without mutations in the ARS coding sequence. *Eur J Dermatol.* 2002;12(2):129-132.
172. Charfeddine C, Mokni M, Kassar S, et al. Further evidence of the clinical and genetic heterogeneity of recessive transgressive PPK in the Mediterranean region. *J Hum Genet.* 2006;51(10):841-845.
173. Nellen RG, Steijlen PM, van Geel M, et al. Comment on Zhao et al. "Palmoplantar keratoderma of the Gamborg-Nielsen type is caused by mutations in the SLURP1 gene and represents a variant of Mal de Meleda." *Acta Derm Venereol.* 2015;95(8):1034-1035.
174. Arredondo J, Chernyavsky AI, Webber RJ, et al. Biological effects of SLURP-1 on human keratinocytes. *J Invest Dermatol.* 2005;125(6):1236-1241.
175. Fujii T, Horiguchi K, Sunaga H, et al. SLURP-1, an endogenous alpha7 nicotinic acetylcholine receptor allosteric ligand, is expressed in CD205(+) dendritic cells in human tonsils and potentiates lymphocytic cholinergic activity. *J Neuroimmunol.* 2014;267(1-2):43-49.
176. Pham CT, Ivanovich JL, Raptis SZ, et al. Papillon-Lefevre syndrome: correlating the molecular, cellular, and clinical consequences of cathepsin C/dipeptidyl peptidase I deficiency in humans. *J Immunol.* 2004;173(12):7277-7281.
177. Arredondo J, Chernyavsky AI, Grando SA. Overexpression of SLURP-1 and -2 alleviates the tumorigenic action of tobacco-derived nitrosamine on immortalized oral epithelial cells. *Biochem Pharmacol.* 2007;74(8):1315-1319.
178. Pettersson A, Nordlander S, Nylund G, et al. Expression of the endogenous, nicotinic acetylcholine receptor ligand, SLURP-1, in human colon cancer. *Auton Autacoid Pharmacol.* 2008;28(4):109-116.
179. Horiguchi K, Horiguchi S, Yamashita N, et al. Expression of SLURP-1, an endogenous alpha7 nicotinic acetylcholine receptor allosteric ligand, in murine bronchial epithelial cells. *J Neurosci Res.* 2009;87(12):2740-2747.
180. Wang H, Yu M, Ochani M, et al. Nicotinic acetylcholine receptor alpha7 subunit is an essential regulator of inflammation. *Nature.* 2003;421(6921):384-388.
181. Adeyo O, Allan BB, Barnes RH 2nd, et al. Palmoplantar keratoderma along with neuromuscular and metabolic phenotypes in Slurp1-deficient mice. *J Invest Dermatol.* 2014;134(6):1589-1598.
182. Elias PM, Williams ML, Holleran WM, et al. Pathogenesis of permeability barrier abnormalities in the ichthyoses: inherited disorders of lipid metabolism. *J Lipid Res.* 2008;49(4):697-714.
183. Moriwaki Y, Takada K, Nagasaki T, et al. IL-22/STAT3-induced increases in SLURP1 expression within psoriatic lesions exerts antimicrobial effects against Staphylococcus aureus. *PloS One.* 2015;10(10):e0140750.
184. Chernyavsky AI, Kalantari-Dehaghi M, Phillips C, et al. Novel cholinergic peptides SLURP-1 and -2 regulate epithelialization of cutaneous and oral wounds. *Wound Repair Regen.* 2012;20(1):103-113.
185. Frenk E, Guggisberg D, Mevorah B, et al. Meleda disease: report of two cases investigated by electron microscopy. *Dermatology.* 1996;193(4):358-361.
186. Favre B, Plantard L, Aeschbach L, et al. SLURP1 is a late marker of epidermal differentiation and is absent in Mal de Meleda. *J Invest Dermatol.* 2007;127(2):301-308.
187. Nagashima M. Palmoplantar keratoses [in Japanese]. *Jinrui Idengaku Shosho.* 1977;9:23-27.
188. Mitsuhashi Y, Hashimoto I, Takahashi M. Meleda type of keratosis palmoplantaris [in Japanese]. *Hifubyoh Shinryou.* 1989;11:298-299.
189. Kubo A, Shiohama A, Sasaki T, et al. Mutations in SERPINB7, encoding a member of the serine protease inhibitor superfamily, cause Nagashima-type palmoplantar keratosis. *Am J Hum Genet.* 2013;93(5):945-956.
190. Yin J, Xu G, Wang H, et al. New and recurrent SERPINB7 mutations in seven Chinese patients with Nagashima-type palmoplantar keratosis. *J Invest Dermatol.* 2014;134(8):2269-2272.
191. Isoda H, Kabashima K, Tokura Y. "Nagashima-type" keratosis palmoplantaris in two siblings. *J Eur Acad Dermatol Venereol.* 2009;23(6):737-738.
192. Kabashima K, Sakabe J, Yamada Y, et al. "Nagashima-type" keratosis as a novel entity in the palmoplantar keratoderma category. *Arch Dermatol.* 2008;144(3):375-379.
193. Miyauchi T, Nomura T, Suzuki S, et al. Extensive erythema and hyperkeratosis on the extremities and lumbar area as an unusual manifestation of Nagashima-type palmoplantar keratosis. *Acta Derm Venereol.* 2016;96(6):856-858.
194. Nakamizo S, Katoh N, Miyachi Y, et al. Atypical nail dystrophy in a possible case of Nagashima-type palmoplantar keratosis. *J Dermatol.* 2012;39(5):470-471.
195. Nonomura Y, Otsuka A, Miyachi Y, et al. Suspected Nagashima-type palmoplantar keratosis with

atypical hyperkeratotic lesions on the ears. *Eur J Dermatol.* 2012;22(3):392-393.
196. Iwata M, Tanizaki H, Endo Y, et al. Malignant melanoma arising in the skin lesions of Nagashima-type palmoplantar keratosis. *Eur J Dermatol.* 2014;24(2):259-260.
197. Kubo A. Nagashima-type palmoplantar keratosis: a common Asian type caused by SERPINB7 protease inhibitor deficiency. *J Invest Dermatol.* 2014;134(8): 2076-2079.
198. Shiohama A, Sasaki T, Sato S, et al. Identification and characterization of a recessive missense mutation p.P277L in SERPINB7 in Nagashima-type palmoplantar keratosis. *J Invest Dermatol.* 2016;136(1):325-328.
199. Mizuno O, Nomura T, Suzuki S, et al. Highly prevalent SERPINB7 founder mutation causes pseudodominant inheritance pattern in Nagashima-type palmoplantar keratosis. *Br J Dermatol.* 2014;171(4): 847-853.
200. Meyer-Hoffert U. Reddish, scaly, and itchy: how proteases and their inhibitors contribute to inflammatory skin diseases. *Arch Immunol Ther Exp (Warsz).* 2009;57(5):345-354.
201. Ovaere P, Lippens S, Vandenabeele P, et al. The emerging roles of serine protease cascades in the epidermis. *Trends Biochem Sci.* 2009;34(9):453-463.
202. Sakabe JI, Kabashima K, Sugita K, et al. Possible involvement of T lymphocytes in the pathogenesis of Nagashima-type keratosis palmoplantaris. *Clin Exp Dermatol.* 2009;34(7):e282-284.
203. Olmsted HC. Keratodermia palmaris et plantaris congenitalis: report of a case showing associated lesions of unusual location. *Am J Dis Child.* 1927;33:757-764.
204. Wilson NJ, Cole C, Milstone LM, et al. Expanding the phenotypic spectrum of Olmsted syndrome. *J Invest Dermatol.* 2015;135(11):2879-2883.
205. Duchatelet S, Hovnanian A. Olmsted syndrome: clinical, molecular and therapeutic aspects. *Orphanet J Rare Dis.* 2015;10:33.
206. Duchatelet S, Guibbal L, de Veer S, et al. Olmsted syndrome with erythromelalgia caused by recessive transient receptor potential vanilloid 3 mutations. *Br J Dermatol.* 2014;171(3):675-678.
207. Duchatelet S, Pruvost S, de Veer S, et al. A new TRPV3 missense mutation in a patient with Olmsted syndrome and erythromelalgia. *JAMA Dermatol.* 2014;150(3):303-306.
208. Nofal A, Assaf M, Nassar A, et al. Nonmutilating palmoplantar and periorificial kertoderma: a variant of Olmsted syndrome or a distinct entity? *Int J Dermatol.* 2010;49(6):658-665.
209. He Y, Zeng K, Zhang X, et al. A gain-of-function mutation in TRPV3 causes focal palmoplantar keratoderma in a Chinese family. *J Invest Dermatol.* 2015;135(3):907-909.
210. Alotaibi AK, Alotaibi MK, Alsaeed S, et al. Olmsted syndrome with oral involvement, including premature teeth loss. *Odontology.* 2015;103(2):241-245.
211. Poulin Y, Perry HO, Muller SA. Olmsted syndrome—congenital palmoplantar and periorificial keratoderma. *J Am Acad Dermatol.* 1984;10(4):600-610.
212. Attia AM, Bakry OA. Olmsted syndrome. *J Dermatol Case Rep.* 2013;7(2):42-45.
213. Tharini GK, Hema N, Jayakumar S, et al. Olmsted syndrome: report of two cases. *Indian J Dermatol.* 2011;56(5):591-593.
214. Yaghoobi R, Omidian M, Sina N, et al. Olmsted syndrome in an Iranian family: report of two new cases. *Arch Iran Med.* 2007;10(2):246-249.
215. Frias-Iniesta J, Sanchez-Pedreno P, Martinez-Escribano JA, et al A. Olmsted syndrome: report of a new case. *Br J Dermatol.* 1997;136(6):935-938.
216. Judge MR, Misch K, Wright P, et al. Palmoplantar and perioroficial keratoderma with corneal epithelial dysplasia: a new syndrome. *Br J Dermatol.* 1991;125(2): 186-188.
217. Dogra D, Ravindraprasad JS, Khanna N, et al. Olmsted syndrome with hypotrichosis. *Indian J Dermatol Venereol Leprol.* 1997;63(2):120-122.
218. Mevorah B, Goldberg I, Sprecher E, et al. Olmsted syndrome: mutilating palmoplantar keratoderma with periorificial keratotic plaques. *J Am Acad Dermatol.* 2005;53(5 suppl 1):S266-272.
219. Tao J, Huang CZ, Yu NW, et al. Olmsted syndrome: a case report and review of literature. *Int J Dermatol.* 2008;47(5):432-437.
220. Requena L, Manzarbeitia F, Moreno C, et al. Olmsted syndrome: report of a case with study of the cellular proliferation in keratoderma. *Am J Dermatopathol.* 2001;23(6):514-520.
221. Cambiaghi S, Tadini G, Barbareschi M, et al. Olmsted syndrome in twins. *Arch Dermatol.* 1995;131(6):738-739.
222. Bergonse FN, Rabello SM, Barreto RL, et al. Olmsted syndrome: the clinical spectrum of mutilating palmoplantar keratoderma. *Pediatr Dermatol.* 2003; 20(4):323-326.
223. Larregue M, Callot V, Kanitakis J, et al. Olmsted syndrome: report of two new cases and literature review. *J Dermatol.* 2000;27(9):557-568.
224. Barnett JH, Estes SA. Multiple epitheliomata cuniculata occurring in a mutilating keratoderma. *Cutis.* 1985;35(4):345-347.
225. Dessureault J, Poulin Y, Bourcier M, et al. Olmsted syndrome-palmoplantar and periorificial keratodermas: association with malignant melanoma. *J Cutan Med Surg.* 2003;7(3):236-242.
226. Ogawa F, Udono M, Murota H, et al. Olmsted syndrome with squamous cell carcinoma of extremities and adenocarcinoma of the lung: failure to detect loricrin gene mutation. *Eur J Dermatol.* 2003;13(6):524-528.
227. Yoshizaki Y, Kanki H, Ueda T, et al. A further case of plantar squamous cell carcinoma arising in Olmsted syndrome. *Br J Dermatol.* 2001;145(4):685-686.
228. Ni C, Yan M, Zhang J, et al. A novel mutation in TRPV3 gene causes atypical familial Olmsted syndrome. *Sci Rep.* 2016;6:21815.
229. Georgii A, Przybilla B, Schmoeckel C. Olmstedt syndrome—associated with primary sclerosing cholangitis and immune deficiency of uncertain origin. *Hautarzt.* 1989;40(11):708-712.
230. Atherton DJ, Sutton C, Jones BM. Mutilating palmoplantar keratoderma with periorificial keratotic plaques (Olmsted's syndrome). *Br J Dermatol.* 1990;122(2):245-252.
231. Lai-Cheong JE, Sethuraman G, Ramam M, et al. Recurrent heterozygous missense mutation, p.Gly573Ser, in the TRPV3 gene in an Indian boy with sporadic Olmsted syndrome. *Br J Dermatol.* 2012; 167(2):440-442.
232. Eytan O, Fuchs-Telem D, Mevorach B, et al. Olmsted syndrome caused by a homozygous recessive mutation in TRPV3. *J Invest Dermatol.* 2014;134(6):1752-1754.
233. Cao X, Wang H, Li Y, et al. Semidominant inheritance in Olmsted syndrome. *J Invest Dermatol.* 2016;136(8):1722-1725.
234. Haghighi A, Scott CA, Poon DS, et al. A missense mutation in the MBTPS2 gene underlies the X-linked

form of Olmsted syndrome. *J Invest Dermatol.* 2013;133(2):571-573.
235. Kress DW, Seraly MP, Falo L, et al. Olmsted syndrome. Case report and identification of a keratin abnormality. *Arch Dermatol.* 1996;132(7):797-800.
236. Huang SM, Lee H, Chung MK, et al. Overexpressed transient receptor potential vanilloid 3 ion channels in skin keratinocytes modulate pain sensitivity via prostaglandin E2. *J Neurosci.* 2008;28(51):13727-13737.
237. Yamamoto-Kasai E, Imura K, Yasui K, et al. TRPV3 as a therapeutic target for itch. *J Invest Dermatol.* 2012;132(8):2109-2112.
238. Borbiro I, Lisztes E, Toth BI, et al. Activation of transient receptor potential vanilloid-3 inhibits human hair growth. *J Invest Dermatol.* 2011;131(8):1605-1614.
239. Cheng X, Jin J, Hu L, et al. TRP channel regulates EGFR signaling in hair morphogenesis and skin barrier formation. *Cell.* 16 2010;141(2):331-343.
240. Valdes-Rodriguez R, Kaushik SB, Yosipovitch G. Transient receptor potential channels and dermatological disorders. *Curr Top Med Chem.* 2013;13(3):335-343.
241. Montell C. Preventing a Perm with TRPV3. *Cell.* 2010; 141(2):218-220.
242. Asakawa M, Yoshioka T, Matsutani T, et al. Association of a mutation in TRPV3 with defective hair growth in rodents. *J Invest Dermatol.* 2006;126(12):2664-2672.
243. Megarbane H, Megarbane A. Ichthyosis follicularis, alopecia, and photophobia (IFAP) syndrome. *Orphanet J Rare Dis.* 2011;6:29.
244. Wang HJ, Tang ZL, Lin ZM, et al. Recurrent splice-site mutation in MBTPS2 underlying IFAP syndrome with Olmsted syndrome-like features in a Chinese patient. *Clin Exp Dermatol.* 2014;39(2):158-161.
245. Bedard MS, Powell J, Laberge L, et al. Palmoplantar keratoderma and skin grafting: postsurgical long-term follow-up of two cases with Olmsted syndrome. *Pediatr Dermatol.* 2008;25(2):223-229.
246. Kenner-Bell BM, Paller AS, Lacouture ME. Epidermal growth factor receptor inhibition with erlotinib for palmoplantar keratoderma. *J Am Acad Dermatol.* 2010;63(2):e58-59.
247. Wigley J. A case of hyperkeratosis palmaris et plantaris associated with ainhum-like constriction of the fingers. *Br J Dermatol.* 1929;41:188-191.
248. Bassetto F, Tiengo C, Sferrazza R, et al. Vohwinkel syndrome: treatment of pseudo-ainhum. *Int J Dermatol.* 2010;49(1):79-82.
249. Gibbs RC, Frank SB. Keratoma hereditaria mutilans (Vohwinkel). Differentiating features of conditions with constriction of digits. *Arch Dermatol.* 1966;94(5):619-625.
250. Maestrini E, Korge BP, Ocana-Sierra J, et al. A missense mutation in connexin26, D66H, causes mutilating keratoderma with sensorineural deafness (Vohwinkel's syndrome) in three unrelated families. *Hum Mol Genet.* 1999;8(7):1237-1243.
251. McGibbon DH, Watson RT. Vohwinkel's syndrome and deafness. *J Laryngol Othol.* 1977;91(10):853-857.
252. Wereide K. Mutilating palmoplantar keratoderma successfully treated with etretinate. *Acta Derm Venereol.* 1984;64(6):566-569.
253. Chadhuri A, Haldar B. Keratoderma hereditaria mutilans with acanthosis nigricans (Vohwinkel disease). *Indian J Dermatol Venereol Leprol.* 1980;46:299-304.
254. Gamborg Nielsen P. A curious genetic coincidence found in a study of palmoplantar keratoderma. *Dermatologica.* 1983;167(6):310-313.
255. Sensi A, Bettoli V, Zampino MR, et al. Vohwinkel syndrome (mutilating keratoderma) associated with craniofacial anomalies. *Am J Med Genet.* 1994; 50(2):201-203.
256. Solis RR, Diven DG, Trizna Z. Vohwinkel's syndrome in three generations. *J Am Acad Dermatol.* 2001;44 (2 suppl):376-378.
257. Bhatia KK, Chaudhary S, Pahwa US, et al. Keratoma hereditaria mutilans (Vohwinkel's disease) with congenital alopecia universalis (atrichia congenita). *J Dermatol.* 1989;16(3):231-236.
258. Kikuchi I, Nagata T, Abe S. Keratosis palmoplantaris mutilans. *J Dermatol.* 1976;3:85-88.
259. Serrano Castro PJ, Naranjo Fernandez C, Quiroga Subirana P, et al. Vohwinkel Syndrome secondary to missense mutation D66H in GJB2 gene (connexin 26) can include epileptic manifestations. *Seizure.* 2010;19(2):129-131.
260. Martinez Castrillo JC, Medina S, Gobernado Serrano J. Complex partial seizures in a case of Vohwinkel syndrome (keratoma hereditaria mutilans). *Neurologia.* 1992;7(1):39.
261. Caceres-Rios H, Tamayo-Sanchez L, Duran-Mckinster C, et al. Keratitis, ichthyosis, and deafness (KID syndrome): review of the literature and proposal of a new terminology. *Pediatr Dermatol.* 1996;13(2):105-113.
262. Skinner BA, Greist MC, Norins AL. The keratitis, ichthyosis, and deafness (KID) syndrome. *Arch Dermatol.* 1981;117(5):285-289.
263. Burns FS. A case of generalized congenital erythroderma. *J Cutaneous Dis.* 1915;33.
264. Jan AY, Amin S, Ratajczak P, et al. Genetic heterogeneity of KID syndrome: identification of a Cx30 gene (GJB6) mutation in a patient with KID syndrome and congenital atrichia. *J Invest Dermatol.* 2004;122(5):1108-1113.
265. Wilson FM 2nd, Grayson M, Pieroni D. Corneal changes in ectodermal dysplasia. Case report, histopathology, and differential diagnosis. *Am J Ophthalmol.* 1973;75(1):17-27.
266. Zhang XB, Wei SC, Li CX, et al. Mutation of GJB2 in a Chinese patient with keratitis-ichthyosis-deafness syndrome and brain malformation. *Clin Exp Dermatol.* 2009;34(3):309-313.
267. Derelioglu SS, Yilmaz Y, Keles S. Dental treatments under the general anesthesia in a child with keratitis, ichthyosis, and deafness syndrome. *Case Rep Dent.* 2013;2013:618468.
268. Baden HP, Alper JC. Ichthyosiform dermatosis, keratitis, and deafness. *Arch Dermatol.* 1977;113(12): 1701-1704.
269. Lancaster L Jr, Fournet LF. Carcinoma of the tongue in a child: report of case. *J Oral Surg.* 1969;27(4): 269-270.
270. Tuppurainen K, Fraki J, Karjalainen S, et al. The KID-syndrome in Finland. A report of four cases. *Acta Ophthalmol.* 1988;66(6):692-698.
271. Lazic T, Li Q, Frank M, et al. Extending the phenotypic spectrum of keratitis-ichthyosis-deafness syndrome: report of a patient with GJB2 (G12R) Connexin 26 mutation and unusual clinical findings. *Pediatr Dermatol.* 2012;29(3):349-357.
272. Miteva L. Keratitis, ichthyosis, and deafness (KID) syndrome. *Pediatr Dermatol.* 2002;19(6):513-516.
273. Markova TG, Brazhkina NB, Bliznech EA, et al. Phenotype in a patient with p.D50N mutation in GJB2 gene resemble both KID and Clouston syndromes. *Int J Pediatr Otorhinolaryngol.* 2016;81:10-14.
274. Kutkowska-Kazmierczak A, Niepokoj K, Wertheim-Tysarowska K, et al. Phenotypic variability in gap

junction syndromic skin disorders: experience from KID and Clouston syndromes' clinical diagnostics. *J Appl Genet*. 2015;56(3):329-337.
275. Szymko-Bennett YM, Russell LJ, Bale SJ, et al. Auditory manifestations of keratitis-ichthyosis-deafness (KID) syndrome. *Laryngoscope*. 2002;112(2):272-280.
276. Gilliam A, Williams ML. Fatal septicemia in an infant with keratitis, ichthyosis, and deafness (KID) syndrome. *Pediatr Dermatol*. 2002;19(3):232-236.
277. Haruna K, Suga Y, Oizumi A, et al. Severe form of keratitis-ichthyosis-deafness (KID) syndrome associated with septic complications. *J Dermatol*. 2010;37(7): 680-682.
278. Morris MR, Namon A, Shaw GY, et al. The keratitis, ichthyosis, and deafness syndrome. *Otolaryngol Head Neck Surg*. 1991;104(4):526-528.
279. Helm K, Lane AT, Orosz J, et al. Systemic cytomegalovirus in a patient with the keratitis, ichthyosis, and deafness (KID) syndrome. *Pediatr Dermatol*. 1990;7(1): 54-56.
280. Coggshall K, Farsani T, Ruben B, et al. Keratitis, ichthyosis, and deafness syndrome: a review of infectious and neoplastic complications. *J Am Acad Dermatol*. 2013;69(1):127-134.
281. Nyquist GG, Mumm C, Grau R, et al. Malignant proliferating pilar tumors arising in KID syndrome: a report of two patients. *Am J Med Genet A*. 2007;143A(7):734-741.
282. Kim KH, Kim JS, Piao YJ, et al. Keratitis, ichthyosis and deafness syndrome with development of multiple hair follicle tumours. *Br J Dermatol*. 2002;147(1): 139-143.
283. de Alonso A, Cesarios G, Pecoraro V, et al. Syndrome KID (queratitis, ictiosis sordera) con poromas ecrinos multiples. *Rev Arg Dermatol*. 1993;74:10-14.
284. Bergman R, Mercer A, Indelman M, et al. KID syndrome: histopathological, immunohistochemical and molecular analysis of precancerous and cancerous skin lesions. *Br J Dermatol*. 2012;166(2): 455-457.
285. Homeida L, Wiley RT, Fatahzadeh M. Oral squamous cell carcinoma in a patient with keratitis-ichthyosis-deafness syndrome: a rare case. *Oral Surg Oral Med Oral Pathol Oral Radiol*. 2015;119(4):e226-232.
286. Mazereeuw-Hautier J, Bitoun E, Chevrant-Breton J, et al. Keratitis-ichthyosis-deafness syndrome: disease expression and spectrum of connexin 26 (GJB2) mutations in 14 patients. *Br J Dermatol*. 2007;156(5): 1015-1019.
287. van Steensel MA, Steijlen PM, Bladergroen RS, et al. A phenotype resembling the Clouston syndrome with deafness is associated with a novel missense GJB2 mutation. *J Invest Dermatol*. 2004;123(2):291-293.
288. Carey AB, Burke WA, Park HM. Malignant fibrous histiocytoma in keratosis, ichthyosis, and deafness syndrome. *J Am Acad Dermatol*. 1988;19(6):1124-1126.
289. Kaku Y, Tanizaki H, Tanioka M, et al. Sebaceous carcinoma arising at a chronic candidiasis skin lesion of a patient with keratitis-ichthyosis-deafness (KID) syndrome. *Br J Dermatol*. 2012;166(1):222-224.
290. Fozza C, Poddie F, Contini S, et al. Keratitis-ichthyosis-deafness syndrome, atypical connexin gjb2 gene mutation, and peripheral T-cell lymphoma: more than a random association? *Case Rep Hematol*. 2011;2011:848461.
291. Maintz L, Betz RC, Allam JP, et al. Keratitis-ichthyosis-deafness syndrome in association with follicular occlusion triad. *Eur J Dermatol*. 2005;15(5):347-352.
292. Montgomery JR, White TW, Martin BL, et al. A novel connexin 26 gene mutation associated with features of the keratitis-ichthyosis-deafness syndrome and the follicular occlusion triad. *J Am Acad Dermatol*. 2004;51(3):377-382.
293. Meigh L, Hussain N, Mulkey DK, et al. Connexin26 hemichannels with a mutation that causes KID syndrome in humans lack sensitivity to CO2. *eLife*. 2014;3:e04249.
294. Sbidian E, Feldmann D, Bengoa J, et al. Germline mosaicism in keratitis-ichthyosis-deafness syndrome: pre-natal diagnosis in a familial lethal form. *Clin Genet*. 2010;77(6):587-592.
295. Ogawa Y, Takeichi T, Kono M, et al. Revertant mutation releases confined lethal mutation, opening Pandora's box: a novel genetic pathogenesis. *PLoS Genet*. 2014;10(5):e1004276.
296. Bart RS, Pumphrey RE. Knuckle pads, leukonychia and deafness. A dominantly inherited syndrome. *N Engl J Med*. 1967;276(4):202-207.
297. Ramer JC, Vasily DB, Ladda RL. Familial leuconychia, knuckle pads, hearing loss, and palmoplantar hyperkeratosis: an additional family with Bart-Pumphrey syndrome. *J Med Genet*. 1994;31(1):68-71.
298. Richard G. Connexin disorders of the skin. *Clin Dermatol*. 2005;23(1):23-32.
299. Alexandrino F, Sartorato EL, Marques-de-Faria AP, et al. G59S mutation in the GJB2 (connexin 26) gene in a patient with Bart-Pumphrey syndrome. *Am J Med Genet A*. 2005;136(3):282-284.
300. Balighi K, Moeineddin F, Lajevardi V, et al. A family with leukonychia totalis. *Indian J Dermatol*. 2010;55(1): 102-104.
301. Gonul M, Gul U, Hizli P, et al. A family of Bart-Pumphrey syndrome. *Indian J Dermatol Venereol Leprol*. 2012;78(2):178-181.
302. Richard G, Brown N, Ishida-Yamamoto A, et al. Expanding the phenotypic spectrum of Cx26 disorders: Bart-Pumphrey syndrome is caused by a novel missense mutation in GJB2. *J Invest Dermatol*. 2004;123(5):856-863.
303. Heathcote K, Syrris P, Carter ND, et al. A connexin 26 mutation causes a syndrome of sensorineural hearing loss and palmoplantar hyperkeratosis (MIM 148350). *J Med Genet*. 2000;37(1):50-51.
304. Richard G, White TW, Smith LE, et al. Functional defects of Cx26 resulting from a heterozygous missense mutation in a family with dominant deafmutism and palmoplantar keratoderma. *Hum Genet*. 1998;103(4):393-399.
305. Uyguner O, Tukel T, Baykal C, et al. The novel R75Q mutation in the GJB2 gene causes autosomal dominant hearing loss and palmoplantar keratoderma in a Turkish family. *Clin Genet*. 2002;62(4):306-309.
306. Kelsell DP, Wilgoss AL, Richard G, et al. Connexin mutations associated with palmoplantar keratoderma and profound deafness in a single family. *Eur J Hum Genet*. 2000;8(2):141-144.
307. Lee JY, In SI, Kim HJ, et al. Hereditary palmoplantar keratoderma and deafness resulting from genetic mutation of Connexin 26. *J Korean Med Sci*. 2010;25(10):1539-1542.
308. Birkenhager R, Lublinghoff N, Prera E, et al. Autosomal dominant prelingual hearing loss with palmoplantar keratoderma syndrome: variability in clinical expression from mutations of R75W and R75Q in the GJB2 gene. *Am J Med Genet A*. 2010;152A(7): 1798-1802.

309. de Zwart-Storm EA, van Geel M, van Neer PA, et al. A novel missense mutation in the second extracellular domain of GJB2, p.Ser183Phe, causes a syndrome of focal palmoplantar keratoderma with deafness. *Am J Pathol.* 2008;173(4):1113-1119.
310. Simon AM, Goodenough DA. Diverse functions of vertebrate gap junctions. *Trends Cell Biol.* 1998;8(12): 477-483.
311. Oshima A, Doi T, Mitsuoka K, et al. Roles of Met-34, Cys-64, and Arg-75 in the assembly of human connexin 26. Implication for key amino acid residues for channel formation and function. *J Biol Chem.* 2003;278(3): 1807-1816.
312. del Castillo FJ, Rodriguez-Ballesteros M, Alvarez A, et al. A novel deletion involving the connexin-30 gene, del(GJB6-d13s1854), found in trans with mutations in the GJB2 gene (connexin-26) in subjects with DFNB1 non-syndromic hearing impairment. *J Med Genet.* 2005;42(7):588-594.
313. Guex N, Peitsch MC. SWISS-MODEL and the Swiss-PdbViewer: an environment for comparative protein modeling. *Electrophoresis.* 1997;18(15): 2714-2723.
314. Martinez AD, Acuna R, Figueroa V, et al. Gap-junction channels dysfunction in deafness and hearing loss. *Antioxid Redox Signal.* 2009;11(2):309-322.
315. Scott CA, Tattersall D, O'Toole EA, et al. Connexins in epidermal homeostasis and skin disease. *Biochim Biophys Acta.* 2012;1818(8):1952-1961.
316. Wang CM, Lincoln J, Cook JE, et al. Abnormal connexin expression underlies delayed wound healing in diabetic skin. *Diabetes.* 2007;56(11):2809-2817.
317. Richard G, Rouan F, Willoughby CE, et al. Missense mutations in GJB2 encoding connexin-26 cause the ectodermal dysplasia keratitis-ichthyosis-deafness syndrome. *Am J Hum Genet.* 2002;70(5):1341-1348.
318. Coutinho P, Qiu C, Frank S, et al. Dynamic changes in connexin expression correlate with key events in the wound healing process. *Cell Biol Int.* 2003;27(7):525-541.
319. Lucke T, Choudhry R, Thom R, et al. Upregulation of connexin 26 is a feature of keratinocyte differentiation in hyperproliferative epidermis, vaginal epithelium, and buccal epithelium. *J Invest Dermatol.* 1999;112(3):354-361.
320. Rouan F, White TW, Brown N, et al. trans-dominant inhibition of connexin-43 by mutant connexin-26: implications for dominant connexin disorders affecting epidermal differentiation. *J Cell Sci.* 2001; 114(Pt 11):2105-2113.
321. Kelsell DP, Dunlop J, Stevens HP, et al. Connexin 26 mutations in hereditary non-syndromic sensorineural deafness. *Nature.* 1997;387(6628):80-83.
322. Kikuchi T, Kimura RS, Paul DL, et al. Gap junctions in the rat cochlea: immunohistochemical and ultrastructural analysis. *Anat Embryol.* 1995;191(2): 101-118.
323. Rabionet R, Lopez-Bigas N, Arbones ML, et al. Connexin mutations in hearing loss, dermatological and neurological disorders. *Trends Mol Med.* 2002;8(5): 205-212.
324. Bergoffen J, Scherer SS, Wang S, et al. Connexin mutations in X-linked Charcot-Marie-Tooth disease. *Science.* 1993;262(5142):2039-2042.
325. Shiels A, Mackay D, Ionides A, et al. A missense mutation in the human connexin50 gene (GJA8) underlies autosomal dominant "zonular pulverulent" cataract, on chromosome 1q. *Am J Hum Genet.* 1998;62(3):526-532.
326. Paznekas WA, Boyadjiev SA, Shapiro RE, et al. Connexin 43 (GJA1) mutations cause the pleiotropic phenotype of oculodentodigital dysplasia. *Am J Hum Genet.* 2003;72(2):408-418.
327. van Steensel MA, van Geel M, Nahuys M, et al. A novel connexin 26 mutation in a patient diagnosed with keratitis-ichthyosis-deafness syndrome. *J Invest Dermatol.* 2002;118(4):724-727.
328. Lamartine J, Munhoz Essenfelder G, Kibar Z, et al. Mutations in GJB6 cause hidrotic ectodermal dysplasia. *Nat Genet.* 2000;26(2):142-144.
329. Richard G, Smith LE, Bailey RA, et al. Mutations in the human connexin gene GJB3 cause erythrokeratodermia variabilis. *Nat Genet.* 1998;20(4):366-369.
330. Yeager M, Nicholson BJ. Structure of gap junction intercellular channels. *Curr Opin Struct Biol.* 1996;6(2):183-192.
331. Marziano NK, Casalotti SO, Portelli AE, et al. Mutations in the gene for connexin 26 (GJB2) that cause hearing loss have a dominant negative effect on connexin 30. *Hum Mol Genet.* 2003;12(8):805-812.
332. Stauffer KA. The gap junction proteins beta 1-connexin (connexin-32) and beta 2-connexin (connexin-26) can form heteromeric hemichannels. *J Biol Chem.* 1995;270(12):6768-6772.
333. Cohen-Salmon M, Ott T, Michel V, et al. Targeted ablation of connexin26 in the inner ear epithelial gap junction network causes hearing impairment and cell death. *Curr Biol.* 2002;12(13):1106-1111.
334. Kudo T, Kure S, Ikeda K, et al. Transgenic expression of a dominant-negative connexin26 causes degeneration of the organ of Corti and non-syndromic deafness. *Hum Mol Genet.* 2003;12(9):995-1004.
335. Bakirtzis G, Choudhry R, Aasen T, et al. Targeted epidermal expression of mutant Connexin 26(D66H) mimics true Vohwinkel syndrome and provides a model for the pathogenesis of dominant connexin disorders. *Hum Mol Genet.* 2003;12(14): 1737-1744.
336. Senter TP, Jones KL, Sakati N, et al. Atypical ichthyosiform erythroderma and congenital neurosensory deafness—a distinct syndrome. *J Pediatr.* 1978;92(1): 68-72.
337. Rycroft RJ, Moynahan EJ, Wells RS. Atypical ichthyosiform erythrodernam deafness and keratitis. A report of two cases. *Br J Dermatol.* 1976;94(2):211-217.
338. Titeux M, Mendonca V, Decha A, et al. Keratitis-ichthyosis-deafness syndrome caused by GJB2 maternal mosaicism. *J Invest Dermatol.* 2009;129(3): 776-779.
339. Neoh CY, Chen H, Ng SK, et al. A rare connexin 26 mutation in a patient with a forme fruste of keratitis-ichthyosis-deafness (KID) syndrome. *Int J Dermatol.* 2009;48(10):1078-1081.
340. Richard G. Connexin disorders of the skin. *Adv Dermatol.* 2001;17:243-277.
341. Sanchez HA, Verselis VK. Aberrant Cx26 hemichannels and keratitis-ichthyosis-deafness syndrome: insights into syndromic hearing loss. *Front Cell Neurosci.* 2014;8:354.
342. Yotsumoto S, Hashiguchi T, Chen X, et al. Novel mutations in GJB2 encoding connexin-26 in Japanese patients with keratitis-ichthyosis-deafness syndrome. *Br J Dermatol.* 2003;148(4):649-653.
343. van Geel M, van Steensel MA, Kuster W, et al. HID and KID syndromes are associated with the same connexin 26 mutation. *Br J Dermatol.* 2002;146(6):938-942.
344. Maeda S, Nakagawa S, Suga M, et al. Structure of the connexin 26 gap junction channel at 3.5 A resolution. *Nature.* 2009;458(7238):597-602.

345. Shurman DL, Glazewski L, Gumpert A, et al. In vivo and in vitro expression of connexins in the human corneal epithelium. *Invest Ophthalmol Visual Sci.* 2005;46(6):1957-1965.
346. Levit NA, Sellitto C, Wang HZ, et al. Aberrant connexin26 hemichannels underlying keratitis-ichthyosis-deafness syndrome are potently inhibited by mefloquine. *J Invest Dermatol.* 2015;135(4):1033-1042.
347. Smith FJ, Morley SM, McLean WH. A novel connexin 30 mutation in Clouston syndrome. *J Invest Dermatol.* 2002;118(3):530-532.
348. Feldmann D, Denoyelle F, Blons H, et al. The GJB2 mutation R75Q can cause nonsyndromic hearing loss DFNA3 or hereditary palmoplantar keratoderma with deafness. *Am J Med Genet A.* 2005;137(2):225-227.
349. Palungwachira P, Iwahara K, Ogawa H. Keratoderma hereditaria mutilans. Etretinate treatment and electron microscope studies. *Australas J Dermatol.* 1992;33(1):19-30.
350. de Berker D, Branford WA, Soucek S, et al. Fatal keratitis ichthyosis and deafness syndrome (KIDS). Aural, ocular, and cutaneous histopathology. *Am J Dermatopathol.* 1993;15(1):64-69.
351. Atabay K, Yavuzer R, Latifoglu O, et al. Keratoderma hereditarium mutilans (Vohwinkel syndrome): an unsolved surgical mystery. *Plast Reconstr Surg.* 2001;108(5):1276-1280.
352. Liebman JJ, Liu Y. Successful surgical management of keratoderma hereditaria mutilans. *Hand.* 2013;8(1):102-104.
353. Zhang M, Song K, Ding N, et al. Using a distant abdominal skin flap to treat digital constriction bands: a case report for Vohwinkel syndrome. *Medicine.* 2016;95(6):e2762.
354. Djalilian AR, Kim JY, Saeed HN, et al. Histopathology and treatment of corneal disease in keratitis, ichthyosis, and deafness (KID) syndrome. *Eye.* 2010;24(4):738-740.
355. Sonoda S, Uchino E, Sonoda KH, et al. Two patients with severe corneal disease in KID syndrome. *Am J Ophthalmol.* 2004;137(1):181-183.
356. Caye L, Scheid K, Pizzol MM, et al. Use of bevacizumab (Avastin) in KID syndrome: case report. *Arq Bras Oftalmol.* 2010;73(3):285-290.
357. Basaran E, Yilmaz E, Alpsoy E, et al. Keratoderma, hypotrichosis and leukonychia totalis: a new syndrome? *Br J Dermatol.* 1995;133(4):636-638.
358. Rai VM, Shenoi SD. Ichthyosis follicularis with congenital atrichia, nail dystrophy and palmoplantar keratoderma. Variant of IFAP syndrome or a new entity? *Dermatol Online J.* 2005;11(3):36.
359. Stevanovic DV. Alopecia congenita: the incomplete dominant form of inheritance with varying expressivity. *Acta Genet Stat Med.* 1959;9:127-132.
360. Stratton RF, Jorgenson RJ, Krause IC. Possible second case of tricho-oculo-dermo-vertebral (Alves) syndrome. *Am J Med Genet.* 1993;46(3):313-315.
361. Wallis C, Ip FS, Beighton P. Cataracts, alopecia, and sclerodactyly: a previously apparently undescribed ectodermal dysplasia syndrome on the island of Rodrigues. *American J Med Genet.* 1989;32(4):500-503.
362. Castori M, Valiante M, Ritelli M, et al. Palmoplantar keratoderma, pseudo-ainhum, and universal atrichia: a new patient and review of the palmoplantar keratoderma-congenital alopecia syndrome. *Am J Med Genet A.* 2010;152A(8):2043-2047.
363. Castori M, Morlino S, Sana ME, et al. Clinical and molecular characterization of two patients with palmoplantar keratoderma-congenital alopecia syndrome type 2. *Clin Exp Dermatol.* 2016;41(6):632-635.
364. Wang H, Cao X, Lin Z, et al. Exome sequencing reveals mutation in GJA1 as a cause of keratoderma-hypotrichosis-leukonychia totalis syndrome. *Hum Mol Genet.* 2015;24(22):6564.
365. Dahl E, Winterhager E, Traub O, et al. Expression of gap junction genes, connexin40 and connexin43, during fetal mouse development. *Anat Embryol.* 1995;191(3):267-278.
366. Tada J, Hashimoto K. Ultrastructural localization of gap junction protein connexin 43 in normal human skin, basal cell carcinoma, and squamous cell carcinoma. *J Cutan Pathol.* 1997;24(10):628-635.
367. Kelly SC, Ratajczak P, Keller M, et al. A novel GJA 1 mutation in oculo-dento-digital dysplasia with curly hair and hyperkeratosis. *Eur J Dermatol.* 2006;16(3):241-245.
368. van Steensel MA, Spruijt L, van der Burgt I, et al. A 2-bp deletion in the GJA1 gene is associated with oculo-dento-digital dysplasia with palmoplantar keratoderma. *Am J Med Genet A.* 2005;132A(2):171-174.
369. Vreeburg M, de Zwart-Storm EA, Schouten MI, et al. Skin changes in oculo-dento-digital dysplasia are correlated with C-terminal truncations of connexin 43. *Am J Med Genet A.* 2007;143(4):360-363.
370. Nicolle G, Hallipre A. Maladie familiale characterisee par des alterations des cheveux et des ongles. *Ann Dermatol Syphilol.* 1895;6(675):804.
371. Clouston HR. A hereditary ectodermal dystrophy. *Can Med Assoc J.* 1929;21(1):18-31.
372. Clouston HR. The major forms of hereditary ectodermal dysplasia (with an autopsy and biopsies on the anhydrotic type). *Can Med Assoc J.* 1939;40(1):1-7.
373. Ando Y, Tanaka T, Horiguchi Y, et al. Hidrotic ectodermal dysplasia: a clinical and ultrastructural observation. *Dermatologica.* 1988;176(4):205-211.
374. Kibar Z, Dube MP, Powell J, et al. Clouston hidrotic ectodermal dysplasia (HED): genetic homogeneity, presence of a founder effect in the French Canadian population and fine genetic mapping. *Eur J Hum Genet.* 2000;8(5):372-380.
375. McNaughton PZ, Pierson DL, Rodman OG. Hidrotic ectodermal dysplasia in a black mother and daughter. *Arch Dermatol.* 1976;112(10):1448-1450.
376. Patel RR, Bixler D, Norins AL. Clouston syndrome: a rare autosomal dominant trait with palmoplantar hyperkeratosis and alopecia. *J Craniofac Genet Dev Biol.* 1991;11(3):176-179.
377. Radhakrishna U, Blouin JL, Mehenni H, et al. The gene for autosomal dominant hidrotic ectodermal dysplasia (Clouston syndrome) in a large Indian family maps to the 13q11-q12.1 pericentromeric region. *Am J Med Genet.* 1997;71(1):80-86.
378. Rajagopalan K, Tay CH. Hidrotic ectodermal dysplasia: study of a large Chinese pedigree. *Arch Dermatol.* 1977;113(4):481-485.
379. Yang R, Hu Z, Kong Q, et al. A known mutation in GJB6 in a large Chinese family with hidrotic ectodermal dysplasia. *J Eur Acad Dermatol Venereol.* 2016;30(8):1362-1365.
380. Marakhonov A, Skoblov M, Galkina V, et al. Clouston syndrome: first case in Russia. *Balkan J Med Genet.* 2012;15(1):51-54.
381. Hassed SJ, Kincannon JM, Arnold GL. Clouston syndrome: an ectodermal dysplasia without significant dental findings. *Am J Med Genet.* 1996;61(3):274-276.

382. Hazen PG, Zamora I, Bruner WE, et al. Premature cataracts in a family with hidrotic ectodermal dysplasia. *Arch Dermatol.* 1980;116(12):1385-1387.
383. Zhang XJ, Chen JJ, Yang S, et al. A mutation in the connexin 30 gene in Chinese Han patients with hidrotic ectodermal dysplasia. *J Dermatol Sci.* 2003;32(1):11-17.
384. Baris HN, Zlotogorski A, Peretz-Amit G, et al. A novel GJB6 missense mutation in hidrotic ectodermal dysplasia 2 (Clouston syndrome) broadens its genotypic basis. *Br J Dermatol.* 2008;159(6):1373-1376.
385. van Steensel MA, Jonkman MF, van Geel M, et al. Clouston syndrome can mimic pachyonychia congenita. *J Invest Dermatol.* 2003;121(5):1035-1038.
386. Hu YH, Lin YC, Hwu WL, et al. Pincer nail deformity as the main manifestation of Clouston syndrome. *Br J Dermatol.* 2015;173(2):581-583.
387. Hale GI, Wilson NJ, Smith FJ, et al. Mutations in GJB6 causing phenotype resembling pachyonychia congenita. *Br J Dermatol.* 2015;172(5):1447-1449.
388. Fraser FC, Der Kaloustian VM. A man, a syndrome, a gene: Clouston's hidrotic ectodermal dysplasia (HED). *Am J Med Genet.* 2001;100(2):164-168.
389. Liu YT, Guo K, Li J, et al. Novel mutations in GJB6 and GJB2 in Clouston syndrome. *Clin Exp Dermatol.* 2015;40(7):770-773.
390. Sugiura K, Teranishi M, Matsumoto Y, et al. Clouston syndrome with heterozygous GJB6 mutation p.Ala88Val and GJB2 variant p.Val27Ile revealing mild sensorineural hearing loss and photophobia. *JAMA Dermatol.* 2013;149(11):1350-1351.
391. Copeland DD, Lamb WA, Klintworth GK. Calcification of basal ganglia and cerebellar roof nuclei in mentally defective patient with hidrotic ectodermal dysplasia. Analysis of intracranial concretions by electron microprobe. *Neurology.* 1977;27(11):1029-1033.
392. Unger VM, Kumar NM, Gilula NB, et al. Three-dimensional structure of a recombinant gap junction membrane channel. *Science.* 1999;283(5405): 1176-1180.
393. Sosinsky G. Mixing of connexins in gap junction membrane channels. *Proc Natl Acad Sci U S A.* 1995;92(20):9210-9214.
394. Dahl E, Manthey D, Chen Y, et al. Molecular cloning and functional expression of mouse connexin-30,a gap junction gene highly expressed in adult brain and skin. *J Biol Chem.* 1996;271(30):17903-17910.
395. Lautermann J, Frank HG, Jahnke K, et al. Developmental expression patterns of connexin26 and -30 in the rat cochlea. *Dev Genet.* 1999;25(4):306-311.
396. Nagy JI, Patel D, Ochalski PA, et al. Connexin30 in rodent, cat and human brain: selective expression in gray matter astrocytes, co-localization with connexin43 at gap junctions and late developmental appearance. *Neuroscience.* 1999;88(2):447-468.
397. Essenfelder GM, Bruzzone R, Lamartine J, et al. Connexin30 mutations responsible for hidrotic ectodermal dysplasia cause abnormal hemichannel activity. *Hum Mol Genet.* 2004;13(16):1703-1714.
398. Essenfelder GM, Larderet G, Waksman G, et al. Gene structure and promoter analysis of the human GJB6 gene encoding connexin 30. *Gene.* 2005;350(1):33-40.
399. Fujimoto A, Kurban M, Nakamura M, et al. GJB6, of which mutations underlie Clouston syndrome, is a potential direct target gene of p63. *J Dermatol Sci.* 2013;69(2):159-166.
400. Bosen F, Schutz M, Beinhauer A, et al. The Clouston syndrome mutation connexin30 A88V leads to hyperproliferation of sebaceous glands and hearing impairments in mice. *FEBS Lett.* 2014;588(9):1795-1801.
401. Berger AC, Kelly JJ, Lajoie P, et al. Mutations in Cx30 that are linked to skin disease and non-syndromic hearing loss exhibit several distinct cellular pathologies. *J Cell Sci.* 2014;127(Pt 8):1751-1764.
402. Kellermayer R, Keller M, Ratajczak P, et al. Bigenic connexin mutations in a patient with hidrotic ectodermal dysplasia. *Eur J Dermatol.* 2005;15(2): 75-79.
403. Grifa A, Wagner CA, D'Ambrosio L, et al. Mutations in GJB6 cause nonsyndromic autosomal dominant deafness at DFNA3 locus. *Nat Genet.* 1999;23(1):16-18.
404. Huriez C, Deminati M, Agache P, et al. Sclero-atrophying and keratodermic genodermatosis of the extremities. *Ann Dermatol Syphiligr (Paris).* 1969; 96(2):135-146.
405. Guerriero C, Albanesi C, Girolomoni G, et al. Huriez syndrome: case report with a detailed analysis of skin dendritic cells. *Br J Dermatol.* 2000;143(5): 1091-1096.
406. Hamm H, Traupe H, Brocker EB, et al. The scleroatrophic syndrome of Huriez: a cancer-prone genodermatosis. *Br J Dermatol.* 1996;134(3):512-518.
407. Kavanagh GM, Jardine PE, Peachey RD, et al. The scleroatrophic syndrome of Huriez. *Br J Dermatol.* 1997;137(1):114-118.
408. Lambert D, Planche H, Chapuis JL. Sclero-atrophic and keratodermic genodermatosis of the extremities. *Ann Dermatol Venereol.* 1977;104(10):654-657.
409. Watanabe E, Takai T, Ichihashi M, et al. A nonfamilial Japanese case of Huriez syndrome: p53 expression in squamous cell carcinoma. *Dermatology.* 2003; 207(1):82-84.
410. Yesudian P, Premalatha S, Thambiah AS. Genetic tylosis with malignancy: a study of a South Indian pedigree. *Br J Dermatol.* 1980;102(5):597-600.
411. Vernole P, Terrinoni A, Didona B, et al. An SRY-negative XX male with Huriez syndrome. *Clin Genet.* 2000;57(1):61-66.
412. Kharge P, Fernendes C, Jairath V, et al. Poikiloderma a varied presentation—Huriez syndrome. *Indian Dermatol Online J.* 2015;6(1):27-30.
413. Patrizi A, Di Lernia V, Patrone P. Palmoplantar keratoderma with sclerodactyly (Huriez syndrome). *J Am Acad Dermatol.* 1992;26(5 Pt 2):855-857.
414. Levi F, Franceschi S, Te VC, et al. Trends of skin cancer in the Canton of Vaud, 1976-92. *Br J Cancer.* 1995;72(4):1047-1053.
415. Deminatti M, Delmas-Marsalet Y, Mennecier M, et al. Study of a probable linkage between a genodermatosis with an autosomal dominant transmission and the MNSs blood group system. *Ann Genet.* 1968;11(4):217-224.
416. Lee YA, Stevens HP, Delaporte E, et al. A gene for an autosomal dominant scleroatrophic syndrome predisposing to skin cancer (Huriez syndrome) maps to chromosome 4q23. *Am J Hum Genet.* 2000;66(1):326-330.
417. Hamon Y, Legowska M, Fergelot P, et al. Analysis of urinary cathepsin C for diagnosing Papillon-Lefevre syndrome. *FEBS J.* 2016;283(3):498-509.
418. Hart TC, Hart PS, Bowden DW, et al. Mutations of the cathepsin C gene are responsible for Papillon-Lefevre syndrome. *J Med Genet.* 1999;36(12):881-887.
419. Papillon M, Lefevre P. 2 Cases of symmetrically, familiarly palmar and plantar hyperkeratosis (Meleda disease) within brother and sister combined with severe dental alterations in both cases. 31, 82-84. *Bull Soc Fr Dermatol Syphiligr.* 1924;31:82-84.

420. Toomes C, James J, Wood AJ, et al. Loss-of-function mutations in the cathepsin C gene result in periodontal disease and palmoplantar keratosis. *Nat Genet.* 1999;23(4):421-424.
421. Wang X, Liu Y, Liu Y, et al. Long-term change of disease behavior in Papillon-Lefevre syndrome: seven years follow-up. *Eur J J Med Genet.* 2015;58(3):184-187.
422. Gorlin RJ, Sedano H, Anderson VE. The syndrome of palmar-plantar hyperkeratosis and premature periodontal destruction of the teeth. A clinical and genetic analysis of the Papillon-Lef'evre syndrome. *J Pediatr.* 1964;65:895-908.
423. Haneke E. The Papillon-Lefevre syndrome: keratosis palmoplantaris with periodontopathy. Report of a case and review of the cases in the literature. *Hum Genet.* 1979;51(1):1-35.
424. Dhanrajani PJ. Papillon-Lefevre syndrome: clinical presentation and a brief review. *Oral Surg Oral Med Oral Pathol Oral Radiol Endod.* 2009;108(1):e1-7.
425. Ullbro C, Crossner CG, Nederfors T, et al. Dermatologic and oral findings in a cohort of 47 patients with Papillon-Lefevre syndrome. *J Am Acad Dermatol.* 2003;48(3):345-351.
426. Pilger U, Hennies HC, Truschnegg A, et al. Late-onset Papillon-Lefevre syndrome without alteration of the cathepsin C gene. *J Am Acad Dermatol.* 2003;49(5 suppl):S240-S243.
427. Ragunatha S, Ramesh M, Anupama P, et al. Papillon-Lefevre syndrome with homozygous nonsense mutation of cathepsin C gene presenting with late-onset periodontitis. *Pediatr Dermatol.* 2015;32(2): 292-294.
428. Kobayashi T, Sugiura K, Takeichi T, et al. The novel CTSC homozygous nonsense mutation p.Lys106X in a patient with Papillon-Lefevre syndrome with all permanent teeth remaining at over 40 years of age. *Br J Dermatol.* 2013;169(4):948-950.
429. Shanavas M, Chatra L, Shenai P, et al. Partial expression of the Papillon-Lefevre syndrome. J Coll Physicians Surg Pak. 2014;24(suppl 3):S230-S232.
430. Iqtadar S, Mumtaz SU, Abaidullah S. Papillon-Lefevre syndrome with palmoplantar keratoderma and periodontitis, a rare cause of pyrexia of unknown origin: a case report. *medical Med Case Rep.* 2015;9:288.
431. Almuneef M, Al Khenaizan S, Al Ajaji S, et al. Pyogenic liver abscess and Papillon-Lefevre syndrome: not a rare association. *Pediatrics.* 2003;111(1):e85-88.
432. Kanthimathinathan HK, Browne F, Ramirez R, et al. Multiple cerebral abscesses in Papillon-Lefevre syndrome. *Childs Nerv Syst.* 2013;29(8):1227-1229.
433. Wen X, Wang X, Duan X. High immunoglobulin E in a Chinese Papillon-Lefevre syndrome patient with novel compound mutations of cathepsin C. *J Dermatol.* 2012;39(7):664-665.
434. Li Z, Liu J, Fang S, et al. Novel compound heterozygous mutations in CTSC gene cause Papillon-Lefevre syndrome with high serum immunoglobulin E. *J Dermatol Sci.* 2014;76(3):258-260.
435. Nakajima K, Nakano H, Takiyoshi N, et al. Papillon-Lefevre syndrome and malignant melanoma. A high incidence of melanoma development in Japanese palmoplantar keratoderma patients. *Dermatology.* 2008;217(1):58-62.
436. Nagy N, Valyi P, Csoma Z, et al. CTSC and Papillon-Lefevre syndrome: detection of recurrent mutations in Hungarian patients, a review of published variants and database update. *Mol Genet Genom Med.* 2014;2(3):217-228.
437. Sulak A, Toth L, Farkas K, et al. One mutation, two phenotypes: a single nonsense mutation of the CTSC gene causes two clinically distinct phenotypes. *Clin Exp Dermatol.* 2016;41(2):190-195.
438. Hart TC, Hart PS, Michalec MD, et al. Haim-Munk syndrome and Papillon-Lefevre syndrome are allelic mutations in cathepsin C. *J Med Genet.* 2000; 37(2):88-94.
439. Hart TC, Hart PS, Michalec MD, et al. Localisation of a gene for prepubertal periodontitis to chromosome 11q14 and identification of a cathepsin C gene mutation. *J Med Genet.* 2000;37(2):95-101.
440. Janjua SA, Iftikhar N, Hussain I, et al. Dermatologic, periodontal, and skeletal manifestations of Haim-Munk syndrome in two siblings. *J Am Acad Dermatol.* 2008;58(2):339-344.
441. Adkison AM, Raptis SZ, Kelley DG, et al. Dipeptidyl peptidase I activates neutrophil-derived serine proteases and regulates the development of acute experimental arthritis. *J Clin Invest.* 2002;109(3): 363-371.
442. Dolenc I, Turk B, Pungercic G, et al. Oligomeric structure and substrate induced inhibition of human cathepsin C. *J Biol Chem.* 1995;270(37):21626-21631.
443. Meade JL, de Wynter EA, Brett P, et al. A family with Papillon-Lefevre syndrome reveals a requirement for cathepsin C in granzyme B activation and NK cell cytolytic activity. *Blood.* 2006;107(9):3665-3668.
444. Rawlings ND, Barrett AJ. Evolutionary families of peptidases. *Biochem J.* 1993;290 (Pt 1):205-218.
445. Turk D, Janjic V, Stern I, et al. Structure of human dipeptidyl peptidase I (cathepsin C): exclusion domain added to an endopeptidase framework creates the machine for activation of granular serine proteases. *EMBO J.* 2001;20(23):6570-6582.
446. Wolters PJ, Pham CT, Muilenburg DJ, et al. Dipeptidyl peptidase I is essential for activation of mast cell chymases, but not tryptases, in mice. *J Biol Chem.* 2001;276(21):18551-18556.
447. Rao NV, Rao GV, Hoidal JR. Human dipeptidyl-peptidase I. Gene characterization, localization, and expression. *J Biol Chem.* 1997;272(15):10260-10265.
448. Zhang Y, Hart PS, Moretti AJ, et al. Biochemical and mutational analyses of the cathepsin c gene (CTSC) in three North American families with Papillon Lefevre syndrome. *Hum Mutat.* 2002;20(1):75.
449. Sorensen OE, Clemmensen SN, Dahl SL, et al. Papillon-Lefevre syndrome patient reveals species-dependent requirements for neutrophil defenses. *J Clin Invest.* 2014;124(10):4539-4548.
450. McKoy G, Protonotarios N, Crosby A, et al. Identification of a deletion in plakoglobin in arrhythmogenic right ventricular cardiomyopathy with palmoplantar keratoderma and woolly hair (Naxos disease). *Lancet.* 2000;355(9221):2119-2124.
451. Protonotarios N, Tsatsopoulou A, Patsourakos P, et al. Cardiac abnormalities in familial palmoplantar keratosis. *Br Heart J.* 1986;56(4):321-326.
452. Bukhari I, Juma'a N. Naxos disease in Saudi Arabia. *J Eur Acad Dermatol Venereol.* 2004;18(5):614-616.
453. Meera G, Prabhavathy D, Jayakumar S, et al. Naxos disease in two siblings. *Int J Trichol.* 2010;2(1):53-55.
454. Narin N, Akcakus M, Gunes T, et al. Arrhythmogenic right ventricular cardiomyopathy (Naxos disease): report of a Turkish boy. *Pacing Clin Electrophysiol.* 2003;26(12):2326-2329.
455. Protonotarios N, Tsatsopoulou A, Anastasakis A, et al. Genotype-phenotype assessment in autosomal

recessive arrhythmogenic right ventricular cardiomyopathy (Naxos disease) caused by a deletion in plakoglobin. *J Am Coll Cardiol.* 2001;38(5):1477-1484.
456. Protonotarios N, Tsatsopoulou A, Fontaine G. Naxos disease: keratoderma, scalp modifications, and cardiomyopathy. *J Am Acad Dermatol.* 2001;44(2):309-311.
457. Coonar AS, Protonotarios N, Tsatsopoulou A, et al. Gene for arrhythmogenic right ventricular cardiomyopathy with diffuse nonepidermolytic palmoplantar keratoderma and woolly hair (Naxos disease) maps to 17q21. *Circulation.* 1998;97(20):2049-2058.
458. Basso C, Tsatsopoulou A, Thiene G, et al. "Petrified" right ventricle in long-standing naxos arrhythmogenic right ventricular cardiomyopathy. *Circulation.* 2001;104(23):E132-E133.
459. Gregoriou S, Kontochristopoulos G, Chatziolou E, et al. Palmoplantar keratoderma, woolly hair and arrhythmogenic right ventricular cardiomyopathy. *Clin Exp Dermatol.* 2006;31(2):315-316.
460. Protonotarios N, Tsatsopoulou A. Naxos disease and Carvajal syndrome: cardiocutaneous disorders that highlight the pathogenesis and broaden the spectrum of arrhythmogenic right ventricular cardiomyopathy. *Cardiovasc Path.* 2004;13(4):185-194.
461. Samuelov L, Sprecher E. Inherited desmosomal disorders. *Cell Tissue Res.* 2015;360(3):457-475.
462. Antoniades L, Tsatsopoulou A, Anastasakis A, et al. Arrhythmogenic right ventricular cardiomyopathy caused by deletions in plakophilin-2 and plakoglobin (Naxos disease) in families from Greece and Cyprus: genotype-phenotype relations, diagnostic features and prognosis. *Eur Heart J.* 2006;27(18):2208-2216.
463. Cabral RM, Liu L, Hogan C, et al. Homozygous mutations in the 5′ region of the JUP gene result in cutaneous disease but normal heart development in children. *J Invest Dermatol.* 2010;130(6):1543-1550.
464. Asimaki A, Syrris P, Wichter T, et al. A novel dominant mutation in plakoglobin causes arrhythmogenic right ventricular cardiomyopathy. *Am J Hum Genet.* 2007;81(5):964-973.
465. Erken H, Yariz KO, Duman D, et al. Cardiomyopathy with alopecia and palmoplantar keratoderma (CAPK) is caused by a JUP mutation. *Br J Dermatol.* 2011;165(4):917-921.
466. Green KJ, Simpson CL. Desmosomes: new perspectives on a classic. *J Invest Dermatol.* 2007;127(11):2499-2515.
467. Hobbs RP, Green KJ. Desmoplakin regulates desmosome hyperadhesion. *J Invest Dermatol.* 2012;132(2):482-485.
468. Nie Z, Merritt A, Rouhi-Parkouhi M, et al. Membrane-impermeable cross-linking provides evidence for homophilic, isoform-specific binding of desmosomal cadherins in epithelial cells. *J Biol Chem.* 2011;286(3):2143-2154.
469. Chitaev NA, Troyanovsky SM. Direct Ca2+-dependent heterophilic interaction between desmosomal cadherins, desmoglein and desmocollin, contributes to cell-cell adhesion. *J Cell Biol.* 1997;138(1):193-201.
470. Garrod D, Chidgey M. Desmosome structure, composition and function. *Biochim Biophys Acta.* 2008;1778(3):572-587.
471. Holthofer B, Windoffer R, Troyanovsky S, et al. Structure and function of desmosomes. *Int Rev Cytol.* 2007;264:65-163.
472. Simpson MA, Mansour S, Ahnood D, et al. Homozygous mutation of desmocollin-2 in arrhythmogenic right ventricular cardiomyopathy with mild palmoplantar keratoderma and woolly hair. *Cardiology.* 2009;113(1):28-34.
473. Ramot Y, Molho-Pessach V, Meir T, et al. Mutation in KANK2, encoding a sequestering protein for steroid receptor coactivators, causes keratoderma and woolly hair. *J Med Genet.* 2014;51(6):388-394.
474. Micali G, Nasca MR, Innocenzi D, et al. Association of palmoplantar keratoderma, cutaneous squamous cell carcinoma, dental anomalies, and hypogenitalism in four siblings with 46,XX karyotype: a new syndrome. *J Am Acad Dermatol.* 2005;53(5 suppl 1):S234-S239.
475. Radi O, Parma P, Imbeaud S, et al. XX sex reversal, palmoplantar keratoderma, and predisposition to squamous cell carcinoma: genetic analysis in one family. *Am J Med Genet A.* 2005;138A(3):241-246.
476. Tomaselli S, Megiorni F, De Bernardo C, et al. Syndromic true hermaphroditism due to an R-spondin1 (RSPO1) homozygous mutation. *Hum Mutat.* 2008;29(2):220-226.
477. Kim KA, Zhao J, Andarmani S, et al. R-Spondin proteins: a novel link to beta-catenin activation. *Cell Cycle.* 2006;5(1):23-26.
478. Parma P, Radi O, Vidal V, et al. R-spondin1 is essential in sex determination, skin differentiation and malignancy. *Nat Genet.* 2006;38(11):1304-1309.
479. Martin L, Toutain A, Guillen C, et al. Inherited palmoplantar keratoderma and sensorineural deafness associated with A7445G point mutation in the mitochondrial genome. *Br J Dermatol.* 2000;143(4):876-883.
480. Sevior KB, Hatamochi A, Stewart IA, et al. Mitochondrial A7445G mutation in two pedigrees with palmoplantar keratoderma and deafness. *Am J Med Genet.* 1998;75(2):179-185.
481. Caria H, Matos T, Oliveira-Soares R, et al. A7445G mtDNA mutation present in a Portuguese family exhibiting hereditary deafness and palmoplantar keratoderma. *J Eur Acad Dermatol Venereol.* 2005;19(4):455-458.
482. Reid FM, Vernham GA, Jacobs HT. A novel mitochondrial point mutation in a maternal pedigree with sensorineural deafness. *Hum Mutat.* 1994;3(3):243-247.
483. Milingou M, Wood P, Masouye I, et al. Focal palmoplantar keratoderma caused by an autosomal dominant inherited mutation in the desmoglein 1 gene. *Dermatology.* 2006;212(2):117-122.
484. Nomura T, Mizuno O, Miyauchi T, et al. Striate palmoplantar keratoderma: report of a novel DSG1 mutation and atypical clinical manifestations. *J Dermatol Sci.* 2015;80(3):223-225.
485. Zamiri M, Smith FJ, Campbell LE, et al. Mutation in DSG1 causing autosomal dominant striate palmoplantar keratoderma. *Br J Dermatol.* 2009;161(3):692-694.
486. Lovgren ML, McAleer MA, Irvine AD, et al. Mutations in desmoglein-1 cause diverse inherited palmoplantar keratoderma phenotypes: implications for genetic screening. *Br J Dermatol.* 2017;176(5):1345-1350.
487. Barber AG, Wajid M, Columbo M, et al. Striate palmoplantar keratoderma resulting from a frameshift mutation in the desmoglein 1 gene. *J Dermatol Sci.* 2007;45(3):161-166.
488. Dua-Awereh MB, Shimomura Y, Kraemer L, et al. Mutations in the desmoglein 1 gene in five Pakistani

families with striate palmoplantar keratoderma. *J Dermatol Sci.* 2009;53(3):192-197.
489. Hershkovitz D, Lugassy J, Indelman M, et al. Novel mutations in DSG1 causing striate palmoplantar keratoderma. *Clin Exp Dermatol.* 2009;34(2):224-228.
490. Hunt DM, Rickman L, Whittock NV, et al. Spectrum of dominant mutations in the desmosomal cadherin desmoglein 1, causing the skin disease striate palmoplantar keratoderma. *Eur J Hum Genet.* 2001;9(3):197-203.
491. Kljuic A, Gilead L, Martinez-Mir A, et al. A nonsense mutation in the desmoglein 1 gene underlies striate keratoderma. *Exp Dermatol.* 2003;12(4):523-527.
492. Keren H, Bergman R, Mizrachi M, et al. Diffuse nonepidermolytic palmoplantar keratoderma caused by a recurrent nonsense mutation in DSG1. *Arch Dermatol.* 2005;141(5):625-628.
493. Armstrong DK, McKenna KE, Purkis PE, et al. Haploinsufficiency of desmoplakin causes a striate subtype of palmoplantar keratoderma. *Hum Mol Genet.* 1999;8(1):143-148.
494. Rickman L, Simrak D, Stevens HP, et al. N-terminal deletion in a desmosomal cadherin causes the autosomal dominant skin disease striate palmoplantar keratoderma. *Hum Mol Genet.* 1999;8(6):971-976.
495. Whittock NV, Ashton GH, Dopping-Hepenstal PJ, et al. Striate palmoplantar keratoderma resulting from desmoplakin haploinsufficiency. *J Invest Dermatol.* 1999;113(6):940-946.
496. Samuelov L, Sarig O, Harmon RM, et al. Desmoglein 1 deficiency results in severe dermatitis, multiple allergies and metabolic wasting. *Nat Genet.* 2013;45(10):1244-1248.
497. Getsios S, Huen AC, Green KJ. Working out the strength and flexibility of desmosomes. *Nat Rev Mol Cell Biol.* 2004;5(4):271-281.
498. Dusek RL, Getsios S, Chen F, et al. The differentiation-dependent desmosomal cadherin desmoglein 1 is a novel caspase-3 target that regulates apoptosis in keratinocytes. *J Biol Chem.* 2006;281(6):3614-3624.
499. Green KJ, Gaudry CA. Are desmosomes more than tethers for intermediate filaments? *Nat Rev Mol Cell Biol.* 2000;1(3):208-216.
500. Hakimelahi S, Parker HR, Gilchrist AJ, et al. Plakoglobin regulates the expression of the anti-apoptotic protein BCL-2. *J Biol Chem.* 2000;275(15):10905-10911.
501. Harmon RM, Simpson CL, Johnson JL, et al. Desmoglein-1/Erbin interaction suppresses ERK activation to support epidermal differentiation. *J Clin Invest.* 2013;123(4):1556-1570.
502. Hammers CM, Stanley JR. Desmoglein-1, differentiation, and disease. *J Clin Invest.* 2013;123(4):1419-1422.
503. Wan H, South AP, Hart IR. Increased keratinocyte proliferation initiated through downregulation of desmoplakin by RNA interference. *Exp Cell Res.* 2007;313(11):2336-2344.
504. Bergman R, Hershkovitz D, Fuchs D, et al. Disadhesion of epidermal keratinocytes: a histologic clue to palmoplantar keratodermas caused by DSG1 mutations. *J Am Acad Dermatol.* 2010;62(1):107-113.
505. Miteva L, Schwartz RA. Hereditary keratosis palmoplantaris varians of Wachters (keratosis palmoplantaris striata et areata). *Acta Dermatovenerol Alp Pannonica Adriat.* 2010;19(1):33-37.
506. Miteva L, Dourmishev AL. Hereditary palmoplantar keratoderma with nail changes and periodontosis in a father and son. *Cutis.* 1999;63(2):65-68.
507. Paoli S, Mastrolorenzo A. Keratosis palmoplantaris varians of Wachters. *J Eur Acad Dermatol Venereol.* 1999;12(1):33-37.
508. Rubegni P, Poggiali S, Cuccia A, et al. Acral malignant melanoma and striated palmoplantar keratoderma (Brunauer-Fohs-Siemens syndrome): a fortuitous association? *Dermatol Surg.* 2004;30(12 Pt 2):1539-1542.
509. Wachters D. *Over de verschillende morphologische vormen van de keratosis palmoplantaris, in het bijzonder over de "keratosis palmoplantaris varians"* Leiden, The Netherlands: Leiden University; 1963.
510. Fartasch M, Vigneswaran N, Diepgen TL, et al. Abnormalities of keratinocyte maturation and differentiation in keratosis palmoplantaris striata. Immunohistochemical and ultrastructural study before and during etretinate therapy. *Am J Dermatopathol.* 1990;12(3):275-282.
511. Jackson AD, Lawler SD. Pachyonychia congenita; a report of six cases in one family, with a note on linkage data. *Ann Eugen.* 1951;16(2):142-146.
512. Jadassohn J, Lewandowski P. *Pachyonychia congenita: keratosis disseminata circumscripts (follicularis). Tylomata. Leukokeratosis linguae.* Berlin: Urban and Schwarzenberg; 1906.
513. McLean WH, Rugg EL, Lunny DP, et al. Keratin 16 and keratin 17 mutations cause pachyonychia congenita. *Nat Genet.* 1995;9(3):273-278.
514. Munro CS, Carter S, Bryce S, et al. A gene for pachyonychia congenita is closely linked to the keratin gene cluster on 17q12-q21. *J Med Genet.* 1994;31(9):675-678.
515. Smith FJ, Jonkman MF, van Goor H, et al. A mutation in human keratin K6b produces a phenocopy of the K17 disorder pachyonychia congenita type 2. *Hum Mol Genet.* 1998;7(7):1143-1148.
516. Kaspar RL. Challenges in developing therapies for rare diseases including pachyonychia congenita. *J Invest Dermatol Symp Proc.* 2005;10(1):62-66.
517. Wallis T, Poole CD, Hoggart B. Can skin disease cause neuropathic pain? A study in pachyonychia congenita. *Clin Exp Dermatol.* 2016;41(1):26-33.
518. Eliason MJ, Leachman SA, Feng BJ, et al. A review of the clinical phenotype of 254 patients with genetically confirmed pachyonychia congenita. *J Am Acad Dermatol.* 2012;67(4):680-686.
519. McLean WH, Hansen CD, Eliason MJ, et al. The phenotypic and molecular genetic features of pachyonychia congenita. *J Invest Dermatol.* 2011; 131(5):1015-1017.
520. Harris K, Hull PR, Hansen CD, et al. Transgrediens pachyonychia congenita (PC): case series of a nonclassical PC presentation. *Br J Dermatol.* 2012;166(1):124-128.
521. Goldberg I, Sprecher E, Schwartz ME, et al. Comparative study of high-resolution multifrequency ultrasound of the plantar skin in patients with various types of hereditary palmoplantar keratoderma. *Dermatology.* 2013;226(4):365-370.
522. Feng YG, Xiao SX, Ren XR, et al. Keratin 17 mutation in pachyonychia congenita type 2 with early onset sebaceous cysts. *Br J Dermatol.* 2003;148(3):452-455.
523. Guo H, Liu D, Wu J, et al. Pachyonychia congenita with corneal dystrophy. *J Dermatol.* 2013;40(8):681-682.
524. Wilson NJ, Perez ML, Vahlquist A, et al. Homozygous dominant missense mutation in keratin 17 leads to alopecia in addition to severe pachyonychia congenita. *J Invest Dermatol.* 2012;132(7):1921-1924.

525. Haber RM, Drummond D. Pachyonychia congenita with laryngeal obstruction. *Pediatr Dermatol.* 2011;28(4):429-432.
526. O'Toole EA, Kaspar RL, Sprecher E, et al. Pachyonychia congenita cornered: report on the 11th Annual International Pachyonychia Congenita Consortium Meeting. *Br J Dermatol.* 2014;171(5):974-977.
527. Shamsher MK, Navsaria HA, Stevens HP, et al. Novel mutations in keratin 16 gene underly focal non-epidermolytic palmoplantar keratoderma (NEPPK) in two families. *Hum Mol Genet.* 1995;4(10): 1875-1881.
528. Liao H, Sayers JM, Wilson NJ, et al. A spectrum of mutations in keratins K6a, K16 and K17 causing pachyonychia congenita. *J Dermatol Sci.* 2007;48(3): 199-205.
529. Paris F, Hurtado C, Azon A, et al. A new KRT16 mutation associated with a phenotype of pachyonychia congenita. *Exp Dermatol.* 2013;22(12):838-839.
530. Smith FJ, Fisher MP, Healy E, et al. Novel keratin 16 mutations and protein expression studies in pachyonychia congenita type 1 and focal palmoplantar keratoderma. *Exp Dermatol.* 2000;9(3):170-177.
531. Spaunhurst KM, Hogendorf AM, Smith FJ, et al. Pachyonychia congenita patients with mutations in KRT6A have more extensive disease compared with patients who have mutations in KRT16. *Br J Dermatol.* 2012;166(4):875-878.
532. Wilson NJ, Messenger AG, Leachman SA, et al. Keratin K6c mutations cause focal palmoplantar keratoderma. *J Invest Dermatol.* 2010;130(2):425-429.
533. Wee JS, Smith FJ, Wilson NJ, et al. Focal PPK secondary to a novel KRT6C mutation (Pachyonychia congenita-K6c). *J Eur Acad Dermatol Venereol.* 2016;30(8):1415-1416.
534. Moll R, Franke WW, Schiller DL, et al. The catalog of human cytokeratins: patterns of expression in normal epithelia, tumors and cultured cells. *Cell.* 1982;31(1):11-24.
535. Moll R, Moll I, Wiest W. Changes in the pattern of cytokeratin polypeptides in epidermis and hair follicles during skin development in human fetuses. *Differentiation.* 1982;23(2):170-178.
536. Wilson NJ, O'Toole EA, Milstone LM, et al. The molecular genetic analysis of the expanding pachyonychia congenita case collection. *Br J Dermatol.* 2014;171(2):343-355.
537. Haber RM, Rose TH. Autosomal recessive pachyonychia congenita. *Arch Dermatol.* 1986;122(8): 919-923.
538. Pho LN, Smith FJ, Konecki D, et al. Paternal germ cell mosaicism in autosomal dominant pachyonychia congenita. *Arch Dermatol.* 2011;147(9):1077-1080.
539. Steinert PM, Yang JM, Bale SJ, et al. Concurrence between the molecular overlap regions in keratin intermediate filaments and the locations of keratin mutations in genodermatoses. *Biochem Biophys Res Commun.* 1993;197(2):840-848.
540. Godsel LM, Hobbs RP, Green KJ. Intermediate filament assembly: dynamics to disease. *Trends Cell Biol.* 2008;18(1):28-37.
541. Koster MI. Building models for keratin disorders. *J Invest Dermatol.* 2012;132(5):1324-1326.
542. Cao YA, Hickerson RP, Seegmiller BL, et al. Gene expression profiling in pachyonychia congenita skin. *J Dermatol Sci.* 2015;77(3):156-165.
543. Carabott F, Archer CB, Griffiths WA. Etretinate-responsive pachyonychia congenita. *Br J Dermatol.* 1988;119(4):551-553.
544. Gruber R, Edlinger M, Kaspar RL, et al. An appraisal of oral retinoids in the treatment of pachyonychia congenita. *J Am Acad Dermatol.* 2012;66(6):e193-199.
545. Soyuer U, Candan MF. Failure of etretinate therapy in pachyonychia congenita. *Br J Dermatol.* 1987;117(2):264.
546. Thomas DR, Jorizzo JL, Brysk MM, et al. Pachyonychia congenita. Electron microscopic and epidermal glycoprotein assessment before and during isotretinoin treatment. *Arch Dermatol.* 1984;120(11):1475-1479.
547. Gonzalez-Ramos J, Sendagorta-Cudos E, Gonzalez-Lopez G, et al. Efficacy of botulinum toxin in pachyonychia congenita type 1: report of two new cases. *Dermatol Ther.* 2016;29(1):32-36.
548. Goldberg I, Fruchter D, Meilick A, et al. Best treatment practices for pachyonychia congenita. *J Eur Acad Dermatol Venereol.* 2014;28(3):279-285.
549. Swartling C, Karlqvist M, Hymnelius K, et al. Botulinum toxin in the treatment of sweat-worsened foot problems in patients with epidermolysis bullosa simplex and pachyonychia congenita. *Br J Dermatol.* 2010;163(5):1072-1076.
550. Swartling C, Vahlquist A. Treatment of pachyonychia congenita with plantar injections of botulinum toxin. *Br J Dermatol.* 2006;154(4):763-765.
551. Hickerson RP, Leake D, Pho LN, et al. Rapamycin selectively inhibits expression of an inducible keratin (K6a) in human keratinocytes and improves symptoms in pachyonychia congenita patients. *J Dermatol Sci.* 2009;56(2):82-88.
552. Leachman SA, Hickerson RP, Schwartz ME, et al. First-in-human mutation-targeted siRNA phase Ib trial of an inherited skin disorder. *Mol Ther.* 2010;18(2):442-446.
553. Leachman SA, Hickerson RP, Hull PR, et al. Therapeutic siRNAs for dominant genetic skin disorders including pachyonychia congenita. *J Dermatol Sci.* 2008;51(3):151-157.
554. Kaspar RL, Leachman SA, McLean WH, et al. Toward a treatment for pachyonychia congenita: report on the 7th Annual International Pachyonychia Congenita Consortium meeting. *J Invest Dermatol.* 2011;131(5):1011-1014.
555. Smith FJ, Hickerson RP, Sayers JM, et al. Development of therapeutic siRNAs for pachyonychia congenita. *J Invest Dermatol.* 2008;128(1):50-58.
556. Hickerson RP, Smith FJ, McLean WH, et al. SiRNA-mediated selective inhibition of mutant keratin mRNAs responsible for the skin disorder pachyonychia congenita. *Ann N Y Acad Sci.* 2006;1082:56-61.
557. Trochet D, Prudhon B, Vassilopoulos S, et al. Therapy for dominant inherited diseases by allele-specific RNA interference: successes and pitfalls. *Curr Gene Ther.* 2015;15(5):503-510.
558. Howel-Evans W, McConnell RB, Clarke CA, et al. Carcinoma of the oesophagus with keratosis palmaris et plantaris (tylosis): a study of two families. *Q J Med.* 1958;27(107):413-429.
559. de Souza CA, Santos Ada C, Santos Lda C, et al. Hereditary tylosis syndrome and esophagus cancer. *An Bras Dermatol.* 2009;84(5):527-529.
560. Ellis A, Field JK, Field EA, et al. Tylosis associated with carcinoma of the oesophagus and oral leukoplakia in a large Liverpool family—a review of six generations. *Eur J Cancer B Oral Oncol.* 1994;30B(2):102-112.
561. Harper PS, Harper RM, Howel-Evans AW. Carcinoma of the oesophagus with tylosis. *Q J Med.* 1970;39(155):317-333.
562. Hennies HC, Hagedorn M, Reis A. Palmoplantar keratoderma in association with carcinoma of the

esophagus maps to chromosome 17q distal to the keratin gene cluster. *Genomics.* 1995;29(2):537-540.
563. Saarinen S, Vahteristo P, Lehtonen R, et al. Analysis of a Finnish family confirms RHBDF2 mutations as the underlying factor in tylosis with esophageal cancer. *Fam Cancer.* 2012;11(3):525-528.
564. Stevens HP, Kelsell DP, Bryant SP, et al. Linkage of an American pedigree with palmoplantar keratoderma and malignancy (palmoplantar ectodermal dysplasia type III) to 17q24. Literature survey and proposed updated classification of the keratodermas. *Arch Dermatol.* 1996;132(6):640-651.
565. Varela AB, Blanco Rodriguez MM, Boullosa PE, et al. Tylosis A with squamous cell carcinoma of the oesophagus in a Spanish family. *Eur J Gastroenterol Hepatol.* 2011;23(3):286-288.
566. Ellis A, Risk JM, Maruthappu T, et al. Tylosis with oesophageal cancer: diagnosis, management and molecular mechanisms. *Orphanet J Rare Dis.* 2015;10:126.
567. Grundmann JU, Weisshaar E, Franke I, et al. Lung carcinoma with congenital plantar keratoderma as a variant of Clarke-Howel-Evans syndrome. *Int J Dermatol.* 2003;42(6):461-463.
568. Simon M, Hagedorn M. The Clark-Howel-Evans-McConnell syndrome. Observations in one family over 5 generations. *Hautarzt.* 1997;48(11):800-805.
569. Kelsell DP, Risk JM, Leigh IM, et al. Close mapping of the focal non-epidermolytic palmoplantar keratoderma (PPK) locus associated with oesophageal cancer (TOC). *Hum Mol Genet.* 1996;5(6):857-860.
570. McQuibban GA, Saurya S, Freeman M. Mitochondrial membrane remodelling regulated by a conserved rhomboid protease. *Nature.* 2003;423(6939):537-541.
571. Lee MY, Nam KH, Choi KC. iRhoms; its functions and essential roles. *Biomol Ther (Seoul).* 2016;24(2):109-114.
572. Adrain C, Strisovsky K, Zettl M, et al. Mammalian EGF receptor activation by the rhomboid protease RHBDL2. *EMBO Rep.* 2011;12(5):421-427.
573. Adrain C, Zettl M, Christova Y, et al. Tumor necrosis factor signaling requires iRhom2 to promote trafficking and activation of TACE. *Science.* 2012;335(6065):225-228.
574. Blaydon DC, Etheridge SL, Risk JM, et al. RHBDF2 mutations are associated with tylosis, a familial esophageal cancer syndrome. *Am J Hum Genet.* 2012;90(2):340-346.
575. Wojnarowicz PM, Provencher DM, Mes-Masson AM, et al. Chromosome 17q25 genes, RHBDF2 and CYGB, in ovarian cancer. *Int J Oncol.* 2012; 40(6):1865-1880.
576. Zettl M, Adrain C, Strisovsky K, et al. Rhomboid family pseudoproteases use the ER quality control machinery to regulate intercellular signaling. *Cell.* 2011;145(1):79-91.
577. Brooke MA, Etheridge SL, Kaplan N, et al. iRHOM2-dependent regulation of ADAM17 in cutaneous disease and epidermal barrier function. *Hum Mol Genet.* 2014;23(15):4064-4076.
578. Maney SK, McIlwain DR, Polz R, et al. Deletions in the cytoplasmic domain of iRhom1 and iRhom2 promote shedding of the TNF receptor by the protease ADAM17. *Science Signal.* 2015;8(401):ra109.
579. Kitagawa Y, Ueda M, Ando N, et al. Further evidence for prognostic significance of epidermal growth factor receptor gene amplification in patients with esophageal squamous cell carcinoma. *Clin Cancer Res.* 1996;2(5):909-914.
580. Liu HB, Yang QC, Shen Y, et al. [Clinicopathological and prognostic significance of the expression of ADAM17 mRNA and protein in esophageal squamous cell carcinoma]. *Zhonghua Zhong Liu Za Zhi.* 2013;35(5):361-365.
581. Leemans CR, Braakhuis BJ, Brakenhoff RH. The molecular biology of head and neck cancer. *Nat Rev Cancer.* 2011;11(1):9-22.
582. Charfeddine C, Monastiri K, Mokni M, et al. Clinical and mutational investigations of tyrosinemia type II in Northern Tunisia: identification and structural characterization of two novel TAT mutations. *Mol Genet Metab.* 2006;88(2):184-191.
583. Maydan G, Andresen BS, Madsen PP, et al. TAT gene mutation analysis in three Palestinian kindreds with oculocutaneous tyrosinaemia type II; characterization of a silent exonic transversion that causes complete missplicing by exon 11 skipping. *J Inherit Metab Dis.* 2006;29(5):620-626.
584. Hanhart E. Neue Sonderformen von keratosis palmoplantaris, u.a.eine regelmaessigdominante mit systematisierten Lipomen, ferner 2 einfach-rezessive mit Schwachsinn und z.T.mit Hornhautveraenderungen des Auges (Ektodermatosyndrom). *Dermatologica.* 1947(94):286-308.
585. Richner H. Hornhautaffektion bei keratoma palmare et plantare hereditarium. *Klin Mbl Augenheilk.* 1938(100):9.
586. Minami-Hori M, Ishida-Yamamoto A, Katoh N, et al. Richner-Hanhart syndrome: report of a case with a novel mutation of tyrosine aminotransferase. *J Dermatol Sci.* 2006;41(1):82-84.
587. Culic V, Betz RC, Refke M, et al. Tyrosinemia type II (Richner-Hanhart syndrome): a new mutation in the TAT gene. *EurJ Med Genet.* 2011;54(3):205-208.
588. Li M, Yang L, Shi H, et al. Loss-of-function mutation in AAGAB in Chinese families with punctuate palmoplantar keratoderma. *Br J Dermatol.* 2013;169(1):168-171.
589. Brauer A. Uber eine besondere Form des hereditaren Keratoms (keratoderma disseminatum hereditarium palmare et plantare). *Arch Dermatol Syph.* 1913;114:211-236.
590. Buschke A, Fischer W. Keratodermia mauculosa disseminate symmetrica palmaris and plantaris. *Ikonographia Dermatologica* 1910;51:183-192.
591. Giehl KA, Herzinger T, Wolff H, et al. Eight novel mutations confirm the role of AAGAB in punctate palmoplantar keratoderma type 1 (Buschke-Fischer-Brauer) and show broad phenotypic variability. *Acta Derm Venereol.* 2016;96(4):468-472.
592. Gokay S, Kendirci M, Soylu Ustkoyuncu P, et al. Tyrosinemia type II: novel mutations in the TAT gene in a boy with unusual presentation. *Pediatr Int.* 2016;58(10):1069-1072.
593. Pasternack SM, Betz RC, Brandrup F, et al. Identification of two new mutations in the TAT gene in a Danish family with tyrosinaemia type II. *Br J Dermatol.* 2009;160(3):704-706.
594. Legarda M, Wlodarczyk K, Lage S, et al. A large TAT deletion in a tyrosinaemia type II patient. *Mol Genet Metab.* 2011;104(3):407-409.
595. Natt E, Kida K, Odievre M, et al. Point mutations in the tyrosine aminotransferase gene in tyrosinemia type II. *Proc Natl Acad Sci U S A.* 1992;89(19):9297-9301.
596. Natt E, Westphal EM, Toth-Fejel SE, et al. Inherited and de novo deletion of the tyrosine aminotransferase

gene locus at 16q22.1—q22.3 in a patient with tyrosinemia type II. *Hum Genet.* 1987;77(4):352-358.
597. Rettenmeier R, Natt E, Zentgraf H, et al. Isolation and characterization of the human tyrosine aminotransferase gene. *Nucleic Acids Res.* 1990;18(13):3853-3861.
598. Scott CR. The genetic tyrosinemias. *Am J Med Genet C Semin Med Genet.* 2006;142C(2):121-126.
599. Hargrove JL, Scoble HA, Mathews WR, et al. The structure of tyrosine aminotransferase. Evidence for domains involved in catalysis and enzyme turnover. *J Biol Chem.* 1989;264(1):45-53.
600. Huhn R, Stoermer H, Klingele B, et al. Novel and recurrent tyrosine aminotransferase gene mutations in tyrosinemia type II. *Hum Genet.* 1998;102(3):305-313.
601. Bouyacoub Y, Zribi H, Azzouz H, et al. Novel and recurrent mutations in the TAT gene in Tunisian families affected with Richner-Hanhart syndrome. *Gene.* 2013;529(1):45-49.
602. Nouspikel T. DNA repair in mammalian cells: nucleotide excision repair: variations on versatility. *Cell Mol Life Sc.* 2009;66(6):994-1009.
603. Gipson IK, Anderson RA. Response of the lysosomal system of the corneal epithelium to tyrosine-induced cell injury. *J Histochem Cytochem.* 1977;25(12):1351-1362.
604. Gipson IK, Burns RP, Wolfe-Lande JD. Crystals in corneal epithelial lesions of tyrosine-fed rats. *Invest Ophthalmol.* 1975;14(12):937-941.
605. Goldsmith LA. Tyrosine-induced skin disease. *Br J Dermatol.* 1978;98(1):119-123.
606. Shimizu N, Ito M, Ito K, et al. Richner-Hanhart's syndrome. Electron microscopic study of the skin lesion. *Arch Dermatol.* 1990;126(10):1342-1346.
607. Bohnert A, Anton-Lamprecht I. Richner-Hanhart's syndrome: ultrastructural abnormalities of epidermal keratinization indicating a causal relationship to high intracellular tyrosine levels. *J Invest Dermatol.* 1982;79(2):68-74.
608. Viglizzo GM, Occella C, Bleidl D, et al. Richner-Hanhart syndrome (tyrosinemia II): early diagnosis of an incomplete presentation with unusual findings. *Pediatr Dermatol.* 2006;23(3):259-261.
609. Tallab TM. Richner-Hanhart syndrome: importance of early diagnosis and early intervention. *J Am Acad Dermatol.* 1996;35(5 Pt 2):857-859.
610. Farag TI. Dietetic therapy of Richner-Hanhart syndrome. *J R Soc Med.* 1993;86(8):495.
611. Meissner T, Betz RC, Pasternack SM, et al. Richner-Hanhart syndrome detected by expanded newborn screening. *Pediatr Dermatol.* 2008;25(3):378-380.
612. Fraser NG, MacDonald J, Griffiths WA, et al. Tyrosinaemia type II (Richner-Hanhart syndrome)—report of two cases treated with etretinate. *Clin Exp Dermatol.* 1987;12(6):440-443.
613. Crovato F, Desirello G, Gatti R, et al. Richner-Hanhart syndrome spares a plantar autograft. *Arch Dermatol.* 1985;121(4):539-540.
614. Carvajal-Huerta L. Epidermolytic palmoplantar keratoderma with woolly hair and dilated cardiomyopathy. *J Am Acad Dermatol.* 1998;39(3):418-421.
615. Rao BH, Reddy IS, Chandra KS. Familial occurrence of a rare combination of dilated cardiomyopathy with palmoplantar keratoderma and curly hair. *Indian Heart J.* 1996;48(2):161-162.
616. Alcalai R, Metzger S, Rosenheck S, et al. A recessive mutation in desmoplakin causes arrhythmogenic right ventricular dysplasia, skin disorder, and woolly hair. *J Am Coll Cardiol.* 2003;42(2):319-327.
617. Antonov NK, Kingsbery MY, Rohena LO, et al. Early-onset heart failure, alopecia, and cutaneous abnormalities associated with a novel compound heterozygous mutation in desmoplakin. *Pediatr Dermatol.* 2015;32(1):102-108.
618. Bitar F, Najjar T, Hayashi R, et al. A novel heterozygous mutation in desmoplakin gene in a Lebanese patient with Carvajal syndrome and tooth agenesis. *J Eur Acad Dermatol Venereol.* 2016;30(12):e217-e219.
619. Chalabreysse L, Senni F, Bruyere P, et al. A new hypo/oligodontia syndrome: Carvajal/Naxos syndrome secondary to desmoplakin-dominant mutations. *J Dent Res.* 2011;90(1):58-64.
620. Stollberger C, Vujic I, Wollmann E, et al. Carvajal syndrome with oligodontia, hypoacusis, recurrent infections, and noncompaction. *Int J Cardiol.* 2016;203:825-827.
621. Uzumcu A, Norgett EE, Dindar A, et al. Loss of desmoplakin isoform I causes early onset cardiomyopathy and heart failure in a Naxos-like syndrome. *J Med Genet.* 2006;43(2):e5.
622. Huber O. Structure and function of desmosomal proteins and their role in development and disease. *Cell Mol Life Sci.* 2003;60(9):1872-1890.
623. Alibardi L, Bernd N. Immunolocalization of junctional proteins in human hairs indicates that the membrane complex stabilizes the inner root sheath while desmosomes contact the companion layer through specific keratins. *Acta Histochem.* 2013;115(5):519-526.
624. Bierkamp C, Schwarz H, Huber O, et al. Desmosomal localization of beta-catenin in the skin of plakoglobin null-mutant mice. *Development.* 1999;126(2):371-381.
625. Brooke MA, Nitoiu D, Kelsell DP. Cell-cell connectivity: desmosomes and disease. *J Pathol.* 2012;226(2):158-171.
626. Molho-Pessach V, Sheffer S, Siam R, et al. Two novel homozygous desmoplakin mutations in Carvajal syndrome. *Pediatr Dermatol.* 2015;32(5):641-646.
627. Keller DI, Stepowski D, Balmer C, et al. De novo heterozygous desmoplakin mutations leading to Naxos-Carvajal disease. *Swiss medical weekly.* 2012;142:w13670.
628. Norgett EE, Lucke TW, Bowers B, et al. Early death from cardiomyopathy in a family with autosomal dominant striate palmoplantar keratoderma and woolly hair associated with a novel insertion mutation in desmoplakin. *J Invest Dermatol.* 2006;126(7):1651-1654.
629. Lesot H, Kieffer-Combeau S, Fausser JL, et al. Cell-cell and cell-matrix interactions during initial enamel organ histomorphogenesis in the mouse. *Connect tissue Res.* 2002;43(2-3):191-200.
630. Fausser JL, Schlepp O, Aberdam D, et al. Localization of antigens associated with adherens junctions, desmosomes, and hemidesmosomes during murine molar morphogenesis. *Differentiation.* 1998;63(1):1-11.
631. Jonkman MF, Pasmooij AM, Pasmans SG, et al. Loss of desmoplakin tail causes lethal acantholytic epidermolysis bullosa. *Am J Hum Genet.* 2005;77(4):653-660.
632. Rampazzo A, Nava A, Malacrida S, et al. Mutation in human desmoplakin domain binding to plakoglobin causes a dominant form of arrhythmogenic right ventricular cardiomyopathy. *Am J Hum Genet.* 2002;71(5):1200-1206.
633. Charfeddine C, Ktaifi C, Laroussi N, et al. Clinical and molecular investigation of Buschke-Fischer-Brauer

in consanguineous Tunisian families. *J Eur Acad Dermatol Venereol.* 2016;30(12):2122-2130.
634. Eytan O, Sarig O, Israeli S, et al. A novel splice-site mutation in the AAGAB gene segregates with hereditary punctate palmoplantar keratoderma and congenital dysplasia of the hip in a large family. *Clin Exp Dermatol.* 2014;39(2):182-186.
635. Giehl KA, Eckstein GN, Pasternack SM, et al. Nonsense mutations in AAGAB cause punctate palmoplantar keratoderma type Buschke-Fischer-Brauer. *Am J Hum Genet.* 2012;91(4):754-759.
636. Poonawalla T, Xia L, Patten S, et al. Clouston syndrome and eccrine syringofibroadenomas. *Am J Dermatopathol.* 2009;31(2):157-161.
637. Stanimirovic A, Kansky A, Basta-Juzbasic A, et al. Hereditary palmoplantar keratoderma, type papulosa, in Croatia. *J Am Acad Dermatol.* 1993;29(3):435-437.
638. Kono M, Fukai K, Shimizu N, et al. Punctate palmoplantar keratoderma type 1 with a novel AAGAB frameshift mutation: intrafamilial phenotype variation due to aging. *J Eur Acad Dermatol Venereol.* 2017;31(3):e175-e176.
639. Guo BR, Zhang X, Chen G, et al. Exome sequencing identifies a COL14A1 mutation in a large Chinese pedigree with punctate palmoplantar keratoderma. *J Med Genet.* 2012;49(9):563-568.
640. Miljkovic J, Kansky A. Hereditary palmoplantar keratoderma type papulosa in Slovenia. *Acta Dermatovenerol Alp Pannonica Adriat.* 2009;18(3):114-116.
641. Pohler E, Mamai O, Hirst J, et al. Haploinsufficiency for AAGAB causes clinically heterogeneous forms of punctate palmoplantar keratoderma. *Nat Genet.* 2012;44(11):1272-1276.
642. Emmert S, Kuster W, Hennies HC, et al. 47 patients in 14 families with the rare genodermatosis keratosis punctata palmoplantaris Buschke-Fischer-Brauer. *Eur J Dermatol.* 2003;13(1):16-20.
643. Erkek E, Ayva S. Wood's light excites white fluorescence of type I hereditary punctate keratoderma. *J Eur Acad Dermatol Venereol.* 2007;21(7):993-994.
644. Gorynia S, Lorenz TC, Costaguta G, et al. Yeast Irc6p is a novel type of conserved clathrin coat accessory factor related to small G proteins. *Mol Biol Cell.* 2012;23(22):4416-4429.
645. Page LJ, Sowerby PJ, Lui WW, et al. Gamma-synergin: an EH domain-containing protein that interacts with gamma-adaptin. *J Cell Biol.* 1999;146(5):993-1004.
646. Brown FC. Punctate keratoderma. *Arch Dermatol.* 1971;104(6):682-683.
647. Lestringant GG, Berge T. Porokeratosis punctata palmaris et plantaris. A new entity? *Arch Dermatol.* 1989;125(6):816-819.
648. Sakas EL, Gentry RH. Porokeratosis punctata palmaris et plantaris (punctate porokeratosis). Case report and literature review. *J Am Acad Dermatol.* 1985;13(5 Pt 2): 908-912.
649. Schiff BL, Hughes D. Palmoplantar keratosis acuminata with facial sebaceous hyperplasia. *Arch Dermatol.* 1974;109(1):86-87.
650. Erkek E, Atasoy P. Fluorescence of hereditary type II punctate porokeratotic keratoderma (spiny keratoderma) with a Wood's light: stars under the moonlight. *J Am Acad Dermatol.* 2007;57(2 suppl):S63-64.
651. Bianchi L, Orlandi A, Iraci S, et al. Punctate porokeratotic keratoderma—its occurrence with internal neoplasia. *Clin Exp Dermatol.* 1994;19(2):139-141.
652. Kondo S, Shimoura T, Hozumi Y, et al. Punctate porokeratotic keratoderma: some pathogenetic analyses of hyperproliferation and parakeratosis. *Acta Derm Venereol.* 1990;70(6):478-482.
653. Lewis KG, Bercovitch L, Dill SW, et al. Acquired disorders of elastic tissue: part II. decreased elastic tissue. *J Am Acad Dermatol.* 2004;51(2):165-185; quiz 186-168.
654. Costa OG. Akrokerato-elastoidosis; a hitherto undescribed skin disease. *Dermatologica.* 1953;107(3): 164-168.
655. Hu W, Cook TF, Vicki GJ, et al. Acrokeratoelastoidosis. *Pediatr Dermatol.* 2002;19(4):320-322.
656. Johansson EA, Kariniemi AL, Niemi KM. Palmoplantar keratoderma of punctate type: acrokeratoelastoidosis Costa. *Acta Derm Venereol.* 1980;60(2):149-153.
657. Poiraud C, Vourc'h-Jourdain M, Cassagnau E, et al. Aquagenic palmoplantar keratoderma associated with acrokeratoelastoidosis. *Clin Exp Dermatol.* 2014;39(5):671-672.
658. Klekowski N, Shwayder T. Unilateral acrokeratoelastoidosis—second reported case. *Pediatr Dermatol.* 2011;28(1):20-22.
659. AlKahtani HS, AlHumidi AA, Al-Hargan AH, et al. A sporadic case of unilateral acrokeratoelastoidosis in Saudi Arabia: a case report. *J Med Case Rep.* 2014;8:143.
660. van Steensel MA, Verstraeten VL, Frank J. Acrokeratoelastoidosis with nail dystrophy: a coincidence or a new entity? *Arch Dermatol.* 2006;142(7):939-941.
661. Scuderi G, Palazzolo A, Massimino SD, et al. Costa's acrokeratoelastoidosis. Apropos of a sporadic case. *G Ital Dermatol Venereol.* 1990;125(10):465-469.
662. Tajima S, Tanaka N, Ishibashi A, et al. A variant of acrokeratoelastoidosis in systemic scleroderma: report of 7 cases. *J Am Acad Dermatol.* 2002; 46(5):767-770.
663. Yoshinaga E, Ohnishi Y, Tajima S. Acrokeratoelastoidosis associated with nodular scleroderma. *Eur J Dermatol.* 2003;13(5):490-492.
664. Khamaysi Z, Bergman R, Sprecher E. Nail dystrophy in focal acral hyperkeratosis: a distinctive feature? *J Eur Acad Dermatol Venereol.* 2008;22(7):891-893.
665. Dowd PM, Harman RR, Black MM. Focal acral hyperkeratosis. *Br J Dermatol.* 1983;109(1):97-103.
666. Rongioletti F, Betti R, Crosti C, et al. Marginal papular acrokeratodermas: a unified nosography for focal acral hyperkeratosis, acrokeratoelastoidosis and related disorders. *Dermatology.* 1994;188(1):28-31.
667. van Steensel MA, Frank J. Focal acral hyperkeratosis and acrokeratoelastoidosis: birds of a feather? *J Eur Acad Dermatol Venereol.* 2009;23(9):1113-1114.
668. Erkek E, Kocak M, Bozdogan O, et al. Focal acral hyperkeratosis: a rare cutaneous disorder within the spectrum of Costa acrokeratoelastoidosis. *Pediatr Dermatol.* 2004;21(2):128-130.
669. Matthews CN, Harman RR. Acrokerato-elastoidosis in a Somerset mother and her two sons. *Br J Dermatol.* 1977;97(suppl 15):42-43.
670. Parker CM. Tender linear lesions of the fingers. Acrokeratoelastoidosis (acquired type) or degenerative collagenous plaques of the hands. *Arch Dermatol.* 1991;127(1):114-115, 117-118.
671. Greiner J, Kruger J, Palden L, et al. A linkage study of acrokeratoelastoidosis. Possible mapping to chromosome 2. *Hum Genet.* 1983;63(3):222-227.
672. Jung EG. Acrokeratoelastoidosis. *Humangenetik.* 1973; 17(4):357-358.
673. Masse R, Quillard A, Hery B, et al. Costa's acrokeratoelastoidosis. Ultrastructural study (author's transl). *Ann Dermatol Venereol.* 1977;104(6-7):441-445.

674. Abulafia J, Vignale RA. Degenerative collagenous plaques of the hands and acrokeratoelastoidosis: pathogenesis and relationship with knuckle pads. *Int J Dermatol.* 2000;39(6):424-432.
675. Cole LA. Hypopigmentation with punctate keratosis of the palms and soles. *Arch Dermatol.* 1976; 112(7):998-1000.
676. Moore MM, Orlow SJ, Kamino H, et al. Cole disease: guttate hypopigmentation and punctate palmoplantar keratoderma. *Arch Dermatol.* 2009;145(4):495-497.
677. Schmieder A, Hausser I, Schneider SW, et al. Palmoplantar hyperkeratoses and hypopigmentation. Cole disease. *Acta Derm Venereol.* 2011;91(6):737-738.
678. Vignale R, Yusin A, Panuncio A, et al. Cole disease: hypopigmentation with punctate keratosis of the palms and soles. *Pediatr Dermatol.* 2002;19(4):302-306.
679. Eytan O, Morice-Picard F, Sarig O, et al. Cole disease results from mutations in ENPP1. *Am J Hum Genet.* 2013;93(4):752-757.
680. Schlipf NA, Traupe H, Gilaberte Y, et al. Association of Cole disease with novel heterozygous mutations in the somatomedin-B domains of the ENPP1 gene: necessary, but not always sufficient. *Br J Dermatol.* 2016;174(5):1152-1156.
681. Goding JW, Grobben B, Slegers H. Physiological and pathophysiological functions of the ecto-nucleotide pyrophosphatase/phosphodiesterase family. *Biochim Biophys Acta.* 2003;1638(1):1-19.
682. Jansen S, Perrakis A, Ulens C, et al. Structure of NPP1, an ectonucleotide pyrophosphatase/ phosphodiesterase involved in tissue calcification. *Structure.* 2012;20(11):1948-1959.
683. Lorenz-Depiereux B, Schnabel D, Tiosano D, et al. Loss-of-function ENPP1 mutations cause both generalized arterial calcification of infancy and autosomal-recessive hypophosphatemic rickets. *Am J Hum Genet.* 2010;86(2):267-272.
684. Nitschke Y, Baujat G, Botschen U, et al. Generalized arterial calcification of infancy and pseudoxanthoma elasticum can be caused by mutations in either ENPP1 or ABCC6. *Am J Hum Genet.* 2012;90(1):25-39.
685. Rutsch F, Ruf N, Vaingankar S, et al. Mutations in ENPP1 are associated with 'idiopathic' infantile arterial calcification. *Nat Genet.* 2003;34(4):379-381.
686. Kato K, Nishimasu H, Okudaira S, et al. Crystal structure of Enpp1, an extracellular glycoprotein involved in bone mineralization and insulin signaling. *Proc Natl Acad Sci U S A.* 2012;109(42):16876-16881.
687. Maddux BA, Goldfine ID. Membrane glycoprotein PC-1 inhibition of insulin receptor function occurs via direct interaction with the receptor alpha-subunit. *Diabetes.* 2000;49(1):13-19.
688. Boissy RE. Melanosome transfer to and translocation in the keratinocyte. *Exp Dermatol.* 2003;12(suppl 2):5-12.
689. Edmondson SR, Murashita MM, Russo VC, et al. Expression of insulin-like growth factor binding protein-3 (IGFBP-3) in human keratinocytes is regulated by EGF and TGFbeta1. *J Cell Physiol.* 1999;179(2):201-207.
690. Hyun E, Ramachandran R, Cenac N, et al. Insulin modulates protease-activated receptor 2 signaling: implications for the innate immune response. *J Immunol.* 2010;184(5):2702-2709.
691. Stachelscheid H, Ibrahim H, Koch L, et al. Epidermal insulin/IGF-1 signalling control interfollicular morphogenesis and proliferative potential through Rac activation. *EMBO J.* 2008;27(15):2091-2101.
692. Kim JM, Cho HH, Ko HC. Cole disease: a case report and literature review. *J Eur Acad Dermatol Venereol.* 2015;29(12):2492-2493.

Chapter 49 :: Keratosis Pilaris and Other Follicular Keratotic Disorders

:: Anna L. Bruckner

This chapter discusses conditions with the common finding of *follicular keratosis*, defined as orthokeratosis of the follicular ostium and infundibulum. Keratotic plugs protrude from the orifices, producing a rough sensation on palpation of the skin. Keratosis pilaris (KP) is a common, benign form of follicular keratosis; less common variants are associated with follicular inflammation, atrophy, scarring, alopecia, and in rare cases noncutaneous abnormalities. Trichodysplasia spinulosa (TS), a recently described, virally induced follicular dysplasia with similar findings, is also reviewed.

KERATOSIS PILARIS

AT-A-GLANCE

- Common condition of keratotic follicular plugging with variable erythema.
- Mainly involves the cheeks, extensor arms, and thighs.
- Usually improves gradually over years.
- Nonspecific histology of hyperkeratosis distending the follicular orifice.
- Variable response to emollients and keratolytics.
- Variants:
  - Keratosis pilaris rubra: erythema extends beyond perifollicular skin.
  - Erythromelanosis follicularis faciei et colli: erythema and hyperpigmentation.

KP is a common condition characterized by keratotic follicular papules with varying degrees of surrounding erythema. It is common in children and can improve by late adolescence but is often persistent.[1] Studies of healthy school-aged children suggest a prevalence of 1% to 34%.[2-7] The prevalence is higher in populations with associated conditions.

CLINICAL FEATURES

The primary lesions of KP are small (typically 1-mm), keratotic, follicular papules with varying degrees of perifollicular erythema. Expression ranges from a subtle, incidental finding to conspicuous and aesthetically displeasing, often because of striking erythema. Affected areas include the lateral cheeks, extensor aspects of the upper arms (Fig. 49-1), thighs, and buttocks, and it rarely may be more extensive, extending to the distal limbs and the trunk. Whereas in younger children, the face and arms are mainly involved, the extensor arms and legs are favored in adolescents and adults.

KP is likely accentuated by environmental factors such as ambient humidity. Many with KP experience improvement during the summer as opposed to the winter months or after moving from arid to more humid climates.

Keratosis pilaris rubra (KPR, also called keratosis follicularis rubra) is a variant of KP in which erythema is markedly noticeable, extending beyond the perifollicular skin.[8] Findings are usually limited to the cheeks (Fig. 49-2), forehead, and neck. *Erythromelanosis follicularis faciei et colli* (EFFC) is a similar and likely related condition characterized by hyperpigmentation in addition to erythema and follicular papules.[9] It involves the preauricular and maxillary areas, usually in a symmetric distribution, with spread in some cases to the temples and sides of the neck (the suffix "colli" refers to the neck) and trunk. EFFC is seen primarily in adolescents and young adults, most commonly in males. The hyperpigmentation noted in EFFC may be related to intrinsic skin pigmentation because darker skin types show more evidence of hyperpigmentation (Fig. 49-3). Thus, it is likely that KPR and EFFC are variants of the same clinical spectrum.

ASSOCIATIONS OF KERATOSIS PILARIS

KP is strongly associated with ichthyosis vulgaris (IV) and atopic dermatitis (AD), although the association with AD is not independent of IV.[7,10,11] Other conditions in which KP is more prevalent or more prominent include hypothyroidism, Cushing syndrome, insulin-dependent diabetes, obesity or high body mass index,[12] and Down syndrome. The association of KP with Noonan syndrome (NS) and cardiofaciocutaneous (CFC) syndrome is discussed in the following section. Generalized KP-like skin changes have recently been described as a common cutaneous side effect of RAF inhibition.[13]

ETIOLOGY AND PATHOGENESIS

The etiology and pathogenesis of KP are not well understood, and the clinical phenotype may arise

Figure 49-1 Keratosis pilaris in a characteristic distribution on the upper outer arm in a child.

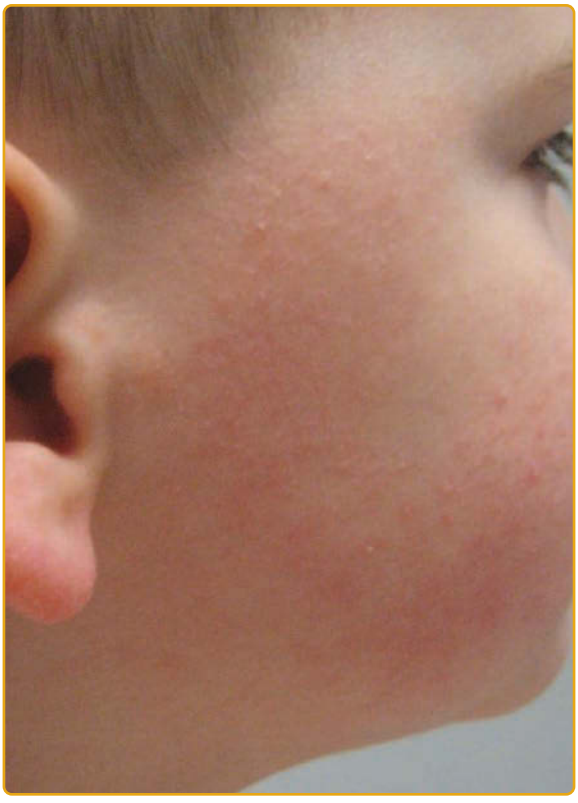

Figure 49-2 Keratosis pilaris rubra with dramatic perifollicular erythema on the cheeks.

Figure 49-3 Keratosis pilaris rubra with overlapping features of erythromelanosis follicularis faciei et colli in an adolescent with darker skin.

by more than one mechanism. KP has been postulated to arise because of defective keratinization of the follicular epithelium. Follicular hyperkeratosis could arise because of mutations in *FLG* (the cause of IV), hyperandrogenism, insulin resistance, or other genetic or metabolic abnormalities. More recent alternative hypotheses include a hair shaft defect or sebaceous etiology. In a study of 25 patients with KP, Thomas and Khopkar identified coiled hair shafts in lesional KP skin, suggesting KP is primarily caused by a hair shaft defect.[14] Gruber and colleagues found atrophic or absent sebaceous glands in KP samples from 20 patients and postulated that this feature could result in follicular plugging and hair shaft defects.[15]

DIAGNOSIS

KP is typically a straightforward clinical diagnosis based on lesional morphology and distribution. Dermoscopic findings of thin, short hair shafts that are coiled or twisted within the follicular ostia are supportive.[14,15]

Biopsy is usually not needed, and the histologic findings are nonspecific. Varying degrees of follicular hyperkeratosis, dilation of the upper dermal vessels, perivascular lymphocytic inflammation, and atrophy or absence of sweat glands are appreciated. In EFFC, hyperpigmentation of the basal layer is also seen.

DIFFERENTIAL DIAGNOSIS

Typical KP should be distinguished from other disorders in the KP spectrum and from other causes of follicular keratosis. Table 49-1 reviews a differential for follicular keratosis.

TABLE 49-1
Differential Diagnosis of Follicular Keratosis

DISORDER	CONSIDERATIONS
Keratosis pilaris	Common; affects lateral cheeks, arms, and legs; associated with xerosis, ichthyosis vulgaris, atopic dermatitis
Ulerythema ophryogenes	Uncommon; loss of eyebrows; strongly associated with Noonan syndrome and cardiofaciocutaneous syndrome
Atrophoderma vermiculatum	Uncommon; honeycomb atrophy affects cheeks
Keratosis follicularis spinulosa decalvans or ichthyosis follicularis, alopecia, and photophobia syndrome	Rare; X-linked; triad of follicular hyperkeratosis, alopecia or atrichia, photophobia
Atrichia with papular lesions	Rare; autosomal recessive; scalp hair fails to regrow after being shed in infancy; follicular plugs or cysts appear later
Hereditary mucoepithelial dysplasia	Rare; autosomal dominant; follicular keratosis, psoriasiform intertrigo, alopecia, fiery-red mucosa, photophobia, pulmonary disease; presumed abnormality of desmosomes or gap junctions
Keratitis, ichthyosis, deafness syndrome	Rare; autosomal dominant; mutations in *GJB2*; characteristic sandpaper-like keratoderma; sensorineural hearing loss
Lichen planopilaris (and Graham Little-Piccardi-Lassueur syndrome)	Adult onset; favors women; keratotic plugs surrounded by violaceous erythema; scarring alopecia
Lichen spinulosus	Round to oval groups of keratotic follicular papules
Monilethrix	Rare; autosomal dominant; characteristic "beaded" pattern of hair on microscopy; perifollicular erythema and follicular keratosis are common; nail changes may occur
Phrynoderma	Caused by vitamin A deficiency; xerosis, keratotic plugs, abnormal hair; ocular disease; poor growth; increased risk of infection-related mortality
Pityriasis rubra pilaris	Erythematous follicular papules; lesions coalesce into plaques with "islands of sparing"; orange-red keratoderma
Trichostasis spinulosa	Comedo-like lesions composed of keratin and vellus hairs; middle to lower central face affected
Trichodysplasia spinulosa	Uncommon; associated with immune suppression; keratotic papules with spiny follicular spicules; most commonly affects central face; variable alopecia (mainly of eyebrows)

CLINICAL COURSE, PROGNOSIS, AND MANAGEMENT

KP tends to improve by adolescence or early adulthood, but it persists into later adult life in at least one third of patients.[1] Patients should be counseled about the benign nature of KP, and expectations should be tempered because treatment may minimize the symptoms but does not eradicate the condition. Most treatments address the rough texture of the skin. Simple steps such as avoiding drying or irritating skin care products and the regular use of bland emollients are reasonable first steps, especially in young children. Keratolytic preparations containing urea, lactic acid, or salicylic acid may soften and smooth KP. Patients should be counseled about the potential burning or stinging sensation of acidic products. Topical retinoids may also be tried if keratolytics are not helpful, but these preparations may aggravate associated erythema, limiting their value. Gentle mechanical exfoliation may also help but has the potential to cause irritation as well.

Short courses of low-potency topical corticosteroids calm irritation and itch that may be seen with KP. Patients should be counseled that corticosteroids do not improve the keratotic plugging, however.

Treatment with vascular- or pigment-specific lasers modestly improves the erythema or hyperpigmentation associated with KP. In a small, randomized clinical trial, Ibrahim and colleagues found a modest reduction in the roughness or bumpiness of KP after three treatments with an 810-nm diode laser. Erythema was unchanged, and long-term outcomes were not evaluated.[16]

KERATOSIS PILARIS ATROPHICANS

AT-A-GLANCE

- Conditions in the keratosis pilaris (KP) spectrum with variable degrees of inflammation and secondary atrophic scarring, alopecia, or both
- Ulerythema ophryogenes (KP atrophicans faciei) predominantly affects the eyebrow area, causing scarring alopecia.
- Commonly seen in patients with Noonan and cardiofaciocutaneous syndromes
- Atrophoderma vermiculatum predominantly involves the cheeks and leads to a striking honeycomb-like atrophy.

Keratosis pilaris atrophicans (KPA) is a group of rare disorders characterized by follicular keratosis; inflammation; and secondary atrophic scarring, alopecia, or both. The umbrella of KPA has classically covered three clinical entities: ulerythema ophryogenes (UO; also called keratosis pilaris atrophicans faciei [KPAF]), atrophoderma vermiculatum (AV; also called folliculitis ulerythematosa reticulata), and keratosis follicularis spinulosa decalvans (KFSD). Recent work has shown that KFSD is allelic to ichthyosis follicularis, atrichia, and photophobia (IFAP) syndrome, and these two disorders will be discussed in the following section.

KPAF was originally described by Erasmus Wilson in 1878 as folliculitis rubra, and the term *ulerythema ophryogenes*, referring to scarring of the eyebrows, was coined by Taenzer in 1889. AV was originally described by Unna as ulerythema acneiforme in 1894.

Figure 49-4 Ulerythema ophryogenes involving the forehead and eyebrows in a child with Noonan syndrome. Note the near complete alopecia of the eyebrows.

CLINICAL FEATURES

UO particularly affects the eyebrows. The onset is in infancy, with erythema and small keratotic follicular papules involving the lateral third of the eyebrows. It may slowly progress through childhood to involve more of the eyebrows, leading to alopecia (Fig. 49-4). Progression usually ceases after puberty, but the sequelae are permanent. Involvement of the cheeks and forehead can occur, but the scalp and eyelash hair are normal. UO is frequently associated with typical KP affecting the arms, legs, or a more generalized distribution. The term *UO* is used interchangeably with *KPAF*, but some prefer the diagnosis of KPAF for patients in whom the initial erythema starts on the cheeks as opposed to the eyebrows.

The characteristic findings of AV are erythema and follicular plugging on the cheeks that progresses to reticular, atrophic scarring (Fig. 49-5). Descriptors such as "worm-eaten" and "honeycomb" aptly capture the morphology. In addition to the cheeks, the forehead, ears, upper lip, and rarely the neck and extremities can be affected as well. Alopecia is not a feature of AV. Sparse open and closed comedones and milia may

Figure 49-5 Atrophoderma vermiculatum demonstrating honeycomb atrophy on the cheek of an adolescent girl.

Figure 49-6 Curvilinear follicular atrophy. This finding had been present since early childhood and was stable.

be found. Typical KP of the extensor aspects of arms and legs is common. AV usually starts in childhood, between 5 and 12 years old, although later onset has also been described.[17] The condition is often sporadic, although an affected father and daughter have been reported, suggesting possible autosomal dominant inheritance.[18] A handful of unilateral, somewhat linear cases have been described, suggesting a mosaic form of the condition (Fig. 49-6).[19] These cases seem to present in infancy, and two have been associated with ipsilateral congenital cataracts.[19,20]

An autosomal recessive form of KPA with overlapping features of AV and KFSD has been described in four children from a large, consanguineous Pakistani family.[21]

SYNDROMES ASSOCIATED WITH ULERYTHEMA OPHRYOGENES AND KERATOSIS PILARIS ATROPHICANS

Although UO may be seen as an isolated finding in otherwise healthy individuals, KP and UO are strongly associated with NS and CFC syndrome. About 80% of patients with genetically confirmed CFC have KP, and 90% have UO.[22] NS affects 1 in 1000 to 2000 newborns, but CFC is quite rare.[23] Both are inherited in an autosomal dominant manner. There is significant overlap in the phenotype of NS and CFC, which includes characteristic craniofacial dysmorphism, congenital cardiac defects, neurocognitive delays, and short stature. Hair anomalies, including sparse, curly, woolly, or brittle hair, are described.

UO has also been reported in association with isolated woolly hair,[24] Rubinstein-Taybi syndrome,[25] Cornelia de Lange syndrome,[26] and 18p monosomy.[27] A family with KP, UO, and koilonychia without evidence of monilethrix has been described.[28]

The occurrence of AV in patients with Loeys-Dietz syndrome caused by mutations in *TGFBR2* was recently described.[29] AV-like changes have been reported in adolescents with autosomal dominant hyper-IgE syndrome caused by mutations in *STAT3*.[30]

ETIOLOGY AND PATHOGENESIS

Although the etiology and pathogenesis of UO and AV are not well understood, insights from associated disorders may be informative. NS and CFC are RASopathies, disorders arising because of mutations in genes that encode components or regulators of the Ras–MAPK (mitogen-activated protein kinase) pathway that regulates the cell cycle, cellular growth, differentiation, and senescence.[23] Activating mutations in seven genes have been implicated in NS, the most common being *PTPN11*, *SOS1*, *RAF1*, and *KRAS*. CFC is caused by activating mutations in the *BRAF*, *KRAS*, *MAP2K1*, and *MAP2K2* genes.

A homozygous missense mutation in the *LRP1* gene was identified in the Pakistani family with KPA with features of AV and KFSD. The encoded protein, LRP1, is a multifunctional cell surface receptor that belongs to the low-density lipoprotein receptor family. The pathogenesis of how decreased LRP1 activity produces the phenotype is unclear, and an aberrant inflammatory response or altered follicular adhesion has been hypothesized.[21]

DIAGNOSIS

Like KP, UO and AV are clinical diagnoses. Histologic findings are supportive but not pathognomonic. Follicular hyperkeratosis with atrophy of the pilosebaceous units and varying degrees of perifollicular and perivascular inflammation and perifollicular fibrosis are seen.

DIFFERENTIAL DIAGNOSIS

Follicular atrophy may occur secondary to inflammatory disorders of the pilosebaceous unit such as acne. Table 49-2 reviews other conditions and syndromes in which follicular atrophoderma is a prominent feature.

CLINICAL COURSE, PROGNOSIS, AND MANAGEMENT

Although the progression of UO and AV remit, the resultant changes of alopecia and atrophic scarring are permanent and can negatively impact self-esteem.

TABLE 49-2
Syndromes Associated with Follicular Atrophoderma

CONDITION	INHERITANCE	MAIN FEATURES	COMMENTS
Bazex syndrome (Bazex-Dupre-Christol syndrome)	X-linked dominant	Hypotrichosis, pili torti, hypohidrosis, milia, development of basal cell carcinomas in adolescence	—
Rombo syndrome	Autosomal dominant	Hypotrichosis, especially of eyelashes; peripheral cyanosis; basal cell carcinomas and trichoepitheliomas	—
Conradi-Hunermann-Happle syndrome (X-linked dominant chondrodysplasia punctate)	X-linked dominant, lethal in males	Congenital onset; blaschkoid erythema with adherent scale; lesions resolve in months, replaced by follicular atrophoderma; cataracts, shortening of limbs, frontal bossing, saddle nose, low-set ears	Mutation in *EBP*, encoding emopamil-binding protein, relevant in cholesterol biosynthesis
Congenital ichthyosis, follicular atrophoderma, hypotrichosis, and hypohidrosis	Autosomal recessive	Congenital, diffuse ichthyosis, hypohidrosis, hypotrichosis; woolly hair in one pedigree	Described in consanguineous families; mutations in *ST14*, encoding matriptase, identified
Nevus comedonicus	Somatic mutation	Blaschkoid distribution of comedo-like plugs in dilated follicular orifices; cribriform atrophy follows extrusion of comedones	Mutations in *FGFR2*, identified in lesional skin (germline mutations in *FGFR2* cause Apert syndrome)

Unfortunately, the response to therapy is poor for patients with both disorders. Topical options include corticosteroids or calcineurin inhibitors to address inflammation and keratolytics or retinoids for the follicular plugging.[31] Modest improvement with oral isotretinoin has been reported.[32,33] Pulsed-dye laser may improve the associated erythema, and laser resurfacing can be considered to correct scarring when the condition is quiescent.

KERATOSIS FOLLICULARIS SPINULOSA DECALVANS AND ICHTHYOSIS FOLLICULARIS, ATRICHIA, AND PHOTOPHOBIA SYNDROME

AT-A-GLANCE

- Ultra rare, X-linked disorders characterized by the triad of follicular hyperkeratosis, alopecia or atrichia, and photophobia
- Whereas progressive, scarring alopecia that begins in childhood is seen in KFSD, nonscarring, congenital atrichia is seen in IFAP.
- Females are variably affected with manifestations in a mosaic pattern following the lines of Blaschko.

The term *keratosis follicularis spinulosa decalvans* (KFSD) was first used by Siemens in 1926, who described a scarring follicular condition in a German family and several Dutch cases. IFAP was first reported as a syndrome by McLeod in 1909.

CLINICAL FEATURES

KFSD and IFAP share the features of follicular hyperkeratosis (ichthyosis), alopecia or atrichia, and photophobia. There is significant overlap between the phenotypes, and differentiation on clinical grounds may be difficult. In general, the KFSD phenotype is less severe than IFAP and is distinguished by the hallmark of progressive scarring alopecia. Inheritance of both disorders is X-linked. Males are fully affected, but expression in females varies and follows the lines of Blaschko.

KFSD begins in infancy with spiny lesions affecting hair-bearing areas, especially the scalp (Fig. 49-7), and later the eyebrows, eyelashes, and elsewhere. Varying degrees of inflammation are seen. Progressive, scarring alopecia presents in childhood and continues through adolescence. It is often patchy and is rarely total. Facial lanugo hair is absent, and axillary and pubic hair is often thinned. Associated nail dystrophy and hyperkeratosis of the elbows, knees, palms, and soles occurs.

Ocular findings include photophobia, punctate corneal epithelial defects, corneal dystrophy, and blepharitis.

A variant of KFSD called *folliculitis spinulosa decalvans* is characterized by persistent pustule formation, especially on the scalp.[34] Unlike KFSD, there is more severe inflammation, and alopecia is progressive after puberty. In addition, inheritance appears to be autosomal dominant.

In IFAP syndrome, noninflammatory, spiny, follicular projections occur in a generalized distribution with a predilection for the extensor surfaces and scalp, imparting a rough, "nutmeg-grater" texture to the skin.

Figure 49-7 Keratosis follicularis spinulosa decalvans with severe scarring alopecia of scalp. (Photograph used with permission from Dr. Peter Hogan.)

A lamellar ichthyotic variant has been described, and psoriasiform plaques, keratoderma, angular cheilitis, nail dystrophy, and periungal inflammation may be seen as well.[35] Nonscarring congenital atrichia, often complete, involves the scalp, eyebrows, eyelashes, and body hair. Affected neonates can be born with hair, but their hair does not grow back after being shed in the first few months after birth.

Photophobia can present in infancy or childhood and is thought to arise from abnormal corneal adhesion that leads to superficial corneal erosions, neovascularization, and progressive scarring. Additional noncutaneous findings occur in a subset of patients, including mental retardation, brain anomalies, Hirschsprung disease, corneal opacifications, kidney dysplasia, cryptorchidism, cleft palate, and skeletal malformations, particularly of the vertebrae (the so-called BRESEK or BRESHECK syndrome).[35] A patient with IFAP and additional features of pachyonychia and palmoplantar and periorificial keratoderma reminiscent of Olmsted syndrome has been described.[36]

ETIOLOGY AND PATHOGENESIS

Oeffner and colleagues identified mutations in *MBTPS2* leading to deficiency in MBTPS2, a metalloprotease essential for cholesterol homeostasis and endoplasmic reticulum stress response, as the cause of IFAP syndrome.[37] Mutations in the *MBTPS2* gene have subsequently been confirmed in both sporadic cases and kindreds with a range of IFAP phenotypes.[35,38-40] Aten and colleagues identified a missense change, c.1523A>G, in *MBTPS2* as the cause of KFSP.[41] This finding was recently verified in a British family as well.[42] The range of genetic variations described thus far includes only missense and intronic mutations, suggesting that changes leading to loss of function in MBTPS2 are nonviable. The range of disease expression in females is due to skewed inactivation of the X chromosome.[35,40]

DIAGNOSIS

The diagnoses of KFSD and IFAP syndrome are suspected in individuals presenting with the triad of follicular keratosis, alopecia or atrichia, and photophobia. A complete ophthalmologic evaluation is recommended. Identification of a pathogenic mutation in the *MBTPS2* gene is confirmatory and should be pursued. Histologic findings are similar to those of KP and KPA, showing follicular hyperkeratosis, perifollicular and dermal inflammation, fibrosis, and distorted follicles at different stages of the condition.

DIFFERENTIAL DIAGNOSIS

See Table 49-1.

CLINICAL COURSE, PROGNOSIS, AND MANAGEMENT

There is a wide range of severity in the KFSP–IFAP spectrum. Aside from patients with IFAP with BRESEK or BRESHECK syndrome, much of the long-term morbidity is associated with ocular disease. The involvement of a skilled ophthalmologist is important. There is no cure or disease-modifying treatment for KFSP or IFAP syndrome at this time, and in general, the results of treatment are unsatisfactory. Improvement of some of the cutaneous changes and regrowth of eyelashes has been reported with oral acitretin.[38,43]

TRICHODYSPLASIA SPINULOSA

AT-A-GLANCE

- Increasingly recognized disorder of viral-induced follicular hyperproliferation that occurs in the setting of immune compromise.
- Characterized by folliculocentric, skin-colored to erythematous papules with spiny spicules, typically affecting the central face

(Continued)

AT-A-GLANCE (*Continued*)

- Histology demonstrates hypertrophic hair bulbs with an expanded inner root sheath containing numerous eosinophilic trichohyaline granules.
- Caused by trichodysplasia spinulosa-associated polyomavirus
- Challenging to manage but tends to resolve when immune function improves

The term *trichodysplasia spinulosa* was proposed in 1999 by Haycox and colleagues,[44] who described an unusual folliculocentric viral infection occurring in the setting of immune suppression. Synonyms include viral-associated trichodysplasia, cyclosporine-induced folliculodystrophy, and pilomatrix dysplasia. TS is rare, although exact epidemiologic data are lacking. Case reports and reviews have increased in the medical literature, and milder forms may be underrecognized. All ages may be affected, and there is no gender predilection.

CLINICAL FEATURES

The distinct skin findings of TS are skin-colored to erythematous, folliculocentric papules with brittle, keratotic spicules (Fig. 49-8A). The central face, including the nose and forehead, is the most common distribution. The entire face, ears, and other parts of the body may be involved. In more severe or long-standing cases, the skin becomes thickened, distorting normal features and sometimes progressing to "leonine" facies. Alopecia is variable, often affecting the eyebrows and eyelashes, and partial loss of scalp and body hair can occur.

TS occurs in the setting of immune compromise because of immune suppression for organ transplantation or treatment of autoimmune disease, chemotherapy for hematopoietic malignancy, or HIV infection. The onset of symptoms varies. Among organ transplant patients, initial lesions appear 8 to 30 months after transplant.[45] There is no consistent pattern of timing with regards to the course of chemotherapy.

ETIOLOGY AND PATHOGENESIS

Haycox and colleagues were the first to identify intracellular viral particles in affected skin.[44] In 2010, van der Meijden and colleagues characterized this novel polyomavirus, trichodysplasia spinulosa-associated polyomavirus (TSPyV).[46] A precise pathomechanism for TSPyV infection producing clinical symptoms is still being elucidated. The cells of the inner root sheath of the hair follicle are infected in TS. Viral load is high (typically 10^5 copies per cell) in clinically apparent cases, but no or very few asymptomatic control participants have evidence of TSPyV.[47] Seroprevalence studies suggest that asymptomatic infection occurs with increasing prevalence from infancy through adulthood; 70% of adults have IgG antibodies to TSV.[48] A recent publication documenting extensive serologic and viral testing in two adults with TS demonstrates that the disorder is caused by disseminated primary TSPyV infection, not reactivation, in the setting of immune compromise.[49]

DIAGNOSIS

The cutaneous findings of TS are unique, and the diagnosis should be considered in immune compromised

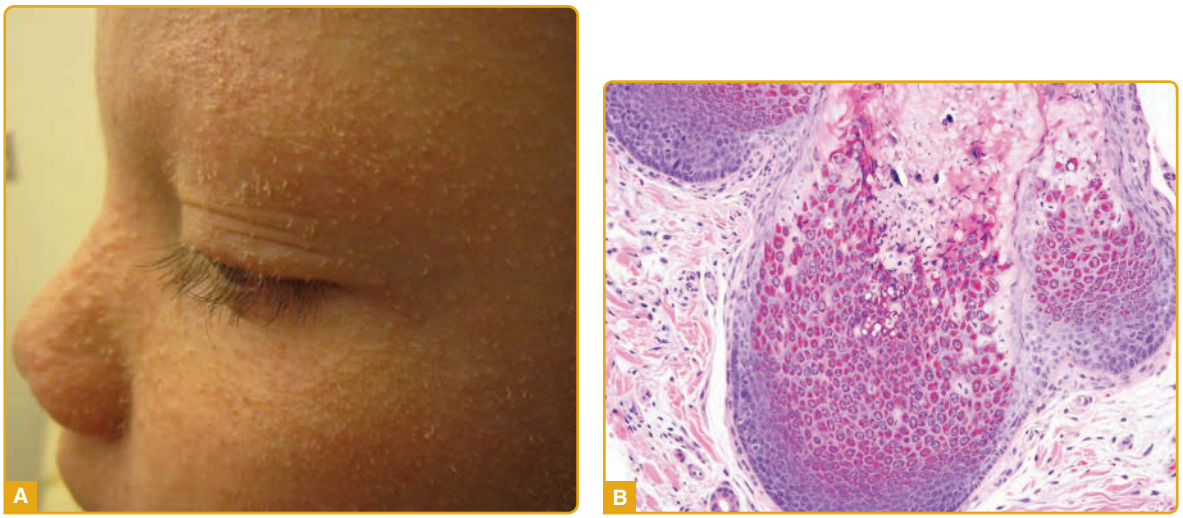

Figure 49-8 Trichodysplasia spinulosa. **A,** Erythematous, folliculocentric papules with keratotic spicules on the face of a child with acute lymphocytic leukemia. Eyebrow alopecia is also seen. **B,** Biopsy from this patient showed an expanded inner root sheath with eosinophilic trichohyaline granules (20× magnification). (Images courtesy of Dr. Lori Prok; used with permission.)

patients who develop spiny, folliculocentric papules. Microscopic examination of plucked spicules demonstrates thick concretions of inner root sheath material surrounding a poorly formed hair shaft.[50] The distinct histopathologic finding of TS is a hypertrophic hair bulb with an expanded inner root sheath whose cells contain numerous eosinophilic trichohyaline granules (Fig. 49-8B). In addition, keratotic plugging of the follicular infundibulum and abnormal hair shafts are seen. The presence of the virus can be confirmed by electron microscopy or polymerase chain reaction studies, although the latter may not be widely available.

DIFFERENTIAL DIAGNOSIS

See Table 49-1.

CLINICAL COURSE, PROGNOSIS, AND MANAGEMENT

The clinical findings of TS gradually improve and resolve as immune function is restored. Decreasing immune suppression should be considered when possible. Typical treatments for follicular keratosis, such as emollients, humectants, and retinoids, are not effective for TS. Antiviral therapy with topical cidofovir or systemic valacyclovir is associated with improvement.[47,51]

ACKNOWLEDGMENTS

The author acknowledges the contributions of Paradi Mirmirani and Maureen Rogers, the former authors of this chapter.

REFERENCES

1. Poskitt L, Wilkinson JD. Natural history of keratosis pilaris. *Br J Dermatol.* 1994;130(6):711-713.
2. Fung WK, Lo KK. Prevalence of skin disease among school children and adolescents in a Student Health Service Center in Hong Kong. *Pediatr Dermatol.* 2000; 17(6):440-446.
3. Dogra S, Kumar B. Epidemiology of skin diseases in school children: a study from northern India. *Pediatr Dermatol.* 2003;20(6):470-473.
4. Popescu R, Popescu CM, Williams HC, et al. The prevalence of skin conditions in Romanian school children. *Br J Dermatol.* 1999;140(5):891-896.
5. Inanir I, Sahin MT, Gunduz K, et al. Prevalence of skin conditions in primary school children in Turkey: differences based on socioeconomic factors. *Pediatr Dermatol.* 2002;19(4):307-311.
6. Tay YK, Kong KH, Khoo L, et al. The prevalence and descriptive epidemiology of atopic dermatitis in Singapore school children. *Br J Dermatol.* 2002;146(1): 101-106.
7. Brown SJ, Relton CL, Liao H, et al. Filaggrin haploinsufficiency is highly penetrant and is associated with increased severity of eczema: further delineation of the skin phenotype in a prospective epidemiological study of 792 school children. *Br J Dermatol.* 2009;161(4):884-889.
8. Marqueling AL, Gilliam AE, Prendiville J, et al. Keratosis pilaris rubra: a common but underrecognized condition. *Arch Dermatol.* 2006;142(12):1611-1616.
9. Sardana K, Relhan V, Garg V, et al. An observational analysis of erythromelanosis follicularis faciei et colli. *Clin Exp Dermatol.* 2008;33(3):333-336.
10. Mevorah B, Marazzi A, Frenk E. The prevalence of accentuated palmoplantar markings and keratosis pilaris in atopic dermatitis, autosomal dominant ichthyosis and control dermatological patients. *Br J Dermatol.* 1985;112(6):679-685.
11. Bremmer SF, Hanifin JM, Simpson EL. Clinical detection of ichthyosis vulgaris in an atopic dermatitis clinic: implications for allergic respiratory disease and prognosis. *J Am Acad Dermatol.* 2008;59(1):72-78.
12. Yosipovitch G, Mevorah B, Mashiach J, et al. High body mass index, dry scaly leg skin and atopic conditions are highly associated with keratosis pilaris. *Dermatology.* 2000;201(1):34-36.
13. Macdonald JB, Macdonald B, Golitz LE, et al. Cutaneous adverse effects of targeted therapies: part II: inhibitors of intracellular molecular signaling pathways. *J Am Acad Dermatol.* 2015;72(2):221-236; quiz 237-228.
14. Thomas M, Khopkar US. Keratosis pilaris revisited: is it more than just a follicular keratosis? *Int J Trichol.* 2012;4(4):255-258.
15. Gruber R, Sugarman JL, Crumrine D, et al. Sebaceous gland, hair shaft, and epidermal barrier abnormalities in keratosis pilaris with and without filaggrin deficiency. *Am J Pathol.* 2015;185(4):1012-1021.
16. Ibrahim O, Khan M, Bolotin D, et al. Treatment of keratosis pilaris with 810-nm diode laser: a randomized clinical trial. *JAMA Dermatol.* 2015;151(2):187-191.
17. Luria RB, Conologue T. Atrophoderma vermiculatum: a case report and review of the literature on keratosis pilaris atrophicans. *Cutis.* 2009;83(2):83-86.
18. Frosch PJ, Brumage MR, Schuster-Pavlovic C, et al. Atrophoderma vermiculatum. Case reports and review. *J Am Acad Dermatol.* 1988;18(3):538-542.
19. Bhoyrul B, Jones H, Blackford S. Extensive unilateral atrophoderma vermiculatum associated with ipsilateral congenital cataract. *Clin Exp Dermatol.* 2016; 41(2):159-161.
20. Hsu S, Nikko A. Unilateral atrophic skin lesion with features of atrophoderma vermiculatum: a variant of the epidermal nevus syndrome? *J Am Acad Dermatol.* 2000;43(2 Pt 1):310-312.
21. Klar J, Schuster J, Khan TN, et al. Whole exome sequencing identifies LRP1 as a pathogenic gene in autosomal recessive keratosis pilaris atrophicans. *J Med Genet.* 2015;52(9):599-606.
22. Siegel DH, McKenzie J, Frieden IJ, et al. Dermatological findings in 61 mutation-positive individuals with cardiofaciocutaneous syndrome. *Br J Dermatol.* 2011;164(3): 521-529.
23. Rauen KA. The RASopathies. *Ann Rev Genom Hum Genet.* 2013;14:355-369.
24. Chien AJ, Valentine MC, Sybert VP. Hereditary woolly hair and keratosis pilaris. *J Am Acad Dermatol.* 2006;54(2 suppl):S35-39.

25. Gomez Centeno P, Roson E, Peteiro C, et al. Rubinstein-Taybi syndrome and ulerythema ophryogenes in a 9-year-old boy. *Pediatr Dermatol.* 1999;16(2):134-136.
26. Florez A, Fernandez-Redondo V, Toribio J. Ulerythema ophryogenes in Cornelia de Lange syndrome. *Pediatr Dermatol.* 2002;19(1):42-45.
27. Liakou AI, Esteves de Carvalho AV, Nazarenko LP. Trias of keratosis pilaris, ulerythema ophryogenes and 18p monosomy: Zouboulis syndrome. *J Dermatol.* 2014;41(5):371-376.
28. Thai KE, Sinclair RD. Keratosis pilaris and hereditary koilonychia without monilethrix. *J Am Acad Dermatol.* 2001;45(4):627-629.
29. van Dijk FS, Brittain H, Boerma R, et al. Atrophoderma vermiculatum: a cutaneous feature of Loeys-Dietz Syndrome. *JAMA Dermatol.* 2015;151(6):675-677.
30. Olaiwan A, Chandesris MO, Fraitag S, et al. Cutaneous findings in sporadic and familial autosomal dominant hyper-IgE syndrome: a retrospective, single-center study of 21 patients diagnosed using molecular analysis. *J Am Acad Dermatol.* 2011;65(6):1167-1172.
31. Morton CM, Bhate C, Janniger CK, et al. Ulerythema ophryogenes: updates and insights. *Cutis.* 2014;93(2):83-87.
32. Layton AM, Cunliffe WJ. A case of ulerythema ophryogenes responding to isotretinoin. *Br J Dermatol.* 1993;129(5):645-646.
33. Weightman W. A case of atrophoderma vermiculatum responding to isotretinoin. *Clin Exp Dermatol.* 1998;23(2):89-91.
34. Castori M, Covaciu C, Paradisi M, et al. Clinical and genetic heterogeneity in keratosis follicularis spinulosa decalvans. *Eur J Med Genet.* 2009;52(1):53-58.
35. Bornholdt D, Atkinson TP, Bouadjar B, et al. Genotype-phenotype correlations emerging from the identification of missense mutations in MBTPS2. *Hum Mutat.* 2013;34(4):587-594.
36. Wang HJ, Tang ZL, Lin ZM, et al. Recurrent splice-site mutation in MBTPS2 underlying IFAP syndrome with Olmsted syndrome-like features in a Chinese patient. *Clin Exp Dermatol.* 2014;39(2):158-161.
37. Oeffner F, Fischer G, Happle R, et al. IFAP syndrome is caused by deficiency in MBTPS2, an intramembrane zinc metalloprotease essential for cholesterol homeostasis and ER stress response. *Am J Hum Genet.* 2009;84(4):459-467.
38. Ming A, Happle R, Grzeschik KH, et al. Ichthyosis follicularis, alopecia, and photophobia (IFAP) syndrome due to mutation of the gene MBTPS2 in a large Australian kindred. *Pediatr Dermatol.* 2009;26(4):427-431.
39. Oeffner F, Martinez F, Schaffer J, et al. Intronic mutations affecting splicing of MBTPS2 cause ichthyosis follicularis, alopecia and photophobia (IFAP) syndrome. *Exp Dermatol.* 2011;20(5):447-449.
40. Fong K, Takeichi T, Liu L, et al. Ichthyosis follicularis, atrichia, and photophobia syndrome associated with a new mutation in MBTPS2. *Clin Exp Dermatol.* 2015;40(5):529-532.
41. Aten E, Brasz LC, Bornholdt D, et al. Keratosis follicularis spinulosa decalvans is caused by mutations in MBTPS2. *Hum Mutat.* 2010;31(10):1125-1133.
42. Fong K, Wedgeworth EK, Lai-Cheong JE, et al. MBTPS2 mutation in a British pedigree with keratosis follicularis spinulosa decalvans. *Clin Exp Dermatol.* 2012;37(6):631-634.
43. Khandpur S, Bhat R, Ramam M. Ichthyosis follicularis, alopecia and photophobia (IFAP) syndrome treated with acitretin. *J Eur Acad Dermatol Venereol.* 2005;19(6):759-762.
44. Haycox CL, Kim S, Fleckman P, et al. Trichodysplasia spinulosa—a newly described folliculocentric viral infection in an immunocompromised host. *J Invest Dermatol Symp Proc.* 1999;4(3):268-271.
45. Tan BH, Busam KJ. Virus-associated Trichodysplasia spinulosa. *Adv Anat Pathol.* 2011;18(6):450-453.
46. van der Meijden E, Janssens RW, Lauber C, et al. Discovery of a new human polyomavirus associated with trichodysplasia spinulosa in an immunocompromised patient. *PLoS Pathog.* 2010;6(7):e1001024.
47. Kazem S, van der Meijden E, Feltkamp MC. The trichodysplasia spinulosa-associated polyomavirus: virological background and clinical implications. *APMIS.* 2013;121(8):770-782.
48. Chen T, Mattila PS, Jartti T, et al. Seroepidemiology of the newly found trichodysplasia spinulosa-associated polyomavirus. *J Infect Dis.* 2011;204(10):1523-1526.
49. van der Meijden E, Horvath B, Nijland M, et al. Primary polyomavirus infection, not reactivation, as the cause of Trichodysplasia spinulosa in immunocompromised patients. *J Infect Dis.* 2017;215(7):1080-1084.
50. Lee JS, Frederiksen P, Kossard S. Progressive trichodysplasia spinulosa in a patient with chronic lymphocytic leukaemia in remission. *Australas J Dermatol.* 2008;49(1):57-60.
51. Wu JH, Nguyen HP, Rady PL, et al. Molecular insight into the viral biology and clinical features of trichodysplasia spinulosa. *Br J Dermatol.* 2016;174(3):490-498.

Chapter 50 :: Acantholytic Disorders of the Skin

:: Alain Hovnanian

AT-A-GLANCE

- The acantholytic diseases are a heterogeneous group of diseases with overlapping clinical and histologic features.
- Darier-White disease (DD) and Hailey-Hailey disease (HHD) are uncommon diseases inherited in an autosomal dominant pattern. A defective calcium pump of the sarcoplasmic/endoplasmic reticulum causes DD, and a faulty calcium and manganese pump of the Golgi apparatus underlies HHD.
- Whereas typical DD presents with greasy keratotic papules in a seborrhoeic distribution, HHD is characterized by painful, oozing erosions in flexures and at sites of trauma.
- Nail changes (DD and HHD), flat-topped warty papules on dorsa of hands and feet (DD), and palmar pits (DD and HHD) or palmar keratotic papules (DD) help to confirm the diagnosis.
- Hypertrophic malodorous flexural disease is particularly disabling in DD and HHD.
- Grover disease (GD) is a sporadic papular condition of uncertain etiology that presents most often in sun-damaged skin. Intractable pruritus is common.
- Histopathologicl examination of involved skin in DD, HH, and GD reveals breakdown of intercellular contacts between suprabasal keratinocytes (acantholysis) with variable dyskeratosis.
- Mosaic forms (type 1 and 2) following the lines of Blaschko have been identified in DD and HHD.
- Acrokeratosis verruciformis of Hopf (AKV) mimics acral DD with flat-topped, warty papules on the dorsal hands and feet and nail dystrophy. The histology of AKV is not acantholytic, but several reports have identified a specific *ATP2A2* mutation in patients with AKV, which indicate that some (if not most) cases are allelic variants of DD with limited manifestations.
- Papular acantholytic dyskeratosis (PAD) presents as whitish papules of the genitocrural or anogenital areas (or both). PAD has been associated with a somatic *ATP2A2* mutation and with constitutive *ATP2C1* mutations, indicating that it can be part of the clinical spectrum of DD or HHD.
- Treatment options for these diseases include topical corticosteroids (DD, HHD, GD) and topical or oral retinoids (DD, GD, AKV), but disease-specific therapies are lacking.

INTRODUCTION

Acantholytic diseases are characterized by loss of intercellular cohesion between keratinocytes, resulting in cell separation. Acantholysis can be the major histologic finding but can also be associated with dyskeratosis corresponding to abnormal keratinization with "corps ronds and grains." Acantholysis is caused by rupture of the desmosomal junctions. However, the most frequent acantholytic diseases (pemphigus, Darier disease [DD], Hailey-Hailey disease [HHD], and Grover disease [GD]) are not caused by primary defects in desmosomal components. This chapter describes DD, HHD, and GD; pemphigus is covered in Chap. 52. The relationship between acrokeratosis verruciformis (AKV), also known as Hopf disease, and DD has been debated for decades. AKV can now be considered as a clinical variant of DD since the same Pro602Leu mutation in *ATP2A2* has been identified in five unrelated patients with AKV. Papular acantholytic dyskeratosis (PAD) is presented as a possible clinical form of DD and HHD because PAD has been associated with a somatic *ATP2A2* mutation and germinal *ATP2C1* mutations in distinct patients.

DARIER DISEASE

EPIDEMIOLOGY

DD (Online Mendelian Inheritance in Man [OMIM] #124200) is an autosomal dominant disease affecting both sexes and all ethnic groups. DD was described independently by Darier and by White in 1889 and is also known as Darier-White disease or keratosis follicularis.[1,2] Estimates of prevalence range from 1 in 30,000 (Northeast England, Scotland, Slovenia)[3-5] to 1 in 100,000 (Denmark).[6] Penetrance is complete, but spontaneous mutations are frequent.

CLINICAL FEATURES

CUTANEOUS FINDINGS

The first manifestations usually appear between the ages of 6 and 20 years with a peak between 11 and 15 years, but DD may also develop in infants or older adults.[1,3,7,8] Symptoms include itch, malodor, and pain. Heat, sweating, friction, and sunlight (ultraviolet B [UVB]) exacerbate the signs, which may be noticed for the first time in hot summer months.[2,3]

Figure 50-1 Hyperkeratotic, pigmented papules on the trunk of a patient with Darier disease.

Figure 50-3 Malodorous confluent keratotic papules on the chest with fissuring and hyperkeratosis of the nipples in Darier disease.

The discrete, greasy, yellowish-brown keratotic papules (only some are perifollicular) have a predilection for seborrheic areas, including the central chest and upper back, scalp (hair growth is not affected), forehead, neck including the supraclavicular fossae, ears, and skin creases (axillae, groins, and perineum) (Figs. 50-1 and 50-2). Papules tend to coalesce into crusted plaques (Fig. 50-3). Foul-smelling, hypertrophic disease in the groin is particularly disabling (Fig. 50-4). White described the "intolerable stench" that accompanies severe disfiguring disease.[2] DD may affect schooling, work, and relationships.[1,9]

The hands, nails, or both are affected in more than 96% of patients and may be the first signs of disease.[1,3] Nail fragility, painful longitudinal splits, or distinctive red and white longitudinal bands terminating in V-shaped nicks are frequent and highly suggestive (Fig. 50-5). Pits or keratotic papules on palms and sometimes soles help to confirm the diagnosis (Fig. 50-6). Many patients (50%–70%) have skin-colored, flat-topped papules on the dorsa of the hands,

Figure 50-4 Hypertrophic flexural Darier disease may suggest squamous cell carcinoma.

Figure 50-2 Darier disease. Inflammatory plaques with fissures and maceration may simulate Hailey-Hailey disease. Note that the fingernails are dystrophic.

Figure 50-5 Dystrophic fingernails showing fragility, splitting, and red and white longitudinal bands in Darier disease.

Figure 50-6 Keratotic papules of the palms in Darier disease.

feet, or both like those of acrokeratosis verruciformis of Hopf (AKV).[10] Hemorrhagic macules with jagged margins, possibly linked to trauma, are the least common acral sign and may blister (Fig. 50-7). Hemorrhagic DD has been reported in some kindreds as well as individuals.[11-14]

Clinical Variants: Variants include painful erosive DD,[15] vesiculobullous DD,[16] grossly hyperkeratotic plaques (cornifying DD),[17-19] nipple hyperkeratosis,[20] keratoderma (Fig. 50-8), comedonal DD,[21-23] freckled "Groveroid" DD,[24] and guttate leukoderma with confetti-like hypopigmented macules or papules (or both) in pigmented skin.[25,26] AKV is a clinical variant of DD (see later).

Segmental Disease: Type 1 mosaicism presents with one or more unilateral bands of keratotic papules following Blaschko lines. The hands, nails, or both may be affected on the same side.[27,28] This distribution reflects a postzygotic somatic mutation in *ATP2A2* early in embryogenesis.[29-31] Hypopigmented, segmental DD following Blaschko lines has recently been reported on dark skin.[32] Theoretically, patients with segmental Darier and gonadal mosaicism could transmit generalized disease, but no such cases have been reported. Type 2 mosaicism is very rare and was reported only twice. In one case, an excessively pronounced unilateral linear band of DD with a segmental pattern was superimposed on generalized disease.[33] In a second case, a 1-year-old boy born to a mother affected with classic DD developed erosive patches confined to one side of the abdomen. Molecular analysis of the lesional skin suggested loss of heterozygosity caused by a postzygotic mutation at the *ATP2A2* locus.[34]

Figure 50-7 Hemorrhagic macule and nail dystrophy in Darier disease.

Figure 50-8 Keratoderma in Darier disease.

NONCUTANEOUS FINDINGS

Oral,[1,35-37] esophageal,[38,39] rectal,[40] and cervical[41] mucosa may be affected in the form of multiple white papules. Corneal abnormalities have been recorded.[42-44] Bone changes, particularly bone cysts, have been reported infrequently.[45-47]

RELATED PHYSICAL FINDINGS

DD has been reported in association with neuropsychiatric disease, including seizures, bipolar disorder, and schizophrenia.[1,48-51] Lithium, which may be prescribed for bipolar disorder, exacerbates DD, possibly by suppressing levels of epidermal SERCA2.[52-55] The lifetime prevalence of major depression (30%), suicide attempts (13%), and suicidal thoughts (31%) appears higher than in the general population, highlighting the need for careful assessment.[51,56] Reports of cosegregation of DD with bipolar disorder in some families support

Figure 50-9 Widespread papulovesicular rash caused by infection with herpes simplex virus in Darier disease.

the existence of a bipolar disorder susceptibility gene in the DD region, but *ATP2A2* has been excluded as a common susceptibility gene for bipolar disease.[57-59] Learning difficulties reported in some patients may be, at least in part, secondary to social disability caused by disfigurement.

COMPLICATIONS

Impetiginization and eczematization may complicate the picture, and patients have an increased susceptibility to widespread infection with herpes simplex (eczema herpeticum) (Fig. 50-9) and herpes zoster viruses.[60,61] Blockage of salivary glands has been reported.[1,35,62] Squamous cell carcinoma (SCC; scalp, scrotal, vulval, thigh, subungual) has been recorded infrequently, sometimes associated with the presence of human papillomavirus (HPV) 16.[63-66]

ETIOLOGY AND PATHOGENESIS

The gene for DD was mapped by linkage analysis to chromosome region 12q23-24 in 1993,[67] and *ATP2A2* was identified as the defective gene in 1999.[68] *ATP2A2* encodes sarco- and endoplasmic reticulum (ER) Ca^{2+} adenosine triphosphatase (ATPase) isoform 2 (SERCA2), a calcium pump transporting Ca^{2+} from the cytosol to the lumen of the ER.[69-72] DD is caused by mutations inactivating one *ATP2A2* allele.

ATP2A2 spans 76 kilobases (kb), is organized in 21 exons, and encodes a 4.4-kb transcript, which is alternatively spliced into three isoforms: SERCA2a, SERCA2b, and SERCA2c.[73,74] SERCA2a is expressed in slow-twitch skeletal muscles and cardiac muscle, unaffected in DD.[75,76] SERCA2b and SERCA2c are expressed ubiquitously, but SERCA2b is the major isoform detected in the human epidermis.[77] Mutations specific for SERCA2b are sufficient to cause DD (despite the presence of functional SERCA2a from the same allele), confirming that SERCA2b is the predominant functional isoform in epidermis.[78,79] Most tissues may compensate for deficiencies in SERCA2 by mechanisms involving SERCA3, which is not expressed in keratinocytes.[77]

SERCA2 pumps belong to the P-type Ca^{2+} ATPase family. The pumps catalyze the hydrolysis of adenosine triphosphate (ATP) coupled with the translocation of two Ca^{2+} ions from the cytosol to the ER lumen, where Ca^{2+} is stored at high concentrations. SERCA pumps comprise three cytoplasmic domains (the actuator, phosphorylation, and ATP-binding domains) linked to a transmembrane domain with 10 transmembrane helices that contain the two Ca^{2+}-binding sites. After binding of cytosolic Ca^{2+} ions and phosphorylation, the pump undergoes conformational changes and releases Ca^{2+} into the ER lumen.[80]

A recent database of *ATP2A2* mutations created by The Leiden Open Variation Database reported 279 unique *ATP2A2* mutations.[81] A majority (46%) of these mutations are missense mutations, 8% are nonsense mutations, and 10% are splice-site mutations with remaining mutations predicting frameshifts or in-frame deletions or insertions. They are distributed throughout the gene and are mostly family specific. No consistent correlation has been demonstrated between genotype and phenotype, although missense mutations appear to be more often associated with severe forms.[21,48,68,78,79,82-93] The considerable phenotypic variability within and among families suggests that other genetic or environmental factors modify the phenotype.

Although the etiology has been explained, the pathogenesis of DD is only partially understood. High concentrations of Ca^{2+} are required for normal keratinocyte intercellular adhesion and differentiation. Normally, the epidermis displays an increasing epidermal Ca^{2+} gradient from the basal to the superficial layers, but in DD, this gradient is disturbed. The level of Ca^{2+} is reduced in basal cells from both affected and unaffected skin.[94]

The earliest ultrastructural change is breakdown of desmosomes with aggregation of keratin filaments around the cell nucleus.[95] Immunohistologic studies of acantholytic cells reveal internalization of desmosomal components.[96-98] The dyskeratotic cells in the epidermis (grains, corps ronds) are formed through apoptosis, which appears to be triggered by the loss of adhesion.[99] The expression of antiapoptotic proteins in the Bcl-2 gene family is reduced in DD, possibly as a secondary

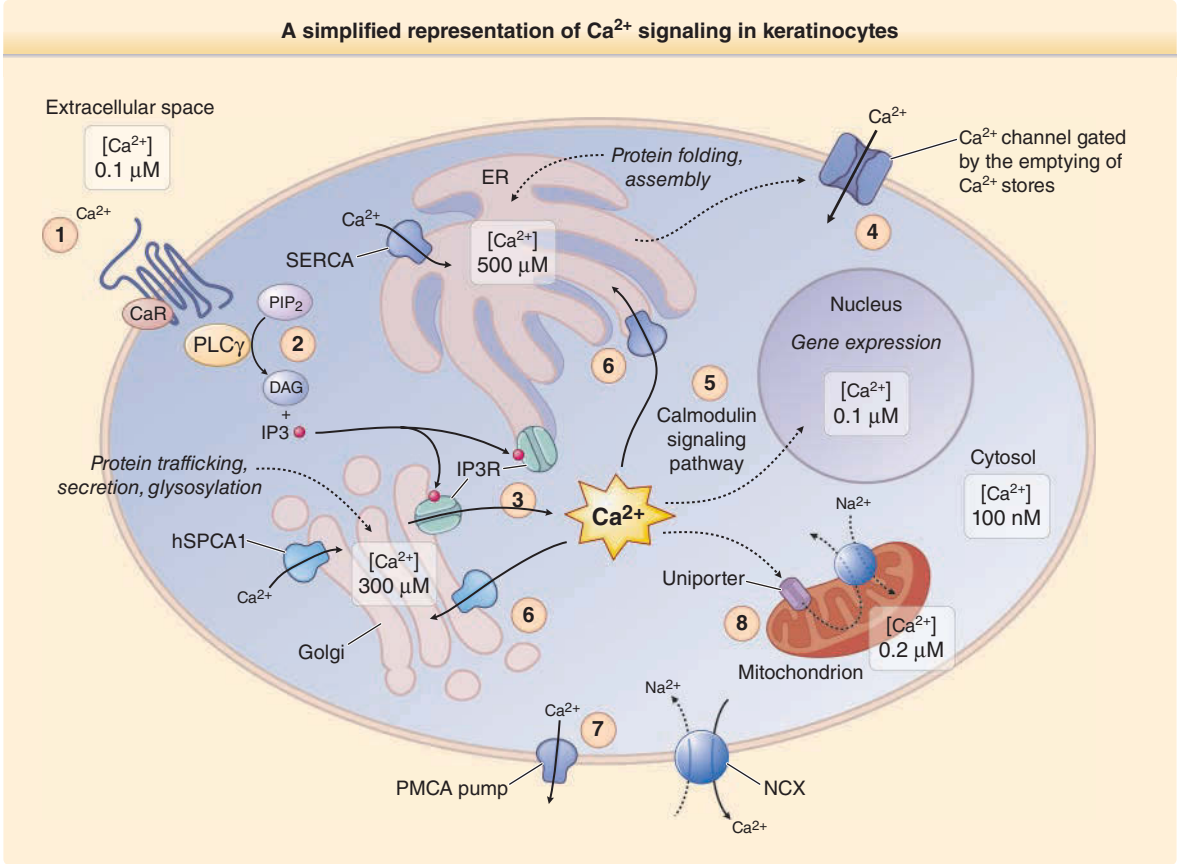

Figure 50-10 A simplified representation of Ca^{2+} signaling in keratinocytes. (*1*) Ca^{2+} binding to its plasma membrane receptor (CaR) activates phospholipase Cγ (PLCγ). (*2*) This causes the hydrolysis of phosphatidylinositol 4,5-bisphosphate (PIP2) into inositol 1,4,5-tris-phosphate (IP3) and diacylglycerol.[188] (*3*) IP3 binds to its receptor (IP3R) at the surface of the endoplasmic reticulum (ER) and Golgi apparatus, which causes the depletion of intracellular stores and induces an increase in intracellular Ca^{2+} levels. (*4*) This increase triggers the opening of Ca^{2+} release–activated channels in the plasma membrane (store-operated-channels [SOCs]), which leads to a sustained increase in Ca^{2+} intracellular levels. SOCs involve the interaction of stromal interacting molecule (STIM) at the ER membrane with Ora1 at the plasma membrane, which are not shown here. (*5*) Ca^{2+} binds to calmodulin; this activates calcineurin and calmodulin-dependent protein kinases, which regulate gene transcription through phosphorylation/dephosphorylation of transcription factors. (*6*) Active Ca^{2+} transport by the different sarcoplasmic reticulum and ER calcium adenosine triphosphatase (ATPase) pumps (SERCA1 to SERCA3) and human secretory pathway Ca^{2+}/Mn^{2+}-ATPase (SPCA1) pump is essential to replenish ER and Golgi Ca^{2+} stores, respectively. SPCA1 is also required for Mn^{2+} influx into the Golgi apparatus (not indicated here). (*7*) Ca^{2+} efflux to the extracellular space involves plasma membrane Ca^{2+}–ATPases (PMCA) and Na^{+}/Ca^{2+} exchangers (NCX). (*8*) Mitochondria take up Ca^{2+} released from the internal stores during Ca^{2+} signaling via the Ca^{2+} uniporter and return it to the cytosol through an NCX. Thus, Ca^{2+} homeostasis requires differential Ca^{2+} concentrations in the cytosol, the sarcoplasmic reticulum and ER, the Golgi apparatus, the mitochondria, and the nucleus of the cell. The largest store of cellular Ca^{2+} is located in the ER lumen and in Ca^{2+}-binding proteins. Ca^{2+} signaling is highly regulated and generated by influx through Ca^{2+} receptors, release from internal stores (ER, Golgi apparatus, mitochondrion), and sequestration by Ca^{2+} pumps (SERCAs, SPCA1) and Ca^{2+} exchangers. mNCX, mitochondria Na^{2+}/Ca^{2+} exchanger.

phenomenon, but an alteration in Bcl-2 proteins might also contribute to apoptosis.[100-102] The epidermis is papillomatous and differentiation is abnormal, with the expression of hyperproliferative keratins and premature expression of cornified envelope precursors such as involucrin.[94,103-105] Variations in cellular Ca^{2+} concentrations are likely to have an effect on the expression of Ca^{2+}-dependent genes involved in keratinocyte differentiation and adhesion.

SERCA pumps replenish the ER Ca^{2+} pool from cytosolic Ca^{2+} . They play a key role in Ca^{2+} homeostasis of the epidermis, which is described in Fig. 50-10. Because Ca^{2+} signaling plays a major role in keratinocyte growth, differentiation, and cell-to-cell adhesion, SERCA2 dysfunction is expected to have profound consequences in keratinocytes from patients with DD. Mutations disrupting critical functional domains or leading to premature termination codons lead to loss of function of the mutated allele. As a result, global SERCA2 pump activity is reduced, and the ER Ca^{2+} pool is diminished.[69,71] Darier keratinocytes (DK) display abnormal patterns of Ca^{2+} regulation.[106] Several lines of evidence indicate that ER Ca^{2+} store depletion plays a central role in DD pathogenesis. DK and normal keratinocytes treated with the SERCA2-inhibitor thapsigargin (TG) have reduced ER Ca^{2+} stores.[107]

Decreased Ca^{2+} stores were shown to impair adherens-junction and desmosome formation and to induce a constitutive ER stress with increased sensitivity to ER stressors in DK and/or TG-treated human keratinocytes (HKs).[108] Specifically, early studies showed that desmoplakin (DP) trafficking was impaired in DK in culture and in HKs treated with thapsigargin.[109,110] This indicated that defective anchorage of desmosomes to the intermediate filament (IF) network is associated with Ca^{2+} store depletion and is likely to contribute to reduced cell-to-cell adhesion in DD. Possible mechanisms for impaired DP localization may involve direct interaction with SERCA2b,[78] impaired membrane translocation of protein kinase Ca (PKCa), a known regulator of DP-IF association and desmosome assembly to the plasma membrane[110] or other mechanisms related to depleted ER Ca^{2+} stores. E-cadherin, desmoglein 3, and desmocollin 2/3 also show reduced expression at the plasma membrane with partial intrcellular retention in DK and in TG-treated HKs in culture, providing evidence that immature adherens junctions and desmosomes are associated with Ca^{2+} store depletion and contribute to reduced cell-to-cell adhesion in DD.[108,111,112]

Sphingolipids have recently been implicated in ER Ca^{2+} store depletion and possibly in DD pathogenesis. Among the multiple sphingolipid metabolites, sphingosine can promote cell death, but sphingosine 1-phosphate (S1P) enhances keratinocyte growth and differentiation, inhibits apoptosis,[113,114] and can mobilize Ca^{2+} from the ER stores in HKs.[115] S1P is synthesized from sphingosine by sphingosine kinase (SPHK1) and is degraded by sphingosine phosphatase lyase (SGPL1). Intracellular sphingosine levels were shown to be increased after inactivating SERCA2b with TG (10 nM) or small interfering RNA (siRNA) to SERCA2b in cultured human keratinocytes, but sphingosine kinase levels were reduced.[111] Conversely, inhibiting sphingosine lyase with siRNA rescued the defects in keratinocyte differentiation, E-cadherin and desmoplakin localization, and ER Ca^{2+} stores observed in TG-treated keratinocytes. Extracellular S1P was ineffective to rescue these defects, indicating that intracellular S1P is essential for normalizing the cell phenotype. Although the mechanisms by which sphingosine metabolism interacts with SERCA2 Ca^{2+} signaling are not well understood, these studies suggest that modulating the sphingolipid pathway could have therapeutic implications in DD.

Reduced Ca^{2+} concentration in the ER lumen also predicts dysfunction of Ca^{2+}-dependent proteins involved in posttranslational modifications such as glucosidases involved in glycosylation processes and chaperone molecules implicated in protein folding, which are essential for the proper maturation of transmembrane proteins, such as desmosomal proteins. Exposure of DK or TG-treated HKs to miglustat, a glucosidase inhibitor and pharmacologic chaperone used to treat Gaucher disease, was shown to restore normal E-cadherin and desmosomal localization.[108] Miglustat-treated DK were also less susceptible to mechanical dissociation than untreated DKs. Altogether, these results provided evidence that miglustat restored desmosome and adherens junction formation and improved intercellular strength in DKs. Of note, miglustat treatment did not revert the biochemical markers of ER stress. Possible modes of actions could involve the prevention of interactions between lectins (eg, calnexin) and misfolded E-cadherin or desmosomal proteins during ER quality-control, as described for miglustat and DF508-CFTR mutation.[116] Conversely, miglustat could indirectly impact on sphingosine metabolism and modulate sphingosine and S1P levels. Additional studies are required to test these hypotheses.

Another study has shown that the transport of nascent desmosomal cadherins (DCs) from the ER to the Golgi apparatus is blocked in SERCA2-inhibited keratinocytes.[112] Dsc2/3 and Dsg3 displayed unprocessed high-mannose type N-glycans which were sensitive to EndoH digestion. Dsg3 pro-domain was uncleaved and was sensitive to furin. Dsg3 and Dsc3 colocalized with calnexin and were retained in the ER. These effects were the consequence of a reduction of ER Ca^{2+} below a critical level. However, because neither glycosylation nor prodomain cleavage is required for Dsg trafficking,[117] blockade of DC transport is likely to be due to another consequence of ER Ca^{2+} depletion. A high concentration of Ca^{2+} in the ER is usually thought to be essential for proper folding of the secretory pathway proteins by ER chaperone molecules, which are Ca^{2+}-dependent proteins. Nevertheless, not all secretory pathway proteins are impacted by ER Ca^{2+}depletion. It is therefore possible that Ca^{2+}-binding proteins such as adherens junctions and DC cadherins could be highly sensitive to the reduction of ER Ca^{2+} below a critical level, leading to protein misfolding and subsequent retention by chaperone molecules as described during unfolded protein response.

Overall, these studies have shown that ER Ca^{2+} depletion is crucial for the maturation and trafficking of adherens junction (E-cadherin), DCs (Dsg2-3, Dsc2-3) and the cytolinker molecule desmoplakin. They have pointed to new potential therapeutic directions for DD through modulation of sphingolipids synthesis, the use of miglustat or molecular chaperones to release adhesion molecules trapped in the ER, or the increase of ER Ca^{2+} concentration above the threshold that triggers the disease manifestations.

Other studies have revealed abnormal distribution of purigenic ATP receptors in Darier epidermis.[94] These receptors transmit extracellular calcium and calcium waves into the cytosol. They include direct calcium channels (P2X) and G protein-coupled ATP receptors (P2Y), which result in the production of 1,4,5-triphosphate and calcium signaling (see Fig. 50-10). Impaired expression of these sensors may contribute to dyskeratosis and hyperproliferation.[69,94]

Abnormalities in the regulation of store-operated calcium entry were also reported in DD.[118] This important mechanism allows influx of extracellular Ca^{2+} through plasma membrane Ca^{2+} channels and is triggered by calcium depletion of the ER. It involves stromal interacting molecules (STIMs), calcium release–activated calcium modulator 1 (ORAi1), and transient receptor

potential canonical 1 (TRPC1). TRPC1 was shown to be upregulated in keratinocytes from patients with DD or a SERCA2+/- mouse model as a result of depletion of ER Ca^{2+} stores. Increased TRPC1 expression enhanced Ca^{2+} influx, promoted proliferation, restricted apoptosis, and was proposed to contribute to dyskeratosis.[118]

Much of the skin may be able to compensate for the deficiency in SERCA2 by increasing the expression of the normal SERCA2 allele or by upregulating other mechanisms such as the human secretory-pathway Ca^{2+}/Mn^{2+} ATPase isoform 1 (SPCA1) in the Golgi.[107] However, external factors such as UVB irradiation or friction, which are known to exacerbate DD, may disrupt this subtle balance by downregulating ATP2A2 or by increasing the requirement for SERCA2 until the protein reaches a critical level. This hypothesis is supported by the observation that UVB irradiation and proinflammatory cytokines reduce levels of ATP2A2 mRNA in cultured normal keratinocytes, and that retinoids and corticosteroids (used in treatment of DD) prevent this reduction.[119] Lithium, another well-known trigger for DD, reduces epidermal expression of SERCA2 in rats.[52]

Importantly, Serca2 knockout heterozygote mice do not develop signs of DD but papillomas and SCCs.[120] SERCA2 haploinsufficiency in cultured mouse keratinocytes is associated with upregulation of proliferation and downregulation of differentiation markers.[121] SCC has been reported rarely in DD, sometimes in association with HPV16.[63-66,122]

HISTOPATHOLOGY

Histologic examination shows downgrowths of narrow cords of keratinocytes, suprabasal acantholysis with suprabasal clefts (lacunae), dyskeratosis (premature and abnormal keratinization), and hyperkeratosis (Fig. 50-11). Apoptosis results in rounded eosinophilic dyskeratotic cells in the epidermis (corps ronds) and flattened parakeratotic cells in the cornified layer (grains).[99] The warty papules on the backs of the hands show the histology of AKV (see later).

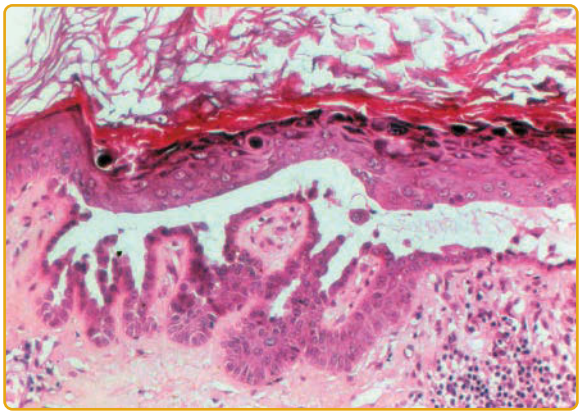

Figure 50-11 Histology of affected skin in Darier disease showing a suprabasal cleft of the epidermis containing acantholytic cells, rounded eosinophilic dyskeratotic cells (corps ronds), hyperkeratosis, and flattened parakeratotic cells in the cornified layer (grains).

DIFFERENTIAL DIAGNOSIS (SEE TABLE 50-1)

DD may be misdiagnosed as seborrheic dermatitis or acne, particularly in patients without a family history. Signs of DD in the hands or nails are often present. Acneiform facial DD may be confused with familial dyskeratotic comedones[123,124] or comedo-like acantholytic dyskeratosis.[125]

Erosive, bullous, or hypertrophic flexural disease simulates HHD, but HHD tends to present later and patients do not have keratotic papules or nail fragility.[126] Erosive or hypertrophic DD may also resemble pemphigus vulgaris or vegetans (see Chap. 52), but patients do not have mucosal ulcers, and intercellular immunoglobulin and complement are not detected in the epidermis. Localized hypertrophic DD may suggest malignancy (see Fig. 50-4). Freckled or papulovesicular forms may resemble Grover disease (GD, see later),[24] but GD is not familial,

TABLE 50-1
Darier Disease: Differential Diagnosis

Seborrheic
- Seborrheic dermatitis (scalp, trunk)
- Grover disease (trunk)
- Acne (forehead)
- Confluent and reticulate papillomatosis (trunk)
- Candida infection (infra-mammary)

Erosive
- Herpes simplex infection
- Bullous impetigo
- Hailey-Hailey disease
- Pemphigus vulgaris

Vegetating Flexural
- Hailey-Hailey disease
- Pemphigus vegetans
- Squamous cell carcinoma

Comedonal
- Acne
- Familial dyskeratotic comedones
- Comedo-like acantholytic dyskeratosis

Acral
- Plane warts
- Acrokeratosis verruciformis of Hopf

Freckled
- Grover disease
- Dowling-Degos disease, acantholytic variant (Galli-Galli disease)

Genital
- Genital warts
- Vulval intraepithelial neoplasia
- Hailey-Hailey disease
- Papular vulvocrural acantholytic disease

or the rare acantholytic variant of Dowling-Degos disease (Galli-Galli disease).[127]

Acral papules resemble flat warts or AKV.[10,128,129] Localized papular vulvocrural acantholytic disease or papular acantholytic disease[10] may be part of the spectrum of DD or HHD.[130-133]

CLINICAL COURSE AND PROGNOSIS

DD pursues a chronic and relapsing course. The severity is unpredictable and can be influenced by pregnancies. In about 30% of patients, disease becomes less severe in old age, but in others, DD persists or gradually worsens.[1]

MANAGEMENT

Table 50-2 emphasizes several points that are important in the evaluation and ongoing counseling of patients with DD, such as reducing the impact of triggers such as heat and sun. Table 50-3 reviews therapeutic options. These treatments may control, but will not cure, DD.

MEDICATIONS

Emollients containing urea or lactic acid may reduce hyperkeratosis. Topical antiseptics (washes, bath additives), antibiotics, and antifungals help to prevent or treat infection. Herpes simplex causes painful flares that require oral acyclovir or valaciclovir.[60] Topical corticosteroids in combination with antibiotics reduce inflammation. Limited disease may respond to a topical retinoids such as tazarotene[134-136] or (iso)tretinoin[137] prescribed in combination with a topical corticosteroid to reduce irritation. Other topical agents such as adapalene,[138,139] 5-fluorouracil,[140,141] and tacrolimus[142] have been reported to be effective in small numbers of cases.

Oral retinoids such as acitretin 0.25 mg to 0.5 mg/kg, isotretinoin 0.5 mg/kg or alitretinoin (10 or 30 mg/day) reduce hyperkeratosis and malodor but will take 3 to 4 months to achieve maximal effect.[143] The dose needs to be tailored to the response, and adverse effects should be monitored (see Chap. 185). Pregnancy is contraindicated for 2 years after stopping treatment with acitretin and for 1 month after stopping isotretinoin or alitretinoin. Oral antibiotics are useful if lesions are extensive and/or infected. Oral cyclosporin has been advocated for eczematization[144] and in severe vulval disease,[145] but controlled trials are lacking.

Approaches for severe hypertrophic or erosive disease include dermabrasion, laser ablation, and photodynamic therapy, but controlled studies are needed to evaluate these approaches.[15,143,146,147] Botulinum toxin may control flexural exacerbations by reducing sweating. Reduction mammoplasty has been advocated for severe inframammary disease.[148,149]

GENETIC COUNSELING

Genetic counseling should be provided by a medical geneticist, taking into account disease expression and severity within affected members of the family.

TABLE 50-2
Darier Disease: What Should I Look for?

- A family history
- Symptoms such as malodor (many patients are relieved to have an opportunity to discuss this distressing problem) or pain (may indicate infection with herpes simplex virus)
- Exacerbating factors: What happens in heat or sun (eg, summer)?
- History of cold sores: Discuss the risk of eczema herpeticum
- Explore the impact of disease, including mood change. Darier disease is associated with depression and suicidal ideation.

TABLE 50-3
Darier Disease: Treatment

FIRST LINE	SECOND LINE	THIRD LINE (UNPROVEN EFFICACY)
Discuss how to avoid triggers (heat, sweating, friction) and minimize ultraviolet B–induced exacerbations	Oral acitretin 0.25 mg–0.5 mg/kg/day. Takes 3 months to have a maximal effect. Acitretin should be stopped for 2 years before a woman attempts to conceive.	Topical 5-fluorouracil
Antiseptic cleansing products and bath additives	Oral isotretinoin 0.5 mg/kg/day or alitretinoin 10 mg or 30 mg/day. Less effective than acitretin but may be indicated in young women. Isotretinoin and alitretinoin should be stopped for 1 month before a woman attempts to conceive.	Oral ciclosporin for eczematization. Initially 2.5 mg/kg/day
Topical antimicrobials (antibacterial, antifungal)		Laser surgery, electrosurgery, or dermabrasion
Emollients containing urea or lactic acid		Photodynamic therapy
Moderate or potent topical corticosteroids with topical antibiotics		Botulinum toxin to reduce sweating in recalcitrant flexural disease
Topical retinoids: isotretinoin, tretinoin, tazarotene, adapalene		Reduction mammoplasty for severe inframammary disease

ACROKERATOSIS VERRUCIFORMIS OF HOPF OR ACRAL DARIER DISEASE

AKV (OMIM #101900), described by Hopf in 1931,[10] is inherited in an autosomal dominant fashion.[128]

Figure 50-12 Small, skin-colored papules over the dorsum of the hand in acrokeratosis verruciformis of Hopf.

Sporadic and familial cases have been reported. Whether AKV is a limited form of DD has been debated for decades. The identification of a specific *ATP2A2* mutation in several unrelated patients with familial AKV established that AKV is allelic to DD.[129]

CLINICAL FEATURES

AKV usually presents at birth or in early childhood. The asymptomatic, skin-colored, flat-topped warty papules are distributed symmetrically on the dorsum of the hands and feet (Fig. 50-12). Papules may also develop on knees, elbows, and extensor aspects of the legs and forearms.[10] As in acral DD, punctate keratoses and pits may be present on palms and soles; palmar skin may be thickened; and patients may have subungual hyperkeratosis, longitudinal striations, splits, and V-shaped nicks at the free margin of the nail plates. A linear variant with persistent localized unilateral lesions has been reported in two unrelated Saudi patients.[150]

ETIOLOGY AND PATHOGENESIS

The same heterozygous Pro602Leu missense mutation in *ATP2A2*, the gene that is defective in DD, was identified in five large pedigrees of different geographic origin.[81,129,151,152] The mutation causes complete loss of Ca^{2+} transport activity.[129] Thus, AKV and DD are allelic disorders, and AKV can be considered as a clinical variant of DD, a conclusion that is entirely consistent with the overlapping clinical features. This is further supported by the coexistence (or segregation) of both entities within affected members of the same pedigrees carrying the same Pro602Leu mutation in *ATP2A2*. Nevertheless, mutations in *ATP2A2* were not identified in a Chinese family with AKV in which linkage with the chromosomal region 12q23-12q24 was excluded.[153]

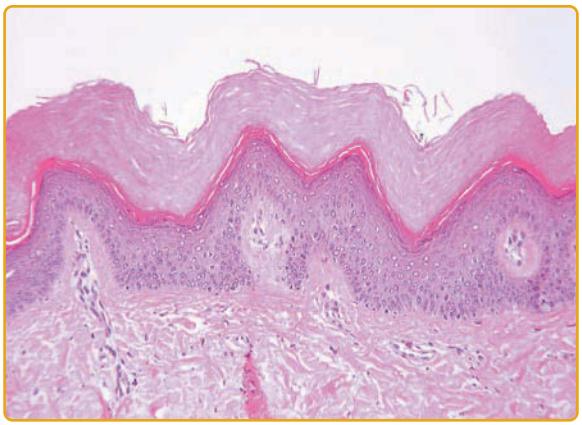

Figure 50-13 Histopathologic features of acrokeratosis verruciformis showing acanthosis and hyperkeratosis with "church spire" elevations of the epidermis but no acantholysis or dyskeratosis. (Used with permission from Dr. Laurence Lamant, Department of Pathology, Purpan Hospital, Toulouse, France.)

HISTOPATHOLOGY

The classic histopathologic findings are hyperkeratosis, hypergranulosis, and acanthosis with papillomatosis. The spiky elevations of the epidermis are said to resemble "church spires" (Fig. 50-13). The epidermis is neither dyskeratotic nor acantholytic.

DIFFERENTIAL DIAGNOSIS

Acral DD and AKV present similarly, particularly in childhood, when other features of DD may not be apparent. AKV may resemble plane warts, stucco keratoses, or seborrheic warts. However, the family history, symmetrical distribution, and nail changes will suggest the diagnosis.

CLINICAL COURSE AND PROGNOSIS

AKV persists and may worsen slowly with age.

MANAGEMENT

No therapy may be needed. Topical retinoids may flatten lesions. Destruction by cryosurgery, shave, curettage, or laser surgery can be effective. Oral acitretin has been helpful.[154]

HAILEY-HAILEY DISEASE

EPIDEMIOLOGY

HHD (OMIM #169600), also known as familial benign chronic pemphigus, was described by the Hailey brothers in 1939. HHD has an incidence of at least 1 in 50,000, but the prevalence may be higher because misdiagnosis is frequent.[126]

CLINICAL FEATURES (TABLE 50-4)

CUTANEOUS FINDINGS

HHD usually presents between the second and fourth decades of life, predominantly at sites of friction (neck, axillae, inframammary, groin, perineum).[126] The diagnosis is often delayed because HHD simulates common dermatoses such as eczema, tinea, and impetigo. Itch, pain, and malodor are common complaints.

Signs include crusted weeping erosions, vesicopustules, expanding annular plaques with peripheral scaly borders (Figs. 50-14 and 50-15), and vegetating plaques with fissures (rhagades). Postinflammatory hyperpigmentation is frequent. Some patients have longitudinal white lines on the fingernails, and these can help to confirm the diagnosis (Fig. 50-16).[126,155] Disease may be limited to one or two sites, more widespread, or rarely generalized with erythroderma,[156] but even mild disease reduces quality of life.[9,157] Painful malodorous inguinal or perineal disease is particularly disabling. HHD koebnerizes into inflammatory dermatoses and has been exacerbated (or diagnosed) after triggers such as contact dermatitis, removal of adherent patch tests, UV irradiation, cutaneous infections, and scabies infestation.[158-166]

CLINICAL VARIANTS

Segmental Disease: Type 1 mosaicism, in which a postzygotic mutation in *ATP2C1* manifested as localized streaks of HHD along Blaschko lines, was reported in one patient.[167] Type 2 mosaicism has been confirmed in a patient with severe linear involvement superimposed on symmetrical HHD. In the more severely affected skin, a postzygotic mutation caused loss of heterozygosity at the *ATP2C1* locus.[168]

Papular Acantholytic Dyskeratosis: PAD[10] presents as localized, whitish papules that tend to cluster on the genitalia and the inguinal folds. The identification of *ATP2C1* mutations in two unrelated cases[169,170] and occurrence of PAD and HHD in a single

TABLE 50-4
Hailey-Hailey Disease: What Should I Look for?

Consider the possibility of HHD in any young adult with chronic "eczema" at sites of friction such as the neckline, axilla, or groin. The diagnosis is often missed. Look for:

- Family history
- Exacerbating factors, such as friction, heat, or sweating
- Postinflammatory hyperpigmentation (common)
- Longitudinal white bands in nails (uncommon but very helpful if present)

Figure 50-14 Crusted plaques with postinflammatory hyperpigmentation in a patient with Hailey-Hailey disease.

Figure 50-15 Hailey-Hailey disease with a hypertrophic macerated axillary plaque and painful fissures (rhagades).

Figure 50-16 White longitudinal lines on the nail of a patient with Hailey-Hailey disease.

family[171] indicate that PAD can be part of the spectrum of HHD.[130,133,172-174]

NONCUTANEOUS FINDINGS

Generally, HHD does not involve mucosa. Rare instances of conjunctival, oral, esophageal, or vaginal involvement may have been initiated by trauma or infection.[175-177]

COMPLICATIONS

Superimposed bacterial or candidal infections are common.[178] Herpes simplex[179,180] causes painful exacerbations, which may disseminate.[181-183] Tinea was a cause of treatment failure in one patient.[184] Allergic contact dermatitis has been described, but the frequency of positive patch tests is probably not increased.[185,186] Skin cancers (SCC more often than basal cell carcinoma) have been reported in association with HHD.[179,180,187,188] SCC may be associated with the presence of HPV.[189-191] SCC of the vulva has been reported in a patient with HHD.[192] Affective disorder cosegregated with HHD in three families.[193-195]

ETIOLOGY AND PATHOGENESIS

The discovery of *ATP2A2* as the causative DD gene raised the possibility that defects in another calcium pump located in chromosomal region 3q21-24 where the HHD locus had been mapped could underlie acantholysis in HHD. Indeed, the defective gene, *ATP2C1*, encodes an ATP-powered calcium and manganese pump on the Golgi membrane, the human secretory-pathway Ca^{2+}/Mn^{2+} ATPase isoform 1 (SPCA1).[196,197] SPCA1 belongs to the family of P-type cation transport ATPases. HHD is dominantly inherited with complete penetrance and is caused by mutations inactivating one *ATP2C1* allele.

The gene spans approximately 30 kb and comprises 28 exons encoding a 4.5-kb transcript. The predicted protein is approximately 115 kDa. Alternative splicing of *ATP2C1* primary transcripts in keratinocytes leads to four splice variants, *ATP2C1a* to *ATP2C1d*, which differ by different splicing of exon 27, 28, or both. *ATP2C1d* is the largest variant, containing exons 27 and 28 in their entirety. The structure of SPCA is similar to that of SERCA, but SPCA only transports a single Ca^{2+} or Mn^{2+} ion into the Golgi lumen.[80,198-200]

The database of *ATP2C1* mutations in the Leiden Open Variation Database reported 177 distinct mutations in HHD scattered across the *ATP2C1* gene.[79,81,196,197,201-212] No correlations have been found between genotype and phenotype, and clinical features show a large range of variability.[201] A majority of these mutations are missense mutations (27%), 16% are nonsense mutations, and 19% are splice-site mutations, with the remaining mutations predicting frameshifts or in-frame deletions or insertions. Mutations predict marked reduction of SPCA1 or cause changes in highly conserved domains that are critical for function.[196,197,205,213,214] Haploinsufficiency appears to be the mechanism for dominant inheritance, but it is not clear how loss of one functional *ATP2C1* allele causes acantholysis.

Ultrastructural studies of acantholytic cells reveal desmosomal breakdown with retraction of keratin filaments from desmosomal plaques to form perinuclear aggregates.[215,216] Desmosomal components, E-cadherin, and connexins are internalized in acantholytic cells, and the expression of keratins is abnormal in lesional skin.[94,96,97,217-221] The abnormality in cell adhesion may be revealed in normal-looking skin in patients with HHD using suction.[222]

Immunohistochemical studies suggest that SPCA1 is localized to the basal layer of normal epidermis.[223] SPCA1 localizes to the Golgi of human keratinocytes and controls Golgi Ca^{2+} stores.[224] Total Ca^{2+} in the epidermal granular layer is reduced, and the normal epidermal Ca^{2+} gradient attenuated in both affected and unaffected skin.[196,224] Golgi Ca^{2+} stores are reduced, Ca^{2+} signaling is abnormal, and the normal upregulation of transcription of *ATP2C1* mRNA by Ca^{2+} stimulation is suppressed in HHD keratinocytes.[196,198,224] Abnormal cytosolic Ca^{2+} levels could influence Ca^{2+}-dependent gene expression or signaling cascades. In addition, low Ca^{2+} or Mn^{2+} concentrations in the Golgi lumen could impair posttranslational modifications, such as Ca^{2+}-dependent proteolytic processing or Mn^{2+}-dependent glycosylation, trafficking, or sorting of proteins important in epidermal cell-to-cell adhesion.

Cultured keratinocytes from involved skin display altered patterns of calcium metabolism and reduced proliferative capacity. Increased oxidative stress in HHD keratinocytes may lead to reduced expression of proteins involved in regulation of the balance between proliferation and differentiation such as Itch and Notch 1.[225] Reorganization of actin is defective, cellular ATP is decreased, and synthesis of involucrin is reduced.[106,226,227] Mice deficient for SPCA1 develop squamous cell papillomas and carcinomas similar to those seen in SERCA2-deficient mice.[228]

Although *ATP2C1* mRNA is expressed ubiquitously, HHD is limited to the skin. Keratinocytes may be more sensitive to levels of SPCA1 than other cells because, unlike most other cells, the Golgi in keratinocytes lack SERCA to compensate for deficient SPCA1.[200] UVB irradiation and proinflammatory cytokines reduce expression of *ATP2C1* mRNA in cultured normal keratinocytes, but suppression is inhibited by retinoids, corticosteroids, cyclosporin, tacrolimus, and vitamin D_3.[119] External factors (UVB, sweating, friction) may reduce the amount of SPCA1 to a critical level, leading to the expression of disease.[200]

In addition to the maintenance of Ca^{2+} and Mn^{2+} concentrations in the Golgi lumen, SPCA1 could also affect cytosolic Ca^{2+} signaling and protein trafficking. For example, Ca^{2+} release from the Golgi results in a localized increase in cytosolic Ca^{2+} levels, which induces vesicle fusion and cargo transport.[229,230] It is therefore conceivable that cell adhesion protein trafficking, such as desmosomal proteins, could be impaired in HHD. In parallel, increased oxidative stress and reduced Notch 1 expression have been reported in cultured keratinocytes derived from skin lesions of patients with HHD.[225,231] Differential gene expression using RNA-sequencing between lesional and nonlesional skin of subjects with HHD showed increased oxidative stress and Notch 1 activation.[232] The DNA damage response, a major target of oxidative stress–induced Notch 1 activation, was downregulated, and the mutation burden was increased in HHD lesions. These results suggested that the *ATP2C1*/NOTCH1 axis may be involved in the pathogenesis of HHD through ROS-induced DNA damage.[232]

HISTOPATHOLOGY

Involved skin displays widespread partial loss of cohesion (keratinocytes may still be linked together by adherens junctions)[233] between suprabasal keratinocytes with an appearance likened to a dilapidated brick wall (Fig. 50-17). Clusters of loosely coherent cells float in suprabasal clefts or bullae. Dyskeratosis, when present, is usually mild, but changes may resemble those in DD.

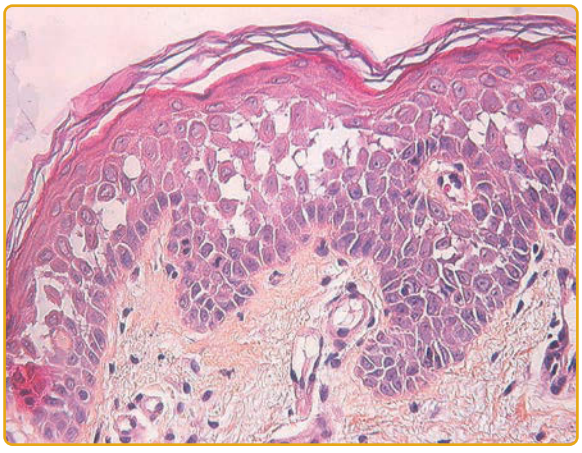

Figure 50-17 Histology of Hailey-Hailey disease. Extensive partial loss of intercellular contacts within the epidermis produces the appearance of a "dilapidated brick wall."

TABLE 50-5
Hailey-Hailey Disease: Differential Diagnosis

Annular or Crusted Plaques
- Eczema, including allergic contact dermatitis
- Impetigo
- Candidal infection
- Tinea corporis
- Darier disease

Vesicopustules
- Eczema
- Bullous impetigo
- Herpes simplex
- Grover disease
- Pemphigus vulgaris
- Toxic epidermal necrolysis (if widespread)

Vegetating Flexural
- Darier disease
- Pemphigus vegetans
- Squamous cell carcinoma

Localized Genital
- Papular vulvocrural acantholytic disease
- Genital warts
- Darier disease
- Vulval intraepithelial neoplasia

DIFFERENTIAL DIAGNOSIS (TABLE 50-5)

Eczema or infection (bacterial, fungal or viral) are the most common misdiagnoses. Hypertrophic flexural HHD resembles DD, but acantholysis is more widespread and dyskeratosis less prominent in HHD than in DD. Eroded or vesiculobullous HHD may simulate toxic epidermal necrolysis[234] or pemphigus vulgaris (intercellular immunoglobulin G and complement are not detected in the epidermis). Genital HHD may simulate viral warts[132,235] or vulval intraepithelial neoplasia.[236] PAD[10] limited to the genitalia may be a separate entity, but the identification of *ATP2C1* mutations in two unrelated cases[169,170] and occurrence of PAD and HHD in a single family[171] have shown that PAD can be part of the spectrum of HHD.[133,172-174] A recent report showed that PAD could also be caused by a somatic *ATP2A2* mutation (see section on DD),[134] showing the importance of searching for a familial history of DD and HHD in the presence of PAD.

CLINICAL COURSE AND PROGNOSIS

The course is chronic, punctuated by relapses and remissions, and can be influenced by pregnancies. In some patients, it improves in old age.

TABLE 50-6
Hailey-Hailey Disease: Treatment

FIRST LINE	SECOND LINE	THIRD LINE (UNPROVEN EFFICACY)
Minimize friction and sweating Antiseptic cleansing products and bath additives Topical antimicrobials (antibacterial, antifungal) Moderately potent or potent topical corticosteroids in combination with topical or oral antibiotics or topical antifungal agents to control secondary infection Pain relief (topical or oral). Some patients require narcotics	Ultrapotent topical corticosteroids in combination with topical or oral antibiotics or antifungal agents to control secondary infection Prednisolone 20-30 mg/day; then tapered gradually to control acute exacerbations	Antistaphylococcal antibiotics (eg, low-dose tetracycline) for 6 mo or longer Topical tacrolimus Topical tacalcitol or calcitriol Topical 5-fluorouracil Oral cyclosporin 2.5 mg/kg Oral retinoids: start with a low dose to minimize irritation Methotrexate 10–15 mg/wk Excision, laser surgery, or dermabrasion Botulinum toxin to reduce sweating in recalcitrant flexural disease Reduction mammoplasty for severe inframammary disease

MANAGEMENT (TABLE 50-6)

The chronicity of the disease and the multiple recurrence of flares make the management of HHD a challenge for the physicians. Treatment is difficult, and no controlled trials have been performed. Recommendations in the literature are subject to citation bias, and most are based on the response of one or two cases without any long-term follow-up. Suggested recent reviews include Chiaravalotti and coworkers Arora and coworkers, and Farahnik and coworkers.[237-239] Treatment options include nonpharmacologic recommendations, topical and systemic agents, and surgery.

NONPHARMACOLOGIC RECOMMENDATIONS

Triggers such as heat, sweating, and friction should be minimized. Clothing should be soft, loose fitting, and cool. Personal hygiene and frequent cleaning and drying of flexural areas should be recommended to reduce flares. Weight loss may be helpful in case of excess body mass to avoid friction. Physical activity that causes friction should be reduced.

MEDICATIONS

Topical and systemic medications control skin microbial colonization, infection, and inflammation.

Microbial colonization and infections are frequent aggravating factors that can exacerbate lesions or prevent healing. Patients should wash with antimicrobial cleansers during flares, especially when lesions are malodorous or vegetating. Skin swabs should be taken for bacterial and yeast culture to guide local antibacterial and antifungal agents when infection is documented. Testing for herpes simplex virus infection by polymerase chain reaction should be performed with a personal history of herpes or persistence of lesions despite antibiotic or antifungal therapy. Nonadhesive dressings are useful to reduce friction and pain at the site of large erosions and to facilitate reepithelialization. When skin lesions are extensive and infected, oral antibiotics, such as doxycycline, which also has an antiinflammatory effect, can be helpful. Nevertheless, the role of long-term, low-dose systemic antibiotics is unproven. It has been suggested that topical gentamicin may be particularly effective in patients harboring a nonsense mutation in *ATP2C1* through aminoglycoside-induced read-through of nonsense mutations in human cells.[240] Topical application reduces the potential hearing and kidney toxicity of this class of drugs. Considering that 16% of *ATP2C1* mutations are nonsense mutations, patients with HHD carrying such mutations may be eligible for read-through therapy. However, the efficiency by which aminoglycosides induce read-through depends on the nature of the nonsense mutation and its nucleotidic environment. Skin penetration of the molecule may also be limited in the absence of erosions and fissures. Controlled clinical trials are therefore warranted.

Topical corticosteroids are often required to control skin inflammation and to help resolve flares.[126,241] They should be used in combination with topical antimicrobial agents to prevent exacerbation of infection. Pain may limit their application, but potent or ultrapotent topical corticosteroids (aqueous lotions, foams, creams, or ointments) are often efficacious. Their application should be limited to the treatment of acute flares. Prolonged treatment with potent corticosteroids favors superimposed infections, thereby limiting their chronic efficacy. Infection should be prevented or treated with local antiseptics, topical antibiotics, or both. Extensive use of potent topical steroids also increases the risk for cutaneous atrophy, which increases skin fragility. Very early application of topical steroids when only pruritus or limited vesiculopapules are present can significantly reduce the progression of lesions.

Topical calcineurin inhibitors represent a useful alternative to topical steroids for the control of inflammation. Tacrolimus ointment (0.03% or 0.1%) produced lesion resolution in several case reports[241-246] but was ineffective in others.[247,248] Superinfection and irritant contact dermatitis may explain lack of efficacy. Other topical agents that have been recommended include calcitriol,[249,250] tacalcitol,[251] and topical 5-fluorouracil.[252] Analgesia is crucial, and narcotics may be needed in severe disease.

Systemic corticosteroids are a short-term option for widespread disease.[253] Other systemic agents that have been advocated include retinoids,[254,255] methotrexate,[256] cyclosporin,[257,258] dapsone,[259] etanercept,[260] and alefacept.[261] Recently, a phase II open-label pilot study reported the successful use of the α-melanocortin analogue with antioxidant properties, afamelanotide, in two patients.[262] Oral glycopyrrolate (1 mg/day), a systemic anticholinergic drug that reduces hyperhidrosis, was reported to be effective and well tolerated in a patient with a long-standing history of relapsing HHD. Low-dose naltrexone also showed variable efficacy.

PROCEDURES

Alternative approaches have been used in recalcitrant disease. They include excision with or without grafting,[264-266] dermabrasion,[267,268] and laser surgery.[269-271] Other interventions that have been tried include breast reduction surgery for inframammary disease, superficial x-ray therapy (unhelpful),[272] electron-beam therapy,[273] and photodynamic therapy (very painful with variable outcomes).[274,275] Botulinum toxin type A (BTA) may help flexural disease by reducing sweating.[276-279] BTA therapy requires numerous injections at each affected site, which can be painful; has a high cost for a temporary relief; and needs to be regularly repeated every 4 to 6 months.

GENETIC COUNSELING

Genetic counseling should be provided by a medical geneticist, who will take into account the disease severity of the proband and other affected members of the family.

GROVER DISEASE

EPIDEMIOLOGY

GD (also called transient or persistent acantholytic dermatosis) is an acquired condition, first described in 1970, that is most common in fair skinned men older than 40 years old. The male-to-female ratio is 3 to 1.[280-283]

CLINICAL FEATURES

Unlike the other disorders in the chapter, GD is nonfamilial and often self-limited. It typically presents with an itchy rash on sun-damaged skin of the trunk. Itch may be intense and out of proportion to the signs, which comprise scattered pinkish or red-brown papules with variable hyperkeratosis, papulovesicles (rarely bullae), or less often eczematous plaques (Figs. 50-18 and 50-19). The neck, proximal limbs or both can be affected.[283-288] GD has been described in association with widespread sun-induced lentigines.[289,290] Guttate leukoderma, similar to that seen in DD, has been observed in dark skin.[291] Unilateral GD has been reported, but this may have been segmental DD.[292,293]

Figure 50-18 Grover disease. Itchy papules on the trunk resembling folliculitis in a 60-year-old man.

ETIOLOGY AND PATHOGENESIS

Although GD shares clinical, histologic, and ultrastructural features with DD, no mutation in *ATP2A2* has been identified in GD[289,294]; the pathogenesis remains unknown.

GD may be triggered by factors that promote sweating, such as febrile illnesses, bed confinement, or

Figure 50-19 Grover disease. Discrete papulovesicular lesions with crusts in a 53-year-old man.

occlusion,[295-298] but is also common in the winter in older men with dry skin.[283,284,299,300] GD has been associated with other factors, including UV or ionizing radiation, inflammatory dermatoses such as atopic eczema, renal failure, HIV infection, malignancies, organ transplant, and some drugs.[282,283,301-305] An observation reported onset of the disease associated with varenicline, a partial agonist of the nicotinic acetylcholine receptor.[306] Electron microscopy shows clumping of keratin filaments with loss of desmosomes, and immunostaining reveals that desmosomal components are internalized.[97] Considering the number of conditions associated with GD, it is possible that multiple causes could result in the clinical and histologic features recognized as GD.[307]

HISTOPATHOLOGY

The histologic picture shows different patterns of acantholysis, which may suggest spongiotic dermatitis, DD, HHD, or pemphigus (although no immunoglobulin or complement are found in the epidermis), the latter being the most frequent pattern. These patterns may occur singly or in combination, which is very suggestive of GD. However, acantholysis can be subtle and focal (Fig. 50-20).[281,284]

DIFFERENTIAL DIAGNOSIS (SEE TABLE 50-7)

Other causes of itching such as scabies, insect bites, and eczema should be excluded. Clinicopathological correlation, including family history and examination of nails and mucous membranes, helps to exclude other causes of acantholysis. Because GD has been associated with many inflammatory and neoplastic conditions, it is essential to search for concomitant disorders, including hematologic malignancies.[307]

TABLE 50-7
Grover Disease: Differential Diagnosis

- Papular eczema or prurigo
- Folliculitis
- Sun damage with solar lentigines and solar keratoses
- Scabies
- Insect bites
- Miliaria rubra
- Darier disease
- Hailey-Hailey disease
- Pemphigus vulgaris

CLINICAL COURSE AND PROGNOSIS

GD may clear within a few months (transient acantholytic dermatosis), or the itch may persist with fluctuating intensity for years (persistent acantholytic dermatosis), especially in older adults.[308,309]

MANAGEMENT

Treatment is symptomatic and difficult, and the therapeutic response (or lack thereof) can be often disappointing.[283,288,310-314] Precipitating factors, including heat, sweating, sunlight, and topical irritants, should be avoided. Emollients and antipruritics may be soothing.

MEDICATIONS

Topical medicaments, such as corticosteroids, retinoids, calcipotriol, or tacalcitol, relieve irritation. Oral retinoids (acitretin), oral corticosteroids, UVB, psoralen and ultraviolet A light (PUVA), and methotrexate

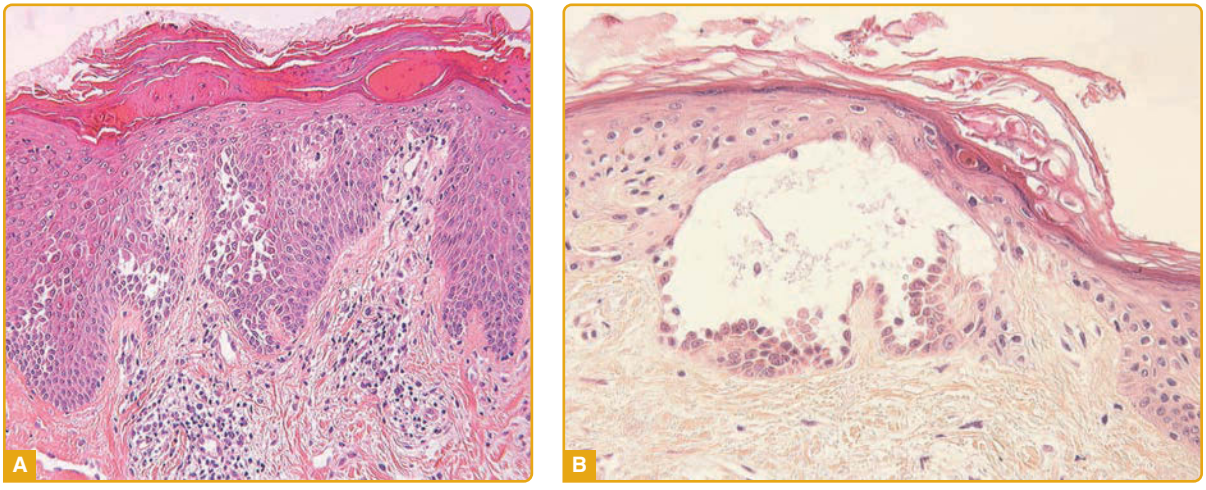

Figure 50-20 **A,** Hailey-Hailey–like histologic pattern in Grover disease with detached keratinocytes (acantholysis), focal spongiosis, and epidermal hyperplasia. **B,** Pemphigus-like pattern in Grover disease with suprabasal acantholytic cleavage.

Differentiating the acantholytic disorders

	Darier Disease	Hailey-Hailey Disease	Grover Disease
Distribution	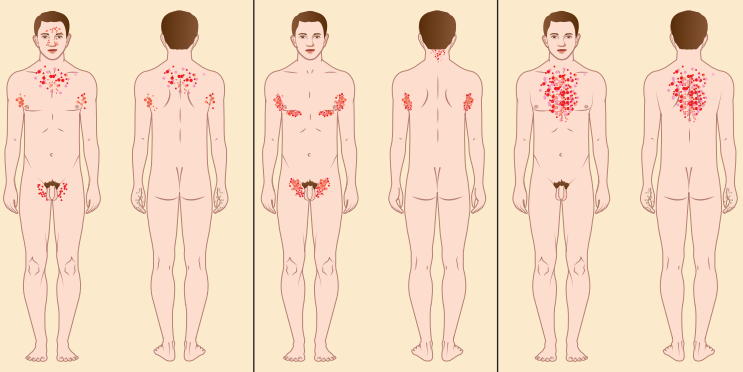		
Age at onset	First to second decade	Third to fourth decade	Fifth decade and onward
Gene affected	*ATP2A2*	*ATP2C1*	(Acquired)
Characteristic lesion	Greasy, yellow-brown keratotic papules	Vesicopustules and fissured, vegetating plaques	Papules, crusted or hyperkeratotic
Mucosal involvement	–	–	–
Nail involvement	+	–	–

Figure 50-21 Differentiating the acantholytic disorders.

have been advocated for persistent disease, but controlled trials are lacking at this time. The combination of acitretin and phototherapy has been reported to suppress symptoms.[288]

SUMMARY

See Fig. 50-21.

REFERENCES

1. Burge SM, Wilkinson JD. Darier-White disease: a review of the clinical features in 163 patients. *J Am Acad Dermatol*. 1992;27(1):40-50.
2. Burge S. Darier's disease-the clinical features and pathogenesis. *Clin Exp Dermatol*. 1994;19(3):193-205.
3. Munro CS. The phenotype of Darier's disease: penetrance and expressivity in adults and children. *Br J Dermatol*. 1992;127(2):126-130.
4. Tavadia S, Mortimer E, Munro CS. Genetic epidemiology of Darier's disease: a population study in the west of Scotland. *Br J Dermatol*. 2002;146(1):107-109.
5. Godic A, Miljkovic J, Kansky A, et al. Epidemiology of Darier's disease in Slovenia. *Acta Dermatovenerol Alp Pannonica Adriat*. 2005;14(2):43-48.
6. Svendsen IB, Albrectsen B. The prevalence of dyskeratosis follicularis (Darier's disease) in Denmark: an investigation of the heredity in 22 families. *Acta Derm Venereol*. 1959;39:256-269.
7. Fong G, Capaldi L, Sweeney SM, et al. Congenital Darier disease. *J Am Acad Dermatol*. 2008;59(2 suppl 1):S50-51.
8. Parwanda N, Kumari N, Bhardwaj P. Darier-White disease. *Indian Pediatr*. 2013;50(7):717-718.
9. Harris A, Burge SM, Dykes PJ, et al. Handicap in Darier's disease and Hailey-Hailey disease. *Br J Dermatol*. 1996;135(6):959-963.
10. Rallis E, Economidi A, Papadakis P, et al. Acrokeratosis verruciformis of Hopf (Hopf disease): case report and review of the literature. *Dermatol Online J*. 2005;11(2):10.
11. Jones WN, Nix TE Jr, Clark WH Jr. Hemorrhagic Darier's disease. *Arch Dermatol*. 1964;89:523-527.
12. Coulson IH, Misch KJ. Haemorrhagic Darier's disease. *J R Soc Med*. 1989;82(6):365-366.
13. Foresman PL, Goldsmith LA, Ginn L, et al. Hemorrhagic Darier's disease. *Arch Dermatol*. 1993;129(4):511-512.
14. Regazzini R, Zambruno G, DeFilippi C, et al. Isolated acral Darier's disease with haemorrhagic lesions in a kindred. *Br J Dermatol*. 1996;135(3):495-496.
15. Brown VL, Kelly SE, Burge SM, et al. Extensive recalcitrant Darier disease successfully treated with laser ablation. *Br J Dermatol*. 2010;162(1):227-229.

16. Telfer NR, Burge SM, Ryan TJ. Vesiculo-bullous Darier's disease. *Br J Dermatol*. 1990;122(6):831-834.
17. Rongioletti F, Cestari R, Rebora A. Verrucous and malodorous vegetations on the legs. Darier's disease, cornifying type. *Arch Dermatol*. 1992;128(3): 399, 402.
18. Katta R, Reed J, Wolf JE. Cornifying Darier's disease. *Int J Dermatol*. 2000;39(11):844-845.
19. Aliagaoglu C, Atasoy M, Anadolu R, et al. Comedonal, cornifying and hypertrophic Darier's disease in the same patient: a Darier combination. *J Dermatol*. 2006;33(7):477-480.
20. Fitzgerald DA, Lewis-Jones MS. Darier's disease presenting as isolated hyperkeratosis of the breasts. *Br J Dermatol*. 1997;136(2):290.
21. Tsuruta D, Akiyama M, Ishida-Yamamoto A, et al. Three-base deletion mutation c.120_122delGTT in ATP2A2 leads to the unique phenotype of comedonal Darier disease. *Br J Dermatol*. 2010;162(3):687-689.
22. Derrick EK, Darley CR, Burge S. Comedonal Darier's disease. *Br J Dermatol*. 1995;132(3):453-455.
23. Lee MW, Choi JH, Sung KJ, et al. Two cases of comedonal Darier's disease. *Clin Exp Dermatol*. 2002; 27(8):714-715.
24. Millard TP, Dhitavat J, Hollowood K, et al. "Groveroid" Darier's disease? *Br J Dermatol*. 2004;150(3):600-602.
25. Ohtake N, Takano R, Saitoh A, et al. Brown papules and leukoderma in Darier's disease: clinical and histological features. *Dermatology*. 1994;188(2):157-159.
26. Goh BK, Ang P, Goh CL. Darier's disease in Singapore. *Br J Dermatol*. 2005;152(2):284-288.
27. Munro CS, Cox NH. An acantholytic dyskeratotic epidermal naevus with other features of Darier's disease on the same side of the body. *Br J Dermatol*. 1992;127(2):168-171.
28. Reese DA, Paul AY, Davis B. Unilateral segmental Darier disease following Blaschko lines: a case report and review of the literature. *Cutis*. 2005;76(3):197-200.
29. Sakuntabhai A, Dhitavat J, Burge S, et al. Mosaicism for ATP2A2 mutations causes segmental Darier's disease. *J Invest Dermatol*. 2000; 115(6):1144-1147.
30. Wada T, Shirakata Y, Takahashi H, et al. A Japanese case of segmental Darier's disease caused by mosaicism for the ATP2A2 mutation. *Br J Dermatol*. 2003; 149(1):185-188.
31. Gilaberte M, Puig L, Vidal D, et al. Acantholytic dyskeratotic naevi following Blaschko's lines: a mosaic form of Darier's disease. *J Eur Acad Dermatol Venereol*. 2003;17(2):196-199.
32. Morin CB, Netchiporouk E, Billick RC, et al. Hypopigmented segmental Darier disease. *J Cutan Med Surg*. 2015;19(1):69-72.
33. Happle R, Itin PH, Brun AM. Type 2 segmental Darier disease. *Eur J Dermatol*. 1999;9(6):449-451.
34. Folster-Holst R, Nellen RG, Jensen JM, et al. Molecular genetic support for the rule of dichotomy in type 2 segmental Darier disease. *Br J Dermatol*. 2012;166(2):464-466.
35. Macleod RI, Munro CS. The incidence and distribution of oral lesions in patients with Darier's disease. *Br Dent J*. 1991;171(5):133-136.
36. Cardoso CL, Freitas P, Taveira LA, et al. Darier disease: case report with oral manifestations. *Med Oral Patol Oral Circ Bucal*. 2006;11(5):E404-406.
37. Bernabe DG, Kawata LT, Beneti IM, et al. Multiple white papules in the palate: oral manifestation of Darier's disease. *Clin Exp Dermatol*. 2009;34(7):e270-271.
38. Vieites B, Seijo-Rios S, Suarez-Penaranda JM, et al. Darier's disease with esophageal involvement. *Scan J Gastroenterol*. 2008;43(8):1020-1021.
39. Al Robaee A, Hamadah IR, Khuroo S, et al. Extensive Darier's disease with esophageal involvement. *Int J Dermatol*. 2004;43(11):835-839.
40. Klein A, Burns L, Leyden JJ. Rectal mucosa involvement in keratosis follicularis. *Arch Dermatol*. 1974; 109(4):560-561.
41. Adam AE. Ectopic Darier's disease of the cervix: an extraordinary cause of an abnormal smear. *Cytopathology*. 1996;7(6):414-421.
42. Blackman HJ, Rodrigues MM, Peck GL. Corneal epithelial lesions in keratosis follicularis (Darier's disease). *Ophthalmology*. 1980;87(9):931-943.
43. Mielke J, Grub M, Besch D, et al. Recurrent corneal ulcerations with perforation in keratosis follicularis (Darier-White disease). *Br J Ophthalmol*. 2002; 86(10):1192-1193.
44. Lagali N, Dellby A, Fagerholm P. In vivo confocal microscopy of the cornea in Darier-White disease. *Arch Ophthalmol*. 2009;127(6):816-818.
45. Ramien ML, Prendiville JS, Brown KL, et al. Cystic bone lesions in a boy with Darier disease: a magnetic resonance imaging assessment. *J Am Acad Dermatol*. 2009;60(6):1062-1066.
46. Castori M, Barboni L, Duncan PJ, et al. Darier disease, multiple bone cysts, and aniridia due to double de novo heterozygous mutations in ATP2A2 and PAX6. *Am J Med Genet A*. 2009;149A(8):1768-1772.
47. Crisp AJ, Payne CM, Adams J, et al. The prevalence of bone cysts in Darier's disease: a survey of 31 cases. *Clin Exp Dermatol*. 1984;9(1):78-83.
48. Bchetnia M, Charfeddine C, Kassar S, et al. Clinical and mutational heterogeneity of Darier disease in Tunisian families. *Arch Dermatol*. 2009;145(6):654-656.
49. Ehrt U, Brieger P. Comorbidity of keratosis follicularis (Darier's Disease) and bipolar affective disorder: an indication for valproate instead of lithium. *Gen Hosp Psychiatry*. 2000;22(2):128-129.
50. Wang SL, Yang SF, Chen CC, et al. Darier's disease associated with bipolar affective disorder: a case report. *Kaohsiung J Med Sci.* 2002;18(12):622-626.
51. Gordon-Smith K, Jones LA, Burge SM, et al. The neuropsychiatric phenotype in Darier disease. *Br J Dermatol*. 2010;163(3):515-522.
52. Sule N, Teszas A, Kalman E, et al. Lithium suppresses epidermal SERCA2 and PMR1 levels in the rat. *Pathol Oncol Res.* 2006;12(4):234-236.
53. Clark RD Jr, Hammer CJ, Patterson SD. A cutaneous disorder (Darier's disease) evidently exacerbated by lithium carbonate. *Psychosomatics.* 1986;27(11):800-801.
54. Milton GP, Peck GL, Fu JJ, et al. Exacerbation of Darier's disease by lithium carbonate. *J Am Acad Dermatol*. 1990;23(5 Pt 1):926-928.
55. Rubin MB. Lithium-induced Darier's disease. *J Am Acad Dermatol*. 1995;32(4):674-675.
56. Denicoff KD, Lehman ZA, Rubinow DR, et al. Suicidal ideation in Darier's disease. *J Am Acad Dermatol*. 1990;22(2 Pt 1):196-198.
57. Jones I, Jacobsen N, Green EK, et al. Evidence for familial cosegregation of major affective disorder and genetic markers flanking the gene for Darier's disease. *Mol Psychiatry*. 2002;7(4):424-427.
58. Jacobsen NJ, Franks EK, Elvidge G, et al. Exclusion of the Darier's disease gene, ATP2A2, as a common susceptibility gene for bipolar disorder. *Mol Psychiatry*. 2001;6(1):92-97.

59. Green EK, Grozeva D, Raybould R, et al. P2RX7: a bipolar and unipolar disorder candidate susceptibility gene? *Am J Med Genet B*. 2009;150B(8):1063-1069.
60. Parham DM, Gawkrodger DJ, Vestey JP, Beveridge GW. Disseminated herpes simplex infection complicating Darier's disease: successful treatment with oral acyclovir. *J Infect*. 1985;10(1):77-78.
61. Kandasamy R, Hecker M, Choi M, et al. Darier disease complicated by disseminated zoster. *Dermatol Online J*. 2009;15(2):6.
62. Tegner E, Jonsson N. Darier's disease with involvement of both submandibular glands. *Acta Derm Venereol*. 1990;70(5):451-452.
63. Alexandrescu DT, Dasanu CA, Farzanmehr H, et al. Development of squamous cell carcinomas in Darier disease: a new model for skin carcinogenesis? *Br J Dermatol*. 2008;159(6):1378-1380.
64. Matsui K, Makino T, Nakano H, et al. Squamous cell carcinoma arising from Darier's disease. *Clin Exp Dermatol*. 2009;34(8):e1015-1016.
65. Vazquez J, Morales C, Gonzalez LO, et al. Vulval squamous cell carcinoma arising in localized Darier's disease. *Eur J Obstet Gynecol Reprod Biol*. 2002;102(2): 206-208.
66. Orihuela E, Tyring SK, Pow-Sang M, et al. Development of human papillomavirus type 16 associated squamous cell carcinoma of the scrotum in a patient with Darier's disease treated with systemic isotretinoin. *J Urol*. 1995;153(6):1940-1943.
67. Craddock N, Dawson E, Burge S, et al. The gene for Darier's disease maps to chromosome 12q23-q24.1. *Hum Mol Genet*. 1993;2(11):1941-1943.
68. Sakuntabhai A, Ruiz-Perez V, Carter S, et al. Mutations in ATP2A2, encoding a Ca^{2+} pump, cause Darier disease. *Nat Genet*. 1999;21(3):271-277.
69. Pani B, Singh BB. Darier's disease: a calcium-signaling perspective. *Cell Mol Life Sci*. 2008;65(2):205-211.
70. Hovnanian A. Darier's disease: from dyskeratosis to endoplasmic reticulum calcium ATPase deficiency. *Biochem Biophys Res Commun*. 2004;322(4):1237-1244.
71. Hovnanian A. SERCA pumps and human diseases. *Subcell Biochem*. 2007;45:337-363.
72. Dhitavat J, Fairclough RJ, Hovnanian A, et al. Calcium pumps and keratinocytes: lessons from Darier's disease and Hailey-Hailey disease. *Br J Dermatol*. 2004;150(5):821-828.
73. Verboomen H, Wuytack F, De Smedt H, et al. Functional difference between SERCA2a and SERCA2b Ca^{2+} pumps and their modulation by phospholamban. *Biochem J*. 1992;286 (Pt 2):591-595.
74. Verboomen H, Wuytack F, Van den Bosch L, et al. The functional importance of the extreme C-terminal tail in the gene 2 organellar Ca(2+)-transport ATPase (SERCA2a/b). *Biochem J*. 1994;303 (Pt 3):979-984.
75. Tavadia S, Tait RC, McDonagh TA, et al. Platelet and cardiac function in Darier's disease. *Clin Exp Dermatol*. 2001;26(8):696-699.
76. Mayosi BM, Kardos A, Davies CH, et al. Heterozygous disruption of SERCA2a is not associated with impairment of cardiac performance in humans: implications for SERCA2a as a therapeutic target in heart failure. *Heart*. 2006;92(1):105-109.
77. Tavadia S, Authi KS, Hodgins MB, et al. Expression of the sarco/endoplasmic reticulum calcium ATPase type 2 and 3 isoforms in normal skin and Darier's disease. *Br J Dermatol*. 2004;151(2):440-445.
78. Dhitavat J, Dode L, Leslie N, et al. Mutations in the sarcoplasmic/endoplasmic reticulum Ca^{2+} ATPase isoform b cause Darier's disease. *J Invest Dermatol*. 2003;121(3):486-489.
79. Ikeda S, Mayuzumi N, Shigihara T, et al. Mutations in ATP2A2 in patients with Darier's disease. *J Invest Dermatol*. 2003;121(3):475-477.
80. Wuytack F, Raeymaekers L, Missiaen L. Molecular physiology of the SERCA and SPCA pumps. *Cell Calcium*. 2002;32(5-6):279-305.
81. Nellen RG, Steijlen PM, van Steensel MA, et al. Mendelian disorders of cornification caused by defects in intracellular calcium pumps: mutation update and database for variants in atp2a2 and atp2c1 associated with Darier disease and Hailey-Hailey disease. *Hum Mutat*. 2017;38(4):343-356.
82. Sakuntabhai A, Burge S, Monk S, et al. Spectrum of novel ATP2A2 mutations in patients with Darier's disease. *Hum Mol Genet*. 1999;8(9):1611-1619.
83. Jacobsen NJ, Lyons I, Hoogendoorn B, et al. ATP2A2 mutations in Darier's disease and their relationship to neuropsychiatric phenotypes. *Hum Mol Genet*. 1999;8(9):1631-1636.
84. Ruiz-Perez VL, Carter SA, Healy E, et al. ATP2A2 mutations in Darier's disease: variant cutaneous phenotypes are associated with missense mutations, but neuropsychiatric features are independent of mutation class. *Hum Mol Genet*. 1999;8(9):1621-1630.
85. Ringpfeil F, Raus A, DiGiovanna JJ, et al. Darier disease-novel mutations in ATP2A2 and genotype-phenotype correlation. *Exp Dermatol*. 2001;10(1): 19-27.
86. Takahashi H, Atsuta Y, Sato K, et al. Novel mutations of ATP2A2 gene in Japanese patients of Darier's disease. *J Dermatol Sci*. 2001;26(3):169-172.
87. Yang Y, Li G, Bu D, et al. Novel point mutations of the ATP2A2 gene in two Chinese families with Darier disease. *J Invest Dermatol*. 2001;116(3):482-483.
88. Pecina-Slaus N, Milavec-Puretic V, Kubat M, et al. Clinical case of acral hemorrhagic Darier's disease is not caused by mutations in exon 15 of the ATP2A2 gene. *Coll Antropol*. 2003;27(1):125-133.
89. Godic A, Glavac D, Korosec B, et al. P160L mutation in the Ca(2+) ATPase 2A domain in a patient with severe Darier disease. *Dermatology*. 2004;209(2):142-144.
90. Onozuka T, Sawamura D, Yokota K, et al. Mutational analysis of the ATP2A2 gene in two Darier disease families with intrafamilial variability. *Br J Dermatol*. 2004;150(4):652-657.
91. Racz E, Csikos M, Kornsee Z, et al. Identification of mutations in the ATP2A2 gene in patients with Darier's disease from Hungary. *Exp Dermatol*. 2004; 13(6):396-399.
92. Racz E, Csikos M, Benko R, et al. Three novel mutations in the ATP2A2 gene in Hungarian families with Darier's disease, including a novel splice site generating intronic nucleotide change. *J Dermatol Sci*. 2005;38(3):231-234.
93. Ren YQ, Gao M, Liang YH, et al. Five mutations of ATP2A2 gene in Chinese patients with Darier's disease and a literature review of 86 cases reported in China. *Arch Dermatol Res*. 2006;298(2):58-63.
94. Leinonen PT, Hagg PM, Peltonen S, et al. Reevaluation of the normal epidermal calcium gradient, and analysis of calcium levels and ATP receptors in Hailey-Hailey and Darier epidermis. *J Invest Dermatol*. 2009;129(6):1379-1387.
95. Caulfield JB, Wilgram GF. An electron-microscope study of dyskeratosis and acantholysis in Darier's disease. *J Invest Dermatol*. 1963;41:57-65.

96. Burge SM, Garrod DR. An immunohistological study of desmosomes in Darier's disease and Hailey-Hailey disease. *Br J Dermatol*. 1991;124(3):242-251.
97. Hashimoto K, Fujiwara K, Tada J, et al. Desmosomal dissolution in Grover's disease, Hailey-Hailey's disease and Darier's disease. *J Cutan Pathol*. 1995; 22(6):488-501.
98. Hakuno M, Shimizu H, Akiyama M, et al. Dissociation of intra- and extracellular domains of desmosomal cadherins and E-cadherin in Hailey-Hailey disease and Darier's disease. *Br J Dermatol*. 2000;142(4):702-711.
99. Gniadecki R, Jemec GB, Thomsen BM, et al. Relationship between keratinocyte adhesion and death: anoikis in acantholytic diseases. *Arch Dermatol Res*. 1998;290(10):528-532.
100. Dremina ES, Sharov VS, Kumar K, et al. Anti-apoptotic protein Bcl-2 interacts with and destabilizes the sarcoplasmic/endoplasmic reticulum Ca^{2+}-ATPase (SERCA). *Biochem J*. 2004;383(Pt 2):361-370.
101. Bongiorno MR, Arico M. The behaviour of Bcl-2, Bax and Bcl-x in Darier's disease. *Br J Dermatol*. 2002;147(4):696-700.
102. Pasmatzi E, Badavanis G, Monastirli A, et al. Reduced expression of the antiapoptotic proteins of Bcl-2 gene family in the lesional epidermis of patients with Darier's disease. *J Cutan Pathol*. 2007;34(3): 234-238.
103. Burge SM, Fenton DA, Dawber RP, et al. Darier's disease: an immunohistochemical study using monoclonal antibodies to human cytokeratins. *Br J Dermatol*. 1988;118(5):629-640.
104. Koizumi H, Kartasova T, Tanaka H, et al. Differentiation-associated localization of small proline-rich protein in normal and diseased human skin. *Br J Dermatol*. 1996;134(4):686-692.
105. Kassar S, Charfeddine C, Zribi H, et al. Immunohistological study of involucrin expression in Darier's disease skin. *J Cutan Pathol*. 2008;35(7):635-640.
106. Leinonen PT, Myllyla RM, Hagg PM, et al. Keratinocytes cultured from patients with Hailey-Hailey disease and Darier disease display distinct patterns of calcium regulation. *Br J Dermatol*. 2005;153(1): 113-117.
107. Foggia L, Aronchik I, Aberg K, et al. Activity of the hSPCA1 Golgi Ca^{2+} pump is essential for Ca^{2+}-mediated Ca^{2+} response and cell viability in Darier disease. *J Cell Sci*. 2006;119(Pt 4):671-679.
108. Savignac M, Simon M, Edir A, et al. SERCA2 dysfunction in Darier disease causes endoplasmic reticulum stress and impaired cell-to-cell adhesion strength: rescue by Miglustat. *J Invest Dermatol*. 2014;134(7):1961-1970.
109. Dhitavat J, Cobbold C, Leslie N, et al. Impaired trafficking of the desmoplakins in cultured Darier's disease keratinocytes. *J Invest Dermatol*. 2003; 121(6):1349-1355.
110. Hobbs RP, Amargo EV, Somasundaram A, et al. The calcium ATPase SERCA2 regulates desmoplakin dynamics and intercellular adhesive strength through modulation of PKCα signaling. FASEB J. 2011;25(3):990-1001.
111. Celli A, Mackenzie DS, Zhai Y, et al. SERCA2-controlled Ca(2)+-dependent keratinocyte adhesion and differentiation is mediated via the sphingolipid pathway: a therapeutic target for Darier's disease. *J Invest Dermatol*. 2012;132(4):1188-1195.
112. Li N, Park M, Xiao S, et al. ER-to-Golgi blockade of nascent desmosomal cadherins in SERCA2-inhibited keratinocytes: implications for Darier's disease. *Traffic*. 2017;18(4):232-241.
113. Hong JH, Youm JK, Kwon MJ, et al. K6PC-5, a direct activator of sphingosine kinase 1, promotes epidermal differentiation through intracellular Ca^{2+} signaling. *J Invest Dermatol*. 2008;128(9):2166-2178.
114. Lichte K, Rossi R, Danneberg K, et al. Lysophospholipid receptor-mediated calcium signaling in human keratinocytes. *J Invest Dermatol*. 2008;128(6):1487-1498.
115. Meyer zu Heringdorf D, Liliom K, Schaefer M, et al. Photolysis of intracellular caged sphingosine-1-phosphate causes Ca^{2+} mobilization independently of G-protein-coupled receptors. *FEBS Lett*. 2003; 554(3):443-449.
116. Norez C, Noel S, Wilke M, et al. Rescue of functional delF508-CFTR channels in cystic fibrosis epithelial cells by the alpha-glucosidase inhibitor miglustat. *FEBS Lett*. 2006;580(8):2081-2086.
117. Pasdar M, Nelson WJ. Kinetics of desmosome assembly in Madin-Darby canine kidney epithelial cells: temporal and spatial regulation of desmoplakin organization and stabilization upon cell-cell contact.II.Morphologicalanalysis.*JCellBiol*.1988;106(3): 687-695.
118. Pani B, Cornatzer E, Cornatzer W, et al. Up-regulation of transient receptor potential canonical 1 (TRPC1) following sarco(endo)plasmic reticulum Ca^{2+} ATPase 2 gene silencing promotes cell survival: a potential role for TRPC1 in Darier's disease. *Mol Biol Cell*. 2006;17(10):4446-4458.
119. Mayuzumi N, Ikeda S, Kawada H, et al. Effects of ultraviolet B irradiation, proinflammatory cytokines and raised extracellular calcium concentration on the expression of ATP2A2 and ATP2C1. *Br J Dermatol*. 2005;152(4):697-701.
120. Liu LH, Boivin GP, Prasad V, et al. Squamous cell tumors in mice heterozygous for a null allele of Atp2a2, encoding the sarco(endo)plasmic reticulum Ca^{2+}-ATPase isoform 2 Ca^{2+} pump. *J Biol Chem*. 2001;276(29):26737-26740.
121. Hong JH, Yang YM, Kim HS, et al. Markers of squamous cell carcinoma in sarco/endoplasmic reticulum Ca^{2+} ATPase 2 heterozygote mice keratinocytes. *Prog Biophys Mol Biol.* 2010;103(1):81-87.
122. Downs AM, Ward KA, Peachey RD. Subungual squamous cell carcinoma in Darier's disease. *Clin Exp Dermatol*. 1997;22(6):277-279.
123. Hall JR, Holder W, Knox JM, et al. Familial dyskeratotic comedones. A report of three cases and review of the literature. *J Am Acad Dermatol*. 1987;17(5 Pt 1): 808-814.
124. Hallermann C, Bertsch HP. Two sisters with familial dyskeratotic comedones. *Eur J Dermatol*. 2004; 14(4):214-215.
125. Nakagawa T, Masada M, Moriue T, et al. Comedo-like acantholytic dyskeratosis of the face and scalp: a new entity? *Br J Dermatol*. 2000;142(5):1047-1048.
126. Burge SM. Hailey-Hailey disease: the clinical features, response to treatment and prognosis. *Br J Dermatol*. 1992;126(3):275-282.
127. Gilchrist H, Jackson S, Morse L, et al. Galli-Galli disease: a case report with review of the literature. *J Am Acad Dermatol*. 2008;58(2):299-302.
128. Niedleman ML, Mc KV. Acrokeratosis verruciformis (Hopf). A follow-up study. *Arch Dermatol*. 1962;86:779-782.
129. Dhitavat J, Macfarlane S, Dode L, et al. Acrokeratosis verruciformis of Hopf is caused by mutation in

ATP2A2: evidence that it is allelic to Darier's disease. *J Invest Dermatol*. 2003;120(2):229-232.
130. Browne F, Keane H, Walsh M, et al. Papular acantholytic dyskeratosis presenting as genital warts. *Int J STD AIDS*. 2007;18(12):867-868.
131. Salopek TG, Krol A, Jimbow K. Case report of Darier disease localized to the vulva in a 5-year-old girl. *Pediatr Dermatol*. 1993;10(2):146-148.
132. Langenberg A, Berger TG, Cardelli M, et al. Genital benign chronic pemphigus (Hailey-Hailey disease) presenting as condylomas. *J Am Acad Dermatol*. 1992;26(6):951-955.
133. Cooper PH. Acantholytic dermatosis localized to the vulvocrural area. *J Cutan Pathol*. 1989;16(2):81-84.
134. Knopp EA, Saraceni C, Moss J, et al. Somatic ATP2A2 mutation in a case of papular acantholytic dyskeratosis: mosaic Darier disease. *J Cutan Pathol*. 2015;42(11):853-857.
135. Brazzelli V, Prestinari F, Barbagallo T, et al. Linear Darier's disease successfully treated with 0.1% tazarotene gel "short-contact" therapy. *Eur J Dermatol*. 2006;16(1):59-61.
136. Micali G, Nasca MR. Tazarotene gel in childhood Darier disease. *Pediatr Dermatol*. 1999;16(3):243-244.
137. Burge SM, Buxton PK. Topical isotretinoin in Darier's disease. *Br J Dermatol*. 1995;133(6):924-928.
138. Casals M, Campoy A, Aspiolea F, et al. Successful treatment of linear Darier's disease with topical adapalene. *J Eur Acad Dermatol Venereol*. 2009;23(2):237-238.
139. Cianchini G, Colonna L, Camaioni D, et al. Acral Darier's disease successfully treated with adapalene. *Acta Derm Venereol*. 2001;81(1):57-58.
140. Knulst AC, De La Faille HB, Van Vloten WA. Topical 5-fluorouracil in the treatment of Darier's disease. *Br J Dermatol*. 1995;133(3):463-466.
141. Schmidt H, Ochsendorf FR, Wolter M, et al. Topical 5-fluorouracil in Darier disease. *Br J Dermatol*. 2008;158(6):1393-1396.
142. Rubegni P, Poggiali S, Sbano P, et al. A case of Darier's disease successfully treated with topical tacrolimus. *J Eur Acad Dermatol Venereol*. 2006;20(1):84-87.
143. Cooper SM, Burge SM. Darier's disease: epidemiology, pathophysiology, and management. *Am J Clin Dermatol*. 2003;4(2):97-105.
144. Shahidullah H, Humphreys F, Beveridge GW. Darier's disease: severe eczematization successfully treated with cyclosporin. *Br J Dermatol*. 1994;131(5):713-716.
145. Stewart LC, Yell J. Vulval Darier's disease treated successfully with ciclosporin. *J Obstet Gynaecol*. 2008;28(1):108-109.
146. Exadaktylou D, Kurwa HA, Calonje E, et al. Treatment of Darier's disease with photodynamic therapy. *Br J Dermatol*. 2003;149(3):606-610.
147. Minsue Chen T, Wanitphakdeedecha R, Nguyen TH. Carbon dioxide laser ablation and adjunctive destruction for Darier-White disease (keratosis follicularis). *Dermatol Surg*. 2008;34(10):1431-1434.
148. Santiago-et-Sanchez-Mateos JL, Bea S, Fernandez M, et al. Botulinum toxin type A for the preventive treatment of intertrigo in a patient with Darier's disease and inguinal hyperhidrosis. *Dermatol Surg*. 2008;34(12):1733-1737.
149. Cohen PR. Darier disease: sustained improvement following reduction mammaplasty. *Cutis*. 2003;72(2):124-126.
150. Bukhari I. Acrokeratosis verruciformis of Hopf: a localized variant. *J Drugs Dermatol*. 2004;3(6):687-688.
151. Bergman R, Sezin T, Indelman M, et al. Acrokeratosis verruciformis of Hopf showing P602L mutation in ATP2A2 and overlapping histopathological features with Darier disease. *Am J Dermatopathol*. 2012;34(6):597-601.
152. Ronan A, Ingrey A, Murray N, et al. Recurrent ATP2A2 p.(Pro602Leu) mutation differentiates Acrokeratosis verruciformis of Hopf from the allelic condition Darier disease. *Am J Med Genet A*. 2017.
153. Wang PG, Gao M, Lin GS, et al. Genetic heterogeneity in acrokeratosis verruciformis of Hopf. *Clin Exp Dermatol*. 2006;31(4):558-563.
154. Serarslan G, Balci DD, Homan S. Acitretin treatment in acrokeratosis verruciformis of Hopf. *J Dermatolog Treat*. 2007;18(2):123-125.
155. Kirtschig G, Effendy I, Happle R. Leukonychia longitudinalis as the primary symptom of Hailey-Hailey disease. *Hautarzt*. 1992;43(7):451-452.
156. Marsch WC, Stuttgen G. Generalized Hailey-Hailey disease. *Br J Dermatol*. 1978;99(5):553-560.
157. Gisondi P, Sampogna F, Annessi G, et al. Severe impairment of quality of life in Hailey-Hailey disease. *Acta Derm Venereol*. 2005;85(2):132-135.
158. Meffert JJ, Davis BM, Campbell JC. Bullous drug eruption to griseofulvin in a man with Hailey-Hailey disease. *Cutis*. 1995;56(5):279-280.
159. Richard G, Linse R, Harth W. Hailey-Hailey disease. Early detection of heterozygotes by an ultraviolet provocation tests—clinical relevance of the method. *Hautarzt*. 1993;44(6):376-379.
160. Galimberti RL, Kowalczuk AM, Bianchi O, et al. Chronic benign familial pemphigus. *Int J Dermatol*. 1988;27(7):495-500.
161. Marren P, Burge S. Seborrhoeic dermatitis of the scalp—a manifestation of Hailey-Hailey disease in a predisposed individual? *Br J Dermatol*. 1992;126(3):294-296.
162. Ponyai G, Karpati S, Ablonczy E, et al. Benign familial chronic pemphigus (Hailey-Hailey) provoked by contact sensitivity in 2 patients. *Contact Dermatitis*. 1999;40(3):168-169.
163. Peppiatt T, Keefe M, White JE. Hailey-Hailey disease—exacerbation by herpes simplex virus and patch tests. *Clin Exp Dermatol*. 1992;17(3):201-202.
164. Rudolph CM, Kranke B, Turek TD, et al. Contact irritation provoking Hailey-Hailey disease. *Contact Dermatitis*. 2001;44(6):371.
165. Gerdsen R, Hartl C, Christ S, et al. Hailey-Hailey disease: exacerbation by scabies. *Br J Dermatol*. 2001;144(1):211-212.
166. Walker SL, Beck MH. Undiagnosed Hailey-Hailey disease causing painful erosive skin changes during patch testing. *Br J Dermatol*. 2005;153(1):233-234.
167. Hwang LY, Lee JB, Richard G, et al. Type 1 segmental manifestation of Hailey-Hailey disease. *J Am Acad Dermatol*. 2003;49(4):712-714.
168. Poblete-Gutierrez P, Wiederholt T, Konig A, et al. Allelic loss underlies type 2 segmental Hailey-Hailey disease, providing molecular confirmation of a novel genetic concept. *J Clin Invest*. 2004;114(10):1467-1474.
169. Pernet C, Bessis D, Savignac M, et al. Genitoperineal papular acantholytic dyskeratosis is allelic to Hailey-Hailey disease. *Br J Dermatol*. 2012;167(1):210-212.
170. Lipoff JB, Mudgil AV, Young S, et al. Acantholytic dermatosis of the crural folds with ATP2C1 mutation is a possible variant of Hailey-Hailey Disease. *J Cutan Med Surg*. 2009;13(3):151-154.

171. Yu WY, Ng E, Hale C, et al. Papular acantholytic dyskeratosis of the vulva associated with familial Hailey-Hailey disease. *Clin Exp Dermatol*. 2016;41(6):628-631.
172. Wong TY, Mihm MC Jr. Acantholytic dermatosis localized to genitalia and crural areas of male patients: a report of three cases. *J Cutan Pathol*. 1994;21(1):27-32.
173. Dittmer CJ, Hornemann A, Rose C, et al. Successful laser therapy of a papular acantholytic dyskeratosis of the vulva: case report and review of literature. *Arch Gynecol Obstet*. 2010;281(4):723-725.
174. Al-Muriesh M, Abdul-Fattah B, Wang X, et al. Papular acantholytic dyskeratosis of the anogenital and genitocrural area: case series and review of the literature. *J Cutan Pathol*. 2016;43(9):749-758.
175. Kahn D, Hutchinson E. Esophageal involvement in familial benign chronic pemphigus. *Arch Dermatol.* 1974;109(5):718-719.
176. Vaclavinkova V, Neumann E. Vaginal involvement in familial benign chronic pemphigus (Morbus Hailey-Hailey). *Acta Derm Venereol*. 1982;62(1):80-81.
177. Oguz O, Gokler G, Ocakoglu O, et al. Conjunctival involvement in familial chronic benign pemphigus (Hailey-Hailey disease). *Int J Dermatol*. 1997;36(4):282-285.
178. Mashiko M, Akiyama M, Tsuji-Abe Y, et al. Bacterial infection-induced generalized Hailey-Hailey disease successfully treated by etretinate. *Clin Exp Dermatol*. 2006;31(1):57-59.
179. Holst VA, Fair KP, Wilson BB, et al. Squamous cell carcinoma arising in Hailey-Hailey disease. *J Am Acad Dermatol*. 2000;43(2 Pt 2):368-371.
180. Cockayne SE, Rassl DM, Thomas SE. Squamous cell carcinoma arising in Hailey-Hailey disease of the vulva. *Br J Dermatol*. 2000;142(3):540-542.
181. Otsuka F, Niimura M, Harada S, et al. Generalized herpes simplex complicating Hailey-Hailey's disease. *J Dermatol*. 1981;8(1):63-68.
182. Schirren H, Schirren CG, Schlupen EM, et al. Exacerbation of Hailey-Hailey disease by infection with herpes simplex virus. Detection with polymerase chain reaction. *Hautarzt*. 1995;46(7):494-497.
183. Stallmann D, Schmoeckel C. Hailey-Hailey disease with dissemination and eczema herpeticatum in therapy with etretinate. *Hautarzt*. 1988;39(7):454-456.
184. Mak RK, Reynaert SM, Agar N, et al. Hailey-Hailey disease failing to respond to treatment. *Clin Exp Dermatol*. 2005;30(5):598-599.
185. Reitamo S, Remitz A, Lauerma AI, et al. Contact allergies in patients with familial benign chronic pemphigus (Hailey-Hailey disease). *J Am Acad Dermatol*. 1989;21(3 Pt 1):506-510.
186. Remitz A, Lauerma AI, Stubb S, et al. Darier's disease, familial benign chronic pemphigus (Hailey-Hailey disease) and contact hypersensitivity. *J Am Acad Dermatol*. 1990;22(1):134.
187. Furue M, Seki Y, Oohara K, et al. Basal cell epithelioma arising in a patient with Hailey-Hailey's disease. *Int J Dermatol*. 1987;26(7):461-462.
188. Mohr MR, Erdag G, Shada AL, et al. Two patients with Hailey-Hailey disease, multiple primary melanomas, and other cancers. *Arch Dermatol*. 2011;147(2):211-215.
189. Ochiai T, Honda A, Morishima T, et al. Human papillomavirus types 16 and 39 in a vulval carcinoma occurring in a woman with Hailey-Hailey disease. *Br J Dermatol*. 1999;140(3):509-513.
190. Chen MY, Chiu HC, Su LH, et al. Presence of human papillomavirus type 6 DNA in the perineal verrucoid lesions of Hailey-Hailey disease. *J Eur Acad Dermatol Venereol*. 2006;20(10):1356-1357.
191. Chan CC, Thong HY, Chan YC, et al. Human papillomavirus type 5 infection in a patient with Hailey-Hailey disease successfully treated with imiquimod. *Br J Dermatol*. 2007;156(3):579-581.
192. von Felbert V, Hampl M, Talhari C, et al. Squamous cell carcinoma arising from a localized vulval lesion of Hailey-Hailey disease after tacrolimus therapy. *Am J Obstet Gynecol*. 2010;203(3):e5-7.
193. Korner J, Rietschel M, Nothen MM, et al. Familial cosegregation of affective disorder and Hailey-Hailey disease. *Br J Psychiatry*. 1993;163:109-110.
194. Wilk M, Rietschel M, Korner J, et al. Pemphigus chronicus benignus familiaris (Hailey-Hailey disease) and bipolar affective disease in 3 members of a family. *Hautarzt*. 1994;45(5):313-317.
195. Yokota K, Sawamura D. Hailey-Hailey disease with affective disorder: report of a case with novel ATP2C1 gene mutation. *J Dermatol Sci*. 2006;43(2):150-151.
196. Hu Z, Bonifas JM, Beech J, et al. Mutations in ATP2C1, encoding a calcium pump, cause Hailey-Hailey disease. *Nat Genet.* 2000;24(1):61-65.
197. Sudbrak R, Brown J, Dobson-Stone C, et al. Hailey-Hailey disease is caused by mutations in ATP2C1 encoding a novel Ca(2+) pump. *Hum Mol Genet*. 2000;9(7):1131-1140.
198. Missiaen L, Dode L, Vanoevelen J, et al. Calcium in the Golgi apparatus. *Cell Calcium*. 2007;41(5):405-416.
199. Vanoevelen J, Dode L, Raeymaekers L, et al. Diseases involving the Golgi calcium pump. *Subcell Biochem*. 2007;45:385-404.
200. Missiaen L, Raeymaekers L, Dode L, et al. SPCA1 pumps and Hailey-Hailey disease. *Biochem Biophys Res Commun.* 2004;322(4):1204-1213.
201. Dobson-Stone C, Fairclough R, Dunne E, et al. Hailey-Hailey disease: molecular and clinical characterization of novel mutations in the ATP2C1 gene. *J Invest Dermatol*. 2002;118(2):338-343.
202. Chao SC, Tsai YM, Yang MH. Mutation analysis of ATP2C1 gene in Taiwanese patients with Hailey-Hailey disease. *Br J Dermatol*. 2002;146(4):595-600.
203. Yokota K, Yasukawa K, Shimizu H. Analysis of ATP2C1 gene mutation in 10 unrelated Japanese families with Hailey-Hailey disease. *J Invest Dermatol*. 2002;118(3):550-551.
204. Li H, Sun XK, Zhu XJ. Four novel mutations in ATP2C1 found in Chinese patients with Hailey-Hailey disease. *Br J Dermatol*. 2003;149(3):471-474.
205. Fairclough RJ, Lonie L, Van Baelen K, et al. Hailey-Hailey disease: identification of novel mutations in ATP2C1 and effect of missense mutation A528P on protein expression levels. *J Invest Dermatol*. 2004;123(1):67-71.
206. Majore S, Biolcati G, Barboni L, et al. ATP2C1 gene mutation analysis in Italian patients with Hailey-Hailey disease. *J Invest Dermatol*. 2005;125(5):933-935.
207. Ohtsuka T, Okita H, Hama N, et al. Novel mutation in ATP2C1 gene in a Japanese patient with Hailey-Hailey disease. *Dermatology.* 2006;212(2):194-197.
208. Racz E, Csikos M, Karpati S. Novel mutations in the ATP2C1 gene in two patients with Hailey-Hailey disease. *Clin Exp Dermatol*. 2005;30(5):575-577.
209. Zhang XQ, Wu HZ, Li BX, et al. Mutations in the ATP2C1 gene in Chinese patients with Hailey-Hailey disease. *Clin Exp Dermatol*. 2006;31(5):702-705.

210. Li X, Xiao S, Peng Z, et al. Two novel mutations of the ATP2C1 gene in Chinese patients with Hailey-Hailey disease. *Arch Dermatol Res*. 2007;299(4): 209-211.
211. Nemoto-Hasebe I, Akiyama M, Osawa R, et al. Diagnosis of Hailey-Hailey disease facilitated by DNA testing: a novel mutation in ATP2C1. *Acta Derm Venereol*. 2008;88(4):399-400.
212. Hamada T, Fukuda S, Sakaguchi S, et al. Molecular and clinical characterization in Japanese and Korean patients with Hailey-Hailey disease: six new mutations in the ATP2C1 gene. *J Dermatol Sci*. 2008;51(1):31-36.
213. Fairclough RJ, Dode L, Vanoevelen J, et al. Effect of Hailey-Hailey disease mutations on the function of a new variant of human secretory pathway Ca^{2+}/Mn^{2+}-ATPase (hSPCA1). *J Biol Chem*. 2003; 278(27):24721-24730.
214. Rice WJ, MacLennan DH. Scanning mutagenesis reveals a similar pattern of mutation sensitivity in transmembrane sequences M4, M5, and M6, but not in M8, of the Ca^{2+}-ATPase of sarcoplasmic reticulum (SERCA1a). *J Biol Chem*. 1996;271(49):31412-31419.
215. Wilgram GF, Caulfield JB, Lever WF. An electron-microscopic study of acantholysis and dyskeratosis in Hailey's disease. *J Invest Dermatol*. 1962;39: 373-381.
216. Gottlieb SK, Lutzner MA. Hailey-Hailey disease—an electron microscopic study. *J Invest Dermatol*. 1970;54(5):368-376.
217. Inohara S, Tatsumi Y, Tanaka Y, et al. Immunohistochemical localization of desmosomal and cytoskeletal proteins in the epidermis of healthy individuals and patients with Hailey-Hailey's disease. *Acta Derm Venereol*. 1990;70(3):239-241.
218. Bergman R, Levy R, Pam Z, et al. A study of keratin expression in benign familial chronic pemphigus. *Am J Dermatopathol*. 1992;14(1):32-36.
219. Burge SM, Schomberg KH. Adhesion molecules and related proteins in Darier's disease and Hailey-Hailey disease. *Br J Dermatol*. 1992;127(4):335-343.
220. Harada M, Hashimoto K, Fujiwara K. Immunohistochemical distribution of CD44 and desmoplakin I & II in Hailey-Hailey's disease and Darier's disease. *J Dermatol*. 1994;21(6):389-393.
221. Haftek M, Kowalewski C, Mesnil M, et al. Internalization of gap junctions in benign familial pemphigus (Hailey-Hailey disease) and keratosis follicularis (Darier's disease). *Br J Dermatol*. 1999;141(2):224-230.
222. Burge SM, Millard PR, Wojnarowska F. Hailey-Hailey disease: a widespread abnormality of cell adhesion. *Br J Dermatol*. 1991;124(4):329-332.
223. Yoshida M, Yamasaki K, Daiho T, et al. ATP2C1 is specifically localized in the basal layer of normal epidermis and its depletion triggers keratinocyte differentiation. *J Dermatol Sci*. 2006;43(1):21-33.
224. Behne MJ, Tu CL, Aronchik I, et al. Human keratinocyte ATP2C1 localizes to the Golgi and controls Golgi Ca^{2+} stores. *J Invest Dermatol*. 2003;121(4): 688-694.
225. Cialfi S, Oliviero C, Ceccarelli S, et al. Complex multipathways alterations and oxidative stress are associated with Hailey-Hailey disease. *Br J Dermatol*. 2010;162(3):518-526.
226. Aberg KM, Racz E, Behne MJ, et al. Involucrin expression is decreased in Hailey-Hailey keratinocytes owing to increased involucrin mRNA degradation. *J Invest Dermatol*. 2007;127(8):1973-1979.
227. Aronchik I, Behne MJ, Leypoldt L, et al. Actin reorganization is abnormal and cellular ATP is decreased in Hailey-Hailey keratinocytes. *J Invest Dermatol*. 2003;121(4):681-687.
228. Okunade GW, Miller ML, Azhar M, et al. Loss of the Atp2c1 secretory pathway Ca(2+)-ATPase (SPCA1) in mice causes Golgi stress, apoptosis, and midgestational death in homozygous embryos and squamous cell tumors in adult heterozygotes. *J Biol Chem*. 2007;282(36):26517-26527.
229. Micaroni M, Perinetti G, Berrie CP, et al. The SPCA1 Ca^{2+} pump and intracellular membrane trafficking. *Traffic*. 2010;11(10):1315-1333.
230. Micaroni M, Giacchetti G, Plebani R, et al. ATP2C1 gene mutations in Hailey-Hailey disease and possible roles of SPCA1 isoforms in membrane trafficking. *Cell Death Dis*. 2016;7(6):e2259.
231. Manca S, Magrelli A, Cialfi S, et al. Oxidative stress activation of miR-125b is part of the molecular switch for Hailey-Hailey disease manifestation. *Exp Dermatol*. 2011;20(11):932-937.
232. Cialfi S, Le Pera L, De Blasio C, et al. The loss of ATP2C1 impairs the DNA damage response and induces altered skin homeostasis: consequences for epidermal biology in Hailey-Hailey disease. *Sci Rep*. 2016;6:31567.
233. Metze D, Hamm H, Schorat A, et al. Involvement of the adherens junction-actin filament system in acantholytic dyskeratosis of Hailey-Hailey disease. A histological, ultrastructural, and histochemical study of lesional and non-lesional skin. *J Cutan Pathol*. 1996;23(3):211-222.
234. Chave TA, Milligan A. Acute generalized Hailey-Hailey disease. *Clin Exp Dermatol*. 2002;27(4):290-292.
235. Ewald K, Gross G. Perianal Hailey-Hailey disease: an unusual differential diagnosis of condylomata acuminata. *Int J STD AIDS*. 2008;19(11):791-792.
236. Evron S, Leviatan A, Okon E. Familial benign chronic pemphigus appearing as leukoplakia of the vulva. *Int J Dermatol*. 1984;23(8):556-557.
237. Chiaravalloti A, Payette M. Hailey-Hailey disease and review of management. *J Drugs Dermatol*. 2014;13(10):1254-1257.
238. Arora H, Bray FN, Cervantes J, et al. Management of familial benign chronic pemphigus. *Clin Cosmet Investig Dermatol*. 2016;9:281-290.
239. Farahnik B, Blattner CM, Mortazie MB, et al. Interventional treatments for Hailey-Hailey disease. *J Am Acad Dermatol*. 2017;76(3):551-558;e553.
240. Kellermayer R, Szigeti R, Keeling KM, et al. Aminoglycosides as potential pharmacogenetic agents in the treatment of Hailey-Hailey disease. *J Invest Dermatol*. 2006;126(1):229-231.
241. Umar SA, Bhattacharjee P, Brodell RT. Treatment of Hailey-Hailey disease with tacrolimus ointment and clobetasol propionate foam. *J Drugs Dermatol*. 2004;3(2):200-203.
242. Rabeni EJ, Cunningham NM. Effective treatment of Hailey-Hailey disease with topical tacrolimus. *J Am Acad Dermatol*. 2002;47(5):797-798.
243. Reuter J, Termeer C, Bruckner-Tuderman L. Tacrolimus-a new therapeutic option for Hailey-Hailey-disease?. *J Dtsch Dermatol Ges*. 2005;3(4):278-279.
244. Sand C, Thomsen HK. Topical tacrolimus ointment is an effective therapy for Hailey-Hailey disease. *Arch Dermatol*. 2003;139(11):1401-1402.
245. Persic-Vojinovic S, Milavec-Puretic V, Dobric I, et al. Disseminated Hailey-Hailey disease treated with

topical tacrolimus and oral erythromycin: case report and review of the literature. *Acta Dermatovenerol Croat*. 2006;14(4):253-257.
246. Rocha Paris F, Fidalgo A, Baptista J, et al. Topical tacrolimus in Hailey-Hailey disease. *Int J Tissue React*. 2005;27(4):151-154.
247. Laffitte E, Panizzon RG. Is topical tacrolimus really an effective therapy for Hailey-Hailey disease? *Arch Dermatol*. 2004;140(10):1282.
248. Pagliarello C, Paradisi A, Dianzani C, et al. Topical tacrolimus and 50% zinc oxide paste for Hailey-Hailey disease: less is more. *Acta Derm Venereol*. 2012; 92(4):437-438.
249. Bianchi L, Chimenti MS, Giunta A. Treatment of Hailey-Hailey disease with topical calcitriol. *J Am Acad Dermatol*. 2004;51(3):475-476.
250. Rajpara SM, King CM. Hailey-Hailey disease responsive to topical calcitriol. *Br J Dermatol*. 2005;152(4): 816-817.
251. Aoki T, Hashimoto H, Koseki S, et al. 1alpha, 24-dihydroxyvitamin D3 (tacalcitol) is effective against Hailey-Hailey disease both in vivo and in vitro. *Br J Dermatol*. 1998;139(5):897-901.
252. Dammak A, Camus M, Anyfantakis V, et al. Successful treatment of Hailey-Hailey disease with topical 5-fluorouracil. *Br J Dermatol*. 2009;161(4):967-968.
253. Defresne C, Adam C, de Marneffe K. Benign familial chronic pemphigus Hailey-Hailey. *Dermatologica*. 1982;165(6):624-626.
254. Hunt MJ, Salisbury EL, Painter DM, et al. Vesiculobullous Hailey-Hailey disease: successful treatment with oral retinoids. *Australas J Dermatol.* 1996; 37(4):196-198.
255. Berger EM, Galadari HI, Gottlieb AB. Successful treatment of Hailey-Hailey disease with acitretin. *J Drugs Dermatol*. 2007;6(7):734-736.
256. Vilarinho C, Ventura F, Brito C. Methotrexate for refractory Hailey-Hailey disease. *J Eur Acad Dermatol Venereol*. 2010;24(1):106.
257. Berth-Jones J, Smith SG, Graham-Brown RA. Benign familial chronic pemphigus (Hailey-Hailey disease) responds to cyclosporin. *Clin Exp Dermatol*. 1995; 20(1):70-72.
258. Varada S, Ramirez-Fort MK, Argobi Y, et al. Remission of refractory benign familial chronic pemphigus (Hailey-Hailey disease) with the addition of systemic cyclosporine. *J Cutan Med Surg*. 2015; 19(2):163-166.
259. Sire DJ, Johnson BL. Benign familial chronic pemphigus treated with dapsone. *Arch Dermatol*. 1971;103(3): 262-265.
260. Norman R, Greenberg RG, Jackson JM. Case reports of etanercept in inflammatory dermatoses. *J Am Acad Dermatol*. 2006;54(3 suppl 2):S139-142.
261. Hurd DS, Johnston C, Bevins A. A case report of Hailey-Hailey disease treated with alefacept (Amevive). *Br J Dermatol*. 2008;158(2):399-401.
262. Biolcati G, Aurizi C, Barbieri L, et al. Efficacy of the melanocortin analogue Nle4-D-Phe7-alpha-melanocyte-stimulating hormone in the treatment of patients with Hailey-Hailey disease. *Clin Exp Dermatol*. 2014;39(2):168-175.
263. Kaniszewska M, Rovner R, Arshanapalli A, et al. Oral glycopyrrolate for the treatment of Hailey-Hailey disease. *JAMA Dermatol*. 2015;151(3):328-329.
264. Shons AR. Wide excision of perineal Hailey-Hailey disease with healing by secondary intention. *Br J Plast Surg*. 1989;42(2):230-232.
265. Menz P, Jackson IT, Connolly S. Surgical control of Hailey-Hailey disease. *Br J Plast Surg*. 1987;40(6): 557-561.
266. Guerin-Surville H, Guerin-Surville L, Le Louarn C, et al. Surgical treatment of Hailey-Hailey disease by surgical grafting (2d report): results after a 5-year follow-up. *Ann Dermatol Venereol*. 1989;116(11):904-905.
267. Hamm H, Metze D, Brocker EB. Hailey-Hailey disease. Eradication by dermabrasion. *Arch Dermatol*. 1994;130(9):1143-1149.
268. Kirtschig G, Gieler U, Happle R. Treatment of Hailey-Hailey disease by dermabrasion. *J Am Acad Dermatol*. 1993;28(5 Pt 1):784-786.
269. Kartamaa M, Reitamo S. Familial benign chronic pemphigus (Hailey-Hailey disease). Treatment with carbon dioxide laser vaporization. *Arch Dermatol*. 1992;128(5):646-648.
270. Kruppa A, Korge B, Lasch J, et al. Successful treatment of Hailey-Hailey disease with a scanned carbon dioxide laser. *Acta Derm Venereol*. 2000;80(1):53-54.
271. McElroy JA, Mehregan DA, Roenigk RK. Carbon dioxide laser vaporization of recalcitrant symptomatic plaques of Hailey-Hailey disease and Darier's disease. *J Am Acad Dermatol*. 1990;23(5 Pt 1):893-897.
272. Roos DE, Reid CM. Benign familial pemphigus: little benefit from superficial radiotherapy. *Australas J Dermatol*. 2002;43(4):305-308.
273. Narbutt J, Lesiak A, Arkuszewska C, et al. Effective treatment of recalcitrant Hailey-Hailey disease with electron beam radiotherapy. *J Eur Acad Dermatol Venereol*. 2007;21(4):567-568.
274. Ruiz-Rodriguez R, Alvarez JG, Jaen P, et al. Photodynamic therapy with 5-aminolevulinic acid for recalcitrant familial benign pemphigus (Hailey-Hailey disease). *J Am Acad Dermatol*. 2002;47(5):740-742.
275. Fernandez Guarino M, Ryan AM, Harto A, et al. Experience with photodynamic therapy in Hailey-Hailey disease. *J Dermatolog Treat*. 2008;19(5):288-290.
276. Konrad H, Karamfilov T, Wollina U. Intracutaneous botulinum toxin A versus ablative therapy of Hailey-Hailey disease—a case report. *J Cosmet Laser Ther*. 2001;3(4):181-184.
277. Koeyers WJ, Van Der Geer S, Krekels G. Botulinum toxin type A as an adjuvant treatment modality for extensive Hailey-Hailey disease. *J Dermatolog Treat*. 2008;19(4):251-254.
278. Lapiere JC, Hirsh A, Gordon KB, et al. Botulinum toxin type A for the treatment of axillary Hailey-Hailey disease. *Dermatol Surg*. 2000;26(4):371-374.
279. Ho D, Jagdeo J. Successful botulinum toxin (onabotulinumtoxinA) treatment of Hailey-Hailey disease. *J Drugs Dermatol*. 2015;14(1):68-70.
280. Grover RW. Transient acantholytic dermatosis. *Arch Dermatol*. 1970;101(4):426-434.
281. Chalet M, Grover R, Ackerman AB. Transient acantholytic dermatosis: a reevaluation. *Arch Dermatol*. 1977;113(4):431-435.
282. Heenan PJ, Quirk CJ. Transient acantholytic dermatosis. *Br J Dermatol*. 1980;102(5):515-520.
283. Parsons JM. Transient acantholytic dermatosis (Grover's disease): a global perspective. *J Am Acad Dermatol*. 1996;35(5 Pt 1):653-666; quiz 667-670.
284. Davis MD, Dinneen AM, Landa N, et al. Grover's disease: clinicopathologic review of 72 cases. *Mayo Clinic proceedings*. 1999;74(3):229-234.
285. Maghraoui S, Crickx B, Grossin M, et al. [Transient acantholytic dermatosis (Grover disease)]. *Ann Dermatol Venereol*. 1995;122(11-12):801-806.

286. Streit M, Paredes BE, Braathen LR, et al. Transitory acantholytic dermatosis (Grover disease). An analysis of the clinical spectrum based on 21 histologically assessed cases. *Hautarzt*. 2000;51(4):244-249.
287. Waisman M, Stewart JJ, Walker AE. Bullous transient acantholytic dermatosis. *Arch Dermatol*. 1976; 112(10):1440-1441.
288. Quirk CJ, Heenan PJ. Grover's disease: 34 years on. *Australas J Dermatol*. 2004;45(2):83-86; quiz 87-88.
289. Cooper SM, Dhittavat J, Millard P, et al. Extensive Grover's-like eruption with lentiginous "freckling": report of two cases. *Br J Dermatol*. 2004;150(2): 350-352.
290. Girard C, Durand L, Guillot B, et al. Persistent acantholytic dermatosis and extensive lentiginous 'freckling': a new entity? *Br J Dermatol*. 2005;153(1):217-218; author reply 218.
291. Rowley MJ, Nesbitt LT Jr, Carrington PR, et al. Hypopigmented macules in acantholytic disorders. *Int J Dermatol*. 1995;34(6):390-392.
292. Fantini F, Kovacs E, Scarabello A. Unilateral transient acantholytic dermatosis (Grover's disease) along Blaschko lines. *J Am Acad Dermatol*. 2002;47(2): 319-320.
293. Garcon N, Karam A, Lemasson G, et al. Paraneoplastic transient acantholytic dermatosis (Grover's disease) along Blaschko lines. *Eur J Dermatol*. 2009;19(4): 405-406.
294. Powell J, Sakuntabhai A, James M, et al. Grover's disease, despite histological similarity to Darier's disease, does not share an abnormality in the ATP2A2 gene. *Br J Dermatol*. 2000;143(3):658.
295. Hu CH, Michel B, Farber EM. Transient acantholytic dermatosis (Grover's disease). A skin disorder related to heat and sweating. *Arch Dermatol*. 1985;121(11):1439-1441.
296. French LE, Piletta PA, Etienne A, et al. Incidence of transient acantholytic dermatosis (Grover's disease) in a hospital setting. *Dermatology*. 1999;198(4):410-411.
297. Fujita Y, Sato-Matsumura KC, Ohnishi K. Transient acantholytic dermatosis associated with B symptoms of follicular lymphoma. *Clin Exp Dermatol*. 2007;32(6):752-754.
298. Guana AL, Cohen PR. Transient acantholytic dermatosis in oncology patients. *J Clin Oncol*. 1994; 12(8):1703-1709.
299. Scheinfeld N, Mones J. Seasonal variation of transient acantholytic dyskeratosis (Grover's disease). *J Am Acad Dermatol*. 2006;55(2):263-268.
300. Grover RW, Rosenbaum R. The association of transient acantholytic dermatosis with other skin diseases. *J Am Acad Dermatol*. 1984;11(2 Pt 1):253-256.
301. Rosina P, Melzani G, Marcelli M, et al. Grover's disease (transient acantholytic dermatosis) associated with atopy. *J Eur Acad Dermatol Venereol*. 2005; 19(3):390-391.
302. Ishibashi M, Nagasaka T, Chen KR. Remission of transient acantholytic dermatosis after the treatment with rituximab for follicular lymphoma. *Clin Exp Dermatol*. 2008;33(2):206-207.
303. Held JL, Bank D, Grossman ME. Grover's disease provoked by ionizing radiation. *J Am Acad Dermatol*. 1988;19(1 Pt 1):137-138.
304. Tscharner GG, Buhler S, Borner M, et al. Grover's disease induced by cetuximab. *Dermatology*. 2006;213(1):37-39.
305. Boutli F, Voyatzi M, Lefaki I, et al. Transient acantholytic dermatosis (Grover's disease) in a renal transplant patient. *J Dermatol*. 2006;33(3):178-181.
306. Paslin D. Grover disease may result from the impairment of keratinocytic cholinergic receptors. *J Am Acad Dermatol*. 2012;66(2):332-333.
307. Weaver J, Bergfeld WF. Grover disease (transient acantholytic dermatosis). *Arch Pathol Lab Med*. 2009;133(9):1490-1494.
308. Simon RS, Bloom D, Ackerman AB. Persistent acantholytic dermatosis. A variant of transient acantholytic dermatosis (Grover disease). *Arch Dermatol*. 1976; 112(10):1429-1431.
309. Fawcett HA, Miller JA. Persistent acantholytic dermatosis related to actinic damage. *Br J Dermatol*. 1983;109(3):349-354.
310. Eros N, Kovacs A, Karolyi Z. Successful treatment of transient acantholytic dermatosis with systemic steroids. *J Dermatol*. 1998;25(7):469-475.
311. Keohane SG, Cork MJ. Treatment of Grover's disease with calcipotriol (Dovonex). *Br J Dermatol*. 1995;132(5):832-833.
312. Mota AV, Correia TM, Lopes JM, et al. Successful treatment of Grover's disease with calcipotriol. *Eur J Dermatol*. 1998;8(1):33-35.
313. Hayashi H, Yokota K, Koizumi H, et al. Treatment of Grover's disease with tacalcitol. *Clin Exp Dermatol*. 2002;27(2):160-161.
314. Miljkovic J, Marko PB. Grover's disease: successful treatment with acitretin and calcipotriol. *Wien Klin Wochenschr*. 2004;116(suppl 2):81-83.

Chapter 51 :: Porokeratosis

:: Cathal O'Connor, Grainne M. O'Regan, & Alan D. Irvine

AT-A-GLANCE

- Porokeratosis is a chronic progressive disorders of keratinization characterized clinically by hyperkeratotic papules or plaques surrounded by a threadlike, elevated border that expands centrifugally.
- Porokeratosis is genetically heterogeneous; the majority are inherited as autosomal dominant traits.
- At least six clinical variants of porokeratosis have been described.
- The classic form, porokeratosis of Mibelli, presents in infancy or childhood as asymptomatic, small, brown to skin-colored, annular papules with a characteristic raised border.
- The most common type, disseminated superficial actinic porokeratosis, presents with multiple papules distributed symmetrically on sun-exposed areas.
- Linear porokeratosis presents at birth or in childhood with lesions distributed along Blaschko lines.
- Punctate porokeratosis appears during or after adolescence as 1- to 2-mm papules on the palms or soles.
- In all variants, a thin column of parakeratotic cells (cornoid lamella) corresponds to the hyperkeratotic border and extends throughout the stratum corneum in histologic sections.
- Malignant epithelial neoplasms are reported in all subtypes except the punctate variety.

INTRODUCTION

Porokeratosis is a morphologically distinct disorder of keratinization characterized clinically by hyperkeratotic papules or plaques surrounded by a threadlike elevated border that expands centrifugally. Histologically, a thin column of parakeratotic cells extends throughout the stratum corneum and is seen in all variants. This distinctive histopathologic feature, known as the *cornoid lamella*, corresponds to the raised hyperkeratotic border evident clinically.

At least six clinical variants of porokeratosis are recognized, and recent genetic progress has additionally allowed classification according to the underlying mutation (Table 51-1). Reports of one type of porokeratosis coexisting with other forms and different types developing in multiple members of an affected family suggest more similarities than disparities, particularly in the disseminated forms. Thus, it is important to allow for some flexibility around clinical subcategorization.[1-3]

EPIDEMIOLOGY

The most common variants are disseminated superficial actinic porokeratosis and porokeratosis of Mibelli. The other forms are rare. Porokeratosis usually occurs in fair-skinned individuals and is rare in darker-skinned people. Porokeratosis of Mibelli and porokeratosis palmaris et plantaris disseminata are twice as likely to affect men. Disseminated superficial actinic porokeratosis is twice as likely to occur in women.[4] Linear porokeratosis is seen with equal incidence in men and women. Porokeratosis of Mibelli usually develops in childhood. Disseminated superficial porokeratosis generally develops in the third or fourth decade of life. Porokeratosis palmaris et plantaris disseminata and linear porokeratosis can be seen at any age from birth to adulthood.

CLINICAL FINDINGS

POROKERATOSIS OF MIBELLI

Classic porokeratosis of Mibelli (PM) begins during infancy or childhood as asymptomatic, small, brown to skin-colored, annular papules with a characteristic annular border (Fig. 51-1). The well-demarcated hyperkeratotic border is usually more than 1 mm in height, with a characteristic longitudinal furrow. The center of the lesion may be hyperpigmented, hypopigmented, depressed, atrophic, or anhidrotic. Lesions range in diameter from millimeters to several centimeters, but giant lesions measuring up to 20 cm may occur. Such giant porokeratoses are rare and occur predominantly on the lower leg and foot. Large lesions are associated with a higher malignant potential.[5] Multiple lesions may arise; however, they are usually regionally localized and unilateral. The condition is inherited as an autosomal dominant trait. Lesions persist indefinitely.

DISSEMINATED SUPERFICIAL ACTINIC POROKERATOSIS

Disseminated superficial actinic porokeratosis (DSAP) is the most common of the porokeratoses. Lesions are

TABLE 51-1
Clinical Variants of Porokeratosis and Genes and Genetic Loci Identified to Date

CONDITION	GENE	LOCUS	OMIM	INHERITANCE
Porokeratosis 1 (porokeratosis of Mibelli)	*PMVK*	1q21.3	175800	AD
Porokeratosis 2 (porokeratosis palmaris et plantaris disseminata)	Not yet identified	12q24.1–q24.2	175850	AD
Porokeratosis 3 (disseminated superficial actinic porokeratosis 1)	*MVK*	12q24.11	175900	AD
Porokeratosis 4 (disseminated superficial actinic porokeratosis 2)	Not yet identified	15q25.1–15q26.1	607728	AD
Porokeratosis 5 (disseminated superficial actinic porokeratosis 3)	Not yet identified	1p31.3–1p31.1	612293	AD
Porokeratosis 6 (disseminated superficial porokeratosis)	Not yet identified	18p11.3	612353	AD
Porokeratosis 7 (multiple types)	*MVD*	16q24.2	614714	AD
Porokeratosis 8 (disseminated superficial actinic porokeratosis 4)	*SLC17A9*	20q13.33	616063	AD
Porokeratosis 9 (multiple types)	*FDPS*	1q22	616631	
CDAGS syndrome	?*RUNX2*	22q12–22q13	603116	AR

AD, autosomal dominant; AR, autosomal recessive; CDAGS, craniosynostosis and clavicular hypoplasia, *d*elayed closure of the fontanel, *a*nal anomalies, *g*enitourinary malformations, skin eruption; OMIM, Online Mendelian Inheritance in Man.

characteristically uniformly small, annular, asymptomatic, or mildly pruritic papules ranging from 2 to 5 mm in diameter, distributed symmetrically on the extremities. Lesions are more generalized than other forms of porokeratosis, with typically more than 50 lesions located predominantly in sun-exposed sites (Fig. 51-2). Although widespread, lesions typically spare the palms, soles, and mucous membranes. Compared with porokeratosis of Mibelli, the hyperkeratotic border is subtler. As the lesions progress, the older, central area becomes atrophic and anhidrotic. DSAP is inherited as an autosomal dominant disorder, with the earliest reported age of onset at 7 years, and is usually fully penetrant by the third or fourth decade of life.[6] Initial reports of induction of lesions by exposure to ultraviolet (UV) light and hypersensitivity of DSAP-derived fibroblasts to x-rays have not been consistently reproduced, and the pathogenesis of DSAP remains unknown.[7-10]

Figure 51-1 Porokeratosis of Mibelli is characterized by a single large lesion with a clearly defined edge. The scaling is not clearly seen at the border because of the interdigital location of this lesion.

DISSEMINATED SUPERFICIAL POROKERATOSIS

Disseminated superficial porokeratosis (DSP) also shows an autosomal dominant pattern of inheritance and has its onset in the third or fourth decade of life. Lesions primarily are morphologically identical to those of DSAP, occur on the extremities, and are typically distributed symmetrically but do not spare sun-protected areas as in DSAP. Similar to DSAP, more than 100 lesions may be present, with a predilection for the extensor surfaces of the extremities. Notably, involvement of the face is rare in both DSAP and DSP. In both disseminated forms, there is a reported female predominance, with a female-to-male ratio of 2 to 1.

DISSEMINATED SUPERFICIAL POROKERATOSIS OF IMMUNOSUPPRESSION

Disseminated superficial porokeratosis in the context of immunosuppression is recognized after renal,

Figure 51-2 **A,** Disseminated superficial actinic porokeratosis with multiple lesions on the forearm in this severely affected individual. **B,** The characteristic furrowing (*arrows*) is clearly demonstrated on the forearm of this patient.

hepatic, and cardiac transplantation; electron-beam irradiation;[11] immunosuppressive chemotherapy; monoclonal antibodies;[12] systemic corticosteroids with hematopoietic malignancies;[13] and in the setting of HIV infection.[14] It has recently been described in association with type 2 diabetes mellitus as well.[15] Porokeratosis has also been reported after bone marrow transplantation in the absence of ongoing immunosuppressive therapy, which suggests a more complex association than immunosuppression alone.[16] The distribution and morphology of DSP of immunosuppression are similar to those of DSAP, but a history of sun exposure is less evident.

LINEAR POROKERATOSIS

Linear porokeratosis is an uncommon variant, traditionally categorized as a separate entity, but is increasingly recognized as a mosaic manifestation of one of the other types of porokeratosis.[17] Typically, it presents in early childhood, although congenital presentations have been reported.[18] Two distinct clinical variants have been described. The more common presentation consists of a unilateral lesion confined to an extremity following Blaschko lines (Fig. 51-3). In the rare generalized form, multiple lesions affect several extremities and may involve the trunk. Linear variants have the highest potential for malignant degeneration of all the porokeratoses.

It has been postulated that this association can be attributed to allelic loss caused by a postzygotic mutation.[19] The proband in Mibelli's original publication most likely had coexistent linear porokeratosis and DSAP, with several subsequent reports confirming this phenomenon.[3,17,20,21] These findings may be explained by the loss of heterozygosity for the DSAP allele and provides an example of the type 2 segmental manifestations of an autosomal dominant disorder.[22,23]

Figure 51-3 Linear porokeratosis showing the characteristic distribution along Blaschko lines.

POROKERATOSIS PALMARIS ET PLANTARIS DISSEMINATA

Porokeratosis palmaris et plantaris disseminata (porokeratosis punctata palmaris et plantaris) is a genodermatosis with an autosomal dominant inheritance pattern characterized by small, relatively uniform lesions (Fig. 51-4) that initially appear on the palms and soles. Subsequently, lesions spread to involve other parts of the body, including the mucous membranes and non–sun-exposed sites. The palmar and plantar lesions are generally more hyperkeratotic, and the characteristic longitudinal furrow along this ridge may be quite pronounced (Fig. 51-5). Typically, the lesions appear during adolescence or early adulthood and are bilateral and distributed symmetrically. Porokeratosis palmaris et plantaris disseminata affects males twice as often as females.

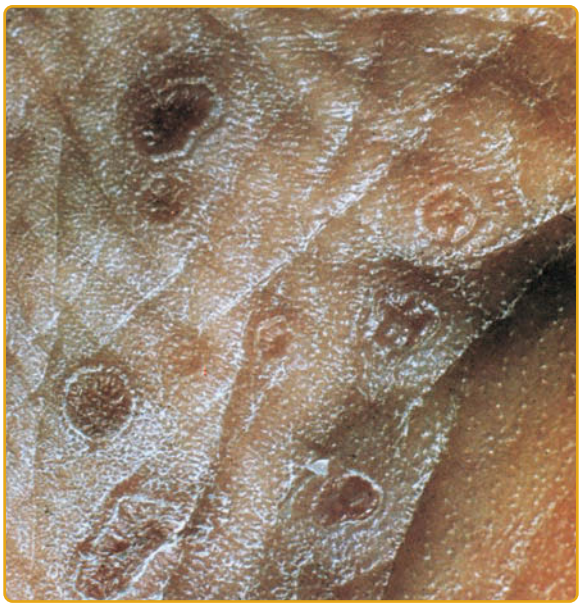

Figure 51-5 Sole of the foot in a patient with porokeratosis palmaris et plantaris disseminata. The ridge and furrow are clearly seen.

PUNCTATE POROKERATOSIS

Punctate porokeratosis usually appears during adolescence or adulthood and may be seen concomitantly with other types of porokeratosis. Multiple minute and discrete punctate, hyperkeratotic lesions surrounded by a thin, raised margin are present on the palms and soles. Lesions may occur in a linear arrangement, or they may aggregate to form plaques. Punctate porokeratosis must be differentiated clinically and histologically from punctate keratoderma, also referred to as punctate porokeratotic keratoderma or as porokeratosis punctata palmaris et plantaris (see Chap. 48).

Figure 51-4 Porokeratosis palmaris et plantaris disseminata showing multiple superficial lesions on the calf. Note the similarity to disseminated superficial actinic porokeratosis shown in Fig. 51-2A.

CDAGS SYNDROME

CDAGS syndrome (*c*raniosynostosis and clavicular hypoplasia, *d*elayed closure of the fontanel, *a*nal anomalies, *g*enitourinary malformations, *s*kin eruption), also referred to as CAP syndrome (*c*raniosynostosis, *a*nal anomalies, and *p*orokeratosis), is a rare genodermatosis reported in four ethnically diverse families to date.[24,25] The main phenotypic features consist of craniosynostosis and clavicular hypoplasia, anal anomalies, and porokeratosis. It appears to segregate as an autosomal recessive trait, with possible linkage to chromosome band 22q12–13.[25] The cutaneous manifestations are strikingly consistent, with the development of small, widespread porokeratotic papules from 1 month of age in affected individuals, predominantly affecting the face and extremities, with reported photoaggravation of lesions.

ETIOLOGY AND PATHOGENESIS

Porokeratosis is a genetically heterogeneous disorder with multiple loci identified to date. A splicing mutation in phosphomevalonate kinase (*PMVK*), involved in the cholesterol biosynthetic pathway, has been shown to cause PM.[26] The mevalonate kinase (*MVK*) gene on

chromosome 12q24 has recently been identified as a causative gene in DSAP.[27] The product of this gene has a role in regulating calcium-induced keratinocyte differentiation and may confer protection against apoptosis induced by ultraviolet A radiation. Loci at chromosome bands 12q23.2–24.1 and 15q25 (DSAP1 and DSAP2) have been reported in other forms of familial disseminated superficial actinic porokeratoses; a further locus has been identified for disseminated superficial porokeratosis (DSP) at 18p11.3.[28,29] The locus at *DSAP1* includes several candidate genes, including *SART3* (squamous cell antigen recognized by T cells 3), *SSH1* (slingshot 1), and *ARPC3*.[30,31] Porokeratosis punctata palmaris et plantaris maps to a region at chromosome band 12q24.1–24.2, overlapping with the region identified for DSAP1, suggesting that the two forms may be allelic.[32] The centrifugal expansion of lesions is postulated to reflect the migration of a mutant clone of keratinocytes.[33,34] The tumor suppressor proteins p53 and pRb are overexpressed in keratinocytes immediately beneath and adjacent to the cornoid lamella, although to date p53 mutations have not been identified, and there is no significant expression of p53 at the mRNA level.[7,35-38] The increased prevalence of porokeratosis in immunosuppressed patients suggests that impaired immunity may be permissive in genetically predisposed individuals.[39-42] Other reported triggering factors such as exposure to UV light, together with the increased potential for malignant transformation, highlight the dysplastic potential of affected keratinocytes. Malignant degeneration has been described in all variants of porokeratosis, except for the punctate variety.[5,43,44]

HISTOPATHOLOGY

Histopathologic patterns are similar in all forms of porokeratosis, with the characteristic changes evident at the raised and advancing edge of the lesion. The stratum corneum is hyperkeratotic, with a thin column of poorly staining parakeratotic cells, the cornoid lamella, running through the surrounding normal-staining cells (Fig. 51-6). The underlying keratinocytes are edematous with spongiosis and shrunken nuclei, and a striking dermal lymphocytic pattern may be evident. Underlying the cornoid lamella, the granular layer is either absent or markedly reduced but is of normal thickness in other areas of the lesion. The epidermis in the central portion of porokeratosis may be normal, hyperplastic, or atrophic. Although characteristic of porokeratosis, the cornoid lamella is not pathognomonic and may also be found in other conditions, such as viral warts, some ichthyoses, and nevoid hyperkeratoses.

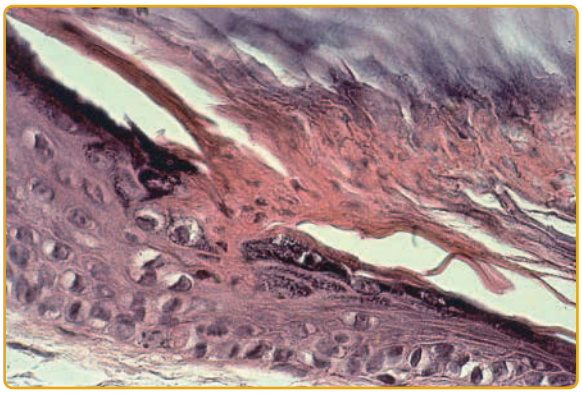

Figure 51-6 The cornoid lamella arises from an indentation of the epidermis and extends as a thin column throughout the stratum corneum. The underlying granular layer is either absent or reduced.

DIFFERENTIAL DIAGNOSIS

The classic lesions of porokeratosis are clinically distinctive, and the diagnosis is usually clinically apparent. However, atypical lesions may require differentiation (Table 51-2). Actinic keratoses, for example, may show cornoid lamellae but also show cytologic atypia. Verruca vulgaris often shows mounds of parakeratosis that are sometimes identical to cornoid lamellae, but koilocytosis is usually present. Linear porokeratosis may be clinically confused with other linear lesions (see Table 51-2), none of which has a cornoid lamella.

TREATMENT

Lesions of porokeratosis are chronic, slowly progressive, and relatively asymptomatic, although intense pruritus has been reported.[45] Intervention is usually unnecessary, and disease surveillance is standard. If the lesions are problematic or cosmetically unacceptable, treatment with potent topical steroids, keratolytics, topical retinoids, topical 5-fluorouracil,[46] imiquimod 5%, calcipotriol,[47] anthralin,[48] cryotherapy,[49] carbon dioxide laser,[50] pulsed dye laser,[51] or Nd:YAG (neodymium-doped yttrium aluminum garnet) laser may be considered (Table 51-3). Tacrolimus 0.1% has been shown to be useful in treating patients with linear porokeratosis.[52] Electrochemotherapy with intralesional bleomycin has been successful in treating

TABLE 51-2
Differential Diagnosis of Porokeratosis

Localized Lesions

Most Likely

- Granuloma annulare
- Tinea corporis
- Actinic keratosis
- Viral warts

Consider

- Elastosis perforans
- Lichen planus
- Focal dermal hypoplasia (Goltz syndrome)

Linear

Consider

- Linear inflammatory verrucous epidermal nevus
- Incontinentia pigmenti (stage II)
- Linear lichen planus
- Ichthyosis linearis circumflexa

TABLE 51-3
Treatment for Porokeratosis

	TOPICAL	SURGICAL	SYSTEMIC
First line	Photoprotection 5-Fluorouracil	Cryotherapy	
Second line	Calcipotriol Imiquimod Topical corticosteroids Topical retinoids	CO_2 laser vaporization	Oral retinoids
Third line	Dermabrasion Nd:YAG laser Grenz ray	Surgical excision	

Nd:YAG, neodymium-doped yttrium aluminum garnet.

patients with squamous cell carcinomas (SCCs) associated with linear porokeratosis.[53] To prevent residual lesions or recurrence, ablative measures that reach the middermis are required. Techniques such as curettage, excision, and dermabrasion[54] have been used with variable degrees of success. Oral retinoids have been shown to give the most reproducible results, although the disease typically recurs after their discontinuation. Given the association with malignancy, closer disease surveillance and a lower threshold for biopsy of suspicious lesions may be warranted in cases of giant porokeratoses or linear lesions and in immunosuppressed individuals.

COURSE AND PROGNOSIS

The porokeratoses are generally chronic and progressive, with lesions increasing in size and number with time. Typically, this process occurs over decades in PM, but may be rapid in DSAP, particularly after sun exposure. In cases of immune compromise, fluctuations in severity may parallel the state of immune competence, and there are reports of remission after removal of primary malignancy.[42] The disease is generally considered a benign process; however, malignant degeneration may occur. Malignancy is thought to arise in 7% to 11% of individuals, although these figures are likely overestimated. SCC is the most frequently associated tumor and may be invasive. Bowen disease and basal cell carcinoma have also been reported. Spontaneous resolution of lesions has been reported, although it is exceptionally rare.[55]

SUMMARY

A summary of the porokeratosis subtypes can be found in Table 51-4.

TABLE 51-4
Summary of Porokeratosis Subtypes

	INHERITANCE AND RISK FACTORS	EPIDEMIOLOGY	CLINICAL FINDINGS	SPECIAL CONCERNS
Porokeratosis of Mibelli	Autosomal dominant	Onset in infancy or childhood; male predominance	Asymptomatic, small, brown to skin-colored annular papules with an annular border	Large lesions have malignant potential
Disseminated superficial actinic porokeratosis (DSAP)	Autosomal dominant	Most common porokeratosis; as early as childhood; often present by third to fourth decade of life; female predominance	Uniform, small, annular, papules from 2-5 mm, with symmetrical distribution on photoexposed extremities; asymptomatic or mildly pruritic	—
Disseminated superficial porokeratosis	Autosomal dominant	Onset by third to fourth decade of life; female predominance	Similar to above but with distribution to photoprotected sites	—
Disseminated superficial porokeratosis of immunosuppression	Immunosuppression after organ transplantation, drugs, or infections (see text)	Dependent on exposure (see risk factors)	Similar to DSAP	—
Linear porokeratosis	Mosaic manifestation of other porokeratosis variants	Uncommon; presents in early childhood	Primary manifestation dependent on particular variant, however configuration follows lines of Blaschko	Highest potential for malignant degeneration
Porokeratosis palmaris et plantaris disseminata	Autosomal dominant	Appear during adolescence or early adulthood; male predominance	Small, uniform lesions appearing on palms and soles with involvement to other sites; bilateral, symmetric involvement	—
Punctate porokeratosis	Concomitant occurrence with other forms of porokeratosis	Appears during adolescence or adulthood	Multiple discrete punctate hyperkeratotic lesions; may aggregate to form plaques	—

REFERENCES

1. Lin JH, Hsu MM, Sheu HM, et al. Coexistence of three variants of porokeratosis with multiple squamous cell carcinomas arising from lesions of giant hyperkeratotic porokeratosis. *J Eur Acad Dermatol Venereol*. 2006;20:621.
2. Kaur S, Thami GP, Mohan H, et al. Coexistence of variants of porokeratosis: a case report and a review of the literature. *J Dermatol*. 2002;29:305.
3. Mibelli V. Contributo allo studio della ipercheratosi dei canali sudoriferi. *G Ital Mal Venereol Pelle*. 1893;28:313.
4. Sertznig P, von Felbert V, Megahed M. Porokeratosis: present concepts. *J Eur Acad Dermatol Venereol*. 2012; 26(4):404-412.
5. Sasson M, Krain AD. Porokeratosis and cutaneous malignancy. A review. *Dermatol Surg*. 1996;22:339.
6. Zhang SQ, Jiang T, Li M, et al. Exome sequencing identifies MVK mutations in disseminated superficial actinic porokeratosis. *Nat Genet*. 2012;44(10):1156-1160.
7. Arranz-Salas I, Sanz-Trelles A, Ojeda DB. p53 alterations in porokeratosis. *J Cutan Pathol*. 2003;30:455.
8. Chernosky ME, Anderson DE. Disseminated superficial actinic porokeratosis. Clinical studies and experimental production of lesions. *Arch Dermatol*. 1969;99:401.
9. D'Errico M, Teson M, Calcagnile A, et al. Characterization of the ultra-violet B and X-ray response of primary cultured epidermal cells from patients with disseminated superficial actinic porokeratosis. *Br J Dermatol*. 2004;150:47.
10. Schamroth JM, Zlotogorski A, Gilead L. Porokeratosis of Mibelli. Overview and review of the literature. *Acta Derm Venereol*. 1997;77:207.
11. Leibovici V, Zeidenbaum M, Goldenhersh M. Porokeratosis and immunosuppressive treatment for pemphigus foliaceus. *J Am Acad Dermatol*. 1988;19:910.
12. Frew JW, Parsi K. Adalimumab-induced porokeratosis. *Australas J Dermatol*. 2015;56(3):e80-e81.
13. Luelmo-Aguilar J, Gonzalez-Castro U, Mieras-Barcelo C, et al. Disseminated porokeratosis and myelodysplastic syndrome. *Dermatology*. 1992;184:289.
14. Rodriguez EA, Jakubowicz S, Chinchilla DA, et al. Porokeratosis of Mibelli and HIV infection. *Int J Dermatol*. 1996;35:402.
15. Yalcin B, Uysal PI, Kadan E, et al. Eruptive disseminated porokeratosis in a patient with type 2 diabetes mellitus. *Am J Dermatopathol*. 2016;38(8):e125-e127.
16. Alexis AF, Busam K, Myskowski PL. Porokeratosis of Mibelli following bone marrow transplantation. *Int J Dermatol*. 2006;45:361.
17. Happle R. Mibelli revisited: a case of type 2 segmental porokeratosis from 1893. *J Am Acad Dermatol*. 2010; 62(1):136-138.
18. Zhang ZH, Xiang LH, Chen LJ, et al. Congenital facial linear porokeratosis. *Clin Exp Dermatol*. 2005;30:361.
19. Sasaki S, Urano Y, Nakagawa K, et al. Linear porokeratosis with multiple squamous cell carcinomas: study of p53 expression in porokeratosis and squamous cell carcinoma. *Br J Dermatol*. 1996;134:1151.
20. Suh DH, Lee HS, Kim SD, et al. Coexistence of disseminated superficial porokeratosis in childhood with congenital linear porokeratosis. *Pediatr Dermatol*. 2000;17:466.
21. Welton WA. Linear porokeratosis in a family with DSAP. *Arch Dermatol*. 1972;106:263.
22. Happle R. A rule concerning the segmental manifestation of autosomal dominant skin disorders. Review of clinical examples providing evidence for dichotomous types of severity. *Arch Dermatol*. 1997;133:1505.
23. Happle R. Somatic recombination may explain linear porokeratosis associated with disseminated superficial actinic porokeratosis. *Am J Med Genet*. 1991;39:237.
24. Flanagan N, Boyadjiev SA, Harper J, et al. Familial craniosynostosis, anal anomalies, and porokeratosis: CAP syndrome. *J Med Genet*. 1998;35:763.
25. Mendoza-Londono R, Lammer E, Watson R, et al. Characterization of a new syndrome that associates craniosynostosis, delayed fontanel closure, parietal foramina, imperforate anus, and skin eruption: CDAGS. *Am J Hum Genet*. 2005;77:161.
26. Zeng K, Zhang QG, Li L, et al. Splicing mutation in MVK is a cause of porokeratosis of Mibelli. *Arch Dermatol Res*. 2014;306(8):749-755.
27. Wu LQ, Yang YF, Zheng D, et al. Confirmation and refinement of a genetic locus for disseminated superficial actinic porokeratosis (DSAP1) at 12q23.2-24.1. *Br J Dermatol*. 2004;150:999.
28. Xia K, Deng H, Xia JH, et al. A novel locus (DSAP2) for disseminated superficial actinic porokeratosis maps to chromosome 15q25.1-26.1. *Br J Dermatol*. 2002;147:650.
29. Wei S, Yang S, Lin D, et al. A novel locus for disseminated superficial porokeratosis maps to chromosome 18p11.3. J *Invest Dermatol*. 2004;123:872.
30. Zhang Z, Niu Z, Yuan W, et al. Fine mapping and identification of a candidate gene SSH1 in disseminated superficial actinic porokeratosis. *Hum Mutat*. 2004;24:438.
31. Zhang ZH, Huang W, Niu ZM, et al. Two closely linked variations in actin cytoskeleton pathway in a Chinese pedigree with disseminated superficial actinic porokeratosis. *J Am Acad Dermatol*. 2005;52:972.
32. Wei SC, Yang S, Li M, et al. Identification of a locus for porokeratosis palmaris et plantaris disseminata to a 6.9-cM region at chromosome 12q24.1-24.2. *Br J Dermatol*. 2003;149:261.
33. Reed RJ, Leone P. Porokeratosis—a mutant clonal keratosis of the epidermis. I. Histogenesis. *Arch Dermatol*. 1970;101:340.
34. Otsuka F, Shima A, Ishibashi Y. Porokeratosis has neoplastic clones in the epidermis: microfluorometric analysis of DNA content of epidermal cell nuclei. *J Invest Dermatol*. 1989;92:231S.
35. Chang SE, Lim Y, Lee H, et al. Expression of p53, pRb, p16 and proliferating cell nuclear antigen in squamous cell carcinomas arising on a giant porokeratosis. *Br J Dermatol*. 1999;141:575.
36. Magee JW, McCalmont TH, LeBoit PE. Overexpression of p53 tumor suppressor protein in porokeratosis. *Arch Dermatol*. 1994;130:187.
37. Ninomiya Y, Urano Y, Yoshimoto K, et al. p53 gene mutation analysis in porokeratosis and porokeratosis-associated squamous cell carcinoma. *J Dermatol Sci*. 1997;14:173.
38. Puig L, Alegre M, Costa I, et al. Overexpression of p53 in disseminated superficial actinic porokeratosis with and without malignant degeneration. *Arch Dermatol*. 1995;131:353.
39. Bencini PL, Tarantino A, Grimalt R, et al. Porokeratosis and immunosuppression. *Br J Dermatol*. 1995;132:74.
40. Herranz P, Pizarro A, De Lucas R, et al. High incidence of porokeratosis in renal transplant recipients. *Br J Dermatol*. 1997;136:176.
41. Silver SG, Crawford RI. Fatal squamous cell carcinoma arising from transplant-associated porokeratosis. *J Am Acad Dermatol*. 2003;49:931.

42. Tsambaos D, Spiliopoulos T. Disseminated superficial porokeratosis: complete remission subsequent to discontinuation of immunosuppression. *J Am Acad Dermatol*. 1993;28:651.
43. Maubec E, Duvillard P, Margulis A, et al. Common skin cancers in porokeratosis. *Br J Dermatol*. 2005;152:1389.
44. Otsuka F, Iwata M, Watanabe R, et al. Porokeratosis: clinical and cellular characterization of its cancer-prone nature. *J Dermatol*. 1992;19:702.
45. Kanzaki T, Miwa N, Kobayashi T, et al. Eruptive pruritic papular porokeratosis. *J Dermatol*. 1992;19:109.
46. McDonald SG, Peterka ES. Porokeratosis (Mibelli): treatment with topical 5-fluorouracil. *J Am Acad Dermatol*. 1983;8:107.
47. Harrison PV, Stollery N. Disseminated superficial actinic porokeratosis responding to calcipotriol. *Clin Exp Dermatol*. 1994;19:95.
48. Kosogabe M, Tada J, Arata J. [Punctate porokeratotic keratoderma]. *Nippon Hifuka Gakkai Zasshi*. 1991;101:553.
49. Dereli T, Ozyurt S, Ozturk G. Porokeratosis of Mibelli: successful treatment with cryosurgery. *J Dermatol*. 2004;31:223.
50. Barnett JH. Linear porokeratosis: treatment with the carbon dioxide laser. *J Am Acad Dermatol*. 1986;14:902.
51. Alster TS, Nanni CA. Successful treatment of porokeratosis with 585 nm pulsed dye laser irradiation. *Cutis*. 1999;63:265.
52. Parks AC, Conner KJ, Armstrong CA. Long-term clearance of linear porokeratosis with tacrolimus, 0.1%, ointment. *JAMA Dermatol*. 2014;150(2):194-196.
53. Sommerlad M, Lock A, Moir G, et al. Linear porokeratosis with multiple squamous cell carcinomas successfully treated by electrochemotherapy. *Br J Dermatol*. 2016;175(6):1342-1345.
54. Spencer JM, Katz BE. Successful treatment of porokeratosis of Mibelli with diamond fraise dermabrasion. *Arch Dermatol*. 1992;128:1187.
55. Adriaans B, Salisbury JR. Recurrent porokeratosis. *Br J Dermatol*. 1991;124:383.

Vesiculobullous Disorders

PART 9

Chapter 52 :: Pemphigus

:: Aimee S. Payne & John R. Stanley

AT-A-GLANCE

- Two major types: pemphigus vulgaris and pemphigus foliaceus.
- Pemphigus vulgaris: erosions on mucous membranes and skin; flaccid blisters on skin.
- Pemphigus foliaceus: crusted, scaly skin lesions.
- Pemphigus vulgaris histology: suprabasal acantholysis.
- Pemphigus foliaceus histology: subcorneal acantholysis.
- Autoantigens are desmogleins, transmembrane desmosomal adhesion molecules.
- Diagnosis depends on histology showing intraepidermal acantholysis, immunofluorescence studies documenting the presence of cell surface autoantibodies, either bound to patient skin or in the serum, and/or enzyme-linked immunosorbent assay showing anti-desmoglein antibodies
- Therapy includes topical and systemic corticosteroids, oral immunosuppressive agents, intravenous immunoglobulin, and rituximab (anti-CD20 monoclonal antibody).

INTRODUCTION

DEFINITIONS

The term *pemphigus* refers to a group of autoimmune blistering diseases of skin and mucous membranes that are characterized histologically by intraepidermal blisters due to acantholysis (ie, separation of epidermal cells from each other) and immunopathologically by in vivo bound and circulating immunoglobulin directed against the cell surface of keratinocytes. The nosology of this group of diseases is outlined in Table 52-1. Essentially, pemphigus can be divided into 4 major types: vulgaris, foliaceus (Table 52-2), paraneoplastic (Chap. 53), and IgA pemphigus (Chap. 57). In pemphigus vulgaris (PV), the blister occurs in the deeper part of the epidermis, just above the basal layer, and in pemphigus foliaceus (PF), also called *superficial pemphigus*, the blister is in the granular layer.

HISTORICAL PERSPECTIVE

The history of the discovery of pemphigus, and its various forms, is covered in Walter Lever's classic monograph *Pemphigus* and *Pemphigoid*.[1] Both PV and PF display a spectrum of disease. Various points along these spectra have been given unique names, but because the presentation of these diseases is fluid, patients' disease usually crosses these artificial designations over time. Thus, patients with PV may present with more localized disease, one form of which is called *pemphigus vegetans of Hallopeau*. This may become slightly more extensive and may merge into *pemphigus vegetans of Neumann*. Finally, with more severe disease, full-blown PV may appear. Similarly, patients with PF may present with more localized disease, represented by *pemphigus erythematosus*. However, these patients often go on to more widespread PF.

The discovery by Ernst Beutner and Robert Jordon in 1964 of circulating antibodies against the cell surface of keratinocytes in the sera of patients with PV pioneered our understanding that PV is a tissue-specific autoimmune disease of skin and mucosa.[2] Ultimately, their work led the way to the discoveries of autoantibodies in other autoimmune bullous diseases of the skin.

TABLE 52-1
Nosology and Differential Diagnosis of Pemphigus

Pemphigus Subtypes
- Pemphigus vulgaris
- Pemphigus vegetans
- Pemphigus foliaceus
- Pemphigus erythematosus
- Endemic pemphigus foliaceus (eg, fogo selvagem)
- Immunoglobulin A (IgA) pemphigus
- Subcorneal pustular dermatosis
- Intraepidermal neutrophilic dermatosis
- Paraneoplastic pemphigus

Intraepidermal Blistering Diseases Without Autoantibodies
- Familial benign pemphigus (Hailey-Hailey disease)
- Bullous impetigo, staphylococcal scalded-skin syndrome
- Blisters from herpes simplex and zoster
- Allergic contact dermatitis (eg, rhus dermatitis)
- Epidermolysis bullosa simplex
- Incontinentia pigmenti

Mouth Ulcers/Erosion Without Autoantibodies
- Aphthous ulcers
- Candidiasis
- Lichen planus
- Behçet disease

Subepidermal Blistering Diseases With Autoantibodies
- Bullous pemphigoid
- Herpes gestationis
- Cicatricial pemphigoid
- Epidermolysis bullosa acquisita
- Linear IgA disease and chronic bullous disease of childhood
- Dermatitis herpetiformis
- Bullous lupus erythematosus

Subepidermal Blistering Diseases Without Autoantibodies
- Erythema multiforme
- Toxic epidermal necrolysis
- Porphyria
- Junctional or dystrophic epidermolysis bullosa

EPIDEMIOLOGY

INCIDENCE, PREVALENCE, AND SEX RATIO

A few prospective and several retrospective surveys of patients with pemphigus clearly indicate that the epidemiology of pemphigus is dependent on both the area in the world that is studied and the ethnic population in that area.[3-11] PV is more common in Jews and probably in people of Mediterranean descent and from the Middle East. This same ethnic predominance does not exist for PF. Therefore, in areas where the Jewish, Middle Eastern, and Mediterranean population predominates, the ratio of PV to PF cases tends to be higher. For example, in New York, Los Angeles, and Croatia, the ratio of PV to PF cases is approximately 5:1; in Iran the ratio is 12:1; whereas in Singapore it is 2:1 and in Finland, it is only 0.5:1. Similarly, the incidence of pemphigus varies by region. In Jerusalem, the incidence of PV has been estimated to be 1.6 per 100,000 people per year and in Iran approximately 10.0 per 100,000 people per year. In Europe, the incidences are lower, ranging from a high of 0.7 PV cases per 100,000 person years in the United Kingdom to 10-fold less, 0.5 to 1.0 per million person years, in Finland, France, Germany, and Switzerland. In Taiwan, the incidence is 4.7 per million per year.

The prevalence and incidence of PF are also very dependent on its location, as best exemplified by the finding of endemic foci of PF in Brazil, Colombia, and Tunisia. The first recognition of endemic PF was in Brazil and is called *fogo selvagem*, which means "wild fire" in Portuguese. It is a disease that is clinically, histologically, and immunopathologically the same as sporadic PF in any individual patient, but its epidemiology is unique.[12,13] Fogo selvagem is endemic in the rural areas of Brazil, especially along inland riverbeds. The prevalence in some well-studied Indian reservations in rural Brazil can be as high as 3.4%, with the incidence up to 0.8 to 4.0 new cases per 1000 people per year.[13,14] On the reservation in Limao Verde, up to 55% of unaffected individuals have a low-level IgG1 antibody response against desmoglein 1, the PF autoantigen, which becomes an IgG4 response of higher titer against a more pathogenic epitope in disease.[13] Fogo selvagem occurs often in children and young adults, unlike sporadic PF, which is a disease of mostly middle-aged and older patients. Also unlike PF, fogo selvagem occurs not infrequently in genetically related family members, although it is not contagious. There is no known racial or ethnic predominance, and anyone moving into an endemic area may be susceptible to disease. Furthermore, the urban development of rural endemic areas of Brazil decreased the incidence of disease (Fig. 52-1).

These epidemiologic associations suggest that an environmental agent may trigger a low-level autoantibody response that in some genetically susceptible individuals becomes pathogenic against desmoglein 1 by intermolecular epitope spreading. With this theory in mind, it is interesting that 40% to 80% of patients from Brazil with the insect-borne diseases onchocerciasis, leishmaniasis, and Chagas disease have low-level anti-desmoglein 1 antibodies, but patients with other infectious diseases from Brazil rarely have such antibodies.[15] Subsequent studies have shown that IgG4 and IgE antibodies from fogo selvagem patients recognize salivary gland antigens from the sand fly *Lutzomyia longipalpis*, the vector of leishmaniasis.[16] The current theory is that fogo selvagem may initiate with an IgE response against the sand fly salivary antigen LJM11, which cross-reacts with desmoglein 1 and then generalizes to an IgG4 response.[17,18] This fascinating disease holds clues to understanding how this autoimmune response is triggered.

The sex ratio of pemphigus in women versus men ranges from 1.33 to 2.25.[7,9,19-24] Notable outliers to this estimate are the predominance of women (4:1) in an endemic focus of PF in Tunisia,[6] and a predominance of men (19:1) in an endemic focus of PF in Colombia.[25]

TABLE 52-2
Pemphigus Subtypes and Variants

	CUTANEOUS FINDINGS	MUCOUS MEMBRANE INVOLVEMENT	PATHOLOGY	IMMUNOFLUORESCENCE		ELISA (QUANTITATIVE)
				DIRECT (NONQUANTITATIVE)	INDIRECT (SEMIQUANTITATIVE)	
Pemphigus vulgaris	Flaccid blisters, typically sparing palmoplantar surface Large erosions are common presentations (+) Nikolsky sign	Oral and nasal mucous membranes most commonly affected Esophageal Vulvar, cervical, vaginal Ocular	Suprabasal blister with acantholysis "row of tombstones" appearance	IgG bound to surface of keratinocytes (intercellular pattern)	Monkey esophagus substrate ideal IgG in cell surface pattern	Desmogleins 1, 3 (mucosal and skin involvement) Desmoglein 3 (mucosal dominant)
Pemphigus vegetans[a]	Erosions develop excessive papillomatosis tissue and crusting; intertriginous areas, scalp, or face	Oral involvement is common[*]	Suprabasal acantholysis, with papillomatosis of the dermal papillae and downward growth of epidermal strands into the dermis; presence of hyperkeratosis and scale-crust; eosinophilic or neutrophilic intraepidermal abscesses	IgG on cell surface of keratinocytes[*]	IgG in cell surface pattern[*]	Desmoglein 3, sometimes desmoglein 1
Pemphigus foliaceus	Scaly, crusted lesions on erythematous base; seborrheic distribution (face, scalp, upper trunk); small flaccid blisters are transient primary lesions	Very rare	Early lesions show eosinophilic spongiosis; histopathology demonstrates acantholysis below stratum corneum; epidermis beneath the granular layer remains intact; subcorneal pustules containing neutrophils and acantholytic epidermal cells in the blister cavity	IgG bound to surface of keratinocytes (intercellular pattern)	Guinea pig esophagus or human skin substrate ideal IgG in intercellular pattern	Desmoglein 1
Pemphigus erythematosus[b]	Crusted lesions in seborrheic distribution	Rare	Similar to pemphigus foliaceus	IgG and C3 deposition at granular basement membrane zone, IgG with intercellular pattern		Desmoglein 1[†]
Endemic pemphigus foliaceus *(fogo selvagem)*[c]	Similar to pemphigus foliaceus; characterized by burning sensation, and exacerbation on sun exposure	Rare	Similar to pemphigus foliaceus	Similar to pemphigus foliaceus		Desmoglein 1

[a]Variant of pemphigus vulgaris.

[b]Variant of pemphigus foliaceus.

[c]Similar to pemphigus foliaceus clinically, histologically, and serologically, however with distinct epidemiologic features.[‡]

[*]Ruoco V, Ruocco E, Caccavale S, et al. Pemphigus vegetans of the folds (intertriginous areas). *Clin Dermatol*. 2015;33(4):471-476.

[†]Oktarina D, Poot A, Kramer D. The IgG "lupus-band" deposition pattern of pemphigus erythematosus. Association with the desogein 1 ectodomain as revealed by 3 cases. *Arch Dermatol*. 2012;148(10):1173-1178.

[‡]Rocha-Alvares R, Ortega-Loayza A, Friedman H. Endemic pemphigus vulgaris. *Arch Dermatol*. 2007;143(7):895-899.

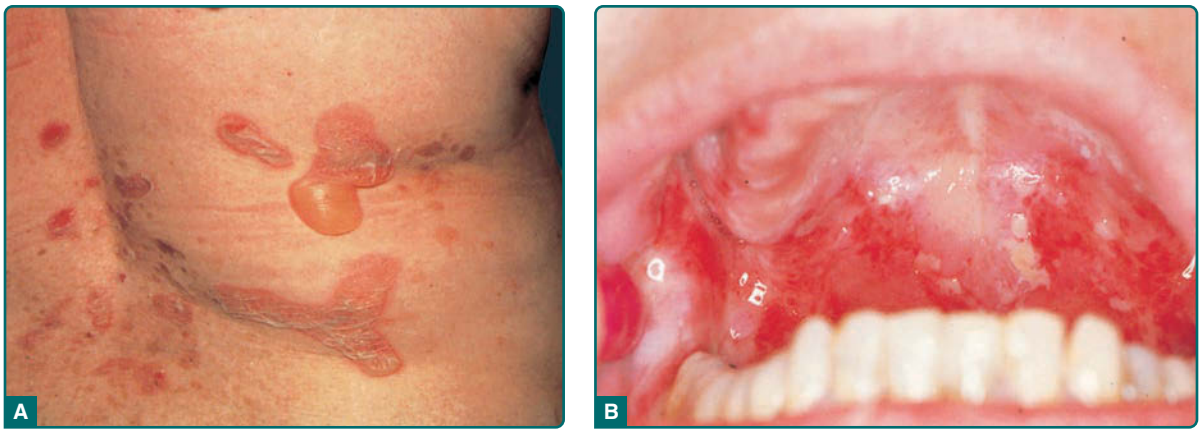

Figure 52-1 Pemphigus vulgaris. **A,** Flaccid blisters. (Used with permission from Lawrence Lieblich, MD.) **B,** Oral erosions.

AGE OF ONSET

The average age of disease onset also varies by region. In Turkey, Saudi Arabia, Tunisia, and Iran, the mean age of onset is approximately 40 years.[6,19,21,26] Studies in the United States, Europe, and Taiwan demonstrate an average age of onset between 50 and 70 years.[5,6,9-11,20,22,27-29] Pemphigus rarely occurs in children,[30] except in regions of endemic disease.

CLINICAL FEATURES

PEMPHIGUS VULGARIS

CUTANEOUS FINDINGS

The skin lesions in PV can be pruritic or painful. Exposure to ultraviolet radiation may exacerbate disease activity.[31,32] The primary lesion of PV is a flaccid blister, which may occur anywhere on the skin surface, but typically not the palms and soles (Fig. 52-1A, Table 52-2). Usually, the blister arises on normal-appearing skin, but it may develop on erythematous skin. Because PV blisters are fragile, the most common skin lesions observed in patients are erosions resulting from broken blisters. These erosions are often quite large, as they have a tendency to spread at their periphery (Fig. 52-2).

A characteristic finding in pemphigus patients is that erosions can be extended into visibly normal skin by pulling the remnant of the blister wall or rubbing at the periphery of active lesions; additionally, erosions can be induced in normal-appearing skin distant from active lesions by pressure or mechanical shear force. This phenomenon is known as the *Nikolsky sign*.[33] This sign helps differentiate pemphigus from other blistering diseases of the skin such as pemphigoid (Table 52-1); however, similar findings also can be elicited in staphylococcal scalded skin syndrome, Stevens-Johnson syndrome, and toxic epidermal necrolysis.

In certain patients, erosions have a tendency to develop excessive papillimatosis and crusting, referred to as vegetating lesions (Fig. 52-3). This type of lesion tends to occur more frequently in intertriginous areas, in the scalp, or on the face. Generally, the prognosis for these so-called pemphigus vegetans patients is thought to be better, with milder disease and a higher chance of remission compared to typical PV patients.[34] Some ordinary PV lesions heal with a vegetating morphology and can remain for long periods of time in one place. Thus, vegetating lesions seem to be one reactive pattern of the skin to the autoimmune insult of PV.

Figure 52-2 Pemphigus vulgaris. Extensive erosions due to blistering. Almost the entire back is denuded. Note intact, flaccid blisters at the lower border of eroded lesions.

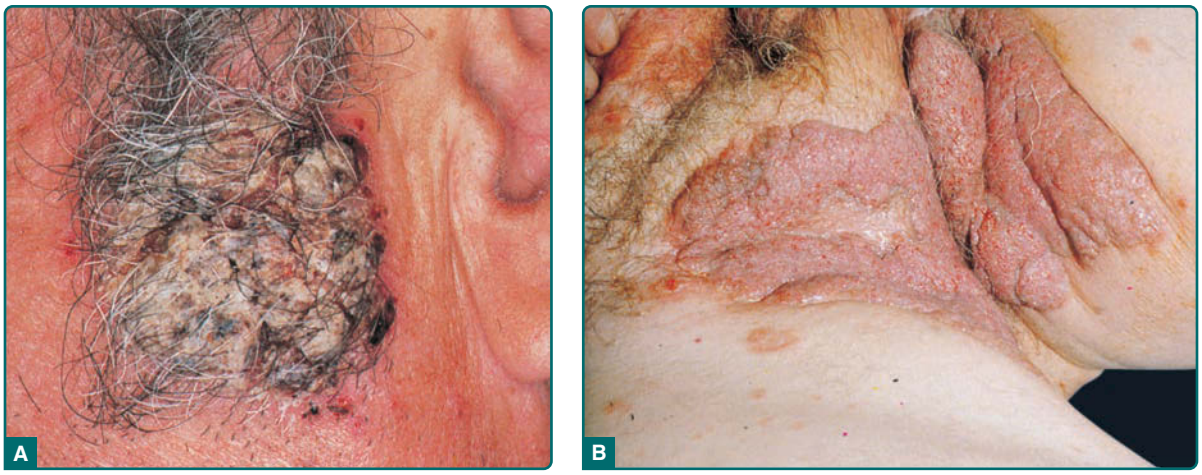

Figure 52-3 **A,** Crusted, vegetating lesions in pemphigus vulgaris. **B,** Extensive, vegetating lesions in intertriginous regions in pemphigus vegetans-type pemphigus vulgaris.

Although hair loss is not a usual feature in pemphigus, temporary hair loss can be seen in about 5% of patients and can rarely be a presenting sign of disease.[35]

MUCOUS MEMBRANE LESIONS

The mucous membranes most often affected by PV are those of the oropharyngeal cavity (Fig. 52-1B) and nasal mucosa.[36,37] Endoscopic evaluation revealed that 87% of PV patients had ear, nose, or throat lesions, with involvement of nasal mucosa, pharynx, and larynx being most common at 76%, 66%, and 55%, respectively.[38] Laryngeal involvement was often asymptomatic. As with cutaneous lesions, intact blisters are rare. Oropharyngeal erosions can be so painful that the patient is unable to eat or drink. The inability to eat or drink adequately may require inpatient hospitalization for disease control and intravenous fluid and nutrient repletion.

In the majority of patients, painful mucous membrane erosions are the presenting sign of PV and may be the only sign for an average of 5 months before skin lesions develop.[3] However, the presenting symptoms may vary; in a study from Croatia, painful oral lesions were the presenting symptom in 32% of patients.[23] Most of these patients progressed to a more generalized eruption in 5 months to 1 year; however, some had oral lesions for more than 5 years before generalization. On the other hand, in Tehran, 62% of patients presented with oral lesions only.[7] Skin involvement without mucous membrane involvement in PV is less common, accounting in one study for 11% of PV cases.[39]

GI tract involvement with PV has been described in the esophagus, stomach, duodenum, and anus, although only biopsies of the esophagus have proven the lesions were due to suprabasal acantholysis.[7,40,41] About 27% of PV patients demonstrate such PV histology on blind biopsies of the esophagus.[41] Furthermore, esophageal involvement may be asymptomatic but may also lead to esophagitis dissecans, evidenced by sloughing of esophageal casts.[41,42] Involvement of other mucous membranes can also occur, including the vulvovaginal and ocular epithelia.[43-46] Vulvar and cervicovaginal lesions may be found in up to 51% of women with active disease but these lesions may be asymptomatic. Vulvar lesions are most common and may cause severe burning with urination. Even without obvious lesions, Pap smears may be positive in women with pemphigus and the acantholytic cells may be misinterpreted as indicative of cervical dysplasia.[47,48] There is ocular involvement in about 16% of PV patients, some with erosions of the conjunctiva, but findings may be nonspecific.[49] There are rare case reports of corneal erosions in PV patients, but without histologic confirmation of acantholysis.[50]

PEMPHIGUS FOLIACEUS

CUTANEOUS FINDINGS

The characteristic clinical lesions of PF are scaly, crusted erosions, often on an erythematous base. In more localized and early disease, these lesions are usually well demarcated and scattered in a seborrheic distribution, including the face, scalp, and upper trunk (Fig. 52-4A, Table 52-2). The primary lesions of small flaccid blisters are typically not found. Disease may stay localized for years, or it may rapidly progress to generalized involvement, resulting in an exfoliative erythroderma (Fig. 52-4B). Like PV, PF may be exacerbated by ultraviolet radiation.[32,51,52] Patients with PF often complain of pain and burning in the skin lesions. In contrast to patients with PV, those with PF very rarely, if ever, have mucous membrane involvement, even with widespread disease.

The colloquial term for Brazilian endemic pemphigus, fogo selvagem (Portuguese for "wild fire"), takes into account many of the clinical aspects of this disease: the burning feeling of the skin, the exacerbation of disease by the sun, and the crusted lesions that make the patients appear as if they had been burned.

Figure 52-4 Pemphigus foliaceus. **A.** Scaly, crusted lesions on upper back. **B.** Exfoliative erythroderma due to confluent lesions.

PEMPHIGUS ERYTHEMATOSUS

In 1926, Francis Senear and Barney Usher described 11 patients with features of a pemphigus-lupus erythematosus overlap (*Senear-Usher syndrome*).[53] Over the next several decades, debate over whether these patients had lupus erythematosus, pemphigus, seborrheic dermatitis, or features of all 3 disorders continued, with Senear concluding that the disease is best considered a variant of pemphigus, termed *pemphigus erythematosus*.[54] As these observations were made prior to the development of immunofluorescence testing for both pemphigus and lupus, the diagnosis was primarily based on the clinical presentation: crusted erosions in a seborrheic distribution, at times concurrent with more lupuslike discoid lesions with "carpet-tack" scale. Walter Lever noted that many patients initially categorized as pemphigus erythematosus went on to develop systemic lupus, or more widespread pemphigus foliaceus, or even pemphigus vulgaris, in some cases because of incorrect initial diagnosis. Therefore, rather than perpetuate the use of one term for different diseases, he proposed that pemphigus erythematosus be used to describe a localized form of PF with better prognosis.[1] After the development of immunofluorescence and antinuclear antibody testing for pemphigus and lupus, it was discovered that pemphigus erythematosus patients demonstrate immunologic overlap features; by definition, all demonstrate the cell surface staining pattern classic for pemphigus, approximately 30% have positive antinuclear antibody titers, and 80% have positive lupus band tests, although the latter test is only positive in 20% to 40% of biopsies on non–sun-exposed skin.[55] Subsequent studies have shown that the positive "lupus band" test in pemphigus erythematosus patients is due to granular deposits of IgG and cleaved desmoglein 1 ectodomain deposited at the basement membrane zone, which is thought to occur after ultraviolet light exposure.[56] Thus, because most patients with pemphigus erythematosus do not develop systemic signs or symptoms of lupus, and some may progress from localized disease to generalized PF,[57] the diagnosis of the pemphigus erythematosus variant of PF is largely one of historic, rather than clinical, significance.

NEONATAL PEMPHIGUS

Infants born to mothers with PV may display clinical, histologic, and immunopathologic signs of pemphigus vulgaris.[58,59] The degree of involvement varies from none to severe enough to result in a stillbirth. If the infant survives, disease tends to remit as maternal antibody is catabolized. Mothers with PF may also transmit their autoantibodies to the fetus, but, as discussed in the section "Pathophysiology of Acantholysis", neonatal PF occurs only rarely.[60-62] Neonatal pemphigus should be distinguished from PV and PF that occur in childhood, which are similar to the autoimmune diseases seen in adults.[63]

DRUG-INDUCED PEMPHIGUS

Although there are sporadic case reports of pemphigus associated with the use of several different drugs, the association with penicillamine, and perhaps captopril, is the most significant.[64] The prevalence of pemphigus in penicillamine users is estimated to be approximately 7%. PF (including pemphigus erythematosus) is more common than PV in these penicillamine-treated patients, although either may occur. The findings of direct and indirect immunofluorescence are positive in most of these patients. Three patients with drug-induced PF and one with drug-induced PV have been shown to have autoantibodies to the same molecules involved in sporadic pemphigus, namely, desmoglein 1 and desmoglein 3, respectively.[65] Therefore, by immunofluorescence and immunochemical determinations, these patients with drug-induced pemphigus resemble those with sporadic disease.

Both penicillamine and captopril contain sulfhydryl groups that are postulated to interact with the sulfhydryl groups in desmoglein 1, 3, or both, thereby causing pemphigus either by directly interfering with these adhesion molecules[66] or, alternatively, by modifying them so that they become more antigenic. The use of these drugs may also lead to a more generalized dysregulation of the immune response, as penicillamine has been associated with the onset of several other autoantibody-mediated diseases including myasthenia gravis,[67] Goodpasture syndrome,[68] and antineutrophil cytoplasmic antibody vasculitis.[69] Some, but not all, patients with drug-induced pemphigus go into remission after they stop taking the offending drug.

Additionally, rare anecdotal reports have suggested the association of dietary intake and pemphigus, proposing the hypothesis that thiol-containing foods such as garlic, leeks, and onions may precipitate disease.[70,71] Some patients may note that certain foods aggravate oral lesions, but it is unlikely that dietary intervention alone will remit disease in most patients.

Interestingly, anecdotal case reports have reported improvement of PV with cigarette smoking,[72] as well as with the cholinergic agonists pyridostigmine, carbachol, and pilocarpine.[73,74] Studies suggest that activation of cholinergic receptors may regulate signaling pathways modulated by PV IgG, thereby affecting cell adhesion.[75] These results are intriguing given the clinical benefit of nicotine noted in other inflammatory diseases, such as ulcerative colitis.[76]

ASSOCIATED DISEASES

Myasthenia gravis, thymoma, or both have been associated with pemphigus.[77-79] Approximately one-half of thymoma-associated pemphigus cases are vulgaris; one-half, foliaceus or erythematosus. Most of these data, however, were reported before the recognition of paraneoplastic pemphigus as a distinct entity. Therefore, although thymoma may clearly be associated with PV and PF, it also may be associated with paraneoplastic pemphigus (Chap. 53). Myasthenia gravis is a tissue-specific autoantibody-mediated disease leading to skeletal muscle weakness. Early disease usually affects facial muscles, leading to symptoms of dysarthria, dysphagia, ptosis, or diplopia. Disease may then progress to affect the larger muscles of the trunk and extremities, with potential fatal complications from respiratory muscle involvement. Thymoma, in contrast, is typically asymptomatic in adults. In children, thymomas are more likely to be symptomatic with cough, chest pain, superior vena cava syndrome, dysphagia, and/or hoarseness from localized tumor encroachment. Myasthenia gravis would be best evaluated by a neurologist, who can complete a full neurologic examination and may test for the presence of serum acetylcholine receptor autoantibodies. The course of myasthenia gravis and the course of pemphigus appear to be independent of each other. Likewise, thymic abnormalities may either precede or follow the onset of pemphigus. Posteroanterior and lateral chest radiographs with or without computed tomography follow-up can detect most thymomas. Irradiation of the thymus or thymectomy, although clearly beneficial for myasthenia gravis, may or may not improve the pemphigus disease activity.[80]

Recent epidemiologic studies have identified that pemphigus vulgaris patients have a higher prevalence of autoimmune thyroid disease, rheumatoid arthritis, and Type 1 diabetes compared with the general population.[81] Higher prevalences of these autoimmune diseases are also observed in the family members of PV patients, suggesting a common genetic element that may underlie autoimmune susceptibility.

ETIOLOGY AND PATHOGENESIS

The discovery of pemphigus as an organ-specific, autoantibody-mediated disease of desmosomes highlights the synergy between clinical care and basic science research. The development of light microscopy and electron microscopy allowed dermatologists to identify the morphology and immunopathology of disease. Patient serum IgG served as a key reagent to help identify both the PF and PV antigens.[82-84] The cloning and characterization of the pemphigus antigens have subsequently led to the development of enzyme-linked immunosorbent assays (ELISAs) to improve the sensitivity and specificity of disease diagnosis, and continued studies on pemphigus pathophysiology aim to develop safer and effective therapies for these potentially fatal diseases. A recent in-depth review discusses these issues.[85]

PEMPHIGUS AUTOANTIGENS

Pemphigus antigens are desmogleins, transmembrane glycoproteins of desmosomes (cell-to-cell adhesion structures, reviewed in Chap. 15).[86,87] Desmogleins are part of the cadherin superfamily of calcium-dependent cell-adhesion molecules. The original members of this family (eg, E-cadherin) demonstrate homophilic adhesive interactions (binding between like molecules). Desmogleins similarly demonstrate homophilic binding but likely participate in predominantly heterophilic adhesion by binding desmocollins, the other major transmembrane glycoprotein of desmosomes.[88-90]

The PF antigen (as well as the fogo selvagem antigen) is desmoglein 1, a 160-kDa protein.[82,83,91] The PV antigen is desmoglein 3, a 130-kDa protein that is 64%

similar and 46% identical in amino acid sequence to desmoglein 1.[84] All patients with PV have anti–desmoglein 3 antibodies, and some of these patients also have anti–desmoglein 1 antibodies.[92,93] Patients with mucosal-dominant PV tend to have only anti–desmoglein 3 antibodies, whereas those with mucocutaneous disease usually have both anti–desmoglein 3 and anti–desmoglein 1 antibodies.[94-96] PF patients typically have antibodies against only desmoglein 1. However, these rules are not true for every patient.[97,98]

IgG antibodies against another desmosomal cadherin, desmocollin, can be found infrequently in PV, pemphigus vegetans, and atypical pemphigus patients.[99,100] Furthermore, mice with a targeted deletion of desmocollin 3 have PV-like skin lesions,[101] and anti-desmocollin antibodies can cause acantholysis in vitro.[99,102]

Other cell surface molecules such as acetylcholine receptors and E-cadherin also have been identified as immunologic targets of pemphigus serum, although their direct involvement in the pathophysiology of pemphigus has not been well validated.[103-106]

ELECTRON MICROSCOPY

Early ultrastructural studies of the blisters in pemphigus vulgaris and foliaceus focused on the appearance of desmosomes, because these are the most prominent cell-to-cell adhesion junctions in stratified squamous epithelia (Chap. 15). Almost all studies confirm that at various time points during acantholysis, the desmosome is affected and ultimately destroyed, consistent with the cell biologic data discussed in the section below. However, conclusions from electron microscopy studies as to the mechanism of desmosome destruction have varied. Several groups have proposed that the first pathologic event in pemphigus is intercellular widening of interdesmosomal cell membranes, with intact desmosomal junctions.[107-110] Other studies have demonstrated half-split desmosomes without keratin tonofilament retraction, suggesting that pemphigus autoantibodies directly interfere with the trans-adhesive interface of desmosomes, and that keratin retraction is secondary to the loss of intercellular adhesion. Half-desmosomes without tonofilament collapse also have been observed in a mouse model of PV.[111,112] Others have proposed that keratin retraction is a primary pathogenic event in pemphigus, triggered by cellular signaling after PV autoantibody binding.[113] As a potential reconciliation of these findings, one study found that electron microscopic findings may differ depending on the site analyzed: in early blisters, half-desmosomes without keratin retraction are observed; in well-developed lesions, keratin retraction from half-desmosomes occurs; and in spongiotic non-blistered skin, intercellular widening with intact desmosomal junctions can be found, similar to electron microscopy findings in other spongiotic epidermal diseases.[114] Similarly, large-scale electron microscopic maps ("nanotomy") have identified evidence of both half desmosomes and smaller desmosomes in pemphigus patients,[115] and super-resolution microscopy indicates that desmosomes are smaller in PV patients,[116] consistent with a desmoglein nonassembly/desmosome depletion model for pathogenesis as discussed below.

Currently, electron microscopy studies are not part of the clinical diagnostic workup for pemphigus.

PATHOPHYSIOLOGY OF ACANTHOLYSIS

Autoantibodies in pemphigus are pathogenic as suggested by neonatal pemphigus, discussed above, in which mothers with even mild PV can pass IgG autoantibodies to the fetus, causing blistering oral and skin disease that resolves by approximately 6 months, concurrent with the disappearance of maternal IgG from the circulation.[58]

Several lines of evidence indicate that it is the anti-desmoglein 1 and 3 antibodies in pemphigus patients who directly cause blisters and hence are the etiologic agents of disease. Passive transfer of PV or PF IgG to neonatal mice or human skin causes blisters that clinically and histologically mimic the corresponding type of pemphigus in patients.[117-119] The anti-desmoglein antibodies are responsible for blister formation in the passive transfer model, because affinity purified anti-desmoglein 1 and 3 autoantibodies cause PF and PV blisters, respectively, and adsorption of desmoglein-reactive autoantibodies from PF or PV IgG abrogates disease.[120-124] Finally, mice with a targeted deletion of the desmoglein 3 gene have clinical and histologic lesions similar to PV patients,[125] suggesting that inactivation of desmoglein 3 results in a PV-like blister. Similarly, exfoliative toxin, the staphylococcus toxin that causes blisters in bullous impetigo and staphylococcal scalded skin syndrome, cleaves desmoglein 1 and results in a blister with a histology similar or identical to PF.[126]

Unlike many other autoantibody-mediated diseases, such as pemphigoid and epidermolysis bullosa acquisita, in which the constant region of the antibody is required for blister formation to activate complement or bind antibody receptors on inflammatory cells, in pemphigus the variable region of the antibody is sufficient to cause blisters in neonatal mice or human skin.[119,127-129] Furthermore, IgG4, which does not fix complement, has been shown to be both pathogenic and the predominant IgG subclass in both PF and PV.[130-132] For this reason, a significant amount of research on disease pathophysiology has focused on the epitopes bound by pathogenic autoantibodies, as these regions are likely critical for maintaining desmosomal cell adhesion. Epitope mapping studies have shown that pathogenic PV and PF autoantibodies bind calcium-sensitive, conformational epitopes in the amino terminal extracellular domains of desmogleins, whereas nonpathogenic antibodies tend to bind more membrane proximal extracellular domains.[133-136] The amino terminal domains bound by pathogenic autoantibodies are the same domains that are predicted

to form the key molecular interactions for desmoglein intercellular adhesion, based on studies of cadherin ultrastructure.[90,137,138] Furthermore, PV IgG have been shown to directly inhibit desmoglein 3–mediated trans-interactions by atomic force microscopy.[139] Collectively, these data form the basis for the "steric hindrance" hypothesis, which proposes that pathogenic antibodies directly interfere with desmoglein adhesive interactions, causing acantholysis.

Studies on cultured keratinocytes have indicated that loss of intercellular adhesion by pathogenic autoantibodies leads to internalization and degradation of desmogleins,[140-143] thereby amplifying the loss of desmoglein function. As discussed above, loss of desmoglein 3 and 1 function results in PV- and PF-like blisters in model systems in which desmogleins are targeted genetically or by enzyme cleavage.

If inactivation of desmoglein isoforms results in blistering, then why do blisters in PV and PF have specific tissue localizations that do not necessarily correlate with the sites at which the antibodies bind by immunofluorescence? In PF, for example, the anti–desmoglein 1 antibodies bind throughout the epidermis and mucous membranes,[144] yet blisters occur only in the superficial epidermis. This apparent paradox can be explained by desmoglein compensation, as outlined in Fig. 52-5. The concept of desmoglein compensation originates in the assumption that autoantibodies against one desmoglein isoform inactivate only that isoform and that another isoform co-expressed in the same area can compensate in adhesion.[145-147] Desmoglein compensation explains why neonatal PF is so unusual, because even though the maternal anti–desmoglein 1 antibodies cross the placenta, in neonatal skin, but not in adult skin, desmoglein 3 is co-expressed with desmoglein 1 in the superficial epidermis, thereby providing protection against the loss of desmoglein 1-based adhesion.[146,148] Desmoglein compensation also offers an explanation for the differing sites of blister formation in PV and PF, both in regard to the histology (ie, suprabasal or superficial), as well as the areas of involvement (mucosa and/or skin).

Further studies have suggested that perturbation of cell signaling pathways can mediate and/or modulate blister formation in pemphigus. For example, inhibition of the p38 mitogen activated protein kinase (MAPK) pathway and activation of Rho GTPases, among others, can prevent blister formation after passive transfer of pemphigus IgG in the neonatal mouse model.[149-151] The p38 MAPK pathway has been most studied in this regard. It activates EGF receptor after PV antibody binding, and blocking of this receptor also blocks loss of cell adhesion.[152] Although p38 activation may be secondary to loss of cell adhesion, blocking it does decrease the degree of acantholysis, suggesting that it would be a useful target in pemphigus therapy.[153,154] A more specific target in this pathway, downstream of p38, is MAPK activated protein kinase 2 (MK2), which also can be blocked to modulate pemphigus blister activity, especially spontaneous blistering as opposed to blistering due to trauma (ie, Nikolsky blistering).[155] Finally, in vitro studies with monoclonal anti-desmoglein 3 antibodies and human pemphigus antibodies suggest that acantholysis is a net result of both direct steric hindrance of pathogenic monoclonal antibodies and polyclonal antibodies that may not directly cause steric hindrance but that cause internalization of desmogleins by crosslinking them. This latter effect is dependent on MAPK signaling.[156]

The depletion of desmogleins by pemphigus antibodies may lead to loss of desmogleins in desmosomes resulting in smaller desmosomes and/or their defective function in adhesion, a scenario referred to as the *Dsg nonassembly depletion hypothesis*.[115,140,141,157,158] Consistent with this idea is the observation by direct immunofluorescence of clustering of Dsgs in both PV and PF patients' skin and that forced increased expression of Dsg3 can prevent acantholysis by pemphigus antibodies.[159]

The current general consensus is that desmosomal adhesion is a dynamic process that is perturbed by pemphigus autoantibodies both directly and by signaling pathways.[160] Therefore, therapies that aim to strengthen keratinocyte adhesion by modulation of signaling pathways may have a beneficial effect on pemphigus, regardless of whether cell signaling is a primary pathologic cause of disease.

GENETIC CHARACTERIZATION OF THE PEMPHIGUS IMMUNE RESPONSE

Compared to a matched population, patients with PV have a markedly increased frequency of certain class II major histocompatibility complex (MHC) antigens. Among Ashkenazi Jews with PV, the serologically defined HLA-DR4 haplotype is predominant, whereas in other ethnic groups with PV, the DQ1 allele is more common.[161] However, the association with disease susceptibility becomes even more striking in an analysis of these MHC alleles at a genetic level. Patients with the DR4 serotype almost all have the unusual allele DRB1*0402, and patients with the DQ1 serotype almost all have the rare allele DQB1*0503. Similar, but less restricted, HLA-DR alleles are associated with PF.[162] The protein chains encoded by these PV MHC II alleles vary from those found in HLA-DR4 and DQ1 controls without disease by only a few amino acids. Other studies have confirmed that the immune response in pemphigus is restricted to certain desmoglein peptides and MHC class II alleles.[163-166]

MHC class II alleles encode cell surface molecules that are necessary for antigen presentation to the immune system; therefore, it is hypothesized that PV-associated MHC class II molecules facilitate presentation of desmoglein 3 peptides to T cells.[167] Consistent with this hypothesis, certain peptides from desmoglein 3, predicted to fit into the DRB1*0402 peptide-binding pocket, were found to stimulate T cells from patients.[168] More direct proof of the importance of the

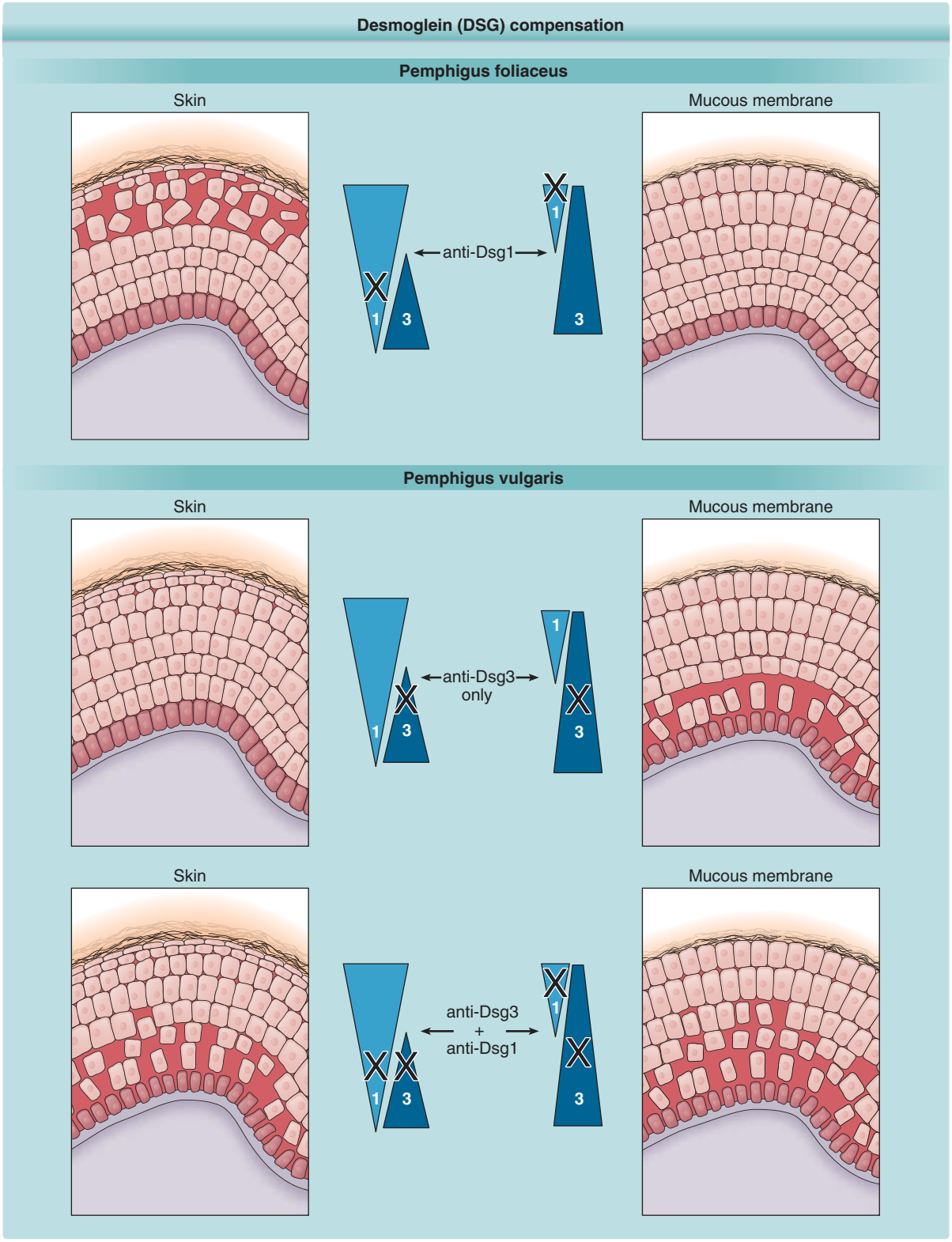

Figure 52-5 Desmoglein (Dsg) compensation. Triangles represent the distribution of Dsg1 and Dsg3 in skin and mucous membranes. Anti-Dsg1 antibodies in pemphigus foliaceus cause acantholysis only in the superficial epidermis of skin. In the deep epidermis and in mucous membranes, Dsg3 compensates for antibody-induced loss of function of Dsg1. In mucosal pemphigus vulgaris, antibodies against Dsg3 are predominant, which cause blisters only in the deep mucous membrane where Dsg3 is present without compensatory Dsg1. However, in mucocutaneous pemphigus, antibodies against both Dsg1 and Dsg3 are present, and blisters form in both mucous membrane and skin. The blister is deep probably because antibodies diffuse from the dermis and interfere first with the function of desmosomes at the base of the epidermis.

DRB1*0402 allele comes from a study of a humanized HLA-transgenic mouse for this allele in which presentation of the immunodominant Dsg3 peptides to human T cells results in production of pemphigus antibodies and the epidermal pathology of PV.[169]

Expression of Dsg3 in the thymus, mediated by the Aire transcription factor, promotes tolerance of CD4 T cells to stimulation by Dsg3.[170] An unexpected observation was that T cells of normal people with the DRB1*0402 or DQB1*0503 respond just as well as those of pemphigus patients to the same desmoglein 3 peptides,[167,171] indicating that T-cell reactivity to desmoglein 3 peptides is not sufficient for disease onset. Dsg-specific $CD4^+$ T cells provide help to simulate anti-Dsg B cells to produce antibodies.[172] In this context, $CD4^+$ T follicular helper cells are thought to be particularly important. Concordantly, there are increased T follicular helper cells with their associated cytokine, IL-27, in PV patients.[173] Another factor that may determine who gets pemphigus and who does not has been proposed to be the presence of regulatory T cells that can suppress the autoimmune response in those who do not.[174] Likely, multiple factors prevent T-cell Dsg responsiveness and subsequent help for B-cell anti-Dsg antibody production.

Cloning of anti-desmoglein B-cell repertoires from PV and PF patients has elucidated the diversity of the antibody variable region genes contributing to the pemphigus immune response.[128,129,175] Shared VH1-46 gene usage has been identified in anti-Dsg3 B cells among PV patients, probably because antibodies using this gene require few or no mutations to bind Dsg3, which may favor the selection of VH1-46 B cells early in the autoimmune response.[176] However, multiple other VH genes have been identified in anti-Dsg3 antibodies among PV patients that are more highly mutated and may not be shared,[128,177-179] although anti-Dsg antibodies from different PV patients have been shown to bind at or near common epitopes on desmoglein 3.[177] Analysis of anti-Dsg1 IgG B-cell repertoires in fogo selvagem patients has identified enrichment for VH3-23 heavy chain gene usage, as well as IGKV1D-39 light chain gene usage, with evidence of shared mutations as well as an increased number of somatic mutations in the antigen-binding regions of Dsg1-reactive antibodies, suggesting antigen-driven selective pressure.[180]

Cross-reactivity in the B-cell repertoire to foreign and self-antigen has been proposed as a mechanism for the onset of autoimmunity in both PV and PF. In addition to the autoantibody cross-reactivity to LJM11 sand fly antigen and Dsg1 discussed previously,[16] Dsg3 autoantibodies in PV have been shown to cross-react with rotavirus VP6 coat protein, and VH1-46 mAbs that both induce suprabasal blisters and inhibit rotavirus infectivity have been identified.[176] Unmutated IgM VH1-46 B cells have a propensity to bind both rotavirus VP6 coat protein,[181] as well as the PV autoantigen Dsg3.[176] However, cross-reactivity to VP6 and Dsg3 in the IgG compartment is rare because of the differing nature of somatic mutations that confer VP6 versus Dsg3 reactivity, thus preventing the onset of pemphigus after rotavirus exposure.

To produce anti-Dsg autoantibodies, B cells must lose tolerance to Dsg, which is a self-antigen. Studies of cloned anti-Dsg B cells have shown that throughout the course of PV, over the years, the same clones of anti-Dsg B cells persist and new ones generally are not produced.[182] These data suggest that some event causes a time-limited loss of tolerance of B cells to Dsg, and if these B-cell clones can be completely eliminated, patients might be cured, thus explaining the rationale for B-cell depletion therapy in pemphigus.

DIAGNOSIS

Diagnosis of pemphigus relies on skin biopsy of a fresh lesion for histology to determine the site of blister formation, as well as a confirmatory immunochemical study to document the presence of skin autoantibodies, either by direct immunofluorescence of perilesional skin, or indirect immunofluorescence or ELISA of patient serum.

LABORATORY TESTING

IMMUNOFLUORESCENCE

The hallmark of pemphigus is the finding of immunoglobulin G (IgG) autoantibodies against the cell surface of keratinocytes. These autoantibodies were first discovered in patients' sera by indirect immunofluorescence techniques and soon thereafter were discovered by direct immunofluorescence of patients' skin.[183]

Direct Immunofluorescence: Essentially all patients with active PV or PF have a positive finding on a direct immunofluorescence study, which tests for IgG bound to the cell surface of keratinocytes in perilesional skin (Fig. 52-6A, Table 52-2).[184] This is a non-quantitative test (either negative or positive). The diagnosis of pemphigus should be seriously questioned if the test result of direct immunofluorescence is negative. It is important that the biopsy for direct immunofluorescence be performed on normal-appearing perilesional skin, as the immune reactants can be difficult to detect in blistered inflamed epidermis (leading to a false negative result). In some cases of pemphigus erythematosus, IgG and C3 are deposited at the basement membrane zone of erythematous facial skin, in addition to the epidermal cell surface IgG, representing a positive lupus band test in addition to the typical pemphigus intercellular pattern.[185] In at least some cases, this band may be the result of UV-induced cleavage of Dsg1 with its accumulation at the basement membrane.[56]

Indirect Immunofluorescence: Indirect immunofluorescence is performed by incubating serial dilutions of patients' sera with epithelial substrates. It is reported as a semiquantitative titer (indicating the last dilution at which the serum demonstrates a positive cell surface staining pattern). The test is offered by most major national laboratories and can remain positive for

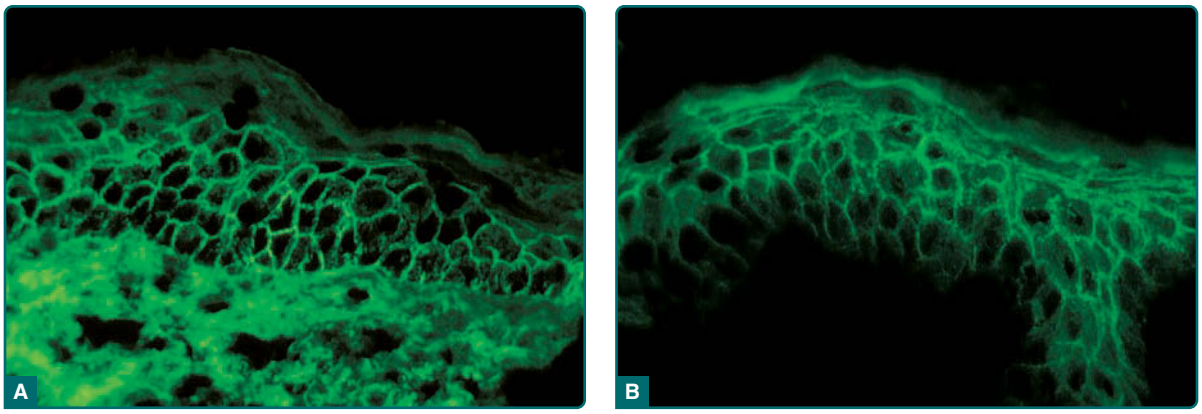

Figure 52-6 Immunofluorescence in pemphigus. **A,** Direct immunofluorescence for immunoglobulin G (IgG) of perilesional skin from a patient with pemphigus vulgaris. Cell surface staining is observed throughout the epidermis with a slight basal predominance. **B,** Indirect immunofluorescence with the serum from a patient with pemphigus foliaceus on normal human skin. IgG is observed on the cell surface throughout the epidermis with a slight superficial predominance.

weeks to months after healing of skin lesions, making it a good diagnostic test if a patient should present with no active skin lesions, for example due to empiric treatment with prednisone by a referring physician. Depending on the substrate used for indirect immunofluorescence, more than 80% of patients with pemphigus have circulating anti–epithelial cell surface IgG (Fig. 52-6B, Table 52-2).[186] The substrate used to detect pemphigus antibody binding in indirect immunofluorescence greatly influences the sensitivity of the test. In general, monkey esophagus is more sensitive for detecting PV antibodies, and guinea pig esophagus or normal human skin is a superior substrate for detecting PF antibodies. Patients with early localized disease and those in remission are most likely to have negative findings on an indirect immunofluorescence test; for these patients, the increased sensitivity of ELISA may help in diagnosis (see below).

Patients with PV and PF usually display similar direct and indirect immunofluorescence findings with IgG on the cell surface of epidermal cells throughout the epidermis, despite the different autoantigen profiles in these 2 diseases. Therefore, it is usually not possible to differentiate the 2 diseases by the pattern of immunofluorescence. There is a positive, but imperfect, correlation between the titer of circulating anti–cell surface antibody and the disease activity in PV and in PF.[187] Although this correlation may hold in general, and although patients in remission often show serologic remission with negative direct and indirect immunofluorescence findings,[188,189] disease activity in individual patients does not necessarily correlate with indirect immunofluorescence titer. Therefore, in the day-to-day management of these patients, following disease activity is more important than following antibody titer.

ENZYME-LINKED IMMUNOSORBENT ASSAY

For diagnosis of disease, antigen-specific ELISAs have been shown to be more sensitive and specific than immunofluorescence, and their titer correlates better than that of indirect immunofluorescence with disease activity.[92,190,191] Additionally, ELISAs are easier to perform and less subjective than immunofluorescence, and have for many physicians replaced the latter as the preferred first diagnostic test for pemphigus (Table 52-2). These assays use desmogleins 1 and 3 bound to plates, which are then incubated with patient sera and developed with anti-human IgG reagents (Fig. 52-7). As an advantage over indirect

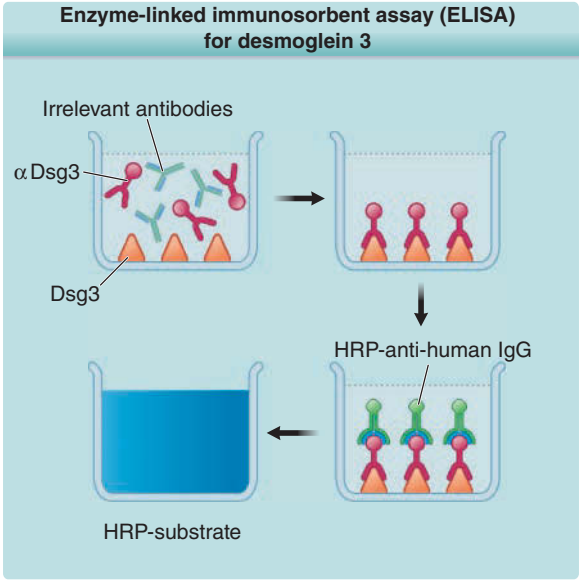

Figure 52-7 Enzyme-linked immunosorbent assay (ELISA) for desmoglein 3. Anti-Dsg3 antibodies (αDsg3) from pemphigus serum binds Dsg3 on the ELISA plate; irrelevant antibodies, that do not bind, are washed off. The plate is then incubated with horseradish peroxidase (HRP) conjugated anti-human IgG, which binds the anti-Dsg3 IgG that is on the plate. HRP is an enzyme that turns a clear substrate blue, and the amount of color, read on spectrophotometer, correlates with the amount of pemphigus (ie, anti-Dsg3) antibody in the patient's serum.

immunofluorescence, ELISAs can help differentiate between PV and PF because of the different autoantigen profiles in these 2 diseases.[92,190] In most cases, ELISA is positive for desmoglein 3 (but not desmoglein 1) in mucosal PV, is positive for both desmogleins 3 and 1 in PV with both mucosal and significant skin involvement, and is positive for only desmoglein 1 in PF. PV has rarely evolved into PF, and vice versa, as determined by clinical, histologic, and immunochemical criteria.[192-194] A small minority of PF patients may also demonstrate autoantibodies to desmoglein 3[195]; therefore, diagnosis should be made based on the clinical-serologic correlation. Additionally, some patients (eg, those with bullous pemphigoid) may demonstrate a low level of anti–desmoglein 3 autoantibodies,[190] which are detectable because of the high sensitivity of the ELISA. Therefore, a result in the indeterminate range should be interpreted carefully, as this may represent a true positive or a false positive, the latter presumably because of formation of nonpathogenic bystander autoantibodies after epidermal damage. As with indirect immunofluorescence, the correlation of ELISA index value with disease activity is not perfect. For example, although ELISA titers correlate with clinical activity, patients in clinical remission (often still on corticosteroid therapy) whose titers have dropped from peak values may still have positive results.[196] In making treatment decisions, a negative result on desmoglein ELISA is more helpful than a positive result, as a patient with the former is more likely to achieve remission off immunosuppressives, whereas a patient with the latter may or may not. In other words, disease activity is the mainstay for determining treatment.

PATHOLOGY

The characteristic histopathologic finding in PV is a suprabasal blister with acantholysis (Fig. 52-8, Table 52-2). Just above the basal cell layer, epidermal cells lose their normal cell-to-cell contacts and form a blister. Often, a few rounded up (acantholytic) keratinocytes are in the blister cavity. The basal cells stay attached to the basement membrane, but may lose the contact with their neighbors; as a result, they may appear to be a "row of tombstones," symbolic of the potentially fatal prognosis of this disease. Usually, the upper epidermis (from 1 or 2 cell layers above the basal cells) remains intact, as these cells maintain their cell adhesion. Pemphigus vegetans shows not only suprabasal acantholysis but also papillomatosis of the dermal papillae and downward growth of epidermal stands into the dermis, with hyperkeratosis and scale-crust formation. In addition, pemphigus vegetans lesions may show intraepidermal abscesses composed of eosinophils and/or neutrophils.[197] Early PV lesions may show eosinophilic spongiosis.[198]

The histopathology of early blisters in PF patients demonstrates acantholysis (loss of cell-to-cell contact) just below the stratum corneum and in the granular layer (Fig. 52-9A). The stratum corneum is often lost from the surface of these lesions. The deeper epidermis, below the granular layer, remains intact. Another frequent finding is subcorneal pustules, with neutrophils and acantholytic epidermal cells in the blister cavity (Fig. 52-9B). Histologic findings in PF are often indistinguishable from those seen in bullous impetigo/staphylococcal scalded skin syndrome, because blisters in these latter diseases also result from dysfunction of desmoglein 1, in these cases due to proteolytic cleavage by Staphylococcal exfoliative toxins.[87] Therefore, immunochemical studies are essential to confirm a diagnosis of PF, as these would be negative in Staphylococcal-mediated skin blisters. The site of

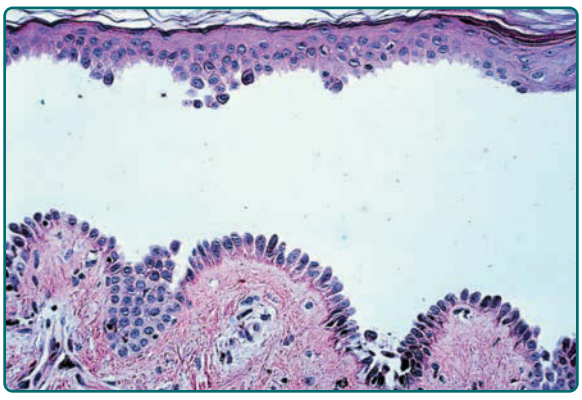

Figure 52-8 Histopathology of pemphigus vulgaris. Suprabasal acantholysis. The row of tombstones.

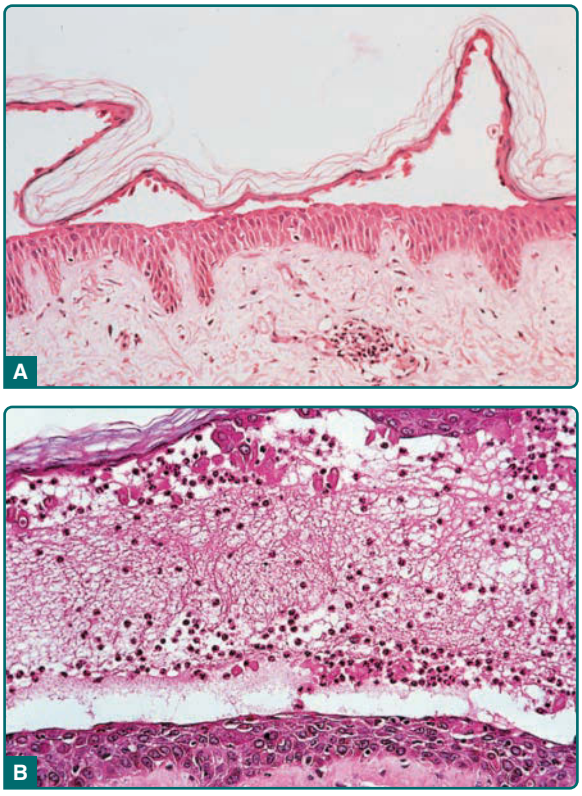

Figure 52-9 Histopathology of pemphigus foliaceus. **A,** Acantholysis in the granular layer. **B,** Subcorneal pustule with acantholysis.

blister formation in pemphigus erythematosus is identical to PF. As in PV lesions, very early PF lesions may show eosinophilic spongiosis.[198]

DIFFERENTIAL DIAGNOSIS

See Table 52-1.

CLINICAL COURSE AND PROGNOSIS

Before the advent of glucocorticoid therapy, PV was almost invariably fatal due to severe blistering of the skin and mucous membranes, leading to malnutrition, dehydration, and sepsis. PF was fatal in approximately 60% of patients. PF was almost always fatal in elderly patients with concurrent medical problems; however, in other patients, its prognosis, without therapy, was much better than PV.[199,200]

The systemic administration of glucocorticoids and the use of immunosuppressive therapy have dramatically improved the prognosis for patients with pemphigus; however, pemphigus is still a disease associated with a significant morbidity and mortality.[201,202] In the United States, the annual mortality rate from pemphigus (age-adjusted to the standard population) is estimated to be 0.023 deaths per 100,000.[203] The inpatient mortality from pemphigus has been estimated at 1.6% to 3.2%, with increased mortality likely due to numerous comorbid health conditions.[79] The risk of death in pemphigus vulgaris patients is 2.36 to 3.3 times greater than for controls in the United Kingdom and Taiwan.[9,11] Infection is often the cause of death, and by causing the immunosuppression necessary in the treatment of active disease, therapy is frequently a contributing factor.[11,204] With glucocorticoid and oral immunosuppressive therapy, the mortality (from disease or therapy) of PV patients followed from 4 to 10 years is approximately 10% or less, whereas that of PF is probably even less. In a study of 40 patients with PV, 2 patients (5%) died of sepsis and 17%, after an average of 18 months of therapy, went into a complete and long-lasting (>4 years, average, thought to be permanent) remission requiring no further therapy.[205] Another 37% of patients achieved remission but relapsed at times after therapy was stopped; most of these also eventually achieved long-lasting remissions. The remainder of patients required continual therapy. In a group of 159 patients with PV from Croatia, only approximately 12% went into long-term remission after therapy with glucocorticoids and immunosuppressives, but most relapsed.[23] In a study from Tehran of 1206 pemphigus patients seen over 20 years, 6.2% of PV and 0.2% of PF patients died, mostly of septicemia; only 9.3% were in complete remission without therapy.[7] Another study showed that; with the use of corticosteroids, about 50% of patients went into at least transient complete remission off therapy after a mean of 3 years.[206] Immunosuppressive adjuvant therapy may reduce the risk of relapse.[207] With the advent of rituximab therapy, complete remission in pemphigus has become more common and is quicker to achieve. Approximately 50-90% of PV patients go into remission off all other immunosuppressive therapy, after 1 or more courses of rituximab.[208] Similar remission rates are found in PF.[209]

MANAGEMENT

Several consensus guidelines for pemphigus disease therapy have been published.[211-214] It is generally agreed that PV, even if initially limited in extent, should be treated at its onset, because it will ultimately generalize and the prognosis without therapy is very poor. In addition, it is probably easier to control early disease than widespread disease, and mortality may be higher if therapy is delayed.[215] Because PF may be localized for many years, and the prognosis without systemic therapy may be good, patients with this type of pemphigus do not necessarily require treatment with systemic therapy; the use of topical corticosteroids may suffice. When the disease is active and widespread, however, the therapy for PF is, in general, similar to that for PV.

A consensus statement on disease definitions and endpoints was proposed by an international committee of pemphigus experts.[216] Additionally, clinical instruments have been developed for tracking disease activity that have been shown to be reliable and valid.[217,218] The standardization of disease definitions and activity scoring will facilitate future clinical trials for pemphigus.

There has been a tremendous advance in the armamentarium of therapies for pemphigus since the time before the development of glucocorticoids when PV was a fatal disease. Thanks to these advances, the "row of tombstones" seen in the pathology of PV no longer alludes to its prognosis for most patients.

CORTICOSTEROIDS

The systemic administration of glucocorticoids, usually prednisone, remains the mainstay of therapy for pemphigus. Before adjuvant immunosuppressive therapy was available, very high initial doses of prednisone (>2.0 mg/kg/d) were used for treatment, although such regimens have retrospectively been associated with significant morbidity and mortality from therapy.[204,219,220] The full systemic dose of glucocorticoids has been defined in the consensus guidelines as 1.5 mg/kg/d of prednisone equivalent for 2 to 3 weeks.[216] However, many patients can be brought under control with a 0.5- to 1.0-mg/kg/d single daily dose, especially if used in combination with adjunctive immunosuppressive therapy, which is thought to result in fewer complications and decreased mortality as compared to higher-dose glucocorticoid regimens.[221,222] For patients who do not initially respond or worsen, splitting the dose using a twice- or 3-times-daily schedule may achieve disease control.

Once disease activity is controlled, tapering prednisone to as low a dose as possible should be the goal. Minimal therapy is defined as 5 to 10 mg daily of prednisone equivalent. Although there are no set guidelines, if disease activity can be fully controlled on minimal-dose prednisone or lower, then glucocorticoid monotherapy may be feasible depending on the patient's other comorbidities and contraindications to alternative immunosuppressive agents. If patients have continued relapses, with daily prednisone doses approaching or exceeding 5 to 10 mg, adjunctive immunosuppressive agents are warranted.

Interestingly, prednisone can control blistering within days, at a time when the autoantibody titer would be unchanged. A possible explanation is that prednisone increases the synthesis of desmogleins or other cell-adhesion molecules or change their posttranscriptional processing to prolong their half-life.[223,224] If pemphigus IgG depletes desmosomes of desmogleins, as discussed above, then prednisone could counteract this effect.

Topical corticosteroids may be used as monotherapy in mild forms of disease, especially PF, or as adjunctive therapy to help heal new lesions. Patients with mucosal disease may benefit from the use of glucocorticoid elixirs as a swish and spit for dental trays to help apply class I corticosteroid gels or ointments to the gingiva. Additionally, class I-IV corticosteroids can be used as topical therapy to help resolve new blisters, even in patients on systemic glucocorticoids.

RITUXIMAB

A very effective therapy for pemphigus, even in cases refractory to standard immunosuppressive therapy, is a monoclonal anti-CD20 antibody, rituximab, which was approved by the FDA for therapy of pemphigus vulgaris in 2018. Rituximab targets B cells, the precursors of antibody-producing plasmablasts. The B cell also acts to process autoantigen and present it to T cells that provide "help" in stimulating the autoantibody response.[225] Rituximab is infused intravenously at a dose of 1000 mg on day 1 and day 15. A maintenance dose of 500 mg can be infused at 12 months and every 6 months thereafter based on clinical evaluation, or a 1000 mg dose if clinical relapse occurs. A pivotal clinical trial comparing first line rituximab therapy plus short-term prednisone (0.5-1.0 mg/kg/day) to high dose (1.5 mg/kg/day) prednisone alone for moderate to severe pemphigus showed superior rates of complete remission off prednisone in the rituximab-treated group (89% versus 34%), although maintenance dosing appears to be required to prevent disease relapse. Although not the FDA-approved dose, a lymphoma dose regimen of 375 mg/m^2 once weekly for four weeks has also been evaluated in a prospective clinical trial.[226] A single cycle of rituximab using the lymphoma dose has been shown to be effective even in relapsed and refractory pemphigus, with 86% of patients experiencing complete healing of skin lesions on or off prednisone.[226] Approximately 80% of patients relapse and require additional therapy to regain disease control,[209] but with repeat cycles of rituximab and/or additional prednisone therapy after clinical relapse, 48% of PV and PF patients, including those with previously refractory disease, are ultimately able to achieve complete remission off prednisone. Disease activity usually begins to remit within 3 months of rituximab infusion; with first-line rituximab therapy, the median time to complete remission off steroids is 9 months. Rituximab has also been shown to be an effective therapy for children with refractory pemphigus.[227-229]

Therapy with rituximab, as with other immunosuppressive treatments, has significant risks.[230] 37% of PV patients treated with rituximab plus prednisone experienced treatment-related infections, similar to the rate (42%) observed in patients treated with high-dose prednisone alone. Grade 3 or higher infectious adverse events requiring hospitalization were observed in 8% of rituximab and prednisone-treated patients, compared to 3% treated with prednisone alone. Fatal infections with rituximab and prednisone therapy have been observed with chronic rituximab therapy, including sepsis, Pneumocystis pneumonia, reactivation of hepatitis B, and JC virus infection reactivation causing progressive multifocal leukoencephalopathy.[209,231-233] In addition, 56% of PV patients treated with rituximab develop anti-drug antibodies. Although the clinical significance of this immunogenicity is currently unclear, one PV patient was reported to develop neutralizing anti-chimeric antibodies to rituximab, associated with infusion reactions and lack of clinical efficacy.[234]

ORAL IMMUNOSUPPRESSIVE AGENTS

As rituximab is not accessible to all pemphigus patients, many experts still use oral immunosuppressive therapy, usually with, but also without, prednisone, from the beginning of therapy. Certainly, when continued doses of glucocorticoids greater than 5 to 10 mg are required for disease control, or if there are contraindications to or intolerable side effects from oral glucocorticoids, adjunctive immunosuppressive agents are used for pemphigus therapy. Prospective randomized studies have shown that immunosuppressive agents such as mycophenolate mofetil and azathioprine have a steroid-sparing effect; retrospective studies suggest decreased mortality with use of adjuvants plus steroids compared to steroids alone.[199,235-238]

Because patients may die from complications of therapy, it is important to monitor all patients closely for potential side effects, such as blood count, liver and kidney laboratory abnormalities, GI ulcer disease, high blood pressure, diabetes, glaucoma, cataracts, osteoporosis, and infection. The decision to use immunosuppressive agents, particularly in young patients, must also take into account the potential incidence of malignancies that

might be associated with the long-term use of these drugs, as well as the risks of teratogenicity (for mycophenolate mofetil, azathioprine, and methotrexate). Use of mycophenolate in women of child-bearing potential requires counseling and monitoring regarding pregnancy.

AZATHIOPRINE

Azathioprine is an effective adjunctive immunosuppressive agent for pemphigus, with clinical remission rates of approximately 50% in retrospective studies.[189,229] In a prospective randomized trial of high-dose methylprednisolone (2.0 mg/kg/d) plus azathioprine (2.0 mg/kg/d), 72% of patients achieved clinical remission within a mean of 74 days, although 33% experienced significant adverse effects of therapy, including hyperglycemia, dizziness, abnormal liver enzyme tests, and infection.[235]

Azathioprine is a prodrug, which is converted to active mercaptopurine, thioguanine, and thioinosine metabolites, in part by thiopurine methyltransferase (TPMT), an enzyme whose levels can vary widely in the population. Overall, 89% of whites demonstrate normal to high levels of TPMT, 11% are intermediate, and 0.3% are deficient for TPMT, the latter group representing those who do not tolerate azathioprine therapy.[240] Additionally, 1% to 2% of whites may have "super high" levels of TPMT, which is correlated with both treatment resistance and increased hepatotoxicity from excessive metabolite production.[241] Azathioprine toxicity has also been associated with genetic polymorphisms in nucleotide triphosphate diphosphatase (NUDT15), particularly in Asian populations, and inosine triphosphate pyrophosphatase (ITPA).[242] Altogether, it is estimated that approximately 5% of patients will be azathioprine intolerant.[243]

In patients with normal TPMT levels, the consensus dosing regimen that defines treatment failure is 2.5 mg/kg/d for 12 weeks.[216] From a practical standpoint, however, not all laboratories offer TPMT testing. Additionally, because patients with normal levels of TPMT may also experience azathioprine toxicity, it is reasonable to start all patients at a lower dose (eg, 50 to 100 mg daily) and titrate upward until clinical remission, the target dose of 2.5 mg/kg/d, or unacceptable side effects result. Frequent blood and liver monitoring should continue, particularly over the first 8 to 12 weeks when delayed toxicity from the accumulation of metabolites may emerge.

MYCOPHENOLATE MOFETIL

Mycophenolate mofetil is also an effective steroid-sparing agent for pemphigus. Typical doses range from 30 to 40 mg/kg/d (maximum dose 3 g/d) dosed twice daily (2.0 to 3.0 g/d), although certain patients such as the elderly may achieve disease control with doses as low as 1.0 g/d.

In case series, mycophenolate mofetil has been shown to have a rapid effect in lowering pemphigus antibody titers and decreasing disease activity, even in patients whose disease is unresponsive to azathioprine.[244,245] A prospective randomized trial comparing methylprednisolone (2 mg/kg/d) with azathioprine (2 mg/kg/d) or mycophenolate mofetil (2.0 g/d) in pemphigus patients showed 72% in the azathioprine group and 95% in the mycophenolate mofetil group went in clinical remission in a mean of 74 and 91 days, respectively.[235] Nineteen percent of patients experienced significant side effects of mycophenolate mofetil therapy, compared to 33% in the azathioprine group. None of these differences were statistically significant. Another trial showed that mycophenolate mofetil adjuvant therapy decreased the time to initial response and increased the duration of response to therapy and tended to decrease prednisone dosage, although the latter was not statistically significant.[238] A prospective randomized study indicated that azathioprine was significantly more effective than mycophenolate mofetil as a steroid-sparing agent, although this study compared a full dose of azathioprine (2.5 mg/kg/d) to a partial dose of mycophenolate mofetil (2.0 g/d).[224] Mycophenolate mofetil also has been reported to be an effective therapy for pediatric PV.[246]

Caution with use of mycophenolate mofetil is warranted, as fatal infection and sepsis occurred in 2% to 5% of transplant patients receiving mycophenolate mofetil, and increased risk of infection with or reactivation of cytomegalovirus, herpes zoster, atypical mycobacteria, tuberculosis, and JC virus (in progressive multifocal leukoencephalopathy) have been noted in postmarketing surveillance.[247] Interestingly, mycophenolate mofetil may offer protection against *Pneumocystis carinii* infection.[248]

METHOTREXATE

Once-a-week use of methotrexate is another option for an immunosuppressive therapy in pemphigus, although it is not used as frequently as azathioprine or mycophenolate mofetil.[249]

INTRAVENOUS IMMUNOGLOBULIN

Another method of decreasing serum autoantibodies is the intravenous use of γ-globulin (IVIg) in high doses. IVIg is thought to function by saturating neonatal Fc receptor, thereby increasing catabolism of the patient's serum antibodies, which include the pathogenic autoantibodies.[250-252] It may be useful as adjuvant therapy in those pemphigus patients whose condition does not respond to more conventional therapy.[253,254] A multicenter, randomized, placebo-controlled, double blind study has confirmed its efficacy in pemphigus,[255] but it is expensive and probably requires continued infusions for maintenance of remission. There also can be significant side effects with this therapy, including stroke, deep venous thrombosis, and aseptic meningitis.[256] Some centers will use IVIg to establish

initial control of blistering in severely affected patients because it does not increase the risk of infection as do corticosteroids and immunosuppressants. IVIg also has been used in combination with rituximab,[257,258] although it is unclear whether the combination is safer or more effective compared to either alone.

OTHER THERAPIES

There are additional therapies that can be used as adjuncts to standard treatments, or have historically been used for severe or refractory cases of pemphigus.

Cyclophosphamide, although more toxic than azathioprine, mycophenolate mofetil, or rituximab, is thought to be very effective in controlling severe disease, with one report of 19 of 23 patients with pemphigus achieving complete remission in a median time of 8.5 months.[259] A variety of small case series have evaluated different cyclophosphamide regimens for pemphigus, including daily oral therapy (1.1-2.5 mg/kg/d), daily oral therapy (50 mg) with intermittent high-dose intravenous dexamethasone and cyclophosphamide, and immunoablative intravenous cyclophosphamide.[239,260-263] All methods were effective in the short term, although none were curative. Significant side effects, including hematuria, infection, and transitional cell carcinoma of the bladder, were observed with higher dose regimens, although one study using a lower daily dose of cyclophosphamide (1.0-1.5 mg/kg/d) did not report a significantly different safety profile compared with other immunosuppressive agents. Together with the risk of infertility, cyclophosphamide is not considered a first-line steroid-sparing agent in the treatment of PV.

In a case series and randomized double-blind trial, dapsone demonstrated a trend toward efficacy as a steroid-sparing drug in maintenance phase PV, although these results were not statistically significant.[264,265] Dapsone may be used in conjunction with other immunosuppressive agents, particularly rituximab, where it offers the additional benefit of *Pneumocystis* pneumonia prophylaxis.

Plasmapheresis is sometimes used for severe pemphigus, or for pemphigus that is unresponsive to a combination of prednisone and immunosuppressive agents. Although one controlled study found it to be ineffective,[266] other studies have found that it both reduces serum levels of pemphigus autoantibodies and controls disease activity.[267] Plasmapheresis plus intravenous pulse therapy with cyclophosphamide has been reported to result in remissions of PV.[268] For maximum effectiveness, it is necessary to have patients take immunosuppressive agents to prevent the antibody-rebound phenomenon that can follow the removal of IgG. Protein A immunoadsorption, which removes IgG selectively from plasma, also has been used.[269]

Intravenous, pulse administration of methylprednisolone 250 to 1000 mg given over approximately 3 hours daily for 4 to 5 consecutive days, can result in long-term remissions and decrease the total dose of glucocorticoids necessary to control disease.[270] Although the purpose of this therapy is to decrease the incidence of complications of long-term steroid use, it can result in all the usual glucocorticoid complications, as well as cardiac arrhythmias with sudden death, and its use is controversial.[271] Furthermore, a controlled trial found that adjuvant oral dexamethasone pulse therapy in addition to standard therapy with prednisolone and azathioprine for PV is not beneficial.[272] It may be that simply giving divided lower doses of prednisone could accomplish the same result with fewer side effects.

PERSPECTIVES FOR FUTURE THERAPEUTIC STRATEGIES

Given the well-defined nature of disease in pemphigus and unmet need for safe and effective therapies, clinical trials in pemphigus are increasing. As discussed above, inhibitory anti-chimeric antibodies can cause resistance to rituximab. Fc gamma receptor polymorphisms, which can cause decreased antibody-dependent cellular cytotoxic killing of B lymphocytes after rituximab therapy, also have been proposed as a cause of rituximab resistance,[273-276] although these polymorphisms may not always correlate with therapeutic outcome in patients with B-cell cancers.[277,278] Newer, fully humanized or glycoengineered anti-CD20 antibodies may be useful in these situations[279,280], although none are currently in clinical development for pemphigus. PRN1008, an oral covalent inhibitor of the Bruton tyrosine kinase (Btk) required for mature peripheral B cell survival, has entered Phase 2 trials for pemphigus (NCT02704429). The successful clinical development of these B cell–targeted therapies may offer novel strategies for pemphigus treatment in the future.

Agents that block the neonatal Fc receptor (FcRn) have also recently entered clinical trials in pemphigus, including SYNT001 (NCT03075904) and ARGX-113 (NCT03334058). FcRn maintains the serum half-life of IgG and regulates cross-presentation of immune complexes, among other immune functions. Additionally, a phase 1 study (NCT03239470) has been initiated to evaluate the safety and preliminary efficacy of ex vivo expansion and infusion of autologous polyclonal regulatory T cells, which are hypothesized to restore immune tolerance in pemphigus patients. Finally, a novel approach to targeted therapy for pemphigus, called chimeric autoantibody receptor T cell or CAAR-T therapy, has demonstrated preclinical efficacy in experimental PV models.[281] CAAR-T therapy uses the disease autoantigen, Dsg3, as part of a chimeric immunoreceptor to program a patient's own T cells to specifically kill Dsg-specific B cells, and offers the hope of a potentially lasting remission of disease without generalized immune suppression due to the potential for long-term CAART cell engraftment. Efforts are underway to determine the clinical efficacy of CAAR-T technology in pemphigus patients.

REFERENCES

1. Lever WF. *Pemphigus and Pemphigoid.* Springfield, IL: Charles C. Thomas; 1965.
2. Beutner EH, Jordon RE. Demonstration of skin antibodies in sera of pemphigus vulgaris patients by indirect immunofluorescent staining. *Proc Soc Exp Biol Med.* 1964;117:505-510.
3. Krain LS. Pemphigus. Epidemiologic and survival characteristics of 59 patients, 1955-1973. *Arch Dermatol.* 1974;110(6):862-865.
4. Pisanti S, Sharav Y, Kaufman E, et al. Pemphigus vulgaris: incidence in Jews of different ethnic groups, according to age, sex, and initial lesion. *Oral Surg Oral Med Oral Pathol.* 1974;38(3):382-387.
5. Hietanen J, Salo OP. Pemphigus: an epidemiological study of patients treated in Finnish hospitals between 1969 and 1978. *Acta Derm Venereol (Stockh).* 1982;62(6):491-496.
6. Bastuji-Garin S, Souissi R, Blum L, et al. Comparative epidemiology of pemphigus in Tunisia and France: unusual incidence of pemphigus foliaceus in young Tunisian women. *J Invest Dermatol.* 1995;104(2):302-305.
7. Chams-Davatchi C, Valikhani M, Daneshpazhooh M, et al. Pemphigus: analysis of 1209 cases. *Int J Dermatol.* 2005;44(6):470-476.
8. Goon AT, Tan SH. Comparative study of pemphigus vulgaris and pemphigus foliaceus in Singapore. *Australas J Dermatol.* 2001;42(3):172-175.
9. Langan SM, Smeeth L, Hubbard R, et al. Bullous pemphigoid and pemphigus vulgaris—incidence and mortality in the UK: population based cohort study. *BMJ.* 2008;337:a180.
10. Marazza G, Pham HC, Scharer L, et al. Incidence of bullous pemphigoid and pemphigus in Switzerland: a 2-year prospective study. *Br J Dermatol.* 2009; 161(4):861-868.
11. Huang YH, Kuo CF, Chen YH, et al. Incidence, mortality, and causes of death of patients with pemphigus in Taiwan: a nationwide population-based study. *J Invest Dermatol.* 2012;132(1):92-97.
12. Diaz LA, Sampaio SAP, Rivitti EA, et al. Endemic pemphigus foliaceus (fogo selvagem): II. Current and historical epidemiological aspects. *J Invest Dermatol.* 1989;92(1):4-12.
13. Aoki V, Millikan RC, Rivitti EA, et al. Environmental risk factors in endemic pemphigus foliaceus (fogo selvagem). *J Investig Dermatol Symp Proc.* 2004;9(1):34-40.
14. Warren SJ, Lin MS, Giudice GJ, et al. The prevalence of antibodies against desmoglein 1 in endemic pemphigus foliaceus in Brazil. Cooperative Group on Fogo Selvagem Research. *N Engl J Med.* 2000;343(1): 23-30.
15. Diaz LA, Arteaga LA, Hilario-Vargas J, et al. Anti-desmoglein-1 antibodies in onchocerciasis, leishmaniasis and Chagas disease suggest a possible etiological link to fogo selvagem. *J Invest Dermatol.* 2004;123(6):1045-1051.
16. Qian Y, Jeong JS, Maldonado M, et al. Cutting edge: Brazilian pemphigus foliaceus anti-desmoglein 1 autoantibodies cross-react with sand fly salivary LJM11 antigen. *J Immunol.* 2012;189(4):1535-1539.
17. Qian Y, Jeong JS, Abdeladhim M, et al. IgE anti-LJM11 sand fly salivary antigen may herald the onset of fogo selvagem in endemic Brazilian regions. *J Invest Dermatol.* 2015;135(3):913-915.
18. Qian Y, Jeong JS, Ye J, et al. Overlapping IgG4 responses to self- and environmental antigens in endemic pemphigus foliaceus. *J Immunol.* 2016;196(5):2041-2050.
19. Uzun S, Durdu M, Akman A, et al. Pemphigus in the Mediterranean region of Turkey: a study of 148 cases. *Int J Dermatol.* 2006;45(5):523-528.
20. V'lckova-Laskoska MT, Laskoski DS, Kamberova S, et al. Epidemiology of pemphigus in Macedonia: a 15-year retrospective study (1990-2004). *Int J Dermatol.* 2007;46(3):253-258.
21. Salmanpour R, Shahkar H, Namazi MR, et al. Epidemiology of pemphigus in south-western Iran: a 10-year retrospective study (1991-2000). *Int J Dermatol.* 2006; 45(2):103-105.
22. Michailidou EZ, Belazi MA, Markopoulos AK, et al. Epidemiologic survey of pemphigus vulgaris with oral manifestations in northern Greece: retrospective study of 129 patients. *Int J Dermatol.* 2007; 46(4):356-361.
23. Ljubojevic S, Lipozencic J, Brenner S, et al. Pemphigus vulgaris: a review of treatment over a 19-year period. *J Eur Acad Dermatol Venereol.* 2002;16(6):599-603.
24. Mimouni D, Bar H, Gdalevich M, et al. Pemphigus—analysis of epidemiological factors in 155 patients. *J Eur Acad Dermatol Venereol.* 2008;22(10):1232-1235.
25. Abreu-Velez AM, Hashimoto T, Bollag WB, et al. A unique form of endemic pemphigus in northern Colombia. *J Am Acad Dermatol.* 2003;49(4):599-608.
26. Tallab T, Joharji H, Bahamdan K, et al. The incidence of pemphigus in the southern region of Saudi Arabia. *Int J Dermatol.* 2001;40(9):570-572.
27. Simon DG, Krutchkoff D, Kaslow RA, et al. Pemphigus in Hartford County, Connecticut, from 1972 to 1977. *Arch Dermatol.* 1980;116(9):1035-1037.
28. Tsankov N, Vassileva S, Kamarashev J, et al. Epidemiology of pemphigus in Sofia, Bulgaria. A 16-year retrospective study (1980-1995). *Int J Dermatol.* 2000;39(2):104-108.
29. Micali G, Musumeci ML, Nasca MR. Epidemiologic analysis and clinical course of 84 consecutive cases of pemphigus in eastern Sicily. *Int J Dermatol.* 1998;37(3):197-200.
30. Metry DW, Hebert AA, Jordon RE. Nonendemic pemphigus foliaceus in children. *J Am Acad Dermatol.* 2002;46(3):419-422.
31. Muramatsu T, Iida T, Ko T, et al. Pemphigus vulgaris exacerbated by exposure to sunlight. *J Dermatol.* 1996;23(8):559-563.
32. Reis VM, Toledo RP, Lopez A, et al. UVB-induced acantholysis in endemic pemphigus foliaceus (fogo selvagem) and pemphigus vulgaris. *J Am Acad Dermatol.* 2000;42(4):571-576.
33. Grando SA, Grando AA, Glukhenky BT, et al. History and clinical significance of mechanical symptoms in blistering dermatoses: a reappraisal. *J Am Acad Dermatol.* 2003;48(1):86-92.
34. Ahmed AR, Blose DA. Pemphigus vegetans. Neumann type and Hallopeau type. *Int J Dermatol.* 1984;23(2):135-141.
35. Veraitch O, Ohyama M, Yamagami J, et al. Alopecia as a rare but distinct manifestation of pemphigus vulgaris. *J Eur Acad Dermatol Venereol.* 2013;27(1):86-91.
36. Hale EK, Bystryn JC. Laryngeal and nasal involvement in pemphigus vulgaris. *J Am Acad Dermatol.* 2001;44(4):609-611.
37. Espana A, Fernandez S, del OJ, et al. Ear, nose and throat manifestations in pemphigus vulgaris. *Br J Dermatol.* 2007;156(4):733-737.

38. Kavala M, Altintas S, Kocaturk E, et al. Ear, nose and throat involvement in patients with pemphigus vulgaris: correlation with severity, phenotype and disease activity. *J Eur Acad Dermatol Venereol.* 2011;25(11):1324-1327.
39. Yoshida K, Takae Y, Saito H, et al. Cutaneous type pemphigus vulgaris: a rare clinical phenotype of pemphigus. *J Am Acad Dermatol.* 2005;52(5):839-845.
40. Trattner A, Lurie R, Leiser A, et al. Esophageal involvement in pemphigus vulgaris: a clinical, histologic, and immunopathologic study. *J Am Acad Dermatol.* 1991;24(2, pt 1):223-226.
41. Rao PN, Samarth A, Aurangabadkar SJ, et al. Study of upper gastrointestinal tract involvement in pemphigus by esophago-gastro-duodenoscopy. *Indian J Dermatol Venereol Leprol.* 2006;72(6):421-424.
42. Hokama A, Yamamoto Y, Taira K, et al. Esophagitis dissecans superficialis and autoimmune bullous dermatoses: a review. *World J Gastrointest Endosc.* 2010;2(7):252-256.
43. Malik M, Ahmed AR. Involvement of the female genital tract in pemphigus vulgaris. *Obstet Gynecol.* 2005;106(5, pt 1):1005-1012.
44. Hodak E, Kremer I, David M, et al. Conjunctival involvement in pemphigus vulgaris: a clinical, histopathological and immunofluorescence study. *Br J Dermatol.* 1990;123(5):615-620.
45. Daoud YJ, Cervantes R, Foster CS, et al. Ocular pemphigus. *J Am Acad Dermatol.* 2005;53(4):585-590.
46. Kavala M, Topaloglu Demir F, Zindanci I, et al. Genital involvement in pemphigus vulgaris (PV): correlation with clinical and cervicovaginal Pap smear findings. *J Am Acad Dermatol.* 2015;73(4):655-659.
47. Akhyani M, Chams-Davatchi C, Naraghi Z, et al. Cervicovaginal involvement in pemphigus vulgaris: a clinical study of 77 cases. *Br J Dermatol.* 2008;158(3):478-482.
48. Onuma K, Kanbour-Shakir A, Modery J, et al. Pemphigus vulgaris of the vagina—its cytomorphologic features on liquid-based cytology and pitfalls: case report and cytological differential diagnosis. *Diagn Cytopathol.* 2009;37(11):832-835.
49. Akhyani M, Keshtkar-Jafari A, Chams-Davatchi C, et al. Ocular involvement in pemphigus vulgaris. *J Dermatol.* 2014;41(7):618-621.
50. Suami M, Kato M, Koide K, et al. Keratolysis in a patient with pemphigus vulgaris. *Br J Ophthalmol.* 2001;85(10):1263-1264.
51. Igawa K, Matsunaga T, Nishioka K. Involvement of UV-irradiation in pemphigus foliaceus. *J Eur Acad Dermatol Venereol.* 2004;18(2):216-217.
52. Kano Y, Shimosegawa M, Mizukawa Y, et al. Pemphigus foliaceus induced by exposure to sunlight. Report of a case and analysis of photochallenge-induced lesions. *Dermatology.* 2000;201(2):132-138.
53. Senear FE, Usher B. An unusual type of pemphigus combining features of lupus erythematosus. *Arch Dermatol Syphilol.* 1926;13:761-781.
54. Senear FE, Kingery LB. Pemphigus erythematosus. *Arch Dermatol Syphilol.* 1949;60(2):238-252.
55. Jablonska S, Chorzelski T, Blaszczyk M, et al. Pathogenesis of pemphigus erythematosus. *Arch Dermatol Res.* 1977;258(2):135-140.
56. Oktarina DA, Poot AM, Kramer D, et al. The IgG "lupus-band" deposition pattern of pemphigus erythematosus: association with the desmoglein 1 ectodomain as revealed by 3 cases. *Arch Dermatol.* 2012;148(10):1173-1178.
57. Amerian ML, Ahmed AR. Pemphigus erythematosus. Senear-Usher syndrome. *Int J Dermatol.* 1985;24(1):16-25.
58. Chowdhury MMU, Natarajan S. Neonatal pemphigus vulgaris associated with mild oral pemphigus vulgaris in the mother during pregnancy. *Br J Dermatol.* 1998;139(3):500-503.
59. Fainaru O, Mashiach R, Kupferminc M, et al. Pemphigus vulgaris in pregnancy: a case report and review of literature. *Hum Reprod.* 2000;15(5):1195-1197.
60. Eyre RW, Stanley JR. Maternal pemphigus foliaceus with cell surface antibody bound in neonatal epidermis. *Arch Dermatol.* 1988;124(1):25-27.
61. Avalos-Diaz E, Olague-Marchan M, Lopez-Swiderski A, et al. Transplacental passage of maternal pemphigus foliaceus autoantibodies induces neonatal pemphigus. *J Am Acad Dermatol.* 2000;43(6):1130-1134.
62. Hirsch R, Anderson J, Weinberg JM, et al. Neonatal pemphigus foliaceus. *J Am Acad Dermatol.* 2003;49(2)(Suppl Case Reports):S187-S189.
63. Kanwar AJ, Dhar S, Kaur S. Further experience with pemphigus in children. *Pediatr Dermatol.* 1996;11(2):107-111.
64. Mutasim DF, Pelc NJ, Anhalt GJ. Drug-induced pemphigus. *Dermatol Clin.* 1993;11(3):463-471.
65. Korman NJ, Eyre RW, Zone J, et al. Drug-induced pemphigus: autoantibodies directed against the pemphigus antigen complexes are present in penicillamine and captopril-induced pemphigus. *J Invest Dermatol.* 1991;96(2):273-276.
66. Yokel BK, Hood AF, Anhalt GJ. Induction of acantholysis in organ explant culture by penicillamine and captopril. *Arch Dermatol.* 1989;125(10):1367-1370.
67. Drosos AA, Christou L, Galanopoulou V, et al. D-Penicillamine induced myasthenia gravis: clinical, serological and genetic findings. *Clin Exp Rheumatol.* 1993;11(4):387-391.
68. Sternlieb I, Bennett B, Scheinberg IH. D-Penicillamine induced Goodpasture's syndrome in Wilson's disease. *Ann Intern Med.* 1975;82(5):673-676.
69. Lee Y, Lee ST, Cho H. D-Penicillamine-induced ANA (+) ANCA (+) vasculitis in pediatric patients with Wilson's disease. *Clin Nephrol.* 2016;85(5):296-300.
70. Ruocco V, Brenner S, Lombardi ML. A case of diet-related pemphigus. *Dermatology.* 1996;192(4):373-374.
71. Tur E, Brenner S. Diet and pemphigus. In pursuit of exogenous factors in pemphigus and fogo selvagem. *Arch Dermatol.* 1998;134(11):1406-1410.
72. Mehta JN, Martin AG. A case of pemphigus vulgaris improved by cigarette smoking. *Arch Dermatol.* 2000;136(1):15-17.
73. Nguyen VT, Arredondo J, Chernyavsky AI, et al. Pemphigus vulgaris acantholysis ameliorated by cholinergic agonists. *Arch Dermatol.* 2004;140(3):327-334.
74. Iraji F, Yoosefi A. Healing effect of pilocarpine gel 4% on skin lesions of pemphigus vulgaris. *Int J Dermatol.* 2006;45(6):743-746.
75. Chernyavsky AI, Arredondo J, Piser T, et al. Differential coupling of M1 muscarinic and alpha 7 nicotinic receptors to inhibition of pemphigus acantholysis. *J Biol Chem.* 2008;283(6):3401-3408.
76. Pullan RD, Rhodes J, Ganesh S, et al. Transdermal nicotine for active ulcerative colitis. *N Engl J Med.* 1994;330(12):811-815.
77. Patten SF, Dijkstra JW. Associations of pemphigus and autoimmune disease with malignancy or thymoma. *Int J Dermatol.* 1994;33(12):836-842.

78. Maize JC, Dobson RL, Provost TT. Pemphigus and myasthenia gravis. *Arch Dermatol.* 1975;111(10):1334-1339.
79. Hsu DY, Brieva J, Sinha AA, et al. Comorbidities and inpatient mortality for pemphigus in the U.S.A. *Br J Dermatol.* 2016;174(6):1290-1298.
80. Yoshida M, Miyoshi T, Sakiyama S, et al. Pemphigus with thymoma improved by thymectomy: report of a case. *Surg Today.* 2013;43(7):806-808.
81. Parameswaran A, Attwood K, Sato R, et al. Identification of a new disease cluster of pemphigus vulgaris with autoimmune thyroid disease, rheumatoid arthritis and type I diabetes. *Br J Dermatol.* 2015;172(3):729-738.
82. Koulu L, Kusumi A, Steinberg MS, et al. Human autoantibodies against a desmosomal core protein in pemphigus foliaceus. *J Exp Med.* 1984;160(5):1509-1518.
83. Stanley JR, Koulu L, Klaus Kovtun V, et al. A monoclonal antibody to the desmosomal glycoprotein desmoglein I binds the same polypeptide as human autoantibodies in pemphigus foliaceus. *J Immunol.* 1986;136(4):1227-1230.
84. Amagai M, Klaus-Kovtun V, Stanley JR. Autoantibodies against a novel epithelial cadherin in pemphigus vulgaris, a disease of cell adhesion. *Cell.* 1991;67(5):869-877.
85. Hammers CM, Stanley JR. Mechanisms of disease: pemphigus and bullous pemphigoid. *Annu Rev Pathol.* 2016;11:175-197.
86. Payne AS, Hanakawa Y, Amagai M, et al. Desmosomes and disease: pemphigus and bullous impetigo. *Curr Opin Cell Biol.* 2004;16(5):536-543.
87. Stanley JR, Amagai M. Pemphigus, bullous impetigo, and the staphylococcal scalded-skin syndrome. *N Engl J Med.* 2006;355(17):1800-1810.
88. Amagai M, Karpati S, Klaus-Kovtun V, et al. The extracellular domain of pemphigus vulgaris antigen (desmoglein 3) mediates weak homophilic adhesion. *J Invest Dermatol.* 1994;102(4):402-408.
89. Chitaev NA, Troyanovsky SM. Direct Ca^{2+}-dependent heterophilic interaction between desmosomal cadherins, desmoglein and desmocollin, contributes to cell-cell adhesion. *J Cell Biol.* 1997;138(1):193-201.
90. Harrison OJ, Brasch J, Lasso G, et al. Structural basis of adhesive binding by desmocollins and desmogleins. *Proc Natl Acad Sci U S A.* 2016;113(26):7160-7165.
91. Stanley JR, Klaus Kovtun V, Sampaio SA. Antigenic specificity of fogo selvagem autoantibodies is similar to North American pemphigus foliaceus and distinct from pemphigus vulgaris autoantibodies. *J Invest Dermatol.* 1986;87(2):197-201.
92. Ishii K, Amagai M, Hall RP, et al. Characterization of autoantibodies in pemphigus using antigen-specific enzyme-linked immunosorbent assays with baculovirus-expressed recombinant desmogleins. *J Immunol.* 1997;159(4):2010-2017.
93. Eyre RW, Stanley JR. Identification of pemphigus vulgaris antigen extracted from normal human epidermis and comparison with pemphigus foliaceus antigen. *J Clin Invest.* 1988;81(3):807-812.
94. Ding X, Aoki V, Mascaro JM Jr, et al. Mucosal and mucocutaneous (generalized) pemphigus vulgaris show distinct autoantibody profiles. *J Invest Dermatol.* 1997;109(4):592-596.
95. Amagai M, Tsunoda K, Zillikens D, et al. The clinical phenotype of pemphigus is defined by the anti-desmoglein autoantibody profile. *J Am Acad Dermatol.* 1999;40(167):170.
96. Miyagawa S, Amagai M, Iida T, et al. Late development of antidesmoglein 1 antibodies in pemphigus vulgaris: correlation with disease progression. *Br J Dermatol.* 1999;141(6):1084-1087.
97. Naseer SY, Seiffert-Sinha K, Sinha AA. Detailed profiling of anti-desmoglein autoantibodies identifies anti-Dsg1 reactivity as a key driver of disease activity and clinical expression in pemphigus vulgaris. *Autoimmunity.* 2015;48(4):231-241.
98. Flores G, Culton DA, Prisayanh P, et al. IgG autoantibody response against keratinocyte cadherins in endemic pemphigus foliaceus (fogo selvagem). *J Invest Dermatol.* 2012;132(11):2573-2580.
99. Mao X, Nagler AR, Farber SA, et al. Autoimmunity to desmocollin 3 in pemphigus vulgaris. *Am J Pathol.* 2010;177(6):2724-2730.
100. Ishii N, Teye K, Fukuda S, et al. Anti-desmocollin autoantibodies in nonclassical pemphigus. *Br J Dermatol.* 2015;173(1):59-68.
101. Chen J, Den Z, Koch PJ. Loss of desmocollin 3 in mice leads to epidermal blistering. *J Cell Sci.* 2008;121 (pt 17):2844-2849.
102. Rafei D, Muller R, Ishii N, et al. IgG autoantibodies against desmocollin 3 in pemphigus sera induce loss of keratinocyte adhesion. *Am J Pathol.* 2011;178(2):718-723.
103. Nguyen VT, Ndoye A, Grando SA. Pemphigus vulgaris antibody identifies pemphaxin. *J Biol Chem.* 2000;275(38):29466-29476.
104. Evangelista F, Dasher DA, Diaz LA, et al. E-cadherin is an additional immunological target for pemphigus autoantibodies. *J Invest Dermatol.* 2008;128(7):1710-1718.
105. Oliveira ME, Culton DA, Prisayanh P, et al. E-cadherin autoantibody profile in patients with pemphigus vulgaris. *Br J Dermatol.* 2013;169(4):812-818.
106. Kalantari-Dehaghi M, Anhalt GJ, Camilleri MJ, et al. Pemphigus vulgaris autoantibody profiling by proteomic technique. *PLoS One.* 2013;8(3):e57587.
107. Wilgram GF, Caulfield JB, Madgic EB. An electron microscopic study of acantholysis and dyskeratosis in pemphigus foliaceus. *J Invest Dermatol.* 1964;43:287-299.
108. Guedes AC, Rotta O, Leite HV, et al. Ultrastructural aspects of mucosas in endemic pemphigus foliaceus. *Arch Dermatol.* 2002;138(7):949-954.
109. Hashimoto K, Lever WF. An electron microscopic study on pemphigus vulgaris of the mouth and the skin with special reference to the intercellular cement. *J Invest Dermatol.* 1967;48(6):540-552.
110. Diercks GF, Pas HH, Jonkman MF. The ultrastructure of acantholysis in pemphigus vulgaris. *Br J Dermatol.* 2009;160(2):460-461.
111. Shimizu A, Ishiko A, Ota T, et al. Ultrastructural changes in mice actively producing antibodies to desmoglein 3 parallel those in patients with pemphigus vulgaris. *Arch Dermatol Res.* 2002;294(7):318-323.
112. Shimizu A, Ishiko A, Ota T, et al. IgG binds to desmoglein 3 in desmosomes and causes a desmosomal split without keratin retraction in a pemphigus mouse model. *J Invest Dermatol.* 2004;122(5):1145-1153.
113. Bystryn JC, Grando SA. A novel explanation for acantholysis in pemphigus vulgaris: the basal cell shrinkage hypothesis. *J Am Acad Dermatol.* 2006;54(3):513-516.
114. Wang W, Amagai M, Ishiko A. Desmosome splitting is a primary ultrastructural change in the acantholysis of pemphigus. *J Dermatol Sci.* 2009;54(1):59-61.

115. Sokol E, Kramer D, Diercks GF, et al. Large-scale electron microscopy maps of patient skin and mucosa provide insight into pathogenesis of blistering diseases. *J Invest Dermatol.* 2015;135(7):1763-1770.
116. Stahley SN, Warren MF, Feldman RJ, et al. Super-resolution microscopy reveals altered desmosomal protein organization in tissue from patients with pemphigus vulgaris. *J Invest Dermatol.* 2016;136(1):59-66.
117. Schiltz JR, Michel B. Production of epidermal acantholysis in normal human skin in vitro by the IgG fraction from pemphigus serum. *J Invest Dermatol.* 1976;67(2):254-260.
118. Anhalt GJ, Labib RS, Voorhees JJ, et al. Induction of pemphigus in neonatal mice by passive transfer of IgG from patients with the disease. *N Engl J Med.* 1982;306(20):1189-1196.
119. Rock B, Labib RS, Diaz LA. Monovalent Fab' immunoglobulin fragments from endemic pemphigus foliaceus autoantibodies reproduce the human disease in neonatal Balb/c mice. *J Clin Invest.* 1990;85(1):296-299.
120. Amagai M, Karpati S, Prussick R, et al. Autoantibodies against the amino-terminal cadherin-like binding domain of pemphigus vulgaris antigen are pathogenic. *J Clin Invest.* 1992;90(3):919-926.
121. Amagai M, Hashimoto T, Shimizu N, et al. Absorption of pathogenic autoantibodies by the extracellular domain of pemphigus vulgaris antigen (Dsg3) produced by baculovirus. *J Clin Invest.* 1994;94(1):59-67.
122. Ding X, Diaz LA, Fairley JA, et al. The anti-desmoglein 1 autoantibodies in pemphigus vulgaris sera are pathogenic. *J Invest Dermatol.* 1999;112(5):739-743.
123. Amagai M, Hashimoto T, Green KJ, et al. Antigen-specific immunoabsorption of pathogenic autoantibodies in pemphigus foliaceus. *J Invest Dermatol.* 1995;104(6):895-901.
124. Langenhan J, Dworschak J, Saschenbrecker S, et al. Specific immunoadsorption of pathogenic autoantibodies in pemphigus requires the entire ectodomains of desmogleins. *Exp Dermatol.* 2014;23(4):253-259.
125. Koch PJ, Mahoney MG, Ishikawa H, et al. Targeted disruption of the pemphigus vulgaris antigen (desmoglein 3) gene in mice causes loss of keratinocyte cell adhesion with a phenotype similar to pemphigus vulgaris. *J Cell Biol.* 1997;137(5):1091-1102.
126. Amagai M, Matsuyoshi N, Wang ZH, et al. Toxin in bullous impetigo and staphylococcal scalded-skin syndrome targets desmoglein 1. *Nat Med.* 2000; 6(11):1275-1277.
127. Anhalt GJ, Till GO, Diaz LA, et al. Defining the role of complement in experimental pemphigus vulgaris in mice. *J Immunol.* 1986;137(9):2835-2840.
128. Payne AS, Ishii K, Kacir S, et al. Genetic and functional characterization of human pemphigus vulgaris monoclonal autoantibodies isolated by phage display. *J Clin Invest.* 2005;115(4):888-899.
129. Ishii K, Lin CY, Siegel DL, et al. Isolation of pathogenic monoclonal anti-desmoglein 1 human antibodies by phage display of pemphigus foliaceus autoantibodies. *J Invest Dermatol.* 2008;128(4):939-948.
130. Rock B, Martins CR, Theofilopoulos AN, et al. The pathogenic effect of IgG4 autoantibodies in endemic pemphigus foliaceus (fogo selvagem). *N Engl J Med.* 1989;320(22):1463-1469.
131. Futei Y, Amagai M, Ishii K, et al. Predominant IgG4 subclass in autoantibodies of pemphigus vulgaris and foliaceus. *J Dermatol Sci.* 2001;26(1):55-61.
132. Funakoshi T, Lunardon L, Ellebrecht CT, et al. Enrichment of total serum IgG4 in patients with pemphigus. *Br J Dermatol.* 2012;167(6):1245-1253.
133. Futei Y, Amagai M, Sekiguchi M, et al. Use of domain-swapped molecules for conformational epitope mapping of desmoglein 3 in pemphigus vulgaris. *J Invest Dermatol.* 2000;115(5):829-834.
134. Li N, Aoki V, Hans-Filho G, et al. The role of intramolecular epitope spreading in the pathogenesis of endemic pemphigus foliaceus (fogo selvagem). *J Exp Med.* 2003;197(11):1501-1510.
135. Hacker-Foegen MK, Janson M, Amagai M, et al. Pathogenicity and epitope characteristics of anti-desmoglein-1 from pemphigus foliaceus patients expressing only IgG1 autoantibodies. *J Invest Dermatol.* 2003;121(6):1373-1378.
136. Sekiguchi M, Futei Y, Fujii Y, et al. Dominant autoimmune epitopes recognized by pemphigus antibodies map to the N-terminal adhesive region of desmogleins. *J Immunol.* 2001;167(9):5439-5448.
137. Boggon TJ, Murray J, Chappuis-Flament S, et al. C-cadherin ectodomain structure and implications for cell adhesion mechanisms. *Science.* 2002; 296(5571):1308-1313.
138. Al-Amoudi A, Diez DC, Betts MJ, et al. The molecular architecture of cadherins in native epidermal desmosomes. *Nature.* 2007;450(7171):832-837.
139. Heupel WM, Zillikens D, Drenckhahn D, et al. Pemphigus vulgaris IgG directly inhibit desmoglein 3-mediated transinteraction. *J Immunol.* 2008; 181(3): 1825-1834.
140. Aoyama Y, Kitajima Y. Pemphigus vulgaris-IgG causes a rapid depletion of desmoglein 3 (Dsg3) from the Triton X-100 soluble pools, leading to the formation of Dsg3-depleted desmosomes in a human squamous carcinoma cell line, DJM-1 cells. *J Invest Dermatol.* 1999;112(1):67-71.
141. Sato M, Aoyama Y, Kitajima Y. Assembly pathway of desmoglein 3 to desmosomes and its perturbation by pemphigus vulgaris-IgG in cultured keratinocytes, as revealed by time-lapsed labeling immunoelectron microscopy. *Lab Invest.* 2000;80(10): 1583-1592.
142. Calkins CC, Setzer SV, Jennings JM, et al. Desmoglein endocytosis and desmosome disassembly are coordinated responses to pemphigus autoantibodies. *J Biol Chem.* 2006;281(11):7623-7634.
143. Mao X, Choi EJ, Payne AS. Disruption of desmosome assembly by monovalent human pemphigus vulgaris monoclonal antibodies. *J Invest Dermatol.* 2009;129(4):908-918.
144. Rivitti EA, Sanches JA, Miyauchi LM, et al. Pemphigus foliaceus autoantibodies bind both epidermis and squamous mucosal epithelium, but tissue injury is detected only in the epidermis. The Cooperative Group on Fogo Selvagem Research. *J Am Acad Dermatol.* 1994;31(6):954-958.
145. Mahoney MG, Wang Z, Rothenberger K, et al. Explanation for the clinical and microscopic localization of lesions in pemphigus foliaceus and vulgaris. *J Clin Invest.* 1999;103(4):461-468.
146. Wu H, Wang ZH, Yan A, et al. Protection of neonates against pemphigus foliaceus by desmoglein 3. *N Engl J Med.* 2000;343(1):31-35.
147. Hanakawa Y, Matsuyoshi N, Stanley JR. Expression of desmoglein 1 compensates for genetic loss of desmoglein 3 in keratinocyte adhesion. *J Invest Dermatol.* 2002;119(1):27-31.

148. Rocha-Alvarez R, Friedman H, et al. Pregnant women with endemic pemphigus foliaceus (Fogo Selvagem) give birth to disease-free babies. *J Invest Dermatol.* 1992;99(1):78-82.
149. Berkowitz P, Hu P, Warren S, et al. p38MAPK inhibition prevents disease in pemphigus vulgaris mice. *Proc Natl Acad Sci U S A.* 2006;103(34):12855-12860.
150. Waschke J, Spindler V, Bruggeman P, et al. Inhibition of Rho A activity causes pemphigus skin blistering. *J Cell Biol.* 2006;175(5):721-727.
151. Sharma P, Mao X, Payne AS. Beyond steric hindrance: the role of adhesion signaling pathways in the pathogenesis of pemphigus. *J Dermatol Sci.* 2007;48(1):1-14.
152. Bektas M, Jolly PS, Berkowitz P, et al. A pathophysiologic role for epidermal growth factor receptor in pemphigus acantholysis. *J Biol Chem.* 2013;288(13):9447-9456.
153. Mao X, Sano Y, Park JM, et al. p38 MAPK activation is downstream of the loss of intercellular adhesion in pemphigus vulgaris. *J Biol Chem.* 2011;286(2):1283-1291.
154. Vielmuth F, Waschke J, Spindler V. Loss of desmoglein binding is not sufficient for keratinocyte dissociation in pemphigus. *J Invest Dermatol.* 2015;135(12):3068-3077.
155. Mao X, Li H, Sano Y, et al. MAPKAP kinase 2 (MK2)-dependent and -independent models of blister formation in pemphigus vulgaris. *J Invest Dermatol.* 2014;134(1):68-76.
156. Saito M, Stahley SN, Caughman CY, et al. Signaling dependent and independent mechanisms in pemphigus vulgaris blister formation. *PLoS One.* 2012;7(12):e50696.
157. Oktarina DA, van der Wier G, Diercks GF, et al. IgG-induced clustering of desmogleins 1 and 3 in skin of patients with pemphigus fits with the desmoglein nonassembly depletion hypothesis. *Br J Dermatol.* 2011;165(3):552-562.
158. van der Wier G, Pas HH, Kramer D, et al. Smaller desmosomes are seen in the skin of pemphigus patients with anti-desmoglein 1 antibodies but not in patients with anti-desmoglein 3 antibodies. *J Invest Dermatol.* 2014;134(8):2287-2290.
159. Jennings JM, Tucker DK, Kottke MD, et al. Desmosome disassembly in response to pemphigus vulgaris IgG occurs in distinct phases and can be reversed by expression of exogenous Dsg3. *J Invest Dermatol.* 2011;131(3):706-718.
160. Kitajima Y. 150(th) anniversary series: Desmosomes and autoimmune disease, perspective of dynamic desmosome remodeling and its impairments in pemphigus. *Cell Commun Adhes.* 2014;21(6): 269-280.
161. Wucherpfennig KW, Strominger JL. Selective binding of self peptides to disease-associated major histocompatibility complex (MHC) molecules: a mechanism for MHC- linked susceptibility to human autoimmune diseases [comment]. *J Exp Med.* 1995;181(5): 1597-1601.
162. Pavoni DP, Roxo VM, Marquart FA, et al. Dissecting the associations of endemic pemphigus foliaceus (fogo selvagem) with HLA-DRB1 alleles and genotypes. *Genes Immun.* 2003;4(2):110-116.
163. Lin MS, Swartz SJ, Lopez A, et al. Development and characterization of desmoglein-3 specific T cells from patients with pemphigus vulgaris. *J Clin Invest.* 1997;99(1):31-40.
164. Hertl M, Karr RW, Amagai M, et al. Heterogeneous MHC II restriction pattern of autoreactive desmoglein 3 specific T cell responses in pemphigus vulgaris patients and normals. *J Invest Dermatol.* 1998;110(4):388-392.
165. Hertl M, Amagai M, Sundaram H, et al. Recognition of desmoglein 3 by autoreactive T cells in pemphigus vulgaris patients and normals. *J Invest Dermatol.* 1998;110(1):62-66.
166. Yan L, Wang JM, Zeng K. Association between HLA-DRB1 polymorphisms and pemphigus vulgaris: a meta-analysis. *Br J Dermatol.* 2012;167(4):768-777.
167. Hertl M, Eming R, Veldman C. T cell control in autoimmune bullous skin disorders. *J Clin Invest.* 2006;116(5):1159-1166.
168. Wucherpfennig KW, Yu B, Bhol K, et al. Structural basis for major histocompatibility complex (MHC)-linked susceptibility to autoimmunity: charged residues of a single MHC binding pocket confer selective presentation of self-peptides in pemphigus vulgaris. *Proc Natl Acad Sci U S A.* 1995;92(25):11935-11939.
169. Eming R, Hennerici T, Backlund J, et al. Pathogenic IgG antibodies against desmoglein 3 in pemphigus vulgaris are regulated by HLA-DRB1*04:02-restricted T cells. *J Immunol.* 2014;193(9):4391-4399.
170. Wada N, Nishifuji K, Yamada T, et al. Aire-dependent thymic expression of desmoglein 3, the autoantigen in pemphigus vulgaris, and its role in T-cell tolerance. *J Invest Dermatol.* 2011;131(2):410-417.
171. Veldman CM, Gebhard KL, Uter W, et al. T cell recognition of desmoglein 3 peptides in patients with pemphigus vulgaris and healthy individuals. *J Immunol.* 2004;172(6):3883-3892.
172. Zhu H, Chen Y, Zhou Y, et al. Cognate Th2-B cell interaction is essential for the autoantibody production in pemphigus vulgaris. *J Clin Immunol.* 2012;32(1):114-123.
173. Hennerici T, Pollmann R, Schmidt T, et al. Increased frequency of T follicular helper cells and elevated interleukin-27 plasma levels in patients with pemphigus. *PLoS One.* 2016;11(2):e0148919.
174. Veldman C, Höhne A, Dieckmann D, et al. Type I regulatory T cells specific for desmoglein 3 are more frequently detected in healthy individuals than in patients with pemphigus vulgaris. *J Immunol.* 2004; 172(10):6468-6475.
175. Yamagami J, Kacir S, Ishii K, et al. Antibodies to the desmoglein 1 precursor proprotein but not to the mature cell surface protein cloned from individuals without pemphigus. *J Immunol.* 2009;183(9):5615-5621.
176. Cho MJ, Lo AS, Mao X, et al. Shared VH1-46 gene usage by pemphigus vulgaris autoantibodies indicates common humoral immune responses among patients. *Nat Commun.* 2014;5:4167.
177. Yamagami J, Payne AS, Kacir S, et al. Homologous regions of autoantibody heavy chain complementarity-determining region 3 (H-CDR3) in patients with pemphigus cause pathogenicity. *J Clin Invest.* 2010;120(11):4111-4117.
178. Di Zenzo G, Di Lullo G, Corti D, et al. Pemphigus autoantibodies generated through somatic mutations target the desmoglein-3 cis-interface. *J Clin Invest.* 2012;122(10):3781-3790.
179. Qian Y, Diaz LA, Ye J, et al. Dissecting the anti-desmoglein autoreactive B cell repertoire in pemphigus vulgaris patients. *J Immunol.* 2007;178(9):5982-5990.
180. Qian Y, Clarke SH, Aoki V, et al. Antigen selection of anti-DSG1 autoantibodies during and before the

onset of endemic pemphigus foliaceus. *J Invest Dermatol.* 2009;129(12):2823-2834.
181. Tian C, Luskin GK, Dischert KM, et al. Immunodominance of the VH1-46 antibody gene segment in the primary repertoire of human rotavirus-specific B cells is reduced in the memory compartment through somatic mutation of nondominant clones. *J Immunol.* 2008;180(5):3279-3288.
182. Hammers CM, Chen J, Lin C, et al. Persistence of antidesmoglein 3 IgG(+) B-cell clones in pemphigus patients over years. *J Invest Dermatol.* 2015;135(3): 742-749.
183. Beutner EH, Lever WF, Witebsky E, et al. Autoantibodies in pemphigus vulgaris. *JAMA.* 1965;192:682-688.
184. Judd KP, Lever WF. Correlation of antibodies in skin and serum with disease severity in pemphigus. *Arch Dermatol.* 1979;115(4):428-432.
185. Chorzelski T, Jablonska S, Blaszczyk M. Immunopathological investigations in the Senear-Usher syndrome (coexistence of pemphigus and lupus erythematosus). *Br J Dermatol.* 1968;80(4):211-217.
186. Harman KE, Gratian MJ, Bhogal BS, et al. The use of two substrates to improve the senstivity of indirect immunofluorscence in the diagnosis of pemphigus. *Br J Dermatol.* 2000;142(6):1135-1139.
187. Krasny SA, Beutner EH, Chorzelski TP. Specificity and sensitivity of indirect and direct immunofluorescent findings in the diagnosis of pemphigus. In: Beutner EH, Chorzelski TP, Kumar V, eds. *Immunopathology of the Skin*. New York, NY: John Wiley; 1987:207-247.
188. O'Loughlin S, Goldman GC, Provost TT. Fate of pemphigus antibody following successful therapy. Preliminary evaluation of pemphigus antibody determinations to regulate therapy. *Arch Dermatol.* 1978;114(12):1769-1772.
189. Aberer W, Wolff-Schreiner EC, Stingl G, et al. Azathioprine in the treatment of pemphigus vulgaris. A long-term follow-up. *J Am Acad Dermatol.* 1987; 16(3, pt 1):527-533.
190. Amagai M, Komai A, Hashimoto T, et al. Usefulness of enzyme-linked immunosorbent assay using recombinant desmogleins 1 and 3 for serodiagnosis of pemphigus. *Br J Dermatol.* 1999;140(2):351-357.
191. Cheng SW, Kobayashi M, Kinoshita-Kuroda K, et al. Monitoring disease activity in pemphigus with enzyme-linked immunosorbent assay using recombinant desmogleins 1 and 3. *Br J Dermatol.* 2002; 147(2):261-265.
192. Ishii K, Amagai M, Ohata Y, et al. Development of pemphigus vulgaris in a patient with pemphigus foliaceus: antidesmoglein antibody profile shift confirmed by enzyme-linked immunosorbent assay. *J Am Acad Dermatol.* 2000;42(5, pt 2):859-861.
193. Komai A, Amagai M, Ishii K, et al. The clinical transition between pemphigus foliaceus and pemphigus vulgaris correlates well with the changes in autoantibody profile assessed by an enzyme-linked immunosorbent assay. *Br J Dermatol.* 2001;144(6): 1177-1182.
194. Tsuji Y, Kawashima T, Yokota K, et al. Clinical and serological transition from pemphigus vulgaris to pemphigus foliaceus demonstrated by desmoglein ELISA system. *Arch Dermatol.* 2002;138(1):95-96.
195. Arteaga LA, Prisayanh PS, Warren SJ, et al. CGoFS. A subset of pemphigus foliaceus patients exhibits pathogenic autoantibodies against both desmoglein-1 and desmoglein-3. *J Invest Dermatol.* 2002; 118(5):806-811.
196. Kwon EJ, Yamagami J, Nishikawa T, et al. Antidesmoglein IgG autoantibodies in patients with pemphigus in remission. *J Eur Acad Dermatol Venereol.* 2008;22(9):1070-1075.
197. Udey MC, Stanley JR. Pemphigus: diseases of anti-desmosomal autoimmunity. *JAMA.* 1999;282(6):572-576.
198. Emmerson RW, Wilson-Jones E. Eosinophilic spongiosis in pemphigus. A report of an unusual hitological change in pemphigus *Arch Dermatol.* 1968;97(3):252-257.
199. Carson PJ, Hameed A, Ahmed AR. Influence of treatment on the clinical course of pemphigus vulgaris. *J Am Acad Dermatol.* 1996;34(4):645-652.
200. Bystryn JC, Rudolph JL. Pemphigus. *Lancet.* 2005; 366(9479):61-73.
201. Stanley JR. Therapy of pemphigus vulgaris. *Arch Dermatol.* 1999;135:76-78.
202. Bystryn JC, Steinman NM. The adjuvant therapy of pemphigus. An update. *Arch Dermatol.* 1996; 132(2): 203-212.
203. Risser J, Lewis K, Weinstock MA. Mortality of bullous skin disorders from 1979 through 2002 in the United States. *Arch Dermatol.* 2009;145(9):1005-1008.
204. Ahmed AR, Moy R. Death in pemphigus. *J Am Acad Dermatol.* 1982;7(2):221-228.
205. Herbst A, Bystryn JC. Patterns of remission in pemphigus vulgaris. *J Am Acad Dermatol.* 2000;42(3):422-427.
206. Almugairen N, Hospital V, Bedane C, et al. Assessment of the rate of long-term complete remission off therapy in patients with pemphigus treated with different regimens including medium- and high-dose corticosteroids. *J Am Acad Dermatol.* 2013;69(4):583-588.
207. Atzmony L, Hodak E, Leshem YA, et al. The role of adjuvant therapy in pemphigus: a systematic review and meta-analysis. *J Am Acad Dermatol.* 2015;73(2):264-271.
208. Colliou N, Picard D, Caillot F, et al. Long-term remissions of severe pemphigus after rituximab therapy are associated with prolonged failure of desmoglein B cell response. *Sci Transl Med.* 2013;5(175):175ra30.
209. Joly P, Maho-Vaillant M, Prost-Squarcioni C, et al. First-line rituximab combined with short-term prednisone versus prednisone alone for the treatment of pemphigus (Ritux 3): a prospective, multicentre, parallel-group, open-label randomised trial. *Lancet*. 2017 May 20;389(10083):2031-2040.
210. Mimouni D, Nousari CH, Cummins DL, et al. Differences and similarities among expert opinions on the diagnosis and treatment of pemphigus vulgaris. *J Am Acad Dermatol.* 2003;49(6):1059-1062.
211. Committee for Guidelines for the Management of Pemphigus Disease; Amagai M, Tanikawa A, Shimizu T, et al. Japanese guidelines for the management of pemphigus. *J Dermatol.* 2014;41(6):471-486.
212. Hertl M, Jedlickova H, Karpati S, et al. Pemphigus. S2 Guideline for diagnosis and treatment—guided by the European Dermatology Forum (EDF) in cooperation with the European Academy of Dermatology and Venereology (EADV). *J Eur Acad Dermatol Venereol.* 2015;29(3):405-414.
213. Harman et al, British Association of Dermatologists' guidelines for the management of pemphigus vulgaris 2017, https://doi.org/10.1111/bjd.15930.
214. Murrell et al. Diagnosis and management of pemphigus, *JAAD* 2018, doi: 10.1016/j.*JAAD*.2018.02.021.
215. Seidenbaum M, David M, Sandbank M. The course and prognosis of pemphigus. A review of 115 patients. *Int J Dermatol.* 1988;27(8):580-584.
216. Murrell DF, Dick S, Amagai M, et al. Consensus statement on definitions of disease endpoints and

therapeutic response for pemphigus. *J Am Acad Dermatol.* 2008;58(6):1043-1046.
217. Pfütze M, Niedermeier A, Hertl M, et al. Introducing a novel Autoimmune Bullous Skin Disorder Intensity Score (ABSIS) in pemphigus. *Eur J Dermatol.* 2007;17(1):4-11.
218. Rosenbach M, Murrell DF, Bystryn JC, et al. Reliability and convergent validity of two outcome instruments for pemphigus. *J Invest Dermatol.* 2008; 129(10):2404-2410.
219. Rosenberg FR, Sanders S, Nelson CT. Pemphigus: a 20-year review of 107 patients treated with corticosteroids. *Arch Dermatol.* 1976;112(7):962-970.
220. Hirone T. Pemphigus: a survey of 85 patients between 1970 and 1974. *J Dermatol.* 1978;5(2):43-47.
221. Ratnam KV, Phay KL, Tan CK. Pemphigus therapy with oral prednisolone regimens. A 5-year study. *Int J Dermatol.* 1990;29(5):363-367.
222. Fine JD. Management of acquired bullous skin diseases. *N Engl J Med.* 1995;333(22):1475-1484.
223. Nguyen VT, Arredondo J, Chernyavsky AI, et al. Pemphigus vulgaris IgG and methylprednisolone exhibit reciprocal effects on keratinocytes. *J Biol Chem.* 2004;279(3):2135-2146.
224. Mao et al. *JCI Insight* 2017. doi: 10.1016/j.jaad. 2018.02.021.
225. Eming R, Nagel A, Wolff-Franke S, et al. Rituximab exerts a dual effect in pemphigus vulgaris. *J Invest Dermatol.* 2008;128(12):2850-2858.
226. Joly P, Mouquet H, Roujeau JC, et al. A single cycle of rituximab for the treatment of severe pemphigus. *N Engl J Med.* 2007;357(6):545-552.
227. Kincaid L, Weinstein M. Rituximab therapy for childhood pemphigus vulgaris. *Pediatr Dermatol.* 2016;33(2):e61-e64.
228. Vinay K, Kanwar AJ, Sawatkar GU, et al. Successful use of rituximab in the treatment of childhood and juvenile pemphigus. *J Am Acad Dermatol.* 2014;71(4):669-675.
229. Connelly EA, Aber C, Kleiner G, et al. Generalized erythrodermic pemphigus foliaceus in a child and its successful response to rituximab treatment. *Pediatr Dermatol.* 2007;24(2):172-176.
230. Rituxan [package insert]. South San Francisco: Genentech, 2018.
231. Allen KJ, Wolverton SE. The efficacy and safety of rituximab in refractory pemphigus: a review of case reports. *J Drugs Dermatol.* 2007;6(9):883-889.
232. Cianchini G, Corona R, Frezzolini A, et al. Treatment of severe pemphigus with rituximab: report of 12 cases and a review of the literature. *Arch Dermatol.* 2007;143(8):1033-1038.
233. Kolstad A, Holte H, Fossa A, et al. *Pneumocystis jirovecii* pneumonia in B-cell lymphoma patients treated with the rituximab-CHOEP-14 regimen. *Haematologica.* 2007;92(1):139-140.
234. Teichmann LL, Woenckhaus M, Vogel C, et al. Fatal Pneumocystis pneumonia following rituximab administration for rheumatoid arthritis. *Rheumatology (Oxford).* 2008;47(8):1256-1257.
235. Beissert S, Werfel T, Frieling U, et al. A comparison of oral methylprednisolone plus azathioprine or mycophenolate mofetil for the treatment of pemphigus. *Arch Dermatol.* 2006;142(11):1447-1454.
236. Chams-Davatchi C, Esmaili N, Daneshpazhooh M, et al. Randomized controlled open-label trial of four treatment regimens for pemphigus vulgaris. *J Am Acad Dermatol.* 2007;57(4):622-628.
237. Chams-Davatchi C, Mortazavizadeh A, Daneshpazhooh M, et al. Randomized double blind trial of prednisolone and azathioprine, vs. prednisolone and placebo, in the treatment of pemphigus vulgaris. *J Eur Acad Dermatol Venereol.* 2013;27(10):1285-1292.
238. Beissert S, Mimouni D, Kanwar AJ, et al. Treating pemphigus vulgaris with prednisone and mycophenolate mofetil: a multicenter, randomized, placebo-controlled trial. *J Invest Dermatol.* 2010;130(8):2041-2048.
239. Olszewska M, Kolacinska-Strasz Z, Sulej J, et al. Efficacy and safety of cyclophosphamide, azathioprine, and cyclosporine (ciclosporin) as adjuvant drugs in pemphigus vulgaris. *Am J Clin Dermatol.* 2007;8(2):85-92.
240. Weinshilboum RM, Sladek SL. Mercaptopurine pharmacogenetics: monogenic inheritance of erythrocyte thiopurine methyltransferase activity. *Am J Hum Genet.* 1980;32(5):651-662.
241. Schaeffeler E, Fischer C, Brockmeier D, et al. Comprehensive analysis of thiopurine S-methyltransferase phenotype-genotype correlation in a large population of German-Caucasians and identification of novel TPMT variants. *Pharmacogenetics.* 2004;14(7):407-417.
242. Yang SK, et al. A common missense variant in NUDT15 confers susceptibility to thiopurine-induced leukopenia. *Nat Genet.* 2014;46:1017-1020.
243. Reuther LO, Vainer B, Sonne J, et al. Thiopurine methyltransferase (TPMT) genotype distribution in azathioprine-tolerant and -intolerant patients with various disorders. The impact of TPMT genotyping in predicting toxicity. *Eur J Clin Pharmacol.* 2004;59(11):797-801.
244. Enk AH, Knop J. Mycophenolate mofetil is effective in the treatment of pemphigus vulgaris. *Arch Dermatol.* 1999;135:54-56.
245. Mimouni D, Anhalt GJ, Cummins DL, et al. Treatment of pemphigus vulgaris and pemphigus foliaceus with mycophenolate mofetil. *Arch Dermatol.* 2003; 139(6):739-742.
246. Baratta A, Camarillo D, Papa C, et al. Pediatric pemphigus vulgaris: durable treatment responses achieved with prednisone and mycophenolate mofetil (MMF). *Pediatr Dermatol.* 2013;30(2):240-244.
247. Cellcept [package insert]. South San Francisco: Genentech, 2015.
248. Oz HS, Hughes WT. Novel anti-*Pneumocystis carinii* effects of the immunosuppressant mycophenolate mofetil in contrast to provocative effects of tacrolimus, sirolimus, and dexamethasone. *J Infect Dis.* 1997;175(4):901-904.
249. Tran KD, Wolverton JE, Soter NA. Methotrexate in the treatment of pemphigus vulgaris: experience in 23 patients. *Br J Dermatol.* 2013;169(4):916-921.
250. Yu Z, Lennon VA. Mechanism of intravenous immune globulin therapy in antibody-mediated autoimmune diseases. *N Engl J Med.* 1999;340(3):227-228.
251. Li N, Zhao M, Hilario-Vargas J, et al. Complete FcRn dependence for intravenous Ig therapy in autoimmune skin blistering diseases. *J Clin Invest.* 2005;115(12):3440-3450.
252. Czernik A, Beutner EH, Bystryn JC. Intravenous immunoglobulin selectively decreases circulating autoantibodies in pemphigus. *J Am Acad Dermatol.* 2008;58(5):796-801.
253. Engineer L, Bhol KC, Ahmed AR. Analysis of current data on the use of intravenous immunoglobulins in management of pemphigus vulgaris. *J Am Acad Dermatol.* 2000;43(6):1049-1057.

254. Ahmed AR, Dahl MV. Consensus statement on the use of intravenous immunoglobulin therapy in the treatment of autoimmune mucocutaneous blistering diseases. *Arch Dermatol.* 2003;139(8):1051-1059.
255. Amagai M, Ikeda S, Shimizu H, et al. A randomized double-blind trial of intravenous immunoglobulin for pemphigus. *J Am Acad Dermatol.* 2009;60(4):595-603.
256. Katz KA, Hivnor CM, Geist DE, et al. Stroke and deep venous thrombosis complicating intravenous immunoglobulin infusions. *Arch Dermatol.* 2003;139(8):991-993.
257. Ahmed AR, Spigelman Z, Cavacini LA, et al. Treatment of pemphigus vulgaris with rituximab and intravenous immune globulin. *N Engl J Med.* 2006;355(17):1772-1779.
258. Ahmed AR, Kaveri S, Spigelman Z. Long-term remissions in Recalcitrant Pemphigus Vulgaris. *N Engl J Med.* 2015;373(27):2693-2694.
259. Cummins DL, Mimouni D, Anhalt GJ, et al. Oral cyclophosphamide for treatment of pemphigus vulgaris and foliaceus. *J Am Acad Dermatol.* 2003;49(2):276-280.
260. Pasricha JS, Das SS. Curative effect of dexamethasone-cyclophosphamide pulse therapy for the treatment of pemphigus vulgaris. *Int J Dermatol.* 1992;31(12):875-877.
261. Kanwar AJ, Kaur S, Thami GP. Long-term efficacy of dexamethasone-cyclophosphamide pulse therapy in pemphigus. *Dermatology.* 2002;204(2):228-231.
262. Hayag MV, Cohen JA, Kerdel FA. Immunoablative high-dose cyclophosphamide without stem cell rescue in a patient with pemphigus vulgaris. *J Am Acad Dermatol.* 2000;43(6):1065-1069.
263. Nousari CH, Brodsky R, Anhalt GJ. Evaluating the role of immunoablative high-dose cyclophosphamide therapy in pemphigus vulgaris. *J Am Acad Dermatol.* 2003;49(1):148-150.
264. Heaphy MR, Albrecht J, Werth VP. Dapsone as a glucocorticoid-sparing agent in maintenance-phase pemphigus vulgaris. *Arch Dermatol.* 2005; 141(6):699-702.
265. Werth VP, Fivenson D, Pandya AG, et al. Multicenter randomized, double-blind, placebo-controlled, clinical trial of dapsone as a glucocorticoid-sparing agent in maintenance-phase pemphigus vulgaris. *Arch Dermatol.* 2008;144(1):25-32.
266. Guillaume JC, Roujeau JC, Morel P, et al. Controlled study of plasma exchange in pemphigus. *Arch Dermatol.* 1988;124(11):1659-1663.
267. Turner MS, Sutton D, Sauder DN. The use of plasmapheresis and immuosupression in the treatment of pemphigus vulgaris. *J Am Acad Dermatol.* 2000;43(6):1058-1064.
268. Euler HH, Loffler H, Christophers E. Synchronization of plasmapheresis and pulse cyclophosphamide therapy in pemphigus vulgaris. *Arch Dermatol.* 1987;123(9):1205-1210.
269. Shimanovich I, Herzog S, Schmidt E, et al. Improved protocol for treatment of pemphigus vulgaris with protein A immunoadsorption. *Clin Exp Dermatol.* 2006;31(6):768-774.
270. Werth VP. Treatment of pemphigus vulgaris with brief, high-dose intravenous glucocorticoids. *Arch Dermatol.* 1996;132(12):1435-1439.
271. Roujeau JC. Pulse glucocorticoid therapy. The "big shot" revisited. *Arch Dermatol.* 1996;132(12): 1499-1502.
272. Mentink LF, Mackenzie MW, Toth GG, et al. Randomized controlled trial of adjuvant oral dexamethasone pulse therapy in pemphigus vulgaris: PEMPULS trial. *Arch Dermatol.* 2006;142(5):570-576.
273. Wu J, Edberg JC, Redecha PB, et al. A novel polymorphism of FcgammaRIIIa (CD16) alters receptor function and predisposes to autoimmune disease. *J Clin Invest.* 1997;100(5):1059-1070.
274. Dall'Ozzo S, Tartas S, Paintaud G, et al. Rituximab-dependent cytotoxicity by natural killer cells: influence of FCGR3A polymorphism on the concentration-effect relationship. *Cancer Res.* 2004;64(13): 4664-4669.
275. Weng WK, Levy R. Two immunoglobulin G fragment C receptor polymorphisms independently predict response to rituximab in patients with follicular lymphoma. *J Clin Oncol.* 2003;21(21):3940-3947.
276. Cartron G, Dacheux L, Salles G, et al. Therapeutic activity of humanized anti-CD20 monoclonal antibody and polymorphism in IgG Fc receptor FcgammaRIIIa gene. *Blood.* 2002;99(3):754-758.
277. Farag SS, Flinn IW, Modali R, et al. Fc gamma RIIIa and Fc gamma RIIa polymorphisms do not predict response to rituximab in B-cell chronic lymphocytic leukemia. *Blood.* 2004;103(4):1472-1474.
278. Weng WK, Weng WK, Levy R. Immunoglobulin G Fc receptor polymorphisms do not correlate with response to chemotherapy or clinical course in patients with follicular lymphoma. *Leuk Lymphoma.* 2009;50(9):1494-1500.
279. Ellebrecht CT, Choi EJ, Allman DM, et al. Subcutaneous veltuzumab, a humanized anti-CD20 antibody, in the treatment of refractory pemphigus vulgaris. *JAMA Dermatol.* 2014;150(12):1331-1335.
280. Huang A, Madan RK, Levitt J. Future therapies for pemphigus vulgaris: Rituximab and beyond. *J Am Acad Dermatol.* 2016;74(4):746-753.
281. Ellebrecht CT, Bhoj VG, Nace A, et al. Reengineering chimeric antigen receptor T cells for targeted therapy of autoimmune disease. *Science.* 2016;353(6295); 179-184.

Chapter 53 :: Paraneoplastic Pemphigus

:: Grant J. Anhalt & Daniel Mimouni

AT-A-GLANCE

- Rare complication of malignancy, most commonly non-Hodgkin lymphoma, chronic lymphocytic leukemia, or Castleman disease.
- Painful, erosive stomatitis and polymorphous cutaneous lesions that may be blistering and erosive (resembling erythema multiforme), morbilliform, or lichenoid.
- Serum autoantibodies directed against plakin proteins that are detected by indirect immunofluorescence against rodent bladder epithelium.
- High mortality rate, with death from sepsis, complications of treatment, or bronchiolitis obliterans.
- No consistently effective therapy, but some success with the combined use of rituximab, systemic corticosteroids, and other immunosuppressive agents.

Paraneoplastic pemphigus (PNP) is an autoimmune disorder that is almost always linked to an underlying lymphoproliferative disorder. These features define it (Table 53-1): (a) Painful stomatitis and a polymorphous cutaneous eruption with lesions that may be blistering, lichenoid, or resemble erythema multiforme. (b) Histologic findings that reflect the variability of the cutaneous lesions, showing acantholysis, lichenoid, or interface change. (c) Direct immunofluorescence findings of immunoglobulin (Ig) G and complement deposition in the epidermal intercellular spaces, and, often, granular/linear complement deposition along the epidermal basement membrane zone. (d) Serum autoantibodies that bind to the cell surface of skin and mucosae in a pattern typical of pemphigus, which, in addition, also bind to simple, columnar and transitional epithelia. (e) The serum autoantibodies identify desmogleins 1 and 3, in addition to members of the plakin family of epithelial proteins, such as desmoplakins, envoplakins, and periplakins.[1] Non-Hodgkin lymphoma (NHL), chronic lymphocytic leukemia (CLL), and Castleman disease are the neoplasms most commonly associated with PNP. There is no regularly effective treatment. Most patients die from complications of the disease such as pulmonary involvement with respiratory failure.

EPIDEMIOLOGY

The incidence of PNP is unknown, although it is less common than pemphigus vulgaris or foliaceus (see Chap. 52). In an adverse events reporting analysis including 100,000 patients with known NHL and CLL, 12 were found to have PNP.[2] Only 3 of the 12 patients were identified by the reporting physician, and the remainder were identified only by retrospective data analysis, suggesting that the majority of cases of PNP are not being properly diagnosed. In this series, the most common misdiagnoses were erythema multiforme, Stevens-Johnson syndrome, toxic epidermal necrolysis (TEN), and drug reaction.

ETIOLOGY AND PATHOGENESIS

In almost all cases, PNP is associated with a limited number of lymphoproliferative neoplasms. On the basis of 140 cases of PNP confirmed by immunoprecipitation findings of the characteristic autoantibody profile, the estimated frequencies of specific neoplasms are 44% NHL, 19% CLL, 16% Castleman disease (giant follicular hyperplasia), 8% thymoma (malignant and benign), 7% sarcomas that are retroperitoneal and often poorly differentiated, 4% Waldenström macroglobulinemia, and in 2% the neoplasms were too poorly differentiated to categorize (Fig. 53-1). The disproportionate representation of Castleman disease is notable, given its overall rarity. In children with PNP, Castleman disease is almost always the underlying neoplasm.[3] Before the description of PNP, many cases of Castleman disease associated with atypical forms of pemphigus had been reported, and we suspect that most were PNP. Furthermore, this association was emphasized in a retrospective study of 114 patients with Castleman disease identified 37 cases of PNP confirmed by the specific autoantibodies.[4]

With very rare exceptions, more common cancers, such as adenocarcinomas of breast, bowel, and lung, or basal cell and squamous cell carcinoma of skin, have not been associated with PNP. There are a few reports of PNP and squamous cell carcinoma, but in most of them, the diagnosis was made with immunofluorescent techniques only, which have significant false-positive and false-negative rates, and were not confirmed immunochemically, so the association remains unproven.

The mechanisms by which these tumors induce autoimmunity against epithelial proteins remain speculative. One hypothesis states that the tumors constitutively or anomalously express epithelial proteins. These proteins are targeted by the antitumor immune response that cross-reacts with normal constitutive epithelial proteins of the host. This mechanism occurs in several neurologic paraneoplastic syndromes.[5] This antitumor immune response may be initiated by reactivity against plakin proteins, and the antitumor immune response may cross-react with normal

TABLE 53-1
Defining Features of Paraneoplastic Pemphigus

a. Painful stomatitis and a polymorphous cutaneous eruption
b. Histologic findings that reflect cutaneous lesions (acantholysis, lichenoid or interface changes)
c. IgG complement deposition in the epidermal intercellular spaces and/or along basement membrane zone with granular/linear component (Direct Immunofluorescence)
d. Serum IgG autoantibodies that bind of cell surface of skin and mucosae, but also to simple, columnar and transitional epithelia
e. Serum IgG autoantibodies to desmogleins 1 and 3, desmoplakins, envoplakin and periplakin

constitutive proteins of epithelia. However, to date, there are no data to support this hypothesis.

It is more likely that this autoimmune disease is a result of more complex interactions between the tumor cells, the immune system, and specific genetic background. In many autoimmune diseases, specific genetic predispositions have been found, and human leukocyte antigen (HLA) studies performed on 2 different series of PNP patients revealed a significant predominance of HLA-class II DRB*03 and HLA-class I Cw*14 genes. It is interesting to note that these 2 HLA molecules are not those associated with development of pemphigus vulgaris, providing another argument to consider PNP as a distinct entity.[6,7]

There is evidence that dysregulated cytokine production by tumor cells drives the development of autoimmunity. Patients with PNP have evidence of markedly elevated levels of interleukin (IL)-6.[8] It has been observed that in a subset of cases of NHLs,[9] CLL, and Castleman tumors, the tumor cells secrete massive amounts of IL-6 in vitro. IL-6 is known to promote B-cell differentiation and to drive Ig production, and dysregulated IL-6 production has been implicated in certain autoimmune diseases. Castleman tumors are known to be associated with other autoimmune phenomena such as myasthenia gravis and autoimmune



Figure 53-1 Tumors associated with paraneoplastic pemphigus.

cytopenias, and these patients also have high serum levels of IL-6. Symptoms attributable to Castleman tumors are routinely reversed by complete excision of the affected node(s), and, coincidentally, serum IL-6 levels revert to normal. Administration of anti–IL-6 receptor monoclonal antibodies also effectively reverses systemic manifestations of Castleman disease and is currently being studied in clinical trials.[10]

It had also been proposed that the autoantibody may derive from the lymphoid tumor itself. Cultures of Castleman tumors have been shown to contain B cells that produce specific autoantibody.[11] However, Castleman tumors are unique in that they are not clonal neoplasms, and these studies showed the expansion of several immunologically active B-cell clones within the tumors. In Waldenström macroglobulinemia, the autoantibody is polyclonal and IgG class, not IgM, and therefore, cannot be produced by the tumor cells.

Almost all patients with PNP have autoantibodies against desmogleins, demonstrable by enzyme-linked immunosorbent assay (ELISA), and when the desmoglein autoantibodies from these patients are affinity purified and injected into neonatal mice, acantholytic skin lesions are induced.[12] It also has been demonstrated that pathogenic autoantibodies from PNP patients bind to the middle portion of desmoglein 3—extracellular domains 2 and 3—in contrast to pemphigus vulgaris patients where the pathogenic autoantibodies bind to extracellular domain 1.[13] However, none of features of the disease that appear to be induced by cell-mediated autoimmunity are recreated by the Ig injections. No internal organs, like the lungs are involved, and there are no findings of lymphocyte-mediated lichenoid or interface epithelial injury. This is another indication that humoral immunity alone reproduces features of acantholysis, but passive transfer of autoimmune cells from these patients may be necessary to induce the complete spectrum of the disease in animals.

It has been demonstrated in a mouse model that the cellular autoimmune response, which is represented by interface dermatitis, is caused by desmoglein 3–specific CD4+ T cells. This specific response is mediated by interferon-γ and is the dominant response in the lichenoid variant of PNP.[14]

There is evidence that ectopic desmoglein 3 expression is present in the lungs in the PNP mouse model. This squamous metaplasia of the lungs is probably the cause for the fatal bronchiolitis obliterans involvement in PNP.[15]

CLINICAL FINDINGS

HISTORY

CUTANEOUS LESIONS

The most constant clinical feature of the disease is the presence of intractable stomatitis (Fig. 53-2A,B). It is the earliest presenting sign and the one feature that persists throughout the course of the disease, even

Figure 53-2 **A,** Extensive erosions involving the vermilion of the lips in a patient presenting with paraneoplastic pemphigus and lymphoma. The characteristic severe stomatitis, accompanied by polymorphous cutaneous lesions, is the most consistent feature of the disease. **B,** Painful ulcerations tend to localize to the lateral border of the tongue. **C,** Widespread erosions and sloughing involving the majority of the back from the same patient pictured in **A**. **D,** Lesions from the axilla of a patient with paraneoplastic pemphigus. These lesions clinically resemble lichen planus.

after treatment and is extremely resistant to therapy. This finding is so consistent that in its absence, PNP should not be considered in the differential diagnosis.

This stomatitis consists of erosions and ulcerations that can affect all surfaces of the oropharynx. The lesions differ from those seen in pemphigus vulgaris in that they show more necrosis and lichenoid change. They also preferentially localize to the lateral borders of the tongue, and characteristically extend onto and involve the vermilion of the lips. Occasionally, oral lesions are the only manifestation of the disease.

The cutaneous lesions of PNP are quite variable, and different morphologies may occur in an individual patient according to the stage of the disease (see Fig. 53-2C,D). The initial patients reported with the syndrome had episodes of waves of blistering affecting the upper trunk, head and neck, and proximal extremities. These lesions consisted of blisters that ruptured easily,

leaving erosions. The blisters on the extremities were sometimes quite tense, resembling those seen in bullous pemphigoid, or they had surrounding erythema, clinically resembling erythema multiforme (see Fig. 53-2D). On the upper chest and back, confluent erosive lesions can develop, producing a picture resembling TEN. The similarity of the mucocutaneous features to erythema multiforme and TEN explains why this is the most common differential diagnosis for PNP. However, it is important to note that erythema multiforme and TEN are self-limited events that evolve and resolve over several weeks, whereas PNP is a relentlessly progressive and evolves continuously over months.

Cutaneous lichenoid eruptions are very common, and they may be the only cutaneous signs of the disease, or may develop in lesions that had previously been blistered. When cutaneous lichenoid lesions are present, severe stomatitis is also invariably present. In the chronic form of the disease and after treatment, this lichenoid eruption may predominate over blistering on the cutaneous surface. The common presence of both blisters and lichenoid lesions affecting the palms and the soles as well as the paronychial tissues helps distinguish PNP from pemphigus vulgaris, in which acral and paronychial lesions are uncommon.

There are a small number of patients who appear to have PNP but who do not have demonstrable circulating autoantibodies.[16] These patients tend to have predominantly lichenoid skin and mucosal lesions, but behave in every other way like antibody-positive patients. They have the same underlying neoplasms, and frequently develop bronchiolitis obliterans. Because the definition of the disease relies so heavily on demonstration of the specific autoantibody markers, further study is required to determine the exact classification of what is presently termed the *lichenoid variant of paraneoplastic pemphigus*.

The disease also has been identified in a horse and 2 dogs. In animal species, the disease is associated with the same neoplasms and has the same clinical outcomes.[17]

RELATED CLINICAL FINDINGS

PNP is the only form of pemphigus that involves nonstratified squamous epithelium. Approximately 30% to 40% of cases develop pulmonary injury, often with a fatal outcome.[18] The earliest symptoms are progressive dyspnea associated initially with an absence of findings on chest radiography. Pulmonary functions studies show airflow obstruction in large and small airways. Inflammation of the large airways evolves and is evidenced by endoscopic biopsy showing acantholysis of bronchial respiratory epithelium. Pulmonary function deteriorates in most cases despite immunosuppressive therapy, and radiologic, histologic, and functional changes characteristic of bronchiolitis obliterans develop. Another interesting clinical association of PNP is with myasthenia gravis, diagnosed in 20 (35%) of patients in a recent cohort of 59 patients with PNP.[19]

LABORATORY TESTS

The key finding is the serologic identification of polyclonal IgG autoantibodies against plakin proteins and, in most cases, desmogleins 1 and 3. The plakins are a group of sequence-related proteins that form the intracellular plaque of desmosomes and hemidesmosomes, and mediate attachment of cytoskeletal intermediate filaments to transmembrane adhesion molecules such as the desmogleins (see Chap. 48). Autoantibodies against these proteins are the most characteristic surrogate markers for the disease. The pattern of antigens recognized by individual patients shows considerable variability, but the most characteristic and consistently recognized plakin antigens are envoplakin[20] and periplakin[21] (210 and 190 kDa, respectively; Fig. 53-3). The next most frequently detected are antibodies against desmoplakin I and desmoplakin II (250 and 210 kDa, respectively). Autoantibodies against α_2-macroglobulin-like-1 a 170-kDa protein, was identified in the sera of 70% of PNP patients. This recently reported autoantibody may be pathogenic by decreasing the normal keratinocyte adhesion.[22] Less commonly, patients recognize bullous pemphigoid Ag 1 (230 kDa), plectin (400 kDa), and plakoglobin (82 kDa) (Table 53-2). PNP patients may also have clinical and serologic evidence of other autoimmune phenomena such as myasthenia gravis and autoimmune cytopenias (Fig. 53-3).

To screen for PNP autoantibodies, one can test for IgG autoantibodies by indirect immunofluorescence reactive with rodent urinary bladder epithelium. A positive result implies the presence of plakin autoantibodies; however, the sensitivity and specificity of this serologic test are only approximately 75% and 83%, respectively.[23] ELISA kits using recombinant proteins containing subdomains of envoplakin and periplakin have been developed and demonstrate high sensitivity and specificity for the diagnosis of PNP.[24,25] More specific and sensitive tests, which are more time-consuming, technically demanding, and of limited availability, include immunoblotting against epidermal cell extracts that can effectively detect antibodies against envoplakin, periplakin, and desmoplakin, and immunoprecipitation, using radiolabeled keratinocyte extracts, which can detect antibodies against any of the plakin proteins. The combination of rodent urinary bladder and immunoblotting has equal specificity and sensitivity to the detection of autoantibodies against the plakin proteins and the α_2-macroglobulin-like-1 protein.[26]

The PNP autoantibody profile is more complex than that observed in pemphigus vulgaris or foliaceus, where there are autoantibodies produced only against the desmogleins. The humoral immunity in PNP may represent an example of epitope spreading in which patients develop autoantibodies against structurally related plakin proteins and structurally unrelated transmembrane cell-surface proteins (the desmogleins) that are physically linked to the plakin proteins in the desmosome and hemidesmosome.

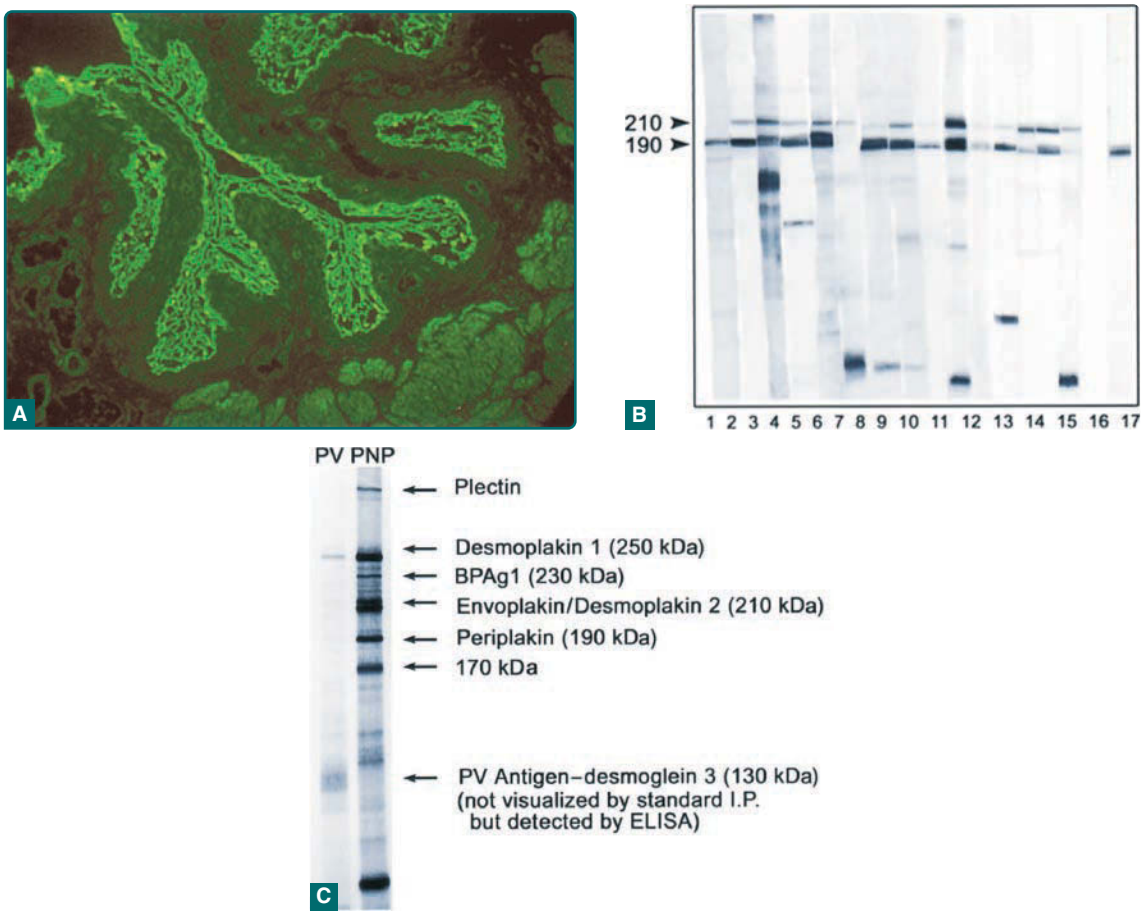

Figure 53-3 Diagnosis of paraneoplastic pemphigus (PNP) depends on the demonstration of antiplakin antibodies. **A,** This can be accomplished by indirect immunofluorescence of patient serum on rodent urinary bladder demonstrating binding of immunoglobulin G to the cell surface of transitional epithelial cells. A positive result implies the presence of antiplakin antibodies. This technique, although easily performed, has the lowest sensitivity and specificity. **B,** Immunoblotting against epidermal cell extracts is much more sensitive and specific. This shows detection of envoplakin (210 kDa) and/or periplakin (190 kDa) in 15 patients with PNP. Lane 16 is a normal control, and lane 17 shows a monoclonal antibody against periplakin. This technique uses denatured antigen extracts, so it does not reliably detect some of the PNP antigens, but antibodies against the most characteristic plakin antigens, envoplakin and periplakin, are easily detected. **C,** Immunoprecipitation using radiolabeled, nondenatured epidermal extracts and serum from a patient with PNP and pemphigus vulgaris (PV). In this case, the PNP patient's serum identifies all the plakin antigens. Envoplakin and desmoplakin II migrate as a doublet at 210 kDa. This technique is the most sensitive and specific test for demonstration of antiplakin antibodies in PNP, but has limited availability. Although this technique readily detects the antiplakin antibodies, desmoglein 3 is not always efficiently identified, and this is best shown by using enzyme-linked immunosorbent assay (ELISA).

TABLE 53-2
Target Antigens in Paraneoplastic Pemphigus

AUTOANTIGEN	MOLECULAR WEIGHT (KDA)
Desmoglein 1	160
Desmoglein 3	130
Desmoplakin 1	250
Desmoplakin 2	210
Bullous pemphigoid antigen 1	230
Envoplakin	210
Periplakin	190
Plectin	500
α_2-Macroglobulin-like-1 protease inhibitor	170

HISTOPATHOLOGY

The histopathology of PNP is distinctive from that of pemphigus vulgaris and foliaceus for 2 reasons. First, because the lesions can be clinically very polymorphous, there is substantial variability in the histologic findings.[27] Second, findings resulting from cell-mediated cytotoxicity are frequently observed.

Owing to the severe mucositis, many biopsies of oral lesions yield nonspecific changes of inflammation and ulceration. If one can biopsy perilesional epithelium, a lichenoid mucositis with variable degrees of individual cell necrosis and suprabasilar acantholysis can be observed.

TABLE 53-3
Typical Histologic Findings

RESULTING FROM HUMORAL IMMUNE RESPONSE	RESULTING FROM CELLULAR IMMUNE RESPONSE
Suprabasilar acantholysis	Individual keratinocyte necrosis
	Thick lichenoid band along the dermal–epidermal junction
	Basal cell vacuolar changes

When evaluating biopsies from skin lesions, one must recognize that lesions with different clinical morphologies yield differing histologic findings (Table 53-3). In noninflammatory cutaneous blisters, suprabasilar acantholysis is expected to be more prominent than the interface/lichenoid change (Fig. 53-4A). When erythematous macules and papules are sampled, interface and lichenoid dermatitis is predominant (Fig. 53-4B,C). Lesions with a mixed clinical pattern also show mixed histologic features of concomitant suprabasilar acantholysis and interface/lichenoid dermatitis.

There is also observed variability of the interface and lichenoid dermatitis. The spectrum of changes can include: (a) individual keratinocyte necrosis with lymphocytic infiltration into the epidermis, reminiscent of that seen in erythema multiforme or graft-versus-host disease; (b) vacuolar interface change with sparse lymphocytic infiltrate of the basilar epithelium, resembling cutaneous lupus erythematosus or dermatomyositis; and (c) a thick lichenoid band along the dermal–epidermal junction similar to that seen in lichen planus. Although most of the specimens show a complex overlap of histologic patterns, there is a relatively good correlation between the clinical and the predominant histologic pattern.

The histopathologic variability of this disease may be related to the fact that it is a presumed antitumor immune response. If this speculation is correct, one would expect to observe a combination of both humoral and cell-mediated immunity that is aberrantly directed against normal epithelium. In such a setting, one would expect to see changes of the sort described in the previous paragraph. This degree of cell-mediated immunity is not seen in pemphigus vulgaris or foliaceus (see Chap. 52); hence the unique histopathologic features, and, presumably, the unique clinical features as well. the presence of T-cell–mediated epithelial cytotoxicity has been demonstrated in histologic studies.[2]

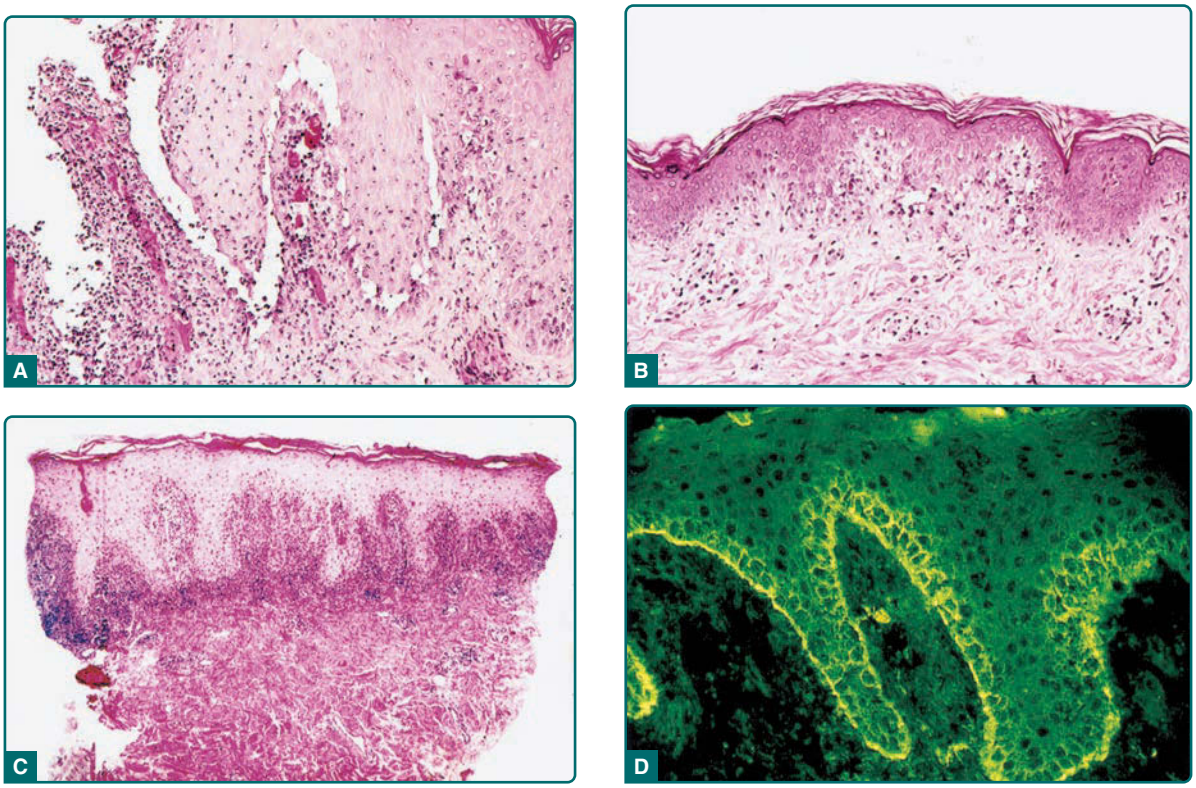

Figure 53-4 **A,** Histopathology of a blistering cutaneous lesion in paraneoplastic pemphigus. This demonstrates the characteristic presence of vacuolar interface change and suprabasilar acantholysis (Hematoxylin and eosin [H&E], ×200). **B,** Macular and papular lesions may show just vacuolar interface change (H&E, ×100). **C,** Lichenoid lesions demonstrate lichenoid infiltrates on histologic examination (H&E, ×40). The presence of these varied histologic findings help differentiate paraneoplastic pemphigus from pemphigus vulgaris. **D,** Direct immunofluorescence can be negative in a significant number of cases, but when positive, the most characteristic changes are those of deposition of immunoglobulin G and complement components on both the surface of basilar and suprabasilar keratinocytes and along the epidermal basement membrane zone (immunofluorescence with fluoresceinated anti–immunoglobulin G, ×200).

IMMUNOPATHOLOGY

Patients with PNP should have evidence of IgG autoantibodies bound to the cell surface of affected epithelium by direct immunofluorescence. However, false negatives are more common in PNP than in pemphigus vulgaris, and repeated biopsies may be necessary, as well as careful investigation of the adnexal structures, which may be the only positive site.[28] In a minority of cases, one might also see a combination of both cell-surface and basement membrane zone deposition of IgG and complement components, but the absence of this combined cell-surface/basement membrane zone staining does not negate the diagnosis (see Fig. 53-4D).

SPECIAL TESTS

Approximately one-third of patients have an occult malignancy at the time they develop PNP. Neoplasms that would not be detected by routine complete blood count, serum chemistries, and physical examination are most likely to be intraabdominal lymphoma, intrathoracic or retroperitoneal Castleman tumors, or retroperitoneal sarcomas. The most effective and efficient method for screening for these tumors is either computer-aided tomography or MRI of the body from the neck to the base of the bladder. If available, positron emission tomography/CT using fluorodeoxyglucose as a biologically active molecule, can be a more specific technique for identifying an occult lymphoma. Other studies, such as endoscopy, are not required.

DIAGNOSIS AND DIFFERENTIAL DIAGNOSIS

The diagnosis can best be made if the algorithm shown in Figure 53-5 is followed. Table 53-4 summarizes the clinical differential diagnosis.

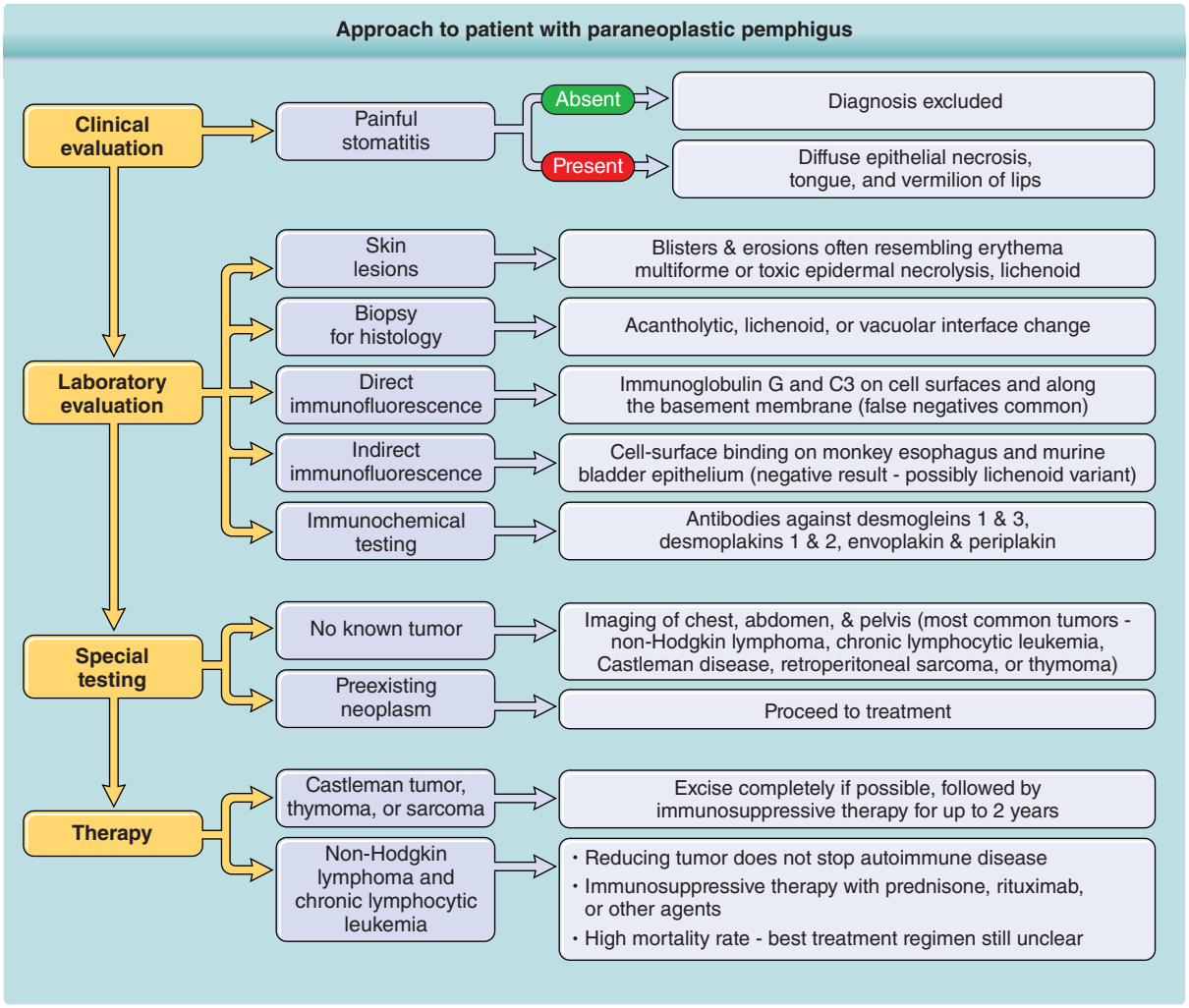

Figure 53-5 Approach to a patient with paraneoplastic pemphigus.

TABLE 53-4
Differential Diagnosis of Paraneoplastic Pemphigus

- Oral lesions
  - Pemphigus vulgaris
  - Stevens-Johnson syndrome
  - Mucous membrane pemphigoid
  - Oral lichen planus
  - Chemotherapy-induced stomatitis
  - Major aphthous stomatitis
- Cutaneous lesions
  - Erythema multiforme/Stevens-Johnson syndrome/toxic epidermal necrolysis
  - Pemphigus vulgaris
  - Drug eruption
  - Lichen planus
  - Subepidermal blistering disorders

PROGNOSIS AND CLINICAL COURSE

It is not known why PNP is so refractory to the type of immunosuppressive treatments that are usually effective in pemphigus vulgaris and other autoimmune diseases.

In those patients who do succumb, death has been attributed in individual cases to multiple factors, including sepsis, GI bleeding, "multiorgan failure," and respiratory failure. Patients with autoimmune disease associated with B-cell neoplasms are known to have a high frequency of autoimmune cytopenias, and some fatal episodes of sepsis are suspected to have occurred because of sudden and unexplained neutropenia, possibly caused by this mechanism. Respiratory failure is a common terminal event. The development of shortness of breath with obstructive disease progressing to bronchiolitis obliterans is a terminal complication in most cases. Because these patients have autoantibodies that react with desmoplakins, and because desmoplakins are present in respiratory epithelium, respiratory failure may be a result of autoantibody-mediated injury to bronchial epithelium, with plugging of terminal bronchioles, resulting in airflow obstruction and ventilation–perfusion abnormalities. Additionally, direct damage to alveolar epithelium could cause a diffusion barrier and subsequent intractable hypoxia. One autopsy study showed an absence of autoantibodies and a marked infiltration of bronchioles with cytotoxic T cells in a patient who died from PNP and bronchiolitis obliterans. This shows that there may be similar complex humoral and cell-mediated autoimmune injury to the lung, similar to what is seen in the skin. The pulmonary injury does not respond well to medical treatment, and the development of shortness of breath and hypoxia in a patient with this syndrome is an ominous prognostic sign. A recent long-term multicenter retrospective cohort study with 18 years of followup performed in France found that presentation with erythema multiforme–like lesions and keratinocyte necrosis in skin histology examination with were significant negative prognostic factors[29]

There is no definite correlation between tumor burden and the activity of the autoimmune syndrome in patients with malignant neoplasms. Treatment of the primary malignancy does not affect the activity of the autoimmune disease. It seems that once the process is initiated by the malignancy, the autoimmunity progresses independently. An example of the disconnect between tumor burden and autoimmunity is found in the case reported by Fullerton et al,[30] in which PNP occurred after successful autologous bone marrow transplantation for NHL. This patient was free of detectable tumor burden at the time of his death, but died from pulmonary injury secondary to PNP. It is notable that the patient underwent autologous bone marrow transplantation, and therefore received his own memory T cells, or possibly individual malignant lymphoid cells that were not detectable by routine autopsy methods.

TREATMENT

Table 53-5 summarizes PNP treatment options.

Individuals with benign or encapsulated tumors such as Castleman tumors or thymoma should have

TABLE 53-5
Treatments for Paraneoplastic Pemphigus

	DRUG	USUAL DOSE	OTHER DOSING
First line	Prednisone	0.5-1.0 mg/kg	Methylprednisolone, 1000 mg
			IV daily × 3 days
	Rituximab	375 mg/m^2 IV weekly × 4 wk, repeat every 6 months	1000 mg IV weekly × 2 wk
	Daclizumab	2 mg/kg IV weekly × 4 wk, then every other week indefinitely	
	Basiliximab	20 mg IV on day 0 and day 4, repeat every 3-4 months	
Second line	Cyclosporine	5 mg/kg daily	
	Cyclophosphamide	2.5 mg/kg daily	
	Mycophenolate mofetil	1000 mg by mouth twice daily	
	High-dose IV immunoglobulin	2 g/kg IV, repeat every 3-4 wk	
	Plasmapheresis	Every other day for 6 total treatments	

them surgically excised. If the entire lesion is removed, the disease generally improves substantially or goes into complete remission. The remission of the autoimmune disease may take 1 to 2 years after surgery, so continued immunosuppression during this period is required. The usual treatment involves combined use of prednisone and rituximab.[31] In pediatric cases with respiratory disease, the persistent autoimmunity immediately after surgery can cause ongoing pulmonary injury, and lung transplantation might be required for long-term survival.[32]

In patients with malignant neoplasms, there is no consensus regarding a therapeutic regimen that is consistently effective. Despite scattered individual reports of long-term survivors, almost all patients with NHL or CLL succumb in a period of 1 month to 2 years after diagnosis. Oral corticosteroids in a dose of 0.5 to 1.0 mg/kg produce partial improvement, but not complete resolution of lesions. Cutaneous lesions respond quickly to therapy, but the stomatitis is generally quite refractory to any treatment. Systemic corticosteroids and many other agents have been tried in individual cases, but none has proven to be particularly effective. Methods that have been tried and often failed include immunosuppression with cyclophosphamide, mycophenolate mofetil or azathioprine, gold, dapsone, plasmapheresis, and photopheresis. A small number of patients have shown a good response to combination treatment directed at both humoral and cell-mediated autoimmunity. These patients received oral prednisone, rituximab, and daclizumab or basiliximab (both are nondepleting monoclonal antibody against CD25, the high-affinity IL-2 receptor of T cells). This appears to be a less toxic way of downregulating both humoral and cell-mediated autoimmunity, with promising early results.

PREVENTION

There is no known intervention that may prevent the development of PNP in a patient with a known lymphoid malignancy. Although there have been individual case reports of PNP perhaps being triggered by certain drugs, radiation therapy, or cytokine administration, it is still not clear that any of these treatments triggered the autoimmune disease, and it appears more likely that the neoplasm itself triggers the autoimmunity.

REFERENCES

1. Anhalt GJ, Kim SC, Stanley JR, et al. Paraneoplastic pemphigus: an autoimmune mucocutaneous disease associated with neoplasia. *N Engl J Med*. 1990;323:1729.
2. Nguyen VT, Ndoye A, Bassler KD, et al. Classification, clinical manifestations, and immunopathological mechanisms of the epithelial variant of paraneoplastic autoimmune multiorgan syndrome: a reappraisal of paraneoplastic pemphigus. *Arch Dermatol*. 2001; 137:193.
3. Mimouni D, Anhalt GJ, Lazarova Z, et al. Paraneoplastic pemphigus in children and adolescents. *Br J Dermatol*. 2002;147:725.
4. Dong Y, Wang M, Nong L, et al. Clinical and laboratory characterization of 114 cases of Castleman disease patients from a single centre: paraneoplastic pemphigus is an unfavourable prognostic factor. *Br J Haematol*. 2015;169:834.
5. Posner JB. Immunology of paraneoplastic syndromes: Overview. *Ann N Y Acad Sci*. 2003;998:178.
6. Martel P, Loiseau P, Joly P, et al. Paraneoplastic pemphigus is associated with the DRB1*03 allele. *J Autoimmun*. 2003;20:91.
7. Liu Q, Bu DF, Li D, et al. Genotyping of HLA-I and HLA-II alleles in Chinese patients with paraneoplastic pemphigus. *Br J Dermatol*. 2008;158:587.
8. Nousari HC, Kimyai-Asadi A, Anhalt GJ. Elevated levels of interleukin-6 in paraneoplastic pemphigus. *J Invest Dermatol*. 1999;112:396.
9. Nishimoto N, Kanakura Y, Aozasa K, et al. Humanized anti-interleukin-6 receptor antibody treatment of multicentric Castleman disease. *Blood*. 2005;06:2627.
10. Nishimoto N, Terao K, Mima T, et al. Mechanisms and pathologic significances in increase in serum interleukin-6 (IL-6) and soluble IL-6 receptor after administration of an anti-IL-6 receptor antibody, tocilizumab, in patients with rheumatoid arthritis and Castleman disease. *Blood*. 2008;112:3959.
11. Wang L, Bu D, Yang Y, et al. Castleman's tumors and production of auto antibody in paraneoplastic pemphigus. *Lancet*. 2004;363:525.
12. Amagai M, Nishikawa T, Nousari HC, et al. Antibodies against desmoglein 3 (pemphigus vulgaris antigen) are present in sera from patients with paraneoplastic pemphigus and cause acantholysis in vivo in neonatal mice. *J Clin Invest*. 1998;102:775.
13. Sugiura K, Koga H, Ishikawa R, et al. Paraneoplastic pemphigus with anti-laminin-332 autoantibodies in a patient with follicular dendritic cell sarcoma. *JAMA Dermatol*. 2013;149:111.
14. Hata T, Nishimoto S, Nagao K, et al. Ectopic expression of epidermal antigens renders the lung a target organ in paraneoplastic pemphigus. *J Immunol*. 2013;191:89.
15. Takahashi H, Kouno M, Nagao K, et al. Desmoglein 3-specific CD4+ T cells induce pemphigus vulgaris and interface dermatitis in mice. *J Clin Invest*. 2011; 121:3677.
16. Cummins DL, Mimouni D, Tzu J, et al. Lichenoid paraneoplastic pemphigus in the absence of detectable antibodies. *J Am Acad Dermatol*. 2007;56:153.
17. de Bruin A, Müller E, Wyder M, et al. Periplakin and envoplakin are target antigens in canine and human paraneoplastic pemphigus. *J Am Acad Dermatol*. 1999;40:682.
18. Nousari HC, Deterding R, Wojtczack H, et al: The mechanism of respiratory failure in paraneoplastic pemphigus. *N Engl J Med*. 1999;340:1406.
19. Wang R, Li J, Wang M, et al. Prevalence of myasthenia gravis and associated autoantibodies in paraneoplastic pemphigus and their correlations with symptoms and prognosis. *Br J Dermatol*. 2015;172:968.
20. Kim SC, Kwon YD, Lee IJ, et al. cDNA cloning of the 210-kDa paraneoplastic pemphigus antigen reveals that envoplakin is a component of the antigen complex. *J Invest Dermatol*. 1997;109:365.
21. Mahoney MG, Aho S, Uitto J, et al. The members of the plakin family of proteins recognized by paraneoplastic pemphigus antibodies include periplakin. *J Invest Dermatol*. 1998;111:308.

22. Numata S, Teye K, Tsuruta D, et al. Anti-α-2-macroglobulin-like-1 autoantibodies are detected frequently and may be pathogenic in paraneoplastic pemphigus. *J Invest Dermatol*. 2013;133:1785.
23. Huang Y, Li J, Zhu X. Detection of anti-envoplakin and anti-periplakin autoantibodies by ELISA in patients with paraneoplastic pemphigus. *Arch Dermatol Res*. 2009;301:703.
24. Probst C, Schlumberger W, Stöcker W, et al. Development of ELISA for the specific determination of autoantibodies against envoplakin and periplakin in paraneoplastic pemphigus. *Clin Chim Acta*. 2009;410:13.
25. Helou J, Allbritton J, Anhalt GJ. Accuracy of indirect immunofluorescent testing in the diagnosis of paraneoplastic pemphigus. *J Am Acad Dermatol*. 1995;32:441.
26. Poot AM, Diercks GF, Kramer D, et al. Laboratory diagnosis of paraneoplastic pemphigus. *Br J Dermatol*. 2013;169:1016.
27. Horn TD, Anhalt GJ. Histologic features of paraneoplastic pemphigus. *Arch Dermatol*. 1991;128:1091.
28. Barnadas MA, Curell R, Alomar A, et al. Paraneoplastic pemphigus with negative direct immunofluorescence in epidermis or mucosa but positive findings in adnexal structures. *J Cutan Pathol*. 2009;36:34.
29. Leger S, Picard D, Ingen-Housz-Oro S, et al. Prognostic factors of paraneoplastic pemphigus. *Arch Dermatol*. 2012;148:1165.
30. Fullerton SH, Woodley DT, Smoller BR, et al. Paraneoplastic pemphigus with immune deposits in bronchial epithelium. *JAMA*. 1992;267:1550.
31. Borradori L, Lombardi T, Samson J, et al. Anti-CD20 monoclonal antibody (rituximab) for refractory erosive stomatitis secondary to CD20(+) follicular lymphoma-associated paraneoplastic pemphigus. *Arch Dermatol*. 2001;137:269.
32. Chin AC, Stich D, White FV, et al. Paraneoplastic pemphigus and bronchiolitis obliterans associated with a mediastinal mass: a rare case of Castleman's disease with respiratory failure requiring lung transplantation. *J Pediatr Surg*. 2001;36:E22.

Chapter 54 :: Bullous Pemphigoid

:: Donna A. Culton, Zhi Liu, & Luis A. Diaz

AT-A-GLANCE

- Bullous pemphigoid usually occurs in older adults.
- The yearly mortality rate varies from 6% to 40%.
- Bullous pemphigoid consists of pruritic urticarial plaques and tense, large blisters. Oral mucous membrane erosions occur in a minority of patients.
- Skin pathology shows subepidermal blisters with eosinophils and other inflammatory cells.
- Direct immunofluorescence (IF) shows C3 and immunoglobulin (Ig) G at epidermal basement membrane zone of perilesional skin. Indirect IF shows IgG anti–basement membrane autoantibodies in the serum.
- The autoantigens BP180 and BP230 are proteins of the keratinocyte hemidesmosome, a basal cell–basement membrane adhesion structure.
- Therapy includes topical and systemic corticosteroids and immunosuppressives.

INTRODUCTION

Bullous pemphigoid is the most common autoimmune blistering disorder in the adult population. The disease typically presents as pruritic, tense blisters often on a background of urticarial plaques. It occurs most frequently in older adults. It is mediated by autoantibodies directed against hemidesmosomal proteins BP180 and BP230, which trigger an inflammatory cascade that ultimately leads to blister formation. This chapter addresses the epidemiology, clinical features, pathogenesis, diagnosis, and treatment of bullous pemphigoid.

HISTORICAL PERSPECTIVE

Bullous pemphigoid was originally described as a subepidermal blistering disease with distinctive clinical and histologic features by Walter Lever in 1953.[1] Antibodies against the dermal–epidermal junction were first described in perilesional skin and in the serum of patients by Jordon and Beutner 14 years later, confirming the separation of bullous pemphigoid from pemphigus.[2] Over the following years, the antigenic targets were fully characterized as hemidesmosomal proteins BP180 and BP230.[3-5]

EPIDEMIOLOGY

Bullous pemphigoid typically occurs in patients older than 60 years of age, with a peak incidence in the 70s.[6] There are exceptions in which classic bullous pemphigoid occurs in middle-aged adults and even infants and children, which is especially rare.[7-10] There is no known ethnic, racial, or sexual predilection for developing bullous pemphigoid.

The incidence of bullous pemphigoid is estimated to be 7 per 1 million per year in Germany and 14 per 1 million per year in Scotland.[6,11] Recent studies suggest that the incidence of bullous pemphigoid is increasing and may be as high as 22 to 24 per 1 million per year in the United States and France and 43 per 1 million per year in the United Kingdom.[12-14]

CLINICAL FEATURES

CUTANEOUS FINDINGS

The classic form of bullous pemphigoid is characterized by large, tense blisters arising on normal skin or on an erythematous or urticarial base (Fig. 54-1A).[15,16] These lesions are most commonly found on flexural surfaces, the lower abdomen, and the thighs, although they may occur anywhere. The bullae are typically filled with serous fluid but may be hemorrhagic. The Nikolsky and Asboe-Hansen signs are negative. Eroded skin from ruptured blisters usually heals spontaneously without scarring, although milia can occur, and postinflammatory pigmentation is common. Pruritus is usually intense but may be minimal in some patients.

Although the more classic presentation of bullous pemphigoid consists of tense bullae on an erythematous or urticarial base, a noninflammatory form of bullous pemphigoid may also be seen presenting as tense bullae on normal-appearing skin (Fig. 54-1B). The noninflammatory form of bullous pemphigoid may be associated with a sparser inflammatory infiltrate histologically (see Diagnosis: Pathology).

Nonbullous lesions are the first manifestation of bullous pemphigoid in almost half of patients.[17] Often, urticarial type lesions precede the more classic tense bullae early in the course of disease. Other early nonbullous findings include eczematous, serpiginous, or targetoid erythema multiforme-like lesions (Fig. 54-1C). Atypical clinical presentations can also be seen in more established disease and include erythroderma and prurigo nodularis–like or vegetative lesions.[18-24]

Although bullous pemphigoid is typically widespread, localized forms of disease have been reported and are becoming increasingly recognized.[14] Localized

Figure 54-1 Bullous pemphigoid. **A,** Large, tense bullae, some of which are denuded on the upper leg. **B,** An example of the noninflammatory form of bullous pemphigoid. **C,** Urticarial and erythema multiforme–like lesions of bullous pemphigoid on the thighs.

disease often presents as tense bullae restricted to localized areas of involvement, most commonly the lower legs.[18,25] Dyshidrotic dermatitis–like lesions have also been reported localized to the hands and feet.[26-30] Changes induced by radiation, trauma, or surgery (colostomy, urostomy, or skin graft donor site) may precipitate localized disease in these areas.[31-39] Childhood bullous pemphigoid, although rare, most often presents as localized disease with acral and vulvar or perivulvar distribution being common.[7-10,40-42] In these cases, the diagnosis is confirmed by routine histology, direct immunofluorescence (IF), and indirect IF or enzyme-linked immuinosorbent assay (ELISA) studies. Autoantibodies from these patients show typical IF localization and bind classic pemphigoid antigens, although resuls of indirect IF and ELISA may be negative because of low levels of circulating autoantibodies.[19-24,28-30,43]

Mucous membrane lesions occur in approximately 10% of patients and are almost always limited to the oral mucosa.[15,44-46] Intact blisters are rare, with erosions more commonly seen. The lesions heal without scarring. The presence of scarring or mucosal predominant disease in the absence of classic cutaneous findings is more suggestive of mucous membrane pemphigoid as discussed in Chap. 55.

Bullous pemphigoid may also coexist with other cutaneous diseases, notably lichen planus. Lichen planus pemphigoides describes the coexistence of bullous pemphigoid and lichen planus with typical clinical, histologic, and immunopathologic features of both diseases.[47-50] Lichen planus pemphigoides more often presents in middle-aged patients (mean age of onset, 35 to 45 years of age) and is more localized to the extremities with a less severe clinical course compared with classic bullous pemphigoid.

The Bullous Pemphigoid Disease Area Index (or BPDAI) is a recently developed and validated tool that may be used to objectively measure of clinical disease activity in patients with bullous pemphigoid.[51,52] Although originally designed for use in clinical trials, it can be useful in the clinical setting as well to objectively document the level of disease activity.

NONCUTANEOUS FINDINGS

Approximately 75% of patients have elevated total serum immunoglobulin (Ig) E levels, which often correlates with titers of bullous pemphigoid IgG autoantibodies by IF.[53-55] More than half of patients have peripheral blood eosinophilia as well.[55-58]

COMPLICATIONS

Complications in untreated patients include skin infection developing within denuded bullae, dehydration, electrolyte imbalance, and possibly death from sepsis. Most often complications are related to treatment with systemic corticosteroids or other immunosuppressive medications. Complications caused by bacterial (pneumonia, urinary tract infection, soft tissue infection) and viral (disseminated or localized herpes) mediated infections are common, especially among patients with low functional status and dementia, and contribute to morbidity and mortality.[59-61]

ETIOLOGY AND PATHOGENESIS

Most cases of bullous pemphigoid occur sporadically without any obvious precipitating factors. However, there are reports in which bullous pemphigoid appears to be triggered by ultraviolet (UV) light, either UVB or after psoralen and ultraviolet A light (PUVA) therapy, and radiation therapy.[62-64] Certain medications have also been associated with the development of bullous pemphigoid, including penicillamine, efalizumab, etanercept, and furosemide, among others.[65-71] Recent reports suggest that bullous pemphigoid may also develop after immune checkpoint blockade with anti–programmed cell death receptor 1 (anti–PD-1) treatment.[72-74]

IMMUNOPATHOLOGY

Remarkable advances have been made characterizing the pathophysiology of bullous pemphigoid as a multistep process involving autoantibody binding to hemidesmosomal antigens, which triggers an inflammatory cascade that ultimately results in blister formation. The development of animal models has been instrumental in demonstrating the pathogenicity of bullous pemphigoid autoantibodies and dissecting the factors that contribute to blister formation.

BULLOUS PEMPHIGOID ANTIGENS

IF techniques demonstrate that patients with bullous pemphigoid exhibit circulating and tissue-bound autoantibodies directed against antigens of the cutaneous basement membrane zone (BMZ).[2] Immunoelectron microscopy studies localize bullous pemphigoid antigens to the hemidesmosome, an organelle that is important in anchoring the basal cell to the underlying basement membrane.[75] These autoantibodies bind to both the intracellular plaque of the hemidesmosome and the extracellular face of the hemidesmosome. Bullous pemphigoid autoantibodies recognize two distinct antigens with molecular weights of 230 kDa and 180 kDa by immunoblot analysis of human skin extracts.[76]

The 230-kDa molecule is termed BP230, BPAG1, or BPAG1e (indicating epidermal expression).[4,76-78] BP230 belongs to the plakin family of proteins.[79,80] By immunoelectron microscopy, BP230 is located in the intracellular plaque of the hemidesmosome, where keratin intermediate filaments insert.[81] Analysis of BP230-deficient mouse strain generated by transgenic knockout technology further demonstrates that the function of BP230 is to anchor keratin intermediate filaments to the hemidesmosome.[82] Mice lacking BP230 show fragility of basal cells caused by collapse of the keratin filament network but no epidermal-dermal adhesion defect. Interestingly, an alternatively spliced form of BP230 is expressed in neural tissue, termed BPAG1n. BPAG1n stabilizes the cytoskeleton of sensory neurons[83,84] just as BP230 stabilizes the cytoskeleton of epidermal cells. The lack of dermal–epidermal separation in the BP230-null mice indicates that pathogenic autoantibodies in bullous pemphigoid do not act simply by inhibiting the function of BP230.

The 180-kDa bullous pemphigoid autoantigen is termed BP180, BPAG2, or type XVII collagen.[3,85,86] BP180 is a transmembrane protein of the collagen family with an intracellular amino-terminal domain and an extracellular carboxy-terminal domain that spans the lamina lucida and projects into the lamina densa of the basement membrane.[87-91] Its intracellular or cytoplasmic domain is located in the plaque of the hemidesmosome, and its extracellular domain is linked to anchoring filaments.[92-94] The extracellular domain of BP180 contains a series of 15 collagen regions interrupted by 16 noncollagen sequences.[89] The noncollagen region 16A, also known as the NC16A domain, is adjacent to the membrane-spanning region and harbors the major autoantibody-reactive epitopes.[95,96] ELISA to measure antibodies against the BP180 NC16A domain is both sensitive and specific for a diagnosis

of bullous pemphigoid,[97-99] and its titers correlate with disease activity.[98,100] Further evidence that BP180 mediates dermal–epidermal adhesion comes from analysis of the gene defect in patients with the inherited junctional subepidermal blistering disease, non-Herlitz junctional epidermolysis bullosa (JEB-nH), previously known as generalized atrophic benign epidermolysis bullosa. These patients have recessively inherited mutations in the *BP180* gene that result in a missing or dysfunctional protein.[101-103]

PATHOPHYSIOLOGY OF SUBEPIDERMAL BLISTERING

The distinctive feature of bullous pemphigoid is the presence of circulating and tissue-bound autoantibodies against BP180 and BP230. Autoantibodies of various Ig isotypes and IgG subclasses are present in bullous pemphigoid sera with IgG being predominant followed by IgE.[104-106] Serum levels of anti-BP180-NC16A IgG correlate well with disease activity in bullous pemphigoid patients.[85,86,100]

Inflammatory cells are present in the upper dermis and bullous cavity, including eosinophils (the predominant cell type), neutrophils, lymphocytes, and monocytes and macrophages. Both intact and degranulating eosinophils, neutrophils, and mast cells (MCs) are found in the dermis.[107-110] Local activation of these cells may occur via the multiple inflammatory mediators present in the lesional skin or blister fluid.[54,111-118] Several proteinases are found in bullous pemphigoid blister fluid, including plasmin, collagenase, neutrophil elastase, and matrix metalloproteinase (MMP)-9,[119-126] which may play a crucial role in subepidermal blister formation by their ability to degrade extracellular matrix (ECM) proteins.

Both in vitro and in vivo data demonstrate that autoantibodies, particularly those against BP180, are pathogenic suggesting that the autoantibodies trigger the entire inflammatory cascade that ultimately leads to tissue injury and blister formation. In vitro studies using normal human skin sections indicate that bullous pemphigoid IgG is capable of generating dermal–epidermal separation in the presence of complement and leukocytes.[127,128] Early attempts to demonstrate the pathogenicity of patient autoantibodies by a passive transfer mouse model were unsuccessful because bullous pemphigoid anti-BP180-NC16A autoantibodies fail to cross-react with the murine BP180.[129] To overcome this difficulty, rabbit antibodies were raised against the epitope on mouse BP180. Passive transfer of these rabbit antibodies to neonatal mice induces blisters that show some of the key features of human bullous pemphigoid, including in situ deposition of rabbit IgG and mouse C3 at the BMZ, dermal–epidermal separation, and an inflammatory cell infiltrate.[129] These and other studies demonstrate that experimental blistering in animals requires activation of the classical pathway of complement system, MC degranulation, and neutrophil infiltration.[130-134] A well-orchestrated proteolytic event occurs during the disease progression. Plasmin activates proenzyme MMP-9 and activated MMP-9 then degrades α1-proteinase inhibitor, the physiological inhibitor of neutrophil elastase. Unchecked neutrophil elastase degrades BP180 and other ECM components, resulting dermal–epidermal junction separation[135-138] (Fig. 54-2). To directly test the pathogenicity of anti-BP180 IgG autoantibodies from bullous pemphigoid patients, humanized BP180 mouse strains were generated, in which the human BP180 or NC16A domain replaces the murine BP180 or corresponding domain.[139,140] These humanized mice, upon injection with anti-BP180 IgG from bullous pemphigoid patients, develop subepidermal blisters.[139,140] Like the rabbit antimurine BP180 IgG-induced model, the humanized NC16A mouse model of bullous pemphigoid also requires complement, MCs, and neutrophils (Fig. 54-3).[139]

IgE anti-BP180 autoantibodies may also play a role in blister formation. Human skin grafts onto immune-deficient mice injected with an IgE hybridoma to the extracellular portion of BP180 or total IgE from bullous pemphigoid patients' sera exhibit histologic dermal–epidermal separation,[141,142] suggesting that anti-BP180 IgE antibodies may also participate in pathogenesis of bullous pemphigoid through activating MCs and recruitment of eosinophils.

Although most animal model studies clearly show that complement deposition and the subsequent inflammatory cascade triggered by BP180-specific antibodies is essential for blister formation, direct interference of hemidesmosome-mediated cell–cell matrix adhesion by anti-BP180 autoantibodies and BP180 depletion via the ubiquitin/proteasome pathway may represent complement-independent mechanisms of anti-BP180 autoantibody pathogenicity.[143,144] Interestingly, recent studies have shown that deletion of the dominant BP180 epitope domain results in the development of anti-BP180 antibodies, blistering and itching in mice, suggesting a more complex and expanding role for this region.[145] Involvement of anti-BP230 autoantibodies in bullous pemphigoid blistering is also implicated in some animal model studies[146,147]; however, direct evidence in humans is lacking.

Autoreactive T lymphocytes that recognize BP180 are present in addition to autoreactive B lymphocytes,[148-151] supporting the concept that bullous pemphigoid is a T cell–dependent antibody-mediated skin autoimmune disease. As in most autoimmune diseases, the initial trigger for induction of autoreactive lymphocytes and autoantibody production in bullous pemphigoid remains unknown.

Several other subepidermal blistering diseases also show autoimmune responses to BP180. These include pemphigoid gestationis (or herpes gestationis), cicatricial pemphigoid (or mucous membrane pemphigoid), linear IgA bullous dermatosis, and lichen planus pemphigoid.[152-162] It is possible they may share some common immunopathological mechanisms with bullous pemphigoid.

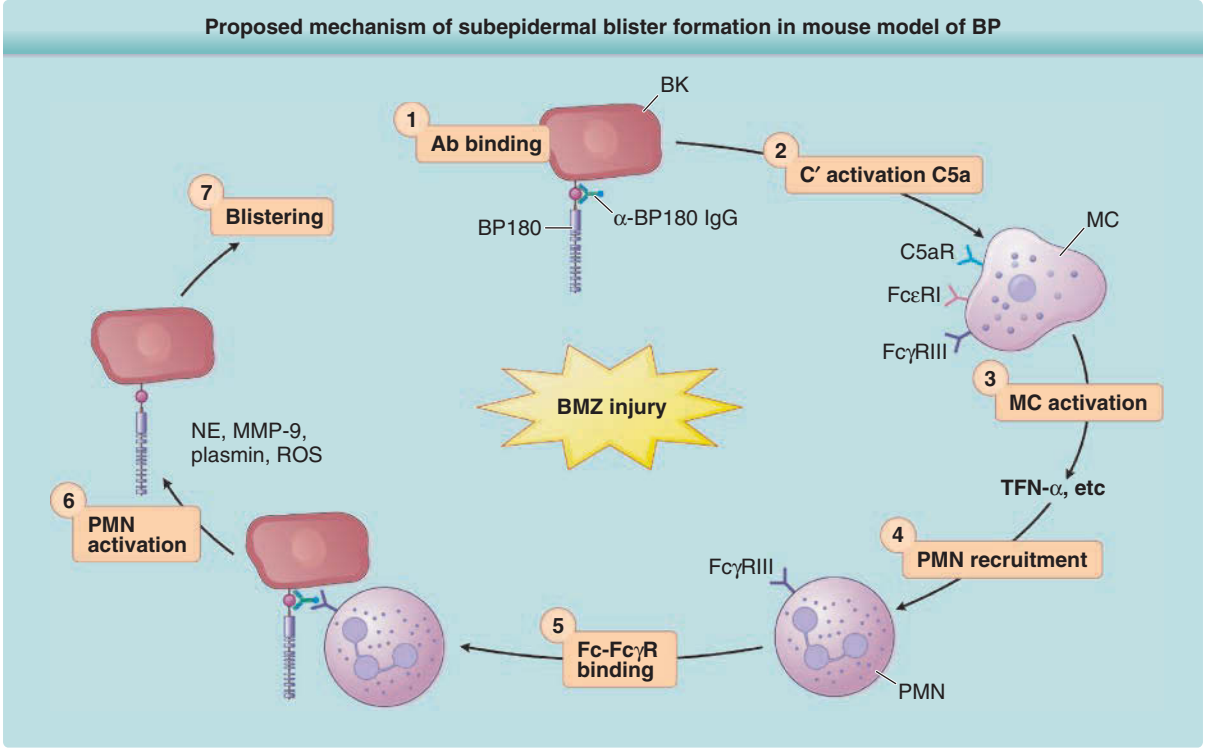

Figure 54-2 Proposed mechanism of subepidermal blister formation in mouse model of bullous pemphigoid (BP). Subepidermal blistering is an inflammatory process that involves the following steps: (1) anti-BP180 IgG binds to the pathogenic epitope of BP180 antigen on the surface of basal keratinocytes (BK). (2) The molecular interaction between BP180 antigen and anti-BP180 IgG activates the classical pathway of the complement system (C′) (3) C′ activation products C3a and C5a cause mast cells (MCs) to degranulate. (4) Tumor necrosis factor-α and other proinflammatory mediators released by MCs recruit neutrophils (PMNs). (5) Infiltrating PMNs bind to the BP180-anti-BP180 immune complex via the molecular interaction between Fcγ receptor III (FcγRIII) on neutrophils and the Fc domain of anti-BP180 IgG. (6) The interaction between Fc and FcγRIII activates PMNs to release neutrophil elastase (NE), gelatinase B (MMP-9), plasminogen activators (PAs), and reactive oxygen species (ROS). (7) Proteolytic enzymes and ROS work together to degrade BP180 and other extracellular matrix proteins, leading to subepidermal blistering.

RISK FACTORS

No specific environmental risk factors have been identified for bullous pemphigoid. In terms of genetic risk factors, certain human leukocyte antigens (HLA) alleles have been associated with bullous pemphigoid. HLA-DQB1*0301 has been associated with classic bullous pemphigoid, as well as cicatricial pemphigoid in whites.[163,164] HLA-DRB1*04, DRB1*1101, and DQB1*0302 alleles are associated with an increased risk of bullous pemphigoid among patients of Japanese descent.[165]

Neurologic disease is seen frequently in bullous pemphigoid patients. Recent studies have shown that patients with neurologic disease, including dementia, stroke, and Parkinson disease, have a significantly higher risk of developing bullous pemphigoid than those without neurological disease.[166,167]

Although there have been many case reports of bullous pemphigoid associated with malignancy, case-control studies have revealed conflicting data regarding the frequency of malignancy in bullous pemphigoid patients compared with age-matched control participants.[168-171] Most studies have shown no increased risk of malignancy in bullous pemphigoid patients.[172,173] However, recent evidence suggests that hematologic malignancies may be increased in patients with bullous pemphigoid.[174] Although a thorough review of systems and symptom guided workup is indicated in patients with a new diagnosis of bullous pemphigoid, extensive screening for an asymptomatic malignancy is not necessary.

DIAGNOSIS

The diagnosis of bullous pemphigoid is made based on clinical, histologic, and IF features.

PATHOLOGY

Biopsy of an early small vesicle is diagnostic with histology revealing a subepidermal blister with a superficial dermal infiltrate consisting of eosinophils, neutrophils, lymphocytes, and monocytes and

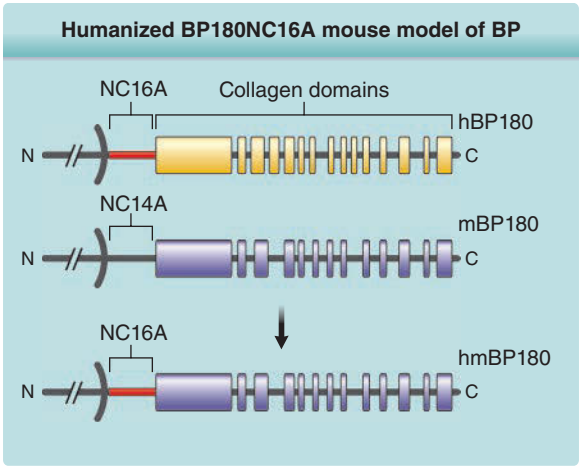

A

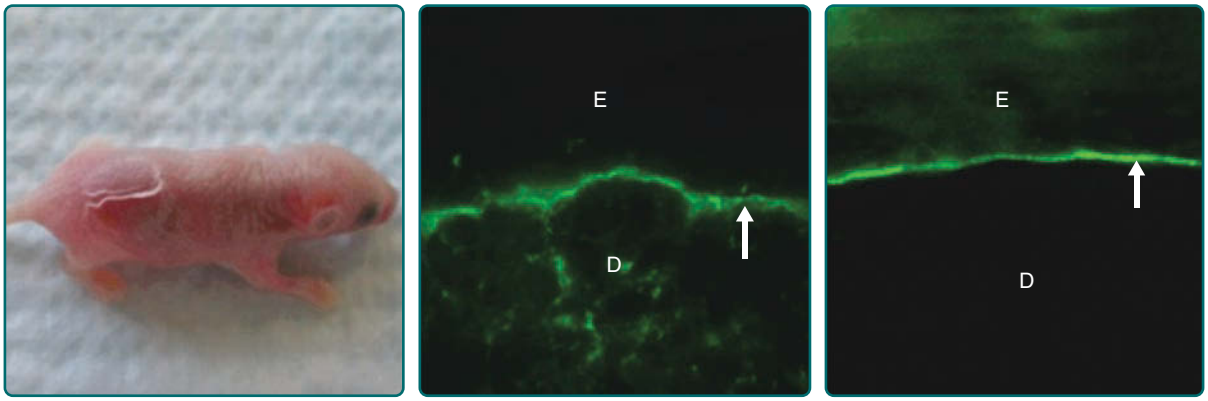

(a) Clinical (b) IgG (c) C3

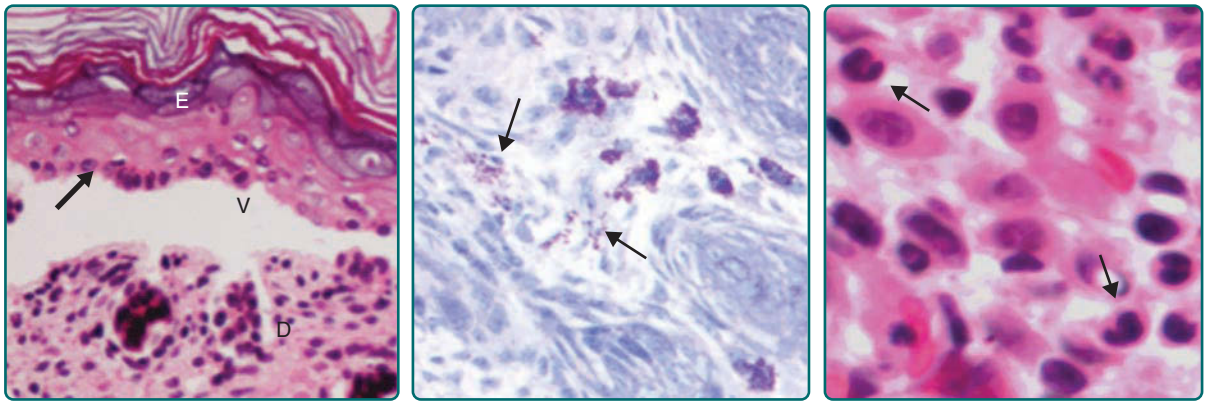

B

(d) Dermal–epidermal separation (e) MC (f) PMN

Figure 54-3 Humanized BP180NC16A mouse model of bullous pemphigoid (BP). **A,** Human BP180 (*top panel*) is a transmembrane protein of basal keratinocytes. It contains a single transmembrane domain. The extracellular region is consisted of 15 interrupted collagen domains (yellow bars) and 16 noncollagen domains (black lines). The NC16A domain (red line) harbors immunodominant epitopes recognized by BP autoantibodies. The extracellular region of mouse BP180 (*middle panel*) contains 13 collagen domains (blue bars) and 14 noncollagen domain (black lines). In humanized BP180NC16A mice, the mouse BP180NC14A domain was replaced by the human NC16A domain (*lower panel*). **B,** Neonatal NC16A mice injected intradermally (i.d.) with BP180NC16A-specific immunoglobulin (Ig) G autoantibodies developed clinical blistering (*a*). Direct immunofluorescence showed basement membrane zone (BMZ)deposition of human IgG (*b*) and murine C3 (*c*). Histologic sections of lesional skin showed dermal–epidermal separation (*d*). Examination of toluidine blue–stained skin sections revealed degranulating mast cells (MCs) (*e*). Hematoxylin and eosin staining showed infiltrating neutrophils (PMNs) in the upper dermis (400× magnification). (*f*).Arrows in *b* to *d* indicate basal keratinocytes. D, dermis; E, epidermis; V, vesicle.

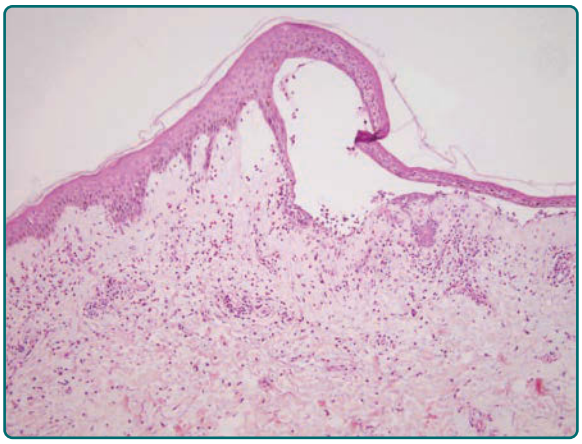

Figure 54-4 Histopathology of bullous pemphigoid. Subepidermal blister with an inflammatory cell infiltrate containing eosinophils in the superficial dermis (100× magnification).

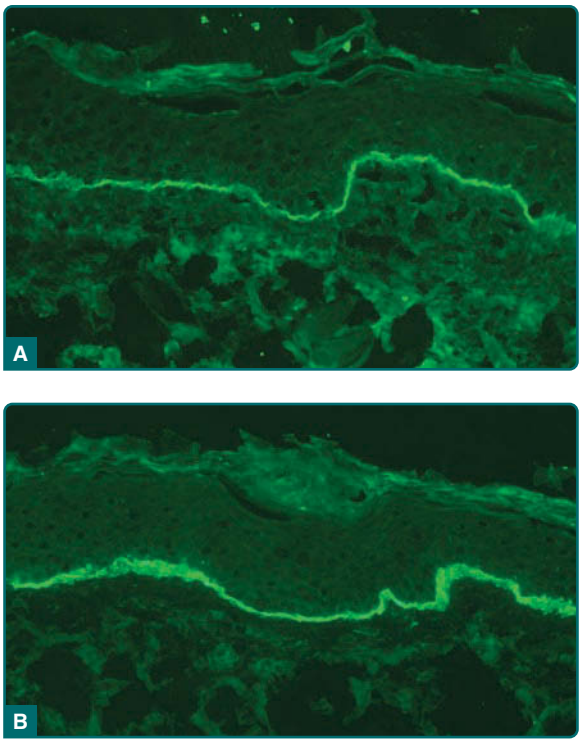

Figure 54-5 Direct immunofluorescence of bullous pemphigoid perilesional tissue shows a linear pattern of immunoglobulin G (**A**) and C3 (**B**) deposition along the epidermal–dermal junction.

macrophages (Fig. 54-4).[15] The infiltrate ranges from intense (classic) to sparse (cell poor) but characteristically contains eosinophils and neutrophils, which may also be seen in the blister cavity. The blister roof is usually viable without evidence of necrosis. Histology of urticarial lesions may only show a superficial dermal infiltrate of lymphocytes, monocytes and macrophages, and eosinophils with papillary dermal edema or eosinophilic spongiosis.[175]

IMMUNOFLUORESCENCE

Direct IF of perilesional skin shows linear IgG (usually IgG1 and IgG4, although all IgG subclasses and IgE have been reported) and C3 along the basement membrane[2,44,55,176,177] (Fig. 54-5). In approximately 70% of patients, there are circulating IgG autoantibodies that bind the BMZ on normal human skin or monkey esophagus by indirect IF.[44,55,57,105,176,178-180] The use of 1-*M* NaCl split skin, which separates the epidermis from the dermis at the lamina lucida, as the substrate for indirect IF testing is more sensitive for the detection of circulating anti-BMZ autoantibodies.[181,182] In addition to being more sensitive, the other advantage of the 1-*M* NaCl-split skin substrate is that it allows for the differentiation between bullous pemphigoid and epidermolysis bullosa acquisita (EBA) antibodies. Whereas bullous pemphigoid antibodies bind the epidermal side of the artificially induced blister (ie, the bottom of the basal cells), antibodies from EBA bind the dermal side of split skin (Fig. 54-6). In contrast to pemphigus,

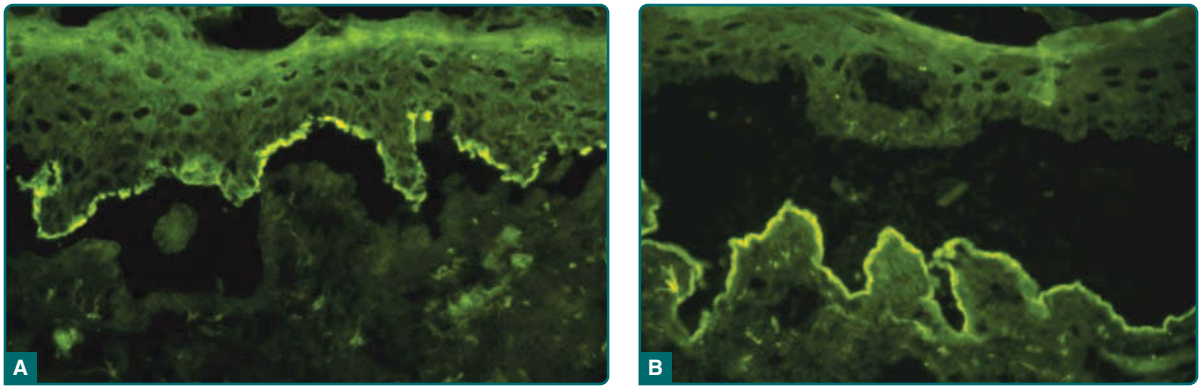

Figure 54-6 Indirect immunofluorescence on normal skin previously incubated in 1-*M* NaCl to induce a split through the lamina lucida of the dermal epidermal junction. **A,** Immunoglobulin (Ig) G antibodies from bullous pemphigoid serum binds to the epidermal side (roof) of the artificial blister (BP180 and BP230 of hemidesmosomes). **B,** IgG antibodies from epidermolysis bullosa acquisita (EBA) serum binds to the dermal side (floor) of the split (collagen VII of anchoring fibers).

indirect IF antibody titers do not usually correlate with disease extent or activity in bullous pemphigoid.[183]

ELISA testing has also proven to be useful in both clinical and research settings for the detection of circulating antigen-specific autoantibodies. Commercial kits are available for detection of both BP-180 (NC16A and total) and BP-230 IgG antibodies. A sensitivity of 89% and specificity of 98% when used with appropriate cutoff values are reported with these assays.[97]

As many as 75% of patients also have antigen specific IgE with anti-BP180 and anti-BP230 IgE antibodies detectable by IF and ELISA.[104,106,179,184-187] Antigen-specific IgE antibodies may correlate with disease severity and could play a role in recruiting eosinophils to skin lesions.[141,184,188]

Approximately 7% of the normal population has anti-BP180 antibodies detectable by ELISA in the absence of clinical and histologic features of disease without age or gender predilection. The relevance of this positivity is not known because long-term follow-up data are not available. However, this finding underscores the importance of using ELISA in appropriate clinical settings and not as a screening tool in patients who lack other features of disease.[189,190]

DIFFERENTIAL DIAGNOSIS

The differential diagnosis for bullous pemphigoid includes other autoimmune-mediated blistering diseases, such as linear IgA disease, dermatitis herpetiformis, EBA and pemphigus (Table 54-1) but also non–autoimmune-mediated disorders that can result in blistering, including contact dermatitis, dyshidrosis, bullous bite reactions, and stasis dermatitis with bullae formation. Histology, direct IF, and indirect IF studies can easily distinguish bullous pemphigoid from these diseases (Table 54-2). Distinguishing bullous pemphigoid from EBA and cicatricial pemphigoid may be difficult because histology and direct IF may be identical.[46,191] EBA can usually be distinguished from bullous pemphigoid by indirect or direct IF on salt split skin as stated earlier.[192]

As opposed to bullous pemphigoid, cicatricial pemphigoid usually presents with mucosal lesions predominantly, if not exclusively (see Chap. 55). Cicatricial pemphigoid is characterized by desquamative gingivitis as well as inflammation and scarring of conjunctiva. If there is blistering of the skin, it may be localized to the head and neck and may also result in scarring. Large, tense blisters, which are characteristic of bullous pemphigoid, are usually not seen in cicatricial pemphigoid.

CLINICAL COURSE AND PROGNOSIS

Bullous pemphigoid is characterized by a waxing and waning course with occasional spontaneous remission in the absence of treatment. Localized disease is more likely to resolve spontaneously, but spontaneous

TABLE 54-1
Comparison of Bullous Pemphigoid and Pemphigus Vulgaris

BULLOUS PEMPHIGOID	PEMPHIGUS VULGARIS
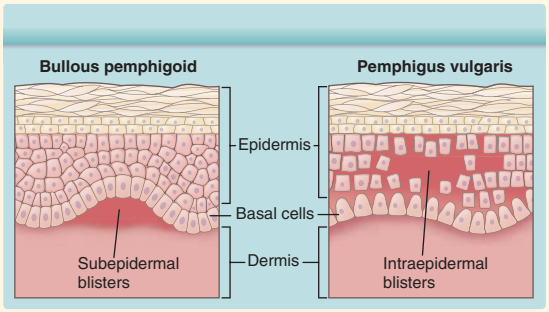	
Subepidermal blister, eosinophil predominant infiltrate, with neutrophils, lymphocytes, and monocytes and macrophages	Suprabasal blister with acantholysis; characteristic "row of tombstones"
Nikolsky sign (–)	Nikolsky sign (+)
Asboe-Hansen sign (–)	Asboe-Hansen sign (+)
Urticarial lesions precede tense bullae	Flaccid blister on any skin surface; erosions most commonly observed
Mucous membrane lesions present in ~10%	Mucous membrane lesions presenting sign for majority of patients
BPAg1 (230-kDa) or BPAg2 (180-kDa) or type XVII collagen	Desmoglein 3 (130 kDa); desmoglein 1 (160 kDa)
DIF IgG in basement membrane	DIF IgG in intercellular pattern
Waxing and waning course, occasional spontaneous remission	Fatal if untreated

DIF, direct immunofluorescence; IgG, immunoglobulin G.

TABLE 54-2
Differential Diagnosis of Bullous Pemphigoid

Subepidermal Blistering Diseases with Autoantibodies
- Pemphigoid gestationis
- Cicatricial pemphigoid
- Epidermolysis bullosa acquisita (EBA)
- Linear immunoglobulin A disease
- Dermatitis herpetiformis
- Bullous lupus erythematosus, described as an EBA phenotype

Subepidermal Blistering Diseases without Autoantibodies
- Erythema multiforme and toxic epidermal necrolysis
- Porphyria
- Epidermolysis bullosa (genodermatoses)

Intraepidermal Blistering Diseases with Autoantibodies
- Pemphigus

Intraepidermal Blistering Diseases without Autoantibodies
- Allergic contact dermatitis
- Bullous impetigo, staphylococcal scalded-skin syndrome
- Friction blisters
- Hailey-Hailey disease
- Incontinentia pigmenti

remission can even occur in patients with more generalized disease. For example, before the availability of systemic corticosteroids, Lever reported that 8 of 30 adults with bullous pemphigoid went into remission after approximately 15 months (range, 3 to 38 months) of active disease.[15] In treated patients, the length of disease ranges from 9 weeks to 17 years with a median treatment period of 2 years and 50% remission rates in patients followed for at least 3 years.[193] Clinical remission with reversion of direct and indirect IF to negative has been noted in patients, even those with severe generalized disease treated with oral corticosteroids alone or with azathioprine.[55,194] High ELISA titers and positive direct IF at the time of therapy cessation has been associated with a high risk of relapse within the first year after cessation of therapy.[194,195] At least one of these tests should be considered before therapy is discontinued. Old age, poor general health, neurologic disease, extensive disease, and the presence of anti-BP180 antibodies have been associated with a poor prognosis and relapse within the first year of treatment.[196-200]

Early mortality rates in untreated patients were reported to be 25%.[15] Newer studies have shown the 1-year mortality rate of patients with bullous pemphigoid to be between 19% and 40% in Europe but possibly lower (6% to 19%) in the United States.[13,14,196-198,201-204] The factors underlying this discrepancy in mortality rates between Europe and the United States are not clear; in fact, recent studies have suggested a slow, steady increase in mortality rate over the past 24 years in the United States.[205] Extent of disease does not contribute to differences in overall survival.[14]

MANAGEMENT

MEDICATIONS

Treatment depends on multiple factors, including extent of disease and patient comorbidities.[206] Patients with localized bullous pemphigoid often can be treated successfully with topical corticosteroids alone (Table 54-3).[55,176,207]

Patients with more extensive disease are usually treated with oral prednisone.[207-209] Despite the lack of randomized controlled trials, oral prednisone remains the mainstay of therapy. Studies also suggest that potent topical steroids, such as clobetasol proprionate cream 0.05% applied twice daily, are also effective in both moderate and severe bullous pemphigoid and may be safer than oral prednisone.[203] High-potency topical treatment does result in significant systemic absorption and therefore may act via local and systemic effects.[210] Such topical therapy can be expensive and difficult to apply, which may prove prohibitive in many patients.

In older adult patients, the complications of systemic glucocorticoid therapy (eg, osteoporosis, diabetes, and immunosuppression) may be especially severe.[211] Therefore, it is important to try to minimize the total dose and duration of therapy with oral glucocorticoids. Starting doses of prednisone of 0.75 to 1.0 mg/kg/day or even less may be adequate for disease control.[212] In addition, immunosuppressive agents such as methotrexate, azathioprine, and mycophenolate mofetil are often used in conjunction with prednisone for their potential steroid-sparing effects,[207,209,213-222] although very few controlled trials have addressed this common approach to therapy. After the development of blisters has been arrested (consolidation phase), a careful tapering of the prednisone is recommended.[51] A weekly lowering of 5 mg to reach 30 mg is recommended, after which an alternating-day tapering regimen is typically initiated. Prednisone tapering must be done according to the clinical response and side effects of the patient. The majority of disease may be controlled with small amounts of prednisone and immunosuppressive drugs.

Sulfones may be effective in a minority of patients. Dapsone and sulfapyridine have been reported to control disease activity in 15% to 44% of patients with bullous pemphigoid.[209,223-225] Reports have described successful treatment of some bullous pemphigoid patients with tetracycline and nicotinamide or variations on this theme, such as erythromycin and nicotinamide or tetracycline alone.[226-228] Other effective therapies include plasmapheresis,[229] intravenous immunoglobulins,[230-232] omalizumab,[233,234] and rituximab.[235,236]

TABLE 54-3
Treatments for Bullous Pemphigoid

Corticosteroids
▪ High-potency topical steroids
▪ Prednisone
Other Immunosuppressive Agents
▪ Azathioprine
▪ Mycophenolate mofetil
▪ Methotrexate
Modulators of Antibody Levels
▪ Intravenous gammaglobulin
▪ Plasmapheresis
Other
▪ Tetracycline or erythromycin and nicotinamide
▪ Dapsone
▪ Omalizumab
B-Cell Depletion
▪ Rituximab

REFERENCES

1. Lever WF. Pemphigus. *Medicine (Baltimore)*. 1953; 32(1):1-123.
2. Jordon RE, Beutner EH, Witebsky E, et al. Basement zone antibodies in bullous pemphigoid. *JAMA*. 1967;200(9):751-756.
3. Labib RS, Anhalt GJ, Patel HP, et al. Molecular heterogeneity of the bullous pemphigoid antigens as detected by immunoblotting. *J Immunol*. 1986;136(4):1231-1235.
4. Stanley JR, Hawley-Nelson P, Yuspa SH, et al. Characterization of bullous pemphigoid antigen: a

unique basement membrane protein of stratified squamous epithelia. *Cell*. 1981;24(3):897-903.
5. Mutasim DF, Takahashi Y, Labib RS, et al. A pool of bullous pemphigoid antigen(s) is intracellular and associated with the basal cell cytoskeleton-hemidesmosome complex. *J Invest Dermatol*. 1985; 84(1):47-53.
6. Gudi VS, White MI, Cruickshank N, et al. Annual incidence and mortality of bullous pemphigoid in the Grampian Region of North-east Scotland. *Br J Dermatol*. 2005;153(2):424-427.
7. Amos B, Deng JS, Flynn K, et al. Bullous pemphigoid in infancy: case report and literature review. *Pediatr Dermatol*. 1998;15(2):108-111.
8. Fisler RE, Saeb M, Liang MG, et al. Childhood bullous pemphigoid: a clinicopathologic study and review of the literature. *Am J Dermatopathol*. 2003; 25(3):183-189.
9. Gajic-Veljic M, Nikolic M, Medenica L. Juvenile bullous pemphigoid: the presentation and follow-up of six cases. *J Eur Acad Dermatol Venereol*. 2010;24(1):69-72.
10. Trueb RM, Didierjean L, Fellas A, et al. Childhood bullous pemphigoid: report of a case with characterization of the targeted antigens. *J Am Acad Dermatol*. 1999;40(2 Pt 2):338-344.
11. Zillikens D, Wever S, Roth A, et al. Incidence of autoimmune subepidermal blistering dermatoses in a region of central Germany. *Arch Dermatol*. 1995;131(8):957-958.
12. Joly P, Baricault S, Sparsa A, et al. Incidence and mortality of bullous pemphigoid in France. *J Invest Dermatol*. 2012;132(8):1998-2004.
13. Langan SM, Smeeth L, Hubbard R, et al. Bullous pemphigoid and pemphigus vulgaris—incidence and mortality in the UK: population based cohort study. *BMJ*. 2008;337:a180.
14. Brick KE, Weaver CH, Lohse CM, et al. Incidence of bullous pemphigoid and mortality of patients with bullous pemphigoid in Olmsted County, Minnesota, 1960 through 2009. *J Am Acad Dermatol.* 2014;71(1): 92-99.
15. Lever WF. *Pemphigus and Pemphigoid*. Springfield, IL: Charles C Thomas;1965.
16. Yancey KB, Egan CA. Pemphigoid: clinical, histologic, immunopathologic, and therapeutic considerations. *JAMA*. 2000;284(3):350-356.
17. Sun C, Chang B, Gu H. Non-bullous lesions as the first manifestation of bullous pemphigoid: a retrospective analysis of 24 cases. *J Dermatolog Treat*. 2009;20(4):233-237.
18. Borradori L, Prost C, Wolkenstein P, et al. Localized pretibial pemphigoid and pemphigoid nodularis. *J Am Acad Dermatol*. Nov 1992;27(5 Pt 2):863-867.
19. Amato L, Gallerani I, Mei S, et al. Erythrodermic bullous pemphigoid. *Int J Dermatol*. 2001;40(5):343-346.
20. Chan LS, Dorman MA, Agha A, et al. Pemphigoid vegetans represents a bullous pemphigoid variant. Patient's IgG autoantibodies identify the major bullous pemphigoid antigen. *J Am Acad Dermatol*. 1993;28(2 Pt 2):331-335.
21. Kim J, Chavel S, Girardi M, et al. Pemphigoid vegetans: a case report and review of the literature. *J Cutan Pathol*. 2008;35(12):1144-1147.
22. Korman NJ, Woods SG. Erythrodermic bullous pemphigoid is a clinical variant of bullous pemphigoid. *Br J Dermatol*. 1995;133(6):967-971.
23. Scrivener Y, Heid E, Grosshans E, et al. Erythrodermic bullous pemphigoid. *J Am Acad Dermatol*. 1999; 41(4):658-659.
24. Tashiro H, Arai H, Hashimoto T, et al. Pemphigoid nodularis: two case studies and analysis of autoantibodies before and after the development of generalized blistering. *J Nippon Med Sch*. 2005;72(1):60-65.
25. Person JR, Rogers RS 3rd, Perry HO. Localized pemphigoid. *Br J Dermatol*. 1976;95(5):531-534.
26. Provost TT, Maize JC, Ahmed AR, et al. Unusual subepidermal bullous diseases with immunologic features of bullous pemphigoid. *Arch Dermatol*. 1979;115(2):156-160.
27. Ogbechie OA, Eastham AB, Vleugels RA. Tense bullae on the palms and soles. *JAMA Dermatol*. 2015; 151(1):99-100.
28. Kim YJ, Kim MY, Kim HO, et al. Dyshidrosiform bullous pemphigoid. *Acta Derm Venereol*. 2004;84(3): 253-254.
29. Sugimura C, Katsuura J, Moriue T, et al. Dyshidrosiform pemphigoid: report of a case. *J Dermatol*. 2003;30(7): 525-529.
30. Yasuda M, Miyachi Y, Utani A. Two cases of dyshidrosiform pemphigoid with different presentations. *Clin Exp Dermatol*. 2009;34(5):e151-153.
31. Calikoglu E, Anadolu R, Erdem C, et al. Localized bullous pemphigoid as an unusual complication of radiation therapy. *J Eur Acad Dermatol Venereol*. 2002;16(6):646-647.
32. Hafejee A, Coulson IH. Localized bullous pemphigoid 20 years after split skin grafting. *Clin Exp Dermatol*. 2005;30(2):187-188.
33. Macfarlane AW, Verbov JL. Trauma-induced bullous pemphigoid. *Clin Exp Dermatol*. 1989;14(3):245-249.
34. Massa MC, Freeark RJ, Kang JS. Localized bullous pemphigoid occurring in a surgical wound. *Dermatol Nurs*. 1996;8(2):101-103.
35. Melani L, Giomi B, Antiga E, et al. Radiation therapy as a trigger factor for initially localized bullous pemphigoid. *Breast J*. 2005;11(6):485-486.
36. Ohata C, Shirabe H, Takagi K, et al. Localized bullous pemphigoid after radiation therapy: two cases. *Acta Derm Venereol*. 1997;77(2):157.
37. Pardo J, Rodrguez-Serna M, Mercader P, et al. Localized bullous pemphigoid overlying a fistula for hemodialysis. *J Am Acad Dermatol*. 2004;51(2 suppl):S131-132.
38. Torchia D, Caproni M, Ketabchi S, et al. Bullous pemphigoid initially localized around a urostomy. *Int J Dermatol*. 2006;45(11):1387-1389.
39. Vande Maele DM, Reilly JC. Bullous pemphigoid at colostomy site: report of a case. *Dis Colon Rectum*. 1997;40(3):370-371.
40. Nemeth AJ, Klein AD, Gould EW, et al. Childhood bullous pemphigoid. Clinical and immunologic features, treatment, and prognosis. *Arch Dermatol*. 1991; 127(3):378-386.
41. Farrell AM, Kirtschig G, Dalziel KL, et al. Childhood vulval pemphigoid: a clinical and immunopathological study of five patients. *Br J Dermatol*. 1999;140(2):308-312.
42. Schumann H, Amann U, Tasanen K, et al. A child with localized vulval pemphigoid and IgG autoantibodies targeting the C-terminus of collagen XVII/BP180. *Br J Dermatol*. 1999;140(6):1133-1138.
43. Domloge-Hultsch N, Utecht L, James W, et al. Autoantibodies from patients with localized and generalized bullous pemphigoid immunoprecipitate the same 230-kd keratinocyte antigen. *Arch Dermatol*. 1990;126(10):1337-1341.
44. Person JR, Rogers RS 3rd. Bullous and cicatricial pemphigoid. Clinical, histopathologic, and

immunopathologic correlations. *Mayo Clin Proc*. 1977;52(1):54-66.
45. Sollecito TP, Parisi E. Mucous membrane pemphigoid. *Dent Clin North Am*. 2005;49(1):91-106, viii.
46. Venning VA, Frith PA, Bron AJ, et al. Mucosal involvement in bullous and cicatricial pemphigoid. A clinical and immunopathological study. *Br J Dermatol*. 1988;118(1):7-15.
47. Demircay Z, Baykal C, Demirkesen C. Lichen planus pemphigoides: report of two cases. *Int J Dermatol*. 1;40(12):757-759.
48. Hsu S, Ghohestani RF, Uitto J. Lichen planus pemphigoides with IgG autoantibodies to the 180 kd bullous pemphigoid antigen (type XVII collagen). *J Am Acad Dermatol*. 000;42(1 Pt 1):136-141.
49. Maceyko RF, Camisa C, Bergfeld WF, et al. Oral and cutaneous lichen planus pemphigoides. *J Am Acad Dermatol*. 1992;27(5 Pt 2):889-892.
50. Stingl G, Holubar K. Coexistence of lichen planus and bullous pemphigoid. A immunopathological study. *Br J Dermatol*. 1975;93(3):313-320.
51. Murrell DF, Daniel BS, Joly P, et al. Definitions and outcome measures for bullous pemphigoid: recommendations by an international panel of experts. *J Am Acad Dermatol*. 2012;66(3):479-485.
52. Wijayanti A, Zhao CY, Boettiger D, et al. The reliability, validity and responsiveness of two disease scores (BPDAI and ABSIS) for bullous pemphigoid: which one to use? *Acta Derm Venereol*. 2017, 4; 97(1): 24-31.
53. Arbesman CE, Wypych JI, Reisman RE, et al. IgE levels in sera of patients with pemphigus or bullous pemphigoid. *Arch Dermatol*. 1974;110(3): 378-381.
54. Baba T, Sonozaki H, Seki K, et al. An eosinophil chemotactic factor present in blister fluids of bullous pemphigoid patients. *J Immunol*. 1976;116(1):112-116.
55. Hadi SM, Barnetson RS, Gawkrodger DJ, et al. Clinical, histological and immunological studies in 50 patients with bullous pemphigoid. *Dermatologica*. 1988;176(1):6-17.
56. Bernard P, Venot J, Constant F, et al. Blood eosinophilia as a severity marker for bullous pemphigoid. *J Am Acad Dermatol*. 1987;16(4):879-881.
57. Bushkell LL, Jordon RE. Bullous pemphigoid: a cause of peripheral blood eosinophilia. *J Am Acad Dermatol*. 1983;8(5):648-651.
58. van Beek N, Schulze FS, Zillikens D, et al. IgE-mediated mechanisms in bullous pemphigoid and other autoimmune bullous diseases. *Expert Rev Clin Immunol*. 2016;12(3):267-277.
59. Phoon YW, Fook-Chong SM, Koh HY, et al. Infectious complications in bullous pemphigoid: an analysis of risk factors. *J Am Acad Dermatol*. 2015;72(5): 834-839.
60. Lehman JS, el-Azhary RA. Kaposi varicelliform eruption in patients with autoimmune bullous dermatoses. *Int J Dermatol*. 2016;55(3):e136-140.
61. Barrick BJ, Barrick JD, Weaver CH, et al. Herpes zoster in patients with bullous pemphigoid: a population-based case-control and cohort study. *Br J Dermatol*. 2016;174(5):1112-1114.
62. Cram DL, Fukuyama K. Immunohistochemistry of ultraviolet-induced pemphigus and pemphigoid lesions. *Arch Dermatol*. 1972;106(6):819-824.
63. Mul VE, van Geest AJ, Pijls-Johannesma MC, et al. Radiation-induced bullous pemphigoid: a systematic review of an unusual radiation side effect. *Radiother Oncol*. 2007;82(1):5-9.
64. Thomsen K, Schmidt H. PUVA-induced bullous pemphigoid. *Br J Dermatol*. 1976;95(5):568-569.
65. Bastuji-Garin S, Joly P, Picard-Dahan C, et al. Drugs associated with bullous pemphigoid. A case-control study. *Arch Dermatol*. 1996;132(3):272-276.
66. Bordignon M, Belloni-Fortina A, Pigozzi B, et al. Bullous pemphigoid during long-term TNF-alpha blocker therapy. *Dermatology*. 2009;219(4):357-358.
67. Duong TA, Buffard V, Andre C, et al. Efalizumab-induced bullous pemphigoid. *J Am Acad Dermatol*. 2010;62(1):161-162.
68. Lee JJ, Downham TF 2nd. Furosemide-induced bullous pemphigoid: case report and review of literature. *J Drugs Dermatol*. 2006;5(6):562-564.
69. Monnier-Murina K, Du Thanh A, Merlet-Albran S, et al. Bullous pemphigoid occurring during efalizumab treatment for psoriasis: a paradoxical auto-immune reaction? *Dermatology*. 2009;219(1):89-90.
70. Popadic S, Skiljevic D, Medenica L. Bullous pemphigoid induced by penicillamine in a patient with Wilson disease. *Am J Clin Dermatol*. 2009;10(1): 36-38.
71. Stavropoulos PG, Soura E, Antoniou C. Drug-induced pemphigoid: a review of the literature. *J Eur Acad Dermatol Venereol*. 2014;28(9):1133-1140.
72. Jour G, Glitza IC, Ellis RM, et al. Autoimmune dermatologic toxicities from immune checkpoint blockade with anti-PD-1 antibody therapy: a report on bullous skin eruptions. *J Cutan Pathol*. 2016;43(8):688-696.
73. Naidoo J, Schindler K, Querfeld C, et al. Autoimmune bullous skin disorders with immune checkpoint inhibitors targeting PD-1 and PD-L1. *Cancer Immunol Res*. 2016;4(5):383-389.
74. Hwang SJ, Carlos G, Chou S, et al. Bullous pemphigoid, an autoantibody-mediated disease, is a novel immune-related adverse event in patients treated with anti-programmed cell death 1 antibodies. *Melanoma Res*. 2016;26(4):413-416.
75. Mutasim DF, Morrison LH, Takahashi Y, et al. Definition of bullous pemphigoid antibody binding to intracellular and extracellular antigen associated with hemidesmosomes. *J Invest Dermatol*. 1989;92(2): 225-230.
76. Stanley JR. Cell adhesion molecules as targets of autoantibodies in pemphigus and pemphigoid, bullous diseases due to defective epidermal cell adhesion. *Adv Immunol*. 1993;53:291-325.
77. Thoma-Uszynski S, Uter W, Schwietzke S, et al. BP230- and BP180-specific auto-antibodies in bullous pemphigoid. *J Invest Dermatol*. 2004;122(6):1413-1422.
78. Yoshida M, Hamada T, Amagai M, et al. Enzyme-linked immunosorbent assay using bacterial recombinant proteins of human BP230 as a diagnostic tool for bullous pemphigoid. *J Dermatol Sci*. 2006; 41(1):21-30.
79. Green KJ, Virata ML, Elgart GW, et al. Comparative structural analysis of desmoplakin, bullous pemphigoid antigen and plectin: members of a new gene family involved in organization of intermediate filaments. *Int J Biol Macromol*. 1992;14(3):145-153.
80. Stanley JR, Tanaka T, Mueller S, et al. Isolation of complementary DNA for bullous pemphigoid antigen by use of patients' autoantibodies. *J Clin Invest*. 1988;82(6):1864-1870.
81. Tanaka T, Korman NJ, Shimizu H, et al. Production of rabbit antibodies against carboxy-terminal epitopes encoded by bullous pemphigoid cDNA. *J Invest Dermatol*. 1990;94(5):617-623.

82. Guo L, Degenstein L, Dowling J, et al. Gene targeting of BPAG1: abnormalities in mechanical strength and cell migration in stratified epithelia and neurologic degeneration. *Cell*. 1995;81(2):233-243.
83. Brown A, Bernier G, Mathieu M, et al. The mouse dystonia musculorum gene is a neural isoform of bullous pemphigoid antigen 1. *Nat Genet*. 1995; 10(3):301-306.
84. Yang Y, Dowling J, Yu QC, et al. An essential cytoskeletal linker protein connecting actin microfilaments to intermediate filaments. *Cell*. 1996;86(4): 655-665.
85. Haase C, Budinger L, Borradori L, et al. Detection of IgG autoantibodies in the sera of patients with bullous and gestational pemphigoid: ELISA studies utilizing a baculovirus-encoded form of bullous pemphigoid antigen 2. *J Invest Dermatol*. 1998;110(3):282-286.
86. Zillikens D, Mascaro JM, Rose PA, et al. A highly sensitive enzyme-linked immunosorbent assay for the detection of circulating anti-BP180 autoantibodies in patients with bullous pemphigoid. *J Invest Dermatol*. 1997;109(5):679-683.
87. Bedane C, McMillan JR, Balding SD, et al. Bullous pemphigoid and cicatricial pemphigoid autoantibodies react with ultrastructurally separable epitopes on the BP180 ectodomain: evidence that BP180 spans the lamina lucida. *J Invest Dermatol*. 1997;108(6):901-907.
88. Diaz LA, Ratrie H 3rd, Saunders WS, et al. Isolation of a human epidermal cDNA corresponding to the 180-kD autoantigen recognized by bullous pemphigoid and herpes gestationis sera. Immunolocalization of this protein to the hemidesmosome. *J Clin Invest*. 1990;86(4):1088-1094.
89. Giudice GJ, Emery DJ, Diaz LA. Cloning and primary structural analysis of the bullous pemphigoid autoantigen BP180. *J Invest Dermatol*. 1992;99(3):243-250.
90. Giudice GJ, Squiquera HL, Elias PM, et al. Identification of two collagen domains within the bullous pemphigoid autoantigen, BP180. *J Clin Invest*. 1991;87(2): 734-738.
91. Hopkinson SB, Riddelle KS, Jones JC. Cytoplasmic domain of the 180-kD bullous pemphigoid antigen, a hemidesmosomal component: molecular and cell biologic characterization. *J Invest Dermatol*. 1992;99(3):264-270.
92. Borradori L, Koch PJ, Niessen CM, et al. The localization of bullous pemphigoid antigen 180 (BP180) in hemidesmosomes is mediated by its cytoplasmic domain and seems to be regulated by the beta4 integrin subunit. *J Cell Biol*. 1997;136(6):1333-1347.
93. Ishiko A, Shimizu H, Kikuchi A, et al. Human autoantibodies against the 230-kD bullous pemphigoid antigen (BPAG1) bind only to the intracellular domain of the hemidesmosome, whereas those against the 180-kD bullous pemphigoid antigen (BPAG2) bind along the plasma membrane of the hemidesmosome in normal human and swine skin. *J Clin Invest*. 1993;91(4):1608-1615.
94. Masunaga T, Shimizu H, Yee C, et al. The extracellular domain of BPAG2 localizes to anchoring filaments and its carboxyl terminus extends to the lamina densa of normal human epidermal basement membrane. *J Invest Dermatol*. 1997;109(2):200-206.
95. Giudice GJ, Emery DJ, Zelickson BD, et al. Bullous pemphigoid and herpes gestationis autoantibodies recognize a common non-collagenous site on the BP180 ectodomain. *J Immunol*. 1993;151(10): 5742-5750.
96. Zillikens D, Rose PA, Balding SD, et al. Tight clustering of extracellular BP180 epitopes recognized by bullous pemphigoid autoantibodies. *J Invest Dermatol*. 1997;109(4):573-579.
97. Sakuma-Oyama Y, Powell AM, Oyama N, et al. Evaluation of a BP180-NC16a enzyme-linked immunosorbent assay in the initial diagnosis of bullous pemphigoid. *Br J Dermatol*. 2004;151(1):126-131.
98. Schmidt E, Obe K, Brocker EB, et al. Serum levels of autoantibodies to BP180 correlate with disease activity in patients with bullous pemphigoid. *Arch Dermatol*. 2000;136(2):174-178.
99. Tsuji-Abe Y, Akiyama M, Yamanaka Y, et al. Correlation of clinical severity and ELISA indices for the NC16A domain of BP180 measured using BP180 ELISA kit in bullous pemphigoid. *J Dermatol Sci*. 2005;37(3): 145-149.
100. Hofmann S, Thoma-Uszynski S, Hunziker T, et al. Severity and phenotype of bullous pemphigoid relate to autoantibody profile against the NH2- and COOH-terminal regions of the BP180 ectodomain. *J Invest Dermatol*. 2002;119(5):1065-1073.
101. Jonkman MF, de Jong MC, Heeres K, et al. 180-kD bullous pemphigoid antigen (BP180) is deficient in generalized atrophic benign epidermolysis bullosa. *J Clin Invest*. 1995;95(3):1345-1352.
102. McGrath JA, Darling T, Gatalica B, et al. A homozygous deletion mutation in the gene encoding the 180-kDa bullous pemphigoid antigen (BPAG2) in a family with generalized atrophic benign epidermolysis bullosa. *J Invest Dermatol*. 1996;106(4):771-774.
103. McGrath JA, Gatalica B, Christiano AM, et al. Mutations in the 180-kD bullous pemphigoid antigen (BPAG2), a hemidesmosomal transmembrane collagen (COL17A1), in generalized atrophic benign epidermolysis bullosa. *Nat Genet*. 1995;11(1):83-86.
104. Christophoridis S, Budinger L, Borradori L, et al. IgG, IgA and IgE autoantibodies against the ectodomain of BP180 in patients with bullous and cicatricial pemphigoid and linear IgA bullous dermatosis. *Br J Dermatol*. 2000;143(2):349-355.
105. Dimson OG, Giudice GJ, Fu CL, et al. Identification of a potential effector function for IgE autoantibodies in the organ-specific autoimmune disease bullous pemphigoid. *J Invest Dermatol*. 2003;120(5):784-788.
106. Dopp R, Schmidt E, Chimanovitch I, et al. IgG4 and IgE are the major immunoglobulins targeting the NC16A domain of BP180 in Bullous pemphigoid: serum levels of these immunoglobulins reflect disease activity. *J Am Acad Dermatol*. 2000;42(4):577-583.
107. Borrego L, Maynard B, Peterson EA, et al. Deposition of eosinophil granule proteins precedes blister formation in bullous pemphigoid. Comparison with neutrophil and mast cell granule proteins. *Am J Pathol*. 1996;148(3):897-909.
108. Czech W, Schaller J, Schopf E, et al. Granulocyte activation in bullous diseases: release of granular proteins in bullous pemphigoid and pemphigus vulgaris. *J Am Acad Dermatol*. 1993;29(2 Pt 1):210-215.
109. Dvorak AM, Mihm MC Jr, Osage JE, et al. Bullous pemphigoid, an ultrastructural study of the inflammatory response: eosinophil, basophil and mast cell granule changes in multiple biopsies from one patient. *J Invest Dermatol*. 1982;78(2):91-101.
110. Wintroub BU, Mihm MC Jr, Goetzl EJ, et al. Morphologic and functional evidence for release of mast-cell products in bullous pemphigoid. *N Engl J Med*. 1978;298(8):417-421.

111. D'Auria L, Cordiali Fei P, Ameglio F. Cytokines and bullous pemphigoid. *Eur Cytokine Netw*. 1999; 10(2):123-134.
112. Diaz-Perez JL, Jordon RE. The complement system in bullous pemphigoid. IV. Chemotactic activity in blister fluid. *Clin Immunol Immunopathol*. 1976; 5(3):360-370.
113. Katayama I, Doi T, Nishioka K. High histamine level in the blister fluid of bullous pemphigoid. *Arch Dermatol Res*. 1984;276(2):126-127.
114. Kawana S, Ueno A, Nishiyama S. Increased levels of immunoreactive leukotriene B4 in blister fluids of bullous pemphigoid patients and effects of a selective 5-lipoxygenase inhibitor on experimental skin lesions. *Acta Derm Venereol*. 1990;70(4):281-285.
115. Schmidt E, Ambach A, Bastian B, et al. Elevated levels of interleukin-8 in blister fluid of bullous pemphigoid compared with suction blisters of healthy control subjects. *J Am Acad Dermatol*. 1996;34(2 Pt 1): 310-312.
116. Schmidt E, Bastian B, Dummer R, et al. Detection of elevated levels of IL-4, IL-6, and IL-10 in blister fluid of bullous pemphigoid. *Arch Dermatol Res* 1996;288(7):353-357.
117. Schmidt E, Mittnacht A, Schomig H, et al. Detection of IL-1 alpha, IL-1 beta and IL-1 receptor antagonist in blister fluid of bullous pemphigoid. *J Dermatol Sci*. 1996;11(2):142-147.
118. Wakugawa M, Nakamura K, Hino H, et al. Elevated levels of eotaxin and interleukin-5 in blister fluid of bullous pemphigoid: correlation with tissue eosinophilia. *Br J Dermatol*. 2000;143(1):112-116.
119. Baird J, Lazarus GS, Belin D, et al. mRNA for tissue-type plasminogen activator is present in lesional epidermis from patients with psoriasis, pemphigus, or bullous pemphigoid, but is not detected in normal epidermis. *J Invest Dermatol*. 1990;95(5):548-552.
120. Gissler HM, Simon MM, Kramer MD. Enhanced association of plasminogen/plasmin with lesional epidermis of bullous pemphigoid. *Br J Dermatol*. 1992;127(3):272-277.
121. Kramer MD, Reinartz J. The autoimmune blistering skin disease bullous pemphigoid. The presence of plasmin/alpha 2-antiplasmin complexes in skin blister fluid indicates plasmin generation in lesional skin. *J Clin Invest*. 1993;92(2):978-983.
122. Lauharanta J, Salonen EM, Vaheri A. Plasmin-like proteinase associated with high molecular weight complexes in blister fluid of bullous pemphigoid. *Acta Derm Venereol*. 1989;69(6):527-529.
123. Oikarinen AI, Zone JJ, Ahmed AR, et al. Demonstration of collagenase and elastase activities in the blister fluids from bullous skin diseases. Comparison between dermatitis herpetiformis and bullous pemphigoid. *J Invest Dermatol*. 1983;81(3):261-266.
124. Schaefer BM, Jaeger C, Drepper E, et al. Plasminogen activation in bullous pemphigoid immunohistology reveals urokinase type plasminogen activator, its receptor and plasminogen activator inhibitor type-2 in lesional epidermis. *Autoimmunity*. 1996;23(3): 155-164.
125. Stahle-Backdahl M, Inoue M, Guidice GJ, et al. 92-kD gelatinase is produced by eosinophils at the site of blister formation in bullous pemphigoid and cleaves the extracellular domain of recombinant 180-kD bullous pemphigoid autoantigen. *J Clin Invest*. 1994; 93(5):2022-2030.
126. Verraes S, Hornebeck W, Polette M, et al. Respective contribution of neutrophil elastase and matrix metalloproteinase 9 in the degradation of BP180 (type XVII collagen) in human bullous pemphigoid. *J Invest Dermatol*. 2001;117(5):1091-1096.
127. Gammon WR, Merritt CC, Lewis DM, et al. An in vitro model of immune complex-mediated basement membrane zone separation caused by pemphigoid antibodies, leukocytes, and complement. *J Invest Dermatol*. 1982;78(4):285-290.
128. Sitaru C, Schmidt E, Petermann S, et al. Autoantibodies to bullous pemphigoid antigen 180 induce dermal-epidermal separation in cryosections of human skin. *J Invest Dermatol*. 2002;118(4):664-671.
129. Liu Z, Diaz LA, Troy JL, et al. A passive transfer model of the organ-specific autoimmune disease, bullous pemphigoid, using antibodies generated against the hemidesmosomal antigen, BP180. *J Clin Invest*. 1993;92(5):2480-2488.
130. Chen R, Ning G, Zhao ML, et al. Mast cells play a key role in neutrophil recruitment in experimental bullous pemphigoid. *J Clin Invest*. 2001;108(8):1151-1158.
131. Liu Z, Giudice GJ, Swartz SJ, et al. The role of complement in experimental bullous pemphigoid. *J Clin Invest*. 1995;95(4):1539-1544.
132. Liu Z, Giudice GJ, Zhou X, et al. A major role for neutrophils in experimental bullous pemphigoid. *J Clin Invest*. 1997;100(5):1256-1263.
133. Nelson KC, Zhao M, Schroeder PR, et al. Role of different pathways of the complement cascade in experimental bullous pemphigoid. *J Clin Invest*. 2006; 116(11):2892-2900.
134. Liu Z. Bullous pemphigoid: using animal models to study the immunopathology. *J Investig Dermatol Symp Proc*. 2004;9(1):41-46.
135. Liu Z, Li N, Diaz LA, et al. Synergy between a plasminogen cascade and MMP-9 in autoimmune disease. *J Clin Invest*. 2005;115(4):879-887.
136. Liu Z, Shapiro SD, Zhou X, et al. A critical role for neutrophil elastase in experimental bullous pemphigoid. *J Clin Invest*. 2000;105(1):113-123.
137. Liu Z, Shipley JM, Vu TH, et al. Gelatinase B-deficient mice are resistant to experimental bullous pemphigoid. *J Exp Med*. 1998;188(3):475-482.
138. Liu Z, Zhou X, Shapiro SD, et al. The serpin alpha1-proteinase inhibitor is a critical substrate for gelatinase B/MMP-9 in vivo. *Cell*. 2000;102(5):647-655.
139. Liu Z, Sui W, Zhao M, et al. Subepidermal blistering induced by human autoantibodies to BP180 requires innate immune players in a humanized bullous pemphigoid mouse model. *J Autoimmun*. 2008;31(4):331-338.
140. Nishie W, Sawamura D, Goto M, et al. Humanization of autoantigen. *Nat Med*. 2007;13(3):378-383.
141. Fairley JA, Burnett CT, Fu CL, et al. A pathogenic role for IgE in autoimmunity: bullous pemphigoid IgE reproduces the early phase of lesion development in human skin grafted to nu/nu mice. *J Invest Dermatol*. 2007;127(11):2605-2611.
142. Zone JJ, Taylor T, Hull C, et al. IgE basement membrane zone antibodies induce eosinophil infiltration and histological blisters in engrafted human skin on SCID mice. *J Invest Dermatol*. 2007;127(5):1167-1174.
143. Kitajima Y, Nojiri M, Yamada T, et al. Internalization of the 180 kDa bullous pemphigoid antigen as immune complexes in basal keratinocytes: an important early event in blister formation in bullous pemphigoid. *Br J Dermatol*. 1998;138(1):71-76.

144. Ujiie H, Sasaoka T, Izumi K, et al. Bullous pemphigoid autoantibodies directly induce blister formation without complement activation. *J Immunol*. 2014;193(9):4415-4428.
145. Hurskainen T, Kokkonen N, Sormunen R, et al. Deletion of the major bullous pemphigoid epitope region of collagen XVII induces blistering, autoimmunization, and itching in mice. *J Invest Dermatol*. 2015;135(5):1303-1310.
146. Hall R 3rd, Murray JC, McCord MM, et al. Rabbits immunized with a peptide encoded for by the 230-kD bullous pemphigoid antigen cDNA develop an enhanced inflammatory response to UVB irradiation: a potential animal model for bullous pemphigoid. *J Invest Dermatol*. 1993;101(1):9-14.
147. Kiss M, Husz S, Janossy T, et al. Experimental bullous pemphigoid generated in mice with an antigenic epitope of the human hemidesmosomal protein BP230. *J Autoimmun*. 2005;24(1):1-10.
148. Budinger L, Borradori L, Yee C, et al. Identification and characterization of autoreactive T cell responses to bullous pemphigoid antigen 2 in patients and healthy controls. *J Clin Invest*. 1998;102(12):2082-2089.
149. Leyendeckers H, Tasanen K, Bruckner-Tuderman L, et al. Memory B cells specific for the NC16A domain of the 180 kDa bullous pemphigoid autoantigen can be detected in peripheral blood of bullous pemphigoid patients and induced in vitro to synthesize autoantibodies. *J Invest Dermatol*. 2003;120(3):372-378.
150. Warren SJ, Lin MS, Giudice GJ, et al. The prevalence of antibodies against desmoglein 1 in endemic pemphigus foliaceus in Brazil. Cooperative Group on Fogo Selvagem Research. *N Engl J Med*. 2000;343(1):23-30.
151. Pickford WJ, Gudi V, Haggart AM, et al. T cell participation in autoreactivity to NC16a epitopes in bullous pemphigoid. *Clin Exp Immunol*. 2015;180(2): 189-200.
152. Balding SD, Prost C, Diaz LA, et al. Cicatricial pemphigoid autoantibodies react with multiple sites on the BP180 extracellular domain. *J Invest Dermatol*. 1996;106(1):141-146.
153. Bernard P, Prost C, Durepaire N, et al. The major cicatricial pemphigoid antigen is a 180-kD protein that shows immunologic cross-reactivities with the bullous pemphigoid antigen. *J Invest Dermatol*. 1992;99(2):174-179.
154. Jordon RE, Heine KG, Tappeiner G, et al. The immunopathology of herpes gestationis. Immunofluorescence studies and characterization of "HG factor." *J Clin Invest*. 1976;57(6):1426-1431.
155. Katz SI, Hertz KC, Yaoita H. Herpes gestationis. Immunopathology and characterization of the HG factor. *J Clin Invest*. 1976;57(6):1434-1441.
156. Lin MS, Gharia MA, Swartz SJ, et al. Identification and characterization of epitopes recognized by T lymphocytes and autoantibodies from patients with herpes gestationis. *J Immunol*. 1999;162(8):4991-4997.
157. Murakami H, Nishioka S, Setterfield J, et al. Analysis of antigens targeted by circulating IgG and IgA autoantibodies in 50 patients with cicatricial pemphigoid. *J Dermatol Sci*. 1998;17(1):39-44.
158. Provost TT, Tomasi TB Jr. Evidence for complement activation via the alternate pathway in skin diseases, I. Herpes gestationis, systemic lupus erythematosus, and bullous pemphigoid. *J Clin Invest*. 1973;52(7): 1779-1787.
159. Shornick JK, Bangert JL, Freeman RG, et al. Herpes gestationis: clinical and histologic features of twenty-eight cases. *J Am Acad Dermatol*. 1983;8(2):214-224.
160. Tamada Y, Yokochi K, Nitta Y, et al. Lichen planus pemphigoides: identification of 180 kd hemidesmosome antigen. *J Am Acad Dermatol*. 1995;32(5 Pt 2):883-887.
161. Zone JJ, Taylor TB, Kadunce DP, et al. Identification of the cutaneous basement membrane zone antigen and isolation of antibody in linear immunoglobulin A bullous dermatosis. *J Clin Invest*. 1990;85(3):812-820.
162. Zone JJ, Taylor TB, Meyer LJ, et al. The 97 kDa linear IgA bullous disease antigen is identical to a portion of the extracellular domain of the 180 kDa bullous pemphigoid antigen, BPAg2. *J Invest Dermatol*. 1998;110(3):207-210.
163. Delgado JC, Turbay D, Yunis EJ, et al. A common major histocompatibility complex class II allele HLA-DQB1* 0301 is present in clinical variants of pemphigoid. *Proc Natl Acad Sci U S A*. 1996;93(16):8569-8571.
164. Oyama N, Setterfield JF, Powell AM, et al. Bullous pemphigoid antigen II (BP180) and its soluble extracellular domains are major autoantigens in mucous membrane pemphigoid: the pathogenic relevance to HLA class II alleles and disease severity. *Br J Dermatol*. 2006;154(1):90-98.
165. Okazaki A, Miyagawa S, Yamashina Y, et al. Polymorphisms of HLA-DR and -DQ genes in Japanese patients with bullous pemphigoid. *J Dermatol*. 2000; 27(3):149-156.
166. Langan SM, Groves RW, West J. The relationship between neurological disease and bullous pemphigoid: a population-based case-control study. *J Invest Dermatol*. 2011;131(3):631-636.
167. Bastuji-Garin S, Joly P, Lemordant P, et al. Risk factors for bullous pemphigoid in the elderly: a prospective case-control study. *J Invest Dermatol*. 2011; 131(3):637-643.
168. Jedlickova H, Hlubinka M, Pavlik T, et al. Bullous pemphigoid and internal diseases—a case-control study. *Eur J Dermatol*.2010;20(1):96-101.
169. Lindelof B, Islam N, Eklund G, et al. Pemphigoid and cancer. *Arch Dermatol*. 1990;126(1):66-68.
170. Stone SP, Schroeter AL. Bullous pemphigoid and associated malignant neoplasms. *Arch Dermatol*. 1975; 111(8):991-994.
171. Venning VA, Wojnarowska F. The association of bullous pemphigoid and malignant disease: a case control study. *Br J Dermatol*. 1990;123(4):439-445.
172. Cai SC, Allen JC, Lim YL, et al. Association of bullous pemphigoid and malignant neoplasms. *JAMA Dermatol*. 2015;151(6):665-667.
173. Ong E, Goldacre R, Hoang U, et al. Associations between bullous pemphigoid and primary malignant cancers: an English national record linkage study, 1999-2011. *Arch Dermatol Res*. 2014;306(1):75-80.
174. Schulze F, Neumann K, Recke A, et al. Malignancies in pemphigus and pemphigoid diseases. *J Invest Dermatol*. 2015;135(5):1445-1447.
175. Crotty C, Pittelkow M, Muller SA. Eosinophilic spongiosis: a clinicopathologic review of seventy-one cases. *J Am Acad Dermatol*. 1983;8(3):337-343.
176. Ahmed AR, Maize JC, Provost TT. Bullous pemphigoid. Clinical and immunologic follow-up after successful therapy. *Arch Dermatol*. 1977;113(8):1043-1046.
177. Beutner EH, Lever WF, Witebsky E, et al. Autoantibodies in pemphigus vulgaris: response to an intercellular substance of epidermis. *JAMA*. 1965;192: 682-688.
178. Beutner EH, Jordon RE, Chorzelski TP. The immunopathology of pemphigus and bullous pemphigoid. *J Invest Dermatol*. 1968;51(2):63-80.

179. Fairley JA, Fu CL, Giudice GJ. Mapping the binding sites of anti-BP180 immunoglobulin E autoantibodies in bullous pemphigoid. *J Invest Dermatol*. 2005;125(3):467-472.
180. Parodi A, Rebora A. Serum IgE antibodies bind to the epidermal side of the basement membrane zone splits in bullous pemphigoid. *Br J Dermatol*. 1992;126(5):526-527.
181. Gammon WR, Briggaman RA, Inman AO 3rd, et al. Differentiating anti-lamina lucida and anti-sublamina densa anti-BMZ antibodies by indirect immunofluorescence on 1.0 M sodium chloride-separated skin. *J Invest Dermatol*. 1984;82(2):139-144.
182. Kelly SE, Wojnarowska F. The use of chemically split tissue in the detection of circulating anti-basement membrane zone antibodies in bullous pemphigoid and cicatricial pemphigoid. *Br J Dermatol*. 1988;118(1):31-40.
183. Sams WM Jr, Jordon RE. Correlation of pemphigoid and pemphigus antibody titres with activity of disease. *Br J Dermatol*. 1971;84(1):7-13.
184. Ishiura N, Fujimoto M, Watanabe R, et al. Serum levels of IgE anti-BP180 and anti-BP230 autoantibodies in patients with bullous pemphigoid. *J Dermatol Sci*. 2008;49(2):153-161.
185. Iwata Y, Komura K, Kodera M, et al. Correlation of IgE autoantibody to BP180 with a severe form of bullous pemphigoid. *Arch Dermatol*. 2008;144(1):41-48.
186. Messingham KA, Noe MH, Chapman MA, et al. A novel ELISA reveals high frequencies of BP180-specific IgE production in bullous pemphigoid. *J Immunol Methods*. 2009;346(1-2):18-25.
187. Woodley DT. The role of IgE anti-basement membrane zone autoantibodies in bullous pemphigoid. *Arch Dermatol*. 2007;143(2):249-250.
188. Kalowska M, Ciepiela O, Kowalewski C, et al. Enzyme-linked Immunoassay Index for anti-NC16a IgG and IgE auto-antibodies correlates with severity and activity of bullous pemphigoid. *Acta Derm Venereol*. 2016;96(2):191-196.
189. Wieland CN, Comfere NI, Gibson LE, et al. Anti-bullous pemphigoid 180 and 230 antibodies in a sample of unaffected subjects. *Arch Dermatol*. 2010;146(1):21-25.
190. Keller JJ, Kittridge AL, Debanne SM, et al. Evaluation of ELISA testing for BP180 and BP230 as a diagnostic modality for bullous pemphigoid: a clinical experience. *Arch Dermatol Res*. 2016;308(4): 269-272.
191. Gammon WR, Inman AO 3rd, Wheeler C, Jr. Differences in complement-dependent chemotactic activity generated by bullous pemphigoid and epidermolysis bullosa acquisita immune complexes: demonstration by leukocytic attachment and organ culture methods. *J Invest Dermatol*. 1984;83(1): 57-61.
192. Gammon WR, Kowalewski C, Chorzelski TP, et al. Direct immunofluorescence studies of sodium chloride-separated skin in the differential diagnosis of bullous pemphigoid and epidermolysis bullosa acquisita. *J Am Acad Dermatol* 1990;22(4):664-670.
193. Venning VA, Wojnarowska F. Lack of predictive factors for the clinical course of bullous pemphigoid. *J Am Acad Dermatol*. 1992;26(4):585-589.
194. Bernard P, Reguiai Z, Tancrede-Bohin E, et al. Risk factors for relapse in patients with bullous pemphigoid in clinical remission: a multicenter, prospective, cohort study. *Arch Dermatol*. 2009;145(5):537-542.
195. Ingen-Housz-Oro S, Plee J, Belmondo T, et al. Positive direct immunofluorescence is of better value than ELISA-BP180 and ELISA-BP230 values for the prediction of relapse after treatment cessation in bullous pemphigoid: a retrospective study of 97 patients. *Dermatology*. 2015;231(1):50-55.
196. Joly P, Benichou J, Lok C, et al. Prediction of survival for patients with bullous pemphigoid: a prospective study. *Arch Dermatol*. 2005;141(6):691-698.
197. Roujeau JC, Lok C, Bastuji-Garin S, et al. High risk of death in elderly patients with extensive bullous pemphigoid. *Arch Dermatol*. 1998;134(4):465-469.
198. Rzany B, Partscht K, Jung M, et al. Risk factors for lethal outcome in patients with bullous pemphigoid: low serum albumin level, high dosage of glucocorticosteroids, and old age. *Arch Dermatol*. 2002;138(7):903-908.
199. Tanaka M, Hashimoto T, Dykes PJ, et al. Clinical manifestations in 100 Japanese bullous pemphigoid cases in relation to autoantigen profiles. *Clin Exp Dermatol*. 1996;21(1):23-27.
200. Fichel F, Barbe C, Joly P, et al. Clinical and immunologic factors associated with bullous pemphigoid relapse during the first year of treatment: a multicenter, prospective study. *JAMA Dermatol*. 2014;150(1):25-33.
201. Bystryn JC, Rudolph JL. Why is the mortality of bullous pemphigoid greater in Europe than in the US? *J Invest Dermatol*. 2005;124(3):xx-xxi.
202. Colbert RL, Allen DM, Eastwood D, et al. Mortality rate of bullous pemphigoid in a US medical center. *J Invest Dermatol*. 2004;122(5):1091-1095.
203. Joly P, Roujeau JC, Benichou J, et al. A comparison of oral and topical corticosteroids in patients with bullous pemphigoid. *N Engl J Med*. 2002;346(5): 321-327.
204. Parker SR, Dyson S, Brisman S, et al. Mortality of bullous pemphigoid: an evaluation of 223 patients and comparison with the mortality in the general population in the United States. *J Am Acad Dermatol*. 2008;59(4):582-588.
205. Risser J, Lewis K, Weinstock MA. Mortality of bullous skin disorders from 1979 through 2002 in the United States. *Arch Dermatol*. 2009;145(9):1005-1008.
206. Feliciani C, Joly P, Jonkman MF, et al. Management of bullous pemphigoid: the European Dermatology Forum consensus in collaboration with the European Academy of Dermatology and Venereology. *Br J Dermatol*. 2015;172(4):867-877.
207. Fine JD. Management of acquired bullous skin diseases. *N Engl J Med*. 1995;333(22):1475-1484.
208. Patton T, Korman NJ. Bullous pemphigoid treatment review. *Expert Opin Pharmacother*. 2006;7(17): 2403-2411.
209. Wojnarowska F, Kirtschig G, Highet AS, et al. Guidelines for the management of bullous pemphigoid. *Br J Dermatol*. 2002;147(2):214-221.
210. Bystryn JC, Wainwright BD, Shupack JL. Oral and topical corticosteroids in bullous pemphigoid. *N Engl J Med*. 2002;347(2):143-145; author reply 143-145.
211. Savin JA. The events leading to the death of patients with pemphigus and pemphigoid. *Br J Dermatol*. 1979;101(5):521-534.
212. Khumalo NP, Murrell DF, Wojnarowska F, et al. A systematic review of treatments for bullous pemphigoid. *Arch Dermatol*. Mar 2002;138(3):385-389.
213. Bara C, Maillard H, Briand N, et al. Methotrexate for bullous pemphigoid: preliminary study. *Arch Dermatol*. Nov 2003;139(11):1506-1507.

214. Gurcan HM, Ahmed AR. Analysis of current data on the use of methotrexate in the treatment of pemphigus and pemphigoid. *Br J Dermatol*. 2009;161(4):723-731.
215. Kjellman P, Eriksson H, Berg P. A retrospective analysis of patients with bullous pemphigoid treated with methotrexate. *Arch Dermatol*. 2008;144(5):612-616.
216. Bohm M, Beissert S, Schwarz T, et al. Bullous pemphigoid treated with mycophenolate mofetil. *Lancet*. 1997;349(9051):541.
217. Burton JL, Harman RR, Peachey RD, et al. Azathioprine plus prednisone in treatment of pemphigoid. *Br Med J*. 1978;2(6146):1190-1191.
218. Guillaume JC, Vaillant L, Bernard P, et al. Controlled trial of azathioprine and plasma exchange in addition to prednisolone in the treatment of bullous pemphigoid. *Arch Dermatol*. 1993;129(1):49-53.
219. Heilborn JD, Stahle-Backdahl M, Albertioni F, et al. Low-dose oral pulse methotrexate as monotherapy in elderly patients with bullous pemphigoid. *J Am Acad Dermatol*. 1999;40(5 Pt 1):741-749.
220. Nousari HC, Griffin WA, Anhalt GJ. Successful therapy for bullous pemphigoid with mycophenolate mofetil. *J Am Acad Dermatol*. 1998;39(3):497-498.
221. Paul MA, Jorizzo JL, Fleischer AB Jr, et al. Low-dose methotrexate treatment in elderly patients with bullous pemphigoid. *J Am Acad Dermatol*. 1994;31(4):620-625.
222. Beissert S, Werfel T, Frieling U, et al. A comparison of oral methylprednisolone plus azathioprine or mycophenolate mofetil for the treatment of bullous pemphigoid. *Arch Dermatol*. 2007;143(12):1536-1542.
223. Bouscarat F, Chosidow O, Picard-Dahan C, et al. Treatment of bullous pemphigoid with dapsone: retrospective study of thirty-six cases. *J Am Acad Dermatol*. 1996;34(4):683-684.
224. Person JR, Rogers RS 3rd. Bullous pemphigoid responding to sulfapyridine and the sulfones. *Arch Dermatol*. 1977;113(5):610-615.
225. Venning VA, Millard PR, Wojnarowska F. Dapsone as first line therapy for bullous pemphigoid. *Br J Dermatol*. 1989;120(1):83-92.
226. Berk MA, Lorincz AL. The treatment of bullous pemphigoid with tetracycline and niacinamide. A preliminary report. *Arch Dermatol*. 1986;122(6):670-674.
227. Fivenson DP, Breneman DL, Rosen GB, et al. Nicotinamide and tetracycline therapy of bullous pemphigoid. *Arch Dermatol*. 1994;130(6):753-758.
228. Kolbach DN, Remme JJ, Bos WH, et al. Bullous pemphigoid successfully controlled by tetracycline and nicotinamide. *Br J Dermatol*. 1995;133(1):88-90.
229. Roujeau JC, Guillaume JC, Morel P, et al. Plasma exchange in bullous pemphigoid. *Lancet*. 1984;2(8401):486-488.
230. Ahmed AR. Intravenous immunoglobulin therapy for patients with bullous pemphigoid unresponsive to conventional immunosuppressive treatment. *J Am Acad Dermatol*. 2001;45(6):825-835.
231. Ahmed AR, Dahl MV. Consensus statement on the use of intravenous immunoglobulin therapy in the treatment of autoimmune mucocutaneous blistering diseases. *Arch Dermatol*. 2003;139(8):1051-1059.
232. Engineer L, Ahmed AR. Role of intravenous immunoglobulin in the treatment of bullous pemphigoid: analysis of current data. *J Am Acad Dermatol*. 2001;44(1):83-88.
233. Fairley JA, Baum CL, Brandt DS, et al. Pathogenicity of IgE in autoimmunity: successful treatment of bullous pemphigoid with omalizumab. *J Allergy Clin Immunol*. 2009;123(3):704-705.
234. Yu KK, Crew AB, Messingham KA, et al. Omalizumab therapy for bullous pemphigoid. *J Am Acad Dermatol*. 2014;71(3):468-474.
235. Cho YT, Chu CY, Wang LF. First-line combination therapy with rituximab and corticosteroids provides a high complete remission rate in moderate-to-severe bullous pemphigoid. *Br J Dermatol*. 2015;173(1):302-304.
236. Shetty S, Ahmed AR. Treatment of bullous pemphigoid with rituximab: critical analysis of the current literature. *J Drugs Dermatol*. 2013;12(6):672-677.

Chapter 55 :: Mucous Membrane Pemphigoid

:: Kim B. Yancey

AT-A-GLANCE

- A chronic autoimmune subepithelial blistering disease characterized by erosive lesions of mucous membranes and skin that typically results in scarring in at least some sites of involvement.
- Lesions commonly involve the oral and ocular mucosae; other sites that may be involved include the nasopharyngeal, laryngeal, esophageal, and anogenital mucosae.
- A rare disorder with a predominance in the elderly and an estimated incidence of 1 to 2 cases per million annually; females are affected 1.5 to 2 times as often as males.
- A progressive disorder that may result in serious complications (eg, blindness, loss of the airway, esophageal stricture formation).
- Severity of involvement in one organ does not necessarily correlate with the presence or severity of disease at other sites.
- Immunopathologic studies of perilesional mucosa and skin demonstrate in situ deposits of immunoreactants in epithelial basement membranes; circulating anti–basement membrane autoantibodies are detected in the sera of some but not all patients.
- A variety of different autoantigens are recognized by autoantibodies from patients, suggesting that mucous membrane pemphigoid is not a single nosologic entity but a disease phenotype.

DEFINITION

Mucous membrane pemphigoid (MMP) is a rare chronic autoimmune subepithelial blistering disease characterized by erosive lesions of mucous membranes and skin that typically results in scarring of at least some sites of involvement.[1-4]

HISTORICAL PERSPECTIVE

In 1794, Wichmann described a chronic blistering disorder characterized by ocular involvement.[5] What are thought to be related cases were reported by Thost in 1911.[6] In 1949, Civatte separated this disorder from pemphigus on the basis of histopathologic findings.[5] Lever affirmed this distinction and suggested that this disorder be named "benign mucous membrane pemphigoid," a designation now regarded a misnomer given the potential devastating consequences of MMP.[4] Over the years, a variety of alternate designations, such as cicatricial pemphigoid, oral pemphigoid, desquamative gingivitis, ocular pemphigoid, ocular cicatricial pemphigoid, essential shrinkage of the conjunctivae, ocular pemphigus, have been applied to MMP.

In 2002, an international consensus conference agreed upon the designation of this disorder as MMP in that this nomenclature is inclusive of patients with disease affecting any mucosal surface and that it emphasizes the mucosal predominant character of this disorder.[1] In 2015, an international panel of experts issued a consensus statement providing accurate and reproducible definitions for disease extent, activity, outcome measures, end points, and therapeutic response.[7]

EPIDEMIOLOGY

MMP has been estimated to have an incidence of 1 to 2 cases per million annually; females are affected 1.5 to 2.0 times as often as males.[8-10] MMP has a mean age of onset in the early to middle 60s.[10] Although there is no known racial or geographic predilection, the *HLADQB1*0301* allele is significantly increased in frequency in patients with oral, ocular, and generalized bullous pemphigoid; amino acid residues at positions 57 and 71 to 77 of the DQB1 protein may represent a disease-susceptibility marker.[11-15]

CLINICAL FEATURES

CUTANEOUS FINDINGS

Patients typically describe the onset of painful, erosive, and/or blistering lesions on 1 or more mucosal surfaces.[16] A few skin lesions on the upper body are also sometimes noted. Associated symptoms are typically site specific. The mouth is the most frequent site of involvement in patients with MMP; it is often the first (and only) site affected.[1,5,16] In the mouth, lesions often involve the gingiva, buccal mucosa, and palate (Fig. 55-1); other sites, such as the alveolar ridge, tongue, and lips, are also susceptible. Erosive lesions of the gingiva resulting in tissue retraction and loss are a frequent manifestation of MMP. Other sites of intraoral involvement may show tense blisters that rupture easily or mucosal erosions that form as a consequence of epithelial fragility. Lesions in the mouth may result in a delicate white pattern of reticulated scarring; oral lesions can heal without scarring in some instances. In severe disease, adhesions may develop between the buccal mucosa and the alveolar process, around the

Figure 55-1 Denuded and inflamed sites on the oral mucosa are seen in association with sites of gingiva recession and loss.

uvula and tonsillar fossae, and between the tongue and the floor of the mouth. Gingival involvement can result in tissue loss and dental complications (eg, caries, periodontal ligament damage, and loss of bone mass and teeth).

Ocular involvement in patients with MMP is common and may become sight threatening (Figs. 55-2 and 55-3).[17,18] Ocular lesions typically manifest as conjunctivitis that progresses insidiously to scarring. Early ocular disease can be quite subtle and nonspecific. Although disease is usually bilateral, it often begins unilaterally and progresses to both eyes within several years. Patients may complain of burning, dryness, or a foreign-body sensation in one or both eyes; frank blisters on conjunctival surfaces are rarely seen. Early disease is best appreciated by slitlamp examination. Because disease may be localized to the upper tarsal conjunctiva, it may escape detection without eversion of the eyelids. Chronic ocular involvement can result in scarring characterized by shortened fornices, symblepharons (ie, fibrous tracts between bulbar and palpebral conjunctival surfaces), and, in severe disease, ankyloblepharons (ie, fibrous tracts fusing the superior and inferior palpebral conjunctivae with obliteration of the conjunctival sac). Conjunctival scarring also can cause entropion and trichiasis (ie, in-turning of the eyelashes) that result in corneal irritation, superficial punctate keratopathy, corneal neovascularization, corneal ulceration, and/or blindness. Additional ocular complications include scarring of the lacrimal ducts, decreased tear secretion, and loss of mucosal goblet cells leading to decreased tear mucus content and unstable tear films. It is very important for patients with suspected ocular involvement to be examined by an ophthalmologist because early disease may be subtle, only identified by slitlamp examination, and hold potential for severe complications. MMP may be limited to the eyes.

Figure 55-2 The medial aspects of the lower conjunctival fornix and eyelid show shortening, fibrosis, and malaligned eyelashes.

Figure 55-3 Ocular involvement has resulted in conjunctivitis, a shortened conjunctival fornix, and symblepharon formation.

Other sites that may be affected by MMP include the nasopharyngeal, laryngeal, esophageal, and anogenital mucosae. Nasopharyngeal lesions can result in discharge, epistaxis, excessive crust formation, impaired airflow, chronic sinusitis, scarring, and tissue loss. Laryngeal involvement may present as hoarseness, sore throat, and/or loss of phonation. Chronic laryngeal erosions, edema, and scarring may result in supraglottic stenosis and airway compromise that eventually necessitates tracheostomy. Esophageal involvement may result in stricture formation, dysphagia, odynophagia, weight loss, and/or aspiration. It has been suggested that esophageal dysfunction and gastroesophageal reflux may elicit or exacerbate laryngeal disease and/or bronchospasm in such patients. Although involvement of the genital and/or rectal mucosae in patients with MMP is relatively rare, it can be a source of substantial pain and morbidity (Fig. 55-4). Cases of urethral stricture, vaginal stenosis, and anal narrowing have developed as a consequence of this disease.

Figure 55-4 Scalloped erosions and sites of denuded vulvar and vaginal mucosae represent painful sites of disease in a patient with mucous membrane pemphigoid.

The skin is involved in 25% to 35% of patients with MMP. The most frequently affected areas are the scalp, head, neck, and upper trunk (Fig. 55-5). Lesions typically consist of small vesicles or bullae situated on erythematous and/or urticarial bases. Lesions rupture easily and are often seen as small, crusted papules or plaques. The extent and number of cutaneous lesions are generally small; lesions sometimes recur in the same areas.

In 1957, Brunsting and Perry described 7 patients with recurrent scarring subepidermal blistering lesions on the head or neck that for many years was considered a variant form of MMP.[19] Similar patients were subsequently identified by others.[20-25] Although such patients are typically elderly and demonstrate deposits of immunoreactants in epidermal basement membranes like other patients with MMP, Brunsting-Perry pemphigoid predominates in men, lacks mucous membrane involvement, and only in selected cases is associated with immunoglobulin (Ig) G autoantibodies against BP230 (also termed bullous pemphigoid antigen 1 [BPAG1] or dystonin) or BP180 (also termed bullous pemphigoid antigen 2 [BPAG2] or type XVII collagen).[21-24] Because some patients with the same clinical, histologic, and immunopathologic features have been reported to have autoantibodies directed against type VII collagen and blister planes beneath the lamina densa, it has been suggested that a subset of such patients may have a localized forms of epidermolysis bullosa acquisita.[21,22] Rare patients with this phenotype and autoantibodies directed against laminin-332 and/or other skin autoantigens also have been described.[24,25]

Figure 55-5 The scalp displays scarring alopecia and a focal hemorrhagic crust as a consequence of involvement with mucous membrane pemphigoid.

NONCUTANEOUS FINDINGS

In 2001, a cohort of 35 patients with MMP and IgG autoantibodies directed against laminin-332 (ie, anti–laminin 332 MMP [formerly called antiepiligrin cicatricial pemphigoid]) was shown to have an increased relative risk for cancer.[26] Ten patients in this cohort had solitary solid cancers (3 lung, 3 gastric, 2 colon, 2 endometrial); 8 patients developed cancer after the onset of MMP (6 within a year, 7 within 14 months). The time between blister onset and cancer diagnosis was approximately 14 months in 9 of the 10 patients. Eight patients in this cohort died as a consequence of their cancer; all deaths occurred within 21 months. This study showed that this form of MMP has an increased relative risk for malignancy that approximates that for adults with dermatomyositis; as is true for dermatomyositis, the risk for cancer appears to be particularly high in the first year of disease. Other patients with this form of MMP and cancer have been described by numerous sources.[26-36] Interestingly, subsequent studies suggest that the relative risk for cancer among patients with ocular or oral MMP and autoantibodies versus integrin subunit β_4 or integrin subunit α_6, respectively, may be reduced.[37,38]

COMPLICATIONS

Site-specific complications of MMP were outlined earlier and are summarized in Table 55-1.

ETIOLOGY AND PATHOGENESIS

RISK FACTORS FOR DISEASE

Risk factors for disease include advanced age, female gender, and possession of the *HLADQB1*0301* allele.[1,5,16,39] In rare cases, disease may be provoked by prescription drugs, trauma (eg, eye surgery), or hypersensitivity reactions.

Autoantibodies directed against autoantigens in epidermal basement membrane are held responsible

TABLE 55-1
Potential Complications of Mucous Membrane Pemphigoid

SITE	POTENTIAL COMPLICATIONS
Mouth	
Mucosa	Painful, erosive scarring lesions; adhesions between the buccal mucosa and the alveolar process, the uvula and the tonsillar fossae, and the tongue and the floor of the mouth
Gingiva	Painful, erosive scarring lesions; loss of gingival tissue; caries; periodontal ligament damage; loss of alveolar bone; loss of teeth
Eyes	
Conjunctivae	Painful, erosive conjunctivitis; foreign-body sensations; photophobia; scarring; shortened fornices; loss of goblet cells; decrease in tear mucus content and unstable tear films; symblepharons; ankyloblepharons
Eyelids	Ectropion; trichiasis; ankyloblepharons
Cornea	Corneal irritation; superficial punctate keratopathy; corneal neovascularization; corneal ulcers, blindness
Tear ducts	Scarring; occlusion; secondary infection
Nose	Discharge; epistaxis; excessive crust formation; impaired airflow; recurrent and chronic sinusitis; scarring and tissue loss
Larynx	Hoarseness; impaired phonation; loss of voice; scarring, supraglottic stenosis, airway compromise and loss
Esophagus	Dysphagia, odynophagia, impaired swallowing; stricture formation; weight loss; aspiration
Anogenital region	Painful erosions; stenosis and strictures; secondary infections

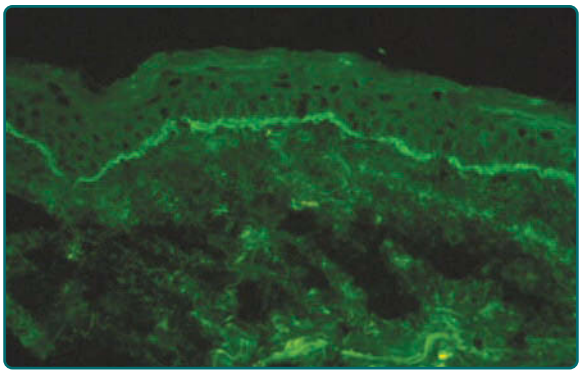

Figure 55-6 Direct immunofluorescence microscopy of normal-appearing perilesional skin from a patient with mucous membrane pemphigoid shows continuous linear deposits of C3 in the epidermal basement membrane.

for the pathogenesis of MMP (Fig. 55-6).[1,5,16,39] Because different autoantigens are recognized by circulating autoantibodies from different patients with MMP, this disorder is considered a disease phenotype rather than a single nosologic entity. Table 55-2 summarizes the autoantigens recognized by autoantibodies from patients with MMP. Even though autoantibodies directed against some of these autoantigens are pathogenic in vivo (Table 55-2), it is conceivable that other mechanisms may contribute to disease pathogenesis. As scarring is a major pathologic manifestation of MMP, profibrotic processes have been studied in biopsy samples and cultured fibroblasts from lesional tissue. Examples of profibrotic factors that have been identified in such studies include serpin h1; transforming growth factor beta; interleukins 4, 5, and 13; and connective tissue growth factor.[40,41] What accounts for the loss of immunologic tolerance to skin in patients with MMP is unknown.

TABLE 55-2
Major Mucous Membrane Pemphigoid Autoantigens

AUTOANTIGEN	MW (KDA)	LOCATION SSS/ULTRA	PASSIVE TRANSFER STUDIES
BP230	230	Epid/HD	
BP180	180	Epid/HD-af	IgG vs. the NC16A domain of BP180 creates subepidermal blisters in newborn mice that resemble those seen in patients with BP[94,95]
Integrin β_4	~205	Epid/HD-af	
Integrin α_6	~120	Epid/HD-af	
Laminin 332	400–440	Derm/LL-LD interface	Experimental IgG (intact IgG and Fab fragments alone) vs. laminin 332 create subepidermal blisters in newborn and adult mice that resemble those seen in patients with AECP[96]
			Patient IgG creates subepidermal blisters in human skin grafts on immunodeficient adult mice that resemble those seen in patients with AECP[97]
Type VII collagen	290	Derm/AF	Experimental and patient IgG vs. the NC1 domain of type VII collagen create subepidermal blisters in adult mice that resemble those seen in patients with EBA[98-100]

AECP, antiepiligrin cicatricial pemphigoid; AF, anchoring fibril; BP, bullous pemphigoid; BP230, bullous pemphigoid antigen 1; BP180, bullous pemphigoid antigen 2; Derm, dermal; EBA, epidermolysis bullosa acquisita; Epid, epidermal; HD, hemidesmosome; HD-af, hemidesmosome–anchoring filament complexes; IgG, immunoglobulin G; LL-LD interface, lamina lucida–lamina densa interface; Location SSS/Ultra, localization in 1 M NaCl–split-skin/ultrastructural localization in epidermal basement membrane; MW (kDa), molecular weight in kilodaltons.

BP180 appears to represent a major MMP autoantigen[16,42-44]; other autoantigens of particular interest include laminin 332, integrin subunit β_4, integrin subunit α_6, type VII collagen, and BP230.[16] Most patients with MMP have IgG anti–basement membrane autoantibodies; some patients have IgA anti–basement membrane autoantibodies alone or in conjunction with IgG anti–basement membrane autoantibodies. The most common IgA autoantigen linked to the MMP phenotype is BP180.[45-47]

DIAGNOSIS

LIGHT MICROSCOPY

Although the findings of light microscopy studies of lesional skin or mucosa from patients with MMP are often nonspecific, they characteristically show a subepidermal blister and a dermal leukocytic infiltrate composed of lymphocytes and histiocytes as well as variable numbers of neutrophils and eosinophils.[1,20,48,49] Plasma cells can be seen in mucosal lesions, whereas eosinophils and neutrophils are more commonly seen in skin lesions. Biopsy specimens of older lesions may be relatively "cell poor" and show features that correlate with the noninflammatory character of such sites clinically. Light microscopy studies of older lesions often show fibroblast proliferation and lamellar fibrosis (ie, fibrosis characterized by collagen bundles ordered parallel to the surface epithelium). It is not always possible (or in the case of ocular disease, appropriate) to biopsy blistered mucosa for light microscopy studies.

ELECTRON MICROSCOPY

Ultrastructural studies of lesional skin or mucosa from patients with MMP show that blisters typically develop within the lamina lucida and eventuate in partial or complete destruction of the basal lamina in older lesions.[48-52] A generally held idea is that blisters form below those of bullous pemphigoid, because scarring is more common in patients with this disease. Reports of patients with blisters in the sublamina densa region are thought to represent mucosa-predominant forms of epidermolysis bullosa acquisita.

IMMUNOFLUORESCENCE MICROSCOPY

Direct immunofluorescence microscopy of normal-appearing perilesional tissue from patients with MMP shows continuous deposits of immunoreactants in epithelial basement membranes.[1,3,5,16,52] The most commonly detected immunoreactants are IgG and C3 (see Fig. 55-6); the predominant subclass of these autoantibodies is IgG_4.[53] In situ deposits of IgA, IgM, and/or fibrin are found in some patients.[54] Multiple biopsies may be required to demonstrate in situ deposits of immunoreactants in some patients. One study comparing direct immunofluorescence microscopy findings on skin and mucosal samples from 10 patients found immunoreactants more commonly in perilesional mucosal biopsy specimens, suggesting that mucous membranes are the preferred biopsy site for direct immunofluorescence microscopy studies in these patients.[52] Subsequent studies showed that splitting tissue samples with 1 M NaCl increases the sensitivity of direct immunofluorescence microscopy and facilitates identification of immunoreactants as well as their relative distribution within epithelial basement membranes.[55,56]

Indirect immunofluorescence microscopy studies using intact skin or mucosa often find low-titer IgG (and/or IgA) anti–basement membrane autoantibodies in the blood of patients with MMP.[1,5,16,52,57] The use of 1 M NaCl split-skin as a test substrate in these studies substantially increases the detection of such autoantibodies.[58-61] In such studies, IgG (and/or IgA) binding is usually directed against the epidermal side of 1 M NaCl split-skin, although combined epidermal and dermal or exclusively dermal binding can occur. In fact, this heterogeneity in autoantibody binding patterns was one of the first clues that MMP is a disease phenotype that is associated with different autoantigens (see Table 55-2). Although some studies suggest that the use of human mucosal tissue substrates increases the likelihood of detecting autoantibodies in patients with MMP by indirect immunofluorescence microscopy, other studies have not obtained such results.[4,52] Patients with both IgG and IgA anti–basement membrane autoantibodies appear to have a worse prognosis as defined by requirements for medications to control disease as well as overall clinical severity score.[45,47]

OTHER IMMUNOPATHOLOGY STUDIES

Selected cases may require specialized immunochemical studies (eg, immunoblot studies of keratinocyte or skin extracts, immunoprecipitation studies of biosynthetically radiolabeled keratinocytes) to identify the autoantigen targeted by circulating anti–basement membrane autoantibodies from patients with MMP. Perilesional tissue from seronegative patients may be further characterized by immunoelectron microscopy to determine if in situ deposits of immunoreactants reside above or below the lamina densa of epidermal basement membrane.

DIAGNOSTIC ALGORITHM

The diagnosis of MMP should be based on alignment of all clinical, histopathologic, and/or immunopathologic findings.

DIFFERENTIAL DIAGNOSIS

The diagnosis of MMP is suggested when patients present with erosive lesions of mucous membranes, subepidermal bullae, and continuous deposits of immunoreactants in epithelial basement membranes of perilesional tissue. Participants in a 2002 international consensus conference concluded that clinical features and direct immunofluorescence microscopy features are essential findings that should be demonstrated before the diagnosis of MMP is assigned.[1] Distinguishing MMP from other autoimmune bullous diseases can be difficult and may require specialized immunopathologic studies. The differential diagnosis of MMP includes other immunobullous diseases (eg, pemphigus vulgaris, paraneoplastic pemphigus, bullous pemphigoid, linear IgA dermatosis, epidermolysis bullosa acquisita), erythema multiforme, Stevens-Johnson syndrome, toxic epidermal necrolysis, drug reactions (ie, hypersensitivity reactions or chemotherapy-induced mucositis), lichen planus, and lupus erythematosus (Table 55-3). In respect to early disease in the mouth, MMP may resemble pemphigus vulgaris, paraneoplastic pemphigus, erosive lichen planus, erythema multiforme, Stevens-Johnson syndrome, or early toxic epidermal necrolysis; in respect to early disease in the genital region, MMP may resemble pemphigus vulgaris, bullous pemphigoid, erosive lichen planus, or lichen sclerosus. In the case of ocular disease, cicatrizing or inflammatory conjunctivitis resembling MMP can result from long-term use of certain ophthalmologic preparations (eg, pilocarpine, guanethidine, or ephedrine used in the treatment of glaucoma or idoxuridine used as an antiviral) or exposure to selected biologics (eg, epidermal growth factor receptor tyrosine kinase inhibitors).[5,18,39] It has also been demonstrated that some cases of ocular MMP can develop after severe ocular inflammatory injury caused by Stevens-Johnson syndrome or toxic epidermal necrolysis.[5,62] Interestingly, the time between the development of Stevens-Johnson syndrome and the onset of ocular MMP in these patients ranges from a few months to more than 30 years. Finally, rare patients with cicatrizing conjunctivitis who lack in situ deposits of immunoreactants in conjunctival or epidermal basement membranes are sometimes encountered. Although immunopathology studies in such patients are negative, because their disease is inflammatory and sight-threatening, they are often treated with immunosuppressive agents as if they have MMP.

TABLE 55-3
Differential Diagnosis of Mucous Membrane Pemphigoid

Most Likely

- Pemphigus
  - Pemphigus vulgaris
  - Paraneoplastic pemphigus
- Other subepidermal immunobullous diseases
  - Epidermolysis bullosa acquisita
  - Bullous pemphigoid
  - Linear immunoglobulin A dermatosis
- Erythema multiforme
- Lupus erythematosus
- Lichen planus

Consider

- Drug-induced hypersensitivity reactions
- Lichen sclerosus (especially in the anogenital area)

Always Rule Out

- Pemphigus (specifically, pemphigus vulgaris, paraneoplastic pemphigus)
- Other subepidermal immunobullous diseases
- Erythema multiforme
- Lupus erythematosus
- Lichen planus

CLINICAL COURSE AND PROGNOSIS

MMP is typically a chronic disease. Involvement may be limited to a given anatomic site (eg, the mouth, the eyes) for years; some cases show progressive involvement of other mucosae. Even localized involvement can have a major negative impact on quality of life. In many ways, sites of involvement significantly influence the prognosis of MMP. Uncontrolled or aggressive disease in the eyes, hypopharynx, esophagus, or genital regions can compromise vision, respiration, swallowing, and genitourinary function. MMP rarely goes into spontaneous remission; its treatment is largely determined by its severity and sites of involvement. Scarring can only be prevented in these patients; it cannot be reversed. As noted above, some reports have suggested that patients with high titers and/or dual isotypes of anti–basement membrane autoantibodies (ie, both IgG and IgA anti–basement membrane autoantibodies) tend to have more severe and/or persistent disease.

MANAGEMENT

The primary goal of treatment of MMP is to halt progression of disease and prevent tissue inflammation, destruction, and scarring. Treatment of MMP is largely determined by its site(s) of involvement, its relative severity, and its rate of progression. Treatment regimens are largely derived from clinical experience rather than clinical trials; virtually all treatment interventions are "off-label."[63-65] All patients with MMP require long-term followup because of the possibility for this chronic disease to relapse.

LOCAL CARE MEASURES

Table 55-4 summarizes the treatment options for MMP. Mild lesions of the oral mucosa and skin can often be treated effectively with moderate- to high-potency topical glucocorticoids (or calcineurin inhibitors such as tacrolimus) in a gel or ointment base applied 2 to 4 times each day.[64-67] Blotting lesional sites dry with a soft disposable tissue can enhance the adherence and effectiveness of topical agents applied to lesional sites in the mouth. These agents are particularly effective before bed, because oral secretions tend to diminish during sleep. These agents are easily applied, can be used widely on mucosal surfaces, and lack the grittiness encountered with agents formulated in dental pastes. Because it is difficult to maintain contact of topical corticosteroids with mucous membranes (and because lesions often are localized to the gingiva), customized delivery trays to occlude topical glucocorticoids over lesional sites in the mouth are also useful.[64,65,68,69] Such delivery trays should be fashioned in soft vinyl and fitted to cover the patient's gingiva (ie, not the patient's teeth). Topical agents can be applied under occlusion in such trays for 10 to 20 minutes 1 to 4 times daily for 1 to 2 weeks then tapered (or interrupted for a break in therapy). Patients with intraoral involvement should follow a strict regimen of oral hygiene that includes brushing of the teeth 2 to 3 times each day along with daily flossing and regular dental cleanings 2 to 3 times each year. These interventions are essential to avert the accumulation of plaque, the loss of gingiva, and acceleration of tooth decay. Use of a pediatric toothbrush with soft bristles, toothpaste that lacks sodium lauryl sulfate, and mouthwashes free of alcohol facilitate patient compliance with oral hygiene measures. Some sources recommend use of topical anesthetics for painful intraoral lesions in patients with MMP. Such agents should be applied carefully and locally (ie, not as a "rinse") before meals, brushing teeth, dental procedures, or other occasions when pain control is required. Care should be taken to avoid introduction of topical anesthetics into pharyngeal, hypopharyngeal, or laryngeal areas to diminish the likelihood of aspiration. Medicated mouthwashes (eg, dexamethasone 100 mcg/mL, 5 mL per rinse) used in a "swish-and-spit" regimen for 5 minutes 2 to 3 times each day represents another approach for topical therapy. For oral disease resistant to topical glucocorticoids, these agents can (in some instances) be administered intralesionally. Comanagement of such patients with a dentist familiar with MMP is key.

Because of potentially severe complications, ocular, laryngeal, esophageal, and/or anogenital involvement requires aggressive management by teams of physicians familiar with specialized care of these organ systems.[1,5,16,64,65] Early and regular evaluation by an ophthalmologist experienced in the management of patients with MMP is also important. Local eye care measures include prompt identification of ocular inflammation and management of eyelid hygiene, ocular lubrication, and secondary ocular infections (infections are more common in patients undergoing treatment with immunosuppressive drugs than in other patients). Patients whose ocular disease is complicated by trichiasis (ie, misdirected eyelashes that grow inward toward the eye and damage the cornea, conjunctivae, or under surface of the eyelid) may benefit from epilation, although this decision is best made by an ophthalmologist. Patients with

TABLE 55-4
Treatments for Mucous Membrane Pemphigoid

Mild Involvement	
SITES	**LOCAL CARE MEASURES**
Mouth	Topical corticosteroid (gels or ointments) twice daily/4 times daily; topical corticosteroids under occlusion (eg, dental trays); topical calcineurin inhibitors; intralesional corticosteroids
Nose	Irrigation with isotonic saline twice daily/thrice daily; nasal lubricants; topical corticosteroids (eg, via sprays, inhalers)
Anogenital region	Topical corticosteroids; topical calcineurin inhibitors
Skin	Topical corticosteroids; topical calcineurin inhibitors
Moderate Involvement	
SITES	**THERAPEUTIC OPTIONS**
Mouth, eyes, nose, larynx, esophagus, anogenital region	Local care measures outlined above plus dapsone 50-200 mg daily, prednisone 20-60 mg each morning, or both of these agents simultaneously
Severe Involvement	
SITES	**THERAPEUTIC OPTIONS**
Mouth, eyes, nose, larynx, esophagus, anogenital region	Local care measures outlined above plus prednisone (1 mg/kg each morning), intravenous immunoglobulin (2 g/kg body weight over 2-3 days every 2-6 weeks for 4-6 months), or both of these agents simultaneously in conjunction with azathioprine (2-2.5 mg/kg/day), mycophenolate mofetil (1-2.5 g/day), cyclophosphamide (1-2 mg/kg/day), or rituximab (375 mg/m^2 weekly × 4 then every 4-6 months as needed, or 1000 mg on days 1 and 15 and then 500 mg at month 6)

nasal involvement benefit from irrigations, humidified environments, emollients, and topical corticosteroids (sprays or drops). Twice daily irrigation of nasal passages with saline or tap water delivered via bulb syringe, piston syringe, or other nasal irrigation devices removes crusts over mucosal erosions and diminishes the likelihood of secondary complications such as infection and/or bleeding. Irrigations also increase the relative efficacy of topical corticosteroids delivered to nasal passages by spray or drops. Use of intranasal emollients after irrigation of nasal passages limits reaccumulation of crusts. Esophageal involvement requires early diagnosis and aggressive medical management to avert esophageal dysfunction, gastroesophageal reflux, stricture formation, aspiration, laryngeal irritation, and/or bronchospastic pulmonary disease. Soft diets, agents to diminish gastroesophageal reflux and/or gastric acidity, and/or esophageal dilation may be required. Urologists and colorectal surgeons provide important care for the rare patients who develop anogenital lesions. Such patients may require local topical therapy, dilations, stool softeners, and/or evaluation of adjacent internal mucosal surfaces.

SYSTEMIC THERAPIES

For patients with disease resistant to local therapy or of greater severity, treatment with systemic agents in combination with local care measures is indicated. A number of reports suggest that dapsone (50 to 200 mg by mouth daily) may be effective.[70-73] Others have found that patients with MMP do not respond to this agent. Other systemic agents reported to be of benefit in patients with mild disease include sulfapyridine, minocycline, or a combination of tetracycline and niacinamide. For mild or moderate ocular involvement, systemic glucocorticoids (eg, 20 to 60 mg of prednisone by mouth each morning) alone or in conjunction with daily dapsone may be effective. For nonresponsive or severe disease affecting the ocular, pharyngeal, or urogenital epithelia, a combination of systemic glucocorticoids and an additional immunosuppressive is indicated.[74-79] In such cases, azathioprine (2.0 to 2.5 mg/kg/day), mycophenolate mofetil (1.0 to 2.5 g/day), or cyclophosphamide (1 to 2 mg/kg/day) are often used in conjunction with daily prednisone (1 mg/kg/day). In this regimen, daily prednisone is tapered gradually over approximately 6 months, and the patient is maintained on the alternate agent alone for an additional 6 to 12 months before further reductions in therapy are pursued. Such combined regimens have had success in halting the progression of severe disease, limiting scarring, and producing long-term remissions. In an effort to avoid adverse effects and complications produced by prolonged treatment with immunosuppressive agents, some groups treat patients with intravenous Ig (ie, intravenous Ig 2 g/kg of body weight administered over 2 to 3 days every 2 to 6 weeks for 4 to 6 months).[80-85] Biologic agents that antagonize tumor necrosis factor-α (eg, etanercept, infliximab) have shown efficacy in selected patients with MMP.[86] Increasing numbers of patients with MMP are being treated with daily corticosteroids (alone or in combination with the other immunosuppressive agents listed above) plus rituximab (1000 mg on days 1 and 15, 500 mg at month 6; or 375 mg/m^2 weekly × 4 then every 4-6 months as needed).[87-93]

When MMP is stabilized, treatment should be tapered slowly (eg, over 6 to 12 months). Flares of disease justify reinstitution of systemic therapies. Some patients require long-term maintenance therapy. In selected cases, immunopathology studies (eg, indirect immunofluorescence microscopy studies of 1 M NaCl split-skin, autoantibody-specific enzyme-linked immunosorbent assays) can be used to determine if seropositive patients convert to a seronegative status following treatment—a laboratory observation that may identify patients who are better candidates for a reduction (or cessation) of therapy.

REFERENCES

1. Chan LS, Ahmed AR, Anhalt GJ, et al. The first international consensus on mucous membrane pemphigoid: definition, diagnostic criteria, pathogenic factors, medical treatment, and prognostic indicators. *Arch Dermatol*. 2002;138(3):370.
2. Yancey KB, Egan CA. Pemphigoid: clinical, histologic, immunopathologic, and therapeutic considerations. *JAMA*. 2000;284(3):350.
3. Bean SF, Waisman M, Michel B, et al. Cicatricial pemphigoid. Immunofluorescent studies. *Arch Dermatol*. 1972;106(2):195.
4. Lever WF. *Pemphigus and Pemphigoid*. Springfield, IL: Charles C Thomas; 1965.
5. Bernard P, Borradori L. Pemphigoid group. In: Bolognia J, Jorizzo J, Schaffer J, eds. *Dermatology*. 3rd ed. Oxford, UK: Elsevier; 2012:475-490.
6. Thost A. Der chronische Schleimhautpemphigus der oberen Luftwege. *Arch Laryng Rhinol*. 1911;25:459.
7. Murrell DF, Marinovic B, Caux F, et al. Definitions and outcome measures for mucous membrane pemphigoid: recommendations of an international panel of experts. *J Am Acad Dermatol*. 2015;72(1):168.
8. Bernard P, Vaillant L, Labeille B, et al. Incidence and distribution of subepidermal autoimmune bullous skin diseases in three French regions. Bullous Diseases French Study Group. *Arch Dermatol*. 1995;131(1):48.
9. Zillikens D, Wever S, Roth A, et al. Incidence of autoimmune subepidermal blistering dermatoses in a region of central Germany. *Arch Dermatol*. 1995;131(8):957.
10. Laskaris G, Sklavounou A, Stratigos J. Bullous pemphigoid, cicatricial pemphigoid, and pemphigus vulgaris. A comparative clinical survey of 278 cases. *Oral Surg Oral Med Oral Pathol*. 1982;54(6):656.
11. Ahmed AR, Foster S, Zaltas M, et al. Association of DQw7 (DQB1*0301) with ocular cicatricial pemphigoid. *Proc Natl Acad Sci U S A*. 1991;88(24):11579.
12. Yunis JJ, Mobini N, Yunis EJ, et al. Common major histocompatibility complex class II markers in clinical variants of cicatricial pemphigoid. *Proc Natl Acad Sci U S A*. 1994;91(16):7747.
13. Delgado JC, Turbay D, Yunis EJ, et al. A common major histocompatibility complex class II allele

HLA-DQB1*0301 is present in clinical variants of pemphigoid. *Proc Natl Acad Sci U S A*. 1996;93(16):8569.
14. Chan LS, Hammerberg C, Cooper KD. Significantly increased occurrence of HLA-DQB1*0301 allele in patients with ocular cicatricial pemphigoid. *J Invest Dermatol*. 1997;108(2):129.
15. Setterfield J, Theron J, Vaughan RW, et al. Mucous membrane pemphigoid: HLA-DQB1*0301 is associated with all clinical sites of involvement and may be linked to antibasement membrane IgG production. *Br J Dermatol*. 2001;145(3):406.
16. Schmidt E, Zillikens D. Pemphigoid diseases. *Lancet*. 2013;381(9863):320.
17. Foster CS. Cicatricial pemphigoid. *Trans Am Ophthalmol Soc*. 1986;84:527.
18. Thorne JE, Anhalt GJ, Jabs DA. Mucous membrane pemphigoid and pseudopemphigoid. *Ophthalmology*. 2004;111(1):45.
19. Brunsting LA, Perry HO. Benign pemphigoid; a report of seven cases with chronic, scarring, herpetiform plaques about the head and neck. *AMA Arch Derm*. 1957;75(4):489.
20. Fleming TE, Korman NJ. Cicatricial pemphigoid. *J Am Acad Dermatol*. 2000;43(4):571.
21. Kurzhals G, Stolz W, Meurer M, et al. Acquired epidermolysis bullosa with the clinical feature of Brunsting-Perry cicatricial bullous pemphigoid. *Arch Dermatol*. 1991;127(3):391.
22. Joly P, Ruto F, Thomine E, et al. Brunsting-Perry cicatricial bullous pemphigoid: a clinical variant of localized acquired epidermolysis bullosa? *J Am Acad Dermatol*. 1993;28(1):89.
23. Daito J, Katoh N, Asai J, et al. Brunsting-Perry cicatricial pemphigoid associated with autoantibodies to the C-terminal domain of BP180. *Br J Dermatol*. 2008;159(4):984.
24. Jedlickova H, Niedermeier A, Zgazarova S, et al. Brunsting-Perry pemphigoid of the scalp with antibodies against laminin 332. *Dermatology*. 2011;222(3):193.
25. Fukuda S, Tsuruta D, Uchiyama M, et al. Brunsting-Perry type pemphigoid with IgG autoantibodies to laminin-332, BP230 and desmoplakins I/II. *Br J Dermatol*. 2011;165(2):433.
26. Egan CA, Lazarova Z, Darling TN, et al. Anti-epiligrin cicatricial pemphigoid and relative risk for cancer. *Lancet*. 2001;357(9271):1850.
27. Egan CA, Lazarova Z, Darling TN, et al. Anti-epiligrin cicatricial pemphigoid: clinical findings, immunopathogenesis, and significant associations. *Medicine (Baltimore)*. 2003;82(3):177.
28. Matsushima S, Horiguchi Y, Honda T, et al. A case of anti-epiligrin cicatricial pemphigoid associated with lung carcinoma and severe laryngeal stenosis: review of Japanese cases and evaluation of risk for internal malignancy. *J Dermatol*. 2004;31(1):10.
29. Chamberlain AJ, Cooper SM, Allen J, et al. Paraneoplastic immunobullous disease with an epidermolysis bullosa acquisita phenotype: two cases demonstrating remission with treatment of gynaecological malignancy. *Australas J Dermatol*. 2004;45(2):136.
30. Shannon JF, Mackenzie-Wood A, Wood G, et al. Cicatricial pemphigoid in non-Hodgkin's lymphoma. *Intern Med J*. 2003;33(8):396.
31. Parisi E, Raghavendra S, Werth VP, et al. Modification to the approach of the diagnosis of mucous membrane pemphigoid: A case report and literature review. *Oral Surg Oral Med Oral Pathol Oral Radiol Endod*. 2003;95(2):182.
32. Sadler E, Lazarova Z, Sarasombath P, et al. A widening perspective regarding the relationship between anti-epiligrin cicatricial pemphigoid and cancer. *J Dermatol Sci*. 2007;47(1):1.
33. Fukushima S, Egawa K, Nishi H, et al. Two cases of anti-epiligrin cicatricial pemphigoid with and without associated malignancy. *Acta Derm Venereol*. 2008;88(5):484.
34. Mitsuya J, Hara H, Ito K, et al. Metastatic ovarian carcinoma-associated subepidermal blistering disease with autoantibodies to both the p200 dermal antigen and the gamma 2 subunit of laminin 5 showing unusual clinical features. *Br J Dermatol*. 2008;158(6):1354.
35. Demitsu T, Yoneda K, Iida E, et al. A case of mucous membrane pemphigoid with IgG antibodies against all the alpha3, beta3 and gamma2 subunits of laminin-332 and BP180 C-terminal domain, associated with pancreatic cancer. *Clin Exp Dermatol*. 2009;34(8):e992.
36. Takahara M, Tsuji G, Ishii N, et al. Mucous membrane pemphigoid with antibodies to the beta(3) subunit of Laminin 332 in a patient with acute myeloblastic leukemia and graft-versus-host disease. *Dermatology*. 2009;219(4):361.
37. Malik M, Gurcan HM, Christen W, et al. Relationship between cancer and oral pemphigoid patients with antibodies to alpha6-integrin. *J Oral Pathol Med*. 2007;36(1):1.
38. Letko E, Gurcan HM, Papaliodis GN, et al. Relative risk for cancer in mucous membrane pemphigoid associated with antibodies to the beta4 integrin subunit. *Clin Exp Dermatol*. 2007;32(6):637.
39. Xu HH, Werth VP, Parisi E, et al. Mucous membrane pemphigoid. *Dent Clin North Am*. 2013;57(4):611.
40. Foster CS, Sainz De La Maza M. Ocular cicatricial pemphigoid review. *Curr Opin Allergy Clin Immunol*. 2004;4(5):435.
41. Saw VP, Offiah I, Dart RJ, et al. Conjunctival interleukin-13 expression in mucous membrane pemphigoid and functional effects of interleukin-13 on conjunctival fibroblasts in vitro. *Am J Pathol*. 2009;175(6):2406.
42. Bernard P, Prost C, Durepaire N, et al. The major cicatricial pemphigoid antigen is a 180-kD protein that shows immunologic cross-reactivities with the bullous pemphigoid antigen. *J Invest Dermatol*. 1992;99(2):174.
43. Balding SD, Prost C, Diaz LA, et al. Cicatricial pemphigoid autoantibodies react with multiple sites on the BP180 extracellular domain. *J Invest Dermatol*. 1996;106(1):141.
44. Bedane C, McMillan JR, Balding SD, et al. Bullous pemphigoid and cicatricial pemphigoid autoantibodies react with ultrastructurally separable epitopes on the BP180 ectodomain: evidence that BP180 spans the lamina lucida. *J Invest Dermatol*. 1997;108(6):901.
45. Setterfield J, Shirlaw PJ, Bhogal BS, et al. Cicatricial pemphigoid: serial titres of circulating IgG and IgA antibasement membrane antibodies correlate with disease activity. *Br J Dermatol*. 1999;140(4):645.
46. Egan CA, Taylor TB, Meyer LJ, et al. The immunoglobulin A antibody response in clinical subsets of mucous membrane pemphigoid. *Dermatology*. 1999;198(4):330.
47. Setterfield J, Shirlaw PJ, Kerr-Muir M, et al. Mucous membrane pemphigoid: a dual circulating antibody response with IgG and IgA signifies a more severe and persistent disease. *Br J Dermatol*. 1998;138(4):602.

48. Mutasim DF, Pelc NJ, Anhalt GJ. Cicatricial pemphigoid. *Dermatol Clin*. 1993;11(3):499.
49. Rose C, Schmidt E, Kerstan A, et al. Histopathology of anti-laminin 5 mucous membrane pemphigoid. *J Am Acad Dermatol*. 2009;61(3):433.
50. Bernard P, Prost C, Lecerf V, et al. Studies of cicatricial pemphigoid autoantibodies using direct immunoelectron microscopy and immunoblot analysis. *J Invest Dermatol*. 1990;94(5):630.
51. Meyer JR, Migliorati CA, Daniels TE, et al. Localization of basement membrane components in mucous membrane pemphigoid. *J Invest Dermatol*. 1985; 84(2):105.
52. Fine JD, Neises GR, Katz SI. Immunofluorescence and immunoelectron microscopic studies in cicatricial pemphigoid. *J Invest Dermatol*. 1984;82(1):39.
53. Hsu R, Lazarova Z, Yee C, et al. Noncomplement fixing, IgG4 autoantibodies predominate in patients with anti-epiligrin cicatricial pemphigoid. *J Invest Dermatol*. 1997;109(4):557.
54. Leonard JN, Wright P, Williams DM, et al. The relationship between linear IgA disease and benign mucous membrane pemphigoid. *Br J Dermatol*. 1984;110(3):307.
55. Gammon WR, Kowalewski C, Chorzelski TP, et al. Direct immunofluorescence studies of sodium chloride-separated skin in the differential diagnosis of bullous pemphigoid and epidermolysis bullosa acquisita. *J Am Acad Dermatol*. 1990;22(4):664.
56. Domloge-Hultsch N, Bisalbutra P, Gammon WR, et al. Direct immunofluorescence microscopy of 1 mol/L sodium chloride-treated patient skin. *J Am Acad Dermatol*. 1991;24:946.
57. Oyama N, Setterfield JF, Powell AM, et al. Bullous pemphigoid antigen II (BP180) and its soluble extracellular domains are major autoantigens in mucous membrane pemphigoid: the pathogenic relevance to HLA class II alleles and disease severity. *Br J Dermatol*. 2006;154(1):90.
58. Domloge-Hultsch N, Anhalt GJ, Gammon WR, et al. Antiepiligrin cicatricial pemphigoid. A subepithelial bullous disorder. *Arch Dermatol*. 1994;130(12):1521.
59. Lazarova Z, Yancey KB. Reactivity of autoantibodies from patients with defined subepidermal bullous diseases against 1 mol/L salt-split skin. Specificity, sensitivity, and practical considerations. *J Am Acad Dermatol*. 1996;35(3, pt 1):398.
60. Kelly SE, Wojnarowska F. The use of chemically split tissue in the detection of circulating anti-basement membrane zone antibodies in bullous pemphigoid and cicatricial pemphigoid. *Br J Dermatol*. 1988;118(1):31.
61. Lazarova Z, Sitaru C, Zillikens D, et al. Comparative analysis of methods for detection of anti-laminin 5 autoantibodies in patients with anti-epiligrin cicatricial pemphigoid. *J Am Acad Dermatol*. 2004;51(6):886.
62. Chan LS, Soong HK, Foster CS, et al. Ocular cicatricial pemphigoid occurring as a sequela of Stevens-Johnson syndrome. *JAMA*. 1991;266(11):1543.
63. Kirtschig G, Murrell D, Wojnarowska F, et al. Interventions for mucous membrane pemphigoid/cicatricial pemphigoid and epidermolysis bullosa acquisita: a systematic literature review. *Arch Dermatol*. 2002; 138(3):380.
64. Kourosh AS, Yancey KB. Therapeutic approaches to patients with mucous membrane pemphigoid. *Dermatol Clin*. 2011;29(4):637.
65. Yancey KB. Management of mucous membrane pemphigoid. *UpToDate*. 2016. https://www.uptodate.com/contents/management-of-mucous-membrane-pemphigoid?search=Yancey%20KB.%20Management%20of%20mucous%20membrane%20pemphigoid&source=search_result&selectedTitle=1~150&usage_type=default&display_rank=1
66. Assmann T, Becker J, Ruzicka T, et al. Topical tacrolimus for oral cicatricial pemphigoid. *Clin Exp Dermatol*. 2004;29(6):674.
67. Lee HY, Blazek C, Beltraminelli H, et al. Oral mucous membrane pemphigoid: complete response to topical tacrolimus. *Acta Derm Venereol*. 2011;91(5):604.
68. Lee MS, Wakefield PE, Konzelman JL Jr, et al. Oral insertable prosthetic device as an aid in treating oral ulcers. *Arch Dermatol*. 1991;127(4):479.
69. Gonzalez-Moles MA, Ruiz-Avila I, Rodriguez-Archilla A, et al. Treatment of severe erosive gingival lesions by topical application of clobetasol propionate in custom trays. *Oral Surg Oral Med Oral Pathol Oral Radiol Endod*. 2003;95(6):688.
70. Rogers RS 3rd, Seehafer JR, Perry HO. Treatment of cicatricial (benign mucous membrane) pemphigoid with dapsone. *J Am Acad Dermatol*. 1982;6(2):215.
71. Ciarrocca KN, Greenberg MS. A retrospective study of the management of oral mucous membrane pemphigoid with dapsone. *Oral Surg Oral Med Oral Pathol Oral Radiol Endod*. 1999;88(2):159.
72. Arash A, Shirin L. The management of oral mucous membrane pemphigoid with dapsone and topical corticosteroid. *J Oral Pathol Med*. 2008;37(6):341.
73. Hegarty AM, Ormond M, Sweeney M, et al. Dapsone efficacy and adverse events in the management of mucous membrane pemphigoid. *Eur J Dermatol*. 2010;20(2):223.
74. Korman NJ. Update on the use of azathioprine in the management of pemphigus and bullous pemphigoid. *Med Surg Dermatol*. 1996;3:209.
75. Korman NJ. Update on the use of cyclophosphamide in the management of pemphigus, bullous pemphigoid, and cicatricial pemphigoid. *Med Surg Dermatol*. 1998;5.
76. Megahed M, Schmiedeberg S, Becker J, et al. Treatment of cicatricial pemphigoid with mycophenolate mofetil as a steroid-sparing agent. *J Am Acad Dermatol*. 2001;45(2):256.
77. Saw VP, Dart JK, Rauz S, et al. Immunosuppressive therapy for ocular mucous membrane pemphigoid strategies and outcomes. *Ophthalmology*. 2008;115(2):253.
78. Doycheva D, Deuter C, Blumenstock G, et al. Long-term results of therapy with mycophenolate mofetil in ocular mucous membrane pemphigoid. *Ocul Immunol Inflamm*. 2011;19(6):431.
79. Staines K, Hampton PJ. Treatment of mucous membrane pemphigoid with the combination of mycophenolate mofetil, dapsone, and prednisolone: a case series. *Oral Surg Oral Med Oral Pathol Oral Radiol*. 2012;114(1):e49.
80. Ahmed AR, Dahl MV. Consensus statement on the use of intravenous immunoglobulin therapy in the treatment of autoimmune mucocutaneous blistering diseases. *Arch Dermatol*. 2003;139(8):1051.
81. Foster CS, Ahmed AR. Intravenous immunoglobulin therapy for ocular cicatricial pemphigoid: a preliminary study. *Ophthalmology*. 1999;106(11):2136.
82. Sami N, Letko E, Androudi S, et al. Intravenous immunoglobulin therapy in patients with ocular-cicatricial pemphigoid: a long-term follow-up. *Ophthalmology*. 2004;111(7):1380.

83. Wetter DA, Davis MD, Yiannias JA, et al. Effectiveness of intravenous immunoglobulin therapy for skin disease other than toxic epidermal necrolysis: a retrospective review of Mayo Clinic experience. *Mayo Clin Proc*. 2005;80(1):41.
84. Letko E, Miserocchi E, Daoud YJ, et al. A nonrandomized comparison of the clinical outcome of ocular involvement in patients with mucous membrane (cicatricial) pemphigoid between conventional immunosuppressive and intravenous immunoglobulin therapies. *Clin Immunol*. 2004;111(3):303.
85. Ahmed AR, Colon JE. Comparison between intravenous immunoglobulin and conventional immunosuppressive therapy regimens in patients with severe oral pemphigoid: effects on disease progression in patients nonresponsive to dapsone therapy. *Arch Dermatol*. 2001;137(9):1181.
86. Sacher C, Rubbert A, Konig C, et al. Treatment of recalcitrant cicatricial pemphigoid with the tumor necrosis factor alpha antagonist etanercept. *J Am Acad Dermatol*. 2002;46(1):113.
87. Ross AH, Jaycock P, Cook SD, et al. The use of rituximab in refractory mucous membrane pemphigoid with severe ocular involvement. *Br J Ophthalmol*. 2009;93(4):421.
88. Foster CS, Chang PY, Ahmed AR. Combination of rituximab and intravenous immunoglobulin for recalcitrant ocular cicatricial pemphigoid: a preliminary report. *Ophthalmology*. 2010;117(5):861.
89. Le Roux-Villet C, Prost-Squarcioni C, Alexandre M, et al. Rituximab for patients with refractory mucous membrane pemphigoid. *Arch Dermatol*. 2011;147(7):843.
90. Kasperkiewicz M, Shimanovich I, Ludwig RJ, et al. Rituximab for treatment-refractory pemphigus and pemphigoid: a case series of 17 patients. *J Am Acad Dermatol*. 2011;65(3):552.
91. Shetty S, Ahmed AR. Critical analysis of the use of rituximab in mucous membrane pemphigoid: a review of the literature. *J Am Acad Dermatol*. 2013;68(3):499.
92. Heelan K, Walsh S, Shear NH. Treatment of mucous membrane pemphigoid with rituximab. *J Am Acad Dermatol*. 2013;69(2):310.
93. Maley A, Warren M, Haberman I, et al. Rituximab combined with conventional therapy versus conventional therapy alone for the treatment of mucous membrane pemphigoid (MMP). *J Am Acad Dermatol*. 2016;74(5):835.
94. Liu Z, Diaz LA, Troy JL, et al. A passive transfer model of the organ-specific autoimmune disease, bullous pemphigoid, using antibodies generated against the hemidesmosomal antigen, BP180. *J Clin Invest*. 1993;92(5):2480.
95. Nishie W, Sawamura D, Goto M, et al. Humanization of autoantigen. *Nat Med*. 2007;13(3):378.
96. Lazarova Z, Yee C, Darling T, et al. Passive transfer of anti-laminin 5 antibodies induces subepidermal blisters in neonatal mice. *J Clin Invest*. 1996;98(7):1509.
97. Lazarova Z, Hsu R, Yee C, et al. Human anti-laminin 5 autoantibodies induce subepidermal blisters in an experimental human skin graft model. *J Invest Dermatol*. 2000;114(1):178.
98. Woodley DT, Ram R, Doostan A, et al. Induction of epidermolysis bullosa acquisita in mice by passive transfer of autoantibodies from patients. *J Invest Dermatol*. 2006;126(6):1323.
99. Sitaru C, Mihai S, Otto C, et al. Induction of dermal-epidermal separation in mice by passive transfer of antibodies specific to type VII collagen. *J Clin Invest*. 2005;115(4):870.
100. Woodley DT, Chang C, Saadat P, et al. Evidence that anti-type VII collagen antibodies are pathogenic and responsible for the clinical, histological, and immunological features of epidermolysis bullosa acquisita. *J Invest Dermatol*. 2005;124(5):958.

Chapter 56 :: Epidermolysis Bullosa Acquisita

:: David T. Woodley & Mei Chen

AT-A-GLANCE

- Rare, autoimmune subepidermal bullous disease due to immunoglobulin G autoantibodies to Type VII collagen.
- Etiology is unknown.
- Skin fragility, subepidermal blisters, residual scarring, and milia formation. Common sites are trauma-prone areas such as hands, feet, elbows, knees, sacrum, nails, and mouth.
- Related features may include an underlying systemic disease such as inflammatory bowel disease. May have erosions of the mucosa and esophageal stenosis.
- Pathology shows subepidermal bulla, fibrosis, milia formation, and positive direct immunofluorescence for immunoglobulin G deposits at the epidermal–dermal junction.
- Treatment options are limited and often difficult.

EPIDEMIOLOGY

Epidermolysis bullosa acquisita (EBA) is a sporadic autoimmune bullous disease of unknown etiology. The disease has no gender, racial, ethnic, or geographical predisposition. There may be some genetic predisposition to EBA and autoimmunity in African Americans who live in the southeastern part of the United States.[1] African American patients in the southeastern part of the United States who have either EBA or bullous systemic lupus erythematosus (SLE) have a high incidence of the HLA-DR2 phenotype. The calculated relative risk for EBA in HLA-DR2+ individuals is 13.1 in these patients. These results also suggest that EBA and bullous SLE are immunogenetically related and that the *HLADR2* gene either is involved with autoimmunity to anchoring fibril collagen or is some sort of a marker for some other gene that exists in linkage disequilibrium with it.[1]

In another study examining HLA genotypes in EBA patients, it was found that HLA-DRB1*15:03 was overrepresented.[2]

In concordance with the genetic permissiveness towards EBA in humans, an active murine model of EBA in which mice are immunized with murine Type VII collagen, the development of EBA depends on the strain of mouse used.[3,4]

EBA is an exceedingly rare disease and considerably less frequent than other autoimmune bullous diseases (bullous pemphigoid, pemphigus vulgaris, dermatitis herpetiformis, etc.), which themselves are quite rare. In unselected bullous disease patients who exhibited an anti–basement membrane zone autoantibody in their blood, approximately 5% had the diagnosis of EBA or bullous SLE.[5] This incidence is similar to those reported by other investigators.[6] A prospective French study using electron and immune-electron microscopy to confirm the diagnosis of EBA, found an incidence rate as 0.17 to 0.26 per million people and accounted for only 2% to 3% of all patients with a subepidermal autoimmune bullous disease.[7] The incidence of EBA in a region of Germany was 0.17, again confirming the rarity of EBA.[8]

ETIOLOGY AND PATHOGENESIS

EBA is a chronic, subepidermal blistering disease associated with autoimmunity to the collagen (Type VII collagen) within anchoring fibril structures that are located at the dermal–epidermal junction (DEJ). Although the precise etiology of EBA is unknown, most of the evidence suggests an autoimmune etiology. The immunoglobulin G (IgG) autoantibodies to Type VII collagen are associated with a paucity of normal anchoring fibrils at the basement membrane zone (BMZ) separating the epidermis from the dermis and poor epidermal–dermal adherence. Although it is an acquired disease that usually begins in adulthood, it was placed in the category epidermolysis bullosa (EB) more than 100 years ago because physicians were struck by how similar the clinical lesions of EBA were to those seen in children with hereditary dystrophic forms of EB. Direct immunofluorescence (DIF) of perilesional skin biopsies from EBA patients reveals IgG deposits at the DEJ.[9] EBA antibodies bind to Type VII collagen within anchoring fibrils.[10,11]

Anchoring fibrils anchor the epidermis and its underlying BMZ to the papillary dermis. Patients with hereditary forms of dystrophic EB (Chap. 60) and EBA have decreased numbers of anchoring fibrils in their DEJ. This paucity of anchoring fibrils is associated with 2 similar clinical phenotypes, EBA and dystrophic forms of hereditary EB, because both diseases are characterized by skin fragility, subepidermal blisters, milia formation, and scarring. Although both EBA and hereditary forms of dystrophic EB are etiologically unrelated in terms of their underlying pathogenesis, they share the common feature of decreased anchoring fibrils. In the case of dystrophic forms of hereditary EB, the cause of decreased or absent anchoring fibrils is a genetic defect in the *COL7A1* gene, which encodes for Type VII collagen α chains, that ultimately results in small, nonfunctional, or decreased anchoring fibrils.[12,13] The gene coding for Type VII collagen is located on the short arm of chromosome 3.[14] The gene defects involved in hereditary forms of dystrophic EB have been identified

at variable locations, but the severity of the disease appears to correlate with the degree of Type VII collagen and anchoring fibril perturbations.[13] In EBA, the IgG autoantibodies binding to the Type VII collagen α chains result in decreased anchoring fibrils, but the pathway leading to this reduction is unknown. It may be that Type VII collagen α chains that are newly synthesized but decorated with EBA autoantibodies cannot form triple-helical structures and stable anchoring fibrils. Healed burn wounds that have been covered with cultured keratinocyte sheets also have decreased numbers of anchoring fibrils within the first year after transplantation, and this is associated with spontaneous blister formation, shortened suction blistering times, and skin fragility.[15] These observations provide indirect evidence that anchoring fibrils play a role in maintaining adherence between the epidermis and dermis.

The Type VII collagen α chain has a molecular mass of 290 kDa and the collagen consists of a homotrimer of 3 identical α chains (Chap. 15). Each α chain consists of a large globular noncollagenous amino terminus called the *noncollagenous 1* (NC-1) *domain* that is approximately one-half the entire mass of the α chain. Next, there is a helical domain with typical glycine-X-Y repeats. At the carboxyl terminus is a second globular noncollagenous domain, NC-2, that is much smaller than NC-1.[16] Most EBA autoantibodies recognize 4 predominant antigenic epitopes within the NC-1 domain and do not recognize the helical or NC-2 domains.[17,18] There may be something intrinsically "antigenic" about the NC-1 domain because the available monoclonal antibodies that have been generated against Type VII collagen (anti–C-VII antibodies) specifically recognize only NC-1 subdomains.

A reduction in the number of anchoring fibrils is seen in the lesional and perilesional skin of EBA patients, but the pathway leading to this reduction is unknown.

Several independent lines of evidence have implicated autoimmune responses as a key element in the pathogenesis of EBA. First, the pathogenic role of EBA antibodies is suggested by the observation that when patients with SLE develop autoantibodies to the Type VII collagen, they develop widespread skin blisters and fall into a rare subset of SLE called *bullous SLE*.[19] This "experiment of nature" suggests that EBA autoantibodies are pathogenic and capable of inducing disadherence between the epidermis and dermis. Second, direct proof that EBA autoantibodies are pathogenic comes from recent passive transfer studies. We immunized rabbits and raised a high-titer antiserum to the NC-1 domain of human Type VII collagen. We injected this antibody into hairless immune-competent mice, and the mice developed bullous skin disease with many of the features of EBA in humans.[20] The mice developed subepidermal blisters and lost nails on their feet. They also had circulating NC-1 antibodies in their blood and anti–NC-1 IgG antibody deposits at their DEJ. In addition, the mice had murine complement deposits at the DEJ induced by the autoantibody–antigen complex.[20] Another study by Sitaru and colleagues[21] showed that the injection of rabbit polyclonal antibodies to the NC-1 domain of mouse Type VII collagen into mice also induced subepidermal skin blisters that were reminiscent of human EBA.[21] Further, we have also affinity-purified human EBA autoantibodies against an NC-1 column and injected them into mice. The mice then developed clinical, histologic, immunologic, and ultrastructural features akin to human EBA.[22] Taken together, these successful passive transfer experiments and the observations with bullous SLE strongly suggest that EBA autoantibodies are "pathogenic" and capable of causing epidermal–dermal separation in skin.

Using clinical patient studies, *in vitro* assays and murine models of EBA, much has been learned about the details of the immune responses of EBA patients harboring anti–Type VII collagen autoantibodies. EBA IgG autoantibodies in both the patients' blood and tissue bound in the patients' DEJ represent all 4 subclasses of IgG, particulary IgG1 and IgG4.[23] Circulating EBA autoantibodies consist of both complement binding and non–complement binding populations.[24] Nevertheless, when compared with BP, EBA patients had a higher presence of C3b and C5 (90% vs 33%, 90% vs 58%, respectively). These studies provided evidence[3] for complement activation at the DEJ in the majority of EBA patients and that EBA antibodies were more potent activators of C5 than BP antibodies.[25] Gammon and co-workers developed an *in vitro* assay to look at the functions of bullous pemphigoid and EBA immune complexes in skin. A slide chamber was made consisting of a cryostat section of human skin (normal skin or skin from patients with BP or EBA) with and without the additions of leukocytes and the additions of complement. The readout was the migration and attraction of the leukocytes to the DEJ of the human skin cryosections.[26] When cryostat sections of bullous pemphigoid skin and EBA skin were compared, the EBA immune complexes again generated more complement activation than bullous pemphigoid immune complexes.

In addition to murine models of EBA created by the passive transfer of anti–Type VII collagen antibodies, as noted in the sections "Epidemiology" above, an active murine model of EBA has been established by immunizing certain strains of mice with murine Type VII collagen. This active murine EBA model invokes complement fixing anti-Type VII collagen antibodies and requires T cells for disease induction.

CLINICAL FINDINGS

See Fig. 56-1. If a patient presents with bullae on the skin with no reasonable explanation despite a thorough history and physical examination, 3 tests should be done: a skin biopsy for routine hematoxylin and eosin histology, a second biopsy juxtaposed to a lesion but on normal-appearing skin for DIF and a blood draw to test for antibodies against the BMZ and/or Type VII collagen by indirect immunofluorescence (IIF) or enzyme-linked immunosorbent assay (ELISA).

The cutaneous lesions of EBA can be quite varied and can mimic other types of acquired autoimmune

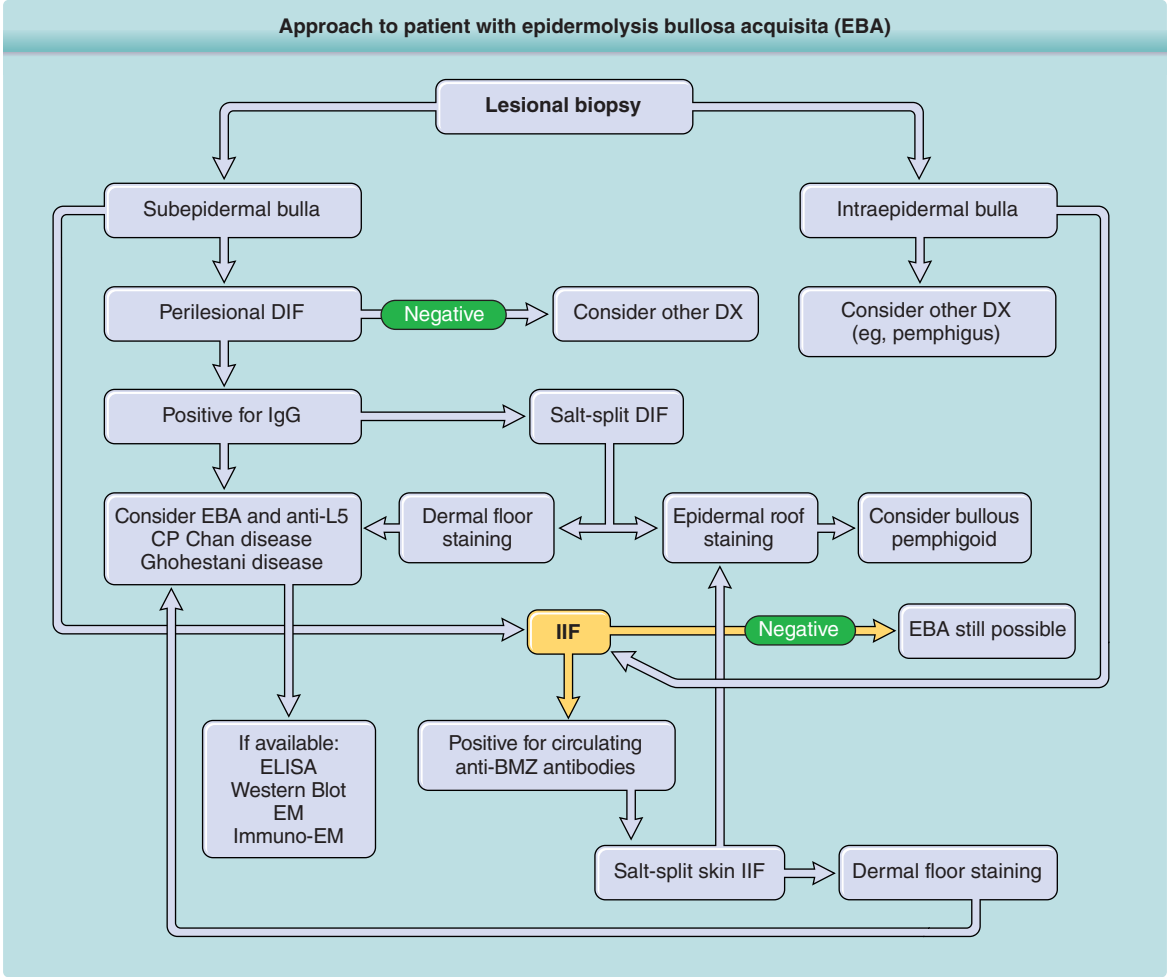

Figure 56-1 Approach to the patient with epidermolysis bullosa acquisita (EBA). BMZ, basement membrane zone; DIF, direct immunofluorescence; DX, diagnosis; ELISA, enzyme-linked immunosorbent assay; IgG, immunoglobulin G; IIF, indirect immunofluorescence.

bullous diseases. The common denominator for patients with EBA is autoimmunity to Type VII (anchoring fibril) collagen. There are at least 5 clinical presentations: (1) a classic presentation, (2) a bullous pemphigoid (BP)-like presentation, (3) a mucous membrane pemphigoid (MMP)-like presentation, (4) a presentation reminiscent of Brunsting–Perry pemphigoid with scarring lesions and a predominant head and neck distribution, and (5) a presentation reminiscent of linear IgA bullous dermatosis or chronic bullous disease of childhood. The classical presentation and the BP-like presentation are the most commonly reported presentations of this very rare disease.

CLASSIC PRESENTATION

The classic presentation (Figs. 56-2 and 56-3A) is of a noninflammatory bullous disease with an acral distribution that heals with scarring and milia formation. This presentation is reminiscent of porphyria cutanea tarda (PCT; Chap. 124) when it is mild and of the hereditary form of recessive dystrophic EB when it is severe (Chap. 60). The classic form of EBA is thus a mechanobullous disease marked by skin fragility. These patients have erosions, tense blisters within noninflamed skin, and scars over trauma-prone surfaces such as the backs

Figure 56-2 Patient with epidermolysis bullosa acquisita who has severe blistering, erosions, scarring, and milia formation on trauma-prone areas of her skin. This is the classic presentation.

Figure 56-3 **A,** Classic presentation of epidermolysis bullosa acquisita with scarring and milia over trauma-prone areas of skin. **B,** Bullous pemphigoid–like presentation of epidermolysis bullosa acquisita with a widespread inflammatory vesiculobullous dermatosis. **C,** Cicatricial pemphigoid–like presentation of epidermolysis bullosa acquisita with a mucosal-centered bullous scarring eruption. **D,** Brunsting–Perry pemphigoid–like presentation of epidermolysis bullosa acquisita with bullous and scarring lesions predominantly on the head and neck.

of the hands, knuckles, elbows, knees, sacral area, and toes (Figs. 56-2, 56-3A, and 56-4). Some blisters may be hemorrhagic or develop scales, crusts, or erosions. The lesions heal with scarring and frequently with the formation of pearl-like milia cysts within the scarred areas (Fig. 56-3A). Although this presentation may be reminiscent of PCT, these patients do not have other hallmarks of PCT, such as hirsutism, a photodistribution of the eruption, or scleroderma-like changes, and their urinary porphyrins are within normal limits. A scarring alopecia and some degree of nail dystrophy may be seen.

Although the disease is usually not as severe as that of patients with hereditary forms of recessive dystrophic EB, EBA patients with the classic form of the disease may have many of the same sequelae, such as scarring, loss of scalp hair, loss of nails, fibrosis of the hands and fingers, and esophageal stenosis.[27]

BULLOUS PEMPHIGOID–LIKE PRESENTATION

A second clinical presentation of EBA is of a widespread, inflammatory vesiculobullous eruption involving the trunk, central body, and skin folds in addition to the extremities.[6] The bullous lesions are tense and surrounded by inflamed or even urticarial skin. Large areas of inflamed skin may be seen without any blisters and only erythema or urticarial plaques. These patients often complain of pruritus and do not demonstrate prominent skin fragility, scarring, or milia formation. This clinical constellation is more reminiscent of BP (Figs. 56-3B and 56-4) than a mechanobullous disorder. Similar to BP, the distribution of the lesions may show an accentuation within flexural areas and skin folds.

Figure 56-4 An epidermolysis bullosa acquisita patient with involvement of the leg. Note bullae, erosions, and crusts.

MUCOUS MEMBRANE PEMPHIGOID-LIKE PRESENTATION

Both the classic and BP-like forms of EBA may have involvement of mucosal surfaces. However, EBA also may present with such predominant mucosal involvement that the clinical appearance is reminiscent of MMP (Fig. 56-3C).[28] These patients usually have erosions and scars on the mucosal surfaces of the mouth, upper esophagus, conjunctiva, anus, or vagina with or without similar lesions on the glabrous skin.

BRUNSTING–PERRY PEMPHIGOID–LIKE PRESENTATION

Brunsting–Perry cicatricial BP is a chronic, recurrent vesiculobullous eruption localized to the head and neck and characterized by residual scars, subepidermal bullae, IgG deposits at the DEJ, and minimal or no mucosal involvement. The antigenic target for the IgG autoantibodies, however, has not been defined. Nevertheless, a patient reported with this constellation of findings had IgG autoantibodies directed to anchoring fibrils below the lamina densa.[29] We have seen 3 additional patients with the features of Brunsting–Perry pemphigoid and autoantibodies directed to Type VII collagen (unpublished observations). Therefore, it appears that EBA patients may present with a clinical phenotype of Brunsting–Perry pemphigoid (Fig. 56-3D).

IMMUNOGLOBULIN A BULLOUS DERMATOSIS–LIKE PRESENTATION

IgA bullous dermatosis–like presentation of EBA is manifested by a subepidermal bullous eruption, a neutrophilic infiltrate, and linear IgA deposits at the BMZ when viewed by DIF. It may resemble linear IgA bullous dermatosis (LABD), dermatitis herpetiformis, or chronic bullous disease of childhood and may feature tense vesicles arranged in an annular fashion and involvement of mucous membranes.[30] The autoantibodies are usually IgA, IgG, or both.

The diagnosis of these subepidermal blistering cases with IgA anti–Type VII collagen antibodies showing linear IgA deposition at the BMZ is disputable. Some clinicians regard the patients as having purely LABD, whereas others regard them as having a subset of EBA. Further, the majority of EBA patients have low-titer IgA antibodies in their blood directed against Type VII collagen.

Childhood EBA is a rare disease. It has a variable presentation, including an LABD-like disease, a BP-like disease, and the classic mechanobullous EBA presentation. Although mucosal involvement is frequent and severe in childhood EBA, the overall prognosis is more favorable than in adult EBA.

INCIDENCE OF THE CLINICAL PRESENTATIONS OF EPIDERMOLYSIS BULLOSA ACQUISITA

According to the authors' experience, approximately 25% of patients with EBA may present with a BP-like clinical appearance. The disease of some of these patients eventually smolders into a more non-inflammatory mechanobullous form. However, both the classic and BP-like forms of the disease may coexist in the same patient (Fig. 56-5). The clinical phenotype of EBA that is reminiscent of pure CP occurs in fewer than 10% of all EBA cases.

RELATED PHYSICAL FINDINGS

EBA patients may have many physical findings similar to patients with hereditary dystrophic EB due to

Figure 56-5 An epidermolysis bullosa acquisita patient demonstrating 2 presentations of the disease: The classic mechanobullous presentation with erosions, scarring, and milia over the elbows and the more inflammatory bullous pemphigoid–like lesions on her trunk.

gene defects in the Type VII collagen gene. These include oral erosions, esophageal strictures, hypo- and hyperpigmentation skin mottling, nail loss, milia formation, scarring, and a degree of fibrosis of the hands.

A number of published reports suggest that EBA may be associated with various systemic diseases[18] such as inflammatory bowel disease, SLE, amyloidosis, thyroiditis, multiple endocrinopathy syndrome, rheumatoid arthritis, pulmonary fibrosis, chronic lymphocytic leukemia, thymoma, diabetes, multiple myeloma and other diseases in which an autoimmune pathogenesis has been implicated. At the University of North Carolina, Stanford, Northwestern, and University of Southern California, with a combined experience of following more than 62 EBA patients, it appears that inflammatory bowel disease is the systemic disease most frequently associated with EBA.

LABORATORY TESTS

HISTOPATHOLOGY

Routine histologic examination of lesional skin obtained from EBA patients shows a subepidermal blister and a clean separation between the epidermis and dermis. The degree of inflammatory infiltrate within the dermis usually reflects the degree of inflammation of the lesion observed by the clinician. Lesions that are reminiscent of recessive dystrophic EB or PCT usually have a notable scarcity of inflammatory cells within the dermis. Lesions that are clinically reminiscent of BP usually have significantly more inflammatory cells within the dermis, and these cells may be a mixture of lymphocytes, monocytes, neutrophils, and eosinophils. The histology of EBA skin specimens obtained from BP-like lesions may be difficult to distinguish from BP itself.

DIRECT IMMUNOFLUORESCENCE

Patients with EBA have IgG deposits within the DEJ of their skin.[10,27] This is best detected by DIF of a biopsy specimen obtained from a perilesional site (Fig. 56-6). IgG is the predominant immunoglobulin class, but deposits of complement, IgA, IgM, factor B, and properdin also may be detected. The DIF staining demonstrates an intense linear fluorescent band at the DEJ. Yaoita et al.[9] have suggested that a positive DIF and IgG deposits within the sublamina densa zone are necessary criteria for the diagnosis of EBA.

Patients with PCT, which may mimic EBA clinically, frequently have IgG and complement deposits at the DEJ similar to those of EBA patients (Chap. 124). However, the DIF feature that distinguishes PCT from EBA is that PCT skin also demonstrates immune deposits around the dermal blood vessels.

Patients with EBA may have autoantibodies in their blood directed against the DEJ.[10] These antibodies can be detected by IIF of the patient's serum on a substrate of monkey or rabbit esophagus or human skin and stain the DEJ in a linear fashion that may be indistinguishable from BP sera.[22]

IMMUNOELECTRON MICROSCOPY

The localization of the immune deposits within the DEJ of the skin of EBA patients by immunoelectron microscopy is the "gold standard" for the diagnosis. As demonstrated by Nieboer et al.[31] and Yaoita et al.,[9] patients with EBA have immune deposits within the sublamina densa zone of the cutaneous BMZ. This localization is clearly distinct from the deposits in BP, which are higher up in the hemidesmosome area or lamina lucida area of the basement membrane. It is

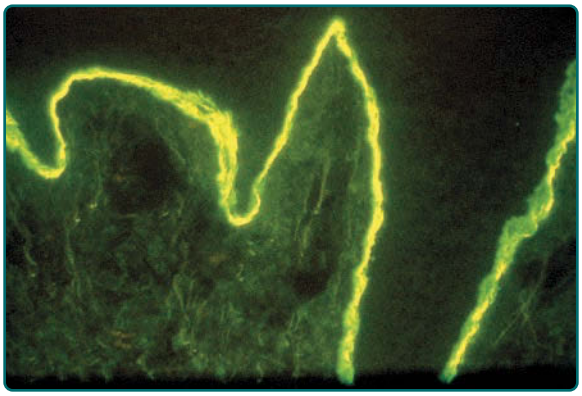

Figure 56-6 Direct immunofluorescence staining for immunoglobulin G deposits in perilesional skin of an epidermolysis bullosa acquisita patient. Note the dense deposits within the dermal–epidermal junction (the epidermis is on top in this section).

also distinct from CP, which has antigenic targets confined to the lamina lucida.

INDIRECT SALT-SPLIT SKIN IMMUNOFLUORESCENCE

When human skin is incubated in 1 molar sodium chloride, the DEJ fractures cleanly through the lamina lucida zone. This fracture places the BP antigen on the epidermal side of the split and all other basement membrane structures on the dermal side of the separation. Salt-split skin substrate can be used to distinguish EBA and BP sera.[10]

If the serum antibody is IgG and labels the epidermal roof, the patient does not have EBA, and BP should be considered. If, on the other hand, the antibody labels the dermal side of the separation, the patient usually has either EBA or bullous SLE. The latter can be ruled out by other serology and by clinical criteria.

DIRECT SALT-SPLIT SKIN IMMUNOFLUORESCENCE

Perilesional skin incubated in cold 1 molar sodium chloride is fractured through the DEJ, which effectively places the BP antigen (and any associated immune deposits) on the epidermal roof and the EBA antigen (and any associated immune deposits) on the dermal floor of the separation (Fig. 56-7).[27] If the patient has EBA, IgG immune deposits are detected on the dermal side of the separation by a routine DIF method using fluorescein-conjugated anti-human IgG.

WESTERN IMMUNOBLOTTING

Antibodies in EBA sera bind to a 290-kDa band in Western blots of human skin basement membrane proteins containing Type VII collagen, whereas sera from all other primary blistering diseases do not.[10] This band is the α chain of Type VII collagen. Often, a second band of 145 kDa is labeled with EBA antibodies. This band is the amino-terminal globular NC-1 domain of the Type VII collagen α chain, which is rich in carbohydrate and contains the antigenic epitopes of EBA autoantibodies, bullous SLE autoantibodies, and monoclonal antibodies against Type VII collagen.[17]

ENZYME-LINKED IMMUNOSORBENT ASSAY

Chen et al.[30] have produced milligram quantities of recombinant, purified, posttranslationally modified NC-1 in stably transfected human cells and have used this NC-1 to develop an ELISA for autoantibody detection in EBA patients and in patients with bullous SLE. This ELISA is more sensitive than immunofluorescence and Western blotting, and yet it is very specific for antibodies to Type VII collagen. There is now a commercially available ELISA for the detection of anti–Type VII collagen in the sera of patients.

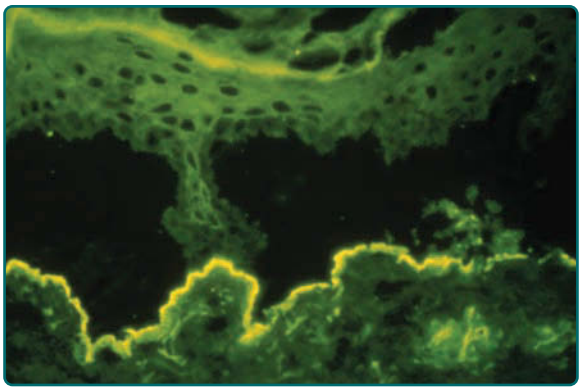

Figure 56-7 Direct immunofluorescence (DIF) staining of a patient's perilesional skin biopsy after incubation in 1 molar cold saline for 72 hours and probed with anti-human IgG antibodies. The cold salt incubation fractures the dermal–epidermal junction of the skin specimen. In EBA patients, the IgG deposits remain with the dermal floor of the fractured skin. In contrast, in patients with bullous pemphigoid, the deposits would remain with the epidermal roof of the fractured skin (not shown). Likewise, if the serum of an EBA patient has a circulating IgG antibody to Type VII (anchoring fibril) collagen and indirect immunofluorescence (IIF) is performed, the serum will label the dermal floor of salt-split human skin substrate and leave the epidermal roof unlabeled. These results are because incubating human skin in cold 1 molar salt fractures the dermal–epidermal junction such that the hemidesmosomes of the epidermis and the bullous pemphigoid autoantigens associated with hemidesmosomes remain with the epidermal roof, whereas anchoring fibrils and Type VII collagen, the autoantigen in EBA, remain with the dermal floor.

DIFFERENTIAL DIAGNOSIS

See Table 56-1. Because EBA has been described in infants and children, it is worth considering that a patient thought to have genetic dystrophic EB just might be a rare childhood patient with EBA. This can be ruled out by the antibody tests outlined in the section "Laboratory Tests." PCT can look clinically very much like classic EBA and can be ruled out by a urine or plasma test for uroporphyrins. Pseudo-PCT, usually caused by drugs such as nonsteroidal anti-inflammatory agents, can look similar to EBA with skin fragility, erosions, and blisters over trauma-prone areas, scarring, and milia formation. Nevertheless, the DIF appears different in that pseudo-PCT, like PCT, shows IgG deposits at both the BMZ at the DEJ and around dermal blood vessels (which are not stained in EBA).

TABLE 56-1
Differential Diagnosis of Epidermolysis Bullosa Acquisita

Most Likely
- Porphyria cutanea tarda
- Pseudo-porphyria cutanea tarda
- Bullous pemphigoid
- Cicatricial pemphigoid

Consider
- Linear immunoglobulin A bullous disease
- Brunsting–Perry pemphigoid
- Bullous systemic lupus erythematosus

The BP-like EBA can be eliminated by several methods listed above, but the first-line test would be indirect and direct salt-split immunofluorescence.

DIAGNOSIS

The diagnostic criteria developed by Yaoita et al.[9] for the diagnosis of EBA still stand. These criteria, with slightly updated modifications, are shown in Table 56-2. Alternatives for the last item in the table are indirect or direct salt-split skin immunofluorescence, Western blotting, and ELISA.

COMPLICATIONS

The complications caused by EBA include secondary skin infections, usually due to *Staphylococcus* or *Streptococcus*, because the blisters and erosions compromise the skin's barrier. Scarring and milia formation are naturally occurring complications or sequelae of the deep blistering process. Severe EBA patients may develop significant fibrosis of the hands with decreased range of motion of the palm and digits. Because of wounds and fibrosis of the soles of the feet and toes, some EBA patients have difficulty walking. Many patients with EBA lose their fingernails. EBA patients with significant mucosal involvement may develop esophageal strictures and even laryngeal scarring.

TABLE 56-2
Diagnostic Criteria for Epidermolysis Bullosa Acquisita

- A bullous disorder within the clinical spectrum outlined earlier (see "Clinical Findings").
- No family history of a bullous disorder.
- Histology showing a subepidermal blister.
- Deposition of immunoglobulin G deposits within the dermal–epidermal junction (ie, a positive direct immunofluorescence of perilesional skin).
- Immunoglobulin G deposits localized to the lower lamina densa and/or sublamina densa zone of the dermal–epidermal junction when perilesional skin is examined by direct immunoelectron microscopy.

TREATMENT

EBA usually responds poorly to treatment. Supportive therapy is warranted in all patients with EBA. This includes instruction in open wound care and strategies for avoiding trauma. Patients should be warned not to over wash or overuse hot water or harsh soaps and to avoid prolonged or vigorous rubbing of their skin with a washcloth or towel. In some patients, it appears that prolonged sun exposure may aggravate or promote new lesions on the dorsal hands and knuckles. Thus, avoidance of prolonged sun exposure and the use of sunscreens are helpful. The patient should be educated to recognize localized skin infections and to seek medical care and antibiotic therapy promptly when they occur.

EBA patients are often refractory to high doses of systemic glucocorticoids, azathioprine, methotrexate, and cyclophosphamide, especially when they have the classic mechanobullous form of the disease. These agents may be somewhat helpful in controlling EBA when it appears as an inflammatory BP-like disease. Some EBA patients improve on dapsone, especially when neutrophils are present in their dermal infiltrate.

Cyclosporine has been shown to be beneficial in EBA.[32] However, the long-term toxicity of this drug limits its use.

There are also independent reports of EBA patients responding to high doses of colchicine.[33] This is often used as a first-line drug because its side effects are relatively benign compared with other therapeutic choices. Diarrhea is a common side effect of colchicine, however, which makes it difficult for many patients to achieve a high enough dose to control the disease. Moreover, because of this side effect, we are hesitant to use colchicine in EBA patients who also have inflammatory bowel disease. In addition, there are patients who do not respond to colchicine. Colchicine is a well-known microtubule inhibitor, but it also appears to have properties that have the potential to inhibit antigen presentation to T cells, which could downregulate autoimmunity.

Photopheresis improves the clinical features of EBA and remarkably lengthens the suction blistering times of the patients, suggesting an improvement in their dermal–epidermal adherence.[34]

In addition to photophoresis, plasmapheresis and removal of the antibodies to Type VII collagen in an EBA patient's plasma is useful for gaining control of EBA patients similar to pemphigus patients. Given that the autoantibodies are pathogenic, this is not surprising, but when plasmapheresis is performed it is necessary to have the patient also treated with a chemotherapy agent (such as azathioprine, cyclophosphamide, mycotile mofelate, methotrexate).

Intravenous immunoglobulin (IVIG) has been reported to be effective in patients with EBA.[35] The mechanism by which γ-globulin may invoke a positive response in EBA is unknown.

The anti–TNF-α biologics (such as infliximab) have been tried in EBA with some success in uncontrolled open trials. Rituximab, a monoclonal antibody against

TABLE 56-3
Treatments for Epidermolysis Bullosa Acquisita (EBA)

MEDICATION	DOSE RANGE
Colchicine[a]	0.6-3.0 mg/d
Cyclosporine A	6 mg/kg/d
Dapsone[b]	100-300 mg/d
Cytoxan	50-200 mg/d
Prednisone[c]	1.0-1.5 mg/kg
Intravenous immunoglobulin[d]	3 g/kg divided over 5 d
Infliximab	5 mg/kg at 0, 2, 4, and 6 wk
Rituximab	375 mg/m^2 of BSA, IV weekly × 4 wk Or 1000 mg IV on week 1 and week 3

[a]Must start with 0.4 to 0.6 mg/d and each 1 to 2 weeks double this dose as tolerated. When patient develops diarrhea, back off 1 tablet (0.4-0.6 mg).

[b]Begin at 25 mg/d and double each week after the complete blood count and liver function tests. Most patients need between 100 and 250 mg/d. Increasing the dose slowly helps the patient tolerate the anemia that develops (ie, less orthostatic light-headedness, etc.). Expect a 1- to 2-g drop in the patient's hemoglobin on therapeutic doses.

[c]Usually does not help the classic, mechanobullous type of EBA with minimal inflammation. However, it may be somewhat helpful in the bullous pemphigoid–like type of EBA.

[d]Intravenous immunoglobulin is given over 4 to 5 days every month for 5 or 6 months to give it an adequate trial.

the CD20 protein on the surface of B lymphocytes induces markedly decreased B-cell lymphocytes in the patients and has shown efficacy in recalcitrant EBA patients.[36,37] Table 56-3 outlines treatment options in EBA that have some support in the medical literature.

REFERENCES

1. Gammon WR, Heise ER, Burke WA, et al. Increased frequency of HLA DR2 in patients with autoantibodies to EBA antigen: evidence that the expression of autoimmunity to type VII collagen is HLA class II allele associated. *J Invest Dermatol.* 1988;91:228-232.
2. Zumelzu C, Le Roux-Villet C, Loiseau P, et al. Black patients of African Descent and HLA-DRB1*15:03 frequency overrepresented in epidermolysis bullosa acquisita. *J Invest Dermatol.* 2011;131(12):2366-2393.
3. Sitaru C, Chiriac MT, Mihai S, et al. Induction of complement fixing autoantibodies against type VII collagen results in subepidermal blistering in mice. *J Immunol.* 2006;177(5):3461-3468.
4. Ludwig RJ, Recke A, Bieber K, et al. Generation of antibodies of distinct subclasses and specificity is linked to H2s in an active mouse model of epidermolysis bullosa acquisita. *J Invest Dermatol.* 2011;131(1):167-176.
5. Zhu X-J, Niimi Y, Bystryn J-C. Epidermolysis bullosa acquisita. Incidence in patients with basement membrane zone antibodies. *Arch Dermatol.* 1990; 126(2):171-174.
6. Gammon WR, Briggaman RA, Woodley DT, et al. Epidermolysis bullosa acquisita: a pemphigoid-like disease. *J Am Acad Dermatol.* 1984;11(5, pt 1):820-832.
7. Bernard P, Vaillant L, Labeille B, et al. Incidence and distribution of subepidermal autoimmune bullous skin diseases in three French regions. Bullous Diseases French Study Group. *Arch Dermatol.* 1995;131(1): 48-52.
8. Zillikens D, Wever S, Roth A, et al. Incidence of autoimmune subepidermal blistering dermatoses in a region of central Germany. *Arch Dermatol.* 1995;131(8):957-958.
9. Yaoita H, Briggaman RA, Lawley TJ, et al. Epidermolysis bullosa acquisita: ultrastructural and immunological studies. *J Invest Dermatol.* 1981;76(4):288-292.
10. Woodley DT, Briggaman RA, O'Keefe EJ, et al. Identification of the skin basement membrane autoantigen in epidermolysis bullosa acquisita. *N Engl J Med.* 1984;310(16):1007-1013.
11. Woodley DT, Burgeson RE, Lunstrum G, et al. The epidermolysis bullosa acquisita antigen is the globular carboxyl terminus of type VII procollagen. *J Clin Invest.* 1988;81(3):683-687.
12. Christiano AM, D'Alessio M, Paradisi M, et al. A common insertion mutation in COL7A1 in two Italian families with recessive dystrophic epidermolysis bullosa. *J Invest Dermatol.* 1996;106(4):679-684.
13. Shimizu H. Molecular basis of recessive dystrophic epidermolysis bullosa: genotype/phenotype correlation in a case of moderate clinical severity. *J Invest Dermatol.* 1996;106(1):119-124.
14. Parente MG, Chung LC, Ryynänen J, et al. Human type VII collagen: cDNA cloning and chromosomal mapping of the gene. *Proc Natl Acad Sci U S A.* 1991;88(16): 6931-6935.
15. Woodley DT, Peterson HD, Herzog SR, et al. Burn wounds resurfaced by cultured epidermal autografts show abnormal reconstitution of anchoring fibrils. *JAMA.* 1988;259(17):2566-2571.
16. Christiano AM, Greenspan DS, Lee S, et al. Cloning of human type VII collagen: complete primary sequence of the alpha 1(VII) chain and identification of intragenic polymorphisms. *J Biol Chem.* 1994;269(32):20256.
17. Lapiere J-C, Woodley DT, Parente MG, et al. Epitope mapping of type VII collagen: identification of discrete peptide sequences recognized by sera from patients with acquired epidermolysis bullosa. *J Clin Invest.* 1993;92(4):1831-1839.
18. Jones DA, Hunt SW 3rd, Prisayanh PS, et al. Immunodominant autoepitopes of type VII collagen are short, paired peptide sequences within the fibronectin type III homology region of the non-collagenous (NC1) domain. *J Invest Dermatol.* 1995;104(2):231-235.
19. Gammon WR, Woodley DT, Dole KC, et al. Evidence that antibasement membrane zone antibodies in bullous eruption of systemic lupus erythematosus recognize epidermolysis bullosa acquisita autoantigens. *J Invest Dermatol.* 1985;84(6):472-476.
20. Woodley DT, Chang C, Saadat P, et al. Evidence that anti-type VII collagen antibodies are pathogenic and responsible for the clinical, histological, and immunological features of epidermolysis bullosa acquisita. *J Invest Dermatol.* 2005;124(5):958-964.
21. Sitaru C, Mihai S, Otto C, et al. Induction of dermal-epidermal separation in mice by passive transfer of antibodies specific to type VII collagen. *J Clin Invest.* 2005;115(4):870-878.
22. Woodley DT, Ram R, Doostan A, et al. Induction of epidermolysis bullosa acquisita in mice by passive transfer of autoantibodies from patients. *J Invest Dermatol.* 2006;126(6):1323-1330.

23. Mooney E, Gammon WR. Heavy and light chain isotypes of immunoglobulin in epidermolysis bullosa acquisita. *J Invest Dermatol.* 1990;95(3):317-319.
24. Briggaman RA, Gammon WR, Woodley DT. Epidermolysis bullosa acquisita of the immunopathological type (dermolytic pemphigoid). *J Invest Dermatol.* 1985;85(1)(suppl):79s–84s.
25. Mooney E, Falk RJ, Gammon WR. Studies on complement deposits in epidermolysis bullosa and bullous pemphigoid. *Arch Dermatol.* 1992;128(1):58-60.
26. Gammon WR, Lewis DM, Carlo JR, et al. Pemphigoid antibody mediated attachment of peripheral blood leukocytes at the dermal-epidermal junction of human skin. *J Invest Dermatol.* 1980;75(4):334-339.
27. Woodley DT. Epidermolysis bullosa acquisita. *Prog Dermatol.* 1988;22:1-13.
28. Roenigk HH Jr, Ryan JG, Bergfeld WF. Epidermolysis bullosa acquisita: report of three cases and review of all published cases. *Arch Dermatol.* 1971;103(1):1-10.
29. Kurzhals G, Stolz W, Meurer M, et al. Acquired epidermolysis bullosa with the clinical features of Brunsting-Perry cicatricial bullous pemphigoid. *Arch Dermatol.* 1991;127(3):391-395.
30. Chen M, Chan LS, Cai X, et al. Development of an ELISA for rapid detection of anti-type VII collagen autoantibodies in epidermolysis bullosa acquisita. *J Invest Dermatol.* 1997;108(1):68-72.
31. Nieboer C, Boorsma DM, Woerdeman MJ, et al. Epidermolysis bullosa acquisita: immunofluorescence, electron microscopic and immunoelectron microscopic studies in four patients. *Br J Dermatol.* 1980;102(4):383-392.
32. Crow LL, Finkle JP, Gammon WR, et al. Clearing of epidermolysis bullosa acquisita on cyclosporin A. *J Am Acad Dermatol.* 1988;19(5, pt 2):937-942.
33. Cunningham BB, Kirchmann TT, Woodley D. Colchicine for epidermolysis bullosa (EBA). *J Am Acad Dermatol.* 1996;34(5, pt 1):781-784.
34. Gordon KB, Chan LS, Woodley DT. Treatment of refractory epidermolysis bullosa acquisita with extracorporeal photochemotherapy. *Br J Dermatol.* 1997;136(3):415-420.
35. Meier F, Sönnichsen K, Schaumburg-Lever G, et al. Epidermolysis bullosa acquisita: efficacy of high dose intravenous immunoglobulins. *J Am Acad Dermatol.* 1993;29(2, pt 2):334-337.
36. Schmidt E, Benoit S, Brocker EB, et al. Successful adjuvant treatment of recalcitrant epidermolysis bullosa acquisita with anti-CD20 antibody rituximab. *Arch Dermatol.* 2006;142(2):147-150.
37. Sadler E, Schafleitner B, Lanschueter C, et al. Treatment-resistant classical epidermolysis bullosa acquisita responding to rituximab. *Br J Dermatol.* 2007;157(2):417-419.

Chapter 57 :: Intercellular Immunoglobulin (Ig) A Dermatosis (IgA Pemphigus)

:: Takashi Hashimoto

AT-A-GLANCE

- Intercellular immunoglobulin (Ig) A dermatosis (IAD) is a chronic vesicular and/or pustular autoimmune skin disease caused by IgA, not by IgG, antibodies.
- Two major types: subcorneal pustular dermatosis (SPD)-type IAD and intraepidermal neutrophilic IgA dermatosis (IEN)-type IAD.
- SPD-type IAD clinically shows superficial pustules on the intertriginous areas.
- IEN-type IAD clinically shows atypical pustular skin lesions with a sunflower-like configuration.
- Diagnosis is made by histopathology showing intraepidermal pustules, immunofluorescence detecting in vivo bound and/or circulating IgA antikeratinocyte cell-surface autoantibodies, and various biochemical and molecular biologic methods demonstrating reactivity with various autoantigens.
- SPD-type IAD shows histopathologically subcorneal neutrophilic pustules.
- IEN-type IAD shows histopathologically neutrophilic pustules in the middle epidermis.
- Major autoantigens are desmogleins (Dsg) and desmocollins (Dsc), cadherin-type cell-to-cell adhesion molecules found in desmosomes.
- Patients are treated mainly with dapsone and systemic corticosteroids; other treatment options include immunosuppressive agents, tetracycline, colchicine, plasmapheresis, retinoids, adalimumab, and psoralen and ultraviolet A.

This chapter discusses findings, pathogenesis, diagnosis, and treatments for intercellular immunoglobulin (Ig) A dermatosis (also called IgA pemphigus): Other synonyms are intraepidermal neutrophilic IgA dermatosis, intercellular IgA vesiculopustular dermatosis and IgA pemphigus foliaceus.

In addition to clinical and histopathologic assessments, detection of autoantibodies to the skin by immunofluorescence is still a hallmark for the diagnoses of various autoimmune bullous diseases (AIBDs), which are organ-specific autoimmune diseases of the skin and mucous membranes.[1-4] In addition, according to the progress in recent biochemical and molecular biologic techniques, various methods detecting autoantigen, including immunoblotting and enzyme-linked immunosorbent assays (ELISAs), are performed to make precise diagnoses of various AIBDs.[1-8] Based on the results of these antigen detection analyses, AIBDs are currently classified into a large number of different diseases with distinct autoantibodies and autoantigens.[1,2]

The term *intercellular IgA dermatosis* (IAD) (also frequently called *IgA pemphigus*) refers to a group of AIBDs of skin and mucous membranes. IAD is characterized clinically by pustular skin lesions, histopathologically by intraepidermal neutrophilic pustules, and immunopathologically by in vivo bound and circulating IgA antibodies directed against the keratinocytes cell surfaces.[9-14]

This disease entity was first reported by Daniel Wallach.[15] IAD/IgA pemphigus shows variable clinical, histopathologic, and immunologic features. As a result, this condition has been reported under a variety of names, including IAD,[14] intraepidermal neutrophilic IgA dermatosis (IEN),[16] intercellular IgA vesiculopustular dermatosis,[17] and IgA pemphigus foliaceus.[18]

However, clinical, histopathologic, and immunologic features of this disease are considerably different from those in classical IgG types of pemphigus. Therefore, the term IAD was proposed as the name most suitable for this disorder.[9-11,14]

In the current classification of IAD,[9-13] 2 major subtypes of IAD are subcorneal pustular dermatosis (SPD)-type IAD and IEN-type IAD. There also are minor subtypes, including IgA pemphigus vegetans (PVeg), IgA pemphigus foliaceus (PF), IgA pemphigus vulgaris (PV), and undetermined-type IAD. Table 57-1 outlines the classification of the IAD subtypes with their autoantigens.

SPD-type IAD develops the pustules in the uppermost epidermis, just below the cornified layer, whereas IEN-type IAD develops the pustule in the middle or entire epidermis. IgA PVeg clinically shows PVeg-like vegetating skin lesions, whereas IgA PF and IgA PV show IgA autoantibodies against desmoglein (Dsg) 1 and Dsg3, respectively.

EPIDEMIOLOGY

PV, the representative disease of classical IgG-type pemphigus, is known to have human leukocyte antigen–related genetic background and to be more prevalent in Jewish, Middle Eastern, and Japanese populations. In contrast, the epidemiology of IAD has not been studied because of IAD's rarity. However, because sporadic cases have been reported through the world evenly,[9-13] incidence and prevalence of IAD seem to

TABLE 57-1
Classification of Subtypes of Intercellular IgA Dermatosis and Their Autoantigens

DISEASES	AUTOANTIGENS
Subcorneal pustular dermatosis (SPD)-type intercellular IgA dermatosis (IAD)	Desmocollin 1 (Dsc1)
Intraepidermal neutrophilic IgA dermatosis (IEN)-type IAD	Unknown
IgA pemphigus vegetans (PVeg)	Desmogleins or desmocollins
IgA pemphigus foliaceus (PF)	Desmoglein 1 (Dsg1)
IgA pemphigus vulgaris (PV)	Desmoglein 3 (Dsg3)
Undetermined-type IAD	Undetermined, desmogleins or desmocollins

be independent of the ethnic population. There is no gender prevalence.[9] The average age of disease onset is around 45.9 years.[9] This age of onset is younger than those in other AIBDs. There are also a few cases of IAD occurring in a child.[9]

ETIOLOGY AND PATHOGENESIS

AIBDs show autoantibodies of either IgG or IgA classes, which react with various cutaneous structural components at either keratinocyte cell surfaces or epidermal basement membrane zone. IAD is one of AIBDs, and shows anti–cell-surface autoantibodies exclusively of IgA class. Basic research revealed that various types of IAD have IgA autoantibodies against different autoantigens, mainly desmogleins and desmocollins, and suggested that the IgA autoantibodies are related to development of the skin lesions.

Although a passive transfer of IgG from patients to neonatal mice induced blisters with typical histology for PV or PF, no animal disease models were able to reproduce the human phenotype of IAD. Thus, the pathogenic role of IgA autoantibodies is still unclear.

AUTOANTIGENS

Earlier studies using immunoblotting techniques suggested that IAD sera contained IgA autoantibodies reactive most frequently with desmocollins,[17] and less frequently desmogleins.[19] However, sensitivity of immunoblotting to detect antigens for IgA autoantibodies in IAD sera was very low, probably because the IgA autoantibodies react with conformation dependent epitopes on the autoantigens, which are destroyed during the immunoblotting procedure.[17]

Desmogleins[6] and desmocollins[8] are transmembrane glycoproteins, and consist of the desmosomal cadherin superfamily of calcium-dependent cell-adhesion molecules. Each desmocollin (ie, Dsc1, Dsc2, and Dsc3) is composed of the 110-kDa a form (ie, Dsc1a, Dsc2a, Dsc3a) and the 100-kDa b form (ie, Dsc1b , Dsc2b , Dsc3b), which are produced by alternative splicing.[8] Dsc1 is expressed in the keratinocyte cell surfaces in the uppermost epidermis,[8] where subcorneal pustules and IgA deposition are found in the skin lesions of SPD-type IAD, strongly suggesting that IgA anti-Dsc1 autoantibodies play a pathogenic role in SPD-type IAD. In contrast, Dsc2 is expressed in the entire epidermis and Dsc3 is expressed more strongly in the low epidermis.

Then, the sophisticated technique of transfection of complementary DNAs (cDNAs) of human Dsc1, Dsc2, and Dsc3 into cultured COS-7 cells was developed.[20] In the cDNA transfection method, IgA autoantibodies in the SPD-type IAD sera react with Dsc1, while IgA antibodies in IEN-type IAD sera react with none of Dsc1, Dsc2, or Dsc3.[20]

Subsequently, IgA ELISAs using baculovirus-producing recombinant proteins of Dsg1 and Dsg3 were developed.[21] In this ELISA, IgA antibodies in IgA PF and IgA PV sera react with Dsg1 and Dsg3, respectively.[21]

To detect autoantibodies to Dsc1, Dsc2, and Dsc3 for both IgG and IgA antibodies, ELISAs using baculovirus-producing recombinant proteins of human Dsc1, Dsc2, and Dsc3 were developed.[22] However, sensitivity of this method was proved to be very low, and even IgA antibodies in SPD-type IAD sera rarely reacted with Dsc1. The reason for this low sensitivity was thought to be because antidesmocollin autoantibodies cannot react with baculovirus-producing desmocollin-recombinant proteins, whereas antidesmoglein autoantibodies can react with baculovirus-producing desmoglein-recombinant proteins.

Consequently, novel ELISAs were developed using mammalian recombinant proteins of human Dsc1, Dsc2, and Dsc3, in which IgG antibodies in sera from patients with paraneoplastic pemphigus and atypical pemphigus, but not classical IgG-types of pemphigus, frequently reacted with desmocollins.[8] Subsequently, using the IgG ELISAs of mammalian recombinant proteins of Dsc1, Dsc2, and Dsc3, IgA ELISAs were developed.[23] In the IgA ELISAs, IgA antibodies in sera from most patients with SPD-type IAD react with Dsc1, whereas Dsc2 and Dsc3 react with sera from particular IAD sera.[23]

The autoantigen for IEN-type IAD are still unidentified. Immunoelectron-microscopy study indicated that IgA antibodies in IEN-type IAD sera react with cell surfaces at the interdesmosomal area in keratinocytes, suggesting that an autoantigen for IEN-type IAD is nondesmosomal protein.[24] Previous biochemical studies using either immunoblotting[17] or proteomics techniques[25] have not identified autoantigen in IEN-type IAD.

CLINICAL FINDINGS

Table 57-2 provides a summary of IAD subtypes.

TABLE 57-2
Summary of Intercellular IgA Dermatosis Subtypes

IAD SUBTYPE	CLINICAL FEATURES
SPD-type IAD	Superficial flaccid pustules in the periphery of annular of herpetiform erythemas, most prominent in axillae and groin; (–) Nikolsky; no mucosal involvement
IEN-type IAD	Demarcated atypical pustular lesions scattered on entire body; "sunflower like" configuration; may have mucosal involvement
PVeg-type IAD	Vegetating skin lesions with erosions; scalp and intertriginous areas most affected
PF and PV-type IAD	Clinical and histopathologic similarity to PF and PV, but with IgA reactivity mainly with Dsg1 and Dsg3
Undetermined-type IAD	IAD patients that do not meet any of the above-mentioned subtypes.

Dsg, desmoglein; IAD, intercellular IgA dermatosis; IEN, intraepidermal neutrophilic IgA dermatosis; PF, pemphigus foliaceus; PV, pemphigus vulgaris; PVeg, pemphigus vegetans; SPD, subcorneal pustular dermatosis.

SUBCORNEAL PUSTULAR DERMATOSIS–TYPE INTERCELLULAR IgA DERMATOSIS

The typical skin lesions of SPD-type IAD are superficial flaccid pustules developed in the periphery of annular or herpetiform erythemas on the entire body, most prevalently intertriginous regions, such as axillae and groins (Figs. 57-1 and 57-2).[9,10,13,14,26,27] Because pustules in SPD-type IAD are extremely superficial, the most pustular skin lesions turn into erosions and crusts, resulting in postinflammatory pigmentation. The Nikolsky sign is usually absent. These clinical features are indistinguishable from those seen in patients with classical SPD without IgA autoantibodies.

INTRAEPIDERMAL NEUTROPHILIC IgA DERMATOSIS–TYPE INTERCELLULAR IgA DERMATOSIS

The characteristic skin lesions of IEN-type IAD are demarcated atypical pustular lesions scattered on the

Figure 57-1 Clinical feature of subcorneal pustular dermatosis–type intercellular IgA dermatosis showing superficial pustules on herpetiform erythemas and hypopyon. (From Hashimoto T, Inamoto N, Nakamura K, et al. Intercellular IgA dermatosis with clinical features of subcorneal pustular dermatosis. *Arch Dermatol*. 1987; 123(8):1062-1065, with permission. Copyright © 1987 American Medical Association. All rights reserved.)

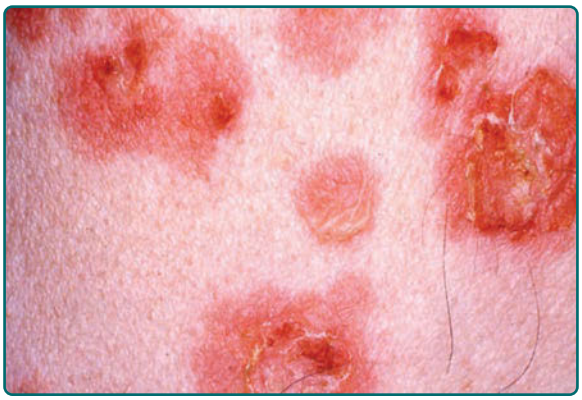

Figure 57-2 Clinical feature of subcorneal pustular dermatosis–type intercellular IgA dermatosis showing superficial pustules and flaccid bullae on the herpetiform erythemas. (From Hashimoto T, Teye K, Ishii N. Clinical and immunological studies of 49 cases of various types of intercellular IgA dermatosis and 13 cases of classical subcorneal pustular dermatosis examined at Kurume University. *Br J Dermatol*. 2017;176(1):168-75, with permission. Copyright © 2017, John Wiley & Sons.)

Figure 57-3 Clinical feature of intraepidermal neutrophilic IgA dermatosis–type intercellular IgA dermatosis showing elevated annular erythema with pustules on the periphery and crusts in the center.

entire body, in which relatively deep pustules develop on the slightly elevated periphery of annular erythemas of 10 mm to 30 mm and generate a so-called sunflower-like configuration (Figs. 57-3 and 57-4).[9,10,13,16,27] Whereas SPD-type IAD never develops mucous membrane lesions, particular cases of IEN-type IAD show oral mucosal lesions.

PEMPHIGUS VEGETANS–TYPE INTERCELLULAR IgA DERMATOSIS

PVeg-type IAD patients develop PVeg-like vegetating skin lesions with erosions, prevalently in the intertriginous areas and the scalp (Fig. 57-5).[9,10,13,28]

Figure 57-4 Clinical feature of intraepidermal neutrophilic IgA dermatosis–type intercellular IgA dermatosis showing atypical pustular skin lesion with so-called sunflower-like configuration.

Figure 57-5 Clinical feature of IgA pemphigus vegetans showing vegetating erosive skin lesions. (From Weston WL, Friednash M, Hashimoto T, et al. A novel childhood pemphigus vegetans variant of intraepidermal neutrophilic IgA dermatosis. *J Am Acad Dermatol*. 1998;38(4): 635-38, with permission. Copyright © American Academy of Dermatology.)

PEMPHIGUS FOLIACEUS AND PEMPHIGUS VULGARIS–TYPE INTERCELLULAR IgA DERMATOSIS

While SPD-type IAD, IEN-type IAD, and PVeg-type IAD are diagnosed based on the clinical and histopathologic features, the diagnoses of PF-type IAD and PV-type IAD are made for the patients who show IgA reactivity mainly or exclusively with Dsg1 and Dsg3, respectively, in ELISAs or immunoblotting.[9,10,13,21] PF-type IAD shows clinical and histopathologic features that mimick either PF or IEN-type IAD.[9,10,13,19] PV-type IAD shows mainly clinical and histopathologic features of either PV or IEN-type IAD.[9,10,13,29] Some patients with PV-type IAD show PV-like oral mucosal erosive lesions (Fig. 57-6).[29]

UNDETERMINED-TYPE INTERCELLULAR IgA DERMATOSIS

Some IAD patients show clinical and histopathologic features that do not meet the criteria of SPD-type IAD, IEN-type IAD, or PVeg-type IAD, and do not show exclusive IgA reactivity with either Dsg1 or Dsg3. These cases are tentatively classified as undetermined-type IAD.[9] One patient with

Figure 57-6 Clinical feature of IgA pemphigus vulgaris showing blisters and erosions on the oral mucosa. (From Hashimoto T, Teye K, Ishii N. Clinical and immunological studies of 49 cases of various types of intercellular IgA dermatosis and 13 cases of classical subcorneal pustular dermatosis examined at Kurume University. *Br J Dermatol*. 2017;176(1):168-75, and used with permission from Professor Hiroyuki Matsue, Department of Dermatology, Chiba University School of Medicine, Chiba, Japan.)

undetermined-type IAD showed paraneoplastic pemphigus–like clinical features with severe oral mucosal lesions.[30] However, these cases may progress to show characteristics of other types of IAD. Alternatively, futures studies may suggest additional types of IAD for these patients.

ASSOCIATED DISEASES

Underlying disease most frequently found in IAD is ulcerative colitis.[9] Interestingly, ulcerative colitis is associated with either IEN-type IAD or PV-type IAD, but never with SPD-type IAD.[9] IAD is also associated with either multiple myeloma[9,31] or B-cell lymphoma.[32] Considering that elevation of total serum level of IgA is also found in IAD patients,[9] B-cell or plasma cell proliferative disorders may trigger development of IAD. There is no particular association with nonhematologic malignant tumors.

DIAGNOSIS

For the diagnosis of IAD, in addition to inspection of skin lesions, various laboratory tests are necessary.[9-13] Histopathologic examination and direct immunofluorescence of biopsies taken from lesional skin and perilesional skin, respectively, are first performed. In serologic tests, circulating IgA autoantibodies and their autoantigens are determined by indirect immunofluorescence, immunoblotting mainly using normal human epidermal extracts, and ELISAs using recombinant proteins of desmogleins and desmocollins, as well as cDNA transfection methods for Dsc1, Dsc2, and Dsc3.[9-13]

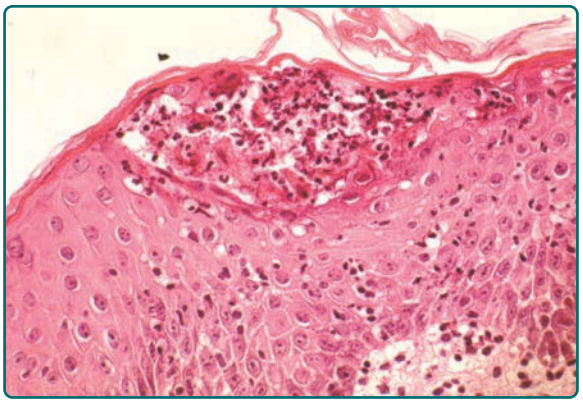

Figure 57-7 Histopathologic feature of subcorneal pustular dermatosis–type intercellular IgA dermatosis showing subcorneal pustules in the upper epidermis. (From Robinson ND, Hashimoto T, Amagai M, et al. The new pemphigus variants. *J Am Acad Dermatol*. 1999;40(5, pt 1): 649-71, Table II, 5th picture, with permission. Copyright © American Academy of Dermatology.)

HISTOPATHOLOGY

Histopathologically, SPD-type IAD shows subcorneal neutrophilic pustule in the uppermost epidermis (Fig. 57-7), which is identical to histopathologic findings seen in classical SPD without IgA antibodies. In contrast, IEN-type IAD develops intraepidermal neutrophilic pustules in the middle or entire epidermis (Fig. 57-8). In both SPD-type and IEN-type IAD, eosinophils and acantholytic cells are also occasionally seen in the pustules. PVeg-type IAD shows PVeg-like acanthosis with intraepidermal neutrophilic/eosinophilic pustules. PF-type IAD usually shows either IEN-type IAD-like intraepidermal neutrophilic pustules in the entire epidermis or PF-like acantholytic blister in the upper epidermis. PV-type IAD usually shows

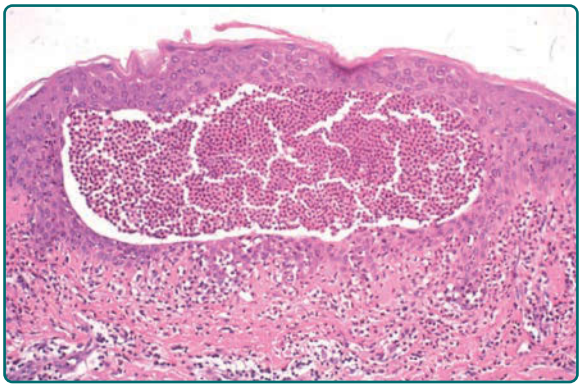

Figure 57-8 Histopathologic feature of intraepidermal neutrophilic IgA dermatosis–type intercellular IgA dermatosis showing neutrophilic pustule formation in the middle epidermis. (From Hashimoto T, Yasumoto S, Nagata Y, et al. Clinical, histopathological and immunological distinction in two cases of IgA pemphigus. *Clin Exp Dermatol*. 2002; 27(8):636-40, Fig. 2. Copyright © 2002, John Wiley & Sons.)

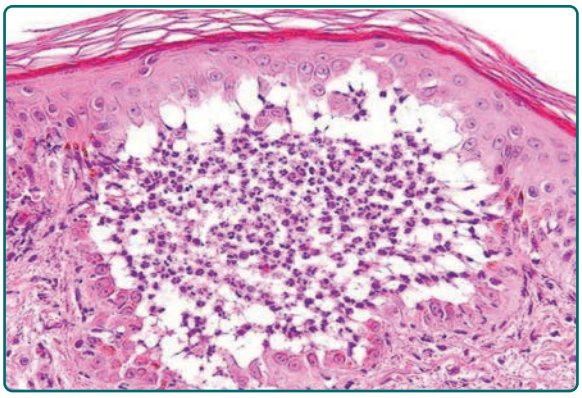

Figure 57-9 Histopathologic feature of IgA pemphigus vulgaris showing suprabasal blister containing neutrophils. (From Hashimoto T, Teye K, Ishii N. Clinical and immunological studies of 49 cases of various types of intercellular IgA dermatosis and 13 cases of classical subcorneal pustular dermatosis examined at Kurume University. *Br J Dermatol*. 2017;176(1):168-75, and used with permission from Professor Hiroyuki Matsue, Department of Dermatology, Chiba University School of Medicine, Chiba, Japan.)

IEN-type IAD-like pustules containing either neutrophils or eosinophils in the entire epidermis, or PV-like suprabasilar acantholytic blisters (Fig. 57-9).

IMMUNOFLUORESCENCE

DIRECT IMMUNOFLUORESCENCE

For the diagnosis of IAD, direct immunofluorescence using perilesional skin biopsy, which detects in vivo bound IgA autoantibodies, is essential. When a negative result is obtained for direct immunofluorescence, the diagnosis of IAD should be seriously doubted. SPD-type IAD shows IgA deposition to keratinocyte cell surfaces in the uppermost epidermis (Fig. 57-10). In contrast, IEN-type IAD shows IgA deposition to the cell surfaces in the entire epidermis (Fig. 57-11). PVeg-type IAD shows IgA deposition to various levels in the epidermis, which depends on the autoantigens in each patient. PF-type IAD shows IgA deposition to the cell surfaces in the entire epidermis, being stronger in the upper epidermis. PV-type IAD shows IgA deposition to the cell surfaces in the lower epidermis (Fig. 57-12). Undermined-type IAD shows IgA reactivity with

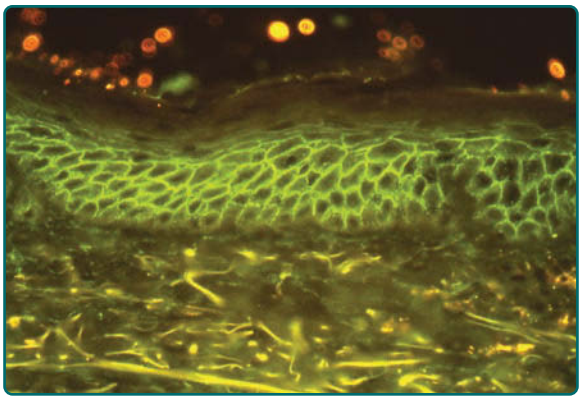

Figure 57-11 Direct immunofluorescence result of intraepidermal neutrophilic IgA dermatosis–type intercellular IgA dermatosis showing IgA reactivity with keratinocyte cell surfaces in the entire epidermis. (From Hashimoto T, Teye K, Ishii N. Clinical and immunological studies of 49 cases of various types of intercellular IgA dermatosis and 13 cases of classical subcorneal pustular dermatosis examined at Kurume University. *Br J Dermatol*. 2017;176(1):168-75, with permission. Copyright © 2017, John Wiley & Sons.)

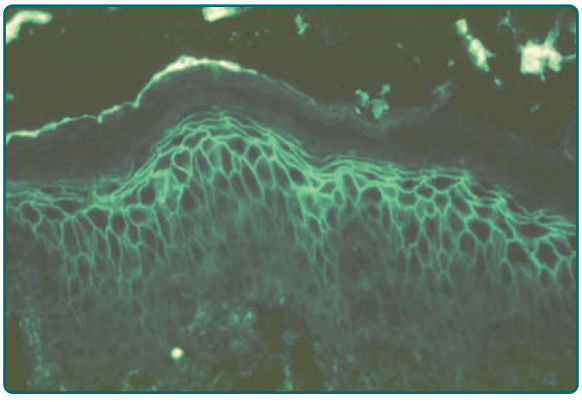

Figure 57-10 Direct immunofluorescence result of subcorneal pustular dermatosis–type intercellular IgA dermatosis showing IgA reactivity with keratinocyte cell surfaces in the uppermost epidermis. (From Hashimoto T, Teye K, Ishii N. Clinical and immunological studies of 49 cases of various types of intercellular IgA dermatosis and 13 cases of classical subcorneal pustular dermatosis examined at Kurume University. *Br J Dermatol*. 2017;176(1):168-75, with permission. Copyright © 2017, John Wiley & Sons.)

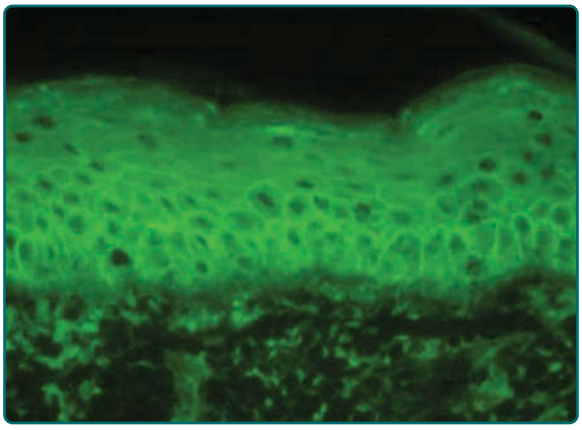

Figure 57-12 Direct immunofluorescence result of pemphigus vulgaris–type intercellular IgA dermatosis showing IgA reactivity with keratinocyte cell surfaces in the lower epidermis. (From Hashimoto T, Teye K, Ishii N. Clinical and immunological studies of 49 cases of various types of intercellular IgA dermatosis and 13 cases of classical subcorneal pustular dermatosis examined at Kurume University. *Br J Dermatol*. 2017;176(1):168-75, and used with permission from Professor Hiroyuki Matsue, Department of Dermatology, Chiba University School of Medicine, Chiba, Japan.)

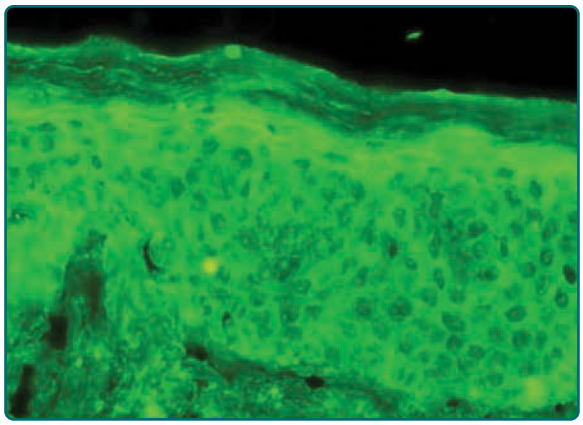

Figure 57-13 Indirect immunofluorescence result of subcorneal pustular dermatosis–type intercellular IgA dermatosis showing IgA reactivity with keratinocyte cell surfaces in the uppermost epidermis.

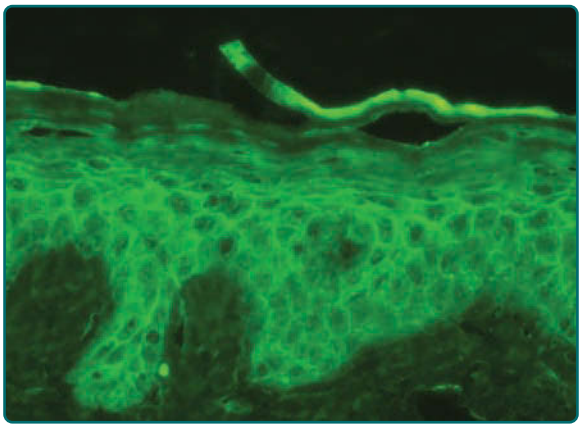

Figure 57-15 Indirect immunofluorescence result of pemphigus foliaceus–type intercellular IgA dermatosis showing IgA reactivity with keratinocyte cell surfaces in the entire epidermis, being stronger in the upper epidermis.

various epidermal layers, depending on the autoantigens in each patient.

INDIRECT IMMUNOFLUORESCENCE

Because titers of IgA antikeratinocyte cell-surface autoantibodies in the sera of various types of IAD are in general very low, IAD patient sera occasionally shows negative results in indirect immunofluorescence with sections of normal human skin or monkey esophagus as substrates. Thus, sensitivity of indirect immunofluorescence for the diagnosis of IAD is lower than that of direct immunofluorescence.

In indirect immunofluorescence using normal human skin, circulating IgA antibodies in various types of IAD show IgA reactivity to keratinocyte cell surfaces at the same levels in the epidermis as those of IgA deposition detected by direct immunofluorescence. Thus, the sera of SPD-type IAD show exclusive IgA binding to cell surfaces in the uppermost epidermis (Fig. 57-13), whereas IEN-type IAD shows IgA reactivity with the cell surfaces in the entire epidermis (Fig. 57-14). PVeg-type IAD shows IgA binding to various levels in the epidermis. IgA PF shows IgA reactivity with the cell surfaces in the entire epidermis, being stronger in the upper epidermis (Fig. 57-15), whereas PV-type IAD shows IgA reactivity with the cell surfaces in the lower epidermis (Fig. 57-16). Undetermined-type IAD shows IgA reactivity with various epidermal layers.

Although direct immunofluorescence is nonquantitative test, indirect immunofluorescence is performed for serially diluted patient sera and thus is a semiquantitative method. In some reported cases, titers of IgA anti–cell-surface antibodies in IAD sera decreased or disappeared after the resolution of the skin lesions. Thus, the titers in indirect immunofluorescence may be a good parameter to determine disease activity in IAD patients, and may be useful for choosing treatment options and determining doses of drugs during disease course. However, the correlation of IgA antibody titers with disease activity is, in general, less apparent than that in classical IgG-types of pemphigus.

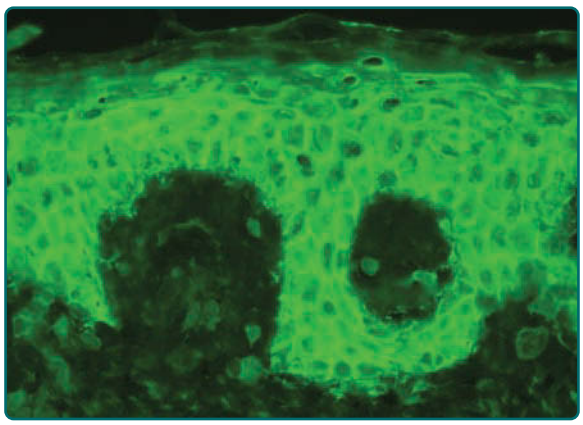

Figure 57-14 Indirect immunofluorescence result of intraepidermal neutrophilic IgA dermatosis–type intercellular IgA dermatosis showing IgA reactivity with keratinocyte cell surfaces in the entire epidermis.

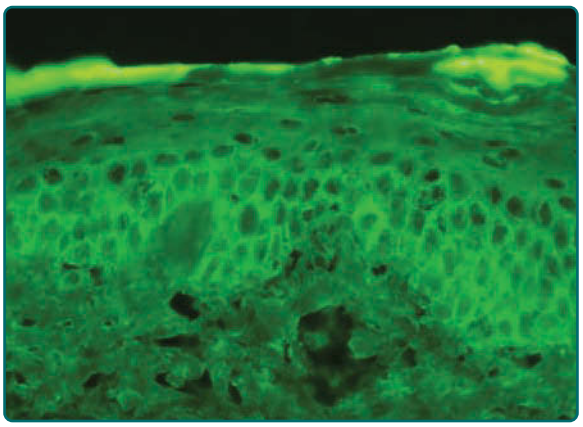

Figure 57-16 Indirect immunofluorescence result of pemphigus vulgaris–type intercellular IgA dermatosis showing IgA reactivity with keratinocyte cell surfaces in the lower epidermis.

IMMUNOBLOTTING

In original studies to determine autoantigens for classical IgG-types of pemphigus, immunoprecipitation using extracts of radiolabeled cultured keratinocytes was performed. However, because the procedures of immunoprecipitation are time-consuming and hazardous, this method is not widely used today.

Following immunoprecipitation, immunoblotting using various substrates are used to determine the autoantigens for patients in various AIBDs.[1,2] Immunoblotting of normal human epidermal extracts is currently most frequently performed for detection of autoantigen in various types of pemphigus.[1,2]

Immunoblotting was also applied to determine the autoantigens in various types of IAD. In earlier immunoblotting studies using either purified bovine desmosome or normal human epidermal extract, sera of a few IAD patients showed IgA reactivity with 2 protein bands corresponding to the a and b forms of the desmocollins.[17] However, because the sensitivity of immunoblotting for diagnosis of IAD is very low, this technique is infrequently used to determine the autoantigens in IAD today.

COMPLEMENTARY DNA TRANSFECTION METHOD

The cDNA transfection method is a more sensitive method for detecting IgA autoantibodies to Dsc1, Dsc2, and Dsc3 in the sera from patients with various types of IAD because this method can detect IgA reactivity with the epitopes on the native desmocollin proteins.[20] In this method, full-length cDNAs of human desmocollins are transfected into COS-7 cells, and reactivity of IgA autoantibodies in IAD sera with each desmocollin molecule expressed on the cell surface of the transfected COS-7 is detected by immunofluorescence without fixation.[20] In this method, almost all patients with SPD-type IAD show IgA reactivity with Dsc1 (Figs. 57-17 and 57-18), while the IEN-type of IAD does not react with Dsc1, Dsc2, or Dsc3.[20] However, this method needs a special molecular biologic facility and is time-consuming. In addition, high background staining may interfere with detection of positive reactivity.

ENZYME-LINKED IMMUNOSORBENT ASSAYS

Currently, ELISAs using recombinant proteins of Dsg1, Dsg3, BP180, BP230, and Type VII collagen are commercially available, and are useful for the diagnosing various types of pemphigus, bullous pemphigoid, and epidermolysis bullosa acquisita. In general, ELISA is more sensitive than either indirect immunofluorescence, immunoblotting, or cDNA transfection. In addition, ELISA is a quantitative method and can manipulate many samples simultaneously; as a result, ELISA is the preferred diagnostic method for various AIBDs.

To detect IgA autoantibodies to Dsg1 and Dsg3, IgA ELISAs of Dsg1 and Dsg3 were developed by modification of IgG ELISAs using baculovirus-producing recombinant proteins.[21] These ELISAs detect IgA antibodies to Dsg1 and Dsg3 in the sera from minor subsets of IAD, which are diagnosed as PF-type IAD and PV-type IAD, respectively.

IgA ELISA using mammalian recombinant proteins of Dsc1, Dsc2, and Dsc3 can detect IgA anti-Dsc1 antibodies in most cases of SPD-type IAD.[8] In addition, this method also detects IgA antibodies to Dsc1, Dsc2, and Dsc3 in various combinations in some cases of other types of IAD. Thus, the IgA ELISA using mammalian recombinant proteins is the preferred test for

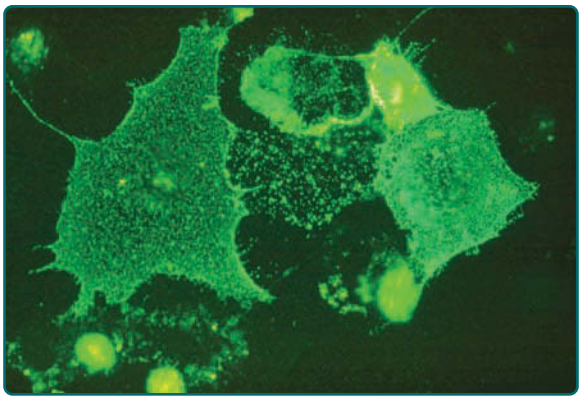

Figure 57-17 Result of complementary DNA transfection method for positive reactivity with Dsc1 by IgA antibodies in the serum of the subcorneal pustular dermatosis–type intercellular IgA dermatosis patient.

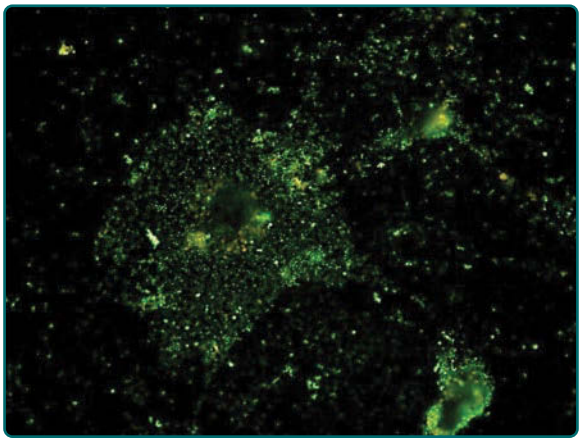

Figure 57-18 Result of complementary DNA transfection method for negative reactivity with Dsc1 by IgA antibodies in healthy normal serum.

TABLE 57-3
Differential Diagnoses for Intercellular IgA Dermatosis

- Classical subcorneal pustular dermatosis
- Pemphigus foliaceus
- Pemphigus vulgaris
- Pemphigus vegetans
- Paraneoplastic pemphigus
- Dermatitis herpetiformis
- Linear IgA bullous dermatosis
- Pustular psoriasis
- Erythema multiforme
- Sjögren syndrome
- Subacute cutaneous lupus erythematosus

detecting IgA reactivity with Dsc1, Dsc2, and Dsc3 in various types of IAD.

DIFFERENTIAL DIAGNOSIS

Table 57-3 summarizes the differential diagnoses for IAD.

Because SPD-type IAD and classical SPD without IgA antibodies show exactly the same clinical and histopathologic features,[9] these 2 diseases should be differentiated by detection IgA anti–cell-surface antibodies by direct immunofluorescence.

IAD also needs to be differentiated from other AIBDs. IAD shows clinically and histopathologically bullous and pustular skin lesions, which are similar to those seen in PF, PV, PVeg, and paraneoplastic pemphigus. Therefore, these IgG types of pemphigus should also be differentiated. Because IAD frequently shows annular and herpetiform erythematous lesions, dermatitis herpetiformis Duhring and linear IgA bullous dermatosis are also considered to be differential diagnoses.

Pustular psoriasis, particularly recurrent annular-type pustular psoriasis, also shows clinical and histopathologic features indistinguishable from IAD. Erythema multiforme, Sjögren syndrome and subacute cutaneous lupus erythematosus may show annular erythematous skin lesions, which are similar to those seen in IAD. These diseases should also be differentiated.

To exclude the possibility of the patient having one of the diseases mentioned above, both direct and indirect immunofluorescence tests, as well as other immunologic and biochemical examination, are necessary.

PROGNOSIS AND CLINICAL COURSE

In contrast to various classical IgG types of pemphigus, IAD has a much better prognosis and is rarely fatal. Although the systemic administration of high doses of corticosteroids and immunosuppressive agents are inevitable therapy in classical IgG types of pemphigus, except for PF and pemphigus erythematosus, these aggressive therapies are unnecessary in most IAD patients. In general, IAD patients can be controlled with dapsone with or without low doses of systemic corticosteroids.

The disease course of IAD is usually refractory, and skin lesions frequently recur upon withdrawal of the drugs. Some patients, who could be followed for a long time, continued to show recurrence after more than 30 years.[9,14] Thus, IAD is considered to be not fatal disease but extremely intractable disease condition. Various types of treatments are tried, but show inconsistent effectiveness among individual IAD patients.

TREATMENTS

Because of the rarity of IAD, systematic clinical trial studies have never been performed for any treatments for IAD.[33] Therefore, no satisfactory guidelines of treatment of IAD are currently available.

DAPSONE AND OTHER SULFONES

Oral dapsone 50 to 200 mg/day is the most common therapy in IAD.[9,10,13] Other sulfones, including salazosulfapyridine, sulfamethoxypyridazine, and sulfamethoxazole-trimethoprim, were also occasionally used in patients, who showed less response to dapsone. A considerable number of IAD patients can be controlled sufficiently or even completely by sole treatment of dapsone or other sulfones.[9,10,13] However, in IAD cases with insufficient response to dapsone or sulfones, a variety of other types of treatments are used.

CORTICOSTEROIDS AND IMMUNOSUPPRESSIVE AGENTS

The systemic corticosteroids, most commonly prednisolone, are the second choice of therapy for IAD.[9,10,13] In contrast to classical IgG types of pemphigus, which are treated with high doses of glucocorticoids (0.5 to 1.0 mg/kg/day, equivalent to prednisolone), relatively low doses of corticosteroids (0.2 to 0.5 mg/kg/day, equivalent to prednisolone) are given in IAD. A combination of dapsone and low-dose systemic corticosteroids is also frequently used. Either pulsed corticosteroid (intravenous administration of a high dose of methylprednisolone) or various types of immunosuppressive agents are rarely used in IAD. However, very refractory IAD patients have been treated with aggressive immunosuppressive therapy with either high-dose systemic corticosteroids or various immunosuppressive agents, including azathioprine,

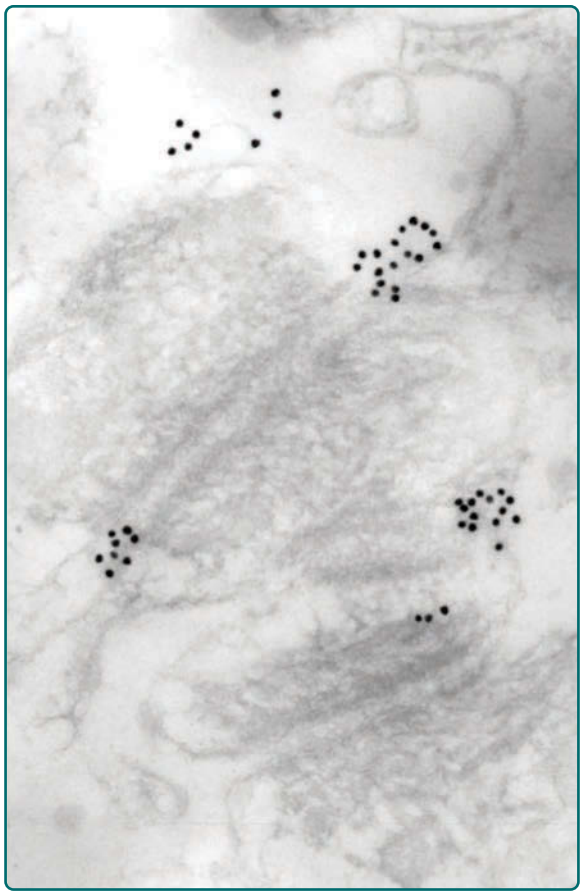

Figure 57-19 Immunogold electron microscopy with sera from intraepidermal neutrophilic dermatosis–type intercellular IgA dermatosis showing binding of gold particles to cell surfaces in the interdesmosomal region, but not in desmosomes, in cultured normal human keratinocyte. (From Ishii N, Ishida-Yamamoto A, Hashimoto T. Immunolocalization of target autoantigens in IgA pemphigus. *Clin Exp Dermatol*. 2004;29(1):62-66, Fig. 3D, with permission. Copyright © 2004, John Wiley & Sons.)

mycophenolate mofetil, cyclosporine, cyclophosphamide, and methotrexate.[34]

OTHER THERAPIES

A number of other types of therapy are used in IAD patients in whom systemic dapsone and corticosteroids are not effective.

Like treatments for bullous pemphigoid, antibiotics, including tetracycline, minocycline, doxycycline, and macrolides, are used in IAD, mainly for their antiinflammatory effects. To suppress activity of neutrophils, colchicine is also used. However, the effectiveness of these drugs in IAD is inconsistent.

Although experimental disease models have not been established, IgA autoantibodies in IAD are considered to be pathogenic. Therefore, plasmapheresis is sometimes used for patients with severe IAD to remove IgA autoantibodies. Intravenous Ig therapy is another therapy used to reduce activity of autoantibodies, but its use in IAD has not been reported.

Because of the clinical and histopathologic similarity of IAD to pustular psoriasis, IAD patients are also treated with therapies for psoriasis and pustular psoriasis; that is, systemic retinoids, including etretinate, isotretinoin,[35] and acitretin,[36] adalimumab infusion, and psoralen and ultraviolet A.[14] These treatments show some effectiveness in particular IAD patients, but not in all IAD patients. A combination of dapsone and acitretin also has been successfully used.[37]

Because IAD usually shows very refractory disease course, treatment with anti-CD20 monoclonal antibodies, most commonly rituximab, may be a therapeutic option for IAD in the future, particularly for patients with extremely intractable IAD and frequent recurrences.

PERSPECTIVES

Because IAD is a very rare disease, a number of questions about its pathophysiology remain unsolved and should be the subject of study. Among the questions to resolved are these: The pathogenic activity of IgA autoantibodies in the sera of IAD patients should be examined by specific disease models in the future. As mentioned above, the autoantigen for IEN-type IAD is considered to be a nondesmosomal protein (Fig. 57-19),[24] and therefore may be a unique protein as an autoantigen in pemphigus. Finally, the mechanism for production of IgA autoantibodies in IAD, including class-switch from IgM to IgA, should also be examined.

REFERENCES

1. Hashimoto T, Tsuruta D, Koga H, et al. Summary of results of serological tests and diagnoses for 4774 cases of various autoimmune bullous diseases consulted to Kurume University. *Br J Dermatol*. 2016;175(5):953-965.
2. Otten JV, Hashimoto T, Hertl M, et al. Molecular diagnosis in autoimmune skin blistering conditions. *Curr Mol Med*. 2014;14(1):69-95.
3. Hashimoto T, Ishii N, Ohata C, et al. Pathogenesis of epidermolysis bullosa acquisita, an autoimmune subepidermal bullous disease. *J Pathol*. 2012;228(1):1-7.
4. Tsuruta D, Ishii N, Hashimoto T. Diagnosis and treatment of pemphigus. *Immunotherapy*. 2012;4(7):735-745.
5. Hashimoto T, Ogawa MM, Konohana A, et al. Detection of pemphigus vulgaris and pemphigus foliaceus antigens by immunoblot analysis using different antigen sources. *J Invest Dermatol*. 1990;94(3):327-331.
6. Ishii K, Amagai M, Hall RP, et al. Characterization of autoantibodies in pemphigus using antigen-specific enzyme-linked immunosorbent assays with baculovirus-expressed recombinant desmogleins. *J Immunol*. 1997;159(4):2010-2017.
7. Ohzono A, Sogame R, Li X, et al. Clinical and immunological findings in 104 cases of paraneoplastic pemphigus. *Br J Dermatol*. 2015;173(6):1447-1452.
8. Ishii N, Teye K, Fukuda S, et al. Anti-desmocollin autoantibodies in nonclassical pemphigus. *Br J Dermatol*. 2015;173(1):59-68.

9. Hashimoto T, Teye K, Ishii N. Clinical and immunological studies of 49 cases of various types of intercellular IgA dermatosis and 13 cases of classical subcorneal pustular dermatosis examined at Kurume University. *Br J Dermatol*. 2017;176(1):168-175.
10. Hashimoto T, Nishikawa T. Nomenclature for diseases with IgA antikeratinocyte cell surface autoantibodies. *Br J Dermatol*. 2015;173(3):868-869.
11. Nishikawa T, Hashimoto T, Teraki Y, et al. The clinical and histopathological spectrum of IgA pemphigus. *Clin Exp Dermatol*. 1991;16(5):401-402.
12. Hashimoto T. Immunopathology of IgA pemphigus. *Clin Dermatol*. 2001;19(6):683-689.
13. Tsuruta D, Ishii N, Hamada T, et al. IgA pemphigus. *Clin Dermatol*. 2011;29(4):437-442.
14. Hashimoto T, Inamoto N, Nakamura K, et al. Intercellular IgA dermatosis with clinical features of subcorneal pustular dermatosis. *Arch Dermatol*. 1987; 123(8):1062-1065.
15. Wallach D, Cottenot F, Pelbois G, et al. Subcorneal pustular dermatosis and monoclonal IgA. *Br J Dermatol*. 1982;107(2):229-234.
16. Huff JC, Golitz LE, Kunke KS. Intraepidermal neutrophilic IgA dermatosis. *N Engl J Med*. 1985;313(26):1643-1645.
17. Ebihara T, Hashimoto T, Iwatsuki K, et al. Autoantigens for IgA anti-intercellular antibodies of intercellular IgA vesiculopustular dermatosis. *J Invest Dermatol*. 1991;97(4):742-745.
18. Beutner EH, Chorzelski TP, Wilson RM, et al. IgA pemphigus foliaceus. Report of two cases and a review of the literature. *J Am Acad Dermatol*. 1989;20(1):89-97.
19. Karpati S, Amagai M, Liu WL, et al. Identification of desmoglein 1 as autoantigen in a patient with intraepidermal neutrophilic IgA dermatosis type of IgA pemphigus. *Exp Dermatol*. 2000;9(3):224-228.
20. Hashimoto T, Kiyokawa C, Mori O, et al. Human desmocollin 1 (Dsc1) is an autoantigen for the subcorneal pustular dermatosis type of IgA pemphigus. *J Invest Dermatol*. 1997;109(2):127-131.
21. Hashimoto T, Komai A, Futei Y, et al. Detection of IgA autoantibodies to desmogleins by an enzyme-linked immunosorbent assay: the presence of new minor subtypes of IgA pemphigus. *Arch Dermatol*. 2001;137(6):735-738.
22. Hisamatsu Y, Amagai M, Garrod DR, et al. The detection of IgG and IgA autoantibodies to desmocollins 1-3 by enzyme-linked immunosorbent assays using baculovirus-expressed proteins, in atypical pemphigus but not in typical pemphigus. *Br J Dermatol*. 2004;151(1):73-83.
23. Teye K, Numata S, Ohzono A, et al. Establishment of IgA ELISAs of mammalian recombinant proteins of human desmocollins 1-3. *J Dermatol Sci*. 2016;83(1):75-77.
24. Ishii N, Ishida-Yamamoto A, Hashimoto T. Immunolocalization of target autoantigens in IgA pemphigus. *Clin Exp Dermatol*. 2004;29(1):62-66.
25. Tsuchisaka A, Ishii N, Hamada T, et al. Epidermal polymeric immunoglobulin receptors: leads from intraepidermal neutrophilic IgA dermatosis-type IgA pemphigus. *Exp Dermatol*. 2015;24(3):217-219.
26. Yasuda H, Kobayashi H, Hashimoto T, et al. Subcorneal pustular dermatosis type of IgA pemphigus: demonstration of autoantibodies to desmocollin-1 and clinical review. *Br J Dermatol*. 2000;143(1):144-148.
27. Hashimoto T, Yasumoto S, Nagata Y, et al. Clinical, histopathological and immunological distinction in two cases of IgA pemphigus. *Clin Exp Dermatol*. 2002;27(8):636-640.
28. Weston WL, Friednash M, Hashimoto T, et al. A novel childhood pemphigus vegetans variant of intraepidermal neutrophilic IgA dermatosis. *J Am Acad Dermatol*. 1998;38(4):635-638.
29. Tajima M, Mitsuhashi Y, Irisawa R, et al. IgA pemphigus reacting exclusively to desmoglein 3. *Eur J Dermatol*. 2010;20(5):626-629.
30. Ueda A, Ishii N, Temporin K, et al. IgA pemphigus with paraneoplastic pemphigus-like clinical features showing IgA antibodies to desmoglein 1/3 and desmocollin 3, and IgG and IgA antibodies to the basement membrane zone. *Clin Exp Dermatol*. 2013;38(4):370-373.
31. Espana A, Gimenez-Azcarate A, Ishii N, et al. Antidesmocollin 1 autoantibody negative subcorneal pustular dermatosis-type IgA pemphigus associated with multiple myeloma. *Br J Dermatol*. 2015;172(1):296-298.
32. Asahina A, Koga H, Suzuki Y, et al. IgA pemphigus associated with diffuse large B-cell lymphoma showing unique reactivity with desmocollins: unusual clinical and histopathological features. *Br J Dermatol*. 2013;168(1):224-226.
33. Moreno AC, Santi CG, Gabbi TV, et al. IgA pemphigus: case series with emphasis on therapeutic response. *J Am Acad Dermatol*. 2014;70(1):200-201.
34. Sibley Hash K, Rencic A, Hernandez MI, et al. Aggressive immunosuppressive therapy for a refractory case of IgA pemphigus. *Arch Dermatol*. 2002;138(6):744-746.
35. Gruss C, Zillikens D, Hashimoto T, et al. Rapid response of IgA pemphigus of subcorneal pustular dermatosis type to treatment with isotretinoin. *J Am Acad Dermatol*. 2000;43(5, pt 2):923-926.
36. Ruiz-Genao DP, Hernandez-Nunez A, Hashimoto T, et al. A case of IgA pemphigus successfully treated with acitretin. *Br J Dermatol*. 2002;147(5):1040-1042.
37. Monshi B, Richter L, Hashimoto T, et al. IgA pemphigus of the subcorneal pustular dermatosis type. Successful therapy with a combination of dapsone and acitretin [in German]. *Hautarzt*. 2012;63(6):482-486.

Chapter 58 :: Linear Immunoglobulin A Dermatosis and Chronic Bullous Disease of Childhood

:: Matilda W. Nicholas, Caroline L. Rao, & Russell P. Hall III

AT-A-GLANCE

Linear Immunoglobulin A Dermatosis

- Rare blistering disease with onset typically after fourth decade of life.
- Linear band of immunoglobulin (Ig) A at the dermal–epidermal basement membrane.
- Clinical presentations may mimic dermatitis herpetiformis, bullous pemphigoid, and cicatricial pemphigoid.
- May occur in association with many drugs, including vancomycin.
- May occur in association with inflammatory bowel diseases, but is only rarely associated with gluten-sensitive enteropathy.
- Rarely seen in association with malignancy, specifically lymphoid malignancy.
- Histology shows subepidermal collection of neutrophils at the basement membrane, often collecting in papillary tips with subepidermal blisters.
- Patients have relatively low titers of circulating IgA autoantibodies, most frequently against portions of BPAG2 (type XVII collagen), or rarely against BPAG1, LAD 285, type VII collagen, and others.
- Most patients respond dramatically to treatment with dapsone; some require adjunctive systemic corticosteroids.
- Prognosis is variable with both spontaneous remissions and longstanding disease.

Chronic Bullous Disease of Childhood

- Rare blistering disorder of childhood presenting predominantly in children younger than 5 years of age.
- Linear IgA at the dermal–epidermal basement membrane.
- Clinical presentation of tense bullae, often in perineum and perioral regions, giving a "cluster-of-jewels" appearance. New lesions sometimes appear around the periphery of previous lesions with a collarette of blisters.
- Histology shows subepidermal collection of neutrophils at the basement membrane, similar to linear IgA bullous dermatosis.
- Most patients respond dramatically to treatment with dapsone.
- Spontaneous remissions, often within 2 years, are frequent.

Linear immunoglobulin (Ig) A dermatosis is a rare, immune-mediated, blistering skin disease that is defined by the presence of homogeneous linear deposits of IgA at the cutaneous basement membrane (Fig. 58-1). Although in the original description of patients with linear IgA dermatosis it was considered to be a manifestation of dermatitis herpetiformis (DH), it has now been clearly separated from DH on the basis of its immunopathology, immunogenetics, and lack of consistent association with a gluten-sensitive enteropathy.[1-4] Patients with linear IgA dermatosis can present with lesions suggestive of epidermolysis bullosa acquisita (EBA), DH, bullous pemphigoid (BP), lichen planus, prurigo nodularis, or cicatricial pemphigoid.[1-6]

Drug-induced linear IgA was initially described in association with vancomycin and is now associated with a wide variety of drugs.[7-15] Drug-induced linear IgA differs somewhat from classic linear IgA in clinical presentation with a wider variety of clinical presentations, including morbilliform, erythema multiforme–like, and toxic epidermal necrolysis–like.[7-11,16-18]

Chronic bullous disease of childhood (CBDC) is a rare blistering disease that occurs predominantly in children younger than 5 years of age and has an identical pattern of homogeneous linear IgA deposits at the epidermal basement membrane.[19,20] Studies demonstrate that in some patients CBDC and linear IgA dermatosis represent different presentations of the same disease process.[21,22]

EPIDEMIOLOGY

Linear IgA dermatosis occurs most often after puberty, with most patients presenting after the fourth decade of life.[2,4,23] A slight predominance of females has been noted in several studies,[2,4,23] although others have

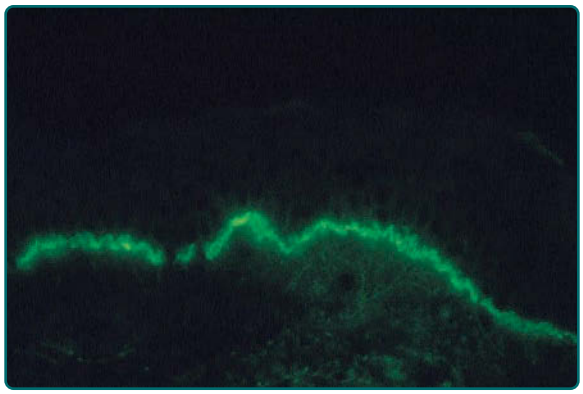

Figure 58-1 Direct immunofluorescence of normal-appearing perilesional skin from a patient with linear immunoglobulin A dermatosis. A homogeneous band of immunoglobulin A is present at the dermal–epidermal junction.

noted the opposite.[24,25] In contrast, CBDC presents most often before the age of 5 years.[26] As in patients with linear IgA dermatosis, there is a slight female predominance in patients with CBDC in several,[20,26] but not all, studies.[24,27]

Evaluation of the human leukocyte antigen (HLA) association in patients with linear IgA dermatosis and CBDC has yielded conflicting results. Some investigators have found an increased frequency of the human histocompatibility antigen HLA-B8 in patients with linear IgA dermatosis, whereas others have found no increased frequency.[28-30] In CBDC, an increased frequency of HLA-B8 has been noted, with up to 76% of patients expressing HLA-B8.[26] Collier et al demonstrated an increased frequency of HLA-B8, HLA-DR3, and HLA-DQ2 in CBDC that was not seen in adults with linear IgA dermatosis.[28] These authors suggested that these haplotypes may have a role in earlier disease presentation. In addition, the *TNF2* allele was found with increased frequency in both adults and children with linear IgA disease when compared with unaffected subjects. There was, however, no increase seen in either adults or children when compared with HLA-DR3+ controls.

ETIOLOGY AND PATHOGENESIS: IMMUNOPATHOLOGY

Linear IgA dermatosis and CBDC are defined by the presence of a homogeneous linear band of IgA at the dermal–epidermal basement membrane zone (Table 58-1). A minority of patients in both groups have additional deposits of other immunoreactants, most often IgG and occasionally the third component of complement (C3).[26] A recent retrospective study noted that 40% of cases of idiopathic linear IgA disease had C3 deposits on direct immunofluorescence, but no cases of drug-induced linear IgA dermatosis in adults had C3 deposits.[24] Because IgA is the predominant Ig of the secretory immune system, numerous investigators have attempted to determine if the IgA present in the skin of these patients is of mucosal origin. Characterization of the IgA subclass in the skin has revealed almost exclusively IgA1 and not the subclass most often associated with mucosa, IgA2.[23,31,32] In addition, neither secretory piece nor J chain, both of which are present in secretory IgA, has been found in the IgA present in the skin of patients with linear IgA deposits.[33] Although these data have led to suggestions that the IgA is not of mucosal origin, the true origin of the IgA deposits in the skin of these patients is not known.

Initially it was thought that patients with linear IgA dermatosis and CBDC rarely had circulating IgA antibodies against the epidermal basement membrane (see Table 58-2). Indirect immunofluorescence, using 1 M NaCl-split normal human skin as a substrate, demonstrates that the majority of patients with CBDC have low-titer circulating antibodies against the epidermal side of the split skin.[10,23] Circulating low-titer IgA antibodies directed against the epidermal basement membrane also have been found in adults with linear IgA dermatosis.[26,34] Others have reported binding of IgA antibodies from some patients to the dermal side of normal human split skin, suggesting that more than 1 antigen may be the target for the IgA anti–basement membrane antibodies.[34-36] Immunoelectron

TABLE 58-1
Immunoreactants and Circulating Antibodies

TYPE	COMPOSITION OF CUTANEOUS IMMUNOREACTANTS	LOCATION OF IMMUNOREACTANTS	CIRCULATING IgA AUTOANTIBODIES
Linear IgA	40% have C3 24% have IgG Almost all IgA1	1. Lamina lucida (BP-like) 2. At and below lamina lucida (EBA-like) 3. Above and below lamina lucida	May have low titer against epidermal basement membrane antigens
Drug-induced IgA	None reported with C3 Almost all have IgA1		
CBDC	9% have IgG May have C3 Almost all have IgA1	Lamina lucida or sublamina densa	Most have low titer against epidermal side of sodium split-skin

BP, bullous pemphigoid; CBDC, chronic bullous disease of childhood; EBA, epidermolysis bullosa acquisita; Ig, immunoglobulin.

TABLE 58-2
Pharmacological Treatments

First-line	Dapsone
	Sulfapyridine
First-line adjuvant	Low-dose prednisone
Second-line	Mycophenolate mofetil
	Intravenous immunoglobulin
Second-line adjuvant	Antibiotics (including trimethoprim-sulfamethoxazole, dicloxacillin, erythromycin, flucloxacillin)
	Topical tacrolimus

microscopy studies have been performed to determine the exact location of the IgA in the skin of patients with both linear IgA dermatosis and CBDC. Immunoelectron microscopy of the skin of patients with linear IgA deposits has revealed 3 distinct patterns of immunoreactants. In some patients with linear IgA dermatosis, the IgA deposits are found in the lamina lucida region of the basement membrane zone, similar to the location of immunoreactants present in the skin of patients with BP.[35,37] A second pattern of IgA deposition has been detected in which the IgA deposits are present at and below the lamina densa in a pattern similar to that seen in EBA.[35,37,38] Prost et al have described a third pattern of immunoreactants in some patients with linear IgA dermatosis in which the IgA deposits are found both above and below the lamina densa.[35] In a similar manner, immunoelectron microscopy studies of skin of patients with CBDC have shown the IgA immunoreactants to be in either the lamina lucida or a sublamina densa location.[21,38] These findings further support the probability that multiple antigens may be involved as the targets in both adults and children with linear IgA deposits in the skin. Horiguchi et al reviewed 213 cases of linear IgA in Japan and found a strong association between older age of onset and both IgG/IgA type and dermal binding. IgG was found in approximately 9% of patients with the infantile (CBDC) type whereas in adults (older than age 16 years), IgG was found in 24% of patients. Interestingly, when comparing the different groups based on patterns of antigen binding (eg, dermal vs epidermal and IgA vs IgG/IgA) no significant clinical differences were found.[39]

Although the relatively low titer of IgA antibodies against the basement membrane present in the sera of patients with both linear IgA dermatosis and CBDC has complicated the search for specific antigenic targets for the IgA, several investigators have made significant observations regarding the antigenic targets in these diseases (see Table 58-2). Zone et al studied sera from patients who had circulating IgA antibodies that bound to the epidermal side of 1 M NaCl-split normal human skin, as shown by indirect immunofluorescence.[40] They found that serum IgA from patients with either CBDC or linear IgA dermatosis bound to a 97-kDa protein. Immunoelectron microscopy revealed that the 97-kDa antigen is present in the lamina lucida, below the hemidesmosome of normal human skin, in a location similar to where the IgA is localized in patients with CBDC and linear IgA dermatosis.[41] Subsequently, Zone et al determined that the 97-kDa linear IgA bullous disease antigen is identical to a portion of the extracellular domain of the 180-kDa BP antigen (BPAG2 or collagen XVII), which is essential in anchoring basal keratinocytes to the epidermal basement membrane.[42] The BP antigen (BPAG2) consists of a 180-kDa transmembrane protein and 120-kDa portion that corresponds to the collagenous ectodomain. Roh et al and Schumann et al reported that autoantibodies in patients with linear IgA dermatosis recognize the soluble 120-kDa ectodomain of type XVII collagen.[43,44] The 120-kDa antigen target is not unique to linear IgA dermatosis because it is also the antigen targeted by autoantibodies in some patients with cicatricial pemphigoid and BP.[43,44] Furthermore, IgA antibodies and T cells from patients with linear IgA bullous dermatosis have been found to be directed against the NC-16A region of collagen type XVII, which is the same region against which the IgG and T cells from patients with BP are directed.[45,46] This may explain in part the overlap in clinical and histologic features of these conditions. Wojnarowska et al identified another possible target antigen in patients with linear IgA dermatosis and CBDC. Using sera from patients in whom the IgA bound to the epidermal side of 1 M NaCl split-skin on routine indirect immunofluorescence, they found that IgA in the sera of some patients with these diseases bound to a 285-kDa protein (LAD 285) that was not the 230-kDa BP antigen or type VII collagen, the EBA antigen.[47] Allen and Wojnarowska have analyzed the sera of more than 70 patients with both linear IgA dermatosis and CBDC and found that the predominant antigenic target in these patients is the BP180 antigen (collagen XVII), but that some patients react with multiple antigens including the BP230, LAD 285, and other yet-to-be-identified proteins.[48] Ishii et al described a patient with Linear IgA who had antibodies directed at the NC16a domain of BP180 without evidence of antibody formation to 120-kDa LAD-1.[49] Izaki et al reported a case of linear IgA/IgG bullous dermatosis with anti–laminin-332 autoantibodies.[50] Tsuchisaka et al showed that in 8 of 12 patients with sublamina densa pattern direct immunofluorescence, type VII collagen appeared to be the antibody target.[51] In many patients, IgA appears to bind to several different antigenic targets, suggesting the possibility that there is epitope spreading. The clinical significance of these findings however, has not been established.[48]

CLINICAL FINDINGS

CUTANEOUS MANIFESTATIONS

The clinical manifestations of linear IgA dermatosis are heterogeneous and often indistinguishable from those seen in patients with DH.[2,4,26,52] Patients may present with combinations of annular or grouped

Figure 58-2 Patient with linear immunoglobulin A dermatosis with crusted erosions, papules, and vesicles on the back and neck.

papules, vesicles, and bullae (Figs. 58-2 and 58-3). Typically, these lesions are distributed symmetrically on extensor surfaces, including elbows, knees, and buttocks. Lesions most often are very pruritic, resulting in numerous crusted papules (Fig. 58-4). The clinical presentation can be difficult to distinguish from that seen in patients with DH. However, the degree of pruritus seen in patients with linear IgA dermatosis is variable and, in general, less severe than that seen in patients with DH. Some patients with linear IgA dermatosis present with larger bullae, in a pattern more consistent with that seen in patients with BP, or occasionally with cutaneous findings similar to those seen in patients with EBA.

Patients with drug-induced linear IgA bullous dermatosis have been reported with erythema multiforme–like findings and a toxic epidermal necrolysis–like

Figure 58-3 Patient with linear immunoglobulin A dermatosis with annular erythematous plaques on the thighs.

Figure 58-4 Patient with linear immunoglobulin A dermatosis with grouped urticarial papules on the back with scattered crusted erosions.

presentation, with widespread bullae.[7,11,17] Localized palmar and morbilliform variants also have been described.[16,18,53] The Koebner phenomenon has also been reported in drug-induced linear IgA dermatosis.[54] While vancomycin is most closely associated with the drug-induced linear IgA, a number of other medications also have been implicated, including lithium, phenytoin, sulfamethoxazole-trimethoprim, furosemide, atorvastatin, captopril, diclofenac, ketoprofen, and infliximab.[13,14,17] In addition, a localized linear IgA in the setting of an acute contact dermatitis has been reported.[55] Recovery has been reported with discontinuation of the offending agent alone, but these patients may benefit from dapsone therapy (see "Treatment and Prognosis" below).[7,11,56]

The clinical presentation of CBDC is characterized most often by the development of tense bullae, often on an inflammatory base.[19] These lesions occur most frequently in the perineum and perioral region, and often may occur in clusters, giving a "cluster of jewels" appearance (Figs. 58-5, 58-6, and 58-7). New lesions sometimes appear around the periphery of previous lesions, with a resulting "collarette" of blisters. Patients often report significant pruritus and/or a burning of the skin with the development of skin lesions. Patients with CBDC often present with the acute development of large numbers of tense blisters, which may rupture and become secondarily infected. CBDC differs from linear IgA bullous dermatosis of adults in its typical clinical appearance, relative paucity of serious mucosal involvement, and good prognosis.[39]

Rarely, patients with linear IgA dermatosis may present with an acute febrile illness with arthritis, arthralgias, and generalized malaise.[57,58] The presence

Figure 58-5 Patient with chronic bullous disease of childhood. Tense bullae and crusted papules are present on the abdomen, with a clustering of bullae noted in the perineal region.

Figure 58-7 Extensive chronic bullous disease of childhood. Note tense and flaccid blisters without notable inflammation.

of multiple papules and vesicles in a patient with systemic signs and symptoms has led to the evaluation of these patients for systemic infections, including viral infections. Routine direct immunofluorescence, however, has revealed linear deposits of IgA, and these patients have responded to conventional therapy.

MUCOSAL INVOLVEMENT

Mucosal involvement is an important clinical manifestation seen in patients with linear IgA dermatosis and CBDC. This involvement can range from largely asymptomatic oral ulcerations and erosions to severe oral disease alone, as well as to severe conjunctival and oral disease typical of that seen in cicatricial pemphigoid.[26,59,60] Oral lesions may occur in up to 70% of patients with linear IgA disease.[26] Mucosal invasion with complication is less often seen in CBDC.[39,61] Although most patients with linear IgA dermatosis and mucosal involvement have significant cutaneous disease, cases have been reported in the literature in which the presenting and predominant clinical manifestations are lesions of the mucous membranes.[60,62] These patients may present with desquamative gingivitis and oral lesions consistent with those seen in patients with cicatricial pemphigoid (see Chap. 55). Patients also may present with conjunctival disease and scar formation typical of that seen in patients with cicatricial pemphigoid (see Chap. 55). Mucosal involvement also appears to be less prominent in patients with drug-induced linear IgA.[17] Patients with linear IgA bullous dermatosis also have been reported to present with severe laryngeal and pharyngeal involvement before the development of more typical cutaneous manifestitations.[63,64]

Figure 58-6 Chronic bullous disease of childhood. Tense blisters on erythematous bases in the pubic and inguinal areas.

DISEASE ASSOCIATIONS

The similar clinical presentation of many patients with linear IgA disease to that seen in patients with DH led to the investigation of patients with linear IgA disease for an associated gluten-sensitive enteropathy. Although some investigators have found evidence of minimal inflammatory changes in the small bowel of patients with linear IgA disease, numerous investigators have been unable to show that the majority of

patients with linear IgA disease have significant evidence of the villous atrophy characteristically seen in patients with DH.[3,65] In addition, the clinical manifestations of linear IgA disease have not been controlled by the use of a gluten-free diet.[66] Circulating autoantibodies against tissue transglutaminase, which occur with high frequency in patients with untreated gluten-sensitive enteropathy and DH, have not been found in most patients with linear IgA diseases.[67]

Other conditions have been reported in association with linear IgA disease. One example is ulcerative colitis and Crohn disease, which can result in a clinical syndrome where the activity of both diseases is linked (ie, as one disease flares, so does the other).[68,69] Paige and coworkers reviewed 70 patients with linear IgA bullous dermatosis and found 5 (7.1%) had associated ulcerative colitis. The extent and reason for this association has yet to be established. Perhaps, the abnormal mucosal IgA1 production seen in patients with ulcerative colitis may play a role.[69] In 1 case, an ulcerative colitis patient developed linear IgA disease only after treatment with infliximab.[14] In patients with CBDC, Horiguchi reported associated systemic disease in only 13 of 213 cases reviewed.[39] CBDC also has been reported in association with acute mononucleosis and *Paecilomyces* lung infection in the setting of chronic granulomatous disease.[70] The relationship between these conditions and CBDC has yet to be established.

The relatively acute onset of clinical, histologic, and immunopathologic findings consistent with linear IgA disease has been seen in patients who have been taking a variety of drugs, including vancomycin, lithium phenytoin, sulfamethoxazole-trimethoprim, furosemide, atorvastatin, captopril, diclofenac, ketoprofen, and infliximab.[7-9,13,14,17,56] Vancomycin is the most common drug that is associated with the development of linear IgA bullous dermatosis, and linear IgA bullous dermatosis is the most common nonimmediate hypersensitivity reaction to vancomycin.[71] Linear IgA dermatosis has similarly been described with interferon-α2a and was temporally related to the influenza vaccine. While these may reflect an induction of a previously unrecognized autoimmune process, in both cases the eruption was self-limited, in contrast to classic linear IgA, which follows a chronic, waxing-and-waning course.[72,73] The mechanism of this interaction is not known; however, a small number of patients with vancomycin-induced linear IgA disease have been reported to have circulating IgA antibodies directed against the BP180, BP230, and LAD 285 antigens.[74,75] In 1 case of vancomycin-induced linear IgA bullous dermatosis, rechallenge with vancomycin in a gradual manner did not result in a recurrence of the eruption.[76] Identifying the causative agent in a patient receiving multiple potential triggers may be difficult, although recently, a drug-induced lymphocyte stimulation test was successfully employed to identify the triggering agent in 1 patient.[77] This has yet to be studied more broadly.

Rarely, physical exposures can also trigger linear IgA bullous dermatosis, chief among them ultraviolet light.[78] Development in association with varicella zoster has also been reported.[79]

Linear IgA disease also has been associated rarely with a variety of malignancies. Patients with linear IgA disease have been reported with both lymphoid and nonlymphoid malignancies.[80-82] An unusual urticarial form of linear IgA with oral lesions was reported as a presenting sign of chronic lymphocytic leukemia.[83] Godfrey et al reported 3 cases of lymphoid malignancies in 70 patients with linear IgA disease followed for a mean of 8.5 years. This represented an increase over the predicted number of 0.2 cases in an age- and sex-matched population.[80] No increase in the rate of nonlymphoid malignancies was seen. These findings suggest a small risk of lymphoid malignancy in these patients. However, larger population-based studies need to be done to confirm these findings.

Although limitation of manifestations to the skin and mucous membranes is the rule, a few cases of IgA nephropathy in association with linear IgA dermatosis have been reported.[12]

HISTOPATHOLOGY

Routine histopathology of an early lesion in patients with linear IgA dermatosis and CBDC reveals a subepidermal bulla with collections of neutrophils along the basement membrane, often accumulating at the papillary tips (Fig. 58-8). A mild lymphocytic infiltrate may be present around the superficial dermal blood vessels without any evidence of neutrophilic vasculitis. Occasionally, the inflammatory infiltrate is composed of eosinophils, but most frequently neutrophils are the major component of the subepidermal inflammation.[26,84,85] Electron microscopic examination of the blisters found in patients with both linear IgA dermatosis and CBDC revealed that the blister forms either within the lamina lucida or in a sublamina densa location.[21,37] Usually the histopathology seen in linear IgA disease is difficult to distinguish from that seen in patients with DH. Smith et al[85] reported that patients with linear IgA disease tended to have fewer papillary microabscesses and a more diffuse infiltrate of neutrophils at the basement membrane zone. However,

Figure 58-8 Histopathology of lesional skin from a patient with linear immunoglobulin A dermatosis showing a subepidermal blister filled with neutrophils. (Used with permission from Kim B. Yancey, MD.)

Blenkinsopp et al found no significant difference between the histopathology found in patients with linear IgA disease and those with DH.[84] In general, the histopathology of blisters in linear IgA disease, CBDC, and DH is virtually indistinguishable.

DIFFERENTIAL DIAGNOSIS

Linear IgA dermatosis often closely mimics the clinical pattern seen in patients with DH. Some patients may have findings that resemble those seen in patients with BP, cicatricial pemphigoid, EBA, and, rarely, toxic epidermal necrolysis. In a similar manner, patients with CBDC must be differentiated from those with DH of childhood and childhood BP. The findings of linear IgA deposits at the basement membrane by direct immunofluorescence, most often in the absence of IgG and C3, can distinguish this disease from BP, cicatricial pemphigoid, and EBA, whereas granular IgA deposits are found at the basement membrane in patients with DH (Table 58-3).

TABLE 58-3
Linear Immunoglobulin A Bullous Dermatosis Differential Diagnosis

- Dermatitis herpetiformis
- Bullous pemphigoid
- Epidermolysis bullosa acquisita
- Bullous eruption of systemic lupus erythematosus
- Cicatricial pemphigoid
- Lichen planus
- Toxic epidermal necrolysis

TREATMENT AND PROGNOSIS

Table 58-4 provides a clinical comparison between linear IgA, drug-induced IgA, and CBDC. Adults with linear IgA dermatosis have an unpredictable course.[4,26] Many patients have disease that continues for years,

TABLE 58-4
Clinical Comparison between Linear IgA, Drug-Induced IgA, and Chronic Bullous Disease of Childhood

	EPIDEMIOLOGY	CLINICAL PRESENTATION	MUCOSAL INVOLVEMENT	DISEASE ASSOCIATIONS AND TRIGGERS	COURSE	TREATMENT
Linear IgA dermatosis	Often adults at the 4th decade of life; slight female predominance	Similar to Dermatitis herpetiformis (DH; see Chap. 59); annular or grouped papules, vesicles, and bullae on extensors, including elbows, knees, and buttocks; pruritus is less severe than in DH	Oral involvement in up to 70% of patients with linear IgA disease	Possible association with ulcerative colitis; ultraviolet light is the chief physical trigger	Unpredictable course; varies from spontaneous remission to longstanding disease	Dapsone, sulfapyridine; response within 24-48 h; low-dose prednisone may suppress blister formation
Drug-induced linear IgA	Adults[a]	Vary from erythema multiforme–like, to toxic epidermal necrolysis–like with widespread bullae; Koebner phenomenon may be present	Mucosal involvement less prominent than with linear IgA dermatosis	Vancomycin most commonly implicated; interferon-α, influenza vaccine, lithium, phenytoin, sulfamethoxazole-trimethoprim, furosemide, atorvastatin, captopril, diclofenac, ketoprofen, and infliximab	Rechallenge of drug may not result in recurrence	Discontinuation of causative drug; sometimes initiation of dapsone is helpful
Chronic bullous disease of childhood	Occurs before 5 years of age; slight female predominance	Tense bullae in a "cluster-of-jewels" appearance; collarette of blisters may be present	Mucosal involvement noted, but less commonly than in linear IgA dermatosis	Possible association with infectious mononucleosis and *Paecilomyces* lung infection in the setting of chronic granulomatous disease	Self-limited; remission within 2 years of onset	Dapsone, sulfapyridine; small doses of prednisone may be of use. mycophenolate mofetil as a steroid-sparing agent; topical tacrolimus

[a]In a single-center cohort study of 28 patients comparing drug-induced linear IgA bullous dermatosis and linear IgA bullous dermatosis, the median age of occurrence in drug-induced cases was 75 years, whereas the median age of occurrence in spontaneous linear IgA bullous dermatosis was 44.5 years. (Data from Chanal J, Ingen-Housz-Oro S, Ortonne N, et al. Linear IgA bullous dermatosis: comparison between the drug-induced and spontaneous forms. *Br J Dermatol*. 2013;169(5):1041-1048.)

with few, if any, episodes of remission. Occasionally, patients may have a spontaneous remission with loss of clinical features of the disease and disappearance of the linear IgA deposits in the skin. Patients with severe mucosal disease, especially of the eyes, may have persistent problems with symblepharon formation and resulting structural problems with the eyelids and cornea, even after active blistering has remitted. Untreated ocular involvement can lead to cicatrix and loss of vision.[86]

Patients with linear IgA disease most often respond dramatically to dapsone or sulfapyridine (see Table 58-2). This response usually occurs within 24 to 48 hours, in a manner similar to that seen with DH; as such, it is not a helpful diagnostic sign for linear IgA disease.[2,4,26] Although most patients are well controlled with dapsone or sulfapyridine alone, some patients require low-dose prednisone therapy to suppress blister formation.[26] In patients who are unresponsive or intolerant of these medications, mycophenolate mofetil is useful as a steroid-sparing agent.[87] Trimethoprim-sulfamethoxazole is reported to be helpful when used in conjunction with other immunosuppressives.[88] The majority of patients with linear IgA disease cannot control their skin disease with a gluten-free diet.[66]

CBDC is most often a self-limited disease, with most children going into remission within 2 years of the onset of the disease.[19,20,26] Occasionally, the disease persists well into puberty, but often is less severe than the initial eruption. Patients with CBDC respond in a similar dramatic fashion to dapsone or sulfapyridine.[19,20,26] Many children, however, require the addition of relatively small doses of prednisone to bring the disease under control.[19,20] Mycophenolate mofetil is used as a steroid-sparing agent in isolated cases.[89] Intravenous immunoglobulins also have been proposed in the rare patient who is not responding to, or is intolerant of, dapsone therapy.[90,91] Topical tacrolimus also may be a useful tool in minimizing systemic therapy.[92] Several case reports suggest that some patients with CBDC may respond to antibiotics, including sulfonamides, dicloxacillin, and erythromycin.[93,94] In one case series, 7 children with linear IgA disease were treated with flucloxacillin and demonstrated improvement, with 4 children achieving remission within 3 months.[95] However, spontaneous remission in these patients cannot be ruled out.

REFERENCES

1. Chorzelski TP, Beutner EH, Jablonska S, et al. Immunofluorescence studies in the diagnosis of dermatitis herpetiformis and its differentiation from bullous pemphigoid. *J Invest Dermatol*. 1971;56:373-380.
2. Chorzelski TP, Jablonska S, Maciejowska E. Linear IgA bullous dermatosis of adults. *Clin Dermatol*. 1991;9:383-392.
3. Lawley TJ, Strober W, Yaoita H, et al. Small intestinal biopsies and HLA types in dermatitis herpetiformis patients with granular and linear IgA skin deposits. *J Invest Dermatol*. 1980;74:9-12.
4. Leonard JN, Haffenden GP, Ring NP, et al. Linear IgA disease in adults. *Br J Dermatol*. 1982;107:301-316.
5. Cohen DM, Bhattacharyya I, Zunt SL, et al. Linear IgA disease histopathologically and clinically masquerading as lichen planus. *Oral Surg Oral Med Oral Pathol Oral Radiol Endod*. 1999;88:196-201.
6. Torchia D, Caproni M, Del Bianco E, et al. Linear IgA disease presenting as prurigo nodularis. *Br J Dermatol*. 2006;155(2):479-480.
7. Armstrong AW, Fazeli A, Yeh SW, et al. Vancomycin-induced linear IgA disease manifesting as bullous erythema multiforme. *J Cutan Pathol*. 2004;31:393-397.
8. Baden LA, Apovian C, Imber MJ, et al. Vancomycin-induced linear IgA bullous dermatosis. *Arch Dermatol*. 1988;124:1186-1188.
9. Carpenter S, Berg D, Sidhu-Malik N, et al. Vancomycin-associated linear IgA dermatosis. *J Am Acad Dermatol*. 1992;26:45-48.
10. McWhirter JD, Hashimoto K, Fayne S, et al. Linear IgA bullous dermatosis related to lithium carbonate. *Arch Dermatol*. 1987;123:1120-1122.
11. Waldman MA, Black DR, Callen JP. Vancomycin-induced linear IgA bullous disease presenting as toxic epidermal necrolysis. *Clin Exp Dermatol*. 2004;29:633-636.
12. Kim JS, Choi M, Nam CH, et al. Concurrent drug-induced linear immunoglobulin A dermatosis and immunoglobulin A nephropathy. *Ann Dermatol*. 2015;27(3):315-318.
13. Concha-Garzón MJ, Pérez-Gala S, Solano-López G, et al. Ketoprofen-induced lamina lucida-type linear IgA bullous dermatosis. *J Eur Acad Dermatol Venereol*. 2016;30(2):350-352.
14. Hoffmann J, Hadaschik E, Enk A, et al. Linear IgA bullous dermatosis secondary to infliximab therapy in a patient with ulcerative colitis. *Dermatology*. 2015;231(2):112-115.
15. Akasaka E, Kayo SJ, Nakano H, et al. Diaminodiphenyl sulfone-induced hemolytic anemia and alopecia in a case of linear IgA bullous dermatosis. *Case Rep Dermatol*. 2015;7(2):183-186.
16. Billet SE, Kortuem KR, Gibson LE, et al. A morbilliform variant of vancomycin-induced linear IgA bullous dermatosis. *Arch Dermatol*. 2008;144(6):774-778.
17. Khan I, Hughes R, Curran S, et al. Drug-associated linear IgA disease mimicking toxic epidermal necrolysis. *Clin Exp Dermatol*. 2009;34(6):715-717.
18. Walsh SN, Kerchner K, Sangueza OP. Localized palmar vancomycin-induced linear IgA bullous dermatosis occurring at supratherapeutic levels. *Arch Dermatol*. 2009;145(5):603-604.
19. Chorzelski TP, Jablonska S. IgA linear dermatosis of childhood (chronic bullous disease of childhood). *Br J Dermatol*. 1979;101:535-542.
20. Jabłońska S, Chorzelski TP, Rosinska D, et al. Linear IgA bullous dermatosis of childhood (chronic bullous dermatosis of childhood). *Clin Dermatol*. 1992;9:393-401.
21. Dabrowski J, Chorzelski TP, Jablońska S, et al. The ultrastructural localization of IgA deposits in chronic bullous disease of childhood (CBDC). *J Invest Dermatol*. 1979;72:291-295.
22. Zone JJ, Pazderka Smith E, Powell D, et al. Antigenic specificity of antibodies from patients with linear basement membrane deposition of IgA. *Dermatology*. 1994;189(suppl 1):64-66.
23. Wojnarowska F, Bhogal BS, Black MM. Chronic bullous disease of childhood and linear IgA disease of adults are IgA1-mediated diseases. *Br J Dermatol*. 1994;131:201-204.

24. Ling, K, Bygum A. Linear IgA bullous dermatosis: a retrospective study of 23 patients in Denmark. *Acta Derm Venereol*. 2015;95(4):466-471.
25. Sobjanek M, Sokolowska-Wojdylo M, Sztaba-Kania M, et al. Clinical and immunopathological heterogeneity of 22 cases of linear IgA bullous dermatosis. *J Eur Acad Dermatol Venereol*. 2008;22(9):1131.
26. Wojnarowska F, Marsden RA, Bhogal B, et al. Chronic bullous disease of childhood, childhood cicatricial pemphigoid and linear IgA disease of adults. A comparative study demonstrating clinical and immunopathologic overlap. *J Am Acad Dermatol*. 1988;19(5, pt 1):792-805.
27. Kanwar AJ, Sandhu K, Handa S. Chronic bullous dermatosis of childhood in north India. *Pediatr Dermatol*. 2004;21(5):610-612.
28. Collier PM, Wojnarowska F, Welsh K, et al. Adult linear IgA disease and chronic bullous disease of childhood: the association with human lymphocyte antigens Cw7, B8, DR3 and tumour necrosis factor influences disease expression. *Br J Dermatol*. 1999;141:867-875.
29. Sachs JA, Leonard J, Awad J, et al. A comparative serological and molecular study of linear IgA disease and dermatitis herpetiformis. *Br J Dermatol*. 1988;118: 759-764.
30. Venning VA, Taylor CJ, Ting A, et al. HLA type in bullous pemphigoid, cicatricial pemphigoid and linear IgA disease. *Clin Exp Dermatol*. 1989;14:283-285.
31. Flotte TJ, Olbricht SM, Collins AB, et al. Immunopathologic studies of adult linear IgA bullous dermatosis. *Arch Pathol Lab Med*. 1985;109:457-459.
32. Hall RP, Lawley TJ. Characterization of circulating and cutaneous IgA immune complexes in patients with dermatitis herpetiformis. *J Immunol*. 1985;135:1760-1765.
33. Leonard JN, Haffenden GP, Unsworth DJ, et al. Evidence that the IgA in patients with linear IgA disease is qualitatively different from that of patients with dermatitis herpetiformis. *Br J Dermatol*. 1983;110:315-321.
34. Wojnarowska F, Collier PM, Allen J, et al. The localization of the target antigens and antibodies in linear IgA disease is heterogeneous and dependent on the methods used. *Br J Dermatol*. 1995;132:750-757.
35. Prost C, De Leca AC, Combemale P, et al. Diagnosis of adult linear IgA dermatosis by immunoelectronmicroscopy in 16 patients with linear IgA deposits. *J Invest Dermatol*. 1989;92:39-45.
36. Kárpáti S, Meurer M, Stolz W, et al. Ultrastructural binding sites of endomysium antibodies from sera of patients with dermatitis herpetiformis and coeliac disease. *Gut*. 1992;33(2):191-193.
37. Kárpáti S, Stolz W, Meurer M, et al. Ultrastructural immunogold studies in two cases of linear IgA dermatosis. Are there two distinct types of this disease? *Br J Dermatol*. 1992;127:112-118.
38. Bhogal B, Wojnarowska F, Marsden RA, et al. Linear IgA bullous dermatosis of adults and children: an immunoelectron microscopic study. *Br J Dermatol*. 1987;117:289-296.
39. Horiguchi Y, Ikoma A, Sakai R, et al. Linear IgA dermatosis: report of an infantile case and analysis of 213 cases in Japan. *J Dermatol*. 2008;35(11):737-743.
40. Zone JJ, Taylor TB, Kadunce DP, et al. Identification of the cutaneous basement membrane zone antigen and isolation of antibody in linear immunoglobulin A bullous dermatosis. *J Clin Invest*. 1990;85:812-820.
41. Ishiko A, Shimizu H, Masunaga T, et al. 97-kDa linear IgA bullous dermatosis (LAD) antigen localizes to the lamina lucida of the epidermal basement membrane. *J Invest Dermatol*. 1996;106:739-743.
42. Zone JJ, Taylor TB, Meyer LJ, et al. The 97 kDa linear IgA bullous disease antigen is identical to a portion of the extracellular domain of the 180 kDa bullous pemphigoid antigen, BPAg2. *J Invest Dermatol*. 1998;110:207-210.
43. Roh JY, Yee C, Lazarova Z, et al. The 120-kDa soluble ectodomain of type XVII collagen is recognized by autoantibodies in patients with pemphigoid and linear IgA dermatosis. *Br J Dermatol*. 2000;143:104-111.
44. Schumann H, Baetge J, Tasanen K, et al. The shed ectodomain of collagen XVII/BP 180 is targeted by autoantibodies in different blistering skin diseases. *Am J Pathol*. 2000;156:685-695.
45. Lin MS, Fu CL, Olague-Marchan M, et al. Autoimmune responses in patients with linear IgA bullous dermatosis: both autoantibodies and T lymphocytes recognize the NC16A domain of the BP180 molecule. *Clin Immunol*. 2002;102:310-319.
46. Zillikens D, Herzele K, Georgi M, et al. Autoantibodies in a subgroup of patients with linear IgA disease react with the NC16A domain of BP1801. *J Invest Dermatol*. 1999;113:947-953.
47. Wojnarowska F, Whitehead P, Leigh IM, et al. Identification of the target antigen in chronic bullous disease of childhood and linear IgA disease of adults. *Br J Dermatol*. 1991;124:157-162.
48. Allen J, Wojnarowska F. Linear IgA disease: the IgA and IgG response to the epidermal antigens demonstrates that intermolecular epitope spreading is associated with IgA rather than IgG antibodies, and is more common in adults. *Br J Dermatol*. 2003;149:977-985.
49. Ishii N, Ohyama B, Yamaguchi Z, et al. IgA autoantibodies against the NC16a domain of BP180 but not 120-kDa LAD-1 detected in a patient with linear IgA disease. *Br J Dermatol*. 2008;158(5):1151-1153.
50. Izaki S, Mitsuya J, Okada T, et al. A case of linear IgA/IgG bullous dermatosis with anti-laminin-332 autoantibodies. *Acta Derm Venereol*. 2015;95(3):359-360.
51. Tsuchisaka A, Ohara K, Ishii N, et al. Type VII collagen is the major autoantigen for sublamina densa-type linear IgA bullous dermatosis. *J Invest Dermatol*. 2015;135(2):626-629.
52. Peters MS, Rogers RS III. Clinical correlations of linear IgA deposition at the cutaneous basement membrane zone. *J Am Acad Dermatol*. 1989;20:761-770.
53. Norris IN, Haeberle MT, Callen JP, et al. Generalized linear IgA dermatosis with palmar involvement. *Dermatol Online J*. 2015;21(9).
54. Choudhry SZ, Kashat M, Lim HW. Vancomycin-induced linear IgA bullous dermatosis demonstrating the isomorphic phenomenon. *Int J Dermatol*. 2015;54(11):1211-1213.
55. Perrett CM, Evans AV, Russell-Jones R. Tea tree oil dermatitis associated with linear IgA disease. *Clin Exp Dermatol*. 2003;28(2):167-170.
56. Tran D, Kossard S, Shumack S. Phenytoin-induced linear IgA dermatosis mimicking toxic epidermal necrolysis. *Australas J Dermatol*. 2003;44:284-286.
57. Blockmans D, Bossuyt L, Degreef H, et al. Linear IgA dermatosis: a new cause of fever of unknown origin. *Neth J Med*. 1995;47:214-218.
58. Leigh G, Marsden RA, Wojnarowska F. Linear IgA dermatosis with severe arthralgia. *Br J Dermatol*. 1988; 119:789-792.
59. Kelly SE, Frith PA, Millard PR, et al. A clinicopathological study of mucosal involvement in linear IgA disease. *Br J Dermatol*. 1988;119:161-170.
60. Leonard JN, Wright P, Williams DM, et al. The relationship between linear IgA disease and benign

mucous membrane pemphigoid. *Br J Dermatol*. 1984;110:307-314.
61. Romani L, Diociaiuti A, D'Argenio P, et al. A case of neonatal linear IgA bullous dermatosis with severe eye involvement. *Acta Derm Venereol*. 2015;95(8):1015-1017.
62. Porter SR, Bain SE, Scully CM. Linear IgA disease manifesting as recalcitrant desquamative gingivitis. *Oral Surg*. 1992;74:179-182.
63. Sato K, Hanazawa H, Sato Y, et al. Initial presentation and fatal complications of linear IgA bullous dermatosis in the larynx and pharynx. *J Laryngol Otol*. 2005;119:314-318.
64. Joseph TI, Sathyan P, Goma Kumar KU. Linear IgA dermatosis adult variant with oral manifestation: a rare case report. *J Oral Maxillofac Pathol*. 2015;19(1):83-87.
65. deFranchis R, Primignani M, Cipolla M, et al. Small-bowel involvement in dermatitis herpetiformis and in linear IgA bullous dermatosis. *J Clin Gastroenterol*. 1983;5:429-436.
66. Leonard JN, Griffiths CE, Powles AV, et al. Experience with a gluten free diet in the treatment of linear IgA disease. *Acta Derm Venereol*. 1987;67:145-148.
67. Rose C, Dieterich W, Bröcker EB, et al. Circulating autoantibodies to tissue transglutaminase differentiate patients with dermatitis herpetiformis from those with linear IgA disease. *J Am Acad Dermatol*. 1999;41:957-961.
68. Birnie AJ, Perkins W. A case of linear IgA disease occurring in a patient with colonic Crohn's disease. *Br J Dermatol*. 2005;153(5):1050-1052.
69. Paige DG, Leonard JN, Wojnarowska F, et al. Linear IgA disease and ulcerative colitis. *Br J Dermatol*. 1997;136:779-782.
70. Sillevis Smitt JH, Leusen JH, Stas HG, et al. Chronic bullous disease of childhood and a paecilomyces lung infection in chronic granulomatous disease. *Arch Dis Child*. 1997;77:150-152.
71. Minhas JS, Wickner PG, Long AA, et al. Immune-mediated reactions to vancomycin: a systematic case review and analysis. *Ann Allergy Asthma Immunol*. 2016;116(6):544-553.
72. Alberta-Wszolek L, Mousette AM, Mahalingam M, et al. Linear IgA bullous dermatosis following influenza vaccination. *Dermatol Online J*. 2009;15(11):3.
73. Kocyigit P, Akay BN, Karaosmanoglu N. Linear IgA bullous dermatosis induced by interferon-alpha 2a. *Clin Exp Dermatol*. 2009;34(5):e123-124.
74. Palmer RA, Ogg G, Allen J, et al. Vancomycin-induced linear IgA disease with autoantibodies to BP180 and LAD 285. *Br J Dermatol*. 2001;145:816-820.
75. Paul C, Wolkenstein P, Prost C, et al. Drug-induced linear IgA disease: target antigens are heterogeneous. *Br J Dermatol*. 1997;136(3):406-411.
76. Joshi S, Scott G, Looney RJ. A successful challenge in a patient with vancomycin-induced linear IgA dermatosis. *Ann Allergy Asthma Immunol*. 2004;93:101-103.
77. Tomida E, Kato Y, Ozawa H, et al. Causative drug detection by drug-induced lymphocyte stimulation test in drug-induced linear IgA bullous dermatosis. *Br J Dermatol*. 2016;175(5):1106-1108.
78. Wozniak K, Kalinska-Bienias A, Hashimoto T, et al. Ultraviolet-induced linear IgA bullous dermatosis: a case report and literature survey. *Br J Dermatol*. 2014;171(6):1578-1581.
79. Blickenstaff RD, Perry HO, Peters MS. Linear IgA deposition associated with cutaneous varicella-zoster infection: a case report. *J Cutan Pathol*. 1988;15(1):49-52.
80. Godfrey K, Wojnarowska F, Leonard J. Linear IgA disease of adults: association with lymphoproliferative malignancy and possible roel of other triggering factors. *Br J Dermatol*. 1990;123:447-452.
81. McEvoy MT, Connolly SM. Linear IgA dermatosis: Association with malignancy. *J Am Acad Dermatol*. 1990;22:59-63.
82. Yang CS, Robinson-Bostom L, Landow S. Linear IgA bullous dermatosis associated with metastatic renal cell carcinoma. *JAAD Case Rep*. 2015;1(2):91-92.
83. Tiger JB, Rush JT, Barton DT, et al. Urticarial linear IgA bullous dermatosis (LABD) as a presenting sign of chronic lymphocytic leukemia (CLL). *JAAD Case Rep*. 2015;1(6):412-414.
84. Blenkinsopp WK, Haffenden GP, Fry L, et al. Histology of linear IgA disease, dermatitis herpetiformis and bullous pemphigoid. *Am J Dermatopathol*. 1983;5:547-554.
85. Smith SB, Harrist TJ, Murphy GF, et al. Linear IgA bullous dermatosis v dermatitis herpetiformis: quantitative measurements of dermoepidermal alterations. *Arch Dermatol*. 1984;120:324-328.
86. Talhari C, Althaus C, Megahed M. Ocular linear IgA disease resulting in blindness. *Arch Dermatol*. 2006;142(6):786-787.
87. Talhari C, Mahnke N, Ruzicka T, et al. Successful treatment of linear IgA disease with mycophenolate mofetil as a corticosteroid sparing agent. *Clin Exp Dermatol*. 2005;30(3):297-298.
88. Peterson JD, Chan LS. Linear IgA bullous dermatosis responsive to trimethoprim-sulfamethoxazole. *Clin Exp Dermatol*. 2007;32(6):756-758.
89. Farley-Li J, Mancini AJ. Treatment of linear IgA bullous dermatosis of childhood with mycophenolate mofetil. *Arch Dermatol*. 2003;139:1121-1124.
90. Goebeler M, Seitz C, Rose C, et al. Successful treatment of linear IgA disease with salazosulphapyridine and intravenous immunoglobulins. *Br J Dermatol*. 2003;149:912-914.
91. Kroiss MM, Vogt M, Landthaler WS. High-dose intravenous immune globulin is also effective in linear IgA disease. *Br J Dermatol*. 2000;142:582-582.
92. Dauendorffer JN, Mahe E, Saiag P. Tacrolimus ointment, an interesting adjunctive therapy for childhood linear IgA bullous dermatosis. *J Eur Acad Dermatol Venereol*. 2008;22(3):364-365.
93. Cooper SM, Powell J, Wojnarowska F. Linear IgA disease: successful treatment with erythromycin. *Clin Exp Dermatol*. 2002;27(8):677-679.
94. Siegfried EC, Sirawan S. Chronic bullous disease of childhood: successful treatment with dicloxacillin. *J Am Acad Dermatol*. 1998;39:797-800.
95. Alajlan A, Al-Khawajah M, Al-Sheikh O, et al. Treatment of linear IgA bullous dermatosis of childhood with flucloxacillin. *J Am Acad Dermatol*. 2006;54:652-656.

Chapter 59 :: Dermatitis Herpetiformis

:: Stephen I. Katz

AT-A-GLANCE

- Intensely itchy, chronic papulovesicular eruption distributed symmetrically on extensor surfaces.
- Characterized histologically by dermal papillary collections of neutrophils.
- Granular immunoglobulin A deposits in normal-appearing skin are diagnostic.
- Epidermal transglutaminases appear to be the dominant autoantigens.
- Most, if not all, dermatitis herpetiformis patients have an associated gluten-sensitive enteropathy.
- The rash responds rapidly to dapsone therapy and, in many patients, to strict adherence to a gluten-free diet.

HISTORICAL PERSPECTIVE

In 1884, Louis Duhring first described the clinical features and natural history of a polymorphous pruritic disorder that he called *dermatitis herpetiformis* (DH); however, the critical elements in the pathogenesis of DH remained unknown until the 1960s.[1] In 1888, Brocq described patients with a very similar disorder and called it *dermatite polymorphe prurigineuse*.[2] In addition, he analyzed Duhring's report and excluded several types of patients from the diagnosis. Since 1888, several important discoveries have been made. In 1940, Costello[3] demonstrated the efficacy of sulfapyridine in the treatment of DH. In early 1960s, Pierard and Whimster[4] and MacVicar et al[5] found that early lesions of DH are characterized by neutrophilic microabscesses in the dermal papillae. In 1967, Cormane[6] found that the skin of DH patients contained granular immunoglobulin deposits in dermal papillary tips, and in 1969, van der Meer[7] extended these studies and found that the most regularly detected immunoglobulin (Ig) deposited in DH is IgA. The association between DH and intestinal abnormalities was first observed by Marks et al[8] in 1966. Fry et al[9] and Shuster et al[10] identified the intestinal findings as a gluten-sensitive enteropathy. In 1973, Fry et al[11] demonstrated that strict adherence to a gluten-free diet would improve the skin disease as well as reverse the intestinal abnormality, as occurs in celiac disease. Katz et al[12] identified a strong association between DH and certain histocompatibility antigens in 1972. In 1979, Jablonska and Chorzelski[13] distinguished those patients with linear IgA deposits from those with granular IgA deposits and defined a distinct entity. In 1999, Dieterich et al[14] identified antibodies to tissue transglutaminases in the sera from DH patients. Distinguishing between various types of transglutaminases enabled Sárdy et al,[15] in 2002, to demonstrate that epidermal transglutaminase (eTG) is the dominant autoantigen in DH. In 2016, Görög et al[16] demonstrated circulating transglutaminase 3–IgA immune complexes in DH patients.

EPIDEMIOLOGY

The prevalence of DH in various white populations varies between 10 in 100,000 persons and 75 in 100,000 persons.[17-19] The male-to-female ratio ranges from 1.1 to 1 to 1.5 to 1. It may start at any age, including in childhood; however, the second, third, and fourth decades of life are the most common ages. After presentation, DH persists indefinitely in most patients, although with varying severity.

Patients with DH have an associated gluten-sensitive enteropathy (celiac disease) that is usually asymptomatic.

CLINICAL FEATURES

CUTANEOUS FINDINGS

The primary lesion of DH is an erythematous papule, an urticaria-like plaque, or, most commonly, a vesicle (Figs. 59-1, 59-2, and 59-3). Large bullae occur infrequently. Vesicles, especially if they occur on the palms, may be hemorrhagic. The continual appearance and disappearance of lesions may result in hyperpigmentation and/or hypopigmentation. Patients may present with only crusted lesions, and a thorough search may not reveal a primary lesion. The herpetiform (herpes-like) grouping of lesions is often present in some areas (Figs. 59-1 and 59-3), but patients also may have many individual nongrouped lesions. Symptoms vary considerably from the usually severe burning and itching in most patients to the almost complete lack of symptoms in a rare patient. Most patients usually can predict the eruption of a lesion as much as 8 to 12 hours before its appearance because of localized stinging, burning, or itching. The usual symmetric distribution of lesions on elbows, knees, buttocks, shoulders, and sacral areas is seen in most patients at one time or another (Figs. 59-1 to 59-4). Although these regions are affected most commonly, most patients have scalp lesions and/or lesions in the posterior nuchal area. Another commonly affected area is the face, especially along the mandible, on the upper eyelid, and facial hairline. Mucous membrane lesions are rare.

Figure 59-1 Extensive eruption with grouped papules, vesicles, and crusts on the back.

NONCUTANEOUS FINDINGS

GASTROINTESTINAL FINDINGS

Most, if not all, DH patients have an associated GI abnormality that is caused by gluten sensitivity.[8-10,20]

Figure 59-2 Papules, vesicles, and crusts on knees.

Figure 59-3 This patient has many firm-topped vesicles and bullae, some erosions, and residual hyperpigmentation. Some of the vesicles are arranged in an annular pattern.

The pathology of the gluten-sensitive enteropathy (gluten-sensitive enteropathy) is described below.

MALIGNANCY

Most large studies have reported a significant increase in non-Hodgkin lymphomas in patients with DH and an occasional GI lymphoma, but no other increased risk of malignancy.[21-23] Retrospective studies suggest a protective role for a gluten-free diet against GI lymphomas.[24] Hervonen and coworkers reported that 11 (1%) of 1104 patients with DH developed a

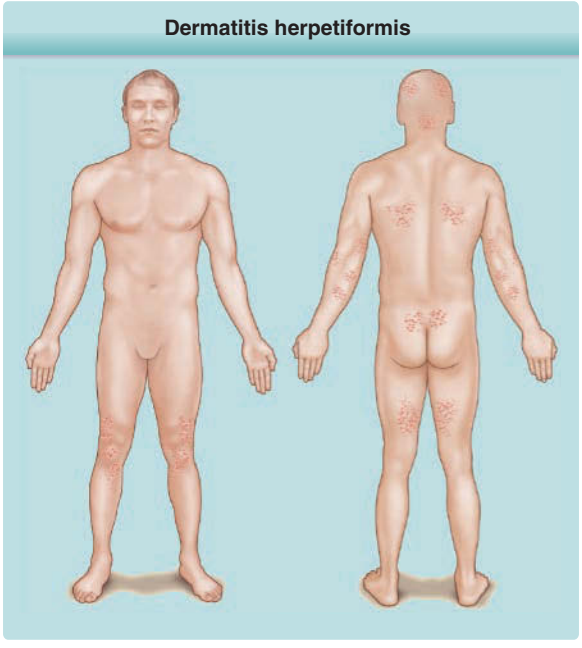

Figure 59-4 Pattern of distribution.

lymphoma from 2 to 31 years after the diagnosis of DH.[25] Of interest, only 2 lymphomas were of the enteropathy-associated type, whereas 8 were B-cell type lymphomas and 1 was unclassified. The patients with DH who developed lymphoma had adhered to a gluten-free diet less strictly than did patients without lymphoma.[25] Of interest, the mortality rate for patients with DH was equal to or lower than in the general population.[23,26] Lewis et al used the General Practice Research Database in the United Kingdom to study a cohort of 846 DH patients and 4225 matched controls. They report no increased risk of malignancy in the DH patients. They suggest a population bias of hospitalized patients in smaller studies resulted in either differences in the degree of intestinal inflammation or unrelated illnesses increasing frequencies of malignancy in the DH patients.[26] These studies suggest that patients with DH may not have an increased risk of malignancy.

OTHER DISEASES

In addition to celiac disease, atrophic gastritis, and pernicious anemia, DH patients have a higher incidence of other autoimmune diseases, such as thyroid disease, insulin-dependent diabetes, lupus erythematosus, Sjögren syndrome, and vitiligo.[27-29] This predilection for associated autoimmune diseases may be a result of the high frequency of the 8.1 ancestral haplotype in these DH patients.[30] Neurologic disease has been reported in patients with isolated celiac disease, including epilepsy, ataxia, opsoclonus-myoclonus, and dementia; however, confirmation of these findings awaits confirmation with large epidemiologic studies.[31,32] Some authors have proposed that patients with DH may be at higher risk for these neurologic complications as a consequence of longstanding ingestion of gluten; however, Wills and coworkers found no evidence of immune-mediated neurologic disease in their evaluation of patients with DH.[33]

Patients with untreated celiac disease also have been found to have an increased frequency of bone loss.[34] Patients with DH frequently continue on gluten-containing diets with a longstanding, albeit low grade, malabsorption. Di Stefano et al demonstrated a significantly reduced bone mineral density in patients with DH on gluten-containing diets.[35] Other studies have refuted this and still others have found no increase in fracture rate in patients with DH.[27,36]

ETIOLOGY AND PATHOGENESIS

Gluten, a protein found in wheat, barley, and rye, plays a critical role in the pathogenesis of DH. Oats, long thought to contain gluten and play a role in inducing DH lesions, are devoid of toxicity in patients with DH.[37,38] As in celiac disease, there is an increased density of small bowel intraepithelial T cells with a γ/δ T-cell receptor in the jejunum of patients with DH.[39] The finding that T-cell lines from patients with DH produce significantly more interleukin (IL) 4 than those from patients with celiac disease and that gut biopsies from symptomatic patients with isolated celiac disease show increased expression of interferon-γ suggests that different cytokine patterns may play a role in the varied clinical manifestations of these 2 diseases.[40,41] Systemic evidence of the gut mucosal immune response has also been found in the serum and the skin of patients with DH. Patients with DH on regular gluten-containing diets have increased serum IL-2 receptor levels and serum IL-8 levels, increased endothelial cell E-selectin expression in skin, and an increased expression of CD11b on circulating neutrophils.[42-44] These systemic manifestations of the gut mucosal immune response may play a role in creating the proinflammatory environment in the skin necessary for the development of skin lesions. The enteropathy seen in DH patients probably relates to the IgA deposits that are found in the skin of these patients, although a direct relationship has not been demonstrated. Patients with a clinical picture consistent with DH and partial IgA deficiency have been reported.[45]

eTGs appear to be the dominant autoantigens in DH.[14,15] Dermal deposits of eTG have been shown to colocalize with cutaneous deposits of IgA, in the papillary tips and because eTGs are strongly expressed in the upper epidermis, it has been suggested that in regions of trauma they may diffuse through the basement membrane after release from epidermal keratinocytes.[46] eTGs were also found in uninvolved skin at least 5 cm away from the lesion suggesting additional factors involved in the production of DH lesions.[46] It is also known that patients with both gluten-sensitive enteropathy and DH have circulating IgA antibodies directed against eTGs.[14,47] There appears to be a predilection for these circulating IgA autoantibodies to bind to eTG in DH, whereas the predilection is for autoantibodies to bind tissue transglutaminases in patients with celiac disease.[15] The precise role of the circulating IgA anti-eTG in the development of skin lesions in patients with DH is not known but circulating IgA anti-eTG does decrease after the institution of a gluten-free diet.[48] However, children with celiac disease have lower levels of circulating IgA anti-eTG when compared to adults with celiac disease, whereas levels of circulating IgA antibodies against tissue transglutaminase are not significantly different between children and adults with celiac disease.[49] This observation has led to the hypothesis that epitope spread over time results in the development of IgA anti-eTG and that this late onset of IgA anti-eTG antibodies may play a role in the typical development of DH in the second to third decade of life.[49] The mechanism whereby the IgA anti-eTG binds to skin in patients with DH is not fully understood. One longstanding hypothesis is that IgA-containing circulating immune complexes are responsible for the IgA deposits in DH skin. The discovery of IgA anti-eTG antibodies has led to the suggestion that IgA–eTG immune complexes may be depositing in the skin of DH patients. This concept has recently received considerable traction in that circulating IgA–TG immune complexes have been identified in DH patients

at higher levels before instituting a gluten-free diet.[16] It is possible that the IgA anti-eTG binds initially via antigen–antibody circulating immune complexes and that ability of transglutaminase to crosslink proteins results in the IgA crosslinking to dermal proteins, perhaps fibrin or fibrinogen, resulting in the stable, long-lasting IgA deposits seen in the skin of patients with DH.[50] This hypothesis awaits confirmation. Whether the IgA skin deposits play a role in the pathophysiology of blister formation is not known. The finding of IgA and complement in almost all skin sites, not only in lesional skin, makes one postulate that if IgA (either alone or as a part of an immune complex) does play a role, additional factors are still needed to explain the initiation of lesions. Takeuchi et al demonstrated that minor trauma to skin results in increased expression of IL-8 and E-selectin, both of which may predispose to a neutrophilic inflammatory infiltrate.[51] These findings, coupled with the typical appearance of DH lesions on extensor surfaces at sites of trauma, suggest that local cytokine/chemokine production after trauma may be one of the inciting factors of DH skin lesions. It may be that after the initial neutrophilic infiltrate binds to the cutaneous IgA, factors such as cytokines, chemokines, and proteases are released that both directly result in blister formation and induce basal keratinocytes to produce collagenases or stromelysin-1 that further contributes to the formation of blisters.[52,53] Other studies suggest that T cells may play a role in the pathogenesis of the skin lesions; however, no specific T-cell responses to gluten have been detected.[54,55]

It has been known for some time that iodides, administered orally, can exacerbate or elicit eruptions of DH, and this has, in former times, been used for diagnostic purposes. The availability of immunopathologic techniques for the detection of IgA deposits in skin has made such provocation tests obsolete.

There is a marked increase in the incidence of certain major histocompatibility complex antigens in patients with DH. Worldwide studies have found that 77% to 87% of DH patients have human leukocyte antigen (HLA)-B8 (compared with 20% to 30% of unaffected individuals).[12,55,56,57] In addition, the class II major histocompatibility complex antigens HLA-DR and HLA-DQ are associated with DH even more frequently than is HLA-B8.[58,59] Park et al[60] reported that more than 90% of patients expressed Te24, which was later shown to be similar to HLA-DQw2; this finding has been confirmed by others. Molecular studies indicate that susceptibility to DH is not associated with a unique HLA-DQw2 molecule.[61,62] Virtually all patients with DH have genes that encode the HLA-DQ (α1*0501, β1*02) or the HLA-DQ (α1*03, β1*0302) heterodimers, a pattern identical to that seen in celiac disease.[61,63] This strong association between susceptibility genes and DH and celiac disease is important clinically and pathophysiologically in that there is a strong concordance of these 2 diseases in monozygotic twins.[62] Furthermore, first-degree relatives of both DH and celiac disease patients are often (4% to 5%) affected with one or the other of these diseases.[64] Non–major histocompatibility complex susceptibility genes are also associated with DH.

DNase-hypersensitivity regions 1 and 2, which function as enhancers for the Ig heavy-chain regulatory region, are found with higher frequencies in DH patients.[65]

Marietta et al have reported an HLA-DQ8 transgenic nonobese diabetic mouse that when immunized with gluten developed neutrophilic skin lesions along with cutaneous deposits of IgA; withdrawal of dietary gluten resulted in resolution of the skin lesions.[66] Although differences between the animal model and DH in patients exist, further investigation of this mouse model may provide important information regarding the pathogenesis of DH.

DIAGNOSIS

LABORATORY TESTING

DIRECT IMMUNOFLUORESCENCE

After Cormane demonstrated that both perilesional and uninvolved skin of patients with DH contained granular Ig deposits located in dermal papillary tips, van der Meer found that the most regularly detected Ig class in DH skin was IgA (Fig. 59-5).[6,7] Although most patients have granular IgA deposits in their skin, some deposits have a more distinct fibrillary pattern of IgA deposits.[67] For the most part, IgA deposits have not been seen in the skin of patients with celiac disease except for the study of Cannistraci et al.[68,69]

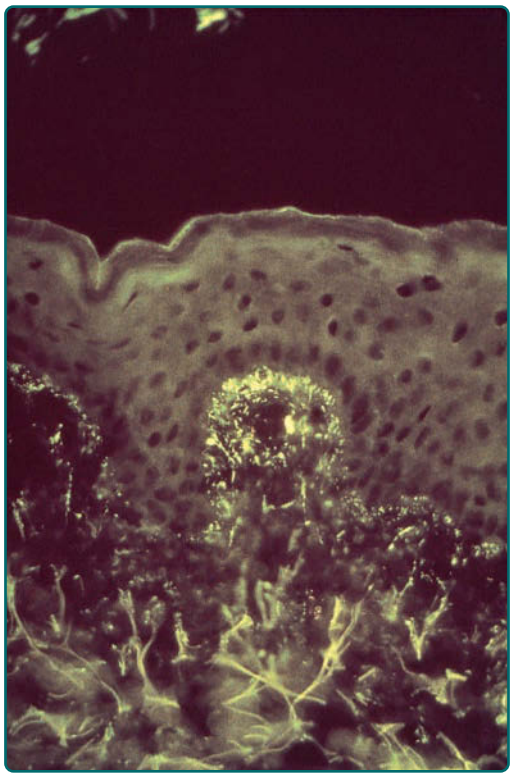

Figure 59-5 Direct immunofluorescence showing granular dermal papillary deposits of immunoglobulin A.

The significance of the latter findings in the pathogenesis of DH is not known.[69]

Finding granular IgA deposits in normal-appearing skin is the most reliable criterion for the diagnosis of DH.[70,71] These IgA deposits are unaffected by treatment with drugs, but may decrease in intensity or disappear after long-term adherence to a gluten-free diet.[72,73] The IgA deposits are not uniformly intense throughout the skin and may be detected more easily in normal-appearing skin near active lesions.[74] In DH, other immunoglobulins are sometimes bound to the skin in the same areas as the IgA.[71] IgA deposits also may be seen in the skin of patients with bullous pemphigoid, scarring pemphigoid, Henoch-Schönlein purpura, and alcoholic liver disease, although in different patterns of distribution than those seen in DH.

Because of the IgA skin deposits and the association between DH and celiac disease, several groups have studied the IgA subclasses in DH. IgA1 is the predominant (or exclusive) subclass that has been identified in the skin of DH patients.[75,76] Most IgA1 is produced in the bone marrow, whereas most IgA2 is produced at mucosal sites. This does not negate the possibility that the IgA1 in skin may still be of mucosal origin because IgA1 is the predominant IgA subclass of IgA antibodies directed against dietary proteins produced in gut secretions in patients with DH.[77,78]

Kantele et al reported a DH association with an increase in circulating IgA1-plasmoblasts with skin-homing receptors (CLA) as compared to those with IgA2.[78] The third component of complement (C3) is frequently found in the same location as IgA. The presence of C3 in both perilesional and normal-appearing skin is not affected by treatment with dapsone (diaminodiphenyl sulfone), but C3 may not be detectable after treatment with a gluten-free diet.[73,80] C5 and components of the alternative complement pathway also may be seen in areas corresponding to the IgA deposits. The C5–C9 membrane attack complex, which is formed as the terminal event in complement activation, is also seen in normal-appearing and perilesional skin of patients.[81] The exact site of the IgA deposits in DH skin has been studied by immunoelectron microscopy. Early studies indicated that IgA is preferentially associated with bundles of microfibrils and with anchoring fibrils of the papillary dermis immediately below the basal lamina.[82,83] Other studies, however, indicate that some or almost all of the IgA deposits are related to nonfibrillar components of skin and other connective tissues.[83-85] There is also no agreement as to whether the IgA deposits in DH colocalize to fibrillin, a major component of the elastic microfibrillar bundles.[85,86]

SERUM STUDIES

Chorzelski et al described an IgA antibody that binds to an intermyofibril substance (endomysium) of smooth muscle.[87] Sárdy et al showed that these IgA autoantibodies have specificity for transglutaminase, particularly for eTG.[15] Although a majority of DH patients on gluten-containing diets have circulating anti eTG antibodies, and this serum assay is thought to be quite sensitive, a significant number of patients do not have circulating anti-eTG antibodies.[49,88,89]

PATHOLOGY

The histology of an early skin lesion (clinically nonvesicular) is characterized by dermal papillary collections of neutrophils (microabscesses), neutrophilic fragments, varying numbers of eosinophils, fibrin, and, at times, separation of the papillary tips from the overlying epidermis (Fig. 59-6). In addition, in such early lesions, the upper and middle dermal blood vessels are surrounded by a lymphohistiocytic infiltrate, as well as some neutrophils and an occasional eosinophil.[4,5] At times, early lesions may be difficult or impossible to differentiate from those of linear IgA disease (see Chap. 58), the bullous eruption of lupus erythematosus (see Chap. 61), bullous pemphigoid (see Chap. 54), or the neutrophil-rich form of epidermolysis bullosa acquisita (see Chap. 56). The histology of older lesions shows subepidermal vesicles that may be impossible to differentiate from other subepidermal bullous eruptions, such as bullous pemphigoid, erythema multiforme, bullous drug eruption, and pemphigoid gestationis. Immunofluorescent localization and ultrastructural studies of the site of blister formation in DH demonstrate that the blister forms above the

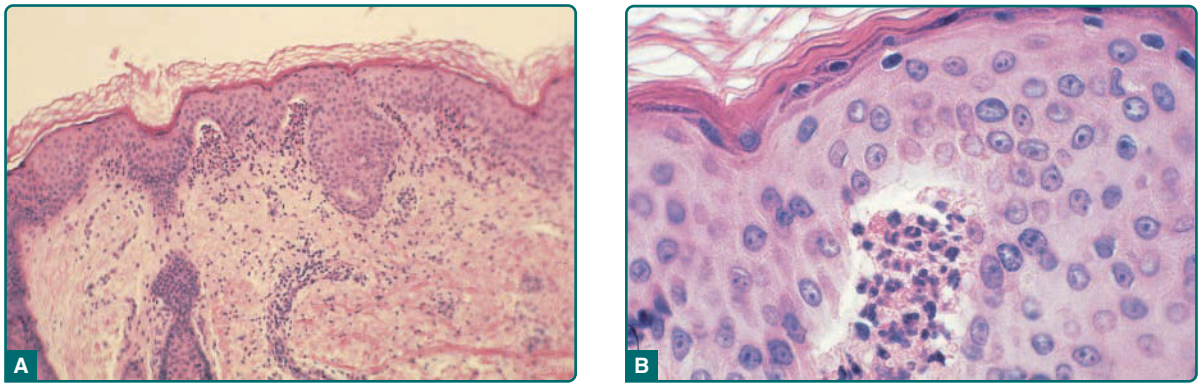

Figure 59-6 Biopsy of an early lesion showing dermal papillary collections of neutrophils and eosinophils and subepidermal vesiculation at low (**A**) and high (**B**) magnification.

lamina densa, within the lamina lucida. This is thought to occur because the lamina lucida is the most vulnerable component of the dermal–epidermal junction.[90]

The pathology of the DH-associated enteropathy is essentially the same as seen in celiac disease that is unassociated with DH, although the lesion in the latter is usually much more severe; this applies to the epithelial cell derangement as well as to the character of the lymphoplasmacytic infiltrate. Over the past 45 years the prevalence of severe villous atrophy in DH patients has decreased in Finland.[91] The distribution of the GI lesion in the small intestine is, as a general rule, more widespread in celiac disease. The functional changes in the bowel and clinical sequelae encountered in the enteropathy associated with DH and those seen in celiac disease are similar but again differ in degree, those in the latter being more severe. Thus, in DH one observes steatorrhea (20% to 30% of patients), abnormal D-xylose absorption (10% to 33% of patients), and occasional anemia secondary to iron or folate deficiency. In patients not taking dapsone or related drugs, the anemia is usually caused by malabsorption. In addition to the small intestinal lesion, patients with DH have an increased incidence of achlorhydria and atrophic gastritis.[92,93] Reports of pernicious anemia and antibodies to gastric parietal cells are thus likely to be more than the result of chance.

DIFFERENTIAL DIAGNOSIS

DH may be confused with numerous other conditions because of its pleomorphic manifestations and the occasional lack of diagnostic lesions (Table 59-1). Neurotic excoriations, eczema, papular urticaria, transient acantholytic dermatosis, pemphigoid, pemphigoid gestationis, erythema multiforme, and various other dermatoses can be differentiated easily on the basis of histologic and immunologic criteria. Linear IgA disease may be more difficult to differentiate clinically and histologically, but it is distinctive immunologically. A high index of suspicion is very helpful in that even in the absence of primary lesions, DH can be diagnosed based on the typical in vivo–bound granular IgA deposits in normal-appearing skin.

TABLE 59-1
Differential Diagnosis of Dermatitis Herpetiformis

Consider
- Eczema
- Atopic dermatitis
- Papular urticaria
- Neurotic excoriations
- Bullous pemphigoid
- Pemphigoid gestationis
- Linear immunoglobulin A dermatosis
- Atopic dermatitis

Rule Out
- Scabies

CLINICAL COURSE AND PROGNOSIS

After presentation, DH persists indefinitely in most patients, although with varying severity. A rare patient will have extreme waxing and waning of disease whereby they may be free of disease for up to a year at a time even without treatment. Two long-term studies of immunologically verified patients have suggested that the disease in approximately 10% to 12% of DH patients eventually remits.[94,95] Nonsteroidal antiinflammatory drugs may cause an exacerbation of the DH even in those who disease is well controlled with either dapsone or gluten-free diet.[96]

MANAGEMENT

SULFONES

Diaminodiphenyl sulfone (dapsone), sulfoxone (diazone—not available in the United States), and sulfapyridine (not generally available in the United States) provide prompt improvement in symptoms and signs of the disease. Symptoms may abate in as few as 3 hours or as long as a few days after the first pill is taken, and new lesions no longer erupt after 1 to 2 days of treatment. Exacerbations occur from hours to days after cessation of treatment. This response to therapy was, for a long time, the most important element in making a diagnosis. The preferred treatment for an adult is dapsone at an initial dosage of 100 to 150 mg/day (this usually can be taken once a day). A rare patient may require 300 to 400 mg of dapsone for initial improvement. Patients should be instructed to take the minimal dose required to suppress signs and symptoms. Not all patients require daily treatment; in rare cases, 25 mg weekly is sufficient. Sulfapyridine, in a dosage of 1.0 to 1.5 g daily, is particularly useful in patients intolerant of dapsone, in elderly patients, and in those with cardiopulmonary problems. The pharmacology, mechanism(s) of action, adverse effects, and monitoring of dapsone are discussed in Chap. 187.

GLUTEN-FREE DIET

EFFECT ON THE SMALL INTESTINE

The intestinal lesion in DH responds to dietary gluten withdrawal. The time course of the response in adults with DH is the same as that in adults with celiac disease.

EFFECT ON THE SKIN DISEASE

Strict adherence to a gluten-free diet will, after variable periods of time (from 4 months to 1 year), reduce or completely eliminate the requirement for medication

in most, but not all, patients. The most extensive early study by Fry et al has been confirmed by several groups.[97] However, it is only the very highly motivated patient who can adhere to the diet, which requires counseling by a dietitian who is very familiar with its use. The general availability of gluten-free foods (and standardized labelling in the United States) in most food markets has made adherence to this diet much easier than in previous times. Despite this, there are still patients who remain refractory to gluten-free diet treatment.[97]

ELEMENTAL AND OTHER DIET THERAPY

Studies in small numbers of DH patients have indicated that elemental diets (composed of free amino acids, short-chain polysaccharides, and small amounts of triglycerides) can be very beneficial in alleviating the skin disease within a few weeks.[98,99] The beneficial effect on the skin disease may be achieved even if the patient ingests large amounts of gluten.[100] Unfortunately, elemental diets are difficult to tolerate for long periods. Interestingly, complete resolution of the skin lesions of DH has also been reported by adherence to the high-protein, unlimited fat, low-carbohydrate diet popularized as the "Atkins Diet."[100] Further studies are needed to confirm this report.

REFERENCES

1. Duhring LA. Dermatitis herpetiformis. *J Am Med Assoc*. 1884;3:225.
2. Brocq L. De la dermatite herpetiforme de Duhring. *Ann Dermatol Syphiligr (Paris)*. 1888:152.
3. Costello M. Dermatitis herpetiformis treated with sulfapyridine. *Arch Dermatol Syph*. 1974;41:134.
4. Pierard J, Whimster I. The histological diagnosis of dermatitis herpetiformis, bullous pemphigoid and erythema multiforme. *Br J Dermatol*. 1961;73:253-266.
5. MacVicar DN, Graham JH, Burgoon CF. Dermatitis herpetiformis, erythema multiforme and bullous pemphigoid: a comparative histopathological and histochemical study. *J Invest Dermatol*. 1963;41:289-300.
6. Cormane RH. Immunofluorescent studies of the skin in lupus erythematosus and other diseases. *Pathol Eur*. 1967;2:170-187.
7. van der Meer JB. Granular deposits of immunoglobulins in the skin of patients with dermatitis herpetiformis: an immunofluorescent study. *Br J Dermatol*. 1969;81:493-503.
8. Marks J, Shuster S, Watson AJ. Small bowel changes in dermatitis herpetiformis. *Lancet*. 1966;2(7476):1280-1282.
9. Fry L, McMinn RM, Cowan JD, et al. Effect of gluten free-diet on dermatological, intestinal and haematological manifestations of dermatitis herpetiformis. *Lancet*. 1968;1:557-561.
10. Shuster S, Watson AJ, Marks J. Coeliac syndrome in dermatitis herpetiformis. *Lancet*. 1968;1(7552): 1101-1106.
11. Fry L, Seah PP, Riches DJ, et al. Clearance of skin lesions in dermatitis herpetiformis after gluten withdrawal. *Lancet*. 1973;1(7798):288-291.
12. Katz SI, Falchuk ZM, Dahl MV, et al. HL-A8: a genetic link between dermatitis herpetiformis and gluten-sensitive enteropathy. *J Clin Invest*. 1972;51(11):2977-2980.
13. Jablonska S, Chorzelski T. IgA linear dermatosis. *Ann Dermatol Venereol*. 1979;106 (8-9):651-655.
14. Dieterich W, Ehnis T, Bauer M, et al. Identification of tissue transglutaminase as the autoantigen of celiac disease. *Nat Med*. 1997;3:797-801.
15. Sárdy M, Kárpáti S, Merkl B, et al: Epidermal transglutaminase (TGase 3) is the autoantigen of dermatitis herpetiformis. *J Exp Med*. 2002;195:747-757.
16. Görög A, Németh K, Kolev K, et al. Circulating transglutaminase 3-immunoglobulin A immune complexes in dermatitis herpetiformis. *J Invest Dermatol*. 2016;136(8):1729-1731.
17. Salmi TT, Hervonen K, Kautiainen H, et al. Prevalence and incidence of dermatitis herpetiformis: a 40-year prospective study from Finland. *Br J Dermatol*. 2011;165(2):354-359.
18. Bolotin D, Petronic-Rosic V. Dermatitis herpetiformis. Part I. Epidemiology, pathogenesis, and clinical presentation. *J Am Acad Dermatol*. 2011;64(6):1017-1024.
19. Smith JB, Tulloch JE, Meyer LJ, et al. The incidence and prevalence of dermatitis herpetiformis in Utah. *Arch Dermatol*. 1992;128(12):1608-1610.
20. Reunala T, Lokki J. Dermatitis herpetiformis in Finland. *Acta Derm Venereol*. 1978;58:505-510.
21. Leonard JN, Tucker WF, Fry JS, et al. Increased incidence of malignancy in dermatitis herpetiformis. *Br Med J (Clin Res Ed)*. 1983;286(6358):16-18.
22. Collin P, Pukkala E, Reunala T. Malignancy and survival in dermatitis herpetiformis: a comparison with coeliac disease. *Gut*. 1996;38:528-530.
23. Grainge MJ, West J, Solaymani-Dodaran M, et al. The long-term risk of malignancy following a diagnosis of coeliac disease or dermatitis herpetiformis: a cohort study. *Aliment Pharmacol Ther*. 2012;35(6):730-739.
24. Lewis HM, Renaula TL, Garioch JJ, et al. Protective effect of gluten-free diet against development of lymphoma in dermatitis herpetiformis. *Br J Dermatol*. 1996;135(3):363-367.
25. Hervonen K, Vornanen M, Kautiainen H, et al. Lymphoma in patients with dermatitis herpetiformis and their first-degree relatives. *Br J Dermatol*. 2005;152(1):82-86.
26. Viljamaa M, Kaukinen K, Pukkala E, et al. Malignancy and mortality in patients with coeliac disease and dermatitis herpetiformis: 30-year population based study. *Dig Liver Dis*. 2006;38:374-380.
27. Lewis NR, Logan RF, Hubbard RB, et al. No increase in risk of fracture, malignancy or mortality in dermatitis herpetiformis: a cohort study. *Aliment Pharmacol Ther*. 2008;27(11):1140-1147.
28. Fry L. Dermatitis herpetiformis. *Baillieres Clin Gastroenterol*. 1995;9:371-393.
29. Reunala T, Collin P. Diseases associated with dermatitis herpetiformis. *Br J Dermatol*. 1997;136:315-318.
30. Price P, Witt C, Allcock R, et al. The genetic basis for the association of the 8.1 ancestral haplotype (A1, B8, DR3) with multiple immunopathological diseases. *Immunol Rev*. 1999;167:257-274.
31. Bushara KO. Neurologic presentation of celiac disease. *Gastroenterology*. 2005;128:S92-S97.
32. Helsing P, Froen H. Dermatitis herpetiformis presenting as ataxia in a child. *Acta Derm Venereol*. 2007;87: 163-165.

33. Wills AJ, Turner B, Lock RJ, et al. Dermatitis herpetiformis and neurological dysfunction. *J Neurol Neurosurg Psychiatry*. 2002;72(2):259-261.
34. Corazza GR, Di Stefano M, Mauriño E, et al. Bones in coeliac disease: diagnosis and treatment. *Best Pract Res Clin Gastroenterol*. 2005;19(3):453-465.
35. Di Stefano M, Jorizzo RA, Veneto G, et al. Bone mass and metabolism in dermatitis herpetiformis. *Dig Dis Sci*. 1999;44(10):2139-2143.
36. Abuzakouk M, Barnes L, O'Gorman N, et al. Dermatitis herpetiformis: no evidence of bone disease despite evidence of enteropathy. *Dig Dis Sci*. 2007;52(3):659-664.
37. Reunala T, Collin P, Holm K, et al. Tolerance to oats in dermatitis herpetiformis. *Gut*. 1998;43(4):490-493.
38. Hardman CM, Garioch JJ, Leonard JN, et al. Absence of toxicity of oats in patients with dermatitis herpetiformis. *N Engl J Med*. 1997;337(26):1884-1887.
39. Savilahti E, Ormälä T, Arato A, et al. Density of gamma/delta+ T cells in the jejunal epithelium of patients with coeliac disease and dermatitis herpetiformis is increased with age. *Clin Exp Immunol*. 1997;109(3):464-467.
40. Smith AD, Bagheri B, Streilein RD, et al. Expression of interleukin-4 and interferon-gamma in the small bowel of patients with dermatitis herpetiformis and isolated gluten-sensitive enteropathy. *Dig Dis Sci*. 1999;44(10):2124-2132.
41. Hall RP, Smith AD, Streilein RD. Increased production of IL-4 by T cell lines from patients with dermatitis herpetiformis compared to patients with isolated gluten sensitive enteropathy. *Dig Dis Sci*. 2000;45:2036-2043.
42. Hall RP 3rd, Takeuchi F, Benbenisty KM, et al. Cutaneous endothelial cell activation in normal skin of patients with dermatitis herpetiformis associated with increased serum levels of IL-8, sE-Selectin and TNF-alpha. *J Invest Dermatol*. 2006;126(6):1331-1337.
43. Ward MM, Pisetsky DS, Hall RP. Soluble interleukin-2 receptor levels in patients with dermatitis herpetiformis. *J Invest Dermatol*. 1991;97:568-572.
44. Smith AD, Streilein RD, Hall RP. Neutrophil CD11b, L-selectin and Fc IgA receptors in patients with dermatitis herpetiformis. *Br J Dermatol*. 2002;147:1109-1117.
45. Samolitis NJ, Hull CM, Leiferman KM, et al. Dermatitis herpetiformis and partial IgA deficiency. *J Am Acad Dermatol*. 2006;54(5 suppl):S206-S209.
46. Dieterich W, Laag E, Bruckner-Tuderman L, et al. Antibodies to tissue transglutaminase as serologic markers in patients with dermatitis herpetiformis. *J Invest Dermatol*. 1999;113(1):133-136.
47. Donaldson MR, Zone JJ, Schmidt LA, et al. Epidermal transglutaminase deposits in perilesional and uninvolved skin in patients with dermatitis herpetiformis. *J Invest Dermatol*. 2007;127(5):1268-1271.
48. Reunala T, Salmi TT, Hervonen K, et al. IgA antiepidermal transglutaminase antibodies in dermatitis herpetiformis: a significant but not complete response to a gluten-free diet treatment. *Br J Dermatol*. 2015;172:1139-1141.
49. Hull CM, Liddle M, Hansen N, et al. Elevation of IgA antiepidermal transglutaminase antibodies in dermatitis herpetiformis. *Br J Dermatol*. 2008;159(1):120-124.
50. Taylor TB, Schmidt LA, Meyer LJ, et al. Transglutaminase 3 present in the IgA aggregates in dermatitis herpetiformis skin is enzymatically active and binds soluble fibrinogen. *J Invest Dermatol*. 2015;135(2):623-625.
51. Takeuchi F, Streilein RD, Hall RP. Increased E-selectin, IL-8 and IL-10 gene expression in human skin after minimal trauma: a potential explanation of regional distribution of skin lesions. *Exp Dermatol*. 2003;12:777-783.
52. Airola K, Vaalamo M, Reunala T, et al. Enhanced expression of interstitial collagenase, stromelysin-1, and urokinase plasminogen activator in lesions of dermatitis herpetiformis. *J Invest Dermatol*. 1995;105(2):184-189.
53. Salmela MT, Pender SL, Reunala T, et al. Parallel expression of macrophage metalloelastase (MMP-12) in duodenal and skin lesions of patients with dermatitis herpetiformis. *Gut*. 2001;48(4):496-502.
54. Baker BS, Garioch JJ, Bokth S, et al. Lack of proliferative response by gluten specific T cells in the blood and gut of patients with dermatitis herpetiformis. *J Autoimmun*. 1995;8(4):561-574.
55. Garioch JJ, Baker BS, Leonard JN, et al. T lymphocytes in lesional skin of patients with dermatitis herpetiformis. *Br J Dermatol*. 1994;131(6):822-826.
56. Katz SI, Hertz KC, Rogentine N, et al. HLA-B8 and dermatitis herpetiformis in patients with IgA deposits in skin. *Arch Dermatol*. 1977;113(2):155-156.
57. Reunala T, Salo OP, Tiilikainen A, et al. Histocompatibility antigens and dermatitis herpetiformis with special reference to jejunal abnormalities and acetylator phenotype. *Br J Dermatol*. 1976;94(2):139-143.
58. Thomsen M, Platz P, Marks J, et al. Association of LD-8a and LD-12a with dermatitis herpetiformis. *Tissue Antigens*. 1976;7(1):60-62.
59. Keuning, JJ, Peña AS, van Leeuwen A, et al. HLA-DW3 associated with coeliac disease. *Lancet*. 1976;1(7958):506-508.
60. Park MS, Terasaki PI, Ahmed AR, et al. The 90% incidence of HLA antigen (Te24) in dermatitis herpetiformis. *Tissue Antigens*. 1983;22(4):263-266.
61. Otley CC, Wenstrup RJ, Hall RP. DNA sequence analysis and restriction fragment length polymorphism (RFLP) typing of the HLA-DQw2 alleles associated with dermatitis herpetiformis. *J Invest Dermatol*. 1991;97:318-322.
62. Hervonen K, Karell K, Holopainen P, et al. Concordance of dermatitis herpetiformis and celiac disease in monozygous twins. *J Invest Dermatol*. 2000;115(6):990-993.
63. Spurkland A, Ingvarsson G, Falk ES, et al. Dermatitis herpetiformis and celiac disease are both primarily associated with the HLA-DQ (alpha 1*0501, beta 1*02) or the HLA- DQ (alpha 1*03, beta 1*0302) heterodimers. *Tissue Antigens*. 1997;49(1):29-34.
64. Hervonen K, Hakanen M, Kaukinen K, et al. First-degree relatives are frequently affected in coeliac disease and dermatitis herpetiformis. *Scand J Gastroenterol*. 2002;37(1):51-55.
65. Cianci R, Giambra V, Mattioli C, et al. Increased frequency of Ig heavy-chain HS1,2-A enhancer *2 allele in dermatitis herpetiformis, plaque psoriasis, and psoriatic arthritis. *J Invest Dermatol*. 2008;128(8):1920-1924.
66. Marietta EV, Rashtak S, Pittelkow MR. Experiences with animal models of dermatitis herpetiformis: a review. *Autoimmunity*. 2012;45(1):81-90.
67. Ko CJ, Colegio OR, Moss JE, et al. Fibrillar IgA deposition in dermatitis herpetiformis–an underreported pattern with potential clinical significance. *J Cutan Pathol*. 2010;37(4):475-477.

68. Seah PP, Fry L, Stewart JS, et al. Immunoglobulins in the skin in dermatitis herpetiformis and coeliac disease. *Lancet*. 1972;1(7751):611-614.
69. Cannistraci C, Lesnoni La Parola I, Cardinali G, et al. Co-localization of IgA and TG3 on healthy skin of coeliac patients. *J Eur Acad Dermatol Venereol*. 2007;21(4):509-514.
70. Seah PP, Fry L. Immunoglobulins in the skin in dermatitis herpetiformis and their irrelevance in the diagnosis. *Br J Dermatol*. 1975;92:157-166.
71. Leonard J, Haffenden G, Tucker W, et al. Gluten challenge in dermatitis herpetiformis. *N Engl J Med*. 1983;308(14):816-819.
72. Reunala T. Gluten-free diet in dermatitis herpetiformis II. Morphological and immunological findings in the skin and small intestine of 12 patients and matched controls. *Br J Dermatol*. 1978;98:69-78.
73. Zone JJ, Meyer LJ, Petersen MJ. Deposition of granular IgA relative to clinical lesions in dermatitis herpetiformis. *Arch Dermatol*. 1996;132:912-918.
74. Hall RP, Lawley TJ. Characterization of circulating and cutaneous IgA immune complexes in patients with dermatitis herpetiformis. *J Immunol*. 1985;135:1760-1765.
75. Barghuthy FS, Kumar V, Valeski E, et al. Identification of IgA subclasses in skin of dermatitis herpetiformis patients. *Int Arch Allergy Appl Immunol*. 1988;85(3):268-271.
76. Hall RP, Waldbauer GV. Characterization of the mucosal immune response to dietary antigens in patients with dermatitis herpetiformis. *J Invest Dermatol*. 1988;90:658-663.
77. Hall RP, McKenzie KD. Comparison of the intestinal and serum antibody response in patients with dermatitis herpetiformis. *Clin Immunol Immunopathol*. 1992;62(1, pt 1):33-41.
78. Kantele JM, Savilahti E, Westerholm-Ormio M, et al. Decreased numbers of circulating plasmablast and differences in IgA1-plasmablast homing to skin in coeliac disease and dermatitis herpetiformis. *Clin Exp Immunol*. 2009;156(3):535-541.
79. Katz SI, Hertz KC, Crawford PS, et al. Effect of sulfones on complement deposition in dermatitis herpetiformis and on complement-mediated guinea-pig reactions. *J Invest Dermatol*. 1976;67(6):688-690.
80. Ljunghall K, Tjernlund U. Dermatitis herpetiformis: effect of gluten-restricted and gluten-free diet on dapsone requirement and on IgA and C3 deposits in uninvolved skin. *Acta Derm Venereol*. 1983;63:129-136.
81. Dahlback K, Lofberg H, Dahlback B. Vitronectin colocalizes with Ig deposits and C9 neoantigen in discoid lupus erythematosus and dermatitis herpetiformis, but not in bullous pemphigoid. *Br J Dermatol*. 1989;120:725-733.
82. Stingl G, Hönigsmann H, Holubar K, et al: Ultrastructural localization of immunoglobulins in skin of patients with dermatitis herpetiformis. *J Invest Dermatol*. 1976;67(4):507-512.
83. Yaoita H. Identification of IgA binding structures in skin of patients with dermatitis herpetiformis. *J Invest Dermatol*. 1978;71:213-216.
84. Kárpáti S, Meurer M, Stolz W, et al. Dermatitis herpetiformis bodies. Ultrastructural study on the skin of patients using direct preembedding immunogold labeling. *Arch Dermatol*. 1990;126(11):1469-1474.
85. Lightner VA, Sakai LY, Hall RP. IgA-binding structures in dermatitis herpetiformis skin are independent of elastic-microfibrillar bundles. *J Invest Dermatol*. 1991;96:88-92.
86. Dahlback K, Sakai L. IgA immunoreactive deposits colocal with fibrillin immunoreactive fibers in dermatitis herpetiformis skin. *Acta Derm Venereol*. 1990;70:194-198.
87. Chorzelski TP, Sulej J, Tchorzewska H, et al. IgA class endomysium antibodies in dermatitis herpetiformis and coeliac disease. *Ann N Y Acad Sci*. 1983;420:325-334.
88. Rose C, Armbruster FP, Ruppert J, et al. Autoantibodies against epidermal transglutaminase are a sensitive diagnostic marker in patients with dermatitis herpetiformis on a normal or gluten-free diet. *J Am Acad Dermatol*. 2009;61(1):39-43.
89. Borroni G, Biagi F, Ciocca O, et al. IgA anti-epidermal transglutaminase autoantibodies: a sensible and sensitive marker for diagnosis of dermatitis herpetiformis in adult patients. *J Eur Acad Dermatol Venereol*. 2013;27(7):836-841.
90. Smith JB, Taylor TB, Zone JJ. The site of blister formation in dermatitis herpetiformis is within the lamina lucida. *J Am Acad Dermatol*. 1992;27:209-213.
91. Mansikka E, Hervonen K, Salmi TT, et al. The decreasing prevalence of severe villous atrophy in dermatitis herpetiformis: a 45-year experience in 393 patients. *J Clin Gastroenterol*. 2017;51(3):235-239.
92. Stockbrugger R, Andersson H, Gillberg R, et al: Auto-immune atrophic gastritis in patient with dermatitis herpetiformis. *Acta Derm Venereol*. 1997;56(2):111-113.
93. O'Donoghue DP, Lancaster-Smith M, Johnson GD, et al. Gastric lesion in dermatitis herpetiformis. *Gut*. 1976;17(3):185-188.
94. Paek SY, Steinberg SM, Katz SI. Remission in dermatitis herpetiformis: a cohort study. *Arch Dermatol*. 2011;147(3):301-305.
95. Garioch JJ, Lewis HM, Sargent SA, et al. 25 years' experience of a gluten-free diet in the treatment of dermatitis herpetiformis. *Br J Dermatol*. 1994;131(4):541-545.
96. Griffiths CE, Leonard JN, Fry L. Dermatitis herpetiformis exacerbated by indomethacin. *Br J Dermatol*. 1985;112:443-445.
97. Hervonen K, Salmi TT, Ilus T, et al. Dermatitis herpetiformis refractory to gluten-free dietary treatment. *Acta Derm Venereol*. 2016;96(1):82-86.
98. Kadunce DP, McMurry MP, Avots-Avotins A, et al. The effect of an elemental diet with and without gluten on disease activity in dermatitis herpetiformis. *J Invest Dermatol*. 1991;97(2):175-182.
99. Zeedijk N, van der Meer JB, Poen H, et al. Dermatitis herpetiformis: consequences of elemental diet. *Acta Derm Venereol*. 1986;66(4):316-320.
100. Sladden MJ, Johnston GA. Complete resolution of dermatitis herpetiformis with the Atkins' diet. *Br J Dermatol*. 2006;154:565-566.

Chapter 60 :: Inherited Epidermolysis Bullosa

:: M. Peter Marinkovich

AT-A-GLANCE

- Epidermolysis bullosa is a family of inherited genodermatoses characterized by blistering in response to minor trauma.
- Blistering level categories are the simplex, hemidesmosomal, junctional, and dystrophic subtypes.
- Cutaneous involvement varies from localized to widespread blistering depending on subtype.
- Extracutaneous involvement varies from none to severely debilitating or lethal.
- The oropharynx, trachea, esophagus, eyes, teeth, nails, hair can be involved depending on subtype.
- Diagnosis is made by immunofluorescent or electron microscopy followed by DNA analysis.

INTRODUCTION

Inherited epidermolysis bullosa (EB, is a family of diseases with the common feature of blistering in response to mild trauma. Patients with EB can show blistering in the form of small vesicles or larger bullae, occurring on cutaneous surfaces and, in the severe forms, on mucosal tissues as well. Although skin and mucosa fragility and trauma-induced painful blisters are hallmarks across the EB spectrum, the distribution of the involvement, the depth of blister formation, any associated extracutaneous involvement, and the severity of the blistering process vary with the different EB subtypes and depend on the underlying heritable molecular defect. EB diseases vary also in the way in which blistered areas heal. The wound repair responses are often abnormal and can eventuate into chronic erosions, hypertrophic granulation tissue, scarring, or even invasive carcinoma. Although the milder EB subtypes are associated with a normal lifespan and little or no internal involvement, the most severe recessively inherited forms are mutilating, multiorgan disorders that threaten both the quality and length of life.

A number of early studies identified the major subtypes of EB. Studies of von Hebra.[1-3] were the first to distinguish pemphigus from inherited blistering, and the term *epidermolysis bullosa hereditaria* was first suggested by Koebner.[4] Hallopeau was the first to distinguish between simplex (nonscarring) and dystrophic (scarring) forms of the disease,[5] and Weber,[6] and Cockayne,[7] Dowling and Meara,[8] and Koebner[4] each described unique forms of epidermolysis bullosa simplex. Hoffman,[9] Cockayne,[10] Touraine,[11], Pasini,[12] and Bart[13] provided much of the information about subtypes of DEB. Herlitz described epidermolysis bullosas letalis,[14] which was later found to be a part of the third major category of EB: the junctional form. The use of electron microscopy in EB diagnosis led to the studies of Pearson and collaborators,[15] who classified the patients not only on the basis of clinical findings but also on the existence of ultrastructural changes. A comprehensive classification of EB based on a combination of ultrastructural and clinical findings was completed in an early landmark treatise by Gedde-Dahl.[16] Recent major advances have led to the identification of protein and genetic abnormalities in most types of EB patients. These studies have led to an improved understanding of the biological basis of EB and culminating in the current EB classification based on genetic and protein defects,[17] which provides a rational approach to specific molecular therapy.

ETIOLOGY AND PATHOGENESIS

OVERVIEW

EB arises from defects of attachment of basal keratinocytes to the underlying dermis. These defects can arise from inside the keratinocyte plasma membrane or extracellularly in the dermal-epidermal basement membrane zone (BMZ). Many tissues such as the skin and cornea, which are subjected to external disruptive forces, contain a complex BMZ composed of a group of specialized components that assemble into anchoring complexes (Fig. 60-1). At the most superior aspect of the BMZ, keratin-containing intermediate filaments of the basal cell cytoskeleton insert upon electron-dense condensations of the basal cell plasma membrane termed *hemidesmosomes*. Anchoring filaments span the lamina lucida, connecting hemidesmosomes with the lamina densa and anchoring filaments. At the most inferior aspect of the BMZ, collagen VII–containing anchoring fibrils extend from the lamina densa into the papillary dermis and combine with the lamina densa and anchoring plaques, trapping interstitial collagen fibrils. Thus, the cutaneous BMZ connects the extensive basal cell cytoskeletal network with the abundant network of interstitial collagen fibrils in the dermis.[18,19]

KERATIN FILAMENTS

Keratins are obligate heteropolymers that are composed of pairs of acidic and basic monomers. The

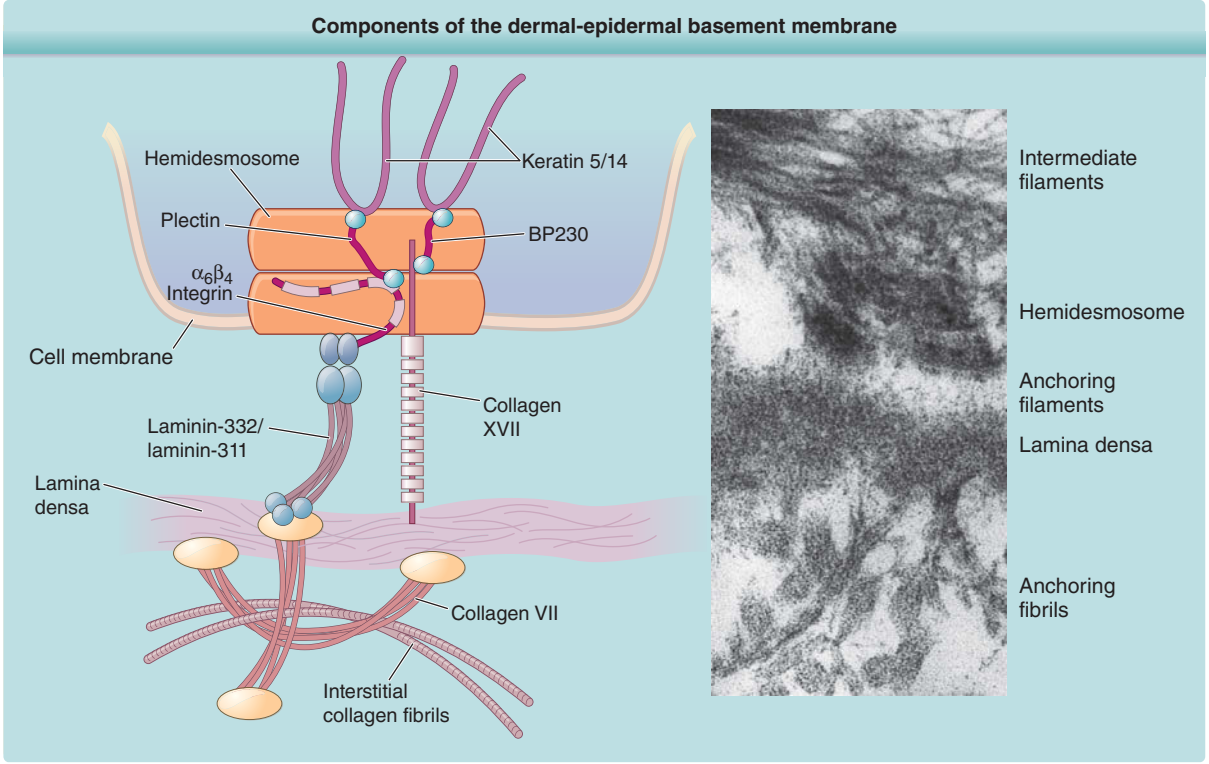

Figure 60-1 Schematic of the components of the dermal–epidermal basement membrane on the left compared with ultrastructural appearance of basement membrane morphological entities on the right.

keratin pair 5 and 14 assemble to form the extensive intermediate filament network of the basal cell cytoskeleton.[20] Keratins contain a central α-helical rod with several nonhelical interruptions as well as nonhelical carboxy and amino terminal regions. The regions of highest conservation between the keratins are located on the ends of the keratin rod in the helix boundary motifs. Whereas extensive mutagenesis studies suggest that helical regions near the ends of the central rod are important in keratin filament elongation, the nonhelical domains may be important in forming lateral associations.[21] Keratin intermediate filaments insert upon electron-dense structures known as hemidesmosomes.

HEMIDESMOSOMES

Hemidesmosomes contain intracellular proteins including plectin and BP230. Plectin is a 500-kD protein that acts as an intermediate filament binding protein. It is possible that plectin also interacts with microfilaments because plectin contains a domain with similarity to the actin binding domain of spectrin.[22,23] BP230, also known as BPAG1, is a 230-kD protein that has homology both to desmoplakin[24] and to plectin. Several splicing variants of BP230 are of vital importance in the nervous system.[25-27] BP230 localizes to a region referred to as the inner plate on the cytoplasmic surface of the hemidesmosome and like plectin functions in the connection between hemidesmosomes and intermediate filaments. BP230 negative transgenic mice lack a hemidesmosomal inner plate and the connection between hemidesmosomes and intermediate filaments is severed, creating a cytoplasmic zone of mechanical fragility just above the hemidesmosomes.

ANCHORING FILAMENTS

Hemidesmosomes also contain the transmembrane proteins collagen XVII (also termed BPAG2 and BP180)[28] and α6β4 integrin.[29] The cytoplasmic portions of these molecules make up part of the hemidesmosome-dense plaque, and the extracellular portions of these molecules make up portions of the anchoring filament and probably contribute to the structure known as the subbasal dense plate that underlies hemidesmosomes in the lamina lucida region. β4 Integrin only pairs with the α6 subunit, but the α6 subunit can combine either with the β4 integrin or with the β1 integrin. Both the α6β1 or α6β4 integrin combinations have been shown to act as receptors for laminins, and α6β4 integrin acts as a specific receptor for laminin-332. α6β4 Integrin plays a central role in organization of the hemidesmosome. The β4 integrin contains an especially large cytoplasmic domain, which functions in the interaction with other proteins of the hemidesmosomal plaque including collagen XVII and

plectin.[30] Skin from transgenic mice lacking β4 integrin is devoid of hemidesmosomes and shows severe deficits in cell adhesion.[31] Interactions between plectin and α6β4 integrin appear to be critical both in the assembly as well as the disassembly of hemidesmosomes.[32]

Collagen XVII (BPAG2, BP180) is a collagenous protein with a type II transmembrane orientation. Based on electron microscopy and crosslinking studies, collagen XVII assembles into a triple-helical homotrimer and contains three main regions: an intracellular amino-terminal globular head, a central rod, and an extracellular flexible tail.[33] Collagen XVII associates with laminin-332 and α6β4 integrin in adhesion structures termed *stable anchoring contacts* formed by keratinocytes in vivo, which are thought to represent prehemidesmosomes.[34] The autoantigen in linear immunoglobulin (Ig) A bullous dermatosis, LAD-1,[35,36] is a 120-kD protein that has been shown by peptide sequencing to be the cleaved exodomain of collagen XVII.[37] Collagen XVII undergoes processing in keratinocyte cultures and in skin through the action of sheddases, membrane-associated proteases that solubilize cell surface receptors.[38,39]

In addition to α6β4 integrin and collagen XVII, anchoring filaments contain the molecules laminin-332 and laminin-311. Like all members of the family of laminin proteins,[40-42] laminin-332 is a large heterotrimeric molecule and contains α3, β3, and γ2 chains.[43,44] The first laminins to be described contained 3 short arms and 1 long arm, forming a cross shape as shown by rotary shadowing analysis. In contrast, laminin-332 contains truncations of each short arm.[45-47] Because of these short arm truncations, laminin-332 cannot self-polymerize with other laminins or bind to nidogen. Instead, laminin-332 forms a disulfide bonded attachment to laminin-311,[48] the other known anchoring filament laminin[43] that contains α3, β1, and γ1 chains. Laminin-332 also undergoes processing of its γ2 and α3 chains.[49] Although rat laminin γ2 chain has been previously been shown to be processed by metalloproteinase-2[50] and membrane-type metalloproteinase type 1,[51] the predominant site of cleavage by these enzymes is not conserved in human laminin-332.[52] Other studies have shown that processing of laminin γ2 chain takes place through a special class of proteins termed C-proteinases, which also process C-terminal domains of procollagen molecules.[53] Although one member of this class of proteins, bone morphogenic protein 1,[54] is capable of performing this action, a splice variant of this protein termed *mammalian tolloid* is the enzyme that is predominantly expressed in keratinocytes and fibroblasts, and mammalian tolloid is the thus the enzyme that likely performs this function in the skin.[52] Mammalian tolloid also processes the laminin α3 chain,[52] although other enzymes such as plasmin,[55] matrix metalloproteinase (MMP)-2[50] and membrane type MMP-1[51] are also capable of this function. The γ2 chain short arm appears important in the assembly of laminin-332 into basement membrane.[56] The antigen recognized by monoclonal antibody (mAb) 19-DEJ-1[57] also localizes to anchoring filaments, but its molecular identity remains unknown.

ANCHORING FIBRILS

Collagen VII is the major constituent of anchoring fibrils. Analysis of the deduced amino acid sequence of collagen VII[58] reveals the presence of a long central collagenous region characterized by repeating Gly-X-Y sequences that contains a number of noncollagenous interruptions, including a 39–amino acid noncollagenous segment in the center of the helix that corresponds to the "hinge region" predicted by biochemical studies.[59,60] These interruptions account for the flexibility of the collagen VII molecule and explain its ability to loop around and entrap dermal matrix molecules to provide its function of stabilizing the basement membrane to the underlying papillary dermis.[61] A 50-kD component of anchoring fibrils has also been identified that appears to localize to the insertion sites of anchoring fibrils to the lamina densa.[62]

The 145-kD N-terminal end of collagen VII contains the largest noncollagenous domain that inserts onto the lamina densa and anchoring plaques. Collagen IV, the most abundant component of these structures, binds to the collagen VII NC1 domain. A direct interaction between anchoring filaments and anchoring fibrils exists from a specific interaction between the anchoring filament component laminin-332 and collagen VII NC1 domain.[63,64] Collagen VII binds the β3 chain on laminin-332.[63,65-67] This appears to be a critical factor in the maintenance of dermal–epidermal cohesion. Like all collagens, collagen VII assembles into a triple helix. Only one chain of collagen VII, the α1 chain, has been identified; one gene codes for an entire molecule, and thus collagen VII is a homotrimer. Collagen VII triple helices are joined together at their processed NC-2 globular domains to form antiparallel dimers.[61,68] Processing of the NC-2 domains takes place via the same family of C-proteinases (bone morphogenic protein 1 and/or mammalian tolloid) that are known to process laminin-332, a closely associated molecule. Anchoring fibrils may derive from lateral associations of collagen VII antiparallel dimers.

CLINICAL FINDINGS

A classification of EB is made based on the ultrastructural level within which the cleavage plane of the blister occurs. EB has been traditionally classified according to the level of BMZ separation on transmission electron microscopy into simplex, junctional, and dystrophic subtypes[69] (Fig. 60-2). Although traditionally the diagnostic "gold standard" for grouping EB has been electron microscopy, immunomapping of basement membrane antigens as viewed by indirect immunofluorescence can also be quite useful in distinguishing subtypes of EB. Within each of these groups, there are several distinct types of EB based on clinical, genetic, histologic, and biochemical evaluation.[17] When possible, molecular characterization at the protein or DNA levels should be appended to the clinical subtype (termed the "onion skin approach") to better delineate the diagnosis and to aid in delivery of emerging molecular therapies. These clinical subtypes are summarized in Table 60-1.

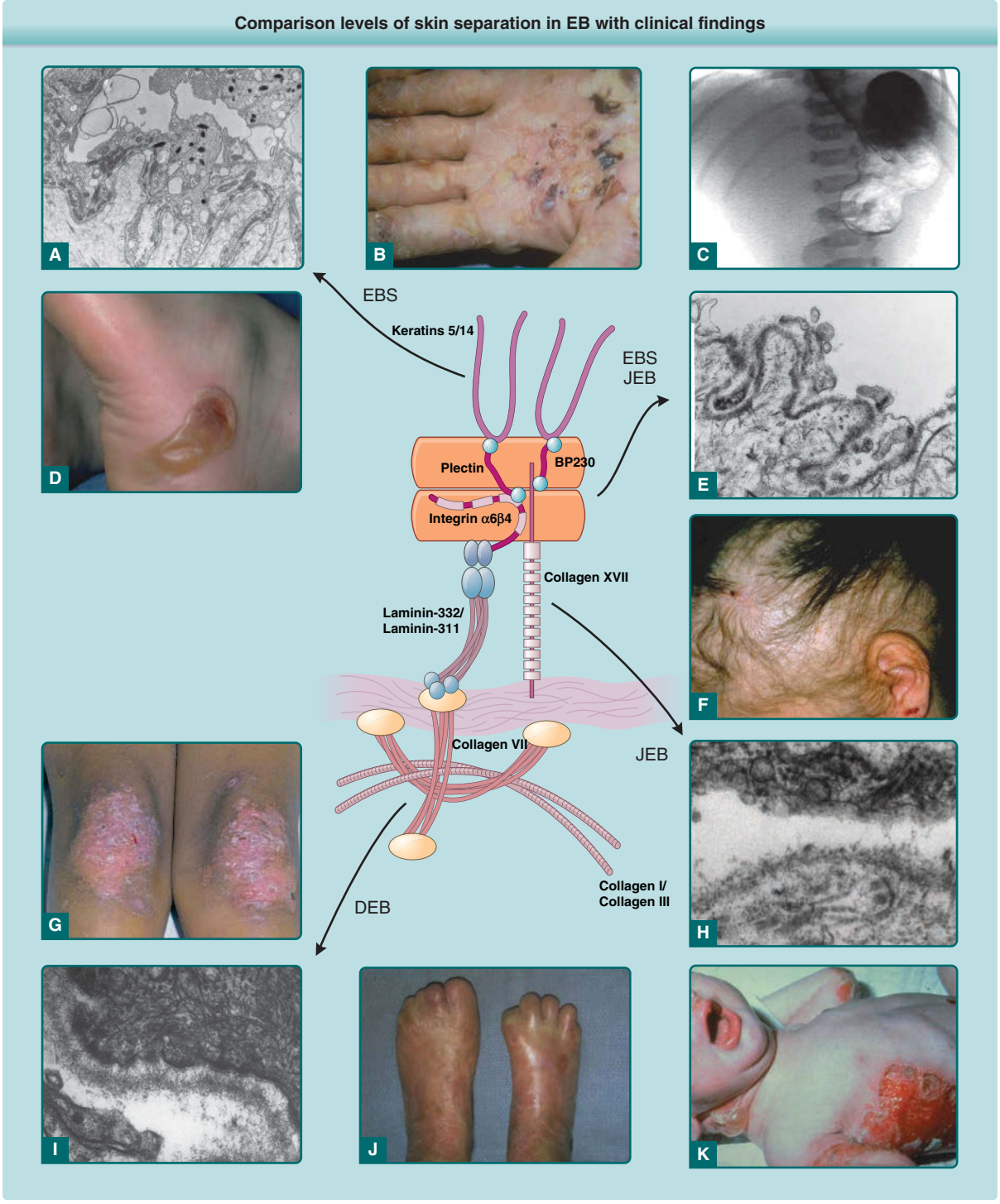

Figure 60-2 Comparison of levels of skin separation in epidermolysis bullosa (EB) with clinical findings. **A,** Transmission electron micrograph showing typical intraepidermal separation in epidermolysis bullosa simplex (EBS). **B,** Palmar hyperkeratosis and erosions in EB herpetiformis. **C,** Radiograph showing pyloric atresia associated with EB. **D,** Localized blister on heel in EBS Weber-Cockayne. **E,** Transmission electron micrograph showing typical separation at level of hemidesmosome in EB with pyloric atresia, alternatively classified as EBS or junctional epidermolysis bullosa (JEB). **F,** Nonscarring diffuse alopecia and scalp erosions in generalized atrophic benign epidermolysis bullosa. **G,** Localized dystrophic changes with milia in dominant dystrophic epidermolysis bullosa (DEB). **H,** Transmission electron microscopy showing typical intralamina lucida separation in JEB. **I,** Transmission electron microscopy showing typical sublamina densa separation in DEB. **J,** Pseudosyndactly in recessive DEB. **K,** Generalized blistering in Herlitz JEB.

TABLE 60-1
Classification of Epidermolysis Bullosa

DISEASE	AFFECTED GENE	AFFECTED PROTEIN
Simplex		
Generalized severe	*KRT5/KRT14*	Keratin 5/keratin 14
Generalized intermediate	*RT5/KRT14*	Keratin 5/keratin 14
Localized	*RT5/KRT14*	Keratin 5/keratin 14
Mottled pigmentation	*KRT5*	Keratin 5
EB with muscular dystrophy	*PLEC1*	Plectin
Superficialis	Unknown	Unknown
Acantholytic	*DSP, JUP*	Desmoplakin, plakoglobin
Plakophillin deficiency	*PKP1*	Plakophillin 1
Plakoglobin deficiency	*JUP*	Plakoglobin
Ogna	*PLEC1*	Plectin
BP230 deficiency	*DST-e*	BP230/BPAG1
Exophillin-5 deficiency	*EXPH5*	Exophillin 5
Acral peeling skin syndrome	*TGM5*	Transglutaminase 5
Junctional		
EB with pyloric atresia[a]	*ITGB4/ITGA6/PLEC1*	Integrin α6, integrin β4, plectin
Generalized severe	*LAMB3/LAMA3/LAMC2*	Laminin-332
Generalized intermediate	*LAMB3/LAMA3/LAMC2/COL17A1*	Laminin-332, collagen XVII
Localized	*LAMB3/LAMA3/LAMC2/COL17A1*	Laminin-332, collagen XVII
Inversa	*LAMB3/LAMA3/LAMC2*	Laminin-332
Laryngo-onycho-cutaneous	*LAMA3A*	Laminin α3
Respiratory and Renal	*ITGA3*	Integrin α3
Dystrophic		
Generalized dominant	*COL7A1*	Collagen VII
Localized dominant	*COL7A1*	Collagen VII
Generalized severe recessive	*COL7A1*	Collagen VII
Generalized interme-diate recessive	*COL7A1*	Collagen VII
Localized recessive	*COL7A1*	Collagen VII
Inversa recessive	*COL7A1*	Collagen VII
Bullous dermolysis of the newborn	*COL7A1*	Collagen VII
Kindler syndrome	*KIND1*	Kindlin

[a]Alternatively classified as simplex.
EB, epidermolysis bullosa.

EPIDERMOLYSIS BULLOSA SIMPLEX

Epidermolysis bullosa simplex (EBS) is a disease group characterized by intraepidermal blistering and most often is associated with keratin gene mutations. The range of disease phenotypes range from mild to severe among different subgroups.[70] The common EBS types are dominantly inherited and include generalized severe (Dowling-Meara), generalized intermediate (Koebner), and localized (Weber-Cockayne). There are several uncommon varieties, which include EBS Ogna, EBS with muscular dystrophy, EBS with mottled pigmentation, and a group of suprabasal EBS subtypes.

GENERALIZED SEVERE EPIDERMOLYSIS BULLOSA SIMPLEX

This subtype is also known as the Dowling Meara, herpetiformis variant of EBS. It presents at birth, has a generalized distribution, and is regarded as the most severe of the EBS subtypes (Fig. 60-3). It differs from the generalized intermediate variant in that the oral mucosa is more often involved, occasionally showing extensive erosions. Milium formation may sometimes occur in infancy in patients with this subtype; however, this postwound phenomenon usually resolves later in childhood. The disease can often be associated with spontaneous appearance of grouped or "herpetiform" blisters. These occur on the trunk and proximal extremities and heal without scarring. It should be noted that often when patients show a generalized blistering, this herpetiform pattern is not seen; therefore, its absence should not be used as a basis to exclude this EB subtype. Generalized severe EBS often shows nail involvement. In this disease, nails may become shed and may regrow with dystrophy. Interestingly, although heat exacerbates the blistering in

Figure 60-3 Characteristic blister formation on trunk and arm in patient with Dowling-Meara epidermolysis bullosa simplex.

other EBS subtypes, it does not appear to have a major impact in generalized severe EBS. Hyperkeratosis of the palms and soles often develops beginning in early childhood and can progress to confluent keratoderma of the palms and soles. These can be quite painful, and occasionally interference with ambulation has led to flexural contractures. Occasionally, involvement of the esophagus in generalized severe EBS ranging from erosions to pyloric atresia[71] has been reported. The upper respiratory tract can also be affected, including the laryngeal mucosa.[72]

GENERALIZED INTERMEDIATE EPIDERMOLYSIS BULLOSA SIMPLEX

The other common form of generalized EBS is the intermediate form, also known as the Koebner EBS. This subtype shows an onset of generalized blistering at birth or at latest during early infancy. The hands, feet, and extremities usually show the most involvement. Lesions often heal with postinflammatory hyper or hypopigmentation, and although occasional atrophy and milia can occur, they are rare and much less frequent than in generalized severe EBS. Palmar-plantar hyperkeratosis and erosions may be present (Fig. 60-4). Thickening of the soles is common but often does not present until later childhood. The oral mucosa sometimes shows mild erosive activity, but these usually improve with increasing age. Usually there is not a severe growth retardation in this EB subtype.

LOCALIZED EPIDERMOLYSIS BULLOSA SIMPLEX

This is a mild form of EB, previously referred to as the Weber-Cockayne subtype of EBS (Fig. 60-5). This disease is the most common form of EB and often presents during infancy or childhood. Occasionally, it presents in early adulthood, such as when blisters are noted after marching during military service. It is speculated that there are a number of undiagnosed cases of this form of EB because it can be mild enough to escape reporting or detection during clinical visits. Hyperhidrosis of the palms and soles is a common association. Blisters can occasionally become secondarily infected. Postinflammatory pigmentary abnormalities occur with this variant, but milia and scarring as a rule are absent. Blistering activity usually follows areas of trauma, with the hands and feet being the most common and the scalp being the least common. Mild oral erosions are present only rarely and usually resolve with increasing age. Nail involvement is rare with this EB subtype.

Figure 60-5 Trauma-induced blistering from clothing in patient with localized epidermolysis bullosa simplex.

Figure 60-4 Widespread blistering in an infant with generalized epidermolysis bullosa simplex.

ADDITIONAL VARIANTS OF EPIDERMOLYSIS BULLOSA SIMPLEX

Epidermolysis Bullosa Simplex of Ogna: Onset in infancy is common with seasonal blistering (summer) on the acral areas. Small hemorrhagic and serous blisters occur primarily on the extremities. Healing occurs without scarring. This disease was originally reported in patients from Norway. These patients also show a characteristic onychogryphosis of the great toenails.

Epidermolysis Bullosa Simplex with Muscular Dystrophy: This rare clinical entity is an autosomal recessive disorder that consists of generalized blistering of the skin at birth or shortly thereafter. This is accompanied by a progressive muscular dystrophy.[73] It presents with generalized blistering

similar to generalized intermediate EBS. These patients have been shown to harbor mutations in the gene coding for HD1/plectin.[74-76]

Epidermolysis Bullosa Simplex with Mottled Pigmentation: This form of EB, as its name implies, is characterized by mottled hyperpigmentation of the trunk and proximal extremities. There is blistering in a generalized distribution beginning at birth or early infancy. Pigmentary alterations and blistering may improve with increasing age. Mild oral mucosal involvement may be present in infancy. This condition is distinct from the large melanocytic nevi, which can be seen in all three EB types.[77]

Epidermolysis Bullosa Simplex Superficialis: This is an uncommon form of EBS is named after the subcorneal separation that produces the blisters in this disease.[78] Erosions and crusts, rather than intact bullae, are usually seen in these patients, and heal with postinflammatory pigmentary changes. Despite the superficial cleavage plane, nail involvement, atrophic scarring, and milia have been observed in this disease.

Acantholytic Epidermolysis Bullosa Simplex: This subtype[79] is a rare recessively inherited and lethal disorder characterized by generalized erosions at birth. As in the superficialis subtype, blisters are not normally seen because of the very superficial level of epidermal separation, which has been described as sheetlike. Nails are dystrophic. Alopecia, neonatal teeth, oral erosions, and respiratory involvement distinguish this disorder from other superficial EBS subtypes.

Plakophilin Deficiency: This subtype, also known as ectodermal dysplasia skin fragility syndrome, is another inherited disorder of suprabasilar epidermal separation characterized by generalized erosions and sometimes superficial blisters at birth.[80] Alopecia is also very common, as are palmoplantar keratoderma, painful fissures, and nail dystrophy. Patients may sometimes demonstrate failure to thrive, cheilitis, hypohidrosis, and pruitis. Like the other superficial EBS subtypes, this disorder is associated with dystrophic nails.

BP230 Deficiency: This is an extremely rare variant of EB caused by mutations of the *DST-e* gene, which has been described in a small collection of Kuwaiti and Iranian families. Blistering onset is usually at birth, and the phenotype is localized, often affecting the feet, without significant mucosal or other extracutaneous involvement. Like other forms of EBS, blisters may heal with postinflammatory pigment changes but no scarring. Inheritance appears autosomal recessive, but some heterozygous carriers have also reported self-limiting mild blistering in the first and second decades of life.

Exophillin-5 Deficiency: This is a very rare autosomal recessive EBS variant caused by mutations of the *EXPH5* gene. Blistering is high in the epidermis, resulting in trauma-induced crusting or fragile blisters and vesicles. The disease is overall mild and has no extracutaneous involvement, and remission or improvement during childhood is characteristic of this disease.[81]

Acral Peeling Skin Syndrome: This EB variant[82] is characterized by superficial and painless skin peeling occurring most commonly on the hands and feet. Humidity, heat, and water exposure can exacerbate this condition. The level of separation histologically is between the stratum granulosum and stratum corneum.

MOLECULAR PATHOLOGY OF EPIDERMOLYSIS BULLOSA SIMPLEX

Most of the patients with EB simplex analyzed at the genetic level have been found to be associated with mutations of the genes coding for keratins 5 and 14.[21,70] The level of separation of the skin in these patients is at the midbasal cell, shown in Fig. 60-4, associated with variable intermediate filament clumping. Hemidesmosomes and other BMZ structures are normal by electron microscopy. The majority of keratin gene mutations associated with EBS are dominantly inherited because of abnormalities in the multimeric assembly of keratin filaments. There is a smaller subset of patients with recessively inherited disease of varying severity.[83,84]

Mutations coding for the most conserved regions of keratins 5 and 14, the helix boundary domains.[85] correlate with the most severe forms of EBS, such as the Dowling-Meara subtype, which exhibits intermediate filament clumping seen by transmission electron microscopy. On the other hand, milder types of disease, such as the Weber-Cockayne subtype, are associated with mutations coding for regions of keratins 5 and 14, which are less conserved. Mutations that code for a specific region of the amino terminus of keratin 5 are present in patients having EBS with mottled pigmentation.[86] Although significance of this type of mutation and its association with pigmentary abnormalities remains unclear,[87,88] it has been suggested that the keratin 5 globular head domain is responsible for keratin filament insertion onto melanosomes. Recent studies have shown that some mutations of the keratin 5 gene may produce protein that is unstable under increased temperatures.[89] This could help to explain the well observed exacerbation of some subtypes of EBS to warm temperatures.

The mutations associated with EBS with muscular dystrophy produce premature termination codons, splice-site, or other mutations that result in lack of expression or defective expression of plectin.[90] Although the form of EB associated with plectin abnormalities is classified as simplex, it has an identical level of skin separation to that seen in junctional epidermolysis bullosa (JEB) with pyloric atresia.[69] Specifically, the separation is present just above the level of the hemidesmosome in the intracellular part of the BMZ. This separation of EBS with muscular dystrophy and JEB with pyloric atresia, diseases with identical levels

of separation, into two distinct EB categories illustrates the limitations of the current EB classification system. Plectin defects, like α6β4 integrin defects, can also be associated with pyloric atresia.[90]

Plectin is normally expressed in a wide range of tissues, including muscle.[22] Although the mechanism of muscular dystrophy in plectin-deficient patients is unknown, it has been observed that disorganization of muscle sarcomeres occurs in the absence of plectin. It is possible that absence of plectin's spectrin-like domain, which may normally interact with actin filaments in muscle, may be a key factor in the muscle pathology.[91]

The underlying molecular defect of ectodermal dysplasia skin fragility syndrome has been shown to be loss of function of the desmosomal protein plakophilin 1.[80] Plakophilin is expressed mainly in suprabasilar keratinocytes and outer root sheath cells. Microscopic findings in this disease usually show intraepidermal acantholysis located in the areas where plakophilin 1 is normally expressed. The molecular defect involves loss-of-function mutations in the PKP1 gene coding for plakophilin 1.[92-97]

Deficiency of BP230 (an alternatively spliced dystrophic variant sometimes termed DST-e) is characterized by decreased or absent expression of BP230 by immunofluorescence microscopy and loss of the inner hemidesmosomal plate as seen by transmission electron microscopy. Homozygous premature termination codon mutations as well as point mutations of the *DST*-e gene in the area coding for the coiled-coil domain of BP230 have been associated with this disorder.[81] Exophillin-5 deficiency is associated with loss-of-function mutations of the *EXPH5* gene. This disease can show a complete absence of expression of this protein in the skin by immunofluorescence microscopy, and electron microscopy may show abnormal collections of basal keratinocyte perinuclear vesicles.[98,99] Mutations of TGM5, which encodes a member of the multigene transglutaminase family, produces alterations of transglutaminase expression associated with the underlying cause of acral peeling skin syndrome.[82]

JUNCTIONAL EPIDERMOLYSIS BULLOSA

All patients with JEB share the common histopathologic feature of blister formation within the lamina lucida of the BMZ caused by either a defect of anchoring filaments located in the lamina lucida and superior lamina densa. This group of diseases is inherited in an autosomal recessive manner, and there is considerable variation of the individual clinical phenotypes depending on the molecular defect. Three principal forms of JEB are most common. Patients with severe generalized JEB (previously termed Herlitz disease, JEB gravis, or lethal JEB) present with the most severe disease phenotype.[14,100] It is unfortunate that this most severe subtype of JEB is also the most common.

Figure 60-6 Widespread blistering at birth in an infant with Herlitz junctional epidermolysis bullosa.

GENERALIZED SEVERE JUNCTIONAL EPIDERMOLYSIS BULLOSA

Generalized severe JEB is one of the most severe EB subtypes, resulting in lethality during infancy or early childhood.[101] This disease is characterized by generalized and often extensive blistering at birth (Fig. 60-6). Later during infancy, a distinctive perioricial granulation tissue manifests. This can occur around the mouth, eyes, and nares most commonly but also can be present in the scalp; around the ears; and less frequently, in other locations besides the head and neck. This hypertrophic granulation tissue can also occur in nonlethal subtypes. Nails are usually severely affected and often are lost during infancy. When nails are still present, they are usually dystrophic and often associated with hypertrophic granulation tissue. Dental defects are present in this disease characterized by pitting of the tooth enamel. Oropharyngeal mucosal erosions are usually present and may be widespread. Erosions of all stratified squamous epithelial tissues, including nasal, conjunctival, esophageal, tracheal, laryngeal, rectal, and urethral mucosa can be affected. Associated systemic findings in severe cases are important factors in the lethality of this disease. Involvement of the large airways including tracheolaryngeal stenosis or obstruction are commonly associated with Herlitz JEB disease and hoarseness in early infancy is an ominous sign. There is a characteristic failure to thrive and growth retardation in this disease, often with a mixed anemia. Sepsis is a common and often lethal complication.

GENERALIZED INTERMEDIATE JUNCTIONAL EPIDERMOLYSIS BULLOSA

Sometimes patients initially presenting with a generalized severe phenotype survive infancy. These

patients eventually prove to have a severity of blistering and oral erosions less than the lethal form. In particular, a lack of significant hoarseness is regarded as a favorable prognostic sign, indicative of less severe internal disease manifestations. Scalp and nail lesions and periorificial nonhealing erosions are among the most common findings in these patients during childhood. Despite the lack of lethality in infancy, these patients nonetheless can have severe epithelial adhesion abnormalities, and tracheostomies or gastrostomy tubes may help in patient survival (Fig. 60-7). The nonlethal status of these patients distinguishes them from the Herlitz group and the terms *nonlethal JEB* or *JEB mitis* have been used in the past to describe these patients. They are much less common than severe generalized JEB patients. There are other rare variants of nonlethal JEB that present with localized junctional blistering of the extremities or with blistering in an inversa distribution on the trunk and intertriginous areas.

A distinct subset of generalized intermediate JEB (previously term*ed generalized atrophic benign EB*) presents at birth with generalized cutaneous involvement.[102] However, despite the widespread cutaneous blistering, there is a relative paucity of oral erosions or other mucosal disease. Although enamel pitting is present, resulting in extensive dental caries, and nail dystrophy can often be severe, there is little other extracutaneous involvement noted in these patients. The blisters in these patients, which heal with a characteristic atrophic scarring, are debilitating and can be widespread, but nonetheless these patients generally have a normal lifespan. Blistering improves with age, growth is normal, and anemia is rarely seen. Some patients with this disease subtype have undergone normal uncomplicated pregnancies and deliveries. One peculiar characteristic of these patients is a progressive alopecia of the scalp and terminal hairs elsewhere in the body. The hair loss starts to become severe after the onset of puberty, and although patchy hair loss associated with atrophic scarring has been described, often the alopecia is quite diffuse, and scarring is subtle or nonexistent.

Figure 60-7 Periorificial erosions and hypertrohic granulation tissue in a patient with non-Herlitz junctional epidermolysis bullosa.

LOCALIZED JUNCTIONAL EPIDERMOLYSIS BULLOSA

A rare subtype of JEB is the localized variant, previously known as minimus JEB. These patients generally show mild disease, which can be accentuated in localized areas, most often the hands, feet, and pretibial regions. Nails can sometimes be shed or become dystrophic, and enamel pitting can occur. Oral or nasal erosions can also occur, but there is an absence of any internal involvement. These patients generally have a favorable prognosis and a normal lifespan.

JUNCTIONAL EPIDERMOLYSIS BULLOSA WITH PYLORIC ATRESIA

These patients exhibit extreme mucosal and cutaneous fragility and may also have various urologic abnormalities, including hydronephrosis and nephritis. Mutations of the genes coding for the β4 and α6 integrin have been associated with EB,[103] and in this group of diseases, pyloric atresia is present. Although pyloric stenosis is relatively more common, the distinct association of pyloric atresia, a rare condition, with EB makes this disease particularly unique. In these patients, hemidesmosomes are usually absent or rudimentary, and the level of separation is a low intrabasal epidermal at the level of the hemidesmosome as seen in EBS with muscular dystrophy described earlier. Most cases of this disease are quite severe and lethal in infancy caused by extensive extracutaneous epithelial sloughing in addition to widespread blistering of the skin and mucosa. Rare nonlethal cases of this disease have been characterized that appear to result from a partial loss of function of β4 integrin.[104] Interestingly, nonlethal JEB can sometimes ameliorate itself through alterations in mRNA splicing.[105,106]

JUNCTIONAL EPIDERMOLYSIS BULLOSA WITH RESPIRATORY AND RENAL INVOLVEMENT

Blistering of the skin starts early in life, is generally mild or even absent, and may be associated with a diffuse alopecia and nail dystrophy. Extracutaneous involvement, however, presents at birth and is quite severe, consisting of interstitial lung disease, resulting in respiratory distress and lung infections. Kidney manifestations of this disease include renal failure, nephrotic syndrome, renal hypoplasia, and hydronephrosis. Despite aggressive neonatal supportive care, patients die in infancy because of these severe respiratory or renal complications.

LARYNGO-ONYCHO-CUTANEOUS SYNDROME

This rare autosomal recessive condition[107] is characterized by nail dystrophy, cutaneous erosions, and extensive granulation tissue, especially localizing to the conjunctiva and larynx. Sites of cutaneous involvement include areas of repeated trauma or pressure such as the elbows, knees, fingers, and toes.

MOLECULAR PATHOLOGY OF JUNCTIONAL EPIDERMOLYSIS BULLOSA

JEB can be associated with mutations of the genes coding for the α3, β3, or γ2 subunits of laminin-332.[108,109] Absence of any of the three chains results in a lack of trimeric laminin-332 assembly and secretion, which results in a similar blistering phenotype. Patients with mutations of genes coding for the α3 or γ2 laminin subunits still show normal expression of laminin-311, which contains α3, β1, and γ1 chains.[44] Therefore, positive linear BMZ staining of JEB skin for α3 chain on indirect immunofluorescence microscopy (IDIF) with absent expression of the other chains is an indication of either a α3 or γ2 chain defect. Conversely, absence of α3 staining on IDIF can be indicative of a mutation of the α3 gene. About 80% of laminin-332 mutations can be traced to one of two recurrent nonsense mutations in the *LAMB3* gene, making prenatal testing for laminin-332 lesions easier than other EB candidate genes.[110] In patients with Herlitz disease, all of the mutations so far detected have been those producing premature termination codons, resulting in absence of expression of laminin-332. Although patients with Herlitz disease generally show a complete lack of expression of laminin-332, patients without Herlitz disease who have abnormal granulation tissue and significant mucosal involvement often show reduced expression of laminin-332. This is due to expression of a molecule with deletions or missense mutations resulting in partial loss of laminin-332 function. This can lead to cases clinically classified as non-Herlitz JEB, especially cases with significant mucosal involvement.[76,111,112] In some cases, spontaneous amelioration of blistering in severe JEB cases has taken place, which has been associated with genetic mechanisms that result in the reexpression of laminin-332.[106]

In the non-Herlitz JEB variant, generalized atrophic benign junctional EB (GABEB), blistering occurs in the lamina lucida region and abnormalities of hemidesmosomes or anchoring filaments are usually present (Fig. 60-8). Although laminin-332 mutations underlie a subset of GABEB patients, the majority of these patients have abnormalities of the hemidesmosomal protein collagen XVII (also known as BP180 or BPAG2). A number of mutations of the gene coding for collagen XVII have been described in patients with GABEB, including premature termination codon mutations, missense mutations, splice-site mutations, truncations, and a glycine substitution mutation.[113,114]

Figure 60-8 Loss of nails and skin atrophy a patient with non-Herlitz junctional epidermolysis bullosa or generalized atrophic benign epidermolysis bullosa.

Although intralamina lucida or junctional skin separation has been shown in all patients with this disease, one patient was described with a cytoplasmic deletion of collagen XVII who showed intrabasal epidermal skin separation.[115] Localized JEB has been shown to be associated with COL17A1 mutations.[116] Laryngo-onycho-cutaneous syndrome is characterized by N-terminal mutations of the *LAMA3* gene leading to deletion of the laminin α3 LE domain.[107]

Of interest, mosaic GABEB patients have been identified who demonstrate well defined areas of blistering associated with absence of collagen XVII expression as well as areas of nonblistering skin associated with normal collagen XVII expression. Careful analysis of these patients' keratinocytes revealed reversion of one of the two alleles of the mutation, most likely caused by a mitotic gene conversion involving nonreciprocal exchange of parental allele DNA.[117,118] Understanding how EB can undergo spontaneous molecular correction in these cases could help in the design of future molecular therapeutic strategies.

JEB with respiratory and renal involvement is caused by mutations of the *ITGA3* gene.[119,120] These patients can show an absence of expression of integrin α3 in skin biopsies by immunofluorescence microscopy. Electron microscopy shows intralamina lucida separation, like other JEB subtypes.[119]

DYSTROPHIC EPIDERMOLYSIS BULLOSA

Dystrophic EB (DEB) is characterized by blisters that heal with scarring and milium formation. DEB can be inherited either in an autosomal recessive (RDEB) or dominant fashion (DDEB). One of the most important

Figure 60-9 Localized trauma-induced blistering with secondary milia in a patient with dominant dystrophic epidermolysis bullosa.

reasons to distinguish between these two subtypes is the increased prevalence of invasive squamous cell carcinoma (SCC) associated with the recessive but not the dominant form. Regardless of the mode of inheritance, DEB is derived from defects of the ultrastructural entity known as the anchoring fibril, which results in sublamina densa separation.

LOCALIZED AUTOSOMAL DOMINANT DYSTROPHIC EPIDERMOLYSIS BULLOSA

The localized subtype of dominant DDEB (sometimes called the Cockayne-Touraine of DDEB) can present at birth, but occasionally it is not appreciated until childhood. Although generalized blistering can sometimes take place, especially early in life, the blistering usually becomes localized to repetitively traumatized areas such as the knees, sacrum, and acral surfaces (Figs. 60-9 and 60-10). These areas show a characteristic scarred, dystrophic appearance. Often the scarring is hypertrophic. Milia are common accompanying features of the healing process in these patients (Fig. 60-11). Nail

Figure 60-10 Cutaneous lesions in siblings with dominant dystrophic epidermolysis bullosa.

Figure 60-11 Milia in a patient with dominant dystrophic epidermolysis bullosa.

dystrophy and nail loss with atrophic scarring of the distal digits are common. Occasionally, nail abnormalities can be the only presenting abnormality in DDEB. Oral lesions are not common, and teeth are usually unaffected. These patients have a good prognosis and a normal lifespan.

GENERALIZED AUTOSOMAL DOMINANT DYSTROPHIC EPIDERMOLYSIS BULLOSA

The generalized form of DDEB (sometimes referred to as the Pasini subtype of DDEB) presents at birth with a generally more severe and widespread blistering phenotype compared with the localized subtype. Blisters in generalized DDEB heal with scarring plaques and milia in a fashion similar to other DEB subtypes. In addition, this disease is sometimes distinguished by the spontaneous appearance of distinctive scarlike, flesh-colored papules on the truck. These albopapuloid lesions are not pathognomonic because these lesions can also be seen in other EB subtypes. As patients get older, the generalized blistering may eventually localize to the extremities. Patients often show dystrophic or absent nails. Oral erosions can often be present but usually are not extensive, and enamel defects can be seen in some patients. A rare variant of self-remitting generalized DDEB, termed *bullous dermolysis of the newborn*, consists of generalized blistering that gradually recedes after infancy.[121] Skin biopsies from these patients often show basal epidermal intracytoplasmic accumulations of collagen VII when examined by immunofluorescence microscopy.[122]

RECESSIVE DYSTROPHIC EPIDERMOLYSIS BULLOSA

Recessive DEB (RDEB) can be quite variable in its severity. Although the severe subtype is the most common, a localized form can occasionally be seen that has been previously termed *RDEB mitis*. Similar to localized DDEB, localized RDEB is usually confined to repetitively traumatized skin surfaces, most often in an acral distribution. Scarring and milium formation

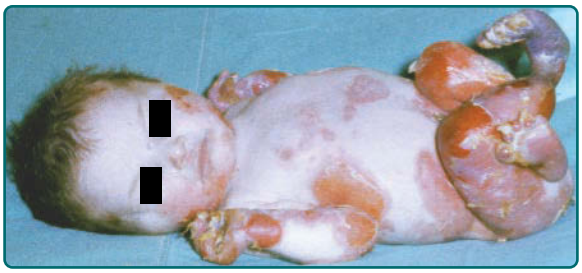

Figure 60-12 Widespread blistering with localized absence of skin at birth in a patient with recessive dystrophic epidermolysis bullosa.

accompany the healing of blisters. Mucosal involvement in localized RDEB, if present, is mild.

Severe RDEB, previously known by the eponym the Hallopeau-Siemens, is a devastating disease (Fig. 60-12). This disease presents with generalized blistering at birth. Occasionally, there is extensive denudation of an entire region of skin at birth, often involving one of the limbs. This congenital absence of skin is sometimes termed Bart syndrome. Healing and blistering cycles occurring during infancy can lead to a progressive scarring, which can become quite extensive. Pseudosyndactyly resulting from a closure of the digits in a "mitten" of skin is an extremely common feature of this disease (Fig. 60-13). Scarring can lead to flexion contracture of the hands (Fig. 60-14), as well as the limbs. In contrast to the patients with severe JEB, these patients do not show significant periorificial involvement. Instead, the scalp is the most commonly affected area on the head and neck of these patients.

The oropharynx can be extensively involved in both dominant and recessive DEB (Fig. 60-15) with generalized erosions evolving into a scarring that limits the movement of the tongue and narrows the opening of the oral cavity. The teeth can show significant enamel pitting, and caries can be extensive, leading to loss of

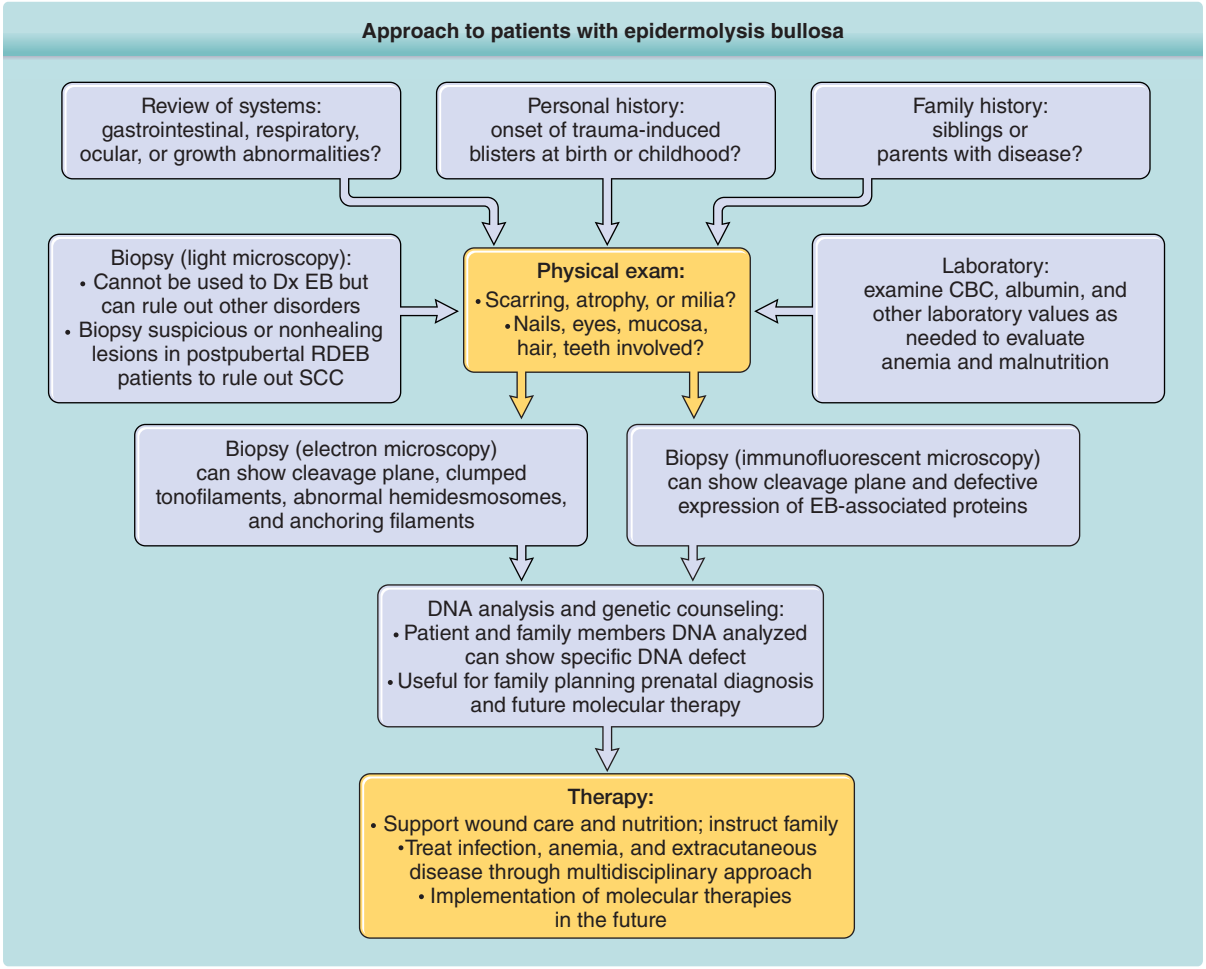

Figure 60-13 Approach to patients with epidermolysis bullosa (EB). A complete history, including family history and review of systems, is essential. Physical examination can provide important clues, and laboratory values can help identify associated anemia and malnutrition. Electron microscopy or indirect immunofluorescent microscopy is required for diagnosis. DNA analysis is helpful for determining prognosis and family planning. Therapy is mainly supportive. Teaching and working with nursing staff and especially families is critical, as are interdisciplinary interactions with other specialists in the treatment of extracutaneous complications. CBC, complete blood count; Dx, diagnosis; RDEB, autosomal recessive epidermolysis bullosa; SCC, squamous cell carcinoma.

Figure 60-14 Scarring of the hands in patient with recessive dystrophic epidermolysis bullosa.

teeth. Involvement of the trachea or larynx can lead to a narrowing of the airway, which could require intervention with a tracheostomy. Mucosal erosions of the esophagus can lead to stricture formation and webbing. The combination of oral lesions, dental caries, esophageal strictures, and increased caloric needs from extensive wound healing can lead these patients toward malnutrition and growth retardation. These patients usually have problems with anemia and may show a deficiency of iron absorption.

In the more distant past, most severe RDEB patients died in infancy of sepsis and other complications of extensive blistering. More recently, with improved nutritional, infection, and wound support, these patients usually can survive into their teens or into adulthood. However, after puberty, another devastating complication, SCC, can and often does appear (Fig. 60-16).

Figure 60-15 Oral erosions in a patient with dominant dystrophic epidermolysis bullosa.

Figure 60-16 Squamous cell carcinoma in patient with recessive dystrophic epidermolysis bullosa.

It is estimated that 50% to 80% of patients with severe-RDEB eventually develop these carcinomas, and many of these die of metastatic disease. RDEB-associated carcinomas are distinct from most other cutaneous SCCs in that they are extremely aggressive with strong tendencies for invasion and metastasis.

MOLECULAR PATHOLOGY OF DYSTROPHIC EPIDERMOLYSIS BULLOSA

Abnormalities of anchoring fibrils are present in DEB patients, which range from subtle changes in some patients with dominant disease to absence of anchoring fibrils in patients with the severe recessive form of this disease, are present, and a sublamina densa plane of blister cleavage is present (see Fig. 60-4). These observations correlate with indirect immunofluorescent microscopic analysis of patients with DEB, which demonstrates varying degrees of linear collagen VII staining at the dermal–epidermal junction in dominant patients and totally absent staining in severe recessive patients. In some patients, there is a cytoplasmic retention of collagen VII, which can be demonstrated in patient biopsy sections and analysis of patient keratinocytes.[123]

DEB has been shown to be associated in all cases thus far with mutations of the gene coding for collagen VII (COL7A1). In the recessive forms, mutations usually cause premature termination codons, which result in lack of collagen VII in tissue. It is known that mRNAs bearing premature stop codons show accelerated turnover.[124] In addition, truncated proteins that are not secreted or not assembled into anchoring fibrils may also show accelerated turnover. Either or both of these mechanisms can explain the lack of detectable collagen VII in the tissue of individuals with severe RDEB associated with mutations that produce premature termination codons.[61,125,126] However, even in individuals who show absent collagen VII tissue staining by immunofluorescence microscopy, analysis of patient keratinocytes can in many cases still demonstrate low levels of mutant collagen VII expression.[127,128] Recently, in addition to cases reported in JEB patients, a revertant mosaicism phenotype has also been reported in RDEB.[129]

Generally, COL7A1 mutations that do not cause premature termination codons produce less severe disease.[108,114] For example, mutations that produce glycine substitutions of the triple helical region interfere with triple helical assembly of the collagen VII molecule. These types of mutations are present in many patients with milder dominant forms of this disease. In these patients, collagen VII molecules may not be able to assume the proper conformation needed to polymerize into anchoring fibrils. One subtype of DEB associated with increased pruritis, EB pruriginosa, has also been described to be associated with glycine mutations.[130] Other COL7A1 mutations have been shown to be associated with impaired secretion of collagen VII, resulting in intracellular accumulation of this molecule. In one study, DEB patient mutations that involve the area of the gene coding for the collagen VII NC2 domain were shown to interfere with NC2 processing and the assembly of anchoring fibrils.[131]

KINDLER SYNDROME

New advances in our understanding of the molecular pathology of the skin have brought to light the underlying pathophysiology of a disease related to EB, Kindler syndrome. Kindler syndrome was first described by Theresa Kindler in 1954.[132] It is characterized by EB-like trauma-induced blistering at birth and during infancy, with atrophic changes during healing reminiscent or JEB or DEB.[133-139] However, in late childhood, the blistering usually subsides and gives way to a progressive poikiloderma, which distributes to sun-exposed areas. The poikiloderma may show areas of atrophy and hyperkeratosis, as well as hypopigmentation, hyperpigmentation, and telangiectasias. These patients often show photosensitivity. Nail changes and webbing of the toes and fingers are also sometimes present. Internal complications include oral inflammation, esophageal or ureteral strictures, and ectropion. Ultrastructurally, these patients show reduplication of the basement membrane, which is the most consistent feature seen. Although there is often a sublamina densa split with anchoring fibril abnormalities, sometimes lamina lucida or intraepidermal separation can be seen associated with the blistering phenotype. Molecular investigation of this disease led to the discovery of a new epidermal protein, kindlin-1, which shows decreased expression by immunofluorescent microscopy in this disease. Kindlin-1 appears to have some homology to signaling proteins such as talin, which suggests a signaling function, but its role in Kindler syndrome remains unclear.[140] A number of mutations of the gene coding for kindlin-1, KIND1, have been described.[141-143] These include nonsense, frameshift, and splice-site mutations that underlie the observed decreased kindlin-1 expression in affected skin. Why the disease evolves from a blistering to a poikilodermatous phenotype and the exact function of kindlin-1 in epidermal homeostasis remains to be fully elucidated.

DIAGNOSIS

The first step toward making the diagnosis of EB begins with a thorough history and physical examination (see Fig. 60-13). Useful historical information includes the age of onset of blistering and the presence of blistering in other family members. A review of gastrointestinal (GI), respiratory, ocular, dental, and genitourinary systems is important as is evaluation of general growth and development. Physical examination requires not only a complete skin examination but also a thorough evaluation of mucosal tissues, hair, nails, and teeth. Laboratory measurements of importance in the initial visit include evaluation for anemia and for measures of nutrition, such as serum albumin.

Skin biopsy is another important diagnostic step. Routine histologic analysis cannot be used to diagnose EB but can be useful for excluding other causes of blistering. The dermal–epidermal BMZ is simply too small to be visualized by light microscopy. To differentiate levels of BMZ separation in skin biopsies, transmission electron microscopy (TEM) or indirect immunofluorescent microscopy (IDDF) must be used. The interior of blisters rapidly reepithelialize, which can obscure correct determination of blister levels. For this reason, it is critical to biopsy a blister that is as fresh as possible. One way to ensure a fresh blister is for the clinician to induce it in the office. This can be accomplished by gently rotating a pencil eraser over an intact area of patient's skin until separation of the epidermis from the dermis can be observed. This is more easily performed with patients who have more severe disease variants compared with patients with milder disease. When actually doing the biopsy, its best to place the circular biopsy punch so that only 10% of the punch covers the visible blister with 90% covering intact skin. This is because it is helpful to have both intact and blistered skin on the same biopsy specimen, and extension of the blister is likely to occur either during the biopsy process or during shipping.

TEM has been regarded for many years as the gold standard for determining the level of blistering in EB subtypes. In addition to determining the level of blistering, ultrastructural entities can also be analyzed by TEM for characteristic alterations. For example, clumping of keratin intermediate filaments in basal keratinocyte cytoplasm is a pathognomonic finding for severe generalized (Dowling-Meara) EBS. Rudimentary hemidesmosomes can be an important clue to the diagnosis of JEB. Absent or altered anchoring fibrils often occur in DEB subtypes, especially the recessive forms.

IDDF microscopy can provide additional information on the level of blistering, as well as important clues to the underlying molecular defects. In this technique, an antibody panel against known BMZ antigens is applied to frozen sections of blistered patient

skin. The localization of the antigens to the epidermal or dermal portion of the blister indicates the level of skin separation in the BMZ. In EBS samples, for example, intracellular hemidesmosomal components such as BP230 and a lamina densa protein such as type IV collagen would each localize to the floor of the blister. In JEB cases, BP230 would localize to the roof of the blister, and type IV collagen would localize to the floor. In DEB, collagen VII and BP230 would localize to the roof of the blister. The specific absence or presence of staining with a particular antibody in frozen sections of intact portions of patient skin give important clues to the specific molecular defect. Whereas samples that lack staining with antibodies specific to laminin-332 would further support a JEB diagnosis, a lack of staining for collagen VII would support a DEB diagnosis. Absence of staining for collagen XVII would support a generalized intermediate JEB diagnosis.

A complete panel of antibodies to support IDDF-based diagnosis of EB would include antibodies against laminin-332 (Herlitz and non-Herlitz JEB), as well as antibodies against BP180/collagen XVII (non-Herlitz JEB or generalized atrophic benign EB), collagen VII (RDEB), α6 and β4 integrins (JEB with pyloric atresia), plectin (EBS with muscular dystrophy), and keratins 5 and 14 (recessive EBS). Antibodies against the individual chains α3, γ2, and β3 chains of laminin-332 are especially helpful.

Its known that laminin-311 (which shares the same laminin α3 chain as laminin-332) is expressed in Herlitz JEB associated with null mutations of genes coding for β3 chain (LAMB3) and γ2 chain (LAMC2) but not in Herlitz JEB associated with null mutations of the α3 chain gene (LAMA3).[44] Therefore, if laminin β3 and γ2 antibodies are negative and α3 antibody is positive, this could point the genetic analysis to examine the LAMB3 and LAMC2. Conversely, if all three laminin-332 chains are absent by IDIF, this could point the genetic investigation toward LAMA3, saving time and effort in arriving at the final molecular diagnosis.

Gene mutation analysis has revolutionized our understanding of the EB family of diseases and is considered the ultimate final step in arriving at the molecular diagnosis in EB. Concurrent advances in our knowledge of the biochemical structure and supramolecular assembly of BMZ proteins have both facilitated and complemented the molecular biology studies. Thus, EB patient diagnosis requires both clinical and molecular information. Blood samples or buccal swabs are taken from the patient as well as the parents and siblings for genetic analysis. Whole-exome sequencing will likely make EB mutation detection easier, faster and less expensive as this practice becomes more widespread.[144]

DIFFERENTIAL DIAGNOSIS

See Table 60-2.

TABLE 60-2
Differential Diagnosis of Epidermolysis Bullosa

Most Likely
- Pompholyx
- Insect bites
- Friction blisters
- Thermal burns
- Bullous impetigo

Consider
- Chronic bullous dermatosis of childhood (linear immunoglobulin A disease)
- Bullous pemphigoid
- Epidermolysis bullosa acquisita
- Bullous systemic lupus erythematosus
- Cicatritial pemphigoic
- Pemphigus vulgaris

Always Rule Out
- Stevens-Johnson syndrome
- Toxic epidermal necrolysis

GENETIC COUNSELING

DNA mutation analyses can be extremely helpful to EB patients. The prognostic benefit to the patient can often be highly significant. For example, recessive DEB cases may have equivalent blistering activity compared with the more severe dominant cases, but their risk of invasive SCC is much greater. Through DNA diagnosis, these two groups can be distinguished, thereby identifying patients potentially at risk for invasive SCC.

Prenatal diagnosis of EB in affected families can be an extremely accurate technique, especially if the original proband has previously had mutational analysis or identification of the defective gene. Fetal skin biopsies and fetoscopy with their increased risk of pregnancy loss can now be avoided by analysis of either chorionic villus sampling as early as 8 to 10 weeks[145] or gestation or amniocentesis in the second trimester.[146] The development of highly informative intragenic and flanking polymorphic DNA markers in EB candidate genes together with rapid screening of genetic "hotspots" makes genetic screening of at-risk pregnancies a viable option.[110,147] Coupling of the technique of in vitro fertilization with EB prenatal diagnosis, preimplantation diagnosis has now been successfully performed for EB cases.[148] Another promising area of prenatal diagnosis with potential future applications to EB is the detection and analysis of fetal cells in the maternal circulation.[149]

TREATMENT

Most therapy for EB is supportive in nature. The regimen is tailored to the severity and extent of skin and systemic involvement and usually entails a combination of wound management, infection control, surgical management as needed, and nutritional support. Skin care and supportive care for other organ systems

in certain EB subtypes are most optimally coordinated through a multidisciplinary approach. Comprehensive topical therapy is a mainstay of treatment in EB, with avoidance of trauma as a primary goal. Wound healing is impaired by endogenous factors, including foreign bodies, bacteria, nutritional deficiencies, anemia, and repeated trauma. Therefore, optimizing wound healing in patients with EB involves control of all of these factors.[150]

SUPPORTIVE SKIN CARE

Extensive areas of denuded skin can result in the loss of the barrier provided by the stratum corneum. Subsequent microbial penetration can result in the accumulation of serum and moisture that further enhances bacterial propagation. The above factors combined with immunosuppressive therapy facilitate development of infections. Prevention of infection is obviously the preferred strategy.

A modified Dakin solution (0.025% w/v sodium hypochlorite) can be helpful in reducing the bacterial load in patient skin. Soaking wounds in this solution for 20 minutes before dressing changes also helps to free adherent bandages that have dried onto the wound bed. After soaking, wounds can be dressed with mupirocin or other topical antibiotics and covered with semiocclusive nonadhesive dressings. Tape causes further blistering and peeling of the skin, so it is essential to use self-adhering (clinging) gauze or self-adherent paper to hold nonadherent dressings in place.

For patients with generalized or localized subtypes of EBS, controlling exposure to heat may prove helpful in controlling blister formation. Advising patients to use soft, well-ventilated shoes is also recommended. Patients with Herlitz JEB, lacking functional laminin-332, an extracellular matrix protein shown to be involved in keratinocyte adhesion and migration, may have especially difficult problems with wound healing. For patients with DEB, use of finger splinting or diligent hand wrapping and appropriate hand protection against trauma are helpful, especially after hand surgery (see later).

INFECTION

Management of skin infections is a critical part of EB patient care. Large areas of denuded skin, a common finding in patients with EB, provides an inadequate barrier to microbial penetration and can lead to both skin infections as well as the more devastating complication of sepsis. *Staphylococcus aureus* and *Streptococcus pyogenes* are common infectious agents. Gram-negative infections with *Pseudomonas aeruginosa* can also occur. Skin cultures and the use of the appropriate systemic antibiotics are indicated for wound infection. Gentle whirlpool therapy, frequent (daily) dressing changes, dilute chlorine baths, rotation of topical antibiotics, and use of topical disinfectants such as iodine–povidone are all helpful ways to reduce resistant bacteria.

SURGICAL TREATMENT

Among the EB patient population, those with the severe recessive DEB (Hallopeau-Siemens) variant are generally the most in need of surgical intervention.[151] Mitten pseudosyndactyly in these patients can be surgically released; however, this procedure may have to be repeated periodically because of the strong tendency of this condition to recur.[151-154] Splinting after surgery is essential to reducing recurrence of hand deformities. Surgery may also be used to correct limb, perioral, and perineal contracture deformities, but unfortunately, a high rate of recurrence is common. Extra care must be taken to minimize trauma to oral mucosa in EB patients during intubation.

TUMORS

SCC often arises after puberty in patients with recessive DEB. SCC may arise in multiple primary sites, especially in nonhealing areas. Careful surveillance of nonhealing areas is of utmost importance because patients often die from metastatic disease.[155] Surgical excision using either Mohs or non-Mohs approaches is an important first-line modality with radiation therapy as a useful adjunct in some cases.[156] Isotretinoin has been used for patients with RDEB for chemoprevention of SCC. Although it appears well tolerated, it is not clear whether in can increase the overall survival rate of these patients.[157] Cetuximab therapy has been demonstrated to offer some benefit,[155,158] but the cutaneous side effects can sometimes be problematic.

CARE FOR EXTRACUTANEOUS INVOLVEMENT

GASTROINTESTINAL MANAGEMENT

Esophageal lesions are often the most disabling complication found in recessive DEB and JEB of both the severe and intermediate generalized variants. Esophageal strictures usually respond to dilation; however, recurrence of strictures after dilation is common.[159] Colonic interposition has proven effective in advanced cases but is rarely used. Gastrostomy tube insertion has been effective in providing nutrition to individuals with esophageal strictures.[160]

Increased fluid and fiber intake and stool softeners may also be of value in EB patients with constipation and colitis.[161]

EYE LESIONS

Patients with EBS, particularly those with the Dowling-Meara subtype, can experience recurrent inflammation of the eyelid, with bullous lesions in the conjunctivae. Patients with JEB and patients with recessive DEB can experience corneal ulcerations with scarring, obliteration of tear ducts, and eyelid lesions.[162] Cicatricial conjunctivitis can also occur in patients with recessive DEB. Corneal erosions are treated supportively with application of antibiotic ointments and use of cycloplegic agents to reduce ciliary spasms and provide comfort. Moisture chambers and ocular lubricants are also commonly used. Severely affected upper eyelids may be surgically managed with full-thickness skin grafting. Complete correction of any eye disorder in EB patients is difficult to achieve. Proper management of eye lesions in EB patients must include the assistance of an ophthalmologist to prevent serious visual compromise.[163] Surgical and ocular surface reconstruction can help reduce granulation tissue in laryngo-onycho-cutaneous syndrome.[164]

OROPHARYNGEAL LESIONS

Good dental hygiene is essential for EB patients, and regular visits to the dentist are especially important. Enamel defects in JEB patients and pain on brushing and flossing in patients with severe JEB and DEB often lead to dental carries.[165,166] The softest brush available should be used for regular cleansing. Oral mucosal blistering may also accompany forms of JEB and DEB, especially in severe DEB subtypes such as the severe generalized recessive form, narrowing of the mouth opening (microstomia), and scarring induced limitation of movement of the tongue (ankyloglossia) and be particularly debilitating. Normal saline rinses are effective for gentle cleaning of the mucosal surfaces. Mouthwashes containing alcohol or other harsh agents should be avoided. Erosions and scarring involving the trachea and larynx with resultant narrowing of the airway. In patients with airway involvement, there is danger of pulmonary aspiration.[167] Surgical intubation should be performed gently with small bore airways by anesthesiologists experienced in the care of EB patients.[168]

NUTRITION, ANEMIA, AND CARDIOVASCULAR DISEASE

Nutritional assessment and support can be critical in patients with EB[169] for several reasons. Extensive cutaneous injury is associated with marked alterations in hemodynamic and metabolic responses, with increased caloric and protein requirements. Oropharyngeal and GI lesions provide the greatest overall threat to nutritional well-being. These include oral blistering, abnormal esophageal motility, strictures, dysphagia, diarrhea, malabsorption, and dental problems. Nutritional assessment must take into account these factors to develop a supplemental regimen to replenish nutritional deficiencies.[170] Patients are often unable to increase their food intake to balance this increased caloric need. For example, hypoplastic enamel formation in JEB may lead to tooth decay, mucosal blistering, and oral candidiasis. All of these potential complications may compromise patients' ability to eat. Extensive internal mucosal disadhesion in the GI tract may cause abnormal GI motility, strictures, and diarrhea are complications that may lead to malabsorption of iron and other nutrients. Anemia of chronic disease can certainly affect all severe EB subtypes. Recessive DEB patients often show a particularly severe iron deficiency that may not responsive to oral iron supplementation. For these patients, parenteral iron can be helpful. Furthermore, if a lack of a reticulocyte response to iron supplementation is seen in iron-deficient patients, it is helpful to assess the erythropoietin level and to treat with recombinant erythropoietin if necessary.[171] Transfusion is also useful in the treatment of anemia in EB, especially when symptoms require a rapid correction. Dilated cardiomyopathy is a devastating and potentially fatal complication of severe DEB and JEB patients that is highly associated with chronic anemia.[172]

PSYCHOLOGICAL ASPECTS OF EPIDERMOLYSIS BULLOSA

Patients with EB, especially the severe subtypes, can be plagued with chronic pain.[173-175] Although many, despite extremely adverse conditions, seem to find a way to maintain a surprisingly positive outlook on life, others lapse into depression.[176,177] Patients with severe EB can also create stress for their families and loved ones.[178,179] Thus, it is important to identify the warning signs of depression when they arise and to work in a multidisciplinary approach with psychiatrists and clinical psychologists as needed. Supportive psychotherapy and patient support group meetings can help patients and their families in this regard. An additional source of support for patients and families include several important patient-based organizations that assist with education and support, including the Dystrophic Epidermolysis Bullosa Research Association and Epidermolysis Bullosa Medical Research Foundation.

ANTIINFLAMMATORY THERAPIES

A number of new therapies are emerging for EB, which are listed in Fig. 60-17 and described later.

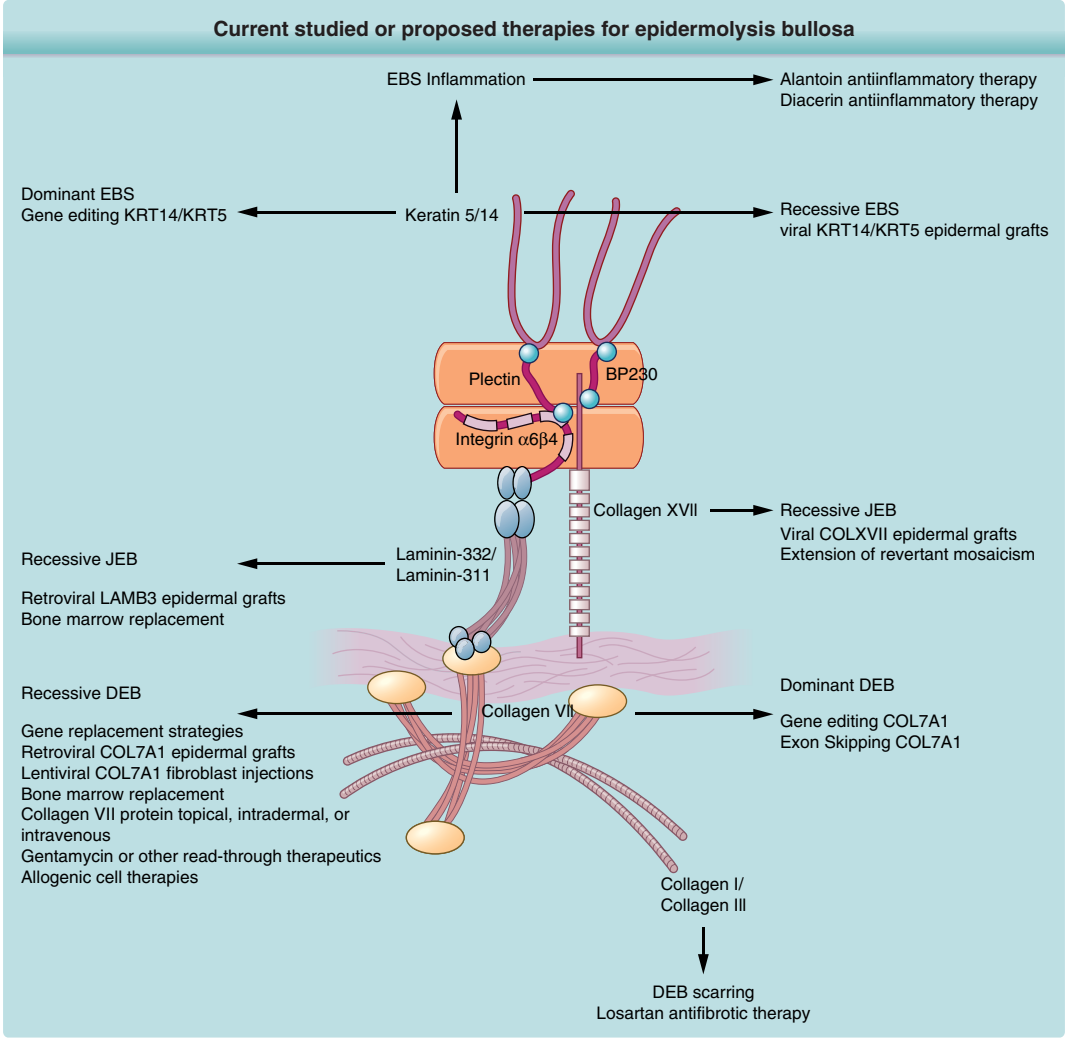

Figure 60-17 Current studied or proposed therapies for epidermolysis bullosa. DEB, dystrophic epidermolysis bullosa; EBS, epidermolysis bullosa simplex; JBS, junctional epidermolysis bullosa.

Repetitive scratching–induced trauma and an exuberant inflammatory wound each contribute to wound chronicity, especially in patients with inflammatory subtypes of EBS or EB pruriginosa. Although topical corticosteroids can produce short-term relief from itching and reduce inflammation, in the long term, these agents induce skin atrophy, which exacerbates the intrinsic fragility of EB skin and worsens blistering/healing. Tetracycline and phenytoin have been used in the past for EB but are not currently indicated treatment.[180] The naturally occurring component of rhubarb root, and interleukin-β blocker diacerein[181] was found to be well tolerated and to reduce blister formation in patients with severe EBS with inflammatory skin phenotypes.[182] Losartan, a small-molecule angiotensin II type I receptor antagonist used to treat hypertension, has shown promise in preclinical studies in reducing the fibrosis accompanying DEB wounding. Losartan achieves this effect by reducing transforming growth factor-β expression in the skin.[183]

ALLOGENEIC CELL THERAPIES

Allogeneic cell therapies including, allogeneic keratinocyte skin equivalents,[184] allogeneic fibroblast injections,[185,186] and mesenchymal stem cell infusions,[187] have shown positive short-term effects on EB wound healing. However, they fail to show any long-term benefits. Allogeneic bone marrow transplantation performed on a group of seven children with recessive DEB. Some patients demonstrated noticeable clinical benefit, as well as collagen VII staining at the dermal–epidermal junction for 1 year or longer; however, restoration of anchoring fibrils was incomplete.[188] Of note, this procedure demonstrated a mortality rate of approximately 30%. Contributing to the mortality rate observed may have been the combination of widespread cutaneous erosions and the immunomyeloablative-induced immunosuppression required for successful bone marrow transplant take.

TABLE 60-3
Summary of the Types of Epidermolysis Bullosa and their Clinical Manifestations

	AGE OF ONSET	DISTRIBUTION	CLINICAL MANIFESTATIONS	SEQUELAE AND COMPLICATIONS
Epidermolysis Bullosa Simplex (EBS)				
Generalized severe (Dowling-Meara)	Birth	Generalized; oral mucosal involvement; nail involvement	Sudden onset of grouped or herpetiform blisters, extensive erosions; nail shedding and dystrophy palmoplantar hyperkeratosis in older children	Milia formation, contractures, esophageal erosions, pyloric atresia
Generalized intermediate (Koebner)	Birth	Generalized but most prominent on hands, feet, and extremities; mild oral mucosal involvement	Erosions, palmoplantar hyperkeratosis	Postinflammatory hyperpigmentation or hypopigmentation, milia formation
Localized (Weber-Cockayne)	Infancy, childhood, occasionally adulthood	Areas of friction or trauma, most commonly the hands and feet; mild oral involvement	Blistering after trauma; palmoplantar hyperhidrosis	No milia formation; no scarring sequelae
Junctional Epidermolysis Bullosa (JEB)				
Generalized severe JEB (Herlitz)	Birth	Generalized; mucosal involvement (nasal, conjunctival, esophageal, tracheal, laryngeal, rectal, urethral); nail involvement; dental involvement	Extensive blistering; periorificial granulation tissue (mouth, eyes, nares); loss of nails or dystrophic nails with granulation tissue; pitted tooth enamel	Tracheolaryngeal stenosis or obstruction, failure to thrive, sepsis
Generalized intermediate JEB	Birth	Generalized; minimal oral or other mucosal involvement; dental involvement	Widespread blistering; extensive dental caries; nail dystrophy; may have progressive alopecia of scalp	Atrophic scars, normal growth
Localized JEB		Localized (most often hands, feet, pretibial regions); oral mucosal involvement (minimal); nail involvement; dental involvement	Localized erosions; nail shedding and dystrophy; enamel pitting; oral and nasal erosions	
JEB with pyloric atresia	Birth	Generalized; mucosal involvement; systemic involvement	Extensive cutaneous sloughing, with widespread blistering	Pyloric stenosis, hydronephrosis, nephritis
Dystrophic Epidermolysis Bullosa (DEB)				
Localized DDEB (Cockayne-Touraine)	Birth or childhood	Generalized early in life but localizes to sites of trauma (knees, sacrum, acral areas); nail involvement	Blisters; nail dystrophy or nail loss may be presenting symptoms	Milia, hypertrophic scarring
Generalized DDEB (Pasini)	Birth	Generalized early in life but may localize to extremities; nail involvement	Widespread severe blistering; albopauloid lesions; oral erosions; dystrophic or absent nails; enamel defects	Milia, scarring plaques
Localized RDEB	Birth	Acral distribution	Blisters; mild oral mucosal erosions	Milia, scarring
Severe RDEB (Hallopeau-Siemens)	Birth	Generalized; mucosal involvement; dental involvement	Extensively denuded skin; enamel pitting with caries and loss of teeth	Pseudosyndactyly, flexion contractures of hands and limbs, tracheal and laryngeal involvement, esophageal structures, malnutrition, growth retardation, anemia, iron deficiency, SCC

DDEB, dominant dystrophic epidermolysis bullosa; RDEB, recessive dystrophic epidermolysis bullosa; SSC, squamous cell carcinoma.

AUTOLOGOUS GENETIC THERAPIES

Retroviral ex vivo gene therapy using autologous keratinocytes was performed for one patient with JEB.[189] In this study, a patient with a missense mutation of laminin-332 was grafted with genetically corrected keratinocyte monolayers expressing wild-type laminin-332. After 6.5 years of postgrafting follow-up, grafts still showed positive expression of laminin-332 and resistance to blistering.[190] More recently, this therapy was extended in a widespread and remarkable manner to another JEB patient with genetically corrected epidermal grafts covering more than 80% of skin surfaces.[191] A similar approach was more recently performed on a clinical trial of four patients with recessive DEB.[127] In this study, full-length *COL7A1* gene, coding for collagen VII was transferred ex vivo to primary recessive DEB patient keratinocytes. Collagen VII engineered patient cells were expanded then grafted as monolayers to patient wounds (six grafts per patient). Results showed clinical improvement as well as restoration of collagen VII expression and anchoring fibril formation as long as 1 year. Gene editing via CRISPER/Cas9 combined with the use of induced pluripotent stem cells[192-194] is another promising future therapy for Exon skipping has shown promise in as a potential future therapy in both JEB[195] as well as DEB skin.[196,197] The potential to extend skin in patients with COL17A1 and COL7A1 self-correcting mutations by autologous grafting has also been proposed as a novel therapy.[198]

SUMMARY

A summary of the types of EB and their clinical manifestations is shown in Table 60-3.

REFERENCES

1. Hebra FV. *Arztlicher Bericht des K.K allegemeinen Krankenhauses zu Wien vom Jare 1870*. Pemphigus. Vienna; 1870:362.
2. Fox T. Notes on unusual or rare forms of skin disease. *Lancet*. 1879;1:766.
3. Goldscheider A. Hereditare Neigung zer Blasenbildung. *Monatsschr Prakt Dermatol*. 1882;1:163.
4. Koebner H. Hereditare Anlage zur Blasenbildung. *Dtsch Med Wochenschr*. 1886;12:21.
5. Hallopeau MH. Nouvelle etude sur la dermatite bulleuse congenitale avec kysts epidermiques. *Ann Dermatol Syphiligr (Paris)*. 1896;7:453.
6. Weber FP. Recurrent bullous eruption on the feet in a child. *Proc R Soc Med*. 1926;19:72.
7. Cockayne EA. Recurrent bullous eruption of feet. *Br J Dermatol*. 1938;50:358.
8. Dowling GB. Epidermolysis bullosa resembling juvenile dermatitis herpetiformis. *Br J Dermatol*. 1954; 66:139.
9. Hoffman E. Uber den Erbgang bei Epidermolysis bullosa hereditaria. *Arch Rassen Gesellsch Biol*. 1926; 18:353.
10. Cockayne EA. *Inherited Abnormalities of the Skin and Its Appendages*. London: Oxford University Press; 1933.
11. Touraine MA. Classification des epidermolyses bulleuses. *Ann Dermatol Syphiligr (Paris)*. 1942;2:141.
12. Pasini A. Dystrophie cutanee bulleuse atrophiante et albopapuloide. *Ann Dermatol Syphiligr (Paris)*. 1928;9:1044.
13. Bart BJ, Gorlin RJ, Anderson VE, et al. Congenital localized absence of skin and associated abnormalities resembling epidermolysis bullosa. *Arch Dermatol*. 1966;93:293.
14. Herlitz G. Kongenitaler, nicht syphilitischer Pemphigus: Eine Ubersicht nebst Beschreibung einer neuen Krankheitsform. *Acta Paediatr*. 1935;7:315.
15. Pearson RW. Studies on the pathogenesis of epidermolysis bullosa. *J Invest Dermatol*. 1962;39:551-575.
16. Gedde-Dahl T. *Epidermolysis Bullosa: A Clinical, Genetic and Epidemiologic Study*. Baltimore: The John Hopkins Press; 1971:1-180.
17. Fine JD, Bruckner-Tuderman L, Eady RA, et al. Inherited epidermolysis bullosa: updated recommendations on diagnosis and classification. *J Am Acad Dermatol*. 2014;70(6):1103-1126.
18. Kanasaki K, Kanda Y, Palmsten K, et al. Integrin beta1-mediated matrix assembly and signaling are critical for the normal development and function of the kidney glomerulus. *Dev Biol*. 2008;313(2):584-593.
19. Yoshida-Moriguchi T, Yu L, Stalnaker SH, et al. O-mannosyl phosphorylation of alpha-dystroglycan is required for laminin binding. *Science*. 2010;327(5961):88-92.
20. Arin MJ. The molecular basis of human keratin disorders. *Hum Genet*. 2009;125(4):355-373.
21. Coulombe PA, Kerns ML, Fuchs E. Epidermolysis bullosa simplex: a paradigm for disorders of tissue fragility. *J Clin Invest*. 2009;119(7):1784-1793.
22. Rezniczek GA, Janda L, Wiche G. Plectin. *Methods Cell Biol*. 2004;78:721-755.
23. Andreu P, Johansson M, Affara NI, et al. FcRγ activation regulates inflammation-associated squamous carcinogenesis. *Cancer Cell*. 2010;17(2):121-134.
24. Jefferson JJ, Ciatto C, Shapiro L, et al. Structural analysis of the plakin domain of bullous pemphigoid antigen1 (BPAG1) suggests that plakins are members of the spectrin superfamily. *J Mol Biol*. 2007; 366(1):244-257.
25. Young KG, Kothary R. Dystonin/Bpag1 is a necessary endoplasmic reticulum/nuclear envelope protein in sensory neurons. *Exp Cell Res*. 2008;314(15): 2750-2761.
26. Young KG, Kothary R. Dystonin/Bpag1—a link to what? *Cell Motil Cytoskeleton*. 2007;64(12):897-905.
27. Leung CL, Zheng M, Prater SM, et al. The BPAG1 locus: Alternative splicing produces multiple isoforms with distinct cytoskeletal linker domains, including predominant isoforms in neurons and muscles. *J Cell Biol*. 2001;154(4):691-697.
28. Has C, Kern JS. Collagen XVII. *Dermatol Clin*. 2010;28(1): 61-66.
29. Litjens S, de Pereda J, Sonnenberg A. Current insights into the formation and breakdown of hemidesmosomes. *Trends Cell Biol*. 2006;16:376-383.
30. de Pereda JM, Lillo MP, Sonnenberg A. Structural basis of the interaction between integrin alpha6beta4 and plectin at the hemidesmosomes. *EMBO J*. 2009;28: 1180-1190.

31. Dowling J, Yu QC, Fuchs E. Beta4 integrin is required for hemidesmosome formation, cell adhesion and cell survival. *J Cell Biol*. 1996;134(2):559-572.
32. Margadant C, Frijns E, Wilhelmsen K, Sonnenberg A. Regulation of hemidesmosome disassembly by growth factor receptors. *Curr Opin Cell Biol*. 2008;20(5): 589-596.
33. Hirako Y, Usukura J, Nishizawa Y, et al. Demonstration of the molecular shape of BP180, a 180-kDa bullous pemphigoid antigen and its potential for trimer formation. *J Biol Chem*. 1996;271(23):13739-13745.
34. Carter WG, Kaur P, Gil SG, et al. Distinct functions for integrins alpha 3 beta 1 in focal adhesions and alpha 6 beta 4/bullous pemphigoid antigen in a new stable anchoring contact (SAC) of keratinocytes: relation to hemidesmosomes. *J Cell Biol*. 1990;111(6 Pt 2): 3141-3154.
35. Zone JJ, Taylor TB, Kadunce DP, et al. Identification of the cutaneous basement membrane antigen in linear IgA bullous dermatosis. *J Clin Invest*. 1990;85: 812-820.
36. Marinkovich MP, Taylor TB, Keene DR, et al. LAD-1, the linear IgA bullous dermatosis autoantigen, is a novel 120- kDa anchoring filament protein synthesized by epidermal cells. *J Invest Dermatol*. 1996;106(4): 734-738.
37. Zone JJ, Taylor TB, Meyer LJ, et al. The 97 kDa linear IgA bullous disease antigen is identical to a portion of the extracellular domain of the 180 kDa bullous pemphigoid antigen, BPAg2. *J Invest Dermatol*. 1998;110(3):207-210.
38. Franzke CW, Bruckner P, Bruckner-Tuderman L. Collagenous transmembrane proteins: recent insights into biology and pathology. *J Biol Chem*. 2005; 280(6):4005-4008.
39. Franzke CW, Tasanen K, Borradori L, et al. Shedding of collagen XVII/BP180: structural motifs influence cleavage from cell surface. *J Biol Chem*. 2004;279(23): 24521-24529.
40. Durbeej M. Laminins. *Cell Tissue Res*. 2010;339(1): 259-268.
41. Miner JH. Laminins and their roles in mammals. *Microsc Res Tech*. 2008;71(5):349-356.
42. Schéele S, Nyström A, Durbeej M, et al. Laminin isoforms in development and disease. *J Mol Med*. 2007;85:825-836.
43. Marinkovich MP, Lunstrum GP, Keene DR, et al. The dermal-epidermal junction of human skin contains a novel laminin variant. *J Cell Biol*. 1992;119(3): 695-703.
44. Meneguzzi G, Marinkovich MP, Aberdam D, et al. Kalinin is abnormally expressed in epithelial basement membranes of Herlitz's junctional epidermolysis bullosa patients. *Exp Dermatol*. 1992;1(5):221-229.
45. Gerecke DR, Cordon MK, Wagman WW. Hemidesmosomes, anchoring fibrils. In: Mecham RP, Birk DE, Yurchenko PD, eds. *Extracellular Matrix Assembly and Structure*. San Diego: Academic Press; 1994:417-439.
46. Ryan MC, Tizard R, VanDevanter DR, et al. Cloning of the LamA3 gene encoding the alpha 3 chain of the adhesive ligand epiligrin. Expression in wound repair. *J Biol Chem*. 1994;269(36):22779-22787.
47. Kallunki P, Sainio K, Eddy R, et al. A truncated laminin chain homologous to the B2 chain: structure, spatial expression, and chromosomal assignment. *J Cell Biol*. 1992;119(3):679-693.
48. Champliaud MF, Lunstrum GP, Rousselle P, et al. Human amnion contains a novel laminin variant, laminin 7, which like laminin 6, covalently associates with laminin 5 to promote stable epithelial-stromal attachment. *J Cell Biol*. 1996;132(6):1189-1198.
49. Marinkovich M, Lunstrum G, Burgeson R. The anchoring filament protein kalinin is synthesized and secreted as a high molecular weight precursor. *J Biol Chem*. 1992;267(25):17900-17906.
50. Giannelli G, Falk-Marzillier J, Schiraldi O, et al. Induction of cell migration by matrix metalloprotease-2 cleavage of laminin-5. *Science*. 1997;277(5323): 225-228.
51. Koshikawa N, Giannelli G, Cirulli V, et al. Role of cell surface metalloprotease MT1-MMP in epithelial cell migration over laminin-5. *J Cell Biol*. 2000;148(3): 615-624.
52. Veitch DP, Nokelainen P, McGowan KA, et al. Mammalian tolloid metalloproteinase, and not matrix metalloprotease 2 or membrane type 1 metalloprotease, processes laminin-5 in keratinocytes and skin. *J Biol Chem*. 2003;278(18):15661-15668.
53. Ge G, Greenspan D. Developmental roles of the BMP1/TLD metalloproteinases. *Birth Defects Res C Embryo Today*. 2006;78(1):47-68.
54. Amano S, Scott IC, Takahara K, et al. Bone morphogenetic protein 1 is an extracellular processing enzyme of the laminin 5 gamma 2 chain. *J Biol Chem*. 2000;275(30):22728-22735.
55. Goldfinger LE, Hopkinson SB, deHart GW, et al. The alpha3 laminin subunit, alpha6beta4 and alpha-3beta1 integrin coordinately regulate wound healing in cultured epithelial cells and in the skin. *J Cell Sci*. 1999;112:2615-2629.
56. Gagnoux-Palacios L, Allegra M, Spirito F, et al. The short arm of the laminin gamma2 chain plays a pivotal role in the incorporation of laminin 5 into the extracellular matrix and in cell adhesion. *J Cell Biol*. 2001;153(4):835-850.
57. Fine JD, Horiguchi Y, Couchman JR. 19-DEJ-1, a hemidesmosome-anchoring filament complex associated monoclonal antibody. Definition of a new skin basement membrane antigenic defect in junctional and dystrophic epidermolysis bullosa. *Arch Dermatol*. 1989;125:520-523.
58. Parente MG, Chung LC, Ryynänen J, et al. Human type VII collagen: cDNA cloning and chromosomal mapping of the gene (COL7A1) on chromosome 3 to dominant dystrophic epidermolysis bullosa. *Am J Hum Genet*. 1991;24:119-135.
59. Burgeson RE, Lundstrum GP, Rokosova B. The structure and function of type VII collagen. *Ann N Y Acad* Sci. 1990;580:32-43.
60. Bachinger HP, Morris NP, Lundstrum GP. The relationship of the biophysical and biochemical characteristics of type VII collagen to the function of anchoring fibrils. *J Biol Chem*. 1990;265:10095-10101.
61. Bruckner-Tuderman L, Hopfner B, Hammami-Hauasli N. Biology of anchoring fibrils: lessons from dystrophic epidermolysis bullosa. *Matrix Biol*. 1999; 18(1):43-54.
62. Gayraud B, Höpfner B, Jassim A, et al. Characterization of a 50-kDa component of epithelial basement membranes using GDA-J/F3 monoclonal antibody. *J Biol Chem*. 1997;272(14):9531-9538.
63. Chen M, Marinkovich MP, Jones JC, et al. NC1 domain of type VII collagen binds to the beta3 chain of laminin 5 via a unique subdomain within the fibronectin-like repeats. *J Invest Dermatol*. 1999; 112(2):177-183.

64. Rousselle P, Keene DR, Ruggiero F, et al. Laminin 5 binds the NC-1 domain of type VII collagen. *J Cell Biol*. 1997;138(3):719-728.
65. Nakashima Y, Kariya Y, Yasuda C, et al. Regulation of cell adhesion and type VII collagen binding by the beta3 chain short arm of laminin-5: effect of its proteolytic cleavage. *J Biochem (Tokyo)*. 2005;138(5):539-552.
66. Waterman EA, Sakai N, Nguyen NT, et al. A laminin-collagen complex drives human epidermal carcinogenesis through phosphoinositol-3-kinase activation. *Cancer Res*. 2007;67(9):4264-4270.
67. Ortiz-Urda S, Garcia J, Green CL, et al. Type VII collagen is required for Ras-driven human epidermal tumorigenesis. *Science*. 2005;307(5716):1773-1776.
68. Chen M, Keene DR, Costa FK, et al. The carboxyl terminus of type VII collagen mediates antiparallel-dimer formation and constitutes a new antigenic epitope for EBA autoantibodies. *J Biol Chem*. 2001;27:27.
69. Smith LT. Ultrastructural findings in epidermolysis bullosa. *Arch Dermatol*. 1993;129(12):1578-1584.
70. Sprecher E. Epidermolysis bullosa simplex. *Dermatol Clin*. 2010;28(1):23-32.
71. Morrell DS, Rubenstein DS, Briggaman RA, et al. Congenital pyloric atresia in a newborn with extensive aplasia cutis congenita and epidermolysis bullosa simplex. *Br J Dermatol*. 2000;143(6):1342-1343.
72. Shemanko CS, Horn HM, Keohane SG, et al. Laryngeal involvement in the Dowling-Meara variant of epidermolysis bullosa simplex with keratin mutations of severely disruptive potential. *Br J Dermatol*. 2000;142(2):315-320.
73. Chavanas S, Pulkkinen L, Gache Y, et al. A homozygous nonsense mutation in the PLEC1 gene in patients with epidermolysis bullosa simplex with muscular dystrophy. *J Clin Invest*. 1996;98(10):2196-2200.
74. Gache Y, Chavanas S, Lacour JP, et al. Defective expression of plectin/HD1 in epidermolysis bullosa simplex with muscular dystrophy. *J Clin Invest*. 1996;97(10):2289-2298.
75. McLean WH, Pulkkinen L, Smith FJ, et al. Loss of plectin causes epidermolysis bullosa with muscular dystrophy: cDNA cloning and genomic organization. *Genes Dev*. 1996;10(14):1724-1735.
76. Dang M, Pulkkinen L, Smith FJ, et al. Novel compound heterozygous mutations in the plectin gene in epidermolysis bullosa with muscular dystrophy and the use of protein truncation test for detection of premature termination codon mutations. *Lab Invest*. 1998;78(2):195-204.
77. Bauer JW, Schaeppi H, Kaserer C, et al. Large melanocytic nevi in hereditary epidermolysis bullosa. *J Am Acad Dermatol*. 2001;44(4):577-584.
78. Fine JD, Johnson L, Wright T. Epidermolysis bullosa simplex superficialis. *Arch Dermatol*. 1989;125:633-638.
79. McGrath JA, Bolling MC, Jonkman MF. Lethal acantholytic epidermolysis bullosa. *Dermatol Clin*. 2010;28(1):131-135.
80. McGrath J. A novel genodermatosis caused by mutations in plakophilin 1, a structural component of desmosomes. *J Dermatol*. 1999;26(11):764-769.
81. McGrath JA. Recently identified forms of epidermolysis bullosa. *Ann Dermatol*. 2015;27(6):658-666.
82. Kiritsi D, Cosgarea I, Franzke CW, et al. Acral peeling skin syndrome with TGM5 gene mutations may resemble epidermolysis bullosa simplex in young individuals. *J Invest Dermatol*. 2010;130(6):1741-1746.
83. Hovnanian A, Duquesnoy P, Amselem S. Genetic linkage of recessive epidermolysis bullosa to the type VII collagen gene. *J Clin Invest*. 1992;90:1033-1037.
84. Jonkman MF, Heeres K, Pas HH, et al. Effects of keratin 14 ablation on the clinical and cellular phenotype in a kindred with recessive epidermolysis bullosa simplex. *J Invest Dermatol*. 1996;107(5):764-769.
85. Coulombe PA. The cellular and molecular biology of keratins: beginning a new era. *Curr Opin Cell Biol*. 1993;5(1):17-29.
86. Uttam J, Hutton E, Coulombe PA, et al. The genetic basis of epidermolysis bullosa simplex with mottled pigmentation. *Proc Natl Acad Sci U S A*. 1996;93(17):9079-9084.
87. Irvine AD, Rugg EL, Lane EB, et al. Molecular confirmation of the unique phenotype of epidermolysis bullosa simplex with mottled pigmentation. *Br J Dermatol*. 2001;144(1):40-45.
88. Moog U, de Die-Smulders CE, Scheffer H, et al. Epidermolysis bullosa simplex with mottled pigmentation: clinical aspects and confirmation of the P24L mutation in the KRT5 gene in further patients. *Am J Med Genet*. 1999;86(4):376-379.
89. Chamcheu JC, Virtanen M, Navsaria H, et al. Epidermolysis bullosa simplex due to KRT5 mutations: mutation-related differences in cellular fragility and the protective effects of trimethylamine N-oxide in cultured primary keratinocytes. *Br J Dermatol*. 2010;162(5):980-989.
90. Rezniczek GA, Walko G, Wiche G. Plectin gene defects lead to various forms of epidermolysis bullosa simplex. *Dermatol Clin*. 2010;28(1):33-41.
91. Konieczny P, Wiche G. Muscular integrity—a matter of interlinking distinct structures via plectin. *Adv Exp Med Biol*. 2008;642:165-175.
92. Fassihi H, Grace J, Lashwood A, et al. Preimplantation genetic diagnosis of skin fragility-ectodermal dysplasia syndrome. *Br J Dermatol*. 2006;154(3):546-550.
93. Ersoy-Evans S, Erkin G, Fassihi H, et al. Ectodermal dysplasia-skin fragility syndrome resulting from a new homozygous mutation, 888delC, in the desmosomal protein plakophilin 1. *J Am Acad Dermatol*. 2006;55(1):157-161.
94. Fassihi H, Wessagowit V, Ashton GH, et al. Complete paternal uniparental isodisomy of chromosome 1 resulting in Herlitz junctional epidermolysis bullosa. *Clin Exp Dermatol*. 2005;30(1):71-74.
95. Hamada T, South AP, Mitsuhashi Y, et al. Genotype-phenotype correlation in skin fragility-ectodermal dysplasia syndrome resulting from mutations in plakophilin 1. *Exp Dermatol*. 2002;11(2):107-114.
96. Whittock N, Haftek M, Angoulvant N, et al. Genomic amplification of the human plakophilin 1 gene and detection of a new mutation in ectodermal dysplasia/skin fragility syndrome. *J Invest Dermatol*. 2000;115(3):368-374.
97. McGrath J, Hoeger PH, Christiano AM, et al. Skin fragility and hypohidrotic ectodermal dysplasia resulting from ablation of plakophilin 1. *Br J Dermatol*. 1999;140(2):297-307.
98. Bruckner Tuderman L, McGrath JA, Robinson EC, et al. Progress in epidermolysis bullosa research: summary of DEBRA International Research Conference 2012. *J Invest Dermatol*. 2013;133(9):2121-2126.
99. Rashidghamat E, Ozoemena L, Liu L, et al. Mutations in EXPH5 underlie a rare subtype of autosomal recessive epidermolysis bullosa simplex. *Br J Dermatol*. 2016;174(2):452-453.

100. Fattah A. Epidermolysis bullosa hereditaria letalis (Herlitz). *Dermatologica*. 196;133(6):475-481.
101. Laimer M, Lanschuetzer CM, Diem A, et al. Herlitz junctional epidermolysis bullosa. *Dermatol Clin*. 2010; 28(1):55-60.
102. Hintner H, Wolff K. Generalized atrophic benign epidermolysis bullosa. *Arch Dermatol*. 1982;118(6): 375-384.
103. Vidal F, Aberdam D, Miquel C, et al. Integrin beta 4 mutations associated with junctional epidermolysis bullosa with pyloric atresia. *Nat Genet*. 1995;10(2):229-234.
104. Inoue M, Tamai K, Shimizu H, et al. A homozygous missense mutation in the cytoplasmic tail of beta4 integrin, G931D, that disrupts hemidesmosome assembly and underlies non-Herlitz junctional epidermolysis bullosa without pyloric atresia? *J Invest Dermatol*. 2000;114(5):1061-1064.
105. Chavanas S, Gache Y, Vailly J, et al. Splicing modulation of integrin beta4 pre-mRNA carrying a branch point mutation underlies epidermolysis bullosa with pyloric atresia undergoing spontaneous amelioration with ageing. *Hum Mol Genet*. 1999;8(11):2097-2105.
106. Gache Y, Allegra M, Bodemer C, et al. Genetic bases of severe junctional epidermolysis bullosa presenting spontaneous amelioration with aging. *Hum Mol Genet*. 2001;10(21):2453-2461.
107. McLean WH, Irvine AD, Hamill KJ, et al. An unusual N-terminal deletion of the laminin alpha3a isoform leads to the chronic granulation tissue disorder laryngo-onycho-cutaneous syndrome. *Hum Mol Genet*. 2003;12(18):2395-2409.
108. Pfendner EG, Bruckner A, Conget P, et al. Basic science of epidermolysis bullosa and diagnostic and molecular characterization: proceedings of the IInd International Symposium on Epidermolysis Bullosa, Santiago, Chile, 2005. *Int J Dermatol*. 2007;46(8):781-794.
109. Varki R, Sadowski S, Pfendner E, et al. Epidermolysis bullosa. I. Molecular genetics of the junctional and hemidesmosomal variants. *J Med Genet*. 2006;43(8): 641-652.
110. Kivirikko S, McGrath JA, Pulkkinen L, et al. Mutational hotspots in the LAMB3 gene in the lethal (Herlitz) type of junctional epidermolysis bullosa. *Hum Mol Genet*. 1996;5:231-237.
111. McGrath JA, Pulkkinen L, Christiano AM, et al. Altered laminin 5 expression due to mutations in the gene encoding the B3 chain in generalized atrophic benign epidermolysis bullosa. *J Invest Dermatol*. 1995;104:467-474.
112. Cserhalmi-Friedman PB, Baden H, Burgeson RE, et al. Molecular basis of non-lethal junctional epidermolysis bullosa: identification of a 38 basepair insertion and a splice site mutation in exon 14 of the LAMB3 gene. *Exp Dermatol*. 1998;7(2-3):105-111.
113. Varki R, Sadowski S, Uitto J, et al. Epidermolysis bullosa. II. Type VII collagen mutations and phenotype-genotype correlations in the dystrophic subtypes. *J Med Genet*. 2007;44(3):181-192.
114. Vaisanen L, Has C, Franzke C, et al. Molecular mechanisms of junctional epidermolysis bullosa: Col 15 domain mutations decrease the thermal stability of collagen XVII. *J Invest Dermatol*. 2005;125(6): 1112-1118.
115. Fontao L, Tasanen K, Huber M, et al. Molecular consequences of deletion of the cytoplasmic domain of bullous pemphigoid 180 in a patient with predominant features of epidermolysis bullosa simplex. *J Invest Dermatol*. 2004;122(1):65-72.
116. Floeth M, Fiedorowicz J, Schäcke H, et al. Novel homozygous and compound heterozygous COL17A1 mutations associated with junctional epidermolysis bullosa. *J Invest Dermatol*. 1998;111(3):528-533.
117. Jonkman MF, Scheffer H, Stulp R, et al. Revertant mosaicism in epidermolysis bullosa caused by mitotic gene conversion. *Cell*. 1997;88(4):543-551.
118. Pasmooij A, Pas HH, Deviaene FC, et al. Multiple correcting COL17A1 mutations in patients with revertant mosaicism of epidermolysis bullosa. *Am J Hum Genet*. 2005;77(5):727-740.
119. Has C, Spartà G, Kiritsi D, et al. Integrin alpha3 mutations with kidney, lung, and skin disease. *N Engl J Med*. 2012;366(16):1508-1514.
120. He Y, Balasubramanian M, Humphreys N, et al. Intronic ITGA3 mutation impacts splicing regulation and causes interstitial lung disease, nephrotic syndrome, and epidermolysis bullosa. *J Invest Dermatol*. 2016;136(5):1056-1059.
121. Hashimoto K, Matsumoto M, Iacobelli D. Transient bullous dermolysis of the newborn. *Arch Dermatol*. 1985;121:1429-1438.
122. Heinecke G, Marinkovich MP, Rieger KE. Intraepidermal type VII collagen by immunofluorescence mapping: a specific finding for bullous dermolysis of the newborn. *Pediatr Dermatol*. 2017;34(3):308-314.
123. Smith LT, Sybert VP. Intra-epidermal retention of type VII collagen in a patient with recessive dystrophic epidermolysis bullosa. *J Invest Dermatol*., 1990;94:261.
124. Cui Y, Hagan KW, Zhang S, et al. Identification and characterization of genes that are required for the accelerated degradation of mRNAs containing a premature translational termination codon. *Genes Dev*. 1995;9:423-436.
125. Uitto J, Pulkkinen L, Christiano AM. Molecular basis of the dystrophic and junctional form of epidermolysis bullosa: mutations in the type VII collagen and kalinin (laminin-5) genes. *J Invest Dermatol*. 1994;103:39S-45S.
126. Christiano AM, Anhalt G, Gibbons S, et al. Premature termination codons in the type VII collagen gene (COL7A1) underlie severe, mutilating recessive dystrophic epidermolysis bullosa. *Genomics*. 1994;21(1):160-168.
127. Siprashvili Z, Nguyen NT, Gorell ES, et al. Safety and wound outcomes following genetically corrected autologous epidermal grafts in patients with recessive dystrophic epidermolysis bullosa. *JAMA*. 2016;316(17):1808-1817.
128. Gorell ES, Nguyen N, Siprashvili Z, et al. Characterization of patients with dystrophic epidermolysis bullosa for collagen VII therapy. *Br J Dermatol*. 2015;173(3):821-823.
129. Almaani N, Liu L, Perez A, et al. Epidermolysis bullosa pruriginosa in association with lichen planopilaris. *Clin Exp Dermatol*. 2009;34(8):e825-e828.
130. Mellerio JE, Ashton GH, Mohammedi R, et al. Allelic heterogeneity of dominant and recessive COL7A1 mutations underlying epidermolysis bullosa pruriginosa. *J Invest Dermatol*. 1999;112(6):984-987.
131. Bruckner-Tuderman L, Nilssen O, Zimmermann DR, et al. Immunohistochemical and mutation analyses demonstrate that procollagen VII is processed to collagen VII through removal of the NC-2 domain. *J Cell Biol*. 1995;131(2):551-559.
132. Kindler T. Congenital poikiloderma with traumatic bulla formation and progressive cutaneous atrophy. *Br J Dermatol*. 1954;66(3):104-111.

133. Ashton G, McLean WH, South AP, et al. Recurrent mutations in kindlin-1, a novel keratinocyte focal contact protein, in the autosomal recessive skin fragility and photosensitivity disorder, Kindler syndrome. *J Invest Dermatol*. 2004;122(1):78-83.
134. Patrizi A, Pauluzzi P, Neri I, et al. Kindler syndrome: report of a case with ultrastructural study and review of the literature. *Pediatr Dermatol*. 1996;13(5):397-402.
135. Haber R, Hanna W. Kindler syndrome. Clinical and ultrastructural findings. *Arch Dermatol*. 1996;132(12): 1487-1490.
136. Forman A, Prendiville JS, Esterly NB, et al. Kindler syndrome: report of two cases and review of the literature. *Pediatr Dermatol*. 1989;6(2):91-101.
137. Hovnanian A, Blanchet-Bardon C, de Prost Y. Poikiloderma of Theresa Kindler: report of a case with ultrastructural study, and review of the literature. *Pediatr Dermatol*. 1989;6(2):82-90.
138. Hacham-Zadeh S, Garfunkel A. Kindler syndrome in two related Kurdish families. *Am J Med Genet*. 1985;20(1):43-48.
139. Verret J, Avenel M, Larrègue M, et al. Kindler syndrome. Case report with ultrastructure study. *Ann Dermatol Venereol*. 1984;111(3):259-269.
140. Lai-Cheong JE, Tanaka A, Hawche G, et al. Kindler syndrome: a focal adhesion genodermatosis. *Br J Dermatol*. 2009;160(2):233-242.
141. Has C, Wessagowit V, Pascucci M, et al. Molecular basis of Kindler syndrome in Italy: novel and recurrent Alu/Alu recombination, splice site, nonsense, and frameshift mutations in the KIND1 gene. *J Invest Dermatol*. 2006;126(8):1776-1783.
142. Lanschuetzer C, Muss WH, Emberger M, et al. Gene symbol: Kind1. Disease: Kindler syndrome. *Hum Genet*. 2004;115(2):175.
143. Ashton G. Kindler syndrome. *Clin Exp Dermatol*. 2004;29(2):116-121.
144. Takeichi T, Liu L, Fong K, et al. Whole-exome sequencing improves mutation detection in a diagnostic epidermolysis bullosa laboratory. *Br J Dermatol*. 2015;172(1):94-100.
145. Fassihi H, Eady RA, Mellerio JE, et al. Prenatal diagnosis for severe inherited skin disorders: 25 years' experience. *Br J Dermatol*. 2006;154(1):106-113.
146. Marinkovich MP, Meneguzzi G, Burgeson RE, et al. Prenatal diagnosis of Herlitz junctional epidermolysis bullosa by amniocentesis. *Prenat Diagn*. 1995;15(11):1027-1034.
147. Ashton GH, Mellerio JE, Dunnill MG, et al. A recurrent laminin 5 mutation in British patients with lethal (Herlitz) junctional epidermolysis bullosa: evidence for a mutational hotspot rather than propagation of an ancestral allele. *Br J Dermatol*. 1997;136(5): 674-677.
148. Cserhalmi-Friedman PB, Tang Y, Adler A, et al. Preimplantation genetic diagnosis in two families at risk for recurrence of Herlitz junctional epidermolysis bullosa. *Exp Dermatol*. 2000;9(4):290-297.
149. Kaiser J. Prenatal diagnosis. An earlier look at baby's genes. *Science*. 2005;309(5740):1476-1478.
150. Lin AN, Carter DM. Medical and surgical treatment of the skin in epidermolysis bullosa. In: Lin AN, Carter DM, eds. *Epidermolysis Bullosa—Basic and Clinical Aspects*. New York: Springer-Verlag; 1992.
151. Terrill PJ, Mayou BJ, Pemberton J. Experience in the surgical management of the hand in dystrophic epidermolysis bullosa. *Br J Plast Surg*. 1992;45(6): 435-442.
152. Ladd AL, Kibele A, Gibbons S. Surgical treatment and postoperative splinting of recessive dystrophic epidermolysis bullosa. *J Hand Surg*. 1996;21(5):888-897.
153. Greider JL, Flatt AE. Surgical restoration of the hand in epidermolysis bullosa. *Arch Dermatol*. 1988;124: 765-767.
154. Glicenstein J, Mariani D, Haddad R. The hand in recessive dystrophic epidermolysis bullosa. *Hand Clin*. 2000;16(4):637-645.
155. Mellerio JE, Robertson SJ, Bernardis C, et al. Management of cutaneous squamous cell carcinoma in patients with epidermolysis bullosa: best clinical practice guidelines. *Br J Dermatol*. 2016;174(1): 56-67.
156. Bastin KT, Steeves RA, Richards MJ. Radiation therapy for squamous cell carcinoma in dystrophic epidermolysis bullosa: case reports and literature review. *Am J Clin Oncol*. 1997;20(1):55-58.
157. Fine J, Johnson LB, Weiner M, et al. Chemoprevention of squamous cell carcinoma in recessive dystrophic epidermolysis bullosa: results of a phase 1 trial of systemic isotretinoin. *J Am Acad Dermatol*. 2004;50(4):563-571.
158. Arnold AW, Bruckner-Tuderman L, Zuger C, et al. Cetuximab therapy of metastasizing cutaneous squamous cell carcinoma in a patient with severe recessive dystrophic epidermolysis bullosa. *Dermatology*. 2009;219(1):80-83.
159. Ergun G, Schaefer RA. Gastrointestinal aspects of epidermolysis bullosa. In: Lin AN, Carter DM, eds. *Epidermolysis Bullosa—Basic and Clinical Aspects*. New York: Springer-Verlag; 1992.
160. Haynes L, Atherton DJ, Ade-Ajayi N, et al. Gastrostomy and growth in dystrophic epidermolysis bullosa. *Br J Dermatol*. 1996;134(5):872-879.
161. Freeman EB, Köglmeier J, Martinez AE, et al. Gastrointestinal complications of epidermolysis bullosa in children. *Br J Dermatol*. 2008;158(6):1308-1314.
162. McDonnell PJ, Schofield OMV, Spalton DJ. Eye involvement in junctional epidermolysis bullosa. *Arch Ophthalmol*. 1989;107:1635-1637.
163. Tong L, Hodgkins PR, Denyer J, et al. The eye in epidermolysis bullosa. *Br J Ophthalmol*. 1999;83(3):323-326.
164. Kadyan A, Aralikatti A, Shah S, et al. Laryngo-onychocutaneous syndrome. *Ophthalmology*. 2010;117(5): 1056-1056; e2.
165. Kirkham J, Robinson C, Strafford SM, et al. The chemical composition of tooth enamel in junctional epidermolysis bullosa. *Arch Oral Biol*. 2000;45(5):377-386.
166. Serrano Martinez C, Silvestre Donat FJ, et al. Hereditary epidermolysis bullosa. Dental management of three cases. *Med Oral*. 2001;6(1):48-56.
167. Travis SP, McGrath JA, Turnbull AJ, et al. Oral and gastrointestinal manifestation s of epidermolysis bullosa. *Lancet*. 1992;340:1505-1506.
168. Lin AN, Lateef F, Kelly R, et al. Anesthetic management in epidermolysis bullosa: review of 129 anesthetic episodes in 32 patients. *J Am Acad Dermatol*. 1994;30(3):412-416.
169. Tesi D, Lin AN. Nutritional management of the epidermolysis bullosa patient. In: Lin AN, Carter DM, eds. *Epidermolysis Bullosa—Basic and Clinical Aspects*. New York: Springer-Verlag; 1992.
170. Hubbard L, Haynes L, Sklar M, et al. The challenges of meeting nutritional requirements in children and adults with epidermolysis bullosa: proceedings of a multidisciplinary team study day. *Clin Exp Dermatol*. 2011;36(6):579-583; quiz 583-584.

171. Fridge JL, Vichinsky EP. Correction of the anemia of epidermolysis bullosa with intravenous iron and erythropoietin. *J Pediatr*. 1998;132(5):871-873.
172. Lara-Corrales I, Mellerio JE, Martinez AE, et al. Dilated cardiomyopathy in epidermolysis bullosa: a retrospective, multicenter study. *Pediatr Dermatol*. 2010;27(3):238-243.
173. Dietz M. A day in the life of a patient with DDEB. *J Am Acad Dermatol*. 2004;51(1 suppl):S58-S59.
174. Goldschneider KR, Lucky AW. Pain management in epidermolysis bullosa. *Dermatol Clin*. 2010;28(2): 273-282, ix.
175. Tabolli S, Sampogna F, Di Pietro C, et al. Quality of life in patients with epidermolysis bullosa. *Br J Dermatol*. 2009;161(4):869-877.
176. Schomer H, Vergunst R. Psychological factors in epidermolysis bullosa. *S Afr Med J*. 1992;81(11):580.
177. Moss K. Contact at the borderline: psychoanalytic psychotherapy with EB patients. *Br J Nurs*. 2008;17(7):449-455.
178. Lansdown R, Atherton D, Dale A, et al. Practical and psychological problems for parents of children with epidermolysis bullosa. *Child Care Health Dev*. 1986;12(4):251-256.
179. Fine JD, Johnson LB, Weiner M, et al. Impact of inherited epidermolysis bullosa on parental interpersonal relationships, marital status and family size. *Br J Dermatol*. 2005;152(5):1009-1014.
180. Caldwell-Brown D, Stern RS, Lin AN, et al. Lack of efficacy of phenytoin in recessive dystrophic epidermolysis bullosa. Epidermolysis Bullosa Study Group. *N Engl J Med*. 1992;327(3):163-167.
181. Wally V, Lettner T, Peking P, et al. The pathogenetic role of IL-1beta in severe epidermolysis bullosa simplex. *J Invest Dermatol*. 2013;133(7):1901-1903.
182. Wally V, Kitzmueller S, Lagler F, et al. Topical diacerein for epidermolysis bullosa: a randomized controlled pilot study. *Orphanet J Rare Dis*. 2013;8:69.
183. Nystrom A, Thriene K, Mittapalli V, et al. Losartan ameliorates dystrophic epidermolysis bullosa and uncovers new disease mechanisms. *EMBO Mol Med*. 2015;7(9):1211-1228.
184. Falabella AF, Valencia IC, Eaglstein WH, et al. Tissue-engineered skin (Apligraf) in the healing of patients with epidermolysis bullosa wounds. *Arch Dermatol*. 2000;136(10):1225-1230.
185. Petrof G, Martinez-Queipo M, Mellerio JE, et al. Fibroblast cell therapy enhances initial healing in recessive dystrophic epidermolysis bullosa wounds: results of a randomized, vehicle-controlled trial. *Br J Dermatol*. 2013;169(5):1025-1033.
186. Venugopal SS, Yan W, Frew JW, et al. A phase II randomized vehicle-controlled trial of intradermal allogeneic fibroblasts for recessive dystrophic epidermolysis bullosa. *J Am Acad Dermatol*. 2013;69(6):898-908; e7.
187. Petrof G, Lwin SM, Martinez-Queipo M, et al. Potential of systemic allogeneic mesenchymal stromal cell therapy for children with recessive dystrophic epidermolysis bullosa. *J Invest Dermatol*. 2015;135(9):2319-2321.
188. Wagner JE, Ishida-Yamamoto A, McGrath JA, et al. Bone marrow transplantation for recessive dystrophic epidermolysis bullosa. *N Engl J Med*. 2010;363(7):629-639.
189. Mavilio F, Pellegrini G, Ferrari S, et al. Correction of junctional epidermolysis bullosa by transplantation of genetically modified epidermal stem cells. *Nat Med*. 2006;12(12):1397-1402.
190. De Rosa L, Carulli S, Cocchiarella F, et al. Long-term stability and safety of transgenic cultured epidermal stem cells in gene therapy of junctional epidermolysis bullosa. *Stem Cell Reports*. 2014;2(1):1-8.
191. Hirsch T, Rothoeft T, Teig N, et al. Regeneration of the entire human epidermis using transgenic stem cells. *Nature*. 2017;551(7680):327-332.
192. Hainzl S, Peking P, Kocher T, et al. COL7A1 Editing via CRISPR/Cas9 in recessive dystrophic epidermolysis bullosa. *Mol Ther*. 2017;25(11):2573-2584.
193. Webber BR, Osborn M, McElroy AN, et al. CRISPR/Cas9-based genetic correction for recessive dystrophic epidermolysis bullosa. *NPJ Regen Med*. 2016;1.
194. Sebastiano V, Zhen HH, Haddad B, et al. Human COL7A1-corrected induced pluripotent stem cells for the treatment of recessive dystrophic epidermolysis bullosa. *Sci Transl Med*. 2014;6(264):264ra163.
195. Kowalewski C, Bremer J, Gostynski A, et al. Amelioration of junctional epidermolysis bullosa due to exon skipping. *Br J Dermatol*. 2016;174(6): 1375-1379.
196. Bornert O, Kühl T, Bremer J, et al. Analysis of the functional consequences of targeted exon deletion in COL7A1 reveals prospects for dystrophic epidermolysis bullosa therapy. *Mol Ther*. 2016;24(7):1302-1311.
197. Schwieger-Briel A, Weibel L, Chmel N, et al. A COL7A1 variant leading to in-frame skipping of exon 15 attenuates disease severity in recessive dystrophic epidermolysis bullosa. *Br J Dermatol*. 2015;173(5): 1308-1311.
198. Kiritsi D, Garcia M, Brander R, et al. Mechanisms of natural gene therapy in dystrophic epidermolysis bullosa. *J Invest Dermatol*. 2014;134(8):2097-2104.

This page intentionally left blank

PART 10 Autoimmune Connective Tissue and Rheumatologic Disorders

Chapter 61 :: Lupus Erythematosus

:: Clayton J. Sontheimer, Melissa I. Costner, & Richard D. Sontheimer

AT-A-GLANCE

- A group of heterogeneous illnesses that have in common the development of immunity to self-nucleic acids and their associated proteins, with skin-only disease at one end of the spectrum and severe visceral involvement at the other.
- Skin lesions may be specific to lupus or nonspecific, being seen in other conditions as well.
- Acute cutaneous lupus erythematosus (malar rash) is almost always associated with underlying visceral involvement. Subacute cutaneous lupus patients meet American College of Rheumatology systemic lupus erythematosus criteria approximately 50% of the time (but typically express only mild systemic clinical manifestations). Chronic cutaneous lupus (classic discoid lupus erythematosus, lupus panniculitis, chilblain lupus, and tumid lupus erythematosus) patients most often have skin-only or skin-predominant disease.
- Classical discoid lupus erythematosus causes scarring and can be permanently disfiguring. Subacute cutaneous lupus and acute cutaneous lupus erythematosus are highly photosensitive and are characteristically nonscarring.
- Lupus erythematosus–nonspecific skin lesions include nonscarring alopecia, mouth ulcers, photosensitivity, Raynaud phenomenon, vasculitis/vasculopathy, and bullous systemic lupus erythematosus, among others. They often herald a systemic lupus erythematosus flare.
- Treatment consists of physical sun protection, topical sunscreens, local and short-term systemic glucocorticoids, antimalarials, retinoids, thalidomide/lenalidomide, conventional immunosuppressives, and biologic therapies.
- Lupus erythematosus occurs much more commonly in women (9:1 female-to-male ratio).
- Both systemic lupus erythematosus and cutaneous lupus erythematosus are associated with upregulation of type 1 interferon signaling.

Lupus erythematosus (LE) is the root designation for a diverse array of clinical illnesses that are linked together by the development of autoimmunity directed predominantly at the molecular constituents of nucleosomes and ribonucleoproteins. Some patients present with life-threatening manifestations of systemic LE (SLE), whereas others, who are affected with what represents the same basic underlying disease process, express little more than isolated discoid LE (DLE) skin lesions throughout their illness. It is convenient to conceptualize LE as a clinical spectrum (Fig. 61-1) ranging from mildly affected patients with only localized DLE skin lesions to those at risk of dying from the systemic manifestations of LE such as nephritis, CNS disease, or vasculitis. The pattern of skin involvement expressed by an individual patient with LE can provide insight about the position on the spectrum where the patient's illness might best be placed.

The nomenclature and classification system originally devised by James N. Gilliam divides the cutaneous manifestations of LE into those lesions that show characteristic histologic changes of LE (LE-specific skin disease; ie, an interface dermatitis) and those that are not histopathologically distinct for LE and/or may

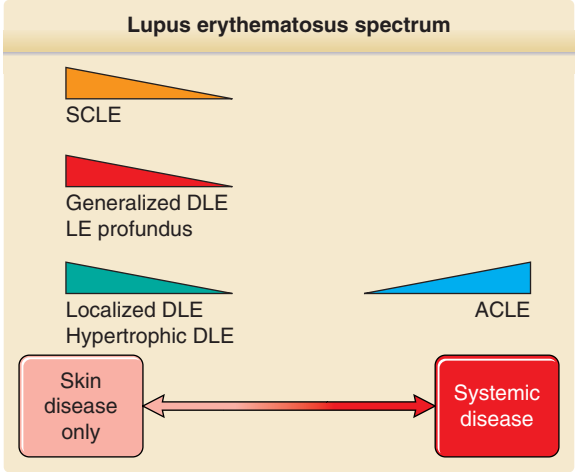

Figure 61-1 Spectrum of disease: local involvement to systemic disease. ACLE, acute cutaneous lupus erythematosus; DLE, discoid lupus erythematosus; LE, lupus erythematosus; SLE, systemic lupus erythematosus.

be seen as a feature of another disease processes (LE-nonspecific skin disease).[1] Within this context, the term *LE-specific* relates to those lesions displaying an interface dermatitis. The term *cutaneous LE* (CLE) is often used synonymously with "LE-specific skin disease" as an umbrella designation for the 3 major categories of LE-specific skin disease: acute cutaneous LE (ACLE), subacute cutaneous LE (SCLE), and chronic cutaneous LE (CCLE). This will be the framework used in our discussion of the extraordinarily diverse set of cutaneous lesions that occur in patients with LE (Table 61-1).

The essence of LE is in its heterogeneity, and the challenge for those who treat it is to recognize clinically useful patterns within the mosaic of features that constitute this protean illness. An overview of the systemic manifestations of LE can be seen in the American College of Rheumatology's (ACR) classification criteria for SLE,[2] which are presented in Table 61-2, and from the outline of the systemic manifestations of SLE presented in Table 61-3.

EPIDEMIOLOGY

The epidemiology and socioeconomic impact of LE in general,[3] and CLE specifically,[4] have been reviewed. Skin disease is the second most frequent clinical manifestation of LE after joint inflammation. As many as 45% of patients with CLE experience some degree of vocational handicap. Recent quality-of-life studies suggested that the impact of skin manifestations in patients with SLE was preceded only by pain and fatigue related to their disease.[5] The Dermatology Life Quality Index and SF-36 have been used to measure quality of life in patients with CLE. Both questionnaires showed that patients with active skin lesions had lower quality of life and that patients with associated alopecia were particularly impacted.[6]

TABLE 61-1
The Gilliam Classification of Skin Lesions Associated with Lupus Erythematosus

LE-SPECIFIC SKIN DISEASE (CUTANEOUS LE/CLE)	LE-NONSPECIFIC SKIN DISEASE
A. ACLE	A. Cutaneous vascular disease
1. Localized ACLE (malar rash, butterfly rash)	1. Vasculitis
2. Generalized ACLE (lupus maculopapular lupus rash, SLE rash, rash, photosensitive lupus dermatitis)	a. Leukocytoclastic
a. TEN-like ACLE	i. Palpable purpura
B. SCLE	ii. Urticarial vasculitis
1. Annular SCLE (syn. Lupus marginatus, symmetric erythema centrifugum, autoimmune annular erythema, lupus erythematosus gyrates repens)	b. Polyarteritis nodosa-like cutaneous lesions
2. Papulosquamous SCLE (syn. Disseminated DLE, subacute disseminated LE, superficial disseminated LE, psoriasiform LE, pityriasiform LE, maculopapular photosensitive LE)	2. Vasculopathy
C. CCLE	a. Degos disease-like lesions
1. Classic DLE	b. Secondary atrophie blanche (syn. livedoid vasculitis, livedo vasculitis)
a. Localized DLE	3. Periungual telangiectasia
b. Generalized DLE	4. Livedo reticularis
2. Hypertrophic/verrucous DLE	5. Thrombophlebitis
3. Lupus profundus/lupus panniculitis	6. Raynaud phenomenon
4. Mucosal DLE	7. Erythromelalgia
5. Oral DLE	B. Nonscarring alopecia
6. Conjunctival DLE	1. "Lupus hair"
7. Lupus tumidus (urticarial plaque phase of LE)	2. Telogen effluvium
8. Chilblain LE (chilblain lupus, perniotic lupus)	3. Alopecia areata
9. Lichenoid DLE (LE/lichen planus overlap, lupus planus)	C. Sclerodactyly
	D. Rheumatoid nodules
	E. Calcinosis cutis
	F. LE-nonspecific bullous lesions
	G. Urticaria
	H. Papulonodular mucinosis
	I. Cutis laxa/anetoderma
	J. Acanthosis nigricans
	K. Erythema multiforme (syn. Rowell syndrome)
	L. Leg ulcers
	M. Lichen planus

ACLE, acute cutaneous lupus erythematosus; CCLE, chronic cutaneous lupus erythematosus; DLE, discoid lupus erythematosus; LE, lupus erythematosus; SCLE, subacute cutaneous lupus erythematosus; SLE, systemic lupus erythematosus; TEN, toxic epidermal necrolysis.

Adapted from Sontheimer RD. The lexicon of cutaneous lupus erythematosus—a review and personal perspective on the nomenclature and classification of the cutaneous manifestations of lupus erythematosus. *Lupus*. 1997;6(2):84-95. Copyright © Stockton Press. Reprinted with permission of SAGE Publications.

Malar, or butterfly rash (localized ACLE), has been reported in 20% to 60% of large cohorts of patients with LE. Limited data suggest that the maculopapular or SLE rash of generalized ACLE is present in approximately 35% to 60% of patients with SLE. ACLE, like SLE in general, is 8 times more common in women than men. All races are affected; however, the early

TABLE 61-2
The 1982 Revised Criteria for Classification of Systemic Lupus Erythematosus[a]

CRITERION	DEFINITION
1. Malar rash	Fixed erythema, flat or raised, over the malar eminences, tending to spare the nasolabial folds
2. Discoid rash	Erythematous raised patches with adherent keratotic scaling and follicular plugging; atrophic scarring may occur in older lesions
3. Photosensitivity	Skin rash as a result of unusual reaction to sunlight, by patient history or physician observation
4. Oral ulcers	Oral or nasopharyngeal ulceration, usually painless, observed by a physician
5. Arthritis	Nonerosive arthritis involving 2 or more peripheral joints, characterized by tenderness, swelling, or effusion
6. Serositis	a. Pleuritis—convincing history of pleuritic pain or rub heard by a physician or evidence of pleural effusion
	or
	b. Pericarditis—documented by electrocardiogram or rub or evidence of pericardial effusion
7. Renal disorder	a. Persistent proteinuria— >0.5 g/day or greater than 3+ if quantitation not performed
	or
	b. Cellular casts—may be red cell, hemoglobin, granular, tubular, or mixed
8. Neurologic disorder	a. Seizures—in the absence of offending drugs or known metabolic derangements (eg, uremia, ketoacidosis, or electrolyte imbalance)
	or
	b. Psychosis—in the absence of offending drugs or known metabolic derangements (eg, uremia, ketoacidosis, or electrolyte imbalance)
9. Hematologic disorder	a. Hemolytic anemia—with reticulocytosis
	or
	b. Leukopenia— <4000 µL total on 2 or more occasions
	or
	c. Lymphopenia— <1500/µL on 2 or more occasions
	or
	d. Thrombocytopenia— <100,000 µL in the absence of offending drugs
10. Immunologic disorder	a. Anti-DNA—antibody to native DNA in abnormal titer
	or
	b. Anti–Smith antigen—presence of antibody to Smith nuclear antigen
	or
	c. Positive finding of antiphospholipid antibodies based on (1) an abnormal serum level of immunoglobulin G or immunoglobulin M anticardiolipin antibodies, (2) a positive test result for lupus anticoagulant using a standard method, or (3) a false-positive serologic test for syphilis known to be positive for at least 6 months and confirmed by *Treponema pallidum* immobilization or fluorescent treponemal antibody absorption test
11. Antinuclear antibody	An abnormal titer of antinuclear antibody by immunofluorescence of an equivalent assay at any point in time and in the absence of drugs known to be associated with "drug-induced lupus" syndrome

[a]The proposed classification is based on 11 criteria. For the purpose of identifying patients in clinical studies, a person shall be said to have systemic lupus erythematosus if any 4 or more of the 11 criteria are present, serially or simultaneously, during any interval or observation.

From Tan EM, Cohen AS, Fries JF, et al. The 1982 revised criteria for the classification of systemic lupus erythematosus. *Arthritis Rheum*. 1982;25(11): 1271-1277, copyright 1982, with permission of the American College of Rheumatology.

clinical manifestations of ACLE can be overlooked in a dark-skinned individual.

Patients presenting with SCLE lesions constitute 7% to 27% of LE patient populations. SCLE is primarily a disease of white females, with the mean age of onset being in the fifth decade. Drug-induced SCLE patients are somewhat older at disease onset, perhaps reflecting greater exposure to drugs for age-related medical problems (hypertension, cardiovascular disease).

The most common form of CCLE, a classic DLE skin lesion, is present in 15% to 30% of SLE populations selected in various ways. Approximately 5% of patients presenting with isolated localized DLE subsequently develop SLE. Published population-based data have argued strongly that the incidence and prevalence of isolated forms of CLE are equivalent to those of SLE.[7] Although DLE can occur in infants and the elderly, it is most common in individuals between 20 and 40 years of age. DLE has a female-to-male ratio of 3:2 to 3:1, which is much lower than that of SLE. All races are affected, but investigations suggest that DLE might be more prevalent in blacks.

TABLE 61-3

Overview of the Extracutaneous Manifestations of Systemic Lupus Erythematosus

- General
  - Fever, fatigue, malaise, weight loss
  - Alopecia
- Musculoskeletal
  - Arthralgia, arthritis, morning stiffness
  - Myalgia, myositis
  - Avascular necrosis
- Hematologic
  - Anemia
    - Anemia of chronic disease (normocytic)
    - Autoimmune hemolytic anemia (Coombs positive)
  - Leukopenia, lymphopenia, neutropenia
  - Thrombocytopenia
  - Antiphospholipid syndrome, thrombosis (thrombophlebitis, deep vein thrombosis)
- Cardiopulmonary
  - Pleurisy, pleural effusion, aseptic pneumonitis, pulmonary hemorrhage, Interstitial lung disease, pulmonary embolism, coronary artery disease
  - Chest pain, pericarditis, myocarditis Libman-Sacks endocarditis
- Renal
  - Membranoproliferative glomerulonephritis (World Health Organization [WHO] classes II-IV)
    - Proteinuria, hematuria, red blood cell casts
  - Membranous glomerulonephritis (WHO class V)
    - Severe proteinuria, nephrotic syndrome
- Neuropsychiatric
  - Peripheral neuropathy, transverse myelitis, Guillain-Barré syndrome
  - Chorea, choreoathetosis
  - Seizures
  - Headaches
  - Acute confusional state, psychosis
  - Cognitive dysfunction
  - Aseptic meningitis
- GI
  - Anorexia, nausea, vomiting, abdominal pain
  - Hepatitis, hepatomegaly
  - Pancreatitis
  - Mesenteric vasculitis
  - Protein-losing enteropathy
- Ocular
  - Retinal vascular disease, optic neuropathy
  - Conjunctivitis, episcleritis
  - Dry eyes, keratitis
- Nasooral
  - Palatal ulceration
  - Sicca syndrome, secondary Sjögren Syndrome
- Lymphatic system
  - Lymphadenopathy
  - Splenomegaly

ETIOLOGY AND PATHOGENESIS

The cause(s) of and pathogenic mechanisms responsible for LE-specific skin disease are not fully understood, although recent work has provided many new insights. The pathogenesis of LE-specific skin disease is inextricably intertwined with SLE pathogenesis. Simply put, SLE is a disorder in which the interplay between host factors (susceptibility genes, hormonal milieu, etc) and environmental factors (ultraviolet [UV] radiation, viruses, and drugs) leads to loss of self-tolerance, and induction of autoimmunity. This is followed by activation and expansion of the immune system, and eventuates in immunologic injury to end organs and clinical expression of disease.[8] Recent work highlights the important role of interferon-α signaling in the pathogenesis of both SLE and LE-specific skin disease.

IMMUNOLOGIC FACTORS

Multiple studies highlight the important role of plasmacytoid dendritic cells (PDCs) and type 1 interferon (IFN) signaling, comprised of interferon-α and interferon-β, in the pathogenesis of both SLE and LE-specific skin disease. type 1 IFN is the most upregulated gene pathway identified in microarray studies in SLE patients, and increased type 1 IFN has been seen in the blood and skin of patients with CLE.[9,10] Large numbers of PDCs are present in skin lesions of patients with CLE.[11] PDCs produce large amounts of type 1 IFN in response to DNA and RNA stimulation through toll-like receptors 7 and 9. In healthy state conditions, PDCs recognize viral DNA and RNA and not self-DNA; however, immune complexes generated by autoantibody binding of DNA and RNA from apoptotic cells are recognized by PDCs and lead to activation and production of type 1 IFN. Chronic type 1 IFN, in turn, promotes loss of tolerance in SLE through its actions of B and T cells.[12,13]

Recent work has identified a separate DNA-sensing and RNA-sensing pathway, termed the *immunostimulatory DNA pathway*, that is active within the cytoplasm in contrast to endosomal toll-like receptors. Monogenetic syndrome caused by mutations in immunostimulatory DNA pathway genes, as seen in Aicardi-Goutières syndrome and SAVI, result in upregulated immunostimulatory DNA pathway activity and chronic IFN-β production, and share many features with spontaneous LE.[14] Single-nucleotide polymorphisms in immunostimulatory DNA pathway genes are associated with CLE and SLE.[15] Insights from these diseases, termed *interferonopathies*, further support the role for inappropriate type 1 IFN activity, whether IFN-α or IFN-β, as a proximal and driving event in lupus pathogenesis.

ENVIRONMENTAL FACTORS

Genetic predisposition for a lupus diathesis does not, in itself, produce disease. Rather, it appears that induction of autoimmunity in such patients is triggered by some inciting event, likely an environmental exposure.

Drugs, viruses, UV light, and, possibly, tobacco induce development of SLE.

UV radiation is probably the most important environmental factor in the induction phase of SLE, especially of LE-specific skin disease. UV light likely leads to self-immunity and loss of tolerance because it causes apoptosis of keratinocytes, which in turn, makes previously cryptic peptides available for immunosurveillance. UVB radiation displaces autoantigens such as Ro/SS-A and related autoantigens, La/SS-B, and calreticulin, from their normal locations inside epidermal keratinocytes to the cell surface.[16] UVB irradiation induces the release of CCL27 (cutaneous T cell-attracting chemokine), which upregulates the expression of chemokines that activate autoreactive T cells and type 1 IFN, producing dendritic cells, which likely play a central role in lupus pathogenesis.[17,18]

A recent, large, case-control study reported that smokers are at a greater risk of developing SLE than are nonsmokers and former smokers. A cross-sectional analysis of a collaborative Web-based database established by Werth and colleagues documented that patients with treatment-resistant CLE were much more likely to smoke.[19] Several authors have shown that patients with LE-specific skin disease who smoke are less responsive to antimalarial treatment.[20-22]

Numerous drugs are implicated in inducing various features of SLE (Table 61-4). The drugs that induce CLE can be linked by their photosensitizing properties. It is suggested that these drugs cause an increase in keratinocyte apoptosis, exposure of previously intracellular peptides on epidermal cell surfaces, and enhance proinflammatory cytokines such as tumor necrosis factor (TNF)-α and type 1 IFN.[23,24]

There is much speculation about the role of infectious agents, particularly viruses, in the induction of SLE and CLE. Seroconversion to Epstein-Barr virus among patients with SLE is nearly universal, and recent data demonstrate that patients with SLE have defective control of latent Epstein-Barr virus infection that probably stems from altered T-cell responses against Epstein-Barr virus.

TABLE 61-4
Causes of Drug-Induced Lupus

Drug-Induced Subacute Cutaneous Lupus Erythematosus

Antacids[a]
- *Protein pump inhibitors* (esomeprazole, lansoprazole, omeprazole, pantoprazole)

Antibiotics (Amoxicillin/clavulanic acid, doxycycline, minocycline, nitrofurantoin, norfloxacin)

Anticonvulsants/antiepileptics (carbamazepine, phenytoin, lamotrigine)

Antifungals[a] (griseofulvin, terbinafine)

Antihistamines (brompheniramine, ranitidine)

Antiinflammatory
- *Nonsteroidal antiinflammatories* (naproxen, piroxicam)

Immunomodulators (hydroxychloroquine, imiquimod, interferon-α, interferon-β, leflunomide)

Biologics[a] (adalimumab, bevacizumab, efalizumab, etanercept, golimumab, infliximab, ranibizumab, rituximab)

Cardiovascular
- *Antihypertensives*
  - *Angiotensin-converting enzyme (ACE) inhibitors* (captopril, cilazapril, enalapril, lisinopril, ramipril)
  - *ACEII receptor antagonists* (losartan)
  - *Beta blockers* (acebutolol, oxypurinol)
  - *Calcium channel blockers* (amlodipine, diltiazem, nifedipine, nitrendipine, verapamil)
  - *Diuretics* (chlorothiazide, hydrochlorothiazide, hydrochlorothiazide/triamterene)
- *Statins* (pravastatin, simvastatin)

Chemotherapeutic[a] (capecitabine, docetaxel, doxorubicin, doxorubicin/cyclophosphamide, fluorouracil, gemcitabine, mitotane, paclitaxel, pazopanib, pemetrexed/carboplatin, tamoxifen)

Hormone-altering (anastrozole, leuprorelin)

Ultraviolet therapy (psoralen and ultraviolet A [PUVA])

Others (allopurinol, amiodarone, bupropion, citalopram, iodine-131, torsemide, tiotropium, ticlopidine)

Drug-Induced Systemic Lupus Erythematosus (Typically without Skin Involvement)

Antihyperlipidemic agents
Anti–tumor necrosis factor biologics
Hydralazine
Isoniazid
Minocycline
Procainamide

[a]Indicates most commonly imputed drug classes. Imputed drugs are listed alphabetically by class.

Data summarized from Michaelis TC, Sontheimer RD, Lowe GC. An update in drug-induced subacute cutaneous lupus erythematosus. *Dermatol Online J*. 2017;23(3).

CLINICAL FINDINGS

It is important to distinguish among the subtypes of LE-specific skin disease, because the type of skin involvement in LE can reflect the underlying pattern of SLE activity. In fact, the designations acute, subacute, and chronic, in regard to CLE, refer to the pace and severity of any associated SLE and are not necessarily related to how long individual lesions have been present. For example, ACLE almost always occurs in the setting of acutely flaring SLE, whereas CCLE often occurs in the absence of SLE or in the presence of mild, smoldering SLE. SCLE occupies an intermediate position in this clinical spectrum. Subclassification, although important for assigning risk, is sometimes difficult, as it is not uncommon to see more than 1 subtype of LE-specific skin disease in the same patient, especially in patients with SLE.

ACUTE CUTANEOUS LUPUS ERYTHEMATOSUS

Although ACLE localized to the face is the usual pattern of presentation, ACLE can assume a generalized distribution. Localized ACLE has commonly been referred to as the *classic butterfly rash* or *malar rash of SLE* (Fig. 61-2). In localized ACLE, confluent symmetric erythema and edema are centered over the malar eminences and bridges over the nose (unilateral involvement with ACLE has been described). The nasolabial folds are

Figure 61-2 Localized acute cutaneous lupus erythematosus. Erythematous, slightly edematous, sharply demarcated erythema is seen on the malar areas in a "butterfly" distribution.

characteristically spared. The forehead, chin, and V area of the neck can be involved, and severe facial swelling may occur. Occasionally, ACLE begins as small macules and/or papules on the face that later may become confluent and hyperkeratotic. Generalized ACLE presents as a widespread morbilliform or exanthematous eruption often focused over the extensor aspects of the arms and hands and characteristically sparing the knuckles (Fig. 61-3A). Although perivascular nail fold erythema and telangiectasia can occur (Fig. 61-3B), they are considerably more common and occur in more exaggerated forms in dermatomyositis and systemic sclerosis. Generalized ACLE has been indiscriminately referred to as the *maculopapular rash of SLE*, *photosensitive lupus dermatitis*, and *SLE rash*. An extremely acute form of ACLE is rarely seen that can simulate toxic epidermal necrolysis (TEN; Fig. 61-4). This form of LE-specific vesiculobullous disease results from widespread apoptosis of epidermal keratinocytes, and eventuates in areas of full-thickness epidermal skin necrosis, which is subsequently denuded. ACLE can be differentiated from true TEN because it occurs on predominantly sun-exposed skin and has a more insidious onset. The mucosa may or may not be involved, as in TEN.

ACLE is typically precipitated or exacerbated by exposure to UV light. This form of CLE can be quite ephemeral, lasting only hours, days, or weeks; however, some patients experience more prolonged periods of activity. Postinflammatory pigmentary change is most prominent in patients with heavily pigmented skin. Atrophic scarring does not occur in ACLE unless the process is complicated by secondary bacterial infection.

SUBACUTE CUTANEOUS LUPUS ERYTHEMATOSUS

The presence of SCLE skin lesions was first characterized as a distinctive immunogenetic subset of LE in 1979.[25] A disease presentation dominated by SCLE lesions marks the presence of a distinct subset of LE having characteristic clinical, serologic, and genetic features. Although a finding of circulating autoantibodies to the Ro/SS-A ribonucleoprotein particle strongly supports a diagnosis of SCLE, the presence of this autoantibody specificity is not required to make a diagnosis of SCLE.

SCLE initially presents as erythematous macules and/or papules that evolve into hyperkeratotic papulosquamous or annular/polycyclic plaques (Fig. 61-5). Whereas most patients have either annular

Figure 61-3 Generalized acute cutaneous lupus erythematosus. **A,** Well-demarcated patches of erythema with fine overlying scale on the dorsal aspect of the hands, fingers, and periungual areas. Note the characteristic sparing of the knuckles, which are preferentially involved in dermatomyositis. **B,** Closeup view of periungual erythema and grossly visible telangiectasia. Although these lesions can be seen in lupus erythematosus, they are much more typical of dermatomyositis.

Figure 61-4 Toxic epidermal necrolysis (TEN)-like acute cutaneous lupus in a 16-year-old boy. **A,** Widespread erythematous papules with vesiculobullous changes over the trunk. **B,** Similar changes over the arm. **C,** Severe epidermal loss and denuding over the face in a 16-year-old boy. **D,** Painless palatal ulceration characteristic of systemic lupus erythematosus was present as opposed to severe mucosal involvement of TEN.

Figure 61-5 Subacute cutaneous lupus erythematosus (SCLE). **A,** Annular SCLE on the upper back of a 38-year-old woman. Note the central areas of hypopigmentation in which no dermal atrophy is present. **B,** Papulosquamous SCLE over the extensor aspect of the forearm of a 26-year-old woman.

or papulosquamous SCLE, a few develop elements of both morphologic varieties. SCLE lesions are characteristically photosensitive and occur in predominantly sun-exposed areas (ie, upper back, shoulders, extensor aspects of the arms, V area of the neck, and, less commonly, the face). SCLE lesions typically heal without scarring but can resolve with long-lasting, if not permanent, vitiligo-like leukoderma, and telangiectasias.

Several variants of SCLE have been described. On occasion, SCLE lesions present initially with an appearance of erythema multiforme. Such cases are similar to Rowell syndrome (erythema multiforme–like lesions occurring in patients with SLE in the presence of La/SS-B autoantibodies). As a result of intense injury to epidermal basal cells, the active edge of an annular SCLE lesion occasionally undergoes a vesiculobullous change that can subsequently produce a strikingly crusted appearance. Such lesions can mimic Stevens-Johnson syndrome/TEN. Pathogenesis is similar to that described above for TEN-like ACLE. Rarely, SCLE presents with exfoliative erythroderma or displays a curious acral distribution of annular lesions. Pityriasiform and exanthematous variants of SCLE have been reported. The skin lesions of neonatal LE (transient, photosensitive, nonscarring LE-specific skin lesions in neonates who have received immunoglobulin (Ig) G anti-Ro/SS-A, and, occasionally, other autoantibody specificities transplacentally) share many features with SCLE.

Unlike ACLE skin lesions, SCLE lesions tend to be less transient than ACLE lesions and heal with more pigmentary change. They are also less edematous and more hyperkeratotic than ACLE lesions. SCLE more commonly involves the neck, shoulders, upper extremities, and trunk, whereas ACLE more commonly affects the malar areas of the face. When the face is involved with SCLE, it is most often the lateral face, with sparing of the central, malar regions. In comparison to SCLE lesions, DLE lesions are generally associated with a greater degree of hyperpigmentation and hypopigmentation, atrophic dermal scarring, follicular plugging, and adherent scale. A consistent clinical difference is that DLE lesions are characteristically indurated, whereas SCLE lesions are not; this difference reflects the greater depth of inflammation seen histopathologically in DLE lesions.

Approximately one-half of patients with SCLE meet the ACR's revised criteria for the classification of SLE. However, manifestations of severe SLE, such as nephritis, CNS disease, and systemic vasculitis, develop in only 10% to 15% of patients with SCLE. It has been suggested that the papulosquamous type of SCLE, leukopenia, high titer of antinuclear antibody (ANA) (>1:640), and anti–double-stranded DNA (dsDNA) antibodies are risk factors for the development of SLE in a patient presenting with SCLE lesions.

SCLE can overlap with other autoimmune diseases that share the 8.1 ancestral haplotype (human leukocyte antigen A1-B8-DR3-DQ2), including Sjögren's syndrome, dermatitis herpetiformis, sarcoidosis, and Hashimoto thyroiditis. Other disorders that have been anecdotally related to SCLE are rheumatoid arthritis, Sweet syndrome, porphyria cutanea tarda, gluten-sensitive enteropathy, and Crohn disease. There has also been the suggestion anecdotally that SCLE may be associated with internal malignancy (breast, lung, gastric, uterine, hepatocellular, and laryngeal carcinomas, as well as with Hodgkin lymphoma).[26] Several different types of chemotherapeutic agents are known to be capable of triggering drug-induced SCLE. This could perhaps confound the possibility that SCLE has a significant association with internal malignancy.

CHRONIC CUTANEOUS LUPUS ERYTHEMATOSUS

CLASSIC DISCOID LUPUS ERYTHEMATOSUS

Classic DLE lesions, the most common form of CCLE, begin as red-purple macules, papules, or small plaques and rapidly develop a hyperkeratotic surface. Early classic DLE lesions typically evolve into sharply demarcated, coin-shaped (ie, discoid) erythematous plaques covered by a prominent, adherent scale that extends into the orifices of dilated hair follicles (Fig. 61-6).

DLE lesions typically expand with erythema and hyperpigmentation at the periphery, leaving hallmark atrophic central scarring, telangiectasia, and hypopigmentation (Fig. 61-7). DLE lesions at this stage can merge to form large, confluent, disfiguring plaques. DLE in persons of certain ethnic backgrounds, such as Asian Indians, can present clinically as isolated

Figure 61-6 Classic discoid lupus erythematosus. Typical early erythematous plaque on the forehead demonstrating hyperkeratosis and accentuation of follicle orifices in a 60-year-old man with a 25-year history of cutaneous lupus erythematosus. The lesion had been present for 3 months; no dermal atrophy was present at this stage.

Figure 61-7 Classic discoid lupus erythematosus. Sharply demarcated, round-to-ovoid slightly indurated, erythematous plaques on the neck and face. Most plaques show a mild degree of hyperkeratosis, and some show dermal atrophy. Noninflamed areas of hypopigmentation and scarring mark the sites of prior lesions that have resolved.

areas of macular hyperpigmentation. When present on hair-bearing skin (scalp, eyelid margins, and eyebrows), DLE causes scarring alopecia, which can lead to disfigurement and markedly impact quality of life. Follicular involvement in DLE is a prominent feature. Keratotic plugs accumulate in dilated follicles that soon become devoid of hair. When the adherent scale is lifted from more advanced lesions, keratotic spikes similar in appearance to carpet tacks can be seen to project from the undersurface of the scale (ie, the "carpet tack" sign). DLE lesions can be difficult to diagnose in white patients because the characteristic peripheral hyperpigmentation is often absent. Hypertrophic DLE lesions can be confused with hypertrophic actinic keratosis, keratoacanthoma, and squamous cell carcinoma.

DLE lesions are most frequently encountered on the face, scalp, ears, V area of the neck, and extensor aspects of the arms. Any area of the face, including the eyebrows, eyelids, nose, and lips, can be affected. A symmetric, hyperkeratotic, butterfly-shaped DLE plaque is occasionally found over the malar areas of the face and bridge of the nose. Such lesions should not be confused with the more transient, edematous, minimally scaling ACLE erythema reactions that occur in the same areas. Facial DLE, like ACLE and SCLE, usually spares the nasolabial folds. It may be difficult to distinguish early lesions of malar DLE from ACLE, but induration and recalcitrance to topical steroids/calcineurin inhibitors favor the former diagnosis. When DLE lesions occur periorally, they can resolve with a striking acneiform pattern of pitted scarring. DLE characteristically affects the external ear, including the conchal bowl and outer portion of the external auditory canal (Fig. 61-8A). Such lesions often present initially as dilated, hyperpigmented follicles. The scalp is involved in 60% of patients with DLE; irreversible, scarring alopecia resulting from such involvement has been reported in one-third of patients (Fig. 61-8B). The irreversible, scarring alopecia resulting from DLE differs from the reversible, nonscarring alopecia that patients with SLE often develop during periods of systemic disease activity. This type of hair loss, so-called *lupus hair*, may represent telogen effluvium occurring as the result of flaring systemic disease.

Localized DLE lesions occur only on the head or neck, whereas generalized DLE lesions occur both above and below the neck. Generalized DLE is more commonly associated with underlying SLE and is often more recalcitrant to standard therapy, frequently requiring layering of antimalarial and immunosuppressive medications. DLE lesions below the neck most commonly occur on the extensor aspects of the arms, forearms, and hands, although they can occur at virtually any site on the body. The palms and soles can be the sites of painful, and at times disabling, erosive DLE lesions. On occasion, small DLE lesions occurring only around follicular orifices appear at the elbow and elsewhere (follicular DLE). We have observed that elbow/extensor arm lesions seem to occur with acral finger lesions of DLE, and that patients with this combination of findings more frequently have active systemic disease. DLE activity can localize to the nail unit. The nail can be impacted by other forms of CLE as well as SLE, producing nail fold erythema and telangiectasia, red lunulae, clubbing, paronychia, pitting, leukonychia striata, and onycholysis.

DLE lesions can be potentiated by sunlight exposure but to a lesser extent than ACLE and SCLE lesions. DLE, as well as other forms of LE skin disease activity, can be precipitated by any form of cutaneous trauma (ie, the Koebner phenomenon or isomorphic effect).

The relationship between classic DLE and SLE has been the subject of much debate.[27] The following summary points can be made: (a) 5% of patients presenting with classic DLE lesions subsequently develop unequivocal evidence of SLE and (b) patients with generalized DLE (ie, lesions both above and below the neck) have somewhat higher rates of immunologic abnormalities, a higher risk for progressing to SLE, and a higher risk for developing more severe manifestations of SLE than patients with localized DLE.

Roughly one-fourth of patients with SLE develop DLE lesions at some point in the course of their disease, and such patients tend to have less-severe forms of SLE.

Aside from classic DLE, there are several other less-common variants of CCLE, which are subclassified as such because of their overlapping histologies and tendency to occur in a low frequency in association with underlying SLE.

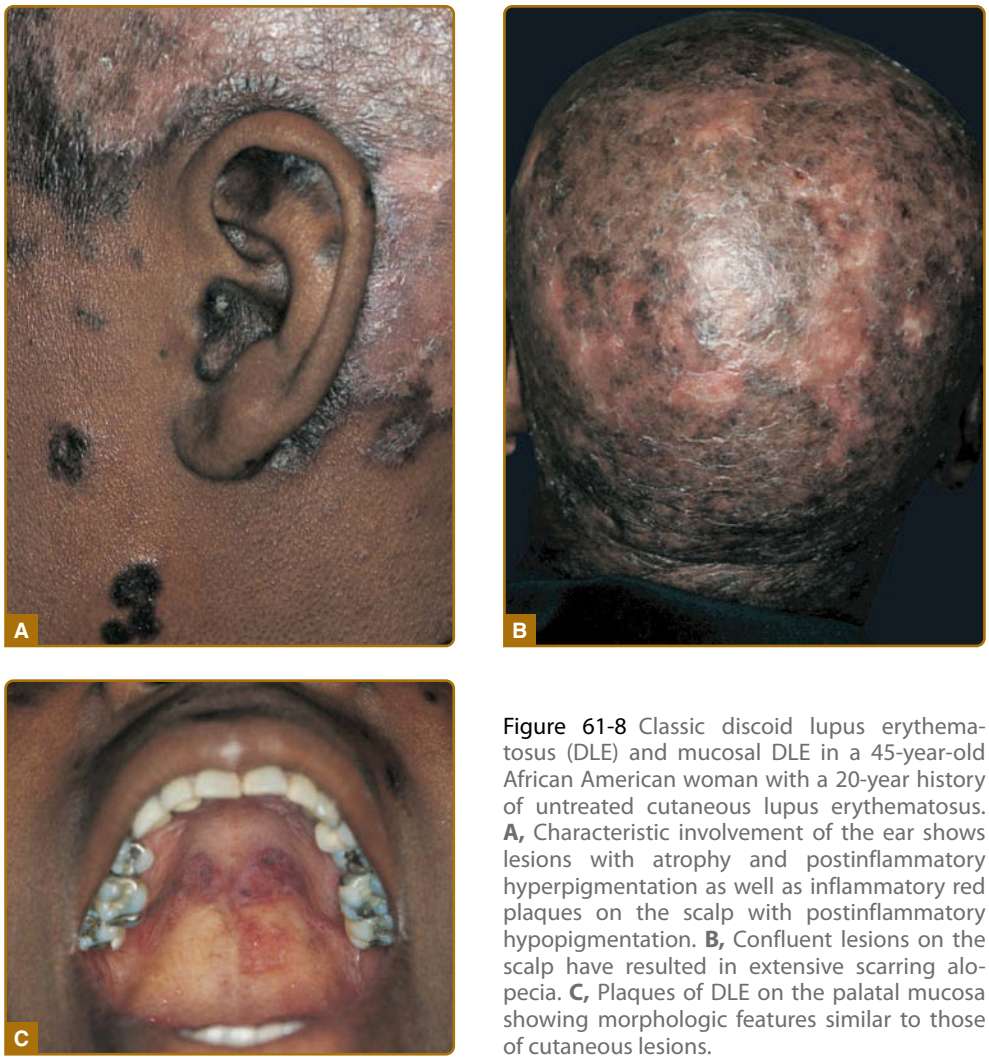

Figure 61-8 Classic discoid lupus erythematosus (DLE) and mucosal DLE in a 45-year-old African American woman with a 20-year history of untreated cutaneous lupus erythematosus. **A,** Characteristic involvement of the ear shows lesions with atrophy and postinflammatory hyperpigmentation as well as inflammatory red plaques on the scalp with postinflammatory hypopigmentation. **B,** Confluent lesions on the scalp have resulted in extensive scarring alopecia. **C,** Plaques of DLE on the palatal mucosa showing morphologic features similar to those of cutaneous lesions.

HYPERTROPHIC DISCOID LUPUS ERYTHEMATOSUS

Hypertrophic DLE, also referred to as *hyperkeratotic* or *verrucous DLE,* is a rare variant of CCLE in which the hyperkeratosis normally found in classic DLE lesions is greatly exaggerated. The extensor aspects of the arms, the upper back, and the face are the areas most frequently affected. Overlapping features of hypertrophic LE and lichen planus have been described under the rubric *lupus planus.* The entity *lupus erythematosus hypertrophicus et profundus* appears to represent a rare form of hypertrophic DLE. Patients with hypertrophic DLE probably do not have a greater risk for developing SLE than do patients with classic DLE lesions.

MUCOSAL DISCOID LUPUS ERYTHEMATOSUS

Mucosal DLE occurs in approximately 25% of patients with CCLE. The oral mucosa is most frequently affected; however, nasal, conjunctival, and genital mucosal surfaces can be targeted. In the mouth, the buccal mucosal surfaces are most commonly involved, with the palate, alveolar processes, and tongue being sites of less frequent involvement. Lesions begin as painless, erythematous patches that evolve to chronic plaques that can be confused with lichen planus. Chronic buccal mucosal plaques are sharply marginated and have irregularly scalloped, white borders with radiating white striae and telangiectasia. The surfaces of these plaques overlying the palatal mucosa often have a honeycomb appearance. Central depression often occurs in older lesions, and painful ulceration can develop. Rarely, oral mucosal DLE lesions can degenerate into squamous cell carcinoma, similar to longstanding cutaneous DLE lesions. Any degree of nodular asymmetry within a mucosal DLE lesion should be evaluated for the possibility of malignant degeneration. Chronic DLE plaques also appear on the vermilion border of the lips. At times, DLE involvement of the lips can present as a diffuse cheilitis, especially on the more sun-exposed lower lip.

DLE lesions may present on the nasal, conjunctival, and anogenital mucosa. Perforation of the nasal

septum is more often associated with SLE than DLE. Conjunctival DLE lesions affect the lower lid more often than the upper lid. Lesions begin as focal areas of nondescript inflammation most commonly affecting the palpebral conjunctivae or the lid margin. Scarring becomes evident as lesions mature, and the permanent loss of eyelashes and ectropion can develop, producing considerable disability.

LUPUS ERYTHEMATOSUS PROFUNDUS/LUPUS ERYTHEMATOSUS PANNICULITIS

LE profundus/LE panniculitis (Kaposi-Irrgang disease) is a rare form of CCLE typified by inflammatory lesions in the lower dermis and subcutaneous tissue. Approximately 70% of patients with this type of CCLE also have typical DLE lesions, often overlying the panniculitis lesions. Some have used the term *LE profundus* to designate those patients who have both LE panniculitis and DLE lesions, and *LE panniculitis* to refer to those having only subcutaneous involvement. Typical subcutaneous lesions present as firm nodules, 1 to 3 cm in diameter. The overlying skin often becomes attached to the subcutaneous nodules and is drawn inward to produce deep, saucerized depressions (Fig. 61-9). The head, proximal upper arms, chest, back, breasts, buttocks, and thighs are the sites frequently affected. LE panniculitis, in the absence of overlying DLE, may produce breast nodules that can mimic carcinoma clinically and radiologically (lupus mastitis). Medically unresponsive extensive breast involvement can be so severe as to require radical mastectomy. Confluent facial involvement can simulate the appearance of lipoatrophy. Dystrophic calcification frequently occurs in older lesions of LE profundus/LE panniculitis, and pain associated with such calcification can, at times, be the dominant clinical problem. Roughly 50% of patients with LE profundus/panniculitis have evidence of SLE. However, the systemic features of patients with LE panniculitis/profundus tend to be less severe, similar to those of patients with SLE who have DLE skin lesions.

Figure 61-9 Lupus erythematosus panniculitis. Lupus panniculitis has resulted in large, sunken areas of overlying skin; erythema and atrophy of the skin are present.

CHILBLAIN LUPUS ERYTHEMATOSUS

Chilblain LE lesions initially develop as purple-red patches, papules, and plaques on the toes, fingers, and face, which are precipitated by cold, damp climates and are clinically and histologically similar to idiopathic chilblains (pernio) (Fig. 61-10). As they evolve, these lesions usually assume the appearance of scarred atrophic plaques with associated telangiectases. They may resemble old lesions of DLE or may mimic acral lesions of small vessel vasculitis. Histologic findings include a superficial and deep lymphocytic vascular reaction in addition to fibrin deposition in reticular, dermal-based blood vessels. Patients with chilblain LE often have typical DLE lesions on the face and head. It is possible that chilblain LE begins as a classic acral, cold-induced lesion that then Koebnerizes DLE lesions, thus explaining the spectrum of clinicohistologic findings, which seem to vary based on when, in the course of the lesion, the biopsy sample is taken.

Chilblain LE appears to be associated with anti-Ro/SS-A antibodies,[28] and is linked to Raynaud phenomenon in many cases.[29] Persistence of lesions beyond the cold months, a positive ANA, or presence of one of the other ACR criteria for SLE at the time of diagnosis of chilblain lesions helps to distinguish chilblain LE from idiopathic chilblains.[30] Approximately 20% of patients presenting with chilblain LE later develop SLE. Chilblain LE is an underrecognized entity, yet it is likely that it is one of the most common causes of digital lesions in patients with LE. It is sometimes misdiagnosed as vasculitis and may overlap with acral DLE as mentioned above. An autosomal dominant, familial form of Chilblain LE has been described, and is caused

Figure 61-10 Chilblain lupus. Chilblain lesions affecting the fingers in a patient with longstanding lupus and lupus nephritis. The skin lesions were chronic and occurred without cold exposure.

Figure 61-11 Lupus erythematosus tumidus. Note succulent, indurated plaques.

by a missense mutation in the *TREX 1* (endonuclease repair) gene.[31]

LUPUS ERYTHEMATOSUS TUMIDUS

Lupus erythematosus tumidus (LET; tumid LE) is a variant of CCLE in which the dermal findings of DLE, namely, excessive mucin deposition and superficial perivascular and periadnexal inflammation, are found on histologic evaluation. The characteristic epidermal histologic changes of LE-specific skin disease are only minimally expressed, if at all. This results in succulent, edematous, urticaria-like plaques with little surface change (Fig. 61-11). Annular urticaria-like plaques can also be seen. The paucity of epidermal change often produces confusion concerning the diagnosis of LET as a form of CCLE.[32,33]

Several recent reports support this subclassification and further characterize this subtype of CCLE.[34-39] Although described to occur in some patients with SLE, most patients with LET have a negative ANA and a benign disease course. LET appears to be the most photosensitive subtype of cutaneous lupus, and typically demonstrates a good response to antimalarials. Additionally, LET lesions tend to resolve completely without either scarring or atrophy.

There continues to be debate about the validity of LET as an authentic form of LE-skin disease. Some argue that LET lesions may in fact not be a form of CLE[32] while others feel that LET deserves to be recognized as a distinct type of CLE (intermittent CLE) equivalent in importance to ACLE, SCLE, and CCLE.[35] Evidence of type I interferon upregulation in skin lesions of UV light-induced LE tumidus support the latter argument.[40]

OTHER VARIANTS

Other rare forms of CCLE CLE have been described. These include, LE hypertrophicus et profundus, lichenoid DLE, LE vermiculatus, LE telangiectaticus, linear CLE, and LE edematous (probably a historical designation for urticaria-like plaque variant of DLE and/or tumid LE). Further information on these clinical entities is available.[41]

LUPUS ERYTHEMATOSUS NONSPECIFIC SKIN DISEASE

Many other cutaneous findings have been found in patients with lupus patients, particularly SLE; they are listed in Table 61-1. Of note, the presence of LE-nonspecific skin changes, especially when seen in conjunction with LE-specific rashes, corresponds with higher systemic disease activity.[42] Specific findings such as livedo reticularis, thrombophlebitis, or cutaneous infarct may suggest the presence of secondary antiphospholipid syndrome. Space constraints do not allow specific discussions of these entities here.

NONCUTANEOUS FINDINGS

Systemic lupus can cause a myriad of extracutaneous manifestations, which manifestations are outlined in Table 61-3.

DIAGNOSIS

Figure 61-12 outlines approaches to the patient with skin lesions suspicious for CLE.

LABORATORY TESTING

Because of the strong association between ACLE and SLE, the immunologic laboratory features of ACLE are those associated with SLE (high-titer ANA, anti-dsDNA, anti-Smith antigen, hypocomplementemia, hypergammaglobinemia, etc). Other laboratory findings, such as cytopenias, decreased kidney function, and urine changes (hematuria, proteinuria), reflect disease activity and can vary from patient to patient depending on the extent of end-organ involvement.

The laboratory markers for SCLE are the presence of anti-Ro/SS-A (70% to 90%) and, less commonly, anti-La/SS-B (30% to 50%) autoantibodies. ANA are present in 60% to 80% of patients with SCLE, and rheumatoid factor is present in approximately 33%. Other autoantibodies in patients with SCLE include false-positive serologic tests for syphilis (Venereal Disease Research Laboratory [VDRL] rapid plasma reagin; 7% to 33%), anticardiolipin (10% to 16%), antithyroid (18% to 44%), anti-Smith antigen (10%), anti-dsDNA (10%), and anti-U1 ribonucleoprotein (10%). Patients with SCLE, particularly those with systemic involvement, may have a number of laboratory abnormalities, including anemia, leukopenia, thrombocytopenia, elevated erythrocyte sedimentation rate, hypergammaglobulinemia, proteinuria, hematuria, urine casts,

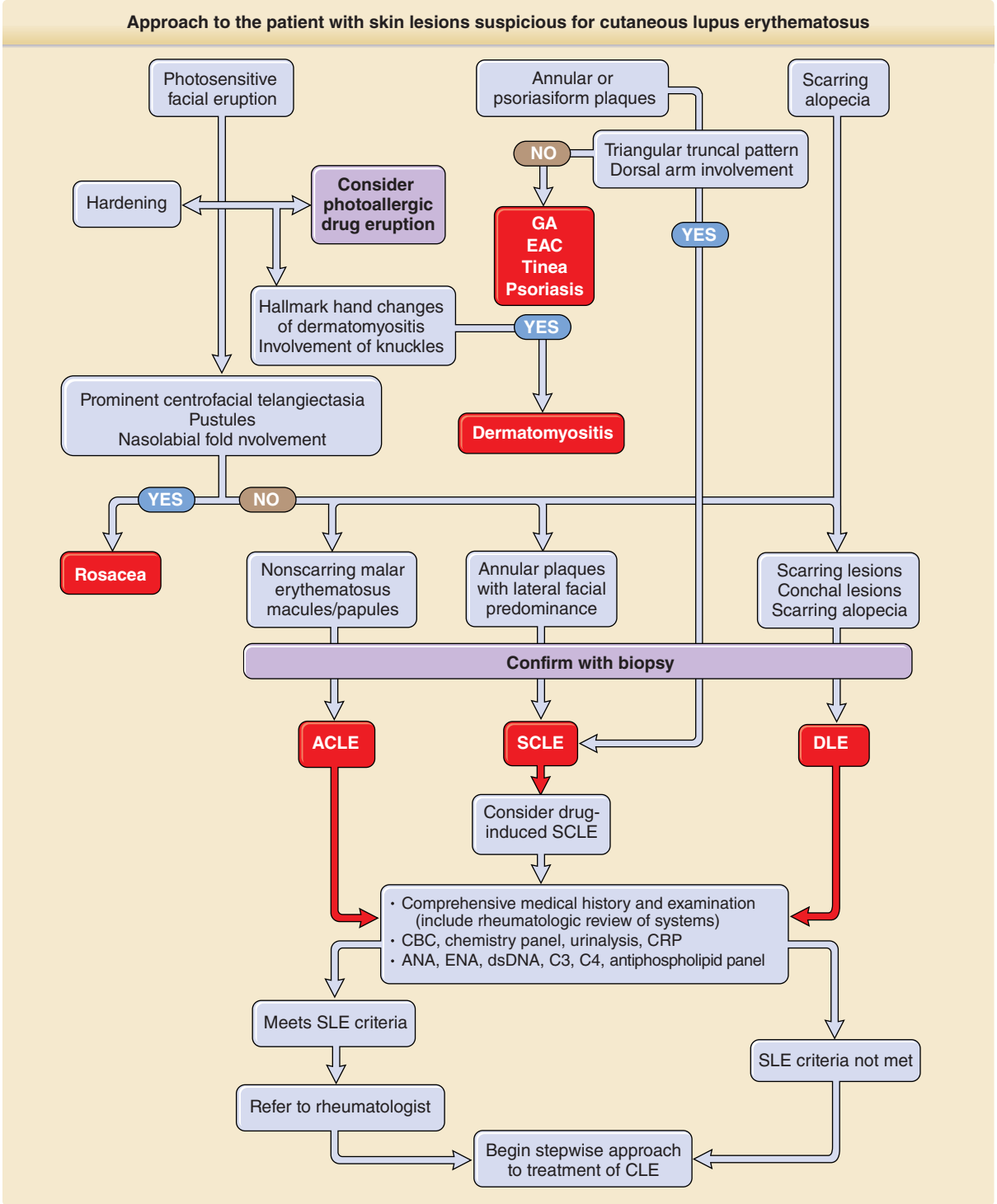

Figure 61-12 Approach to the patient with skin lesions suspicious for cutaneous lupus erythematosus. ACLE, acute cutaneous lupus erythematosus; ANA, antinuclear antibody; CBC, complete blood cell count; CLE, cutaneous lupus erythematosus; CRP, C-reactive protein; DLE, discoid lupus erythematosus; dsDNA, doubled-stranded DNA; EAC, erythema annulare centrifugum; ENA, extractable nuclear antibody; GA, granuloma annulare; SCLE, subacute cutaneous lupus erythematosus; SLE, systemic lupus erythematosus.

elevated serum creatine and blood urea nitrogen, and depressed complement levels (resulting from genetic deficiency or increased complement consumption).

ANA are present in low titer in 30% to 40% of patients with DLE; however, fewer than 5% have the higher ANA levels that are characteristic of patients with overt SLE (>1:320 titer by indirect immunofluorescence assay). Antibodies to single-stranded DNA are not uncommon in DLE, but antibodies to dsDNA are distinctly uncommon. Precipitating antibodies to U1 ribonucleoprotein

are sometimes found in patients whose disease course is dominated by DLE lesions; however, such patients usually have only mild manifestations of SLE or overlapping connective tissue disorders such as mixed connective tissue disease. Precipitating Ro/SS-A and La/SS-B autoantibodies are rare in patients with DLE; low levels of anti-Ro/SS-A antibody detected by enzyme-linked immunoassay are more common. A small percentage of patients with DLE have low-grade anemia, biologic false-positive serologic tests for syphilis (VDRL rapid plasma reagent), positive rheumatoid factor tests, slight depressions in serum complement levels, modest elevations in γ-globulin, and modest leukopenia. It has been suggested that such findings are risk factors for the development of SLE. ANA are present in 70% to 75% of patients with LE profundus/panniculitis, but anti-dsDNA antibodies are rare.

The laboratory findings associated with SLE, as well as with CLE, in both adults and children, are reviewed elsewhere.[43,44] It should be noted that the assay methodologies for the detection of the autoantibodies discussed above continue to evolve over time. Commercial reference laboratoriesat the time of this publication have largely moved to the use of solid-phase immunoassay techniques, especially multiplex flow immunoassay. The disease incidence/prevalence of the autoantibodies discussed in the section above might vary somewhat from the results of the autoantibody assays that one might receive from commercial laboratories today.

HISTOPATHOLOGY

The LE-specific skin disease histopathology is a distinctive constellation of hyperkeratosis, epidermal atrophy, vacuolar basal cell degeneration, dermal–epidermal junction basement membrane thickening, dermal edema, dermal mucin deposition, and mononuclear cell infiltration of the dermal–epidermal junction and dermis, focused in a perivascular and periappendageal distribution. Variable degrees of these features are encountered in the different forms of LE-specific skin disease. Differences of opinion exist as to whether ACLE, SCLE, and DLE lesions can be distinguished reliably on the basis of their histopathologic appearances alone.[44-46]

ACUTE CUTANEOUS LUPUS ERYTHEMATOSUS

The histopathologic changes in ACLE lesions are generally less impressive than those in SCLE and DLE lesions, and are mainly those of a cell-poor interface dermatitis (Fig. 61-13A). The lymphohistiocytic

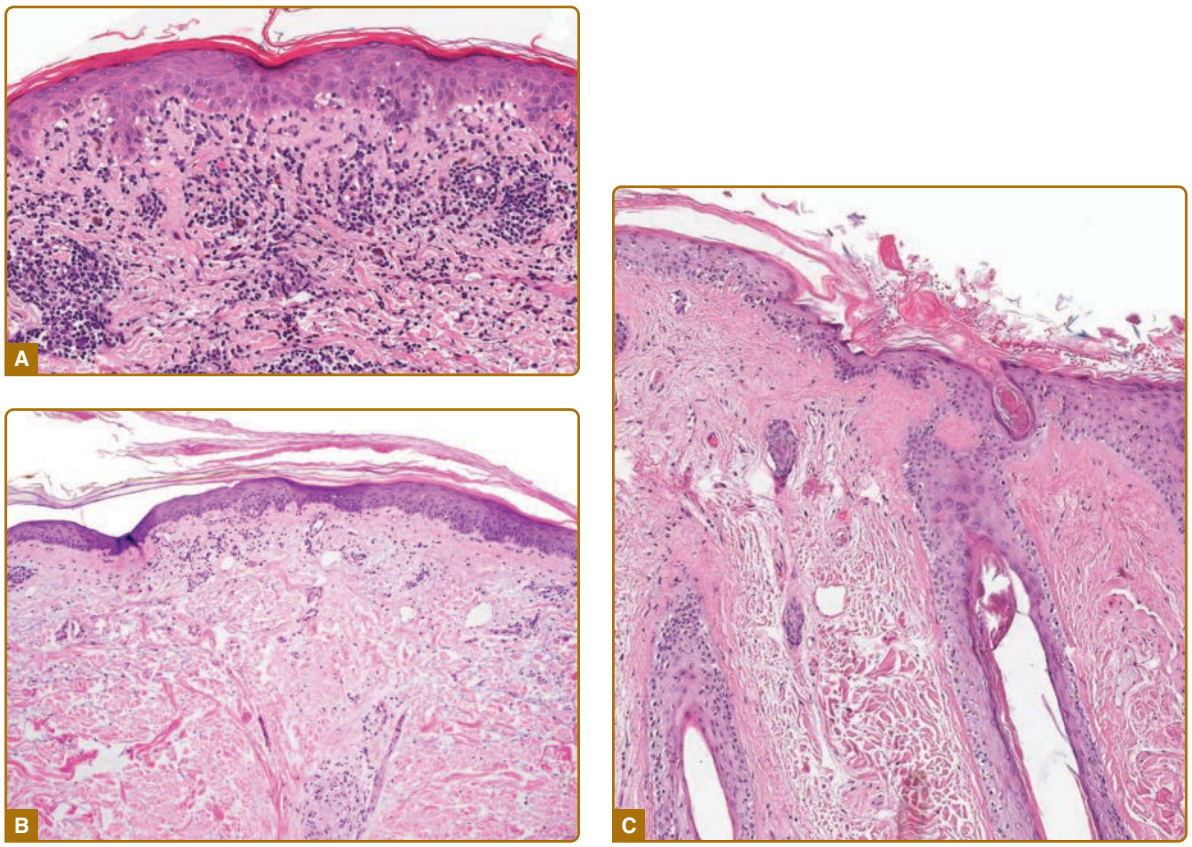

Figure 61-13 Histopathology of lupus erythematosus-specific skin disease. **A,** Acute cutaneous lupus lesion (hematoxylin and eosin [H&E] stain) showing interface dermatitis and vacuolar changes as well as perivascular inflammatory cell infiltrate (×128). **B,** Subacute cutaneous lupus lesion (H&E stain) with mild interface dermatitis, vacuolar changes, and mild hyperkeratosis. Mild epidermal atrophy and prominent mucinosis in upper dermis are also seen (×100). **C,** Discoid lupus lesion showing typical interface changes as well as hyperkeratosis, follicular plugging. Mild dermal fibroplasia is also seen (×84).

cellular infiltrate is relatively sparse. Some authors have noted an increase in the number of neutrophils in the infiltrate, especially when recent-onset lesions are biopsied. A mild degree of focal vacuolar alteration of basal keratinocytes can be seen, in addition to telangiectases and extravasation of erythrocytes. One may see individually necrotic keratinocytes, and in its most severe form, ACLE can display extensive epidermal necrosis similar to TEN. The upper dermis usually shows pronounced mucinosis and may be very helpful in distinguishing ACLE from other causes of a cell-poor interface dermatitis. It is uncommon to see basement membrane zone thickening, follicular plugging, or alteration of epidermal thickness in ACLE, although epidermal atrophy is sometimes present.[45,46]

SUBACUTE CUTANEOUS LUPUS ERYTHEMATOSUS

SCLE also typically presents as an interface dermatitis, with foci of vacuolar alteration of basal keratinocytes alternating with areas of lichenoid dermatitis (see Fig. 61-13B). Pronounced epidermal atrophy is often present. SCLE is in the differential diagnosis of atrophic lichenoid dermatitis, along with atrophic lichen planus and lichenoid drug eruptions. Dermal changes include edema, prominent mucin deposition, and sparse mononuclear cell infiltration usually limited to areas around blood vessels and periadnexal structures in the upper one-third of the dermis. Lesser degrees of hyperkeratosis, follicular plugging, mononuclear cell infiltration of adnexal structures, and dermal melanophages might help distinguish SCLE lesions from DLE lesions. It has not been possible to reliably differentiate papulosquamous from annular SCLE by histopathologic criteria alone.[43]

CHRONIC CUTANEOUS LUPUS ERYTHEMATOSUS

In classic DLE lesions, epidermal changes include hyperkeratosis, variable atrophy, and interface changes similar to those described for SCLE (see Fig. 61-13C). The epidermal basement membrane is markedly thickened. Dermal changes include a dense mononuclear cell infiltrate composed primarily of CD4 T lymphocytes and macrophages predominantly in the periappendageal and perivascular areas, melanophages, and dermal mucin deposition. The infiltrate is often quite dense and typically extends well into the deeper reticular dermis and/or subcutis, which may help to distinguish it from ACLE or SCLE. In chronic scarring DLE lesions, the dense inflammatory cell infiltrate subsides and is replaced by dermal fibroplasia. A folliculotropic variant of DLE, in which the inflammatory infiltrate is predominantly around hair follicles, has been described, as have lymphomatoid variants, in which there are extremely dense infiltrates that may contain atypical lymphoid cells.[45]

IMMUNOHISTOLOGY

Immunohistology is often helpful in confirming a diagnosis of LE-specific skin disease and has been shown to boost the sensitivity and specificity of diagnosis.[45] Because it is not uncommon to see negative immunofluorescence studies in patients with acute, subacute, and chronic LE, and false-positive studies in healthy individuals, immunohistology must be interpreted in the context of clinical and histologic findings in a given patient.

IgG, IgA, IgM, and complement components (C3, C4, Clq, properdin, factor B, and the membrane attack complex C5b-C9) deposited in a continuous granular or linear band-like array at the dermal–epidermal junction have been observed in the lesional and nonlesional skin of patients with LE since the early 1960s (Fig. 61-14). However, debate about terminology in this area continues to cloud the field. Some restrict the use of the term *lupus band test* to refer to the examination of nonlesional skin biopsies for the presence of this band-like array of immunoreactants at the dermal-epidermal junction. Others qualify the lupus band test as being either "lesional" or "nonlesional." Less confusion might exist if the terms *lesional lupus band test* and *nonlesional lupus band test* were uniformly adopted.

ACUTE CUTANEOUS LUPUS ERYTHEMATOSUS

The sparse data that exist suggest that 60% to 100% of ACLE lesions display a lesional lupus band. However, the realization that sun-damaged skin from otherwise healthy individuals can display similar immunopathology has diluted the clinical value of this finding.

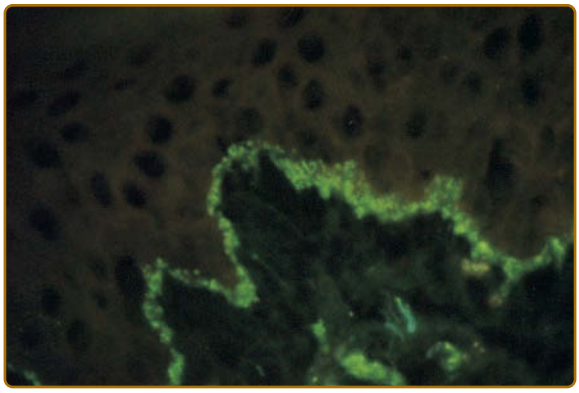

Figure 61-14 Immunopathology of lupus erythematosus–specific skin disease. Direct immunofluorescence examination of a discoid lupus erythematosus lesional skin biopsy showing a continuous band of granular fluorescence at the dermal–epidermal junction as a result of staining with fluorescein isothiocyanate–conjugated goat anti–immunoglobulin G.

SUBACUTE CUTANEOUS LUPUS ERYTHEMATOSUS

Initial studies indicated that approximately 60% of patients with SCLE had lesional lupus bands. A "dust-like particle" pattern of IgG deposition focused around epidermal basal keratinocytes has been suggested to be more specific for SCLE by reflecting the presence of in vivo bound Ro/SS-A autoantibody.

CHRONIC CUTANEOUS LUPUS ERYTHEMATOSUS

Early reports suggested that more than 90% of classic DLE lesions had lesional immunoreactants at the dermal–epidermal junction, often extending along the basement membrane of the hair follicle, but subsequent studies report somewhat lower rates. Lesions on the head, neck, and arms are positive more frequently (80%) than those on the trunk (20%). The lesional lupus band also appears to be a function of the age of the lesion being examined, with older lesions (>3 months) being positive more often than younger ones. Ultrastructural localization of immunoglobulin at the dermal–epidermal junction confirms that these proteins are deposited on the upper dermal collagen fibers and along the lamina densa of the epidermal basement membrane zone.

In LE profundus, immunoglobulin and complement deposits are usually found in blood vessel walls of the deep dermis and subcutis. Immunoglobulin deposits at the dermal–epidermal junction may or may not be present, depending on the site biopsied, the presence or absence of accompanying SLE, and the presence or absence of overlying changes of DLE at the dermal–epidermal junction.

NONLESIONAL LUPUS BAND TEST

There has been much debate over the past 3 decades regarding the diagnostic and prognostic significance of an immunoglobulin/complement band at the dermal–epidermal junction of nonlesional skin taken from patients with LE.[44] When totally sun-protected nonlesional skin (eg, buttocks) is sampled, the diagnostic specificity for SLE appears to be very high when 3 or more immunoreactants are present at the dermal–epidermal junction. Prospectively ascertained followup data also suggest that the presence of a nonlesional lupus band test correlates positively with risk for developing LE nephritis. However, the nonlesional lupus band test has fallen out of favor as a clinical tool largely because the information gained has not been proven to be of significantly greater value than the results of more readily available serologic assays such as antibody to dsDNA.

DIFFERENTIAL DIAGNOSIS

Table 61-5 outlines the differential diagnosis of CLE. In addition, reticulated erythematosus mucinosis has been suggested by some to be a form of photosensitive CLE perhaps related to LE tumidus. Reticulated erythematosus mucinosis presents as a reticulated array of macules and/or papules on the upper chest and back.

CLINICAL COURSE AND PROGNOSIS

ACUTE CUTANEOUS LUPUS ERYTHEMATOSUS

Both localized and generalized forms of ACLE lesions flare and abate in parallel with underlying SLE disease activity. Therefore, the prognosis for any given patient with ACLE is dictated by the pattern of the underlying SLE. Both 5-year (80% to 95%) and 10-year (70% to 90%) survival rates for SLE have progressively improved over the past 4 decades as a result of earlier diagnosis made possible by more sensitive laboratory testing and improved immunosuppressive treatment regimens. Ominous prognostic signs in SLE are hypertension, nephritis, systemic vasculitis, and CNS disease.

SUBACUTE CUTANEOUS LUPUS ERYTHEMATOSUS

Because SCLE has been recognized as a separate disease entity for only 2 decades, the long-term outcome associated with SCLE lesions has yet to be determined. It is the authors' experience that most patients with SCLE have intermittent recurrences of skin disease activity over long periods of time without significant progression of systemic involvement (we are aware of only 1 death directly attributable to SLE in approximately 150 patients with SCLE). Other patients enjoy long-term if not permanent remissions of their skin disease activity. A few patients have experienced unremitting cutaneous disease.

It has also been the authors' experience that approximately 10% of the patients with SCLE develop active SLE, including lupus nephritis. This subgroup of patients is marked by the presence of papulosquamous SCLE, localized ACLE, high-titer ANA, leukopenia, and/or antibodies to dsDNA. Long-term followup studies of SCLE are required to determine the true risk of severe systemic disease progression in patients presenting with SCLE skin lesions. CCLE lesions, typically classic DLE, have also arisen in patients initially presenting with SCLE.

Evidence suggests that overlap occurs between SCLE and Sjögren syndrome. Patients with SCLE who develop Sjögren syndrome are at risk for developing the extraglandular systemic complications associated with Sjögren syndrome, including vasculitis, peripheral neuropathy, autoimmune thyroiditis, renal tubular acidosis, myositis, chronic hepatitis, primary biliary cirrhosis, psychosis, lymphadenopathy, splenomegaly, and B-cell lymphoma.

TABLE 61-5
Differential Diagnosis of Lupus Erythematosus

MOST LIKELY	CONSIDER	ALWAYS RULE OUT
▪ ACLE ▪ Localized ▪ Acne rosacea ▪ Dermatomyositis ▪ Generalized ▪ Drug hypersensitivity reaction ▪ Photoallergic/phototoxic drug reactions ▪ Viral exanthems ▪ SCLE ▪ Papulosquamous ▪ Photosensitive psoriasis ▪ Annular ▪ Erythema annulare centrifugum ▪ Granuloma annulare ▪ CCLE ▪ Early DLE/LET ▪ Polymorphous light eruption ▪ Fully evolved DLE/hypertrophic DLE ▪ Squamous cell carcinoma ▪ Hypertrophic actinic keratosis ▪ Keratoacanthoma ▪ Lupus panniculitis ▪ Morphea profundus	▪ ACLE ▪ Localized ▪ Seborrheic dermatitis ▪ Polymorphous light eruption ▪ Photoallergic contact dermatitis ▪ Generalized ▪ Dermatomyositis ▪ SCLE ▪ Papulosquamous ▪ Photoallergic/photo lichenoid drug reaction ▪ Annular ▪ Erythema gyratum repens ▪ DLE ▪ Early DLE/LET ▪ Granuloma faciale ▪ Sarcoidosis ▪ Jessner benign lymphocytic infiltration of the skin ▪ Pseudolymphoma ▪ Lymphoma cutis ▪ Lupus vulgaris/cutaneous tuberculosis ▪ Urticaria ▪ Urticarial vasculitis ▪ Fully evolved DLE/hypertrophic DLE ▪ Prurigo nodularis ▪ Hypertrophic lichen planus ▪ Lupus panniculitis ▪ Subcutaneous sarcoidosis ▪ Traumatic panniculitis ▪ Eosinophilic fasciitis	▪ ACLE ▪ Generalized ▪ Toxic epidermal necrolysis ▪ CCLE ▪ DLE ▪ Tinea incognito ▪ Cutaneous T-cell lymphoma ▪ Lupus panniculitis ▪ Infectious panniculitis (deep fungal/atypical mycobacterial organisms) ▪ Calciphylaxis

ACLE, acute cutaneous lupus erythematosus; CCLE, chronic cutaneous lupus erythematosus; DLE, discoid lupus erythematosus; LET, lupus erythematosus tumidus; SCLE, subacute cutaneous lupus erythematosus.

CHRONIC CUTANEOUS LUPUS ERYTHEMATOSUS

Most patients with untreated classic DLE lesions suffer indolent progression to large areas of cutaneous dystrophy and scarring alopecia that can be psychosocially devastating and occupationally disabling. However, with treatment, skin disease can be largely controlled. Spontaneous remission occurs occasionally, and the disease activity can recrudesce at the sites of older, inactive lesions. Rebound after discontinuation of treatment is typical, and slower taper of medications during periods of inactivity is recommended. Squamous cell carcinoma occasionally develops in chronic smoldering DLE lesions.

Death from SLE is distinctly uncommon in patients who present initially with localized DLE. As discussed in "Epidemiology" above, patients presenting with localized DLE have only a 5% chance of subsequently developing clinically significant SLE disease activity. Generalized DLE and persistent, low-grade laboratory abnormalities appear to be risk factors for such disease progression. Unrecognized squamous cell carcinoma developing within a longstanding DLE skin lesion could be a cause of morbidity and mortality.

OUTCOME MEASURES

The recent development of a validated instrument to measure activity of CLE, the Cutaneous Lupus Erythematosus Disease Area and Severity Index (CLASI), has made it possible to objectively follow patients' disease course and response to therapy. The instrument has separate scores for damage (scarring) and activity which is important, because one would not expect a "burned-out" scarred area to normalize with drugs that were meant to abate LE activity.[47] It has been validated as a useful tool to measure clinical response.[48]

MANAGEMENT

The initial management of patients with any form of CLE should include an evaluation to rule out underlying SLE disease activity at the time of diagnosis. All patients with CLE should receive instruction about protection

from sunlight and artificial sources of UV radiation, and should be advised to avoid the use of potentially photosensitizing drugs such as hydrochlorothiazide, tetracycline, griseofulvin, and piroxicam. With regard to specific medical therapy, local measures should be maximized and systemic agents used if significant local disease activity persists or systemic activity is superimposed.

ACLE lesions usually respond to the systemic immunosuppressive measures required to treat the underlying SLE disease activity that so frequently accompanies this form of CLE (eg, systemic glucocorticoids, azathioprine, and cyclophosphamide). Increasing evidence suggests that aminoquinoline antimalarial agents such as hydroxychloroquine can have a steroid-sparing effect on SLE, and these drugs can be of value in ACLE. The local measures discussed in "Local Therapy" below can also be of value in treating ACLE. Because the lesions of SCLE and CCLE are often found in patients who have little or no evidence of underlying systemic disease activity, unlike the lesions of ACLE, nonimmunosuppressive treatment modalities are preferred for SCLE and CCLE (Table 61-6). For the most part, SCLE and CCLE lesions respond equally to such agents.

Accurate diagnosis is always the key to optimal medical management. In genetically complex clinical disorders that are variably expressed clinically from one person to another, such as LE, there is a tendency to over ascribe new clinical findings to LE once a diagnosis of LE has been established. To call attention to this important clinical axiom, Robert Greenwald, a rheumatologist, formulated his "Law of Lupus." It states that "SLE is often falsely accused of causing *anything and everything* that might happen to a patient subsequent to the diagnosis of SLE."[49] Failure to recognize this principle in an acute medical setting can result in misdiagnosis and potentially serious mismanagement. Common inflammatory skin lesions, such as psoriasis and eczematous dermatitis, can occur in individuals with LE. These skin lesions are completely independent of LE and its treatment. Likewise, confusion can arise as a result of skin changes that occur as a result of systemic immunosuppressive therapy that might be needed to treat LE patients (eg, herpes zoster,

TABLE 61-6
Therapeutic Options for Lupus Erythematosus–Specific Skin Disease

	DRUG	DOSE
First line	Topical glucocorticoids, topical calcineurin inhibitor	Class I topical steroid daily to twice daily for 2 weeks alternating with pimecrolimus 1% or tacrolimus 0.1% twice daily for 2 weeks
	Intralesional triamcinolone acetonide	2.5-10 mg/cc
Second line	Hydroxychloroquine	6.5 mg/kg/day based on ideal body weight
	Chloroquine	3-3.5 mg/kg/day based on ideal body weight
	Quinacrine	100 mg/day (available at compounding pharmacies
	If monotherapy fails, add quinacrine to either hydroxychloroquine or chloroquine	
Short course only (2-16 weeks)	Prednisone	5-60 mg/day
	Thalidomide	50-200 mg/day; taper to 50 mg every other day on response
Third line (safer immunosuppressives)	Azathioprine	1.5-2.5 mg/kg/day
	Mycophenolate mofetil	1-1.5 g/dose, twice daily
	Methotrexate	7.5-25 mg by mouth or subcutaneously, once weekly
Worth considering	Dapsone	50-200 mg/day
	Accutane	0.5-2 mg/kg/day
	Acitretin	10-50 mg/day
	Gold	Titrate to 50 mg intramuscularly weekly, taper after 1 g
Investigational (some currently available for other indications)	Leflunomide	
	Anti–tumor necrosis factor biologics	
	Rituximab	
	Belimumab	
	Abatacept	
	Janus kinase (JAK) inhibitors (tofacitinib, ruxolitinib)	
	Antiinterferon antibodies	
	CXCR3 receptor inhibitors	

steroid-induced acne, drug eruptions, opportunistic infections).

LOCAL THERAPY

SUN PROTECTION

Advise patients to avoid direct sun exposure, wear tightly woven clothing and broad-brimmed hats, and regularly use broad-spectrum, water-resistant sunscreens (SPF [sun protection factor] ≥30 with an efficient ultraviolet A blocking agent such as a photostabilized form of avobenzone [Parsol 1789], micronized titanium dioxide, micronized zinc oxide, or ecamsule [Mexoryl SX]). UV-blocking films should be applied to home and automobile windows, and acrylic diffusion shields should be placed over fluorescent lighting. Corrective camouflage cosmetics such as Dermablend and Covermark offer the dual benefit of being highly effective physical sunscreens as well as aesthetically pleasing cosmetic masking agents. Ting and Sontheimer provide an in-depth discussion of practical and theoretical photoprotection and local therapy for autoimmune connective tissue skin disease.[50]

As a result of the need for sun avoidance, and perhaps of other factors as well, both CLE and SLE patients are often found to be vitamin D insufficient or deficient.[51,52] There are clear human health benefits to normalizing vitamin D metabolism. Whether correcting vitamin D insufficiency/deficiency has a therapeutic impact on the cutaneous and SLE disease activity is under study.

TOPICAL GLUCOCORTICOIDS

Although some prefer intermediate-strength preparations, such as triamcinolone acetonide 0.1%, for sensitive areas such as the face, superpotent topical class I agents, such as clobetasol propionate 0.05% or betamethasone dipropionate 0.05%, produce the greatest benefit in CLE. Twice-daily application of the superpotent preparations to lesional skin for 2 weeks followed by a 2-week rest period can minimize the risk of local complications such as steroid atrophy and telangiectasia. Alternatively, a topical calcineurin inhibitor can be used daily during the 2-week rest period from topical corticosteroids. Ointments are more effective than creams for more hyperkeratotic lesions such as hypertrophic DLE. Occlusive therapy with glucocorticoid-impregnated tape (eg, flurandrenolide) or glucocorticoids with plastic food wrap (eg, Saran or Glad Press-N-Seal) can potentiate the beneficial effects of topical glucocorticoids but also carries a higher risk of local side effects. Class I or class II topical glucocorticoid solutions and gels are best for treating the scalp. Unfortunately, even the most aggressive regimen of topical glucocorticoids by itself does not provide adequate improvement for most patients with SCLE and CCLE.

TOPICAL CALCINEURIN INHIBITORS

Pimecrolimus 1% cream and tacrolimus 0.1% ointment have demonstrated efficacy in the treatment of ACLE, DLE, and SCLE.[53-55] A double-blind, placebo-controlled pilot study showed that pimecrolimus 1% cream had equal efficacy with betamethasone valerate 0.1% cream in treating facial DLE,[56] and a different study demonstrated the efficacy of topical tacrolimus 0.3% compound in clobetasol propionate 0.05% for recalcitrant CLE.[57]

It remains to be demonstrated whether topical delivery of newer classes of targeted nonsteroidal antiinflammatory agents that are being developed for other clinical indications might be of benefit for CLE (eg, topical apremilast, topical tofacitinib).

INTRALESIONAL GLUCOCORTICOIDS

Intralesional glucocorticoids (eg, triamcinolone acetonide suspension, 2.5 to 5 mg/mL for the face with higher concentrations allowable in less-sensitive sites) are more useful in the management of DLE than SCLE. Intralesional glucocorticoids themselves can produce cutaneous and subcutaneous atrophy (deep injections into the subcutaneous tissue enhances this risk). A 30-gauge needle is preferred because it produces only mild discomfort on penetration, especially when injected perpendicularly to the skin. The active borders of lesions should be thoroughly infiltrated. Intralesional therapy is indicated for particularly hyperkeratotic lesions or lesions that are unresponsive to topical glucocorticoids, but most patients with CLE have too many lesions to be managed exclusively by intralesional glucocorticoid injections.

SYSTEMIC THERAPY

ANTIMALARIALS

One or a combination of the aminoquinoline antimalarials can be effective for approximately 75% of patients with CLE who have failed to benefit adequately from the local measures described in "Local Therapy" above. The risks of retinal toxicity should be discussed with the patient, and a pretreatment ophthalmologic examination should be performed. However, the risk of antimalarial retinopathy is extremely rare, particularly in the first 10 years of therapy, if the recommended daily dose maximum levels of these agents are not exceeded (hydroxychloroquine, 6.5 mg/kg/day based on ideal body weight; chloroquine, 3 to 4 mg/kg/day). Patients should have followup ophthalmologic evaluations every 6 to 12 months while on therapy.

Hydroxychloroquine sulfate (Plaquenil), 6 to 6.5 mg/kg of lean body mass, should be given daily, either once daily or in 2 divided doses to prevent GI side effects. Approximately 6 weeks are required to reach equilibrium blood levels of hydroxychloroquine. Patients should be informed about a 2- to 3-month delayed onset of therapeutic benefit. If no response is seen after 8 to 12 weeks, quinacrine hydrochloride, 100 mg/day (currently available in the United States only through compounding pharmacies), can be added

to the hydroxychloroquine without enhancing the risk of retinopathy (quinacrine does not cause retinopathy). If, after 4 to 6 weeks of this combined regimen adequate clinical control has not been achieved, consideration should be given to replacing the hydroxychloroquine in this combined regimen with chloroquine diphosphate (Aralen), 3 to 4 mg/kg/day. Doses may need to be adjusted for patients with decreased renal or hepatic function. In Europe, chloroquine is generally felt to be more efficacious than hydroxychloroquine in treating CLE, perhaps because of the earlier therapeutic responses that might occur as a result of the shorter time period required to reach steady-state blood levels with chloroquine as compared to hydroxychloroquine. Hydroxychloroquine and chloroquine should not be used simultaneously because of enhanced risk for retinal toxicity. There is some evidence that chloroquine may be more retinotoxic than hydroxychloroquine.

It is now possible to assay serum levels of hydroxychloroquine. However, this assay has not yet been made available widely by commercial testing laboratories in the United States. Recent studies examining this end point have found that up to 10% of CLE and SLE patients are not compliant in taking their hydroxychloroquine therapy as prescribed.[58,59] In addition, these and other studies have suggested that hydroxychloroquine serum levels and disease activity measures are inversely correlated in both cutaneous and SLE patients undergoing hydroxychloroquine therapy.[60]

It is now generally agreed that the modern hydroxychloroquine regimen can be used safely in children (with the appropriate dose adjustment based on lean body mass) and in women who are pregnant. However, the therapeutic index in children is quite narrow. Therefore, extra caution should be taken to prevent accidental overdosing of children.

Multiple side effects other than retinal toxicity are associated with the use of antimalarials. Quinacrine is associated with a higher incidence of side effects, such as headache, GI intolerance, hematologic toxicity, pruritus, lichenoid drug eruptions, and mucosal or cutaneous pigmentary deposition, than is either hydroxychloroquine or chloroquine. However, at the currently recommended dose of no more than 100 mg/day, such adverse effects are extremely rare. Quinacrine commonly produces a yellow discoloration of the entire skin and sclera in fair-skinned individuals, which is completely reversible when the dose of the drug is reduced or discontinued altogether. Quinacrine can produce significant hemolysis in patients with glucose-6-phosphate dehydrogenase (G6PD) deficiency (this adverse effect has also been reported to occur rarely with hydroxychloroquine and chloroquine). Each of the aminoquinoline antimalarials can produce bone marrow suppression, including aplastic anemia, although this effect is exceedingly rare with the current dosage regimens. Toxic psychosis, grand mal seizures, neuromyopathy, and cardiac arrhythmias occurred with the use of high doses of these drugs in the past; these reactions are uncommon with the lower daily dose regimens used today.

Before therapy with hydroxychloroquine and chloroquine is begun, complete blood cell counts, as well as liver and renal function tests, should be performed; these tests should be repeated 4 to 6 weeks after therapy is initiated, and every 4 to 6 months thereafter. A screen for hematologic toxicity when quinacrine is used is recommended more often. Patients with overt or subclinical porphyria cutanea tarda are at particularly high risk for developing acute hepatotoxicity, which often simulates an acute surgical abdomen, when treated with therapeutic doses of antimalarials for CLE.

NONIMMUNOSUPPRESSIVE OPTIONS FOR ANTIMALARIAL–REFRACTORY DISEASE

Some patients with refractory CLE (SCLE more than DLE) respond to diaminodiphenylsulfone (dapsone).[61] An initial dose of 25 mg by mouth twice daily can be increased up to 200 to 400 mg/day, if necessary. Significant dose-related hemolysis and/or methemoglobinemia can result from the use of dapsone, especially in individuals deficient in G6PD activity. Consequently, complete blood counts and liver function tests should be performed regularly, and testing for G6PD status should be considered prior to starting treatment, especially in high-risk populations. Isotretinoin, 0.5 to 2.0 mg/kg/day, and acitretin, 10 to 50 mg/day, also have been used in this setting, but their efficacy is limited by their side effects (teratogenicity, mucocutaneous dryness, and hyperlipidemia). In addition, breakthrough of CLE activity has been a problem with the long-term use of retinoids.

Thalidomide (50 to 200 mg/day) is strikingly effective for CLE that is refractory to other medications. Numerous studies cite response rates between 85% and 100%, with many patients experiencing complete remission.[62] However, strict prescribing regulations put in place in the United States in 1998 because of severe teratogenicity, make thalidomide challenging to dispense to women of childbearing potential. Sensory neuropathy is another toxicity associated with thalidomide, and 25% to 75% of patients with CLE develop peripheral neuropathy while taking the drug. Most cases are reversible when therapy is stopped. Neuropathy seems to correlate with total treatment times so that short courses are preferred. Relapses after the drug is stopped are common. Excess somnolence as well as constipation and other minor side effects sometimes limit its use, although these effects usually abate with lower daily doses.[63] Thromboembolism is a serious adverse event that may occur in patients with a preexisting hypercoagulable state (eg, presence of antiphospholipid antibodies). Oncologists who use thalidomide for multiple myeloma frequently initiate concomitant anticoagulation therapy to prevent this side effect. Lenalidomide (Revlimid, Celgene), a thalidomide analog, is U.S. Food and Drug Administration (FDA) approved for the treatment of multiple

myeloma. In preliminary studies, its efficacy rate in CLE appears to be similar to that of thalidomide. Safety data to date indicates a much lower rate of peripheral neuropathy compared to thalidomide; however, it has a similar rate of thromboembolism (especially when combined with glucocorticoids) and leukopenia compared to thalidomide. Its potential teratogenicity in humans has yet to be determined.

Other drugs reported to be of value in the treatment of refractory CLE are gold and clofazimine; however, the benefit varies from case to case and both of these agents are associated with the risk of significant side effects. Vitamin E, phenytoin, sulfasalazine, danazol, DHEA, and phototherapy (UVA1 phototherapy, photopheresis) also have been reported clinical trials to be of potential value in CLE.

IMMUNOSUPPRESSIVE OPTIONS FOR ANTIMALARIAL–REFRACTORY DISEASE

Systemic Glucocorticoids: Every effort should be made to avoid the use of systemic glucocorticoids in patients with LE limited to the skin. However, in occasional patients who have especially severe and symptomatic skin disease, intravenous pulse methylprednisolone has been used. In less-acute cases, moderate daily doses of oral glucocorticoids (prednisone, 20 to 40 mg/day, given as a single morning dose) can be used as supplemental therapy during the loading phase of therapy with an antimalarial agent. The dose should be reduced at the earliest possible time because of the complications of long-term glucocorticoid therapy, especially avascular (aseptic) bone necrosis, a side effect to which patients with LE are particularly susceptible.

Because steroid-induced bone loss occurs most rapidly in the first 6 months of use, all patients who do not have contraindications should begin agents to prevent osteoporosis with the initiation of steroid therapy. An excellent review describing current recommendations for prevention of bone loss and other side effects of systemic glucocorticoids has been published.[64] When the disease activity is controlled, the daily dosage should be reduced by 5- to 10-mg decrements until activity flares again or until a daily dosage of 20 mg/day is achieved. The daily dose should then be lowered by 2.5-mg decrements (some physicians prefer to use 1-mg dose decrements below 10 mg/day). Alternate-day glucocorticoid therapy has not been successful in suppressing disease activity in most patients with CLE or SLE. Prednisolone rather than prednisone should be used in patients who have significant underlying liver disease, because prednisone requires hydroxylation in the liver to become biologically active. Any amount of prednisone given as a single oral dose in the morning has less adrenal-suppressing activity than the same amount given in divided doses throughout the day. However, any given amount of this drug, taken in divided doses, has a greater LE-suppressing activity than does the same amount of drug given as a single morning dose. Daily doses of prednisone less than or equal to 7.5 mg/day eliminate glucocorticoid-induced damage accrual in SLE patients.[65]

Traditional Immunosuppressives: Azathioprine (Imuran) (1.5 to 2 mg/kg per day orally) can play a glucocorticoid-sparing role in the severely affected patient with CLE. Mycophenolate mofetil (CellCept) (2.5 to 3 g divided twice daily orally) is a purine analog similar to azathioprine, but with more specific inhibition of the de novo pathway in lymphocytes. This characteristic may allow for more efficacy and less toxicity in treating severe, recalcitrant CLE, and such results have been reported in several studies.[66,67] Methotrexate (7.5 to 25 mg orally 1 day per week) is effective for severe refractory CLE. A double-blind, randomized, placebo-controlled trial in patients with SLE showed that moderate doses of methotrexate (15 to 20 mg weekly) effectively controlled cutaneous and articular activity and permitted a reduction in prednisone dose.[68] Other immunosuppressives that have been used anecdotally include cytosine arabinoside (Cytarabine) and cyclosporine. Immunotherapy with high-dose IV gammaglobulin has also been used.

Biologic Therapies: There have been reports documenting efficacy of anti-TNF medications (etanercept, adalimumab, infliximab) in the treatment of recalcitrant CLE, particularly SCLE.[69-71] However, these agents are also well-known to induce both SLE and CLE, highlighting the importance of TNF homeostasis in patients predisposed to LE.[72,73]

B-lymphocyte stimulator (BLyS [synonym: B-cell activating factor (BAFF)]), is a recently discovered member of the TNF cytokine family. BLyS is made by monocytes and macrophages with subsequent release when these cells are activated. BLyS binds to a receptor found only on B cells which stimulates maturation into antibody-secreting plasma cells. A fully human monoclonal antibody directed against BLyS (belimumab [Benlysta]) inhibits the biologic activity of BLyS. Belimumab is now FDA approved for SLE. In the clinical trials of belimumab in SLE, the cutaneous end points in SLE patients were met in addition to the systemic end points. However, little has been reported to date concerning the clinical efficacy of belimumab in isolated CLE.

As previously discussed abnormal regulation of interferon-α appears to play a central role in the pathogenesis of both cutaneous and systemic manifestations of LE by upregulating proinflammatory cytokines and chemokines. Three biologics that target type 1 IFN are currently being tested for their efficacy and safety in active SLE patients (2 anti–interferon-α monoclonal antibodies [rontalizumab and sifalimumab] and one monoclonal antibody that binds to a type 1 IFN receptor [anifrolumab]).[74] Recombinant humanized antibodies to type 1 IFN and to the interferon receptor are under development. If these new biologics prove to be of benefit in SLE disease activity, one could extrapolate that they might be helpful in CLE disease activity.

Class I interferon actions are transduced through the Janus kinase (JAK)-signal transducer and activator of transcription (STAT) intracellular signaling pathway. Disrupting this intracellular signaling pathway might provide another approach to downregulating SLE and CLE disease activity and damage. Two orally administered JAK isoenzyme inhibitors have been approved by the FDA for other clinical disorders: tofacitinib (JAK 1/3) for rheumatoid arthritis and ruxolitinib (JAK 1/2) for myelodysplastic disorders. There are case reports in which these 2 drugs appeared to have clinical benefit in both CLE and cutaneous dermatomyositis.[75,76] More specific JAK1 isoenzyme inhibitors are currently under development (eg, filgotinib) which promise to lessen the side effects of this new class of targeted, small-molecule therapy.

SURGICAL AND COSMETIC THERAPY

DLE lesions can produce permanent scarring alopecia, cosmetically disturbing dermal atrophy, and long-lasting pigmentary changes. Patients so affected often ask about the possibility of cosmetic correction of these changes. Surgical interventions such as hair transplantation and dermabrasion carry finite risks because CLE is characterized by a tendency for nonspecific mechanical trauma, including surgical incision or laser ablation, to exacerbate disease activity (ie, Koebner phenomenon/isomorphic phenomenon). Some patients tolerate scar revision techniques, including dermabrasion, if they are on maintenance systemic therapy (eg, antimalarials). There are anecdotal reports of the successful management of active CLE with argon and pulsed-dye laser therapy.[77] Resurfacing of atrophic scars with the Erbium:YAG or Fraxel carbon dioxide resurfacing laser is reported to be beneficial.[78,79] Autologous fat transplantation can be of clinical value in patients with atrophic scarring from burned out lupus panniculitis/profundus. The injection of atrophic lesions with collagen or other similar foreign cosmetic materials should be avoided.

TREATMENT ALGORITHM

Treatment of CLE with the aforementioned agents is typically done in a stepwise manner to minimize the risk of side effects and is outlined in Table 61-6.

PREVENTION

Predicting and preventing the initial clinical manifestation of LE, whether it is skin disease or systemic, is not feasible at this time. However, as many LE patients exhibit worsening of their skin disease activity with UV light exposure, physical protection from sunlight and artificial sources of UV light as well as the regular use of broad-spectrum sunscreens having a SPF of 30 or greater should be encouraged.

CLE patients should be encouraged to discontinue cigarette smoking. CLE patients who smoke cigarettes are not as responsive to antimalarial therapy compared to those who do not smoke. CLE patients who smoke and are not responding to antimalarial therapy have been observed to experience complete remission in their CLE activity after they discontinue smoking with no other change in their therapy. Cigarette smoking does not alter antimalarial metabolism. It has been suggested that cigarette smoking, irrespective of antimalarial therapy, is strongly associated with CLE and somewhat less so with SLE.[80,81]

REFERENCES

1. Gilliam JN, Sontheimer RD. Distinctive cutaneous subsets in the spectrum of lupus erythematosus. *J Am Acad Dermatol*. 1981;4(4):471-475.
2. Tan EM, Cohen AS, Fries JF, et al. The 1982 revised criteria for the classification of systemic lupus erythematosus. *Arthritis Rheum*. 1982;25(11):1271-1277.
3. Watanabe T, Tsuchida T. Classification of lupus erythematosus based upon cutaneous manifestations. Dermatological, systemic and laboratory findings in 191 patients. *Dermatology*. 1995;190(4):277-283.
4. Tebbe B, Orfanos CE. Epidemiology and socioeconomic impact of skin disease in lupus erythematosus. *Lupus*. 1997;6(2):96-104.
5. Robinson D Jr, Aguilar D, Schoenwetter M, et al. Impact of systemic lupus erythematosus on health, family, and work: the patient perspective. *Arthritis Care Res (Hoboken)*. 2010;62(2):266-273.
6. Ferraz LB, Almeida FA, Vasconcellos MR, et al. The impact of lupus erythematosus cutaneous on the quality of life: the Brazilian-Portuguese version of DLQI. *Qual Life Res*. 2006;15(3):565-570.
7. Durosaro O, Davis MD, Reed KB, et al. Incidence of cutaneous lupus erythematosus, 1965-2005: a population-based study. *Arch Dermatol*. 2009;145(3):249-253.
8. Lin JH, Dutz JP, Sontheimer RD, et al. Pathophysiology of cutaneous lupus erythematosus. *Clin Rev Allergy Immunol*. 2007;33(1-2):85-106.
9. Braunstein I, Klein R, Okawa J, Werth VP. The interferon-regulated gene signature is elevated in subacute cutaneous lupus erythematosus and discoid lupus erythematosus and correlates with the cutaneous lupus area and severity index score. *Br J Dermatol*. 2012;166(5):971-975.
10. Bennett L, Palucka AK, Arce E, et al. Interferon and granulopoiesis signatures in systemic lupus erythematosus blood. *J Exp Med*. 2003;197(6):711-723.
11. Farkas L, Beiske K, Lund-Johansen F, et al. Plasmacytoid dendritic cells (natural interferon-alpha/beta-producing cells) accumulate in cutaneous lupus erythematosus lesions. *Am J Pathol*. 2001;159(1):237-243.
12. Jego G, Palucka AK, Blanck JP, et al. Plasmacytoid dendritic cells induce plasma cell differentiation through type I interferon and interleukin 6. *Immunity*. 2003;19(2):225-234.

13. Kiefer K, Oropallo MA, Cancro MP, et al. Role of type I interferons in the activation of autoreactive B cells. *Immunol Cell Biol*. 2012;90(5):498-504.
14. Crow YJ, Chase DS, Lowenstein Schmidt J, et al. Characterization of human disease phenotypes associated with mutations in TREX1, RNASEH2A, RNASEH2B, RNASEH2C, SAMHD1, ADAR, and IFIH1. *Am J Med Genet A*. 2015;167A(2):296-312.
15. Namjou B, Kothari PH, Kelly JA, et al. Evaluation of the TREX1 gene in a large multi-ancestral lupus cohort. *Genes Immun*. 2011;12(4):270-279.
16. Casciola-Rosen L, Rosen A. Ultraviolet light-induced keratinocyte apoptosis: a potential mechanism for the induction of skin lesions and autoantibody production in LE. *Lupus*. 1997;6(2):175-180.
17. Meller S, Winterberg F, Gilliet M, et al. Ultraviolet radiation-induced injury, chemokines, and leukocyte recruitment: an amplification cycle triggering cutaneous lupus erythematosus. *Arthritis Rheum*. 2005;52(5):1504-1516.
18. Lehmann P, Homey B. Clinic and pathophysiology of photosensitivity in lupus erythematosus. *Autoimmun Rev*. 2009;8(6):456-461.
19. Moghadam-Kia S, Chilek K, Gaines E, et al. Cross-sectional analysis of a collaborative Web-based database for lupus erythematosus-associated skin lesions: prospective enrollment of 114 patients. *Arch Dermatol*. 2009;145(3):255-260.
20. Rahman P, Gladman DD, Urowitz MB. Smoking interferes with efficacy of antimalarial therapy in cutaneous lupus. *J Rheumatol*. 1998;25(9):1716-1719.
21. Hardy CJ, Palmer BP, Muir KR, et al. Smoking history, alcohol consumption, and systemic lupus erythematosus: a case-control study. *Ann Rheum Dis*. 1998;57(8):451-455.
22. Jewell ML, McCauliffe DP. Patients with cutaneous lupus erythematosus who smoke are less responsive to antimalarial treatment. *J Am Acad Dermatol*. 2000;42(6):983-987.
23. Kang I, Park SH. Infectious complications in SLE after immunosuppressive therapies. *Curr Opin Rheumatol*. 2003;15(5):528-534.
24. Yung RL, Quddus J, Chrisp CE, et al. Mechanism of drug-induced lupus. I. Cloned Th2 cells modified with DNA methylation inhibitors in vitro cause autoimmunity in vivo. *J Immunol*. 1995;154(6):3025-3035.
25. Sontheimer RD, Thomas JR, Gilliam JN. Subacute cutaneous lupus erythematosus: a cutaneous marker for a distinct lupus erythematosus subset. *Arch Dermatol*. 1979;115(12):1409-1415.
26. Chaudhry SI, Murphy LA, White IR. Subacute cutaneous lupus erythematosus: a paraneoplastic dermatosis? *Clin Exp Dermatol*. 2005;30(6):655-658.
27. Jou IM, Liu MF, Chao SC. Widespread cutaneous necrosis associated with antiphospholipid syndrome. *Clin Rheumatol*. 1996;15(4):394-398.
28. Franceschini F, Calzavara-Pinton P, Quinzanini M, et al. Chilblain lupus erythematosus is associated with antibodies to SSA/Ro. *Lupus*. 1999;8(3):215-219.
29. Hedrich CM, Fiebig B, Hauck FH, et al. Chilblain lupus erythematosus—a review of literature. *Clin Rheumatol*. 2008;27(8):949-954.
30. Viguier M, Pinquier L, Cavelier-Balloy B, et al. Clinical and histopathologic features and immunologic variables in patients with severe chilblains. A study of the relationship to lupus erythematosus. *Medicine (Baltimore)*. 2001;80(3):180-188.
31. Lee-Kirsch MA, Chowdhury D, Harvey S, et al. A mutation in TREX1 that impairs susceptibility to granzyme A-mediated cell death underlies familial chilblain lupus. *J Mol Med (Berl)*. 2007;85(5):531-537.
32. Callen JP. Clinically relevant information about cutaneous lupus erythematosus. *Arch Dermatol*. 2009;145(3):316-319.
33. Maize JC Jr, Costner M. Tumid lupus erythematosus: a form of lupus erythematosus. *Arch Dermatol*. 2010;146(4):451; author reply 450-451.
34. Ruiz H, Sanchez JL. Tumid lupus erythematosus. *Am J Dermatopathol*. 1999;21(4):356-360.
35. Kuhn A, Sonntag M, Richter-Hintz D, et al. Phototesting in lupus erythematosus: a 15-year experience. *J Am Acad Dermatol*. 2001;45(1):86-95.
36. Dekle CL, Mannes KD, Davis LS, et al. Lupus tumidus. *J Am Acad Dermatol*. 1999;41(2, pt 1):250-253.
37. Vieira V, Del Pozo J, Yebra-Pimentel MT, et al. Lupus erythematosus tumidus: a series of 26 cases. *Int J Dermatol*. 2006;45(5):512-517.
38. Stead J, Headley C, Ioffreda M, et al. Coexistence of tumid lupus erythematosus with systemic lupus erythematosus and discoid lupus erythematosus: a report of two cases of tumid lupus. *J Clin Rheumatol*. 2008;14(6):338-341.
39. Tomasini D, Mentzel T, Hantschke M, et al. Plasmacytoid dendritic cells: an overview of their presence and distribution in different inflammatory skin diseases, with special emphasis on Jessner's lymphocytic infiltrate of the skin and cutaneous lupus erythematosus. *J Cutan Pathol*. 2010;37(11):1132-1139.
40. Obermoser G, Schwingshackl P, Weber F, et al. Recruitment of plasmacytoid dendritic cells in ultraviolet irradiation-induced lupus erythematosus tumidus. *Br J Dermatol*. 2009;160(1):197-200.
41. Obermoser G, Sontheimer RD, Zelger B. Overview of common, rare and atypical manifestations of cutaneous lupus erythematosus and histopathological correlates. *Lupus*. 2010;19(9):1050-1070.
42. Zecevic RD, Vojvodic D, Ristic B, et al. Skin lesions—an indicator of disease activity in systemic lupus erythematosus? *Lupus*. 2001;10(5):364-367.
43. Lee LA, Weston WL. Cutaneous lupus erythematosus during the neonatal and childhood periods. *Lupus*. 1997;6(2):132-138.
44. David-Bajar KM, Davis BM. Pathology, immunopathology, and immunohistochemistry in cutaneous lupus erythematosus. *Lupus*. 1997;6(2):145-157.
45. Crowson AN, Magro C. The cutaneous pathology of lupus erythematosus: a review. *J Cutan Pathol*. 2001;28(1):1-23.
46. Baltaci M, Fritsch P. Histologic features of cutaneous lupus erythematosus. *Autoimmun Rev*. 2009;8(6):467-473.
47. Albrecht J, Taylor L, Berlin JA, et al. The CLASI (Cutaneous Lupus Erythematosus Disease Area and Severity Index): an outcome instrument for cutaneous lupus erythematosus. *J Invest Dermatol*. 2005;125(5):889-894.
48. Bonilla-Martinez ZL, Albrecht J, Troxel AB, et al. The cutaneous lupus erythematosus disease area and severity index: a responsive instrument to measure activity and damage in patients with cutaneous lupus erythematosus. *Arch Dermatol*. 2008;144(2):173-180.
49. Greenwald RA. Greenwald's law of lupus. *J Rheumatol*. 1992;19(9):1490.
50. Ting WW, Sontheimer RD. Local therapy for cutaneous and systemic lupus erythematosus: practical and theoretical considerations. *Lupus*. 2001;10(3):171-184.

51. Cusack C, Danby C, Fallon JC, et al. Photoprotective behaviour and sunscreen use: impact on vitamin D levels in cutaneous lupus erythematosus. *Photodermatol Photoimmunol Photomed*. 2008;24(5):260-267.
52. Watad A, Neumann SG, Soriano A, et al. Vitamin D and systemic lupus erythematosus: myth or reality? *Isr Med Assoc J*. 2016;18(3-4):177-182.
53. Kreuter A, Gambichler T, Breuckmann F, et al. Pimecrolimus 1% cream for cutaneous lupus erythematosus. *J Am Acad Dermatol*. 2004;51(3):407-410.
54. Lampropoulos CE, Sangle S, Harrison P, et al. Topical tacrolimus therapy of resistant cutaneous lesions in lupus erythematosus: a possible alternative. *Rheumatology (Oxford)*. 2004;43(11):1383-1385.
55. von Pelchrzim R, Schmook T, Friedrich M, et al. Efficacy of topical tacrolimus in the treatment of various cutaneous manifestations of lupus erythematosus. *Int J Dermatol*. 2006;45(1):84-85.
56. Barikbin B, Givrad S, Yousefi M, et al. Pimecrolimus 1% cream versus betamethasone 17-valerate 0.1% cream in the treatment of facial discoid lupus erythematosus: a double-blind, randomized pilot study. *Clin Exp Dermatol*. 2009;34(7):776-780.
57. Madan V, August PJ, Chalmers RJ. Efficacy of topical tacrolimus 0.3% in clobetasol propionate 0.05% ointment in therapy-resistant cutaneous lupus erythematosus: a cohort study. *Clin Exp Dermatol*. 2010;35(1):27-30.
58. Frances C, Cosnes A, Duhaut P, et al. Low blood concentration of hydroxychloroquine in patients with refractory cutaneous lupus erythematosus: a French multicenter prospective study. *Arch Dermatol*. 2012;148(4):479-484.
59. Mok CC, Penn HJ, Chan KL, et al. Hydroxychloroquine serum concentrations and flares of systemic lupus erythematosus: a longitudinal cohort analysis. *Arthritis Care Res (Hoboken)*. 2016;68(9):1295-1302.
60. Durcan L, Clarke WA, Magder LS, et al. hydroxychloroquine blood levels in systemic lupus erythematosus: clarifying dosing controversies and improving adherence. *J Rheumatol*. 2015;42(11):2092-2097.
61. Neri R, Mosca M, Bernacchi E, et al. A case of SLE with acute, subacute and chronic cutaneous lesions successfully treated with dapsone. *Lupus*. 1999;8(3):240-243.
62. Briani C, Zara G, Rondinone R, et al. Positive and negative effects of thalidomide on refractory cutaneous lupus erythematosus. *Autoimmunity*. 2005;38(7):549-555.
63. Wu JJ, Huang DB, Pang KR, et al. Thalidomide: dermatological indications, mechanisms of action and side-effects. *Br J Dermatol*. 2005;153(2):254-273.
64. Dooley MA, Ginzler EM. Newer therapeutic approaches for systemic lupus erythematosus: immunosuppressive agents. *Rheum Dis Clin North Am*. 2006;32(1): 91-102, ix.
65. Ruiz-Arruza I, Ugarte A, Cabezas-Rodriguez I, et al. Glucocorticoids and irreversible damage in patients with systemic lupus erythematosus. *Rheumatology (Oxford)*. 2014;53(8):1470-1476.
66. Hanjani NM, Nousari CH. Mycophenolate mofetil for the treatment of cutaneous lupus erythematosus with smoldering systemic involvement. *Arch Dermatol*. 2002;138(12):1616-1618.
67. Kreuter A, Tomi NS, Weiner SM, et al. Mycophenolate sodium for subacute cutaneous lupus erythematosus resistant to standard therapy. *Br J Dermatol*. 2007;156(6):1321-1327.
68. Carneiro JR, Sato EI. Double blind, randomized, placebo controlled clinical trial of methotrexate in systemic lupus erythematosus. *J Rheumatol*. 1999;26(6):1275-1279.
69. Norman R, Greenberg RG, Jackson JM. Case reports of etanercept in inflammatory dermatoses. *J Am Acad Dermatol*. 2006;54(3)(suppl 2):S139-S142.
70. Fautrel B, Foltz V, Frances C, et al. Regression of subacute cutaneous lupus erythematosus in a patient with rheumatoid arthritis treated with a biologic tumor necrosis factor alpha-blocking agent: comment on the article by Pisetsky and the letter from Aringer et al. *Arthritis Rheum*. 2002;46(5):1408-1409; author reply 1409.
71. Aringer M, Graninger WB, Steiner G, et al. Safety and efficacy of tumor necrosis factor alpha blockade in systemic lupus erythematosus: an open-label study. *Arthritis Rheum*. 2004;50(10):3161-3169.
72. Ramos-Casals M, Brito-Zeron P, Munoz S, et al. Autoimmune diseases induced by TNF-targeted therapies: analysis of 233 cases. *Medicine (Baltimore)*. 2007;86(4):242-251.
73. Wetter DA, Davis MD. Lupus-like syndrome attributable to anti-tumor necrosis factor alpha therapy in 14 patients during an 8-year period at Mayo Clinic. *Mayo Clin Proc*. 2009;84(11):979-984.
74. Kalunian KC. Interferon-targeted therapy in systemic lupus erythematosus: Is this an alternative to targeting B and T cells? *Lupus*. 2016;25(10):1097-1101.
75. Wenzel J, van Holt N, Maier J, et al. JAK1/2 inhibitor ruxolitinib controls a case of chilblain lupus erythematosus. *J Invest Dermatol*. 2016;136(6):1281-1283.
76. Kurtzman DJ, Wright NA, Lin J, et al. Tofacitinib citrate for refractory cutaneous dermatomyositis: an alternative treatment. *JAMA Dermatol*. 2016;152(8):944-945.
77. Erceg A, Bovenschen HJ, van de Kerkhof PC, et al. Efficacy and safety of pulsed dye laser treatment for cutaneous discoid lupus erythematosus. *J Am Acad Dermatol*. 2009;60(4):626-632.
78. Tremblay JF, Carey W. Atrophic facial scars secondary to discoid lupus erythematous: treatment using the erbium:YAG laser. *Dermatol Surg*. 2001;27(7):675-677.
79. Walker SL, Harland CC. Carbon dioxide laser resurfacing of facial scarring secondary to chronic discoid lupus erythematosus. *Br J Dermatol*. 2000;143(5):1101-1102.
80. Chasset F, Frances C, Barete S, et al. Influence of smoking on the efficacy of antimalarials in cutaneous lupus: a meta-analysis of the literature. *J Am Acad Dermatol*. 2015;72(4):634-639.
81. Jiang F, Li S, Jia C. Smoking and the risk of systemic lupus erythematosus: an updated systematic review and cumulative meta-analysis. *Clin Rheumatol*. 2015;34(11):1885-1892.

Chapter 62 :: Dermatomyositis

:: Matthew Lewis & David Fiorentino

AT-A-GLANCE

- Dermatomyositis (DM) is a systemic autoimmune disease with a bimodal distribution affecting children and adults, characterized by inflammation and damage to the skin and muscle.
- Interstitial lung disease (ILD) affects 20% of patients and is a major source of morbidity and mortality in these patients.
- In adults, DM heralds the diagnosis of a coexisting internal malignancy in 10% to 20% of cases. A thorough review of systems and malignancy workup, including computed tomography scans of the chest, abdomen, and pelvis, may be prudent to detect occult cancers that are missed on routine age-appropriate screening.
- The diagnosis is established with a combination of the hallmark cutaneous findings and supportive skin histopathology, with or without evidence of a proximal myopathy. The diagnosis may be challenging because 20% of patients never manifest clinically significant muscle weakness.
- The cutaneous manifestations are typified by violaceous erythema in many sites, most notably the eyelids, upper chest, back, elbows, knees, and lateral hips in addition to proximal nailfold capillary dilation and pericapillary hemorrhage.
- Characteristic autoantibodies (antisynthetase, anti–Mi-2, anti–transcriptional intermediary factor [TIF1]-γ, anti–melanoma differentiation–associated gene 5 [*MDA5*], anti–nuclear matrix protein 2 [NXP2], and anti–small ubiquitin-like modifier activating enzyme [SAE] autoantibodies) may be useful in identifying clinical subsets and establishing the diagnosis in cases without the classic clinical or histopathologic features.
- The presence or absence of certain autoantibodies assists with risk stratification for organ involvement as well as for associated malignancy. Notably, the presence of anti-MDA5 and antisynthetase autoantibodies is associated with an increased risk of ILD, and the presence of anti–TIF1-γ and anti-NXP2 autoantibodies is associated with an increased risk of having an associated cancer.
- Treatment of cutaneous DM can be challenging, and most patients with significant skin disease require systemic therapy. Multiple agents may be necessary to achieve complete remission; the risks and benefits each agent should be considered carefully given the potentially prolonged treatment course.

INTRODUCTION

DEFINITIONS

Dermatomyositis (DM) continues to be classified as a form of myositis and, in fact, is traditionally considered one of the idiopathic inflammatory myopathies. Implicit in this classification is that myositis is required to make this diagnosis, as well as the characteristic rash—the often used criteria of Bohan and Peter exemplify this.[1,2] This is problematic because it is widely accepted now that a proportion of patients, perhaps 20%,[3] have the characteristic rash but no clinical signs or symptoms of myositis. These patients make up a population now defined as clinically amyopathic dermatomyositis (CADM), a term coined by Sontheimer in 1991.[4] Patients with CADM have the characteristic DM rash (with a consistent skin biopsy) for at least 6 months' duration but no evidence of weakness by history or clinical examination; earlier concepts also require demonstration of normal muscle enzyme levels,[5-7] but this definition was later refined that a patient with normal strength and abnormal muscle enzyme levels could still be included under the CADM definition.[8] If not CADM, then the rest of patients with DM have what is often termed "classic dermatomyositis," referring to the traditionally recognized disease with symptomatic myositis. CADM is a useful term for physicians because it is defined clinically and makes no attempt to deny the presence of subclinical muscle inflammation. The CADM umbrella can further be subclassified into exactly two groups depending on the results of further imaging (eg, magnetic resonance imaging [MRI]), electromyographic, muscle biopsy, or (now) laboratory studies of muscle enzymes: hypomyopathic DM, in which at least one of these test results is abnormal, and amyopathic DM, in which all the test results are normal.

It should be noted that several other groups have proposed classification criteria for DM that focus on muscle histology,[9] clinical findings,[10,11] or combinations of these.[12] It has become clear that muscle histology and clinical findings cannot be defined that are specific to DM, although it remains possible that novel serotypes may have sufficient sensitivity and specificity to play a major role in defining DM.

The definition of exactly what constitutes a "DM rash" has been elusive. Sontheimer has proposed formal cutaneous criteria for making a diagnosis of CADM in 2002.[5] Three major criteria include the pathognomonic heliotrope sign (violaceous erythema on the upper eyelids), Gottron papules (papules overlying the metacarpophalangeal [MCP] and interphalangeal [IP] joints), and Gottron sign (erythema overlying the knees, elbows, or IP joints) and 14 additional minor criteria

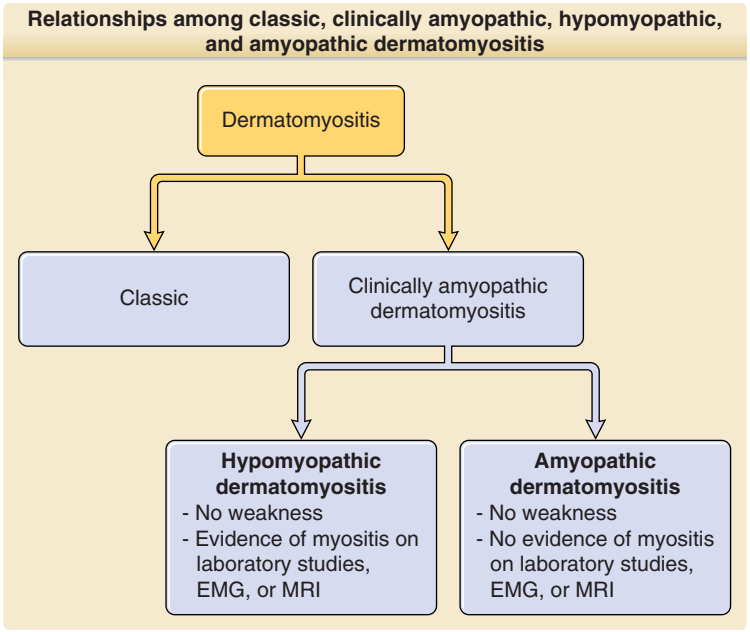

Figure 62-1 Display of the relationships among classic, clinically amyopathic, hypomyopathic, and amyopathic dermatomyositis. EMG, electromyography; MRI, magnetic resonance imaging.

(Fig. 62-1). Sontheimer suggested that a diagnosis of CADM could be made if two major criteria were present or one major criterion and two minor criteria were present in addition to biopsy of at least one region showing histopathologic changes consistent with DM.[5] Although these criteria seem comprehensive and reasonable, they have not yet been validated in any way.

It will continue to be important to recognize patients with CADM even though there is no evidence that this group of patients is pathogenically, histologically, or serologically different from the classic group except with regards to absence of clinical weakness. Even if these patients were managed the same as patients with myositis regarding aggressive immunotherapy (which is not necessarily the case), they are an important group to recognize because these patients appear to harbor the same risks for systemic disease (eg, interstitial lung disease [ILD]) and malignancy as their classic counterparts.[8] Thus, for now, recognizing the prototypical and also atypical or subtle cutaneous presentations of CADM is especially important for dermatologists because these clues may provide the only data upon which the diagnosis is based.

EPIDEMIOLOGY

DM has a bimodal distribution in the age of disease onset, occurring at two peaks, at 5 to 14 years and 45 to 64 years of life. The disease affects women two to three times more than often than men. As discussed earlier, DM is typically classified as an idiopathic inflammatory myopathy, a group of disorders that includes polymyositis, inclusion body myositis, nonspecific myositis, and immune-mediated necrotizing myopathy. Estimating the incidence and prevalence of pure DM is challenging because of a lack of precision and standardization regarding diagnostic criteria (with many studies even grouping DM and polymyositis into one disease), differing methods of case ascertainment, differing study design, and possible geographic influences.[13,14] Despite this, using data from the few population-based studies or largest databases available, estimates of incidence and prevalence are remarkably similar, with incidence rates ranging from 5 to 10 per 1 million per year and prevalence estimates of 10 to 20 per 100,000. Data from the largest population-based study in southeast Norway (>2.6 million people) estimated a point prevalence of total polymyositis or DM of 8.7 (95% confidence interval [CI], 4.5–11.2) per 100,000, of which about half of cases were DM. This study estimated an incidence of 6 to 10 cases per 1 million each year.[15] Bendewald and coworkers provided population estimates for adult-onset DM from Olmstead County, Minnesota. The age- and sex-adjusted incidence was 9.63 (95% CI, 6.09–13.17) per 1 million per decade, and the prevalence was 21.42 per 100,000 persons (95% CI, 13.07–29.77).[3] In their small cohort, 20% (6 of 29 cases) were clinically amyopathic. Analysis of data from large insurance claims databases in Japan and Taiwan estimated an annual incidence of 10 to 13 and 6 to 10 per million annually, respectively.[16,17] Based on registry data, the annual incidence of juvenile-onset DM in the United States among children ages 2 to 17 was estimated between 2.5 and 4.1 per million.[18]

CLINICAL FEATURES

CUTANEOUS FINDINGS

Elements of the patient history may be useful in distinguishing DM from mimicking eruptions. Triggers may be present such as substantial ultraviolet exposure,

strenuous activity (for the patient with concurrent myositis), or recent malignancy. There is often significant pruritus associated with affected skin, particularly on the scalp, which may also be described as a "tightness" or burning or with other dysesthetic qualities such as crawling or tingling. This severe pruritus on the scalp may be caused by structural damage to epidermal small-fiber nerves.[19] The natural history of the eruption is chronic and often progressive, ultimately resulting in a background of dyspigmentation, atrophy, and telangiectasias. An evanescent or wholly intermittent eruption is unlikely to represent DM. With treatment, however, many patients can ultimately enter remission in which no further activity is present but residual damage features (eg, poikiloderma) may remain.

The characteristic cutaneous feature of affected skin in DM is violaceous patches and plaques, varying from a bright pink to a deep violet color. In darker skin types, the erythema is often subtle, and careful examination is important to detect skin involvement. To heighten the sensitivity of the exam and appreciate these, at times, subtle color changes, patient positioning, and proper lighting in the examination room are critical. Many types of overhead direct lighting tend to obscure the subtle color changes seen in DM skin, and thus natural lighting is recommended for the clinical examination. Evaluating the patient in a reclined or supine position helps minimize shadows, particularly on the face, and overexposure with direct lighting.

The scalp is one of the most commonly involved sites, often only with pink to red erythema (Fig. 62-2), but there may be associated fine white scale. The pruritus and dysesthesia are often severe and out of proportion to the erythema on examination. The scalp can be affected in any location but often involves a linear band just above and below the frontal hairline. Examination findings alone are not always specific enough to differentiate it from seborrheic dermatitis, psoriasis, and contact dermatitis. Subtle erythema is often perceptible on the vertex scalp or along the hair part or borders of the hairline even when the remainder of the cutaneous disease is quiescent.

The heliotrope sign (Fig. 62-3) may exemplify the pink to purple violet hue of the eruption, resembling the color of the flower petals after which the sign is named. The eyelid eruption can be associated with periorbital edema, and patients are often initially misdiagnosed with allergic contact dermatitis or angioedema. In addition, erythema of the lateral canthi, medial canthi, and adjacent nasal sidewalls can be seen (Fig. 62-4). The forehead, cheeks, ears, and chin may vary from uninvolved to focal patches or plaques to diffuse erythema.

Figure 62-3 Heliotrope sign. Violaceous to pink erythema and edema on the upper eyelid.

The skin changes in DM are often distributed to prototypical regions on the body Table 62-1). Trunk involvement is often seen on the posterior neck, upper back, and shoulders, known as the shawl sign (Fig. 62-5), which may extend to the posterior upper arms. Patients can display symmetric violaceous erythema, often with a livedo character, symmetrically on the lateral lower back. Confluent violaceous erythema on the sun-exposed areas of the lower anterior neck and anterior chest is termed the V-neck sign (Fig. 62-6). The violaceous to pink papules over the IP and MCP joints are termed Gottron papules (Fig. 62-7). They may display the same range of features seen elsewhere such as poikiloderma, atrophy, hypopigmentation, hyperkeratosis, or ulceration (Fig. 62-8). They may take the form of larger, ill-defined, round circular plaques (often with scale) or of 2- to 4-mm, smooth, well-demarcated, often umbilicated papules. Gottron sign is symmetric macular violaceous erythema over

Figure 62-2 Diffuse pink psoriasiform plaques on the posterior neck and nuchal scalp.

Figure 62-4 Red ill-defined macules on the medial and lateral canthi, often seen in conjunction with the heliotrope sign.

TABLE-62-1

Sontheimer's Proposed Diagnostic Criteria for Cutaneous Dermatomyositis[1]

Diagnosis of cutaneous dermatomyositis requires:

1. Presence of two major criteria or one major criterion and two minor criteria *and*
2. Skin biopsy changes consistent with cutaneous dermatomyositis

Major Criteria

Heliotrope sign

Gottron papules

Gottron sign

Minor Criteria

Macular violaceous erythema involving (each area counts as one minor criterion)

- Scalp or anterior hairline
- Malar eminences of face, forehead, or chin
- V-area of neck or upper chest (V-neck sign)
- Posterior neck or posterior shoulders (shawl sign)
- Extensor surfaces of arms or forearms
- Linear streaking overlying extensor tendons of dorsal hands
- Periungal skin
- Lateral thighs or hips (holster sign)
- Medial malleoli

Nailfold capillary telangiectasia, hemorrhage-infarct

Poikiloderma

Mechanic's hands

Cutaneous calcinosis

Cutaneous ulcers

Pruritus

the IP joints, olecranon processes (Fig. 62-9), patellae, and medial malleoli. Generally, juvenile DM more characteristically displays atrophy and poikiloderma in classic areas of Gottron sign.

Of note, many of sites of cutaneous DM skin involvement areas are *not* necessarily in areas of ultraviolet (UV) exposure (so-called "photodistributed"), including the scalp, lower back, and lateral thighs. Some patients can present with a classic photodistributed eruption, but more often the erythema is patchy even

Figure 62-5 Shawl sign. Pink to red thin patches and plaques, often with thin white scale, on the upper posterior back characteristic of the shawl sign.

Figure 62-6 V-neck sign. Red, ill-defined telangiectatic patches on the upper chest.

in sites with high risk of UV exposure. The violaceous erythema and poikiloderma on the lateral hips and lateral thighs is termed the Holster sign (Fig. 62-10). Often this is patterned as violaceous, folliculocentric macules or subtle papules and can be confused with keratosis pilaris. The violaceous and typically macular nature of the eruption, usually in the absence of involvement of other areas typical for keratosis pilaris (eg, upper outer arms) helps to characterize this finding of DM. In addition, flagellate erythema may be found as widespread linear patches or urticarial plaques, typically on the middle and lower back, and flanks,

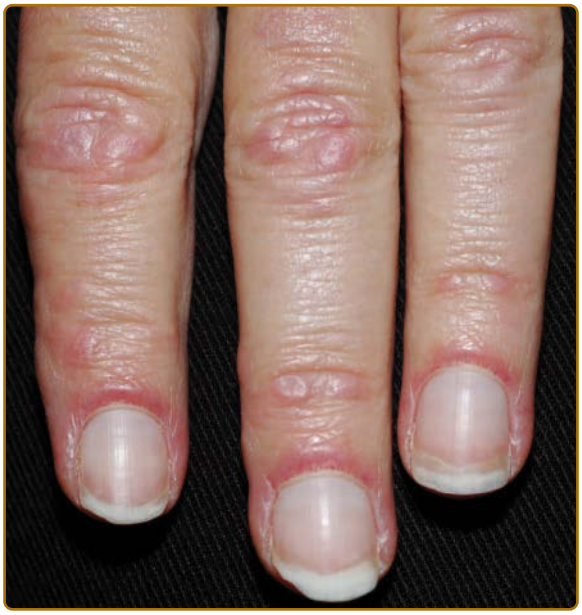

Figure 62-7 Gottron papules. Light pink, ill-defined papules over the proximal and distal interphalangeal joints, few with central umbilication. Deep red erythema, edema of the proximal nailfolds, and dilated nailfold capillaries are evident.

Figure 62-8 Ulcerated Gottron papules. Well-demarcated 3- to 4-mm ulcers with surrounding erythema and edema on the second and third proximal interphalangeal joints exemplify the vasculopathy seen in dermatomyositis.

Figure 62-9 Gottron sign. Ill-defined violaceous erythema on the knees is seen, which has follicular accentuation in this patient.

Figure 62-10 Holster sign. On the lateral thigh are ill-defined pink papules coalescing into plaques are seen with scale and follicular accentuation.

Figure 62-11 Mechanic's hands. On the lateral second digits are hyperkeratotic pink ill-defined papules with scale.

possibly caused by excoriation or imprinting from clothing or bed sheets.

Other characteristic hand findings include the, so-called "mechanic's" hands. This finding was initially described as hyperkeratosis and fissuring along the medial thumb and lateral second and third digits in 1979.[20] This finding may be subtle and often requires palpating the fingers to appreciate the rough texture (Fig. 62-11). This lateral second digit hyperkeratosis seems to differ in quality and severity with the findings in patients with antisynthetase antibodies, the latter associated with fissuring and scaling that tends to also involve the distal fingertips.

In 2012, Sato and coworkers found an increased prevalence of ILD among their patients with DM with mechanic's hands (78%, 7 of 9) compared with without mechanic's hands (40%, 12 of 30),[21] supporting that mechanic's hands is a cutaneous clue to the possible presence of ILD. A recent study by Werth and coworkers found that in 101 patients with DM, mechanic's hands was associated with an odds ratio of 3.28 (95% CI, 1.36–7.88; $P = 0.01$) of having ILD.

Evidence of vasculopathy is manifested in many ways on the skin. Proximal nailfold involvement can present as subtle edema or erythema as well as microscopic or clinically obvious capillary dilation. When pronounced and easily visualized with the naked eye, these nailfold capillary changes can be highly suggestive of DM over other connective tissue disorders. The classic findings include red, edematous, often tender proximal nailfolds with ramified and dilated capillary loops with intervening pale to white avascular areas with capillary drop-out, cuticular hemorrhages, and elongated, ragged cuticles (Fig. 62-12). Although these changes are a sign of ongoing cutaneous disease activity,[22] in longstanding DM, damage may be evident as persistently dilated and arborizing capillaries.[23] Sensitive nailfolds can be a helpful diagnostic symptom for DM. In addition, gingival telangiectasias have been described in DM.[24] In addition, livedo reticularis can be seen in a minority of patients.

Cutaneous ulceration can be an exemplary sign of vasculopathy, although it can also be the result of robust, liquefactive interface dermatitis, or excoriation.

Figure 62-12 Dilated proximal nailfold capillary loops with intervening avascular areas.

Figure 62-13 Ovoid palatal patch. This symmetric violaceous patch is seen symmetrically across the posterior hard palate and may aid in distinguishing dermatomyositis from other cutaneous eruptions, namely lupus.

Ulceration may be present in 30% of patients and often affects the skin over the extensor joint surfaces, although it can be found anywhere.[25] Cutaneous ulceration in DM warrants concern for the presence of anti-MDA5 antibodies or malignancy (especially if necrosis is seen). In the setting of anti-MDA5 antibodies, cutaneous ulceration commonly occurs over Gottron papules (see Fig. 62-8) or in areas of Gottron sign (eg, extensor surfaces).[25,26] Ulcers have been correlated with the presence of ILD, but this is likely through their association with anti-MDA5 antibodies.[25,27] As such, worsening cutaneous ulceration in a patient with anti-MDA5 antibodies may be a cutaneous sign of worsening ILD.

Visualization of the oral mucosa, particularly the hard palate, may provide a valuable sign to aid in the diagnosis of DM. One can observe a symmetric violaceous patch across the midline of the hard palate, termed the *ovoid palatal patch* (Fig. 62-13), most frequently in the subset of patients with DM with anti–transcriptional intermediary factor 1γ (TIF1-γ) antibodies.[28] Biopsies from these lesions appear to demonstrate interface mucositis, consistent with typical findings of DM. Like nailfold capillary changes described later, these hard palate changes appear to fade with control of disease activity. These lesions could be confused with oral findings of discoid lupus or lichen planus, but their consistent localization to the center of the hard palate may aid in the diagnosis of DM when other cutaneous features are nondiagnostic. In addition, other oral mucosal findings include gingival telangiectasias (noted earlier) as well as more classic lichen planus–like lesions around the gingiva or buccal mucosa. Whether or not these latter lesions represent coexisting lichen planus or are part of the DM disease spectrum is not clear.

In general, the clinician should be always differentiating signs of skin activity, which may be reversible with therapy, versus damage. The distinction between activity and damage in DM skin is critical for clinical decision making so immunosuppressive treatments are not escalated for signs of skin damage. Cutaneous disease activity is characterized by erythema, itch, induration (papules or plaques), scale, or ulceration. Although erythema is often an important sign of activity, it can often be a sign of damage as well (eg, diffuse telangiectatic erythema), and thus care must be taken not to inadvertently escalate therapy solely caused by erythema that has no other qualities of disease activity. This phenomenon can be especially true on the face and chest, and faint erythema in the absence of symptoms or other skin changes is often mild damage and may not respond to traditional immunosuppressive therapies. Also, a reticular pattern of pink to red erythema on the palms and volar surfaces (more commonly seen in the anti-MDA5 group, Fig. 62-14), in addition to more classic livedo reticularis (including that found on the lateral flanks) represents vascular changes that have unclear association with disease activity.

When substantial inflammation has been present, a distinctive and pathognomonic pattern may be seen composed of reticulated, sometimes atrophic white macules adjacent to erythema or telangiectasias, which

Figure 62-14 A reticular pattern of deep red erythema on the palmar fingers is more commonly seen in the anti–melanoma differentiation–associated gene 5 (*MDA5*) dermatomyositis group.

the authors have termed "red on white" (Fig. 62-15).[29] The thin skin along the bitemporal hairline is a frequent place to visualize the "red-on-white" pattern, but notably, this pattern does not necessarily follow patterns of sun exposure and may be found on the hair-bearing scalp. It is becoming increasingly clear that many of these areas do not represent permanent damage per se because these lesions may slowly resolve with time, even in areas with atrophy. However, this morphology is a very useful diagnostic tool because it does not seem to be associated with other connective tissue diseases, such as cutaneous lupus.

Skin damage from DM is reflected by brown, often reticulated, postinflammatory hyperpigmented patches in areas of prior disease activity. Longstanding disease activity, typically in sun-exposed areas, results in more significant damage, characterized by atrophy, hypopigmentation, hyperpigmentation, and telangiectasias, termed *poikiloderma* (Fig. 62-16). Poikiloderma (as opposed to the "red-on-white" manifestation discussed earlier) is a late manifestation and is not diagnostically specific because many other acquired and congenital diseases result in poikiloderma such as cutaneous lupus, chronic actinic damage (poikiloderma of Civatte), poikilodermatous mycosis fungoides (poikiloderma vasculare atrophicans), *Borrelia* infection (acrodermatitis chronica atrophicans), chronic radiation dermatitis, graft-versus-host disease, hydroxyurea, and dyskeratosis congenita. Therefore, ancillary cutaneous findings are necessary to discern the cause of poikiloderma.

Calcinosis is typically a late manifestation in the skin, subcutaneous tissue, fascia, or muscle and typically affects the trunk, proximal extremities, or areas of previous disease activity. The prevalences of calcinosis are 20% in adult DM[30] and up to 40% in juvenile DM.[31] Calcinosis also occurs more rapidly after disease onset in juvenile versus adult DM (2.9 years vs 7.9 years, respectively).[32] In juvenile DM, risk factors for development of calcinosis include longer disease duration, younger age of disease onset, sustained disease activity, and internal organ involvement.[33,34]. Calcinosis is most frequent on the extremities in DM, in contrast to systemic sclerosis in which digital calcinosis is most frequent.[32] In both juvenile and adult DM, the presence of anti–nuclear matrix protein 2 (NXP-2) antibodies is associated with an increased risk of calcinosis.[35,36] In adults, fingertip ulceration has been associated with calcinosis,[36] suggesting that vascular insufficiency or damage may be involved in the pathogenesis of calcinosis. Calcinosis is also commonly seen in the anti-MDA5 subset (especially in patients with longstanding disease),[36] which is associated with known vasculopathy.

Figure 62-15 "Red on white." Reticulated white macules surrounded by telangiectatic red macules are seen on the distal thigh and knee. This cutaneous finding is specific to dermatomyositis and is valuable in differentiating dermatomyositis from cutaneous lupus.

Figure 62-16 Poikiloderma. This triad of hyperpigmentation, hypopigmentation, and telangiectasias is a sign of damage, as shown on the chest.

Panniculitis reflects active disease in DM, typically affecting the buttocks, trunk, and proximal extremities; it may progress to calcinosis or lipoatrophy.[37] Histopathology shows a lobular panniculitis but may have features of lupus panniculitis with lipomembranous changes or with septal thickening as in deep morphea.

Alopecia in DM is most commonly nonscarring and diffuse, although patchy involvement, rarely with scarring, can also be seen. Alopecia can be caused by DM disease, coexisting disorders, medications, or telogen effluvium. Patients with anti-MDA5 antibodies have a higher risk of alopecia, which commonly is severe and occurs early in the disease.

RARE PRESENTATIONS OF CUTANEOUS DERMATOMYOSITIS

Subcutaneous edema that is either generalized or located in the limbs has been recognized as a rare manifestation of DM.[38] Interestingly, edema in the distal extremities has recently been found to be associated with anti-NXP2 antibodies and may predict more severe muscle disease.[38,39] It is unclear what the relationship is between anti-NXP2 antibodies and the more severe, generalized presentations described in the literature. Rarely, DM may present erythroderma in which 90% or more of the body surface shows confluent erythema. Generalized ichthyosis can also be a presenting sign of DM.

There is a subset of patients with DM with clinical manifestations with overlapping features of both psoriasis and DM.[40,41] Their skin disease may show psoriasiform, well-demarcated thick plaques over the MCPs and proximal interphalangeal (PIP) joints, elbows, and knees in addition to dilated and abnormal nailfold capillaries. Skin biopsies tend to reveal both epidermal hyperplasia and interface dermatitis. Some of these patients have a history of psoriasis, and it is unclear if these lesions represent concomitant psoriasis or a psoriasiform manifestation of DM.

EXTRACUTANEOUS FINDINGS

PULMONARY INVOLVEMENT

ILD is the most common pulmonary manifestation in DM and is a leading cause of morbidity and mortality in these patients.[42] Other pulmonary manifestations in DM include aspiration pneumonia; drug-induced pneumonitis; and, rarely, pulmonary hypertension. ILD affects between 15% and 50% of patients with DM, depending on the population and autoantibody distribution.[43-46]

There are three clinically described patterns of lung involvement, which may precede or proceed muscle involvement[47,48]: it may be asymptomatic with only radiologic evidence of ILD; it may have an insidious onset with gradual development of decreased exercise capacity, dyspnea on exertion, or a dry cough; finally, it may be acute onset with hypoxia and possibly respiratory failure, necessitating hospitalization.

In a recent study from a large US cohort of 438 patients with polymyositis or DM (n = 393), the presence of ILD in patients with DM was associated with an increased risk of death with a hazard ratio of 2.13 (95% CI, 1.06–4.25; P = 0.03).[49] Large case series have suggested that more than 75% to 86% of patients who have an antisynthetase antibody will develop ILD.[47,50] Similarly, patients with DM with anti-MDA5 antibodies have a marked increased risk of developing ILD with estimates between 50% and 100%[25,51] Table 62-2). Rapidly progressive ILD is an aggressive form that responds poorly to immunosuppressive therapies, having a 6-month survival rate of approximately 40%.[52] Rapidly progressive ILD may affect 40% to 60% of patients with anti-MDA5 antibodies.[53-56]

Pulmonary function tests (PFTs) show a restrictive disease pattern with a decreased forced vital capacity (FVC)[57] or a decreased diffusion capacity of carbon monoxide. Exertional oxygenation desaturation on the 6-minute walk test provides a global assessment of cardiopulmonary function and exercise performance. However, confounding factors such as deconditioning, myopathy, arthritis, respiratory muscle weakness, and pulmonary hypertension may also produce reduced FVC and diffusion capacity of carbon monoxide.[58] Therefore, high-resolution computed tomography (CT) of the chest is a necessary step in establishing the diagnosis of ILD.

High-resolution CT scan of the chest is a valuable diagnostic test and may show subclinical fibrosis before symptom onset. Up to 65% of patients with polymyositis and DM will have subclinical CT evidence of ILD.[59] The most common radiographic and histologic pattern in DM is nonspecific interstitial pneumonia, reported in 81.8% (18 of 22 cases).[60] Radiographically, basilar and peripheral ground-glass opacities and subpleural sparing characterize nonspecific interstitial pneumonia. Other patterns of involvement include usual interstitial pneumonia, cryptogenic organizing pneumonia, and diffuse alveolar damage, the latter with a poor prognosis.

Pulmonary arterial hypertension is a rare manifestation in DM. Symptoms may include increased fatigue, shortness of breath, dyspnea on exertion, palpitations, chest pain, edema, lightheadedness, and rarely presyncopal or syncopal episodes. PFT revealing a disproportionately low diffusion capacity of carbon monoxide compared with a relatively normal FVC should prompt further screening for pulmonary artery hypertension. If a high-resolution CT scan is checked for worsening shortness of breath and abnormal PFT results, it may show an enlarged pulmonary artery but no evidence of ILD. Echocardiographic findings suggestive of pulmonary hypertension include a right ventricular systolic pressure greater than 40 mm Hg, right ventricular

TABLE 62-2
Clinical Associations with Autoantibodies Associated with Dermatomyositis[1,2]

AUTOANTIBODY	AUTOANTIGEN	CLINICAL PHENOTYPE IN ADULT DERMATOMYOSITIS	FREQUENCY IN ADULT DERMATOMYOSITIS	FREQUENCY AND PHENOTYPE IN JUVENILE DERMATOMYOSITIS
Anti-tRNA synthetase	Jo-1: histidyl PL-7: threonyl PL-12: alanyl EJ: glycyl OJ: isoleucyl KS: asparaginyl Ha: tyrosinyl Zo: phenylalanyl	Increased risk of ILD PL-7: mild skin or muscle disease[3] PL-12, KS, OJ: isolated ILD[4-6] Variable spectrum of findings of the antisynthetase syndrome: ILD, fever, arthritis, myositis, mechanic's hands, Raynaud phenomenon	Jo-1 is the most frequent, up to 20% Non–Jo-1 anti-tRNA synthetase antibodies between 1% and 5%[7]	4%–5%[8] Older onset Antisynthetase syndrome with ILD, fever, nonerosive polyarthritis, Raynaud phenomenon, mechanic's hands
Anti–Mi-2	Mi-2; regulates transcription as a component of nucleosome remodeling and deacetylase (NuRD) complex	Hallmark cutaneous disease, good prognosis and response to therapy; relapses common; high CK values (>5000 U/L); rare ILD, cancer; not amyopathic	Ethnogeographic variation: 20% in US[9] and Japan[10] 6.7% in Glasgow 60% in Guatemala[11]	3%[8,12] Classic skin disease Myositis Good therapeutic response; more likely to be in remission at 2 yr
Anti–transcriptional intermediary factor (TIF1)-γ	p155; TIF; role in apoptosis, ubiquitination, and innate immunity	Increased cancer risk in adults Severe cutaneous disease Red-on-white skin lesions Ovoid palatal patch Low ILD risk Low CK values (200–2000 U/L)	21%–38%[13,14]	23%–35%[8] Severe skin disease Lipodystrophy
Anti–melanoma differentiation–associated gene 5 (*MDA5*)	Melanoma differentiation: associated protein 5; cytosolic receptor for viral dsRNA; mediates type I IFN innate immune response	High ILD risk, RP-ILD, especially in Asians Skin ulceration, red palmar papules, alopecia, gingival pain Arthritis Often isolated high aldolase	7%–10% in US[15,16] 20%–35% in Asia[17,18]	7%–14%[19,20] ILD in Japanese cohort Skin ulceration, arthritis, milder myositis
Anti–nuclear matrix protein 2 (NXP2)	Nuclear matrix protein; transcription	Increased cancer risk in adults Increased risk of calcinosis Peripheral edema, myalgia, severe dysphagia Distal weakness	1.6%–30%[14,21-23]	20%–25% [8,12] Calcinosis, more severe myositis, poorer functional status
Anti–small ubiquitin-like modifier activating enzyme (SAE)	Small ubiquitin-like modifier activating enzyme; posttranslational modification	Skin disease onset before myositis May have severe skin disease Dysphagia	1.5%–10%[24-27]	1%[12]

CK, creatine kinase; IFN, interferon; ILD, interstitial lung disease; RP-ILD, rapidly progressive interstitial lung disease.

enlargement, maximum tricuspid regurgitant velocity greater than 3.0 m/s, and presence of a pericardial effusion.[61] Transthoracic echocardiography only has a sensitivity of 82% and specificity of 69% to detect pulmonary hypertension[61] and cannot differentiate patients with pulmonary arterial hypertension from those with left heart disease or ILD associated pulmonary hypertension. The gold standard for the diagnosis of pulmonary arterial hypertension is right heart catheterization showing a mean pulmonary artery pressure of 25 mm Hg or greater at rest and an end-expiratory pulmonary artery wedge pressure of 15 mm Hg or less.[62]

MUSCLE INVOLVEMENT

Myositis in DM typically presents as symmetrical proximal muscle weakness. About 20% of patients with DM, those with CADM, do not have clinical evidence or symptoms of weakness, although it is unclear what proportion of those patients might actually have subclinical myositis. If patients with DM do develop weakness, then about 80% of patients develop weakness within the first year of symptom onset.[63] The temporal course of myositis may be acute, subacute, or chronic and progressive.

Patients often report weakness in the extensor muscles surrounding the shoulder and pelvic girdles and proximal limbs. Quadriceps and gluteal muscle weakness may manifest as difficulty rising from a chair or toilet, climbing stairs, or stepping onto curbs. Patients may report shoulder and upper extremity weakness as difficulty washing their hair or reaching for items in overhead cupboards. Neck flexor muscle involvement is also common with difficulty raising the head off the bed while laying supine.

Patients may also complain of myalgias, which can occur even in the absence of frank clinical weakness. Approximately 30% of patients complain of muscle pain with or without muscle weakness.[9] Myalgias are described as soreness or muscle tightness or burning, but muscles are not tender to palpation. Care should be taken to distinguish this pain from other causes of pain, such as joint pain or fibromyalgia,[64] and care must be taken to not escalate immunosuppression for what may be symptoms of a pain disorder.

Involvement of respiratory muscles of the chest wall or diaphragm may also lead to respiratory insufficiency and occasionally respiratory failure. Patients may note a hoarse or raspy voice (dysphonia) from cricoarytenoid muscle involvement, which occurs in up to 40% of patients with DM.[65] Also, dysphagia may occur in 20% to 50% of cases because of weak pharyngeal musculature and thus an inability to propel food in the pharyngeal phase of swallowing.[66] Interestingly, there is a high correlation between dysphagia and weakness of the anterior neck muscles (eg, sternocleidomastoids).[67] Distal muscle weakness in the hands, manifesting as difficulty opening jars or holding onto objects, more typically occurs late in disease or in patients with anti-NXP2 antibodies.

JOINT INVOLVEMENT

Arthralgias are common in DM, reported in 30% to 40% of patients.[68-70] In general, the arthralgias in DM are mild to moderate in severity and involve the small joints of the hands, including the wrists, MCP and PIP joints, and the shoulders, elbows, and ankles.[71] More rarely, patients can have a true arthritis, often presenting as a symmetric polyarthropathy affecting the distal joints and often clinically indistinguishable from rheumatoid arthritis. Thus, patients with DM with arthritis as the presenting symptom may be diagnosed as having rheumatoid arthritis or a rheumatoid arthritis overlap disease before evolution of the skin, muscle, or pulmonary manifestations.[72,73] Illustrative historical questions eliciting symptoms of an inflammatory arthritis include joint swelling, morning stiffness for 30 minutes or longer, or joint pain that improves with activity. Evaluation for synovitis, indicative of active joint inflammation, can be determined by palpation for warmth; range of motion; swelling or palpable fluid; and tenderness of each small joint of the hand, elbows, shoulders, knees, and other symptomatic joints.

Arthritis and arthralgias are more common among patients with DM with anti-MDA5 and antisynthetase antibodies. However, erosive changes have been reported, more commonly in the anti–synthetase antibody subset.[74-77] Hall and coworkers found that 9 of 11 (81.8%) anti-MDA5 patients versus 40 of 149 (26.7%) non-MDA5 patients with DM exhibited an inflammatory arthritis (P <0.001).[78] Patients with DM with antisynthetase antibodies, the most common of which is Jo-1, may also manifest a nonerosive arthritis in up to 93% of cases.[71] In these patients with antisynthetase antibodies, the nonerosive arthritis may occur in the setting of "antisynthetase syndrome" consisting of fever, arthritis, myositis, ILD, mechanic's hands, or Raynaud phenomenon. The arthritis may flare in 50% of patients during disease relapse.[71]

GASTROINTESTINAL INVOLVEMENT

Gastrointestinal (GI) involvement is an uncommon manifestation in juvenile DM, reported in 4% of juvenile patients with DM.[79] It is associated with more severe disease[80] and is thought to result from a vasculopathy affecting the bowel wall.[81] The sequelae include ulceration and perforation, which may be life threatening. The presenting symptoms include persistent and worsening abdominal pain. They also may have nonspecific accompanying symptoms such as diarrhea, vomiting, constipation, and more rarely frank hematemesis or hematochezia; juvenile patients may not initially have evidence of hemorrhage such as melena, occult blood in the stool, or radiographic evidence of perforation.[82] Therefore, judicious monitoring of juvenile patients with DM with abdominal pain is warranted to recognize and intervene early in cases with GI involvement.

CARDIOVASCULAR INVOLVEMENT

Cardiac involvement in DM is increasingly being recognized as an important clinical feature. Cardiac involvement is usually subclinical. The most common electrocardiographic abnormalities are ST-T segment changes in 12.5% to 56.7% and conduction abnormalities in 25% to 38.5% of patients with DM.[83] Echocardiographic findings have shown left ventricular hypertrophy in 8% to 15% and left ventricular diastolic dysfunction in 42% of patients.[84] Myocarditis may lead to myocardial fibrosis and ventricular dysfunction and thus cardiomyopathy. Rosenbohm and coworkers screened 11 patients with DM with cardiac MRI and found that 54% (6 of 11) displayed evidence of late gadolinium enhancement, consistent with myocardial inflammation.[85] Cardiac troponin I may

be a useful biomarker in detecting subclinical cardiac muscle involvement.[86] Patients with the anti-MDA5 antibody subtype may be at higher risk for cardiac involvement.[87,88]

INTERNAL MALIGNANCY

DM is associated with an internal malignancy in 10% to 20% of cases.[89] Malignancies tend to occur within the first 1 to 2 years of disease onset and can be many types. Multiple population-based studies have estimated a standardized incidence ratio of 4 to 6 for malignancy compared with the normal population.[90] The cancer types that are overrepresented may vary depending on the population studied but appear to involve both solid tumors as well as hematopoietic malignancies. Common types of solid tumors include breast, lung, ovarian, prostate, colorectal, gastric, and pancreatic,[91-93] with nasopharyngeal cancer being more common in Southeast Asians.[94] The mechanism of the relationship between DM and malignancy is unknown but may include increased risk of cancer in the setting of immunosuppressive therapy, increased detection in the setting of heightened surveillance, and DM occurring in the setting of an immunologic response to internal malignancy.

There are several clinical risk factors associated with risk of malignancy, which include increasing age, male gender, cutaneous necrosis, dysphagia, and rapid onset of myositis.[95] Factors protective of malignancy include ILD, arthritis, and Raynaud phenomenon. Recently, malignancies have also been found to be more associated with particular DM-specific autoantibodies. The major antibody associated with malignancy is anti–TIF1-γ, although the precise elevation in risk appears to vary among studies and populations studied.[96,97] More recent data suggest that anti-NXP2 antibodies may also be associated with cancer, although this association is not as strong.[97,98]

Cancer screening is a source of controversy because no guidelines currently exist to direct screening in newly diagnosed patients with DM. Most authorities would agree with age-appropriate, routine cancer screening at a very minimum. However, in a small study, Sparsa and coworkers reported that initial routine cancer screening failed to discover 4 of 13 malignancies in their cohort.[99] A recent study of 400 patients showed that a substantial number of occult cancers (17 of 29) were only discovered using tests, usually CT scans, beyond what would be considered "age appropriate." Identifying which tests to order and in what patient population is of high priority.

ETIOLOGY AND PATHOGENESIS

DM is primarily an immune-mediated disorder with molecular and histologic evidence supporting a role for both innate and adaptive immunity. Muscle and skin biopsies show infiltration of CD3+ T cells, plasmacytoid dendritic cells, and macrophages as well as B cells (especially in muscle).[100,101] Parenchymal cell injury is manifested in the skin by interface dermatitis with keratinocyte injury and in muscle by atrophy, degeneration, and regeneration of muscle fibers, typically in a perifascicular distribution.

There is strong evidence for activation of the innate immune system as a critical step in disease pathogenesis and propagation. High levels of interferon (IFN)-induced genes and proteins found in blood, muscle, and skin and have been shown to correlate with disease activity.[102] There is some evidence that this response may be driven by IFN-β, although this is not yet clear. There are multiple pathways that could lead to activation of IFNs, most arising from so-called pattern recognition receptors in the cytoplasm. Many of these receptors are activated by aberrant quantity or structure of nucleic acids, which could come from viruses or the host, the latter in the form of damaged DNA or improperly processed RNA. High levels of IFN can induce DM autoantigens (eg, MDA5), activate immature dendritic cells to become effective antigen-presenting cells, and upregulate major histocompatibility (MHC) class I expression, and activate lymphocytes. In both skin and muscle, the cells expressing these IFN-induced gene products appear most concentrated in the areas of tissue damage and may play a role in recruiting and activating cytotoxic effector cells.

There is also abundant evidence for activation of the adaptive immune system in DM. Genetic studies have shown that polymorphisms in the human leukocyte antigen (HLA) region are highly associated with risk of DM, implicating activation of T cells. In addition, DM is associated with the presence of several, highly specific, circulating autoantibodies that are evidence of T- and B-cell activation. As mentioned, CD3+ T cells are found in tissue biopsies. The exact role of these antigen-specific responses is at present unclear, but the correlation between clinical phenotypes and specific autoantibodies suggests that these immune responses lie at the heart of disease pathogenesis. In addition, an animal model of myositis can be created by inducing anti–Jo1 immune responses in mice. Although some of these antigens have now been discovered, it remains unclear what cell type(s) or structures are the targets of such an immune response. Of interest, expression of several DM autoantigens is increased in damaged and regenerating muscle cells, suggesting that muscle fibers themselves might be direct targets of antigen-specific CD3+ cells.

The immune response may not be the entire story because histologic data support that a vasculopathy is a primary event in DM. Biopsies of both skin and muscle show endothelial degeneration and capillary dropout as some of the earliest findings. Deposition of the membrane attack complex of complement, consisting of C5b-9, is seen on the capillaries at the dermal–epidermal junction (DEJ) in skin and in the perifascicular blood vessels of the muscle.[103] However, there is no other evidence that membrane attack complex deposition is the result of an immune attack on

the vessels. Greenberg and coworkers have hypothesized that increased production of IFN-α/β–inducible proteins by plasmacytoid dendritic cells and myocytes can also result in endothelial damage.[104]

Genetics likely play a large role in the risk for developing DM. Certain HLA alleles are clearly some of the greatest risk factors for the development of DM. The HLA-B8 allele was the first allele found in increased prevalence in 12 of 17 (75%) juvenile patients with DM compared to 21% of control participants.[105] Subsequently, multiple other HLA alleles, largely consisting of the HLA 8.1 ancestral haplotype (HLA-A*0101, -C*0701, -B*0801, -DRB1*0301, -DQA1*0501, and -DQB1*0201) have been enriched in patients with DM.[106,107] Genome-wide studies have confirmed a role for MHC class I and II genes but have also uncovered other loci conferring risk; these include the *BLK* gene involved in B-cell activation and the *TYK2* gene, which plays a role in signaling from IFN receptors.

In addition, other nonimmune events may play a role in features of the disease. Currently, one area of investigation centers around the endoplasmic reticulum stress response that may be partially responsible for some of the weakness symptoms seen in DM. Endoplasmic stress could be the result of upregulation of MHC class I or other proteins and induces an unfolded protein response that results in activation of inflammatory nuclear factor kappa B (NF-κB) signaling pathways, mitochondrial dysfunction, and elevated reactive oxygen species, all of which can contribute to weakness.

Current models suggest that DM is initiated in a genetically predisposed individual who is then subjected to an environmental trigger. The nature of that trigger could vary and could include UV exposure, infection, and malignancy. On the cellular level, these triggers could result in antigen modification or upregulation, cellular death, and activation of nucleic acid response with increased production of IFN, endoplasmic stress, and activation of the innate immune system. There is likely redundant interplay between the innate and adaptive immune system that allows not only initiation but also disease propagation.

DIAGNOSIS

Unfortunately, there are no adequate, validated diagnostic criteria for DM. Like most rheumatic diseases, DM variably affects different organ systems and with varying degrees of severity. Because of this, it is difficult to define this disease on either clinical or histologic criteria. We have already discussed that using clinical, histologic, electromyographic, or histologic criteria of muscle involvement for diagnosis will not diagnose the population of patients with amyopathic disease. However, the same may hold true for skin disease; although some would argue that the characteristic rash is the key to diagnosis, it is not clear that the skin needs to be involved in the DM disease process any more than does the muscle. A practical approach is not to require specific muscle or skin involvement but to have organ-specific criteria that must be met if indeed an organ is involved. Unfortunately, there are no validated clinical skin criteria that can serve to diagnose DM skin disease. It has been suggested that vascular membrane attack complex deposition may serve to distinguish this disease from cutaneous lupus, but unfortunately, there are no data regarding membrane attack complex deposition in other skin diseases. It is thought that certain features on muscle biopsy characterize DM, namely perifascicular atrophy, but recent studies challenge this notion.[108] The recent characterization of several DM-specific autoantibodies gives the hope of making this diagnosis with a blood test, but sensitivity and specificity data of these assays across multiple mimicking skin and muscle diseases are still lacking. It is likely that optimization of future diagnostic criteria will require a combination of clinical, histologic, and serologic data.

Thus, at present, establishing a diagnosis of DM continues to rely on the clinician's impression based on history and physical examination findings.

HELPFUL SKIN FINDINGS

Features of the skin examination that we find particularly sensitive are microscopic periungual telangiectasias, lateral digit hyperkeratosis, and scalp erythema and dysesthesia. Some elements that are more specific are the "red-on-white" patches, the ovoid palatal patch, grossly visible periungual telangiectasias, and Gottron papules.

MUSCLE DISEASE

As discussed, myositis is not a requirement for the diagnosis. However, tests supporting the presence of an inflammatory myopathy are helpful when a patient presents with a suspicious rash. In this way, a clinical suspicion of DM is a necessary but not always sufficient for diagnosing DM. Muscle involvement by history (including dysphagia, dysphonia, and myalgia) and weakness on examination will serve to increase suspicion for myositis but are not confirmatory. Elevation of muscle enzymes, however, should be the next step in nailing down the diagnosis (see later). Electromyography or MRI can be used in situations when the clinical suspicion is still high for myopathy but muscle enzymes are normal. Finally, a muscle biopsy can be performed in cases in which a cause for muscle symptoms is still not clear.

SYNDROMIC PRESENTATIONS

Certain combinations of symptoms, although not necessarily common, have reasonably high specificity to

be helpful in making a diagnosis of DM, regardless of the presence of the more "typical" cutaneous features of DM. A patient presenting with alopecia, cutaneous or mucosal ulceration, palmar erythematous papules, severe arthralgia or arthritis, and shortness of breath, even with a few of these symptoms, should trigger the clinician to consider anti-MDA5 DM. Patients with mechanic hands, arthritis, Raynaud phenomenon, and lung symptoms are at high risk of having antisynthetase disease, which some consider to fall under the umbrella of DM if there are particular DM-like signs present on the skin. Patients with extreme myalgia, peripheral edema, and distal weakness should be ruled out for DM specifically with anti-NXP2 antibodies even if the rash is subtle. Knowledge of these phenotypes will increase the clinician's sensitivity for making the DM diagnosis.

DIAGNOSTIC LABORATORY EVALUATION

AUTOANTIBODIES

Myositis-specific autoantibodies associated with DM are evolving as key tools in assisting in establishing the diagnosis. These MSAs include TIF1-γ, NXP2, MDA5, small ubiquitin-like modifier activating enzyme (SAE), Mi-2, Jo-1, and the other antisynthetase antibodies (PL-7, PL-12, EJ, OJ, SRP). In our US cohort, these antibody tests have an 80% to 85% sensitivity for diagnosing DM. Thus, these MSAs may provide pivotal information to establish the diagnosis of DM in subtle or complex cases.

Importantly, MSAs are becoming increasingly relevant to identify clinical subsets and disease associations (see Table 62-2). As clinical phenotyping improves with respect to disease features and clinical course and increasing availability of testing for MSAs, this classification method will likely add value to current definitions by allowing improved prognostication, targeted screening, and potentially tailored therapy.

ANA testing, if performed, should be done using method of direct immunofluorescence. ANA test results can be negative in DM 50% of the time but are usually positive in systemic lupus erythematosus, and thus a negative test result can help point away from systemic lupus if that is in the differential diagnosis.

MUSCLE ENZYMES

Early in the course of myositis, serum muscle enzymes (ie, creatine kinase, aldolase, lactate dehydrogenase [LDH], aspartate aminotransferase [AST]), alanine aminotransferase [ALT]) are reasonably sensitive biomarkers of muscle inflammation. However, mid to late in the course of myositis, their sensitivity decreases. It is unclear why the sensitivity of muscle enzyme drops as myositis continues, but it may be a result of perifascicular muscle atrophy and fibrosis, resulting in less dramatic changes in these tests even while inflammation persists. Additionally, often only the creatine kinase or only the aldolase will be elevated in a single patient. To increase the sensitivity of detecting myositis on laboratory testing, the clinician should evaluate creatine kinase, aldolase, and LDH as a group when testing muscle enzymes.

There are a few practical issues to be aware of when evaluating muscle enzymes. First, all muscle enzymes can be elevated after strenuous activity; in questionable cases, the enzyme levels can be rechecked after 10-14 days following the activity. Second, aldolase (and AST and ALT) can be elevated with liver disease or hemolysis of the blood sample. Very high levels should be rechecked. γ-Glutamyl transferase will be elevated with hepatic injury but will not be elevated in myositis and is a helpful addition to laboratory testing for myositis if hepatic sources are suspected.

ELECTROMYOGRAPHIC STUDIES

Similar to muscle enzyme abnormalities, early in the disease course, myositis may be detectable on electromyographic studies in 70% to 90% of patients with DM with active muscle disease and the sensitivity to detect myositis decreases over time. The classic triad electromyographic findings of myositis is small amplitude, short duration, polyphasic motor unit potentials; fibrillations and positive sharp waves; and complex repetitive discharges.[109] These findings reflect active muscle inflammation and may be seen in other inflammatory myopathies such as polymyositis.[110] Late in the course of the disease, the sensitivity decreases.

OTHER DIAGNOSTIC LABORATORY TESTS

Most other laboratory tests performed at disease onset would be to evaluate for target organ involvement and not necessarily be used in making the diagnosis. However, serum ferritin is often highly elevated (>500 mg/dL) in anti-MDA5 patients with DM[111] and may be helpful in diagnosis anti-MDA5 disease when serologic testing is unavailable or of inadequate sensitivity. In addition, it may be a useful biomarker to assess the severity and follow the clinical response of ILD in anti-MDA5 patients with DM.[112,113]

IMAGING

MRI provides a detailed view of the muscle anatomy, allowing for localization and discrimination of the type of pathologic process (eg, edema, inflammation, fibrosis, calcifications, or atrophy). MRI can be useful to differentiate weakness caused by damage or steroid-myopathy versus active myositis when muscle enzymes and electromyographic studies are inconclusive. MRI can also be used in directing the site of a diagnostic biopsy, if needed,[114] or may be used to assess clinical response to treatment.[115] Muscle edema

is a sensitive indicator of myositis and correlates with creatine kinase levels.[116] On short tau inversion recovery, in which normal muscle is dark and inflamed muscle is bright, an increased signal intensity within muscle tissue suggests muscle inflammation, necrosis, or degeneration.[117] Yoshida and coworkers also identified fasciitis on MRI in 12 of 14 patients with DM, suggesting that the fascial microvasculature may be a primary site of involvement.[118] Muscle damage may be identified on T1-weighted images, in which there is fatty replacement of skeletal muscle.[73]

PATHOLOGY

SKIN HISTOPATHOLOGY

Skin biopsies from affected skin in DM classically show a cell-poor interface dermatitis, increased dermal mucin, a perivascular lymphocytic infiltrate, and vascular ectasia (Fig. 62-17). Other inconstant findings include epidermal atrophy and basement membrane thickening. However, frequently many of these findings are subtle or absent. Smith and coworkers reviewed 40 DM skin biopsies and noted that when interface dermatitis was absent (20% of cases), increased dermal mucin was always present.[119] It has been suggested that whereas DM is characterized by increased presence of plasmacytoid dendritic cells in mostly an epidermal location, in cutaneous lupus, they are situated primarily in the dermis.[120]

The role of direct immunofluorescence testing in DM diagnosis is still unclear. It has been reported that DM biopsies do not demonstrate immunoreactants along the DEJ, the so-called "lupus band," but this finding is not uniformly defined in terms of its intensity and antibody composition. Magro and coworkers found that if the definition of a lupus band is made stringent, only 1 of 24 patients with DM has a positive lupus band test result. However, in addition to most patients with DM, more than 35% of cutaneous lupus biopsies were also negative for the lupus band test. So, if a stringently defined lupus band (eg, interrupted deposition of immunoglobulin [Ig] G or continuous deposition of IgM) is present on biopsy, these data suggest that a diagnosis of DM is unlikely. In addition, Mascaró and coworkers found that deposition of the membrane attack complex or C5b-9, at either the DEJ or around vessels of DM occurs in 77% to 86% of patients.[103] Magro and coworkers repeated this testing in 24 patients with DM and found that membrane attack complex deposition at both the DEJ and around vessels along with a negative lupus band test result was 78% sensitive and 93% specific for making a diagnosis of DM over cutaneous lupus.[121]

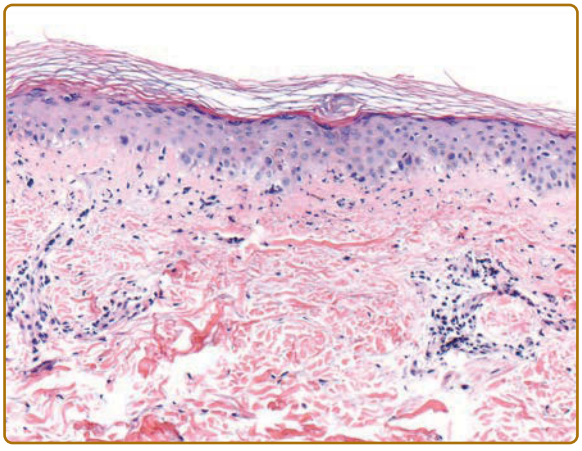

Figure 62-17 Histopathology of cutaneous dermatomyositis. Skin biopsy shows vacuolar interface dermatitis, basement membrane thickening, perivascular lymphocytic infiltrate, and increased dermal mucin.

MUSCLE HISTOPATHOLOGY

In patients referred to a dermatology clinic with a rash and weakness, muscle biopsy is seldom necessary to establish the diagnosis of DM. Evidence of myositis on laboratory testing, electromyography, or MRI is often sufficient in the setting of a cutaneous eruption supporting DM. Muscle biopsy can yield false-negative results, both because of immunosuppressive medications and the patchy nature of the inflammation. MRI can be used to as a guide to selecting a biopsy site. If a muscle biopsy is necessary to confirm the diagnosis of DM, it has the highest yield if performed within 2 weeks of beginning any immunomodulatory therapy.

Typical muscle histopathology findings in DM include perifascicular atrophy, degenerating and regenerating myofibers, membrane attack complex deposition in the endomysial capillary walls,[122] endothelial cell swelling, and capillary necrosis. The inflammatory cell infiltrate consists of CD4+ T cells,[123] plasmacytoid dendritic cells secreting IFN-α,[101] B lymphocytes, macrophages, and plasma cells. However, there is a range of histologic findings even in clear DM cases, and histologic findings of inflammatory myopathies often cluster according to other criteria and do not necessarily respect the clinical boundaries of idiopathic inflammatory myopathy categories that have been defined.

DIFFERNTIAL DIAGNOSIS OF DERMATOMYOSITIS

See Table 62-3.

CLINICAL COURSE AND PROGNOSIS

The long-term survival rate for adults with DM is approximately 65% to 75%, but there are relatively little data regarding specific organ outcomes such as muscle

TABLE 62-3
Patients with Skin Findings That Are Similar to Dermatomyositis

CONDITION	DESCRIPTION
Acute cutaneous lupus	Characterized by malar pink patches and plaques; may generalize to rest of face and body; generally spares PIP and DIP joints; spares nasolabial folds; usually does not have significant pruritus; 5%–15% of patients with SLE may have myositis; patients have systemic lupus and positive lupus serologies
Photoallergic or airborne contact dermatitis	Patients have new exposure before onset of eruption; distribution is to skin that was exposed to allergen or sun exposure, not in DM distribution; patients often have itching or burning; patients do not have nailfold capillary changes or systemic symptoms
Acne rosacea (erythematotelangiectatic or neurogenic)	May have itching, burning quality but erythema is limited to face; absence of damage (hyperpigmentation, atrophy); no systemic symptoms
Polymorphous light eruption	Sun-exposed sites are affected, typically immediately after sun exposure (delayed 1–2 days in DM); rash not in classic DM extensor distribution; eruption may resolve completely in 1–2 wk with sun avoidance; no systemic symptoms
	Characterized by annular or psoriasiform plaques on sun-exposed skin; 30%–60% have SLE; 80% have positive anti-Ro antibody; may be medication associated; lacks pathognomonic DM skin findings (eg, Gottron papules, Gottron sign, heliotrope)
Seborrheic dermatitis	Scalp disease may be challenging to separate from DM; has greasy scale and orange-red quality instead of violaceous; may affect central chest, upper back, and neck but spares extremities; patients do not have systemic symptoms
Psoriasis	Tends to spare the face; lacks characteristic damage of DM; lacks nailfold capillary changes; rarely, patients may have both DM and psoriasis
Phototoxic or photoallergic drug eruption	Patients have a recently added medication; distribution is to sun-exposed areas, not extensor; eruption often has sharp borders and substantial edema; no nailfold capillary changes; patients are without systemic symptoms
Lichenoid drug eruption	Patients are taking medication associated with lichenoid dermatitis; eruption is often widespread and papular; not in DM distribution
Pityriasis rubra pilaris	Typically involves palms and soles; may have islands of sparing; has an orange-red quality as opposed to violaceous; lacks nailfold capillary changes
Atopic dermatitis	Distribution is usually flexural in adults; lichenification present in chronic cases; may have history of seasonal allergies or asthma; generally improves with sun exposure; lacks atrophy; nailfold capillary changes
Patients with Weakness and other Skin or Systemic Findings	
Mixed connective tissue disease	Patients may have facial, chest, or scalp rash with poikiloderma, nailfold capillary changes, calcinosi,s and myositis; patients do not have Gottron papules; arthritis, Raynaud phenomenon, cutaneous sclerosis, GERD, and cytopenias are prominent symptoms; patients have anti-U1RNP antibodies
Systemic sclerosis	May have myositis, depigmented and hyperpigmented patches, nailfold capillary changes, pruritus, and calcinosis but not the erythema of DM; telangiectasias aree matted; patients have Raynaud phenomenon, GERD, and often cutaneous sclerosis
Polymyositis	May have periungual capillary changes but not the cutaneous eruption of DM
Immune-mediated necrotizing myopathy	History of statin use; patients do not have cutaneous eruption of DM

anti-U1RNP, anti-U1 ribonucleoprotein; DM, dermatomyositis; GERD, gastroesophageal reflux disease; PIP, proximal interphalangeal; SLE, systemic lupus erythematosus.

or skin disease.[124] Remission rates of 25% to 70% have been reported, but most studies suggest that number is probably closer to 20% to 40% at 5 years. Major causes of death include malignancy, pulmonary or cardiac disease, and infection, but other predictors have variably been reported, including older age, male gender, nonwhite race, and longer duration of symptoms. Outcomes may also relate to autoantibody status; studies in both Japan and the United States have shown that presence of anti-MDA5 antibodies is a risk factor for death.[125,126]

For children, long-term registries have provided clearer data regarding remission rates, including that for skin disease. Most studies suggest that approximately 60% of patients have chronic disease (eg, past 5 years), with major risk factors for chronicity being a delay in therapy and early persistent (eg, 3 months) skin disease or decline in nailfold capillary density. Most reports suggest that the most common source of persistent disease activity is in the skin over muscles or other organs.[127-129]

MANAGEMENT

PRINCIPLES OF MANAGEMENT

Treatment of DM first requires assessing the potentially affected organs, namely the skin, muscle, and lungs. It should be emphasized that ILD and associated cancers are leading causes of disease-related death and are prioritized during treatment selection. Screening for malignancy is critical because the treatment of a cancer associated with DM may result in a reduced disease severity or, at times, disease remission. Cutaneous DM often has discordant treatment response with the muscle disease,[130] with recalcitrant skin disease continuing years after the muscle disease is in remission. Given the chronicity of the skin disease, it is worthwhile to weigh the long-term toxicity of the prescribed therapy against the achieved or potential cutaneous benefit. With that in mind, one should first select the appropriate agents to target the affected organs, consider patient comorbidities and preferences, and discuss the risks and benefits of each with the patient before deciding upon a regimen. Establishing collaborative relationships with the comanaging providers (rheumatologist, dermatologist, neurologist, and pulmonologist) is critical for the treatment of patients in whom multiple organs are involved.

CANCER SCREENING

Given that 10% to 20% of patients with DM have an associated malignancy, a thorough investigation is justified upon initial diagnosis. In addition to a complete history and physical exam, routine age-appropriate cancer screening studies (colonoscopy, mammogram, prostate examination) and relevant screening blood work (complete blood count, renal and liver function tests) as well as a urinalysis are indicated. The role of other blood work (eg, erythrocyte sedimentation rate, C-reactive protein, cancer markers, serum and urine protein immunofixation electrophoresis) in identifying cancer in a patient with DM is currently not established. The role of testing for anti–TIF1-γ and anti–NXP-2 antibodies in risk stratification is not yet known given the fact that, at least in the US population, most patients with these antibodies still do not harbor a malignancy. The role for more aggressive screening (eg, CT scans, positron emission tomography) is unclear, although as discussed earlier, this imaging may detect occult malignancies not found on routine age-appropriate screening in the higher risk period (2–3 years from diagnosis). The role for rescreening is even less clear. It would be prudent to consider blind rescreening be considered in patients with disease that is difficult to control or who have experienced an unexplained disease flare after a sustained quiescent period, especially in patients with a history of malignancy.

MONITORING OF EXTRACUTANEOUS DISEASE

MUSCLE DISEASE

Manual muscle testing is helpful to gauge changes in strength between visits. Even a busy dermatologist can check a few muscle groups such as the neck flexors, deltoids, and quadriceps at each visit to assess gross changes in muscle strength. If more time is available, then the manual muscle testing for a subset of eight muscle groups (MMT8) may be performed, which is a validated muscle test in which eight major muscle group (neck flexors, deltoids, biceps, wrist extensors, gluteus maximus, gluteus medius, quadriceps, ankles dorsiflexors) that are highest yield in idiopathic inflammatory myopathies.[131] Other factors such as pain, joint contracture, and fatigue may impact this measurement. Serum muscle enzymes (creatine kinase, aldolase, and LDH) are checked at each visit as biomarkers of myositis. However, as the duration of myositis increases, they become insensitive markers of myositis. Electromyography and MRI remain as more sensitive tests for active myositis in the setting of increasing weakness and normal muscle enzymes. The clinician must consider other causes of weakness, including muscle damage from prior myositis versus deconditioning, steroid myopathy, hydroxychloroquine-induced myopathy, or thyroid myopathy, for example. In this way, it is important not to reflexively treat weakness with increased immunosuppression until active myositis is identified as the cause.

PULMONARY DISEASE

Although there are no formalized guidelines for screening for ILD, it is valuable to obtain baseline PFTs with diffusion capacity in case there is future development of pulmonary symptoms and then annual screening as long as other symptoms of DM continue. Screening PFTs with diffusion capacity of carbon monoxide can be performed up to every 3 to 6 months if new pulmonary symptoms develop. PFT results are effort dependent and therefore influenced by following instructions during the test, muscle strength, and energy level. If PFTs show concerning changes for new or worsening ILD, then a high-resolution CT scan of the chest is the next step to evaluate the lung parenchyma.

CARDIOVASCULAR INVOLVEMENT

Consideration should be given to evaluating for cardiac muscle disease. The creatine kinase-MB isoform is found in both cardiac as well as regenerating skeletal

muscle, so it is not a specific test, although it could be used as a screening test for cardiac involvement. We prefer to use cardiac troponin I testing because it is specific for myocardial damage. There are no standard recommendations for screening for cardiac involvement, but some authorities suggest using cardiac troponin I as a screening test for subclinical myocardial involvement followed by echocardiography or electrocardiography if the result is positive.[86] Patients with DM with anti-MDA5 antibodies may be at higher risk for clinically evident and, at times, fatal cardiac involvement.[87,88]

INTERVENTIONS

Evidence for medical therapies and treatment ladders in DM arise largely from single-center, retrospective case reports, case series, and expert opinion[132-136] (Table 62-4).

TOPICAL THERAPY

Although photoprotection is a key first step in management, up to 60% of patients with DM are actually minimally photosensitive, and as few as 20% may report disease exacerbation after UV exposure.[130,137] Despite this finding, it is helpful to carefully review the basic concepts of UV protection.

Topical corticosteroids may have a palliative effect on DM skin disease by reducing erythema, scale, and pruritus and play an adjunctive role to systemic agents. However, they are unlikely to fully control skin symptoms except in the mildest cases. Class I or II topical steroid creams or ointments are used on the thick skin of the elbows, knees, and hyperkeratosis on the hands and can be tried to mitigate the common complaint of nailfold sensitivity, and occlusion with plastic wrap can be added at night to increase the potency further.

TABLE 62-4
Treatment Ladder in Dermatomyositis

	SKIN DISEASE	MUSCLE DISEASE
First Line	Photoprotection Topical steroids Hydroxychloroquine or Chloroquine Quinacrine	Systemic corticosteroids
Second Line	Methotrexate Mycophenolate mofetil Intravenous immune globulin Azathioprine	
Third Line	Tofacitnib Leflunomide Dapsone Thalidomide Cyclosporine Cyclophosphamide	Rituximab Leflunomide Cyclosporine Cyclophosphamide

Scalp pruritus may improve with topical steroid solutions or oils, although systemic agents are often needed in severe cases.

Topical calcineurin inhibitors such as tacrolimus 0.1% ointment or pimecrolimus 1% cream may have modest efficacy in some cases of cutaneous DM.[138-142] In practice, these agents have comparable efficacy to low- to midpotency topical corticosteroids (class IV to class VI). They do offer the benefit of being used safely on the face without concern for atrophy or hypopigmentation.

SYSTEMIC THERAPY

Systemic corticosteroids are undesirable agents as monotherapy for cutaneous DM because they usually elicit only partial responses and are associated with long-term side effects. However, systemic corticosteroids are first-line therapy in the treatment of myositis.[143] Complete clinical responses in muscle inflammation with prednisone monotherapy at doses greater than 0.5 mg/kg/day have been achieved in 27%[144] to 87%[11] of patients with DM.[145] They can also be used for joint disease and ILD, although often a corticosteroid-sparing agent is required.

The addition of corticosteroid-sparing agents may improve control of myositis and extracutaneous manifestations, but their critical role is to minimize toxicities of oral corticosteroids, including the risk for corticosteroid-induced myopathy.[146]

Antimalarials are typically regarded as first-line agents for skin disease. These agents have modest benefit for skin disease in DM with retrospective studies suggesting that improvement is seen in approximately 30% to 50% of patients.[147] In addition, up to 30% of patients with DM may experience a drug eruption on initiation of hydroxychloroquine.[148] The addition of quinacrine to hydroxychloroquine or chloroquine may be more effective than a single agent.[149] Hydroxychloroquine may also be useful for mild symptoms of inflammatory arthritis, and chloroquine has been reported to ameliorate arthritis in DM in one case report.[150]

Methotrexate is effective in significantly reducing cutaneous disease severity in 50% to 100% of patients with DM.[151-154] Similarly, methotrexate is a first-line treatment for myositis in combination with prednisone, and often dosages of 20 to 25 mg/wk are typically necessary to control muscle inflammation.[68,155] Methotrexate is also an effective treatment choice when concomitant arthritis is present.[156] In patients with DM with suspected or diagnosed ILD, it is prudent to select a different agent than methotrexate because of its potential to induce acute pneumonitis and pulmonary fibrosis,[157,158] thereby complicating the evaluation and management of ILD.

Mycophenolate mofetil has been shown to be effective at dosages of 2 to 3 g/day in reducing cutaneous disease severity[159,160] and myositis.[161-163] It is considered a first-line oral agent when ILD is present.[164-168] About 20% of patients experience nausea or diarrhea

at 2 g/day.[169] If GI side effects are dose limiting, then switching to enteric-coated mycophenolate sodium is an option for maintaining a patient on therapy.[170]

Intravenous immunoglobulin (IVIG) is most likely the single most effective agent for cutaneous DM, with consistently 70% to 80% of patients achieving an almost complete or complete response.[171,172] IVIG is also effective for myositis.[173,174] A randomized placebo-controlled crossover trial of 15 patients with DM by Dakalas and coworkers in 1993[175] showed a significant improvement in muscle strength in 9 of 12 patients (75%) and a dramatic improvement in skin disease based on clinical photographs in 8 of 12 patients (67%) who received IVIG. The standard dosing regimen is 2 g/kg/mo divided over 3 to 5 days. The therapeutic effect may be perceived as early as 1 week, but it may not be apparent until the second or third month. Because IVIG works relatively quickly, it can be used in patients who are rapidly declining or are acutely ill with dysphagia or respiratory muscle involvement. Headaches may occur in up to 56% of patients and may be severe and debilitating. The rate of infusion, the total dose,[176] the formulation of IVIG,[177] and the volume status of the patient may influence the occurrence of headache. Aseptic meningitis is a rare adverse event manifesting as fever, headache, photophobia, meningismus, neutrophilic pleocytosis, or eosinophilia in the cerebrospinal fluid.[178,179] Anaphylaxis is also rare but may occur in primary IgA deficiency; therefore, checking serum IgA levels before infusion is recommended. However, there is no evidence that having low but detectable immunoglobulin levels confers any increased risk for anaphylaxis.[176] Also, venous thrombosis and renal injury[179] are risks of IVIG, particularly among patients with preexisting thrombophilias or chronic kidney disease, respectively.

Azathioprine has not been assessed specifically for cutaneous DM. In combined studies of DM and polymyositis, azathioprine has shown efficacy in improving myositis in up to 75% of cases[180-182] and improving survival.[183] The first randomized controlled trial of 28 patients with polymyositis or DM compared prednisolone with azathioprine 2.5 mg/kg/day versus prednisolone with methotrexate 15 mg/wk and found no difference in efficacy for myositis.[187] The second randomized controlled crossover trial of 30 patients with polymyositis or DM showed improved response in the group receiving combination oral methotrexate and azathioprine (8 of 15; 53%) compared with methotrexate alone (3 of 15; 20%).[185] The authors occasionally combine low dose azathioprine with methotrexate when myositis is persistent with methotrexate alone. Azathioprine is commonly used as maintenance therapy in the treatment of ILD associated with idiopathic inflammatory myopathies,[47,60] typically after induction with cyclophosphamide.[186,187]

Rituximab has mixed results in cutaneous DM with a clinical trial reporting no benefit[188] one report of moderate improvement in cutaneous DM.[189] Rituximab can be of benefit for myositis, especially those with anti–Jo-1 and anti–Mi-2 autoantibodies.[190] A large randomized clinical trial did not show benefit with rituximab, although this may center around difficult issues with trial design.[191] Rituximab has been reported to be successful in retrospective studies for the treatment of ILD.[192] Dosing in DM typically follows the rheumatoid arthritis protocol of 1000 mg intravenously on days 0 and 14.[188] Infectious complications are the most frequent[193] serious adverse effects in patients with DM, with rare reports of progressive multifocal leukoencephalopathy.[193-195]

Calcineurin inhibitors (eg, cyclosporine and tacrolimus) are not commonly used to treat muscle or skin inflammation, although a randomized clinical trial of 36 patients with DM (n = 20) or polymyositis (n = 16) comparing cyclosporine (3–3.5 mg/kg/day) with methotrexate (7.5–15 mg/wk) in addition to oral corticosteroids found decreases in creatine kinase, and improvements in strength were comparable between the groups at 6 months.[196] Its primary use is in the setting of ILD, especially severe ILD in the setting of anti-MDA5 or antisynthetase antibodies.[197,198] Nephrotoxicity risk is highest above 3 mg/kg/day and requires careful monitoring of renal function and blood pressure.[199,200]

Other treatments reported for use in DM skin disease include dapsone and thalidomide, but evidence of their efficacy is scant.

PHYSICAL MEDICINE AND REHABILITATION

Strength training has been shown to improve muscle strength and function,[201-203] and aerobic exercise has been shown to improve endurance[204,205] in patients with chronic DM. In active DM and polymyositis, a home strength training program has been shown to be safe[206] but did not show benefit in strength or disease control over the control group that performed range of motion exercises in a randomized clinical trial.[207] We advise all patients to enroll in a physical therapy program early after diagnosis so as to prevent injury and to maintain as much mobility and muscle strength as possible.

SPECIAL CIRCUMSTANCES

Calcinosis remains one of the most formidable therapeutic challenging in DM. Surgical excision for localized lesions remains the most effective and definitive therapy.[208] Multiple medical therapies have been proposed, including anti-inflammatory medications and calcium and phosphate modulators, but no single agent is reliably effective.[31] IVIG has been reported to work well in some cases[209-211] but not in others.[212] Bisphosphonates have been cited as effective for calcinosis in juvenile DM, although controlled studies are needed.[213-215]

REFERENCES

1. Bohan A, Peter JB. Polymyositis and dermatomyositis (second of two parts). *N Engl J Med*. 1975;292:403-407.
2. Bohan A, Peter JB. Polymyositis and dermatomyositis (first of two parts). *N Engl J Med*. 1975;292:344-347.
3. Bendewald MJ, Wetter DA, Li X, et al. Incidence of dermatomyositis and clinically amyopathic dermatomyositis: a population-based study in Olmsted County, Minnesota. *Arch Dermatol*. 2010;146:26-30.
4. Euwer RL, Sontheimer RD. Amyopathic dermatomyositis (dermatomyositis sine myositis). Presentation of six new cases and review of the literature. *J Am Acad Dermatol*. 1991;24:959-966.
5. Sontheimer RD. Dermatomyositis: an overview of recent progress with emphasis on dermatologic aspects. *Dermatol Clin*. 2002;20:387-408.
6. Sontheimer RD. Cutaneous features of classic dermatomyositis and amyopathic dermatomyositis. *Curr Opin Rheumatol*. 1999;11:475-482.
7. Sontheimer RD. Skin disease in dermatomyositis—what patients and their families often want to know. *Dermatol Online J*. 2002;8:6.
8. Gerami P, Schope JM, McDonald L, et al. A systematic review of adult-onset clinically amyopathic dermatomyositis (dermatomyositis sine myositis): a missing link within the spectrum of the idiopathic inflammatory myopathies. *J Am Acad Dermatol*. 2006;54:597-613.
9. Dalakas MC, Hohlfeld R. Polymyositis and dermatomyositis. *Lancet*. 2003;362:971-982.
10. Hoogendijk JE, Amato AA, Lecky BR, et al. 119th ENMC international workshop: trial design in adult idiopathic inflammatory myopathies, with the exception of inclusion body myositis, 10-12 October 2003, Naarden, The Netherlands. *Neuromuscul Disord*. 2004;14:337-345.
11. Troyanov Y, Targoff IN, Tremblay JL, et al. Novel classification of idiopathic inflammatory myopathies based on overlap syndrome features and autoantibodies: analysis of 100 French Canadian patients. *Medicine (Baltimore)*. 2005;84:231-249.
12. Fernandez C, Bardin N, De Paula AM, et al. Correlation of clinicoserologic and pathologic classifications of inflammatory myopathies: study of 178 cases and guidelines for diagnosis. *Medicine (Baltimore)*. 2013;92:15-24.
13. Meyer A, Meyer N, Schaeffer M, et al. Incidence and prevalence of inflammatory myopathies: a systematic review. *Rheumatology (Oxford)*. 2015;54:50-63.
14. Bernatsky S, Joseph L, Pineau CA, et al. Estimating the prevalence of polymyositis and dermatomyositis from administrative data: age, sex and regional differences. *Ann Rheum Dis*. 2009;68:1192-1196.
15. Dobloug C, Garen T, Bitter H, et al. Prevalence and clinical characteristics of adult polymyositis and dermatomyositis; data from a large and unselected Norwegian cohort. *Ann Rheum Dis*. 2015;74:1551-1556.
16. Ohta A, Nagai M, Nishina M, et al. Prevalence and incidence of polymyositis and dermatomyositis in Japan. *Mod Rheumatol*. 2014;24:477-480.
17. Kuo CF, See LC, Yu KH, et al. Incidence, cancer risk and mortality of dermatomyositis and polymyositis in Taiwan: a nationwide population study. *Br J Dermatol*. 2011;165:1273-1279.
18. Mendez EP, Lipton R, Ramsey-Goldman R, et al. US incidence of juvenile dermatomyositis, 1995-1998: results from the National Institute of Arthritis and Musculoskeletal and Skin Diseases Registry. *Arthritis Rheum*. 2003;49:300-305.
19. Hurliman E, Groth D, Wendelschafer-Crabb G, et al. Small fiber neuropathy in a patient with dermatomyositis and severe scalp pruritus. *Br J Dermatol*. 2016.
20. Taggart AJ, Finch MB, Courtney PA, et al. Anti Jo-1 myositis. "Mechanic's hands" and interstitial lung disease. *Ulster Med J*. 2002;71:68-71.
21. Sato Y, Teraki Y, Izaki S, et al. Clinical characterization of dermatomyositis associated with mechanic's hands. *J Dermatol*. 2012;39:1093-1095.
22. Smith RL, Sundberg J, Shamiyah E, et al. Skin involvement in juvenile dermatomyositis is associated with loss of end row nailfold capillary loops. *J Rheumatol*. 2004;31:1644-1649.
23. Manfredi A, Sebastiani M, Cassone G, et al. Nailfold capillaroscopic changes in dermatomyositis and polymyositis. *Clin Rheumatol*. 2015;34:279-284.
24. Ghali FE, Stein LD, Fine JD, et al. Gingival telangiectases: an underappreciated physical sign of juvenile dermatomyositis. *Arch Dermatol*. 1999;135:1370-1374.
25. Narang NS, Casciola-Rosen L, Li S, et al. Cutaneous ulceration in dermatomyositis: association with anti-melanoma differentiation-associated gene 5 antibodies and interstitial lung disease. *Arthritis Care Res (Hoboken)*. 2014;67(5):667-672.
26. Cao H, Xia Q, Pan M, et al. Gottron papules and Gottron sign with ulceration: a distinctive cutaneous feature in a subset of patients with classic dermatomyositis and clinically amyopathic dermatomyositis. *J Rheumatol*. 2016;43(9):1735-1742.
27. Xu Y, Yang CS, Li YJ, et al. Predictive factors of rapidly progressive-interstitial lung disease in patients with clinically amyopathic dermatomyositis. *Clin Rheumatol*. 2016;35:113-116.
28. Bernet LL, Lewis MA, Rieger KE, et al. Ovoid palatal patch in dermatomyositis: a novel finding associated with anti-TIF1gamma (p155) antibodies. *JAMA Dermatol*. 2016;152(9):1049-1051.
29. Fiorentino DF, Kuo K, Chung L, et al. Distinctive cutaneous and systemic features associated with antitranscriptional intermediary factor-1gamma antibodies in adults with dermatomyositis. *J Am Acad Dermatol*. 2015;72:449-455.
30. Walsh JS, Fairley JA. Calcifying disorders of the skin. *J Am Acad Dermatol*. 1995;33:693-706; quiz 707-710.
31. Hoeltzel MF, Oberle EJ, Robinson AB, et al. The presentation, assessment, pathogenesis, and treatment of calcinosis in juvenile dermatomyositis. *Curr Rheumatol Rep*. 2014;16:467-014-0467-y.
32. Balin SJ, Wetter DA, Andersen LK, et al. Calcinosis cutis occurring in association with autoimmune connective tissue disease: the Mayo Clinic experience with 78 patients, 1996-2009. *Arch Dermatol*. 2012;148:455-462.
33. Sallum AM, Pivato FC, Doria-Filho U, et al. Risk factors associated with calcinosis of juvenile dermatomyositis. *J Pediatr (Rio J)*. 2008;84:68-74.
34. Sanner H, Gran JT, Sjaastad I, et al. Cumulative organ damage and prognostic factors in juvenile dermatomyositis: a cross-sectional study median 16.8 years after symptom onset. *Rheumatology (Oxford)*. 2009;48:1541-1547.
35. Gunawardena H, Wedderburn LR, Chinoy H, et al. Autoantibodies to a 140-kd protein in juvenile dermatomyositis are associated with calcinosis. *Arthritis Rheum*. 2009;60:1807-1814.

36. Valenzuela A, Chung L, Casciola-Rosen L, et al. Identification of clinical features and autoantibodies associated with calcinosis in dermatomyositis. *JAMA Dermatol*. 2014;150:724-729.
37. Hansen CB, Callen JP. Connective tissue panniculitis: lupus panniculitis, dermatomyositis, morphea/scleroderma. *Dermatol Ther*. 2010;23:341-349.
38. Milisenda JC, Doti PI, Prieto-Gonzalez S, et al. Dermatomyositis presenting with severe subcutaneous edema: five additional cases and review of the literature. *Semin Arthritis Rheum*. 2014;44:228-233.
39. Tu J, McLean-Tooke A, Junckerstorff R. Increasing recognition of dermatomyositis with subcutaneous edema—is this a poorer prognostic marker? *Dermatol Online J*. 2014;20:21244.
40. Kim NN, Lio PA, Morgan GA, et al. Double trouble: therapeutic challenges in patients with both juvenile dermatomyositis and psoriasis. *Arch Dermatol*. 2011;147:831-835.
41. Sarin KY, Chung L, Kim J, et al. Molecular profiling to diagnose a case of atypical dermatomyositis. *J Invest Dermatol*. 2013;133:2796-2799.
42. Marie I, Hatron PY, Dominique S, et al. Short-term and long-term outcomes of interstitial lung disease in polymyositis and dermatomyositis: a series of 107 patients. *Arthritis Rheum*. 2011;63:3439-3447.
43. Kang EH, Lee EB, Shin KC, et al. Interstitial lung disease in patients with polymyositis, dermatomyositis and amyopathic dermatomyositis. *Rheumatology (Oxford)*. 2005;44:1282-1286.
44. Fiorentino D, Chung L, Zwerner J, et al. The mucocutaneous and systemic phenotype of dermatomyositis patients with antibodies to MDA5 (CADM-140):a retrospective study. *J Am Acad Dermatol*. 2011;65:25-34.
45. Sun Y, Liu Y, Yan B, et al. Interstitial lung disease in clinically amyopathic dermatomyositis (CADM) patients: a retrospective study of 41 Chinese Han patients. *Rheumatol Int*. 2013;33:1295-1302.
46. Mukae H, Ishimoto H, Sakamoto N, et al. Clinical differences between interstitial lung disease associated with clinically amyopathic dermatomyositis and classic dermatomyositis. *Chest*. 2009;136:1341-1347.
47. Connors GR, Christopher-Stine L, Oddis CV, et al. Interstitial lung disease associated with the idiopathic inflammatory myopathies: what progress has been made in the past 35 years? *Chest*. 2010;138:1464-1474.
48. Fathi M, Lundberg IE. Interstitial lung disease in polymyositis and dermatomyositis. *Curr Opin Rheumatol*. 2005;17:701-706.
49. Johnson C, Pinal-Fernandez I, Parikh R, et al. Assessment of mortality in autoimmune myositis with and without associated interstitial lung disease. *Lung*. 2016;194(5):733-737.
50. Richards TJ, Eggebeen A, Gibson K, et al. Characterization and peripheral blood biomarker assessment of anti-Jo-1 antibody-positive interstitial lung disease. *Arthritis Rheum*. 2009;60:2183-2192.
51. Cao H, Pan M, Kang Y, et al. Clinical manifestations of dermatomyositis and clinically amyopathic dermatomyositis patients with positive expression of anti-melanoma differentiation-associated gene 5 antibody. *Arthritis Care Res (Hoboken)*. 2012;64:1602-1610.
52. Chen Z, Cao M, Plana MN, et al. Utility of anti-melanoma differentiation-associated gene 5 antibody measurement in identifying patients with dermatomyositis and a high risk for developing rapidly progressive interstitial lung disease: a review of the literature and a meta-analysis. *Arthritis Care Res (Hoboken)*. 2013;65:1316-1324.
53. Hamaguchi Y, Kuwana M, Hoshino K, et al. Clinical correlations with dermatomyositis-specific autoantibodies in adult Japanese patients with dermatomyositis: a multicenter cross-sectional study. *Arch Dermatol*. 2011;147:391-398.
54. Cao H, Pan M, Kang Y, et al. Clinical manifestations of dermatomyositis and clinically amyopathic dermatomyositis patients with positive expression of anti-melanoma differentiation-associated gene 5 antibody. *Arthritis Care Res (Hoboken)*. 2012;64:1602-1610.
55. Gono T, Kawaguchi Y, Satoh T, et al. Clinical manifestation and prognostic factor in anti-melanoma differentiation-associated gene 5 antibody-associated interstitial lung disease as a complication of dermatomyositis. *Rheumatology (Oxford)*. 2010;49:1713-1719.
56. Labrador-Horrillo M, Martinez MA, Selva-O'Callaghan A, et al. Anti-MDA5 antibodies in a large Mediterranean population of adults with dermatomyositis. *J Immunol Res*. 2014;2014:290797.
57. Martinez FJ, Flaherty K. Pulmonary function testing in idiopathic interstitial pneumonias. *Proc Am Thorac Soc*. 2006;3:315-321.
58. Da Silva JA, Jacobs JW, Kirwan JR, et al. Safety of low dose glucocorticoid treatment in rheumatoid arthritis: published evidence and prospective trial data. *Ann Rheum Dis*. 2006;65:285-293.
59. Fathi M, Dastmalchi M, Rasmussen E, et al. Interstitial lung disease, a common manifestation of newly diagnosed polymyositis and dermatomyositis. *Ann Rheum Dis*. 2004;63:297-301.
60. Douglas WW, Tazelaar HD, Hartman TE, et al. Polymyositis-dermatomyositis-associated interstitial lung disease. *Am J Respir Crit Care Med*. 2001;164:1182-1185.
61. Zhang RF, Zhou L, Ma GF, et al. Diagnostic value of transthoracic Doppler echocardiography in pulmonary hypertension: a meta-analysis. *Am J Hypertens*. 2010;23:1261-1264.
62. Hoeper MM, Bogaard HJ, Condliffe R, et al. Definitions and diagnosis of pulmonary hypertension. *J Am Coll Cardiol*. 2013;62:D42-50.
63. Cosnes A, Amaudric F, Gherardi R, et al. Dermatomyositis without muscle weakness. Long-term follow-up of 12 patients without systemic corticosteroids. *Arch Dermatol*. 1995;131:1381-1385.
64. Smith BW, McCarthy JC, Dawley CA. Suspect myopathy? Take this approach to the work-up. *J Fam Pract*. 2014;63:631-638.
65. Pachman LM, Hayford JR, Chung A, et al. Juvenile dermatomyositis at diagnosis: clinical characteristics of 79 children. *J Rheumatol*. 1998;25:1198-1204.
66. Parodi A, Caproni M, Marzano AV, et al. Dermatomyositis in 132 patients with different clinical subtypes: cutaneous signs, constitutional symptoms and circulating antibodies. *Acta Derm Venereol*. 2002;82:48-51.
67. Mugii N, Hasegawa M, Matsushita T, et al. Oropharyngeal dysphagia in dermatomyositis: associations with clinical and laboratory features including autoantibodies. *PLoS One*. 2016;11:e0154746.
68. Koh ET, Seow A, Ong B, et al. Adult onset polymyositis/dermatomyositis: clinical and laboratory features and treatment response in 75 patients. *Ann Rheum Dis*. 1993;52:857-861.

69. Citera G, Goni MA, Maldonado, et al. Joint involvement in polymyositis/dermatomyositis. *Clin Rheumatol*. 1994;13:70-74.
70. Porkodi R, Shanmuganandan K, Parthiban M, et al. Clinical spectrum of inflammatory myositis in South India—a ten year study. *J Assoc Physicians India*. 2002;50:1255-1258.
71. Klein M, Mann H, Plestilova L, et al. Arthritis in idiopathic inflammatory myopathy: clinical features and autoantibody associations. *J Rheumatol*. 2014;41:1133-1139.
72. Mumm GE, McKown KM, Bell CL. Antisynthetase syndrome presenting as rheumatoid-like polyarthritis. *J Clin Rheumatol*. 2010;16:307-312.
73. Mammen AL. Autoimmune myopathies: autoantibodies, phenotypes and pathogenesis. *Nat Rev Neurol*. 2011;7:343-354.
74. Wasko MC, Carlson GW, Tomaino MM, et al. Dermatomyositis with erosive arthropathy: association with the anti-PL-7 antibody. *J Rheumatol*. 1999;26: 2693-2694.
75. Oddis CV, Medsger TA Jr, Cooperstein LA. A subluxing arthropathy associated with the anti-Jo-1 antibody in polymyositis/dermatomyositis. *Arthritis Rheum*. 1990;33:1640-1645.
76. Schumacher HR, Schimmer B, Gordon GV, et al. Articular manifestations of polymyositis and dermatomyositis. *Am J Med*. 1979;67:287-292.
77. Levin J, Werth VP. Skin disorders with arthritis. *Best Pract Res Clin Rheumatol*. 2006;20:809-826.
78. Hall JC, Casciola-Rosen L, Samedy LA, et al. Anti-melanoma differentiation-associated protein 5-associated dermatomyositis: expanding the clinical spectrum. *Arthritis Care Res (Hoboken)*. 2013;65: 1307-1315.
79. Robinson AB, Hoeltzel MF, Wahezi DM, et al. Clinical characteristics of children with juvenile dermatomyositis: the Childhood Arthritis and Rheumatology Research Alliance Registry. *Arthritis Care Res (Hoboken)*. 2014;66:404-410.
80. Gitiaux C, De Antonio M, Aouizerate J, et al. Vasculopathy-related clinical and pathological features are associated with severe juvenile dermatomyositis. *Rheumatology (Oxford)*. 2016;55:470-479.
81. Tweezer-Zaks N, Ben-Horin S, Schiby G, et al. Severe gastrointestinal inflammation in adult dermatomyositis: characterization of a novel clinical association. *Am J Med Sci*. 2006;332:308-313.
82. Mamyrova G, Kleiner DE, James-Newton L, et al. Late-onset gastrointestinal pain in juvenile dermatomyositis as a manifestation of ischemic ulceration from chronic endarteropathy. *Arthritis Rheum*. 2007;57:881-884.
83. Zhang L, Wang GC, Ma L, et al. Cardiac involvement in adult polymyositis or dermatomyositis: a systematic review. *Clin Cardiol*. 2012;35:686-691.
84. Gonzalez-Lopez L, Gamez-Nava JI, Sanchez L, et al. Cardiac manifestations in dermato-polymyositis. *Clin Exp Rheumatol*. 1996;14:373-379.
85. Rosenbohm A, Buckert D, Gerischer N, et al. Early diagnosis of cardiac involvement in idiopathic inflammatory myopathy by cardiac magnetic resonance tomography. *J Neurol*. 2015;262:949-956.
86. Hughes M, Lilleker JB, Herrick AL, et al. Cardiac troponin testing in idiopathic inflammatory myopathies and systemic sclerosis-spectrum disorders: biomarkers to distinguish between primary cardiac involvement and low-grade skeletal muscle disease activity. *Ann Rheum Dis*. 2015;74:795-798.
87. Pau-Charles I, Moreno PJ, Ortiz-Ibanez K, et al. Anti-MDA5 positive clinically amyopathic dermatomyositis presenting with severe cardiomyopathy. *J Eur Acad DermatolJ Eur Acad Dermatol Venereol*. 2014;28:1097-1102.
88. Sakurai N, Nagai K, Tsutsumi H, et al. Anti-CADM-140 antibody-positive juvenile dermatomyositis with rapidly progressive interstitial lung disease and cardiac involvement. *J Rheumatol*. 2011;38:963-964.
89. Madan V, Chinoy H, Griffiths CE, et al. Defining cancer risk in dermatomyositis. Part I. *Clin Exp Dermatol*. 2009;34:451-455.
90. Olazagasti JM, Baez PJ, Wetter DA, et al. Cancer risk in dermatomyositis: a meta-analysis of cohort studies. *Am J Clin Dermatol*. 2015;16:89-98.
91. Hill CL, Zhang Y, Sigurgeirsson B, et al. Frequency of specific cancer types in dermatomyositis and polymyositis: a population-based study. *Lancet*. 2001;357:96-100.
92. Chow WH, Gridley G, Mellemkjaer L, et al. Cancer risk following polymyositis and dermatomyositis: a nationwide cohort study in Denmark. *Cancer Causes Control*. 1995;6:9-13.
93. Sigurgeirsson B, Lindelof B, Edhag O, et al. Risk of cancer in patients with dermatomyositis or polymyositis. A population-based study. *N Engl J Med*. 1992;326:363-367.
94. Huang YL, Chen YJ, Lin MW, et al. Malignancies associated with dermatomyositis and polymyositis in Taiwan: a nationwide population-based study. *Br J Dermatol*. 2009;161:854-860.
95. Lu X, Yang H, Shu X, et al. Factors predicting malignancy in patients with polymyositis and dermatomyostis: a systematic review and meta-analysis. *PLoS One*. 2014;9:e94128.
96. Trallero-Araguas E, Rodrigo-Pendas JA, Selva-O'Callaghan A, et al. Usefulness of anti-p155 autoantibody for diagnosing cancer-associated dermatomyositis: a systematic review and meta-analysis. *Arthritis Rheum*. 2012;64:523-532.
97. Fiorentino DF, Chung LS, Christopher-Stine L, et al. Most patients with cancer-associated dermatomyositis have antibodies to nuclear matrix protein NXP-2 or transcription intermediary factor 1gamma. *Arthritis Rheum*. 2013;65:2954-2962.
98. Ichimura Y, Matsushita T, Hamaguchi Y, et al. Anti-NXP2 autoantibodies in adult patients with idiopathic inflammatory myopathies: possible association with malignancy. *Ann Rheum Dis*. 2012;71:710-713.
99. Sparsa A, Liozon E, Herrmann F, et al. Routine vs extensive malignancy search for adult dermatomyositis and polymyositis: a study of 40 patients. *Arch Dermatol*. 2002;138:885-890.
100. Caproni M, Torchia D, Cardinali C, et al. Infiltrating cells, related cytokines and chemokine receptors in lesional skin of patients with dermatomyositis. *Br J Dermatol*. 2004;151:784-791.
101. Greenberg SA, Pinkus JL, Pinkus GS, et al. Interferon-alpha/beta-mediated innate immune mechanisms in dermatomyositis. *Ann Neurol*. 2005;57:664-678.
102. Baechler EC, Bauer JW, Slattery CA, et al. An interferon signature in the peripheral blood of dermatomyositis patients is associated with disease activity. *Mol Med*. 2007;13:59-68.
103. Mascaro JM Jr, Hausmann G, Herrero C, et al. Membrane attack complex deposits in cutaneous lesions of dermatomyositis. *Arch Dermatol*. 1995;131:1386-1392.

104. Greenberg SA. Dermatomyositis and type 1 interferons. *Curr Rheumatol Rep*. 2010;12:198-203.
105. Reed AM, Pachman LM, Hayford J, et al. Immunogenetic studies in families of children with juvenile dermatomyositis. *J Rheumatol*. 1998;25:1000-1002.
106. Mallen SR, Essex MN, Zhang R. Gastrointestinal tolerability of NSAIDs in elderly patients: a pooled analysis of 21 randomized clinical trials with celecoxib and nonselective NSAIDs. *Curr Med Res Opin*. 2011;27:1359-1366.
107. Reed AM, Pachman L, Ober C. Molecular genetic studies of major histocompatibility complex genes in children with juvenile dermatomyositis: increased risk associated with HLA-DQA1 *0501. *Hum Immunol*. 1991;32:235-240.
108. Pinal-Fernandez I, Casciola-Rosen LA, Christopher-Stine L, et al. The prevalence of individual histopathologic features varies according to autoantibody status in muscle biopsies from patients with dermatomyositis. *J Rheumatol*. 2015;42:1448-1454.
109. Bohan A, Peter JB, Bowman RL, et al. Computer-assisted analysis of 153 patients with polymyositis and dermatomyositis. *Medicine (Baltimore)*. 1977;56:255-286.
110. Briani C, Doria A, Sarzi-Puttini P, et al. Update on idiopathic inflammatory myopathies. *Autoimmunity*. 2006;39:161-170.
111. Horai Y, Koga T, Fujikawa K, et al. Serum interferon-alpha is a useful biomarker in patients with anti-melanoma differentiation-associated gene 5 (MDA5) antibody-positive dermatomyositis. *Mod Rheumatol*. 2015;25:85-89.
112. Gono T, Sato S, Kawaguchi Y, et al. Anti-MDA5 antibody, ferritin and IL-18 are useful for the evaluation of response to treatment in interstitial lung disease with anti-MDA5 antibody-positive dermatomyositis. *Rheumatology (Oxford)*. 2012;51:1563-1570.
113. Mimori T, Nakashima R, Hosono Y. Interstitial lung disease in myositis: clinical subsets, biomarkers, and treatment. *Curr Rheumatol Rep*. 2012;14:264-274.
114. Del Grande F, Carrino JA, Del Grande M, et al. Magnetic resonance imaging of inflammatory myopathies. *Top Magn Reson Imaging*. 2011;22:39-43.
115. Curiel RV, Jones R, Brindle K. Magnetic resonance imaging of the idiopathic inflammatory myopathies: structural and clinical aspects. *Ann N Y Acad Sci*. 2009;1154:101-114.
116. Barsotti S, Zampa V, Talarico R, et al. Thigh magnetic resonance imaging for the evaluation of disease activity in patients with idiopathic inflammatory myopathies followed in a single center. *Muscle Nerve*. 2016;54(4):666-672.
117. Adams EM, Chow CK, Premkumar A, et al. The idiopathic inflammatory myopathies: spectrum of MR imaging findings. *Radiographics*. 1995;15:563-574.
118. Yoshida K, Kurosaka D, Joh K, et al. Fasciitis as a common lesion of dermatomyositis, demonstrated early after disease onset by en bloc biopsy combined with magnetic resonance imaging. *Arthritis Rheum*. 2010;62:3751-3759.
119. Smith ES, Hallman JR, DeLuca AM, et al. Dermatomyositis: a clinicopathological study of 40 patients. *Am J Dermatopathol*. 2009;31:61-67.
120. McNiff JM, Kaplan DH. Plasmacytoid dendritic cells are present in cutaneous dermatomyositis lesions in a pattern distinct from lupus erythematosus. *J Cutan Pathol*. 2008;35:452-456.
121. Magro CM, Crowson AN. The immunofluorescent profile of dermatomyositis: a comparative study with lupus erythematosus. *J Cutan Pathol*. 1997;24:543-552.
122. Kissel JT, Mendell JR, Rammohan KW. Microvascular deposition of complement membrane attack complex in dermatomyositis. *N Engl J Med*. 1986;314:329-334.
123. Arahata K, Engel AG. Monoclonal antibody analysis of mononuclear cells in myopathies. I: quantitation of subsets according to diagnosis and sites of accumulation and demonstration and counts of muscle fibers invaded by T cells. *Ann Neurol*. 1984;16:193-208.
124. Marie I. Morbidity and mortality in adult polymyositis and dermatomyositis. *Curr Rheumatol Rep*. 2012;14:275-285.
125. Moghadam-Kia S, Oddis CV, Sato S, et al. Anti-melanoma differentiation-associated gene 5 is associated with rapidly progressive lung disease and poor survival in US patients with amyopathic and myopathic dermatomyositis. *Arthritis Care Res (Hoboken)*. 2016;68:689-694.
126. Koga T, Fujikawa K, Horai Y, et al. The diagnostic utility of anti-melanoma differentiation-associated gene 5 antibody testing for predicting the prognosis of Japanese patients with DM. *Rheumatology (Oxford)*. 2012;51:1278-1284.
127. Christen-Zaech S, Seshadri R, Sundberg J, et al. Persistent association of nailfold capillaroscopy changes and skin involvement over thirty-six months with duration of untreated disease in patients with juvenile dermatomyositis. *Arthritis Rheum*. 2008;58:571-576.
128. Stringer E, Singh-Grewal D, Feldman BM. Predicting the course of juvenile dermatomyositis: significance of early clinical and laboratory features. *Arthritis Rheum*. 2008;58:3585-3592.
129. Sanner H, Sjaastad I, Flato B. Disease activity and prognostic factors in juvenile dermatomyositis: a long-term follow-up study applying the Paediatric Rheumatology International Trials Organization criteria for inactive disease and the myositis disease activity assessment tool. *Rheumatology (Oxford)*. 2014;53:1578-1585.
130. Dourmishev L, Meffert H, Piazena H. Dermatomyositis: comparative studies of cutaneous photosensitivity in lupus erythematosus and normal subjects. *Photodermatol Photoimmunol Photomed*. 2004;20:230-234.
131. Rider LG, Koziol D, Giannini EH, et al. Validation of manual muscle testing and a subset of eight muscles for adult and juvenile idiopathic inflammatory myopathies. *Arthritis Care Res (Hoboken)*. 2010;62:465-472.
132. Femia AN, Vleugels RA, Callen JP. Cutaneous dermatomyositis: an updated review of treatment options and internal associations. *Am J Clin Dermatol*. 2013;14:291-313.
133. Lam C, Vleugels RA. Management of cutaneous dermatomyositis. *Dermatol Ther*. 2012;25:112-134.
134. Strowd LC, Jorizzo JL. Review of dermatomyositis: establishing the diagnosis and treatment algorithm. *J Dermatolog Treat*. 2013;24:418-421.
135. Jorizzo J, Vleugels RA. Dermatomyositis. In: Bolognia J, Jorizzo J, Schaffer J, eds. *Dermatology*. Vol 1. 3rd ed. St. Louis: Saunders; 2012:639.
136. Mathai SC, Danoff SK. Management of interstitial lung disease associated with connective tissue disease. *BMJ*. 2016;352:h6819.
137. Cheong WK, Hughes GR, Norris PG, et al. Cutaneous photosensitivity in dermatomyositis. *Br J Dermatol*. 1994;131:205-208.

138. Peyrot I, Sparsa A, Loustaud-Ratti V, et al. Topical tacrolimus and resistant skin lesions of dermatomyositis. *Rev Med Interne*. 2006;27:730-735.
139. Lampropoulos CE, D'Cruz DP. Topical tacrolimus treatment in a patient with dermatomyositis. *Ann Rheum Dis*. 2005;64:1376-1377.
140. Hollar CB, Jorizzo JL. Topical tacrolimus 0.1% ointment for refractory skin disease in dermatomyositis: a pilot study. *J Dermatolog Treat*. 2004;15:35-39.
141. Yoshimasu T, Ohtani T, Sakamoto T, et al. Topical FK506 (tacrolimus) therapy for facial erythematous lesions of cutaneous lupus erythematosus and dermatomyositis. *Eur J Dermatol*. 2002;12:50-52.
142. Kim JE, Jeong MG, Lee HE, et al. Successful treatment of cutaneous lesions of dermatomyositis with topical pimecrolimus. *Ann Dermatol*. 2011;23:348-351.
143. Iorizzo LJ 3rd, Jorizzo JL. The treatment and prognosis of dermatomyositis: an updated review. *J Am Acad Dermatol*. 2008;59:99-112.
144. Chwalinska-Sadowska H, Maldykowa H. Polymyositis-dermatomyositis:25 years of follow-up of 50 patients disease course, treatment, prognostic factors. *Mater Med Pol*. 1990;22:213-218.
145. Marie I, Hachulla E, Hatron PY, et al. Polymyositis and dermatomyositis: short term and long term outcome, and predictive factors of prognosis. *J Rheumatol*. 2001;28:2230-2237.
146. Dalakas MC. Inflammatory myopathies: management of steroid resistance. *Curr Opin Neurol*. 2011; 24:457-462.
147. Woo TY, Callen JP, Voorhees JJ, et al. Cutaneous lesions of dermatomyositis are improved by hydroxychloroquine. *J Am Acad Dermatol*. 1984;10:592-600.
148. Pelle MT, Callen JP. Adverse cutaneous reactions to hydroxychloroquine are more common in patients with dermatomyositis than in patients with cutaneous lupus erythematosus. *Arch Dermatol*. 2002;138: 1231-1233; discussion 1233.
149. Ang GC, Werth VP. Combination antimalarials in the treatment of cutaneous dermatomyositis: a retrospective study. *Arch Dermatol*. 2005;141:855-859.
150. Climent-Albaladejo A, Saiz-Cuenca E, Rosique-Roman J, et al. Dermatomyositis sine myositis and antisynthetase syndrome. *Joint Bone Spine*. 2002;69:72-75.
151. Zieglschmid-Adams ME, Pandya AG, Cohen SB, et al. Treatment of dermatomyositis with methotrexate. *J Am Acad Dermatol*. 1995;32:754-757.
152. Kasteler JS, Callen JP. Low-dose methotrexate administered weekly is an effective corticosteroid-sparing agent for the treatment of the cutaneous manifestations of dermatomyositis. *J Am Acad Dermatol*. 1997;36:67-71.
153. Hornung T, Ko A, Tuting T, et al. Efficacy of low-dose methotrexate in the treatment of dermatomyositis skin lesions. *Clin Exp Dermatol*. 2012;37:139-142.
154. Click JW, Qureshi AA, Vleugels RA. Methotrexate for the treatment of cutaneous dermatomyositis. *J Am Acad Dermatol*. 2013;68:1043-1045.
155. Metzger AL, Bohan A, Goldberg LS, et al. Polymyositis and dermatomyositis: combined methotrexate and corticosteroid therapy. *Ann Intern Med*. 1974;81:182-189.
156. Tse S, Lubelsky S, Gordon M, et al. The arthritis of inflammatory childhood myositis syndromes. *J Rheumatol*. 2001;28:192-197.
157. Camus P, Fanton A, Bonniaud P, et al. Interstitial lung disease induced by drugs and radiation. *Respiration*. 2004;71:301-326.
158. Kim YJ, Song M, Ryu JC. Mechanisms underlying methotrexate-induced pulmonary toxicity. *Expert Opin Drug Saf*. 2009;8:451-458.
159. Edge JC, Outland JD, Dempsey JR, et al. Mycophenolate mofetil as an effective corticosteroid-sparing therapy for recalcitrant dermatomyositis. *Arch Dermatol*. 2006;142:65-69.
160. Gelber AC, Nousari HC, Wigley FM. Mycophenolate mofetil in the treatment of severe skin manifestations of dermatomyositis: a series of 4 cases. *J Rheumatol*. 2000;27:1542-1545.
161. Majithia V, Harisdangkul V. Mycophenolate mofetil (CellCept): an alternative therapy for autoimmune inflammatory myopathy. *Rheumatology (Oxford)*. 2005;44:386-389.
162. Pisoni CN, Cuadrado MJ, Khamashta MA, et al. Mycophenolate mofetil treatment in resistant myositis. *Rheumatology (Oxford)*. 2007;46:516-518.
163. Rowin J, Amato AA, Deisher N, et al. Mycophenolate mofetil in dermatomyositis: is it safe? *Neurology*. 2006;66:1245-1247.
164. Tsuchiya H, Tsuno H, Inoue M, et al. Mycophenolate mofetil therapy for rapidly progressive interstitial lung disease in a patient with clinically amyopathic dermatomyositis. *Mod Rheumatol*. 2014;24:694-696.
165. Cozzani E, Cinotti E, Felletti R, et al. Amyopathic dermatomyositis with lung involvement responsive to mycophenolate mofetil. *Immunopharmacol Immunotoxicol*. 2013;35:687-692.
166. Morganroth PA, Kreider ME, Werth VP. Mycophenolate mofetil for interstitial lung disease in dermatomyositis. *Arthritis Care Res (Hoboken)*. 2010;62:1496-1501.
167. Mira-Avendano IC, Parambil JG, Yadav R, et al. A retrospective review of clinical features and treatment outcomes in steroid-resistant interstitial lung disease from polymyositis/dermatomyositis. *Respir Med*. 2013;107:890-896.
168. Saketkoo LA, Espinoza LR. Experience of mycophenolate mofetil in 10 patients with autoimmune-related interstitial lung disease demonstrates promising effects. *Am J Med Sci*. 2009;337:329-335.
169. Kitchin JE, Pomeranz MK, Pak G, et al. Rediscovering mycophenolic acid: a review of its mechanism, side effects, and potential uses. *J Am Acad Dermatol*. 1997;37:445-449.
170. Sterneck M, Settmacher U, Ganten T, et al. Improvement in gastrointestinal and health-related quality of life outcomes after conversion from mycophenolate mofetil to enteric-coated mycophenolate sodium in liver transplant recipients. *Transplant Proc*. 2014;46:234-240.
171. Femia AN, Eastham AB, Lam C, et al. Intravenous immunoglobulin for refractory cutaneous dermatomyositis: a retrospective analysis from an academic medical center. *J Am Acad Dermatol*. 2013;69:654-657.
172. Bounfour T, Bouaziz JD, Bezier M, et al. Clinical efficacy of intravenous immunoglobulins for the treatment of dermatomyositis skin lesions without muscle disease. *J Eur Acad Dermatol Venereol*. 2014;28:1150-1157.
173. Cherin P, Herson S, Wechsler B, et al. Efficacy of intravenous gammaglobulin therapy in chronic refractory polymyositis and dermatomyositis: an open study with 20 adult patients. *Am J Med*. 1991;91: 162-168.
174. Cherin P, Herson S, Wechsler B, et al. Intravenous immunoglobulin for polymyositis and dermatomyositis. *Lancet*. 1990;336:116.

175. Dalakas MC, Illa I, Dambrosia JM, et al. A controlled trial of high-dose intravenous immune globulin infusions as treatment for dermatomyositis. *N Engl J Med*. 1993;329:1993-2000.
176. Caress JB, Kennedy BL, Eickman KD. Safety of intravenous immunoglobulin treatment. *Expert Opin Drug Saf*. 2010;9:971-979.
177. Feldmeyer L, Benden C, Haile SR, et al. Not all intravenous immunoglobulin preparations are equally well tolerated. *Acta Derm Venereol*. 2010;90:494-497.
178. Sekul EA, Cupler EJ, Dalakas MC. Aseptic meningitis associated with high-dose intravenous immunoglobulin therapy: frequency and risk factors. *Ann Intern Med*. 1994;121:259-262.
179. Obando I, Duran I, Martin-Rosa L, et al. Aseptic meningitis due to administration of intravenous immunoglobulin with an unusually high number of leukocytes in cerebrospinal fluid. *Pediatr Emerg Care*. 2002;18:429-432.
180. Ramirez G, Asherson RA, Khamashta MA, et al. Adult-onset polymyositis-dermatomyositis: description of 25 patients with emphasis on treatment. *Semin Arthritis Rheum*. 1990;20:114-120.
181. Hollingworth P, de Vere Tyndall A, Ansell BM, et al. Intensive immunosuppression versus prednisolone in the treatment of connective tissue diseases. *Ann Rheum Dis*. 1982;41:557-562.
182. Joffe MM, Love LA, Leff RL, et al. Drug therapy of the idiopathic inflammatory myopathies: predictors of response to prednisone, azathioprine, and methotrexate and a comparison of their efficacy. *Am J Med*. 1993;94:379-387.
183. Yu KH, Wu YJ, Kuo CF, et al. Survival analysis of patients with dermatomyositis and polymyositis: analysis of 192 Chinese cases. *Clin Rheumatol*. 2011;30:1595-1601.
184. Miller J, Walsh Y, Saminaden S, et al. Randomised double blind controlled trial of methotrexate and steroids compared with azathioprine and steroids in the treatment of idiopathic inflammatory myopathy *J Neurol Sci*. 2002;199:S53.
185. Villalba L, Hicks JE, Adams EM, et al. Treatment of refractory myositis: a randomized crossover study of two new cytotoxic regimens. *Arthritis Rheum*. 1998;41:392-399.
186. Hoyles RK, Ellis RW, Wellsbury J, et al. A multicenter, prospective, randomized, double-blind, placebo-controlled trial of corticosteroids and intravenous cyclophosphamide followed by oral azathioprine for the treatment of pulmonary fibrosis in scleroderma. *Arthritis Rheum*. 2006;54:3962-3970.
187. Mok CC, To CH, Szeto ML. Successful treatment of dermatomyositis-related rapidly progressive interstitial pneumonitis with sequential oral cyclophosphamide and azathioprine. *Scand J Rheumatol*. 2003;32:181-183.
188. Chung L, Genovese MC, Fiorentino DF. A pilot trial of rituximab in the treatment of patients with dermatomyositis. *Arch Dermatol*. 2007;143:763-767.
189. Dinh HV, McCormack C, Hall S, et al. Rituximab for the treatment of the skin manifestations of dermatomyositis: a report of 3 cases. *J Am Acad Dermatol*. 2007;56:148-153.
190. Aggarwal R, Bandos A, Reed AM, et al. Predictors of clinical improvement in rituximab-treated refractory adult and juvenile dermatomyositis and adult polymyositis. *Arthritis Rheumat*. 2014;66:740-749.
191. Oddis CV, Reed AM, Aggarwal R, et al. Rituximab in the treatment of refractory adult and juvenile dermatomyositis and adult polymyositis: a randomized, placebo-phase trial. *Arthritis Rheum*. 2013;65:314-324.
192. Andersson H, Sem M, Lund MB, et al. Long-term experience with rituximab in anti-synthetase syndrome-related interstitial lung disease. *Rheumatology (Oxford)*. 2015;54(8):1420-1428.
193. Marie I, Menard JF, Hachulla E, et al. Infectious complications in polymyositis and dermatomyositis: a series of 279 patients. *Semin Arthritis Rheum*. 2011;41:48-60.
194. Belhassen-Garcia M, Rabano-Gutierrez A, Velasco-Tirado V, et al. Atypical progressive multifocal leukoencephalopathy in a patient with antisynthetase syndrome. *Intern Med*. 2015;54:519-524.
195. Vulliemoz S, Lurati-Ruiz F, Borruat FX, et al. Favourable outcome of progressive multifocal leucoencephalopathy in two patients with dermatomyositis. *J Neurol Neurosurg Psychiatry*. 2006;77:1079-1082.
196. Vencovsky J, Jarosova K, Machacek S, et al. Cyclosporine A versus methotrexate in the treatment of polymyositis and dermatomyositis. *Scand J Rheumatol*. 2000;29:95-102.
197. Takada K, Nagasaka K, Miyasaka N. Polymyositis/dermatomyositis and interstitial lung disease: a new therapeutic approach with T-cell-specific immunosuppressants. *Autoimmunity*. 2005;38:383-392.
198. Kameda H, Nagasawa H, Ogawa H, et al. Combination therapy with corticosteroids, cyclosporin A, and intravenous pulse cyclophosphamide for acute/subacute interstitial pneumonia in patients with dermatomyositis. *J Rheumatol*. 2005;32:1719-1726.
199. Ryan C, Amor KT, Menter A. The use of cyclosporine in dermatology: part II. *J Am Acad Dermatol*. 2010;63:949-972; quiz 973-974.
200. Amor KT, Ryan C, Menter A. The use of cyclosporine in dermatology: part I. *J Am Acad Dermatol*. 2010;63:925-946; quiz 947-948.
201. Mattar MA, Gualano B, Perandini LA, et al. Safety and possible effects of low-intensity resistance training associated with partial blood flow restriction in polymyositis and dermatomyositis. *Arthritis Res Ther*. 2014;16:473-014-0473-5.
202. Alexanderson H, Dastmalchi M, Esbjornsson-Liljedahl M, et al. Benefits of intensive resistance training in patients with chronic polymyositis or dermatomyositis. *Arthritis Rheum*. 2007;57:768-777.
203. Wiesinger GF, Quittan M, Aringer M, et al. Improvement of physical fitness and muscle strength in polymyositis/dermatomyositis patients by a training programme. *Br J Rheumatol*. 1998;37:196-200.
204. Riisager M, Mathiesen PR, Vissing J, et al. Aerobic training in persons who have recovered from juvenile dermatomyositis. *Neuromuscul Disord*. 2013;23:962-968.
205. Omori CH, Silva CA, Sallum AM, et al. Exercise training in juvenile dermatomyositis. *Arthritis Care Res (Hoboken)*. 2012;64:1186-1194.
206. Alexanderson H, Stenstrom CH, Jenner G, Lundberg I. The safety of a resistive home exercise program in patients with recent onset active polymyositis or dermatomyositis. *Scand J Rheumatol*. 2000;29:295-301.
207. Alexanderson H, Munters LA, Dastmalchi M, et al. Resistive home exercise in patients with recent-onset polymyositis and dermatomyositis—a randomized controlled single-blinded study with a 2-year followup. *J Rheumatol*. 2014;41:1124-1132.
208. Welborn MC, Gottschalk H, Bindra R. Juvenile dermatomyositis: a case of calcinosis cutis of the elbow

and review of the literature. *J Pediatr Orthop*. 2014 35(5):e43-e46.
209. Shahani L. Refractory calcinosis in a patient with dermatomyositis: response to intravenous immune globulin. *BMJ Case Rep*. 2012;pii: bcr2012006629.
210. Penate Y, Guillermo N, Melwani P, et al. Calcinosis cutis associated with amyopathic dermatomyositis: response to intravenous immunoglobulin. *J Am Acad Dermatol*. 2009;60:1076-1077.
211. Schanz S, Ulmer A, Fierlbeck G. Response of dystrophic calcification to intravenous immunoglobulin. *Arch Dermatol*. 2008;144:585-587.
212. Kalajian AH, Perryman JH, Callen JP. Intravenous immunoglobulin therapy for dystrophic calcinosis cutis: unreliable in our hands. *Arch Dermatol*. 2009;145:334; author reply 335.
213. Palaniappan P, Lionel AP, Kumar S. Successful treatment of calcinosis cutis in juvenile dermatomyositis with pamidronate. *J Clin Rheumatol*. 2014;20:454-455.
214. Tayfur AC, Topaloglu R, Gulhan B, et al. Bisphosphonates in juvenile dermatomyositis with dystrophic calcinosis. *Mod Rheumatol*. 2015:1-6.
215. Saini I, Kalaivani M, Kabra SK. Calcinosis in juvenile dermatomyositis: frequency, risk factors and outcome. *Rheumatol Int*. 2016;36:961-965.

Chapter 63 :: Systemic Sclerosis

:: Pia Moinzadeh, Christopher P. Denton, Carol M. Black, & Thomas Krieg

AT-A-GLANCE

- Scleroderma (systemic sclerosis [SSc]) is a multisystemic autoimmune disease characterized by vasculopathy, inflammation, and fibrosis of the skin and many other organs.
- Differential diagnosis of SSc includes severe forms of localized scleroderma, as well as many other scleroderma-like conditions.
- Raynaud phenomenon, circulating autoantibodies, and skin sclerosis are almost always present and are important for the early diagnosis.
- Patients with SSc are classified into 2 major subtypes depending on the extent of skin sclerosis (diffuse cutaneous systemic sclerosis and limited cutaneous systemic sclerosis).
- Patients with an overlap syndrome, including mixed connective tissue disease, are characterized by additional clinical features of other rheumatic diseases.
- Involvement of internal organs (digestive tract, lung, kidney, and heart) can lead to severe dysfunction and determines the prognosis.
- The heterogeneity and clinical course of SSc and SSc overlap syndromes require the urgent need of interdisciplinary collaborations and regular followup visits.
- Although the disease is still not curable, there have been substantial advances in developing new therapeutic approaches and treating organ-based complications based on a better understanding of the pathophysiology.

DEFINITIONS

Scleroderma (systemic sclerosis [SSc]) is a multisystem disease, characterized by autoimmunologic processes, vascular endothelial cell injury, inflammation, and an extensive activation of fibroblasts. There is a large individual variability in the extent of skin and organ involvement, as well as in disease progression and prognosis. Skin, esophagus, lung, heart, and kidneys are the most frequently affected organs.

EPIDEMIOLOGY

Women are more frequently affected by SSc, with a female-to-male ratio between 3:1 and 14:1.[1-4] The age of disease onset ranges between 30 and 50 years.[1] However, male patients have earlier onset than female patients. Blacks with SSc are frequently younger than whites.

SSc is a rare disease; however, incidence rates increased from 0.6 to 16 patients per million inhabitants and prevalence rates rose from 2 to 233 patients per million inhabitants per year,[2-5] depending on methodologic differences in case definition and ascertainment as well as the investigated time period. It can be assumed that these numbers represent an underestimation as patients with mild disease remain often undiagnosed.

SSc has the highest case-specific mortality of any of the autoimmune rheumatic diseases, but it varies individually, depending on racial or ethnic differences, presence and severity of organ involvement, SSc subsets, age at diagnosis, and gender differences. Although not curable, there have been substantial advances in treatment options for organ-based complications of SSc.

CLINICAL FEATURES OF SYSTEMIC SCLEROSIS

SSc usually starts with a Raynaud phenomenon, which can precede the disease for many years. The clinical manifestations depend to a large extent on the subset and stage of disease. The clinical features of established SSc are diverse with severe fibrosis of the skin and all additional cutaneous manifestations. These include hardening of the skin, development of contractures, digital ulcerations and calcifications. They also reflect the multiple patterns of internal organ involvement and the consequences of progression of the underlying pathologic processes of vasculopathy, inflammation, and fibrosis. Particular consideration must be given to the hallmark complications of hypertensive scleroderma renal crisis (SRC), pulmonary arterial hypertension (PAH), pulmonary fibrosis (PF), and GI dysmotility.

CLASSIFICATION AND DEFINITION OF DIFFERENT SSc SUBSETS

The heterogeneity of SSc arises from the range of disease manifestations that vary in extent and severity of organ involvement between patients. However, some

clinical features that are almost always present are Raynaud phenomenon (RP) and skin sclerosis. The extent of skin sclerosis defines each major disease subset, each of which has particular clinical characteristics, although there are also common features to each.

In 1980, the American College of Rheumatology (ACR) published preliminary classification criteria for SSc for patients with established disease,[6] which criteria showed 97% sensitivity and 98% specificity for SSc. According to the criteria, the diagnosis is proven, if either 1 major criterion or at least 2 minor criteria are found. The major criterion are scleroderma proximal to the metacarpophalangeal or metatarsophalangeal joints; the minor criteria include sclerodactyly, digital ulcerations and/or pitting digital scars, and bibasilar PF. Although these criteria have been used for many years they do not allow the inclusion of patients with early SSc and some patients with limited cutaneous systemic sclerosis. As a result, new ACR/European League Against Rheumatism criteria were developed, which are based on a score system and consider several additional criteria such as abnormal nailfold capillaries, fingertip lesions, and autoantibodies. These new criteria now allow early diagnosis of patients and include those patients in clinical trials before extensive fibrosis develops.[7]

In 1988, a descriptive subclassification of limited versus diffuse SSc was introduced by LeRoy,[8] which was primarily associated with the extent of cutaneous involvement. This classification has been widely accepted and used in clinical practice. In 2001, LeRoy and Medsger[9] published amended criteria, with the additional presence of autoantibodies and nailfold capillaroscopic alterations. Furthermore, these criteria include a separate group of patients with early onset of SSc, with minimal skin thickening. It was mandatory that patients with early (limited) SSc have evidence of RP plus scleroderma-specific autoantibodies and/or nailfold capillaroscopic manifestations.[10,11] Although there are several other classifications published, for example, by Nadashkevich and colleagues and by Maricq and Valter,[10,12] the initial LeRoy classification is still widely used in daily clinical practice.

Diffuse cutaneous SSc is defined as a progressive form of SSc with an early onset of RP, usually within 1 year of onset of skin thickening. This subset is characterized by rapid skin involvement of trunk, face, upper arms, and thighs, showing very frequently, anti–scleroderma 70 (antitopoisomerase-I) or anti-RNA polymerase III antibodies.[8] Furthermore, there is a higher propensity to develop PF, cardiac involvement, and SRC (Fig. 63-1).

Limited cutaneous SSc is characterized by a long preexisting history of RP and skin changes of the extremities distal to the knee and elbow joints, including facial skin.[8] This SSc-subset variant often (50% to 70% of cases) presents with anticentromere antibodies and is frequently associated with isolated PAH. The traditional acronym CREST (calcinosis, RP, esophageal dysmotility, sclerodactyly, and telangiectasias) is assigned to the limited form of SSc (Fig. 63-2).

Patients suffering from early SSc, also known as undifferentiated SSc, are defined by positive RP and at least 1 additional feature of SSc (positive nailfold capillary alterations, puffy fingers, pulmonary hypertension) and/or detectable scleroderma-associated autoantibodies without fulfilling the ACR criteria.[1,13,14]

A very small proportion of cases (1.5%) develop vascular (RP and/or PAH), immunologic (most commonly anticentromere antibodies), and organ-based fibrotic features of SSc, but do not show skin sclerosis.[15] Patients suffering from this subset are classified as *SSc sine scleroderma*.

Patients with features of scleroderma together with those of another autoimmune rheumatic disease are designated *SSc overlap syndrome* (Fig. 63-3 and Table 63-1). SSc overlap syndrome is defined as a disease occurring with clinical aspects of SSc (according to the ACR criteria) or main symptoms of SSc simultaneously with those of other connective tissue diseases or other autoimmune diseases, such as dermatomyositis, Sjögren syndrome, systemic lupus erythematosus, vasculitis, and polyarthritis. These patients present mostly high titers of anti-U1RNP, anti-nRNP, antifibrillarin, or anti-PmScl antibodies.[16]

This group of patients includes well-defined patients suffering from mixed connective tissue disease (MCTD), characterized by high titers of circulating anti-U1RNP antibodies (Table 63-2). There is still an ongoing discussion, whether MCTD represents a distinct disease entity or may be an early form of another connective tissue disease. These MCTD patients have varying clinical features with symptoms of systemic lupus erythematosus or rheumatoid arthritis with Raynaud syndrome, and later developing sclerodermatous lesions. They have swollen fingers and puffy hands. Non-Raynaud symptoms are skin sclerosis at acral regions and internal manifestations that occur later. There are often intense inflammatory symptoms with heavy arthralgia. MCTD patients can develop pericarditis, pleuritis, and pulmonary hypertension. However, there is a good response to antiinflammatory/anti-immune therapy and the prognosis is clearly better than in patients with classic scleroderma.[17,18]

Another already well-defined subset within the overlap syndromes are patients with sclerodermatous lesions, who also suffer from an intense myositis. These patients are usually characterized by specific Pm-Scl autoantibodies, have typical mechanic hands, and develop early intense subcutaneous calcifications. Similar to MCTD patients, they respond well to an early antiinflammatory treatment (eg, methotrexate/glucocorticosteroids).[19]

Other overlap syndromes include patients with Raynaud and lupus erythematosus or rheumatoid arthritis symptoms, who later develop sclerodermatous lesions. Many of these patients have specific circulating autoantibodies that probably represent distinct disease entities. However further studies using molecular markers are still required to clarify their disease identity within the spectrum of scleroderma-related diseases.[19]

Figure 63-1 Extensive skin involvement in patients with diffuse cutaneous systemic sclerosis. **A,** Sclerodactyly with dermatogenous contractures (restricted mobility of digital joints) and salt-and-pepper hyperpigmentations and hypopigmentations. **B,** Microstomia (radial furrowing around the mouth) with frenulum sclerosis. **C,** Skin thickening proximal of the metacarpophalangeal joints. **D,** Typical scleroderma facial physiognomy with hypermimia, microstomia, telangiectasias, and a beaked nose.

Figure 63-2 Clinical feature of patients with early disease. **A,** Raynaud phenomenon with typical discoloration (blue-white pallor), localized mostly at fingers and/or toes as the result of vasospasm. Coldness and emotional stress are the most frequent triggers for these attacks. **B,** Limited disease with puffy fingers.

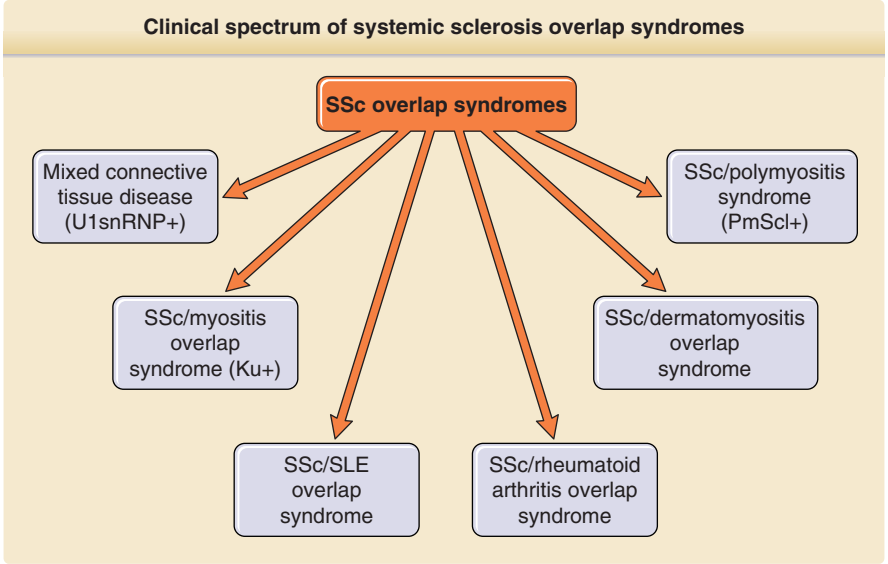

Figure 63-3 Clinical spectrum of systemic sclerosis (SSc) overlap syndromes. Patients with clinical features of scleroderma together with features of at least 1 additional autoimmune rheumatic disease are designated SSc overlap syndromes. SLE, systemic lupus erythematosus.

In addition, the frequency and timing of different visceral manifestations of SSc differs between major subsets. However, there is some overlap between subsets in terms of organ-based disease and the extent and severity of skin sclerosis.

In all patients, the extent and severity of skin sclerosis can be assessed by the modified Rodnan skin score. Skin score at baseline correlates with disease severity and outcome in diffuse cutaneous SSc. Thickening and fibrosis of the skin as one of the first recognized phenomenon in SSc still forms the basis of most classification criteria and proposed subsets of this disease spectrum.

It also has to be mentioned that another classification of SSc-related diseases, which is completely based on autoantibodies, has been proposed. There is evidence from association studies that this may be clinically meaningful, as indicated in Table 63-3. Moreover, genetic association analysis using a candidate gene approach has demonstrated an association between serologically based subsets of SSc that are stronger than with SSc overall. The significance of this is uncertain, and it should be noted that a genetic basis for autoantibody reactivity has been well described, leading to the suggestion that the serologic subsets may be more genetically homogeneous than unselected SSc cases or clinically defined subsets of SSc. Large-scale studies in multinational patient cohorts using molecular and clinical markers are probably required to revise the current classification system of this heterogeneous spectrum of diseases.

TABLE 63-1

Clinical Features of Systemic Sclerosis/Myositis Overlap Syndrome

- Raynaud phenomenon
- Sclerodactyly
- Mechanic hands
- Myositis
- Pulmonary involvement
- Calcinosis cutis
- Serositis
- PmScl autoantibodies

TABLE 63-2

Clinical Features of Mixed Connective Tissue Disease[17,18]

- Raynaud phenomenon
- Puffy fingers/hands
- Sclerodactyly
- Oesophageal involvement
- Pulmonary hypertension/interstitial lung disease
- Myositis
- Arthritis and arthralgia
- Serositis
- Anemia/lymphopenia
- High titers of U1RNP antibodies

ORGAN MANIFESTATION

RAYNAUD PHENOMENON

Distinctive for this disease is the initial onset of RP, which appears in more than 90% of SSc patients (see Fig. 63-2).[1] It is defined by recurrent attacks of vasospasm of small digital arterioles/arteries at fingers and toes, usually caused by cold and/or other stimuli, for example, emotional stress. RP clinically appears

TABLE 63-3
Clinical Association of Hallmark Autoantibodies in Systemic Sclerosis[47]

REACTIVITY	TARGET ANTIGEN	FREQUENCY IN SSc (%)	HLA ASSOCIATION	CLINICAL ASSOCIATION
Centromere	CENP proteins speckled pattern	20 to 30	HLA-DRB1 HLA-DQB1	Limited skin sclerosis, severe gut disease, isolated PAH, calcinosis
Scl-70	Topoisomerase-1 speckled pattern	15 to 20	HLA-DRB1 HLA-DQB1 HLA-DPB1	Diffuse skin sclerosis, pulmonary fibrosis and secondary PAH, increased SSc-related mortality rate
RNAP III	RNA polymerase III speckled pattern	20	HLA-DQB1	Diffuse skin sclerosis, hypertensive renal crisis, correlated with a higher mortality rate
nRNP	U1RNP speckled pattern	15	HLA-DR2, HLA-DR4 HLA-DQw5, DQw8	Overlap features of SLE, arthritis
Pm-Scl	Polymyositis/Scl nuclear staining pattern	3	HLA-DQA1 HLA-DRB1	Limited skin sclerosis, myositis–sclerosis overlap, calcinosis
Fibrillarin	U3RNP nuclear staining pattern	4	HLA-DQB1	Diffuse skin sclerosis, myositis, PAH, renal disease
Th/To	7-2RNP nuclear staining pattern	2–5	HLA-DRB1	Limited skin sclerosis, pulmonary fibrosis

PAH, pulmonary arterial hypertension; SLE, systemic lupus erythematosus; SSc, systemic sclerosis.

suddenly and is clearly restricted and is accompanied by painful pallor/ischemia of single or several digits/toes, followed by reactive hyperemia after reheating at the end of a RP attack, in some cases cyanosis (triphasic RP) also ensues (see Fig. 63-2).

SKIN INVOLVEMENT

Skin involvement is a cardinal feature of SSc and usually appears first in the fingers and hands. Within time, patients develop nonpitting edema of the fingers (puffy fingers), hands, and extremities, followed by an increasing induration and skin thickening (sclerodactyly) (see Figs. 63-1 and 63-2). Depending on the localization of skin thickening, restricted mobility of joints (dermatogenous contractures), and/or restricted breath excursion may be present. Typical facial features include telangiectasias, a beak-shaped nose, and reduced mouth aperture (microstomia). The typical facial appearance of SSc patients is characterized by a radial furrowing around the mouth, no expression, a stiff and mask-like facial appearance, and sclerosis of the frenulum. Besides cosmetic/aesthetic problems, this causes considerable difficulties regarding eating and oral hygiene (see Fig. 63-1).

The abnormal deposition of cutaneous and/or subcutaneous calcium (calcinosis cutis), usually occurs over pressure points (acral, joints) (Fig. 63-4). Calcinosis cutis next to joints is Thibierge-Weissenbach syndrome. Further skin manifestations include hypopigmented and hyperpigmented (salt-and-pepper) skin (see Fig. 63-1), and loss of hair follicles and sweat glands (hypohidrosis/anhydrosis).[20]

Approximately 50% of patients with SSc are affected by digital ulceration associated with vasculopathy at some point in their disease. This is the major external feature of structural vessel disease, probably attributable to thickened intima and lumen-occluded vessels. Tender and painful pitting scars are very frequent and, on occasion, progress to ulcers. These occur on the finger- or toe-tips, over the extensor surfaces of the joints as a result of microtrauma or in association with the abovementioned calcinosis cutis. Digital ulcers are associated with strong, local pain and a major impact on quality of life regarding all-day functions (eg, dressing, eating). Other complications include critical digital ischemia, paronychia, infections, gangrene, osteomyelitis, and finger pulp loss or amputation.

CARDIOPULMONARY MANIFESTATIONS

There are different ways that the cardiopulmonary system may be involved, most often appearing as fibrosis and PAH. The differentiation between these manifestations is often clinically difficult because of similar overlapping clinical features, such as dyspnea, nonproductive cough, disturbed diffusion capacity, and cyanoses. PAH is currently the most common cause of disease-related death in SSc.[21] It occurs in both limited and diffuse cutaneous subsets, although the most typical cases are those of limited SSc associated with isolated PAH. This condition has substantial similarities to idiopathic PAH. Thus, 2 patterns of disease occur in SSc. Most cases have PAH, but there are some patients with late-stage extensive interstitial lung fibrosis in SSc that develop a true secondary pulmonary hypertension.[22] Besides the right-heart worsening caused by PAH, the heart could also be involved by diffuse or focal fibrosis or from inflammatory myocarditis. This may lead to diastolic or systolic dysfunction, as well as a restricted contractibility of the myocardium. These patients clinically

Figure 63-4 Digital alterations with complications. **A,** Digital ulcerations at the fingertips. **B,** Digital ulcerations and necrosis of the fingertips. **C,** Severe calcifications with deposition of subcutaneous masses. **D,** Multiple ulcerations at bone protuberants with inflammation in the surrounding sclerotic skin.

present cardiac arrhythmia, paroxysmal tachycardia, incomplete or complete right-heart blocks, and heart insufficiency.[23]

GI INVOLVEMENT

GI involvement is the most common internal organ involvement in patients suffering from both limited and diffuse SSc (>60%).[1] Many parts of the GI tract may be impaired, affecting motility, digestion, absorption, and excretion.[24]

Esophageal involvement includes symptoms like dysphagia, heartburn resulting from reflux, nausea, and/or vomiting. A weakened lower esophageal sphincter and impaired peristalsis increase the risk for esophagitis. If untreated, this could lead to peptic esophagitis, gastric/esophageal ulcerations, peptic stricture formations, and fistulae. Chronic gastroesophageal reflux can be complicated after a time by a higher risk for Barrett esophagus, which may progress into an adenocarcinoma.

Possible gastric manifestations include atrophy of mucous membrane–associated ulcerations and delayed gastric emptying. Gastric antral vascular ectasia is also an important complication in some SSc patients and needs to be detected by endoscopy because it can lead to severe, often not recognized, bleeding.[25]

SSc can also affect the intestine, and includes atonic dilation, constrictions, malabsorption, pseudoobstruction, diarrhea, constipation, fecal incontinence, and severe malnutrition.

KIDNEY INVOLVEMENT

SRC appears in 5% to 10% of SSc patients, and may cause an abrupt onset of significant systemic hypertension (>140/90 mm Hg, or a rise in systolic/diastolic blood pressure ≥30/≥20 mm Hg), together with an increase in serum creatinine, proteinuria, hematuria, thrombocytopenia, or hemolysis followed by an acute renal failure.[26] Studies suggest that a chronic vasculopathy with reduced glomerular filtration rate is frequent. In addition, there is evidence of an increase in fibrillar collagen deposition within the renal interstitium in SSc. Many cases occur within the first 12 months of disease, and in up to 25% of patients with SRC, the diagnosis of SSc is made at the time of the renal presentation. End-organ damage can result in encephalopathy with generalized seizures or flash pulmonary edema. Microangiopathic anemia is common, and sometimes disseminated, intravascular coagulation develops. Nephrotoxic drugs and high-dose prednisolone (>7.5 mg/day) should be avoided in patients suffering from SSc.[27]

ETIOLOGY AND PATHOGENESIS

The pathogenesis of this complex autoimmune disease involves multiple cell types (endothelial cells, epithelial cells, fibroblasts, and lymphocytic cells) interacting through a variety of mechanisms that are dependent on their microenvironment and several key mediators.

Major facets of the disease include inflammation, vasculature, and the activation of connective tissue-producing cells (Fig. 63-5). The clinical heterogeneity of SSc makes it likely that distinct pathogenetic mechanisms predominate in particular patients or subsets of disease. Similarly, the key pathways are not necessarily

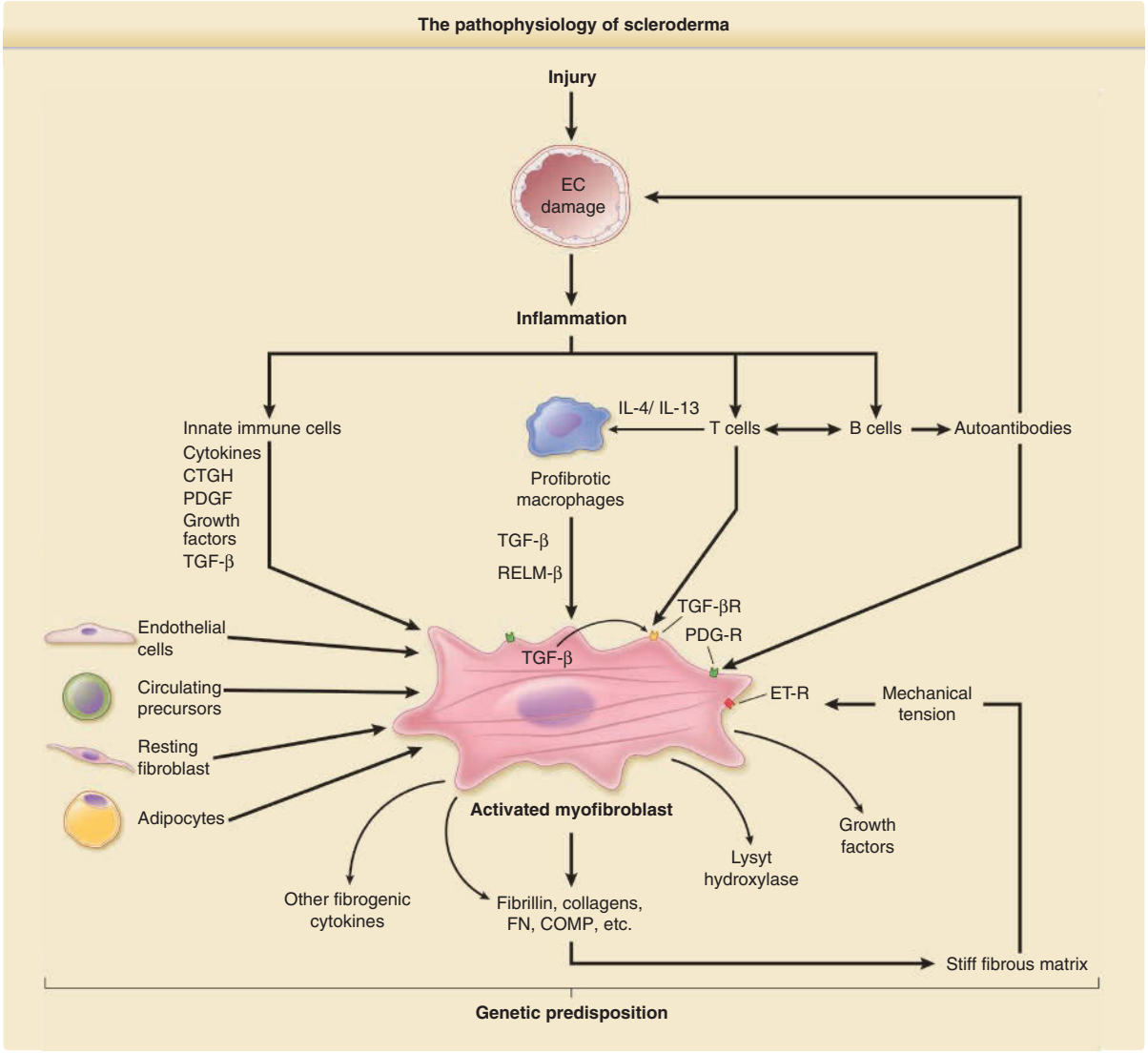

Figure 63-5 Pathogenesis of systemic sclerosis. The schematic shows how the development of systemic sclerosis results from a complex interplay between cells within the immune system, including adaptive and innate compartments, the vasculature, and the connective tissue. Cell–matrix interactions are important regulators of cellular functions. Early vascular events lead to later development of an autonomous population of activated fibroblasts and myofibroblasts that contract soft tissue and deposit excessive extracellular matrix proteins. These cells may develop from resident connective tissue fibroblasts; transdifferentiation from other cell types, including activated microvascular pericytes; and recruitment of circulating progenitor cells (fibrocytes). The contribution of each lineage to the fibrotic lesion is still unclear. Many growth factors and cytokines are implicated as mediators of this process, and complex reciprocal networks may lead to a profibrotic microenvironment. Potential disease-modifying therapies could target individual mediators alone or in combination (eg, tumor growth factor-β [TGF-β], endothelin [ET-1], connective tissue growth factor [CTGF], platelet-derived growth factor [PDGF]) or modulate immune cells (eg, cyclophosphamide) or the endothelial cell (eg, prostacyclin analogs). The extracellular matrix is an important repository for mediators that are later released and play a key role in pathogenesis. CCL, CC chemokine ligand; COMP, cartilage oligomeric matrix protein; EC, extracellular; ET-R, endothelin receptor; FN, fibronectin; Ig, immunoglobulin; IL, interleukin; RELM-β, resistin like molecule-β.

the same at different stages of SSc. Although a genetic component to etiopathogenesis is likely and evidence supports genetic factors determining severity and susceptibility, there are also strong arguments, supporting environmental and chemical factors as triggers for the disease.[28]

GENETIC FACTORS

The best evidence for a genetic contribution to SSc and related diseases comes from studies that report familial clustering and from the limited twin studies that have been undertaken. Although the absolute risk for familial-occurring SSc is relative low, the relative risk for first-degree relatives is 13-fold higher compared to the normal population.[29] Several studies suggest that a positive family history for SSc is the strongest risk factor, but ethnicity also contributes.[29] Assassi and colleagues suggest that members of SSc-affected families tend to show concordant scleroderma-specific autoantibodies.[30] Further support is provided from genetic association studies with candidate gene approaches. Most success has been observed in genetic analysis of individual components of the disease such as autoantibody profiles. These appear to have a strong genetic determinant, and this may underlie the apparent mutual exclusivity of the SSc hallmark reactivities. It has been demonstrated that the ability to mount an immune response to a particular SSc-associated antigen is restricted by major histocompatibility complex haplotype. Several studies suggest an association of HLA-DRB1*1302 and HLA-DQB1*0604/0605 haplotypes with antifibrillarin-positive patients,[31] while HLA-SRB1*0301 occurs in patients with anti–Pm-Scl antibodies.[32] Observation from a large number of studies examining genetic markers has identified a number of candidate genes (eg, anemia-inducing factor [AIF]-1, cluster of differentiation [CD] 19, CD22, CD86, cytotoxic T-lymphocyte antigen [CTLA]-4, CCL-2, CCL-5, chemokine ligand [CXCL]-8, chemokine-related receptor [CXCR]-2, interleukin [IL]-1α, IL-1β, IL-2, IL-10, IL-13, macrophage migration inhibitory factor (MIF), protein tyrosine phosphatase non-receptor 22 (PTPN22) tumor necrosis factor [TNF]-α).[29,33] Most of the more recent genome-wide association studies have identified loci relevant for the innate immune system; some of these associations are already rather robust and might lead to new therapeutic approaches. Others reflect the altered connective tissue response. However, as with other complex diseases, in very many instances, it has not always possible to replicate initially promising data. Studies of genetically homogeneous populations have been especially informative, including those of the Choctaw Nation of Native Americans. However, it is of interest that some of the associations are very plausible in terms of molecular pathogenesis. It is likely that epistasis and the effect of multiple modifier genes confound simple genetic association studies in SSc, just as in other complex diseases.[34] There is increasing evidence that epigenetic mechanisms by modulating chromatin structure and gene expression of cytokines/growth factors critical for the activation of the immune response and/or the fibrotic reaction are important additional factors contributing to the development of scleroderma.

ENVIRONMENTAL FACTORS

Scleroderma-like syndromes have been reported in association with numerous environmental toxins and drugs. These agents include solvents (vinyl chloride, benzene, toluene, epoxy resins), drugs (bleomycin, carbidopa, pentazocine, cocaine, docetaxel, metaphenylenediamine), and miscellaneous substances.[35]

SSc was reported to occur in underground coal and gold miners. In male patients with silicosis who were older than 40 years of age, the likelihood of developing SSc was approximately 190 times greater than in males not exposed to silica, and 50 times greater than in males without silicosis but exposed to silica dust.[36] The role of silicone gel implants and other silicone products in the development of scleroderma has been questioned.[37] However, most epidemiologic studies have failed to show a significant association. An unusual form of scleroderma characterized by RP, morphea-like skin changes, capillary abnormalities of the nailfold (similar to those in SSc), osteolysis of the distal phalanges, and hepatic and PF may occur in workers exposed to polyvinyl chloride. Bleomycin also produces PF, RP, and cutaneous changes indistinguishable from those of SSc.[37] The development of these changes appears to be dose-dependent and is reversible on discontinuation of the drug. Collectively, chemical exposures account for a small fraction of scleroderma-like diseases. Large epidemiologic studies have not yet revealed a significant role for toxins and drugs in scleroderma.

HISTOPATHOLOGY

The histopathology of SSc shows fibrosis of the lower two-thirds of the dermis and the subcutaneous fibrous trabeculae, because of excessive deposition of extracellular matrix (ECM) proteins, most notably collagen Types I and III (Fig. 63-6).[28]

Panniculitis and mucoid edema also may be prominent features in the early stages, whereby subcutaneous fat is replaced by a fibrous connective tissue. It is possible to differentiate histologically an early cellular stage on the one hand and a later fibrotic stage on the other hand. In the early stages, the dermis presents pathologically collagen bundles within the reticular dermis, and appear pale, homogenous, running parallel to the skin surface, and swollen, and there is often a perivascular lymphocytic infiltrate. These inflammatory cell infiltrates are localized between the collagen bundles but mainly around the vessels, and can also spread into subcutaneous fat tissue. The infiltrate can also entrap sweat glands. The epidermis often becomes

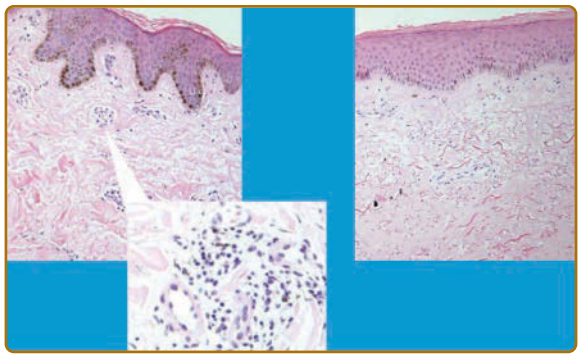

Figure 63-6 Histologic appearance of skin in early and late-stage diffuse cutaneous systemic sclerosis (SSc). In SSc, there is perivascular mononuclear cell infiltrate at the early stages of disease. This precedes the development of skin sclerosis. Perivascular changes are shown at high power in the *left panel*. Later stage disease is accompanied by skin sclerosis, a low density of blood vessels, and absence of inflammatory cells. At this stage, there may be associated epidermal changes with thickening and loss of secondary skin structures, including hair follicles and sweat glands. Absence of the rete ridges is also characteristic at the later stages of diffuse cutaneous SSc. Similar changes are predicted in localized cutaneous SSc, but this is rarely biopsied because of limited skin sclerosis and concerns about healing.

atrophic in the overlying areas. Vessels of all sizes may be involved in SSc. In the early stages, there may only be dilation of capillaries, then endothelial proliferation and complete occlusion of vessels occur. With the progression of scleroderma, the involved skin becomes more avascular and inflammation decreases. In later stages, pilosebaceous units and eccrine glands disappear, collagen bundles appear to be packed closely, and there may be an effacement of the rete ridges.[20]

VASCULOPATHY

Vasculopathy in SSc is an early event and is based on inappropriate vascular remodeling and repair processes. It involves the microcirculation and arterioles and is very likely a primary event in the pathogenetic processes of the disease. Vascular abnormalities are characterized by vasoconstriction, adventitial and intimal proliferation, inflammation, and thrombosis.[28] The earliest signs of vascular dysfunction are represented by enhanced vascular permeability with an imbalance between vasodilatory (nitric oxide, prostacyclin, calcitonin gene-related peptide) and vasoconstrictive mediators (endothelin-1, angiotensin II, α_2-adrenoreceptors). Consequently, the impaired blood flow leads to tissue hypoxia, which induces strong expression of vascular endothelial growth factor and its receptors, associated with a defect of vasculogenesis. However, inflammatory cytokines like TNF-α may stimulate or inhibit angiogenesis depending on the duration of the stimulus.[38]

In addition to these functional abnormalities, intravascular and structural changes contribute to overt RP, and in the course of time to progressive reduction of vessels and blood flow. This pattern of obliterative vasculopathy may clinically manifest in all vessels of virtually all organs. Early lesions in the microcirculation because of structural damage are initially seen in the nailfold capillaries and as vasospastic responses in RP. Furthermore, vascular changes, that is, overgrowth of the endothelium and deposition of scar tissue, produce some of the major complications of SSc, including PAH, SRC, and digital vasculopathy.

IMMUNE EVENTS

There are early inflammatory changes in the skin and lung of patients with SSc. The first inflammatory infiltrates in lesional skin are predominantly cells of the monocyte lineage (T cells, macrophages, B cells, and mast cells).[39] There are several lines of evidence for the crucial role of the innate immune system in SSc. This is underlined by the association of interferon regulatory factor-5 variants with scleroderma.[40,41] Several studies also demonstrate the role of macrophages as important contributors of cytokines, which influence the fibrotic response.[42]

Later, T lymphocytes predominate and are detectable in both the circulation and affected organs. These T cells are predominantly CD4+, bear markers of activation, exhibit oligoclonal expansion, which suggests an antigen-driven proliferation, and show a predominant T-helper 2 phenotype.[43,44] Consequently, increased serum levels of T-helper 2 cell–derived cytokines (IL-2, IL-4, IL-10, IL-13, and IL-17) have been observed in scleroderma patients.[45,46]

In addition to T cells, B cells are also found in involved skin. Several studies suggest that B cells are able to induce ECM production through secretion of IL-6 and transforming growth factor-β (TGF-β) and are involved in the production of autoantibodies.

Several of these autoantibodies are associated with defined subsets of the disease and are important diagnostic markers (see Table 63-3).[47] The potential role of autoantibodies in pathogenesis is a fascinating and exciting area. The majority of SSc cases have circulating antibodies. These include a number of hallmark reactivities, as well as autoantibodies, that occur in other autoimmune rheumatic diseases (eg, anticyclic citrullinated peptide, rheumatoid factor) but also antibodies that may have functional significance, as they are directed against cell-surface antigens (eg, antiendothelial cell antibodies, antifibrillin antibodies, anti–platelet-derived growth factor [PDGF] receptor antibodies) (Table 63-4).[48-50] However, functional impact of these antibodies remains an area of investigation. There is growing evidence of functional significance for antiendothelial cell autoantibodies and for antifibroblast-reacting antibodies. Reports also suggest the presence of antifibrillin autoantibodies and stimulatory autoantibodies reacting with PDGF

TABLE 63-4
Functional Autoantibodies in Systemic Sclerosis and Their Association to Pathophysiology[48-50]

FUNCTIONAL ANTIBODY	FREQUENCY IN SYSTEMIC SCLEROSIS	CLINICAL ASSOCIATION
Anti–platelet-derived growth factor receptor	33% to 100%	▪ Seem to induce skin fibrosis as a result of activation of fibroblasts into myofibroblasts and fibroblast-like cells ▪ First functional antibodies discovered in systemic sclerosis (SSc)
Antiendothelial cell antibodies	44% to 84%	▪ Mediates endothelial cell damage and activation of fibroblasts resulting from stimulation of proinflammatory and fibrotic cytokines ▪ Associated with severe organ manifestation ▪ Associated with perivascular, vascular (digital ulcers [DUs]) and lung involvement (pulmonary arterial hypertension [PAH]) ▪ Also found in other rheumatic diseases
Antifibroblast antibodies	26% to 58%	▪ Associated with Scl-70 antibodies and the prevalence of interstitial lung disease and PAH ▪ Increased prevalence in diffuse cutaneous SSc compared to limited cutaneous SSc
Antifibrillin-1	>50%	▪ Activates fibroblasts by stimulation of the release of transforming growth factor-ββ
Anti–matrix metallo-proteinase (MMP) 1, anti-MMP3	49% to 52%	▪ Inhibits the degradation of extracellular matrix proteins, because of an inhibition of MMP collagenase activity ▪ Correlates with the extent of fibrosis (skin, lung, kidney)
Angiotensin II Type 1 receptor and endothelin Type A receptor	82% to 83%	▪ Simultaneous presence has been described in SSc patients (cross-reactivity) ▪ Associated with early and severe disease, PAH, DUs, renal crisis, diffuse cutaneous SSc, and lung fibrosis

receptors.[48-50] Microchimerism and graft-versus-host disease mechanisms have been suggested in some cases, although the relatively high frequency of microchimerism in healthy individuals or other disease states suggests that this may be contributory rather than causal if it has a role in SSc.

Careful clinical studies have identified a subset of SSc patients (characterized by RNA polymerase antibodies), who develop the disease in association with the occurrence of malignancies.[51-53] This led to the hypothesis that fibrosis may represent an immune response against tumor antigens and initiated a discussion on the relationship of autoimmunity and malignancy in general. Further studies are required to clarify this issue.

FIBROSIS

SSc is a multisystem fibrotic disease. The initial inflammation and hypoxia induces in fibroblasts the production of several proteins that are involved in ECM remodeling as, for example, thrombospondin-1, fibronectin-1, lysylhydroxylase-2, and TGF-β–induced proteins.[54] At the same time there is a disturbed balance between synthesis and degradation mechanisms leading to the excess of ECM in specialized organs, which is then responsible for much of the morbidity and mortality of the disease. The key event in the development of fibrosis is the induction of fibroblasts into activated myofibroblasts. Alternatively, also other cell types (eg, circulating precursor cells, endothelial cells, and epithelial cells) can be converted into myofibroblasts. The initiation of this process includes a number of key cytokines and growth factors that may represent logical therapeutic targets. These include fibrogenic cytokines such as TGF-β, connective tissue growth factor, PDGF, and endothelin-1.[28,55-57] Especially TGF-β has been shown to play a central role,[58] which is also underscored by extensive expression profiling studies using skin biopsies from scleroderma patients in different stages of the diseases.[59] This has already led to therapeutic approaches using antibodies against TGF-β in early clinical studies.[60]

Myofibroblasts are characterized by a high contractility, ECM production, and cytokine release. This function together with altered biophysical properties of the resulting connective tissue lead to persistent activation of fibroblasts with an excessive deposition of ECM components. However, crucial for understanding the mechanisms of this disease is the close connection between autoimmunity, vasculopathy, and fibrosis. This was recently demonstrated in a mouse model characterized by downregulation of the transcription factors Friend leukemia integration 1 (Fli1) and Kruppel-like factor 5 (KLF5), which develop a scleroderma like disease with the production of autoantibodies.[61]

Figure 63-5 is a schematic that summarizes the pathogenetic mechanisms.

DIAGNOSIS

RAYNAUD PHENOMENON

Patients presenting only with RP should be studied for capillary alterations as well as autoantibody status. All these are predictors for the development of SSc, which together make the diagnosis of SSc rather likely.

TABLE 63-5
Recommended Diagnostic Procedures in Systemic Sclerosis[71]

ORGAN INVOLVEMENT	CLINICAL FEATURE	DIAGNOSTIC PROCEDURES
Vascular system	Raynaud phenomenon	▪ Coldness provocation ▪ Nailfold capillaroscopy ▪ Antinuclear antibody levels
Skin	Scleroderma Calcinosis cutis	▪ Clinical assessment regarding puffy fingers, telangiectasias, mechanic hands, hypopigmentations/hyperpigmentations, digital ulcerations, dermatogenous contractures ▪ Modified Rodnan skin score ▪ 20-MHz ultrasonography ▪ Radiography (X-ray, MRI, CT)
Musculoskeletal system	Arthralgia Synovitis Muscle weakness	▪ Clinical assessment regarding fist closure deficiency, joint contractures, tendon friction rub, muscle weakness ▪ Laboratory parameters: erythrocyte sedimentation rate, rheumatoid factor, antinuclear autoantibodies ▪ Creatine kinase (greater than threefold?) ▪ MRI, electromyography ▪ Muscle biopsy
GI tract	Reflux Dysphagia Gastric antral vascular ectasia Diarrhea, obstipation	▪ Gastro-/esophageal endoscopy ▪ Esophageal scintigraphy, esophagus manometry ▪ Gastro-/esophageal endoscopy with laser coagulation, if necessary ▪ Colonoscopy
Respiratory system	Dyspnea	▪ Lung function test (carbon monoxide transfer factor corrected for hemoglobin [TLCOc] single breath (SB), total lung capacity [TLC], forced vital capacity [FVC]) ▪ Radiography (X-ray or high resolution CT) ▪ Bronchioalveolar lavage (BAL) (optional)
Cardiac system	Dyspnea, arrhythmia	▪ Electrocardiography (conduction blocks?) ▪ Echocardiography (mean pulmonary artery pressure, diastolic dysfunction?, ventricular ejection fraction) ▪ (Spiro-)Ergometry ▪ 24-Hour blood pressure controls ▪ Right-heart catheterization ▪ Cardio MRI
Kidney	Renal function failure	▪ Regular blood pressure controls (>140/90 mm Hg) ▪ Ultrasonography ▪ Serum levels of creatinine, urine analyses (protein, albuminuria, microelectrophoresis)

To identify and visualize vascular cutaneous alterations caused by SSc, nailfold capillaroscopy is a noninvasive, simple, and one of the most useful diagnostic and prognostic methods (Table 63-5). Furthermore, it is a useful tool to categorize capillary changes into early, active, and late patterns. Laser Doppler perfusion imaging is also a noninvasive microvascular imaging technique able to provide maps of the cutaneous blood flow.[62]

SKIN SCLEROSIS

Skin involvement should be evaluated using the modified Rodnan Skin Score. Usually, 17 sites are assessed and skin thickness is categorized to grade 1, 2, or 3, corresponding to mild, medium, and severe, according to palpation of the skin by a trained examiner (Fig. 63-7). Newer techniques for calculating skin thickening also have been evaluated. In addition to the modified Rodnan skin score,[63] the 20-MHz ultrasonography,[64] MRI,[65] and plicometer[66] methods are useful for assessing skin thickening (recommended diagnostic procedures are listed in Table 63-5). Further physical procedures to monitor skin fibrosis are the durometer,[67] cutometer,[68] and elastometer.[69] In addition to these noninvasive methods, skin biopsy with histologic evaluation of the dermal skin thickness is an appropriate but invasive method. This method enables the characterization of the inflammatory infiltrates.

CARDIOPULMONARY INVOLVEMENT

Individuals with SSc and cardiopulmonary symptoms should be followed up at least annually using pulmonary function tests, echocardiography, a 6-minute walk test, and high-resolution CT (HRCT).[70] Pulmonary

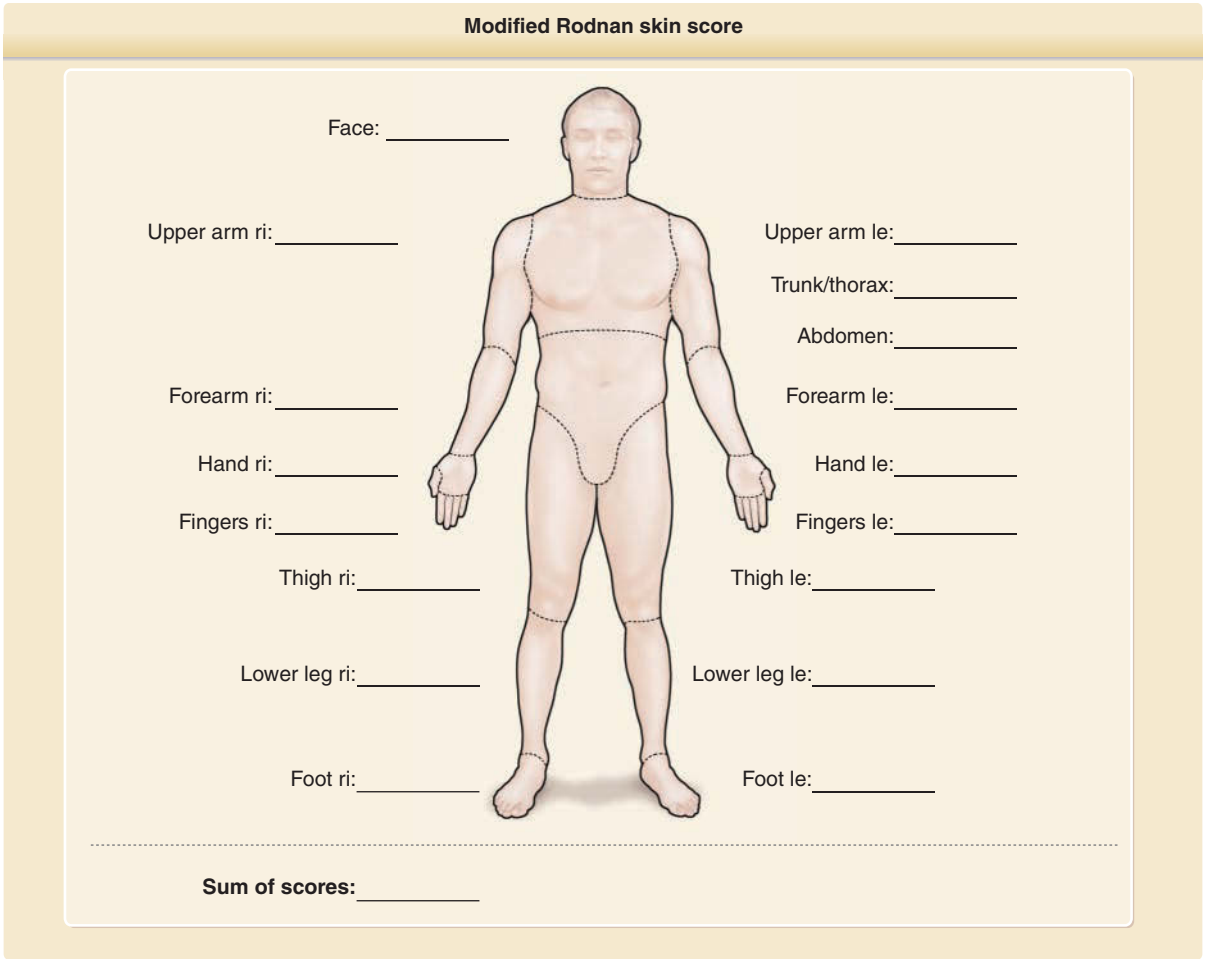

Figure 63-7 Modified Rodnan skin score (mRSS). Skin hardening evaluation using the modified mRSS is usually performed by assessing the skin thickness at 17 different areas. The skin sclerosis is categorized by palpation to grade 1, corresponding to mild, grade 2, corresponding to moderate, and grade 3, corresponding to severe. le, Left; ri, right.

function tests are the most important techniques to determine possible cardiopulmonary involvement, because of impaired diffusion capacity of the lung for carbon monoxide (DLCO ≤75%) being an early marker of both lung fibrosis and PAH.[71]

To determine the presence of interstitial lung involvement, that is, subpleural localized line opacities, ground-glass opacities, and subpleural cysts with honeycomb formations, HRCT and/or thoracic radiography should be used.

Followup should also include transthoracic Doppler echocardiography, a noninvasive procedure, that can indicate a hypertrophy with or without enlargement of the right ventricle, paradoxical motion of the interventricular septum, tricuspid valve insufficiency, and pericardial effusion. Right-heart catheterization is indeed the gold standard, but is an invasive diagnostic procedure to determine PAH. PAH is defined as a mean pulmonary artery pressure of ≥25 mm Hg at rest together with a pulmonary capillary wedge pressure of ≤15 mm Hg as determined by right-heart catheterization.[70,72,73]

Cardiac MRI is also a potential strategy for assessing myocardiac involvement in SSc. Besides imaging procedures, there is also some promise for the use of *N*-terminal brain natriuretic peptide to detect right ventricular impairment (see Table 63-5). Early detection of cardiac involvement is crucial to prevent and to allow early treatment of cardiomyopathy and severe cardiac arrhythmias.[70]

GI INVOLVEMENT

The presence of esophagitis can be determined by upper GI endoscopy with histologic evaluations. Impaired motility of the esophagus can usually be diagnosed by scintigraphic evaluation following a radiolabeled meal or 24-hour pH manometry (see Table 63-5).[71]

KIDNEY INVOLVEMENT

Early diagnosis is the key role in improving the outcome of SRC using regular blood pressure monitoring, urine analysis microelectrophoresis, and determination of creatinine clearance (see Table 63-5).[26]

DIFFERENTIAL DIAGNOSIS

The diagnosis of SSc is clinical. Although there are criteria that were developed to facilitate the distinction of SSc from other connective tissue diseases, no formal diagnostic criteria have been developed. However, determination of the correct subset of the disease, including the SSc overlap syndromes, is required to enable judging of prognosis and involvement of certain organs and for determining the therapeutic approach. There are several differential diagnoses that imitate scleroderma: circumscript (localized) scleroderma; eosinophilic fasciitis; sclerodermiform genodermatoses; acrodermatitis chronica atrophicans; scleroderma-like syndromes induced by environmental factors; scleroderma adultorum Buschke; scleroderma diabeticorum; scleromyxedema; nephrogenic fibrosing dermopathy; porphyria cutanea tarda; graft-versus-host disease; and scleroderma-like lesions in malignancies. These certainly have to be excluded. Table 63-6 outlines the differential diagnosis of SSc.

CLINICAL COURSE AND PROGNOSIS

The development of the disease depends very much on the specific subset. Patients with the limited form develop RP already many years prior to the onset of other organ manifestations. Skin fibrosis remains localized to the acral areas and the main complications are the development of digital ulcerations and pulmonary hypertension. In the diffuse form, however, fibrosis occurs early and together with inflammation, joint pain and shows a rapid spreading to almost all parts of the integument. In these patients, manifestations of the lung (lung fibrosis), heart, and kidney occur early in the disease course and often determine the prognosis. There is still a high number of deaths associated with this disease subset. Several studies indicate that the diffuse cutaneous SSc patients show a rapid worsening of the disease in the initial years. In later years, the activity of the disease is reduced and symptoms can improve. Surprisingly, the sclerotic skin also can become softer and contractures can be diminished.

Although SSc is still a life-threatening disease, a multidisciplinary management of the patients with early detection and treatment of complications may lead to a much-improved prognosis during the patient's life.

TABLE 63-6

Differential Diagnosis of Systemic Sclerosis

Differential Diagnosis
▪ Circumscript (localized) scleroderma (morphea)
▪ Eosinophilic fasciitis
▪ Lichen sclerosus et atrophicans
▪ Sclerodermiform genodermatoses (eg, progeria, acrogeria)
▪ Sclerodermiform acrodermatitis chronica atrophicans
▪ Scleroderma adultorum Buschke
▪ Scleroderma diabeticorum
▪ Scleroderma amyloidosus
▪ Scleromyxedema
▪ Mixed connective tissue disease (MCTD)
▪ Nephrogenic fibrosing dermopathy
▪ Sclerodermiform porphyria cutanea tarda
▪ Sclerodermiform chronic graft-versus-host disease
▪ Eosinophilia-myalgia syndrome

MANAGEMENT

DISEASE-MODIFYING TREATMENT

Three facets of SSc are potentially amenable to therapeutic modulation, which raises the possibility of true disease-modifying treatment. At present, vascular therapies and immunomodulation have the widest range of candidate therapies. Tables 63-7 and 63-8 summarize these approaches. General immunosuppression can be of benefit by improving skin involvement and interstitial lung disease. The best evidence is available for cyclophosphamide but more recently mycophenolate mofetil (MMF) has been shown to be as effective as oral cyclophosphamide and is used by many centers.[74,75] There is also evidence that rituximab can lead to improvement of the disease course in a select group of patients, if standard immunosuppression has failed.[76] Efficiency of immunosuppression in general is demonstrated by trials from the United States and Europe using high-intensity immunosuppression with autologous hemopoietic stem cell transplantation in some selected patients.[77-80] However, side effects always have to be considered (Table 63-9).

Antifibrotic treatment remains still a challenge, although during the last few years a number of new approaches have been generated mainly based on the better understanding of the underlying mechanisms. A newer study using a new antibody against TGF-β led to an improvement of the severity of skin involvement and a reduction of the expression of several TGF-β–dependent genes.[60] Some encouragement is also provided by newer clinical trials of idiopathic PF. However, at present there is no proven antifibrotic agent. Figure 63-8 is a simplified schematic for integrating putative disease-modifying therapy with programs of screening and surveillance that permit timely intervention in SSc with organ-based strategies that currently form the basis of the majority of SSc therapeutics. Possibilities for targeted disease modifying therapy depend on the availability of therapeutic agents and a clear understanding of their role in pathogenesis.

There has been much more success in the field of organ-based therapeutics in SSc, which already had a high impact especially on the quality of life of many patients. Early detection of these organ-specific complications is required to enable early intervention.

TABLE 63-7
Recommended Therapeutic Strategies for Internal Organ Involvement in Systemic Sclerosis[105]

ORGAN INVOLVEMENT	CLINICAL FEATURE	THERAPEUTIC OPTIONS
Vasculopathy	Raynaud phenomenon	Consistent warm keeping, paraffin-bath, patient education
		Calcium channel blockers (eg, nifedipine) by mouth
		Angiotensin receptor antagonists
		Alternatives: selective serotonin reuptake inhibitors (SSRIs), α-blockers, sympathectomy with or without botulinum toxin injection
	Digital ulcers	Prostacyclin (eg, iloprost) IV[87,88]
		Endothelin receptor blockade (eg, bosentan by mouth)[81,106]
		Phosphodiesterase Type 5 inhibitors (off-label)[90]
		Wound dressing (hydrocolloid membrane, Mepilex)
Musculoskeletal system	Synovitis/myositis	Methotrexate (by mouth, IM), rituximab (off-label)
GI tract	Reflux	Proton pump inhibitors, prokinetics
	Dysphagia	H_2-receptor antagonists
	Diarrhea, obstipation	Change habit of eating, parenteral nutrition
		Antibiotics (eg, ciprofloxacin)
		Symptomatic management with antidiarrheal agents or laxatives
Respiratory system	Dyspnea	Oxygen, if necessary
	Alveolitis/lung fibrosis	Cyclophosphamide IV
		Mycophenolate mofetil by mouth (used as an alternative or after cyclophosphamide)
		Glucocorticoids (short dated, if necessary)
Cardiac system	Pulmonary arterial hypertension	Oxygen, if necessary
		Diuretics
		Endothelin receptor blockade (eg, bosentan by mouth, macitentan)[107]
		Inhaled iloprost[107]
		Phosphodiesterase Type 5 inhibitors (eg, sildenafil by mouth, tadalafil)[107,108]
		Epoprostenol by mouth[107]
		Combination of different agents
	Systolic heart failures	Immunosuppression with or without pacemaker
		Cardioverter defibrillator
		Angiotensin-converting enzyme inhibitors and carvedilol (selective β-blockers may be considered, but consider worsening of Raynaud phenomenon)
	Diastolic heart failure	Diuretics
		Calcium channel inhibitors
Kidney	Scleroderma renal crisis	Angiotensin-converting enzyme–Hemmer (high-dosed)

DIGITAL VASCULOPATHY AND ITS COMPLICATIONS

Simple but important recommendations for reducing the frequency of Raynaud attacks include reducing vasoconstriction by avoiding precipitating factors like nicotine, sympathomimetics, emotional stress and coldness, and instead to have good home heating, thick and airtight clothes, thermochemical or microwaveable hand warmers, electrically heated gloves, soles, or infrared hyperthermy, regular paraffin wax bath treatments, and minimizing finger trauma.

Therapy requires a close interaction between several medical disciplines applying topical and systemic therapies. Current local management of digital ulcers includes a combination of nonpharmacologic care, antibiotics (in case of infection), analgesia, and individually applied wound dressings, if necessary.

Potential pharmacologic treatment requires optimal therapy for RP, including agents that have the potential for vascular remodeling and/or dilation, such as calcium channel blockers and angiotensin II receptor antagonists,[81,82] which should be considered first-line therapy. The results have been contradictory with other pharmacologic treatment options, such as diltiazem and angiotensin-converting enzyme inhibitors.[83-86]

TABLE 63-8
Therapeutic Options for Skin Involvement in Systemic Sclerosis[20,105]

CLINICAL FEATURE	THERAPEUTIC OPTIONS
Skin hardening	▪ Lymphatic drainage ▪ Physiotherapy ▪ Topical treatment with steroids or calcineurin inhibitors ▪ Systemic treatment with steroids (short dated) and/or immunosuppressants ▪ Phototherapy (psoralen and ultraviolet A, ultraviolet A1, extracorporeal photochemotherapy)
Dryness and itching	▪ Topical treatment with steroids, capsaicin ▪ Cannabinoid agonists ▪ Emollients ▪ Phototherapy (psoralen and ultraviolet A, ultraviolet A1) ▪ Systemic treatment with antihistamines or gabapentin
Digital ulcerations	▪ IV iloprost ▪ Bosentan by mouth ▪ Hydrocolloid dressings ▪ Skin substitutes ▪ Physical therapy
Calcifications	▪ Bisphosphonate by mouth ▪ Local corticosteroid injection ▪ Laser therapy ▪ Surgery
Telangiectases	▪ Laser therapy ▪ Camouflage
Hyperpigmentation and hypopigmentation	▪ Bleaching agents, camouflage, sunscreens ▪ Salicylic acid and chemical peelings ▪ Hydroquinone, retinoids, corticosteroids

Parenteral prostacyclin derivatives, in particular iloprost, are widely used, and help to heal digital ulcers and may prevent recurrent lesions. Prostacyclin derivatives by IV infusion are the mainstay of therapy for critical digital ischemia.[87,88] Antiplatelet agents, such as aspirin and clopidogrel, are also used, especially in critical digital ischemia.

There has been enthusiasm about therapies that are effective for PAH in digital vasculopathy. Thus, in 2 large, controlled trials, bosentan, an oral dual-specificity endothelin receptor antagonist, was shown to significantly reduce the number of new digital ulcers, compared with placebo.[89] However, no positive effect on healing of established ulcers was demonstrated. Other agents, such as phosphodiesterase Type 5 inhibitors sildenafil and tadalafil, also have been used for treatment of RP and digital ulcers, but prospective clinical trial data are not available.[90] Surgical treatments include digital microarteriolysis, which can benefit single fingers with refractory ulcers. Whenever possible, surgical amputation of digits is avoided, and prolonged treatment with parenteral prostacyclin in combination with phosphodiesterase Type 5 inhibitors and potent analgesia may help with this. Lumbar sympathectomy may be helpful for lower-limb RP or ulceration. Generally, a temporary procedure is performed initially to determine the likely benefit from a definitive sympathectomy. In cases of critical digital ischemia, antiplatelet therapies are often given, with anecdotal reports of the benefit of clopidogrel in preventing digital infarction (see Table 63-7).

TABLE 63-9
Stem Cell Transplantation (ASCT) for Early Diffuse Cutaneous Systemic Sclerosis[78-80]

- Recommended in poor-prognosis diffuse cutaneous systemic sclerosis (SSc)
- Patients should not have severe organ manifestations, which render this option highly toxic

Pro	Contra
▪ Improved long-term survival ▪ Improved event-free survival	▪ 10% Transplant-related mortality ▪ Patients with cardiopulmonary disease have to be excluded

Algorithm summarizing current approach to management of systemic sclerosis

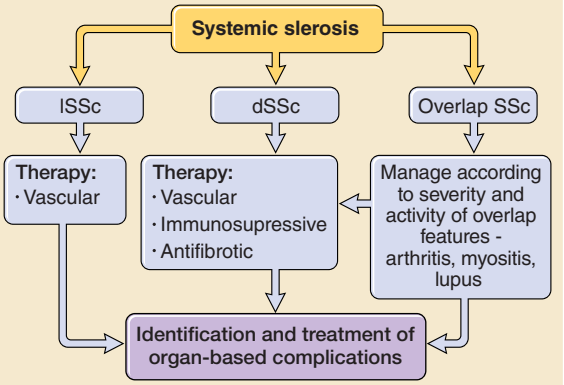

Figure 63-8 Algorithm summarizing the current approach to management of systemic sclerosis (SSc). The principles of therapy for SSc include accurate diagnosis and treatment according to the disease subset, the presence of overlap features, and the likely predominant pathologic process according to the stage of disease. In all cases, screening for and treatment of organ-based complications has a major role in successful management. Education of patients and a multidisciplinary team, including specialist nurses, physiotherapists, occupational therapists and many subspecialty physicians, and surgeons, are central to providing appropriate care for severe cases of SSc. dSSc, Diffuse cutaneous systemic sclerosis; lSSc, limited cutaneous systemic sclerosis.

SKIN INVOLVEMENT

Key elements in the management of skin manifestations of SSc are physical therapy and regular exercise

to maintain circulation, joint mobility, and muscle strength, all aimed at improving the quality of life of SSc patients. Skin affected by scleroderma tends to be very dry, taut, and susceptible to trauma.

Skin hardening can be improved by physical therapy and exercise, lymphatic drainage, topical treatment with steroids, calcineurin inhibitors, and moisturizing crèmes. Systemic therapies include immunosuppressive drugs, systemic steroids (for just a short time), and phototherapy (ultraviolet A1 or psoralen and ultraviolet A). Ultraviolet A1 phototherpay appears to inhibit fibrotic and inflammatory processes and reduce the amount of sclerotic skin.[91]

Dry and itching skin should be treated topically with corticosteroids, cannabinoid agonists, capsaicin, emollients, and phototherapy (see above). Local steroid injections and laser or surgical therapies could also be tried for the treatment of calcinosis cutis.

Laser therapies or noninvasive methods like camouflage have been used for telangiectases. Bleaching agents, salicylic acids, and chemical peels, as well as camouflage, retinoids, and corticosteroids, may have the potential to improve hyperpigmentation or hypopigmentations (see Table 63-8).

Two randomized clinical trials have shown that methotrexate improves the skin score in early diffuse SSc, while positive effects on other organ manifestations have not been established.[92,93] On the other hand, in two randomized clinical trials, cyclophosphamide improved skin sclerosis.[94,95] For balancing efficacy and side effects, MMF might be an interesting option to influence skin fibrosis.[74] Protein kinase inhibitors (eg, imatinib) have been used, but as of this writing, controlled clinical trials have been mixed and suggest poor tolerability.[96,97]

CARDIOPULMONARY MANIFESTATIONS

It is increasingly appreciated that a group of patients with some lung fibrosis have predominantly PAH and that this group may respond to standard PAH therapies. There have been substantial advances in the treatment of PAH over the past decade. Most cases are treated with oral agents, either an endothelin receptor antagonist (eg, bosentan, ambrisentan) or a phosphodiesterase 5 inhibitor (eg, sildenafil, tadalafil), once the PAH is significantly functionally limited (New York Heart Association class III). Later, if progression takes place, a combination of oral treatment or introduction of parenteral prostacyclin is used, by either the IV or subcutaneous route. Inhaled delivery systems for iloprost are available.

Although PAH is probably responsible for more deaths than lung fibrosis in SSc, lung fibrosis remains an important complication. Treatment of SSc-PF remains challenging.[98] Adding to a substantial body of uncontrolled or retrospective data suggesting benefit for cyclophosphamide in SSc-PF, the results of 2 randomized, double-blind, placebo-controlled trials have been reported. Both show a modest placebo-subtracted benefit for cyclophosphamide.[99-101] For change in forced vital capacity (percent predicted), this was statistically significant for the Scleroderma Lung Study comparing oral cyclophosphamide with placebo, showing a strong trend ($p = 0.06$) in the trial of IV cyclophosphamide followed by oral azathioprine. At present, most centers use cyclophosphamide as treatment for severe or progressive SSc-PF, defining the extent and severity by pulmonary function tests and HRCT. The extent of disease by HRCT and a history of progressive restrictive abnormality on pulmonary function tests is the best predictor of future decline in lung function and is generally used to make decisions about therapy. Newer clinical trials have shown equal efficacy in the treatment of both MMF and cyclophosphamide for stabilizing lung function of patients with scleroderma and ILD.[74] MMF therapy is associated with a stability of lung function for up to 36 months, with a better side-effect profile than in patients treated with azathioprine.[102] Other therapies that are in use include carbocysteine and low-dose corticosteroids. The place of other immunosuppressive strategies remains uncertain and requires evaluation in prospective multicenter clinical trials. It is noteworthy that despite there being a strong theoretic rationale for using the endothelin receptor antagonist bosentan as a therapy for lung fibrosis, bosentan was not superior to placebo in a recent large multicenter study of SSc-PF cases.

Cardiac involvement from SSc is also an important contributor to mortality but remains one of the least-well understood and poorly recognized of the internal organ complications of SSc. A large number of studies confirm that radionuclide imaging, electrophysiologic, and functional abnormalities are frequent in SSc, but the significance of these findings is uncertain. Hemodynamically significant cardiac involvement occurs in up to 10% of cases of diffuse cutaneous SSc. An inflammatory component of myocarditis may respond to immunosuppressive treatment, and so an operational approach to management of cardiac scleroderma. Although this is not yet based on sufficient reliable data, it could form a basis for prospective evaluation of the significance of impaired left ventricular ejection fraction and elevated circulating troponin levels in SSc.

There have been many advances in SSc, including a better appreciation of the diversity of the condition, improved understanding of the underlying pathologic mechanisms, and major progress in treating organ-based complications. This includes the accumulation of robust clinical trial data that demonstrate effectiveness or lack of benefit of individual therapies and in validation of measures of disease assessment.[103]

GI INVOLVEMENT

Involvement of the GI tract occurs frequently in SSc. Esophageal symptoms can respond very well to proton pump inhibitors and agents that increase lower esophageal sphincter tone such as domperidone, although high-dose treatment may be associated with an increased risk of cardiac arrhythmia. Midgut

involvement takes many forms. Pseudoobstruction requires conservative management initially, but subsequently may require parenteral nutritional supplementation. Small intestinal bacterial overgrowth can be treated using broad-spectrum antibiotics, and pancreatic insufficiency may require enzyme supplements. Large bowel involvement is a major challenge. Anorectal incontinence sometimes responds well to an implanted sacral nerve stimulator or to less-elaborate approaches, such as bioplastic injection to increase the internal anal sphincter bulk. Associated rectal prolapse may require additional surgical intervention. Chronic constipation, sometimes with overflow diarrhea, is a common problem. An adjustment to diet and judicious use of stimulating, softening, or bulking aperients is recommended, but an individualized approach with substantial patient involvement is generally the most successful approach. On occasion, defunctioning colostomy is needed, but this is only appropriate in a very limited number of cases.

SCLERODERMA RENAL CRISIS

Overall, approximately two-thirds of the cases of SRC that present to a specialist center require renal replacement therapy. Of these, approximately one-half of cases eventually recover sufficiently to discontinue dialysis. This can occur over 24 months after the renal crisis, and so decisions about renal transplantation should be postponed depending on the outcome. The possibility of late recovery distinguishes SRC from other causes of end-stage renal failure. These outcomes are possible through the use of angiotensin-converting enzyme inhibitors as routine therapy for SRC. Before their availability, the mortality from established SRC was greater than 90% at 12 months. The most critical aspect of management of SRC is prompt identification and treatment of significant hypertension in the context of scleroderma, with initiation of angiotensin-converting enzyme inhibitors. This is a medical emergency and any features of renal impairment or end-organ damage should prompt hospitalization.[104]

Table 63-10 illustrates the frequency of organ involvement in 2 networks for SSc (Germany and United Kingdom).

OTHER SUPPORTIVE PROCEDURES

All these organ-specific therapeutic approaches have to be supported by several general measures to help the patients. These general measures include recommendations for keeping the home and the body warm, and for optimizing nutritional status. Paraffin waxing and physical therapy has to be provided. Patients need to be taught to deal with the complications of daily life and to recognize early those symptoms that indicate disease progression and new organ involvement.

TABLE 63-10

Frequency of Organ Involvement in Two Networks for Systemic Sclerosis (Germany and United Kingdom)

	DIFFUSE CUTANEOUS SYSTEMIC SCLEROSIS		LIMITED CUTANEOUS SYSTEMIC SCLEROSIS	
CLINICAL FEATURES	GERMANY (*n* = 780)	UNITED KINGDOM (*n* = 741)	GERMANY (*n* = 1190)	UNITED KINGDOM (*n* = 1505)
Raynaud phenomenon	95.3%	97%	96.3%	99%
Skin Hardening	95.9%	100%	90%	90%
Digital ulcerations	36%	28%	24.3%	13%
PAH	20.2%	12%	14%	15%
Lung fibrosis	62.9%	38%	26.7%	16%
GI tract involvement	65.2%	90%	60.7%	90%
Heart involvement	20%	3%	9.9%	1%
Kidney involvement	15.9%	19%	9.7%	3%
Musculoskeletal involvement	48.8%	45%	38.8%	35%

REFERENCES

1. Hunzelmann N, Genth E, Krieg T, et al. The registry of the German Network for Systemic Scleroderma: frequency of disease subsets and patterns of organ involvement. *Rheumatology (Oxford).* 2008;47(8):1185-1192.
2. Mayes MD, Lacey JV Jr, Beebe-Dimmer J, et al. Prevalence, incidence, survival, and disease characteristics of systemic sclerosis in a large US population. *Arthritis Rheum.* 2003;48(8):2246-2255.
3. Silman AJ. Epidemiology of scleroderma. *Curr Opin Rheumatol.* 1991;3(6):967-972.
4. Tamaki T, Mori S, Takehara K. Epidemiological study of patients with systemic sclerosis in Tokyo. *Arch Dermatol Res.* 1991;283(6):366-371.
5. Medsger TA Jr, Masi AT. Epidemiology of systemic sclerosis (scleroderma). *Ann Intern Med.* 1971;74(5):714-721.
6. Preliminary criteria for the classification of systemic sclerosis (scleroderma). Subcommittee for scleroderma criteria of the American Rheumatism Association Diagnostic and Therapeutic Criteria Committee. *Arthritis Rheum.* 1980;23(5):581-590.
7. van den Hoogen F, Khanna D, Fransen J, et al. 2013 Classification criteria for systemic sclerosis: an American College of Rheumatology/European League Against Rheumatism collaborative initiative. *Arthritis Rheum.* 2013;65(11):2737-2747.

8. LeRoy EC, Black C, Fleischmajer R, et al. Scleroderma (systemic sclerosis): classification, subsets and pathogenesis. *J Rheumatol.* 1988;15(2):202-205.
9. LeRoy EC, Medsger TA Jr. Criteria for the classification of early systemic sclerosis. *J Rheumatol.* 2001;28(7):1573-1576.
10. Nadashkevich O, Davis P, Fritzler MJ. Revising the classification criteria for systemic sclerosis. *Arthritis Rheum.* 2006;55(6):992-993.
11. Walker JG, Pope J, Baron M, et al. The development of systemic sclerosis classification criteria. *Clin Rheumatol.* 2007;26(9):1401-1409.
12. Maricq HR, Valter I. A working classification of scleroderma spectrum disorders: a proposal and the results of testing on a sample of patients. *Clin Exp Rheumatol.* 2004;22(3)(suppl 33):S5-S13.
13. LeRoy EC, Maricq HR, Kahaleh MB. Undifferentiated connective tissue syndromes. *Arthritis Rheum.* 1980;23(3):341-343.
14. Alarcon GS. Unclassified or undifferentiated connective tissue disease. *Baillieres Best Pract Res Clin Rheumatol.* 2000;14(1):125-137.
15. Poormoghim H, Lucas M, Fertig N, et al. Systemic sclerosis sine scleroderma: demographic, clinical, and serologic features and survival in forty-eight patients. *Arthritis Rheum.* 2000;43(2):444-451.
16. Bennett RM. Scleroderma overlap syndromes. *Rheum Dis Clin North Am.* 1990;16(1):185-198.
17. Ciang NC, Pereira N, Isenberg DA. Mixed connective tissue disease-enigma variations? *Rheumatology (Oxford).* 2017;56(3):326-333.
18. Gunnarsson R, Hetlevik SO, Lilleby V, et al. Mixed connective tissue disease. *Best Pract Res Clin Rheumatol.* 2016;30(1):95-111.
19. Iaccarino L, Gatto M, Bettio S, et al. Overlap connective tissue disease syndromes. *Autoimmun Rev.* 2013;12(3):363-373.
20. Krieg T, Takehara K. Skin disease: a cardinal feature of systemic sclerosis. *Rheumatology (Oxford).* 2009;48(suppl 3):iii14-iii18.
21. Chaisson NF, Hassoun PM. Systemic sclerosis-associated pulmonary arterial hypertension. *Chest.* 2013;144(4):1346-1356.
22. Thakkar V, Nikpour M, Stevens WM, et al. Prospects for improving outcomes in systemic sclerosis-related pulmonary hypertension. *Intern Med J.* 2015;45(3):248-254.
23. Allanore Y, Meune C, Kahan A. Outcome measures for heart involvement in systemic sclerosis. *Rheumatology (Oxford).* 2008;47(suppl 5):v51-v53.
24. Forbes A, Marie I. Gastrointestinal complications: the most frequent internal complications of systemic sclerosis. *Rheumatology (Oxford).* 2009;48(suppl 3):iii36-iii39.
25. Parrado RH, Lemus HN, Coral-Alvarado PX, et al. Gastric antral vascular ectasia in systemic sclerosis: current concepts. *Int J Rheumatol.* 2015;2015:762546.
26. Hudson M. Scleroderma renal crisis. *Curr Opin Rheumatol.* 2015;27(6):549-554.
27. Hunzelmann N, Moinzadeh P, Genth E, et al. High frequency of corticosteroid and immunosuppressive therapy in patients with systemic sclerosis despite limited evidence for efficacy. *Arthritis Res Ther.* 2009;11(2):R30.
28. Gabrielli A, Avvedimento EV, Krieg T. Scleroderma. *N Engl J Med.* 2009;360(19):1989-2003.
29. Agarwal SK, Tan FK, Arnett FC. Genetics and genomic studies in scleroderma (systemic sclerosis). *Rheum Dis Clin North Am.* 2008;34(1):17-40; v.
30. Assassi S, Arnett FC, Reveille JD, et al. Clinical, immunologic, and genetic features of familial systemic sclerosis. *Arthritis Rheum.* 2007;56(6):2031-2037.
31. Arnett FC, Reveille JD, Goldstein R, et al. Autoantibodies to fibrillarin in systemic sclerosis (scleroderma). An immunogenetic, serologic, and clinical analysis. *Arthritis Rheum.* 1996;39(7):1151-1160.
32. Marguerie C, Bunn CC, Copier J, et al. The clinical and immunogenetic features of patients with autoantibodies to the nucleolar antigen PM-Scl. *Medicine (Baltimore).* 1992;71(6):327-336.
33. Assassi S, Tan FK. Genetics of scleroderma: update on single nucleotide polymorphism analysis and microarrays. *Curr Opin Rheumatol.* 2005;17(6):761-767.
34. Herrick AL, Worthington J. Genetic epidemiology: systemic sclerosis. *Arthritis Res.* 2002;4(3):165-168.
35. Nietert PJ, Silver RM. Systemic sclerosis: environmental and occupational risk factors. *Curr Opin Rheumatol.* 2000;12(6):520-526.
36. Mayes MD. Epidemiologic studies of environmental agents and systemic autoimmune diseases. *Environ Health Perspect.* 1999;107(suppl 5):743-748.
37. Jablonska S, Blaszczyk M. Scleroderma-like disorders. *Semin Cutan Med Surg.* 1998;17(1):65-76.
38. Sainson RC, Johnston DA, Chu HC, et al. TNF primes endothelial cells for angiogenic sprouting by inducing a tip cell phenotype. *Blood.* 2008;111(10):4997-5007.
39. Kraling BM, Maul GG, Jimenez SA. Mononuclear cellular infiltrates in clinically involved skin from patients with systemic sclerosis of recent onset predominantly consist of monocytes/macrophages. *Pathobiology.* 1995;63(1):48-56.
40. Saigusa R, Asano Y, Taniguchi T, et al. Multifaceted contribution of the TLR4-activated IRF5 transcription factor in systemic sclerosis. *Proc Natl Acad Sci U S A.* 2015;112(49):15136-15141.
41. Xu Y, Wang W, Tian Y, et al. Polymorphisms in STAT4 and IRF5 increase the risk of systemic sclerosis: a meta-analysis. *Int J Dermatol.* 2016;55(4):408-416.
42. Stifano G, Christmann RB. Macrophage involvement in systemic sclerosis: do we need more evidence? *Curr Rheumatol Rep.* 2016;18(1):2.
43. Mavalia C, Scaletti C, Romagnani P, et al. Type 2 helper T-cell predominance and high CD30 expression in systemic sclerosis. *Am J Pathol.* 1997;151(6):1751-1758.
44. Roumm AD, Whiteside TL, Medsger TA Jr, et al. Lymphocytes in the skin of patients with progressive systemic sclerosis. Quantification, subtyping, and clinical correlations. *Arthritis Rheum.* 1984;27(6):645-653.
45. Hasegawa M, Fujimoto M, Kikuchi K, et al. Elevated serum levels of interleukin 4 (IL-4), IL-10, and IL-13 in patients with systemic sclerosis. *J Rheumatol.* 1997;24(2):328-332.
46. Kurasawa K, Hirose K, Sano H, et al. Increased interleukin-17 production in patients with systemic sclerosis. *Arthritis Rheum.* 2000;43(11):2455-2463.
47. Ho KT, Reveille JD. The clinical relevance of autoantibodies in scleroderma. *Arthritis Res Ther.* 2003;5(2):80-93.
48. Choi MY, Fritzler MJ. Progress in understanding the diagnostic and pathogenic role of autoantibodies associated with systemic sclerosis. *Curr Opin Rheumatol.* 2016;28(6):586-594.

49. Gunther J, Rademacher J, van Laar JM, et al. Functional autoantibodies in systemic sclerosis. *Semin Immunopathol.* 2015;37(5):529-542.
50. Kill A, Riemekasten G. Functional autoantibodies in systemic sclerosis pathogenesis. *Curr Rheumatol Rep.* 2015;17(5):34.
51. Moinzadeh P, Fonseca C, Hellmich M, et al. Association of anti-RNA polymerase III autoantibodies and cancer in scleroderma. *Arthritis Res Ther.* 2014;16(1):R53.
52. Shah AA, Casciola-Rosen L. Cancer and scleroderma: a paraneoplastic disease with implications for malignancy screening. *Curr Opin Rheumatol.* 2015;27(6):563-570.
53. Shah AA, Hummers LK, Casciola-Rosen L, et al. Examination of autoantibody status and clinical features associated with cancer risk and cancer-associated scleroderma. *Arthritis Rheumatol.* 2015;67(4):1053-1061.
54. Brinckmann J, Kim S, Wu J, et al. Interleukin 4 and prolonged hypoxia induce a higher gene expression of lysyl hydroxylase 2 and an altered cross-link pattern: important pathogenetic steps in early and late stage of systemic scleroderma? *Matrix Biol.* 2005;24(7):459-468.
55. Abraham DJ, Krieg T, Distler J, et al. Overview of pathogenesis of systemic sclerosis. *Rheumatology (Oxford).* 2009;48(suppl 3):iii3-iii7.
56. Baroni SS, Santillo M, Bevilacqua F, et al. Stimulatory autoantibodies to the PDGF receptor in systemic sclerosis. *N Engl J Med.* 2006;354(25):2667-2676.
57. Kawakami T, Ihn H, Xu W, et al. Increased expression of TGF-beta receptors by scleroderma fibroblasts: evidence for contribution of autocrine TGF-beta signaling to scleroderma phenotype. *J Invest Dermatol.* 1998;110(1):47-51.
58. Lafyatis R. Transforming growth factor beta—at the centre of systemic sclerosis. *Nat Rev Rheumatol.* 2014;10(12):706-719.
59. Pendergrass SA, Lemaire R, Francis IP, et al. Intrinsic gene expression subsets of diffuse cutaneous systemic sclerosis are stable in serial skin biopsies. *J Invest Dermatol.* 2012;132(5):1363-1373.
60. Rice LM, Padilla CM, McLaughlin SR, et al. Fresolimumab treatment decreases biomarkers and improves clinical symptoms in systemic sclerosis patients. *J Clin Invest.* 2015;125(7):2795-2807.
61. Noda S, Asano Y, Nishimura S, et al. Simultaneous downregulation of KLF5 and Fli1 is a key feature underlying systemic sclerosis. *Nat Commun.* 2014;5:5797.
62. Rosato E, Roumpedaki E, Pisarri S, et al. Digital ischemic necrosis in a patient with systemic sclerosis: the role of laser Doppler perfusion imaging. *Vasa.* 2009;38(4):390-393.
63. Clements PJ, Hurwitz EL, Wong WK, et al. Skin thickness score as a predictor and correlate of outcome in systemic sclerosis: high-dose versus low-dose penicillamine trial. *Arthritis Rheum.* 2000;43(11):2445-2454.
64. Moore TL, Lunt M, McManus B, et al. Seventeen-point dermal ultrasound scoring system—a reliable measure of skin thickness in patients with systemic sclerosis. *Rheumatology (Oxford).* 2003;42(12):1559-1563.
65. Akesson A, Fiori G, Krieg T, et al. Assessment of skin, joint, tendon and muscle involvement. *Clin Exp Rheumatol.* 2003;21(3)(suppl 29):S5-S8.
66. Nives Parodi M, Castagneto C, Filaci G, et al. Plicometer skin test: a new technique for the evaluation of cutaneous involvement in systemic sclerosis. *Br J Rheumatol.* 1997;36(2):244-250.
67. Kissin EY, Schiller AM, Gelbard RB, et al. Durometry for the assessment of skin disease in systemic sclerosis. *Arthritis Rheum.* 2006;55(4):603-609.
68. Balbir-Gurman A, Denton CP, Nichols B, et al. Non-invasive measurement of biomechanical skin properties in systemic sclerosis. *Ann Rheum Dis.* 2002;61(3):237-241.
69. Enomoto DN, Mekkes JR, Bossuyt PM, et al. Quantification of cutaneous sclerosis with a skin elasticity meter in patients with generalized scleroderma. *J Am Acad Dermatol.* 1996;35(3, pt 1):381-387.
70. Vandecasteele EH, De Pauw M, Brusselle G, et al. The heart and pulmonary arterial hypertension in systemic sclerosis. *Acta Clin Belg.* 2016;71(1):1-18.
71. Hunzelmann N, Genth E, Krieg T, et al. Organ-specific diagnosis in patients with systemic sclerosis: Recommendations of the German Network for Systemic Sclerosis (DNSS) [in German]. *Z Rheumatol.* 2008;67(4):334-336, 337-340.
72. Badesch DB, Abman SH, Simonneau G, et al. Medical therapy for pulmonary arterial hypertension: updated ACCP evidence-based clinical practice guidelines. *Chest.* 2007;131(6):1917-1928.
73. Wells AU, Steen V, Valentini G. Pulmonary complications: one of the most challenging complications of systemic sclerosis. *Rheumatology (Oxford).* 2009;48(suppl 3):iii40-iii44.
74. Shenoy PD, Bavaliya M, Sashidharan S, et al. Cyclophosphamide versus mycophenolate mofetil in scleroderma interstitial lung disease (SSc-ILD) as induction therapy: a single-centre, retrospective analysis. *Arthritis Res Ther.* 2016;18(1):123.
75. Tashkin DP, Roth MD, Clements PJ, et al. Mycophenolate mofetil versus oral cyclophosphamide in scleroderma-related interstitial lung disease (SLS II): a randomised controlled, double-blind, parallel group trial. *Lancet Respir Med.* 2016;4(9):708-719.
76. Giuggioli D, Lumetti F, Colaci M, et al. Rituximab in the treatment of patients with systemic sclerosis. Our experience and review of the literature. *Autoimmun Rev.* 2015;14(11):1072-1078.
77. Burt RK, Shah SJ, Dill K, et al. Autologous non-myeloablative haemopoietic stem-cell transplantation compared with pulse cyclophosphamide once per month for systemic sclerosis (ASSIST): an open-label, randomised phase 2 trial. *Lancet.* 2011;378(9790):498-506.
78. Tyndall A, Furst DE. Adult stem cell treatment of scleroderma. *Curr Opin Rheumatol.* 2007;19(6):604-610.
79. van Laar JM, Farge D, Sont JK, et al. Autologous hematopoietic stem cell transplantation vs intravenous pulse cyclophosphamide in diffuse cutaneous systemic sclerosis: a randomized clinical trial. *JAMA.* 2014;311(24):2490-2498.
80. van Laar JM, Farge D, Tyndall A. Stem cell transplantation: a treatment option for severe systemic sclerosis? *Ann Rheum Dis.* 2008;67(suppl 3):iii35-iii38.
81. Denton CP, Howell K, Stratton RJ, et al. Long-term low molecular weight heparin therapy for severe Raynaud's phenomenon: a pilot study. *Clin Exp Rheumatol.* 2000;18(4):499-502.
82. Dziadzio M, Denton CP, Smith R, et al. Losartan therapy for Raynaud's phenomenon and scleroderma: clinical and biochemical findings in a fifteen-week, randomized, parallel-group, controlled trial. *Arthritis Rheum.* 1999;42(12):2646-2655.

83. Challenor VF. Angiotensin converting enzyme inhibitors in Raynaud's phenomenon. *Drugs.* 1994;48(6): 864-867.
84. Kahan A, Foult JM, Weber S, et al. Nifedipine and alpha 1-adrenergic blockade in Raynaud's phenomenon. *Eur Heart J.* 1985;6(8):702-705.
85. Meyrick Thomas RH, Rademaker M, Grimes SM, et al. Nifedipine in the treatment of Raynaud's phenomenon in patients with systemic sclerosis. *Br J Dermatol.* 1987;117(2):237-241.
86. Rhedda A, McCans J, Willan AR, et al. A double blind placebo controlled crossover randomized trial of diltiazem in Raynaud's phenomenon. *J Rheumatol.* 1985;12(4):724-727.
87. Wigley FM, Korn JH, Csuka ME, et al. Oral iloprost treatment in patients with Raynaud's phenomenon secondary to systemic sclerosis: a multicenter, placebo-controlled, double-blind study. *Arthritis Rheum.* 1998;41(4):670-677.
88. Wigley FM, Seibold JR, Wise RA, et al. Intravenous iloprost treatment of Raynaud's phenomenon and ischemic ulcers secondary to systemic sclerosis. *J Rheumatol.* 1992;19(9):1407-1414.
89. Korn JH, Mayes M, Matucci Cerinic M, et al. Digital ulcers in systemic sclerosis: prevention by treatment with bosentan, an oral endothelin receptor antagonist. *Arthritis Rheum.* 2004;50(12):3985-3993.
90. Fries R, Shariat K, von Wilmowsky H, et al. Sildenafil in the treatment of Raynaud's phenomenon resistant to vasodilatory therapy. *Circulation.* 2005;112(19): 2980-2985.
91. Rose RF, Turner D, Goodfield MJ, et al. Low-dose UVA1 phototherapy for proximal and acral scleroderma in systemic sclerosis. *Photodermatol Photoimmunol Photomed.* 2009;25(3):153-155.
92. Das SN, Alam MR, Islam N, et al. Placebo controlled trial of methotrexate in systemic sclerosis. *Mymensingh Med J.* 2005;14(1):71-74.
93. van den Hoogen FH, Boerbooms AM, Swaak AJ, et al. Comparison of methotrexate with placebo in the treatment of systemic sclerosis: a 24 week randomized double-blind trial, followed by a 24 week observational trial. *Br J Rheumatol.* 1996;35(4):364-372.
94. Nadashkevich O, Davis P, Fritzler M, et al. A randomized unblinded trial of cyclophosphamide versus azathioprine in the treatment of systemic sclerosis. *Clin Rheumatol.* 2006;25(2):205-212.
95. Tashkin DP, Elashoff R, Clements PJ, et al. Cyclophosphamide versus placebo in scleroderma lung disease. *N Engl J Med.* 2006;354(25):2655-2666.
96. Gordon J, Udeh U, Doobay K, et al. Imatinib mesylate (Gleevec) in the treatment of diffuse cutaneous systemic sclerosis: results of a 24-month open label, extension phase, single-centre trial. *Clin Exp Rheumatol.* 2014;32(6)(suppl 86):S189-S193.
97. Prey S, Ezzedine K, Doussau A, et al. Imatinib mesylate in scleroderma-associated diffuse skin fibrosis: a phase II multicentre randomized double-blinded controlled trial. *Br J Dermatol.* 2012;167(5):1138-1144.
98. Hachulla E, Coghlan JG. A new era in the management of pulmonary arterial hypertension related to scleroderma: endothelin receptor antagonism. *Ann Rheum Dis.* 2004;63(9):1009-1014.
99. Merkel PA, Clements PJ, Reveille JD, et al. Current status of outcome measure development for clinical trials in systemic sclerosis. Report from OMERACT 6. *J Rheumatol.* 2003;30(7):1630-1647.
100. Steen VD. The lung in systemic sclerosis. *J Clin Rheumatol.* 2005;11(1):40-46.
101. Khanna D, Yan X, Tashkin DP, et al. Impact of oral cyclophosphamide on health-related quality of life in patients with active scleroderma lung disease: results from the scleroderma lung study. *Arthritis Rheum.* 2007;56(5):1676-1684.
102. Owen C, Ngian GS, Elford K, et al. Mycophenolate mofetil is an effective and safe option for the management of systemic sclerosis-associated interstitial lung disease: results from the Australian Scleroderma Cohort Study. *Clin Exp Rheumatol.* 2016;34(5)(suppl 100):170-176.
103. Denton CP, Black CM. Targeted therapy comes of age in scleroderma. *Trends Immunol.* 2005;26(11):596-602.
104. Ghossein C, Varga J, Fenves AZ. Recent developments in the classification, evaluation, pathophysiology, and management of scleroderma renal crisis. *Curr Rheumatol Rep.* 2016;18(1):5.
105. Denton CP, Hughes M, Gak N, et al. BSR and BHPR guideline for the treatment of systemic sclerosis. *Rheumatology (Oxford).* 2016;55(10):1906-1910.
106. Wise RA, Wigley FM, White B, et al. Efficacy and tolerability of a selective alpha(2C)-adrenergic receptor blocker in recovery from cold-induced vasospasm in scleroderma patients: a single-center, double-blind, placebo-controlled, randomized crossover study. *Arthritis Rheum.* 2004;50(12):3994-4001.
107. Murdaca G, Spano F, Puppo F. Current therapies for the treatment of systemic sclerosis-related pulmonary arterial hypertension: efficacy and safety. *Expert Opin Drug Saf.* 2014;13(3):295-305.
108. Kumar U, Sankalp G, Sreenivas V, et al. Prospective, open-label, uncontrolled pilot study to study safety and efficacy of sildenafil in systemic sclerosis-related pulmonary artery hypertension and cutaneous vascular complications. *Rheumatol Int.* 2013;33(4):1047-1052.

Chapter 64 :: Morphea and Lichen Sclerosus

:: Nika Cyrus & Heidi T. Jacobe

MORPHEA

AT-A-GLANCE

- Occurs in children and adults.
- Linear subtype predominates in children.
- Circumscribed and generalized predominate in adults.
- A self-limited or chronically relapsing autoimmune disorder targeting the skin with the following major features:
  - Inflammatory, sclerotic, atrophic phases.
  - Thickened sclerotic skin.
  - Systemic disease, including arthritis and neurologic disorders, in a minority.
  - Differentiated from scleroderma by lack of acrosclerosis/sclerodactyly.
- Complications may cause significant irreversible cosmetic and functional impairment including the following:
  - Atrophy of dermis, fat, and subcutaneous structures.
  - Contracture.
  - Limb-length discrepancy.
  - Bony abnormalities.
- Effective treatment reduces signs of disease activity and does not produce complete resolution of lesions. Treatment based on the following:
  - Disease subtype.
  - Depth of involvement.
  - Stage (inflammatory, sclerotic, atrophic).
  - Potential for complications.

Morphea is a chronic inflammatory disease characterized by sclerosis of the skin. The term *localized scleroderma* is also used in some texts. This causes confusion with systemic sclerosis (scleroderma), often resulting in unnecessary evaluation and anxiety. It is the opinion of the authors that the term *localized scleroderma* should be avoided. Morphea itself has a spectrum of manifestations ranging from skin only to multiple organ involvement. Of note, organ involvement in morphea is distinctly different from systemic sclerosis (Table 64-1).

EPIDEMIOLOGY

Morphea has an estimated incidence of 2.7 per 100,000 with a female-to-male ratio of 2 to 3:1.[1] Morphea is more common in whites, although population-based studies have not verified this observation.[2-5] The relative frequency of the different subtypes varies between studies. This is likely due to use of different classification systems. Twenty to thirty percent of morphea begins in childhood, but it can occur at any age.[2-5] Linear morphea is the most common pediatric subtype (although all subtypes occur at any age).[1,2,6] Twenty-five percent to 87% of pediatric cases are linear morphea, with limb or trunk involvement in approximately 70% to 80% and en coup de sabre or progressive hemifacial atrophy (formerly described as Parry-Romberg syndrome) in 22% to 30%.[1,2,4,5,7,8] In adults, circumscribed and generalized subtypes predominate.[5] Deep morphea/morphea profunda is uncommon in both adults and children, with a frequency of 2% to 4%.[1,2,4,7,8] Periods of disease activity vary from 3 to 6 years.[2,8] Newer studies demonstrate morphea has a relapsing remitting course in some patients. Although longitudinal studies are needed to better determine the frequency and associated clinical factors of recurrence, the frequency of recurrence maybe 20% of cases or more. Others have a chronic course persisting for decades. The prognostic markers for recurrent or chronic disease have yet to be determined.[9,10]

CLINICAL FEATURES

Morphea is currently divided into 5 putative subtypes (Table 64-2).[11] Superficial or deep disease (involving subcutis, fascia, or below) may occur with any subtype. Morphea lesions may also occur with overlying lichen sclerosus change (Fig. 64-1).

CUTANEOUS FINDINGS

Stages of Cutaneous Lesions: Figure 64-2 outlines the stages of morphea lesions.

Morphea begins as erythematous plaques or patches, sometimes with a reticulated appearance. Later, hypopigmented sclerotic plaques develop at the center of the lesion, surrounded by an erythematous or violaceous border (inflammatory stage) (Fig. 64-3A). Pain and/or itching can occur with active lesions. Sclerosis develops centrally, has a shiny white color with surrounding hyperpigmentation (sclerotic stage). There may be loss of hair follicles, producing alopecia. Over months to years, the sclerotic plaque softens and becomes atrophic with hypopigmentation or hyperpigmentation (atrophic stage) (Fig. 64-3B). The atrophic stage is associated with cigarette paper wrinkling (papillary dermis), cliff drop (dermal), or deep indentions altering the contour of the affected body part (subcutis or deeper atrophy).

TABLE 64-1
Differential Diagnosis of Morphea

Most Likely

- Scleroderma (systemic sclerosis)
- Lipodermatosclerosis
- Eosinophilic fasciitis
- Morpheaform injection-site reactions
- Nephrogenic systemic fibrosis
- Chronic graft-versus-host disease

Consider

- Lichen sclerosus
- Pretibial myxedema
- Connective tissue nevi
- Morpheaform basal cell carcinoma
- Chemical-mediated sclerosing skin conditions (toxic oil syndrome, rapeseed oil, etc)
- Lyme disease (acrodermatitis atrophicans)
- Phenylketonuria
- Scleromyxedema, scleredema, pretibial myxedema
- Polyneuropathy, organomegaly, endocrinopathy, M protein, and skin changes (POEMS) syndrome

Always Rule Out

- Carcinoma of the breast metastatic to skin (carcinoma en cuirasse)
- Porphyria cutanea tarda

Circumscribed Morphea: Circumscribed morphea presents as oval to round lesions that are of limited cutaneous distribution so do not meet criteria for generalized disease (see Table 64-2). Patients with circumscribed morphea should be closely followed, as both linear and generalized morphea may begin with circumscribed lesions.

Figure 64-1 Lichen sclerosis can overlie morphea lesions.

Atrophoderma of Pasini and Pierini is thought to be the residua of plaque-type morphea. The borders of the atrophoderma lesions have a "cliff-drop" appearance resembling "burnt-out" morphea lesions.

Generalized Morphea: Generalized morphea is characterized by more than or equal to 4 lesions on at least 2 of 7 different anatomic sites. There are likely 3 variants of generalized morphea: (a) isomorphic, (b) symmetric, and (c) pansclerotic (see Table 64-2 and Figs. 64-3 and 64-4).[12-14] In direct contrast to systemic sclerosis, generalized morphea does not present with acrosclerosis or sclerodactyly. Instead, lesions frequently begin on the trunk and spread acrally, sparing the fingers and toes (Fig. 64-4).

Linear Morphea: Linear morphea usually affects the extremities and face, but it can occur on the trunk (where it is often misclassified as circumscribed) (see Table 64-2 and Fig. 64-5A). The presence of multiple

TABLE 64-2
Proposed Classification of Morphea Subtypes

MORPHEA SUBTYPE	MODIFIERS	CLINICAL
Circumscribed	Superficial	Single or multiple oval/round lesions limited to epidermis and dermis
	Deep	Single or multiple oval/round lesions involving subcutaneous tissue, fascia, or muscle
Linear	Trunk/limbs	Linear lesions involving dermis subcutaneous tissue with/without involvement of skin, dermis, subcutaneous tissue, muscle, or bone
	Head	En coup de sabre, progressive facial hemiatrophy, linear lesions of the face (may involve underlying soft tissue, bone, or brain/gingiva/etc.)
Generalized		
1. Coalescent plaque		More than or equal to 4 plaques in at least 2 of 7 anatomic sites (head–neck, right/left upper extremity, right/left lower extremity, anterior/posterior trunk); isomorphic pattern: coalescent plaques inframammary fold, waistline, lower abdomen, proximal thighs; symmetric pattern: symmetric plaques circumferential around breasts, umbilicus, arms, and legs
2. Pansclerotic		Circumferential involvement of majority of body surface area (sparing fingertips and toes), affecting skin, subcutaneous tissue, muscle or bone; no internal organ involvement
3. Mixed		Combination of any above subtype: eg, linear-circumscribed

Adapted from Laxer RM, Zulian F. Localized scleroderma. *Curr Opin Rheumatol*. 2006;18:606-613, with permission. https://journals.lww.com/co-rheumatology.

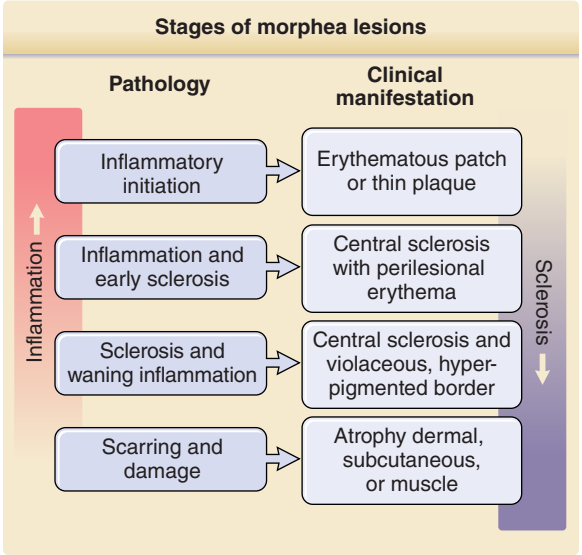

Figure 64-2 Stages of morphea lesions. (Reproduced with permission from Jacobe H. Pathogenesis, clinical manifestations, and diagnosis of morphea [localized scleroderma] in adults. In: Post TW, ed. *UpToDate*. Waltham, MA: UpToDate, Inc. Copyright © 2017. For more information visit www.uptodate.com.)

linear lesions is not uncommon. A recent study suggests that linear morphea may follow the Blaschko lines.[15] Linear morphea may involve the dermis, subcutaneous tissue, muscle, or even underlying bone, causing significant cosmetic and functional impairment. Bone marrow inflammation has also been reported.[16,17]

En coup de sabre ("cut of the sword") may present as an atrophic linear plaque on the forehead (Fig. 64-5B), extending to the scalp (where cicatricial alopecia occurs), brow, nose, and lip. These lesions start with an inflammatory phase, but because of their location on the scalp, they do not illicit the patients' attention until pigmentary change and atrophy develops. Other linear lesions on the head and neck present on any part of the face, and are generally hyperpigmented atrophic plaques (Fig. 64-5C). Progressive hemifacial atrophy is characterized by a slowly progressive, unilateral atrophy of skin, soft tissues, muscles, and/or bony structures. The atrophy may be accompanied by classic linear morphea lesions on the face or elsewhere. Examination of the face from multiple perspectives and with facial expressions can elicit subtle anatomic asymmetry in early progressive hemifacial atrophy.

Deep Morphea: Deep morphea, or morphea profunda, involves the deep dermis, subcutaneous tissue, fascia, and muscle. Plaques are poorly circumscribed and symmetrical (Fig. 64-6). The skin feels thickened and bound down to the underlying fascia and muscle. A "groove sign" (depression) may be present at the site of tendons and ligaments. Deep morphea lesions may underlie any clinical subtype of morphea, particularly linear and generalized, or occur alone. Progressive hemifacial atrophy is simply deep morphea affecting the face.

Mixed Morphea: Mixed morphea is a combination of any of the above subtypes, although most commonly it denotes linear and circumscribed lesions in combination.[11]

Figure 64-3 Generalized morphea. **A.** Isomorphic plaques involving bra and waistband areas. **B.** Symmetric plaques on a patient with generalized morphea. (Reproduced with permission from Jacobe H. Pathogenesis, clinical manifestations, and diagnosis of morphea [localized scleroderma] in adults. In: Post TW, ed. *UpToDate*. Waltham, MA: UpToDate, Inc. Copyright © 2017. For more information visit www.uptodate.com.)

Figure 64-4 Pansclerotic morphea: sclerosis encompassing majority of body surface area (**A**), characteristically sparing the fingertips (**B**). (Reproduced with permission from Jacobe H. Pathogenesis, clinical manifestations, and diagnosis of morphea [localized scleroderma] in adults. In: Post TW, ed. *UpToDate*. Waltham, MA: UpToDate, Inc. Copyright © 2017. For more information visit www.uptodate.com.)

Figure 64-5 **A,** Multiple linear lesions involving trunk. **B,** En coup de sabre. **C,** Multiple hyperpigmented linear morphea lesions on the face. (Reproduced with permission from Jacobe H. Pathogenesis, clinical manifestations, and diagnosis of morphea [localized scleroderma] in adults. In: Post TW, ed. *UpToDate*. Waltham, MA: UpToDate, Inc. Copyright © 2017. For more information visit www.uptodate.com.)

Figure 64-6 Morphea profunda: involved areas have "cobblestone" appearance with subcutaneous atrophy. (Reproduced with permission from Jacobe H. Pathogenesis, clinical manifestations, and diagnosis of morphea [localized scleroderma] in adults. In: Post TW, ed. *UpToDate*. Waltham, MA: UpToDate, Inc. Copyright © 2017. For more information visit www.uptodate.com.)

Eosinophilic Fasciitis: Eosinophilic fasciitis, or Shulman syndrome, is a related disorder presenting with rapid onset of symmetric areas of pain and poorly circumscribed indurated, plaques, usually on the extremities. Eosinophilic fasciitis may occur with cutaneous lesions similar to morphea in 30% of cases, or remain without skin involvement. Deep subcutaneous and fascial involvement and peripheral eosinophilia are common.[18]

NONCUTANEOUS FINDINGS

Extracutaneous manifestations develop in 22% to 56% of morphea patients.[1,4,5,7,8,19] Musculoskeletal involvement is the most common finding (12%) and can occur unrelated to skin lesions.[20,21] Musculoskeletal involvement can include arthritis, myalgias, neuropathies, and carpal tunnel syndrome. En coup de sabre is associated with neurologic and ocular complications (3.6%) including seizures, headaches, adnexal abnormalities (eyelids, eyelashes), uveitis, and episcleritis.[20-24] Rarely, serious complications, such as CNS vasculitis, can develop, which is an emergency. Facial morphea may produce dental malocclusion, altered dentition, gingivitis, deviation of the uvula, and atrophy of the tongue and salivary glands. Morphea can also rarely involve the genitals typically in postmenopausal women with generalized subtype[25] or coexist with genital lichen sclerosus.

COMPLICATIONS

Cutaneous disease itself produces limited range of motion, limb-length discrepancy, joint deformity, and contracture (45% to 56% linear morphea). Patients with lesions crossing joint lines are most at risk.[8,19,20]

Children with morphea can have significant morphea-related morbidity, including effects on growth, function, and quality of life (fewer studies exist in adults).[26,27] Muscle weakness may occur in affected extremities or face. Behavioral changes, learning disabilities, and seizure (sometimes preceding cutaneous lesions)[23,24] have been reported in children with (and without) facial involvement. In addition, disfigurement and physical symptoms (fatigue, pain, itch) associated with morphea affect psychosocial development and play a substantial role in the quality of life for patients with morphea.

Panssclerotic morphea is associated with an increased risk of squamous cell carcinoma caused by chronic ulcers. The resulting sclerosis of the skin can cause significant contracture, and produces restrictive pulmonary defects and dysphagia. Circumferential sclerosis of the arms or legs may also produce compartment syndrome, bullae, and ulcers.[13]

Morphea can coexist with other autoimmune diseases such as lichen sclerosus, systemic lupus erythematosus, vitiligo, primary biliary sclerosis, autoimmune hepatitis, Hashimoto thyroiditis, and myasthenia gravis.[22,28-33] In particular, generalized morphea is associated with an increased rate of autoimmune disease.[5] Despite this association, screening in the absence of symptoms is not indicated.

ETIOLOGY AND PATHOGENESIS

The etiology and pathogenesis of morphea is poorly understood. Most pathologic events ascribed to morphea are extrapolated from studies in systemic sclerosis (assuming the 2 disorders arise from the same etiology). Morphea likely arises from a genetic background that increases disease susceptibility, combined with other causative factors (eg, infectious, environmental exposures) that modulate disease expression. HLA-DRB1*04:04 and HLA-B37 confer an increased risk for morphea.[34] The presence of a human leukocyte antigen association along with familial clustering and higher-than-expected rates of familial autoimmune disorders implicate a genetic predisposition.[9,35,36] Although there are no definitive associations, development of morphea lesions is linked to local tissue trauma, including radiation, surgery, insect bites, and intramuscular injections.[12] Sixteen percent of patients develop initial lesions of morphea at sites of trauma resulting from chronic friction or surgery.[12]

Increasing amounts of evidence support autoimmune-mediated inflammation early in the course of morphea.[37] Early morphea lesions are characterized by the influx of large amounts of mononuclear lymphocytes (usually activated T lymphocytes), plasma cells, and eosinophils. This is likely the result of autoimmunity, as there is widespread autoimmune reactivity

in morphea patients (elevated antinuclear antibodies [ANAs], cytokines, and adhesion molecules). Morphea patients also have concomitant autoimmune disease at a higher-than-expected frequency than occurs in a healthy population.[31] Vessel damage and upregulation of adhesion molecules (intercellular adhesion molecule-1, vascular cell adhesion molecule-1, and E-selectin) occur related to the inflammatory cell infiltrate that facilitates local monocyte recruitment.[38]

T-helper (Th) 1-associated cytokines and chemokines including interleukin (IL)-12, IL-2 interferon (IFN)-γ, IFN-α2, and CXCL-10 are increased in the serum of morphea patients compared to controls.[39,40] Macrophage cytokines and growth factors including granulocyte-macrophage colony-stimulating factor and monocyte chemoattractant protein-1 are also increased in morphea serum.[39] In addition, CXCL-9, a key Th1 chemokine, is significantly elevated in the sera of patients with active morphea compared to controls (unpublished data). CXCL-9 and CXCL-10 are produced by macrophages after stimulation by IFN-γ. CXCL-9 subsequently binds to CXCR3 on T cells, leading to migration of Th1 and cytotoxic T cells from peripheral blood into target tissues. Interestingly, there is a positive correlation between CXCL-9 levels and disease severity scores in morphea, suggesting that CXCL-9 may potentially serve as a useful biomarker in morphea (unpublished data). CXCL-10 levels in serum also correlate with disease activity in morphea patients.[39] Gene expression analysis of inflammatory border of morphea also shows upregulation of Th1 and IFN-regulated pathways compared to unaffected skin, which is consistent with the findings in serum (unpublished data).

On the other hand, there is also evidence of elevation of Th2-related cytokines in morphea including IL-4 and IL-13.[40,41] These cytokines (especially IL-4) upregulate transforming growth factor-β, initiating a cascade of events resulting in increased production of collagen and other extracellular matrix components via induction of connective tissue growth factor, platelet-derived growth factor, and matrix metalloproteinases. These cytokines and growth factors inhibit IFN-γ (a suppressor of collagen synthesis and Th1-related cytokine). Taken together, the pathogenesis of morphea appears to involve a transition from a predominantly Th1 profile in the early inflammatory stage of morphea to a Th2 profile in the later sclerotic stage. The factors mediating the transition of Th1 to Th2 remain unknown. Some reports indicate that chimerism or nonself cells may play a role in the pathogenesis of morphea by initiating a local inflammatory reaction.[42]

DIAGNOSIS

The diagnosis of morphea is usually made by the characteristic clinical appearance of the lesions. Histologic examination should be used to exclude other disorders on the differential, particularly in the case of lesions on the breast, in which carcinoma of the breast should be excluded. Histologic examination may aid therapeutic decision making because it is sometimes difficult to determine the degree of activity or depth of involvement by clinical examination alone. Biopsy of the advancing edge of a lesion may provide insight into both (Fig. 64-7).

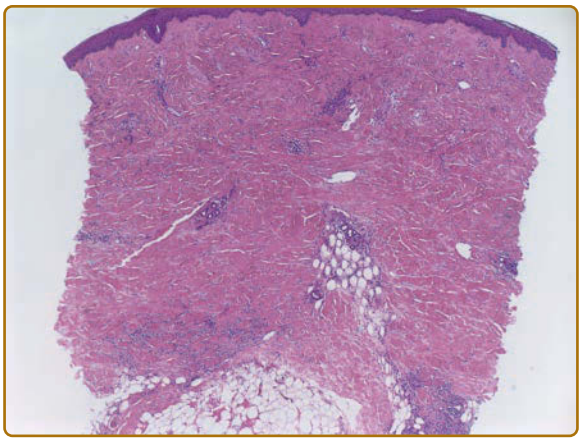

Figure 64-7 Morphea histology demonstrates perivascular, interstitial, and subcutaneous inflammatory cell infiltrate with marked dermal fibrosis.

LABORATORY TESTING

Although a large number of laboratory-based assessments are reported to reflect disease activity and prognosis in morphea, promising new biomarkers need further validation. Consequently, laboratory-based tests are not recommended for evaluation morphea in the absence of specific signs and symptoms indicating the need for further assessment.

Serum Autoantibodies: Autoantibodies reported in patients with morphea include ANA, anti–single-stranded DNA, anti–double-stranded DNA, antihistone, antitopoisomerase IIα, antiphospholipid, anticentromere, anti–Scl-70, rheumatoid factor, and matrix metalloproteinase-1.[5,19,43-48] ANAs occur in 34% to 80% of patients and are more common in patients with linear or generalized disease.[58,19,43,49] A case-control study of 187 adults and children showed positive ANA and antihistone antibodies in 34% and 12% of morphea patients compared to 11% and 2% of controls respectively ($P < 0.001$).[49] The majority (81%) had a speckled pattern of ANA. In terms of prognostic significance, only in the subset of linear morphea, antihistone antibodies were associated with functional limitation, and ANA was associated with extensive body surface area involvement.[49] Overall, the clinical and prognostic significance of autoantibodies in morphea remains unclear and testing for them is not indicated.

Other Serum Abnormalities: Peripheral eosinophilia, hypergammaglobulinemia, and increased erythrocyte sedimentation rate or C-reactive protein may occur with active disease of any type, but particularly deep morphea. Additionally, patients with muscle involvement may have elevation of creatine kinase and aldolase.

PATHOLOGY

Biopsies should be taken from the inflammatory or indurated border when present (indicate on pathology requisition) or sclerotic center and include subcutaneous fat. For lesions with minimal clinical change, biopsy of site-matched unaffected skin is helpful. Findings depend on where the biopsy was taken, stage of the lesion, and depth of involvement (see Fig. 64-7). The inflammatory phase demonstrates an interstitial and perivascular inflammatory cell infiltrate in the dermis and sometimes subcutaneous tissue, composed mostly of lymphocytes and plasma cells, but eosinophils, mast cells, and macrophages also may be present. There is also tissue edema, enlarged tortuous vessels, and thickened collagen bundles. In sclerotic lesions there is homogenization of the papillary dermis and sclerosis extending to the reticular dermis (or beyond depending on depth of involvement) with thickened collagen bundles. With severe sclerosis there is compression and loss of appendageal structures. In deep morphea, the deep reticular dermis, subcutis, and fascia show similar changes. The atrophic phase is characterized by loss of inflammatory cell infiltrate, lessening of sclerosis, and absence of appendageal structures. Telangiectasia may occur.

IMAGING

Assessment via MRI and ultrasonography is becoming increasingly useful for determination of lesion activity and depth and should be considered when deep morphea is present or suspected. MRI provides a complete assessment of the extent of disease, including depth of involvement and disease activity.[50] MRI findings include fascial thickening and enhancement, subcutaneous septal thickening, articular synovitis, tenosynovitis, perifascial enhancement, myositis, enthesitis, and, rarely, bone marrow involvement.[50] Musculoskeletal involvement was seen with MRI in 38% of patients in whom it was not clinically suspected.[50] It is also possible to evaluate the response to treatment, although not currently routine practice.

Ultrasonography is a sensitive tool usable for evaluating or monitoring tissue thickness, loss of subcutaneous fat and muscle, or other architectural alterations. Disease activity can be correlated with the detection of hyperemia and echogenicity.[51] Discussion with the radiologist performing the MRI or ultrasonography studies is crucial to adequately detect and evaluate change related to the morphea.

DIFFERENTIAL DIAGNOSIS

The differential diagnosis of morphea includes systemic sclerosis and other sclerodermoid conditions, including graft-versus-host disease, sclerodermoid porphyria cutanea tarda (especially with photodistributed sclerodermoid eruptions), lipodermatosclerosis, lichen sclerosus, and others (see Table 64-1). It is important to note that morphea and systemic sclerosis are distinct entities. Systemic sclerosis is characterized by acral sclerosis/sclerodactyly, nail-fold capillary changes, Raynaud phenomenon, characteristic internal organ involvement (eg, pulmonary, renal, and GI), and hallmark autoantibodies. These features are absent in morphea. For a morpheaform plaque on the breast, carcinoma en cuirasse resulting from metastatic breast cancer is an important diagnosis to rule out. Morpheaform reactions can also develop secondary to vitamin K_1 injections, taxanes, IFN-β1a, and balicatib.[52-55]

CLINICAL COURSE AND PROGNOSIS

Although morphea causes functional and aesthetic impairment, it is rarely life-threatening. Morphea may be self-limited, but frequently has a remitting relapsing or chronic course that produces significant disease burden over time.[9] Recurrences occur in approximately 25% of patients.[56] A higher risk of recurrence (31% of patients) has been reported for linear morphea of the extremities as compared to other subtypes.[56]

MANAGEMENT

OVERVIEW

The natural history of morphea is poorly understood. At least some cases undergo spontaneous remission after a few years of activity. However, even when spontaneous remission occurs, residual damage created by active disease remains. In addition, new evidence suggests at least a subset of morphea patients has continued disease activity over many years, ultimately leading to extensive disease burden and related morbidity.[9] Despite the large number of reported treatments, no consistent recommendations exist for therapy. This section provides an evidence-based algorithm for the rational evaluation and management of morphea patients (Fig. 64-8). It is important to understand what constitutes therapeutic success in morphea when treating patients. Therapeutic success is defined by resolution of erythema, typically over 2 to 3 months, lesion softening, which can take 12 months or more, cessation of lesion growth, and no new lesion development. In general, active lesions are most amenable to treatment. A morphea-specific outcome measure known as localized scleroderma cutaneous assessment tool (LoSCAT) has been validated and consists of 2 scores: LoSSI (localized scleroderma severity index) and LoSDI (localized scleroderma damage index), which are useful for monitoring disease activity and damage, respectively, especially in clinical trials and research. Serial photography is helpful in clinical practice.

PATIENT EVALUATION

In determining which therapy is appropriate, the following must be considered:

- ***Disease activity and damage*:** Existing studies indicate that early, active disease is most responsive to therapy.[57] Indicators of active disease include development of new lesions or extension of existing lesions (photographs are critical), erythema and/or induration of the advancing edge of the lesion, and patient-reported symptoms, such as itch or tingling. Disease damage (reversible or irreversible) includes pigmentary change, sclerosis of the lesion center, atrophy (dermal, subcutaneous, muscle), contracture, limb-length discrepancy, and scarring alopecia. Disease damage is much more difficult to treat and therapy should be aimed at preventing disease damage. Furthermore, patients with active disease at risk for significant damage (facial lesions, progressive hemifacial atrophy, lesions crossing joint lines, large body surface area involvement, rapid progression) likely need aggressive therapy (phototherapy and/or systemic immunosuppressives).
- ***Depth of involvement*:** Morphea involving the superficial to mid-dermis would logically be amenable to topical therapy or phototherapy; however, involvement of the deep dermis and beyond should be treated systemically. Deep involvement can occur in all subtypes of morphea, but is especially prominent among linear and some generalized patients, and is associated with functional impairment and pain.
- ***Disease progression*:** Many generalized and linear morphea patients are initially diagnosed with circumscribed morphea, but progress to have much more extensive disease.[9] Therefore, patients who initially present with 1 to 3 plaques (which may be amenable to localized therapy) should

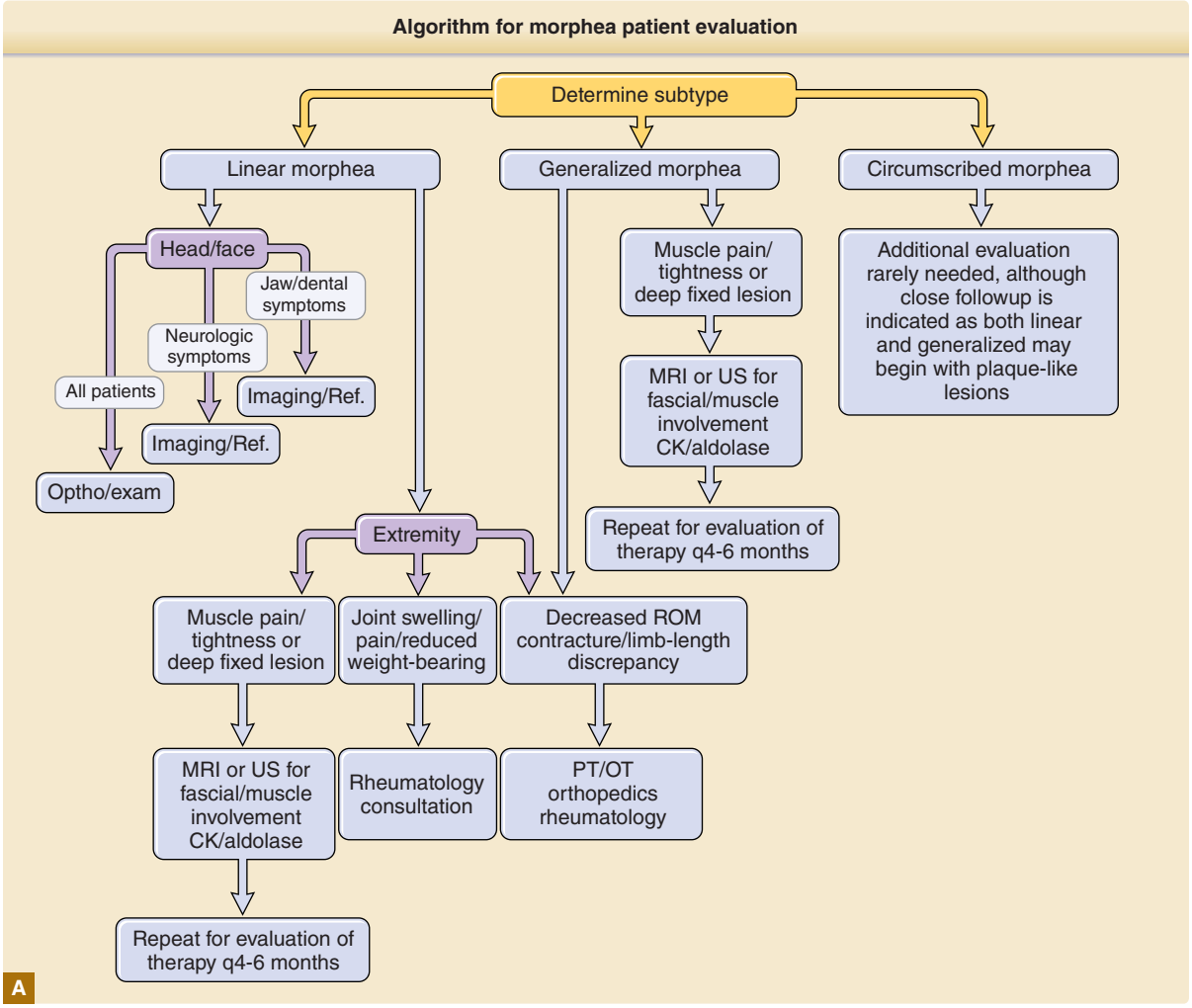

Figure 64-8 **A,** Algorithm for the evaluation of patients with morphea. Optho, ophthalmologic; OT, occupational therapy; PT, physical therapy; ROM, range of motion; US, ultrasonography.

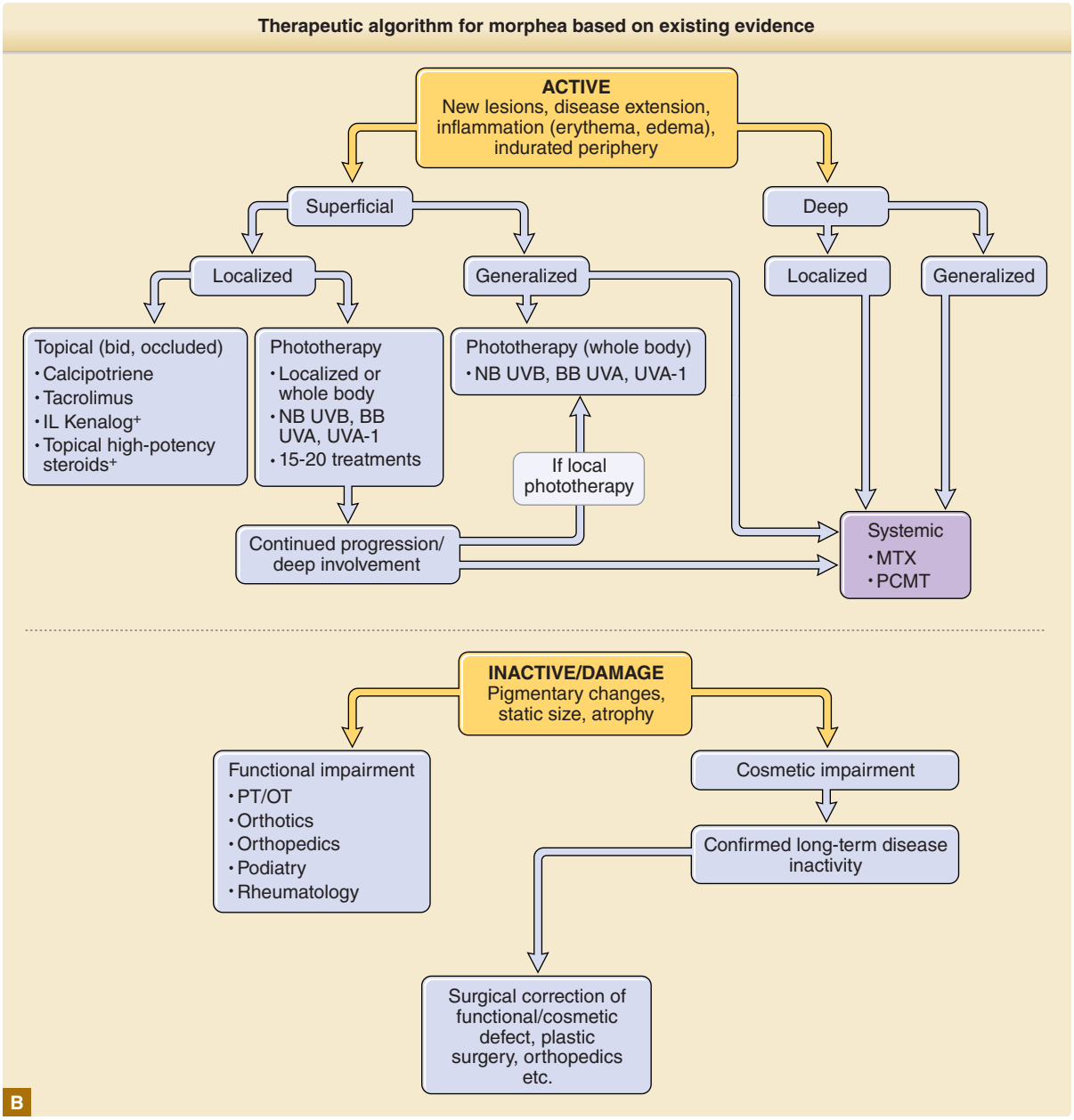

Figure 64-8 (*continued*) **B,** Therapeutic algorithm for morphea based on existing evidence. Superficial involvement is defined by histologic evidence of papillary dermal involvement. Deep involvement is defined as sclerosis or inflammation of the deep dermis, subcutis, fascia, or muscle. Histologic examination and/or MRI are encouraged to evaluate lesions for depth of involvement and, likewise, determine appropriate treatment as well as evaluation of therapeutic efficacy. BB, broadband; MTX, methotrexate; NB, narrowband; OT, occupational therapy; PCMT, pulsed corticosteroids and methatrexate; PT, physical therapy; UVA/B, ultraviolet A/B. (Reproduced with permission from Jacobe H. Pathogenesis, clinical manifestations, and diagnosis of morphea (localized scleroderma) in adults. In: Post TW, ed. *UpToDate*. Waltham, MA: UpToDate, Inc. Copyright © 2017. For more information visit www.uptodate.com.)

be closely followed. If these patients progress, therapy should then be aimed at preventing further progression (ie, phototherapy or systemic therapy).

- ***Systemic involvement*:** Systemic involvement is an indication for systemic immunosuppressive therapy.
- ***Disease subtype*:** Patients with linear and generalized (particularly those with rapid onset of confluent plaques) are likely at risk for severe, extensive disease and should be treated aggressively either with phototherapy or systemic immunosuppressives depending on the depth of involvement.

TREATMENT ALGORITHM

Table 64-3 outlines morphea therapy.

Phototherapy: Phototherapy has level 1 evidence for efficacy (level 1, randomized controlled trials: broadband ultraviolet (UV) A, narrowband UVB, and UVA-1; level 2: psoralen and UVA systemic and topical).[58-63] Narrowband UVB should be considered for lesions affecting the superficial dermis (relatively thin on palpation or with sclerosis and inflammation in the papillary and superficial reticular dermis). UVA-based therapies are more appropriate for deeper dermal lesions because of a greater depth of penetration. UVA-1 in particular has evidence for normalization of dermal collagen and effect on inflammation in morphea so is appropriate for both inflammatory and sclerotic disease.[63] In the absence of access to UVA-1 phototherapy, use of broadband UVA is also supported by the literature.[58] Disease is expected to improve (progression halted and erythema improved) after 10 to 20 treatments and most trials stopped after 20 to 30 treatments. Evidence suggests that patients continue to improve after cessation of therapy, and some authors recommend using a greater number of treatments[9,12,29,30,34-36,48-51,54,60-67] for further therapeutic benefit. Uncontrolled trials demonstrated increased benefit with a medium to high dose of UVA-1 versus a low dose, but controlled trials were less convincing.[59] Typically, UVA-1 is administered 3 to 5 times a week for 30 to 40 treatments. Optimum dose and regimen for UVA-1 phototherapy has yet to be determined. Recurrence can develop in approximately half of patients within 3 years of stopping UVA-1 phototherapy, emphasizing the need for close follow up.[65] A second course of UVA-1 phototherapy or systemic treatments can be considered in these cases of recurrence. Phototherapy is likely ineffective for deep involvement (subcutis, fascia, muscle), and therefore should not be considered as primary therapy.

Vitamin D Derivative: Only 1 study provides level 1 evidence on the effect of vitamin D derivatives in morphea, and it showed no difference between oral calcitriol and placebo.[66] In fact, placebo and treatment groups improved equally. The authors also point out that the study was underpowered by their own calculations, making definitive conclusions regarding the efficacy of oral calcitriol difficult. The efficacy of topical vitamin D derivatives has been explored via uncontrolled trials and case reports[67] (level 2 evidence) and showed improvement in most or all patients, albeit over several months of therapy (an interval in which lesions might improve independent of therapy). Importantly, calcipotriene was applied under occlusion in these studies.

TABLE 64-3
Morphea Therapy

TREATMENT	LEVEL OF EVIDENCE[a]
BB UVA	1,2
UVA-1	1,2
Calcitriol, oral (inefficacy 1)	1,2
IFN-γ (inefficacy 1)	1
PUVA bath	2
PUVA cream	2
ECP	2
Calcipotriene, topical	2
MTX monotherapy, MTX plus steroids	1,2
PCMT	2
Tacrolimus, topical	2
Steroids, oral	2
Hydroxychloroquine, MMF, cyclosporine, Bosentan, infliximab, imiquimod, antimicrobials, D-penicillamine, 585-nm long-pulse laser, wide surgical resection, orthopedic surgery, Apligraf	Minimal evidence (≥level 3)

[a]Level of Evidence: 1, indicates randomized controlled trial; 2, uncontrolled trial; and 3, case report, case series.

BB, broadband; ECP, eosinophil cationic protein; IFN, IF; MMF, mycophenolate mofetil; MTX, methotrexate; PUVA, psoralen and ultraviolet A; UVA/B, ultraviolet A/B.

Reproduced with permission from Jacobe H. Pathogenesis, clinical manifestations, and diagnosis of morphea (localized scleroderma) in adults. In: Post TW, ed. *UpToDate*. Waltham, MA: UpToDate, Inc. Copyright © 2017. For more information visit www.uptodate.com.

IMMUNOMODULATORS

Methotrexate with or without Corticosteroids: The use of methotrexate (monotherapy) and methotrexate combined with systemic corticosteroids is effective based on level 1 evidence.[22,57,68-71] Methotrexate is considered a first-line systemic treatment for morphea, especially for deep morphea and rapidly progressive or disabling morphea. In most studies with combined therapy, corticosteroids are used for induction therapy either orally or via intravenous pulse (intravenous methylprednisolone 30 mg/kg/day for 3 days per month or 1 mg/kg/day prednisone) over the first 3 to 4 months. Methotrexate is used as steroid-sparing agent and started simultaneously (0.6 mg/kg/week in children or 15 to 25 mg/week in adults administered orally or with subcutaneous injection). Most study participants responded in a mean of 2 to 5 months defined by no new lesions and resolution of inflammation, not resolution of sclerosis. The best responders were all early in their disease course. In a randomized, double-blind, controlled trial, methotrexate plus prednisone was compared to prednisone alone in pediatric morphea.[71] Prednisone was administered for 4 months, while methotrexate or placebo were continued for 12 months. Responders met 3 criteria: absence of new lesions, computerized skin score rate ≤1, and decreased percentage temperature change of at least 10% compared to baseline. Methotrexate was

significantly more effective than prednisone alone at 12 months (67.4% vs 29.2%). In addition, the chance of recurrence in the prednisone-only group was 3 times higher than in the methotrexate group. Optimum dose, route, and indications for addition of corticosteroids, and duration of therapy have not been determined. The authors taper methotrexate after 6 months of inactivity by 2.5 to 5 mg every 4 weeks. The average duration of methotrexate use ranges from 21 to 27 months. Approximately 15% of patients relapse at 2-year followup after starting methotrexate, which suggests the need for close followup.[72]

Mycophenolate Mofetil: Case series using oral mycophenolate mofetil indicate potential utility in patients refractory to methotrexate or sensitive to side effects.[57,73-75] In the experience of the authors, mycophenolate mofetil can be used as a second-line systemic treatment, and is effective for morphea refractory to methotrexate or patients with contraindications or intolerance of methotrexate. In a case series of 10 patients with morphea refractory to methotrexate and prednisone, all patients treated with mycophenolate mofetil experienced clinical improvement on average 3.5 months after starting treatment.[74] Further controlled trials are needed to clarify the role of mycophenolate mofetil in treatment of morphea.

Other Immunomodulators: Level 2 evidence suggests the use of occluded topical tacrolimus 0.1% ointment might be effective for active, inflammatory superficial plaque-type morphea.[76,77] Case reports on the use of oral cyclosporine, imatinib, bosentan, abatacept, infliximab, and topical imiquimod also have reported some efficacy, but more definitive studies are lacking.

Antimicrobials: Despite the widespread use of antimicrobials in morphea (antibiotics and hydroxychloroquine), no published clinical trials exist.[78] Literature supporting the use of antimalarials is limited to a case series in which 2 patients improved with hydroxychloroquine (while simultaneously receiving oral steroids and methotrexate).[79] In a retrospective review, 7 (64%) of 11 patients continued to have active disease 3 to 15 months after starting hydroxychloroquine.[4] At this time, the use of these agents in severe morphea is not indicated pending more definitive evidence of efficacy.

Lack of Evidence: The most commonly used treatment for morphea, topical steroids, has not been investigated in a clinical trial. There are also no studies investigating the use of intralesional steroids. In the hands of the authors, intralesional steroids have been extremely effective in treating circumscribed plaques or as an adjuvant for recalcitrant areas in patients receiving phototherapy or systemic treatment. Current evidence does not support the use of penicillamine or IFN-γ.[80]

Adjunctive Therapy: A significant number of morphea patients suffer irreversible sequelae. When these patients come to medical attention, they may no longer have disease activity, but rather damage from the past or a mixture of active disease and damage. Consequently, every morphea patient should be examined for the presence of limitation in range of motion, contracture, limb-length discrepancy, or other functional impairment. In these cases, consultation with rheumatology, physical/occupational therapy, physical medicine and rehabilitation, plastic surgery, orthopedics, and oral maxillofacial surgery is highly recommended to maximize cosmesis, function, and minimize further damage.

LICHEN SCLEROSUS

AT-A-GLANCE

- Infrequent chronic inflammatory dermatosis with anogenital and extragenital manifestations.
- Preferentially affects women in the fifth or sixth decade of life and children younger than age 10 years; the female-to-male ratio is 5:1.
- Antibodies to extracellular matrix protein-1 and predominance of Th1 pathway point to an autoimmune pathogenesis.
- Anogenital manifestations cause severe discomfort (pruritus, dyspareunia, dysuria, and painful defecation) and present with polygonal papules and porcelain-white plaques, erosions, and various degrees of sclerosis. If left untreated, scarring and resultant functional impairment can occur.
- Vulvar lichen sclerosus is associated with an increased risk of squamous cell carcinoma.
- Potent topical corticosteroids and skin care are the most successful therapeutics; calcineurin inhibitors have also demonstrated benefit.
- Interdisciplinary management is essential for long-term control.

Lichen sclerosus (LS) is a chronic inflammatory dermatosis of the anogenital area that affects quality of life because of severe itching, scarring, and anatomic/functional impairment. LS may also present with extragenital manifestations. Of note, vulvar disease has an increased risk of squamous cell carcinoma, particularly if untreated.

EPIDEMIOLOGY

The incidence of LS has not been precisely determined. It has been estimated to be in the order of 14 per 100,000 persons per year.[81] LS is more frequent in females, accounting for a 5:1 female-to-male ratio. It preferentially affects women in the fifth or sixth decade of life and children younger than age 10 years.[81,82] Up to 15% of LS cases occur in children, particularly in girls, and one study reported a prevalence

of 1 in 900 premenarchal girls.[83] A 0.07% incidence in males was determined in a study of 153,432 male soldiers.[84] Among blacks and Hispanics, the incidence was 1.06%, whereas the incidence was only 0.051% in white soldiers.[84] LS seems to be a prominent cause of phimosis; in one study, 14% of adolescent boys with phimosis had LS, whereas 40% of phimosis cases in adult men were associated with LS.[84] Similarly, a study of foreskins examined after therapeutic circumcision for phimosis confirmed many cases of unrecognized LS.[85] As genital LS in males is almost exclusively seen in uncircumcised men, the rate of circumcision in a given population has a strong impact on the occurrence of the disease.

CLINICAL FEATURES

CUTANEOUS FINDINGS

Vulvar LS presents with porcelain-white atrophic papules coalescing into plaques on the labia minora and majora.[86] Follicular plugging may be seen in early LS.[86] Fissures, erosions, telangiectasias, purpura, erythema, hyperkeratosis, and different degrees of sclerosis can be present in the anogenital area (Fig. 64-9); often the classical figure-8 pattern of the vulva and anus may be observed (Fig. 64-9E). Bullae (occasionally hemorrhagic) may develop when the lichenoid infiltrate separates

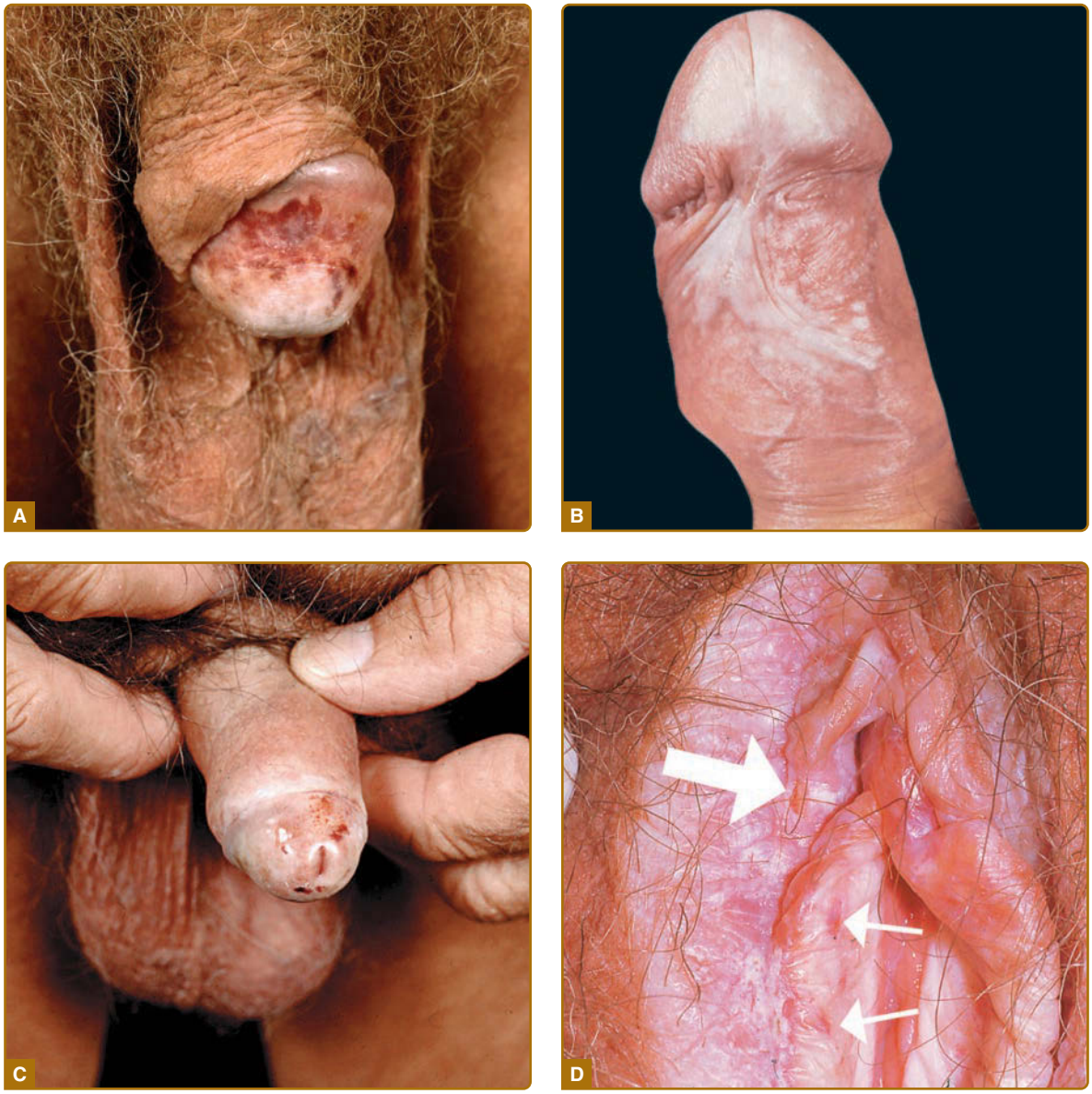

Figure 64-9 **A,** Early sclerosis and significant hemorrhage on the glans in early lichen sclerosus. **B,** Sclerosis of the frenulum and increased vulnerability with bleeding upon sexual intercourse. **C,** Significant sclerosis of the glans and conglutination with the preputium in advanced lichen sclerosus. Note narrowing of the urethral orifice and hemorrhage. **D,** In addition to the well-demarcated white vulvar plaque that is classic for lichen sclerosus, the waxy and crinkled texture, purpura (*small arrows*), and erosions (*large arrow*) are diagnostic.

Figure 64-9 (*continued*) **E,** Sclerotic vulva with disappearance of the smaller labia and shrinkage of the introitus. Significant erythema and erosions are seen on the vulva and the anus in a figure-8 configuration. The patient complained of severe pruritus and dyspareunia. **F,** Erosive, sclerotic vulva in an 8-year-old girl.

epidermis from the sclerotic dermis. Anogenital LS frequently causes intractable itching, soreness, dyspareunia, dysuria, discomfort with defecation, or genital bleeding, and, with time, may lead to destructive scarring (Fig. 64-9F). Gradual obliteration or synechiae of the labia minora and clitoris, burying of the clitoris, as well as stenosis of the introitus, may also result. Male genital LS (also known as balanitis xerotica obliterans) is usually confined to the glans penis, prepuce, or foreskin remnants (Fig. 64-9A–C). Penile shaft involvement is less common, whereas scrotal involvement is rare. Many male genital LS cases are simply diagnosed as phimosis. In severe cases, erections may become painful. Urethral strictures with decreased urinary stream and difficulty voiding can result.

Extragenital LS typically affects the thighs, neck, trunk, and lips; lesions are associated with pruritus, burning, or maybe asymptomatic (Fig. 64-10). The size of LS lesions may vary from a few millimeters to large portions of the trunk. A clinical histopathologic study has revealed 27 adult cases with lip involvement.[87] Clinical presentation consisted of asymptomatic vitiligo-like lesions in 70% with a variable degree of dermal sclerosis confined to the papillary layer. Consequently, vitiligo-like LS needs to be added to this spectrum of oral lichenoid lesions.

NONCUTANEOUS FINDINGS

Except for the association with autoimmune thyroid disease, alopecia areata, pernicious anemia, morphea, and vitiligo, no additional related findings have been reported. Except in cases where a thorough history and examination indicate the presence of concomitant autoimmune diseases, laboratory testing is not recommended.

COMPLICATIONS

Dyspareunia, urinary obstruction, constipation, secondary infection related to ulceration, steroid use, and

Figure 64-10 Extragenital lichen sclerosus with confluent whitish papules and plaques on the skin over the thoracic and lumbar spine.

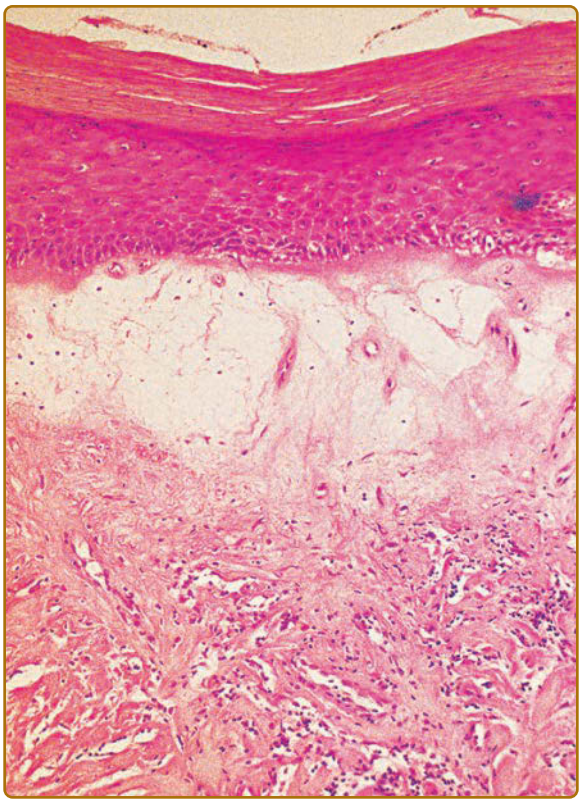

Figure 64-11 Hyperkeratotic epithelium without rete ledges and basal degeneration of keratinocytes. Collagen fibers are homogenized in the papillary dermis, and a lichenoid lymphocytic infiltrate is present. The dermal vessels are dilated.

squamous cell carcinoma represent the main complications in females (Fig. 64-11). The lifetime risk of developing squamous cell carcinoma as a complication of longstanding LS has been estimated in the order of 4% to 6%.[81,88] In a study of 2875 women with LS, incidence of vulvar squamous cell carcinoma was 2.1% after 5 years, 3.3% after 10 years, and 6.7% after 20 years, highlighting the need for long-term followup.[89] Age, long duration of LS, human papillomavirus infection, and evidence of hyperplastic changes represent significant risk factors.[90,91] *IRF6*, a tumor-suppressor gene, is downregulated in vulvar squamous cell carcinoma associated with LS, and maybe involved in early carcinogenesis of squamous cell carcinoma in LS.[92] In males, painful erections and urinary obstruction represent the most frequent complications.

ETIOLOGY AND PATHOGENESIS

The cause of LS is unknown. A recent cohort study reported a high rate of familial LS cases.[93] Of 1052 females with LS, 126 (12%) had a positive family history of LS. Vulvar cancer was significantly increased in those patients with a family history of LS compared with those without (4.1% vs. 1.2%).[93] This report proposes a likely genetic component in the etiology of LS. Local irritation and trauma (Koebner phenomenon) also seem to play a role in some cases. The disturbed function of fibroblasts with increased production of collagen has been demonstrated in LS.[94,95] Evidence for a presumed infectious cause, such as acid-fast rods, spirochetes, or *Borrelia*, has not been found.[96]

Autoimmune diseases are found at increased frequency in LS patients, which suggests that LS may result from a common genetic predisposition to this group of disorders. A study of 350 patients with LS revealed that 21.5% had 1 or more autoimmune diseases.[96] Serologic and clinical evidence of thyroid disease, alopecia areata, pernicious anemia, and vitiligo suggested an association with LS. Low-titer autoantibodies against the extracellular matrix protein-1 (ECM-1) and collagen XVII have been identified in 67% of LS cases.[97,98] ECM-1 may be involved in basement membrane and interstitial collagenous fiber assembly and growth-factor binding,[99] and may also regulate blood vessel function.[100]

The immune infiltrate in LS contains abundant T cells, B cells, and antigen-presenting dendritic cells.[101,102] Further characterization of the infiltrate has shown a predominance of CD8 cytotoxic T cells over CD4 T cells, and presence of regulatory T cells.[103,104] A monoclonal T-cell receptor γ-chain rearrangement has alluded to the existence of an LS antigen, potentially the ECM-1 protein, which is also recognized by anti–ECM-1 autoantibodies.[93,105] Gene expression profiling of LS has shown significant upregulation of Th1 and Type I IFN-regulated cytokines and chemokines, including IFN-γ, CXCL-9, CXCL-10, CXCL-11, CXCR3, CCR5, CCL4, and CCL5.[104] No upregulation of Th2 or Th17 pathways was seen. Plasmacytoid dendritic cells, present in LS lesions, may be the source of Type I IFN production.[103] The IFN-regulated chemokines, CXCL-9, CXCL-10, and CXCL-11, are involved in migration of Th1 cells into tissues through binding to CXCR3. Notably, these findings are similar to pathogenesis of active inflammatory morphea as described earlier. Extragenital and genital LS is commonly seen in association with plaque-type morphea, and some authors have suggested a common pathomechanism. Pathogenesis of LS is likely a multifactorial process involving the interaction of genetic predisposition, autoimmunity (with predominance of Th1 cells), and local factors, such as trauma and chronic irritation. Further studies are needed to elucidate the pathogenesis of LS.

DIAGNOSIS

A skin punch biopsy of a mature lesion will confirm the diagnosis if the diagnosis is not obvious by clinical examination. Despite the described association with autoimmune diseases, an autoimmune workup (eg, antinuclear antibody, parietal cell antibody, vitamin B_{12} levels, thyroid function tests) is not generally recommended because of their relatively low

Figure 64-12 **A.** A 1.5-cm, sharply demarcated ulcer of longstanding lichen sclerosus on the right labia majora. **B.** Histology reveals squamous cell carcinoma.

occurrence, but should be considered if review of systems raises the possibility of a concomitant autoimmune disease.[106] *Borrelia* antibody titers should not be analyzed, as they are not associated with LS.[107] To exclude squamous cell carcinoma, serial biopsies may be indicated or involvement of gynecology oncology.

PATHOLOGY

Classical LS shows an atrophic epidermis and a lichenoid infiltrate at the dermal–epidermal junction.[108] Papillary edema is usually seen in early LS, but is gradually replaced by fibrosis with homogenization of collagen and acid mucopolysaccharides as the lesion matures (Fig. 64-12). Epidermal hyperplasia and/or dysplasia associated with LS on vulvar specimens are associated with an increased risk of malignant transformation, especially in conjunction with infection by high-risk human papillomaviruses.

IMAGING

Imaging studies are only needed in special situations (eg, urinary obstruction secondary to stenosing genital LS). High-resolution ultrasonography is occasionally used to document the depth of sclerosis.

DIFFERENTIAL DIAGNOSIS

The differential diagnosis of LS includes a variety of other conditions including lichen simplex chronicus, lichen planus, contact dermatitis, morphea, vitiligo, and other conditions (Table 64-4). Vulvar lichen planus more commonly involves the vagina, whereas LS spares the vagina. Clinically, extragenital LS maybe confused with morphea or lichen planus (see Fig. 64-12). Typical early plaque-type morphea lesions show an erythematous ring with progressive central induration and whitening. Patients have been described with lesions typical of both plaque-type morphea and the chalky white, atrophic plaques of LS.[109]

Constipation is a common complication in children with anogenital LS.[110] The associated purpura and discoloration often raise a concern about child abuse, especially if LS is not recognized. It should be noted, however, that LS and child abuse may coexist[111] and that some cases of LS have been linked with trauma of the anogenital region. LS in children has occasionally been associated with a perineal pyramidal protrusion, a common lesion that can be confused with condyloma and is also associated with constipation. Table 64-5 outlines the pitfalls in diagnosing LS.

CLINICAL COURSE AND PROGNOSIS

LS is a chronic, relapsing condition with possibility of long-term functional and anatomic impairment if left untreated. The prognosis of LS is generally favorable in patients who are diagnosed and treated in the early nonscarring stages, and in patients compliant with initial and maintenance therapy with topical corticosteroids. Importantly, childhood-onset vulvar LS does not

TABLE 64-4
Differential Diagnosis of Lichen Sclerosus

Genital Manifestations

Consider
- Zoon balanitis
- Child abuse (sexual)
- Radiation dermatitis (for vulvar cancer)
- Contact dermatitis, including excessive genital hygiene
- Lichen planus
- Lichen simplex chronicus
- Vitiligo

Rule Out
- Cicatricial pemphigoid
- Erythroplasia of Queyrat (Bowen disease)
- Leukoplakia
- Squamous cell carcinoma
- Paget disease

Extragenital Manifestations

Consider
- Anetoderma
- Atrophoderma of Pasini and Pierini
- Idiopathic guttate hypomelanosis
- Lipoid proteinosis (mild forms; see Chap. 133)
- Lichen planus
- Morphea
- Pinta
- Tinea versicolor

Rule Out
- Discoid lupus erythematosus
- Graft-versus-host disease (scleroderma-like)
- Extramammary Paget disease
- Squamous cell carcinoma

always resolve at puberty and may remain persistent.[112] A prospective study of 12 cases of childhood LS showed that 9 patients, still had active LS at puberty, and continued to require maintenance therapy after menarche. Six of the 12 experienced significant disturbance of the vulvar architecture. A further case series reported the efficacy of topical clobetasol propionate 0.05% in childhood LS.[113] Nine of 15 young girls suffered from a relapse approximately 1 year following the first clearing of the lesions. The authors also concluded that early aggressive treatment with ultrapotent corticosteroids enables the best clinical course of childhood LS.[113] Recalcitrant chronic LS that causes erosions and progressive scarring may result in severe dysfunction of urination, sexual function, and defecation. Furthermore, the scarring nature of advanced LS produces resorption of the labia, alopecia, and altered anatomic structure of the vulva.

TABLE 64-5
Pitfalls in the Diagnosis of Lichen Sclerosus

- Wrong/incomplete diagnosis in the case of squamous cell carcinoma.
- Lichen sclerosus, especially when bullous, hemorrhagic, or erosive; may be confused with child abuse.
- Inappropriate surveillance for steroid adverse effects.
- Irritant dermatitis caused by overwashing of the anogenital area may imitate lichen sclerosus and facilitate the occurrence of contact dermatitis.

MANAGEMENT

TOPICAL TREATMENTS

Treatment should be initiated in all patients with LS, not only to improve symptoms, but also to prevent long-term complications such as anatomic distortion, scarring, and impaired function. Ultrapotent topical corticosteroids, most commonly clobetasol propionate 0.05%, are the first-line treatment for genital LS based on randomized controlled trials (RCTs).[114-116] A metaanalysis including 7 RCTs supported efficacy of clobetasol, mometasone, and calcineurin inhibitors in the treatment of genital LS, but showed no evidence for topical androgens or progesterone.[117] Consequently, the use of topical androgens and progesterone as monotherapy is not supported by current evidence. Head-to-head RCTs comparing clobetasol versus pimecrolimus, and clobetasol versus tacrolimus, have demonstrated superior efficacy of clobetasol compared to calcineurin inhibitors.[115,116] Clobetasol should also be used for treatment of vulvar LS in children. A study of 72 children demonstrated efficacy and safety of clobetasol for vulvar LS.[118] Mometasone furoate 0.1% is also effective in the treatment of vulvar LS.[119] Mometasone furoate 0.1% and clobetasol propionate 0.05% had comparable efficacy for treatment of vulvar LS in a head-to-head RCT.[119]

We typically initiate therapy with clobetasol propionate 0.05% ointment once to twice daily until remission is achieved, typically after 2 to 3 months. Alternatively, a tapering regimen with clobetasol once daily for 4 weeks, every other day for 4 weeks, and then twice a week for 4 weeks can be used.[120] Approximately 50% to 60% of patients experience complete remission. Ointments tend to be less irritating and better tolerated than creams. A lower-potency corticosteroid or calcineurin inhibitors can be considered if there is cutaneous atrophy from use of ultrapotent topical steroids. It is important for patients to receive exact instructions on where to apply ointment.

PHOTOTHERAPY AND SYSTEMIC TREATMENTS

Evidence for phototherapy and systemic treatments is limited to small clinical trials and case series. A small RCT comparing clobetasol versus UVA-1

phototherapy in 30 female patients with vulvar LS showed clinical improvement with both treatments.[121] However, clobetasol was more effective than UVA-1 in relief of pruritus and quality of life. In the authors' experience, phototherapy should be used as an adjunct to topical steroids, not in place of them as severe flares may occur. Preliminary studies with photodynamic therapy with 5-aminolevulinic acid have shown efficacy in treatment of vulvar LS.[122] UVA-1 or photodynamic therapy can be considered as a second-line treatment if topical corticosteroids are ineffective or not tolerated. Systemic therapy with acitretin has been effective in small RCTs for penile and severe vulvar LS.[123,124]

ADJUNCTIVE TREATMENTS

It is thought that irritation from urinary and fecal incontinence exacerbates vulvar LS. Therefore, referral for treatment of these conditions is important. Furthermore, addition of barrier creams containing zinc oxide is important to protect the vulvar and perianal skin. The functional impairment from advanced LS is a significant problem and needs to be discussed with the patient. This can include difficulty with urination, sexual intercourse, and defecation/constipation. Referral to urogynecology and gastroenterology should be considered. In addition, pelvic floor therapists can teach patients gentle stretching exercises and counselors can help address the emotional toll of the disease. These interventions can have a positive impact on the quality of life of patients with LS.

MAINTENANCE THERAPY

The importance of maintenance therapy in treatment of genital LS has been recognized. In a prospective longitudinal cohort of 507 women with vulvar LS, clinical outcomes were compared between compliant patients, who used topical corticosteroids consistently as maintenance therapy, versus partially compliant patients over the period of 2 to 7 years.[125] Compliant patients had improved symptom control and function compared to partially compliant patients. In addition, vulvar carcinoma developed in 0% of compliant patients versus 4.7% of partially compliant patients ($P < 0.001$).[125] The risk of relapse of LS is also reduced with maintenance therapy. For instance, use of mometasone furoate twice a week reduces the risk of relapse of vulvar LS compared to placebo over a 52-week period (0% in mometasone vs. 62% in placebo).[119] Taken together, current evidence supports continuation of maintenance therapy with topical corticosteroids twice to 3 times a week, even with asymptomatic genital LS. Both clobetasol and mometasone are effective for maintenance treatment.[126] Potency of topical corticosteroids should be adjusted based on level of hyperkeratosis or presence of corticosteroid-induced atrophy.[125] Further studies are needed to elucidate the duration of maintenance therapy in LS.

TREATMENT OF MALE GENITAL LICHEN SCLEROSUS

In general, much less is known about the treatment and course of male genital LS. Circumcision will generally resolve male genital LS and the associated phimosis, although potent topical steroids may obviate the need for surgery.

TREATMENT OF EXTRAGENITAL LICHEN SCLEROSUS

Current evidence for treatment of extragenital LS is limited to case series and uncontrolled trials. Overall, the treatment modalities utilized for treatment of extragenital LS are similar to morphea. Active lesions may present with peripheral erythema like morphea. Extragenital LS lesions may respond to treatment with topical corticosteroids, topical calcineurin inhibitors, UVA-1 phototherapy, or methotrexate in combination with prednisone.[127,128] Extragenital LS, with a limited surface area of involvement, can be treated with superpotent topical steroids such as clobetasol propionate. For generalized extragenital LS or for cases resistance to topical steroids, UVA-1 phototherapy can be beneficial. In a case series of patients with extragenital LS, 10 patients were treated with low-dose UVA-1 phototherapy (20 J/cm^2) 4 times a week for 10 weeks.[127] All patients experienced decreased number of sclerotic skin lesions, softening of lesions, and repigmentation after completing therapy. Systemic therapy is rarely used for treatment of extragenital LS. Use of pulsed glucocorticoids plus methotrexate, is supported by a small retrospective study of 7 patients.[128] Further controlled trials are warranted to elucidate the treatment of extragenital LS.

PREVENTION

No truly preventive measures of LS have been reported. An interdisciplinary management team is essential for the long-term control of LS. Specialists from gynecology, urology, pediatrics, and pain medicine should be involved in patient care and collaborate to prevent significant complications, including the monitoring for squamous cell carcinoma and corticosteroid adverse events. It has also been helpful to circulate information via patient organizations for LS.

ACKNOWLEDGMENTS

We acknowledge the contribution of previous authors Stephanie Saxton-Daniels and Ulrich R. Hengge.

REFERENCES

1. Peterson LS, Nelson AM, Su WP, et al. The epidemiology of morphea (localized scleroderma) in Olmsted County 1960-1993. *J Rheumatol*. 1997;24:73-80.
2. Greenberg A, Falanga V. Localized cutaneous sclerosis. In: *Cutaneous Manifestations of Rheumatic Diseases*. Baltimore, MD: Williams & Wilkins; 1996.
3. Sehgal VN, Srivastava G, Aggarwal AK, et al. Localized scleroderma/morphea. *Int J Dermatol*. 2002;41:467-475.
4. Christen-Zaech S, Hakim MD, Afsar FS, et al. Pediatric morphea (localized scleroderma): review of 136 patients. *J Am Acad Dermatol*. 2008;59:385-396.
5. Leitenberger JJ, Cayce RL, Haley RW, et al. Distinct autoimmune syndromes in morphea: a review of 245 adult and pediatric cases. *Arch Dermatol*. 2009;145:545-550.
6. Vierra E, Cunningham BB. Morphea and localized scleroderma in children. *Semin Cutan Med Surg*. 1999;18:210-225.
7. Zulian F, Athreya BH, Laxer R, et al. Juvenile localized scleroderma: clinical and epidemiological features in 750 children. An international study. *Rheumatology (Oxford)*. 2006;45:614-620.
8. Marzano AV, Menni S, Parodi A, et al. Localized scleroderma in adults and children. Clinical and laboratory investigations on 239 cases. *Eur J Dermatol*. 2003;13:171-176.
9. Saxton-Daniels S, Jacobe HT. An evaluation of long-term outcomes in adults with pediatric-onset morphea. *Arch Dermatol*. 2010;146:1044-1045.
10. Condie D, Grabell D, Jacobe H. Comparison of outcomes in adults with pediatric-onset morphea and those with adult-onset morphea: a cross-sectional study from the morphea in adults and children cohort. *Arthritis Rheumatol*. 2014;66:3496-3504.
11. Laxer RM, Zulian F. Localized scleroderma. *Curr Opin Rheumatol*. 2006;18:606-613.
12. Grabell D, Hsieh C, Andrew R, et al. The role of skin trauma in the distribution of morphea lesions: a cross-sectional survey of the Morphea in Adults and Children cohort IV. *J Am Acad Dermatol*. 2014;71:493-498.
13. Kim A, Marinkovich N, Vasquez R, et al. Clinical features of patients with morphea and the pansclerotic subtype: a cross-sectional study from the Morphea in Adults and Children cohort. *J Rheumatol*. 2014;41:106-112.
14. Teske N, Welser J, Jacobe H. Skin mapping for the classification of generalized morphea. *J Am Acad Dermatol*. 2016;78:351-357.
15. Weibel L, Harper JI. Linear morphoea follows Blaschko's lines. *Br J Dermatol*. 2008;159:175-181.
16. Muroi E, Ogawa F, Yamaoka T, et al. Case of localized scleroderma associated with osteomyelitis. *J Dermatol*. 2010;37:81-84.
17. Horger M, Fierlbeck G, Kuemmerle-Deschner J, et al. MRI findings in deep and generalized morphea (localized scleroderma). *AJR Am J Roentgenol*. 2008;190:32-39.
18. Lakhanpal S, Ginsburg WW, Michet CJ, et al. Eosinophilic fasciitis: clinical spectrum and therapeutic response in 52 cases. *Semin Arthritis Rheum*. 1988;17:221-231.
19. Falanga V, Medsger TA Jr, Reichlin M. Antinuclear and anti-single-stranded DNA antibodies in morphea and generalized morphea. *Arch Dermatol*. 1987;123:350-353.
20. Zulian F, Vallongo C, Woo P, et al. Localized scleroderma in childhood is not just a skin disease. *Arthritis Rheum*. 2005;52:2873-2881.
21. Zulian F. New developments in localized scleroderma. *Curr Opin Rheumatol*. 2008;20:601-607.
22. Tollefson MM, Witman PM. En coup de sabre morphea and Parry-Romberg syndrome: a retrospective review of 54 patients. *J Am Acad Dermatol*. 2007;56:257-263.
23. Sartori S, Martini G, Calderone M, et al. Severe epilepsy preceding by four months the onset of scleroderma en coup de sabre. *Clin Exp Rheumatol*. 2009;27:64-67.
24. Chiang KL, Chang KP, Wong TT, et al. Linear scleroderma "en coup de sabre": initial presentation as intractable partial seizures in a child. *Pediatr Neonatol*. 2009;50:294-298.
25. Schlosser BJ. Practice gaps. Missing genital lichen sclerosus in patients with morphea: don't ask? Don't tell?: comment on "high frequency of genital lichen sclerosus in a prospective series of 76 patients with morphea." *Arch Dermatol*. 2012;148:28-29.
26. Klimas NK, Shedd AD, Bernstein IH, et al. Health-related quality of life in morphea. *Br J Dermatol*. 2015;172:1329-1337.
27. Das S, Bernstein I, Jacobe H. Correlates of self-reported quality of life in adults and children with morphea. *J Am Acad Dermatol*. 2014;70:904-910.
28. Gonzalez-Lopez MA, Drake M, Gonzalez-Vela MC, et al. Generalized morphea and primary biliary cirrhosis coexisting in a male patient. *J Dermatol*. 2006;33:709-713.
29. Khalifa M, Ben Jazia E, Hachfi W, et al. Autoimmune hepatitis and morphea: a rare association [in French]. *Gastroenterol Clin Biol*. 2006;30:917-918.
30. Dervis E, Acbay O, Barut G, et al. Association of vitiligo, morphea, and Hashimoto's thyroiditis. *Int J Dermatol*. 2004;43:236-237.
31. Harrington CI, Dunsmore IR. An investigation into the incidence of auto-immune disorders in patients with localized morphoea. *Br J Dermatol*. 1989;120:645-648.
32. Bonifati C, Impara G, Morrone A, et al. Simultaneous occurrence of linear scleroderma and homolateral segmental vitiligo. *J Eur Acad Dermatol Venereol*. 2006;20:63-65.
33. Majeed M, Al-Mayouf SM, Al-Sabban E, et al. Coexistent linear scleroderma and juvenile systemic lupus erythematosus. *Pediatr Dermatol*. 2000;17:456-459.
34. Jacobe H, Ahn C, Arnett F, et al. Major histocompatibility complex (MHC) class I and II alleles which confer susceptibility or protection in the Morphea in Adults and Children (MAC) cohort. *Arthritis Rheumatol*. 2014;66:3170-3177.
35. Wadud MA, Bose BK, Al Nasir T. Familial localised scleroderma from Bangladesh: two case reports. *Bangladesh Med Res Counc Bull*. 1989;15:15-19.
36. Rees RB, Bennett J. Localized scleroderma in father and daughter. *AMA Arch Derm Syphilol*. 1953;68:360.
37. Gabrielli A, Avvedimento EV, Krieg T. Scleroderma. *N Engl J Med*. 2009;360:1989-2003.
38. Gruschwitz MS, Hornstein OP, von Den Driesch P. Correlation of soluble adhesion molecules in the peripheral blood of scleroderma patients with their in situ expression and with disease activity. *Arthritis Rheum*. 1995;38:184-189.

39. Torok KS, Kurzinski K, Kelsey C, et al. Peripheral blood cytokine and chemokine profiles in juvenile localized scleroderma: T-helper cell-associated cytokine profiles. *Semin Arthritis Rheum*. 2015;45:284-293.
40. Ihn H, Sato S, Fujimoto M, et al. Demonstration of interleukin-2, interleukin-4 and interleukin-6 in sera from patients with localized scleroderma. *Arch Dermatol Res*. 1995;287:193-197.
41. Hasegawa M, Sato S, Nagaoka T, et al. Serum levels of tumor necrosis factor and interleukin-13 are elevated in patients with localized scleroderma. *Dermatology*. 2003;207:141-147.
42. McNallan KT, Aponte C, el-Azhary R, et al. Immunophenotyping of chimeric cells in localized scleroderma. *Rheumatology (Oxford)*. 2007;46:398-402.
43. Takehara K, Moroi Y, Nakabayashi Y, et al. Antinuclear antibodies in localized scleroderma. *Arthritis Rheum*. 1983;26:612-616.
44. Rosenberg AM, Uziel Y, Krafchik BR, et al. Antinuclear antibodies in children with localized scleroderma. *J Rheumatol*. 1995;22:2337-2343.
45. Sato S, Kodera M, Hasegawa M, et al. Antinucleosome antibody is a major autoantibody in localized scleroderma. *Br J Dermatol*. 2004;151:1182-1188.
46. Sato S, Ihn H, Soma Y, et al. Antihistone antibodies in patients with localized scleroderma. *Arthritis Rheum*. 1993;36:1137-1141.
47. Tomimura S, Ogawa F, Iwata Y, et al. Autoantibodies against matrix metalloproteinase-1 in patients with localized scleroderma. *J Dermatol Sci*. 2008; 52:47-54.
48. Kroft EB, de Jong EM, Evers AW. Psychological distress in patients with morphea and eosinophilic fasciitis. *Arch Dermatol*. 2009;145:1017-1022.
49. Dharamsi JW, Victor S, Aguwa N, et al. Morphea in Adults and Children cohort III: nested case-control study: the clinical significance of autoantibodies in morphea. *JAMA Dermatol*. 2013;149:1159-1165.
50. Schanz S, Fierlbeck G, Ulmer A, et al. Localized scleroderma: MR findings and clinical features. *Radiology*. 2011;260:817-824.
51. Li SC, Liebling MS, Haines KA. Ultrasonography is a sensitive tool for monitoring localized scleroderma. *Rheumatology (Oxford)*. 2007;46:1316-1319.
52. Alonso-Llamazares J, Ahmed I. Vitamin K1-induced localized scleroderma (morphea) with linear deposition of IgA in the basement membrane zone. *J Am Acad Dermatol*. 1998;38:322-324.
53. Bouchard SM, Mohr MR, Pariser RJ. Texane-induced morphea in a patient with CREST syndrome. *Dermatol Reports*. 2010;2:23-24.
54. Bezalel SA, Strober BE, Ferenczi K. Interferon beta-1a-induced morphea. *JAAD Case Rep*. 2015;1:15-17.
55. Runger TM, Adami S, Benhamou CL, et al. Morphea-like skin reactions in patients treated with the cathepsin K inhibitor balicatib. *J Am Acad Dermatol*. 2012;66:e89-e96.
56. Mertens JS, Seyger MM, Kievit W, et al. Disease recurrence in localized scleroderma: a retrospective analysis of 344 patients with paediatric- or adult-onset disease. *Br J Dermatol*. 2015;172:722-728.
57. Uziel Y, Feldman BM, Krafchik BR, et al. Methotrexate and corticosteroid therapy for pediatric localized scleroderma. *J Pediatr*. 2000;136:91-95.
58. El-Mofty M, Zaher H, Bosseila M, et al. Low-dose broad-band UVA in morphea using a new method for evaluation. *Photodermatol Photoimmunol Photomed*. 2000;16:43-49.
59. Kreuter A, Hyun J, Stucker M, et al. A randomized controlled study of low-dose UVA1, medium-dose UVA1, and narrowband UVB phototherapy in the treatment of localized scleroderma. *J Am Acad Dermatol*. 2006;54:440-447.
60. de Rie MA, Enomoto DN, de Vries HJ, et al. Evaluation of medium-dose UVA1 phototherapy in localized scleroderma with the cutometer and fast Fourier transform method. *Dermatology*. 2003;207:298-301.
61. Kerscher M, Meurer M, Sander C, et al. PUVA bath photochemotherapy for localized scleroderma. Evaluation of 17 consecutive patients. *Arch Dermatol*. 1996;132:1280-1282.
62. Grundmann-Kollmann M, Behrens S, Gruss C, et al. Chronic sclerodermic graft-versus-host disease refractory to immunosuppressive treatment responds to UVA1 phototherapy. *J Am Acad Dermatol*. 2000;42:134-136.
63. El-Mofty M, Mostafa W, Esmat S, et al. Suggested mechanisms of action of UVA phototherapy in morphea: a molecular study. *Photodermatol Photoimmunol Photomed*. 2004;20:93-100.
64. Torrelo A, Suarez J, Colmenero I, et al. Deep morphea after vaccination in two young children. *Pediatr Dermatol*. 2006;23:484-487.
65. Vasquez R, Jabbar A, Khan F, et al. Recurrence of morphea after successful ultraviolet A1 phototherapy: a cohort study. *J Am Acad Dermatol*. 2014;70:481-488.
66. Hulshof MM, Bouwes Bavinck JN, Bergman W, et al. Double-blind, placebo-controlled study of oral calcitriol for the treatment of localized and systemic scleroderma. *J Am Acad Dermatol*. 2000;43:1017-1023.
67. Cunningham BB, Landells ID, Langman C, et al. Topical calcipotriene for morphea/linear scleroderma. *J Am Acad Dermatol*. 1998;39:211-215.
68. Seyger MM, van den Hoogen FH, de Boo T, et al. Low-dose methotrexate in the treatment of widespread morphea. *J Am Acad Dermatol*. 1998;39:220-225.
69. Kreuter A, Gambichler T, Breuckmann F, et al. Pulsed high-dose corticosteroids combined with low-dose methotrexate in severe localized scleroderma. *Arch Dermatol*. 2005;141:847-852.
70. Weibel L, Sampaio MC, Visentin MT, et al. Evaluation of methotrexate and corticosteroids for the treatment of localized scleroderma (morphoea) in children. *Br J Dermatol*. 2006;155:1013-1020.
71. Zulian F, Martini G, Vallongo C, et al. Methotrexate treatment in juvenile localized scleroderma: a randomized, double-blind, placebo-controlled trial. *Arthritis Rheum*. 2011;63:1998-2006.
72. Zulian F, Vallongo C, Patrizi A, et al. A long-term follow-up study of methotrexate in juvenile localized scleroderma (morphea). *J Am Acad Dermatol*. 2012;67:1151-1156.
73. Schlaak M, Friedlein H, Kauer F, et al. Successful therapy of a patient with therapy recalcitrant generalized bullous scleroderma by extracorporeal photopheresis and mycophenolate mofetil. *J Eur Acad Dermatol Venereol*. 2008;22:631-633.
74. Martini G, Ramanan AV, Falcini F, et al. Successful treatment of severe or methotrexate-resistant juvenile localized scleroderma with mycophenolate mofetil. *Rheumatology (Oxford)*. 2009;48:1410-1413.
75. Mertens JS, Marsman D, van de Kerkhof PC, et al. Use of mycophenolate mofetil in patients with severe localized scleroderma resistant or intolerant to methotrexate. *Acta Derm Venereol*. 2016;96:510-513.

76. Mancuso G, Berdondini RM. Localized scleroderma: response to occlusive treatment with tacrolimus ointment. *Br J Dermatol*. 2005;152:180-182.
77. Kroft EB, Groeneveld TJ, Seyger MM, et al. Efficacy of topical tacrolimus 0.1% in active plaque morphea: randomized, double-blind, emollient-controlled pilot study. *Am J Clin Dermatol*. 2009;10:181-187.
78. Mohrenschlager M, Jung C, Ring J, Abeck D. Effect of penicillin G on corium thickness in linear morphea of childhood: an analysis using ultrasound technique. *Pediatr Dermatol*. 1999;16:314-316.
79. Maragh SH, Davis MD, Bruce AJ, et al. Disabling pansclerotic morphea: clinical presentation in two adults. *J Am Acad Dermatol*. 2005;53:S115-S119.
80. Hunzelmann N, Anders S, Fierlbeck G, et al. Double-blind, placebo-controlled study of intralesional interferon gamma for the treatment of localized scleroderma. *J Am Acad Dermatol*. 1997;36:433-435.
81. Powell JJ, Wojnarowska F. Lichen sclerosus. *Lancet*. 1999;353:1777-1783.
82. Marini A, Blecken S, Ruzicka T, et al. Lichen sclerosus. New aspects of pathogenesis and treatment [in German]. *Hautarzt*. 2005;56:550-555.
83. Powell J, Wojnarowska F. Childhood vulvar lichen sclerosus: an increasingly common problem. *J Am Acad Dermatol*. 2001;44:803-806.
84. Kizer WS, Prarie T, Morey AF. Balanitis xerotica obliterans: epidemiologic distribution in an equal access health care system. *South Med J*. 2003;96:9-11.
85. Tokgoz H, Polat F, Tan MO, et al. Histopathological evaluation of the preputium in preschool and primary school boys. *Int Urol Nephrol*. 2004;36:573-576.
86. Funaro D. Lichen sclerosus: a review and practical approach. *Dermatol Ther*. 2004;17:28-37.
87. Attili VR, Attili SK. Lichen sclerosus of lips: a clinical and histopathologic study of 27 cases. *Int J Dermatol*. 2010;49:520-525.
88. Hagedorn M, Buxmeyer B, Schmitt Y, et al. Survey of genital lichen sclerosus in women and men. *Arch Gynecol Obstet*. 2002;266:86-91.
89. Bleeker MC, Visser PJ, Overbeek LI, et al. Lichen sclerosus: incidence and risk of vulvar squamous cell carcinoma. *Cancer Epidemiol Biomarkers Prev*. 2016;25:1224-1230.
90. von Krogh G, Dahlman-Ghozlan K, Syrjanen S. Potential human papilloma-virus reactivation following topical corticosteroid therapy of genital lichen sclerosus and erosive lichen planus. *J Eur Acad Dermatol Venereol*. 2002;16:130.
91. Jones RW, Sadler L, Grant S, et al. Clinically identifying women with vulvar lichen sclerosus at increased risk of squamous cell carcinoma: a case-control study. *J Reprod Med*. 2004;49:808-811.
92. Rotondo JC, Borghi A, Selvatici R, et al. Hypermethylation-induced inactivation of the *IRF6* gene as a possible early event in progression of vulvar squamous cell carcinoma associated with lichen sclerosus. *JAMA Dermatol*. 2016;152:928-933.
93. Sherman V, McPherson T, Baldo M, et al. The high rate of familial lichen sclerosus suggests a genetic contribution: an observational cohort study. *J Eur Acad Dermatol Venereol*. 2010;24:1031-1034.
94. Carli P, Moretti S, Spallanzani A, et al. Fibrogenic cytokines in vulvar lichen sclerosus. An immunohistochemical study. *J Reprod Med*. 1997;42: 161-165.
95. Scrimin F, Rustja S, Radillo O, et al. Vulvar lichen sclerosus: an immunologic study. *Obstet Gynecol*. 2000;95:147-150.
96. Meyrick Thomas RH, Ridley CM, McGibbon DH, et al. Lichen sclerosus et atrophicus and autoimmunity—a study of 350 women. *Br J Dermatol*. 1988;118:41-46.
97. Oyama N, Chan I, Neill SM, et al. Autoantibodies to extracellular matrix protein 1 in lichen sclerosus. *Lancet*. 2003;362:118-123.
98. Howard A, Dean D, Cooper S, et al. Circulating basement membrane zone antibodies are found in lichen sclerosus of the vulva. *Australas J Dermatol*. 2004;45:12-15.
99. Chan I. The role of extracellular matrix protein 1 in human skin. *Clin Exp Dermatol*. 2004;29:52-56.
100. Kowalewski C, Kozlowska A, Chan I, et al. Three-dimensional imaging reveals major changes in skin microvasculature in lipoid proteinosis and lichen sclerosus. *J Dermatol Sci*. 2005;38:215-224.
101. Farrell AM, Marren P, Dean D, et al. Lichen sclerosus: evidence that immunological changes occur at all levels of the skin. *Br J Dermatol*. 1999;140:1087-1092.
102. Carlson JA, Grabowski R, Chichester P, et al. Comparative immunophenotypic study of lichen sclerosus: epidermotropic CD57+ lymphocytes are numerous—implications for pathogenesis. *Am J Dermatopathol*. 2000;22:7-16.
103. Wenzel J, Wiechert A, Merkel C, et al. IP10/CXCL10-CXCR3 interaction: a potential self-recruiting mechanism for cytotoxic lymphocytes in lichen sclerosus et atrophicus. *Acta Derm Venereol*. 2007;87:112-117.
104. Terlou A, Santegoets LA, van der Meijden WI, et al. An autoimmune phenotype in vulvar lichen sclerosus and lichen planus: a Th1 response and high levels of microRNA-155. *J Invest Dermatol*. 2012;132:658-666.
105. Regauer S, Reich O, Beham-Schmid C. Monoclonal gamma-T-cell receptor rearrangement in vulvar lichen sclerosus and squamous cell carcinomas. *Am J Pathol*. 2002;160:1035-1045.
106. Foldes-Papp Z, Reich O, Demel U, et al. Lack of specific immunological disease pattern in vulvar lichen sclerosus. *Exp Mol Pathol*. 2005;79:176-185.
107. De Vito JR, Merogi AJ, Vo T, et al. Role of *Borrelia burgdorferi* in the pathogenesis of morphea/scleroderma and lichen sclerosus et atrophicus: a PCR study of thirty-five cases. *J Cutan Pathol*. 1996;23:350-358.
108. Fung M, LeBoit P. Light microscopic criteria for the diagnosis of early vulvar lichen sclerosus: a comparison with lichen planus. *Am J Surg Pathol*. 1998;22:473-478.
109. Khachemoune A, Guldbakke KK, Ehrsam E. Infantile perineal protrusion. *J Am Acad Dermatol*. 2006;54:1046-1049.
110. Maronn ML, Esterly NB. Constipation as a feature of anogenital lichen sclerosus in children. *Pediatrics*. 2005;115:e230-e232.
111. Powell J, Wojnarowska F. Childhood vulval lichen sclerosus and sexual abuse are not mutually exclusive diagnoses. *BMJ*. 2000;320:311.
112. Smith SD, Fischer G. Childhood onset vulvar lichen sclerosus does not resolve at puberty: a prospective case series. *Pediatr Dermatol*. 2009;26:725-729.
113. Patrizi A, Gurioli C, Medri M, et al. Childhood lichen sclerosus: a long-term follow-up. *Pediatr Dermatol*. 2010;27:101-103.
114. Bracco GL, Carli P, Sonni L, et al. Clinical and histologic effects of topical treatments of vulval lichen sclerosus. A critical evaluation. *J Reprod Med*. 1993;38:37-40.
115. Goldstein AT, Creasey A, Pfau R, et al. A double-blind, randomized controlled trial of clobetasol versus

pimecrolimus in patients with vulvar lichen sclerosus. *J Am Acad Dermatol*. 2011;64:e99-e104.
116. Funaro D, Lovett A, Leroux N, et al. A double-blind, randomized prospective study evaluating topical clobetasol propionate 0.05% versus topical tacrolimus 0.1% in patients with vulvar lichen sclerosus. *J Am Acad Dermatol*. 2014;71:84-91.
117. Chi CC, Kirtschig G, Baldo M, et al. Systematic review and meta-analysis of randomized controlled trials on topical interventions for genital lichen sclerosus. *J Am Acad Dermatol*. 2012;67:305-312.
118. Casey GA, Cooper SM, Powell JJ. Treatment of vulvar lichen sclerosus with topical corticosteroids in children: a study of 72 children. *Clin Exp Dermatol*. 2015;40:289-292.
119. Virgili A, Borghi A, Minghetti S, et al. Mometasone fuoroate 0.1% ointment in the treatment of vulvar lichen sclerosus: a study of efficacy and safety on a large cohort of patients. *J Eur Acad Dermatol Venereol*. 2014;28:943-948.
120. Neill SM, Lewis FM, Tatnall FM, et al; British Association of Dermatologists. British Association of Dermatologists' guidelines for the management of lichen sclerosus 2010. *Br J Dermatol*. 2010;163: 672-682.
121. Terras S, Gambichler T, Moritz RK, et al. UV-A1 phototherapy vs clobetasol propionate, 0.05%, in the treatment of vulvar lichen sclerosus: a randomized clinical trial. *JAMA Dermatol*. 2014;150:621-627.
122. Shi L, Miao F, Zhang LL, et al. Comparison of 5-aminolevulinic acid photodynamic therapy and clobetasol propionate in treatment of vulvar lichen sclerosus. *Acta Derm Venereol*. 2016;96:684-688.
123. Ioannides D, Lazaridou E, Apalla Z, et al. Acitretin for severe lichen sclerosus of male genitalia: a randomized, placebo controlled study. *J Urol*. 2010; 183:1395-1399.
124. Bousema MT, Romppanen U, Geiger JM, et al. Acitretin in the treatment of severe lichen sclerosus et atrophicus of the vulva: a double-blind, placebo-controlled study. *J Am Acad Dermatol*. 1994;30:225-231.
125. Lee A, Bradford J, Fischer G. Long-term management of adult vulvar lichen sclerosus: a prospective cohort study of 507 women. *JAMA Dermatol*. 2015;151:1061-1067.
126. Corazza M, Borghi A, Minghetti S, et al. Clobetasol propionate vs. mometasone furoate in 1-year proactive maintenance therapy of vulvar lichen sclerosus: results from a comparative trial. *J Eur Acad Dermatol Venereol*. 2016;30:956-961.
127. Kreuter A, Gambichler T, Avermaete A, et al. Low-dose ultraviolet A1 phototherapy for extragenital lichen sclerosus: results of a preliminary study. *J Am Acad Dermatol*. 2002;46:251-255.
128. Kreuter A, Gambichler T. Narrowband UV-B phototherapy for extragenital lichen sclerosus. *Arch Dermatol*. 2007;143:1213.

Chapter 65 :: Psoriatic Arthritis and Reactive Arthritis

:: Ana-Maria Orbai & John A. Flynn

PSORIATIC ARTHRITIS

AT-A-GLANCE

- Psoriatic arthritis is a progressive inflammatory musculoskeletal disease occurring in about a third of people with psoriasis.
- Psoriatic arthritis is underdiagnosed.
- Clinical presentation is heterogeneous and variably includes the following manifestations: peripheral arthritis, spondyloarthritis (inflammatory arthritis of the spine), enthesitis (inflammation at the insertion sites of ligaments and tendons onto bone), and dactylitis (full-thickness inflammation of digits and toes).
- Associated extramusculoskeletal manifestations in addition to skin and nail psoriasis are inflammatory eye disease and inflammatory bowel disease.
- Several genetic risk factors have been identified for psoriatic arthritis.
- Serology for the rheumatoid factor is usually negative and inflammatory markers may be normal.
- Prompt recognition, pharmacologic treatment, and disease monitoring are necessary to prevent damage and improve long-term outcomes for psoriatic arthritis.

Psoriatic arthritis (PsA) was first linked to psoriasis in 1818 by French dermatologist Jean L. M. Alibert while caring for patients with chronic diseases at Hopital Saint-Louis in Paris. He noticed the association of psoriasis with inflammatory joint disease flares. The first case series was described by French dermatologist Charles Bourdillon in his doctoral thesis in 1888 and included descriptions of the PsA characteristic involvement of the distal interphalangeal joints as well as the disability potentially associated with PsA.[1,2]

Almost a century later, in 1973 John H. M. Moll and Verna Wright characterized PsA in great clinical detail and developed the first classification rule for PsA[3] consisting of inflammatory arthritis compatible with a PsA phenotype, psoriasis, and seronegative status for the rheumatoid factor. Several other classification schemes were developed. The Classification criteria for PsA (CASPAR)[4] are now the most widely accepted and define inclusion of participants in PsA clinical trials (Table 65-1).

Much progress has been made in recent years in understanding PsA pathophysiology through the discovery of specific molecular pathways involved in disease initiation and progression. A number of new targeted pharmacologic treatments have become available in addition to traditional medications.

Early diagnosis and treatment of PsA have been recognized as key to preventing damage and improving function and long-term outcomes. In addition, PsA has a significant association with multiple health risk factors and comorbidities that need to be identified and concomitantly managed.

EPIDEMIOLOGY

PsA prevalence is highly variable depending on the study and the case definition used, and it is estimated to be 0.02% to 0.25% in the general population. PsA occurs most frequently in people with psoriasis, and prevalence estimates in this population range from 3.2% to 41%.[5] PsA is underdiagnosed in people with psoriasis worldwide based on studies from Australia,[6] China,[7] North America, and Europe,[8,9] as well as a systematic literature review and meta-analysis.[10] Prevalence is equal in men and women and unlike psoriasis which has a bimodal incidence, PsA onset is most commonly seen in adulthood with a mean age of onset at 39.2 years.[7]

The annual incidence rate of PsA was 2.7 cases per 100 psoriasis patients (95% confidence interval [CI] 2.1-3.6) in the Toronto cohort.[11] The incidence of PsA mirrors incidence of psoriasis without evidence of change in PsA risk over time for people with psoriasis.[11,12]

Clinical predictors of PsA are nail psoriasis,[7,11,12] severe psoriasis,[7,11] scalp, intergluteal, or perianal psoriasis,[7,12] and the presence of uveitis.[11]

CLINICAL FEATURES

CUTANEOUS FINDINGS

Scalp and intergluteal psoriasis are more likely to be associated with PsA. Severity of skin psoriasis also has been linked to higher PsA risk.[13] Clinical nail disease with a prevalence of 40% in psoriasis is a known risk factor for PsA. In PsA, nail disease prevalence is 80%. Both the nail plate and nail matrix are affected, with nail pitting being the most common.[14] Association of nail psoriasis with distal interphalangeal joint arthritis

TABLE 65-1
The Classification Criteria for PsA (CASPAR)

ENTRY CRITERIA: INFLAMMATORY ARTICULAR DISEASE OF THE JOINTS, SPINE, OR ENTHESES

Classification Criteria	Points
1. Psoriasis (mutually exclusive categories for scoring)	
▪ Current	2 points
▪ Personal history	1 point
▪ Family history (first- or second-degree relative)	1 point
2. Nail dystrophy typical of psoriasis (onycholysis, pitting, hyperkeratosis), must be current	1 point
3. Negative rheumatoid factor (any method except latex)	1 point
4. Dactylitis (current, or historical if recorded by a rheumatologist)	1 point
5. Juxtaarticular new bone formation (ill-defined ossification near joint margins excluding osteophytes) on plain hand/feet radiographs	1 point

A classification of PsA is met if the final score is equal to or more than 3 points. Specificity is 98.7% and sensitivity is 91.4% against the criterion standard, which is a diagnosis established by the rheumatologist.

Adapted from Taylor W, et al. Classification criteria for PsA. *Arthritis Rheum.* 2006;54(8):2665-2673, Table 6, p. 2671.

has been noted since the initial descriptions of PsA. Association of onycholysis with axial PsA has recently been described.[15] Severe psoriasis, nail, scalp, and intergluteal psoriasis should prompt dermatologists to consider PsA when caring for patients with psoriasis (Fig. 65-1).

NONCUTANEOUS FINDINGS

It has recently been recognized that PsA is preceded by nonspecific musculoskeletal and systemic symptoms consisting of joint pain, fatigue, and stiffness in the year prior to diagnosis.[16] This is relevant to dermatologists and primary care physicians caring for patients with psoriasis and should prompt referral to a rheumatologist. The clinical spectrum of PsA musculoskeletal

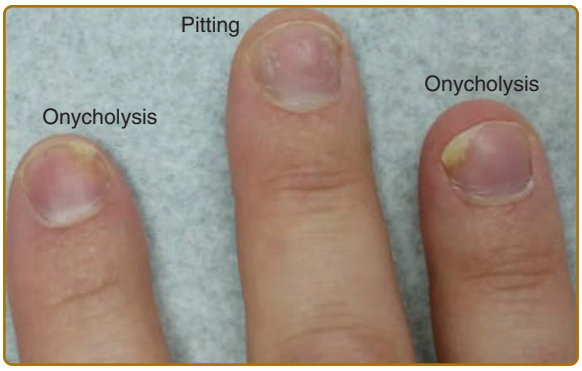

Figure 65-1 Psoriatic nail pitting at the third finger and onycholysis at the index and fourth fingers. Small splinter hemorrhages also can be observed at the index nail.

TABLE 65-2
Psoriatic Arthritis Phenotypes

Oligoarthritis	>70%
Polyarthritis/symmetric	15%
Distal interphalangeal joint predominant	5%
Spondyloarthritis	5%
Arthritis mutilans	5%

manifestations is heterogeneous (Table 65-2), encompassing not only inflammatory arthritis but also enthesitis, dactylitis, and spondylitis, all described below.

Arthritis: PsA clinical presentations have been described by Moll and Wright[3] as 5 distinct phenotypes (percentage of patients): oligoarticular (>70%), polyarticular/symmetrical (15%), distal interphalangeal joint predominant (5%), spondyloarthritis (5%), and arthritis mutilans (5%).[3] These phenotypes tend to overlap with cumulative disease duration. For example, the oligoarticular presentation tends to become symmetric over time as more joints become involved.[17] Spondyloarthritis occurs more frequently than previously thought in association with peripheral PsA. Correct quantification of joints affected is important for treating and monitoring PsA. Joint inflammation in PsA is more vascular and less tender than in rheumatoid arthritis, and joint tenderness and swelling each predict subsequent joint damage (Fig. 65-2).[18]

Dactylitis: Dactylitis is full-thickness inflammation of a digit (finger or toe). Acute dactylitis is tender. It has a prevalence of 20% to 59%[19-23] in PsA and is a sign of disease severity associated with radiographic damage.[24,25] Inflammation affects the joints, entheses, and subcutaneous tissues of the digits. Dactylitis assessed with high-resolution MRI is characterized by multiple lesions spanning multiple musculoskeletal structures: diffuse extracapsular soft tissue edema (92%), diffuse or focal increased bone marrow edema (83%), enthesitis at

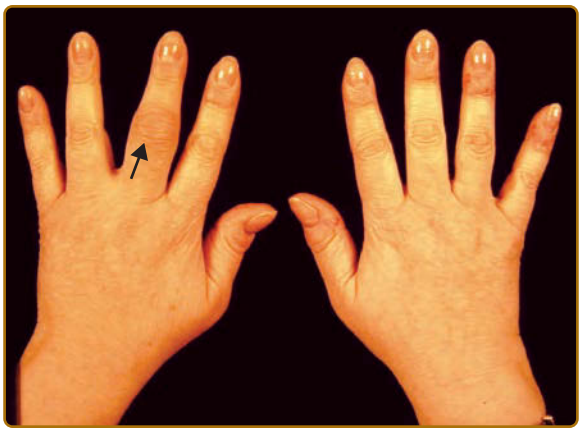

Figure 65-2 Swelling and erythema of the left third metacarpophalangeal joint (*arrow*) indicating inflammatory arthritis in a patient with psoriatic arthritis.

Figure 65-3 Psoriatic nail dystrophy and arthritis of the fifth distal interphalangeal joint in a patient with psoriatic arthritis. (Image used with permission from Dr. Umut Kalyoncu, Division of Rheumatology, Hacettepe University School of Medicine, Ankara, Turkey.)

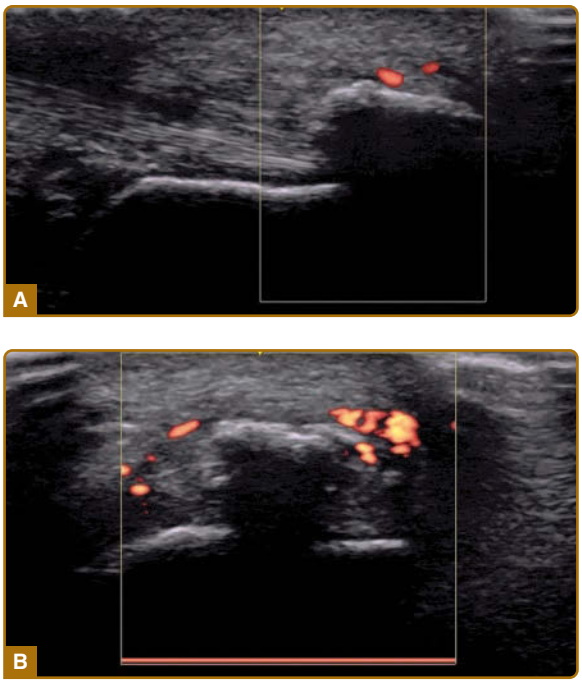

Figure 65-4 **A,** Enthesitis of the Achilles tendon is illustrated on ultrasonograph. Longitudinal tendon microfibers are disrupted. Image inset shows red Doppler signal corresponding to abnormal vascularity secondary to inflammation. **B,** Enthesitis of the Achilles tendon illustrated on ultrasonograph. Inset pictures enthesophyte (light gray with dark shadow) and red Doppler signal corresponding to abnormal vascularity at the entheseal insertion site. (Images used with permission from Dr. Jemima Albayda, Division of Rheumatology, Johns Hopkins University School of Medicine.)

the collateral ligament (75%) and extensor tendon (50%) insertions, flexor tenosynovitis (75%), synovitis (68%), signal intensity changes in the tendon pulleys (fingers), and fibrous sheaths (toes). Dactylitis is one of the criteria scored in the CASPAR classification as a result of its specificity for PsA. In the CASPAR sample, acute dactylitis increased the odds of PsA by 20 (95% CI 5.9-67) whereas historical dactylitis increased the odds for PsA by 5.5 (95% CI 1.8-17) (Fig. 65-3).[4]

Enthesitis: Entheses are anatomical structures formed by tendon, ligament, and joint capsule insertions on bone. They function together with bone and synovium as the synovio-entheseal complex (SEC) to distribute biomechanical stress in musculoskeletal structures.[26,27] Enthesitis is inflammation at entheseal sites and has an important role in PsA pathophysiology, with studies supporting a link between biomechanical damage as the initiating event of autoimmunity in PsA. Clinically, enthesitis is diagnosed as tenderness to pressure at entheseal insertion sites. There are multiple enthesitis indices that differ by the location and number of entheseal sites included in the count. Clinical enthesitis occurs in 35% of people with PsA, with an annual incidence of 0.9%. The most common sites of involvement are the Achilles tendons, plantar fascia, and lateral epicondyles at the elbows (Figs. 65-4, 65-5 and 65-15).[28] Subclinical enthesitis demonstrated with ultrasonography has been shown to exist in a significant proportion of patients (7% to 11%) with psoriasis.[29] In addition, the nail–entheseal complex has been invoked as a mediator of nail psoriasis based on evidence from nail ultrasonographic studies.[30]

Spondyloarthritis: Spondyloarthritis is defined as inflammatory arthritis affecting the axial skeleton leading to spondylitis and/or sacroiliitis. An isolated spondyloarthritis/axial phenotype is rare in PsA and occurs in 2% to 4% of cases. More commonly, axial PsA overlaps with peripheral PsA, and 30% to 40% or people with PsA are affected.[15,21] Risk factors for axial PsA are the presence of onycholysis, inflammatory back pain symptoms, PsA duration/young age at onset, positive HLA-B27, and inflammatory bowel disease. There are significant differences between axial PsA and ankylosing spondylitis (AS), which were explored in several studies. AS is significantly more likely to present with bilateral sacroiliitis, complete ankylosis of the sacroiliac joints, bridging syndesmophytes formed in a caudal to cranial progression, and more severe osteoproliferation than axial PsA.[15,31,32] Axial PsA is more likely to present as isolated spondylitis, manifest with random syndesmophyte formation, isolated involvement of the cervical spine,[32] and although sacroiliitis is also most commonly symmetric it is less likely so than in AS.[15] Axial PsA with isolated spondylitis is about 4 times more likely to be asymptomatic than axial PsA with sacroiliitis (OR 0.26, 95% CI 0.11-0.61, P = .002) (Fig. 65-6).[15]

Noncutaneous Extraarticular Manifestations:

Eye Disease: Eye involvement manifests in a third of people with PsA[33] and about 10% in people with psoriasis.[34] Complications from psoriatic skin

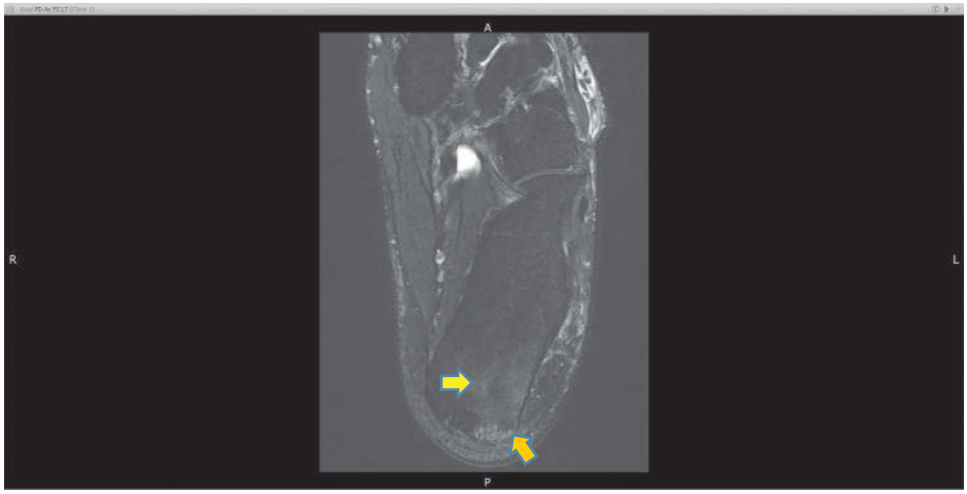

Figure 65-5 Enthesitis of the Achilles tendon demonstrated on MRI.

inflammation can cause blepharitis and dry eye. In addition, people with PsA may also develop conjunctivitis, uveitis, episcleritis, scleritis, keratoconjunctivitis sicca, and keratitis.[33] Uveitis is defined as inflammation of the iris, ciliary body, or choroid, and prevalence is variably estimated at 7% to 25% in people with PsA.[33,35] This is much less than in AS, where uveitis occurs in about 40%.[34] Uveitis risk is higher in PsA than in psoriasis.[35,36] There are differences in ocular manifestations of uveitis between people with axial versus peripheral PsA. In axial PsA, uveitis is diagnosed at a younger age (mean [standard deviation] 37.9 [9.6] years) than in psoriasis (43.3 [16.5]) and peripheral PsA (48.3 [22.4]), more likely to present in males who are HLA-B27 positive and more likely to involve the anterior segment. In contrast, uveitis in peripheral PsA is more likely to be insidious, bilateral, and to involve the posterior segment.[37] Perhaps because of later diagnosis or increased severity, uveitis in patients with PsA is more likely to lead to ocular complications than in psoriasis (Figs. 65-7 and 65-8).[35]

Inflammatory Bowel Disease: Psoriasis, PsA, and inflammatory bowel disease partially overlap in their genetic determinants, immune effectors, and therapeutics. Risk of inflammatory bowel disease was increased in a Danish nationwide study in psoriasis and PsA versus the general population without psoriatic disease.[38] In the US Nurses' Health Study II (NHS II), women with psoriasis and especially with PsA had an increased risk of incident Crohn disease: relative risk (RR) for Crohn disease in psoriasis 3.86 (95% CI 2.23-6.67) and RR for Crohn disease in PsA 6.43 (95% CI 2.04-20.32).[39] In a case–control study of 15 patients with active psoriasis and PsA but without any GI symptoms versus normal controls, all PsA patients had microscopic colitis with increased lamina propria cellularity and lymphoid aggregates. Additionally, the

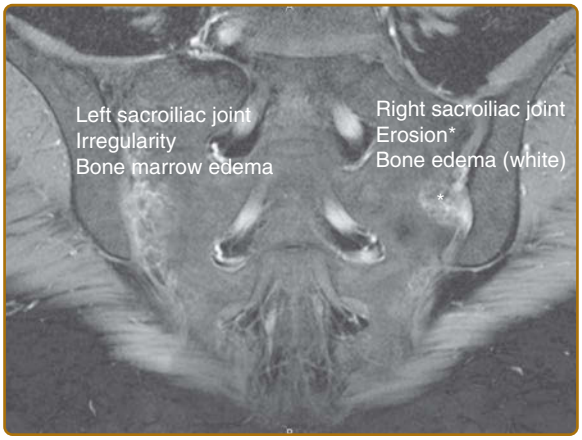

Figure 65-6 Sacroiliitis illustrated on MRI: at the left sacroiliac joint, there is joint space narrowing and irregularity with adjacent subchondral bone marrow edema in the ilium and the sacrum. At the right sacroiliac joint, there is joint space narrowing and an erosion with adjacent subchondral bone marrow edema in the sacrum.

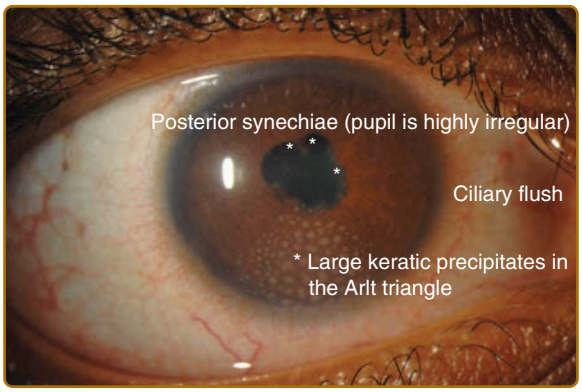

Figure 65-7 Large keratic precipitates in the Arlt's triangle region, mild ciliary flush (conjunctival injection at the limbus), and posterior synechiae (adhesions of the iris to the lens). (Image used with permission from Dr. Bryn Melissa Burkholder, Wilmer Eye Institute, Johns Hopkins University School of Medicine.)

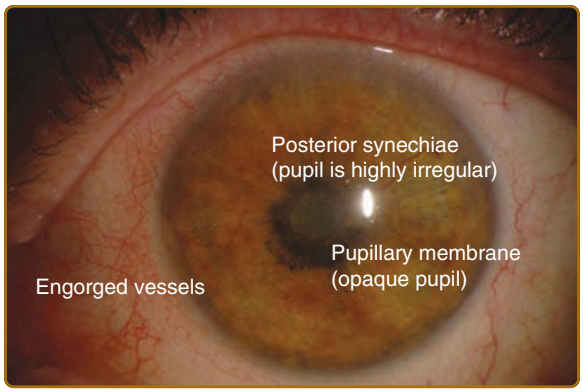

Figure 65-8 HLA-B27-associated uveitis demonstrates extensive posterior synechiae, a pupillary membrane, and engorged iris vessels. (Image used with permission from Dr. Bryn Melissa Burkholder, Wilmer Eye Institute, Johns Hopkins University School of Medicine.)

majority had active inflammation, with polymorphonuclear leukocyte infiltration.[40]

MEDICAL RISK FACTORS AND COMORBIDITIES ASSOCIATED WITH PsA

Cardiovascular risk is increased in people with PsA versus the general population as recently shown in a systematic review and meta-analysis of observational studies. Pooled relative risk for myocardial infarction was 1.57 (95% CI 1.19-2.06), and there was also evidence of increased risk for cerebrovascular events and congestive heart failure.[41] In the Toronto longitudinal cohort study, 1091 PsA patients followed over 35 years had the following independent predictors of cardiovascular events in the multivariate analysis: hypertension, diabetes, the number of dactylitis digits, and elevated erythrocyte sedimentation rate—the latter a predictor only in women.[42] The implications of these studies are that cardiovascular risk may be underestimated by taking into account traditional cardiovascular risk factors only, and that PsA activity may need to be considered as an independent predictor. Current recommendations state to control disease activity to lower cardiovascular risk in rheumatoid arthritis as well as PsA and AS.[43] However, evidence for psoriasis and PsA treatment specific effects on cardiovascular risk is inconclusive as of this writing.

In addition to cardiovascular disease, obesity, type 2 diabetes mellitus, nonalcoholic fatty liver disease, and the metabolic syndrome are all increased in people with PsA versus the general population. These potential comorbidities are relevant for PsA disease activity and treatment and should be taken into account for a comprehensive management of patients with PsA.[44] An important link between obesity and PsA disease activity has been identified in several studies. Overweight and obese patients are less likely to achieve minimal disease activity compared to PsA patients with normal weight in 2 independent cohort studies.[45,46] Furthermore, overweight and obese patients who lost 5% or more of their body weight were more likely to achieve minimal disease activity on tumor necrosis factor (TNF) inhibitor therapy compared to controls that did not lose weight.[47]

ETIOLOGY AND PATHOGENESIS

GENETICS

Moll and Wright were the first to study PsA heritability in families with PsA (including 253 first-degree relatives of 88 PsA probands) and concluded that prevalence of PsA in first-degree relatives is 5.5%.[48] This translates to a PsA risk around 100 times higher in first-degree relatives than the general population, suggesting a strong genetic component for the disease. As of this writing, HLA-B27 has the strongest evidence for being a genetic risk factor for PsA in people with psoriasis.[49,50] HLA-B27 haplotypes also hold prognostic value through association with disease characteristics: PsA onset within 1 year from psoriasis diagnosis, axial PsA, enthesitis, dactylitis, and uveitis.[33,49,50] However, HLA-B27 prevalence in PsA is 19% to 35%, supporting the notion that PsA heritability is multifactorial.

Additional HLA-independent genetic risk factors specific for PsA (vs psoriasis) have been discovered and confirmed in the past few years using genomewide association studies. These additional PsA-specific susceptibility genes are located as follows: upstream of *IL23R* gene on chromosome 1,[51,52] in the *PTPN22* gene on chromosome 1,[53] the 5q31 locus,[54] and upstream of *TNFAIP3* on chromosome 6.[51] Interestingly, susceptibility loci for both psoriasis and PsA have been confirmed within the *IL23R* and *TNFAIP3* genes, whereas the signals upstream of these genes represent PsA-specific variants.[51] PTPN22 encodes a lymphoid-specific intracellular phosphatase involved in T-cell signaling pathways and has been associated with rheumatoid arthritis, type 1 diabetes, systemic lupus erythematosus, and Grave disease, whereas the 5q31 locus is common to inflammatory bowel disease, juvenile idiopathic arthritis, and asthma.

We are now beginning to discern genetic susceptibilities specific to PsA versus psoriasis that support the existence of differences in pathophysiology inferred from clinical experience, tissue studies, and differential response to targeted therapeutics. PsA susceptibility genes encode multiple immune functions from antigen presentation and processing to innate and adaptive immunity pathways. In addition to genetic susceptibility and possibly other host factors, environmental factors must also play a role in determining the significant heterogeneity observed in PsA expression among individuals.

RISK FACTORS

Implicit to the PsA case definition, people with psoriasis represent the population at greatest risk for developing PsA. Several risk factors associated with developing PsA have been identified in people with psoriasis: psoriasis type/location such as scalp and intergluteal, psoriasis severity, psoriatic nail disease, positive HLA-B27,[13] and uveitis.[11] In addition to these clinical factors, the following environmental and individual factors increase the risk of PsA: physical trauma, smoking, overweight, and obese physique.[55] Increased weight has been recognized as a risk factor for incident PsA in several population studies. In the U.S. NHS II, incident PsA relative risk in overweight and obese versus ideal BMI range was RR 1.83 (95% CI 1.15-2.89) for BMI 25 to 29.9, RR 3.12 (95% CI 1.9-5.11) for BMI 30 to 34.9, and RR 6.46 (95% CI 4.11-10.16) for BMI greater than 35.[56] In the UK Health Improvement Network study, PsA risk in people with psoriasis who were obese versus normal weight was RR 1.22 (95% CI 1.02-1.47) for BMI 30 to 34.9 and RR 1.48 (95% CI 1.2-1.81) for BMI greater than 35.[57] Smoking was a factor increasing the relative risk of incident PsA versus nonsmokers in U.S. women NHS II participants with an RR 3.13 (95% CI 2.08-4.71), a dose–response relationship for smoking duration and pack-years, as well as an association between smoking and higher disease severity.[58] Congruently, smoking has been shown to be associated with poor PsA functional outcome in the Bath longitudinal cohort.[59] However, in the Toronto cohort, findings were divergent and current smoking status versus lifetime nonsmoker status was associated with lower odds of incident PsA.[60]

PATHOGENESIS

PsA is associated with genetic risk factors encoding immune system functions that include antigen presentation (MHC class I alleles, especially HLA-B27 for PsA), antigen processing, and innate and adaptive immune responses. Central to innate immunity in both psoriasis and PsA is TNF-induced NF-kB signaling with transcription of inflammatory mediators.[61] Adaptive immune system responses are characterized by selective transcription of mediators favoring Th1 and Th17 cells: IL12/Tbet signaling leading to Th1 cell differentiation and proliferation; and RORγt signaling in the presence of IL23 leading to Th17 cell differentiation and proliferation.[62,63] The agent precipitating the cascade of immune events leading to PsA phenotypes is currently unknown, and therefore alternate hypothesis have been sought. The biomechanical stress/synovio-entheseal complex (SEC) hypothesis connects damage at entheseal insertion sites in the presence of a genetically susceptible background with erroneous tissue repair responses and self-propagating inflammation leading to PsA.[26,27] This model posits that micro-damaged entheses release local tissue factors that in turn couple with pattern recognition molecules and activate the innate immune system. These events are followed by aberrant adaptive immune responses central to the pathophysiology of the disease. In mouse models of PsA, innate IL23 responsive cells localized at the entheseal bone interface were inducible (with IL23 stimulation) to express IL22, which promoted entheseal inflammation and periosteal new bone formation through STAT3 phosphorylation and signaling.[63,64] The SEC hypothesis corresponds with the fact that as of this writing no specific autoantigens have been identified in PsA.

Comparatively, in psoriasis there are protein targets that have been hypothesized to catalyze initiation of immune system responses in the skin. Cathelicidin LL37 complexed with damaged keratinocyte DNA has long been postulated as the initiator of psoriatic inflammation via toll-like receptor 9 in the presence of damaged skin. This leads to interferon-α, which together with TNF-α, IL-1β, and IL-6 stimulate dermal dendritic cells to migrate to lymphoid organs and stimulate Th1 and Th17 cell differentiation.[65] Just recently, an autoantigen was discovered and shown to trigger psoriasis-specific cytokines in the skin supporting the exciting hypothesis that psoriasis is an autoimmune disease. The melanocyte-derived protein ADAMTSL5 was shown to mediate MHC class I–dependent $CD8^+$ T-cell activation in the skin, leading to overproduction of IL-17—the signature cytokine of psoriatic lesions.[66]

DIAGNOSIS

EARLY PsA

It is increasingly recognized that delaying rheumatologic care in PsA is linked not only to suffering but also to long-term joint damage and disability. Current estimates from research studies have shown that delay in diagnosis of 6 months or more versus less than 6 months are linked to significantly more disability in people with PsA.[59,67] Furthermore, associated manifestations (lower extremity arthritis, uveitis, sacroiliitis, enthesitis, inflammatory bowel disease, etc.), and health risk factors (cardiovascular disease, hypertension, metabolic syndrome, liver disease) in individuals with PsA are underrecognized and undertreated without a specialist's care, compromising chances of improved patient outcomes.[44] There is increased interest in screening for early PsA, with dermatology clinics representing the ideal setting. Several PsA screening questionnaires have been validated in patients with psoriasis, and a positive score should prompt referral to a rheumatologist (Table 65-3).

Unfortunately, screening questionnaires may miss a significant proportion of PsA patients, close to 30%, because of best performance of these questionnaires in the polyarticular PsA pattern and therefore dermatologists' high index of suspicion remains key for detecting PsA.[9] Recent findings that a diagnosis of PsA is preceded by stiffness, fatigue and joint pain support implementation of screening procedures and keeping a high index of suspicion for PsA in the psoriasis patient population.[16]

TABLE 65-3
PsA Screening Tools for People with Psoriasis

QUESTIONNAIRES	PASE[a]	TOPAS[b]	TOPAS[2]	PEST[c]	EARP[d]
Target population	Psoriasis	Psoriasis and general population	Psoriasis and general population	Psoriasis	Psoriasis
Domains	Symptom and function subscales	Skin, joint, nail	Skin, joint, nail, spine	Joint, nail, enthesitis, dactylitis	Joint, antiinflammatories, low back pain, stiffness, dactylitis, enthesitis
Number of items	15	12	13	5	10
Feasibility completion, min, mean (SD)	4-6	NR	NR	NR	2 (1.5)
Feasibility scoring, min	1	NR Weighted sum	NR Weighted sum	NR Simple sum	NR Simple sum
Reliability, (ICC)	0.9	NR	NR	NR	NR
Internal consistency Cronbach's alpha	NR	NR	NR	NR	0.83
Sensitivity % (95% CI)	82 (57-96)	86.8	87.2 92	92	85.2
Specificity, % (95% CI)	73 (59-84)	93.1	82.7 77.2	78	91.6
Score range	15-75	0-12	0-12	0-5	0-10
Value of cut-off score suggestive of PsA	≥47 ≥44	≥8	≥7 ≥8	≥3	≥3

[a]PsA Screening and Evaluation.[68,69]
[b]Toronto PsA Screen.[70]
[c]Psoriasis Epidemiology Screening Tool.
[d]The Early PsA Screening Questionnaire.[71]
NR, not reported.

PsA CLASSIFICATION

The CASPAR criteria (Table 65-1) are used for classification of PsA and participant inclusion in PsA clinical trials. Even after meeting CASPAR criteria patients with PsA represent a highly heterogeneous clinical population. The involvement of a rheumatologist early in the PsA course is essential. To diagnose PsA, several clinical indicators in people with psoriasis are helpful, as outlined in the discussion above on risk factors for PsA. Laboratory tests for rheumatoid factor and anticyclic citrullinated peptides (anti-CCP) are important to exclude rheumatoid arthritis. Genotyping for HLA-B27 has clinical and prognostic value because HLA-B27-positive individuals are at higher risk for early PsA, axial PsA, severe enthesitis, and uveitis. Radiographs are recommended to evaluate PsA characteristic joint damage such as juxta-articular bone erosions and new bone formation. These may also show enthesophytes at sites of prior entheseal trauma or inflammation. For capturing disease activity, imaging techniques that can distinguish tissue edema and vascularization are needed. These are musculoskeletal ultrasonography and MRI. Images of power Doppler signal for enthesitis are presented in Figs. 65-5, and MRI showing enthesitis, enthesophyte, and bone marrow edema are represented in Fig. 65-6.

DIFFERENTIAL DIAGNOSIS

Other types of inflammatory arthritis that can co-occur with psoriasis should be considered (please see diagnostic algorithm in Fig. 65-9). Rheumatoid arthritis is usually positive for the rheumatoid factor or anti-CCP. Reactive arthritis is more likely to occur after a GI or sexually transmitted infection (see section "Reactive Arthritis"). Gout is more common in people with psoriasis than in the general population likely due to increased skin turnover and increased association with cardiovascular comorbidities and medications used to treat them. The most common differential diagnosis may be osteoarthritis (OA) because of its high prevalence and overlapping predilection for a similar patient population in terms of comorbidities. OA is usually less inflammatory than PsA, worsening with activities and at the end of the day, and lacking PsA-specific manifestations like dactylitis, enthesitis, and/or spondylitis. In the subset of patients with erosive OA, differentiation may be difficult and needs to be determined by the treating rheumatologist while considering additional clinical, laboratory, and imaging characteristics. Techniques such as musculoskeletal ultrasonography and MRI may be useful to make the distinction.

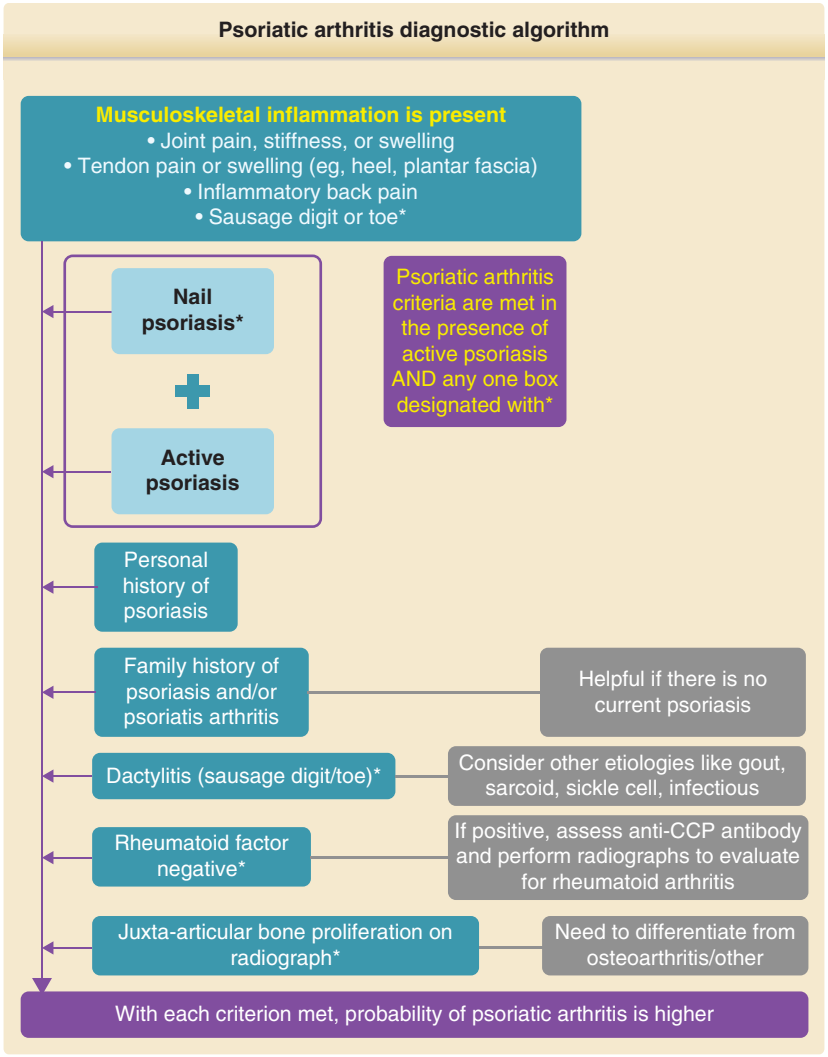

Figure 65-9 Psoriatic arthritis (PsA) diagnostic algorithm.

CLINICAL COURSE AND PROGNOSIS

Delayed PsA diagnosis and effective treatment are associated with disability and radiographic damage. There is a window of opportunity of about 6 months to initiate therapy to maximize chances of minimal disease damage. Multiple new therapeutic agents have been approved in PsA in the past 5 years. These therapeutics showed efficacy in decreasing PsA disease activity, slowing damage progression and improving fatigue and additional patient health outcomes.[72] There is now evidence that disease-modifying treatment for PsA is effective for controlling disease activity and decreasing work disability in PsA.[73]

MANAGEMENT

The highest quality evidence underlying PsA management is extrapolated based on the efficacy of therapeutic interventions in PsA randomized controlled trials. However, PsA is a complex disease with multiple pathophysiologic manifestations and broad life impact, as well as significant heterogeneity among individuals. Although as of this writing is has been difficult to capture individual heterogeneity in clinical trials, advances in the science of outcome measurement are making this increasingly possible. To this end, the core set of PsA outcomes to be measured in upcoming PsA clinical trials has recently been updated to reflect PsA manifestations and both patients' and physicians' priorities (Fig. 65-10).[74] In addition to comprehensive assessment of pathophysiologic manifestations like musculoskeletal and skin disease activity, fatigue is now included as a mandatory outcome, whereas additional patient relevant aspects such as participation in daily life activities (according the International Classification of Functioning definition, participation is the ability to be involved in life, to perform societal tasks and responsibilities, to work, and to take part in social events, leisure and family life) and emotional well-being are strongly recommended to be measured in clinical trials. As these

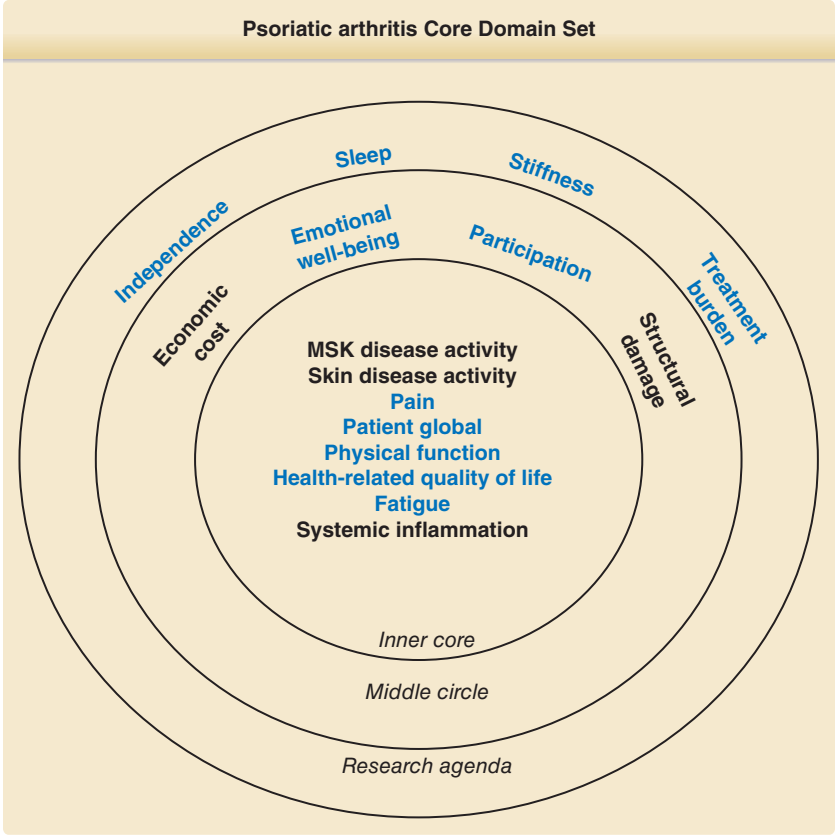

Figure 65-10 Psoriatic arthritis (PsA) Core Domain Set to be measured in PsA clinical trials and longitudinal observational studies. Blue font represents patient reported outcomes. (Reproduced with permission from BMJ Publishing Group Ltd: Orbai AM, et al. *Ann Rheum Dis*. 2017;76(4):673-680, Fig. 3.)

outcomes begin to be systematically measured and reported, information on treatment efficacy for multiple aspects of PsA will become more complete and helpful for decision making in clinical care.

Current treatment recommendations for PsA mandate beginning treatment according to the clinical phenotype and assessing disease activity every 3 months at least in the beginning or until the treatment target is achieved. The goal of therapy is to achieve minimal or low disease activity and escalating therapy until this goal is achieved as standard of care.[72] However, in a recent U.S. national survey of psoriasis and PsA, among patients reporting high disease burden, only 10% with psoriasis and only 25% with PsA reported treatment with biologics.[75]

PsA treatment guideline sets have been updated in 2015-2016.[76] The disease-modifying antirheumatic drugs (DMARDs) methotrexate, sulfasalazine, and leflunomide (Table 65-4) are generally recommended as first-line agents. Antimalarials (hydroxychloroquine) are not used in PsA because of the potential for worsening or precipitating development of psoriasis. Methotrexate is approved for treating psoriasis and is being used off-label in the United States to treat PsA based on data extrapolated from rheumatoid arthritis and clinical practice. The MIPA randomized controlled trial (RCT) of methotrexate versus placebo for PsA[77] showed numerical benefit but no significant treatment effect difference between methotrexate and placebo groups; however, the RCT used a low target methotrexate dose (15 mg/wk) and had a high drop-out rate (30%). In the Toronto longitudinal cohort methotrexate >15 mg/wk versus 15 mg/wk or lower improved disease activity and slowed damage progression, suggesting a benefit for methotrexate doses above 15 mg/wk.[78] However, experts still question the utility of methotrexate as a disease-modifying drug in PsA as it has not been consistently linked to comprehensive long-term patient outcomes such as PsA-specific manifestations or slowing damage progression, improving quality of life for patients, and reducing comorbidities. As an adjunct to biologic therapy, infliximab methotrexate in particular, not only prevented the formation of antiinfliximab antibodies but also increased efficacy.[79] Methotrexate can cause mucosal ulcerations and an oral exam should be part of any routine rheumatologic examination. Kidney function is an important consideration with methotrexate dosing. Daily folic acid supplementation is recommended with both sulfasalazine and methotrexate.

Sulfasalazine has been shown to improve psoriatic joint swelling with no effect on psoriasis or enthesitis. Sulfasalazine is the preferred DMARD in peripheral spondyloarthritis considering risk and benefits in individual patients.

TABLE 65-4
Medications

DRUG	PSORIATIC DISEASE SPECIFIC INDICATIONS							SIDE EFFECTS AND SPECIAL CONSIDERATIONS
	CUTANEOUS		MUSCULOSKELETAL					
	SKIN	NAIL	ARTHRITIS	DACTYLITIS	ENTHESITIS	AXIAL SPONDYLOARTHRITIS	OTHER	
methotrexate	+		+					Risk of mucosal ulcerations, hepatotoxicity, teratogenic. Liver function tests, blood counts and renal function need to be monitored Folic acid 1 mg daily mandatory for the duration of methotrexate therapy
Sulfasalazine			+					Monitor liver function, blood counts Reversible azoorspermia Folic acid supplementation indicated
Leflunomide	+		+					Risk of hepatotoxicity, teratogenic. Monitor liver function, blood counts. Long half-life, stores in adipose tissue.
Etanercept	+	+	+			+		Drug induced SLE, Demyelinating disease, CHF, cancer
Infliximab	+	+	+	+	+	+	+uveitis +IBD	
Adalimumab	+	+	+	+[d]	+[d]	+	+uveitis +IBD	
Certolizumab	+	+	+	+	+	+	+IBD [*Crohn disease*]	
Golimumab	+	+	+	+	+	+	+IBD [*Ulcerative colitis*]	
Apremilast	+	+	+	+[d]	+[d]			Weight loss (10%) Depression (1%)
Ustekinumab	+	+	+	+[d]	+[d]		+IBD [*Crohn disease*]	Increased risk of eosinophilic pneumonia, cancer
Secukinumab	+	+	+	+	+	+		Increased risk of candidiasis, exacerbation of IBD
Ixekizumab	+	+	+	+	+[d]			Increased risk of candidiasis, exacerbation of IBD, neutropenia
Tofacitinib	+	+	+	+[d]	+[d]		+IBD [*Ulcerative colitis*]	Increased risk of elevated LDL and HDL (10-19%), pulmonary embolism, herpes zoster, neutropenia, lymphopenia, GI perforation, cancer
Abatacept			+					Chronic obstructive pulmonary disease exacerbation, cancer

[a]Eye disease, Inflammatory bowel disease.
[b]First line agents in the treatment of PsA.
[c]First line biologic agents; first line treatments for enthesitis, spondyloarthritis PsA.
[d]Efficacy not reproduced in some trials.
PsA, psoriatic arthritis; IBD, inflammatory bowel disease.

Leflunomide is effective for both psoriasis and PsA with mild to moderate improvements.[80] Hepatic toxicity and the risk of anemia need to be considered during use of traditional synthetic disease-modifying drugs and therapy monitored with serial liver function tests and complete blood counts, particularly in the beginning of therapy and regularly thereafter.

Apremilast, a selective inhibitor of the enzyme phosphodiesterase 4 (PDE4), is a targeted synthetic disease-modifying medication with moderate effects for PsA for skin, nails, arthritis, enthesitis, dactylitis, as well as patient-reported outcomes including physical function. Long-term structural damage data are currently lacking for this medication. Side-effect profile is favorable; however, a 1% risk of depression has been observed and needs to be considered in this patient population.

In some patients, it is difficult to achieve current treatment targets with classical synthetic DMARDs even in combination, and side effects can be severe for patients.[81] However, in the era of multiple targeted therapies for PsA and psoriasis, disease remission is possible more than ever before. TNF inhibitors (adalimumab, certolizumab, golimumab, etanercept, infliximab) are generally the first-line biologic agents and have been used for PsA for almost 2 decades. They have excellent efficacy for all PsA pathophysiologic manifestations including skin disease, arthritis, dactylitis, enthesitis, spondylitis, and nail disease. Adalimumab and infliximab are also effective for PsA-associated manifestations of uveitis and inflammatory bowel disease (it should be noted that certolizumab is also effective for Crohn disease, whereas golimumab is effective for ulcerative colitis). These agents are first-line treatment for enthesitis and axial PsA, where classical synthetic disease-modifying drugs will not help. There are no head-to-head trials of TNF inhibitors in PsA, and these are prescribed taking into account the patient's context and potential additional indications or risks.

Ustekinumab, an inhibitor of the common p40 subunit of both IL12 and IL23, is approved for the treatment of psoriasis and PsA. In psoriasis, it is labeled for people who are candidates for phototherapy or systemic therapy. Ustekinumab is also approved for Crohn disease in people who failed TNF inhibitors.

IL17 inhibitors are the most efficacious medication class approved as of this writing for psoriasis. Secukinumab and ixekizumab are both IL17 inhibitors. Secukinumab is labeled for PsA and AS, in addition to psoriasis. Ixekizumab is approved for psoriasis and psoriatic arthritis and is being evaluated in phase III clinical trials for AS. Tofacitinib, a jak/stat inhibitor was recently labeled for psoriatic arthritis and ulcerative colitis. Abatacept, an anti-T cell therapy/CTLA4 inhibitor was labeled for psoriatic arthritis. For both these therapies, efficacy for psoriasis has not met primary endpoints in clinical trials.

NEW MOLECULES

Additional molecules are under study with 3 IL23 inhibitors currently in various clinical trial stages. Guselkumab is an IgG1 antibody binding the p19 subunit specific to IL23. This is being evaluated in 3 Phase III studies for psoriasis, and results are awaited. Tildrakizumab is another IL23 monoclonal antibody currently in Phase III psoriasis studies. Risankizumab is a third compound in the IL23/p19 inhibitor family and also currently in Phase III psoriasis clinical trials.

Additional JAK pathway inhibitors are being developed. Upadacitinib is a JAK inhibitor in phase III clinical trials in psoriatic arthritis.

There are also additional IL17 inhibitors being developed with one of them, bimekizumab, currently in phase III clinical trials.

An additional immunologic target being evaluated in psoriasis/PsA is RORγt, a transcription factor on which IL17 production is dependent.

TREATMENT ALGORITHM

The European League against Rheumatism (EULAR) and the Group for Research and Assessment of Psoriasis and PsA (GRAPPA) have both designed treatment guidelines for PsA (Fig. 65-11).[76] The underlying principles of these guidelines are tight control of PsA inflammation until a status of PsA minimal disease activity or PsA remission is reached. Regular assessment is required ideally every 3 months and at least every 6 months to assess PsA disease activity and tailor therapy to target.

The treatment algorithm starts with initiation of DMARDs followed by biologic medications with TNF inhibitors as first-line biologics. It should be noted that in the case of enthesitis or spondylitis, the first-line medication becomes a TNF inhibitor as DMARDs are not effective for these manifestations. Second-line biologics are interleukin 12/23 inhibitors (IL12/23i, ustekinumab), which are highly effective for skin disease, followed by arthritis, enthesitis, dactylitis, and inflammatory back pain symptoms. Ustekinumab is also U.S. FDA–approved for Crohn inflammatory bowel disease. Interleukin 17 (IL17) inhibitors have the highest efficacy of any approved PsA medication as of this writing for psoriasis, and one is approved for AS. IL17i are also effective for arthritis, dactylitis, enthesitis, and psoriatic nail disease. There is a concern for worsening inflammatory bowel disease with IL17 inhibitors and that aspect is currently under study. There are no data on efficacy of IL12/23 and IL17 inhibitors for uveitis.

The GRAPPA treatment guideline requires systematic PsA assessments for all pathophysiologic domains potentially affected, including arthritis, dactylitis, enthesitis, spondylitis, skin psoriasis, and nail psoriasis. Treatment is adjusted at every assessment to cover most efficiently all disease manifestations, considering each patient's individual health context.[72]

PREVENTION/SCREENING

Prevention of PsA is an area worthy of further exploration. The population at risk, people with psoriasis,

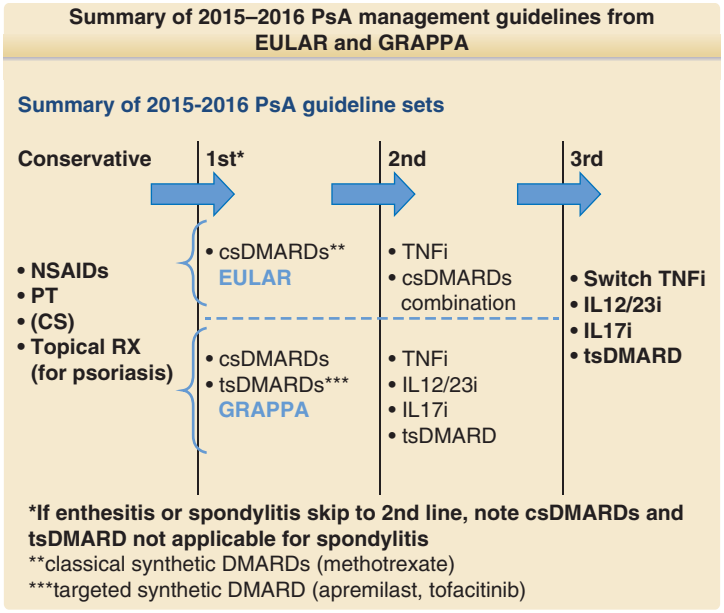

Figure 65-11 Summary of 2015-2016 PsA management guidelines from EULAR and GRAPPA. NSAIDs, Nonsteroidal anti-inflammatory drugs; PT, physical therapy; CS, corticosteroid injections recommended with caution; DMARD, disease-modifying antirheumatic drug; TNFi, tumor necrosis factor inhibitor; IL12/23i, interleukin 12/23 inhibitor; IL17i, interleukin 17 inhibitor. [a]If enthesitis or spondylitis skip to second line, note csDMARDs not applicable for enthesitis and tsDMARD not applicable for spondylitis. [b]Classical synthetic DMARDs (methotrexate, sulfasalazine, or leflunomide). [c]Targeted synthetic DMARD (apremilast). Dashed arrows designate less stringent concept of first- and second-line agents, with the algorithm being tailored to as many affected pathophysiologic domains as possible with the simplest regimen and the patients' individual health context.

is well defined, and there is considerable overlap between psoriasis and PsA treatment. However, it is unknown if biologic treatments in psoriasis prevent PsA onset. This seems unlikely given the need for chronic treatment and high rate of PsA relapse with discontinuation of therapy even for people in remission. Because both skin and joint disease require monitoring to ensure achievement of treatment targets, it is highly recommended that musculoskeletal symptoms be assessed and monitored on therapy by a rheumatologist for best patient outcomes. Prevention and modification of known personal and environmental risk factors for PsA (smoking, obesity, and physical trauma) have a plausible role in preventing or delaying PsA onset.

There is increased focus on the importance of early diagnosis of PsA.[13] It was recently described in a PsA inception cohort that musculoskeletal pain, fatigue, and stiffness preceded PsA onset by several months. It is therefore important that high-risk psoriasis patients be quickly referred to rheumatologists for diagnostic evaluation for PsA[16] so they can commence treatment and monitoring. PsA screening questionnaires attempt to capture people with psoriasis and those with a high probability of inflammatory musculoskeletal disease. These are easy to administer in the waiting room (Table 65-3). Probing for musculoskeletal symptoms during the dermatology visit could help close the gap of undiagnosed PsA in people with psoriasis.

REACTIVE ARTHRITIS

AT-A-GLANCE

- Reactive arthritis is typically an oligoarthritis that develops 1 to 4 weeks following an enteric or urethral infection.
- Inciting infections agents include *Chlamydia trachomatis*, *Yersinia*, *Shigella*, *Salmonella*, *Campylobacter*, *Clostridium difficile*, and *Escherichia coli*.
- It is classified as a spondyloarthritis, with common clinical features including arthritis of the spine and sacroiliac joints, enthesitis, dactylitis, and the absence of serologies associated with rheumatoid arthritis.
- Cutaneous manifestations include keratoderma blenorrhagicum, circinate balanitis, aphthous ulcers, and nail changes.
- Associated extramusculoskeletal manifestations in addition to cutaneous findings include inflammatory eye and cardiac disease.
- The HLA-B27 haplotype appears to be a risk factor and is associated with a more chronic prognosis.
- Although reactive arthritis often is self-limited in weeks to months, as much as a third of patients may develop chronic disease.

INTRODUCTION

Reactive arthritis (ReA), formerly referred to as Reiter or Fiessinger–Leroy syndrome, along with PsA, is an inflammatory arthritis classified within the spondyloarthritis (SpA) family.[82,83] SpA also includes AS and the arthritis of inflammatory bowel disease. The classic triad of symptoms in ReA, which does not develop in the majority of patients, encompasses urethral, ocular, and articular inflammation. This inflammation occurs as a reaction to an antecedent infection and is generally self-limited. Within articular structures, it is a separate entity from septic arthritis due to the inability to recover any infectious agent directly from the inflamed joints. Cutaneous manifestations include keratoderma blenorrhagicum, circinate balanitis, aphthous ulcers, and nail changes. The infectious agents most commonly implicated in reactive arthritis include the GI pathogens (*Yersinia*, *Shigella*, *Salmonella*, *Campylobacter*, and *Clostridium difficile*) as well as venereal urogenital infection (*Chlamydia trachomatis*).

EPIDEMIOLOGY

The lack of consensus and standardization of the diagnostic criteria for reactive arthritis makes epidemiologic studies challenging. The post-venereal urogenital type typically presents in younger adults in their third to fifth decade of life where there is a male predominance. Studies have suggested that up to 8% of patients with chlamydial infections may develop a subsequent reactive arthritis.[84] Unlike enteric infections that are nearly always symptomatic, urogenital infections may be asymptomatic in the majority of patients. Most epidemiologic studies of reactive arthritis are in the setting of infection by enteric pathogens. In outbreaks of enteric infection due to food contamination, up to 20% of patients have developed articular symptoms. The overall prevalence is estimated at 20 to 40 per 100,000, with a yearly incidence of 25 per 100,000.[85]

CLINICAL FEATURES

One to 4 weeks following the triggering infection, the patent will develop an oligoarthritis (2 to 4 joints) that is asymmetric.[86] The predominant symptom in patients with enteric infection is diarrhea, which can be bloody. With urogenital infections, the patient may describe dysuria with a purulent urethral discharge or may be without symptoms. The classic triad of urethral, ocular, and articular inflammation is rarely present together. Although it is felt that the majority of patients with reactive arthritis have a self-limited course, a significant portion can have symptoms extending beyond 6 months at which point they are considered as having chronic ReA.

Figure 65-12 Circinate balanitis.

CUTANEOUS

Several cutaneous manifestations are seen in ReA. Circinate balanitis is the inflammatory skin lesion that develops on the shaft or glans of the penis and more rarely on the scrotum (Figs. 65-12 and 65-13). This erythematous lesion can be both papular and pustular and develop raised borders around the meatus. In an uncircumcised patient, identification of the lesion will require retraction of the foreskin where the lesions are moist and generally painless. In a circumcised patient, the lesions may harden to a hyperkeratotic dry crust resembling a psoriatic plaque that can be painful

Figure 65-13 Scrotal involvement.

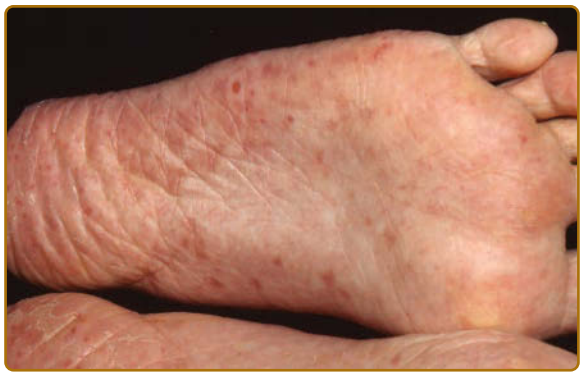

Figure 65-14 Keratoderma blenorrhagicum.

with subsequent scarring. Rarely, female patients can develop erythematous vulvar ulcerative lesions.

Keratoderma blenorrhagicum resembles a pustular psoriasis and is generally found on the palms and soles. Initially it is an erythematous vesicular lesion that develops into pustular keratotic lesions before coalescing into psoriatic-like plaques. These skin lesions occur in 10% to 30% of cases and sometimes be seen in other parts of the body (Fig. 65-14).

A typically self-limited stomatitis may rarely develop. This is characterized by superficial ulcerations or erythematous grayish plaques involving the buccal mucosa, palate, and tongue. These are painless, though they may bleed.

Psoriatic-like nail lesions may develop with subungual accumulation of debris and potential abscess formation. Onycholysis, nail pitting, transverse ridging, or periungual scaling can be seen in the minority of patients.

MUSCULOSKELETAL

The typical pattern of joint involvement is an asymmetric peripheral oligoarthritis that may also involve the axial skeleton with the symptoms of inflammatory back and buttock pain.[87] These axial symptoms manifest with spinal stiffness and pain early in the morning and after periods of prolonged rest, as a result of inflammation involving the spine and sacroiliac joints. The lumbar spine is more frequently involved than the cervical and thoracic spine. Although an oligoarthritis in the lower extremities is the most common pattern of peripheral joint involvement, there also may be a monoarticular or polyarticular presentation.

ENTHESITIS

As described in PsA, enthesitis includes inflammation of tendons, fascia, and ligaments with a predilection for where these structures insert onto bone. This is a common finding in all forms of spondyloarthritis. In ReA, swelling and discomfort of the heel ("Lover's heel") results from Achilles tendon involvement (Fig. 65-15). With inflammation of the plantar fascial insertion site, patients will describe the early morning posterior foot when first getting out of bed.

Figure 65-15 Enthesitis of left Achilles tendon ("Lover's heel").

DACTYLITIS

As described above, this is the result of enthesitis involving the toes and fingers leading to a diffuse swelling of the entire digit, sometimes referred to as a "sausage digit." Seen predominately in SpA, this also has been described in sarcoidosis and polyarticular gout.[88]

OCULAR

Although the original description of ReA included conjunctivitis, other forms of inflammatory eye disease can develop, including keratitis, scleritis, episcleritis, and iritis. Presenting symptoms typically include photophobia and visual clouding from inflammatory cells in the anterior chamber. This can be a relapsing condition leading to a chronic uveitis with visual loss.

CARDIAC

Cardiac involvement with aortic valvular inflammation is rare. This can lead to aortic insufficiency and has been described in both the acute and chronic settings.[89] Heart block may also develop if there is involvement of the atrioventricular node or conducting pathway.

GENETICS

Genetic susceptibility appears to play a role in ReA.[90] Similar to the other forms of spondyloarthritis, HLA-B27 is seen as a risk factor with studies suggesting, depending in part on the background genetic prevalence of HLA-B27, that up to 30% to 40% of patients with ReA are positive for this antigen. Given that this haplotype is seen in 7% to 9% of the white population, there is a greater prevalence of ReA in this group compared with

other ethnic populations such as Asians with a lower prevalence of HLA-B27. Multiple studies demonstrate that HLA-B27-positive patients have more severe symptoms and are more likely to develop chronic disease.

RISK FACTORS

In addition to the genetic susceptibility, the infectious agents most commonly implicated in ReA are the GI pathogens (*Yersinia*, *Shigella*, *Salmonella*, *Campylobacter*, and *C. difficile*) as well as venereal urogenital infection with *C. trachomatis*.[91,92] It also has been described with *Chlamydia pneumoniae*, *Ureaplasma urealyticum*, and intravesicular Bacille Calmette-Guérin.

DIAGNOSIS

There are no standardized criteria for ReA that have been validated. In 1995, the Third International Workshop on Reactive Arthritis established criteria for diagnosing ReA.[93] These criteria are:

- The arthritis should predominantly involve the lower limb, involve one or only a few joints, and not equally involve both sides of the body (asymmetric).
- There should be evidence or a history of preceding infection. Although it is ideal to have a culture that is positive for an infectious agent that is recognized to be associated with this condition, if the patient has documented diarrhea or urethritis in the prior 4 weeks, laboratory confirmation is not required.
- The patient should not have evidence that the joint itself is infected (ie, septic arthritis). Also, other causes of monoarthritis (such as gout) or oligoarthritis (such as rheumatoid arthritis) should be ruled out.

LABORATORY FINDINGS

There are no definitive laboratory tests available to diagnosis ReA. Although nonspecific acute-phase reactants (eg, erythrocyte sedimentation rate, C-reactive protein, platelet count) may be elevated, there is no association with known autoantibodies such as rheumatoid factor or antinuclear antibody. The presence of the HLA-B27 haplotype can be seen in up to half of the patients who develop sacroiliitis. Its presence is more helpful in suggesting a prognosis of greater chronicity than in establishing the diagnosis, given the background prevalence of up to 8% HLA-B27 positivity in asymptomatic individuals.

Synovial fluid analysis of an involved joint typically show evidence of sterile inflammation with 4,000 to 50,000 white blood cells per microliter with a polymorphonuclear cell predominance. Crystal analysis is negative as is Gram stain and microbial culture.

Given the association with precedent GI and urogenital infections, it is important to determine if there is ongoing infection. With symptoms of urethritis, appropriate cultures should be obtained for *C. trachomatis*.[94] For gastroenteritis, cultures for active disease or serologic testing can be obtained for *Shigella*, *Salmonella*, *Yersinia*, *Campylobacter*, and *C. difficile*. Serologic testing for antibodies to these causative organisms is not reliable.

IMAGING

Plain radiographic findings develop in the minority of patients with ReA, typically only after months of ongoing inflammation. Axial imaging can demonstrate sacroiliac erosions that are frequently unilateral.[95] Similar to other forms of spondyloarthritis, there also can be formation of syndesmophytes where the longitudinal spinal ligaments calcify, leading to ankyloses and the development of a "bamboo spine." Periosteal inflammation may develop in the involved peripheral joints, leading to a "whiskering" appearance along with bone erosions.

DIFFERENTIAL DIAGNOSIS

Other infectious etiologies must be considered. These include disseminated gonococcal infection, Lyme disease, and subacute bacterial endocarditis. These present frequently with an oligoarthritis and different skin manifestations. Viral infections such as HIV and parvovirus B19 will present as a polyarthritis. Septic arthritis is generally a monoarthritis in which the infectious agent can be cultured directly from the joint. Arthrocentesis demonstrates highly inflamed synovial fluid, typically greater than 50,000 leukocytes/μL with neutrophilic predominance. A Gram stain may visualize the organism, and the culture will be positive. With ReA, the synovial fluid has a lower leukocyte count with a sterile culture.

Microcrystalline disease in the form of gout or pseudogout generally presents with a severe monoarthritis or more rarely as an oligoarthritis. Arthrocentesis demonstrates highly inflammatory synovial fluid with the diagnostic findings of monosodium urate crystals in gout and calcium pyrophosphate dehydrate crystals in pseudogout.

The articular manifestation of systemic lupus erythematosus and rheumatoid arthritis is generally quite distinct from ReA in that these conditions usually present with a symmetric and progressive small joint polyarthritis. The characteristic serologies, rheumatoid factor and anticyclic citrullinated peptide in rheumatoid arthritis and antinuclear antibody in lupus, are typically not seen in ReA. Other forms of SpA (PsA, arthritis of inflammatory bowel disease and AS) may mimic ReA with the presence of oligoarthritis, enthesitis, dactylitis, and the presence of HLA-B27.

TREATMENT

ANTIBIOTICS

Given the correlation of specific infections with the subsequent development of ReA, it is understandable that treating any underlying infection is often attempted. In most cases the underlying infection is self-limited and can no longer be identified. If the inciting infectious agent can be determined, it must be treated aggressively with antibiotics. In the case of infection with *C. trachomatis*, the appropriate partners should be treated as well. There is no convincing evidence to support the long-term use of antibiotics in patients with ongoing synovitis.[96]

NONSTEROIDAL ANTIINFLAMMATORY DRUGS

In the acute setting, a symptomatic approach with nonsteroidal antiinflammatory drugs (NSAIDs) is appropriate initial therapy for both antiinflammatory and analgesic effects, especially given that the natural history of many of the symptoms of acute ReA is self-limiting. Various preparations have been studied at prescription strength.[90] Appropriate caution should be used in patients with underlying renal or hepatic insufficiency and in those with GI side effects.

CORTICOSTEROIDS

When ReA involves only a few joints, intraarticular injection of corticosteroids can be administered to provide short-term relief of joint inflammation. For more involved articular inflammation, systemic steroid administration can be considered, though this rarely provides sufficient benefit to the symptoms of axial inflammation.

Topical corticosteroids are also used as initial treatment of many of the extraarticular features of ReA, including inflammatory eye disease along with the cutaneous manifestations of keratoderma blenorrhagicum and circinate balanitis. Other treatments for these cutaneous manifestations are similar to what has been used for cutaneous psoriasis including keratolytics, coal tar, and phototherapy, with etretinate and oral methotrexate being reserved for more severe cases.

DISEASE-MODIFYING ANTIRHEUMATIC DRUGS

In patients who do not respond to NSAIDs and corticosteroids, several DMARDs have been used in the treatments of ReA. These include sulfasalazine, methotrexate, azathioprine, and cyclosporine. In chronic ReA, sulfasalazine also has been shown in clinical trials to provide marginal benefit in overall response.[97] There have been no such trials conducted for methotrexate, azathioprine, and cyclosporine though there are numerous case reports suggesting benefit with peripheral arthritis.

With the remarkable success of biologic therapies, especially TNF inhibitors, in other forms of spondyloarthritis (namely AS and PsA) their use has been reported. Several case reports along with an open-label study indicate there may be clinical benefit with these drugs in the treatment of ReA, though no randomized controlled studies have been conducted.[98,99]

PROGNOSIS

Although the majority of patients with ReA have a self-limited course within a few months of onset of the condition, relapses can develop leading to a chronic course manifested by recurrent uveitis, urethritis or erosive arthritis.

CONCLUSION

Unlike the other forms of SpA, the etiologic triggers of ReA are well described. While the association with specific infectious agents is undeniable, it is also clear that the involved articular and extraarticular tissues remain culture-free. The diagnosis, in the absence of any available definitive testing, remains to be established on clinical grounds. Fortunately, the natural history in the majority of cases is self-limited. The cornerstone of therapy remains suppression of inflammation in a supportive fashion.

REFERENCES

1. Moll JM. Psoriatic arthritis. *Br J Rheumatol.* 1984; 23(4): 241-244.
2. Pasero G, Marson P. The antiquity of psoriatic arthritis. *Clin Exp Rheumatol.* 2006;24(4):351-353.
3. Moll JM, Wright V. Psoriatic arthritis. *Semin Arthritis Rheum.* 1973;3(1):55-78.
4. Taylor W, Gladman D, Helliwell P, et al. Classification criteria for psoriatic arthritis: development of new criteria from a large international study. *Arthritis Rheum.* 2006;54(8):2665-2673.
5. Ogdie A, Weiss P. The epidemiology of psoriatic arthritis. *Rheum Dis Clin North Am.* 2015;41(4):545-568.
6. Spelman L, Su JC, Fernandez-Penas P, et al. Frequency of undiagnosed psoriatic arthritis among psoriasis patients in Australian dermatology practice. *J Eur Acad Dermatol Venereol.* 2015;29(11):2184-2191.
7. Yang Q, Qu L, Tian H, et al. Prevalence and characteristics of psoriatic arthritis in Chinese patients with psoriasis. *J Eur Acad Dermatol Venereol.* 2011;25(12): 1409-1414.
8. Mease PJ, Gladman DD, Papp KA, et al. Prevalence of rheumatologist-diagnosed psoriatic arthritis in patients with psoriasis in European/North American dermatology clinics. *J Am Acad Dermatol.* 2013;69(5): 729-735.

9. Haroon M, Kirby B, FitzGerald O. High prevalence of psoriatic arthritis in patients with severe psoriasis with suboptimal performance of screening questionnaires. *Ann Rheum Dis.* 2013;72(5):736-740.
10. Villani AP, Rouzaud M, Sevrain M, et al. Prevalence of undiagnosed psoriatic arthritis among psoriasis patients: systematic review and meta-analysis. *J Am Acad Dermatol.* 2015;73(2):242-248.
11. Eder L, Haddad A, Rosen CF, et al. The incidence and risk factors for psoriatic arthritis in patients with psoriasis: a prospective cohort study. *Arthritis Rheumatol.* 2016;68(4):915-923.
12. Wilson FC, Icen M, Crowson CS, et al. Incidence and clinical predictors of psoriatic arthritis in patients with psoriasis: a population-based study. *Arthritis Rheum.* 2009;61(2):233-239.
13. McHugh NJ. Early psoriatic arthritis. *Rheum Dis Clin North Am.* 2015;41(4):615-622.
14. Choi JW, Kim BR, Seo E, et al. Identification of nail features associated with psoriasis severity. *J Dermatol.* 2017;44(2):147-153.
15. Jadon DR, Sengupta R, Nightingale A, et al. Axial disease in psoriatic arthritis study: defining the clinical and radiographic phenotype of psoriatic spondyloarthritis. *Ann Rheum Dis.* 2017;76(4):701-707.
16. Eder L, Polachek A, Rosen CF, et al. The development of PsA in patients with psoriasis is preceded by a period of non-specific musculoskeletal symptoms: a prospective cohort study. *Arthritis Rheumatol.* 2017;69(3):622-629.
17. Helliwell PS, Hetthen J, Sokoll K, et al. Joint symmetry in early and late rheumatoid and psoriatic arthritis: comparison with a mathematical model. *Arthritis Rheum.* 2000;43(4):865-871.
18. Cresswell L, Chandran V, Farewell VT, et al. Inflammation in an individual joint predicts damage to that joint in psoriatic arthritis. *Ann Rheum Dis.* 2011;70(2):305-308.
19. Ranza R, Carneiro S, Qureshi AA, et al. Prevalence of psoriatic arthritis in a large cohort of Brazilian patients with psoriasis. *J Rheumatol.* 2015;42(5):829-834.
20. Gladman DD, Ziouzina O, Thavaneswaran A, et al. Dactylitis in psoriatic arthritis: prevalence and response to therapy in the biologic era. *J Rheumatol.* 2013;40(8):1357-1359.
21. Gladman DD. Clinical features and diagnostic considerations in psoriatic arthritis. *Rheum Dis Clin North Am.* 2015;41(4):569-579.
22. Helliwell PS, Porter G, Taylor WJ. Polyarticular psoriatic arthritis is more like oligoarticular psoriatic arthritis, than rheumatoid arthritis. *Ann Rheum Dis.* 2007;66(1):113-117.
23. Yamamoto T, Ohtsuki M, Sano S, et al. Epidemiological analysis of psoriatic arthritis patients in Japan. *J Dermatol.* 2016;43(10):1193-1196.
24. Brockbank JE, Stein M, Schentag CT, et al. Dactylitis in psoriatic arthritis: a marker for disease severity? *Ann Rheum Dis.* 2005;64(2):188-190.
25. Geijer M, Lindqvist U, Husmark T, et al. The Swedish Early Psoriatic Arthritis Registry 5-year followup: substantial radiographic progression mainly in men with high disease activity and development of dactylitis. *J Rheumatol.* 2015;42(11):2110-2117.
26. McGonagle D, Lories RJ, Tan AL, et al. The concept of a "synovio-entheseal complex" and its implications for understanding joint inflammation and damage in psoriatic arthritis and beyond. *Arthritis Rheum.* 2007;56(8):2482-2491.
27. Benjamin M, McGonagle D. Histopathologic changes at "synovio-entheseal complexes" suggesting a novel mechanism for synovitis in osteoarthritis and spondylarthritis. *Arthritis Rheum.* 2007;56(11):3601-3609.
28. Polachek A, Li S, Chandran V, et al. Clinical enthesitis in a prospective longitudinal psoriatic arthritis cohort: incidence, prevalence, characteristics and outcome. *Arthritis Care Res (Hoboken).* 2017;69(11):1685-1691.
29. Naredo E, Moller I, de Miguel E, et al. High prevalence of ultrasonographic synovitis and enthesopathy in patients with psoriasis without psoriatic arthritis: a prospective case-control study. *Rheumatology (Oxford).* 2011;50(10):1838-1848.
30. Aydin SZ, Castillo-Gallego C, Ash ZR, et al. Ultrasonographic assessment of nail in psoriatic disease shows a link between onychopathy and distal interphalangeal joint extensor tendon enthesopathy. *Dermatology.* 2012;225(3):231-235.
31. Gladman DD, Brubacher B, Buskila D, et al. Differences in the expression of spondyloarthropathy: a comparison between ankylosing spondylitis and psoriatic arthritis. *Clin Invest Med.* 1993;16(1):1-7.
32. Helliwell PS, Hickling P, Wright V. Do the radiological changes of classic ankylosing spondylitis differ from the changes found in the spondylitis associated with inflammatory bowel disease, psoriasis, and reactive arthritis? *Ann Rheum Dis.* 1998;57(3):135-140.
33. Lambert JR, Wright V. Eye inflammation in psoriatic arthritis. *Ann Rheum Dis.* 1976;35(4):354-356.
34. Murray PI, Rauz S. The eye and inflammatory rheumatic diseases: the eye and rheumatoid arthritis, ankylosing spondylitis, psoriatic arthritis. *Best Pract Res Clin Rheumatol.* 2016;30(5):802-825.
35. Abbouda A, Abicca I, Fabiani C, et al. Psoriasis and psoriatic arthritis-related uveitis: different ophthalmological manifestations and ocular inflammation features. *Semin Ophthalmol.* 2017;32(6):715-720.
36. Egeberg A, Khalid U, Gislason GH, et al. Association of psoriatic disease with uveitis: a Danish nationwide cohort study. *JAMA Dermatol.* 2015;151(11):1200-1205.
37. Paiva ES, Macaluso DC, Edwards A, et al. Characterisation of uveitis in patients with psoriatic arthritis. *Ann Rheum Dis.* 2000;59(1):67-70.
38. Egeberg A, Mallbris L, Warren RB, et al. Association between psoriasis and inflammatory bowel disease: a Danish nationwide cohort study. *Br J Dermatol.* 2016;175(3):487-492.
39. Li WQ, Han JL, Chan AT, et al. Psoriasis, psoriatic arthritis and increased risk of incident Crohn's disease in US women. *Ann Rheum Dis.* 2013;72(7):1200-1205.
40. Scarpa R, Manguso F, D'Arienzo A, et al. Microscopic inflammatory changes in colon of patients with both active psoriasis and psoriatic arthritis without bowel symptoms. *J Rheumatol.* 2000;27(5):1241-1246.
41. Polachek A, Touma Z, Anderson M, et al. Risk of cardiovascular morbidity in patients with psoriatic arthritis: a meta-analysis of observational studies. *Arthritis Care Res (Hoboken).* 2017;69(1):67-74.
42. Eder L, Wu Y, Chandran V, et al. Incidence and predictors for cardiovascular events in patients with psoriatic arthritis. *Ann Rheum Dis.* 2016;75(9):1680-1686.
43. Agca R, Heslinga SC, Rollefstad S, et al. EULAR recommendations for cardiovascular disease risk management in patients with rheumatoid arthritis and other forms of inflammatory joint disorders: 2015/2016 update. *Ann Rheum Dis.* 2017;76(1):17-28.
44. Husni ME. Comorbidities in psoriatic arthritis. *Rheum Dis Clin North Am.* 2015;41(4):677-698.

45. Eder L, Thavaneswaran A, Chandran V, et al. Obesity is associated with a lower probability of achieving sustained minimal disease activity state among patients with psoriatic arthritis. *Ann Rheum Dis.* 2015;74(5):813-817.
46. Hojgaard P, Glintborg B, Kristensen LE, et al. The influence of obesity on response to tumour necrosis factor-alpha inhibitors in psoriatic arthritis: results from the DANBIO and ICEBIO registries. *Rheumatology (Oxford).* 2016;55(12):2191-2199.
47. Di Minno MN, Peluso R, Iervolino S, et al. Weight loss and achievement of minimal disease activity in patients with psoriatic arthritis starting treatment with tumour necrosis factor alpha blockers. *Ann Rheum Dis.* 2014;73(6):1157-1162.
48. Moll JM, Wright V. Familial occurrence of psoriatic arthritis. *Ann Rheum Dis.* 1973;32(3):181-201.
49. Eder L, Chandran V, Pellet F, et al. Human leucocyte antigen risk alleles for psoriatic arthritis among patients with psoriasis. *Ann Rheum Dis.* 2012;71(1):50-55.
50. Winchester R, Minevich G, Steshenko V, et al. HLA associations reveal genetic heterogeneity in psoriatic arthritis and in the psoriasis phenotype. *Arthritis Rheum.* 2012;64(4):1134-1144.
51. Stuart PE, Nair RP, Tsoi LC, et al. Genome-wide association analysis of psoriatic arthritis and cutaneous psoriasis reveals differences in their genetic architecture. *Am J Hum Genet.* 2015;97(6):816-836.
52. Budu-Aggrey A, Bowes J, Loehr S, et al. Replication of a distinct psoriatic arthritis risk variant at the IL23R locus. *Ann Rheum Dis.* 2016;75(7):1417-1418.
53. Bowes J, Loehr S, Budu-Aggrey A, et al. PTPN22 is associated with susceptibility to psoriatic arthritis but not psoriasis: evidence for a further PsA-specific risk locus. *Ann Rheum Dis.* 2015;74(10):1882-1885.
54. Bowes J, Budu-Aggrey A, Huffmeier U, et al. Dense genotyping of immune-related susceptibility loci reveals new insights into the genetics of psoriatic arthritis. *Nat Commun.* 2015;6:6046.
55. Thorarensen SM, Lu N, Ogdie A, et al. Physical trauma recorded in primary care is associated with the onset of psoriatic arthritis among patients with psoriasis. *Ann Rheum Dis.* 2017;76(3):521-525.
56. Li W, Han J, Qureshi AA. Obesity and risk of incident psoriatic arthritis in US women. *Ann Rheum Dis.* 2012;71(8):1267-1272.
57. Love TJ, Zhu Y, Zhang Y, et al. Obesity and the risk of psoriatic arthritis: a population-based study. *Ann Rheum Dis.* 2012;71(8):1273-1277.
58. Li W, Han J, Qureshi AA. Smoking and risk of incident psoriatic arthritis in US women. *Ann Rheum Dis.* 2012;71(6):804-808.
59. Tillett W, Jadon D, Shaddick G, et al. Smoking and delay to diagnosis are associated with poorer functional outcome in psoriatic arthritis. *Ann Rheum Dis.* 2013;72(8):1358-1361.
60. Eder L, Shanmugarajah S, Thavaneswaran A, et al. The association between smoking and the development of psoriatic arthritis among psoriasis patients. *Ann Rheum Dis.* 2012;71(2):219-224.
61. De Wilde K, Martens A, Lambrecht S, et al. A20 inhibition of STAT1 expression in myeloid cells: a novel endogenous regulatory mechanism preventing development of enthesitis. *Ann Rheum Dis.* 2017;76(3):585-592.
62. Manel N, Unutmaz D, Littman DR. The differentiation of human T(H)-17 cells requires transforming growth factor-beta and induction of the nuclear receptor RORgammat. *Nat Immunol.* 2008;9(6):641-649.
63. Sherlock JP, Joyce-Shaikh B, Turner SP, et al. IL-23 induces spondyloarthropathy by acting on ROR-gammat+ CD3+CD4-CD8- entheseal resident T cells. *Nat Med.* 2012;18(7):1069-1076.
64. Barnas JL, Ritchlin CT. Etiology and pathogenesis of psoriatic arthritis. *Rheum Dis Clin North Am.* 2015;41(4):643-663.
65. Nestle FO, Kaplan DH, Barker J. Psoriasis. *N Engl J Med.* 2009;361(5):496-509.
66. Arakawa A, Siewert K, Stohr J, et al. Melanocyte antigen triggers autoimmunity in human psoriasis. *J Exp Med.* 2015;212(13):2203-2212.
67. Haroon M, Gallagher P, FitzGerald O. Diagnostic delay of more than 6 months contributes to poor radiographic and functional outcome in psoriatic arthritis. *Ann Rheum Dis.* 2015;74(6):1045-1050.
68. Husni ME, Meyer KH, Cohen DS, et al. The PASE questionnaire: pilot-testing a psoriatic arthritis screening and evaluation tool. *J Am Acad Dermatol.* 2007;57(4):581-587.
69. Dominguez PL, Husni ME, Holt EW, et al. Validity, reliability, and sensitivity-to-change properties of the psoriatic arthritis screening and evaluation questionnaire. *Arch Dermatol Res.* 2009;301(8):573-579.
70. Gladman DD, Schentag CT, Tom BD, et al. Development and initial validation of a screening questionnaire for psoriatic arthritis: the Toronto Psoriatic Arthritis Screen (ToPAS). *Ann Rheum Dis.* 2009;68(4):497-501.
71. Tinazzi I, Adami S, Zanolin EM, et al. The early psoriatic arthritis screening questionnaire: a simple and fast method for the identification of arthritis in patients with psoriasis. *Rheumatology (Oxford).* 2012;51(11):2058-2063.
72. Coates LC, Kavanaugh A, Mease PJ, et al. Group for research and assessment of psoriasis and psoriatic arthritis 2015 treatment recommendations for psoriatic arthritis. *Arthritis Rheumatol.* 2016;68(5):1060-1071.
73. Tillett W, Shaddick G, Jobling A, et al. Effect of anti-TNF and conventional synthetic disease-modifying anti-rheumatic drug treatment on work disability and clinical outcome in a multicentre observational cohort study of psoriatic arthritis. *Rheumatology (Oxford).* 2017;56(4):603-612.
74. Orbai AM, de Wit M, Mease P, et al. International patient and physician consensus on a psoriatic arthritis core outcome set for clinical trials. *Ann Rheum Dis.* 2017;76(4):673-680.
75. Lebwohl MG, Kavanaugh A, Armstrong AW, et al. US Perspectives in the management of psoriasis and psoriatic arthritis: patient and physician results from the population-based Multinational Assessment of Psoriasis and Psoriatic Arthritis (MAPP) Survey. *Am J Clin Dermatol.* 2016;17(1):87-97.
76. Gossec L, Coates LC, de Wit M, et al. Management of psoriatic arthritis in 2016: a comparison of EULAR and GRAPPA recommendations. *Nat Rev Rheumatol.* 2016;12(12):743-750.
77. Kingsley GH, Kowalczyk A, Taylor H, et al. A randomized placebo-controlled trial of methotrexate in psoriatic arthritis. *Rheumatology (Oxford).* 2012;51(8):1368-1377.
78. Chandran V, Schentag CT, Gladman DD. Reappraisal of the effectiveness of methotrexate in psoriatic arthritis: results from a longitudinal observational cohort. *J Rheumatol.* 2008;35(3):469-471.
79. Baranauskaite A, Raffayova H, Kungurov NV, et al. Infliximab plus methotrexate is superior to methotrexate alone in the treatment of psoriatic arthritis in methotrexate-naive patients: the RESPOND study. *Ann Rheum Dis.* 2012;71(4):541-548.

80. Behrens F, Finkenwirth C, Pavelka K, et al. Leflunomide in psoriatic arthritis: results from a large European prospective observational study. *Arthritis Care Res (Hoboken)*. 2013;65(3):464-470.
81. Coates LC, Moverley AR, McParland L, et al. Effect of tight control of inflammation in early psoriatic arthritis (TICOPA): a UK multicentre, open-label, randomised controlled trial. *Lancet*. 2015;386(10012):2489-2498.
82. Reiter H. Uber eine bisher unerkannte Spirochatenin-fektion (Spirochetosis arthritica). *Dtsch Med Wochensohr.* 1916;42:1535.
83. Fiessinger M, Leroy E. Contribution a l'etude d'une epidemie de dysenterie dans le somme. *Bull Mem Soc Med Hop Paris.* 1916;40:2030.
84. Rich E, Hook EW 3rd, Alarcón GS, et al. Reactive arthritis in patients attending and urban sexually transmitted disease clinic. *Arthritis Rheum.* 1996;39:1172.
85. Townes JM, Deodhar AA, Laine ES, et al. Reactive arthritis following culture-confirmed infections with bacterial enteric pathogens in Minnesota and Oregon: a population-based study. *Ann Rheum Dis.* 2008; 67(12):1689.
86. Carter JD, Hudson AP. Reactive arthritis: clinical aspects and medical management. *Rheum Dis Clin North Am.* 2009;35:21.
87. Leirisalo-Repo M. Reactive arthritis. *Scand J Rheumatol.* 2005;34:251.
88. Rothschild BM, Pingitore C, Eaton M. Dactylitis: implications for clinical practice. *Semin Arthritis Rheum.* 1998;28:41.
89. Brown LE, Forfia P, Flynn JA. Aortic insufficiency in a patient with reactive arthritis: case report and review of the literature. *HSS J.* 2011;7(2):187.
90. Hannu T. Reactive arthritis. *Best Pract Res Clin Rheumatol.* 2011;25(3):347.
91. Carter JD, Inman RD. Chlamydia-induced reactive arthritis: hidden in plain sight? *Best Pract Res Clin Rheumatol.* 2011;25(3):359.
92. Kvien TK, Glennås A, Melby K, et al. Reactive arthritis: incidence, triggering agents and clinical presentation. *J Rheumatol.* 1994;21(1):115-122.
93. Kingsley G, Sieper J. Third international workshop on reactive arthritis. 23-26 September 1995, Berlin, Germany. Report and abstracts. *Ann Rheum Dis.* 1996;55: 564-584.
94. Fendler C, Laitko S, Sörensen H, et al. Frequency of triggering bacteria in patients with reactive arthritis and undifferentiated oligoarthritis and the relative importance of the tests used for diagnosis. *Ann Rheum Dis.* 2001;60(4):337-343.
95. Ozgül A, Dede I, Taskaynatan MA, et al. Clinical presentations of chlamydial and non-chlamydial reactive arthritis. *Rheumatol Int.* 2006;26(10):879-885.
96. Kvien TK, Gaston JS, Bardin T, et al. Three month treatment of reactive arthritis with azithromycin: a EULAR double blind, placebo controlled study. *Ann Rheum Dis.* 2004;63(9):1113-1119.
97. Clegg DO, Reda DJ, Weisman MH, et al. Comparison of sulfasalazine and placebo in the treatment of reactive arthritis. *Arthritis Rheum.* 1996;39(12):2021-2027.
98. Meyer A, Chatelus E, Wendling D, et al. Safety and efficacy of anti-tumor necrosis factorαtherapy in ten patients with recent-onset refractory reactive arthritis. *Arthritis Rheum.* 2011;63(5):1274-1280.
99. Flagg SD, Meador R, Hsia E, et al. Decreased pain and synovial inflammation after etanercept therapy in patients with reactive and undifferentiated arthritis: an open-label trial. *Arthritis Rheum.* 2005;53(4):613-617.

Chapter 66 :: Rheumatoid Arthritis, Juvenile Idiopathic Arthritis, Adult-Onset Still Disease, and Rheumatic Fever

:: Warren W. Piette

This chapter discusses common rheumatologic diseases that have predominantly musculoskeletal presentations; however, all of these conditions have cutaneous manifestations.

RHEUMATOID ARTHRITIS

AT-A-GLANCE

- Affects roughly 1% of the world population.
- Chronic, disfiguring, inflammatory condition.
- Genetics and environment play a role in etiology.
- Symmetric arthritis of the proximal interphalangeal and metacarpophalangeal joints most common.
- Skin findings quite varied, including papules, plaques, and nodules with multiple histologic types, vasculitis/Bywaters lesions, pyoderma gangrenosum/Felty ulcers.
- Treatment based on severity of disease.

Rheumatoid arthritis (RA) is a systemic inflammatory autoimmune disease that is characterized by debilitating chronic, symmetric polyarthritis. Important extraarticular manifestations are many, including, in part, rheumatoid nodules, pyoderma gangrenosum, granulomatous and other skin lesions, vasculitis, and internal organ involvement. The disease process is often progressive, resulting in limitation of joint function, decline in functional status, and possibly premature death. Permanent remission is unusual.

DEFINITIONS

The revised diagnostic criteria approved in 2010 by the board of directors of the American College of Rheumatology and the executive directors of the European League Against Rheumatism focuses on identifying patients earlier in the course of their disease than was allowed by previous criteria.[1] Table 66-1 outlines these revised criteria. Even though cutaneous findings may be a key to diagnosis, none are considered diagnostic as no extraarticular physical findings are included in the criteria.

EPIDEMIOLOGY

RA has an annual incidence of approximately 0.4 per 1000 in females and 0.2 per 1000 in males, with a prevalence of approximately 0.4% to 1% of the adult population in diverse populations worldwide.[2-4] RA has a peak onset of approximately 50 years of age.[2,3]

CLINICAL FEATURES

RA often begins with general constitutional symptoms such as fatigue, anorexia, vague musculoskeletal complaints, and generalized weakness. It may be weeks or months before the characteristic synovitis presents. It is in these early stages that diagnosis is most difficult, but early diagnosis and treatment are essential because most joint damage occurs early in the disease process. The American College of Rheumatology guidelines proposed in 1987 were thought to be too insensitive to recognize RA during this critical early phase, leading to the revised criteria in 2010 (see Table 66-1).[1]

CUTANEOUS FINDINGS

Rheumatoid Nodules and Nodulosis: The most common dermatologic finding in RA has been the rheumatoid nodule, although as patients are treated earlier and more aggressively, this cutaneous finding may become less common. Classically a subcutaneous nodule, the rheumatoid nodule occurs in approximately 25% of patients with RA (Fig. 66-1A).[5-8] More than 90% of patients with rheumatoid nodules have seropositive RA. The usual location is over pressure points such as the olecranon, the extensor surface of the forearms, and the Achilles tendon, but they have been described in almost every location, including viscera.[7,8] The main histologic findings (Fig. 66-1B) are palisaded granulomas in the deep dermis or subcutaneous tissues with fibrinoid degeneration of collagen, a multitude of neutrophils and neutrophilic dust, with surrounding fibrosis and proliferation of vessels. The main differential diagnoses histopathologically include subcutaneous granuloma annulare, necrobiosis lipoidica, foreign-body or infectious granulomatous reaction, and epithelioid sarcoid. Although rheumatoid nodules are benign, they can lead to complications, including ulceration, infection, joint effusion

TABLE 66-1

2010 American College of Rheumatology/European League Against Rheumatism Classification Criteria for Arthritis[a]

Target population: patients who (a) have at least 1 joint with definite clinical synovitis (swelling), (b) with the synovitis not better explained by another disease.[a]

CLASSIFICATION CRITERIA FOR RHEUMATOID ARTHRITIS (RA) (ADD SCORE OF CATEGORIES A TO D; SCORE ≥6/10 IS NEEDED FOR DEFINITE RA CLASSIFICATION)	SCORE
A. Joint Involvement: tender or swollen joint on examination, ***excluding*** distal IP joints, first MCP joints, and first MTP joints	
1 large joint (shoulder, elbow, hip, knee, or ankle)	0
2 to 10 large joints	1
1 to 3 small joints (MCP, proximal IP, 2nd to 5th MTP, thumb IP, wrists) with or without large joints	2
4-10 small joints with or without large joints	3
>10 joints (must have at least 1 small joint; other joints can include joints not specifically listed elsewhere, eg, TM, AC, SC)	5
B. Serology (at least 1 test result is needed for classification)	
Negative RF and negative ACPA	0
Low-positive RF or low-positive ACPA[b]	2
High-positive RF or high-positive ACPA[b]	3
C. Acute-phase reactants (at least 1 result needed for classification)	
Normal CRP *and* normal ESR	0
Abnormal CRP *or* abnormal ESR	1
D. Duration of symptoms[c]	
<6 weeks	0
≥6 weeks	1

[a]Differential diagnosis to exclude other diseases varies by presentation, but may include, for example, systemic lupus erythematosus, psoriatic arthritis, and gout.
[b]Negative = less than upper limits normal (ULN); low-positive = greater than ULN but <3 times ULN; high-positive = >3 times ULN.
[c]Patient self-report of the duration of signs or symptoms of synovitis (eg, pain, swelling, tenderness) of joints that are clinically involved at the time of assessment, regardless of treatment status.
AC, acromioclavicular; ACPA, anticitrullinated protein antibody; CRP, C-reactive protein; ESR, erythrocyte sedimentation rate; IP, interphalangeal; MCP, metacarpophalangeal; MTP, metatarsophalangeal; RF, rheumatoid factor; SC, sternoclavicular; TM, temporomandibular.
Criteria aimed at newly presenting patients. Patients with erosive disease or with longstanding but now inactive disease meeting prior 2010 requirements are considered to have RA.
Modified from Aletaha D, Neogi T, Silman AJ, et al. 2010 Rheumatoid arthritis classification criteria. An American College Rheumatology/European League Against Rheumatism collaborative initiative. *Arthritis Rheum*. 2010;62(9):2569-2581. With permission of John Wiley & Sons. Copyright © 2010, American College of Rheumatology.

(rheumatoid chyliform bursitis), and fistulas (fistulous rheumatism). All conditions may lead to the need for surgical excision, although excision of asymptomatic nodules can itself lead to complications.[5,8]

Rheumatoid nodulosis is the development of rheumatoid nodules in patients without chronic synovitis or radiographic findings, and mild or no systemic manifestations. This involves men predominantly, and

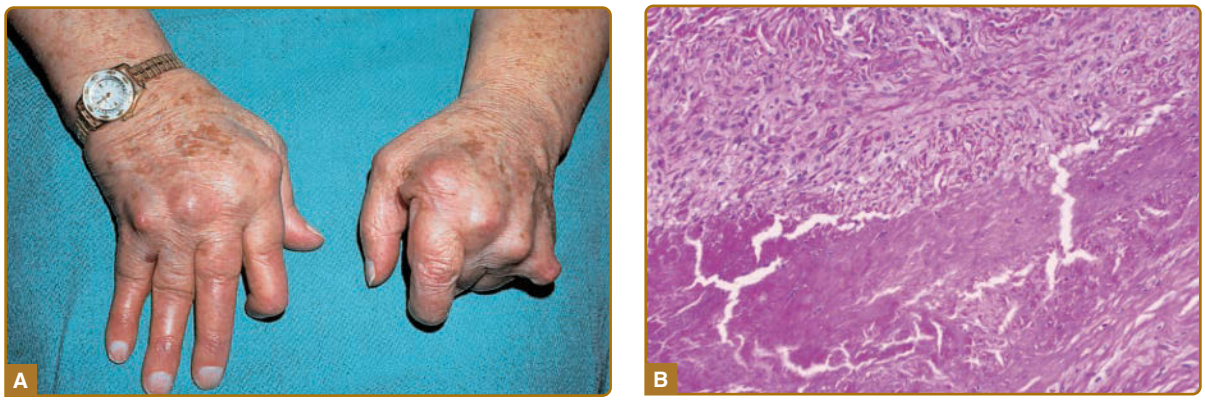

Figure 66-1 Rheumatoid nodules. **A,** Severely affected joints of a patient with rheumatoid arthritis with overlying rheumatoid nodules. **B,** Histopathologically, rheumatoid nodules are palisaded granulomas in the deep reticular dermis surrounding degenerated collagen.

TABLE 66-2
Differential Diagnosis of Rheumatoid Nodules

Consider
- Subcutaneous granuloma annulare
- Pseudorheumatoid nodulosis (children)
- Foreign-body granuloma
- Infectious granuloma
- Sarcoid granuloma
- Myxoid cyst
- Traumatic epidermal cyst
- Xanthoma

Rule Out
- Epithelioid sarcoma
- Fibromatous nodules in Lyme borreliosis

many develop frank RA. In children, similar lesions are termed *pseudorheumatoid nodulosis*. Their distribution differs by localizing over the tibia, the dorsal foot, or scalp. They may be large but there is no systemic disease nor positive serology. Most regress within 2 years; progression to RA is extremely rare.[8] Table 66-2 outlines the differential diagnosis of rheumatoid nodules.

Methotrexate-Related Cutaneous Reactions: Low-dose methotrexate, often used for the treatment of RA, may precipitate erythema in and enlargement of preexisting rheumatoid nodules, known as *accelerated nodulosis*.[5-8] Regression of these changes is expected when the methotrexate dose is decreased or discontinued.

A papular reaction to methotrexate has been reported as a syndrome of clustered, erythematous, indurated papules arising most commonly on the proximal extremities and buttocks.[6] This has been reported not only in patients with RA, but also in association with other diseases, especially collagen vascular diseases. In rare instances, some lesions may develop erosions or surrounding livedo. The histologic pattern seen is mostly a histiocytic infiltrate arranged interstitially between collagen bundles in the dermis, intermixed with a few neutrophils. Small rosettes of histiocytes may surround thick collagen bundles in the reticular dermis.

Yet another possible cutaneous complication of methotrexate therapy (occasionally other immunosuppressive drugs) in RA is the development of Epstein-Barr virus-associated multifocal cutaneous lymphoproliferative disease, which may regress on discontinuation of therapy.[9,10]

Granulomatous Dermatoses (Reactive Granulomatous Dermatitis): Reactive granulomatous dermatitis has been proposed as an inclusive term for the following 3 syndromes: interstitial granulomatous dermatitis (IGD), palisaded neutrophilic and granulomatous dermatitis (PNGD), and interstitial granulomatous drug reaction (IGDR). IGD and PNGD are associated with autoimmune diseases, including RA; IGDR is a drug-associated syndrome that may be included in IGD and PNGD.[11]

PNGD has been reported as Churg-Strauss granuloma, cutaneous extravascular necrotizing granuloma, rheumatoid papules, Winkelmann granuloma, and, by some authors, IGD.[11] It presents as symmetric skin-colored to erythematous smooth, umbilicated, or crusted papules, primarily on elbows and extremities: 51% involve upper extremities, 27% lower extremities, 21% trunk, head, and neck. Less common are urticarial plaques; erythematous nodules with scale; papulonodules; pink-to-red papules and plaques; erythematous edematous plaques; violaceous patches and plaques; annular papules and plaques; annular gyrate plaques; and linear bands.[6,11]

Histopathologically, early features include intense neutrophilic inflammation, karyorrhectic debris, and leukocytoclastic vasculitis. Later findings are piecemeal areas of collagen degeneration and palisades of histiocytes and small granulomas, eventually accompanied by areas of fibrosis.

Spontaneous resolution occurs in 20%, sometimes as quickly as 1 week. Most treatment is directed at underlying disease. Tumor necrosis factor (TNF) inhibitors and allopurinol have been implicated as causes, so stopping them may induce remission. Treatments include intralesional corticosteroid, nonsteroidal anti-inflammatory drugs (NSAIDs), dapsone, colchicine, systemic corticosteroids, oral tacrolimus, and TNF inhibitors. Topical therapy is generally not effective.[6,11]

IGD has been previously reported as IGD with arthritis, IGD with cords and arthritis, linear subcutaneous bands of RA, linear rheumatoid nodules, linear granuloma annulare, railway track dermatitis, and Ackerman syndrome. IGD also has been described in association with a number of disorders, including RA. Usually asymptomatic, this syndrome presents symmetrically on the lateral upper trunk and proximal inner arms and thighs, and occasionally on the buttocks, abdomen, breast, and umbilicus.[6,11] Initially, IGD was reported in patients with inflammatory arthritis and pathognomonic linear bands or cords on the upper trunk. It is now recognized that less than 10% of IGD cases present this way. Other morphologic presentations include erythematous to violaceous patches or plaques; diffuse macular erythema; annular plaques; polycyclic indurated plaques; cockades of color with violaceous centers surrounded by erythema; annular scaly plaques; subcutaneous nodules; large atrophic hyperpigmented plaques; disseminated indurated violaceous papules and plaques; periungual and mucosal erythema; and elbow papules and nodules similar to those of PNGD.[6,11]

Histopathologic findings include a dense, diffuse infiltrate of histiocytes arranged in a band-like configuration in middle or deep reticular dermis. There may be foci of basophilic collagen surrounded by palisaded histiocytes. These cells may also exhibit large and pleomorphic nuclei; scattered mitotic figures are readily seen. Neutrophils and eosinophils may be present, most notably in areas of degenerated collagen. Variably dense interstitial CD68+ epithelioid histiocytes often surround foci of abnormal collagen, which leads to clefting away of the altered collagen and histiocyte section (the "floating sign," reported in 67% of cases). Vasculitis is usually absent. Lymphocytes abutting

epidermis with basal vacuolization is rarely seen, but may distinguish IGDR from pure IGD. Mucin deposition is minimal or absent. Most medications are actually associated with IGDR; previous IGD associations with TNF inhibitors, soy, angiotensin-converting enzyme inhibitors, and furosemide may actually be IGDR. Treatment includes stopping any causative drug and treating underlying disease.

Probably often used interchangeably with IGD, IGDR was reported to present as erythematous to violaceous plaques, often annular, concentrated on inner arms, proximal medial thighs, proximal trunk, and intertriginous sites.[11] Subsequent reports added isolated plaque, erythroderma, subcutaneous nodules on palms and soles, erythema nodosum-like lesions, and scalp, cheeks, and extensor forearms involvement.

Histologic findings are similar to IGD and include diffuse interstitial histiocytes with granulomas, and rare giant cells surrounding piecemeal fragmentation of collagen. Mucin is scant; vasculitis absent. IGDR should include interface dermatitis with basal vacuolar degeneration, areas of dyskeratosis, and prominent tissue eosinophilia. Lymphoid atypia is frequent, with large cells, hyperchromatic nuclei, and occasional convoluted nuclei. Commonly implicated drugs include calcium channel blockers, beta-blockers, lipid-lowering agents, and angiotensin-converting enzyme inhibitors. Treatment involves stopping the drug.

Neutrophilic Dermatoses: Rheumatoid neutrophilic dermatosis is a very rare cutaneous manifestation in patients with severe RA; it was first described by Ackerman in 1978. Lesions are usually chronic, erythematous, and urticaria-like plaques and papules that are sharply marginated (Fig. 66-2A). Histopathologically, these lesions have a dense infiltrate of neutrophils without leukocytoclasia, in the setting of a mixed infiltrate and papillary edema (Fig. 66-2B).[12,13] It may be difficult to differentiate from acute febrile neutrophilic dermatosis (Sweet syndrome) (see Chap. 36). Some authors accept PNGD as a histologic finding consistent with rheumatoid neutrophilic dermatitis.[13] However, in the absence of granuloma formation, it seems reasonable to separate rheumatoid neutrophilic dermatitis from multiple named entities that seem to be now included under the term *IGD*. Five patents have been reported with tense blister formation, typically on the lower extremities in older females.[14]

Autoimmune neutrophilic dermatoses syndrome produces urticarial lesions in association with systemic lupus erythematosus, RA, and secondary Sjögren syndrome, which lesions regress within 24 hours, but unlike urticaria they are typically nonpruritic. Histopathologically, lesions show interstitial and perivascular neutrophilic infiltrate with leukocytoclasia without vasculitis, vacuolar alteration at the dermal–epidermal junction. Remission follows administration of immunomodulating drugs.[15,16] A figurate erythema, consisting of annular lesions, often with vesicles or purpura, with a histology resembling mild Sweet syndrome has been reported as a mostly idiopathic condition, but association with systemic lupus erythematosus (not yet with RA) has been reported.[17]

Patients treated with TNFα inhibitors may develop an eruption that is clinically and histologically indistinguishable from psoriasis. This can occur in those receiving these agents for any condition, but those with RA appear to be at greatest risk. The eruption typically clears with drug cessation, and may or may not reoccur during treatment with other drugs of this class.[6]

VASCULAR MANIFESTATIONS

Rheumatoid Vasculitis: With an estimated annual incidence of less than 1%, this syndrome most often affects men and smokers with longstanding disease, who are seropositive to rheumatoid factor and to citrullinated peptides.[6,18-22] Previously, rheumatoid vasculitis affected 1 in 8 males with RA versus 1 in 38 females; male sex is now associated with an odds ratio of 1.98.[17,19] Smoking remains the most consistently demonstrated environmental risk factor for rheumatoid vasculitis, particularly in male seropositive patients. A declining trend in the incidence of rheumatoid vasculitis was noted beginning in the 1990s and reconfirmed

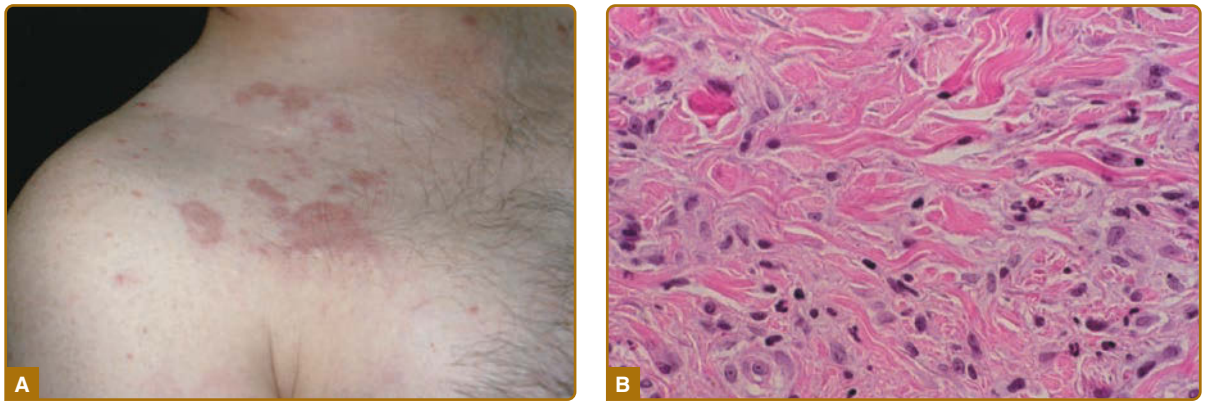

Figure 66-2 Rheumatoid neutrophilic dermatosis. **A,** Lesions are erythematous urticarial papules that often coalesce into plaques in a patient with rheumatoid arthritis. **B,** Histopathologically, there is an interstitial mixed dermal infiltrate that is predominated by neutrophils without leukocytoclasis. This infiltrate is often accompanied by papillary edema.

in newer studies. Population-based data from the Norwich cohort in the United Kingdom noted a drop in the average incidence of rheumatoid vasculitis from 9.1 per million between 1988 and 2002 to 3.9 per million between 2001 and 2010. These declines are largely attributed to improved treatment of RA, roughly coinciding with the advent of biologic response modifiers, but another explanation may be the decline in rates of cigarette smoking.[19,20] There also appears to be a higher risk of rheumatoid vasculitis among RA patients with peripheral vascular disease (odds ratio: 3.98) and cerebrovascular disease (odds ratio: 6.48).[19]

In a large study of rheumatoid vasculitis, the median age of participants at presentation was 63 years and the median duration of RA was 10.8 years. One-third of participants were current smokers. The majority were seropositive and had elevated inflammatory markers.[19] In rheumatoid vasculitis patients, the mean duration between the diagnosis of RA and the onset of vasculitic symptoms was 10 to 14 years, and presentation within the first 5 years of the RA diagnosis is unusual.[19,20] Cutaneous vasculitis was the most common presentation, followed by vasculitic neuropathy. Patients often have rheumatoid nodules, although newer studies find a lower percentage than was previously reported (44% of patients compared with 86%).[19] These observations may be the result of improved control of RA in recent years.

Although severe RA increases the odds of rheumatoid vasculitis, the vasculitis often develops at a time when the inflammatory arthritis has burned out. Despite this, the onset of rheumatoid vasculitis is often heralded by constitutional symptoms (fever, weight loss), an escalation of the acute-phase markers (erythrocyte sedimentation rate and/or C-reactive protein), thrombocytosis, and anemia of chronic disease. Although complement levels are normal or elevated in RA, hypocomplementemia is often seen in patients with rheumatoid vasculitis.

Vasculitis Pathology: Rheumatoid vasculitis primarily affects small- to medium-sized vessels systemically and shares many features with polyarteritis nodosa, albeit without the development of microaneurysms.[20] Histopathologic examination reveals mononuclear or neutrophilic infiltration of the vessel walls and elements of vessel wall destruction (necrosis, leukocytoclasis, and disruption of the elastic laminae).[20] Isolated capillaritis or perivascular infiltrates without vessel wall involvement can be seen in RA, but are not adequate for a histopathologic diagnosis of rheumatoid vasculitis.

Cutaneous Rheumatoid Vasculitis: The skin is involved in 75% to 89% of patients with rheumatoid vasculitis, often as the presenting sign of the condition.[6] Somewhat confusing the interpretation of vasculitis incidence in many studies is the inclusion of purpura, livedo reticularis, atrophie blanche, and ulcers as cutaneous signs of rheumatoid vasculitis, despite the often nonvasculitic histology.[6] Exclusion of nailfold involvement in a recent study found rheumatoid vasculitis involved skin in 65% of patients. Some patients may have nailfold telangiectasias, with minute digital ulcerations or petechiae and digital pulp papules (Bywaters lesions; Fig. 66-3). These papules are a manifestation of mild vasculitis and typically occur without systemic signs of vasculitis.

Figure 66-3 Bywaters lesions. Note the purpuric papule on the dorsal finger.

Pyoderma Gangrenosum and Felty Syndrome Ulcers: Vasculitis, along with certain other extraarticular manifestations of RA (pericarditis, pleuritis, amyloidosis sacculitis) can present as lower-extremity ulcers. However, pyoderma gangrenosum (see Chap. 37) should be suspected if deep liquefying ulcers with a characteristic purple, undermined border occur in patients with RA. The ulcers may occur at any site, but are most common on the lower extremities and abdomen. Pyoderma gangrenosum occurs more frequently and more severely in females and may take years to heal. Leg ulcers may also appear in patients with Felty syndrome, a combination of chronic RA, hypersplenism, and leukopenia (Fig. 66-4).[12] In some instances, the ulcers of Felty syndrome exhibit the same morphologic characteristics and behavior of pyoderma gangrenosum ulcers, suggesting that these ulcers are not necessarily a manifestation of rheumatoid vasculitis.

Figure 66-4 Felty syndrome ulcer. A refractory ulcer on the foot of a patient with rheumatoid arthritis and hypersplenism.

TNF-inhibitor therapy is associated with both onset and improvement of rheumatoid vasculitis. Other vasculitis syndromes, such as cryoglobulinemic vasculitis (see Chap. 144), erythema elevatum diutinum (see Chap. 140), benign cutaneous polyarteritis nodosa, and livedo vasculitis (segmental hyalinizing vasculitis/atrophie blanche; see Chap. 148), and reactive angioendotheliomatosis,[12] also have been described in patients with RA. Treatment with argatroban, an antithrombin agent, in a patient with antiphosphatidylserine prothrombin complex antibodies led to resolution of ulcers refractory to immunosuppressive therapy, consistent with occlusive, rather than vasculitic, mechanisms in some patients. Raynaud phenomenon affects 5% to 17% of RA patients.[7]

Intravascular or Intralymphatic Histiocytosis: Indurated erythema, livedo-like erythema, and papules over the elbows have been reported as clinical findings of intravascular or intralymphatic histiocytosis in RA.[23,24]

OTHER SKIN MANIFESTATIONS

Palmar erythema, erythromelalgia, autoimmune bullous diseases such as epidermolysis bullosa acquisita (see Chap. 56), yellow nail syndrome (see Chap. 91), erythema multiforme (see Chap. 43), erythema nodosum (see Chap. 73), and urticaria (see Chap. 41) also have been reported in patients with RA.[25]

NONCUTANEOUS FINDINGS

In addition to systemic vasculitis, which can affect numerous organ systems, there are multiple nondermatologic extraarticular manifestations of RA. Table 66-3 lists the more common ones.

Articular Manifestations: The articular manifestations of RA relate to an inflammatory synovitis that can affect joints, tendons, and bursae. Synovial inflammation usually results in warmth, but not erythema of the affected area. Significant pain is associated with stretching of the joint capsule. Hand and foot involvement is predominant in most patients. Although the initial manifestations in the hand may be asymmetric, the clinical course subsequently takes on a symmetric and diffuse pattern. The pattern of joint involvement is highly suggestive of the diagnosis with characteristic involvement of the proximal interphalangeal and metacarpophalangeal joints with sparing of the distal interphalangeal joints.

Chronic inflammation may result in irreversible structural damage of the joint, including cartilage destruction and bony erosion. Late structural deformities may result from soft-tissue contractures or from bony ankylosis. Characteristic deformities include radial deviation of the hand with ulnar deviation of the digits, the "swan neck" deformity from hyperextension of the proximal interphalangeal joint and compensatory flexion of the distal interphalangeal joint, and the boutonnière deformity from flexion contracture of the proximal interphalangeal joint and extension of the distal interphalangeal joint. Similar structural deformities can occur in the feet, and all can be debilitating. Involvement of the thoracic and lumbar spine in RA is exceptional. Although the shoulder joint is often affected, it is soft-tissue structures, which include the rotator cuff tendons and muscles and the subacromial bursa, that are usually symptomatic.[26]

TABLE 66-3
Nondermatologic Manifestations of Rheumatoid Arthritis

TYPE	MANIFESTATIONS
Ocular	Keratoconjunctivitis sicca, scleritis, episcleritis, scleromalacia
Renal	Amyloidosis, vasculitis
Hematologic	Anemia, thrombocytosis, lymphadenopathy, Felty syndrome
Neurologic	Entrapment neuropathy, cervical myelopathy, mononeuritis multiplex (from vasculitis), peripheral neuropathy
Lung	Pleural effusions, pulmonary fibrosis, bronchiolitis obliterans, rheumatoid nodules, vasculitis
Cardiac	Pericarditis, premature atherosclerosis, vasculitis, nodules, aortic root dilation

ETIOLOGY AND PATHOGENESIS

An important posttranslational modification of protein is the conversion of arginine to its polar analog, citrulline. This greatly enhances immune recognition of joint-associated proteins, which are selectively targeted by autoreactive T and B cells in patients with RA.[21,22] The selective recognition of citrullinated synovial proteins is important in pathogenesis.[21,22] Anticitrullinated protein antibodies (ACPAs) are of particular interest, as these autoantibodies are highly specific for RA and can be found in approximately 50% of early RA patients. In addition, the presence of anticyclic citrullinated peptide antibodies predicts disease severity and radiologic damage. Therefore, ACPA could also be used as a biomarker for patients with a more-severe disease phenotype to target those patients for more aggressive treatment. In addition, the number of citrullinated antigens identified by ACPA increases exponentially through epitope spreading leading up to disease onset.

It is now known that breaking tolerance to posttranslationally modified proteins in arthritis is not exclusively confined to citrullination. Proteins that have undergone a different type of posttranslational modification are also recognized by autoantibodies. One of these posttranslational processes is carbamylation,

where the amino acid lysine is changed to become homocitrulline. Smoking can enhance carbamylation and extensive carbamylation is especially likely during chronic inflammation. Antibodies to carbamylated proteins were found to be present not only in ACPA+ patients but also in ACPA– RA patients.[21,22]

The progression toward RA almost certainly begins long before the disease manifests as arthritis, and this progression depends on both important genetic factors and less-well-defined environmental factors.[22] Twin studies have shown heritability of RA to be 60%, with the remaining risk presumably a result of environmental factors. More than 100 genetic loci are associated with RA, the most important being within the human leukocyte antigen (HLA) class II region, encoding the HLA-DRB1 molecule. Recent evidence suggests that this locus is associated not with a risk of becoming ACPA+, but rather with the risk of progressing from ACPA+ to ACPA+ RA.

DIAGNOSIS

Several conditions can mimic RA, and must be considered in the differential diagnosis of early disease, such as viral syndromes (especially parvovirus B19, rubella, hepatitides B and C); psoriatic arthritis; polymyalgia rheumatica; remitting seronegative symmetric synovitis with pitting edema; palindromic rheumatism; adult Still disease; systemic lupus erythematosus; gout; multicentric reticulohistiocytosis; and leprosy.[26-28] Table 66-1 lists the diagnostic criteria.

SUPPORTIVE STUDIES AND LABORATORY TESTING

There is no one specific histologic, radiographic, or laboratory test that conclusively permits the diagnosis of RA. Rheumatoid factor, an autoantibody that reacts with the Fc portion of immunoglobulin G, is found in sera of 85% of patients with RA. Rheumatoid factor positivity is not definitive because it can be found in other disease processes, for example, lupus erythematosus, Sjögren/sicca syndrome, myositis, sarcoidosis, liver diseases, pulmonary fibrotic processes, and cryoglobulinemia. It is also found in 3% to 5% of the unaffected population.[29] A false-positive rheumatoid factor can be caused by many factors, including chronic bacterial infections such as infective endocarditis, hepatitis C, tuberculosis, and Lyme disease, as well as by viral diseases such as rubella and infectious mononucleosis.[30,31]

ACPAs are a more specific marker than rheumatoid factor, particularly in early disease where specificity ranges from 94% to 100%, compared to 23% to 94% for rheumatoid factor, with roughly equivalent sensitivities.[32]

Several studies confirm the increased sensitivity of ultrasonography compared with the standard clinical examination to define typical joint or tissue pathologies. Ultrasonography provides detailed information about the status of the synovial membrane, tendons, cartilage, bursae, and cortical bones. Ultrasonography allows the detection and characterization of intraarticular and periarticular inflammatory processes, such as effusion versus synovial hypertrophy, fundamental to the correct interpretation of the pathologic process.[33]

CLINICAL COURSE, PROGNOSIS, AND MANAGEMENT

Because the exact cause of RA is unknown, treatment has been directed against various components of the inflammatory process.[22] In the past, most patients with early disease were started on NSAIDs until joint erosions were evident. Although useful to alleviate symptoms, these medications do not alter disease progression. The genetic susceptibility variants identified as of this writing strongly implicate several immune pathways in the development of RA.[22] In addition, there is already significant overlap between the targets of several approved RA therapies and identified susceptibility genes for RA (cytotoxic T-lymphocyte antigen [CTLA]-4: abatacept; tyrosine kinase [TYK]-2: tofacitinib; interleukin [IL]-6: tocilizumab) demonstrating the potential of genetics not only to identify biologic pathways that lead to RA, but also that these pathways can be targeted and lead to the successful treatment of disease symptoms.

European League Against Rheumatism recommendations for management of RA were updated in 2016.[34] In part, they maintain that rheumatologists are the specialists who should primarily care for patients with RA, that treatment decisions should be shared with the patient, and that treatment decisions should be based on disease activity, progression of structural damage, comorbidities, and safety issues. This new recommendation means that therapy with disease-modifying antirheumatic drugs (DMARDs) should be started as soon as the diagnosis is made, with the aim of sustained remission or low disease activity.[34] Methotrexate should be part of the first treatment strategy unless contraindicated, when leflunomide or sulfasalazine are suggested. Short-term glucocorticoids should be considered when initiating or changing conventional DMARDs. Failure of response or poor prognostic factors should prompt consideration for use of biologic DMARDs, including TNF inhibitors (adalimumab, certolizumab, etanercept, golimumab, and infliximab), a costimulation inhibitor (abatacept), an IL-6 receptor blocker (tocilizumab, possibly sarilumab in the future), IL-6 inhibitors (possibly clazakizumab or sirukumab in the future), an anti–B-cell agent (rituximab), as well as synthetic targeted DMARDs, primarily Janus kinase (JAK) inhibitors, tofacitinib, and perhaps baricitinab.[34-36] Anakinra competitively inhibits IL-1

effects, but is currently thought to be a less-effective biologic DMARD for RA.[37]

Treatment of rheumatoid vasculitis is difficult. Use of hydroxychloroquine and low-dose aspirin is associated with lower odds of developing rheumatoid vasculitis among RA patients, thus conferring a possible protective effect.[20] Despite aggressive use of cyclophosphamide and biologics, rheumatoid vasculitis remains difficult to treat, with high relapse and mortality rates that have not changed in more than 40 years, with 5-year mortality rates ranging from 26% to 60%.[20]

JUVENILE IDIOPATHIC ARTHRITIS

AT-A-GLANCE

- There are multiple forms of juvenile idiopathic arthritis (JIA) (formerly juvenile rheumatoid arthritis).
- The multisystemic form of JIA is often referred to as juvenile Still syndrome (sJIA).
- The eruption, along with fever and arthralgia/arthritis can trigger consideration of this systemic form, and is limited to this form.
- There are more recently recognized variants of the eruption.

Juvenile idiopathic arthritis (JIA) is a group of conditions encompassing all forms of arthritis of unknown etiology lasting for at least 6 weeks and with an onset before 16 years of age.[38] It replaces the previous terms juvenile RA and Still disease, and currently encompasses 7 entities: systemic onset arthritis, oligoarthritis (persistent or extended), rheumatoid factor–negative polyarthritis, rheumatoid factor–positive polyarthritis, psoriatic arthritis, enthesitis-related arthritis, and undifferentiated.[38,39] Of these, only the systemic-onset form (sJIA) and the psoriatic arthritis form have skin findings. The diagnosis of juvenile psoriatic arthritis requires the coexistence of arthritis and a typical psoriatic rash or, when the rash is missing, the presence of arthritis and any 2 of the following: family history of psoriasis in a first-degree relative, dactylitis (sausage-like swelling of individual digits that extends beyond the joint margins), and nail pitting or onycholysis.[38] There is increasing evidence that juvenile psoriatic arthritis is not a homogeneous disease entity, but includes at least 2 distinct subgroups: one shares the same characteristics as early-onset antinuclear antibody–positive JIA (antinuclear antibody positivity bridges several subsets); the other belongs to the spectrum of spondyloarthropathies.[38] As psoriatic skin disease is well characterized elsewhere, this chapter focuses predominantly on sJIA.

EPIDEMIOLOGY

The reported incidence and prevalence of JIA in European and North American populations range from 2 to 20 and from 16 to 150 per 100,000, respectively.[38,40] sJIA accounts for 5% to 15% of children with JIA in North America and Europe.[38] One study of JIA patients over a 53-year period (1960-2013) found no significant change in overall incidence; however, the incidence decreased among females (P = 0.003).[40] A cyclic pattern of incidence was observed, with peaks approximately every 10 years.

CLINICAL FEATURES

sJIA accounts for 5% to 15% of children with JIA in North America and Europe.[38] The Internation League of Associations for Rheumatology criteria for sJIA require the presence of arthritis accompanied or preceded by a documented quotidian fever of at least 2 weeks duration, plus at least 1 of the following: characteristic rash, generalized symmetrical lymphadenopathy, enlargement of liver or spleen, or serositis (pericarditis, pleural or pericardial effusion, [rarely] peritonitis).[38] The fever has a typical intermittent pattern, with 1 or 2 daily spikes, up to 39°C (102.2°F)or higher, followed by rapid return to baseline. The erythematous, salmon pink, evanescent macular rash usually appears with the fever. Arthritis is often symmetrical and polyarticular, but may be absent at onset and develop much later. Diagnosis cannot be considered definite until arthritis is present. Signs of systemic inflammation are invariably present, but there are no specific laboratory abnormalities.[38,39]

CUTANEOUS FINDINGS

The classic sJIA eruption has been a very transient salmon pink mostly macular eruption (Fig. 66-5)

Figure 66-5 Juvenile idiopathic arthritis. (Used with permission from the William Weston, MD Collection.)

coincident with febrile episodes. It may at times be indistinguishable from urticaria but is typically not pruritic. The eruption is identical to that often seen in adult-onset Still disease.[38] However, very different cutaneous presentations have been newly recognized in adult-onset Still disease. Of these variants, one also has been described (rarely) in sJIA—persistent pruritic papules and plaques (see section "Adult-onset Still Disease"). Perhaps the others will subsequently be reported in JIA.

NONCUTANEOUS FINDINGS

Enthesitis: Because enthesitis is common to both the psoriatic arthritis and the enthesitis-related arthritis category of JIA, it is important to be aware of enthesitis-related arthritis. It usually affects boys older than age 6 years and presents with lower-limb asymmetrical arthritis associated with enthesitis. Later, these children can develop inflammatory lumbosacral pain and are at risk of developing acute anterior uveitis. Almost two-third of patients with enthesitis-related arthritis have persistent disease. The presence of hip or ankle arthritis and a family history of spondyloarthropathy or polyarticular joint involvement at onset are associated with poorer prognosis. Psoriatic arthritis can also present as enthesitis, with evolution of cutaneous findings later.[41,42]

Macrophage Activation Syndrome: A secondary or acquired form of hemophagocytic lymphohistiocytosis (HLH), macrophage activation syndrome (MAS) is a potentially life-threatening complication of rheumatic disorders, most commonly with sJIA and adult-onset Still disease.[38,43] The full syndrome is thought to occur in roughly 10% of children with sJIA, but may be partially expressed in as high as 30% to 40%. A change in the fever pattern from the intermittent spikes of sJIA to a continuous high level is often the heralding clinical manifestation. Hepatosplenomegaly, generalized lymphadenopathy may worsen acutely. CNS dysfunction develops in one-third of children, typically as lethargy, irritability, disorientation, headache, seizures, or coma. These may be explained by the association of MAS with thrombotic thrombocytopenic purpura. Skin or mucosal hemorrhage may be seen in 20% of all MAS. Heart, lung, and kidney failure may eventuate in the sickest patients. Typically, cytopenia, abnormal liver function tests, a prolonged prothrombin time and partial thromboplastin time, and serum ferritin 5000 to 10,000 ng/mL are present.[39]

In 2016, collaborative guidelines were proposed for the classification of MAS in sJIA. MAS is considered present if a *febrile* patient with *known* or *suspected sJIA* who has a *ferritin* value >684 ng/mL also exhibits any 2 of the following: *platelet count* ≤181 × 10^9/L, *aspartate aminotransferase* >48 units/L, *triglycerides* >156 mg/dL, or *fibrinogen* ≤360 mg/dL.[43] It was also noted that treatments for sJIA such as IL-1 blocker canakinumab and IL-6 blocker tocilizumab might inhibit the full expression of MAS, thereby clouding the diagnosis.

ETIOLOGY AND PATHOGENESIS

The factors leading to JIA are poorly understood. The concordance rates for JIA among monozygotic twins ranges from 25% to 40%, and disease phenotypes are very similar in both twin and sibling pairs for onset and disease course.[44] There appears to be a familial link between RA and JIA, as well a familial risk of autoimmunity, such as thyroid disease. Gene associations vary between the subsets of JIA. sJIA seems to be strongly associated with HLA DRB1:11,[44] while HLA-B27, the microbiome, γ/δ-T cells and the IL-23/IL-17 axis all likely contribute to enthesitis-related arthritis pathogenesis.[45]

DIAGNOSIS

Dermatologic expertise can be crucial to recognizing the expanding spectrum of cutaneous findings in sJIA and adult-onset Still disease, especially with the newly recognized cutaneous variants of these syndromes (see "Adult-Onset Still Disease" below). In addition, dermatologists can offer insight into the differential diagnosis of the variable morphologic patterns seen in sJIA and their associations with other conditions, especially with autoimmune and autoinflammatory syndromes.

SUPPORTIVE STUDIES AND LABORATORY TESTING

Conventional radiographs are poor at assessing joint inflammation in JIA.[38] An MRI is more sensitive but difficult to use routinely, especially in children. Ultrasonography may be very sensitive in detecting early inflammation and minimal effusions, but is also very operator dependent and not routinely available in clinic or at bedside.

DIFFERENTIAL DIAGNOSIS

The differential diagnosis of JIA, in the absence of helpful skin findings, is extensive and is essentially a diagnosis of exclusion. The systemic onset form can be mimicked or confused with many different syndromes in pediatric patients, such as: (a) infections (septicemia, bacterial endocarditis, brucellosis, typhoid fever, leishmaniasis, viral); (b) malignancy/lymphoproliferative (leukemia, lymphoma, neuroblastoma, Castleman syndrome); (c) acute rheumatic fever; (d) connective tissue diseases (especially systemic lupus, Kawasaki syndrome, systemic vasculitides); (e) inflammatory bowel disease; (f) sarcoidosis; and (g) autoinflammatory syndromes.[38] Other than sJIA and the psoriatic subset of JIA, dermatologists will probably not be involved in the diagnosis of JIA.

CLINICAL COURSE, PROGNOSIS, AND MANAGEMENT

Because JIA affects individuals who are rapidly developing physically, mentally, and socially, treatment must be multifaceted and include counseling and encouragement to negotiate the challenges of participating in daily activities, along with physical therapy and occupational therapy. NSAIDs have been used as short-term monotherapy for JIA, but are not disease modifying. Intraarticular corticosteroid injections are frequently used, particularly in oligoarthritis.[38] Methotrexate remains the most widely used conventional DMARD in management of JIA; leflunomide may have similar effectiveness but there is little experience in children. Systemic glucocorticoids are mainly used to manage more-severe extraarticular manifestations such as high fever unresponsive to NSAIDs, severe anemia, myocarditis, pericarditis, and MAS.[38] TNF inhibitors are increasingly used to treat JIA.[38,46,47] Other biologics have been reported successful in treating JIA, including anakinra (anti–IL-1) abatacept (inhibits T-cell activation), tocilizumab (inhibits IL-6), and rituximab (anti–B-cell), but none are yet approved for treating JIA. Unfortunately, TNF blockers, and anti–IL-1 and anti–IL-6 agents, while improving some patients with JIA, also have been implicated in triggering MAS.[47] Whether this is a causal association is not known.

Treatment of MAS is less certain. High-dose corticosteroids are typically given, but cyclosporine and IL-1 inhibitors have shown some efficacy in resistant cases, as has etoposide, which is used for hemophagocytic lymphohistiocytosis.[48]

ADULT-ONSET STILL DISEASE

AT-A-GLANCE

- Multisystem syndrome that can mimic infection.
- Classic eruption is well described, but several new atypical variants are now recognized.
- Appears to have an association with malignancy, perhaps more so in those with atypical cutaneous presentations.

The expression *adult-onset Still disease* (AOSD) was introduced by Bywaters in 1971 to characterize a syndrome of seronegative polyarthritis, salmon-colored mostly macular and evanescent eruption, fever, and raised erythrocyte sedimentation rate, which, along with neutrophilic leukocytosis, mirrors the presentation of sJIA.[49,50]

EPIDEMIOLOGY

This syndrome most often affects younger adults, and females more often in Eastern than in Western countries.[49] Its incidence has been estimated at 0.16 per 100,000 in France, and 0.22 and 0.34 per 100,000 for men and women in Japan. Its prevalence was calculated at 0.73 and 1.74 for men and women in Japan.[49,50]

CLINICAL FEATURES

High fever of unknown origin exceeding 39°C is the presenting sign of AOSD in most patients.[49-51] Classically, patients present with 1 to 2 daily fever spikes above 39°C (102.2°F) occurring in the afternoon or evening and receding within hours. A retrospective review of 245 Italian patients combined with other recent series of AOSD patients resulted in a total of 731 patients.[51] Findings in the cumulative group included 61% were female, the average age at onset was 42.4 years, and there was an average delay in diagnosis of 2.33 months. The frequency of symptoms and signs in descending order was fever 93%, arthralgia 90%, rash 70% (Fig. 66-6), sore throat 64%, lymphadenopathy/splenomegaly 53%, hepatomegaly 39%, and pericarditis 13%.[51] Myalgia was not reported but other reviews find that myalgia occurred in 35% to 44% of patients.[49,50] The course of the disease was monocyclic in 24% to 30%, polycyclic in 41% to 44% (intermittent

Figure 66-6 Adult-onset Still disease. Lesions are discrete pink to red macules and slightly edematous papules. (Used with permission from James E. Fitzpatrick, MD.)

episodes with remission in between), and chronic articular in 26% to 36% of patients.[49,51]

CUTANEOUS FINDINGS

Table 66-4 outlines the cutaneous manifestations of AOSD.

Classical Cutaneous Presentation: The skin is involved in 60% to 70% of cases.[49,51] It is seen more often in the febrile presentation than in the solely arthritic form of disease. It most characteristically occurs on the chest, abdomen, and extensor surfaces of the arms, and tends to peak with the fever in the late afternoon, and then disappears, only to recur with fever the following day.[52] The rash consists of discrete pink to red macules or slightly edematous papules ranging in size from 5 to 10 mm (see Fig. 66-6). The lesions tend to be relatively fixed in shape and site during their daily eruption and seldom itch. Koebner phenomena may be seen. This is also the typical eruption of sJIA.

Atypical Cutaneous Presentations: In one series of 81 patients with atypical cutaneous AOSD, 87% were female, ages ranged from 8 to 83 years (median: 36 ± 16 years), and 64% were from East Asia.[53] Atypical cutaneous features were often present in addition to the typical evanescent rash,[54] but in 30% to 43% of the cases the only skin manifestations were atypical.[53,54] The most often reported atypical presentation is that of persistent, pruritic papules and plaques,[54,55] which are present in 75% of patients, and pruritic 87% of the time.[53] Rarely, this presentation also is seen in sJIA.[55] These lesions may develop fine scale, and are most commonly located on trunk, extremities, head, and/or neck. In some cases, plaques are linear suggesting triggering by local trauma (Koebner phenomenon). The color of the atypical eruption was either erythematous or brown, and less commonly violaceous.[54] Table 66-4 lists other less-common atypical variants. More than one morphology or distribution pattern was observed in several patients. The most commonly involved areas were the back, followed by chest, abdomen, and extensor surface of extremities.[53]

TABLE 66-4
Cutaneous Manifestations of Adult-Onset Still Disease

Classical Presentations
- Salmon-colored, macular or slightly papular evanescent eruption usually concurrent with fever spikes; may show Koebner phenomenon[52]
- Urticarial eruption morphologically, but typically nonpruritic

Atypical Variants
- Up to 81% had concurrent classical eruption with adult-onset Still disease[54]

Most Common
- Persistent, pruritic papules and plaques[54,55]
- Pigmented >50% cases[53]

Rare
- Urticarial erythema and papules
- Dermatographism-like
- Generalized or widespread persistent nonpruritic erythema[53]
- Flagellate erythema
- Lichenoid papules
- Dermatomyositis-like
- Dermatomyositis-like edema of lids without other findings[53]
- Lichen amyloidosis-like
- Prurigo pigmentosa-like
- Vesiculopustular eruption hands and feet or trunk and limbs[53]
- Widespread peau d'orange skin change (cutaneous mucinosa)[53]
- Photoaccentuation noted occasionally
- More than one morphology or distribution pattern observed in several patients
- Most commonly involved

NONCUTANEOUS FINDINGS

In 731 patients with arthritis, 23.7% had monoarthritis, 44.3% had oligoarthritis, and 32% had polyarthritis.[51] Fever >39.5°C (103.1°F) seemed predictive of monocyclic AOSD, whereas arthritis and thrombocytopenia were associated with chronic and complicated AOSD, respectively.[49]

COMPLICATIONS

Two serious complications associated with AOSD are reactive hemophagocytic syndrome (2.85% to 6%) and thrombotic thrombocytopenic purpura.[49,51,53,56,57] Reactive hemophagocytic syndrome is similar if not identical to MAS, and both are essentially part of the hemophagocytic lymphohistiocytosis spectrum. Both are rare, and the reasons for these associations are unknown.

An important newly recognized complication of AOSD is its association with malignancy.[54,58] Initially, this association was thought to be more common with the classical skin eruption,[54] but there is conflicting data suggesting atypical skin disease may increase the risk.[58] Malignancy may precede, appear concurrently, or present months or years after symptoms and signs of AOSD.[54] The diagnosis of malignancy did not precede or immediately follow a clinical presentation otherwise consistent with AOSD in a considerable subset of patients (42%).[54] Median time between diagnosis of AOSD and detection of malignancy was 9 months.[58] The malignancies were 50% hematopoietic (mostly lymphomas), 50% solid tumors (breast, lung, esophagus, and liver angiosarcoma).[58] Others were myeloproliferative, myelodysplastic, papillary thyroid, laryngeal squamous cell, melanoma, ovarian, kidney.[54,58] In some patients, AOSD resolved after successful therapy for tumor.[58] With regard to hematologic malignancies, lactate dehydrogenase, atypical cells in the blood count, and possibly also elevated soluble IL-2 receptor levels are red flags. A bone marrow biopsy should be of considered in the initial workup and any accessible enlarged lymph node should be biopsied.[58]

Myocarditis is a rare but potentially life-threatening complication that responds positively to corticosteroids and other immunomodulatory drugs.[59]

DIAGNOSIS

AOSD remains difficult to diagnose. Exclusion of causes of fever of unknown origin is essential, and use of published criteria for AOSD is important. The standard criteria set for AOSD has been the Yamaguchi criteria. Alternative criteria have been proposed; one (Fautrel) has a recent supportive large comparison study, includes glycosylated ferritin as a specific criteria, and does not require exclusion criteria. Table 66-5 includes both sets of criteria.[60,61]

SUPPORTIVE STUDIES AND LABORATORY TESTING

In the largest review of AOSD, leukocytosis occurred in 85% of patients and was composed of ≥80% polymorphonuclear neutrophils in 69% of patients.[51] In decreasing order of frequency, the following values were noted: increased C-reactive protein 93%, elevated erythrocyte sedimentation rate (≥20 mm/h) 85%, elevated hepatic enzymes 62%, and thrombocytosis (>400 × 10^9/L) 46%. Antinuclear antibody, rheumatoid factor, and cyclic citrullinated peptide antibodies were rarely positive.[51] Anemia <10 g/dL has been reported in 50% to 75% of patients.[61]

Serum ferritin above normal levels was observed in 56.4% of patients with elevations of more than 3 times normal in 60%.[51] A very elevated serum ferritin with a lowered concentration of glycosylated ferritin, is strongly suggestive of, but not specific for, this diagnosis. Perhaps more specific is the fraction of glycosylated ferritin. In healthy individuals, 50% to 80% of serum ferritin is glycosylated, but this drops to 20% to 50% in patients with inflammatory diseases.[61] The assessment of glycosylated ferritin was correlated with early diagnosis in one study.[49]

TABLE 66-5
Adult-Onset Still Disease Criteria

Yamaguchi et al	Fautrel et al
▪ At least 5 criteria, 2 of which must be major, *and* ▪ No exclusion criteria	▪ Four major criteria *or* ▪ Three major criteria and 2 minor criteria
Major Criteria	**Major Criteria**
▪ Fever ≥39°C (102.2°F) lasting 1 week or more ▪ Arthralgia lasting 2 weeks or more ▪ Typical skin rash: maculopapular, nonpruritic, salmon-pink rash with concomitant fever spikes ▪ Leucocytosis ≥10,000/mm³ with neutrophil polymorphonuclear count ≥80%	▪ Spiking fever 39°C (102.2°F) ▪ Arthralgia ▪ Transient erythema ▪ Pharyngitis ▪ Neutrophil polymorphonuclear count ≥80% ▪ Glycosylated ferritin fraction ≤20%
Minor	**Minor**
▪ Pharyngitis or sore throat ▪ Lymphadenopathy and/or splenomegaly ▪ Liver enzyme abnormalities (aminotransferases) ▪ Negative for rheumatoid factor or antinuclear antibodies	▪ Typical rash ▪ Leucocytosis >10,000/mm³
Exclusion Criteria	**Exclusion Criteria**
▪ Absence of infection, especially sepsis and Epstein-Barr viral infection ▪ Absence of malignant diseases, especially lymphomas ▪ Absence of inflammatory disease, especially polyarteritis nodosa	▪ None

PATHOLOGY

Classical Cutaneous: The histopathology of the classical eruption of AOSD is characterized by a mild inflammatory cell infiltration (lymphocytic, lymphohistiocytic, mixed, or predominantly neutrophilic, occasionally eosinophilic) in the upper dermis, basal vacuolization, keratinocyte necrosis, presence of karyorrhexis, and mucin in the dermis. Some of the histologic findings from lesions submitted to pathology as acute (such as acanthosis, parakeratosis, and rarely reported neutrophilic eccrine hidradenitis and neutrophilic urticarial dermatosis) seem to be more chronic changes.[62-64] Whether the specimens were actually from some of the more chronic lesions of atypical skin in AOSD patients who had both classical and atypical lesions will no doubt be sorted out in future studies.

Atypical Cutaneous: The histopathology of lesions in the persistent pruritic papule and plaque variant includes dyskeratosis present mainly in the superficial epidermis without accompanying basilar dyskeratosis, and a sparse superficial dermal infiltrate often with neutrophils but without vasculitis.[54,55] Occasionally dermal mucin deposition, subcorneal or intracorneal pustules, acanthosis or spongiosis were noted.[55]

Extracutaneous: Aside from the skin, pathologic findings have shown lymph node findings of paracortical or diffuse hyperplasia pattern with immunoblastic and vascular proliferation, which can mimic angioimmunoblastic T-cell lymphoma in nodes.[64] Liver biopsies showed sparse portal and sinusoidal inflammatory cell infiltration, with various degrees of Kupffer cell hyperplasia. The cellularity of bone marrow varied from 20% to 80%. Myeloid cell hyperplasia was frequent. On immunohistochemistry, the number of CD8+ lymphocytes was greater than that of CD4+ lymphocytes in the skin, liver, and bone marrow, but the number of CD4+ lymphocytes was greater than that of CD8+ lymphocytes in the lymph nodes.[64]

DIFFERENTIAL DIAGNOSIS

The differential diagnosis of the cutaneous manifestations is extensive, based on the cutaneous manifestations present, as listed in Table 66-4. The differential diagnosis of AOSD in general often falls into the category of fever of unknown origin, and is quite extensive, focusing particularly on acute or subacute infections autoinflammatory diseases, and systemic autoimmune diseases.

CLINICAL COURSE AND PROGNOSIS

Acute disease is often treated with NSAIDs, particularly enteric-coated aspirin, although this is often ineffective, with response rates of 20% to 25%.[51] Corticosteroids are often used acutely. Steroid-sparing medications are often required, and include IM gold, D-penicillamine, sulfasalazine, hydroxychloroquine, methotrexate, thalidomide, azathioprine, cyclosporine, cyclophosphamide, and IV immunoglobulin. Biologic agents are increasingly reported for resistant or chronic cases, and are sometimes used as first-line therapy. These include anti-TNF agents, anakinra (anti–IL-1), rituximab, tocilizumab, and canakinumab (an IL-6 receptor inhibitor).[41,42,47,49,51,53]

The treatment guidelines for reactive hemophagocytic syndrome in AOSD have not been established. For JIA-associated reactive hemophagocytic syndrome, the main treatment is the administration of high-dose steroids.[65] However, refractory cases of reactive hemophagocytic syndrome require additional therapy. In adults, medications which may be effective include methotrexate, azathioprine, high-dose IV immunoglobulins, cyclosporine, cyclophosphamide, plasma exchange, etoposide, and anti-TNF agents.[65]

RHEUMATIC FEVER

AT-A-GLANCE

- Incidence has rapidly declined in more-developed nations.
- Rare complication of oropharyngeal group A streptococcal infection.
- Distinctive but uncommon cutaneous manifestation of erythema marginatum.
- Erythema marginatum has been used to describe different skin manifestations in other clinical settings, which can be confusing.

Acute rheumatic fever is an inflammatory response to group A streptococcal infection, which typically occurs 2 to 3 weeks after a throat infection.[66] It is a delayed sequel to group A β-hemolytic streptococcal infection of the oropharynx. It is an inflammatory disease that can affect the heart, joints, CNS, skin, and subcutaneous tissues. It is a clinical diagnosis made on the basis of criteria, the latest from 2015.[67] Treatment of the underlying infection, if recognized, prevents rheumatic fever,

EPIDEMIOLOGY

The incidence of acute rheumatic fever (ARF) and the prevalence of rheumatic heart disease substantially declined in the last century in Europe, North America, and other developed nations.[67] This decline is attributed to improved hygiene, improved access to antibiotic drugs and medical care, reduced household crowding, and possibly changes in the epidemiology of specific group A streptococcal strains, as well as other social and economic changes. The major burden is currently found in low- and middle-income countries and in selected indigenous populations elsewhere, especially among Pacific people, New Zealand Maori, and indigenous Australians.[66,67] A resurgence of ARF in the intermountain areas of the United States, occurred in the 1980s.[66]

The pattern of disease in the high-prevalence regions is often hyperendemic, with cases occurring throughout the year and near absence of outbreaks. In contrast, high-income settings experience a low background incidence of ARF with periodic outbreaks.[67] Currently, the average incidence in most developed communities is less than 5 per 100,000 population.[68] Most cases of ARF occur in children ages 5 to 15 years, but it may occasionally occur in young adults.[66]

Streptococcal pharyngitis is a common infection in childhood. Pharyngitis caused by rheumatogenic strains of group A *Streptococcus* in a susceptible host triggers an abnormal immune inflammatory response.[66] This response most probably involves cross reactivity of streptococcal antibodies against myocardium, synovial tissue, and, in chorea, the basal ganglia. In carditis, activated monoclonal autoantibodies produce T-cell infiltration in the valve endothelium.[66] Oddly, however, the morbidity and mortality of rheumatic fever results from valvular disease rather than acute carditis.[68]

CLINICAL FEATURES

ARF is characterized by a clinical syndrome, typically presenting as migratory polyarthritis, especially knees, ankles, elbows, and wrists.[66,67] Carditis occurs in approximately 80% of people with rheumatic fever and commonly affects the mitral and aortic valves, resulting in regurgitation. Other less-common clinical features include abnormal involuntary movements (chorea), and the skin findings of erythema marginatum and subcutaneous nodules.[66,67] A history

TABLE 66-6

Diagnosis of Acute Rheumatic Fever in Patient Populations with Evidence of Preceding Group A Streptococcal Infection Using the 2015 Revised Jones Criteria[a]

- Diagnosis of initial acute rheumatic fever: 2 major criteria *or* 1 major plus 2 minor criteria
- Diagnosis of recurrent acute rheumatic fever: 2 major criteria *or* 1 major plus 2 minor *or* 3 minor criteria

MAJOR CRITERIA	MINOR CRITERIA
Carditis: clinical and/or subclinical	*ECG abnormality*[b]: prolonged PR interval, after accounting for age variability
Chorea	*Laboratory values*: ■ CRP ≥3.0 mg/dL and/or ESR ≥60 mm/h in LR population ■ CRP ≥3.0 mg/dL and/or ESR ≥30 mm/h in MR and HR populations
Erythema marginatum	*Fever*: ■ ≥38.5°C (101.3°F) in LR population ■ ≥38°C (100.4°F) in MR and HR populations
Subcutaneous nodules	
Arthritis: ■ Polyarthritis only in LR population ■ Monoarthritis or polyarthritis or polyarthralgia in MR and HR populations	*Arthritis*[c]: ■ Polyarthralgia in LR population ■ Monoarthralgia in MR and HR populations

[a]LR population defined as acute rheumatic fever incidence ≤2/100,000 school-aged children *or* rheumatic heart disease prevalence of ≤1 per 1,000 all-age population per year.

[b]Unless carditis is a major criterion.

[c]Unless joint manifestation is a major criterion.

CRP, C-reactive protein; ECG, electrocardiogram; ESR, erythrocyte sedimentation rate; HR, high risk; LR, low risk; MR, moderate risk.

Data from Gewitz MH, Baltimore RS, Tani LY, et al. Revision in the Jones Criteria for the diagnosis of acute rheumatic fever in the era of Doppler echocardiography. A scientific statement from the American Heart Association. *Circulation.* 2015;131:1806-1818.

of rapid improvement with salicylates or NSAIDs is also characteristic. Generally, the arthritis in ARF runs a self-limited course, even without therapy, lasting approximately 4 weeks.[67] In practice, the joint manifestations can be difficult to assess because of good response to NSAIDs, which can mask the symptoms. Monoarthritis, particularly involving the hip, also has been described as a presenting feature in populations with a high incidence of rheumatic fever, and is included in diagnostic guidelines (Table 66-6).[66]

CUTANEOUS FINDINGS

Both erythema marginatum and subcutaneous nodules are rare in ARF, each occurring in less than 5% of cases.[66,67] Erythema marginatum, much like the eruption in sJIA and Still disease, is evanescent, but differs by its tendency to develop annular or serpiginous erythema (Fig. 66-7). It typically occurs on the torso, upper arms, and legs, and spares the face. Erythema marginatum can fluctuate over many weeks, may be exacerbated by heat, and blanches with pressure. It is not itchy or painful. Histopathologically, there is a sparse superficial perivascular infiltrate of lymphocytes and neutrophils.

Figure 66-7 Erythema marginatum of rheumatic fever. Enlarging and shifting transient annular and polycyclic lesions.

In dermatologic literature erythema marginatum is usually considered unique to ARF. However, other literature does contain very different cutaneous syndromes given the same name, both as part of hereditary angioedema and as an unusual drug eruption. Skin findings may be the presenting sign of hereditary angioedema attacks, and a prodrome of erythema marginatum had been reported in up to 25% of patients.[69] Recently, 49 (56%) of 87 patients with hereditary angioedema were reported with erythema marginatum. It had frequently been confused with urticaria, leading to a delay in the correct diagnosis in half the patients with the rash. It often preceded angioedema attacks, but could develop concurrently or even recur independently of the angioedema attacks.[70] The term "chicken wire erythema" also has been applied to this eruption. The second non-ARF syndrome involving a marginatum-type eruption is as a side effect of the oral multikinase inhibitor sorafenib, reported as erythema marginatum hemorrhagicum. This was distinguished by a purpuric margin and presumably was less labile than the erythema marginatum of ARF.[71]

Subcutaneous nodules are typically less than 2 cm in diameter, firm, painless, and mobile nodules that usually appear during the first weeks of the inflammatory phase. They tend to localize over extensor surfaces—elbows, wrists, knees, and ankles, and sometimes Achilles tendon, occiput, or thoracic or lumbar spine.[66,67] Nodules may last for up 2 weeks, and often occur in association with carditis. The histopathology generally consists of a central zone of fibrinoid necrotic

material surrounded by histiocytes and fibroblasts and around small vessels are collection of lymphocytes and polymorphs.[72] Small focal lesions similar or identical to the myocardial Aschoff nodule are frequently seen. Surprisingly, the nodules heal without residual damage.

NONCUTANEOUS FINDINGS

Globally, approximately 50% to 65% of people with rheumatic fever have clinically detectable carditis (inflammation of the heart valve leaflets leading to valvular regurgitation). The mitral valve is most often affected, followed by the aortic valve. Pericarditis and myocarditis also occasionally occur, though isolated pericarditis or myocarditis should never be considered rheumatic in origin.[66,67] Severe carditis can occur and can lead to congestive heart failure.[66] Milder rheumatic carditis may be subclinical in approximately 30% of all individuals with rheumatic fever—that is, detected by echocardiography but not audible by stethoscope.[66,67] Rheumatic carditis can evolve over weeks to months, underscoring the importance of repeating echocardiography in 2 to 4 weeks if the first echocardiogram is normal. Chorea affects up to 15% of people with ARF, is more common in females and adolescents, and consists of purposeless, involuntary, jerky movements which may be asymmetrical (hemichorea), facial grimacing, fidgeting, clumsiness, and emotional lability. Patients may experience deterioration in handwriting, inability to feed themselves, and unsteady gait leading to falls.[66,67] Chorea typically occurs after a longer latent period (up to 6 months) after a streptococcal infection, by which time the other inflammatory features of rheumatic fever have resolved. It can follow a fluctuating course over many months or years, before eventually resolving.[67]

DIAGNOSIS

The diagnosis of ARF depends exclusion of other syndromes that may mimic ARF, similar to those diseases to be excluded in the differential of sJIA and Still disease, and on the constellation of clinical findings as detailed by current criteria, which now also support the use of echocardiographic findings to confirm subclinical carditis. Table 66-6 details these criteria.

TREATMENT

Treatment is first directed at eradication of group A β-hemolytic streptococci from the oropharynx using phenoxymethylpenicillin (penicillin VK) (250 mg twice daily in children; 500 mg twice daily in adolescents) or a single dose of IM benzathine penicillin, followed by institution of long-term prophylaxis. Erythromycin is the recommended alternative in instances of penicillin allergy.[66] Neither salicylates nor corticosteroids have shown sustained effects on outcome, but both are sometimes still used. Chorea treatment is supportive, and even though the course may last for months, it generally enters remission. Naproxen 10 to 20 mg/kg/day is given divided into 2 daily doses for treatment of acute joint manifestations. Patients require long-term followup, primarily for complications of valvulitis.

SUMMARY

Table 66-7 summarizes the common dermatologic findings and associations for RA, JIA, AOSD, and rheumatic fever.

TABLE 66-7
Summary of Common Dermatologic Findings and Associations

DERMATOLOGIC FINDING	CLINICAL APPEARANCE
Rheumatoid Arthritis	
Rheumatoid nodule	Subcutaneous nodule over pressure points (olecranon, extensor forearm, Achilles tendon)
Rheumatoid vasculitis	Purpura, livedo reticularis, atrophie blanche, ulcers
Pyoderma gangrenosum	Deep, liquefying ulcers with a purple, undermined border, commonly affecting the lower extremities and abdomen
Juvenile Idiopathic Arthritis	
Classic cutaneous presentation	Transient, salmon pink macular eruption coincident with febrile episodes
Adult-Onset Still Disease	
Classic cutaneous presentation	Transient, discrete, pink to red macules or edematous papules distributed over the chest, abdomen, and extensor arms, peaking with febrile episodes
Atypical cutaneous presentation	Persistent pruritic papules and plaques with or without a fine scale, distributed over trunk, extremities, head, or neck; Koebner phenomenon may occur
Rheumatic Fever	
Erythema marginatum	Evanescent, erythematous patches in annular or serpiginous configuration distributed over the torso, upper arms, and legs with facial sparing
Subcutaneous nodules	Firm, painless, and mobile nodules localizing over extensor surfaces (elbows, wrists, knees), and often associated with carditis

REFERENCES

1. Aletaha D, Neogi T, Silman AJ, et al. 2010 Rheumatoid arthritis classification criteria. An American College Rheumatology/European League Against Rheumatism collaborative initiative. *Arthritis Rheum.* 2010;62(9):2569-2581.
2. Alamanos Y, Drosos AA. Epidemiology of adult rheumatoid arthritis. *Autoimmun Rev.* 2005;4:130-136.
3. Scott D, Wolfe F, Huizinga TW. Rheumatoid arthritis. *Lancet.* 2010;376(9746):1094-1108.
4. Liao KP, Karlson EW. Classification and epidemiology of rheumatoid arthritis. In: Hochberg MC, Silman AJ, Smolen JS, et al, eds. *Rheumatology.* 5th ed. Philadelphia, PA: Mosby; 2010.
5. Sayah A, English JC 3rd. Rheumatoid arthritis: a review of the cutaneous manifestations. *J Am Acad Dermatol.* 2005;53:191-2009.
6. Clarke JT, Werth VP. Rheumatic manifestations of skin disease. *Curr Opin Rheumatol.* 2010;22:78-84.
7. Prete M, Racanelli V, Digiglio L, et al. Extra-articular manifestations of rheumatoid arthritis: an update. *Autoimmun Rev.* 2011:11:123-131.
8. Tilstra JS, Lienesch DW. Rheumatoid nodules. *Dermatol Clin.* 2015;33:361-371.
9. Maruani A, Wierzbicka E, Machet MC, et al. Reversal of multifocal cutaneous lymphoproliferative disease associated with Epstein-Barr virus after withdrawal of methotrexate therapy for rheumatoid arthritis. *J Am Acad Dermatol.* 2007;57(5)(suppl):S69-S71.
10. Kameda T, Dobashi H, Miyatake N, et al. Association of higher methotrexate dose with lymphoproliferative disease onset in rheumatoid arthritis patients. *Arthritis Care Res (Hoboken).* 2014;56:1302-1309.
11. Rosenbach M, English JC 3rd. Reactive granulomatous dermatitis. A review of palisaded granulomatous dermatitis, interstitial granulomatous dermatitis, interstitial granulomatous drug reaction, and a proposed reclassification. *Dermatol Clin*. 2015;33(3):373-387.
12. Magro CM, Crowson AN. The spectrum of cutaneous lesions in rheumatoid arthritis: a clinical and pathological study of 43 patients. *J Cutan Pathol.* 2003;30:1-10.
13. Sangueza OP, Caudell MD, Mengesha YM, et al. Palisaded neutrophilic granulomatous dermatitis in rheumatoid arthritis. *J Am Acad Dermatol.* 2002;47:251-257.
14. Fujio Y, Funakoshi T, Nakayama K, et al. Rheumatoid neutrophilic dermatosis with tense blister formation: a case report and review of the literature. *Australas J Dermatol.* 2014;5:e12-e14.
15. Saeb-Lima M, Charli-Joseph Y, Rodriguez-Acosta ED, et al. Autoimmunity-related neutrophilic dermatosis: a newly described entity that is not exclusive of systemic lupus erythematosus. *Am J Dermatopathol.* 2013;35:655-660.
16. Gasdorf L, Bessis D, Lipsker D. Lupus erythematosus and neutrophilic urticarial dermatosis. A retrospective study of 7 patients. *Medicine (Baltimore).* 2014;93:e351.
17. Wu YH, Hsiao PF. Neutrophilic figurate erythema. *Am J Dermatopathol.* 2017;39:344-350.
18. Watts RA, Carruthers DM, Symmons DP, et al. The incidence of rheumatoid vasculitis in the Norwich Health Authority. *Br J Rheumatol.* 1994;33(9):832-833.
19. Makol A, Crowson CS, Wetter DA, et al. Vasculitis associated with rheumatoid arthritis: a case control study. *Rheumatology (Oxford).* 2014;53:890-899.
20. Makol A, Matteson EL, Warrington KJ. Rheumatoid vasculitis: an update. *Curr Opin Rheumatol.* 2015;27:63-70.
21. Nguyen H, James EA. Immune recognition of citrullinated epitopes. *Immunology.* 2016;149:131-1388.
22. Yarwood A, Huizinga TW, Worthington J. The genetics of rheumatoid arthritis: risk and protection in different stages of the evolution of RA. *Rheumatology (Oxford).* 2016;55(2):199-209.
23. Requena L, El-Shabrawi-Caelen L, Walsh S, et al. Intralymphatic histiocytosis. A clinicopathologic study of 16 cases. *Am J Dermatopathol.* 2009;31:140-151.
24. Huang HY, Liang CW, Hu SL, et al. Cutaneous intravascular histiocytosis associated with rheumatoid arthritis: a case report and review of the literature. *Clin Exp Dermatol.* 2009;34:e302-e303.
25. Jorizzo JL, Daniels JC. Dermatologic conditions reported in patients with rheumatoid arthritis. *J Am Acad Dermatol.* 1983;8:439.
26. Brasington RD Jr. Clinical features of rheumatoid arthritis. In: Hochberg MC, Silman AJ, Smolen JS, et al, eds. *Rheumatology.* 5th ed. Philadelphia, PA: Mosby; 2010.
27. Kerr JR. Role of parvovirus B19 in the pathogenesis of autoimmunity and autoimmune disease. *J Clin Pathol.* 2016;69:279-291.
28. El-Gendy HJ, El-Gohary RM, Shohdy KS, et al. Leprosy masquerading as systemic rheumatic diseases. *Clin Rheumatol.* 2016;22:264-271.
29. Meyer PW, Ally MM, Anderson R. Reliable and cost-effective serodiagnosis of rheumatoid arthritis. *Rheumatol Int.* 2016;36:751-758.
30. Harris E, Budd R, Firestein G, et al, eds. *Kelley's Textbook of Rheumatology*. 7th ed. Philadelphia, PA: Elsevier Saunders; 2004.
31. Gardner GC, Kadel NJ. Ordering and interpreting rheumatologic laboratory tests. *J Am Acad Orthop Surg.* 2003;11:60-67.
32. Liao KP, Karlson EW. Classification and epidemiology of rheumatoid arthritis. In: Hochberg MC, Silman AJ, Smolen JS, et al, eds. *Rheumatology.* 5th ed. Philadelphia, PA: Mosby; 2010.
33. Ruta S, Reginato AM, Pineda C, et al. General applications of ultrasound in rheumatology. Why we need it in our daily practice. *J Clin Rheumatol.* 2015;21(3):133-143.
34. Smolen JS, Landewe R, Bijlsma J, et al. EULAR recommendations for the management of rheumatoid arthritis with synthetic and biological disease-modifying antirheumatic drugs: a 2016 update. *Ann Rheum Dis.* 2017;76:960-977.
35. Lee YH, Bae SC. Comparative efficacy and safety of tocilizumab, rituximab, abatacept and tofacitinib in patients with active rheumatoid arthritis that inadequately responds to tumor necrosis factor inhibitors: a Bayesian network meta-analysis of randomized controlled trials. *Int J Rheum Dis.* 2016;19:1103-1111.
36. Alfons-Cristancho R, Armstrong N, Arjunji R, et al. Comparative effectiveness of biologics for the management of rheumatoid arthritis: a systematic review and network meta-analysis. *Clin Rheumatol.* 2017;36:25-34.
37. Singh JA, Christensen R, Wells GA, et al. Biologics for rheumatoid arthritis: an overview of Cochrane reviews. *Cochrane Database Syst Rev.* 2009;(4):CD007848.
38. Giancane G, Consolaro A, Lanni S, et al. Juvenile idiopathic arthritis: diagnosis and treatment. *Rheumatol Ther.* 2016;3:187-207.
39. Eisenstein EM, Berkun Y. Diagnosis and classification of juvenile idiopathic arthritis. *J Autoimmun.* 2014;48-49:31-33.

40. Krause ML, Crowson CS, Michet CJ, et al. Juvenile idiopathic arthritis in Olmsted County, Minnesota, 1960-2013. *Arthritis Rheum.* 2016;68:247-254.
41. Aggarwal A, Misra DP. Enthesitis-related arthritis. *Clin Rheumatol.* 2015;34(11):1839-1846.
42. Weiss PF. Update on enthesitis-related arthritis. *Curr Opin Rheumatol.* 2016;28:530-536.
43. Ravelli A, Minoia F, Davi S, et al. Classification criteria for macrophage activation syndrome complicating systemic juvenile idiopathic arthritis: a European League Against Rheumatism/American College of Rheumatology/Paediatric Rheumatology International Trials Organization collaborative initiative. *Arthritis Rheumatol.* 2016;68:566-576.
44. Hersh AO, Prahalad S. Genetics of juvenile idiopathic arthritis. *Rheum Dis Clin North Am.* 2017;43:435-448.
45. Weiss PF. Update on enthesitis-related arthritis. *Curr Opin Rheumatol.* 2016;28:530-536.
46. Cimaz R, Marino A, Martini A. How I treat juvenile idiopathic arthritis: a state of the art review. *Autoimmun Rev.* 2017;16:1008-1015.
47. Vanoni F, Minoia F, Malattia C. Biologics in juvenile idiopathic arthritis: a narrative review. *Eur J Pediatr.* 2017;176:1147-1153.
48. Ravelli A, Davi S, Minoia F, et al. Macrophage activation syndrome. *Hematol Oncol Clin North Am.* 2015;29: 927-941.
49. Gerfaud-Valentin M, Maucort-Boulch D, Hot A, et al. Adult-onset Still disease: Manifestations, treatment, outcome, and prognostic factors. *Medicine (Baltimore).* 2014;93(2):91-99.
50. Lebrun D, Mestrallet S, Dehoux M, et al. Validation of the Fautrel classification criteria for adult-onset Still's disease. *Semin Arthritis Rheum.* 2018;47(4):578-585.
51. Sfriso P, Priori R, Valesini G, et al. Adult-onset Still's disease: an Italian multicenter retrospective observational study of manifestations and treatments in 245 patients. *Clin Rheumatol.* 2016;35:1683-1689.
52. Braverman IM. Hypersensitivity syndromes. In: *Skin Signs of Systemic Disease*. 3rd ed. Philadelphia, PA: Saunders; 1998.
53. Narvaez Garcia FJ, Pascual M, Lopez de Recalde M, et al. Adult-onset Still's disease with atypical cutaneous manifestations. *Medicine (Baltimore).* 2017;96(11): e6318.
54. Sun N, Brezinski EA, Berliner J, et al. Updates in adult-onset Still disease: atypical cutaneous manifestations and associations with delayed malignancy. *J Am Acad Dermatol.* 2015;73(2):294-303.
55. Fortna RR, Gudjonsson JE, Seidel G, et al. Persistent pruritic papules and plaques: a characteristic histopathologic presentation seen in a subset of patients with adult-onset and juvenile Still's disease. *J Cutan Pathol.* 2010;37(9):932-937.
56. Gopal M, Cohn CD, McEntire MR, et al. Thrombotic thrombocytopenic purpura and adult onset Still's disease. *Am J Med Sci.* 2009; 337(5):373-376.
57. Hot A, Toh ML, Coppéré B, et al. Reactive hemophagocytic syndrome in adult-onset Still disease: clinical features and long-term outcome: a case-control study of 8 patients. *Medicine (Baltimore).* 2010;89(1):37-46.
58. Hofheinz K, Schett G, Manger B. Adult onset Still's disease associated with malignancy—cause or coincidence? *Semin Arthritis Rheum.* 2016;45:621-626.
59. Gerfaud-Valentin M, Seve P, Iwaz J, et al. Myocarditis in adult-onset Still disease. *Medicine (Baltimore).* 2014;93:280-289.
60. Yamaguchi M, Ohta A, Tsunematsu T, et al. Preliminary criteria for classification of adult Still's disease. *J Rheumatol.* 1992;19:424-430.
61. Fautrel B, Zing E, Golmard JL, et al. Proposal for a new set of classification criteria for adult-onset still disease. *Medicine (Baltimore).* 2002;81:194-200.
62. Kiefer C, Bernard C, Dan L. Neutrophilic urticaria dermatosis: a variant of neutrophilic urticaria strongly associated with systemic disease. Report of 9 cases and review of the literature. *Medicine (Baltimore).* 2009;88:23-31.
63. Larson AR, Laga AC, Granter SR. The spectrum of histopathologic findings in cutaneous lesions in patients with Still disease. *Am J Clin Pathol.* 2015;144:945-951.
64. Kim HA, Kwon JE, Yim H, et al. The pathologic findings of skin, lymph node, liver, and bone marrow in patients with adult-onset Still disease. A comprehensive analysis of 40 cases. *Medicine (Baltimore).* 2015;94:1-9.
65. Bae CB, Jung JY, Kim HA, et al. Reactive hemophagocytic syndrome in adult-onset Still disease: clinical features, predictive factors, and prognosis in 21 patients. *Medicine (Baltimore).* 2015;94(4):e451.
66. Webb RH, Grant C, Hamden A. Acute rheumatic fever. *BMJ.* 2015;351:h3443.
67. Gewitz MH, Baltimore RS, Tani LY, et al. Revision of the Jones Criteria for the diagnosis of acute rheumatic fever in the era of Doppler echocardiography: a scientific statement from the American Heart Association. *Circulation.* 2015;131(20):1806-1818.
68. Carapetis JR, McDonald M, Wilson NJ. Acute rheumatic fever. *Lancet.* 2005;366:155-168.
69. Parish LC. Hereditary angioedema: diagnosis and management—a perspective for the dermatologist. *J Am Acad Dermatol.* 2011;65:843-850.
70. Rasmussen ER, Valente de Freitas P, Bygum A. Urticaria and prodromal symptoms including erythema marginatum in Danish patients with hereditary angioedema. *Acta Derm Venereol.* 2001;81:376-377.
71. Rubsam K, Flaig MJ, Ruzicka T, et al. Erythema marginatum hemorrhagicum: a unique cutaneous side effect of sorafenib. *J Am Acad Dermatol.* 2011;64:1194-1196.
72. Tandon R. Rheumatic fever pathogenesis: approach in research needs change. *Ann Pediatr Cardiol.* 2012;5:169-178.

Chapter 67 :: Scleredema and Scleromyxedema

:: Roger H. Weenig & Mark R. Pittelkow

Skin disorders that are characterized by increased mucin content, excessive collagen deposition, or fibrocyte hyperplasia are designated as mucinoses, sclerosing disorders, or fibrosing disorders, respectively. As the fibrocyte (fibroblast) is the cellular component of their pathogenesis, these conditions are aptly viewed as various forms of "fibropathy." In some conditions, one fibrocyte product predominates, such as excessive mucin production in pretibial myxedema or collagen deposition in scleroderma. In others conditions there is a combination of excessive mucin and collagen deposition (scleredema) or excessive mucin deposition and fibrocyte hyperplasia (scleromyxedema and nephrogenic systemic fibrosis). Hence, the nosology of some of these conditions does not accurately describe what is observed histopathologically. For example, "fibromyxedema" more accurately depicts the histopathogenesis of scleromyxedema, as scleromyxedema implies a combination of sclerosis and mucinosis, which more accurately describes scleredema.

Fibroblasts are derived from CD34-positive hematopoietic precursors that originate in the bone marrow and populate the skin during development and wound repair. The chief role of the skin fibroblast is to deposit collagen, elastin, and ground substance, the major constituents of the dermis and pannicular septae and the substrate to which the epidermis and skin appendages attach.

Stimuli that cause fibrocytes to overproduce mucin or collagen, or to proliferate are protean and broad ranging. Infectious triggers, inflammatory states, diabetes mellitus, drugs, heavy metals (eg, gadolinium), genetic mutations, and toxins (eg, tainted rapeseed oil and L-tryptophan in eosinophilia myalgia syndrome), as well as specific mediators, such as eicosenoids, growth factors, cytokines, chemokines, immunoglobulins-paraproteins, and other circulating factors, have been implicated, but the precise mechanisms that result in the varied forms of fibrocyte pathology (fibropathy) are poorly characterized. Some of these stimuli may recruit bone-marrow derived fibrocyte precursors to the skin; others may act directly on fibrocytes already residing in the skin.

This chapter focuses on the distinctive conditions of scleredema and scleromyxedema (Table 67-1.). Other diseases relevant to cutaneous fibrocytes are discussed separately in other chapters and are listed in Table 67-2.

SCLEREDEMA

AT-A-GLANCE

- Acute skin induration characterized by dermal mucinosis and mild sclerosis.
- Disease associations:
  - Postinfectious scleredema of youth.
  - Diabetes mellitus–associated scleredema of adulthood.
  - Paraproteinemia-associated scleredema.
  - Rare associations: hyperparathyroidism, connective tissue disease, HIV infection.
- Histopathology: pandermal thickening with broad collagen bundles separated by mucin deposits, chiefly hyaluronate.
- Clinical course:
  - Postinfectious: usually resolves in 1 to 2 years.
  - Diabetes mellitus–associated: may improve with better control of diabetes, but a prolonged course is expected.
  - Paraprotein associated: often more chronic although remissions observed with specific treatments.
  - Treatment: treat underlying disease; UVA-1; psoralen plus ultraviolet A light.

HISTORICAL ASPECTS

Scleredema was described by Buschke in 1902[1] and is also designated as scleredema of Buschke and scleredema adultorum, although the latter is a misleading term because children or adolescents can develop the condition.

EPIDEMIOLOGY

Scleredema is rare, although the precise incidence and prevalence are unknown. Men and women are affected with equal frequency. More than half of cases of scleredema occur in childhood or adolescence, most commonly after an upper respiratory tract infection.[2]

TABLE 67-1
Scleredema and Scleromyxedema

CONDITION	EPIDEMIOLOGY	ASSOCIATED CONDITIONS	CLINICAL MANIFESTATIONS	HISTOLOGIC FINDINGS	COURSE/ PROGNOSIS	TREATMENT OPTIONS
Scleredema	Childhood or adolescence Adulthood Adulthood	Postinfectious Diabetes mellitus Paraproteinemia Also hyperparathyroidism, connective tissue disease, HIV	Acute onset, nonpitting neck induration; shoulders, upper back, face, and arms may be affected. Affected skin feels smooth and waxy.	"Squared" appearance on low-power microscopy; more dermis in affected skin compared to adjacent unaffected skin; decreased number/higher placement of eccrine glands; mucin stains (Alcian blue, colloidal iron) can identify mucin deposits	Abates in 1-2 years Protracted course Chronic, resistant to therapies	Treatment of underlying condition (except for postinfectious scleredema); UVA-1 phototherapy may be effective
Scleromyxedema (also, lichen myxedematosus)	Mid to late adulthood, males and females equally affected	Paraproteinemia	Generalized lichenoid eruption has minute papules on extremities and trunk Confluent, lichenoid plaques	Superficial to mid-dermal fibroplasia and mucin deposition	Chronic, progressive course	Treatment of underlying cause

Streptococcal infection is most commonly identified, but other infectious agents also have been implicated. Disease development in adulthood in association with adult-onset diabetes mellitus is the second most common presentation of scleredema. Uncommonly, scleredema occurs in association with paraproteinemia or multiple myeloma, and this association possibly is becoming more common as other causes diminish in frequency with better treatment and management of underlying disease.

PATHOGENESIS

Type 1 collagen and hyaluronate appear to be the major fibroblast products that are increased in scleredema-affected skin.[3-5] The precise mechanism(s) for increased collagen and glycosaminoglycan production in scleredema is not known. Stimulation of fibroblasts by serum factors or immunoglobulin may be related to the pathogenesis of scleredema, particularly cases associated with infectious agents or a paraproteinemia. Serum from a patient with scleredema associated with paraproteinemia was able to increase collagen production by cultured fibroblasts in vitro.[6] However, the factor(s) involved has not been elucidated. Other soluble circulating cytokines and small molecule mediators likely also play critical roles.

CLINICAL FINDINGS

The clinical findings of scleredema are distinctive. An acute onset of nonpitting induration of neck, shoulders, and upper back skin may be followed by involvement of the face and arms. Characteristically, the affected skin appears smooth and waxy, with tense dermal induration and prominent follicular ostia, at times imparting a "peau d'orange" appearance (Fig. 67-1). In general, however, skin changes are better felt on palpation than seen. The skin of the upper trunk (especially the back) is a favored site for scleredema, but more widespread involvement may be observed. The affected and unaffected skin blend imperceptibly. Scleredema involving the esophagus, bone marrow, nerve, liver, or salivary glands has been described rarely.[7,8] However, investigations to identify internal organ involvement by scleredema are infrequently pursued. Patients may report symptoms of restricted motion of joints, the tongue, or eyes, as well as weak or tender muscles.

HISTOPATHOLOGY

Punch biopsies of affected skin reveal a nontapered (square) appearance on low power. The proportion of dermis in dramatically increased in comparison to adjacent nonaffected skin (Fig. 67-2A). A decreased number or higher placement of eccrine units may be appreciated. Fibroblasts are normal in number and morphology. The collagen bundles are slightly thickened and separated from each other by subtle deposits of mucin. Stains for mucin (Alcian blue, colloidal iron) are often used to identify the mucin deposits (Fig. 67-2B).

TABLE 67-2
Selected Fibroblast Disorders

	CHAPTER
Excessive Collagen Production by Fibroblasts—*Sclerosing Disorders*	
▪ Scleroderma	63
▪ Morphea	64
▪ Sclerodermoid graft-versus-host disease	129
▪ Sclerodermoid porphyria cutanea tarda	124
▪ Eosinophilic fasciitis	40, 63
▪ Sclerodermoid drug reactions (bleomycin, epoxy resin, pentazocine)	63
▪ Lipodermatosclerosis (sclerosing panniculitis)	73, 148
▪ Collagenoma	136
Fibroblast Hyperplasia—*Fibrosing Disorders*	
▪ Fibromatosis (Dupuytren contracture, Peyronie disease)	72
Excessive Collagen and Mucin Production by Fibroblasts—*Scleromucinoses*	
▪ Scleredema	67
Fibroblast Hyperplasia and Excessive Mucin Production by Fibroblasts—*Fibromucinoses*	
▪ Lichen myxedematosus and scleromyxedema	67
▪ Nephrogenic systemic fibrosis/ nephrogenic fibrosing dermopathy	133
▪ Toxic oil syndrome	64
▪ Eosinophilia-myalgia syndrome	40
Fibroblast Hyperplasia and Excessive Collagen Production by Fibroblasts—*Fibrosclerosing Disorders*	
▪ Juvenile hyaline fibromatosis	72
▪ Gingival fibromatosis	72
Excessive Mucin Production by Fibroblasts—*Mucinoses*	
▪ Pretibial myxedema	137
▪ Generalized myxedema	137
▪ Localized myxedema	137
▪ Reticular erythematous mucinosis and plaque-like mucinosis	62
▪ Connective tissue disease	61, 62, 63, 66, 68, 69
▪ Degos disease	146

Figure 67-1 Scleredema. Waxy, nonpitting induration of back skin.

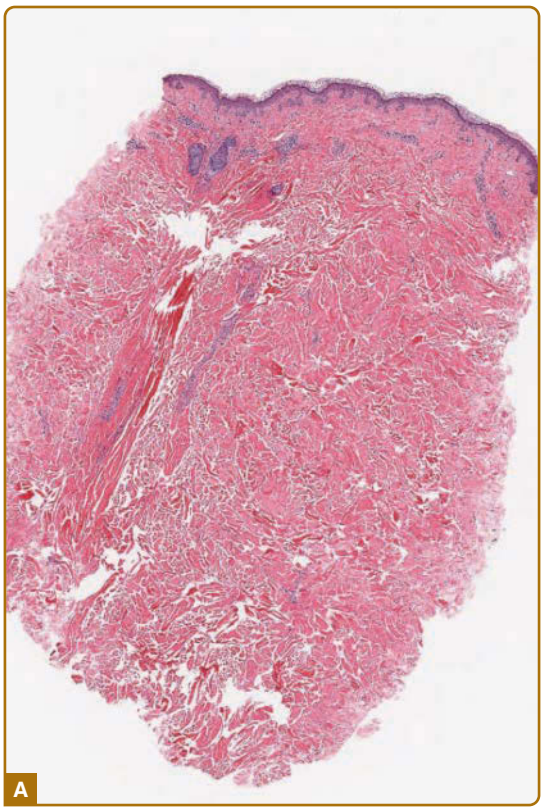

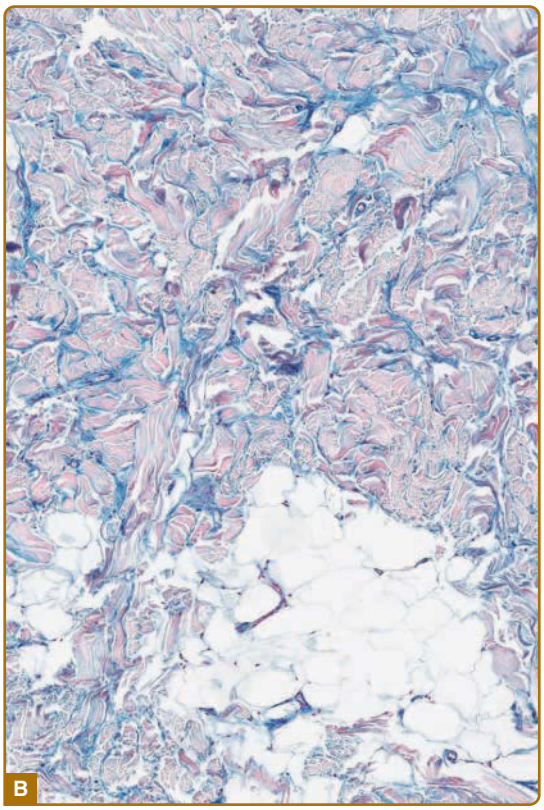

Figure 67-2 **A,** Scleredema. Thickened dermis characterized by enlarged collagen bundles separated by clear spaces (×15 original magnification). **B,** Scleredema. Mucin deposition identified in clear spaces by acid mucopolysaccharide stain (×80 original magnification).

PROGNOSIS AND CLINICAL COURSE

Postinfectious scleredema usually abates in 1 to 2 years. Scleredema associated with adult-onset diabetes tends to be protracted, although some patients appear to improve with better glucose control. Gammopathy-associated scleredema is more chronic and can be resistant to many therapies.

TREATMENT

Antibiotics do not appear to affect the course of postinfectious scleredema. Treatment of the associated disease (eg, improved glucose control or treatment of paraproteinemia) may lead to improvement. Ultraviolet A1 phototherapy has been variably effective in some patients,[9-11] as has psoralen plus ultraviolet A phototherapy.[11,12] Treatment with methotrexate did not provide benefit in a series of cases of scleredema. Scleredema has responded to local radiotherapy or electron-beam irradiation. Scleredema associated with monoclonal gammopathy has responded to extracorporeal photopheresis and intravenous immunoglobulin.[13]

SCLEROMYXEDEMA

AT-A-GLANCE

- Chronic, progressive condition characterized by dermal fibrosis and mucinosis and normal thyroid function.
- Usually associated with paraproteinemia (typically immunoglobulin G-kappa).
- Clinical variants
  - Generalized, confluent lichenoid eruption (scleromyxedema).
  - Discrete papular (rarely nodular) eruption on the trunk or extremities (lichen myxedematosus).
    - Papular mucinosis of infancy.
    - Papular mucinosis of adulthood.
    - Self-healing papular mucinosis.
    - Acral persistent papular mucinosis.
    - Nodular variant.
  - Localized or generalized lichenoid plaques (but distinct from plaque-like mucinosis/reticulated erythematous mucinosis).
  - Urticarial plaques
- Histopathology: superficial to mid-dermal fibroplasia and mucin deposition.
- Clinical course: chronic progressive course and poor outcome in generalized, systemic cases; localized and self-healing forms have a better prognosis.
- Treatment: correct paraproteinemia: through clonal plasma cell targeted therapies, intravenous immune globulin, autologous stem-cell transplant.

EPIDEMIOLOGY

Lichen myxedematosus/scleromyxedema is a rare disease afflicting men and women with equal frequency and symptom onset in mid to later life.[14-16]

PATHOGENESIS

The pathogenesis of scleromyxedema is unknown. Most patients with scleromyxedema have a monoclonal paraproteinemia, typically designated as monoclonal gammopathy of undetermined significance. Rare patients meet criteria for multiple myeloma. Excessive hyaluronate production and fibroblast proliferation are observed, but support for a direct effect of the monoclonal protein on fibroblasts is lacking.[17,18] Indirect mechanisms appear to include circulating cytokines, inflammatory mediators, and fibroblast precursor cell lineages that migrate from the blood, take up residence in the dermis and, in more extensive cases, in other tissues, and synthesize mucin.

CLINICAL FINDINGS

Several distinct clinical presentations, and hence nosologic designations have been recognized. Although there is considerable clinical overlap and patients may show progression from limited to widespread involvement, it is useful to distinguish localized from generalized disease as well as patients that present with discrete papules from those with confluent plaques. The generalized lichenoid eruption consists of numerous minute (1 to 3 mm) papules scattered on the extremities and the trunk. Scleromyxedema presents with confluent lichenoid plaques. Individual lesions and plaques may exhibit marked erythema or hyperpigmentation. The face is involved in most cases, resulting in significant deformity, "bovine facies" (Fig. 67-3). The trunk and extremities are usually affected (Fig. 67-4A) and often results in decreased flexibility and range of motion in the involved areas (Fig. 67-4B).

A monoclonal paraproteinemia of undetermined significance, usually immunoglobulin G λ (IgG-λ) type

Figure 67-3 Scleromyxedema. Marked, nodular induration of facial skin with accentuation of skin folds.

is identified in most patients. Paraproteinemia is less common in localized variants. Progression to multiple myeloma occurs rarely.

Muscle weakness, contractures, restrictive lung disease, upper airway involvement, pulmonary hypertension, esophageal dysmotility, and neurologic disorders (seizures, motor impairment, carpal tunnel syndrome, depression, memory loss, aphasia, peripheral neuropathy, and psychosis) have been reported in association with scleromyxedema. Thyroid function is normal by definition.

HISTOPATHOLOGY

The classical histopathologic findings in scleromyxedema consist of superficial to mid-dermal mucin deposition with admixed fibroblast proliferation (Fig. 67-5). Recently, Rongioletti et al reported an interstitial proliferation of epithelioid histiocytes imparting a granuloma annulare-like pattern in 10 of 44 patients studied.[19] A mild perivascular and interstitial T-cell infiltrate is also seen, but inflammation is rarely a prominent feature. Occasional multinucleated histiocytes with or without elastophagocytosis may be identified in biopsies of scleromyxedema. A highly unusual histologic presentation with a marked dermal granulomatous infiltrate was observed in association with fibromucinous deposition in a 56-year-old male with scleromyxedema.[20]

Moreover, scleromyxedema is histologically distinct from other mucinoses as well as sclerosing and

Figure 67-4 **A,** Scleromyxedema. Thickened bound-down skin of the back. **B,** Scleromyxedema. Confluent lichenoid papules and indurated skin of the hand and wrist.

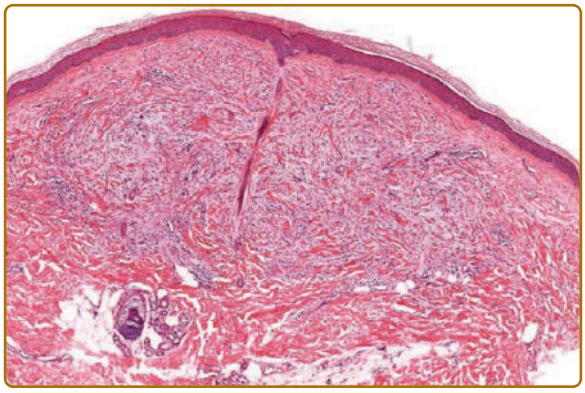

Figure 67-5 Scleromyxedema. Superficial to mid-dermal fibroplasia and increased mucin (×40 original magnification).

fibrosing conditions. Nephrogenic systemic fibrosis (previously designated nephrogenic fibrosing dermopathy) shows close histologic resemblance to scleromyxedema. However, the pannicular septae are the focus for histologic distinction: they are consistently involved in nephrogenic systemic fibrosis and never involved in scleromyxedema. Moreover, scleromyxedema tends to be restricted to the upper half of the dermis and nephrogenic systemic fibrosis becomes more prominent in the lower dermis and then extends to pannicular septae.

PROGNOSIS AND CLINICAL COURSE

Localized, "self-healing" variants are usually confined to the skin and are self-limiting. However, prospective followup and caution is advised as some cases fitting criteria for localized disease have been associated with internal organ involvement or progression to more generalized disease (so-called atypical papular mucinosis). Scleromyxedema usually follows a chronic and progressive clinical course with more systemic organ and tissue involvement, and a poor outcome is expected. Respiratory failure, cerebral disease, and infection usually lead to a gradual decline and death.

TREATMENT

Melphalan had been used for decades to treat scleromyxedema with variable efficacy.[21-23] Other therapies directed toward quantitatively reducing or ameliorating the effects of the paraproteinemia have shown variable results. Agents or therapies with reported efficacy include: glucocorticoids,[24] intravenous immunoglobulin,[25] thalidomide,[26] extracorporeal photophoresis,[27] interferon-α,[28] combination chemotherapy,[29] and psoralen and ultraviolet A.[30] Partial to complete remission was achieved in 8 of 10 patients treated with intravenous immunoglobulin.[31] Autologous peripheral blood stem cell transplantation has resulted in dramatic remission of scleromyxedema in patients with severe disease.[32]

REFERENCES

1. Buschke A. Ueber Sclerodermie. *Berl Klin Wochenschr*. 1902;39:955.
2. Greenberg LM, Geppert C, Worthen HG, et al. Scleredema adultorum in children. *Pediatrics*. 1963;32:1044.
3. Oikarinen A, Ala-Kokko L, Palatsi R, et al. Scleredema and paraproteinemia. Enhanced collagen production and elevated type I procollagen messenger RNA level in fibroblasts grown from cultures from the fibrotic skin of a patient. *Arch Dermatol*. 1987;123:226.
4. Haapasaari KM, Kallioinen M, Tasanen K, et al. Increased collagen propeptides in the skin of a scleredema patient but no change in re-epithelialisation rate. *Acta Derm Venereol*. 1996;76:305.
5. Kobayashi T, Yamasaki Y, Watanabe T. Diabetic scleredema: a case report and biochemical analysis for glycosaminoglycans. *J Dermatol*. 1997;24:100.
6. Ohta A, Uitto J, Oikarinen AI, et al. Paraproteinemia in patients with scleredema: clinical findings and serum effects on skin fibroblasts in vitro. *J Am Acad Dermatol*. 1987;16:96.
7. Wright RA, Bernie H. Scleredema adultorum of Buschke with upper esophageal involvement. *Am J Gastroenterol*. 1982;77:9.
8. Basarab T, Burrows NP, Munn SE, et al. Systemic involvement in scleredema of Buschke associated with IgG-kappa paraproteinaemia. *Br J Dermatol*. 1997;136:939.
9. Janiga JJ, Ward DH, Lim HW. UVA-1 as a treatment for scleredema. *Photodermatol Photoimmunol Photomed*. 2004;20:210.
10. Eberlein-König B, Vogel M, Katzer K, et al. Successful UVA1 phototherapy in a patient with scleredema adultorum. *J Eur Acad Dermatol Venereol*. 2005;19:203.
11. Rongioletti F, Kaiser F, Cinotti E, et al. Scleredema. A multicentre study of characteristics, comorbidities, course and therapy in 44 patients. *J Eur Acad Dermatol Venereol*. 2015;29:2399.
12. Hager CM, Sobhi HA, Hunzelmann N, et al. Bath-PUVA therapy in three patients with scleredema adultorum. *J Am Acad Dermatol*. 1998;38:240.
13. Eastham AB, Femia AN, Velez NF, et al. Paraproteinemia-associated scleredema treated successfully with intravenous immunoglobulin. *JAMA Dermatol*. 2014;150:788.
14. Montgomery H, Underwood LJ. Lichen myxedematosus; differentiation from cutaneous myxedemas or mucoid states. *J Invest Dermatol*. 1953;20:213.
15. Gottron HA. Skleromyxodem (eine eigenartige euscheinungs-form von myxothesaurodermie). *Arch Dermatol Syph*. 1954;199:71.
16. Montgomery H. Diseases of metabolism. In: *Dermatopathology*. NewYork, NY: Harper & Row; 1967:830.
17. Harper RA, Rispler J. Lichen myxedematosus serum stimulates skin fibroblast proliferation. *Science*. 1978;199:545.
18. Yaron M, Yaron I, Yust I, et al. Lichen myxedematosus (scleromyxedema) serum stimulates hyaluronic acid and prostaglandin E production by human fibroblasts. *J Rheumatol*. 1985;12:171.
19. Rongioletti F, Merlo G, Carli C, et al. Histopathologic characteristics of scleromyxedema: a study of a series of 34 cases. *J Am Acad Dermatol*. 2016;74:1194.
20. Stetsenko GY, Vary JC Jr, Olerud JE, et al. Unusual granulomatous variant of scleromyxedema. *J Am Acad Dermatol*. 2008;59:346.
21. Feldman P, Shapiro L, Pick AI, et al. Scleromyxedema. A dramatic response to melphalan. *Arch Dermatol*. 1969;99:51.
22. Harris RB, Perry HO, Kyle RA, et al. Treatment of scleromyxedema with melphalan. *Arch Dermatol*. 1979;115:295.
23. Dinneen AM, Dicken CH. Scleromyxedema. *J Am Acad Dermatol*. 1995;33:37-43.
24. Rayson D, Lust JA, Duncan A, et al. Scleromyxedema: a complete response to prednisone. *Mayo Clin Proc*. 1999;74:481.

25. Lister RK, Jolles S, Whittaker S, et al. Scleromyxedema: response to high-dose intravenous immunoglobulin (hdIVIg). *J Am Acad Dermatol*. 2000;43:403.
26. Caradonna S, Jacobe H. Thalidomide as a potential treatment for scleromyxedema. *Arch Dermatol*. 2004;140:277.
27. Berkson M, Lazarus GS, Uberti-Benz M, et al. Extracorporeal photochemotherapy: a potentially useful treatment for scleromyxedema. *J Am Acad Dermatol*. 1991;25:724.
28. Tschen JA, Chang JR. Scleromyxedema: treatment with interferon alfa. *J Am Acad Dermatol*. 1999;40:303.
29. Farr PM, Ive FA. PUVA treatment of scleromyxoedema. *Br J Dermatol*. 1984;110:347.
30. Laimer M, Namberger K, Massone C, et al. Vincristine, idarubicin, dexamethasone and thalidomide in scleromyxedema. *Acta Derm Venereol*. 2009;89:631.
31. Blum M, Wigley FM, Hummers LK. Scleromyxedema: a case series highlighting long-term outcomes of treatment with intravenous immunoglobulin (IVIG). *Medicine (Baltimore)*. 2008;87:10.
32. Lacy MQ, Hogan WJ, Gertz MA, et al. Successful treatment of scleromyxedema with autologous peripheral blood stem cell transplantation. *Arch Dermatol*. 2005;141:1277.

Chapter 68 :: Sjögren Syndrome

:: Akiko Tanikawa

AT-A-GLANCE

- A chronic, multisystem autoimmune disease, characterized by chronic inflammation involving the exocrine glands.
- Salivary and lachrymal glands are affected predominantly, leading to dry mouth and dry eyes.
- May occur alone (primary Sjögren syndrome, pSS), or may coexist with other systemic connective tissue disorders (secondary Sjögren syndrome).
- Extraglandular manifestations of primary Sjögren syndrome include fatigue, Raynaud phenomenon, purpura, arthritis, vasculitis, interstitial pulmonary disease, peripheral or central neuropathy, and autonomic nervous dysfunction.
- Patients with systemic manifestations are at higher risk of developing lymphoma.
- Treatment of sicca symptoms is mainly symptomatic, whereas management of extraglandular manifestations is similar to that of other autoimmune diseases.
- Both innate and adaptive immunity contribute to pSS pathogenesis and pSS is associated with upregulation of the Type 1 interferon signaling pathway.

INTRODUCTION

Sjögren syndrome (SS) is a chronic systemic autoimmune disorder characterized by lymphocytic infiltration and destruction of exocrine glands and epithelia leading to dry mouth, dry eyes, and B lymphocyte hyperreactivity. SS can occur as an isolated disorder; primary Sjögren syndrome (pSS); it also may occur in association with other autoimmune condition such as rheumatoid arthritis, systemic lupus erythematosus (SLE) and other collagen disease; secondary SS. Disease may be localized to the salivary and lachrymal glands, but more than one-third of patients develop systemic manifestations. The clinical presentation can vary from mild sicca symptoms, fatigue, and arthralgias to severe systemic symptoms involving multiple organ systems. A small but definitely number of patients of the pSS develop lymphoma with higher incidence than that of the general population or patients with other autoimmune diseases (Fig. 68-1).

EPIDEMIOLOGY

SS is one of the most common rheumatic autoimmune diseases. SS predominantly affects women, with a female to male ratio of 9:1. Patients are most commonly diagnosed in their fourth and fifth decades of life, but it can affect any age, including the elderly and children. SS has a worldwide distribution. The estimated annual incidence rate of pSS ranged from 3.9 to 5.3 per 100,000 in several studies.[1] The prevalence rates can vary considerably, depending on the classification criteria used. The estimated prevalence rate in the adult general population from previous studies, mainly in whites, was between 0.2% and 2.7%, whereas the estimated prevalence rate from Asian studies was 0.03% to 0.77%.[2,3]

ETIOLOGY AND PATHOGENESIS

Although the precise pathogenesis of SS remains largely unknown, genetic and epigenetic disposition, various environmental factors, including viral and other pathogenic infections, and hormones have been implicated in the pathogenesis of the disease. Recent studies have shown that both innate and adaptive immunity contribute to the development of pSS; the Type 1 interferon (IFN) signaling pathway plays a central role in the pathogenesis of the disease. Increasing apoptosis in epithelial cells of damaged salivary glands, plasmacytoid dendritic cells (pDCs), autoreactive lymphocytes, and autoantibodies are considered to play significant roles in perpetuating the chronic auto-feedback inflammatory process.[4]

IMMUNOGENETIC FACTORS

The role of genetic factors in SS was recognized in family studies where first-degree relatives of patients had an increased prevalence of SS.[5,6] Such family clustering was further observed among first-degree relatives of individuals with anti-Ro/SSA antibodies, regardless of their clinical diagnoses (SS, systemic lupus erythematosus, or even healthy controls).[7]

There is a well-established association between SS or anti-Ro/SSA and anti-La/SSB antibodies with HLA class genes.[8] The genetic loci significantly associated with pSS are HLA DQA1*0501 and HLA DQB1*0201 in white patients, but the pattern differs among ethnic groups, studies, and populations.[9,10] In 2013, the first genomewide association study (GWAS) identified several susceptibility genes, such as IRF5 (interferon regulatory factor), STAT4 (signal transducer and activator of transcription 4), IL12A (gene regulating innate and adaptive immunity), BLK (B lymphoid tyrosine kinase), and CXCR5 (encoding a protein related to

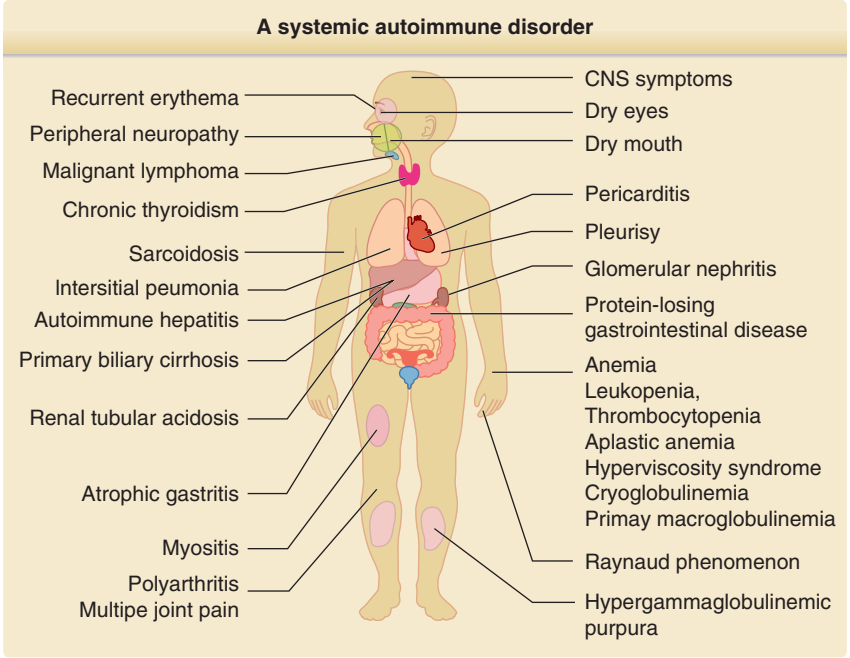

Figure 68-1 Sjögren syndrome. A systemic autoimmune disorder.

B-cell activation and localization), as risk variant genes related to SLE and SS.[11] IRF5 is an important transcription factor involved in upregulating the Type I IFN pathway, which is activated by toll-like receptor (TLR) signals or viral infection and the production of inflammatory cytokines, whereas STAT 4 is a protein involved in the Type II IFN pathway and activating the adaptive immune system.[11-13] TNFAIP3 and TNIP genes were also identified in GWAS, which regulate nuclear factor kappa-light-chain enhancer of activated B-cell (NF-κB) signaling. A TNFAIP3 mutation found in the coding region of TNFAIP3 has been correlated with an increased risk of lymphoma.[14]

A recent epigenome-wide DNA methylation association study (EWAS) highlighted new links between epigenetic changes and disease-related inflammatory processes in the salivary glands, which is a major target organ in pSS. It also suggests the possibility that epigenetic factors contribute to the pathogenesis of pSS. MicroRNA expression patterns in the salivary glands have been demonstrated linked with the disease.[15] Recent studies have shown that the Ro60 autoantigen binds endogenous retroelements and regulates inflammatory gene expression,[16] but knowledge in this area is still limited.[4]

INNATE AND ADAPTIVE IMMUNITY

Type I IFN (IFN) is a key cytokine in the innate immune system, activating antigen- presenting cells and influencing autoimmune responses. Increased Type I IFN activity has been shown in the sera of pSS patients, and IFN-α also has been detected in the minor salivary glands of patients. Many IFN-stimulated genes and proteins are overexpressed, which has been called the "IFN signature." This has been found in about 50% of pSS patients and confirmed in the peripheral blood and/or salivary glands of patients.[17] Previous studies have shown that when the Type I IFN receptor or IFN itself is eliminated, many features of the disease are also eliminated. This supports the theory, based on previous SS research, that Type I IFN has a central role in the pathogenesis of SS.[18-22] Discovery of risk variants in IRF5, STAT4, and other susceptibility loci suggests that genetic polymorphism is a major factor in the onset of SS, activating the IFN pathway that regulates T-cell and B-cell immune responses.

BAFF (B-cell activating factor), a member of the TNF family and a cytokine produced by the activated IFN signaling pathway, is related to the adaptive immune system. BAFF promotes B-cell maturation, proliferation, and survival. BAFF has been shown to contribute to the pathogenesis of SS. First, levels of BAFF are increased in the salivary glands of SS patients and upregulated by IFN-α.[23] Second, transgenic mice that overexpress BAFF develop clinical manifestations of SS and SLE and have an increased risk of developing lymphoma versus wild-type mice.[24] Third, BAFF is usually produced in innate immune responses, but after damage to salivary gland cells by RNA viruses or TLR3 ligands, large amounts of BAFF can be produced by epithelial cells. Furthermore, the serum level of BAFF is known to correlate with the levels of anti-Ro/SSA antibodies, anti-La/SSB antibodies, and rheumatoid factor.[25] BAFF is also related to follicular structure (also called germinal center [GC]-like structure) formation. GC-like structures are known to be associated with an increased risk of lymphoma and may occur in one-fifth of patients with pSS.[26]

ENVIRONMENTAL FACTORS

Several factors are considered major environmental triggers that interact with genetic and epigenetic factors to cause disease onset. The strong predominance of females with the disease suggests gender-specific predisposing factors. Although sex hormones are obvious targets, there is no proof that the difference in the pathogenesis between males and females is due to sex hormones alone.[27,28]

Viruses, especially Epstein–Barr virus (EBV), are known to replicate in oropharyngeal and lachrymal glands, resulting in the hypothesis that these viruses may be involved in the pathogenesis of SS. In fact, genetic material from EBV was detected by DNA hybridization in SS salivary tissue, but it was also found in normal individuals, so the result is controversial.[29,30] In a Japanese cohort, defective human T-lymphotropic virus-I genome was isolated from salivary gland tissue.[31] Hepatitis C virus[32-34] and HIV are also thought of as initiators of the disease, with the presence of chronic inflammation in salivary glands, and presenting clinical symptoms similar to SS.[35] Other viruses, such as cytomegalovirus,[36] coxsackie A virus,[37] and endogenous retroviruses, also have been proposed as causative agents.[38] Recent studies further showed that EBV infections promoted the release of Ro/SSA and La/SSB ribonucleoprotein complexes through epithelial apoptosis.[39] The EBV-encoded small RNA and La/SSB complex is known to activate Type I IFN expression through activating TLR 3.[40] However, no single virus has been clearly implicated in the pathogenesis of SS. Animal model studies support the hypothesis that there can be a delay, for years, between viral infections (such as cytomegalovirus) and the development of SS.[36] Stress,[41] occupational exposure,[42] and personality features also have been proposed as triggers of the disease.[43,44]

GLANDULAR EPITHELIUM

In histopathology, sections of salivary and lachrymal glands in pSS are characterized by periductal mononuclear infiltrate. Most of the infiltrating cells are $CD4^+$ T lymphocytes, although $CD8^+$ cytotoxic T cells and plasmacytoid dendritic cells (pDCs) are also detected. Activated B lymphocytes, including immunoglobulin-secreting cells, are also present.

The salivary glands are thought to be the first and main target in pSS. The role of the salivary gland epithelial cells in pSS has been established. Studies have indicated that epithelial cells play an active role in disease pathogenesis and this is referred to as "autoimmune epithelitis."[45] First, glandular cells, including duct and acinar epithelial cells, express HLA class II major histocompatibility complex (MHC) molecules and costimulator CD86; these interact with CD28 on T cells and contribute to recruiting inflammatory cells.[46] Second, damage to the salivary gland by environmental factors, such as viruses, causes dysfunction in the gland, leading to activation of epithelial cells, increasing apoptosis, and elevated Type I IFN production by pDCs. Apoptotic keratinocytes are known to relocalize Ro/SSA and La/SSB from the nucleus to the cell surfaces in a complex, presenting autoantigens to autoantibodies. Thus, epithelial cells may not only be the target of the disease but may also function as antigen-presenting cells, inducing further autoimmune responses through activating TLR and IFN signaling pathways.[47-49] Previous studies have shown that epithelial cells express TLR 3, 7, and 9 when in an activated condition.[39,50] They can also produce Type I IFN by themselves, inappropriately, through activated TLR 3 within the gland[50] and become involved in perpetuating this chronic autofeedback inflammation. Third, such epithelial cells also produce large amounts of BAFF.[17] Finally, some epithelial cells express Fas and Fas ligand[51] and, as a consequence, undergo apoptosis; others may be destroyed by perforin, granzymes, and other cytotoxins produced by lymphocytes.[52] Extraglandular manifestations occur as a result of similar lymphocytic infiltration in other organs. "Autoimmune epithelitis" well describes the systemic nature of SS.

AUTOANTIBODIES

Autoantibodies are hallmarks of systemic autoimmune diseases, including SS. The best-defined autoantibodies in SS are the anti-Ro/SSA and anti-La/SSB antibodies.[53] Although the pathogenic role of any particular autoantibody remains undefined, both are targeted against ribonucleoprotein antigens. Anti-Ro/SSA recognizes 2 RNA-binding proteins (the 52-kDa or the 60-kDa protein), whereas anti-La/SSB antibodies recognize RNA polymerase III. Anti-Ro/SSA antibodies are found in more than 70% of patients with SS but are not specific for SS and are frequently found in SLE and other autoimmune diseases, even when there is no symptom or sign of oral or ocular dryness. Anti-La/SSB antibodies are more specific; it is present in 50% of patients with pSS or SS/SLE but is rarely seen in other diseases.[54] Although the pathogenic role of these antibodies is undefined, previous studies showed that Ro and La are expressed on the surface of apoptotic epithelial cells[48]; it is possible that an immune response against these antigens contributes to inflammation in the gland and further immunoreactive pathways. The most compelling in vivo evidence for a pathogenic role for these autoantibodies comes from newborns with fetal heart block, born to women with anti-Ro/SSA and/or anti-La/SSB antibodies. These antibodies can cross the placenta and bind to Ro and La antigens located on the cell surface of fetal myocardial tissue, leading to fetal heart block.[55] Other autoantibodies, such as antinuclear antibodies (ANA) and rheumatoid factor (RF), are frequently present in patients with both primary and secondary SS. Although they lack specificity, they are markers of a systemic autoimmune response and thus can help distinguish SS from other causes of salivary or lachrymal gland dysfunction. A large clinical study

performed in Spain suggested the group of patients with anti-Ro/La antibodies had the highest prevalence among most systemic, hematologic, and immunologic alternations (higher frequency of Raynaud phenomenon, altered parotid scintigraphy, positive salivary gland biopsies, peripheral neuropathy, thrombocytopenia, and rheumatoid factor). Hypocomplementemia was associated with a higher frequency of vasculitis, lymphoma, and cryoglobulins, and higher frequencies of parotid enlargement, vasculitis, and leucopenia.[56] SSA positivity could also be related to extraglandular manifestations, vasculitis, hematologic abnormalities, and serological hyperreactivity.[57,58]

Further research has focused on identifying antibodies more specific for SS, such as anti-α-fodrin and antimuscarinic acetylcholine receptor antibodies,[59] but the results have been controversial. The major stimulus for saliva production is the binding of acetylcholine to muscarinic acetylcholine receptors. The hypothesis that oral and ocular dryness could result from antibodies antagonizing the muscarinic acetylcholine receptor-3 is intriguing.[59] These antibodies have been demonstrated to play an essential role in glandular dysfunction in the non-obese diabetic (NOD) mouse model of SS, possibly through an inhibitory effect on the receptor.[60] In humans, however, results are still contradictory because multiple attempts to detect these antibodies with conventional immunologic methods have failed.[61,62]

A small group of patients positive for anticentromere autoantibody (ACA) present a clinical picture similar to that of limited scleroderma. About 1% to 17% of SS patients have been reported to be positive for ACA.[55,63] There is no difference between ACA-positive and ACA-negative patients in terms of female dominance or salivary gland damage and dysfunction. The ACA-positive group usually has a higher prevalence of Raynaud phenomenon and thyroid dysfunction than ACA-negative patients. This group also shows a higher frequency of vasculitis, peripheral neuropathy, and primary biliary cirrhosis, but lymphoma is the same as in the ACA-negative group.[64-68] Positivity for antimitochondrial antibody (AMA) also has been demonstrated to be related to primary biliary cirrhosis.[69]

CLINICAL FINDINGS

Sjögren syndrome (SS) is a multifocal autoimmune disease, with systemic involvement in one-third of patients. The clinical presentation is very wide-ranging, from dry eyes, dry mouth, general fatigue, subfever, myalgia, and arthralgia, to multiple organ dysfunction.[70]

EXOCRINE GLAND INVOLVEMENT

The characteristic feature of SS is exocrine gland dysfunction, leading to the classic sicca symptoms of xerostomia (dry mouth) and xerophthalmia or keratoconjunctivitis sicca (dry eyes).

XEROSTOMIA

Oral dryness is a principal symptom of SS, caused by decreased saliva secretion, which is persistent and continuous throughout the day and night and can significantly compromise quality of life. Reduced salivation causes difficulty in chewing and swallowing dry foods. Dryness of the tongue and oral mucosa leads to an altered sense of taste and, at times, produces burning discomfort, especially when eating acidic or spicy foods. Physical examination may reveal a red and fissured tongue with characteristic atrophy of the filiform papillae (Fig. 68-2) or angular cheilitis. Ulcerations may be found, particularly in SS patients with dentures, usually in proximity to the mucosal surface that makes contact with the denture.

Normal saliva has antimicrobial properties, so a lack of saliva can predispose to infections. Oral thrush is common and can be manifested as pseudomembranous or erythematous mucosal lesions. Furthermore, patients with SS have an increased incidence of caries. A characteristic feature of caries in SS is its primary location, at the cervical and incisal regions of the teeth.

Bilateral salivary gland enlargement typically occurs in the parotid glands of SS patients. It is frequently nontender, and it can be recurrent or chronic. Painful, unilateral parotid enlargement should raise the suspicion of an infection or a salivary gland stone. In cases of persistent unilateral parotid gland enlargement, the presence of lymphoma should be excluded (Table 68-1). Medical causes of oral dryness, such as dehydration, diabetes, viral infections, and drug treatment, should be considered when evaluating a patient for Sjögren syndrome.

Figure 68-2 The characteristic tongue of patients with Sjögren syndrome. A red and fissured tongue with characteristic atrophy of the filiform papillae.

TABLE 68-1
Differential Diagnosis of Parotid Gland Swelling[a]

Bilateral	Viral infections	Mumps Epstein–Barr, cytomegalovirus, coxsackie, influenza HIV, Human T-lymphotropic virus-I (HTLV-I) Hepatitis C
	Immune mediated	Sjögren syndrome Sarcoidosis IgG4-related disease Amyloidosis
	Metabolic	Diabetes mellitus Hyperlipoproteinemia Hepatic cirrhosis Chronic pancreatitis
	Endocrine	Acromegaly Gonadal hypofunction
Unilateral	Other	Alcohol Recurrent parotitis of the childhood
	Bacterial infections	
	Neoplasms	Mainly lymphomas, salivary gland tumor
	Sialolithiasis	

[a]Medical causes of oral dryness, such as dehydration, diabetes, viral infections, or drug treatment, should be considered when evaluating a patient for Sjögren syndrome.

KERATOCONJUNCTIVITIS SICCA

Ocular dryness is the other dominant feature of SS. A burning and itching sensation in the eyes, commonly exacerbated by smoke, is caused by lack of tear production. Patients frequently complain of intolerance to contact lenses. Paradoxically, the quantity of tears produced during crying may not be affected. Physical evaluation shows corneal injection and mucous discharge in the lower fornix. Enlarged lachrymal glands have been described in Sjögren patients, but occur less commonly than enlarged salivary glands. The constellation of symptoms and signs indicating dry eyes constitutes keratoconjunctivitis sicca.

OTHER SICCA MANIFESTATIONS

Cutaneous xerosis, a term used to describe dryness of the skin, is very common in SS, with a frequency varying between 23% and 68%. The most common symptoms of xerosis are nonspecific pruritus, burning sensations, and a pin prick–like feeling. Physical examination reveals roughness, fine scaling, and loss of elasticity in the skin. The pathogenesis of xerosis is unknown. Impairment of the sweat glands is considered an important factor because decreased sweating has been reported in SS patients. A recent study indicated that xerosis may be related to increased epidermal proliferation with disturbed epidermal differentiation.[71]

Xerostomia predisposes to angular cheilitis, which presents as recurrent, symmetric, itching fissures.

Eyelid dermatitis is defined by the presence of erythematous, infiltrated, and lichenified lesions of the eyelids associated with itching and foreign body sensations.

Anhidrosis/hypohidrosis also has been reported as an exocrine manifestation, but is rare.[72,73]

Dryness of the upper respiratory tract can cause epistaxis, hoarseness, and bronchial hyperresponsiveness. Another common complaint in women with the disease is vaginal dryness, which may lead to an increased incidence of vaginal infections and dyspareunia.

EXTRAGLANDULAR INVOLVEMENT

SKIN INVOLVEMENT

Cutaneous manifestations are common extraglandular features of SS (Table 68-2).[74]

Hypergammaglobulinemic Purpura: Purpuric macules are very common in SS (Fig. 68-3). Flat, nonpalpable, blanching purpura has been associated with an entity called benign hyperglobulinemic purpura, characterized by polyclonal hypergammaglobulinemia and rheumatoid factor positivity. Skin biopsies reveal ruptured blood vessels with complement deposition.[75]

Cutaneous Vasculitis: Cutaneous vasculitis (CV) can present as palpable purpura or urticarial vasculitis and occurs in about 9% of patients.[76]

TABLE 68-2
Cutaneous Manifestations of Sjögren Syndrome

- Hypergammaglobulinemic purpura
- Cutaneous vasculitis
  - Nonpalpable purpura
  - Palpable purpura
  - Urticarial vasculitis
  - Necrotizing vasculitis
- Annular erythema associated with primary Sjögren syndrome
- Erythema multiforme
- Erythema perstans
- Erythema nodosum
- Oral
  - Dry mucous membranes
  - Papillary atrophy of the tongue
  - Candidiasis
  - Angular cheilosis
- Eyelid dermatitis
- Alopecia
- Vitiligo

Figure 68-3 Non-palpable purpura with pigmentation in a patient with primary Sjögren syndrome.

Palpable purpura, which does not blanch when pressure is applied to the skin, is due to dermal vasculitis with extravasation of red blood cells, and typically involves the lower extremities and buttocks (Chap. 138). It represents an important marker of more severe disease and is associated with an increased risk of lymphoma development and mortality.[55] Histopathologically, palpable purpura can be divided into 2 groups. Neutrophilic inflammatory vascular disease is characterized by a predominantly neutrophilic infiltrate, fibrinoid necrosis, occlusion of the lumen, and extravasation of red blood cells, and is indistinguishable from classical leukocytoclastic vasculitis (Chap. 138). However, mononuclear inflammatory vascular disease is characterized by a mononuclear inflammatory infiltrate, with invasion of the blood vessel walls. Fibrinoid necrosis is present but less prominent. The clinical presentation of these 2 forms are indistinguishable, but neutrophilic inflammatory vascular disease is associated more strongly with markers of systemic autoimmunity, such as antinuclear antibodies and anti-Ro/SSA and anti-La/SSB antibodies, hypergammaglobulinemia, rheumatoid factor, and hypocomplementemia. Cryoglobulinemic vasculitis also can be seen in Sjögren patients and has the same cutaneous manifestations (Chap. 138).

Urticarial vasculitis is the second most frequent form of CV in SS and presents as pruritic wheals with erythema (Chap. 138). In contrast to true urticaria, individual lesions last for more than 24 hours and often resolve with hyperpigmentation. Biopsy of the skin lesions demonstrates a perivascular neutrophilic infiltrate, accompanied by leukocytoclasia.

Necrotizing vasculitis is not commonly seen in Sjögren syndrome.[77] It can present as palpable purpuric lesions of the lower extremities, which may ulcerate, finally resolving within 1 to 4 weeks. They heal with atrophy or scar tissue formation. This form of vasculitis has been observed more frequently in patients with more active disease; it has been associated with arthritis, Raynaud phenomenon, peripheral neuropathy, fever, and pulmonary or glomerular involvement. Antineutrophil cytoplasmic antibodies with perinuclear fluorescence can be found, but are uncommon in SS.

Annular Erythema Associated with Primary Sjögren Syndrome: Annular erythema associated with pSS is found primarily among Asian pSS patients who have anti-Ro/SSA (> 90%) and anti-La/SSB (~70%) antibodies. The characteristic and typical rash is an erythematous lesion with a wide elevated border and central clearing; fine scale, erosion, or a crust can be seen in some cases.[78,79] The lesion usually starts from a small indurate erythema that expands to an annular form; it can sometimes be polycyclic, and may heal without atrophy, scar, or pigmentation (Fig. 68-4). They are localized mainly on the faces of Asian patients (81%), but can also occur on the arms, trunk, and proximal thighs. Sunlight and cold exposure, mental stress, and pregnancy may be triggers of the lesions. Annular erythema associated with pSS occur in Asian patients with an occurrence of up to 47%, but is less common in whites, with an

Figure 68-4 Annular erythema associated with primary Sjögren syndrome in a young female patient presented with figurate annular erythema with raised border.

occurrence of 9%.[80] Because annular erythema associated with pSS shares a clinical presentation with subacute cutaneous lupus (SCLE), it is still debatable whether annular erythema associated with pSS is a variant of SCLE (annular SCLE), as proposed by Sontheimer in 1979,[81] but it seems to represent a distinct clinical and histopathologic entity.

The 2 conditions can hardly be distinguished from clinical presentations or laboratory investigations, such as positivity for anti-SSA/Ro and anti-SSB/La antibodies; they even show similar Ro/SS-A autoantibody epitopes and titer responses, but there are some distinct differences between the 2 conditions. First, annular erythema associated with pSS are located mainly on the face (>80%) in Oriental patients, but mainly on the trunk in white patients; second, the percentage of anti-SSA/Ro antibody–positive patients is different between annular erythema associated with pSS in Asians and SCLE in non-Asian patients; third, in histopathologic findings and finally, in HLA DR3 and 8 expression.[80,82,83] In histopathology, SCLE presents with liquefaction degeneration in the basal membrane zone, positivity for IgM/IgG in the dermal–epidermal junction with direct immunofluorescence (DIF), and cell infiltration being, basically, in the upper dermis, whereas in annular erythema associated with pSS, the dense cell infiltration is localized mainly around sweat glands, and nuclear dust also can be seen when they have vasculitis. Usually, no vacuolar changes are found in the dermal–epidermal junction, and no other findings suggest lupus erythematosus, such as epidermal atrophy or follicular plugging, and are usually negative for DIF.

SS and SLE share common genetic polymorphisms, such as IRF5, STAT4, and BLK[11]; thus, it is possible patients present similar manifestations in both conditions.[84] However, other studies have demonstrated notable differences in populations with risk haplotypes and risk alleles, including HLA.[85] Previous studies have also shown that Oriental patients have higher anti-SSA/Ro antibody titers and are more commonly negative for HLA DR3 and DR8, which show a high incidence in American patients.[82] It is well known that annular erythema associated with pSS are common in Asians but rare in whites, whereas SCLE are more common in whites but rare in Asians. The similarity between annular erythema associated with pSS and SCLE may be explained as a phenotype variation, from sharing the same genetic polymorphisms but having different risk haplotypes/alleles in different ethnic groups. At present, annular erythema associated with pSS is included in the EULAR-SS Disease Activity Index (ESSDAI), cutaneous domain, and classified as a moderate activity level manifestation in SS.[86]

Erythema Nodosum: Erythema nodosum, a painful nodular eruption of the anterior surface of the lower extremities, may occur but is rare in SS patients. Its presence should raise suspicion for sarcoidosis. Erythema multiforme–like lesions and superficial ill-defined patches (erythema perstans) also have been described in SS.

Figure 68-5 Pernio-like eruption in a patient with primary Sjögren syndrome.

Other Skin Manifestations Related to Peripheral Circulation and Temperature: Raynaud phenomenon is probably the most common abnormality. It can be seen in 15% to 35% of patients and can precede sicca symptoms by many years. Raynaud phenomenon in SS is not accompanied by telangiectasias, as seen in systemic sclerosis. Calcifications have been described, but are uncommon. Although Raynaud phenomenon is usually mild in pSS, it is a marker of a subgroup with increased risk of extraglandular manifestations.[87] Acrocyanosis, pernio-like eruptions (Fig. 68-5), livedo, and periungual hemorrhage also may be observed.

Other Cutaneous Manifestations: Other cutaneous manifestations including photosensitivity, indurated erythema, alopecia, vitiligo vulgaris, lichen planus, sarcoidosis, granuloma annulare, and psoriasis also may be seen in SS, albeit infrequently.

NONCUTANEOUS EXTRAGLANDULAR MANIFESTATIONS

Musculoskeletal Manifestations: A symmetric nonerosive polyarthritis is frequently seen in pSS. The distinction between pSS and rheumatoid arthritis may be difficult in this regard; the absence of rheumatoid factor and anti-CCP antibodies, and the absence of erosions on radiographs would favor SS over rheumatoid arthritis. Arthralgias and myalgias are common complaints but true myositis is rare in pSS.

Fatigue and Fibromyalgia: Fatigue is a common complaint in SS, but the pathogenesis remains unknown. Fibromyalgia is a distinct condition, rather similar to SS, and should always be considered in the differential diagnosis.

Thyroid Dysfunction: Thyroid dysfunction is a very common symptom, occurring in 10% to 70% of SS patients. It often presents as fatigue and patients easily become tired.

Visceral Manifestations: *Lungs*. Dry cough due to dryness of the tracheal mucosa is common (tracheobronchitis sicca). Rarely, patients may develop interstitial pneumonitis. Patients may also develop mucosa-associated lymphoid tissue (MALT) lymphoma in the lungs.

Renal and genitourinary manifestations include interstitial cystitis (50%), renal tubular acidosis, interstitial nephritis and, rarely, glomerulonephritis.

Gastrointestinal. Dysphagia due to xerostomia and esophageal dysmotility is common. *Helicobacter pylori* is associated with an increased risk of MALT lymphomas; thus, patients with gastritis should be checked for *H. pylori* and treated if found positive. An asymptomatic, chemical pancreatitis with high-serum amylase concentrations has been reported in 25% of patients.

Other conditions, such as celiac disease, primary biliary cirrhosis, and hypothyroidism may also occur with pSS. Because of these associations, a high index of diagnostic suspicion is warranted to identify and treat these conditions.

Neurologic manifestations can be divided into those that involve the CNS, and those that involve the peripheral nervous system and autonomic dysfunction.

The peripheral nervous system is involved in ~20% of patients with pSS.[88] However, this can increase to 70% when the patient has cutaneous vasculitis. The most common manifestations are peripheral axonal polyneuropathies, which are typically sensory. Another entity that has been described is a ganglionopathy involving the sensory ganglia of the posterior column. This starts with unilateral peripheral paresthesias, evolving over months to years to deep sensory impairment, positive Romberg sign, generalized areflexia, and ataxia.[89] Cranial neuropathies are also frequent. The most common form is unilateral trigeminal neuropathy; it usually spares the ophthalmic division, preserving the corneal reflex. Other cranial neuropathies may lead to Bell palsy (facial nerve), neural deafness, vestibular dysfunction (vestibule-cochlear), and diplopia (oculomotor, trochlear, abducent nerve).

The CNS also may be involved, although the prevalence and the spectrum of manifestations remain controversial. Manifestations similar to multiple sclerosis as well as transverse myelitis have been described. The latter is frequently associated with antiaquaporin-4 autoantibodies.

Lymphoma/Lymphoproliferative Disease: The incidence of lymphoma in SS patients is increased 15- to 44-fold, according to various studies[90]; 4% of patients during the first 5 years, 10% at 15 years, and 18% after 20 years, postdiagnosis, develop lymphomas.[91] Most of these are indolent, extranodal, marginal-zone B-cell lymphomas of MALT, but higher-grade lymphomas are also seen.[90] It has been proposed that at least a proportion of DLBCLs arise from MALT transformation, and lifelong follow-up of patients with pSS and MALT lymphoma is recommended.[92]

Various clinical and laboratory features have been correlated with an increased risk of lymphoma development. Lymphadenopathy, parotid enlargement, palpable purpura, low C4 serum levels, and cryoglobulins are the most consistent non-Hodgkin lymphoma/lymphoproliferative disease predictors. Some studies have also identified splenomegaly, low C3 serum levels, lymphopenia, and neutropenia as significant prognostic factors. Histopathologically, the presence of germinal center–like (GC-like) lesions in salivary biopsies of pSS are associated with an enhanced possibility of developing lymphoma. *TNFAIP3* and *TNIP1* gene variants were identified together with the *IRF5*, *STAT4*, and *CXCR5* genes in GWAS; polymorphisms in these genes also have been suggested to contribute to GC-like structure formation, and further studies have demonstrated associations between the gene variants and pSS and non-Hodgkin lymphoma.[93-95] In contrast, anti-Ro, anti-La, and antinuclear antibodies, rheumatoid factor, male gender, hypergammaglobulinemia, and anemia were not associated with lymphoma/lymphoproliferative diseases.[91,96-98]

Pregnancy: Recent studies have suggested that women with pSS may experience more complications in pregnancy than healthy controls. Significant increases in the rates of spontaneous abortions, preterm deliveries, and low-body-weight infants were reported. The mechanism of the lower body weight was suggested to be due to underlying placental insufficiency, related to the autoimmune background.[99] Moreover, carriers of the Ro/SSA and La/SSB antibody can transmit it through the placental circulation to the fetus. These antibodies (anti-Ro/SSA, anti-La/SSB) can cause congenital heart block (CHB) or neonatal lupus (NLE), characterized by an annular rash with central regression or mild atrophy in the scalp and around the eyes, as well as hepatic and hematologic abnormalities. The skin lesions can be variable and appears in infants at a few weeks of age. Although the rash typically resolves spontaneously at 6-8 months of age, the heart block is permanent and requires the placement of a pacemaker in ~60% of patients. Expectant mothers with Ro/SSA and La/SSB antibodies should be counseled about this risk, and their fetuses should be followed closely for the development of fetal heart block.

DIAGNOSIS AND DIAGNOSIS TESTS

The diagnosis of SS in a patient with complaints of oral and ocular dryness requires evaluation by a dentist or salivary gland specialist, such as an otorhinolaryngologist, and an ophthalmologist, for specialized tests to quantify mucosal dryness, as well as laboratory evidence of autoantibodies and a salivary gland biopsy for evidence of inflammation within the gland itself. Unlike other autoimmune disorders, SS still lacks universally accepted classification criteria. Several sets of diagnostic criteria have been developed and used by various groups over time, creating some confusion with regard to how to define SS. Recently, an international consensus group agreed on a set of criteria, and this revised American–European classification system

TABLE 68-3
Revised International Classification Criteria for Sjögren Syndrome

I. Ocular Symptoms: A positive response to at least one of the following questions:
1. Have you had daily, persistent, troublesome dry eyes for more than 3 mo?
2. Do you have a recurrent sensation of sand or gravel in the eyes?
3. Do you use tear substitutes more than 3 times a day?

II. Oral symptoms: A positive response to at least one of the following questions:
1. Have you had a daily feeling of dry mouth for more than 3 mo?
2. Have you had recurrently or persistently swollen salivary glands as an adult?
3. Do you frequently drink liquids to aid in swallowing dry food?

III. Ocular signs: Objective evidence of ocular involvement defined as a positive result for at least one of the following 2 tests:
1. Schirmer test, performed without anesthesia (≤5 mm in 5 min)
2. Rose Bengal score or other ocular dye score (≥4 according to the van Bijsterveld scoring system)

IV. Histopathology: In minor salivary glands (obtained through normal-appearing mucosa) focal lymphocytic sialoadenitis, evaluated by an expert histopathologist, with a focus score ≥1, defined as a number of lymphocytic foci (which are adjacent to normal-appearing mucous acini and contain more than 50 lymphocytes) per 4 mm^3 per glandular tissue

V. Salivary gland involvement: Objective evidence of salivary gland involvement defined as a positive result for at least one of the following diagnostic tests:
1. Unstimulated whole salivary flow (<1.5 mL/15 min)
2. Parotid sialography showing the presence of diffuse sialectasias (punctuate, cavitary, or destructive pattern), without evidence of obstruction in the major ducts
3. Salivary scintigraphy showing delayed uptake, reduced concentration, and/or reduced excretion of tracer

VI. Autoantibodies: Presence in the serum of the following autoantibodies: antibodies to Ro/SSA, La/SSB or both

Reproduced with permission from BMJ Publishing Group Ltd: Vitali C et al. Classification criteria for Sjögren's syndrome: A revised version of the European criteria proposed by the American- European Consensus Group. *Ann Rheum Dis*. 2002;61:554.

TABLE 68-4
Proposed Classification Criteria for Sjögren Syndrome

The classification of SS, which applies to individuals with signs/symptoms that may be suggestive of SS, will be met in patients who have at least 2 of the following 3 objective features:
1. Positive serum anti-SSA/Ro and/or anti-SSB/La or (positive rheumatoid factor and ANA titer ≥1:320)
2. Keratoconjunctivitis sicca with ocular staining score ≥3 (assuming that individual is not currently using daily eye drops for glaucoma and has not had corneal surgery or cosmetic eyelid surgery in the last 5 y)
3. Labial salivary gland biopsy exhibiting focal lymphocytic sialadenitis with a focus score of ≥1 focus/4 mm^2

Exclusion Criteria
History of head and neck radiation treatment
Acquired immunodeficiency syndrome
Hepatitis C infection
Sarcoidosis
Amyloidosis
Graft-vs-host disease
IgG4-related disease

Modified from Shiboski SC, et al. American College of Rheumatology classification criteria for Sjögren's syndrome: A data-driven, expert consensus approach in the Sjögren's International Collaborative Clinical Alliance cohort. *Arthritis Care Res (Hoboken)*. 2012;64(4):475-87, with permission.

has been widely accepted (Table 68-3).[100] Six features are taken into consideration: subjective complaints and objective evidence of dry eyes or dry mouth, objective evidence of salivary gland inflammation, and the presence of specific autoantibodies in the serum. For the diagnosis of pSS, at least 4 criteria should be present, and at least one of them should be evidence of lymphocytic infiltration or the presence of autoantibodies. Patients with a coexisting connective tissue disease are labeled secondary SS. Exclusions include other diseases and medications that may cause sicca symptoms.

In 2012, the American College of Rheumatology provided new criteria (Table 68-4).[101] The new criteria require at least 2 of the following 3:

- Positive serum anti-SSA/anti-SSB antibodies or positive rheumatoid factor (RF) and antinuclear antibody titer ≥1:320,
- Keratoconjunctivitis sicca with ocular staining score ≥3,
- Labial salivary gland biopsy showing focal lymphocytic sialadenitis with a focus score ≥1 focus/4 mm^2.

These criteria are thought to be stricter than those previously applied, and so the prevalence may decline.[102]

ORAL DRYNESS

SIALOMETRY

Sialometry involves measurement of the total saliva produced from all salivary glands in a time period of 15 min. The whole unstimulated salivary flow is considered suggestive of SS if it is <1.5 mL in 15 minutes. A "stimulated" salivary flow can be measured after administration of lemon juice or citric acid, and low values are also suggestive of SS.

SALIVARY GLAND SCINTIGRAPHY

Salivary gland scintigraphy (SGS) is a functional study to assess saliva production by measuring the secretion of a radioisotope (^{99m}technetium sodium pertechnetate) into the oral cavity. SGS provides functional information about individual salivary glands and can potentially distinguish between decreased production and/or decreased excretion of saliva. The past decade has seen a shift toward the quantitative evaluation of SGS

based on various parameters generated from time-activity curves.[103] Given the high cost and the exposure to radiation, routine use may not yet be justified but it is a useful diagnostic tool in selected cases. Sialography is an imaging method based on retrograde injection of contrast media into the parotid duct. Dilation of salivary ducts and sialolithiases are the most common findings.

OCULAR DRYNESS

The diagnosis of keratoconjuctivitis sicca is based on the demonstration of decreased tear production, corneal damage, or both. Tear production is usually measured using Schirmer test. This is performed by placing a standardized paper strip in the inferior fornix of each eye and measuring the length of filter paper that becomes wet after 5 minutes. The American–European classification system uses a cut-off value of 5 mm in 5 minutes, below which a diagnosis of dry eye is made. An alternative method is staining with a dye (rose Bengal or lissamine green) that preferentially stains the devitalized cornea and conjunctiva. This staining is evaluated through the van Bijsterveld scoring system; a score of 4 or more indicates keratoconjunctivitis sicca. These tests have high sensitivity but low specificity; they identify ocular dryness, but cannot attribute abnormal findings to SS.

LABORATORY TESTING

High levels of inflammatory markers, such as high sedimentation rates and signs of chronic inflammation (anemia, hypoalbuminemia), are common in SS patients. Serologic tests may demonstrate hyperglobulinemia in as many as 80% of pSS patients. Autoantibodies commonly include Ro/SSA and La/SSB antibodies, as well as rheumatoid factor and ANA. Hypocomplement has been associated with a higher frequency of vasculitis and lymphoma, and cryoglobulins with higher frequencies of parotid enlargement, vasculitis, and leukoplakia.

HISTOPATHOLOGY

None of the above diagnostic procedures is specific for SS. The most reliable objective diagnostic feature is seen on a biopsy of the minor salivary gland. A small incision is made on the inner surface of the lip, and a minor salivary gland tissue sample is collected. Evidence of a focal, periductal infiltrate, composed of T and B lymphocytes and few plasma cells, is the histologic hallmark of SS (Fig. 68-6). The degree of lymphocytic infiltration is evaluated semiquantitatively by means of a focus scoring system. Evidence of one or more foci is considered indicative of SS, and a focus is considered a conglomeration of at least 50 lymphocytes per 4 mm^2 of glandular tissue. GC-like

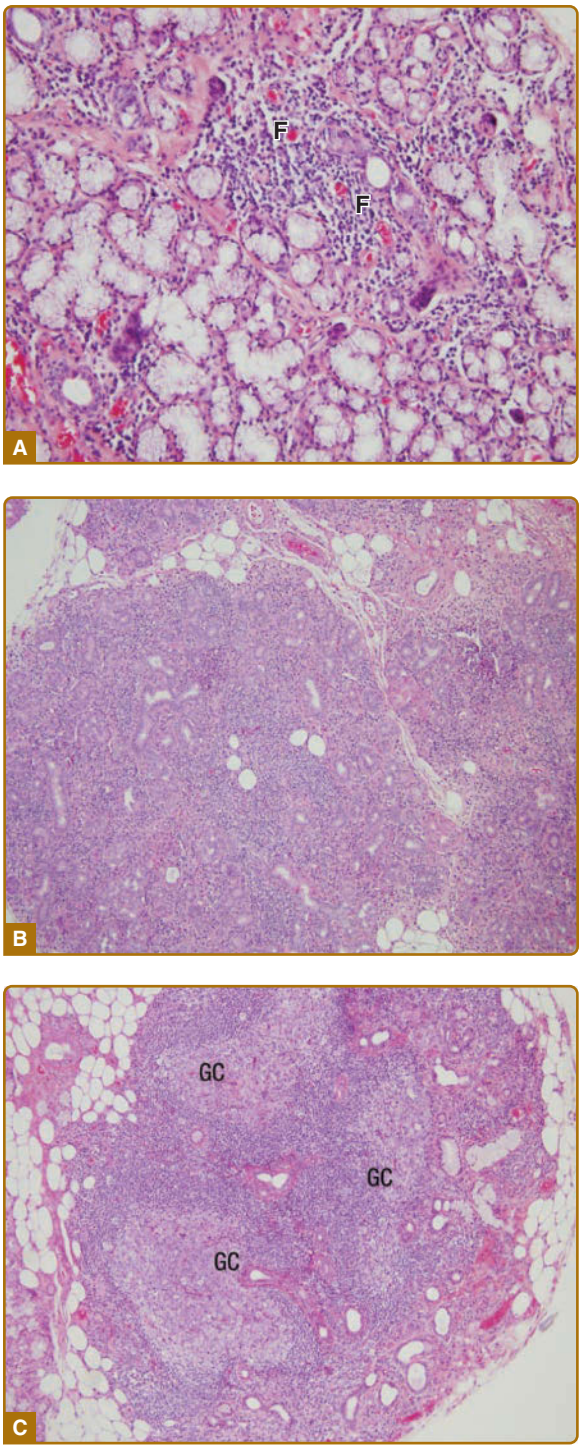

Figure 68-6 Histopathology of the minor salivary gland in Sjögren's syndrome. The degree of lymphocytic infiltration varies from moderate (**A**) to diffuse (**B**). In the most severe forms, germinal center formation can be observed (**C**). F = lymphocytic focus; GC = germinal center.

structures are thought to be a risk factor for developing lymphoma.[104] Atrophy and fat tissue are other findings that may be present in SS patients, but also can be present in healthy, elderly individuals. Although a salivary gland biopsy provides important clues that may lead to a definitive diagnosis, some controversy still exists

regarding its sensitivity and specificity. Some patients with pSS, diagnosed on the basis of reduced salivary flow and evidence of anti-SSA and anti-SSB antibodies, have no lymphocytic infiltration in biopsy specimens from the minor salivary glands. Additionally, some healthy individuals may demonstrate lymphocytic foci in their salivary glands.

CLINICAL COURSE AND PROGNOSIS

There are 2 patterns of pSS that define 2 distinct disease categories with very different clinical risks. Patients with low complement C4 levels and/or palpable purpura early in their disease course may be classified as a high-risk disease syndrome (Type I). This group comprises ~20% of pSS diagnoses and carries a significantly increased risk of lymphoproliferative disease; it also has an increased mortality rate. Most severe extraglandular manifestations also occur in this group. Patients without these 2 predictors (80% of all pSS diagnoses) may be reassured that they have a low-risk (Type II) form of pSS that carries no increased risk of death and, in general, has a more benign course, dominated by sicca symptom.[97,105,106]

TREATMENT

TREATMENT OF DRY MOUTH (TABLE 68-5)

The treatment of oral dryness is largely symptomatic.[107] Nonpharmacologic strategies remain the mainstay of treatment. Adequate hydration, and reducing irritants like coffee, alcohol, and nicotine, as well as the substitution of drugs that can lead to dry mouth (diuretics, tricyclics, antihistamines, β-blockers) when possible are important. Frequent sips of water are recommended initially to maintain moisture. Patients should also be encouraged to use sugar-free candies and chewing gum to increase saliva production. Saliva substitutes are available in the form of gels, oils, and sprays, but the need for frequent application is inconvenient for many patients.

Sugar-containing foods should be avoided because they contribute to an increased risk of dental caries and oral candidiasis. Meticulous dental hygiene is essential for SS patients to prevent or treat dental caries. Caries prevention with fluoride application, including prescription-strength toothpaste, fluoride gels, and oral rinses, is further recommended.

Oral candidiasis is treated with oral and systemic antifungal therapy. To prevent candidiasis, patients should not wear dentures at night and dentures should be soaked in 2% chlorhexidine. Nystatin or clotrimazole cream can be used to treat angular cheilitis.

If dry mouth is not adequately controlled with replacement methods, pharmacologic therapy with secretagogue drugs is an option. Two drugs are approved for this indication: (1) pilocarpine (5 mg 4 times/d)[108] and (2) cevimeline (30 mg 3 times/d).[109] Both act on muscarinic receptors and increase exocrine gland secretion. They are contraindicated in narrow-angle glaucoma and uncontrolled asthma. Cholinergic side effects, such as excessive sweating, urinary frequency, flushing, and headaches, are common with both. Tolerability may be increased if treatment is started at a lower dose, which is then increased gradually (Table 68-5).

TABLE 68-5
Management of Sicca Symptoms in Sjögren Syndrome

Dry mouth	▪ Frequent water ▪ Mechanical stimulation of saliva secretion (sugar-free gum and candies) ▪ Artificial saliva ▪ Meticulous oral hygiene ▪ Caries prevention with fluoride-containing toothpaste and rinses ▪ Aggressive treatment of candidiasis with topical and systemic antifungals ▪ Sialogogues: pilocarpine (5 mg orally 3 times/d) or cevimeline (30 mg orally 3 times/d)
Dry eyes	▪ Frequent use of preservative-free artificial tears ▪ Nighttime use of moisturizing ointments ▪ Topical cyclosporine ophthalmic solution (0.05%, one drop every 12 h) ▪ Surgical: punctal plug placement ▪ Sialogogues

TREATMENT OF DRY EYES (TABLE 68-5)

Nonpharmacologic measures are important therapeutic interventions; avoidance of dry, smoky, and windy environments; avoiding contact lenses or opting for those higher in water content; and minimizing medications that inhibit tear production (diuretics, β-blockers, tricyclic antidepressants, antihistamines) are first-line measures.

Many tear substitutes are available and are commonly used by patients to alleviate ocular dryness. Preservative-free preparations are preferred, especially if used more than 4 times per day. Methylcellulose-containing ointments may provide longer relief, but their use is limited to nighttime use because of the risk of blurred vision.

A frequently used surgical option is occlusion of the puncta to block tear drainage and, consequently, increase moisture. The occlusion can be transient, with the insertion of collagen or silicone plugs, or permanent, with electrocautery.

Cyclosporine 0.05% ophthalmic solution has been approved by the FDA for the treatment of

keratoconjunctivitis sicca.[110] Topical corticosteroids are rarely needed and should probably only be prescribed after an ophthalmic examination. Infections may present with aggravation of symptoms or increased mucus secretion and should be promptly treated with topical antibiotics. Pilocarpine and cevimeline can be effective for dry eyes, too, especially in patients with the most severe dryness.[109]

TREATMENT OF EXTRAGLANDULAR MANIFESTATIONS

The treatment of the musculoskeletal manifestations of SS is similar to that of other systemic rheumatologic diseases.[111] Because of reduced saliva production and esophageal dysmotility, these patients have reduced tolerance to nonsteroidal antiinflammatory drugs. Antimalarial drugs, such as hydroxychloroquine, are effective for arthralgia/arthritis, myalgia, fatigue, and annular erythema.[112] Dryness of the eyes and mouth may also improve slightly in some cases.[113] Visceral manifestations, such as vasculitis, pneumonitis, and glomerulonephritis, and neurologic manifestations are treated with corticosteroids and immunosuppressive drugs, it doses similar to those used in systemic lupus erythematosus.[114] Recently, a large-scale cohort study of pSS patients from Spain focused on the adequacy of therapies for the level of systemic activity, measured by the ESSDAI score.[115]

Treatment of lymphoma in SS is the same as in the population generally. Most SS-associated lymphomas are low-grade B-cell lymphomas, localized to the exocrine glands. For these cases, watchful waiting may be the most appropriate approach. Higher-grade lymphomas require more aggressive treatment with a rituximab, cytotoxic regimen, and/or radiation therapy.

MOLECULAR TARGET THERAPY

Several randomized case–control studies have focused on therapy for SS using biologic agents, such as the TNF-blocking agents, infliximab[116] and etanercept,[117] but none of the studies showed clinical benefit. There is increasing interest in therapies targeting B cells, such as monoclonal antibodies against CD20 (rituximab) or CD22 (epratuzumab). A recent randomized placebo-controlled study demonstrated the efficacy of rituximab over placebo in patients with active pSS.[118] Rituximab improved stimulated salivary flows, laboratory parameters of inflammation, and subjective symptoms. This clinical efficacy was supported by reduced glandular infiltration and morphologic improvements in epithelial cells on salivary gland biopsies.[119,120] Other potential targets for biologic therapy include cytokines, such as IL-6 and BlyS (BAFF), interferons, adhesion molecules, and chemokines. However, even if effective, systemic immunomodulatory therapy may be associated with unwanted side effects and may not be justified in patients with pSS whose disease is limited to exocrine glands. An alternative approach is to develop a localized form of immunotherapy by using gene therapy restricted to the salivary and lachrymal glands. This approach would most likely alter the abnormal immune response locally, but possibly avoid the systemic side effects.[114,121,122]

REFERENCES

1. Patel R, Shahane A. The epidemiology of Sjögren's syndrome. *Clin Epidemiol.* 2014;6:247-255.
2. Qin B, Wang J, Yang Z, et al. Epidemiology of primary Sjögren's syndrome: a systematic review and meta-analysis. *Ann Rheum Dis.* 2015;74(11):1983-1989.
3. Miyasaka N. Epidemiology and pathogenesis of Sjögren's syndrome. *Nihon Rinsho.* 1995;53(10): 2367-2370.
4. Nocturne G, Marette X. Advances in understanding the pathogenesis of primary Sjögren's syndrome. *Nat Rev Rheumatol.* 2013;9(9):544-556.
5. Foster H, Walker D, Charles P, et al. Association of DR3 with susceptibility to and severity of primary Sjögren's syndrome in a family study. *Br J Rheumatol.* 1992;31(5):309-314.
6. Kuo CF, Grainge MJ, Valdes AM, et al. Familial risk of Sjögren's syndrome and co-aggregation of autoimmune disease in affected families. A nation wide study. *Arthritis Rheum.* 2015;67(7):1904-1912.
7. Arnett FC, Hamilton RG, Reveille JD, et al. Genetic studies of Ro (SS-A) and La (SS-B) autoantibodies in families with systemic lupus erythematosus and primary Sjögren's syndrome. *Arthritis Rheum.* 1989;32(4):413-419.
8. Cobb BL, Lessard CJ, Harley JB, et al. Genes and Sjogren's syndrome. *Rheum Dis Clin North Am.* 2008;34(4):847-868.
9. Li YZ, Zhabg KL, Chen H, et al. A genome-wide association study in Han Chinese identifies a susceptibility locus for primary Sjögren's syndrome at 7q11.23. *Nat Genet.* 2013;45(11):1361-1365.
10. Hernandez-Molina G, Vargas-Alarcon G, Rodriguez-Perez JM, et al. High-resolution HLA analysis of primary and secondary Sjögren's syndrome: a common immunogenetic background in Mexican patients. *Rheumatol Int.* 2015;35(4):643-649.
11. Lessard CJ, Li H, Adrianto I, et al. Variants at multiple loci implicated in both innate and adaptive immune responses are associated with Sjögren's syndrome. *Nat Genet.* 2013;45(11):1284-1292.
12. Nordmark G, Kristjansdottir G, Theander E, et al. Additive effects of the major risk alleles of IRF5 and STAT4 in primary Sjögren's syndrome. *Genes Immun.* 2009;10(1):68-76.
13. Gestermann N, Mekinian A, Comets E, et al. STAT4 is a confirmed genetic risk factor for Sjögren's syndrome and could be involved in type 1 interferon pathway signaling. *Genes Immun.* 2010;11(5):432-438.
14. Noctume G, Tam J, boudaoud S, et al. Germline variation of INFAIP3 in primary Sjögren's syndrome-associated lymphoma. *Ann Rheum Dis.* 2016;75(4):780-783.

15. Alevizos I, Alexander S, Turner RJ, et al. MicroRNA expression profiles as biomarkers of minor salivary gland inflammation and dysfunction in Sjögren's syndrome. *Arthritis Rheum.* 2011;63(2):535-544.
16. Hung T, Pratt GA, Sundaraman B, et al. The Ro60 autoantigen binds endogenous retroelements and regulates inflammatory gene expression. *Science.* 2015;350(6259):455-459.
17. Brkic Z, Maria NI, van Helden-Meeuwsen CG. Prevalence of interferon type I signature in CD14 monocytes of patients with Sjögren's syndrome and association with disease activity and BAFF gene expression. *Ann Rheum Dis.* 2013;72(5):728-735.
18. Ambrus JL, Suresh L, Peck A. Multiple roles for B-lymphocytes in Sjogren's syndrome. *J Clin Med.* 2016;5(10):87.
19. Szczerba BM, Rybakowska PD, Dey P, et al. Type I interferon receptor deficiency prevents murine Sjögren's syndrome. *J Dent Res.* 2013;92(5):444-449.
20. Banchereau J, Pascual V. Type I interferon in systemic lupus erythematosus and other autoimmune diseases. *Immunity.* 2006;25(3):383-392.
21. Bave U, Nordmark G, Lovgren T, et al. Activation of the type I interferon system in primary Sjögren's syndrome—a possible etiopathogenic mechanism. *Arthritis Rheum.* 2005;52(4):1185-1195.
22. Brkic Z, Versnel MA. Type I IFN signature in primary Sjögren's syndrome patients. *Expert Rev Clin Immunol.* 2014;10(4):457-467.
23. Groom J, Kalled SL, Cutler AH, et al. Association of BAFF/BLyS overexpression and altered B cell differentiation with Sjögren's syndrome. *J Clin Invest.* 2002;109(1):59-68.
24. Mackay F, Woodcock SA, Lawton P, et al. Mice transgenic for Baff develop lymphocytic disorders along with autoimmune manifestations. *J Exp Med.* 1999;190(11):1697-1710.
25. Mariette X, Roux S, Zhang J, et al. The level of BLyS (BAFF) correlates with the titer of autoantibodies in human Sjögren's syndrome. *Ann Rheum Dis.* 2003;62(2):168-171.
26. Theander E, Vasaitis L, Baecklund E, et al. Lymphoid organization in labial salivary gland biopsies is a possible predictor for the development of malignant lymphoma in primary Sjögren's syndrome. *Ann Rheum Dis.* 2011;70(8):1363-1368.
27. Porola P, Virkki L, Przybyla BD, et al. Androgen deficiency and defective intracrine processing of dehydroepiandrosterone in salivary glands in Sjögren's syndrome. *J Rheumatol.* 2008;35(11):2229-2235.
28. Liu K, Kurien BT, Zimmerman SL, et al. X chromosome dose and sex bias in autoimmune diseases: increased 47,XXX in systemic lupus erythematosus and Sjögren's syndrome. *Arthritis Rheumatol.* 2016;68(5):1290-1300.
29. Xavier M, Joel G, Didier C, et al. Detection of Epstein-Barr virus DNA by in situ hybridization and polymerase chain reaction in salivary gland biopsy specimens from patients with Sjögren's syndrome. *Am J Med.* 1991;90(1):286-294.
30. Karameris A, Gorgoulis V, Lliopoulos A, et al. Detection of Epstein Barr viral genome by an in situ hybridization method in salivary gland biopsies from patients with secondary Sjögren's syndrome. *Clin Exp Rheumatol.* 1992;10(4):327-332.
31. Sumida T, Yonaha F, Maeda T, et al. Expression of sequences homologous to HTLV-I tax gene in the labial salivary glands of Japanese patients with Sjögren's syndrome. *Arthritis Rheum.* 1994;37(4):545-550.
32. Mariette X, Zerbib M, Jaccar A, et al. Hepatitis C virus and Sjögren's syndrome. *Arthritis Rheum.* 1993;36(2):280-281.
33. Manuel RC, Sandra M, Pilar BZ. Hepatitis C virus and Sjögren's syndrome: trigger or mimic? *Rheum Dis Clin North Am.* 2008;34(4):869-884.
34. Wang Y, Dou H, Liu G, et al. Hepatitis C virus infection and the risk of Sjögren's or sicca syndrome: a meta-analysis. *Microbiol Immunol.* 2014;58(12):675-687.
35. Kordossis T, Paikos S, Aroni K, et al. Prevalence of Sjögren's-like syndrome in a cohort of HIV-1-positive patients: descriptive pathology and immunopathology. *Br J Rheumatol.* 1998;37(6):691-695.
36. Fleck M, Kern ER, Zhou T, et al. Murine cytomegalovirus induces a Sjögren's syndrome-like disease in C57Bl/6-lpr/lpr mice. *Arthritis Rheum.* 1998;41(12):2175-2184.
37. Triantafyllopoulou A, Tapinos N, Moutsopoulos HM. Evidence for coxsackievirus infection in primary Sjögren's syndrome. *Arthritis Rheum.* 2004;50(9):2897-2902.
38. Moyes DL, Martin A, Sawcer S, et al. The distribution of the endogenous retroviruses HERV-K113 and HERV-K115 in health and disease. *Genomics.* 2005;86(3):337-341.
39. Nocturne G, Mariette X. Advances in understanding the pathogenesis of primary Sjögren's syndrome. *Nat Rev Rheumatol.* 2013;9(9):544-556.
40. Iwakiri D, Zhou L, Samanta M, et al. Epstein-Barr virus (EBV)-encoded small RNA is released from EBV-infected cells and activates signaling from Toll-like receptor 3. *J Exp Med.* 2009;206(10):2091-2099.
41. Karaiskos D, Mavragani CP, Makaroni S, et al. Stress, coping strategies and social support in patients with primary Sjögren's syndrome prior to disease onset: a retrospective case-control study. *Ann Rheum Dis.* 2009;68(1):40-46.
42. Chaigne B, Lasfargues G, Marie I, et al. Primary Sjögren's syndrome and occupational risk factors: a case-control study. *J Autoimmun.* 2015;60:80-85.
43. Karaiskos D, Mavragani CP, Sinno MF, et al. Psychopathological and personality features in primary Sjögren's syndrome—associations with autoantibodies to neuropeptides. *Rheumatology (Oxford).* 2010;49(9):1762-1769.
44. Nezos A, Mavragani CP. Contribution of genetic factors to Sjögren's syndrome and related lymphogenesis. *J Immunol Res.* 2015;2015:754825.
45. Mitsias DI, Kapsogeorgou EK, Moutsopoulos HM. The role of epithelial cells in the initiation and perpetuation of autoimmune lesions: lessons from Sjögren's syndrome (autoimmune epithelitis). *Lupus.* 2006;15(5):255-261.
46. Jonsson R, Klareskog L, Backman K, et al. Expression of HLA-D-locus (DP, DQ, DR)-coded antigens, beta 2-microglobulin, and the interleukin 2 receptor in Sjögren's syndrome. *Clin Immunol Immunopathol.* 1987;45(2):235-243.
47. Mavragani CP, Moutsopoulos HM. The geoepidemiology of Sjögren's syndrome. *Autoimmun Rev.* 2010;9(5):A305-A310.
48. Ohlsson M, Jonsson R, Brokstad KA. Subcellular redistribution and surface exposure of the Ro52, Ro60 and La48 autoantigens during apoptosis in human ductal epithelial cells: a possible mechanism in the pathogenesis of Sjögren's syndrome. *Scand J Immunol.* 2002;56(5):456-469.
49. Bolstad AI, Jonsson R. The role of apoptosis in Sjögren's syndrome. *Ann Med Onterne (Paris).* 1998; 149(1):25-29.

50. Spachidou MP, Bourazopoulou E, Maratheftis CI, et al. Expression of functional Toll-like receptors by salivary gland epithelial cells: increased mRNA expression in cells derived from patients with primary Sjögren's syndrome. *Clin Exp Immunol.* 2007;147(3):497-503.
51. Bolstad AI, Eiken HG, Rosenlund B, et al. Increased salivary gland tissue expression of Fas, Fas ligand, cytotoxic T lymphocyte-associated antigen 4, and programmed cell death 1 in primary Sjögren's syndrome. *Arthritis Rheum.* 2003;48(1):174-185.
52. Alperr S, kang HI, Weissman I, et al. Expression of granzyme A in salivary gland biopsies from patients with primary Sjögren's syndrome. *Arthritis Rheum.* 1994;37(7):1046-1054.
53. Mavragani CP, Tzioufas AG, Moutsopoulos HM. Sjögren's syndrome: autoantibodies to cellular antigens. Clinical and molecular aspects. *Int Arch Allergy Immunol.* 2000;123(1): 46-57.
54. Tzioufas AG, Tatouli IP, Moutsopoulos HM. Autoantibodies in Sjögren's syndrome: clinical presentation and regulatory mechanisms. *Presse Med.* 2012; 41(9, pt 2):e451-e460.
55. Kyriakidis NC, Kapsogeorgou EK, Tzioufas AG. A comprehensive review of autoantibodies in primary Sjögren's syndrome: clinical phenotypes and regulatory mechanisms. *J Autoimmun.* 2014;51:67-74.
56. Manuel RC, Roser S, Jose R, et al. Primary Sjögren's syndrome in Spain: clinical and immunologic expression in 1010 patients. *Medicine (Baltimore).* 2008; 87(4):210-219.
57. Mario GC, Claudia MP, Cesar JH, et al. Serologic features of primary Sjögren's syndrome: clinical and prognostic correlation. *Int J Clin Rheumatol.* 2012;7(6):651-659.
58. Alexander EL, Arnett FC, Provost TT, et al. Sjögren's syndrome: association of anti-Ro (SS-A) antibodies with vasculitis, hematologic abnormalities, and serologic hyperreactivity. *Ann Intern Med.* 1983;98(2):155-159.
59. Zuo J, Willicams AEG, Park YJ, et al. Muscarinic type 3 receptor autoantibodies are associated with anti-SSA/Ro autoantibodies in Sjögren's syndrome. *J Immunol Methods.* 2016;437:28-36.
60. Robinson CP, Brayer J, Yamachika S, et al. Transfer of human serum IgG to non-obese diabetic Igmu null mice reveals a role for autoantibodies in the loss of secretory function of exocrine tissues in Sjögren's syndrome. *Proc Natl Acad Sci U S A.* 1998;95(13): 7538-7543.
61. Dawson L, Tobin A, Smith P, et al. Antimuscarinic antibodies in Sjögren's syndrome: where are we, and where are we going? *Arthritis Rheum.* 2005;52(10): 2984-2995.
62. Roescher N, Kingman A, Shirota Y, et al. Peptide-based ELISAs are not sensitive and specific enough to detect muscarinic receptor type 3 autoantibodies in serum from patients with Sjögren's syndrome. *Ann Rheum Dis.* 2011;70(1):235-236.
63. Baer AN, Medrano L, DeMacro MM, et al. Association of anticentromere antibodies with more severe exocrine glandular dysfunction in Sjögren's Syndrome: analysis of the Sjögren's international collaborative clinical alliance cohort. *Arthritis Care Res (Hoboken).* 2016;68(10): 1554-1559.
64. Lee KE, Kang JH, Lee JW, et al. Anti-centromere antibody-positive Sjögren's syndrome: a distinct clinical subgroup? *Int J Rheum Dis.* 2015;18(7):776-782.
65. Katano K, Kawano M, Koni I, et al. Clinical and laboratory features of anticentromere antibody positive primary Sjögren's syndrome. *J Rheumatol.* 2001;28(10): 2238-2244.
66. Kitagawa T, Shibasaki K, Toya S. Clinical significance and diagnostic usefulness of anti-centromere antibody in Sjögren's syndrome. *Clin Rheumatol.* 2012;31(1):105-112.
67. Nakamura H, Kawakami A, Hayashi T, et al. Anti-centromere antibody-seropositive Sjögren's syndrome differs from conventional subgroup in clinical and pathological study. *BMC Musculoskelet Disord.* 2010;11:140.
68. Bournia VK, Diamanti KD, Vlachoyiannopoulos PG, et al. Anticentromere antibody positive Sjögren's syndrome: a retrospective descriptive analysis. *Arthritis Res Ther.* 2010;12(2):R47.
69. Selmi C, Meroni PL, Gershwin ME. Primary biliary cirrhosis and Sjögren's syndrome: Autoimmune epithelitis. *J Autoimmun.* 2012;39(1-2):34-42.
70. Malladi AS, Sack KE, Shiboski SC, et al. Primary Sjögren's syndrome as a systemic disease: a study of participants enrolled in an international Sjögren's syndrome registry. *Arthritis Care Res (Hoboken).* 2012;64(6):911-918.
71. Bernacchi E, Bianchi B, Amato L, et al. Xerosis in primary Sjögren's syndrome: immunohistochemical and functional investigations. *J Dermatol Sci.* 2005;39(1):53-55.
72. Mitchell J, Greenspan J, Daniels T, et al. Anhidrosis (hypohidrosis) in Sjögren's syndrome. *J Am Acad Dermatol.* 1987;16(1, pt 2):233-235.
73. Katayama I, Yokozeki H, Nishioka K. Impaired sweating as an exocrine manifestation in Sjögren's syndrome. *Br J Dermatol.* 1995;133(5):716-720.
74. Roguedas AM, Misery L, Sassolas B, et al. Cutaneous manifestations of primary Sjögren's syndrome are underestimated. *Clin Exp Rheumatol.* 2004;22(5):632-636.
75. Fox RI, Liu AY. Sjögren's syndrome in dermatology. *Clin Dermatol.* 2006;24(5):393-413.
76. Ramos-Casals M, Anaya JM, García-Carrasco M, et al. Cutaneous vasculitis in primary Sjögren syndrome: classification and clinical significance of 52 patients. *Medicine (Baltimore).* 2004;83(2):96-106.
77. Scofield RH. Vasculitis in Sjögren's syndrome. *Curr Rheumatol Rep.* 2011;13(6):482-488.
78. Teramoto N, Katayama I, Arai H, et al. Annular erythema: a possible association with primary Sjögren's syndrome. *J Am Acad Dermatol.* 1989;20(4):596-601.
79. Katayama I, Teramoto N, Arai H, et al. Annular erythema. A comparative study of Sjögren syndrome with subacute cutaneous lupus erythematosus. *Int J Dermatol.* 1991;30(9):635-639.
80. Brito-Zerón P, Retamozo S, Akasbi M, et al. Annular erythema in primary Sjögren's syndrome: description of 43 non-Asian cases. *Lupus.* 2014;23(2):166-175.
81. Sontheimer RD, Thomas JR, Gilliam JN. Subacute cutaneous lupus erythematosus: a cutaneous marker for a distinct lupus erythematosus subset. *Arch Dermatol.* 1979;115(12):1409-1415.
82. Provost TT. Anti-Ro (SSA) and andi-La(SSB) antibodies in lupus erythematosus and Sjögren's syndrome. *Keio J Med.* 1991;40(2):72-77.
83. McCauliffe DP, Faircloth E, Wang L, et al. Similar Ro/SS-A autoantibody epitope and titer responses in annular erythema of Sjögren's syndrome and subacute cutaneous lupus erythematosus. *Arch Dermatol.* 1996;132(5):528-531.
84. Ramos-Casals M, Brito-Zeron P, Font J. The overlap of Sjögren's syndrome with other systemic autoimmune diseases. *Semin Arthritis Rheum.* 2007;36(4):246-255.
85. Tushiya N, Ito I, Kawasaki A. Association of IRF5, STAT4, and BLK with systemic erythematosus and other rheumatic disease. *Nihon Rinsho Meneki Gakkai Kaishi.* 2010;33(2):57-65.

86. Ramos-Casals M, Brito-Zeron P, Seror R, et al. Characterization of systemic disease in primary Sjögren's syndrome: EULAR-SS Task Force recommendations for articular, cutaneous, pulmonary and renal involvements. *Rheumatology (Oxford).* 2015;54(12):2230-2238.
87. Mario GC, Antoni S, Manuel RC, et al. Raynaud's phenomenon in primary Sjögren's syndrome. Prevalence and clinical characteristics in a series of 320 patients. *J Rheumatol.* 2002;29(4):726-730.
88. Mellgren SI, Goransson LG, Omdal R. Primary Sjögren's syndrome associated neuropathy. *Can J Neurol Sci.* 2007;34(3):280-287.
89. Mori K, Iijima M, Koike H, et al. The wide spectrum of clinical manifestations in Sjögren's syndrome-associated neuropathy. *Brain.* 2005;128(pt 11): 2518-2534.
90. Kassan SS, Moutsopoulos HM. Clinical manifestations and early diagnosis of Sjögren's syndrome. *Arch Intern Med.* 2004;164(12):1275-1284.
91. Nishishinya MB, Pereda CA, Muñoz-Fernández S, et al. Identification of lymphoma predictors in patients with primary Sjögren's syndrome: a systematic literature review and meta-analysis. *Rheumatology (Oxford).* 2015;35(1):17-26.
92. Solans LR, Lopez HA, Bosch GJA, et al. Risk, predictors, and clinical characteristics of lymphoma development in primary Sjögren's syndrome. *Semin Arthritis Rheum.* 2011;41(3):415-423.
93. Song H, Tong D, Cha Z, et al. C-X-C chemokine receptor type 5 gene polymorphisms are associated with non-Hodgkin lymphoma. *Mol Biol.* 2012;39(9): 8629-8635.
94. Urban N, Andrea R, Ivo K, et al. The NF-κB negative regulator TNFAIP3 (A20) is inactivated by somatic mutations and genomic deletions in marginal zone lymphomas. *Blood.* 2009;113(20):4918-4921.
95. Charbonneau B, Wang AH, Maurer MJ, et al. CXCR5 polymorphisms in non-Hodgkin lymphoma risk and prognosis. *Cancer Immunol Immunother.* 2013;62(9):1475-1484.
96. Baimpa E, Dahabreh IJ, Voulgarelis M, et al. Hematologic manifestations and predictors of lymphoma development in primary Sjögren's syndrome: clinical and pathophysiologic aspects. *Medicine (Baltimore).* 2009;88(5):284-293.
97. Ioannidis JP, Vassiliou VA, Moutsopoulos HM. Long-term risk of mortality and lymphoproliferative disease and predictive classification of primary Sjögren's syndrome. *Arthritis Rheum.* 2002;46(3):741-747.
98. Giannouli S, Voulgarelis M. Predicting progression to lymphoma in Sjögren's syndrome patients. *Expert Rev Clin Immunol.* 2014;10(4):501-512.
99. Carolis SD, Salvi S, Botta A, et al. The impact of primary Sjögren's syndrome on pregnancy outcome: our series and review of the literature. *Autoimmun Rev.* 2013;13(2):103-107.
100. Vitali C, Bombardieri S, Jonsson R. Classification criteria for Sjögren's syndrome: a revised version of the European criteria proposed by the American-European Consensus Group. *Ann Rheum Dis.* 2002;61(6): 554-558.
101. Shiboski SC, Shibioski CH, Criswell LA, et al. American College of Rheumatology classification criteria for Sjogren syndrome: a data-driven, expert consensus approach in the Sjögren's international collaborative clinical alliance cohort. *Arthritis Care Res.* 2012;64(4): 475-487.
102. Mario GC, Claidoa MP, Cesar JH, at al. Serologic features of primary Sjögren's syndrome: clinical and prognostic correlation. *Int J Clin Rheumatol.* 2012;7(6): 651-659.
103. Roescher N, Illei GG. Can quantified salivary gland scintigraphy results aid diagnosis of patients with sicca symptoms? *Nat Clin Pract Rheumatol.* 2008; 4(4):178-179.
104. Theander E, Vasaitis L, Baecklind E, et al. Lymphoid organization in labral salivary gland biopsies is a possible predictor for the development of malignant lymphoma in primary Sjögren's syndrome. *Ann Rheum Dis.* 2011;70(8):1363-1368.
105. Horvath IF, Szanto A, Papp G, et al. Clinical course, prognosis, and cause of death in primary Sjögren's syndrome. *J Immunol Res.* 2014;2014:647507.
106. Moutsopoulos HM. Sjögren's syndrome: a forty-year scientific journey. *J Autoimmun.* 2014;51:1-9.
107. Mavragani CP, Moutsopoulos NM, Moutsopoulos HM. The management of Sjögren's syndrome. *Nat Clin Pract Rheumatol.* 2006;2(5):252-261.
108. Vivino FB, Al-Hashimi I, Khan Z, et al. Pilocarpine tablets for the treatment of dry mouth and dry eye symptoms in patients with Sjögren Syndrome: a randomized, placebo-controlled, fixed-dose, multicenter trial. *Arch Intern Med.* 1999;159(2): 174-181.
109. Petrone D, Condemi JJ, Fife R, et al. A double-blind, randomized, placebo-controlled study of cevimeline in Sjögren's syndrome patients with xerostomia and keratoconjunctivitis sicca. *Arthritis Rheum.* 2002; 46(3):748-754.
110. Sall K, Stevenson OD, Mundorf TK, et al. Two multicenter, randomized studies of the efficacy and safety of cyclosporine ophthalmic emulsion in moderate to severe dry eye disease. CsA Phase 3 Study Group. *Ophthalmology.* 2000;107(4):631-639.
111. Mavragani CP, Moutsopoulos HM. Conventional therapy of Sjögren's syndrome. *Clin Rev Allergy Immunol.* 2007;32(3):284-291.
112. Fos RI, Chan E, Benton L, et al. Treatment of primary Sjögren's syndrome with hydroxychloroquine. *Am J Med.* 1988;85(4A):62-67.
113. Tishler M, Yaron I, Shirazi I, et al. Hydroxychloroquine treatment for primary Sjögren's syndrome: its effect on salivary and serum inflammatory markers. *Ann Rheum Dis.* 1999;58(4):253-256.
114. Saraux A, Pers JO, Devauchelle-Pensec V. Treatment of primary Sjögren syndrome. *Nat Rev Rheumatol.* 2016;12(8):456-471.
115. Gheitasi H, Kostov B, Solans R, et al. How are we treating our systemic patients with primary Sjögren syndrome? Analysis of 1120 patients. *Int Immunopharmacol.* 2015;27(2):194-199.
116. Mariette X, Ravaud P, Steinfeld S, et al. Inefficacy of infliximab in primary Sjögren's syndrome: Results of the randomized, controlled Trial of Remicade in Primary Sjogren's Syndrome (TRIPSS). *Arthritis Rheum.* 2004;50(4):1270-1276.
117. Sankar V, Brennan MT, Kok MR, et al. Etanercept in Sjögren's syndrome: a twelve-week randomized; double-blind, placebo-controlled pilot clinical trial. *Arthritis Rheum.* 2004;50(7):2240-2245.
118. Meijer JM, Meiners PM, Vissink A, et al. Effectiveness of rituximab treatment in primary Sjögren's syndrome: a randomized, double-blind, placebo-controlled trial. *Arthritis Rheum.* 2010;62(4): 960-968.

119. Carubbi F, Alunno A, Cipriani P, et al. Rituximab in primary Sjögren's syndrome: a ten-year journey. *Lupus*. 2014;23(13):1337-1349.
120. Pijpe J, Meijer JM, Bootsma H, et al. Clinical and histologic evidence of salivary gland restoration supports the efficacy of rituximab treatment in Sjögren's syndrome. *Arthritis Rheum*. 2009;60(11): 3251-3256.
121. Lodde BM, Baum BJ, Tak PP, et al. Experience with experimental biological treatment and local gene therapy in Sjögren's syndrome: implications for exocrine pathogenesis and treatment. *Ann Rheum Dis*. 2006;65(11):1406-1413.
122. Ramos-Casals M, Tzioufas AG, Stone JH, et al. Treatment of primary Sjögren's syndrome: a systematic review. *JAMA*. 2010;304(4):452-460.

Chapter 69 :: Relapsing Polychondritis

:: Camille Francès

AT-A-GLANCE

- Relapsing polychondritis is a rare multisystem autoimmune disease.
- Different factors are implicated in the pathogenesis, including a genetic susceptibility, immunization against cartilaginous structures, and modification of cytokine and chemokine signatures.
- More than 30% of patients have an associated disease, mainly of autoimmune or hematologic origin.
- Recurrent episodes of chondritis lead to progressive destruction of cartilaginous structures.
- Other proteoglycan-rich structures, such as eyes, blood vessels, or inner ear, are also affected.
- Dermatologic manifestations occur frequently, especially in association with myelodysplasia. They are nonspecific and resemble those observed in Behçet disease and inflammatory bowel diseases.

EPIDEMIOLOGY

Relapsing polychondritis (RP) is a rare inflammatory disease with an estimated prevalence of 4.5 per million people.[1] The incidence of RP has been estimated to be 0.71/million/year in the United Kingdom, being slightly higher in women than men (0.76 vs 0.66). The mean age (range) at diagnosis in men was 55 years (range: 17-81 years) and in women 51 years (range: 11-79 years).[2] Development of the disease may occur in young children and in the elderly. Although most cases have been reported in whites, there is no evidence supporting the role of ethnic or geographical factors.

CLINICAL FEATURES

Disease onset is usually sudden with characteristic chondritis, and/or, less frequently, arthritis or ocular inflammation. Nonspecific initial symptoms, such as fever or weight loss, are rare.

CUTANEOUS FINDINGS

Attacks of chondritis usually occur in a relapsing–remitting pattern. Inflammatory episodes generally last a few days or weeks and may subside spontaneously or upon treatment; recurrences after weeks or months occur and subsequently result in cartilage destruction.[3] Auricular chondritis is the most frequent occurrence (85% of cases), causing pain, redness, and swelling of the cartilaginous portion of the pinna, sparing the noncartilaginous lobe (Fig. 69-1). Biopsy of the auricular cartilage is unnecessary for diagnosis. After several attacks, the pinna may become soft and sloppy with a cauliflower aspect (Fig. 69-2); sometimes it is stiff from calcifications. Nasal chondritis (65% of cases) is less inflammatory, presenting with nasal pain, stuffiness, rhinorrhea, and sometimes epistaxis. The characteristic saddle-nose deformity (Fig. 69-3) may appear secondly or without previous inflammatory episodes.

Other dermatologic manifestations are sometimes the presenting feature of RP (12% of cases), noticed subsequently in more than one-third of patients of a large series.[4] The other dermatologic manifestations are nonspecific and include nodules on the limbs (Fig. 69-4) with an aspect of erythema nodosum, fixed annular urticarial papules on the trunk,[5] purpura (Fig. 69-5), oral or complex aphthosis (Fig. 69-6), superficial phlebitis, livedo reticularis (Fig. 69-7), ulcerations on the limbs, distal necrosis. Neutrophilic dermatoses are mainly observed in association with hematologic abnormalities: sterile pustules (Fig. 69-8), Sweet syndrome and its histiocytoid subtype, erythema elevatum diutinum, and pyoderma gangrenosum. Skin lesions appear either concomitantly or not with attacks of chondritis. Pathologic features include neutrophilic or lymphocytic vasculitis, thrombotic vascular lesions, neutrophil infiltrates, and nonspecific inflammation of the dermis or subcutis. Patients with and without dermatologic manifestations have similar clinical manifestations of RP. However, the frequency of dermatologic manifestations (>90%), age at first chondritis, and male-to-female ratio seems higher when RP is associated with myelodysplasia[4]; so, their presence in an old person warrants repeated blood cell counts to detect a smouldering myelodysplasia.

NONCUTANEOUS FINDINGS

Respiratory tract chondritis, although uncommon at presentation, occurs in up to 50% of RP patients, and may be lethal. Respiratory involvement is manifested by hoarseness, nonproductive persistent cough, dyspnea, and/or wheezing. Complications of respiratory tract chondritis include upper airway collapse, obstructive respiratory insufficiency, and secondary infections. Costochondritis (35% of RP patients) induces parietal pains, which may also compromise respiration.

Joint pain is a common presenting feature (30% of RP patients). Large and small joints of the peripheral or

Figure 69-1 Relapsing polychondritis. Painful inflammation of the cartilaginous portion of ear.

axial skeleton may all be affected. Arthritis is intermittent, migratory, asymmetric, seronegative, and usually nonerosive.

Nearly 60% of RP patients developed ocular inflammation. Episcleritis and scleritis (Fig. 69-9) are the most common manifestations, followed by keratoconjunctivitis sicca, iritis, retinopathy, and keratitis. Rarely, corneal perforation, retinal vasculitis, and optic neuritis will lead to blindness.

Conductive hearing loss is secondary to stenosis of the external auditory canal, eustachian tube chondritis, or serous otitis media, whereas perception hearing loss may occur as a consequence of sensorineural involvement. Symptoms of vestibular dysfunction such as dizziness, ataxia, nausea, and vomiting are usually acute and improve with time.

Figure 69-2 Relapsing polychondritis. Soft and sloppy ear with a "cauliflower" aspect.

Figure 69-3 Relapsing polychondritis. Saddle-nose deformity.

The spectrum of cardiovascular manifestations is wide and includes different heart tissues (aortic and/or mitral regurgitation, impairment of the conduction system, pericarditis) and all types of vessels (thoracic and abdominal aortitis leading to aneurysms, Takayasu-like aortic arch syndrome, medium-vessel and large-vessel vasculitis, leukocytoclastic vasculitis, and thrombophlebitis). Lesions are inflammatory and/or thrombotic. Some, but not all, thrombotic manifestations have been linked to antiphospholipid syndrome. Large-vessel vasculitis tends to occur after several years of smoldering and, often, occult disease, despite immunosuppressive therapy.

Figure 69-4 Relapsing polychondritis. Nodules of the limbs that may be secondary to septal panniculitis, vasculitis, thrombosis, or deep neutrophils infiltrate.

Figure 69-5 Relapsing polychondritis. Purpura secondary to leukocytoclastic vasculitis.

Figure 69-7 Relapsing polychondritis. Necrotic livedo secondary to leukocytoclastic vasculitis.

ETIOLOGY AND PATHOGENESIS

To date, the etiology of RP is still poorly known.

The inflammation is initially perichondrial, characterized by an inflammatory polymorphic infiltrate with lymphocytes, neutrophils, macrophages, and plasma cells. The T cells are primarily CD4; the antigen-presenting cells are activated with expression of human leukocyte antigen-D related (HLA-DR). Direct immunofluorescence inconsistently shows immunoglobulins and C3 deposits at the junction perichondrium-cartilage. With the progression of the disease, the

Figure 69-8 Relapsing polychondritis. Sterile pustule as observed in Behçet disease.

Figure 69-6 Relapsing polychondritis. Giant vulvar aphtha contemporary to acute auricular chondritis.

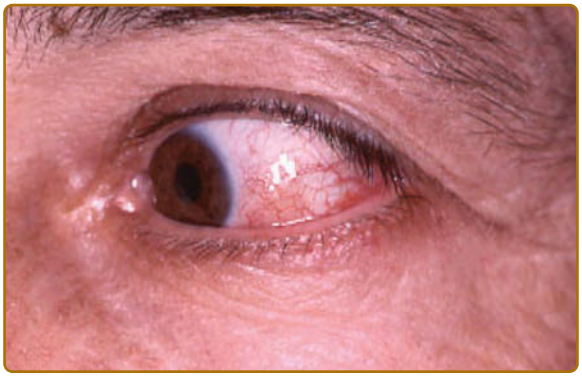

Figure 69-9 Relapsing polychondritis. Red eye suggestive of scleritis, which must be confirmed by an ophthalmologist.

cartilage is invaded by inflammatory cells with release of proteolytic enzymes such as matrix proteinase (MMP)-3 and cathepsins K and L. MMP-8, MMP-9, and elastase are localized at the periphery of the cartilage that gradually deteriorated with loss of basophilia, release of glycosaminoglycans, fragmentation of collagen and elastic tissue. At a late stage, it is replaced by fibrous connective tissue that may contain gelatinous cysts and calcifications.

The role of the humoral immune response was based on the presence of antibodies to collagen type II in a third of patients with RP, especially in the acute phase of RP. Antibody titers seemed to correlate with the severity of symptoms. Other antibodies also detected in patients with RP include antibodies to collagen type IX and type XI; minor collagens that represent 5% to 10% of cartilage collagens; antibodies to matrilin-1, an extracellular matrix protein, predominantly expressed in upper respiratory tract cartilage; and antibodies to cartilage oligomeric matrix protein, additional cartilage protein, expressed in auricular, tracheal, and nasal cartilage. Several animal models have been published in which immunization with these various cartilage proteins induced a variety of chondritis manifestations that mimic those seen in patients.[6] Although human studies and murine models strongly support a prominent role for collagen type II, matrilin-1, and cartilage oligomeric matrix protein, as potential target antigens, the detection of antibodies toward these proteins has low sensitivity and specificity, and therefore not used in clinical practice. Triggering events of RP include mechanical stimuli such as traumas and piercing, which may expose cryptic antigens of the cartilaginous matrix and induce an autoimmune process.

Influence of T cells in RP pathogenesis, although less investigated, also has been demonstrated in patients and in animal models with specificity against the same cartilage proteins. T-cell clones isolated from an RP patient were found to be specific for a peptide corresponding to residues 261 to 273 of the type II collagen and were restricted to either the DRBI*0101 or the DRBI*0401 allele.[7] RP is likely a T-helper-1–mediated disease as serum levels of interferon-γ, interleukin (IL)-12, and IL-2 parallel changes in disease activity, while the levels of T-helper-2 cytokines do not. Other mediators are involved in the pathogenesis such as sTREM-1, MCP-1, MIP-1β, and IL-8. A complex cytokine network orchestrates the recruitment of infiltrating cells in RP lesions.

The genetic background of RP seems to be different according to the different populations. HLA-DR4 was found to be associated with RP in the German but not in the Japanese population. In the Japanese population RP was associated with HLA-DRB*16:02, HLA-DQB1*05:02, and HLA-B*67:01, and differs genetically from other rheumatic diseases.[8]

DIAGNOSIS

The different diagnostic criteria for RP are based on characteristic clinical manifestations.[9] A positive histologic confirmation is rarely required (Table 69-1). Table 69-2 shows the main differential diagnoses and diseases that may be associated with RP.

TABLE 69-1
Different Diagnostic Criteria[9]

1. McAdam et al.[10]
   (1) Bilateral auricular chondritis
   (2) Nonerosive seronegative inflammatory polyarthritis
   (3) Nasal chondritis
   (4) Ocular inflammation
   (5) Respiratory chondritis
   (6) Cochlear and/or vestibular damage

   For the diagnosis of RP, patients must have 3 of 6 of the above criteria.
2. Damiani and Levine[11]
   For the diagnosis of RP, patients must have
   (1) At least 3 of the McAdam clinical criteria
   (2) One or more of the McAdam clinical criteria + biopsy confirmation of cartilage inflammation
   (3) Chondritis at 2 or more separate anatomic locations with response to steroids and/or dapsone
3. Michet et al.[12]
   (1) Major criteria
      – Auricular chondritis
      – Nasal chondritis
      – Laryngotracheal chondritis
   (2) Minor criteria
      – Conjunctivitis, episcleritis, scleritis, or uveitis
      – Hearing loss
      – Vestibular dysfunction
      – Seronegative polyarthritis

   For the diagnosis of RP, patients must have 2 major criteria or 1 major criteria + 2 minor criteria.

Laboratory findings in RP are nonspecific, but consistent with an acute or chronic inflammation. Urinalysis may be abnormal in case of renal involvement (mesangial expansion, immunoglobulin A nephropathy, tubulointerstitial nephritis, or necrotizing glomerulonephritis).

Pulmonary function tests, including inspiratory and expiratory flow volume curves, should be performed systematically to detect occult involvement. Imaging diagnosis delivers information about the degree of disease activity that correlates better with clinical features than unspecific inflammatory laboratory markers. Additionally, clinically unapparent cartilage involvement can be detected. Indeed, most disease manifestations can be objectified by means of cross-sectional imaging (computed tomography or MRI). The complementary use of functional data like those obtained with aid of diffusion-weighted imaging and glucose metabolism analysis (eg, fluorodeoxyglucose-positron emission tomography [FDG-PET]), allow a correct evaluation of the disease activity.[13]

CLINICAL COURSE AND PROGNOSIS

The clinical course of RP is progressive with intermittent flares. The number of different organ manifestations, their severity, and the response to treatment

TABLE 69-2
Differential Diagnosis

AURICULAR CHONDRITIS	**NASAL CHONDRITIS**
Bacterial cellulitis	Sinusitis
Leishmaniasis	Infectious perichondritis
Leprosy	Granulomatosis with polyangiitis
Traumatisms (rugbyman, boxer)	Congenital syphilis
Main Diseases Associated with Relapsing Polychondritis and/or with Clinical Similar Manifestations	
Autoimmune Diseases	**Vascular Diseases**
Rheumatoid arthritis	Leukocytoclastic vasculitis
Systemic lupus erythematosus	Granulomatosis with polyangiitis
Sjögren syndrome	Polyarteritis nodosa
Mixed connective tissue disease	Microscopic polyangiitis
Thyroid autoimmune disease	Eosinophilic granulomatosis with polyangiitis
Diabetes mellitus	Behçet disease
	MAGIC (mouth and genital ulcers with inflamed cartilage) syndrome
	Takayasu arteritis
	Antiphospholipid syndrome
Hematologic Disorders	
Myelodysplastic syndromes	
Immunoglobulin A myeloma	
Immunoglobulin A deficiency	
Others	
Skin Diseases	**Intestinal Diseases**
Vitiligo	Crohn disease
Psoriasis	Ulcerative colitis
Alopecia areata	**Others**
Lichen planus	Ankylosing spondylitis
	Reiter syndrome

are unpredictable.[3] The Relapsing Polychondritis Disease Activity Index (RPDAI) was developed to assess disease activity thanks to an international cooperation.[14] Cluster analysis of a large series of patients permitted to separate patients into 3 clinical phenotypes: hematologic, respiratory, and mild. The first group of patients with myelodysplasia was associated with death; the second group of patients with tracheobronchial involvement was associated with infections. By contrast, patients included in the mild phenotype had no severe complication and the possible occurrence of clinical remission. Factors associated with death on multivariable analysis were male sex, cardiac abnormalities, and concomitant myelodysplasia.[15] The United Kingdom population-based cohort study suggested that the relative mortality in RP may be 2 to 3 times higher than in the general population.[2]

MANAGEMENT

Because of the highly variable course of RP, individualized therapy is the key to optimum management without standardized guidelines. An algorithm for treatment cannot be established. General therapeutic guidelines are based on retrospective analyses of series of patients or isolated case reports. Nonsteroidal antiinflammatory drugs, colchicine, or dapsone may be useful for patients with mild auricular or nasal chondritis, arthralgia, or mild arthritis. More serious manifestations required oral corticosteroids in dose of 0.3 to 1 mg/kg of body weight according to their severity. Pulse intravenous steroids are prescribed for acute airway obstruction, sudden hearing loss, and/or before surgical intervention (tracheostomy, aortic aneurysm repair, cardiac valve replacement). Long-term corticosteroids decrease the frequency and severity of recurrences, although they do not prevent vital organ involvement. Whether steroid therapy should be continued during clinical remission periods remains unclear. Many kinds of immunosuppressants have been used with some success as disease-modifying and steroid-sparing agents. Methotrexate (0.3 mg/kg/week) is often effective. Cyclophosphamide is used in severe forms of RP. Azathioprine, mycophenolate mofetil, cyclosporine, leflunomide, and chlorambucil have produced inconsistent effects.

Although serum levels of IL-6 and tumor necrosis factor-α are usually not elevated in patients with active RP, infliximab has been the most frequently used biologic agent with variable results—frequently partial or complete efficacy, sometimes secondary to loss of efficacy or severe infection. Rituximab usually has no treatment effect. Other biologic agents tried in RP include tocilizumab, anakinra, etanercept, adalimumab, and certolizumab. The number of treated patients is too low to allow definitive conclusions.[3] In a few patients with refractory severe RP, treatment intensification followed by autologous stem cell transplantation has been performed.

REFERENCES

1. Mathew SD, Battafarano DF, Morris MJ. Relapsing polychondritis in the Department of Defense population and review of the literature. *Semin Arthritis Rheum*. 2012;42(1):70.
2. Hazra N, Dregan A, Charlton J, et al. Incidence and mortality of relapsing polychondritis in the UK: a population-based cohort study. *Rheumatology (Oxford)*. 2015;54(12):2181.
3. Vitale A, Sota J, Rigante D, et al. Relapsing polychondritis: an update on pathogenesis, clinical features, diagnostic tools and therapeutic perspectives. *Curr Rheumatol Rep*. 2016;18(1):3.
4. Frances C, El Rassi R, Laporte JL, et al. Dermatologic manifestations of relapsing polychondritis. *Medicine (Baltimore)*. 2001;80(3):173.
5. Tronquoy AF, de Quatrebarbes J, Picard D, et al. Papular and annular fixed urticarial eruption: a characteristic skin manifestation in patients with relapsing polychondritis. *J Am Acad Dermatol*. 2011;65(6):1161.

6. Arnaud L, Mathian A, Haroche J, et al. Pathogenesis of relapsing polychondritis: a 2013 update. *Autoimmun Rev*. 2014;13(2):90.
7. Buckner JH, Van Landeghen M, Kwok WW, et al. Identification of type II collagen peptide 261-273-specific T-cell clones in a patient with relapsing polychondritis. *Arthritis Rheum*. 2002;46(1):238.
8. Terao C, Yoshifuji H, Yamano Y, et al. Genotyping of relapsing polychondritis identified novel susceptibility HLA alleles and distinct genetic characteristics from other rheumatic diseases. *Rheumatology (Oxford)*. 2016;55(9):1686-1692.
9. Longo L, Greco A, Rea A, et al. Relapsing polychondritis: a clinical update. *Autoimmun Rev*. 2016;15(6):539.
10. McAdam LP, O'Hanlan MA, Bluestone R, Pearson CM. Relapsing polychondritis: prospective study of 23 patients and a review of the literature. *Medicine (Baltimore)*. 1976;55(3):193-215.
11. Damiani JM, Levine HL. Relapsing polychondritis–report of ten cases. *Laryngoscope*. 1979;89(6 Pt 1):929-946.
12. Michet CJ Jr, McKenna CH, Luthra HS, O'Fallon WM. Relapsing polychondritis. Survival and predictive role of early disease manifestations. *Ann Intern Med*. 1986;104(1):74-78.
13. Thaiss WM, Nikolaou K, Spengler W, et al. Imaging diagnosis in relapsing polychondritis and correlation with clinical and serological data. *Skeletal Radiol*. 2016;45(3):339.
14. Arnaud L, Devilliers H, Peng SL, et al. The relapsing polychondritis activity index: development of a disease activity score for relapsing polychondritis. *Autoimmun Rev*. 2012;12(2):204.
15. Dion J, Costedoat-Chalumeau N, Sène D, et al. Relapsing polychondritis can be characterized by 3 different clinical phenotypes: analysis of a recent series of 142 patients. *Arthritis Rheumatol*. 2016;68(12):2992-3001.

This page intentionally left blank

Dermal Connective Tissue Disorders

PART 11

Chapter 70 :: Anetoderma and Other Atrophic Disorders of the Skin

:: Catherine Maari & Julie Powell

ANETODERMA

AT-A-GLANCE

- Circumscribed 1- to 2-cm areas of flaccid skin that may be elevated, macular, or depressed.
- Often circumscribed sac-like protrusions.
- Primary or secondary to a preceding dermatosis in the same location.
- Association with antiphospholipid syndrome.
- Pathology consists of loss of elastic tissue in the dermis.

EPIDEMIOLOGY

The lesions in anetoderma usually occur in young adults between the ages of 15 and 30 years and more often in women than men. Anetoderma is rare, and the incidence is unknown. Several hundred cases have been reported.[1-4]

PATHOGENESIS

The pathogenesis of anetoderma is unknown. The key defect is damage to the dermal elastic fibers. Anetoderma may be considered to be unusual scars, because scars also have decreased elastic tissue. The loss of dermal elastin could be the result of an impaired turnover of elastin caused by either increased destruction or decreased synthesis of elastic fibers.[4,5] Recently, a decrease in fibulin protein expression was described, suggesting that not only elastolytic overactivity, but also defective elastic fiber reassembly, may be involved.[6] Immunologic mechanisms may also play a role, as it can be associated with various systemic conditions, primarily antiphospholipid antibodies.

CLINICAL FEATURES

All types of anetoderma are characterized by a circumscribed loss of normal skin elasticity. The characteristic lesions are flaccid circumscribed areas of slack skin with the impression of loss of dermal substance forming depressions, wrinkling, or sac-like protrusions (Fig. 70-1). These atrophic, skin-colored, or blue-white lesions are 5 to 30 mm in diameter. The number varies from a few to hundreds. The skin surface can be wrinkled, thinned, and often depigmented, and a central depression may be seen. Coalescence of smaller lesions can give rise to larger herniations. The examining finger sinks without resistance into a distinct pit with sharp borders as if into a hernia ring (buttonhole sign). The protrusion reappears as soon as the pressure from the finger is removed.[4]

The most common sites for these asymptomatic lesions are the chest, back, neck, and upper extremities. They usually develop in young adults, and new lesions often continue to form for many years as the older lesions fail to resolve.

Primary anetoderma occurs when there is no underlying associated skin disease (ie, it arises on clinically normal skin). It is historically subdivided into 2 types: (a) those with preceding inflammatory lesions, mainly erythema (the Jadassohn-Pellizzari type), and (b) those without preceding inflammatory lesions (the Schweninger-Buzzi type). This classification is only of historical interest, because the 2 types of lesions can

Figure 70-1 Anetoderma. Primary anetoderma. **A,** Multiple, sharply defined, depressed lesions that look punched out in the supraclavicular region. **B,** Soft, sac-like protrusions on the back. When depressed, there is the buttonhole phenomenon. This is the same patient as in **A**.

coexist in the same patient; the prognosis and the histopathology are also the same.[4]

True secondary anetoderma implies that the characteristic atrophic lesion has appeared in the exact same site as a previous specific pathology; the most common causes are probably acne and varicella. Numerous and heterogeneous dermatoses have been associated with secondary anetoderma (Table 70-1), namely infectious (syphilis, Lyme disease, leprosy, molluscum contagiosum), inflammatory (granuloma annulare, discoid lupus, sarcoidosis, lichen planus) and tumoral (pilomatricomas, juvenile xanthogranuloma, xanthomas, involuted infantile hemangiomas, cutaneous B-cell lymphoma) to mention only a few. Anetoderma

TABLE 70-1
Conditions Associated with Secondary Anetoderma

Infectious
▪ Syphilis
▪ Lyme disease
▪ Leprosy
▪ Molluscum contagiosum
Inflammatory
▪ Granuloma annulare
▪ Discoid lupus erythematosus
▪ Sarcoidosis
▪ Lichen planus
Tumoral
▪ Pilomatricomas
▪ Juvenile xanthogranuloma
▪ Xanthomas
▪ Involuted infantile hemangiomas
▪ Cutaneous B-cell lymphoma
Other Conditions[a]
▪ Antiphospholipid syndrome
▪ Autoimmune thyroiditis
▪ HIV

[a]Also associated with primary anetoderma.

also has been described in premature infants, possibly related to the use of cutaneous monitoring leads or adhesives as well as extreme prematurity.[7] Both primary and secondary types of anetoderma may be associated with an underlying disease, mainly antiphospholipid syndrome[8] autoimmune thyroiditis and HIV, in which cases the atrophic lesions do not necessarily develop in areas of skin inflammation. Although most cases are sporadic, rare cases of familial anetoderma have been recently described and are usually not associated with preexisting lesions.[9]

PATHOLOGY

In routinely stained sections, the collagen fibers within the dermis of affected skin appear normal. Perivascular lymphocytes, in majority T-helper cells, are often present in all types of anetoderma and do not correlate with clinical inflammatory findings.[10]

The predominant defect as revealed by elastic tissue stains is a focal partial or complete loss of elastic tissue in the papillary and/or midreticular dermis. There are usually some residual abnormal, irregular, and fragmented elastic fibers (Fig. 70-2). Presumably, the weakening of the elastic network leads to flaccidity and herniation. Direct immunofluorescence sometimes shows linear or granular deposits of immunoglobulins and complement along the dermal–epidermal junction or around the dermal blood vessels in affected skin.[11] Electron microscopy demonstrates that the elastic fibers are fragmented and irregular in shape, occasionally engulfed within macrophages.

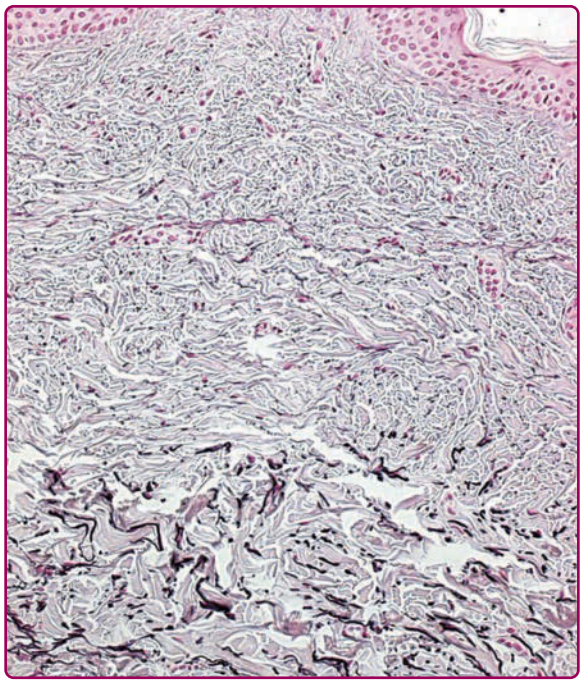

Figure 70-2 Anetoderma. Pathology shows decrease of elastic fibers in the papillary and reticular dermis (Weigert stain). (Used with permission from Victor Kokta, MD.)

DIFFERENTIAL DIAGNOSIS

Anetoderma must be differentiated from other disorders of elastic tissue as well as atrophies of the connective tissue (Table 70-2).

Keloids form nodules that are much firmer on palpation. A history of trauma is often elicited, and the pathology is very distinct.

Glucocorticoid-induced atrophy occurs most commonly over the triceps or buttocks at sites where injections are usually given. Clinically, the lesions resemble atrophoderma. History is obviously most helpful in making the diagnosis. On histopathology, polarization may show the steroid crystals in the dermis.

Nevus lipomatosus superficialis of Hoffman and Zurhelle presents as a clustered group of soft, skin-colored to yellow nodules usually on the lower trunk and buttocks and present since birth. Histology shows ectopic mature lipocytes located in the dermis.

TABLE 70-2
Differential Diagnosis of Primary Anetoderma

ELEVATED	DEPRESSED
Secondary anetoderma	Secondary anetoderma
Acne scars	Glucocorticoid-induced atrophy
Keloids	Acne scars
Nevus lipomatosus superficialis	
Papular elastorrhexis	
Connective tissue nevi	

Papular elastorrhexis is an acquired disorder characterized by white, firm nonfollicular papules measuring 1 to 3 mm, evenly scattered on the chest, abdomen, and back. It usually appears in adolescence or early adulthood. The pathology demonstrates focal degeneration of elastic fibers and normal collagen. There are no associated extracutaneous abnormalities. This is believed by some authors to be a variant of connective tissue nevi[12] or an abortive form of the Buschke-Ollendorff syndrome,[13] whereas others think that these represent papular acne scars.[14] They are differentiated from anetoderma by being firm noncompressible lesions.

Middermal elastolysis (MDE) usually consists of larger areas with diffuse wrinkling without herniation and with elastolysis limited to the middermis (see "Middermal Elastolysis" section).

TREATMENT

There is no regularly effective treatment. In secondary anetoderma, appropriate treatment of the inflammatory underlying condition might prevent new lesions. Various therapeutic modalities have been tried but with no improvement of existing atrophic lesions, including intralesional injections of triamcinolone, and systemic administration of aspirin, dapsone, phenytoin, penicillin G (benzylpenicillin), and vitamin E. Some authors have reported improvement with hydroxychloroquine. In patients with limited lesions that are cosmetically objectionable, surgical excision may be useful. Ablative and nonablative fractionated lasers have shown some improvement in limited cases.[15,16] The use of soft-tissue fillers is inconclusive.

OTHER ATROPHIC DISORDERS OF THE SKIN

MIDDERMAL ELASTOLYSIS

MDE is a rare acquired disorder of elastic tissue. It is characterized by patches and plaques of diffuse, fine, wrinkled skin, most often located on the trunk, neck, and arms. In 1977, Shelley and Wood reported the first case of "wrinkles due to idiopathic loss of middermal elastic tissue."[17] Since then, approximately 100 cases have been reported. The vast majority of patients are white women between the ages of 30 and 50 years.[17-19]

PATHOGENESIS

The pathogenesis of this acquired elastic tissue degeneration is still unknown. Ultraviolet exposure has been postulated to be a major contributing factor in the degeneration of elastic fibers,[20] including natural sunlight and narrowband ultraviolet B phototherapy.[21] Other possible mechanisms include defects in the synthesis of elastic fibers, autoimmunity against elastic

fibers, and damage to elastic fibers through the release of elastase by inflammatory cells or fibroblasts. Of interest, MDE has been reported in a case of immune reconstitution inflammatory syndrome.[22] Some data suggest that inflammatory processes and an imbalance between matrix metalloproteinases and tissue inhibitor of metalloproteinases are probably involved in the pathogenesis of MDE, in addition to CD34+ dendritic fibroblasts.[23] A decrease of lysyl oxidase-like 2 expression potentially has an effect on elastin renewal.[24] A recent study has shown that dermal fibulin-4 and fibulin-5 are significantly diminished in MDE compared with controls. This data indicates that the pathogenesis is not only secondary to an elastolytic overactivity, but also altered reassembly of elastic fibers.[6]

CLINICAL FEATURES

MDE is characterized by asymptomatic, well-demarcated, or diffuse areas of fine wrinkling (type I), usually in a symmetric distribution (Fig. 70-3A). Discrete perifollicular papules can be seen in some cases (type II), leaving the hair follicle itself as an indented center. More rarely, a reticular pattern (type III) with erythematous patches and telangiectasia can be seen. Lesions are typically found on the trunk, neck, and upper extremities. They are chronic and give the skin a prematurely aged appearance. There is usually no history of a preceding inflammatory dermatosis, but some patients report mild-to-moderate erythema and more rarely urticarial lesions or granuloma annulare. There is usually no associated systemic involvement.

Although the diagnosis of MDE is mainly based on clinical and histopathologic features, noninvasive diagnostic techniques (optical coherence microscopy or high-frequency ultrasound) may be helpful.[25]

PATHOLOGY

Histopathology shows a normal epidermis and, occasionally, a mild perivascular infiltrate in the dermis. The characteristic features are seen on elastic tissue stains (such as Verhoeff-van Gieson or Weigert) and reveal a selective band-like loss of elastic fibers in the middermis (see Fig. 70-3B). Macrophagic elastophagocytosis can occasionally be seen. There is preservation of normal elastic tissue in the superficial papillary dermis above, in the reticular dermis below, and along adjacent hair follicles. Electron microscopy studies have shown phagocytosis by macrophages of both normal and degenerated elastic fiber tissue.[26]

DIFFERENTIAL DIAGNOSIS

MDE must be differentiated from the other common disorders of elastic tissue.

Solar elastosis differs by its onset in an older age group, location in only sun-exposed areas, yellowish color, and coarser wrinkling, as well as by hyperplasia and abnormalities of elastic fibers and basophilic degeneration of the collagen in the papillary dermis.

Anetoderma is characterized clinically by smaller soft macules and papules instead of diffuse wrinkling, and histologically by elastolysis that can occur in any layer of the dermis.

Perifollicular elastolysis[27] differs by a selective and almost complete loss of elastic fibers surrounding hair follicles compared with preservation of elastic fibers around follicles in MDE. Elastase-producing *Staphylococcus epidermidis* was found in the hair follicles and is the presumed etiology of this condition.

Postinflammatory elastolysis and cutis laxa were originally described in young girls of African descent.

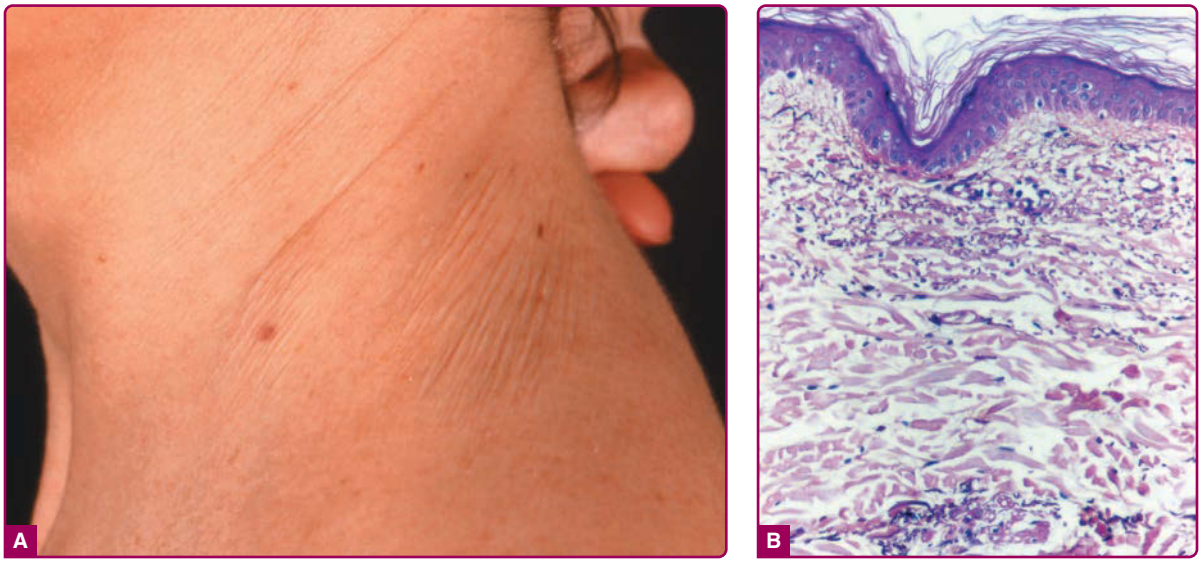

Figure 70-3 Middermal elastolysis. **A,** Well-circumscribed area of fine wrinkling on the neck of a middle-aged woman. (Used with permission from Richard Dubuc, MD.) **B,** Histology of middermal elastolysis. Note selective loss of elastic fibers in the middermis. Normal elastic tissue is preserved in the superficial papillary dermis and in the reticular dermis (Weigert stain). (Used with permission from Danielle Bouffard, MD.)

An inflammatory phase, consisting of indurated plaques or urticaria, malaise, and fever, preceded the diffuse wrinkling, atrophy, and severe disfigurement. Insect bites may be the trigger for the initial inflammatory lesions.[28]

TREATMENT

There is no known effective treatment for MDE. Sunscreens, colchicine, chloroquine, vitamin E, and topical retinoic acid have been tried without good success.[17-19] Topical soybean extract and eicosapentaenoic acid may prove to be interesting options.[18]

STRIAE

Chapters 105 and 137 provide additional discussion of striae.

Striae are very common and usually develop between the ages of 5 and 50 years.[29] They occur about twice as frequently in women as in men. They commonly develop during puberty, with an overall incidence of 25% to 35%,[30] or during pregnancy, with an incidence of up to 90%.[31]

PATHOGENESIS

The factors leading to the development of striae have not been fully elucidated. Striae distensae are the results of breaks in the connective tissue, resulting in dermal atrophy. Many factors, including hormones (particularly corticosteroids), mechanical stress, and genetic predisposition, appear to play a role.

CLINICAL FEATURES

Striae are usually multiple, symmetric, well-defined linear atrophic lesions that follow the lines of cleavage. Initially, striae appear as red-to-violaceous elevated lines (striae rubra). Over time, the color gradually fades, and the lesions become atrophic, with the skin surface exhibiting a fine, white, wrinkled appearance (striae alba). The striae can measure several centimeters in length and a few millimeters to a few centimeters in width.

During puberty, striae appear in areas where there is a rapid increase in size. In girls, the most common sites are the breasts, thighs, hips, and buttocks, whereas in boys, they are seen on the shoulders, lumbosacral region, and thighs. Other less-common sites include the abdomen, upper arms, neck, and axillae.

Striae distensae are a common finding on the abdomen, and less so on the breasts and thighs, of pregnant women, especially during the last trimester. They are more common in younger primigravidas than in older pregnant women, and are associated with larger weight gain and/or with babies of higher birth weight. Striae gravidarum can be associated with a higher risk of lacerations during vaginal delivery,[32] as well as the development of pelvic relaxation and clinical prolapse.[33]

The striae associated with systemic corticosteroid therapy and Cushing syndrome can be larger and more widely distributed.

PATHOLOGY

Histologic findings show a decrease in dermal thickness and in collagen in the upper dermis. The collagen bundles are thinned and lie parallel to the epidermis, but they are also arranged transversely to the direction of the striae. Alterations in elastic fibers are variable, but dermal elastin can be fragmented, and specific elastin staining can demonstrate a marked reduction in visible elastin content compared with adjacent normal dermis.[34] There is absence of both hair follicles and other appendages.

DIFFERENTIAL DIAGNOSIS

The diagnosis of striae distensae is usually straightforward, but the differential diagnosis does include linear focal elastosis (elastotic striae) that was first described by Burket and colleagues in 1989.[35] Linear focal elastosis is characterized by rows of yellow palpable striae-like bands on the lower back. Unlike striae, the lesions are raised and yellow rather than depressed and white. Elderly men are most commonly affected, although cases in teenagers have been described. Linear focal elastosis is probably not an uncommon condition. Histologically, there is a focal increase in the number of elongated or fragmented elastic fibers and a thickened dermis. It is postulated that linear focal elastosis may represent an excessive regenerative process of elastic fibers and could be thought of as a keloidal repair of striae distensae.[36]

TREATMENT[37]

Striae distensae have no medical consequences, but they are frequently distressing to those affected. As stretch marks tend to regress spontaneously to some degree over time, the usefulness of treatments that have been tried without case controls is difficult to assess. Topical treatments that have shown some improvement of early stage striae are tretinoin 0.1% cream,[38] a combination of 0.05% tretinoin/20% glycolic acid, or 10% L-ascorbic acid/20% glycolic acid.[39] Several lasers[40] have been used in treating striae: the 585-nm pulsed-dye laser has been demonstrated to be of some efficacy in improving the appearance of striae rubra but has no effect on striae alba. Preliminary data have shown improvement of striae alba with fractionated microneedle radiofrequency in combination with fractional carbon dioxide laser.[41] Microneedling and combination treatment with radiofrequency and pulsed magnetic fields also appear promising.[42,43] The long-term future of treatment strategies is encouraging with the advance in laser technologies.

IDIOPATHIC ATROPHODERMA OF PASINI AND PIERINI

Idiopathic atrophoderma of Pasini and Pierini is a form of dermal atrophy that presents as 1 or several sharply demarcated depressed patches with no outpouching, usually on the back of adolescents or young adults.[44] Whether atrophoderma is a nonsclerotic, primarily atrophic variant of morphea or a separate distinct entity is still debated.[45]

EPIDEMIOLOGY AND PATHOGENESIS

This disorder is more frequently encountered in women than in men, with a ratio of 6:1. It usually starts insidiously in young individuals in the second or third decades of life. Congenital cases have been reported.[46]

Its relationship to morphea is favored by its striking clinical and histologic similarities to the atrophy seen at sites of regressing plaques of morphea. Antibodies to *Borrelia burgdorferi* have been reported.[47] Typical lesions of morphea, lichen sclerosus, and atrophoderma have been observed to occur simultaneously in the same patient, but in different areas, supporting the view that these conditions are related.[48] In a series of 139 patients, 24 (17%) had white induration in the central portions of their atrophic lesions, and 30 (22%) had superficial plaques of morphea coexisting in areas outside of their atrophic foci.[49] However, to some, the different course and outcome of atrophoderma of Pierini and Pasini as compared with morphea justifies preservation of a distinct name.

CLINICAL FEATURES

The lesions are well-demarcated depressed patches, usually occurring on the trunk, especially on the back and lumbosacral region, followed in frequency by the chest, arms, and abdomen.[47,49] The distribution is often symmetric and bilateral.

The lesions are single or multiple and usually round or ovoid, ranging in size from a few centimeters to patches covering large areas of the trunk (Fig. 70-4). They are usually asymptomatic and lack inflammation. When lesions coalesce, they can form large, irregular, brown patches but can be hypopigmented.[49] The surface of the skin is normal in appearance, and there is no skin induration or sclerosis.

The borders or edges of these lesions are sharply defined, and they are usually described as abrupt, "cliff-drop" borders ranging from 1 to 8 mm in depth, although they can have a gradual slant.[46] These depressed patches are characteristic and give the impression of inverted plateaus, or, if multiple lesions are present, they can have the appearance of Swiss cheese. They are even more apparent when present on the back because the dermis is thicker in this area. The skin surrounding the patches is normal in appearance, and there is no erythema or lilac ring as in morphea.

Figure 70-4 Atrophoderma of Pasini and Pierini. Brownish depressed lesions on the lower back.

The course of this benign disease is progressive, and lesions can continue to appear for decades before reaching a standstill. Transformation to generalized morphea has not been observed.

PATHOLOGY

The histologic picture is generally not diagnostic.[47,49] The epidermis is usually normal. Collagen bundles in the middermis and reticular dermis show varying degrees of homogenization and clumping. Dermal thickness is eventually reduced when compared with adjacent normal skin. Some irregular clumping and loss of elastic fibers were described in earlier case reports, but in most series, no abnormality was seen with elastic tissue stains; consequently, this is not of diagnostic value. The appendages are usually preserved. If sclerodermatous changes appear in preexisting patches, the histology reveals varying degrees of collagen sclerosis resembling morphea. A recent study using multiphoton microscopy suggests that the atrophic appearance of atrophoderma lesions reflect changes in the organization of collagen and elastic fibers and not variation in their content.[50]

DIFFERENTIAL DIAGNOSIS

The differential diagnosis is to be made with active lesions of morphea that usually present as indurated, often hyperpigmented plaques with a characteristic peripheral lilac rim.

TREATMENT

No treatment has proven effective. Penicillin and doxycycline have been used with poor results. Dramatic response to oral hydroxychloroquine was reported in 1 patient.[51] Q-switched alexandrite laser can maybe help decrease hyperpigmentation.[52]

FOLLICULAR ATROPHODERMA

Follicular atrophoderma refers to dimple-like depressions at the follicular orifices. It can occur as an isolated defect of limited extent, in association with a variety of disorders in which hair follicles are plugged with keratin, or with rare genodermatoses.[53, 54]

Distinctive ice-pick depressions around hair follicles can be seen most commonly on the cheeks and on the back of the hands or feet. These pitted scars can present at birth or early in life. A family history may be present. Follicular atrophoderma occurs in the conditions described in the following sections.

ATROPHODERMA VERMICULATUM

Atrophoderma vermiculatum is a term that applies when the lesions are found exclusively on the cheeks.[55] It is a condition that can either occur sporadically, be inherited as an autosomal dominant disorder, be part of a group of related diseases including keratosis pilaris atrophicans, or be associated with various syndromes.

Multiple inflammatory symmetric papules on the cheeks, presumably centered around hair follicles, may precede the atrophic lesions. These papules then go on to develop pitted, atrophic, and depressed scars in a reticulated or honeycomb pattern (Fig. 70-5). These lesions can extend to the forehead and preauricular regions. This condition usually has its onset in childhood or, less often, around puberty. Men and women seem to be affected equally. It usually has a slow progressive course.

KERATOSIS PILARIS ATROPHICANS

Keratosis pilaris atrophicans[55,56] can include atrophoderma vermiculatum but also a group of closely related disorders that includes keratosis follicularis spinulosa decalvans and ulerythema ophryogenes. These conditions are characterized by keratotic follicular papules, variable degrees of inflammation, and secondary atrophic scarring. Keratosis follicularis spinulosa decalvans begins in infancy with keratotic follicular papules

Figure 70-5 Atrophoderma vermiculatum. Multiple, small, pitted scars on the cheek of a young girl.

over the malar area and progresses to involve the eyebrows, scalp, and extremities, with scarring alopecia. This condition is inherited in an X-linked recessive fashion in some patients. Ulerythema ophryogenes (or keratosis pilaris atrophicans faciei) differs from atrophoderma vermiculatum by affecting primarily the lateral portion of the eyebrows (ophryogenes) with erythema, follicular papules, and alopecia (Fig. 70-6).

The underlying pathologic defect in these disorders appears to be abnormal follicular hyperkeratinization of the upper third of the hair shaft leading to obstruction of the growing hair and production of chronic inflammation. The end result of this process is scarring below that level. Histopathology is usually not very

Figure 70-6 Ulerythema ophryogenes. Erythematous follicular papules and scarring alopecia of the eyebrow.

helpful and shows dilated follicles, sometimes associated with plugging, inflammation, and sclerosis of dermal collagen.

ASSOCIATED SYNDROMES

The various syndromes that include atrophoderma vermiculatum are Rombo syndrome (milia, telangiectasias, basal cell carcinomas, hypotrichosis, acral cyanosis, and, rarely, trichoepitheliomas), Nicolau-Balus syndrome (syringomas and milia), Tuzun syndrome (scrotal tongue), Loeys-Dietz syndrome,[57] and finally the Braun-Falco-Marghescu syndrome (palmoplantar hyperkeratosis and keratosis pilaris).

THERAPY

These disorders are mainly a cosmetic but vexing problem. Various topical treatments, including emollients, corticosteroids, tretinoin, and keratolytics, have shown no consistent benefit. Systemic isotretinoin has been shown to stop progression and to induce remission in some cases.[55] Dermabrasion as well as carbon dioxide and 585-nm pulsed-dye lasers are other options to improve the appearance of the atrophic scars.[58]

BAZEX-DUPRÉ-CHRISTOL SYNDROME (OMIM 301845)

Bazex-Dupré-Christol syndrome is characterized by follicular atrophoderma, milia, multiple basal cell carcinomas, hypotrichosis, and localized hypohidrosis.[59] The follicular atrophoderma described as multiple ice-pick marks or patulous follicles can be found most commonly on the dorsa of the hands. It is inherited in an X-linked dominant fashion, and the gene has been linked to Xq24-q27.[60] Additional reported findings include facial hyperpigmentation, hair shaft dystrophy, and multiple trichoepitheliomas. This syndrome might be better considered as an ectodermal dysplasia.[61]

CONRADI-HÜNERMANN-HAPPLE SYNDROME (X-LINKED DOMINANT CHONDRODYSPLASIA PUNCTATA, CDPX2, OMIM 302960)

Conradi-Hünermann-Happle syndrome is an X-linked dominant disorder that occurs only in girls because it is usually lethal in hemizygous males. The underlying molecular defect consists of mutations in the emopamil-binding protein gene at Xp11.23-p11.22.[62] The clinical manifestations include an ichthyosiform scaling erythroderma patterned along the lines of Blaschko that usually resolves during the first year of life and is replaced by bands of follicular atrophoderma. Hyperpigmentation, cataracts, scarring alopecia, saddle-nose deformity, asymmetric limb reduction defects, and stippled calcifications of the epiphyses can be seen. Ichthyosis with keratotic follicular plugs containing dystrophic calcification in newborns are distinctive histopathologic features.[63]

OTHER ATROPHIES OF THE CONNECTIVE TISSUE

Many systemic conditions (scleroderma [see Chap. 63], lupus erythematosus [see Chap. 61], dermatomyositis [see Chap. 62]), and genodermatoses (poikiloderma congenitale, dyskeratosis congenita, Cockayne syndrome, Hallermann-Streiff syndrome) have skin atrophy as an associated finding and are described in other chapters.

REFERENCES

1. Jadassohn J. Uber eine eigenartige form von "atrophica maculosa cutis". *Arch Derm Syphilol.* 1892;24:342-358.
2. Schweninger E, Buzzi F. Multiple benign tumor-like new growths of the skin. In: Internationaler Atlas Sellltener Hautkrankheiten, plate 15. Leipzig, Germany: L Voss; 1891.
3. Venencie PY, Winkelmann RK, Moore BA. Anetoderma: clinical findings, associations, and long-term follow-up evaluations. *Arch Dermatol.* 1984;120:1032-1039.
4. Kineston DP, Xia Y, Turiansky GW. Anetoderma: a case report and review of the literature. *Cutis.* 2008; 81:501-506.
5. Venencie PY, Bonnefoy A, Gogly B, et al. Increased expression of gelatinases A and B by skin explants from patients with anetoderma. *Br J Dermatol.* 1997;137:517-525.
6. Gambichler T, Reininghaus L, Skrygan M, et al. Fibulin protein expression in mid-dermal elastolysis and anetoderma: a study of 23 cases. *Acta Derm Venereol.* 2016;96:708-710.
7. Gougeon E, Beer F, Gay S, et al. Anetoderma of prematurity: an iatrogenic consequence of neonatal intensive care. *Arch Dermatol.* 2010;146:565-567.
8. Hodak E, David M. Primary anetoderma and antiphospholipid antibodies—review of the literature. *Clin Rev Allergy Immunol.* 2007;32:162-166.
9. Patrizi A, Neri I, Virdi A, et al. Familial anetoderma: a report of two families. *Eur J Dermatol.* 2011;21:680-685.
10. Venecie PY, Wilkelmann RK. Histopathologic findings in anetoderma. *Arch Dermatol.* 1984;120:1040-1044.
11. Bergman R, Friedman-Birnbaum R, Hazaz B, et al. An immunofluorescence study of primary anetoderma. *Clin Exp Dermatol.* 1990;15:124-130.
12. Sears J, Stone M, Argenyi Z. Papular elastorrhexis: a variant of connective tissue nevus: case reports

and review of the literature. *J Am Acad Dermatol.* 1988;19:409-414.
13. Schirren H, Schirren C, Stolz W, et al. Papular elastorrhexis: a variant of dermatofibrosis lenticularis disseminata (Buschke-Ollendorff syndrome). *Dermatology.* 1994;189:368-372.
14. Wilson B, Dent C, Cooper P. Papular acne scars; a common cutaneous finding. *Arch Dermatol.* 1990;126: 797-800.
15. Wang K, Ross NA, Saedi N. Anetoderma treated with combined 595-nm pulsed-dye laser and 1550-nm non-ablative fractionated laser. *J Cosmet Laser Ther.* 2016;18:38-40.
16. Cho S, Jung JY, Lee JH. Treatment of anetoderma occurring after resolution of Stevens-Johnson syndrome using an ablative 10,600-nm carbon dioxide fractional laser. *Dermatol Surg.* 2012;38:677-679.
17. Shelley WB, Wood MG. Wrinkles due to idiopathic loss of mid-dermal elastic tissue. *Br J Dermatol.* 1977; 97:441-445.
18. Hardin J, Dupuis E, Haber RM. Mid-dermal elastolysis: a female-centric disease; case report and updated review of the literature. *Int J Women's Dermatol*. 2015;1:126-130.
19. Gambichler T. Mid-dermal elastolysis revisited. *Arch Dermatol Res.* 2010;302:85-93.
20. Snider RL, Lang PG, Maize JC. The clinical spectrum of mid-dermal elastolysis and the role of UV light in its pathogenesis. *J Am Acad Dermatol.* 1993;28: 938-942.
21. Vatve M, Morton R, Bilsland D. A case of mid-dermal elastolysis after narrowband ultraviolet B phototherapy. *Clin Exp Dermatol.* 2009;34:263-264.
22. Cota C, Latini A, Lora V, et al. Mid-dermal elastolysis as a manifestation of immune reconstitution inflammatory syndrome in an HIV-infected patient. *J Am Acad Dermatol.* 2014;71:e134-e135.
23. Gambichler T, Breuckmann F, Kreuter A, et al. Immunohistochemical investigation of mid-dermal elastolysis. *Clin Exp Dermatol.* 2004;29:192-195.
24. Gambichler T, Skyrgan M. Decreased lysyl oxidase-like 2 expression in mid-dermal elastolysis. *Arch Dermatol Res*. 2013;305:359-363.
25. Scola N, Goulimus A, Gambichler T. Non-invasive imaging of mid-dermal elastolysis. *Clin Exp Dermatol.* 2011;36:155-160.
26. Harmon CB, Su WP, Gagne EJ, et al. Ultrastructural evaluation of mid-dermal elastolysis. *J Cutan Pathol.* 1994;21:233-238.
27. Varadi DP, Saqueton AC. Perifollicular elastolysis. *Br J Dermatol.* 1970;83:143.
28. Verhagen AR, Woederman MJ. Post-inflammatory elastolysis and cutis laxa. *Br J Dermatol.* 1975;92:183-190.
29. Garcia-Hidalgo L, Orozco-Topete R, Gonzalez-Barranco J, et al. Dermatoses in 156 obese adults. *Obes Res.* 1999;7:299-302.
30. Ammar NM, Rao B, Schwartz RA, et al. Adolescent striae. *Cutis.* 2000;65:69-70.
31. Farahnik B, Park K, Kroumpouzos G, et al. Striae gravidarum: risk factors, prevention and management. *Int J Womens Dermatol.* 2017;3:77-85.
32. Wahman AJ, Finan MA, Emerson SC. Striae gravidarum as a predictor of vaginal lacerations at delivery. *South Med J.* 2000;93:873-876.
33. Salter SA, Batra RS, Rohrer TE, et al. Striae and pelvic relaxation: two disorders of connective tissue with a strong association. *J Invest Dermatol.* 2006; 126:1745-1748.
34. Arem A, Ward Kisher C. Analysis of striae. *Plast Reconstr Surg.* 1980;65:22-29.
35. Burket JM, Zelickson AS, Padilla RS. Linear focal elastosis (elastotic striae). *J Am Acad Dermatol.* 1989; 20:633-636.
36. Hashimoto K. Linear focal elastosis: keloidal repair of striae distensae. *J Am Acad Dermatol.* 1998;39:309-313.
37. Al-Himdani S, Ud-Din S, Gilmore S, et al. Striae distensae: a comprehensive review and evidence-based evaluation of prophylaxis and treatment. *Br J Dermatol.* 2014;170:527-547.
38. Kang S. Topical tretinoin therapy for management of early striae. *J Am Acad Dermatol.* 1998;39:S90-S92.
39. Ash K, Lord J, Zukowski M, et al. Comparison of topical therapy for striae alba (20% glycolic acid/0.05% tretinoin versus 20% glycolic acid/10% L-ascorbic acid). *Dermatol Surg.* 1998;24:849-856.
40. Aldahan AS, Shah VV, Mlacker S, et al. Laser and light treatments for striae distensae: a comprehensive review of the literature. *Am J Clin Dermatol.* 2016; 17:239-256.
41. Fatemi Naeini F, Behfar S, Abtahi-Naeini B, et al. Promising option for treatment of striae alba: fractionated microneedle radiofrequency in combination with fractional carbon dioxide laser. *Dermatol Res Pract.* 2016;2016:2896345.
42. Ramaut L, Hoeksema H, Pirayesh A, et al. Microneedling: where do we stand now? A systematic review of the literature. *J Plast Reconstr Aesthet Surg.* 2018;71:1-14.
43. Dover JS, Rothaus K, Gold MH. Evaluation of safety and patient subjective efficacy of using radiofrequency and pulsed magnetic fields for the treatment of striae (stretch marks). *J Clin Aesthet Dermatol.* 2014;7:30-33.
44. Canizares O, Sachs PM, Jaimovich L, et al. Idiopathic atrophoderma of Pasini and Pierini. *Arch Dermatol.* 1958;77:42-60.
45. Jablonska S, Blaszczyk M. Is superficial morphea synonymous with atrophoderma Pierini-Pasini? *J Am Acad Dermatol.* 2004;50:979-980.
46. Kang CY, Lam J. Congenital idiopathic atrophoderma of Pierini and Pasini. *Int J Dermatol.* 2015;54:e44-e46.
47. Buechner SA, Rufli T. Atrophoderma of Pasini and Pierini: clinical and histopathologic findings and antibodies to *Borrelia burgdorferi* in thirty-four patients. *J Am Acad Dermatol.* 1994;30:441-446.
48. Amano H, Nagai Y, Ishikawa O. Multiple morphea coexistent with atrophoderma of Pierini-Pasini (APP): APP could be abortive morphea. *J Eur Acad Dermatol Venereol.* 2007;21:1254-1256.
49. Saleh Z, Abbas O, Dahdah MJ, et al. Atrophoderma of Pierini and Pasini: a clinical and histopathological study. *J Cutan Pathol.* 2008;35:1108-1114.
50. Vieira-Damiani G, Lage D, Christofoletti Daldon PÉ, et al. Idiopathic atrophoderma of Pasini and Pierini: a case study of collagen and elastin texture by multiphoton microscopy. *J Am Acad Dermatol.* 2017;77:930-937.
51. Carter JD, Valeriano J, Vasey FB. Hydroxychloroquine as treatment for atrophoderma of Pierini and Pasini. *Int J Dermatol.* 2006;45:1255-1256.
52. Arpey CJ, Patel DS, Stone MS, et al. Treatment of atrophoderma of Pierini and Pasini-associated hyperpigmentation with the Q-switched alexandrite laser: a clinical, histologic, and ultrastructural appraisal. *Lasers Surg Med.* 2000;27:206-212.
53. Miescher G. Atypische Chondrodystrophie, Typus morquino kombiniert mit follikularer atrophodermie. *Dermatologica.* 1944;89:38-51.

54. Curth HO. The genetics of follicular atrophoderma. *Arch Dermatol*. 1978;114:1479-1483.
55. Luria RB, Conologue T. Atrophoderma vermiculatum: a case report and review of the literature on keratosis pilaris atrophicans. *Cutis*. 2009;83:83-86.
56. Callaway SR, Lesher JL. Keratosis pilaris atrophicans: case series and review. *Pediatr Dermatol*. 2004;21:14-17.
57. van Dijk FS, Brittain H, Boerma R, et al. Atrophoderma vermiculatum: a cutaneous feature of Loeys-Dietz syndrome. *JAMA Dermatol*. 2015;151:675-677.
58. Handrick C, Alster T. Laser treatment of atrophoderma vermiculata. *J Am Acad Dermatol*. 2001;44:693-695.
59. Torrelo A, Sprecher E, Medeiro IG, et al. What syndrome is this? Basex-Dupré-Christol syndrome. *Pediatr Dermatol*. 2006;23:286-290.
60. Parren LJ, Abuzahra F, Wagenvoort T, et al. Linkage refinement of Bazex-Dupré-Christol syndrome to an 11·4-Mb interval on chromosome Xq25-27.1. *Br J Dermatol*. 2011;165:201-203.
61. Castori M, Castiglia D, Passarelli F, et al. Bazex-Dupré-Christol syndrome: an ectodermal dysplasia with skin appendage neoplasms. *Eur J Med Genet*. 2009:52:250-255.
62. Canueto J, Giros M, Ciria S, et al. Clinical, molecular and biochemical characterization of nine Spanish families with Conradi-Hünermann-Happle syndrome: new insights into X-linked dominant chondrodysplasia punctata with a comprehensive review of the literature. *Br J Dermatol*. 2012;166:830-838.
63. Hoang MP, Carder KR, Pandya AG, et al. Ichthyosis and keratotic follicular plugs containing dystrophic calcification in newborns: distinctive histopathologic features of X-linked dominant chondrodysplasia punctata (Conradi-Hünermann-Happle syndrome). *Am J Dermatopathol*. 2004;26:53-58.

Chapter 71 :: Acquired Perforating Disorders

:: Garrett T. Desman & Raymond L. Barnhill

AT-A-GLANCE

- Acquired perforating disorders represent a group of separately identified cutaneous disorders that occur most often in the setting of chronic renal disease or diabetes mellitus.
- The previously recognized Kyrle disease (KD), acquired elastosis perforans serpiginosa (AEPS), acquired perforating collagenosis (APC), and perforating folliculitis (PF) are now classified under the umbrella term of acquired perforating dermatosis.
- Lesions present as umbilicated papules and/or nodules with a central keratotic plug or crust distributed preferentially on extensor surfaces of the extremities.
- Histopathologic examination of lesional skin demonstrates invagination of the epidermis with extrusion of dermal material (collagen, elastin, and/or fibrin) through the cup-shaped epidermal depression.
- Treatment is challenging with no universally effective therapy, and patients often exhibit a chronic course.

The perforating disorders are a group of conditions characterized by the transepidermal elimination of connective tissue elements. Although this finding may be the primary manifestation of familial or acquired systemic conditions (ie, chronic renal failure, diabetes mellitus), the perforation of dermal elements also may be seen as a secondary component to other primary dermatoses (eg, perforating granuloma annulare, gout, perforating pseudoxanthoma elasticum) (Table 71-1). Rare familial primary perforating disorders typically present in childhood and are characterized histopathologically by the transepidermal elimination of collagen (reactive perforating collagenosis) or elastic fibers (elastosis perforans serpiginosa). Similar adult-onset nonfamilial/acquired lesions are most commonly associated with chronic kidney disease and diabetes mellitus. These cases were originally given various appellations within the medical literature, complicating the subject matter (Table 71-2). Eventually, comprehensive review of the literature concluded that 4 separate clinicopathologic entities characterized the adult-onset acquired primary perforating disorders: Kyrle disease (KD), acquired perforating collagenosis (APC), perforating folliculitis, and acquired elastosis perforans serpiginosa (AEPS).[1-4] Further studies, however, have reported more clinicopathologic similarities than differences among these acquired conditions, in particular, a varied composition of extruded contents (ie, collagen, elastin fibers, fibrin) from lesion to lesion in the same patient. This has resulted in some authors advocating for a combined designation of acquired perforating dermatosis (APD).[5,6] Although the use of this unified designation is encouraged, an acknowledgment of the clinical and histopathologic manifestations of these 4 described conditions is important for understanding the spectrum of findings as well as possible correlations with systemic disease (Table 71-3).

CLINICAL FEATURES

APD is an umbrella designation for adult-onset acquired perforating disease encompassing KD, APC, perforating folliculitis, and AEPS, with AEPS exhibiting distinctive clinical findings and disease associations. No geographic or clear racial predilection has been established. APD is characterized clinically by round, umbilicated, skin-colored, erythematous or hyperpigmented papules and nodules with a central crust or keratotic plug, predominantly involving the extensor surfaces of the extremities and the trunk (APC, KD) (Fig. 71-1). Lesions less commonly involve the face or scalp. Although the central keratotic core is the most specific clinical finding, it is occasionally removed by the patient, leaving behind only a shallow crater. Mucous membranes are spared. In rare cases, purple annular plaques or pustules mixed with papules have been observed. Scratching of APD lesions can lead to koebnerization with linear umbilicated papules arising in excoriated skin. Some lesions may exhibit a follicular-based distribution with minimal Koebner response (perforating folliculitis; Fig. 71-2). Lesional pain and pruritus, ranging from mild-to-severe and intractable, have been reported.[6]

Elastosis perforans serpiginosa, whether familial or acquired, exhibits papules in a serpiginous configuration, often with central atrophy, and typically is localized to 1 region of the body, such as the neck, trunk, or the extremities (Fig. 71-3). These lesions are frequently asymptomatic and only occasionally manifest a koebnerization response. Elastosis perforans serpiginosa affects nearly 4 times more males than females. The familial form of the disease has a reported autosomal dominant mode of inheritance.[7]

The term *reactive perforating collagenosis* refers to an extremely rare familial disorder that most commonly presents in early childhood with an equal sex distribution. Both autosomal dominant and recessive modes of inheritance have been reported. Similar to KD and APC, following superficial trauma, small keratotic papules develop on the upper and lower extremities,

TABLE 71-1
Secondary Perforating Disorders

Hematomas
Perforating calcinosis cutis
Gout (urate crystals)
Papular mucinosis (mucin)
Perforating pseudoxanthoma elasticum
Granuloma annulare
Necrobiosis lipoidica
Rheumatoid nodule
Sarcoidosis
Foreign body (silica, wood splinter, glass, metal)
Infection (chromomycosis, leprosy)
Tumor cells (melanoma, pilomatrixoma, epithelioid sarcoma)

TABLE 71-2
Synonyms for Acquired Perforating Dermatosis

Acquired reactive perforating collagenosis[38]
Hyperkeratosis follicularis et parafollicularis in cutem penetrans[4]
Hyperkeratosis penetrans[39]
Keratosis follicularis serpiginosa[40]
Kyrle disease[41]
Kyrle-like lesions[42]
Perforating disorder[23]
Perforating folliculitis[43]
Perforating folliculitis of hemodialysis[35]
Reactive perforating collagenosis of diabetes mellitus and renal failure[44]
Uremic follicular hyperkeratosis[45]

TABLE 71-3
Presentations of Acquired Perforating Dermatosis

	KYRLE DISEASE/ACQUIRED PERFORATING COLLAGENOSIS	PERFORATING FOLLICULITIS	ACQUIRED ELASTOSIS PERFORANS SERPIGINOSA
Age of onset	4th decade (average)	3rd decade (average)	2nd decade (average)
Site	Extensor lower and upper extremities; head, neck, and trunk	Hair-bearing portions of extremities	Nape of neck; upper extremities; face; lower extremities
Cutaneous findings	Round, umbilicated, skin-colored, erythematous or hyperpigmented papules and nodules with a central crust or keratotic plug	Similar to Kyrle disease/acquired perforating collagenosis, but with follicular distribution and variable central crusting	Papules in serpiginous configuration with central atrophy
Disease associations	Renal failure, hemodialysis, diabetes mellitus, hepatic insufficiency	Idiopathic, minor association with renal failure, hemodialysis, diabetes mellitus	Down syndrome; Ehlers-Danlos syndrome; osteogenesis imperfecta; pseudoxanthoma elasticum; minor association with renal failure
Koebner phenomenon	Positive	Negative	Occasionally

Figure 71-1 Acquired perforating dermatosis. **A,** Acquired perforating collagenosis type. Multiple, round, hyperpigmented papules, each with a central keratotic plug, distributed on the extensor aspects of the hand and wrist in a patient with chronic kidney disease. **B,** Kyrle disease type. Multiple large crateriform nodules with central keratinous contents on the back of a patient with hypothyroidism. (Image **B**, used with permission from Drs. Megan Rogge and Tamara Lazic-Strugar, Icahn School of Medicine at The Mount Sinai Hospital, New York, NY.)

Figure 71-2 Acquired perforating dermatosis, perforating folliculitis type. Multiple follicular, erythematous, firm papules with variable central crusting.

and occasionally on the face. This form of disease has the strongest koebnerization response.[8]

ASSOCIATIONS OF ACQUIRED PERFORATING DISORDERS

The most common systemic conditions associated with adult-onset APD are chronic kidney disease (CKD) and diabetes mellitus (DM). APD has been documented in 4.5% to 10% of hemodialysis patients in North America and in 11% of a dialysis population (both hemodialysis and peritoneal dialysis) in Great Britain.[9,10] Not surprisingly, the most common cause of CKD among APD patients is diabetic nephropathy.[10] APD also has occurred in patients with chronic renal dysfunction who are not undergoing dialysis, as well as in those patients who have received renal transplants.

Figure 71-3 Acquired perforating dermatosis, acquired elastosis perforans serpiginosa type. Annular plaque with variably crusted erythematous papules at the periphery and central cribriform scarring in a patient taking penicillamine for Wilson disease.

Interestingly, in a series of 22 patients with APD, 3 were healthy with no known associated illnesses.[6] Some advocate that the phenomenon of APD simply represents a form of prurigo nodularis owing to its association with other pruritic conditions, such as insect bites and scabies, lymphoma, and hepatobiliary diseases.[11-18] Lesions associated with CKD and DM typically follow a chronic course that parallels systemic disease (KD, acquired reactive perforating collagenosis). Follicular-based lesions unassociated with CKD or DM typically lack a Koebner response and may follow a waxing-and-waning course. APD has rarely been associated with the use of certain therapeutics, including tumor necrosis factor-α inhibitors, indinavir, and sorafenib.[19-22] AEPS is well recognized as a potential adverse effect of prolonged D-penicillamine therapy.[22] As mentioned earlier in this section, some elastosis perforans serpiginosa cases are familial and associated with an autosomal dominant mode of inheritance. Other associations include Down syndrome and various inborn disorders of connective tissue metabolism, such as Ehlers-Danlos syndrome, Marfan syndrome, osteogenesis imperfecta, scleroderma, and pseudoxanthoma elasticum. However, rare cases of AEPS have been reported in patients with CKD in the absence of penicillamine exposure or other known associations.[1] Table 71-3 lists less-commonly reported associations with APD.

ETIOLOGY AND PATHOGENESIS

Although the precise etiology and pathogenesis of APD are unknown, a complex interaction between epithelium, connective tissue, and inflammatory mediators is most likely involved. According to the current trend for unification, perforating folliculitis and APC may be phenotypic variants of a disease spectrum or merely different stages in lesional development. KD most likely represents an extreme phenotype or end-stage manifestation of the 2 former conditions. Controversy still exists regarding whether perforating folliculitis represents a true primary perforating disease as ruptured follicles with extruded stromal elements are a feature of many infectious conditions, such as *Pityrosporum* folliculitis.

Regardless, as APD is most strongly associated with pruritic conditions, superficial trauma to the epidermis most likely represents the primary inciting factor in susceptible patients. This is highlighted by the fact that many patients have common prurigo nodules in addition to classic perforating lesions. Additionally, resolution of APD lesions with discontinuation of manipulation/trauma supports this mechanism.[6] Predisposing conditions include vasculopathy/angiopathy (related to DM), microdeposition of exogenous materials within the dermis (including calcium salts and silicon, pertinent to the increased frequency of APD in dialysis patients), and epidermal or dermal change related to metabolic derangements including vitamin A deficiency.[10,23-26]

A recent study indicates a role of advanced glycation end product–modified collagens I and III, where traumatized keratinocytes bind to these extracellular matrix proteins via advanced glycation end product receptor CD36, inducing keratinocyte terminal differentiation and upward movement of keratinocytes along with glycated collagen.[27] Fibronectin also has been implicated because it links keratinocytes with Type IV collagen within the basement membrane and plays a vital role in epithelial cell signaling, migration, and differentiation. Increased fibronectin levels have been documented in the serum of patients with DM and uremia, as well as within the skin at sites of transepidermal elimination.[28] Imbalances in transforming growth factor-β3, matrix metalloproteinase-1, and tissue inhibitor of metalloproteinase-1 also have been demonstrated in APD lesions; whether these alterations are pathogenic or reflective of normal wound healing is currently unknown.[26,29]

Whether the pathogenesis of the familial primary perforating dermatoses is different from the acquired forms is also unknown. Transepidermal elimination of Type IV collagen has been documented in both familial reactive perforating collagenosis and APC.[30] In elastosis perforans serpiginosa, enhanced expression of elastin receptors has been detected in the epidermis surrounding the elastic material in both familial and acquired conditions.[31] However, in penicillamine-associated AEPS, it is hypothesized that penicillamine alters dermal elastic fibers in affected patients.[32] Elastic fiber abnormalities, including "bramble bush–appearing" fibers of variable thickness and increased numbers of fibers in the papillary and reticular dermis, have been described in patients with penicillamine-induced AEPS.[33]

DIAGNOSIS

HISTOPATHOLOGY

The diagnosis of APD is based on clinical and histopathologic findings. Folliculitis and prurigo nodularis may occur concomitantly, especially in patients with CKD, therefore multiple biopsies should be taken if lesions show different clinical morphologies. APD is characterized histologically by transepidermal elimination of dermal material through an epidermal invagination, which may be follicular or perifollicular. Lesions typically demonstrate a central keratotic plug with crusting or hyperkeratosis; parakeratosis is variable. Within the dermis surrounding the perforation, there is often a focal inflammatory infiltrate with neutrophils predominating in early lesions and lymphocytes, macrophages, or multinucleated giant cells present in older lesions.

The 4 initially identified acquired perforating disorders (APC, AEPS, KD, and perforating folliculitis) were classically differentiated histopathologically on the basis of the nature of the eliminated dermal material. In APC, collagen bundles are detected within the plug (Fig. 71-4); in AEPS, elastic fibers are instead noted (Fig. 71-5). In KD, amorphous dermal material with fibrin and/or keratin comprises the extruded contents. Perforating folliculitis is characterized by perforation of the follicular epithelium by degenerating collagen and extracellular matrix (Fig. 71-6).

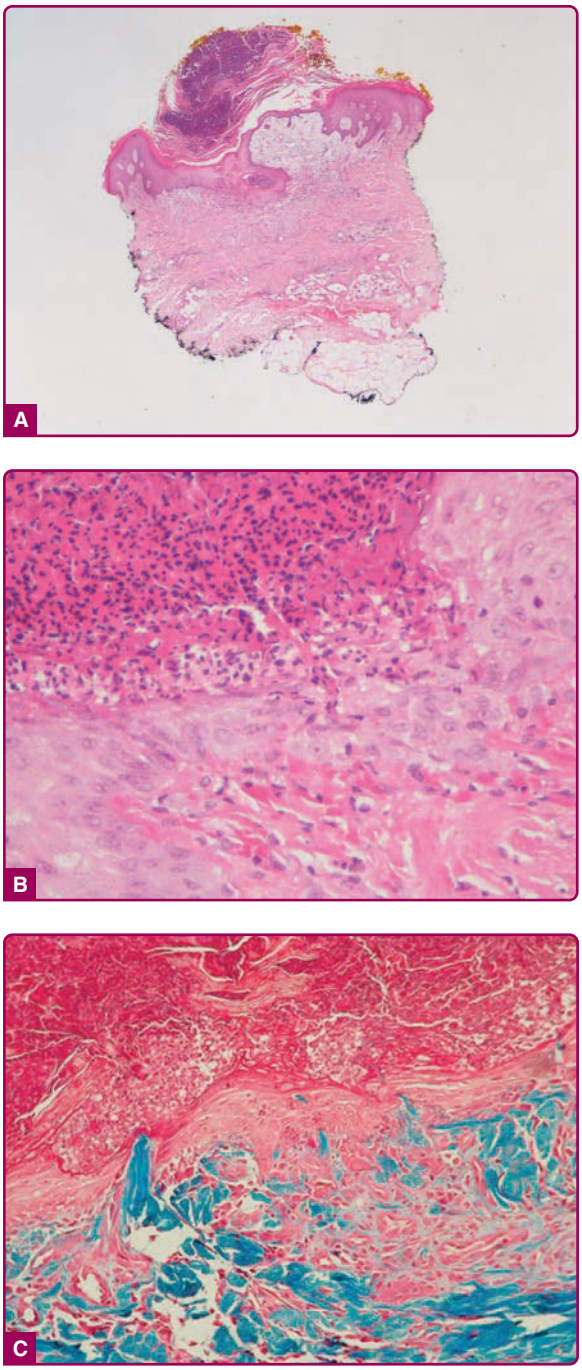

Figure 71-4 Acquired perforating dermatosis, acquired perforating collagenosis type. **A,** There is a crateriform epidermal invagination filled with necrotic material and inflammatory cells. **B,** Individual collagen bundles penetrate through the epidermis and into the core of necrotic material. **C,** Trichrome stain highlights the collagen bundles *(blue)* from the reticular dermis penetrating through the epidermis.

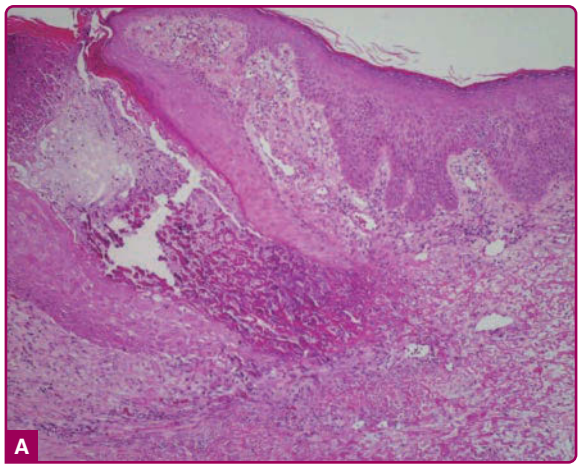

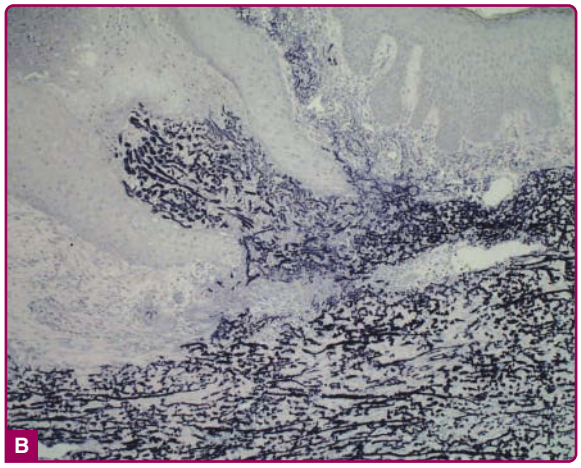

Figure 71-5 Acquired perforating dermatosis, acquired elastosis perforans serpiginosa type. **A,** Dilated follicular structure with transepidermal elimination of densely eosinophilic elongated bundles (hematoxylin and eosin stain). **B,** Transepidermally eliminated elongated bundles are elastin fibers (elastin stain).

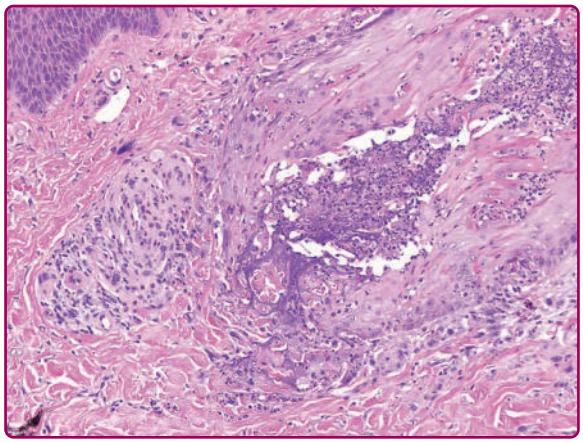

Figure 71-6 Acquired perforating dermatosis, perforating folliculitis type. A dilated follicular unit exhibits disruption of the outer root sheath epithelium by perforating dermal collagen. The follicular ostium is filled with necrotic debris and acute inflammatory cells. (Used with permission from Garrett Desman, MD. From Desman GT, Barnhill RL: *Barnhill's Dermatopathology Challenge*. New York, NY: McGraw-Hill Education; 2016:346.)

TABLE 71-4
Conditions Associated with Acquired Perforating Dermatosis

Common Associations
Chronic kidney disease
Diabetes mellitus (insulin-dependent and noninsulin-dependent)
Scabies[12,13]
Rare Associations
AIDS[46,47]
Arthropod bites[14,48]
Atopic dermatitis[34]
Cutaneous cytomegalovirus infection[49]
Hyperparathyroidism[38]
Liver diseases (hepatitis C, hepatitis B, steatohepatitis, primary biliary cirrhosis)[6,15]
Lupus vulgaris[50]
Myelodysplastic syndrome[49]
Malignancy (Hodgkin lymphoma, mixed histiocytic–lymphocytic lymphoma, hepatocellular carcinoma, pancreatic carcinoma, prostate carcinoma, papillary thyroid carcinoma)[17,18,51-56]
Mikulicz disease[57]
Neurodermatitis[38]
Poland syndrome[58]
Primary sclerosing cholangitis[59]
Pulmonary aspergillosis[60]
Pulmonary fibrosis[34]
Salt water application[23]
Thyroid disease (hypothyroidism, sick euthyroid syndrome, Hashimoto thyroiditis)[15,38,61]
Vitamin A deficiency[24]

Clear identification of the eliminated material may be impossible and, in addition, multiple substances (ie, collagen and elastic fibers) may be simultaneously detected, reinforcing the clinical and histopathologic overlap within APD.[5,6]

Lesions of familial reactive perforating collagenosis and elastosis perforans serpiginosa characteristically contain extruded collagen and elastin, respectively.[7,8]

LABORATORY TESTS

Laboratory evaluation for comorbidities should include fasting blood glucose; glucose tolerance test; serum creatinine; glomerular filtration rate or creatinine clearance; serum uric acid; liver function tests; and thyroid function tests. A comprehensive family and past medical history, as well as review of systems, should be obtained. Additional diagnostic testing for associated conditions (Table 71-4) should be performed as indicated.

DIFFERENTIAL DIAGNOSIS

The differential diagnosis of APD is broad and includes infectious, inflammatory, and neoplastic disorders, including those that koebnerize (Table 71-5). APD can

TABLE 71-5
Differential Diagnosis of Acquired Perforating Dermatosis

- Actinic granuloma (annular elastolytic giant cell granuloma)
- Arthropod bites
- Discoid lupus erythematous
- Flegel disease (hyperkeratosis follicularis perstans)
- Folliculitis (bacterial, yeast)
- Keratosis follicularis (Darier disease)
- Keratosis pilaris
- Lichen planus
- Multiple keratoacanthomas (Ferguson-Smith familial keratoacanthomas, Grzybowski eruptive keratoacanthomas)
- Perforating granuloma annulare
- Perforating periumbilical calcific elastosis
- Perforating pseudoxanthoma elasticum
- Porokeratosis
- Prurigo nodularis
- Psoriasis
- Sarcoidosis
- Scabies

be especially difficult to differentiate from prurigo nodularis. Perforating pseudoxanthoma elasticum should be distinguished from AEPS.

CLINICAL COURSE, PROGNOSIS, AND MANAGEMENT

COMPLICATIONS

Most complications that occur in patients with APD arise from underlying systemic illnesses. However, patients should be monitored for secondary infection (bacterial, fungal, and viral) as well as parasitic infestation. In an attempt to relieve the associated pruritus, patients may apply products to their skin that may result in irritant or allergic contact dermatitis. In darker-skinned patients with more excoriations, postinflammatory pigmentary alteration and scarring can be significant.

PROGNOSIS

The prognosis of APD is heavily linked to the presence of underlying diseases. Some studies have shown that APD may improve with successful treatment of the underlying illness.[34] Most cases of APD continue for years unless treated.

MANAGEMENT

Treatment of APD is difficult. Table 71-6 details the therapeutic options that are described in the literature

TABLE 71-6
Treatment of Acquired Perforating Dermatosis

TREATMENT	ACTION	DOSING
Topical Therapies		
Retinoic acid[a]	Retinoid	0.025% gel[62]
Tretinoin[a]	Retinoid	0.1% cream one to three times daily[63,64]
Tazarotene[a]	Retinoid	0.1% gel daily[65]
Beclomethasone[a]	Corticosteroid	0.1% cream[9]
Triamcinolone acetonide[a]	Corticosteroid	10 mg/mL intralesional injection[9]
Imiquimod	Immune response modifier	Daily for 6 weeks then 3 times per week for 4 weeks[32]
Phenol	Antipruritic	0.5% phenol with 10% glycerin in Sorbolene cream[66]
Capsaicin	Capsaicinoid	0.025%-0.075% ointment
Systemic Therapies		
Isotretinoin[b]	Retinoid	Isotretinoin 0.5 mg/kg/day[67,68]
Acitretin[b]	Retinoid	25-30 mg daily [66,69]
Prednisolone	Corticosteroid	30 mg daily[70]
Allopurinol[b]	Xanthine oxidase inhibitor	100 mg daily[71,72]
Doxycycline	Antibiotic	100 mg daily[13,73,74]
Metronidazole	Antibiotic	500 mg twice daily[75]
Clindamycin	Antibiotic	300 mg three times daily[76]
Hydroxychloroquine	Antimalarial	200 mg daily[77]
Physical Modalities		
UVB[a]	Phototherapy	MED for 2 minutes every other day with increments of 30 seconds for 2–4 weeks[78]
NUVB[a]	Phototherapy	Three times a week for 2-3 months[33] 400 mJ/cm^2 increased to 1,500 mJ/cm^2, two to three times per week, 10–15 exposures[37]
PUVA[b,74]	Phototherapy	Four times per week for total of 326 J/cm[79]
Liquid nitrogen	Cryotherapy	10 seconds, on five occasions over 4 months, one occasion 3 months later[80]
Carbon dioxide laser	Laser	Five lesional passes at 300 J (pattern 5, size 7, density 7), followed by 3 resurfacing passes at 300 J (pattern 2, size 8, density 5), power of 80 W[81]
TENS	Other	1 hour daily for 3 weeks[82]
Surgical debridement[76,83]		

[a]First-line therapy.
[b]Second-line therapy.
NUVB, narrowband ultraviolet B; PUVA, psoralen and ultraviolet A; TENS, transcutaneous electrical nerve stimulation; UVB, ultraviolet B.

to date. There have not been any well-designed clinical trials of treatment for APD, and current treatment strategies are based largely on anecdotal reports. In patients with CKD, improvement in APD lesions has been reported after changing the type of dialysis tubing or modification of the dialysis procedure.[10] In a few cases, APD has resolved following renal transplantation.[9,35,36] The most commonly employed treatments for APD include topical and oral retinoids, topical and intradermal corticosteroids, and ultraviolet B phototherapy. Phototherapy is effective for uremic pruritus and therefore may be particularly beneficial for patients with CKD by reducing koebnerization.[37] Several authors have reported improvement in APD following treatment with allopurinol in cases of elevated or normal uric acid levels.[37] Currently available therapeutic options may not provide complete resolution of APD lesions or associated symptoms.

REFERENCES

1. Schamroth JM, Kellen P, Grieve TP. Elastosis perforans serpiginosa in a patient with renal disease. *Arch Dermatol*. 1986;122(1):82-84.
2. Poliak SC, Lebwohl MG, Parris A, et al. Reactive perforating collagenosis associated with diabetes mellitus. *N Engl J Med*. 1982;306(2):81-84.
3. Mehregan AH, Coskey RJ. Perforating folliculitis. *Arch Dermatol*. 1968;97(4):394-399.
4. Kyrle J. Uber einen ungewohnlichen fall von universeller follicularer und parafollikularer hyperkeratose (hyperkeratosis follicularis et parafollicularis in cutem penetrans). *Arch Dermatol Syph*. 1916;123.
5. Rapini RP, Herbert AA, Drucker CR. Acquired perforating dermatosis. Evidence for combined transepidermal elimination of both collagen and elastic fibers. *Arch Dermatol*. 1989;125(8):1074-1078.
6. Saray Y, Seckin D, Bilezikci B. Acquired perforating dermatosis: clinicopathological features in twenty-two cases. *J Eur Acad Dermatol Venereol*. 2006;20(6):679-688.
7. Langeveld-Wildschut EG, Toonstra J, van Vloten WA, et al. Familial elastosis perforans serpiginosa. *Arch Dermatol*. 1993;129(2):205-207.
8. Pai VV, Naveen KN, Athanikar SB, et al. Familial reactive perforating collagenosis: a report of two cases. *Indian J Dermatol*. 2014;59(3):287-289.
9. Morton CA, Henderson IS, Jones MC, et al. Acquired perforating dermatosis in a British dialysis population. *Br J Dermatol*. 1996;135(5):671-677.
10. Kurban MS, Boueiz A, Kibbi AG. Cutaneous manifestations of chronic kidney disease. *Clin Dermatol*. 2008;26(3):255-264.
11. Kestner RI, Stander S, Osada N, et al. Acquired reactive perforating dermatosis is a variant of prurigo nodularis. *Acta Derm Venereol*. 20178;97(2):249-254.
12. Hinrichs W, Breuckmann F, Altmeyer P, et al. Acquired perforating dermatosis: a report on 4 cases associated with scabies infection. *J Am Acad Dermatol*. 2004;51(4):665-667.
13. Brinkmeier T, Herbst RA, Frosch PJ. Reactive perforating collagenosis associated with scabies in a diabetic. *J Eur Acad Dermatol Venereol*. 2004;18(5):588-590.
14. Kim EJ, Kim MY, Kim HO, et al. Acquired reactive perforating collagenosis triggered by insect bite. *J Dermatol*. 2007;34(9):677-679.
15. Chiu MW, Haley JC. Acquired perforating dermatosis associated with primary biliary cirrhosis and Hashimoto thyroiditis. *Cutis*. 2007;79(6):451-455.
16. Karpouzis A, Tsatalas C, Sivridis E, et al. Acquired reactive perforating collagenosis associated with myelodysplastic syndrome evolving to acute myelogenous leukaemia. *Australas J Dermatol*. 2004;45(1):78-79.
17. Eigentler TK, Metzler G, Brossart P, et al. Acquired perforating collagenosis in Hodgkin's disease. *J Am Acad Dermatol*. 2005;52(5):922.
18. Henry JC, Jorizzo JL, Apisarnthanarax P. Reactive perforating collagenosis in the setting of prurigo nodularis. *Int J Dermatol*. 1983;22(6):386-387.
19. Gilaberte Y, Coscojuela C, Vázquez C, et al. Perforating folliculitis associated with tumour necrosis factor-alpha inhibitors administered for rheumatoid arthritis. *Br J Dermatol*. 2007;156(2):368-371.
20. Calista D, Morri M. Acquired reactive perforating collagenosis induced by indinavir in 2 patients with HIV disease. *Eur J Dermatol*. 2008;18(1):84-85.
21. Wolber C, Udvardi A, Tatzreiter G, et al. Perforating folliculitis, angioedema, hand-foot syndrome—multiple cutaneous side effects in a patient treated with sorafenib. *J Dtsch Dermatol Ges*. 2009;7(5):449-452.
22. Pass F, Goldfischer S, Sternlieb I, et al. Elastosis perforans serpiginosa during penicillamine therapy for Wilson disease. *Arch Dermatol*. 1973;108(5):713-715.
23. Lee SJ, Jang JW, Lee WC, et al. Perforating disorder caused by salt-water application and its experimental induction. *Int J Dermatol*. 2005;44(3):210-214.
24. Barr DJ, Riley RJ, Greco DJ. Bypass phrynoderma. Vitamin A deficiency associated with bowel-bypass surgery. *Arch Dermatol*. 1984;120(7):919-921.
25. Kawakami T, Saito R. Acquired reactive perforating collagenosis associated with diabetes mellitus: eight cases that meet Faver's criteria. *Br J Dermatol*. 1999;140(3):521-524.
26. Patterson JW. Progress in the perforating dermatoses. *Arch Dermatol*. 1989;125(8):1121-1123.
27. Fujimoto E, Kobayashi T, Fujimoto N, et al. AGE-modified collagens I and III induce keratinocyte terminal differentiation through AGE receptor CD36: epidermal-dermal interaction in acquired perforating dermatosis. *J Invest Dermatol*. 2010;130(2):405-414.
28. Bilezikci B, Seckin D, Demirhan B. Acquired perforating dermatosis in patients with chronic renal failure: a possible pathogenetic role for fibronectin. *J Eur Acad Dermatol Venereol*. 2003;17(2):230-232.
29. Gambichler T, Birkner L, Stücker M, et al. Up-regulation of transforming growth factor-beta3 and extracellular matrix proteins in acquired reactive perforating collagenosis. *J Am Acad Dermatol*. 2009;60(3):463-469.
30. Herzinger T, Schirren CG, Sander CA, et al. Reactive perforating collagenosis-transepidermal elimination of type IV collagen. *Clin Exp Dermatol*. 1996;21(4):279-282.
31. Fujimoto N, Akagi A, Tajima S, et al. Expression of 67-kDa elastin receptor in perforating skin disorders. *Br J Dermatol*. 2002;146(1):74-79.
32. Kelly SC, Purcell SM. Imiquimod therapy for elastosis perforans serpiginosa. *Arch Dermatol*. 2006;142(7):829-830.
33. Hashimoto K, McEvoy B, Belcher R. Ultrastructure of penicillamine-induced skin lesions. *J Am Acad Dermatol*. 1981;4(3):300-315.

34. Tsuboi H, Katsuoka K. Characteristics of acquired reactive perforating collagenosis. *J Dermatol*. 2007;34(9):640-644.
35. White CR Jr, Heskel NS, Pokorny DJ. Perforating folliculitis of hemodialysis. *Am J Dermatopathol*. 1982;4(2):109-116.
36. Saldanha LF, Gonick HC, Rodriguez HJ, et al. Silicon-related syndrome in dialysis patients. *Nephron*. 1997;77(1):48-56.
37. Ohe S, Danno K, Sasaki H, et al. Treatment of acquired perforating dermatosis with narrowband ultraviolet B. *J Am Acad Dermatol*. 2004;50(6):892-894.
38. Faver IR, Daoud MS, Su WP. Acquired reactive perforating collagenosis. Report of six cases and review of the literature. *J Am Acad Dermatol*. 1994;30(4):575-580.
39. Abele DC, Dobson RL. Hyperkeratosis penetrans (Kyrle's disease). Report of a case in a Negro with autopsy findings. *Arch Dermatol*. 1961;83:277-283.
40. Lutz W. Keratosis follicularis serpiginosa [in undetermined language]. *Dermatologica*. 1953;106(3-5):318-319.
41. Hood AF, Hardegen GL, Zarate AR, et al. Kyrle's disease in patients with chronic renal failure. *Arch Dermatol*. 1982;118(2):85-88.
42. Stone RA. Kyrle-like lesions in two patients with renal failure undergoing dialysis. *J Am Acad Dermatol*. 1981;5(6):707-709.
43. Mehregan AH, Schwartz OD, Livingood CS. Reactive perforating collagenosis. *Arch Dermatol*. 1967;96(3):277-282.
44. Cochran RJ, Tucker SB, Wilkin JK. Reactive perforating collagenosis of diabetes mellitus and renal failure. *Cutis*. 1983;31(1):55-58.
45. Garcia-Bravo B, Rodriguez-Pichardo A, Camacho F. Uraemic follicular hyperkeratosis. *Clin Exp Dermatol*. 1985;10(5):448-454.
46. Bank DE, Cohen PR, Kohn SR. Reactive perforating collagenosis in a setting of double disaster: acquired immunodeficiency syndrome and end-stage renal disease. *J Am Acad Dermatol*. 1989;21(2, pt 2):371-374.
47. Rubio FA, Herranz P, Robayna G, et al. Perforating folliculitis: report of a case in an HIV-infected man. *J Am Acad Dermatol*. 1999;40(2, pt 2):300-302.
48. Ghosh SK, Bandyopadhyay D, Chatterjee G. Acquired reactive perforating collagenosis following insect bite. *Indian J Dermatol Venereol Leprol*. 2009;75(3):306-307.
49. Yamashita N, Watanabe D, Ozawa H, et al. Reactive perforating collagenosis with cutaneous cytomegalovirus infection. *Eur J Dermatol*. 2006;16(6):696-697.
50. Zelger B, Hintner H, Auböck J, et al. Acquired perforating dermatosis. Transepidermal elimination of DNA material and possible role of leukocytes in pathogenesis. *Arch Dermatol*. 1991;127(5):695-700.
51. Pedragosa R, Knobel HJ, Huguet P, et al. Reactive perforating collagenosis in Hodgkin's disease. *Am J Dermatopathol*. 1987;9(1):41-44.
52. Bong JL, Fleming CJ, Kemmett D. Reactive perforating collagenosis associated with underlying malignancy. *Br J Dermatol*. 2000;142(2):390-391.
53. Chae KS, Park YM, Cho SH, et al. Reactive perforating collagenosis associated with periampullary carcinoma. *Br J Dermatol*. 1998;139(3):548-550.
54. Boeck K, Mempel M, Hein R, et al. Acquired perforating collagenosis in a patient with carcinoma of the prostate. *Acta Derm Venereol*. 1997;77(6):486-487.
55. Kilic A, Gönül M, Cakmak SK, et al. Acquired reactive perforating collagenosis as a presenting sign of hepatocellular carcinoma. *Eur J Dermatol*. 2006;16(4):447.
56. Yazdi S, Saadat P, Young S, et al. Acquired reactive perforating collagenosis associated with papillary thyroid carcinoma: a paraneoplastic phenomenon? *Clin Exp Dermatol*. 2010;35(2):152-155.
57. Shiomi T, Yoshida Y, Horie Y, et al. Acquired reactive perforating collagenosis with the histological features of IgG4-related sclerosing disease in a patient with Mikulicz's disease. *Pathol Int*. 2009;59(5):326-331.
58. Fistarol SK, Itin PH. Acquired perforating dermatosis in a patient with Poland syndrome. *Dermatology*. 2003;207(4):390-394.
59. Skiba G, Milkiewicz P, Mutimer D, et al. Successful treatment of acquired perforating dermatosis with rifampicin in an Asian patient with sclerosing cholangitis. *Liver*. 1999;19(2):160-163.
60. Kim JH, Kang WH. Acquired reactive perforating collagenosis in a diabetic patient with pulmonary aspergillosis. *Cutis*. 2000;66(6):425-430.
61. Fatani MI, Al-Ghamdi YM, Al-Afif KA, et al. Acquired reactive perforating collagenosis associated with sick euthyroid syndrome. *Saudi Med J*. 2002;23(11):1408-1410.
62. Berger RS. Reactive perforating collagenosis of renal failure/diabetes responsive to topical retinoic acid. *Cutis*. 1989;43(6):540-542.
63. Petrozzi JW, Warthan TL. Kyrle disease. Treatment with topically applied tretinoin. *Arch Dermatol*. 1974;110(5):762-765.
64. Cullen SI. Successful treatment of reactive perforating collagenosis with tretinoin. *Cutis*. 1979;23(2):187-191, 193.
65. Outland JD, Brown TS, Callen JP. Tazarotene is an effective therapy for elastosis perforans serpiginosa. *Arch Dermatol*. 2002;138(2):169-171.
66. Satchell AC, Crotty K, Lee S. Reactive perforating collagenosis: a condition that may be underdiagnosed. *Australas J Dermatol*. 2001;42(4):284-287.
67. Ratnavel RC, Norris PG. Penicillamine-induced elastosis perforans serpiginosa treated successfully with isotretinoin. *Dermatology*. 1994;189(1):81-83.
68. Jan V, Saugier J, Arbeille B, et al. Elastosis perforans serpiginosa with vitamin A deficiency in a child with trisomy 21 [in French]. *Ann Dermatol Venereol*. 1996;123(3):188-190.
69. Baumer FE, Wolter M, Marsch WC. The Kyrle disease entity and its therapeutic modification by acitretin (etretin) [in German]. *Z Hautkr*. 1989;64(4):286, 289-291.
70. Iwamoto I, Baba S, Suzuki H. Acquired reactive perforating collagenosis with IgA nephropathy. *J Dermatol*. 1998;25(9):597-600.
71. Hoque SR, Ameen M, Holden CA. Acquired reactive perforating collagenosis: four patients with a giant variant treated with allopurinol. *Br J Dermatol*. 2006;154(4):759-762.
72. Gnanaraj P, Venugopal V, Sangitha C, et al. A giant variant of acquired reactive perforating collagenosis associated with hydronephrosis: successful treatment with allopurinol. *Int J Dermatol*. 2009;48(2):204-206.
73. Gönül M, Cakmak SK, Gül U, et al. Two cases of acquired perforating dermatosis treated with doxycycline therapy. *Int J Dermatol*. 2006;45(12):1461-1463.

74. Brinkmeier T, Schaller J, Herbst RA, et al. Successful treatment of acquired reactive perforating collagenosis with doxycycline. *Acta Derm Venereol*. 2002;82(5):393-395.
75. Khalifa M, Slim I, Kaabia N, et al. Regression of skin lesions of Kyrle's disease with metronidazole in a diabetic patient. *J Infect*. 2007;55(6):e139-e140.
76. Kasiakou SK, Peppas G, Kapaskelis AM, et al. Regression of skin lesions of Kyrle's disease with clindamycin: implications for an infectious component in the etiology of the disease. *J Infect*. 2005;50(5):412-416.
77. Lubbe J, Sorg O, Malé PJ, et al. Sirolimus-induced inflammatory papules with acquired reactive perforating collagenosis. *Dermatology*. 2008;216(3):239-242.
78. Hurwitz RM. The evolution of perforating folliculitis in patients with chronic renal failure. *Am J Dermatopathol*. 1985;7(3):231-239.
79. Serrano G, Aliaga A, Lorente M. Reactive perforating collagenosis responsive to PUVA. *Int J Dermatol*. 1988;27(2):118-119.
80. Tuyp EJ, McLeod WA. Elastosis perforans serpiginosa: treatment with liquid nitrogen. *Int J Dermatol*. 1990;29(9):655-656.
81. Abdullah A, Colloby PS, Foulds IS, et al. Localized idiopathic elastosis perforans serpiginosa effectively treated by the Coherent Ultrapulse 5000C aesthetic laser. *Int J Dermatol*. 2000;39(9):719-720.
82. Chan LY, Tang WY, Lo KK. Treatment of pruritus of reactive perforating collagenosis using transcutaneous electrical nerve stimulation. *Eur J Dermatol*. 2000;10(1):59-61.
83. Oziemski MA, Billson VR, Crosthwaite GL, et al. A new treatment for acquired reactive perforating collagenosis. *Australas J Dermatol*. 1991;32(2):71-74.

Chapter 72 :: Genetic Disorders Affecting Dermal Connective Tissue

:: Jonathan A. Dyer

Inherited connective tissue disorders are clinically and genetically diverse conditions affecting the skin, joints, and a variety of extracutaneous tissues, including the cardiovascular (CV) system. The nature and severity of the skin phenotype is dependent on the type of mutation as well as the role of the affected protein on dermal structure and function (see Chaps. 15 and 18). The diagnosis of many inherited connective tissue disorders is clinical, although Clinical Laboratory Improvement Amendments (1988) (CLIA)-approved genetic testing is increasingly available. A listing of research laboratories that might offer testing can be found at http://www.genetests.org.

EHLERS-DANLOS SYNDROMES

AT-A-GLANCE

- Combined incidence of almost 1 in 5000 persons.
- Thirteen subtypes.
- Most commonly autosomal dominant (classical and hypermobile types).
- Defects in the Type V collagen gene most commonly cause the classical subtype.
- Cutaneous features include varying degrees of skin fragility and hyperextensibility. The classical subtype exhibits soft, velvety skin that bruises easily and wounds that heal as thin, atrophic, gaping scars.
- Extracutaneous manifestations include hypermobile joints with frequent dislocations, complications with pregnancy and delivery, and, less commonly, cardiovascular manifestations, particularly aortic root dilation.
- Information for patients and professionals at http://www.ehlers-danlos.org and https://www.ehlers-danlos.com/.

A variety of genetically and clinically heterogeneous inherited conditions characterized by varying degrees of skin fragility and hyperextensibility, and joint hypermobility have been collected under the rubric of the Ehlers-Danlos syndromes (EDS). A new classification system published in 2017[1] attempted to consolidate and simplify existing subgroups (Table 72-1) as well as reconcile new genetic discoveries with existing clinical phenotypes. Major and minor diagnostic criteria were developed for each major subtype of EDS. Despite these revisions, many patients defy clear-cut classification. The spectrum of EDS severity ranges from subtle clinical findings to severe, debilitating disease.

EPIDEMIOLOGY

EDS prevalence may be as high as 1:5000 individuals. Classical EDS (cEDS) occurs in 1 in 10,000 to 20,000 newborns. The vascular subtype is the most clinically significant EDS subtype because of the risk of arterial or major organ rupture. Inherited in an autosomal dominant (AD) fashion, the incidence is approximately 1 in 50,000 to 200,000 individuals.[2] The kyphoscoliosis, arthrochalasia, and dermatosparaxis subtypes are considerably less common than the classical, hypermobility, and vascular types. Confusion over the diagnosis of the hypermobility type and its overlap with joint hypermobility syndrome interferes with prevalence estimates, but if inclusive definitions are used, it may be the most common subtype.

CLINICAL FEATURES

Table 72-2 summarizes the clinical diagnostic criteria for EDS subtypes.

CLASSICAL EHLERS-DANLOS SYNDROME

Patients with cEDS (Online Mendelian Inheritance in Man [OMIM]: 130000) typically exhibit skin hyperextensibility and fragility along with atrophic scarring, and generalized joint hypermobility. In the past, patients exhibiting very mild features were termed "mitis." The skin in cEDS patients is hyperextensible (Fig. 72-1) but recoils easily to its normal position after stretching, in contrast to the skin in cutis laxa (CL).

Skin hyperextensibility should be assessed using the Remvig et al[3] criteria (Table 72-3) by pinching and lifting the skin, pulling until resistance is met, at a site not subjected to mechanical forces or scarring, such as the volar surface of the nondominant forearm. Hyperextensibility is present if the skin can be stretched beyond 1.5 cm on the distal forearms and/or dorsal hands and beyond 3 cm at the neck, elbow, and/or knees.

TABLE 72-1

The Ehlers-Danlos Syndromes: Clinical Subtypes and Associated Defects

CLINICAL EDS SUBTYPE (ABBREVIATION: OMIM #)	CLINICAL FEATURES	INHERITANCE	PROTEIN/(GENE DEFECT)
Classical (cEDS:130000 and 130010)	Hyperextensible skin; easy bruising; wide, atrophic scars; hypermobile joints	AD	Collagen Type V/(*COL5A1*, *COL5A2*)
Classical-like EDS (clEDS: 606408)	Similar to cEDS but without atrophic scarring; foot deformities; muscle weakness; acrogeria; axonal polyneuropathy	AR	Tenascin XB/(TNXB)
Cardiac-valvular EDS (cvEDS:225320)	Similar to cEDS but with severe, progressive, cardiac valvular disease	AR	Type I collagen/(COL1A2—biallelic mutations leading to nonsense-mediated messenger RNA decay and loss of pro a2(I) collagen chains
Vascular EDS (vEDS:130050)	Thin, translucent skin with easy bruising; arterial and visceral rupture; typical facies	AD	Major: collagen Type III/(*COL3A1*) Rare: Type I collagen/(COL1A1: c.934C>T, p.[Arg312 Cys]; c.1720C>T, p.[Arg574Cys]; c.3227C>T, p.[Arg1093Cys])
Hypermobile EDS (hEDS: 130020)	Smooth, velvety skin; joint hypermobility	AD/AR	Unclear for most; collagen Type III; tenascin XB/(*COL3A1*; *TNXB*)[a]
Arthrochalasia EDS (aEDS: 130060)	Hyperextensible and fragile skin; severe joint hypermobility; congenital hip dislocation	AD	Collagen Type I/(*COL1A1*; *COL1A2*)
Dermatosparaxis EDS (dEDS: 225410)	Severely fragile, sagging, redundant skin; hernias and premature rupture of fetal membranes	AR	Procollagen I *N*-peptidase/(*ADAMTS2*)
Kyphoscoliotic EDS (kEDS: 225400 and 229200)	Atrophic scars, easy bruising; neonatal hypotonia; scoliosis; ocular rupture; marfanoid habitus	AR	Lysyl hydroxylase/(*PLOD1*) FKBP22/(*FKBP14*)
Brittle cornea syndrome (BCS: 229200/614170)	Thin cornea; early-onset progressive keratoconus/keratoglobus; blue sclerae; corneal scarring; retinal detachment; deafness; developmental hip dysplasia; scoliosis; arachnodactyly; distal joint hypermobility; soft, velvety, thin skin	AR	ZNF469/(*ZNF469*) PRDM5/(*PRDM5*)
Spondylodysplastic EDS (spEDS: 612350/130070/271640)	Progressive short stature; variable muscle hypotonia; limb bowing; hyperextensible skin; delayed motor and cognitive development; osteopenia; characteristic radiographic findings	AR	B4GalT7/(*B4GALT7*) B3GalT6/(*B3GALT6*) ZIP13/(*SLC39A13*)
Musculocontractural EDS (mcEDS: 601776)	Congenital multiple contractures; characteristic craniofacial features; skin hyperextensibility; easy bruising; skin fragility with atrophic scars; increased palmar wrinkling; recurrent/chronic dislocations; chronic constipation and colonic diverticula; pneumothorax/pneumohemothorax	AR	D4ST1/(*CHST14*) DSE/(*DSE*)
Myopathic EDS (mEDS: 616470)	Congenital muscle hypotonia and/or atrophy improving with age; proximal joint contractures; distal joint hypermobility; soft, doughy skin with atrophic scarring; motor developmental delay with myopathy on biopsy	AD/AR	Type XII collagen/(*COL12A1*)
Periodontal EDS (pEDS: 130080/617174)	Severe, intractable, early-onset periodontitis; gingival detachment; pretibial plaques; family history; easy bruising; distal joint hypermobility; skin hyperextensibility, fragility, abnormal scarring (wide/atrophic); increased rate of infections; marfanoid facial features; acrogeria; prominent vasculature	AD	C1r/(*C1R*) C1s/(*C1S*)

[a]Few reported cases.

AD, autosomal dominant; AR, autosomal recessive; EDS, Ehlers-Danlos syndrome; OMIM, Online Mendelian Inheritance in Man.

Table adapted from Malfait F, Francomano C, Byers P, et al. The 2017 international classification of the Ehlers-Danlos syndromes. *Am J Med Genet C Semin Med Genet*. 2017;175(1):8-26.

TABLE 72-2
Revised Diagnostic Criteria for Ehlers-Danlos Syndrome Subtypes

EHLERS-DANLOS SYNDROME (EDS) SUBTYPE	MAJOR CRITERIA	MINOR CRITERIA	MINIMAL DIAGNOSTIC CRITERIA
Classical EDS (cEDS)	1. Skin hyperextensibility (Remvig; see Table 72-3) and atrophic scarring 2. Generalized joint hypermobility (GJH) (Beighton; see Table 72-4)	1. Easy bruising 2. Soft, doughy skin 3. Skin fragility (or traumatic splitting) 4. Molluscoid pseudotumors 5. Subcutaneous spheroids 6. Hernia (or history thereof) 7. Epicanthal folds 8. Complications of joint hypermobility (eg, sprains, luxation/subluxation, pain, flexible flatfoot) 9. Family history of a first-degree relative who meets clinical criteria	– Major criterion (1): skin hyperextensibility and atrophic scarring *plus* – Either major criterion (2): GJH – And/or: at least 3 minor criteria Confirmatory molecular testing obligatory to reach a final diagnosis
Classical-like EDS (clEDS)	1. Skin hyperextensibility, velvety skin texture, but *no* atrophic scarring 2. GJH with or without dislocations (shoulder/ankle) 3. Easy or spontaneous bruising	1. Foot deformities including brachydactyly with excessive skin; piezogenic papules; hallux valgus; pes planus; a "broad/plump forefoot" 2. Leg edema—without cardiac failure 3. Mild proximal and distal muscle weakness 4. Axonal polyneuropathy 5. Muscle atrophy of hands/feet 6. Acrogeria (hands) 7. Prolapse of the vagina/uterus/rectum	3 Major *and* family history consistent with autosomal recessive (AR) transmission Confirmatory molecular testing is necessary for diagnosis
Cardiac-valvular EDS (cvEDS)	1. Severe progressive cardiac-valvular problems (aortic valve, mitral valve) 2. Skin involvement: skin hyperextensibility, atrophic scars, thin skin, easy bruising 3. Joint hypermobility (generalized or restricted to small joints)	1. Inguinal hernia 2. Pectus deformity (especially excavatum) 3. Joint dislocations 4. Foot deformities: pes planus, pes planovalgus, hallux valgus	Major criterion (1): severe progressive cardiac-valvular problems *and* a family history compatible with AR inheritance *plus* – Either: 1 other major criterion – And/or: at least 2 minor criteria Confirmatory molecular testing is obligatory to reach a final diagnosis
Vascular EDS (vEDS)	1. Family history of vEDS with documented causative variant in *COL3A1* 2. Arterial rupture at a young age 3. Spontaneous sigmoid colon perforation in the absence of known diverticular disease or other bowel pathology 4. Uterine rupture during the third trimester in the absence of previous C-section and/or severe peripartum perineum tears 5. Carotid-cavernous sinus fistula (CCSF) formation in the absence of trauma	1. Bruising unrelated to identified trauma and/or in unusual sites such as cheeks and back 2. Thin, translucent skin with increased venous visibility 3. Characteristic facial appearance 4. Spontaneous pneumothorax 5. Acrogeria 6. Talipes equinovarus 7. Congenital hip dislocation 8. Hypermobility of small joints 9. Tendon and muscle rupture 10. Keratoconus 11. Gingival recession and gingival fragility 12. Early-onset varicose veins (younger than age 30 years and nulliparous if female)	1. A family history consistent with or suggestive of vEDS *or*: 2. Arterial rupture/dissection in individual younger than age 40 years 3. Unexplained sigmoid colon rupture 4. Spontaneous pneumothorax + other suggestive features 5. Any of the above should lead to testing to rule out vEDS; if multiple other "minor" features listed above are present then testing should also be considered; because of the difficulty in making a clinical diagnosis of vEDS, there is a very low threshold for genetic testing of *COL3A1* in patients with suspicious findings

(*Continued*)

TABLE 72-2
Revised Diagnostic Criteria for Ehlers-Danlos Syndrome Subtypes (*Continued*)

EHLERS–DANLOS SYNDROME (EDS) SUBTYPE	MAJOR CRITERIA	MINOR CRITERIA	MINIMAL DIAGNOSTIC CRITERIA
Hypermobile EDS (hEDS)	1. GJH (varies with gender/age) a. Beighton score: ≥6 (prepubertal children/adolescents); ≥5 (puberty to 50 years old); ≥4 (>50 years old) b. If acquired joint limitations affecting score calculation then include 5-point questionnaire (5PQ) 2. Two or more of the following a. Systemic manifestations of a more generalized connective tissue disorder (total of 5 of the following) i. Unusually soft/velvety skin ii. Mild skin hyperextensibility iii. Unexplained striae iv. Bilateral piezogenic papules of the heel v. Recurrent/multiple abdominal hernia (umbilical/inguinal crural) vi. Atrophic scarring of at least 2 sites (but not as severe as cEDS) vii. Pelvic floor, rectal, and/or uterine prolapse in children, men, nullipa-rous women without predisposing conditions viii. Dental crowding/high/narrow palate ix. Arachnodactyly + Wrist (Steinberg) sign bilaterally + Thumb (Walker) sign bilaterally x. Arm span-to-height ratio ≥1.05 xi. Mitral valve prolapse: mild or greater xii. Aortic root dilation with Z-score greater than +2 b. Positive family history (using current diagnostic criteria) c. Musculoskeletal complications (at least 1) i. Musculoskeletal pain in 2 or more limbs; daily for at least 3 months ii. Chronic, widespread pain for ≥3 months iii. Recurrent joint dislocations/joint instability without trauma Three or more atraumatic disloca-tions of same joint or 2 or more atraumatic dislocations in 2 dif-ferent joints at different times Medical confirmation of joint instability at 2 or more sites not related to trauma 3. All of the following: a. No unusual skin fragility b. Exclusion of other inherited/acquired connective tissue disorders c. Exclusion of alternative diagnoses causing joint hypermobility	–	All 3 of the major criteria must be met

(*Continued*)

TABLE 72-2
Revised Diagnostic Criteria for Ehlers-Danlos Syndrome Subtypes (*Continued*)

EHLERS-DANLOS SYNDROME (EDS) SUBTYPE	MAJOR CRITERIA	MINOR CRITERIA	MINIMAL DIAGNOSTIC CRITERIA
Arthrochalasia EDS (aEDS)	1. Congenital bilateral hip dislocation (1 unilateral case) 2. Severe GJH—multiple dislocations/subluxations 3. Skin hyperextensibility	1. Muscle hypotonia 2. Kyphoscoliosis 3. Radiologically mild osteopenia 4. Tissue fragility; atrophic scars 5. Easy bruising	Major criterion 1 plus either major criterion 2 and at least 2 minor criteria or major criterion 3 Confirmatory molecular testing is necessary Heterozygous mutations in *COL1A1* or *COL1A2* causing partial/entire loss of exon 6
Dermatosparaxis EDS (dEDS)	1. Extreme skin fragility: congenital or postnatal skin tearing 2. Typical craniofacial features: may present at birth or develop in childhood a. Prominent/protuberant eyes—puffy eyelids with edema b. Excess periorbital skin c. Epicanthal folds d. Downslanting palpebral fissures e. Blue sclerae f. Large fontanels/wide cranial sutures; delayed closure of fontanels g. Hypoplastic chin 3. Redundant skin, excess folds at wrists/ankles—almost lax 4. Increased palmar wrinkling 5. Severe bruising: subcutaneous hematoma/hemorrhage 6. Umbilical hernia 7. Postnatal growth retardation 8. Short limbs, hands, feet 9. Perinatal complications from connective tissue fragility: congenital skull fractures, intracerebral hemorrhage, friable umbilical cord, congenital skin tearing, neonatal pneumothorax	1. Soft, doughy skin 2. Skin hyperextensibility 3. Atrophic scars 4. GJH 5. Complications of visceral fragility a. Bladder rupture b. Diaphragm rupture c. Rectal prolapse 6. Delayed motor development 7. Osteopenia 8. Hirsutism 9. Abnormal teeth 10. Refractive errors 11. Strabismus	Major criteria 1 and 2 plus 1 other major and/or 3 minor criteria Confirmatory testing is necessary: *ADAMTS2* # encodes ADAMTS-2, the main procollagen I *N*-proteinase
Kyphoscoliotic (kEDS)	1. Congenital muscle hypotonia—often striking 2. Congenital/early-onset kyphoscoliosis (progressive or nonprogressive) 3. GJH with dislocations/subluxation (especially shoulders/hips/knees)	1. Skin hyperextensibility 2. Easy bruising 3. Rupture/aneurysms of medium sized arteries 4. Osteopenia/osteoporosis 5. Blue sclerae 6. Hernia (umbilical/inguinal) 7. Pectus 8. Marfanoid habitus 9. Talipes equinovarus 10. Refractive errors *Gene-specific minor criteria:* 1. *PLOD1* (Majority of kEDS patients) a. Skin fragility (easy bruising; friable skin; poor healing; widened atrophic scars) b. Scleral/ocular fragility/rupture c. Microcornea d. Facial dysmorphology: i. Low-set ears ii. Epicanthal folds iii. Down-slanting palpebral fissures iv. Synophrys v. High palate 2. *FKBP14* a. Congenital hearing impairment b. Follicular hyperkeratosis c. Muscle atrophy d. Bladder diverticula	Major criteria 1 and 2 plus major criterion 3 and/or 3 minor criteria (general or gene-specific) Confirmatory molecular testing is necessary Laboratory confirmation of kEDS: quantification of deoxypyridinoline and pyridinoline crosslinks in urine by high-performance liquid chromatography; an increased deoxypyridinoline-to-pyridinoline ratio (often 2-9 [10 to 40 times the reference range of 0.2]) is a highly sensitive and specific test for kEDS caused by biallelic PLOD1 mutations (kEDS-PLOD1), but is normal for biallelic *FKBP14* mutations (kEDS-FKBP14); this rapid and cost-effective test can also determine the importance of variants of uncertain significance detected in PLOD1

(*Continued*)

TABLE 72-2
Revised Diagnostic Criteria for Ehlers-Danlos Syndrome Subtypes (*Continued*)

EHLERS-DANLOS SYNDROME (EDS) SUBTYPE	MAJOR CRITERIA	MINOR CRITERIA	MINIMAL DIAGNOSTIC CRITERIA
Brittle cornea syndrome (BCS)	1. Thin cornea—with or without rupture 2. Early-onset progressive keratoconus 3. Early-onset progressive keratoglobus 4. Blue sclerae	1. Enucleation/corneal scarring from previous rupture 2. Progressive loss of corneal stromal depth 3. High myopia 4. Retinal detachment 5. Deafness 6. Hypercompliant tympanic membranes 7. Developmental dysplasia of the hip 8. Infantile hypotonia (mild) 9. Scoliosis 10. Arachnodactyly 11. Distal joint hypermobility 12. Pes planes; hallux valgus 13. Mild fifth finger contracture 14. Soft, velvety skin; translucent skin	Major criterion 1 plus 1 other major criterion and/or 3 minor criteria Confirmatory molecular testing is necessary AR mutations in *ANF469* (encodes ZNF469, a zinc finger protein) or PRDM5 (encodes a DNA binding transcription factor of the PR-SET protein family and lacks intrinsic histone methyltransferase activity)
Spondylodysplastic EDS (spEDS)	1. Short stature (progressive during childhood) 2. Muscle hypotonia (variable severity) 3. Limb bowing	1. Skin hyperextensibility, soft, doughy skin, thin translucent skin 2. Pes planus 3. Delayed motor development 4. Osteopenia 5. Delayed cognitive development *Gene-specific minor criteria:* *B3GALT6* 1. Kyphoscoliosis 2. Joint hypermobility: either GJH or distal joints 3. Joint contractures (especially hands) 4. Abnormal fingers (slender; tapered; arachnodactyly; spatulate, broad distal phalanges) 5. Talipes 6. Characteristic Craniofacial features 7. Tooth discoloration, dysplasia 8. Characteristic radiologic findings 9. Osteoporosis with multiple spontaneous fractures 10. Ascending aortic aneurysm 11. Lung hypoplasia; restrictive lung disease *B4GALT7* 1. Radioulnar synostosis 2. Bilateral elbow contracture/limited movement 3. GJH 4. Single transverse palmar crease 5. Characteristic facial features 6. Characteristic radiographic findings 7. Severe hypermetropia 8. Clouded cornea *SLC39A13* 1. Protuberant eyes/bluish sclerae 2. Fine palmar wrinkles 3. Thenar muscle atrophy; tapered fingers 4. Distal joint hypermobility 5. Characteristic radiologic findings	Major criteria 1 and 2 plus characteristic radiographic findings and at least 3 minor criteria (general or type specific)

(*Continued*)

TABLE 72-2
Revised Diagnostic Criteria for Ehlers-Danlos Syndrome Subtypes (*Continued*)

EHLERS-DANLOS SYNDROME (EDS) SUBTYPE	MAJOR CRITERIA	MINOR CRITERIA	MINIMAL DIAGNOSTIC CRITERIA
Musculocontractural EDS (mcEDS)	1. Congenital multiple contractures 2. Characteristic craniofacial features (birth/early infancy) 3. Skin hyperextensibility; easy bruising; skin fragility with atrophic scars; increased palmar wrinkling	1. Recurrent/chronic dislocations 2. Pectus 3. Spinal deformities 4. Abnormal fingers 5. Progressive talipes deformities 6. Large subcutaneous hematomas 7. Chronic constipation 8. Colonic diverticulae 9. Pneumothorax/pneumohemothorax 10. Nephrolithiasis/cystolithiasis 11. Hydronephrosis 12. Cryptorchidism 13. Strabismus 14. Refractive errors 15. Glaucoma	*Birth thru early childhood:* Major criteria 1 and 2 *Adolescence thru Adulthood:* Major criteria 1 and 3 Confirmatory molecular testing is necessary to confirm
Myopathic EDS (mEDS)	1. Congenital muscle hypotonia and/or atrophy a. Improves with age 2. Proximal joint contractures 3. Distal joint hypermobility	1. Soft, doughy skin 2. Atrophic scarring 3. Motor developmental delay 4. Muscle biopsy shows myopathy	Major criterion 1 plus 1 other major criterion and/or 3 minor criteria Confirmatory molecular testing is necessary to confirm mEDS caused by heterozygous or biallelic mutations in *COL12A1*—encodes Type XII collagen; high overlap with Type VI related myopathies such as Bethlem myopathy and Ulrich congenital muscular dystrophy
Periodontal EDS (pEDS)	1. Severe, intractable periodontitis—early onset 2. Lack of attached gingiva 3. Pretibial plaques 4. Family history: first-degree relative meeting diagnostic criteria	1. Easy bruising 2. Joint hypermobility—mostly distal 3. Skin hyperextensibility, fragility, abnormal scarring (wide/atrophic) 4. Increase rate of infections 5. Hernia 6. Marfanoid facial features 7. Acrogeria 8. Prominent vasculature	Major criterion 1 or 2 plus at least 2 other major criteria and 1 minor criteria Confirmatory molecular testing is necessary to confirm pEDS caused by heterozygous gain-of-function mutations in *C1R* or *C1S*—first components (subunits C1r and C1s) of classical complement pathway

Adapted from Malfait F, Francomano C, Byers P, et al. The 2017 international classification of the Ehlers-Danlos syndromes. *Am J Med Genet C Semin Med Genet*. 2017;175(1):8-26.

The skin is velvety, thin, and bruises easily. Fetuses with cEDS may exhibit growth retardation, hernias, and joint dislocations. Bruising manifests early in childhood and is often persistent in areas prone to trauma, especially the shins (Fig. 72-2). Tissue fragility can be striking, with innocuous trauma resulting in disproportionately large skin tears that are relatively painless without excessive bleeding. Wounds often gape.

Even with surgical repair, wounds in EDS often exhibit slow healing and frequent infection. Postoperative wound dehiscence is common, especially if wounds are inadequately secured, often necessitating repeated repairs or secondary intention healing (Fig. 72-3). Even with surgical repair, dehiscence upon suture removal can occur. Healed wounds result in atrophic, often widened cigarette paper-like (or "fish mouth") scars, especially on pressure points (knees, elbows, forehead, chin) (see Figs. 72-2 and 72-3). Hematoma formation and/or recurrent ecchymoses often results in persistent hyperpigmentation. Calcification and fibrosis of hematomas produce subcutaneous, nodular molluscoid pseudotumors, most frequently around the elbows, fingers, and knee. These are often associated with scars. Spheroids are small subcutaneous spherical hard nodules, usually on the forearms and shins that may become calcified and thus detectable radiographically. Additionally, subcutaneous fat herniation on the medial or lateral aspects of the heels or wrists with pressure (piezogenic pedal

Figure 72-1 Classical Ehlers-Danlos syndrome. Dermal elasticity is demonstrated. Unlike cutis laxa, the skin returns to original shape after stretching.

papules) may be seen. Epicanthal folds are often present in childhood, although they may not persist in adulthood. Acrocyanosis and chilblains also have been described in affected individuals.

Joint hypermobility is frequent (Fig. 72-4), and often greatest at the fingers and/or wrists. In suspected patients, including older children and adolescents, it is assessed using the Beighton scale (Table 72-4) with a score of 5 or greater out of 9 confirming joint hypermobility. Sprains, dislocations or subluxations, scoliosis, and pes planus are common complications and patients frequently describe chronic joint and limb pain, although skeletal radiographs may be normal. Patients are typically "double-jointed" and often able to perform various "tricks" with their joints as a result. It is important to recognize that chronic and excessive joint hypermobility frequently leads to early-onset osteoarthritis. Joint laxity decreases with age and criteria have been developed (5-point questionnaire; Table 72-5) to address this when evaluating adult patients. Osteoporosis is more common when compared to age-matched controls. Muscle hypotonia and delayed gross motor development are also described. EDS patients are often diagnosed with chronic fatigue syndrome or fibromyalgia because of persistent fatigue and chronic pain. Temporomandibular joint dysfunction is common and a frequent cause of secondary headache in cEDS.

TABLE 72-3
Criteria for Skin Hyperextensibility[3]

1. Pinch and lift the skin,[a] pulling until resistance is met. Hyperextensibility is present if the skin can be stretched beyond:
2. 1.5 cm on distal forearms and/or dorsal hands
3. 3 cm at neck, elbow, and/or knees.

[a]Best assessed at a site not subjected to mechanical forces or scarring, such as the volar surface of the nondominant forearm.

Figure 72-2 Classical Ehlers-Danlos syndrome. Chronic discolored scars on the shin and ankle after repeated trauma. This is often associated with firm subcutaneous nodules that can be confused with subcutaneous granuloma annulare. Note the widened scars along the anterior shin (arrow).

Most patients with cEDS or hypermobile EDS (hEDS) are able to extend the tongue to touch the tip of the nose (Gorlin sign; Fig. 72-5), although this sign can be displayed by approximately 10% of individuals without

Figure 72-3 Classical Ehlers-Danlos syndrome. After suturing for a laceration, the wound dehisced with secondary infection and marked widening. Note the evidence of former sutures at the lower border, now 3 weeks after the injury and treatment with antibiotics. Scars tend to stretch further in the 6 months after closure.

Figure 72-4 Classical Ehlers-Danlos syndrome. Hyperextensibility of digits is demonstrated.

inherited disorders of connective tissue. Lack of lingual and labial frenula has been described as a minor feature of EDS, and is particularly common in patients with the vascular type.[4] Hypermobility and absence of the frenula allow some EDS patients to "swallow" their own tongue. Hiatal and postoperative hernias, as well as anal prolapse, have been noted as manifestations of the tissue hyperextensibility and fragility. Sexual dysfunction, including dyspareunia is reported, and functional bowel disorders occur in up to half of patients.

Approximately 40% to 50% of affected individuals (in addition to approximately 20% of infants born to affected mothers) are born prematurely (32 to 37 weeks), either as a result of premature rupture of fetal membranes or chorioamnionitis.[5] Monitoring during pregnancy and the postpartum period is recommended, because of the risk of premature labor during the third trimester, the increased risk for skin tears, postpartum hemorrhage, and uterine/bladder prolapse. The fragility of the already abnormal connective tissue may be worsened by the effect of pregnancy-related hormones that soften connective tissue, such as relaxin.

Patients with cEDS occasionally exhibit structural heart malformations. Mitral valve prolapse (MVP), and less often tricuspid valve prolapse, has been noted in approximately 6% of cEDS patients; recent reports suggest that aortic root dilation (typically nonprogressive) may occur more frequently than previously thought.[6] Arterial rupture, intracranial aneurysms, and arteriovenous fistulas have been described in classic EDS, typically in patients exhibiting severe clinical phenotypes, but are much less common than in Marfan syndrome. Baseline echocardiography with measurement of aortic diameter is recommended with CT or MRI examinations if needed. The current recommendation is yearly echocardiogram if cardiac abnormalities (aortic dilation, MVP) are present. If no abnormalities are noted, subsequent studies are only recommended as dictated by symptoms. Blood pressure control, including β-blocker therapy, has been anecdotally successful and should be considered if patients have a glycine substitution near the C-terminus of the triple helix as a result of increased vascular fragility concerns.

TABLE 72-4
Beighton Criteria for Joint Hypermobility

1. Passive dorsiflexion of the fifth finger >90 degrees.
2. Passive apposition of the thumbs to the flexor aspect of the forearm (Beighton sign).
3. Hyperextension of the elbow >10 degrees.
4. Hyperextension of the knees >10 degrees.
5. Ability of the palms to completely touch the floor during forward flexion of the trunk with knees fully extended.

Numbers 1 to 4 are scored for each side, so that a maximal score of 2 is possible if both left and right sides meet criterion; number 5 is scored as 1. A person who scores 5 or greater out of 9 is hypermobile.

TABLE 72-5
5-Point Questionnaire

An answer in the affirmative to 2 or more of the questions has 85% sensitivity and specificity (tested internationally and in different languages):

1. Can you now (or could you ever) place your hands flat on the floor without bending your knees?
2. Can you now (or could you ever) bend your thumb to touch your forearm?
3. As a child did you amuse your friends by contorting your body into strange shapes or could you do the splits?
4. As a child or teenager did your shoulder or kneecap dislocate on more than 1 occasion?
5. Do you consider yourself double-jointed?

Figure 72-5 Classical Ehlers-Danlos syndrome (EDS). Gorlin sign is the ability to touch the tip of the nose with the tongue and is described in approximately 50% of patients with Ehlers-Danlos, in contrast to 10% of individuals who do not have EDS.

Several rare forms of EDS present with skin and joint findings similar to cEDS but with additional important clinical features.

Classical-like EDS with propensity for arterial rupture/vascular-like cEDS is caused by heterozygous COL1A1 c.934C>T, p.(Arg312Cys) substitutions. The substitution of arginine for cysteine in COL1A1 increases the risk for vascular rupture mimicking COL3A1-vascular Ehlers-Danlos syndrome (vEDS). The clinical similarity between this rare variant and cEDS because of *COL5A* mutations reinforces the value of genetic testing even in "typical" cEDS patients, and the importance of investigating the family history for vascular rupture.[7,8]

An autosomal recessive (AR) *cardiac valvular subtype of EDS* exhibits clinical findings of cEDS as well as the onset of severe cardiac valve problems later in life and results from total loss of the proa2(I) chains of Type I collagen as a result of homozygous or compound heterozygous mutations in *COL1A2*.[7]

Osteogenesis imperfecta EDS overlap syndrome occurs as a result of mutations at the N-terminal end of both *COL1A1* and *COL1A2*, which affect processing of the *N*-propeptide; such patients phenotypically present as EDS rather than osteogenesis imperfecta. Mutations in the same area that do not result in delays in Type I procollagen *N*-propeptide processing present as osteogenesis imperfecta.

CLASSICAL-LIKE EHLERS-DANLOS SYNDROME

An AR form of EDS resembling a mild version of cEDS can result from homozygous tenascin-XB (TNXB) deficiency. Heterozygotes (especially females) for these mutations may exhibit hypermobility EDS.[9,10]

VASCULAR TYPE

The classic quadrad of vEDS includes a characteristic facial appearance (which may be subtle), thin, translucent skin with a prominent venous pattern (Fig. 72-6), extensive bruising or hematomas, and vascular or visceral rupture (or both).[2] Excessive bleeding with circumcision may occur. Joint hypermobility is usually minimal and limited to the digits. The facial features include a thin nose and upper lip, small earlobes, and sunken, pigmented periocular regions. Subcutaneous fat is decreased, especially of the face and limbs. Acrogeria is described, but rare, and often associated with mutations near the carboxyl-terminal end of the COL3A1 triple helical domain. Alopecia is a variable finding but has been significant in some female patients. Widened, thin (papyraceous) scars may be noted on bony prominences. Hematomas, which may be frequent and/or quite large, may develop after minimal to no trauma, such as sphygmomanometer inflation. Ecchymoses during childhood may raise concerns for abuse, similar to cEDS. The development of superficial venous insufficiency before the age of 20 years can be a clinical indicator of vEDS. Superficial venous insufficiency is more common in vEDS, and an unusually complicated response to a vein stripping procedure in a relatively young patient should raise concern for vEDS. Endovenous laser and radiofrequency ablations have been successfully reported in vEDS patients. Gum fragility has been noted in some vEDS patients with loss of gingival tissue and tooth loss that mimics periodontal EDS.

Figure 72-6 Vascular Ehlers-Danlos syndrome. The venous pattern is apparent in a fair-skinned individual. (To enhance visibility of the venous network, the image was colorized.)

Spontaneous rupture of arteries, particularly mid-sized arteries, may occur during childhood, although the peak age of incidence is the third or fourth decade of life. There may be an increased risk of sudden death from spontaneous vascular rupture in males younger than 20 years old. Mesenchymal abdominal, splenic, and renal arteries are often involved, as is the descending aorta. Aortic rupture/dissection is typically not preceded by detectable aortic dilation,[6] occurs distal to the midaortic arch, and exhibits distal extension. Arterial or intestinal rupture often presents as acute abdominal or flank pain; arterial rupture is the most common cause of death. Stroke is also reported in vEDS. A carotid-cavernous sinus fistula may occur in these patients and represents a medical emergency. Patients note the sudden onset of a temporal swishing sound, with injection of the affected eye, pain, and protrusion of the globe. Pregnancies may be complicated by prepartum and postpartum arterial bleeding, and by intrapartum uterine rupture. Pregnancies carry a 12% to 25% fatality rate. Vaginal and perineal tears from delivery heal poorly and caesarean wounds often dehisce.[2]

Bowel rupture occurs in approximately 25% to 30% of vEDS patients and usually occurs in the sigmoid colon. Spontaneous pneumothorax occurs in approximately 12% of vEDS patients, often later in childhood, and there is a high risk of recurrence. The median life span for vEDS patients is approximately 51 years.[2]

HYPERMOBILITY TYPE

The diagnosis of hEDS is difficult and new diagnostic criteria (see Table 72-2) were developed in an attempt to clarify this complicated category of EDS. Current criteria are clinical and based on appropriate examination and family history. Phenotypic findings are quite variable and many patients who seek medical care are female. Patients with hEDS have abnormal skin, with changes similar to, yet more subtle than cEDS or vEDS. Patients with hEDS have soft, velvety skin with occasional mild hyperextensibility but no fragility. Because hyperextensibility in hEDS can be subtle, the so-called rubber glove skin test is used to distinguish hEDS skin from normal. In this clinical test, the skin of the patient's dorsal hand is pulled upwards and is noted to stretch over a much wider area than typical, often extending to the wrist and beyond. The stretching of the skin mimics that seen when pulling on the back of a rubber glove while wearing it on the hand.

Patients often note easy bruising and piezogenic papules may be seen. The skin may be slightly transparent with more visible veins and tendons, yet it is not nearly as striking as vEDS. In occasional patients, mild prolongation of bleeding can mimic von Willebrand disease. Scarring is variable, and even though some atrophic changes may be noted, these changes are milder and less striking than the changes seen in cEDS. Striae may occur during adolescence in the absence of sudden weight gain. Molluscoid pseudotumors are not seen.[11]

Joint hypermobility is generalized and dislocations of the shoulder, patella, and temporomandibular joints are particularly common. The hips and digits also may be involved and scoliosis and pes planus are also seen. Musculoskeletal pain often has an early onset, is chronic, and often debilitating. Fatigue and sleep disturbances are typical and hEDS patients are often diagnosed with a variety of psychiatric conditions or fibromyalgia. Headaches are common. Temporomandibular joint disorder is more frequent and a pain syndrome (regional) is associated with hEDS that may result from chronic stretch injury to the nerves passing over hypermobile joints as well as the fragility of the neural connective tissue. Depression is common in these patients, often related to their chronic pain. Early onset of osteoarthritis may occur and osteoporosis is more common than in age-matched controls. Functional bowel disorders may occur in up to 50% of patients. Pelvic prolapse and dyspareunia also have been noted.

One-third to one-half of hEDS patients will note some type of atypical chest pain, heart palpitations, and/or orthostatic intolerance. Aortic root dilation can occur in 25% to 33% of hEDS patients; however, it is usually mild and in the absence of significant dilation its long-term risk is unclear. Increased elastic fiber degeneration relative to unaffected controls has been demonstrated on electron microscopy and dilation and/or rupture of the ascending aorta has been described in these patients.

Three discreet phases of clinical progression are recognized in hEDS, although the timing of individual phases is highly variable and not all patients exhibit all 3 phases. Infants first exhibit the "hypermobility" phase, which by the second decade evolves to a "pain" phase, during which joint hypermobility decreases (although still hypermobile by the Beighton scale), but worsening pain progressively impacts quality of life and function. During childhood pain is often described in the lower limbs, often termed *growing pains*, and pain with repetitive tasks also may be noted. The third phase, *stiffness*, is characterized by progressive limitation of joint mobility and a dramatic impact on the quality of life. Depression and anxiety are common during this phase. Additional findings in these patients are dysphonia, headache, and dolichocolon.[11]

ETIOLOGY AND PATHOGENESIS

CLASSICAL EHLERS-DANLOS SYNDROME

More than 90% of cEDS cases are caused by AD mutations in the α_1 or α_2 chain of Type V collagen (COL5A1 and COL5A2) with the majority occurring in COL5A1. Approximately 50% are de novo mutations. Type V collagen is a minor fibrillar collagen that regulates collagen fibril diameter. These mutations may result in dominant negative or haploinsufficient states and approximately one-third of cases are caused by haploinsufficiency of the *COL5A1* gene.[9] Mutations in the signal peptide region of COL5A1, which disrupt Type V collagen secretion, also have been identified in patients with cEDS.[12] *COL5A2* mutations may result in more-severe phenotypes overall. An additional locus may exist, as several families do not exhibit linkage to *COL5A1* or *COL5A2*.

Patients with features of cEDS exhibiting defective Type I collagen caused by AD *COL1A1* mutations also have been described. In particular, patients with the heterozygous COL1A1 c.934C>T, p.(Arg312Cys) substitution are at high risk for vascular rupture,[8] similar to the complications of the vEDS subtype. The Classical-like and cardiac-valvular subtypes, which may exhibit skin and joint findings similar to cEDS are described above.

Electron microscopy of the skin in EDS reveals thickened collagen fibrils, highlighting the role of Type V collagen in regulating their size. It is proposed that the amino terminus of α_1(V) carries a negative charge, conferred by abundant tyrosine residues, and appears to limit fibril growth. Less than 5% of fibrils may exhibit "collagen flowers," which are rare composite fibrils.[13]

VASCULAR EHLERS-DANLOS SYNDROME

vEDS is associated with dominant negative mutations in the Type III collagen gene (*COL3A1*), resulting in reduced amounts of Type III collagen in the dermis, vessels, and

viscera, as well as decreased production and secretion of Type III collagen by cultured fibroblasts. More than 320 different mutations (exon-skipping or missense) have been reported; these mutations typically lead to disruption of the triple-helical structure of Type III collagen. As Type III collagen is a homotrimer, mutant proα1(III) chains affect most fibrils, interfering with secretion and leading to intracellular accumulation. Type III collagen plays an important role in the integrity of the walls of both blood vessels and hollow organs, in addition to the upper dermis. Analysis of Type III procollagen and collagen chains and direct genetic testing of *COL3A1* have been used to test for vEDS.

The inheritance of hEDS is typically AD. The molecular basis for hEDS is largely unclear. One family was found to have haploinsufficiency of *COL3A1*. Approximately 5% of patients with the hypermobility form show diminished levels of tenascin X from heterozygous mutations in the *TNXB* gene, which encodes tenascin-X (TNX). The phenotype in these patients is intermediate between cEDS and hEDS; approximately 40% of patients exhibit abnormal skin findings similar to cEDS but milder and without atrophic scarring. *TNXB* is located near the *CYP21A2* gene, which is associated with congenital adrenal hyperplasia, and microdeletions in the region affecting both genes have been described in patients with congenital adrenal hyperplasia who also exhibit clinical features of hEDS.

LABORATORY INVESTIGATION

Routine histopathologic examination of the skin from EDS patients is typically normal. Electron microscopy demonstrates abnormalities in the appearance of collagen fibrils as noted above. Despite the bruising and increased bleeding, tests of platelet function and coagulation are usually normal, further highlighting the underlying defects in skin and blood vessel structural integrity. As noted above for specific subtypes, while genetic diagnosis is possible, especially as a research tool, a variety of biochemical tests are available as well.

MOLECULAR TESTING IN EHLERS-DANLOS SYNDROME SUBTYPES

Advances in next-generation sequencing have allowed more frequent genetic evaluation of patients suspected of having EDS and broadened the spectrum of genetic etiologies recognized to cause EDS subtypes. For patients suspected of having a variant of EDS, current guidelines recommend, where possible, using next-generation sequencing strategies for parallel sequencing of multiple known EDS genes. For those patients where no mutation or only a single AR mutation is identified, further investigations, such as copy number variant analysis or whole-exome sequencing/whole-genome sequencing, with focus on EDS genes of interest and their regulatory regions, should be undertaken.

Even though more frequent employment of these testing strategies enables the identification of new mutations and new genes of interest in the pathogenesis of EDS, it also generates variants of uncertain significance (VUS), which complicate the genetic evaluation of these patients. Appropriate interpretation of VUS, especially missense variants, must be correlated with the clinical phenotype. American College of Medical Genetics and Genomics (ACMG) guidelines suggest that VUS supported by other data regarding pathogenicity, such as strong in silico predictive scoring or mutations occurring in known functionally active areas of a protein, can be considered "likely pathogenic." Further workups, including familial studies and more detailed protein assays, are necessary in such cases to better clarify the relationship of the VUS with the individual patient's clinical condition. While further evaluations are being done, patients with "likely pathogenic" mutations should be followed as clinically appropriate. The rapid expansion of the availability of genetic testing highlights the critical role of medical genetics in evaluating and managing these patients. Where possible, genetic testing and interpretation should include a medical geneticist or genetic counselors.

For patients who meet minimum clinical criteria for a specific EDS subtype but either lack genetic confirmation, or have a VUS, or have no known causative genetic variants detected, a "provisional clinical diagnosis" of EDS may be made. Clinical followup in such patients is warranted.

Additionally, a pathogenetic classification of EDS subtypes has been proposed with subtypes grouped by known or suspected shared molecular pathways.[1]

DIFFERENTIAL DIAGNOSIS

EDS must be distinguished clinically and histologically from CL. In CL, the hyperelastic skin does not return to its normal position after stretching. The kyphoscoliotic and hypermobility forms of EDS must be distinguished from Marfan syndrome, which additionally is characterized by ectopia lentis and characteristic skeletal abnormalities. Molluscoid pseudotumors of the lower legs may mimic subcutaneous granuloma annulare. The easy bruisability and poor wound healing of EDS patients has led to concerns of child abuse.[2]

vEDS exhibits significant clinical similarities to Loeys-Dietz syndrome Type 2, an aortic aneurysm syndrome caused by mutations in transforming growth factor (TGF)-β receptors 1 and 2 (*TGFBR1* and *TGFBR2*) genes. These patients also exhibit skin findings, including velvety translucent skin, easy bruising, and widened, atrophic scars.[14] Prior to detection of arterial anomalies Loeys-Dietz syndrome patients may be misdiagnosed as cEDS or hEDS.

PREVENTION AND TREATMENT

A multidisciplinary preventive strategy is the most productive approach to the management of EDS patients. Early identification of affected patients with appropriate intervention (pain management, physical therapy, surgery) and education is important. Non–weight-bearing exercise (eg, swimming) can promote muscle development. Exercise regimens are typically designed to strengthen muscles to stabilize joints and relieve stress. Physical therapy focused on shoulder girdle strengthening has decreased the frequency of shoulder dislocations in patients with a history of chronic or recurrent dislocation. Some patients use orthopedic devices, such as orthotics and braces, with benefit.

Avoiding and preventing injuries is of great importance. Assessment of the home environment with modifications to make homes "EDS safe," such as avoiding hard, sharp edges on furniture and arrangement to prevent or minimize falls, can be helpful. Patients with significant skin fragility or bruising may require protective padding or bandaging and should avoid contact sports and heavy exercise.

When cutaneous wounds do occur, they should be sutured using both subcuticular and cuticular sutures, which are tightly spaced and left in place for a prolonged duration (at least twice as long as standard). Adhesive tapes, bolsters, or pressure bandages are necessary to aid healing, diminish scarring, and lower the risk of hematoma and pseudotumor formation. Close monitoring for postoperative infection is critical and preventive antibiotic therapy is often employed. Pseudotumors of the elbows or knees are typically more easily surgically removed than those on the heels.[9]

Ongoing rheumatologic and orthopedic care may be required to prevent progressive joint disease in certain patients. Low-impact sports are preferable to contact sports and weight training for patients with hEDS. Ascorbate therapy (approximately 2 g/day in adults with proportional decreases in pediatric patients) may improve bruising (but not other findings) in cEDS. Antiinflammatory drugs may improve the musculoskeletal pain associated with EDS, but those interfering with platelet function (especially aspirin) should be avoided in patients with significant bruising. Patients with valvular heart disease should be followed by cardiologists, and a baseline echocardiogram with measurement of aortic diameter is recommended before 10 years of age.[9]

Joint dislocation (with the exception of congenital dislocation of the hip) in EDS typically spontaneously resolves or can be remedied with closed reduction. Patients with EDS (especially hEDS) may benefit from a variety of physical therapy interventions, such as myofascial release therapies and low-resistance exercises for muscle toning. Exercise progression should involve increasing the number of repetitions, frequency, or duration of exercise, rather than increasing resistance and should progress slowly. Isometric exercises and swimming are often beneficial in cEDS and hEDS. Pain from writing utensils can be lessened by altering the grip to rest the shaft of writing utensils on the thenar web and holding the tip between the index and ring fingers. Transvaginal pelvic physical therapy has been successfully used for abdominal and back pain, as well as for radicular pain of the lower extremities and dyspareunia. Braces are commonly used to stabilize joints. Intervention is typically multidisciplinary and should involve rheumatology, orthopedic surgery, physical and occupational therapy, and pain management specialists, as appropriate. Pain in hEDS is often undertreated. Even though reparative or corrective surgical procedures are often delayed as long as possible, the perioperative complication rate in patients with hEDS is not increased. GI symptoms may be quite troublesome and require aggressive therapy with proton pump inhibitors, H_2-blockers, and other agents. Calcium and vitamin D supplementation is typically encouraged.

Ideally, patients with vEDS are cared for by a team of physicians with expertise or awareness of the condition at a center with the capabilities to handle the medical complications that can arise. A protocol for managing suspected complications should be devised between the medical team and the vEDS patient. Patients with vEDS should have an emergency care card or medical alert document (a "vEDS passport") describing the condition so that emergency department physicians caring for the patient in an emergency situation can be made aware of the disease. vEDS patients who are or are planning to become pregnant should be cared for by high-risk obstetrics teams. No consensus exists for surveillance recommendations in patients with vEDS; however, a recent review suggested annual review of the vascular tree by Doppler ultrasonography, CT angiography, or magnetic resonance angiography when feasible.[2]

Patients with vEDS should refrain from contact sports and avoid medications that impair platelet function. Invasive vascular procedures should be avoided, unless absolutely necessary (such as with arterial rupture), because of the extremely high risk of vascular rupture. Many symptomatic vascular events in vEDS patients are dissections that resolve on their own. However, arterial ruptures must be repaired. When necessary, tissues must be handled with extreme caution because of pronounced intraoperative tissue fragility. One published series suggested early intervention by skilled surgeons could be more safely performed than previously thought and provided suggestions for management.[15] Maintaining blood pressure in the normal to low-normal reference range and preventing blood pressure surges is often a goal of therapy. Studies examining the use of β blockers in vEDS are in progress.

Fatigue is present in more than 75% of EDS patients of most types. It appears most often in hEDS, but is seen in other forms of EDS as well. Contributing factors include disruptions of sleep, impaired self-efficacy, and

pain.[11] A variety of neuromuscular findings, including reduction in vibration sense and mild-to-moderate muscle weakness, were commonly found in a small group of multiple types of EDS. These symptomatic findings correlated with myopathic features on needle electromyography (a mixed neurogenic–myopathic pattern in 60%), as well as with muscle ultrasonography, showing increased echo intensity and atrophy. The subset of patients with hEDS resulting from TNXB haploinsufficiency seem to have fewer neuromuscular issues, although TNXB levels correlate inversely with neuromuscular symptoms.[16]

Pregnancy in the EDS patient should be considered high risk. The effects of hormonally mediated connective tissue softening on the abnormal connective tissue of EDS have not been studied, but may account for the increased skin fragility and other EDS sequelae that occur during pregnancy and the immediate postpartum period. Prenatal diagnosis is possible by genetic and biochemical analyses. Unless children are severely affected by their disorder, they generally adjust well to the skin findings and joint hypermobility.

The Ehlers-Danlos Society is a national support group that can be contacted through its website (https://www.ehlers-danlos.com).

MARFAN SYNDROME

AT-A-GLANCE

- Incidence: ~1 in 5000 (OMIM: 154700).
- Autosomal dominant; caused by mutations in fibrillin 1 (*FBN1*; chromosome 15q21.1).
- Cutaneous features include striae distensae (two-thirds of patients), inguinal or incisional hernias, and, rarely, elastosis perforans serpiginosa.
- Extracutaneous manifestations include hyperextensible joints, upward lens displacement, skeletal abnormalities, and cardiac aberrations, such as aortic aneurysm and rupture.
- Information for patients and professionals is available at The Marfan Foundation website (http://www.marfan.org).

Marfan syndrome is an AD disorder that primarily affects the skeletal, ocular, and cardiovascular (CV) systems.[17] The prognosis for patients with Marfan syndrome has improved over the past three decades as a result of better medical and surgical treatments.[18]

EPIDEMIOLOGY

Approximately 25% of Marfan syndrome cases occur sporadically, particularly in patients born of older fathers. Parental germline mosaicism has been described.[19] Marfan syndrome is a very common connective tissue disorder, with the overall prevalence estimated at approximately 1:3000 to 5000 persons with no racial, gender, or geographic predilection.[14]

CLINICAL FEATURES

Marfan syndrome is a generalized connective tissue disorder exhibiting abnormalities of 3 primary organ systems: ocular (typically lens dislocation), skeletal (excessive extremity length, loose joints, anterior chest deformities, and kyphoscoliosis), and most importantly, CV (classically aortic aneurysm and mitral valve redundancy). Many of the typical physical features of Marfan syndrome are age-dependent, making diagnosis in childhood more difficult. No single clinical sign is pathognomonic.[14,20]

Marfan syndrome patients may present to the dermatologist for evaluation of striae or for other skin disorders unrelated to the condition. Recognition of the other clinical findings of Marfan syndrome may trigger the detection of unrecognized patients.

The "marfanoid habitus" is characteristically dolichostenomelic (tall and thin), with a lower-body segment (pubic symphysis to floor) that is longer than the upper segment (height minus lower segment) (Fig. 72-7). Characteristically, the arm span exceeds

Figure 72-7 Marfan syndrome. Frontal view of teenage boy with Marfan syndrome. Note the tall stature, arachnodactyly, long arms, and ability to cross them behind the back and nearly reach around to the umbilicus.

the person's height by several centimeters. The distal bones are excessively long (arachnodactyly). Skeletal features of Marfan syndrome are characterized by bone overgrowth and joint laxity. Kyphoscoliosis may be severe and increases with the adolescent growth spurt. Thoracic cage abnormalities, such as pectus excavatum (sternal depression) and carinatum (sternal projection), result from excessive rib overgrowth and are common. The combination of kyphoscoliosis and pectus excavatum rarely compromises cardiopulmonary function. Joint laxity from capsular, ligamentous, and tendinous involvement may cause flat feet, knee or elbow hyperextensibility (genu recurvatum), and occasional joint dislocation. Patellar dislocation is not uncommon; dislocation of the hip, often detected during the newborn period, may be the first sign of Marfan syndrome. Screening tests for joint hypermobility are the thumb (or Steinberg) sign, in which the thumb extends well beyond the ulnar border of the hand when overlapped by the fingers, and the wrist (or Walker-Murdoch) sign, in which the thumb overlaps the fifth finger as they grasp the opposite wrist. The underlying joint hyperextensibility and long extremities of Marfan patients often enable them to reach around their back and touch their umbilicus from the opposite side (Fig. 72-7).

Most patients with Marfan syndrome exhibit myopia caused by flattening of the corneas and an abnormally long anterior–posterior orbital axis. An estimated 50% to 70% of patients have ectopia lentis, typically with upward lens displacement. Subluxation and complete dislocation of the lens often lead to secondary ocular abnormalities, including ametropia, myopia, acute glaucoma, and increased risk of retinal detachment. As mild displacements may be missed with standard ocular exams, referral to an ophthalmologist for a dilated slitlamp examination is necessary if a diagnosis of Marfan syndrome is suspected.

CV abnormalities are responsible for the majority of the morbidity and mortality in Marfan patients. CV abnormalities are detected in approximately 40% of patients with Marfan syndrome by cardiac examination and almost 100% of patients by autopsy examination. Medial necrosis of the aorta is the most common defect and diffuse dilation of the proximal segment of the ascending aorta with aortic regurgitation often occurs. Such dilation is progressive, and may even be detected in utero. The progression of dilation is not always continuous and this unpredictability mandates frequent monitoring. Death in Marfan patients usually occurs in adulthood as a result of CV sequelae, most commonly secondary to dilation of the aortic root, leading to aortic dissection or rupture and pericardial tamponade. MVP results from dilation of the mitral valve annulus, with stretching of the chordae and mitral valve leaflet redundancy. It occurs in approximately 25% of affected children and adolescents, and in 86% of those with associated pectus excavatum.[21] MVP increases with age, and eventually occurs in approximately 75% of patients. MVP may lead to abnormal findings on electrocardiogram, mitral valvular regurgitation, and even cardiac arrhythmias leading to sudden death.[20]

Lack of subcutaneous fat and the presence of striae, most prominent on the upper chest, arms, thighs, and abdomen, are the most common cutaneous manifestations of Marfan syndrome. These cutaneous features are found in up to two-third of patients. Elastosis perforans serpiginosa (see Chap. 71) is more common in individuals with Marfan syndrome, and inguinal or incisional hernias may occur. Skin findings are considered minor diagnostic features in the revised diagnostic criteria.[14,20]

Dural ectasia (stretching of the dural sac in the lumbosacral region) often develops in patients with Marfan syndrome. Emphysema has been described, and lung bullae increase the risk of pneumothorax, particularly involving the upper lobes. Oral findings may include a high-arched palate and crowding of anterior teeth.

NEONATAL MARFAN SYNDROME

Infants with the neonatal form of Marfan syndrome have the body disproportion of Marfan syndrome in addition to lax skin, emphysema, ocular abnormalities, joint contractures, kyphoscoliosis, adducted thumbs, crumpled ears, micrognathia, muscle hypoplasia, and deficient subcutaneous fat over joints. Severe cardiac valve insufficiency and aortic dilation result in death during the first 2 years of life.[20,22]

MARFAN SYNDROME IN PEDIATRIC PATIENTS

The clinical features necessary for diagnosing Marfan syndrome develop with age. Pediatric patients often do not meet international criteria for the diagnosis of Marfan syndrome at the time of first examination. Followup examination is critical in suspected pediatric cases to identify affected patients.[23]

ETIOLOGY AND PATHOGENESIS

Even though standard histopathology of affected skin appears normal, with electron microscopy dermal collagen in Marfan syndrome exhibits abnormal thickness, array, and shape, including fibrils of variable thickness, disarray, twisted fibrils, and fibrils with a flower-like appearance and ragged margins, similar to those found in EDS. The content ratio of collagen Type I to collagen Type III is also decreased.[24] Defects occur in the architecture of the collagen microfibrils of large vessels, rather than collagen content or crosslinking.[25] These defects are similar to those seen in abdominal aortic aneurysms and are proposed to explain the weakened aneurysmal vessels in Marfan syndrome.

Marfan syndrome results from heterozygous mutations in the profibrillin 1 gene on chromosome 15q21.1. The spectrum of clinical phenotypes resulting from *FBN1* defects extends beyond classical Marfan syndrome, and these disparate conditions have been termed *fibrillopathies* or *fibrillinopathies*.[26] These range from the severe neonatal Marfan phenotype to isolated aortic root dilation or marfanoid skeletal features without typical CV pathology or ectopia lentis.

Fibrillin is a 350-kDa glycoprotein that is a major component of extracellular matrix (ECM) microfibrils, which are structural components of the zonular fibers of the suspensory ligament of the lens and associated with elastic fibers in the aorta and skin. Virtually every family's mutation is different and more than 500 mutations have been reported occurring in any of the 65 exons of the gene. No hot spots have been identified, except in cases of neonatal Marfan syndrome. Mutations creating premature termination codons appear to lead to milder disease, whereas those in exons 24 to 31 are associated with neonatal Marfan syndrome and more-severe disease. Marfan syndrome Type II is caused by mutations at the *TGFBR2* gene locus. Recently, mutations in *FBN1* were found in 4% of patients with sporadic nonsyndromic aortic dissection.[27]

Fibrillin also modulates the activities of adjacent cells via interactions with mechanosensors as well as syndecan and integrin receptors. Fibrillin also interacts with latent TGF-β binding protein, sequestering it, and controlling TGF-β availability. Deficiency of fibrillin increases TGF-β availability and fibrillin-1 mutation leads to constitutive activation of latent TGF-β signaling through both "classic" and noncanonical TGF-β pathways. How this results in the phenotypic changes seen in Marfan patients is unclear but under investigation.[28] In addition to the action of activated TGF-β, macroaggregates of fibrillin monomers form the basic scaffold on which mature elastin fibers are assembled; as a result, abnormal fibrillin creates a disordered microfibril matrix that may further lead to disordered and weak elastic fiber formation and disruption of the microfibril network that connects elastic lamellae to neighboring interstitial cells.[29]

Research into the impact of these pathways and their potential therapeutic implications for Marfan syndrome is ongoing.

LABORATORY INVESTIGATION

The diagnosis of Marfan syndrome is based on a constellation of clinical findings. There is no diagnostic laboratory test or histologic abnormality. Referral to medical genetics with genetic testing in suspected cases is typical. Diagnosis of Marfan syndrome in a new patient (without a known family history of Marfan syndrome) is made with detection of a FBN1 pathogenic variant of known association with Marfan syndrome along with 1 of the following features: (a) aortic root enlargement (Z-score ≥2) or (b) ectopia lentis. Alternatively, a positive Z-score along with enough additional clinical features to yield a systemic score of 7 or higher is diagnostic. A systemic score calculator is available on the website of the Marfan Foundation (http://www.marfan.org/dx/score). For patients with a known family history of Marfan syndrome, the presence of any of these features is adequate to make the diagnosis: (a) ectopia lentis; (b) a systemic score of 7 or higher; or (c) significant aortic root dilation (Z-score ≥2 if older than 20 years and ≥3 if younger than 20 years).[14]

DIFFERENTIAL DIAGNOSIS

Although Marfan syndrome in its most typical form is rarely confused with other conditions, milder cases share great phenotypic overlap with other hereditary aneurysmal and connective tissue disorders, such as homocystinuria. A number of different conditions exhibit partial phenotypic overlap with Marfan syndrome, including some also caused by fibrillin-1 mutations. Table 72-6 summarizes these conditions.

TREATMENT

Management of Marfan syndrome has focused on prevention of the disabling and life-threatening potential complications. Medical genetics coordination with a multidisciplinary team composed of cardiology, ophthalmology, orthopaedics, and cardiothoracic surgery is typical where available. With appropriate management the life expectancy of patients with Marfan syndrome is similar to the general population.[20]

Early and regular ophthalmologic examinations are required to detect correctable amblyopia and retinal detachment. Ectopia lentis and even complete subluxation may be tolerated for decades. Lens extraction may be required to treat diplopia, glaucoma, cataracts, or retinal detachment. LASIK (laser-assisted in situ keratomileusis) surgery is contraindicated.

Repair of pectus excavatum is appropriate if cardiopulmonary compromise develops, but is delayed until skeletal maturation is nearly complete to prevent recurrence and should use internal stabilization. Scoliosis may be lessened in adolescent girls by estrogen therapy, but this may produce an overall decrease in height. Bracing, physical therapy, and vertebral fusion may all be required to prevent severe scoliosis.

A family history of early aortic dissection mandates aggressive monitoring. At a minimum, patients with Marfan syndrome should undergo yearly monitoring.

TABLE 72-6
Differential Diagnoses for Marfan Syndrome

DISORDER	CLINICAL SIMILARITIES TO MARFAN	CLINICAL DIFFERENCES FROM MARFAN	DEFECT
Homocystinuria	Dolichostenomelia Orthopedic abnormalities Ectopia lentis (downward displacement)	Elevated fasting homocysteine levels Autosomal recessive	Cystathionine β synthetase deficiency causes abnormal methionine metabolism and increased levels of urinary homocysteine
MASS (mitral valve prolapse, aortic root diameter, stretch marks, skeletal features) syndrome	Mitral valve prolapse Myopia Skin—striae Skeletal findings Autosomal dominant (AD)	Borderline aortic enlargement is not progressive	Heterozygous fibrillin-1 mutations
Mitral valve prolapse (MVP) syndrome	MVP Skeletal findings AD	Lack of other features	Fibrillin-1
Familial ectopia lentis	Ectopia lentis Skeletal changes	Questionable risk of eventual aortic enlargement; current recommendations are for periodic imaging	Heterozygous fibrillin-1 mutations
Shprintzen-Goldberg syndrome	Dolichostenomelia Arachnodactyly Scoliosis Pectus Highly arched palate Occasional aortic root enlargement	Craniosynostosis Developmental delay Hypertelorism Proptosis Rib anomalies Chiari malformation Equinovarus deformity	Fibrillin mutations not present in most cases
Loeys-Dietz syndrome (LDS)	Generalized arterial tortuosity with aneurysms and dissection occurring throughout Aneurysms more labile than Marfan syndrome Early dissections and ruptures even in childhood AD	No ectopia lentis Dolichostenomelia less frequent/obvious Hypertelorism Cleft palate with broad/bifid uvula Learning disabilities Chiari I malformation Hydrocephalus Blue sclerae Craniosynostosis Talipes Exotropia Soft, velvety, translucent, easily bruised skin	Mutations in *TGFBR1* and *TGFBR2*
Hemizygous X-linked biglycan deficiency syndrome	Early-onset thoracic aortic aneurysms Dissection occurs	Pectus Hypertelorism Joint hypermobility Contractures Mild skeletal dysplasia	*BGN*—hemizygous mutations; loss of function; X-linked gene
Familial thoracic aortic aneurysms and aortic dissection (FTAAD) syndrome	Vascular disease AD	No other typical clinical features	*TGFBR2* mutations and other loci
Ehlers-Danlos syndrome (EDS)	Kyphoscoliotic form EDS may exhibit increased risk for rupture of medium-sized arteries Vascular EDS has joint laxity (often only small joints), translucent skin, characteristic facies, organ rupture, and tendency for aneurysm or dissection of medium to large muscular arteries AD	Vascular pathology not limited to the aortic root, although this may be involved	

(*Continued*)

TABLE 72-6
Differential Diagnoses for Marfan Syndrome (*Continued*)

DISORDER	CLINICAL SIMILARITIES TO MARFAN	CLINICAL DIFFERENCES FROM MARFAN	DEFECT
Weil-Marchesani syndrome	Ectopia lentis	Orthopedic features differ Short stature Brachydactyly Spherophakia Stiff joints	
Congenital contractural arachnodactyly (CCA; Beals syndrome)	Congenital contractures (elbows, knees, hips, and fingers)—improve with time Ocular (keratoconus) and/or cardiovascular (aortic root dilation, MVP, and septal defects) findings rare Arachnodactyly, progressive severe Kyphoscoliosis High-arched palate Muscular hypoplasia/weakness	Characteristic folded upper helix—"crumpled" appearance of ear—improves with time	Defects in second fibrillin gene (*FBN2*- typically in the "neonatal region" of exons 23 to 34) Likely locus heterogeneity

Aortic complications have not been reported in patients with an aortic diameter normal for age or less than 40 mm in diameter (in adults). Long-term propranolol therapy has been administered to prevent aortic dilation by decreasing myocardial contractility, but may not affect survival. An early small trial in children with Marfan syndrome who were recalcitrant to β blockers using angiotensin II Type 1 receptor blockers (losartan and irbesartan) led to a significant decrease in aortic root diameter and dilation of the sinotubular junction. Larger randomized trials, however, did not show any greater benefit of these therapies over β-adrenergic blockers. Aneurysmal and valvular heart defects may require prosthetic replacement, but this should be delayed for as long as possible to avoid recurrent prosthesis replacement, particularly in growing children. Replacement of the aortic root has led to increased life expectancy and is indicated once the maximal measurement is greater than 5 cm in adults and older children, the rate of size increase is approximately 1 cm/year, or progressive aortic regurgitation develops. Patients with pulmonary involvement should avoid situations with rapid changes in air pressure, such as scuba diving or flying, and, of course, should not smoke. Doxycycline inhibits matrix metalloproteinase, and in mouse models has been shown to improve aortic wall architecture and delay aortic dissection. Prophylaxis is recommended for dental work in Marfan syndrome patients with mitral or aortic valve regurgitation. Historically, patients with known aortic dilation were instructed to avoid caffeine, stressful circumstances, and vigorous exercise. Newer studies, however, in mouse models of Marfan syndrome have shown a benefit from regular moderate exercise with reduced aneurysm progression. Further studies are needed to assess whether these findings are applicable to human Marfan syndrome patients.[30,31]

Children should be excused from participation in physical education so as to avoid potentially harmful exertion, contact sports, and isometric exercises, which might lead to aortic rupture or congenital heart failure. Unfortunately, this can add to the isolation of a child who may already be concerned about an unusual body image or is socially ostracized because of looking "different" or being excessively tall. Importantly, not all patients with Marfan syndrome exhibit striking "classic" phenotypes. When the diagnosis in a patient with an atypical presentation is suspected, one must make certain that appropriate studies are performed, so that potentially lethal internal manifestations are not neglected. The website for the National Marfan Foundation is www.marfan.org.

PSEUDOXANTHOMA ELASTICUM

AT-A-GLANCE

- Incidence: 1 in 25,000 to 100,000 live births (OMIM: 177850 and 264800).
- Autosomal recessive inheritance, occasionally pseudodominant.
- Mutations in *ABCC6* gene on chromosome 16q13.1.
- Cutaneous features include yellow, flat papules in the neck, flexures, and periumbilical areas. Less-frequent skin lesions include acneiform lesions, elastosis perforans serpiginosa, reticulate pigmentation, and granulomatous nodules.

(Continued)

AT-A-GLANCE (*Continued*)

- Extracutaneous manifestations include angioid streaks, visual impairment, peau d'orange retinal hyperpigmentation, cardiovascular disease, and bleeding. Breast and testicular microcalcifications occur and may be mistaken for malignancy.
- Histopathology shows swollen, clumped, fragmented elastic fibers and calcium deposits in the mid and deep reticular dermis. Alterations are easily visualized with calcium (ie, von Kossa) and elastic (ie, Verhoeff-van Gieson or orcein) stains.
- Information for patients and professionals is available at the PXE International (http://www.pxe.org) and the National Association for Pseudoxanthoma Elasticum (http://www.napeusa.com) websites.

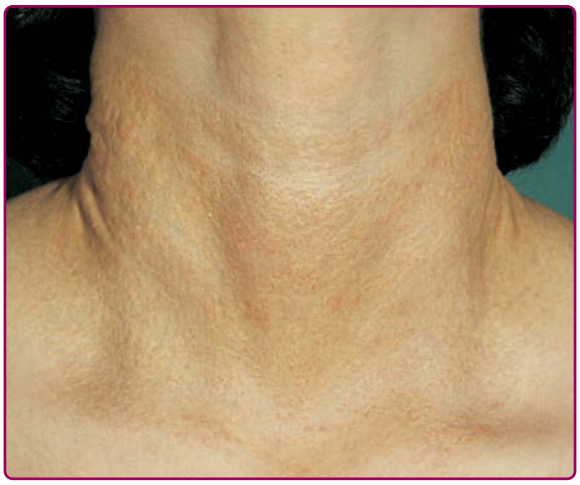

Figure 72-8 Pseudoxanthoma elasticum papules on the neck. There is a distinct yellowish hue. Loose, thickened skin with a pebbled appearance on the neck.

EPIDEMIOLOGY

Also known as *Grönblad-Strandberg syndrome*, this rare entity is a heritable ectopic mineralization disorder exhibiting progressive deposition of calcium hydroxyapatite on elastic tissue. It occurs in approximately 1 in 25,000 to 100,000 individuals, but is likely underdiagnosed. Now classified as an AR disorder, occasional pseudodominance is reported and heterozygous carriers may exhibit a phenotype closely resembling pseudoxanthoma elasticum (PXE).[32] PXE appears to be more severe in female patients.[33] The average age of diagnosis in patients with a positive family history is 8 to 12 years.[34]

CLINICAL FEATURES

Patients with PXE show marked clinical heterogeneity, with some patients displaying lesions of the skin, eye, and systemic vasculature (eg, GI and coronary vessels), while others in the same family (presumably with the same gene mutations) show only involvement of 1 system. Typically, the skin in PXE demonstrates yellowish, flat-topped, discrete, and confluent papules in the skin creases of the sides and nape of the neck (Fig. 72-8), perineum, axillae, umbilicus, and flexural folds with skin redundancy that increases with advancing age. These changes are often termed *plucked chicken skin*. Calcification of affected skin is common. Multiple comedones have been described in association with the typical skin changes, likely related to elastic fiber degeneration similar to solar elastosis.[34] Perforating periumbilical PXE also has been described.[35] Infiltrative oral, anal, and vaginal mucosal lesions may also occur.[36] The dermatologic features generally begin in the second decade, but are often subtle and overlooked. Rarely, progression may lead to diffuse skin involvement and/or CL-like laxity in the flexures. Some authors suggest that prominence of the horizontal and oblique mental creases (which separate the lower lip from the chin) prior to 30 years of age is highly specific for PXE. Skin biopsy can be quite helpful, as the typical histologic findings may be found even with minimal or absent skin lesions.[37] Table 72-7 outlines a differential diagnosis for the characteristic skin lesions of PXE.

Elastosis perforans serpiginosa is reported in patients with PXE (see Chap. 71). Hyperpigmented, reticulated macules, lip telangiectasias, and acneiform and granulomatous lesions also have been described.[38] Although cosmetic concerns over cutaneous lesions may prompt some patients to seek medical input, it is more commonly a visual or vascular complication, such as a GI tract hemorrhage, which prompts patients to seek medical attention.

The most common ophthalmologic finding are angioid streaks (87% of patients). These are radial curvilinear extensions of gray, brown, or reddish coloration from the optic disc, caused by visualization of the choroid through tears in the elastic-rich Bruch membrane. Calcification of its outer layer, the lamina elastica, leads to fragility and fissuring. Angioid streaks often develop during the third or fourth decade of life, although the youngest patient described was 10 years of age.[39] Angioid streaks rarely interfere with visual acuity and may progress or remain stationary. Trauma is likely a precipitating factor in the development of neovascularization and hemorrhagic complications. Characteristic irregular retinal epithelial mottling ("peau d'orange") is commonly seen resulting from degenerated elastic tissue. Peau d'orange retinal changes precede angioid streaks and are the more common ocular finding in children with PXE. Drusen of the optic nerve also have been described, and drusen-like lesions of the posterior pole have been reported in a 12-year-old boy with PXE. Additional ocular changes reported in PXE include healing subretinal hemorrhages ("salmon patches");

TABLE 72-7
Differential Diagnosis of the Skin Lesions of Pseudoxanthoma Elasticum

DISORDER	MORPHOLOGY	DISTRIBUTION	ASSOCIATIONS	DIFFERENTIATION
Dermatofibroma lenticularis	Asymptomatic, flat-topped yellowish papules and nodules, which, when grouped, form large plaques several centimeters in diameter	Often proximal extremities, truncal; symmetric; may be more widespread	Osteopoikilosis, fractures in Buschke-Ollendorff syndrome—caused by *LEMD3* (*MAN1*) mutations	Clinical; biopsy shows increased elastic tissue
Localized acquired cutaneous pseudoxanthoma elasticum (PXE)	Asymptomatic, coalescing yellow macules and papules, occasional reticulate or checkered pattern; lax, redundant areas	Neck, axillae, groin, flexural surfaces, areas exposed to saltpeter fertilizer (calcium-ammonium-nitrate)	Older age, exposure to saltpeter fertilizer in Norwegian farmers, uremia	Histology shows fragmented, thickened, mineralized elastic fibers in mid- and deep-reticular dermis
Perforating periumbilical PXE[35]	Asymptomatic or pruritic, erythematous lesions that progress to hyperpigmented plaques, with central atrophy, a red, scaly border, and peripheral hyperkeratotic papules, sometimes expressing elastotic debris	Periumbilical or breast area	Multiparity, ascites, abdominal surgery; uremia, and hyperphosphatemia in chronic renal failure	Histopathology shows elimination of basophilic, elastotic debris through channels in addition to thickened and mineralized elastic fibers in mid- and deep-reticular dermis
Long-term penicillamine therapy[44,46]	Varied presentations; may resemble PXE, elastosis perforans serpiginosa, cutis laxa, and anetoderma	Similar to those seen in idiopathic forms of disease (ie, neck and flexures for PXE, flexures in elastosis perforans serpiginosa)	Use of D-penicillamine	Histopathology shows thickened elastic bundles with prominent lateral protrusions ("bramble-bush"), granulomatous dermal inflammation, infrequent calcification, and transepidermal elimination of elastic fibers
Actinic damage to neck	Numerous small, asymptomatic, discrete, white papules	Neck	Middle-aged to elderly individuals	Histology shows elastolysis and fibrosis in papillary and midreticular dermis
Papular elastorrhexis	Asymptomatic, firm, nonfollicular 1- to 5-mm whitish papules on trunk and upper extremities	Chest, abdomen, shoulders, back, proximal extremities	Sporadic occurrence; rarely familial	Loss of elastic tissue in reticular dermis (relative increase in fibrillar component) and fragmentation, with occasional perivascular mixed infiltrate

small scars or white foci that represent residua of past hemorrhage ("pearls"); and pigmented foci from previous hemorrhage ("black dots").

Loss of vision in PXE tends to occur later in life and is a result of scarring and fibrosis from choroidal neovascularization and retinal hemorrhage. It can lead to a disc-shaped degeneration of the central visual area causing central visual loss, although peripheral vision often remains intact.

Calcification of degenerated elastic tissue of the internal lamina of blood vessels with subsequent hemorrhage and/or intimal proliferation is a common and potentially serious complication of PXE. The GI tract and renal vasculature are sites of early manifestations of this degenerative damage, which often presents as acute-onset hemorrhage in the second to fourth decade. It is estimated that 10% to 15% of PXE patients will have at least 1 GI hemorrhagic event. Both hypertension from renal artery stenosis and GI bleeding (especially gastric) may occur as early as adolescence. Late vascular sequelae in PXE include cerebrovascular accidents (subarachnoid hemorrhage has been a significant cause of mortality in PXE), intermittent claudication (most common), and myocardial infarction. Severe coronary artery disease has been noted, even in adolescents with PXE; coronary artery bypass surgery may be ameliorative.[40] Physical signs may include diminished peripheral pulses, hypertension (3 times more common in persons with PXE than in the general population), murmurs related to MVP and/or congestive heart failure, and peripheral gangrene. Rectovesical prolapse may also occur.[36] Pulmonary and pulmonary vascular involvement is described, but not common.

Breast and testicular microcalcifications occur and may be mistaken for malignancy. There is not an increased risk for breast or testicular cancer in PXE.[34]

Pregnancy is not contraindicated, but miscarriage rates may be higher in the first trimester, and multiple pregnancies may accelerate the pace of the disease.[36]

ETIOLOGY AND PATHOGENESIS

The mutated gene in typical PXE is *ABCC6*, a member of the adenosine triphosphate-binding cassette transmembrane transporter family (subfamily C member 6; OMIM: 603234) located on chromosome 16p13.1. Most mutations are unique, although 2 occur more frequently: *R1141X*, found predominantly in Europe (28.4% of European patients and 18.8% overall), and *ABCC6del23-29*, which occurs at an overall frequency of 12.9% and is most prevalent in U.S. patients (28.4%).[41] The ABCC6 protein is a putative efflux transporter expressed primarily in the basolateral plasma membrane of liver hepatocytes and proximal tubules of the kidney, 2 sites not affected by PXE. Little to no ABCC6 is expressed in tissues affected by PXE. Evidence supports the concept that PXE is a "metabolic" disease, with deficiency of hepatic ABCC6 leading to the deficiency of adenosine triphosphate excretion into the intracellular space, where it is typically hydrolyzed to produce the potent mineralization inhibitor inorganic pyrophosphate. The ratio of inorganic pyrophosphate to inorganic phosphate is tightly controlled to prevent tissue mineralization, and when disturbed, triggers ectopic mineralization as seen in PXE, generalized arterial calcification of infancy (GACI), and arterial calcification caused by deficiency of CD73.[42]

The great phenotypic heterogeneity exhibited by PXE patients suggests that additional genes or environmental factors contribute to and modify the development of clinical findings. Certain polymorphisms in the promoter of the *SPP1* gene (osteopontin) are more frequent in PXE patients than controls, and 1 is associated with a significantly reduced PXE risk.

Mutations in *GGCX*, which encodes an enzyme necessary for γ-glutamyl carboxylation of gla proteins, have been described in patients with PXE associated with multiple coagulation factor deficiency.

GACI (OMIM: 208000) is an AR disorder characterized by onset of widespread arterial calcification in infancy. A variety of extracardiac findings are reported, including skin and retinal findings identical to PXE. Mutations in ectonucleotide pyrophosphatase/phosphodiesterase 1 (OMIM: 173335) or, less commonly, ABCC6 have been reported in these patients.

Arterial calcification caused by CD73 (OMIM: 129190) deficiency (OMIM: 211800) is a late-onset AR mineralization disorder with vascular calcification similar to PXE and GACI.[34]

LABORATORY INVESTIGATION

The histologic changes on biopsy of lesional skin from patients with PXE are diagnostic, showing distinctive broken curls of basophilic elastic fibers with routine hematoxylin and eosin or Verhoeff-van Gieson staining (Fig. 72-9). Calcium deposition on elastic fibers can be easily detected with von Kossa stain. Similar dystrophic fibers have been noted histologically as an incidental finding in inflammatory skin diseases in patients who do not have PXE.[43] Electron microscopy shows calcification in a centripetal pattern within elastic fibers.[44] Soft-tissue radiographs of the upper and lower extremities may reveal vessel wall calcification. Dental radiographs may demonstrate early vascular calcification. Ultrasonography shows a characteristic pattern of dotted increased echogenicity of renal arteries.[45] Similar patterns have been described on ultrasonography of affected pancreas and spleen. Table 72-8 summarizes the recommended testing for patients with PXE.

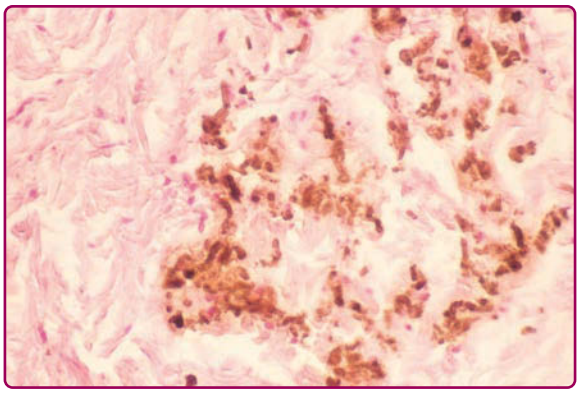

Figure 72-9 Pseudoxanthoma elasticum, elastic tissue stain. The elastic fibers show marked degeneration: They are swollen, tortuous, and irregularly clumped.

TABLE 72-8

Monitoring Studies for Patients with Pseudoxanthoma Elasticum

STUDY	REASON
Complete blood cell count	Occult blood loss; iron-deficiency anemia
Calcium, phosphate	Rare reports of hypercalcemia and hyperphosphatemia
Fasting lipids	Hyperlipidemia aggravates risk of cardiovascular disease
Urinalysis	Hemorrhage from urinary tract
Fecal test for blood	Occult blood loss from GI hemorrhage
Eye examination	To detect angioid streaks, retinal hemorrhage, early retinopathy
Endoscopy	If evidence of GI bleeding
Echocardiography	If murmur, angina, or personal or family history of coronary artery disease
Doppler blood pressure (ankle, brachial)	To investigate claudication or if decreases peripheral pulses
CT of head	If focal neurologic problems or evidence of cerebral hemorrhage
Radiographs	If seeking calcifications

DIFFERENTIAL DIAGNOSIS

Table 72-7 outlines the differential diagnosis of PXE.

The pebbly pattern and yellow discoloration of flexural skin of classical PXE is quite distinctive. The later development of redundancy may be confused with the sagging skin of CL. Ten percent of patients with β-thalassemia have both angioid streaks and the skin manifestations of PXE, while 16% have only the skin lesions that are clinically and histopathologically typical of PXE.[43] D-Penicillamine may induce an acquired form of PXE, but elastic fibers do not become calcified.[44,46] PXE-like changes also have been noted both clinically and histologically in longstanding nephrogenic systemic fibrosis.[47]

Angioid streaks have been described in a variety of disorders, among them EDS, Marfan syndrome, lead poisoning, sickle cell anemia, thalassemia, Paget disease of bone, acromegaly and other pituitary disorders, and familial hyperphosphatemia.[39]

PREVENTION AND TREATMENT

There is no cure for PXE and a multidisciplinary approach is required to address the myriad manifestations of the disease. Plastic surgery may improve the appearance of sagging skin, although extrusion of calcium particles through the surgical wound may result in delayed healing and unsightly scars.[48] Fillers or autologous fat injections have been used to soften the prominent facial creases. GI bleeding can usually be managed conservatively with iced saline lavage and transfusion and rarely requires balloon embolization or surgery for control.[49] Anticoagulants (nonsteroidal antiinflammatory drugs/aspirin) are typically avoided in PXE patients. All patients should be followed by a retina specialist and instructed in the use of an Amsler grid to detect early symptoms of retinal hemorrhage. Laser photocoagulation (such as verteporfin photodynamic therapy every 3 months) has been used to treat the choroidal neovascularization.[50] Recently, intravitreal injections of the vascular endothelial growth factor inhibitor bevacizumab have been rapidly adopted to stop the choroidal neovascularization of PXE.[34]

With recent progress in elucidating the pathogenesis of PXE, a variety of treatments are under investigation. Bisphosphonates, such as etidronate, are stable inorganic pyrophosphate analogs that have been tested in mouse models of PXE with promising results. Additionally, etidronate has been used as prenatal therapy for pregnant mothers with a history of GACI or when fetal GACI is detected on ultrasonography with apparent decrease in maternal mortality. A variety of additional approaches have been considered, including the use of amlexanox to promote read through of premature termination codons.[34]

Although low calcium (60 to 1200 mg/day) and low-lipid diets have been advocated, their value has not been clinically tested and following the recommended daily allowance for these nutrients is recommended. A report describing the use of aluminum hydroxide as an oral phosphate binder noted improvement in PXE skin lesions in 3 of 6 patients treated.[51] Oral ascorbic acid and tocopherol were administered to a single patient with apparent positive response after several years.[52] A diet with fivefold the standard of magnesium to ABCC6 null mice prevented the development of connective tissue mineralization.[53]

Dietary supplementation with magnesium carbonate, which is used as an antacid and commonly added to table salt to prevent caking, is a simple and attractive therapeutic intervention and studies have been completed assessing magnesium supplementation as a treatment for PXE.[34]

Regular evaluation and followup with a cardiologist should be encouraged. Patients should be advised to protect their eyes from even mild trauma, and about the potential for future visual loss. Because of the potential risk to eyes and calcified vessels when traumatized, contact sports and high-intensity CV exercise should be prohibited for persons with PXE. This can be quite life altering for the child or adolescent who may not fully understand the consequences of the seemingly minor skin changes. Avoidance of high-cholesterol foods and smoking, control of blood pressure, and safe aerobic exercises may be recommended by the physician. Patient support groups include the National Association for Pseudoxanthoma Elasticum (www.napeusa.com) and PXE International (www.pxe.org).

CUTIS LAXA (GENERALIZED ELASTOLYSIS)

AT-A-GLANCE

- Inheritance may be autosomal dominant (AD; OMIM: 123700), autosomal recessive (AR; OMIM: 219100 or 219200), or X-linked recessive (XLR; also known as *occipital horn syndrome* [OMIM: 304150]).
- Mutations in elastin (*ELN*) or fibulin-5 (*FBLN5*) in AD; in fibulin-5 (*FBLN5, EVEC, DANCE*) or fibulin-4 (*FBLN4*), or variety of additional genes (see Table 72-9) in AR; in copper transport adenosine triphosphatase (*ATP7A*) in XLR.
- Cutaneous features include pendulous, inelastic skin, with an aged facies.
- Extracutaneous manifestations may include pulmonary emphysema, aortic aneurysm, pulmonary artery and valve stenosis, hernias, GI diverticula, joint laxity, low serum ceruloplasmin, and bilateral exostoses of the occiput (or occipital horn syndrome).

(Continued)

AT-A-GLANCE (*Continued*)

- Histopathology shows sparse and fragmented elastic fibers, better visualized with stains (ie, Verhoeff-van Gieson or orcein).
- Information for patients and professionals is available at the Cutis Laxa International website (http://www.cutislaxa.org).

CL is a heterogeneous group of disorders (Table 72-9) that result from abnormalities in elastic tissue. It is characterized by widespread laxity of skin and, in some cases, involvement of other organs.

EPIDEMIOLOGY

AD, AR, and X-linked forms exist, with recessive forms the most common. Estimated incidence is 1 in 1,000,000 live births. Review of the world literature suggests only a few hundreds of cases reported in approximately 400 families. Importantly, historically only a minority of CL patients have had identified molecular causes, although this is changing because of next-generation sequencing. It is estimated that the success for detecting mutations in patients with the AR form of CL (ARCL) Type I is only approximately 10%.[54]

CLINICAL FEATURES

The skin in CL is inelastic and appears pendulous. At birth infants appear to have unusually soft and loose skin. The skin is hyperextensible, but does not resume or slowly resumes its normal shape after stretching. Persons with CL are often described as having a bloodhound-like facial appearance (Fig. 72-10) and loose skin of the face, neck, shoulders, and thighs often first attracts attention. Young, affected children appear aged. Signs of skin fragility, easy bruising, or abnormal scarring are typically absent in contrast to EDS. The viscoelastic modulus of the skin in patients with CL is significantly altered compared to normal patients and CL appears to result in similar changes in skin mechanics as aging.[55] Both AR and X-linked forms of CL can exhibit congenital onset. Joint hypermobility can occur. Internal organ involvement may be seen with both inherited and acquired CL. Table 72-9 summarizes the clinical features of the described CL subtypes.

Autosomal dominant cutis laxa (ADCL) (OMIM: 123700) primarily affects the skin. It may present at any age, from infancy to adulthood and all ages in between, and tends to be relatively benign with a normal/near-normal life expectancy. Patients may exhibit distinctive facial features, including a beaked nose, long philtrum, high forehead, and large ears. Internal involvement is less common but may occur.

X-linked CL (OMIM: 304150) typically affects males and includes patients with the *occipital horn syndrome* and Menkes disease. Clinical findings in X-linked CL often begin around 2 to 3 months of age. Patients exhibit hypotonia, skin laxity (often distal), a thin face with long philtrum and short columella, inverted lower eyelids, a high forehead, and a hooked/beaked nose, as well as large fontanels and brittle hair. Without treatment there is progressive failure to thrive and developmental delay. In severe forms, seizures may develop with progressive neurologic decline, and respiratory and feeding difficulties. Patients may die within the first decade. In less-severe cases, mild mental retardation is common and progressive development of the characteristic occipital exostoses occurs. These exostosis are often first detectable by 5 to 10 years of age. Early intervention with copper replacement therapy can be helpful in some patients.

Clinical findings in the ARCL syndromes are heterogeneous in both severity and organ involvement. ARCL Type 1 (ARCL1; OMIM: 219100) can exhibit great variability. ARCL1A often presents with a severe phenotype that includes emphysema, hernias, pulmonary artery stenosis, and visceral involvement such as GI and genitourinary (GU) diverticula, as well as early lethality resulting from profound elastic tissue defects in several organs. Cardiopulmonary insufficiency may develop with time. The cutaneous findings in such patients are often pronounced, with loose, hanging, pendulous skin. Some patients with ARCL Type 1 have milder involvement.

ARCL1B (OMIM: 614437) is also highly variable. Some patients exhibit severe complications such as CV or pulmonary failure early in life. Arterial tortuosity is often a prominent feature. Other patients with milder presentations exhibit craniofacial abnormalities and additional vascular issues such as aneurysms and pulmonary artery hypoplasia. Cardiac hypertrophy can occur. Emphysema of the lungs can develop in some patients and may lead to pulmonary failure. Patients with hypotonia and bone fragility, as well as diaphragmatic hernias, are described. Characteristic facial features include hypertelorism, abnormal ears, high-arched palate, and retrognathia. Patients often exhibit lax joints and arachnodactyly.

ARCL1C (OMIM: 613177) is also known as Urban-Rifkin-Davis syndrome. Patients exhibit CL of the skin and severe pulmonary, GU, and GI complications; CV complications, however, are often quite mild. Pulmonary emphysema, cystic degeneration, and atelectasis can occur. Tracheomalacia, as well as diaphragmatic hernias and pulmonary artery stenosis, develop in some patients. Hydronephrosis and GI diverticula are reported. Characteristic facial features such as macrognathia, wide anterior fontanels, hypertelorism, and (occasionally) a flattened midface or prominent ears may be noted. Some patients have had growth deficiencies.

TABLE 72-9
Cutis Laxa Syndromes: Clinical Subtypes and Associated Defects

SUBTYPE (OMIM #)	CLINICAL FEATURES	INHERITANCE	PROTEIN (GENE DEFECT/OMIM #)	CELLULAR DEFECT
ADCL (123700)	Congenital Primarily cutaneous (hyperextensible loose hanging skin folds) Hernias Rare vascular complications Acute respiratory disease, 55%; emphysema, approximately 35% (Near-)normal life expectancy Some clinical variability	AD	Elastin (*ELN*/130160) Fibulin 5 (*FBLN5*/604580)	Abnormal elastic fibers
XLR (304150)	Mild mental retardation Exostoses Congenital wrinkling of the skin (mainly distal) and skin hyperextensibility Pili torti Distal joint laxity Progressive exostoses including "occipital horns" Skeletal abnormalities Failure to thrive Genitourinary (GU) diverticula Retinal artery tortuosity	XLR	α Polypeptide of Cu^{2+} transporting adenosine triphosphatase (ATPase) (*ATP7A*/300011)	Defective copper metabolism Reduced functionality of Cu^{2+}-dependent enzymes including lysyl oxidases
ARCL Type 1 (219100) (including Urban-Rifkin-Davis syndrome [URDS])	Emphysema Congenital Severe Loose hanging redundant skin Early lethality Supravalvular and aortic and Pulmonary artery stenosis Hernias (various including diaphragmatic) Mucosal prolapse (Congenital or early onset) No hip dislocation GI and GU diverticula with secondary infections Arterial tortuosity Aneurysm formation (more common in FBLN4-related CL) Marfanoid habitus Osteoporosis (*FBLN4*) Diaphragmatic hernia; corneal thinning (*SLC2A10*)	AR	Fibulin 5 (ARCL1a) (*FBLN5*/604580) LTBP4 (URDS) Fibulin 4 (ARCL1b) (*FBLN4*/EFEMP2/604633) *SLC2A10*; facilitative glucose transporter GLUT10	Defective elastic fiber assembly Severely underdeveloped elastic fibers
Metabolic CL Type 2 (ARCL)	No ocular involvement + abnormal glycosylation = ATP6V subunit mutations			
ARCL2A ranges from Debre type (severe) to wrinkly skin (mild) (219200)	Clinical variability Downslanting palpebral fissures Long philtrum Microcephaly Developmental delay Hypotonia Congenital hip dislocation Mental retardation Delayed fontanel closure Cobblestone brain malformation Congenital CL improves over time, especially after puberty Dental caries common Cardiopulmonary involvement is very rare Apolipoprotein C-III isoelectric focusing is diagnostic	AR	α_2 Subunit of V-type H^+–ATPase (*ATP6V0A2*/611716)	Congenital disorder of glycosylation (CDG-II) Abnormal pH regulation of Golgi compartments Leads to impaired retrograde Golgi trafficking Increased cellular apoptosis ?Impaired transport of tropoelastin from cell Increased vascularization of dermis; reduced collagen

(*Continued*)

TABLE 72-9
Cutis Laxa Syndromes: Clinical Subtypes and Associated Defects (*Continued*)

SUBTYPE (OMIM #)	CLINICAL FEATURES	INHERITANCE	PROTEIN (GENE DEFECT/OMIM #)	CELLULAR DEFECT
ARCL2 (ATP6V1E1, ATP6V1A)	Generalized CL Dysmorphic facies Hypotonia Joint contractures Congenital hip dysplasia Cardiac abnormalities[a] Pneumothorax Aortic root dilation Marfanoid habitus ATP6V1E1 – generalized skin wrinkling ATP6V1A – larger skin folds/abnormal fat distribution	AR	V-ATPase: E1 subunit of V1 domain/(ATP6V1E1: 108746) Subunit A of V1 domain/(ATP6V1A: 607027)	Also CDG-II
ARCL2 – conserved oligomeric Golgi (COG) 7	Severe phenotype Neurologic symptoms Microcephaly Intrauterine growth retardation (IUGR) Cholestatic liver disease: elevated transaminases; creatine kinase; bilirubin Skeletal dysplasia Cardiac anomalies Recurrent infections Hyperthermia Early fatality	AR	Conserved oligomeric Golgi complex subunit 7/(COG7)	Combined *N*- and *O*-glycosylation defects present
ARCL2B (progeroid forms) (612940)	Progeroid appearance Osteopenia Wormian bones Variable connective tissue weakness Wrinkly, lax skin—especially over hands Finger contractures Triangular facies with mandibular hypoplasia causing prognathism Adulthood: long facies with prominent chin Lipodystrophy Variable Intellectual disability is common Agenesis of corpus callosum Cataracts/corneal clouding Athetoid movements	AR	Pyrroline-5-carboxylate reductase 1(*PYCR1*/179035)	Abnormal mitochondrial proline metabolism PYCR1 catalyzes reduction of Δ^1-pyrroline-5-carboxylate (P5C) to proline; final step in proline synthesis from glutamate Increased cellular apoptosis Mitochondrial defects Elastic fiber abnormalities similar to other ARCL Highly variable severity
ARCL Type 3a (ARCL3A) (219150)	CL Joint laxity/hypotonia Microcephaly Intrauterine and postnatal growth retardation Congenital hip dislocation Bilateral subcapsular cataract Severe mental retardation Structural brain abnormalities Progressive neurodegeneration Seizures Dystonia (hands/feet) Peripheral neuropathy Paradoxical hyperammonemia with hyperprolinemia and urea cycle deficiency in some patients	AR	Δ^1-Pyrroline-5-carboxylate synthase (P5CS) deficiency/*ALDHI8AI*	Catalyzes reduction of glutamate to P5C, a precursor of proline and ornithine Proline may play role in neurotransmission Ornithine is urea cycle intermediate Dietary arginine temporarily restores urea cycle, leading to paradoxical hyperammonemia
ARCL Type 3b (ARCL3B) (614438) - De Barsy syndrome (DBS)	CL Significant mental retardation Eye anomalies (cataract) Dystonia Progeroid features Progressive No glycosylation defects	AR	PYCR1	Frayed elastic fibers

(*Continued*)

TABLE 72-9
Cutis Laxa Syndromes: Clinical Subtypes and Associated Defects (*Continued*)

SUBTYPE (OMIM #)	CLINICAL FEATURES	INHERITANCE	PROTEIN (GENE DEFECT/OMIM #)	CELLULAR DEFECT
Gerodermia osteodysplastica (GO) (231070)	Progeroid features Malar/maxillary hypoplasia "Droopy" face: oblique furrows from lateral edge of supraorbital ridge to outer canthus Sagging cheeks Joint laxity Short-stature dwarfism but may be normal weight/length at birth Normal mental development Osteoporosis/osteopenia Frequent fractures, especially vertebral Improvement in progeroid features and joint laxity over time No glycosylation defects	AR	SCYL1-binding protein 1 (GORAB /607983)	Soluble protein present in both skin and osteoblasts Interacts with Rab6, which interacts with COG complex Disrupted Golgi trafficking
MACS/RIN2 syndrome (macrocephaly; alopecia; CL; scoliosis) (613075)	Characteristic facial features: puffy eyelids; soft, redundant facial skin; sagged cheeks; lower lip eversion; micrognathia; gingival hypertrophy; abnormal dentition; sparse scalp hair Macrocephaly Severe joint laxity Scoliosis Normal psychomotor development	AR	Ras and Rab interactor 2 protein (RIN2/610222)	RIN2 interacts with Rab5 protein, which is important for endosomal and likely other intracellular trafficking RIN proteins can act as regulators of Ras pathway, which suggests weak pathomechanistic overlap with Costello syndrome
Additional Syndromes				
Transaldolase deficiency	Congenital CL in some patients Cutaneous telangiectasia Hydrops fetalis Aortic coarctation Bleeding tendency Dysmorphic features Hypertrichosis Variable multiorgan involvement Hepatosplenomegaly Clitoral enlargement Cirrhosis Liver failure Hemolytic anemia GU malformation Renal Thrombocytopenia Erythronic acid is novel biomarker of disease Many exhibit gradual improvement including skin—except for liver and renal	AR	Transaldolase/*TALDO1* gene/(602063)	Inborn error in pentose phosphate metabolic pathway
Costello syndrome (218040); Noonan syndrome (163950); Cardiofaciocutaneous syndrome (115150)	Loose, soft doughy skin Inguinal, axillary, hands/feet Feeding problems Pulmonary artery stenosis Bleeding tendency Dry skin Characteristic facies	AD	Ras-MAPK pathway defects	

[a]Patients with mutations in these genes have been reported as wrinkly skin syndrome prior to identification of their underlying mutation.
AD, autosomal dominant; AR, autosomal recessive; CL, cutis laxa; OMIM, Online Mendelian Inheritance in Man; XLR, X-linked recessive.
Data from Mohamed M, Voet M, Gardeitchik T, et al. Cutis laxa. *Adv Exp Med Biol*. 2014;802:161-184; and Morava E, Lefeber DJ, Urban Z, et al. Defining the phenotype in an autosomal recessive cutis laxa syndrome with a combined congenital defect of glycosylation. *Eur J Hum Genet*. 2008;16(1):28-35.

Figure 72-10 Cutis laxa caused by fibulin-4 mutation. The facial skin hangs in loose folds, giving the appearance of premature aging. Note the prominent periorbital vessels. The tracheostomy was placed for diaphragmatic eventration and respiratory difficulty.

Children with ARCL Type 2 have distinct clinical findings and can be divided into 2 groups based on the presence or absence of *N*- and *O*-linked glycosylation defects (congenital disorder of glycosylation [CDG] Type II). While these subtypes share many common features such as CL, hyperextensible joints (including flat feet), and progeroid features, other clinical differences between these subtypes are becoming evident.[56]

ARCL2A (OMIM: 219200) is caused by ATP6V0A2 (OMIM: 611716) mutations (a subunit of the V-adenosine triphosphatase [ATPase] pump). The clinical findings in these patients range from mild wrinkly skin to severe ("Debre-type") CL. Often patients with more pronounced wrinkly skin phenotypes (OMIM: 278250) exhibit milder developmental delays and neurodegeneration, while the more severe "Debre-type" individuals exhibit milder skin involvement but more pronounced neurologic and developmental abnormalities. Improvement in the skin symptoms with time may be noted. CNS malformations are common leading to developmental delay and intellectual disability. Microcephaly may occur. Neurologic regression may begin near the end of the first decade of life and may present with slurring of speech, ataxia, and progressive spasticity. Seizures may develop, often between 8 and 12 years of age. Affected infants may exhibit hypotonia, feeding problems, and failure to thrive. Enlarged fontanels with delayed closure are described. Characteristic facial features include downslanting palpebral fissures; a long philtrum; a broadened and flattened nasal bridge; large, anteverted nares; enlarged ears; and microstomia. Full, sagging cheeks are common. Joint laxity, including congenital hip dislocation, may occur, as well as inguinal hernias, and ocular abnormalities such as strabismus and myopia. Of note, these patients very rarely exhibit cardiopulmonary involvement.

ARCL2 caused by ATP6V1E1 (ARCL Type IIC; OMIM: 617402; OMIM: 108746) and ATP6V1A (ARCL Type IID; OMIM: 617403; OMIM: 607027) mutations exhibit generalized CL, dysmorphic facies, hypotonia, joint contractures, congenital hip dysplasia, and cardiac abnormalities. ATP6V1E1 mutations led to generalized skin wrinkling whereas ATP6V1A mutations led to larger skin folds and abnormal fat distribution that improved over time. CNS abnormalities were noted with nearly 80% of reported ARCL2A patients exhibiting intellectual disabilities. Both ATP6V1E1 and ATP6V1A mutations led to increased risk for life-threatening complications such as pneumothorax, aortic root dilation, cardiomyopathy, and congenital heart defects. These features also distinguish these forms of ARCL from the more common forms.[57]

ARCL2B (OMIM: 612940) includes so called "progeroid" forms of CL and is caused by pyrroline-5-carboxylate reductase (PYCR; OMIM: 179035) mutations. CL is most notable in the arms and legs. Affected infants often exhibit failure to thrive and growth and developmental delays. Agenesis or hypoplasia of the corpus callosum is common. Distinctive facial features noted in this subtype of ARCL include a thin, pinched nose, large ears and forehead, blue sclera, triangular facies with a wizened appearance, and thin skin. The sagging cheeks noted in ARCL1A are not typically present. Severe wrinkling of the dorsal hands and feet, wormian bones, lipodystrophy, cataracts/corneal clouding, and athetoid movements may occur, and when present, strongly suggest the diagnosis of ARCL2B. As patients age the triangular facies disappear and by adulthood these patients exhibit elongated facies with a prominent chin. Lipodystrophy is commonly noted in adults with ARCL2B. Scoliosis, bowing of the long bones of the upper and lower extremities, arachnodactyly, osteopenia, osteoporosis, and congenital hip dislocation are described.

ARCL Type 3a (ARCL3A; OMIM: 219150) results from mutations in *ALDH18A1* (OMIM: 138250), which encodes Δ^1-pyrroline-5-carboxylate synthase (P5CS). Affected infants exhibit CL, loose joints, growth impairment, intellectual delay that is moderate to severe, cataracts, and corneal anomalies. Some patients develop dystonia and posturing. CV or pulmonary involvement is rare. This ARCL subgroup includes many infants previously diagnosed with de Barsy syndrome. ARCL Type 3b (ARCL3B; OMIM: 614438) results from PYCR1 (OMIM: 179035) defects leading to a more-severe phenotype.

Gerodermia osteodysplastica (GO; OMIM: 231070) also has been termed *Walt Disney dwarfism*. Affected infants/children exhibit loose skin acrally, as well as on the face and stomach. Oblique furrows from the lateral border of the supraorbital ridge to the outer canthus are a recently reported distinguishing finding.[56] Malar/maxillary hypoplasia, prognathism, sagging

cheeks, and a prematurely aged appearance are noted. Even though GO patients may exhibit growth deficiency and short stature, they often have normal weights and lengths at birth. Lax joints, hip dislocations and hernias occur. Osteopenia/osteoporosis is common and pathologic fractures (particularly of vertebral column) occur, but CV or pulmonary involvement is rare. Patients have normal cognition. Improvement of progeroid features and joint laxity over time occurs in most patients with these ARCL subtypes.[56,57]

Table 72-9 summarizes additional syndromes considered to be subtypes of CL.

ETIOLOGY AND PATHOGENESIS

Skin elasticity (reversible deformability), as well as elasticity of other tissues such as lung or larger arterial vessels, results from a network composed of elastin fibers. Abnormalities in elastic fiber synthesis, stabilization, or degradation may all lead to the clinical phenotype of CL.

Elastic fibers are composed of an amorphous elastin component (90% of fibril) surrounded by a microfibrillar sheath based on fibrillin. Elastic fibers do not spontaneously assemble; their construction requires a carefully orchestrated sequence of reactions.[58] Elastin is synthesized from individual tropoelastin molecules aligned on a network of elastic fibers and the alignment is stabilized via the formation of intermolecular crosslinks mediated by copper-dependent lysyl oxidase. Mutations in the elastin gene (45 kb in length and mapped to 7q11.2.) typically shift the reading frame at the 3′ end, causing read through of the 3′ untranslated region. The resulting abnormal protein is deposited in the ECM and the tropoelastin monomers prematurely activate, disrupting deposition on microfibrils and preventing maturation to insoluble elastin. These abnormal elastic fibers are responsible for many cases of ADCL (OMIM: 123700).

Interestingly some patients with acquired CL have an underlying p.(G773D) variant at the C-terminus of the elastin gene, which increases the protein's sensitivity to inflammation-mediated destruction.[59]

The structure of the elastic fiber network is diverse and varies based on location within the dermis. Superficial oxytalan fibers extend from the dermoepidermal junction and are composed primarily of microfibril bundles. These extend through elaunin fibers, which run perpendicularly in the papillary dermis and contain a small amount of elastin. Deeper, in the reticular dermis, thick horizontal elastic fibers contain higher amounts of elastin.[60] Mutations in genes whose protein products form part of the elastic fiber interface such as fibulin 4 (*FBLN4*; OMIM: 604633) and fibulin 5 (*FBLN5*, *EVEC*, or *DANCE*; OMIM: 604580) are associated with the frequently fatal ARCL Type I (OMIM: 219100) in humans. Fibulin 5 binds cell surface integrin receptors and key components of elastic fibers, suggesting a role in cell-directed elastic fiber assembly. ARCL Type I fibulin 5 mutations lead to abnormal protein folding, decreased secretion, and decreased interaction with elastin and fibrillin-1. One patient with ADCL and a duplication in the fibulin 5 gene has been reported.[61] Missense mutations in fibulin 4 (epidermal growth factor–containing fibulin-like ECM protein 2 [EFEMP2]; OMIM: 604633) have been noted in several patients with unusually severe ARCL Type I with a primary CV phenotype. These patients have severe arterial tortuosity, arterial stenosis, along with aneurysms. Elastic fibers in these patients are severely underdeveloped.

ARCL Type 1c (Urban-Rifkin-Davis syndrome; OMIM: 604710) also exhibits lung, GI, and GU abnormalities and is caused by mutations in LTBP4 (latent TGF-β binding protein 4), which binds the latent TGF-β complex resulting in TGF-β sequestration. LTBP4 may function to guide FBLN5-coated elastin globules toward microfibrils, explaining the phenotypic similarities between patients deficient in either FBLN5 or LTBP4.

DEFECTS IN INTRACELLULAR TRAFFICKING

ARCL2A (Debre type; OMIM: 219200) patients exhibit loss-of-function mutations in *ATP6V0A2*, which encodes the a2 subunit of the V-type H^+ ATPase, which is mainly located in the Golgi apparatus. Defects in *ATP6V0A2* result in CDG-II, as a consequence of defective serum protein *N*- and *O*-linked glycosylation. Increased intravesicular pH in dermal fibroblasts likely leads to impaired crosslinking and maturation of elastin as well as affect function of glycosylation enzymes. Fibroblasts from affected patients demonstrate impaired Golgi trafficking, likely because of abnormal pH regulation in the Golgi compartments. Increased cellular apoptosis also occurs. Analysis of apolipoprotein C-III isoelectric focusing is diagnostic in all cases.

Recently, biallelic mutations in *ATP6V1E1* (OMIM: 108746) and *ATP6V1A* (OMIM: 607027) encoding the E1 and A subunits of the V1 domain of V-ATPase were reported in patients with ARCL2 (see Table 72-9). The causative mutations affected assembly and structure of the V-ATPase, glycosylation of proteins, and trafficking in the Golgi, as well as lysosomal function, which caused defects in ECM architecture and homeostasis.[57]

Mutations in COG7 (component of oligomeric Golgi complex subunit 7; OMIM: 606978) exhibit a severe phenotype, with pronounced neurologic symptoms, intrauterine growth retardation and cholestatic liver disease causing early fatality. Glycosylation defects are also present, likely because of defective localization of glycosylation enzymes caused by impaired retrograde Golgi transport.[62]

The MACS/RIN2 syndrome (macrocephaly, alopecia, CL, and scoliosis [OMIM: 613075]/Ras and Rab interactor 2 [OMIM: 610222]) exhibits hyperextensible/lax skin, macrocephaly, distinct facies, slow/thin hair growth, and scoliosis. It is considered part of the ARCL2 spectrum and mild protein hypoglycosylation

can be observed. The protein encoded by the RIN2 gene is a guanine nucleotide exchange factor which interacts with R-RAS and Rab5 in early endocytosis.

GO (OMIM: 231070) results from mutations in *SCYL1BP1* whose protein product, termed GORAB (OMIM: 607983), is a soluble protein highly expressed both in skin and osteoblasts. It interacts with RAB6 and ARF5, which interact with the conserved oligomeric Golgi complex and is important in Golgi trafficking.[63] In contrast to ARCL of the Debre type, no glycosylation defects are present in GO.

DEFECTS IN METABOLISM

Mutations in PYCR1 (OMIM: 179035), a mitochondrial enzyme involved in proline synthesis from pyrroline-5-carboxylate (P5C), were initially reported in a group of patients who had previously been diagnosed with a variety of disorders, including wrinkly skin syndrome, De Barsy syndrome, and GO. The resulting abnormal proline metabolism leads to mitochondrial defects and increased cellular apoptosis. ARCL2B (OMIM: 612940) also has been termed *PYCR1-related CL*.

ARCL Type 3 (ARCL3A [OMIM: 219150] and ARCL3B [OMIM: 614438]) include patients historically termed *De Barsy syndrome*. These patients represent an extreme form of the ARCL2B spectrum with more striking progeroid appearance, cataracts/corneal clouding, and significant intellectual disability. Most ARCL3 patients have PYCR1 mutations. PYCR2 (OMIM: 616406) mutations result in a phenotype devoid of cutaneous findings, although affected patients exhibit microcephaly and hypomyelination.[64]

Patients with defects in *ALDH18A1* (ARCL3B; OMIM: 138250), which encodes the mitochondrial enzyme Δ^1-P5C synthase, responsible for converting glutamic acid to P5C, often manifest a similar, yet strikingly severe, phenotype of ARCL Type 3a, including thin translucent skin and occasional arterial malformations. Increased sensitivity to oxidative stress may play a role in the clinical findings.

Mutations in the *ATP7A* gene (OMIM: 300011), which encodes a protein member of the *P*-type ATPase family responsible for copper transport into the Golgi apparatus, cause X-linked CL, which is allelic to Menkes disease (OMIM: 309400) and occipital horn syndrome (OMIM: 304150). *ATP7A* mediates copper transport from the GI tract, efflux of excess copper from cells, and delivery of intracellular stores of copper to cuproenzymes such as lysyl oxidase.

Acquired forms of CL present after skin inflammation and structural damage of elastic fibers. Increased neutrophil elastase present in affected skin is presumed to disrupt elastic fiber integrity. Abnormalities in the genes in which mutations lead to hereditary CL may also play a role in acquired forms of CL. For example, a patient with compound heterozygous elastin mutations showed partial rescue of elastic fiber synthesis by a heterozygous missense mutation in fibulin 5. The resultant elastic fiber system functioned normally, until challenged by *Toxocara canis* parasite infestation during adolescence, leading to acquired CL.[59]

LABORATORY INVESTIGATION

Special stains for elastic tissue (Verhoeff-van Gieson stain) of skin biopsy specimens demonstrate significantly decreased or absent dermal elastic fibers (in both AD and AR forms of CL). Remaining fibers are often clumped, short, granular, and fragmented. Increased elastin-associated microfibrils are noted on electron microscopy. Calcification is not typically seen. Electron microscopy is considered diagnostic for most cases of ARCL, revealing moth-eaten elastic fibers, with abnormal elastin fiber branching and reduced elastin synthesis creating loose microfibrils. Importantly, in both ADCL and ARCL some patients exhibit relatively normal electron microscopy and thus the presence or absence of histologic or electron microscopic findings is not necessary for the diagnosis of CL in the clinical setting of loose, hanging skin with decreased elasticity.[54] In acquired cases, a mononuclear or mixed inflammatory infiltrate containing neutrophils may be present.

Transferrin isoelectric focusing studies and apolipoprotein C-III immunoelectric focusing should be considered in all patients with AR or sporadic CL (especially those with typical facies, late fontanel closure, and developmental delay or CNS involvement). It is important to note that CDG may be missed by the transferrin immunoelectric focusing method in young children. However, the apolipoprotein C-III immunoelectric focusing pattern is typically abnormal, even in very young patients. In cases where suspicion is high but these studies are normal early in infancy, they should likely both be repeated after 6 months of age.[54]

DIFFERENTIAL DIAGNOSIS

Patients with EDS have skin that regains a normal appearance when released after stretching. Other features of EDS, including joint laxity, increased bruising, and poor wound healing, are not seen with CL. Older patients with PXE may have laxity of skin, especially in flexural areas, but the skin shows a pebbly, yellow appearance. Histologic examination of lesional skin further distinguishes these entities. A disorder with features of both PXE and CL, as well as deficiency in multiple coagulation factors, results from mutations in the γ-glutamyl carboxylase (*GGCX*) gene. These patients exhibit mineralized elastic fibers with positive dermal von Kossa staining, and mild retinopathy similar to PXE, but with the pronounced skin folds more typical of CL. Patients also exhibit an abnormal bleeding tendency from deficiency of vitamin K–dependent clotting factors (factors II, VII, IX, and X), atherosclerosis, and possibly cerebral aneurysms.[65] As in PXE,

CL-like changes are also reported in longstanding nephrogenic systemic fibrosis.[66]

ACQUIRED CUTIS LAXA

Acquired forms of generalized and localized CL occasionally occur. In Type I-acquired CL, ill-defined areas of loose skin appear insidiously but progressively with elastolysis occurring beyond inflammatory areas in many cases. Type I skin lesions involve the head and neck and progress in a cephalocaudal direction. The development of CL is preceded by an inflammatory eruption (urticaria, erythema multiforme, eczematous eruption) in approximately 50% of cases. Although Type I acquired CL usually begins in adulthood, children have been described with this condition. Pulmonary involvement presents as emphysema and is the most frequent cause of death in acquired cases.[67] Severe tracheobronchomegaly is described. Aortic aneurysms with subsequent rupture, and GI and GU diverticula have also lead to mortality in these patients. Most affected children have not had evidence of systemic elastolysis.

Type II-acquired CL (Marshall syndrome) is a postinflammatory elastolysis characterized by more localized, well-demarcated, nonpruritic erythematous plaques that extend peripherally and have a hypopigmented center. These appear in crops over a period of days to weeks, often in association with fever, malaise, and peripheral eosinophilia. Localized, or less commonly generalized, areas of CL gradually occur at sites of previous inflammation.[68] Although systemic involvement is rare, fatal aortitis has been reported.[69]

Acquired CL may develop after drug exposure to penicillin, D-penicillamine,[70] or isoniazid. It has been associated with α_1-antitrypsin deficiency, complement deficiency (C3, C4), sarcoidosis, syphilis, systemic lupus erythematosus, systemic amyloidosis, cutaneous mastocytosis,[71] and multiple myeloma.

Acquired CL is one of the primary presenting features of hereditary gelsolin amyloidosis (AGel amyloidosis), an AD condition resulting from mutations in gelsolin, an actin-modulating protein. Cleavage of the mutant protein creates amyloidogenic protein fragments, which accumulate into amyloid fibrils and are deposited in most tissues. While normal at birth, CL develops with age, initially involving eyelid and scalp skin, but eventually becoming more widespread. Patients also note dry skin, pruritus, and fissuring, as well as loss of hair. Petechiae and ecchymoses are also common. Noncutaneous findings includes corneal lattice dystrophy, as well as cranial and peripheral polyneuropathy. Skin biopsy reveals elastic fiber diminution and fragmentation, as well as widespread deposition of AGel amyloid, including around elastic fibers. How this leads to destruction of the elastic fibers over time is unknown.[72]

A transient form of neonatal CL with generalized skin laxity and inguinal hernias has been described in infants born to mothers who were administered D-penicillamine during pregnancy.[73,74] In these cases, the loose skin resolved during the first year of life.

TREATMENT

Although some forms of CL improve with time, others worsen with age. The physical sequelae of the more-severe forms of CL require a multidisciplinary approach to address complications. In addition to the physical complications associated with CL, it is important for the clinician to recognize that patients with CL often sustain significant psychological trauma because of their appearance. Intervention as appropriate or desired by the patient, addressing not only the physical aspects of the disease, but the psychological and emotional aspects as well, is critical.

Genetic testing should be undertaken to determine the underlying genetic defect where possible. Identification of a specific genetic defect can guide further testing and monitoring. Avoiding environmental exposures known to exacerbate CL-related changes (ultraviolet light for the skin or smoking for the lungs) is important. When appropriate, ongoing regular cardiac and pulmonary evaluations and monitoring are typical. In cases where cardiopulmonary failure occurs, appropriate drug and ventilatory support is managed by the appropriate specialties.

Plastic surgery has been somewhat successful in improving the physical appearance of some patients temporarily and is a reasonable consideration as vasculature and wound healing capability are normal.[75] Numerous procedures may be necessary. Herniations are typically repaired when clinically indicated.

Acquired CL is often recalcitrant to treatment. Dapsone is reported to control acute swelling, which may support a role for neutrophil elastase.[76] Botulinum toxin has been used to improve facial cosmesis.[77] Recently, rescue of elastin insufficiency in mice via introduction of the human elastin gene was described, suggesting a potential avenue for future molecular therapies.[34]

Lastly, a variety of resources exist to support CL patients and their families, including Cutis Laxa Internationale (www.cutislaxa.org).

BUSCHKE-OLLENDORFF SYNDROME

AT-A-GLANCE

- Autosomal dominant syndrome with an incidence of 1:20,000 people (OMIM: 166700).
- Mutations in *LEMD3* gene (OMIM: 607844).
- Cutaneous features include elastomas and collagenomas (dermatofibrosis lenticularis disseminata).
- Extracutaneous manifestations include osteopoikilosis, which may be mistaken for malignancy.
- No serious systemic sequelae.

Buschke and Ollendorff originally reported the association of connective tissue nevi and osteopoikilosis.[78]

EPIDEMIOLOGY

The disorder is inherited in an AD manner with variable expressivity, but usually complete penetrance. The estimated incidence is 1:20,000 people.[79]

CLINICAL FEATURES

CUTANEOUS FINDINGS

Characteristic connective tissue nevi appear as collections of skin-colored to yellow papules or plaques (dermatofibrosis lenticularis disseminata) most commonly located on the buttocks, proximal trunk, and limbs. Many patients begin to develop lesions in early childhood, although later onset and emergence of new lesions while others disappear also have been reported. Histopathologic examination of lesional skin may show increased amounts of elastic tissue (elastoma) or collagen, although decreased or normal amounts of elastic tissue and abnormalities of collagen also have been described.

NONCUTANEOUS FINDINGS

The bony lesions most frequently appear after 15 years of age. They are discrete spherical areas of increased radiodensity, most frequently noted in the epiphyses and metaphyses of long bone, pelvis, scapulae, carpal, and tarsal bones. The radiographic appearance of the lesions may raise concerns for neoplasia. Although the osteopoikilosis is typically asymptomatic, functional limitation as a consequence of decreased mobility of an affected cutaneous area has been reported. Other skeletal abnormalities, including short stature, otosclerosis, and supernumerary vertebrae and ribs have been described. Cataracts and peptic ulcer disease have rarely been reported in patients with Buschke-Ollendorff syndrome.

COMPLICATIONS

No complications from Buschke-Ollendorff syndrome have been reported.

ETIOLOGY AND PATHOGENESIS

Buschke-Ollendorff syndrome results from loss-of-function mutations in the *LEMD3* gene (also called *MAN1*). *LEMD3* appears to antagonize both bone morphogenetic protein and TGF-β signaling pathways in human cell lines; consequently, loss of *LEMD3* leads to enhanced TGF-β signaling. Defects in *LEMD3* also have been detected in cases of both isolated osteopoikilosis and osteopoikilosis with melorheostosis ("flowing" hyperostosis over the cortex of tubular bones), but not in cases of sporadic isolated melorheostosis.[80]

DIAGNOSIS

The diagnosis of Buschke-Ollendorff syndrome is primarily based on clinical suspicion or the detection of characteristic bony abnormalities on radiography.

DIFFERENTIAL DIAGNOSIS

Connective tissue nevi without associated bony changes, morphea, and PXE are the most frequent disorders considered in the differential diagnosis.

CLINICAL COURSE AND PROGNOSIS

No interventions are typically necessary apart from informing the patient of the suspected diagnosis and the associated bony findings.

MANAGEMENT

No therapy is available or necessary.

LIPOID PROTEINOSIS

AT-A-GLANCE

- Rare worldwide, with the greatest incidence (1 in 300 population) in the Namaqualand region of South Africa.
- Autosomal recessive disorder with variable phenotype, even within families.
- Caused by defects in extracellular matrix protein-1 (ECM-1; OMIM: 602201).
- Hoarseness is the most frequent finding, occurring from infancy.
- Skin fragility and blistering occur in some affected children; blisters heal as infiltrated lesions with scar-like appearance.
- Progressive development of infiltrated papules and plaques is seen, as well as verrucous hyperkeratotic lesions, especially on the elbows and extensor aspects of the arms and lower legs.

(Continued)

AT-A-GLANCE (*Continued*)

- Beaded papules on the eyelid margin (moniliform blepharosis) are a classic finding in adolescents and adults, but are not always present.
- Calcification of the temporal lobes and amygdala may lead to neurologic and/or psychiatric symptoms such as epilepsy, neuropsychiatric disorders, and spontaneous CNS hemorrhage.
- Upper airway infiltration can lead to airway compromise.
- Periodic acid–Schiff–positive, diastase-resistant thickening is seen at the dermal–epidermal junction, perivascularly, and along adnexal epithelia with hyaline material in the dermis.
- Electron microscopy reveals deposited dermal material and excess basement membrane material around blood vessels with irregular duplication of the lamina densa at the dermal–epidermal junction.
- No effective treatment exists. Laser ablation/dermabrasion of papules is helpful in some cases.

EPIDEMIOLOGY

Lipoid proteinosis (LP) is also known as *hyalinosis cutis et mucosae* or Urbach-Wiethe disease (OMIM: 247100). Fewer than 500 cases have been reported worldwide. However, it is relatively common in the Namaqualand area of Northern Cape Province in South Africa (frequency of 1 in 300 population). As of this writing, all South African LP patients studied have carried the same mutation (*Q276X*), likely contributed by a German settler who arrived in 1652 (founder effect).[81]

CLINICAL FEATURES

The most reliable clinical signs for diagnosing LP are a hoarse voice and thickened sublingual frenulum, which prevents patients from protruding the tongue. Secondary features include beaded eyelid papules, infiltration of warty papules of the skin around the elbows and extensor forearms, and mild alopecia. Increased scarring and photoaging of sun-exposed skin may be seen. Scars or scar-like lesions are present in areas of minor trauma but are not increased at sites of surgery or vaccination. Figure 72-11 is an algorithm outlining an approach to the patient with suspected LP.

CUTANEOUS LESIONS

The phenotypic features of LP are quite variable, even within families. This is well demonstrated in studies of South African patients, all of whom share the same mutation yet exhibit highly variable phenotypes. The variable expressivity can lead to difficulty in diagnosis

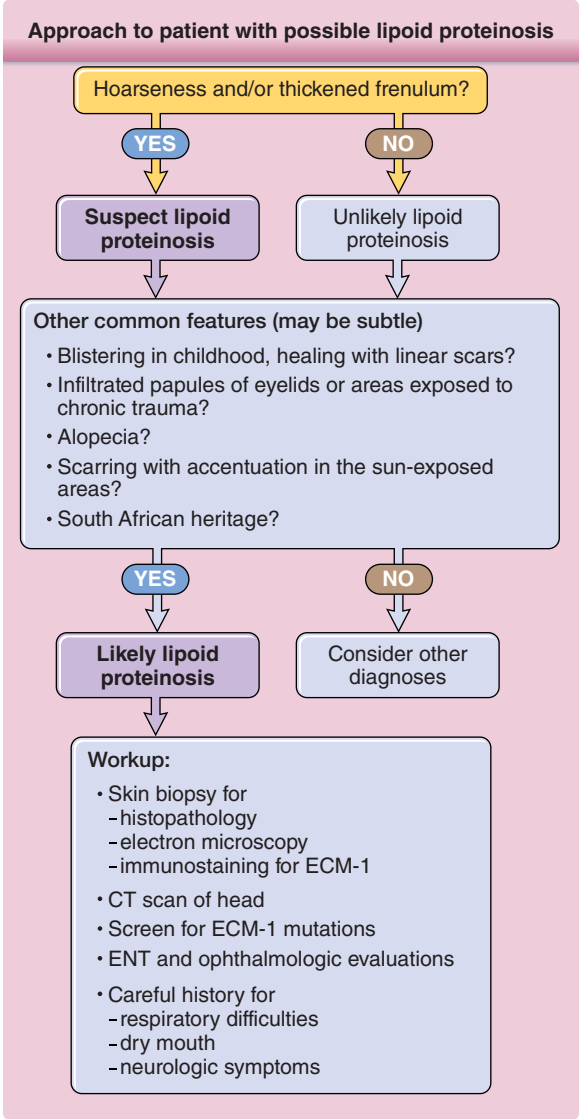

Figure 72-11 Approach to the patient with possible lipoid proteinosis. ECM-1, extracellular matrix protein-1; ENT, ear, nose, and throat.

of affected patients. The earliest finding in LP is hoarseness from vocal cord infiltration, which occurs at birth or in the first few years of life. Initially, this may be noted as a faint or weak cry and is one of the most striking and consistent features. Hoarseness may progress during the lifetime of a patient. Dysphagia may occur from involvement of the upper aerodigestive tract and esophagus.[82] Skin lesions usually develop in the first years of life, although the timing of their onset is variable.

Importantly, 2 stages of skin lesions may be noted. An underappreciated clinical feature of LP is erosions that can develop during childhood in up to 50% of patients. Blistering can be extensive enough to mimic epidermolysis bullosa. The associated vesicles (and rarely bullae) are typically noninflammatory and heal slowly with hemorrhagic crusting and resultant scarring (Fig. 72-12). Scars may be linear and resemble

Figure 72-12 Lipoid proteinosis. **A,** Early bullous lesion with typical hemorrhagic crust. **B,** Healing with scarring. (From Dyer JA, Yu QC, Paller AS. "Free-floating" desmosomes in lipoid proteinosis: an inherent defect in keratinocyte adhesion? *Pediatr Dermatol.* 2006;23:1, with permission. Copyright © 2006 John Wiley & Sons.)

pseudoporphyria on the face. In some patients, blistering is worse during warmer weather. Skin fragility and easy wounding with minor trauma or friction are noted. Spontaneous development of extrafacial pustular lesions also has been noted. Shedding of sheets of skin, which leaves red oozing areas, also has been described.

The skin lesions of the second stage are better recognized. Although beaded papules along the eyelid margins (moniliform blepharosis; Fig. 72-13) are considered a pathognomonic clinical finding, they are variable and may be subtle. Other cutaneous stigmata include generalized skin thickening with a waxy, yellow appearance and areas of distinct papules and nodules. Areas subject to repeated friction or trauma, such as the elbows, halluces, and extensor aspects of the arms and lower legs, may develop overlying hyperkeratosis, which may be quite striking and verrucous.

Figure 72-13 Lipoid proteinosis. Beaded papules along margin of the eyelids (moniliform blepharosis). Note increased severity of yellowish, waxy lesions in sun-exposed areas. (Used with permission from O. Braun-Falco, Munich.)

The scarring usually begins during childhood and is often worst on the face. It may follow trauma or occur spontaneously, yet no tendency to excessive scarring is noted after surgery or vaccination. Pock-like and acneiform scarring are well described in LP, especially on the face and extremities. Some areas may resemble solar elastosis. Flexural lichenification also may be seen, and patients with LP have been misdiagnosed as having atopic dermatitis. Some patients report increased photosensitivity, and, in some patients, sun-exposed areas exhibit the greatest amount of scarring. Significant pruritus, alterations in the ability to sweat, and abnormal pain sensation have been noted. Alopecia may occur, although it is variable in severity. Nails are normal.

RELATED PHYSICAL FINDINGS

The mucosa of patients with LP exhibit infiltration and thickening. Early in life, oral erosions may be noted and these may persist.[83] Thickening of the lingual frenulum leads to inability to protrude the tongue (Fig. 72-14). The pharynx, tongue, soft palate, tonsils, and lips are typically involved and loss of the tongue papillae resulting in a smooth surface may occur. Laryngeal and pharyngeal involvement may be severe enough to trigger respiratory difficulty, and tracheostomy has been required in rare cases. Shortness of breath or worsening of respiratory difficulties, as well as swelling of the salivary glands (submandibular and parotid), may be triggered by upper respiratory tract infections. Xerostomia and dental caries may be seen.[84] Dental abnormalities (absent permanent upper lateral incisors) also have been described. Parotitis from infiltration of the Stenson duct and subsequent blockage can occur.

CNS involvement is a well-recognized, but variable, feature of LP. Amygdala dysfunction has been described, which leads to abnormal perception and

Figure 72-14 Restricted mobility of the tongue as a result of infiltration of the frenulum is seen in most patients with lipoid proteinosis. Note discoloration of the lips as well. (Used with permission from O. Braun-Falco, Munich.)

appraisal of fear. More recent studies have demonstrated subtle differences between LP patients and normal controls in the judgment of facial expression and emotion, in memory for negative and positive pictures, and in odor-figure association tests. Because of the frequent bilateral amygdala damage, LP has been used as a model disorder for investigation of the function of the amygdala. Neurologic and psychiatric findings include seizures (often temporal lobe), memory deficits, social and behavioral changes, paranoid symptoms, mental retardation, and aggressiveness. Severe generalized dystonia also has been reported.[85] Calcification of the temporal lobes in the region of the amygdala or hippocampi may be detected on brain imaging. Spontaneous hemorrhage in the CNS may also occur.[82]

The ocular examination may reveal drusen-like fundal lesions. Eyelid infiltration may induce corneal ulcers caused by abnormal eyelash positioning, and alopecia of the eyebrows and eyelashes can occur. The abnormal deposition of hyaline material has been detected histopathologically in many internal organs, although this is typically asymptomatic.

ETIOLOGY AND PATHOGENESIS

LP is inherited in an AR fashion and is caused by mutations in the gene encoding ECM-1 (OMIM: 602201). Although given this name because of its discovery among various connective tissue proteins in a murine stromal cell line, ECM-1 likely has broader functions. ECM-1 is known to inhibit bone mineralization, contribute to epidermal differentiation, and stimulate angiogenesis.[86]

The *ECM1* gene is located next to the epidermal differentiation complex on chromosome band 1q21. ECM-1 is present both in the epidermis and as a secreted protein in the dermis. There are 4 splice variants: ECM-1a is encoded by the full gene, ECM-1b lacks exon 7, ECM-1c contains an additional exon 5a, and a fourth form shows truncation of 57 amino acids.[86] ECM-1a is widely expressed, whereas ECM-1b is expressed only in tonsils, keratinocytes, and the upper respiratory tract. ECM-1c is also expressed in the skin.

ECM-1 appears to have several functions. In the skin, it interacts with several ECM proteins, including perlecan (a heparin sulfate proteoglycan present in basement membranes), fibulin 1C, fibulin 1D, fibulin 3, matrix metalloproteinase 9, fibronectin, the β_3 chain of laminin 332, and collagen Type IV. ECM-1 may well serve as a "binding core" for cutaneous extracellular and basement membrane proteins.[87] The second tandem repeat of ECM-1, encoded by exon 7, binds fibulin-1, an extracellular component of most basement membranes. Thus, ECM-1a binds to fibulin, whereas ECM-1b, lacking exon 7, does not.[87] Whereas ECM-1a is expressed in basal keratinocytes, ECM-1b is only expressed in terminally differentiated keratinocytes. Given the differential expression of ECM-1 isoforms in skin, the ability to bind fibulin-1 may be important in keratinocyte differentiation. A report describing ultrastructural evidence of desmosomal detachment in cultured keratinocytes from a pediatric patient with the vesicular lesions of LP suggests a role in normal differentiation as well.[88] A recent report in mice found no epidermal alteration in association with overexpression or underexpression of ECM-1, arguing against a role in epidermal differentiation in murine systems, but the relevance for human skin is unclear. Both ECM-1a and ECM-1b may stimulate blood vessel endothelial cell proliferation and promote angiogenesis in chicken embryo. Abnormalities of the cutaneous vasculature are described in LP.[89]

Mutations in *ECM1* in LP lead to loss-of-function of ECM-1. The majority of mutations occur in exon 7, with frameshift mutations leading to ablation of the ECM-1a transcript but not that of ECM-1b, which typically lacks exon 7. Mutations outside of exon 7 typically occur in exon 6 and are nonsense or frameshift mutations. Patients with exon 7 mutations may have a slightly milder phenotype than those with non–exon 7 mutations with regard to respiratory and skin (but not neurologic) manifestations.

Antibodies to ECM-1 have been detected in adult patients with lichen sclerosus (see Chap. 64).[90]

LABORATORY INVESTIGATION

Light microscopic evaluation of lesional sections reveals deposition of amorphous eosinophilic material at the dermal–epidermal junction, perivascularly, and along adnexal epithelia. There is deposition of hyaline material in the dermis, often perpendicular to the basement membrane (Fig. 72-15). The hyaline material is periodic acid–Schiff positive and diastase resistant, with a composition similar to that of basement membrane. Often arranged in concentric, "onion-skin"

Figure 72-15 Extensive deposition of periodic acid–Schiff–positive, diastase-resistant hyaline material in the dermis of a scar-like lesion of lipoid proteinosis.

layers around vessels, these layers include Type III and Type IV collagen, as well as laminin. Electron microscopy reveals irregular duplication of the lamina densa at the dermal–epidermal junction. Cytoplasmic vacuoles are noted in dermal fibroblasts.[91] The presence of lipids varies and is considered a secondary phenomenon that results from lipid adherence to glycoproteins present in the hyaline material rather than a primary defect of LP.

The histologic features of the early bullous lesions of LP have only recently been described. Acantholysis of keratinocytes apparently is the cause.[92] Electron microscopy suggests an abnormality of desmosomal attachment, with "free-floating" desmosomes noted in bullous lesions. These preliminary findings require confirmation; but are intriguing given the pattern of expression of ECM-1 in the epidermis.[88]

Three-dimensional analysis of the cutaneous vasculature in LP shows enlarged vessels in the mid- and deep dermis with an orientation parallel to the dermal–epidermal junction. The dermal papillary plexus also lacks capillary loops. As in lichen sclerosus, the subcutaneous plexus and transverse connecting vessels are atretic or poorly formed.[89] Such vascular abnormalities may reflect a disturbance of ECM-1 function during angiogenesis.

SPECIAL TESTS

CT scans of the brain reveal bilateral anterior medial temporal lobe calcifications, often bean-shaped, and especially within the amygdala, in 50-75% of LP patients.[82,93]

Histopathologic evaluation of these lesions shows amorphous masses of calcium and bone along with multiple haphazardly arranged small blood vessels with wall calcification and gliotic adjacent tissue. The cortex and white matter show isolated blood vessels occluded by fibrin, parietal calcification, small perivascular infarctions, and demyelination.[93] Immunohistochemical staining of skin biopsy specimens may show absence or attenuation of ECM-1. This may prove to be a valid diagnostic test, not only to aid in diagnosis in mild cases but also potentially to direct molecular investigations.[94]

DIFFERENTIAL DIAGNOSIS

Table 72-10 outlines the differential diagnosis of LP.

PROGNOSIS AND CLINICAL COURSE

The prognosis of LP is variable. Often, there is progressive worsening of cutaneous features, with clearance during childhood of blistering lesions and progressive development of infiltrative lesions. The hoarseness and mucosal lesions also may progress with time. Although some patients have experienced respiratory complications from upper respiratory tract infiltration that have, in rare cases, led to early mortality, most patients have a normal life span. It is important to recognize the impact of LP on the quality of life of affected patients. The disfiguring nature of the skin lesions, along with the abnormal voice, significantly impacts

TABLE 72-10
Differential Diagnosis of Lipoid Proteinosis

Clinical

Most Likely

- Erythropoietic protoporphyria (EPP) or pseudoporphyria (clinically and histologically)—in EPP most changes are in sun-exposed areas, whereas in lipoid proteinosis they are present in non–sun-exposed sites as well; EPP has no beading of the eyelids
- Variegate porphyria—especially in South Africa
- Epidermolysis bullosa—hoarseness with blistering (infancy)
- Impetigo—childhood blisters and erosions

Consider

- Scarring from acne
- Scleromyxedema
- Amyloidosis
- Residual lichenification from atopic dermatitis

Histopathologic

- Erythropoietic protoporphyria
- Diabetic microangiopathy
- Amyloidosis
- Lichen sclerosus

the interactions of LP patients with others. Patients have increased difficulty in holding jobs.[81]

TREATMENT

Many agents, including topical and systemic corticosteroids, oral dimethyl sulfoxide,[95] and intralesional heparin, have been investigated and used in the treatment of LP. None of these agents has demonstrated any sustained benefits. Improvement of various aspects of LP following treatment with acitretin is described in individual case reports.[96,97] Given the apparent photoexacerbation of lesions in a subset of LP patients, photoprotection is reasonable, although there are no data confirming benefit. Additionally, avoidance of friction or trauma may be helpful given the prominence of lesions on frequently traumatized sites. Early intervention for developmental problems is important, and management of other stigmata by the appropriate specialists is warranted. Various surgical modalities, such as dermabrasion and CO_2 laser procedures, have been used to treat cutaneous lesions. CO_2 laser surgery for vocal cord lesions and eyelid papules has been helpful. Microlaryngoscopic excision of laryngeal lesions has improved voice quality and airway access in some patients. Seizures and other neurologic complications should be managed by a neurologist.[82]

PREVENTION

Prenatal genetic testing in families at risk is theoretically possible using DNA-based analysis.

REFERENCES

1. Malfait F, Francomano C, Byers P, et al. The 2017 international classification of the Ehlers-Danlos syndromes. *Am J Med Genet C Semin Med Genet.* 2017;175(1):8-26.
2. Byers PH, Belmont J, Black J, et al. Diagnosis, natural history, and management in vascular Ehlers-Danlos syndrome. *Am J Med Genet C Semin Med Genet.* 2017; 175(1):40-47.
3. Remvig L, Duhn PH, Ullman S, et al. Skin extensibility and consistency in patients with Ehlers-Danlos syndrome and benign joint hypermobility syndrome. *Scand J Rheumatol.* 2009;38(3):227-230.
4. Machet L, Huttenberger B, Georgesco G, et al. Absence of inferior labial and lingual frenula in Ehlers-Danlos syndrome: a minor diagnostic criterion in French patients. *Am J Clin Dermatol.* 2010;11(4):269-273.
5. Ramos-E-Silva M, Libia Cardozo Pereira A, Bastos Oliveira G, et al. Connective tissue diseases: pseudoxanthoma elasticum, anetoderma, and Ehlers-Danlos syndrome in pregnancy. *Clin Dermatol.* 2006; 24(2):91-96.
6. Wenstrup RJ, Meyer RA, Lyle JS, et al. Prevalence of aortic root dilation in the Ehlers-Danlos syndrome. *Genet Med.* 2002;4(3):112-117.
7. Brady AF, Demirdas S, Fournel-Gigleux S, et al. The Ehlers-Danlos syndromes, rare types. *Am J Med Genet C Semin Med Genet.* 2017;175(1):70-115.
8. Malfait F, Symoens S, De Backer J, et al. Three arginine to cysteine substitutions in the pro-alpha (I)-collagen chain cause Ehlers-Danlos syndrome with a propensity to arterial rupture in early adulthood. *Hum Mutat.* 2007;28(4):387-395.
9. Bowen JM, Sobey GJ, Burrows NP, et al. Ehlers-Danlos syndrome, classical type. *Am J Med Genet C Semin Med Genet.* 2017;175(1):27-39.
10. Burch GH, Gong Y, Liu W, et al. Tenascin-X deficiency is associated with Ehlers-Danlos syndrome. *Nat Genet.* 1997;17(1):104-108.
11. Tinkle B, Castori M, Berglund B, et al. Hypermobile Ehlers-Danlos syndrome (a.k.a. Ehlers-Danlos syndrome type III and Ehlers-Danlos syndrome hypermobility type): clinical description and natural history. *Am J Med Genet C Semin Med Genet.* 2017;175(1):48-69.
12. Symoens S, Malfait F, Renard M, et al. COL5A1 signal peptide mutations interfere with protein secretion and cause classic Ehlers-Danlos syndrome. *Hum Mutat.* 2009;30(2):E395-E403.
13. Mao JR, Bristow J. The Ehlers-Danlos syndrome: on beyond collagens. *J Clin Invest.* 2001;107(9):1063-1069.
14. Bradley TJ, Bowdin SC, Morel CF, et al. The expanding clinical spectrum of extracardiovascular and cardiovascular manifestations of heritable thoracic aortic aneurysm and dissection. *Can J Cardiol.* 2016;32(1):86-99.
15. Brooke BS, Arnaoutakis G, McDonnell NB, et al. Contemporary management of vascular complications associated with Ehlers-Danlos syndrome. *J Vasc Surg.* 2010;51(1):131-138; discussion 138-139.
16. Voermans NC, van Alfen N, Pillen S, et al. Neuromuscular involvement in various types of Ehlers-Danlos syndrome. *Ann Neurol.* 2009;65(6):687-697.
17. Pyeritz RE. The Marfan syndrome. *Annu Rev Med.* 2000;51:481-510.
18. Pearson GD, Devereux R, Loeys B, et al. Report of the National Heart, Lung, and Blood Institute and National Marfan Foundation Working Group on research in Marfan syndrome and related disorders. *Circulation.* 2008;118(7):785-791.
19. Rantamaki T, Kaitila I, Syvanen AC, et al. Recurrence of Marfan syndrome as a result of parental germ-line mosaicism for an FBN1 mutation. *Am J Hum Genet.* 1999;64(4):993-1001.
20. Dietz H. Marfan syndrome. In: Adam MP, Ardinger HH, Pagon RA, et al, eds. GeneReviews(R) [Internet]. Seattle (WA): University of Washington; 1993-2018. Last update: October 12, 2017. Available at https://www.ncbi.nlm.nih.gov/books/NBK1335/
21. Seliem MA, Duffy CE, Gidding SS, et al. Echocardiographic evaluation of the aortic root and mitral valve in children and adolescents with isolated pectus excavatum: comparison with Marfan patients. *Pediatr Cardiol.* 1992;13(1):20-23.
22. Liu LH, Lin SM, Lin DS, et al. Losartan in combination with propranolol slows the aortic root dilatation in neonatal Marfan syndrome. *Pediatr Neonatol.* 2018;59(2):211-213.
23. Faivre L, Masurel-Paulet A, Collod-Beroud G, et al. Clinical and molecular study of 320 children with Marfan syndrome and related type I fibrillinopathies in a series of 1009 probands with pathogenic FBN1 mutations. *Pediatrics.* 2009;123(1):391-398.
24. Kobayasi T. Dermal elastic fibres in the inherited hypermobile disorders. *J Dermatol Sci.* 2006;41(3):175-185.

25. Lindeman JH, Ashcroft BA, Beenakker JW, et al. Distinct defects in collagen microarchitecture underlie vessel-wall failure in advanced abdominal aneurysms and aneurysms in Marfan syndrome. *Proc Natl Acad Sci U S A.* 2010;107(2):862-865.
26. Robinson PN, Arteaga-Solis E, Baldock C, et al. The molecular genetics of Marfan syndrome and related disorders. *J Med Genet.* 2006;43(10):769-787.
27. Tan L, Li Z, Zhou C, et al. FBN1 mutations largely contribute to sporadic non-syndromic aortic dissection. *Hum Mol Genet.* 2017;26(24):4814-4822.
28. Ramirez F, Caescu C, Wondimu E, et al. Marfan syndrome; a connective tissue disease at the crossroads of mechanotransduction, TGFβ signaling and cell stemness. *Matrix Biol.* 2017 [Epub ahead of print].
29. Goumans MJ, Liu Z, ten Dijke P. TGF-beta signaling in vascular biology and dysfunction. *Cell Res.* 2009;19(1):116-127.
30. Mas-Stachurska A, Siegert AM, Batlle M, et al. Cardiovascular benefits of moderate exercise training in Marfan syndrome: insights from an animal model. *J Am Heart Assoc.* 2017;6(9).
31. de Waard V. Marfan on the move. *J Am Heart Assoc.* 2017;6(9).
32. Martin L, Maitre F, Bonicel P, et al. Heterozygosity for a single mutation in the ABCC6 gene may closely mimic PXE: consequences of this phenotype overlap for the definition of PXE. *Arch Dermatol.* 2008;144(3):301-306.
33. Uitto J, Jiang Q. Pseudoxanthoma elasticum-like phenotypes: more diseases than one. *J Invest Dermatol.* 2007;127(3):507-510.
34. Uitto J, Li Q, van de Wetering K, et al. Insights into pathomechanisms and treatment development in heritable ectopic mineralization disorders: summary of the PXE International Biennial Research Symposium-2016. *J Invest Dermatol*. 2017;137(4):790-795.
35. Kazakis AM, Parish WR. Periumbilical perforating pseudoxanthoma elasticum. *J Am Acad Dermatol.* 1988;19(2, pt 2):384-388.
36. Viljoen DL, Beatty S, Beighton P. The obstetric and gynaecological implications of pseudoxanthoma elasticum. *Br J Obstet Gynaecol.* 1987;94(9):884-888.
37. Lebwohl M, Phelps RG, Yannuzzi L, et al. Diagnosis of pseudoxanthoma elasticum by scar biopsy in patients without characteristic skin lesions. *N Engl J Med.* 1987;317(6):347-350.
38. Li TH, Tseng CR, Hsiao GH, et al. An unusual cutaneous manifestation of pseudoxanthoma elasticum mimicking reticulate pigmentary disorders. *Br J Dermatol.* 1996;134(6):1157-1159.
39. Georgalas I, Papaconstantinou D, Koutsandrea C, et al. Angioid streaks, clinical course, complications, and current therapeutic management. *Ther Clin Risk Manag.* 2009;5(1):81-89.
40. Nishida H, Endo M, Koyanagi H, et al. Coronary artery bypass in a 15-year-old girl with pseudoxanthoma elasticum. *Ann Thorac Surg.* 1990;49(3):483-485.
41. Le Saux O, Beck K, Sachsinger C, et al. Evidence for a founder effect for pseudoxanthoma elasticum in the Afrikaner population of South Africa. *Hum Genet.* 2002;111(4-5):331-338.
42. Zhao J, Kingman J, Sundberg JP, et al. Plasma PPi deficiency is the major, but not the exclusive, cause of ectopic mineralization in an abcc6−/− mouse model of PXE. *J Invest Dermatol.* 2017;137(11):2336-2343.
43. Aessopos A, Farmakis D, Loukopoulos D. Elastic tissue abnormalities resembling pseudoxanthoma elasticum in beta thalassemia and the sickling syndromes. *Blood.* 2002;99(1):30-35.
44. Becuwe C, Dalle S, Ronger-Savle S, et al. Elastosis perforans serpiginosa associated with pseudo-pseudoxanthoma elasticum during treatment of Wilson's disease with penicillamine. *Dermatology.* 2005;210(1):60-63.
45. Suarez MJ, Garcia JB, Orense M, et al. Sonographic aspects of pseudoxanthoma elasticum. *Pediatr Radiol.* 1991;21(7):538-539.
46. Coatesworth AP, Darnton SJ, Green RM, et al. A case of systemic pseudo-pseudoxanthoma elasticum with diverse symptomatology caused by long-term penicillamine use. *J Clin Pathol.* 1998;51(2):169-171.
47. Lewis KG, Lester BW, Pan TD, et al. Nephrogenic fibrosing dermopathy and calciphylaxis with pseudoxanthoma elasticum-like changes. *J Cutan Pathol.* 2006;33(10):695-700.
48. Viljoen DL, Bloch C, Beighton P. Plastic surgery in pseudoxanthoma elasticum: experience in nine patients. *Plast Reconstr Surg.* 1990;85(2):233-238.
49. Cunningham JR, Lippman SM, Renie WA, et al. Pseudoxanthoma elasticum: treatment of gastrointestinal hemorrhage by arterial embolization and observations on autosomal dominant inheritance. *Johns Hopkins Med J.* 1980;147(4):168-173.
50. Browning AC, Chung AK, Ghanchi F, et al. Verteporfin photodynamic therapy of choroidal neovascularization in angioid streaks: one-year results of a prospective case series. *Ophthalmology.* 2005;112(7):1227-1231.
51. Sherer DW, Singer G, Uribarri J, et al. Oral phosphate binders in the treatment of pseudoxanthoma elasticum. *J Am Acad Dermatol.* 2005;53(4):610-615.
52. Takata T, Ikeda M, Kodama H, et al. Treatment of pseudoxanthoma elasticum with tocopherol acetate and ascorbic acid. *Pediatr Dermatol.* 2007;24(4):424-425.
53. LaRusso J, Li Q, Jiang Q, et al. Elevated dietary magnesium prevents connective tissue mineralization in a mouse model of pseudoxanthoma elasticum (Abcc6(−/−)). *J Invest Dermatol.* 2009;129(6):1388-1394.
54. Morava E, Lefeber DJ, Urban Z, et al. Defining the phenotype in an autosomal recessive cutis laxa syndrome with a combined congenital defect of glycosylation. *Eur J Hum Genet.* 2008;16(1):28-35.
55. Kozel BA, Su CT, Danback JR, et al. Biomechanical properties of the skin in cutis laxa. *J Invest Dermatol.* 2014;134(11):2836-2838.
56. Kariminejad A, Afroozan F, Bozorgmehr B, et al. Discriminative features in three autosomal recessive cutis laxa syndromes: cutis laxa IIa, cutis laxa IIb, and geroderma osteoplastica. *Int J Mol Sci.* 2017;18(3). pii: E635.
57. Van Damme T, Gardeitchik T, Mohamed M, et al. Mutations in ATP6V1E1 or ATP6V1A cause autosomal-recessive cutis laxa. *Am J Hum Genet.* 2017;100(2):216-227.
58. Vanakker O, Callewaert B, Malfait F, et al. The genetics of soft connective tissue disorders. *Annu Rev Genomics Hum Genet.* 2015;16:229-255.
59. Hu Q, Reymond JL, Pinel N, et al. Inflammatory destruction of elastic fibers in acquired cutis laxa is associated with missense alleles in the elastin and fibulin-5 genes. *J Invest Dermatol.* 2006;126(2):283-290.
60. Baldwin AK, Simpson A, Steer R, et al. Elastic fibres in health and disease. *Expert Rev Mol Med.* 2013;15:e8.
61. Markova D, Zou Y, Ringpfeil F, et al. Genetic heterogeneity of cutis laxa: a heterozygous tandem duplication within the fibulin-5 (*FBLN5*) gene. *Am J Hum Genet.* 2003;72(4):998-1004.

62. Wu X, Steet RA, Bohorov O, et al. Mutation of the COG complex subunit gene COG7 causes a lethal congenital disorder. *Nat Med.* 2004;10(5):518-523.
63. Hennies HC, Kornak U, Zhang H, et al. Gerodermia osteodysplastica is caused by mutations in SCYL1BP1, a Rab-6 interacting golgin. *Nat Genet.* 2008;40(12):1410-1412.
64. Fischer-Zirnsak B, Escande-Beillard N, Ganesh J, et al. Recurrent de novo mutations affecting residue Arg138 of pyrroline-5-carboxylate synthase cause a progeroid form of autosomal-dominant cutis laxa. *Am J Hum Genet.* 2015;97(3):483-492.
65. De Vilder EY, Debacker J, Vanakker OM. GGCX-associated phenotypes: an overview in search of genotype-phenotype correlations. *Int J Mol Sci.* 2017;18(2).
66. Bangsgaard N, Marckmann P, Rossen K, et al. Nephrogenic systemic fibrosis: late skin manifestations. *Arch Dermatol.* 2009;145(2):183-187.
67. Lewis KG, Bercovitch L, Dill SW, et al. Acquired disorders of elastic tissue: part II. Decreased elastic tissue. *J Am Acad Dermatol.* 2004;51(2):165-185; quiz 186-188.
68. Haider M, Alfadley A, Kadry R, et al. Acquired cutis laxa type II (Marshall syndrome) in an 18-month-old child: a case report. *Pediatr Dermatol.* 2010;27(1):89-91.
69. Muster AJ, Bharati S, Herman JJ, et al. Fatal cardiovascular disease and cutis laxa following acute febrile neutrophilic dermatosis. *J Pediatr.* 1983;102(2):243-248.
70. Hill VA, Seymour CA, Mortimer PS. Penicillamine-induced elastosis perforans serpiginosa and cutis laxa in Wilson's disease. *Br J Dermatol.* 2000;142(3):560-561.
71. Mahajan VK, Sharma NL, Garg G. Cutis laxa acquisita associated with cutaneous mastocytosis. *Int J Dermatol.* 2006;45(8):949-951.
72. Kiuru-Enari S, Keski-Oja J, Haltia M. Cutis laxa in hereditary gelsolin amyloidosis. *Br J Dermatol.* 2005; 152(2):250-257.
73. Linares A, Zarranz JJ, Rodriguez-Alarcon J, et al. Reversible cutis laxa due to maternal D-penicillamine treatment. *Lancet.* 1979;2(8132):43.
74. Solomon L, Abrams G, Dinner M, et al. Neonatal abnormalities associated with D-penicillamine treatment during pregnancy. *N Engl J Med.* 1977;296(1): 54-55.
75. Nahas FX, Sterman S, Gemperli R, et al. The role of plastic surgery in congenital cutis laxa: a 10-year follow-up. *Plast Reconstr Surg.* 1999;104(4):1174-1178; discussion 1179.
76. Fisher BK, Page E, Hanna W. Acral localized acquired cutis laxa. *J Am Acad Dermatol.* 1989;21(1):33-40.
77. Tamura BM, Lourenco LM, Platt A, et al. Cutis laxa: Improvement of facial aesthetics by using botulinum toxin. *Dermatol Surg.* 2004;30(12, pt 2):1518-1520.
78. Gass JK, Hellemans J, Mortier G, et al. Buschke-Ollendorff syndrome: a manifestation of a heterozygous nonsense mutation in the LEMD3 gene. *J Am Acad Dermatol.* 2008;58(5)(suppl 1):S103-S104.
79. Schena D, Germi L, Zamperetti MR, et al. Buschke-Ollendorff syndrome. *Int J Dermatol.* 2008;47(11): 1159-1161.
80. Hellemans J, Preobrazhenska O, Willaert A, et al. Loss-of-function mutations in LEMD3 result in osteopoikilosis, Buschke-Ollendorff syndrome and melorheostosis. *Nat Genet.* 2004;36(11):1213-1218.
81. Van Hougenhouck-Tulleken W, Chan I, Hamada T, et al. Clinical and molecular characterization of lipoid proteinosis in Namaqualand, South Africa. *Br J Dermatol.* 2004;151(2):413-423.
82. Vahidnezhad H, Youssefian L, Uitto J. Lipoid proteinosis. In: Adam MP, Ardinger HH, Pagon RA, et al, eds. GeneReviews(R). Seattle (WA): University of Washington.; 1993-2018. Initially posted: January 21, 2016. Available at https://www.ncbi.nlm.nih.gov/books/NBK338540/
83. Sargenti Neto S, Batista JD, Durighetto AF Jr. A case of oral recurrent ulcerative lesions in a patient with lipoid proteinosis (Urbach-Wiethe disease). *Br J Oral Maxillofac Surg.* 2010;48(8):654-655.
84. Cote DN. Head and neck manifestations of lipoid proteinosis. *Otolaryngol Head Neck Surg.* 1998;119(1): 144-145.
85. Siebert M, Markowitsch HJ, Bartel P. Amygdala, affect and cognition: evidence from 10 patients with Urbach-Wiethe disease. *Brain.* 2003;126(pt 12):2627-2637.
86. Hamada T, Wessagowit V, South AP, et al. Extracellular matrix protein 1 gene (ECM1) mutations in lipoid proteinosis and genotype-phenotype correlation. *J Invest Dermatol.* 2003;120(3):345-350.
87. Sercu S, Lambeir AM, Steenackers E, et al. ECM1 interacts with fibulin-3 and the beta 3 chain of laminin 332 through its serum albumin subdomain-like 2 domain. *Matrix Biol.* 2009;28(3):160-169.
88. Dyer JA, Yu QC, Paller AS. "Free-floating" desmosomes in lipoid proteinosis: an inherent defect in keratinocyte adhesion? *Pediatr Dermatol.* 2006;23(1):1-6.
89. Kowalewski C, Kozlowska A, Chan I, et al. Three-dimensional imaging reveals major changes in skin microvasculature in lipoid proteinosis and lichen sclerosus. *J Dermatol Sci.* 2005;38(3):215-224.
90. Oyama N, Chan I, Neill SM, et al. Autoantibodies to extracellular matrix protein 1 in lichen sclerosus. *Lancet.* 2003;362(9378):118-123.
91. Paller AS. Histology of lipoid proteinosis. *JAMA.* 1994; 272(7):564-565.
92. Ko C, Barr RJ. Vesicular lesions in a patient with lipoid proteinosis: a probable acantholytic dermatosis. *Am J Dermatopathol.* 2003;25(4):335-337.
93. Teive HA, Pereira ER, Zavala JA, et al. Generalized dystonia and striatal calcifications with lipoid proteinosis. *Neurology.* 2004;63(11):2168-2169.
94. Chan I, South AP, McGrath JA, et al. Rapid diagnosis of lipoid proteinosis using an anti-extracellular matrix protein 1 (ECM1) antibody. *J Dermatol Sci.* 2004;35(2):151-153.
95. Ozkaya-Bayazit E, Ozarmagan G, Baykal C, et al. Oral DMSO therapy in 3 patients with lipoidproteinosis. Results of long-term therapy [in German]. *Hautarzt.* 1997;48(7):477-481.
96. Carnevale C, Castiglia D, Diociaiuti A, et al. Lipoid proteinosis: a previously unrecognized mutation and therapeutic response to acitretin. *Acta Derm Venereol.* 2017;97(10):1249-1251.
97. Toosi S, Ehsani AH. Treatment of lipoid proteinosis with acitretin: a case report. *J Eur Acad Dermatol Venereol.* 2009;23(4):482-483.
98. Banne E, Meiner V, Shaag A, et al. Transaldolase deficiency: a new case expands the phenotypic spectrum. *JIMD Rep.* 2016;26:31-36.

This page intentionally left blank

Subcutaneous Tissue Disorders

PART 12

Chapter 73 :: Panniculitis

:: Eden Pappo Lake, Sophie M. Worobec, & Iris K. Aronson

Inflammation in subcutaneous fat (panniculitis) often poses a diagnostic problem as the clinical and histopathologic findings in the various inflammatory disorders of adipose tissue (AT) have overlapping features (Table 73-1). A useful histopathologic classification divides the panniculitides into "septal" and "lobular" (Table 73-2), although several diagnoses exhibit overlapping features.[1] This classification is expanded by noting the presence or absence of vasculitis,[2] and the composition of the inflammatory infiltrate (Table 73-1).

AT functions in energy storage and expenditure, appetite modulation, insulin sensitivity, endocrine and reproductive systems, bone metabolism, inflammation, and immunity.[3] Its origin is traced back to the invertebrate fat body, which has innate immune system, metabolic, and lipid, glycogen and protein storage functions. In the evolution of vertebrates these functions were divided up between the liver and AT with both retaining innate immune system functions.[4,5] The human adipocyte is equipped to protect the organism from pathogenic microbes by recognition of pathogen-associated molecular patterns via receptors called pattern recognition receptors (PRRs).[6] Toll-like receptors (TLRs) are a type of transmembrane PRR, expressed either on the plasma membrane where they detect cell-surface microbial patterns such as lipopolysaccharides of Gram-negative bacteria, or in endosomal/lysosomal organelles, where they recognize mainly microbial nucleic acids.[4,7] Secreted PRRs bind to the surface of microbes, activate the complement system, and opsonize microbes for phagocytosis.[7] Once activated, the PRRs activate proinflammatory signaling pathways, especially activation of transcription factors nuclear factor κB, interferon regulatory factor 3, or nuclear factor of activated T cells, that promote expression of genes involved in the immune response.[7,8] TLRs also trigger activation of adaptive immunity responses that include antibody responses, T-helper type 1, T-helper type 17 CD4+ T cell, CD8+ T-cell responses, and T-helper type 2 (via TLR4) and immunoglobulin E response.[7]

Adipocytes are the most abundant cells in white AT, but other cell types include pericytes, fibroblasts, endothelial cells, vascular smooth muscle cells and inflammatory cells, especially macrophages.[3,9] Macrophage-derived cytokines and chemokines, including tumor necrosis factor (TNF)-α, induce adipocyte lipolysis, which leads to release of free fatty acids from the adipocyte, which induces proinflammatory signaling.[10] This paracrine loop involving inflammatory cytokines and free fatty acids propagates inflammation.[11] AT also contains lymphocytes that contribute to AT inflammation.[5] Adipocytes interact with blood vessels, and bidirectional crosstalk between perivascular AT and blood vessels exists.[12] Perivascular AT secretes high levels of proinflammatory cytokines such as interleukin (IL)-6, IL-8, and monocyte chemotactic protein-1 compared to antiinflammatory adiponectin, when compared to other AT depots.[13] Adipocyte transmembrane PRRs and TLRs, and receptors for interaction with macrophages and lymphocytes, as well as production and secretion of multiple cytokines and adipokines reflect the role of the adipocyte in protecting the host from infectious disease and other environmental dangers.

TABLE 73-1
Summary of Different Types of Panniculitis

PANNICULITIS	AGE GROUPS	ASSOCIATED FACTORS	CLINICAL COURSE AND MANIFESTATIONS	HISTOPATHOLOGY	TREATMENT
Erythema nodosum	Young women, 2nd to 4th decades	Infections (commonly streptococcal), medications, malignancies (leukemias, lymphomas)	Acute onset; symmetric, tender, nodules & plaques Affecting anterior lower extremities Fever, fatigue, arthralgias, arthritis, headache, no ulceration, no atrophy, no scarring	Septal Panniculitis No vasculitis Neutrophils (early), Meischer granulomas (late)	Bed rest, aspirin, NSAIDs SSKI, 2-10 drops thrice daily Colchicine Corticosteroids (rarely indicated)
Erythema induratum	Young/middle-aged women	Venous insufficiency, obesity Infectious etiology: MTB, hepatitides B, C	Erythematous SQ nodules on lower extremities May affect calves, anterolateral leg Tenderness, ulceration, scarring Protracted course, with recurrent episodes 3-6 weeks duration	Lobular, often with vasculitis (90%). Early central necrosis of adipocytes; neutrophilic infiltrate In older lesions, epithelioid histiocytes, multinucleated giant cells	If MTB testing is positive, full course of multidrug therapy Treat underlying cause SSKI, NSAIDs, colchicine, antimalarials, corticosteroids, gold Bed rest Pentoxifylline, compression
Lipodermatosclerosis (sclerosing panniculitis, hypodermitis sclerodermiformis, chronic panniculitis with lipomembranous changes, sclerotic atrophic cellulitis, venous stasis panniculitis)	Overweight women older than 40 years	Venous insufficiency Obesity Systemic sclerosis Pulmonary Infarction Hypertension	Indurated, woody plaques on lower extremities, with acute & chronic changes (most commonly, anteromedial calf area) Intense pain is the most frequent symptom Stage: acute inflammatory Chronic fibrosis Inverted champagne bottle	Stasis changes Lobular panniculitis No vasculitis Ischemic necrosis at center Thickened, fibrotic septa, atrophy of subcutaneous fat Membranocystic changes	Compression therapy is the major recommended treatment (30-40 mm Hg) Stanozolol: to decrease pain, erythema, induration Pentoxifylline, horse chestnut seed extract, oxerutins, flavonoid fraction Weight loss
Infectious panniculitis	—	Wide variety of bacteria, fungi, parasites, viruses Either primarily inoculated, or hematogenous *Staphylococcus aureus* panniculitis with juvenile diabetes Panniculitis of mycetoma, chromoblastomycosis, sporotrichosis	Erythematous plaques, nodules, abscess with purulent discharge (fluctuant/abscess-type lesions) Most commonly on legs and feet Upper extremities, trunk, face may be involved	Mostly lobular panniculitis, but with a mixed pattern Pattern dependent on whether infection was inoculation related or hematogenous Neutrophilic infiltrate	Depends on the known organisms

α_1-Antitrypsin panniculitis	Most common in 30-60 years of age groups MM: most common phenotype (normal AAT) ZZ: 10%-15% of N levels; associated with >60% of cases	Pulmonary and hepatic disease (emphysema in COPD, cirrhosis, hepatocellular CA), highest risk ZZ phenotype Panniculitis uncommon in AAT deficiency	Painful erythematous nodules and plaques Cellulitis, fluctuant abscess type Most common site: lower trunk, also buttocks, proximal extremities May be life-threatening	Early necrosis of SQ fat Splaying of neutrophils between collagen bundles is characteristic Liquefactive necrosis	MILD-MODERATE: dapsone, doxycycline SEVERE: protein replacement therapy
Pancreatic panniculitis	Occurs in 2%-3% of patients with pancreatic disorders	Pancreatitis, pancreatic CA	Erythematous nodules with spontaneous ulceration Lower extremities, especially periarticular areas (knee, ankle) Crops of lesions; red-brown Atrophic, hyperpigmented scarring Oily abscesses	Lobular panniculitis No vasculitis Intense necrosis at center of lobule Ghost adipocytes Saponification and calcification	Octreotide Plasmapheresis
Lupus panniculitis	Females more frequently affected than males (4:1) 30-60 years old, also in childhood May occur before or after diagnosis of lupus erythematosus or discoid lupus erythematosus	Systemic lupus erythematosus Sjogren's Syndrome Rheumatoid arthritis	UPPER ARMS (lateral), shoulders, face, scalp, hips, buttocks, breasts Rare on lower extremities Deep, tender SQ nodules; no surface changes Resolves with depressed lipoatrophic areas Chronic, with yearly/periodic flares Duration: average of 6 years	Vacuolar alteration of basal cell layer, thickened basement membrane, mucin deposition, superficial and deep perivascular infiltrate Mostly lobular panniculitis, with lymphoid follicles, variable hyaline fat necrosis, sclerotic collagen bundles, lymphocytic and plasma cell infiltrate	Hydroxychloroquine is first-line treatment Quinacrine
Panniculitis with dermatomyositis	Very rare	Dermatomyositis	Erythematous nodules and plaques, affecting arms, buttocks, thighs, abdomen	Mixed septal and lobular panniculitis, lymphocytic and plasma cell infiltrate, hyaline sclerosis of septal collagen; calcification, membranocystic changes in late stages	Corticosteroids alone, or corticosteroids with methotrexate
Cytophagic histiocytic panniculitis	Rare; seen in adults, adolescents, and children	HLH MAS	SQ erythematous to violaceous plaques on extremities, trunk Fulminant cases may have: ulceration, fever, hepatosplenomegaly, hemocytophagocytosis in BM, LN, liver, CNS May be acute and intermittent, or have a rapidly fatal course	Lobular panniculitis No vasculitis Bean bag cells: macrophages with intact or fragmented erythrocytes, leukocytes, or platelets Necrosis	Corticosteroids Cyclosporine Multidisciplinary care in a hospital setting

(*Continued*)

TABLE 73-1
Summary of Different Types of Panniculitis (*Continued*)

PANNICULITIS	AGE GROUPS	ASSOCIATED FACTORS	CLINICAL COURSE AND MANIFESTATIONS	HISTOPATHOLOGY	TREATMENT
Subcutaneous fat necrosis of the newborn	Rare, first few weeks of life	History of perinatal complications (meconium aspiration, hypothermia, hypoxemia, gestational diabetes)	Erythematous to violaceous, firm nodules or plaques affecting buttocks, back, shoulders, cheeks, thighs Anterior trunk spared Oily/chalky white material Late hypercalcemia (monitor for 6 months)	Lobular panniculitis No vasculitis Needle-shaped clefts in radial array Nodules and plaques, resolving spontaneously	Spontaneous resolution Monitor serum calcium for hypercalcemia Systemic glucocorticoids may be considered; nephrocalcinosis
Cold panniculitis (Haxthausen disease)	Scrotal cold panniculitis in 9–14-year-old males	Exposure to cold weather, popsicles, ice packs, swimming	Indurate, erythematous plaques or nodules at sites of cold exposure; affects face, thighs, scrotal fat of prepubertal boys Resolution within 3 months	Lobular panniculitis No vasculitis Perivascular lymphohistiocytic infiltrate	Spontaneous resolution
Factitial panniculitis	—	Associated with personality aberrations	SQ implantation (medications, cosmetic fillers, oils, human waste)	Lobular panniculitis No vasculitis Suppurative granuloma involving fat lobule Refractile foreign material	Psychiatric treatment; Intralesional steroids, surgical excision

AAT, α_1-antitrypsin; BM, bone marrow; CA, cancer; COPD, chronic obstructive pulmonary disease; HLH, hemophagocytic lymphohistiocytosis; MAS, macrophage activation syndrome; MTB, *Mycobacterium tuberculosis*; NSAID, nonsteroidal antiinflammatory drug; SQ, subcutaneous; SSKI, saturated solution of potassium iodide.

TABLE 73-2
Differentiating Septal vs Lobular Panniculitis

	SEPTAL PANNICULITIS	LOBULAR PANNICULITIS
Origin of inflammation	Interlobular septa	Primarily the lobule or blood vessel
Appearance of lobule	Lobule appears intact, individual adipocytes well defined	Lobule is necrotic, lipophages common; free liquid may accumulate in pools of varying shapes
Necrosis	Absent	Common
Inflammatory cell	Neutrophils (acute) Mononuclear cells, multinucleated giant cells (chronic)	Lymphoid infiltrates Plasma cells are common
Vasculitis	Absent	May be present
Characteristic findings	Miescher granuloma	
Associated conditions	Erythema nodosum	Erythema induratum Lupus panniculitis Pancreatic panniculitis Lipodermatosclerosis α_1-Antitrypsin deficiency

ERYTHEMA NODOSUM

AT-A-GLANCE

Clinical

- Symmetric, tender, erythematous, nodules, and plaques on the anterior aspects of the lower extremities.
- Acute onset; no ulceration or scarring.
- Fever, fatigue, arthralgias, arthritis, headache are common.
- More common in women.
- Lasts from 3 to 6 weeks, with new lesions appearing for up to 6 weeks.

Histopathology

- Mostly septal panniculitis without vasculitis.
- Thickened, fibrotic septae with inflammatory cells.
- Neutrophils in early lesions.
- Histiocytes and Miescher granulomas in late-stage lesions.

Treatment

- Treatment of any associated disorder.
- Bed rest, aspirin, nonsteroidal antiinflammatory drugs.

Erythema nodosum (EN) is the prototypic septal panniculitis. It is a common panniculitis and multiple etiologies are associated with EN, although many cases are idiopathic. The frequency of EN caused by a single agent has changed greatly over the past century, and is influenced by geography and endemic disease.[14,15] Although the diagnosis is often clinical, the histopathology can be helpful, demonstrating septal inflammation and thickened and fibrotic septae. The clinical findings are usually self-limiting, but an underlying etiology must be investigated as associated diseases have significance for the patient.

EPIDEMIOLOGY

EN occurs in person of all ages, and most cases affect young women in the second to fourth decades of life.[15] Larger studies show more than 80% of EN patients are female, or a female-to-male ratio of 5:1.[16] However, in pediatric cases there is no gender difference.[17] Prevalence in England and Spain varies from 0.38% to 0.5% of patients seen in clinics.[18,19]

CLINICAL FEATURES

EN presents with tender, erythematous, warm nodules and plaques on the lower legs (see Fig. 73-1). The anterior lower legs and ankles are most commonly involved, but the forearms, upper legs, trunk, and even the face can be involved; with more atypical locations seen in children.[17,18] The nodules may become confluent and violaceous and bruise-like, termed *erythema contusiformis* when hemorrhage is present.[15] Ulceration and scarring are not seen.[15] EN may be associated with systemic symptoms of fever, malaise, fatigue, arthralgia, arthritis, headache, and, more rarely, abdominal pain, vomiting, diarrhea, or cough.[15,16] Upper respiratory tract infection precedes the onset of EN in 20% to 30% of cases.[16,18,19] Laboratory abnormalities frequently indicate the etiology; that is, a positive throat culture and leukocytosis in streptococcal infections.[20,21] A positive purified protein derivative suggests tuberculosis infection in endemic areas and high-risk individuals. An abnormal chest radiograph may be seen with either sarcoidosis or pulmonary infections.

Figure 73-1 Erythema nodosum. Erythematous nodules located mainly on the anterior lower legs.

ETIOLOGY AND PATHOGENESIS

ETIOLOGY

EN is associated with numerous etiologies (Table 73-3). The abundance of idiopathic cases of EN (37% to 60%) reported in large reviews,[17,22] reflects the difficulty of defining a specific causation of EN. Infections, medications, malignancies, autoimmune disease, and inflammatory disorders have all been documented to provoke the clinical findings of EN. Infectious causes include bacterial, viral, fungal, and protozoan, with streptococcal respiratory tract infections being the most common etiology in pediatric cases of EN.[16,17] Viral etiologies are difficult to diagnose and may confound idiopathic EN.[16] EN secondary to tuberculosis varies with higher rates seen in endemic areas but is rare in the United States and Europe.[16]

Common causative medications include antibiotics, oral contraceptives and other hormonal therapies, and nonsteroidal antiinflammatories.[16,23] More recent cases have suggested an association between EN and omeprazole use,[24] leukotriene inhibitors,[20] and vemurafenib.[25] The prevalence of oral contraceptive-induced EN has decreased since the introduction of low-dose estrogen therapy.[23] Malignancies related to EN most often include leukemias or lymphomas.[15] Sarcoidosis and inflammatory bowel disease are also known etiologies. Sarcoidosis-induced EN prevalence varies by geography and patient population but can be a cause of up to one-third of EN cases.[26] Temporal arteritis also has been noted to cause EN.[22]

PATHOGENESIS

The cutaneous findings of EN are considered to be a hypersensitivity reaction to the above etiologies. Other theories suggest immune complex deposition[27] and neutrophilic involvement.[28] Overall, the pathophysiologic mechanism is not understood. Early studies showed the presence of interferon-γ and IL-2, activation of leukocytes,[29] upregulation of various adhesion molecules,[30] and genetic polymorphisms in TNF-α promoter, macrophage migration inhibitory factor, or RANTES (regulated upon activation, normal T-cell expressed and secreted).[31-33]

AT can activate innate and adaptive immune responses to destroy pathogens.[34] Excessive adipocyte production and secretion of proinflammatory adipokines and adipocytokines is associated with obesity, cardiovascular disease, hypertension, and diabetes.[34] In contrast, EN is associated with a more limited coccidiomycosis infection[35] and with a less severe and shorter duration of sarcoidosis,[35,36] especially in those carrying the HLA-DRB1*03-positive leukocyte antigen.[37] Therefore, certain genetic mutations associated with enhanced inflammatory reactions may confer resistance to certain pathogens.[35,37] Further evidence of the innate immune system's function is the neutrophilic involvement seen in EN cytokine profiles, with high expression of TNF-α, IL-8, IL-6, monocyte chemoattractant protein-1, and granulocyte colony-stimulating factor.[28]

DIAGNOSIS

All of the above etiologies present with similar histopathologic features, and the spectrum of histopathologic features in EN and other panniculitides may be variable.[38] This necessitates correlation with clinical features, including location of lesions, systemic symptoms, and laboratory findings. Examination of AT requires large excisional biopsies, as the inflammatory infiltrate can be missed. Inflammation in AT is not a static process, and more than 1 biopsy may be necessary to come to a conclusive diagnosis. EN is generally a "septal" pattern with inflammation confined predominantly to the septa. Of note the "lobular" form implies inflammation predominantly involving the fat lobule itself.

Early EN shows edema of the adipose septae with neutrophils and extravasated red blood cells. As EN develops, the septae widen and become fibrosed, and a mixed infiltrate that includes lymphocytes, histiocytes, neutrophils, and some eosinophils is seen.[15] Fibrotic, wide septae characterize late EN lesions, often with granulomas, and fat lobules may be encroached upon and partially effaced (Fig. 73-2A). An overlying superficial and deep dermal perivascular infiltrate is frequently present in EN.[39]

EN has characteristic, but not sensitive or specific, groupings of histiocytes surrounding a central stellate cleft called Miescher granuloma (see

TABLE 73-3
Reported Etiologies of Erythema Nodosum

Bacterial Infections
- **Streptococcal infections**
- **Tuberculosis**
- ***Yersinia* infections**
- ***Salmonella* infections**
- ***Campylobacter* infections**
- Brucellosis
- Tularemia
- Atypical mycobacterial infections
- Chancroid
- Meningococcemia
- *Corynebacterium diphtheriae* infections
- Cat-scratch disease
- *Propionibacterium acnes*
- *Shigella* infections
- Gonorrhea
- Syphilis
- Leptospirosis
- Q fever
- Lymphogranuloma venereum
- *Chlamydophila psittaci* infections
- *Mycoplasma pneumoniae* infections
- *Helicobacter pylori* infection

Viral Infections
- Infectious mononucleosis
- Hepatitis B
- Milker nodules
- Orf (contagious ecthyma)
- Herpes simplex
- Measles
- Cytomegalovirus infections

Fungal Infections
- Dermatophytes
- Blastomycosis
- Histoplasmosis
- Coccidioidomycosis
- Sporotrichosis
- Aspergillosis

Protozoal Infections
- Toxoplasmosis
- Ancylostomiasis
- Amebiasis
- Giardiasis
- Ascariasis

Drugs
- **Sulfonamides**
- **Bromides**
- **Iodides**
- **Oral contraceptives, progesterone**
- Minocycline
- Gold salts
- **Penicillin**
- Salicylates
- Chlorothiazides
- Phenytoin
- Aminopyrine
- Arsphenamine
- Hepatitis B vaccine
- Nitrofurantoin
- Pyritinol
- D-Penicillamine
- Thalidomide
- Isotretinoin
- Interleukin-2
- Omeprazole
- Valproate
- Tdap (tetanus, diphtheria, and pertussis) vaccine
- Leukotriene-modifying agents
- Vemurafenib

Miscellaneous Conditions
- **Sarcoidosis**
- Ulcerative colitis
- Colon diverticulosis
- **Crohn disease**
- Behçet disease
- Reactive arthritis
- Sweet syndrome
- Pregnancy
- Takayasu arteritis
- Immunoglobulin A nephropathy
- Chronic active hepatitis
- Granulomatous mastitis
- Vogt-Koyanagi disease
- Sjögren syndrome
- Temporal arteritis
- Systemic lupus erythematosus
- Dental infection

Malignant Diseases
- Hodgkin disease
- Non-Hodgkin lymphoma, including mucosa-associated lymphoid tissue (MALT) lymphoma
- Leukemia
- Sarcoma
- Renal carcinoma
- Postradiotherapy for pelvic carcinoma

Fig. 73-2B).[15] It is considered characteristic of early EN, but is not universally found in EN,[39] and has been described in other types of panniculitis.[39] Some authors believe the Miescher granulomas are consistently found in EN.[15] Late EN lesions may demonstrate lipomembranous change.[15,40] Although by definition, vasculitis is characteristically absent in EN, thrombophlebitis has been emphasized by some as a feature in early EN,[41] and medium-vessel arteritis may (rarely) occur.[38]

DIFFERENTIAL DIAGNOSIS

Table 73-4 outlines the differential diagnosis of EN.

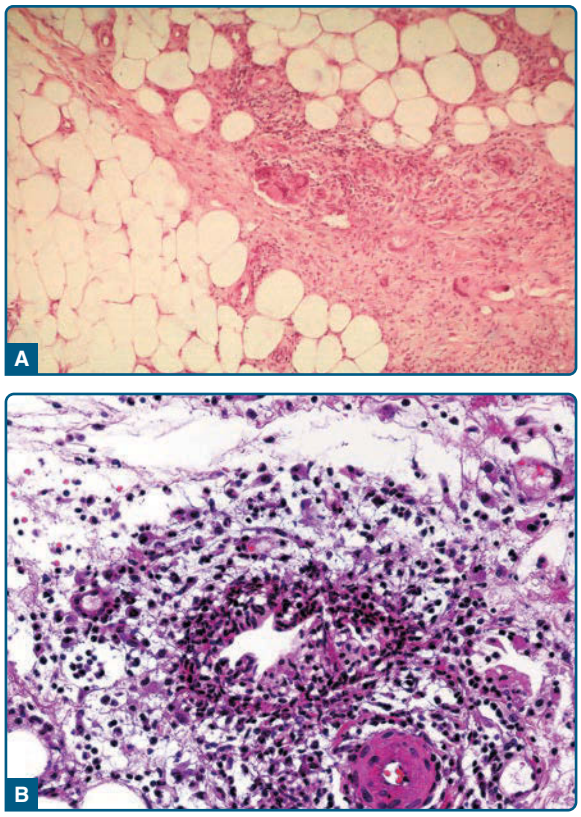

Figure 73-2 **A,** Widened septa with inflammatory infiltrate including multinucleated giant cells. **B,** High-power magnification of a Miescher granuloma shows a discrete micronodular aggregate of small histiocytes around a central stellate cleft.

CLINICAL COURSE AND PROGNOSIS

EN is a benign, self-limiting subcutaneous disease that resolves a few weeks after initial presentation; the course, however, varies based on the etiology. Medication-induced EN may improve after discontinuation of the drug with reappearance of clinical findings when the drug is reintroduced. New lesions of EN are uncommon after 6 weeks, with persistent and recurrent cases reported.[18] After avoidance of causative factors, recurrence is more common if no etiology is identified.[21] EN secondary to a malignancy, a severe systemic disease, or infection may have a more complicated course as a result of the prognosis of the primary disease. Patients with EN secondary to sarcoidosis have an improved prognosis.[36] Patients with Crohn disease and EN are more likely to have colonic involvement of inflammatory bowel disease.[42] While recurrence of EN is rare, it is more frequent when associated with sarcoidosis, hormonal therapy and pregnancy, and streptococcal infection.[26] Most cases of EN heal well with no recurrence, but relapses occur in 6% to 34% of reported cases.[20]

TABLE 73-4
Differential Diagnosis of Erythema Nodosum

DIAGNOSIS	CHARACTERISTIC FEATURES
Erythema induratum/ nodular vasculitis	Most common on posterior calves with ulceration.
Simple bruising	History of trauma or anticoagulation, with no history of ongoing lesions. Lack of inflammatory features such as warmth. Tender only to palpation and heal spontaneously.
Cutaneous polyarteritis nodosa	Nodules in association with livedo reticularis and arterial inflammation on histology, possibly with neuropathy.
Sarcoidosis	Can occur as nodules or plaques or patches on extremities. Sarcoidal granulomas in dermis or subcutis of cutaneous nodules on skin biopsy. Often with systemic sarcoidosis.
Cellulitis	Larger plaques that are erythematous and lack the violaceous bruising. More tender and warm.
Lipodermatosclerosis	Firm plaques nearly circumferential around lower leg.
Pancreatic panniculitis	Occurs anywhere on the legs; ulceration and drainage. Serum lipase and amylase often elevated.
Behçet syndrome occurring in the fat	Vasculitis occurring in the fat tissue, either lymphocytic or neutrophilic, small arterial involvement with either lobular or mixed lobular and septal pattern.
Sweet syndrome	Erythematous nodules may be present on the face, neck, upper trunk, as well as extremities. Nodules may have vesicles, pustules, or bullae. Histology with intense dermal edema; diffuse, deep neutrophilic infiltrate with karyorrhexis.
Subcutaneous tuberculosis or other atypical mycobacterial infection	Nodules or plaques occurring in endemic areas. Habitation or travel to endemic areas; possible history of trauma. Characteristic features on microbiology and positive acid-fast bacilli on histopathology.

MANAGEMENT

If there is an identifiable etiologic factor, management of EN focuses on eliminating the exposure, or treating the underlying diseases. Potential infection must be sought and treated and suspected medications should be discontinued. An extensive review of all medications (including nonprescription and supplemental products), medical supplements and a thorough medical history, including symptoms several weeks prior to the EN onset, travel history, and family history of infections are critical to the workup.[18]

Supportive care is the mainstay of treatment after removing or treating the provoking factors: bed rest if severe, with lower-extremity elevation, and

nonsteroidal antiinflammatory agents are recommended. Supersaturated potassium iodide solution (SSKI) can be used, but thyroid disorder and pregnancy screening must be done prior to administration, and there are risks of hypothyroidism, goiter, and heart and lung toxicity.[43] Dosing SSKI is via drops in water or juice, using 2-10 drops (1 drop = 0.03 mL = 30 mg) 3 times per day.[43] Colchicine is effective in Behçet-related EN specifically.[44] Etanercept[45] and infliximab[46] are options for inflammatory bowel disease–associated EN. Other potential treatment options include oxyphenbutazone[47] and hydroxychloroquine,[48] with limited, randomized, controlled trials. Corticosteroids are not first-line therapy as there is a risk of infectious etiology in idiopathic EN.

ERYTHEMA INDURATUM AND NODULAR VASCULITIS

AT-A-GLANCE

Clinical

- Erythematous subcutaneous nodules and plaques of lower legs; common on calves, but also on anterolateral legs, feet, and thighs; rarely also on arms, forearms, and face.
- Associated with venous insufficiency; more frequent in middle-aged women.
- Often, ulceration and scarring present.
- Chronic, relapsing course.
- Infectious etiologies include bacterial (especially *Mycobacterium tuberculosis*), fungal, viral, and protozoal.

Histopathology

- Mostly lobular or mixed lobular and septal panniculitis with vasculitis in 90%.
- Extensive necrosis of the adipocytes in the center of the adipose lobule.
- Variable inflammatory infiltrate: neutrophils in early lesions and epithelioid histiocytes and multinucleated giant cells in fully developed lesions.
- Vasculitis of the small veins and venules of the fat lobule.

Treatment

- With positive *Mycobacterium tuberculosis* studies: a full course of antituberculosis triple-agent therapy.
- Complete treatment of infectious etiologies.
- In other cases: potassium iodide, other antiinflammatory drugs, supporting bandages and hose, leg elevation, bed rest.

Erythema induratum (EI) and nodular vasculitis (NV) also present as nodular lesions on the legs. They were first described as early as 1945, with a relationship with *Mycobacterium tuberculosis* (MTB).[49] The clinical presentation and histopathology differentiate EI/NV from EN, cutaneous polyarteritis nodosa, or other nodules seen on the legs. EI most commonly presents with ulcerated nodules on the calves, and is associated with MTB infection. A similar disorder, appearing in calves and other lower-extremity sites was subsequently described without MTB association and was called NV. However, clinically the 2 nodular leg syndromes are so similar that it is impossible to separate them.[50-52] Consequently, the terms are most often used interchangeably.

EPIDEMIOLOGY

The EI/NV grouping is the most common diagnosis of a panniculitis with vasculitis.[53] EI/NV is seen most commonly in young to middle-aged women,[51,54] as dominant as a 9:1 ratio.[55] Ages range from 8 months to 66 years with a mean age of 36.6 years.[56,57] In a review of 165 patients with cutaneous tuberculosis (TB), only 2 presented with EI.[58] This varies by time of study and location, as a study in Hong Kong showed 79.5% of cutaneous TB cases to be EI.[59] Pediatric cutaneous TB accounts for 1% to 2% of cases. The highest rates of pediatric cutaneous TB are seen in Pakistan.[60] EI lesions develop more frequently during winter, and are associated with obesity and venous insufficiency.[51]

CLINICAL FEATURES

EI/NV is known for affecting the calves as recurrent, erythematous to violaceous nodules and deep plaques that may be tender[51] (Fig. 73-3) but often are not painful.[50] Ulceration often leads to scarring.[51] Surface changes include crusting of the ulcers and a surrounding collarette of scale (Fig. 73-4).[50] Although the posterior calf is the most frequent location, lesions may also appear in the anterolateral areas of the feet,[61] thighs, and, rarely, the arms and face.[50] A consistent systemic finding in patients with MTB-associated EI is a positive tuberculoid skin test, including the Mantoux test or tuberculin-purified protein derivative. Systemic findings related to the etiology, TB or otherwise, vary greatly.

ETIOLOGY AND PATHOGENESIS

Although EI was frequently associated with MTB, the etiology was controversial because organisms are not always identified in the biopsies and tissue cultures. With the advent of polymerase chain reaction (PCR) techniques, multiple culture-negative cases were shown to contain MTB DNA.[62]

Figure 73-3 Erythema induratum. Erythematous to brown and bluish nodules with ulceration on calves.

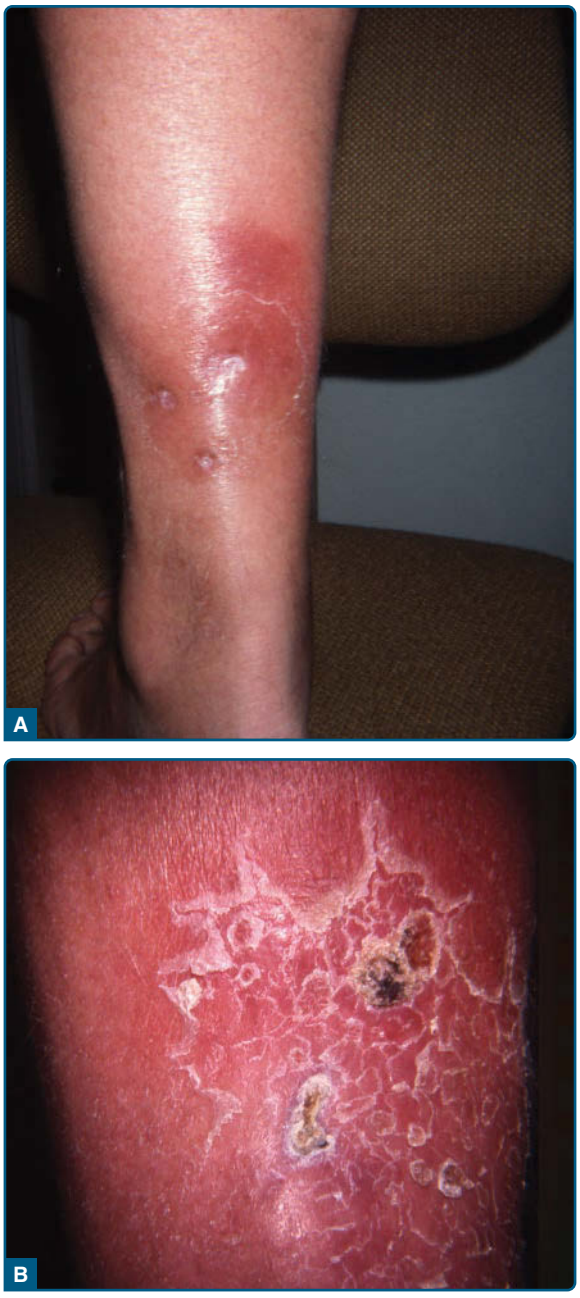

Figure 73-4 **A** and **B,** Erythema induratum with surrounding collarette of scale.

In vitro studies show that MTB can bind to scavenger receptors, enter adipocytes, and, via the nearly 20 lipases of MTB, can appropriate the host lipids, accumulate intracytoplasmic lipid inclusions, and survive in a nonreplicating state that is insensitive to the major antimycobacterial medication isoniazid.[63] However, rifampin and ethambutol can reduce MTB bacterial load in adipocytes by 80% to 90%.[63] Other organisms that can infect adipocytes and serve as a reservoir of reactivation include cytomegalovirus, *Chlamydophila pneumoniae*, adenovirus, influenza virus, respiratory syncytial virus, *Rickettsia prowazekii*, and *Trypanosoma cruzi*.[64-67] Infection of adipocytes leads to activation of cytokines and adipokines that bring other innate immune cells (macrophages, neutrophils, mast cells, natural killer cells) as well as adaptive immune cells (sensitized T cells) to the infection site to help contain the infection.[57]

EI is considered to be a hypersensitivity disorder mediated by immune complexes or cell-mediated hypersensitivity, manifested by the presence of tuberculin skin tests and highly positive interferon-γ release assay tests to MTB.[68,69] The T cells, monocytes, and macrophages as well as Langerhans cells may suggest a type IV hypersensitivity reaction.[70]

Extracutaneous MTB is found in many EI patients, and may be present in the lung, lymph nodes, kidney, bowel,[51] or adrenal glands, presenting as Addison disease.[55] Rare species, including *Mycobacterium monacense*, can also cause the EI/NV clinical and histopathologic presentation.[71] Other infections and disorders also have been associated with NV, including hepatitis B, hepatitis C (red finger syndrome and panniculitis), ulcerative colitis, leukemia, rheumatoid arthritis, hypothyroidism, and *Nocardia* infection.[51,72-74] Crohn disease is also a rare cause of NV, and when present it may be metastatic disese.[75] *Chlamydophila pneumoniae* has been reported to induce NV.[76] Medications, including propylthiouracil[77] and etanercept,[78] also are associated with NV. Bacillus Calmette-Guérin vaccination is reported to cause EI, 2 and 3 months after injection.[56,57]

DIAGNOSIS

Histopathologic findings correlate with lesion duration, but the common denominator is a mostly lobular or mixed septal and lobular panniculitis (Fig. 73-5A). In early lesions, fat lobules contain discrete aggregates of inflammatory cells, with neutrophils predominating

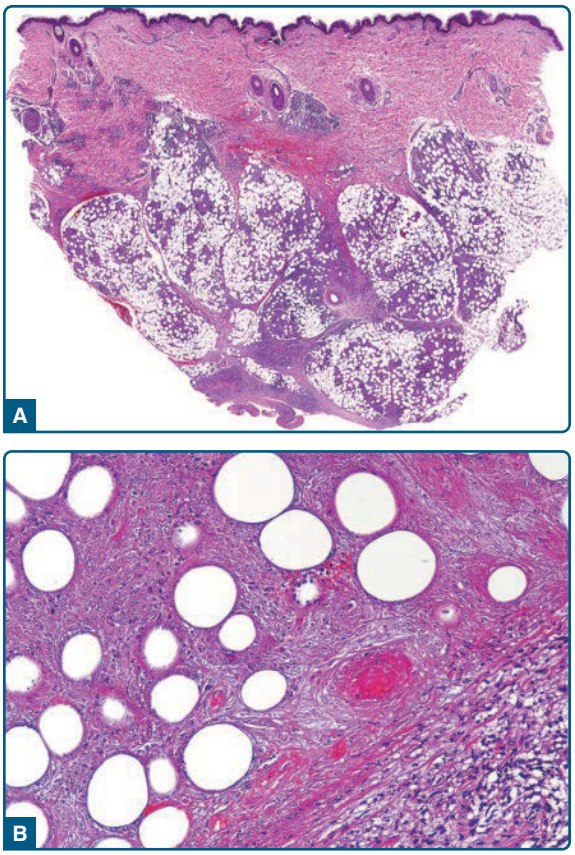

Figure 73-5 Erythema induratum nodular vasculitis. **A,** Low-power magnification shows a mostly lobular panniculitis. **B,** Higher-power magnification shows extensive adipocyte necrosis and vascular damage—necrotizing vasculitis of small venules in the fat lobule.

without leukocytoclasia.[53] Adipocyte necrosis is present, which leads to foamy histiocytes. In established lesions of EI/NV, collections of epithelioid histiocytes, multinucleated giant cells, and lymphocytes produce a granulomatous appearance.[52,53] Intense vascular damage, when present, is accompanied by extensive areas of caseous necrosis (Fig. 73-5B), eventuating in tuberculoid granuloma formation.[52] The caseous necrosis may involve the overlying dermis to such an extent that ulceration occurs.[52] Eosinophils may be present and do not conflict the diagnosis.[79]

In a review of 101 cases consistent with EI, vasculitis (of lobular venules, septal veins, and septal arteries) was present in 90% of cases.[51] Lack of vasculitis has been seen on the histopathology in severely immunocompromised patients.[80] Importantly, MTB can cause both EN and EI, and thus in a patient with appropriate travel and exposures, clinical and pathologic characteristics may not rule out a diagnosis of TB.[81]

DIFFERENTIAL DIAGNOSIS

Table 73-5 outlines the differential diagnosis of erythema induratum/nodular vasculitis.

TABLE 73-5
Differential Diagnosis of Erythema Induratum/Nodular Vasculitis

DIAGNOSIS	CHARACTERISTIC FEATURES
Erythema nodosum	Most common on anterior legs with no ulceration and no scarring.
Cutaneous polyarteritis nodosa	Nodules in association with livedo reticularis and arterial inflammation on histology, possibly with neuropathy.
Sarcoidosis	Can occur as nodules or plaques or patches on extremities. Sarcoidal granulomas in dermis or subcutis of cutaneous nodules on ski biopsy. Often occurs with systemic sarcoidosis.
Lipodermatosclerosis	Firm plaques that can become nearly circumferential around lower leg. In morbid obesity, can occur on breasts and abdomen.
Pancreatic panniculitis	Occurs anywhere on the legs, with ulceration and drainage. Serum lipase and amylase are often elevated.
Behçet syndrome occurring in the fat	Vasculitis occurring in the fat tissue, either lymphocytic or neutrophilic; small arterial involvement with either lobular or mixed lobular and septal pattern.
Subcutaneous Sweet syndrome	Erythematous nodules may be present on the face, neck, and upper trunk, as well as extremities. Nodules may have vesicles, pustules, or bullae. Histology with intense dermal edema; diffuse, deep neutrophilic infiltrate with karyorrhexis.

CLINICAL COURSE AND PROGNOSIS

EI/NV can have a protracted course with recurrent episodes over months[50] to years.[51,52] Patients with EI/NV are generally healthy, except for the associated disease. The course of EI is also often more chronic than EN, and the ulceration and scarring of EI leads to a worse cosmetic and potentially debilitating outcome than EN.[70]

MANAGEMENT

In patients with positive MTB cultures, positive tuberculoid skin test or positive interferon-γ release assay such as the QuantiFERON-TB Gold in-tube assay, treatment with multiple agent anti-TB therapy is indicated.[70] If an interferon-γ release assay is negative but clinical suspicion in a high-risk TB area persists, lesional PCR is recommended.[82] Patients with hepatitis B or hepatitis C should receive appropriate antiviral intervention. Other infectious etiologies should be sought and treated if present. Potentially causative medications should be discontinued.

Antiinflammatory treatments that have been used in NV not associated with MTB include SSKI, nonsteroidal antiinflammatory agents, corticosteroids, and gold, as well as bed rest with leg elevation, and treatment of venous insufficiency with compression and pentoxifylline, and even mycophenolate mofetil.[54,83,84] If immunosuppressive agents are used, monitoring for possible infectious etiology is recommended.

LIPODERMATOSCLEROSIS

AT-A-GLANCE

Clinical

- Indurated, firm plaques of wood-like consistency on the lower legs.
- Associations: chronic venous insufficiency, elevated body mass index, female gender, arterial hypertension, arterial ischemia, and thrombophlebitis.

Histopathology

- Background of stasis changes; mostly lobular panniculitis without vasculitis.
- Ischemic necrosis at the center of fat lobule.
- Thickened and fibrotic septae and atrophy of the subcutaneous fat, with marked fibrosis and sclerosis in late-stage severe cases.

Treatment

- Compression stockings, ultrasound therapy, pentoxifylline.
- Successful response to anabolic steroids, platelet-rich plasma, in cases.

Lipodermatosclerosis (LDS) has multiple synonyms, including sclerosing panniculitis, hypodermitis sclerodermiformis, chronic panniculitis with lipomembranous changes, sclerotic atrophic cellulitis, and venous stasis panniculitis. It is a form of sclerosing panniculitis involving the lower legs, often related to vascular malfunction. The first name used was *hypodermitis sclerodermiformis*, which was used as early as the 1950s.[85]

EPIDEMIOLOGY

LDS is the most common form of panniculitis, seen by clinicians far more frequently than EN. LDS occurs with venous insufficiency, mostly in overweight women older than 40 years,[86,87] with age ranges varying from 31 to 74 years and older.[88] The female-to-male ratio is 4:1,[88] and in some studies it is as high as 12:1.[89] White race has been associated more often with LDS.[89] Obesity is common, with 85% of affected patients having a body mass index greater than 30.[90] Comorbidities include hypertension, thyroid disease, diabetes mellitus, prior history of lower-extremity cellulitis, and deep vein thrombosis.[90] Obstructive sleep apnea and arthritis (both osteoarthritic and rheumatoid) also are associated with LDS.[88]

CLINICAL FEATURES

LDS has an acute inflammatory stage and a chronic fibrotic stage. In patients presenting with the acute form, very painful, poorly demarcated, cellulitis-like erythematous plaques persist and evolve to violaceous, edematous, or indurated plaques or nodules, which are seen on the lower legs, most commonly on the lower anteromedial calf (Fig. 73-6).[87,91] Unilateral

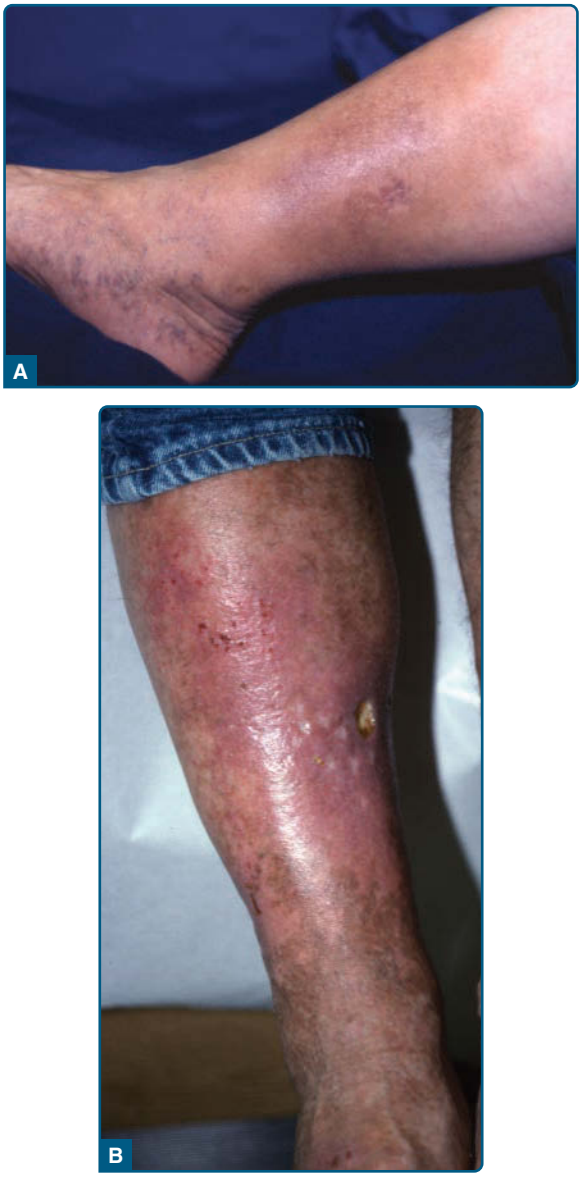

Figure 73-6 **A,** Chronic lipodermatosclerosis (LDS) with mild erythema of the medial lower leg, indicating presence of active inflammation. Cellulitis-like plaques on the medial lower leg. **B,** Severe acute inflammation with ulcerations superimposed on chronic LDS.

Figure 73-7 Chronic lipodermatosclerosis with champagne bottle/bowling pin deformity.

involvement is seen in 55%, a localized plaque in 51%, and ulceration in 13% of cases.[90] Lesions can be very painful, leading to misdiagnoses of EN, cellulitis, or thrombophlebitis.[87,91] Although patients in this acute phase may lack obvious venous disease,[87] vascular studies show venous insufficiency in the majority.[91] In those patients with normal venous studies, most have a high body mass index.[90]

The chronic form of LDS does not always follow an obvious acute phase.[87] Chronic LDS presents as indurated[92] to sclerotic, depressed and hyperpigmented skin. These findings occur on the lower portion of the lower leg, predominantly on the medial aspect, or in a stocking distribution. This is described as an "inverted champagne bottle" or a "bowling pin" appearance (Fig. 73-7).[86,87,91]

ETIOLOGY AND PATHOGENESIS

A few medications are reported to induce LDS, including gemcitabine[93] and pemetrexed.[94] Additional pathogenic features may include elevated hydrostatic pressure-induced vascular permeability secondary to downregulation of tight junctions[95] with extravascular diffusion of fibrin[90]; microthrombi[96]; abnormalities in protein S and protein C[97]; hypoxia[98]; damage to endothelial cells by inflammatory cells[99]; upregulation of intercellular adhesion molecules and platelet-derived and endothelial-derived factors[100]; and inflammation with wound healing and local collagen stimulation leading to fibrosis and further vascular and lymphatic damage.[90] The fibrosis is accompanied by increased transforming growth factor-β1 gene and protein expression,[101] as well as an increase in procollagen type 1 gene expression.[102]

Hypoxia in AT induces chronic inflammation with macrophage infiltration and inflammatory cytokine expression.[103] The adipocyte produces multiple matrix metalloproteinases as well as tissue inhibitors of metalloproteinases,[104] which may contribute to tissue remodeling seen in LDS. Studies have linked expansion of AT (as in obesity) to hypoxia, causing an increase in hypoxia-inducible factor 1α expression.[105] This stimulates extracellular factors, including collagen I and collagen III, leading to fibrosis.[106]

DIAGNOSIS

The diagnosis is often clinical, and biopsy of LDS skin can have a difficult course of healing.[92] Of note, concern for poor healing and delay of biopsy would have failed to identify 2 cases of malignancy in case reports of cutaneous T-cell lymphoma[107] and angiosarcoma.[108] Biopsies are best taken from the proximal edge of involvement for highest rates of healing. Less-invasive options, such as MRI, have been used to view the extent of disease.[109]

Histopathologic findings reflect the evolution of disease. Dermal stasis changes are present at any stage, including a proliferation of capillaries and venules, small thick-walled blood vessels, extravasated erythrocytes, hemosiderin-laden macrophages, lymphohistiocytic inflammation, and fibrosis.[52,110] In the subcutis, early lesions of LDS show a sparse infiltrate of lymphocytes in the septa, with central lobular ischemic fat necrosis. Capillary congestion is observed within fat lobules, often with endothelial cell necrosis, thrombosis, red cell extravasation, and hemosiderin deposition.[52,110]

Lipomembranous or membranocystic changes may be present with small pseudocystic spaces within necrotic fat. The spaces are lined by a membranous lining of hyaline eosinophilic material, which is highlighted by periodic acid-Schiff staining. Lipomembranous changes are not exclusive to LDS.[52,111]

With progression of LDS, the spectrum of histopathologic changes encompasses increasing degrees of fat necrosis, septal fibrosis, and thickening; an inflammatory infiltrate of lymphocytes, histiocytes, and foamy macrophages; and partial to extensive atrophy of fat lobules.[52,87,110] Advanced lesions show septal sclerosis with marked atrophy of fat lobules secondary to lipophagic fat necrosis, accompanied by lipomembranous change and a marked reduction in inflammation.[52,110]

DIFFERENTIAL DIAGNOSIS

Table 73-6 outlines the differential diagnosis of LDS.

CLINICAL COURSE AND PROGNOSIS

The course of LDS is variable and depends on the patient's comorbidities and compliance with the treatment regimen, particularly compression, which can be difficult to adhere to daily. The acute form may last months or even a year.[91] The chronic form can last years and can be refractory to standard treatment regimens. The ulcerations and resulting scarring are permanent and can be cosmetically distressful. Secondary infection of ulcers must be avoided. Dermatosclerosis in patients with systemic sclerosis has been associated with pulmonary infarction and hypertension secondary to leg thrombi.[112] Additionally, untreated LDS can result in venolymphedema.[92]

TABLE 73-6
Differential Diagnosis of Lipodermatosclerosis

DIAGNOSIS	CHARACTERISTICS
Erythema nodosum (EN)	Warm, tender, erythematous subcutaneous nodules on pretibial areas; a lack of preceding venous insufficiency is common. Sarcoidosis or other high-risk medication exposure.
Erythema induratum (EI)/ nodular vasculitis	Tender nodules and plaques on calf areas; living in an area endemic for tuberculosis (EI). Vasculitis on histopathology.
Cellulitis	Can occur with chronic edema, venous insufficiency. More likely unilateral and after injury or animal bite.
Infection-induced panniculitis	EN-like nodules, deep inflamed nodules or abscesses; older lesions may show fibrosis. Commonly on legs. Often seen in severely immunosuppressed patients with malignancies.
Scleroderma/ morphea	Scleroderma or morphea involvement elsewhere. May have associated venous insufficiency of legs.
Deep vein thrombosis	Pain and edema of posterior calf with positive Doppler examination.
Nephrogenic systemic fibrosis	Subsequent to MRI with gadolinium exposure in patients with renal dysfunction. Can occur on areas other than legs.
Malignancies	Persistent, worsening disease, often with systemic symptoms. Presence of cutaneous T-cell lymphoma, angiosarcoma, or other sarcomas on leg. More likely in patients who underwent transplantation and in immunosuppressed patients.
Necrobiosis lipoidica	Clinically, the lesions consist of yellow-brown, indurated plaques with an atrophic, depressed area.
Eosinophilic fasciitis/Shulman syndrome	Coarse, thickened skin with peau d'orange appearance. A "groove sign" or "dry riverbed sign" can be seen along lines of vessels when arms are lifted or extended laterally. Peripheral blood eosinophilia and hyperglobulinemia are common.

MANAGEMENT

Diagnostic tests to evaluate peripheral vascular disease include the ankle brachial index for arterial evaluation, as well as venous Doppler examinations to detect thrombi and duplex sonography to detect direction of flow and severity of venous reflux.[91] A patient with arterial compromise should not undergo compression therapy, which is a first-line treatment for LDS.[87,90] Higher compression gradient (30 to 40 mm Hg) may be more effective, but lower pressure (15 to 20 mm Hg or 20 to 30 mm Hg) encourages compliance, especially in the elderly, and effectively decreases edema.[113] Compression tightens vascular tight junctions, inhibiting permeability of fluid into the perivascular tissue.[95,114] Stockings must be worn all day; a few days without compression may lead to recurrence of edema and inflammation.[113] Because of the difficulty of wearing stockings, adaptive compression modalities have been developed, which use sustained or intermittent pneumatic compression.

Stanozolol is effective in LDS; it decreases pain, erythema, and induration.[115] Patients tolerate the treatment well, and the risk of hepatotoxicity has been evaluated as an asymptomatic increase in liver transaminases that resolves with medication cessation.[116] This drug is not available in the United States. Other anabolic steroids, such as oxandrolone and danazol, also have been used.[117,118]

Pentoxifylline has been successfully used in LDS cases with and without associated ulceration and is a useful adjunct to compression for treating venous ulcers and may be effective as monotherapy.[119] In fact, in one study, hydroxychloroquine and pentoxifylline combined therapy, without compression, led to a 50% reduction in pain from baseline.[120]

Ultrasound therapy can reduce and even resolve induration, tenderness, and erythema.[121,122] Available through physical therapy departments, it is a simple and safe treatment and may be used as adjunctive therapy.[121,122] Because obesity is a common condition among affected patients, weight loss is critical. Capsaicin may alleviate pain associated with LDS.[123] Finally, refractory disease has responded to intralesional, autologous, platelet-rich plasma, injected in a grid-like pattern, and repeated every 2 weeks.[124]

One author (IKA) has noted improvement in patients treated with rutin and vitamin C, particularly adjunctive to compression therapy.

INFECTION-INDUCED PANNICULITIS

AT-A-GLANCE

Clinical

- Caused by multiple infectious agents: bacteria, fungi, parasites, and viruses.
- AT may serve as reservoir for various infections.
- Patients may be immunosuppressed with primary inoculation or hematogenous spread.
- Erythematous plaques, nodules, abscesses, ulcers with purulent discharge.

Histopathology

- Suppurative granulomas within fat lobule.
- In primary cutaneous infections, epicenter of inflammation is superficial dermis; in secondary infections, epicenter is deep reticular dermis and subcutaneous fat.
- Special stains, cultures, and serologic studies for detection of microorganisms.

Treatment

- Appropriate antimicrobial therapy selected according to susceptibility tests.

Infection-induced panniculitis (IIP), also termed *infectious panniculitis* and *infective panniculitis*, is panniculitis directly caused by an infectious agent.[74] AT infection can be caused by bacteria, mycobacteria, fungi, protozoa, or viruses.[52,74,125] Primary infections produced by direct inoculation at a wound site (injury, surgical procedure, catheter, injection, acupuncture) usually result in a single lesion which may spread locally.[52,74,125] Secondary infections caused by sepsis and hematogenous spread may manifest as single or multiple lesions.[52,74,125] In immunosuppressed patients, microorganisms may be numerous and identified on routine histopathology, or with special stains. In immunocompetent patients, microorganisms may be sparse, requiring positive cultures, lesional PCR, or serologic studies for identification.[52,74,125]

EPIDEMIOLOGY

IIP is most frequently seen in immunocompromised hosts, including those with diabetes mellitus.[126] The epidemiology depends on the infectious etiology with geographic and host susceptibility. Recent reports of infectious etiologies in association with various autoimmune disorders include *Staphylococcus aureus* panniculitis with juvenile dermatomyositis,[127] mucormycosis in systemic lupus erythematosus (SLE),[126] *Mycobacterium*-associated and *Histoplasma*-associated panniculitis with rheumatoid arthritis,[128,129] as well as *Histoplasma* causing panniculitis in 2 patients with polymyositis.[130] Complicating these associations is the fact that autoimmune disorders are often treated with immunosuppressive therapies.

CLINICAL FEATURES

The clinical appearance of IIP varies from fluctuant or abscess-like lesions with purulence and ulcerations to nonspecific erythematous, firm subcutaneous plaques, purpuric plaques, and EN-like lesions.[74,125,131] Deep nodules or plaques may not always appear fluctuant, and pustules, fluctuant papules, and ulcers can be superimposed on top of firm, deep nodules.[125] The most common sites of infection are the legs and feet, but upper extremities, trunk, and face also may be involved.[74,125] Immunosuppression of varying etiology is the most frequent association.[52,74,125] Immunosuppression is associated with more widespread and abscess-type lesions. In immunocompetent patients, granulomas are common.[125,132] Clinical features vary with the setting, the infective organism and patient's immunocompetence.[125,131]

ETIOLOGY AND PATHOGENESIS

Innumerable infectious agents can cause IIP via direct inoculation or hematologic spread. Diffuse fusariosis has presented with panniculitis in a patient with acute lymphoblastic leukemia.[133] One case reported cutaneous aspergillosis panniculitis in a patient with acute lymphoblastic leukemia, and gouty panniculitis was suspected with the presence of urate crystals. This patient also had the characteristic "ghost cell" changes of pancreatic panniculitis, which along with the urate crystals may be secondary to fungal enzymatic changes.[134] These findings have been appreciated in mucormycoses as well.[126] Transplantation patients are at risk for disseminated infections, as seen in a review of 15 solid-organ transplantation patients (mainly renal transplantations) with cryptococcal panniculitis. Duration between transplantation and infection ranged from 3 months to 31 years.[135] Cryptococcal infection in the transplantation group is highest in heart transplant recipients.[136] *Pseudomonas aeruginosa* may cause panniculitis, most often as a disseminated infection, but it has presented without septicemia.[137] Epstein-Barr virus also has been reported to cause IIP localized to the trunk in a patient with methotrexate-associated lymphoproliferative disorder, with resolution after discontinuation of methotrexate.[138]

Immunocompetent patients with IIP also have been reported. Panniculitis caused by syphilis has presented with cutaneous findings of secondary syphilis, with an infiltrate containing many plasma cells and positive *Treponema pallidum* immunohistochemical staining.[139] Cutaneous leishmaniasis has also presented as inflammation of the AT, noted in 2 Iraqi cases with both septal and lobular histopathology, improving with local treatment standard for cutaneous leishmaniasis.[140] *Borrelia burgdorferi* is also associated with panniculitis, in an immunocompetent host, mimicking a subcutaneous panniculitis-like T-cell lymphoma (SPTCL), which responded promptly to doxycycline.[141]

The adipocyte is an innate immune cell that tailors specific and distinct receptor-mediated transcriptional responses to the various microbial infections.[142] Adipocytes can be infected in vitro with infectious agents, including *Chlamydophila pneumoniae*, cytomegalovirus, adenovirus, respiratory syncytial virus, influenza,[64] MTB,[63] *R. prowazekii*,[65] *T. cruzi*,[143] *Coxiella burnetii*,[65] and HIV.[144]

In vitro infection of adipocytes with *T. cruzi* (the cause of Chagas disease) results in increased expression of multiple proinflammatory cytokines and chemokines, increased expression of TLR2 and TLR9 and acute-phase reactants, but decreased expression of adiponectin and peroxisome-proliferator-activated receptor γ, the negative regulators of inflammation.[9,66] In mice, real-time PCR has shown that at 300 days postinfection with *T. cruzi*, a comparable number of parasites are present in both AT and heart tissue, indicating that AT is a reservoir for the parasites.[9] Interestingly, the *T. cruzi* amastigotes are more numerous in brown AT than in white α_1-antitrypsin.[9]

In another murine study, *Mycobacterium leprae* had very limited growth potential in AT, as preadipocytes and adipocytes were not permissive for *M. leprae* multiplication and logarithmic growth.[145] Because adipocytes have high expression of TLR4, adipocytes are responsive to endotoxin, producing proinflammatory

cytokines at comparable or higher levels than macrophages.[9] TLR2 induction in adipocytes confers a high degree of sensitivity to fungal cell-wall components.[9]

Mutations coding TLRs or downstream signaling proteins can increase the risk of infections.[146] The genetic variants in TLRs, and other innate immune signaling components and their effect on adipocyte function and development of panniculitis are not yet known.

DIAGNOSIS

Evaluation includes histopathologic studies with stains for organisms as well as tissue culture, with sensitivities. Immunosuppression may lead to the presence of numerous microorganisms but diagnosis is more difficult in immunocompetent patients.[52,74,125] Molecular PCR techniques have increased detection of mycobacterium infections.[62,79] Histopathologic features vary with the organism and its virulence, the host immune status, and the duration of the lesion.[74] A mostly lobular panniculitis,[52] IIP often reveals a mixed septal and lobular pattern.[74] The superficial dermis has more inflammation in infections acquired by direct inoculation, while infections secondary to hematogenous spread involve the deep reticular dermis and subcutaneous fat.[52]

Additional features of IIP include hemorrhage, vascular proliferation, foci of basophilic necrosis, and sweat gland necrosis.[74] Overlying epidermal changes, such as parakeratosis, acanthosis, and spongiosis are seen in nonulcerated specimens. Dermal findings include edema, a diffuse perivascular inflammatory infiltrate, proliferation of thick-walled vessels, and focal or diffuse hemorrhage.[74] Observation of these features warrants stains for bacteria, mycobacteria, and fungi, and additional immunohistochemistry or PCR amplification techniques may be necessary. Occasionally histopathologic changes suggest a particular etiology. Suppurative granulomas formed by epithelioid histiocytes surrounding aggregated neutrophils are common with atypical mycobacteria.[52] Viral inclusions within endothelial cells may be seen in cytomegalovirus-associated panniculitis.[147]

DIFFERENTIAL DIAGNOSIS

Table 73-7 outlines the differential diagnosis of IIP.

CLINICAL COURSE AND PROGNOSIS

The clinical course and prognosis of IIP are affected by the infective organism and whether the organism was introduced locally or hematologically. Organisms treated with antibiotics, and a prompt diagnosis, portend a good prognosis. Immunocompromised patients are at risk for a more complicated course.

TABLE 73-7
Differential Diagnosis of Infection-Induced Panniculitis

DIAGNOSIS	CHARACTERISTICS
α_1-Antitrypsin panniculitis	Nodules, plaques, and cellulitis-like lesions to fluctuant abscess-like lesions that tend to ulcerate and drain, and appear on lower trunk and proximal extremities.
Pancreatic panniculitis	Occurs anywhere on the legs, with ulceration and drainage. Serum lipase and amylase often elevated. Fungal strains should be used to rule out mucormycosis or aspergillosis which can cause "ghost cell" adipocytes, especially in immunocompromised patients.
Traumatic/factitial panniculitis	Variable nodules, plaques, ulceration. Need high index of suspicion by caring physicians. Trauma can predispose to infection-induced panniculitis.
Erythema induratum/ nodular vasculitis	Crops of tender nodules and plaques on posterior lower legs, often develop ulceration and drainage.
Pyoderma gangrenosum	Can present at any location. Highly inflammatory with characteristic rolled, elevated edges. Related to trauma. Not classically confined to the lower legs.
Cutaneous/ subcutaneous lymphomas	Nodules and plaques, some with ulceration, predominantly on legs. Can be mimicked by *Borrelia burgdorferi*–induced panniculitis in an immunocompetent host.[141]
Lymphoproliferative disorders	Immunocompromised or posttransplantation patient (but not restricted to such). Must be differentiated into benign and malignant behavior/characteristics both clinically and with histopathology.

MANAGEMENT

Treatment varies depending on the suspected or known organisms and their cultures and sensitivities. In cases involving bacteria such as MTB and parasites such as *T. cruzi*, the capability to remain dormant in AT necessitates the use of appropriate antibiotics, often for extended treatment courses.[9,63]

α_1-ANTITRYPSIN PANNICULITIS

AT-A-GLANCE

Clinical

- ZZ-, MZ-, MS-, and SS-phenotype-associated panniculitis. Rare, with >60% occurring in ZZ cases.
- Low levels of α_1-antitrypsin are associated with emphysema, hepatitis, cirrhosis, vasculitis, and angioedema.

(Continued)

AT-A-GLANCE (*Continued*)

- Subcutaneous nodules mostly located on the lower abdomen, buttocks, and proximal extremities.
- Frequent ulceration, draining lesions, poor healing after surgery, and isomorphic phenomenon.

Histopathology

- Mostly lobular panniculitis without vasculitis.
- Dense inflammatory infiltrate of neutrophils and neutrophils between collagen bundles of deep reticular dermis.
- Normal fat adjacent to necrotic adipocytes.

Treatment

- Dapsone, doxycycline.
- Supplemental intravenous infusion of α_1-antitrypsin or liver transplantation for severe forms of homozygous ZZ disease.

α_1-Antitrypsin (α_1AT) is a glycoprotein made in the liver. It is a serine protease inhibitor that has widespread function as well as an acute phase reactant, increased in times of stress. α_1AT deficiency is inherited as a codominant disorder, and more than 100 alleles have been identified.[148,149] The α_1AT phenotypes are classified according to gel electrophoresis migration as F (fast), M (medium), S (slow), and Z (very slow), and null variants that do not produce any α_1AT and patients may have dysfunctional α_1AT with normal levels.[150] Deficiency in α_1AT was first seen in the 1960s with protein electrophoresis isolation.[151] The first description of panniculitis secondary to glycoprotein deficiency was in 1972.[152]

EPIDEMIOLOGY

Panniculitis uncommonly occurs in α_1AT deficiency, fewer than 50 cases having been reported[153] in ZZ, MZ, MS, and SS phenotypes. More than 60% involve ZZ phenotypes and 65% affect women.[153] Homozygous MM represents 90% to 97% of the population.[154] Presenting in all ages, panniculitis is most often seen between ages 30 and 60 years.[153,155] The estimated prevalence of α_1AT deficiency in whites is 1 per 3000 to 5000 in the United States, with incidence in white newborns similar to that of cystic fibrosis.[150] Cases also have been noted to initially present after pregnancy as acute-phase reactants (including α_1AT) rise and fall.[156] Up to 35% of cases have preceding trauma.[154]

CLINICAL FEATURES

Patients present with painful erythematous nodules and plaques, but early lesions may have a cellulitic or fluctuant abscess-type appearance (Fig. 73-8A).

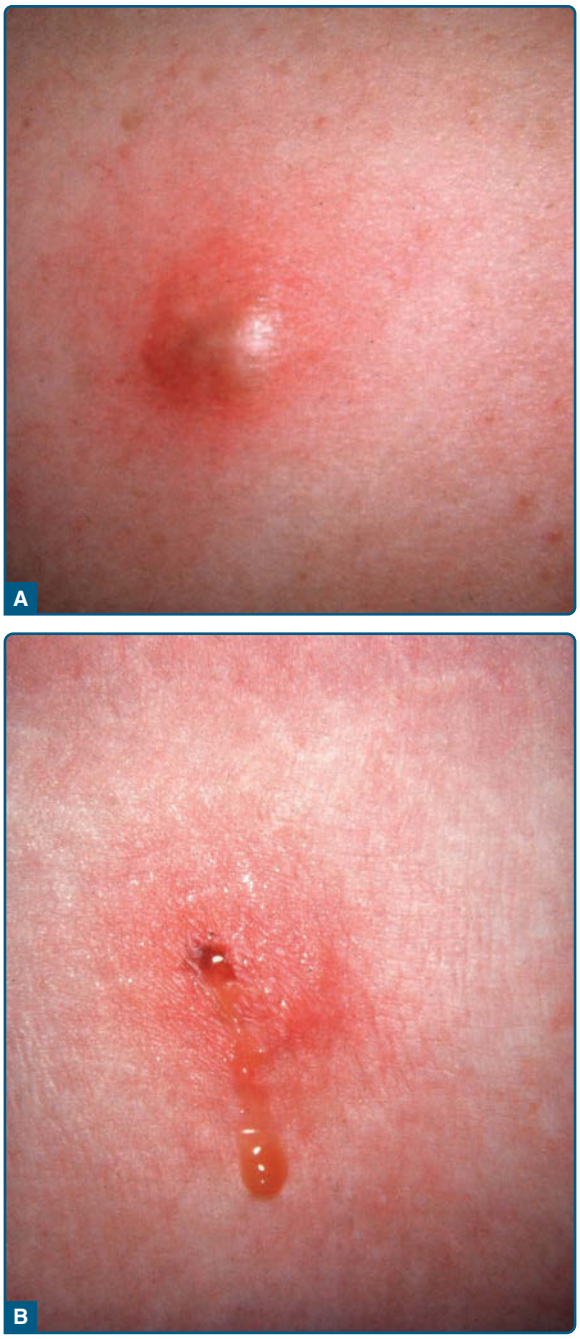

Figure 73-8 α_1-Antitrypsin deficiency–associated panniculitis. **A,** Fluctuant abscess appearance. **B,** Discharge of oily material from lesion.

Lesions may ulcerate with oily or serosanguinous discharge (Fig. 73-8B) and resolve with atrophic scars.[52] The lesions appear most commonly on the lower trunk (buttocks) (Fig. 73-9) and proximal extremities, but the lower legs and other sites may be affected.[52,153,157] α_1AT panniculitis may coexist with autoimmune disease, cancer, or infection,[158,159] thus the presence of α_1AT deficiency in association with panniculitis should not preclude a search for infection or other underlying medical problems such as autoimmune disorders or malignancies.

Figure 73-9 α_1-Antitrypsin deficiency–associated panniculitis. Nodular lesion on the buttock.

α_1AT deficiency is associated with pulmonary and hepatic disease, leading to chronic obstructive pulmonary disease, hepatic cirrhosis, or hepatocellular carcinoma[150]; the ZZ phenotype is at highest risk. There is no association of the null variant with hepatic disease, as it is the accumulation of polymerized α_1AT in the liver that induces damage, and accumulation does not occur in this variant.[150]

ETIOLOGY AND PATHOGENESIS

α_1AT is a glycoprotein that is produced and secreted mainly by hepatocytes, but also in small amounts by monocytes/macrophages and neutrophils,[160] and is known to inhibit numerous proteases. α_1AT may also help regulate complement activation.[161,162]

Homozygous MM is associated with normal levels of α_1AT (90 to 220 mg/dL),[163] whereas those homozygous for ZZ have low levels at 10% to 15% of normal, and those heterozygous for S or Z allele have levels in between.[150] ZZ is the most common phenotype to induce panniculitis. MS heterozygous individuals may have low-normal serum levels causing panniculitis clinically[164,165] and the F variant may increase lung disease[166] and is associated with panniculitis only as the FZ phenotype.[154,167]

Possible mechanisms leading to the development of α_1AT panniculitis include lack of interference with the various proteases that lead to activation of lymphocytes, macrophages, complement, activation of the autoinflammatory cascade mediated by activation of IL-1 and IL-1β,[168] and lysis and destruction of connective tissue at sites of inflammation. Trauma to adipocytes may result in release of adipokines and cytokines that are chemotactic to inflammatory cells, whose released proteases are unopposed because of the absence of the α_1AT, leading to severe damage in involved tissue.[154,169,170] Animal models of soft-tissue injury show elevated levels of IL-6 and monocyte chemotactic protein-1, and increased systemic inflammatory mediators.[169] Interestingly, a case has been reported of a patient with MM phenotype acquiring a ZZ phenotype from a donor liver; after the transplantation patient developed panniculitis.[171]

DIAGNOSIS

Histopathologic findings vary with the age and type of lesion biopsied. Early in development, nodular lesions reveal edema and degeneration of adipocytes, with ruptured and collapsed cell membranes and a perivascular mononuclear infiltrate.[172] Also reported at this stage is a mild infiltrate of neutrophils and macrophages in septa and lobules, with foci of early necrosis of subcutaneous fat. This may be accompanied by splaying of neutrophils between collagen bundles throughout the overlying reticular dermis, considered an early and distinctive diagnostic clue.[173] More advanced lesions have masses of neutrophils and histiocytes associated with necrosis and replacement of fat lobules (Fig. 73-10). Involvement

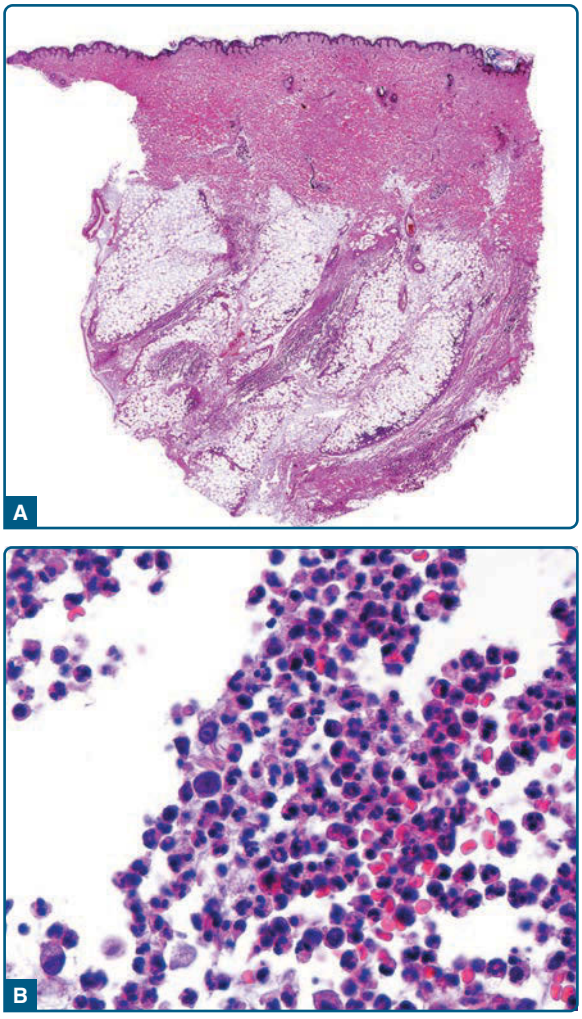

Figure 73-10 α_1-Antitrypsin deficiency–associated panniculitis. **A,.** Low-power magnification shows a mostly lobular panniculitis. **B,** High-power magnification shows dense inflammatory infiltrate of neutrophils in the fat lobule.

also may be focal, manifested by large areas of normal fat in immediate proximity to necrotic septa and fat lobules.[174] Liquefactive necrosis and dissolution of dermal collagen may be accompanied by ulceration, and degeneration of elastic tissue may lead to septal destruction and the appearance of "floating" necrotic fat lobules.[159,175] Neutrophils and necrotic adipocytes are less prevalent in late-stage lesions, with replacement by lymphocytes, foamy histiocytes, and variable amount of fibrosis within fat lobules.[159,176]

At times the histopathology fails to demonstrate the characteristic features.[177] These rare cases suggest that this disease should be considered in a patient with ulcerative lesions if pathology is not suggestive of a diagnosis with serum protein levels and phenotype testing in the correct clinical setting. Because of the complex nature of these proteins, it is best to obtain serum protein levels as well as phenotyping.[150]

DIFFERENTIAL DIAGNOSIS

Table 73-8 outlines the differential diagnosis of α_1AT. Neutrophilic panniculitis can be seen as part of the histopathology in numerous diseases: α_1AT-deficiency panniculitis, IIP, factitial or traumatic panniculitis, pancreatic panniculitis, medication-associated panniculitis (vemurafenib, ponatinib); subcutaneous sweets syndrome or neutrophilic panniculitis associated with myelodysplasia. Additionally cutaneous Crohn disease, familial Mediterranean fever, rheumatoid arthritis and cases of idiopathic neutrophilic panniculitis can cause a neutrophilic panniculitis.

TABLE 73-8
Differential Diagnosis of α_1-Antitrypsin Deficiency Panniculitis

DIAGNOSIS	CHARACTERISTICS
Infection-induced panniculitis	Erythema nodosum–like nodules, deep inflamed nodules or abscesses; older lesions may show fibrosis. Commonly on legs. Often seen in severely immunosuppressed patients with malignancies.
Factitial panniculitis	Geometric morphology. Patient often has an underlying psychiatric disturbance. Identifying foreign material is helpful. Histopathology varies based on mechanism.
Erythema induratum/ nodular vasculitis	Tender nodules and plaques on calf areas, living in an area endemic for tuberculosis (erythema induratum). Vasculitis on histopathology.
Pancreatic panniculitis	Occurs anywhere on the legs, ulceration and drainage. Serum lipase and amylase often elevated.
Subcutaneous Sweet syndrome	Erythematous nodules may be present on the face, neck, upper trunk, as well as extremities. Nodules may have vesicles, pustules or bullae. Histology with intense dermal edema; diffuse, deep neutrophilic infiltrate with karyorrhexis.
Pyoderma gangrenosum	Violaceous, undermined borders with isomorphic response.

CLINICAL COURSE AND PROGNOSIS

Cutaneous and subcutaneous necrosis can develop rapidly. Fatal cases have been reported, mainly the ZZ variant.[178,179] A rare fatal case with MZ phenotype that mimicked pyoderma gangrenosum also has been reported.[180] Prompt diagnosis and treatment of severe disease with α_1AT augmentation may significantly improve the panniculitis and may induce clinical remission, requiring augmentation therapy infusions only with recurrence. Although the panniculitis may lead to significant morbidity, the lung and liver disease associated with α_1AT deficiency are a much higher priority and comanagement with pulmonologists and hepatologists is ideal.

MANAGEMENT

Many medications have been used in the treatment of α_1AT-deficiency panniculitis including colchicine, antimalarials, dapsone, doxycycline, plasma infusion and plasma exchange, intravenous augmentation therapy of α_1AT protein, and liver transplantation.[157,181,182] Steroids, immunosuppressives, and cytotoxic agents are less effective. Doxycycline, and especially dapsone, may be useful in mild to moderate disease, especially in heterozygous cases such as MZ. Severe panniculitis unresponsive to standard treatment requires protein-replacement therapy (augmentation therapy).[183] For severe panniculitis, α_1AT infusions are recommended at 60 mg/kg, often with a few weekly infusions, with repeat infusions for recurrence.[183] Long-term supplementation may be required in severe cases.[149]

Panniculitis has also resolved with liver transplantation,[184] and panniculitis acquired after liver transplantation has successfully been treated with retransplantation.[171] It is critical to note the tendency of α_1AT-deficiency panniculitis for poor wound healing, as a case of an untreated α_1AT patient resulted in poor healing after intraabdominal surgery.[185] Not initiating augmentation therapy in a timely fashion may cause significant complications and must be considered in the appropriate clinical setting.[185] As trauma may induce lesions in one-third of patients, debridement is discouraged.[52]

PANCREATIC PANNICULITIS

AT-A-GLANCE

Clinical

- Erythematous subcutaneous nodules that often ulcerate spontaneously.
- Lower extremities (around ankles and knees) are the most frequent sites of involvement.
- Regression of pancreatitis-associated cutaneous lesions occurs as pancreas improves, but those associated with pancreatic carcinoma tend to persist; may be fatal.

Histopathology

- Mostly lobular panniculitis without vasculitis.
- Intense necrosis of adipocytes at center of fat lobule.
- "Ghost cell" adipocytes with finely granular and basophilic intracytoplasmic material.

Treatment

- Treatment of the underlying pancreatic disease.
- Additional treatment options: octreotide, plasmapheresis.
- Stop precipitating medications.

Panniculitis associated with and secondary to underlying pancreatic disease was first noted in 1883.[186] Variable pathologies of the pancreas can induce panniculitis, including acute pancreatitis, even following endoscopic retrograde cholangiopancreatography procedures.[187] The panniculitis resolves as the pancreatic disease improves, which may be difficult or impossible in cases of malignancy.

EPIDEMIOLOGY

Panniculitis in association with pancreatic disease is an uncommon occurrence, developing in 0.3% to 3% of patients with pancreatic disorders such as acute or chronic pancreatitis, pancreatic carcinoma, or pancreatic pseudocysts.[188-190] Pancreatic disease of any kind may be associated with pancreatic panniculitis. Although pancreatitis is most commonly a result of alcohol abuse, cholelithiasis, medications, trauma, and viral infections are also known etiologic factors.[190,191] Congenital pancreatic abnormalities may also cause panniculitis.[190]

CLINICAL FEATURES

The cutaneous lesions appear as crops on the lower legs, especially the periarticular areas, but are also on the arms, wrists,[192] thighs, and trunk.[188] The lesions are ill-defined erythematous to red-brown edematous and tender nodules, which may involute and resolve with atrophic hyperpigmented scars.[188] They may have central "softer" areas or may become fluctuant, abscess-like, and drain an oily material similar to lesions of α_1AT-deficiency panniculitis (Fig. 73-11).[188] The cutaneous panniculitis may precede the diagnosis of the associated pancreatic disease by weeks to months in up to 45% of patients.[188,191]

Extracutaneous manifestations include periarticular fat necrosis with concomitant arthritis,[188,193] and painful medullary fat necrosis in bone.[194,195] Monoarticular or oligoarticular arthritis secondary to periarticular fat necrosis may be present in more than half of patients.[188] This triad of pancreatic disease, panniculitis, and polyarthritis (PPP syndrome) is very rare and is associated with both pancreatitis and pancreatic carcinoma.[194,196] Osteonecrosis may also develop as enzymes extend to the joint capsules and cause purulent joints.[195]

Pleural effusions and serositis also may be seen with pancreatic panniculitis,[194,197] and pleural effusions are associated with a high mortality rate.[197] Eosinophilia may be seen in pancreatic panniculitis resulting from either pancreatitis or pancreatic malignancies.[190,197] A pancreatic tumor (or pancreatitis) in association with panniculitis, polyarthritis, and eosinophilia (the Schmid triad) imparts a poor prognosis.[198,199] An important complication of pancreatic panniculitis is secondary infection.[200]

ETIOLOGY AND PATHOGENESIS

Pancreatic panniculitis has generally been attributed to release of pancreatic enzymes such as lipase, amylase, and trypsin into the circulation, promoting vascular permeability and damage, leading to release of fatty

Figure 73-11 Pancreatic panniculitis. Erythematous subcutaneous nodules that ulcerate and exude an oily material.

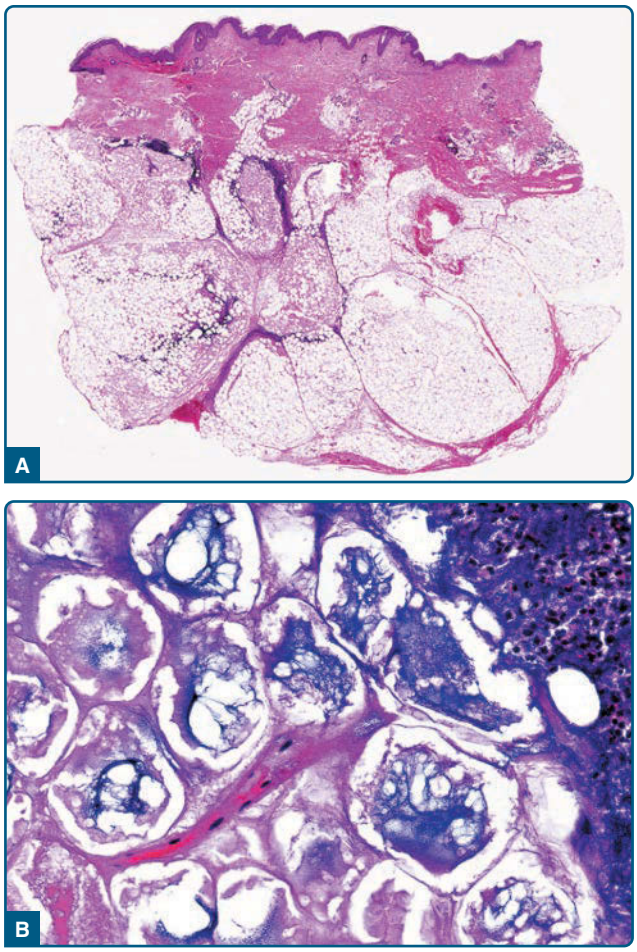

Figure 73-12 Pancreatic panniculitis. **A,** Low-power magnification shows a mostly lobular panniculitis with adipocyte necrosis at the center of the fat lobule. **B,** Higher-power magnification shows ghost adipocytes, necrotic adipocytes without nuclei and with cytoplasmic fine, granular basophilic material resulting from calcification.

acids from adipocytes and subsequent fat necrosis.[194,201] However, there are reports of pancreatic panniculitis in the setting of normal serum levels of pancreatic enzymes.[188] Additionally, incubation of normal AT with amylase, lipase and a pancreatitis patient's serum failed to induce fat necrosis in vitro.[202] Resistin and leptin are potential markers of extrapancreatic fat necrosis.[203]

Other than the more common causes of pancreatitis, pancreatic panniculitis may be seen in association with pancreatitis following renal or combined renal and pancreatic transplantation,[204,205] liver transplantation,[206] with SLE with hemophagocytic syndrome,[207] as well as HIV with hemophagocytic syndrome.[208] Pancreatic cancer and metastatic disease can cause a panniculitis that improves with resection of the malignant tissue.[209] Panniculitis also may be associated with acute fatty liver of pregnancy and HELLP syndrome (hemolysis, elevated liver enzymes, low platelet count).[210] Rare drug-induced cases have been reported, including to L-asparaginase in the setting of treating acute lymphoblastic leukemia,[211] and treatment of hepatitis C.[212] Identical histopathology has been seen at the site of subcutaneous interferon β injections.[213]

DIAGNOSIS

Developed lesions of pancreatic panniculitis demonstrate lobular fat necrosis (Fig. 73-12A). Adipocytes lose their nuclei but maintain peripheral outlines, forming characteristic "ghost cells" (Fig. 73-12B). Saponification causes calcification, producing fine, granular basophilic deposits within and around necrotic adipocytes. The ghost cells are frequently aggregated in small clusters at the center of fat lobules, with a peripheral inflammatory infiltrate of neutrophils.[52] In older lesions, necrosis and ghost cells are replaced by foamy histiocytes, multinucleated giant cells, lymphocytes, and, eventually, fibrosis.[52,214]

DIFFERENTIAL DIAGNOSIS

Table 73-9 outlines the differential diagnosis of pancreatic panniculitis.

TABLE 73-9
Differential Diagnosis of Pancreatic Panniculitis

DIAGNOSIS	CHARACTERISTICS
α_1-Antitrypsin deficiency	Tender, erythematous nodules, often with a suppurative exudate. Located on the abdomen, buttocks, and proximal extremities.
Erythema induratum/nodular vasculitis	Tender nodules and plaques on calf areas, living in an area endemic for tuberculosis (erythema induratum). Vasculitis present on histopathology.
Cutaneous polyarteritis nodosa	Nodules in association with livedo reticularis and arterial inflammation on histology, possibly with neuropathy.
Infection-induced panniculitis	Erythema nodosum–like nodules, deep inflamed nodules or abscesses; older lesions may show fibrosis. Most commonly on legs. Often seen in severely immunosuppressed patients. "Ghost cell" changes and urate crystals secondary to fungal enzymatic changes can be seen in mucormycosis and aspergillosis associated pancreatitis.[126,134]
Pyoderma gangrenosum	Violaceous, undermined borders with isomorphic response.
Malignancies	Persistent, worsening disease, often with systemic symptoms. Presence of cutaneous T-cell lymphoma, angiosarcoma, or other sarcomas on leg with/without venous hypertension. More likely in patients with solid-organ transplants or other immunosuppressed states.
Behçet syndrome occurring in the fat	Vasculitis occurring in the fat tissue, either lymphocytic or neutrophilic, small arterial involvement with either lobular or mixed lobular and septal pattern.

CLINICAL COURSE AND PROGNOSIS

Overall, when the pancreatic pathology resolves, the cutaneous symptoms subsequently improve. Panniculitis associated with pancreatic disease may be fatal, with a mortality rate of 24%[196] to 42%,[197] and mortality rates near 100% in those with pancreatic carcinoma. Acute pancreatitis may be treated and may resolve promptly with supportive care, however pancreatic carcinoma and associated panniculitis is far more difficult to treat.

MANAGEMENT

The focus of treatment of pancreatic panniculitis is on the underlying pancreatic disease. Care is often supportive. Because patients may lack abdominal symptoms at presentation, pancreatic panniculitis should be considered in any patient with panniculitis. Octreotide,[215] a somatostatin analog, and plasmapheresis are associated with resolution of pancreatic panniculitis.[216] Treating pancreatic cancer with surgical resection and combination chemotherapy may ameliorate the cutaneous findings.[192]

LUPUS PANNICULITIS

AT-A-GLANCE

Clinical

- Erythematous nodules on face, shoulders, upper arms, scalp, chest, buttocks; rarely on lower extremities.
- Persistent areas of lipoatrophy in regressed lesions.

Histopathology

- Mostly lobular panniculitis (with or without lymphocytic vasculitis).
- Lobular lymphocytic infiltrate; may include plasma cells and eosinophils.
- Lymphoid follicles and sclerotic collagen bundles within septae.
- Hyaline necrosis and atrophy of entire fat lobule in late-stage lesions.
- Interface changes of discoid lupus erythematosus in 20% to 30% of cases.

Treatment

- Antimalarials, thalidomide, topical steroids.
- If active and severely inflamed, short oral courses of corticosteroids.
- Dapsone, cyclosporine, methotrexate, intravenous immunoglobulin, rituximab, azathioprine, tacrolimus.

Lupus erythematosus panniculitis (LEP), also termed *lupus profundus*, *subcutaneous lupus erythematosus*, and *Irrgang-Kaposi syndrome*, was first described in 1883 by Kaposi and named lupus erythematous profundus by Irrgang in 1940.[217] Overall, it is very rare, even among the lupus erythematosus cohort.

EPIDEMIOLOGY

LEP is a rare variant of lupus erythematosus, presenting as inflammation in the AT. LEP may appear as the sole manifestation of lupus erythematosus or may occur prior to or after the onset of discoid lupus erythematosus (DLE) or SLE.[218,219] The incidence of SLE in patients with LEP is reported to range from 10% to 41%.[220] DLE in patients with LEP has a higher incidence, ranging from 21% to 60%.[218] Among those who have SLE, only 2% to 5% will have LEP.[218] Although rare, LEP occurs worldwide, more frequently among women than men, with a female-to-male ratio of approximately 4:1.[221] LEP is most common between the ages of 30 and 60 years, but may rarely be seen in childhood or even as neonatal lupus.[222,223] When present in

association with SLE, LEP tends to occur with less-severe SLE.[221,224] Patients with LEP may have other autoimmune disorders such as Sjögren syndrome and rheumatoid arthritis.[218] Raynaud phenomenon is present in 10% of LEP patients.[221]

Other associations with LEP include TNF inhibitors, which caused SLE-like reactions as well as LEP in a patient with rheumatoid arthritis.[225] Treatment of a female patient with hairy cell leukemia with interferon has been associated with emergence of disseminated ulcerating lupus panniculitis.[226]

CLINICAL FEATURES

LEP lesions may be tender and painful and usually appear on the lateral upper arms, shoulders, face, scalp, hips, buttocks, breasts, and, rarely, on the lower extremities (Fig. 73-13).[218,224] Orbital involvement may present with periorbital edema,[227] and Blaschko linear patterns have been reported.[228] The lesions are deep subcutaneous nodules either with or without surface changes, including erythema and DLE features such as atrophy, hyperkeratosis, hyperpigmentation or hypopigmentation, telangiectasia, follicular plugging, and focal necrosis.[218] Ulceration can be seen in up to 28% of cases.[221] Areas of ongoing indurated panniculitis may coexist with DLE and lead to subcutaneous atrophy and scar formation on the cutaneous surface. Atrophy of facial lesions leads to severe cosmetic alterations. Lesions may be induced by trauma, including injections and surgical procedures.[218,224]

Serology may be normal or abnormal.[218,224] Patients with associated SLE tend to have higher positive antinuclear antibody (ANA) titers[224] and C4 deficiency may be found.[218,229] Other laboratory findings may include rheumatoid factor, false-positive Venereal Disease Research Laboratory, ANA, leukopenia, anemia, or thrombocytopenia.[230] Antiphospholipid antibodies may be positive, and if thrombi are noted on histopathology, testing for antiphospholipid antibodies should be performed.[231]

Lupus mastitis is a rare form of lupus panniculitis involving the breast. It may clinically mimic Paget disease. On mammography there is calcification paralleling the course of fat necrosis, and early deposition is concerning for malignancy. MRI shows the extent of lupus mastitis and nonspecific fat necrosis; adding contrast may significantly aid in diagnosis.[232]

Figure 73-13 Lupus panniculitis. **A,** Atrophic upper arm lesion with superficial hyperpigmentation. **B,** With superimposed discoid lupus erythematosus and ulceration.

ETIOLOGY AND PATHOGENESIS

The innate immune system plays a significant role in the development of LEP. Adipocytes are important cells of the innate immune system expressing TLR1, TLR2, TLR3, TLR4, and TLR6.[233] The stromovascular fraction of AT expresses TLR5, TLR7, TLR8, TLR9, and TLR10.[233] In SLE, TLR7 and TLR9 recognize RNA and DNA patterns, respectively, and appear to provide a mechanism for recognition of self-DNA or self-RNA, with subsequent activation of the adaptive immune system and production of autoantibodies to nucleic acids and proteins bound to nucleic acids.[234,235] Inhibitors of TLR7 and TLR9 can prevent disease in mouse models of autoimmunity.[234] Genetic variations in TLR9 receptor predispose to SLE[236] and regression of SLE was seen in a patient who acquired TLR7 and TLR9 defects and antibody deficiency.[237] Both receptors have

been suggested as therapeutic targets.[234,235] Interestingly, hydroxychloroquine blocks intracellular TLRs in vitro.[238]

DIAGNOSIS

Histopathologic features of DLE are seen in approximately 20% to 30% of LEP cases. These features include vacuolization of the basal cell layer, thickened basement membrane, mucin deposition between dermal collagen bundles, and a superficial and deep perivascular inflammatory infiltrate of lymphocytes.[52,224] The AT shows a lobular or mixed lobular and septal panniculitis, with lymphocytes, formation of lymphoid follicles (20% germinal centers),[218] variable hyaline fat necrosis,[52,224] and hyalinized and sclerotic septal collagen bundles associated with an interstitial infiltrate of lymphocytes and plasma cells.[52] Karyorrhexis, lymphocytic vasculitis, and membranocystic changes may be seen.[218] Calcification and/or fibrin thrombi also may be noted in 10% of cases.[224] Eosinophils may be seen in 22% to 41% of cases.[218]

Direct immunofluorescence of blood vessels and basement membrane demonstrates positive findings in almost all SLE-associated LEP, and a high percentage of positive findings in LEP without SLE.[224] Immunohistochemical studies of LEP show a predominance of lymphocytes, with both αβ T-helper (CD4+) and cytotoxic (CD8+) lymphocytes mixed with (CD20+) B cells and plasma cells.[220]

In cases with only AT involvement and without other features specific for DLE or SLE, differentiation from subcutaneous T-cell lymphoma is essential and difficult.[239] Anaplastic large-cell lymphoma may also have overlapping features with LEP.[240] There are reports of a spectrum of subcutaneous lymphoid dyscrasias, with lesions originally diagnosed as LEP, progressing to indeterminate lymphocytic lobular panniculitis and eventuating in a diagnosis of SPTCL.[241] Lymphocytic atypia and lymphocytic rimming is seen in SPTCL.[242] SPTCL may coexist with LEP, and must be distinguished from atypical lymphocytic panniculitis in which clonal T-cell infiltrates are associated with indolent behavior.[243-245] There may be epidermal involvement in SPTCL,[246-248] making the distinction more difficult from LEP. Lack of adipocyte membrane disruption suggests LEP.[242] Hyaline lipomembranous change is common in LEP, but seen infrequently in SPTCL.[242]

In 1 study, high levels of the interferon-α protein marker human myxovirus resistance protein 1 (MxA) were found in the infiltrate of LEP lesions.[249] Minimal, less than 20% staining, with MxA suggests a lymphoma.[249] CCL5 (the ligand of the receptor often expressed in adipocytes CCR5) expression is much higher in lymphomas compared to LEP.[250] Ki-67 staining of greater than 20% and focal areas of increased uptake are more suggestive of SPTCL.[242,251] Presence of CD123-positive staining also suggests LEP[242] and is an important prognostic indicator.

Even though serology is not specific it should be added to the workup, because SLE will require further treatment. ANA serology has a high false-positive rate, and may be positive in patients with SPTCL.[242]

DIFFERENTIAL DIAGNOSIS

Table 73-10 outlines the differential diagnosis of LEP.

CLINICAL COURSE AND PROGNOSIS

LEP is a chronic inflammatory disorder with periodic flares or long remissions. Average disease duration is 6 years, with a range of less than 1 year to 38 years.[221] CD123 immunohistochemical staining can be a helpful prognostic indicator, as a higher percentage of CD123 positive cells has a greater response to steroid therapy.[252] Prompt treatment aids in reducing permanent and potentially disfiguring scarring.

TABLE 73-10
Differential Diagnosis of Lupus Erythematosus Panniculitis

DIAGNOSIS	CHARACTERISTICS
Tumid lupus	Erythematous, edematous plaques mainly in photoexposed areas with extensive mucin deposition on histopathology without epidermal change.
Cutaneous lymphoma (including subcutaneous panniculitis-like T-cell lymphoma [SPTCL])	Persistent, worsening disease, often with systemic symptoms. Histopathology is critical if no surface changes or additional signs or symptoms suggest lupus erythematosus panniculitis (LEP). LEP more often involves the face, whereas SPTCL more often involves the scalp, lower extremities, and buttocks.[242] Lymphocytic atypia and lymphocytic rimming is seen in SPTCL. Up to 19% of SPTCL cases with an αβ phenotype can have an associated autoimmune disorder with lupus erythematosus being the most common.[247]
Erythema induratum/nodular vasculitis	Tender nodules and plaques on calf areas, living in an area endemic for tuberculosis (erythema induratum). Vasculitis on histopathology.
Morphea/systemic sclerosis	Early lymphocytic panniculitis with subsequent subcutaneous septal and dermal sclerosis. In association with clinical features of morphea and systemic sclerosis.
Pancreatic panniculitis	Occurs most commonly on the legs with ulceration and drainage. Serum lipase and amylase often elevated.

MANAGEMENT

Treatment is challenging, as is assessment of response to therapy, other than clinical assessment of erythema, induration, and tenderness. Just as in other forms of cutaneous lupus, sun protection and avoidance are often recommended.[253] Antimalarials are the first-line treatment of LEP[218,254] and may be the only medications needed.[254] When monotherapy with hydroxychloroquine is ineffective, combination with quinacrine has been used successfully but is difficult to obtain.[218,255] Antimalarials interfere with both inflammatory cytokines[256] and TLRs.[238] Antimalarials have a diminished effect in smokers.[257,258]

Topical steroids also may be successful, particularly under occlusion.[253] Systemic corticosteroids are effective and useful if the disease is active and severe,[224] and used as short courses or during antimalarial initiation. Long-term use of corticosteroids is avoided because of the chronic nature of LEP. Intralesional steroids are not recommended as the trauma may induce further activation as well as atrophy. Other treatments include dapsone,[259] thalidomide,[260] cyclosporine,[261] methotrexate,[262] azathioprine,[253] intravenous immunoglobulin (IVIG),[262] and tacrolimus.[263] Severe, recalcitrant cases may require rituximab[264] or infliximab, although caution must be advised with this modality because of its association with known activation of lupus erythematosus in some instances.[265] Considering the common calcification seen in LEP histopathology, calcium-channel blockers such as diltiazem are effective adjuncts, improving the calcinosis.[266]

CYTOPHAGIC HISTIOCYTIC PANNICULITIS

AT-A-GLANCE

Clinical

- Subcutaneous erythematous to violaceous plaques and nodules on extremities, trunk, and less frequently elsewhere; lesions may ulcerate.
- Fever, hepatosplenomegaly, 2 or more cytopenias; hemocytophagocytosis in bone marrow, lymph nodes, liver, or CNS.
- Hypertriglyceridemia, ferritin >500 mg/L; increased soluble CD25, CD163 levels.
- Low or absent natural killer cell activity, fibrinogen levels.
- Potentially rapidly fatal disease course if associated with hemophagocytic lymphohistiocytosis and macrophage activation syndrome; intermittent remissions and exacerbations prior to death; or nonfatal acute or intermittent course.

Histopathologic

- Mostly lobular panniculitis without vasculitis.
- Histiocytes and mature lymphocytes within fat lobules with necrosis of adipocytes.
- "Bean-bag" cells: macrophages that contain intact or fragmented erythrocytes, leukocytes or platelets within their cytoplasm; may be focal.

Treatment

- First-line treatment is immunosuppression with cyclosporine and corticosteroids. Other options include tacrolimus, azathioprine, anakinra, cyclophosphamide with IVIG.
- Cytophagic histiocytic panniculitis with hemophagocytic lymphohistiocytosis or macrophage activation syndrome requires combined chemotherapy and aggressive supportive care.
- Diagnose and treat associated malignancies or infections.

Cytophagic histiocytic panniculitis (CHP) is a rare panniculitis that varies in duration from 3 months to 27 years and may be fatal.[267-269] It may be an aggressive disease requiring chemotherapy if related to hemophagocytic lymphohistiocytosis (HLH) or macrophage activation syndrome, but a more indolent course requiring immunosuppressant therapy with an excellent remission rate is also reported. Of note, HLH may be primary (genetic) or secondary (to infections, autoimmune disease), but CHP is only secondary in etiology. CHP itself may represent a "smoldering" lymphoma rather than a purely inflammatory disease.[270]

EPIDEMIOLOGY

CHP is rare, but is seen in adults, adolescents, and children. The oldest patient reported was 80[271] years old at time of diagnosis. Children affected include one with a perforin gene mutation (likely suffering from familial HLH).[272] One adult with familial multiple lipomatosis syndrome developed CHP at age 43 years.[273] As a consequence of the variable etiologies, epidemiology is largely based on the cause of CHP.

CLINICAL FEATURES

Lesions are subcutaneous plaques and nodules of variable sizes that may coalesce on the extremities and trunk and less frequently on the head and neck (Fig. 73-14).[267,274,275] Mucosal involvement is rare.[275] Features vary from skin colored to erythematous, purpuric, ecchymotic, or hyperpigmented; flat or raised; well circumscribed or diffuse; and indurated to fluctuant or ulcerated.[269,274] Individual lesions can reach 20 cm in diameter.[276]

Fulminant forms of the disease may be associated with fever, hepatosplenomegaly, lymphadenopathy, serosal effusions, pancytopenia, intravascular coagulation,

Figure 73-14 Cytophagic histiocytic panniculitis. Multiple erythematous plaques and nodules on the lower extremity.

liver failure, hemorrhagic diatheses, and death.[268,269,274,277] Laboratory tests should include a complete blood count with differential, liver function, ferritin, erythrocyte sedimentation rate, and lipid profile. Interestingly, erythrocyte sedimentation rate is often normal or low.[275] Soluble hemoglobin-haptoglobin scavenger receptor CD163 serum levels are associated with hemophagocytic disease activity and correlate with serum ferritin levels.[278] Serum CD163 level in CHP is much higher than levels seen in sepsis and in normal controls.[278] Other tests are determined by history and physical findings and the clinical course. A positive ANA may be detected and does not alone prove LEP.[279,280]

As CHP may cause hypertriglyceridemia, highly elevated serum lipid levels cause pancreatitis, which may improve with plasmapheresis.[281] Elevated cholesterol levels may persist for years after improvement of the panniculitis.[279] The elevated triglycerides during the hemophagocytic disease are secondary to inhibition of lipoprotein lipase, leading to IL-6, IL-1, and TNF secretion from macrophages.[281,282]

ETIOLOGY AND PATHOGENESIS

CHP may belong to a spectrum of panniculitides with benign lymphocytic infiltrate that develop reactive HLH/macrophage activation syndrome.[269,271,275] Secondary HLH is associated with infections, connective tissue diseases, and malignancies, or precipitated by medication.[283-285] Infections associated with HLH/macrophage activation syndrome include Epstein-Barr virus, cytomegalovirus, parvovirus, varicella, human herpesviruses 6 and 8, avian influenza, rubella, adenovirus, hepatitis B, HIV, bacterial, acid-fast bacterial, parasitic, and fungal infections.[285,286] CHP has presented after H1N1 influenza vaccine[287] and visceral leishmaniasis.[288] Trauma-induced CHP also has been reported.[280]

HLH is considered an autoinflammatory disease, with impairment of cytolytic T-cell and natural killer cell functions leading to a compensatory cascade of potentially fatal reactions.[289] Underlying gene mutations affect vesicular transport, granule shedding, and pore-forming cytolytic proteins involved in granule-mediated cytotoxicity.[251,286,289,290] Inability of the cytotoxic cells to eliminate infected cells leads to increased activation and proliferation of T cells, which produce high levels of cytokines that stimulate and activate macrophages without the ability to terminate the reaction via apoptosis.[251,289]

Both LEP and CHP may, in some cases, fit into a spectrum of subcuticular lymphoid dyscrasia, ranging from benign reactive changes to SPTCL, including atypical indeterminate lobular panniculitis.[241-244,270] Immunophenotyping and genotyping studies are important for differentiating malignant SPTCL, which may have αβ or γδ rearranged T cells, from CHP with benign T cells. Monitoring biopsies is prudent as transformation has been reported.[277] Both SPTCL types can be associated with hemophagocytic syndrome/HLH and present with CHP; the incidence of HLH is much higher among γδ cases than among αβ cases.[247]

DIAGNOSIS

Multiple biopsies may be needed to establish the diagnosis of CHP as cytophagocytosis on histopathology may be focal. The histopathology is principally a lobular panniculitis (Fig. 73-15A) with fat lobules containing an infiltrate of histiocytes and mature lymphocytes with variable plasma cells, neutrophils, and eosinophils.[52] Phagocytic histiocytes contain intact or fragmented cells and nuclear debris within their cytoplasm; this represents the characteristic "beanbag cell" (Fig. 73-15B).[52] This is unlike emperipolesis (the presence of an intact cell within the cytoplasm of another cell) in which inflammatory cells pass through a histiocyte and no nuclear debris is seen.[291]

Immunohistochemical studies demonstrate that cytophagic histiocytes express histiocytic markers such as CD68, whereas most lymphocytes show a T-cell immunophenotype. The presence of atypical lymphocytes, lymphocytic rimming of adipocytes, and clonality are concerning for lymphoma.[242,247] In rapidly progressive cases of CHP with HLH, cytophagic features can also be seen in internal organs including

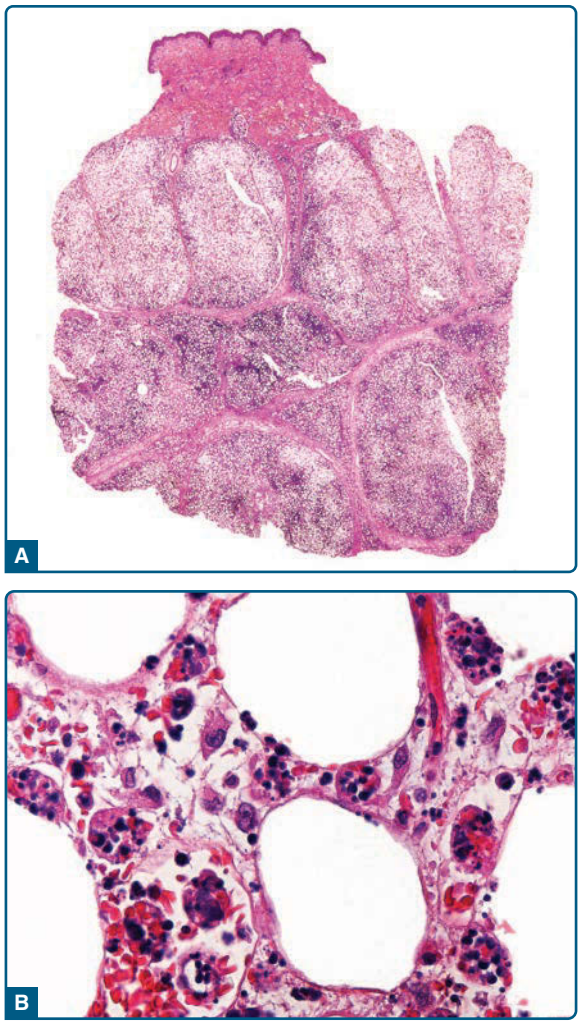

Figure 73-15 Cytophagic histiocytic panniculitis. **A,** Low-power magnification histologic image shows lobular panniculitis. **B.** Cytophagocytic "bean bag" cells in the adipose tissue.

lymph nodes, spleen, liver, and bone marrow, and in cerebrospinal fluid fluid.[267-269,274,277]

DIFFERENTIAL DIAGNOSIS

Table 73-11 outlines the differential diagnosis of CHP.

CLINICAL COURSE AND PROGNOSIS

Patients may have a rapidly fatal disease course, a longer disease course with intermittent remissions and exacerbations for many years prior to death, or a nonfatal acute or intermittent course responsive to treatment.[268,274,277,292] Patients with the benign, nonfatal course were found to have less-severe laboratory abnormalities.[292] Prompt treatment with corticosteroids and cyclosporine in the appropriate patient may reduce a 70% mortality rate to near 0%.[267,279] The panniculitis by itself is not always a marker of disease severity as 1 patient with CHP had resolution of cutaneous lesions with high-dose corticosteroid and cyclosporine therapy followed by recurrence 5 months later, progression, and death with generalized HLH.[293] This 1998 case was the first report of the failure of cyclosporine, and highlights the need for careful followup for systemic involvement even after an apparent therapeutic response.[293]

TABLE 73-11
Differential Diagnosis of Cytophagic Histiocytic Panniculitis

DIAGNOSIS	CHARACTERISTICS
α_1-Antitrypsin deficiency	Tender, erythematous nodules that often have a suppurative exudate. Located on the lower abdomen, buttocks, and proximal extremities. Serology for enzymatic levels and phenotype helpful.
Erythema induratum/ nodular vasculitis	Tender nodules and plaques on calf areas, living in an area endemic for tuberculosis (erythema induratum). Vasculitis present on histopathology.
Cutaneous polyarteritis nodosa	Nodules in association with livedo reticularis and arterial inflammation on histology, possibly with neuropathy.
Infection-induced panniculitis	Erythema nodosum–like nodules, deep and inflamed nodules, or abscesses; older lesions may show fibrosis. Most commonly on legs. Systemic symptoms possible with fever. Often seen in severely immunosuppressed patients with malignancies. "Ghost cell" changes and urate crystals secondary to fungal enzymatic changes can be seen in mucormycosis and aspergillosis associated pancreatitis.[126,134]
Pyoderma gangrenosum	Violaceous, undermined borders with isomorphic response. Rare to mild systemic symptoms.
Malignancies	Persistent, worsening disease, often with systemic symptoms. Subcutaneous panniculitis-like T-cell lymphoma must be distinguished from atypical lymphocytic panniculitis. Presence of cutaneous T-cell lymphoma, angiosarcoma, or other sarcomas on leg with or without venous hypertension. More likely, but not exclusively, in patients with solid-organ transplants or other immunosuppressed states. Systemic symptoms possible.

MANAGEMENT

Multidisciplinary care is critical in CHP management owing to its potentially rapidly fatal course. Hospitalization may be required for a rapid workup and institution of treatment. In HLH associated with an

infection, treating the pathogen may result in recovery, but this is unpredictable.[294]

Treatment of CHP includes immunosuppressive, immunomodulating, or cytotoxic agents that target activated macrophages/histiocytes (steroids, etoposide, high-dose IVIG) and T cells (steroids, cyclosporine, antithymocyte globulin).[275] Among the published cases, cyclosporine and corticosteroids are often used and are often successful. In patients with both SLE and CHP, the combination of corticosteroids with cyclosporine may induce remission of both diseases.[276]

Cyclosporine-resistant disease also has been reported to respond to tacrolimus.[295] Tacrolimus may be an option for patients who have adverse effects with cyclosporine, and it may be a more realistic long-term treatment option for cases of CHP that are not able to taper off therapy.[296] Resistant cases may warrant a trial with cyclophosphamide and IVIG.[297] Addition of combined chemotherapy may be helpful.[275,298] Multiple rounds of combination chemotherapy or autologous stem cell transplantation may be required to induce remission.[299]

Cyclosporine, and cyclosporine with etoposide,[280] are effective regimens for CHP in both children and adults. In 2 pediatric patients, who developed CHP after viral infections, focal areas within the histopathology suggested SPTCL versus a reactive T-cell proliferation with in situ T-cell clonality; however, cyclosporine with corticosteroids induced remission for 69 and 29 months, respectively.[300] This report highlights the need to discriminate between CHP associated with a nonmalignant condition or with SPTCL. This report also suggests that when the diagnosis suggests a reactive T-cell proliferation rather than true lymphoma, cyclosporine may be used because nonmalignant CHP often improves with cyclosporine and prednisone whereas CHP with SPTCL is best treated aggressively.[300] One adolescent with lifelong CHP and severe HLH experienced improvement signs with anakinra, an IL-1 receptor antagonist, in addition to prednisone and cyclosporine.[301]

SUBCUTANEOUS FAT NECROSIS OF THE NEWBORN

AT-A-GLANCE

Clinical

- Circumscribed, red to violaceous, subcutaneous nodules, or plaques with predilection for buttocks, shoulders, cheeks, and thighs.
- Hypercalcemia in some cases, even presenting after the acute episode. Rarely, hypertriglyceridemia, hypoglycemia, thrombocytopenia, anemia.

Histopathology

- Mostly lobular panniculitis without vasculitis.
- Dense inflammatory infiltrate of lymphocytes, histiocytes, lipophages, and multinucleated giant cells.
- Needle-shaped clefts, often in radial array, within cytoplasm of histiocytes and multinucleated giant cells.

Treatment

- Nodules and plaques usually resolve spontaneously.
- Monitor for hypercalcemia for 6 months following onset, treat if hypercalcemia develops.

Subcutaneous fat necrosis of the newborn (SCFN) is a rare panniculitis that occurs in the first few days to weeks of life. Nearly all cases resolve spontaneously. The most common complication is hypercalcemia. Additional secondary effects include hypertriglyceridemia, hypoglycemia, thrombocytopenia, and anemia.[302-304]

EPIDEMIOLOGY

SCFN presents in full-term or postterm newborns (preterm cases also have been noted[305]) with a preceding history of perinatal complications, including meconium aspiration, asphyxia, hypothermia (eg, for cardiac surgery or ice pack application for supraventricular tachycardia, or for hypoxic ischemic encephalopathy complicating lack of respiratory effort[306]), hypoxemia, seizures, sepsis, gestational diabetes, preeclampsia, factors requiring cesarean section, forceps delivery, severe neonatal anemia, maternal cocaine use, and/or failure to thrive.[302-304,307,308] Within the population requiring hypothermic treatment of asphyxia, macrosomia and hemodynamic instability represent additional risk factors.[309]

CLINICAL FEATURES

Lesions are sharply demarcated, erythematous to violaceous, firm, indurated nodules or plaques located on the back, shoulders, arms, buttocks, thighs, or face, but rarely on the anterior trunk or the anterolateral shins (Fig. 73-16A).[303,306,307] Visceral involvement has been reported with MRI findings in one case consistent with abdominal wall, perihepatic, perisplenic, and perirenal fat necrosis.[310] The subcutaneous nodules range in size from several millimeters to up to 11 cm in diameter,[311,312] may be single or multiple, and are usually well defined.[311] Rarely, fluctuant nodules may drain an oily or chalky white material.[312] Larger blisters may form and may need drainage.[306] Lesions are not warm to touch[311] and are commonly painless; rarely, morphine is needed for pain control.[311] While often asymptomatic, the location and the size of the

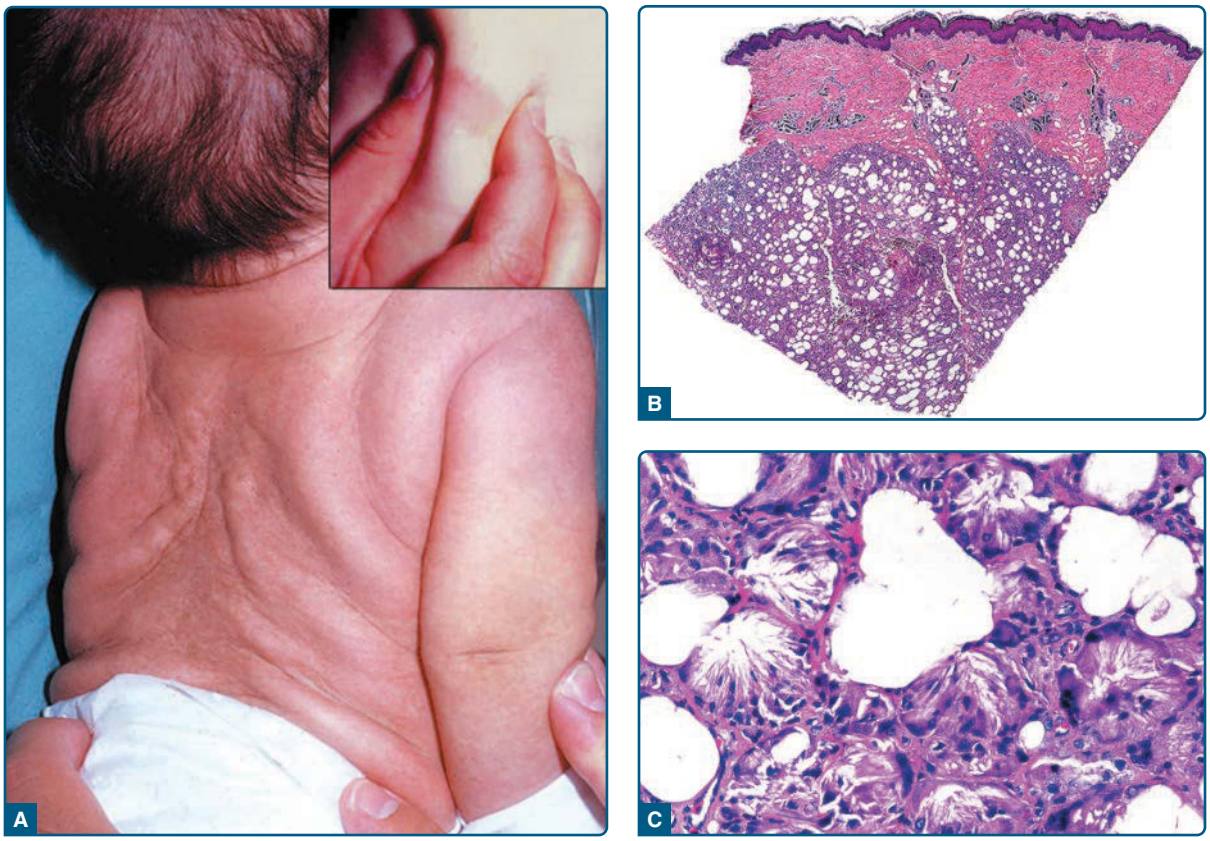

Figure 73-16 Subcutaneous fat necrosis of the newborn. **A,** Circumscribed, indurated subcutaneous nodules on the back. **B,** Low-power magnification histology shows mostly lobular panniculitis. **C,** Higher-power magnification shows needle-shaped clefts of adipocytes, histiocytes, and multinucleated giant cells.

lesions can have local mass effect, such as in a case of radial nerve palsy secondary to SCFN that improved spontaneously within 10 weeks.[313]

There are several metabolic complications that may occur during and even after resolution of the panniculitis.[303] These include hypercalcemia (which affects 36% to 56% of patients with SCFN),[314] thrombocytopenia,[302,303] hypertriglyceridemia (likely related to the fat necrosis), hypoglycemia,[303,304] and anemia.[303] It is unclear if the glucose and hematologic abnormalities are secondary to the SCFN or to the initial insult that provokes the SCFN, as they may precede onset of cutaneous findings.[305,315] Hypercalcemia may be asymptomatic,[304] or may progress to symptomatic failure to thrive, irritability, fever, vomiting, hypotonia, seizures, polyuria and polydipsia, and even death.[311,312] Soft tissue and organ calcification may occur with variable outcomes.[302,311]

ETIOLOGY AND PATHOGENESIS

The ultimate cause of SCFN is not known, but hypothermia and hypoxia are presumed to be involved. Therapeutic hypothermia is used in pediatric intensive care in cases of asphyxia. It is unclear whether the hypothermia assists with the process or is a direct cause of the SCFN.[316] Cold exposure during surgical procedures may also induce SCFN.[317] Possible explanations have included a biochemical defect in the composition or metabolism of neonatal fat, leading to crystallization, fat necrosis, and subsequent inflammation after cold stress.[303,318] The hypercalcemia may be related to increased 25-hydroxyvitamin D_3–1α hydroxylase within the granulomatous infiltrates.[319]

Brown adipose tissue (BAT) in neonates rapidly converts fat stores to heat under conditions of cold stress.[320] SCFN affecting BAT has been confirmed with immunohistochemical staining, as well as uncoupling protein isoform 1, found specifically in BAT.[321] The BAT cells generate heat. The mechanism is complex, and uses uncoupling protein isoform 1, cytosolic fatty acids, and Ca^{2+} ions.[322]

DIAGNOSIS

Characteristically, SCFN is a mostly lobular panniculitis (see Fig. 73-16B), with focal necrosis of the fat lobule and a dense inflammatory infiltrate of lymphocytes, histiocytes, and foreign-body giant cells; a few eosinophils are possible.[52,303,323]

A primarily neutrophilic infiltrate may mimic an infection, especially if lesions are biopsied when 1 day

old.[324] Many adipocytes retain their cellular outlines, but contain fine eosinophilic strands and granules, as well as needle-shaped clefts in radial array (see Fig. 73-16C).[52,303,323] On frozen section, these clefts are occupied by doubly refractile crystals, representing triglycerides. Similar clefts and crystals also may be seen within the cytoplasm of the multinucleated giant cells.[52,303,323] Late-stage lesions may demonstrate fibrosis and calcified areas within fat lobules.[52,311] Fine-needle aspiration may be less painful, more cost-effective, and a more rapid diagnosis.[325,326] Ultrasonography also may be an adjunctive noninvasive diagnostic tool. AT is hyperechoic with high blood flow on Doppler and calcifications are seen.[327]

DIFFERENTIAL DIAGNOSIS

Table 73-12 outlines the differential diagnosis of SCFN.

CLINICAL COURSE AND PROGNOSIS

SCFN is a benign process with an excellent prognosis. Lesions regress in a few weeks to 6 months, with some eventuating in atrophy.[303,304,310] Hypercalcemia is the most severe potential adverse outcome and may cause nephrocalcinosis.[329] Even severe hypercalcemia may be asymptomatic.[314] The hypercalcemia may have a delayed onset up to 6 months after appearance of the skin lesions; therefore, serial monitoring of serum calcium levels is necessary.[303,304]

TABLE 73-12
Differential Diagnosis of Subcutaneous Fat Necrosis of the Newborn

DIAGNOSIS	CHARACTERISTICS
Cellulitis	Larger plaques that are erythematous, usually lacking the violaceous bruising. Tender and warm.
Cold panniculitis	With any exposure to cold in both children and adults, not specific to the setting of hypoxia. Histopathology lacks needle-shaped clefts within the subcutaneous adipose tissue. Resolves with rewarming.
Sclerema neonatorum	Diffuse skin hardening, particularly on buttocks and thighs, in stressed infants in the first week of life, who are often low weight and premature.[52,328] Histopathology also shows needle-shaped clefts, with minimal inflammation. Poor prognosis with systemic illness.[52]
Poststeroid panniculitis	Occurs in children, usually 10 days after rapid cessation of high-dose systemic corticosteroid therapy. Similar histopathology to subcutaneous fat necrosis of the newborn.

MANAGEMENT

SCFN nodules resolve spontaneously, and treatment should be conservative in most cases, except for lesions that may benefit from aspiration to prevent rupture, infections, necrosis, and scarring.[302,303] Surgical management has been used in severe cases that persist for months with incision and curettage of small calcifications.[330]

Serum calcium should be monitored serially, for several months after presentation in case of delayed elevations. If hypercalcemia is present, management includes hydration, use of the calcium-wasting diuretic furosemide, and a low calcium formula.[303,314] Systemic glucocorticoids may be used to inhibit vitamin D production by the macrophages in the inflamed AT.[303,307,312] Bisphosphonates, including alendronate,[331] etidronate,[332] and pamidronate,[333] treat hypercalcemia in SCFN.

Importantly, nephrocalcinosis may still develop in spite of cutaneous response.[301] The degree and duration of hypercalcemia and hypercalciuria may be critical in development of nephrocalcinosis, encouraging early monitoring and recognition of hypercalcemia, as rapid therapeutic intervention may prevent dystrophic calcification.[334] Renal ultrasound detects nephrocalcinosis.[314] Persistent nephrocalcinosis does not result consistently in renal dysfunction.[314]

For prevention of SCFN, a specific nursing protocol has reduced the risk of SCFN while cooling. It includes rotation of the neonate every 3 hours and a gentler cooling surface–cooling device.[335]

COLD PANNICULITIS

AT-A-GLANCE

Clinical

- Circumscribed, red to violaceous, subcutaneous plaques or nodules on the face and thighs, and rarely of the scrotal fat in prepubertal boys.
- Follows exposure to cold weather, water, popsicles, and ice packs.

Histopathology

- Mostly lobular panniculitis with a lymphohistiocytic or mixed infiltrate, without vasculitis.
- Perivascular lymphohistiocytic infiltrate involving blood vessels at the dermal–subcutaneous junction and within overlying dermis.
- Findings may be similar to those seen in perniosis.

Treatment

- Avoid direct ice placement on skin and cold exposure.
- Spontaneous resolution within 3 months.

Cold panniculitis, also known as Haxthausen disease,[336] was first described in 1902 with hardening of a child's chin after cold weather exposure.[337] When occurring in equestrians, the terms *horse rider's pernio* and *equestrian panniculitis* are also used.[338] Cold panniculitis is an inflammatory reaction of AT that occurs after skin is exposed to cold weather and ice application (as in cold pack application for supraventricular tachycardia),[336] and can occur on mucosae as well (popsicle panniculitis).[337,339]

EPIDEMIOLOGY

Cold panniculitis occurs in children and in young female horseback riders as well as other adults with appropriate exposures. Symptoms may be secondary to intraoral frozen teething rings,[340] or after ice packs are applied to treat febrile episodes.[341] Scrotal cold panniculitis presents in 9- to 14-year-old overweight boys after cold exposure (including swimming in cold ocean water).[342] Symptoms of cold panniculitis in horseback riders have been reported in both males and females. A survey in Finland suggested 25% of riders have symptoms in the winter months.[338] Moderate smoking is statistically significant for an increased risk of cold panniculitis in equestrians, as is wearing tight riding clothes throughout the day, riding for long periods, and being younger than 35 years old.[338] Other risk factors for equestrian-like panniculitis include motorbike or open vehicle riding, wading through cold rivers, and young women wearing tight jeans.[343,344]

CLINICAL FEATURES

Clinical findings of indurated, erythematous plaques or nodules occur at sites of cold exposure and may include mucosa. The onset ranges from 6 to 72 hours after exposure,[345] appearing directly at sites that have contact with cold.[336] In equestrians with cold panniculitis, the presentation is on the lateral thighs.[338]

Scrotal cold panniculitis, also known as scrotal fat necrosis, manifests as unilateral or bilateral tender masses below the testes. Recognizing these changes is important to avoid unnecessary biopsy or intervention, as spontaneous resolution over days to several weeks will occur.[342] Equestrian panniculitis appears hours after long outdoor cold exposure while wearing tight-fitting, noninsulated pants. The lesions are pruritic, erythematous nodules and plaques that may focally ulcerate, crust, and drain.[337,338]

ETIOLOGY AND PATHOGENESIS

In affected infants, the mechanism of inflammation has been attributed to a higher proportion of saturated fat to unsaturated fat in infants, with the composition becoming more unsaturated with age.[337,346] Other mechanisms include the effects of cold on BAT, which is more prevalent in infants than adults, and its activation to generate heat.[347] Cold exposure leads to changes in BAT including increased vascular endothelial growth factor, enhanced free fatty acid degradation, and metabolic changes.[348,349] Scrotal cold panniculitis may be related to the greater concentration of scrotal fat and the increased cold sensitivity of the scrotal AT of younger males.[350]

Equestrian panniculitis may represent perniosis/chilblains, rather than a true panniculitis.[343,344,351] Although high levels of cold agglutinins were detected in 2 Scottish women with equestrian panniculitis,[351] other series do not show this abnormality[338,346] and cryoglobulins and cold agglutinins are not thought to play a role.[352]

DIAGNOSIS

The diagnosis is often clinical given the history of the cold exposure to the affected areas. In general, the histopathologic picture of cold panniculitis is a mostly lobular panniculitis, with a lymphohistiocytic or mixed inflammatory infiltrate present within fat lobules.[52,337] There is a superficial and deep perivascular, as well as periadnexal, lymphocytic infiltrate with prominent inflammation of veins most notable at the dermal–subcutaneous fat junction; these histopathologic findings closely resemble those seen in perniosis.[343,346] The title "cold-associated perniosis of the thighs" has been suggested.[343] In scrotal cases, ultrasound findings may help confirm the diagnosis.[342]

DIFFERENTIAL DIAGNOSIS

Table 73-13 outlines the differential diagnosis of cold panniculitis.

CLINICAL COURSE AND PROGNOSIS

Cold panniculitis is self-limiting and resolves upon rewarming without continued exposure to cold. Full improvement may be seen over days[341] to 3 months.[340] Postinflammatory hyperpigmentation may remain.[352]

MANAGEMENT

There is no additional treatment needed of cold panniculitis other than avoidance of further cold exposure; the best prevention is avoidance of cold exposure.[340] Equestrians with cold panniculitis may benefit from warm clothing and local topical corticosteroid application. Prevention in this population includes warm and

TABLE 73-13
Differential Diagnosis of Cold Panniculitis

DIAGNOSIS	CHARACTERISTICS
Cellulitis	Large plaques that are often unilateral, erythematous, tender and warm. Systemic findings may include fever and leukocytosis.
Subcutaneous fat necrosis of the newborn	Cold exposure in infants in the setting of hypoxia. Histopathology with needle-shaped clefts within the adipose tissue. Complications such as hypercalcemia are possible.
Sclerema neonatorum	Diffuse skin hardening, particularly on buttocks and thighs, in stressed infants in the first week of life, who are often low weight and premature.[52,328] Histopathology also shows needle-shaped clefts with minimal inflammation.[52] Poor prognosis with systemic illness.[52]
Poststeroid panniculitis	Occurs in children, usually within 10 days after rapid cessation of high-dose systemic corticosteroid therapy. Similar histopathology to subcutaneous fat necrosis of the newborn.
Erythema nodosum	Violaceous or red plaques on the anterior legs with no ulceration.

loose-fitting clothing both while riding and during the day, as well as smoking cessation.[338] Nifedipine is not an effective treatment.[338,345]

FACTITIAL AND TRAUMATIC PANNICULITIS

AT-A-GLANCE

Clinical

- In factitial panniculitis (a variant of Munchausen syndrome),[353] self-induced trauma (mechanical, physical, or chemical) causes subcutaneous inflammation. In trauma-induced panniculitis the injury is not induced by the patient, such as in a postsurgical panniculitis or panniculitis following a sport injury.[354,355]
- Erythematous geometric papules and nodules with erosions or ulcerations (Fig. 73-17),[356] with disparate location or appearance.
- Factitial panniculitis is often seen in patients with personality aberrations and subcutaneous implantation may include medications, cosmetic fillers, oils, and food or human waste.[356]
- Traumatic panniculitis may be secondary to cupping, acupuncture, and electropuncture,[357,358] or may be iatrogenic from immunizations or therapeutic injections.[356]
- Secondary hypertrichosis at affected sites is rare.[359,360]

Histopathology

- Mostly a nonspecific lobular panniculitis without vasculitis, varying with the cause.
- Suppurative granuloma involving the fat lobule; requires cultures for various organisms. Necrosis is often present.[361]
- Polarization of the slide may identify refractile foreign material within macrophages.[356]
- Late stages may show foamy histocytes with fibrotic changes and dystrophic calcific deposits.[356,362] Foamy lipophagic histiocytes, adipocyte anisocytosis with pseudocystic degeneration, single adipocyte necrosis, erythrocyte extravasation, and foreign-body granuloma with multinucleated giant cells are all potential features. Frank scarring, deep phlebitis, and traumatic neuromas may be present in postsurgical panniculitis.[354]

Treatment

- Psychiatric treatment for self-inflicted factitial panniculitis.[52]
- Supportive care and interference with injection of responsible agents.
- Often the implanted material must be surgically excised.[356,357]
- Prevention of ongoing trauma and supportive care is needed for traumatic panniculitis as it is self-limiting without further trauma.[361]

Figure 73-17 Factitial panniculitis. Self-induced round and angulated ulceration on the leg at sites of injections and trauma.

CONNECTIVE TISSUE DISEASE-ASSOCIATED PANNICULITIS

AT-A-GLANCE

Clinical

- Most often associated with dermatomyositis, and may precede, occur with, or appear late in the disease course, with severity correlating with disease flares.[363]
- Erythematous, tender to painful nodules and plaques on the arms, buttocks, thighs, and abdomen. Complications include ulceration and lipoatrophy.[364,365]
- Rarely, panniculitis is the primary presentation of dermatomyositis,[52,366] and juvenile dermatomyositis-associated panniculitis is uncommon but has been reported.[367] Panniculitis in a child should prompt workup for connective tissue disease.[368]
- Infection may occur concurrently and must be treated prior to immunosuppression.[367]
- Panniculitis is also associated with morphea and systemic sclerosis, but the association is rare.
- SPTCL must be considered in the differential diagnosis of a connective tissue disease panniculitis. Up to 19% of SPTCL with an αβ phenotype in one series had an associated autoimmune disorder.[247] SPTCL with a γδ phenotype was reported as developing in a patient with rheumatoid arthritis after 3 years of anti-TNF therapy.[247] One patient with SPTCL presented with clinical features of dermatomyositis.[369]

Histopathology

- Mostly lobular panniculitis with a lymphocytic and plasma cell infiltrate, with dermal mucin and vacuolar interface change, similar to lupus panniculitis.[52,370]
- Calcification may be present.[363]
- Membranocystic change may be present in late-stage lesions,[52,230] and indicate a worse prognosis.[371]

Treatment

- Same as for dermatomyositis: corticosteroids, immunosuppressants (including azathioprine, mycophenolate mofetil, and methotrexate[370]) and IVIG.[364,366,371,372]
- Calcification within lesions may benefit from IVIG.[373]
- Antimalarials are not effective in dermatomyositis-associated panniculitis.[370]

GOUTY PANNICULITIS

AT-A-GLANCE

Clinical

- Subcutaneous urate crystals are a rare manifestation of gout.[374]
- Most commonly firm, indurated nodules or plaques, with variable tenderness on the lower extremities,[375] with possible urate crystal deposition in bone marrow[375] and otherwise diffuse involvement.[376]
- A chalky substance may overly ulceration.[376,377]
- Massive AT hypertrophy may be seen, requiring surgical resection.[378]
- Hyperuricemia is associated,[379] as well as arthralgias (gouty arthritis).[380]
- The lesions may precede a diagnosis of gout,[376] but they are often a late consequence of chronic gout.[377]
- Differential diagnosis includes foreign-body panniculitis, calcium, and other crystal deposition diseases.[375]

Histopathology

- Fine, radially oriented, needle-shaped urate crystals within AT are surrounded by granulomatous inflammation. The monosodium urate crystals are refractile and negatively birefringent.[375,378,379]
- Alcohol fixation allows for enhanced crystal visualization.[375]
- There is no evidence of vasculitis.[379]

Treatment

- Standard treatments for gout include allopurinol (high doses),[380] probenecid, and antiinflammatory medications, including colchicine, which can be used to reduce uric acid levels.[375]
- Acute panniculitis may benefit from corticosteroids.[379]
- Surgery may be necessary for ulcerated lesions that do not heal.[377]

POSTSTEROID PANNICULITIS

AT-A-GLANCE

Clinical

- Poststeroid panniculitis is rare, most often seen in children after high doses of systemic corticosteroid treatment, days to weeks after abrupt corticosteroid withdrawal.[303,381] Cases in adults are very rare.[382,383]
- Erythematous, tender nodules and plaques on the cheeks, trunk, arms,[382] and legs.[381]

(Continued)

AT-A-GLANCE (*Continued*)

- Resolves in weeks or months without scarring; can leave residual hyperpigmentation. Most common complication is ulceration; systemic symptoms are rare.[382]

Histopathology

- Lobular panniculitis with a lymphocytic and granulomatous infiltrate, without vasculitis. Lipophages and crystals can be present.[382]
- Needle-shaped clefts in a radial orientation are seen, similar to those seen in SCFN and sclerema neonatorum; sclerema neonatorum lacks or has sparse inflammation.[382]
- Multinucleated giant cells may contain the needle-shaped clefts with foamy histiocytes.[382,383]

Treatment

- Lesions resolve within weeks or months without scarring even without treatment, leaving residual hyperpigmentation.[382,383]
- It has been postulated that gradual tapering of steroids can eliminate the risk of poststeroid panniculitis.[381]

ACKNOWLEDGMENTS

The authors wish to acknowledge Dr. Patricia Fishman for her work on the prior edition of this chapter.

REFERENCES

1. Patterson JW. Panniculitis. New findings in the "third compartment." *Arch Dermatol*. 1987;123:1615-1618.
2. Requena L. Normal subcutaneous fat, necrosis of adipocytes and classification of the panniculitides. *Semin Cutan Med Surg*. 2007;26:66-70.
3. Fantuzzi G. Adipose tissue, adipokines, and inflammation. *J Allergy Clin Immunol*. 2005;115:911-919; quiz 920.
4. Ferrandon D, Imler JL, Hetru C, et al. The Drosophila systemic immune response: sensing and signalling during bacterial and fungal infections. *Nat Rev Immunol*. 2007;7:862-874.
5. Caspar-Bauguil S, Cousin B, Galinier A, et al. Adipose tissues as an ancestral immune organ: site-specific change in obesity. *FEBS Lett*. 2005;579:3487-3492.
6. Janeway CA Jr, Medzhitov R. Innate immune recognition. *Annu Rev Immunol*. 2002;20:197-216.
7. Iwasaki A, Medzhitov R. Regulation of adaptive immunity by the innate immune system. *Science*. 2010;327:291-295.
8. Miller LS. Toll-like receptors in skin. *Adv Dermatol*. 2008;24:71-87.
9. Desruisseaux MS, Nagajyothi, Trujillo ME, et al. Adipocyte, adipose tissue, and infectious disease. *Infect Immun*. 2007;75:1066-1078.
10. Schaffler A, Scholmerich J, Salzberger B. Adipose tissue as an immunological organ: Toll-like receptors, C1q/TNFs and CTRPs. *Trends Immunol*. 2007;28:393-399.
11. Nishimura S, Manabe I, Nagai R. Adipose tissue inflammation in obesity and metabolic syndrome. *Discov Med*. 2009;8:55-60.
12. Rajsheker S, Manka D, Blomkalns AL, et al. Crosstalk between perivascular adipose tissue and blood vessels. *Curr Opin Pharmacol*. 2010;10:191-196.
13. Chatterjee TK, Stoll LL, Denning GM, et al. Proinflammatory phenotype of perivascular adipocytes: influence of high-fat feeding. *Circ Res*. 2009;104:541-549.
14. Crawley FE. Erythema nodosum as initial manifestation of Boeck's sarcoidosis. *Br Med J*. 1950;2:1362-1364.
15. Requena L, Yus ES. Panniculitis. Part I. Mostly septal panniculitis. *J Am Acad Dermatol*. 2001;45:163-183; quiz 184-186.
16. Cribier B, Caille A, Heid E, et al. Erythema nodosum and associated diseases. A study of 129 cases. *Int J Dermatol*. 1998;37:667-672.
17. Aydin-Teke T, Tanir G, Bayhan GI, et al. Erythema nodosum in children: evaluation of 39 patients. *Turk J Pediatr*. 2014;56:144-149.
18. Requena L, Requena C. Erythema nodosum. *Dermatol Online J*. 2002;8:4.
19. Garcia-Porrua C, Gonzalez-Gay MA, Vazquez-Caruncho M, et al. Erythema nodosum: etiologic and predictive factors in a defined population. *Arthritis Rheum*. 2000;43:584-592.
20. Papagrigoraki A, Gisondi P, Rosina P, et al. Erythema nodosum: etiological factors and relapses in a retrospective cohort study. *Eur J Dermatol*. 2010;20:773-777.
21. Mert A, Kumbasar H, Ozaras R, et al. Erythema nodosum: an evaluation of 100 cases. *Clin Exp Rheumatol*. 2007;25:563-570.
22. Kisacik B, Onat AM, Pehlivan Y. Multiclinical experiences in erythema nodosum: rheumatology clinics versus dermatology and infection diseases clinics. *Rheumatol Int*. 2013;33:315-318.
23. Bartelsmeyer JA, Petrie RH. Erythema nodosum, estrogens, and pregnancy. *Clin Obstet Gynecol*. 1990;33:777-781.
24. Ricci RM, Deering KC. Erythema nodosum caused by omeprazole. *Cutis*. 1996;57:434.
25. Degen A, Volker B, Kapp A, et al. Erythema nodosum in a patient undergoing vemurafenib therapy for metastatic melanoma. *Eur J Dermatol*. 2013;23:118.
26. Hannuksela M. Erythema nodosum. *Clin Dermatol*. 1986;4:88-95.
27. Jones JV, Cumming RH, Asplin CM. Evidence for circulating immune complexes in erythema nodosum and early sarcoidosis. *Ann N Y Acad Sci*. 1976;278:212-219.
28. De Simone C, Caldarola G, Scaldaferri F, et al. Clinical, histopathological, and immunological evaluation of a series of patients with erythema nodusum. *Int J Dermatol*. 2016;55(5):e289-e294.
29. Kunz M, Beutel S, Brocker E. Leucocyte activation in erythema nodosum. *Clin Exp Dermatol*. 1999;24:396-401.
30. Senturk T, Aydintug O, Kuzu I, et al. Adhesion molecule expression in erythema nodosum-like lesions in Behçet's disease. A histopathological and immunohistochemical study. *Rheumatol Int*. 1998;18:51-57.
31. Labunski S, Posern G, Ludwig S, et al. Tumour necrosis factor-alpha promoter polymorphism in erythema nodosum. *Acta Derm Venereol*. 2001;81:18-21.
32. Amoli MM, Donn RP, Thomson W, et al. Macrophage migration inhibitory factor gene polymorphism is

associated with sarcoidosis in biopsy proven erythema nodosum. *J Rheumatol*. 2002;29:1671-1673.
33. Amoli MM, Miranda-Filloy JA, Vazquez-Rodriguez TR, et al. Regulated upon activation normal T-cell expressed and secreted (RANTES) and epithelial cell-derived neutrophil-activating peptide (ENA-78) gene polymorphisms in patients with biopsy-proven erythema nodosum. *Clin Exp Rheumatol*. 2009;27:S142-S143.
34. Schaffler A, Muller-Ladner U, Scholmerich J, et al. Role of adipose tissue as an inflammatory organ in human diseases. *Endocr Rev*. 2006;27:449-467.
35. Braverman IM. Protective effects of erythema nodosum in coccidioidomycosis. *Lancet*. 1999;353:168.
36. Marcoval J, Mana J, Rubio M. Specific cutaneous lesions in patients with systemic sarcoidosis: relationship to severity and chronicity of disease. *Clin Exp Dermatol*. 2011;36:739-744.
37. Grunewald J, Eklund A. Löfgren's syndrome: human leukocyte antigen strongly influences the disease course. *Am J Respir Crit Care Med*. 2009;179:307-312.
38. Thurber S, Kohler S. Histopathologic spectrum of erythema nodosum. *J Cutan Pathol*. 2006;33:18-26.
39. White WL, Hitchcock MG. Diagnosis: erythema nodosum or not? *Semin Cutan Med Surg*. 1999;18:47-55.
40. Requena L, Sanchez Yus E. Erythema nodosum. *Semin Cutan Med Surg*. 2007;26:114-125.
41. Winkelmann RK, Forstrom L. New observations in the histopathology of erythema nodosum. *J Invest Dermatol*. 1975;65:441-446.
42. Weizman A, Huang B, Berel D, et al. Clinical, serologic, and genetic factors associated with pyoderma gangrenosum and erythema nodosum in inflammatory bowel disease patients. *Inflamm Bowel Dis*. 2014;20:525-533.
43. Sterling JB, Heymann WR. Potassium iodide in dermatology: a 19th century drug for the 21st century—uses, pharmacology, adverse effects, and contraindications. *J Am Acad Dermatol*. 2000;43:691-697.
44. Davatchi F, Sadeghi Abdollahi B, Tehrani Banihashemi A, et al. Colchicine versus placebo in Behçet's disease: randomized, double-blind, controlled crossover trial. *Mod Rheumatol*. 2009;19:542-549.
45. Boyd AS. Etanercept treatment of erythema nodosum. *Skinmed*. 2007;6:197-199.
46. Hanauer SB. How do I treat erythema nodosum, aphthous ulcerations, and pyoderma gangrenosum? *Inflamm Bowel Dis*. 1998;4:70; discussion 73.
47. Golding D. Treating erythema nodosum. *Br Med J*. 1969;4:560-561.
48. Alloway JA, Franks LK. Hydroxychloroquine in the treatment of chronic erythema nodosum. *Br J Dermatol*. 1995;132:661-662.
49. Montgomery H, O'Leary PA, Parker NW. Nodular vascular diseases of the legs: erythema induratum and allied conditions. *JAMA*. 1945;128:335-345.
50. Mascaro JM Jr, Baselga E. Erythema induratum of bazin. *Dermatol Clin*. 2008;26:439-445, v.
51. Segura S, Pujol RM, Trindade F, et al. Vasculitis in erythema induratum of Bazin: a histopathologic study of 101 biopsy specimens from 86 patients. *J Am Acad Dermatol*. 2008;59:839-851.
52. Requena L, Sanchez Yus E. Panniculitis. Part II. Mostly lobular panniculitis. *J Am Acad Dermatol*. 2001;45:325-361; quiz 362-364.
53. Ferrara G, Stefanato CM, Gianotti R, et al. Panniculitis with vasculitis. *G Ital Dermatol Venereol*. 2013;148:387-394.
54. Gilchrist H, Patterson JW. Erythema nodosum and erythema induratum (nodular vasculitis): diagnosis and management. *Dermatol Ther*. 2010;23:320-327.
55. Brandao Neto RA, Carvalho JF. Erythema induratum of Bazin associated with Addison's disease: first description. *Sao Paulo Med J*. 2012;130:405-408.
56. Inoue T, Fukumoto T, Ansai S, et al. Erythema induratum of Bazin in an infant after Bacille Calmette-Guerin vaccination. *J Dermatol*. 2006;33:268-272.
57. Sekiguchi A, Motegi S, Ishikawa O. Erythema induratum of Bazin associated with bacillus Calmette-Guerin vaccination: implication of M1 macrophage infiltration and monocyte chemotactic protein-1 expression. *J Dermatol*. 2016;43:111-113.
58. Sharma S, Sehgal VN, Bhattacharya SN, et al. Clinicopathologic spectrum of cutaneous tuberculosis: a retrospective analysis of 165 Indians. *Am J Dermatopathol*. 2015;37:444-450.
59. Chong LY, Lo KK. Cutaneous tuberculosis in Hong Kong: a 10-year retrospective study. *Int J Dermatol*. 1995;34:26-29.
60. Sethuraman G, Ramesh V. Cutaneous tuberculosis in children. *Pediatr Dermatol*. 2013;30:7-16.
61. Oshio A, Yoshii Y, Ono K, et al. Erythema induratum of Bazin with anti-phospholipid antibodies. *J Dtsch Dermatol Ges*. 2015;13:810-811.
62. Baselga E, Margall N, Barnadas MA, et al. Detection of *Mycobacterium tuberculosis* DNA in lobular granulomatous panniculitis (erythema induratum-nodular vasculitis). *Arch Dermatol*. 1997;133:457-462.
63. Neyrolles O, Hernandez-Pando R, Pietri-Rouxel F, et al. Is adipose tissue a place for *Mycobacterium tuberculosis* persistence? *PLoS One*. 2006;1:e43.
64. Bouwman JJ, Visseren FL, Bouter KP, et al. Infection-induced inflammatory response of adipocytes in vitro. *Int J Obes (Lond)*. 2008;32:892-901.
65. Bechah Y, Paddock CD, Capo C, et al. Adipose tissue serves as a reservoir for recrudescent *Rickettsia prowazekii* infection in a mouse model. *PLoS One*. 2010;5:e8547.
66. Nagajyothi F, Desruisseaux MS, Thiruvur N, et al. *Trypanosoma cruzi* infection of cultured adipocytes results in an inflammatory phenotype. *Obesity (Silver Spring)*. 2008;16:1992-1997.
67. Nagajyothi F, Desruisseaux MS, Weiss LM, et al. Chagas disease, adipose tissue and the metabolic syndrome. *Mem Inst Oswaldo Cruz*. 2009;104(suppl 1):219-225.
68. Angus J, Roberts C, Kulkarni K, et al. Usefulness of the QuantiFERON test in the confirmation of latent tuberculosis in association with erythema induratum. *Br J Dermatol*. 2007;157:1293-1294.
69. Lighter J, Tse DB, Li Y, et al. Erythema induratum of Bazin in a child: evidence for a cell-mediated hyperresponse to *Mycobacterium tuberculosis*. *Pediatr Infect Dis J*. 2009;28:326-328.
70. Cho KH, Lee DY, Kim CW. Erythema induratum of Bazin. *Int J Dermatol*. 1996;35:802-808.
71. Romero JJ, Herrera P, Cartelle M, et al. Panniculitis caused by *Mycobacterium monacense* mimicking erythema induratum: a case in Ecuador. *New Microbes New Infect*. 2016;10:112-115.
72. Gimenez-Garcia R, Sanchez-Ramon S, Sanchez-Antolin G, et al. Red fingers syndrome and recurrent panniculitis in a patient with chronic hepatitis C. *J Eur Acad Dermatol Venereol*. 2003;17:692-694.
73. Pozdnyakova O, Garg A, Mahalingam M. Nodular vasculitis—a novel cutaneous manifestation of autoimmune colitis. *J Cutan Pathol*. 2008;35:315-319.

74. Patterson JW, Brown PC, Broecker AH. Infection-induced panniculitis. *J Cutan Pathol*. 1989;16:183-193.
75. Misago N, Narisawa Y. Erythema induratum (nodular vasculitis) associated with Crohn's disease: a rare type of metastatic Crohn's disease. *Am J Dermatopathol*. 2012;34:325-329.
76. Sakuma H, Niiyama S, Amoh Y, et al. Chlamydophila pneumoniae Infection Induced Nodular Vasculitis. *Case Rep Dermatol*. 2011;3:263-267.
77. Wolf D, Ben-Yehuda A, Okon E, et al. Nodular vasculitis associated with propylthiouracil therapy. *Cutis*. 1992;49:253-255.
78. Park SB, Chang IK, Im M, et al. Nodular vasculitis that developed during etanercept (Enbrel) treatment in a patient with psoriasis. *Ann Dermatol*. 2015;27:605-607.
79. Schneider JW, Jordaan HF, Geiger DH, et al. Erythema induratum of Bazin. A clinicopathological study of 20 cases and detection of *Mycobacterium tuberculosis* DNA in skin lesions by polymerase chain reaction. *Am J Dermatopathol*. 1995;17:350-356.
80. Tehrany YA, Toutous-Trellu L, Trombert V, et al. A case of tuberculous granulomatous panniculitis without vasculitis. *Case Rep Dermatol*. 2015;7:141-145.
81. Chen S, Chen J, Chen L, et al. *Mycobacterium tuberculosis* infection is associated with the development of erythema nodosum and nodular vasculitis. *PLoS One*. 2013;8:e62653.
82. Teramura K, Fujimoto N, Nakanishi G, et al. Disseminated erythema induratum of Bazin. *Eur J Dermatol*. 2014;24:697-698.
83. Shaffer N, Kerdel FA. Nodular vasculitis (erythema induratum): treatment with auranofin. *J Am Acad Dermatol*. 1991;25:426-429.
84. Taverna JA, Radfar A, Pentland A, et al. Case reports: nodular vasculitis responsive to mycophenolate mofetil. *J Drugs Dermatol*. 2006;5:992-993.
85. Huriez C, Desmons F, Agache P, et al. Patchy and diffuse hypodermitis and dermo-hypodermitis [in French]. *Presse Med*. 1962;70:2743-2746.
86. Jorizzo JL, White WL, Zanolli MD, et al. Sclerosing panniculitis. A clinicopathologic assessment. *Arch Dermatol*. 1991;127:554-558.
87. Kirsner RS, Pardes JB, Eaglstein WH, et al. The clinical spectrum of lipodermatosclerosis. *J Am Acad Dermatol*. 1993;28:623-627.
88. Choonhakarn C, Chaowattanapanit S, Julanon N. Lipodermatosclerosis: a clinicopathologic correlation. *Int J Dermatol*. 2016;55:303-308.
89. Walsh SN, Santa Cruz DJ. Lipodermatosclerosis: a clinicopathological study of 25 cases. *J Am Acad Dermatol*. 2010;62:1005-1012.
90. Bruce AJ, Bennett DD, Lohse CM, et al. Lipodermatosclerosis: review of cases evaluated at Mayo Clinic. *J Am Acad Dermatol*. 2002;46:187-192.
91. Greenberg AS, Hasan A, Montalvo BM, et al. Acute lipodermatosclerosis is associated with venous insufficiency. *J Am Acad Dermatol*. 1996;35:566-568.
92. Alavi A, Sibbald RG, Phillips TJ, et al. What's new: management of venous leg ulcers: approach to venous leg ulcers. *J Am Acad Dermatol*. 2016;74:627-640.
93. Chu CY, Yang CH, Chiu HC. Gemcitabine-induced acute lipodermatosclerosis-like reaction. *Acta Derm Venereol*. 2001;81:426-428.
94. Shuster M, Morley K, Logan J, et al. Lipodermatosclerosis secondary to pemetrexed use. *J Thorac Oncol*. 2015;10:e11-e12.
95. Herouy Y, Kahle B, Idzko M, et al. Tight junctions and compression therapy in chronic venous insufficiency. *Int J Mol Med*. 2006;18:215-219.
96. Leu HJ. Morphology of chronic venous insufficiency—light and electron microscopic examinations. *Vasa*. 1991;20:330-342.
97. Falanga V, Bontempo FA, Eaglstein WH. Protein C and protein S plasma levels in patients with lipodermatosclerosis and venous ulceration. *Arch Dermatol*. 1990;126:1195-1197.
98. Schmeller W, Roszinski S, Huesmann M. Tissue oxygenation and microcirculation in dermatoliposclerosis with different degrees of erythema at the margins of venous ulcers. A contribution to hypodermitis symptoms [in German]. *Vasa*. 1997;26:18-24.
99. Saharay M, Shields DA, Porter JB, et al. Leukocyte activity in the microcirculation of the leg in patients with chronic venous disease. *J Vasc Surg*. 1997;26:265-273.
100. Peschen M, Grenz H, Brand-Saberi B, et al. Increased expression of platelet-derived growth factor receptor alpha and beta and vascular endothelial growth factor in the skin of patients with chronic venous insufficiency. *Arch Dermatol Res*. 1998;290:291-297.
101. Pappas PJ, You R, Rameshwar P, et al. Dermal tissue fibrosis in patients with chronic venous insufficiency is associated with increased transforming growth factor-beta1 gene expression and protein production. *J Vasc Surg*. 1999;30:1129-1145.
102. Degiorgio-Miller AM, Treharne LJ, McAnulty RJ, et al. Procollagen type I gene expression and cell proliferation are increased in lipodermatosclerosis. *Br J Dermatol*. 2005;152:242-249.
103. Ye J, Gao Z, Yin J, et al. Hypoxia is a potential risk factor for chronic inflammation and adiponectin reduction in adipose tissue of ob/ob and dietary obese mice. *Am J Physiol Endocrinol Metab*. 2007;293:E1118-E1128.
104. Halberg N, Wernstedt-Asterholm I, Scherer PE. The adipocyte as an endocrine cell. *Endocrinol Metab Clin North Am*. 2008;37:753-768, x-xi.
105. Halberg N, Khan T, Trujillo ME, et al. Hypoxia-inducible factor 1alpha induces fibrosis and insulin resistance in white adipose tissue. *Mol Cell Biol*. 2009;29:4467-4483.
106. Khan T, Muise ES, Iyengar P, et al. Metabolic dysregulation and adipose tissue fibrosis: role of collagen VI. *Mol Cell Biol*. 2009;29:1575-1591.
107. Tidwell WJ, Malone J, Callen JP. Cutaneous T-cell lymphoma misdiagnosed as lipodermatosclerosis. *JAMA Dermatol*. 2016;152:487-488.
108. Jowett AJ, Parvin SD. Angiosarcoma in an area of lipodermatosclerosis. *Ann R Coll Surg Engl*. 2008;90:W15-W16.
109. Chan CC, Yang CY, Chu CY. Magnetic resonance imaging as a diagnostic tool for extensive lipodermatosclerosis. *J Am Acad Dermatol*. 2008;58:525-527.
110. Huang TM, Lee JY. Lipodermatosclerosis: a clinicopathologic study of 17 cases and differential diagnosis from erythema nodosum. *J Cutan Pathol*. 2009;36:453-460.
111. Alegre VA, Winkelmann RK, Aliaga A. Lipomembranous changes in chronic panniculitis. *J Am Acad Dermatol*. 1988;19:39-46.
112. Jinnin M, Ihn H, Asano Y, et al. Sclerosing panniculitis is associated with pulmonary hypertension in systemic sclerosis. *Br J Dermatol*. 2005;153:579-583.
113. Gniadecka M, Karlsmark T, Bertram A. Removal of dermal edema with class I and II compression stockings

in patients with lipodermatosclerosis. *J Am Acad Dermatol*. 1998;39:966-970.
114. Kahle B, Idzko M, Norgauer J, et al. Tightening tight junctions with compression therapy. *J Invest Dermatol*. 2003;121:1228-1229.
115. Vesic S, Vukovic J, Medenica LJ, et al. Acute lipodermatosclerosis: an open clinical trial of stanozolol in patients unable to sustain compression therapy. *Dermatol Online J*. 2008;14:1.
116. Carson P, Hong CJ, Otero-Vinas M, et al. Liver enzymes and lipid levels in patients with lipodermatosclerosis and venous ulcers treated with a prototypic anabolic steroid (stanozolol): a prospective, randomized, double-blinded, placebo-controlled trial. *Int J Low Extrem Wounds*. 2015;14:11-18.
117. Segal S, Cooper J, Bolognia J. Treatment of lipodermatosclerosis with oxandrolone in a patient with stanozolol-induced hepatotoxicity. *J Am Acad Dermatol*. 2000;43:558-559.
118. Hafner C, Wimmershoff M, Landthaler M, et al. Lipodermatosclerosis: successful treatment with danazol. *Acta Derm Venereol*. 2005;85:365-366.
119. Jull A, Arroll B, Parag V, et al. Pentoxifylline for treating venous leg ulcers. *Cochrane Database Syst Rev*. 2007:CD001733.
120. Choonhakarn C, Chaowattanapanit S. Lipodermatosclerosis: improvement noted with hydroxychloroquine and pentoxifylline. *J Am Acad Dermatol*. 2012;66:1013-1014.
121. Rowe L, Cantwell A Jr. Hypodermitis sclerodermiformis. Successful treatment with ultrasound. *Arch Dermatol*. 1982;118:312-314.
122. Damian DL, Yiasemides E, Gupta S, et al. Ultrasound therapy for lipodermatosclerosis. *Arch Dermatol*. 2009;145:330-332.
123. Boyd K, Shea SM, Patterson JW. The role of capsaicin in dermatology. *Prog Drug Res*. 2014;68:293-306.
124. Jeong KH, Shin MK, Kim NI. Refractory lipodermatosclerosis treated with intralesional platelet-rich plasma. *J Am Acad Dermatol*. 2011;65:e157-e158.
125. Delgado-Jimenez Y, Fraga J, Garcia-Diez A. Infective panniculitis. *Dermatol Clin*. 2008;26:471-480, vi.
126. Requena L, Sitthinamsuwan P, Santonja C, et al. Cutaneous and mucosal mucormycosis mimicking pancreatic panniculitis and gouty panniculitis. *J Am Acad Dermatol*. 2012;66:975-984.
127. Spalding SJ, Meza MP, Ranganathan S, et al. *Staphylococcus aureus* panniculitis complicating juvenile dermatomyositis. *Pediatrics*. 2007;119:e528-e530.
128. Chen WS, Lee YF, Wang HP, et al. *Mycobacterium*-associated lobular panniculitis, mimicking a rheumatoid nodule in a patient with rheumatoid arthritis. *J Formos Med Assoc*. 2009;108:673-676.
129. Bourre-Tessier J, Fortin C, Belisle A, et al. Disseminated *Histoplasma capsulatum* infection presenting with panniculitis and focal myositis in rheumatoid arthritis treated with etanercept. *Scand J Rheumatol*. 2009;38:311-316.
130. Quinter S, Cheng CL, Prakash N, et al. Disseminated histoplasmosis presenting as panniculitis in two immunosuppressed patients. *Dermatol Online J*. 2012;18:3.
131. Morrison LK, Rapini R, Willison CB, et al. Infection and panniculitis. *Dermatol Ther*. 2010;23:328-340.
132. Bartralot R, Garcia-Patos V, Sitjas D, et al. Clinical patterns of cutaneous nontuberculous mycobacterial infections. *Br J Dermatol*. 2005;152:727-734.
133. Zhang CZ, Fung MA, Eisen DB. Disseminated fusariosis presenting as panniculitis-like lesions on the legs of a neutropenic girl with acute lymphoblastic leukemia. *Dermatol Online J*. 2009;15:5.
134. Colmenero I, Alonso-Sanz M, Casco F, et al. Cutaneous aspergillosis mimicking pancreatic and gouty panniculitis. *J Am Acad Dermatol*. 2012;67:789-791.
135. Kothiwala SK, Prajapat M, Kuldeep CM, et al. Cryptococcal panniculitis in a renal transplant recipient: case report and review of literature. *J Dermatol Case Rep*. 2015;9:76-80.
136. Abuav R, McGirt LY, Kazin RA. Cryptococcal panniculitis in an immunocompromised patient: a case report and review of the literature. *Cutis*. 2010;85:303-306.
137. Roriz M, Maruani A, Le Bidre E, et al. Locoregional multiple nodular panniculitis induced by Pseudomonas aeruginosa without septicemia: three cases and focus on predisposing factors. *JAMA Dermatol*. 2014;150:628-632.
138. Nemoto Y, Taniguchi A, Kamioka M, et al. Epstein-Barr virus-infected subcutaneous panniculitis-like T-cell lymphoma associated with methotrexate treatment. *Int J Hematol*. 2010;92:364-368.
139. Plotner AN, Mutasim DF. A case of "syphilis panniculitis " caused by direct fat inoculation by treponema pallidum. *Arch Dermatol*. 2012;148:269-270.
140. Sharquie KE, Hameed AF. Panniculitis is an important feature of cutaneous leishmaniasis pathology. *Case Rep Dermatol Med*. 2012;2012:612434.
141. Kempf W, Kazakov DV, Kutzner H. Lobular panniculitis due to *Borrelia burgdorferi* infection mimicking subcutaneous panniculitis-like T-cell lymphoma. *Am J Dermatopathol*. 2013;35:e30-e33.
142. Leber JH, Crimmins GT, Raghavan S, et al. Distinct TLR- and NLR-mediated transcriptional responses to an intracellular pathogen. *PLoS Pathog*. 2008;4:e6.
143. Combs TP, Nagajyothi, Mukherjee S, et al. The adipocyte as an important target cell for *Trypanosoma cruzi* infection. *J Biol Chem*. 2005;280:24085-24094.
144. Maurin T, Saillan-Barreau C, Cousin B, et al. Tumor necrosis factor-alpha stimulates HIV-1 production in primary culture of human adipocytes. *Exp Cell Res*. 2005;304:544-551.
145. Godard CM. Attempts to cultivate *Mycobacterium leprae* in fat tissue. *Acta Leprol*. 1993;8:133-135.
146. Pamer EG. TLR polymorphisms and the risk of invasive fungal infections. *N Engl J Med*. 2008;359:1836-1838.
147. Ballestero-Diez M, Alvarez-Ruiz SB, Aragues Montanes M, et al. Septal panniculitis associated with cytomegalovirus infection. *Histopathology*. 2005;46:720-722.
148. Stoller JK, Aboussouan LS. Alpha1-antitrypsin deficiency. *Lancet*. 2005;365:2225-2236.
149. Gross B, Grebe M, Wencker M, et al. New Findings in PiZZ alpha1-antitrypsin deficiency-related panniculitis. Demonstration of skin polymers and high dosing requirements of intravenous augmentation therapy. *Dermatology*. 2009;218:370-375.
150. Silverman EK, Sandhaus RA. Clinical practice. Alpha1-antitrypsin deficiency. *N Engl J Med*. 2009;360:2749-2757.
151. Erikkson S. Alpha1-antitrypsin deficiency: lessons learned from the bedside to the gene and back again. *Chest*. 1989;95:181-189.
152. Warter J, Storck D, Grosshans E, et al. Weber-Christian syndrome associated with an alpha-1 antitrypsin deficiency. Familial investigation [in French]. *Ann Med Interne (Paris)*. 1972;123:877-882.
153. Geraminejad P, DeBloom JR 2nd, Walling HW, et al. Alpha-1-antitrypsin associated panniculitis: the MS variant. *J Am Acad Dermatol*. 2004;51:645-655.

154. Blanco I, Lipsker D, Lara B, et al. Neutrophilic panniculitis associated with alpha-1 antitrypsin deficiency: an update. *Br J Dermatol*. 2016;174(4):753-762.
155. Pittelkow MR, Smith KC, Su WP. Alpha-1-antitrypsin deficiency and panniculitis. Perspectives on disease relationship and replacement therapy. *Am J Med*. 1988;84:80-86.
156. Yesudian PD, Dobson CM, Wilson NJ. Alpha1-antitrypsin deficiency panniculitis (phenotype PiZZ) precipitated postpartum and successfully treated with dapsone. *Br J Dermatol*. 2004;150:1222-1223.
157. Chng WJ, Henderson CA. Suppurative panniculitis associated with alpha 1-antitrypsin deficiency (PiSZ phenotype) treated with doxycycline. *Br J Dermatol*. 2001;144:1282-1283.
158. Pottage JC Jr, Trenholme GM, Aronson IK, et al. Panniculitis associated with histoplasmosis and alpha 1-antitrypsin deficiency. *Am J Med*. 1983;75:150-153.
159. Smith KC, Su WP, Pittelkow MR, et al. Clinical and pathologic correlations in 96 patients with panniculitis, including 15 patients with deficient levels of alpha 1-antitrypsin. *J Am Acad Dermatol*. 1989;21:1192-1196.
160. Andersen MM. Leucocyte-associated plasma proteins. Association of prealbumin, albumin, orosomucoid, alpha 1-antitrypsin, transferrin and haptoglobin with human lymphocytes, monocytes, granulocytes and a promyelocytic leukaemic cell line (HL-60). *Scand J Clin Lab Invest*. 1983;43:49-59.
161. Breit SN, Wakefield D, Robinson JP, et al. The role of alpha 1-antitrypsin deficiency in the pathogenesis of immune disorders. *Clin Immunol Immunopathol*. 1985;35:363-380.
162. Ades EW, Hinson A, Chapuis-Cellier C, et al. Modulation of the immune response by plasma protease inhibitors. I. Alpha 2-macroglobulin and alpha 1-antitrypsin inhibit natural killing and antibody-dependent cell-mediated cytotoxicity. *Scand J Immunol*. 1982;15:109-113.
163. Olson JM, Moore EC, Valasek MA, et al. Panniculitis in alpha-1 antitrypsin deficiency treated with enzyme replacement. *J Am Acad Dermatol*. 2012;66:e139-e141.
164. Loche F, Tremeau-Martinage C, Laplanche G, et al. Panniculitis revealing qualitative alpha 1 antitrypsine deficiency (MS variant). *Eur J Dermatol*. 1999;9:565-567.
165. Laureano A, Carvalho R, Chaveiro A, et al. Alpha-1-antitrypsin deficiency-associated panniculitis: a case report. *Dermatol Online J*. 2014;20:21245.
166. Sinden NJ, Koura F, Stockley RA. The significance of the F variant of alpha-1-antitrypsin and unique case report of a PiFF homozygote. *BMC Pulm Med*. 2014;14:132.
167. Elsensohn AN, Liaqat M, Powell G, et al. Alpha-1-antitrypsin associated panniculitis and corneal ulcer with a rare allelic variant (PiFZ): a case report. *Int J Dermatol*. 2016;55(6):698-699.
168. Marzano AV, Damiani G. Neutrophilic panniculitis and autoinflammation: what's the link? *Br J Dermatol*. 2016;175(3):646-647.
169. Kobbe P, Vodovotz Y, Kaczorowski DJ, et al. The role of fracture-associated soft tissue injury in the induction of systemic inflammation and remote organ dysfunction after bilateral femur fracture. *J Orthop Trauma*. 2008;22:385-390.
170. Boden G, Silviera M, Smith B, et al. Acute tissue injury caused by subcutaneous fat biopsies produces endoplasmic reticulum stress. *J Clin Endocrinol Metab*. 2010;95:349-352.
171. Fernandez-Torres R, Garcia-Silva J, Robles O, et al. Alfa-1-antitrypsin deficiency panniculitis acquired after liver transplant and successfully treated with retransplant. *J Am Acad Dermatol*. 2009;60:715-716.
172. Eng A, Aronson IK. Dermatopathology of panniculitis. *Semin Dermatol*. 1984;3:1-13.
173. Geller JD, Su WP. A subtle clue to the histopathologic diagnosis of early alpha 1-antitrypsin deficiency panniculitis. *J Am Acad Dermatol*. 1994;31:241-245.
174. Su WP, Smith KC, Pittelkow MR, et al. Alpha 1-antitrypsin deficiency panniculitis: a histopathologic and immunopathologic study of four cases. *Am J Dermatopathol*. 1987;9:483-490.
175. Hendrick SJ, Silverman AK, Solomon AR, et al. Alpha 1-antitrypsin deficiency associated with panniculitis. *J Am Acad Dermatol*. 1988;18:684-692.
176. Smith KC, Pittelkow MR, Su WP. Panniculitis associated with severe alpha 1-antitrypsin deficiency. Treatment and review of the literature. *Arch Dermatol*. 1987;123:1655-1661.
177. Streicher JL, Sheehan MP, Armstrong AB, et al. Cutaneous manifestation of alpha(1)-antitrypsin deficiency: panniculitis absent on biopsy. *Cutis*. 2014;93:303-306.
178. Rubinstein HM, Jaffer AM, Kudrna JC, et al. Alpha1-antitrypsin deficiency with severe panniculitis. Report of two cases. *Ann Intern Med*. 1977;86:742-744.
179. Balk E, Bronsveld W, Van der Deyl JA, et al. Alpha 1-antitrypsin deficiency with vascular leakage syndrome and panniculitis. *Neth J Med*. 1982;25:138-141.
180. Vigl K, Monshi B, Vujic I, et al. Pyoderma gangrenosum-like necrotizing panniculitis associated with alpha-1 antitrypsin deficiency: a lethal course. *J Dtsch Dermatol Ges*. 2015;13:1180-1184.
181. Ortiz PG, Skov BG, Benfeldt E. Alpha1-antitrypsin deficiency-associated panniculitis: case report and review of treatment options. *J Eur Acad Dermatol Venereol*. 2005;19:487-490.
182. Furey NL, Golden RS, Potts SR. Treatment of alpha-1-antitrypsin deficiency, massive edema, and panniculitis with alpha-1 protease inhibitor. *Ann Intern Med*. 1996;125:699.
183. Blanco I, Lara B, de Serres F. Efficacy of alpha1-antitrypsin augmentation therapy in conditions other than pulmonary emphysema. *Orphanet J Rare Dis*. 2011;6:14.
184. O'Riordan K, Blei A, Rao MS, et al. alpha 1-antitrypsin deficiency-associated panniculitis: resolution with intravenous alpha 1-antitrypsin administration and liver transplantation. *Transplantation*. 1997;63:480-482.
185. Cathomas M, Schuller A, Candinas D, et al. Severe postoperative wound healing disturbance in a patient with alpha-1-antitrypsin deficiency: the impact of augmentation therapy. *Int Wound J*. 2015;12:601-604.
186. Zheng ZJ, Gong J, Xiang GM, et al. Pancreatic panniculitis associated with acinar cell carcinoma of the pancreas: a case report. *Ann Dermatol*. 2011;23:225-228.
187. Hu JC, Gutierrez MA. Pancreatic panniculitis after endoscopic retrograde cholangiopancreatography. *J Am Acad Dermatol*. 2011;64:e72-e74.
188. Dahl PR, Su WP, Cullimore KC, et al. Pancreatic panniculitis. *J Am Acad Dermatol*. 1995;33:413-417.
189. Lopez A, Garcia-Estan J, Marras C, et al. Pancreatitis associated with pleural-mediastinal pseudocyst, panniculitis and polyarthritis. *Clin Rheumatol*. 1998;17:335-339.

190. Rongioletti F, Caputo V. Pancreatic panniculitis. *G Ital Dermatol Venereol*. 2013;148:419-425.
191. Hughes SH, Apisarnthanarax P, Mullins F. Subcutaneous fat necrosis associated with pancreatic disease. *Arch Dermatol*. 1975;111:506-510.
192. Callata-Carhuapoma HR, Pato Cour E, Garcia-Paredes B, et al. Pancreatic acinar cell carcinoma with bilateral ovarian metastases, panniculitis and polyarthritis treated with FOLFIRINOX chemotherapy regimen. A case report and review of the literature. *Pancreatology*. 2015;15:440-444.
193. Kalwaniya S, Choudhary P, Aswani Y, et al. Pancreatic panniculitis. *Indian J Dermatol Venereol Leprol*. 2015;81:282-283.
194. Cutlan RT, Wesche WA, Jenkins JJ 3rd, et al. A fatal case of pancreatic panniculitis presenting in a young patient with systemic lupus. *J Cutan Pathol*. 2000;27:466-471.
195. Langenhan R, Reimers N, Probst A. Osteomyelitis: a rare complication of pancreatitis and PPP-syndrome. *Joint Bone Spine*. 2016;83:221-224.
196. Narvaez J, Bianchi MM, Santo P, et al. Pancreatitis, panniculitis, and polyarthritis. *Semin Arthritis Rheum*. 2010;39:417-423.
197. Potts DE, Mass MF, Iseman MD. Syndrome and pancreatic disease, subcutaneous fat necrosis and polyserositis. Case report and review of literature. *Am J Med*. 1975;58:417-423.
198. Beltraminelli HS, Buechner SA, Hausermann P. Pancreatic panniculitis in a patient with an acinar cell cystadenocarcinoma of the pancreas. *Dermatology*. 2004;208:265-267.
199. Arbelaez-Cortes A, Vanegas-Garcia AL, Restrepo-Escobar M, et al. Polyarthritis and pancreatic panniculitis associated with pancreatic carcinoma: review of the literature. *J Clin Rheumatol*. 2014;20:433-436.
200. Omland SH, Ekenberg C, Henrik-Nielsen R, et al. Pancreatic panniculitis complicated by infection with *Corynebacterium tuberculostearicum*: a case report. *IDCases*. 2014;1:45-46.
201. Wilson HA, Askari AD, Neiderhiser DH, et al. Pancreatitis with arthropathy and subcutaneous fat necrosis. Evidence for the pathogenicity of lipolytic enzymes. *Arthritis Rheum*. 1983;26:121-126.
202. Berman B, Conteas C, Smith B, et al. Fatal pancreatitis presenting with subcutaneous fat necrosis. Evidence that lipase and amylase alone do not induce lipocyte necrosis. *J Am Acad Dermatol*. 1987;17:359-364.
203. Schaffler A, Landfried K, Volk M, et al. Potential of adipocytokines in predicting peripancreatic necrosis and severity in acute pancreatitis: pilot study. *J Gastroenterol Hepatol*. 2007;22:326-334.
204. Echeverria CM, Fortunato LP, Stengel FM, et al. Pancreatic panniculitis in a kidney transplant recipient. *Int J Dermatol*. 2001;40:751-753.
205. Pike JL, Rice JC, Sanchez RL, et al. Pancreatic panniculitis associated with allograft pancreatitis and rejection in a simultaneous pancreas-kidney transplant recipient. *Am J Transplant*. 2006;6:2502-2505.
206. Anders M, Gonzalez VM, Ruiz J, et al. An unreported case of pancreatic panniculitis in a liver transplant patient. *Acta Gastroenterol Latinoam*. 2014;44:239-242.
207. Abdallah M, B'Chir Hamzaoui S, Bouslama K, et al. Acute pancreatitis associated with hemophagocytic syndrome in systemic lupus erythematous: a case report [in French]. *Gastroenterol Clin Biol*. 2005;29:1054-1056.
208. Martinez-Escribano JA, Pedro F, Sabater V, et al. Acute exanthem and pancreatic panniculitis in a patient with primary HIV infection and haemophagocytic syndrome. *Br J Dermatol*. 1996;134:804-807.
209. Banfill KE, Oliphant TJ, Prasad KR. Resolution of pancreatic panniculitis following metastasectomy. *Clin Exp Dermatol*. 2012;37:440-441.
210. Kirkland EB, Sachdev R, Kim J, et al. Early pancreatic panniculitis associated with HELLP syndrome and acute fatty liver of pregnancy. *J Cutan Pathol*. 2011;38:814-817.
211. Chiewchengchol D, Wananukul S, Noppakun N. Pancreatic panniculitis caused by L-asparaginase induced acute pancreatitis in a child with acute lymphoblastic leukemia. *Pediatr Dermatol*. 2009;26:47-49.
212. Pfaundler N, Kessebohm K, Blum R, et al. Adding pancreatic panniculitis to the panel of skin lesions associated with triple therapy of chronic hepatitis C. *Liver Int*. 2013;33:648-649.
213. Ball NJ, Cowan BJ, Hashimoto SA. Lobular panniculitis at the site of subcutaneous interferon beta injections for the treatment of multiple sclerosis can histologically mimic pancreatic panniculitis. A study of 12 cases. *J Cutan Pathol*. 2009;36:331-337.
214. Weedon D. Panniculitis. In: *Weedon's Skin Pathology*. 3rd ed. London, UK: Churchill Livingstone Elsevier; 2010,460-480.
215. Hudson-Peacock MJ, Regnard CF, Farr PM. Liquefying panniculitis associated with acinous carcinoma of the pancreasrespondingtooctreotide.*JRSocMed*.1994;87:361-362.
216. Francombe J, Kingsnorth AN, Tunn E. Panniculitis, arthritis and pancreatitis. *Br J Rheumatol*. 1995;34:680-683.
217. Irgang SS. Lupus erythematosus profundus: Report of an example with clinical resemblance to Darier-Roussy sarcoid. *Arch Derm Syphilol*. 1940;42:97-108.
218. Fraga J, Garcia-Diez A. Lupus erythematosus panniculitis. *Dermatol Clin*. 2008;26:453-463, vi.
219. Zhao YK, Wang F, Chen WN, et al. Lupus panniculitis as an initial manifestation of systemic lupus erythematosus: a case report. *Medicine (Baltimore)*. 2016;95:e3429.
220. Massone C, Kodama K, Salmhofer W, et al. Lupus erythematosus panniculitis (lupus profundus): clinical, histopathological, and molecular analysis of nine cases. *J Cutan Pathol*. 2005;32:396-404.
221. Martens PB, Moder KG, Ahmed I. Lupus panniculitis: clinical perspectives from a case series. *J Rheumatol*. 1999;26:68-72.
222. Nitta Y. Lupus erythematosus profundus associated with neonatal lupus erythematosus. *Br J Dermatol*. 1997;136:112-114.
223. Fernandes S, Santos S, Freitas I, et al. Linear lupus erythematosus profundus as an initial manifestation of systemic lupus erythematosus in a child. *Pediatr Dermatol*. 2014;31:378-380.
224. Arai S, Katsuoka K. Clinical entity of lupus erythematosus panniculitis/lupus erythematosus profundus. *Autoimmun Rev*. 2009;8:449-452.
225. Lee H, Kim DS, Chung KY. Adalimumab-induced lupus panniculitis. *Lupus*. 2014;23:1443-1444.
226. Urosevic-Maiwald M, Nobbe S, Kerl K, et al. Disseminated ulcerating lupus panniculitis emerging under interferon therapy of hairy cell leukemia: treatment- or disease-related? *J Dermatol*. 2014;41:329-333.

227. Magee KL, Hymes SR, Rapini RP, et al. Lupus erythematosus profundus with periorbital swelling and proptosis. *J Am Acad Dermatol*. 1991;24:288-290.
228. Tsuzaka S, Ishiguro N, Akashi R, et al. A case of lupus erythematosus profundus with multiple arc-shaped erythematous plaques on the scalp and a review of the literature. *Lupus*. 2012;21:662-665.
229. Nousari HC, Kimyai-Asadi A, Provost TT. Generalized lupus erythematosus profundus in a patient with genetic partial deficiency of C4. *J Am Acad Dermatol*. 1999;41:362-364.
230. Winkelmann RK. Panniculitis in connective tissue disease. *Arch Dermatol*. 1983;119:336-344.
231. Arai S, Katsuoka K, Eto H. An unusual form of lupus erythematosus profundus associated with antiphospholipid syndrome: report of two cases. *Acta Derm Venereol*. 2013;93:581-582.
232. Mosier AD, Boldt B, Keylock J, et al. Serial MR findings and comprehensive review of bilateral lupus mastitis with an additional case report. *J Radiol Case Rep*. 2013;7:48-58.
233. Kopp A, Buechler C, Neumeier M, et al. Innate immunity and adipocyte function: ligand-specific activation of multiple Toll-like receptors modulates cytokine, adipokine, and chemokine secretion in adipocytes. *Obesity (Silver Spring)*. 2009;17:648-656.
234. Barrat FJ, Coffman RL. Development of TLR inhibitors for the treatment of autoimmune diseases. *Immunol Rev*. 2008;223:271-283.
235. Kono DH, Haraldsson MK, Lawson BR, et al. Endosomal TLR signaling is required for anti-nucleic acid and rheumatoid factor autoantibodies in lupus. *Proc Natl Acad Sci U S A*. 2009;106:12061-12066.
236. Tao K, Fujii M, Tsukumo S, et al. Genetic variations of Toll-like receptor 9 predispose to systemic lupus erythematosus in Japanese population. *Ann Rheum Dis*. 2007;66:905-909.
237. Visentini M, Conti V, Cagliuso M, et al. Regression of systemic lupus erythematosus after development of an acquired Toll-like receptor signaling defect and antibody deficiency. *Arthritis Rheum*. 2009;60:2767-2771.
238. Lafyatis R, York M, Marshak-Rothstein A. Antimalarial agents: closing the gate on Toll-like receptors? *Arthritis Rheum*. 2006;54:3068-3070.
239. Arps DP, Patel RM. Lupus profundus (panniculitis): a potential mimic of subcutaneous panniculitis-like T-cell lymphoma. *Arch Pathol Lab Med*. 2013;137:1211-1215.
240. Papalas JA, Wang E. Clinical and histopathologic overlap between subcutaneous panniculitis-like T-cell lymphoma with systemic features and small cell CD8+ ALK+ systemic anaplastic large cell lymphoma with cutaneous involvement. *J Cutan Pathol*. 2016;43:480-481.
241. Magro CM, Crowson AN, Kovatich AJ, et al. Lupus profundus, indeterminate lymphocytic lobular panniculitis and subcutaneous T-cell lymphoma: a spectrum of subcuticular T-cell lymphoid dyscrasia. *J Cutan Pathol*. 2001;28:235-247.
242. LeBlanc RE, Tavallaee M, Kim YH, et al. Useful parameters for distinguishing subcutaneous panniculitis-like T-cell lymphoma from lupus erythematosus panniculitis. *Am J Surg Pathol*. 2016;40(6):745-754.
243. Magro CM, Crowson AN, Byrd JC, et al. Atypical lymphocytic lobular panniculitis. *J Cutan Pathol*. 2004;31:300-306.
244. Magro CM, Schaefer JT, Morrison C, et al. Atypical lymphocytic lobular panniculitis: a clonal subcutaneous T-cell dyscrasia. *J Cutan Pathol*. 2008;35:947-954.
245. Pincus LB, LeBoit PE, McCalmont TH, et al. Subcutaneous panniculitis-like T-cell lymphoma with overlapping clinicopathologic features of lupus erythematosus: coexistence of 2 entities? *Am J Dermatopathol*. 2009;31:520-526.
246. Wang CY, Su WP, Kurtin PJ. Subcutaneous panniculitic T-cell lymphoma. *Int J Dermatol*. 1996;35:1-8.
247. Willemze R, Jansen PM, Cerroni L, et al. Subcutaneous panniculitis-like T-cell lymphoma: definition, classification, and prognostic factors: an EORTC Cutaneous Lymphoma Group Study of 83 cases. *Blood*. 2008;111:838-845.
248. Aguilera P, Mascaro JM Jr, Martinez A, et al. Cutaneous gamma/delta T-cell lymphoma: a histopathologic mimicker of lupus erythematosus profundus (lupus panniculitis). *J Am Acad Dermatol*. 2007;56:643-647.
249. Wang X, Magro CM. Human myxovirus resistance protein 1 (MxA) as a useful marker in the differential diagnosis of subcutaneous lymphoma vs. lupus erythematosus profundus. *Eur J Dermatol*. 2012;22:629-633.
250. Magro CM, Wang X. CCL5 expression in panniculitic T-cell dyscrasias and its potential role in adipocyte tropism. *Am J Dermatopathol*. 2013;35:332-337.
251. Vastert SJ, Kuis W, Grom AA. Systemic JIA: new developments in the understanding of the pathophysiology and therapy. *Best Pract Res Clin Rheumatol*. 2009;23:655-664.
252. Miyashita A, Fukushima S, Makino T, et al. The proportion of lymphocytic inflammation with CD123-positive cells in lupus erythematous profundus predict a clinical response to treatment. *Acta Derm Venereol*. 2014;94:563-567.
253. Braunstein I, Werth VP. Update on management of connective tissue panniculitides. *Dermatol Ther*. 2012;25:173-182.
254. Callen JP. Management of skin disease in patients with lupus erythematosus. *Best Pract Res Clin Rheumatol*. 2002;16:245-264.
255. Chung HS, Hann SK. Lupus panniculitis treated by a combination therapy of hydroxychloroquine and quinacrine. *J Dermatol*. 1997;24:569-572.
256. Wozniacka A, Lesiak A, Boncela J, et al. The influence of antimalarial treatment on IL-1beta, IL-6 and TNF-alpha mRNA expression on UVB-irradiated skin in systemic lupus erythematosus. *Br J Dermatol*. 2008;159:1124-1130.
257. Jewell ML, McCauliffe DP. Patients with cutaneous lupus erythematosus who smoke are less responsive to antimalarial treatment. *J Am Acad Dermatol*. 2000;42:983-987.
258. Kreuter A, Gaifullina R, Tigges C, et al. Lupus erythematosus tumidus: response to antimalarial treatment in 36 patients with emphasis on smoking. *Arch Dermatol*. 2009;145:244-248.
259. Ujiie H, Shimizu T, Ito M, et al. Lupus erythematosus profundus successfully treated with dapsone: review of the literature. *Arch Dermatol*. 2006;142:399-401.
260. Hansen CB, Callen JP. Connective tissue panniculitis: lupus panniculitis, dermatomyositis, morphea/scleroderma. *Dermatol Ther*. 2010;23:341-349.
261. Ishiguro N, Iwasaki T, Kawashima M, et al. Intractable ulceration in a patient with lupus erythematosus profundus successfully treated with cyclosporine. *Int J Dermatol*. 2012;51:1131-1133.

262. Espirito Santo J, Gomes MF, Gomes MJ, et al. Intravenous immunoglobulin in lupus panniculitis. *Clin Rev Allergy Immunol*. 2010;38:307-318.
263. Ueda T, Eto H, Katsuoka K, et al. Lupus erythematosus panniculitis treated with tacrolimus. *Eur J Dermatol*. 2012;22:260-261.
264. Moreno-Suarez F, Pulpillo-Ruiz A. Rituximab for the treatment of lupus erythematosus panniculitis. *Dermatol Ther*. 2013;26:415-418.
265. Gunther C, Aringer M, Lochno M, et al. TNF-alpha blockade with infliximab in a patient with lupus erythematosus profundus. *Acta Derm Venereol*. 2012;92:401-403.
266. Morgan KW, Callen JP. Calcifying lupus panniculitis in a patient with subacute cutaneous lupus erythematosus: response to diltiazem and chloroquine. *J Rheumatol*. 2001;28:2129-2132.
267. Alegre VA, Winkelmann RK. Histiocytic cytophagic panniculitis. *J Am Acad Dermatol*. 1989;20:177-185.
268. Craig AJ, Cualing H, Thomas G, et al. Cytophagic histiocytic panniculitis—a syndrome associated with benign and malignant panniculitis: case comparison and review of the literature. *J Am Acad Dermatol*. 1998;39:721-736.
269. Crotty CP, Winkelmann RK. Cytophagic histiocytic panniculitis with fever, cytopenia, liver failure, and terminal hemorrhagic diathesis. *J Am Acad Dermatol*. 1981;4:181-194.
270. Wick MR, Patterson JW. Cytophagic histiocytic panniculitis—a critical reappraisal. *Arch Dermatol*. 2000;136:922-924.
271. Winkelmann RK, Bowie EJ. Hemorrhagic diathesis associated with benign histiocytic, cytophagic panniculitis and systemic histiocytosis. *Arch Intern Med*. 1980;140:1460-1463.
272. Chen RL, Hsu YH, Ueda I, et al. Cytophagic histiocytic panniculitis with fatal haemophagocytic lymphohistiocytosis in a paediatric patient with perforin gene mutation. *J Clin Pathol*. 2007;60:1168-1169.
273. Krilis M, Miyakis S. Cytophagic histiocytic panniculitis with haemophagocytosis in a patient with familial multiple lipomatosis and review of the literature. *Mod Rheumatol*. 2012;22:158-162.
274. Aronson IK, West DP, Variakojis D, et al. Fatal panniculitis. *J Am Acad Dermatol*. 1985;12:535-551.
275. Aronson IK, Worobec SM. Cytophagic histiocytic panniculitis and hemophagocytic lymphohistiocytosis: an overview. *Dermatol Ther*. 2010;23:389-402.
276. Hasegawa H, Mizoguchi F, Kohsaka H, et al. Systemic lupus erythematosus with cytophagic histiocytic panniculitis successfully treated with high-dose glucocorticoids and cyclosporine A. *Lupus*. 2013;22:316-319.
277. Marzano AV, Berti E, Paulli M, et al. Cytophagic histiocytic panniculitis and subcutaneous panniculitis-like T-cell lymphoma: report of 7 cases. *Arch Dermatol*. 2000;136:889-896.
278. Schaer DJ, Schleiffenbaum B, Kurrer M, et al. Soluble hemoglobin-haptoglobin scavenger receptor CD163 as a lineage-specific marker in the reactive hemophagocytic syndrome. *Eur J Haematol*. 2005;74:6-10.
279. Ostrov BE, Athreya BH, Eichenfield AH, et al. Successful treatment of severe cytophagic histiocytic panniculitis with cyclosporine A. *Semin Arthritis Rheum*. 1996;25:404-413.
280. Pasqualini C, Jorini M, Carloni I, et al. Cytophagic histiocytic panniculitis, hemophagocytic lymphohistiocytosis and undetermined autoimmune disorder: reconciling the puzzle. *Ital J Pediatr*. 2014;40:17.
281. Coman T, Dalloz MA, Coolen N, et al. Plasmapheresis for the treatment of acute pancreatitis induced by hemophagocytic syndrome related to hypertriglyceridemia. *J Clin Apher*. 2003;18:129-131.
282. Tengku-Muhammad TS, Hughes TR, Cryer A, et al. Differential regulation of lipoprotein lipase in the macrophage J774.2 cell line by cytokines. *Cytokine*. 1996;8:525-533.
283. Risdall RJ, McKenna RW, Nesbit ME, et al. Virus-associated hemophagocytic syndrome: a benign histiocytic proliferation distinct from malignant histiocytosis. *Cancer*. 1979;44:993-1002.
284. Janka G, Imashuku S, Elinder G, et al. Infection- and malignancy-associated hemophagocytic syndromes. Secondary hemophagocytic lymphohistiocytosis. *Hematol Oncol Clin North Am*. 1998;12:435-444.
285. Tristano AG. Macrophage activation syndrome: a frequent but under-diagnosed complication associated with rheumatic diseases. *Med Sci Monit*. 2008;14:Ra27-Ra36.
286. Filipovich AH. Hemophagocytic lymphohistiocytosis and other hemophagocytic disorders. *Immunol Allergy Clin North Am*. 2008;28:293-313, viii.
287. Pauwels C, Livideanu CB, Maza A, et al. Cytophagic histiocytic panniculitis after H1N1 vaccination: a case report and review of the cutaneous side effects of influenza vaccines. *Dermatology*. 2011;222:217-220.
288. Merelli M, Quartuccio L, Bassetti M, et al. Efficacy of intravenous cyclosporine in a case of cytophagic histiocytic panniculitis complicated by haemophagocytic syndrome after visceral leishmania infection. *Clin Exp Rheumatol*. 2015;33:906-909.
289. Masters SL, Simon A, Aksentijevich I, et al. Horror autoinflammaticus: the molecular pathophysiology of autoinflammatory disease (*). *Annu Rev Immunol*. 2009;27:621-668.
290. Badolato R, Parolini S. Novel insights from adaptor protein 3 complex deficiency. *J Allergy Clin Immunol*. 2007;120:735-741; quiz 742-743.
291. Rastogi V, Sharma R, Misra SR, et al. Emperipolesis—a review. *J Clin Diagn Res*. 2014;8:Zm01-Zm02.
292. White JW Jr, Winkelmann RK. Cytophagic histiocytic panniculitis is not always fatal. *J Cutan Pathol*. 1989;16:137-144.
293. Guitart J, Sethi R, Gordon K. Fatal cytophagic histiocytic panniculitis after a short response to cyclosporine. *J Eur Acad Dermatol Venereol*. 1998;10:267-268.
294. Rouphael NG, Talati NJ, Vaughan C, et al. Infections associated with haemophagocytic syndrome. *Lancet Infect Dis*. 2007;7:814-822.
295. Miyabe Y, Murata Y, Baba Y, et al. Successful treatment of cyclosporine-A-resistant cytophagic histiocytic panniculitis with tacrolimus. *Mod Rheumatol*. 2011;21:553-556.
296. Rios Fernandez R, Callejas Rubio JL, Sanchez Cano D, et al. Long-term evolution of cytophagic histiocytic panniculitis. *J Cutan Med Surg*. 2010;14:136-140.
297. Mori Y, Sugiyama T, Chiba R, et al. A case of systemic lupus erythematosus with hemophagocytic syndrome and cytophagic histiocytic panniculitis [in Japanese]. *Ryumachi*. 2001;41:31-36.
298. Matsue K, Itoh M, Tsukuda K, et al. Successful treatment of cytophagic histiocytic panniculitis with modified CHOP-E. Cyclophosphamide, adriamycin,

vincristine, predonisone, and etoposide. *Am J Clin Oncol*. 1994;17:470-474.
299. Koizumi K, Sawada K, Nishio M, et al. Effective high-dose chemotherapy followed by autologous peripheral blood stem cell transplantation in a patient with the aggressive form of cytophagic histiocytic panniculitis. *Bone Marrow Transplant*. 1997;20:171-173.
300. Bader-Meunier B, Fraitag S, Janssen C, et al. Clonal cytophagic histiocytic panniculitis in children may be cured by cyclosporine A. *Pediatrics*. 2013;132:e545-e549.
301. Behrens EM, Kreiger PA, Cherian S, et al. Interleukin 1 receptor antagonist to treat cytophagic histiocytic panniculitis with secondary hemophagocytic lymphohistiocytosis. *J Rheumatol*. 2006;33:2081-2084.
302. Tran JT, Sheth AP. Complications of subcutaneous fat necrosis of the newborn: a case report and review of the literature. *Pediatr Dermatol*. 2003;20:257-261.
303. Torrelo A, Hernandez A. Panniculitis in children. *Dermatol Clin*. 2008;26:491-500, vii.
304. Mahe E, Girszyn N, Hadj-Rabia S, et al. Subcutaneous fat necrosis of the newborn: a systematic evaluation of risk factors, clinical manifestations, complications and outcome of 16 children. *Br J Dermatol*. 2007;156:709-715.
305. Mitra S, Dove J, Somisetty SK. Subcutaneous fat necrosis in newborn—an unusual case and review of literature. *Eur J Pediatr*. 2011;170:1107-1110.
306. Thomas JM, Bhandari J, Rytina E, et al. Subcutaneous fat necrosis of the neonate with a delayed second eruption. *Pediatr Dermatol*. 2016;33:e134-e136.
307. Burden AD, Krafchik BR. Subcutaneous fat necrosis of the newborn: a review of 11 cases. *Pediatr Dermatol*. 1999;16:384-387.
308. Carraccio C, Papadimitriou J, Feinberg P. Subcutaneous fat necrosis of the newborn: link to maternal use of cocaine during pregnancy. *Clin Pediatr (Phila)*. 1994;33:317-318.
309. Courteau C, Samman K, Ali N, et al. Macrosomia and hemodynamic instability may represent risk factors for subcutaneous fat necrosis in asphyxiated newborns treated with hypothermia. *Acta Paediatr*. 2016;105(9):e396-e405.
310. Vasireddy S, Long SD, Sacheti B, et al. MRI and US findings of subcutaneous fat necrosis of the newborn. *Pediatr Radiol*. 2009;39:73-76.
311. Norwood-Galloway A, Lebwohl M, Phelps RG, et al. Subcutaneous fat necrosis of the newborn with hypercalcemia. *J Am Acad Dermatol*. 1987;16:435-439.
312. Balfour E, Antaya RJ, Lazova R. Subcutaneous fat necrosis of the newborn presenting as a large plaque with lobulated cystic areas. *Cutis*. 2002;70:169-173.
313. Haider S. Images in paediatrics: subcutaneous fat necrosis causing radial nerve palsy. *BMJ Case Rep*. 2012;2012.
314. Shumer DE, Thaker V, Taylor GA, et al. Severe hypercalcaemia due to subcutaneous fat necrosis: presentation, management and complications. *Arch Dis Child Fetal Neonatal Ed*. 2014;99:F419-F421.
315. Varan B, Gurakan B, Ozbek N, et al. Subcutaneous fat necrosis of the newborn associated with anemia. *Pediatr Dermatol*. 1999;16:381-383.
316. Hakan N, Aydin M, Zenciroglu A, et al. Is therapeutic hypothermia real cause of subcutaneous fat necrosis in newborns? *Indian J Pediatr*. 2013;80:355.
317. Akin MA, Akin L, Coban D, et al. Post-operative subcutaneous fat necrosis in a newborn: a case report. *Fetal Pediatr Pathol*. 2011;30:363-369.
318. Silverman AK, Michels EH, Rasmussen JE. Subcutaneous fat necrosis in an infant, occurring after hypothermic cardiac surgery. Case report and analysis of etiologic factors. *J Am Acad Dermatol*. 1986;15:331-336.
319. Farooque A, Moss C, Zehnder D, et al. Expression of 25-hydroxyvitamin D3-1alpha-hydroxylase in subcutaneous fat necrosis. *Br J Dermatol*. 2009;160:423-425.
320. Heaton JM. The distribution of brown adipose tissue in the human. *J Anat*. 1972;112:35-39.
321. Ichimiya H, Arakawa S, Sato T, et al. Involvement of brown adipose tissue in subcutaneous fat necrosis of the newborn. *Dermatology*. 2011;223:207-210.
322. de Meis L, Ketzer LA, da Costa RM, et al. Fusion of the endoplasmic reticulum and mitochondrial outer membrane in rats brown adipose tissue: activation of thermogenesis by Ca2+. *PLoS One*. 2010;5:e9439.
323. Tajirian A, Ross R, Zeikus P, et al. Subcutaneous fat necrosis of the newborn with eosinophilic granules. *J Cutan Pathol*. 2007;34:588-590.
324. Ricardo-Gonzalez RR, Lin JR, Mathes EF, et al. Neutrophil-rich subcutaneous fat necrosis of the newborn: A potential mimic of infection. *J Am Acad Dermatol*. 2016;75(1):177-185.e17.
325. Schubert PT, Razack R, Vermaak A, et al. Fine-needle aspiration cytology of subcutaneous fat necrosis of the newborn: the cytology spectrum with review of the literature. *Diagn Cytopathol*. 2012;40:245-247.
326. Schubert PT, Razak R, Jordaan HF. Fine-needle aspiration as a method of diagnosis of subcutaneous fat necrosis of the newborn. *Pediatr Dermatol*. 2016;33:e220-e221.
327. Tognetti L, Filippou G, Bertrando S, et al. Subcutaneous fat necrosis in a newborn after brief therapeutic hypothermia: ultrasonographic examination. *Pediatr Dermatol*. 2015;32:427-429.
328. Fretzin DF, Arias AM. Sclerema neonatorum and subcutaneous fat necrosis of the newborn. *Pediatr Dermatol*. 1987;4:112-122.
329. Gomes C, Lobo L, Azevedo AS, et al. Nephrocalcinosis and subcutaneous fat necrosis [in Portuguese]. *Acta Med Port*. 2015;28:119-122.
330. Beuzeboc Gerard M, Aillet S, Bertheuil N, et al. Surgical management of subcutaneous fat necrosis of the newborn required due to a lack of improvement: a very rare case. *Br J Dermatol*. 2014;171:183-185.
331. Hakan N, Aydin M, Zenciroglu A, et al. Alendronate for the treatment of hypercalcaemia due to neonatal subcutaneous fat necrosis. *Eur J Pediatr*. 2011;170:1085-1086; author reply 1087.
332. Perez Martinez E, Camprubi Camprubi M, Ramos Cebrian M, et al. Treatment with bisphosphonates in severe hypercalcemia due to subcutaneous fat necrosis in an infant with hypoxic-ischemic encephalopathy. *J Perinatol*. 2014;34:492-493.
333. Samedi VM, Yusuf K, Yee W, et al. Neonatal hypercalcemia secondary to subcutaneous fat necrosis successfully treated with pamidronate: a case series and literature review. *AJP Rep*. 2014;4:e93-e96.
334. Lombet J. Commentary on "Pamidronate: treatment for severe hypercalcemia in neonatal subcutaneous fat necrosis" by Alos N, et al. *Hormone Research* 2006;65:289-294. *Horm Res*. 2008;70:254-255; author reply 256.
335. Filippi L, Catarzi S, Padrini L, et al. Strategies for reducing the incidence of skin complications in newborns treated with whole-body hypothermia. *J Matern Fetal Neonatal Med*. 2012;25:2115-2121.

336. Bolotin D, Duffy KL, Petronic-Rosic V, et al. Cold panniculitis following ice therapy for cardiac arrhythmia. *Pediatr Dermatol*. 2011;28:192-194.
337. Quesada-Cortes A, Campos-Munoz L, Diaz-Diaz RM, et al. Cold panniculitis. *Dermatol Clin*. 2008;26: 485-489, vii.
338. Pekki A, Sauni R, Vaalasti A, et al. Cold panniculitis in Finnish horse riders. *Acta Derm Venereol*. 2011;91:463-464.
339. Epstein EH Jr, Oren ME. Popsicle panniculitis. *N Engl J Med*. 1970;282:966-967.
340. Bournas VG, Eilbert W. Infant with facial lesions. Cold panniculitis. *Ann Emerg Med*. 2011;58:216-221.
341. Patel AR, Husain S, Lauren CT, et al. Circular erythematous patch in a febrile infant. Cold panniculitis. *Pediatr Dermatol*. 2012;29:659-660.
342. Harkness G, Meikle G, Craw S, et al. Ultrasound appearance of scrotal fat necrosis in prepubertal boys. *Pediatr Radiol*. 2007;37:370-373.
343. Ferrara G, Cerroni L. Cold-associated perniosis of the thighs ("equestrian-type" chilblain): a reappraisal based on a clinicopathologic and immunohistochemical study of 6 cases. *Am J Dermatopathol*. 2016;38(10):726-731.
344. Price RD, Murdoch DR. Perniosis (chilblains) of the thigh: report of five cases, including four following river crossings. *High Alt Med Biol*. 2001;2:535-538.
345. Tlougan BE, Mancini AJ, Mandell JA, et al. Skin conditions in figure skaters, ice-hockey players and speed skaters: part II-cold-induced, infectious and inflammatory dermatoses. *Sports Med*. 2011;41:967-984.
346. West SE, McCalmont TH, North JP. Ice-pack dermatosis: a cold-induced dermatitis with similarities to cold panniculitis and perniosis that histopathologically resembles lupus. *JAMA Dermatol*. 2013;149:1314-1318.
347. Gesta S, Tseng YH, Kahn CR. Developmental origin of fat: tracking obesity to its source. *Cell*. 2007;131:242-256.
348. Fredriksson JM, Nikami H, Nedergaard J. Cold-induced expression of the VEGF gene in brown adipose tissue is independent of thermogenic oxygen consumption. *FEBS Lett*. 2005;579:5680-5684.
349. Gasparetti AL, de Souza CT, Pereira-da-Silva M, et al. Cold exposure induces tissue-specific modulation of the insulin-signalling pathway in Rattus norvegicus. *J Physiol*. 2003;552:149-162.
350. Justrabo E, Martin L, Athias A, et al. Bilateral scrotal panniculitis in a prepubescent child [in French]. *Arch Anat Cytol Pathol*. 1998;46:208-212.
351. De Silva BD, McLaren K, Doherty VR. Equestrian perniosis associated with cold agglutinins: a novel finding. *Clin Exp Dermatol*. 2000;25:285-288.
352. Ter Poorten JC, Hebert AA, Ilkiw R. Cold panniculitis in a neonate. *J Am Acad Dermatol*. 1995;33:383-385.
353. Boyd AS. Revision: cutaneous Munchausen syndrome: clinical and histopathologic features. *J Cutan Pathol*. 2014;41:333-336.
354. Grassi S, Rosso R, Tomasini C, et al. Post-surgical lipophagic panniculitis: a specific model of traumatic panniculitis and new histopathological findings. *G Ital Dermatol Venereol*. 2013;148:435-441.
355. Shellagi N, Rodrigues G. Traumatic panniculitis of the right thigh: a case report. *Oman Med J*. 2011;26:436-437.
356. Sanmartin O, Requena C, Requena L. Factitial panniculitis. *Dermatol Clin*. 2008;26:519-527, viii.
357. Lee JS, Ahn SK, Lee SH. Factitial panniculitis induced by cupping and acupuncture. *Cutis*. 1995;55:217-218.
358. Jeong KH, Lee MH. Two cases of factitial panniculitis induced by electroacupuncture. *Clin Exp Dermatol*. 2009;34:e170-e173.
359. Lee JH, Jung KE, Kim HS, et al. Traumatic panniculitis with localized hypertrichosis: two new cases and considerations. *J Dermatol*. 2013;40:139-141.
360. Oh CC, Tan KB, Thirumoorthy T, et al. Traumatic panniculitis in a Chinese woman. *Skinmed*. 2014;12:127-128.
361. Moreno A, Marcoval J, Peyri J. Traumatic panniculitis. *Dermatol Clin*. 2008;26:481-483, vii.
362. Weedon D. Traumatic fat necrosis. In: *Skin Pathology*. 2nd ed. London, UK: Churchill Livingstone; 2002, 349-368.
363. Chairatchaneeboon M, Kulthanan K, Manapajon A. Calcific panniculitis and nasopharyngeal cancer-associated adult-onset dermatomyositis: a case report and literature review. *Springerplus*. 2015;4:201.
364. Solans R, Cortes J, Selva A, et al. Panniculitis: a cutaneous manifestation of dermatomyositis. *J Am Acad Dermatol*. 2002;46:S148-S150.
365. Hemmi S, Kushida R, Nishimura H, et al. Magnetic resonance imaging diagnosis of panniculitis in dermatomyositis. *Muscle Nerve*. 2010;41:151-153.
366. Neidenbach PJ, Sahn EE, Helton J. Panniculitis in juvenile dermatomyositis. *J Am Acad Dermatol*. 1995;33:305-307.
367. Salman A, Kasapcopur O, Ergun T, et al. Panniculitis in juvenile dermatomyositis: Report of a case and review of the published work. *J Dermatol*. 2016;43(8):951-953.
368. Otero Rivas MM, Vicente Villa A, Gonzalez Lara L, et al. Panniculitis in juvenile dermatomyositis. *Clin Exp Dermatol*. 2015;40:574-575.
369. Chiu HY, He GY, Chen JS, et al. Subcutaneous panniculitis-like T-cell lymphoma presenting with clinicopathologic features of dermatomyositis. *J Am Acad Dermatol*. 2011;64:e121-e123.
370. Girouard SD, Velez NF, Penson RT, et al. Panniculitis associated with dermatomyositis and recurrent ovarian cancer. *Arch Dermatol*. 2012;148:740-744.
371. Douvoyiannis M, Litman N, Dulau A, et al. Panniculitis, infection, and dermatomyositis: case and literature review. *Clin Rheumatol*. 2009;28(suppl 1):S57-S63.
372. Winkelman WJ, Billick RC, Srolovitz H. Dermatomyositis presenting as panniculitis. *J Am Acad Dermatol*. 1990;23:127-128.
373. Penate Y, Guillermo N, Melwani P, et al. Calcinosis cutis associated with amyopathic dermatomyositis: response to intravenous immunoglobulin. *J Am Acad Dermatol*. 2009;60:1076-1077.
374. Snider AA, Barsky S. Gouty panniculitis: a case report and review of the literature. *Cutis*. 2005;76:54-56.
375. Choi CM, Lew BL, Lee SH, et al. Gouty panniculitis also involving the bone marrow. *Acta Derm Venereol*. 2013;93:189-190.
376. Pattanaprichakul P, Bunyaratavej S, McLain PM, et al. Disseminated gouty panniculitis: an unusual presentation of extensive cutaneous tophi. *Dermatol Pract Concept*. 2014;4:33-35.
377. Wang L, Rose C, Mellen P, et al. Gouty panniculitis with ulcerations in a patient with multiple organ dysfunctions. *Case Rep Rheumatol*. 2014;2014:320940.
378. Gaviria JL, Ortega VG, Gaona J, et al. Unusual dermatological manifestations of gout: review of literature and a case report. *Plast Reconstr Surg Glob Open*. 2015;3:e445.
379. Ochoa CD, Valderrama V, Mejia J, et al. Panniculitis: another clinical expression of gout. *Rheumatol Int*. 2011;31:831-835.

380. Penaranda-Parada E, Bejarano NS, Mejia J, et al. Gouty arthritis and panniculitis: extensive involvement of the dermis and severe joint damage. *J Clin Rheumatol*. 2012;18:142-143.
381. Sacchidanand SA, Kanathur S, Somaiah S, et al. Post-steroid panniculitis: a rare case report. *Indian Dermatol Online J*. 2013;4:318-320.
382. de-Andres-del-Rosario A, Verea-Hernando MM, Yebra-Pimentel MT, et al. Poststeroid panniculitis in an adult. *Am J Dermatopathol*. 2011;33:e77-e80.
383. Kim ST, Kim TK, Lee JW, et al. Post-steroid panniculitis in an adult. *J Dermatol*. 2008;35:786-788.

Chapter 74 :: Lipodystrophy

:: Abhimanyu Garg

AT-A-GLANCE

- Lipodystrophies are genetic or acquired disorders characterized by selective loss of body fat. The extent of fat loss determines the severity of associated metabolic complications such as diabetes mellitus, hypertriglyceridemia, hepatic steatosis, and acanthosis nigricans.
- Four loci have been identified for the autosomal recessive congenital generalized lipodystrophy (CGL), namely, *AGPAT2*, *BSCL2*, *CAV1*, and *CAVIN1*.
- Five loci have been identified for autosomal dominant familial partial lipodystrophy (FPL), namely, *LMNA*, *PPARG*, *AKT2*, *PLIN1*, and *ADRA2A*.
- *LIPE*, *CIDEC*, *PCYT1A*, and *RECQL2* are loci for autosomal recessive FPL, and *LMNA* and *ZMPSTE24* are loci for mandibuloacral dysplasia-associated lipodystrophy.
- Molecular basis of many extremely rare forms of genetic lipodystrophies remains to be elucidated.
- The most prevalent variety of lipodystrophy develops after prolonged duration of protease inhibitor containing highly active antiretroviral therapy in HIV-infected patients.
- The acquired generalized lipodystrophy and acquired partial lipodystrophy are mainly autoimmune in origin.
- Localized lipodystrophies occur as a result of drug or vaccine injections, pressure, and panniculitis, as well as other unknown reasons.
- Current management includes cosmetic surgery and early identification and treatment of metabolic and other complications.
- Metreleptin replacement therapy is beneficial for treating metabolic complications in hypoleptinemic patients with generalized lipodystrophies.

Lipodystrophies are a heterogeneous group of disorders characterized by selective loss of adipose tissue.[1,2] The extent of fat loss varies, with some patients losing fat from small areas (localized lipodystrophy), and others having more extensive fat loss, for example, involving the extremities (partial lipodystrophy) or the entire body (generalized lipodystrophy). Depending upon the extent of fat loss, patients may be predisposed to develop complications associated with insulin resistance such as diabetes mellitus, dyslipidemia, hepatic steatosis, acanthosis nigricans, polycystic ovarian disease, and coronary heart disease.[3-5] There are 2 main types of lipodystrophies: genetic and acquired. Table 74-1 provides a detailed classification of various types of lipodystrophies.

EPIDEMIOLOGY

Although the genetic lipodystrophies are rare, recent advances, such as improved definition of the phenotypes and elucidation of the molecular defects, have led to increased recognition of these syndromes. Overall, based on literature reports of approximately 1200 patients, the estimated prevalence of genetic lipodystrophies may be less than 1 in a million. Affected females are recognized easily and thus are reported more often than males.

The autosomal-recessive congenital generalized lipodystrophy (CGL) has been reported in approximately 500 patients, with clustering of patients reported in Lebanon and Brazil, where there is increased prevalence of consanguinity. Recently, prevalence of CGL was reported to be approximately 1 in 2 million general population in Turkey.[6] The autosomal-dominant familial partial lipodystrophy (FPL) of the Dunnigan variety is the most common with approximately 500 patients being reported; and FPL caused by *PPARG* mutations has been reported in approximately 40 patients. As a result of founder mutations, FPL Dunnigan type prevalence has been estimated to be as high as 1:200,000 general population from the Canadian province of Ontario[7] and approximately 1:20,000 of the general population of the Reunion Island located in the Indian Ocean.[8] The autosomal-recessive mandibuloacral dysplasia (MAD) that is caused by *LMNA* mutations has been reported in approximately 30 patients; MAD caused by *ZMPSTE24* mutations has been reported in 15 patients.

Acquired partial lipodystrophy was recognized approximately 125 years ago and only approximately 250 to 300 cases of various ethnicities with a male-to-female ratio of 1:4 have been reported.[9] Acquired generalized lipodystrophy has been reported in fewer than 100 cases, mostly in whites with a male-to-female ratio of 1:3.[10] The most common type at present is highly active antiretroviral therapy (containing protease inhibitors [PIs])-induced lipodystrophy in HIV-infected patients, which is estimated to be affecting more than 100,000 patients in the United States and many more in other countries.[1,11,12]

GENETIC LIPODYSTROPHIES

In the last decade or so, considerable progress has been made in elucidation of the molecular basis of many types of genetic lipodystrophies. In general, mutations

TABLE 74-1
Classification of Lipodystrophies

Genetic Lipodystrophies

1. Autosomal recessive, congenital generalized lipodystrophy (CGL)
   a. Type 1: *AGPAT2* mutations
   b. Type 2: *BSCL2* mutations
   c. Type 3: *CAV1* mutation
   d. Type 4: *CAVIN1* mutations
   e. Others
2. Autosomal dominant, familial partial lipodystrophy (FPL)
   a. Dunnigan variety: *LMNA* mutations
   b. *PPARG* mutations
   c. *AKT2* mutation
   d. *PLIN1* mutations
   e. *ADRA2A* (adrenoceptor α_{2A}) mutation
   f. Others
3. Autosomal recessive, familial partial lipodystrophy (FPL)
   a. *CIDEC* mutation
   b. *LIPE* mutations
   c. *PCYT1A* mutations
   d. *RECQL2* mutations
4. Autosomal recessive, mandibuloacral dysplasia (MAD)–associated lipodystrophy
   a. *LMNA* mutations
   b. *ZMPSTE24* mutations
   c. Others
5. Other lipodystrophies associated with *LMNA* mutations
   a. Atypical progeroid syndrome
   b. Hutchinson-Gilford progeria syndrome
6. SHORT (short stature, hyperextensibility of joints or hernia, ocular depression, Rieger anomaly, teething) syndrome
   a. *PIK3R1* mutations
7. Neonatal progeroid (Weidemann-Rautenstrauch) syndrome
   a. *FBN1* mutations
   b. *CAV1* mutations
   c. *POLR3A* mutation
8. Mandibular hypoplasia, deafness, progeroid (MDP) syndrome
   a. *POLD1* mutations
9. Autoinflammatory lipodystrophy (joint contractures, microcytic anemia, panniculitis-associated [JMP] lipodystrophy syndrome spectrum including chronic atypical neutrophilic dermatosis with lipodystrophy and elevated temperature [CANDLE] syndrome)
   a. *PSMB8* mutations

Acquired Lipodystrophies

1. Highly active antiretroviral therapy–induced lipodystrophy in HIV-infected patients
2. Acquired generalized lipodystrophy
   a. Panniculitis induced
   b. Autoimmune diseases associated
   c. Idiopathic
3. Acquired partial (Barraquer-Simons) lipodystrophy
   a. Autoimmune diseases associated
   b. Membranoproliferative glomerulonephritis associated
   c. Idiopathic
4. Localized lipodystrophies
   a. Panniculitis induced
   b. Pressure induced
   c. Drug induced
   d. Centrifugal
   e. Idiopathic

in genes involved in adipocyte differentiation, triglyceride synthesis, lipid droplet formation, and adipocyte survival have been reported to cause lipodystrophies.

CONGENITAL GENERALIZED LIPODYSTROPHY (BERARDINELLI-SEIP SYNDROME)

CLINICAL FEATURES

This autosomal recessive disorder has 4 subtypes and can be recognized at birth or soon thereafter from the near total lack of body fat.[13] Patients also have marked muscularity, prominent subcutaneous veins, acromegaloid features, acanthosis nigricans, hepatomegaly, and umbilical prominence (Fig. 74-1A, Table 74-2). During childhood, they have a voracious appetite, and accelerated linear growth. Females usually have hirsutism, clitoromegaly, oligomenorrhea, and polycystic ovaries. Only a few women have had successful pregnancies. Fertility may be affected in some men with CGL because of teratozoospermia. Some CGL patients develop hypertrophic cardiomyopathy, mild mental retardation, and focal lytic lesions in the appendicular bones after puberty.[13] Metabolic abnormalities related to insulin resistance, such as diabetes mellitus, hyperlipidemia, and hepatic steatosis, may manifest at a young age and are often difficult to control.

ETIOLOGY AND PATHOGENESIS

Genome-wide linkage analysis with positional cloning strategy and candidate gene approach have led to the identification of 4 genetic loci for CGL: 1-acylglycerol-3-phosphate-*O*-acyltransferase 2 (*AGPAT2*) gene on chromosome 9q34[14,15]; Berardinelli-Seip congenital lipodystrophy 2 (*BSCL2*) gene on chromosome 11q13[16]; caveolin 1 (*CAV1*) gene on chromosome 7q31[17]; and caveolae associated protein 1 (*CAVIN1*), also known as polymerase I and transcript release factor (*PTRF*) gene on chromosome 17q21.[18] AGPAT2 is a critical enzyme involved in the biosynthesis of triglycerides and phospholipids from glycerol-3-phosphate and is expressed highly in the adipose tissue.[19] The *BSCL2*-encoded protein, seipin, plays a role in lipid droplet fusion and also may be involved in adipocyte differentiation.[20-22] Caveolin 1 is an integral component of caveolae, specialized microdomains seen in abundance on adipocyte membranes. Caveolin 1 binds fatty acids and translocates them to lipid droplets. *CAVIN1* is involved in biogenesis of caveolae and regulates expression of caveolins 1 and 3.[18] Patients with *BSCL2* mutations lack mechanical fat located in the orbital region, palm, sole, and in periarticular regions, as well as metabolically active adipose tissue located in the subcutaneous (SQ), intraabdominal, intrathoracic, and other areas as compared to those with *AGPAT2*, *CAV1*, and *PTRF* mutations where mechanical fat is preserved.[17,23] The only reported patient with *CAV1* mutation also had short stature and presumed vitamin D resistance.[17] Only approximately 15 patients with *CAVIN1* mutations have been reported

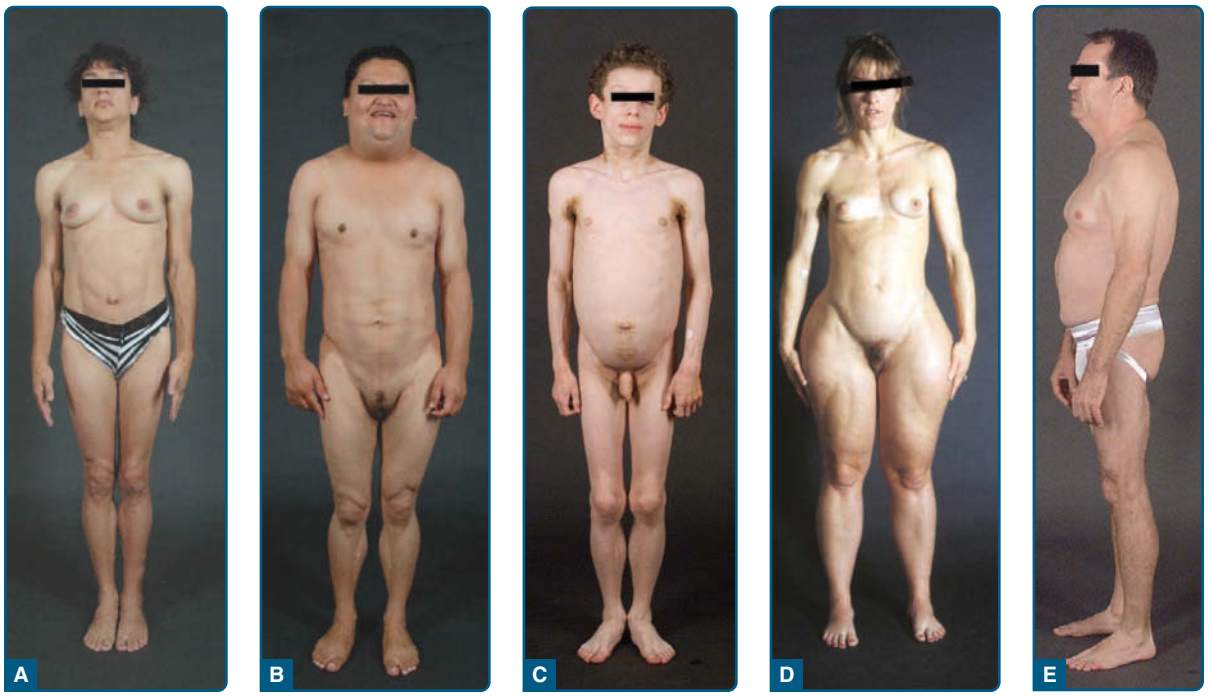

Figure 74-1 Clinical features of patients with various types of lipodystrophies. **A,** Anterior view of a 33-year-old Hispanic female with congenital generalized lipodystrophy (also known as Berardinelli-Seip congenital lipodystrophy), Type 1 caused by homozygous c.589–2A>G; p.(Val197Glufs*32) mutation in the *AGPAT2* gene. The patient had generalized loss of subcutaneous fat with acanthosis nigricans in the axillae and neck. She has umbilical prominence and acromegaloid features (enlarged mandible, hands, and feet). **B,** Anterior view of a 27-year-old Native American Hispanic female with familial partial lipodystrophy of the Dunnigan variety caused by heterozygous p.Arg482Trp mutation in *LMNA* gene. She had marked loss of subcutaneous fat from the limbs and anterior truncal region. The breasts were atrophic. She had increased subcutaneous fat deposits in the face, anterior neck, and vulvar regions. **C,** Anterior view of an 8-year-old German boy with acquired generalized lipodystrophy. He had severe generalized loss of subcutaneous fat with marked acanthosis nigricans in the neck, axillae, and groin. **D,** Anterior view of a 39-year-old white female with acquired partial lipodystrophy (Barraquer-Simons syndrome). She had marked loss of subcutaneous fat from the face, neck, upper extremities, and chest, but had lipodystrophy on localized regions on anterior thighs. She had increased subcutaneous fat deposition in the lower extremities. **E,** Lateral view of a 53-year-old white male infected with HIV with highly active antiretroviral therapy–induced lipodystrophy. He had marked loss of subcutaneous fat from the face and limbs, but had increased subcutaneous fat deposition in the neck region anteriorly and posteriorly showing buffalo hump. Abdomen was protuberant because of excess intraabdominal fat. He had been on protease inhibitor–containing antiretroviral therapy for more than 8 years.

and they have congenital myopathy, increased creatine kinase levels, percussion-induced myoedema, pyloric stenosis, atlantoaxial instability, and cardiac rhythm disturbances including prolonged QT interval and exercise-induced ventricular tachycardia, which can result in sudden death.[18,24,25] Patients of Lebanese origin harbor homozygous c.315_319delGTATC; p.(Tyr106Cysfs*6) mutation in *BSCL2*, whereas those of African origin nearly always have either homozygous or compound heterozygous c.589–2A>G; p.(Val197Glufs*32) mutation in *AGPAT2* gene.[15,16,26]

FAMILIAL PARTIAL LIPODYSTROPHY

CLINICAL FEATURES

FPL in most patients is transmitted in an autosomal dominant fashion and is characterized by fat loss from the limbs with variable fat loss from the trunk and increased SQ fat deposition in nonlipodystrophic regions (see Fig. 74-1B). Most FPL patients have the Dunnigan variety as a result of heterozygous mutations in lamin A/C (*LMNA*) gene. These patients have normal body fat distribution during early childhood, but around the time of puberty, SQ fat from the extremities and trunk is progressively lost (see Fig. 74-1B). The face, neck, and intraabdominal region are spared, and often excess fat accumulates there.[27,28] Affected men are often more difficult to diagnose clinically, as many normal men are also quite muscular. Women are more severely affected metabolically.[29]

Patients with FPL caused by heterozygous mutations in *PPARG* gene also have fat loss from the extremities, especially from distal regions, but the fat from the face, neck, and truncal areas is spared.[30] There is increased prevalence of hypertension among the affected subjects. Four subjects from a single family with diabetes and insulin resistance were reported to harbor a heterozygous mutation in *AKT2* gene.[31] The female proband had lipodystrophy of the

TABLE 74-2
Clinical Features of Various Types of Congenital Generalized Lipodystrophy

	SUBTYPE OF CONGENITAL GENERALIZED LIPODYSTROPHY (CGL)			
CHARACTERISTIC	**CGL1**	**CGL2**	**CGL3**	**CGL4**
Gene	*AGPAT2*	*BSCL2*	*CAV1*	*CAVIN1*
Loss of metabolically active adipose tissue	+++	+++	++	++
Loss of mechanical adipose tissue	–	+	–	–
Bone marrow fat	–	–	+	+
Lytic bone lesions	++	+	–	–
Mild mental retardation	–	+	–	–
Cardiomyopathy	–	+	–	+
Echocardiogram	Normal	Abnormal	Normal	Normal
Catecholaminergic polymorphic ventricular tachycardia	–	–	–	+
Prolonged QT interval	–	–	–	+
Sudden death	–	–	–	+
Congenital pyloric stenosis	–	–	–	+
Atlantoaxial instability	–	–	–	+
Acanthosis nigricans	+++	+++	++	+/–
Hepatomegaly	+	+	+	+
Congenital myopathy	–	–	–	+
Diabetes mellitus	+	+	+	–
Hypertriglyceridemia	+	+	+	+
Hypocalcemia	–	–	+	–
Hyperinsulinemia	+	+	+	+/–
Cirrhosis	+	++	–	–

–, absent; +/–, absent/present; +, mild; ++, moderate; +++, severe.

limbs, although detailed studies of body fat distribution were not performed. Recently, 12 FPL patients were reported to harbor *PLIN1* mutations.[32,33] Three patients from a single family with atypical FPL and marked buffalo hump had a heterozygous *ADRA2A* mutation.[34]

ETIOLOGY AND PATHOGENESIS

FPL results from heterozygous missense mutations in 1 of the 5 genes: lamin A/C (*LMNA*) on chromosome 1q21–22,[35-38] an integral component of nuclear lamina; peroxisome proliferator-activated receptor γ (*PPARG*) on chromosome 3p25,[30,39,40] a key transcription factor involved in adipocyte differentiation; v-AKT murine thymoma oncogene homolog 2 (*AKT2*) on chromosome 19q13,[31] which is involved in downstream insulin signaling; perilipin 1 (*PLIN1*) on chromosome 15q26, a key component of lipid droplets[32]; and adrenoreceptor α_{2A} (*ADRA2A*), the main presynaptic inhibitory feedback G-protein–coupled receptor regulating norepinephrine release.[34] Adipocyte loss in patients with *LMNA* mutations may be a result of disruption of nuclear envelope function and integrity resulting in premature cell death. Some patients with mutations in the aminoterminal region of lamin A/C also develop myopathy, cardiomyopathy, and conduction system abnormalities indicative of a multisystem dystrophy.[41] On the other hand, others with mutations in the extreme C-terminal region of lamin A may have mild lipodystrophy.[42]

MANDIBULOACRAL DYSPLASIA–ASSOCIATED LIPODYSTROPHY

CLINICAL FEATURES

Patients with MAD have characteristic skeletal abnormalities including hypoplasia of the mandible and clavicles, acroosteolysis, cutaneous atrophy, progeroid features such as thin beaked nose, hair loss, thin skin with prominent superficial vasculature and mottled hyperpigmentation, delayed dentition

and closure of cranial sutures, joint stiffness, and lipodystrophy.[43,44]

ETIOLOGY AND PATHOGENESIS

Mutations in *LMNA* and zinc metalloproteinase (*ZMPSTE24*) on chromosome 1p34 cause autosomal-recessive MAD-associated lipodystrophies.[45,46] *ZMPSTE24* is involved in posttranslational proteolytic processing of prelamin A to mature lamin A and its deficiency can result in accumulation of prelamin A in cells which is supposed to cause toxicity. Those persons with *ZMPSTE24* mutations develop clinical manifestations earlier in life, are premature at birth, and can develop focal segmental glomerulosclerosis, calcified skin nodules, and thin shiny skin.[47,48]

OTHER TYPES

CLINICAL FEATURES

My colleagues and I reported a novel syndrome with mandibular hypoplasia, deafness, progeroid features–associated lipodystrophy.[49] All males with mandibular hypoplasia, deafness, progeroid features had undescended testes and were hypogonadal. One adult female showed lack of breast development. Patients with autoinflammatory lipodystrophy present as a spectrum of clinical manifestations, with onset ranging from during the first months of life[50] to later during childhood.[51] Early features are recurrent fevers, annular violaceous plaques, poor weight and height gain, persistent violaceous eyelid swelling, hepatomegaly, arthralgias, variable muscle atrophy, and progressive lipodystrophy.[52-54] Histopathologic examination of lesional skin shows atypical mononuclear infiltrates of myeloid lineage and mature neutrophils, and laboratory abnormalities include chronic anemia, elevated acute-phase reactants, and raised liver enzymes with a cytokine profile showing high levels of interferon-inducible protein–1, monocyte chemotactic protein–1, interleukin-6, and interleukin-1 receptor antagonist, consistent with an interferon signaling signature.[52,53] This presentation has been called CANDLE syndrome (chronic atypical neutrophilic dermatosis with lipodystrophy and elevated temperature).[50] Older individuals with *PSMB8* mutations show joint contractures, muscle atrophy, microcytic anemia, and panniculitis-induced (JMP) childhood-onset lipodystrophy (Fig. 74-2).[51] Other features of JMP syndrome include hypergammaglobulinemia, elevated erythrocyte sedimentation rate, hepatosplenomegaly, and calcification of basal ganglia.[51] Other rare syndromes of lipodystrophy include autosomal-recessive FPL and SHORT (short stature, hyperextensibility or inguinal hernia, ocular depression, Rieger anomaly, and teething delay) syndrome.[55,56] The fat loss is usually confined to the face, upper extremities, and trunk, and sometimes the buttocks.[55,56] Patients with neonatal progeroid (Wiedemann-Rautenstrauch) syndrome present with generalized loss of body fat and muscle mass and progeroid appearance at birth.[57] There is a marked heterogeneity in the phenotype of patients with Wiedemann-Rautenstrauch syndrome.

ETIOLOGY AND PATHOGENESIS

De novo recurrent heterozygous mutation in polymerase (DNA) delta 1, catalytic subunit (*POLD1*) gene has been reported in patients with mandibular hypoplasia, deafness, progeroid features syndrome.[58] Most patients with SHORT syndrome have a de novo recurrent heterozygous missense mutation in phosphoinositide-3-kinase regulatory subunit 1 (PIK3R1) gene.[59] De novo heterozygous mutations in fibrillin 1 (*FBN1*)[60] and caveolin 1 (*CAV1*)[61] and biallelic mutations in RNA polymerase III subunit A (*POLR3A*)[62] have been reported in Wiedemann-Rautenstrauch syndrome patients. Recently, a single patient with autosomal recessive, FPL phenotype was found to harbor a homozygous missense mutation in cell death-inducing DNA fragmentation factor a-like effector c (*CIDEC*) gene on chromosome 3p25, involved in lipid droplet formation.[63] The histopathology of the SQ adipose tissue of the patient revealed multilocular, small lipid droplets in adipocytes. Two additional patients with autosomal recessive partial and generalized lipodystrophy phenotype had mutations in phosphate cytidylyltransferase 1α (*PCYT1A*) gene that encodes the rate-limiting enzyme in phosphatidyl choline biosynthetic pathway.[64] Loss-of-function mutations in hormone sensitive lipase (*LIPE*) gene have been reported to cause an autosomal recessive FPL phenotype with multiple symmetric lipomatosis and myopathy.[65-67] Two women with FPL and features of Werner syndrome have been reported to harbor null mutations in Werner syndrome RecQ like helicase *(WRN)* gene.[68]

Heterozygous *LMNA* mutations can also cause partial or generalized lipodystrophy in patients with atypical progeroid syndrome[69] and generalized loss of SQ fat in Hutchinson-Gilford progeria syndrome.[70] Autoinflammatory lipodystrophy syndrome results from mutations in proteasome subunit, beta-type, 8 (*PSMB8*).[52,53] *PSMB8* encodes the β5i subunit of the immunoproteasome involved in proteolytic cleavage of immunogenic epitopes presented by major histocompatibility complex Class I molecules.[52] The molecular genetic basis of many other genetic lipodystrophy syndromes remains unclear (see Table 74-1).

ACQUIRED LIPODYSTROPHIES

Despite recognition of acquired lipodystrophies for more than a century, progress in understanding underlying pathogenic mechanisms has been slow.

Figure 74-2 Phenotype of patients with joint contractures, muscle atrophy, microcytic anemia, and panniculitis-induced lipodystrophy (JMP) syndrome. **A,** Left lateral view of a 30-year-old Mexican male with JMP syndrome showing marked generalized loss of subcutaneous fat and muscle mass from the face, neck, chest, and extremities. Flexion contracture at the elbow, wrist, and hand are seen. **B,** Left lateral view of a 26-year-old Mexican female with JMP syndrome showing lipodystrophy affecting mostly the upper body, that is, the face, neck, thorax, and upper extremities. **C,** Left lateral view of the face of a 35-year-old Portuguese male with JMP syndrome showing marked loss of subcutaneous fat. **D,** Dorsal view of the hand from a 35-year-old Portuguese male showing flexion contractures of the wrist, proximal and distal interphalangeal joints and hyperextension of the metacarpophalangeal joints. **E,** Posterior view of the chest of a 26-year-old Mexican female with JMP syndrome showing many discrete, small, erythematous maculopapular and nodular skin lesions on the chest and medial side of right arm. (Reproduced with permission from Agarwal AK, Xing C, DeMartino GN, et al. *PSMB8* encoding the β5i proteasome subunit is mutated in joint contractures, muscle atrophy, microcytic anemia, and panniculitis-induced lipodystrophy syndrome. *Am J Hum Genet*. 2010;87:866-872. Copyright © Elsevier.)

ACQUIRED PARTIAL LIPODYSTROPHY (BARRAQUER-SIMONS SYNDROME)

CLINICAL FEATURES

Acquired partial lipodystrophy develops in most patients before age 15 years. Patients lose SQ fat gradually in a symmetric fashion starting with the face and then spreading downward. Most patients present with fat loss from the face, neck, upper extremities, and trunk, with sparing of SQ abdominal fat and lower extremities (see Fig. 74-1C). Approximately, 20% of the patients develop mesangiocapillary (membranoproliferative) glomerulonephritis, and some develop drusen.[9] Usually, patients do not develop metabolic complications.

ETIOLOGY AND PATHOGENESIS

The exact pathogenesis of SQ fat loss remains unclear but there is strong evidence of autoimmune-mediated adipocyte loss as more than 80% of the patients have low levels of complement 3 (C3) and presence of a circulating immunoglobulin G, a C3-nephritic factor that blocks degradation of the enzyme C3 convertase.[9] Loss of fat could be the result of C3-nephritic factor–induced lysis of adipocytes expressing factor D.

ACQUIRED GENERALIZED LIPODYSTROPHY (LAWRENCE SYNDROME)

CLINICAL FEATURES

Acquired generalized lipodystrophies present with variable amount of SQ fat loss usually during childhood. Although many patients have generalized loss of fat, some areas are spared (see Fig. 74-1D). Usually, intraabdominal or bone marrow fat is spared.[10] However, patients develop extremely severe hepatic steatosis and fibrosis, diabetes, and hypertriglyceridemia, which are difficult to manage.

ETIOLOGY AND PATHOGENESIS

The exact mechanisms of fat loss are not known. In approximately 25% of patients, SQ fat loss occurs following development of SQ inflammatory nodules that on biopsy reveal panniculitis.[10] These lesions initially result in localized fat loss followed by generalized loss of fat. Another 25% of the patients have associated autoimmune diseases, especially juvenile dermatomyositis.[10,71] In the remaining patients with the idiopathic variety, multiple unknown mechanisms are likely involved.[10] Patients with the panniculitis-associated variety have less-severe fat loss and metabolic complications than seen in other types. Some patients have been reported to have low serum levels of complement 4.[72]

HIGHLY ACTIVE ANTIRETROVIRAL THERAPY–INDUCED LIPODYSTROPHY IN HIV-INFECTED PATIENTS

CLINICAL FEATURES

Patients infected with HIV who are receiving PI-containing highly active antiretroviral therapy usually lose SQ fat from the face, trunk, and extremities 2 years or more after initiation of therapy (see Figs. 74-1E, 74-3A, and 74-3B). Fat loss from the face can be so severe as to result in an emaciated appearance. Some of them develop buffalo hump, double chin, and also gain intraabdominal fat. The fat loss progressively gets worse with ongoing highly active antiretroviral therapy and does not reverse on discontinuation of PIs. Some cases develop diabetes mellitus and many develop combined hyperlipidemia that can predispose the patients to coronary heart disease.[12]

ETIOLOGY AND PATHOGENESIS

Drugs such as HIV-1 PIs and nucleoside analogs are implicated in causing lipodystrophy in HIV-infected patients. Many, but not all, PIs may induce lipodystrophy by inhibiting ZMPSTE24, resulting in accumulation of prelamin A.[73] Other mechanisms may include PI-induced alteration of expression of key transcription factors involved in lipogenesis and adipocyte differentiation, such as sterol regulatory element-binding protein 1c and PPARG.[74] PIs also reduce glucose transporter 4 expression, which may be a mechanism for inducing insulin resistance.[75] Nucleoside analogs, especially zidovudine and stavudine, may induce fat loss by inhibiting polymerase-γ, a mitochondrial enzyme involved in replication of mitochondrial DNA.[76] As most patients receive multiple antiretroviral drugs together, the individual effects of PIs or nucleoside reverse transcriptase inhibitors on the phenotype are not clear.

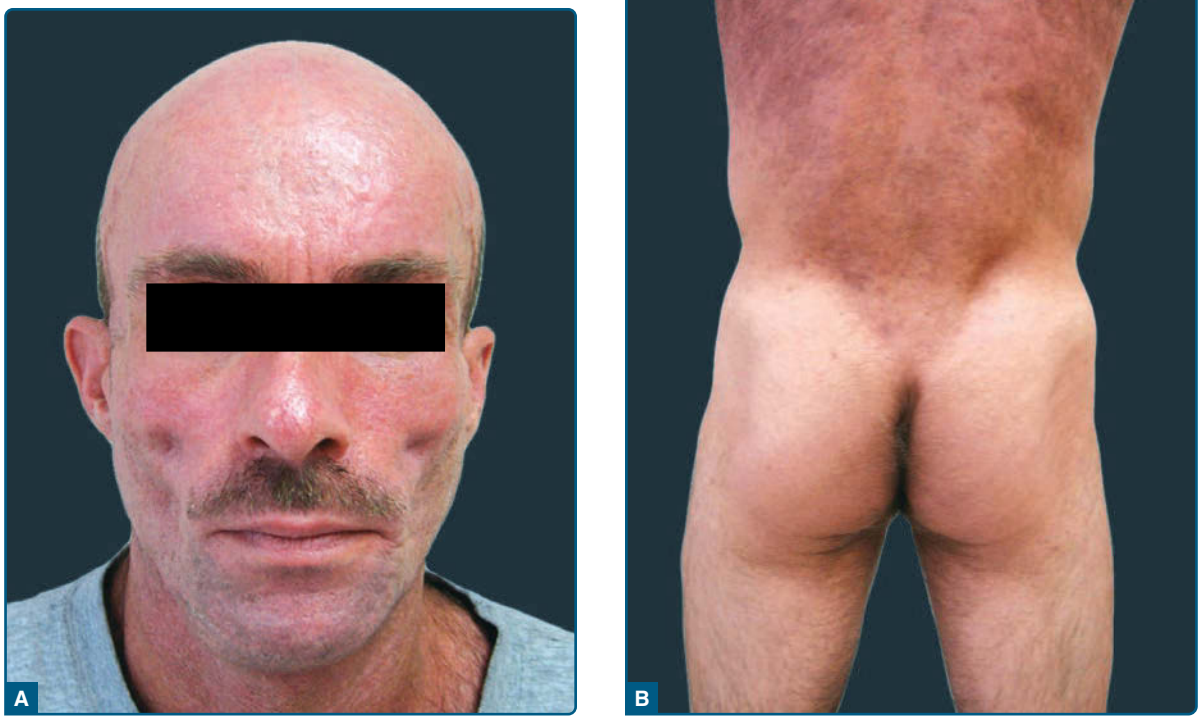

Figure 74-3 **A,** Highly active antiretroviral therapy–induced lipodystrophy in a patient with HIV infection–associated lipodystrophy. Loss of buccal fat results in prominence of the zygomatic arch **B,** Highly active antiretroviral therapy-induced lipodystrophy with loss of subcutaneous fat from the lateral buttock and deposit in the trunk, causing an increased waist-to-hip ratio.

LOCALIZED LIPODYSTROPHY

CLINICAL FEATURES

Localized lipodystrophies present with SQ fat loss from a focal region resulting in a dimple or a crater with overlying skin usually unaffected. In some patients, large contiguous or anatomically distinct areas on any region of the body may be involved.[3]

ETIOLOGY AND PATHOGENESIS

This can occur from SQ injection of various drugs, panniculitis, pressure, and other mechanisms.[3]

DIAGNOSIS

Lipodystrophies should be strongly suspected in "lean or nonobese" patients who present with premature onset of diabetes, hypertriglyceridemia, hepatic steatosis, acanthosis nigricans, and polycystic ovarian syndrome. These patients should be examined carefully for evidence of loss of SQ fat especially from the hips and thighs, as well as excess SQ fat deposition in various anatomic regions. For those presenting with generalized lipodystrophy during childhood, pictures at birth should be evaluated for evidence of fat loss. If lipodystrophy phenotype is discovered at or shortly after birth, CGL should be considered; otherwise, the patient may have acquired lipodystrophy.

HISTORY

Patients should be asked about their age at time of onset and the progression of the lipodystrophy and other associated manifestations. Taking a detailed family history, including the history of consanguinity, is very important to understand the mode of inheritance of genetic lipodystrophies. Associated autoimmune diseases, especially juvenile dermatomyositis, should be considered in patients with acquired lipodystrophies. Those with localized lipodystrophies should be asked about local injections, trauma, pressure, or other insults. A detailed history of duration and type of antiretroviral therapy should be obtained from HIV-infected patients with lipodystrophy.

CUTANEOUS LESIONS

The most common cutaneous lesion seen in patients with lipodystrophies is acanthosis nigricans in the axillae,

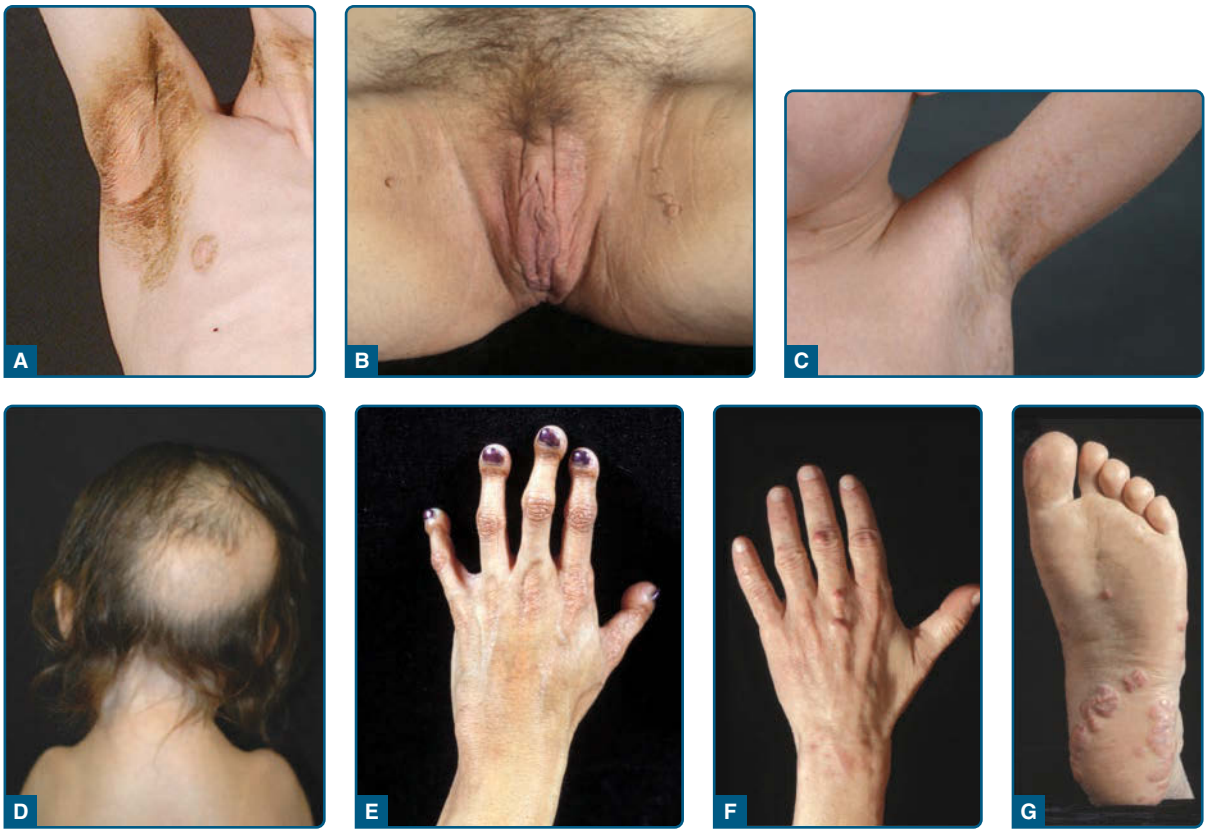

Figure 74-4 Dermatologic manifestations seen in patients with lipodystrophies. **A,** Acanthosis nigricans (brownish discoloration with thickening of the skin) in the axilla and anterior neck in an 8-year-old white boy with acquired generalized lipodystrophy. **B,** Acanthosis nigricans in the perineum and medial parts of the proximal thighs in a 37-year-old female with familial partial lipodystrophy (FPL). Multiple, small skin tags accompany increased pigmentation and thick skin. **C,** Multiple, slightly hyperpigmented flat plaques (freckles) in a 7-year-old boy with atypical progeroid syndrome caused by a heterozygous p.(Cys588Arg) mutation in the *LMNA* gene. **D,** Loss of hair from the posterior scalp region in a 5-year-old girl with severe mandibuloacral dysplasia (MAD) caused by a homozygous p.(Arg527Cys) mutation in the *LMNA* gene. She had narrow shoulders as a result of clavicular hypoplasia. **E,** Acroosteolysis in a 20-year-old Hispanic woman with MAD caused by a homozygous p.(Arg527His) mutation in the *LMNA* gene. The terminal digits appear short and bulbous because of resorption of the terminal phalanges. The skin on the dorsum of the hand is atrophic, especially over the proximal interphalangeal and metacarpophalangeal joints. **F,** Tuberous xanthomas over the middle finger of a 45-year-old white patient with severe hyperlipidemia associated with FPL of the Dunnigan variety caused by a heterozygous p.(Arg482Gln) mutation in the *LMNA* gene. **G,** Planar xanthomas on the sole of the patient described in **F**. (Panel C reproduced with permission from Garg A, Subramanyam L, Agarwal AK, et al. Atypical progeroid syndrome due to heterozygous missense *LMNA* mutations. *J Clin Endocrinol Metab.* 2009;94:4971-4983. Copyright 2009, The Endocrine Society. Panel G reproduced with permission from Simha V, Garg A. Lipodystrophy: lessons in lipid and energy metabolism. *Curr Opin Lipidol.* 2006;17: 162-169. Wolters Kluwer/Lippincott Williams & Wilkins.)

groins, neck, and sometimes even on the knuckles, Achilles tendons, and trunk (Figs. 74-4A and B). Many patients develop clitoromegaly and hirsutism as a result of associated polycystic ovarian syndrome. Freckles were noted in a patient with atypical progeroid syndrome (Fig. 74-4C). A thin, beaked nose with loss of scalp, eyebrow, and axillary hair with cutaneous atrophy and mottled hyperpigmentation can be seen in patients with progeroid syndromes and MAD (Fig. 74-4D), along with acroosteolysis (Fig. 74-4E).[43,69,70] Rare patients with MAD develop shiny, taut, atrophic skin with a tendency to breakdown. Eruptive, tuberous, and planar xanthomas are also commonly seen in patients with extreme hypertriglyceridemia (Figs. 74-4F and G). Loss of SQ fat from the soles can result in plantar calluses. SQ nodules with overlying erythema may be seen in patients with panniculitis.

LABORATORY TESTING

Laboratory testing depends upon the type of lipodystrophy. Except for patients with localized lipodystrophies, a serum chemistry profile for glucose, lipids, liver enzymes, and uric acid should be obtained. Measurement of fasting and postprandial serum glucose and insulin during an oral glucose tolerance test can provide some estimate of insulin resistance. Serum leptin measurements are not diagnostic, but can help guide treatment decisions as far as investigational human recombinant leptin (metreleptin) replacement therapy is concerned. Serum leptin and adiponectin levels are very low in patients with generalized lipodystrophies.[77] Patients with acquired partial

lipodystrophy should be tested for serum C3 and C3-nephritic factor and annually checked for proteinuria. Radiographs can show presence of lytic lesions in appendicular bones in patients with CGL and skeletal defects in those with MAD. Skin biopsy is useful for patients with localized lipodystrophy or panniculitis-associated varieties.

SPECIAL TESTS (INCLUDING IMAGING STUDIES)

Distinction between various types of lipodystrophies can be made by physical examination and supported by anthropometry, including measurement of skinfold thickness with calipers at various sites. For in-depth phenotyping of body fat distribution, whole-body dual-energy X-ray absorptiometry, and T1-weighted MRI can be conducted. For those genetic lipodystrophies whose molecular basis is known, various commercial and research laboratories offer genetic testing. Prenatal genetic testing is also feasible. FPL patients, atypical progeroid syndrome patients and CGL, Type 4 patients who are predisposed to cardiomyopathy should undergo electrocardiography and Holter monitoring to detect arrhythmias and echocardiography to assess cardiac function.

DIFFERENTIAL DIAGNOSIS

The most important differential diagnosis of generalized lipodystrophies is with conditions presenting with severe weight loss, such as malnutrition, famine, starvation, anorexia nervosa, uncontrolled diabetes mellitus, thyrotoxicosis, adrenocortical insufficiency, cancer cachexia, HIV-associated wasting, diencephalic syndrome, and chronic infections. For partial lipodystrophies, distinction should be made with Cushing syndrome, generalized and truncal obesity, and multiple symmetric lipomatosis (Madelung disease). Patients with MAD and progeroid syndromes-associated lipodystrophies should be differentiated from those with Werner syndrome and leprechaunism (Donahue syndrome).

CLINICAL COURSE AND PROGNOSIS

Some patients develop extreme hypertriglyceridemia and chylomicronemia, which result in acute pancreatitis and even death. Long-term complications of diabetes such as nephropathy, neuropathy, and retinopathy are frequently seen. Many patients develop coronary heart disease and other atherosclerotic vascular complications.[29,78] Hepatic steatosis can lead to cirrhosis, necessitating liver transplantation. Sudden death has been reported during childhood in CGL, Type 4, likely from arrhythmias.[24] Some patients with acquired partial lipodystrophy and membranoproliferative glomerulonephritis may require kidney transplantation.[9] Patients with Hutchinson-Gilford progeria syndrome die of acute myocardial infarction or cerebrovascular accidents during their teenage years.[79] Some patients with atypical progeroid syndrome and FPL-Dunnigan develop cardiomyopathy with valvular dysfunction, congestive heart failure, and arrhythmias requiring pacemaker implantation.[41,69] Two adult patients with MAD caused by *ZMPSTE24* mutations died of renal failure resulting from focal segmental glomerulosclerosis.[47] Some patients with acquired generalized lipodystrophy have been reported to develop peripheral T-cell lymphomas.[80]

The prognosis is dependent upon the type of lipodystrophy. In most of the published cases of CGL the patients have been children, resulting in a lack of data about their prognosis. In my experience, some patients have died of complications of acute pancreatitis or cirrhosis, or developed end-stage renal disease, requiring renal transplantation, and blindness as a consequence of diabetic retinopathy. Patients with FPL are also predisposed to metabolic complications and die of atherosclerotic vascular and coronary heart disease or cardiomyopathy and rhythm disturbances. Some patients with MAD have reportedly died during childhood and some died later in their third and fourth decades from complications of renal failure.[47,81] Patients with acquired generalized lipodystrophy suffer severe metabolic complications. Patients with acquired partial lipodystrophy and membranoproliferative glomerulonephritis develop renal failure, but others have a normal life span as do those with localized lipodystrophy. HIV-infected patients with lipodystrophy are predisposed to developing coronary heart disease.

MANAGEMENT

Treatment of various types of lipodystrophies is quite challenging. There is no specific treatment available to reverse the loss of body fat. The mainstay of treatment includes cosmetic surgery and management of complications. Patients with partial lipodystrophies can undergo autologous adipose tissue transplantation or implantation of dermal fillers such as hyaluronic acid, calcium hydroxylapatite, silicone, polyacrylamide gels, or poly-L-lactic acid.[82] Unwanted excess adipose tissue can be surgically excised or removed by liposuction. Those with CGL can undergo reconstructive facial surgery, including facial grafts from thighs, free flaps from anterolateral thigh, anterior abdomen, or temporalis muscle.[1] Support of the parents is critical for preventing unwanted stress and psychological sequelae in children affected with lipodystrophies.

All patients are advised to consume low-fat diets. These diets can improve chylomicronemia in patients with extreme hypertriglyceridemia. However, high carbohydrate intake may also raise very low-density lipoprotein triglyceride concentrations. Increased physical activity should be encouraged to mitigate insulin resistance and its complications except in those who have cardiomyopathy. Lytic bone lesions in appendicular bones in patients with CGL usually do not pose an increased risk of fractures.

There are no well-controlled trials available to guide treatment decisions about how to manage metabolic complications. For severe hypertriglyceridemia, an extremely low-fat diet along with fibrates and n-3 polyunsaturated fatty acids from fish oils should be used.[5] Statins can be added if required. Any form of estrogen therapy should be avoided, as it can pose the risk of severe hypertriglyceridemia-induced acute pancreatitis. Diabetes should be managed initially with metformin. Thiazolidinediones should be used with caution in patients with partial lipodystrophies as they can potentially increase unwanted fat deposition in nonlipodystrophic regions.[83] Although thiazolidinediones can be useful in FPL patients with *PPARG* mutations, the data on their efficacy are equivocal.[84] If hyperglycemia persists despite using various combinations of oral antidiabetic drugs, insulin therapy should be initiated. For those with extreme insulin resistance, highly concentrated U-200 or U-500 insulin should be used. Although SQ metreleptin replacement therapy improves diabetes control, hepatic steatosis, and hypertriglyceridemia in markedly hypoleptinemic patients with generalized lipodystrophies,[85,86] its effects in patients with FPL so far have been equivocal.[87,88] Metreleptin may be effective in selected FPL patients with severe metabolic derangements or low serum leptin levels.[89] Metreleptin therapy is approved by the U.S. Food and Drug Administration for patients with generalized lipodystrophies to treat metabolic complications and in Japan for both generalized and partial lipodystrophies. Frequent side effects of metreleptin include injection-site reactions and hypoglycemia (in patients on concomitant insulin therapy). The significance of reported neutralizing antibodies to leptin remains unclear. There is also a risk of developing T-cell lymphoma in acquired generalized lipodystrophy patients. Switching from PIs and nucleoside reverse transcriptase inhibitors strongly associated with lipodystrophy to other regimens may improve dyslipidemia and insulin resistance in HIV-infected patients with lipodystrophy; however, loss of SQ fat may not improve.[90]

With the discovery of the molecular genetic basis of many types of inherited lipodystrophies, prenatal diagnosis can be offered for those families with an affected child. Premarital genetic counseling can be provided to those with a high prevalence of consanguinity and CGL, such as those from Lebanon and certain regions of Brazil. If the newer highly active antiretroviral therapy regimens (not including PIs) are proven not to be associated with lipodystrophy and are deemed to be efficacious and safe, we may be able to prevent development of lipodystrophy in HIV-infected patients.

REFERENCES

1. Garg A. Acquired and inherited lipodystrophies. *N Engl J Med*. 2004;350:1220-1234.
2. Garg A. Clinical review#: Lipodystrophies: genetic and acquired body fat disorders. *J Clin Endocrinol Metab*. 2011;96:3313-3325.
3. Garg A. Lipodystrophies. *Am J Med*. 2000;108:143-152.
4. Hussain I, Garg A. Lipodystrophy syndromes. *Endocrinol Metab Clin North Am*. 2016;45:783-797.
5. Brown RJ, Araujo-Vilar D, Cheung PT, et al. The diagnosis and management of lipodystrophy syndromes: a multi-society practice guideline. *J Clin Endocrinol Metab*. 2016;101(12):4500-4511.
6. Akinci B, Onay H, Demir T, et al. Natural history of congenital generalized lipodystrophy: a nationwide study from Turkey. *J Clin Endocrinol Metab*. 2016;101:2759-2767.
7. Al-Shali KZ, Hegele RA. Laminopathies and atherosclerosis. *Arterioscler Thromb Vasc Biol*. 2004;24:1591-1595.
8. Andre P, Schneebeli S, Vigouroux C, et al. Metabolic and cardiac phenotype characterization in 37 atypical Dunnigan patients with nonfarnesylated mutated prelamin A. *Am Heart J*. 2015;169:587-593.
9. Misra A, Peethambaram A, Garg A. Clinical features and metabolic and autoimmune derangements in acquired partial lipodystrophy: report of 35 cases and review of the literature. *Medicine (Baltimore)*. 2004;83:18-34.
10. Misra A, Garg A. Clinical features and metabolic derangements in acquired generalized lipodystrophy: case reports and review of the literature. *Medicine (Baltimore)*. 2003;82:129-146.
11. Chen D, Misra A, Garg A. Lipodystrophy in human immunodeficiency virus-infected patients. *J Clin Endocrinol Metab*. 2002;87:4845-4856.
12. Grinspoon S, Carr A. Cardiovascular risk and body-fat abnormalities in HIV-infected adults. *N Engl J Med*. 2005;352:48-62.
13. Patni N, Garg A. Congenital generalized lipodystrophies—new insights into metabolic dysfunction. *Nat Rev Endocrinol*. 2015;11:522-534.
14. Garg A, Wilson R, Barnes R, et al. A gene for congenital generalized lipodystrophy maps to human chromosome 9q34. *J Clin Endocrinol Metab*. 1999;84:3390-3394.
15. Agarwal AK, Arioglu E, De Almeida S, et al. AGPAT2 is mutated in congenital generalized lipodystrophy linked to chromosome 9q34. *Nat Genet*. 2002;31:21-23.
16. Magre J, Delepine M, Khallouf E, et al. Identification of the gene altered in Berardinelli-Seip congenital lipodystrophy on chromosome 11q13. *Nat Genet*. 2001; 28:365-370.
17. Kim CA, Delepine M, Boutet E, et al. Association of a homozygous nonsense caveolin-1 mutation with Berardinelli-Seip congenital lipodystrophy. *J Clin Endocrinol Metab*. 2008;93:1129-1134.
18. Hayashi YK, Matsuda C, Ogawa M, et al. Human PTRF mutations cause secondary deficiency of caveolins resulting in muscular dystrophy with generalized lipodystrophy. *J Clin Invest*. 2009;119:2623-2633.
19. Agarwal AK, Garg A. Congenital generalized lipodystrophy: significance of triglyceride biosynthetic pathways. *Trends Endocrinol Metab*. 2003;14:214-221.
20. Szymanski KM, Binns D, Bartz R, et al. The lipodystrophy protein seipin is found at endoplasmic reticulum lipid droplet junctions and is important for droplet morphology. *Proc Natl Acad Sci U S A*. 2007;104:20890-20895.
21. Fei W, Shui G, Gaeta B, et al. Fld1p, a functional homologue of human seipin, regulates the size of lipid droplets in yeast. *J Cell Biol*. 2008;180:473-482.
22. Payne VA, Grimsey N, Tuthill A, et al. The human lipodystrophy gene BSCL2/seipin may be essential for normal adipocyte differentiation. *Diabetes*. 2008;57:2055-2060.

23. Simha V, Garg A. Phenotypic heterogeneity in body fat distribution in patients with congenital generalized lipodystrophy due to mutations in the *AGPAT2* or *Seipin* genes. *J Clin Endocrinol Metab*. 2003;88:5433-5437.
24. Rajab A, Straub V, McCann LJ, et al. Fatal cardiac arrhythmia and long-QT syndrome in a new form of congenital generalized lipodystrophy with muscle rippling (CGL4) due to PTRF-CAVIN mutations. *PLoS Genet*. 2010;6:e1000874.
25. Shastry S, Delgado MR, Dirik E, et al. Congenital generalized lipodystrophy, type 4 (CGL4) associated with myopathy due to novel PTRF mutations. *Am J Med Genet A*. 2010;152A:2245-2253.
26. Agarwal AK, Simha V, Oral EA, et al. Phenotypic and genetic heterogeneity in congenital generalized lipodystrophy. *J Clin Endocrinol Metab*. 2003;88:4840-4847.
27. Dunnigan MG, Cochrane MA, Kelly A, et al. Familial lipoatrophic diabetes with dominant transmission. A new syndrome. *Q J Med*. 1974;43:33-48.
28. Garg A, Peshock RM, Fleckenstein JL. Adipose tissue distribution in patients with familial partial lipodystrophy (Dunnigan variety). *J Clin Endocrinol Metab*. 1999;84:170-174.
29. Garg A. Gender differences in the prevalence of metabolic complications in familial partial lipodystrophy (Dunnigan variety). *J Clin Endocrinol Metab*. 2000;85:1776-1782.
30. Agarwal AK, Garg A. A novel heterozygous mutation in peroxisome proliferator-activated receptor-g gene in a patient with familial partial lipodystrophy. *J Clin Endocrinol Metab*. 2002;87:408-411.
31. George S, Rochford JJ, Wolfrum C, et al. A family with severe insulin resistance and diabetes due to a mutation in AKT2. *Science*. 2004;304:1325-1328.
32. Gandotra S, Le Dour C, Bottomley W, et al. Perilipin deficiency and autosomal dominant partial lipodystrophy. *N Engl J Med*. 2011;364:740-748.
33. Kozusko K, Tsang VH, Bottomley W, et al. Clinical and molecular characterization of a novel PLIN1 frameshift mutation identified in patients with familial partial lipodystrophy. *Diabetes*. 2015;64:299-310.
34. Garg A, Sankella S, Xing C, et al. Whole-exome sequencing identifies ADRA2A mutation in atypical familial partial lipodystrophy. *JCI Insight*. 2016;16;1(9).
35. Peters JM, Barnes R, Bennett L, et al. Localization of the gene for familial partial lipodystrophy (Dunnigan variety) to chromosome 1q21-22. *Nat Genet*. 1998;18:292-295.
36. Cao H, Hegele RA. Nuclear lamin A/C R482Q mutation in Canadian kindreds with Dunnigan-type familial partial lipodystrophy. *Hum Mol Genet*. 2000;9:109-112.
37. Shackleton S, Lloyd DJ, Jackson SN, et al. *LMNA*, encoding lamin A/C, is mutated in partial lipodystrophy. *Nat Genet*. 2000;24:153-156.
38. Speckman RA, Garg A, Du F, et al. Mutational and haplotype analyses of families with familial partial lipodystrophy (Dunnigan variety) reveal recurrent missense mutations in the globular C-terminal domain of lamin A/C. *Am J Hum Genet*. 2000;66:1192-1198.
39. Hegele RA, Cao H, Frankowski C, et al. PPARG F388L, a transactivation-deficient mutant, in familial partial lipodystrophy. *Diabetes*. 2002;51:3586-3590.
40. Semple RK, Chatterjee VK, O'Rahilly S. PPAR gamma and human metabolic disease. *J Clin Invest*. 2006;116:581-589.
41. Garg A, Speckman RA, Bowcock AM. Multisystem dystrophy syndrome due to novel missense mutations in the amino-terminal head and alpha-helical rod domains of the lamin A/C gene. *Am J Med*. 2002;112:549-555.
42. Garg A, Vinaitheerthan M, Weatherall P, et al. Phenotypic heterogeneity in patients with familial partial lipodystrophy (Dunnigan variety) related to the site of missense mutations in Lamin A/C (*LMNA*) gene. *J Clin Endocrinol Metab*. 2001;86:59-65.
43. Simha V, Garg A. Body fat distribution and metabolic derangements in patients with familial partial lipodystrophy associated with mandibuloacral dysplasia. *J Clin Endocrinol Metab*. 2002;87:776-785.
44. Simha V, Agarwal AK, Oral EA, et al. Genetic and phenotypic heterogeneity in patients with mandibuloacral dysplasia-associated lipodystrophy. *J Clin Endocrinol Metab*. 2003;88:2821-2824.
45. Novelli G, Muchir A, Sangiuolo F, et al. Mandibuloacral dysplasia is caused by a mutation in LMNA-encoding lamin A/C. *Am J Hum Genet*. 2002;71:426-431.
46. Agarwal AK, Fryns JP, Auchus RJ, et al. Zinc metalloproteinase, *ZMPSTE24*, is mutated in mandibuloacral dysplasia. *Hum Mol Genet*. 2003;12:1995-2001.
47. Agarwal AK, Zhou XJ, Hall RK, et al. Focal segmental glomerulosclerosis in patients with mandibuloacral dysplasia due to zinc metalloproteinase deficiency. *J Investig Med*. 2006;54:208-213.
48. Ahmad Z, Zackai E, Medne L, et al. Early onset mandibuloacral dysplasia due to compound heterozygous mutations in ZMPSTE24. *Am J Med Genet A*. 2010;152A:2703-2710.
49. Shastry S, Simha V, Godbole K, et al. A novel syndrome of mandibular hypoplasia, deafness, and progeroid features associated with lipodystrophy, undescended testes, and male hypogonadism. *J Clin Endocrinol Metab*. 2010;95:E192-E197.
50. Torrelo A, Patel S, Colmenero I, et al. Chronic atypical neutrophilic dermatosis with lipodystrophy and elevated temperature (CANDLE) syndrome. *J Am Acad Dermatol*. 2010;62:489-495.
51. Garg A, Hernandez MD, Sousa AB, et al. An autosomal recessive syndrome of joint contractures, muscular atrophy, microcytic anemia, and panniculitis-associated lipodystrophy. *J Clin Endocrinol Metab*. 2010;95:E58-E63.
52. Agarwal AK, Xing C, DeMartino GN, et al. PSMB8 encoding the beta5i proteasome subunit is mutated in joint contractures, muscle atrophy, microcytic anemia, and panniculitis-induced lipodystrophy syndrome. *Am J Hum Genet*. 2010;87:866-872.
53. Liu Y, Ramot Y, Torrelo A, et al. Mutations in proteasome subunit beta type 8 cause chronic atypical neutrophilic dermatosis with lipodystrophy and elevated temperature with evidence of genetic and phenotypic heterogeneity. *Arthritis Rheum*. 2012;64:895-907.
54. Torrelo A, Colmenero I, Requena L, et al. Histologic and immunohistochemical features of the skin lesions in CANDLE syndrome. *Am J Dermatopathol*. 2015;37:517-522.
55. Sensenbrenner JA, Hussels IE, Levin LS. CC-A low birthweight syndrome, Rieger syndrome. *Birth Defects Orig Artic Ser*. 1975;11:423-426.
56. Gorlin RJ, Cervenka J, Moller K, et al. Rieger anomaly and growth retardation (the S-H-O-R-T syndrome). *Birth Defects Orig Artic Ser*. 1975;11:46-48.
57. O'Neill B, Simha V, Kotha V, et al. Body fat distribution and metabolic variables in patients with neonatal progeroid syndrome. *Am J Med Genet A*. 2007;143:1421-1430.

58. Weedon MN, Ellard S, Prindle MJ, et al. An in-frame deletion at the polymerase active site of POLD1 causes a multisystem disorder with lipodystrophy. *Nat Genet*. 2013;45:947-950.
59. Avila M, Dyment DA, Sagen JV, et al. Clinical reappraisal of SHORT syndrome with PIK3R1 mutations: towards recommendation for molecular testing and management. *Clin Genet*. 2015. [Epub ahead of print]
60. Garg A, Xing C. De novo heterozygous FBN1 mutations in the extreme C-terminal region cause progeroid fibrillinopathy. *Am J Med Genet A*. 2014;164A:1341-1345.
61. Garg A, Kircher M, Del Campo M, et al; University of Washington Center for Mendelian Genomics. Whole exome sequencing identifies de novo heterozygous CAV1 mutations associated with a novel neonatal onset lipodystrophy syndrome. *Am J Med Genet A*. 2015;167A:1796-1806.
62. Jay AM, Conway RL, Thiffault I, et al. Neonatal progeriod syndrome associated with biallelic truncating variants in POLR3A. *Am J Med Genet A*. 2016;170:3343-3346.
63. Rubio-Cabezas O, Puri V, Murano I, et al. Partial lipodystrophy and insulin resistant diabetes in a patient with a homozygous nonsense mutation in CIDEC. *EMBO Mol Med*. 2009;1:280-287.
64. Payne F, Lim K, Girousse A, et al. Mutations disrupting the Kennedy phosphatidylcholine pathway in humans with congenital lipodystrophy and fatty liver disease. *Proc Natl Acad Sci U S A*. 2014;111:8901-8906.
65. Farhan SM, Robinson JF, McIntyre AD, et al. A novel LIPE nonsense mutation found using exome sequencing in siblings with late-onset familial partial lipodystrophy. *Can J Cardiol*. 2014;30:1649-1654.
66. Albert JS, Yerges-Armstrong LM, Horenstein RB, et al. Null mutation in hormone-sensitive lipase gene and risk of type 2 diabetes. *N Engl J Med*. 2014;370:2307-2315.
67. Zolotov S, Xing C, Mahamid R, et al. Homozygous LIPE mutation in siblings with multiple symmetric lipomatosis, partial lipodystrophy, and myopathy. *Am J Med Genet A*. 2017;173(1):190-194.
68. Donadille B, D'Anella P, Auclair M, et al. Partial lipodystrophy with severe insulin resistance and adult progeria Werner syndrome. *Orphanet J Rare Dis*. 2013;8:106.
69. Garg A, Subramanyam L, Agarwal AK, et al. Atypical progeroid syndrome due to heterozygous missense LMNA mutations. *J Clin Endocrinol Metab*. 2009;94:4971-4983.
70. Merideth MA, Gordon LB, Clauss S, et al. Phenotype and course of Hutchinson-Gilford progeria syndrome. *N Engl J Med*. 2008;358:592-604.
71. Bingham A, Mamyrova G, Rother KI, et al. Predictors of acquired lipodystrophy in juvenile-onset dermatomyositis and a gradient of severity. *Medicine (Baltimore)*. 2008;87:70-86.
72. Savage DB, Semple RK, Clatworthy MR, et al. Complement abnormalities in acquired lipodystrophy revisited. *J Clin Endocrinol Metab*. 2009;94:10-16.
73. Hudon SE, Coffinier C, Michaelis S, et al. HIV-protease inhibitors block the enzymatic activity of purified Ste24p. *Biochem Biophys Res Commun*. 2008;374:365-368.
74. Bastard JP, Caron M, Vidal H, et al. Association between altered expression of adipogenic factor SREBP1 in lipoatrophic adipose tissue from HIV-1-infected patients and abnormal adipocyte differentiation and insulin resistance. *Lancet*. 2002;359:1026-1031.
75. Murata H, Hruz PW, Mueckler M. The mechanism of insulin resistance caused by HIV protease inhibitor therapy. *J Biol Chem*. 2000;275:20251-20254.
76. Carr A, Miller J, Law M, et al. A syndrome of lipoatrophy, lactic acidaemia and liver dysfunction associated with HIV nucleoside analogue therapy: contribution to protease inhibitor-related lipodystrophy syndrome. *AIDS*. 2000;14:F25-F32.
77. Haque WA, Shimomura I, Matsuzawa Y, et al. Serum adiponectin and leptin levels in patients with lipodystrophies. *J Clin Endocrinol Metab*. 2002;87:2395-2398.
78. Hegele RA. Premature atherosclerosis associated with monogenic insulin resistance. *Circulation*. 2001;103:2225-2229.
79. Hennekam RC. Hutchinson-Gilford progeria syndrome: review of the phenotype. *Am J Med Genet A*. 2006;140:2603-2624.
80. Brown RJ, Chan JL, Jaffe ES, et al. Lymphoma in acquired generalized lipodystrophy. *Leuk Lymphoma*. 2016;57:45-50.
81. Agarwal AK, Kazachkova I, Ten S, et al. Severe mandibuloacral dysplasia-associated lipodystrophy and progeria in a young girl with a novel homozygous Arg527Cys LMNA mutation. *J Clin Endocrinol Metab*. 2008;93:4617-4623.
82. Sturm LP, Cooter RD, Mutimer KL, et al. A systematic review of permanent and semipermanent dermal fillers for HIV-associated facial lipoatrophy. *AIDS Patient Care STDS*. 2009;23:699-714.
83. Arioglu E, Duncan-Morin J, Sebring N, et al. Efficacy and safety of troglitazone in the treatment of lipodystrophy syndromes. *Ann Intern Med*. 2000;133:263-274.
84. Savage DB, Tan GD, Acerini CL, et al. Human metabolic syndrome resulting from dominant-negative mutations in the nuclear receptor peroxisome proliferator-activated receptor-gamma. *Diabetes*. 2003;52:910-917.
85. Oral EA, Simha V, Ruiz E, et al. Leptin-replacement therapy for lipodystrophy. *N Engl J Med*. 2002;346:570-578.
86. Simha V, Szczepaniak LS, Wagner AJ, et al. Effect of leptin replacement on intrahepatic and intramyocellular lipid content in patients with generalized lipodystrophy. *Diabetes Care*. 2003;26:30-35.
87. Simha V, Subramanyam L, Szczepaniak L, et al. Comparison of efficacy and safety of leptin replacement therapy in moderately and severely hypoleptinemic patients with familial partial lipodystrophy of the Dunnigan variety. *J Clin Endocrinol Metab*. 2012;97:785-792.
88. Park JY, Javor ED, Cochran EK, et al. Long-term efficacy of leptin replacement in patients with Dunnigan-type familial partial lipodystrophy. *Metabolism*. 2007;56:508-516.
89. Diker-Cohen T, Cochran E, Gorden P, et al. Partial and generalized lipodystrophy: comparison of baseline characteristics and response to metreleptin. *J Clin Endocrinol Metab*. 2015;100:1802-1810.
90. Carr A, Hudson J, Chuah J, et al. HIV protease inhibitor substitution in patients with lipodystrophy: a randomized, controlled, open-label, multicentre study. *AIDS*. 2001;15:1811-1822.

This page intentionally left blank

Melanocytic Disorders

PART 13

Chapter 75 :: Albinism and Other Genetic Disorders of Pigmentation

:: Masahiro Hayashi & Tamio Suzuki

Albinism is characterized by hypopigmentation of the skin, hair, and eyes, or of eyes only, in the affected individuals. There are 2 albinism subtypes are non-syndromic albinism, with symptoms restricted to impaired melanin biosynthesis (hypopigmentation of skin and hair, and ocular changes such as reduced iris pigment, nystagmus, impaired visual acuity, and foveal hypoplasia), and syndromic albinism, such as Hermansky-Pudlak syndrome, Chediak-Higashi syndrome, and Griscelli syndrome, with various non-pigmentary symptoms, including bleeding diathesis, lung fibrosis, and immunodeficiency. Other congenital disorders involving pigmentation include a wide range of disorders such as piebaldism, Waardenburg syndrome, and reticular pigmentary disorders including dyschromatosis symmetrica hereditaria, dyschromatosis universalis hereditaria, reticulate acropigmentation of Kitamura, and Dowling-Degos disease. This chapter discusses all of the disorders listed above.

- In addition to hypopigmentation, extrapigmentary symptoms in GS1 and GS2 are neurologic abnormalities and hematologic immunodeficiency/abnormalities, respectively. On the other hand, GS3 is restricted to hypopigmentation.
- In some types, hypopigmentation of the skin may gradually improve as the individual grows; the exception is type 1A, where melanin biosynthesis is completely absent.
- Visual disturbances consist of nystagmus, impaired visual acuity, and stereoscopic vision.
- Protection of skin from the sun is required to prevent sunburn and secondary skin change, including solar degeneration and skin cancer.
- Early referral to an ophthalmologist is important to introduce proper ophthalmologic intervention.

OCULOCUTANEOUS ALBINISM

AT-A-GLANCE

- Oculocutaneous albinism is a group of rare genetic disorders with autosomal recessive inheritance, characterized by hypopigmentation of skin, hair, and eyes.
- Seven subtypes and 6 responsible genes (all except for type 5) have been described.

Oculocutaneous albinism (OCA) is a rare genetic condition with autosomal recessive inheritance, and it is characterized by hypopigmentation of skin, hair, and eyes. Currently 7 types of OCA have been identified (Table 75-1), and all of the genes responsible, with the exception of OCA5 (for which the responsible gene has not yet been identified), are associated with melanin biosynthesis or migration of melanocytes/melanocyte precursor cells. The overall prevalence of OCA is estimated at approximately 1:10,000 to 20,000 people; however, the incidence of each type varies depending on geographic region and ethnicity. Some types of albinism are seen more frequently in certain regions as a result of the founder effect.[1]

TABLE 75-1
Ocular Albinism and Oculocutaneous Albinism (Nonsyndromic Albinism)

DISEASE NAME	INHERITANCE	GENES	CHROMOSOMAL LOCATION	OMIM #
OCA1	AR	*TYR*	11q14.3	203100
OCA2	AR	*OCA2*	15q12-q13.1	203200
OCA3	AR	*TYRP-1*	9p23	203290
OCA4	AR	*SLC45A2*	5p13.2	696574
OCA5	AR	Unknown	4q24	615312
OCA6	AR	*SLC24A5*	15q21.1	609802
OCA7	AR	*C10orf11*	10q22.2-q22.3	615179
OA1	X-linked	*GPR143*	Xp22.3	300500

OA, ocular albinism; OCA, oculocutaneous albinism; OMIM, Online Mendelian Inheritance in Man.

CLINICAL FEATURES

OCULOCUTANEOUS ALBINISM TYPE 1

OCA1 appears to be the most common type of albinism in non-Hispanic white, Chinese, and Japanese patients. OCA1, number 203100 in the Online Mendelian Inheritance in Man (OMIM) system, is divided into 4 subtypes: OCA1A, OCA1B, OCA1 temperature sensitive (TS), and OCA1 minimal pigment (MP).

In OCA1A, the classic tyrosinase-negative OCA, there is a complete inability to synthesize melanin in skin, hair, and eyes, resulting in the characteristic "albino" phenotype (Fig. 75-1A). Affected individuals are born with white hair, white skin, and blue eyes, and there are no changes as they mature. The phenotype is the same in all ethnic groups and at all ages. The hair may develop a slight yellow tint as a consequence of the denaturing of the hair protein from sun exposure and/or shampoo use. The irides are translucent, appear pink early in life, and often turn a gray-blue color with time. No pigmented lesions develop in the skin, although amelanotic nevi can be present. The architecture of skin and hair bulb melanocytes is normal. The melanosomes show a normal melanosomal membrane, and normal internal matrix formation is observed in stage 1 and stage 2 melanosomes.

The phenotype of OCA1B can range from minimal hair pigment to skin and hair pigmentation approaching the normal pigment phenotype. Most individuals with OCA1B have very little or no pigment at birth, and develop varying amounts of melanin in the hair and skin in the first or second decade of life. In some cases, the melanin develops within the first year. The hair color changes to light yellow, light blond, or golden blond at first, as a result of residual pheomelanin synthesis, and eventually can turn dark blond or brown in adolescence and adulthood. The irides can develop light-tan or brown pigment, sometimes limited to the inner third of the iris, and iris pigment can be present on globe transillumination. However, some degree of iris translucency, as demonstrated by slitlamp examination, is usually present. Many individuals with OCA1B will have a tanning ability with sun exposure, although it is more common to burn without tanning. Pigmented lesions (nevi, freckles, and lentigines) develop in the skin of individuals who have developed pigmented hair and skin.

One variation of OCA1B is the temperature-sensitive phenotype (OCA1TS). Certain specific mutations in *TYR* cause a conformational change of the TYR protein, leading to the production of a thermolabile variant. TYR activity decreases at 37°C (98.6°F) and is retained, at least in part, at approximately 31°C (87.8°F). Pigmentation is found on the extremities where body temperature is relatively low. In this variation, scalp and axillary hair remain white or slightly yellow, but arm and leg hair becomes pigmented. The skin remains white and does not tan. OCA1MP has no eumelanogenesis but is limited to just pheomelanogenesis. Individuals with OCA1MP show white skin and hair and severe visual impairment, resembling OCA1A, but they do develop some freckles.

OCULOCUTANEOUS ALBINISM TYPE 2

OCA2 (OMIM 203200) occurs worldwide, although somewhat more frequently in African, African American, and certain Native American populations. In African and African American individuals, there is a distinct OCA2 phenotype. Hair is yellow at birth and remains so throughout life, although the color may turn darker. The skin is creamy-white at birth and changes little with time. No generalized skin pigment is present, and no tan develops with sun exposure, but pigmented nevi, lentigines, and freckles often develop, as the cutaneous melanocytes in these individuals both remain susceptible to ultraviolet-induced changes early in life and retain some ability to synthesize melanin later. The irides are blue-gray or light tan or brown.

In white and Asian individuals with OCA2, the amount of hair pigment present at birth or developing

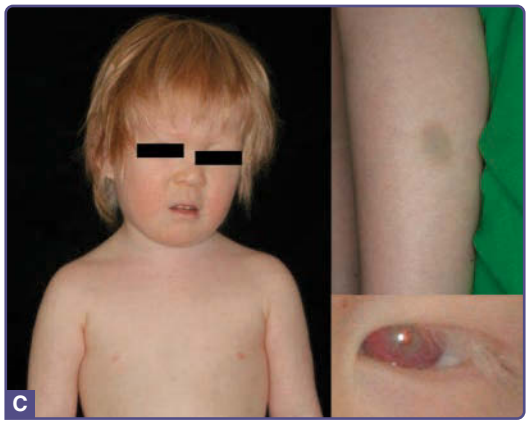

Figure 75-1 Clinical findings of albinism. **A,** OCA1A, 7-month-old boy. He demonstrates complete lack of melanin, and the irides are translucent and reddish. **B,** OCA4, 2-year and 10-month-old girl. Her hair and irides are brown, but the skin is not as pale as for OCA1A. **C,** Hermansky-Pudlak syndrome type 4 (HPS4), 6-year-old girl (reported in Araki Y, Ishii Y, Abe Y, et al[59]). Blonde hair, white skin, and light gray irides with nystagmus are seen. Purpura is also seen on her lower leg.

with time varies from minimal to moderate. The hair can be very lightly pigmented at birth, having a light yellow or blond color, or more pigmented with a definite blond, golden blond, or even red color. The skin is creamy-white and tanning ability varies. The iris color is blue-gray or lightly pigmented, and the amount of translucency correlates with the development of iris pigment. With time, pigmented nevi and lentigines may develop, and freckles are seen in areas with repeated sun exposure. The hair may slowly turn darker through the first 2 or more later decades of life.

OCULOCUTANEOUS ALBINISM TYPE 3

OCA3 (OMIM 203290) is a rare and mild phenotype of OCA. In Africa, distinctive forms of OCA with symptoms different from those of OCA1 and OCA2 have been known, called brown OCA (BOCA) and rufous OCA (ROCA). BOCA and ROCA were stated to be distinguishable based on the color of skin and hair. ROCA is characterized by brick-red, mahogany, or bronze skin color, and the hair color varies from deep mahogany to sandy red; BOCA is characterized by tan or light-brown skin and light-brown hair. Visual disturbances, including nystagmus and impaired visual acuity, tend to be mild or even absent in both BOCA and ROCA.[2] Boissy and associates identified tyrosinase-related protein-1 (*TYRP-1*) as a responsible gene for BOCA in African American males.[3] On the other hand, Manga and associates identified *TYRP-1* as a responsible gene for ROCA by linkage analysis of ROCA families and subsequent DNA sequencing.[2] ROCA and BOCA may be categorized into the same entity by genetic analysis; that is, may share the same responsible gene, *TYRP-1*. The same mutation (c.1103delA, p.K368fs) in *TYRP-1* was reported in both BOCA and ROCA. However, the reason why the phenotypes of BOCA and ROCA differ, although both have the same mutation, is yet to be shown.

The clinical phenotype of OCA3 in non-African individuals, including German, Japanese, and Pakistani patients, has been reported as mild, blond hair, brown eyebrows, dark-brown irides, and lighter skin complexion than those of unaffected parents. There is a possibility that individuals of non-African ethnicity with OCA3 are overlooked, because the effect of diluted pigmentation in OCA3 is mild or even subtle.

OCULOCUTANEOUS ALBINISM TYPE 4

OCA4 (OMIM 696574) is relatively rare in the general population, found in approximately 3% of albino individuals[4]; however, it accounts for 27% of Japanese albinos, and is one of the major types of OCA in Japan.[5] The hypopigmentation of OCA4 varies among individuals (see Fig. 75-1B), similar to OCA2[5] and OCA6,[6] presumably because the responsible genes are found in the same functional entity, ion transporters on

melanosomes (see discussions of OCA2 ["Oculocutaneous Albinism type 2" above] and OCA6 ["Oculocutaneous Albinism type 6" below]). The phenotype of OCA4 ranges from light-yellow to brown hair, from blue to red-brown irides with or without nystagmus, and from severe cutaneous hypopigmentation indistinguishable from OCA1A to mild diluted pigmentation with some tanning ability. Furthermore, pigmentation of some individuals tends to recover as individuals mature.[4]

OCULOCUTANEOUS ALBINISM TYPE 5

OCA5 (OMIM 615312) has been reported in 1 consanguineous Pakistani albino family.[7] Individuals with OCA5 display golden-colored hair, white skin, nystagmus, photophobia, foveal hypoplasia, and impaired visual acuity, regardless of their sex and age.[7] No other individual with OCA5 other than this family member has been reported as of this writing.

OCULOCUTANEOUS ALBINISM TYPE 6

OCA6 (OMIM 609802) was initially identified in a Chinese family,[6] although this type has subsequently been reported in several families and in sporadic individuals of Chinese, European, French Guinean, and Middle Eastern origin. The prevalence of OCA6 has been reported as approximately 3% in European albino populations. The phenotype of individuals with OCA6 varies, and is similar to that of individuals with OCA2 and OCA4 (see section "Oculocutaneous Albinism type 2" and "Oculocutaneous Albinism type 4"), ranging from light-brown to platinum blond hair, lighter skin complexion with or without tanning ability, and mild to moderate visual impairment. Some individuals are likely to gain their pigmentation at a later age.[6]

OCULOCUTANEOUS ALBINISM TYPE 7

OCA7 (OMIM 615179) was initially reported in a consanguineous Danish albino family in the Faroe Islands.[8] Recently, more individuals with OCA7 were reported in Iran. Grønskov and associates detailed the phenotype of OCA7, with most of the affected individuals having a light northern European complexion, with a tendency to lighter pigmentation than that of their relatives. Eye symptoms were predominant: nystagmus and iris transillumination were present in all subjects. Extremely sparse pigmentation of the peripheral ocular fundus was seen. Visual impairment in OCA7 is severe, in contrast to relatively mild hypopigmentation of skin and hair.

ETIOLOGY AND PATHOGENESIS

OCA1

OCA1 is caused by loss-of-function of the melanocytic enzyme tyrosinase resulting from mutation of the *TYR* gene.[9] Most individuals with OCA1 are compound heterozygotes with different mutant maternal and paternal alleles. Missense mutations in the *TYR* gene are distributed among distinct regions of the coding sequence, suggesting that the encoded protein has multiple functional domains. Two of the clusters are in the copper-binding regions, with a third near the aminoterminus of the mature protein, in the extramelanosomal domain of tyrosinase shown to require phosphorylation for enzyme activation. Clustering of mutations in discrete regions of the coding sequence is consistent with the importance of these regions either for the melanogenic activity of tyrosinase or for functions related to its maturation and processing.

OCA1A completely lacks TYR activity, whereas OCA1B retains slight TYR activity and may show a unique clinical manifestation, depending on the impact of the mutation. All nonsense and frameshift mutations are associated with a complete loss of tyrosinase activity, presumably because of the resulting production of a truncated protein. Concerning missense mutations, the picture is more complicated. Sets of missense mutations that were associated with OCA1 patients accumulating pigment with age in either OCA1B or OCA1TS patients[10] were shown to have residual enzymatic activity. Hence, it is likely that subsets of *TYR* missense mutations are responsible for the OCA1B and OCA1TS phenotypes as a result of the reduced, rather than absent, tyrosinase activity in their melanocytes.

OCA2

Mutations of the *OCA2 (P)* gene, which maps to chromosome arm 15q, are responsible for OCA2.[11] From the standpoint of melanin synthesis, the defect in OCA2 appears to involve primarily a reduction in eumelanin synthesis, with less effect on pheomelanin synthesis. The predicted structure of the *OCA2* gene, a melanosomal protein, includes 12 transmembrane domains. In sub-Saharan Africa, a single 2.7-kb deletion allele accounts for 60% to 90% of mutant *OCA2* alleles and is associated with a common haplotype, suggesting a common founder.[12] This single mutation is estimated to be associated with 25% to 50% of all mutant *OCA2* alleles in African Americans.[12] Unlike the mutations in *TYR*, the missense mutations described as of this writing in OCA2 do not seem to cluster in any specific region.

Regarding the function of the *OCA2* gene product, it has been shown that melanosomes from P protein–deficient melanocytes have an abnormal pH. Melanosomes in cultured melanocytes derived from wildtype

mice are typically acidic, whereas melanosomes from P protein–deficient mice are nonacidic. Hence, it is likely that the P protein regulates the pH of melanosomes, perhaps by functioning as an anion cotransporter in conjunction with a distinct proton pump on the melanosomal membrane. One possibility is that the acidic conditions mediated by the P protein favor the normal biogenesis of melanosomes, including the correct targeting of other melanosomal proteins such as tyrosinase.[13]

OCA3

Mutations in the *TYRP-1* gene result in OCA3. TYRP-1 is implicated in steps downstream from the eumelanogenesis pathway.[14] 5,6-Dihydroxyindole-2-carboxylic acid (DHICA), which is generated from dopachrome by decarboxylation, is oxidized and polymerized by TYRP-1, leading to production of eumelanins. Defective TYRP-1 is unable to oxidize DHICA, hence disrupting eumelanogenesis. In addition, TYRP-1 also has been shown to play a role in stabilizing TYR, indicating that decreased function of TYRP-1 may affect melanogenesis in several ways.

The first described OCA3 mutation was in an African American newborn twin initially classified clinically as having BOCA. Mutation analysis revealed a single-base deletion at codon 368 producing a frameshift and premature stop codon in exon 6, causing a slightly truncated TYRP-1 molecule.[3] This mutation is shared by a substantial proportion of the ROCA population in southern Africa.[2] Additional OCA3-associated *TYRP-1* mutations include a single-base substitution at codon 166, resulting in the alteration of a serine to a premature stop codon in exon 3 and a truncated TYRP-1 molecule,[15] also identified in the ROCA population; and, in a Pakistani kindred, individuals were found to be homozygous for a distinct premature termination mutation.[16] A white male was compound heterozygous for a missense mutation in *TYRP-1* located in the second copper-binding domain, inherited from the patient's mother, and a stop codon, which apparently occurred spontaneously.[17] A Japanese individual with OCA3 harboring a homozygous mutation at c.1100delG (p.G367fsX384), has been reported.[18] The phenotype of this individual was apparently tyrosinase-positive OCA, despite the homozygous frameshift mutation, supporting the idea that the TYRP-1 protein is not the sole rate-limiting factor in melanogenesis. Furthermore, an intriguing p.S166X mutation in *TYRP-1* associated with ROCA[15] was found to modify an OCA2 phenotype to a red-haired variant.[5]

OCA4

SLC45A2, a melanosomal transporter protein, is responsible for OCA4. The function and exact localization of SLC45A2 have not been elucidated, although SLC45A2 is considered to be involved in pH control inside the melanosome, together with OCA2.[19] As melanosome pH influences TYR activity and melanogenesis, disruption of SLC45A2, which controls melanosome pH, would affect melanogenesis. A recent functional study demonstrated that OCA2 and SLC45A2 are also involved in trafficking of melanosomal components, including TYR. Thus, mutations in *SLC45A2* would impair melanin biosynthesis with wide clinical variation depending on the impact of each mutation.[20]

OCA5

Linkage analysis mapped the responsible locus to 4q24; however, subsequent sequence analysis of candidate genes failed to detect the pathologic mutation.[7]

OCA6

SLC24A5 acts as an ion transporter on melanosomal membranes together with OCA2 and SLC45A2.[21] The eumelanin content of hair in individuals with OCA6 is significantly lower than that of unaffected family members (heterozygous carriers). Electron microscopy of skin from individuals with OCA6 revealed fewer mature melanosomes (stage IV), but more immature melanosomes (stages II and III) in both the cell body and dendrites of melanocytes compared with cells from unaffected individuals. This finding suggests that the SLC24A5 protein is required for the maturation of melanosomes or for the production of pigment in mature melanosomes.[6]

OCA7

C10orf11, which is considered a melanocyte differentiation gene, is responsible for OCA7.[8] Immunohistochemistry of skin from human fetuses showed C10orf11-positive cells (melanoblasts) on the dermis, which migrate from the neural crest, while no cells positive for C10orf11 were observed in either fetal or adult retinal pigment epithelium. This finding suggests that C10orf11 is also associated with melanocyte migration.

DIAGNOSIS

Previously OCA was placed into 2 categories, tyrosinase-positive OCA and tyrosinase-negative OCA, based on the finding of dihydroxyphenylalanine (DOPA) staining. However, this method can only distinguish between OCA1A and non-OCA1A subtypes; consequently, it is seldom used. As the phenotypes of different types of OCA show significant overlap, genetic analysis is necessary for definitive diagnosis. Recent advances in genetic analysis enable us to detect additional types of albinism and the genes responsible for these disorders.[6-8] On the other hand, no mutations in known albinism-related genes have been detected in approximately 20% of affected individuals. A

genome-wide association study has shown that a single nucleotide polymorphism in the regulatory region upstream of the KIT ligand gene (*KITLG*) is involved in blond hair color in northern European populations,[22] suggesting that genetic alterations in noncoding regions near albinism-related genes also can be associated with the pathogenesis of albinism, as well as mutations in potential albinism genes yet to be identified.

DIFFERENTIAL DIAGNOSIS

The coexistence of systemic symptoms such as bleeding diathesis, interstitial pneumonia, immunodeficiency, and/or neurologic defects is useful in suggesting syndromic OCA. Prader-Willi syndrome and Angelman syndrome, which are characterized by mental retardation, are sometimes accompanied by the symptoms of OCA2 because both conditions are caused by the deletion of chromosome 15q containing the *OCA2* gene. Other congenital or nutritional disorders, including phenylketonuria, histidinemia, homocystinuria, selenium deficiency, copper deficiency, and kwashiorkor, may show hypopigmentation of skin and hair (albinism). These also can be distinguished from OCA by the accompanying symptoms.

CLINICAL COURSE, PROGNOSIS, AND MANAGEMENT

No curative treatment has been found for OCA as of this writing. Early diagnosis is important to allow initiation of appropriate interventions for skin and eye symptoms. For skin, sun protection by wearing of protective clothing and the regular application of sunscreen are essential to prevent sunburn and secondary skin changes, and to decrease the risk of skin cancer in later life. Regular skin checkups for skin cancer are recommended for adult individuals with OCA, especially in cases of severe hypopigmentation. Early referral to an ophthalmologist is mandatory for proper ophthalmologic interventions such as corrective glasses or surgical correction of strabismus and nystagmus. Dark sunglasses may alleviate photophobia. Once pathologic mutations are detected in an affected family member, prenatal diagnosis becomes possible, and diagnosis may be an option for parents and other family members.

The life span of individuals with OCA may be similar to that of unaffected individuals. However, several epidemiologic studies showed that a relatively larger number of albino people is present in the younger age groups.[23] In addition, a retrospective survey of African albinos with skin cancers found that late presentation, mainly attributable to a lack of funding and poor access to health care facilities, led to more-advanced disease status.[24] Lack of preventive resources, including sunscreen, could cause albino people to have more ultraviolet exposure, a major risk factor for skin carcinogenesis.[23] These data may imply that the mortality of people with albinism might be higher than that of people without albinism, although more specific data are required to accurately assess this issue. In terms of public health, albino people have been reported to face social stigma, discrimination, and lower socioeconomic status, particularly in African countries, as a consequence of lack of accurate knowledge and education about albinism.[23]

With the exception of OCA1A, hypopigmentation of skin and hair tends to be alleviated as individuals mature. There are no case-control data regarding whether early ophthalmologic intervention can prevent the progression of visual impairment. However, visual impairment is generally not progressive, and may gradually improve with age. An increased risk for skin cancers, particularly squamous cell carcinoma and basal cell carcinoma, has been reported. The incidence rate of melanoma in individuals with OCA is controversial because of the lack of large population studies; however, it is generally considered that the risk of melanoma is increased in individuals with OCA compared to the risk for unaffected individuals. Melanin is a kind of scavenger that removes free radicals from tissue; thus, decrease or absence of melanin will lead to an increase in the risk of melanoma, squamous cell carcinoma, and basal cell carcinoma.

OCULAR ALBINISM

AT-A-GLANCE

- Ocular albinism is a rare inherited disorder characterized by hypopigmentation of the eyes and visual disturbances.
- The most common type is X-linked ocular albinism (OA), also called OA1, although OA includes heterogeneous conditions accompanied by extraocular symptoms.
- Although hypopigmentation of skin and hair can be seen in some individuals, this is usually mild and not as evident as in the case of oculocutaneous albinism.
- Visual disturbances consist of nystagmus, impaired visual acuity, and stereoscopic vision.
- Early referral to an ophthalmologist is important to introduce proper ophthalmologic intervention.
- Visual acuity is usually stable throughout the life span of an individual, and sometimes improves gradually until adulthood.

Ocular albinism (OA) is a genetic disorder characterized by decreased pigmentation of the eyes and visual disturbances. The most common and recognized form is X-linked OA (also called OA1); however, OA includes heterogeneous conditions accompanied by extraocular

symptoms such as sensorineural deafness, sensorineural deafness with autosomal recessive inheritance, and congenital malformation of the maxillary bone. Although hypopigmentation of skin and hair can be seen in some individuals, these manifestations are usually mild and not as visible as those of OCA.

CLINICAL FEATURES

OA1 is characterized by hypopigmentation in the retinal pigment epithelium and iris, nystagmus, photophobia, impaired visual acuity, and foveal hypoplasia. Misrouting of the optic nerve in the chiasm is also observed in visual evoked potential testing. These ophthalmologic findings greatly overlap with those of OCA subtypes. Theoretically, hypopigmentation of skin is not seen in individuals with OA; however, some individuals show mild dilution of the pigmentation in skin and hair compared to unaffected male siblings.

ETIOLOGY AND PATHOGENESIS

The prevalence of OA has been reported as 1:60,000 and 1:50,000 in Danish and U.S. cohorts, respectively. OA1 is caused by a defective G-protein–coupled receptor 143 gene (*GPR143*) located on chromosome Xp.22.2. GPR143 is a melanosome-associated G-protein–coupled receptor involved in melanosome biogenesis during melanocyte differentiation. Electron microscopy of skin melanocytes and retinal pigment epithelium from OA1 patients showed that the number of melanosomes was decreased but their size had increased. GPR143 regulates melanosome size and number via activation of the microphthalmia-associated transcription factor (MITF), a key regulator of melanocyte differentiation.

DIAGNOSIS

OCA can be excluded by the absence of hypopigmentation of skin and hair. In white individuals with pale skin and blond hair, it may be difficult to determine whether the individuals have hypopigmentation of their skin and hair. In such cases, genetic analysis of the *GPR143* and OCA genes may be needed to obtain a definitive diagnosis.

DIFFERENTIAL DIAGNOSIS

OCA can be excluded by the absence of hypopigmentation of skin and hair. There are rare genetic disorders that demonstrate congenital nystagmus, and these also can be distinguished from OA by the absence of hypopigmentation of the iris and retinal pigment epithelium.

CLINICAL COURSE, PROGNOSIS, AND MANAGEMENT

As with the ocular symptoms of OCA, no curative treatment of OA1 exists as of this writing. Early referral to an ophthalmologist is necessary for appropriate intervention. For visual impairment, wearing corrective glasses is necessary, and dark sunglasses may alleviate photophobia. Surgical correction may be preferred for strabismus and nystagmus in some individuals. Regular ophthalmologic examinations should be performed.

OA1 is likely to be a nonprogressive disorder; visual acuity is usually stable throughout the life span of an individual, and sometimes improves gradually until adulthood. Nystagmus also tends to improve as individuals mature, but is unlikely to disappear.

HERMANSKY-PUDLAK SYNDROME

AT-A-GLANCE

- Hermansky-Pudlak syndrome (HPS) is a rare autosomal recessive genetic disorder characterized by hypopigmentation of skin, hair, and eyes accompanied by nonpigmentary symptoms, including bleeding diathesis, caused by platelet storage pool deficiency and accumulation of ceroid in tissues.
- Ten forms of HPS have been identified as of this writing.
- HPS1 and HPS4 are frequently associated with life-threatening symptoms such as interstitial pneumonia or granulomatous colitis mimicking Crohn disease in affected individuals older than age 30 years.
- HPS2 and HPS10 are associated with immunodeficiency and uncontrolled lymphocyte and macrophage activation, leading to subsequent hemophagocytic syndrome.

Hermansky-Pudlak syndrome (HPS) is a rare autosomal recessive disorder characterized by OCA and other nonpigmentary symptoms, such as bleeding diathesis, caused by platelet storage pool deficiency and accumulation of ceroid in tissues.[25] The estimated prevalence of HPS in the general population is 1:500,000 to 1:1,000,000. The region with the highest known prevalence of HPS is Puerto Rico, where approximately 1 in 1800 persons is

TABLE 75-2
Syndromic Oculocutaneous Albinism

DISEASE NAME	INHERITANCE	GENES	CHROMOSOMAL LOCATION	OMIM #
HPS1	AR	*HPS1*	10q24.2	203300
HPS2	AR	*HPS2/AP3B1*	5q14.1	608233
HPS3	AR	*HPS3*	3q24	614072
HPS4	AR	*HPS4*	22q12.1	614073
HPS5	AR	*HPS5*	11p15.1	614074
HPS6	AR	*HPS6*	10q24.32	614075
HPS7	AR	*HPS7/DTNBP1*	6p22.3	614076
HPS8	AR	*HPS8/BLOC1S3*	19q13.32	614077
HPS9	AR	*HPS9/PLDN*	15q21.1	614171
HPS10	AR	*HPS10/AP3D1*	19p13.3	617050
CHS	AR	*LYST*	1q42.3	214500
GS1	AR	*MYO5A*	15q21.2	214450
GS2	AR	*RAB27A*	15q21.3	607624
GS3	AR	*MLPH* and *MYO5A*	2q37.3	609227

AR, autosomal recessive; CHS, Chediak-Higashi syndrome; GS, Griscelli syndrome; HPS, Hermansky-Pudlak syndrome; OMIM, Online Mendelian Inheritance in Man.

affected, and approximately 1 in 22 is a carrier. Almost all of these individuals are type 1 or type 3. Regarding non–Puerto Rican populations, HPS1 is a relatively common type of albinism in Japan and China.[1] HPS is genetically and clinically heterozygous, with 10 types of HPS and their responsible genes reported as of this writing (Table 75-2). By electron microscopy, platelets from individuals with HPS do not contain dense granules, which is a gold standard diagnostic finding.

CLINICAL FEATURES

Patients with HPS show various degrees of hypopigmentation, impaired visual acuity, and bleeding tendency (see Fig. 75-1C). After middle age, it is noteworthy that patients with HPS1 and HPS4 frequently manifest life-threatening symptoms such as interstitial pneumonia, granulomatous colitis mimicking Crohn disease, and, rarely, cardiomyopathy. Because the affected molecular complex is the same in HPS1 and HPS4 (see section "Etiology and Pathogenesis"), the phenotype is identical and cannot be distinguished clinically. HPS3, HPS5, and HPS6 show relatively mild phenotypes lacking pneumonia and colitis. HPS2 and HPS10 are associated with immunodeficiency and uncontrolled lymphocyte and macrophage activation, leading to subsequent hemophagocytic syndrome.

ETIOLOGY AND PATHOGENESIS

HPS is caused by the disruption of lysosomal-related organelles that play important roles in membrane trafficking in many types of cells and organs. The symptoms, including OCA, bleeding diathesis, and deposition of ceroid bodies, are a result of the disruption of membrane trafficking of melanosome-related proteins, platelet-dense granules, and lysosomes. Lysosomal-related organelles are synthesized by several protein complexes that consist of several HPS proteins, including the BLOC (biogenesis of lysosome-related organelles complex) members—BLOC-1, BLOC-2, and BLOC-3, and the adaptor protein (AP) complex—AP-3. Thus, disruption of HPS proteins results in pigmentary and various nonpigmentary symptoms.

BLOC-3 is composed of 2 subunits, HPS1 and HPS4.[26] Analysis of fibroblasts derived from BLOC-3–deficient mice showed altered distribution of late endosomes/lysosomes, suggesting that BLOC-3 may play a role in the proper distribution and motility of organelles, although its pathophysiology in the development of HPS1 and HPS4 remains to be clarified. Depending on where it is expressed, the AP-3 complex has 2 forms, the ubiquitous form and the neuron-specific form.[27] The ubiquitous form plays a role in the efficient trafficking of TYR and OCA2 in melanocytes.[28] The neuron-specific form is necessary for synaptic vesicle formation from endosomes, thus allowing the release of neurotransmitters along developing axons.[29] Although both forms share 3 subunits, AP-3α, AP-3δ, and AP-3μ, the difference between the 2 forms is the presence of AP-3 β3A in the ubiquitous form and the presence of AP-3 β3B in the neuron-specific form. The gene for HPS2 (AP3B1) encodes the β3A subunit. Recently, AP3D1 encoding AP-3δ has been reported to be the gene responsible for HPS10.[27] Clinical symptoms of HPS2 and HPS10 are consistent with these molecular findings, as a defective β3A subunit (HPS2), which is a component of the ubiquitous form but not the neuron-specific form, does not cause neurologic abnormalities,

whereas a defective AP-3δ subunit (HPS10) is associated with neurologic symptoms.[27] BLOC-2 is composed of 3 subunits that are responsible for HPS3, HPS5, and HPS6. Melanocytes from individuals with HPS with deficient BLOC-2 showed mislocalization of TYR and TYRP-1, and accumulation of TYR-containing vesicular structures in the cytoplasm. These findings suggest that BLOC-2 is located downstream of BLOC-1 and might play a role in fusion of BLOC-1–dependent transport intermediates with maturing melanosomes.[28] BLOC-1 is a large complex consisting of at least 9 subunits, including HPS7, HPS8, and HPS9. BLOC-1 may play a role in the trafficking of TYR and TYRP-1 in cooperation with AP-1 and AP-3, although the details have not been clarified. BLOC-1–deficient mice show prominent hypopigmentation.[30]

DIAGNOSIS

The clinical diagnosis of HPS is rendered by the lack of platelet dense granules on electron microscopy. Genetic analysis of HPS genes is needed to obtain a definitive diagnosis, because the symptoms of some HPS subtypes (eg, HPS1 and HPS4) are identical—the affected molecular complex is the same—and cannot be distinguished clinically.

DIFFERENTIAL DIAGNOSIS

The differential diagnosis of HPS includes nonsyndromic OCA and Chédiak-Higashi syndrome (CHS). The symptoms of nonsyndromic OCA are restricted to hypopigmentation and visual impairment. CHS is characterized by silvery hair, recurrent pyogenic infection, and subsequent fatal hemophagocytic syndrome, considered the "accelerated phase." Large granules are seen in polymorphonuclear cells from individuals with CHS, which is diagnostic. Immunodeficiency is observed in HPS2 and HPS10.

CLINICAL COURSE, PROGNOSIS, AND MANAGEMENT

For hypopigmentation of skin and visual impairment, early intervention should be introduced (see sections "Intervention and Treatment" in the nonsyndromic OCA and OA above). No curative treatment has been found as of this writing for hypopigmentation. Pirfenidone, corticosteroid, and immunosuppressants have been used to treat pulmonary fibrosis, although the efficacy of these therapies remains controversial. Infliximab and granulocyte colony-stimulating factor are suggested to be effective for colitis and neutropenia/immune deficiency, respectively. Colectomy may be necessary for severe colitis. Hematopoietic stem cell transplantation (HSCT) may be required to prevent the development of hemophagocytic syndrome in individuals with HPS2.

Hypopigmentation of skin and hair tends to be alleviated as individuals mature. Visual impairment is usually nonprogressive. The prognosis of individuals with HPS1, the most common subtype of HPS, can be determined by the interstitial pneumonia.

GRISCELLI SYNDROME

AT-A-GLANCE

- Griscelli syndrome is a rare autosomal recessive genetic disorder characterized by hypopigmentation of skin and hair, with large clumps of pigment in the hair shaft on light microscopy.
- Three forms of Griscelli syndrome (GS) have been identified.
- GS1 and GS2 show extrapigmentary symptoms including neurologic and hematologic abnormalities; GS3 is restricted to hypopigmentation.

Griscelli syndrome (GS) is a rare autosomal recessive genetic disorder characterized by hypopigmentation of skin and hair, with large clumps of pigment in the hair shaft on light microscopy. Three forms of GS have been identified as of this writing (see Table 75-2): GS1 is characterized by hypopigmentation with neurologic abnormalities; GS2 features hypopigmentation accompanied by hematologic immunodeficiency and hematologic abnormalities; GS3 is restricted to hypopigmentation.

CLINICAL FEATURES

GS is characterized by hypopigmentation of skin and silvery hair with large clumps of pigment in the hair shaft. GS1 is associated with severe developmental delay and mental retardation. GS2 is associated with recurrent pyogenic infections and uncontrolled T-cell and macrophage activation leading to hemophagocytic syndrome, the so-called accelerated phase, which can be fatal without immunosuppressive treatment or stem cell bone marrow transplantation. GS3 is restricted to hypopigmentation of skin and hair.

ETIOLOGY AND PATHOGENESIS

The genes responsible for the 3 GS types are *MYO5A* (GS1), *RAB27A* (GS2), and *MLPH* (GS3). They form a

complex in melanocytes, connect melanosomes to the actin network, and are involved in melanosome transport at the periphery of melanocytes.[31] MYO5A binds to actin filaments and moves along them like a wheel; MLPH connects RAB27A and MYO5A; and RAB27A connects to melanosomes. Because MYO5A is associated with neurologic development and function,[32] defective MYO5A can cause severe neurologic deterioration. On the other hand, a transcript variant in brain tissue does not contain exon-F of *MYO5A*.[33] Individuals showing hypopigmentation of skin and hair identical to GS3 showed homozygous deletion of *MYO5A* exon-F.[31] RAB27A is also associated with the release of lytic granules from CD8+ T cells. Defective RAB27A causes immunodeficiency and uncontrolled T-cell and macrophage activation leading to fatal hemophagocytic syndrome.[31]

DIAGNOSIS

The presence of large clumps of pigment in the hair shaft is diagnostic for GS, but genetic analysis gives a definitive diagnosis.

DIFFERENTIAL DIAGNOSIS

The differential diagnosis of GS includes nonsyndromic OCA, CHS, and HPS. Nonsyndromic OCA can be excluded based on the presence of nonpigmentary symptoms. GS3 can be distinguished from nonsyndromic OCA by the presence of large clumps of pigment in the hair shaft. Similarly, these observations also can be used to distinguish GS2 from CHS. Peripheral blood smears from individuals with CHS demonstrate giant inclusion bodies in polymorphonuclear neutrophils and some lymphocytes. HPS2 and HPS10 show hypopigmentation together with immunodeficiency, although HPS lacks platelet dense granules on electron microscopy.

CLINICAL COURSE, PROGNOSIS, AND MANAGEMENT

For hypopigmentation of skin and visual impairment, early intervention should be introduced (see "Intervention and Treatment" in the OCA and OA sections above). As of this writing, no curative treatment exists for the neurologic symptoms. However, rehabilitation can alleviate the neurologic symptoms. Stem cell bone marrow transplantation is the only method to cure the hematologic and immunologic abnormalities.

Regarding the prognosis, most patients with GS1 and GS2 reported in the literature died before the age of 10 years. Cağdaş and associates reported healthy 21- and 24-year-old patients with GS3 with only pigmentary dilution.[34]

CHÉDIAK-HIGASHI SYNDROME

AT-A-GLANCE

- Chédiak-Higashi syndrome is a rare genetic disease with autosomal recessive inheritance characterized by reduced pigmentation of skin and eyes, silvery or metallic colored hair, and neurologic and hematologic disorders.
- Approximately 90% of individuals with Chédiak-Higashi syndrome develop lymphoproliferative syndrome, the "accelerated phase" of the disease that tends to be fatal.
- Hematopoietic stem cell transplantation is the only treatment for hematologic and immunologic abnormalities.

CHS is a rare genetic disease with autosomal recessive inheritance characterized by reduced pigmentation of skin and eyes, silvery or metallic colored hair, immunodeficiency, and debilitating neurologic abnormalities. Large granules in polymorphonuclear neutrophils on blood smear are diagnostic, and pigment clumping on the hair shaft is also seen. As of this writing, fewer than 500 cases have been reported. Approximately 90% of individuals with CHS develop lymphoproliferative syndrome, which is known as the "accelerated phase" of the disease and tends to be fatal.

CLINICAL FEATURES

Individuals with CHS show various degrees of hypopigmentation of skin and eyes, silvery or metallic colored hair, and immunodeficiency. Neurologic findings, including low IQ scores, cerebellar ataxia, and peripheral neuropathy, appear in childhood or adolescence and tend to progress gradually. Approximately 90% of individuals with CHS develop lymphoproliferative syndrome, which is called the "accelerated phase" of the disease and tends to be fatal. A case report exists of two brothers with a *LYST* mutation, who showed slowly progressive neurologic symptoms, including spastic paraplegia, cerebral ataxia, and peripheral neuropathy, but lacked hypopigmentation.[35]

ETIOLOGY AND PATHOGENESIS

The gene responsible for CHS is *LYST*, located on 1q42.3, which encodes lysosomal trafficking regulator (LYST), also known as CHS1. Although the biologic

function of CHS1 has not been determined, electron microscopy of epidermal melanocytes from an individual with CHS shows the accumulation of large melanosomes on the periphery of the cytoplasm; these melanosomes are not transferred to neighboring keratinocytes. Peroxidase-positive large inclusion bodies are seen in polymorphonuclear neutrophils and occasionally in lymphocytes, which is a characteristic finding in CHS. Neurologic abnormalities may be caused by lysosome dysfunction in neurons and glial cells.[36] Considering these findings, LYST may play roles in vesicle trafficking in various cell types.

DIAGNOSIS

Peroxidase-positive large inclusion bodies are seen in polymorphonuclear neutrophils and, occasionally, in lymphocytes, which is a characteristic finding in CHS. Genetic analysis of CHS1 assists in making a diagnosis of CHS.

DIFFERENTIAL DIAGNOSIS

Differential diagnosis includes diseases showing hypopigmentation of skin, hair, and eyes, and/or immunodeficiency. Nonsyndromic OCA is restricted to hypopigmentation and ocular symptoms, with a lack of immunodeficiency or neurologic abnormalities. Individuals with HPS2 and HPS10 demonstrate neutropenia and immunodeficiency in addition to albinism. Individuals with GS demonstrate symptoms similar to those of CHS; however, GS can be distinguished from CHS by the lack of large inclusion bodies in polymorphonuclear neutrophils. Individuals with HPS also lack dense granules in platelets.

CLINICAL COURSE, PROGNOSIS, AND MANAGEMENT

HSCT is the only treatment for hematologic and immunologic abnormalities. For hypopigmentation of skin and visual impairment, early intervention should be introduced (see "Intervention and Treatment" in the OCA and OA sections). As of this writing, no curative treatment has been established for hypopigmentation.

Most individuals with CHS are required to undergo HSCT; without this treatment, they will die within the early part of their first decade of life. Individuals with mild symptoms or those who do not develop the accelerated phase may survive for a long period of time, although debilitating neurologic abnormalities, such as loss of balance, difficulty with ambulation, and peripheral neuropathy, may appear.[36]

INCONTINENTIA PIGMENTI

AT-A-GLANCE

- Incontinentia pigmenti is a rare genetic multiorgan disorder with X-linked dominant inheritance.
- Various cutaneous lesions are seen from infancy to adulthood, with eye, CNS or musculoskeletal abnormalities.
- Cutaneous lesions usually heal spontaneously with focal hypopigmentation or scarring, but eye and CNS lesions can have serious consequences for the vision and life of patients.

Incontinentia pigmenti (IP) is a rare genetic multiorgan disorder with X-linked dominant inheritance, characterized by various cutaneous lesions from infancy to adulthood, and extracutaneous symptoms such as eye, CNS, and musculoskeletal abnormalities. Skin lesions include erythema, vesicle, hyperkeratotic papule, and hyperpigmentation, and usually heal spontaneously with focal hypopigmentation, scarring, or alopecia. However, eye and CNS lesions can have serious consequences for the vision and life of patients.

CLINICAL FEATURES

Multiple organs including the skin, eye, CNS, and musculoskeletal tissue can be affected in patients with IP. Although cutaneous lesions tend to be self-healing with occasional scarring (Fig. 75-2), they are one of the major diagnostic criteria and a characteristic symptom of IP.

Cutaneous lesions are classified into 4 stages based on clinical findings. Stage I (vesiculobullous stage) is characterized by vesicular/bullous eruptions and erythema distributed in a linear or whorled pattern on

Figure 75-2 Healing vesicle in an infant with incontinentia pigmenti. (Image used with permission from the Graham Library of Wake Forest Department of Dermatology.)

Figure 75-3 Hypopigmented whorls on the abdomen of an infant with incontinentia pigmenti. (Image used with permission from the Graham Library of Wake Forest Department of Dermatology.)

the trunk and extremities (the face is usually spared) that appear within 1 week of birth (Fig. 75-3). The eruption tends to be bilateral but can be unilateral. Eosinophilia is seen in approximately 30% to 60% of the cases, and eosinophilic infiltration in the lesional skin is a characteristic histologic finding. Stage II (verrucous stage) follows stage I, and is characterized by verrucous or lichen planus-like keratotic eruptions on the extremities (Fig. 75-4), particularly the dorsal hand and foot. The distribution of lesions does not necessarily correspond to that of the stage I eruption. The histopathology of stage II eruption shows dyskeratotic keratinocytes, hyperkeratosis, and acanthosis. Stage II lasts for a few months and occasionally, may last up to a few years. The lesions of stage III (hyperpigmentation stage) appear when individuals are 12 to 16 weeks old, and these are characterized by brown to gray-brown pigmentation distributed in whorled or linear patterns, respecting the Blaschko line. Melanophages are prominent in the upper dermis histologically. The pigmentation disappears almost completely by 4 or 5 years of age and may leave focal hypopigmentation, atrophic scar, or alopecia. The eruptions during stages I and II can often be exacerbated by acute viral infection.

Figure 75-4 Verrucous changes on the leg of deeply pigmented infant with incontinentia pigmenti. (Image used with permission from the Graham Library of Wake Forest Department of Dermatology.)

Several types of eruption may coexist, so each stage may not be clearly determined. Eye abnormalities are seen in 36% to 77% of patients with IP,[37] including both retinal and nonretinal lesions, such as retinal detachment, retinal hemorrhage, strabismus, nystagmus, and uveitis. CNS lesions include seizure, mental retardation, hemiplegia, spasticity, and cerebellar ataxia, some of which can be life-threatening.

ETIOLOGY AND PATHOGENESIS

The responsible gene for IP is *IKBKG* (inhibitor of kappa light polypeptide gene enhancer in B-cells, kinase gamma) located on Xp28. Of patients with IP, 80% harbor an 11.7-kb deletion containing exons 4 to 10 of *IKBKG*, and the function of nuclear factor κB is thereby completely lost. The cells containing aberrant IKBKG are very sensitive to proapoptotic stimuli, and are prone to undergo apoptosis.[37] Abundant eosinophil infiltration is seen in the biopsy from vesicular eruption, and eosinophilia is also observed in 30% to 60% of patients. Jean-Baptiste and associates revealed that the expression of eosinophil-specific chemotactic factor eotaxin in vesicular lesions from IP patients was increased, and keratinocyte expression of eotaxin was induced by the proinflammatory cytokine interleukin-1α in vitro. Overexpression of eotaxin seems to be involved in the eosinophil infiltration and the pathogenesis of IP.[38] The mechanism of eosinophil infiltration can lead to fibrovascular proliferation during the inflammatory process in the eye. The pathogenesis of the CNS lesions in IP has not been determined, although apoptosis and the subsequent inflammatory response caused by the abnormal function of nuclear factor κB seem to be the major events, similar to the pathogenesis of skin lesions.[39]

Because IP is inherited by an X-linked mechanism and a male fetus with aberrant IKBKG is expected to be miscarried, the expected percentage among newborn babies is 33% unaffected females, 33% affected females, and 33% unaffected males. However, more than 100 male patients (6.1% of all IP cases) have been reported. An international IP consortium proposed 3 possible mechanisms for male IP patients. These were less deleterious (hypomorphic) mutations; a 47,XXY karyotype; or somatic mosaicism.[40] Ardelean and Pope reported that the clinicopathologic features of male and female individuals with IP seemed to be similar.[41]

DIAGNOSIS

Landy and Donnai proposed diagnostic criteria for IP in 1993.[42] Their suggestion for a major criterion is cutaneous lesions that occur from infancy to adulthood, while minor criteria include dental, hair, nail, and retinal abnormalities.[37] Mimic and associates suggested

the modification that the presence of at least 1 skin lesion should be one of the major criteria, together with CNS abnormalities, multiple miscarriages of male fetuses, and typical skin histologic findings. Genetic analysis of *IKBKG* would also be helpful to render a definitive diagnosis.

DIFFERENTIAL DIAGNOSIS

As the cutaneous symptoms of IP vary depending on the stage and time course, many skin diseases can be the differential diagnosis. At stages I and II, infectious diseases producing similar symptoms include herpes simplex, impetigo, wart, molluscum contagiosum or epidermolysis bullosa. In later stages, the following resemble IP: nonspecific postinflammatory pigmentation, hypomelanosis of Ito, vitiligo, and Naegeli syndrome (although Naegeli syndrome itself is rare).

CLINICAL COURSE, PROGNOSIS, AND MANAGEMENT

Skin lesions of IP tend to be self-healing but may leave scars or hair loss at the affected areas. Secondary infection and strong inflammation may be possible, particularly in the stage I lesions, requiring topical treatment based on the skin condition. Eye and CNS abnormalities can cause serious impacts to the patients including blindness and death. No curative treatment for IP exists as of this writing. Routine regular followup study for extracutaneous lesions including those affecting the eyes and CNS is needed to allow early initiation of appropriate interventions.

PIEBALDISM

AT-A-GLANCE

- Piebaldism is a rare autosomal dominant disease with congenital white patches.
- The patches mainly occur on the forehead, chest, abdomen, and extremities.
- The distribution and shape of white patches remains the same throughout life.
- Usually there are no complications except for skin phenotypes.

Piebaldism is a rare genetic disorder with congenital white patches on the forehead, chest, abdomen, and extremities that result from impairment of melanoblast migration in embryonal development.

CLINICAL FEATURES

Piebaldism is an autosomal dominant disease in which a congenital white forelock, scattered hypopigmented macules, and a triangular-shaped white patch on the forehead are involved (OMIM 172800). The forehead, chest, abdomen, and extremities are typical sites for involvement. White patches are completely depigmented owing to the absence of melanocytes, and often are strikingly symmetrical. Hyperpigmented macules, which are similar to café-au-lait spots, are sometimes involved. A diamond-shaped white forelock is present in 90% of affected individuals. Within depigmented areas, there may be islands of hyperpigmentation, and the margins of lesions are also often hyperpigmented. The distribution of the lesions remains for the entire life of affected individuals. Intrafamilial variability in the degree of lesions is great.

ETIOLOGY AND PATHOGENESIS

Piebaldism is associated with the *KIT* gene.[43] Melanocytes originate from the dorsal portions of the closing neural tube in vertebrate embryos. Progenitor melanoblasts migrate dorsolaterally between the mesodermal and ectodermal layers to reach their final destinations, including the skin. Early melanoblast development requires the presence of stem cell factor (SCF or c-KIT ligand) expressed by epidermal keratinocytes, and its tyrosine kinase transmembrane receptor c-KIT expressed on melanoblasts. Piebaldism results from mutations of *c-KIT* that cause failure of melanoblast migration from the neural crest to the skin.[43] Because the ventral aspect of the body is the area farthest from the dorsally located neural crest, it is more frequently affected than the dorsal aspect.

There is a report that mutation in *SNAI2*, which encodes a zinc finger transcription factor, can cause piebaldism.[44]

DIAGNOSIS

Piebaldism is typically a straightforward clinical diagnosis based on complete depigmentation in chest, abdomen, and extremities, a characteristic white forelock, and a family history. Skin biopsy from the white lesion shows an absence of melanin and melanocytes. The finding of a mutation of *c-KIT* definitely determines the diagnosis as piebaldism.

DIFFERENTIAL DIAGNOSIS

Piebaldism should be distinguished from vitiligo, Vogt-Koyanagi-Harada disease, nevus depigmentosus,

hypomelanosis of Ito, tuberous sclerosis, and Waardenburg syndrome.

CLINICAL COURSE, PROGNOSIS, AND MANAGEMENT

The distribution, size, and shape of the lesions will not typically change during life. However, islands of repigmentation, especially in the white patch on the forehead, have been reported to develop in some affected individuals after sun exposure. A patient with typical piebaldism but progressive depigmentation also has been reported.

So far, there are some reports that epidermal transplantation was available, although effective management strategies have not been established yet.

WAARDENBURG SYNDROME AND TIETZ SYNDROME

AT-A-GLANCE

- Waardenburg and Tietz syndromes are rare genetic diseases with congenital pigment disorder plus sensorineural deafness.
- Both mostly have autosomal dominant inheritance.
- White patches are frequently found, but mottled or speckled patterns also are found sometimes.
- Some of the 4 subtypes involve musculoskeletal anomalies, Hirschsprung disease, or severe neurologic defects.
- Tietz syndrome is a kind of variation of Waardenburg syndrome with a diffuse pigmentary phenotype plus severe hearing loss.

WAARDENBURG SYNDROME

Waardenburg syndrome (WS), first reported by Waardenburg in 1951, is a genetic disease consisting of congenital pigment anomalies, including white patches, with sensorineural deafness.[45] According to the clinical manifestations and genetic abnormalities, WS is classified into 4 types (Table 75-3).

CLINICAL FEATURES

Pigment anomalies include both white patches and occasionally occurring mottled or speckled patterns. In patients with WS1, white forelock (hair depigmentation), pigmentary anomalies of the iris (Fig. 75-5), congenital sensorineural deafness, and dystopia canthorum are frequently observed. Depigmented macules or patches, synophrys, broad nasal root, and nose hypoplasia are sometimes accompanying symptoms. In WS3, axial and limb musculoskeletal anomalies are additionally observed. In the case of WS2, the clinical features are similar to those of WS1, except for absence of dystopia canthorum and

TABLE 75-3
Subtypes of Waardenburg Syndrome

DISORDER TYPE	CLINICAL FEATURE	SUBTYPE	OMIM #	RESPONSIBLE GENE	MAPPING	INHERITANCE
WS1	White forelock, heterochromia irides, dystopia canthorum		193500	*PAX3*	2q35	AD
WS2	Similar to WS1, but no dystopia canthorum	A	193510	*MITF*	3p14.1-p12.3	AD
		B	600193	?	1p21-p13.3	?
		C	606662	?	8p23	?
		D	608890	*SNAI2*	8q11	AR
		E	611584	*SOX10*	22q13	AD
WS3	Similar to WS1, plus axial and limb musculoskeletal anomalies		148820	*PAX3*	2q35	AD/AR
WS4	Similar to WS1, plus Hirschsprung disease	A	277580	*EDNRB*	13q22	AD/AR
		B	613265	*EDN3*	20q13.2-q13.3	AD/AR
		C	613266	*SOX10*	22q13	AD

AD, autosomal dominant; AR, autosomal recessive; OMIM, Online Mendelian Inheritance in Man; WS, Waardenburg syndrome.

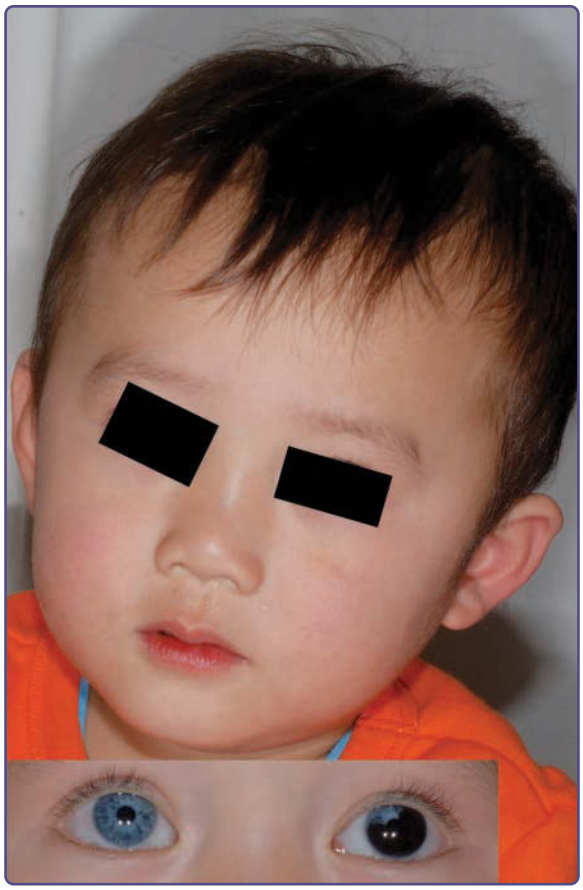

Figure 75-5 Clinical findings of Waardenburg syndrome type 2. Three-year-old boy (reported in Monma F, Hozumi Y, Kawaguchi M, et al[60]). Heterochromia irides are seen, and he showed a frontal white blaze of hair, and leukoderma over his body. Hearing impairment was also reported.

facial abnormalities. WS4 presents with white forelock, isochromatic irides, and the additional feature of Hirschsprung disease (neonatal intestinal obstruction, megacolon).[46]

ETIOLOGY AND PATHOGENESIS

WS1 and WS3 result from loss-of-function mutations in *PAX3*, which encodes a transcription factor regulating expression of MITF. The clinical manifestations observed in WS1 and WS3 can be explained by deregulation of the genes regulated by PAX3, occurring early in embryogenesis in the cells originating from the neural crest. MITF takes a central role in melanogenesis, and also mediates survival of melanocytes via regulation of Bcl2. Defects of MITF cause the pigmentary and hearing symptoms observed in WS1 and WS3.

WS2 is genetically a heterogenic type. Mutations of *MITF* have been found in 89.6% of WS2 cases. *MITF* is a member of the Myc supergene family of transcription factors having a basic helix-loop-helix leucine zipper structure. Two genes, *SNAI2* and *SOX10*, and 2 loci, chromosome 1p and 8p23, have been reported as responsible genes for another WS2 type.[46] WS4 is also a heterogenic type resulting from mutations in several genes, including the endothelin-B receptor (*EDNRB*), endothelin-3 (*EDN3*), and SOX10 (*SOX10*).[46] Interaction between EDNRB and its ligand EDN3 is essential for the embryologic development of neurons of ganglia in the GI tract, and melanocytes. Mutations in *SOX10* cause myelination deficiency in the central and peripheral nervous systems, and can cause a severe phenotype called PCWH (peripheral demyelinating neuropathy, central dysmyelinating leukodystrophy, Waardenburg syndrome, and Hirschsprung disease).[47]

TABLE 75-4
Criteria for Diagnosis of Waardenburg Syndrome[a]

Major Criteria
Characteristic white forelock
Pigmentary anomalies of the iris
Congenital sensorineural deafness
Dystopia canthorum
An affected first-degree relative
Minor Criteria
Depigmented macules or patches
Synophrys
Broad nasal root
Nose hypoplasia
Early graying the hair by age 35 years

[a]Diagnosis requires either 2 major criteria or 1 major and 2 minor criteria.

DIAGNOSIS

Diagnosis requires fulfillment of either 2 major criteria or 1 major and 2 minor criteria (Table 75-4).

CLINICAL COURSE, PROGNOSIS, AND MANAGEMENT

Protection from sunburn is important. In the case of WS4, surgical treatment of the aganglionic segment of bowel is required. Establishing the diagnosis of WS should lead to early detection of hearing loss and appropriate intervention.

TIETZ SYNDROME

Tietz syndrome (OMIM 103500) is caused by specific mutations of *MITF*—Asn210Lys and Arg217del. The hypopigmentation has a diffuse pigmentary phenotype similar to that found in OCA2, not patchy as in WS2. Patients with either mutation present with severe hearing loss. Both mutations are thought to have a dominant-negative effect, resulting in a distinct phenotype, even though mutations exist in the same gene with WS2.[48]

RETICULATE PIGMENT DISORDERS

AT-A-GLANCE

- The category of reticulate pigment disorders includes dyschromatosis symmetrica hereditaria, dyschromatosis universalis hereditaria, reticulate acropigmentation of Kitamura, and Dowling-Degos disease.
- These 4 diseases can be genetically differentiated.
- All of these are genetic diseases with reticulate pigment phenotype, mostly having autosomal dominant inheritance.
- Some anomalies or complications are sometimes found in addition to skin phenotypes in some of the diseases.

Reticulate pigment disorders involve many diseases. Here, dyschromatosis symmetrica hereditaria (DSH), dyschromatosis universalis hereditaria (DUH), reticulate acropigmentation of Kitamura (RAK), and Dowling-Degos disease (DDD) are included. These are recognized as different diseases, and most of these diseases can be differentiated by genetic analysis.

DYSCHROMATOSIS SYMMETRICA HEREDITARIA

CLINICAL FEATURES

DSH (OMIM 127400) (also called "reticulate acropigmentation of Dohi") is an autosomal dominant disease characterized by a mixture of hyperpigmented and hypopigmented macules distributed on the dorsal aspects of the extremities (Fig. 75-6), and freckle-like macules on the face. The skin lesions usually appear in infancy or early childhood.

Patients with DSH usually have no complications; however, some reports showed that patients with the specific mutation Gly1007Arg in *ADAR1* presented with severe neurologic disorders, such as dystonia, mental deterioration, and brain calcification.[49] So far, this is a unique mutation causing neurologic complications.

ETIOLOGY AND PATHOGENESIS

DSH has been reported mainly in East Asia, although it occurs in families of every ethnic origin worldwide. Histologic and electron microscopic examination has revealed that the number of melanocytes in the hypopigmented areas of patients with DSH is

Figure 75-6 Clinical manifestations of dyschromatosis symmetrica hereditaria. Intermingled hyperpigmentation and hypopigmentation of the dorsal aspect of the hand and fingers.

obviously lower than that in normal skin, and that the melanocytes show degenerative vacuolation, indicative of apoptosis.

From linkage analysis and a genome-wide scan, the results indicated that a heterozygous mutation of the RNA-specific adenosine deaminase gene (*ADAR1*) causes DSH.[50] ADAR1 was identified as the first enzyme that converts adenosine to inosine in double-stranded RNA. Previous in vitro studies suggested ADAR1 is involved in several physiologic activities, such as virus inactivation (eg, measles virus, HIV, and hepatitis C virus) and alteration in the properties of the neurotransmitter receptor for L-glutamate (GluR) and serotonin (5-HT2cR) through this A-to-I editing process. Recent studies have revealed that ADAR1 is an important modulator of the innate antiviral response. Haploinsufficiency of ADAR1 causes the phenotypes of DSH, although the mechanisms remain unknown.

DIAGNOSIS

A mixture of hyperpigmented and hypopigmented macules distributed only on the dorsal aspects of the extremities, not on the body, is characteristic of DSH. The frequency of the neurologic complication is very rare. Identification of a pathologic mutation in *ADAR1* makes a definite diagnosis.

DIFFERENTIAL DIAGNOSIS

There are at least 3 diseases showing phenotypes very similar to DSH. One of them is DUH. In DUH, mixtures of hyperpigmented and hypopigmented macules occur all over the body. The other is RAK, which is characterized by "pits" on the palms, and the absence of hypopigmented macules. DDD is another reticulate disease. The DDD phenotype, in which small hyperkeratotic dark-brown papules are found mainly in the flexures, is progressive.

CLINICAL COURSE, PROGNOSIS, AND MANAGEMENT

Skin conditions commonly stop spreading before adolescence and last for life. Transplantation of skin from a normally pigmented area to the white area is a management strategy that has been reported to give good results.

DYSCHROMATOSIS UNIVERSALIS HEREDITARIA

CLINICAL FEATURES

DUH (OMIM 127500) is characterized by asymptomatic hypopigmented and hyperpigmented macules of irregular size and shape in a generalized distribution over the trunk and limbs, and sometimes the face. Skin phenotypes usually appear early in life. Abnormalities of hair and nails have been reported, and DUH may be associated with abnormalities of dermal connective tissue, nerve tissue, or other systemic complications.[51] DUH has been most commonly reported in East Asia, for example, Japan and China, but also has been reported worldwide.

ETIOLOGY AND PATHOGENESIS

Histopathologic examination of a skin lesion showed a pigmented basal layer of the epidermis, pigmentary incontinence in the papillary dermis, and some melanophages and lymphocytes in the upper dermis. These findings indicate that DUH is not a disorder of melanocyte number.

DUH is classified into 3 subtypes. DUH1 (OMIM 127500) is an autosomal dominant disease with linkage to 6q24.2-q25.2. DUH2 (OMIM 612715) is an autosomal recessive disease mapped to chromosome 12q21-q23. DUH3 is caused by heterozygous mutation in the *ABCB6* gene on chromosome 2q35.[51]

DIAGNOSIS

The characteristic phenotype, which is a mixture of hypopigmented and hyperpigmented macules all over the body, can be easily used clinically to diagnose DUH. However, gene analysis is helpful for diagnosis, because subtyping from clinical information is sometimes difficult.

RETICULATE ACROPIGMENTATION OF KITAMURA

CLINICAL FEATURES

RAK (OMIM 615537) is a rare genetic pigmentary disorder that usually shows an autosomal dominant pattern of inheritance with high penetrance, and was first reported worldwide in 1953.[52] RAK is typically characterized by angulate reticulate hyperpigmentation of the dorsum of the extremity (Fig. 75-7A). The palms and soles contain punctate pits (Fig. 75-7B) and breaks in the epidermal rete ridge pattern. Hypopigmented macules are never included in the lesions. The phenotype appears within the first or second decade of life, and continues throughout life. Although RAK has been reported mainly in Japan, considerable numbers of patients have been described from other countries or ethnicities, such as the Middle East, Europe, and Latin America.

Figure 75-7 Clinical finding of reticulate acropigmentation of Kitamura. **A,** Hyperpigmented macules distributed on the dorsal aspects of the hands. **B,** "Pits" on the palm.

ETIOLOGY AND PATHOGENESIS

Histopathologic analyses reported that hyperpigmented macules show hyperkeratosis without parakeratosis, slightly elongated rete ridges, and a small number of inflammatory cells in the upper dermis. In Fontana-Masson staining, the lesion shows hypermelanosis, mainly in the lower epidermis, and absence of obvious IP in the upper dermis. The number of melanocytes is increased in the basal layer of the epidermis.

Investigation with electron microscopy showed that the number of melanosomes in the cytoplasm of keratinocytes was obviously increased in hyperpigmented macules, compared with cells from the perilesional skin. A majority of melanosomes observed in the lesion formed melanosome complexes, membrane-bounded vesicles containing several melanosomes. These melanosome complexes were not detected in the perilesional skin. Some melanosome complexes were also observed in melanocytes. Recently, heterozygous mutations in the *ADAM10* gene have been identified as causing RAK.[53]

DIAGNOSIS

The phenotype of reticulate hyperpigmentation on the dorsum of the extremities without hypopigmented macules, plus the punctate pits on the palms and soles, is helpful for the diagnosis of RAK. Identification of a mutation in *ADAM10* can confirm the diagnosis.

DOWLING-DEGOS DISEASE

CLINICAL FEATURES

DDD is an autosomal dominant genodermatosis with reticulate hyperpigmentation that is progressive.[54] Small, hyperkeratotic, dark-brown papules that affect mainly the flexures and great skin folds appear after puberty. Pitted perioral acneiform scars and genital and perianal reticulated pigmented lesions also have been described.[55] Patients usually show no abnormalities of the hair or nails. Histology shows thin branch-like patterns, filiform epithelial downgrowth of epidermal rete ridges, with a concentration of melanin at the tips.

ETIOLOGY AND PATHOGENESIS

DDD shows genetic heterogeneity and is classified into 4 types (see Table 75-3). DDD1 is caused by heterozygous mutation in the *KRT5* gene on chromosome 12q13.[56] DDD2 is caused by mutation in the *POFUT1* gene on chromosome 20q11.[57] DDD3 has been mapped to chromosome 17p33.3. DDD4 is caused by mutation in the *POGLUT1* gene on chromosome 3q13.[58] Both of the gene products from POFUT1 and POGLUT1 have been reported to play important roles in the Notch receptor signaling pathway.

DIAGNOSIS

The phenotype of reticulate hyperpigmentation is progressive, and is mainly distributed on

TABLE 75-5
Genetic Heterogeneity of Reticulate Pigment Disorders

DISORDER TYPE	CLINICAL FEATURE	SUBTYPE	OMIM #	RESPONSIBLE GENE	MAPPING	INHERITANCE
DDD	Usually in a flexural distribution, sometimes, generalized distribution	1	179850	*KRT5*	12q13.13	AD
		2	615327	*POFUT1*	20q11.21	AD
		3	615674	ND	17q21.3-q22	AD
		4	615696	*POGLUT1*	3q13.33	AD
DSH	In acral distribution with mixed hyper- and hypopigmentation		127400	*ADAR1*	1q21	AD
DUH	In generalized distribution over the trunk with mixed hyper- and hypopigmentation	1	127500	ND	6q24.2-q25.2	AD
		2	612715	ND	12q21-q23	ND
		3	615402	*ABCB6*	2q35	AD
ARK	In an acral distribution		615537	*ADAM10*	15q21.3	AD

AD, autosomal dominant; AR, autosomal recessive; ND, not determined; OMIM, Online Mendelian Inheritance in Man.

the flexures, although sometimes more generally. Genetic analyses can be helpful for the differential diagnosis, because the responsible genes are different, as shown in Table 75-5.

REFERENCES

1. Ito S, Suzuki T, Inagaki K, et al. High frequency of Hermansky-Pudlak syndrome type 1 (HPS1) among Japanese albinism patients and functional analysis of HPS1 mutant protein. *J Invest Dermatol.* 2005; 125(4):715-720.
2. Manga P, Kromberg JG, Box NF, et al. Rufous oculocutaneous albinism in southern African Blacks is caused by mutations in the TYRP1 gene. *Am J Hum Genet.* 1997;61(5):1095-1101.
3. Boissy RE, Zhao H, Oetting WS, et al. Mutation in and lack of expression of tyrosinase-related protein-1 (TRP-1) in melanocytes from an individual with brown oculocutaneous albinism: a new subtype of albinism classified as "OCA3." *Am J Hum Genet.* 1996;58(6):1145-1156.
4. Rundshagen U, Zuhlke C, Opitz S, et al. Mutations in the *MATP* gene in five German patients affected by oculocutaneous albinism type 4. *Hum Mutat.* 2004;23(2): 106-110.
5. Inagaki K, Suzuki T, Shimizu H, et al. Oculocutaneous albinism type 4 is one of the most common types of albinism in Japan. *Am J Hum Genet.* 2004;74(3):466-471.
6. Wei AH, Zang DJ, Zhang Z, et al. Exome sequencing identifies SLC24A5 as a candidate gene for nonsyndromic oculocutaneous albinism. *J Invest Dermatol.* 2013;133(7):1834-1840.
7. Kausar T, Bhatti MA, Ali M, et al. OCA5, a novel locus for non-syndromic oculocutaneous albinism, maps to chromosome 4q24. *Clin Genet.* 2013;84(1):91-93.
8. Gronskov K, Dooley CM, Ostergaard E, et al. Mutations in *c10orf11*, a melanocyte-differentiation gene, cause autosomal-recessive albinism. *Am J Hum Genet.* 2013;92(3):415-421.
9. Spritz RA, Strunk KM, Giebel LB, et al. Detection of mutations in the tyrosinase gene in a patient with type IA oculocutaneous albinism. *N Engl J Med.* 1990; 322(24):1724-1728.
10. King RA, Townsend D, Oetting W, et al. Temperature-sensitive tyrosinase associated with peripheral pigmentation in oculocutaneous albinism. *J Clin Invest.* 1991;87(3):1046-1053.
11. Rinchik EM, Bultman SJ, Horsthemke B, et al. A gene for the mouse pink-eyed dilution locus and for human type II oculocutaneous albinism. *Nature.* 1993;361(6407):72-76.
12. Spritz RA, Fukai K, Holmes SA, et al. Frequent intragenic deletion of the P gene in Tanzanian patients with type II oculocutaneous albinism (OCA2). *Am J Hum Genet.* 1995;56(6):1320-1323.
13. Brilliant M, Gardner J. Melanosomal pH, pink locus protein and their roles in melanogenesis. *J Invest Dermatol.* 2001;117(2):386-387.
14. Hearing VJ. Determination of melanin synthetic pathways. *J Invest Dermatol.* 2011;131(E1):E8-E11.
15. Chiang PW, Fulton AB, Spector E, et al. Synergistic interaction of the OCA2 and OCA3 genes in a family. *Am J Med Genet A.* 2008;146A(18):2427-2430.
16. Kobayashi T, Imokawa G, Bennett DC, et al. Tyrosinase stabilization by Tyrp1 (the brown locus protein). *J Biol Chem.* 1998;273(48):31801-31805.
17. Newton JM, Cohen-Barak O, Hagiwara N, et al. Mutations in the human orthologue of the mouse underwhite gene (uw) underlie a new form of oculocutaneous albinism, OCA4. *Am J Hum Genet.* 2001; 69(5):981-988.
18. Okamura K, Yoshizawa J, Abe Y, et al. Oculocutaneous albinism (OCA) in Japanese patients: five novel mutations. *J Dermatol Sci.* 2014;74(2):173-174.
19. Kondo T, Hearing VJ. Update on the regulation of mammalian melanocyte function and skin pigmentation. *Expert Rev Dermatol.* 2011;6(1):97-108.
20. Inagaki K, Suzuki T, Ito S, et al. Oculocutaneous albinism type 4: six novel mutations in the

membrane-associated transporter protein gene and their phenotypes. *Pigment Cell Res.* 2006;19(5): 451-453.
21. Ito S, Wakamatsu K. Diversity of human hair pigmentation as studied by chemical analysis of eumelanin and pheomelanin. *J Eur Acad Dermatol Venereol.* 2011;25(12):1369-1380.
22. Sulem P, Gudbjartsson DF, Stacey SN, et al. Genetic determinants of hair, eye and skin pigmentation in Europeans. *Nat Genet.* 2007;39(12):1443-1452.
23. Hong ES, Zeeb H, Repacholi MH. Albinism in Africa as a public health issue. *BMC Public Health*. 2006; 6:212.
24. Mabula JB, Chalya PL, McHembe MD, et al. Skin cancers among albinos at a university teaching hospital in Northwestern Tanzania: a retrospective review of 64 cases. *BMC Dermatol.* 2012;12:5.
25. Wei AH, Li W. Hermansky-Pudlak syndrome: pigmentary and non-pigmentary defects and their pathogenesis. *Pigment Cell Melanoma Res.* 2013;26(2): 176-192.
26. Suzuki T, Li W, Zhang Q, et al. Hermansky-Pudlak syndrome is caused by mutations in HPS4, the human homolog of the mouse light-ear gene. *Nat Genet.* 2002;30(3):321-324.
27. Ammann S, Schulz A, Krageloh-Mann I, et al. Mutations in AP3D1 associated with immunodeficiency and seizures define a new type of Hermansky-Pudlak syndrome. *Blood.* 2016;127(8):997-1006.
28. Sitaram A, Marks MS. Mechanisms of protein delivery to melanosomes in pigment cells. *Physiology (Bethesda).* 2012;27(2):85-99.
29. Blumstein J, Faundez V, Nakatsu F, et al. The neuronal form of adaptor protein-3 is required for synaptic vesicle formation from endosomes. *J Neurosci.* 2001;21(20):8034-8042.
30. Dell'Angelica EC. The building BLOC(k)s of lysosomes and related organelles. *Curr Opin Cell Biol.* 2004;16(4):458-464.
31. Ménasché G, Ho CH, Sanal O, et al. Griscelli syndrome restricted to hypopigmentation results from a melanophilin defect (GS3) or a MYO5A F-exon deletion (GS1). *J Clin Invest.* 2003;112(3):450-456.
32. Langford GM, Molyneaux BJ. Myosin V in the brain: mutations lead to neurological defects. *Brain Res Brain Res Rev.* 1998;28(1-2):1-8.
33. Lambert J, Naeyaert JM, Callens T, et al. Human myosin V gene produces different transcripts in a cell type-specific manner. *Biochem Biophys Res Commun.* 1998;252(2):329-333.
34. Cagdas D, Ozgur TT, Asal GT, et al. Griscelli syndrome types 1 and 3: analysis of four new cases and long-term evaluation of previously diagnosed patients. *Eur J Pediatr.* 2012;171(10):1527-1531.
35. Shimazaki H, Honda J, Naoi T, et al. Autosomal-recessive complicated spastic paraplegia with a novel lysosomal trafficking regulator gene mutation. *J Neurol Neurosurg Psychiatry.* 2014;85(9):1024-1028.
36. Tardieu M, Lacroix C, Neven B, et al. Progressive neurologic dysfunctions 20 years after allogeneic bone marrow transplantation for Chediak-Higashi syndrome. *Blood.* 2005;106(1):40-42.
37. Swinney CC, Han DP, Karth PA. Incontinentia Pigmenti: a comprehensive review and update. *Ophthalmic Surg Lasers Imaging Retina*. 2015;46(6):650-657.
38. Jean-Baptiste S, O'Toole EA, Chen M, et al. Expression of eotaxin, an eosinophil-selective chemokine, parallels eosinophil accumulation in the vesiculobullous stage of incontinentia pigmenti. *Clin Exp Immunol.* 2002;127(3):470-478.
39. Minic S, Trpinac D, Obradovic M. Systematic review of central nervous system anomalies in incontinentia pigmenti. *Orphanet J Rare Dis.* 2013;8:25.
40. Kenwrick S, Woffendin H, Jakins T, et al. Survival of male patients with incontinentia pigmenti carrying a lethal mutation can be explained by somatic mosaicism or Klinefelter syndrome. *Am J Hum Genet.* 2001;69(6):1210-1217.
41. Ardelean D, Pope E. Incontinentia pigmenti in boys: a series and review of the literature. *Pediatr Dermatol.* 2006;23(6):523-527.
42. Landy SJ, Donnai D. Incontinentia pigmenti (Bloch-Sulzberger syndrome). *J Med Genet.* 1993;30(1): 53-59.
43. Giebel LB, Spritz RA. Mutation of the KIT (mast/stem cell growth factor receptor) protooncogene in human piebaldism. *Proc Natl Acad Sci U S A.* 1991; 88(19):8696-8699.
44. Sanchez-Martin M, Perez-Losada J, Rodriguez-Garcia A, et al. Deletion of the *SLUG* (*SNAI2*) gene results in human piebaldism. *Am J Med Genet A.* 2003; 122a(2):125-132.
45. Waardenburg PJ. A new syndrome combining developmental anomalies of the eyelids, eyebrows and nose root with pigmentary defects of the iris and head hair and with congenital deafness. *Am J Hum Genet.* 1951;3(3):195-253.
46. Read AP, Newton VE. Waardenburg syndrome. *J Med Genet.* 1997;34(8):656-665.
47. Pingault V, Girard M, Bondurand N, et al. *SOX10* mutations in chronic intestinal pseudo-obstruction suggest a complex physiopathological mechanism. *Hum Genet.* 2002;111(2):198-206.
48. Tassabehji M, Newton VE, Liu XZ, et al. The mutational spectrum in Waardenburg syndrome. *Hum Mol Genet.* 1995;4(11):2131-2137.
49. Kondo T, Suzuki T, Ito S, et al. Dyschromatosis symmetrica hereditaria associated with neurological disorders. *J Dermatol.* 2008;35(10):662-666.
50. Miyamura Y, Suzuki T, Kono M, et al. Mutations of the RNA-specific adenosine deaminase gene (*DSRAD*) are involved in dyschromatosis symmetrica hereditaria. *Am J Hum Genet.* 2003;73(3):693-699.
51. Zhang C, Li D, Zhang J, et al. Mutations in *ABCB6* cause dyschromatosis universalis hereditaria. *J Invest Dermatol.* 2013;133(9):2221-2228.
52. Kitamura K, Akamatsu S, Hirokawa K. A special form of acropigmentation: acropigmentation reticularis [in German]. *Hautarzt.* 1953;4(4):152-156.
53. Kono M, Sugiura K, Suganuma M, et al. Whole-exome sequencing identifies *ADAM10* mutations as a cause of reticulate acropigmentation of Kitamura, a clinical entity distinct from Dowling-Degos disease. *Hum Mol Genet.* 2013;22(17):3524-3533.
54. Dowling GB, Freudenthal W. Acanthosis nigricans. *Proc R Soc Med.* 1938;31(9):1147-1150.
55. Degos R, Ossipowski B. Reticulated pigmentary dermatosis of the folds: relation to acanthosis nigricans [in undetermined language]. *Ann Dermatol Syphiligr (Paris).* 1954;81(2):147-151.
56. Betz RC, Planko L, Eigelshoven S, et al. Loss-of-function mutations in the keratin 5 gene lead to Dowling-Degos disease. *Am J Hum Genet.* 2006;78(3): 510-519.

57. Li M, Cheng R, Liang J, et al. Mutations in POFUT1, encoding protein O-fucosyltransferase 1, cause generalized Dowling-Degos disease. *Am J Hum Genet*. 2013;92(6):895-903.
58. Basmanav FB, Oprisoreanu AM, Pasternack SM, et al. Mutations in *POGLUT1*, encoding protein O-glucosyltransferase 1, cause autosomal-dominant Dowling-Degos disease. *Am J Hum Genet*. 2014;94(1):135-143.
59. Araki Y, Ishii Y, Abe Y, et al. Hermansky-Pudlak syndrome type 4 with a novel mutation. *J Dermatol*. 2014;41(2):186-187.
60. Monma F, Hozumi Y, Kawaguchi M, et al. A novel MITF splice site mutation in a family with Waardenburg syndrome. *J Dermatol Sci*. 2008;52(1):64-66.

Chapter 76 :: Vitiligo

:: Khaled Ezzedine & John E. Harris

AT-A-GLANCE

- Vitiligo is a common autoimmune disease of the skin that causes depigmentation through T-cell–mediated destruction of melanocytes.
- Pathogenesis is multifactorial, including genetic predisposition, autoimmunity, and environmental factors.
- Vitiligo can cause significant social stigma, with serious implications for mental health.
- Correlates with increased risk of other autoimmune diseases, but decreased risk of skin cancer.
- Clinical signs of lesional activity include confetti, trichrome, and inflammatory lesions, as well as koebnerization.
- Reversible with treatment, but only in areas with normally pigmented hair.
- Effective treatments include topical and oral immunosuppressants, phototherapy, and chemical depigmenting agents.
- Emerging treatments include targeted immunotherapy and melanocyte-stimulating hormones.

DEFINITION AND HISTORY

Vitiligo, an acquired skin disease of progressive melanocyte loss, is clinically characterized by well-defined milky-white macules that may also include white hairs, or poliosis. The term *vitiligo* initially appears in the first century, although clinical features consistent with vitiligo were described in ancient medical texts during the second millennium before Christ.[1-3] Historically, vitiligo has been confused with leprosy, an infectious disease of the skin that results in ill-defined hypopigmentation. Some texts sought to differentiate the 2 diseases, while others conflated them. As early as 1500 BC, the *Ebers Papyrus* listed 2 diseases that affected skin color—one associated with "swellings," which may have been leprosy, and another that exclusively affected the color, which was likely vitiligo. In the book of "Leviticus" in the *Bible*, also dated between 1500 and 1400 BC, a number of skin diseases could make one "unclean" and required examination by the priest to determine whether isolation was warranted. Skin swelling, lightening, poliosis, and evolution of lesions over time were assessed to make this determination. This protocol may have been designed to distinguish vitiligo from leprosy or other skin diseases. In India, vitiligo was described in the *Atharva Veda* (1400 BC) and the Buddhist *Vinay Pitak* (224 to 544 BC) under the term "Kilas," a Sanskrit word "derived from kil," meaning white.[3-5] Hippocrates (460 to 355 BC) did not discriminate between vitiligo and leprosy. In fact, he included lichenoid eruptions, leprosy, psoriasis, and vitiligo under the same category. Still, today, in geographic areas with high incidence of leprosy, the 2 diseases are often confused.

EPIDEMIOLOGY

PREVALENCE

There have been very few studies conducted in the general population that aim to determine the prevalence of vitiligo. This is a difficult task, because unlike other diseases that cause significant morbidity and mortality, affected patients may not present to a medical facility to be counted. Thus, most estimates of prevalence are based on prospective surveys, retrospective observational studies, and prospective studies in selected populations, which may underestimate or overestimate the prevalence, depending on the approach. The largest epidemiologic study was performed in 1977 in Denmark, on the island of Bornholm, with a calculated prevalence of 0.38%.[6] A study in black people from the French West Indies found it to be similar to established data for white people.[7] However, peaks of prevalence have been reported in subpopulations in India (8.8%) in relationship to chemically induced depigmentation.[8,9] Similarly, higher incidences of vitiligo in Mexico and Japan have been reported.[9] Although the different prevalence rates of vitiligo in various populations could certainly be the result of genetic or environmental differences, one potential reason could be the different social and/or cultural stigmas that influence reporting.[9] In light of these challenges, the prevalence of disease is typically stated to be similar all over the world, estimated at 0.5% to 1%.[10,11]

PATIENT DEMOGRAPHICS

Vitiligo can begin at any age, although it usually starts before the third decade of life with almost half of patients presenting before the age of 20 years, and a third before the age of 12 years.[9,10,12-14] The segmental variant of vitiligo, affecting only 1 side of the body, tends to occur earlier in life.[14] A study in Jordan reported that the prevalence of vitiligo gradually increases with age (0.45% younger than age 1 year; 1% aged 1 to 5 years old, 2.1% aged 5 to 12 years old).[15] Males and females appear to be affected equally, although females may seek treatment more frequently.[10,11]

QUALITY OF LIFE

Vitiligo is frequently dismissed as "cosmetic," however it is often psychologically devastating for patients.[16] Numerous studies show that patients with vitiligo feel stigmatized, have low self-esteem with poor body image, and suffer a considerable psychosocial burden.[17,18] Thus, vitiligo may have a significant impact on quality of life, and patients reportedly have mental impairment similar to psoriasis and atopic dermatitis.[19] Differences in Dermatology Life Quality Index (DLQI) scores have been noted in various cultural groups, which may reflect different social stigmas of having the disease. For example, the mean of Dermatology Life Quality Index scores was 4.95 in a Belgian population, whereas Indian patients experienced a mean of 7.06 in patients with a successful treatment outcome, and 13.12 in those who failed treatment.[20]

CLINICAL FEATURES

PRESENTATION PATTERNS

Typically, vitiligo lesions are asymptomatic, white, nonscaly macules and patches with distinct margins that fluoresce when illuminated by Wood lamp examination. Although a number of patterns have been described, most can be grouped together, except for the segmental variant of vitiligo, which follows a different disease course and experiences a different treatment response. Thus, we will describe these forms separately and highlight differences important to recognize when developing a management plan.

Vitiligo lesions may involve any part of the body, usually with a symmetrical distribution (Figs. 76-1 and 76-2). The disease can start at any site of the body, although the face, as well as acral and genital locations, are often the initial sites. A number of specific clinical patterns have been defined, which include acrofacial, mucosal, generalized, universal, mixed, and rare forms. However, this distinction is not often easy to make, as there is often overlap among these forms, or evolution from one to another. Because many clinicians are familiar with these forms and describe vitiligo accordingly, we briefly describe each one.

Acrofacial vitiligo is reportedly more common in adults and typically involves the hands, feet, and face, particularly the orifices. This form may evolve to typical generalized vitiligo.

Vitiligo universalis is a rare form of widespread disease. It is usually seen in adults, although cases in children have been reported.[14] The form is named "universalis" because it affects a large proportion of the body, frequently defined as greater than 80% of the body surface area. Despite this widespread involvement, hairs may be spared. Classically, vitiligo universalis results from longstanding disease that steadily progresses to nearly complete whitening of the skin.

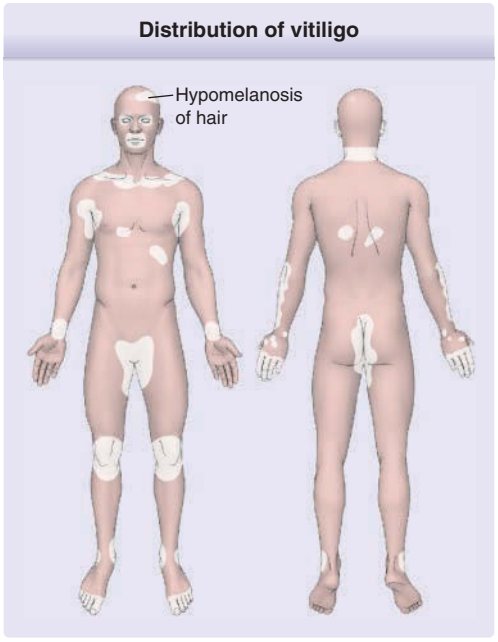

Figure 76-1 Distribution of vitiligo. (From Wolff K, Johnson R, Saavedra AP, et al. *Fitzpatrick's Color Atlas and Synopsis of Clinical Dermatology.* 8th ed. New York, NY: McGraw-Hill; 2017, with permission.)

In *Mucosal vitiligo,* the oral and/or genital mucosae are primarily involved (Fig. 76-3). When strictly limited to the mucosa, the differential diagnosis of lichen sclerosus et atrophicus should be carefully considered (see also section "Differential Diagnosis"). Furthermore, both conditions in the same patients are reported to coexist.[21]

Focal vitiligo consists of small, isolated lesions. In a recent report, long-term followup of 53 cases of focal vitiligo have shown that almost 50% of these cases progress to involve larger areas without any clinical sign that might predict this progression.[22]

The *segmental variant* of vitiligo is seen in 10% to 15% of vitiligo patients who present to the clinic. It is characterized by a unilateral and segmental, or block-shaped,

Figure 76-2 Symmetrical patchy depigmentation of vitiligo.

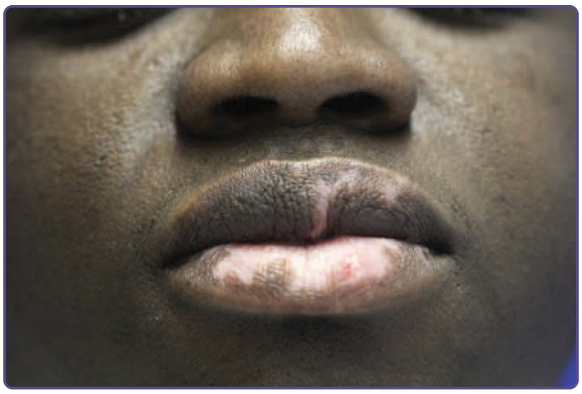

Figure 76-3 Mucosal vitiligo, limited to the lips.

distribution of the lesions (Fig. 76-4). Typically, a single contiguous segment is involved, although 2 or more segments with ipsilateral or contralateral distribution have been described.[23] *Mixed vitiligo* is a rare form of vitiligo that refers to the occurrence of a clear example of segmental vitiligo plus additional macules or patches that do not fit the segment (Fig. 76-5). These additional patches may be remote from the segmental involvement and are bilateral and symmetrical, affecting the contralateral side.[24] In segmental vitiligo, there is frequently early involvement of the follicular melanocyte reservoir, resulting in poliosis. The disease usually spreads over the segment within 6 to 12 months, and then stabilizes.[25] Although this may initially be difficult to distinguish from focal vitiligo, the rapid progression of segmental disease usually makes it clear within a few weeks to months.

Figure 76-4 Unilateral, block-like depigmentation of the segmental variant of vitiligo.

Figure 76-5 Mixed vitiligo, made up of a segmental lesion on the back plus additional bilateral lesions in remote areas.

CLINICAL MARKERS OF DISEASE ACTIVITY

In addition to recognized anatomical patterns of vitiligo, there are lesional patterns that indicate disease activity, which are important to recognize when determining the best treatment approach for patients. These patterns include the Koebner phenomenon, trichrome lesions, confetti-like depigmentation, and inflammatory lesions. For example, one study reported that the Koebner phenomenon in vitiligo patients was associated with higher body surface area involvement in vitiligo and poorer response to treatment.[26] Disease activity also has been partially quantified through scoring systems such as the vitiligo disease activity score (VIDA), which relies on patient recall, and the Koebner phenomenon in vitiligo score (K-VSCOR), which is focused on clinical signs.

The *Koebner phenomenon*, also called the isomorphic response, describes the observation that depigmentation occurs readily at the site of skin trauma in patients with active vitiligo. This can be recognized as linear marks of depigmentation where the skin has been scratched, lacerated, or burned, or nonlinear macules and patches at the site of known skin injury, such as erosions and abrasions (Fig. 76-6).

Trichrome vitiligo is characterized by blurring of lesional borders because of the presence of a hypopigmented

Figure 76-6 Linear depigmentation in locations of skin trauma.

Figure 76-8 Multiple scattered macules of confetti depigmentation in vitiligo.

zone between the depigmented and normally pigmented border. This results in the appearance of 3 distinct colors: the depigmented skin, normally pigmented skin, and hypopigmented skin (Fig. 76-7). This pattern is associated with active, rapidly spreading vitiligo.[27]

Confetti-like depigmentation consists of multiple small macules of depigmentation clustered together, often at the edge of existing vitiligo lesions (Fig. 76-8). One study used serial photography to demonstrate that these small macules grew and coalesced into larger depigmented areas after just a few weeks, identifying this sign as an important marker of disease activity.[28]

Inflammatory vitiligo is a very rare form of vitiligo characterized by the presence of erythema, scale, and itch at the border of hypopigmented or depigmented lesions (Fig. 76-9). This inflammatory phase is typically transient, lasting just a few weeks to months but rapidly progressing to involve large areas of the body. Early histologic studies in vitiligo were done on inflammatory lesions, where the immune infiltrate could be readily observed.[29]

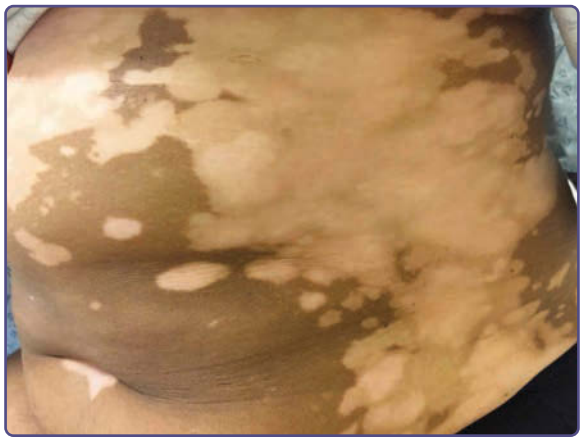

Figure 76-7 Trichrome vitiligo comprised of normal pigmentation, depigmentation, and a zone of hypopigmentation between them.

Figure 76-9 Inflammatory vitiligo characterized by erythema and scaling at the margin of the depigmented lesion. (Used with permission from Dr. Shyam Verma.)

The *VIDA* score is a 6-point scale that was developed with the aim of assessing and monitoring vitiligo activity.[30] Because this scoring is based on the patient's recollection of disease activity, it may be subject to recall bias. Active vitiligo is defined as the spread of existing lesions or onset of new lesions. The VIDA scores range from +4 (activity lasting 6 weeks or less) to −1 (vitiligo stable for 1 year or more with spontaneous repigmentation). One of the limitations of the VIDA score is that different lesions can have different scores, making it difficult to use in daily practice.

Finally, the *K-VSCOR* uses the Koebner phenomenon and anatomical location of lesions to determine disease activity in vitiligo patients.[31] It is based on the presence or absence of vitiligo lesions at 6 different areas of the body (forehead + scalp areas, eyelids, wrists, genital + belt areas, knees and tibial crests) as well as disease duration. The K-VSCOR ranges from 0 to 56, with 56 corresponding to the highest likelihood of having the Koebner phenomenon, which serves as an indicator of disease activity in the clinic. Further validation is needed to predict the extension of lesions over a longer period of time.

DISEASE ASSOCIATIONS

Vitiligo is an autoimmune disease of the skin that is associated with a number of other autoimmune diseases in other organs through increased incidence of type 1 diabetes, autoimmune thyroiditis, pernicious anemia, Addison disease, lupus, and alopecia areata, in both vitiligo patients and their family members.[32,33] This strongly implicates inherited factors that predispose patients and their family members to a group of autoimmune diseases, and the breadth of diseases found in this overlap suggests that the predisposition is toward autoimmunity in general, rather than specific diseases themselves. Up to 20% of vitiligo patients have at least 1 additional autoimmune disease, and most of these patients (13% to 19%) have autoimmune thyroid disease. This increased risk has prompted some to advocate testing thyroid-stimulating hormone (TSH) in all patients with vitiligo, because the pretest probability of finding a positive result is higher in this patient population. Others suggest, however, that this is unnecessary, because many patients will develop thyroid disease much earlier or later than the onset of vitiligo, and recommend that the presence of symptoms should drive TSH screening.[34]

There has always been some concern that vitiligo patients have a higher risk of skin cancers than the general population because of their loss of pigment in the skin. Although this makes some intuitive sense, the data do not support this hypothesis. Two large studies, one of 1307 participants[35] and another of 10,040 participants,[36] reported that vitiligo patients have close to 3-fold lower risk of developing melanoma, basal cell carcinoma, and squamous cell carcinoma compared to controls. This protection was maintained even when factors like reduced sun exposure and/or increased exposure to phototherapy were factored in. Controls included partners of patients in one study and vascular surgery patients in another. The remarkable agreement between these 2 studies strongly suggests that the data are representative, despite the individual weaknesses of each study. Protection from melanoma is least surprising, as immune surveillance against neoplastic melanocytes should be heightened in vitiligo patients, and because genetic risk alleles for vitiligo are simultaneously protective against melanoma.[37] However, why the incidence of basal cell carcinoma and squamous cell carcinoma are also lower in vitiligo patients is not clear.

DISEASE COMPLICATIONS

Melanocytes are found not only in the epidermis of the skin, but also in the mucous membranes, hair follicles, uveal tract, retinal pigment epithelium, membranous labyrinth of the inner ear, heart, and meninges of the brain. Typically, these sites are spared in vitiligo patients, with the exception of hair follicles, which can be involved when present within lesions. However, some studies report hearing changes in vitiligo patients, with sensorineural hearing loss present with a wide range of prevalence (20% to 60%), depending on the study.[38-40] However, sensorineural hearing loss frequently goes undetected by the patient, and is only observed with formal testing. Ocular abnormalities have been reported in vitiligo patients as well, including pigment changes, scarring, and even uveitis in up to 5% of patients.[41,42] Vogt-Koyanagi-Harada syndrome (VKHS) and Alezzandrini syndrome represent severe, rare forms of vitiligo that affect organs other than the skin. VKHS results in skin depigmentation with prominent poliosis, as well as hearing loss, visual changes, meningitis, and flu-like symptoms. The skin manifestations occur after the systemic ones, so those with classic vitiligo are not known to progress to VKHS.[43] Alezzandrini syndrome has been described in 7 patients, and is characterized by segmental vitiligo (unilateral depigmentation) on the face with poliosis, plus ipsilateral hearing loss and visual changes.[44-46]

ETIOLOGY AND PATHOGENESIS

COMPETING HYPOTHESES AND THE CONVERGENCE THEORY

Vitiligo is an autoimmune disease of the skin in which CD8+ T cells target melanocytes and destroy them, leaving areas without pigment production, which is

clinically manifest as white macules and patches. The pathogenesis has been debated for many years, with multiple hypotheses offered as alternative explanations as to what lies at the root of the disease. These alternative hypotheses include cellular stress causing degeneration of melanocytes, chemical toxicity causing melanocyte death, and neural changes that influence melanocytes or their ability to produce melanin. The reason for these alternative explanations were research observations over the years suggesting that much more than simply autoimmune targeting of perfectly normal melanocytes was occurring in vitiligo.

Early clinical observations that other autoimmune diseases occurred frequently in vitiligo patients and their family members hinted, through guilt by association, that vitiligo was itself an autoimmune disease. Additionally, antimelanocyte antibodies appeared to be elevated in vitiligo patients compared to healthy controls, also implicating immune responses in disease pathogenesis. However, others found that melanocytes cultured from vitiligo patients, and thus separated from immune influences, were abnormal—they did not grow well, were susceptible to exogenous oxidative stress, and appeared to have elevated cellular stress. This was manifest by the presence of reactive oxygen species and a dilated endoplasmic reticulum, a marker of activation of the unfolded protein response which is involved in stress responses.[47-52] But histologic studies revealed that CD8+ T cells infiltrated lesional epidermis and were found next to dying melanocytes, strongly supporting T-cell–mediated cytotoxicity as the key event in vitiligo.[29,53] Finally, one group reported that CD8+ T cells isolated from lesional skin of a patient and then coincubated with nonlesional skin from that same patient resulted in melanocyte targeting and death, demonstrating that CD8+ T cells were both necessary and sufficient to cause melanocyte destruction in vitiligo patient skin.[54]

These seemingly unrelated and conflicting observations were later tied together by the convergence theory, which suggested that all of these pathways may synergize to cause vitiligo in patients.[55] Now it appears that melanocytes in vitiligo patients are indeed abnormal and are more sensitive to cellular processes like melanogenesis and energy consumption. This results in the production of reactive oxygen species and activation of the unfolded protein response, which initiate the secretion of signaling intermediates from melanocytes that act as danger signals to alert the innate immune system. Next, innate immune cells activate and recruit adaptive immune CD8+ T cells to the skin, where they find the abnormal melanocytes and kill them. Thus, cellular stress within the melanocyte and autoimmunity work together to cause what we see clinically as vitiligo.[56,57]

Additional studies have now revealed that certain chemicals, typically phenols, induce the cellular stress response in melanocytes by acting as analogs of tyrosine, also a phenol.[56] Thus, these chemicals act as exogenous environmental agents that induce and exacerbate vitiligo by initiating the cellular stress response in otherwise well-compensating melanocytes. Consequently, the "chemical theory" can be incorporated into the inclusive convergence theory as well. Finally, the neural hypothesis was based on the clinical appearance of segmental vitiligo, misinterpreting the unilateral nature of disease for being associated with dermatomes, which is not the case.[58-60] Others reported that catecholamines were increased in the urine of vitiligo patients; however, catecholamines are also secreted by melanocytes, which is a more likely source in vitiligo. Case reports of vitiligo clearing after unilateral nerve injuries suggested nerves as important players in disease pathogenesis, but further observations noted the opposite result as well, eliminating this as strong evidence. The role of emotional stress in worsening vitiligo has been offered as evidence, yet this is common in many diseases that do not appear to be influenced by nerves. Finally, some animals control their pigmentation through innervation (primarily fish), but this has never been observed in mammals. Thus, the "neural hypothesis" remains unsupported by evidence and should be discarded for now.[58]

T CELLS AND CYTOKINES IN AUTOIMMUNITY

As mentioned above, CD8+ T cells play a critical role during the progression of vitiligo, serving as the primary immune effectors that destroy melanocytes. Studies using human tissues and a mouse model of vitiligo have revealed that interferon (IFN)-γ is a key cytokine that drives the disease.[61-64] IFN-γ is secreted by melanocyte-reactive autoimmune CD8+ T cells, and induces the production of CXCL10 and other chemokines from keratinocytes, which promote the further recruitment of additional T cells that progressively destroy more melanocytes as the disease spreads.[64,65] Multiple groups have found that IFN-γ–induced chemokines are elevated in the serum and skin of vitiligo patients, and these may serve as useful biomarkers of disease activity in the future.[64,66-68] In addition, targeting the IFN-γ–chemokine axis during disease may be an effective novel treatment strategy (see section "Emerging Therapies").[69]

THE SEGMENTAL VARIANT OF VITILIGO, A SPECIAL CASE

As mentioned above, segmental vitiligo was initially thought to mirror the distribution of nerves via dermatomes, which led to the "neural hypothesis." Close inspection, however, reveals that segmental vitiligo lesions rarely, if ever, follow dermatomes, and frequently cross these zones in a perpendicular direction.

Depigmented blocks of segmental vitiligo also do not appear to follow blaschkoid lines, especially on the trunk, which are narrow and S-shaped.[59,60] So, the question arises, what defines a segment of vitiligo, and what is the pathogenesis of this variant, considering that immune-mediated disorders do not typically respect the midline? One hypothesis that is gaining acceptance is that segmental vitiligo results from a general autoimmune predisposition combined with melanocytes that have acquired a postzygotic mutation that alters their susceptibility to autoimmune attack, like activation of the cellular stress pathways discussed above. This has the potential to explain (a) why it is unilateral (melanocytes migrate from the neural crest and do not cross the midline), (b) its rapid evolution and stabilization (normal melanocytes create the stable border of the lesion), (c) its resistance to treatments (abnormal melanocytes are unstable and have an impaired ability to repigment the skin), and (d) the successful response to surgical therapies (normal melanocytes transplanted from another region are stable and resistant to autoimmune attack).[70]

RISK FACTORS IN VITILIGO

Similar to other autoimmune diseases, a number of factors influence the risk of developing vitiligo. These include both genetic factors and environmental factors. Vitiligo is more common in family members of affected patients, as 15% to 20% of patients have a family member with the disease, strongly suggesting that genetics influences the risk of getting disease. While the prevalence of vitiligo in the general population is close to 1%, the prevalence in first-degree relatives is 7%, and the prevalence in identical twins of affected individuals is 23%, clearly demonstrating a role for genes in disease. However, the fact that concordance between identical twins is not 100% also clearly demonstrates nongenetic influences in disease, which may represent environmental factors, stochastic influences (those that occur by chance), or both.

Modern genome-wide association studies have identified approximately 50 genetic loci that contribute to the risk of developing vitiligo, clearly demonstrating that it is inherited in a polygenic fashion with a complex interplay among multiple genes that contribute to the total risk. Of these loci, the majority are involved in regulating the immune system, representing key molecules in both innate and adaptive immunity, and thus strongly support the conclusion that disease is immune-mediated. Others appear to influence cellular apoptosis pathways and still others direct melanocyte function, including melanogenesis, supporting a role for the melanocyte in conferring risk for disease. Importantly, those genes involved in melanogenesis also influence the risk of developing melanoma, but in the opposite direction, suggesting that immune responses in vitiligo may be protective against melanoma, and thus may have evolved to protect against the development of this devastating cancer.[37]

In addition to genetic influences, environmental influences are important in vitiligo. The first chemical exposure to be definitively linked to the onset of vitiligo occurred in a group of leather factory workers in 1939. A large proportion of these workers developed depigmentation on their hands and lower arms, and monobenzyl ether of hydroquinone, or monobenzone, was implicated as the cause. Because some of the workers also developed depigmentation at sites remote from the exposure, depigmentation was not simply the result of direct toxicity to the melanocyte, but an exacerbation of the autoimmune destruction.[71] Other chemicals have been similarly implicated since then, including 4-tert-butyl phenol and 4-tert-butylcatechol.[72] An outbreak of vitiligo occurred in Japan in 2013, when a cosmetic company created a new skin lightening cream that resulted in more than 18,000 users getting vitiligo at the site of application and in remote areas.[72] Another study revealed that the use of permanent hair dyes may increase the risk of getting vitiligo by as much as 50%.[73] The common characteristic of implicated chemicals is that they are phenols with a chemical structure that resembles the amino acid tyrosine, also a phenol. Mechanistic studies reveal that these chemicals act as tyrosine analogs, which are taken up by melanocytes instead of tyrosine, interact with tyrosinase, and induce cellular stress pathways that then activate immune inflammation to initiate or exacerbate vitiligo.[56,74-76]

DIAGNOSIS

CLINICAL EXAMINATION

The diagnosis of vitiligo is usually a clinical one, as there is usually no need for additional laboratory or histologic testing to confirm the diagnosis. On physical examination it is important to differentiate vitiligo from its segmental variant, as these 2 forms have different clinical course, prognosis, and treatment responses. Vitiligo is usually characterized by well-defined, symmetrical depigmented lesions that can be distributed on any part of the body, but with a preference for the face (particularly periorificial areas), genitals, and acral areas. Wood lamp examination in a dark room is helpful in differentiating the depigmentation of vitiligo from hypopigmentation seen in other diseases. The disease is also characterized by cycles of flares and stabilization that are unpredictable, which can be distressing for patients. Additional clinical signs that may help with the diagnosis of vitiligo are the presence of multiple halo nevi and poliosis. The presence of repigmentation can be recognized as perifollicular pigmented macules from pigmented hairs at hair-bearing sites (Fig. 76-10) or convex patterns of pigment at lesional borders in glabrous skin (Fig. 76-11). Hair-bearing sites without poliosis repigment easily, whereas glabrous skin and lesions containing mostly white hairs respond poorly.

Figure 76-10 Perifollicular repigmentation. Note the lack of repigmentation from white hairs.

In the segmental variant of vitiligo, the lesions are unilateral, typically do not cross the midline, and are organized into block-like patterns, in contrast to the dermatomes of zoster or blaschkoid lines of keratinocyte disorders like segmental Darier disease. These blocks of depigmentation may represent zones of skin that have been affected by postzygotic mutations that create a mosaic distribution of abnormal melanocytes (discussed under section "Segmental Variant Special Case" above).[59,60] The evolution of segmental vitiligo is distinct in that the onset is usually acute with rapid progression over 6 to 12 months before it becomes stable and unchanging for the remaining life of the individual.

Figure 76-11 Marginal repigmentation in glabrous skin.

LABORATORY TESTING

Because vitiligo is associated with other autoimmune diseases such as thyroid diseases, clinicians should consider laboratory testing for these other diseases when patients' symptoms warrant them. TSH is commonly tested to rule out concomitant Hashimoto thyroiditis, although in the absence of symptoms this testing may not be necessary.[34] Complete blood count and antinuclear antibody testing can be considered in the context of light sensitivity, as phototherapy is a standard in vitiligo treatment. During followup, clinicians should consider testing for other autoimmune markers whenever patients have suggestive signs and symptoms.

HISTOLOGY

When the history and physical examination are consistent with vitiligo, there is usually no need for skin biopsy to confirm the diagnosis. However, when the presentation is unusual, biopsy may help to rule out other disorders of pigment abnormalities that fall within the differential diagnosis (discussed below). When performed, histologic examination and immunohistochemical studies reveal a complete loss of melanocytes within the epidermis,[55] and biopsy near the lesional border during progression may demonstrate an inflammatory infiltrate of CD4+ and CD8+ T cells in an interface pattern, with primarily CD8+ T cells infiltrating the epidermis.[77]

DIFFERENTIAL DIAGNOSIS

The differential diagnosis of vitiligo is broad and is presented concisely in Tables 76-1 and 76-2. In general, inherited hypomelanoses are present at or within a few months after birth, whereas vitiligo is rarely, if ever, present that early. Wood lamp examination helps to differentiate the depigmentation of vitiligo from hypopigmentation of most other diseases. Specifically, vitiligo and its segmental variant have different considerations when thinking about differential diagnoses, because the former is symmetric, often more widespread, and progressive, whereas the latter is focal, unilateral, and stable.

The differential diagnosis of vitiligo includes inflammatory, postinflammatory, neoplastic, and genetic (mostly congenital) disorders of depigmentation. The first helpful step is to determine whether the lesion or lesions are congenital, remembering that in fair skin, lesions may not become apparent until after the first few months of life, often after the first sun exposure. A number of genodermatoses may be initially misdiagnosed as vitiligo, but the most frequent are piebaldism and tuberous sclerosis. In piebaldism, the combination of white forelock, anterior body midline depigmentation,

TABLE 76-1
Differential Diagnoses for Nonsegmental Vitiligo

CONDITION	DISTINGUISHABLE FEATURES
Inherited Hypomelanoses	
Piebaldism (KIT mutation) (Fig. 76-12)	White forelock, anterior body midline depigmentation and bilateral shin depigmentation present at birth (with absence of melanocytes); autosomal dominant
Waardenburg syndrome (PAX3 mutation)	White forelock, white skin macules, hypertelorism, heterochromic or hypoplastic blue irides, deafness, early graying, ± Hirschsprung disease
Tuberous sclerosis (TSC1 and TSC2 mutations) (Fig. 76-13)	Hypomelanotic macules (ash leaf) present within the first years of life; angiofibromas at age 3-4 years; ungual fibromas; cephalic and lumbar (shagreen patch) fibrous plaques; and hypopigmented "confetti" macules appearing in childhood to early adolescence; seizures; autosomal dominant
Ito hypomelanosis	Hypopigmented skin macules and patches along Blaschko lines in a linear pattern, unilateral or bilateral pattern; usually develops within the first 2 years of life; sporadic; chromosomal or genetic mosaicism
Infectious Disorders	
Tinea versicolor (Fig. 76-14)	Well-demarcated finely scaling patches in highly sebaceous areas; yellow-green fluorescence on Wood light
Treponematoses (syphilis and pinta)	Postinflammatory hypopigmented/depigmentated patches) on the neck on trunk, limbs. Positive testing for serologic treponemal infection
Leprosy (tuberculoid/borderline forms) (Fig. 76-15)	Mainly hypopigmented patches; localized anesthesia
Postinflammatory Hypopigmentation	
Discoid lupus erythematosus, scleroderma, lichen sclerosis et atrophicus, psoriasis	History of preexisting condition
Paramalignant Hypomelanoses	
Mycosis fungoides (Fig. 76-16)	Scattered irregular hypopigmented patches on non–sun-exposed areas. Atrophic epidermal surface. Plaque and tumor lesions of mycosis fungoides may be present concurrently. Histology: epidermotropism of atypical lymphocytes
Cutaneous melanoma	Dyschromic lesion combining pigmented areas with depigmentation around or within the tumor
Idiopathic Disorders	
Idiopathic guttate hypomelanosis	Hypopigmented well-circumscribed macules, sharply defined and small in size. Usually localized on photoexposed areas, especially the legs. Very slowly progressive and nonconfluent
Progressive macular hypomelanosis	Nummular, nonscaly hypopigmented spots lesions of the trunk, often confluent. Punctiform red fluorescence on Wood lamp
Postinflammatory pigment loss	History of preceding eruption/injury
Melasma	Hyperpigmented macules and patches, often limited to the face. The contrast between lighter and darker skin may appear hypopigmented; dermoscopy may show capillary network

bilateral shin depigmentation, and large islands of sparing are hallmarks of the disease. Family history will often make the diagnosis of piebaldism straightforward, as it is most often dominantly inherited.

TABLE 76-2
Differential Diagnoses for Segmental Vitiligo

CONDITION	DISTINGUISHABLE FEATURES
Nevus anemicus	Poorly demarcated white macule surrounded by erythema, which disappears with diascopy.
Nevus depigmentosus	Well-delimited hypopigmented macule usually present at birth with irregular, saw-toothed border. Hairs within the lesion generally remain pigmented. The lesion is stable in size but will expand in proportion to growth with age. In fair skin types, parents may note the lesion after first photoexposure of the child

Distinguishing vitiligo from tuberous sclerosis relies on the hypopigmented nature of ash-leaf spots, as well as their stability over time. Of course, the presence of seizures or other cutaneous symptoms that may appear later, such as shagreen patches or angiofibromas, should prompt further investigation for tuberous sclerosis.

If the lesions in question are acquired, the most common differential diagnoses are pityriasis versicolor and postinflammatory hypopigmentation, such as pityriasis alba. Here, a Wood lamp examination is quite helpful, as lesions of vitiligo are depigmented and enhance, while others are hypopigmented and do not. In addition, neoplastic hypomelanoses, in particular hypopigmented mycosis fungoides, should be ruled out. Hypopigmented mycosis fungoides is distributed in sun-protected areas and is hypopigmented, rather than depigmented. Isolated genital involvement should be carefully differentiated from the diagnosis

Figure 76-12 Piebaldism. Note large central midline patch of depigmentation with islands of sparing.

of lichen sclerosus et atrophicus as this diagnosis can be quite destructive and often is irreversible. Lichen sclerosus is often symptomatic, following a figure-of-eight pattern around the anus and introitus in women, frequently with signs of atrophy and fissuring of the skin. In longstanding cases, it may be accompanied by resorption of normal structures like the labia minora as well as narrowing of the introitus. A complicating factor in the differential diagnosis includes reports of concomitant genital lichen sclerosus and vitiligo. Biopsy can be helpful in difficult cases.

For segmental vitiligo, nevus depigmentosus is the most common consideration in the differential

Figure 76-13 Ash-leaf macules in tuberous sclerosis.

Figure 76-14 Scaly, hypopigmented macules of tinea versicolor.

diagnosis. However nevus depigmentosus is usually congenital or recognized within a few months of life and is stable in size, growing only in proportion to the child. In contrast to its name, it is typically hypopigmented rather than depigmented, and the border is frequently jagged rather than smooth, both notable differences from vitiligo. When biopsy is performed, histology displays normal or a slightly decreased number of melanocytes with reduced melanin content, rather than absence of melanocytes. Nevus anemicus is another to condition to rule out and is usually present at birth. Clinically, nevus anemicus corresponds to a poorly demarcated white macule surrounded by erythema, which, contrary to segmental vitiligo, does not

Figure 76-15 Hypopigmented patches of leprosy.

Figure 76-16 Hypopigmented patches of mycosis fungoides.

show accentuation when examined with Wood lamp. It also disappears with diascopy, or other gentle pressure on the skin.

CLINICAL COURSE AND PROGNOSIS

Vitiligo has an unpredictable course with a disposition toward cycles of flares and phases of stability. Early whitening of the hairs is unusual, although this may appear later in the course of the disease. Repigmentation in hair-bearing locations is likely, and may either occur spontaneously, after specific therapeutic intervention, or following sun exposure. However, lesions in glabrous skin are much slower to respond, as they improve from slower marginal repigmentation that is limited to only a few millimeters total, despite long-term treatment. There is some evidence that episodes of stress may trigger disease onset and/or relapse. In contrast, the course of segmental vitiligo is rapid but self-limited, with rapid stabilization and rare progression after this has occurred. The early involvement of hairs makes segmental vitiligo less responsive to treatment, although if caught early good results may be obtained.

MANAGEMENT

When developing a management plan for vitiligo patients, multiple factors should be considered. A thorough examination of patients under natural and Wood lamp light is important to assess the extent of disease. In addition, social and demographic details, family history of the patient, as well as the patient's relevant medical history, should be elicited at the initial consultation. The skin phototype, presence of halo nevi, disease duration and extent, and activity are key items in guiding therapeutic management. Scoring of disease activity by evaluating the probability of Koebner phenomenon also can be considered.[31]

As of this writing most therapies that are effective for vitiligo were developed for other inflammatory skin diseases and are thus used off-label. The management plan for patients with vitiligo will vary according to disease activity and extent. For example, if a patient presents during active progression, combination therapy that includes oral antiinflammatories may be important to halt the progression of disease, as other therapies, such as phototherapy, may take weeks to months to become effective. If the disease is stable, monotherapy is an option as the likelihood of progression while the responses slowly develop is minimal.

TOPICAL THERAPIES

Topical therapies may be used as monotherapy when there is limited surface involvement (less than 5% body surface area); however, they are often used in combination with phototherapy. Two main classes of topical drugs are used in vitiligo: topical steroids and topical calcineurin inhibitors.

The advantages of topical corticosteroids are good efficacy, ease of application, high compliance rate, and low cost. The drawbacks of topical corticosteroids are their side effects, which include skin atrophy, telangiectasia, hypertrichosis, acneiform eruptions, and striae, as well as increased intraocular pressure (exacerbation of glaucoma) when used around the eyes. Typically, ultrapotent formulations are required for reliable efficacy, and most published studies have evaluated the class I steroid clobetasol. They should be applied twice daily and can be used in a discontinuous scheme, such as cycles of 1 week on treatment followed by 1 week off treatment for up to 6 months, to avoid side effects. For childhood vitiligo, a class II potency steroid with a good safety profile, like mometasone, is a good choice. Lower-potency steroids do not have strong evidence to support their use.

Advantages of topical calcineurin inhibitors include their good efficacy and excellent safety profile.[78] They can be used on areas that are not ideal for steroids, such as on the face, neck, intertriginous areas, and on children. Of note, warnings have been placed on the long-term use of topical calcineurin inhibitors in relation to an increased risk of cancer; however, these concerns are based on risks associated with oral dosing of these drugs and have not been observed with topical use. A recent systematic review and meta-analysis concluded that the use of topical steroids and calcineurin inhibitors was unlikely to increase the risk of lymphoma in patients with atopic dermatitis.[79]

Although some concerns about the combining of phototherapy with these drugs promotes skin cancer have been raised, the combination of light therapy with topical calcineurin inhibitors increases their efficacy[80] and there is no clinical data that supports these concerns for increased cancer risk. Thus, clinicians should proceed with these treatments but with caution, and patients should be counseled of these facts when prescribed these therapies, at least until these warnings are removed from the packaging. A recent report tested topical tacrolimus as maintenance therapy in patients who achieved repigmentation through other methods.[81] In this randomized controlled study of 35 patients, more than 90% of those treated with tacrolimus 0.1% only twice weekly maintained their pigmentation without a relapse of their vitiligo, whereas only 60% did so in the placebo group. A small number of studies have compared topical calcineurin inhibitors and topical steroids without significant difference in efficacy between the 2 groups.[82]

PHOTOTHERAPY AND COMBINATION THERAPIES

Because of its efficacy, ease of use, and relatively good safety profile, full-body phototherapy should be considered the first treatment option in patients with more than 5% of the body surface area affected, especially if the disease is rapidly spreading (Fig. 76-17). For those with more limited, focal disease, targeted phototherapy can be considered because of its very high efficacy. However, phototherapy is time-consuming and devices may not be readily accessible to all patients. When this is the case, home phototherapy can be considered, where units are prescribed and purchased for use in the patient's home. Although the strength of home units does not match those in the physician's office, the convenience of getting phototherapy at home often results in excellent responses.[83] Most units require a prescription from a dermatologist, who must provide ongoing codes to enable continued use of the unit after regular in-office assessments. Because some patients with vitiligo have circulating antinuclear antibodies that could sensitize them to light, screening for antinuclear antibodies prior to phototherapy can be considered, particularly if there is a history of sun sensitivity. Overall, the risk-to-benefit profile of all treatments should be considered when developing a management strategy for each patient.

Historically, phototherapy has been administered using different sources, including oral or topical psoralen plus ultraviolet A (PUVA), broadband ultraviolet B, narrowband ultraviolet B (nbUVB), and targeted phototherapy with excimer laser. These are outlined below:

PSORALEN AND ULTRAVIOLET A

PUVA was the first phototherapy treatment reported to be effective for vitiligo; it has since, however, become

Figure 76-17 Excellent response after about 1 year of narrowband ultraviolet B phototherapy; (**A**) before and (**B**) after therapy.

associated with adverse effects that include nausea, ocular damage, and phototoxic reactions, as well as an increased risk of skin cancer.[84] A 2015 Cochrane review reported that the efficacy of PUVA was inferior to nbUVB in achieving greater than 75% repigmentation in vitiligo patients.[85] In another study, color matching of treated areas with normal skin was inferior in PUVA compared to nbUVB.[86] In addition, nbUVB treatment has fewer short-term (painful erythema) and long-term (epidermal thickening, atrophy, and photocarcinogenesis) adverse reactions than PUVA.[56] Thus, PUVA is no longer first-line therapy for vitiligo, and has been largely replaced by nbUVB. However, PUVA may be considered in patients who fail to repigment with other modalities.[86-88] Like other methods of phototherapy, PUVA is typically administered 2 or 3 times weekly.

NARROWBAND ULTRAVIOLET B

nbUVB has largely replaced other modalities because of its efficacy and better safety profile. It provides 2 particular benefits: (a) repigmentation and (b) stabilization, which is important in those who have active disease. Njoo and colleagues achieved greater than 75% repigmentation in 53% and stabilization in 80%

of children with twice-weekly nbUVB.[89] Increased benefit has been reported with the addition of topical corticosteroids and calcineurin inhibitors. The 2015 Cochrane update for interventions in vitiligo reported that 35 of 96 randomized controlled trials used nbUVB as either monotherapy or in combination with other treatments.[90] nbUVB has potent immunosuppressive effects locally and is able to induce melanocyte differentiation and melanin production.[91]

Treatment with nbUVB should be 2 to 3 times weekly, starting with a dose of 200 millijoules (mJ) with an increase of 10% to 20% increments until reaching the minimal erythema dose, which corresponds to the lowest dose resulting in asymptomatic, visible erythema on depigmented skin that lasts less than 24 hours. A total of 9 to 12 months or more of treatment is required to achieve full repigmentation, with at least 6 months of therapy before determining that the disease is nonresponsive.[86] When used on its own, nbUVB has been reported to induce repigmentation rates ranging from 40% to 100%, depending on the location of the lesion.[89,92-95]

TARGETED ULTRAVIOLET B PHOTOTHERAPY

Targeted UVB phototherapy is achieved using excimer lasers and lamps. They reportedly are equally effective, although excimer lamp induces more erythema.[96] Because of their small treatment size, targeted phototherapy is indicated in patients with limited, focal vitiligo (less than 5% of the body surface area affected with stable disease).[97] Targeted phototherapy is also reportedly the treatment that achieves highest efficacy for segmental vitiligo in its early phase (ie, disease onset of less than 6 months to 1 year). It is also reportedly safe and effective for long-term treatment of pediatric vitiligo patients.[98]

COMBINATION THERAPIES

In the most recent update of the Cochrane review, combination therapies using any type of light were considered the most effective treatment for vitiligo. Even though not necessarily synergistic or even additive, the additional benefit of adding topical therapies when undergoing phototherapy appears to be worthwhile. If large areas are involved, sites that are important to the patient, such as the face and hands, may be selected for adjuvant topical therapy. The combination of oral steroid pulse therapy, such as dexamethasone on weekends or prednisone on alternate days, with light therapy is reportedly helpful in controlling rapidly spreading vitiligo until phototherapy achieves a therapeutic dose.[99]

PSYCHOLOGICAL INTERVENTIONS

The psychological impact of vitiligo includes poor self-perception, low quality of life, poor interpersonal relationships, depression, and anxiety.[100-104] Thus, psychological interventions such as cognitive-behavioral therapy and hypnosis have been shown to improve quality of life, reduce anxiety, improve coping with disease, and even enhance repigmentation in vitiligo.[101,105-107] Importantly, adolescents with vitiligo are uniquely susceptible to social pressure and stigma, and thus should be screened for psychological impairment and referred for management.

COSMETICS

Cosmetic camouflage, especially on visible areas such as the face and the hands, can improve quality of life in patients with vitiligo.[108,109] There are now several water-resistant camouflage dyes and creams that are available with a wide range of color and shades covering all skin types.

DEPIGMENTATION THERAPY

Ever since the observation that monobenzone potently induced and exacerbated vitiligo in exposed individuals, it has been used as a treatment for vitiligo to depigment the skin, removing the remaining pigment and evening out the tone.[110] In fact, it is the only Food and Drug Administration–approved medical therapy for vitiligo. For patients with widespread disease that would be difficult to reverse with the conventional treatments discussed above (many suggest greater than 80% body surface area or significant poliosis), monobenzone can be prescribed as a 20% topical cream to be applied 1 to 2 times daily. It can take 1 to 2 years for complete depigmentation, and it even affects areas remote from the site of application, so it cannot be used for just local depigmentation. Up to 20% of patients develop a contact dermatitis to the cream, which is located only in pigmented skin and may limit treatment. If this occurs, the strength can be decreased to 10%, and concurrent use of topical steroids may limit the reaction. Hair, eyes, and other locations where melanocytes are found are typically spared during depigmentation therapy with monobenzone. Even though this is a drastic and permanent approach to therapy, patients are typically happy with the result. They must be counseled that their skin will be sun-sensitive for the rest of their lives, and sun protection must be strictly followed.

NONTRADITIONAL TREATMENTS

There are numerous nontraditional treatments that have been suggested for vitiligo. Of these, khellin, ginkgo biloba, vitamins and nutritional supplements,

Polypodium leukotomos, topical and systemic phenylalanine, topical calcipotriene, and pseudocatalase cream have been used. Current evidence for their efficacy is weak at best and adding them to a therapeutic strategy should be carefully considered in light of this lack of evidence.

SURGICAL THERAPIES

Surgical therapies for vitiligo can be very successful; however, a key part of surgical therapy is patient selection. Surgery in vitiligo should be reserved for patients with highly stable disease, which has been defined as the absence of new or growing lesions for 1 to 2 years.[111] Segmental vitiligo patients are well suited for this approach because their disease stabilizes quickly, but those who do not have this variant have much-less-successful outcomes.

Several techniques for surgical treatment exist for vitiligo, which can broadly be divided into tissue grafting and cellular grafting. Tissue grafts include thin and ultrathin split-thickness skin grafts, suction blister epidermal grafts, mini punch grafts, and hair follicle grafts. These approaches all use solid-tissue grafts whose size is matched to the donor site in a 1:1 ratio. Alternatively, cellular grafts include noncultured epidermal cell suspension, cultured "pure" melanocytes, cultured epithelial grafts, and autologous noncultured extracted hair follicle suspension. These approaches transplant suspensions of keratinocytes and melanocytes and can cover larger surface areas with up to a 1:10 ratio of donor-to-recipient area.

Each technique has advantages and disadvantages. In general, tissue grafts are easier to perform than cellular grafts, but are limited by the need to harvest tissue in a 1:1 ratio to the donor site. Split-thickness grafting is easy and inexpensive, but frequently results in color mismatch and occasional failure of the graft to take. Punch grafting is easy to perform and inexpensive but should be used in limited areas because of frequent side effects, such as cobblestoning, which describes healing at the recipient site with raised grafts that are visible and palpable, like cobblestones on a path.[112] Blister grafting gives better cosmetic results without cobblestoning, but it is time-consuming and may be more difficult to perform because of handling and placement of the very thin blister roof graft.[113-117]

Because of their improved donor-to-recipient-site ratio, excellent outcomes in percent repigmentation and color match, as well as improved healing, cellular grafts are becoming the first-line in surgical management of stable vitiligo (Fig. 76-18). The most commonly used technique, the melanocyte keratinocyte transplant procedure, creates a suspension of keratinocytes and melanocytes from donor epidermis that is enzymatically digested and mechanically disrupted into a single cell suspension. This technique has been optimized and simplified over the past few years and now requires minimal laboratory support. It is usually conducted in 2 steps. The first consists of shaving an ultrathin skin

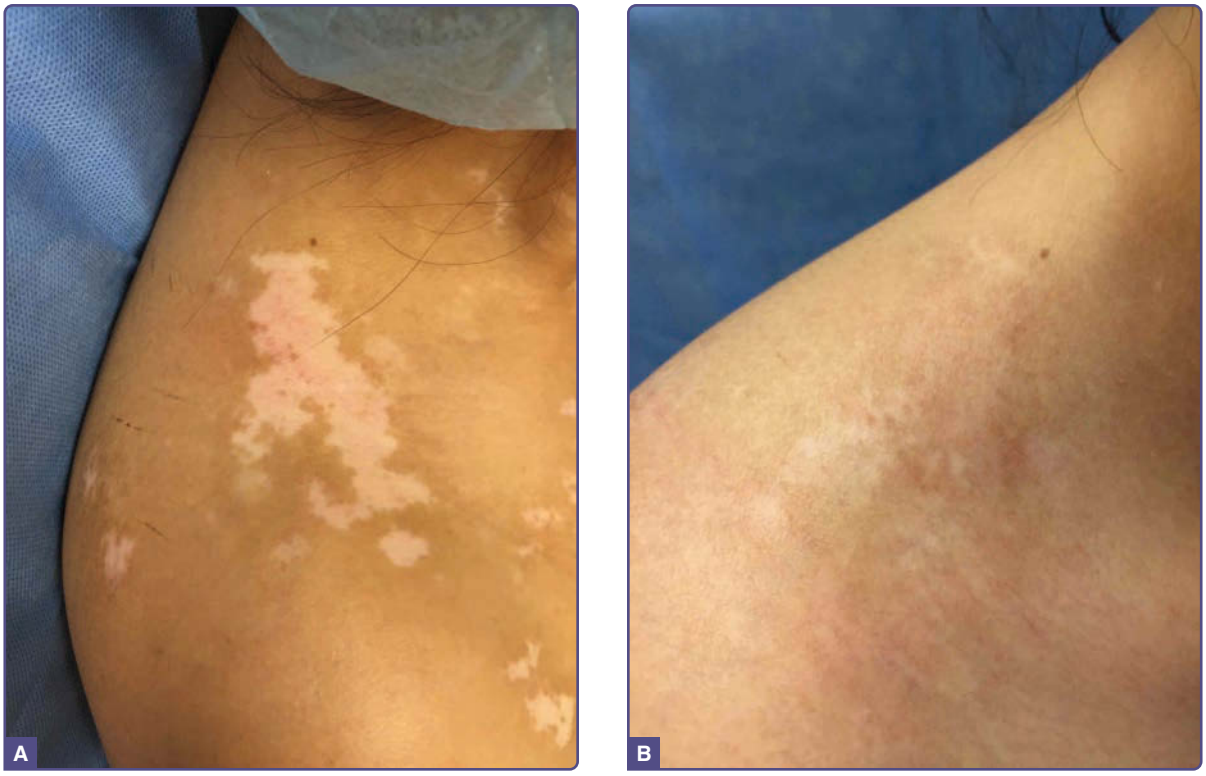

Figure 76-18 Surgical therapy of segmental vitiligo using the melanocyte keratinocyte transplant procedure; (**A**) before and (**B**) after therapy.

donor graft (Fig. 76-19A), which is rinsed and incubated in 0.25% trypsin for 30 minutes at 37°C (98.6°F) before manually removing the epidermis from the dermis, disrupting the epidermis mechanically, and centrifuging the epidermal fragments to create a cellular pellet (Fig. 76-19B, C). This pellet is resuspended in lactated ringers or normal saline in a 1mL syringe. The second step consists of applying this cellular suspension over

Figure 76-19 Melanocyte keratinocyte transplant procedure. **A,** Harvesting of thin skin graft. **B,** Processing of the skin graft to remove the epidermis and mechanically disrupt it into small pieces. **C,** Pellet of melanocytes and keratinocytes after centrifugation. **D,** Dermabraded skin lesions ready for application of cell suspension.

the recipient site that was previously dermabraded or laser treated to remove the epidermis (Fig. 76-19D). The recipient site is then covered with an appropriate dressing for 4 to 7 days, depending on the treated area.[118,119]

TREATMENT ALGORITHM

We propose 2 treatment algorithms, one for vitiligo (Fig. 76-20) and another for the segmental variant of disease (Fig. 76-21).

EMERGING THERAPIES

As discussed above, vitiligo is driven primarily by the destruction of melanocytes by CD8+ T cells that secrete IFN-γ, which induces chemokines that recruit additional T cells in an ongoing, positive feedback loop. Future targeted therapies are likely to target this and other synergistic cytokine pathways, similar to recent advancements in the treatment of psoriasis. However, psoriasis treatments are ineffective for vitiligo because the interleukin-23–interleukin-17–tumor necrosis factor-α cytokine axis that drives psoriasis is not active in vitiligo.[69]

Examples of future targeted therapies include inhibition of Janus kinases (JAKs), which are required for the signaling of many cytokines, including IFN-γ. In small case studies and series, JAK inhibitors have been reported to promote repigmentation of vitiligo patients, including oral tofacitinib, oral ruxolitinib, and topical ruxolitinib.[120-126] Ongoing clinical trials are currently testing JAK inhibitors as new treatments for patients with vitiligo. In addition, biologics that target other members of the IFN-γ–chemokine signaling axis may be effective, such as antibodies against CXCR3 or its ligands, which have been reported effective in a mouse model of vitiligo.[64,127] Additional cytokine-targeted biologics have been developed for other diseases and may be repurposed for vitiligo.[69] Side effects should be considered for any immunotherapy, which may include increased incidence of infections or decreased tumor surveillance.

Finally, in addition to targeted immunotherapy, treatments that promote melanocyte regeneration, proliferation, and/or migration could also be effective treatments, particularly when combined with immunosuppressive treatments. One example that has been tested in vitiligo patients is afamelanotide, an α-melanocyte–stimulating hormone analog, which, in conjunction with nbUVB, increased the rate and extent of repigmentation in vitiligo patients.[128,129] Side effects of this treatment included nausea, abdominal pain, and darkening of the normal skin of patients, which led to

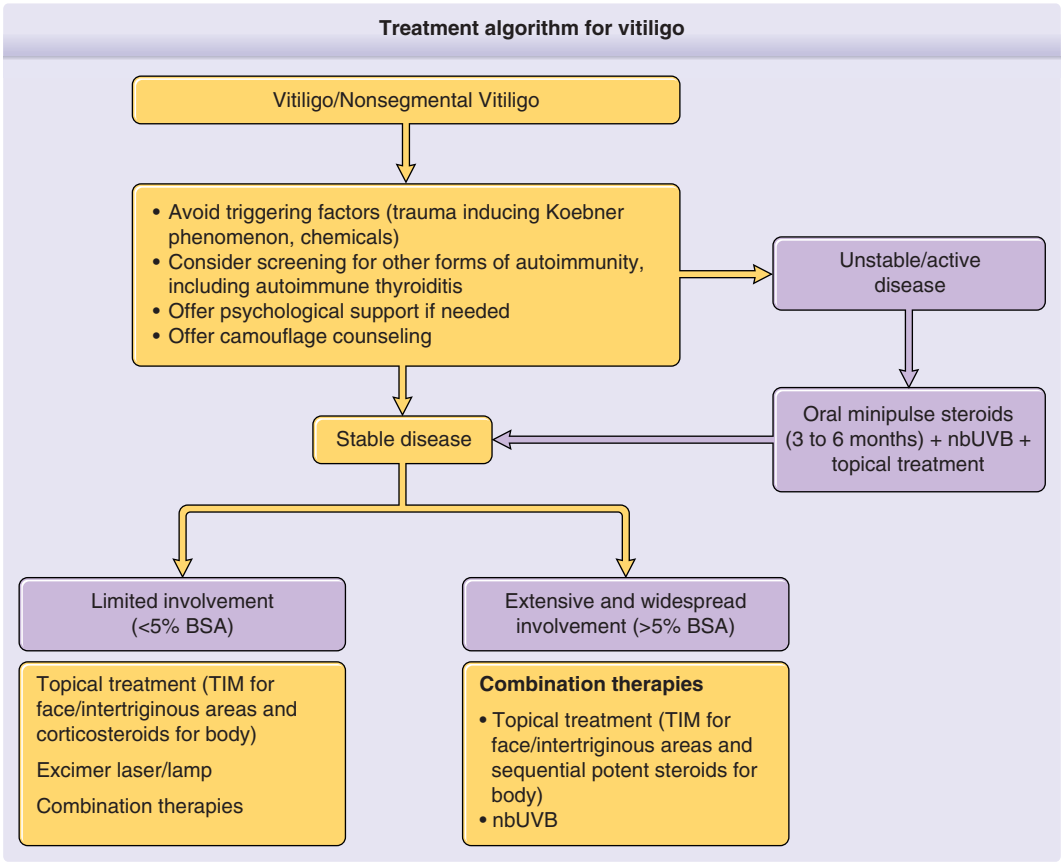

Figure 76-20 Treatment algorithm for vitiligo. BSA, body surface area; nbUVB, narrowband ultraviolet B; TIM, topical immunomodulators.

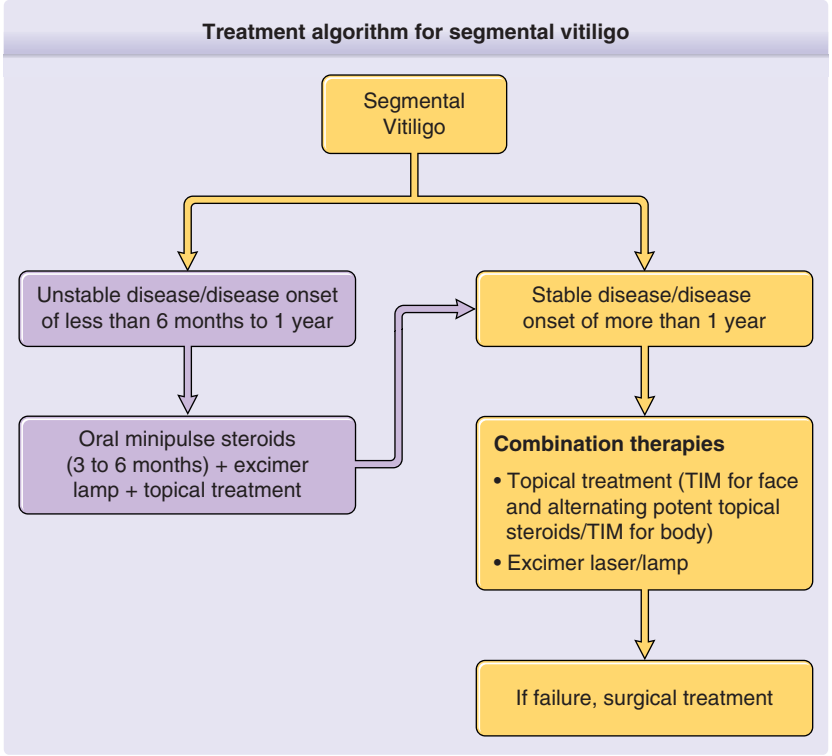

Figure 76-21 Treatment algorithm for segmental vitiligo. TIM, topical immunomodulators.

dissatisfaction and withdrawal of some participants from the study owing to the increased prominence of lesions against the darker background of normal skin.

In summary, recent advances in our understanding of vitiligo have led to the development of new treatment strategies that may have improved efficacy in our treatment of patients with vitiligo. As with any new therapy, safety will have to be monitored and carefully considered when making recommendations for patients suffering with this psychologically, but not physically, debilitating disease. This marks an exciting time for both patients with vitiligo and their caregivers, who are gaining deeper insight into their disease, and may have improved options for management in the near future.

REFERENCES

1. Panda AK. The medico historical perspective of vitiligo (Switra). *Bull Indian Inst Hist Med Hyderabad.* 2005;35(1):41-46.
2. Westerhof W, Njoo MD, Schallreuter KU. Vitiligo [in German]. *Hautarzt.* 1997;48(9):677-693; quiz 693.
3. Goldman L, Moraites RS, Kitzmiller KW. White spots in biblical times. A background for the dermatologist for participation in discussions of current revisions of the bible. *Arch Dermatol.* 1966;93(6):744-753.
4. Donata SR, Kesavan M, Austin SR, et al. Clinical trial of certain ayurveda medicines indicated in vitiligo. *Anc Sci Life.* 1990;4:202-206.
5. Olsson MJ, Juhlin L. Melanocyte transplantation in vitiligo. *Lancet.* 1992;340(8825):981.
6. Howitz J, Brodthagen H, Schwartz M, et al. Prevalence of vitiligo. Epidemiological survey on the Isle of Bornholm, Denmark. *Arch Dermatol.* 1977;113(1):47-52.
7. Boisseau-Garsaud AM, Garsaud P, Calès-Quist D, et al. Epidemiology of vitiligo in the French West Indies (Isle of Martinique). *Int J Dermatol.* 2000;39(1):18-20.
8. Behl PN, Bhatia RK. 400 cases of vitiligo. A clinico-therapeutic analysis. *Indian J Dermatol.* 1972;17(2):51-56.
9. Sehgal VN, Srivastava G. Vitiligo: compendium of clinico-epidemiological features. *Indian J Dermatol Venereol Leprol.* 2007;73(3):149-156.
10. Singh M, Singh G, Kanwar AJ, et al. Clinical pattern of vitiligo in Libya. *Int J Dermatol.* 1985;24(4):233-235.
11. Alikhan A, Felsten LM, Daly M, et al. Vitiligo: a comprehensive overview. Part I. Introduction, epidemiology, quality of life, diagnosis, differential diagnosis, associations, histopathology, etiology, and work-up. *J Am Acad Dermatol.* 2011;65(3):473-491.
12. Das SK, Majumder PP, Chakraborty R, et al. Studies on vitiligo. I. Epidemiological profile in Calcutta, India. *Genet Epidemiol.* 1985;2(1):71-78.
13. Ezzedine K, Diallo A, Léauté-Labrèze C, et al. Pre- vs. post-pubertal onset of vitiligo: multivariate analysis indicates atopic diathesis association in pre-pubertal onset vitiligo. *Br J Dermatol.* 2012;167(3):490-495.
14. Nicolaidou E, Antoniou C, Miniati A, et al. Childhood- and later-onset vitiligo have diverse epidemiologic and clinical characteristics. *J Am Acad Dermatol.* 2012;66(6):954-958.
15. Al-Refu K. Vitiligo in children: a clinical-epidemiologic study in Jordan. *Pediatr Dermatol.* 2012;29(1):114-115.

16. Ezzedine K, Sheth V, Rodrigues M, et al. Vitiligo is not a cosmetic disease. *J Am Acad Dermatol.* 2015;73(5):883-885.
17. Ongenae K, Dierckxsens L, Brochez L, et al. Quality of life and stigmatization profile in a cohort of vitiligo patients and effect of the use of camouflage. *Dermatology.* 2005;210(4):279-285.
18. Ongenae K, Van Geel N, De Schepper S, et al. Effect of vitiligo on self-reported health-related quality of life. *Br J Dermatol.* 2005;152(6):1165-1172.
19. Linthorst Homan MW, Spuls PI, de Korte J, et al. The burden of vitiligo: patient characteristics associated with quality of life. *J Am Acad Dermatol.* 2009; 61(3):411-420.
20. Parsad D, Pandhi R, Dogra S, et al. Dermatology Life Quality Index score in vitiligo and its impact on the treatment outcome. *Br J Dermatol.* 2003;148(2): 373-374.
21. Osborne GE, Francis ND, Bunker CB. Synchronous onset of penile lichen sclerosus and vitiligo. *Br J Dermatol.* 2000;143(1):218-219.
22. Lommerts JE, Schilder Y, de Rie MA, et al. Focal vitiligo: long-term follow-up of 52 cases. *J Eur Acad Dermatol Venereol.* 2016;30(9):1550-1554.
23. Ezzedine K, Lim HW, Suzuki T, et al. Revised classification/nomenclature of vitiligo and related issues: the Vitiligo Global Issues Consensus Conference. *Pigment Cell Melanoma Res.* 2012;25(3):E1-E13.
24. Ezzedine K, Gauthier Y, Léauté-Labrèze C, et al. Segmental vitiligo associated with generalized vitiligo (mixed vitiligo): a retrospective case series of 19 patients. *J Am Acad Dermatol.* 2011;65(5):965-971.
25. Mazereeuw-Hautier J, Bezio S, Mahe E, et al. Segmental and nonsegmental childhood vitiligo has distinct clinical characteristics: a prospective observational study. *J Am Acad Dermatol.* 2010;62(6):945-949.
26. van Geel N, Speeckaert R, De Wolf J, et al. Clinical significance of Koebner phenomenon in vitiligo. *Br J Dermatol.* 2012;167(5):1017-1024.
27. Hann SK, Kim YS, Yoo JH, et al. Clinical and histopathologic characteristics of trichrome vitiligo. *J Am Acad Dermatol.* 2000;42(4):589-596.
28. Sosa JJ, Currimbhoy SD, Ukoha U, et al. Confetti-like depigmentation: a potential sign of rapidly progressing vitiligo. *J Am Acad Dermatol.* 2015;73(2): 272-275.
29. Le Poole IC, van den Wijngaard RM, Westerhof W, et al. Presence of T cells and macrophages in inflammatory vitiligo skin parallels melanocyte disappearance. *Am J Pathol.* 1996;148(4):1219-1228.
30. Njoo MD, Das PK, Bos JD, et al. Association of the Kobner phenomenon with disease activity and therapeutic responsiveness in vitiligo vulgaris. *Arch Dermatol.* 1999;135(4):407-413.
31. Diallo A, Boniface K, Jouary T, et al. Development and validation of the K-VSCOR for scoring Koebner's phenomenon in vitiligo/non-segmental vitiligo. *Pigment Cell Melanoma Res.* 2013;26(3):402-407.
32. Alkhateeb A, Fain PR, Thody A, et al. Epidemiology of vitiligo and associated autoimmune diseases in Caucasian probands and their families. *Pigment Cell Res.* 2003;16(3):208-214.
33. Gill L, Zarbo A, Isedeh P, et al. Comorbid autoimmune diseases in patients with vitiligo: a cross-sectional study. *J Am Acad Dermatol.* 2016;74(2):295-302.
34. Liu M, Murphy E, Amerson EH. Rethinking screening for thyroid autoimmunity in vitiligo. *J Am Acad Dermatol.* 2016;75(6):1278-1280.
35. Teulings HE, Overkamp M, Ceylan E, et al. Decreased risk of melanoma and nonmelanoma skin cancer in patients with vitiligo: a survey among 1307 patients and their partners. *Br J Dermatol.* 2013;168(1): 162-171.
36. Paradisi A, Tabolli S, Didona B, et al. Markedly reduced incidence of melanoma and nonmelanoma skin cancer in a nonconcurrent cohort of 10,040 patients with vitiligo. *J Am Acad Dermatol.* 2014;71(6):1110-1116.
37. Spritz RA. Modern vitiligo genetics sheds new light on an ancient disease. *J Dermatol.* 2013;40(5):310-318.
38. Gopal KV, Rama Rao GR, Kumar YH, et al. Vitiligo: a part of a systemic autoimmune process. *Indian J Dermatol Venereol Leprol.* 2007;73(3):162-165.
39. Akay BN, Bozkir M, Anadolu Y, et al. Epidemiology of vitiligo, associated autoimmune diseases and audiological abnormalities: Ankara study of 80 patients in Turkey. *J Eur Acad Dermatol Venereol.* 2010;24(10):1144-1150.
40. Anbar TS, El-Badry MM, McGrath JA, et al. Most individuals with either segmental or non-segmental vitiligo display evidence of bilateral cochlear dysfunction. *Br J Dermatol.* 2015;172(2):406-411.
41. Albert DM, Wagoner MD, Pruett RC, et al. Vitiligo and disorders of the retinal pigment epithelium. *Br J Ophthalmol.* 1983;67(3):153-156.
42. Wagoner MD, Albert DM, Lerner AB, et al. New observations on vitiligo and ocular disease. *Am J Ophthalmol.* 1983;96(1):16-26.
43. Sakata VM, da Silva FT, Hirata CE, et al. Diagnosis and classification of Vogt-Koyanagi-Harada disease. *Autoimmun Rev.* 2014;13(4-5):550-555.
44. Alezzandrini AA. Unilateral manifestations of tapetoretinal degeneration, vitiligo, poliosis, grey hair and hypoacousia [in French]. *Ophthalmologica.* 1964;147: 409-419.
45. Andrade A, Pithon M. Alezzandrini syndrome: report of a sixth clinical case. *Dermatology.* 2011;222(1):8-9.
46. Gupta M, Pande D, Lehl SS, et al. Alezzandrini syndrome. *BMJ Case Rep.* 2011;2011.
47. Schallreuter KU, Moore J, Wood JM, et al. In vivo and in vitro evidence for hydrogen peroxide (H_2O_2) accumulation in the epidermis of patients with vitiligo and its successful removal by a UVB-activated pseudocatalase. *J Investig Dermatol Symp Proc.* 1999;4(1):91-96.
48. Boissy RE, Liu YY, Medrano EE, et al. Structural aberration of the rough endoplasmic reticulum and melanosome compartmentalization in long-term cultures of melanocytes from vitiligo patients. *J Invest Dermatol.* 1991;97(3):395-404.
49. Puri N, Mojamdar M, Ramaiah A. In vitro growth characteristics of melanocytes obtained from adult normal and vitiligo subjects. *J Invest Dermatol.* 1987;88(4):434-438.
50. Puri N, Mojamdar M, Ramaiah A. Growth defects of melanocytes in culture from vitiligo subjects are spontaneously corrected in vivo in repigmenting subjects and can be partially corrected by the addition of fibroblast-derived growth factors in vitro. *Arch Dermatol Res.* 1989;281(3):178-184.
51. Medrano EE, Nordlund JJ. Successful culture of adult human melanocytes obtained from normal and vitiligo donors. *J Invest Dermatol.* 1990;95(4):441-445.
52. Jimbow K, Chen H, Park JS, et al. Increased sensitivity of melanocytes to oxidative stress and abnormal expression of tyrosinase-related protein in vitiligo. *Br J Dermatol.* 2001;144(1):55-65.

53. van den Wijngaard R, Wankowicz-Kalinska A, Le Poole C, et al. Local immune response in skin of generalized vitiligo patients. Destruction of melanocytes is associated with the prominent presence of CLA+ T cells at the perilesional site. *Lab Invest.* 2000; 80(8):1299-1309.
54. van den Boorn JG, Konijnenberg D, Dellemijn TA, et al. Autoimmune destruction of skin melanocytes by perilesional T cells from vitiligo patients. *J Invest Dermatol.* 2009;129(9):2220-2232.
55. Le Poole IC, Das PK, van den Wijngaard RM, et al. Review of the etiopathomechanism of vitiligo: a convergence theory. *Exp Dermatol.* 1993;2(4):145-153.
56. Harris JE. Cellular stress and innate inflammation in organ-specific autoimmunity: lessons learned from vitiligo. *Immunol Rev.* 2016;269(1):11-25.
57. Strassner JP, Harris JE. Understanding mechanisms of autoimmunity through translational research in vitiligo. *Curr Opin Immunol.* 2016;43:81-88.
58. Ortonne J-P, Mosher DB, Fitzpatrick TB. *Vitiligo and Other Hypomelanoses of Hair and Skin.* New York, NY: Plenum Medical; 1983.
59. van Geel N, Speeckaert R, Melsens E, et al. The distribution pattern of segmental vitiligo: clues for somatic mosaicism. *Br J Dermatol.* 2013;168(1):56-64.
60. van Geel N, Mollet I, Brochez L, et al. New insights in segmental vitiligo: case report and review of theories. *Br J Dermatol.* 2012;166(2):240-246.
61. Gregg RK, Nichols L, Chen Y, et al. Mechanisms of spatial and temporal development of autoimmune vitiligo in tyrosinase-specific TCR transgenic mice. *J Immunol.* 2010;184(4):1909-1917.
62. Harris JE, Harris TH, Weninger W, et al. A mouse model of vitiligo with focused epidermal depigmentation requires IFN-gamma for autoreactive CD8(+) T-cell accumulation in the skin. *J Invest Dermatol.* 2012;132(7):1869-1876.
63. Grimes PE, Morris R, Avaniss-Aghajani E, et al. Topical tacrolimus therapy for vitiligo: therapeutic responses and skin messenger RNA expression of proinflammatory cytokines. *J Am Acad Dermatol.* 2004; 51(1):52-61.
64. Rashighi M, Agarwal P, Richmond JM, et al. CXCL10 is critical for the progression and maintenance of depigmentation in a mouse model of vitiligo. *Sci Transl Med.* 2014;6(223):223ra223.
65. Richmond JM, Bangari DS, Essien KI, et al. Keratinocyte-derived chemokines orchestrate T cell positioning in the epidermis during vitiligo and may serve as biomarkers of disease. *J Invest Dermatol.* 2017;137(2):350-358.
66. Wang X, Wang Q, Wu J, et al. Increased expression of CXCR3 and its ligands in vitiligo patients and CXCL10 as a potential clinical marker for vitiligo. *Br J Dermatol.* 2016;174(6):1318-1326.
67. Maouia A, Sormani L, Youssef M, et al. Study of the comparative expression of CXCL9, CXCL10 and IFN-gamma in vitiligo and alopecia areata patients. *Pigment Cell Melanoma Res.* 2017;30(2):259-261.
68. Strassner JP, Rashighi M, Ahmed Refat M, et al. Suction blistering the lesional skin of vitiligo patients reveals useful biomarkers of disease activity. *J Am Acad Dermatol.* 2017;76(5):847-855.e5.
69. Frisoli ML, Harris JE. Vitiligo: mechanistic insights lead to novel treatments. *J Allergy Clin Immunol.* 2017;140(3):654-662.
70. Harris JE. Immunopathogenesis of vitiligo. In: Hamzavi I, Mahmoud BH, Isedeh PN, eds. *Handbook of Vitiligo: Basic Science and Clinical Management*. London, UK: JP Medical Publishers; 2016:21-36.
71. Oliver EA, Schwartz L, Warren LH. Occupational leukoderma. *JAMA.* 1939;113:927-928.
72. Harris JE. Chemical-induced vitiligo. *Dermatol Clin.* 2017;35(2):151-161.
73. Wu S, Li WQ, Cho E, et al. Use of permanent hair dyes and risk of vitiligo in women. *Pigment Cell Melanoma Res.* 2015;28(6):744-746.
74. Kroll TM, Bommiasamy H, Boissy RE, et al. 4-Tertiary butyl phenol exposure sensitizes human melanocytes to dendritic cell-mediated killing: relevance to vitiligo. *J Invest Dermatol.* 2005;124(4):798-806.
75. Toosi S, Orlow SJ, Manga P. Vitiligo-inducing phenols activate the unfolded protein response in melanocytes resulting in upregulation of IL6 and IL8. *J Invest Dermatol.* 2012;132(11):2601-2609.
76. van den Boorn JG, Picavet DI, van Swieten PF, et al. Skin-depigmenting agent monobenzone induces potent T-cell autoimmunity toward pigmented cells by tyrosinase haptenation and melanosome autophagy. *J Invest Dermatol.* 2011;131(6):1240-1251.
77. Faria AR, Tarle RG, Dellatorre G, et al. Vitiligo—part 2—classification, histopathology and treatment. *An Bras Dermatol.* 2014;89(5):784-790.
78. Taieb A, Alomar A, Bohm M, et al. Guidelines for the management of vitiligo: the European Dermatology Forum consensus. *Br J Dermatol.* 2013;168(1):5-19.
79. Legendre L, Barnetche T, Mazereeuw-Hautier J, et al. Risk of lymphoma in patients with atopic dermatitis and the role of topical treatment: A systematic review and meta-analysis. *J Am Acad Dermatol.* 2015;72(6):992-1002.
80. Bae JM, Yoo HJ, Kim H, et al. Combination therapy with 308-nm excimer laser, topical tacrolimus, and short-term systemic corticosteroids for segmental vitiligo: a retrospective study of 159 patients. *J Am Acad Dermatol.* 2015;73(1):76-82.
81. Cavalie M, Ezzedine K, Fontas E, et al. Maintenance therapy of adult vitiligo with 0.1% tacrolimus ointment: a randomized, double blind, placebo-controlled study. *J Invest Dermatol.* 2015;135(4):970-974.
82. Ho N, Pope E, Weinstein M, et al. A double-blind, randomized, placebo-controlled trial of topical tacrolimus 0.1% vs. clobetasol propionate 0.05% in childhood vitiligo. *Br J Dermatol.* 2011;165(3):626-632.
83. Dillon JP, Ford C, Hynan LS, et al. A cross-sectional, comparative study of home vs in-office NB-UVB phototherapy for vitiligo. *Photodermatol Photoimmunol Photomed.* 2017;33(5):282-283.
84. Veith W, Deleo V, Silverberg N. Medical phototherapy in childhood skin diseases. *Minerva Pediatr.* 2011;63(4):327-333.
85. Whitton ME, Pinart M, Batchelor J, et al. Interventions for vitiligo. *Cochrane Database Syst Rev.* 2015;(2):CD003263.
86. Yones SS, Palmer RA, Garibaldinos TM, et al. Randomized double-blind trial of treatment of vitiligo: efficacy of psoralen-UV-A therapy vs narrowband-UV-B therapy. *Arch Dermatol.* 2007;143(5):578-584.
87. Bhatnagar A, Kanwar AJ, Parsad D, et al. Comparison of systemic PUVA and NB-UVB in the treatment of vitiligo: an open prospective study. *J Eur Acad Dermatol Venereol.* 2007;21(5):638-642.
88. Pathak MA, Mosher DB, Fitzpatrick TB. Safety and therapeutic effectiveness of 8-methoxypsoralen, 4,5′,8-trimethylpsoralen, and psoralen in vitiligo. *Natl Cancer Inst Monogr.* 1984;66:165-173.

89. Njoo MD, Bos JD, Westerhof W. Treatment of generalized vitiligo in children with narrow-band (TL-01) UVB radiation therapy. *J Am Acad Dermatol.* 2000; 42(2, pt 1):245-253.
90. Whitton ME, Pinart M, Batchelor J, et al. Interventions for vitiligo. *Cochrane Database Syst Rev.* 2015;2:CD003263.
91. De Francesco V, Stinco G, Laspina S, et al. Immunohistochemical study before and after narrow band (311 nm) UVB treatment in vitiligo. *Eur J Dermatol.* 2008;18(3):292-296.
92. Arca E, Tastan HB, Erbil AH, et al. Narrow-band ultraviolet B as monotherapy and in combination with topical calcipotriol in the treatment of vitiligo. *J Dermatol.* 2006;33(5):338-343.
93. Welsh O, Herz-Ruelas ME, Gomez M, et al. Therapeutic evaluation of UVB-targeted phototherapy in vitiligo that affects less than 10% of the body surface area. *Int J Dermatol.* 2009;48(5):529-534.
94. Kanwar AJ, Dogra S. Narrow-band UVB for the treatment of generalized vitiligo in children. *Clin Exp Dermatol.* 2005;30(4):332-336.
95. Kanwar AJ, Dogra S, Parsad D, et al. Narrow-band UVB for the treatment of vitiligo: an emerging effective and well-tolerated therapy. *Int J Dermatol.* 2005;44(1):57-60.
96. Le Duff F, Fontas E, Giacchero D, et al. 308-nm excimer lamp vs. 308-nm excimer laser for treating vitiligo: a randomized study. *Br J Dermatol.* 2010;163(1):188-192.
97. Ezzedine K, Eleftheriadou V, Whitton M, et al. Vitiligo. *Lancet.* 2015;386(9988):74-84.
98. Koh MJ, Mok ZR, Chong WS. Phototherapy for the treatment of vitiligo in Asian children. *Pediatr Dermatol.* 2015;32(2):192-197.
99. Rath N, Kar HK, Sabhnani S. An open labeled, comparative clinical study on efficacy and tolerability of oral minipulse of steroid (OMP) alone, OMP with PUVA and broad/narrow band UVB phototherapy in progressive vitiligo. *Indian J Dermatol Venereol Leprol.* 2008;74(4):357-360.
100. Gawkrodger DJ, Ormerod AD, Shaw L, et al. Guideline for the diagnosis and management of vitiligo. *Br J Dermatol.* 2008;159(5):1051-1076.
101. Shah R, Hunt J, Webb TL, et al. Starting to develop self-help for social anxiety associated with vitiligo: using clinical significance to measure the potential effectiveness of enhanced psychological self-help. *Br J Dermatol.* 2014;171(2):332-337.
102. Kruger C, Smythe JW, Spencer JD, et al. Significant immediate and long-term improvement in quality of life and disease coping in patients with vitiligo after group climatotherapy at the Dead Sea. *Acta Derm Venereol.* 2011;91(2):152-159.
103. Kossakowska MM, Ciescinska C, Jaszewska J, et al. Control of negative emotions and its implication for illness perception among psoriasis and vitiligo patients. *J Eur Acad Dermatol Venereol.* 2010;24(4):429-433.
104. Picardi A, Abeni D. Can cognitive-behavioral therapy help patients with vitiligo? *Arch Dermatol.* 2001;137(6):786-788.
105. Papadopoulos L, Bor R, Legg C. Coping with the disfiguring effects of vitiligo: a preliminary investigation into the effects of cognitive-behavioural therapy. *Br J Med Psychol.* 1999;72(pt 3):385-396.
106. Papadopoulos L, Bor R, Legg C, et al. Impact of life events on the onset of vitiligo in adults: preliminary evidence for a psychological dimension in aetiology. *Clin Exp Dermatol.* 1998;23(6):243-248.
107. Shenefelt PD. Hypnosis in dermatology. *Arch Dermatol.* 2000;136(3):393-399.
108. Tedeschi A, Dall'Oglio F, Micali G, et al. Corrective camouflage in pediatric dermatology. *Cutis.* 2007; 79(2):110-112.
109. Ramien ML, Ondrejchak S, Gendron R, et al. Quality of life in pediatric patients before and after cosmetic camouflage of visible skin conditions. *J Am Acad Dermatol.* 2014;71(5):935-940.
110. Mosher DB, Parrish JA, Fitzpatrick TB. Monobenzylether of hydroquinone. A retrospective study of treatment of 18 vitiligo patients and a review of the literature. *Br J Dermatol.* 1977;97(6):669-679.
111. Ezzedine K, Lim HW, Suzuki T, et al. Revised classification/nomenclature of vitiligo and related issues: the Vitiligo Global Issues Consensus Conference. *Pigment Cell Melanoma Res.* 2012;25(3): E1-E13.
112. Linthorst Homan MW, Spuls PI, Nieuweboer-Krobotova L, et al. A randomized comparison of excimer laser versus narrow-band ultraviolet B phototherapy after punch grafting in stable vitiligo patients. *J Eur Acad Dermatol Venereol.* 2012;26(6): 690-695.
113. Feetham HJ, Chan JL, Pandya AG. Characterization of clinical response in patients with vitiligo undergoing autologous epidermal punch grafting. *Dermatol Surg.* 2012;38(1):14-19.
114. Gupta S, Ajith C, Kanwar AJ, et al. Surgical pearl: standardized suction syringe for epidermal grafting. *J Am Acad Dermatol.* 2005;52(2):348-350.
115. Agrawal K, Agrawal A. Vitiligo: repigmentation with dermabrasion and thin split-thickness skin graft. *Dermatol Surg.* 1995;21(4):295-300.
116. Malakar S, Malakar RS. Surgical pearl: composite film and graft unit for the recipient area dressing after split-thickness skin grafting in vitiligo. *J Am Acad Dermatol.* 2001;44(5):856-858.
117. Krishnan A, Kar S. Smashed skin grafting or smash grafting-a novel method of vitiligo surgery. *Int J Dermatol.* 2012;51(10):1242-1247.
118. Huggins RH, Henderson MD, Mulekar SV, et al. Melanocyte-keratinocyte transplantation procedure in the treatment of vitiligo: the experience of an academic medical center in the United States. *J Am Acad Dermatol.* 2012;66(5):785-793.
119. Mulekar SV. Melanocyte-keratinocyte cell transplantation for stable vitiligo. *Int J Dermatol.* 2003;42(2):132-136.
120. Craiglow BG, King BA. Tofacitinib citrate for the treatment of vitiligo: a pathogenesis-directed therapy. *JAMA Dermatol.* 2015;151(10):1110-1112.
121. Harris JE, Rashighi M, Nguyen N, et al. Rapid skin repigmentation on oral ruxolitinib in a patient with coexistent vitiligo and alopecia areata (AA). *J Am Acad Dermatol.* 2016;74(2):370-371.
122. Rothstein B, Joshipura D, Saraiya A, et al. Treatment of vitiligo with the topical Janus kinase inhibitor ruxolitinib. *J Am Acad Dermatol.* 2017;76(6): 1054-1060.e1.
123. Liu LY, Strassner JP, Refat MA, et al. Repigmentation in vitiligo using the Janus kinase inhibitor tofacitinib may require concomitant light exposure. *J Am Acad Dermatol.* 2017;77(4):675-682.e1.
124. Kim SR, Heaton H, Liu LY, et al. Rapid repigmentation of vitiligo using tofacitinib plus low-dose,

narrowband UV-B phototherapy. *JAMA Dermatol.* 2018;154(3):370-371.
125. Joshipura D, Plotnikova N, Goldminz A, et al. Importance of light in the treatment of vitiligo with JAK-inhibitors. *J Dermatolog Treat*. 2018;29(1):98-99.
126. Joshipura D, Alomran A, Zancanaro P, et al. Treatment of vitiligo with the topical Janus kinase inhibitor ruxolitinib: a 32-week open label extension study with optional narrow-band ultraviolet B. *J Am Acad Dermatol.* 2018;78(6):1205-1207.e1.
127. Richmond JM, Masterjohn E, Chu R, et al. CXCR3 depleting antibodies prevent and reverse vitiligo in mice. *J Invest Dermatol.* 2017;137(4):982-985.
128. Lim HW, Grimes PE, Agbai O, et al. Afamelanotide and narrowband UV-B phototherapy for the treatment of vitiligo: a randomized multicenter trial. *JAMA Dermatol.* 2015;151(1):42-50.
129. Grimes PE, Hamzavi I, Lebwohl M, et al. The efficacy of afamelanotide and narrowband UV-B phototherapy for repigmentation of vitiligo. *JAMA Dermatol.* 2013;149(1):68-73.

Chapter 77 :: Hypermelanoses

:: Michelle Rodrigues & Amit G. Pandya

CONGENITAL HYPERMELANOSIS

LINEAR AND WHORLED NEVOID HYPERMELANOSIS

AT-A-GLANCE

- Congenital diffuse streaky hyperpigmented macules in Blaschko lines.
- Typically seen on the trunk and extremities.
- No preceding inflammation or atrophy.
- Onset in the first few weeks of life.
- May fade with advancing age.

Linear and whorled nevoid hypermelanosis is a congenital condition causing diffuse streaky hyperpigmented macules along the lines of Blaschko.[1]

CLINICAL FEATURES

Linear and whorled nevoid hypermelanosis is characterized by widespread streaky hyperpigmented macules along the lines of Blaschko without preceding inflammation or atrophy in the first few weeks of life. Lesions are typically located on the trunk and limbs and do not cross the midline. Face, palms, soles, eyes, and mucous membranes are spared. Similar cases have been described under different descriptive names (*zosteriform hyperpigmentation*, *zosteriform lentiginous nevus*, *zebra-like hyperpigmentation*). Several cases have been reported with both hyperpigmentation and hypopigmentation. *Pigmentary mosaicism* is a useful term to encompass all these different phenotypes.

Rarely, extracutaneous manifestations, such as developmental and growth retardation, facial and body asymmetry, ventricular septal defects, and pseudohermaphroditism, are observed. The frequency of extracutaneous manifestations is unknown, as these observations have been made in case reports only.

ETIOLOGY AND PATHOGENESIS

Most cases are sporadic but the presence of mosaicism has been confirmed in a few cases (mosaic trisomies 7, 14, 18, and 20, and X-chromosomal mosaicism) by chromosomal analysis.[2]

DIAGNOSIS

In addition to the typical clinical appearance, histologic examination reveals increased pigmentation of the basal layer and prominence or vacuolization of melanocytes. Pigment incontinence is usually absent.

DIFFERENTIAL DIAGNOSIS

Linear and whorled nevoid hypermelanosis should be differentiated from incontinentia pigmenti (IP) and epidermal nevus.

CLINICAL COURSE AND PROGNOSIS

Kalter and colleagues[1] described typical onset in the first few weeks of life with progression during the initial years of life. The pigmentation may fade gradually with advancing age.

INCONTINENTIA PIGMENTI

AT-A-GLANCE

- X-linked dominant disorder resulting from mutation in the *IKBKG* (previously called *NEMO*) gene.
- Lethal in male embryos.
- Four clinical phases commencing at birth: vesicular, verrucous, hyperpigmented, and hypopigmented.
- Congenital diffuse linear hyperpigmented macules in Blaschko lines.

IP, also known as Bloch-Sulzberger syndrome, was first described by Garrod and colleagues in 1906. It is an X-linked disorder primarily seen in females, which results in diffuse linear cutaneous hyperpigmentation.

CLINICAL FEATURES

Lesions usually proceed through 4 cutaneous stages, although the stages may sometimes overlap: (a) vesicular stage (from birth or shortly thereafter), which presents with multiple small and medium-sized vesicles following the lines of Blaschko;

(b) verrucous stage (between 2 and 8 weeks of age) consisting of wart-like plaques; (c) hyperpigmented stage (several months of age into adulthood); and (d) hypopigmented stage (from infancy onwards) (Fig. 77-1).

The degree of hyperpigmentation varies among individuals but appears in streaks and whorls along Blaschko lines. Although it can appear on the limbs, it is usually pronounced on the trunk. The hypopigmented stage is characterized by linear, atrophic, hairless scars along Blaschko lines.

Figure 77-1 Incontinentia pigmenti in a mother and her baby. **A,** Verrucous lesions in a 2-week-old baby. **B,** Hypopigmented atrophic lesions following Blaschko lines.

ETIOLOGY AND PATHOGENESIS

IP is an X-linked, dominantly inherited disorder believed to be embryonically lethal in the majority of males. In most cases, IP is caused by a mutation in the *IKBKG* gene (previously called *NEMO* [nuclear factor κB (NF-κB) essential modulator]) on the X chromosome at Xq28.[3,4] The gene encodes a regulatory component of the IKappaB kinase complex that activates the NF-κB pathway, which is required to protect against tumor necrosis factor-α–induced apoptosis.[5]

In females with IP, inactivation of 1 of the 2 X chromosomes through a process termed *lyonization* occurs during embryogenesis. Epidermal cells expressing the defective *IKBKG* gene give rise to typical skin lesions along the lines of Blaschko, reflecting the embryonic migration path of the affected keratinocytes.

The cutaneous lesions in the vesicular stage represent the population of *IKBKG*-deficient cells that fail to activate NF-κB, leading to apoptosis. The number of *IKBKG*-deficient cells decreases secondary to apoptosis and is replaced by cells expressing the normal allele. Subsequently, the inflammatory and vesicular stage ends. The hyperproliferation in the second stage is likely a result of compensatory proliferation of normal IKBKG keratinocytes. Hyperpigmentation in the third stage results from incontinence of epidermal melanin pigment, which then migrates into the dermis and is engulfed by macrophages.

Extracutaneous manifestations occur in a significant number of patients with IP. Ocular (30% to 70%), CNS (40%), dental, and skeletal anomalies are among the most common.

DIAGNOSIS

Histologically, the number of melanocytes appears to be normal, although a reduced number of melanocytes have been noted. The thin epidermis and absence or reduction of skin appendages in the dermis may contribute to the impression of hypopigmentation.

Histologically, the areas of pigmentation show many melanin-laden melanophages, extensive deposits of melanin in the basal cell layer and dermis. Epidermal basal layer vacuolization and degeneration is also noted.

CLINICAL COURSE AND PROGNOSIS

Usually the hyperpigmentation fades gradually over several years, leaving hypopigmented skin (stage 4), which represents postinflammatory dermal scarring.

MANAGEMENT

A beneficial effect of topical steroids and topical tacrolimus in the vesicular stage has been reported.[6] Hypopigmented and atrophic scarring may be amenable to noncultured epidermal cell grafting.[7]

DYSKERATOSIS CONGENITA

AT-A-GLANCE

- Congenital diffuse reticular hyperpigmentation with nail atrophy and leukoplakia.
- Manifests in the first few years of life.
- Extracutaneous manifestations are bone marrow failure and malignancies.

Dyskeratosis congenital (DKC) or *Zinsser-Cole-Engman syndrome* is characterized by cutaneous and hematologic manifestations.

CLINICAL FEATURES

Reticulate skin pigmentation especially on the neck and chest, nail atrophy in fingernails and toenails, and leukoplakia are seen in those with DKC.

Extracutaneous manifestations include bone marrow failure (in more than 80% of cases) and malignancy in the second and third decades of life.

ETIOLOGY AND PATHOGENESIS

In all cases of DKC, the causative mutations are present in components of the telomerase complex. Rapidly dividing somatic cells express low but detectable levels of telomerase activity that slows telomere shortening occurring with each cycle of DNA replication, which eventually leads to cellular senescence (permanent loss of proliferative capacity). It is now thought that DKC is caused by defective telomere maintenance, which limits the proliferative capacity of hematopoietic and epithelial cells. Increased melanin synthesis occurs in senescent melanocytes, which is likely to account for the pigmentary changes noted in DKC. Critically short telomeres may force cells into "replicative crisis," at which time activation of an alternative "ALT" mechanism for lengthening telomeres in the absence of telomerase may lead to development of malignancies. The role of telomeres in cell biology (cellular aging) was actually first demonstrated through the finding of short telomeres in DKC.[8]

X-linked DKC is caused by mutations in the *DKC1* gene located at Xq28, encoding for dyskerin. Females carrying 1 mutated allele are protected by expression of normal telomerase on the unaffected allele. In autosomal dominant DKC, the majority of cases are caused by mutations in TERC, the RNA component of the telomerase complex. TERT (telomerase reverse transcriptase) is affected much less often in autosomal dominant DKC. In the autosomal recessive form of DKC, mutations in telomerase-associated proteins such as NOP10, NHP2, and TINF2 are involved.[9]

DIAGNOSIS

Skin biopsy of hyperpigmented skin does not demonstrate specific changes. Epidermal atrophy and a chronic inflammatory cell infiltrate with numerous melanophages in the upper dermis are usually observed in histology.

DIFFERENTIAL DIAGNOSIS

DKC may be confused with Fanconi syndrome, which is characterized by short stature, hypoplastic or aplastic thumbs, and a reduced number of carpal bones. The patchy hyperpigmentation of the trunk, neck, groin, and axillary regions in Fanconi syndrome appears earlier than in DKC, that is, in the first few years of life.

CLINICAL COURSE AND PROGNOSIS

The autosomal dominant form has a better prognosis than other forms, possibly because of the presence of an unaffected allele with some preservation of telomerase activity. Usually, the hyperpigmentation fades gradually after several years.

NAEGELI-FRANCESCHETTI-JADASSOHN SYNDROME

AT-A-GLANCE

- Autosomal ectodermal dysplasias.
- Reticulate hyperpigmentation on the neck and axillae.
- Nail, teeth, and sweating abnormalities.

CLINICAL FEATURES

Reticulate hyperpigmentation is most prominent in neck and axillae. Palmoplantar diffuse keratoderma, absence of dermatoglyphs, nail and teeth changes, and heat intolerance owing to diminished or absent sweating are characteristic.[10]

ETIOLOGY AND PATHOGENESIS

The Naegeli-Franceschetti-Jadassohn syndrome and the related dermatopathia pigmentosa reticularis are autosomal dominant ectodermal dysplasias caused by mutations in the *KRT14* gene.[11] The *KRT14* gene codes for keratin 14, which, together with keratin 5, forms intermediate keratin filaments. Keratin 14 is predominantly produced by the keratinocytes in the basal cell layer of the epidermis. Mutations in *KRT14* gene lead to fragility of basal keratinocytes. It plays an important role during ontogenesis of dermatoglyphs and sweat glands.[12]

Dermatopathia pigmentosa reticularis has been distinguished from Naegeli-Franceschetti-Jadassohn syndrome by lifelong persistence of skin hyperpigmentation, partial alopecia, and absence of dental anomalies. Both disorders have been mapped to 17q11.2-q21 and are considered to be allelic.[11]

HISTOLOGY

There are numerous melanophages in the upper dermis, next to a patchy epidermal hyperpigmentation. Eccrine glands histologically appear normal in number and structure.

DERMATOPATHIA PIGMENTOSA RETICULARIS

AT-A-GLANCE

- Autosomal dominant.
- Reticulate hyperpigmentation on the trunk.
- Nail, sweating, and ocular abnormalities with nonscarring alopecia.

CLINICAL FEATURES

Reticulate hyperpigmentation on the trunk, palmoplantar keratoderma with punctiform accentuation, nail and ocular changes, noncicatricial alopecia, ichthyosis, hypohidrosis, widespread hyperkeratotic lesions, ainhum formation, severe periodontal disease, mechanic blister formation, and pigmentation of the oral mucosa are all seen in this condition.[13]

ETIOLOGY AND PATHOGENESIS

Dermatopathia pigmentosa reticularis is a rare autosomal dominant condition.

HISTOLOGY

Histologic examination shows pronounced pigmentary incontinence, liquefaction degeneration of the basal cell layer and hyalinization of dermal collagen.

DOWLING-DEGOS DISEASE

AT-A-GLANCE

- Autosomal dominant.
- Reticulate hyperpigmentation in the flexures with acneiform perioral pits and comedo-like hyperkeratotic papules.

CLINICAL FEATURES

Numerous small symmetrical brown-gray macules usually begin in the groin and axillae in the third or fourth decade of life and then spread to intergluteal and inframammary folds, neck, trunk, and arms. Comedo-like hyperkeratotic follicular papules on the neck and axilla and pitted perioral acneiform scars also appear.[14]

ETIOLOGY AND PATHOGENESIS

This rare autosomal dominant genodermatosis (synonym: *reticular pigmented anomaly of the flexures*) is cause by mutations in the *KRT5* gene on chromosome 12q13.13. Betz and colleagues demonstrated that haploinsufficiency in keratin 5 causes epithelial remodeling, melanosome mistargeting, and altered perinuclear organization of intermediate filaments.[14] Keratin 5 and keratin 14 are 2 proteins that together form a keratin intermediate filament. It is hypothesized that keratin 5 haploinsufficiency causes an excess of keratin 14 that could be responsible for the pathology of Dowling-Degos disease by competing with transport adapters. Keratins could regulate the availability and positioning of AP-3 complexes in keratinocytes or alternatively could regulate the interaction of AP-3–dependent vesicles with motor proteins.

HISTOLOGY

The histology is very characteristic with filiform rete projections from both epidermis and follicular infundibulum with hyperpigmented tips, without an increase of melanocytes. The disorder has to be differentiated from acanthosis nigricans, which has a different histologic appearance.

CLINICAL COURSE AND PROGNOSIS

Progression of the hyperpigmentation is slow and usually is visible from early adult life, without sex predilection.

GALLI-GALLI DISEASE

Patients with Galli-Galli disease show the diagnostic features of Dowling-Degos disease with the additional histopathologic finding of acantholysis in suprabasal epidermal layers. It is regarded as the acantholytic variant of Dowling-Degos disease. Mutations in the keratin 5 gene have been found in some patients.[15]

KITAMURA RETICULAR ACROPIGMENTATION

AT-A-GLANCE

- Autosomal dominant.
- Reticulate hyperpigmentation in the flexures with acneiform perioral pits and comedo-like hyperkeratotic papules.

CLINICAL FEATURES

Kitamura reticular acropigmentation is characterized by angular and sharply demarcated reticulate, freckle-like hyperpigmented macules (but no hypopigmentation as seen in Dohi disorder [see section "Mixed Hypomelanosis and Hypermelanosis"]) beginning on the dorsa of the hands during the first decade of life and subsequently spreading to the rest of the body. The macules are slightly depressed; sometimes palmar pits can be observed. Most cases are from Japan.

ETIOLOGY AND PATHOGENESIS

Mutations in the *ADAM10* gene (15q21.3). *ADAM10* encodes for a zinc metalloprotease, a disintegrin, and a metalloprotease domain containing protein 10, which is involved in the shedding of skin substrates.[16]

HISTOLOGY

There is an increased number of melanocytes and melanogenic activity, and epidermal atrophy is present upon histologic examination.

DIFFERENTIAL DIAGNOSIS

Dowling-Degos disease, acropigmentation of Dohi, and dermatopathia pigmentosa reticularis are all in the differential diagnosis of Kitamura reticular acropigmentation.

HABER SYNDROME

Next to a reticulate pigmentation on trunk and axillae, patients with Haber disease also develop verruciformis papular lesions of the trunk and a distinct photosensitive rosacea-like facial erythema and telangiectasias, most commonly presenting in childhood.[17]

NEVUS OF OTA

AT-A-GLANCE

- Congenital circumscribed tan-brown hyperpigmentation with dermal melanocytosis.
- Unilateral pigmentation in the area of the first and second branches of the trigeminal nerve.
- Of those affected, 60% have scleral involvement.
- Mostly occurs in Asian females.

Nevus of Ota (nevus fuscoceruleus ophthalmomaxillaris) was first described by Ota in 1939.[18] It is characterized by blue-black or gray-brown dermal melanocytic pigmentation on the face.

EPIDEMIOLOGY

Even though nevus of Ota has been described in different skin types, it is most commonly seen in the Asian population with 0.6% of this population affected.[19,20] Onset is usually noted at birth and in females, although it may be noted for the first time in early childhood or puberty.

CLINICAL FEATURES

Unilateral blue-black or gray-brown dermal melanocytic pigmentation is typically seen in areas innervated by the first and second branches of the trigeminal nerve.[21] Nevus of Ota is now subclassified as mild (Type 1), moderate (Type 2), intensive (Type 3), and bilateral (Type 4).

Of those affected, 60% have scleral pigmentation. Other sites of mucosal pigmentation include the conjunctiva and tympanic membrane (oculodermal melanocytosis) (Fig. 77-2).

Malignant melanoma may rarely develop in a nevus of Ota. This necessitates careful followup of the lesion, especially if it occurs in white patients, in whom malignant degeneration seems to be more frequent. Malignant melanocytic tumors in association with nevus of Ota have been shown to arise in the choroidea, brain, orbit, iris, ciliary body, and optic nerve. In addition, association with ipsilateral glaucoma and intracranial melanocytosis has been described.

ETIOLOGY AND PATHOGENESIS

Various triggers, including infection, trauma, ultraviolet light exposure, and hormonal influences, have been described.

DIAGNOSIS

The diagnosis is usually made clinically but may be confirmed on histology, which reveals evenly spread melanocytes throughout the entire dermis.

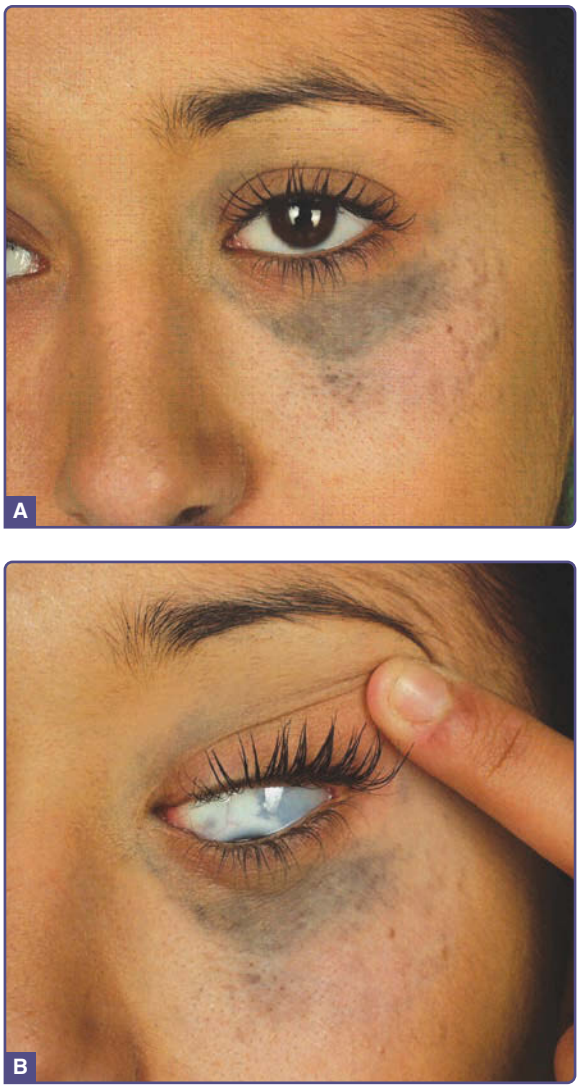

Figure 77-2 Nevus of Ota in a 20-year-old woman. **A,** Hyperpigmentation around the orbit. **B,** The hyperpigmentation extends into the sclera.

DIFFERENTIAL DIAGNOSIS

Bilateral cases should be differentiated from Hori nevus, which is acquired, does not have mucosal involvement, and is less pigmented.

Other dermal melanocytoses include nevus of Ito, Mongolian spots, and dermal melanocyte hamartomas (Table 77-1). Associated vascular malformations have been described in phakomatosis pigmentovascularis (port-wine stain type, Klippel-Trenaunay or Sturge-Weber syndrome).

CLINICAL COURSE AND PROGNOSIS

Nevus of Ota is persistent and does not usually undergo spontaneous regression.

MANAGEMENT

Topical therapies are ineffective in the treatment of this dermal pigmentation. Even though cryotherapy and surgery have been used in the past, they should be avoided because of significant scarring. Laser surgery is the treatment of choice with quality-switched (QS) lasers including quality-switched ruby laser, QS alexandrite laser and QS neodymium:yttrium-aluminum-garnet (Nd:YAG) laser having the most success in the treatment of this condition. Picosecond lasers also have been reported as effective in treating this condition.[22]

NEVUS OF ITO

AT-A-GLANCE

- Congenital circumscribed brown-tan hyperpigmentation with dermal melanocytosis.
- Considered a variant of nevus of Ota.
- Involvement of the acromioclavicular and deltoid region.

Nevus of Ito is a congenital dermal melanocytosis first described by Ito in 1954 as nevus fuscoceruleus acromiodeltoideus.[23] It can be considered as a variant of nevus of Ota.

Clinical, demographic, and histologic characteristics are similar to nevus of Ota and both lesions can occur simultaneously (see Table 77-1 and Fig. 77-3).

MONGOLIAN SPOTS

AT-A-GLANCE

- Congenital circumscribed blue-tinged hyperpigmentation caused by dermal melanocytosis.
- Mainly occurs in persons with skin of color.
- Usually occurs in the sacral region.

EPIDEMIOLOGY

Mongolian spots are more common in the African, Asian, and Hispanic populations and are only rarely seen in whites.[24] They occur in both sexes with a slight male predominance.

TABLE 77-1
Differential Diagnosis and Management of Dermal Melanocytosis

	NEVUS OF OTA	NEVUS OF ITO	MONGOLIAN SPOT	NEVUS OF HORI	DERMAL MELANOCYTE HAMARTOMA
Epidemiology	▪ Mostly congenital ▪ Sporadic (rare familial cases) ▪ Asian and female predominance	▪ Mostly congenital ▪ Sporadic (rare familial cases) ▪ Asian and female predominance	▪ Congenital ▪ Often familial ▪ Asian, African, and Hispanic populations with slight male predominance	▪ Acquired ▪ Familial or sporadic ▪ Asian and female predominance	▪ Congenital
Clinical presentation	▪ Blue to slate-gray mottled macular hyperpigmentation	▪ Blue to slate-gray mottled macular hyperpigmentation	▪ Uniform blue to slate-gray macular hyperpigmentation	▪ Brown-blue progressing to slate-gray mottled macular hyperpigmentation	▪ Mottled hyperpigmentation with small blue-gray macules in a diffuse pigmented patch
Distribution	▪ Trigeminal nerve	▪ Acromioclavicular nerve	▪ Lower back and sacrum	▪ Especially malar region of the cheek (also forehead, upper eyelids, temple)	▪ Dermatomal distribution
Histology	▪ Spindle-shaped melanocytes diffusely throughout the dermal layers; sometimes more band-like melanocytic proliferation and stromal fibrotic reaction	▪ Spindle-shaped melanocytes diffusely throughout the dermal layers; sometimes more band-like melanocytic proliferation and stromal fibrotic reaction	▪ Spindle-shaped melanocytes diffusely throughout the dermal layers	▪ Dermal melanocytes in the upper and mid dermis	▪ Dermal melanocytes in the upper two-thirds of the dermis (including subpapillary layer)
Therapy	▪ Quality-switched laser ▪ Cryotherapy ▪ Surgery	▪ Quality-switched laser ▪ Cryotherapy ▪ Surgery	▪ Usually spontaneous regression during childhood	▪ Quality-switched laser in combination with bleaching cream and chemical peels	▪ None
Associated features	▪ Rare malignant transformation	▪ No associated features of medical concern	▪ Possible association with inborn errors of metabolism	▪ No associated features of medical concern	▪ None

Figure 77-3 Nevus of Ito on the back of a Middle Eastern adolescent.

CLINICAL FEATURES

Well-circumscribed, blue-tinged hyperpigmented macules in the sacral area are most commonly seen (Fig. 77-4). Mongolian spots also can be found in the gluteal and lumbar regions and on the thorax, abdomen, arms, legs, and shoulders.

Several cases are described with extensive Mongolian spots involving large areas of the trunk and extremities that are associated with inborn errors of metabolism, such as lysosomal storage diseases, GM_1-gangliosidosis and mucopolysaccharidosis.[25]

ETIOLOGY AND PATHOGENESIS

Histologically, these macules consist of spindle-shaped melanocytes in the lower dermis that have failed to migrate to the dermal–epidermal junction during fetal life.

Figure 77-4 Classic Mongolian spots in the lumbosacral region and aberrant or extrasacral Mongolian spots on the back.

DIAGNOSIS

The diagnosis is usually made clinically, but may be confirmed on histology.

DIFFERENTIAL DIAGNOSIS

Table 77-1 outlines the differential diagnosis and management of Mongolian spots.

CLINICAL COURSE AND PROGNOSIS

In most cases, Mongolian spots spontaneously regress during childhood, but persistence into adulthood has been described.

MANAGEMENT

Spontaneous resolution usually means treatment can be avoided but laser treatment in childhood or adolescence can give favorable results, especially in sacral Mongolian spots.

DERMAL MELANOCYTE HAMARTOMA

AT-A-GLANCE

- Congenital, circumscribed, blue-tinged hyperpigmentation with dermal melanocytosis.
- Dermatomal patterns have been described.

Dermal melanocyte hamartoma is a distinctive form of congenital dermal melanocytosis, first described by Burkhart and colleagues in 1981.[26] Gray-blue pigmentation, caused by melanocytes residing in the dermis, occurs in a dermatomal pattern.

FAMILIAL LENTIGINOSIS SYNDROMES

AT-A-GLANCE

- Congenital conditions causing well-circumscribed pigmentation with lentiginosis.
- Causes include Peutz-Jeghers syndrome, LEOPARD (lentigines, electrocardiographic abnormalities, ocular hypertelorism, pulmonary stenosis, abnormalities of genitalia, retardation of growth, and deafness) syndrome, Carney complex, Bannayan-Ruvalcaba-Riley syndrome, and centrofacial lentiginosis.

Familial lentiginosis syndromes are characterized by the presence of lentigines—well-circumscribed brown macules (usually <5 mm in diameter), which have an increased number of melanocytes in the epidermis (epidermal melanocytic hypermelanosis) and an increased incidence of cardiovascular, endocrine, or GI neoplasias. Familial lentiginosis syndromes include Carney complex, Peutz-Jeghers syndrome (PJS), LEOPARD syndrome (lentigines, electrocardiogram conduction defects, ocular hypertelorism, pulmonary stenosis, abnormalities of genitalia, retardation of growth, and sensorineural deafness), arterial dissection and lentiginosis, Laugier-Hunziker syndrome, familial benign lentiginosis, Bannayan-Ruvalcaba-Riley syndrome (BRRS), centrofacial lentiginosis, and segmental and agminated lentiginosis.[27] Genetic loci and gene mutations have been identified for Carney complex, PJS, and BRRS.

PEUTZ-JEGHERS SYNDROME

PJS was first described by Peutz (1921) and Jeghers (1949).[28] It is a rare autosomal dominant genodermatosis with a predisposition for development of malignancies. More than half of all cases of PJS can be attributed to a mutation in STK11 (LKB1) on chromosome 19 (19q13.3),[29] which is thought to act as a tumor-suppressor gene. Close surveillance of PJS patients for malignancies from a young age is warranted.

Mucocutaneous pigmentation and intestinal hamartomatous polyposis are hallmarks of the condition (Fig. 77-5). The pigmentary lesions resemble those of Carney complex, with small hyperpigmented (brown-gray) macules typically appearing in childhood (not present at birth) on the lips and buccal mucosa; however, they may also involve the eyelids, hands, and feet. Quality-switched laser or intense pulsed light can be used to treat the pigmented lesions.

The most common malignancies associated with PJS are GI (small intestine, colorectal, stomach, pancreas), but nongastrointestinal neoplasms, such as breast, cervix, and endocrine tumors (thyroid, testicular, ovarian), have been described.

LEOPARD SYNDROME

LEOPARD syndrome is a rare autosomal dominant condition caused by a heterozygous missense mutation in the *PTPN11* gene, coding for the protein tyrosine phosphatase SHP-2 and situated on chromosome 12 (12q24.1). LEOPARD syndrome is allelic to Noonan syndrome and shares several clinical features with this disorder.[30] The characteristic lentigines usually develop during childhood and in the first months of life (Fig. 77-6). Clinical diagnosis is primarily based on the typical facial features and the presence of hypertrophic cardiomyopathy and/or café-au-lait macules (CALMs). Recently, missense mutations in the *RAF1* gene were found in 2 LEOPARD syndrome patients in whom no *PTPN11* mutations could be discovered.

CARNEY COMPLEX

Carney complex is an autosomal dominant disorder first described by Carney and colleagues in 1985.[31] Clinical components of Carney complex include spotty skin pigmentation, myxomas (heart, skin, breast), endocrine tumors (primary pigmented nodular adrenal disease [Cushing syndrome], testicular large-cell calcifying Sertoli cell tumor [sexual precocity], pituitary adenoma [acromegaly], thyroid tumors, ovarian cysts), and schwannomas.[27] Multiple types of hyperpigmentation, such as lentigines, ephelides, blue nevi, junctional, dermal and compound nevi, and café-au-lait spots, have been described.[32] The typical lesions consist of spotty centrofacial pigmentation involving the vermilion border of the lips, the lacrimal caruncle, the conjunctival semilunar fold, and sometimes the sclera. Intraoral-pigmented spots are present in a limited number of cases. In at least half of the patients with Carney complex, a mutation in the gene encoding protein kinase A regulatory subunit 1A (PRKAR1A) mapped to 17q22-24 has been identified.[33]

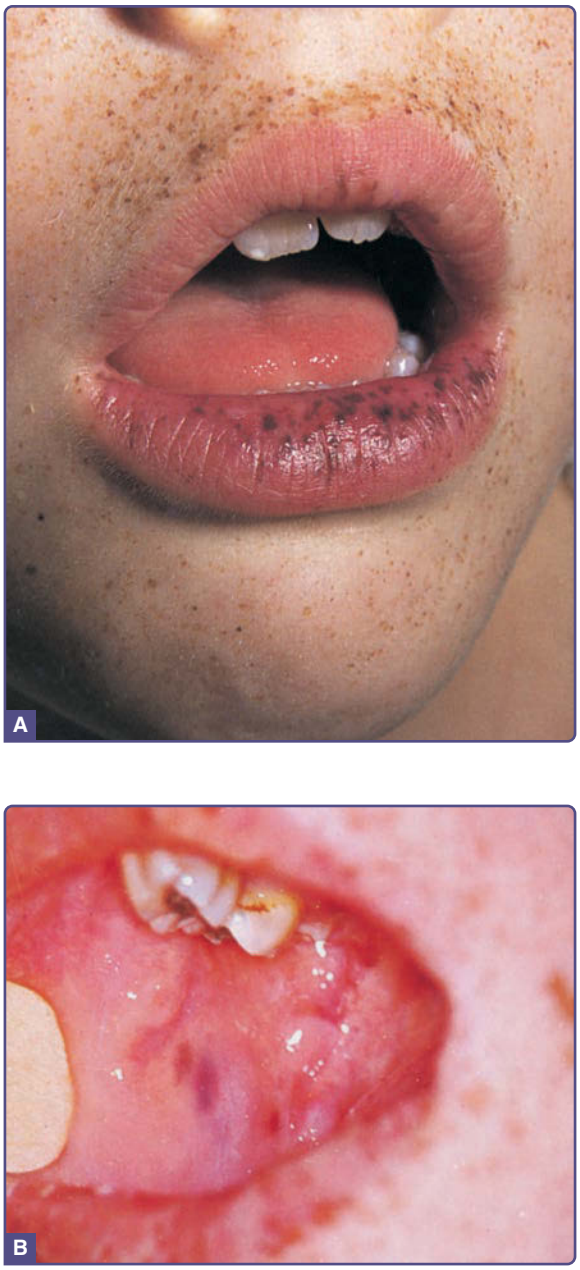

Figure 77-5 Peutz-Jeghers syndrome. **A,** Lentigines, which are dark-brown to gray-blue, appear on the lips, around the mouth, and on the fingers. Lip macules may, over time, disappear. **B,** Macules of the buccal mucosa are blue to blue-black and are pathognomonic; unlike lip lesions, these do not tend to disappear with time.

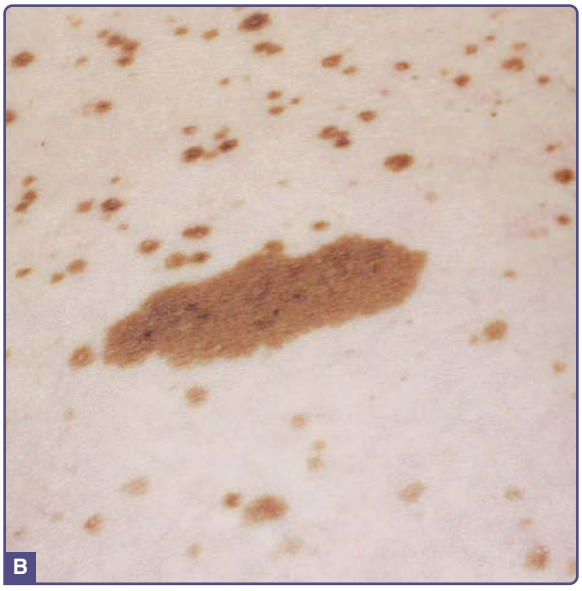

Figure 77-6 LEOPARD (lentigines, electrocardiogram conduction defects, ocular hypertelorism, pulmonary stenosis, abnormalities of genitalia, retardation of growth, and sensorineural deafness) syndrome. **A** and **B,** A 27-year-old woman with LEOPARD syndrome. Note the characteristic widespread lentigines and several café-au-lait macules.

BANNAYAN-RILEY-RUVALCABA SYNDROME

BRRS is a second autosomal dominant hamartomatous polyposis syndrome. This designation replaces 3 previously described entities: (a) Riley-Smith, (b) Bannayan-Zonana, and (c) Ruvalcaba-Myhre-Smith syndromes.[34] It is characterized by the classical triad of macrocephaly, genital lentiginosis, and intestinal polyposis. Besides the genital lentiginosis (sometimes presenting as larger CALMs), mucocutaneous manifestations include vascular malformations, lipomatosis, multiple acrochordons, and verrucous facial papules. More than 60% of BRRS patients show germline mutations in the *PTEN* (phosphatase and tensin homolog) gene on chromosome 10q23.3, a gene that is mutated in Cowden syndrome, which displays partial clinical overlap with BRRS[34] Recently, the PTEN hamartoma tumor syndrome, encompassing 4 allelic disorders (Cowden syndrome, BRRS, Proteus syndrome, and Proteus-like syndrome), has been described.[35]

CENTROFACIAL LENTIGINOSIS

A horizontal band of lentigines across the central face is the hallmark of the autosomal dominant centrofacial lentiginosis syndrome. Other associated signs and symptoms include bone abnormalities, endocrine dysfunctions, neural tube defects, and mental retardation.[36]

FAMILIAL CAFÉ-AU-LAIT SYNDROMES

AT-A-GLANCE

- Congenital circumscribed hypermelanosis with café-au-lait macules (CALMs) are seen in conditions like familial multiple CALMs (Legius syndrome), neurofibromatosis Type 1, McCune-Albright syndrome, Bloom syndrome, Watson syndrome, and Silver-Russel syndrome.
- Well circumscribed hypermelanosis with CALMs.

CALMs consist of well-demarcated hyperpigmented patches of skin, varying in size from 0.5 cm to more than 20 cm. They are often present at birth or appear in the first few months of life. Between 0.3% and 18% of all newborns display isolated CALMs.[37] Histologically, isolated CALMs show a normal number of melanocytes but increased epidermal melanin (epidermal melanotic hypermelanosis). Multiple CALMs are well-known markers for several multisystem disorders.

LEGIUS SYNDROME

Legius syndrome is also known as familial multiple CALMs and is autosomal dominant with mutations in the *SPRED1* gene (15q13.2). Multiple CALMs are present and axillary freckling and lipomas may be seen, but no neurofibromas are demonstrated. Macrocephaly and developmental delays are noted but are less severe than what is seen in neurofibromatosis Type 1.[38,39]

NEUROFIBROMATOSIS TYPE 1

Neurofibromatosis Type 1 (NF1) was first recognized by Friedrich von Recklinghausen in 1882 and is also called von Recklinghausen disease (see Chap. 135 for detailed discussions).

NF1 is an autosomal dominant disease caused by a mutation in the *NF1* gene that encodes the neurofibromin protein. The most important neurofibromin function involves downregulation of the Ras signal transduction pathway; consequently, it is considered a tumor-suppressor gene.

NF1 has been considered a neurocristopathy and is characterized by a number of cutaneous and noncutaneous pigment cell-related manifestations such as CALMs, intertriginous freckling, and iris Lisch nodules. (Chap. 135 discusses the clinical diagnostic criteria for NF1.) The presence of 6 or more CALMs larger than 5 mm in greatest diameter in prepubertal individuals or larger than 15 mm after puberty is one of the hallmarks of the disease. NF1-associated CALMs, contrary to isolated CALMs, contain a significantly increased number of melanocytes in the epidermis. Intertriginous freckles, pathognomonic for NF1, also display increased numbers of epidermal melanocytes, which differentiates them from ordinary freckles (ephelides).

MCCUNE-ALBRIGHT SYNDROME

McCune-Albright syndrome was first described by McCune (1936) and Albright (1937) as a triad of poly/monostotic fibrous dysplasia, CALMs, and hyperfunctioning endocrinopathies, including precocious puberty, hyperthyroidism, hypercortisolism, hypersomatotropism, and hypophosphatemic rickets.[40] The CALMs are fewer in number and have more irregular borders than those seen in NF1. They are classically demarcated at the midline. McCune-Albright syndrome is caused by a postzygotic activating mutation of the α subunit of the cyclic adenosine monophosphate–regulating Gs protein. Consequently, a mosaic distribution of McCune-Albright syndrome cells bears the constitutively active adenylate cyclase.

BLOOM SYNDROME

Bloom syndrome is a rare, autosomal recessive, genetic-immunodeficiency-and-cancer-predisposition syndrome. It is characterized by a growth deficiency, unusual facies, CALMs, and a sun sensitivity with telangiectasia and erythema that can result in atrophy and scarring. Neoplasias that occur frequently in Bloom syndrome are acute leukemia, lymphoma, and squamous cell carcinoma.[41] Bloom syndrome is caused by a DNA repair defect, which results in genomic instability, including a high frequency of sister-chromatid exchanges.[42] The causative gene *BLM* has been mapped to 15q26.1 and encodes the BLM RecQ helicase homolog protein, a well-known member of the DNA helicase family, closely related to the helicases that is also defective in Werner syndrome and Rothmund-Thomson syndrome.[43]

WATSON SYNDROME

Watson syndrome is an autosomal dominant condition made up of pulmonary valvular stenosis, CALMs, and lower intelligence, that was first described by Watson in 1967.[44] Later, the clinical phenotype of Watson syndrome was expanded with features overlapping with NF1 (macrocephaly, Lisch nodules, neurofibromas, short stature, intertriginous freckling), and it was shown to be allelic to NF1.[45] Recent studies suggest an overlap of Watson syndrome with neurofibromatosis-Noonan syndrome.

SILVER-RUSSELL SYNDROME

Silver–Russell syndrome (SRS) is a clinically and genetically heterogeneous disorder first described by Silver (1953) and Russell (1954).[46,47] Cardinal features of the disease are low birth weight, short stature resulting from intrauterine and postnatal growth retardation, and a small triangular face. Other associated symptoms include clinodactyly of the fifth finger, relative macrocephaly, and facial, limb, or body asymmetry. CALMs are a variable SRS feature. One or 2 CALMs are present in up to 20% of SRS patients. Many SRS cases are sporadic, but familial cases with different modes of inheritance have been described. Maternal uniparental disomy for chromosome 7 occurs in approximately 10% of patients, and several candidate regions for the SRS gene mutation have been described on this chromosome (7p11.2-p13, 7q31-qter, and 7q21). Other possible gene candidates could be situated on the long arm of chromosome 17 or on chromosome 11p15. Recently, methylation defects in the H19 imprinted domain chromosome 11p15 has been implicated in 35% to 65% of SRS cases.[48]

ACQUIRED HYPERMELANOSIS

ENDOCRINOPATHIES

AT-A-GLANCE

- Diffuse, nonpatterned hyperpigmentation may be seen in conditions like Addison disease, Cushing syndrome, Nelson syndrome, pheochromocytoma, carcinoid syndrome, hyperthyroidism, acanthosis nigricans, and diabetes.
- Circumscribed hyperpigmentation may be seen in conditions like acanthosis nigricans and maturational dyschromia

ADDISON DISEASE

Chapter 137 discusses endocrine diseases in detail.

Addison disease is a clinical syndrome characterized by salt-wasting and diffuse cutaneous

hyperpigmentation. In the developed world, Addison disease is usually autoimmune. It is associated with adrenal insufficiency with inadequate secretion of corticosteroid and androgenic hormones, leading to compensatory overproduction of adrenocorticotropic hormone (ACTH) by the pituitary gland.

Hyperpigmentation is the most striking cutaneous sign of patients with chronic Addison disease and is the consequence of ACTH binding to the melanocortin-1 receptor. The hyperpigmentation occurs preferentially on sun-exposed areas (face, neck, hands), sites of trauma, scars, chronic pressure (knees, spine, knuckles, elbows, shoulders), in the palmar creases, nipples, areolae, axillae, perineum, and genitalia.

CUSHING SYNDROME

Chapter 137 discusses endocrine diseases in detail.

Cushing syndrome is characterized by clinical signs and symptoms caused by chronic glucocorticoid excess.

Various degrees of hyperpigmentation can be seen. It is usually most severe in patients with the ectopic ACTH syndrome. Patients present with generalized hyperpigmentation with accentuation in areas of sun exposure, chronic mild trauma, and pressure (shoulders, midriff, waist, elbows, knuckles, spine, knees), and on mucosal surfaces.

NELSON SYNDROME

Nelson syndrome comprises an enlarging pituitary tumor associated with elevated fasting plasma ACTH levels, hyperpigmentation, and neuroophthalmologic symptoms in patients with Cushing disease after bilateral adrenalectomy and inadequate hormonal replacement.[49]

PHEOCHROMOCYTOMA

Pheochromocytoma is a chromaffin cell tumor of the adrenal medulla with associated excessive production of catecholamines. Pallor of the face resulting from vasoconstriction may be observed. In contrast, addisonian-like hyperpigmentation has been reported and is probably caused by ectopic ACTH and melanocyte-stimulating hormone production by the tumor. Pigmentation rapidly fades after surgical treatment.[50]

CARCINOID SYNDROME

Diffuse hyperpigmentation resulting from melanocyte-stimulating hormone–producing tumors, such as gastric or thymic carcinoid tumors, have been described in carcinoid syndrome. Carcinoid syndrome also can be accompanied by a pellagra-like rash occurring on light-exposed skin. The rash is secondary to a tryptophan deficiency, as a large amount of dietary tryptophan is diverted to serotonin by the tumor. Treatment of the underlying tumor is critical in the management of affected patients.

HYPERTHYROIDISM

Chapter 137 discusses endocrine diseases in detail.

Thyrotoxicosis has multiple causes. The most common cause is Graves disease, characterized by circulating antibodies against thyroid-stimulating hormone receptors.

The occurrence of hyperpigmentation in thyrotoxic patients has been estimated to be from 2% to as high as 40% in large series. The increased cutaneous pigmentation can be localized or generalized and is more common in those with dark skin. The distribution of hyperpigmentation is often similar to that in Addison disease with pigment deposition in the creases of the palms and soles. However, in contrast to Addison disease, involvement of the mucous membranes is uncommon and pigmentation of the nipples and genital skin is less striking. Hyperpigmentation associated with thyrotoxicosis is thought to be the result of an increased release of pituitary ACTH, compensating for accelerated cortisol degradation. The response of hyperpigmentation to therapy for the hyperthyroidism is reported to be poor.[51] Autoimmune Graves disease has been reported in association with vitiligo.

DIABETES

Chapter 137 discusses diabetes in detail.

Diabetic dermopathy is characterized by asymptomatic, irregular, light-brown, depressed patches on the anterior lower legs, often after mild trauma or the appearance of bullae. The pathogenesis is unknown.

ACANTHOSIS NIGRICANS

Acanthosis nigricans is characterized by thickened hyperpigmented velvety skin most often noted on the neck, axilla, popliteal and antecubital fossae, and inguinal folds (Fig. 77-7). It has, however, also been

Figure 77-7 Acanthosis nigricans on the neck of a young girl of Filipino origin.

described on the face and should be considered in the differential diagnosis of facial hyperpigmentation. When on the face, acanthosis nigricans presents as poorly demarcated hyperpigmentation with a predilection for the malar region inferior to the zygoma and the nasolabial folds, and has even been described on the supraalar creases.[52] Recognizing this entity is becoming steadily more important as the rates of obesity and non–insulin-dependent diabetes increases. Acanthosis nigricans is discussed in more detail in Chap. 137.

MATURATIONAL DYSCHROMIA

Maturational dyschromia is a recently described entity noted in the African and Indian population in the fourth to fifth decades of life. It presents as dark-brown to black poorly demarcated areas of hyperpigmentation on the lateral forehead, temples, and zygoma. Histologic evaluation of hyperpigmented skin reveals mild to moderate proliferation of melanocytes with some reports of a papillomatous epidermis, suggesting a potential link or continuum with acanthosis nigricans.[53] The etiology is still unclear and further research of this disorder is needed (Fig. 77-8).

NUTRITIONAL CONDITIONS

Chapter 123 discusses nutritional disease in detail. Diffuse, nonpatterned pigmentary changes can be secondary to nutritional conditions such as kwashiorkor, vitamin B_{12} deficiency, folic acid deficiency, or pellagra. The skin changes are reversible if the nutritional deficiency is corrected.

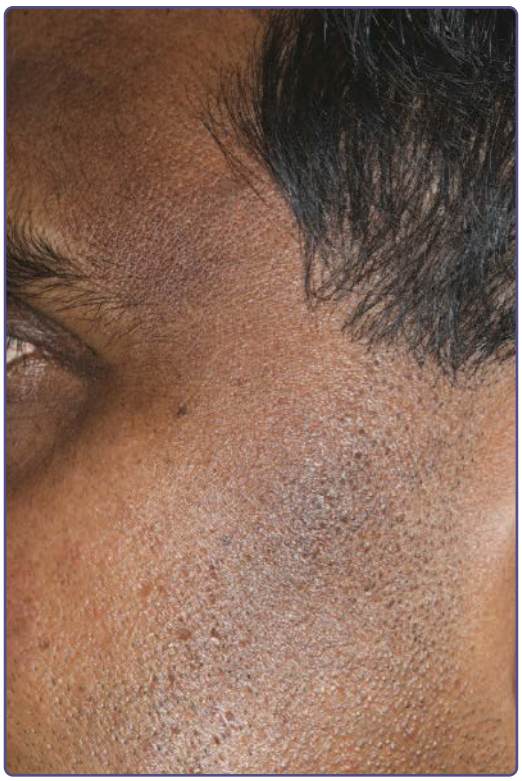

Figure 77-8 Maturational dyschromia on the temple and the lateral zygoma of a middle-aged Indian man.

KWASHIORKOR

Kwashiorkor is the result of severe protein malnutrition in the presence of adequate caloric intake. It is a significant cause of death in children between 6 months and 5 years of age in developing countries, and is often associated with GI parasitoses. A child with kwashiorkor ceases to gain weight and becomes irritable and apathic, and develops edema, hepatomegaly, diarrhea, muscle wasting, and photophobia. Cutaneous manifestations are present in most cases. Skin changes usually begin with hypopigmentation of the face. In areas exposed to friction and pressure, such as knees, elbows, and buttocks, hyperkeratoses and scaling in association with hyperpigmentation develop, giving the skin a "flaky paint" appearance. Removing the scale leaves superficial erosions that turn into pale patches. Hair may become hypopigmented. Sometimes there are bands of hypopigmentation along the hair shafts (flag sign), a result of periods of worse malnutrition. Treatment of kwashiorkor consists of replacing protein sources. Changes in skin and hair are reversed by proper nutritional treatment.[54]

Kwashiorkor-like syndrome also has been described in cases of protein loss and malnutrition secondary to bowel disorders such as ulcerative colitis.

VITAMIN B_{12} DEFICIENCY

Cobalamin or vitamin B_{12} deficiency is caused by atrophic gastritis caused by *Helicobacter pylori* infection or an autoimmune process directed against gastric parietal cells, which lead to severe "intrinsic factor" deficiency (pernicious anemia). Blood examination reveals megaloblastic anemia and low levels of vitamin B_{12}. Associated generalized hyperpigmentation of the skin and hypopigmentation/depigmentation or early graying of the hair have been reported. Skin histology shows increased melanin in the basal layer. Electron microscopy reveals a normal complement of melanosomes in melanocytes and surrounding keratinocytes. These findings suggest that an increase in melanin synthesis rather than a defect in melanin transport causes vitamin B_{12} deficiency–associated hyperpigmentation. Supplementation with vitamin B_{12} reverses the hyperpigmentation.

Pernicious anemia is an autoimmune disorder and has been reported in association with vitiligo.[55]

FOLIC ACID DEFICIENCY

Folic acid deficiency associated with megaloblastic anemia has been reported to cause hyperpigmentation of the skin.

PELLAGRA

Pellagra is caused by a deficiency of niacin (vitamin B_3) or its derivatives. The disease is rare and can be caused

by chronic alcoholism, certain drugs (isoniazid, anticonvulsants), malabsorption secondary to inflammatory bowel disease, celiac disease, and carcinoid tumors. Pellagra is characterized by the clinical triad of dermatitis, dementia, and diarrhea. The first skin changes are erythema and edema following sun exposure, which fade with a dusky brown–red coloration on face, neck, and dorsal surfaces of the hands, arms, and feet. Later on the lesions become hyperpigmented, hyperkeratotic, and scaly with fissures and crusts ("goose-like"). Niacin supplementation causes a rapid clinical response.[56]

METABOLIC CONDITIONS

AT-A-GLANCE

- Porphyria cutanea tarda and hemochromatosis may cause diffuse nonpatterned hyperpigmentation accentuated in photoexposed sites.

PORPHYRIA CUTANEA TARDA

Chapter 124 discusses the porphyrias in detail.

Porphyria cutanea tarda is a metabolic disorder affecting the synthesis of heme. It is associated with diffuse brown hyperpigmentation, which is accentuated in photoexposed areas. In females, a melasma-like hyperpigmentation of the face may be observed.

HEMOCHROMATOSIS

Hemochromatosis is a disease of iron storage with a heterogeneous genetic basis that results in lowered levels of hepcidin. Approximately 10% of the population has a mutation in the hemochromatosis gene, with a lower prevalence noted in Africans and Asians compared with northern Europeans. This leads to increased intestinal absorption and deposition of iron in the liver, pancreas, and other organs, including the skin.[57] Because hemochromatosis is now usually diagnosed early, hyperpigmentation is less frequently observed. Historically, hemochromatosis was diagnosed at an advanced stage with a classic triad of hyperpigmentation, diabetes mellitus ("bronze diabetes"), and hepatic cirrhosis. Darkening of the skin was present in 70% of the patients because of 2 different mechanisms: (a) hemosiderin deposition causing a diffuse, slate-gray color, and (b) increased epidermal melanin production. The pigmentation is usually generalized, but may be more pronounced in photoexposed areas, genitalia, and scars. Skin bronzing is reversible with phlebotomy, which remains the mainstay of treatment for this condition. Deferoxamine is most commonly used in secondary hemochromatosis.

TUMORAL CONDITIONS

MAST CELL DISORDERS AND MELANOMA

Mast cell disorders and melanoma can lead to diffuse, nonpatterned hyperpigmentation and are discussed in Chaps. 42 and 116, respectively. Diffuse, generalized melanosis associated with advanced metastatic melanoma is a rare, although well-documented, condition. It is characterized by a slate bluish-gray to brown discoloration of the skin. Histology reveals melanin particles and melanin-containing histiocytes and dendritic cells in the dermis and subcutaneous fat. No melanoma cells can be detected in the skin, and there is no increase in epidermal melanin pigment or number of melanocytes. Melanosomes circulating in the blood have been detected, supporting the hypothesis that diffuse melanosis may result from tumor lysis with release of their organelles into the circulation and subsequent deposition in the skin.

PHYSICAL CAUSES

AT-A-GLANCE

- Ultraviolet, ionizing, and thermal radiation may cause diffuse nonpatterned hyperpigmentation in the area(s) affected.
- Trauma may cause localized hyperpigmentation in areas of chronic friction.

ULTRAVIOLET RADIATION AND PIGMENTATION

Chapter 20 discusses pigmentation in detail.

A major acute effect of ultraviolet radiation on normal human skin is tanning.

IONIZING RADIATION

Chapter 200 discusses radiotherapy in detail.

Exposure of skin to ionizing radiation during accidents or after local fractionated radiotherapy can give rise to a cutaneous radiation syndrome characterized by fibrosis, keratosis, telangiectasias, and sharply demarcated lentiginous hyperpigmentation, resembling ultraviolet-induced lentigines (radiation dermatitis). Small hypopigmented macules can be intermingled with zones of hyperpigmentation. Histology reveals altered melanin content in melanocytes and basal keratinocytes. Electron-beam therapy

has been reported to induce tan-like transient hyperpigmentation and transverse melanonychia when nails are exposed.[58]

THERMAL RADIATION

In superficial thermal burn injuries, when the melanocyte-bearing basal epidermis has not been destroyed, various degrees of hyperpigmentation result, depending on the patient's skin color and time after the injury. Thermal injury resulting from laser therapy with intense, high-dose visible light also can give rise to hyperpigmentation, especially in dark-skinned patients. Cryotherapy, tissue destruction by application of cold, commonly causes (sometimes permanently) hypopigmentation in combination with peripheral hyperpigmentation in treated skin as a result of melanocyte injury.[59]

FRICTION MELANOSIS

Frictional melanosis in an acquired pigmentary disorder caused by repeated rubbing of the skin, especially over bony prominences. Marked increase in melanin and melanin incontinence is seen histologically.[60] Diffuse hyperpigmentation is noted with some cases revealing mild lichenification.

TOXINS AND MEDICATIONS

AT-A-GLANCE

- Toxins and medications are a common cause of acquired, diffuse, nonpatterned hyperpigmentation.
- Fixed drug eruptions may cause well-demarcated brown-gray mucocutaneous macules.
- Hyperpigmentation may be caused by direct deposition of the drug into the skin, deposition of melanin or melanin-drug complex in the dermis, or nonmelanin pigment produced by the drug.
- Treatment involves cessation of the offending medication, and quality-switched and picosecond lasers.

Hyperpigmentation caused by toxic agents or medication accounts for 10% to 20% of all cases of acquired hyperpigmentation. CNS drugs, antineoplastic agents, antiinfectious drugs, antihypertensive medications, and hormones are most often the responsible agents (Table 77-2).

CLINICAL FEATURES

Clinical features vary with characteristic sites, patterns, and shades of discoloration noted with particular medications and toxins. Bluish-slate gray pigmentation is characteristic of dermal deposition of pigment. Pigmentation associated with melanin accumulation often worsens with sun exposure.

A linear, sometimes flagellate hyperpigmentation can be observed in patients taking bleomycin or zidovudine. A diffuse hyperpigmentation on the palms and soles may be present in patients taking cyclophosphamide or doxorubicin. Diffuse slate-gray pigmentation also may be seen at the site of IV iron infusion (Fig. 77-9). Bleomycin and doxorubicin may produce localized hyperpigmentation around small joints. Estrogen-related hormonal substances and phenytoin-like medication may cause melasma-like pigmentation. Nail unit involvement can be observed with some medications, most frequently chemotherapeutic agents such as cyclophosphamide, zidovudine, psoralens, minocycline, antimalarials, and gold. Mucosal hyperpigmentation has been reported with cyclophosphamide, doxorubicin, zidovudine, minocycline, and some heavy metals.

Amiodarone can produce blue-gray pigmentation in photoexposed areas from accumulation of a lipid-like substance in macrophages. Some of these patients display photosensitivity (Fig. 77-10). Chloroquine may give rise to a yellow-brown to bluish-gray pigmentation on the face, neck, lower extremities, and forearms after several years of intake, a result of deposition of a drug–melanin complex in the dermis. The nail unit and hard palate also may be involved. Exogenous ochronosis has been reported after chronic hydroquinone use (see section "Ochronosis").

Chlorpromazine and related phenothiazines can produce a bluish-gray cutaneous pigmentation that is worse in photoexposed areas with pigmentation of the conjunctivae.

The risk of minocycline-induced pigmentation increases with prolonged therapy at doses above 100 mg daily.[61] Three types of minocycline-induced pigmentation exist: Type 1 consists of blue-gray pigmentation in normal skin and areas of prior inflammation (often on the face) (Fig. 77-11); Type 2 is noted on the lower legs and forearms; and Type 3 is diffuse muddy brown photoexacerbated pigmentation. Pigmentation of the nails, sclerae, oral mucosa, thyroid, bones, and teeth also has been reported.

Argyria patients present with a generalized grayish-blue pigmentation caused by silver ingestion. The nails and the sclerae also may be involved.

Although medication-induced pigmentation usually results in diffuse hyperpigmentation, fixed drug eruptions must be considered when well-demarcated mucocutaneous hyperpigmented macules are the presenting sign (Fig. 77-12). A preceding history of erythema and possible itching with pigmentation as the lesion resolves is classically seen after use of nonsteroidal antiinflammatory medications, certain antibiotics, and drugs containing codeine.

TABLE 77-2
Medications Reported to Cause Hyperpigmentation

TOPICAL TREATMENTS	ANTIINFECTIOUS DRUGS	CNS DRUGS	ANTINEOPLASTIC AGENTS	MISCELLANEOUS
Aminolevulinic acid	Amphotericin B	Amitriptyline	Bevacizumab	Alitretinoin
Carmustine (BCNU)	Ceftriaxone	Carbamazepine	Bleomycin	Amiodarone
Bergamot	Chloroquine	Chlorpromazine	Busulfan	Azathioprine
Bimatoprost	Cidofovir	Citalopram	Capecitabine	Cetirizine
Carteolol	Clofazimine	Clomipramine	Carboplatin	Cevimeline
Chlorhexidine	Dapsone	Clonazepam	Carmustine	Cyclobenzaprine
Hydroquinone	Demeclocycline	Desipramine	Cisplatin	Cyclosporine
Imiquimod	Doxycycline	Diazepam	Cyclophosphamide	Deferoxamine
Latanoprost	Emtricitabine	Donepezil	Dactinomycin	Dicumarol
Nitrogen mustard	Enoxacin	Eletriptan	Daunorubicin	Dinoprostone
Tretinoin	Foscarnet	Fluoxetine	Doxorubicin	Etodolac
Antihypertensive drugs	Ganciclovir	Fluphenazine	Epirubicin	Glatiramer
Acebutolol	Grepafloxacin	Fluvoxamine	Estramustine	Heroin
Betaxolol	Griseofulvin	Haloperidol	Etoposide	Interferon
Bisoprolol	Hydroxychloroquine	Imipramine	Floxuridine	Isotretinoin
Captopril	Indinavir	Kava	Fluorouracil	Ketoprofen
Clonidine	Ketoconazole	Loxapine	Hydroxyurea	Leflunomide
Diltiazem	Linezolid	Mephenytoin	Ifosfamide	Levobupivacaine
Esmolol	Lomefloxacin	Mesoridazine	Irinotecan	Lidocaine
Indapamide	Minocycline	Methamphetamine	Mechlorethamine	Methimazole
Labetalol	Ofloxacin	Molindone	Mercaptopurine	Methoxsalen
Methyldopa	Oxytetracycline	Olanzapine	Methotrexate	Methysergide
Metoprolol	Pyrimethamine	Paroxetine	Mitomycin	Metoclopramide
Minoxidil	Quinacrine	Perphenazine	Mitotane	Niacin
Nisoldipine	Quinine	Phenytoin	Mitoxantrone	Nicotine
Propranolol	Ribavirin	Pimozide	Paclitaxel	Orphenadrine
Spironolactone	Rifabutin	Prochlorperazine	Pentostatin	Pantoprazole
Timolol	Rifapentine	Promazine	Procarbazine	Pentazocine
Heavy metals	Saquinavir	Promethazine	Thiotepa	Phenazopyridine
Arsenic	Sertaconazole	Risperidone	Vinblastine	Phenolphthalein
Bismuth	Smallpox vaccine	Ropinirole	Vincristine	Propylthiouracil
Gold (compounds)	Sparfloxacin	Thioridazine	Vinorelbine	Psoralens
Iron	Sulfadiazine	Thiothixene	Hormones	Quinidine
Lead	Terbinafine	Tiagabine	Chlorotrianisene	Rabeprazole
Mercury	Tetracycline	Tolcapone	Corticosteroids	Riluzole
Silver	Voriconazole	Topiramate	Diethylstilbestrol	Sulfasalazine
	Zidovudine	Trifluoperazine	Estrogens	Tacrolimus
		Venlafaxine	Insulin	Toremifene
		Zaleplon	Leuprolide	Trioxsalen
			Medroxyprogesterone	Vitamin A
			Oral contraceptives	
			Progestins	
			Stanozolol	

ETIOLOGY AND PATHOGENESIS

In the majority of cases of medication-induced hyperpigmentation, the underlying pathogenic mechanism involves one of the following.

1. Deposition of melanin in the dermis, usually in macrophages. Sometimes this melanin is complexed to the drug (drug–pigment complex, eg, hydroxychloroquine). Accumulation of melanin can occur after cutaneous inflammation (postinflammatory) and/or DNA damage (eg, carmustine). This type of hyperpigmentation is often increased by ultraviolet exposure and is usually more pronounced in photoexposed areas.
2. Direct deposition of the medication in the skin (eg, carotene, heavy metals). Sometimes this type of pigmentation is accentuated in photoexposed areas, as ultraviolet light can induce a transformation in the deposited drug, which may then become more visible.
3. Nonmelanin pigments synthesized or produced under the direct or indirect influence of the drug may cause cutaneous pigmentation.

DIAGNOSIS

The diagnosis may be made clinically if the characteristic appearance is seen and a temporal relationship

Figure 77-9 Diffuse gray pigmentation secondary to IV iron infusion in the arm of a white woman.

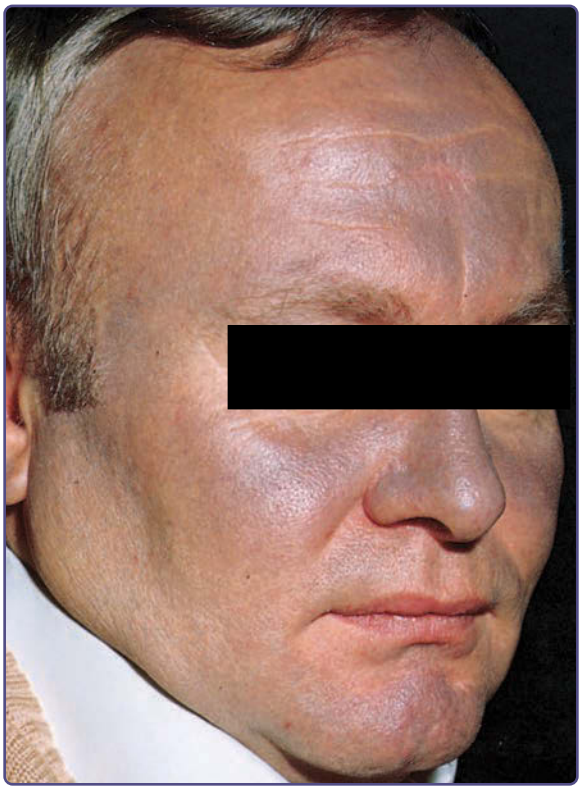

Figure 77-10 Amiodarone hyperpigmentation. This patient exhibits a striking amiodarone-induced, slate-gray pigmentation of the face. The blue color (ceruloderma) is a result of the deposition of a brown pigment in the dermis, contained in macrophages and endothelial cells.

Figure 77-11 Slate-gray minocycline-induced pigmentation on the cheek of a white male.

with exposure to a medication or toxin is noted. A skin biopsy also may be helpful in cases of medication-induced pigmentation.

CLINICAL COURSE AND PROGNOSIS

Ceasing the offending medication is critical, but hyperpigmentation persists in many cases, sometimes for decades, even after discontinuation of the medication.

MANAGEMENT

Sun protection should be advised, especially in forms caused by melanin accumulation. Quality-switched ruby, alexandrite, and Nd:YAG lasers have demonstrated favorable results in some cases (eg, amiodarone and minocycline-induced pigmentation), although multiple treatments spaced over many months is often necessary to achieve clinically notable results. Picosecond lasers have proven efficacious for medication-induced pigmentation in white skin, with fewer treatments over a shorter time frame achieving complete or near complete clearance of the pigmentation.[62]

Figure 77-12 Fixed drug eruption on the face secondary to nonsteroidal antiinflammatory medication in a young Sri Lankan girl.

OCHRONOSIS

AT-A-GLANCE

- May be congenital (autosomal recessive) or caused by the use of certain medications.
- Results in asymptomatic diffuse nonpatterned hyperpigmentation.
- More common in persons with skin of color.
- Characteristic histologic appearance is yellow-brown banana-shaped globules in the dermis.

The term *ochronosis* is derived from the Greek word "ochre," which refers to yellow discoloration. Endogenous and exogenous forms of the condition exist.

EXOGENOUS OCHRONOSIS

Epidemiology: Although the majority of ochronosis cases have been reported in darker racial/ethnic groups in Africa, India, Thailand, China, and Singapore, it also has been described in other skin types. The exact worldwide incidence is unknown but assumed to be low.

Clinical Features: Asymptomatic blue-black and gray-black hyperpigmented macules are characteristic and can be found on the face (malar, temples, lower cheeks), posterolateral neck, back, and extensor skin of the extremities. Later stages include progressive hyperpigmented colloid milium ("caviar-like lesions), papulonodular lesions, and areas of scarring.[63]

No systemic involvement is noted with exogenous ochronosis.

Etiology and Pathogenesis: Exogenous ochronosis results from the use of certain medications, which form a homogentisic acid polymer-like substance during their metabolism. It has been most frequently reported in association with hydroquinone, usually at concentrations greater than 4%, and topicals, such as phenol or resorcinol, and quinine, an oral antimalarial.

Exacerbating factors include unprotected ultraviolet light exposure, prolonged application of the offending medication on large surface areas, and use of topical resorcinol, phenol and mercury.

Diagnosis: Although early stages of exogenous ochronosis may appear similar to melasma, dermoscopy may be helpful in differentiating the two. Dark-brown globules and globular-like structures are seen on a diffuse brown background.[64]

Skin biopsy however, remains the gold standard for diagnosis of exogenous ochronosis. Histopathologically, there is a collection of yellowish-brown (ochronotic) banana-shaped globules in the papillary dermis. Homogenous, edematous dermal collagen also may be seen.

Differential Diagnosis: The early stages of ochronosis may be clinically indistinguishable from melasma, especially in Asians.

Clinical Course and Prognosis: Without cessation of the offending agent, exogenous ochronosis is progressive.

Management: Treatment is rarely helpful, but the offending drug should be stopped to prevent progression. Broad-spectrum sunscreen and sun avoidance are important. Topical retinoids, α-hydroxy acids, corticosteroids and physical therapies, such as chemical peels and quality-switched lasers, have all been reported in the treatment of exogenous ochronosis but there has been no universally efficacious treatment documented as of this writing.

The following disorders can be associated with hyperpigmentation and are discussed in their respective chapters: systemic sclerosis (Chap. 63), pinta (Chap. 171), onchocerciasis (Chap. 177), phytophotodermatitis (Chap. 97), and flagellate pigmentation caused by bleomycin (Chap. 45).

SYSTEMIC SCLEROSIS

Chapter 63 discusses systemic sclerosis in greater detail.

AT-A-GLANCE

- Acquired diffuse hyperpigmentation, focal depigmentation over sites of friction, streaky hyperpigmentation, and reticulated pigmentation have all been described.

Different types of abnormal pigmentation have been described in systemic sclerosis. A diffuse, generalized hyperpigmentation similar to Addison's disease but with normal levels of melanocyte-stimulating hormone can be observed in severe systemic sclerosis.

Focal depigmentation with perifollicular hyperpigmentation may occur, especially on sites of friction (eg, shins, elbows, and dorsum of the hands). There can be localized hyperpigmentation and hypopigmentation.

A streaky hyperpigmentation over blood vessels on a background of depigmentation also has been reported. Diffuse reticulated hyperpigmentation accentuated on the trunk has been reported in 1 case.[65]

INFECTIONS

CHIKUNGUNYA

AT-A-GLANCE

- Acquired circumscribed or diffuse hyperpigmentation.
- Caused by a mosquito-borne virus.
- Persistent pigmentation with symptomatic relief being the only treatment option.

Chikungunya is a mosquito-borne virus first described in the 1950s in Tanzania, Africa.

Epidemiology: While first described in Africa, chikungunya has been noted in several dozen other countries in Africa, Asia, Europe, and the Americas. All age groups are affected.[66]

Clinical Features: Pigmentary changes are the most common cutaneous finding. Lentiginous central facial hyperpigmentation, diffuse hyperpigmentation of acrofacial lesions, and flagellate hyperpigmentation have all been described. Striking pigmentation of the nose also has been reported. A case of neonatal hyperpigmentation has been reported in a case of congenital chikungunya.[67]

A maculopapular eruption is noted at the onset of the illness and resolves over 7 to 10 days. Other mucocutaneous manifestations include vesiculobullous lesions, purpuric lesions, aphthous-like ulcers, and exacerbation of other primary dermatoses such as lichen planus and psoriasis.

Systemic symptoms, such as fever, arthralgia, myalgia, and GI upset, are some of the extracutaneous manifestations.

Etiology and Pathogenesis: *Aedes aegypti* (tropics and subtropics) and *Aedes albopictus* (cooler regions of the world) have been implicated in large outbreaks of this mosquito-borne illness.

The mechanism by which cutaneous hyperpigmentation occurs is not understood but various theories exist, including melanocyte phagocytosis of the invading pathogens[68] followed by intraepidermal melanin dispersion or retention triggered by the virus.

Diagnosis: Lymphocytic vasculopathy and increased intraepidermal melanin is noted histologically. Melanophages are also noted and may account for the persistent cutaneous pigmentation.

Differential Diagnosis: Other viral illnesses and mosquito-borne illness fall into the wide differential diagnosis.

Clinical Course and Prognosis: Pigmentation often persists for many months.

Management: Symptom relief is the mainstay of treatment.

OTHER INFECTIONS

Erythematous, scaly papules termed *pintids* develop during the secondary stage of pinta. These initially red lesions can turn brown, slate-blue, black, or grayish.[69]

Chronic papular onchodermatitis is one of the skin manifestations of onchocerciasis. It is characterized by a severely pruritic maculopapular rash with hyperpigmented macules, most often occurring on shoulders, buttocks, and extremities (see Chap. 177).

PHYSIOLOGIC HYPERPIGMENTATION

PIGMENTARY DEMARCATION LINES

AT-A-GLANCE

- More common in persons with skin of color.
- Linear demarcation with opposing hyperpigmentation and hypopigmentation.
- Seen along "embryonic suture lines" in distinct patterns and areas of the face and limbs.
- Can occur on the face, trunk, and limbs.
- Usually become obvious in childhood.

Pigmentary demarcation lines (PDLs) are also known as Voigt or Futcher lines. They are abrupt changes from lighter to darker skin in a linear pattern mostly seen on the limbs, trunk, and face.

Epidemiology: PDLs are most common in persons with skin of color. PDLs often appear in childhood or puberty and persist throughout life.

Clinical Features: PDLs are classified based on location as follows:

- Type A: This is the most common type and involves the lateral aspect of the upper anterior arms (occasionally extending across the pectoral area);
- Type B: Posterior medial lower limb;
- Type C: Vertical hypopigmented line in sternal and parasternal areas;
- Type D: Vertical line in spinal or paraspinal area;

- Type E: Hypopigmented oval areas, streaks, or bands on bilateral aspects of the chest, from the mid-third of clavicle to periareolar skin;
- Type F: V-shaped hyperpigmented line between the malar prominence and the temple;
- Type G: W-shaped hyperpigmented lines between the malar prominence and the temple; and
- Type H: Linear hyperpigmentation from the angle of the mouth to the lateral aspect of the chin.

A pigmentary demarcation line anterior to the ear has not been described in the literature (at the time of this writing) but should now be added as a new pigmentary demarcation line "Type I" (Fig. 77-13).

Etiology and Pathogenesis: The cause of PDLs is unknown. The debate surrounding topography following lines of Blaschko or cutaneous innervation continues. Hormonal and genetic influences have been postulated with onset during pregnancy and variable inheritance patterns noted, including autosomal dominant inheritance patterns in some families.

Diagnosis: The diagnosis can usually be made clinically without need for biopsy.

Clinical Course and Prognosis: PDLs often appear in childhood or puberty and persist throughout life.

Management: Reassurance that these changes are a normal variant is needed. In addition, sun protection may diminish the difference between affected and unaffected skin.

Figure 77-13 Pigmentary demarcation line anterior to the ear in a boy of Sri Lankan descent.

ACQUIRED IDIOPATHIC FACIAL PIGMENTATION

AT-A-GLANCE

- Can be considered as another group of pigmentary demarcation lines.
- More common in persons with skin of color.
- Linear demarcation with opposing hyperpigmentation and hyperpigmentation.
- Predominantly affects periorbital and perioral zones.
- Usually become obvious in adulthood.

Acquired idiopathic facial pigmentation was described recently in the Indian population and can be considered another group of PDLs.[70] The term *acquired idiopathic facial pigmentation* was coined after observing that some types of idiopathic facial pigmentation were nonnevoid, patterned, and bilateral with a dark-brown–gray color located around the eyes, lateral face, and chin.

Epidemiology: Onset is noted in early adulthood with occurrence in males and females in a 1:1 ratio. It often appears in adulthood and persists throughout life.

Clinical Features: Well-demarcated dark-brown–gray macular hyperpigmentation is noted on periorbital, zygomatic, and malar areas, root of the nose, and perioral and mandibular skin. The pigmentation is noted in a similar pattern to other nevoid conditions with patterns reflecting the normal patterns of embryologic spread of pigmentation on face. The absence of symptoms, scale, erythema, and lichenification should help differentiate it from other dermatoses and pigmentary disorders in the area.

Etiology and Pathogenesis: Although the cause is unknown, it is postulated this is a genetic disorder with exacerbation and accentuation resulting from physiologic factors such as ultraviolet light and aging.

Diagnosis: The diagnosis can usually be made clinically without need for biopsy.

Differential Diagnosis: Conditions like melasma and postinflammatory pigmentation may look similar to acquired idiopathic facial pigmentation and should be differentiated clinically and histologically.

Clinical Course and Prognosis: Acquired idiopathic facial pigmentation often appears in adulthood. It darkens with time and persists throughout life.

Management: Sun protection may help diminish the difference between affected and unaffected skin and occasionally topical hydroquinone can subtly lighten excessive pigmentation in the areas affected.

PERIORBITAL PIGMENTATION

AT-A-GLANCE

- Primary dermatoses, such as lichen planus pigmentosus, medication-induced pigmentation, pigmented contact dermatitis, and postinflammatory hyperpigmentation, should be excluded.
- Familial/racial/constitutional pigmentation is especially common in persons with skin of color.

Periorbital hyperpigmentation is also known as dark circles and is very common in certain racial ethnic types.

Epidemiology: Males and females, mainly with darker-skin types, are commonly affected. Onset is usually noted in young adults.

Clinical Features: Asymptomatic brown-black nonscaly and nonerythematous pigmentation is noted on the upper, lower, or both eyelids. Accentuation of skin creases is noted and visible vessels also may be seen (Fig. 77-14).

Etiology and Pathogenesis: The exact etiology of constitutional pigmentation is yet to be determined.

Diagnosis: A clinical diagnosis is made in most cases. Increased melanin in the basal epidermis and melanophages in the upper dermis are seen histologically in those with constitutional pigmentation.

Differential Diagnosis: Primary dermatoses, like lichen planus pigmentosus, medication-induced pigmentation, and eczema with lichenification, must be excluded.

Clinical Course and Prognosis: Constitutional pigmentation is usually progressive.

Management: Treatment of the underlying dermatosis, if present, is critical. Although topical therapy, peels, lasers, and autologous fat transplants have been reported to be useful, these studies don't often specify the underlying cause of pigmentation, making it difficult to interpret the results.

Figure 77-14 Periorbital pigmentation in an Indian lady.

MUCOSAL MELANOSIS

AT-A-GLANCE

- Physiologic pigmentation in the oral cavity.
- Macular pigmentation on the gingiva, oral mucosa, lips, and tongue.
- More common in persons with skin of color.

Mucosal melanosis is common in persons with skin of color and should be differentiated from other causes of pigmentation in the oral cavity.[71]

Epidemiology: The limited literature available on this topic suggests the onset of pigmentation is gradual and likely to occur in middle-aged adults with richly pigmented skin.

Clinical Features: Diffuse and bilateral pigmentation may be noted but localized macular hyperpigmentation may be seen affecting one or more of the following locations: gingiva, buccal mucosa, lips, hard palate, and papillae of the tongue (Fig. 77-15). A study in China concluded that pigmented fungiform papillae

Figure 77-15 Benign pigmentation of the papillae of the tongue in an Indian man.

of the tongue are relatively common in the Chinese population.

Laugier-Hunziker syndrome is an acquired form of hyperpigmentation that presents as longitudinal melanonychia and pigmentation involving the oral mucosa, genitals, perianal region, fingers, and esophagus.

Etiology and Pathogenesis: The cause is unknown.

Diagnosis: The diagnosis can usually be made clinically without need for biopsy but if the diagnosis is in doubt, a biopsy can be helpful. Histologic examination demonstrates basal cell hypermelanosis, increased dermal melanophages, pigment incontinence, and normal melanocytes that in some instances are increased in number.

Differential Diagnosis: Many conditions can cause oral pigmentation. Drug-induced pigmentation, including fixed drug eruption, oral lichen planus, postinflammatory hyperpigmentation, dental amalgam, Addison disease, and malignancy, need to be excluded.

Brown hyperpigmented macules in childhood should prompt investigation for genodermatoses such as Peutz-Jeghers, Bandler, Carney, and Cronkhite-Canada syndromes.

Clinical Course and Prognosis: Mucosal melanosis appears in childhood and persists without consequence throughout life.

Management: Reassurance is the most important component of management. No treatment is required.

LONGITUDINAL MELANONYCHIA

AT-A-GLANCE

- Benign brown-black linear band of pigmentation of the nail plate.
- More common in persons with skin of color.
- Incidence increases with age.

Chapter 91 discusses longitudinal melanonychia in greater detail. Regular, thin hyperpigmented bands on multiple nails is characteristic of benign longitudinal pigmentation seen in darker individuals. Medications, trauma, and nevi in the nail apparatus may also cause longitudinal melanonychia and should be considered in the differential diagnosis. A single band located on the thumb or great toe, should prompt the clinician to diligently look for signs of melanoma clinically and dermoscopically. A biopsy also may be necessary to differentiate benign longitudinal melanonychia from melanoma.

ACRAL HYPERPIGMENTED MACULES

AT-A-GLANCE

- Benign brown well-demarcated macules on palms and soles.
- More common in persons with skin of color.
- Incidence increases with age.

Well-defined brown macules on the palms and soles reveal increased epidermal melanin histologically. Despite the parallel ridge pattern noted on dermoscopy, the number of lesions noted provides a clue to the benign nature of the lesions.[72] It is important to exclude genodermatoses and drug-induced (especially chemotherapy) pigmentation that may present in a similar fashion.

ACQUIRED PATTERNED HYPERMELANOSIS

AT-A-GLANCE

- Phytophotodermatitis, flagellate pigmentation caused by bleomycin, and flagellate mushroom dermatitis are all causes of patterned hyperpigmentation.

PHYTOPHOTODERMATITIS

Contact with plants containing phototoxic agents such as psoralens, with subsequent ultraviolet exposure, may lead to phytophotodermatitis, which is followed by patterned hyperpigmentation.

FLAGELLATE MUSHROOM DERMATITIS

Shiitake mushroom (*Lentinula edodes*) is typically grown and used in Asian cuisine but the Western world now consumes it in large quantities. Oral ingestion of raw or insufficiently cooked shiitake mushrooms is associated with a "flagellate mushroom dermatitis" that appears 12 hours to 5 days after consumption. While most reports have emerged from Japan, cases in Europe, the United States, and Canada also have been described.[73] It is characterized by linear grouped, erythematous, and intensely pruritic papules that resembles bleomycin-induced flagellate dermatitis. A pustular eruption also has been reported. The trunk and limbs are usually involved. The pathogenesis is not yet known, but it is hypothesized that a toxic reaction results from a thermolabile polysaccharide contained within the mushroom.

ERYTHEMA AB IGNE

AT-A-GLANCE

- Acquired diffuse reticulate pigmentation.
- May also have epidermal atrophy, scaling, and hyperpigmentation.
- Caused by chronic exposure to moderate heat.
- Thyroid function should be checked.

Erythema ab igne is caused by frequent exposure to heat, usually infrared radiation, resulting in reticulate hyperpigmentation. Although it may occur anywhere on the body, it is usually localized to the thighs and lower legs.[74]

CLINICAL FEATURES

Tan–red-brown reticulate transient and blanchable erythema is noted acutely (usually about 3 weeks after the heat exposure) but fixed hyperpigmentation may be accompanied by epidermal atrophy, bullous lesions or hyperkeratosis, and scale in chronic cases. Common sites of involvement include the thighs, lower legs, abdomen, and back.

ETIOLOGY AND PATHOGENESIS

Erythema ab igne is caused by chronic exposure to moderate heat. It was seen in the past in people who frequently sat in front of open fires for warmth, but the introduction of central heating has seen a decline in this presentation. Nevertheless, it is seen after local application of heating pads, hot water bottles, or heating blankets (Fig. 77-16). Widespread cases secondary to hot tub bathing in Japan also has been reported.[45] Modern appliances that have been reported to elicit erythema ab igne are furniture with built-in heaters, car heaters, and laptop computers when rested on the thighs or legs.

The reticulate nature of the cutaneous changes is thought to reflect the distribution of blood vessels. The heat is thought to damage superficial blood vessels in the epidermis, which, in turn, results in extravasation of red blood cells and hemosiderin, causing the cutaneous hyperpigmentation.

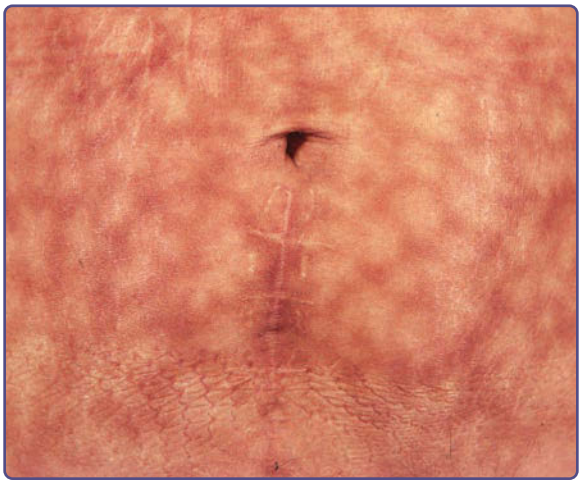

Figure 77-16 Reticular hyperpigmentation (erythema ab igne) on the abdomen resulting from repeated applications of a heating pad over several years.

DIAGNOSIS

The diagnosis is usually made clinically. Thyroid function tests should be considered in patients with symptoms or signs that suggest hypothyroidism.

If a skin biopsy is performed, histologic examination usually reveals vasodilation, extravasation of red blood cells, and deposition of melanin and hemosiderin in the dermis. Dermal edema and lymphohistiocytic dermal infiltration is also noted.[75]

DIFFERENTIAL DIAGNOSIS

Livedo reticularis and its various causes need to be considered, but the history often reveals chronic heat exposure in cases of erythema ab igne.

CLINICAL COURSE AND PROGNOSIS

The pigmentary changes usually resolve when the patient stops using the heat source on the skin, but depending on the chronicity of the exposure, pigmentation may persist for many months. Very rarely squamous cell carcinoma and Merkel cell carcinoma have been reported to arise within chronic lesions of erythema ab igne.

MANAGEMENT

Elimination of the heat source is critical, but topical retinoids and low-fluence quality-switched Nd:YAG laser also have been helpful in some persistent cases.[76]

PRURIGO PIGMENTOSA

AT-A-GLANCE

- Acquired diffuse reticulate pigmentation on the trunk.
- Most common in young females.
- Initial phase of pruritic papules, vesicles, and papulovesicles is followed by asymptomatic hyperpigmentation.
- Tetracyclines and dapsone are helpful for the inflammatory component of the condition.

Prurigo pigmentosa is a rare condition, first described in Japan by Nagashima et al. in 1971.[77] It most commonly affects the trunk and results in reticulated hyperpigmentation.

EPIDEMIOLOGY

While reports as of this writing have largely emerged from Japan, it is becoming increasingly documented in other parts of the world. It is most common in young females in their 20s with a female to male ratio of 4 to 6:1.[78]

CLINICAL FEATURES

Prurigo pigmentosa presents with intensely pruritic symmetrical urticarial, erythematous papules, papulovesicles, and vesicles that evolve into reticulated hyperpigmentation. The lesions develop on the upper back, chest, neck, and lumbosacral region. The papulovesicular lesions heal spontaneously over approximately 1 week, leaving nonpruritic reticular hyperpigmentation in its wake (Fig. 77-17).

No systemic associations have been documented.

ETIOLOGY AND PATHOGENESIS

Environmental and metabolic factors have been suggested as causative agents, but the pathogenesis remains unknown.

DIAGNOSIS

The diagnosis of prurigo pigmentosa requires close clinicopathologic correlation. Histology of early lesions reveals a superficial neutrophilic perivascular and interstitial infiltrate. Later in the disease course, lesions demonstrate lichenoid inflammation with a predominance of lymphocytes. Spongiosis, necrotic keratinocytes, eosinophils, and vesiculation are also noted.[79]

Figure 77-17 Reticulate pigmentation seen in prurigo pigmentosa in a Japanese woman.

DIFFERENTIAL DIAGNOSIS

Confluent reticulated papillomatosis (no preceding erythematous papules), pigmented contact dermatitis (responds to topical steroids), and Dowling-Degos disease (characteristic histologic findings) are the main differential diagnoses.

CLINICAL COURSE AND PROGNOSIS

The disease has a fluctuating course with exacerbations and recurrences.

MANAGEMENT

The eruption and pruritus respond well to minocycline or doxycycline 100-200 mg daily or dapsone 25 to 100 mg daily. The pigmentation resolves spontaneously.

NEVUS OF HORI

AT-A-GLANCE

- Acquired circumscribed hyperpigmentation in the form of symmetrical pinhead-sized macules on the malar region of the face.
- Noted mainly in Asian populations.
- Often coexists with other pigmentary conditions like melasma and flat seborrheic keratoses.
- Best treated with quality-switched Nd:YAG lasers.

Nevus of Hori was first described in 1984 as acquired bilateral nevus of Ota–like macules (ABNOM) or acquired dermal melanocytosis.[80]

EPIDEMIOLOGY

It is a common condition noted in nearly 1% of the Asian population, particularly the Chinese and Japanese population. It is more common in females and appears in the third to fifth decades of life.

CLINICAL FEATURES

Nevus of Hori consists of blue-brown to slate-gray hyperpigmented macules ranging from pinhead size to a few millimeters in diameter (Fig. 77-18). Lesions are found on the face with predilection for the malar

Figure 77-18 Nevus of Hori.

region, although lesions on the temple and nose are not uncommon.

Unlike nevus of Ota, nevus of Hori is bilateral and lacks ocular and mucosal membrane involvement.

ETIOLOGY AND PATHOGENESIS

Hori described 3 possible mechanisms for the pathogenesis of ABNOM: (a) "dropping" of epidermal melanocytes into the dermis, (b) migration of melanocytes from hair bulbs, and (c) reactivation of preexisting latent or immature dermal melanocytes. The third possibility has been suggested as being the most plausible mechanism with ultraviolet radiation and sex hormones as activating factors.

DIAGNOSIS

The diagnosis may require a biopsy, particularly if other pigmentary disorders, such as melasma, coexist in the affected area. Histology often reveals melanocytosis in the upper and mid dermis.

DIFFERENTIAL DIAGNOSIS

In many cases, ABNOM can occur simultaneously with other pigmentary abnormalities such as melasma, freckles, solar lentigines, and nevus of Ota.

CLINICAL COURSE AND PROGNOSIS

Nevus of Hori is usually gradually progressive.

MANAGEMENT

Although various lasers, such as ablative CO_2, quality-switched 532-nm, quality-switched ruby, and fractional nonablative 2940-nm Erbium:YAG, have been used in isolation or in combination,[81] quality-switched lasers are the most commonly used form of treatment. Obtaining complete clearance is not always possible and multiple treatments are required. Quality-switched and picosecond lasers have demonstrated efficacy in lightening or clearing the lesions, but multiple treatments spaced many months apart are required.[82,83]

NEVUS OF BECKER

AT-A-GLANCE

- Presents with acquired circumscribed hyperpigmentation.
- Most commonly found on the trunk.
- Usually associated with hypertrichosis.
- Treatment with lasers can be attempted but current studies lack statistical significance.

This acquired hyperpigmented epidermal nevus was first described in 1949 (Fig. 77-19) and is also known as Becker hamartoma or Becker melanosis.

EPIDEMIOLOGY

Nevus of Becker appears to be androgen-dependent and is noted in approximately 0.5% of the population, usually becoming more prominent during adolescence. It is said to be more common in males but a newer study revealed equal incidence in male and female children.[84]

Figure 77-19 Nevus of Becker on the upper arm and shoulder of a young man. Note the typical localization and marked hypertrichosis.

CLINICAL FEATURES

This benign hamartoma may be cosmetically disfiguring and presents with a hyperpigmented macular or speckled area, most commonly in the scapular region, upper arms and chest, although it has been described in any area of the body. Hypertrichosis is common and often develops years after the hyperpigmentation is noted. The hairs are coarse and dark. Becker nevi are often first noted after an episode of intense sun exposure.

Associated anomalies, such as ipsilateral breast hypoplasia, musculoskeletal abnormalities (eg, scoliosis, ipsilateral limb hypoplasia), maxillofacial abnormalities, and additional cutaneous hypoplasias, occur in the rare nevus of Becker syndrome.

ETIOLOGY AND PATHOGENESIS

Nevus of Becker is suggested to follow a paradominant inheritance pattern, which means it (almost) always occurs sporadically. The rare familial cases that have been described (especially in nevus of Becker syndrome) can be explained by a somatic mutation during embryogenesis, resulting in loss of heterozygosity and formation of a mutant cell population. This hypothesis is supported by the identification of chromosomal mosaicism in fibroblasts derived from a Becker nevus.

The exact cause of the hyperpigmentation is unknown.

DIAGNOSIS

Epidermal acanthosis with variable hyperkeratosis and elongation of the rete ridges is noted on histology. Normal numbers of melanocytes, but increased levels of melanin in the basal epidermal layer are demonstrated. In the dermis, the number of arrector pili muscles is increased, making it difficult to differentiate from smooth muscle hamartomas.

DIFFERENTIAL DIAGNOSIS

Congenital hairy nevus, nevus of Ito, and CALMs are all potential differential diagnoses.

CLINICAL COURSE AND PROGNOSIS

Nevus of Becker may appear to darken during pregnancy and in summer. It persists throughout life.

MANAGEMENT

Treatment of nevus of Becker is challenging. If the lesion is small, surgical excision may be appropriate to consider. Although mechanical abrasion, cryotherapy, and argon and CO_2 lasers have been used in the past for larger lesions, the high risk of scarring and dyspigmentation limit their use. Laser hair removal can give the illusion of lightening the lesion. Long-pulsed and picosecond alexandrite laser, as well as quality-switched Nd:YAG, have been cited as useful in some studies, but the current evidence lacks statistical power and has inconsistent findings.[85]

CAFÉ-AU-LAIT MACULES

AT-A-GLANCE

- Acquired circumscribed hyperpigmentation.
- May exist in isolation or as part of a genodermatosis.
- Lasers may be used to lighten spots but relapses are common.

CALMs, also known as café-au-lait spots, may occur spontaneously or as part of a genodermatosis like NF1 and McCune-Albright syndrome.

EPIDEMIOLOGY

Up to one-third of the general population have CALMs. They are more frequent in darker Fitzpatrick skin types, but occur equally in males and females.[86]

CLINICAL FEATURES

Light-brown–tan–dark-brown well-demarcated homogenously hyperpigmented macules or patches can be noted anywhere on the body. The most commonly involved sites are the trunk, buttocks, and lower limbs (Fig. 77-20).

When 6 or more CALMs are noted, investigation for underlying genodermatoses should be commenced.

ETIOLOGY AND PATHOGENESIS

A normal number of melanocytes produce an abnormal amount of melanin.

DIAGNOSIS

Histopathologic examination shows a normal to reduced number of sometimes hypertrophic melanocytes and increased melanin in the basal epidermal layer.

DIFFERENTIAL DIAGNOSIS

Nevus spilus, early nevus of Becker, and congenital nevus are all differential diagnoses.

CLINICAL COURSE AND PROGNOSIS

CALMs persist throughout life.

Figure 77-20 Café-au-lait macule on the lower leg of a young girl.

MANAGEMENT

For cosmetic reasons, quality-switched lasers can be used for treatment but relapses are common.

EPHELIDES

AT-A-GLANCE

- Acquired circumscribed hyperpigmentation.
- Autosomal dominant.
- Appear on fair-skinned individuals.

EPIDEMIOLOGY

Ephelides appear in sun-exposed skin of fair-skinned individuals, often those with red or blond hair and Celtic ancestry. Males and females are equally affected.

CLINICAL FEATURES

Ephelides, or freckles, are asymptomatic, small, light-brown macules that appear symmetrically on photo-exposed sites.

ETIOLOGY AND PATHOGENESIS

Ephelides are inherited in an autosomal dominant pattern with a relationship noted to a mutation in the *MCR-1* gene, with carriers demonstrating a significantly increased risk of developing these lesions.[87]

MCR-1 is the receptor for α-melanocyte-stimulating hormone, which activates the melanogenesis pathway via cyclic adenosine monophosphate. Decreased activity of this pathway promotes pheomelanin production.

DIAGNOSIS

Histopathologic examination shows a normal to reduced number of sometimes hypertrophic melanocytes but increased melanin in the basal epidermal layer.

DIFFERENTIAL DIAGNOSIS

Lentigines are the main differential diagnosis. The characteristic appearance in lighter-skin phototypes provides a clue to the diagnosis. The oral mucosa, palms, and soles are spared.

CLINICAL COURSE AND PROGNOSIS

They are more pronounced during spring and summer and fade during the winter. They appear in early childhood and often regress later in life.

MANAGEMENT

Photoprotection is important in those with light skin irrespective of the presence of ephelides but is especially important in individuals who wish to prevent darkening of the lesions. Topical depigmenting agents, such as hydroquinone, retinoids, α-hydroxy acids, and botanicals, may help to lighten pigmentation. Physical therapies, such as cryotherapy, are difficult to perform on very small lesions, so intense pulsed light or quality-switched lasers are preferred, but relapse should be expected.

ACROMELANOSIS PROGRESSIVA

AT-A-GLANCE

- Acquired circumscribed hyperpigmentation in newborns.
- Usually involves acral and perineal areas.
- Spontaneously resolves.

EPIDEMIOLOGY

Very few cases have been described.

CLINICAL FEATURES

Diffuse brown hyperpigmentation is noted in newborns or during the first few weeks of life and is located on acral and or perineal areas. Progression to the trunk, oral mucosal involvement, and seizures were reported in one case.[88]

ETIOLOGY AND PATHOGENESIS

The cause is unknown.

DIAGNOSIS

Acromelanosis progressiva is a clinical diagnosis that becomes apparent over time, as the lesions fade. Histology reveals increased basal epidermal melanocytes.

DIFFERENTIAL DIAGNOSIS

Periungual hyperpigmentation, acropigmentation of Dohi, and reticulate acropigmentation of Kitamura are differential diagnoses to consider.

CLINICAL COURSE AND PROGNOSIS

Spontaneous resolution is noted.

MANAGEMENT

Reassurance is important as treatment is not required.

POSTINFLAMMATORY HYPERPIGMENTATION

AT-A-GLANCE

- Acquired circumscribed hyperpigmentation in sites of prior inflammation or injury.
- More common in persons with skin of color.
- Hydroquinone remains the gold standard treatment.
- Spontaneously resolves over a variable period of time.

Postinflammatory hyperpigmentation (PIH) is a common reactive melanosis caused by numerous preceding inflammatory (eg, acne, lichen planus, psoriasis) and cutaneous insults, such as drug and phototoxic reactions, infections, physical injury or trauma, and allergic reactions.

EPIDEMIOLOGY

PIH is far more common in darker-skin types (Fitzpatrick Types III to VI) and can occur at any age. It is observed in a significant number of individuals of African ancestry who are suffering from acne.[89]

CLINICAL FEATURES

PIH consists of a macular hyperpigmentation at the site of inflammation (Fig. 77-21). A Wood lamp examination can determine the depth of the hyperpigmentation (see section "Melasma"). PIH after epidermal inflammation results in brown discoloration while inflammation in the dermis results in a gray-brown discoloration. The severity of PIH is proportional to the severity of the inflammation and degree of basement membrane disruption.

Discovering the cause of the primary dermatosis should involve examination of the entire skin. Adverse effects on quality of life have been documented, especially in persons with skin of color, and should be addressed.

ETIOLOGY AND PATHOGENESIS

It is thought that inflammatory markers stimulate the melanocytes that drive PIH. Conditions causing epidermal inflammation cause an increase in epidermal keratinocytes, whereas dermal inflammation results in pigment incontinence into the dermis. The melanin is eventually cleared by macrophages.

The cause for increased susceptibility of PIH in persons with skin of color has not been fully elucidated but is thought to relate to the increased amount of melanin in melanosomes.

DIAGNOSIS

Histologic features include pigment incontinence with accumulation of melanophages and increased melanin in epidermal layers.

DIFFERENTIAL DIAGNOSIS

When PIH is widespread on the trunk, it may look similar to urticaria pigmentosa but a positive Darier sign and the history of itching associated with the lesions should help to differentiate PIH from urticaria pigmentosa.

CLINICAL COURSE AND PROGNOSIS

The clinical course is variable and depends on the location of the inflammation or injury. It is more persistent in darker-skin types (Fitzpatrick Types III to VI) and after lichenoid inflammatory processes. Epidermal PIH often has spontaneous but slow fading.

Figure 77-21 **A,** Postinflammatory hyperpigmentation secondary to acne on the back of a young African girl. **B,** Postinflammatory hyperpigmentation secondary to psoriasis on the back of a Chinese man.

MANAGEMENT

Management of PIH remains difficult. It is important, especially when treating patients with skin of color, to treat the primary dermatosis early to prevent PIH.

The importance of photoprotection should not be underestimated. Pretreatment and posttreatment regimens are critical after physical therapies, especially for persons with skin of color, and may include sun protection, hydroquinone, hydroquinone alternatives, or topical corticosteroids.[90]

Topical hydroquinone remains the gold standard treatment for PIH (Table 77-3). A plethora of nonprescription cosmeceuticals containing licorice, soy, niacinamide, and various botanicals are available and numerous prescribed topicals, such as kojic acid, retinoids, and α-hydroxy acids may be used as monotherapy or in combination. Kligman's formula and similar triple-therapy combinations containing hydroquinone, tretinoin, and a topical corticosteroid are also commonly prescribed. Physical therapies, including peels and lasers, should be used with caution given they can induce PIH if used too aggressively. Quality-switched and picosecond lasers have been described in isolation or as part of a broader treatment plan for PIH. Epidermal PIH is more amenable to topical therapy than dermal PIH.

MELASMA

AT-A-GLANCE

- Acquired light-brown to dark-brown poorly circumscribed macules.
- More common in persons with skin of color.
- Malar skin, nose, forehead, and upper lip are commonly involved areas.
- Hydroquinone remains the gold standard treatment.
- Physical and oral therapies also can be used.

TABLE 77-3
Lightening Agents

AGENTS	MECHANISM OF ACTION
Hydroquinone	Tyrosinase inhibitor
Retinoids	Stimulate keratinocyte turnover, reduce melanosome transfer, tyrosinase inhibitor
Arbutin	Tyrosinase inhibitor; inhibits melanosome maturation
Azelaic acid	Tyrosinase inhibitor
Kojic acid	Interacts with copper and inhibits tyrosinase
Tranexamic acid	Plasmin inhibition; antioxidant

Adapted from Chaowattanapanit S, Silpa-archa N, Kohli I, et al. Postinflammatory hyperpigmentation: a comprehensive overview: treatment options and prevention. *J Am Acad Dermatol*. 2017;77(4):607-621.

Melasma is one of the most common disorders of pigmentation and is sometimes referred to as chloasma or the mask of pregnancy.

EPIDEMIOLOGY

Melasma affects millions of people with a reported prevalence ranging from 9% in Hispanic populations in southern United States to 40% in Southeast Asians.[91] It is cited as the most common pigmentary disorder in Indian women. It is mainly seen in premenopausal women, although men and postmenopausal women also may be affected.

CLINICAL FEATURES

Melasma typically presents with diffuse light-brown to dark-brown areas of pigmentation on the central face (Figs. 77-22 and 77-23). The malar and mandibular regions, forehead, chin, and upper lip are most commonly affected—centrofacial (63%: forehead, nose, chin, and upper lip); malar (21%: nose and cheeks); and mandibular (16%: ramus mandibulae) patterns are most common. Melasma spares the periorbital skin as well as the lips, neck, and ears. It may be seen less commonly on the forearms (also known as acquired brachial cutaneous dyschromatosis).

The negative impact on quality of life has been documented repeatedly in the literature; consequently, symptoms of depression and anxiety need to be explored by the treating clinician.

ETIOLOGY AND PATHOGENESIS

The pathogenesis is not completely understood. Biologically active melanocytes, genetic and hormonal influences, and ultraviolet light exposure are known to be important. Specific precipitants, particularly oral contraceptives and estrogen replacement therapy, have been implicated in exacerbating the condition.

Figure 77-22 Melasma on the forehead of a young woman. Note the well-demarcated brown macules.

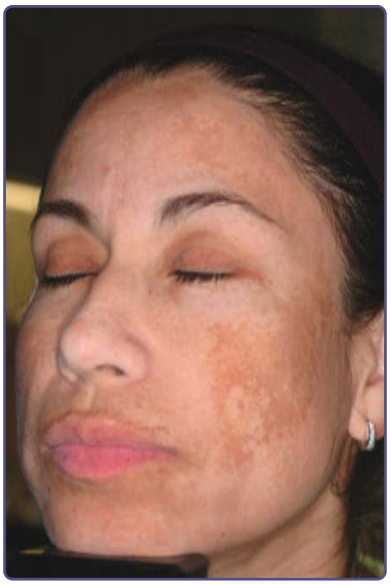

Figure 77-23 Hyperpigmentation of the forehead, cheek, upper lip, and chin caused by melasma in a Latino female.

Recently, visible light in individuals with skin of color and increased vascularity and vascular endothelial growth factor in the epidermis of lesional skin have been implicated in the pathogenesis of melasma.

DIAGNOSIS

A Wood lamp may help differentiate epidermal from dermal and mixed melasma in those with lighter skin types, although even Wood light–enhancing lesions, supposedly signifying epidermal melasma, have dermal melanin.

DIFFERENTIAL DIAGNOSIS

The differential diagnosis may be broad depending on the area affected and the location of the pigment (epidermal, dermal, or mixed). It includes postinflammatory pigmentation, maturational dyschromia, medication-induced pigmentation, lichen planus pigmentosus, and possibly poikiloderma of Civatte.

CLINICAL COURSE AND PROGNOSIS

Despite lightening or resolution with treatment, melasma is a chronic and relapsing condition with exacerbations during pregnancy, sun or visible light exposure, and with certain hormonal treatments.

MANAGEMENT

Managing expectations and counseling on the recurrent and chronic nature of melasma is critical for patient satisfaction. Cessation of any obvious triggers is the first step in management. Photoprotection is central to management and should include sun-avoidance, protective clothing, and regular application

of a broad-spectrum sunscreen with a physical blocker. Care should also be taken to protect from visible light in those with Fitzpatrick skin Types IV to VI.

Epidermal pigmentation is known to be more responsive to topical therapy. Even though 4% hydroquinone remains the gold standard, various other topical agents have been used with variable success. Nonprescription creams containing soy, licorice, lignin peroxidase, and niacinamide are just some of the botanicals and vitamins said to help mild epidermal melasma. Preparations containing tretinoin, azelaic acid, and kojic acid are helpful when used for prolonged periods.

Combining topical therapies is a useful strategy for epidermal melasma. Kligman's formula is a popular combination of 5% hydroquinone, 0.1% tretinoin, and a mild topical corticosteroid. Another treatment, commonly referred to as triple-combination therapy, includes 4% hydroquinone, 0.05% tretinoin, and a topical corticosteroid. Both Kligman's formula and triple-combination therapy have been deemed efficacious for epidermal melasma.

Superficial chemical peels have proven efficacious and are useful when used as a treatment adjunct, but the cost and frequency of treatments must be considered. Furthermore, the risk of postinflammatory hyperpigmentation must be considered with appropriate pretreatment and posttreatment care, especially in individuals with skin of color. Laser therapy may be helpful in the treatment of melasma, but can also result in further unwanted hyperpigmentation. Various lasers, including intense pulsed light, erbium:YAG, and nonablative 1550-nm and 1927-nm fractional lasers have all been reported to be effective for melasma but low-fluence quality-switched Nd:YAG laser (also known as laser toning), is the most popular. This treatment modality has proved efficacious and safe when a few treatments are used in carefully selected cases.

Recently, tranexamic acid has been proven to lighten epidermal and dermal melasma. It has been used in topical, intralesional, and oral forms. When used as an adjunct in low doses (500 to 700 mg daily) over a few months, it is efficacious and safe in treatment-resistant cases.[92]

PARTIAL UNILATERAL LENTIGINOSIS

AT-A-GLANCE

- Acquired circumscribed hyperpigmentation.
- Appears at birth or in childhood.
- May be a variant of mosaic neurofibromatosis Type 1.
- Usually within 1 or more dermatomes.

Partial unilateral lentiginosis (PUL) is a rare pigmentary disorder also known as unilateral lentigines, lentiginous mosaicism, zosteriform lentiginous nevus, segmental lentiginosis, and agminated lentiginosis.

EPIDEMIOLOGY

Usually appears at birth or in childhood.

CLINICAL FEATURES

PUL is characterized by numerous lentigines with sharp margins. Lesions occur in a segmental pattern in the midline in 1 or more dermatomes.[93]

ETIOLOGY AND PATHOGENESIS

Its segmental pattern and presentation, which are accompanied by café-au-lait spots, Lisch nodules, or neurofibromas, suggests that PUL is a variant of mosaic NF1. Genetic studies will help to further elucidate this subject.

DIAGNOSIS

The characteristic history and clinical appearance are often diagnostic.

DIFFERENTIAL DIAGNOSIS

Mosaic NF1.

CLINICAL COURSE AND PROGNOSIS

PUL persists throughout life. No complications have been noted as a result of PUL.

MANAGEMENT

Quality-switched alexandrite and Nd:YAG lasers are reported to be treatment options.

RIEHL MELANOSIS

AT-A-GLANCE

- Acquired gray-brown-blue circumscribed reticulate hyperpigmentation.
- Caused by topical contact sensitizers.
- Mostly middle-aged women.
- Located mainly on the face.
- Lasers have been described as a treatment option.

Riehl melanosis, also known as female facial melanosis and pigmented contact dermatitis, was first described in 1917 by Riehl.

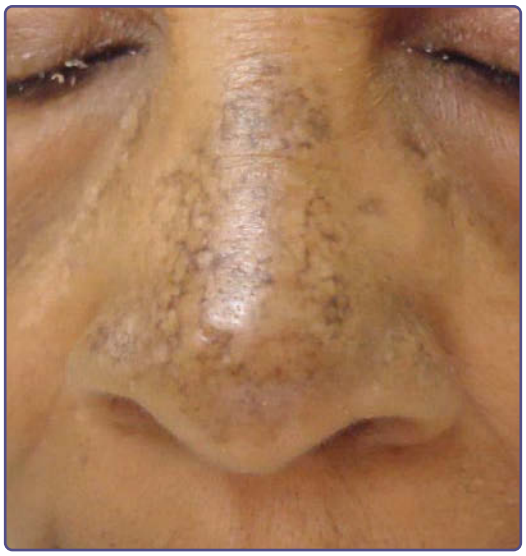

Figure 77-24 Riehl melanosis on the face.

EPIDEMIOLOGY

Riehl melanosis is mostly seen in middle-aged women, especially in darker-skin types, such as Latinos and Asians.

CLINICAL FEATURES

It is characterized by rapid onset of a reticular gray-brown to almost black reticulate hyperpigmentation. The face (especially the forehead, zygomatic area, and temples) and the neck are principally involved, but the hands, forearms, and trunk also may be affected (Fig. 77-24). Inflammatory findings, such as erythema and pruritus, are usually absent although it may be observed in very early stages of the clinical course.

Significant psychological stress may be reported by patients.

ETIOLOGY AND PATHOGENESIS

The pathogenesis is not understood fully understood but the hyperpigmentation has been postulated to be induced by repeated contact with threshold doses of a contact sensitizer such as fragrances, some pigments, and bactericides used in cosmetics and optical whiteners.

DIAGNOSIS

The main histopathologic feature is liquefactive degeneration of the basal layer of the epidermis, resulting in pigment incontinence in the dermis.

DIFFERENTIAL DIAGNOSIS

Poikiloderma of Civatte, erythrose peribuccal pigmentaire of Brocq, erythromelanosis follicularis faciei et colli, and medication-induced pigmentation are all differential diagnoses.

CLINICAL COURSE AND PROGNOSIS

Riehl melanosis is progressive if the contact sensitizer is not avoided. It may take many years to lighten, but no systemic effects are noted.

MANAGEMENT

Unfortunately treatment is challenging. Cessation of the topical sensitizer is critical. Photoprotection and topical depigmenting agents (hydroquinone, α-hydroxy acids, tretinoin) have a limited effect on this dermal pigmentation, with more recent reports describing treatment with lasers and oral tranexamic acid. Intense pulsed-light therapy has been helpful in some cases, but carries the risk of postinflammatory hyperpigmentation. Low-fluence quality-switched Nd:YAG and "laser toning" have demonstrated moderate improvements in Asian skin and have even been used in combination with oral tranexamic acid and hydroquinone.[94]

CRONKHITE-CANADA SYNDROME

AT-A-GLANCE

- Acquired generalized light-brown to dark-brown macules and patches.
- Palms and soles often involved first.
- Onychodystrophy and alopecia are also seen.
- Nutritional supplementation and corticosteroids may help.

Cronkhite-Canada syndrome (CCS) is a very rare condition resulting in cutaneous and GI manifestations.

EPIDEMIOLOGY

Approximately 450 cases are reported in the literature. Adults of Asian (most commonly Japanese) and European extraction are usually affected, starting in the fourth decade of life.

CLINICAL FEATURES

Cronkhite-Canada syndrome initially presents with brown macules and patches noted on the palms and soles. This is followed by generalized pigmentary changes with onychodystrophy and alopecia.[95]

GI symptoms, such as abdominal pain, nausea, diarrhea, and loss of weight, are noted in addition to GI polyposis and occasional malignancies. Complications include, but are not limited to, protein and electrolyte

imbalance, anemia, and even portal vein thrombosis and glomerulonephritis.

Cronkhite-Canada syndrome may be associated with other autoimmune conditions like systemic lupus erythematosus and rheumatoid arthritis.

ETIOLOGY AND PATHOGENESIS

An autoimmune process is suspected but the exact etiology remains elusive.

DIAGNOSIS

Clinicopathologic correlation is required to make the diagnosis. Histologic changes include increased epidermal melanin with dermal melanosis. Acanthosis and compact hyperkeratosis of the epidermis are also seen.

DIFFERENTIAL DIAGNOSIS

The differential diagnosis includes other causes of congenital lentigines.

CLINICAL COURSE AND PROGNOSIS

Cronkhite-Canada syndrome is progressive and may cause significant morbidity and mortality because of the systemic manifestations of the condition.

MANAGEMENT

Immunosuppression with corticosteroids and nutritional supplements may be helpful.

ERYTHROSE PERIBUCCAL OF BROCQ

AT-A-GLANCE

- Very rare dermatosis causing diffuse hyperpigmentation, erythema, and folliculocentric skin-colored papules.
- Occurs mainly in women.

Erythrose peribuccal of Brocq is also known as erythrose pigmenta faciei, erythrosis pigmentosa peribuccalis, and melanosis perioralis et peribuccalis.

EPIDEMIOLOGY

Only a few cases, mainly in women, have been reported.

CLINICAL FEATURES

Erythema followed by diffuse light-brown to dark-brown pigmentation in the perioral region affecting the cutaneous upper and lower lip with sparing around the vermilion border is usually seen. In some cases, scale and loss of vellus hairs are noted.

ETIOLOGY AND PATHOGENESIS

The etiology is unknown, although ultraviolet light exposure and fragrances may play a role.

DIAGNOSIS

The diagnosis is usually made clinically. Histologic findings are nonspecific.

DIFFERENTIAL DIAGNOSIS

Melasma and PIH are the main differential diagnoses.

CLINICAL COURSE AND PROGNOSIS

Persistence and progression are the rule.

MANAGEMENT

Photoprotection and avoidance of triggers is recommended.

CUTANEOUS AMYLOIDOSIS

Macular amyloidosis presents as brown to gray-brown macules coalescing to plaques, mainly on the back (see Chap. 125).

ATROPHODERMA OF PASINI-PIERINI

Chap. 70 discusses atrophic disorders of the skin in greater detail. The cutaneous lesions of atrophoderma of Pasini-Pierini can be described as single or multiple gray to violaceous-brown atrophic patches from 1 cm to more than 10 cm in diameter with slight depression and a characteristic "cliff-drop" border.

FIXED DRUG ERUPTION

Fixed drug eruption can cause hyperpigmentation (see earlier in section "Toxins and Medications" and Chap. 45).

ERYTHEMA DYSCHROMICUM PERSTANS

AT-A-GLANCE

- Acquired idiopathic dermal melanosis.
- Blue-gray well-demarcated hyperpigmented macules and plaques.
- Usually intermediate skin types (eg, Hispanic, Asian populations).
- Seen in photoprotected sites.
- Treatment is challenging and may require systemic therapy.

Erythema dyschromicum perstans (EDP), also known as ashy dermatosis, dermatosis cinecienta, and erythema chronicum figuratum melanodermicum, was first described by Ramirez in 1957.[96] Patients with this eruption were labeled as *los cenicientos*, the ashen ones. The terms EDP, lichen planus pigmentosus, and idiopathic eruptive macular pigmentation have been used interchangeably and are often confused in the literature, even though they appear to be distinct clinical entities.

Figure 77-25 Acquired dermal melanosis–erythema dyschromicum perstans/on the neck of a Hispanic woman.

EPIDEMIOLOGY

EDP is mainly observed in females with intermediate skin types (eg, Hispanics and Asians). It is said to be a disease of young adults with most presenting between the second and third decades of life, although a recent review of Korean patients revealed onset in the third and fourth decades of life.

CLINICAL FEATURES

EDP presents with widespread asymptomatic well-demarcated blue-gray macules that are most commonly seen on photoprotected sites (Figs. 77-25 and 77-26). Lesions slowly expand over time and an erythematous border may be seen at the edge of the lesion in the acute stages of the condition. The erythematous border, especially in darker-skin types, may evolve into a hypopigmented border that accentuates the hyperpigmentation.

Mucous membranes are not involved and no extracutaneous manifestations exist.

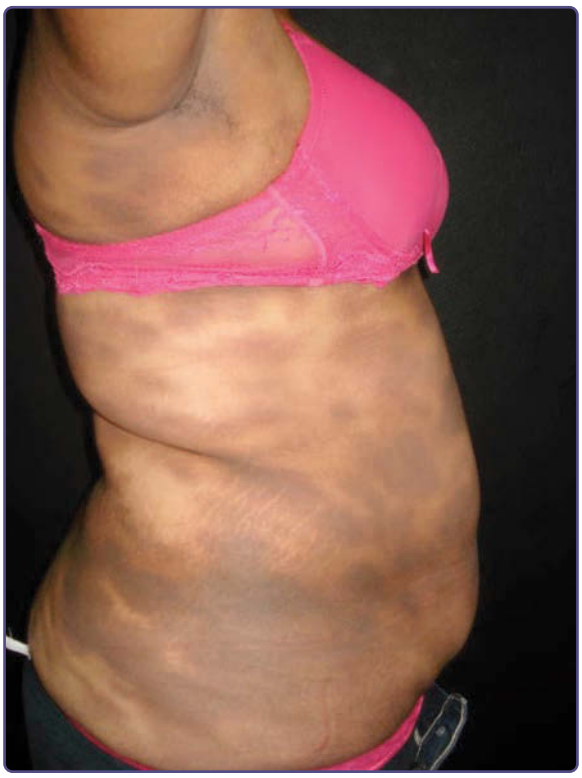

Figure 77-26 Erythema dyschromicum perstans on the trunk. (Used with permission of Juan Carlos Mendez, Department of Dermatology, UANL. Monterrey, México.)

ETIOLOGY AND PATHOGENESIS

The etiology is unknown although human leukocyte antigen-D related (HLA-DR)–associated susceptibility has been described in a Mexican population.[97]

DIAGNOSIS

The diagnosis usually requires clinicopathologic correlation. Histologically, early lesions reveal dermal edema and lichenoid inflammation, basal layer vacuolization and colloid bodies with a perivascular infiltrate. Later, melanin incontinence is noted in the deep dermis along with melanophages.

DIFFERENTIAL DIAGNOSIS

Lichen planus pigmentosus, idiopathic eruptive macular pigmentation, and PIH are the main differential diagnoses. Medication-induced pigmentation must also be excluded.

CLINICAL COURSE AND PROGNOSIS

The condition is chronic and very difficult to treat. There is a slow progression of the lesion over several years, usually without spontaneous regression.

MANAGEMENT

Topical therapies are not helpful for this acquired dermal disorder of pigmentation and improvement with systemic therapy is minimal. An 8- to 12-week course of dapsone 100 mg may lighten pigmentation and clofazimine 100 mg daily has demonstrated improvement in a small study.[98] Unfortunately, even though many other treatments have been evaluated, none have resulted in appreciable lightening. Most recently, laser surgery has been studied by a group in the Netherlands, who concluded fractionated laser was unsuccessful for the treatment of EDP.[99]

LICHEN PLANUS PIGMENTOSUS

AT-A-GLANCE

- Acquired idiopathic dermal melanosis.
- Poorly demarcated brown to gray-brown hyperpigmented macules.
- Usually seen with deeply pigmented skin (eg, South East Asians, Arabic).
- Mostly in photoexposed sites.
- Treatments provide only minimal improvement in pigmentation.

Lichen planus pigmentosus is considered a variant of lichen planus. Lichen planus is discussed in Chap. 32. It is often confused in the literature for EDP and idiopathic eruptive macular pigmentation.

Figure 77-27 Acquired dermal melanosis–erythema dyschromicum perstans/lichen planus pigmentosus on the neck of a Sri Lankan lady.

EPIDEMIOLOGY

Lichen planus pigmentosus is mainly observed in middle-aged (third to fourth decade of life) individuals with more deeply pigmented skin (eg, South Asians, Southeast Asians, and the Arabic population).

CLINICAL FEATURES

Symmetrical brown to gray-brown poorly demarcated macules and patches are seen mainly in photoexposed sites such as the head (forehead and temples) and neck (Fig. 77-27). Lesions also may be seen in skin folds such as the axillae (known as lichen planus pigmentosus–inversus). Lesions may also rarely appear on mucous membranes.

No extracutaneous manifestations exist.

ETIOLOGY AND PATHOGENESIS

The exact etiology is unknown but mustard and amla oils used in cooking and in hair care formulas, respectively, have been listed as possible causes in retrospective studies. Medication-induced pigmentation must also be excluded.

DIAGNOSIS

Biopsy is required and clinicopathologic correlation is critical. Epidermal atrophy, basal layer vacuolation with a perivascular lymphocytic infiltrate, and melanophages in the superficial dermis are noted histologically.

DIFFERENTIAL DIAGNOSIS

EDP, idiopathic eruptive macular pigmentation, and PIH are the main differential diagnoses.

CLINICAL COURSE AND PROGNOSIS

Some cases gradually resolve over many months, but these cases are the exceptions to the rule.

MANAGEMENT

Photoprotection is critical. Topical tacrolimus (0.03% twice daily), topical and systemic corticosteroids, and topical vitamin A may be helpful in lichen planus pigmentosus.[100] Treatment combinations and laser treatments also have been used with variable results. Recently, a prospective study reported low-dose oral isotretinoin (20 mg daily), used over 6 months in conjunction with sunscreen, caused stabilization and decrease in pigmentation, especially when used early in the course of disease.[101]

IDIOPATHIC ERUPTIVE MACULAR HYPERPIGMENTATION

AT-A-GLANCE

- Acquired idiopathic dermal melanosis.
- Well-demarcated brown to gray hyperpigmented macules and plaques.
- Usually smaller lesions than erythema dyschromicum perstans.
- Usually appears in children and adolescents.
- Usually appears on the face, trunk, and proximal extremities.
- Treatments provide only a minimal improvement in pigmentation.

Idiopathic eruptive macular hyperpigmentation is a rare disorder of pigmentation, described initially by Degos and colleagues but first described in English in 1996.[102,103]

EPIDEMIOLOGY

Idiopathic eruptive macular hyperpigmentation is usually seen in children and adolescents.

CLINICAL FEATURES

Idiopathic eruptive macular hyperpigmentation is characterized by an eruption of asymptomatic, well-demarcated, nonscaly, brown macules and plaques (5 mm to several centimeters in diameter) involving the face, neck, trunk, and proximal extremities. No preceding inflammation or erythema is noted.

A subset of patients have been noted to have thickened plaques (epidermal papillomatosis).

No extracutaneous manifestations exist.

ETIOLOGY AND PATHOGENESIS

The etiology is unknown.

DIAGNOSIS

Histopathologically, there is increased melanin in the basal epidermis and melanophages demonstrated in the dermis. The number of mast cells is normal. No basal layer change or lichenoid inflammation is seen.

DIFFERENTIAL DIAGNOSIS

EDP, lichen planus pigmentosus, and PIH are the main differential diagnoses. Drug-induced pigmentation must be excluded.

CLINICAL COURSE AND PROGNOSIS

Lesions spontaneously disappear over several months to years without scarring.

MANAGEMENT

Spontaneous resolution means that in most situations, treatment is not needed. Topical lightening agents like retinoids, α-hydroxy acids, and hydroquinone are possible treatments.

MIXED HYPOMELANOSIS AND HYPERMELANOSIS

AT-A-GLANCE

Causes of mixed hypomelanosis and hypermelanosis include:

- Dyschromatosis hereditaria universalis.
- Dyschromatosis symmetrica hereditaria.
- Reticulate acropigmentation of Dohi.
- Familial progressive hyperpigmentation with (Westerhof syndrome) or without hypopigmentation.
- Vagabond leucoderma.

DYSCHROMATOSIS HEREDITARIA UNIVERSALIS

Dyschromatosis hereditaria universalis is a rare autosomal dominant disorder (mutation in the *ABCB6* gene on chromosome 12q21-q23) that usually presents in infancy or early childhood in Japanese families and is characterized by pinpoint to pea-sized hypopigmented and hyperpigmented macules, distributed in a reticulated pattern over the trunk, abdomen, and limbs, usually sparing the face and palmoplantar surfaces.[104]

RETICULATE ACROPIGMENTATION OF DOHI

Reticulate acropigmentation of Dohi is a localized form of dyschromatosis universalis hereditaria, also called dyschromatosis symmetrica hereditaria. It is characterized by small, symmetric, hyperpigmented and hypopigmented macules on the dorsal hands and feet, and is mainly seen in young children in South American and Asian families.[104]

FAMILIAL PROGRESSIVE HYPERPIGMENTATION WITH (WESTERHOF SYNDROME) OR WITHOUT HYPOPIGMENTATION

Familial progressive hyperpigmentation with or without hypopigmentation is an autosomal dominant condition caused by a heterozygous mutation in the KIT ligand gene (*KITLG*) on chromosome 12q22. It presents at birth or early infancy as diffuse hyperpigmentation and may demonstrate café-au-lait macules and larger hypopigmented ash-leaf macules on the face, neck, trunk, and limbs. The case series of Westerhof syndrome in 1978 described some family members with retarded growth and mental retardation.[105]

VAGABOND LEUKODERMA

Vagabond leukoderma is a condition found in persons living in poor hygienic conditions. Many abuse alcohol, live on an inadequate diet, and are infested with lice and/or scabies. Diffuse light-brown hyperpigmentation is present at the shoulder and waist girdle, and the neck and back are dotted with depigmented macules. The condition improves upon institution of a healthier lifestyle and likely represents a coexistence of many disorders

ACKNOWLEDGMENTS

We would like to acknowledge the contribution of the authors of this chapter in the previous edition: Hilde Lapeere, Barbara Boone, Sofie De Schepper, Evelien Verhaeghe, Mireille Van Gele, Katia Ongenae, Nanja Van Geel, Jo Lambert, and Lieve Brochez.

REFERENCES

1. Kalter DC, Griffiths WA, Atherton DJ. Linear and whorled nevoid hypermelanosis. *J Am Acad Dermatol.* 1988;19:1037-1044.
2. Hartmann A, Hofmann UB, Hoehn H, et al. Postnatal confirmation of prenatally diagnosed trisomy 20 mosaicism in a patient with linear and whorled nevoid hypermelanosis. *Pediatr Dermatol.* 2004;21:636-641.
3. Happle R. A fresh look at incontinentia pigmenti. *Arch Dermatol.* 2003;139:1206-1208.
4. Fusco F, Bardaro T, Fimiani G, et al. Molecular analysis of the genetic defect in a large cohort of IP patients and identification of novel NEMO mutations interfering with NF-kappa B activation. *Hum Mol Genet.* 2004; 13:1763-1773.
5. Conte MI, Pescatore A, Paciolla M, et al. Insight into IKBKG/NEMO locus: report of new mutations and complex genomic rearrangements leading to incontinentia pigmenti disease. *Hum Mutat.* 2014; 35:165-177.
6. Jessup CJ, Morgan SC, Cohen LM, et al. Incontinentia pigmenti: treatment of IP with topical tacrolimus. *J Drugs Dermatol.* 2009;8:944-946.
7. Schmidt M, Serror K, Chaouat M, et al. Management of hypopigmented scars following burn injuries [in French]. *Ann Chir Plast Esthet.* 2018;63(3):246-254.
8. Vulliamy T, Marrone A, Goldman F, et al. The RNA component of telomerase is mutated in autosomal dominant dyskeratosis congenita. *Nature.* 2001; 413:432-435.
9. Walne AJ, Dokal I. Advances in the understanding of dyskeratosis congenita. *Br J Haematol.* 2009; 145:164-172.
10. Lugassy J, Itin P, Ishida-Yamamoto A, et al. Naegeli-Franceschetti-Jadassohn syndrome and dermatopathia pigmentosa reticularis: two allelic ectodermal dysplasias caused by dominant mutations in KRT14. *Am J Hum Genet.* 2006;79:724-730.
11. Komaya G. Symmetrische Pigmentanomalie der Extremitaeten. *Arch Derm Syphilol.* 1924;147:389-393.
12. Amyere M, Vogt T, Hoo J, et al. KITLG mutations cause familial progressive hyper- and hypopigmentation. *J Invest Dermatol.* 2011;131:1234-1239.
13. Rycroft RJ, Calnan CD, Allenby CF. Dermatopathia pigmentosa reticularis. *Clin Exp Dermatol.* 1977; 2:39-44.
14. Betz RC, Planko L, Eigelshoven S, et al. Loss-of-function mutations in the keratin 5 gene lead to Dowling-Degos disease. *Am J Hum Genet.* 2006;78:510-519.
15. Hanneken S, Rütten A, Pasternack SM, et al. Systematic mutation screening of KRT5 supports the hypothesis that Galli-Galli disease is a variant of Dowling-Degos disease. *Br J Dermatol.* 2010;163:197-200.
16. Kono M, Sugiura K, Suganuma M, et al. Whole exome sequencing identifies ADAM10 mutations as a cause of reticulate acropigmentation of Kitamura, a clinical entity distinct from Dowling-Degos disease. *Hum Mol Genet.* 2013;22:3524-3533.
17. Muller CS, Pfohler C, Tilgen W. Changing a concept–controversy on the confusing spectrum of the reticulate pigmented disorders of the skin. *J Cutan Pathol.* 2009; 36:44-48.
18. Ota M. Naevus fusco-caeruleus ophthalmo-maxillaris. *Jpn J Dermatol.* 1939;46:369.
19. Ho SG, Chan HH. The Asian dermatologic patient: review of common pigmentary disorders and cutaneous diseases. *Am J Clin Dermatol.* 2009;10:153-168.
20. Shah VV, Bray FN, Aldahan AS, et al. Lasers and nevus of Ota: a comprehensive review. *Lasers Med Sci.* 2016; 31:179-185.
21. Chan HH, Kono T. Nevus of Ota: clinical aspects and management. *Skinmed.* 2003;2:89-96.
22. Forbat E, Al-Niami F. The use of picosecond lasers beyond tattoos. *J Cosmet Laser Ther.* 2016;16:1-3.
23. Ito M. Naevus fusco-caeruleus acromio-deltoides. *Tohoku J Exp Med.* 1954;60:10-12.
24. Leung AK. Mongolian spots in Chinese children. *Int J Dermatol.* 1988;27:106-108.

25. Mimouni-Bloch A, Finezilber Y, Rothschild M, et al. Extensive Mongolian spots and lysosomal storage diseases. *J Pediatr.* 2016;170:333-e1.
26. Burkhart CG, Gohara A. Dermal melanocyte hamartoma. A distinctive new form of dermal melanocytosis. *Arch Dermatol.* 1981;117:102-104.
27. Stratakis CA. Genetics of Carney complex and related familial lentiginoses, and other multiple tumor syndromes. *Front Biosci.* 2000;5:D353-D366.
28. Jeghers H, McKusick V, Katz KH. Generalized intestinal polyposis and melanin spots of the oral mucosa, lips and digits a syndrome of diagnostic significance. *N Engl J Med.* 1949;241:1031-1036.
29. Shah KR, Boland CR, Patel M, et al. Cutaneous manifestations of gastrointestinal disease: part I. *J Am Acad Dermatol.* 2013;68:189.e1-21.
30. Digilio MC, Sarkozy A, de Zorzi A, et al. LEOPARD syndrome: clinical diagnosis in the first year of life. *Am J Med Genet A.* 2006;140:740-746.
31. Carney JA, Gordon H, Carpenter PC, et al. The complex of myxomas, spotty pigmentation, and endocrine overactivity. *Medicine (Baltimore).* 1985;64:270-283.
32. Mateus C, Palangié A, Franck N, et al. Heterogeneity of skin manifestations in patients with Carney complex. *J Am Acad Dermatol.* 2008;59:801-810.
33. Rothenbuhler A, Stratakis CA. Clinical and molecular genetics of Carney complex. *Best Pract Res Clin Endocrinol Metab.* 2010;24:389-399.
34. Gorlin RJ, Cohen MM Jr, Condon LM, et al. Bannayan-Riley-Ruvalcaba syndrome. *Am J Med Genet.* 1992; 44:307-314.
35. Hobert JA, Eng C. PTEN hamartoma tumor syndrome: an overview. *Genet Med.* 2009;11:687-694.
36. Dociu I, Galaction-Nițelea O, Sirjiță N, et al. Centrofacial lentiginosis. A survey of 40 cases. *Br J Dermatol.* 1976;94:39-43.
37. Alper JC, Holmes LB. The incidence and significance of birthmarks in a cohort of 4,641 newborns. *Pediatr Dermatol.* 1983;1:58-68.
38. Brems H, Chmara M, Sahbatou M, et al. Germline loss-of-function mutations in SPRED1 cause a neurofibromatosis 1-like phenotype. *Nat Genet.* 2007;39:1120-1126.
39. Denayer E, Descheemaeker MJ, Stewart DR, et al. Observations on intelligence and behavior in 15 patients with Legius syndrome. *Am J Med Genet C Semin Med Genet.* 2011;157:123-128.
40. Dumitrescu CE, Collins MT. McCune-Albright syndrome. *Orphanet J Rare Dis.* 2008;3:12.
41. Kaneko H, Kondo N. Clinical features of Bloom syndrome and function of the causative gene, BLM helicase. *Expert Rev Mol Diagn.* 2004;4:393-401.
42. Cheok CF, Bachrati CZ, Chan KL, et al. Roles of the Bloom's syndrome helicase in the maintenance of genome stability. *Biochem Soc Trans.* 2005;33:1456-1459.
43. Ellis NA, German J. Molecular genetics of Bloom's syndrome. *Hum Mol Genet.* 1996;5(spec no):1457-1463.
44. Watson GH. Pulmonary stenosis, cafe-au-lait spots, and dull intelligence. *Arch Dis Child.* 1967;42:303-307.
45. Allanson JE, Upadhyaya M, Watson GH, et al. Watson syndrome: is it a subtype of type 1 neurofibromatosis? *J Med Genet.* 1991;28:752-756.
46. Silver HK, Kiyasu W, George J, et al. Syndrome of congenital hemihypertrophy, shortness of stature and elevated urinary gonadotrophins. *Pediatrics.* 1953;12:386-376.
47. Russel A. A syndrome of intra-uterine dwarfism recognizable at birth with cranio-facial dysostosis, disproportionately short arms, and other anomalies (5 examples). *Proc R Soc Med.* 1954;47:1040-1044.
48. Peñaherrera MS, Weindler S, Van Allen MI, et al. Methylation profiling in individuals with Russel-Silver syndrome. *Am J Med Genet A.* 2010;152A(2): 347-355.
49. Pereira MA, Halpern A, Salgado LR, et al. A study of patients with Nelson's syndrome. *Clin Endocrinol (Oxf).* 1998;49:533-539.
50. Zawar VP, Walvekar R. A pheochromocytoma presenting as generalized pigmentation. *Int J Dermatol.* 2004;43:140-142.
51. Heymann WR. Cutaneous manifestations of thyroid disease. *J Am Acad Dermatol.* 1992;26:885-902.
52. Guffey D, Narahari S, Alinia H. Hyperpigmented plaques of the alar creases: an unusual presentation of acanthosis nigricans. *Pediatr Dermatol.* 2016; 33(2):e160-e161.
53. Alexander A. Maturational hyperpigmentation. In: Kelly A, Taylor S, eds. *Dermatology for Skin of Color*. New York, NY: McGraw-Hill Medical; 2009:344.
54. Heilskov S, Rytter MJ, Vestergaard C, et al. Dermatosis in children with oedematous malnutrition (Kwashiorkor): a review of the literature. *J Eur Acad Dermatol Venereol.* 2014;28(8):995-1001.
55. Mori K, Ando I, Kukita A. Generalized hyperpigmentation of the skin due to vitamin B12 deficiency. *J Dermatol.* 2001;28:282-285.
56. Lee LW, Yan AC. Skin manifestations of nutritional deficiency disease in children: modern day contexts. *Int J Dermatol.* 2012;51:1407-1418.
57. Powell LW, Seckington RC, Deugnier Y. Haemochromatosis. *Lancet.* 2016;388(10045):706-716.
58. Quinlan KE, Janiga JJ, Baran R, et al. Transverse melanonychia secondary to total skin electron beam therapy: a report of 3 cases. *J Am Acad Dermatol.* 2005;53: S112-S114.
59. Kelly KM, Svaasand LO, Nelson JS. Further investigation of pigmentary changes after alexandrite laser hair removal in conjunction with cryogen spray cooling. *Dermatol Surg.* 2004;30:581-582.
60. Al-Aboosi M, Abalkhail A, Kasim O, et al. Friction melanosis: a clinical, histologic, and ultrastructural study in Jordanian patients. *Int J Dermatol.* 2004; 43(4):261-264.
61. Nisar M, Iyer K, Brodell R, et al. Minocycline-induced hyperpigmentation: a comparison of 3 Q-switched lasers to reverse its effects. *Clin Cosmet Investig Dermatol.* 2013;6:159-162.
62. Rodrigues M, Bekhor P. Treatment of minocycline-induced cutaneous pigmentation with the picosecond alexandrite (755-nm) laser. *Dermatol Surg.* 2015; 41(10):1179-1182.
63. Prachi B, Vijay Z, Godse K, et al. Exogenous ochronosis. *Indian J Dermatol.* 2015;60(6):537-543.
64. Romero SA, Pereira PM, Mariano AV, et al. Use of dermoscopy for diagnosis of exogenous ochronosis. *An Bras Dermatol.* 2011;86(suppl 1):S31-S34.
65. Chung, L, Lin J, Furst DE, et al. Systemic and localized scleroderma. *Clin Dermatol.* 2006;24(5): 374-392.
66. Gibney KB, Fischer M, Prince HE, et al. Chikungunya fever in the United States: a fifteen year review of cases. *Clin Infect Dis.* 2011;52:e121-e126.
67. Vasani R, Kanhere S, Chaudhari K, et al. Congenital Chikungunya—a cause of neonatal hyperpigmentation. *Pediatr Dermatol.* 2016;33(2):209-212.
68. Gasque P, Jaffar-Bandjee MC. The immunology and inflammatory responses of human melanocytes in infectious diseases. *J Infect.* 2015;71(4):413-421.

69. Engelkens HJ, Niemel PL, van der Sluis JJ, et al. Endemic treponematoses. Part II. Pinta and endemic syphilis. *Int J Dermatol.* 1991;30(4):221-228.
70. Sarma N, Chakraborty S, Bhattacharya SR. Acquired, idiopathic, patterned facial pigmentation (AIPFP) including periorbital pigmentation and pigmentary demarcation lines on face follows the lines of Blaschko on face. *Indian J Dermatol.* 2014;59:41-48.
71. Gondak RO, da Silva-Jorge R, Jorge J, et al. Oral pigmented lesions: clinicopathologic features and review of the literature. *Med Oral Patol Oral Cir Bucal.* 2012;17: e919-e924.
72. Tanioka M. Benign acral lesions showing parallel ridge pattern on dermoscopy. *J Dermatol.* 2011;38:41-44.
73. Netchiporouk E, Pehr K, Ben-Shoshan M, et al. Pustular flagellate dermatitis after consumption of shiitake mushrooms. *JAAD Case Rep.* 2015;1(3):117-119.
74. Takashima S, Iwata H, Sakata M, et al. Widespread erythema ab igne caused by hot bathing. *J Eur Acad Dermatol Venereol.* 2015;29(11):2259-2261.
75. Huynh N, Sarma D, Huerter C. Erythema ab igne: a case report and review of the literature. *Cutis.* 2011; 88:290-292.
76. Cho S, Jung JY, Lee JH. Erythema ab igne successfully treated using 1,064-nm Q-switched neodymium-doped yttrium aluminum garnet laser with low fluence. *Dermatol Surg.* 2011;37:551-553.
77. Nagashima M, Oshiro A, Shimizu N. A peculiar pruriginous dermatosis with gross reticular pigmentation [in Japanese]. *Jap J Dermatol*. 1971;81:78-91.
78. Corley, S, Mauro P. Erythematous papules evolving into reticulated hyperpigmentation on the trunk: a case of prurigo pigmentosa. *JAAD Case Rep.* 2015;1(2):60-62.
79. Boer A, Misago N, Wolter M, et al. Prurigo pigmentosa: a distinctive inflammatory disease of the skin. *Am J Dermatopathol.* 2003;25(2):117-129.
80. Bhat RM, Pinto HP, Dandekeri S, et al. Acquired bilateral nevus of ota-like macules with mucosal involvement: a new variant of Hori's nevus. *Indian J Dermatol.* 2014; 59:293-296.
81. Tian BW. Novel treatment of Hori's nevus: a combination of fractional nonablative 2,940-nm Er:YAG and low fluence 1,066-nm Q-switched ND;YAG laser. *J Cutan Aesthet Surg.* 2015;8(4):227-229.
82. Cho SB, Park SJ, Kim MJ, et al. Treatment of acquired bilateral nevus of Ota-like macules (Hori's nevus) using 1064-nm Q-switched Nd:YAG laser with low fluence. *Int J Dermatol.* 2009;48:1308-1312.
83. Chan JC, Shek SY, Kono T, et al. A retrospective analysis on the management of pigmented lesions using a picosecond 755-nm alexandrite laser in Asians. *Lasers Surg Med.* 2016;48(1):23-29.
84. Patrizi A, Medri M, Raone B, et al. Clinical characteristics of Becker's nevus in children: a report of 118 cases from Italy. *Pediatr Dermatol.* 2012;29:571-574.
85. Momen S, Mallipeddi R, Al-Niami F. The use of lasers in Becker's naevus: an evidence-based review. *J Cosmet Laser Ther.* 2016;18(4):188-192.
86. Shah KN. The diagnostic and clinical significance of café-au-lait macules. *Pediatr Clin North Am.* 2010; 57:1131-1153.
87. Bastiaens M, ter Huurne J, Gruis N, et al. The melanocortin-1-receptor gene is the major freckle gene. *Hum Mol Genet.* 2001;10:1701-1708.
88. Sopena Barona J, Gamo Villegas R, Guerra Tapia A, et al. Acromelanosis [in Spanish]. *An Pediatr (Barc).* 2003;58:277-280.
89. Callender VD, St Surin-Lord S, Davis EC, et al. Postinflammatory hyperpigmentation: etiologic and therapeutic considerations. *Am J Clin Dermatol.* 2011; 12:87-99.
90. Ho SG, Yeung CK, Chan NP, et al. A retrospective analysis of the management of acne post-inflammatory hyperpigmentation using topical treatment, laser treatment, or combination topical and laser treatments in oriental patients. *Lasers Surg Med.* 2011; 43(1):1-7.
91. Rodrigues M, Pandya AG. Melasma: clinical diagnosis and management options. *Australas J Dermatol.* 2015;56(3):151-163.
92. Lee HC, Thng TG, Goh CL. Oral tranexamic acid (TA) in the treatment of melasma: a retrospective analysis. *J Am Acad Dermatol.* 2016;75(2):385-392.
93. Pretel M, Irarrazaval I, Aguado L, et al. Partial unilateral lentiginosis treated with alexandrite Q-switched laser: case report and review of the literature. *J Cosmet Laser Ther.* 2013;15(4):207-209.
94. Kwon HH, Onh J, Suh DH, et al. A pilot study for triple combination therapy with a low-fluence 1064 nm Q-switched Nd:YAG laser, hydroquinone cream and oral tranexamic acid for recalcitrant Riehl's melanosis. *J Dermatolog Treat.* 2016;27:1-5.
95. Kronborg C, Mahar P, Howard A. Cronkhite-Canada syndrome: a rare disease presenting with dermatological and gastrointestinal manifestations. *Australas J Dermatol.* 2016;57(2):e69-e71.
96. Ramirez CO. Los cenisientos: problema clinica. Proceedings of the first Central American Congress of Dermatology. San Salvador, El Salvador; 1957: 122-130.
97. Rodríguez N, Granados J. HLA-DR association with the genetic susceptibility to develop ashy dermatosis in Mexican Mestizo patients. *J Am Acad Dermatol.* 2007;56(4):617-620.
98. Bahadir S, Cobanoglu U, Cimsit G, et al. Erythema dyschromicum perstans: response to dapsone therapy. *Int J Dermatol.* 2004;43:220-222.
99. Kroon MW, Wind BS, Meesters AA, et al. Non-ablative 1550 nm fractional laser therapy not effective for erythema dyschromicum perstans and postinflammatory hyperpigmentation: a pilot study. *J Dermatolog Treat.* 2012;23:339-344.
100. Al-Mutairi N, El-Khalawany M. Clinicopathological characteristics of lichen planus pigmentosus and its response to tacrolimus ointment: an open label, non-randomized, prospective study. *J Eur Acad Dermatol Venereol.* 2010;24:535-540.
101. Muthu SK, Narang T, Saikia UN, et al. Low-dose oral isotretinoin therapy in lichen planus pigmentosus: an open-label non-randomized prospective pilot study. *Int J Dermatol.* 2016;55(9):1048-1054.
102. Degos R, Civatte J, Belaiche S. Idiopathic eruptive macular pigmentation. *Ann Dermatol Venereol.* 1978; 105:177-182.
103. Sanz de Galdeano C, Léauté-Labrèze C, Bioulac-Sage P, et al. Idiopathic eruptive macular pigmentation: report of five patients. *Pediatr Dermatol.* 1996; 13:274-277.
104. Zhang C, Li D, Zhang J, et al. Mutations in ABCB6 cause dyschromatosis universalis hereditaria. *J Invest Dermatol.* 2013;133(9):2221-2228.
105. Westerhof W, Beemer FA, Cormane RH, et al. Hereditary congenital hypopigmented and hyperpigmented macules. *Arch Dermatol.* 1978;114:931-936.

This page intentionally left blank

Acneiform Disorders

PART 14

Chapter 78 :: Acne Vulgaris

:: Carolyn Goh, Carol Cheng, George Agak, Andrea L. Zaenglein, Emmy M. Graber, Diane M. Thiboutot, & Jenny Kim

AT-A-GLANCE

- Acne vulgaris is a common disorder of the pilosebaceous unit.
- There are four key elements of pathogenesis: (1) follicular epidermal hyperproliferation, (2) sebum production, (3) the presence and activity of *Propionibacterium acnes*, and (4) inflammation and immune response.
- Clinical features include comedones, papules, pustules, and nodules on the face, chest, and back.
- Treatment often includes combinations of oral and topical agents such as antimicrobials, retinoids, and hormonal agents. Laser and light sources are additional treatment options.

INTRODUCTION

Acne vulgaris is a common disorder of the pilosebaceous unit that is seen primarily in adolescents. Most cases of acne present with a pleomorphic array of lesions, consisting of comedones, papules, pustules, and nodules with varying extent and severity. Although the course of acne may be limited in the majority of patients, the sequelae can be lifelong, with scar formation and psychological impairment, especially in young people.

EPIDEMIOLOGY

Acne is one of the top three most common skin diseases, particularly in adolescents and young adults, in whom the prevalence is estimated at 85% (ages 12–25 years).[1,2] Acne has no predilection for ethnicity; thus, it is an important disease worldwide and is considered one of the top 10 most prevalent global diseases.[3-5] It is also considered the third most important disease defined by the global burden of disease.[6] Acne patients report a Dermatology Life Quality Index (DLQI) score of 11.9, considered more detrimental to quality of life than psoriasis (DLQI = 8.8). Thus, acne is not only important for health of a significant number of people in the United States but has an impact globally.

Acne can occur at any age, starting at birth with neonatal acne (presents in the first few weeks of life) and infantile acne (presents between 1 and 12 months) and extending into adulthood. Acne may persist from adolescence into adulthood, or it can have its onset after the adolescent period. The prevalence of acne in adolescents is higher in males, but in adults is higher in females. The prevalence rates in adults have been reported to be as high as 64% in the 20s and 43% in the 30s.[7] After the age of 50 years, 15% of women and 7% of men have been reported to have acne.[8] Because the age of adrenarche appears to be dropping over the years, patients may be presenting with acne at an earlier age.[9] Globally, the incidence of acne vulgaris appears to be rising. The reasons are unclear, although increased exposure to a westernized diet is postulated.[2]

Family history of acne has been reported in 62.9% to 78% of patients.[10,11] Those with family history tend to be male and have an earlier onset of acne, truncal involvement, and scarring.[11] Several twin studies have been done, finding that 81% of acne variation is caused by genetic factors as opposed to 19% environmental factors and that as many as 98% of monozygotic twins both have acne versus 55% of dizygotic twins.[9] The severity of acne may also be genetically determined.[9]

Males tend to have more severe acne, and nodulocystic acne has been reported to be more common in white males than in black males.[6,12] Acne also appears to be more severe in patients with the XYY genotype.[13]

Individual genes responsible for this high heritability remain unclear. Several candidate gene-based studies have identified a few genetic variants associated with acne in *tumor necrosis factor-α (TNF-α)*, *tumor necrosis factor receptor 2(TNFR2)*,[14] *interleukin-1A (IL1A)*,[15,16] *cytochrome P450, family 17 (CYP17)*,[17] *Toll-like receptor 2(TLR2)*,[14] and *Toll-like receptor 4 (TLR4)*.[18] Genome-wide association studies (GWASs)[19] have also been reported on this common skin condition.

Interestingly, there are two indigenous populations that have been described—one in Papua New Guinea and the other in Paraguay—that do not develop acne.[6] Although this may be genetically determined, environmental factors may also be at play because these groups have not been exposed to a westernized diet.

CLINICAL FEATURES

HISTORY

Most patients with acne vulgaris report a gradual onset of lesions around puberty. Some may develop acne in the years preceding puberty, but others may not develop acne until after puberty. Because of the typical gradual onset, careful history should be obtained from patients describing an abrupt onset of acne to potentially reveal an underlying etiology, such as a medication or an androgen-secreting tumor.

Hyperandrogenism should be considered in a female patient whose acne is severe, in the jawline or lower face distribution, sudden in onset, or associated with hirsutism or irregular menstrual periods. The patient should be asked about the frequency and character of her menstrual periods and whether her acne flares with changes in her menstrual cycle. Flares of acne perimenstrually, however, are common in acne vulgaris, with 56% of adult women reporting worsening of acne before menses.[20] Other signs that may suggest a diagnosis of hyperandrogenism include deepening of the voice, an increase in libido, hirsutism, and acanthosis nigricans.

A complete medication history is also important because some medications can cause an abrupt onset of a monomorphous acneiform eruption. Drug-induced acne may be caused by anabolic steroids, corticosteroids, corticotropin, phenytoin, lithium, isoniazid, vitamin B complexes, halogenated compounds, and certain chemotherapy medications, particularly with epidermal growth factor receptor (EGFR) inhibitors. Furthermore, many patients may be on hormonal therapy, which can exacerbate or induce acne vulgaris. Progestin-only contraceptives, including injectables and intrauterine devices, can exacerbate or induce acne vulgaris.[21] Women approaching or in menopause may be on hormone therapy, including progesterone, and some are treated with dehydroepiandrosterone (DHEA) or testosterone.[22] Men may be on testosterone replacement therapy. Finally, inquiring about supplements is important. In particular, those containing whey protein have been associated with onset or worsening of acne vulgaris.[23]

CUTANEOUS FINDINGS

The primary site of acne is the face and to a lesser degree the back, chest, and shoulders. On the trunk, lesions tend to be concentrated near the midline. Acne vulgaris is characterized by several lesion types: noninflammatory comedones (open or closed) and inflammatory lesions (red papules, pustules, or nodules) (Fig. 78-1). Although one type of lesion may predominate, close inspection usually reveals the presence of several types of lesions. Closed comedones are known as "whiteheads" (Fig. 78-1A), and open comedones are known as "blackheads" (Fig. 78-1B). The open comedo appears as a flat or slightly raised lesion with a central dark-colored follicular impaction of keratin and lipid. It is dark because of oxidation (Fig. 78-2). Closed comedones appear as cream to white, slightly elevated, small papules and do not have a clinically visible orifice (Fig. 78-1A). Stretching, side lighting, or palpation of the skin can be helpful in detecting the lesions.

The inflammatory lesions vary from small erythematous papules to pustules and large, tender, fluctuant nodules (see Figs. 78-1C and 78-1D and Figs. 78-2–78-4). Some of the large nodules were previously called "cysts," and the term *nodulocystic* has been used to describe severe cases of inflammatory acne. True cysts are rarely found in acne; this term should be abandoned and substituted with *severe nodular acne* (see Figs. 78-1D and 78-4). The evolution of an acne lesion is unclear. Although the majority of inflammatory lesions appear to originate from comedones (54%), a significant number of inflammatory (26%) lesions arise from normal uninvolved skin.[24] The mechanisms involved in the evolution of an inflammatory lesion are still unclear, but an inflammatory process is thought to play a role. Whether the lesion appears as a papule, pustule, or nodule depends on the extent and location of the inflammatory infiltrate in the dermis.

NONCUTANEOUS FINDINGS

Acne vulgaris is usually an isolated cutaneous finding. However, it can be part of several syndromes, including those that are associated with hyperandrogenism and inflammatory states (see Chap. 80).

COMPLICATIONS

All types of acne lesions have the potential to resolve with sequelae. Almost all acne lesions leave a transient macular erythema after resolution. In darker skin

Figure 78-1 Clinicopathologic correlation of acne lesions. **A,** Closed comedone. The follicular infundibulum is distended, filled with keratin and sebum, and the follicular epithelium is attenuated. The follicular ostium is narrow. **B,** Open comedone. Resembles the closed comedone with the exception of a patulous follicular ostium. **C,** Inflammatory papule. Acute and chronic inflammatory cells surround and infiltrate the follicle, which shows infundibular hyperkeratosis. **D,** Nodule. The follicle is filled with acute inflammatory cells. With the rupture of the distended follicle, there is a foreign body granulomatous response.

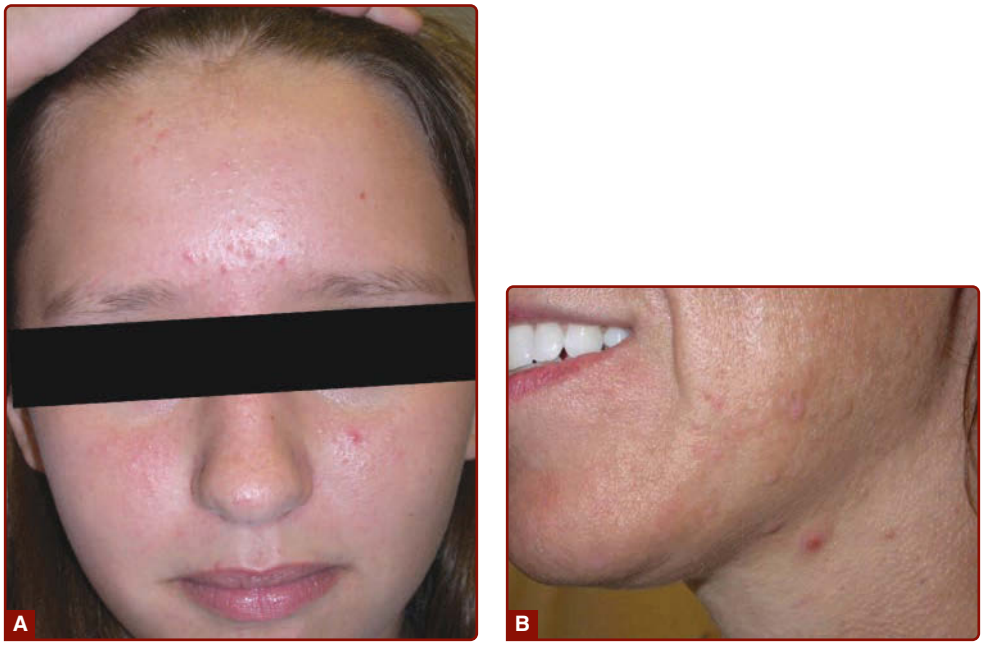

Figure 78-2 Mild acne vulgaris. **A,** A 13-year-old girl with mild acne vulgaris. Scattered comedones or inflammatory lesions (or both) are seen, usually limited to less than half of the face. The T-zone of the face is commonly involved. No nodules are present. **B,** An adult female with primarily inflammatory acne. Note the typical involvement of the jawline.

Figure 78-3 Moderate acne vulgaris. **A,** A 15-year-old male patient with moderate acne. Typically, more than half of the face is involved with increasing numbers of lesions, usually a mix of lesions is seen: papules, pustules, and comedones. Infrequent and limited nodules may be present. Chest and back involvement may also be moderately affected. **B,** A 16-year-old female patient with open and deep closed comedones. Scarring and postinflammatory changes are possible sequelae.

types, postinflammatory hyperpigmentation may persist for months after resolution of acne lesions. In some individuals, acne lesions may result in permanent scarring. Acne scars can be atrophic or hypertrophic.[25] Atrophic scars can be further categorized based on size and shape: ice pick, boxcar, or rolling[26] (Fig. 78-5). Ice pick scars are narrow, deep scars that are widest at the surface of the skin and taper to a point in the dermis, typically less than 2 mm in diameter. Boxcar scars are wide sharply demarcated scars that do not taper to a point at the base and range in size from 1.5 to 4 mm. Rolling scars are shallow, wide scars (often >4–5 mm) that have an undulating appearance. Perifollicular elastolysis is another type of scar, which typically presents as atrophic soft papules on the upper part of the trunk.[27] Hypertrophic and keloidal scars, in addition to sinus tracts, can also form.

Although not life threatening, acne leads to significant morbidity, including depression, anxiety, and psychosocial stress, and is a major cause of psychosocial and psychological impairment for young people,[28,29] triggering anxiety and mood disorders and affecting self-esteem.[30,31] It is ranked third among chronic skin diseases for causing disability, as measured by equivalent years of "healthy" life lost by virtue of being in states of poor health or disability.[3] Patients experience social isolation and are reluctant to participate in group activities. Unemployment rates are higher among adults with acne than those without. Self-esteem issues are also likely to be the driving force behind higher rates of unemployment in people with acne; however, there is also an existing bias whereby patients with acne are more likely to be passed over by prospective employers.[29] A cross-sectional study found that 14% of students reported "problem acne," which was associated with an increased risk of depressive symptoms as well as suicidal thoughts and attempts.[32,33] One study has estimated the prevalence of suicidal ideation in patients with acne as 7%.[34] In adolescents, two large studies have shown that anxiety, depression, and suicidal ideation are higher in those with self-described "problem acne" or "substantial acne." These findings highlight the importance of appropriate psychiatric screening and referral. Importantly, the impact of acne on patients' lives was often independent of severity, such that some patients with only minimal acne experience psychological and psychosocial distress.[35] Thus, although some consider acne "cosmetic," its impact on one's well-being can be significant.

ETIOLOGY AND PATHOGENESIS

Current understanding of acne is that it is a complex and multifactorial inflammatory disease. Recent studies are better defining the cellular and molecular mechanisms involved in acne and the importance of inflammation and the immune response. The pathogenesis of acne is multifaceted, and at least four factors have been identified. These key elements (Fig. 78-6) are (1) follicular epidermal hyperproliferation, (2) sebum production, (3) *Propionibacterium acnes*, and (4) inflammation and immune response. Each of these processes

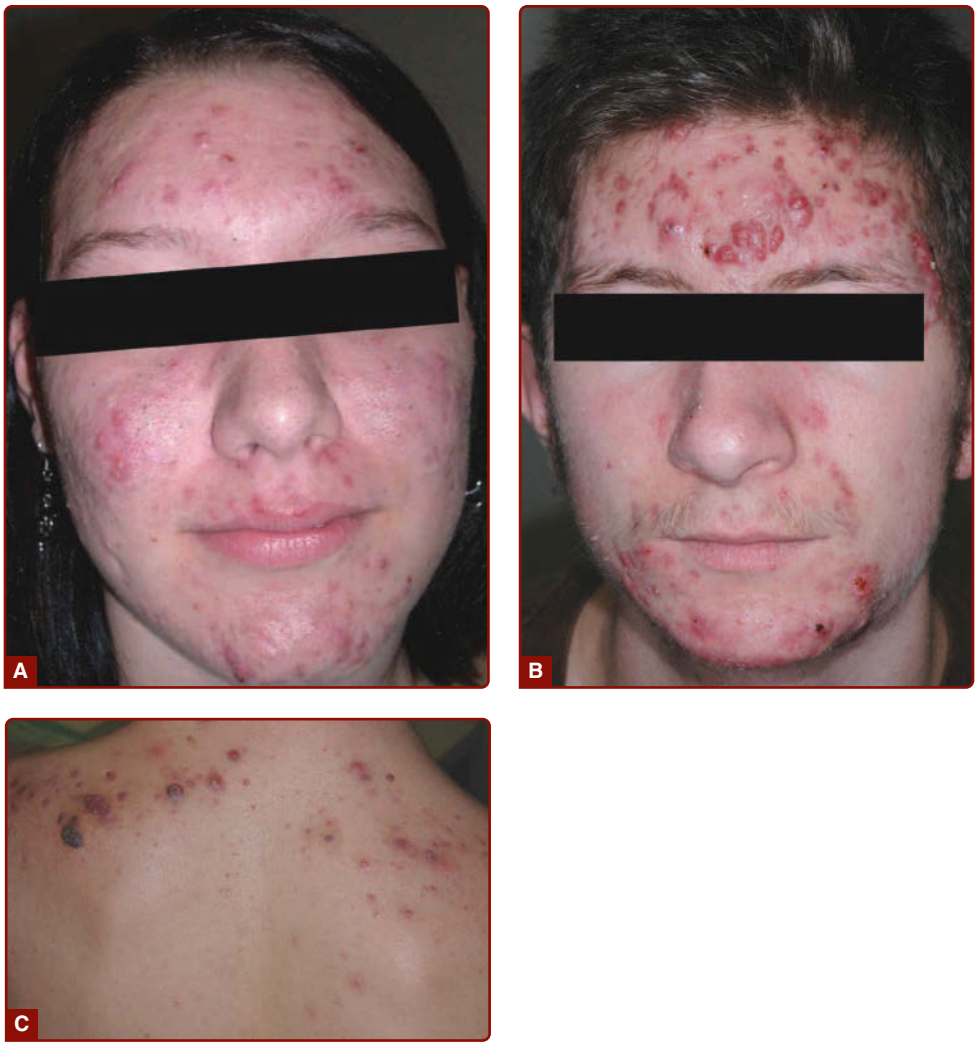

Figure 78-4 Severe acne vulgaris. **A,** A 17-year-old female patient with extensive acne. Numerous pustules and nodular lesions admixed with comedones and smaller papules cover the entire face. **B,** Deep, friable nodules that coalesce into pseudocysts in acne conglobata. **C,** Chest and back involvement can be extensive and severe. Scarring is a common complication in severe acne.

are interrelated and under hormonal and immune influence.

It is thought that all clinical lesions begin with the microcomedo and develop into clinical lesions—comedones, inflammatory lesions, and scarring. Follicular epidermal hyperproliferation results in the formation of a microcomedo. The epithelium of the upper hair follicle, the infundibulum, becomes hyperkeratotic with increased cohesion of the keratinocytes, resulting in the obstruction of the follicular ostium, where keratin, sebum, and bacteria begin to accumulate in the follicle and cause dilation of the upper hair follicle, producing a microcomedo. Exactly what initiates and stimulates the hyperproliferation and increased adhesion of keratinocytes is unknown. Several proposed factors in keratinocyte hyperproliferation include androgen stimulation, decreased linoleic acid, increased IL-1-α activity, and effects of *P. acnes*. Dihydrotestosterone (DHT) is a potent androgen that may play a role in acne. DHT is converted from dehydroepiandrosterone sulfate (DHEA-S) by 17-β hydroxysteroid dehydrogenase (HSD) and 5-α reductase enzymes (Fig. 78-7). Compared with epidermal keratinocytes, follicular keratinocytes have increased 17-β HSD and 5-α reductase, thus enhancing DHT production.[36,37] DHT may stimulate follicular keratinocyte proliferation. Also supporting the role of androgens in acne pathogenesis is the evidence that individuals with complete androgen insensitivity do not develop acne.[38]

Follicular keratinocyte proliferation is also regulated by linoleic acid, an essential fatty acid in the skin. Low levels of linoleic acid induce follicular keratinocyte hyperproliferation and the production of proinflammatory cytokines. The levels of linoleic acid are decreased in individuals with acne and normalize after successful treatment with isotretinoin.[39]

In addition to androgens and linoleic acid, IL-1 α has been shown to contribute to keratinocyte hyperproliferation. IL-1α induces follicular keratinocyte hyperproliferation and microcomedone formation,

Figure 78-5 Acne vulgaris, scarring. **A,** Honeycomb scarring in a young girl with mild to moderate inflammatory acne. **B,** Extensive keloidal scarring occurring as sequelae of acne fulminans. **C.** Rolling scars.

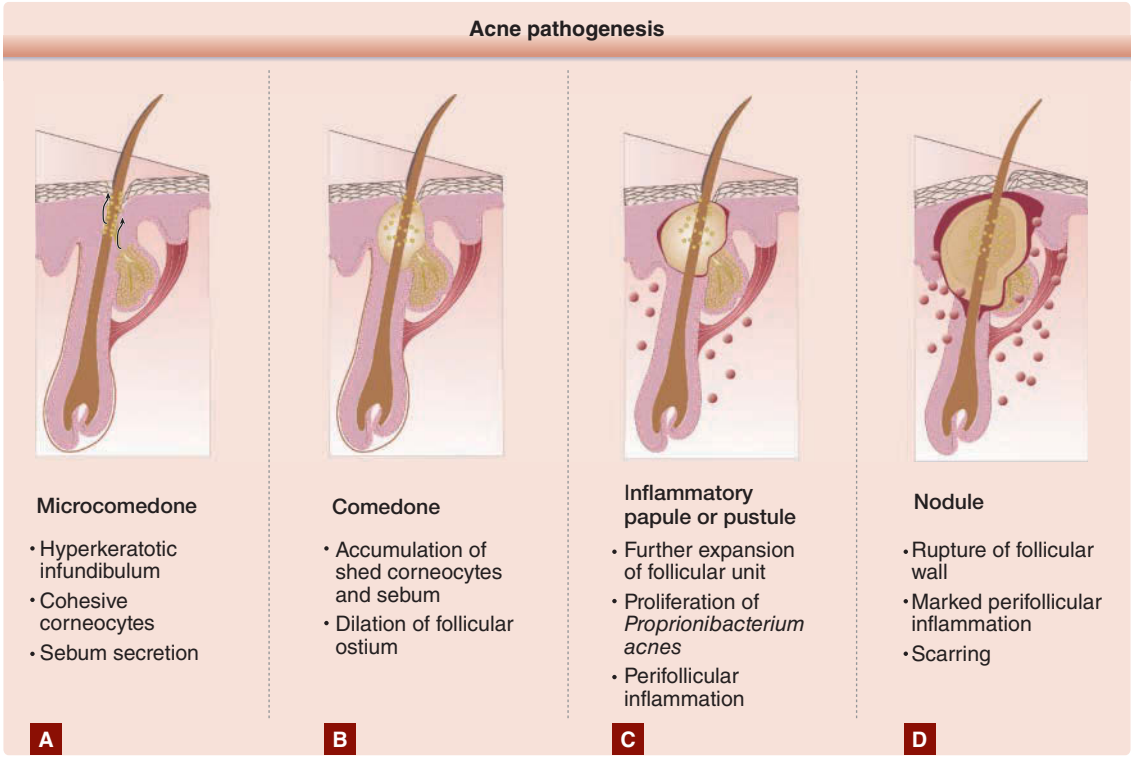

Figure 78-6 **A–D** Acne pathogenesis.

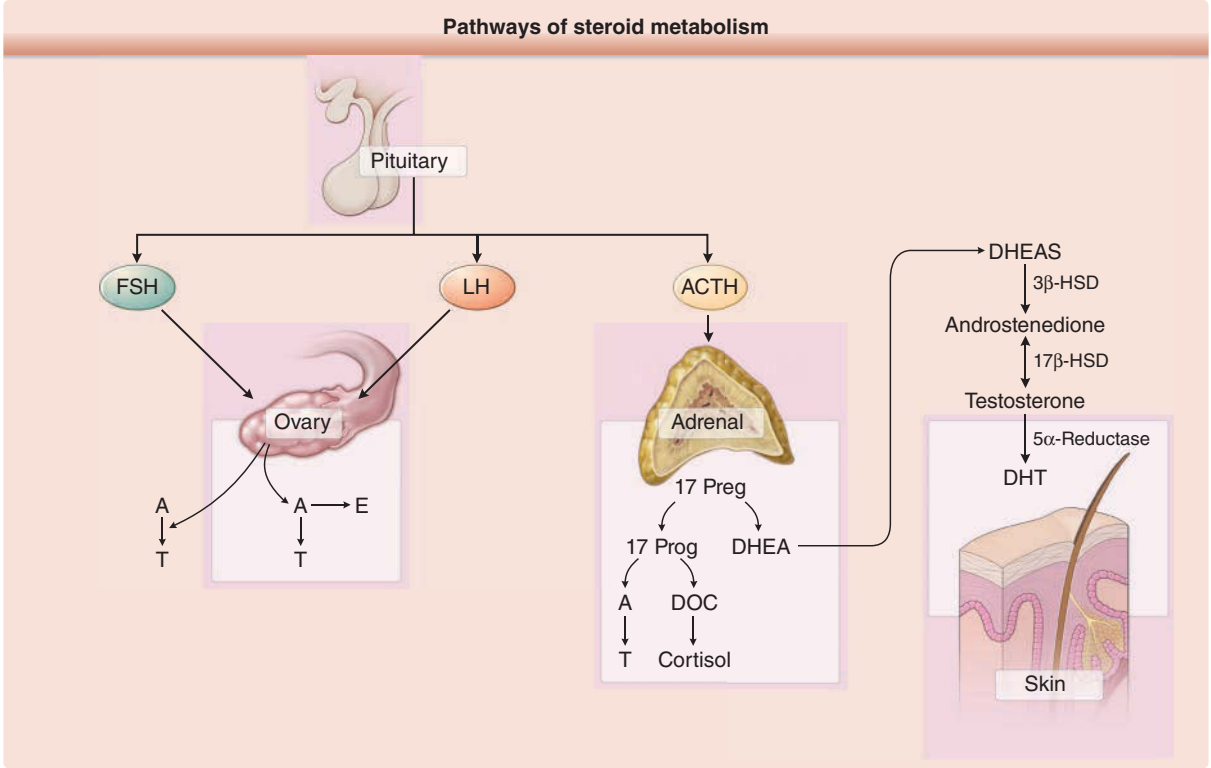

Figure 78-7 Pathways of steroid metabolism. Dehydroepiandrosterone (DHEA) is a weak androgen that is converted to the more potent testosterone by 3β-hydroxysteroid dehydrogenase (HSD) and 17β-HSD. 5-α Reductase then converts testosterone to dihydrotestosterone (DHT), the predominant hormonal effector on the sebaceous gland. The sebaceous gland expresses each of these enzymes. A, androstenedione; ACTH, adrenocorticotropin-stimulating hormone; DHEAS, dehydroepiandrosterone sulfate; DOC, deoxycortisol E, estrogen; FSH, follicle-stimulating hormone; LH, luteinizing hormone; T, testosterone.

and IL-1 receptor antagonists inhibit microcomedone formation.[40,41] The initial event that upregulates the production of IL-1α has not been determined. Fibroblast growth factor receptor (FGFR)-2 signaling is also involved in follicular hyperkeratinization. There is a long-established relationship between acne and Apert syndrome, a complex bony malformation syndrome, caused by a gain-of-function mutation in the gene encoding FGFR-2. Mutations in FGFR-2 in a mosaic distribution underlie a nevus comedonicus-like lesion.[42] The FGFR-2 pathway is androgen dependent, and proposed mechanisms in acne include an increased production of IL-1α and 5-α reductase.[43,44]

The second and key feature in the pathogenesis of acne is the production of sebum from the sebaceous gland. Human sebum are composed mainly of triglycerides found ubiquitously and of unique lipids, such as squalene and wax esters not found anywhere else in the body, including the surface of the skin.[45] Increased sebum secretion has been associated with acne. On average, people with acne excrete more sebum than those without acne, and secretion rates have been shown to correlate with the severity of clinical manifestations, although the quality of sebum is the same between the two groups.[46] The main component of sebum, triglycerides, is important in acne pathogenesis. Triglycerides are broken down into free fatty acids by *P. acnes*, normal flora of the pilosebaceous unit. In return, these free fatty acids promote *P. acnes* colonization and induction of inflammation.[47] Lipoperoxides also found in sebum induce proinflammatory cytokines and activate the peroxisome proliferator-activated receptors (PPAR) pathway, resulting in increased sebum.[48,49]

Androgenic hormones activate sebocyte proliferation and differentiation and the induction of sebum production. Similar to their action on the follicular infundibular keratinocytes, androgen hormones bind to and influence sebocyte activity.[50] Those with acne have higher average serum androgen levels (although still within normal range) than unaffected control participants.[51,52] 5-α Reductase, the enzyme responsible for converting testosterone to the potent DHT, has greatest activity in areas of skin prone to acne, face, chest, and back.[44]

The role of estrogen on sebum production is not well defined. The dose of estrogen required to decrease sebum production is greater than the dose required to inhibit ovulation.[53] The mechanisms by which estrogens may work include (1) directly opposing the effects of androgens within the sebaceous gland, (2) inhibiting the production of androgens by gonadal tissue via a negative feedback loop on pituitary gonadotropin release, and (3) regulating genes that suppress sebaceous gland growth or lipid production.[54]

Corticotropin-releasing hormone may also play a role. It is released by the hypothalamus and increased

in response to stress. Corticotropin-releasing hormone receptors are present on a vast number of cells, including keratinocytes and sebocytes, and are upregulated in the sebocytes of patients with acne.[55]

The microcomedo continue to expand with densely packed keratin, sebum, and bacteria. Eventually, this distension causes follicular wall rupture. The extrusion of the keratin, sebum, and bacteria into the dermis results in a brisk inflammatory response. The predominant cell type within 24 hours of comedo rupture is the lymphocyte. $CD4^+$ lymphocytes are found around the pilosebaceous unit, and $CD8^+$ cells are found perivascularly. One to two days after comedo rupture, the neutrophil becomes the predominant cell type surrounding the burst microcomedo.[56]

It was originally thought that inflammation follows comedo formation, but there is evidence that dermal inflammation may actually precede comedo formation. Biopsies taken from comedo-free acne-prone skin demonstrate increased dermal inflammation compared with normal skin. Biopsies of newly formed comedos demonstrate even greater inflammation.[57] This may suggest that inflammation actually precedes comedo formation, again emphasizing the interplay between all of the pathogenic factors.

P. acnes is one of the key factors involved in acne pathogenesis. *P. acnes* is a gram-positive, anaerobic, microaerophilic bacterium found in the sebaceous follicle and is the dominant bacterial inhabitant of the human sebaceous gland,[58] accounting for almost 90% of the bacterial 16S transcripts.[59] *P. acnes* is generally believed to play a major role in the pathogenesis of acne vulgaris, in part by eliciting a host inflammatory response.[60] *S. epidermidis* is also present in follicles but is located near the surface, suggesting that it does not contribute to the deeper inflammatory process.[58] There is a significant increase in *P. acnes* colonization at puberty, the time when acne commonly develops, and teenagers with acne can have as many as 100-fold more *P. acnes* bacteria present on their skin than healthy age-matched counterparts.[61] However, there are no consistent data correlating the raw number of *P. acnes* organisms present in a sebaceous follicle and the severity of the acne.[61]

Previously, a shotgun approach to target all *P. acnes* with antibiotics has been used, which has led to significant bacterial resistance in up to 60% clinical isolates, directly correlating with antibiotic treatment failure.[61-63]

The recent association of specific *P. acnes* strains with acne versus healthy skin supports the concept that *P. acnes* is an etiologic agent in the pathogenesis of acne. Certain *P. acnes* strains, as identified by multilocus sequence typing, were found to be associated with acne, designated as type IA_1 or IC strains.[64-67] Acne-associated types were further investigated using full genome sequencing in conjunction with ribotyping.[59,68] Specifically, phylotype IB-1 was associated with acne, as were the ribotype 4 and 5 subgroups of phylotype IA-2. The ribotype 1 subgroup of phylotype IA-2, together with phylotypes IA-1, IB-2, and IB-3, was found evenly distributed in acne patients and individuals with healthy skin. These acne-associated types were present in significant quantity in approximately 30% to 40% of patients but with acne rarely in individuals with healthy skin. Conversely, the phylotype II, ribotype 6 subgroup was found to be 99% associated with healthy skin. Additionally, *P. acnes* isolates belonging to phylotype III were not found in acne lesions but composed approximately 20% of isolates from healthy skin.[64] The genomes of acne-enriched and healthy skin–associated strains were sequenced,[59,68] revealing that the phylotypes associated with acne selectively harbor a plasmid and two chromosomal regions that contain genes possibly involved in pathogenesis, adhesion to epithelial tissues, or induction of human immune response.[59,68] Moreover, the levels of porphyrin production and vitamin B_{12} regulation were recently shown to be different between acne- and health-associated strains, suggesting a potential molecular mechanism for disease-associated strains in acne pathogenesis and for health-associated strains in skin health.[69] Metabolite-mediated interactions between the host and the skin microbiota may also play an essential role in acne development.[70]

Sebocyte differentiation and proinflammatory cytokine and chemokine responses are varied depending on the strain of *P. acnes* predominating within the follicle.[35] Certain strains of *P. acnes* induce a differential host immune response. *P. acnes* ribotypes associated with acne induced distinct T helper 1 (Th1) and Th17 responses, which potentially contribute to inflammation in acne, but *P. acnes* ribotypes associated with health-induced high levels of IL-10, which presumably regulate and inhibit inflammatory responses.[71]

P. acnes directly induces inflammation through various mechanisms. The cell wall of *P. acnes* contains a carbohydrate antigen that stimulates antibody development. Patients with the most severe acne have been shown to have the highest titers of antibodies.[72] The antipropionobacterium antibody enhances the inflammatory response by activating complement initiating a cascade of proinflammatory events.[73] *P. acnes* also facilitates inflammation by eliciting a delayed-type hypersensitivity response and by producing lipases, proteases, hyaluronidases, and chemotactic factors.[72,74] Reactive oxygen species (ROS) and lysosomal enzymes are released by neutrophils and levels may correlate with severity.[75] Additionally, *P. acnes* stimulates host innate responses via secretion of proinflammatory cytokines and chemokines from peripheral blood mononuclear cells (PBMCs) and monocytes[60,76] and inflammatory cytokines and antimicrobial peptides such as human β-defensin-2 (hBD2) from KC[77,78] and sebocytes.[35]

The mechanisms by which *P. acnes* triggers the innate immune response has been studied and includes the activation of pattern recognition receptors (PRRs), which recognize conserved pathogen-associated molecular patterns (PAMPs) and activate specific signaling cascades, resulting in the induction of immune response genes. *P. acnes*-induced secretion of proinflammatory cytokines IL-8, IL-12, and TNF-α in monocytes has been shown to involve TLR2,[60] which is expressed on macrophages surrounding the sebaceous follicles of

acne lesions,[60] as well as in the epidermis of inflammatory acne lesions.[79] More recently, *P. acnes* has been shown to induce IL-1β secretion and inflammasome activation via NLRP3 and caspase-1 in monocytes and macrophages,[80,81] as well as sebocytes.[82] Both NLRP3 and caspase-1 colocalize with macrophages in acne lesions,[80] keratinocytes,[77,78] and sebocytes.[35] Although many of the *P. acnes* ligands that trigger these PRRs and pathways are not known, experimental evidence points to a possible role for *P. acnes* peptidoglycan in TLR2 activation[60,76] and a component of peptidoglycan muramyl dipeptide (MDP), which in *P. acnes* is composed of the canonical N-acetylmuramic acid residue linked to the L-alanine D-isoglutamine dipeptide.[83] MDP is a ligand for NOD2,[84,85] a cytoplasmic PRR, and can also activate the inflammasome via NLRP3,[86] hinting at a possible role for NOD2 in *P. acnes*–induced immune activation.

The antimicrobial peptides histone H4 and cathelicidin are also secreted locally in response to *P. acnes*. Histone H4 exerts direct microbial killing, and cathelicidin interacts with components of the innate immune system, such as β defensins and psoriasin, in response to *P. acnes*,[87,88] Another indicator of the role of innate immunity in the pathogenesis of acne is the differentiation of peripheral blood monocytes to $CD209^+$ macrophages and $CD1b^+$ dendritic cells in response to *P. acnes*.[89]

A role for the adaptive immune response has also been suggested based on the detection of $CD4^+$ T cells in the inflammatory infiltrate from early acne lesions,[56] and both Th1 and Th17 responses are prominent in vitro and in vivo at the site of disease.[90-92] Both Th1 and Th17 cells can trigger antimicrobial activity against bacteria, but the lysis of these bacteria can release components that directly activate the innate immune response, resulting in inflammation. Moreover, Th17 characteristically induce the recruitment of neutrophils, which contribute to antibacterial activity but also cause tissue injury. ROS and lysosomal enzymes are also released by neutrophils and levels may correlate with severity.[75,93,94]

The mechanism of acne scarring is not clear, and although scar formation correlates with inflammatory response, there is no direct correlation of severity of disease and development of scar formation can occur in mild to moderate acne.[95]

It has been shown that *P. acnes* induces metalloproteinase (MMP) 1 and 9 and the expression of tissue inhibitors of metalloproteinase (TIMP)-1, the main regulator of MMP-9 and MMP-1. Furthermore, ATRA downregulates MMP and augments TIMP-1, suggesting that one way that ATRA may improve acne scarring is through the modulation of MMP and TIMP expression, shifting from a matrix-degradative phenotype to a matrix-preserving phenotype.

T-cell responses also appear to determine the outcome of scar formation. In nonscarring lesions, initial robust inflammatory response with influx of $CD4^+$ nonspecific response with few memory T cells were shown, which subsided in resolution. In contrast, in scarring lesions, $CD4^+$ T-cell numbers were smaller, although a high proportion were skin-homing memory and effector cells, and inflammation was increased and activated in resolving lesions.[96]

Finally, the impact of diet on acne is an emerging area of interest in the pathogenesis of acne. Recent studies provide evidence that high glycemic load diets may exacerbate acne and dairy ingestion appears to be weakly associated with acne,[97-99] but some studies do not support the role of diet.[100,101] Both are thought to increase insulin-like growth factor (IGF)-1 with possible increase in androgen activity and sebocyte modulation, therefore promoting acne.[97,102] Several studies have reported that molecular interplay of forkhead box transcription factor (Fox)O1 and mammalian target of rapamycin (mTOR)–mediated nutrient signaling are important in acne.[103,104] The roles of omega-3 fatty acids, antioxidants, zinc, vitamin A, and dietary fiber in acne remain to be elucidated. Thus, further randomized controlled studies are needed to have a clear understanding of how diet influences acne.

DIAGNOSIS

The diagnosis of acne vulgaris is typically made by clinical history and physical examination, but in some instances, further workup may be indicated.

LABORATORY TESTING

Laboratory workup may be indicated in patients with acne if hyperandrogenism is suspected, particularly in children ages 1 to 7 years who may have midchildhood acne (see Chap. 80). There are numerous clinical studies relating acne to elevated serum levels of androgens in both adolescents and adults. Among 623 prepubertal girls, girls with acne had increased levels of DHEAS as compared with age-matched control participants without acne.[105] DHEAS can serve as a precursor for testosterone and DHT. Elevated serum levels of androgens have been found in cases of severe nodular acne and in acne associated with a variety of endocrine conditions, including congenital adrenal hyperplasia (11β- and 21β-hydroxylase deficiencies), ovarian or adrenal tumors, and polycystic ovarian syndrome (PCOS). However, in the majority of patients with acne, serum androgens are within the normal range.[93,106]

Excess androgens may be produced by either the adrenal gland or ovary. The laboratory workup should include measurement of serum DHEAS, total testosterone, and free testosterone, with free testosterone considered the most sensitive test for PCOS.[107] Additional tests to consider include the luteinizing hormone (LH) to follicle-stimulating hormone (FSH) ratio or serum 17-hydroxyprogesterone to identify an adrenal source of androgens in cases in which testing does not clearly indicate an adrenal or ovarian source of androgens. Testing should be obtained just before or during the

menstrual period, not midcycle at the time of ovulation. Patients taking contraceptives that prevent ovulation will need to discontinue their medication for at least 1 month before testing. Values of DHEAS in the range of 4000 to 8000 ng/mL (units may vary at different laboratories) may be associated with congenital adrenal hyperplasia. Patients with a serum level of DHEAS greater than 8000 ng/mL could have an adrenal tumor and should be referred to an endocrinologist for further evaluation. An ovarian source of excess androgens can be suspected in cases when the serum total testosterone is greater than 150 ng/dL. Serum total testosterone in the range of 150 to 200 ng/dL or an increased LH-to-FSH ratio (>2.0) can be found in cases of PCOS. Greater elevations in serum testosterone may indicate an ovarian tumor, and appropriate referral should be made. It is important to emphasize that there is a significant amount of variability in individual serum androgen levels. Therefore, in cases in which abnormal results are obtained, repeat testing should be considered before proceeding with additional workup or therapy.

PATHOLOGY

The histopathology of acne vulgaris varies with the clinical lesion. Early lesions, microcomedones, demonstrate a dilated follicle with a narrow follicular orifice filled with shed keratinocytes. Closed comedones show increased distension of the follicle, creating a cystic space that contains eosinophilic keratinous debris, hair, and bacteria. Open comedones show enlarged follicular ostia, with atrophic or absent sebaceous glands. Only mild perivascular inflammation is present at this stage.

As the cystic structure enlarges, its contents begin to infiltrate the dermis, inducing an inflammatory response with neutrophils. If the lesion does not resolve, it may develop a foreign body granulomatous reaction or scarring.

DIFFERENTIAL DIAGNOSIS

Although one type of lesion may predominate, acne vulgaris is diagnosed by a variety of acne lesions (comedones, pustules, papules, and nodules) on the face, back, or chest (Table 78-1). The diagnosis is usually straightforward, but inflammatory acne may be confused with folliculitis, rosacea, or perioral dermatitis. Patients with tuberous sclerosis and facial angiofibromas have been misdiagnosed as having recalcitrant midfacial acne. Facial flat warts or milia are occasionally confused with closed comedones.

As discussed earlier, acne can be seen in association with endocrinologic abnormalities. Patients with hyperandrogenism may have acne plus other stigmata of increased androgen levels (ie, hirsutism, deepened voice, irregular menses). Endocrinologic disorders such as PCOS (including hyperandrogenism, insulin resistance, acanthosis nigricans [HAIR-AN] syndrome), congenital adrenal hyperplasia, and adrenal and ovarian neoplasms often have accompanying acne.

Variants of acne, as reviewed in Chap. 80, must also be differentiated from typical acne vulgaris to guide treatment. These types of acne include neonatal acne, infantile acne, midchildhood acne, acne fulminans, acne conglobata, acne with solid facial edema, and acne excoriée des jeunes filles.

TABLE 78-1
Differential Diagnosis of Acne

Most Likely
- Closed comedonal acne
  - Milia
  - Sebaceous hyperplasia
- Open comedonal acne
  - Dilated pore of Winer
  - Favre–Racouchot syndrome
- Inflammatory acne
  - Rosacea
  - Perioral dermatitis
- Neonatal acne
  - Miliaria rubra
  - Neonatal cephalic pustulosis

Consider
- Closed comedonal acne
  - Osteoma cutis
  - Trichoepitheliomas
  - Trichodiscomas
  - Fibrofolliculomas
  - Eruptive vellus hair cysts, steatocystoma multiplex
  - Colloid milia
  - Flat warts
- Open comedonal acne
  - Trichostasis spinulosa
  - Nevus comedonicus
- Inflammatory acne
  - Pseudofolliculitis barbae, acne keloidalis nuchae
  - Keratosis pilaris
  - Neurotic excoriations/factitial
  - Lupus miliaris disseminatus faciei
- Neonatal acne
  - Sebaceous hyperplasia
  - Milia
  - Transient neonatal pustular melanosis

Always Rule Out
- Closed comedonal acne
  - Acne due to systemic agents (eg, corticosteroids)
  - Contact acne (eg, occupational acne)
  - Chloracne
- Open comedonal acne
  - Acne caused by systemic agents
  - Contact acne
  - Chloracne
- Inflammatory acne
  - Acne caused by systemic agents
  - Staphylococcal folliculitis
  - Gram-negative folliculitis
  - Eosinophilic folliculitis
  - Furuncle or carbuncle
  - Angiofibromas of tuberous sclerosis
- Neonatal acne
  - Candidal infections

Several less common acneiform eruptions can be confused with acne vulgaris. These mimickers include medication-induced acne, halogen acne, chloracne, acne mechanica, tropical acne, radiation acne, and other miscellaneous acneiform disorders that are discussed in Chap. 80.

CLINICAL COURSE AND PROGNOSIS

The typical age of onset of acne vulgaris varies considerably. It may start as early as 8 years of age or it may not appear until the age of 20 years or even later. The course generally lasts several years and is followed by spontaneous remission in most cases. Although the condition clears in the majority of patients by their early 20s, some have acne extending well into the third or fourth decades of life. The extent of involvement varies, and spontaneous fluctuations in the degree of involvement are the rule rather than the exception. In women, there is often variation in relation to the menstrual cycle, with a flare just before the onset of menstruation, especially in those older than 30 years of age.[108] Family history, body mass index, and diet may predict risk for development of moderate to severe acne.[109] Furthermore, prepubescent females with comedonal acne and females with high DHEAS levels are more likely to develop severe or long-standing nodular acne.[110]

MANAGEMENT

Tailoring a patient's acne regimen with the knowledge of the pathogenesis of acne and the mechanism of action of the available acne treatments will ensure maximum therapeutic response. Treatment regimens should be initiated early and be sufficiently aggressive to prevent permanent sequelae. Often multiple treatments are used in combination so as to combat the various factors in the pathogenesis of acne (Table 78-2). The mechanism of action of the most common treatments for acne can be divided in the following categories as they relate to the pathophysiology:

1. Correct the altered pattern of follicular keratinization.
2. Decrease sebaceous gland activity.
3. Decrease the follicular bacterial population, particularly *P. acnes*.
4. Exert an antiinflammatory effect.

TABLE 78-2
Treatment Algorithm for Acne Vulgaris

	MILD	MODERATE	SEVERE		
	COMEDONAL	PAPULAR OR PUSTULAR	PAPULAR OR PUSTULAR	NODULAR	CONGLOBATA OR FULMINANS
First	Topical retinoid or combination[a]	Topical retinoid + topical antimicrobial or combination[a]	Oral antibiotic + topical retinoid ± BPO or combination[a]	Oral antibiotic + topical retinoid ± BPO	Oral isotretinoin ± oral corticosteroids
Second	Topical dapsone or azelaic acid or salicylic acid	Topical dapsone or azelaic acid or salicylic acid	Oral antibiotic + topical retinoid ± BPO or combination[a]	Oral isotretinoin or oral antibiotic + topical retinoid ± BPO–azelaic acid or combination[a]	High-dose oral antibiotic + topical retinoid + BPO or combination[a]
Female	—	—	+ Oral contraceptive–antiandrogen	+ Oral contraceptive–antiandrogen	+ Oral contraceptive–antiandrogen
Additional options	Comedone extraction	Comedone extraction, Laser or light therapy, photodynamic therapy	Comedone extraction, laser or light therapy, photodynamic therapy	Comedone extraction; intralesional corticosteroid, laser or light therapy, photodynamic therapy	Intralesional corticosteroid, laser or light therapy, photodynamic therapy
Refractory to treatment	Check compliance	Check compliance Exclude gram-negative folliculitis Females: exclude PCOS, adrenal or ovarian tumors, CAH Males: exclude ECAH			
Maintenance	Topical retinoid ± BPO, or combination[a]	Topical retinoid ± BPO, or combination[a]	Topical retinoid ± BPO, or combination[a]	Topical retinoid ± BPO, or combination[a]	

[a]Manufactured combination products include benzoyl peroxide (BPO)–erythromycin, BPO–clindamycin, adapalene–BPO, and tretinoin–clindamycin.
CAH, congenital adrenal hyperplasia; PCOS, polycystic ovarian syndrome.
Adapted from Gollnick H, Cunliffe W, Berson D, et al. Management of acne: a report from a Global Alliance to improve outcomes in acne. *J Am Acad Dermatol*. 2003;49(1Suppl):S1.

LOCAL THERAPY

CLEANSING

The importance of cleansing in the treatment of acne is generally intuitive. Twice-daily washing with a gentle cleanser followed by the application of acne treatments may encourage a routine and therefore better compliance. Overcleansing or use of harsh alkaline soaps are likely to increase the skin's pH, disrupt the cutaneous lipid barrier, and compound the irritancy potential of many topical acne treatments. Use of a syndet (synthetic detergent) will allow cleansing without disruption of the skin's normal pH. Medicated cleansers, containing benzoyl peroxide, salicylic acid, or sulfur, offer convenience as a wash and are excellent for hard-to-reach areas such as the back.

TOPICAL MEDICATIONS (SEE TABLE 78-3)

Retinoids: Retinoids are defined by their ability to bind to and activate retinoic acid receptors (RARs) and in turn activate specific gene transcription resulting in a biologic response. Some have chemical structures similar to tretinoin (all-*trans*-retinoic acid), but they may be entirely dissimilar, such as adapalene or tazarotene, and still potentiate a retinoid effect. In general, the binding of these agents to nuclear RAR affects the expression of genes involved in cell proliferation, differentiation, melanogenesis, and inflammation.[111,112] The result is modification of corneocyte accumulation and cohesion and inflammation. Thus, retinoids have both comedolytic and antiinflammatory properties.[112]

Tretinoin is commercially available in several strengths and formulations. Having both potent comedolytic and antiinflammatory properties, it is widely used. In general, all retinoids can be contact irritants, with alcohol-based gels and solutions having the greatest irritancy potential. Some newer formulations use a microsphere delayed-delivery technology (Retin A Micro 0.04%, 0.08% or 0.1% gel) or are incorporated within a polyolprepolymer (PP-2; Avita cream) to decrease the irritancy potential of tretinoin while allowing greater concentration of medication. Advising patients to apply tretinoin on alternate nights during the first few weeks of treatment can help ensure greater tolerability. Patients must also be cautioned about sun exposure because of thinning of the stratum corneum, especially those with any irritant reaction. Regular use of a sunscreen should be advised. The comedolytic and antiinflammatory properties of topical retinoids make them ideal for maintenance therapy of acne. Generic tretinoin is inactivated by concomitant use of benzoyl peroxide and is photolabile. Therefore, patients should be counseled to apply tretinoin at bedtime and not at the same time as benzoyl peroxide.

Adapalene is a synthetic retinoid widely marketed for its greater tolerability. It specifically targets the RARγ receptor. It is both photostable and can be used

TABLE 78-3
Commonly Available Prescription Acne Preparations—Topical

GENERIC	TRADE	VEHICLE	CONCENTRATION	SIZE
Retinoids—Topical				
Tretinoin	Retin-A	Cream	0.025%, 0.05%, 0.1%	20 g, 45 g
		Gel	0.01%, 0.025%	15 g, 45 g (0.025% only)
		Liquid	0.05%	28 mL
	Retin-A micro	Gel with microsponge	0.04%, 0.1%	20 g, 45 g
				50-g pump
	Avita	Cream	0.025%	20 g, 45 g
		Gel	0.025%	20 g, 45 g
	Refissa	Cream	0.05%	40 g
	Tretin-X	Cream	0.025%, 0.05%, 0.1%	35 g (kit with cleanser)
		Gel	0.025%, 0.1%	35 g (kit with cleanser)
	Generic	Cream	0.025%, 0.05%, 0.1%	20 g, 45 g
		Gel	0.01%, 0.025%, 0.05%	15 g, 45 g
Adapalene	Differin	Cream	0.1%	15 g, 45 g
		Gel	0.1%, 0.3%	15 g, 45 g
		Lotion	0.1%	2 oz
	Generic	Gel	0.1%	45 g
Tazarotene	Tazorac	Cream	0.1%	30 g, 60 g
		Gel	0.1%	30 g, 60 g
	Fabior	Foam	0.1%	50 g, 100 g
Retinoid Combinations—Topical				
Tretinoin–clindamycin	Ziana	Gel	0.025%/1.2%	30 g, 60 g
	Veltin	Gel	0.025%/1.2%	30 g, 60 g
Adapalene–benzoyl peroxide	Epiduo	Gel	2.5%/0.1%, 2.5%/0.3%	45 g

(*Continued*)

TABLE 78-3
Commonly Available Prescription Acne Preparations—Topical (*Continued*)

GENERIC	TRADE	VEHICLE	CONCENTRATION	SIZE
Antimicrobials—Topical				
Benzoyl peroxide	Benzac AC	Gel	2.5%, 5%, 10%	60 g
		Wash	2.5%, 5%, 10%	240 mL (2.5%), 226 mL
	Benzac W	Gel	2.5%, 5%, 10%	60 g
		Wash	5%, 10%	226 mL
	Benzashave	Cream	5%, 10%	113.4 g
	Benziq LS	Gel	5.25%	50 g
		Wash	5.25%	175 g
	Brevoxyl	Gel	4%, 8%	42.5 g
		Creamy wash	4%, 8%	170 g (kit with cleanser)
	BenzEFoam	Foam	5.3%, 9.8%	60 g, 100 g
	Clinac	Gel	7%	45 g
	Desquam-E	Gel	2.5%, 5%, 10%	42.5 g
	PanOxyl	Creamy wash	4%	6 oz
		Foamy wash	10%	5.5 oz
	Triaz	Gel	3%, 6%, 9%	42.5 g
		Cleanser	3%, 6%, 9%	6 oz, 12 oz
		Pads	3%, 6%, 9%	1 g (30 or 60/box)
		Foaming cloths	3%, 6%, 9%	3.2 g (30 or 60/box)
	ZoDerm	Cleanser	4.5%. 6.5%, 8.5%	400 mL
		Pads	4.5%. 6.5%, 8.5%	6 mL (30/box)
		Hydrating wash	5.75%	400 mL
	Generic	Gel	5%, 10%	45 g, 60 g, 90 g
		Wash	2.5%, 5%, 10%	142 g, 227 g
Erythromycin	Generic	Gel	2%	30 g, 60 g
		Ointment	2%	25 g
		Solution	2%	60 mL
		Pledget	2%	(60/box)
Clindamycin	Cleocin T	Gel	1%	30 g, 60 g
		Lotion	1%	60 mL
		Solution	1%	30 mL, 60 mL
		Pledget	1%	(60/box)
	Evoclin	Foam	1%	50 g, 100 g
	Clindagel	Gel	1%	40 mL, 75 mL
	ClindaMax	Gel	1%	30 g, 60 g
		Lotion	1%	60 mL
	Clindets	Pledget	1%	60 s
	Generic	Gel	1%	30 g, 60 g
		Lotion	1%	30 g, 60 g
		Solution	1%	30 g
Dapsone	Aczone	Gel	5%, 7.5%	30 g, 60 g, 90 g
Benzoyl peroxide–erythromycin	Benzamycin	Gel	5%/3%	46.6 g, 60/box
	Benzamycin Gel Pak			
	Generic	Gel	5%/3%	23.2 g, 46.6 g
Benzoyl peroxide/clindamycin	BenzaClin	Gel	5%/1%	25 g, 50 g
				50-g pump
	Duac	Gel	5%/1%	45 g
	Acanya	Gel	2.5%/1.2%	50 g
	Generic	Gel	5%/1%	50 g
Benzoyl peroxide/hydrocortisone	Vanoxide HC	Lotion	5%–0.5%	25 mL
Miscellaneous				
Sodium sulfacetamide	Klaron	Lotion	10%	4 oz
	Ovace	Foam	10%	70 g
		Wash	10%	6 oz, 12 oz, 16 oz
Sodium sulfacetamide/sulfur	Avar	Emollient cream	10%–5%	45 g, 2 oz
	Generic	Suspension (cleanser)	8%–4%, 9%–4%, 10%–5%	6 oz, 12 oz
		Foam	10%–5%	60 g60/box
		Topical pad	10%–5%	
Azelaic acid	Finacea	Gel	15%	50 g
	Azelex	Cream	20%	30 g, 50 g

in conjunction with benzoyl peroxide without degradation. Adapalene 0.1% gel has been shown in clinical trials to have greater or equal efficacy to tretinoin 0.025% gel with greater tolerability.[113,114] It is available at a 0.1% concentration in both a nonalcohol gel and cream and as a 0.3% gel. The 0.3% adapalene gel has been shown to have similar efficacy to tazarotene 0.1% gel with increased tolerability.[115] A combination topical agent containing adapalene (0.1% or 0.3%) and 2.5% benzoyl peroxide is also available.[116,117] Adapalene 0.1% gel is the only retinoid recently made available by the U.S. Food and Drug Administration (FDA) for over-the-counter (OTC) treatment of acne in those 12 years and older.[118]

Tazarotene, also a synthetic retinoid, exerts its action through its metabolite, tazarotenic acid, which in turn inhibits the RARγ receptor. It is a potent comedolytic agent and has been shown to be more effective than tretinoin 0.025% gel and tretinoin 0.1% microsphere gel.[119,120] Both the 0.1% cream and gel formulations are approved for the treatment of acne, as well as a 0.1% foam for the chest and back. The irritant properties of tazarotene can be minimized by the use of short-term contact therapy. In this regimen, the medication is applied for 5 minutes and then washed off with a gentle cleanser. The use of tazarotene is not recommended for use during pregnancy (formerly Pregnancy Category X classification), and female patients of childbearing age should be adequately counseled, with consideration of obtaining a negative pregnancy test result before initiation of therapy.

Benzoyl Peroxide: Benzoyl peroxide preparations are among the most common topical medications prescribed by dermatologists and are also readily available OTC. Benzoyl peroxide is a powerful antimicrobial agent, markedly reducing the bacterial population via release of free oxygen radicals.[121] It also has mild comedolytic properties. Benzoyl peroxide preparations are available in creams, lotions, gels, washes, foams, and pledgets in a variety of concentrations ranging from 2.5% to 10%. Products that are left on the skin, such as gels, are generally considered more effective, but data are lacking. Benzoyl peroxide can produce significant dryness and irritation and can bleach clothing and hair. Higher concentrations are not necessarily more efficacious and can cause increased irritation. Allergic contact dermatitis has been uncommonly reported. Of significance, bacteria are unable to develop resistance to benzoyl peroxide, making it the ideal agent for combination with topical or oral antibiotics.[122]

Topical Antibiotics: Erythromycin and clindamycin have historically been the most commonly used topical antibiotics for the treatment of acne. However, over the past few decades, the estimated global incidence rate of *P. acnes* resistance to antibiotics has increased from 20% (in 1978) to 62% (in 1996). In particular, high resistance to erythromycin has resulted in significant reduction in its use in recent years with preferential use of clindamycin. These two agents have also been used in combination preparations with benzoyl peroxide. The development of resistance is less likely in patients who are treated concurrently with benzoyl peroxide[123]; therefore, the combination of these two products is preferable over monotherapy with topical antibiotics. Topical dapsone 5% and 7.5% gel is the most recently approved topical antibiotic for acne. With twice-daily application, topical dapsone has shown better efficacy in controlling inflammatory lesions (58%) versus noninflammatory lesions (19%).[124,125] Unlike oral dapsone, topical dapsone is safe for use even in patients with a glucose-6-phosphate dehydrogenase (G6PD) deficiency.[126] It is generally well tolerated but should not be applied concomitantly with benzoyl peroxide, or it may impart an orange color on the skin.[127] As of submission of this chapter, a phase II clinical trial with topical minocycline 1% and 4% foam for the treatment of moderate to severe acne has been published and shows promising results.[128]

Salicylic Acid: Salicylic acid is a ubiquitous ingredient found in OTC acne preparations (gels and washes) in concentrations ranging from 0.5% to 2%. This lipid-soluble β-hydroxy acid has comedolytic properties but somewhat weaker than those of a retinoid. Salicylic acid also causes exfoliation of the stratum corneum through decreased cohesion of the keratinocytes. Mild irritant reactions may result. It is generally considered less effective than benzoyl peroxide.

Azelaic Acid: Azelaic acid is available by prescription in a 20% cream or 15% gel. This dicarboxylic acid has both antimicrobial and comedolytic properties[129] It is also a competitive inhibitor of tyrosinase and thus may decrease postinflammatory hyperpigmentation.[130] It is generally well tolerated, although transient burning can occur, and is considered safe in pregnancy.

Sulfur, Sodium Sulfacetamide, and Resorcinol: Products containing sulfur, sodium sulfacetamide, and resorcinol, once favored treatments for acne, are still found in several OTC and prescription niche formulations. Sulfonamides are thought to have antibacterial properties through their inhibition of *para*-aminobenzoic acid (PABA), an essential substance for *P. acnes* growth.[131] Sulfur also inhibits the formation of free fatty acids and has presumptive keratolytic properties. It is often combined with sodium sulfacetamide to enhance its cosmetic tolerability due to sulfur's distinctive odor. Resorcinol is also indicated for use in acne for its antimicrobial properties. It is generally found in a 2% concentration in combination with 5% sulfur.

An overview of topical agents for acne treatment is outlined in Table 78-3.

SYSTEMIC THERAPY

ANTIBIOTICS AND ANTIBACTERIAL AGENTS

Tetracyclines: Broad-spectrum antibiotics are widely used in the treatment of inflammatory acne.

The tetracyclines are the most commonly used antibiotics in the treatment of acne. Although the oral administration of tetracyclines does not alter sebum production, it does decrease the concentration of free fatty acids while the esterified fatty acid content increases. Free fatty acids are inflammatory, and their level is an indication of the metabolic activity of *P. acnes* and its secretion of proinflammatory products. This reduction in free fatty acids may be through suppression of *P. acnes* and may take several weeks to become evident. Therefore, several weeks of therapy are often required to observe maximal clinical benefit. The effect, then, is one of prevention; the individual lesions require their usual time to undergo resolution. Decreases in free fatty acid formation also have been reported with erythromycin, demethylchlortetracycline, clindamycin, and minocycline.

Doxycycline and minocycline are the most commonly used tetracycline derivatives for the treatment of acne. They have the distinct advantage that they can be taken with food with minimal impaired absorption. Doxycycline is administered in dosages of 50 to 100 mg twice daily. Its major disadvantage is the potential risk of photosensitivity reactions, including photo-onycholysis, and patients may need to be switched to another antibiotic during summer months. Gastrointestinal (GI) upset is another common side effect; it can be minimized if medication is taken with food.

Minocycline is given in divided doses at a level of 100 to 200 mg/day. Patients taking minocycline should be monitored carefully because the drug can cause blue-black pigmentation, especially in acne scars, as well as the hard palate, alveolar ridge, and anterior shins. Vertigo has occasionally been described. Minocycline-induced autoimmune hepatitis and a systemic lupus erythematosus–like syndrome have been reported during minocycline therapy, but these side effects are very rare.[132,133] Of note, patients who develop lupus-like reactions can be safely switched to an alternative tetracycline. Serum sickness–like reactions and drug reaction with eosinophilia and systemic symptoms (DRESS) syndrome have also been reported with minocycline use.

Tetracycline is usually given initially in dosages of 500 to 1000 mg/day. Higher doses of up to 3500 mg/day have been used in severe cases, but prudent monitoring of liver function is warranted. Tetracycline should be taken on an empty stomach, 1 hour before or 2 hours after meals, to promote absorption; thus, compliance by adolescents with its administration can be challenging. GI upset is the most common side effect, with esophagitis and pancreatitis possible. Uncommon side effects include hepatotoxicity, hypersensitivity reactions, leukocytosis, thrombocytopenic purpura, and pseudotumor cerebri.

Tetracyclines should be used with caution in patients with renal disease because they may increase uremia. Tetracyclines have an affinity for rapidly mineralizing tissues and are deposited in developing teeth, where they may cause irreversible yellow-brown staining; also, tetracyclines have been reported to inhibit skeletal growth in fetuses. Therefore, they should not be administered to pregnant women, especially after the fourth month of gestation, and are not recommended for use in children younger than 9 years of age in the treatment of acne.

Macrolides: Because of the prevalence of erythromycin-resistant strains of *P. acnes*, the use of oral erythromycin is generally limited to pregnant women or children. Azithromycin has been used more often for acne, typically at dosages of 250 to 500 mg orally three times weekly.[134] Azithromycin undergoes hepatic metabolism with GI upset and diarrhea as the most common side effects.

Trimethoprim–Sulfamethoxazole: Trimethoprim–sulfamethoxazole combinations are also effective in acne. In general, because the potential for side effects is greater with their use, they should be used only in patients with severe acne who do not respond to other antibiotics. GI upset and cutaneous hypersensitivity reactions are common. Serious adverse reactions, including the Stevens-Johnson syndrome–toxic epidermal necrolysis spectrum and aplastic anemia, have been described. If trimethoprim–sulfamethoxazole is used, the patient should be monitored for potential hematologic suppression monthly.

Cephalexin: Cephalexin, a first-generation cephalosporin, has been shown in vitro to kill *P. acnes*. However, because it is hydrophilic and not lipophilic, it penetrates poorly into the pilosebaceous unit. Success with oral cephalexin[135] is most likely caused by its antiinflammatory rather than antimicrobial properties. Because of the risk of promoting the development of bacterial resistance, particularly to *Staphylococcus* spp., the authors discourage the use of cephalexin for acne.

Clindamycin and Dapsone: Less commonly used antibiotics include clindamycin and dapsone. Oral clindamycin had been used more readily in the past, but because of the risk of pseudomembranous colitis, it is now rarely used systemically for acne. It is still commonly used topically, however, often in combination with benzoyl peroxide. Dapsone (see Chap. 187), a sulfone often used for cutaneous neutrophilic disorders, may be beneficial in severe markedly inflammatory acne and select cases of resistant acne. It is used at doses of 50 to 100 mg daily for 3 months. G6PD levels should be examined before initiation of therapy, and regular monitoring for hemolysis and liver function abnormalities is warranted. Although not as reliably effective as isotretinoin, it is relatively low cost and should be considered in severe cases when isotretinoin is not an option.

Antibiotics and Bacterial Resistance: Antibiotic resistance is a growing concern worldwide and should be suspected in patients unresponsive to

appropriate antibiotic therapy after 6 weeks of treatment. Increasing propionibacterium resistance has been documented to all macrolides and tetracyclines commonly used in the treatment of acne. A prevalence rate of 65% was documented in one study performed in the United Kingdom.[136] Overall, resistance is highest with erythromycin and lowest with the lipophilic tetracyclines, doxycycline, and minocycline.[63] The least resistance is noted with minocycline. To prevent resistance, prescribers should avoid antibiotic monotherapy, limit long-term use of antibiotics, and combine usage with benzoyl peroxide whenever possible.[137] Recent guidelines recommend limiting the duration of oral antibiotic therapy in acne to 3 to 6 months to reduce risk of resistance.[138]

HORMONAL THERAPY

The goal of hormonal therapy is to counteract the effects of androgens on the sebaceous gland. This can be accomplished with antiandrogens, or agents designed to decrease the endogenous production of androgens by the ovary or adrenal gland, including oral contraceptives, glucocorticoids, or gonadotropin-releasing hormone (GnRH) agonists.

Oral Contraceptives: Oral contraceptives can improve acne by four main mechanisms. First, they decrease the amount of gonadal androgen production by suppressing LH production. Second, they decrease the amount of free testosterone by increasing the production of sex hormone binding globulin. Third, they inhibit the activity of 5-α reductase activity, preventing the conversion of testosterone to the more potent DHT. Last, progestins that have an antiandrogenic effect can block the androgen receptors on keratinocytes and sebocytes. The third-generation progestins—gestodene (not available in the United States), desogestrel, and norgestimate—have the lowest intrinsic androgenic activity.[139] Two progestins have demonstrated antiandrogenic properties: (1) cyproterone acetate (not available in the United States) and (2) drospirenone. There are three oral contraceptives currently FDA approved for the treatment of acne: (1) Ortho Tri-Cyclen, (2) Estrostep, and (3) Yaz (Table 78-4). Ortho Tri-Cyclen is a triphasic oral contraceptive comprised of a norgestimate (180, 215, 250 mg)–ethinyl estradiol (35 µg) combination.[140] In an effort to reduce the estrogenic side effects of oral contraceptives, preparations with lower doses of estrogen (20 µg) have been developed for the treatment of acne. Estrostep contains a graduated dose of ethinyl estradiol (20–35 µg) in combination with norethindrone acetate (1 mg).[141] Yaz contains ethinyl estradiol (20 ug) and the antiandrogen drospirenone (3 mg). Drospirenone is a 17 α-spironolactone derivative that has both antimineralocorticoid and antiandrogenic properties, which may improve estrogen-related weight gain and bloating.[141] An oral contraceptive containing a low dose of estrogen (20 µg) in combination with levonorgestrel (Alesse) has also demonstrated efficacy in acne.[142] Side effects from oral contraceptives include nausea, vomiting, abnormal menses, weight gain, and breast tenderness. Rare but more serious complications include thrombophlebitis, pulmonary embolism, and hypertension. With the use of oral contraceptives containing estrogen and progestin rather than estrogen alone, side effects such as delayed menses, menorrhagia, and premenstrual cramps are uncommon. However, other side effects such as nausea, weight gain, spotting, breast tenderness, amenorrhea, and melasma can occur.

TABLE 78-4

U.S. Food and Drug Administration–Approved Oral Contraceptives for Acne in Women

Ortho Tri-Cyclen (norgestimate + ethinyl estradiol)
Estrostep (norethindrone acetate + ethinyl estradiol)
Yaz (drospirenone + ethinyl estradiol)

Glucocorticoids: Because of their antiinflammatory activity, high-dose systemic glucocorticoids may be of benefit in the treatment of acne. In practice, their use is usually restricted to severely involved patients, often overlapping with isotretinoin to limit any potential flaring from at the start of treatment. Furthermore, because of the potential side effects, these drugs are ordinarily used for limited periods of time, and recurrences after treatment are common. Prolonged use may result in the appearance of steroid acne. Glucocorticoids in low dosages are also indicated in female patients who have an elevation in serum DHEAS associated with an 11- or 21-hydroxylase deficiency or in other individuals with demonstrated androgen excess. Low-dose prednisone (2.5 mg or 5 mg) or dexamethasone can be given orally at bedtime to suppress adrenal androgen production.[106] The combined use of glucocorticoids and estrogens has been used in recalcitrant acne in women based on the inhibition of sebum production by this combination.[143] The mechanism of action is probably related to a greater reduction of plasma androgen levels by combined therapy than is produced by either drug alone.

Gonadotropin-Releasing Hormone Agonists: GnRH agonists, such as leuprolide (Lupron), act on the pituitary gland to disrupt its cyclic release of gonadotropins. The net effect is suppression of ovarian steroidogenesis in women. These agents are used in the treatment of ovarian hyperandrogenism. GnRH agonists have demonstrated efficacy in the treatment of acne and hirsutism in female patients both with and without endocrine disturbance.[144] However, their use is limited by their side effect profile, which includes menopausal symptoms and bone loss.

Antiandrogens: Spironolactone is an aldosterone antagonist and functions in acne as both an androgen-receptor blocker and inhibitor of 5-α reductase. In dosages of 50–100 mg twice a day, it has been shown to reduce sebum production and to improve acne.[145] Side effects include diuresis, potential

hyperkalemia, irregular menstrual periods, breast tenderness, headache, and fatigue. Combining spironolactone treatment with an oral contraceptive can alleviate the symptoms of irregular menstrual bleeding. Although hyperkalemia is a risk of spironolactone, this risk has shown to be minimal, even when spironolactone is administered with other aldosterone antagonists (eg, drospirenone-containing oral contraceptives).[146] A recent study evaluating the usefulness of routine potassium monitoring in healthy young female patients taking spironolactone for acne showed that the rate of hyperkalemia was equivalent to that of the general population and therefore routine monitoring is of low utility.[147] As an antiandrogen, there is a risk of feminization of a male fetus if a pregnant woman takes this medication. Long-term studies in rats receiving high doses of spironolactone demonstrated an increased incidence of adenomas on endocrine organs and the liver, resulting in a black box warning by the FDA (http://www.drugs.com/pro/aldactone). The potential for spironolactone to induce estrogen-dependent malignancies still remains controversial. However, the available data suggest that there is no definitive documented association between breast carcinoma and spironolactone ingestion after more than 30 years of data on spironolactone.[148,149]

Cyproterone acetate is a progestational antiandrogen that blocks the androgen receptor. It is combined with ethinyl estradiol in an oral contraceptive formulation that is widely used in Europe for the treatment of acne. Cyproterone acetate is not available in the United States.

Flutamide, an androgen receptor blocker, has been used at doses of 250 mg twice a day in combination with oral contraceptives for treatment of acne or hirsutism in females.[150] Liver function tests should be monitored because cases of fatal hepatitis have been reported.[151] Pregnancy should be avoided. Use of flutamide in the treatment of acne may be limited by its side effect profile.

ISOTRETINOIN (SEE CHAP. 185)

The use of the oral retinoid isotretinoin has revolutionized the management of treatment-resistant acne.[152] It is approved for use in patients with severe recalcitrant nodular acne. However, it is commonly used in many other acne scenarios, including any significant acne that is unresponsive to treatment with oral antibiotics and acne that results in significant physical or emotional scarring. Isotretinoin is also effective in the treatment of gram-negative folliculitis, pyoderma faciale, and acne fulminans.[153] The remarkable aspects of isotretinoin therapy are the complete remission in almost all cases and the longevity of the remission, which lasts for months to years in the great majority of patients. However, because of its teratogenicity, its use has become highly regulated in the United States with the initiation of the iPledge program in 2006 to ensure that pregnancy-prevention procedures are followed.

The mechanism of action of isotretinoin is not completely known. The drug produces profound inhibition of sebaceous gland activity, and this undoubtedly is of great importance in the initial clearing.[154,155] In some patients, sebaceous gland inhibition continues for at least 1 year, but in the majority of patients, sebum production returns to normal after 2 to 4 months.[154] Thus, this action of the drug cannot be used to explain the long-term remissions. The *P. acnes* population is also decreased during isotretinoin therapy, but this decrease is generally transient.[155,156] Isotretinoin has no inhibitory effect on *P. acnes* in vitro. Therefore, the effect on the bacterial population is probably indirect, resulting from the decrease in intrafollicular lipids necessary for organism growth. Isotretinoin also has antiinflammatory activity and probably has an effect on the pattern of follicular keratinization. These effects also are temporary, and the explanation for long-term remissions remains obscure.

Given the ubiquitous distribution of RAR, isotretinoin almost always causes side effects, mimicking those seen in the chronic hypervitaminosis A syndrome.[157] In general, the severity of side effects tends to be dose dependent. The most common side effects are related to the skin and mucous membranes. Cheilitis of varying degrees is found in virtually all cases. Other side effects that are likely to be seen in more than 50% of patients are dryness of the mucous membranes and skin. An eczematous eruption is occasionally seen, particularly in cold, dry weather. Thinning of hair and granulomatous paronychial lesions are less common. Ophthalmologic findings include xerophthalmia, night blindness, conjunctivitis, keratitis, and optic neuritis. Corneal opacities and hearing loss (both transient and persistent) have also been reported with isotretinoin use. Pseudotumor cerebri, also known as benign intracranial hypertension, is evidenced by severe headache, nausea, and visual changes. The risk of pseudotumor cerebri may be increased with concomitant use of tetracyclines and isotretinoin; therefore, these two medications should not be used together without careful prior consideration. If symptoms suggest benign intracranial hypertension, prompt neurologic evaluation for evidence of papilledema is required. Vague complaints of headache, fatigue, and lethargy are also frequent.

The relationship between isotretinoin use and psychiatric effects is currently being examined. Risks of depression, suicide, psychosis, and aggressive or violent behavior are all listed as possible side effects. Although no clear mechanism of action has been established, some evidence for biologic plausibility does exist. Psychiatric adverse events are described with high-dose vitamin A and etretinate. Also, retinoids have the demonstrated ability to enter the central nervous system (CNS) of rats and mice. And finally, there are documented case reports and studies linking isotretinoin use to depression in certain individuals.[158] A meta-analysis of nine studies looking at

the possible link between isotretinoin and depression found that the incidence of depression in patients on isotretinoin ranged from 1% to 11%.[159] The authors importantly pointed out that this range is similar to control group patients taking oral antibiotics. Another author examining case-control studies on isotretinoin and depression found the relative risk to range from 0.9 to 2.7 with wide confidence intervals.[160] Some studies demonstrate that patients taking isotretinoin have an overall improvement in mood.[161] Retinoids have not been shown to activate genes to induce behavioral or psychiatric changes. Nor is there evidence demonstrating functionality of retinoid signaling pathways in the mature CNS. Large population-based studies have not supported causality. As dermatologists are often on the front line seeing adolescents at risk for depression, careful screening of adolescents is particularly needed because the risk of depression in this population is 10% to 20%.[162]

GI symptoms are generally uncommon, but nausea, esophagitis, gastritis, and colitis can occur. Acute hepatitis is rare, but liver function studies should be regularly monitored because elevations in liver enzymes can occur in 15% of patients, sometimes necessitating dose adjustments. Elevated levels of serum triglycerides occur in approximately 25% of patients taking isotretinoin. This elevation, which is dose related, typically occurs within the first 4 weeks of treatment and is often accompanied by an overall increase in cholesterol with a decrease in the high-density lipoprotein levels. The effect of this transient alteration on overall coronary artery health is unclear. Acute pancreatitis is a rare complication that may or may not be related to triglyceride levels. There are case reports documenting a potential link between isotretinoin and new-onset or flared inflammatory bowel disease (IBD). However, a study that critically examined these case reports found no grounds for a causal relationship between isotretinoin use and IBD.[163] A recent population-based case-control study found that patients with IBD were no more likely to have used isotretinoin than those without IBD.[164] Patients with a family history of IBD and those with a preexisting IBD should be counseled regarding the possibility of isotretinoin-induced IBD.

Isotretinoin has effects on bone mineralization as well. A single course of isotretinoin was not shown to have a significant effect on bone density.[165] However, chronic or repeated courses may result in significant osteopenia. Osteoporosis, bone fractures, and delayed healing of bone fractures have also been reported. The significance of reported hyperostosis is unclear, but the development of bony hyperostoses after isotretinoin therapy is more likely in patients who receive the drug for longer periods of time and in higher dosages, such as for disorders of keratinization.[166] Serial bone densitometry should be done in any patient on long-term isotretinoin. Myalgias are the most common musculoskeletal complaint, seen in 15% of patients. In severe cases, creatine phosphokinase levels should be evaluated for possible rhabdomyolysis.

Other laboratory abnormalities that have been reported with isotretinoin use are an elevated erythrocyte sedimentation rate and platelet count. Alterations in the red blood cell parameters with decreased white cell counts can occur. White blood cells in the urine have rarely been linked to isotretinoin use. Most laboratory changes are mild and spontaneously resolve upon discontinuation of medication use.

Laboratory monitoring while patients are taking isotretinoin includes obtaining a baseline complete blood count, liver function tests and lipid panel, with the greatest attention paid to following serum triglyceride levels. Baseline values for serum triglycerides should be obtained and repeated at 4 and 8 weeks of therapy. If the values are normal at 8 weeks, there is no need to repeat the test during the remaining course of therapy unless there are risk factors. If serum triglycerides increase above 500 mg/dL, the levels should be monitored frequently. Levels above 700 to 800 mg/dL are a reason for interrupting therapy or treating the patient with a lipid-lowering drug. Eruptive xanthomas or pancreatitis can occur at higher serum triglyceride levels.

A recent study evaluating the characteristics of lab abnormalities in 515 patients who underwent isotretinoin therapy for acne reported clinically insignificant leukopenia (1.4%) or thrombocytopenia (0.9%), infrequent transaminitis (1.9%) with the most significant elevations occurring with triglyceride (19.3%) and cholesterol (22.8%) levels. Recommendations for otherwise healthy patients with normal baseline labs are to repeat laboratory studies after 2 months taking isotretinoin therapy, and if results are normal, no further testing may be required. Routine complete blood count monitoring was also found to be unnecessary.[167]

The greatest concern during isotretinoin therapy is the risk of the drug being administered during pregnancy and thereby inducing teratogenic effects in the fetus.[168,169] The drug is not mutagenic; its effect is on organogenesis. Therefore, the production of retinoic embryopathy occurs very early in pregnancy, with a peak near the third week of gestation.[168,169] A significant number of fetal abnormalities have been reported after the use of isotretinoin. For this reason, it should be emphasized that isotretinoin should be given only to patients who have not responded to other therapy. Furthermore, women who are of childbearing age must be fully informed of the risk of pregnancy. The patient must use two highly effective contraception techniques such as the use of an oral contraceptive and condoms with a spermicidal jelly. Contraception must be started at least 1 month before isotretinoin therapy. Female patients must be thoroughly counseled and demonstrate an understanding of contraception techniques before starting isotretinoin. Two forms of contraception should be used throughout the course of isotretinoin and for 1 month after stopping treatment. No more than 1 month's supply of isotretinoin should be given to a female patient so that she can be counseled on a monthly basis on the hazards of

pregnancy during isotretinoin therapy. A pregnancy test must be repeated monthly. Abstinence as the sole form of birth control should only be allowed in special instances. Because the drug is not mutagenic, there is no risk to a fetus conceived by a man who is taking isotretinoin. Although it may seem obvious, it is important to remind men who are taking isotretinoin not to give any of their medication to female companions under any circumstances or to donate blood while taking the medication.

The recommended daily dosage of isotretinoin is in the range of 0.5 to 1 mg/kg/day. A cumulative weight-based dosing formula may also be used with a total dose of 120 to 150 mg/kg of isotretinoin during a course of therapy.[170] This dosing regimen is of particular use in patients who have variable dosages or interrupted periods of treatment because achieving the total dose will ensure the greatest chance of long-term remission. Because back and chest lesions show less of a response than facial lesions, dosages as high as 2 mg/kg/day may be necessary in patients who have very severe truncal involvement. Patients with severe acne, particularly those with granulomatous lesions, often develop marked flares of their disease when isotretinoin is started. Therefore, the initial dosing should be low, even below 0.5 mg/kg/day. These patients often need pretreatment for 1 to 2 weeks with prednisone (40–60 mg/day), which may have to be continued for the first 2 weeks of therapy. A typical course of isotretinoin is 20 weeks, but the length of the course of treatment is not absolute; in patients who have not shown an adequate response, therapy can be extended. Additional improvement may be seen for 1 to 2 months after discontinuation, so that complete clearance may not be a necessary endpoint for determining when to discontinue therapy. Low-dose regimens, 0.1 to 0.4 mg/kg/day, have shown efficacy. However, with such dosages, the incidence of relapses after therapy is greater. Approximately 10% of patients treated with isotretinoin require a second course of the drug. The likelihood for repeat therapy is increased in patients younger than 16 to 17 years of age. It is standard practice to allow at least 2 to 3 months between courses of isotretinoin.

DIET

Several articles suggesting a role for diet in acne exist.[171,172] A recent review of these studies concluded that there may be some link between milk and acne as well as between high-glycemic index foods and acne.[173] Yet overall, the implications of these studies are not clear, and the role of chocolate, sweets, milk, high-glycemic index foods, and fatty foods in patients with acne requires further study. There is no evidence to support the value of elimination of these foods. However, restricting a food firmly thought by the patient to be a trigger is not harmful as long as the patient's nutritional well-being is not compromised.

PROCEDURES

ACNE SURGERY

Acne surgery, a mainstay of therapy in the past used for the removal of comedones and superficial pustules, aids in bringing about involution of individual acne lesions. However, with the advent of comedolytic agents, such as topical retinoids, its use is primarily restricted to patients who do not respond to comedolytic agents. Even in these patients, the comedones are removed with greater ease and less trauma if the patient is pretreated with a topical retinoid for 3 to 4 weeks. Acne surgery should not be performed at home because inaccurate placement of the comedo extractor may rupture the follicle and incite an inflammatory reaction. The Unna type of comedo extractor, which has a broad flat plate and no narrow sharp edges, is preferable. The removal of open comedones is desirable for cosmetic purposes but does not significantly influence the course of the disease. In contrast, closed comedones should be removed to prevent their rupture. Unfortunately, the orifice of closed comedones is often very small, and usually the material contained within the comedo can be removed only after the orifice is gently enlarged with a 25- or 30-gauge needle, lancet, or other suitable sharply pointed instrument. Cotton-tipped applicators are also useful to gently extract follicular content after the orifice is opened.

SUBCISION

Subcision is a minor surgical procedure used for treatment of depressed scars and is most effective for rolling acne scars (distensible, depressed scars with gentle sloping edges). This method involves the use of a small hypodermic needle that is inserted into the periphery of a scar with the sharp edges maneuvered under the defect to loosen the fibrotic adhesions, which results in release of the tethered scar to the underlying subcutaneous tissue and collagen formation during wound healing. Subcision has a reported success rate of 50% in the treatment of rolling scars.[174]

INTRALESIONAL INJECTION OF CORTICOSTEROIDS

Intralesional injection of corticosteroids can dramatically decrease the size of deep nodular lesions. The injection of 0.05 to 0.25 mL per lesion of a triamcinolone acetonide suspension (2.5–10 mg/mL) is recommended as the antiinflammatory agent. This is a very useful form of therapy in patients with nodular acne or for particularly persistent nodular lesions. A major advantage is that it can be done without incising or draining the lesions, thus avoiding the possibility of scar formation. Hypopigmentation, particularly in darker-skinned patients, and atrophy are risks.

CHEMICAL PEELS

Superficial chemical peels can be performed as an adjuvant to the pharmacologic treatment of facial acne or in patients with contraindications for other treatment modalities (eg, pregnancy). Superficial peels aim to remove the stratum corneum, enhancing physiologic cell turnover.[175] The most common peeling agents for use in acne are the α-hydroxy acids such as glycolic acid and trichloroacetic acid (TCA), β-hydroxy acid such as salicylic acid, and combination peels including Jessner solution. Glycolic acid reduces hyperkeratinization by decreasing cohesion of corneocytes at low concentrations and promoting desquamation and epidermolysis at higher concentrations,[176] with one study of 80 patients reporting glycolic acid peels effective at improving comedonal, papulopustular, and nodulocystic acne variants.[177] Salicylic acid is a lipophilic agent that also decreases corneocyte cohesion and promotes desquamation of the stratum corneum. Whereas low concentrations of salicylic acid are found in daily acne cleansers, concentrations of 20% to 30% are typically used for superficial peels, and similar to glycolic acid, have been reported to reduce the number of inflammatory and noninflammatory acne lesions.[178] The most common side effects of chemical peels include erythema, xerosis, exfoliation, burning, and increase in photosensitivity.

PHOTOTHERAPY AND LASERS

Various forms of phototherapy are under investigation for their use in treating acne vulgaris.[179] Ultraviolet (UV) light has long been thought to be beneficial in the treatment of acne. Up to 70% of patients report that sun exposure improves their acne.[180] This reported benefit may be attributable to camouflage by UV radiation–induced erythema and pigmentation, although it is likely that the sunlight has a biologic effect on the pilosebaceous unit and *P. acnes*. Although UVB can also kill *P. acnes* in vitro, UVB penetrates poorly to the dermal follicle, and only high doses causing sunburn have be shown to improve acne.[181,182] UV radiation may have antiinflammatory effects by inhibiting cytokine action.[183] Twice-weekly phototherapy sessions are needed for any clinical improvement. The therapeutic utility of UV radiation in acne is superseded by its carcinogenic potential.[179,184-187]

Other types of phototherapy for acne treatment use porphyrins. Treatment of acne with phototherapy works either by activating the endogenous porphyrins of *P. acnes* or by applying exogenous porphyrins. Coproporphyrin III is the major endogenous porphyrin of *P. acnes*. Coproporphyrin III can absorb light at the near-UV and blue light spectrum of 415 nm.[188] Irradiation of *P. acnes* with blue light leads to photoexcitation of endogenous bacterial porphyrins, singlet oxygen production, and subsequent bacterial destruction.[189] A visible light source—blue, red, or both—may be used to excite the endogenous porphyrins. The high-intensity, enhanced, narrowband (407–420 nm) blue light known as ClearLight (Lumenis) is currently FDA approved for the treatment of moderate inflammatory acne.[187] Red light may also be beneficial because it penetrates deeper into the dermis and has greater antiinflammatory properties but causes less photoactivation of the porphyrins. Therefore, the combination of blue and red light may prove the most beneficial. Treatments should be given twice weekly for 15-minute sessions for the face alone and 45 minutes for the face, chest, and back. A multicenter study has shown that 80% of patients treated with the ClearLight for 4 weeks had a 60% reduction in acne lesions. There was a gradual return of lesions over 3 to 6 months.[190]

The most consistent improvement in acne after light treatment has been demonstrated with photodynamic therapy.[191] Photodynamic therapy involves the topical application of aminolevulinic acid (ALA) 1 hour before exposure to a low-power light source. These sources include the pulsed-dye laser, intense pulsed light, or a broadband red light source. The topical ALA is taken up by the pilosebaceous unit and metabolized to protoporphyrin IX.[192] The protoporphyrin IX is targeted by the light and produces singlet oxygen species, which then damage the sebaceous glands.[193] Several studies using ALA-PDT maintained clinical improvement for up to 20 weeks.[194,195]

Although lasers are beginning to find a role in the treatment of acne, the authors consider them inferior to the traditional medical treatments. They work by emitting minimally divergent, coherent light that can be focused over a small area of tissue. The pulsed KTP laser (532 nm) has demonstrated a 35.9% decrease in acne lesions when used twice weekly for 2 weeks. Although there was no significant decrease in *P. acnes*, there was significantly lower sebum production even at 1 month.[196] The pulsed-dye laser (585 nm) can also be used at lower fluences to treat acne. Instead of ablating blood vessels and causing purpura, a lower fluence can stimulate procollagen production by heating dermal perivascular tissue.[193] The beneficial effects of a single treatment can last 12 weeks.[197] Some of the nonablative infrared lasers, such as the 1450- and 1320-nm laser, have shown to be helpful in improving acne.[198,199] These lasers work by causing thermal damage to the sebaceous glands. The concurrent use of a cryogen spray device protects the epidermis while the laser causes necrosis of the sebaceous gland.[200] In a pilot study, 14 of 15 patients treated with the 1450-nm laser had a significant reduction in inflammatory lesions that persisted for 6 months. The 1320-nm Nd:YAG (neodymium-doped yttrium aluminum garnet) and the 1540 erbium glass lasers have also been demonstrated to improve acne.[201] Multiple treatments are needed with either of these lasers to lessen acne lesions. These treatments tend to be painful and show a gradual modest improvement, limiting their utility.

One of the newer uses of light for treating acne is with a photopneumatic device (Isolaz, Solta Medical). This photopneumatic device has a handpiece that applies negative pressure (ie, suction) to the skin and

then delivers a broadband-pulsed light (400–1200 nm). The suction is used to unplug the infundibulum of the pilosebaceous unit, and the light is delivered to activate the *P. acnes* porphyrins, thus releasing singlet oxygen species. Patients treated with this device may experience some posttreatment erythema or purpura. Results are modest and temporary, and the device is best for inflammatory lesions.[202,203] Although the light-based treatments are beneficial in that they avoid some of the side effects of the oral medications, the cost of these light and laser treatments tends to be prohibitive.

Lasers, however, can be useful for the treatment of acne scars.[204] Pulsed-dye lasers help improve persistent erythema from acne lesions and atrophic scars. Fractional photothermolysis lasers are approved for the treatment of acne scars by the FDA, and studies support improvement of various acne scars. The use of 1550-nm fractional photothermolysis two to six times in a 1-month interval showed the majority of patients achieving a 50% to 75% improvement in facial and back acne scarring, and some patients had greater than 75% in acne scarring. No adverse effects were found including in patients with Fitzpatrick Skin types III to V.[205] Another study showed a clinical improvement averaged 51% to 75% in nearly 90% of patients after three monthly laser treatments,[206] and a long-term improvement can be seen.[207] Ablative CO_2 and fractional CO_2 lasers have also been shown to improve acne scars,[208] but adverse effects can be more common and should be used with caution, particularly in darker skin types.

DERMABRASION

Dermabrasions are used less now since the development of new lasers, lights, and other devices. Dermabrasion is useful in treating larger atrophic scars,[209,210] but because physical removal of uninvolved skin must occur to reach the deeper scarred areas, this treatment is less favored given the prolonged recovery and increase in risk of complications. In particular, there is a greater chance of discoloration of skin in darker-skinned patients (Fitzpatrick types IV–VI). Microdermabrasion, however, has fewer adverse effects and can be used safely in most patients.[211]

MICRONEEDLING

Nonablative radiofrequency microneedling is a relatively novel technique for the treatment of both inflammatory acne lesions and acne scars. Microneedling is a minimally invasive procedure that uses fine needles to puncture the epidermis. The mechanism of action is primarily by reduction of sebaceous gland activity and remodeling of dermis through thermal stimulation.[212,213] The microwounds created also stimulate the release of growth factors and induce collagen production.[214,215] The epidermis remains relatively intact, therefore healing quickly and helping to limit adverse events. It has been shown to have a better safety profile in treating acne scars, particularly in darker skin types population (Fitzpatrick skin types IV–VI), compared with more conventional resurfacing modalities.[216] It has been shown that microneedling can be combined with various adjuvant treatments, including platelet-rich plasma, vitamin C, and glycolic acid, to enhance the clinical improvement of atrophic acne scars.[217,218]

FILLERS

The injection of dermal fillers to improve acne scars is based on soft tissue augmentation. Hyaluronic acid fillers are nonpermanent fillers that stimulate collagen production and are a safe and effective treatment for acne scars including atrophic scars. A stronger stimulation of collagen production is seen with semipermanent or biostimulatory fillers, such as poly-L-lactic acid (PLL) and calcium hydroxylapatite, and permanent fillers.[219,220]

Acne scars can be permanent and have a long-lasting impact on patients who have acne, even after active lesions resolve. In general, multiple and combination treatments using various available modalities can improve acne scars and address patients' physical and psychological concerns.

ACNE THERAPY IN PREGNANCY

Acne vulgaris is a common problem encountered by pregnant and lactating women. During pregnancy, acne may worsen as a result of a rise in serum maternal androgen levels. Inflammatory lesions tend to be more common than noninflammatory lesions, often with involvement of the trunk. Patients with a history of acne are more prone to developing acne during pregnancy.[221] Because pregnant or lactating women are often excluded from clinical trials, current evidence is limited to animal studies, retrospective studies, and case reports. As a general rule, topical agents are safer than oral medications for use during pregnancy and lactation because systemic absorption is lower.[222] Listed in Table 78-5 is a summary of common acne medications used and their safety in pregnancy. Of note, although benzoyl peroxide and salicylic acid are considered Pregnancy Category C, recent changes in pregnancy labeling of drugs suggest that more topical medications may be used during pregnancy, and although inadequate human data may be available, the risk of fetal harm is not expected based on expected limited systemic absorption. No reports of teratogenicity have been associated with either medication. For the retinoids, adapalene is categorized as "may use during pregnancy," but tretinoin is "consider avoiding use during pregnancy," and tazarotene is "use alternative during pregnancy" (Epocrates [2016], Dx version 16.11 [mobile application software]). Safety in lactation may be different from that in pregnancy. For example,

TABLE 78-5
Safety Ratings of Acne Medications in Pregnancy

MEDICATION	PREGNANCY CATEGORY[a]
Topical Therapies	
Azelaic acid	B
Clindamycin	B
Erythromycin	B
Metronidazole	B
Adapalene	C
Benzoyl peroxide	C
Dapsone	C
Salicylic acid	C
Sodium sulfacetamide	C
Tretinoin	C
Tazarotene	X
Oral Therapies	
Amoxicillin	B
Azithromycin	B
Cephalexin	B
Erythromycin	B
Cotrimoxazole	C
Levofloxacin	C
Spironolactone	C
Tetracyclines	D
Isotretinoin	X
Oral contraceptive pills	X
Physical Modalities	
ALA: photodynamic therapy	C
Glycolic acid peels	N
Blue-red light phototherapy	N

[a]Pregnancy categories:
A: Controlled studies show no risk. Adequate well-controlled studies in pregnant women have failed to demonstrate a risk to the fetus.
B: No evidence of risk. Animal reproduction studies have failed to demonstrate a risk to the fetus, and there are no adequate and well-controlled studies in pregnant women.
C: Risk cannot be ruled out. Animal reproduction studies have shown an adverse effect on the fetus, and there are no adequate and well-controlled studies in pregnant women, but use in pregnancy may be justified if potential benefits outweigh risks.
D: Positive evidence of human fetal risk. Investigational or marketing experience show risks to the fetus, but use in pregnancy may be justified if potential benefits outweigh risks.
X: Contraindicated in pregnancy. Studies in animals or humans and/or investigational or marketing experience have shown positive evidence for human fetal risk, which clearly outweighs potential benefits in the patient.
N: No pregnancy category has been assigned.

the World Health Organization considers benzoyl peroxide compatible with breastfeeding (Micromedex Healthcare Series, version 5.1; Thompson Microdex, Greenwood Village, CO).

REFERENCES

1. White GM. Recent findings in the epidemiologic evidence, classification, and subtypes of acne vulgaris. *J Am Acad Dermatol*. 1998;39:S34-37.
2. Lynn DD, Umari T, Dunnick CA, Dellavalle RP. The epidemiology of acne vulgaris in late adolescence. *Adolesc Health Med Ther*. 2016;7:13-25.
3. Hay RJ, Johns NE, Williams HC, et al. The global burden of skin disease in 2010: an analysis of the prevalence and impact of skin conditions. *J Invest Dermatol*. 2014;134:1527-1534.
4. Davis SA, Narahari S, Feldman SR, et al. Top dermatologic conditions in patients of color: an analysis of nationally representative data. *J Drugs Dermatol*. 2012;11:466-473.
5. Yin NC, McMichael AJ. Acne in patients with skin of color: practical management. *Am J Clin Dermatol*. 2014;15:7-16.
6. Tan JK, Bhate K. A global perspective on the epidemiology of acne. *Br J Dermatol*. 2015;172(suppl 1):3-12.
7. Schafer T, Nienhaus A, Vieluf D, et al. Epidemiology of acne in the general population: the risk of smoking. *Br J Dermatol*. 2001;145:100-104.
8. Collier CN, Harper JC, Cafardi JA, et al. The prevalence of acne in adults 20 years and older. *J Am Acad Dermatol*. 2008;58:56-59.
9. Bhate K, Williams HC. Epidemiology of acne vulgaris. *Br J Dermatol*. 2013;168:474-485.
10. Wei B, Pang Y, Zhu H, et al. The epidemiology of adolescent acne in North East China. *J Eur Acad Dermatol Venereol*. 2010;24:953-957.
11. Dreno B, Jean-Decoster C, Georgescu V. Profile of patients with mild-to-moderate acne in Europe: a survey. *Eur J Dermatol*. 2016;26:177-184.
12. Wilkins JW Jr, Voorhees JJ. Prevalence of nodulocystic acne in white and Negro males. *Arch Dermatol*. 1970;102:631-634.
13. Voorhees JJ, Wilkins J Jr, Hayes E, Harrell ER. The XYY syndrome in prisoners and outpatients with cystic acne. *Birth Defects Orig Artic Ser*. 1971;7:186-192.
14. Tian LM, Xie HF, Yang T, et al. Association study of tumor necrosis factor receptor type 2 M196R and toll-like receptor 2 Arg753Gln polymorphisms with acne vulgaris in a Chinese Han ethnic group. *Dermatology*. 2010;221:276-284.
15. Szabo K, Tax G, Teodorescu-Brinzeu D, et al. TNFalpha gene polymorphisms in the pathogenesis of acne vulgaris. *Arch Dermatol Res*. 2011;303:19-27.
16. Szabo K, Tax G, Kis K, Szegedi K, et al. Interleukin-1A +4845(G> T) polymorphism is a factor predisposing to acne vulgaris. Tissue *Antigens*. 2010;76:411-415.
17. He L, Yang Z, Yu H, et al. The relationship between CYP17 -34T/C polymorphism and acne in Chinese subjects revealed by sequencing. *Dermatology*. 2006;212:338-342.
18. Grech I, Giatrakou S, Damoraki G, et al. Single nucleotide polymorphisms of toll-like receptor-4 protect against acne conglobata. *J Eur Acad Dermatol Venereol*. 2012;26:1538-1543.
19. Zhang M, Qureshi AA, Hunter DJ, et al. A genome-wide association study of severe teenage acne in European Americans. *Hum Genet*. 2014;133:259-264.
20. Khunger N, Kumar C. A clinico-epidemiological study of adult acne: is it different from adolescent acne? *Indian J Dermatol Venereol Leprol*. 2012;78:335-341.

21. Del Rosso JQ, Harper JC, Graber EM, et al. Status report from the American Acne & Rosacea Society on medical management of acne in adult women, part 1: overview, clinical characteristics, and laboratory evaluation. *Cutis*. 2015;96:236-241.
22. Scheffers CS, Armstrong S, Cantineau AE, et al. Dehydroepiandrosterone for women in the peri- or postmenopausal phase. *Cochrane Database Syst Rev*. 2015;1:CD011066.
23. Silverberg NB. Whey protein precipitating moderate to severe acne flares in 5 teenaged athletes. *Cutis*. 2012;90:70-72.
24. Do TT, Zarkhin S, Orringer JS, et al. Computer-assisted alignment and tracking of acne lesions indicate that most inflammatory lesions arise from comedones and de novo. *J Am Acad Dermatol*. 2008;58:603-608.
25. Kang S, Lozada VT, Bettoli V, et al. New atrophic acne scar classification: reliability of assessments based on size, shape, and number. *J Drugs Dermatol*. 2016;15:693-702.
26. Jacob CI, Dover JS, Kaminer MS. Acne scarring: a classification system and review of treatment options. *J Am Acad Dermatol*. 2001;45:109-117.
27. Wilson BB, Dent CH, Cooper PH. Papular acne scars. A common cutaneous finding. *Arch Dermatol*. 1990; 126:797-800.
28. Revol O, Milliez N, Gerard D. Psychological impact of acne on 21st-century adolescents: decoding for better care. *Br J Dermatol*. 2015;172(suppl 1):52-58.
29. Tan JK. Psychosocial impact of acne vulgaris: evaluating the evidence. *Skin Therapy Lett*. 2004;9:1-3.
30. Zaraa I, Belghith I, Ben Alaya N, et al. Severity of acne and its impact on quality of life. *Skinmed*. 2013;11:148-153.
31. Mooney T. Preventing psychological distress in patients with acne. *Nurs Stand*. 2014;28:42-48.
32. Niemeier V, Kupfer J, Demmelbauer-Ebner M, et al. Coping with acne vulgaris. Evaluation of the chronic skin disorder questionnaire in patients with acne. *Dermatology*. 1998;196:108-115.
33. Purvis D, Robinson E, Merry S, et al. Acne, anxiety, depression and suicide in teenagers: a cross-sectional survey of New Zealand secondary school students. *J Paediatr Child Health*. 2006;42:793-796.
34. Picardi A, Mazzotti E, Pasquini P. Prevalence and correlates of suicidal ideation among patients with skin disease. *J Am Acad Dermatol*. 2006;54:420-426.
35. Nagy I, Pivarcsi A, Kis K, et al. Propionibacterium acnes and lipopolysaccharide induce the expression of antimicrobial peptides and proinflammatory cytokines/chemokines in human sebocytes. *Microbes Infect*. 2006;8:2195-2205.
36. Thiboutot DM, Knaggs H, Gilliland K, et al. Activity of type 1 5 alpha-reductase is greater in the follicular infrainfundibulum compared with the epidermis. *Br J Dermatol*. 1997;136:166-17.
37. Thiboutot D, Knaggs H, Gilliland K, et al. Activity of 5-alpha-reductase and 17-beta-hydroxysteroid dehydrogenase in the infrainfundibulum of subjects with and without acne vulgaris. *Dermatology*. 1998;196:38-42.
38. Imperato-McGinley J, Gautier T, Cai LQ, et al. The androgen control of sebum production. Studies of subjects with dihydrotestosterone deficiency and complete androgen insensitivity. *J Clin Endocrinol Metab*. 1993;76:524-528.
39. Downing DT, Stewart ME, Wertz PW, et al. Essential fatty acids and acne. *J Am Acad Dermatol*. 1986;14:221-225.
40. Guy R, Green MR, Kealey T. Modeling acne in vitro. *J Invest Dermatol*. 1996;106:176-182.
41. Dinarello CA, Simon A, van der Meer JW. Treating inflammation by blocking interleukin-1 in a broad spectrum of diseases. *Nat Rev Drug Discov*. 2012;11: 633-652.
42. Munro CS, Wilkie AO. Epidermal mosaicism producing localised acne: somatic mutation in FGFR2. *Lancet*. 1998;352:704-705.
43. Melnik B, Schmitz G. FGFR2 signaling and the pathogenesis of acne. *J Dtsch Dermatol Ges*. 2008;6:721-728.
44. Thiboutot D, Harris G, Iles V, et al. Activity of the type 1 5 alpha-reductase exhibits regional differences in isolated sebaceous glands and whole skin. *J Invest Dermatol*. 1995;105:209-214.
45. Picardo M, Ottaviani M, Camera E, Mastrofrancesco A. Sebaceous gland lipids. *Dermatoendocrinol*. 2009; 1:68-71.
46. Harris HH, Downing DT, Stewart ME, et al. Sustainable rates of sebum secretion in acne patients and matched normal control subjects. *J Am Acad Dermatol*. 1983;8:200-203.
47. Kligman AM, Wheatley VR, Mills OH. Comedogenicity of human sebum. *Arch Dermatol*. 1970;102: 267-275.
48. Ottaviani M, Alestas T, Flori E, et al. Peroxidated squalene induces the production of inflammatory mediators in HaCaT keratinocytes: a possible role in acne vulgaris. *J Invest Dermatol*. 2006;126:2430-2437.
49. Trivedi NR, Cong Z, Nelson AM, et al. Peroxisome proliferator-activated receptors increase human sebum production. *J Invest Dermatol*. 2006;126:2002-2009.
50. Pochi PE, Strauss JS. Sebaceous gland response in man to the administration of testosterone, delta-4-androstenedione, and dehydroisoandrosterone. *J Invest Dermatol*. 1969;52:32-36.
51. Thiboutot D, Gilliland K, Light J, et al. Androgen metabolism in sebaceous glands from subjects with and without acne. *Arch Dermatol*. 1999;135:1041-1045.
52. Lucky AW, Biro FM, Simbartl LA, et al. Predictors of severity of acne vulgaris in young adolescent girls: results of a five-year longitudinal study. *J Pediatr*. 1997;130:30-39.
53. Strauss JS, Pochi PE. Effect of cyclic progestin-estrogen therapy on sebum and acne in women. *JAMA*. 1964; 190:815-819.
54. Thiboutot D. Regulation of human sebaceous glands. *J Invest Dermatol*. 2004;123:1-12.
55. Ganceviciene R, Graziene V, Fimmel S, et al. Involvement of the corticotropin-releasing hormone system in the pathogenesis of acne vulgaris. *Br J Dermatol*. 2009;160:345-352.
56. Norris JF, Cunliffe WJ. A histological and immunocytochemical study of early acne lesions. *Br J Dermatol*. 1988;118:651-659.
57. Jeremy AH, Holland DB, Roberts SG, et al. Inflammatory events are involved in acne lesion initiation. *J Invest Dermatol*. 2003;121:20-27.
58. Bek-Thomsen M, Lomholt HB, Kilian M. Acne is not associated with yet-uncultured bacteria. *J Clin Microbiol*. 2008;46:3355-3360.
59. Fitz-Gibbon S, Tomida S, Chiu BH, et al. Propionibacterium acnes strain populations in the human skin microbiome associated with acne. *J Invest Dermatol*. 2013;133:2152-2160.
60. Kim J, Ochoa MT, Krutzik SR, et al. Activation of toll-like receptor 2 in acne triggers inflammatory cytokine responses. *J Immunol*. 2002;169:1535-1541.

61. Leyden JJ, McGinley KJ, Mills OH, et al. Propionibacterium levels in patients with and without acne vulgaris. *J Invest Dermatol*. 1975;65:382-384.
62. Eady EA, Cove JH, Holland KT, et al. Erythromycin resistant propionibacteria in antibiotic treated acne patients: association with therapeutic failure. *Br J Dermatol*. 1989;121:51-57.
63. Ross J, Snelling A, Carnegie E, et al. Antibiotic-resistant acne: lessons from Europe. *Br J Dermatol*. 2003;148:467-478.
64. McDowell A, Nagy I, Magyari M, et al. The opportunistic pathogen Propionibacterium acnes: insights into typing, human disease, clonal diversification and CAMP factor evolution. *PloS One*. 2013;8:e70897.
65. Lomholt HB, Kilian M. Population genetic analysis of Propionibacterium acnes identifies a subpopulation and epidemic clones associated with acne. *PLoS One*. 2010;5:e12277.
66. McDowell A, Gao A, Barnard E, et al. A novel multilocus sequence typing scheme for the opportunistic pathogen Propionibacterium acnes and characterization of type I cell surface-associated antigens. *Microbiology*. 2011;157:1990-2003.
67. McDowell A, Barnard E, Nagy I, et al. An expanded multilocus sequence typing scheme for propionibacterium acnes: investigation of "pathogenic," "commensal" and antibiotic resistant strains. *PLoS One*. 7:e41480, 2012.
68. Tomida S, Nguyen L, Chiu BH, et al. Pan-genome and comparative genome analyses of propionibacterium acnes reveal its genomic diversity in the healthy and diseased human skin microbiome. *MBio*. 2013;4:e00003-00013.
69. Johnson T, Kang D, Barnard E, et al. Strain-level differences in porphyrin production and regulation in propionibacterium acnes elucidate disease associations. *mSphere*. 2016;1(1).e00023-15.
70. Kang D, Shi B, Erfe MC, et al. Vitamin B12 modulates the transcriptome of the skin microbiota in acne pathogenesis. *Sci Transl Med*. 2015;7:293ra103.
71. Yu Y, Champer J, Agak GW, et al. Different Propionibacterium acnes phylotypes induce distinct immune responses and express unique surface and secreted proteomes. *J Invest Dermatol*. 2016;136(11):2221-2228.
72. Webster GF, Indrisano JP, Leyden JJ. Antibody titers to Propionibacterium acnes cell wall carbohydrate in nodulocystic acne patients. *J Invest Dermatol*. 1985;84:496-500.
73. Webster GF, Leyden JJ, Nilsson UR. Complement activation in acne vulgaris: consumption of complement by comedones. *Infect Immun*. 1979;26:183-186.
74. Puhvel SM, Hoffman IK, Reisner RM, et al. Dermal hypersensitivity of patients with acne vulgaris to Corynebacterium acnes. *J Invest Dermatol*. 1967;49: 154-158.
75. Abdel Fattah NS, Shaheen MA, Ebrahim AA, et al. Tissue and blood superoxide dismutase activities and malondialdehyde levels in different clinical severities of acne vulgaris. *Br J Dermatol*. 2008;159: 1086-1091.
76. Vowels BR, Yang S, Leyden JJ. Induction of proinflammatory cytokines by a soluble factor of Propionibacterium acnes: implications for chronic inflammatory acne. *Infect Immun*. 1995;63:3158-3165.
77. Graham GM, Farrar MD, Cruse-Sawyer JE, et al. Proinflammatory cytokine production by human keratinocytes stimulated with Propionibacterium acnes and P. acnes GroEL. *Br J Dermatol*. 2004;150:421-428.
78. Nagy I, Pivarcsi A, Koreck A, et al. Distinct strains of Propionibacterium acnes induce selective human beta-defensin-2 and interleukin-8 expression in human keratinocytes through toll-like receptors. *J Invest Dermatol*. 2005;124:931-938.
79. Jugeau S, Tenaud I, Knol AC, et al. Induction of toll-like receptors by Propionibacterium acnes. *Br J Dermatol*. 2005;153:1105-1113.
80. Qin M, Pirouz A, Kim MH, et al. Propionibacterium acnes Induces IL-1beta secretion via the NLRP3 inflammasome in human monocytes. *J Invest Dermatol*. 2014;134:381-388.
81. Kistowska M, Gehrke S, Jankovic D, et al. IL-1beta drives inflammatory responses to propionibacterium acnes in vitro and in vivo. *J Invest Dermatol*. 2014;134:677-685.
82. Li ZJ, Choi DK, Sohn KC, et al. Propionibacterium acnes activates the NLRP3 inflammasome in human sebocytes. *J Invest Dermatol*. 2014;134:2747-2756.
83. Kamisango K, Saiki I, Tanio Y, et al. Structures and biological activities of peptidoglycans of Listeria monocytogenes and Propionibacterium acnes. *J Biochem*. 1982;92:23-33.
84. Inohara N, Ogura Y, Fontalba A, et al. Host recognition of bacterial muramyl dipeptide mediated through NOD2. Implications for Crohn's disease. *J Biol Chem*. 2003;278:5509-5512.
85. Girardin SE, Boneca IG, Viala J, et al. Nod2 is a general sensor of peptidoglycan through muramyl dipeptide (MDP) detection. *J Biol Chem*. 2003;278:8869-8872.
86. Martinon F, Agostini L, Meylan E, et al. Identification of bacterial muramyl dipeptide as activator of the NALP3/cryopyrin inflammasome. *Curr Biol*. 2004;14: 1929-1934.
87. Lee DY, Huang CM, Nakatsuji T, et al. Histone H4 is a major component of the antimicrobial action of human sebocytes. *J Invest Dermatol*. 2009;129:2489-2496.
88. Lee DY, Yamasaki K, Rudsil J, et al. Sebocytes express functional cathelicidin antimicrobial peptides and can act to kill propionibacterium acnes. *J Invest Dermatol*. 2008;128:1863-1866.
89. Liu PT, Phan J, Tang D, et al. CD209(+) macrophages mediate host defense against Propionibacterium acnes. *J Immunol*. 2008;180:4919-4923.
90. Mouser PE, Baker BS, Seaton ED, et al. Propionibacterium acnes-reactive T helper-1 cells in the skin of patients with acne vulgaris. *J Invest Dermatol*. 2003; 121:1226-1228.
91. Agak GW, Qin M, Nobe J, et al. Propionibacterium acnes Induces an IL-17 response in acne vulgaris that is regulated by vitamin a and vitamin D. *J Invest Dermatol*. 2014;134:366-373.
92. Kistowska M, Meier B, Proust T, et al. Propionibacterium acnes promotes Th17 and Th17/Th1 responses in acne patients. *J Invest Dermatol*. 2015;135: 110-118.
93. Levell MJ, Cawood ML, Burke B, et al. Acne is not associated with abnormal plasma androgens. *Br J Dermatol*. 1989;120:649-654.
94. Chiu A, Chon SY, Kimball AB. The response of skin disease to stress: changes in the severity of acne vulgaris as affected by examination stress. *Arch Dermatol*. 2003;139:897-900.
95. Holland DB, Jeremy AH. The role of inflammation in the pathogenesis of acne and acne scarring. *Semin Cutan Med Surg*. 2005;24:79-83.
96. Holland DB, Jeremy AH, Roberts SG, et al. Inflammation in acne scarring: a comparison of the responses

in lesions from patients prone and not prone to scar. *Br J Dermatol*. 2004;150:72-81.
97. Smith RN, Mann NJ, Braue A, et al. The effect of a high-protein, low glycemic-load diet versus a conventional, high glycemic-load diet on biochemical parameters associated with acne vulgaris: a randomized, investigator-masked, controlled trial. *J Am Acad Dermatol*. 2007;57:247-256.
98. Bowe WP, Joshi SS, Shalita AR. Diet and acne. *J Am Acad Dermatol*. 2010;63:124-141.
99. Berra B, Rizzo AM. Glycemic index, glycemic load: new evidence for a link with acne. *J Am Coll Nutr*. 2009;28(suppl):450S-454S.
100. Kaymak Y, Adisen E, Ilter N, et al. Dietary glycemic index and glucose, insulin, insulin-like growth factor-I, insulin-like growth factor binding protein 3, and leptin levels in patients with acne. *J Am Acad Dermatol*. 2007;57:819-823.
101. Reynolds RC, Lee S, Choi JY, et al. Effect of the glycemic index of carbohydrates on Acne vulgaris. *Nutrients*. 2010;2:1060-1070.
102. Hoyt G, Hickey MS, Cordain L. Dissociation of the glycaemic and insulinaemic responses to whole and skimmed milk. *Br J Nutr*. 2005;93:175-177.
103. Agamia NF, Abdallah DM, Sorour O, et al. Skin expression of mammalian target of rapamycin and forkhead box transcription factor O1, and serum insulin-like growth factor-1 in patients with acne vulgaris and their relationship with diet. *Br J Dermatol*. 2016;174:1299-1307.
104. Melnik BC, Zouboulis CC. Potential role of FoxO1 and mTORC1 in the pathogenesis of Western diet-induced acne. *Exp Dermatol*. 2013;22:311-315.
105. Lucky AW, Biro FM, Huster GA, et al. Acne vulgaris in premenarchal girls. An early sign of puberty associated with rising levels of dehydroepiandrosterone. *Arch Dermatol*. 1994;130:308-314.
106. Marynick SP, Chakmakjian ZH, McCaffree DL, et al. Androgen excess in cystic acne. *N Engl J Med*. 1983;308:981-986.
107. Goodman NF, Cobin RH, Futterweit W, et al. American Association of Clinical Endocrinologists, American College of Endocrinology, and Androgen Excess and PCOS Society disease state clinical review: guide to the best practices in the evaluation and treatment of polycystic ovary syndrome–part 1. *Endocr Pract*. 2015;21:1291-1300.
108. Stoll S, Shalita AR, Webster GF, et al. The effect of the menstrual cycle on acne. *J Am Acad Dermatol*. 2001;45:957-960.
109. Di Landro A, Cazzaniga S, Parazzini F, et al. Family history, body mass index, selected dietary factors, menstrual history, and risk of moderate to severe acne in adolescents and young adults. *J Am Acad Dermatol*. 2012;67:1129-1135.
110. Herane MI, Ando I. Acne in infancy and acne genetics. *Dermatology*. 2003;206:24-28.
111. Brecher AR, Orlow SJ. Oral retinoid therapy for dermatologic conditions in children and adolescents. *J Am Acad Dermatol*. 2003;49:171-182; quiz 183-176.
112. Fisher GJ, Voorhees JJ. Molecular mechanisms of retinoid actions in skin. *FASEB J*. 1996;10:1002-1013.
113. Shalita A, Weiss JS, Chalker DK, et al. A comparison of the efficacy and safety of adapalene gel 0.1% and tretinoin gel 0.025% in the treatment of acne vulgaris: a multicenter trial. *J Am Acad Dermatol*. 1996;34:482-485.
114. Cunliffe WJ, Caputo R, Dreno B, et al. Clinical efficacy and safety comparison of adapalene gel and tretinoin gel in the treatment of acne vulgaris: Europe and U.S. multicenter trials. *J Am Acad Dermatol*. 1997;36:S126-134.
115. Thiboutot D, Arsonnaud S, Soto P. Efficacy and tolerability of adapalene 0.3% gel compared to tazarotene 0.1% gel in the treatment of acne vulgaris. *J Drugs Dermatol*. 2008;7(6 suppl):S3-S10.
116. Tan JK. Adapalene 0.1% and benzoyl peroxide 2.5%: a novel combination for treatment of acne vulgaris. *Skin Therapy Lett*. 2009;14:4-5.
117. Thiboutot DM, Weiss J, Bucko A, et al. Adapalene-benzoyl peroxide, a fixed-dose combination for the treatment of acne vulgaris: results of a multicenter, randomized double-blind, controlled study. *J Am Acad Dermatol*. 2007;57:791-799.
118. Williams C, Layton AM. Persistent acne in women: implications for the patient and for therapy. *Am J Clin Dermatol*. 2006;7:281-290.
119. Webster GF, Berson D, Stein LF, et al. Efficacy and tolerability of once-daily tazarotene 0.1% gel versus once-daily tretinoin 0.025% gel in the treatment of facial acne vulgaris: a randomized trial. *Cutis*. 2001; 67:4-9.
120. Leyden JJ, Tanghetti EA, Miller B, et al. Once-daily tazarotene 0.1 % gel versus once-daily tretinoin 0.1 % microsponge gel for the treatment of facial acne vulgaris: a double-blind randomized trial. *Cutis*. 2002;69:12-19.
121. Hegemann L, Toso SM, Kitay K, et al. Anti-inflammatory actions of benzoyl peroxide: effects on the generation of reactive oxygen species by leucocytes and the activity of protein kinase C and calmodulin. *Br J Dermatol*. 1994;130:569-575.
122. Zaenglein AL, Pathy AL, Schlosser BJ, et al. Guidelines of care for the management of acne vulgaris. *J Am Acad Dermatol*. 2016;74:945-973 e933.
123. Eady EA, Bojar RA, Jones CE, et al. The effects of acne treatment with a combination of benzoyl peroxide and erythromycin on skin carriage of erythromycin-resistant propionibacteria. *Br J Dermatol*. 1996;134:107-113.
124. Raimer S, Maloney JM, Bourcier M, et al. Efficacy and safety of dapsone gel 5% for the treatment of acne vulgaris in adolescents. *Cutis*. 2008;81:171-178.
125. Lucky AW, Maloney JM, Roberts J, et al. Dapsone gel 5% for the treatment of acne vulgaris: safety and efficacy of long-term (1 year) treatment. *J Drugs Dermatol*. 2007;6:981-987.
126. Piette WW, Taylor S, Pariser D, et al. Hematologic safety of dapsone gel, 5%, for topical treatment of acne vulgaris. *Arch Dermatol*. 2008;144:1564-1570.
127. Dubina MI, Fleischer AB, Jr. Interaction of topical sulfacetamide and topical dapsone with benzoyl peroxide. *Arch Dermatol*. 2009;145:1027-1029.
128. Shemer A, Shiri J, Mashiah J, et al. Topical minocycline foam for moderate to severe acne vulgaris: phase 2 randomized double-blind, vehicle-controlled study results. *J Am Acad Dermatol*. 2016;74:1251-1252.
129. Gollnick H, Schramm M. Topical therapy in acne. *J Eur Acad Dermatol Venereol*. 1998;(11 suppl 1):S8-S12; discussion S28-S19.
130. Hjorth N, Graupe K. Azelaic acid for the treatment of acne. A clinical comparison with oral tetracycline. *Acta Derm Venereol Suppl (Stockh)*. 1989;143:45-48.
131. Kaminsky A. Less common methods to treat acne. *Dermatology*. 2003;206:68-73.
132. Gough A, Chapman S, Wagstaff K, et al. Minocycline induced autoimmune hepatitis and systemic lupus erythematosus-like syndrome. *BMJ*. 1996;312:169-172.

133. Goulden V, Glass D, Cunliffe WJ. Safety of long-term high-dose minocycline in the treatment of acne. *Br J Dermatol*. 1996;134:693-695.
134. Fernandez-Obregon AC. Azithromycin for the treatment of acne. *Int J Dermatol*. 2000;39:45-50.
135. Fenner JA, Wiss K, Levin NA. Oral cephalexin for acne vulgaris: clinical experience with 93 patients. *Pediatr Dermatol*. 2008;25:179-183.
136. Eady EA. Bacterial resistance in acne. *Dermatology*. 1998;196:59-66.
137. Gollnick H, Cunliffe W, Berson D, et al. Management of acne: a report from a Global Alliance to Improve Outcomes in Acne. *J Am Acad Dermatol*. 2003;49:S1-3.
138. Barbieri JS, Hoffstad O, Margolis DJ. Duration of oral tetracycline-class antibiotic therapy and use of topical retinoids for the treatment of acne among general practitioners (GP): a retrospective cohort study. *J Am Acad Dermatol*. 2016;75:1142-1150 e1141.
139. Speroff L, DeCherney A. Evaluation of a new generation of oral contraceptives. The Advisory Board for the New Progestins. *Obstet Gynecol*. 1993;81:1034-1047.
140. Lucky AW, Henderson TA, Olson WH, et al. Effectiveness of norgestimate and ethinyl estradiol in treating moderate acne vulgaris. *J Am Acad Dermatol*. 1997;37:746-754.
141. Maloney JM, Dietze P Jr, Watson D, et al. Treatment of acne using a 3-milligram drospirenone/20-microgram ethinyl estradiol oral contraceptive administered in a 24/4 regimen: a randomized controlled trial. *Obstet Gynecol*. 2008;112:773-781.
142. Thiboutot D, Archer DF, Lemay A, et al. A randomized, controlled trial of a low-dose contraceptive containing 20 microg of ethinyl estradiol and 100 microg of levonorgestrel for acne treatment. *Fertil Steril*. 2001;76:461-468.
143. Pochi PE, Strauss JS. Sebaceous gland inhibition from combined glucocorticoid-estrogen treatment. *Arch Dermatol*. 1976;112:1108-1109.
144. Faloia E, Filipponi S, Mancini V, et al. Treatment with a gonadotropin-releasing hormone agonist in acne or idiopathic hirsutism. *J Endocrinol Invest*. 1993;16:675-677.
145. Goodfellow A, Alaghband-Zadeh J, Carter G, et al. Oral spironolactone improves acne vulgaris and reduces sebum excretion. *Br J Dermatol*. 1984;111:209-214.
146. Krunic A, Ciurea A, Scheman A. Efficacy and tolerance of acne treatment using both spironolactone and a combined contraceptive containing drospirenone. *J Am Acad Dermatol*. 2008;58:60-62.
147. Plovanich M, Weng QY, Mostaghimi A. Low usefulness of potassium monitoring among healthy young women taking spironolactone for acne. *JAMA Dermatol*. 2015;151:941-944.
148. Kim GK, Del Rosso JQ. Oral spironolactone in postteenage female patients with acne vulgaris: practical considerations for the clinician based on current data and clinical experience. J Clin Aesthet *Dermatol*. 2012;5:37-50.
149. Mackenzie IS, Morant SV, Wei L, et al. Spironolactone use and risk of incident cancers: a retrospective, matched cohort study. *Br J Clin Pharmacol*. 2017;83(3):653-663.
150. Cusan L, Dupont A, Belanger A, et al. Treatment of hirsutism with the pure antiandrogen flutamide. *J Am Acad Dermatol*. 1990;23:462-469.
151. Wysowski DK, Freiman JP, Tourtelot JB, Horton ML 3rd. Fatal and nonfatal hepatotoxicity associated with flutamide. *Ann Intern Med*. 1993;118:860-864.
152. Peck GL, Olsen TG, Yoder FW, et al. Prolonged remissions of cystic and conglobate acne with 13-cis-retinoic acid. *N Engl J Med*. 1979;300:329-333.
153. Pochi PE. The pathogenesis and treatment of acne. *Annu Rev Med*. 1990;41:187-198.
154. Strauss JS, Stranieri AM. Changes in long-term sebum production from isotretinoin therapy. *J Am Acad Dermatol*. 1982;6:751-756.
155. Leyden JJ, McGinley KJ. Effect of 13-cis-retinoic acid on sebum production and Propionibacterium acnes in severe nodulocystic acne. *Arch Dermatol Res*. 1982;272:331-337.
156. Weissmann A, Wagner A, Plewig G. Reduction of bacterial skin flora during oral treatment of severe acne with 13-cis retinoic acid. *Arch Dermatol Res*. 1981;270:179-183.
157. Windhorst DB, Nigra T. General clinical toxicology of oral retinoids. *J Am Acad Dermatol*. 1982;6:675-682.
158. Wysowski DK, Pitts M, Beitz J. An analysis of reports of depression and suicide in patients treated with isotretinoin. *J Am Acad Dermatol*. 2001;45:515-519.
159. Marqueling AL, Zane LT. Depression and suicidal behavior in acne patients treated with isotretinoin: a systematic review. *Semin Cutan Med Surg*. 2007;26:210-220.
160. Bigby M. Does isotretinoin increase the risk of depression? *Arch Dermatol*. 2008;144:1197-1199; discussion 1234-1195.
161. Kaymak Y, Taner E, Taner Y. Comparison of depression, anxiety and life quality in acne vulgaris patients who were treated with either isotretinoin or topical agents. *Int J Dermatol*. 2009;48:41-46.
162. Birmaher B, Ryan ND, Williamson DE, et al. Childhood and adolescent depression: a review of the past 10 years. Part II. *J Am Acad Child Adolesc Psychiatry*. 1996;35:1575-1583.
163. Crockett SD, Gulati A, Sandler RS, et al. A causal association between isotretinoin and inflammatory bowel disease has yet to be established. *Am J Gastroenterol*. 2009;104:2387-2393.
164. Bernstein CN, Nugent Z, Longobardi T, et al. Isotretinoin is not associated with inflammatory bowel disease: a population-based case-control study. *Am J Gastroenterol*. 2009;104:2774-2778.
165. DiGiovanna JJ, Langman CB, Tschen EH, et al. Effect of a single course of isotretinoin therapy on bone mineral density in adolescent patients with severe, recalcitrant, nodular acne. *J Am Acad Dermatol*. 2004; 51:709-717.
166. Pittsley RA, Yoder FW. Retinoid hyperostosis. Skeletal toxicity associated with long-term administration of 13-cis-retinoic acid for refractory ichthyosis. *N Engl J Med*. 1983;308:1012-1014.
167. Hansen TJ, Lucking S, Miller JJ, et al. Standardized laboratory monitoring with use of isotretinoin in acne. *J Am Acad Dermatol*. 2016;75:323-328.
168. Stern RS, Rosa F, Baum C. Isotretinoin and pregnancy. *J Am Acad Dermatol*. 1984;10:851-854.
169. Fernhoff PM, Lammer EJ. Craniofacial features of isotretinoin embryopathy. *J Pediatr*. 1984;105:595-597.
170. Lehucher-Ceyrac D, Weber-Buisset MJ. Isotretinoin and acne in practice: a prospective analysis of 188 cases over 9 years. *Dermatology*. 1993;186:123-128.
171. Adebamowo CA, Spiegelman D, Danby FW, et al. High school dietary dairy intake and teenage acne. *J Am Acad Dermatol*. 2005;52:207-214.
172. Cordain L, Lindeberg S, Hurtado M, et al. Acne vulgaris: a disease of Western civilization. *Arch Dermatol*. 2002;138:1584-1590.

173. Spencer EH, Ferdowsian HR, Barnard ND. Diet and acne: a review of the evidence. *Int J Dermatol*. 2009;48: 339-347.
174. Alam M, Omura N, Kaminer MS. Subcision for acne scarring: technique and outcomes in 40 patients. *Dermatol Surg*. 2005;31:310-317; discussion 317.
175. Kaminaka C, Uede M, Matsunaka H, et al. Clinical evaluation of glycolic acid chemical peeling in patients with acne vulgaris: a randomized, double-blind, placebo-controlled, split-face comparative study. *Dermatol Surg*. 2014;40:314-322.
176. Kim RH, Armstrong AW. Current state of acne treatment: highlighting lasers, photodynamic therapy, and chemical peels. *Dermatol Online J*. 2011;17:2.
177. Atzori L, Brundu MA, Orru A, et al. Glycolic acid peeling in the treatment of acne. *J Eur Acad Dermatol Venereol*. 1999;12:119-122.
178. Lee HS, Kim IH. Salicylic acid peels for the treatment of acne vulgaris in Asian patients. *Dermatol Surg*. 2003;29:1196-1199; discussion 1199.
179. Mills OH, Kligman AM. Ultraviolet phototherapy and photochemotherapy of acne vulgaris. *Arch Dermatol*. 1978;114:221-223.
180. Momen S, Al-Niaimi F. Acne vulgaris and light-based therapies. *J Cosmet Laser Ther*. 2015;17:122-128.
181. Sigurdsson V, Knulst AC, van Weelden H. Phototherapy of acne vulgaris with visible light. *Dermatology*. 1997;194:256-260.
182. Kjeldstad B, Johnsson A. An action spectrum for blue and near ultraviolet inactivation of Propionibacterium acnes; with emphasis on a possible porphyrin photosensitization. *Photochem Photobiol*. 1986;43:67-70.
183. Suh DH, Kwon TE, Youn JI. Changes of comedonal cytokines and sebum secretion after UV irradiation in acne patients. *Eur J Dermatol*. 2002;12:139-144.
184. Lassus A, Salo O, Forstrom L, et al. [Treatment of acne with selective UV-phototherapy (SUP). An open trial]. *Dermatol Monatsschr*. 1983;169:376-379.
185. Meffert H, Kolzsch J, Laubstein B, et al. [Phototherapy of acne vulgaris with the "TuR" UV 10 body section irradiation unit]. *Dermatol Monatsschr*. 1986;172: 9-13.
186. Meffert H, Laubstein B, Kolzsch J, Sonnichsen N. [Phototherapy of acne vulgaris with the UVA irradiation instrument TBG 400]. *Dermatol Monatsschr*. 1986;172:105-106.
187. van Weelden H, de Gruijl FR, van der Putte SC, et al. carcinogenic risks of modern tanning equipment: is UV-A safer than UV-B? *Arch Dermatol Res*. 1988;280:300-307.
188. Lee WL, Shalita AR, Poh-Fitzpatrick MB. Comparative studies of porphyrin production in Propionibacterium acnes and Propionibacterium granulosum. *J Bacteriol*. 1978;133:811-815.
189. Arakane K, Ryu A, Hayashi C, et al. Singlet oxygen (1 delta g) generation from coproporphyrin in Propionibacterium acnes on irradiation. *Biochem Biophys Res Commun*. 1996;223:578-582.
190. Oberemok SS, Shalita AR. Acne vulgaris, II: treatment. *Cutis*. 2002;70:111-114.
191. Haedersdal M, Togsverd-Bo K, Wulf HC. Evidence-based review of lasers, light sources and photodynamic therapy in the treatment of acne vulgaris. *J Eur Acad Dermatol Venereol*. 2008;22:267-278.
192. Melo TB. Uptake of protoporphyrin and violet light photodestruction of Propionibacterium acnes. *Z Naturforsch C*. 1987;42:123-128.
193. Charakida A, Seaton ED, Charakida M, et al. Phototherapy in the treatment of acne vulgaris: what is its role? *Am J Clin Dermatol*. 2004;5:211-216.
194. Ibbotson SH. Topical 5-aminolaevulinic acid photodynamic therapy for the treatment of skin conditions other than non-melanoma skin cancer. *Br J Dermatol*. 2002;146:178-188.
195. Hongcharu W, Taylor CR, Chang Y, et al. Topical ALA-photodynamic therapy for the treatment of acne vulgaris. *J Invest Dermatol*. 2000;115:183-192.
196. Sadick N. An open-label, split-face study comparing the safety and efficacy of levulan kerastick (aminolevulonic acid) plus a 532 nm KTP laser to a 532 nm KTP laser alone for the treatment of moderate facial acne. *J Drugs Dermatol*. 2010;9:229-233.
197. Seaton ED, Charakida A, Mouser PE, et al. Pulsed-dye laser treatment for inflammatory acne vulgaris: randomised controlled trial. *Lancet*. 2003;362: 1347-1352.
198. Paithankar DY, Ross EV, Saleh BA, et al. Acne treatment with a 1,450 nm wavelength laser and cryogen spray cooling. *Lasers Surg Med*. 2002;31: 106-114.
199. Friedman PM, Jih MH, Kimyai-Asadi A, et al. Treatment of inflammatory facial acne vulgaris with the 1450-nm diode laser: a pilot study. *Dermatol Surg*. 2004;30:147-151.
200. Lloyd JR, Mirkov M. Selective photothermolysis of the sebaceous glands for acne treatment. *Lasers Surg Med*. 2002;31:115-120.
201. Angel S, Boineau D, Dahan S, et al. Treatment of active acne with an Er:Glass (1.54 microm) laser: a 2-year follow-up study. *J Cosmet Laser Ther*. 2006;8:171-177.
202. Wanitphakdeedecha R, Tanzi EL, Alster TS. Photopneumatic therapy for the treatment of acne. *J Drugs Dermatol*. 2009;8:239-241.
203. Gold MH, Biron J. Efficacy of a novel combination of pneumatic energy and broadband light for the treatment of acne. *J Drugs Dermatol*. 2008;7:639-642.
204. Cohen BE, Brauer JA, Geronemus RG. Acne scarring: a review of available therapeutic lasers. *Lasers Surg Med*. 2016;48:95-115.
205. Chrastil B, Glaich AS, Goldberg LH, et al. Second-generation 1,550-nm fractional photothermolysis for the treatment of acne scars. *Dermatol Surg*. 2008;34: 1327-1332.
206. Alster TS, Tanzi EL, Lazarus M. The use of fractional laser photothermolysis for the treatment of atrophic scars. *Dermatol Surg*. 2007;33:295-299.
207. Tanzi EL, Wanitphakdeedecha R, Alster TS. Fraxel laser indications and long-term follow-up. *Aesthet Surg J*. 2008;28:675-678; discussion 679-680.
208. Omi T, Numano K. The role of the CO2 laser and fractional CO2 laser in dermatology. *Laser Ther*. 2014;23:49-60.
209. Levy LL, Zeichner JA. Management of acne scarring, part II: a comparative review of non-laser-based, minimally invasive approaches. *Am J Clin Dermatol*. 2012;13:331-340.
210. Tsao SS, Dover JS, Arndt KA, et al. Scar management: keloid, hypertrophic, atrophic, and acne scars. *Semin Cutan Med Surg*. 2002;21:46-75.
211. Spencer JM. Microdermabrasion. *Am J Clin Dermatol*. 2005;6:89-92.
212. Kim ST, Lee KH, Sim HJ, et al. Treatment of acne vulgaris with fractional radiofrequency microneedling. *J Dermatol*. 2014;41:586-591.

213. Lee SJ, Goo JW, Shin J, et al. Use of fractionated microneedle radiofrequency for the treatment of inflammatory acne vulgaris in 18 Korean patients. *Dermatol Surg*. 2012;38:400-405.
214. Hou A, Cohen B, Haimovic A, et al. Microneedling: a comprehensive review. *Dermatol Surg*. 2017;43(3): 321-339.
215. Liebl H, Kloth LC. Skin cell proliferation stimulated by microneedles. *J Am Coll Clin Wound Spec*. 2012;4(1):2-6.
216. Cohen BE, Elbuluk N. Microneedling in skin of color: a review of uses and efficacy. *J Am Acad Dermatol*. 2016;74:348-355.
217. Asif M, Kanodia S, Singh K. Combined autologous platelet-rich plasma with microneedling verses microneedling with distilled water in the treatment of atrophic acne scars: a concurrent split-face study. *J Cosmet Dermatol*. 2016;15(4):434-443.
218. Sharad J. Combination of microneedling and glycolic acid peels for the treatment of acne scars in dark skin. *J Cosmet Dermatol*. 2011;10:317-323.
219. Hirsch RJ, Lewis AB. Treatment of acne scarring. *Semin Cutan Med Surg*. 2001;20:190-198.
220. Hirsch RJ, Cohen JL. Soft tissue augmentation. *Cutis*. 2006;78:165-172.
221. Murase JE, Heller MM, Butler DC. Safety of dermatologic medications in pregnancy and lactation: part I. Pregnancy. *J Am Acad Dermatol*. 2014;70:401 e401-414; quiz 415.
222. Kong YL, Tey HL. Treatment of acne vulgaris during pregnancy and lactation. *Drugs*. 2013;73:779-787.

Chapter 79 :: Rosacea

:: Martin Steinhoff & Jörg Buddenkotte

AT-A-GLANCE

- Rosacea is a common facial skin disease in many countries.
- Signs and symptoms for rosacea include flushing, transient erythema, persistent erythema, telangiectasia, papules, pustules, phymata, edema, pain, stinging or burning, and (very rarely) pruritus.
- The pathophysiology of rosacea is poorly understood; however, a genetic predisposition along with trigger factors activate a dysregulated neurovascular, innate immune, and adaptive immune system.
- Taking a thorough family and patient history and performing a clinical examination are crucial to diagnose rosacea.
- All clinical features have to be considered with severity scores for a proper treatment, combined with assessing patient's quality of life.
- Approved topical or systemic drugs exist for various, but not all, features of rosacea and should be used on the basis of pathophysiology and while considering efficacy and side effect profiles.
- Knowledge about the beneficial use of physical therapies and their limitations is important for best medical practice in patients with rosacea.
- Education about disease progress, general skin care, cosmetic usage and medication effects and potential adverse events is mandatory; teaching of proper topical use guarantees better treatment results.
- Education to prevent exacerbating "trigger factors" is critical for successful management of patients with rosacea.

INTRODUCTION

Rosacea is a common chronic inflammatory skin disease that almost exclusively affects the central facial skin and rarely affects the extrafacial (neck, forehead) skin. *Rosacea* derives from the Greek word meaning "rose-like," which describes the main symptomatology of repeated flushing alone or in combination with transient or persistent erythema. Clinically, the condition is characterized by prolonged flushing (transient erythema), persistent erythema, telangiectasia, papules, pustules, and phymatous changes, often accompanied by burning, stinging, or even migraine-like pain (cutaneous rosacea). Eyes can be also involved (ocular rosacea). Because of their different pathophysiologies, the terms *acne rosacea* and *adult acne* are no longer used to describe this disorder.[1,2]

Worldwide, more than 20 million patients are estimated to have rosacea, although reliable statistics are lacking.[3] Because of its obvious facial location, rosacea is associated with a significant disease burden and impaired quality of life.[4] The etiology and pathophysiology of rosacea are poorly understood, so the therapy of rosacea is still unsatisfactory; currently used treatment modalities mainly aim to control the clinical signs and symptoms rather than target causes or prevent disease.[5-9]

EPIDEMIOLOGY AND DISEASE BURDEN

In many countries, rosacea is more prevalent than asthma or diabetes. Depending on the country, rosacea affects at least 2% to 18% of individuals, with the highest level reported in Celtic populations. A Swedish study described a prevalence of 10% for rosacea,[10] and a German study found 12.3% of the population to be affected.[11] In 2010, an epidemiologic study from Ireland reported a prevalence of 13.9% for rosacea.[12] The prevalence of rosacea probably depends on the genetic make-up of the population being studied. The condition affects women more often than men (3:1) and typically starts a decade earlier in women than in men; the normal age of onset is generally considered to be 35 to 45 years in women and 45 to 55 years in men, although recent studies suggest an earlier clinical onset with flushing, which is often not recognized as an early sign of rosacea.[1,13,14] Research indicates that the first, often unrecognized, signs can occur in the second decade of a patient's life, more often in women than in men.

Rosacea is often misinterpreted as a disease of alcohol overconsumption or "lying," which can stigmatize patients. The facial distribution of the disease is generally recognized to have a significant negative psychological impact on patients, although the statistical evidence for this effect is poor. Patients report significantly impaired self-esteem and may become unemployed, stop socializing, get divorced, or develop depression.[15] However, not all of the disease burden is psychological because patients may also have potentially severe stinging or burning associated with the flushing or erythema.[3,16]

CLINICAL FINDINGS

Rosacea is, in most cases, a symmetric skin disease affecting the central face, nose, chin, central cheeks, and glabella; the forehead (more common in bald

men), neck, and chest are only rarely affected. The perioral or periorbital regions, or areas behind the ears, are rarely affected. The clinical findings can vary substantially among rosacea-affected patients. In general, all possible signs or symptoms are flushing, transient erythema, persistent erythema, telangiectasia, papules, pustules, phymata, edema, pain, stinging or burning, and (very rarely) pruritus.[16-18] Although flushing is the hallmark of rosacea, some patients develop rosacea without much flushing. Classically, most patients describe the disease development as a "crescendo" manifestation with increased numbers of "flushes" after exposure to trigger factors. Sooner or later, most patients develop persistent erythema with or without telangiectasia. Notably, comedones are absent, which differentiates papulopustular rosacea from acne or Favre-Racouchot disease.

The clinical findings are gender and age dependent: in younger female and male patients, flushing and erythema are often the first symptoms; in older adult patients, telangiectasia can be a first sign. Rhinophyma is a characteristic of male patients. The clinical picture is also dependent on the special susceptibility of the patient toward trigger factors; for example, a patient who has high susceptibility to ultraviolet (UV) radiation as a trigger factor may have an asymmetric facial erythema caused by window exposure (eg, driver vs. co-driver). The progression of rosacea is relatively slow, evident only after thorough history taking.

PERSISTENT ERYTHEMA

Persistent erythema (from Greek *erythros*, red) is defined as erythema that lasts for at least 3 months. It constitutes an abnormal redness of the skin or mucous membranes caused by vasodilation of arterioles or capillaries, resulting in increased perfusion and thus redness. Persistent (perilesional) erythema can be found around papules and pustules. Clinically, patients with persistent erythema present with a striking clinical appearance: there is profound central facial erythema predominant on the projecting facial anatomical features (Fig. 79-1). The erythema depth ranges from pink-red to deep burgundy red.

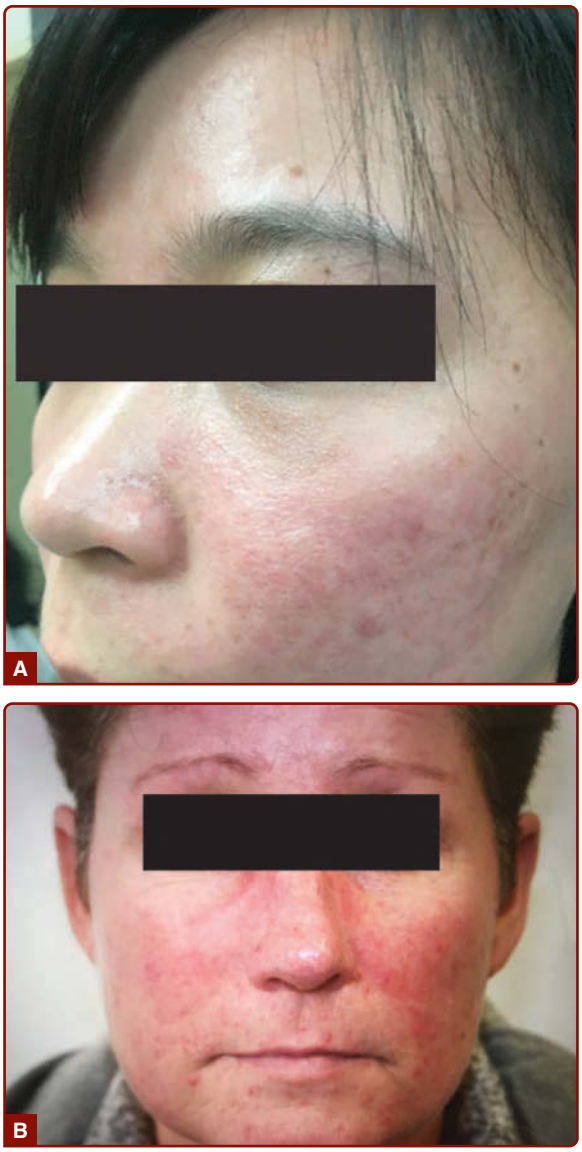

Figure 79-1 **A,** Persistent erythema in patients with rosacea. **B,** Although mostly symmetrical, persistent erythema can present with asymmetrical distribution and intensity based on underlying trigger factor. (Image A, used with permission from Professors H. Xie and J. Li, University Hospital Changsha, China.)

PHYMATA

Phymata (*phyma*, Greek meaning swelling, mass) represents a macroscopic lesion that is uniquely associated with rosacea. Phymatous rosacea is a persistent, firm, nonpainful, nonpitting swelling of the tissue of the nose (rhinophyma), chin (gnathophyma), forehead (metophyma), or eyelids (blepharophyma) that seldom begins before the age of 40 years. Phymatous changes, fortunately, are a rare malady in patients with rosacea, but affected patients are often involuntarily subjected to speculations about insalubrious alcohol consumption. Correspondingly, "brandy nose" has been used as a misleading label to describe rhinophyma. Typically, phymata do not resolve spontaneously.

Rhinophyma, which occurs almost 20 times more often in male patients than in female patients, is often apparent initially in the skin of the alae nasi and at the distal end of the nose as dilated patulous follicles (Fig. 79-2A). Humps and grooves are prominent, resembling a "peau d'orange" appearance of the nose. Compression produces a white pasty matter that is composed of sebum, corneocytes, bacteria, and sometimes Demodex folliculorum mites. When rhinophyma becomes marked (Fig. 79-2B), it leads to the greatest deformity in this region and sometimes affects more proximal areas of the nose, as far as adjacent portions of the cheeks. Rhinophyma of the fibrous form

Figure 79-2 Phymata in patients with rosacea. **A,** In the initial stages, rhinophyma is often apparent only at the distal end of the nose as dilated patulous follicles or plaque. **B,** Marked rhinophyma. **C,** Asymmetric fibrous form of rhinophyma with asymmetrical clinical appearance. **D,** Mild gnathophyma. **E,** Metrophyma in combination with granulomatous plaques on the cheeks. **F,** Blepharophyma. (Image **A,** used with permission from Professors H. Xie and J. Li, University Hospital Changsha, China. Image **F,** used with permission from James E. Fitzpatrick.)

(Fig. 79-2C) manifests with asymmetry of the nasal swelling caused by diffuse hyperplasia of connective tissue and sebaceous hyperplasia. Large actinic comedones can be prominent (sometimes called "potato nose"). In the fibroangiomatous form, the nose then appears copper to dark red, is grossly enlarged, and presents a network of ectatic veins and sometimes pustules. Although gross nasal distortion rarely occurs, the cosmetic impact is very significant in disease management. The incidence of both basal and squamous cell carcinomas has been reported to be higher in rhinophyma-affected skin than in nonlesional skin. However, this observation has not been unambiguously confirmed. There is no consistent relationship between the duration, severity, or any other feature of rosacea and the occurrence of rhinophyma; therefore, rhinophyma should be designated a condition of the skin that is closely associated with rosacea rather than a disorder that occurs as a consequence of the disease.

Gnathophyma (Fig. 79-2D) is a rare occurrence, with the central chin typically being involved, while the lower half of the helices of the ears and the lobes are mainly affected in otophyma. Edema in this region may be present in severe inflammatory papulopustular rosacea. Other locations of phymata can involve the forehead (metrophyma; Fig. 79-2E) and eyelids (blepharophyma; Fig. 79-2F).

The clinical picture of persistent edema and phymatous changes may overlap in some patients. Swelling is often associated with erythema and sometimes with other manifestations of rosacea (papules, pustules, telangiectasias) and occasionally ocular inflammation. Rhinophymata are particularly frequent when associated with seborrhea. Contrarily, seborrhea is not particularly associated with rhinophymata and often occurs in rosacea devoid of phyma.

FLUSHING AND TRANSIENT ERYTHEMA

Flushing involves reactive vascular changes in the face that can be observed in normal individuals for a few seconds or few minutes. Physiologically, it can occur in response to various stimuli, especially heat, certain foods, alcohol, exercising, or stressful emotional stimuli. By contrast, moderate cooling alleviates the redness and has a transient therapeutic effect. Prolonged or more frequent than normal nonphysiological flushing manifests itself over hours to days and can develop into persistent erythema.

Flushing in rosacea is a pathophysiological neurovascular process in the central face experienced for more than 5 to 10 minutes because of neuropeptide release. Because of its sudden noncontrollable appearance, it is embarrassing and very unpleasant for patients and is often associated with sensory symptoms such as stinging, burning pain. Flushing can be associated with persistent erythema, papules, pustules, or phymata or can occur as a single symptom. Both genders are equally susceptible to flushing without age preference, although in women, it is more frequent during menopause. Prolonged and frequent flushing is, with erythema, the most common complaint in patients with rosacea.

Rosacea flushing can often be linked to typical trigger factors, mostly heat, hot steam (kitchen, beverages), red wine and certain other alcoholic beverages, medications such as niacin or topical glucocorticosteroids, noxious cold, and hormonal changes (menopause), rarely systematic disease. It may be accompanied with systemic symptoms such as wheezing, diarrhea, or headache and may be associated with sweating, indicating a role of nerves and mast cells in flushing pathophysiology. In particular, the release of gastrin hormonal mediators from the gastrointestinal (GI) tract have a systematic effect leading to frequent facial flushing and then persistent vasodilatation and telangiectasias on the face.

Transient erythema is a prolonged unphysiological flushing that persists for more than 5 minutes and possibly as long as weeks or a few months but for no more than 3 months.

BLUSHING

Blushing is not a characteristic feature of rosacea. We are briefly mentioning it in this chapter because although different in many aspects, the terms "flushing," "transient erythema," "persistent erythema," and "blushing" are often inappropriately used to describe redness of the facial skin, which leads to confusion. Blushing, in contrast to flushing, is almost exclusively induced by emotionally stressful situations and not by spicy food or other rosacea trigger factors. Blushing has a more pinkish appearance than persistent erythema or flushing and is located on rosacea-atypical sites. It is characterized by sudden transient (mostly <5 minutes), pinkish involuntary redness of the peripheral cheeks, ears, retroauricular areas, neck, and chest, which can occur over years and often starts in early adulthood. "Pale islands" in between the salmon-like redness are also characteristic of blushing and cannot be found in flushing or transient or persistent erythema, indicating that a more autonomic neural process, often associated with enhanced sweating, also a sign of autonomic neural involvement. As with flushing, blushing can be also associated with skin sensations such as stinging or burning, as well as increased sweating but often milder than in flushing.

TELANGIECTASIA

Telangiectasia can be defined as a permanent visible dilated blood vessel on the skin or mucosal surface. Multiple telangiectatic blood vessels build the clinical picture of telangiectasia (Fig. 79-3), which can develop

Figure 79-3 Telangiectasia in a patient with rosacea.

in the absence of any disease (genetically acquired, so-called primary or "essential" telangiectasia) or coexist or even precede skin (eg, rosacea) or systemic (eg, scleroderma) diseases, defined as secondary telangiectasia. In the new classification,[16,19] telangiectasia are classified as a primary feature of rosacea, which can coexist with or without any other rosacea features. They can occur very sparsely or densely and be widely distributed in patients with rosacea.

PAPULES AND PUSTULES

Papules (Fig. 79-4A and B) can occur with or without pustules and can develop into cysts and nodules (rosacea conglobate), depending on the cytokines and chemokines released.[20] Papules and pustules caused by rosacea can be easily recognized in most cases because of their mostly centrofacial distribution and the lack of comedones and scales, although multiple differential diagnoses of course need to be considered (see Differential Diagnosis). The papules in rosacea are mostly small, low pain, dome shaped, and red in color and usually present as multiples. They can also develop into edematous plaques, resembling lupus erythematosus. The lesions tend to occur symmetrically on the centrofacial skin but can extend to the neck, chest (Fig. 79-4B), and forehead, even in children. Forehead rosacea almost exclusively develops in patients with male pattern baldness, supporting the concept that UV radiation is a trigger factor for rosacea.

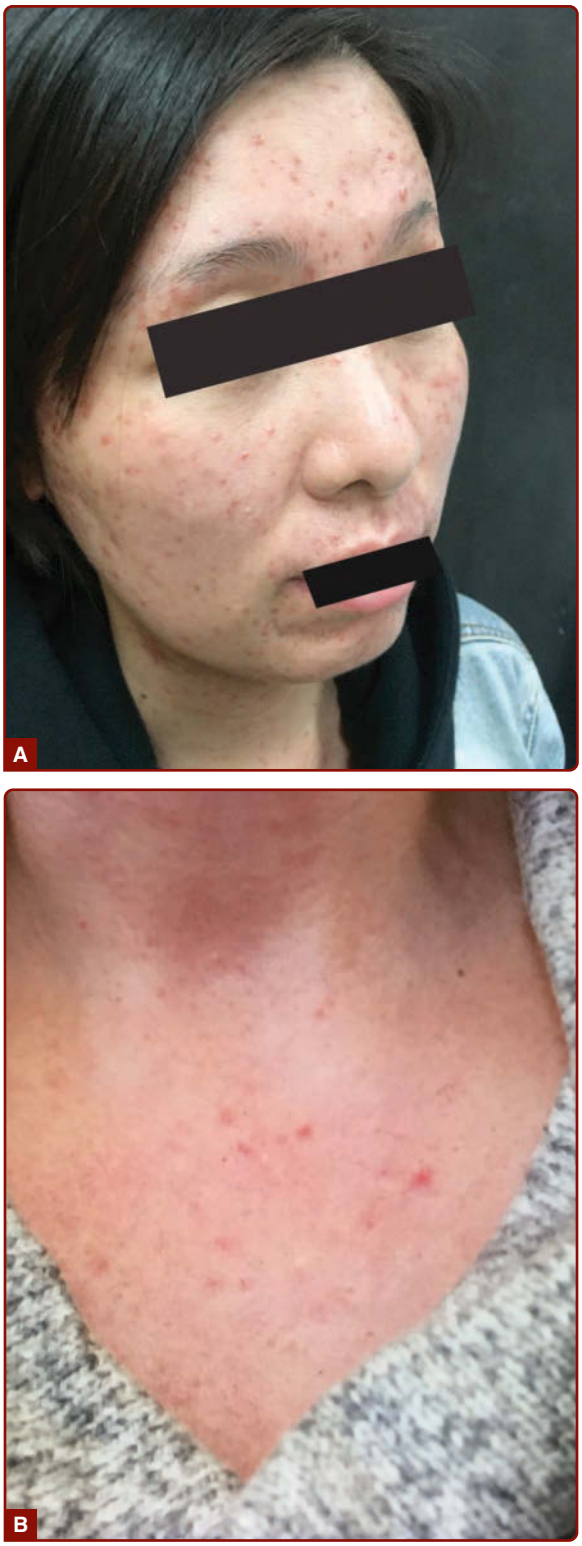

Figure 79-4 Individual with rosacea with mild chronic facial erythema and disseminated facial papules and pustules (**A**). Papules and pustules can develop extrafacially, mostly on the neck, trunk, or bald scalp, indicating ultraviolet light as a trigger factor on bald scalp rosacea (**B**). (Image **A,** used with permission from Professors H. Xie and J. Li, University Hospital Changsha, China.)

Papules and pustules can, rarely, resolve spontaneously after 4 to 8 weeks, notably without scarring. The condition waxes and wanes because of trigger factors, emphasizing the value of maintenance therapy and tapering strategy.

Papules and pustules are often associated with erythema or flushing, which mostly remains after antibiotic therapy (see combination therapy). Telangiectasias, phymatous changes, and ocular rosacea can also accompany papules and pustules.

OCULAR ROSACEA

Ocular rosacea is a frequent, bothersome, and often underestimated feature of rosacea. It involves the eyelids, eyelashes, or eyes of patients with rosacea and, if left untreated, bears risk of blindness. Ocular rosacea occurs in 25% of all patients with rosacea and in as many as 50% of patients with papules and pustules.[21] Rosacea may affect many compartments of the eyes (Fig. 79-5), such as margins of the eyelids, glands of Zeiss, meibomian glands, lacrimal glands, conjunctiva, cornea, sclera, and iris.[9,16,22,23] Typically, patients report a "foreign body" sensation of itching, burning, and stinging in the eyes and grittiness around the eyes. Inspection of the eyes is important; they often have red, swollen, crusty, or scaly margins. Telangiectasia of the conjunctiva may also occur.

RARE SUBFORMS OF ROSACEA

LUPOID OR GRANULOMATOUS ROSACEA

Lupoid rosacea is a distinct subform of rosacea defined by chronic, therapy-resistant, 0.2- to 0.3-cm-sized, often follicular brown-red or red papules that can develop to epithelioid (lupoid), granulomatous plaques and nodules on the cheek, forehead, or chin. The skin appears thickened and erythematous. Typically, the centrofacial and perioral regions of the face are affected. The upper and lower eyelids are involved in some cases. Diascopy reveals a follicle-associated lupoid infiltrate. Rare cases of lupoid rosacea have been observed after treatment with infliximab or etanercept. Whether lupoid rosacea and lupus miliaris disseminates faciei depict distinct disease entities is not yet clarified.

ROSACEA CONGLOBATE

Rosacea conglobate (Fig. 79-6) is a rare, chronic, and severe form of rosacea that resembles acne conglobate with hemorrhagic nodular abscesses and indurated plaques on erythematous background.

ROSACEA FULMINANS (PYODERMA FACIALE-O'LEARY)

Rosacea fulminans is a rare, acute or subacute, developing, maximal variant of rosacea with acne conglobate–like progression and predilection for postadolescent (20–30 years) women, particularly pregnant women; men are affected only rarely. Associations with seborrhoic dermatitis, a common inflammatory skin condition, and Crohn disease, a chronic inflammatory bowel disease, have been described without disclosing a

Figure 79-5 Ocular rosacea may affect many compartments of the eyes. Ophthalmology referral is advised, and systemic therapy is recommended in most cases.

Figure 79-6 Conglobate form of rosacea, which can clinically resemble conglobate form of acne but occurs predominantly in older age groups more often than acne.

mechanistic connection to rosacea fulminans. The clinical findings develop within days to weeks and can affect the complete face—particularly the chin, cheeks, forehead, and nose—or remain localized, especially when present on the neck or trunk. The lesions present papulopustules and coalescent purplish nodules as well as associated abscesses, which often form confluent fistulae that drain a serous, seropurulent, or mucoid discharge. Reddish to violaceous firm swelling of the face is commonly noted. Patients often report an oiliness of the skin before the outbreak of rosacea fulminans. Despite the horrendous clinical picture, systemic symptoms such as fatigue, fever, arthralgia, and anaemia are usually absent. When the disease is controlled, it does not recur.

HALOGEN ROSACEA

Ingestion of iodides or bromides might cause a rosacea-like reaction or deteriorate a persisting rosacea. The clinical findings resemble acne-like rashes or those described for rosacea conglobate. Patients can develop erythematous pustules, vegetative nodules, in extreme cases fungating nodules, small to large blisters, exudative plaques, ulcer (sometimes necrotic), a circumscribed panniculitis, or combinations of these presentations. Potential sources of halogen exposure are citrus-flavored soft drinks (cola drinks), (sea)food, diagnostic radiocontrast media, pool disinfectants, certain topical antiseptics, permanent hair wave formulations, and various products often not considered as potential sources, such as vitamin preparations and medications (eg, thyroid medication, chemotherapeutics). The amount of halogen required to cause a halogen rosacea is variable. The condition typically improves in 4 to 6 weeks after elimination of the exposure. Scarring and postinflammatory pigmentation might occur as residuals.

STEROID ROSACEA

When a patient with rosacea is treated with topical corticosteroids for a prolonged time, the atrophic side effects of the medication sometimes lead to an aggravation of the condition. The complexion changes to a deep flaming red or copper-red covered by a network of telangiectases (Fig. 79-7). The atrophic skin develops patches of scales, follicular papulopustules, nodules, and secondary comedones. The presentation is typically restricted to the area of corticosteroid application. Patients report a severe discomfort and nagging pain sensation.

GRAM-NEGATIVE ROSACEA

Prolonged treatment of a rosacea patient with a topical or systemic antibiotic that covers gram-positive bacteria will select gram-negative pathogens and thereby complicate the rosacea complexion. The characteristic clinical finding is the development of miniscule yellow pustules on a preexisting or newly formed erythema background. The clinical picture is not distinguishable from papulopustular rosacea. However, because of the difference in therapy, the discriminating it from (gram-positive) papulopustular rosacea is essential.

Figure 79-7 Steroid rosacea. **A,** An adult patient with primarily telangiectatic rosacea with rare acneiform papules that was the result of prolonged use of topical glucocorticosteroid (Valisone), which may increase colonization of *Demodex* mites because of immunosuppression. (From the Fitzsimons Army Medical Center Teaching Files.) **B,** A pediatric patient with steroid rosacea. (Used with permission from the William Weston Collection.)

PERSISTENT EDEMA OF ROSACEA

Edema in rosacea should be distinguished from the diffuse idiopathic solid upper-facial edema (sometimes called Morbihan disease or edematous rosacea). Morbihan disease (Fig. 79-8; named after a region of northern France where patients with this problem were

Figure 79-8 Morbihan disease. An adult patient with non to mild erythematous cushionlike edema of the lower eyelids. It may include the forehead, nose, glabella, and central cheeks. It can occur in men and women.

first identified) typically is not preceded by significant cutaneous inflammation. The cause of this type of facial swelling is unknown, and any relationship of chronic Morbihan disease to the typical pathophysiology of rosacea described later is doubtful. However, in rosacea, edema is present as hard, nonpitting swellings of mainly the caudal half of the face (ie, forehead, eyelids, cheeks, and nose) but also the glabella. Although the initial edema might not be constantly experienced, the later swelling is persistent and accompanied by erythema. In particular, swelling of the upper and lower eyelids causing visual difficulties is perceived as aggravating by the patient. Patients also report skin tightness and, infrequently, pruritus. Systemic reactions are profoundly absent. Edema in rosacea tends to become chronic, with flare-ups and periods of partial regression.

ETIOLOGY AND PATHOPHYSIOLOGY

Epidemiologic, clinical, and genetic studies indicate a genetic as well as environmental origin of rosacea; however, the pathophysiological mechanisms that initiate and perpetuate this chronic relapsing inflammatory skin disease are still poorly understood.

GENETICS AND ASSOCIATED CLUES REGARDING MECHANISMS OF DISEASE

A positive family history markedly increases the chances of developing rosacea. Moreover, monozygous twins with rosacea have a higher correlation of National Rosacea Society clinical score criteria than heterozygous twins.[24]

Null mutation polymorphisms in the glutathione S-transferase (GST) gene have been found in patients with rosacea, which indicates that increased oxidative stress may be associated with rosacea pathogenesis.[25,26] Two single-nucleotide polymorphisms (SNPs) found in patients with rosacea of European descent encode for butyrophilin-like 2 (BTNL2) and human leukocyte antigen (HLA)-DRA loci.[26,27] Whereas HLA-DRA showed strong staining at sites of perifollicular inflammatory infiltrates, epidermal Langerhans cells, and endothelial cells, staining using an anti-BTNL2 antibody revealed diffuse expression in keratinocytes, perifollicular inflammatory infiltrates, and endothelial cells of papulopustular patients with rosacea. A polymorphism in NOD2/CARD15 was observed in a patient with granulomatous rosacea;[28] the gene encodes a caspase recruitment protein involved in Toll-like receptor (TLR) function, including the function of TLR-2. Finally, a polymorphic variant of TACR3 was also observed in patients with rosacea;[29] this gene encodes a tachykinin receptor subtype that responds to substance P family members, a neuropeptide critically involved in neurogenic inflammation, flare, and edema.

COMORBIDITIES AND ASSOCIATED CLUES REGARDING MECHANISMS OF DISEASE

Recent studies indicate that an increased risk of rosacea may be associated with inflammatory diseases of the GI tract, such as Crohn's disease, ulcerative colitis, celiac disease or small intestinal bacterial overgrowth (SIBO) syndrome,[26,30-33] probably caused by shared disease susceptibility to the HLA-DRA locus. Other associations to metabolic diseases such as diabetes,[34] hypertension, dyslipidemia, and coronary artery disease[35-37] have been found, possibly owing to low levels of high-density lipoprotein–associated proteins or enzymes (eg, paraoxonase-1),[38,39] increased cathelicidin levels,[40] or endoplasmic reticulum stress.[40-42]

Patients with rosacea notably have various associations to neurologic disorders and neurodegenerative diseases, such as Alzheimer disease,[43] Parkinson disease,[44] migraine,[45] depression,[46] anxiety disorders,[47] complex regional pain syndrome, and glioma.[48]

ENVIRONMENTAL TRIGGER FACTORS AND ASSOCIATED CLUES REGARDING MECHANISMS OF DISEASE

Characteristic trigger factors for the initiation or aggravation of rosacea include heat (and, rarely, noxious

TABLE 79-1
Common Rosacea Triggers and Their Activation Pathways

TRIGGER[a]	REPORTED INCIDENCE (%)	PUTATIVE RECEPTOR OR PATHWAY
Sun exposure	81	NALP3, TLR-2, TRPV4
Emotional stress	79	NALP3, TLR-2, TRPV1
Hot weather	75	TRPV1,2
Wind	57	NALP3, TLR2-, TRPV(?)
Heavy exercise	56	NALP3, TLR-2, TRPV1
Alcohol consumption	52	NALP3, TLR-2, TRPV1
Hot baths	51	TRPV1
Cold weather	46	TRPA1
Spicy foods	45	TRPV1
Humidity or osmotic changes	44	TRPV4
Indoor heat	41	TRPV1
Certain skin-care products	41	NALP3, TLR-2, TRPA1
Heated beverages (steam)	36	TRPV1
Certain cosmetics (eg, formaldehyde)	27	NALP3, TLR-2, TRPA1
Medications	15	NALP3, TLR-2, TRPV(?)
Microorganisms[b]	NR	NALP3, TLR-2
Garlic, mustard oil	NR	TRPA1
Noxious heat (52°C)	NR	TRPA1

[a]Most common patient-reported triggers adapted from the National Rosacea Society (NRS; http://www.rosacea.org/patients/materials/triggersgraph.php) and modified from Holmes and Steinhoff.[6]

[b]Microorganisms not reported as a known trigger in NRS survey.

NALP3, NACHT-, LRR-, and PYD, domains-containing protein 3; NR, not reported; TLR-2, Toll-like receptor 2; TRPA1, transient receptor potential ankyrin 1; TRPV, transient receptor potential vanilloid.

Modified from Holmes AD, Steinhoff M. Integrative concepts of rosacea pathophysiology, clinical presentation and new therapeutics. *Exp Dermatol*. 2017;26(8):659-67; with permission. Copyright © 2017, John Wiley & Sons.

cold), UV radiation, spicy food, certain alcoholic beverages (red wine more than white wine), stress, and microbial infestation on the face or in the gut (eg, demodex, bacterial overgrowth) (Table 79-1).[16,49] Demodex mites are particularly found in association with papulopustular lesions.[50]

Which and how trigger factors induce papules and pustules is still unclarified and may include demodex mites, cutaneous or GI bacteria, a dysbalanced microbiota system in the gut (eg, SIBO syndrome), or stomach infection (eg, *Helicobacter pylori*). Whether the classical rosacea triggers, such as heat, UV radiation, some alcoholic beverages, hormonal dysregulation, or stress, are capable of triggering these eruptions is unknown.

HEAT, NOXIOUS COLD

Recent transcriptome and quantitative immunohistochemistry data indicate a role of transient receptor potential (TRP) ion channels (eg, TRP vanilloid type 1 [TRPV1] and TRP ankyrin type 1 [TRPA1]), which can be activated by temperature changes (Fig. 79-9).[1,51] Whether any noxious cold receptor(s) may trigger rosacea is unknown.

ULTRAVIOLET RADIATION

Sun exposure is a well-accepted trigger factor for rosacea. Indeed, sun exposure may be the trigger factor for rosacea on the bald scalp. However, to what extent UVA, UVB, or temperature increases account for rosacea symptom induction is not clear. The fact that patients behind glass shields develop asymmetric rosacea erythema and flushing indicates a role for at least UVA in rosacea. UV radiation induces neuroinflammation, endoplasmic reticulum stress, and innate immune responses and promotes skin fibrosis or solar elastosis, characteristics of rosacea. UVB triggers TRP vanilloid type 4 (TRPV4) activation on keratinocytes and is increased in tissue of patients with chronic photodermatitis and rosacea, suggesting a molecular pathway of UVB-induced rosacea through TRPV channels (see Fig. 79-9).[52]

MICROORGANISMS

Whether a dysbalance of the skin or GI microbiota contributes to the pathophysiology of rosacea, and if so which microorganisms are involved, is still poorly understood. Demodex folliculorum is a commensal of human and animal skin, predominantly in oily skin close to the pilosebaceous glands,[53,54] and is increased in some patients with rosacea, predominantly in those with phymata as well as papules and pustules.[55] Whether demodex mites are significantly enhanced in erythematous skin is unknown,[56-58] but treatment that reduces demodex mite density positively correlates with clinical improvement.[59,60] Which molecules or substrates produced by, or associated with, demodex mites account for rosacea is unknown. Candidates include *Bacillus oleronius*, proteases or chitins, which can activate protease-activated receptors (eg, PAR-2)[61] or TLRs (eg, TLR-2),[62] thereby releasing cytokines, chemokines, and matrix metalloproteinases (MMPs) and prostanoids, and attracting immune cells (see Fig. 79-9).

MECHANISMS OF DISEASE

The already mentioned trigger factors probably initiate release of proinflammatory mediators from keratinocytes (eg, cathelicidin, vascular endothelial growth factor [VEGF], endothelin-1), endothelial cells (nitric oxide [NO], pituitary adenylate cyclase activating peptide [PACAP]), mast cells (cathelicidin, MMPs, tumor necrosis factor [TNF]-α), macrophages (interferon [IFN]-γ, TNF, MMPs, interleukin [IL]-26), helper-1 T (T_H1) cells (IFN-γ), and helper-17 T (T_H17) cells.

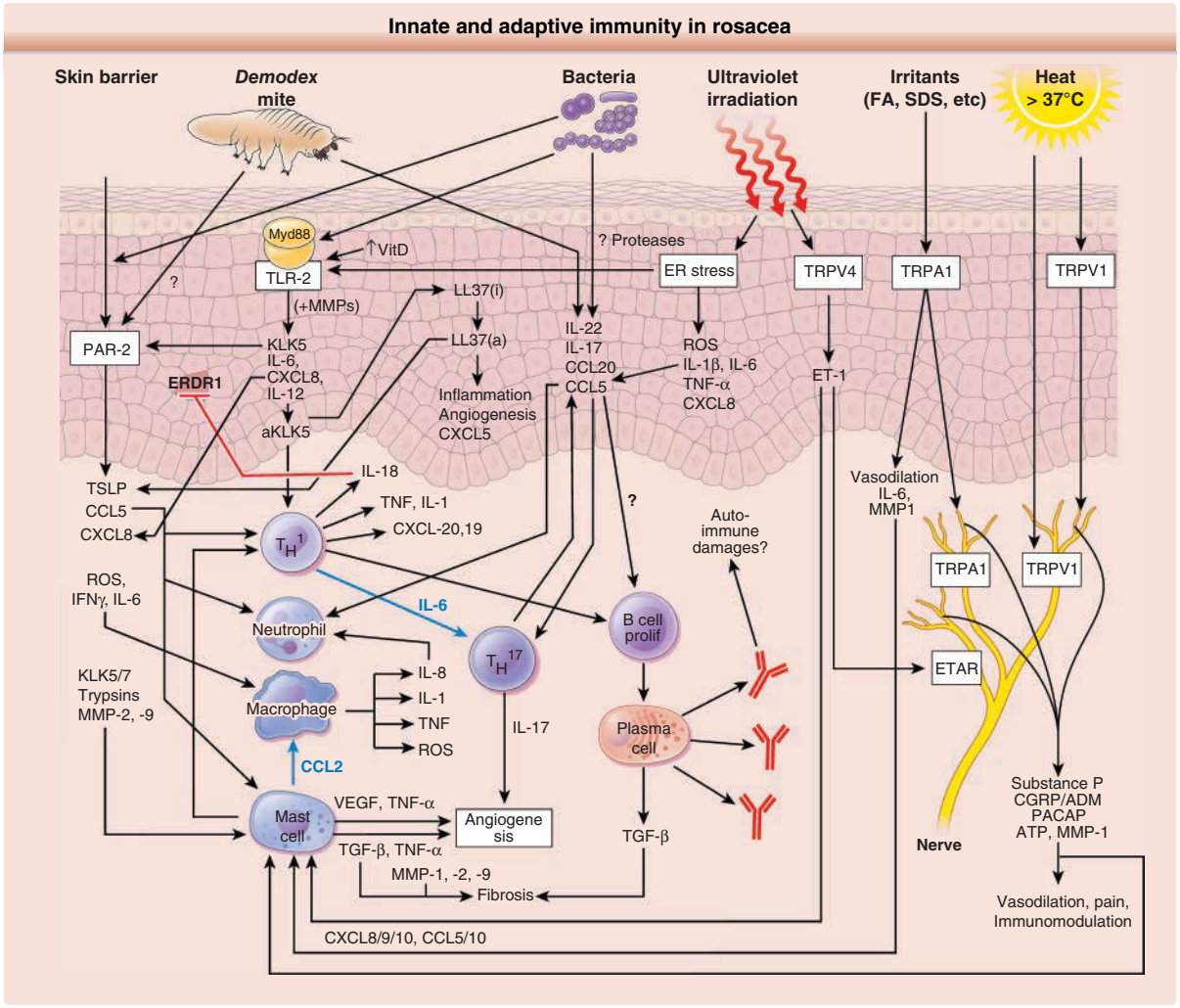

Figure 79-9 Dysregulation of innate and adaptive immune system in rosacea. Environmental triggers are shown at the top of the figure, with their known or assumed downstream signaling effects shown below. Protease-activated receptor-2 (PAR-2) not only induces neuroinflammation or pain but also stimulates release of cytokines such as interleukin (IL)-1, tumor necrosis factor (TNF), IL-6, IL-8, thymic stromal lymphopoietin (TSLP), chemokines, matrix metalloproteinases (MMPs), and prostaglandins; recruits neutrophils and T cells or macrophages to the site of inflammation; and induces mast cell release. Because PAR-2 is expressed by keratinocytes, endothelial cells, mast cells, macrophages, and neutrophils; is regulated by microbial products; and interacts with TLRs, a role of serine proteases and PARs in rosacea innate immune responses can be assumed.[119-124] Cytokine expression profiles of all skin rosacea phenotypes demonstrate elevation of the cytokine interferon (IFN)-γ,[20] which can be produced by type 1 helper T cells and natural killer cells, and because IFN-γ is a potent activator of macrophages, this is likely a close communication of the adaptive and innate immune networks in rosacea. TLR-2 is known to increase the expression of the serine protease KLK-5.[125] Notably, the lesional skin of patients with rosacea was shown to express more KLK-5 than the skin of healthy control participants.[40] In addition, Yamasaki and coworkers[41] revealed that the increased capacity for releasing KLK-5 is calcium dependent; the ligand for TLR-2 triggers an influx of calcium, which in turn induces the increased release of KLK-5. In this process, calcium functions as the stimulus for transcription of KLK-5, with TLR-2 regulating the functional release of KLK-5.[41] Via KLK-5, TLR-2 induces upregulation and activation of the innate immune peptide human cathelicidin (the active form of which is LL-37),[41] leading to erythema, immune response, and angiogenesis through release of serine proteases, MMPs, cytokines, chemokines, and proliferation of endothelial cells.[40,41,73,74,126] KLK-5 protein activity can also be regulated by serine protease inhibitors of Kazal-type (SPINKs).[72] Among these, SPINK6 was identified in human skin as a specific inhibitor of KLKs.[72] However, its putative role in rosacea should be further explored. KLK-5 is also mediated by MMPs. Specifically, the activation of KLK-5 occurs after the cleavage of its proenzyme form by MMP-9.[72] Notably, enhanced expression of MMP-2 and MMP-9 was observed in the skin of patients with rosacea.[127] Such increased expression of MMPs has potential implications for the solar-mediated degeneration that is observed in rosacea.[128] In addition, MMP-mediated initiation of KLK-5 activation leads to further activation of LL-37, the processed form of cathelicidin. Increased expression of transient receptor potential (TRP) channels of the vanilloid subfamily (TRPV1–4) was found in lesional skin of rosacea patients.[51] TRP channels are widely acknowledged as polymodal sensors of environmental and endogenous irritative signals and can be activated by typical rosacea triggers (eg, heat, ultraviolet B, temperature changes, pungent compounds from vegetable and spices, alcohol, mechanical stimuli, irritants). Activation of TRPs increases intracellular calcium concentrations

Triggers such as heat, noxious cold, exercising, spicy food, ethanol (or other ingredients or certain alcoholic beverages), and pH changes can directly activate sensory nerves to release vasoactive and proinflammatory neuromediators. Likewise, exercising and ethanol can activate release of neurotransmitters such as acetylcholine or neuropeptides such as PACAP from autonomic nerves.

Some receptors that are responsive to rosacea trigger factors have indeed been discovered.[41,51,63] Most of the trigger factors activate TRP ion channels on sensory nerves to induce neurogenic inflammation through release of neuropeptides such as substance P or PACAP. Neuropeptides are potent inducers of edema and vasodilation, the basis of flushing and erythema.[56,64,65] The individual reactivity to otherwise innocuous triggers, however, is still not understood, but a genetic predisposition appears to influence this phenomenon. The genes involved have yet to be confirmed, but two SNPs have recently been identified and involve a major histocompatibility complex predisposition.[26] It may well transpire that several of these factors are relevant and that each of the rosacea subtypes has different factors that are important to their initiation and progression.

IMMUNE RESPONSES

Similar to psoriasis and atopic dermatitis, innate immunity is known to have an essential role in the initiation and maintenance of rosacea. However, recent results point also to an important role of cytotoxic T-cell response in the pathophysiology of rosacea.[6,66] How the adaptive and innate immune systems are connected in rosacea is still unclear (see Fig. 79-9).

Skin Barrier Dysfunction: Patients with rosacea suffer from increased transepidermal water loss (TEWL), as well as pH increase of the facial skin, both markers for skin barrier dysfunction.[67,68] Increased TEWL leads to enhanced epidermal "leakage" and thus access for microbes, and an alkali pH enhances enzyme activity, for example, of kallikreins (KLK), such as KLK-5,-6,-7 or -12, which are enhanced in rosacea skin.[1,5] KLK-5 activates LL-37 activity, which stimulates erythema, cytokine release, and angiogenesis.[40,69] In addition, KLKs-5-,7 (and probably others) activate PAR-2, which is involved in several inflammatory responses (see Fig. 79-9). Notably, both LL-37 and PAR-2 are upregulated in rosacea skin tissue, and PAR-2 upregulates LL-37 expression levels.[70] The precise role and therapeutic impact of skin barrier dysfunction and restoration awaits further clarification.

Toll-Like Receptors, Proteases, and Cathelicidin: TLR-2 is upregulated in patients with rosacea[41,71] and induces release of proinflammatory cytokines, chemokines, proangiogenic factors, and proteases.[56,63,72] TLR-2 induces upregulation and activation of the innate immune peptide cathelicidin via KLK-5 (see Fig. 79-9),[41] leading to erythema, immune response, and angiogenesis through release of serine proteases, MMPs, cytokines, chemokines, and proliferation of endothelial cells.[41,73,74] A role of cathelicidins in rosacea inflammation is now widely accepted,[40] although direct functional in vivo data in humans is still missing.

TLR-2 is also able to facilitate the activation of the NLRP3 inflammasome, which mediates IL-1β release and further inflammatory reactions.[75] IL-1β expression is elevated in rosacea and mediates inflammatory responses therein.

The upstream stimulator of TLR-2 in rosacea is still unknown. Microbes can activate TLRs on keratinocytes, although a direct link between demodex mites or certain bacteria, such as *Bacillus oleronius*, and TLRs in rosacea skin has not yet been demonstrated. Likewise, the connection between the intestinal microbiota flora dysbalance and the inflammatory responses in the skin are also unknown. Notably, vitamin D is enhanced in patients with rosacea and has been demonstrated to increase TLR-2 and KLK-5 mRNA expression levels, thereby regulating TLR-2, KLK-5, and LL-37 levels in rosacea.[76]

Inflammasome: The inflammasome consists of the rosacea trigger–responsive NALP3, caspase-1, and the adaptor protein apoptosis-associated speck-like protein (ASC), and orchestrates cleavage and activation of an rosacea-upregulated IL-1.[56,75,77] Nucleotide-binding oligomerization domain (NOD)-like receptor (NALP3) is an integral member of the IL-1β inflammasome complex in keratinocytes that is required for inflammasome activation in rosacea.[56] Inflammasome activation results in neutrophil chemotaxis, IL-1- and TNF-mediated inflammation amplification,

and release of neuropeptides such as substance P, calcitonin gene-related peptide (CGRP), adrenomedullin (ADM), and pituitary adenylate cyclase-activating polypeptide (PACAP), as well as adenosine triphosphate (ATP) from cutaneous sensory nerves, or endothelin-1 (ET-1) and IL-6 from keratinocytes. These products mediate an increase in vasodilation (flushing), vascular permeability (edema), or blood flow and enhance inflammatory circuits of adaptive and innate immune system, such as by leukocyte recruitment, T-cell or macrophage activation, and degranulation of mast cells. The released products of mast cell granules are especially involved in angiogenesis (vascular endothelial growth factor [VEGF], transforming growth factor [TGF]-β) and fibrosis (TGF-β, MMPs-1, -2, and -9). Substance P can induce release of chemokines from mast cells which can modulate function of TH1 cells (through CCL5, CXCL10), macrophages, or dendritic cells (via CCL2), thereby regulating adaptive immunity. It is furthermore known that activation of neuronal TRPA1, TRPV1, and TRPV4 lead to painful burning sensations, which may be similar to that observed in patients with rosacea. Of note, patients with rosacea rarely have pruritus as neural sensation. Through neural mediators, the sensory and autonomic nervous systems contribute to pain, vasodilation (flushing, erythema), plasma extravasation (edema), and immunomodulation (innate and adaptive immune cells). ETAR, endothelin receptor type A; FA, fatty acid; SDS, sodium dodecyl sulfate.

and prostaglandin E2 synthesis, which supports pustule formation, heat pain sensation, and vascular responses, respectively. The inflammasome-activated cellular network of keratinocytes, macrophages, mast cells, and neutrophils (in papulopustular rosacea) creates a highly inflammatory milieu in rosacea. The concomitant production of reactive oxygen species (ROS) and MMPs further contribute to tissue damage, vasorelaxation, vasopermeability, and late-onset fibrosis in rosacea.

Imbalanced Adaptive Immunity: Both, T and B lymphocytes play a role in rosacea. Histological analysis and transcriptome studies reveal the presence of predominantly $CD4^+$ and to a lower extent $CD8^+$ T cells and cytokines in rosacea skin,[20,78,79] with the dominance of $CD4^+$ T_H1 and T_H17 cells and their corresponding cytokines. Cytokine expression profiles of all skin rosacea phenotypes demonstrate elevated T_H1 cytokines IFN-γ, TNF, and T_H17 cytokines IL-17A and IL-22.[20] T_H17 cells induce VEGF, which contributes to angiogenesis in rosacea (see Fig. 79-9). Because IFN-γ is a potent activator of macrophages, a close communication of adaptive and innate immune networks is likely to be present in rosacea.

Rosacea eruptions, however, are also associated with T-cell immunosuppression after infection[80] or therapeutic intervention (eg, corticosteroids, calcineurin inhibitors, phototherapy).[81-83] Patients with eruptions of rosacea commonly present with *Demodex* mite infestation, supporting a parallel between *Demodex* proliferation and T-cell activity, and antibodies against *Demodex* have been found in patients with rosacea.[80,81]

In rosacea, immunologic tolerance is well preserved through relative high numbers of tolerogenic (regulatory) T cells compared with other skin.[79] Other important molecules involved in rosacea pathophysiology through regulating adaptive immune responses are Erdr1[84] and IL-18,[85] supporting the concept that T_H1 immune responses, induction of ROS molecules,[86] and angiogenesis are all important contributors of rosacea.[87]

NEUROVASCULAR DYSREGULATION AND NEUROINFLAMMATION

Skin hypersensitivity and flushing are direct consequences of neural stimulation in any condition or disease, including rosacea.[88] The human face is to a certain extent physiologically unique because it is one of the few regions in the human skin where the blood vessels are under control of the sympathetic, parasympathetic, and sensory nerves. This fact implies that (nor)epinephrine, acetylcholine, and neuropeptides can modulate the state of the blood vessel diameter. Because autonomic nerves also release neuropeptides under certain circumstances and all mediators are involved in inflammatory processes and immune defense control, neuroinflammatory processes are involved in the perpetuation and maintenance of unphysiological ("diseased") flushing and transient erythema. To which extent early immune responses may also induce neurovascular dysregulation is currently unknown. Flushing in patients with rosacea is pathophysiologically neurogenic inflammation, as described by Jancso and Szolcsanyi 50 years ago.[89] Histopathologically, upper dermal edema and leukocytes can be found, which corresponds with neurogenic inflammation in animal ex vivo and in vivo studies. Thus, also not clearly shown in dermatopathological studies, transient erythema can be seen as an inflammatory process and cannot be explained by merely prolonged vasodilation.

The molecular basis of the "neurovascular" genes, mediators, and receptors activated in rosacea are partially clarified (Fig. 79-10). However, it is still unknown whether the neurovascular system is mechanistically up- or downstream of the inflammatory cascade. It is certain that flushing and erythema are part of the inflammatory process and not merely a dilated vessel and cosmetic problem. Prolonged flushing lasting longer than 5 minutes is always part of the neurogenic inflammation cascade[56,90] characterized by erythema (vasodilation), edema (postcapillary plasma extravasation), and recruitment of leukocytes to site of inflammation. Sensory neuron density is moderately increased in the erythematotelangiectatic rosacea.[51,90]

The various TRPs appear to render the thermal, chemical, and mechanical rosacea stimuli into clinical manifestations of rosacea.[91] Because TRP channels can cross-talk with neuropeptide receptors, the interaction between these two types of receptors may be involved in sustaining neurovascular responses and inflammation in rosacea, particularly TRPA1 and TRPV1.[1,51] TRPV1, TRPV2, TRPV3, TRPV4, and TRPA1 ion channels are broadly expressed on neuronal and non-neuronal cells in rosacea skin.[51] Thus, TRPs might thereby establish the neuroimmune and neurovascular communication observed in rosacea.

The variety of neuronal and vascular pathways that seem to be involved in rosacea neuroinflammation and pain, as well as skin hypersensitivity, explains the unique trigger profiles of individual patients with rosacea (see Table 79-1 and Fig. 79-10). Furthermore, pathophysiological outcomes may differ depending on individual receptor activation profiles and downstream cellular activation targets, providing a hypothesis for the phenotypic variability seen in rosacea.

The autonomic nervous system, via stress-induced increase of the skin sympathetic nerve activity (SSNA), may also contribute to the pathophysiology of rosacea through increased blood flow (erythema), neuroinflammatory responses (cytokine release), and pain induction,[92,93] for example, through release of cortisol-releasing hormone (CRH),[94] PACAP,[65] or NO.[95] Clearly, autonomic dysregulation is involved in facial flushing (Fig. 79-11).[66,92,96] This may be due to release of neuropeptides such as PACAP. In contrast, the skin shows normal vascular responses to application of epinephrine, norepinephrine, and acetylcholine in patients with rosacea.

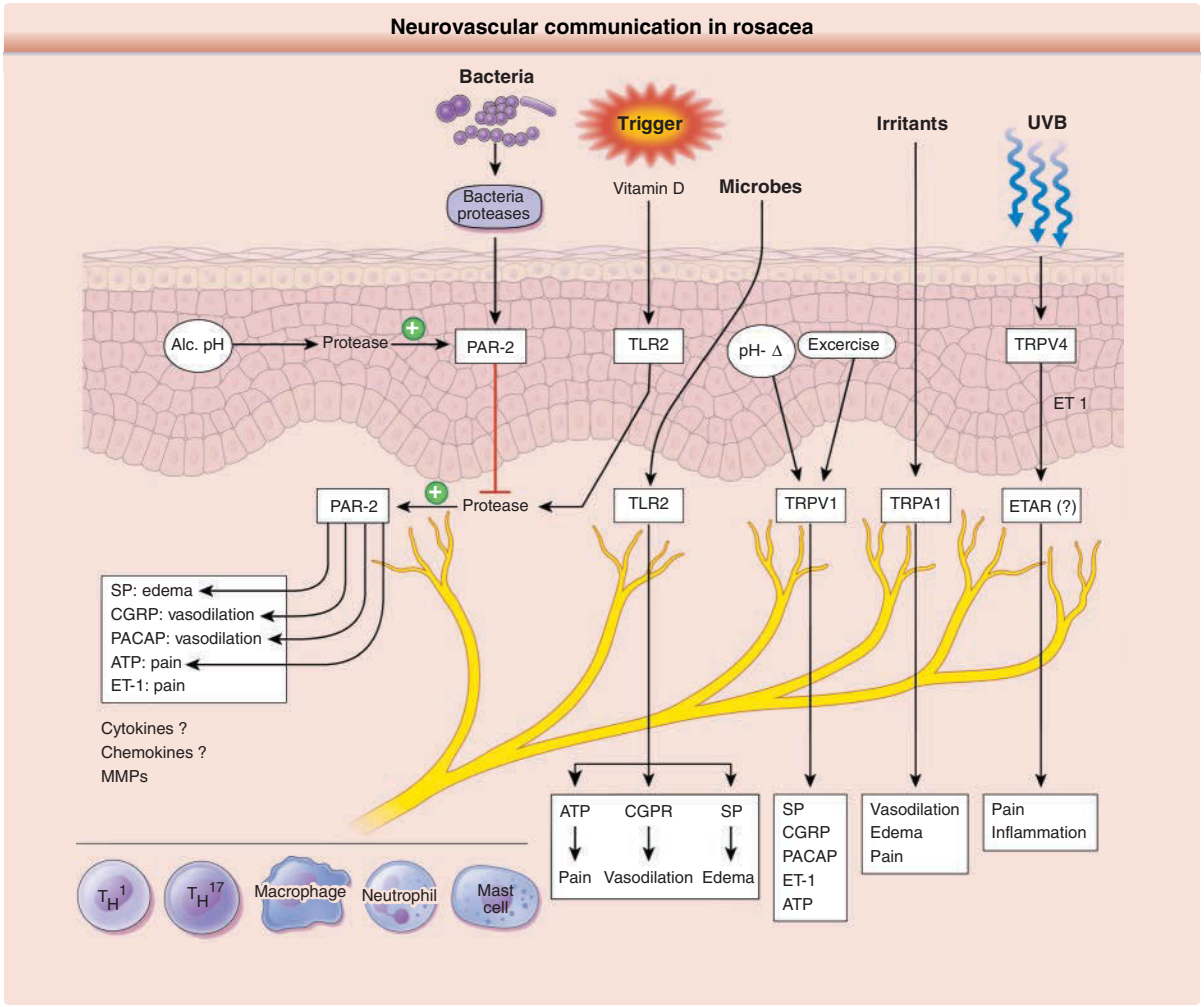

Figure 79-10 Neurovascular communication in rosacea. Notably, a polymorphism in the *TAC3* gene has been identified in rosacea, which encodes for neurokinin receptor-3 and induces neuroinflammation, pain, and immune responses in various tissues. Thus, overstimulation of neurokinin receptor-3 may contribute to neurovascular and neuroimmune changes in rosacea through substance P and other tachykinins.[129] Activation of neuronal transient receptor potential (TRP) ion channels through rosacea trigger factors can lead to release of vasoactive neuropeptides (eg, pituitary adenylate cyclase activating peptide [PACAP], substance P [SP], and calcitonin gene-related peptide [CGRP]),[91] which are involved in rosacea-associated vasodilation,[90] plasma extravasation, and leukocyte recruitment, also via induction of mast cell degranulation.[5] SP-positive nerve fibers are enhanced in patients with rosacea. Also, PACAP-positive nerves are anatomically closely associated with mast cells that release a number of vasoactive mediators.[65] Finally, agonist and one of the receptors for CGRP are increased at mRNA levels in patients with rosacea.[98] Because TRP channels can cross-talk with neuropeptide receptors, the interaction of both receptors may be involved in sustaining neurovascular responses and inflammation in rosacea, particularly TRP ankyrin type 1 (TRPA1) and TRP vanilloid type 1 (TRPV1).[1,51]

Proteases such as kallikreins (KLKs)-5, -6, and -7 activate protease-activated receptor-2 (PAR-2) on keratinocytes, endothelial cells, macrophages, mast cells, and sensory nerves, thereby contributing to innate and adaptive immune activation, vasoregulation and pain. PAR-2 induces release of various neuropeptides (SP, CGRP, PACAP) from nerves, as well as cytokines, chemokines, reactive oxygen species (ROS), and matrix metalloproteinases (MMPs) from cutaneous and immune cells. Although SP primarily promotes plasma extravasation (edema) and CGRP and PACAP vascular dilation, all can initiate pain sensations. PAR-2 is also regulated by various exogenous rosacea trigger factors as well as microbial agents and interacts with Toll-like receptors (TLRs).[119-124] TLRs are pattern recognition receptors (PRR) that sense pathogen-associated molecular patterns (PAMPs). Notably, TLR-2 is also upregulated in patients with rosacea[41,71] and induces release of neuropeptides, proinflammatory cytokines, chemokines, proangiogenic factors, and proteases such as KLK-5.[56,63,72] However, the stimulator of TLR-2 in rosacea is still unknown. Via KLK-5-release, TLR-2 can activate PAR-2 and activate the innate immune peptide cathelicidin,[41] leading to neuropeptide release and subsequent angiogenesis, erythema, plasma extravasation, and immune modulation. Thus, TLR and PAR-2 can be seen as a "forefront" of innate immunity in rosacea. ETAR, endothelin receptor type A; UV, ultraviolet.

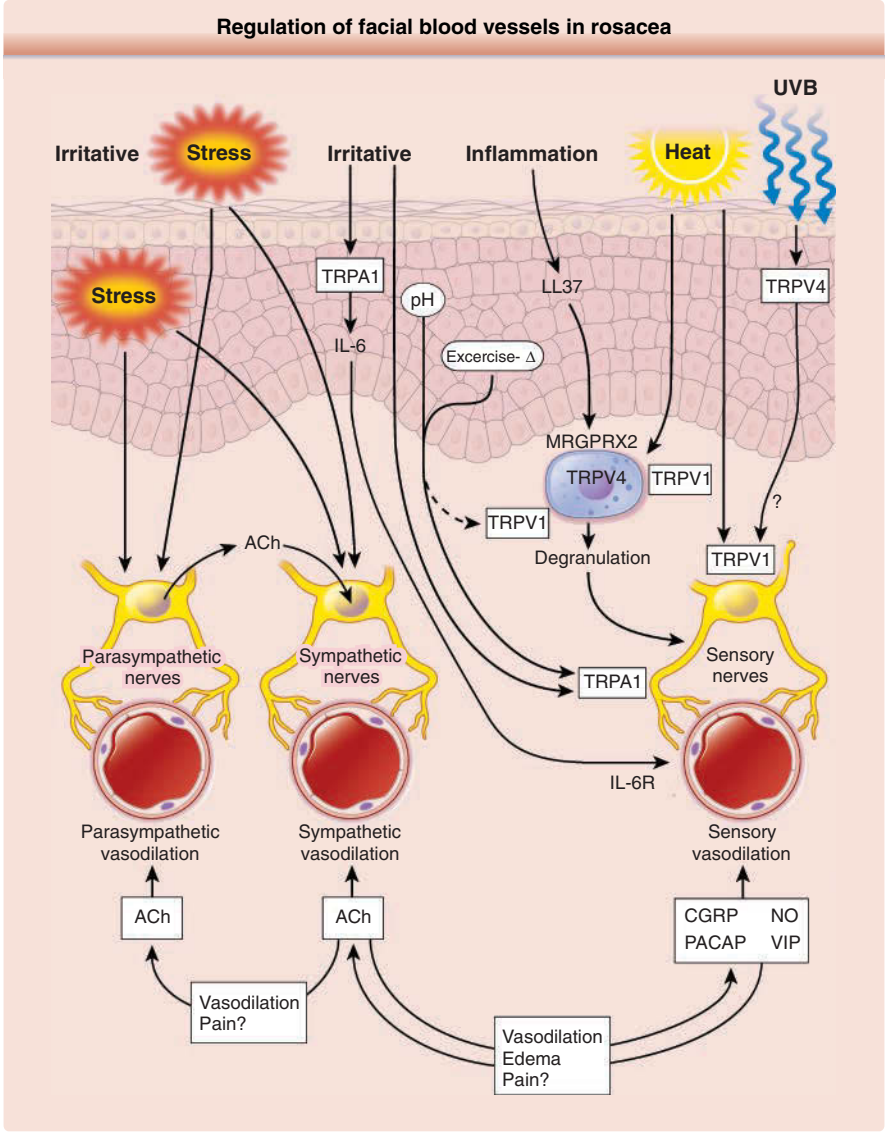

Figure 79-11 Potential pathomechanism of facial flushing in rosacea. Flushing involves an immediate (in contrast to persistent erythema) reactive vascular response to various "irritative" stimuli (within seconds to minutes), induced by trigger factors (eg, spicy food, certain alcohols [Alc], ultraviolet [UV] B, heat, noxious cold, exercising, or stressful emotional stimuli; top of the figure). Most of the trigger factors capably activate transient receptor potential (TRP) ion channels (eg, TRP vanilloid type 1 [TRPV1], TRP ankyrin type 1 [TRPA1], TRP vanilloid type 4 [TRPV4]) on keratinocytes, immune cells, or sensory nerves to induce neurogenic inflammation through release of neuropeptides such as substance P, calcitonin gene-related peptide (CGRP), adrenomedullin (ADM), pituitary adenylate cyclase activating peptide (PACAP), or vasointestinal peptide (VIP) from sensory nerves. Neuropeptide release from sensory nerves is either directly facilitated by the irritant stimulus or established via intermediate signals derived from keratinocytes (eg, interleukin [IL]-6), endothelial cells (eg, tumor necrosis factor [TNF]-α, IL-1), or immune cells (eg, mast cells). Neuropeptides are potent inducers of vasodilation, the basis of flushing and erythema, plasma extravasation (leading to edema), and pain. In addition, stressful stimuli also hyperstimulate the autonomic nervous system, especially sympathetic and parasympathetic vasodilator fibers, thereby regulating release of acetylcholine (ACh), for example, a potent vasoregulator and immunomodulator. NO, nitric oxide.

PHYMATOUS CHANGES, FIBROSIS, AND GLANDULAR HYPERPLASIA

Although a significant percentage of male patients with rosacea develop phymata, mostly on the nose, a pathophysiological link of chronic inflammation and skin fibrosis or sebaceous hyperplasia is unknown. A role of seborrhea has not been demonstrated convincingly for patients with rosacea, and some even have "dry skin."

Mast cells and B cells are critical contributor to skin fibrosis through release of MMPs, which is one plausible pathway for the development of phymata through chronic inflammation.[20,97] The pathophysiological link between chronic inflammation and glandular hyperplasia is still enigmatic (Fig. 79-12).

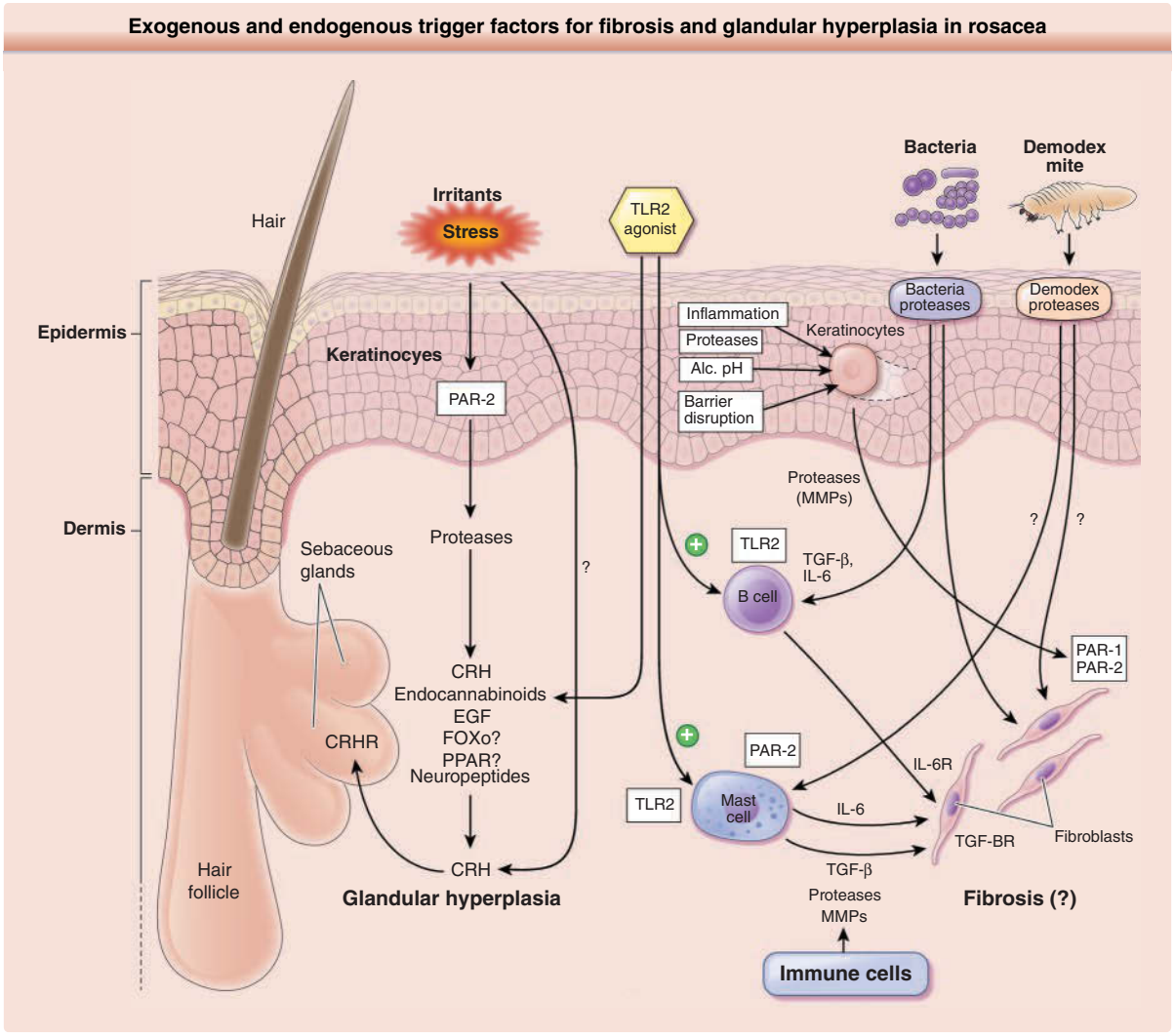

Figure 79-12 Pathomechanism and current therapy strategies for fibrosis and glandular hyperplasia in rosacea. Phymata are verrucous nodules and plaques based on glandular hyperplasia of sebaceous glands and fibroblast activation. They develop through either clinically visible chronic inflammation (chronic erythema, papules or pustules) or sometimes clinically unremarkable skin (subclinical phyma). In any case, they develop because of persistent inflammatory processes accompanied by edema. Histopathologically, phymata are characterized by a perivascular lymphocytic infiltrate, enlarged sebaceous glands and follicles, dilated vessels, remodeled myofibroblasts, and fibrosis. The dysregulated inflammatory process can be triggered by multiple exogenous and endogenous factors. Cell wall components are recognized by Toll-like receptor 2 (TLR2, CD282) leading to the activation of the innate immune system in form of macrophages and mast cell activation or adaptive immune cells (eg, B cells), which readily release a cocktail of profibrotic mediators (eg, interleukin [IL]-6, IL-4, transforming growth factor [TGF]-β, platelet-derived growth factor [PDGF]) that remodel and activate dermal fibroblasts to deposit excessive amounts of extracellular matrix, a hallmark of fibrosis. *Demodex* or bacterial-derived proteases or endogenous proteases (eg, kallikreins, matrix metalloproteinases) can engage in this fibrotic process by activating resident skin cell- (eg, keratinocytes, fibroblasts) and immune cells (eg, mast cells, macrophages) through cytokine receptors (IL-4, IL-6) growth factor receptors (eg, TGF-β, PDGF), protease-activated receptor-2 (PAR-2) or TLRs. Low pH and barrier disruption additionally activate keratinocytes to release profibrotic proteases that can target fibroblast-derived PAR-2. The precise pathomechanism of sebaceous glandular hyperplasia is far from being understood. An important signaling network appears to be triggered by stress that probably activates keratinocytic PAR-2, causing protease release, and might interfere with the corticotropin-releasing hormone and cannabinoid system, the modulation of epidermal growth factor (EGF) and neuropeptide abundance and peroxisome proliferator-activated receptor gamma (PPARγ) activation. Each target is involved in the regulation of lipid and glucose metabolism, cell proliferation and differentiation, or inflammation that fundamentally regulate sebogenesis, sebaceous gland proliferation, and consequently glandular hyperplasia. Alc, alcohol; CRH, cortisol-releasing hormone; MMP, matrix metalloproteinase.

TELANGIECTASIA

The pathophysiology of telangiectasia is unknown but differs from sun damage (chronic photodermatitis, heliodermatitis).[98] One possible explanation is that proteases, MMPs, and growth factors from the transforming growth factor or fibroblast growth factor family destroy the architecture of the extracellular matrix, thereby reducing the tissue resistance for blood vessels, which subsequently leads to irreversible vasodilation.[99] This, however, awaits further clarification through research.

GASTROINTESTINAL TRACT

The role of *H. pylori* in rosacea is controversial.[100,101] More convincing evidence derives from studies in which patients with SIBO syndrome (eg, after surgeries, metabolic diseases) develop a microbiota flora in favor of proinflammatory, instead of protective, bacteria in the GI tract.[102] Rifaximin, a drug that through T-cell modulation reinstalls the physiological flora in the GI tract, alleviates rosacea symptoms in the majority of cases (but not of patients with *H. pylori* through H^+ pump blockers), which supports this hypothesis.[32,103,104]

DIAGNOSIS OF ROSACEA

The diagnosis of rosacea is led by the clinical features (see Clinical Findings) along with taking a thorough patient history (age, gender, trigger factors, hormonal changes, profession, hobbies, gut surgeries, *Demodex* infestation, exercising, heat exposure, noxious cold exposure, drinking and eating habits) and family history (positive family history). No diagnostic markers or laboratory workup exists to diagnose rosacea. To differentiate from other skin or systemic diseases, however, laboratory workup and diagnostic tools may be used. Histopathology, especially in the early erythematous stage, is often nonspecific; however, a biopsy may be helpful to exclude other differential diagnoses (see Differential Diagnosis).

HISTOPATHOLOGY OF ROSACEA

Histologically, rosacea is characterized by numerous features, depending on the presenting symptoms or subtype. In erythematous skin and telangiectasia, a perivascular inflammatory infiltrate consisting mainly of T_H1 and T_H17 cells, as well as macrophages and mast cells, can be observed;[5,20] depending on severity, these cells can be sparse to numerous. In addition, blood and lymphatic vessels are markedly dilated, and a microscopically visible dermal edema can be found in all stages but is rarely found clinically.

Papules consist of $CD4^+$ T_H1 and T_H17 cells, macrophages, mast cells, and plasma cells. In pustules, additional neutrophils can be found.

In phymatous rosacea lesions, the infiltrate still consists of T_H1 and T_H17 cells, macrophages, mast cells, and more plasma cells than in nonphymatous rosacea. Glandular hyperplasia and follicular plugging without comedones can be found as well as fibrosis and increase in fibroblasts.[5] In phymatous rosacea and often follicular or perifollicular inflammation, *Demodex folliculorum* is present up to 50% of tissue specimen; these mites are most abundant in phymatous skin, which may account for the folliculitis and perifolliculitis.

Whether Langerhans cells or dendritic cells are enumerated in all lesions is still unclear. Some authors found increased Langerhans cell density but others not.[5]

In ocular rosacea, dilation of blood and lymphatic vessels as well as obstruction of the meibomian gland can be observed.

Granulomatous rosacea is characterized by dermal edema and vasodilation as well as dermal granulomas of the tuberculoid type with T cells and macrophages as well as multinucleated giant cells and plasma cells. The marked upper dermal vasodilation of blood and lymphatic vessels differentiates it from other granulomatous disorders such as lupus vulgaris.

In rosacea fulminans, besides the infiltrate mentioned earlier, numerous epithelioid cells as well as occasionally granulomas with multinucleated giant cells can be observed.

The histopathologic findings in patients with combined erythema and telangiectasia are relatively mild and not diagnostic. Upper dermal blood vessels usually appear prominent, and there may be a mild perivascular infiltrate composed mainly of lymphocytes with an admixture of histiocytes. The most consistent abnormality is a change in the collagen of the upper dermis, so-called "solar elastosis." This represents the result of chronic actinic damage.

The histopathological changes in some patients are characterized by marked fibrosis in the superficial and reticular dermis, accentuated around follicles and increased number of fibroblasts, but others (especially the obstructive form) show deposition of mucin in the dermis. The collagen in the upper dermis often shows changes of solar elastosis, which is marked in patients with rhinophyma secondary to actinic damage.

CLASSIFICATION

Currently, two classification systems exist: The first, described in 2002, regards rosacea as a syndrome or typology with four distinct clinical subtypes: (1) erythematotelangiectatic, (2) papulopustular, (3) phymatous, and (4) ocular rosacea Table 79-2).[17,105] The severity can be graded as mild, moderate, or severe.[106] These subtypes may be discrete variants or may progress from one subtype to another, with overlaps observed. The improvement brought by this classification was to determine a more structured phenomenology into this enigmatic skin disease and helped physicians on a daily basis to monitor the therapeutic success of each

TABLE 79-2
Classification from 2002 and 2004: Subtypes of Rosacea[17,106]

SUBTYPE (NUMBER AND NAME)[a]	CLINICAL CHARACTERISTICS
Subtype 1: erythematotelangiectatic	Persistent central facial erythema, frequent flushing; may be telangiectatic vessels
Subtype 2: papulopustular	Erythematous dome-shaped papules, some with surmounting postulation in a centrofacial distribution on a background of persistent erythema
Subtype 3: phymatous	Persistent facial swelling with hypertrophy of tissue (rhinophyma); different variants described
Subtype 4: OR	Ocular inflammation (eg, blepharitis, conjunctivitis, or meibomian gland dysfunction; chalazion)

[a]Each subtype can be graded as mild, moderate, and severe.

subtype. The disadvantage is that the clinically accumulated symptoms (eg, erythema and telangiectasia) may be based on different pathophysiologies and are thus preventing a more pathophysiology-based understanding of the disease. Moreover, many patients present with an overlap of all subtypes (eg, papulopustular and ocular or phymatous with or without erythema), which complicates a clear-cut classification. Finally, a frequent, if not dominant symptom—flushing—is neglected or subclassified as erythema, which is pathophysiologically incorrect.

Consequently, a modified classification or grading system was introduced in 2016 to 2017,[16,19] emphasizing each possible symptom in rosacea and subclassifying them as diagnostic, major, or secondary features based on how important or selective the symptom is to make the diagnosis (eg, there are almost no differential diagnoses for a phymata or persistent central facial erythema) Table 79-3). Although also not perfect, the new classification considers more thoroughly the many overlap patients existing in the "real-world situation," outlying the subtype classification and leaving more room for a pathophysiology-based classification and therapy.[13,18,107] Thus, the new classification likely reflects more precisely the clinical reality of the disease presentation, although validating data are missing.[16,13]

A recent expert group assessed phymatous changes as an individually diagnostic sign of rosacea and persistent centrofacial erythema associated with periodic intensification by potential trigger factors as a minimum diagnostic sign of rosacea. Flushing, telangiectasia, and inflammatory papules or pustules are considered major features but are not diagnostic of rosacea. The centrofacial location of diagnostic and major features is essential for rosacea diagnosis. The bilateral facial location of a presentation is considered typical but not essential. Stinging sensation, edema, dry sensation, and burning sensation are considered secondary features (symptoms) of rosacea.

TABLE 79-3
Classification of Rosacea from 2016 and 2017: Diagnostic, Major, and Secondary Features of Rosacea

DIAGNOSTIC FEATURES[a]	MAJOR FEATURES	SECONDARY FEATURES
Persistent centrofacial erythema associated with periodic intensification by potential trigger factors	Flushing or transient erythema	Burning sensation of the skin
Phymatous changes	Inflammatory papules and pustules	Stinging sensation of the skin
	Telangiectasia	Edema
	Ocular manifestations ▪ Eyelid margin telangiectasis ▪ Blepharitis ▪ Keratitis, conjunctivitis, or sclerokeratitis	Dry sensation of the skin

[a]All features can present as mild, moderate, or severe.

Modified from Tan J, Almeida LMC, Bewley A, et al. Updating the diagnosis, classification and assessment of rosacea: recommendations from the global ROSacea COnsensus (ROSCO) panel. *Br J Dermatol*. 2017;176(2): 431-438 and Gallo RL, Granstein RD, Kang S, et al. Standard classification and pathophysiology of rosacea: The 2017 update by the National Rosacea Society Expert Committee. *J Am Acad Dermatol*. 2018;78(1):148-155.

DIAGNOSTIC TOOLS

Diagnostic tools are available for some of the major features of rosacea Table 79-4).

TABLE 79-4
Diagnostic Tools for Different Clinical Features of Rosacea

CLINICAL MANIFESTATION	DIAGNOSTIC TOOL
Flushing	Flushing Assessment Tool (FAST) Global Flushing Severity Score (GFSS)
Persistent erythema	Investigator's Global Assessment (IGA) Clinician's Erythema Assessment (CEA)/ Patient's Self-Assessment (PSA)
Telangiectasia	None
Papules or pustules	Lesion counts Investigator's Global Assessment
Phymatous changes	None
Ocular manifestations	Pending

Modified from Tan J, Almeida LMC, Bewley A, et al. Updating the diagnosis, classification and assessment of rosacea: recommendations from the global ROSacea COnsensus (ROSCO) panel. *Br J Dermatol*. 2017; 176(2):431-38.

TABLE 79-5
Classification of Rhinophymata

GROUP	PRESENTATION
1	Distal end, apex of nose
2	Distal half nose, apex, alae,
3	Distal half of nose, apex, alar nodules
4	Complete nose, including bridge and nasofacial sulci

Modified from Clark DP, Hanke CW. Electrosurgical treatment of rhinophyma. *J Am Acad Dermatol*. 1990;22(5 Pt 1):831-37.

THE GRADING OF SEVERITY OF ROSACEA

The grading of rosacea is divided into mild, moderate, and severe. The grading provides the physician with a practical tool to evaluate the patient's need for a certain therapy and helps to monitor the response to therapeutic intervention.[16]

A clinical scale based on the morphological involvement has been introduced for assessment of the severity of rhinophymata Table 79-5). No widely accepted classification exists for telangiectasia.[17,106] The severity of papules and pustules in rosacea may be graded according to the numbers of papules and pustules (few, several, or many) and whether plaques (confluent inflammatory lesions on a raised area of erythema) are present. Ocular rosacea should be graded Table 79-6), and ophthalmologic consultation should be initiated promptly in moderate to severe cases.

DIFFERENTIAL DIAGNOSIS

Clinically, the classical (vulgaris) rosacea has to be differentiated from various diseases and rarer rosacea forms Table 79-7), such as granulomatous, lupoid, fulminans, conglobata. Most prominent disorders that may be confused with rosacea are seborrheic dermatitis, acne vulgaris, chronic discoid lupus erythematosus, sarcoidosis, polymorphous light eruption, and erysipelas (see Table 79-7). Thorough examination may be necessary to exclude multisystem involvement if other diagnoses are suspected. The list of diseases mimicking the rosacea phenotype is vast and includes disorders of various etiopathologies. Consideration of the differential diagnoses on the basis of the main feature of skin presentation is therefore useful (Tables 79-8 to 79-16). Helpful observations to differentiate various forms of flushing are shown in Table 79-11.

TABLE 79-6
Classification of Ocular Rosacea

Mild: mild itch, dryness or grittiness of the eyes; fine scaling of eyelid margins; telangiectasia and erythema of eyelid margins; mild conjunctival injection.
Moderate: burning of eyes; crusting or irregularity of eyelid margins with erythema and edema; formation of chalazion or hordeolum)
Severe: pain, photosensitivity, blurred vision, loss of eyelashes, severe conjunctival inflammation, corneal changes, scleritis or episcleritis, uveitis, iritis

MANAGEMENT OF ROSACEA

Before therapy, the features and severity of the disease should be rated to define the right therapy, although it should be remembered that some of the features may not be visible or present at consultation. Evaluation of the medical history (including steroids, topical calcineurin inhibitors, brome) should be undertaken, and drug triggers should be ceased. Trigger avoidance is important to improve the condition and protect from relapses and is thus as important as therapy (Fig. 79-13 and Table 79-17).

GENERAL SKIN CARE

Thorough education and instructions for proper general skin care is a critical component of adequate rosacea management because consequent application of adequate nonirritating skin care can significantly prevent or attenuate relapses or tone down dry skin or pain sensations (see Table 79-17). Moreover, educating patients about behavioral strategies and approaches to reduce the facial skin symptoms will reduce the psychological disease burden and significantly improve patient's quality of life and patient outcome.

Essential skin care advice elements are (1) avoidance of trigger factors, (2) usage of foundations and facial coverage without aggravating symptoms of rosacea, (3) use of sunscreen SPF (sun protection factor) of at least 30+, (4) frequent use of moisturizers if dry skin is an issue, (5) usage of drying cleansing for an oily nose, (6) regular use of gentle cleansers for the whole face, (7) use of matte green–toned foundations to mask skin redness, and (9) avoidance of rubbing the face.

FIRST-LINE, SECOND LINE, AND OFF-LABEL TREATMENTS

Based on new knowledge, a phenotype-driven treatment algorithm has recently been developed (see Fig. 79-13) relating to the major cutaneous features of flushing, transient erythema, persistent erythema, papules or pustules, telangiectasia, phymata, and pain sensations. For each feature, first-line therapies vary on the basis of their pathophysiology (Fig. 79-14) and clinical severity. Given that the different symptoms derive from different pathophysiologies, the combination of various topical with systemic treatments or

TABLE 79-7
Most Prominent Differential Diagnosis to Rosacea and Investigations

DIFFERENTIAL DIAGNOSIS	INVESTIGATION
Acne vulgaris	▪ Comedones, no flushing, different age peak, no phymatous changes
Systemic lupus erythematosus (SLE)	▪ Patients with SLE often have other areas of cutaneous involvement such as the sides and V of the neck ▪ Systemic reactions ▪ ANA and anti-DNA (anti-Ro, anti-La) ▪ Skin biopsy, histopathologic examination; direct and indirect immunofluorescence
Chronic discoid lupus erythematosus (CDLE)	▪ Skin biopsy, histopathologic examination ▪ Direct immunofluorescence (IgG, IgM, IgA, C_1, C_3) ▪ Photosensitivity ▪ UV-induced pruritus
Photodamage (heliodermatitis)	▪ History, photosensitive eruptions, distribution more peripheral
Allergic photoreaction	▪ Heliotropic macropattern ▪ Diffusely bordered eczema ▪ Eczematous "satellite" lesions ▪ History, photopatch test
Toxic photoreaction	▪ Heliotropic macropattern ▪ Sharply bordered eczema ▪ History
Polymorphic light eruption	▪ More monomorphic ▪ Photo provocation, early and late assessment ▪ Skin biopsy, histopathologic examination
Dermatomyositis	▪ Muscle weakness ▪ Anti-Jo antibody
Seborrheic dermatitis	▪ Slight yellow to orange tinge or scales on erythematous ground ▪ More itch, less stinging or burning ▪ Distribution and more eczematous
Contact dermatitis	▪ Morphology of eczema ▪ Patient history ▪ Exposition
Facial atopic dermatitis	▪ Blood work (IL-16, ECP, IgE) ▪ Skin biopsy and histopathologic examination ▪ Anamnesis, patient history, eczema morphology, pruritus
Erysipelas	▪ Serology (leucocytosis, CRP) ▪ ASO, ADB titer ▪ Fever
Steroid-induced acneiform folliculitis, steroid rosacea	▪ Medication ▪ History
Jessner lymphocytic infiltrate	▪ No pustules, distribution, history, histology
Sarcoidosis	▪ Serology (ACE, sIL-2R, Neopterin, Ca^{2+}) ▪ Serum electrophoresis (IgG) ▪ Cell count ▪ Histology
Perioral dermatitis	▪ Unaffected perioral zone ▪ History of "intensive" local therapy ▪ No flushing; rarely, erythematous plaques
Obstruction of superior vena cava	▪ Facial swelling in the morning ▪ Breathing difficulty ▪ Upper limb edema ▪ Neck edema ▪ Pemberton's sign ▪ Radiography, CT scan, bronchoscopy
Syphilis	▪ Serology, ▪ TPHA, VDRL, FTA(Abs) test ▪ Liquor serology
Tuberculosis	▪ Skin biopsy, Ziehl-Neelsen stain ▪ QuantiFERON-TB GIT test ▪ Radiography
Haber syndrome	▪ Family history ▪ Hereditary transmission (autosomal dominant ▪ Burning sensation ▪ Brownish pigmentation, induration

ADB, anti-DNase B; ACE, angiotensin converting enzyme; ANA, antinuclear antibody; ASO, anti-streptolysin O; CRP, C-reactive protein; CT, computed tomography; C1, complement component 1; C3, complement component 3; FTA(Abs), fluorescent treponemal antibody absorption; Ig, immunoglobulin; IL, interleukin; sIL-2R, soluble interleukin-2 receptor; TPHA, treponema pallidum hemagglutination assay; UV, ultraviolet; VDRL, Venereal Disease Research Laboratory.

TABLE 79-8
Differential Diagnosis of Rhinophyma

CONDITION	FEATURES
Lupus pernio (sarcoid of the nose)	Shiny brown, red, or violaceous, firm swelling of nose; can be monomorph and singular; may be asymmetrical; may extend to medial cheeks; diascopy reveals "apple jelly nodules" in lupus pernio; dermoscopy and biopsy help establish diagnosis; workup for systemic involvement required
Basal or squamous cell carcinoma	Age; histology; both mimic or occur in association with rhinophyma; rapid growth and surface erosion or ulceration requires biopsy
Lymphoma or angiosarcoma	Rare; intranasal biopsy may be necessary to diagnose lymphoma; nasal lymphomas may be mistaken for rhinophyma but do not show glandular hyperplasia but a shiny surface
Lupus vulgaris (TB)	Geographical differences of prevalence; can mimic rhinophyma, but scarring often present; also extrafacial; histology
Acrocyanosis	Bluish discoloration of nose, especially in cold weather; usually no deformity; no glandular hyperplasia
Lupus erythematosus	Erythema but no flushing history; scales (CDLE); tendency to scarring is a features of CDLE; more rarely, papules and pustules

CDLE, chronic discoid lupus erythematosus; TB, tuberculosis.

TABLE 79-9
Causes and Differential Diagnoses of Persistent Erythema

Rosacea
Demodicosis
Drug induced (eg, cortisone)
Contact dermatitis
Seborrheic dermatitis
Tinea
Dermatomyositis
Lupus erythematosus
Polymorphous light eruption
Disorders of flushing
Facial erysipelas, Jessner lymphocytic infiltrate, polymorphic light eruption
Granuloma faciale, lymphocytoma cutis, facial sarcoid
Heliodermatitis, atopic dermatitis, contact and photo contact dermatitis
Photodermatitis

even topical with systemic treatments and physical therapy has to be considered (see Fig. 79-13).[7,108]

If one of the first-line therapies fails, alternative first-line options should be considered or second-line therapies chosen. These therapies should always be combined with an adequate general skin care and prevention therapy.

PERSISTENT ERYTHEMA

For persistent erythema, approved therapeutic regimens are topical brimonidine gel (1%) and oxymetazoline crème (1%). Beta-blockers such as carvedilol can be used off label and should be tapered down.[109] Intense pulse light as well as lasers can be used but should be avoided in patients with rosacea with somatosensations such as pain without pretreatment to avoid aggravation of pain symptoms through neuroinflammation Table 79-18).[8]

TABLE 79-10
Causes and Differential Diagnoses of Flushing

Rosacea
Benign causes: emotion (blushing), anxiety, stress, climacteric flushing, hyperthermia, temperature (both hot and cold), sun exposure, fever, exercise, fluorescent lights, foods, beverages, drugs, alcohol, sodium nitrate
Drug-induced (eg, bromindione), peptic ulcer episodes of diarrhea
Systemic diseases: carcinoid syndrome, mastocytosis, polycythemia vera, anaphylaxis, allergy, Zollinger-Ellison syndrome, Rovsing syndrome, Frey syndrome
Neurologic: see later
Tumors: medullary carcinoma of thyroid, renal carcinoma, pancreatic cell tumor (VIP, PACAP, and so on), pheochromocytoma, bronchogenic carcinoma
Postsurgical (gastric, prostate, orchiectomy)
Idiopathic

PACAP, pituitary adenylate cyclase activating peptide; VIP, vasoactive intestinal peptide.

TABLE 79-11
Helpful Observations to Differentiate Various Forms of Flushing

- Menopausal flushing is usually diffuse on the face and the skin often appears shiny because this type of flushing is typically associated with sweating (so-called "hot flushes"). The average hot flush lasts about 4 minutes. Women with hot flushes have an increased body core temperature and a reduced thermo-neutral zone (the body core temperature range above which sweating occurs and below which shivering occurs).[130]
- Hormonal therapy (eg, estrogen) is the standard treatment and can decrease the frequency and severity of hot flushes by up to 90%.
- The flushing that occurs with the carcinoid syndrome, mastocytosis, and pheochromocytoma is not usually accompanied by sweating and so fall into the category of "dry flushing."
- Flush associated with the carcinoid syndrome has been classified into four different patterns. One pattern involves the face and chest and is relatively brief, lasting less than 5 minutes. In other patients, the flush can be prolonged for more than 5 minutes. Persistent edema and "leonine facies" have been reported in a patient with longstanding carcinoid syndrome.[131]
- Flushing may occur in patients with mastocytosis after exercise, ingestion of alcohol or codeine, or injection of polymyxin B. Palpitations, diarrhea, and pruritus may accompany it. Dermatographia is often present.
- Hyperhidrosis, piloerection, and episodic hypertension in association with flushing can occur in patients with phaeochromocytoma. It affects the face, neck, chest, and trunk for 15 minutes to several hours.
- Flushing and severe pruritus or a burning sensation after a hot bath has been reported to patients who have polycythemia. This group appears plethoric and can associate with facial telangiectasias, which affect the face but also distal extremities. The veins of the sclera, retina, and oral mucosa may also be distended.

If erythema is associated with mild, moderate, or severe pain, topical or systemic analgesic therapy such as lidocaine gel (up to 4%), polidocanol cream (in mild cases), or even systemics such as nonsteroidal antiinflammatory drugs (eg, ibuprofen) should be applied; antidepressants or neuroleptics (eg, amitriptyline, gabapentin, pregabalin) may also need to be prescribed.[110] If suspicious of the cause of pain, consultation of a neurologists is advised to rule out other pain syndromes, such as trigeminal neuralgia, small-fiber neuropathy, or early multiple sclerosis.

TABLE 79-12
Differential Diagnosis of Telangiectasias

Chronic discoid lupus erythematosus
Drug induced (eg, cortisone)
Senile atrophy
Basal cell carcinoma
Dermatomyositis
Haber syndrome
Carcinoid syndrome
Systemic lupus erythematosus
Heliodermatosis, polymorphous light eruption
Naevus flammeus
Poikiloderma
Sarcoidosis

TABLE 79-13
Differential Diagnosis of Papules and Pustules

Rosaceiform dermatitis (check drug history, eg, steroid, calcineurin inhibitor intake)
Acne vulgaris (comedones, cysts, and scarring on the chest and back in males)
Perioral dermatitis (check topical steroid usage)
Seborrheic dermatitis (pityriasis capitis is often marked)
Pityriasis folliculorum or demodicosis (skin scraping is helpful)
Tinea faciei, Candida spp. (scraping or swabs for culture), contact dermatitis (patch testing is helpful)
Ulerythema ophryogenes, Jessner lymphocytic infiltrate, lymphocytoma cutis, sarcoid (skin biopsy is helpful)
Morbihan disease, polycythemia, polymorphic light eruption, photosensitive eruption (blood tests and phototesting are helpful)
T. faciei

FLUSHING AND TRANSIENT ERYTHEMA

Early rosacea is often associated with flushing or transient erythema. Laser therapy (see discussion of physical therapies) is the common treatment used (see Table 79-18). Off-label use of topical adrenergic receptor modulators (eg, brimonidine, oxymetazoline) may alleviate flushing intensity and frequency. Avoidance of triggers (see Table 79-1) is likely to prevent or alleviate flushing, and thus patients should be advised to keep a diary of events. If unsure with any topical agents, patients should test the medication or cosmetic on one spot on one side of the face first. If pain symptoms are associated, the same applies as for persistent erythema. In addition, topical lidocaine (4%) may be helpful.

TELANGIECTASIA

Telangiectasia can only be treated with either laser therapy (see discussion of physical therapies) or 0.5% to 1.0% aethoxysclerol injections, similar to leg sclerotherapy. However, contraindications have to be considered, and the potential induction of vasoocclusion advocates for a cautious application by specialists. Steroid use and sun exposure should be avoided, and sunscreens are helpful to prevent sun damage followed by destruction of the extracellular matrix.

PAPULES AND PUSTULES

Papules and pustules are primary clinical signs and features of rosacea. The basic therapy (avoiding triggers or irritating substances on the affected skin, application of photoprotective agents, appropriate cosmetic coverage, stress management, and optimized skin cleansing and moisturizing routines) as outlined for patients with erythema also applies to patients who develop rosacea with papules and pustules.

In general, mild to moderate papules and pustules respond well to topical therapy such as ivermectin (1%), metronidazole (0.75%–1%), azelaic acid (15%), sodium sulfacetamide, and sulphur. Successful nonapproved (off-label) therapy has been described with topical erythromycin (2%), tretinoin or isotretinoin, clindamycin, and permethrin. However, good evidence indicates that papules and pustules resolve faster and longer using a combination therapy, for example. using the slow-release doxycycline and topical ivermectin. Off-label use with oxytetracycline 500 mg twice a day, doxycycline 100 mg twice a day, minocycline 50 mg/day, erythromycin 500 mg twice a day has been reported with good success and tolerability. In severe or resistant cases, systemic metronidazole, clarithromycin, and azithromycin have relatively rapid onsets of efficacy and fewer tendencies for GI adverse effects than erythromycin and less hyperpigmentation tendency than minocycline. If *Demodex* mite numbers are increased, a short course of permethrin cream should be applied in addition to approved ivermectin cream therapy.

After 3 or 4 months, depending on improvement, systemic therapy can be tapered down while topical therapy is continued. If erythema remains an issue, topical adrenergic receptor blockers (brimonidine, oxymetazoline) may be continued. Topical maintenance therapy may be beneficial to avoid reoccurrence. Successful treatment of papules and pustules have been reported using laser, light, or photodynamic therapy but remains to be clarified.[8]

TABLE 79-14
Differential Diagnosis of Lupoid Rosacea

Perioral dermatitis
Steroid rosacea
Small nodular sarcoidosis

TABLE 79-15
Differential Diagnosis of Rosacea Fulminans

Acne conglobate
Acne fulminans
Halogen rosacea
Gram-negative folliculitis

PHYMATA

There is substantial evidence that low-dose isotretinoin has a beneficial effect in early as well as

TABLE 79-16
Differential Diagnosis of Halogen Rosacea

Acne vulgaris
Acneiform exanthema
Acneiform syphilid
Rosacea conglobate or fulminans
Follicular pyoderma
Tinea barbae

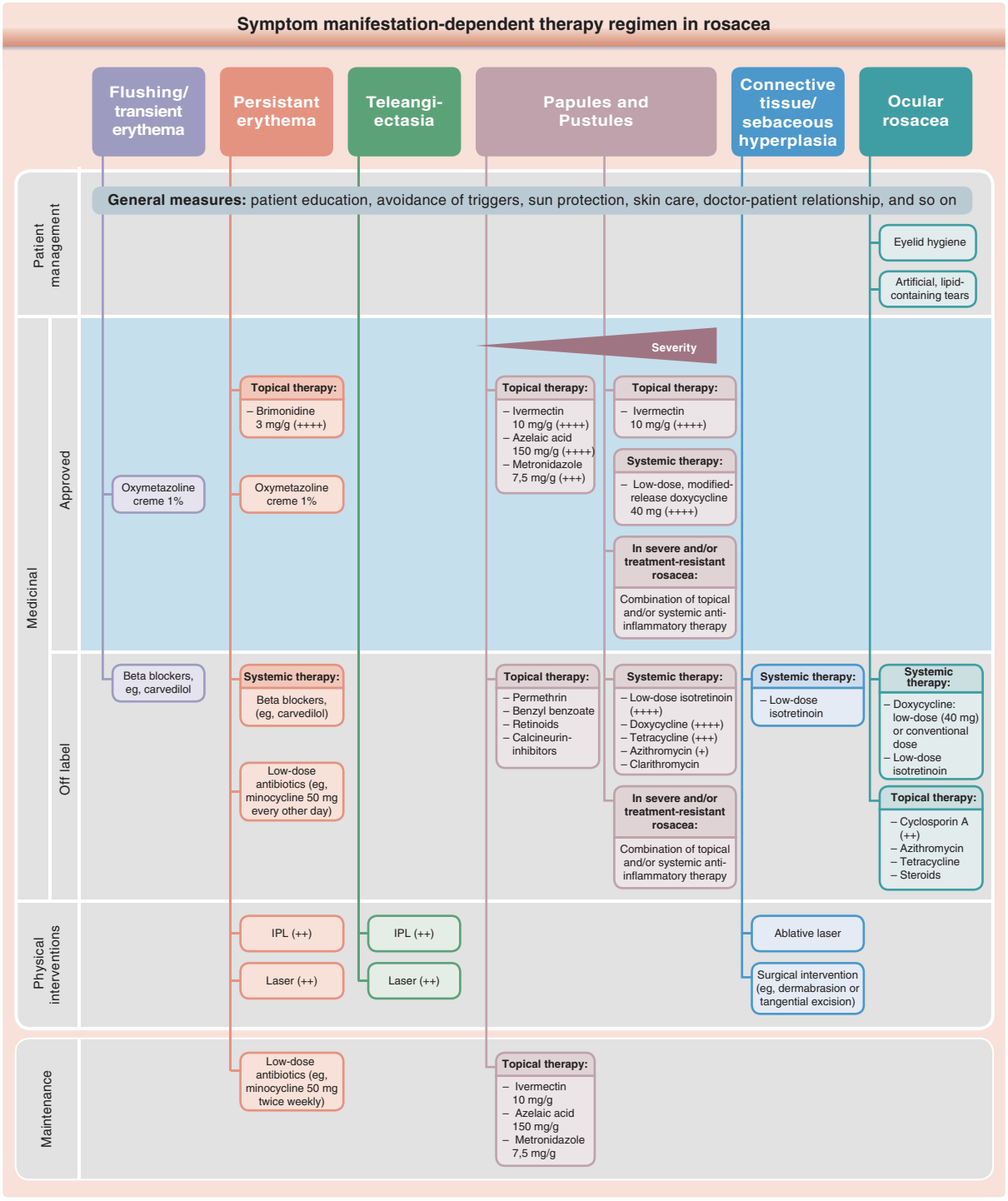

Figure 79-13 Symptom manifestation-dependent therapy regimen in rosacea. IPL, intense pulsed light. (Modified from Schaller M, Schöfer H, Homey B, et al. Rosacea management: update on general measures and topical treatment options. *J Dtsch Dermatol Ges*. 2016;14(Suppl 6):17-27; with permission. Copyright © 2016, John Wiley & Sons.)

established rosacea because of its inhibitory effect on sebaceous glands as well as some antiinflammatory capacity.[111] This can be also used before laser and dermatosurgery procedures to reduce size and inflammation. It is often recommended to stop isotretinoin before surgery because isotretinoin inhibits keratinocyte-mediated wound healing. However, no controlled studies exist to inform whether this is also true for low-dose isotretinoin. Rarely, dapsone is used in these cases.

For laser treatment options or surgical therapy, including surgery, cryosurgery, radiofrequency ablation, electrosurgery, and thermosurgery, see the later discussion of physical and surgical procedures.

TABLE 79-17
Dos and Don'ts for General Rosacea Care

ALLOWED	NOT ALLOWED
Use powder cosmetics with a matte finish; the best is green (complementary color of red).	Use cream or liquid cosmetics.
Try cosmetics before buying them if possible.	Use old cosmetics.
Wear light earth tones (tan, peach, matte green) for eye shadow.	Wear deep eye shadows (blue, purple, red, or pink).
Apply a separate sunblock after topical medication and before cosmetics. Use moisturizer on dry skin with at least SPF20+.	Use cosmetics containing perfume.
Avoid cosmetics using formaldehyde, propylene glycol, alcohol, toners, and palmitic, oleic acid, and other irritants.	Purchase cosmetics with more than 10 ingredients.
Use a flat or soft brush applicator without rubbing.	Apply with a sponge or fingers. Massage creams into the skin. Use peeling "rejuvenating" agents.
Use facial foundation of power or cream variety with matte finish.	Use light-reflective powders containing mica.
Wear only black mascara.	Use nail polish.
Use pencil forms of eyeliner. Start applying new medications or cosmetics on weekends or vacations on one site and take photos to compare sites to reveal potential irritations.	Waterproof eye cosmetics are best avoided.

SPF, sun protection factor.

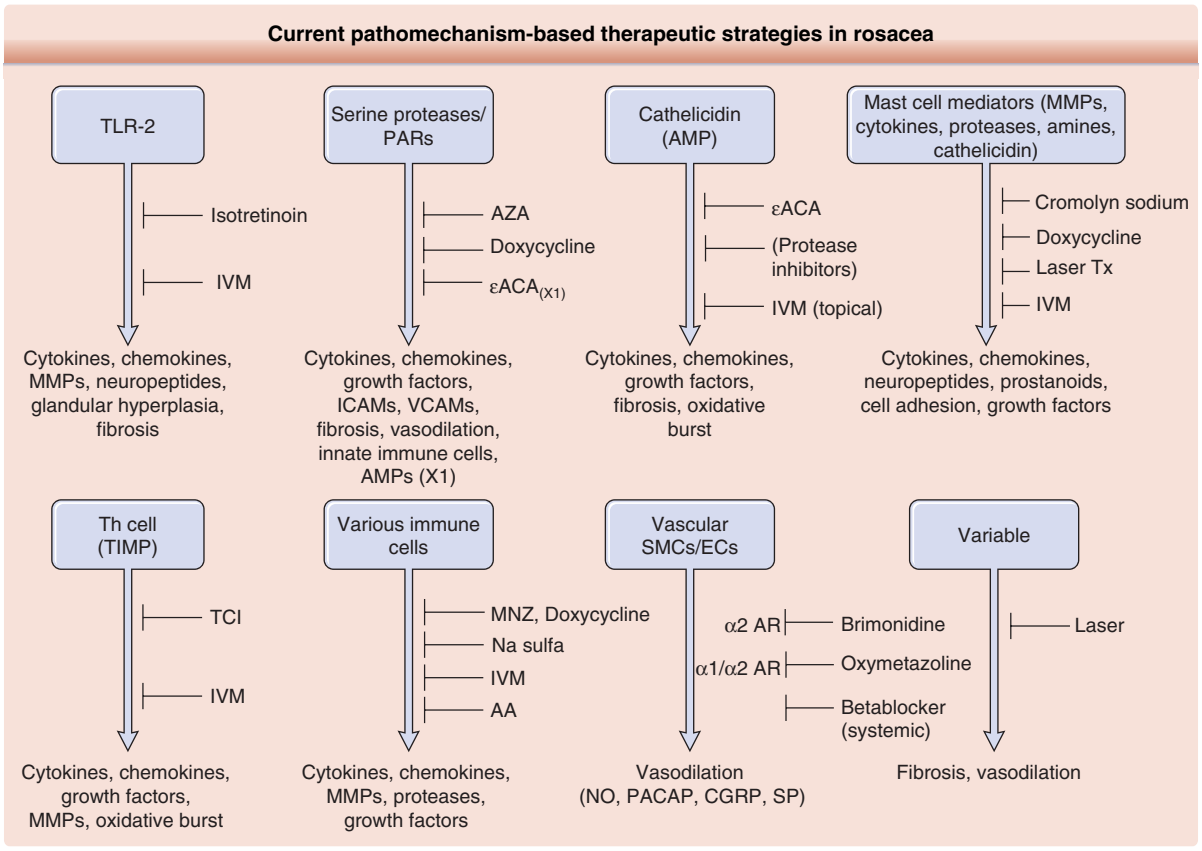

Figure 79-14 Current pathomechanism-based therapeutic strategies in rosacea. AA, azelaic acid; AMP, antimicrobial peptide; AZA, azathioprine; εACA, ε-aminocaproic acid; AR, adrenergic receptor; CGRP, calcitonin gene-related peptide; ECs, endothelial cells; ICAM, intercellular adhesion molecule; IVM, ivermectin; MMP, matrix metalloproteinase; MNZ, minocycline; NO, nitric oxide; PACAP, pituitary adenylate cyclase-activating peptide; PAR, protease-activated receptor; SMC, smooth muscle cell; SP, substance P; TCI, T cell inhibitor; TIMP, tissue inhibitor of metalloproteinases; Th, T helper; TLR, Toll-like receptor; Tx, treatment; VCAM, vascular cell adhesion protein.

TABLE 79-18
Physical Interventions in Rosacea Therapy

	METHOD	SYMPTOM TO TREAT	EVALUATION OR SIDE EFFECTS
Laser therapy	PDL laser	Erythema, telangiectatsia	Advantage over IPL: more selective treatment of blood vessels More effective than Nd:YAG Purpura induction with short pulse duration Prevention of purpura with longer pulse duration of 40–50 ms Side effects: hyper- or hypopigmentation
	PTP laser	Telangiectasia (erythema)	Short healing process, well tolerated Low risk of scaring Better for treatment of telangiectasia than erythema Good safety and tolerability profile
	Nd:YAG laser	Erythema, telangiectasia	Minor pain sensation Less painful than PDL Combination with PDL possible in therapy-resistant cases Risk for atrophic scars
Light therapy	IPL	Erythema, teleangiectatsia, papules or pustules	Good safety and tolerability profile Time-saving procedure
Surgical intervention	Dermabrasion	Phymata	Risk of bleading
	Electrocautery	Phymata	Rapid procedure Potential side effect: cartilage damage Protracted wound healing disorder Atrophic scaring
	Laser (CO_2- or Er:YAG laser)	Phymata	Co_2: low risk for bleeding Er:YAG: low scaring risk CO_2–Er:YAG combination
	Scalpel excision	Phymata	Risk of intraoperative bleeding Deep tissue excisions or resections Risk: resection of excessive tissue

Er:YAG, erbium-doped yttrium aluminium garnet; IPL, intense pulsed light; Nd:YAG, neodymium-doped yttrium aluminum garnet; PDL laser, pulsed-dye laser; PTP, potassium–titanyl–phosphate.

Modified from Hofmann MA, Lehmann P. Physical modalities for the treatment of rosacea. *J Dtsch Dermatol Ges*. 2016;14(Suppl 6):38-43; with permission. Copyright © 2016, John Wiley & Sons.

FACIAL LYMPH EDEMA (MORBIHAN DISEASE)

For facial edema based on lymphatic vessel dilation, no approved or standard therapy exists. Oral isotretinoin, Dapsone, hydroxychloroquine, minocycline, and combined doxycycline–prednisolone have each been tried with mixed results.[112-114]

OCULAR ROSACEA

Every patient with cutaneous rosacea should be questioned about eye symptoms, such as itchy, dry eyes with a foreign body sensation, and avoidance of light. Bloodshot eyes in combination with a thorough family and skin history is often indicative of the disorder.

The management of ocular rosacea has to be defined as a multidisciplinary effort with ophthalmologists and dermatologists involved with or without general practitioners. The severity can range from mild to severe and may lead to chronic defects, even blindness.[9,16,22,23]

General basic includes is eyelid hygiene (warm compresses, meibomian gland expression, dilute baby shampoo scrubs, and lubricating drops) and artificial tear substitutes for mild ocular burning or stinging followed by topical and systemic therapy in more severe cases Table 79-19). UV-blocking sunglasses can also be helpful. A proper education about general eye care improves success of treatment (see Table 79-19). In patients with ocular rosacea, screening for cutaneous features is obligatory.

PAIN

See the section on “Erythema and Flushing.”

MAINTENANCE THERAPY

Compared with other inflammatory skin diseases, such as atopic dermatitis or psoriasis, the rosacea maintenance therapy regimen is poorly validated and depends on available modalities and the patient’s expectance. In the authors’ experience, maintenance therapy is superior to sudden discontinuation. General skin care should always be continued, as recommended earlier.

TABLE 79-19
Treatment of Ocular Rosacea

THERAPY	COMMENT
Artificial tears	Frequently needed for "dry eyes" of ocular rosacea; use several times daily
Eyelid and eyelash hygiene	Using warm soaks or compresses; can use saline or dilute baby shampoo lavage; overnight creams soften scale and remove plugs from meibomian gland orifices
Expression of meibomian glands	Following hygiene gentle manual massage extrudes thickened, wormlike secretions from glands
Topical antibiotics	Effective treatment for infected blepharitis applied twice daily after eyelid hygiene
Topical steroids	Fucidic acid; metronidazole, erythromycin, and azelaic acid are main options; topical steroids should be used with caution; 1% hydrocortisone cream for blepharitis; may be used in antibiotic–steroid combination
Tacrolimus–cyclosporine	Insufficient evidence to know indications or role in therapy as yet
Systematic antibiotics	As used for PPR; minocycline, doxycycline, oxytetracycline, erythromycin commonly used; 6–12 wk of therapy; response begins after 2 wk; metronidazole used rarely; relapse common after course of therapy completed
Surgery	Incision and curettage for chalazion after eyelid everted; required for keratitis if impending perforation
Other therapies	Topical sulfur, zinc, and ichthammol preparations; hexachlorocyclohexane; vitamin B_2 orally or parentally; omega-3 fatty acid dietary supplementation; topically applied cold tea or tea tree oil

PHYSICAL AND SURGICAL THERAPIES IN ROSACEA

PHYSICAL METHODS

Physical methods such as light and laser therapies, as well as surgical interventions, are important and adequate additions to the often symptom-oriented topical or oral therapies used for rosacea. In an efficient and mostly long-lasting fashion, they supplement the conservative treatment and general skin care. Because several features coexist in many patients, multimodal therapy is often demanded. In patients with erythema and telangiectasia, for example, a combination of topical vasoconstrictors with light or laser therapy is incremental because telangiectasias do not respond to topical or systemic treatment. An initial medical therapy of erythema can also unmask telangiectasias, which are then easier to approach with physical methods.[7,115]

In general, long-term efficacy and safety data from controlled, blinded trials for many procedures are very sparse. However, repetitions of laser procedures are regarded as safe. In ablative procedures of phymata, the risk for scarring is enhanced compared with nonablative techniques; however, no scientific data exist that would validate this generally accepted observation.

For the treatment of erythema and telangiectasia, various light and laser systems exist (see Table 79-18). Laser systems are, for example, the frequency-doubled potassium-titanyl-phosphate laser (PTP; 532 nm), neodymium-doped yttrium aluminum garnet laser (Nd:YAG; 1.064 nm), and pulsed-dye laser (585–595 nm). They act in wavelengths, which are absorbed by hemoglobin and subsequently lead to blood vessel destruction.

Light lamps such as intense pulsed lights (spectrum range of 500-1.200 nm) operate using specific filters in the wavelength of hemoglobin absorption. Older laser generations, such as the argon laser, are out of date because the newer generation lasers exert lower adverse event profiles related to dyspigmentation, scaring, pain, and economic downtime.[8,116,117]

A recent Cochrane review performed a meta-analysis on various laser therapies and concluded for all studies a low to moderate evidence level.[118] However, pulsed-dye laser was superior to Nd:YAG laser and comparable to intense pulsed-light laser. Other studies were not comparable.

SURGICAL INTERVENTIONS

Surgical intervention therapies to treat phymata are scalpel excisions, dermabrasion, electrosurgery and CO_2- or erbium:YAG laser (see Table 79-18). The classical surgical excision and resection is a rapid option for large phymata, with a relatively high bleeding rate. This risk is lower with electrosurgery, which in contrast has a higher risk of deeper tissue destruction. Dermabrasion can be used in mild as well as severe phymata. A good option is also the CO_2 laser, which has a relatively lower risk of bleeding.[8]

REFERENCES

1. Steinhoff M, Buddenkotte J, Aubert J, et al. Clinical, cellular, and molecular aspects in the pathophysiology of rosacea. *J Investig Dermatology Symp Proc*. 2011; 15(1):2-11.
2. Del Rosso JQ, Gallo RL, Tanghetti E, et al. An evaluation of potential correlations between pathophysiologic mechanisms, clinical manifestations, and management of rosacea. *Cutis*. 2013;91(3 suppl):1-8.
3. Tan J, Berg M. Rosacea: current state of epidemiology. *J Am Acad Dermatol*. 2013;69(6 suppl 1):S27-S35.
4. Huynh TT. Burden of Disease: the psychosocial impact of rosacea on a patient's quality of life. *Am Heal Drug Benefits*. 2013;6(6):348-354.
5. Schwab VD, Sulk M, Seeliger S, et al. Neurovascular and neuroimmune aspects in the pathophysiology of rosacea. *J Investig Dermatology Symp Proc*. 2011; 15(1):53-62.

6. Holmes AD, Steinhoff M. Integrative concepts of rosacea pathophysiology, clinical presentation and new therapeutics. *Exp Dermatol*. 2017;26(8):659-667.
7. Schaller M, Schöfer H, Homey B, et al. State of the art: systemic rosacea management. *J Dtsch Dermatol Ges*. 2016;14
8. Hofmann MA, Lehmann P. Physical modalities for the treatment of rosacea. *J Dtsch Dermatol Ges*. 2016; 14(suppl 6):38-43.
9. Schaller M, Almeida LMC, Bewley A, et al. Rosacea treatment update: recommendations from the global ROSacea COnsensus (ROSCO) panel. *Br J Dermatol*. 2017;176(2):465-471.
10. Berg M, Lidén S. An epidemiological study of rosacea. *Acta Derm Venereol*. 1989;69(5):419-423.
11. Tan J, Schöfer H, Araviiskaia E, et al. Prevalence of rosacea in the general population of Germany and Russia—the RISE study. *J Eur Acad Dermatol Venereol*. 2016;30(3):428-434.
12. McAleer MA, Fitzpatrick P, Powell FC. Papulopustular rosacea: prevalence and relationship to photodamage. *J Am Acad Dermatol*. 2010;63(1):33-39.
13. Tan J, Blume-Peytavi U, Ortonne JP, et al. An observational cross-sectional survey of rosacea: clinical associations and progression between subtypes. *Br J Dermatol*. 2013;169(3):555-562.
14. Docherty JR, Steinhoff M, Lorton D, et al. Multidisciplinary consideration of potential pathophysiologic mechanisms of paradoxical erythema with topical brimonidine therapy. *Adv Ther*. 2016;33(11): 1885-1895.
15. Abram K, Silm H, Maaroos H-I, et al. Subjective disease perception and symptoms of depression in relation to healthcare-seeking behaviour in patients with rosacea. *Acta Derm Venereol*. 2009;89(5):488-491.
16. Tan J, Almeida LMC, Bewley A, et al. Updating the diagnosis, classification and assessment of rosacea: recommendations from the global ROSacea COnsensus (ROSCO) panel. *Br J Dermatol*. 2017;176(2):431-438.
17. Wilkin J, Dahl M, Detmar M, et al. Standard classification of rosacea: report of the National Rosacea Society Expert Committee on the Classification and Staging of Rosacea. *J Am Acad Dermatol*. 2002;46(4):584-587.
18. Powell FC. Clinical practice. Rosacea. *N Engl J Med*. 2005;352(8):793-803.
19. Gallo RL, Granstein RD, Kang S, et al. Standard classification and pathophysiology of rosacea: the 2017 update by the National Rosacea Society Expert Committee. *J Am Acad Dermatol*. 2018;78(1):148-155.
20. Buhl T, Sulk M, Nowak P, et al. Molecular and morphological characterization of inflammatory infiltrate in rosacea reveals activation of Th1/Th17 pathways. *J Invest Dermatol*. 2015;135(9):2198-2208.
21. Kligman AM. Ocular rosacea. Current concepts and therapy. *Arch Dermatol*. 1997;133(1):89-90.
22. Vieira AC, Mannis MJ. Ocular rosacea: common and commonly missed. *J Am Acad Dermatol*. 2013;69(6 suppl 1):S36-S41.
23. Geerling G, Baudouin C, Aragona P, et al. Emerging strategies for the diagnosis and treatment of meibomian gland dysfunction: proceedings of the OCEAN group meeting. *Ocul Surf*. 2017;15(2):179-192.
24. Aldrich N, Gerstenblith M, Fu P, et al. Genetic vs environmental factors that correlate with rosacea: a cohort-based survey of twins. *JAMA Dermatol*. 2015;151(11):1213-1219.
25. Yazici AC, Tamer L, Ikizoglu G, et al. GSTM1 and GSTT1 null genotypes as possible heritable factors of rosacea. *Photodermatol Photoimmunol Photomed*. 2006;22(4):208-210.
26. Chang ALS, Raber I, Xu J, et al. Assessment of the genetic basis of rosacea by genome-wide association study. *J Invest Dermatol*. 2015;135(6):1548-1555.
27. Woo YR, Lim JH, Cho DH, et al. Rosacea: molecular mechanisms and management of a chronic cutaneous inflammatory condition. *Int J Mol Sci*. 2016;17(9).
28. van Steensel MAM, Badeloe S, Winnepenninckx V, et al. Granulomatous rosacea and Crohn's disease in a patient homozygous for the Crohn-associated NOD2/CARD15 polymorphism R702W. *Exp Dermatol*. 2008;17(12):1057-1058.
29. Karpouzis A, Avgeridis P, Tripsianis G, et al. Assessment of tachykinin receptor 3' gene polymorphism rs3733631 in rosacea. *Int Sch Res Not*. 2015;2015:469402.
30. Silverberg MS, Cho JH, Rioux JD, et al. Ulcerative colitis-risk loci on chromosomes 1p36 and 12q15 found by genome-wide association study. *Nat Genet*. 2009;41(2):216-220.
31. Weinstock LB, Steinhoff M. Rosacea and small intestinal bacterial overgrowth: prevalence and response to rifaximin. *J Am Acad Dermatol*. 2013;68(5):875-876.
32. Drago F, De Col E, Agnoletti AF, et al. The role of small intestinal bacterial overgrowth in rosacea: a 3-year follow-up. *J Am Acad Dermatol*. 2016;75(3): e113-e115.
33. Spoendlin J, Karatas G, Furlano RI, et al. Rosacea in patients with ulcerative colitis and Crohn's disease: a population-based case-control Study. *Inflamm Bowel Dis*. 2016;22(3):680-687.
34. Akin Belli A, Ozbas Gok S, Akbaba G, et al. The relationship between rosacea and insulin resistance and metabolic syndrome. *Eur J Dermatol*. 2016;26(3):260-264.
35. Hua T-C, Chung P-I, Chen Y-J, et al. Cardiovascular comorbidities in patients with rosacea: a nationwide case-control study from Taiwan. *J Am Acad Dermatol*. 2015;73(2):249-254.
36. Duman N, Ersoy Evans S, Atakan N. Rosacea and cardiovascular risk factors: a case control study. *J Eur Acad Dermatol Venereol*. 2014;28(9):1165-1169.
37. Rainer BM, Fischer AH, Luz Felipe da Silva D, et al. Rosacea is associated with chronic systemic diseases in a skin severity-dependent manner: results of a case-control study. *J Am Acad Dermatol*. 2015;73(4): 604-608.
38. Takci Z, Bilgili SG, Karadag AS, et al. Decreased serum paraoxonase and arylesterase activities in patients with rosacea. *J Eur Acad Dermatol Venereol*. 2015;29(2):367-370.
39. Kota SK, Meher LK, Kota SK, et al. Implications of serum paraoxonase activity in obesity, diabetes mellitus, and dyslipidemia. *Indian J Endocrinol Metab*. 2013;17(3):402-412.
40. Yamasaki K, Di Nardo A, Bardan A, et al. Increased serine protease activity and cathelicidin promotes skin inflammation in rosacea. *Nat Med*. 2007;13(8): 975-980.
41. Yamasaki K, Kanada K, Macleod DT, et al. TLR2 expression is increased in rosacea and stimulates enhanced serine protease production by keratinocytes. *J Invest Dermatol*. 2011;131(3):688-697.
42. Melnik BC. Endoplasmic reticulum stress: key promoter of rosacea pathogenesis. *Exp Dermatol*. 2014; 23(12):868-873.
43. Egeberg A, Hansen PR, Gislason GH, et al. Patients with rosacea have increased risk of dementia. *Ann Neurol*. 2016;79(6):921-928.

44. Egeberg A, Hansen PR, Gislason GH, et al. Exploring the association between rosacea and Parkinson Disease: a Danish nationwide cohort study. *JAMA Neurol*. 2016;73(5):529-534.
45. Spoendlin J, Voegel JJ, Jick SS, et al. Migraine, triptans, and the risk of developing rosacea: a population-based study within the United Kingdom. *J Am Acad Dermatol*. 2013;69(3):399-406.
46. Gupta MA, Gupta AK, Chen SJ, et al. Comorbidity of rosacea and depression: an analysis of the National Ambulatory Medical Care Survey and National Hospital Ambulatory Care Survey—Outpatient Department data collected by the U.S. National Center for Health Statistics from 1995 to 2002. *Br J Dermatol*. 2005;153(6):1176-1181.
47. Egeberg A, Hansen PR, Gislason GH, et al. Patients with rosacea have increased risk of depression and anxiety disorders: a Danish nationwide cohort study. *Dermatology*. 2016;232(2):208-213.
48. Egeberg A, Hansen PR, Gislason GH, et al. Association of rosacea with risk for glioma in a Danish nationwide cohort study. *JAMA Dermatol*. 2016;152(5):541-545.
49. Jarmuda S, O'Reilly N, Zaba R, et al. Potential role of Demodex mites and bacteria in the induction of rosacea. *J Med Microbiol*. 2012;61(Pt 11):1504-1510.
50. Lazaridou E, Giannopoulou C, Fotiadou C, et al. The potential role of microorganisms in the development of rosacea. *J Dtsch Dermatol Ges*. 2011;9(1):21-25.
51. Sulk M, Seeliger S, Aubert J, et al. Distribution and expression of non-neuronal transient receptor potential (TRPV) ion channels in rosacea. *J Invest Dermatol*. 2012;132(4):1253-1262.
52. Moore C, Cevikbas F, Pasolli HA, et al. UVB radiation generates sunburn pain and affects skin by activating epidermal TRPV4 ion channels and triggering endothelin-1 signaling. *Proc Natl Acad Sci U S A*. 2013;110(34):E3225-E3234.
53. Bonnar E, Eustace P, Powell FC. The Demodex mite population in rosacea. *J Am Acad Dermatol*. 1993; 28(3):443-448.
54. Forton F, Seys B. Density of Demodex folliculorum in rosacea: a case-control study using standardized skin-surface biopsy. *Br J Dermatol*. 1993;128(6):650-659.
55. Georgala S, Katoulis AC, Kylafis GD, et al. Increased density of Demodex folliculorum and evidence of delayed hypersensitivity reaction in subjects with papulopustular rosacea. *J Eur Acad Dermatol Venereol*. 2001;15(5):441-444.
56. Steinhoff M, Ständer S, Seeliger S, et al. Modern aspects of cutaneous neurogenic inflammation. *Arch Dermatol*. 2003;139(11):1479-1488.
57. Casas C, Paul C, Lahfa M, et al. Quantification of Demodex folliculorum by PCR in rosacea and its relationship to skin innate immune activation. *Exp Dermatol*. 2012;21(12):906-910.
58. Turgut Erdemir A, Gurel MS, Koku Aksu AE, et al. Demodex mites in acne rosacea: reflectance confocal microscopic study. *Australas J Dermatol*. 2017;58(2): e26-e30.
59. Forton FMN. Papulopustular rosacea, skin immunity and Demodex: pityriasis folliculorum as a missing link. *J Eur Acad Dermatol Venereol*. 2012;26(1):19-28.
60. Sattler EC, Hoffmann VS, Ruzicka T, et al. Reflectance confocal microscopy for monitoring the density of Demodex mites in patients with rosacea before and after treatment. *Br J Dermatol*. 2015;173(1):69-75.
61. Steinhoff M, Buddenkotte J, Shpacovitch V, et al. Proteinase-activated receptors: transducers of proteinase-mediated signaling in inflammation and immune response. *Endocr Rev*. 2005;26(1):1-43.
62. Koller B, Müller-Wiefel AS, Rupec R, et al. Chitin modulates innate immune responses of keratinocytes. *PLoS One*. 2011;6(2):e16594.
63. Gerber PA, Buhren BA, Steinhoff M, et al. Rosacea: the cytokine and chemokine network. *J Investig Dermatol Symp Proc*. 2011;15(1):40-47.
64. Steinhoff M, Vergnolle N, Young SH, et al. Agonists of proteinase-activated receptor 2 induce inflammation by a neurogenic mechanism. *Nat Med*. 2000;6(2):151-158.
65. Seeliger S, Buddenkotte J, Schmidt-Choudhury A, et al. Pituitary adenylate cyclase activating polypeptide: an important vascular regulator in human skin in vivo. *Am J Pathol*. 2010;177(5):2563-2575.
66. Steinhoff M, Schmelz M, Schauber J. Facial erythema of rosacea—aetiology, different pathophysiologies and treatment options. *Acta Derm Venereol*. 2016;96(5):579-586.
67. Dirschka T, Tronnier H, Fölster-Holst R. Epithelial barrier function and atopic diathesis in rosacea and perioral dermatitis. *Br J Dermatol*. 2004;150(6):1136-1141.
68. Ní Raghallaigh S, Powell FC. Epidermal hydration levels in patients with rosacea improve after minocycline therapy. *Br J Dermatol*. 2014;171(2):259-266.
69. Yamasaki K, Gallo RL. Rosacea as a disease of cathelicidins and skin innate immunity. *J Investig dermatology Symp Proc*. 2011;15(1):12-15.
70. Kim JY, Kim YJ, Lim BJ, et al. Increased expression of cathelicidin by direct activation of protease-activated receptor 2: possible implications on the pathogenesis of rosacea. *Yonsei Med J*. 2014;55(6):1648-1655.
71. Ozlu E, Karadag AS, Ozkanli S, et al. Comparison of TLR-2, TLR-4, and antimicrobial peptide levels in different lesions of acne vulgaris. *Cutan Ocul Toxicol*. 2016;35(4):300-309.
72. Meyer-Hoffert U, Schröder J-M. Epidermal proteases in the pathogenesis of rosacea. *J Investig Dermatology Symp Proc*. 2011;15(1):16-23.
73. Lee Y, Kim H, Kim S, et al. Activation of toll-like receptors 2, 3 or 5 induces matrix metalloproteinase-1 and -9 expression with the involvement of MAPKs and NF-kappaB in human epidermal keratinocytes. *Exp Dermatol*. 2010;19(8):e44-e49.
74. Kanada KN, Nakatsuji T, Gallo RL. Doxycycline indirectly inhibits proteolytic activation of tryptic kallikrein-related peptidases and activation of cathelicidin. *J Invest Dermatol*. 2012;132(5):1435-1442.
75. Segovia J, Sabbah A, Mgbemena V, et al. TLR2/MyD88/NF-κB pathway, reactive oxygen species, potassium efflux activates NLRP3/ASC inflammasome during respiratory syncytial virus infection. *PLoS One*. 2012;7(1):e29695.
76. Morizane S, Yamasaki K, Kabigting FD, et al. Kallikrein expression and cathelicidin processing are independently controlled in keratinocytes by calcium, vitamin D(3), and retinoic acid. *J Invest Dermatol*. 2010;130(5):1297-1306.
77. Tschopp J, Schroder K. NLRP3 inflammasome activation: the convergence of multiple signalling pathways on ROS production? *Nat Rev Immunol*. 2010; 10(3):210-215.
78. Rufli T, Büchner SA. T-cell subsets in acne rosacea lesions and the possible role of Demodex folliculorum. *Dermatologica*. 1984;169(1):1-5.
79. Brown TT, Choi E-YK, Thomas DG, et al. Comparative analysis of rosacea and cutaneous lupus

erythematosus: histopathologic features, T-cell subsets, and plasmacytoid dendritic cells. *J Am Acad Dermatol*. 2014;71(1):100-107.
80. Jansen T, Kastner U, Kreuter A, et al. Rosacea-like demodicidosis associated with acquired immunodeficiency syndrome. *Br J Dermatol*. 2001;144(1):139-142.
81. Basta-Juzbasić A, Subić JS, Ljubojević S. Demodex folliculorum in development of dermatitis rosaceiformis steroidica and rosacea-related diseases. *Clin Dermatol*. 20(2):135-140.
82. Teraki Y, Hitomi K, Sato Y, et al. Tacrolimus-induced rosacea-like dermatitis: a clinical analysis of 16 cases associated with tacrolimus ointment application. *Dermatology*. 2012;224(4):309-314.
83. McFadden JP, Powles AV, Walker M. Rosacea induced by PUVA therapy. *Br J Dermatol*. 1989;121(3):413.
84. Kim M, Kim K-E, Jung HY, et al. Recombinant erythroid differentiation regulator 1 inhibits both inflammation and angiogenesis in a mouse model of rosacea. *Exp Dermatol*. 2015;24(9):680-685.
85. Salzer S, Ruzicka T, Schauber J. Face-to-face with anti-inflammatory therapy for rosacea. *Exp Dermatol*. 2014;23(6):379-381.
86. Jones D. Reactive oxygen species and rosacea. *Cutis*. 2004;74(3 suppl):17-20, 32-34.
87. Aroni K, Tsagroni E, Kavantzas N, et al. A study of the pathogenesis of rosacea: how angiogenesis and mast cells may participate in a complex multifactorial process. *Arch Dermatol Res*. 2008;300(3):125-131.
88. Drummond PD, Su D. Endothelial and axon reflex vasodilatation to acetylcholine in rosacea-affected skin. *Arch Dermatol Res*. 2012;304(2):133-137.
89. Jancsó N, Jancsó-Gábor A, Szolcsányi J. Direct evidence for neurogenic inflammation and its prevention by denervation and by pretreatment with capsaicin. *Br J Pharmacol ChemoTher*. 1967;31(1):138-151.
90. Aubdool AA, Brain SD. Neurovascular aspects of skin neurogenic inflammation. *J Investig dermatology Symp Proc*. 2011;15(1):33-39.
91. Baylie RL, Brayden JE. TRPV channels and vascular function. *Acta Physiol (Oxf)*. 2011;203(1):99-116.
92. Metzler-Wilson K, Toma K, Sammons DL, et al. Augmented supraorbital skin sympathetic nerve activity responses to symptom trigger events in rosacea patients. *J Neurophysiol*. 2015;114(3):1530-1537.
93. Black PH. Stress and the inflammatory response: a review of neurogenic inflammation. *Brain Behav Immun*. 2002;16(6):622-653.
94. Kim JE, Cho BK, Cho DH, et al. Expression of hypothalamic-pituitary-adrenal axis in common skin diseases: evidence of its association with stress-related disease activity. *Acta Derm Venereol*. 2013;93(4):387-393.
95. Johnson JM, Minson CT, Kellogg DL. Cutaneous vasodilator and vasoconstrictor mechanisms in temperature regulation. *Compr Physiol*. 2014;4(1):33-89.
96. Del Rosso JQ. Management of facial erythema of rosacea: what is the role of topical α-adrenergic receptor agonist therapy? *J Am Acad Dermatol*. 2013;69(6 suppl 1):S44-S56.
97. Muto Y, Wang Z, Vanderberghe M, et al. Mast cells are key mediators of cathelicidin-initiated skin inflammation in rosacea. *J Invest Dermatol*. 2014;134(11):2728-2736.
98. Helfrich YR, Maier LE, Cui Y, et al. Clinical, histologic, and molecular analysis of differences between erythematotelangiectatic rosacea and telangiectatic photoaging. *JAMA dermatology*. 2015;151(8):825-836.
99. Mould TL, Roberts-Thomson PJ. Pathogenesis of telangiectasia in scleroderma. *Asian Pacific J Allergy Immunol*. 2000;18(4):195-200.
100. Holmes AD. Potential role of microorganisms in the pathogenesis of rosacea. *J Am Acad Dermatol*. 2013;69(6):1025-1032.
101. Haber R, El Gemayel M. Comorbidities in rosacea: a systematic review and update. *J Am Acad Dermatol*. 2018;78(4):786-792.e8.
102. Ciccarese G, Parodi A, Rebora A, et al. The usefulness of investigating the possible underlying conditions in rosacea. *J Eur Acad Dermatol Venereol*. 2018;32(3):e88-e89.
103. Parodi A, Paolino S, Greco A, et al. Small intestinal bacterial overgrowth in rosacea: clinical effectiveness of its eradication. *Clin Gastroenterol Hepatol*. 2008;6(7):759-764.
104. Drago F, Ciccarese G, Parodi A. Effects of the treatment for small intestine bacterial overgrowth on rosacea. *J Dermatol*. 2017;44(12):e321.
105. Crawford GH, Pelle MT, James WD. Rosacea: I. Etiology, pathogenesis, and subtype classification. *J Am Acad Dermatol*. 2004;51(3):327-414.
106. Wilkin J, Dahl M, Detmar M, et al. Standard grading system for rosacea: report of the National Rosacea Society Expert Committee on the classification and staging of rosacea. *J Am Acad Dermatol*. 2004;50(6):907-912.
107. Weinkle AP, Doktor V, Emer J. Update on the management of rosacea. *Clin Cosmet Investig Dermatol*. 2015;8:159-177.
108. Steinhoff M, Vocanson M, Voegel JJ, et al. Topical ivermectin 10 mg/g and oral doxycycline 40 mg modified-release: current evidence on the complementary use of anti-inflammatory rosacea treatments. *Adv Ther*. 2016;33(9):1481-1501.
109. Pietschke K, Schaller M. Long-term management of distinct facial flushing and persistent erythema of rosacea by treatment with carvedilol. *J Dermatolog Treat*. 2017:1-4.
110. Scharschmidt TC, Yost JM, Truong SV, et al. Neurogenic rosacea: a distinct clinical subtype requiring a modified approach to treatment. *Arch Dermatol*. 2011;147(1):123-126.
111. Schmidt JB, Gebhart W, Raff M, et al. 13-cis-Retinoic acid in rosacea. Clinical and laboratory findings. *Acta Derm Venereol*. 1984;64(1):15-21.
112. Veraldi S, Persico MC, Francia C. Morbihan syndrome. *Indian Dermatol Online J*. 2013;4(2):122-124.
113. Fujimoto N, Mitsuru M, Tanaka T. Successful treatment of Morbihan disease with long-term minocycline and its association with mast cell infiltration. *Acta Derm Venereol*. 2015;95(3):368-369.
114. Ranu H, Lee J, Hee TH. Therapeutic hotline: successful treatment of Morbihan's disease with oral prednisolone and doxycycline. *Dermatol Ther*. 23(6):682-685.
115. Schaller M, Schöfer H, Homey B, et al. Rosacea management: update on general measures and topical treatment options. *J Dtsch Dermatol Ges*. 2016;14(suppl 6):17-27.
116. Arndt KA. Argon laser therapy of small cutaneous vascular lesions. *Arch Dermatol*. 1982;118(4):220-224.
117. Laube S, Lanigan SW. Laser treatment of rosacea. *J Cosmet Dermatol*. 2002;1(4):188-195.
118. van Zuuren EJ, Fedorowicz Z, Carter B, et al. Interventions for rosacea. *Cochrane database Syst Rev*. 2015;(4):CD003262.

119. Shpacovitch VM, Brzoska T, Buddenkotte J, et al. Agonists of proteinase-activated receptor 2 induce cytokine release and activation of nuclear transcription factor kappaB in human dermal microvascular endothelial cells. *J Invest Dermatol*. 2002;118(2): 380-385.
120. Buddenkotte J, Stroh C, Engels IH, et al. Agonists of proteinase-activated receptor-2 stimulate upregulation of intercellular cell adhesion molecule-1 in primary human keratinocytes via activation of NF-kappa B. *J Invest Dermatol*. 2005;124(1):38-45.
121. Moormann C, Artuc M, Pohl E, et al. Functional characterization and expression analysis of the proteinase-activated receptor-2 in human cutaneous mast cells. *J Invest Dermatol*. 2006;126(4):746-755.
122. Rallabhandi P, Nhu QM, Toshchakov VY, et al. Analysis of proteinase-activated receptor 2 and TLR4 signal transduction: a novel paradigm for receptor cooperativity. *J Biol Chem*. 2008;283(36):24314-24325.
123. Shpacovitch VM, Varga G, Strey A, et al. Agonists of proteinase-activated receptor-2 modulate human neutrophil cytokine secretion, expression of cell adhesion molecules, and migration within 3-D collagen lattices. *J Leukoc Biol*. 2004;76(2):388-398.
124. Nakayama M, Niki Y, Kawasaki T, et al. IL-32-PAR2 axis is an innate immunity sensor providing alternative signaling for LPS-TRIF axis. *Sci Rep*. 2013;3:2960.
125. Yamasaki K, Schauber J, Coda A, et al. Kallikrein-mediated proteolysis regulates the antimicrobial effects of cathelicidins in skin. *FASEB J*. 2006;20(12): 2068-2080.
126. Ramanathan B, Davis EG, Ross CR, et al. Cathelicidins: microbicidal activity, mechanisms of action, and roles in innate immunity. *Microbes Infect*. 2002;4(3):361-372.
127. Jang YH, Sim JH, Kang HY, et al. Immunohistochemical expression of matrix metalloproteinases in the granulomatous rosacea compared with the non-granulomatous rosacea. *J Eur Acad Dermatol Venereol*. 2011;25(5):544-548.
128. Tewari A, Grys K, Kollet J, et al. Upregulation of MMP12 and its activity by UVA1 in human skin: potential implications for photoaging. *J Invest Dermatol*. 2014;134(10):2598-2609.
129. Steinhoff MS, von Mentzer B, Geppetti P, et al. Tachykinins and their receptors: contributions to physiological control and the mechanisms of disease. *Physiol Rev*. 2014;94(1):265-301.
130. Freedman RR. Physiology of hot flashes. *Am J Hum Biol*. 2001;13(4):453-464.
131. Abreu Velez AM, Howard MS. Diagnosis and treatment of cutaneous paraneoplastic disorders. *Dermatol Ther*. 2010;23(6):662-675.

Chapter 80 :: Acne Variants and Acneiform Eruptions

:: Andrea L. Zaenglein, Emmy M. Graber, & Diane M. Thiboutot

AT-A-GLANCE

- Mid-childhood acne warrants evaluation for various causes of hyperandrogenism.
- Acne fulminans and isotretinoin-induced acne fulminans represent severe presentations of acne. Management should include both modified dosing of isotretinoin and systemic corticosteroids.
- Acne conglobata is a severe, nodular form of acne that heals with extensive scarring.
- Acne excoriee, or skin-picking disorder, is a psychological disorder, and patients should be comanaged with psychiatric providers.
- Periorificial dermatitis is a common acneiform eruption often caused by topical or inhaled corticosteroids.

ACNE VARIANTS

NEONATAL ACNE

Neonatal acne can occur in up to 20% of healthy newborns. Lesions usually appear around 2 weeks of age and resolve spontaneously within 3 months. Typically, small, inflamed papules congregate over the nasal bridge and cheeks (Fig. 80-1). Because comedo formation is absent, the pathogenesis of neonatal acne may be different than acne vulgaris. It has been shown that sebum excretion rates in newborns are transiently elevated in the perinatal period.[1] Additionally, *Malassezia sympodialis*, a normal commensal on human skin, may also play a role. Some reports have demonstrated positive cultures of the pustules with *Malassezia* spp. and improvement with ketoconazole cream.[2] Although there appears to be a strong association between *Malassezia* spp. and neonatal acne, definite causality has not yet been proven.[3] *Neonatal cephalic pustulosis* presents with similar but widespread papulopustular lesions over face, scalp, upper chest and back, and shoulders.

INFANTILE ACNE

Infantile acne presents at 3 to 6 months of age classically with open and closed comedones over the cheeks and chin. (Fig. 80-2). Papules, pustules, and nodules can also present on the face. Pitted scarring may occur even with relatively mild disease. Infantile acne is caused in part by the transient elevation of dehydroepiandrosterone (DHEA) produced by the immature adrenal gland.[4] Additionally, during the first 6 to 12 months of life, boys may also have an increased level of luteinizing hormone (LH) that stimulates testosterone production. Around 1 year of age, these hormone levels begin to stabilize until they surge again during adrenarche. As a result, infantile acne usually resolves around 1 to 2 years of age. Treatment generally consists of topical retinoids and benzoyl peroxide. Oral therapy with erythromycin, azithromycin, trimethoprim, or isotretinoin can be used in severe or refractory cases.

MID-CHILDHOOD ACNE

Mid-childhood acne is defined as appearing between 1 and 7 years of age.[5] Typically, acne is very rare in this age group because the adrenal and gonadal production of androgens should be quiescent. Therefore, any child with acne in mid-childhood should be evaluated for other signs of hyperandrogenism (pubic or axillary hair, testicular enlargement or breast development). In addition, the child's growth chart should be compared with the bone age to determine if child's growth is accelerated as well. If any additional abnormalities are noted, further laboratory workup for hyperandrogenism is warranted with the input of a pediatric endocrinologist.

ACNE CONGLOBATA

This severe form of nodular acne is most common in teenage males but can occur in either sex and into adulthood. Acne conglobata (*conglobate* means shaped in a rounded mass or ball) is a mixture of comedones, papules, pustules, nodules, abscesses, and scars arising in a more generalized pattern over the back, buttocks, chest, and, to a lesser extent, on the abdomen, shoulders, neck, face, upper arms, and thighs (see Fig. 78-4). The comedones often have multiple openings. The inflammatory lesions are large, tender, and dusky colored. Draining lesions discharge a foul-smelling serous, purulent, or mucoid material. Subcutaneous dissection with the formation

Figure 80-1 Neonatal acne. Small, erythematous papules and pustules over the face and chest in a newborn.

of multichanneled sinus tracts is common. Healing results in an admixture of depressed and keloidal scars. The management of these patients is challenging. The use of isotretinoin is highly effective in these patients. However, because severe flares may occur when isotretinoin is started, the initial dose should be 0.5 mg/kg/day or less, and systemic glucocorticoids are often required either before initiating isotretinoin therapy or as concomitant therapy. Systemic tetracyclines, intralesional glucocorticoids, systemic glucocorticoids, surgical debridement, surgical incision, and surgical excision may also be required to effectively control acne conglobata.

Figure 80-2 Infantile acne. Primarily open and closed comedones over the cheeks of a 5-month-old infant.

ACNE FULMINANS

Acne fulminans (also known as acute febrile ulcerative acne) is the most severe form of acne and may occur with or without systemic symptoms. The sudden appearance of inflammatory, tender, oozing, friable plaques with hemorrhagic crusts characterizes this extreme presentation. The lesions predominate on the chest and back (Fig. 80-3) and rapidly become ulcerative and heal with scarring. The disease is reported to occur primarily in teenage boys. Systemic symptoms are often present. The patients are febrile; have a leukocytosis of 10,000 to 30,000/mm^3 white blood cells; and usually have polyarthralgia, myalgia, hepatosplenomegaly, and anemia. Bone pain is common, especially at the clavicle and sternum. Radiologic examination may demonstrate lytic bone lesions. Occasionally, there is accompanying erythema nodosum. Although this disease is often classified with acne conglobata, there are basic differences. The onset of acne fulminans is more explosive; nodules and polymorphous comedones are less common; the face is not involved as frequently, and the neck is usually spared; ulcerative and crusted lesions are unique; and systemic symptoms are more common.

Systemic glucocorticoid therapy, along with intralesional glucocorticoids, is first-line treatment for acne fulminans. Systemic glucocorticoids (prednisone 0.5–1.0 mg/kg/day) are started before isotretinoin for 2 to 4 weeks, depending on the severity of systemic symptoms, and continued during the first few weeks to months of isotretinoin therapy. The initial dosing of isotretinoin should be quite low (0.1 mg/kg/day) during the initial weeks of therapy until the inflammation is controlled.[6] The daily dose of glucocorticoids should be slowly decreased as tolerated over weeks to months. Alternately, 0.5 mg/kg/day of isotretinoin started immediately with 10 mg of prednisolone three times daily has been recommended.[7] Dapsone in conjunction with isotretinoin has been reportedly beneficial in the treatment of acne fulminans associated with erythema nodosum.[8] Cyclosporine, anakinra, and tumor necrosis factor (TNF) inhibitors have also been used in difficult cases of acne fulminans.[9-11]

ISOTRETINOIN-INDUCED ACNE FULMINANS

In contrast to the de novo version, isotretinoin-induced acne fulminans arises after starting isotretinoin therapy for acne. An explosive flare of tender, oozing, friable plaques with hemorrhagic crusts occurs with or without associated systemic symptoms. The flaring typically arises within the first month of treatment but may occur later. The pharmacomechanism of this unfortunate adverse reaction is not fully understood. Patients with severe inflammatory acne in particular are at risk. Lower starting doses of isotretinoin

Figure 80-3 **A,** Acne fulminans. An eruptive form of acne with extensive inflammatory papules and nodules on the face, coalescing with ecchymoses and crusting. **B** and, Eruptive, uniform friable papules over the chest and back with crusting. **D,** Resultant keloid scars in the same patient.

(0.3 to 0.5 mg/kg/day) and the concomitant addition of systemic corticosteroids may prevent flaring. If isotretinoin-induced acne fulminans does occur, the isotretinoin dose should be lowered or discontinued and prednisone therapy immediately started, following the guidelines for the management of acne fulminans above.

SAPHO SYNDROME

SAPHO syndrome is manifested by synovitis, acne, pustulosis, hyperostosis, and osteitis. It is predominantly associated with hyperostosis of the anterior chest, palmoplantar pustulosis, hidradenitis suppurativa, and acne fulminans. Its cause is unknown. Reported successful treatments for SAPHO syndrome include nonsteroidal antiinflammatory drugs, sulfasalazine, infliximab, adalimumab, methotrexate.[12] Paradoxically, worsening of SAPHO skin manifestations can be seen with anti-TNF agents.[13,14] The bisphosphonates are beneficial for treating the associated bone pain.[15]

PAPA, PASH, AND PAPSH SYNDROME

PAPA (pyogenic arthritis, pyoderma gangrenosum and acne), PASH (pyoderma gangrenosum, acne and hidradenitis suppurativa) and PAPASH (pyogenic arthritis, acne, pyoderma gangrenosum and hidradenitis suppurativa) are a group of systemic autoinflammatory disorders resulting from dysregulation of the innate immune system and over production of interleukin (IL)-1.[16] Patients with these disorders have a variable combination of sterile neutrophilic skin lesions, including acne, pyogenic granuloma, and hidradenitis suppurativa, and pyogenic arthritis. They may also give a history of inflammatory bowel disease and pancytopenia after administration of sulfa-containing medications. Mutations in the protein serine–threonine phosphatase interacting protein (PSTPIP1) results in an increase in IL-1β production.[17] There have been reports of successful treatment with cyclosporine, dapsone, infliximab, and anakinra.[18,19]

ACNE EXCORIÉE

Acne excoriée (or acne excoriée des jeunes filles) is a variant of skin-picking disorder. Often quite mild acne is systematically and neurotically excoriated, leaving crusted erosions that may scar. It is more common in females. Acne excoriée and skin-picking disorder are now recognized as excoriation disorders by the American Psychiatric Association in the *Diagnostic and Statistical Manual of Mental Disorders*, 5th edition (DSM-5).[20] They are categorized under obsessive-compulsive disorders and as such should be comanaged with psychiatry to address both the acne and the underlying psychogenic excoriation. That said, many patients are lost to follow-up, and there is a low rate of referral to mental health providers.[21]

ACNE MECHANICA

Acneiform eruptions have been observed after repetitive physical trauma to the skin such as pressure, friction, or rubbing. Two types of reactions result, either a flare in acne with comedones and inflammatory papules ("acne mechanica") or follicular inflammatory lesions ("folliculitis mechanica").[22] This can occur from clothing (belts and straps), sports equipment (football helmets and shoulder pads), and with crutches and prosthetics.[23,24] A classic example of acne mechanica is "fiddler's neck," produced where the violin pad repetitively rubs against the player's lateral neck.[25] The pathogenesis of these reactions are not fully understood. Alterations in the barrier function, microbiome, and activation of innate immune system, as well as keratinocyte disruption and increase in IL-1a are purposed to play a role.[22,26]

ACNE WITH SOLID FACIAL EDEMA

A rare and disfiguring variant of acne vulgaris is acne with solid facial edema, also known as Morbihan disease. There is a woody edema of the mid third face with accompanying erythema and acne. Similar changes have been reported with rosacea and Melkerson-Rosenthal syndrome. There may be fluctuations in the severity of the edema, but spontaneous resolution does not occur. Diagnosis can be made clinically. The histology of solid facial edema is nonspecific with dermal edema, fibrosis, dilated blood vessels, and a mixed inflammatory infiltrate.[27] Oral antibiotic treatment in acne with solid facial edema is typically ineffective. Treatment with low-dose isotretinoin (0.2–0.5 mg/kg/day) alone or in combination with oral glucocorticoids, ketotifen (1–2 mg/day), or clofazimine for 4 to 5 months has been reported to be beneficial.[28-30]

ACNE WITH ASSOCIATED ENDOCRINOLOGY ABNORMALITIES

Although the majority of cases of acne vulgaris occur in patients without endocrinologic disturbances, there are specific populations whose acne is driven or worsened by endocrine abnormalities. As mentioned previously, it is important to screen patients for such abnormalities by taking a thorough history. In females, in addition to the presence of acne, hyperandrogenism may be marked by irregular menstrual cycles, a deepened voice, increased libido, and hirsutism. Laboratory work can help define an endocrinologic problem causing acne.

POLYCYSTIC OVARIAN SYNDROME

Polycystic ovarian syndrome (PCOS) occurs in roughly 5% to 10% of women. Hyperandrogenism, acne, insulin resistance, and acanthosis nigricans are clinical markers of this syndrome. PCOS should be suspected in women with any combination of oligomenorrhea, clinical or biochemical hyperandrogenism, or polycystic ovaries on ultrasound scan.[31] Premenarchal women with acne and hirsutism should be screened for PCOS with a serum free testosterone level.[32,33] Additional testing may be indicated if the result is abnormal. In typical cases, testing should be deferred until 2 years after menarche because of the lack of established laboratory norms and inherent irregularity of menstrual cycles in this age group.[34] Women with PCOS are at increased risk of infertility, impaired glucose tolerance, type 2 diabetes, dyslipidemia, endometrial cancer, and cardiovascular disease. Combined oral contraceptives with spironolactone can be helpful in controlling acne and hirsutism.[35,36] The addition of metformin can also beneficial.[37] Additional treatment consists of weight management, lipid control, regulation of insulin resistance, and fertility assistance.[32]

CONGENITAL ADRENAL HYPERPLASIA

Congenital adrenal hyperplasia (CAH) is an autosomal recessive disorder caused by varying enzyme defects in the cortisol production pathway. 21β-hydroxylase, deficiency can result in both a classic severe type and as a nonclassic mild type. Neonates are screened at birth for the classic type and typically present with ambiguous genitalia and salt wasting. The nonclassic type is not identified at birth and can present throughout childhood and adolescence. The prevalence of the nonclassic type in the white population is 0.1%. Patients with this type of CAH have normal cortisol levels but increased androgens. Female patients present with findings similar to PCOS, including precocious puberty, irregular menses, polycystic ovaries, hirsutism, and acne.[38] Values of dehydroepiandrosterone

sulfate (DHEAS) in the range of 4000 to 8000 ng/mL are suggestive of CAH. Findings of CAH in males are often subtle and acne may be the only sign. CAH should be considered in patients who do not respond to treatment.[39] Treatment of patients with CAH consists of low-dose replacement of glucocorticoids, as well as oral contraceptives, spironolactone, or flutamide in females.

ACNEIFORM ERUPTIONS

STEROID FOLLICULITIS

As early as 2 weeks after initiation of systemic glucocorticoids or corticotropin, folliculitis may appear. Similar lesions may follow the prolonged application of topical glucocorticoids to the face or with inhaled steroids for asthma. The pathology of steroid acne is that of a focal folliculitis with a neutrophilic infiltrate in and around the follicle. This type of acne clearly differs from acne vulgaris in its distribution and in the type of lesions observed. The lesions, which are usually all in the same stage of development, consist of small pustules and red papules. In contrast to acne vulgaris, they appear mainly on the trunk, shoulders, and upper arms, with lesser involvement of the face. Postinflammatory hyperpigmentation may occur, but comedones, cysts, and scarring are unusual. Steroid folliculitis is uncommon in younger children. Treatment consists primarily of stopping any corticosteroid use. Typical acne treatments such as topical retinoids and antibiotics may also be helpful.

DRUG-INDUCED ACNE

In addition to glucocorticoids, other medicines can also cause a monomorphic, diffuse papular eruption that mimics steroid folliculitis. Such drugs include phenytoin, lithium, isoniazid, high doses of vitamin B complexes, halogenated compounds, and certain chemotherapy medications (Table 80-1). Halogenated compounds containing either bromides or iodides are often found in cold and asthma remedies, sedatives, radiopaque contrast material, kelp, and other vitamin and mineral combinations. With iodides, in particular, inflammation may be marked.[40,41] The iodine content of iodized salt is low and; therefore, it is extremely unlikely that enough iodized salt could be ingested to cause this type of acne.

TABLE 80-1
Drug-Induced Acneiform Eruptions

- Glucocorticoids
- Phenytoin
- Lithium
- Isoniazid
- High-dose vitamin B complex
- Halogenated compounds
- Epidermal growth factor receptor inhibitors
- BRAF inhibitors

EPIDERMAL GROWTH FACTOR RECEPTOR INHIBITOR ASSOCIATED ERUPTION

Epidermal growth factor receptor (EGFR) inhibitors may also cause a follicular-based eruption. EGFR inhibitors are primarily used to treat non–small-cell lung cancer, colorectal cancer, and breast cancer. Some of the EGFR inhibitors include the monoclonal antibodies cetuximab, panitumumab, necitumumab, pertuzumab, and small-molecule tyrosine kinase inhibitors gefitinib, erlotinib, afatinib, osimertinib, and lapatinib. A frequent side effect of the EGFR inhibitors is a perifollicular, papulopustular eruption distributed on the face and upper torso. The eruption occurs in up to 86% of patients treated with EGFR inhibitors.[42] An associated lateral paronychia may also occur. Histopathological sections of lesional skin show a noninfectious perifolliculitis. The cause of the acneiform eruption is not clear, but it may occur because EGFR is highly expressed in the basal cell layer of the epidermis, follicular keratinocytes, and the sebaceous epithelium. The presence and severity of the eruption correlates with a positive treatment response.[42,43] If the eruption is absent, dosing may be inadequate, or the patient's tumor may be unresponsive to EGFR inhibitor therapy. Treatment consists of managing pruritus with systemic antihistamines, γ-aminobutyric acid agonists, or aprepitant.[44] Management of the rash is based on the severity. The National Cancer Institute's Common Terminology Criteria for Adverse Events (CTCAE) grades the rash using a 1 to 5 scale based on body surface area involved, associated symptoms, and concomitant infection. For mild disease, topical hydrocortisone 2.5% cream or clindamycin 1% lotion is suggested. For more severe disease, higher strength topical steroids, doxycycline or minocycline, or low-dose isotretinoin is recommended.[45]

OCCUPATIONAL ACNE AND CHLORACNE

Several different groups of industrial compounds encountered in the workplace may cause acne. These include coal tar derivatives, insoluble cutting oils, and chlorinated hydrocarbons (chloronaphthalene, chlorobiphenyls, and chlorodiphenyloxide). Chloracne is the term that is used to describe occupational acne caused from chlorinated hydrocarbons. Occupational acne tends to be quite inflammatory and, in addition

to large comedones, is characterized by papules, pustules, large nodules, and true cysts. Tar acne is often accompanied by hyperpigmentation.[46] The lesions of occupational acne are not restricted to the face and, in fact, are more common on covered areas with intimate contact to clothing saturated with the offending compound. Because cutting oils are so widely used, they are the most common cause of industrial acne. However, the chlorinated hydrocarbons, which cause chloracne, have posed a more difficult problem because of the severity of the disease induced with these compounds. Exposure can cause comedones, cysts, and pigmentary changes of the skin but can also affect the ophthalmic, nervous, and hepatic systems. Exposure to the dioxin Agent Orange predisposes to invasive nonmelanoma skin cancer as well.[47] Many cases have occurred as the result of massive exposure in industrial accidents.[48] Chlorinated hydrocarbons are found in fungicides, insecticides, and wood preservatives. Chloracne classically affects the malar, retroauricular, and mandibular regions of the head and neck, as well as the axillae and scrotum. Pathology demonstrates multiple tiny infundibular cysts. Most chloracne lesions clear up within 2 years, providing exposure to the chemical has stopped. Treatment with topical or systemic retinoids or oral antibiotics may be beneficial.

GRAM-NEGATIVE FOLLICULITIS

Gram-negative folliculitis may occur in patients with preexisting acne vulgaris treated with long-term oral antibiotics, especially the tetracyclines. Patients usually give a history of initial success with oral tetracyclines followed by a worsening of their acne. Gram-negative folliculitis may appear as either papulopustules concentrated around the nose or as deep-seated nodules. Culture of these lesions may reveal *Enterobacter*, *Klebsiella*, or *Escherichia* spp. in the papulopustules or *Proteus* spp. in the nodules. An appropriate antimicrobial agent with adequate gram-negative coverage should be used. In recalcitrant cases, gram-negative folliculitis improves with oral isotretinoin for 4 to 5 months. Gram-negative bacteria require a moist environment for survival, and the drying action of isotretinoin will kill the bacteria.

RADIATION ACNE

Different types of radiation such as ionizing and ultraviolet (UV) may induce acneiform eruptions. Infrared radiation has been implicated recently as well.[49] Previous sites of therapeutic ionizing radiation (eg, external beam) can develop comedo-like papules.[50] These lesions begin to appear as the acute phase of radiation dermatitis is resolving. The ionizing rays induce epithelial metaplasia within the follicle, creating adherent hyperkeratotic plugs in the pilosebaceous unit. These keratotic plugs are resistant to extraction. Excessive exposure to UV radiation may produce a yellow, atrophic plaque studded with large open comedones. This condition is known as *Favre-Racouchot syndrome* but has also been called solar comedones, senile comedones, nodular cutaneous elastosis with cysts and comedones, and nodular elastoidosis with cysts and comedones. It has been estimated to occur in 6% of persons older than 50 years of age. The lesions are usually symmetrically distributed on the temporal and periorbital areas. Unilateral presentations have been reported depending on exposure. The exact pathogenesis of Favre-Racouchot syndrome is unknown, but it is suggested that extensive UV exposure as well as exposure to harsh climates and smoking may be risk factors. It can be treated with oral or topical retinoids as well as comedone extraction or CO_2 laser.[51,52]

TROPICAL ACNE

In extreme heat, a severe acneiform folliculitis may develop. This can be seen in tropical climates or in scorching occupational environments, as in furnace workers. This acneiform eruption is a major cause of dermatologic disability in military troops serving in tropical climates. Tropical acne occurs mainly on the trunk and buttocks. It has many deep, large, inflammatory nodules with multiple draining areas, resembling acne conglobata. The pathogenesis of this type of acne is unknown, although secondary infection with coagulase-positive staphylococci almost always ensues. Systemic antibiotics may be given but often removing the patient to a cooler environment is more important.

ACNE AESTIVALIS

This monomorphous eruption consists of multiple, uniform, red, papular lesions seen after sun exposure. It was initially called *Mallorca acne* because it occurred in many Scandinavians after they had been on a sunny vacation in Mallorca in southern Europe after a long, dark winter.[53] Almost all cases have occurred in women, mainly 20 to 30 years old. The lesions are common on the shoulders, arms, neck, and chest. Histologically, the lesions resemble steroid acne in that they show a focal follicular destruction with neutrophilic infiltrate. Comedones are not part of the clinical or histologic picture. The eruption is caused by the effects of UV radiation, primarily UVA. Rarely, a similar clinical picture can be observed after starting psoralen and UVA (PUVA) treatment. The eruption will subside if the patient is protected from UV light for several months. Oral antibiotics are ineffective in speeding up the resolution, but topical retinoids and benzoyl peroxide may be helpful. Like polymorphous light eruption, patients with acne aestivalis will flare on reexposure to UV light.[41]

Figure 80-4 Pseudoacne of the nasal crease. Open and closed comedones and small papules line up along the transverse nasal crease.

PSEUDOACNE OF THE NASAL CREASE

The transverse nasal crease is an anatomic variant that appears as a transverse linear groove across the middle of the nose. Preadolescent patients develop comedones, milia, and acneiform red papules within the nasal crease (Fig. 80-4). It can be familial or associated with the "allergic salute." Histologic examination of the papules reveals keratin granulomas that may be derived from ruptured, inflamed milia. Because of its similarity in clinical appearance to acne but deviation from acne histologically, it has been termed "pseudoacne of the nasal crease."[54]

APERT SYNDROME

Apert syndrome, also known as acrocephalosyndactyly, is an autosomal dominant disorder marked by synostoses of the cranium, vertebral bodies and hands and feet. It is caused by a mutation in the gene encoding FGFR-2. These patients have a diffuse acneiform eruption that often involves the arms, buttocks, and thighs. It is typically very resistant to treatment, but excellent responses to isotretinoin have been reported.[55] Patients with Apert syndrome may also present with severe seborrhea, nail dystrophy, and cutaneous and ocular hypopigmentation.

PERIORAL DERMATITIS (PERIORIFICIAL DERMATITIS)

Perioral dermatitis is an acneiform eruption that occurs in a bimodal distribution young children and young adults.[56] There is female predominance, mostly in adolescents and adults.[57] Small inflammatory papules and pustules group around the mouth in a typically well demarcated pattern, with sparing of the lip margin (Fig. 80-5). There is variable scaling and dryness. If the nose, eyes, or groin region is involved, it

Figure 80-5 Periorificial dermatitis. An 8-month-old girl with perioral and perinasal 2-mm pink papules. Note a few lesions on the lower eyelid as well.

is called periforificial dermatitis. The neck, trunk, and extremities are rarely involved but have been reported in children with the disorder.[58,59] Usually perioral dermatitis is asymptomatic with occasional itchy or burning noted.

A severe variant is called periorificial granulomatous dermatitis. In this version, larger, granulomatous inflammatory papules coalesce into a well delineated plaque around the mouth with more likely involvement of the periocular, perinasal, and groin areas. Rarely, scarring can occur. Blepharitis and chalazion may accompany eye involvement.

The facial Afro-Caribbean eruption (FACE) is another variant of periorificial dermatitis characterized by uniform, granulomatous sarcoidal papules distributed over the typical periorificial areas.[60] (Fig. 80-6) Distinguishing features include involvement of the upper eyelids and helices of the ears.[61] Histology is similar to granulomatous perioral dermatitis.

Figure 80-6 Facial Afro-Caribbean eruption, a variant of granulomatous periorificial dermatitis. Numerous inflammatory papules and pustules with overlying scale scattered around the mouth and nose extending to the lower eyelids.

The diagnosis of periorificial dermatitis is typically made by clinical evaluation, although a biopsy may be indicated in atypical cases. Histologically, periorificial dermatitis resembles rosacea with perifollicular and perivascular lymphohistiocytic infiltrate with variable perifollicular granulomas. In granulomatous periorificial dermatitis, histology is characterized by upper dermal and perifollicular granulomas admixed with lymphocytes, similar to sarcoidosis.

The pathogenesis of perioral dermatitis is not fully understood. The secondary eye changes along with the rosacea-like histology have prompted some to consider the disorder a form of rosacea.[62]

Additionally, demodex may play a role in some cases of periorificial dermatitis, evidenced by response to antiparasitic agents. There are several known triggers for the disorders, including topical or inhaled corticosteroid use, particularly fluorinated steroids and fluoride in dentifrices.

The differential diagnosis of periorificial eruptions includes acne vulgaris, allergic contact or irritant dermatitis, demodicosis, lupus miliaris disseminatus faciei, molluscum, seborrheic dermatitis, systemic lupus erythematosus, and steroid-induced rosacea. For the granulomatous variant, the differential diagnosis would include other granulomatous disorders such as granulomatous rosacea, fungal or mycobacterial infection, familial juvenile systemic granulomatosis (Blau syndrome), and sarcoidosis.

The management of periorificial dermatitis in children and adults is similar. Topical corticosteroid use should be avoided because it tends to perpetuate the eruption. In mild cases resulting from corticosteroid use, discontinuation of steroid application can alone be effective. Alternate therapies include topical antimicrobial and antiinflammatory agents, including metronidazole cream or gel, clindamycin gel or lotion, erythromycin gel, azelaic acid cream, and sodium sulfacetamide lotion. Topical pimecrolimus cream or tacrolimus ointment has also been used in to treat periorificial dermatitis and to diminish flares from topical steroid withdrawal.[63,64] In children, oral erythromycin or azithromycin may be added for refractory or severe cases, but tetracyclines are commonly used in adolescents and adults.[65] Recently, the antiparasitic agents praziquantel and ivermectin (both topical and oral) have been successfully used.[66,67] Although spontaneous resolution upon discontinuation of a known trigger can occur, prolonged and refractory cases are not that uncommon.

REFERENCES

1. Henderson CA, Taylor J, Cunliffe WJ. Sebum excretion rates in mothers and neonates. *Br J Dermatol*. 2000;142(1):110-111.
2. Bernier V, Weill FX, Hirigoyen V, et al. Skin colonization by Malassezia species in neonates: a prospective study and relationship with neonatal cephalic pustulosis. *Arch Dermatol*. 2002;138(2):215-218.
3. Bergman JN, Eichenfield LF. Neonatal acne and cephalic pustulosis: is Malassezia the whole story? *Arch Dermatol*. 2002;138(2):255-257.
4. Lucky AW. A review of infantile and pediatric acne. *Dermatology*. 1998;196(1):95-97.
5. Eichenfield LF, Krakowski AC, Piggott C, et al. Evidence-based recommendations for the diagnosis and treatment of pediatric acne. *Pediatrics*. 2013; 131(suppl 3):S163-S186.
6. Greywal T, Zaenglein AL, Baldwin HE, et al. Evidence-based recommendations for the management of acne fulminans and its variants. *J Am Acad Dermatol*. 2017;77(1):109-117.
7. Massa AF, Burmeister L, Bass D, et al. Acne fulminans: treatment experience from 26 patients. *Dermatology*. 2017; 233(2-3):136-140.
8. Tan BB, Lear JT, Smith AG. Acne fulminans and erythema nodosum during isotretinoin therapy responding to dapsone. *Clin Exp Dermatol*. 1997;22(1):26-27.
9. Giavedoni P, Mascaró-Galy JM, Aguilera P, et al. Acne fulminans successfully treated with cyclosporine and isotretinoin. *J Am Acad Dermatol*. 2014;70(2):e38-39.
10. Oranges T, Insalaco A, Diociaiuti A, et al. Severe osteoarticular involvement in isotretinoin-triggered acne fulminans: two cases successfully treated with anakinra. *J Eur Acad Dermatol Venereol*. 2017;31(6): e277-e279.
11. Lages RB, Bona SH, Silva FV, et al. Acne fulminans successfully treated with prednisone and dapsone. *An Bras Dermatol*. 2012;87(4):612-614.
12. Iqbal M, Kolodney MS. Acne fulminans with synovitis-acne-pustulosis-hyperostosis-osteitis (SAPHO) syndrome treated with infliximab. *J Am Acad Dermatol*. 2005;52(5 suppl 1):S118-120.
13. Li C, Wu X, Cao Y, et al. Paradoxical skin lesions induced by anti-TNF-alpha agents in SAPHO syndrome. *Clin Rheumatol*. https://doi.org/10.1007/s10067-018-4083-5
14. Amano H, Matsuda R, Shibata T, et al. Paradoxical SAPHO syndrome observed during anti-TNFα therapy for Crohn's disease. *Biologics*. 2017;11:65-69.
15. Kerrison C, Davidson JE, Cleary AG, et al. Pamidronate in the treatment of childhood SAPHO syndrome. *Rheumatology (Oxford)*. 2004;43(10):1246-1251.
16. Cugno M, Borghi A, Marzano AV. PAPA, PASH and PAPASH syndromes: pathophysiology, presentation and treatment. *Am J Clin Dermatol*. 2017;18(4): 555-562.
17. Geusau A, Mothes-Luksch N, Nahavandi H, et al. Identification of a homozygous PSTPIP1 mutation in a patient with a PAPA-like syndrome responding to canakinumab treatment. *JAMA Dermatol*. 2013;149(2):209-215.
18. Staub J, Pfannschmidt N, Strohal R, et al. Successful treatment of PASH syndrome with infliximab, cyclosporine and dapsone. *J Eur Acad Dermatol Venereol*. 2015;29(11):2243-2247.
19. Jennings L, Molloy O, Quinlan C, et al. Treatment of pyoderma gangrenosum, acne, suppurative hidradenitis (PASH) with weight-based anakinra dosing in a Hepatitis B carrier. *Int J Dermatol*. 2017;56(6): e128-e129.
20. Force APAAPAD-T. *Diagnostic and Statistical Manual of Mental Disorders*, 5th ed. ed. Washington, DC: American Psychiatric Association; 2013.
21. Anzengruber F, Ruhwinkel K, Ghosh A, et al. Wide range of age of onset and low referral rates to psychiatry in a large cohort of acne excoriee at a Swiss tertiary hospital. *J Dermatolog Treat*. 2017:1-4.

22. Dreno B, Bettoli V, Perez M, et al. Cutaneous lesions caused by mechanical injury. *Eur J Dermatol*. 2015;25(2): 114-121.
23. Kang YC, Choi EH, Hwang SM, et al. Acne mechanica due to an orthopedic crutch. *Cutis*. 1999;64(2):97-98.
24. Strauss RM, Harrington CI. Stump acne: a new variant of acne mechanica and a cause of immobility. *Br J Dermatol*. 2001;144(3):647-648.
25. Knierim C, Goertz W, Reifenberger J, et al. [Fiddler's neck]. *Hautarzt*. 2013;64(10):724-726.
26. Bettoli V, Toni G, Zauli S, et al. Acne mechanica: probable role of IL-1alpha. *G Ital Dermatol Venereol*. 2016;151(6):720-721.
27. Kuhn-Régnier S, Mangana J, Kerl K, et al. A report of two cases of solid facial edema in acne. *Dermatol Ther (Heidelb)*. 2017;7(1):167-174.
28. Friedman SJ, Fox BJ, Albert HL. Solid facial edema as a complication of acne vulgaris: treatment with isotretinoin. *J Am Acad Dermatol*. 1986;15(2 Pt 1):286-289.
29. Jungfer B, Jansen T, Przybilla B, et al. Solid persistent facial edema of acne: successful treatment with isotretinoin and ketotifen. *Dermatology*. 1993;187(1):34-37.
30. Helander I, Aho HJ. Solid facial edema as a complication of acne vulgaris: treatment with isotretinoin and clofazimine. *Acta Derm Venereol*. 1987;67(6):535-537.
31. Rotterdam ESHRE/ASRM-Sponsored PCOS Consensus Workshop Group. Revised 2003 consensus on diagnostic criteria and long-term health risks related to polycystic ovary syndrome. *Fertil Steril*. 2004;81(1):19-25.
32. Goodman NF, Cobin RH, Futterweit W, et al. American Association of Clinical Endocrinologists, American College of Endocrinology, and Androgen Excess and PCOS Society disease state clinical review: guide to the best practices in the evaluation and treatment of polycystic ovary syndrome—part 2. *Endocr Pract*. 2015;21(12):1415-1426.
33. Goodman NF, Cobin RH, Futterweit W, et al. American Association of Clinical Endocrinologists, American College of Endocrinology, and Androgen Excess and PCOS Society disease state clinical review: guide to the best practices in the evaluation and treatment of polycystic ovary syndrome—part 1. *Endocr Pract*. 2015;21(11):1291-1300.
34. Ibanez L, Oberfield SE, Witchel S, et al. An international consortium update: pathophysiology, diagnosis, and treatment of polycystic ovarian syndrome in adolescence. *Horm Res Paediatr*. 2017;88(6):371-395.
35. Leelaphiwat S, Jongwutiwes T, Lertvikool S, et al. Comparison of desogestrel/ethinyl estradiol plus spironolactone versus cyproterone acetate/ethinyl estradiol in the treatment of polycystic ovary syndrome: a randomized controlled trial. *J Obstet Gynaecol Res*. 2015;41(3):402-410.
36. Hagag P, Steinschneider M, Weiss M. Role of the combination spironolactone-norgestimate-estrogen in Hirsute women with polycystic ovary syndrome. *J Reprod Med*. 2014;59(9-10):455-463.
37. Harborne L, Fleming R, Lyall H, et al. Metformin or antiandrogen in the treatment of hirsutism in polycystic ovary syndrome. *J Clin Endocrinol Metab*. 2003;88(9):4116-4123.
38. Falhammar H, Nordenström A. Nonclassic congenital adrenal hyperplasia due to 21-hydroxylase deficiency: clinical presentation, diagnosis, treatment, and outcome. *Endocrine*. 2015;50(1):32-50.
39. Degitz K, Placzek M, Arnold B, et al. Congenital adrenal hyperplasia and acne in male patients. *Br J Dermatol*. 2003;148(6):1263-1266.
40. Harrell B, Rudolph A. Kelp diet: a cause of acneiform eruption. *Arch Dermatol* 1976;112:560.
41. Plewig G, Jansen T. Acneiform dermatoses. *Dermatology*. 1998;196(1):102-107.
42. Perez-Soler R, Delord JP, Halpern A, et al. HER1/EGFR inhibitor-associated rash: future directions for management and investigation outcomes from the HER1/EGFR inhibitor rash management forum. *Oncologist*. 2005;10(5):345-356.
43. Nasu S, Suzuki H, Shiroyama T, et al. Skin rash can be a useful marker for afatinib efficacy. *Anticancer Res*. 2018;38(3):1783-1788.
44. Santini D, Vincenzi B, Guida FM, et al. Aprepitant for management of severe pruritus related to biological cancer treatments: a pilot study. *Lancet Oncol*. 2012; 13(10):1020-1024.
45. Lacouture ME, Anadkat M, Jatoi A, et al. Dermatologic toxicity occurring during anti-EGFR monoclonal inhibitor therapy in patients with metastatic colorectal cancer: a systematic review. *Clin Colorectal Cancer*. 2018;17(2):85-96.
46. Leijs MM, Esser A, Amann PM, et al. Hyperpigmentation and higher incidence of cutaneous malignancies in moderate-high PCB- and dioxin exposed individuals. *Environ Res*. 2018;164:221-228.
47. Clemens MW, Kochuba AL, Carter ME, et al. Association between Agent Orange exposure and nonmelanotic invasive skin cancer: a pilot study. *Plast Reconstr Surg*. 2014;133(2):432-437.
48. Bertazzi PA, Bernucci I, Brambilla G, et al. The Seveso studies on early and long-term effects of dioxin exposure: a review. *Environ Health Perspect*. 1998; 106(suppl 2):625-633.
49. Pizzati A, Passoni E, Nazzaro G. Monolateral Favre-Racouchot syndrome following long-term exposure to infrared waves. *JAMA Dermatol*. 2018;154(5):623-625.
50. Hubiche T, Sibaud V. Localized acne induced by radiation therapy. *Dermatol Online J*. 2014;20(2).
51. Rallis E, Karanikola E, Verros C. Successful treatment of Favre-Racouchot disease with 0.05% tazarotene gel. *Arch Dermatol*. 2007;143(6):810-812.
52. Mavilia L, Campolmi P, Santoro G, et al. Combined treatment of Favre-Racouchot syndrome with a superpulsed carbon dioxide laser: report of 50 cases. *Dermatol Ther*. 2010;23(suppl 1):S4-S6.
53. Hjorth N, Sjolin KE, Sylvest B, et al. Acne aestivalis—Mallorca acne. *Acta Derm Venereol*. 1972;52(1): 61-63.
54. Risma KA, Lucky AW. Pseudoacne of the nasal crease: a new entity? *Pediatr Dermatol*. 2004;21(4): 427-431.
55. Paradisi A, Ghitti F, Capizzi R, et al. Acne treatment with isotretinoin in a patient with Apert syndrome. *Eur J Dermatol*. 2011;21(4):611-612.
56. Hafeez ZH. Perioral dermatitis: an update. *Int J Dermatol*. 2003;42(7):514-517.
57. Lipozenčić J, Hadžavdić SL. Perioral dermatitis. *Clin Dermatol*. 2014;32(1):125-130.
58. Urbatsch AJ, Frieden I, Williams ML, et al. Extrafacial and generalized granulomatous periorificial dermatitis. *Arch Dermatol*. 2002;138(10):1354-1358.
59. Hansen KK, McTigue MK, Esterly NB. Multiple facial, neck, and upper trunk papules in a black child. Childhood granulomatous perioral dermatitis with involvement of the neck and upper trunk. *Arch Dermatol*. 1992;128(10):1396-1397,1399.
60. Cribier B, Lieber-Mbomeyo A, Lipsker D. [Clinical and histological study of a case of facial Afro-Caribbean

childhood eruption (FACE)]. *Ann Dermatol Venereol*. 2008;135(10):663-667.
61. Williams HC, Ashworth J, Pembroke AC, et al. FACE—facial Afro-Caribbean childhood eruption. *Clin Exp Dermatol*. 1990;15(3):163-166.
62. Lucas CR, Korman NJ, Gilliam AC. Granulomatous perioral dermatitis: a variant of granulomatous rosacea in children? *J Cutan Med Surg*. 2009;13(2):115-118.
63. Rodriguez-Martin M, Saez-Rodriguez M, Carnerero-Rodriguez A, et al. Treatment of perioral dermatitis with topical pimecrolimus. *J Am Acad Dermatol*. 2007;56(3):529-530.
64. Oppel T, Pavicic T, Kamann S, et al. Pimecrolimus cream (1%) efficacy in perioral dermatitis—results of a randomized, double-blind, vehicle-controlled study in 40 patients. *J Eur Acad Dermatol Venereol*. 2007;21(9):1175-1180.
65. Goel NS, Burkhart CN, Morrell DS. Pediatric periorificial dermatitis: clinical course and treatment outcomes in 222 patients. *Pediatr Dermatol*. 2015;32(3):333-336.
66. Bribeche MR, Fedotov VP, Jillella A, et al. Topical praziquantel as a new treatment for perioral dermatitis: results of a randomized vehicle-controlled pilot study. *Clin Exp DermatolClin Exp Dermatol*. 2014;39(4):448-453.
67. Noguera-Morel L, Gerlero P, Torrelo A, et al. Ivermectin therapy for papulopustular rosacea and periorificial dermatitis in children: a series of 15 cases. *J Am Acad Dermatol*. 2017;76(3):567-570.

This page intentionally left blank

Disorders of Eccrine and Apocrine Sweat Glands

PART 15

Chapter 81 :: Hyperhidrosis and Anhidrosis

:: Anastasia O. Kurta & Dee Anna Glaser

AT-A-GLANCE

Primary focal (essential) hyperhidrosis:

- Idiopathic and symmetric and can affect the palms, soles, axillae, craniofacial region, groin, other areas, or combination of body sites.
- Treatment is based on severity of symptoms and location and follows a stepwise approach.

Secondary hyperhidrosis:

- Can occur from underlying systemic illnesses, medications, or both (obtaining a detailed medical history is crucial).
- The pattern of sweating is classically generalized, but sometimes can be focal or regional if caused by neurologic disease or trauma, or a primary dermatologic cause (eg, eccrine nevus).
- Treatment should target the underlying disease process or eliminate or change medications that the patient takes, but this is often not feasible.

Anhidrosis:

- Anhidrosis may occur because of congenital or acquired causes (secondary or idiopathic anhidrosis).
- Can become a medical emergency leading to hyperthermia, heat stroke, or death.

INTRODUCTION

Eccrine sweating is regulated by neurohormonal mechanisms; a derangement in any part of the regulatory pathways, such as the thermal center, central or peripheral nerve transmission, or eccrine gland sweat secretion can alter sweating. Eccrine sweat glands are innervated by sympathetic nerve fibers; the main neurotransmitter, acetylcholine, binds to the muscarinic receptors on the eccrine sweat glands to produce sweating. Disorders of eccrine sweating can be subdivided into two main categories: excessive sweating (hyperhidrosis) and reduced sweating (hypohidrosis or anhidrosis). Hyperhidrosis is a condition of excessive sweating beyond what is physiologically necessary to maintain normal body temperature. The prevalence at 4.8%, represents around 15.3 million people in the United States.[1] Hyperhidrosis can be further subdivided into primary and secondary hyperhidrosis. Pathogenesis of primary or essential hyperhidrosis is poorly understood. Secondary hyperhidrosis can result from underlying systemic illnesses, including, but not limited to, central and peripheral neurologic dysfunctions, endocrine disorders, psychiatric disorders, hormonal imbalance, infections, malignancy, certain primary dermatologic disorders, and from medications or toxins.[2] Hyperhidrosis can adversely impact patients' daily activities, be occupationally restrictive, and interfere with interpersonal relationships.

Anhidrosis is characterized by the inability to normally generate sweat when physiologically necessary to dissipate heat. As a result, this can become a medical emergency, leading to hyperthermia, heat stroke, or death. This chapter focuses on reviewing several disorders that can cause focal, regional, and generalized abnormalities in sweating. Please refer to Table 81-1 for an inclusive list of disorders of the eccrine glands and sweating. A review of the normal anatomy and physiology of eccrine sweat glands and sweating may be found in Chap. 6.

PRIMARY FOCAL (ESSENTIAL) HYPERHIDROSIS

Primary focal hyperhidrosis is a neurologic disorder that manifests as excessive sweating at baseline in various anatomic locations, including, but not limited to,

TABLE 81-1

Classification of Disorders of Eccrine Sweating

Primary Focal (Essential) Hyperhidrosis

Palmoplantar, axillary, craniofacial, generalized hyperhidrosis

Secondary Causes of Focal Hyperhidrosis

Caused by cerebral infarction

- Frontal opercular infarct
- Brainstem stroke

Associated with spinal cord injury

- Autonomic dysreflexia
- Posttraumatic syringomyelia
- Orthostatic hypotension triggered

Associated with other central nervous system disorders

- Chiari type I and II malformation
- Myelopathies caused by infarction, syringomyelia, tumor
- Cold-induced sweating syndrome
- Olfactory hyperhidrosis

Associated with peripheral nervous system disorders

- Peripheral motor neuropathy with autonomic dysfunction
- Dermatomal or focal hyperhidrosis caused by nerve trunk irritation
- Compensatory segmental hyperhidrosis (postsympathectomy, Ross syndrome, pure autonomic failure)
- *Gustatory sweating*
- *Physiologic*
- *Idiopathic*
- *Postherpetic*
- *Post nerve injury (postsurgical, diabetic autonomic neuropathy, postinfectious, tumor invasion)*
- Lacrimal sweating
- Harlequin syndrome
- Idiopathic, localized hyperhidrosis
- Idiopathic unilateral circumscribed hyperhidrosis
- Postmenopausal localized hyperhidrosis

Associated with local skin disorders

- Blue rubber bleb nevi
- Eccrine angiomatous hamartoma
- Tufted angioma
- Glomus tumor
- Burning feet syndrome
- Pachydermoperiostosis
- Granulosis rubra nasi
- Pretibial myxedema
- POEMS (polyneuropathy, organomegaly, endocrinopathy, M protein, and skin changes) syndrome

Secondary Causes of Generalized Hyperhidrosis

Associated with central nervous system disorders

- Episodic hypothermia with hyperhidrosis (Hines-Bannick or Shapiro syndrome)
- Posttraumatic or posthemorrhagic "diencephalic epilepsy"
- Fatal familial insomnia and Parkinson disease

Associated with fever and chronic infection

- Tuberculosis, malaria, brucellosis, endocarditis

Associated with metabolic and systemic medical diseases

- Hyperthyroidism, diabetes mellitus, hypoglycemia, hypercortisolism, acromegaly

Associated with malignancy

- Leukemia, lymphoma, pheochromocytoma, Castleman disease, carcinoids, renal cell cancer

Medication induced

- See Table 81-4
- Neuroleptic malignant syndrome
- Serotonin syndrome, other medications

Toxic syndromes

- Alcohol, opioid withdrawal, delirium tremens

Associated with central and peripheral nervous system disorders

- Familial dysautonomia (Riley-Day), Morvan fibrillary chorea

Primary Autonomic Disorders with Acquired Anhidrosis

Isolated sudomotor disorders

- Progressive isolated segmental anhidrosis
- Idiopathic pure sudomotor failure
- Chronic idiopathic anhidrosis

Sudomotor plus other autonomic disorders

- Ross syndrome
- Pure autonomic failure
- Autoimmune autonomic neuropathy

Secondary Autonomic Disorders Associated with Anhidrosis

Central nervous system lesions (eg, stroke, tumor, infection, infiltration, trauma)

- Hypothalamic lesions
- Brainstem lesions
- Spinal cord lesions

Degenerative disorders

- Multiple system atrophy, dementia with Lewy body disease, Parkinson disease—autonomic failure

Peripheral Nerve Lesions Causing Anhidrosis

- Hereditary sensory and autonomic neuropathy types I, II, IV (congenital insensitivity to pain with anhidrosis)
- Guillain-Barré syndrome (acute inflammatory demyelinating polyneuropathy)
- Diabetic autonomic neuropathy
- Amyloidosis
- Lepromatous neuropathy
- Lambert-Eaton myasthenic syndrome
- Alcoholic neuropathy
- Fabry disease
- Idiopathic small-fiber neuropathy
- Erythromelalgia
- Sympathectomy and other surgical lesions
- Harlequin syndrome

Anhidrosis caused by toxins, pharmacologic agents, and heat exposure

- *Botulism*
- Ganglionic blockers, anticholinergics, carbonic anhydrase inhibitors
- Opioids
- Heat hyperpyrexia and heat stroke

Anhidrosis Associated with Diseases of Skin and Sweat Glands

Anhidrosis caused by physical agents damaging skin

- Trauma, burns, pressure, scar formation, radiation therapy

Anhidrosis caused by congenital and acquired skin diseases

- Fabry and other congenital metabolic diseases
- Congenital ectodermal dysplasia
- Ichthyosis
- Neutrophilic eccrine hidradenitis
- Sjögren syndrome
- Systemic sclerosis (scleroderma)
- Incontinentia pigmenti
- Segmental vitiligo
- Bazex-Dupre-Christol syndrome

Disorders affecting the sweat duct

- Miliaria
- Palmoplantar pustulosis
- Psoriasis
- Lichen planus
- Atopic dermatitis

Disorders with abnormal sweat composition

- Atopic dermatitis (reduced dermcidin levels)
- Cystic fibrosis (increased chloride concentration)

the palms and soles, axillae, craniofacial region, groin, or a combination of body sites. It affects males and females equally, typically begins in childhood (palmar-plantar) or during puberty (axillary), and continues to persist into adulthood, with rare reports of spontaneous improvement.

CLINICAL FEATURES

Patients may experience mild (moist or damp skin) to severe (dripping wet) excessive sweating in affected areas. Hyperhidrosis rarely presents with medical complications such as maceration or secondary infections, but it has been reported to predispose the patient to increased risk of cutaneous infection, such as pitted keratolysis, dermatophytosis, and verruca vulgaris or plantaris.[3]

ETIOLOGY AND PATHOGENESIS

The cause of primary focal hyperhidrosis is poorly understood, but is believed to be a result of sympathetic overactivity without structural defects of the eccrine glands. Evidence also suggests that hyperhidrosis has a familial component, proposing a possible genetic cause for the condition.[4-6]

DIAGNOSIS

A thorough clinical history should be obtained from the patient, including age of onset, location and symmetry of sweating, aggravating and alleviating factors, previous treatments, full past medical and surgical history, family history, and current medications that may exacerbate the condition. To establish a diagnosis of primary focal hyperhidrosis, symptoms should be present for at least 6 months without an underlying systemic cause and include at least two of the following characteristics: bilateral and symmetric sweating, impairment of daily activities because of sweating, at least one episode of sweating per week, age of onset younger than 25 years, positive family history, and cessation of sweating during sleep[7] (Table 81-2). In the authors' experience, it is key to understand if the reported sweating is physiologic or not. Sweating can be continuous (mild or severe) or phasic and can be intensified by typical triggers, such as increased temperature, anxiety, stress, and physical activity. A thorough physical examination is necessary and includes inspection for excessive moisture and any other secondary skin conditions, such as bacterial or fungal infections or skin maceration, as well as evidence of systemic findings that might indicate a secondary form of hyperhidrosis. A Minor starch-iodine test is helpful to identify the involved area of hyperhidrosis at baseline, but it does not provide any information on severity of the disease (Fig. 81-1). Gravimetric (weight-based) assessment is an objective measurement of the amount of sweat production, commonly performed in clinical research studies, but it is not practical for routine clinical use. The effect of hyperhidrosis on quality of life can be assessed in multiple ways and can help guide response to therapy. Two commonly used tools are the Dermatology Life Quality Index (DLQI) and The Hyperhidrosis Disease Severity Scale (HDSS), a 4-point scale that measures the severity of patients' hyperhidrosis based on how it affects daily activities[8] (Table 81-3). Both of these tools can also be used to follow the response to therapy. The diagnosis of primary focal hyperhidrosis is generally straight forward; however, based on medical history, review of systems, and physical examination, the differential diagnosis could include the possibility of underlying secondary cause(s), which are reviewed later in this chapter.

TABLE 81-2
Primary Focal (Essential) Hyperhidrosis

Focal visible excessive sweating ≥6 months' duration without apparent cause and at least two of the following:

- Bilateral and relatively symmetric
- Age of onset typically before age of 25 years
- Cessation of sweating from the focal areas during sleep
- Frequency of at least once per week
- Positive family history
- Sweating impairs daily activities

CLINICAL COURSE, PROGNOSIS, AND MANAGEMENT

Primary focal hyperhidrosis is a chronic disorder, and it does not affect life expectancy. It does, however, have a very negative impact on the quality of life, affecting all domains of social life, sense of well-being, and

Figure 81-1 Positive starch iodine test result in a patient with primary axillary hyperhidrosis.

TABLE 81-3
Hyperhidrosis Disease Severity Scale

	IMPACT OF SWEATING ON DAILY ACTIVITIES
4	Intolerable; always interferes
3	Barely tolerable; frequently interferes
2	Tolerable; sometimes interferes
1	Never noticeable; never interferes

mental health.[1] There have been advancements in treatment options. Choosing the right treatment (Table 81-4) involves consideration of body location and severity of the disorder. Properly addressing patients' expectations is crucial in selecting the appropriate treatment and obtaining treatment compliance. First-line therapy includes over-the-counter (OTC) antiperspirants or aluminum chloride hexahydrate (10% to 35%). Aluminum chloride hexahydrate works best when applied to dry skin at bedtime and washed off after 6 to 8 hours. Patients should be counseled carefully on the proper application to reduce the risk of irritation. If moisture is present on the skin when aluminum chloride hexahydrate is applied, this can result in formation of a weak hydrochloric acid, which can cause symptoms of burning, irritation, or desquamation. If irritation occurs, it can usually be minimized by decreasing application to every other night or few times per week. However, this may also reduce efficacy. Thus, the authors recommend use of OTC clinical-strength antiperspirant on the nights when aluminum chloride hexahydrate is not being applied.

There have been several studies showing beneficial results with topical glycopyrrolate ranging in concentrations from 0.5% to 2%, particularly when used for craniofacial hyperhidrosis.[9,10] It is not yet commercially available in the United States at the time of writing this chapter, but it can be compounded at specialty pharmacies.

TABLE 81-4
Treatment Options for Primary Focal Hyperhidrosis

First-Line Topical Options
- Over-the-counter antiperspirants and aluminum chloride hexahydrate (10%–35%)
- Topical glycopyrrolate (0.5%–2%)

Second-Line Agents
- Intradermal botulinum toxin injections
- Electromagnetic energy thermolysis
- Tap water iontophoresis

Severe or Refractory Cases
- Endoscopic thoracic sympathectomy

Systemic Medications
- Glycopyrrolate or oxybutynin
- Clonidine
- Propranolol
- Benzodiazepines

If the patient fails to respond to topical therapy, intradermal injection of botulinum toxin may be administered to areas of excessive sweating. Botulinum toxin acts on the cholinergic synapses, inhibiting the release of acetylcholine. Numerous studies have demonstrated the efficacy and safety of several botulinum toxin A drugs as well as botulinum toxin B to treat hyperhidrosis. However, only onabotulinum toxin A (onabotA), (BOTOX; Allergan, Irvine, CA) was approved by the U.S. Food and Drug Administration (FDA) in 2004 for the treatment of severe primary axillary hyperhidrosis in adults 18 years and older. Although its approval is for adults, the efficacy and safety of onabotA can also be extended to adolescents. A large multicenter, nonrandomized, open-label study evaluated the efficacy and safety of onabotA in adolescents ages 12 to 17 years with severe primary axillary hyperhidrosis and demonstrated that 72% of patients experienced at least a two-grade improvement in the HDSS score at 4 and 8 weeks after each of the first two treatments.[11] The median duration of effect ranged from 4 to 5 months, and fewer than 6% of patients experienced treatment-related adverse effects.[11]

Botulinum toxin injections are also used off-label for treatment of other focal areas, such as the face or scalp, palms, soles, and inframammary and inguinal folds, with average efficacy duration of approximately 4 to 12 months.[12-14] Injections are placed at the dermal subcutaneous junction where the eccrine glands reside.

Electromagnetic energy thermolysis is a non-invasive procedure that can provide long-lasting reduction in axillary sweating; miraDry (Miramar Labs, Sunnyvale, CA) was cleared by the FDA in 2011 for adults with primary axillary hyperhidrosis. Microwave energy is readily absorbed by water molecules and as a result can easily target tissues with high water content, such as the eccrine glands. Eccrine glands do not regenerate, and their destruction theoretically reduces sweating in the treated area permanently. Side effects are generally minor and include edema, erythema, bruising from device vacuum suction, axillary tenderness or pain, paresthesia in the axilla or upper arm, and less commonly, blisters or burns at the treatment site, scar tissue formation, and patchy axillary alopecia (permanent).[15] This technology cannot be applied to nonaxillary body sites at the time of writing this chapter.

Control of palmar-plantar hyperhidrosis can be obtained via tap water iontophoresis therapy, which uses the passage of a direct electrical current onto the skin. Although the underlying mechanism of iontophoresis remains unclear, a controlled trial of 112 patients with palmar hyperhidrosis showed that after eight treatments, sweating was reduced by 81.2% from baseline with use of iontophoresis therapy.[16] Treatments need to be maintained typically once to twice weekly for maximal improvement. An anticholinergic, such as glycopyrrolate, can be crushed and mixed with the water to enhance sweat reduction. Side effects are typically minor (erythema, mild pain or discomfort, and paresthesia in the treatment zone) and related to higher amperage. Severe cases of palmar hyperhidrosis that failed conservative management may be considered

for endoscopic thoracic sympathectomy (ETS). This surgical procedure carries an increased risk of creating minor to severe compensatory sweating in body segments below the treated area, as well as less common complications such as Horner syndrome, bradycardia, pneumothorax requiring chest tube drainage, pleural effusion, acute bleeding or delayed hemothorax, chylothorax, and persistent intercostal neuralgia.[17]

Systemic medications can be used as monotherapy or to supplement the above therapies, especially when symptoms are multifocal. The oral agents that are commonly used are anticholinergics (glycopyrrolate and oxybutynin) or clonidine, a centrally acting α_2-adrenergic agonist.[18] Anticholinergic agents are contraindicated in those with myasthenia gravis, paralytic ileus, and pyloric stenosis and should be used with caution in patients with closed-angle glaucoma, bladder outflow obstruction, gastroesophageal reflux disease, and cardiac insufficiency.[19] They are also associated with many side effects, such as xerostomia, xerophthalmia, constipation, mydriasis, blurred vision, bradycardia (lower doses), tachycardia (higher doses), mental confusion (usually in children or older adults), and urinary hesitancy or retention. Glycopyrrolate is a quaternary amine and has limited passage across lipid membranes, such as the blood–brain barrier. Anticholinergic agents such as oxybutynin, atropine, and scopolamine are tertiary amines and can easily penetrate lipid barriers. This might explain why glycopyrrolate has fewer central nervous system side effects and may have less effect on the heart rate at lower doses.[19] β-Blockers, such as propranolol and benzodiazepines, are oral agents that can be useful in stress-induced hyperhidrosis. However, long-term use of benzodiazepines is not recommended.

SECONDARY HYPERHIDROSIS

Secondary hyperhidrosis can occur because of underlying medical conditions (congenital or acquired) or as a side effect from medications or toxins. Based on a retrospective chart review study conducted over a 13-year period (1993 to 2005) of all patients (children and adults) seen at a university-based outpatient dermatology department with a diagnosis of hyperhidrosis; in patients with secondary hyperhidrosis, endocrine disease accounted for 57% of cases (including diabetes mellitus, hyperthyroidism, and hyperpituitarism); neurologic disease accounted for 32% of cases and more commonly presented as asymmetric hyperhidrosis, and the remaining causes included malignancy (pheochromocytoma), respiratory disease, and psychiatric disease.[20] In this study, secondary hyperhidrosis was more often unilateral or asymmetric, generalized, and present nocturnally.

Localized secondary hyperhidrosis can occur because of physiologic or pathologic gustatory sweating, central or peripheral neurologic dysfunctions, cold-induced sweating syndrome, paroxysmal localized hyperhidrosis, intrathoracic neoplasms, or compensatory segmental hyperhidrosis (as in cases after ETS or as seen in Ross syndrome, which is a degenerative autonomic nervous system disorder). It can also be seen in association with certain cutaneous disorders.

Generalized secondary hyperhidrosis can result from metabolic and other systemic disorders, infections and fever, malignancy (eg, lymphoma or pheochromocytoma), or derangement in the central or peripheral autonomic nervous system (eg, Riley-Day syndrome, or familial dysautonomia) and as a side effect from medications or toxins. Pathogenesis varies depending on the underlying condition.

Several entities associated with secondary hyperhidrosis are highlighted below.

CLINICAL FEATURES

Patients with secondary hyperhidrosis can experience focal, regional, or generalized sweating that often persists during sleep. Although the onset of primary hyperhidrosis is often before age 25 years, secondary hyperhidrosis tends to present in adulthood, especially if it is caused by an underlying acquired disease; new symptoms of excessive sweating in adults should be carefully evaluated to ensure an underlying cause is not overlooked.[20]

ETIOLOGY AND PATHOGENESIS OF LOCALIZED (FOCAL OR REGIONAL) SECONDARY HYPERHIDROSIS

GUSTATORY SWEATING

It is common to experience localized sweating on the lips, forehead, scalp, and nose while eating hot and spicy foods as a physiologic response via trigeminovascular reflex. In contrast, pathologic gustatory sweating is usually asymmetric and intense and can occur in the distribution of the auriculotemporal nerve after injury or surgery in the region of the parotid gland; this is known as Frey syndrome (Fig. 81-2). The pathophysiology is not completely understood, but is thought to be caused by aberrant regeneration of autonomic fibers after local trauma to the auriculotemporal nerve.[21]

Frey syndrome can also be seen in infants and children, often after birth trauma with forceps delivery, but cases of familial, bilateral Frey syndrome without birth trauma have been reported.[22]

Gustatory sweating may also occur after upper thoracic and cervical sympathectomy,[23,24] facial herpes zoster, or chorda tympani injury[25] and has been described in association with cluster headache[26] and diabetes mellitus.[27]

Figure 81-2 A patient with pathologic gustatory sweating and a positive starch iodine test result.

Treatment with topical glycopyrrolate,[10] aluminum chloride, or botulinum toxin injection[27] can be effective; rarely, intracranial section of the glossopharyngeal nerve or tympanic neurectomy is needed.

PAROXYSMAL LOCALIZED HYPERHIDROSIS

Daytime paroxysmal hyperhidrosis affecting the head, neck and upper trunk can occasionally affect older postmenopausal women and less commonly, men. Hot flashes are typically not associated with paroxysmal localized hyperhidrosis, and hormonal replacement therapy is usually ineffective. Reported history of sweating before menopause is normal, distinguishing the syndrome from craniofacial essential hyperhidrosis. Alterations in hypothalamic set point temperature range for sweating could be the contributing factor; however, the pathophysiology is not clearly understood. Symptomatic treatment with clonidine or topical or oral glycopyrrolate may be effective.[28]

LOCALIZED SECONDARY HYPERHIDROSIS ASSOCIATED WITH CUTANEOUS DISORDERS

Excessive sweating has also been reported in association with certain cutaneous disorders such as blue rubber bleb nevus syndrome, perilesional skin of a glomus tumor, tufted angioma, eccrine angiomatous hamartoma or eccrine nevus, Grierson-Gopalan disease, pachydermoperiostosis, and pretibial myxedema.

ECCRINE NEVUS

Eccrine nevus is a rare skin hamartoma histologically defined as focal hyperplasia or hypertrophy of eccrine glands.[29] Clinically, it presents as hyperhidrotic isolated patch of skin with no epidermal changes and is frequently located on the forearm. Treatment decisions depend on the severity of the hyperhidrotic area. Isolated case reports have shown successful response to botulinum toxin injections and topical glycopyrrolate.[29,30]

ETIOLOGY AND PATHOGENESIS OF GENERALIZED SECONDARY HYPERHIDROSIS

METABOLIC, INFECTIOUS, AND OTHER SYSTEMIC DISORDERS

Hyperhidrosis has been previously reported in association with diabetes mellitus, hypoglycemia, thyrotoxicosis, carcinoid syndrome, hyperpituitarism (acromegaly), congestive heart failure, dumping syndrome, menopause, malignancy, and drug withdrawal.

Exogenous bacterial pyrogens that stimulate production of interleukin (IL)-1, IL-6, tumor necrosis factor, and interferons can cause fever and subsequently hyperhidrosis. These inflammatory cytokines act in the brain to induce and increase the synthesis of prostaglandins, resulting in elevation of the thermal set point.[31] The simultaneous activation of antipyretic mechanisms eventually produces excessive sweating. Tuberculosis, malaria, brucellosis, and subacute bacterial endocarditis are some of the infectious etiologies that could present with generalized hyperhidrosis. With regard to malignancy, excessive production of IL-6 by Hodgkin lymphoma cells has been shown to result in fever and subsequent night sweating.[32]

Riley-Day Syndrome: Familial dysautonomia (FD), also known as Riley-Day syndrome, is the most intensively studied of the hereditary sensory-autonomic neuropathies (designated as hereditary sensory and autonomic neuropathy [HSAN] type III). This is an autosomal recessive disorder that affects 1 in 3600 live births in the Ashkenazi Jewish population and is caused by mutations in the *IKAP* gene, located on chromosome 9.[33] FD is characterized by pronounced autonomic dysregulation with profuse sweating and salivation, diminished production of tears, red blotching of the skin, absence of fungiform papillae of the tongue, episodic orthostatic hypotension, arterial hypertension, reduced deep tendon reflexes, and behavioral abnormalities.[33]

MEDICATIONS AND TOXINS

Alteration in sweating can occur as a side effect from diverse classes of medications. Hyperhidrosis can be associated with serotonin (5-hydroxytryptamine) reuptake inhibitors, opioids, and prostaglandin inhibitors (naproxen). The mechanisms may relate to 5-hydroxytryptamine (2A) and dopamine receptor antagonism. Hyperhidrosis that commonly occurs during acute and chronic administration of opioids is mainly caused by stimulation of mast cell degranulation, resulting in the release of histamine.[34] In contrast, tricyclic antidepressants occasionally cause hyperhidrosis because of their sympathomimetic effect. The presumed mechanism is inhibited reuptake of norepinephrine, leading to stimulation of peripheral adrenergic receptors and a generalized diaphoretic response. Cholinergic agonists such as pilocarpine and bethanechol and reversible cholinesterase inhibitors such as pyridostigmine can increase sweating directly or indirectly via activation of M3 cholinergic receptors on sweat glands.

DIAGNOSIS

Just as with primary hyperhidrosis, a thorough clinical history and physical examination are crucial, particularly focusing on constitutional symptoms (fever, unexplained weight loss, chills, night sweats, fatigue) and endocrine and neurologic systems. Inquiring about prescription and OTC medications and supplements taken daily or as needed will also aid in recognizing secondary causes. Primary hyperhidrosis may be present in patients with underlying medical conditions, but generally with an onset of symptoms at a younger age and occurs in more classic focal locations as discussed previously. A Minor starch-iodine test may be used to assess the distribution of excessive sweating. If secondary hyperhidrosis is suspected, baseline vital signs and laboratory studies are warranted, and the patient should be referred to his primary care physician for an evaluation. Neurologic consultation may also be considered if suggested by the medical history or physical exam.

CLINICAL COURSE, PROGNOSIS, AND MANAGEMENT

Clinical course and prognosis will depend on the underlying disease that is manifesting symptoms of hyperhidrosis or discontinuing a culprit medication. Treatment should be focused on correcting or controlling the underlying disease, but symptoms may be reduced with any of the mentioned modalities listed previously.

ANHIDROSIS

Anhidrosis may occur because of congenital absence of sweat glands as in cases of hypohidrotic ectodermal dysplasia, hereditary metabolic disorders (Fabry disease), or acquired causes (secondary or idiopathic anhidrosis).

Secondary anhidrosis or hypohidrosis can result from connective tissue diseases (Sjögren syndrome), eccrine duct obstruction (from chronic dermatoses such as psoriasis or atopic dermatitis, or acute causes such as miliaria), underlying neurologic disorders with autonomic dysfunction (congenital insensitivity to pain with anhidrosis, multiple sclerosis, Shy-Drager syndrome), peripheral neuropathies, and medications or toxins.

CLINICAL FEATURES

Patients with focal or segmental anhidrosis may become aware of their disease because of compensatory hyperhidrosis in other regions (Fig. 81-3). Generalized anhidrosis or anhidrosis with large areas of involvement usually manifests as heat exhaustion, inability to tolerate increased physical activity in a hot environment, or dizziness upon exposure to heat.

HYPOHIDROTIC ECTODERMAL DYSPLASIA

Mutations in the *ED-1* gene encoding for ectodysplasin result in X-linked hypohidrotic ectodermal dysplasia, which is the most common form of the ectodermal dysplasias. These disorders are characterized by an

Figure 81-3 A patient with segmental anhidrosis (*yellow*) with compensatory left-sided hemihyperhidrosis (*purple*) caused by a right greater than left-sided upper thoracic spinal cord injury (sodium alizarin sulfate indicator powder).

abnormal development of eccrine sweat glands, hair, and teeth.[35] Autosomal-recessive and autosomal-dominant modes of inheritance have also been described.[36] Affected children are at risk of experiencing life-threatening hyperpyrexia because of their inability to sweat.

CONGENITAL INSENSITIVITY TO PAIN WITH ANHIDROSIS

Congenital insensitivity to pain with anhidrosis (CIPA), also known as HSAN type IV, is a rare autosomal recessive disorder characterized by the congenital insensitivity to noxious stimuli, anhidrosis, recurrent hyperpyrexia, mental retardation, and self-mutilating behavior.[37] CIPA is reported to occur because of loss-of-function variants in neurotrophic tyrosine receptor kinase 1 (NTRK1) gene. Nearly all of the associated symptoms can be attributed to the inability of NTRK1 signaling pathways to regulate the development of nociceptive, sympathetic, and central cholinergic neurons.[37]

FABRY DISEASE

Fabry disease is an inherited X-linked lysosomal storage disorder caused by deficient activity of α-galactosidase A. It presents during childhood in both male and female patients. Early manifestations include hypohidrosis, telangiectasia, angiokeratoma, acroparesthesia, and gastrointestinal symptoms.[38] Later in adolescence or adulthood, manifestations can include renal, cardiac, and central nervous system dysfunction. Hypohidrosis is the second most common symptom of Fabry disease; the pathogenesis is unclear but could be the result of accumulation of glycosphingolipids in eccrine sweat glands and secondary to autonomic peripheral neuropathy.[39]

ACQUIRED IDIOPATHIC GENERALIZED ANHIDROSIS

Acquired idiopathic generalized anhidrosis (AIGA) is a rare cause of anhidrosis that can result from idiopathic pure sudomotor failure, sudomotor neuropathy, or eccrine sweat gland failure.[40] The majority of AIGA cases, however, lack these pathologic abnormalities. Cases reported in literature affect primarily patients of Asian ethnicity, but it is not entirely clear if this is because of a genetic component or if AIGA is underreported in other populations. AIGA has a heterogenous clinical presentation and can include the following clinical features: acute onset, cholinergic urticaria, elevated serum immunoglobulin E levels, absence of other autonomic dysfunction, and marked response to glucocorticoids.[41] Spontaneous remission has been reported in some cases of AIGA, but anhidrosis tends to persist if it has been present for a long time. Patients with generalized or partial anhidrosis involving at least 30% to 40% of their body surface area should be advised against participation in activities requiring increased endurance or working in high ambient temperatures.[40]

MILIARIA

Miliaria results from obstruction of eccrine sweat ducts and occurs in conditions of increased heat and humidity. There are three types of clinically distinctive miliaria classified based on the level of the obstruction: miliaria crystallina, miliaria rubra, and miliaria profunda. In miliaria crystallina, ductal obstruction occurs at the stratum corneum. It presents as small, 1-mm, clear, fragile, vesicles that rupture easily (Fig. 81-4). They are commonly seen on the face and upper trunk in infants and on the trunk in adults. In miliaria rubra, obstruction occurs deeper within the epidermis and results in pruritic, 1- to 3-mm, nonfollicular, erythematous macules and papules on the upper trunk and neck. Sterile pustules may also develop and are termed *miliaria pustulosa*. When miliaria rubra becomes chronic or recurrent, occlusion of eccrine sweat ducts extends to a deeper level. In miliaria profunda, ductal obstruction occurs at the dermal–epidermal junction and produces asymptomatic, 1- to 3-mm white papules.

DIAGNOSIS

As with hyperhidrosis, a careful medical history is necessary, with special attention to medications, underlying medical conditions, and family history. Examination of the skin may not reveal the presence of anhidrosis, but could indicate compensatory hyperhidrosis. To

Figure 81-4 Miliaria crystallina with delicate, droplike vesicles and no underlying erythema.

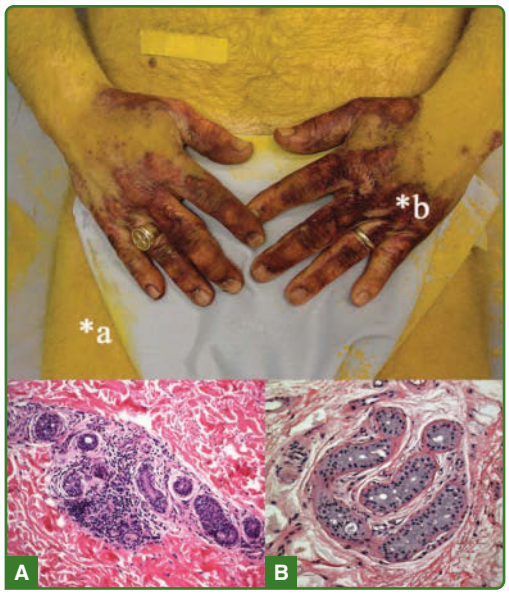

Figure 81-5 Punch skin biopsy from an anhidrotic skin site (**A**) shows marked perieccrine lymphocytic infiltration of sweat gland secretory coils, and sweating skin (**B**) shows normal sweat gland morphology.

identify possible sweat gland abnormalities, a biopsy specimen from the affected area should be obtained in patients with anhidrosis (Fig. 81-5).

CLINICAL COURSE, PROGNOSIS, AND MANAGEMENT

Unlike treatment of hyperhidrosis, options for anhidrosis are limited. The primary cause should be identified first, and any possible contributing medications should be discontinued. Keeping the patient in cool temperatures is crucial to avoid life-threatening overheating. It can also be helpful to wear wet clothing during physical activity; however, the effectiveness of external cooling may be compromised in patients with ectodermal dysplasia, presumably because of poor capillary dilation.[41,42] In cases of miliaria, treatment is usually not indicated for miliaria crystallina because of its self-limited nature. The topical application of anhydrous lanolin has resulted in dramatic improvement in patients with miliaria profunda.[43] Prevention and treatment of miliaria consists of controlling exposure to heat and humidity, treating any underlying febrile illnesses, and removing occlusive clothing.

ACKNOWLEDGMENTS

The authors acknowledge the contribution of Robert D. Fealey and Adelaide A. Hebert, the former authors of this chapter.

REFERENCES

1. Doolittle J, Walker P, Mills T, et al. Hyperhidrosis: an update on prevalence and severity in the United States. *Arch Dermatol Res*. 2016;308(10):743-749.
2. Sato K, Kang WH, Saga K, et al. Biology of sweat glands and their disorders. II. Disorders of sweat gland function. *J Am Acad Dermatol*. 1989;20(5):713-726.
3. Walling HW. Primary hyperhidrosis increases the risk of cutaneous infection: a case-control study of 387 patients. *J Am Acad Dermatol*. 2009;61(2):242-246.
4. Ro KN, Cantor RM, Lange KL, et al. Palmar hyperhidrosis: evidence of genetic transmission. *J Vasc Surg*. 2002;382-386.
5. Chen J, Lin M, Chen X, et al. A novel locus for primary focal hyperhidrosis mapped on chromosome 2q31.1. *Br J Dermatol*. 2015;172:1150-1164.
6. Kaufmann H, Saadia D, Polin C, et al. Primary hyperhidrosis: evidence for autosomal dominant inheritance. *Clin Auton Res*. 2003;13:96-98.
7. Hornberger J, Grimes K, Naumann M, et al. Recognition, diagnosis, and treatment of primary focal hyperhidrosis. *J Am Acad Dermatol*. 2004;51(2):274-286.
8. Solish N, Bertucci V, Dansereau A. A comprehensive approach to the recognition, diagnosis, and severity-based treatment of focal hyperhidrosis: recommendations of the Canadian Hyperhidrosis Advisory Committee. *Dermatol Surg*. 2007;908-923.
9. Kim WO, Kil HK, Yoon KB, et al. Topical glycopyrrolate for patients with facial hyperhidrosis. *Br J Dermatol*. 2008;158:1094-1097.
10. Hays LL. The Frey syndrome: a review and double blind evaluation of the topical use of a new anticholinergic agent. *Laryngoscope*. 1978;88:1796-1824.
11. Glaser DA, Pariser DM, Hebert AA, et al. A prospective, nonrandomized, open-label study of the efficacy and safety of onabotulinumtoxinA in adolescents with primary axillary hyperhidrosis. *Pediatr Dermatol*. 2015;32(5):609-617.
12. Kinklelin I, Hund M, Naumann M, et al. Effective treatment of frontal hyperhidrosis with botulinum toxin A. *Br J Dermatol*. 2000;143:824-827.
13. Shelley WB, Talanin NY, Shelley ED. Botulinum toxin therapy for palmar hyperhidrosis. *J Am Acad Dermatol*. 1998;38:227-229.
14. Hexsel DM, Dal'Forno T, Hexsel CL. Inguinal, or Hexsel's hyperhidrosis. *Clin Dermatol*. 2004;22(1):53-59.
15. Jacob C. Treatment of hyperhidrosis with microwave technology. *Semin Cutan Med Surg*. 2013;32(1):2-8.
16. Karakoc Y, Aydemir EH, Kalkan MT, et al. Safe control of palmoplantar hyperhidrosis with direct current. *Int J Dermatol*. 2002;41:602-605.
17. Cerfolio RJ, De Campos JRM, Bryant AS, et al. The Society of Thoracic Surgeons expert consensus for the surgical treatment of hyperhidrosis. *Ann Thorac Surg*. 2011;91:1642-1648.
18. Walling HW. Systemic therapy for primary hyperhidrosis: a retrospective study of 59 patients treated with glycopyrrolate or clonidine. *J Am Acad Dermatol*. 2012;66(3):387-392.
19. Bajaj V, Langtry JA. Use of oral glycopyrronium bromide in hyperhidrosis. *Br J Dermatol*. 2007;157:118-121.
20. Walling, HW. Clinical differentiation of primary from secondary hyperhidrosis. *J Am Acad Dermatol*. 2011;64(4):690-695.
21. Dunbar EM, Singer TW, Singer K, et al. Understanding gustatory sweating. What have we learned from

Lucja Frey and her predecessors? *Clin Auton Res*. 2002;12:179-184.
22. Sethuraman G, Mancini AJ. Familial auriculotemporal nerve (Frey) syndrome. *Pediatr Dermatol*. 2009;26(3): 302-305.
23. Kurchin A, Adar R, Zweig A, et al. Gustatory phenomena after upper dorsal sympathectomy. *Arch Neurol*. 1977;34:619-623.
24. Bloor K. Gustatory sweating and other responses after cervicothoracic sympathectomy. *Brain*. 1969;92:137-146.
25. Young AG. Unilateral sweating of the submental region after eating (chorda tympani syndrome). *Br Med J*. 1956;12:976-979.
26. Drummond PD. Autonomic disturbances in cluster headache. *Brain*. 1988;111:1199-1209.
27. Restivo DA, Lanza S, Patti F, et al. Improvement of diabetic autonomic gustatory sweating by botulinum toxin type A. *Neurology*. 2002;59:1971-1973.
28. Kuritzky A, Hering R, Goldhammer G, et al. Clonidine treatment in paroxysmal localized hyperhidrosis. *Arch Neurol*. 1984;41:1210-1211.
29. Lera M, Espana A, Idoate MA. Focal hyperhidrosis secondary to eccrine naevus successfully treated with botulinum toxin type A. *Clin Exp Dermatol*. 2015;40(6): 640-643.
30. Dua J, Grabczynska S. Eccrine nevus affecting the forearm of an 11-year-old girl successfully controlled with topical glycopyrrolate. *Pediatr Dermatol*. 2004; 31(5):611-612.
31. Netea MG, Kullberg BJ, Van der Meer JWM. Circulating cytokines as mediators of fever. *Clin Infect Dis*. 2000;31(5):S178-S184.
32. Nagel S, et al. HLXB9 activates IL6 in Hodgkin lymphoma cell lines and is regulated by PI3K signalling involving E2F3. *Leukemia*. 2005;19(5):841-846.
33. Dietrich P, Dragatsis I. Familial dysautonomia: mechanisms and models. *Genet Mol Biol*. 2016;39(4):497-514.
34. Ikeda T, Kurz A, Sessler DI, et al. The effect of opioids on thermoregulatory responses in humans and the special antishivering action of meperidine. *Ann N Y Acad Sci*. 1997;813:792-798.
35. Vincent MC, Biancalana V, Ginisty D, et al. Mutational spectrum of the ED1 gene in X-linked hypohidrotic ectodermal dysplasia. *Eur J Hum Genet*. 2001;9:355-363.
36. Priolo M, Lagana C. Ectodermal dysplasias: a new clinical-genetic classification. *J Med Genet*. 2001;38: 579-585.
37. Wang QL, Guo S, Duan G, et al. Phenotypes and genotypes in five children with congenital insensitivity to pain with anhidrosis. *Pediatr Neurol*. 2016;61:63-69.
38. Zampetti A, Orteu CH, Antuzzi D, et al. Angiokeratoma: decision-making aid for the diagnosis of Fabry disease. *Br J Dermatol*. 2012;166:712-720.
39. Orteu CH, Jansen T, Lidove O, et al. Fabry disease and the skin: data from FOS, the Fabry outcome survey. *Br J Dermatol*. 2007;157:331-317.
40. Tay LK, Chong WS. Acquired idiopathic anhidrosis: a diagnosis often missed. *J Am Acad Dermatol*. 2014; 71(3):499-506.
41. Nakazato Y, Tamura N, Ohkuma A, et al. Idiopathic pure sudomotor failure anhidrosis due to deficits in cholinergic transmission. *Neurology*. 2004;63:1476-1480.
42. Brengelmann GL, Freund PR, Rowell LB, et al. Absence of active cutaneous vasodilation associated with congenital absence of sweat glands in human. *Am J Physiol*. 1981;240:H571-H575.
43. Kirk JF, Wilson BB, Chun W, et al. Miliaria profunda. *J Am Acad Dermatol*. 1996;35(5 Pt 2):854-856.

Chapter 82 :: Bromhidrosis and Chromhidrosis

:: Christos C. Zouboulis

BROMHIDROSIS

AT-A-GLANCE

- *Bromhidrosis* refers to an offensive or unpleasant body odor arising from apocrine or eccrine gland secretions.
- Chronic disorder that most often develops in the axillae, but may also involve the genitals or plantar aspect of the feet.
- The best-characterized short-chain fatty acid causing odor is ε-3-methyl-2-hexenoic acid.
- Surgical removal of affected glands may be effective.

Body odor, *osmidrosis*, is a common phenomenon in a postpubertal population. *Bromhidrosis* refers to offensive body odor that is excessive or particularly unpleasant, which prominently arises from apocrine and eccrine glands. Bromhidrosis is most often reported in the axillae (apocrine bromhidrosis). This condition may contribute to impairment of an individual's psychosocial functioning. The terminology in the literature is sometimes confusing, using *osmidrosis* to imply offensive odor, and *bromhidrosis* to imply osmidrosis in the setting of concomitant hyperhidrosis (excessive eccrine sweat gland secretion).[1]

EPIDEMIOLOGY

Apocrine bromhidrosis usually occurs after puberty. It exhibits a male predominance, which may be a reflection of greater apocrine gland activity in men than in women. There is no seasonal or geographic predilection, although summer months or warm climates may aggravate the disease. Poor personal hygiene also may be a contributing factor. Bromhidrosis is usually an individual condition, whereas apocrine bromhidrosis has been reported in asian families.[2]

ETIOLOGY AND PATHOGENESIS

Apocrine secretion is predominantly responsible for odor production, primarily through bacterial action on its components.[3] It is accepted that the odorous steroids, the so-called pheromones, among them 16-androstenes, 5α-androstenol, and 5α-androstenone, contribute to osmidrosis.[4,5] 5α-Reductase type I is expressed in apocrine glands. Individuals with osmidrosis have increased levels of 5α-reductase in their apocrine glands. Because this enzyme catalyzes the conversion of testosterone to 5α-dihydrotestosterone, levels of 5α-dihydrotestosterone may be greater than testosterone in the skin of affected individuals.[6] The biotransformation of these steroids is complex and further research is required to delineate these pathways.

Moreover, the axilla hosts many different bacteria, most of which are Gram-positive. Bromhidrosis has been particularly associated with the action of aerobic *Corynebacterium* species.[3] Axillary bacterial florae produce the distinctive axillary odor by transforming nonodoriferous precursors in sweat to ammonia and short-chain, malodorous, volatile fatty acids. The most common of these are ε-3-methyl-2-hexenoic acid and (RS)-3-hydroxy-3-methlyhexanoic acid, which are released through the action of a specific zinc-dependent *N*-alpha-acyl-glutamine aminoacylase from *Corynebacterium* species.[6,7] ε-3-Methyl-2-hexenoic acid is delivered to the surface of the skin on 2 binding proteins, apocrine-secretion binding proteins 1 (ASOB1) and 2 (ASOB2). ASOB2 has been identified as apolipoprotein D.[8]

One study proposed an autosomal dominant inheritance pattern for apocrine bromhidrosis. Newer studies have found a strong relationship between bromhidrosis and wet ear wax associated with the single nucleotide polymorphism rs 17822931 of the *ABCC11* gene.[9,10]

Eccrine secretions are distributed in a generalized fashion, are usually odorless, and serve a thermoregulatory function. The effect of hyperhidrosis on eccrine osmidrosis and bromhidrosis is unclear. Some advocate that excessive eccrine sweat improves apocrine bromhidrosis by flushing away excessive apocrine secretions. Others postulate that eccrine sweat augments apocrine bromhidrosis by encouraging local spread of apocrine sweat components and enhancing the moist environment in which bacteria flourish; that is, eccrine bromhidrosis may develop from the action of bacteria on keratin that has been softened by eccrine secretions. A plantar location is characteristic for eccrine bromhidrosis. Certain foods (garlic, curry, alcohol), drugs (bromides), toxins, or metabolic causes (disorders of amino acid metabolism) may result in eccrine bromhidrosis; the latter being fish odor syndrome (trimethylaminuria), phenylketonuria, cat syndrome, isovaleric acidemia, hypermethioninemia, and food, drug, toxin ingestion.[2]

CLINICAL FINDINGS

HISTORY

Patients complain of an unpleasant body odor. The axillae are the most commonly affected site, although the genitals or plantar feet also may be affected.[3] The diagnosis is usually clinical. What constitutes a "normal" amount of body odor varies considerably among individuals and ethnic groups. In Asian populations, only slight odor is often considered diagnostic.[11,12]

CUTANEOUS LESIONS

Physical examination of the affected individual is usually unremarkable.

LABORATORY TESTS

There are no associated laboratory abnormalities.

PATHOLOGY

Although some reports do not reveal any abnormalities in the apocrine glands of affected individuals, an increase in the numbers and size of apocrine glands has been reported.[11]

DIFFERENTIAL DIAGNOSIS

Apocrine bromhidrosis can be distinguished from eccrine bromhidrosis, which is far less common. Moreover, further conditions should be distinguished from bromhidrosis; Table 82-1 outlines the differential diagnosis of bromhidrosis.

TABLE 82-1
Differential Diagnosis of Bromhidrosis[13]

- Apocrine bromhidrosis
- Eccrine bromhidrosis
  - Fish odor syndrome (trimethylaminuria)
  - Phenylketonuria
  - Sweaty feet syndrome
  - Odor of cat syndrome
  - Isovaleric acidemia
  - Hypermethioninemia
  - Food, drug, toxin ingestion
- Liver failure (fetor hepaticus)
- Renal failure
- Nasal foreign body in children
- Poor hygiene
- Olfactory hallucinations/Schisophenia
- Body dysmorphic disorder
- Erythrasma
- Trichomycosis axillaris

TREATMENT

GENERAL MEASURES

Frequent washing of the axillae, use of a deodorant or antiperspirant (aluminum chloride hexahydrate), perfumes, and changing of soiled clothing can help. Removal of axillary hair may minimize odor by preventing bacteria and sweat accumulation on the hair shafts. Antibacterial soaps or topical antibacterial agents also may be beneficial.

NONSURGICAL THERAPY

The injection of botulinum toxin A has been reported to successfully treat genital[13] and axillary bromhidrosis.[14] The frequency-doubled, quality-switched neodymium:yttrium-aluminum-garnet laser also has been reported to be an effective noninvasive therapy for axillary bromhidrosis.[15]

SURGERY

Several surgical measures have been investigated in the treatment of apocrine bromhidrosis. Patient selection is important because surgery is potentially associated with postoperative scar formation, prolonged healing times, infection, and other complications. Upper thoracic sympathectomy has been successful in treating apocrine bromhidrosis either in isolation or in association with palmar hyperhidrosis.[1] Surgical removal of the culprit apocrine glands can be achieved either by the removal of subcutaneous tissue in isolation or in combination with axillary skin.[16-20] Surgical subcutaneous tissue removal also has been used in association with CO_2 laser ablation.[21,22] Although surgical excision may be highly efficacious, depending on the depth of tissue removed and surgical technique used, regeneration and return of apocrine function/osmidrosis and bromhidrosis may develop. Superficial liposuction,[21] tumescent superficial liposuction with curettage,[23] and ultrasound-assisted liposuction,[24] as well as their combinations,[25] have efficacy in the management of apocrine bromhidrosis. Liposuction curettage can be considered the primary choice among surgical procedures used to treat patients with bromhidrosis because of its fewer complications.[24] In a series of 375 patients, more than 90% reported a satisfactory reduction in odor after ultrasound-assisted liposuction.[26] This technique uses ultrasound to liquefy fat and sweat glands. In contrast, laser hair removal may be associated with intensification of bromhidrosis.[27] The newly reported treatment using a microwave-based device may be an effective alternative treatment for axillary hyperhidrosis/bromhidrosis.[28]

PROGNOSIS AND CLINICAL COURSE

Apocrine bromhidrosis is a chronic and nonremitting condition.[29] Patients with apocrine bromhidrosis often feel self-conscious and embarrassed by their condition and may develop a psychosocial functioning impairment. Patients with body dysmorphic disorders may present claiming bromhidrosis.

CHROMHIDROSIS

AT-A-GLANCE

- Rare, chronic condition characterized by the secretion of colored sweat.
- Axillary and facial involvement is most common. Areola involvement has been reported.
- Caused by an increased number of lipofuscin granules in the luminal secretory cells of the apocrine glands.
- Secretions may be yellow, blue, green, brown, or black.
- Wood light examination may demonstrate fluorescence of secretions and stained clothes.
- Adequate therapy is lacking. Reports of treatment efficacy with manual expression, capsaicin, and botulinum toxin.

Chromhidrosis is a rare condition characterized by the secretion of colored apocrine sweat. Two variants of apocrine chromhidrosis are recognized: axillary and facial.[29] Involvement of the mammary areola also has been described.[30,31] Yonge first recognized facial chromhidrosis in 1709. Shelley and Hurley described this entity in 1954 and associated it with an increased number of lipofuscin granules in apocrine glands.[32]

EPIDEMIOLOGY

Chromhidrosis is a rare disease. The worldwide prevalence is unknown. Onset of chromhidrosis is usually at puberty, at the time of increased apocrine gland activity. However, rare cases of onset in infancy have been reported.[33] The disease persists throughout life, improving in the aged. It is reported most commonly in African Americans.[29] Geographic predilections have never been described. Most of the cases reported in the literature involve women; however, there is a lack of sound scientific evidence supporting a female preponderance.

ETIOLOGY AND PATHOGENESIS

The pigment responsible for causing apocrine chromhidrosis is lipofuscins that are produced in the apocrine secretory cells and excreted to the skin surface. Lipofuscin is a golden-colored pigment that is not specific to apocrine glands. In chromhidrosis, the lipofuscin granules are in a higher state of oxidation, thereby imparting various colors of pigment, such as yellow, green, blue, or black. Higher states of oxidation produce darker colors.[29,34] It is uncertain why this only develops in some individuals. One case of facial chromhidrosis was successfully treated with capsaicin.[35] Nerve endings with receptors for substance P have been found around eccrine sweat glands, suggesting that substance P, a potent vasodilator, may play a role in sweat production and chromhidrosis.[29]

True eccrine chromhidrosis is very rare and occurs when water-soluble pigments are excreted from eccrine glands after the ingestion of certain dyes or drugs, such as quinine or cranberry juice.[34,36] Eccrine chromhidrosis also has been reported in association with alkaptonuria (ochronosis), hyperbilirubinemia[37,38] and hematohidrosis (bleeding diathesis).

CLINICAL FINDINGS

HISTORY

Individuals with chromhidrosis often describe a sensation of warmth, a prickling sensation, or tingling feeling before apocrine gland secretion. Triggers for colored sweating are usually emotional or physical stimuli.[29] The morbidity associated with chromhidrosis stems from the emotional distress experienced by affected individuals.[39] Staining of undershirts and handkerchiefs are common complaints.

CUTANEOUS LESIONS

Individuals with chromhidrosis develop colored sweat in the axillae, face, or mammary areolae area (Fig. 82-1).[29-31] The pigment produced ranges in color from yellow to blue, green, brown, or black. The quantity of pigmented sweat produced is usually quite small (approximately 0.001 mL at each follicular orifice).[41] The droplets are odorless and dry quickly. Dried secretions appear as dark flecks within affected areas. Axillary involvement causes staining of shirts and undergarments. Facial chromhidrosis commonly develops close to the lower eyelid, including the malar cheeks, and occasionally the forehead.[39,40] Colored sweat also can be manually expressed by squeezing in the affected area. Such a maneuver also may be therapeutic.[29]

Figure 82-1 **A,** Blue-black sweat produced in a patient with facial apocrine chromhidrosis after gentle squeezing of the cheeks. (Reproduced with permission from Chang YC, Anderson N, Soeprono F. Bilateral facial pigmentation. *Dermatol Online J.* 2007;13[3]:16.) **B,** Blue-black apocrine pigmentation of the axilla and the inflammatory boils of a male patient with hidradenitis suppurativa.

SPECIAL TESTS

An examination of yellow, blue, or green secretions using a Wood light (360 nm) produces a characteristic yellow fluorescence. Black or brown pigment rarely autofluoresces.[29] Secretions can be manually expressed if not present at the time of examination. Stained clothing may also fluoresce with Wood lamp examination.[41] Apocrine glands can be stimulated to produce colored secretions by the injection of epinephrine or oxytocin.

LABORATORY TESTS

It is reasonable to check a complete blood cell count to exclude a bleeding diathesis, homogentisic levels in urine to exclude alkaptonuria, and bacterial and fungal cultures of affected areas to exclude pseudoeccrine chromhidrosis.[34]

PATHOLOGY

The luminal cells of the apocrine sweat glands have an eosinophilic cytoplasm, a large nucleus, and may contain lipofuscin, iron, lipid, or periodic acid–Schiff–positive and diastase-resistant granules.[42] Under light microscopy using hematoxylin-and-eosin staining, an increased number of (yellow to brown) lipofuscin granules may be present in the apical portion of luminal secretory cells of the apocrine glands. The number of granules varies. Additionally, autofluorescence of paraffin-embedded nonstained sections can be demonstrated using a 360-nm wavelength.[41] The granules are positive on periodic acid–Schiff stains. Schmorl stain also may be weakly positive.[43]

DIFFERENTIAL DIAGNOSIS

Chromhidrosis must be distinguished from pseudochromhidrosis (Table 82-2).[34,44] *Pseudoeccrine chromhidrosis* refers to the development of colored sweat when surface compounds or molecules mix with sweat to produce pigment. A classic example of this type is the formation of blue sweat in copper workers.[39] Extrinsic dyes, paints, fungi, and chromogenic bacteria (eg, *Corynebacterium* species) are other causes of pseudochromhidrosis.[29,34]

TREATMENT

Adequate therapy for chromhidrosis is lacking. Manual expression of colored secretions may result in a temporary improvement in symptoms for the following 48 to 72 hours.[35] Botulinum toxin type A has been reported as being successful in one patient with facial chromhidrosis. This patient experienced a substantial reduction in pigmented sweat and the results were sustained for 4 months.[45] Capsaicin is a topical cream that depletes and prevents reaccumulation of substance P levels in unmyelinated, slow-conducting type C sensory fibers.

TABLE 82-2
Differential Diagnosis of Chromhidrosis[34]

- Pseudoeccrine chromhidrosis[42]
  - Blue sweat with copper exposure
  - Extrinsic dyes, paints
- Chromogenic bacteria (eg, *Corynebacterium* species), *Pseudomonas*

Case reports demonstrate the efficacy of capsaicin in the treatment of facial chromhidrosis.[35] For pseudochromhidrosis, topical and oral erythromycin seems to be the most effective treatment, both in unidentified and identified chromogenic bacteria cases.[44]

PROGNOSIS AND CLINICAL COURSE

Apocrine chromhidrosis is a chronic disease that improves in old age as apocrine gland activity diminishes. Disease-associated morbidity is a result of psychosocial dysfunction experienced by affected individuals.

REFERENCES

1. Kao TH, Pan HC, Sun MH, et al. Upper thoracic sympathectomy for axillary osmidrosis or bromidrosis. *J Clin Neurosci*. 2004;11:719.
2. Teegee N, Rehmus W. Bromhidrosis. *Medscape*. Updated May 24, 2018. https://emedicine.medscape.com/article/1072342-overview.
3. Pinto M, Hundi GK, Bhat RM, et al. Clinical and epidemiological features of coryneform skin infections at a tertiary hospital. *Indian Dermatol Online J*. 2016;7:168.
4. Decréau RA, Marson CM, Smith KE, et al. Production of malodorous steroids from androsta-5, 16-dienes and androsta-4,16-dienes by Corynebacteria and other human axillary bacteria. *J Steroid Biochem Mol Biol*. 2003;87:327.
5. Austin C, Ellis J. Microbial pathways leading to steroidal malodour in the axilla. *J Steroid Biochem Mol Biol*. 2003;87:105.
6. Sato T, Sonoda T, Itami S, et al. Predominance of type I 5-reductase in apocrine sweat glands of patients with excessive or abnormal odour derived from apocrine sweat (osmidrosis). *Br J Dermatol*. 1998;139:806.
7. Spielman AI, Sunavala G, Harmony JA, et al. Identification and immunohistochemical localization of protein precursors to human axillary odors in apocrine glands and secretions. *Arch Dermatol*. 1998;134:813.
8. Zeng C, Spielman AI, Vowels BR, et al. A human axillary odorant is carried by apolipoprotein D. *Proc Natl Acad Sci U S A*. 1996;93:6626.
9. Nakano M, Miwa N, Hirano A, et al. A strong association of axillary osmidrosis with the wet earwax type determined by genotyping of the ABCC11 gene. *BMC Genet*. 2009;10:42.
10. Shang D, Zhang X, Sun M, et al. Strong association of the SNP rs17822931 with wet earwax and bromhidrosis in a Chinese family. *J Genet*. 2013;92:289.
11. Bang YH, Kim JH, Paik SW, et al. Histopathology of apocrine bromhidrosis. *Plast Reconstr Surg*. 1996;98:288.
12. Hurley HJ. Diseases of the apocrine sweat glands. In: Moschella SL, Hurley HJ, eds. *Dermatology*. 3rd ed. Philadelphia, PA: Saunders; 1992:1495.
13. He J, Wang T, Dong J. Effectiveness of botulinum toxin A injection for the treatment of secondary axillary bromhidrosis. *J Plast Reconstr Aesthet Surg*. 2017;70:1641.
14. Wang T, Dong J, He J. Long-term safety and efficacy of botulinum toxin A treatment in adolescent patients with axillary bromhidrosis. *Aesthetic Plast Surg*. 2018; 42:560.
15. Kunachak S, Wongwaisayawan S, Leelaudomlipi P. Non-invasive treatment of bromhidrosis by frequency doubled Q-switched Nd:YAG laser. *Aesthetic Plast Surg*. 2000;24:198.
16. Yoshikata R, Yanai A, Takei T, et al. Surgical treatment of axillary osmidrosis. *Br J Plast Surg*. 1990;43:483.
17. Breach NM. Axillary hyperhidrosis: surgical cure with aesthetic scars. *Ann R Coll Surg Engl*. 1979;61:295.
18. Endo T, Nakayama Y. Surgical treatment of axillary osmidrosis. *Ann Plast Surg*. 1993;30:136.
19. Zhao H, Li S, Nabi O, et al. Treatment of axillary bromhidrosis through a mini-incision with subdermal vascular preservation: a retrospective study in 396 patients. *Int J Dermatol*. 2016;55:919.
20. Dai Y, Xu AE, He J. A refined surgical treatment modality for bromhidrosis: subcutaneous scissor with micropore. *Dermatol Ther*. 2017;30:e12484.
21. Kim IH, Seo SL, Oh CH. Minimally invasive surgery for axillary osmidrosis: combined operation with CO_2 laser and subcutaneous tissue remover. *Dermatol Surg*. 1999;25:875.
22. Park JH, Cha SH, Park SD. Carbon dioxide laser treatment vs. subcutaneous resection of axillary osmidrosis. *Dermatol Surg*. 1997;23:247.
23. Seo SH, Jang BS, Oh CK, et al. Tumescent superficial liposuction with curettage for treatment of axillary bromhidrosis. *J Eur Acad Dermatol Venereol*. 2008; 22:30.
24. Zhang L, Chen F, Kong J, et al. The curative effect of liposuction curettage in the treatment of bromhidrosis: a meta-analysis. *Medicine (Baltimore)*. 2017;96: e7844.
25. He J, Wang T, Zhang Y, et al. Surgical treatment of axillary bromhidrosis by combining suction-curettage with subdermal undermining through a miniature incision. *J Plast Reconstr Aesthet Surg*. 2018;71:913.
26. Hong JP, Shin HW, Yoo SC. Ultrasound-assisted lipoplasty treatment for axillary bromidrosis: clinical experience of 375 cases. *Plast Reconstr Surg*. 2004; 113:1264.
27. Hélou J, Soutou B, Jamous R, et al. Novel adverse effects of laser-assisted axillary hair removal [in French]. *Ann Dermatol Venereol*. 2009;136:495.
28. Hsu TH, Chen YT, Tu YK, et al. A systematic review of microwave-based therapy for axillary hyperhidrosis. *J Cosmet Laser Ther*. 2017;19:275.
29. Hurley SJ. Apocrine chromhidrosis. In: Freedberg MI, Eisen AZ, Wolff K, et al, eds. *Fitzpatrick's Dermatology in General Medicine*. 5th ed. MI New York, NY: McGraw-Hill; 1999:811.
30. Saff DM, Owens R, Kahn TA. Apocrine chromhidrosis involving the areolae in a 15-year-old amateur figure skater. *Pediatr Dermatol*. 1995;12:48.
31. Griffith JR. Isolated areolar apocrine chromhidrosis. *Pediatrics*. 2005;115:e239.
32. Shelley WD, Hurley HJ Jr. Localized chromhidrosis: a survey. *Arch Derm Syphilol*. 1954;69:449.
33. Yöntem A, Kör D, Hızlı-Karabacak B, et al. Blue-colored sweating: four infants with apocrine chromhidrosis. *Turk J Pediatr*. 2015;57:290.
34. Kim J, Rhemus W. Chromhidrosis. *Medscape*. Updated May 14, 2018. https://emedicine.medscape.com/article/1072254-overview.

35. Marks JG Jr. Treatment of apocrine chromhidrosis with topical capsaicin. *J Am Acad Dermatol*. 1989; 21:418.
36. Jaiswal AK, Ravikiran SP, Roy PK. Red eccrine chromhidrosis with review of literature. *Indian J Dermatol*. 2017;62:675.
37. Uzoma M, Singh G, Kohen L. Green palmoplantar vesicular eruption in a patient with hyperbilirubinemia. *JAAD Case Rep*. 2017;3:273.
38. Park JG, Prose NS, Garza R. Eccrine chromhidrosis in an adolescent with sickle cell disease. *Pediatr Dermatol*. 2017;34:e273.
39. Barankin B, Alanen K, Ting PT, et al. Bilateral facial apocrine chromhidrosis. *J Drugs Dermatol*. 2004;3:184.
40. Daoud MS, Dicken CH. Disorders of the apocrine sweat glands. In: Freedberg MI, Eisen AZ, Wolff K, et al, eds. *Fitzpatrick's Dermatology in General Medicine*. 6th ed. New York, NY: McGraw-Hill; 2003:708.
41. Cox NH, Popple AW, Large DM. Autofluorescence of clothing as an adjunct in the diagnosis of apocrine chromhidrosis. *Arch Dermatol*. 1992;128:275.
42. Urmacher CD. Normal skin. In: Sternberg SS, ed. *Histology for Pathologists*. 2nd ed. Philadelphia, PA: Lippincott-Raven; 1997:25.
43. Cilliers J, de Beer C. The case of the red lingerie—chromhidrosis revisited. *Dermatology*. 1999;199:149.
44. Tempark T, Wittayakornrerk S, Jirasukprasert L, et al. Pseudochromhidrosis: report and review of literature. *Int J Dermatol*. 2017;56:496.
45. Matarasso SL. Treatment of facial chromhidrosis with botulinum toxin type A. *J Am Acad Dermatol*. 2005;52:89.

Chapter 83 :: Fox-Fordyce Disease

:: Powell Perng & Inbal Sander

AT-A-GLANCE

- A rare, itchy, chronic papular eruption localized to apocrine gland–bearing areas of the body with unclear etiology.
- Females are disproportionately affected compared to males (9:1), with age of onset most commonly between 13-35 years of age.
- Hyperkeratotic plugging of the follicular infundibulum at the apocrine gland duct insertion site is thought to be the primary pathophysiologic event, leading to duct dilation, rupture, inflammation, and pruritus.
- No definitive cure; oral antihistamines and topical clindamycin may help alleviate symptoms and induce remission.

Fox-Fordyce disease is a chronic, itchy, papular eruption involving apocrine gland–rich areas of the body. Lesions are characterized by numerous firm, flesh-colored, follicular-based papules arranged in a grouped configuration.[1] Fox-Fordyce disease was first described in 1902 by George Henry Fox and John Addison Fordyce in 2 patients with axillary disease.[2] The pubic, perineal, areolar, umbilicus, and sternal areas also can be involved.[3,4] Fox-Fordyce disease is otherwise known as *apocrine miliaria*; however, the centrality of apocrine gland dysfunction to the disease pathophysiology remains controversial.[1,5]

EPIDEMIOLOGY

The incidence of Fox-Fordyce disease is unknown; however, it is considered a rare disease. Epidemiologic studies suggest Fox-Fordyce disease disproportionately affects females.[3,6] Females between the ages of 13 and 35 years comprise more than 90% of cases. Fox-Fordyce disease is rarely reported before puberty or after menopause.[7] There is no known racial predilection for the disease.

CLINICAL FEATURES

HISTORY

Fox-Fordyce disease typically manifests after the onset of puberty, most commonly in the axillae. Patients may notice lesions for the first time with shaving.[8] Diagnosis is often delayed for years,[9-11] as the eruptions may only itch initially with onset[12] or not at all.[11] The number of lesions accumulate slowly over time.[13] Pruritus is intermittent and intense. Itchiness is made worse by sympathetic stimulation, including sweating, emotional stress or excitement, and warm weather.[13] Family history is usually unremarkable.

CUTANEOUS FINDINGS

Fox-Fordyce lesions manifest as grouped, symmetrically distributed, monomorphic, dome-shaped papules (1 to 3 mm) that are typically follicular based, flesh-colored to mildly erythematous, and intermittently pruritic (Figs. 83-1 and 83-2). Excoriations and lichenification are often present secondary to scratching. The axillae are most commonly affected. The pubic, perineal, areolar, umbilicus, and sternal areas also can be involved. Diminished sweat production is frequently observed in affected areas.[11]

COMPLICATIONS

Localized superinfections secondary to repeated scratching can be managed with antihistamines and standard antibiotic therapy. Although hidradenitis suppurativa has been observed in conjunction with Fox-Fordyce disease, there is no evidence that Fox-Fordyce disease progresses to hidradenitis suppurativa.[6,14]

ETIOLOGY AND PATHOGENESIS

The etiology of Fox-Fordyce disease is unclear. The tendency of Fox-Fordyce disease to present at puberty and remit after menopause suggests a hormonal component to the disease.[15,16] Improvements also have been reported during pregnancy[16,17] and with use of oral contraceptives.[18,19] Alterations in follicle-stimulating hormone,[20] estrogen,[21] and premenstrual urinary gonadotropins[21] have been noted in case reports. Rarely, Fox-Fordyce disease has been observed in men,[13,20] preadolescent girls,[7,9,22] and postmenopausal women,[21] suggesting hormonal factors may not be responsible in all cases. In fact, hormonal analyses in 2 patients with Fox-Fordyce disease found no aberrations.[11,23]

Genetics likely play a role in Fox-Fordyce disease; however, no clear genetic defect or polymorphism has been reported. The disease has been observed among siblings[17] and monozygotic twins,[8,24] as well as sisters[17] and father and daughter.[25] Two patients with Turner syndrome[26] and 1 patient with a small deletion on

Figure 83-1 Fox-Fordyce disease with skin-colored papules involving the axilla. (Image used with permission from the Graham Library of Wake Forest Department of Dermatology.)

chromosome 21 were also reported to have had Fox-Fordyce disease.[20]

Several case reports have described Fox-Fordyce–like eruptions developing after laser hair removal.[12,27,28] It is thought that laser-induced thermal damage to the follicular infundibulum causes altered keratinocyte maturation and subsequent plugging of the apocrine gland duct insertion site.[12] Eruptions tend to occur several months after initiating laser hair removal[27] and do not appear to be associated with particular laser wavelengths.[27]

PATHOPHYSIOLOGY

Hyperkeratotic obstruction of the follicular infundibulum at the apocrine gland duct insertion site is believed to be the primary pathophysiologic event.[4] The intraluminal obstruction leads to glandular distension and eventual ductal rupture. The subsequent expulsion of glandular contents into the surrounding dermis then causes an inflammatory response that manifests clinically as the intensely pruritic, dome-shaped, perifollicular papules. However, attempts to recreate the disease process by blocking the apocrine ducts in the experimental setting have failed to elicit the clinical manifestations.[29] Notably, Fox-Fordyce disease has been described in cases with histologic evidence of intraepidermal sweat duct obstruction, suggesting that apocrine and/or eccrine duct obstruction may be another trigger for the disease.[4,9]

Figure 83-2 Fox-Fordyce in a dark-skin patient with well-demarcated papules on the axilla. (Image used with permission from the Graham Library of Wake Forest Department of Dermatology.)

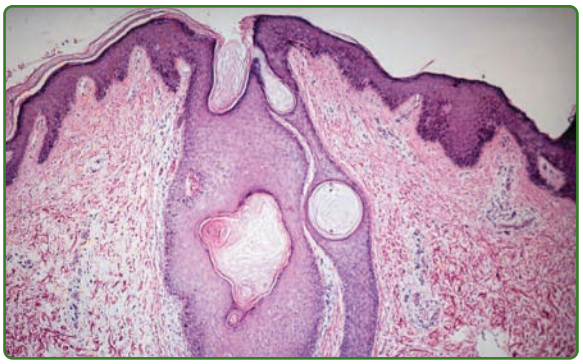

Figure 83-3 Follicular infundibular and excretory duct of apocrine gland with dilation, hyperkeratosis, and plugging. (Image used with permission from the Graham Library of Wake Forest Department of Dermatology.)

DIAGNOSIS

Fox-Fordyce disease is a clinical diagnosis based on careful history and cutaneous findings. Histopathologic analysis can facilitate with diagnosis, but findings are variable and nonspecific. Imaging and laboratory testing are not useful.

HISTOPATHOLOGY

Histopathologic features of Fox-Fordyce lesions (Figs. 83-3 and 83-4) are variable and should not be relied upon for making or excluding the diagnosis.[1] The most consistent finding is hyperkeratosis of the infundibular epithelium and dilation of the follicular infundibulum (Fig. 83-3).[1] Perifollicular and periductal xanthomatosis cells are frequently seen.[30]

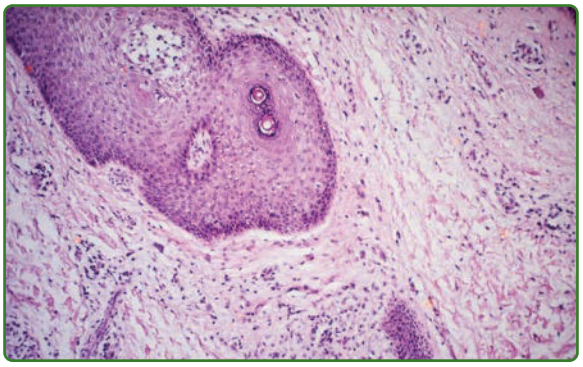

Figure 83-4 Fox-Fordyce disease in the nipple region. (Image used with permission from the Graham Library of Wake Forest Department of Dermatology.)

Focal spongiosis of the upper infundibulum along with perifollicular adventitial fibrosis and lymphohistiocytic infiltrate also were consistently observed.[3,30] Other findings include vacuolar alterations at the dermato–epithelial junction of the infundibula; smatterings of dyskeratotic cells throughout the infundibula; and tiny columns of cornoid lamella-like parakeratosis in close proximity to the acrosyringium of the apocrine duct, with eosinophilic keratinocytes found underneath.[1] The existence of pathognomonic "sweat retention" vesicles described by Shelly and Levy[6] is controversial, as these vesicles are rarely demonstrated in histologic specimens. There is evidence that transverse sectioning, rather than conventional vertical sectioning, produces a higher yield of hair follicle units and more readily demonstrates the histopathologic features of Fox-Fordyce disease.[31]

DIFFERENTIAL DIAGNOSIS

Fox-Fordyce eruptions can be mistaken for irritant contact dermatitis, lichen amyloidosis, granular hyperkeratosis, lichen nitidus, eruptive syringoma, or infectious folliculitis (Table 83-1). Fox-Fordyce disease should also be distinguished from early stages of hidradenitis suppurativa,[6,14] a chronic pustular dermatosis that also localizes to apocrine gland–rich regions of the body; however, the purulence, discharge, and sinus tracking of hidradenitis suppurativa are not observed in Fox-Fordyce disease.

CLINICAL COURSE AND PROGNOSIS

Fox-Fordyce disease is chronic, difficult to treat, and has no definitive cure. On occasion, remission has occurred after menopause.[15,16]

MANAGEMENT

Therapeutic knowledge is derived primarily from case reports. Table 83-2 summarizes select therapeutic strategies for Fox-Fordyce disease.

TABLE 83-1
Differential Diagnosis for Fox-Fordyce Disease

- Irritant contact dermatitis
- Chronic dermatitis
- Lichen amyloidosis
- Granular hyperkeratosis
- Lichen nitidus
- Syringoma
- Axillary papillary mucinosis
- Infectious folliculitis
- Early-stage hidradenitis suppurativa
- Scabies

TABLE 83-2
Select Therapeutic Strategies for Fox-Fordyce

Symptomatic therapies
- Oral antihistamines
- Low-dose doxepin

Topical therapies
- Short-term steroids
- Calcineurin inhibitors
- Tretinoin
- Adapalene
- Clindamycin in propylene glycol solution

Oral therapies
- Isotretinoin
- Oral contraceptives

Procedural therapies
- Intralesional steroid injection
- Intralesional botulinum toxin injection
- Surgical excision
- Microwave thermal ablation

CONSERVATIVE AND SYMPTOMATIC MEASURES

Stress reduction and heat avoidance may help minimize pruritus. First-generation oral antihistamines can be useful for alleviating itch, especially during the night. Low doses of doxepin (<10 mg), up to 3 times a day, can be used as an alternative to oral antihistamines.[32] There is no evidence to suggest that shaving or deodorant use worsen symptoms; however, thick creams and lotions, which can exacerbate follicular obstruction, should be avoided.

TOPICAL AND MEDICAL THERAPIES

Topical steroid creams are first-line therapies and can temporarily relieve itching; however, continuous application for more than 10 to 14 days is discouraged because of the risk of skin thinning and formation of striae.[33] Intradermal triamcinolone[34] may help alleviate itching during acute flares, but can also cause cutaneous atrophy with repeated administrations. Topical calcineurin inhibitors (1% pimecrolimus cream, 0.1% tacrolimus) can be used as alternatives to steroids and will not thin the skin. Pimecrolimus 1% cream applied twice daily over 8 weeks induced complete remission in 1 patient and partial remissions in 2 patients.[35] Topical tretinoin can be effective[36] but is often abandoned because of excessive irritation of the skin. Topical 0.1% adapalene gel, which is better tolerated than tretinoin, produced mild-to-moderate improvements in itch and number of papules in 1 case when applied every other day for 2 months.[37] Side effects of adapalene included erythema and burning sensation.[37] In 2 cases, topical

clindamycin in propylene glycol solution led to rapid resolution of papules after 1 month of treatment without recurrence at 6 to 9 months.[17,38]

Other medical therapies include diethylstilbestrol,[6] oral contraceptives,[19] testosterone,[39] corticotropin,[6] ultraviolet light therapy,[40] and X-ray therapy.[23] Oral isotretinoin dosed at 15 to 30 mg daily for 16 weeks induced near-complete remission of lesions and pruritus in 1 case[20]; however, lesions recurred 3 months after discontinuing therapy, accompanied by a more intense pruritus than before.[20] A one-time injection of botulinum toxin type A (2 units diluted into 2.5 mL of 0.9% saline at multiple points 2-cm apart in axillae) produced complete remission 15 days after injections without recurrence at 8 months of followup.[41]

PROCEDURAL THERAPIES

Case reports suggest different procedural therapies, including electrocautery, excision-liposuction with curettage, microwave thermal ablation,[42] and laser-based excisions,[43,44] can be curative, but are generally late-line options because of concern about infection, hypertrophic scarring, and/or disfiguration.[44]

REFERENCES

1. Boer A. Patterns histopathologic of Fox-Fordyce disease. *Am J Dermatopathol*. 2004;26(6):482-492.
2. Fox GH, Fordyce JA. Two cases of a rare, papular disease affecting the axilla region, with a report on the histopathology. *J Cutan Dis*. 1902;20:1-5.
3. Kao PH, Hsu CK, Lee JY. Clinicopathological study of Fox-Fordyce disease. *J Dermatol*. 2009;36(9):485-490.
4. Kamada A, Saga K, Jimbow K. Apoeccrine sweat duct obstruction as a cause for Fox-Fordyce disease. *J Am Acad Dermatol*. 2003;48(3):453-455.
5. Ackerman AB. *Resolving Quandaries in Dermatology, Pathology, and Dermatopathology*. Philadelphia, PA: Promethean Medical Press; 1995.
6. Shelley WB, Levy EJ. Apocrine sweat retention in man. II. Fox-Fordyce disease (apocrine miliaria). *AMA Arch Derm*. 1956;73(1):38-49.
7. Sandhu K, Gupta S, Kanwar AJ. Fox Fordyce disease in a prepubertal girl. *Pediatr Dermatol*. 2005;22(1):89-90.
8. Guiotoku MM, Lopes PT, Marques ME, et al. Fox-Fordyce disease in monozygotic female twins. *J Am Acad Dermatol*. 2011;65(1):229-230.
9. Ranalletta M, Rositto A, Drut R. Fox-Fordyce disease in two prepubertal girls: histopathologic demonstration of eccrine sweat gland involvement. *Pediatr Dermatol*. 1996;13(4):294-297.
10. Shackelton J, English JC 3rd. Fox-Fordyce disease (apocrine miliaria). *J Pediatr Adolesc Gynecol*. 2011;24(3):108-109.
11. Ballester I, Lopez-Avila A, Ortiz S. Fox-Fordyce disease with an atypical clinical presentation. *Actas Dermosifiliogr*. 2013;104(9):832-834.
12. Tetzlaff MT, Evans K, DeHoratius DM, et al. Fox-Fordyce disease following axillary laser hair removal. *Arch Dermatol*. 2011;147(5):573-576.
13. Alikhan A, Gorouhi F, Zargari O. Fox-Fordyce disease exacerbated by hyperhidrosis. *Pediatr Dermatol*. 2010; 27(2):162-165.
14. Spiller RF, Knox JM. Fox-Fordyce disease with hidradenitis suppurativa. *J Invest Dermatol*. 1958;31(2):127-135.
15. Bolognia JL, Jorizzo JL, Rapini RP. *Dermatology*. London, UK: Mosby Elsevier; 2008.
16. Cornbleet T. Pregnancy and apocrine gland diseases: hidradenitis, Fox-Fordyce disease. *AMA Arch Derm Syphilol*. 1952;65(1):12-19.
17. Miller ML, Harford RR, Yeager JK. Fox-Fordyce disease treated with topical clindamycin solution. *Arch Dermatol*. 1995;131(10):1112-1113.
18. Yang CS, Teeple M, Muglia J, et al. Inflammatory and glandular skin disease in pregnancy. *Clin Dermatol*. 2016;34(3):335-343.
19. Kronthal HL, Pomeranz JR, Sitomer G. Fox-Fordyce disease: treatment with an oral contraceptive. *Arch Dermatol*. 1965;91:243-245.
20. Effendy I, Ossowski B, Happle R. Fox-Fordyce disease in a male patient—response to oral retinoid treatment. *Clin Exp Dermatol*. 1994;19(1):67-69.
21. Montes LF, Caplan RM, Riley GM, et al. Fox-Fordyce disease. An endocrinological study. *Arch Dermatol*. 1961;84:452-458.
22. Senear FE, Cornbleet T, Brunner M. Fox-Fordyce disease before puberty. *Arch Derm Syphilol*. 1948;57(3, pt 2):438.
23. Turner TW. Hormonal levels in Fox-Fordyce disease. *Br J Dermatol*. 1976;94(3):317-318.
24. Graham JH, Shafer JC, Helwig EB. Fox-Fordyce disease in male identical twins. *Arch Dermatol*. 1960;82:212-221.
25. Scroggins L, Kelly E, Kelly B. Fox-Fordyce disease in daughter and father. *Dermatology*. 2009; 218(2):176-177.
26. Patrizi A, Orlandi C, Neri I, et al. Fox-Fordyce disease: two cases in patients with Turner syndrome. *Acta Derm Venereol*. 1999;79(1):83-84.
27. Sammour R, Nasser S, Debahy N, et al. Fox-Fordyce disease: an under-diagnosed adverse event of laser hair removal? *J Eur Acad Dermatol Venereol*. 2016; 30(9):1578-1582.
28. Yazganoglu KD, Yazici S, Buyukbabani N, et al. Axillary Fox-Fordyce-like disease induced by laser hair removal therapy. *J Am Acad Dermatol*. 2012;67(4):e139-e140.
29. Hurley HJ Jr, Shelley WB. Apocrine sweat retention in man. I. Experimental production of asymptomatic form. *J Invest Dermatol*. 1954;22(5):397-404.
30. Bormate AB Jr, Leboit PE, McCalmont TH. Perifollicular xanthomatosis as the hallmark of axillary Fox-Fordyce disease: an evaluation of histopathologic features of 7 cases. *Arch Dermatol*. 2008;144(8):1020-1024.
31. Stashower ME, Krivda SJ, Turiansky GW. Fox-Fordyce disease: diagnosis with transverse histologic sections. *J Am Acad Dermatol*. 2000;42(1, pt 1):89-91.
32. Smith PF, Corelli RL. Doxepin in the management of pruritus associated with allergic cutaneous reactions. *Ann Pharmacother*. 1997;31(5):633-635.
33. Coondoo A, Phiske M, Verma S, et al. Side-effects of topical steroids: a long overdue revisit. *Indian Dermatol Online J*. 2014;5(4):416-425.
34. Helfman RJ. A new treatment of Fox-Fordyce disease. *South Med J*. 1962;55:681-684.
35. Pock L, Svrckova M, Machackova R, et al. Pimecrolimus is effective in Fox-Fordyce disease. *Int J Dermatol*. 2006;45(9):1134-1135.
36. Giacobetti R, Caro WA, Roenigk HH Jr. Fox-Fordyce disease. Control with tretinoin cream. *Arch Dermatol*. 1979;115(11):1365-1366.

37. Kassuga LE, Medrado MM, Chevrand NS, et al. Fox-Fordyce disease: response to adapalene 0.1%. *An Bras Dermatol*. 2012;87(2):329-331.
38. Feldmann R, Masouye I, Chavaz P, et al. Fox-Fordyce disease: successful treatment with topical clindamycin in alcoholic propylene glycol solution. *Dermatology*. 1992;184(4):310-313.
39. Cornbleet T. Testosterone for apocrine diseases: hidrosadenitis, Fox-Fordyce disease. *AMA Arch Derm Syphilol*. 1952;65(5):549-552.
40. Pinkus H. Treatment of Fox-Fordyce disease. *JAMA*. 1973;223(8):924.
41. Gonzalez-Ramos J, Alonso-Pacheco ML, Goiburu-Chenu B, et al. Successful treatment of refractory pruritic Fox-Fordyce disease with botulinum toxin type A. *Br J Dermatol*. 2016;174(2):458-459.
42. Taylor D, Au J, Boen M, et al. A novel modality using microwave technology for the treatment of Fox-Fordyce disease (FFD). *JAAD Case Rep*. 2016;2(1):1-3.
43. Ahmed Al-Qarqaz F, Al-Shannag R. Fox-Fordyce disease treatment with fractional CO_2 laser. *Int J Dermatol*. 2013;52(12):1571-1572.
44. Han HH, Lee JY, Rhie JW. Successful treatment of areolar Fox-Fordyce disease with surgical excision and 1550-nm fractionated erbium glass laser. *Int Wound J*. 2016;13(5):1016-1019.

Chapter 84 :: Hidradenitis Suppurativa

:: Ginette A. Okoye

AT-A-GLANCE

- Hidradenitis suppurativa is a chronic and debilitating inflammatory disorder of the hair follicles that localizes to intertriginous and anogenital regions of the body.
- Lesions are characterized by inflammatory nodules, subcutaneous abscesses, and sinus tracts.
- Reproductive-age women are disproportionately affected.
- Hyperkeratotic plugging of the terminal hair follicle is a consistent histologic finding of early disease and is thought to be the primary pathophysiologic event.

Hidradenitis suppurativa (HS), otherwise known as *acne inversa*, is a multifactorial, chronic inflammatory disorder of the hair follicles in intertriginous and anogenital regions of the body. HS is characterized by recurrent, deep-seated, painful, subcutaneous nodules, sinus tracts, and hypertrophic scarring. The long-term sequelae, including chronic pain, skin contractures, and disfigurement, can detrimentally impact activities of daily living, social functioning, and psychosocial well-being.[1,2]

EPIDEMIOLOGY

Robust epidemiologic data on HS is lacking. The reported point prevalence of HS worldwide is between 0.00033% and 4.1%.[3] As of this writing, only 1 population-based incidence study has been published.[4] Among residents of Olmsted County, Minnesota (population 144,000 in 2010), the overall annual age- and sex-adjusted incidence rate of HS was 6 per 100,000 person-years over a 40-year period.[4] Between 1970 and 2008, the age- and sex-adjusted incidence rate rose steadily from 4.3 per 100,000 person-years to 9.6 per 100,000 person-years.[4] The etiology of this trend is unclear but may be related to concomitant rises in risk factors among the general population, including obesity and metabolic syndrome, as well as improved physician recognition of HS.[5]

For unknown reasons, women are disproportionately affected (female-to-male ratio is 3.3:1) and more likely to develop axillary and genitofemoral lesions.[4] Men, on the other hand, tend to develop perineal and perianal disease.[4] Among women, the impact of menstruation, menopause, and pregnancy on the natural history of HS is inconsistent and warrants further study. Although unconfirmed by population-based studies, data suggests that black patients may be disproportionately affected by HS.[6-9]

CLINICAL FEATURES

HS is a chronic relapsing and remitting disease with an unpredictable clinical course, leading to detrimental impacts on quality of life. Lesions may begin as tenderness or pruritus that progresses to a tender papule or deep-rooted nodule (Fig. 84-1). Nodules can become quite large and painful. They may resolve slowly without drainage or progress to an abscess-like lesion that eventually ruptures and drains purulent material before involuting (Fig. 84-2). Involution may take 7 to 10 days,[10] but in some patients, healing may be delayed, resulting in persistent open wounds with variable amounts of granulation tissue (Fig. 84-3). The process then reoccurs in adjacent and/or other intertriginous sites. With repeated episodes, epithelial strands may develop from ruptured follicular epithelium,[11] leading to sinus tract formation and intermittent drainage of foul-smelling serosanguinous and/or purulent material (Fig. 84-4). Over time, the healing process leads to exuberant scar formation, depositing densely fibrotic dermal plaques and rope-like bands (Fig. 84-5). The long-term disease sequelae, including dermal contractures and disfigurement, can detrimentally impact activities of daily living, social functioning, and psychosocial well-being (Figs. 84-6 to 84-8).[1,2]

COMPLICATIONS

QUALITY OF LIFE

HS is a burdensome and distressing disease that has a detrimental impact on quality of life. The degree of quality-of-life impairment, as measured by the Dermatology Life Quality Index, is more severe for HS than for other dermatologic conditions, including alopecia, psoriatic arthritis, and chronic urticaria.[1,12] The highest single Dermatology Life Quality Index score is for disease-associated pain and discomfort.[12] Anogenital involvement is associated with a significantly worse Dermatology Life Quality Index score compared to other sites.[13] HS-associated debility may cause professional setbacks. In one report, HS resulted in work absences in 58.1% of patients.[13] Work absences occurred 1 to 10 times per year, totaling 33.6 days lost on average per patient per year (SD: 26.1 days).[13] Twenty-three percent of patients reported hindrance of professional advancement secondary to disease-related morbidity.[13]

Figure 84-1 Inflammatory subcutaneous nodule of hidradenitis suppurativa with adjacent scars from previous lesions.

SYSTEMIC COMPLICATIONS

A small number of patients (4% to 6%) may develop a normocytic and/or microcytic anemia of little clinical significance secondary to chronic inflammation.[14] Rare cases of renal amyloidosis associated with severe HS have been reported.[15] Sepsis arising from infected lesions is a rare but fatal complication.[16]

Figure 84-2 Multiple inflammatory nodules of hidradenitis suppurativa in the axilla.

Figure 84-3 Inflammatory nodules of hidradenitis suppurativa rupture and drain, leaving behind persistent ulcerations in the axilla. (Copyright © Katherine Püttgen, MD. Used with permission.)

LOCAL COMPLICATIONS

Fibrosis and dermal contractures can limit joint mobility. Vaginal, urethral, and/or anal strictures can develop from chronic anogenital and perineal inflammation, leading to incontinence.[17] Urethral fistulization secondary to genital involvement has been reported.[8] Inflammation, scarring, and destruction of lymphatic drainage routes can lead to disfiguring elephantiasis (see Fig. 84-7)[18] and verrucous lymphangiomas,[19] requiring surgical reconstruction.

Figure 84-4 Sinus tracts and purulent drainage associated with chronic hidradenitis suppurativa in the axilla.

Figure 84-5 Dense fibrotic plaques and rope-like scars associated with chronic hidradenitis suppurativa in the axilla. (Copyright © Katherine Püttgen, MD. Used with permission.)

SQUAMOUS CELL CARCINOMA

Squamous cell carcinoma (SCC) is an infrequent complication of longstanding chronically inflamed lesions, occurring in 4.6% of HS cases (see Fig. 84-8).[20] As of this writing, a total of 86 cases of SCC arising from HS lesions had been recorded in the literature.[21] Males with anogenital disease are preferentially affected.[20,21] HS-associated anogenital SCC is often associated with high-risk human papillomavirus strains, most commonly human papillomavirus-16.[22] HS-associated SCC also tends to be more locally aggressive and metastasizes to lymph nodes with greater frequency (50% of cases) than SCC from any cause (5% to 10% of cases).[20] Thus, practitioners should have a low threshold to biopsy any nonhealing wound in an area of chronic HS. Patients with HS are deemed to be at 50% greater risk of developing malignancies of any kind compared to the healthy individuals,[23] although smoking status is not accounted for in the calculation of this statistic.

Figure 84-6 Disfiguring atrophic scars in the groin from recurrent lesions of hidradenitis suppurativa.

Figure 84-7 Scrotal lymphedema associated with long-term hidradenitis suppurativa in the inguinal folds.

ETIOLOGY AND PATHOGENESIS

The etiology of HS is multifactorial and remains to be fully elucidated. It is likely that a combination of factors, including genetic predisposition, aberrant immunity, hormonal dysregulation, and environmental modifiers, are involved in the pathophysiology of this complex disease.

Figure 84-8 Squamous cell carcinoma arising in long-standing hidradenitis suppurativa on the buttocks.

FOLLICULAR OCCLUSION

Keratinous occlusion of the terminal hair follicle is a consistent histologic finding of early HS[24] and is thought to be the primary pathophysiologic event.[25] An aberrant immune response to commensal flora[25] and/or shear forces causing microtrauma to the deep part of the hair follicles in intertriginous skin[26] are believed to contribute to the initial lymphocytic perifolliculitis, hyperkeratosis, and hyperplasia of the infundibular epithelium.[24] This accumulation of keratinous debris leads to plugging and dilation of hair follicles. With subsequent rupture, follicles expel their contents (keratin, hair, sebum, bacteria) into the surrounding dermis. This incites a florid lymphohistiocytic foreign-body–type inflammatory response that engulfs the pilosebaceous units and adnexal structures, giving rise to the clinical findings.

ADNEXAL STRUCTURES

HS was once thought to originate in the apocrine glands. It is now clear, however, that the apocrine glands are only secondarily involved.[27] On the other hand, sebaceous gland atrophy appears to be an early event in disease pathogenesis, preceding the onset of lymphocytic follicular inflammation and hyperkeratosis of the infundibulum.[28] Whether sebaceous gland atrophy represents a primary event or is a reflection of upstream processes remains to be determined.

GENETICS

HS can develop sporadically or be inherited in familial forms. One-third of patients with HS report a positive family history of the disease.[29] Familial forms are thought to arise from autosomal dominant inheritance of highly penetrant single gene mutations, whereas sporadic cases are thought to result from defects in several genes.[29,30] Loss-of-function mutations in the genes encoding subunit proteins of the γ-secretase complex—presenilin (PSEN1/PSEN2), presenilin enhancer-2 (PSENEN), nicastrin (NCSTN)—also have been identified in families with HS.[31,32] In animal models, γ-secretase deficiency leads to sebaceous gland atrophy, a histologic finding in HS, as well as epidermal cyst formation.[33] Defective γ-secretase also impairs the Notch signaling pathway, which mediates normal hair follicle development, promotes antiinflammatory regulatory T-cell activity, and suppresses toll-like-receptor–induced proinflammatory responses.[34,35] Together, these data suggest that defective γ-secretase and/or Notch signaling may serve a pathophysiologic role in HS. No associations between human leukocyte antigen antigens and HS have been reported.[36,37]

SMOKING

According to a multivariate analysis, the odds of having HS are substantially higher among current smokers than nonsmokers (odds ratio [OR] 12.55; 95% confidence interval [CI] 8.58 to 18.38).[38] Smoking also is associated with the development of more-severe disease.[39] Whether smoking is merely a risk factor or plays a direct role in disease pathogenesis is still controversial. Nicotine is thought to promote follicular occlusion by increasing sweat gland secretion and inducing hyperplasia of the follicular infundibulum.[39] Nicotine is also thought to induce neutrophil chemotaxis and stimulate release of proinflammatory cytokines.[40] Smoking cessation may improve symptoms[41] as well as reduce the rates of de novo lesion formation following excisional surgery.[42]

ANDROGENS

The propensity for HS to develop after puberty suggests an androgenic basis for the disease. However, the role of androgen remains unclear. Androgen modulation therapy has demonstrated therapeutic benefit equivalent to that of oral antibiotic therapy.[43] Yet, after adjusting for body mass index, there was no significant difference in the level of circulating androgens between women with HS and healthy controls.[44,45] Additionally, the expression of androgen receptors[46] and the 5-α-reductase enzyme[47] on the apocrine glands is similar in HS lesions and healthy skin.

OBESITY

A higher body mass index is associated with greater odds of having HS (OR 1.12; 95% CI 1.08 to 1.15).[38] Obesity is likely not causative but rather exacerbates HS via augmenting tissue mechanics, that is, promoting sweat retention and occlusion, and increasing friction and maceration in skinfolds.[39] Greater adiposity may also alter the androgenic milieu by reducing global levels of sex hormone-binding globulin[44] and/or augmenting peripheral conversion of sex hormones.[47,48] Weight loss is recommended in overweight patients with HS. A study found that weight loss of more than 15% after bariatric surgery was associated with a 20% reduction in active disease.[41]

IMMUNE DYSREGULATION

A growing body of literature implicates immune dysregulation as an integral part of disease pathogenesis.[49] The proinflammatory cytokine, tumor necrosis factor (TNF)-α, is markedly elevated in HS lesions and in the serum of patients with HS compared to healthy

controls.[50] Interleukin (IL)-1β, another potent proinflammatory cytokine, is also strikingly elevated in lesional and perilesional skin (34- to 115-fold higher in lesional compared to healthy skin).[49] IL-1β can promote inflammation by driving differentiation of IL-17–secreting CD4+ helper T cells (Th17) cells. The IL-23/Th17 pathway is implicated in numerous autoimmune diseases, including rheumatoid arthritis, lupus, multiple sclerosis, and psoriasis.[51] Levels of IL-12 and IL-23 are significantly elevated (2.6- to 5.2-fold) in lesional HS skin compared to that of healthy controls,[52] with an increased number of Th17 cells infiltrating the dermis in the lesional HS skin compared to healthy skin.[52]

BACTERIA

Whether bacterial involvement of HS lesions is a primary or secondary pathophysiologic event remains controversial. Traditional bacterial cultures taken from involved sites are often negative or grow commensal skin flora.[53] Coagulase-negative staphylococcus and anaerobic bacteria are the most frequently isolated organisms.[53] Deep-tissue samples from the dermis grow a preponderance of coagulase-negative staphylococcus.[53] It has been postulated that an overzealous immune response to commensal flora within hair follicles triggers the initial follicular inflammation.[25,54] Topical and oral antibiotics tend to improve symptoms in most patients; however, long courses of therapy are often needed, and relapse is common. Bacterial biofilm formation may help explain the intractability of skin lesions despite long-term antibiotic therapies.[55]

COMORBIDITIES AND ASSOCIATED DISEASES

HS is frequently associated with other diseases of follicular occlusion. The tetrad of HS, acne conglobata, dissecting cellulitis of the scalp, and pilonidal cysts is well documented.[56] HS also has been described as a component of several autoinflammatory syndromes, including PASH (pyoderma gangrenosum, acne, and HS),[57] PAPASH (pyogenic arthritis, pyoderma gangrenosum, acne, and HS),[58] and PsAPASH (psoriatic arthritis and PASH).[59] Mutations in the *NCSTN*[60] and *PSTPIP1* (proline-serine-threonine phosphatase interacting protein 1)[61] genes have been observed in PASH. Improvement of PASH and PAPASH with IL-1 receptor antagonist therapy suggests IL-1β may also play a pathogenic role.[57,58] HS is also associated with inflammatory bowel disease.[62,63] Twenty-six percent of patients with Crohn disease and 18% of patients with ulcerative colitis reported having HS.[62] Coexistence of Crohn disease and HS is associated with a more fulminant disease course, especially in patients with perianal involvement.[64] However, patients with HS do not appear to harbor CARD15/NOD2 polymorphisms associated with the inflammatory pathways of Crohn disease.[65,66] Clinical improvement of concurrent Crohn disease and HS with anti–TNF-α therapy has been reported.[67] Seronegative spondyloarthropathies, amyloidosis, genetic keratin disorders, and SCCs are also commonly cited in patients with HS.[56] Several large studies have demonstrated that disease of hormonal and/or metabolic disequilibrium are frequently comorbid with HS.[68-70] Patients with HS had significantly higher odds of also having metabolic syndrome (OR 1.61; 95% CI 1.36 to 1.89), diabetes mellitus (OR 1.41; 95% CI 1.19 to 1.66), obesity (OR 1.71; 95% CI 1.53 to 1.91), and hypertension (OR 1.14; 95% CI 1.02 to 1.28).[70]

DIAGNOSIS

HS is a clinical diagnosis based on 3 criteria (Table 84-1), all of which must be present for the definitive diagnosis. First, typical lesions must be present. These include deep-seated painful nodules, abscesses, draining sinuses, double-open comedones (Fig. 84-9), and bridged scars. It is important to distinguish HS lesions from common mimickers, including simple folliculitis and bacterial furunculosis (Table 84-2 outlines the differential diagnosis for HS). Second, lesions must exhibit a typical distribution, with 1 or more typical lesions in the axillae, groin, buttocks, perineal, or inframammary region. Nonclassical or ectopic sites may be present (eg, thighs, abdominal skinfolds) but must be accompanied by lesions in typical areas. Sites of involvement, in decreasing frequency, are: axillary, inguinal, perineal and perianal, mammary and inframammary, buttock, pubic region, chest, scalp, retroauricular, and eyelid.[71] Third, there must be a clear history of symptom chronicity and recurrence.[38,72] No formal guidelines for the clear history criteria exist. Delays in diagnosis are not uncommon, with 7 years being the average time from symptom onset to diagnosis.[10] Having 2 recurrences over a 6-month period has been suggested as one measure of chronicity.[3] Figure 84-10 provides an example of a proposed diagnostic algorithm.[73]

SEVERITY

The Hurley staging system (Table 84-3) is the most widely used approach to assessing disease severity.

TABLE 84-1
Diagnostic Criteria

1. **Typical lesion (1 or more):** painful nodules, abscesses, draining sinuses, double-open comedones, bridged scars
2. **Typical distribution[a]:** axillae, groin, buttocks, perineal, and inframammary regions
3. **Chronicity and recurrence** of symptoms

[a]Atypical or ectopic sites may be affected but at least 1 typical area must be involved.

Figure 84-9 Atrophic scars and double-open comedones associated with hidradenitis suppurativa in the axilla.

Stage I is defined by recurrent abscesses without scarring or sinus tracts; stage II is defined by recurrent abscesses with scarring and sinus tract(s), separated by normal skin; and stage III is defined by recurrent abscesses with diffuse scarring and interconnected sinus tracts with minimal to no normal skin between lesions.[74] The vast majority of HS patients (68%) have stage I disease; stage II and stage III disease develop in 28% and 4% of HS patients, respectively.[74,75]

Although useful for rapid classification of disease severity, the Hurley system does not account for the dynamic changes of lesion progression and regression, which are important for assessing therapeutic response. Other scoring systems have been developed to more accurately capture disease nuance. These systems include the Sartorius score,[76] an HS-specific Physician Global Assessment,[77] the HS Severity Index,[78] and the HS Clinical Response Score.[79] These systems, however, are generally considered too cumbersome for clinical practice but remain useful in research settings.

TABLE 84-2
Differential Diagnosis for Hidradenitis Suppurativa

EARLY LESIONS	LATE LESIONS
Acne vulgaris	Actinomycosis
Carbuncle	Anal fistula
Cellulitis	Cat scratch disease
Cutaneous blastomycosis	Crohn disease
Dermoid cyst	Granuloma inguinale
Erysipelas	Ischiorectal abscess
Folliculitis	Lymphogranuloma venereum
Furuncle	*Nocardia* infection
Inflamed epidermoid cysts	Noduloulcerative syphilis
Lymphadenopathy	Pilonidal disease
Perirectal abscess	Tuberculosis abscess
Pilonidal cyst	Tularemia

Adapted from Alikhan A, Lynch PJ, Eisen DB. Hidradenitis suppurativa: a comprehensive review. *J Am Acad Dermatol.* 2009;60(4):539-61.

CLINICAL PHENOTYPES

Several clinical phenotypes of HS have been proposed.[72,80] Using latent class analysis (a multivariate regression model) without any a priori hypotheses, Canoui-Poitrine and colleagues identified 3 distinct phenotypes from a large, prospective cross-sectional study of 618 patients.[80] The classic "axillary–mammary" subtype, characterized by breast and axillary involvement with hypertrophic scarring, accounted for 48% of the patients. The "follicular" subtype, characterized by a predilection for follicular lesions (eg, epidermal cysts, pilonidal sinus, comedones, severe acne) and atypical topography involving the ears, chest, back, or legs, comprised 26% of the patients. Compared to those of the classic axillary–mammary subtype, patients of the follicular subtype were also more likely to be male smokers with a family history of HS and greater disease severity.[80] The "gluteal" subtype, characterized by follicular papules, folliculitis, and gluteal involvement, comprised 26% of patients. Patients with the gluteal subtype tended to be smokers with lower body mass indexes and more indolent disease compared to the axillary–mammary subtype.[80]

LABORATORY TESTING

Patients with acute lesions may exhibit leukocytosis, elevated erythrocyte sedimentation rate, low serum iron levels, and serum protein abnormalities on serum electrophoresis.[81] Chemistries, complete blood counts, and blood cultures should be sent for patients who are febrile or appear toxic.[81] Purulent drainage should be sent for bacterial cultures and sensitivities.[81] If there is a concern for infection, a deep-tissue culture should be sent for bacterial and fungal organisms.

IMAGING

Ultrasonography and MRI may be used to visualize lesions for staging and surgical planning, although these strategies are rarely used.[82] Ultrasonography features may reveal subclinical fluid collections in 76.4% of the patients, fistulous tracts in 29.4%, dermal pseudocysts in 70.6%, and widening of the hair follicles in 100%.[83] MRI findings are nonspecific. Skin thickening and induction of subcutaneous tissue that are low signal on T1-weighted images and high-signal on T2-weighted and short tau inversion recovery (STIR) images are typical.[84] With IV contrast, abscesses appear as subcutaneous rim-enhancing collections that are low signal on T1-weighted images and high-signal on T2-weighted and STIR images.[84]

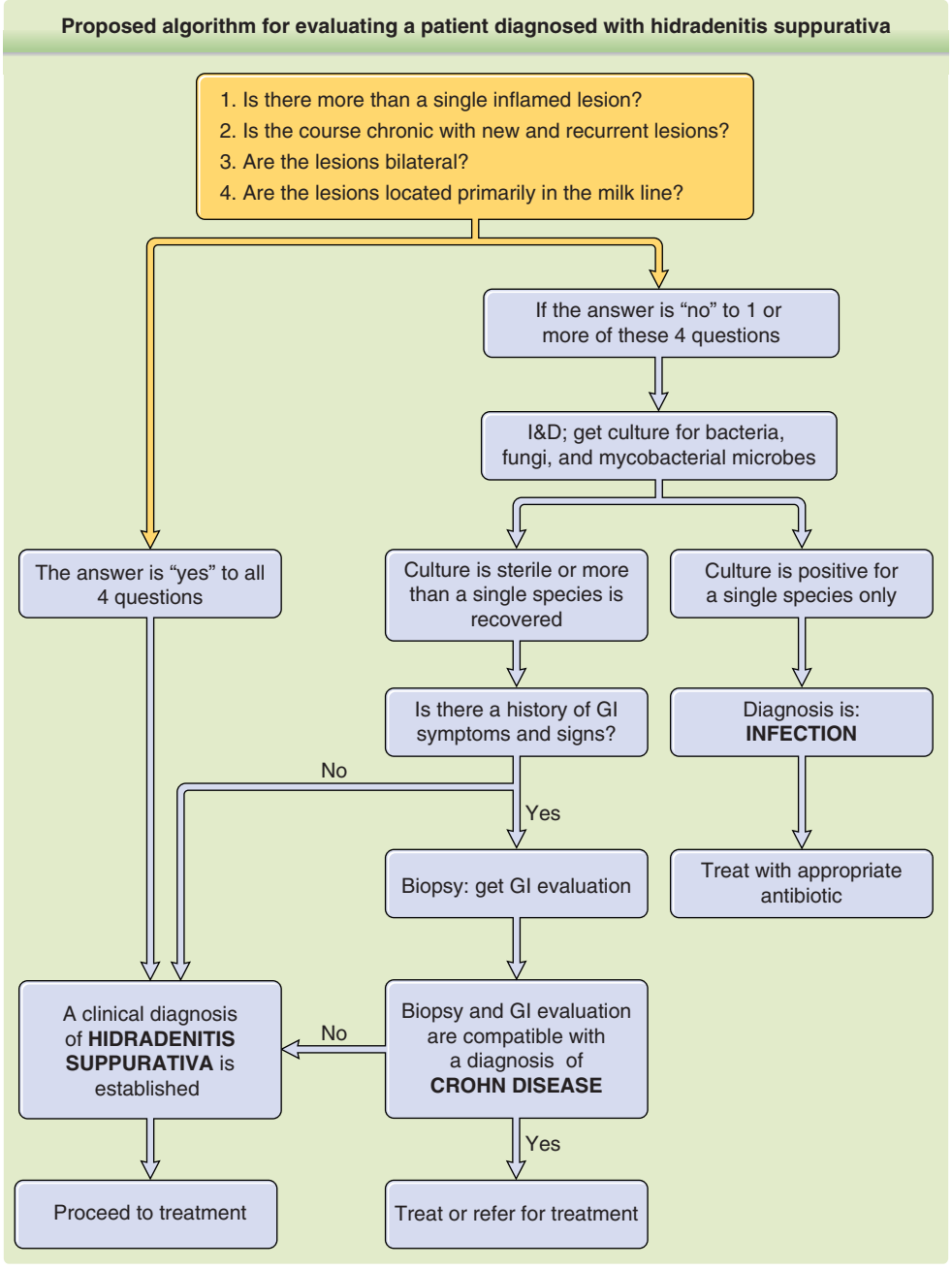

Figure 84-10 Proposed algorithm for evaluating a patient in whom a diagnosis of hidradenitis suppurativa is being considered. I&D, incision and drainage. (From Alikhan A, Lynch PJ, Eisen DB. Hidradenitis suppurativa: a comprehensive review. *J Am Acad Dermatol*. 2009;60[4]:539-561, with permission. Copyright © American Academy of Dermatology.)

TABLE 84-3
Hurley Staging

HURLEY STAGE	CHARACTERISTICS
I	Recurrent abscesses without scarring or sinus tract formation
II	Recurrent abscesses with scarring and sinus tract formation separated by normal skin
III	Recurrent abscesses, diffuse scarring, and interconnecting sinus tracts with minimal to no normal skin between lesions

HISTOPATHOLOGY

Follicular occlusion is a nonspecific but universal histopathologic finding in HS irrespective of disease duration.[85] Early lesions are characterized by follicular hyperkeratosis of the terminal hair follicles, hyperplasia of the follicular infundibulum, and perifolliculitis.[24,86] These processes lead to keratinous plugging of the terminal hair follicles, a consistent histologic finding that precedes follicular dilation and rupture.[24] Epidermal psoriasiform hyperplasia

(lacking parakeratosis) and subepidermal perifollicular collections of lymphocytes also have been observed in early disease.[24] More mature lesions may exhibit noncaseating granulomas, abscesses, epidermal cysts, sinus tracts, granulation tissue, and dermal fibrosis.[27,87] Subcutaneous inflammation, fibrosis, and fat necrosis also can be observed. Apocrinitis may occur by extension; however, apocrine gland involvement is seen in 12% to 30% of cases.[27,85,87] However, secondary inflammation of the eccrine glands is more often present (19% to 32% of cases).[27,85,87] Primary inflammation of the apocrine glands is rare, occurring in 5% of lesions.[27,85,87]

Acutely, the inflammatory infiltrate is largely comprised of T-lymphocytes and neutrophils at the follicular epithelium with variable extension into the adnexal structures.[24] A histopathologic analysis of surgical specimens found a marked CD8+ T-lymphocyte epitheliotropism in the follicular and subepidermal inflammatory infiltrates of early HS lesions.[24] The ratio of CD8+ cytotoxic T-lymphocytes to CD4+ helper T-lymphocytes also appears to increase over the lifetime of active lesions.[86] In chronic lesions, lymphocytes, histiocytes, and multinucleated giant cells predominate, generating foreign-body granulomas around ruptured hair follicles and skin adnexa.[88] Eosinophils and plasma cells are also seen on occasion.[87] Notably, recent immunohistochemistry studies report elevated IL-17 and IL-23 expression along with distinct dermal infiltrates of Th17 helper T cells within lesional and perilesional skin.[49,52]

CLINICAL COURSE AND PROGNOSIS

Disease onset is typically after puberty, with a reported age range from 16 to 81 years.[4] Because HS can resemble other pustular dermatoses, delays in diagnosis of 7 to 12 years are not uncommon.[89] In one cross-sectional survey, patients reported having 4.6 painful boils per month, with each boil lasting an average of 6.9 days.[90] Mean duration of disease was 18.8 years, with the most-severe symptoms occurring early in the disease course (after a mean of 6.4 years from disease onset).[90] Disease activity generally declines after 50 years of age.[38] Remissions are significantly more likely in nonsmokers, those who have quit smoking, and in nonobese individuals.[41]

MANAGEMENT

HS is a complex, heterogeneous disease with unpredictable responses to therapy. Therefore, formal treatment guidelines for HS do not exist, and therapeutic decisions are generally guided by disease severity. Hurley stage I disease (mild) is typically amenable to medical therapy alone; Hurley stage II disease (moderate) may require both medical therapy and localized surgical excisions; Hurley stage III disease (severe) often requires extensive, wide excisional surgical procedures with advanced grafting and flap procedures. There is no cure for HS. The overall goals of therapy are to prevent formation of primary lesions and to reduce the impact of disease sequelae (eg, fibrosis, contractures, sinus tracts) on quality of life. Tables 84-4 and 84-5 and Fig. 84-11 offer a proposed management algorithm.

LIFESTYLE MODIFICATIONS AND HOME REMEDIES

Smoking cessation and weight management are important components of symptom mitigation at all stages of disease. Nonsmokers achieved a higher rate of remission (40%) than active smokers (29%) over a mean followup period of 22 years.[41] Rates of new lesion formation following excisional surgery were lower among those who ceased smoking versus those who continued smoking.[42] Weight loss of 15% or more from baseline after bariatric surgery was also associated with a 20% reduction in number of active, eruptive sites.[41]

Conservative measures, such as stress reduction, warm baths, warm compresses, and hydrotherapy, may help alleviate symptoms.[91] Taking "bleach baths" (ie, one-quarter cup of regular bleach diluted in a full tub or 40 gallons of water) and/or washing the affected areas with topical cleansing agents (eg, chlorhexidine gluconate or benzoyl peroxide solution) 2 to 3 times per week can reduce bacterial load and decrease malodor.[9] Resorcinol 10% to 15% cream, a topical peeling agent traditionally used for acne, can improve pain and reduce the duration of painful abscesses.[92] Dressings are useful for managing drainage, decreasing malodor, and protecting apparel from stains. Wound dressings are sometimes covered by insurance; abdominal (eg, ABD) gauze pads and sanitary pads can be used as alternatives. Short courses of nonsteroidal antiinflammatory drugs can help alleviate pain and reduce inflammation.

Patients should be counseled to avoid tight clothing, prolonged exposure to heat and humidity, and shaving, if these are noted as triggers.[90] Consumption of insulinotropic milk and dairy products, as well as hyperglycemic foods, upregulate the PI3K/Akt-signaling pathway, leading to nuclear deficiency of FoxO1 transcription factor.[93,94] Deficiency in FoxO1 is thought to play a role in acne vulgaris and acne-like eruptions.[94] Further research is needed in this area, but decreasing exposure to dairy and high-glycemic-index foods may be an adjunct to medical therapy, either directly or indirectly, by promoting weight loss.

Applying minced turmeric root as a poultice to active sites or ingesting diluted turmeric (1 teaspoon of turmeric powder diluted in one-quarter cup liquid) 3 times daily has had anecdotal success in ameliorating symptoms. Curcumin, the active ingredient in turmeric, may help reduce inflammation via suppression of TNF-α.[95]

A 6-month course of high-dose zinc gluconate supplementation (90 mg daily, tapered by 15 mg every 2 months) improved clinical status in a cohort

TABLE 84-4
Ratings of Select Therapies for Hidradenitis Suppurativa Based on Category of Evidence and Strength of Recommendation

THERAPY	CATEGORY OF EVIDENCE	STRENGTH OF RECOMMENDATION
First-line		
▪ Clindamycin (topical)[a]	IIb	Possible B
▪ Clindamycin/rifampicin (oral)[b]	III	C
▪ Adalimumab (subcutaneous)[c]	I	A
▪ Tetracycline (oral)	IIb	B
Second-line		
▪ Zinc gluconate	III	C
▪ Resorcinol (cream)	III	C
▪ Intralesional corticosteroid	IV	D
▪ Systemic corticosteroid	IV	D
▪ Infliximab	Ib/IIa	B
▪ Acitretin/etretinate	III	C
Third-line		
▪ Colchicine	IV	D
▪ Botulinum toxin (subcutaneous)	IV	D
▪ Isotretinoin	IV	D
▪ Dapsone	IV	D
▪ Cyclosporine	IV	D
▪ Hormones	IV	D
Surgery		
▪ Excision or curettage of individual lesions	III	C
▪ Total excision of lesions and surrounding hair-bearing skin	IIb	B
▪ Secondary intension healing	IIb	B
▪ Primary closure	III	C
▪ Reconstruction with skin grafting and negative pressure wound therapy	III	C
▪ Reconstruction with flap plasty	Ia/IIa	A/B
▪ Deroofing	IV	D
▪ CO_2 laser therapy	Ib	A
▪ Neodymium:yttrium-aluminum-garnet (Nd:YAG) laser	Ib	A
▪ Intense pulsed light	IV	D
Pain Control		
▪ Nonsteroidal antiinflammatory drugs	IV	D
▪ Opiates	IV	D
Dressings		
▪ No studies have been published as of this writing on the use of specific dressings or wound care methodology in hidradenitis suppurativa; choice of dressing is based on clinical experience	IV	D

[a]Single double-blind, placebo-controlled, randomized trial. Hurley stages I to II.

[b]Evaluated in case series.

[c]Multiple prospective, randomized, double-blind, placebo-controlled trials (Pioneer 1 and 2).

Adapted from Gulliver W, Zouboulis CC, Prens E, et al. Evidence-based approach to the treatment of hidradenitis suppurativa/acne inversa, based on the European guidelines for hidradenitis suppurativa. *Rev Endocr Metab Disord*. 2016;17(3):343-351, with permission.

TABLE 84-5
Category of Evidence/Strength of Recommendation Grading Scale

CATEGORY OF EVIDENCE	STRENGTH OF RECOMMENDATION
Ia: Metaanalysis of randomized controlled trials Ib: Randomized controlled trial	A: Category I evidence
IIa: Controlled study without randomization IIb: Quasiexperimental study	B: Category II evidence or extrapolated from category I evidence
III: Nonexperimental descriptive studies such as comparative, correlation, and case-control studies	C: Category III evidence or extrapolated from category I or II evidence
IV: Expert committee reports or opinion or clinical experience of respected authorities, or both	D: Category IV evidence or extrapolated from category II or III evidence

Data from Guyatt G, Oxman AD, Vist GE, et al. GRADE: An emerging consensus on rating quality of evidence and strength of recommendations. *BMJ*. 2008; 336:924; and from Gulliver W, Zouboulis CC, Prens E, et al. Evidence-based approach to the treatment of hidradenitis suppurativa/acne inversa, based on the European guidelines for hidradenitis suppurativa. *Rev Endocr Metab Disord*. 2016;17(3):343-351, with permission.

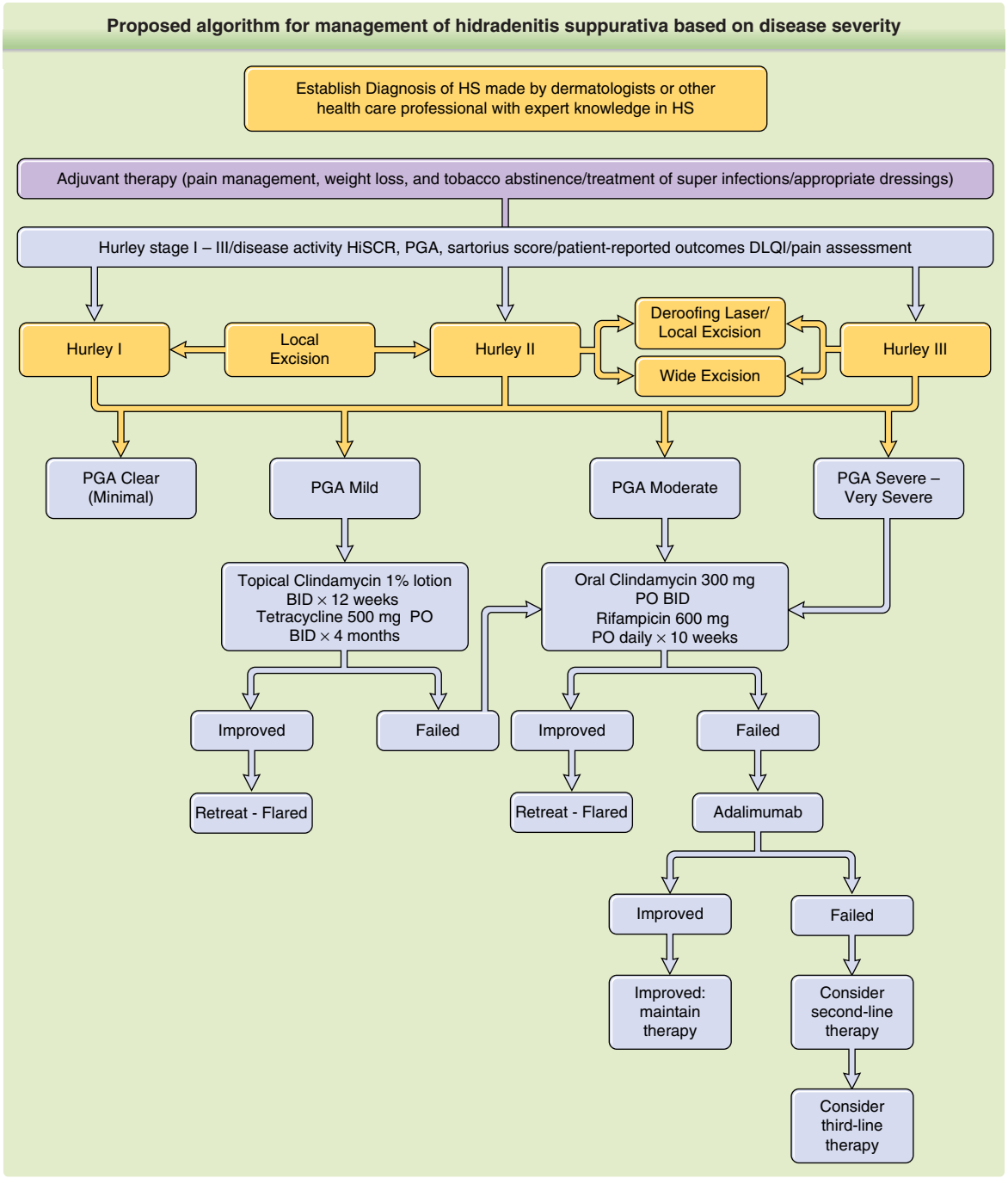

Figure 84-11 Proposed algorithm for management of hidradenitis suppurativa (HS) based on disease severity. BID, twice daily; DLQI, Dermatology Life Quality Index; HiSCR, Hidradenitis Suppurativa Clinical Response; OD, once daily; PGA, Physician Global Assessment; PO, by mouth. (From Gulliver W, Zouboulis CC, Prens E, et al. Evidence-based approach to the treatment of hidradenitis suppurativa/acne inversa, based on the European guidelines for hidradenitis suppurativa. *Rev Endocr Metab Disord*. 2016;17[3]:343-351, with permission.)

of 22 patients with therapy-resistant mild-to-moderate HS.[96] Eight patients achieved complete remission while 14 patients achieved partial remission.[96] Mild side effects (nausea, vomiting, abdominal distension, esophagitis) were reported in 14% of patients.[96] Therapeutic benefit is thought to derive from the antioxidant and antiinflammatory properties of zinc gluconate.

MEDICAL THERAPY

ANTIBIOTIC THERAPY

Topical and oral antibiotic therapy are the mainstays of management of mild-to-moderate HS. A randomized,

double-blind, placebo-controlled trial demonstrated that clindamycin 1% lotion applied twice daily to affected areas reduced the number of pustules, inflammatory nodules, and abscesses in patients with Hurley stage I and mild stage II disease.[97,98] Topical metronidazole 0.75% or erythromycin 2% can be trialed as alternatives to clindamycin. A 4-month trial of oral tetracyclines can be used for their antiinflammatory effect in any disease stage.

For more-severe disease (Hurley stage II) that is refractory to topical clindamycin and/or oral tetracyclines, a regimen of 300 mg of clindamycin and 300 mg of rifampin taken 2 to 3 times daily may be effective.[99] Triple therapy with rifampin (10 mg/kg/day), moxifloxacin (400 mg/day), and metronidazole (500 mg 3 times daily) can be used as an alternative antibiotic regimen for resistant or severe disease.[100] There is weak-to-moderate evidence supporting a course of dapsone (50 to 200 mg daily for 4 to 12 weeks) in refractory HS.[101]

BIOLOGIC THERAPY

Patients with moderate-to-severe HS who are unresponsive to, or intolerant of, antibiotic therapy may benefit from 40 mg weekly subcutaneous adalimumab, a monoclonal antibody specific to TNF-α.[77] Nonresponders to adalimumab therapy may benefit from infliximab, a chimeric monoclonal antibody inhibitor of TNF-α, dosed at 5 mg/kg at weeks 0, 2, and 6, followed by every 8 weeks thereafter.[78] Ustekinumab (an IL-12 and IL-23 inhibitor) and anakinra (an IL-1α and IL-1β inhibitor) have been used in small numbers of patients for HS with anecdotal success.[102,103]

IMMUNOSUPPRESSANT THERAPY

Overall, there is weak evidence supporting use of oral glucocorticoids, colchicine, cyclosporine, azathioprine,[104] and methotrexate in HS.[105] Intralesional steroid injections of triamcinolone acetonide suspension, 5 to 10 mg/mL, can decrease inflammation in acutely flaring lesions, but is not an effective long-term strategy.[105,106]

HORMONAL THERAPY

Androgen modulation therapy can be trialed as second-line therapy for patients with mild-to-moderate HS. Small case series have shown improvement with spironolactone 100 to 150 mg daily,[107] as well as finasteride 5 mg daily.[108]

METFORMIN

Metformin, an insulin-sensitizing biguanide agent used in Type 2 diabetes mellitus, is an appealing second-line option for women with HS and comorbid polycystic ovarian syndrome and/or metabolic syndrome. By improving insulin sensitivity, metformin is thought to counter insulin resistance–induced ovarian androgen production. In a small prospective study of 25 patients with HS who had failed standard-line therapies, metformin dosed at 500 mg to 1500 mg daily reduced clinical severity and improved quality of life in 72% of patients over a course for 24 weeks.[109]

RETINOIDS

Topical tretinoin and oral isotretinoin are largely ineffective for HS[110] but are still commonly prescribed.[111] In a retrospective study of 88 patients with HS who had been treated with oral isotretinoin (dosing range 20 to 140 mg/kg/day) over a mean duration of 7.8 months, only 14 (16%) demonstrated clinical response.[112] Case reports suggest that acitretin, a second-generation retinoid, may have better efficacy in HS compared to isotretinoin.[110] In 1 retrospective study, 12 of 12 patients treated with 0.25 to 0.88 mg/kg acitretin for 9 to 12 months showed clinical improvement.[113] More recently, alitretinoin, a first-generation retinoid with similar properties to acitretin, produced 50% reduction in Sartorius score in 6 of 14 patients when dosed at 10 mg daily for 24 weeks.[114]

SURGICAL THERAPY

EXCISIONAL SURGERY

Excisional surgical interventions are a cornerstone for managing chronic HS. The vast majority of patients (>90%) are satisfied with results after surgery.[115] For milder disease, simple incision and drainage procedures, local excisions, and/or deroofing of sinus tracts typically suffice.[116] More-severe disease will likely require wide local excisions with primary closure, split-thickness grafting, flap advancements, and/or healing by secondary intention.[117] Optimal surgical closure is controversial and depends on characteristics of the surgical site, a topic that has been well reviewed elsewhere.[117]

Unfortunately, disease recurrence is common after surgery and many patients will require reexcisions throughout the lifetime of the disease.[118] A recent systematic review of surgical interventions for HS reported a 13% recurrence rate for wide local excisions; 22% recurrence rate for local incision; and 27% recurrence rate after deroofing.[119] Interestingly, the recurrence rate after wide local excision was lower for graft (6%) and flap (8%) closure than for primary closure (15%).[119] Some authors maintain, however, that disease recurrence after surgery is likely related to the adequacy of original excision and/or severity of disease rather than type of surgical closure.[120]

LASER THERAPY

Lasers are growing in use as adjunctive therapies for HS. Laser therapies mitigate flares by debulking tissue

as well as reducing the number of hair follicles, sebaceous glands, and bacteria in affected areas.[121] Long-pulse 1065-nm neodymium-doped yttrium aluminum garnet (Nd:YAG) laser surgery, and both ablative and fractional CO_2 laser surgery have been used successfully in the management of HS[122] and are amenable to outpatient settings.

OTHER THERAPY OPTIONS

Cryotherapy improved symptoms in 8 of 10 patients with limited, painful nodules[123]; however, most patients reported significant pain with the procedure, postprocedure ulceration and/or infection, and long healing times (average of 25 days).[123]

Radiotherapy for HS was popular in the past but fell out of favor in the 1970s following the advent of cheaper, more easily administered topical and oral therapies.[124] Recent case series have reported moderate success among patients with chronic HS who have failed medical and traditional surgical therapies.[124,125] Prospective studies are needed to better evaluate its efficacy in chronic HS.

Intralesional botulinum toxin A injections may have efficacy for HS.[126] Botulinum toxin A is thought to alleviate HS by diminishing or even abolishing eccrine, apocrine, and pilosebaceous gland function,[126] which prevents excretions and follicular rupture. Substantive trials are lacking.

PAIN MANAGEMENT

Current approaches to managing pain in HS derive from expert opinions as well as general pain management guidelines.[127] Topical analgesics, oral acetaminophen, and oral nonsteroidal antiinflammatory drugs are considered first-line therapy for pain in HS.[127] Persistent and breakthrough pain may require stepup therapy with oral opioid analgesics. Pharmacotherapy targeting neuropathic pain pathways may be beneficial, especially given that they may concomitantly ameliorate comorbid depression and itch.[127] More studies are needed to determine optimal pain regimens for patients with HS as well as to educate dermatologists, pain management specialists, and general practitioners about the pain associated with HS.

MENTAL HEALTH

Literature concerning the management of mental health morbidity in HS is scant. Qualitative studies indicate that a majority of patients feel symptoms of depression.[128] Whether incidence of clinical depression is higher among patients with HS compared to patients without HS is unclear.[129] A cross-sectional study in Israel reported that the incidence of depression (5.9% vs 3.5%) and anxiety (3.9% vs 2.4%) were significantly higher among patients with HS when compared to age- and gender-matched controls without HS.[130] No formal management guidelines exist for the psychosocial comorbidities of HS. Nevertheless, routine screening and referral of patients with signs of depression to mental health specialists are important. Patient support groups and forums also may be beneficial.

ACKNOWLEDGMENTS

The author would like to acknowledge Powell Perng, BS, for his invaluable contribution to this chapter.

REFERENCES

1. Matusiak L, Bieniek A, Szepietowski JC. Psychophysical aspects of hidradenitis suppurativa. *Acta Derm Venereol*. 2010;90(3):264-268.
2. Wolkenstein P, Loundou A, Barrau K, et al; Quality of Life Group of the French Society of Dermatology. Quality of life impairment in hidradenitis suppurativa: a study of 61 cases. *J Am Acad Dermatol*. 2007; 56(4):621-623.
3. Vinding GR, Miller IM, Zarchi K, et al. The prevalence of inverse recurrent suppuration: a population-based study of possible hidradenitis suppurativa. *Br J Dermatol*. 2014;170(4):884-889.
4. Vazquez BG, Alikhan A, Weaver AL, et al. Incidence of hidradenitis suppurativa and associated factors: a population-based study of Olmsted County, Minnesota. *J Invest Dermatol*. 2013;133(1):97-103.
5. Sung S, Kimball AB. Counterpoint: analysis of patient claims data to determine the prevalence of hidradenitis suppurativa in the United States. *J Am Acad Dermatol*. 2013;69(5):818-819.
6. Vlassova N, Kuhn D, Okoye GA. Hidradenitis suppurativa disproportionately affects African Americans: a single-center retrospective analysis. *Acta Derm Venereol*. 2015;95(8):990-991.
7. Anderson BB, Cadogan CA, Gangadharam D. Hidradenitis suppurativa of the perineum, scrotum, and gluteal area: presentation, complications, and treatment. *J Natl Med Assoc*. 1982;74(10):999-1003.
8. Chaikin DC, Volz LR, Broderick G. An unusual presentation of hidradenitis suppurativa: case report and review of the literature. *Urology*. 1994;44(4):606-608.
9. Paletta C, Jurkiewicz MJ. Hidradenitis suppurativa. *Clin Plast Surg*. 1987;14(2):383-390.
10. Jemec GB. Clinical practice. Hidradenitis suppurativa. *N Engl J Med*. 2012;366(2):158-164.
11. Mortimer PS, Lunniss PJ. Hidradenitis suppurativa. *J R Soc Med*. 2000;93(8):420-422.
12. von der Werth JM, Jemec GB. Morbidity in patients with hidradenitis suppurativa. *Br J Dermatol*. 2001; 144(4):809-813.
13. Matusiak L, Bieniek A, Szepietowski JC. Hidradenitis suppurativa markedly decreases quality of life and professional activity. *J Am Acad Dermatol*. 2010;62(4): 706-708, 708.e1.
14. Miller IM, Johansen ME, Mogensen UB, et al. Is hidradenitis suppurativa associated with anaemia?: a population-based and hospital-based cross-sectional study from Denmark. *J Eur Acad Dermatol Venereol*. 2016;30(8):1366-1372.

15. Utrera-Busquets M, Romero-Mate A, Castano A, et al. Severe hidradenitis suppurativa complicated by renal AA amyloidosis. *Clin Exp Dermatol*. 2016; 41(3):287-289.
16. Verdelli A, Antiga E, Bonciani D, et al. A fatal case of hidradenitis suppurativa associated with sepsis and squamous cell carcinoma. *Int J Dermatol*. 2016; 55(1):e52-e53.
17. Williams ST, Busby RC, DeMuth RJ, et al. Perineal hidradenitis suppurativa: presentation of two unusual complications and a review. *Ann Plast Surg*. 1991; 26(5):456-462.
18. Good LM, Francis SO, High WA. Scrotal elephantiasis secondary to hidradenitis suppurativa. *J Am Acad Dermatol*. 2011;64(5):993-994.
19. Chu EY, Kovarik CL, Lee RA. Lymphedematous verrucous changes simulating squamous cell carcinoma in long-standing hidradenitis suppurativa. *Int J Dermatol*. 2013;52(7):808-812.
20. Lavogiez C, Delaporte E, Darras-Vercambre S, et al. Clinicopathological study of 13 cases of squamous cell carcinoma complicating hidradenitis suppurativa. *Dermatology*. 2010;220(2):147-153.
21. Pena ZG, Sivamani RK, Konia TH, et al. Squamous cell carcinoma in the setting of chronic hidradenitis suppurativa; report of a patient and update of the literature. *Dermatol Online J*. 2015;21(4).
22. De Vuyst H, Clifford GM, Nascimento MC, et al. Prevalence and type distribution of human papillomavirus in carcinoma and intraepithelial neoplasia of the vulva, vagina and anus: a meta-analysis. *Int J Cancer*. 2009;124(7):1626-1636.
23. Lapins J, Ye W, Nyren O, et al. Incidence of cancer among patients with hidradenitis suppurativa. *Arch Dermatol*. 2001;137(6):730-734.
24. von Laffert M, Helmbold P, Wohlrab J, et al. Hidradenitis suppurativa (acne inversa): early inflammatory events at terminal follicles and at interfollicular epidermis. *Exp Dermatol*. 2010;19(6):533-537.
25. Prens E, Deckers I. Pathophysiology of hidradenitis suppurativa: an update. *J Am Acad Dermatol*. 2015;73(5)(suppl 1):S8-S11.
26. Danby FW, Jemec GB, Marsch W, et al. Preliminary findings suggest hidradenitis suppurativa may be due to defective follicular support. *Br J Dermatol*. 2013; 168(5):1034-1039.
27. Jemec GB, Hansen U. Histology of hidradenitis suppurativa. *J Am Acad Dermatol*. 1996;34(6):994-999.
28. Kamp S, Fiehn AM, Stenderup K, et al. Hidradenitis suppurativa: a disease of the absent sebaceous gland? Sebaceous gland number and volume are significantly reduced in uninvolved hair follicles from patients with hidradenitis suppurativa. *Br J Dermatol*. 2011;164(5):1017-1022.
29. Fitzsimmons JS, Guilbert PR, Fitzsimmons EM. Evidence of genetic factors in hidradenitis suppurativa. *Br J Dermatol*. 1985;113(1):1-8.
30. Fitzsimmons JS, Guilbert PR. A family study of hidradenitis suppurativa. *J Med Genet*. 1985;22(5):367-373.
31. Ingram JR. The genetics of hidradenitis suppurativa. *Dermatol Clin*. 2016;34(1):23-28.
32. Chen S, Mattei P, You J, et al. γ-Secretase mutation in an African American family with hidradenitis suppurativa. *JAMA Dermatol*. 2015;151(6):668-670.
33. Pan Y, Lin MH, Tian X, et al. Gamma-secretase functions through Notch signaling to maintain skin appendages but is not required for their patterning or initial morphogenesis. *Dev Cell*. 2004;7(5):731-743.
34. Radtke F, Fasnacht N, Macdonald HR. Notch signaling in the immune system. *Immunity*. 2010;32(1):14-27.
35. Zhang Q, Wang C, Liu Z, et al. Notch signal suppresses toll-like receptor-triggered inflammatory responses in macrophages by inhibiting extracellular signal-regulated kinase 1/2-mediated nuclear factor kappaB activation. *J Biol Chem*. 2012;287(9):6208-6217.
36. Lapins J, Olerup O, Emtestam L. No human leukocyte antigen-A, -B or -DR association in Swedish patients with hidradenitis suppurativa. *Acta Derm Venereol*. 2001;81(1):28-30.
37. O'Loughlin S, Woods R, Kirke PN, et al. Hidradenitis suppurativa. Glucose tolerance, clinical, microbiologic, and immunologic features and HLA frequencies in 27 patients. *Arch Dermatol*. 1988;124(7):1043-1046.
38. Revuz JE, Canoui-Poitrine F, Wolkenstein P, et al. Prevalence and factors associated with hidradenitis suppurativa: results from two case-control studies. *J Am Acad Dermatol*. 2008;59(4):596-601.
39. Woodruff CM, Charlie AM, Leslie KS. Hidradenitis suppurativa: a guide for the practicing physician. *Mayo Clin Proc*. 2015;90(12):1679-1693.
40. Totti N 3rd, McCusker KT, Campbell EJ, et al. Nicotine is chemotactic for neutrophils and enhances neutrophil responsiveness to chemotactic peptides. *Science*. 1984;223(4632):169-171.
41. Kromann CB, Deckers IE, Esmann S, et al. Risk factors, clinical course and long-term prognosis in hidradenitis suppurativa: a cross-sectional study. *Br J Dermatol*. 2014;171(4):819-824.
42. Kurzen H, Schönfelder-Funcke, S, Hartschuh W. Surgical treatment of acne inversa at the University of Heidelberg. *Coloproctology*. 2000;22:76-80.
43. Kraft JN, Searles GE. Hidradenitis suppurativa in 64 female patients: retrospective study comparing oral antibiotics and antiandrogen therapy. *J Cutan Med Surg*. 2007;11(4):125-131.
44. Barth JH, Layton AM, Cunliffe WJ. Endocrine factors in pre- and postmenopausal women with hidradenitis suppurativa. *Br J Dermatol*. 1996;134(6):1057-1059.
45. Jemec GB. The symptomatology of hidradenitis suppurativa in women. *Br J Dermatol*. 1988;119(3): 345-350.
46. Buimer MG, Wobbes T, Klinkenbijl JH, et al. Immunohistochemical analysis of steroid hormone receptors in hidradenitis suppurativa. *Am J Dermatopathol*. 2015;37(2):129-132.
47. Barth JH, Kealey T. Androgen metabolism by isolated human axillary apocrine glands in hidradenitis suppurativa. *Br J Dermatol*. 1991;125(4):304-308.
48. Kurzen H, Kurokawa I, Jemec GB, et al. What causes hidradenitis suppurativa? *Exp Dermatol*. 2008;17(5): 455-456; discussion 457-472.
49. Kelly G, Prens EP. Inflammatory mechanisms in hidradenitis suppurativa. *Dermatol Clin*. 2016;34(1): 51-58.
50. Kelly G, Sweeney CM, Tobin AM, et al. Hidradenitis suppurativa: the role of immune dysregulation. *Int J Dermatol*. 2014;53(10):1186-1196.
51. Waite JC, Skokos D. Th17 response and inflammatory autoimmune diseases. *Int J Inflam*. 2012;2012: 819467.
52. Schlapbach C, Hanni T, Yawalkar N, et al. Expression of the IL-23/Th17 pathway in lesions of hidradenitis suppurativa. *J Am Acad Dermatol*. 2011;65(4): 790-798.
53. Ring HC, Emtestam L. The microbiology of hidradenitis suppurativa. *Dermatol Clin*. 2016;34(1):29-35.

54. van der Zee HH, Laman JD, Boer J, et al. Hidradenitis suppurativa: viewpoint on clinical phenotyping, pathogenesis and novel treatments. *Exp Dermatol*. 2012;21(10):735-739.
55. Kathju S, Lasko LA, Stoodley P. Considering hidradenitis suppurativa as a bacterial biofilm disease. *FEMS Immunol Med Microbiol*. 2012;65(2):385-389.
56. Scheinfeld N. Diseases associated with hidradenitis suppurativa: part 2 of a series on hidradenitis. *Dermatol Online J*. 2013;19(6):18558.
57. Braun-Falco M, Kovnerystyy O, Lohse P, et al. Pyoderma gangrenosum, acne, and suppurative hidradenitis (PASH)—a new autoinflammatory syndrome distinct from PAPA syndrome. *J Am Acad Dermatol*. 2012;66(3):409-415.
58. Marzano AV, Trevisan V, Gattorno M, et al. Pyogenic arthritis, pyoderma gangrenosum, acne, and hidradenitis suppurativa (PAPASH): a new autoinflammatory syndrome associated with a novel mutation of the PSTPIP1 gene. *JAMA Dermatol*. 2013;149(6):762-764.
59. Saraceno R, Babino G, Chiricozzi A, et al. PsAPASH: a new syndrome associated with hidradenitis suppurativa with response to tumor necrosis factor inhibition. *J Am Acad Dermatol*. 2015;72(1):e42-e44.
60. Duchatelet S, Miskinyte S, Join-Lambert O, et al. First nicastrin mutation in PASH (pyoderma gangrenosum, acne and suppurative hidradenitis) syndrome. *Br J Dermatol*. 2015;173(2):610-612.
61. Calderon-Castrat X, Bancalari-Diaz D, Roman-Curto C, et al. PSTPIP1 gene mutation in a pyoderma gangrenosum, acne and suppurative hidradenitis (PASH) syndrome. *Br J Dermatol*. 2016;175(1):194-198.
62. van der Zee HH, de Winter K, van der Woude CJ, et al. The prevalence of hidradenitis suppurativa in 1093 patients with inflammatory bowel disease. *Br J Dermatol*. 2014;171(3):673-675.
63. van der Zee HH, van der Woude CJ, Florencia EF, et al. Hidradenitis suppurativa and inflammatory bowel disease: are they associated? Results of a pilot study. *Br J Dermatol*. 2010;162(1):195-197.
64. Burrows NP, Jones RR. Crohn's disease in association with hidradenitis suppurativa. *Br J Dermatol*. 1992;126(5):523.
65. Nassar D, Hugot JP, Wolkenstein P, et al. Lack of association between CARD15 gene polymorphisms and hidradenitis suppurativa: a pilot study. *Dermatology*. 2007;215(4):359.
66. van Rappard DC, Mekkes JR. Hidradenitis suppurativa not associated with CARD15/NOD2 mutation: a case series. *Int J Dermatol*. 2014;53(1):e77-e79.
67. Martinez F, Nos P, Benlloch S, et al. Hidradenitis suppurativa and Crohn's disease: response to treatment with infliximab. *Inflamm Bowel Dis*. 2001;7(4):323-326.
68. Shlyankevich J, Chen AJ, Kim GE, et al. Hidradenitis suppurativa is a systemic disease with substantial comorbidity burden: a chart-verified case-control analysis. *J Am Acad Dermatol*. 2014;71(6):1144-1150.
69. Miller IM, Ellervik C, Vinding GR, et al. Association of metabolic syndrome and hidradenitis suppurativa. *JAMA Dermatol*. 2014;150(12):1273-1280.
70. Shalom G, Freud T, Harman-Boehm I, et al. Hidradenitis suppurativa and metabolic syndrome: a comparative cross-sectional study of 3207 patients. *Br J Dermatol*. 2015;173(2):464-470.
71. Slade DE, Powell BW, Mortimer PS. Hidradenitis suppurativa: pathogenesis and management. *Br J Plast Surg*. 2003;56(5):451-461.
72. van der Zee HH, Jemec GB. New insights into the diagnosis of hidradenitis suppurativa: Clinical presentations and phenotypes. *J Am Acad Dermatol*. 2015;73(5)(suppl 1):S23-S26.
73. Alikhan A, Lynch PJ, Eisen DB. Hidradenitis suppurativa: a comprehensive review. *J Am Acad Dermatol*. 2009;60(4):539-561; quiz 562-563.
74. Canoui-Poitrine F, Revuz JE, Wolkenstein P, et al. Clinical characteristics of a series of 302 French patients with hidradenitis suppurativa, with an analysis of factors associated with disease severity. *J Am Acad Dermatol*. 2009;61(1):51-57.
75. Hurley HJ. Axillary hyperhidrosis, apocrine bromhidrosis, hidradenitis suppurativa, and familial benign pemphigus: surgical approach. In: Roenigk RK, Roenigk HH, eds. *Dermatologic Surgery*. New York, NY: Marcel Dekker; 1989:729-739.
76. Sartorius K, Lapins J, Emtestam L, et al. Suggestions for uniform outcome variables when reporting treatment effects in hidradenitis suppurativa. *Br J Dermatol*. 2003;149(1):211-213.
77. Kimball AB, Kerdel F, Adams D, et al. Adalimumab for the treatment of moderate to severe Hidradenitis suppurativa: a parallel randomized trial. *Ann Intern Med*. 2012;157(12):846-855.
78. Grant A, Gonzalez T, Montgomery MO, et al. Infliximab therapy for patients with moderate to severe hidradenitis suppurativa: a randomized, double-blind, placebo-controlled crossover trial. *J Am Acad Dermatol*. 2010;62(2):205-217.
79. Kimball AB, Jemec GB, Yang M, et al. Assessing the validity, responsiveness and meaningfulness of the Hidradenitis Suppurativa Clinical Response (HiSCR) as the clinical endpoint for hidradenitis suppurativa treatment. *Br J Dermatol*. 2014;171(6):1434-1442.
80. Canoui-Poitrine F, Le Thuaut A, Revuz JE, et al. Identification of three hidradenitis suppurativa phenotypes: latent class analysis of a cross-sectional study. *J Invest Dermatol*. 2013;133(6):1506-1511.
81. Ferri FF. Hidradenitis suppurativa. In: *Ferri's Clinical Advisor 2017*. St. Louis, MO: Elsevier; 2017:588-589.
82. Wortsman X. Imaging of hidradenitis suppurativa. *Dermatol Clin*. 2016;34(1):59-68.
83. Wortsman X, Jemec G. A 3D ultrasound study of sinus tract formation in hidradenitis suppurativa. *Dermatol Online J*. 2013;19(6):18564.
84. Kelly AM, Cronin P. MRI features of hidradenitis suppurativa and review of the literature. *AJR Am J Roentgenol*. 2005;185(5):1201-1204.
85. Attanoos RL, Appleton MA, Douglas-Jones AG. The pathogenesis of hidradenitis suppurativa: a closer look at apocrine and apoeccrine glands. *Br J Dermatol*. 1995;133(2):254-258.
86. Boer J, Weltevreden EF. Hidradenitis suppurativa or acne inversa. A clinicopathological study of early lesions. *Br J Dermatol*. 1996;135(5):721-725.
87. Jemec GB, Thomsen BM, Hansen U. The homogeneity of hidradenitis suppurativa lesions. A histological study of intra-individual variation. *APMIS*. 1997;105(5):378-383.
88. Fismen S, Ingvarsson G, Moseng D, et al. A clinical-pathological review of hidradenitis suppurativa: using immunohistochemistry one disease becomes two. *APMIS*. 2012;120(6):433-440.
89. Poli F, Jemec GB, Revuz J. Clinical presentation. In: *Hidradenitis Suppurativa*. Heidelberg, Germany: Springer; 2006:11-24.

90. von der Werth JM, Williams HC. The natural history of hidradenitis suppurativa. *J Eur Acad Dermatol Venereol*. 2000;14(5):389-392.
91. Shah N. Hidradenitis suppurativa: a treatment challenge. *Am Fam Physician*. 2005;72(8):1547-1552.
92. Boer J, Jemec GB. Resorcinol peels as a possible self-treatment of painful nodules in hidradenitis suppurativa. *Clin Exp Dermatol*. 2010;35(1):36-40.
93. Kumari R, Thappa DM. Role of insulin resistance and diet in acne. *Indian J Dermatol Venereol Leprol*. 2013;79(3):291-299.
94. Melnik BC. Acneigenic stimuli converge in phosphoinositol-3 kinase/Akt/Foxo1 signal transduction. *J Clin Exp Dermatol Res*. 2010;1(1):1-8.
95. Sahebkar A, Cicero AF, Simental-Mendia LE, et al. Curcumin downregulates human tumor necrosis factor-alpha levels: a systematic review and meta-analysis ofrandomized controlled trials. *Pharmacol Res*. 2016;107:234-242.
96. Brocard A, Knol AC, Khammari A, et al. Hidradenitis suppurativa and zinc: a new therapeutic approach. A pilot study. *Dermatology*. 2007;214(4):325-327.
97. Clemmensen OJ. Topical treatment of hidradenitis suppurativa with clindamycin. *Int J Dermatol*. 1983; 22(5):325-328.
98. Jemec GB, Wendelboe P. Topical clindamycin versus systemic tetracycline in the treatment of hidradenitis suppurativa. *J Am Acad Dermatol*. 1998;39(6):971-974.
99. Bettoli V, Zauli S, Borghi A, et al. Oral clindamycin and rifampicin in the treatment of hidradenitis suppurativa-acne inversa: a prospective study on 23 patients. *J Eur Acad Dermatol Venereol*. 2014;28(1):125-126.
100. Join-Lambert O, Coignard H, Jais JP, et al. Efficacy of rifampin-moxifloxacin-metronidazole combination therapy in hidradenitis suppurativa. *Dermatology*. 2011;222(1):49-58.
101. Yazdanyar S, Boer J, Ingvarsson G, et al. Dapsone therapy for hidradenitis suppurativa: a series of 24 patients. *Dermatology*. 2011;222(4):342-346.
102. Tzanetakou V, Kanni T, Giatrakou S, et al. Safety and efficacy of anakinra in severe hidradenitis suppurativa: a randomized clinical trial. *JAMA Dermatol*. 2016;152(1):52-59.
103. Gulliver WP, Jemec GB, Baker KA. Experience with ustekinumab for the treatment of moderate to severe hidradenitis suppurativa. *J Eur Acad Dermatol Venereol*. 2012;26(7):911-914.
104. Nazary M, Prens EP, Boer J. Azathioprine lacks efficacy in hidradenitis suppurativa: a retrospective study of nine patients. *Br J Dermatol*. 2016;174(3):639-641.
105. Lam J, Krakowski AC, Friedlander SF. Hidradenitis suppurativa (acne inversa): management of a recalcitrant disease. *Pediatr Dermatol*. 2007;24(5):465-473.
106. Revuz J. Hidradenitis suppurativa. *J Eur Acad Dermatol Venereol*. 2009;23(9):985-998.
107. Lee A, Fischer G. A case series of 20 women with hidradenitis suppurativa treated with spironolactone. *Australas J Dermatol*. 2015;56(3):192-196.
108. Joseph MA, Jayaseelan E, Ganapathi B, et al. Hidradenitis suppurativa treated with finasteride. *J Dermatolog Treat*. 2005;16(2):75-78.
109. Verdolini R, Clayton N, Smith A, et al. Metformin for the treatment of hidradenitis suppurativa: a little help along the way. *J Eur Acad Dermatol Venereol*. 2013;27(9):1101-1108.
110. Boer J, van Gemert MJ. Long-term results of isotretinoin in the treatment of 68 patients with hidradenitis suppurativa. *J Am Acad Dermatol*. 1999;40(1):73-76.
111. Ingram JR, McPhee M. Management of hidradenitis suppurativa: a U.K. survey of current practice. *Br J Dermatol*. 2015;173(4):1070-1072.
112. Soria A, Canoui-Poitrine F, Wolkenstein P, et al. Absence of efficacy of oral isotretinoin in hidradenitis suppurativa: a retrospective study based on patients' outcome assessment. *Dermatology*. 2009;218(2):134-135.
113. Boer J, Nazary M. Long-term results of acitretin therapy for hidradenitis suppurativa. Is acne inversa also a misnomer? *Br J Dermatol*. 2011;164(1):170-175.
114. Verdolini R, Simonacci F, Menon S, et al. Alitretinoin: a useful agent in the treatment of hidradenitis suppurativa, especially in women of child-bearing age. *G Ital Dermatol Venereol*. 2015;150(2):155-162.
115. Harrison BJ, Mudge M, Hughes LE. Recurrence after surgical treatment of hidradenitis suppurativa. *Br Med J (Clin Res Ed)*. 1987;294(6570):487-489.
116. van der Zee HH, Prens EP, Boer J. Deroofing: a tissue-saving surgical technique for the treatment of mild to moderate hidradenitis suppurativa lesions. *J Am Acad Dermatol*. 2010;63(3):475-480.
117. Mitchell KM, Beck DE. Hidradenitis suppurativa. *Surg Clin North Am*. 2002;82(6):1187-1197.
118. Mandal A, Watson J. Experience with different treatment modules in hidradenitis suppuritiva: a study of 106 cases. *Surgeon*. 2005;3(1):23-26.
119. Mehdizadeh A, Hazen PG, Bechara FG, et al. Recurrence of hidradenitis suppurativa after surgical management: a systematic review and meta-analysis. *J Am Acad Dermatol*. 2015;73(5 Suppl 1):S70-S77.
120. Rompel R, Petres J. Long-term results of wide surgical excision in 106 patients with hidradenitis suppurativa. *Dermatol Surg*. 2000;26(7):638-643.
121. Hamzavi IH, Griffith JL, Riyaz F, et al. Laser and light-based treatment options for hidradenitis suppurativa. *J Am Acad Dermatol*. 2015;73(5)(suppl 1):S78-S81.
122. Gulliver W, Zouboulis CC, Prens E, et al. Evidence-based approach to the treatment of hidradenitis suppurativa/acne inversa, based on the European guidelines for hidradenitis suppurativa. *Rev Endocr Metab Disord*. 2016;17(3):343-351.
123. Bong JL, Shalders K, Saihan E. Treatment of persistent painful nodules of hidradenitis suppurativa with cryotherapy. *Clin Exp Dermatol*. 2003;28(3): 241-244.
124. Patel SH, Robbins JR, Hamzavi I. Radiation therapy for chronic hidradenitis suppurativa. *J Nucl Med Radiat Ther*. 2013;4(146).
125. Trombetta M, Werts ED, Parda D. The role of radiotherapy in the treatment of hidradenitis suppurativa: case report and review of the literature. *Dermatol Online J*. 2010;16(2):16.
126. Khoo AB, Burova EP. Hidradenitis suppurativa treated with *Clostridium botulinum* toxin A. *Clin Exp Dermatol*. 2014;39(6):749-750.
127. Horvath B, Janse IC, Sibbald GR. Pain management in patients with hidradenitis suppurativa. *J Am Acad Dermatol*. 2015;73(5)(suppl 1):S47-S51.
128. Esmann S, Jemec GB. Psychosocial impact of hidradenitis suppurativa: a qualitative study. *Acta Derm Venereol*. 2011;91(3):328-332.
129. Onderdijk AJ, van der Zee HH, Esmann S, et al. Depression in patients with hidradenitis suppurativa. *J Eur Acad Dermatol Venereol*. 2013;27(4):473-478.
130. Shavit E, Dreiher J, Freud T, et al. Psychiatric comorbidities in 3207 patients with hidradenitis suppurativa. *J Eur Acad Dermatol Venereol*. 2015;29(2):371-376.

Disorders of the Hair and Nails

PART 16

Chapter 85 :: Androgenetic Alopecia

:: Ulrike Blume-Peytavi & Varvara Kanti

AT-A-GLANCE

- Androgenetic alopecia (AGA) is a nonscarring progressive miniaturization of the hair follicle in genetically predisposed men and women, usually in a specific pattern distribution.
- AGA onset may be at any age following puberty, showing an increasing frequency with age.
- The etiology of AGA is multifactorial and polygenic with, as of this writing, 12 genetic regions recognized to associate with AGA in men. In men, AGA is an androgen-dependent trait. Even though the role of androgens in female AGA is less certain than in men, there is a subset of women with AGA and associated hormonal dysregulation.
- Generally, diagnosis of AGA is based on history and clinical examination. Depending on patient history and clinical evaluation, however, additional diagnostics may become necessary to exclude differential diagnoses; for example, ferritin level or thyroid-stimulating hormone in diffuse effluvium or endocrinologic workup in women with signs of hyperandrogenism.
- Biopsy is very rarely indicated in AGA. Biopsy is indicated only if, for example, the differential diagnoses cicatricial alopecia or diffuse alopecia areata are suspected.
- AGA has a naturally progressive course, meaning that the main therapeutic aim is the prevention of disease progression or enhancement of hair growth during the early, mild to moderate stages of the disease.
- The best clinical evidence according to current study data exists for topical application of minoxidil in both genders and for the oral intake of finasteride in men. Alternatively, cosmetically satisfactory results can be achieved using hair transplantation in nonprogressive stable AGA with sufficient available donor area.

DEFINITION

Androgenetic alopecia (AGA) is the most common type of hair loss, a nonscarring progressive miniaturization of the hair follicle with shortening of the anagen phase in genetically predisposed men and women, usually in a specific pattern distribution.[1] Life quality may be significantly impaired in affected individuals, independent of severity, age, or gender.

EPIDEMIOLOGY

Although AGA onset may be at any age following puberty, there is an increasing frequency with age. Reportedly, approximately 50% to 60% of men are affected by the age of 50 years increasing to approximately 80% by the age of 70 years and beyond.[2,3] The prevalence of AGA is reportedly lower and its severity less among Asians, Native Americans, and African Americans compared to the European population.[4,5] Approximately 10% to 20% of Chinese men are affected by the age of 40 to 49 years, rising to 40% to 60% by the age of 70 years and beyond.[6,7]

The frequency and severity of AGA is lower in women than in men, but it still affects a sizeable proportion of the population. Reported prevalence rates in white women in the United Kingdom and United States range between 3% and 6% in women younger than 30 years of age, increasing to 29% to 42% in women 70 years of age and older.[8,9] AGA is less common and appears to start later in life in Asian women with a reported prevalence of 25% in Korean[10] and of 12% to 15% in Chinese women 70 years of age and older.[6,7]

CLINICAL FEATURES

MALE PATTERN HAIR LOSS

MALE PATTERN, HAMILTON-NORWOOD TYPE

This is the most frequent clinical pattern in men with AGA, and only occasionally observed in women. Recession of the frontal hairline, mainly in a triangular pattern is the characteristic finding, later followed by a vertex thinning with progression until the top of the scalp is completely bald (Figs. 85-1 and 85-2). Occipital area and sides of the scalp are spared even in long-standing male pattern hair loss.

FEMALE PATTERN HAIR LOSS

FEMALE PATTERN, LUDWIG TYPE

The so-called female pattern hair loss is characterized by a diffuse thinning of the centroparietal region with maintenance of the frontal hair line (Fig. 85-3). It is the most common type of AGA in women; it is occasionally observed in men. There are 2 scales describing this pattern, the 3-point Ludwig scale (Fig. 85-4) and the 5-point Sinclair scale (Fig. 85-5).

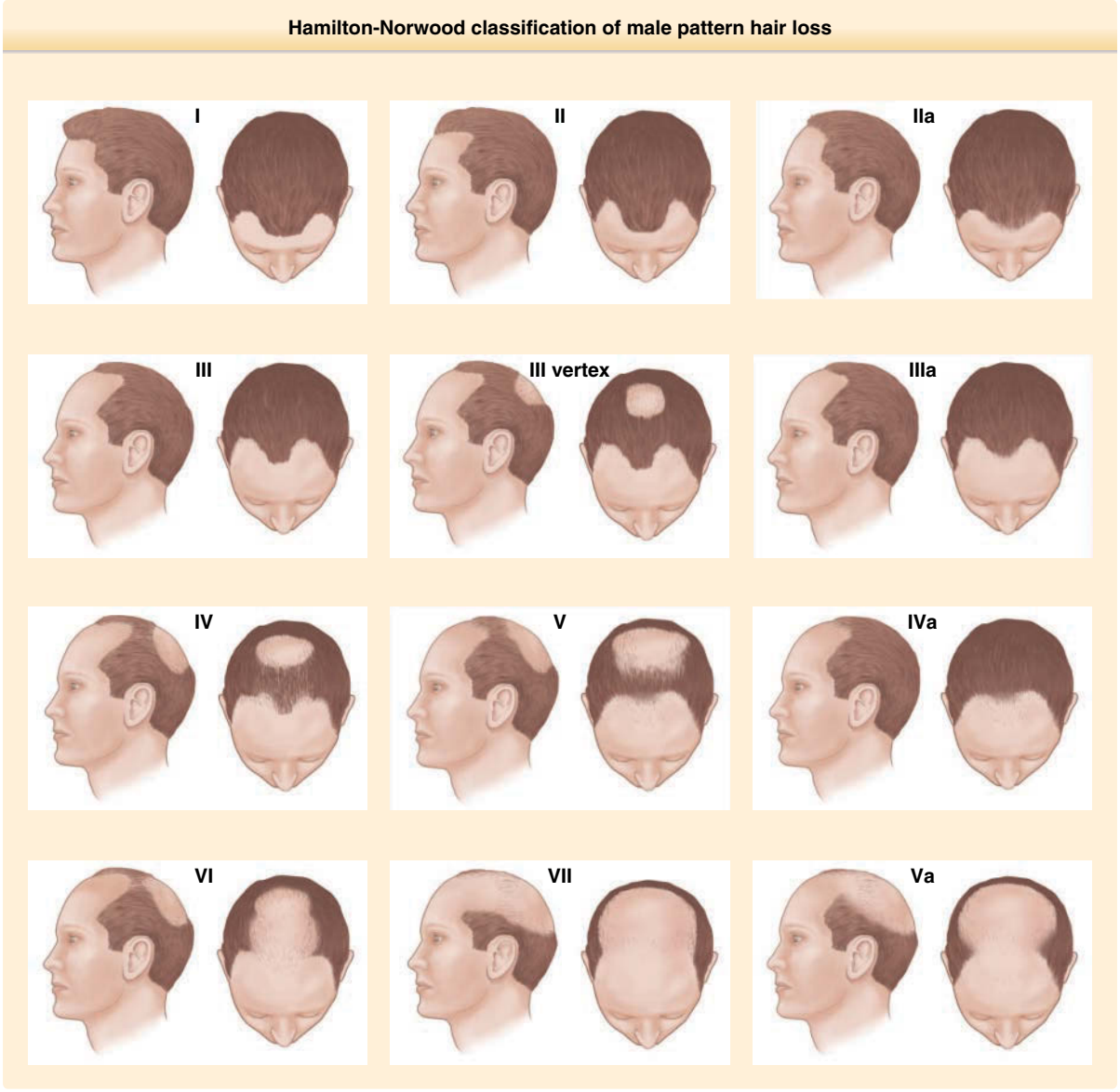

Figure 85-1 Hamilton-Norwood classification. (Redrawn from Blume-Peytavi U, Blumeyer A, Tosti A, et al. S1 guideline for diagnostic evaluation in androgenetic alopecia in men, women and adolescents. *Br J Dermatol*. 2011;164[1]:5-15.)

Figure 85-2 Male-pattern androgenetic alopecia, grade III vertex according to the Hamilton-Norwood classification. Standardized global photography overview (Canfield system).

CHRISTMAS TREE PATTERN

Frequently observed in women, the Christmas tree pattern shows diffuse centroparietal thinning similar to the Ludwig pattern with an additional breaching of the frontal hair line (Fig. 85-6).

Figure 85-3 Female pattern androgenetic alopecia, grade III according to the Ludwig classification.

ETIOLOGY AND PATHOGENESIS

RISK FACTORS

The etiology of AGA is multifactorial and polygenic.[1]

MEN

Male AGA is largely determined by genetic factors.[11,12] There is a strong paternal influence on the risk of balding.[3] Although once thought to be an autosomal dominant trait, it is now clear that AGA has a complex polygenic basis. As of this writing, molecular studies

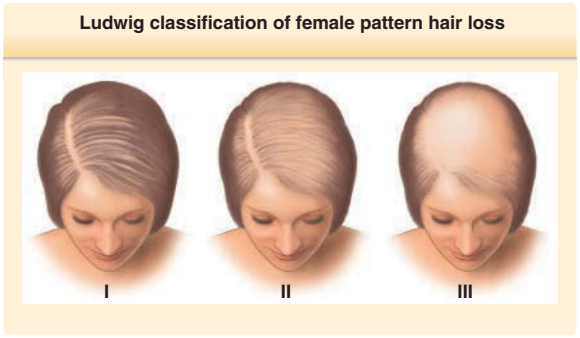

Figure 85-4 Ludwig pattern of hair loss (3-point scale). (Redrawn from Blume-Peytavi U, Blumeyer A, Tosti A, et al. S1 guideline for diagnostic evaluation in androgenetic alopecia in men, women and adolescents. *Br J Dermatol*. 2011;164[1]:5-15.)



Figure 85-5 Sinclair scale for grading female pattern hair loss (5-point scale). (Redrawn from Blume-Peytavi U, Blumeyer A, Tosti A, et al. S1 guideline for diagnostic evaluation in androgenetic alopecia in men, women and adolescents. *Br J Dermatol*. 2011;164[1]:5-15.)

have recognized 12 genetic regions associated with AGA. Candidate genes include genes for the androgen receptor (*AR*), histone-deacetylases (*HDAC*) 4 and 9, and the WNT molecule *WNT10A*.[13]

In men, AGA is an androgen-dependent trait.[14] Dihydrotestosterone is the androgen chiefly responsible for the follicular pathology. Dihydrotestosterone probably acts primarily on dermal papilla, the predominant site of androgen receptor and type II 5α-reductase expression within the hair follicle. A number of signaling molecules have been implicated in the inhibition of hair growth in AGA including transforming growth factor (TGF)-β_1 and transforming growth factor-β_2,[14] dickkopf 1 (a member of the WNT signaling family),[15] and interleukin-6.[16] There is also evidence for involvement of prostaglandins in AGA. The enzyme prostaglandin D_2 synthase and its product prostaglandin D_2 are elevated in balding scalp skin; prostaglandin D_2 has an inhibitory effect on hair growth in animal and in in vitro experiments.[17]

WOMEN

Less is known about the etiology of AGA in women. There is an increased frequency of balding in first-degree male relatives of women with AGA, which suggests there is at least some genetic commonality between female and male AGA.[18] Case-control gene-association studies have found a weak association between the *AR/EDA2* locus and early-onset female AGA, but no association with the 11 autosomal loci that associate with male AGA.[19-21] There is a weak association with the gene for estrogen receptor 2 (*ESR2*), which suggests the involvement of estrogenic pathways in female AGA.[22,23] As of this writing there have been no genome-wide studies in women.

The role of androgens in female AGA is also less certain than in men. Nevertheless, there is a subset of women with AGA and associated hormonal dysregulation.

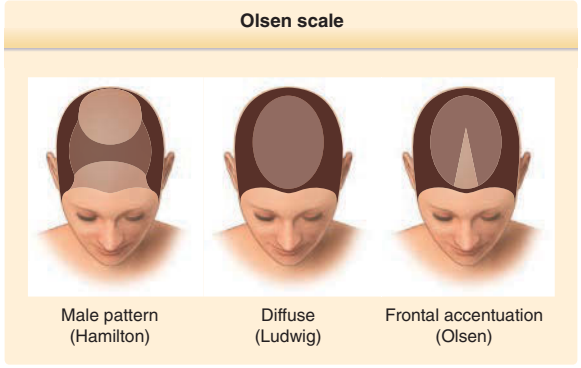

Figure 85-6 Olsen scale: Christmas tree pattern in female pattern hair loss. (Redrawn from Blume-Peytavi U, Blumeyer A, Tosti A, et al. S1 guideline for diagnostic evaluation in androgenetic alopecia in men, women and adolescents. *Br J Dermatol*. 2011;164[1]:5-15.)

DIAGNOSIS

Generally, AGA is a clinical diagnosis. Depending on patient history and clinical evaluation, further diagnostics may be necessary.

PATIENT HISTORY

Patient and family history of the first manifestation of hair loss and of the course of hair loss (chronic or intermittent) should be documented. Patients with AGA usually complain about a longstanding, slowly progressing reduction of hair density, sometimes even without noticing significant hair loss. Patients typically describe hair thinning with an accentuation of the frontal, parietal, or vertex region, but diffuse thinning is possible as well. Pruritus and trichodynia may present as initial signs of AGA. The family history for AGA is often positive. A positive family history for other hair disorders may facilitate differential diagnostic conclusions and lead to further diagnostic procedures.

In women, especially in those with peripheral signs of hyperandrogenism (Fig. 85-7), a gynecologic history is recommended, including among other possibilities, menstrual cycle disturbances and intake of hormonal contraception.

Furthermore, a detailed patient history should be performed to rule out other causes for the hair loss or

Figure 85-7 Female pattern androgenetic alopecia, facial hypertrichosis, and seborrhea oleosa in an adolescent 15-year old girl.

aggravating factors. Patient interview should include systemic and newly diagnosed diseases (eg, infections, thyroid function disorders, and surgical procedures) that occurred 6 months to 1 year prior to the first signs of hair loss, and nutritional behavior (especially chronic deficient diet or rapid significant weight loss) possibly leading to diffuse effluvium (see section "Differential Diagnosis"). Lifestyle procedures, such as special hairstyles causing traction, and environmental factors like smoking and ultraviolet radiation exposure should be considered.[1] A drug history should be taken to identify a possibly drug-related hair loss, such as after treatment with chemotherapeutic agents, hormones with proandrogenic or antithyroid action, intake of anabolic steroids, or supplemental androgens. Allergies and intolerances should be recorded as they might be important for the choice of the appropriate therapy (eg, contact dermatitis caused by propylene glycol in topical solutions)[1] as well as cosmetic habits (eg, hair care and color, hair style).

CLINICAL EXAMINATION

Clinical examination should involve the scalp skin and hair, facial and body hair, and skin, as well as the nails.

SCALP EXAMINATION

The scalp skin usually appears normal in AGA, but frequently associated findings include seborrhea and/or seborrheic dermatitis.[1] Inflammatory or infectious diseases, as well as alopecia areata and scarring alopecia like lichen planopilaris or frontal fibrosing alopecia, which can mimic AGA, should be considered (see section "Differential Diagnosis"). Balding scalp examination should include checking for photodamage and field cancerization. Thus, clinical examination of the scalp should focus on possible signs of inflammation, like erythema, scaling, or hyperkeratosis, and signs of scarring, such as skin atrophy and loss of hair follicle ostia. However, atrophy of scalp skin also may be present in longstanding AGA.[1]

HAIR EXAMINATION

Scalp Hair: Hair should be parted to assess scalp hair density. Part width should be compared between the frontal, occipital, and temporal regions to examine the distribution of alopecia (see Figs. 85-1 through 85-6, Hamilton-Norwood, Ludwig, and Olsen scales). Dermoscopy/trichoscopy can be helpful in assessing hair follicle openings to exclude scarring alopecia and in identifying short and fine miniaturized hairs. Hair caliber variations might also be present.

The hair pull test (Sabouraud maneuver) can be implemented to provide information on hair shedding. For this test, approximately 50 to 60 hairs are grasped between the thumb, index, and middle fingers from the base of the hairs near the scalp and firmly, but not forcefully, tugged away from the scalp. If more than 10% of the grasped hairs are pulled away from the scalp, this constitutes a positive pull test and confirms active hair shedding.[1] In AGA, the hair pull test may be positive in the frontal region, while it is typically negative in the occipital region.

Facial and Body Hair Examination: Facial and body hair density and/or distribution changes can be found as a result of ethnic hypertrichosis, hypertrichosis caused by medications, or hirsutism. Signs of acne, seborrhea, oily skin, and obesity might present peripheral signs of hyperandrogenism. Even though some women with AGA complain of reduction of eyebrows or eyelashes, this finding points to other types of alopecia, like alopecia areata or frontal fibrosing alopecia (see section "Differential Diagnosis")[24] rather than to AGA.

NAIL EXAMINATION

Nail abnormalities are not characteristic for AGA, but may contribute to differential work up of alopecia areata, certain deficiencies, and lichen planus.[1]

DIAGNOSTIC TOOLS

DERMOSCOPY

Dermoscopy, a noninvasive technique, improves examination of scalp skin and hair shafts by magnification (eg, assessment of hair follicle openings, hair shaft caliber variations). The findings can be saved for future comparison using videodermoscopy. In AGA, hair diameter variations, loss of trio groups with single terminal hairs, and an increased number of vellus hairs can be seen.

GLOBAL PHOTOGRAPHY

Global photographs are helpful tools for the objective evaluation of the course of hair growth, hair volume, and hair density in clinical studies, and for long-term followup in daily practice. For followup assessment, a standardized technique should be implemented, for example, by using a stereotactic device assuring a constant view, magnification, and lighting.

AUTOMATIC DIGITALIZED SYSTEM FOR HAIR DENSITY AND ANAGEN/TELOGEN HAIRS (PHOTOTRICHOGRAM)

These systems allow measurement of hair density and the anagen-to-telogen ratio for diagnostic and followup purposes, but they are mainly used for standardized and reproducible tools in clinical studies. Typical findings in AGA are reduced hair density in a pattern distribution compared to the occipital area. The anagen-to-telogen ratio is normal or decreased when comparing frontal or vertex to the occiput. These techniques are helpful for long-term followup and quantification of hair density.

TRICHOGRAM

The trichogram is not indicated as a routine diagnostic tool in AGA. It should only be considered in individual cases to rule out other differential diagnoses or comorbidities.[1] The trichogram should only be performed by dermatologists who are familiar with this technique and perform it routinely.

BIOPSY

A biopsy, mostly performed as a deep, 4-mm, cylindrical punch, is indicated in AGA only in cases where the diagnosis is uncertain, such as where scalp changes are suggestive of cicatricial alopecia or diffuse alopecia areata. Scalp biopsies should be evaluated by dermatopathologists who are experienced in hair pathology using both vertical and horizontal sectioning. The preferred area for biopsy is the central scalp in an area representative of the hair loss process. Biopsies should not be taken from the bitemporal area as miniaturized hairs may be present in this region independent of AGA.[1] Histologically AGA presents an increased number and proportion of miniaturized (vellus-like) hair follicles with a typically less than 3:1 ratio of terminal to vellus-like hair follicles, compared with a greater than 7:1 ratio in the normal scalp. Other features include an increased telogen-to-anagen ratio and an increase in the number of follicular stelae (tracts beneath miniaturized follicles). A mild perifollicular lymphohistiocytic infiltration, primarily around the upper hair follicle, also may be present, as well as perifollicular fibrosis, in longstanding AGA.

LABORATORY TESTING

In men, laboratory testing for the diagnosis of AGA is not necessary, except if the history or clinical examination indicate another underlying disorder or associated disease. Literature data indicate a possible positive association between AGA and insulin resistance, metabolic syndrome, hypertension, and benign prostate hyperplasia in men.[25] Furthermore, laboratory testing might be indicated before introducing specific therapies (eg, measurement of the prostate-specific antigen value before introducing finasteride therapy; see section "Medications").

In women, an extensive endocrinologic workup is not necessary, except if the history and clinical examination indicate androgen excess. In this case, an interdisciplinary approach involving gynecologists, endocrinologists, and dermatologists is recommended to rule out/distinguish between the different causes associated with hyperandrogenism, such as polycystic ovary syndrome, congenital adrenal hyperplasia, androgen-secreting tumors, or Cushing syndrome. For this purpose the free androgen index, sex hormone-binding globulin, and prolactin should be determined and further laboratory testing (eg, 17-OH-progesterone, follicle-stimulating hormone, estradiol, or cortisol) should be considered. The measurements should be optimally taken between 8:00 and 9:00 AM, ideally between the second and fifth day of the menstrual cycle, in order to standardize and

facilitate interpretation. Furthermore, it is advisable to perform blood hormone testing at least 2 months after stopping any hormonal intake, including oral contraception, as estrogens lead to elevated sex hormone-binding globulin levels and consequently falsify the outcome of the free androgen index.[1]

Measurement of ferritin level or thyroid-stimulating hormone may be considered depending on patient history, especially when diffuse effluvium is suspected. Literature data indicate a possible supportive role of adequate serum ferritin levels during treatment of diffuse androgen-dependent alopecia in women, even though contradictory data also have been published.[1]

Interdisciplinary evaluation must be decided individually, based on age, clinical findings, and associated findings. Especially in children and adolescents with premature onset of AGA, an interdisciplinary approach involving the dermatologist and pediatric endocrinologist should be taken. If significant psychological distress is observed, especially in women and young patients with early onset of AGA, psychological referral should be considered for the development of coping strategies.

DIAGNOSTIC ALGORITHM

A diagnostic evaluation form for AGA has been proposed by the European Consensus Group that includes history, clinical examination, laboratory and hair examination tests, diagnostic techniques and clinical documentation (Fig. 85-8).[1]

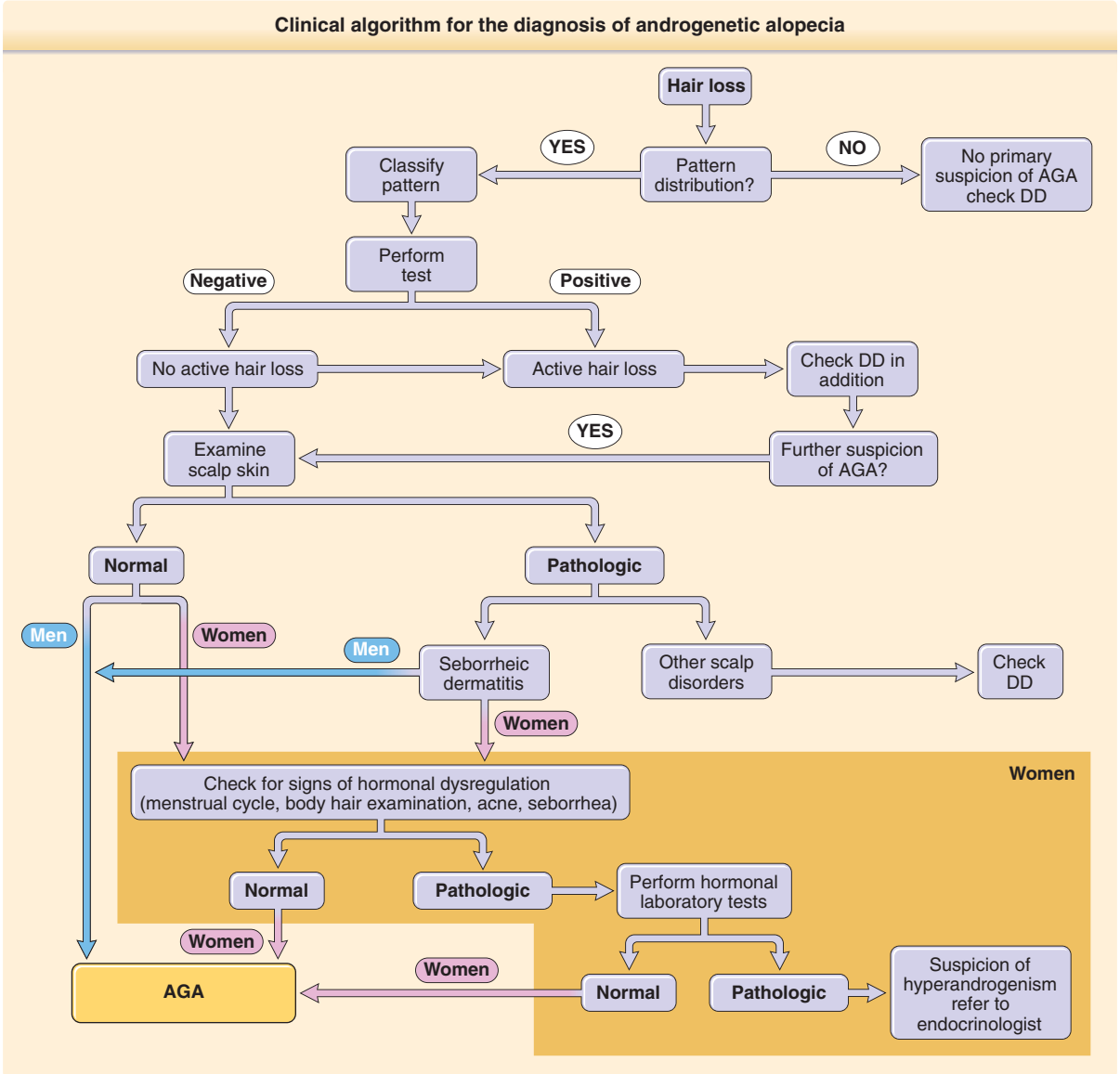

Figure 85-8 Clinical algorithm for the diagnosis of androgenetic alopecia (AGA). DD, differential diagnosis. (Adapted from Blume-Peytavi U, Blumeyer A, Tosti A, et al. S1 guideline for diagnostic evaluation in androgenetic alopecia in men, women and adolescents. *Br J Dermatol*. 2011;164[1]:5-15, with permission. Copyright © 2011 John Wiley & Sons.)

DIFFERENTIAL DIAGNOSIS

Table 85-1 outlines the differential diagnosis of AGA. Multiple hair and scalp disorders may present with clinical features that resemble or coexist with AGA.

TELOGEN EFFLUVIUM

Telogen effluvium is an acute or chronic diffuse hair loss caused by an increased number of hair follicles in telogen, possibly leading in the time course to a reduced hair density over the entire scalp. Telogen effluvium is usually associated with a precipitating event, like a severe illness or psychological trauma, crash diet or certain medications, and the results of the hair pull test are diffusely positive (Fig. 85-9B).

DIFFUSE ALOPECIA AREATA

Diffuse alopecia areata typically does not follow a patterned distribution. Although not always present, a personal or family history of alopecia areata, the detection of patchy or total hair loss, hair loss in other body sites, and nail abnormalities offer support to this diagnosis. A biopsy is useful for confirming the diagnosis if clinically not distinct (see Fig. 85-9A).

TABLE 85-1
Differential Diagnoses for Androgenetic Alopecia

Telogen Effluvium
- Associated with precipitating event
- Hair pull test diffusely positive

Diffuse Alopecia Areata
- No pattern of distribution
- Personal or family history of alopecia areata
- Hair loss in other body sites
- Nail changes

Central Centrifugal Cicatricial Alopecia
- Scarring alopecia of the vertex region
- Most commonly in women of African descent
- Dermoscopy and histologic evaluation shows scarring alopecia

Frontal Fibrosing Alopecia
- Frontotemporal, band-like scarring
- Associated with loss of eyebrows
- Perifollicular erythema and hyperkeratosis
- Histology shows lymphocytic scarring alopecia

Early Traction Alopecia
- History of chronic tension in the hair shaft (tight braiding)

Hypotrichosis Simplex
- Diffuse, progressive loss of scalp and body hair from early childhood
- No anomalies of skin, nails, or teeth

Ectodermal Dysplasia
- Skin, appendages, nails, and teeth associated
- Delayed physical/psychological development and sweating disorders

CENTRAL CENTRIFUGAL CICATRICIAL ALOPECIA

Central centrifugal cicatricial alopecia is a scarring alopecia of the vertex region that most commonly occurs in women of African descent (Fig. 85-10A). The dermoscopic detection of loss of follicular ostia confirms the scarring type. Biopsies can be useful to confirm the diagnosis.

FRONTAL FIBROSING ALOPECIA

Frontal fibrosing alopecia is a frontotemporal band-like scarring alopecia, characterized by frontotemporal band like recession, loss of eyebrows, perifollicular erythema and hyperkeratosis (see Fig. 85-10C, D). The detection of clinical and histologic signs consistent with a lymphocytic scarring alopecia aid in diagnosis.

TRACTION ALOPECIA

Traction alopecia occurs as a result of chronic tension on the hair shaft (see Fig. 85-10B). Although the hair loss is reversible initially, hair loss may become permanent if tension on the hair follicles continues. History of tight braiding of the hair is useful for diagnosis.

HYPOTRICHOSIS SIMPLEX OR ECTODERMAL DYSPLASIA

It is important to differentiate between congenital or acquired hair loss in adolescents. Hereditary hypotrichosis simplex is characterized by diffuse and progressive hair loss of the scalp and the body, beginning during early childhood. There are no anomalies of the skin, nails, or teeth. The group of ectodermal dysplasias comprise a large, heterogenous group of inherited disorders involving the skin, its appendages, nails, and teeth. Delayed physical/psychological development and sweating disorders may be present.

CLINICAL COURSE AND PROGNOSIS

The course of AGA is naturally progressive, meaning that the main therapeutic aim is the improvement or even merely prevention of disease progression. This can mainly be achieved during the early, mild to

Figure 85-9 Differential diagnosis between female pattern androgenetic alopecia and (**A**) diffuse alopecia areata or (**B**) diffuse effluvium may present a challenge; a detailed patient and family history, laboratory testing and/or biopsy might be necessary.

Figure 85-10 Hair disorders mimicking androgenetic alopecia. **A,** Central centrifugal cicatricial alopecia; **B,** traction alopecia; **C,** frontal fibrosing alopecia; and **D,** coexisting frontal fibrosing alopecia and androgenetic alopecia Ludwig grade III in a postmenopausal woman.

moderate stages of the disease. Irrespective of its clinical progression, AGA provokes significant distress and has an often underestimated psychosocial impact on the affected patients.[26]

MANAGEMENT

MEDICATIONS

The best clinical evidence according to current study data concerns the topical application of minoxidil. Minoxidil prevents further progression of the disease and leads to an increase in hair density and hair thickness both in male patients older than 18 years of age with mild to moderate AGA (2% to 5% solution; 1 mL or half a cap of 5% foam twice daily) and female patients older than 18 years of age (2% solution; 1 mL twice daily or half a cap of 5% foam once daily). The response to treatment should be assessed at 6 months. If successful, treatment needs to be continued to maintain efficacy.[27]

The patients should be informed about transitory increased telogen hair shedding, usually appearing within the first 8 weeks of therapy initiation. Furthermore, after end of therapy with topical minoxidil, increased hair loss follows.

The main side effect of topical minoxidil is hypertrichosis, mostly from local spreading or excessive continuous topical application. To avoid contamination of the pillow with subsequent facial contact patients should be advised to apply the drug at least 2 hours before going to bed. Irritant and allergic contact dermatitis may also occur. Irritation is more common with the 5% solution because of its higher content in propylene glycol. Contact dermatitis resulting from propylene glycol or from minoxidil itself should be confirmed by patch testing. It is recommended to pause topical minoxidil use during pregnancy and lactation, owing to the lack of data during this period.[27]

In male patients older than 18 years of age with mild to moderate AGA, a systemic therapy with the 5α-reductase type 2 inhibitor finasteride (1 mg/day) improves or to prevents progression of AGA. For greater efficacy, the combination of oral finasteride (1 mg once daily) and topical minoxidil can be considered. Patients under treatment with finasteride should be aware of reduction of prostate-specific antigen, which is important in prostate cancer screening in men. Further reported side effects of finasteride are impaired sexual function, including erectile dysfunction, ejaculation dysfunction, reduced ejaculate volume, and loss of libido. A possible negative impact of finasteride on those who have a constitutive predisposition to psychological disorders, leading to alteration of mood/depression has been reported; gynecomastia; testicular pain; hypersensitivity reactions; and possible negative impact on spermatogenesis in those men with preexisting conditions relating to infertility should be mentioned. Post-finasteride syndrome, defined as various symptoms persisting for months or years after discontinuation of finasteride treatment, including sexual dysfunction, loss of libido, depression, suicidal ideation, impaired cognition, fatigue, and decreased penile sensitivity, probably occurring in men with a history of sexual dysfunction or a personal or family history of psychiatric illness, are also discussed in the literature. Consequently, finasteride is contraindicated in patients with active depression or current sexual dysfunction.

The response to treatment should be assessed at 6 months, although in some men it may not become evident before 12 months. If successful, treatment needs to be continued to maintain efficacy. In case of ineffective treatment with 1 mg finasteride over 12 months, the off-label use of the 5α-reductase inhibitor dutasteride, which inhibits the isoenzymes type 1 and type 2, at a dose of 0.5 mg a day can be considered.

Finasteride is not indicated in women and is contraindicated in pregnant women and women of childbearing potential, because of the risk of feminization of a male fetus. Finasteride-treated men must avoid donating their blood.[27]

In female postmenopausal patients, finasteride 1 mg failed to show efficacy; however, finasteride 5 mg may be effective in female normoandrogenic premenopausal and postmenopausal patients. However, no placebo-controlled trials are available in this population. In women of childbearing age, the use of a safe contraceptive method is indispensable.[27]

Clinical studies on the efficacy of topical finasteride preparations are currently underway.

Antiandrogens and estrogenic drugs are being used in the treatment of AGA, although evidence of efficacy for any of these treatments is insufficient. In male patients, the use of systemic estrogens or androgen-receptor antagonists is not recommended. In women with AGA and clinical or biochemical evidence of hyperandrogenism, the use of oral antiandrogens (chlormadinone acetate, cyproterone acetate, drospirenone, spironolactone, flutamide) in combination with an estrogen as an oral contraceptive pill can be considered. Side effects of cyproterone acetate include depressive mood changes and liver toxicity. There is an increased risk of venous thromboembolism in patients taking estrogen-containing oral contraceptives, which may be greater in those taking cyproterone acetate than other oral contraceptives. Spironolactone 100 to 200 mg per day taken continuously is an alternative option because of its antiandrogenic effect, but should also be combined with a safe contraceptive in women of childbearing age. Side effects include menstrual disturbances and hyperkalaemia.[27]

As of this writing, there is insufficient literature evidence on the effect of topical alfatradiol, topical natural estrogens or progesterones, or topical fluridil.[27]

PROCEDURES

SURGERY

In AGA, hairless or thinning areas can be cosmetically covered, albeit with a decreased density, using

hair restoration surgery. Hair restoration surgery involves hair transplantation, scalp reduction surgery, or a combination of both. Hair transplantation is less invasive than scalp reduction surgery. Over the last decades, hair transplantation has evolved into a microsurgical procedure. Follicular units of 1 to 4 hairs are transplanted in large numbers and high densities. Hair surgery, especially follicular unit transplantation, can be considered to improve AGA in suitable patients with sufficient donor hair supply and medically controlled or spontaneously stabilized AGA, especially in the frontoparietal area. The result greatly depends on the skills of the surgical team and the adjustment of the surgical plan to individual patient characteristics. As hair surgery does not influence progression of AGA, long-term results in early stages depend on spontaneous or medical stabilization of AGA. In men, a combination of finasteride 1 mg and/or topical minoxidil with follicular unit transplantation may reduce postoperative progression of AGA.[27]

NONPERMANENT HAIR REPLACEMENT MEASURES

Nonsurgical hair replacement methods include, in addition to full and partial hair replacement measures (wigs), various hair-binding techniques and hair extension and supplementation techniques, either performed by the patients themselves (eg, sprinkle hair) or by specialized personnel (eg, camouflage techniques, bonding).[28]

INTERVENTIONS

Low-Level Laser Therapy: Low-level laser therapy, including the exposure of tissues to low levels of visible or near infrared light, can be used as an ancillary treatment for AGA. Low-level laser therapy can be performed at home, using a LaserComb or wearing for a certain amount of time a helmet whose power cord is plugged into a standard outlet. Duration of therapy and frequency varies for the different devices. Current studies evaluating laser devices show inconsistent results thus providing low quality evidence.[27] However, an improvement in total hair count has been partly reported after using such devices.[29,30]

MISCELLANEOUS

Besides the above-mentioned evidence-based therapeutic approaches, there is a wide range of molecules, products, and interventions claiming to promote hair growth in AGA. These include platelet-rich plasma, mesotherapy, botulinum toxin injections, pulsed electromagnetic/static field devices, topically applied caffeine, melatonin, retinoids, biochanin A, adenosine, prostaglandin analogs, herbal preparations, and nutritional supplements (eg, biotin, zinc, copper, amino acids, micronutrients and combination preparations). For most of these products controlled clinical studies are scarce and largely of low evidence level. Detailed information on these products and the available literature can be found in the current S3 guidelines for the treatment of AGA in women and in men.[27] Based on currently available literature data no evidence-based recommendation can be given for these miscellaneous products. Their use as a supportive strategy within an individually tailored management approach is at the discretion of the treating dermatologist and the decision of the patient. Further controlled studies to prove the relevance of these and other new approaches in the treatment of AGA are needed.

COUNSELING

AGA is the most common hair loss disorder, affecting both men and women. Taking into account the high prevalence and the psychosocial burden and the often significant impairment of life of affected patients, the need for competent counseling and development of a trusting patient–physician relationship becomes apparent. To enhance therapy compliance, the patient must be informed in detail about the therapeutic goal, the possible treatment options, and their potential side effects. The naturally progressive nature of the disease should be pointed out, as well as the often limited response to therapy, particularly in advanced AGA. Practical counseling with tips on handling the disease in daily life should be offered. In individual cases with high emotional overlay, particularly in women, professional psychological help might be helpful. Overall, counseling dermatologists should develop a therapeutic personalized plan for each patient based on clinical status, demands, needs, and complaints. The individualized concept should comprise pharmacologic evidence-based recommendations, hair care and cosmetic tips, and psychological counseling. The physician and patient must decide together on the best suited individualized therapy, considering the expected results, practicality, and compliance.

SCREENING

Early diagnosis and treatment to prevent progression of AGA is important in genetically predisposed families. In patients with longstanding advanced AGA, especially in male pattern baldness, scalp examination should include screening for benign and malignant skin lesions, such as actinic keratoses, squamous cell carcinoma or basal cell carcinoma as a result of increased ultraviolet exposure of the balding scalp and the lack of protecting full hair.

REFERENCES

1. Blume-Peytavi U, Blumeyer A, Tosti A, et al. S1 guideline for diagnostic evaluation in androgenetic alopecia in men, women and adolescents. *Br J Dermatol*. 2011;164(1):5-15.
2. Norwood OT. Male pattern baldness: classification and incidence. *South Med J*. 1975;68(11):1359-1365.
3. Birch MP, Messenger AG. Genetic factors predispose to balding and non-balding in men. *Eur J Dermatol*. 2001;11:309-314.
4. Tsuboi R, Arano O, Nishikawa T, et al. Randomized clinical trial comparing 5% and 1% topical minoxidil for the treatment of androgenetic alopecia in Japanese men. *J Dermatol*. 2009;36(8):437-446.
5. Hoffmann R, Happle R. Current understanding of androgenetic alopecia. Part II: clinical aspects and treatment. *Eur J Dermatol*. 2000;10(5):410-417.
6. Xu F, Sheng YY, Mu ZL, et al. Prevalence and types of androgenetic alopecia in Shanghai, China: a community-based study. *Br J Dermatol*. 2009;160(3):629-632.
7. Wang TL, Zhou C, Shen YW, et al. Prevalence of androgenetic alopecia in China: a community-based study in six cities. *Br J Dermatol*. 2010;162(4):843-847.
8. Birch MP, Messenger JF, Messenger AG. Hair density, hair diameter and the prevalence of female pattern hair loss. *Br J Dermatol*. 2001;144:297-304.
9. Norwood OT. Incidence of female androgenetic alopecia (female pattern alopecia). *Dermatol Surg*. 2001;27(1):53-54.
10. Paik JH, Yoon JB, Sim WY, et al. The prevalence and types of androgenetic alopecia in Korean men and women. *Br J Dermatol*. 2001;145(1):95-99.
11. Nyholt DR, Gillespie NA, Heath AC, et al. Genetic basis of male pattern baldness. *J Invest Dermatol*. 2003;121(6):1561-1564.
12. Rexbye H, Petersen I, Iachina M, et al. Hair loss among elderly men: etiology and impact on perceived age. *J Gerontol A Biol Sci Med Sci*. 2005;60(8):1077-1082.
13. Heilmann-Heimbach S, Hochfeld LM, Paus R, et al. Hunting the genes in male-pattern alopecia: how important are they, how close are we and what will they tell us? *Exp Dermatol*. 2016;25(4):251-257.
14. Inui S, Itami S. Androgen actions on the human hair follicle: perspectives. *Exp Dermatol*. 2013;22(3):168-171.
15. Kwack MH, Kim MK, Kim JC, et al. Dickkopf 1 promotes regression of hair follicles. *J Invest Dermatol*. 2012;132(6):1554-1560.
16. Kwack MH, Ahn JS, Kim MK, et al. Dihydrotestosterone-inducible IL-6 inhibits elongation of human hair shafts by suppressing matrix cell proliferation and promotes regression of hair follicles in mice. *J Invest Dermatol*. 2012;132(1):43-49.
17. Garza LA, Liu Y, Yang Z, et al. Prostaglandin D2 inhibits hair growth and is elevated in bald scalp of men with androgenetic alopecia. *Sci Transl Med*. 2012;4(126):126ra34.
18. Smith MA, Wells RS. Male-type alopecia, alopecia areata, and normal hair in women. *Arch Dermatol*. 1964;89:155-158.
19. Redler S, Brockschmidt FF, Tazi-Ahnini R, et al. Investigation of the male pattern baldness major genetic susceptibility loci AR/EDA2R and 20p11 in female pattern hair loss. *Br J Dermatol*. 2012;166(6):1314-1318.
20. Heilmann S, Kiefer AK, Fricker N, et al. Androgenetic alopecia: identification of four genetic risk loci and evidence for the contribution of WNT signaling to its etiology. *J Invest Dermatol*. 2013;133(6):1489-1496.
21. Redler S, Dobson K, Drichel D, et al. Investigation of six novel susceptibility loci for male androgenetic alopecia in women with female pattern hair loss. *J Dermatol Sci*. 2013;72(2):186-188.
22. Yip L, Zaloumis S, Irwin D, et al. Association analysis of oestrogen receptor beta gene (*ESR2*) polymorphisms with female pattern hair loss. *Br J Dermatol*. 2012;166(5):1131-1134.
23. Redler S, Birch P, Drichel D, et al. The oestrogen receptor 2 (*ESR2*) gene in female-pattern hair loss: replication of association with rs10137185 in German patients. *Br J Dermatol*. 2014;170(4):982-985.
24. Badawy A, Elnashar A. Treatment options for polycystic ovary syndrome. *Int J Womens Health*. 2011;3(1):25-35.
25. Agamia NF, Abou Youssif T, El-Hadidy A, et al. Benign prostatic hyperplasia, metabolic syndrome and androgenic alopecia: is there a possible relationship? *Arab J Urol*. 2016;14(2):157-162.
26. Harth W, Blume-Peytavi U. Psychotrichology: psychosomatic aspects of hair diseases. *J Dtsch Dermatol Ges*. 2013;11(2):125-135.
27. Kanti V, Messenger A, Dobos G, et al. Evidence-based (S3) guideline for the treatment of androgenetic alopecia in women and in men–short version. *J Eur Acad Dermatol Venereol*. 2018;32(1):11-22.
28. Blume-Peytavi U, Vogt A. Current standards in the diagnostics and therapy of hair diseases-hair consultation. *J Dtsch Dermatol Ges*. 2011;9(5):394-410; quiz 411-412.
29. Leavitt M, Charles G, Heyman E, et al. HairMax LaserComb laser phototherapy device in the treatment of male androgenetic alopecia: a randomized, double-blind, sham device-controlled, multicentre trial. *Clin Drug Investig*. 2009;29(5):283-292.
30. Avci P, Gupta GK, Clark J, et al. Low-level laser (light) therapy (LLLT) for treatment of hair loss. *Lasers Surg Med*. 2014;46(2):144-151.

Chapter 86 :: Telogen Effluvium

:: Manabu Ohyama

AT-A-GLANCE

- Telogen effluvium is characterized by increased telogen club hair shedding.
- Telogen effluvium is the most common cause of diffuse hair loss.
- Telogen effluvium is subdivided into acute telogen effluvium, chronic diffuse telogen hair loss, and chronic telogen effluvium.
- Differential diagnoses include alopecia areata incognita and psychogenic pseudoeffluvium.
- Spontaneous recovery can be expected once a cause is identified and eliminated.

INTRODUCTION

Telogen effluvium (TE) was originally described by Kligman in 1961.[1] TE is best characterized by a premature termination of the anagen (growing) phase of hair follicles, with a resultant increase in telogen (resting) phase hairs leading to excessive and diffuse loss of club hairs.[1] Classically, TE refers to an acute hair loss subsequent to a variety of stresses including those caused by febrile diseases, childbirth, emotional disturbance, chronic systemic diseases, or the administration of heparin.[1] TE can be a physiologic event in the newborn.[1] Later studies revealed that the trigger and manifestation of TE were variable.[2,3] TE represents the most common cause of diffuse hair loss.[3] In clinics, truly diffuse hair loss is not often encountered.[4] The most common reason bringing TE patients to the clinic is the increase in hair shedding after shampooing or brushing alone.[4] Typically, TE is self-limiting, and full recovery can be expected once the specific causes are identified and corrected.[3,4] However, especially in nonclassical chronic TE in women, distinction between female pattern hair loss is often challenging.[5] In this chapter, the clinical features, pathophysiology, and differential diagnoses of TE are discussed.

EPIDEMIOLOGY

Approximately, the loss of more than 25% of scalp hairs has been reported to be necessary to clinically detect diffuse hair loss.[1] Therefore, most TE cases are likely to be subclinical, making estimation of its real incidence or prevalence quite difficult.[2,4] Female predominance has been noted in TE, probably because of stronger awareness of daily hair conditions and more dynamic hormonal changes including menstruation and gestation.[4,6] In theory, incidence of classic acute TE following known triggering events would not be distinct between the sexes.[4] TE can occur in children but the incidence has been reported to be low.[7] Elderly women are more likely to suffer from classic acute TE.[4] Chronic TE (CTE) represents a unique form of unknown etiology that affects the whole scalp and is mostly seen in middle-aged women.[8,9]

CLINICAL FEATURES

Depending on the clinical course and symptoms, TE can be subdivided into 3 subgroups: classic acute TE,[1] chronic diffuse telogen hair loss,[2,4,10] and chronic telogen effluvium[8,9] (Table 86-1). Irrespective of clinical subtypes, the most representative manifestation of TE is diffuse excessive shedding of club hairs.[1,2,4,8,9] It should be noted that in severe TE cases, apparent diffuse or bitemporal hair thinning can be observed; however, hair loss is often subclinical and increased hair shedding can be the only objective sign in TE.[1,4] In some cases, hair shedding has already peaked out and shed hairs carried by a patient alone is indicative of TE history.[4] The clinical features of each subset are listed below.

ACUTE TE

This is the most classic type of TE originally described by Kligman in 1961.[1] Typically, acute and diffuse hair shedding is noted 2 to 4 months from causative events.[1-3] The presence of this latency period, probably reflecting the duration of catagen and telogen periods, has been considered to be characteristic for this type of TE.[1] No sign of inflammation or scarring is observed on the scalp.[3] Usually, shed hairs demonstrate the morphology of club hairs in the late stage of telogen without an enclosing sac (root sheath cells) and pigmentation.[1] The amount of shedding hairs is significantly influenced by age, gender, race, or sampling methods, yet, in the original study by Kligman, the average number of hairs shed daily during classic TE ranged from 109 (postpartum case) to 646 (heparin-induced case).[1] Usually gradual decrease and termination of hair shedding and the regrowth of new anagen hairs can be expected by 3 to 6 months.[1,2]

CHRONIC DIFFUSE TELOGEN HAIR LOSS

A temporal insult usually triggers sudden-onset diffuse hair shedding as seen in acute TE, which recovers after the elimination of triggering stress.[2] However,

TABLE 86-1
Clinical Subtypes and Potential Etiologies of Telogen Effluvium

CLINICAL SUBTYPE	ETIOLOGY[a]
Acute telogen effluvium (acute TE)	Effluvium of the newborn Febrile illness Surgery Pregnancy Weight loss (crash diet) Drugs (may cause CDTHL)
Chronic diffuse telogen hair loss (CDTHL)	Thyroid disease Aging Malnutrition Iron deficiency (controversial) Zinc deficiency (severe cases) Systemic illness Psychological stress (controversial) STD (HIV infection and syphilis) Miscellaneous
Chronic telogen effluvium (CTE)	Idiopathic (shortening of anagen)

[a]Each etiology may explain both acute TE and CDTHL.

telogen hair shedding may last longer than 6 months.[2,4] Chronic diffuse telogen hair loss (CDTHL) is one such condition that is secondary to various causes, including thyroid disorders, acrodermatitis enteropathica, malnutrition, and drugs (Fig. 86-1).[2,4,10] The relation between CDTHL and the causative factors needs to be reversible and reproducible.

CHRONIC TELOGEN EFFLUVIUM

CTE is an idiopathic form of diffuse club hair loss seen in middle-aged women in their fourth to sixth decade

Figure 86-1 Chronic diffuse telogen hair loss due to Hashimoto disease.

Figure 86-2 Chronic telogen effluvium in a middle-aged woman.

(Fig. 86-2).[8,9] Telogen hair shedding extends more than 6 months to several years with fluctuation. The patient tends to have denser hair than average before the onset and could have been able to grow very long hair, especially in their childhood,[8,11,12] implying that anagen duration is intrinsically prolonged.[2] Typically, the onset of CTE is abrupt, and the amount of shed hairs is quite large. The patient may claim that the shed hairs block the drain after shower or bring a sack of shed hair to convince excessive hair loss.[8] Telogen club hairs can be pulled out easily from the vertex and occipital areas.[2] Marked bitemporal recession of hair is frequently observed.[8,9] Female pattern hair loss needs to be excluded. A rare male case of CTE also has been reported.[13]

ETIOLOGY AND PATHOGENESIS

ETIOLOGY

In the normal human scalp, the number of total hair follicles and the ratio between anagen and telogen hair are maintained as constant.[14] On average, telogen hair accounts for around 10% of scalp hairs.[15] Any factors that affect the duration of each phase of hair cycles with resultant abnormal increase of club hair loss can be potential TE triggers. As described above, TE consists of heterogeneous subsets with distinct pathophysiology, and therefore it is technically difficult to fully delineate the etiology. However, past observations listed definitive/probable causative factors (Table 86-1).

EFFLUVIUM OF THE NEWBORN

Physiologic type of TE can be seen in infants.[1] The shedding starts within 4 months after birth. This type of effluvium may be regarded as "total replacement

of the first pelage completed before the first 6 month of life."[1] Telogen counts in this form of effluvium are around 60% to 80% and higher than other pathogenic TEs. The hair loss pattern may resemble that of androgenetic alopecia in some cases.[1]

FEBRILE ILLNESS

Hair loss in the influenza epidemic of 1971 has been described.[16] Kligman reported 4 pediatric cases of acute TE that developed after pertussis, pneumonia, and influenza.[1] Hair shedding appeared 3 to 4 months after the illness and continued for 3 to 4 weeks. Complete hair regrowth was achieved in these cases. Febrile illness was probably a common cause of TE in the preantibiotic era, and it still needs to be counted as a trigger in critically ill patients, including those with acute sepsis.[16] High fever can cause physiologic stress to hair-producing matrix cells and lead to early anagen release,[14] or alternatively, high levels of interferons may contribute to the development of acute TE.[17,18]

SURGERY

Major surgery can trigger postoperative TE.[15,19] It is a matter of debate whether surgery alone or other factors accompanying surgery, for example, fever; general anesthesia; and changes in hormone, cytokine, or nutrition levels triggered acute TE. Rhytidectomy has been reported to cause "local" TE.[20]

PREGNANCY

Postpartum alopecia or telogen gravidarum is probably the most widely recognized form of classic TE observed 2 to 3 months after childbirth.[14,21] Using a trichogram (forced plucking of hairs), progressive increase in anagen hairs during pregnancy has been reported.[21,22] Lynfiend reported a high anagen hair rate (94.4% on average) during the second and third trimesters, whereas telogen hairs accounted for 25.5% at 6 weeks postpartum.[21] A recent analysis of 116 pregnant women with digital image analysis software (Trichoscan) has confirmed the increase in anagen rate during pregnancy.[23] However, the increase in telogen rate after delivery was only 3% and the authors suggested that postpartum TE may not be as frequent as generally thought.[23] This observation is supported by other investigators.[24,25] Accumulated clinical observations suggest that postpartum TE exists[1]; however, as most descriptions are based on studies conducted in the 1960s, further revisit and dissection of the pathophysiology using modern technology is needed to draw definitive conclusions.

THYROID DISEASE

Association between hypothyroidism and TE has been well established.[26] The manifestation is more likely to be CDTHL rather than acute TE (Fig. 86-1).[4] Hair regrowth can be observed around 8 weeks after the initiation of thyroid hormone replacement in patients with hypothyroidism, with telogen hair loss clearly indicating their link.[27] No correlation between the severity of thyroid dysfunction and the degree of effluvium has been demonstrated.[26]

Compared with hypothyroidism, the role of hyperthyroidism in TE, especially in CDTHL, is less clear and requires further investigation.[26,28]

AGING

Diffuse hair loss in the scalp and body can be seen in elderly subjects with histopathologic increase in telogen ratio.[29] Incidence of TE tends to be higher in elder individuals.[30] Senility may be a risk factor for TE or CDTHL.

WEIGHT LOSS (CRASH DIET)

A vigorous weight loss (11.7 to 24.75 kg within 3 weeks to 3 months) can result in remarkable increase in telogen counts (25% to 50%) and lead to acute TE (Fig. 86-3).[31] Calorie restriction of 0 to 1200 kcal per day has been reported to be associated with hair loss.[26]

MALNUTRITION

An increase in telogen hair ratio has been noted in protein-deficient elderly subjects and children with protein-calorie malnutrition, though only in severely affected cases.[32,33] The effect of malnutrition on the hair cycle may be variable, and CDTHL may be observed in those seriously malnourished.[26]

Figure 86-3 Acute telogen effluvium started 3 months after crash diet (weight loss of more than 10 kg within 2 to 3 months).

IRON DEFICIENCY

Iron deficiency has been implicated in the pathogenesis of TE.[26] Previous studies demonstrated that iron supplementation to CTE patients resulted in a reduction of hair shed or a decrease in telogen rate.[34] Recent studies revealed that serum ferritin levels were reduced in women but not significantly in CTE patients compared with control subjects.[35,36] Thus, the role of iron deficiency in TE is still controversial, and the efficacy of iron supplementation in CDTHL or CTE needs to be assessed in further clinical trials. A serum ferritin level less than 40 ng/ml may be considered as iron deficient in the general population.[35]

ZINC DEFICIENCY

Acrodermatitis enteropathica is an autosomal recessive disorder characterized by zinc malabsorption with resultant hair loss, acral and periorificial dermatitis, diarrhea, immunodeficiency, mental and neurologic disturbances, and growth retardation.[26] CDTHL is a typical pathophysiology for hair loss.[4] Supplemental zinc should improve all symptoms, including hair loss.[26]

Acquired zinc deficiency resembling acrodermatitis enteropathica may develop in parenteral alimentation, GI tract surgery, pancreatitis, inflammatory bowel disease, or AIDS nephropathy as well as in premature infants[26] and cause acute TE or CDTHL.

In contrast, the contribution of moderately low serum zinc levels to the development of CTE remains elusive.[36]

SYSTEMIC DISEASE

In addition to one-time-only febrile illness or endocrine/metabolic disorders, a variety of systemic diseases have been reported to be associated with diffuse hair loss.[26] CDTHL in connection with lymphoproliferative disease, advanced malignancy, collagen disease (systemic lupus erythematosus and dermatomyositis), hepatic disease, chronic renal failure, systemic amyloidosis, eosinophilia-myalgia syndrome, and inflammatory bowel disease have been reported.[4,26] Extensive acute TE has been reported to be characteristic for Cronkhite-Canada syndrome but full recovery can be expected once the underlying condition is healed.[37]

PSYCHOLOGICAL STRESS

The general perception is that psychological stress can play a role in the increase in hair shedding. In fact, Kligman in his original report of TE mentioned about psychological events as a potential cause of effluvium.[1] The contribution of psychological stress to the development of TE has been suggested; however, it is not fully supported by a high level of scientific evidence.[26]

SEXUALLY TRANSMITTED DISEASES

HIV infection and secondary syphilis have been reported to be associated with CDTHL.[4] The mechanism is not fully elucidated but the observations suggest that HIV and syphilis tests need to be included when screening for TE causes.

DRUGS

Many drugs have been reported to cause TE (Table 86-2).[4,26,38-42] However, exact incidence rates have not been documented in most agents.[26] To conclude an etiologic role of some drug in TE, other potential causes of TE need to be excluded and the hair loss should resolve after the discontinuation of the medication.[26,41] The cause-effect relationship can further be supported with the reappearance of TE when a drug is readministered. Early entry of anagen hair follicles into telogen (immediate anagen release) represents a main mechanism of drug-induced TE.[41] In many cases, the shedding starts 2 to 3 months after the initiation of the

TABLE 86-2
Representative Drugs Cause Telogen Effluvium

- Androgen hormone (testosterone, anabolic steroids, proandrogenic supplements [DHEA], contraceptives containing progesterone)
- Anticoagulants (heparins, warfarin, [possible; dabigatran, rivaroxaban])
- Antihistamines (cimetidine, ranitidine)
- Anti-infective agents
  - Antifungals (clotrimazole, fluconazole, itraconazole, terbinafine)
  - Antivirals (acyclovir, imiquimod, indinavir)
  - Antituberculosis (ethambutol, isoniazid)
  - Antiparasitic drug (albendazole, mebendazole)
- Antimitotic agents (colchicine, methotrexate)
- Antithyroid agents (propylthiouracil, methimazole)
- Cardiovascular drugs
  - ACE inhibitors (captopril, enalapril, moexipril, ramipril)
  - Beta-adrenoceptor antagonists (metoprolol, propranolol)
- Disease-modifying antirheumatic drug (leflunomide)
- HPV vaccine
- Dopamine precursor and agonists (levodopa, bromocriptine, pergolide pramipexole,)
- Interferons (interferon a-2b, γ)
- Intravenous immunoglobulin
- Metabolic disease therapeutics (allopurinol, cholestyramine, clofibrate, fenofibrate, triparanol, nicotinic acid)
- Minoxidil (at initiation or withdrawal)
- Nonsteroidal antiinflammatories (ibuprofen, naproxen, salicylates)
- Oral contraceptives (cyproterone, drospirenone)
- Psychotropics
  - Amphetamines
  - Anticonvulsants (lamotrigine, phenytoin, valproic acid)
  - Antidepressants (fluoxetine, sertraline, tricyclic antidepressants)
  - Mood stabilizers (lithium, sodium valproate)
- Pyridostigmine bromide
- Retinoid, vitamin A and its derivatives (acitretin, etretinate, isotretinoin)
- Spironolactone
- Sulfasalazine

ACE; angiotensin-converting enzyme.

Figure 86-4 Acute telogen effluvium triggered by the administration of warfarin.

medication.[1,41] Usually, the recovery from TE can be expected around 3 months after the termination of a causative drug.[41]

Anticoagulants, such as heparin and warfarin, have been recognized as a trigger of TE (Fig. 86-4).[1,42] Other important TE inducers include antiinfective agents, cardiovascular drugs, psychotropics, oral contraceptives, and retinoids (Table 86-2).[4,26,41,42]

MISCELLANEOUS

Biotin or fatty acid deficiency; exposure to heavy metals including arsenic, thallium, and selenium; sunlight and UV ray exposure; and contact dermatitis are reported to be possible triggers for TE.[4]

PATHOGENESIS

Exact mechanisms modulating hair cycle to increase telogen hairs have not been fully delineated. Headington proposed 5 distinct pathogeneses accounting for TE.[14] Recently, the concept that exogen, a hair-shedding process, is an actively controlled biochemical event independent from each phase of hair cycle has been widely accepted,[43,44] which sheds new light on the pathophysiology of TE.

IMMEDIATE ANAGEN RELEASE

Premature termination of anagen and entry into telogen can be a common mechanism for acute TE.[14] Many drug- or stress-induced TE respectively represented by those induced by heparin and drugs in the heparin family or febrile illness[1] can be explained by this phenomenon.[14] Recovery can be expected once external insults are withdrawn and the normal hair cycle restarts.[14]

DELAYED ANAGEN RELEASE

The anagen period is prolonged in most hair follicles but eventually terminated, resulting in an abrupt increase in telogen hairs. This may cause synchronous telogen hair shedding.[14] Delayed anagen release has been observed in the postpartum period[21,23]; however, whether or not this prolongation truly leads to TE remains an open question.[23-25]

SHORT ANAGEN

Headington suggested that idiopathic anagen shortening could be observed in some individuals (a short anagen syndrome).[14] Theoretically, shorter anagen results in a higher telogen rate, with resultant effluvium. An example of this phenomenon is a decrease in anagen period in etretinate-treated patients.[45]

IMMEDIATE TELOGEN RELEASE

The hair follicle is programmed to release club hair to approximately 100 days after the end of previous anagen and enters into new anagen.[46] TE may result from earlier entry into anagen as the frequency of hair shedding should increase.[14] The shedding phase observed at the initiation of topical minoxidil can be explained by this mechanism.[46]

DELAYED TELOGEN RELEASE

The telogen phase is sustained in this case but immediately after, the anagen is initiated, resulting in an increase in shedding club hairs.[14] This situation is observed in seasonal molting in mammals and, probably, in humans traveling from low-daylight to high-daylight conditions.[14]

MODULATED EXOGEN (PROVISIONAL)

Exogen refers to a term during which club hairs are shed from the telogen root sheath sac.[44] Recent studies have suggested that exogen is not a passive process cued by the new anagen hair shaft but a step characterized by proteolytic activity.[47] In rodents, the club hair is retained in the hair follicle even after the initiation of new anagen and contributes to protection from external insults.[44] In the human scalp, exogen is believed to take place sometime around the transition between telogen and anagen.[44] The presence of "kenogen" follicles, the telogen hair follicle without the hair shaft, suggests that shedding of club hair and the anagen-telogen transition do not always keep their orders.[44]

To what extent does exogen play a role in the pathogenesis of TE remains elusive. Technically, immediate or delayed telogen release also can be explained by accelerated or delayed exogen. Consideration of the role of exogen may enable further dissection of TE pathophysiology

DIAGNOSIS

TE should be suspected when a patient claims diffuse hair shedding exclusively consisting of club hairs. In typical acute TE cases with large amounts of telogen hair loss, detailed history attempting to identify possible triggers as described above in the preceding 3 to 4 months is helpful for the diagnosis of TE.[3] It should be noted that triggering events are not identifiable in up to 33% of acute TE cases.[14,48] The diagnosis of TE needs to be made based on the medical history and the findings implying increased telogen hair shedding obtained by the examinations listed below.

HAIR EXAMINATION

HAIR APPEARANCE

The assessment of global hair thickness and part width may be useful; however, as described above, TE can be subclinical in many cases and needs to be evaluated by quantitative approaches.

HAIR LOSS COUNT

Patients often bring shed hairs collected after shampooing or brushing during a certain period. Counting shed hair in such way can be quantitative with patient cooperation and skilled hands[49] but usually not. At the same time, hair loss count alone can allow making the diagnosis in severe TE cases. In addition, it gives an idea for the patient condition and further evaluation. Thus, hair loss count still provides valuable information for clinicians.

Despite hard efforts by investigators, the definitive "normal hair loss count" has not been fixed.[4] In his landmark study, Kligman reported that daily telogen hair loss by regular combing and brushing was 11 to 113, varying considerably among individuals, with an average number of 47.[1] A later study reports the daily shed count to be 40 to 180.[50] A daily telogen hair loss more than 100 has been widely used as the "gold standard" for distinguishing abnormal hair loss.[1,50] This number can be a useful yardstick. Yet, it should be noted that the score is not fully supported by scientific evidence.[50]

HAIR PULL TEST

To be strict, the hair pull test is performed in a patient who has not shampooed for more than 24 hours prior to examination.[51] About 40 to 60 hairs are grasped between the thumb and fingers and pulled firmly alongside with hair shafts.[51] The process needs to be repeated in at least 3 scalp areas, including the frontal, occipital, and temporal regions.[52] Active hair shedding is indicated when more than 10% of tested hairs were collected.[51] Careful attention needs to be paid to the morphology of hair roots as positive findings can be observed in other hair loss disorders (Fig. 86-5).[4] Of note, the presence of tapered "pencil point" hairs suggests alopecia areata.[4]

Figure 86-5 Telogen club hairs with intact hair roots collected by hair pull test.

In clinics, the hair pull test can be more casually adopted to patients at any time to check if effluvium is present. Perhaps, the increase in hair loss is suggested when more than 5 to 6 hairs were consistently pulled from 2 or more areas. The examiner should be aware that negative hair pull does not exclude TE.[4]

TRICHOGRAM

Trichogram is a semiinvasive technique and represents the most commonly used technique to evaluate hair cycles in the past.[4,52] The patient undergoing this procedure should not wash her or his hair 3 to 5 days before examination.[4,52] Fifty to 100 hairs were clumped by rubber-armed forceps or needle holder and forcibly plucked and investigated for the root morphology under a light microscope.[1,4,52] Usually, sites 2 cm from the front line and midline are sampled.[52] The procedure may yield artifacts if an examiner is unskilled and if it is uncomfortable for the patient, but it provides the telogen-anagen ratio, which is crucial for TE diagnosis.[4,52] Normal values vary among the reports: telogen 13% ranging from 4 to 20% may set a standard.[1] Acute TE can be suggested if the telogen rate exceeds 25%.[1]

PHOTOTRICHOGRAM AND TRICHOSCAN

The phototrichogram is basically a comparison of sequential photographs of a shaved scalp area to detect growing hairs.[52] The procedure is noninvasive but, as it requires shaving, can be refused by a patient. The method provides little quantitative information with regard to the hair cycle phase and may be useful when a remarkable increase in telogen (nongrowing) hairs

is observed.[52] Trichoscan is an automated version of phototrichogram using digital software for analyzing dermoscopy images.[52] These techniques are more frequently adopted for the evaluation of hair growth (in clinical trials) rather than effluvium.

TRICHOSCOPY (DERMOSCOPY)

Recently, trichoscopy (dermoscopy without immersion gel; dry-dermoscopy) attracts great interest as a method for the diagnosis of hair disorders.[53] The technique enables the distinction of clinically resembling disorders including TE, androgenetic alopecia (AGA) and diffuse alopecia areata (AA).[53] The decrease in hair density and empty hair openings (active phase) or short-vellus hairs (recovery phase) may be seen in TE (Fig. 86-6). Other signs suggestive of AGA or AA, such as hair diameter diversity, broken hairs, black dots, and tapering hairs, should be absent. In this sense, the diagnosis of TE by this technique is rather based on the exclusion.[54] Trichoscopy is useful for early detection of regrowth of short vellus hairs in the recovery phase of TE.

HISTOLOGY

Histopathologic examination is an invasive but most reliable and informative method for the evaluation of hair loss disorders.[15] For the diagnosis of TE, a quantitative assessment by means of hair counts (eg, total hair numbers, terminal vs vellus hair ratio [indicating miniaturization], telogen-anagen ratio) is indispensable, which can be achieved by horizontal sectioning of a 4-mm punch biopsy specimen at the level between reticular dermis and subcutaneous tissue.[9,55]

The histopathologic findings of TE are a normal total hair count, an increase in telogen hair ratio, normal hair size, and absence of significant inflammation or fibrotic changes.[55] The telogen count greater than 20% support the diagnosis of TE; however, the number can vary depending on the baseline of each patient.[55] In CTE, histologically-detectable increase in telogen hairs can be moderate, around 11% on average.[9] Again, the number can be variable, and multiple biopsies can enhance the accuracy of the diagnosis.[56]

Figure 86-6 The most characteristic dermoscopic finding of telogen effluvium is an increase in short-vellus hairs.

GENERAL EXAMINATION

MEDICAL HISTORY AND PHYSICAL EXAMINATION

Interview of medical history and daily medication potentially associated with telogen hair loss can be beneficial, especially in CDTHL cases. Varying degrees of trichodynia has been reported to be seen in TE and may help the diagnosis.[57] Physical examination for thyroid swelling, skin, and nail condition can be performed to detect subclinical thyroid or collagen disease.

LABORATORY EXAMINATION

A battery of laboratory tests should be performed when the cause is not identified or needs to be evaluated for its status. Recommended items include urine analysis, complete blood count, erythrocyte sedimentation rate, total protein and albumin, aspartate transaminase and alanine transaminase, blood urea nitrogen/creatinine, lactate dehydrogenase, serum ferritin and zinc, T3, T4, thyroid-stimulating hormone, antinuclear antibody, sex hormones (testosterone, luteinizing hormone, and follicle-stimulating hormone in females), prolactin, C-reactive protein, syphilis, and HIV tests.[3,4]

DIFFERENTIAL DIAGNOSIS

A condition that possibly manifests diffuse hair loss needs to be included in the differential diagnoses. Of note, female pattern hair loss, alopecia areata incognita, and psychogenic pseudoeffluvium can present quite similar clinical features and thus should be excluded.[4,46] Their distinction can be very challenging, especially in women.[46,56]

FEMALE PATTERN HAIR LOSS

Female pattern hair loss (FPHL) preferentially affects the top of the scalp, and the frontal hairline is usually preserved.[46] Some patients can demonstrate a triangular reduction in hair density in the frontal scalp behind a preserved fringe resembling a Christmas tree.[46] FPHL can be distinguished from TE in cases at an advanced stage with typical "patterned" hair loss. However, an early-stage FPHL without apparent hair loss may

report an increase in hair shedding with diffuse distribution similar to that in CTE.[46,56] The history and common approaches, such as hair pull test, trichogram, as well as laboratory investigation are usually not valuable in distinction.[2,4,46,52] Dermoscopic investigation of an affected area may enable the differentiation when characteristic FPHL signs, including hair diameter diversity, peripilar signs (a brown halo around the follicular ostium), and empty follicles, are present.[46] A quantitative histopathologic examination using horizontal sections adopting the terminal to vellus-like hair ratio (FPHL<CTE) can help confirm the diagnosis; however, multiple biopsies are necessary for diagnostic accuracy.[56]

ALOPECIA AREATA INCOGNITA

Alopecia areata incognita is a rare variant of alopecia areata characterized by acute and diffuse loss of hairs without apparent alopecic patches.[58] Hair pull test is strongly positive and collects telogen hairs.[59] Exclamation mark hairs with dystrophic roots are hardly found.[4] The diagnosis can be challenging.[4,46] Detection of numerous yellow dots of various size and uniform in color by dermoscopy or peribulbar lymphocytic infiltration by histopathologic examination can help establish the diagnosis.[4,46,59]

PSYCHOGENIC PSEUDOEFFLUVIUM

Psychogenic pseudoeffluvium is typically seen in women aged between 35 and 50 years or in men under 35 years.[4] The affected individuals claim hair shedding; however, clinicopathologic examinations fail to detect any evidence of active hair loss.[4,46] The condition is included in body dysmorphic disorder and, in some cases, underlying depressive or anxiety disorders may be present which require appropriate psychiatric management.[4,46]

CLINICAL COURSE, PROGNOSIS, AND MANAGEMENT

Clinical course and prognosis of TE can be variable. However, normal hair regrowth can be expected within several months once a triggering cause is successfully identified and eliminated.[1,4,46] In some cases, the hair texture may be altered.[46] CTE represents an idiopathic form of TE, and its chronology remains elusive.[4] A long-term follow-up of CTE cases reported no visible reduction in hair density even after continuous and fluctuating hair loss for more than 7 to 8 years, suggesting a favorable prognosis.[60]

Figure 86-7 Packs of shed hairs collected by periodical sampling confirm spontaneous resolution.

In principle, the management of TE consists of observation until spontaneous resolution, reassurance that hair loss should terminate and not lead to total baldness and psychological support represented by counseling.[1,2,4,46] The explanation of hair cycle and the pathophysiology of TE may help reducing frustration and anxiety of the patients. For those not convinced, periodical sampling of shed hairs under a constant condition (eg, after shampooing everyday [Fig. 86-7]) or demonstration of an image of regrowing hairs can enable a patient to realize the recovery.

Distinction between CDTHL and CTE requires exclusion of etiologic factors.[2] Well-organized clinical and laboratory examinations assessing possible causes listed above should be performed. Medications tend to be less regarded as a cause and needs to be fully evaluated.[2]

Currently, treatment options for CTE are limited.[4,46] Topical minoxidil may be beneficial; however, increase in telogen hair loss may be experienced 2 to 6 weeks after treatment initiation.[26]

Further dissection of the pathophysiology of TE, especially that of CTE, and the elucidation of the mechanism of exogen are indispensable to better manage this common hair loss.

ACKNOWLEDGMENTS

The author would like to thank the Department of Dermatology, Keio University School of Medicine, for permitting the use of images.

REFERENCES

1. Kligman AM. Pathologic dynamics of human hair loss. I. Telogen effluvium. *Arch Dermatol.* 1961;83:175-198.
2. Harrison S, Sinclair R. Telogen effluvium. *Clin Exp Dermatol.* 2002;27(5):389-385.

3. Malkud S. Telogen effluvium: a review. *J Clin Diagn Res.* 2015;9(9):WE01-WE03.
4. Grover C, Khurana A. Telogen effluvium. *Indian J Dermatol Venereol Leprol.* 2013;79(5):591-603.
5. Rebora A. Telogen effluvium. *Dermatology.* 1997;195(3): 209-212.
6. Mirmirani P. Managing hair loss in midlife women. *Maturitas.* 2013;74(2):119-122.
7. Nnoruka EN, Obiagboso I, Maduechesi C. Hair loss in children in South-East Nigeria: common and uncommon cases. *Int J Dermatol.* 2007;46(suppl 1):18-22.
8. Whiting DA. Chronic telogen effluvium. *Dermatol Clin.* 1996;14(4):723-731.
9. Whiting DA. Chronic telogen effluvium: increased scalp hair shedding in middle-aged women. *J Am Acad Dermatol.* 1996;35(6):899-906.
10. Dawber RPR, Simpson NB, Barth JH. Diffuse alopeica: endocrine, metabolic and chemical influences on the follicular cycle. In: Dawber RP, ed. *Disease of the Hair and Scalp*. Oxford, UK: Blackwell Science; 1997.
11. Sinclair R. Diffuse hair loss. *Int J Dermatol.* 1999;38 (suppl 1):8-18.
12. Rushton DH, Ramsay ID, James KC, et al. Biochemical and trichological characterization of diffuse alopecia in women. *Br J Dermatol.* 1990;123(2):187-197.
13. Thai KE, Sinclair RD. Chronic telogen effluvium in a man. *J Am Acad Dermatol.* 2002;47(4):605-607.
14. Headington JT. Telogen effluvium. New concepts and review. *Arch Dermatol.* 1993;129(3):356-363.
15. Sperling LC. Hair and systemic disease. *Dermatol Clin.* 2001;19(4):711-726, ix.
16. Bernstein GM, Crollick JS, Hassett JM Jr. Postfebrile telogen effluvium in critically ill patients. *Crit Care Med.* 1988;16(1):98-99.
17. Brown TD, Koeller J, Beougher K, et al. A phase I clinical trial of recombinant DNA gamma interferon. *J Clin Oncol.* 1987;5(5):790-798.
18. Olsen EA, Rosen ST, Vollmer RT, et al. Interferon alfa-2a in the treatment of cutaneous T cell lymphoma. *J Am Acad Dermatol.* 1989;20(3):395-407.
19. Desai SP, Roaf ER. Telogen effluvium after anesthesia and surgery. *Anesth Analg.* 1984;63(1):83-84.
20. Kim JH, Lew BL, Sim WY. Localized telogen effluvium after face lift surgery. *Ann Dermatol.* 2015;27(1):119-120.
21. Lynfield YL. Effect of pregnancy on the human hair cycle. *J Invest Dermatol.* 1960;35:323-327.
22. Pecoraro V, Barman JM, Astore I. The normal trichogram of pregnant women. *Adv Biol Skin.* 1967;9:203-210.
23. Gizlenti S, Ekmekci TR. The changes in the hair cycle during gestation and the post-partum period. *J Eur Acad Dermatol Venereol.* 2014;28(7):878-881.
24. Mirallas O, Grimalt R. The postpartum telogen effluvium fallacy. *Skin Appendage Disord.* 2016;1(4):198-201.
25. Rebora A, Guarrera M, Drago F. Postpartum telogen effluvium. *J Eur Acad Dermatol Venereol.* 2016;30(3): 518.
26. Fiedler VC, Gray AC. Diffuse alopecia: telogen hair loss. In: Olsen EA, ed. *Disorders of Hair Growth: Diagnosis and Treatment*. 2nd ed. New York, NY: McGraw-Hill; 2003:303-320.
27. Freinkel RK, Freinkel N. Hair growth and alopecia in hypothyroidism. *Arch Dermatol.* 1972;106(3):349-352.
28. Baldari M, Guarrera M, Rebora A. Thyroid peroxidase antibodies in patients with telogen effluvium. *J Eur Acad Dermatol Venereol.* 2010;24(8):980-982.
29. Kligman AM. The comparative histopathology of male-pattern baldness and senescent baldness. *Clin Dermatol.* 1988;6(4):108-118.
30. Reszke R, Pelka D, Walasek A, et al. Skin disorders in elderly subjects. *Int J Dermatol.* 2015;54(9):e332-e338.
31. Goette DK, Odom RB. Alopecia in crash dieters. *JAMA.* 1976;235(24):2622-2623.
32. Jordan VE. Protein status of the elderly as measured by dietary intake, hair tissue, and serum albumin. *Am J Clin Nutr.* 1976;29(5):522-528.
33. Johnson AA, Latham MC, Roe DA. An evaluation of the use of changes in hair root morphology in the assessment of protein-calorie malnutrition. *Am J Clin Nutr.* 1976;29(5):502-511.
34. Trost LB, Bergfeld WF, Calogeras E. The diagnosis and treatment of iron deficiency and its potential relationship to hair loss. *J Am Acad Dermatol.* 2006;54(5):824-844.
35. Olsen EA, Reed KB, Cacchio PB, et al. Iron deficiency in female pattern hair loss, chronic telogen effluvium, and control groups. *J Am Acad Dermatol.* 2010; 63(6):991-999.
36. Abdel Aziz AM, Sh Hamed S, Gaballah MA. Possible relationship between chronic telogen effluvium and changes in lead, cadmium, zinc, and iron total blood levels in females: a case-control study. *Int J Trichol.* 2015;7(3):100-106.
37. Watanabe-Okada E, Inazumi T, Matsukawa H, et al. Histopathological insights into hair loss in Cronkhite-Canada syndrome: diffuse anagen-telogen conversion precedes clinical hair loss progression. *Australas J Dermatol.* 2014;55(2):145-148.
38. Tosti A, Pazzaglia M. Drug reactions affecting hair: diagnosis. *Dermatol Clin.* 2007;25(2):223-231, vii.
39. Conde J, Davis K, Ntuen E, et al. A case of imiquimod-induced alopecia. *J Dermatolog Treat.* 2010;21(2):122-124.
40. Sperling LC. Telogen effluvium. In: Sperling LC, Cowper SE, Knopp EA, eds. *An Atlas of Hair Pathology With Clinical Correlation*. 2nd ed. New York: CRC Press; 2012:53-59.
41. Patel M, Harrison S, Sinclair R. Drugs and hair loss. *Dermatol Clin.* 2013;31(1):67-73.
42. Watras MM, Patel JP, Arya R. Traditional anticoagulants and hair loss: a role for direct oral anticoagulants? A Review of the Literature. *Drugs Real World Outcomes.* 2016;3(1):1-6.
43. Milner Y, Sudnik J, Filippi M, et al. Exogen, shedding phase of the hair growth cycle: characterization of a mouse model. *J Invest Dermatol.* 2002;119(3): 639-644.
44. Higgins CA, Westgate GE, Jahoda CA. From telogen to exogen: mechanisms underlying formation and subsequent loss of the hair club fiber. *J Invest Dermatol.* 2009;129(9):2100-2108.
45. Berth-Jones J, Hutchinson PE. Novel cycle changes in scalp hair are caused by etretinate therapy. *Br J Dermatol.* 1995;132(3):367-375.
46. Trueb RM. Systematic approach to hair loss in women. *J Dtsch Dermatol Ges.* 2010;8(4):284-297, 284-298.
47. Higgins CA, Westgate GE, Jahoda CA. Modulation in proteolytic activity is identified as a hallmark of exogen by transcriptional profiling of hair follicles. *J Invest Dermatol.* 2011;131(12):2349-2357.
48. Harrison S, Sinclair R. Optimal management of hair loss (alopecia) in children. *Am J Clin Dermatol.* 2003;4(11):757-770.
49. Guarrera M, Fiorucci MC, Rebora A. Methods of hair loss evaluation: a comparison of TrichoScan((R)) with the modified wash test. *Exp Dermatol.* 2013;22(7): 482-484.

50. Van Neste MD. Assessment of hair loss: clinical relevance of hair growth evaluation methods. *Clin Exp Dermatol.* 2002;27(5):358-365.
51. Pierard GE, Pierard-Franchimont C, Marks R, et al. EEMCO guidance for the assessment of hair shedding and alopecia. *Skin Pharmacol Physiol.* 2004;17(2):98-110.
52. Olszewska M, Warszawik O, Rakowska A, et al. Methods of hair loss evaluation in patients with endocrine disorders. *Endokrynol Pol.* 2010;61(4):406-411.
53. Inui S. Trichoscopy for common hair loss diseases: algorithmic method for diagnosis. *J Dermatol.* 2011;38(1):71-75.
54. Jain N, Doshi B, Khopkar U. Trichoscopy in alopecias: diagnosis simplified. *Int J Trichology.* 2013;5(4):170-178.
55. Sperling LC, Lupton GP. Histopathology of non-scarring alopecia. *J Cutan Pathol.* 1995;22(2):97-114.
56. Sinclair R, Jolley D, Mallari R, et al. The reliability of horizontally sectioned scalp biopsies in the diagnosis of chronic diffuse telogen hair loss in women. *J Am Acad Dermatol.* 2004;51(2):189-199.
57. Rebora A. Trichodynia: a review of the literature. *Int J Dermatol.* 2016;55(4):382-384.
58. Rebora A. Alopecia areata incognita: a hypothesis. *Dermatologica.* 1987;174(5):214-218.
59. Tosti A, Whiting D, Iorizzo M, et al. The role of scalp dermoscopy in the diagnosis of alopecia areata incognita. *J Am Acad Dermatol.* 2008;59(1):64-67.
60. Sinclair R. Chronic telogen effluvium: a study of 5 patients over 7 years. *J Am Acad Dermatol.* 2005;52(2)(suppl 1):12-16.

Chapter 87 :: Alopecia Areata

:: Nina Otberg & Jerry Shapiro

AT-A-GLANCE

- Alopecia areata is a nonscarring hair disorder.
- It occurs in both genders equally and can affect every age group, although incidence at in younger age groups is higher.
- It is the most common form of hair loss in children. Clinically, it presents with well-demarcated round or oval bald spots on the scalp or other parts of the body.
- Of patients with alopecia areata, 5% develop hair loss of their entire scalp hair (alopecia areata totalis) and 1% develop alopecia areata universalis (loss of total body hair).
- Nail changes include pitting or sandpaper nails.
- Alopecia areata is thought to be an autoimmune disease with a possible hereditary component.
- In general, alopecia areata is a medically friendly condition, but it can coexist with other autoimmune disorders such as Hashimoto thyroiditis and vitiligo.

Alopecia areata is a common autoimmune hair disorder. This nonscarring, usually patchy hair loss condition can affect any hair-bearing area. At any given time, approximately 0.2% of the world population is suffering from alopecia areata. It has an estimated lifetime risk of 1.7%[1,2]; it is a common cause of abrupt-onset hair loss, but occurs less often than androgenetic alopecia or telogen effluvium. Both sexes are equally affected. Although it may occur at any age, incidence at younger ages is higher. Alopecia areata is the most common form of alopecia seen in children. The familial occurrence is approximately 15%, but expression of the disorder is variable between different family members. Of patients suffering from alopecia areata, 5% develop hair loss of their entire scalp hair (alopecia areata totalis) and 1% develop alopecia areata universalis (loss of total body hair).

CLINICAL FEATURES

Alopecia areata is characterized by an acute onset. It typically presents with oval- or round-shaped, well-circumscribed, bald, patches with a smooth surface in a diffuse distribution (Figs. 87-1 and 87-2). Alopecia totalis results in the loss of the entire scalp hair and may occur suddenly or follow partial alopecia (Fig. 87-3). Partial alopecia may be observed in other areas of the body as well. Loss of total body hair is called *alopecia areata universalis* and may occur suddenly or follow longstanding partial alopecia.

Characteristic hallmarks of alopecia areata are so-called black dots (cadaver hairs, point noir), resulting from hair that breaks off by the time it reaches the skin surface. Exclamation point hairs, which have a blunt distal end and taper proximally, appear when the broken hairs (black dots) are pushed out of the follicle. Localization of the initial patch occurs most often on the scalp, but may occur on any hair-bearing part of the body. Patches are usually without further symptoms, but may cause mild itching and erythema. In addition to this well-demarcated localized form, alopecia areata can also present in a diffuse generalized pattern that resembles androgenic alopecia or telogen effluvium. Involvement of nails can occur with nail pitting and a sandpaper-like appearance.

Alopecia areata has been described in association with a variety of other disorders, including cataracts, thyroid disease, vitiligo, atopic dermatitis, psoriasis, Cronkhite-Canada, and Down syndrome.[3,4]

ETIOLOGY AND PATHOGENESIS

Alopecia areata is a chronic, organ-specific autoimmune disease. Autoactive cytotoxic CD8 T cells, which affect hair follicles and sometimes nails,[5-11] and an interferon-γ–driven immune response, which includes interferon-γ and interferon-γ–induced chemokines, have been identified as the main drivers of disease pathogenesis.[12] The importance of a cytotoxic subset of CD8+ NKG2D+ (natural-killer group 2 member D-positive) T cells within the inflammatory infiltrate in alopecia areata and an upregulation in the hair follicle itself of 2 NKG2D ligands have been discovered in several studies.[10,11] Furthermore, other cell types, including natural killer cells, may play a regulatory role in alopecia areata.[5,8,13,14]

Patients with alopecia areata seem to have a genetic predisposition to the disease. There is a high frequency of a positive family history of alopecia areata in affected individuals, ranging from 10% to 42% of cases,[15] and a much higher incidence of a positive family history in early-onset alopecia areata.[16] A genome-wide association study[10] and a large genome-wide association study metaanalysis[17] have identified numerous loci that imply a strong role for variants in genes that direct and influence immune responses.[13]

Many patients report the experience of major emotional stress prior to the onset of alopecia. Stress

Figure 87-1 Patch of alopecia areata with mild peachy erythema and some fine residual hairs.

Figure 87-2 Patient with patchy alopecia areata.

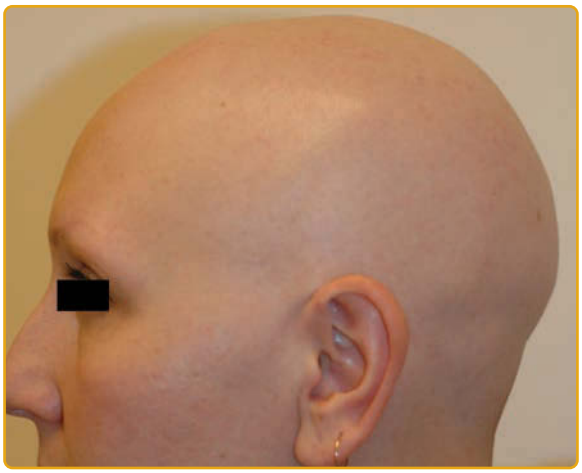

Figure 87-3 Patient with alopecia areata totalis.

Figure 87-4 Patch of alopecia area with exclamation point hair.

perception seems to be a risk factor that may influence the onset and exacerbation of alopecia areata.[18] Moreover, an antioxidant–oxidant imbalance can be found in many autoimmune disorders as well as in patients suffering from emotional and environmental stress. Several studies support an association between oxidative stress and alopecia areata.[19-24]

DIAGNOSIS

Clinical features, such as shape and look of the patches, presence of exclamation point hairs, and nail changes (pitting or sandpaper nails), lead to the diagnosis of alopecia areata (Fig. 87-4). In most patients the physical findings are so characteristic that the diagnosis is obvious. Patchy or complete loss of eyebrows and eyelashes can also lead to the diagnosis of alopecia areata (Fig. 87-5). Sudden and rapid loss of the entire scalp hair (alopecia areata totalis) or the entire body hair (alopecia areata universalis) are diagnostic for alopecia areata. A dermatoscopic evaluation will help to support the diagnosis by showing the presence of follicular ostia. The presence of either follicular ostia, exclamation point hair, cadaver hair (residual hair shafts visible as black dots in the follicular ostia), or yellow dots that will confirm the diagnosis. These features are even

Figure 87-5 Patient with alopecia areata of the eyebrows.

more visible with a trichoscopic evaluation at higher magnification.[25,26] In the acute stages gentle pulling from the periphery of bald areas will yield more than 10 hairs. White hairs are sometimes spared by the disease. This can lead to canities subita, a sudden whiting of the hair. In this case, all pigmented hairs fall out and the patient is left with only white hair. Moreover, positive family history and/or the presence of associated diseases may give further evidence. Diffuse alopecia areata can be very difficult to diagnose. In cases of doubt, a scalp biopsy (a 4-mm punch processed for horizontal sections) should be taken to confirm the diagnosis of alopecia areata.

Additionally, laboratory tests should be performed to rule out thyroid dysfunction[27] and iron or vitamin deficiencies.

PATHOLOGY

Scalp biopsy reveals a generalized miniaturization and a marked increase in catagen and telogen hair follicles. In the acute phase, alopecia areata is characterized by a peribulbar immune infiltrate centered around the hair bulb which has been described as a "swarm of bees." This infiltrate is made up of predominantly CD4 and CD8 T cells and natural killer cells.[28] Sometimes mast cell, plasma cells and eosinophils also can be seen.[13,14,29] The histopathologic features of alopecia areata, however, are stage-dependent. The classic inflammatory infiltrate may be missing or markedly less in subacute or chronic forms.[30] Sometimes an immune infiltrate is visible around the bulb of miniaturized hairs in the upper dermis.[30] Alopecia areata should be in the differential diagnosis whenever high percentages of telogen hairs or miniaturized hairs are present, even in the absence of peribulbar inflammation.

DIFFERENTIAL DIAGNOSIS

Table 87-1 outlines the differential diagnosis of alopecia areata.

COMPLICATIONS

Relapsing course and progress of hair loss to severe forms of alopecia totalis or universalis are dreaded complications. Missing hair on the scalp and face, including nasal hair and eyelashes and eyebrows can increase incidence of sunburns and skin cancers, as well as of nasopharyngeal and ophthalmologic inflammation. Although the condition is not life threatening, changes in appearance frequently cause a diminished sense of personal well-being and self-esteem, leading to severe depressive mood and withdrawal from social situations.

PROGNOSIS AND CLINICAL COURSE

The course of the disease is very variable and characterized by an irregular relapsing course, with approximately 25% of affected individuals having a solitary episode. Spontaneous regrowth of hair is common. Different body areas appear to regrow independently. Approximately 60% of patients have at least a partial regrowth by 1 year, but this is often followed by repeated episodes of hair loss. Approximately 40% of the relapses occur within the first year, but a large percentage of patients may relapse after 5 years. Hair can regrow white but may change to the patient's natural color over time. Poor prognosis is linked to involvement of the occiput and/or hairline, chronic relapsing course, presence of nail changes, and when onset is in childhood.[31-33]

Patients with alopecia areata have a 5% risk of losing their entire scalp hair (alopecia areata totalis) and an estimated 1% risk for progressing to alopecia areata universalis, characterized by total body and scalp hair loss. The number of patients progressing to alopecia areata totalis is higher in the younger age groups, and in patients with hair loss from the trunk and extremities.

TREATMENT

Very little evidence-based data is available for the treatment of alopecia areata; recommendations are mainly based on case series and clinical experience (Fig. 87-6). At this time there is no single therapy that can alter the natural course of the disease. All available treatments for alopecia areata are palliative, only controlling the ongoing episode of hair loss and not curing the condition itself. However, helpful treatment guidelines have been published.[31-33]

TABLE 87-1
Differential Diagnosis

- Temporal triangular alopecia
- Tinea capitis
- Early scarring alopecia
- Trichotillomania
- Secondary syphilis (alopecia areolaris)
- Androgenetic alopecia
- Telogen effluvium
- Anagen effluvium

CONSERVATIVE MANAGEMENT

Alopecia areata shows a high rate of spontaneous remission, especially in those patients with a short history and limited scalp involvement. On the other hand, in alopecia areata totalis and universalis, treatments have a high failure rate. After the discussion of possible risks and benefits of all options, no treatment may be a legitimate option for some patients.

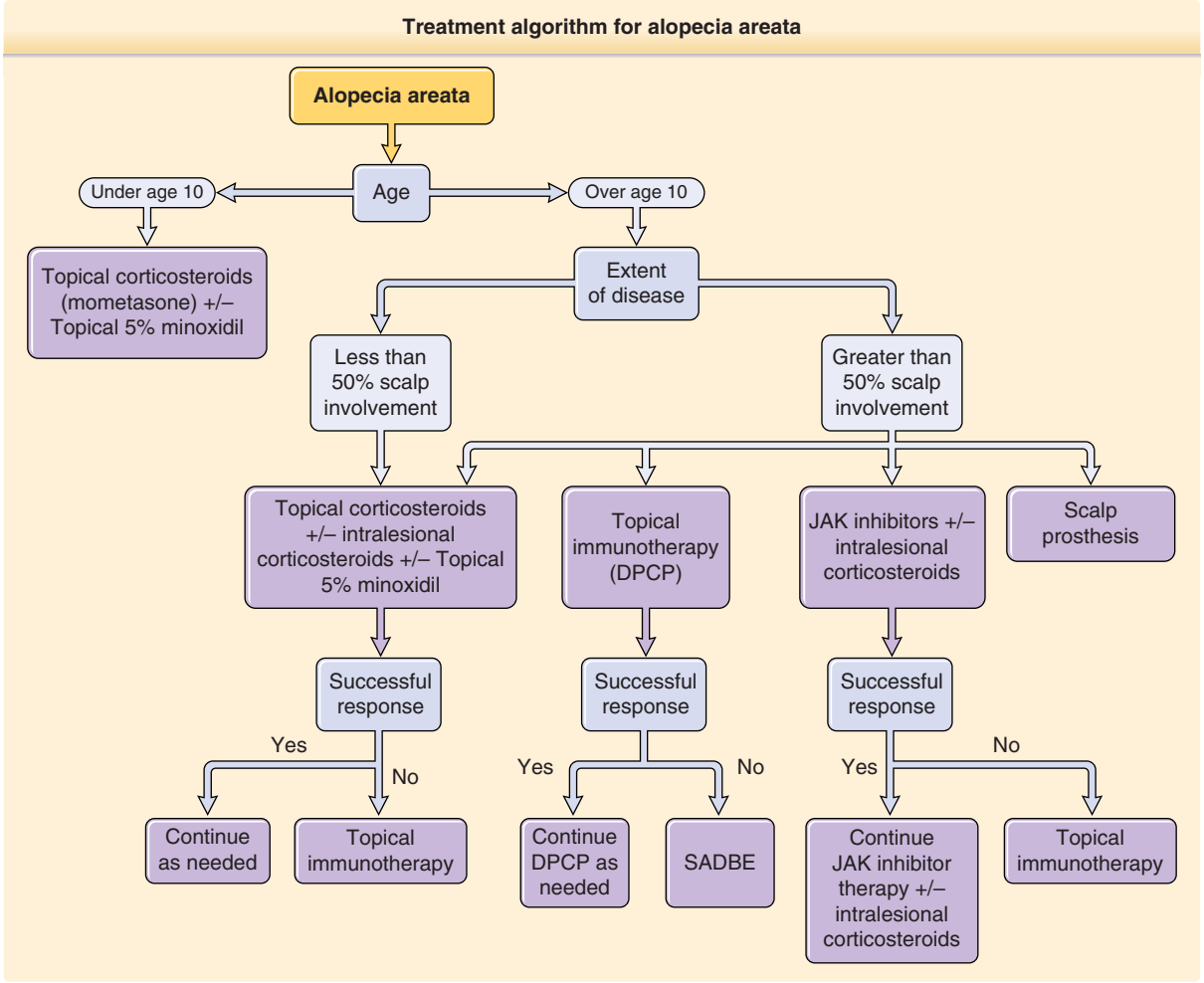

Figure 87-6 Treatment algorithm for alopecia areata. DNCB, dinitrochlorobenzene; DPCP, diphenylcyclopropenone; PUVA, psoralen and ultraviolet A; SADBE, squaric acid dibutylester. (From Strazzulla LC, Wang EHC, Avila L et al. Alopecia areata: An appraisal of new treatment approaches and overview of current therapies. *J Am Acad Dermatol*. 2018;78:15-24. Copyright © Lauren Strazzulla, Lorena Avila, and Jerry Shapiro, with permission.)

TOPICAL CORTICOSTEROIDS

Superpotent (class I) and potent (class II) topical corticosteroids are widely used to treat alopecia areata. Evidence of efficacy has been proven for class I corticosteroids when applied under occlusion[34] and for class II corticosteroids when used in combination with minoxidil.[35]

INTRALESIONAL CORTICOSTEROIDS

Intralesional corticosteroid (triamcinolone acetonide or triamcinolone hexacetonide) injection is first-line therapy for adult patients with less than 50% scalp involvement. Triamcinolone acetonide is used at concentrations from 2.5 to 10 mg/mL. Treatment is repeated every 4 to 6 weeks; the total amount injected per session varies from 15 to 40 mg.[31-33,36-38] An initial response is often seen after 4 to 8 weeks. Some patients experience indentation of the scalp skin in the injection sites as the result of a nonpermanent atrophy of the subcutaneous fat. Permanent skin atrophy can occur if the same skin area is injected repeatedly over months and years. If no regrowth can be seen after 4 months of treatment, other treatment options should be considered. Intralesional corticosteroids injections are usually used on the scalp, eyebrows and beard area and can be combined with topical treatment.

PLATELET-RICH PLASMA

Reports state that the use of platelet-rich plasma injections as monotherapy or in combination with other therapies are beneficial in the treatment of alopecia areata.[39-41] In a double-blind trial, platelet-rich plasma was superior to low-dose triamcinolone acetonide and placebo injection.[42,43] Further studies are necessary to determine the effectiveness of platelet-rich plasma in the therapy of alopecia areata.[41]

SYSTEMIC CORTICOSTEROIDS

Systemic corticosteroids are effective in the treatment of alopecia areata. However, the regrown hair frequently falls out again when the treatment is discontinued. The use of systemic corticosteroids is controversial. They should not be used as routine treatments because they do not alter the long-term prognosis and can cause side effects, such as striae, acne, obesity, cataracts, and hypertension. Dosages vary from an initial 20 to 40 mg dose of prednisone daily, with tapering down to 5 mg daily in a few weeks or different pulse therapies regimens with short-term high doses of oral prednisolone (100 to 300 mg) or IV methylprednisolone (250 mg).[31,32,34,36]

TOPICAL MINOXIDIL

There is some evidence of clinically acceptable hair regrowth using topical minoxidil 5% solution.[44,45] Better results can be achieved when minoxidil is used in combination with class I or class II topical corticosteroids or anthralin.[35] Minoxidil shows little efficacy in alopecia areata totalis and universalis.

PROSTAGLANDIN ANALOGS

Prostaglandin analogs like latanoprost and bimatoprost have been studied for their use in the treatment of alopecia areata of eyelashes and eyebrows. Some studies showed hair regrowth of eyelashes and eyebrows after the treatment with prostaglandin analogs.[46] However, several reports showed a negative outcome after the use of latanoprost and bimatoprost.[47-49] Prostaglandin analogs may have some use as an adjuvant therapy.

ANTHRALIN

Anthralin is an irritant that may have a nonspecific immunomodulating effect (anti–Langerhans cell) and is usually used in the treatment of psoriasis.[50] Several studies have shown efficacy in the treatment of alopecia areata with cosmetically acceptable varying from 20% to 25% for patchy alopecia areata.[51,52] Anthralin is used as a 0.2% to 1% cream or ointment. It is usually applied daily to the affected scalp areas and left on for 20 to 30 minutes for the first 2 weeks, and then for 45 minutes daily for 2 weeks, up to a maximum of 1 hour daily. Some patient may tolerate overnight therapy.[36,51] When therapy is effective, new hair growth can usually be seen after 2 to 3 months of treatment. Because of its good safety profile, anthralin is a good treatment choice for children. Side effects of anthralin are irritation, scaling, folliculitis, and regional lymphadenopathy. Anthralin is not suitable for the treatment of eyebrows and the beard area. Patients should be cautious not to get anthralin in the eyes and to protect the treated skin areas from ultraviolet radiation. Brown discoloration of the treated skin and brown staining of clothes and linen may occur. The patient should be advised to rinse off the anthralin with cool or lukewarm water, as hot water increases the likelihood of brown stains of tiles and bathtub.

TOPICAL IMMUNOTHERAPY

Although not approved by the U.S. Food and Drug Administration (FDA), topical immunotherapy seems to be a very effective therapeutic option with a good safety profile in the treatment of chronic severe alopecia areata. The exact mechanism of action is not fully understood. A decrease in the peribulbar CD4+/CD8+ lymphocyte ratio and a shift in the position of T-lymphocytes away from the perifollicular area to the interfollicular area and dermis are thought to be responsible for the immunomodulating effect.[53-55] The desired effect of the treatment is the creation of a contact dermatitis. Diphenylcyclopropenone is the most commonly used contact sensitizer. Diphenylcyclopropenone is compounded in an acetone base and stored in opaque bottles to protect the solution from photodegradation. Applying a small amount of a 2% solution to a small scalp area 1 week prior to treatment start, sensitizes the patient. The diphenylcyclopropenone solution is then applied weekly to the scalp, starting at a concentration of 0.0001%. The scalp should not be washed for 48 hours after treatment and should be protected from ultraviolet radiation. Carefully increase the concentration every week until the patient develops a mild erythema and mild itching. The treatment is continued with this concentration; the usual highest concentration used is 2%. Success rates vary from 17% to 75%, with the lowest success rates being in patients with alopecia areata totalis and universalis.[56] Side effects include lymphadenopathy in 100% of patients, severe contact eczema, discoloration of the skin including vitiliginous patches and hyperpigmentation on the scalp and other parts of the body. Extreme caution is indicated in patients with atopic dermatitis and dark skin types.

PHOTO(CHEMO)THERAPY

Ultraviolet B light has been reported to be useful in some patients with alopecia areata.[57] Further therapeutic options include both oral and topical administration of psoralen followed by ultraviolet A irradiation. Psoralen and ultraviolet A therapy may affect T-cell function and antigen presentation, and possibly inhibit the local immunologic attack against the hair follicle by depleting Langerhans cells.[58] Photo(chemo)therapy shows a very high relapse rate, especially after tapering

the treatment. Today's major concern about long-term ultraviolet irradiation of any kind is its promotion of all types of skin cancer, including melanoma. Consequently, phototherapy should only be considered in exceptional cases.[56]

CYCLOSPORINE

Systemic cyclosporine at doses of 4 to 6 mg/kg/day has been shown to have a beneficial effect in some patients with alopecia areata.[56,59] Side effects of oral cyclosporine include elevated serum transaminases and cholesterol levels, as well as headaches, dysesthesia, fatigue, diarrhea, gingival hyperplasia, flushing, and myalgia. Cyclosporine can be combined with low-dose oral prednisone and may be considered in patients with severe atopic dermatitis and alopecia areata. However, because of its side-effect profile and the high recurrence rate observed after discontinuation, cyclosporine seems to be a relatively impractical treatment for alopecia areata.

JANUS KINASE INHIBITORS

Recent mechanistic data support a role for Janus kinase (JAK)-mediated pathways in alopecia areata[11,60] Interferon-γ, interleukin-2, and interleukin-15 play a significant role in maintaining the autoreactive CD8+ T-cell infiltrate in alopecia areata. Their receptors signal through JAK1, JAK2, and JAK3. The inhibition of these cytokine receptors with JAK inhibitors can lead to a reversal of alopecia areata.

Several case reports show that JAK inhibitors are a promising class of drugs for alopecia areata even in cases of severe or widespread disease. Oral baricitinib and tofacitinib citrate (approved by the FDA for mild rheumatoid arthritis) and oral ruxolitinib (approved by the FDA for myelofibrosis) have shown a good treatment outcome with full regrowth of scalp hair in widespread alopecia areata.[61-65]

CAMOUFLAGE, WIGS, AND HAIRPIECES

When despite treatment alopecia is progressive and there is no hope for hair regrowth, permanent adaptation to the disease is necessary. Extensive alopecia areata of the scalp can be camouflaged with wigs and hair pieces. In women with alopecia areata of the eyebrows, permanent makeup may be considered.

The treating physician should provide psychological support. Local alopecia areata support groups and annual meetings of the National Alopecia Areata Foundation (www.naaf.org) can be very helpful for patients and their relatives.

REFERENCES

1. Price VH. Alopecia areata: clinical aspects. *J Invest Dermatol.* 1991;96(5):S68.
2. Safavi K. Prevalence of alopecia areata in the First National Health and Nutrition Examination Survey. *Arch Dermatol.* 1992;128:702.
3. Allbritton J, Simmons-O'Brien E, Hutcheons D, et al. Cronkhite-Canada syndrome: report of two cases, biopsy findings in the associated alopecia, and a new treatment option. *Cutis.* 1998;61(4):229-232.
4. Sethuraman G, Malhotra AK, Sharma VK. Alopecia universalis in Down syndrome: response to therapy. *Indian J Dermatol Venereol Leprol.* 2006;72(6):454-455.
5. Gilhar A, Kalish RS. Alopecia areata: a tissue specific autoimmune disease of the hair follicle. *Autoimmun Rev.* 2006;5:64.
6. Gilhar A, Paus R, Kalish R. Lymphocytes, neuropeptides, and genes involved in alopecia areata. *J Clin Invest.* 2007;111:2019.
7. McDonagh AJ, Messenger AG. The pathogenesis of alopecia areata. *Dermatol Clin.* 1996;14:661.
8. Paus R, Nickoloff BJ, Ito T. A "hairy" privilege. *Trends Immunol.* 2005;26:32.
9. McElwee KJ, Freyschmidt-Paul P, Hoffmann R, et al. Transfer of CD8(+) cells induces localized hair loss whereas CD4(+)/CD25(–) cells promote systemic alopecia areata and CD4(+)/CD25(+) cells blockade disease onset in the C3H/HeJ mouse model. *J Invest Dermatol.* 2005;124:947-957.
10. Petukhova L, Duvic M, Hordinsky M, et al. Genome-wide association study in alopecia areata implicates both innate and adaptive immunity. *Nature.* 2010;466:113-117.
11. Xing L, Dai Z, Jabbari A, et al. Alopecia areata is driven by cytotoxic T lymphocytes and is reversed by JAK inhibition. *Nat Med.* 2014;20(9):1043-1049.
12. Rork JF, Rashighi M, Harris JE. Understanding autoimmunity of vitiligo and alopecia areata. *Curr Opin Pediatr.* 2016;28(4):463-469.
13. Jabbari A, Cerise JE, Chen JC, et al. Molecular signatures define alopecia areata subtypes and transcriptional biomarkers. *EBioMedicine.* 2016;7:240-247.
14. Kaufman G, d'Ovidio R, Kaldawy A, et al. An unexpected twist in alopecia areata pathogenesis: are NK cells protective and CD49b+ T cells pathogenic? *Exp Dermatol.* 2010;19(8):e347-e349.
15. Shellow WV, Edwards JE, Koo JY. Profile of alopecia areata: a questionnaire analysis of patient and family. *Int J Dermatol.* 1992;31(3):186-189.
16. Price VH, Colombe BW. Heritable factors distinguish two types of alopecia areata. *Dermatol Clin.* 1996;14(4):679-689.
17. Betz RC, Petukhova L, Ripke S, et al. Genome-wide meta-analysis in alopecia areata resolves HLA associations and reveals two new susceptibility loci. *Nat Commun.* 2015;22(6):5966.
18. Brajac I, Tkalcic M, Dragojević DM, et al. Roles of stress, stress perception and trait-anxiety in the onset and course of alopecia areata. *J Dermatol.* 2003; 30(12):871-878.
19. Prie BE, Voiculescu VM, Ionescu-Bozdog OB, et al. Oxidative stress and alopecia areata. *J Med Life.* 2015; 8(spec issue):43-46.
20. Abdel Fattah NS, Ebrahim AA, El Okda ES. Lipid peroxidation/antioxidant activity in patients with alopecia areata. *J Eur Acad Dermatol Venereol.* 2011;25:403-408.
21. Akar A, Arca E, Erbil H, et al. Antioxidant enzymes and lipid peroxidation in the scalp of patients with alopecia areata. *J Dermatol Sci.* 2002;29:85-90.

22. Bakry OA, Elshazly RM, Shoeib MA, et al. Oxidative stress in alopecia areata: a case-control study. *Am J Clin Dermatol.* 2014;15:57-64.
23. Naziroglu M, Kokcam I. Antioxidants and lipid peroxidation status in the blood of patients with alopecia. *Cell Biochem Funct.* 2000;18:169-173.
24. Motor S, Ozturk S, Ozcan O, et al. Evaluation of total antioxidant status, total oxidant status and oxidative stress index in patients with alopecia areata. *Int J Clin Exp Med.* 2014;7:1089-1093.
25. Rudnicka L, Olszewska M, Rakowska A, et al. Trichoscopy update 2011. *J Dermatol Case Rep.* 2011;5(4):82-88.
26. Gordon KA, Tosti A. Alopecia: evaluation and treatment. *Clin Cosmet Investig Dermatol.* 2011;4:101-106.
27. Saylam Kurtipek G, Cihan FG, Erayman Demirbaş Ş, et al. The frequency of autoimmune thyroid disease in alopecia areata and vitiligo patients. *Biomed Res Int.* 2015;2015:435947.
28. Todes-Taylor N, Turner R, Wood GS. T cell subpopulations in alopecia areata. *J Am Acad Dermatol.* 1984; 11(2):216-223.
29. Sperling LC, Lupton GP. Histopathology of nonscarring alopecia. *J Cutan Pathol.* 1995;22(2):97-114.
30. Whiting DA. Histopathologic features of alopecia areata: a new look. *Arch Dermatol.* 2003;139(12):1555-1559.
31. Alkhalifah A, Alsantali A, Wang E, et al. Alopecia areata update: part I. Clinical picture, histopathology, and pathogenesis. *J Am Acad Dermatol.* 2010;62(2): 177-188.
32. Alkhalifah A, Alsantali A, Wang E, et al. Alopecia areata update: part II. Treatment. *J Am Acad Dermatol.* 2010;62(2):191-202.
33. Shapiro J. Alopecia areata. Update on therapy. *Dermatol Clin.* 1993;11(1):35-46.
34. Friedli A, Labarthe MP, Engelhardt E, et al. Pulse methylprednisolone therapy for severe alopecia areata: an open prospective study of 45 patients. *J Am Acad Dermatol.* 1998;39(4, pt 1):597-602.
35. Fiedler VC. Alopecia areata: current therapy. *J Invest Dermatol.* 1991;96(5):S69-S70.
36. Price VH. Treatment of hair loss. *N Engl J Med.* 1999; 341(13):964-973.
37. Whiting DA. The treatment of alopecia areata. *Cutis.* 1987;40(3):247-250.
38. Chu TW, AlJasser M, Alharbi A, et al. Benefit of different concentrations of intralesional triamcinolone acetonide in alopecia areata: an intrasubject pilot study. *J Am Acad Dermatol.* 2015;73(2):338-340.
39. Singh S. Role of platelet-rich plasma in chronic alopecia areata: our centre experience. *Indian J Plast Surg.* 2015;48(1):57-59.
40. Donovan J. Successful treatment of corticosteroid-resistant ophiasis-type alopecia areata (AA) with platelet-rich plasma (PRP). *JAAD Case Rep.* 2015;1(5):305-307.
41. Bagherani N. Is platelet-rich plasma effective in the treatment of alopecia areata? *Dermatol Ther.* 2016;29(4):284.
42. Spano F, Donovan JC. Alopecia areata: part 2: treatment. *Can Fam Physician.* 2015;61(9):757-761.
43. Trink A, Sorbellini E, Bezzola P, et al. A randomized, double-blind, placebo- and active-controlled, half-head study to evaluate the effects of platelet-rich plasma on alopecia areata. *Br J Dermatol.* 2013;169(3):690-694.
44. Price VH. Topical minoxidil in extensive alopecia areata, including 3-year follow-up. *Dermatologica.* 1987;175(suppl 2):36-41.
45. Price VH. Double-blind, placebo-controlled evaluation of topical minoxidil in extensive alopecia areata. *J Am Acad Dermatol.* 1987;16(3, pt 2):730-736.
46. Vila TO, Camacho Martinez FM. Bimatoprost in the treatment of eyelash universalis alopecia areata. *Int J Trichology.* 2010;2(2):86-88.
47. Ross EK, Bolduc C, Lui H, et al. Lack of efficacy of topical latanoprost in the treatment of eyebrow alopecia areata. *J Am Acad Dermatol.* 2005;53(6):1095-1096.
48. Roseborough I, Lee H, Chwalek J, et al. Lack of efficacy of topical latanoprost and bimatoprost ophthalmic solutions in promoting eyelash growth in patients with alopecia areata. *J Am Acad Dermatol.* 2009;60(4):705-706.
49. Faghihi G, Andalib F, Asilian A. The efficacy of latanoprost in the treatment of alopecia areata of eyelashes and eyebrows. *Eur J Dermatol.* 2009;19(6):586-587.
50. Morhenn VB, Orenberg EK, Kaplan J, et al. Inhibition of a Langerhans cell-mediated immune response by treatment modalities useful in psoriasis. *J Invest Dermatol.* 1983;81(1):23-27.
51. Fiedler-Weiss VC, Buys CM. Evaluation of anthralin in the treatment of alopecia areata. *Arch Dermatol.* 1987;123(11):1491-1493.
52. Schmoeckel C, Weissmann I, Plewig G, et al. Treatment of alopecia areata by anthralin-induced dermatitis. *Arch Dermatol.* 1979;115(10):1254-1255.
53. Happle R, Klein HM, Macher E. Topical immunotherapy changes the composition of the peribulbar infiltrate in alopecia areata. *Arch Dermatol Res.* 1986;278(3):214-218.
54. MacDonald N, Wiseman MC, Shapiro J. Alopecia areata: topical immunotherapy—application and practical problems. *J Cutan Med Surg.* 1999;3(suppl 3):S36-S40.
55. Shapiro J, Sundberg JP, Bissonnette R, et al. Alopecia areata-like hair loss in C3H/HeJ mice and DEBR rats can be reversed using topical diphencyprone. *J Investig Dermatol Symp Proc.* 1999;4(3):239.
56. Shapiro J. Assessment of the patient with alopecia. In: *Hair Loss: Principles of Diagnosis and Management of Alopecia*. London, UK: Martin Dunitz; 2002.
57. Krook G. Treatment of alopecia areata with Kromayer's ultra-violet lamp. *Acta Derm Venereol.* 1961;41:178-181.
58. Mitchell AJ, Douglass MC. Topical photochemotherapy for alopecia areata. *J Am Acad Dermatol.* 1985;12(4):644-649.
59. Gupta AK, Ellis CN, Cooper KD, et al. Oral cyclosporine for the treatment of alopecia areata. A clinical and immunohistochemical analysis. *J Am Acad Dermatol.* 1990;22(2, pt 1):242-250.
60. Jabbari A, Dai Z, Xing L, et al. Reversal of alopecia areata following treatment with the JAK1/2 inhibitor baricitinib. *EBioMedicine.* 2015;2(4):351-355.
61. Harris JE, Rashighi M, Nguyen N, et al. Rapid skin repigmentation on oral ruxolitinib in a patient with coexistent vitiligo and alopecia areata (AA). *J Am Acad Dermatol.* 2016;74(2):370-371.
62. Anzengruber F, Maul JT, Kamarachev J, et al. Transient efficacy of tofacitinib in alopecia areata universalis. *Case Rep Dermatol.* 2016;8(1):102-106.
63. Higgins E, Al Shehri T, McAleer MA, et al. Use of ruxolitinib to successfully treat chronic mucocutaneous candidiasis caused by gain-of-function signal transducer and activator of transcription 1 (STAT1) mutation. *J Allergy Clin Immunol.* 2015;135:551-553.
64. Pieri L, Guglielmelli P, Vannucchi AM. Ruxolitinib-induced reversal of alopecia universalis in a patient with essential thrombocythemia. *Am J Hematol.* 2015;90:82-83.
65. Craiglow BG, King BA. Killing two birds with one stone: oral tofacitinib reverses alopecia universalis in a patient with plaque psoriasis. *J Invest Dermatol.* 2014;134:2988-2990.

Chapter 88 :: Cicatricial Alopecias

:: Nina Otberg & Jerry Shapiro

AT-A-GLANCE

- Scarring alopecia occurs in a heterogeneous etiologic group of various disorders.
- The inflammatory process leads to permanent destruction of hair follicular stem cell structure and subsequent replacement with fibrous tissue.
- The destructive process can occur as a primary or secondary cicatricial alopecia.
- Loss of hair-producing attribute finalizes this process and results clinically in permanent alopecia.
- No evidence-based treatment is available.

Cicatricial or scarring alopecias comprise a diverse group of scalp disorders that result in permanent hair loss (Fig. 88-1). The destructive process can occur as a primary or secondary cicatricial alopecia. *Primary cicatricial alopecia* refers to a group of idiopathic inflammatory diseases, characterized by a folliculocentric inflammatory process that ultimately destroys the hair follicle. *Secondary cicatricial alopecias* can be caused by almost any cutaneous inflammatory process of the scalp skin or by physical trauma, which injures the skin and skin appendages. Regardless of whether a cicatricial alopecia is primary or secondary in nature, all scarring alopecias are characterized clinically by a loss of follicular ostia and pathologically by a replacement of hair follicles with fibrous tissue.

Cicatricial alopecias are psychosocially distressing for the affected patient and medico-surgically challenging for the treating physician.

PRIMARY CICATRICIAL ALOPECIAS

EPIDEMIOLOGY

Inflammatory cicatricial alopecias are rare skin diseases. The epidemiology is basically unknown.

CLASSIFICATION[1]

Table 88-1 outlines the classification of primary cicatricial alopecias.

ETIOLOGY AND PATHOGENESIS

Little is known about most of the etiologies. Hence the exact mechanisms that cause follicle stem cell destruction are not completely understood, and there is no cure as of this writing. Primary cicatricial alopecias are characterized by an inflammatory infiltrate affecting the upper, permanent portion of the follicle referred to as the infundibulum, and below it, the isthmus of the follicle. The isthmus is the home of pluripotent hair stem cells, which are found in the bulge region where the arrector pili muscle attaches to the outer root sheath. Pluripotent hair follicle stem cells are responsible for the renewal of the upper part of the hair follicle and sebaceous glands, and for the restoration of the lower cyclical component of the follicles at the onset of a new anagen period.[1,2] Damage to the bulge area and the sebaceous gland with the isthmus may result in an incomplete hair cycle and can be associated with chronic follicular inflammation and foreign-body reaction.[3] It has been assumed that scarring hair loss is a consequence of damage to the isthmus, affecting either stem cells or sebaceous glands.[4-7]

CLINICAL FEATURES

Primary cicatricial alopecia usually affects the central and parietal scalp before progressing to other sites of the scalp. Isolated alopecic patches showing atrophy and a lack of follicular ostia with inflammatory changes, such as diffuse or perifollicular erythema, follicular hyperkeratosis, pigment changes, tufting, and pustules, provide hints to the diagnosis.[8,9] However, clinically visible inflammatory change might be absent in the affected lesions and may present histologically as inflammatory infiltrates in the deep dermis and subcutaneous tissue.

DIAGNOSIS

Diagnostic tools such as a 10-fold magnifying dermatoscope with and without polarized light can help to identify the presence or absence of follicular ostia, perifollicular erythema, and follicular hyperkeratosis in the affected areas.

A thorough examination of the entire scalp, a detailed clinical history, as well as skin biopsies of an

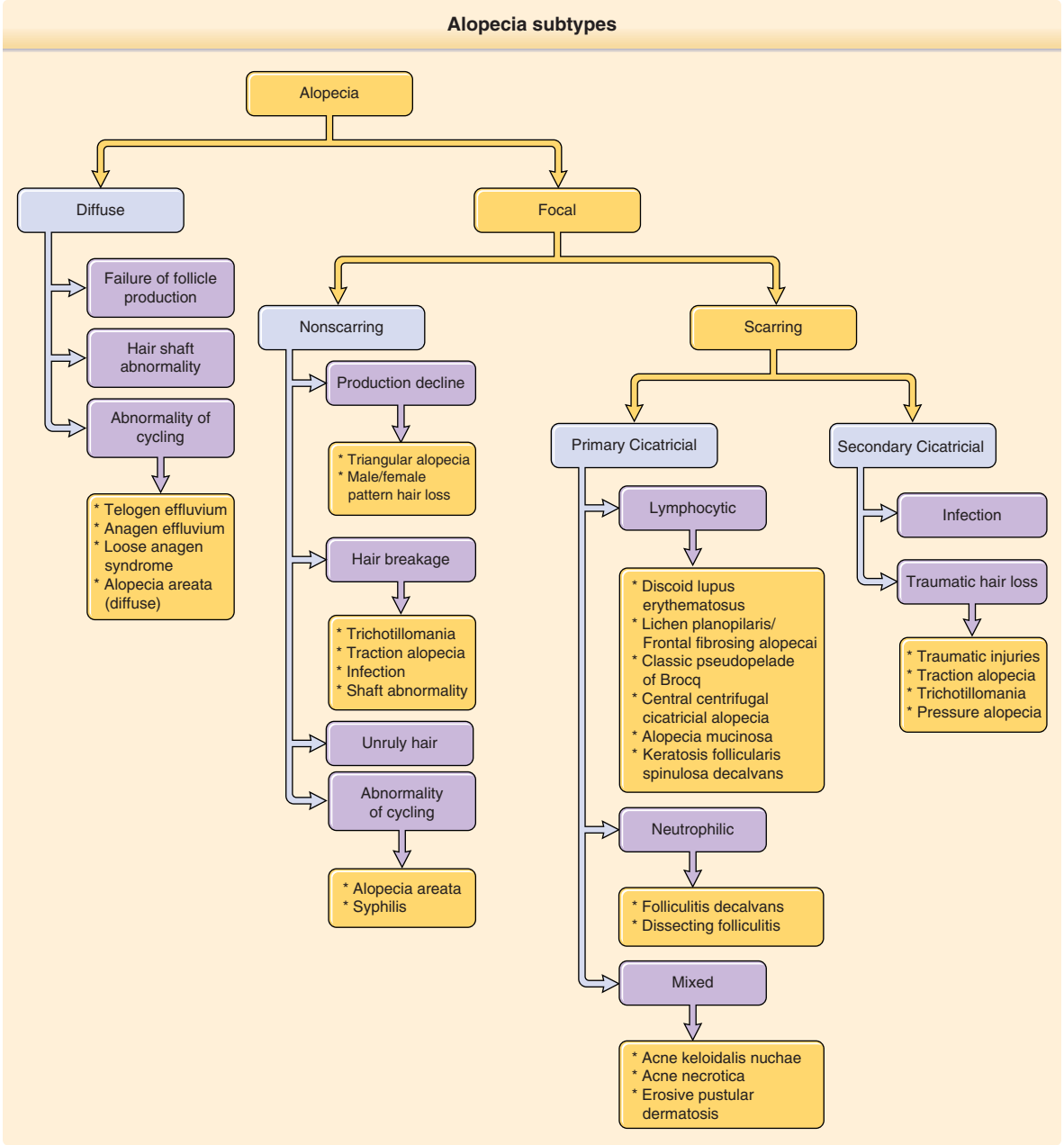

Figure 88-1 Alopecia subtypes.

active lesion are crucial in the correct diagnosis of most cicatricial alopecias. Patient-reported symptoms, such as itching or pain, might be used as approximate indicators of disease activity but also can be completely absent. Presence of other indirectly related symptoms, such as sun sensitivity, can also help support a particular diagnosis (eg, discoid lupus erythematosus [DLE]).

A scalp biopsy is necessary to confirm a scarring alopecia diagnosis. The following recommendations were developed at the consensus meeting on cicatricial alopecia[1] in February 2001: One 4-mm punch biopsy including subcutaneous tissue should be taken from a clinically active area, processed for horizontal sections and stained with hematoxylin and eosin. Elastin (acid alcoholic orcein), mucin, and periodic acid–Schiff stains may provide additional diagnosis-defining information. A second 4-mm punch biopsy from a clinically active disease-affected area should be cut vertically into 2 equal pieces. One half provides tissue for transverse cut routine histologic sections, and the other half can be used for direct immunofluorescence studies.[10-12]

PROGNOSIS/CLINICAL COURSE

Once the hair follicle is destroyed and replaced by fibrous tissue, there is no hope for hair regrowth.

TABLE 88-1
Classification of Primary Cicatricial Alopecias

Lymphocytic Primary Cicatricial Alopecia
- Chronic cutaneous lupus erythematosus (discoid lupus erythematosus)
- Lichen planopilaris
- Classic lichen planopilaris
- Frontal fibrosing alopecia
- Graham-Little syndrome
- Classic pseudopelade of Brocq
- Central centrifugal cicatricial alopecia
- Alopecia mucinosa
- Keratosis follicularis spinulosa decalvans

Neutrophilic Primary Cicatricial Alopecia
- Folliculitis decalvans
- Dissecting cellulites/folliculitis (perifolliculitis abscedens et suffodiens)

Mixed Cicatricial Alopecia
- Folliculitis (acne) keloidalis
- Folliculitis (acne) necrotica
- Erosive pustular dermatosis

Various medical treatment options may fail and the inflammatory process may continue and leave the patient with a disfiguring permanent alopecia.

TREATMENT

The main goal in treating primary cicatricial alopecia is to stop the inflammation and further progression of the disease. If hair loss is already extensive and/or medical treatment fails, patients should be advised about camouflage techniques, such as hairpieces and wigs. Women with extensive scarring lesion on the crown and vertex benefit highly from a well-designed hairpiece, which can look very natural, particularly if the frontal hair line is preserved and is usually more comfortable to wear than a full wig.

Hair restoration surgery, including hair transplantation and scalp reduction, can be an option for burned out cicatricial alopecia. No disease activity should occur on the scalp for at least 1 year after therapy after which hair restoration surgery can begin. The patient has to be warned about a possible limited graft survival and disease recurrence, which seems to be higher in neutrophilic primary scarring alopecia.

LYMPHOCYTIC PRIMARY CICATRICIAL ALOPECIAS

CHRONIC CUTANEOUS LUPUS ERYTHEMATOSUS (DISCOID LUPUS ERYTHEMATOSUS)

DLE, together with lichen planopilaris (LPP), is the most common cause of inflammatory cicatricial alopecia.[8] Females are more often affected than males and the disease is more common in adults (with first onset typically at 20 to 40 years of age) than in children.[13-15] Of patients with DLE, approximately 26% to 31% of children and 5% to 10% of adults will develop systemic lupus erythematosus.[15,16] Patients with DLE also have a higher incidence of concurrent alopecia areata. Moreover, DLE also is associated with verruciform xanthoma and papulonodular dermal mucinosis.[17]

Clinical Presentation: DLE usually presents with 1 or more erythematous, atrophic, and alopecic patches on the scalp. Follicular hyperkeratosis, hyperpigmentation, hypopigmentation, and telangiectasia can be present.[3,18] Hyperpigmentation is frequently found in the center of the lesion. Active lesions can be sensitive or pruritic, and the patient might report a worsening after ultraviolet light exposure (Fig. 88-2).

Pathology: Characteristic features of early, active DLE lesions are lymphocyte-mediated interface dermatitis with vacuolar degeneration of the basal cell layer and necrotic keratinocytes, a thickening of the basement membrane and destruction of sebaceous glands. Elastic fibers are frequently destroyed throughout the reticular dermis.[5,10] The lymphocytic infiltrate is predominantly found in the upper part of the follicle but also can be found in deeper parts of the follicle, in the interfollicular epidermis, and around the periadnexal vessels.[19-22] Direct immunofluorescence typically shows a linear granular deposition of immunoglobulin (Ig) G and C3 at the dermoepidermal junction. IgM, C1q, and, rarely, IgA also can be found.

Management and Treatment: Hydroxychloroquine at a dose of 200 to 400 mg daily in adults or 4 to 6 mg/kg in children is highly effective at managing. A baseline ophthalmologic examination and complete blood count is required before the therapy is started.[13,15] Bridge therapy with oral prednisone (1 mg/kg) tapered over the first 8 weeks of treatment might be helpful in adult patients with rapidly progressive disease.[8,9] In limited or slowly progressive DLE, intralesional triamcinolone acetonide should be used at a concentration of 10 mg/mL every 4 to 6 weeks, alone or in addition to oral therapy.[8] Intralesional triamcinolone acetonide can

Figure 88-2 Discoid lupus erythematosus.

be used with or without topical class I or class II corticosteroids. Topical corticosteroids alone also are effective at managing in milder forms of DLE.[9,10,15,20] Oral acitretin and isotretinoin have also shown some effectiveness at managing.[23,24] Immunosuppressive therapies, such as mycophenolate mofetil, methotrexate, and azathioprine, should only be considered if the above therapies fail. Multimodal aggressive therapy in rapidly progressive DLE might reverse early alopecic patches and save hair follicles from the destructive process.[25]

LICHEN PLANOPILARIS AND FRONTAL FIBROSING ALOPECIA

LPP is a follicular variant of lichen planus. Together with DLE, this is the most common cause of primary cicatricial alopecia. LPP can be divided into classic LPP, Graham-Little syndrome, and frontal fibrosing alopecia (FFA). The typical age of onset of classic LPP is around the fifth decade, and women are more often affected than men. Extracranial lichen planus may occur in up to 28% of patients.[6,26,27] Graham-Little syndrome is a very rare condition that predominantly affects female adults. It is characterized by LPP of the scalp, noncicatricial of the eyebrows, axilla, and groin, and keratosis pilaris.

FFA was first described by Kossard in 1992.[28] FFA predominantly affects postmenopausal women. However, some cases of affected men or premenopausal women are reported.[29-31] Although as of this writing there are no epidemiologic data on the incidence or prevalence of FFA, FFA seems to be fast on the rise. In many hair clinics, FFA has become the most frequently seen form of cicatricial alopecia.[32] Causes and trigger factors and whether FFA is a variant of LPP or its own entity is as of this writing unknown.

Lichenoid drug eruptions can be triggered by many drugs. Some of the most common drugs that cause lichenoid drug eruption are gold, antimalarials, and captopril. Actinic lichenoid drug eruption is confined to sun-exposed sites. The most likely drugs to cause lichenoid drug eruption are quinine and thiazide diuretics.[33-35] Whether drugs play a role as trigger factors in LPP and FFA is not clear.

Clinical Presentations of Lichen Planopilaris and Frontal Fibrosing Alopecia: Classic LPP typically starts at the crown and vertex area. In classic LPP, the affected areas usually show perifollicular erythema and follicular hyperkeratosis. The alopecic areas of LPP are often smaller, irregularly shaped and interconnected, which can lead to a reticulated clinical pattern as compared to DLE. However, overlapping clinical features with those of DLE are frequently seen. Patients complain about itching, burning sensations and sensitivity of the scalp (Fig. 88-3).

FFA is characterized by a frontal, band-like or circumferential scarring alopecia.[5] In some cases, a few hairs are spared in the original frontal hairline. Follicular hyperkeratosis and perifollicular erythema may be found in a band-like pattern in the frontal hairline. Alopecia of the eyebrows is also frequently seen in FFA (Fig. 88-4).

Figure 88-3 Extensive lichen planopilaris.

Graham-Little syndrome presents with lesions of classic LPP on the scalp, nonscarring alopecia of axillae, pubic area, and eyebrows, as well as keratosis pilaris of the trunk and extremities.

Pathology: LPP and FFA show similar histopathologic features. A lymphocytic infiltrate and interface dermatitis are predominantly found in and around the upper permanent part of the hair follicle. Unlike DLE, the vascular plexus is not affected by inflammation and mucin deposits are absent.[5] Direct immunofluorescence typically shows globular cytoid depositions of IgM, and, rarely, IgA, IgG, or C3, in the dermis around the infundibulum.[36]

Management and Treatment: First-line treatment for moderately active classic LPP lesions is intralesional triamcinolone acetonide at a concentration of 10 mg/mL every 4 to 6 weeks or in combination with topical class I or class II corticosteroids.[8,24] For FFA

Figure 88-4 Frontal fibrosing alopecia.

near the face, triamcinolone acetonide at 2.5 mg/mL injected 1 cm behind the hair line should be used. Topical minoxidil may be given in patients with concomitant androgenetic alopecia to improve thickness of the remaining hair. Newer studies suggest preliminarily that injections of platelet-rich plasma might be useful as additional treatment.[37] More studies are required. Studies on the efficacy of oral medication are limited. Oral cyclosporine, retinoids, antimalarials, and griseofulvin[3,18,38-41] have a positive effect in patients with rapidly progressive LPP. Oral corticosteroids as bridge therapy in the first weeks of treatment might be considered in very active cases. The treatment of Graham-Little syndrome is typically similar to the management of classic LPP. In FFA a lower dose of intralesional triamcinolone acetonide (2.5 to 5 mg/mL) and topical application of minoxidil or topical tacrolimus can be considered, although no effective treatment has yet been reported.

CLASSIC PSEUDOPELADE OF BROCQ

Pseudopelade of Brocq (PPB) is classified as an idiopathic lymphocytic primary cicatricial alopecia that predominantly affects the scalp. Women between 30 and 50 years of age are most frequently affected.[6]

Clinical Presentation: PPB usually affects the vertex and occipital area of the scalp. It presents with small flesh-toned alopecic patches with irregular margins. This pattern has been described as "foot prints in the snow."[42] PPB can also present as a noninflammatory, centrifugally spreading, patch of alopecia, which might be seen as a variant of central centrifugal cicatricial alopecia (CCCA) in whites. Follicular hyperkeratosis and perifollicular or diffuse erythema are mostly absent.[18] Clinically, the features may overlap with LPP.

Pathology: Early PPB lesions typically show a sparse to moderate lymphocytic infiltrate around the follicular infundibulum with a complete destruction of the sebaceous glands.[43] In later disease stages, hair follicles are completely replaced by fibrous tracts. Unlike DLE and LPP, interface dermatitis is usually absent and the elastic fibers are preserved and thickened in PPB.[44]

Management and Treatment: Intralesional triamcinolone acetonide at a concentration of 10 mg/mL every 4 to 6 weeks in combination with topical corticosteroids is the treatment of first choice. Hydroxychloroquine, oral prednisone, and isotretinoin have shown some effectiveness in treating PPB.[6,18,45,46]

CENTRAL CENTRIFUGAL CICATRICIAL ALOPECIA

CCCA is the most common form of primary cicatricial alopecia in women of African descent. The etiology of CCCA is not fully understood. An autosomal mode of inheritance, chemical hair grooming practices, and traction-inducing hair styles seem to be the major pathogenic factors.[20,47-50] CCCA is rarely seen in whites (sometimes called "central elliptical pseudopelade") and African American men. Because of clinical and histopathologic similarities, there is a debate as to whether or not CCCA is a variant of PPB.

Clinical Presentation: CCCA presents with a skin-colored patch of scarring alopecia on the crown, gradually progressing centrifugally to the parietal areas. In 2008, Olsen and associates developed a photographic scale to identify the pattern and severity of CCCA in the general community.[51] Perifollicular hyperpigmentation and polytrichia might be present.[8] Patients may complain about pain, itching, tenderness, and "pins-and-needle" sensations (Fig. 88-5).[52]

Pathology: Pathologic features of CCCA include dermal hyalinization, hair fiber granulomas, loss of follicular epithelium, follicular lymphocytic inflammation of the lower infundibulum and up to the isthmus, premature desquamation of the inner root sheath, and fibrous connective tissue. Similarities to PPB have been discussed.[3,20]

Management and Treatment: Early diagnosis is crucial in the management of CCCA. Early screening is suggested because CCCA has been described in children.[53] More natural, less traumatizing hair care practices are recommended.[10,18,54,55] Screening of family members also may be useful because of the genetic pathogenicity.[48] Topical and intralesional corticosteroids, and tetracycline are effective in active progressive cases.[20] Systemic treatment with tetracyclines, hydroxychloroquine, immunosuppressive medication (eg, mycophenolate mofetil and cyclosporine), and antiandrogens also have been described to be successful.[55] Wigs and hairpieces can help camouflage the alopecia and are frequently used by women with CCCA.

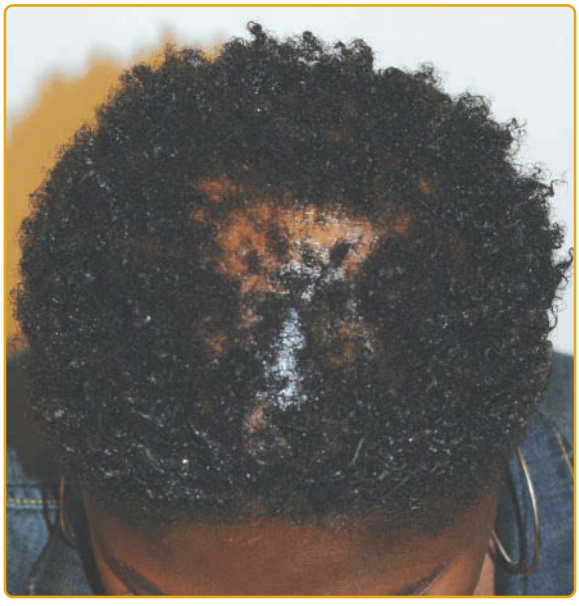

Figure 88-5 Central centrifugal cicatricial alopecia.

ALOPECIA MUCINOSA

Alopecia mucinosa can present as indurated, well-demarcated erythematosus or skin-colored patches of scarring or nonscarring alopecia that can be accompanied by diffuse hair loss[56] and alopecia of the eyebrows.[57] Grouped follicular papules, follicular cysts, and follicular hyperkeratosis may be present in some cases. Early lesions of alopecia mucinosa show mucin deposition in the outer root sheath and replacement of the entire pilosebaceous unit by pools of mucin in more advanced lesions.[5,57] Strictly speaking, alopecia mucinosa is not a primary cicatricial alopecia because the hair follicle is not replaced by a true scar.[5]

Alopecia mucinosa can occur idiopathically or in the setting of cutaneous T-cell lymphoma or mycosis fungoides.[58] Cell atypia and monoclonal populations of T-lymphocytes can be present in the idiopathic form of alopecia mucinosa as well as in mycosis fungoides.[58]

Management and Treatment: A complete workup is necessary to rule out an underlying malignancy such as mycosis fungoides and Sézary syndrome, its advanced end point. Oral corticosteroids, minocycline, and isotretinoin are effective. Topical and intralesional corticosteroids, dapsone, indomethacin, and light therapy also have been used with variable outcomes.[59]

KERATOSIS FOLLICULARIS SPINULOSA DECALVANS

Keratosis follicularis spinulosa decalvans together with keratosis atrophicans faciei (also called *ulerythema ophryogenes* or *keratosis pilaris rubra atrophicans faciei*) and atrophoderma vermiculata belongs to a heterogeneous group of congenital follicular keratinizing disorders. Keratosis follicularis spinulosa decalvans is X-linked, usually develops during adolescence, and mostly presents with scarring alopecic patches, follicular hyperkeratosis, and, rarely, pustules.[5] Eyebrow and eyelash involvement also can be present.

Keratosis follicularis spinulosa decalvans shows an inflammatory infiltrate consisting of lymphocytes and neutrophils in the infundibular area in early lesions. Later, the infiltrate is predominantly lymphocytic and the follicle is eventually replaced by fibrous tissue.

The condition may improve with age. Careful calculation of risks and benefits in the treatment of children, teenagers, and young adults is important. Topical and intralesional corticosteroids as well as oral retinoids have shown some effectiveness.[60]

NEUTROPHILIC PRIMARY CICATRICIAL ALOPECIA

FOLLICULITIS DECALVANS

Approximately, 11% of all primary cicatricial alopecia cases are diagnosed with folliculitis decalvans (FD).[3,6] FD predominantly occurs in young and middle-aged adults with a slight preference for the male gender.

A bacterial infection involving *Staphylococcus aureus*, in combination with hypersensitivity reaction to "superantigens" and defect in host cell–mediated immunity have all been suspected as possible pathogenetic factors.[3,61,62]

Clinical Presentation: FD frequently starts at the vertex area of the scalp with erythematous alopecic patches, follicular pustules and follicular hyperkeratosis. Tufted folliculitis is typically found in FD but can also occur in other cicatricial inflammatory alopecias. Tufted folliculitis is characterized by multiple hairs (5 to 15) emerging from a single, dilated, follicular orifice. In older lesions, pustules might be absent but progressive scarring may still continue (Fig. 88-6). An overlap with acne keloidalis is possible as some patients with acne keloidalis not only develop cicatricial lesion on the nape of the neck but also develop progressive cicatricial alopecia that resembles FD in other areas of the scalp. Patients frequently complain about pain, itching, and/or burning sensations.

Pathology: Early lesions are characterized by keratin aggregation in the infundibulum with numerous intraluminal neutrophils, as well as an intrafollicular and perifollicular neutrophilic infiltrate.[3,5,18] Sebaceous glands are destroyed early. In advanced lesions, the infiltrate may consist of neutrophils, lymphocytes, and plasma cells, and extend into the dermis.[8,18] Hair-shaft granulomas with foreign-body giant cells are frequently found.[3,18] In end-stage lesions, follicular and interstitial dermal fibrosis, as well as hypertrophic scarring, can be observed.[18]

Management and Treatment: Treatment of FD in general is difficult and disease activity can be noted over many years. Bacterial cultures with the testing of antibiotic sensitivities are recommended. Eradication of *S. aureus* with minocycline, erythromycin, cephalosporins, and sulfamethoxazole-trimethoprim has shown some effectiveness. Relapse can often be observed after the antibiotics are discontinued.[9,61,63] If so, the patient might have to stay on low-dose antibiotics for many years. Although rifampin in combination

Figure 88-6 Folliculitis decalvans.

with clindamycin has shown good response, this combination also has shown a higher incidence of side effects.[61,64] Oral fucidic acid alone or in combination with other agents has also shown to be effective in some patients.[65] Oral therapy should be combined with topical antibiotics such as mupirocin, 1.5% fusidic acid, and 2% erythromycin,[64,65] and antibacterial cleansers. Intralesional triamcinolone acetonide at a concentration of 10 mg/mL every 4 to 6 weeks might help to reduce the inflammation and symptoms such as itching, burning, and pain.[6,9] Intranasal eradication of *S. aureus* with topical antibacterial agents are described as useful.[18]

DISSECTING FOLLICULITIS

Dissecting folliculitis (or *dissecting cellulites* or *perifolliculitis capitis abscedens et suffodiens of Hoffman*) is related to acne conglobata and hidradenitis suppurativa. These 3 diseases have been described as the follicular occlusion triad. Dissecting folliculitis predominantly occurs in young men between 18 and 40 years of age.[8] African American men seem to be more commonly affected than white men. The pathogenesis of dissecting folliculitis may include follicular occlusion, seborrhea, androgens, and secondary bacterial overpopulation, as well as an abnormal host response to bacterial antigens.[66-73]

Clinical Presentation: Dissecting folliculitis typically presents with fluctuating nodules, abscesses, and sinuses, which frequently show spontaneous discharge of pus, as well as with erythematous, follicular papules and pustules. Initial lesions are mostly found on the vertex and occipital scalp. Multifocal lesions can form an intercommunicating ridge and seropurulent exudates can be discharged when pressure is applied to 1 region of the scalp (Fig. 88-7). The lesions can be pruritic and tender. Chronic and relapsing courses results in cicatricial alopecia that can occur as hypertrophic or keloidal scars.[73]

Pathology: The main histologic feature is an intrafollicular and perifollicular neutrophilic infiltrate with follicular occlusion in early lesions.[5] In more advanced stages, interconnecting sinus tracts lined by squamous epithelium, follicular perforation, and perifollicular and deep dermal abscesses are typical findings.[5,18,22]

Management and Treatment: Multimodal treatment has been reported with successful results, such as systemic antibiotics (minocycline, tetracycline, cloxacillin, erythromycin, cephalosporin, or clindamycin with or without rifampin), intralesional corticosteroids, and oral prednisolone.[74,75] The benefits of systemic antibiotics are most likely a result of their antiinflammatory effects rather than their antibacterial action. Isotretinoin at a dose of 0.5 to 1 mg/kg/day prolongs remission.[76,77] Incision and drainage of therapy-resistant, painful nodules, marsupialization with curettage of the cyst wall, and complete scalp extirpation with skin grafting have been reported, but should be an exception for extreme and therapy refractory cases.[77-80]

MIXED PRIMARY CICATRICIAL ALOPECIAS

ACNE KELOIDALIS NUCHAE

Acne keloidalis nuchae predominantly occurs in African American men 14 to 25 years of age. This idiopathic primary cicatricial alopecia might be triggered by trauma (shirt collars) or infection (*Demodex* or bacteria). Clinically, acne keloidalis nuchae presents with skin-colored follicular papules, pustules, and plaques, as well as keloid-like scarred lesions in the occipital scalp (Fig. 88-8). Histologically, acne keloidalis is characterized by an acute inflammation with neutrophilic or lymphocytic infiltration and chronic granulomatous inflammation around the isthmus and the lower infundibulum. Monthly intralesional triamcinolone acetonide (10 to 40 mg/mL) alone or combined with topical 2% clindamycin or oral (tetracyclines) antibiotics is the treatment of first choice.[3,10,20,81,82] Class I or class II topical steroids alone or in combination with topical antibiotics for mild cases of acne keloidalis nuchae, as well as topical retinoids, cryotherapy, and laser therapy,

Figure 88-7 Dissecting cellulitis.

Figure 88-8 Acne keloidalis nuchae.

have shown some success. Surgical excision of extensive keloidal lesions may be considered but should be reserved for therapy refractory, extensive, and symptomatic cases.

ACNE NECROTICA (VARIOLIFORMIS)

Acne necrotica varioliformis is a very rare, chronic condition, which predominantly occurs in adults. Frontal and parietal scalp, as well as seborrheic areas of the face are most commonly affected. Acne necrotica presents with umbilicated, pruritic, or painful papules that undergo central necrosis. The condition leaves varioliform, or smallpox-like scars.[83,84] Histology shows a suppurative, necrotic, infundibular folliculitis with lymphocytic or mixed inflammatory infiltrate.[84]

Oral antibiotics, isotretinoin, and intralesional or topical corticosteroids have shown success.[85] Excision of larger scarred areas can be considered.

EROSIVE PUSTULAR DERMATOSIS

Erosive pustular dermatosis is an uncommon disorder predominantly occurring in elderly women.[86,87] The characteristic lesion is a suppurative, necrotic, erosive papule or plaque.[86,88] Histology of early lesions is nonspecific, but older lesions show an extensive, chronic, mixed inflammatory infiltrate in the dermis, and later dermal fibrosis. Treatment includes class I or class II topical steroids with or without topical antibiotics, systemic antibiotics, and oral isotretinoin.[86,88]

DIFFERENTIAL DIAGNOSIS

Table 88-2 outlines the differential diagnosis of primary cicatricial alopecias.

SECONDARY CICATRICIAL ALOPECIA

ETIOLOGY AND PATHOGENESIS

In secondary cicatricial alopecias, permanent hair loss is caused by various other scalp conditions not related to the hair follicle. In these conditions, the primary event develops outside the follicular unit, and leads to incidental destruction of the follicle. Possible causes are congenital defects, trauma, inflammatory conditions, infections, neoplasms, and, rarely, drugs (Table 88-3). Permanent, chronic traction alopecia and scars from surgery can be considered secondary scarring alopecias as well.[89]

TABLE 88-2
Differential Diagnosis for Primary Cicatricial Alopecias

- Alopecia areata
- Secondary cicatricial alopecia
- Temporal triangular alopecia
- Trichotillomania
- Secondary syphilis (alopecia areolaris)

CLINICAL FEATURES

A thorough clinical history is crucial in the diagnosis of secondary cicatricial alopecia. Diagnosis in early stages can sometimes be made based on specific clinical and histologic features of the underlying disorder. Follicular orifices are lost clinically, and histology shows extensive scarring with fibrosis, loss of elastic fibers and adnexal structures.[89]

PROGNOSIS AND CLINICAL COURSE

Prognosis and clinical course of secondary cicatricial alopecia depend on the underlying disease. Once scar tissue has formed and the adnexal structures are destroyed no hair regrowth can be expected.

TREATMENT

Treatment is specific in active conditions, whereas in localized end-stage lesions, specific medical treatment is no longer efficient and hair restoration surgery techniques become the mainstay of therapy.

TINEA CAPITIS

Tinea capitis is a common cause of hair loss in children secondary to an infection with dermatophytes species. The etiologic agent varies in different parts of the world. Presently, *Trichophyton tonsurans* accounts for approximately 90% of cases of tinea capitis in the United States and United Kingdom.[90]

Ectothrix infection, most commonly caused by *Microsporum* spp. (especially *Microsporum canis*) and *Epidermophyton* spp. destroy the hair cuticle and masses of spores are located outside of the hair shaft. The alopecic patches usually show signs of inflammation and scaling with brittle grayish hair stumps. The areas may show a yellow-green fluorescence under Wood light examination. Endothrix infections are most commonly caused by *Trichophyton* spp. (especially *T. tonsurans* subspecies *sulfureum*).[91,92] The fungus is capable of invading the hair and masses of spores can be found

TABLE 88-3
Secondary Cicatricial (Permanent) Alopecias: A Classification Based on Etiology

Genodermatoses and developmental defects with permanent alopecia (excluding congenital hypotrichoses and atrichias)	▪ Ectodermal dysplasias ▪ Aplasia cutis congenita ▪ Incontinentia pigmenti ▪ Porokeratosis of Mibelli ▪ Ichthyosis ▪ Hereditary epidermolysis bullosa ▪ Meningocele ▪ Hamartoma ▪ Organoid nevi (sebaceous, epidermal) vascular malformations ▪ Darier disease ▪ Fibrodysplasia
Physical and chemical injury	▪ Mechanical trauma and pressure ▪ Scratching ▪ Burns ▪ Freezing ▪ Chemical injury ▪ Insect bites ▪ Radiation
Infections	***Bacterial*** ▪ Carbuncle ▪ Leprosy ▪ Tertiary syphilis ▪ Tuberculosis–lupus vulgaris ***Viral*** ▪ Zoster ▪ Varicella ***Tinea capitis*** ▪ Kerion ▪ Favus ***Protozoal*** ▪ *Leishmania*
Inflammatory dermatoses	▪ Psoriasis (rarely) ▪ Pityriasis amiantacea ▪ Arteritis temporalis ▪ Pyoderma gangrenosum ▪ Graft-versus-host disease ***Sclerosing*** ▪ Morphea ▪ Scleroderma en coup de sabre and Parry-Romberg syndrome ▪ Lichen sclerosus et atrophicus ***Bullous*** ▪ Cicatricial pemphigoid ▪ Porphyria cutanea tarda ▪ Acquired epidermolysis bullosa ***Granulomatous*** ▪ Sarcoidosis ▪ Granuloma anulare ▪ Necrobiosis lipoidica (including Miescher granulomatosis)
Neoplastic	***Infiltration*** ▪ Lymphoproliferative disorders ▪ Mastocytosis ***Benign solid neoplasms*** ▪ Cysts ▪ Vascular tumors ▪ Adnexal tumors ▪ Plasmacytoma ***Malignant solid tumors*** ▪ Angiosarcoma ▪ Dermatofibrosarcoma protuberans ▪ Malignant fibrous histiocytoma ▪ Melanoma ▪ Squamous cell carcinoma ▪ Basal cell carcinoma ▪ Metastasis (alopecia neoplastica) ▪ Lymphoma

Adapted by permission from Springer: Finner AM, Shapiro J. Secondary cicatricial and other permanent alopecias. In: Blume-Peytavi U, Tosti A, Whiting DA, et al, eds. *Hair Growth and Disorders*. Berlin, Germany: Springer-Verlag; 2008:229, Table 12.1. Copyright © 2008.

within the hair shaft on microscopic examination. The hair breaks off directly at the skin surface, which clinically presents as "black dots." Hair loss, inflammation, and scaling may be minimal; consequently, this type of tinea capitis is often dismissed as seborrheic or atopic dermatitis. Favus is a specific type of tinea capitis characterized by patelliform scales (scutula), which are sulfuric-yellow concretions of hyphae and skin debris in the follicular orifices and exhibit a distinct malodorous smell. A kerion is a deep, highly inflammatory fungal infection of the scalp. It presents as a highly suppurative, boggy, nodular, deep folliculitis with fistulas and pus secretion. To establish a diagnosis, hair shafts should be plugged out and cultured, as well as examined after potassium hydroxide preparation. Favus and kerion may lead to scarring hair loss and should be treated aggressively. [93-96]

Systemic antifungal treatment such as terbinafine, itraconazole, ketoconazole, griseofulvin, and fluconazole is indispensable to treat tinea capitis. The choice of the systemic antifungal agent depends on the type of fungus.[95,97,98] Especially in children, social contacts must be sought and treated to prevent reinfection. Topical sporicidal agents, such as selenium or ketoconazole help to limit the spread of the infectious spores.[99]

TRAUMATIC HAIR LOSS

An acute or chronic mechanical insult to the scalp hair may lead to reversible or irreversible alopecia of the scalp. Traumatic alopecias are usually of 3 types: acute trauma, prolonged traction, and pressure.

TRAUMATIC INJURIES

Minimal or severe injuries to the scalp can result in alopecia. It usually presents with fine streaks of hair loss in the injured scalp area, but if the wound borders undergo contusion or destruction, this may result

in irregular and large patches of hair loss. Traumatic hair loss can occur after scalp surgery, especially after extensive scalp reduction or large donor strip harvesting in hair restoration surgery, if too much tension is applied with wound closure. This type of hair loss is usually reversible but also can be permanent. Traumatic birth induced alopecia is infrequent; causes include mechanical extractor marks, tears or contusions or resulting infections. Aplasia cutis congenita should be considered in the differential diagnosis of cicatricial alopecia at birth.[100]

TRACTION ALOPECIA

Prolonged traction of the hair may lead to transient or if continued over a period of time, may lead to follicular atrophy, resulting in cicatricial alopecia. Chronic traction can be caused by tight pony tails, braids, heavy dead locks or extensive use of rollers. As a consequence of ethnic differences in hair fragility and cultural differences in hair-styling practices, marginal traction alopecia is more commonly seen in African American women from hair braiding and weaving procedures (Fig. 88-9).[101] Patchy traction alopecia in the frontal hairline or temples is commonly seen in Sikh boys, whose hair is usually tight up in a "topknot."[102] Cicatricial alopecia caused by prolonged traction can be treated with hair transplantation, if the patient discontinues the injuring hairstyles and sufficient donor hair supply is available.

TRICHOTILLOMANIA (HAIR PULLING DISORDER)

Trichotillomania (greek: *tricho* = hair, *tillo* = pull, *mania* = excessive excitement) is a form of traumatic alopecia caused by an irresistible compulsion to pull out or twist or break of one's own hair. Two forms of trichotillomania can be distinguished: infantile or early-onset trichotillomania, which starts in early childhood, is typically of short duration and may resolve spontaneously or with simple interventions.[103,104] The clinical presentation is usually quite distinctive with a single or multiple asymmetrical, occasionally geometrically shaped, areas of hair loss on the scalp or other areas of the body (Fig. 88-10). The areas are not smoothly devoid of hairs, as seen in alopecia areata, but display short or bristly anagen hair. Most important in the therapy of trichotillomania is the education of patient and/or parents, and in late-onset trichotillomania, the treatment of the underlying psychopathology. Especially if patients deny the self-inflicting nature of their hair loss, a referral to a psychiatrist or psychologist is usually refused and treatment becomes difficult.

Figure 88-9 Traction alopecia.

Figure 88-10 Trichotillomania.

PRESSURE ALOPECIA

Pressure alopecia can occur after a patient was unconscious and completely immobile for a certain length of time. Hair loss is presumably a result of ischemia caused by the pressure of the body weight to a certain scalp area. The ischemic injury may lead to permanent hair loss.

DIFFERENTIAL DIAGNOSIS

Table 88-4 outlines the differential diagnosis of secondary cicatricial alopecias.

TABLE 88-4

Differential Diagnosis for Secondary Cicatricial Alopecias

- Primary cicatricial alopecia
- Alopecia areata
- Temporal triangular alopecia
- Trichotillomania
- Secondary syphilis (alopecia areolaris)

REFERENCES

1. Olsen EA, Bergfeld WF, Cotsarelis G, et al. Summary of North American Hair Research Society (NAHRS)-sponsored Workshop on Cicatricial Alopecia, Duke University Medical Center, February 10 and 11, 2001. *J Am Acad Dermatol.* 2003;48(1):103-110.
2. Olsen E, Stenn K, Bergfeld W, et al. Update on cicatricial alopecia. *J Investig Dermatol Symp Proc.* 2003; 8(1):18-19.
3. Whiting DA. Cicatricial alopecia: clinico-pathological findings and treatment. *Clin Dermatol.* 2001;19(2): 211-215.
4. Cotsarelis G, Sun TT, Lavker RM. Label-retaining cells reside in the bulge area of pilosebaceous unit: implications for follicular stem cells, hair cycle, and skin carcinogenesis. *Cell.* 1990;61(7):1329-1337.
5. Sellheyer K, Bergfeld WF. Histopathologic evaluation of alopecias. *Am J Dermatopathol.* 2006;28(3):236-259.
6. Tan E, Martinka M, Ball N, et al. Primary cicatricial alopecias: clinicopathology of 112 cases. *J Am Acad Dermatol.* 2004;50(1):25-32.
7. Taylor G, Lehrer MS, Jensen PJ, et al. Involvement of follicular stem cells in forming not only the follicle but also the epidermis. *Cell.* 2000;102(4):451-461.
8. Ross EK, Tan E, Shapiro J. Update on primary cicatricial alopecias. *J Am Acad Dermatol.* 2005;53(3):1-37.
9. Shapiro J. Assessment of the patient with alopecia. In: *Hair Loss: Principles of Diagnosis and Management of Alopecia*. London, UK: Martin Dunitz, 2002.
10. Bergfeld WF, Elston DM. Cicatricial alopecia. In: Olsen EA, ed. *Disorders of Hair Growth: Diagnosis and Treatment*. 2nd ed. New York, NY: McGraw-Hill; 2003:363-398.
11. Otberg N, Wu WY, McElwee KJ, et al. Diagnosis and management of primary cicatricial alopecia: part I. *Skinmed.* 2008;7(1):19-26.
12. Wu WY, Otberg N, McElwee KJ, et al. Diagnosis and management of primary cicatricial alopecia: part II. *Skinmed.* 2008;7(2):78-83.
13. Callen JP. Chronic cutaneous lupus erythematosus. Clinical, laboratory, therapeutic, and prognostic examination of 62 patients. *Arch Dermatol.* 1982;118(6): 412-416.
14. Wilson CL, Burge SM, Dean D, et al. Scarring alopecia in discoid lupus erythematosus. *Br J Dermatol.* 1992; 126(4):307-314.
15. George PM, Tunnessen WW Jr. Childhood discoid lupus erythematosus. *Arch Dermatol.* 1993;129(5):613-617.
16. Moises-Alfaro C, Berrón-Pérez R, Carrasco-Daza D, et al. Discoid lupus erythematosus in children: clinical, histopathologic, and follow-up features in 27 cases. *Pediatr Dermatol.* 2003;20(2):103-107.
17. Meyers DC, Woosley JT, Reddick RL. Verruciform xanthoma in association with discoid lupus erythematosus. *J Cutan Pathol.* 1992;19(2):156-158.
18. Headington JT. Cicatricial alopecia. *Dermatol Clin.* 1996;14(4):773-782.
19. Kossard S. Lymphocytic mediated alopecia: histological classification by pattern analysis. *Clin Dermatol.* 2001;19(2):201-210.
20. Sperling LC. Hair density in African Americans. *Arch Dermatol.* 1999;135:656-658.
21. Solomon AR. The transversely sectioned scalp biopsy specimen: the technique and an algorithm for its use in the diagnosis of alopecia. *Adv Dermatol.* 1994;9: 127-157.
22. Templeton SF, Solomon AR. Scarring alopecia: a classification based on microscopic criteria. *J Cutan Pathol.* 1994;21(2):97-109.
23. Ruzicka T, Sommerburg C, Goerz G, et al. Treatment of cutaneous lupus erythematosus with acitretin and hydroxychloroquine. *Br J Dermatol.* 1992;127(5): 513-518.
24. Newton RC, Jorizzo JL, Solomon AR Jr, et al. Mechanism-oriented assessment of isotretinoin in chronic or subacute cutaneous lupus erythematosus. *Arch Dermatol.* 1986;122(2):170-176.
25. Hamilton T, Otberg N, Wu WY, et al. Successful hair regrowth with multimodal treatment of early cicatricial alopecia in discoid lupus erythematosus. *Acta Derm Venereol.* 2009;89(4):417-418.
26. Eisen D. The evaluation of cutaneous, genital, scalp, nail, esophageal, and ocular involvement in patients with oral lichen planus. *Oral Surg Oral Med Oral Pathol Oral Radiol Endod.* 1999;88(4):431-436.
27. Chieregato C, Zini A, Barba A, et al. Lichen planopilaris: report of 30 cases and review of the literature. *Int J Dermatol.* 2003;74(6):784-786.
28. Kossard S. Postmenopausal frontal fibrosing alopecia. Scarring alopecia in a pattern distribution. *Arch Dermatol.* 1994;130(6):770-774.
29. Atarguine H, Hocar O, Hamdaoui A, et al. Frontal fibrosing alopecia: report on three pediatric cases [in French]. *Arch Pediatr.* 2016;23(8):832-835.
30. Ormaechea-Pérez N, López-Pestaña A, Zubizarreta-Salvador J, et al. Frontal fibrosing alopecia in men: presentations in 12 cases and a review of the literature. *Actas Dermosifiliogr.* 2016;7310(16):30260-30265.
31. Vañó-Galván S, Molina-Ruiz AM, Serrano-Falcón C, et al. Frontal fibrosing alopecia: a multicenter review of 355 patients. *J Am Acad Dermatol.* 2014; 70(4):670-678.
32. Holmes S. Frontal fibrosing alopecia. *Skin Therapy Lett.* 2016;21(4):5-7.
33. Phillips WG, Vaughan-Jones S, Jenkins R, et al. Captopril-induced lichenoid eruption. *Clin Exp Dermatol.* 1994;19(4):317-320.
34. Katta R. Lichen planus. *Am Fam Physician.* 2000; 61(11):3319-3324.
35. Kang H, Alzolibani AA, Otberg N, et al. Lichen planopilaris. *Dermatol Ther.* 2008;21(4):249-256.
36. Mehregan DA, Van Hale HM, Muller SA. Lichen planopilaris: clinical and pathologic study of forty-five patients. *J Am Acad Dermatol.* 1992;27(6):935-942.
37. Bolanča Ž, Goren A, Getaldić-Švarc B, et al. Platelet-rich plasma as a novel treatment for lichen planopillaris. *Dermatol Ther.* 2016;29(4):233-235.
38. Ott F, Bollag W, Geiger JM. Efficacy of oral low-dose tretinoin (all-trans-retinoic acid) in lichen planus. *Dermatology.* 1997;192(4):334-336.
39. Mirmirani P, Willey A, Price VH. Short course of oral cyclosporine in lichen planopilaris. *J Am Acad Dermatol.* 2003;49(4):667-671.
40. Cribier B, Frances C, Chosidow O. Treatment of lichen planus. An evidence-based medicine analysis of efficacy. *Arch Dermatol.* 1998;134(12):1521-1530.
41. Massa MC, Rogers RS 3rd. Griseofulvin therapy of lichen planus. *Acta Derm Venereol.* 1981;61(6): 547-550.
42. Ronchese F. Pseudopelade. *Arch Dermatol.* 1960;82: 336-343.
43. Schmoeckel C, Weissmann I, Plewig G, et al. Treatment of alopecia areata by anthralin-induced dermatitis. *Arch Dermatol.* 1979; 115(10):1254-1255.

44. Elston DM, McCollough ML, Warschaw KE, et al. Elastic tissue in scars and alopecia. *J Cutan Pathol.* 2000;27(3):147-152.
45. Bulengo-Ransby SM, Headington JT. Pseudopelade of Brocq in a child. *J Am Acad Dermatol.* 1990; 23(5):944-945.
46. Alzolibani AA, Kang H, Otberg N, et al. Pseudopelade of Brocq. *Dermatol Ther.* 2008;21(4):257-263.
47. Olsen EA. Disorders of hair growth. In: Cotsarelis G, Millar SE, Chan EF, eds. *Embryology and Anatomy of the Hair Follicle*. 2nd ed. Vol. 1. New York, NY: McGraw-Hill; 2003:544.
48. Dlova NC, Jordaan FH, Sarig O, et al. Autosomal dominant inheritance of central centrifugal cicatricial alopecia in black South Africans. *J Am Acad Dermatol.* 2014;70(4):679-682.
49. Dlova NC, Salkey KS, Callender VD, et al. Central centrifugal cicatricial alopecia: new insights and a call for action. *J Investig Dermatol Symp Proc.* 2017; 18(2):S54-S56.
50. Suchonwanit P, Hector CE, Bin Saif GA, et al. Factors affecting the severity of central centrifugal cicatricial alopecia. *Int J Dermatol.* 2016;55(6):e338-e343.
51. Olsen EA, Callender V, Sperling L, et al. Central scalp alopecia photographic scale in African American women. *Dermatol Ther.* 2008;21(4):264-267.
52. Sperling LC, Sau P. The follicular degeneration syndrome in black patients. "Hot comb alopecia" revisited and revised. *Arch Dermatol.* 1992;128(1):68-74.
53. Eginli AN, Dlova NC, McMichael A. Central centrifugal cicatricial alopecia in children: a case series and review of the literature. *Pediatr Dermatol.* 2017;34(2):133-137.
54. Callender VD, McMichael AJ, Cohen GF. Medical and surgical therapies for alopecias in black women. *Dermatol Ther.* 2004;17(2):164-176.
55. Ogunleye TA, McMichael A, Olsen EA. Central centrifugal cicatricial alopecia: what has been achieved, current clues for future research. *Dermatol Clin.* 2014;32(2):173-181.
56. Gibson LE, Muller SA, Peters MS. Follicular mucinosis of childhood and adolescence. *Pediatr Dermatol.* 1988;5(4):231-235.
57. van Doorn R, Scheffer E, Willemze R. Follicular mycosis fungoides, a distinct disease entity with or without associated follicular mucinosis: a clinicopathologic and follow-up study of 51 patients. *Arch Dermatol.* 2002; 138(2):191-198.
58. Boer A, Guo Y, Ackerman AB. Alopecia mucinosa is mycosis fungoides. *Am J Dermatopathol.* 2004;26(1):33-52.
59. Emmerson RW. Follicular mucinosis. A study of 47 patients. *Br J Dermatol.* 1969;81(6):395.
60. Baden HP, Byers HR. Clinical findings, cutaneous pathology, and response to therapy in 21 patients with keratosis pilaris atrophicans. *Arch Dermatol.* 1994;130(4):469-475.
61. Powell JJ, Dawber RP, Gatter K. Folliculitis decalvans including tufted folliculitis: clinical, histological and therapeutic findings. *Br J Dermatol.* 1999;140(2): 328-333.
62. Powell J, Dawber RP. Successful treatment regime for folliculitis decalvans despite uncertainty of all aetiological factors. *Br J Dermatol.* 2001;144:428-429.
63. Brooke RC, Griffiths CE. Folliculitis decalvans. *Clin Exp Dermatol.* 2001;26(1):120-122.
64. Brozena SJ, Cohen LE, Fenske NA. Folliculitis decalvans: response to rifampin. *Cutis.* 1988;42:512-515.
65. Abeck D, Korting HC, Braun-Falco O. Folliculitis decalvans. Long-lasting response to combined therapy with fusidic acid and zinc. *Acta Derm Venereol.* 1992;72(2):143-145.
66. Sivakumaran S, Meyer P, Burrows NP. Dissecting folliculitis of the scalp with marginal keratitis. *Clin Exp Dermatol.* 2001;26:490-492.
67. Ramasastry SS, Granick MS, Boyd JB, et al. Severe perifolliculitis capitis with osteomyelitis. *Ann Plast Surg.* 1987;18:241-244.
68. Ongchi DR, Fleming MG, Harris CA. Sternocostoclavicular hyperostosis: two cases with differing dermatologic syndromes. *J Rheumatol.* 1990;17:1415-1418.
69. Libow L, Friar DA. Arthropathy associated with cystic acne, hidradenitis suppurativa, and perifolliculitis capitis abscedens et suffodiens: treatment with isotretinoin. *Cutis.* 1999;64:87-90.
70. Curry SS, Gaither DH, King LE Jr. Squamous cell carcinoma arising in dissecting perifolliculitis of the scalp. A case report and review of secondary squamous cell carcinomas. *J Am Acad Dermatol.* 1981;4:673-678.
71. Boyd AS, Zemtsov A. A case of pyoderma vegetans and the follicular occlusion triad. *J Dermatol.* 1992;19(1):61-63.
72. Bergeron JR, Stone OJ. Follicular occlusion triad in a follicular blocking disease (pityriasis rubra pilaris). *Dermatologica.* 1968;136(5):362-367.
73. Scheinfeld NS. A case of dissecting cellulitis and a review of the literature. *Dermatol Online J.* 2003;9(1):8.
74. Goldsmith PC, Dowd PM. Successful therapy of the follicular occlusion triad in a young woman with high dose oral antiandrogens and minocycline. *J R Soc Med.* 1993;86:729-730.
75. Adrian RM, Arndt KA. Perifolliculitis capitis: successful control with alternate-day corticosteroids. *Ann Plast Surg.* 1980;4:166-169.
76. Scerri L, Williams HC, Allen BR. Dissecting cellulitis of the scalp: response to isotretinoin. *Br J Dermatol.* 1996;134:1105-1108.
77. Koca R, Altinyazar HC, Ozen OI, et al. Dissecting cellulitis in a white male: response to isotretinoin. *Int J Dermatol.* 2002;41:509-513.
78. Stites PC, Boyd AS. Dissecting cellulitis in a white male: a case report and review of the literature. *Cutis.* 2001;67:37-40.
79. Otberg N, Kang H, Alzolibani AA, et al. Folliculitis decalvans. *Dermatol Ther.* 2008;21(4):238-244.
80. Scheinfeld N. Dissecting cellulitis (perifolliculitis capitis abscedens et suffodiens): a comprehensive review focusing on new treatments and findings of the last decade with commentary comparing the therapies and causes of dissecting cellulitis to hidradenitis suppurativa. *Dermatol Online J.* 2014;20(5):22692.
81. Halder RM. Pseudofolliculitis barbae and related disorders. *Dermatol Clin.* 1988;6:407-412.
82. Dinehart SM, Herzberg AJ, Kerns BJ, et al. Acne keloidalis: a review. *J Dermatol Surg Oncol.* 1989;15: 642-647.
83. Stritzler C, Friedman R, Loveman AB. Acne necrotica; relation to acne necrotica miliaris and response to penicillin and other antibiotics. *Arch Derm Syphilol.* 1951;64:464-469.
84. Kossard S, Collins A, McCrossin I. Necrotizing lymphocytic folliculitis: the early lesion of acne necrotica (varioliformis). *J Am Acad Dermatol.* 1987;16(1):1007-1014.
85. Maibach HI. Acne necroticans (varioliformis) versus *Propionibacterium acnes* folliculitis. *J Am Acad Dermatol.* 1989;21:323.

86. Grattan CE, Peachey RD, Boon A, Evidence for a role of local trauma in the pathogenesis of erosive pustular dermatosis of the scalp. *Clin Exp Dermatol.* 1988;13:7-10.
87. Ena P, Lissia M, Doneddu GM, et al. Erosive pustular dermatosis of the scalp in skin grafts: report of three cases. *Dermatology.* 1997;194:80-84.
88. Pye RJ, Peachey RD, Burton JL. Erosive pustular dermatosis of the scalp. *Br J Dermatol.* 1979;100:559-566.
89. Finner AM, Otberg N, Shapiro J. Secondary cicatricial and other permanent alopecias. *Dermatol Ther.* 2008;21(4):279-294.
90. Elewski BE. Tinea capitis: a current perspective. *J Am Acad Dermatol.* 2000;42:1.
91. Hebert AA. Tinea capitis. Current concepts. *Arch Dermatol.* 1988;124(10):1554-1557.
92. Tanz RR, Hebert AA, Esterly NB. Treating tinea capitis: should ketoconazole replace griseofulvin? *J Pediatr.* 1988;112(6):987-991.
93. Fiedler L, Rückauer K, Faber M, et al. Surgical and ketoconazole treatment of a kerion Celsi caused by *Trichophyton mentagrophytes* and *Candida tropicalis*. *Mycoses.* 1988;(suppl 1):81-87.
94. Kron C, Oger P, Traxer O, et al. Bulky superinfected tinea capitis of the scalp. Treatment by surgical resection and reconstruction by cutaneous expansion [in French]. *Arch Pediatr.* 1998;5:992-995.
95. Otberg N, Tietz HJ, Henz BM, et al. Kerion due to *Trichophyton mentagrophytes*: responsiveness to fluconazole versus terbinafine in a child. *Acta Derm Venereol.* 2001;81(6):444-445.
96. Thoma-Greber E, Zenker S, Röcken M, et al. Surgical treatment of tinea capitis in childhood. *Mycoses.* 2003;46(8):351-354.
97. Chen X, Jiang X, Yang M, et al. Systemic antifungal therapy for tinea capitis in children: an abridged Cochrane Review. *J Am Acad Dermatol.* 2017; 76(2):368-374.
98. Kaul S, Yadav S, Dogra S. Treatment of dermatophytosis in elderly, children, and pregnant women. *Indian Dermatol Online J.* 2017;8(5):310-318.
99. Trovato MJ, Schwartz RA, Janniger CK. Tinea capitis: current concepts in clinical practice. *Cutis.* 2006;77:93.
100. Roberts JL, De Villez R. Infectious, and physical, and inflammatory causes of hair and scalp abnormalities. In: Olsen EA, ed. *Disorders of Hair Growth*. 2nd ed. Vol. 1. New York, NY: McGraw-Hill; 2003.
101. Wilborn WS. Disorders of hair growth in African-Americans. In: Olsen EA, ed. *Disorders of Hair Growth*. 2nd ed. Vol. 1. New York, NY: McGraw-Hill; 2003.
102. Singh G, Traction alopecia in Sikh boys. *Br J Dermatol.* 1975;92:232.
103. Swedo SE, Leonard HL. Trichotillomania. An obsessive compulsive spectrum disorder? *Psychiatr Clin North Am.* 1992;15(4):777-790.
104. Winchel RM, Jones JS, Stanley B, et al. Clinical characteristics of trichotillomania and its response to fluoxetine. *J Clin Psychiatry.* 1992;53(9):304-308.

Chapter 89 :: Hair Shaft Disorders

:: Leslie Castelo-Soccio & Deepa Patel

AT-A-GLANCE

- Hair shaft disorders associated with hair breakage include trichorrhexis nodosa, trichoschisis, pili torti, trichorrhexis invaginata, and monilethrix.
- Hair shaft disorders associated with unruly hair, but none or little hair breakage, include uncombable hair syndrome, wooly hair, Marie Unna hereditary hypotrichosis, and hypotrichosis.
- Other hair shaft disorders that don't distinctly fall into either of the above categories are loose anagen syndrome and pili annulati.

Hair shaft disorders can be classified as primary and secondary. A primary disorder is caused by a gene defect that changes the shape or composition of the hair shaft, and a secondary disorder is caused by external factors applied to the hair leading to weakness and often breakage of the hair shaft. Classically, hair shaft disorders are also divided into those that cause hair breakage and those that cause unruly hair, although there can be overlap between the 2 categories.

HAIR SHAFT DISORDERS ASSOCIATED WITH HAIR BREAKAGE

TRICHORRHEXIS NODOSA

EPIDEMIOLOGY

Trichorrhexis nodosa (TN) is the most common hair shaft disorder associated with breakage.

CLINICAL FEATURES

TN presents as brittle, easily broken, and lusterless hair with white nodular swellings at irregular intervals along the hair shaft.[1] Patients with TN often complain of inability to grow hair past a certain length.

ETIOLOGY/RISK FACTORS

TN can either be acquired or inherited. Acquired TN is the more common subtype and is caused by external trauma, which includes mechanical, chemical, and thermal injury. Acquired TN has been divided into 3 groups based on localized, proximal, or distal location.[2] Localized TN usually presents as isolated patches that occurs from mechanical trauma secondary to a pruritic dermatosis.[1] Proximal TN has primarily been observed in the African American population where the use of strong chemical and heat-straightening treatments is more common. Distal TN is described in white and Asian populations and is associated with frequent shampoo use, brushing, and chemical treatments such as bleaching. Other causes of acquired disease include malnutrition, iron deficiency, and hypothyroidism.

There are also instances where TN is either inherited or congenital. When TN is inherited, it occurs at birth or within a few months of birth and is an isolated autosomal dominant condition. Congenital TN can be associated with ectodermal dysplasias or with metabolic disorders such as arginosuccinic aciduria. Arginosuccinic aciduria leads to a buildup of toxic levels of ammonia and presents within a few days of birth with infants displaying lethargy, temperature instability and ataxia.[3] Occasionally, an individual may inherit a milder form of the disorder where ammonia builds up in the bloodstream only during periods of illness. The gene defect is in the *ASL* gene, which provides instructions for making the protein arginosuccinase lyase. Testing for this disorder is included in many state newborn screens. Workup includes genetic testing for *ASL* gene as well as a complete metabolic panel looking for acidosis, hyperammonemia, and low serum arginine. Treatment results in resolution to normal hair and involves supplementation with arginine and dietary restriction of protein.

Table 89-1 reviews additional metabolic and congenital syndromes that are associated with TN.

DIAGNOSIS

Diagnosis of TN can be made with light and electron microscopy. The characteristic finding is a splayed paint brush bristle appearance (Fig. 89-1), which is caused by a breach in the cuticle leading to exposure of the fibers and increasing their susceptibility to fracture. Additional analysis of hair shaft, as well as blood tests such as complete blood count, thyroid function, and copper levels, may reveal other acquired or congenital causes of TN.

DIFFERENTIAL DIAGNOSIS

Differential diagnosis for TN (Table 89-2) includes conditions associated with hair loss and increased hair fragility, as well as the associated syndromes discussed above.

TABLE 89-1
Syndromes Associated with Trichorrhexis Nodosa

CONDITION	INHERITANCE PATTERN AND GENE DEFECT	CLINICAL FEATURES	TREATMENT AND PROGNOSIS
Multiple carboxylase deficiency	Autosomal recessive Early onset: holocarboxylase synthetase gene (*HLCS*) Late onset: biotinidase gene (*BTD*)	Hypotonia, failure to thrive, seizures, TN, and generalized rash	Most features, including hair symptoms, will resolve with biotin supplementation
Trichohepatoenteric syndrome (THE)	Autosomal recessive *TTC37* gene	Intractable diarrhea, facial dysmorphism, intrauterine growth restriction, immune system dysfunction, and hair that is wooly or easily removable	Supportive care; total parenteral nutrition (TPN) for nutrition; prognosis poor with main complications that include infection and severe liver disease
Menkes syndrome	X-linked recessive ATP7A copper-transporter gene defect	Hypotonia, failure to thrive, seizures, developmental delay, pale skin, and sparse, coarse, lighter-colored hair	Early copper supplementation may be of some benefit, but most patients will not live past age 3 years
Goltz syndrome	X-linked dominant ectodermal dysplasia PORCN (porcupine O-acyltransferase) mutation	Craniofacial, skeletal, ocular, renal, and GI involvement can occur, as well as hair shaft abnormalities	Corrective treatment and medical management of various associated anomalies
Netherton syndrome	Autosomal recessive *SPINK5* (serine peptidase inhibitor, Kazal type 5) gene	Atopic diathesis, severe dehydration, growth retardation, ichthyosis linearis circumflexa, and hair shaft abnormalities, including trichorrhexis nodosa, trichorrhexis invaginata, and pili torti	No known cure, but intravenous immunoglobulin has become treatment of choice along with supportive care
Wooly hair	Autosomal dominant *KRT74* (keratin 74) gene	Hair shaft disorder with fine, tightly curled hair; can display associated structural anomalies such as trichorrhexis nodosa	No effective treatments have been found; avoidance of harsh chemicals and application of oils can make hair more manageable
Trichothiodystrophy (TTD)	Autosomal recessive There are 4 known gene mutations: MPLKIP (M-phase specific PLK1 interacting protein), ERCC2 (ERCC excision repair 2), ERCC3 (ERCC excision repair 3), GTF2H5 (general transcription factor IIH subunit 5)	Severe forms may be associated with developmental delay, short stature, dry skin, abnormal toenails and fingernails, congenital cataracts, and increased risk for respiratory tract infections; milder forms can be limited to hair changes and are associated with both trichorrhexis nodosa and trichoschisis	No effective treatments have been found for TTD; avoidance of trauma may prevent further hair breakage or loss

CLINICAL COURSE AND PROGNOSIS

Patients with inherited causes of TN have a varying course. Those with external causes can improve with removal of the external trauma to the hair shaft.



Figure 89-1 Microscopic findings of trichorrhexis nodosa.

MANAGEMENT

Acquired TN is often a self-limited and reversible disease. Management involves avoiding harsh chemical treatments, excessive hair brushing, heat exposure, and mechanical trauma such as rubbing or scratching. Resolution to normal hair will occur within 2 to 4 years. Additional use of a protein-enriched shampoo, as well as cutting the hair in cases of distal damage, may prevent future reoccurrence of TN.[1]

TABLE 89-2
Differential Diagnosis of Trichorrhexis Nodosa

- Alopecia areata
- Androgenic alopecia
- Monilethrix
- Piedra
- Seborrheic dermatitis
- Telogen effluvium
- Trichotillomania

TRICHOSCHISIS AND TRICHOTHIODYSTROPHY

Trichoschisis refers to a localized absence of cuticle that leads to exposure and a clean transverse fracture of the hair shaft. Trichoschisis is associated with low-sulfur-containing hair seen in trichothiodystrophy (TTD), but can also occur secondary to external trauma.

EPIDEMIOLOGY

TTD is an extremely rare condition occurring in 1 in 1 million live births.[4] TTD is associated with defects in genes involved in DNA repair and transcription and occurs as part of multiple inherited syndromes. In addition to being a characteristic finding in TTD, trichoschisis can more frequently be caused by external trauma from heat, chemicals, relaxants, and excessive brushing.

CLINICAL FEATURES

Trichoschisis is characterized by brittle, easily broken hair as well as short, brittle eyebrows and eyelashes. When trichoschisis occurs as part of TTD, possible clinical features include cutaneous findings such as lamellar ichthyosis, brittle nails, short stature, mental retardation, facial dysmorphisms, and gonadal dysgenesis.[4,5] A recent review of the literature noted an increased risk for severe infections in patients with TTD, especially of the respiratory tract.[6] Photosensitivity is seen in some forms of TTD although no accompanying increased risk for skin cancer has been found.[6] Associated abnormalities seen in TTD are specific to each group of inherited disorders and are outlined in Table 89-3.

TABLE 89-3
Inherited Syndromes of Trichothiodystrophy

CONDITION	CLINICAL FEATURES
BIDS (Amish brittle hair syndrome)	Brittle hair, brittle nails, intellectual deficiency, decreased fertility, short stature, ataxia, seizures, and microcephaly
IBIDS (Tay syndrome)	Brittle hair, brittle nails, intellectual deficiency, decreased fertility, short stature, ichthyosis, ectodermal dysplasia
PIBIDS	Brittle hair, brittle nails, intellectual deficiency, decreased fertility, short stature, ichthyosis, photosensitivity
PBIDS	Brittle hair, brittle nails, intellectual deficiency, decreased fertility, short stature, photosensitivity
Sabinas syndrome	Brittle hair, brittle nails, intellectual deficiency, decreased fertility, and ocular symptoms such as retinopathy

ETIOLOGY/RISK FACTORS

The localized absence of cuticle seen in trichoschisis can be a consequence of mechanical trauma from excessive styling, brushing, or combing. Chemical treatments, such as dye or bleach, may strip away the cuticle and cause local breakage. When it occurs congenitally, trichoschisis is seen in TTD and is associated with sulfur-deficient and cysteine-deficient hair. TTD is an autosomal recessive disorder that is linked to 4 major genes: *ERCC2 (XPD)*, *ERCC3 (XPB)*, *p8 (TTDA)*, and *C7Orf11* (*TTDN1* or *MPLKIP*).[7] The photosensitive forms of TTD are clinically grouped into 1 class and include alterations in the *XPD*, *XPB*, and *TTDA* genes. These genes encode a subunit of the transcription factor II H (TFIIH) complex, which initiates nucleotide excision repair when damage in the DNA is detected. The photosensitivity in this group is thus caused by a defect in nucleotide excision repair that prevents removal of modified or damaged DNA secondary to ultraviolet light. Nonphotosensitive forms of TTD are linked to patients with TTDN1 mutations. Although the exact function of TTDN1 is unknown, it is thought to regulate the cell cycle, namely mitosis and cytokinesis.[8]

DIAGNOSIS

In TTD, "tiger tail" hair with light and dark alternating bands is seen on polarized light microscopy (Fig. 89-2). This alternating pattern is related to irregular sulfur content of the hair, with lighter areas representing lower sulfur concentrations. Diagnosis can be confirmed by genetic testing of the genes described above or by sulfur and amino acid analysis of the hair shaft. The hair cysteine and sulfur content in TTD is less than 50% of normal in the cuticle and the cortex of the hair.[5]

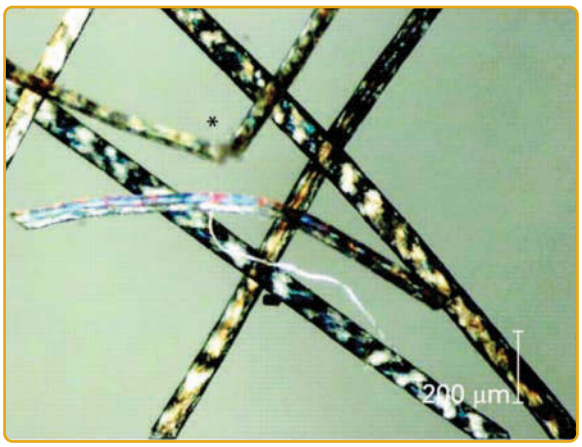

Figure 89-2 Tiger tail pattern seen with trichoschisis in trichothiodystrophy. (From Faghri S, Tamura D, Kraemer KH, et al. Trichothiodystrophy: a systematic review of 112 published cases characterises a wide spectrum of clinical manifestations. *J Med Genet*. 2008;45(10):609-21, with permission from BMJ Publishing Group Ltd.)

DIFFERENTIAL DIAGNOSIS

Because of variation in presentation and potential effects on multiple organ systems, TTD has an extensive differential diagnosis. Most commonly, xeroderma pigmentosum and Cockayne syndrome are considered because of the increased photosensitivity of TTD, as well as the mechanism of defect in the DNA repair pathway. However, clinical presentation, low sulfur content, and hair pathology all help to distinguish TTD from other disorders.

CLINICAL COURSE AND PROGNOSIS

Patients with acquired trichoschisis often have good clinical prognosis with return to normal hair after reduction in mechanical or chemical trauma. Those with TTD have varying phenotypes that result in a spectrum from mild disease with only hair involvement to severe disease with profound developmental delay and high mortality. A systemic review of the literature found a 20-fold higher rate of mortality in children younger than the age of 10 years with TTD when compared to the general U.S. population.[6] The majority of these cases were the result of complications from severe infections. This same literature review by Faghri et al noted that patients can develop complications such as intellectual impairment (86%), short stature (73%), ocular abnormalities (51%), and ichthyosis (65%) at any point during their lifetime.[6]

MANAGEMENT

If trichoschisis is acquired, reducing hair manipulation can result in resolution of symptoms. In cases of TTD, no effective treatment modality has been identified. However, potential complications of TTD can be managed by regular monitoring of patients. Because of the extensive systemic effects of TTD, a multidisciplinary approach including, but not limited to, dermatologic, ophthalmologic, audiologic, skeletal, and developmental evaluations is required.

PILI TORTI

Pili torti ("twisted hair") is characterized by hair shafts that are flattened and twisted 180 degrees along their long axis.

EPIDEMIOLOGY

Pili torti often presents within the first 3 years of life. A less common, postpubertal form has been described.[9]

CLINICAL FEATURES

Hair is brittle, dry, and appears spangled as a result of uneven light reflections (Fig. 89-3). Fractures within the weak points of the twists result in shorter hair with increased fragility. Coarse hair or areas of alopecia are especially prevalent in the parietal and occipital areas. Hair is fair in appearance, except in postpubertal cases where darker hair, areas of alopecia, and late-onset intellectual disability is observed.[9] The scalp is the primary area affected, but eyebrows, eyelashes, and other body hairs may be involved. Neurologic disorders, hearing loss, and ectodermal dysplasia may be found in cases of pili torti.[10] Pili torti occurring as a feature of a clinical syndrome is associated with many cutaneous and extracutaneous features (Table 89-4).

Figure 89-3 Brittle and broke hair typical of pili torti.

ETIOLOGY/RISK FACTORS

Pili torti is either inherited or acquired. Isolated inherited cases occur in an autosomal dominant pattern, but can also be autosomal recessive or sporadic.[10] When occurring as part of a clinical syndrome, inheritance patterns of pili torti vary. Acquired cases of pili torti have been seen in cases of anorexia nervosa, malnutrition, after oral retinoid treatment, and with inflammatory conditions affecting the scalp such as alopecia areata.[10] Pathogenesis is most likely caused by abnormalities of the inner root sheath and perifollicular fibrosis in cases of acquired pili torti.[11,12] Pili torti is seen in Menkes syndrome in combination with other hair shaft disorders including TN, trichoclasis, and trichoptilosis. Menkes is an X-linked recessive disorder occurring secondary to a defect in the *ATP7A* gene encoding for a copper transporter. Clinical signs become apparent in infancy with hypopigmentation of the skin, mental disability, depigmented hair, and neurologic impairment. Diagnosis is made by low copper and ceruloplasmin levels. Prognosis for Menkes is poor with most patients dying by age 3 years. Immediate supplementation with copper-histidine may have some benefit in preventing severe neurologic features.

DIAGNOSIS

Diagnosis of pili torti is made with light microscopy. Microscopic examination reveals flattened, twisted

TABLE 89-4
Syndromes Associated with Pili Torti

CONDITION	INHERITANCE PATTERN AND GENE DEFECT	CLINICAL FEATURES
Menkes syndrome	X-linked recessive *ATP7A* gene encoding copper transporter	Hypotonia, failure to thrive, seizures, developmental delay, pale skin, and sparse, coarse, lighter-colored hair
Bazex syndrome	X-linked dominant Xq24-27	Follicular atrophoderma, facial milia, sweating disorders, and congenital hypotrichosis with pili torti
Beare syndrome	Autosomal dominant Chromosome 10q26.13 *FGFR2* gene	Alopecia after puberty, decreased beard and body hair, and pili torti
Björnstad syndrome	Autosomal recessive Chromosome 2q35 *BCS1L* gene	Sensorineural deafness and pili torti
Crandall syndrome	Autosomal recessive	Sensorineural deafness, hypopituitarism, and congenital hypotrichosis with pili torti
Goltz syndrome (focal dermal hypoplasia)	X-linked dominant *PORCN* gene	Facial abnormalities (asymmetry of the face, narrow nasal bridge), short stature, skeletal features (adactyly, claw hands, clinodactyly), cognitive impairment, CNS (seizures, microcephaly), ocular abnormalities (heterochromia, aniridia, colobomas), malformation of ears, atopic dermatitis, hypohidrosis, alteration in pigment, photosensitivity, nail changes (V-nicking, micronychia), GI features (omphalocele, gastric polyps), genitourinary findings (horseshoe kidney, hypoplasia, or absent kidney) hair shaft disorders (pili torti, pili trianguli et canaliculi, trichorrhexis nodosa)
Netherton syndrome	Autosomal recessive Chromosome 5q32 *SPINK5* gene, serine protease inhibitor	Ichthyosis linearis circumflexa, atopic diathesis, and hair shaft abnormalities (pili torti, trichorrhexis nodosa, trichorrhexis invaginata)
Rapp-Hodgkin syndrome	Autosomal dominant Chromosome 3q28 *TP63* gene	Anhidrotic ectodermal dysplasia, cleft lip and palate, hypodontia, nail abnormalities, hypospadia, and pili torti
Ronchese syndrome	X-linked recessive *EDA* gene	Ichthyosis, keratosis pilaris, nail dystrophy, dental abnormalities, leukonychia, and pili torti
Trichothiodystrophy (TTD1), photosensitive type	Autosomal recessive Chromosome 19q13 *ERCC2/XPD* gene	Ichthyosiform erythroderma, mental delay, short stature, brittle nails, brittle hair (torti pili or trichorrhexis nodosa)

hair occurring at irregular intervals along the hair shaft (Fig. 89-4). Twists occur in groups of 3 to 10 and are 0.4 to 0.9 mm wide.[12,13] With scanning electron microscopy, a spiral pattern of the hair follicle is evident.[11]

DIFFERENTIAL DIAGNOSIS

In addition to the associated syndromes discussed above, other hair shaft disorders are considered in the differential diagnosis for pili torti (Table 89-5).

Figure 89-4 Pili torti under light microscopy: irregularly spaced 180-degree twists.

CLINICAL COURSE AND PROGNOSIS

In most cases, hair spontaneously improves after puberty.

MANAGEMENT

No effective treatment for pili torti has been identified. Chemical and/or mechanical trauma should be reduced to avoid further breakage.

TABLE 89-5
Differential Diagnosis of Pili Torti

- Hypotrichosis
- Monilethrix
- Pseudomonilethrix
- Trichorrhexis nodosa

TRICHORRHEXIS INVAGINATA

Trichorrhexis invaginata (bamboo hair) is commonly associated with Netherton syndrome and is characterized by invagination of the distal hair shaft into the proximal portion. It may also occur as an isolated condition or sporadically with other hair shaft abnormalities.

EPIDEMIOLOGY

Isolated trichorrhexis invaginata is a rare condition. Incidence of Netherton syndrome is estimated to be 1 in 200,000 live births.

CLINICAL FEATURES

Hair has a dry, lusterless, brittle appearance with increased fragility. Areas of diffuse thinning with some instances of complete alopecia are present. Eyebrows and eyelashes are also affected. The Netherton syndrome clinical triad includes atopic diathesis, ichthyosiform erythroderma, and trichorrhexis invaginata. Few cases of Netherton syndrome with only ichthyosis linearis circumflexa and no other clinical features have been described.[14] Atopic diathesis occurs in approximately 75% of Netherton syndrome cases,[15] and includes atopic dermatitis, asthma, allergic rhinitis, angioedema, urticarial, hypereosinophilia, and elevated immunoglobulin E levels.[16] Hair shaft abnormalities become clinically apparent after infancy in Netherton syndrome with trichorrhexis invaginata being the most common, but abnormalities may also include pili torti and trichorrhexis invaginata. Ichthyosis appears at birth as a collodion baby or during the first few months of life with ichthyosis linearis circumflexa, which is classically described as migratory hyperkeratosis with polycyclic and serpiginous erythematous plaques that have double-edged margins at the scale. Additional extracutaneous include recurrent infections, hypogammaglobulinemia, neurologic deficits, hypernatremia, hypothermia, mental disability, delayed growth, and short stature.[17,18]

ETIOLOGY/RISK FACTORS

Netherton syndrome is an autosomal recessive disorder involving the gene serine protease inhibitor, Kazal type-5 (*SPINK5*). The *SPINK5* gene is located on chromosome 5q32 and encodes an inhibitor of lymphoepithelial Kazal-type–related inhibitor (LEKTI). As a serine protease enzyme, LEKTI is responsible for the breakdown of intracellular adhesions resulting in desquamation of epidermal cells.[16] LEKTI is also present in the inner root sheaths of hair follicles. Hair shaft abnormalities seen in Netherton syndrome may be the result of intermittent incomplete formation of disulfide bonds in the keratogenous zone.[16,19]

Figure 89-5 Golf-tee appearance of hair shaft under light microscopy.

DIAGNOSIS

Under light microscopy, intussusception of the distal hair shaft into the proximal portion, which is soft and incompletely keratinized, leads to a "golf-tee" deformity (Fig. 89-5).[20] Because of increased fragility in these areas, nodular fractures can also be seen along the shafts at irregular intervals.[17] Electron microscopy reveals defects in keratinization of the inner root sheath.[21] Trichoscopic examination of the hair shaft also has been proposed as an accurate and quick diagnostic tool.[22] Additional laboratory findings that may aid in diagnosis include immunohistochemistry of skin biopsies to detect LEKTI deficiency, elevated levels of immunoglobulin E, and moderate eosinophilia.[18]

DIFFERENTIAL DIAGNOSIS

Differential diagnosis for trichorrhexis invaginata includes black piedra, monilethrix, and TN.[21] When diagnosing Netherton syndrome, additional disorders to consider include Leiner disease, acrodermatitis enteropathica, erythrokeratoderma variabilis, generalized seborrheic dermatitis, erythrodermic psoriasis, staphylococcal scalded skin syndrome, and nonbullous ichthyosiform erythroderma.[17,18,21]

CLINICAL COURSE AND PROGNOSIS

Those with milder phenotypes in Netherton syndrome often see improvement of their condition with age in addition to resolution of hair anomalies. Patients with more-severe phenotypes with erythroderma have a more persistent and severe disease course. Recurrent infections, as well as early mortality, are commonly observed in these cases.

MANAGEMENT

Cutaneous features of Netherton syndrome are managed with the use of emollients, topical steroids, and topical immunomodulators such as tacrolimus and pimecrolimus. Caution is taken when using these treatments as patients with Netherton syndrome have an increased susceptibility to absorption of topical

Figure 89-6 Typical beaded appearance of hair as seen under light microscopy in monilethrix.

medications.[16] Systemic therapies include low-dose corticosteroids, retinoids, and phototherapy.[16]

MONILETHRIX

Monilethrix is a rare genetic disorder associated with increased fragility and a pathognomonic beaded hair appearance (Fig. 89-6).

EPIDEMIOLOGY

Monilethrix appears early in infancy and generally occurs in an autosomal dominant pattern, although reports of autosomal recessive inheritance have been documented.[23,24] Clinical presentation varies widely with mild involvement involving only a few follicles to severe disease with complete alopecia.

CLINICAL FEATURES

Monilethrix becomes clinically apparent within the first few months of life after lanugo hair is shed and replaced with short, dry, and lusterless hair. Hair is sparse with increased fragility. Beaded hairs emerge from keratotic follicular papules that are primarily seen in the occiput.[25] Mild disease may involve only the scalp, but more severe forms can affect eyebrows, eyelashes, and generalized body hair.[26] Cases resulting in scarring alopecia also have been reported.[26] Monilethrix may occur as an isolated condition or in association with keratosis pilaris, nail defects (koilonychias), cataracts, teeth abnormalities, syndactyly, oligophrenia, and mental disability.[25,26]

ETIOLOGY/RISK FACTORS

Autosomal dominant forms of monilethrix are associated with mutations in genes for type II hair keratins including hHb1 (KRT81), hHb3 (KRT83), and hHb6 (KRT86).[24,27] These genes have been mapped to chromosome 12q11-q13.[24,26] Rare cases of autosomal recessive inheritance are linked to mutations in desmoglein 4.[26,28]

DIAGNOSIS

Light microscopy reveals a pearl necklace appearance with areas of knots and narrowing along the hair shaft. Nonmedullated elliptical nodes can be seen at regular intervals, 0.7 to 1 mm apart.[29] Trichoscopy of the hair shaft will show both dilated nodes and constricted internodes.

TABLE 89-6
Differential Diagnosis of Monilethrix

- Alopecia areata
- Alopecia secondary to chemotherapy
- Monilethrix-like autosomal recessive hypotrichosis
- Pseudomonilethrix
- Trichorrhexis nodosa

DIFFERENTIAL DIAGNOSIS

Table 89-6 outlines the differential diagnosis of monilethrix. Pseudomonilethrix presents with the same beaded morphology as monilethrix. However, unlike monilethrix, elliptical nodes are not seen at regular intervals along the hair shaft and keratotic follicular papules are not seen on physical examination.

CLINICAL COURSE AND PROGNOSIS

Clinical course is variable although hair often improves with age.[27]

MANAGEMENT

No definitive treatment has been identified.[30] Oral retinoids and topical minoxidil may be of some benefit.[31,32] *N*-acetyl cysteine provides initial improvement but its effects do not persist long-term.[24]

UNRULY HAIR

UNCOMBABLE HAIR SYNDROME

Uncombable hair syndrome (pili trianguli et canaliculi or spun glass hair) is a rare disorder of the scalp hair that is characterized by a structural anomaly of the inner and outer hair sheath.[33,34]

EPIDEMIOLOGY

Uncombable hair most commonly presents within the first few months, but can occur up to 12 years of age.[35] It affects males and females equally. The majority of cases are autosomal dominant with complete or incomplete penetrance though sporadic forms of uncombable hair have been observed. Acquired forms are more common in dark, curly hair individuals and tend to occur later in life. A partial variant with patchy, well-demarcated involvement, typically in frontal and occipital areas also has been described.

Figure 89-7 Clinical appearance of uncombable hair syndrome.

CLINICAL FEATURES

Patients with familial uncombable hair have unruly, frizzy, and dry hair that sticks out from scalp and is difficult to comb flat (Fig. 89-7). Hair is normally red-blond to light blond in color and has a spangled appearance. There is no increased fragility and hair is generally normal in both quantity and length. Eyebrows, eyelashes, and body hair are not affected. Several systemic disorders have been known to present concurrently with uncombable hair, including various forms of ectodermal dysplasia such as Bork syndrome, multiple epiphyseal dysplasia, and type I neurofibromatosis.[33,34,36-38] Other conditions, such as digital abnormalities, juvenile cataracts, retinal dysplasia, pigmentary dystrophy, tooth enamel anomalies, oligodontia, and phalangoepiphyseal dysplasia, have been reported.[37]

ETIOLOGY/RISK FACTORS

In 2016, 3 genes were implicated in the autosomal recessive variants: PADI3 (peptidylarginine deiminase 3), TGM3 (transglutaminase 3), and TCHH (trichohyalin).[38A] Premature keratinization or a structural anomaly of the dermal papillae of the inner and outer hair shaft of the follicle may result in the rigid configuration that is characteristic of uncombable hair.[39,40]

DIAGNOSIS

Under closer analysis of hair cross-sections with electron microscopy, the affected hairs exhibit a triangular or kidney shape with shallow longitudinal grooving. It is thought that this longitudinal grooving is responsible for the physical manifestation of the hair's appearance. In normal hair, the largest amount of light refraction occurs at the center of the hair because of the dark longitudinal band. However, in uncombable hair, the presence of longitudinal hair grooving of the hair shaft causes hair to have more of a characteristically glistening appearance at the edges of the hair strand.[41]

DIFFERENTIAL DIAGNOSIS

Table 89-7 outlines the differential diagnosis of uncombable hair syndrome. Other closely associated hair disorders may mimic the clinical features of uncombable hair syndrome.

TABLE 89-7
Differential Diagnosis of Uncombable Hair

- Acquired progressive hair kinking
- Drug-induced kinking
- Loose anagen syndrome
- Marie Unna hypotrichosis
- Monilethrix
- Pili torti
- Rapp-Hodgkin syndrome
- Wooly hair

CLINICAL COURSE AND PROGNOSIS

Hair typically improves with age and most cases resolve after puberty.

MANAGEMENT

No treatment has been identified and is generally not necessary. Biotin supplementation has been reported to have a positive effect on uncombable hair.[39,41,42]

MARIE-UNNA HEREDITARY HYPOTRICHOSIS

Marie-Unna hereditary hypotrichosis (MUHH) is an autosomal dominant condition that presents at birth with sparse or absent hair.

EPIDEMIOLOGY

MUHH is most commonly seen in those of European descent but occurrences in China have been reported.[43] Males and females are equally affected. Clinical features are normally seen at birth. A single case series, notes a few individuals with normal hair at birth with later progression to hair loss.[43]

CLINICAL FEATURES

Clinical features vary over time. Hair is typically sparse or completely absent at birth with regrowth of coarse, wiry, and unruly hair during childhood. Around puberty, nonscarring hair loss is again seen. Pattern of hair loss may be similar to androgenic alopecia with thick hair scattered in thinning areas that are especially noted on vertex, parietal, and occipital regions.[44] Total alopecia may be observed. Scalp, eyebrows, eyelashes, secondary sexual hairs, and generalized body hair are affected. Other cutaneous features associated with MUHH include milia-like lesions on the face as well as follicular hyperkeratosis.[43]

TABLE 89-8
Differential Diagnosis of Marie Unna Hereditary Hypotrichosis

- Androgenetic alopecia
- Alopecia areata
- Congenital atrichia with popular lesions
- Hereditary hypotrichosis simplex
- Loose anagen syndrome
- Uncombable hair syndrome

ETIOLOGY/RISK FACTORS

MUHH is inherited in an autosomal dominant pattern. MUHH is caused by a heterozygous mutation in *U2HR*, which is an upstream open reading frame that normally acts to inhibit the *HR* gene on chromosome 8p21. Up to 17 different mutations in the *U2HR* gene are described in the literature.[45]

DIAGNOSIS

Clinical examination reveals multiple anagen hairs on pull test. Scalp biopsy may show a reduced number of follicles with inflammation, but no fibrosis or scarring.[43] Both light and electron microscopy reveal irregular twisting of the hair along with longitudinal ridges and peeling of the cuticle.[51]

DIFFERENTIAL DIAGNOSIS

Table 89-8 outlines the differential diagnosis of MUHH. Hereditary hypotrichosis has a large clinical overlap with MUHH, but is distinguished by normal hair at birth as well as no associated hair shaft abnormalities. The characteristic clinical course of MUHH, as well as the twisted hair morphology, differentiates MUHH from other disorders.[43]

CLINICAL COURSE/PROGNOSIS

Hair features of MUHH are persistent.

MANAGEMENT

There is no known treatment.

WOOLY HAIR

Wooly hair is a congenital disorder that is characterized by unruly and tightly coiled hair (Fig. 89-8).[46]

EPIDEMIOLOGY

Wooly hair is a rare condition although exact incidence has not been reported. It is primarily seen in white and Asian individuals and appears during childhood or adolescence.[47] Males and females are affected equally.[48] Autosomal dominant and recessive forms of wooly hair have been described, although it can occur sporadically.[46]

Figure 89-8 Wooly hair syndrome clinical presentation.

CLINICAL FEATURES

Hair is characterized by tight curls that have an average diameter of 0.5 cm. Hair may occasionally be shorter because of a briefer anagen phase, although rate of growth and telogen-to-anagen ratio is often normal.[49] Brittle hair with no increased fragility is observed. Wooly hair can also show signs of TN.[49]

Four variants have been identified including hereditary wooly hair, familial wooly hair, symmetrical circumscribed allotrichia, and wooly hair nevus.[50] Hereditary wooly hair (autosomal dominant) is often associated with ocular anomalies such as persistent pupillary membranes, retinal defects, and cataracts.[51] Familial wooly hair (autosomal recessive) may occur concomitantly with palmoplantar hyperkeratosis and cardiac anomalies.[52] Naxos disease and Carvajal syndrome are 2 variants of this association. Naxos disease is caused by a plakoglobin gene mutation and is characterized by wooly hair, right ventricular cardiomyopathy, and nonepidermolytic diffuse palmoplantar keratoderma (Vörner-Unna-Thost type).[53] Carvajal syndrome is caused by a defect in desmoplakin and also presents with wooly hair, but presents with left ventricular dilated cardiomyopathy and striate palmoplantar keratoderma.[52] Wooly hair nevus can be accompanied by melanocytic or epidermal nevi in addition to delayed bone growth, periodontal changes, and developmental delay.[54] Noonan syndrome, cardiofaciocutaneous syndrome, and keratosis pilaris also have been reported with wooly hair.[49]

ETIOLOGY/RISK FACTORS

Autosomal dominant forms occur as a result of a mutation in the keratin gene, *KRT71*, on chromosome

TABLE 89-9
Differential Diagnosis of Wooly Hair

- Acquired progressive kinky hair
- Allotrichia circumscripta symmetrica
- Drug-induced kinky hair

12q13.[54] There are 2 forms of autosomal recessive disease, both of which occur with or without hypotrichosis. Autosomal recessive wooly hair type I is caused by a mutation of the P2RY5 or LPAR6 gene on chromosome 13q14 that encodes for a G-protein–coupled receptor that is known to play a role in hair growth.[55] Autosomal recessive wooly hair type II is caused by a mutation in the *LIPH* gene, which is found on chromosome 3q27.[56]

DIAGNOSIS

Diagnosis is made by clinical presentation. Light microscopy and scalp biopsy are normal.

DIFFERENTIAL DIAGNOSIS

Table 89-9 outlines the differential diagnosis of wooly hair.

CLINICAL COURSE AND PROGNOSIS

Wooly hair appearance is most pronounced in childhood and becomes significantly less evident in adulthood.

MANAGEMENT

No treatment has been established for wooly hair. Harsh chemical and physical injury should be avoided.

HYPOTRICHOSIS

Hereditary hypotrichosis simplex (HHS) is a nonsyndromic hereditary condition that presents with normal hair at birth and progressively thins with age.

EPIDEMIOLOGY

Prevalence is unknown. Both genders are affected equally.

CLINICAL FEATURES

HHS is characterized by diffusely sparse, fine, short hairs. Follicular miniaturization and noninflammatory alopecia are characteristic of the disease. It can either affect the scalp only or can be more generalized with complete body hair involvement. HHS occurs as an isolated condition with no reports of associated cutaneous or extracutaneous anomalies.

TABLE 89-10
Subtypes of Hypotrichosis

SUBTYPE	INHERITANCE PATTERN	GENE DEFECT AND/OR LOCATION
HYPT1	Autosomal dominant	Heterozygous mutation APCDD1 Chromosome 18p1
HYPT2	Autosomal dominant	Heterozygous mutation CDSN Chromosome 6p21.3
HYPT3	Autosomal dominant	Heterozygous mutation KRT74 Chromosome 12q13
HYPT4	Autosomal dominant	Heterozygous mutation 5′ UTR (untranslated region) region of *HR* gene Chromosome 8p21.3
HYPT5	Autosomal recessive	Chromosome 1p21.1-q21.3
HYPT6	Autosomal recessive	Homozygous or compound heterozygous mutation DSG4 Chromosome 18q12
HYPT7 Wooly hair autosomal recessive II	Autosomal recessive	Homozygous or compound heterozygous mutation LIPH Chromosome 3q27
HYPT8 Wooly hair autosomal recessive I	Autosomal recessive	Homozygous or compound heterozygous mutation P2RY5 Chromosome 13q14
HYPT9	Autosomal recessive	Chromosome 10q11.23-q22.3
HYPT10	Autosomal recessive	Chromosome 7p22.3-p21.3

ETIOLOGY/RISK FACTOR

Ten subtypes of HHS have been identified based on gene mutations, including 4 autosomal dominant (HYPT1 to HYPT4) and 6 autosomal recessive forms (HYPT5 to HYPT10) (Table 89-10).[57]

DIAGNOSIS

Light and electron microscopy of HHS show normal findings in early stages and later may reveal focal areas of defect in the cuticle.[58] Scalp biopsy in HHS demonstrates a decreased number of follicles in the telogen phase.[58]

DIFFERENTIAL DIAGNOSIS

Hypotrichosis has been identified as a feature of many other conditions including wooly hair and MUHH. HHS must be distinguished from other hair shaft abnormalities that may have similar clinical presentations.

CLINICAL COURSE AND PROGNOSIS

Hair becomes progressively thinner with age. Most patients have complete baldness by 30 years of age.[59]

MANAGEMENT

No treatment is available.

OTHER

LOOSE ANAGEN SYNDROME

Loose anagen syndrome (LAS) is a sporadic or inherited hair condition characterized by hair that is loosely attached to the scalp. Hair loss in this condition is nonscarring and noninflammatory.

EPIDEMIOLOGY

LAS is most often diagnosed in children between the ages of 2 and 6 years[60] and may present for the first time in adulthood. LAS has been reported to occur in a 6:1 female-to-male ratio,[61] although cases in males are underreported because of differences in hairstyles.[62] Classically described in lighter skin and hair individuals, those with darker skin and hair can also be affected.[63-65] The diagnosis should be considered in all presentations with scant, thinning hair.

CLINICAL FEATURES

Hair in LAS is diffusely sparse and is easily pulled from the scalp without pain. Inability to grow long hair and rare need for a haircut is common. LAS is especially evident in the posterior scalp where hair becomes matted. Hair has no increased fragility, although it can be unruly and difficult to comb. Three groups of LAS have been established based on phenotype.[63,66] LAS type A is characterized by sparse, dull, and unruly hair that does not grow long. Patients with LAS type B have diffuse or patchy unruly hair and patients with type C LAS typically present as adults with excessive shedding.[63,66]

Most cases of LAS are isolated although associated systemic diseases have been identified. Atopic diseases such as eczema and asthma are most commonly seen with LAS. Other concomitant disorders reported in the literature include coloboma, ectodermal dysplasia, ectrodactyly-ectodermal dysplasia-clefting syndrome, trichorhinophalangeal syndrome, nail-patella syndrome, neurofibromatosis, trichotillomania, woolly hair, AIDS, and alopecia areata.[67] Noonan syndrome and Noonan-like syndrome also have been linked to LAS.[68]

ETIOLOGY/RISK FACTORS

When it occurs in a familial pattern, LAS has an autosomal dominant inheritance.[69] LAS presents secondary to defects in keratinization of the inner root sheath, which impairs adhesion to the cuticle of the hair shaft. Studies suggest an E337K mutation in the K6HF keratin gene, although other genes may be involved.[66] LAS with Noonan-like syndrome is linked to a heterozygous mutation of *SHOC2* gene on chromosome 10q25.[68]

DIAGNOSIS

Diagnosis of LAS is made by pull-test, examination of hair under microscope, and trichogram analysis. Pull-test typically results in 3 to 10 hairs that are easily and painlessly plucked from hair. Light microscopy reveals predominantly anagen hairs with distorted hair bulbs and abnormal keratinization of root sheaths. Flattening of hair and longitudinal grooving can be found on electron microscope.[70] Cuticles are also characteristically ruffled, baggy, twisted, and have a floppy sock appearance. Trichogram shows at least 70% anagen hairs.[71] Trichoscopy also may be helpful in diagnosing LAS with typical features including solitary rectangular black granular structures, solitary yellow dots, and follicles with single hairs.[72]

DIFFERENTIAL DIAGNOSIS

Table 89-11 outlines the differential diagnosis of LAS. Any type of diffuse, nonscarring alopecia is considered in the differential diagnosis for LAS. Clinical findings, as well as evaluation with trichography, will help differentiate LAS from the other conditions.

CLINICAL COURSE AND PROGNOSIS

LAS typically resolves with age. If it presents at an older age, hair loss is more likely to be persistent.

MANAGEMENT

No treatment specific for LAS is available. Gentle hair care is advised to prevent further shedding of hair. Biotin use has been suggested, although there is no evidence of benefit in the literature. Use of topical 5% minoxidil has been used successfully in some severe cases of LAS.[73]

TABLE 89-11
Differential Diagnosis of Loose Anagen Syndrome

- Alopecia areata
- Hypothyroidism or hyperthyroidism
- Iron-deficiency anemia
- Medication related hair loss
- Telogen effluvium
- Traction alopecia
- Trichotillomania
- Uncombable hair syndrome

PILI ANNULATI

Pili annulati presents with ringed hair that is not usually associated with increased fragility. Hair in pili annulati is characterized by alternating light and dark bands.[74]

EPIDEMIOLOGY

Pili annulati typically presents at birth or during infancy, but can appear later in life. Familial patterns show an autosomal dominant inheritance pattern with both reduced and variable penetrance. Pili annulati can be sporadic and isolated, but also has been observed in patients with woolly hair and alopecia areata.[75] Patients with light blond or brown hair present more often with pili annulati in comparison to darker hair individuals where the banding pattern characteristic of this condition is difficult to detect.

CLINICAL FEATURES

Alternating shiny and dull segments gives the hair an overall shiny, speckled appearance. The scalp is the primary site affected with involvement of 20% to 80% of hair and a decrease in number of bands distally. Localized involvement of axillary, pubic, and beard hair also has been reported.[76-78] Hair strength and growth are typically normal, although 6 cases of increased fragility with pili annulati have been found in the literature.[79-82] Conditions previously associated with pili annulati include alopecia areata, blue nevi, syndactyly, polydactylism, and leukonychia.[83] More commonly, however, pili annulati is limited to the hair shaft with no associated cutaneous or extracutaneous features.

ETIOLOGY/RISK FACTORS

In inherited cases, pili annulati is caused by a single defect on chromosome 12q24.33.[74,84] A recent study mapped the gene locus to a 2.9-Mb region between D12S343 and the telomeric end of chromosome 12. This region contains 24 genes for hair expression.[84] Exact pathology has yet to be established although proposed mechanisms include defects in cytokeratin, abnormal matrix formation, and a malfunction of the protein that regulates the structure of the extracellular matrix.[76,84-87]

Pili annulati is not frequently associated with increased fragility, but some cases have been reported in the literature.[79-82] In these cases, analysis of amino acid content revealed an elevated lysine and decreased cysteine content in affected hair when compared to normal.[79,88] These findings suggest a role for biochemical makeup in the pathogenesis of pili annulati. Exogenous trauma such as from rigorous brushing also contribute to the changes that are seen in instances of fragility in pili annulati.[79-81]

DIAGNOSIS

Trichoscopy of pili annulati demonstrates alternating white and dark bands along the hair shaft with lighter segments representing air-filled cavities. Under light microscope, the visual effects are switched with clinically light bands appearing dark under microscopy, a result of air cavities scattering the light.[79] With the addition of potassium hydroxide for mounting, banding in hair disappears as the liquid fills the cavities.[79] Transmission electron microscopy and scanning electron microscopy will further reveal air cavities of varying sizes and shapes as well as a cobblestone appearance of the cuticle.[86] In some cases, scanning electron microscopy and transmission electron microscopy may also demonstrate areas of cuticle weathering.[79-82]

DIFFERENTIAL DIAGNOSIS

Because of the similar clinical appearance of color banding, pseudopili annulati is important to consider for the differential diagnosis. Pseudopili annulati, however, is not caused by an underlying physical defect, but instead occurs from periodic twisting of the hair. Unlike in pili annulati, in pseudopili annulati, light microscopy, scanning electron microscopy, and transmission electron microscopy of hair all demonstrate normal findings. Other conditions to consider for differential diagnosis include fragmented medulla, bubble hair, and pseudopili torti.

CLINICAL COURSE AND PROGNOSIS

Pili annulati frequently goes undiagnosed because of its subtle clinical features. Although it is a lifelong condition, lack of abnormalities in skin and other organs make its course relatively benign. Clinical features do become more prominent with age,[83] but the shiny appearance of hair is often appealing to patients.

MANAGEMENT

Specific treatment of pili annulati is not available. Gentle hair care practices should be employed to prevent further weathering.

SUMMARY

Table 89-12 summarizes hair shaft disorders.

TABLE 89-12
Summary of Hair Shaft Disorders

	ETIOLOGY/RISK FACTORS/MODE OF INHERITANCE	CLINICAL MANIFESTATION	DIAGNOSIS	CLINICAL COURSE	MANAGEMENT	RELATED SYNDROMES & CONDITIONS
Associated with Hair Breakage						
Trichorrhexis nodosa (TN)	Acquired–external trauma	Brittle, lusterless hair with white nodular swellings along hair shaft	Light and electron microscopy: splayed paint brush bristle appearance (see Fig. 89-1)	Acquired TN may improve with removal of external trauma Inherited TN may have varying courses	For acquired TN, avoidance of harsh chemical treatments	None
	Inherited—autosomal dominant					None
	Congenital—ectodermal dysplasias, or metabolic disorders					Ectodermal dysplasias, arginosuccinic aciduria and other metabolic disorders
Trichoschisis & trichothiodystrophy (TTD)	Trichoschisis—may occur from external trauma or secondary to TTD	Brittle, easily broken hair with short, brittle eyebrows and eyelashes; clinical and cutaneous features of TTD may accompany hair findings	Polarized light microscopy: "tiger tail" hair Genetic testing and amino acid analysis of the hair shaft: low cysteine and sulfur content (<50% of normal)	Acquired trichoschisis improves with removal of external trauma; course of TTD depends on the clinical phenotype	For acquired trichoschisis, reducing hair manipulation is helpful TTD with systemic effects requires multidisciplinary care	See Table 89-3
	TTD–congenital (autosomal recessive; ERCC2, ERCC3, p8, C7Orf11); photosensitive types (XPD, XPB, TTDA genes); nonphotosensitive types (TTDN1)					
Pili torti	Acquired—anorexia nervosa, severe malnutrition, oral retinoid treatment, inflammatory scalp conditions	Brittle, dry, and spangled from uneven light reflections	Light microscopy: flattened, twisted hair occurring at irregular intervals along the hair shaft	Most cases show spontaneous improvement after puberty	Although no effective treatment, mechanical trauma should be reduced	Menke syndrome
	Isolated cases may be autosomal dominant, autosomal recessive, or sporadic Menke syndrome is X-linked recessive					

(*Continued*)

TABLE 89-12
Summary of Hair Shaft Disorders (*Continued*)

	ETIOLOGY/RISK FACTORS/MODE OF INHERITANCE	CLINICAL MANIFESTATION	DIAGNOSIS	CLINICAL COURSE	MANAGEMENT	RELATED SYNDROMES & CONDITIONS
Trichorrhexis invaginata	Isolated cases; inherited (as in Netherton syndrome–autosomal recessive disorder; SPINK5)	Dry, lusterless, brittle appearance with increased fragility. Eyebrows and eyelashes are also affected	Light microscopy: intussusception of the distal hair shaft into the proximal portion; "golf tee" deformity Trichoscopy may be helpful	Milder phenotypes of Netherton syndrome may improve with age; severe phenotypes have a persistent and severe course	Treatment for cutaneous features of Netherton syndrome are available	Netherton syndrome
Monilethrix	Autosomal dominant inheritance (KRT81, KRT83, KRT86) Rarely, autosomal recessive (DSG4)	Short, dry, lusterless hair. Beaded hairs emerge from keratotic follicular papules. Eyebrows, eyelashes, and body hair may be affected	Light microscopy: "pearl necklace" appearance with areas of knots and narrowing along the hair shaft Trichoscopy: dilated nodes and constricted internodes	Variable; hair often improves with age	Oral retinoids and topical minoxidil. No definitive treatment	May have associated cutaneous, renal, and dental abnormalities
Unruly Hair						
Uncombable hair syndrome (pili trianguli et canaliculi; spun glass hair)	Autosomal dominant Acquired forms are common in dark, curly haired individuals	Unruly, frizzy, dry hair. No increased fragility. Eyebrows, eyelashes, and body hair are not affected	Electron microscopy: triangular/kidney-shaped cross-sectional appearance with longitudinal grooving	Usually resolves after puberty	Biotin supplementation may be of help. Treatment is generally not necessary	Ectodermal dysplasia syndrome, Bork syndrome, multiple epiphyseal dysplasia, type I neurofibromatosis
Marie-Unna hereditary hypotrichosis	Autosomal dominant condition (U2HR)	Sparse, absent hair; regrowth may be coarse, wiry and unruly in childhood, but hair loss may recur at puberty Total alopecia may be present Associated milia-like lesions and follicular hyperkeratosis	Pull test: multiple anagen hairs Scalp biopsy: reduced number of follicles and no evidence of fibrosis. Light and electron microscopy: irregular twisting of the hair, with longitudinal ridging and peeling of the cuticle	Persistent	No known treatment	None
Wooly hair	Autosomal dominant (KRT71) and autosomal recessive (type I: P2RY5 or LPAR6, type II: LIPH), as well as sporadic forms	Tight curls with an average diameter of 0.5 cm; brittle hair with no increased fragility. Trichorrhexis nodosa may be seen	Clinical presentation Light microscopy and scalp biopsy are normal	Less pronounced in adulthood	No treatment, but harsh chemical and mechanical injury should be avoided	Hereditary wooly hair Naxos disease Carvajal syndrome Noonan syndrome
Hereditary hypotrichosis simplex (HHS)	4 Autosomal dominant subtypes (HYPT1-4) and 6 autosomal recessive subtypes (HYPT 5-10)	Diffusely sparse, fine, short hairs. Follicular miniaturization and inflammatory alopecia; body hair may be involved	Light and electron microscopy: focal areas of defect in cuticle Scalp biopsy: decreased number of follicles	Complete baldness by age 30 years	No treatment available	None

Other						
Loose anagen syndrome (LAS)	Sporadic and inherited condition (autosomal dominant; K6HF gene)	Hair is diffusely sparse, and easily pulled from the scalp without pain. Individuals rarely need a haircut. No increased hair fragility, but hair may be difficult to comb. LAS has 3 phenotypes	Pull test: increased anagen hairs Light microscopy: anagen hairs with distorted bulbs, cuticles have a "floppy sock" appearance. Trichogram: 70% anagen hairs	Resolves with age; when LAS presents late, hair loss more likely to be persistent	Gentle hair care, 5% minoxidil	Atopic diseases Ectodermal dysplasia Nail-patella syndrome Neurofibromatosis Noonan syndrome Noonan-like syndrome
Pili annulati	Sporadic, or inherited (autosomal dominant, single defect on chromosome 12q24.33)	Characterized by alternating light and dark bands; hair has a "speckled" appearance	Trichoscopy: alternating white and dark bands; light microscopy: reversal of white and dark bands; electron microscopy: shows a cobblestone appearance of the cuticle	Clinical features become more prominent with age; course is benign	Gentle hair care practices; no specific treatment available	None

REFERENCES

1. Sisto T, Bussoletti C, D'amore A. Inability to grow long hair: a presentation of trichorrhexis nodosa. *Cutis*. 2015;95(4):E15-E16.
2. Whiting DA. Structural abnormalities of hair shaft. *J Am Acad Dermatol*. 1987;16(1, pt 1):1-25.
3. Allan, JD, Cusworth, DC, Dent, CE, et al. A disease, probably hereditary, characterized by severe mental deficiency and a constant gross abnormality of amino acid metabolism. *Lancet*. 1958;271:182-187.
4. Moslehi R, Signore C, Tamura D, et al. Adverse effects of trichothiodystrophy DNA repair and transcription gene disorder on human fetal development. *Clin Genet*. 2010;77(4):365-373.
5. Hansen LK, Wulff K, Brandrup F. Trichothiodystrophy. Hair examination as a diagnostic tool. *Ugeskr Laeger*. 1993;155(25):1949-1952.
6. Faghri S, Tamura D, Kraemer KH, et al. Trichothiodystrophy: a systematic review of 112 published cases characterises a wide spectrum of clinical manifestations. *J Med Genet*. 2008;45:609-621.
7. Stefanini M, Botta E, Lanzafame M, et al. Trichothiodystrophy: from basic mechanisms to clinical implications. *DNA Repair (Amst)*. 2010 2;9(1):2-10.
8. Heller ER, Khan SG, Kuschal C, et al. Mutations in the TTDN1 gene are associated with a distinct trichothiodystrophy phenotype. *J Invest Dermatol*. 2015;135(3):734-741.
9. Beare JM. Congenital pilar defect showing features of pili torti. *Br J Dermatol*. 1952;64:366-372.
10. Yang JJ, Cade KV, Rezende FC, et al. Clinical presentation of pili torti—case report. *An Bras Dermatol*. 2015;90(3)(suppl 1):29-31.
11. Maruyama T, Toyoda M, Kanei A, et al. Pathogenesis in pili torti: morphological study. *J Dermatol Sci*. 1994;7:S5-S12.
12. Whiting DA. Hair shaft defects. In: Olsen EA, ed. *Disorders of Hair Growth: Diagnosis and Treatment*. 2nd ed. New York, NY: McGraw-Hill; 2003:123-175.
13. Price V. Structural anomalies of the hair shaft: pili torti. In: Orfanos CE, Happle R, eds. *Hair and Hair Diseases*. Heidelberg, Germany: Springer-Verlag; 1990:384-390.
14. Guerra L, Fortugno P, Pedicelli C, et al. Ichthyosis linearis circumflexa as the only clinical manifestation of Netherton syndrome. *Acta Derm Venereol*. 2015;95(6):720-724.
15. Salodkar AD, Choudhary SV, Jadwani G, et al. Bamboo hair in Netherton's syndrome. *Int J Trichology*. 2009;1:143-144.
16. Kumar R, Abhinandan HB, Mehta P, et al. Netherton's syndrome. *Indian J Paediatr Dermatol*. 2014;15:120-122.
17. Blume-Peytavi U. Hair loss in children. In: *Hair Growth and Disorders*. Berlin, Germany: Springer; 2008:273-309.
18. Tadini G, Brena M, Gelmetti C, et al. Icthyoses. In: *Atlas of Genodermatoses,* 2nd ed. Milan, Italy: CRC Press; June 2015:65-69.
19. Jain SP, Jain PA, Pandey N. The arid melancholy-Netherton syndrome with protein energy malnutrition. *J Clin Diagn Res*. 2016;10(4):WD01-WD02.
20. Elewski BE. Tinea capitis: a current perspective. *J Am Acad Dermatol*. 2000;42:1.
21. Bittencourt Mde J, Moure ER, Pies OT, et al. Trichoscopy as a diagnostic tool in trichorrhexis invaginata and Netherton syndrome. *An Bras Dermatol*. 2015;90(1): 114-116.
22. Burk C, Hu S, Lee C, et al. Netherton syndrome and trichorrhexis invaginata—a novel diagnostic approach. *Pediatr Dermatol*. 2008;25:287-288.
23. Kljuic A, Bazzi H, Sundberg JP, et al. Desmoglein 4 in hair follicle differentiation and epidermal adhesion: evidence from inherited hypotrichosis and acquired pemphigus vulgaris. *Cell*. 2003;113:249-260.
24. Vikramkumar AG, Kuruvila S, Ganguly S. Monilethrix: a rare hereditary condition. *Indian J Dermatol*. 2013;58(3):243.
25. Olsen EA. Hair disorders. In: Irvine AD, Hoeger PH, Yan AC, eds. *Harper's Textbook of Pediatric Dermatology*. Oxford, UK: Wiley-Blackwell; 2011:148-149.
26. Ferrando J, Galve J, Torres-Puente M, et al. Monilethrix: a new family with the novel mutation in KRT81 gene. *Int J Trichology*. 2012;4:53-55.
27. De Oliveira EF, Araripe AL. Monilethrix: a typical case report with microscopic and dermatoscopic findings. *An Bras Dermatol*. 2015;90(1):126-127.
28. Jain N, Khopkar U. Monilethrix in pattern of distribution in siblings: diagnosis by trichoscopy. *Int J Trichology*. 2010;2:56-59.
29. Rogers M, Tay YK, Wong LC. Hair disorders. In: Schachner LA, Hansen RC, eds. *Pediatric Dermatology*. Philadelphia, PA: Mosby Elsevier; 2011:752-753.
30. Narmatha GR, Chithra S, Balasubramanian N. Monilethrix. *Indian J Dermatol Venereol Leprol*. 2002;68: 220-221.
31. Rossi A, Iorio A, Scali E, et al. Monilethrix treated with minoxidil. *Int J Immunopathol Pharmacol*. 2011;24:239-242.
32. Karincaoglu Y, Coskun BK, Seyhan ME, et al. Monilethrix: improvement with acitretin. *Am J Clin Dermatol*. 2005;6:407-410.
33. Rieubland C, de Viragh PA, Addor MC. Uncombable hair syndrome: a clinical report. *Eur J Med Genet*. 2007;50:309-314.
34. Kiliç A, Oğuz D, Can A, et al. A case of uncombable hair syndrome: light microscopy, trichoscopy, and scanning electron microscopy. *Acta Dermatovenerol Croat*. 2013;21(3):209-211.
35. Wagner AM, Cunningham BB, Weinstein JM, et al. Uncombable hair syndrome: light microscopy diagnosis. *Pediatr Dermatol*. 2005;22:369-370.
36. Jarell AD, Hall MA, Sperling LC. Uncombable hair syndrome. *Pediatr Dermatol*. 2007;24(4):436-438.
37. Fritz TM, Trueb RM. Uncombable hair syndrome with angel-shaped phalango-epiphyseal dysplasia. *Pediatr Dermatol*. 2000;17(1):21-24.
38. Schena D, Germi L, Zamperetti MR, et al. Uncombable hair syndrome, mental retardation, single palmar crease and arched palate in a patient with neurofibromatosis type 1. *Pediatr Dermatol*. 2007;24(5):E73-E75.

38A. Ü Basmanav FB, Cau L, Tafazzoli A, Méchin MC, Wolf S, Romano MT, et al. Mutations in three genes encoding proteins involved in hair shaft formation cause uncombable hair syndrome. *Am J Hum Genet*. 2016;99 (6):1292-1304.

39. Boccaletti, Zendri E, Giordano G, et al. Familial uncombable hair syndrome: ultra-structural hair study and response to biotin. *Pediatr Dermatol*. 2007;24(3):e14-e16.
40. Ahmed I, Subtil A, Thomas D. Pili trianguli et canaliculi is a defect of inner root sheath keratinization: ultrastructural observations of anomalous tonofilament organization in a case. *Am J Dermatopathol*. 2005;27(3):232-236.

41. Hicks J, Metry DW, Barrish J, et al. Uncombable hair (cheveux incoiffables, pili trianguli et canaliculi) syndrome: brief review and role of scanning electron microscopy in diagnosis. *Ultrastruct Pathol*. 2001;25: 99-103.
42. Shelley WB, Shelley ED. Uncombable hair syndrome: observations on response to biotin and occurrence in siblings with ectodermal dysplasia. *J Am Acad Dermatol*. 1985;13:97-102.
43. Srinivas SM, Hiremagalore R. Marie-Unna hereditary hypotrichosis. *Int J Trichology*. 2014;6(4):182-184.
44. Roberts JL, Whiting DA, Henry D, et al. Marie Unna congenital hypotrichosis: clinical description, histopathology, scanning electron microscopy of a previously unreported large pedigree. *J Investig Dermatol Symp Proc*. 1999;4:261-267.
45. Yun SK, Cho YG, Song KH, et al. Identification of a novel *U2HR* mutation in a Korean woman with Marie Unna hereditary hypotrichosis. *Int J Dermatol*. 2014;53(11):1358-1361.
46. Venugopal V, Karthikeyan S, Gnanaraj P, et al. Woolly hair nevus: a rare entity. *Int J Trichology*. 2012;4(1):42-43.
47. Prasad GK. Familial woolly hair. *Indian J Dermatol Venereol Leprol*. 2002;68:157.
48. Stieler W, Otte HG, Stadler R. Multiple woolly hair nevi with linear epidermal nevus and persistent pupillary membrane [in German]. *Hautarzt*. 1992;43:441-445.
49. Singh SK, Manchanda K, Kumar A, et al. Familial woolly hair: a rare entity. *Int J Trichology*. 2012;4(4):288-289.
50. Hutchinson PE, Cairns RJ, Wells RS. Woolly hair. Clinical and general aspects. *Trans St Johns Hosp Dermatol Soc*. 1974;60:160-177.
51. Taylor AE. Hereditary woolly hair with ocular involvement. *Br J Dermatol*. 1990;123:523-525.
52. Chien AJ, Valentine MC, Sybert VP. Hereditary woolly hair and keratosis pilaris. *J Am Acad Dermatol*. 2006;54:S35-S39.
53. McKoy G, Protonotarios N, Crosby A, et al. Identification of a deletion in plakoglobin in arrhythmogenic right ventricular cardiomyopathy with palmoplantar keratoderma and woolly hair (Naxos disease) *Lancet*. 2000;355:2119-2124.
54. Fujimoto A, Farooq M, Fujikawa H, et al. A missense mutation within the helix initiation motif of the keratin K71 gene underlies autosomal dominant woolly hair/hypotrichosis. *J Invest Dermatol*. 2012;132:2342-2349.
55. Azeem Z, Jelani M, Naz G, et al. Novel mutations in G protein-coupled receptor gene (P2RY5) in families with autosomal recessive hypotrichosis (LAH3). *Hum Genet*. 2008;123:515-519.
56. Ali G, Chishti MS, Raza SI, et al. A mutation in the lipase H (LIPH) gene underlie autosomal recessive hypotrichosis. *Hum Genet*. 2007;121:319-325.
57. Al Aboud D, Al Aboud K, Al Hawsawi K, et al. Hereditary hypotrichosis simplex of the scalp: a report of 2 additional families. *Sudan J Dermatol*. 2005;3:128-131.
58. Betz RC, Lee, YA, Bygum, A, et al. A gene for hypotrichosis simplex of the scalp maps to chromosome 6p21.3. *Am J Hum Genet*. 2000;66:1979-1983.
59. Toribio J, Quinones PA. Hereditary hypotrichosis simplex of the scalp: evidence for autosomal dominant inheritance. *Br J Dermatol*. 1974;91:687-696.
60. Srinivas SM. Loose anagen hair syndrome. *Int J Trichology*. 2015;7(3):138-139.
61. Sinclair R, Cargnello J, Chow CW. Loose anagen syndrome. *Exp Dermatol*. 1999;8 297-298.
62. Pham CM, Krejci-Manwaring J. Loose anagen hair syndrome: an underdiagnosed condition in males. *Pediatr Dermatol*. 2010;27:408-409.
63. Dey V, Thawani M. Loose anagen hair syndrome in black-haired Indian children. *Pediatr Dermatol*. 2013;30:579-583.
64. Agi C, Cohen B. A case of loose anagen syndrome in an African American girl. *Pediatr Dermatol*. 2015;32:128-129.
65. Swink SM, Castelo-Soccio L. Loose anagen syndrome: a retrospective chart review of 37 cases. *Pediatr Dermatol*. 2016;33:507-510.
66. Chapalain V, Winter H, Langbein L, et al. Is the loose anagen hair syndrome a keratin disorder? A clinical and molecular study. *Arch Dermatol*. 2002;138:501-506.
67. Dey VK, Thawani M. Loose anagen hair syndrome: is there any association with atopic dermatitis? *Indian Dermatol Online J*. 2016;7(1):56-57.
68. Mazzanti L, Cacciari E, Cicognani A, et al. Noonan-like syndrome with loose anagen hair: a new syndrome? *Am J Med Genet*. 2003;118A:279-286.
69. Baden HP, Kvedar JC, Magro CM. Loose anagen hair as a cause of hereditary hair loss in children. *Arch Dermatol*. 1992;128:1349-1353.
70. Hamm H, Traupe H. Loose anagen hair of childhood: the phenomenon of easily pluckable hair. *J Am Acad Dermatol*. 1989;20:242-248.
71. Tosti A, Piraccini BM. Loose anagen hair syndrome and loose anagen hair. *Arch Dermatol*. 2002;138:521-522.
72. Rakowska A, Zadurska M, Czuwara J, et al. Trichoscopy findings in loose anagen hair syndrome: rectangular granular structures and solitary yellow dots. *J Dermatol Case Rep*. 2015;9(1):1-5.
73. Chandran NS, Oranje AP. Minoxidil 5% solution for topical treatment of loose anagen hair syndrome. *Pediatr Dermatol*. 2014;31:389-390.
74. Green J, Fitzpatrick E, de Berker D, et al. A gene for pili annulati maps to the telomeric region of chromosome 12q. *J Invest Dermatol*. 2004;123: 1070-1072.
75. Castelli E, Fiorella S, Caputo V. Pili annulati coincident with alopecia areata, autoimmune thyroid disease, and primary IgA deficiency: case report and considerations on the literature. *Case Rep Dermatol*. 2012;4(3):250-255.
76. Musso LA. Pili annulati. *Australas J Dermatol*. 1970;11:67-75.
77. Amichai B, Grunwald MH, Halevy S. Hair abnormality present since childhood. Pili annulati. *Arch Dermatol*. 1996;132:575, 578.
78. Montgomery RM, Binder AI. Ringed hair. *Arch Derm Syphilol*. 1970;58:177-179.
79. Giehl KA, Ferguson DJ, Dawber RP, et al. Update on detection, morphology and fragility in pili annulati in three kindreds. *J Eur Acad Dermatol Venereol*. 2004;18:654-658.
80. Werner K, St-Surin-Lord S, Sperling LC. Pili annulati associated with hair fragility: cause or coincidence? *Cutis*. 2013;91:36-38.
81. Akoglu G, Emre S, Metin A, et al. Pili annulati with fragility: electron microscopic findings of a case. *Int J Trichology*. 2012;4(2):89-92.
82. Feldmann KA, Dawber RP, Pittelkow MR, et al. Newly described weathering pattern in pili annulati hair shafts: a scanning electron microscopic study. *J Am Acad Dermatol*. 2001;45:625-627.

83. Green J, Sinclair RD, de Bereker D. Disappearance of pili annulati following an episode of alopecia areata. *Clin Exp Dermatol*. 2002;27:458-460.
84. Giehl KA, Rogers MA, Radivojkov M, et al. Pili annulati: refinement of the locos on chromosome 12q24.33 to a 2.9-MB interval and candidate gene analysis. *Br J Dermatol*. 2009;160:527-533.
85. Giehl KA, Ferguson DJ, Dean D, et al. Alterations in the basement membrane zone in pili annulati hair follicles as demonstrated by electron microscopy and immunohistochemistry. *Br J Dermatol*. 2004;150:722-727.
86. Gummer CL, Dawber RP. Pili annulati: electron histochemical studies on affected hairs. *Br J Dermatol*. 1981;105:303-309.
87. Ito M, Hashimoto K, Sakamoto F, et al. Pathogenesis of pili annulati. *Arch Dermatol Res*. 1988;280:308-318.
88. Dawber R. Investigations of a family with pili annulati associated with blue naevi. *Trans St Johns Hosp Dermatol Soc*. 1972;58:51-58.

Chapter 90 :: Hirsutism and Hypertrichosis

:: Thusanth Thuraisingam & Amy J. McMichael

HIRSUTISM

AT-A-GLANCE

- Hirsutism is defined as terminal body hair growth in women in a male distribution.
- Women with a Ferriman-Gallwey score of 8 or higher are considered hirsute.
- Women with mild to moderate hirsutism and regular menstrual cycles are most likely diagnosed with idiopathic hirsutism; hormone testing is not necessary.
- Hormone testing is necessary in women with moderate to severe hirsutism and all women with hirsutism and irregular menstrual cycles or signs of virilisation.

INTRODUCTION

Hirsutism is a condition in which excessive hair in women grows in a male pattern distribution. It has a significant psychosocial impact on the affected individual as well as a number of medical consequences for the skin. The main driving factors are the higher-than-normal androgen levels, either in circulation or locally, and an increased sensitivity of the hair follicle to androgens. This condition differs from hypertrichosis in which the excess hair has a more generalized distribution and independent of androgens. Hirsutism may result from various causes, with polycystic ovarian syndrome (PCOS), nonclassical congenital adrenal hyperplasia (CAH), and adrenal or ovarian tumors being among the major causes, or hirsutism may be idiopathic.

Hirsutism can cause the affected individual embarrassment, leading to social withdrawal and even depression.[1,2] A recent study has identified that patients view their condition as more severe than do their clinicians, which is associated with a negative effect on their quality of life.[3] The authors suggest that treatment be guided by the level of patient's distress with the hair growth.

EPIDEMIOLOGY

The prevalence of hirsutism is unknown. Approximately 5% to 15% of the female population of reproductive age is thought to be affected by hirsutism, and it is one of the most common complaints of patients presenting to dermatology offices.[4,5] The variability in concentration of hair follicles is influenced by ethnicity and strong family inheritance. Asians, with lower hair concentration, are much less likely to present with hirsutism resulting from an androgen excess state compared with their Mediterranean counterparts.[6] As a result, the cut-off value for diagnosis of hirsutism varies among different ethnic populations. The prevalences of hirsutism were estimated to be 38% in Greece, 21.2% in Australia, 10.8% in Iran, 10.5% in India, 8.3% in Turkey, 7.1% in Spain, and 2% in Thailandand.[7,8] A study of North American women with hirsutism identified that 25% to 33% of white women have terminal hairs on the upper lip and periareolar area, as well as the linear alba, with normal androgen levels. The degree of facial and body terminal hair was similar in black and white women in North America with a prevalence of 4.3% and 5.4%, respectively.[9] Hirsutism may also be influenced by age. Most of the patients are women of reproductive age, and the growth pattern is heaviest at a younger age compared with older age.[10]

PATHOGENESIS

The hair growth cycle is made up of three phases: anagen (growth phase), catagen (involution), and telogen (rest phase). The cycle is under hormonal influence in a site-specific pattern. The maturation of vellus (small, straight, and nonpigmented) hair to terminal (long, curlier, and pigmented) hair is the result of the activation of androgen receptors in the hair follicle.[11] During puberty, an increase in androgen levels drives vellus hair to differentiate into terminal hair, as well as sebaceous gland development (see Chap. 6 for more detail).

In women, the androgens are produced in the ovaries and adrenal glands and are subject to peripheral conversion. Enzymatic conversion of cholesterol to pregnenolone is the rate-limiting step of all steroid hormone production. This step is under the influence of luteinizing hormone (LH) in the ovary and adrenocorticotropic hormone (ACTH) in the adrenal cortex.[11] Although both testosterone and dihydrotestosterone (DHT) are capable of converting vellus hair to terminal hair, DHT is the most potent androgen. DHT is produced from the peripheral enzymatic conversion of testosterone by 5α-reductase within the hair follicle.[11] Binding of DHT to its nuclear receptor activates genes responsible for conversion of vellus hair to terminal hair in androgen sensitive areas of the body. However, excess circulating androgens

alone do not explain the pathogenesis of hirsutism because some women have hirsutism without evidence of androgen excess (idiopathic hirsutism; see below).[12] In these individuals, local factors and variability in end-organ sensitivity are thought to be the underlying cause.

CLINICAL FINDINGS AND DIAGNOSIS

Hirsutism can be categorized as primary or idiopathic in 5% to 15% of affected patients with regular menstrual cycles and normal levels of circulating androgens[12] versus secondary hirsutism associated with underlying causes (Table 90-1). In evaluating patients, it is important to obtain a thorough history of their symptoms and signs. Apart from hirsutism, other cutaneous signs of hyperandrogenism include acne, acanthosis nigricans, androgenetic alopecia, seborrheic dermatitis, and signs of virilization. Signs of virilization include clitoromegaly, male pattern balding, deepening voice, or decreased breast size.[13] It is also important to review the patient's list of medications and supplements to be assured that these are not contributing to androgen excess. The abrupt and rapid onset of hirsutism should raise suspicion of malignancy. The most commonly involved areas are the upper lip > thighs > lower abdomen > upper back.[14]

The modified Ferriman and Gallwey (mFG) scoring scale is a systematic assessment tool for the degree of hirsutism of nine body locations, which when combined, allow for an overall diagnosis of hirsutism. It was developed by Ferriman in 1961 and later modified by Hatch in 1981.[15,16] It assigns a score of 1 to 4 in nine body areas, with an increasing numeric score corresponding to greater hair density (Fig. 90-1). Excess hair distribution in the nine anatomical areas evaluated by the mFG scale (upper lip, chin and cheeks, chest, abdomen, pubic area and lower abdomen, arms, legs, upper back and lower back, and buttocks) characterize patients with hirsutism.[15,17] The score varies from 0 (no hair) to 4 (extensive hair growth) in each area. Normal hair growth is defined by a score of 8 or less, mild hirsutism is defined by a score of 8 to 14, and a score of greater than 15 indicates moderate to severe hirsutism.[18] The anatomical distribution and the extent of body involvement may vary among individual patients. An alternative simplified scoring system with three body parts (upper abdomen, lower abdomen, and chin) with

TABLE 90-1
Causes of Hirsutism

ETIOLOGY	FINDINGS	COMMENT
Idiopathic hirsutism (IH)	Regular ovulation and normal to slightly elevated androgen levels Often presents with mild to moderate hirsutism	Mean age, BMI, and hip and waist circumference higher in IH vs patients with metabolic disturbance[13]
Polycystic ovarian syndrome (PCOS)	Hyperandrogenism; menstrual irregularities, including oligomenorrhea, amenorrhea, and infertility; and impaired glucose tolerance, hyperlipidemia, and obesity	Cutaneous findings of acanthosis nigricans may also be observed in 5% of obese women with insulin resistance Warrants endocrinology evaluation for impaired glucose tolerance as increased risk for type 2 diabetes mellitus[16,18]
Nonclassic congenital adrenal hyperplasia	Autosomal recessive inheritance of 21-hydroxylase deficiency Rarely secondary to 11β-hydroxylase deficiency Hirsutism, acne, alopecia, anovulation, and menstrual dysfunction	Patients often present accelerated bone age maturation and increased basal or stimulated 17-OHP
HAIR-AN	Hyperandrogenism (HA), insulin resistance (IR), and acanthosis nigricans (AN) Considered a subtype of PCOS	Insulin elevated; elevated or high-normal levels of testosterone and androstenedione but normal levels of LH and prolactin[30]
SAHA	Seborrhea (S), acne (A), hirsutism (H), and alopecia (A)	
Hyperprolactinemia	Presents with amenorrhoea, galactorrhea, and infertility	Associated with stress, pituitary adenoma, pregnancy, drug intake, and primary hypothyroidism with elevated TSH
Cushing syndrome	Centripetal fat distribution, thinning of the skin with striae, glucose intolerance, osteoporosis, and proximal muscle weakness; signs and symptoms of hyperandrogenism and menstrual irregularities	▪ Multiple causes: ▪ Adrenal neoplasm ▪ Ectopic ACTH-secreting tumor ▪ Pituitary tumor (Cushing disease)
Pregnancy	Most common areas involved are the upper abdomen, lower abdomen, lower back, upper lip, and thighs[52]	Serum total testosterone levels and mFG score increase with the progression of pregnancy Associated with physiological changes of pregnancy
Acromegaly	Elevated random serum GH and IGF-1	Patients can present with abnormal growth of the hands and feet, arthritis, sleep apnea, headache, and impaired vision

ACTH, adrenocorticotropic hormone; BMI, body mass index; GH, growth hormone; HCG, human chorionic gonadotropin; IGF, insulin-like growth factor; LH, luteinizing hormone; mFG, modified Ferriman and Gallwey;17-OHP; 17-hydroxyprogesterone; TSH, thyroid-stimulating hormone.

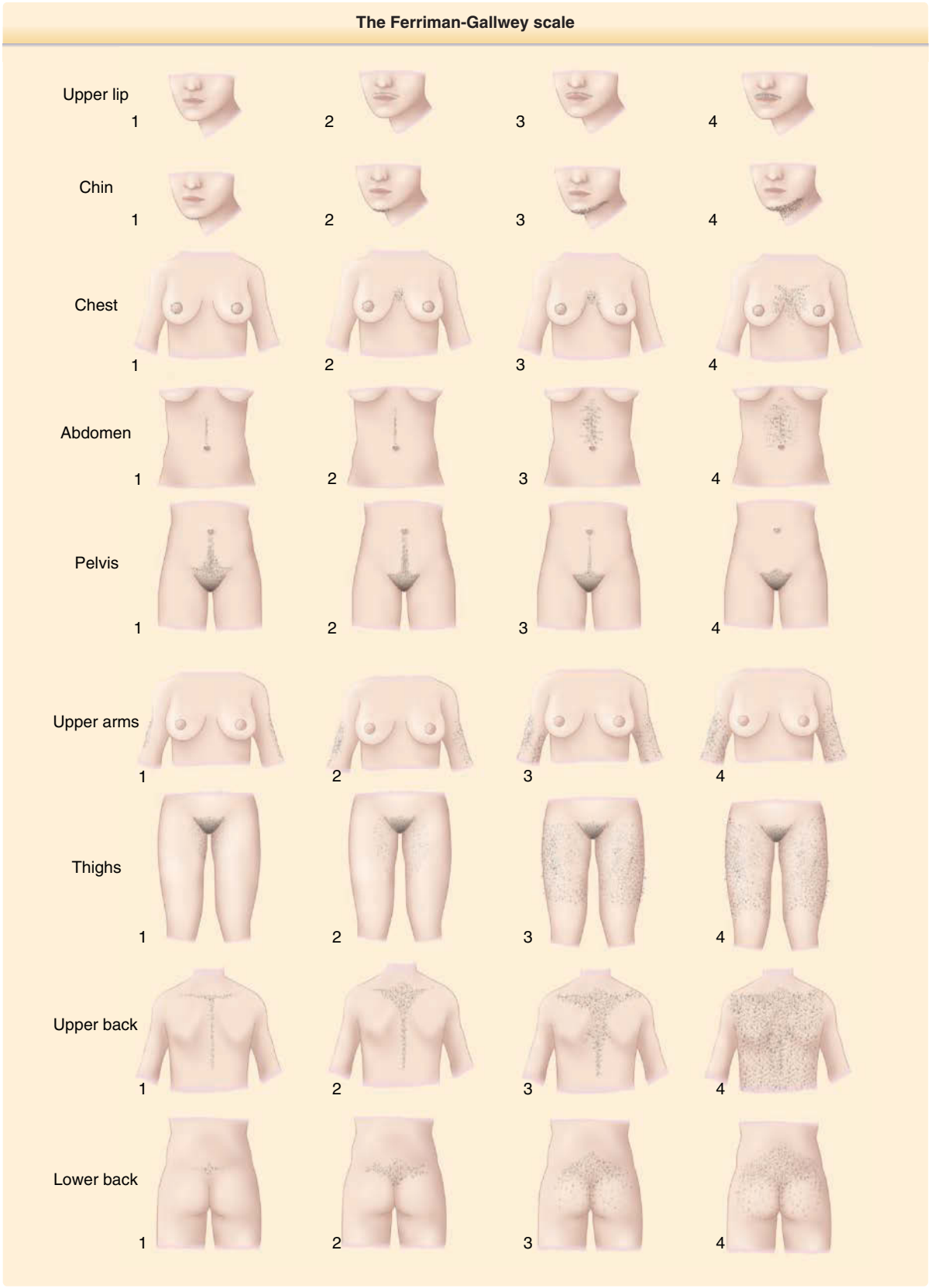

Figure 90-1 The Ferriman-Gallwey scale.

a cut-off score of 3 was able to distinguish hirsute from nonhirsute women with an accuracy of 87.5%.[19]

The diagnosis of hirsutism can be challenging because many physicians are not familiar with the Ferriman and Gallwey scoring scale and, among those who are, discrepancies exist in their interpretation of the scoring value. Furthermore, the diagnostic score varies among different ethnic populations: for example, 2 or 3 or greater for Asians and 9 to 10 or greater for Mediterraneans.[7,20] Also, there is no consensus on how many body regions are to be included in the scoring system. Another challenge is that most patients presenting for evaluation will have used various cosmetic measures to remove excess hair, thus leading to an inaccurate assessment.

Figure 90-3 Hirsutism of the lateral face and jawline in the young woman.

ASSOCIATED CAUSES

IDIOPATHIC HIRSUTISM

Idiopathic hirsutism occurs in a subgroup of hirsute patients who present with hirsutism, regular ovulation, and normal to slightly elevated androgen levels in the absence of features that suggest other causes of hirsutism. Its prevalence is 4% to 7%, and it is a diagnosis of exclusion[21] (Figs. 90-2 and 90-3). The pathogenesis remains unclear. The intrinsic hyperresponsiveness of androgen receptors to normal circulating levels of androgens and increased activity of the 5α-reductase enzyme at the hair follicle are postulated thoeries.[12] The increased local circulation of androgens is caused by increased gene expression of the steroid-converting enzymes 17β-hydroxysteroid dehydrogenase and steroid sulfatase, resulting in decreased levels of estradiol/testosterone.[22]

POLYCYSTIC OVARIAN SYNDROME

Polycystic ovarian syndrome, also known as Stein-Leventhal syndrome after the clinicians who first described the condition, is the most common associated cause of hyperandrogenism in women of reproductive age and is a common secondary cause of hirsutism[23] (Fig. 90-4). The other clinical characteristics of PCOS can include chronic anovulation, insulin resistance, and infertility.[24] Apart from hirsutism, the hyperandrogenic state causes PCOS patients to also present with other cutaneous manifestations, including acne, acanthosis nigricans, alopecia, and seborrheic dermatitis.[25] More than 50% of women with PCOS present with hirsutism that tends to have a more truncal distribution.[26] Alternatively, individuals of certain ethnicities may lack the feature of hirsutism, as in the Asian patient with PCOS.[20,27] PCOS increases the risk of type 2 diabetes mellitus and cardiovascular dysfunction. Both the reproductive and the metabolic manifestations of PCOS are exacerbated by being overweight or obese.[28]

HAIR-AN

A subset of PCOS patients are classified as HAIR-AN because of the presence of hyperandrogenism (HA),

Figure 90-2 Dark terminal hair of the upper lip and chin in a middle-age woman.

Figure 90-4 Hirsutism of the chin with associated pseudofolliculitis barbae.

insulin resistance (IR), and acanthosis nigricans (AN). This syndrome is found in 1% to 5% in women presenting with hyperandrogenism. The underlying cause is associated with insulin resistance with compensatory hyperinsulinemia.[29] The clinical presentation can include various combinations of oily skin, hirsutism, acne, menstrual irregularities, androgenic alopecia, signs of virilization (deepening of voice, clitoromegaly and changes in muscle mass), insulin resistance with diabetic symptoms, as well as acanthosis nigricans.[30] If ovarian biopsy is performed, the most consistent histopathologic finding is islands of hyperplastic theca cells in ovarian stroma known as hyperthecosis, with normal adrenal function. There are reports of association with other autoimmune or endocrine diseases such as Hashimoto thyroiditis, Graves disease, vitiligo, Cushing syndrome, Cohen syndrome, acromegaly, CAH, and insulinoma.[30,31]

SAHA SYNDROME

The constellation of cutaneous manifestations such as seborrhea, acne, hirsutism, and androgenetic alopecia is identified as SAHA syndrome. Apart from seborrhea, which is present in 100% of the cases, the other conditions can be variable in presentation. The condition is further divided into idiopathic, ovarian, adrenal, and hyperprolactinemic types,[32] and it can be associated with PCOS, cystic mastitis, obesity, and infertility. SAHA syndrome is prevalent in 17.7 % of PCOS patients, and this variety of PCOS is associated with greater insulin resistance.[33]

ADRENAL AND OVARIAN HIRSUTISM

Adrenal hyperplasia is associated with a defect in the enzyme responsible for the synthesis of cortisol, which leads to the accumulation of precursors that are diverted into androgen synthesis. Late onset or nonclassic CAH is an autosomal recessive disorder caused by mutations in the *CYP21A2* gene, which causes deficiency in 21 hydroxylases. This results in the defective conversion of 17-hydroxyprogesterone (17-OHP) to 11-deoxycortisol. Rarely, it also can be caused by a deficiency in 11–hydroxylase. It is often diagnosed after the age of 10 years and can present with peripubertal hirsutism, oligomenorrhea, acne, infertility, alopecia, primary amenorrhea, and premature pubarche.[34] An elevated 17-OHP, substrate of 21-hydroxylase, level is the biochemical hallmark of the disease. Increased circulation of ACTH as in Cushing syndrome (pituitary origin) or ectopic origin can also be associated with overstimulation of adrenal androgens production.

Adrenal tumors are a rare cause of hirsutism. Whereas adrenal adenomas secrete testosterone, adrenal carcinomas secrete testosterone, dehydroepiandrosterone sulfate (DHEAS), and cortisol. Symptoms may be acute and quite severe.

Hirsutism with galactorrhea must raise suspicions of hyperprolactinemia. Hyperprolactinemia may be associated with various conditions, either physiological or nonphysiological. Whereas some drugs (phenothiazines, benzodiazepines, and others) as well as prolactinoma, hypothyroidism, or idiopathic hyperprolactinemia are nonphysiological, lactation and stress represent physiological causes.

Apart from PCOS, in women of reproductive age, pregnancy as a possible cause of hirsutism should also be ruled out. The excess androgens produced during pregnancy can be caused by luteoma of pregnancy, hyperreactio luteinalis, or aromatase deficiency in the fetus.

Sertoli-Leydig cell tumors, granulosa-theca cell tumors, and hilus cell tumors are the ovarian tumors known to secrete excess androgens. They have low metastatic potential, and the treatment is surgical.

Hirsutism can also be associated with other endocrinopathies, including acromegaly, hyperprolactinemia, and thyroid dysfunction.

EVALUATION

To determine the cause of hirsutism, a detailed clinical, medication, and family history with physical examination is needed. After diagnosing hirsutism by an increased mFG score, diagnostic studies should focus on identification of the most likely cause (see Table 90-1). Functional causes almost always have a peripubertal onset with slow progression. Signs of virilization such as clitoromegaly or balding or of defeminization such as breast tissue atrophy are extremely rare.[35] Often, the severity of the hirsutism does not correlate well with the magnitude of androgen excess. Signs of infertility with oligo- or amenorrhea, insulin resistance, abdominal obesity, or acanthosis nigricans favor PCOS.

The chronicity of the symptoms may direct the investigation. If the hirsutism is long standing and mild to moderate, testosterone or androstenedione measurements are recommended. Free testosterone is a more sensitive biochemical marker of hyperandrogenism than total testosterone, but as stated earlier, the levels can be normal in women with hirsutism. With sudden onset of hirsutism, with or without virilization or high testosterone levels, other measurement of adrenal marker levels (cortisol and DHEAS) and ovarian and adrenal imaging are highly recommended (Fig. 90-5).

After androgen excess is confirmed, further tests should be considered such as a pregnancy test (if the patient has amenorrhea), pelvic ultrasonography (if an ovarian neoplasm or PCOS is suspected), measurement of DHEAS and early morning 17-OHP (if CAH or adrenal neoplasm is suspected), and a prolactin level. Further testing may also include measurement of thyroid function, adrenocortical function, and insulin-like growth factor 1. Further workup typically begins with dexamethasone suppression testing to determine the source of androgen excess production. If androgen

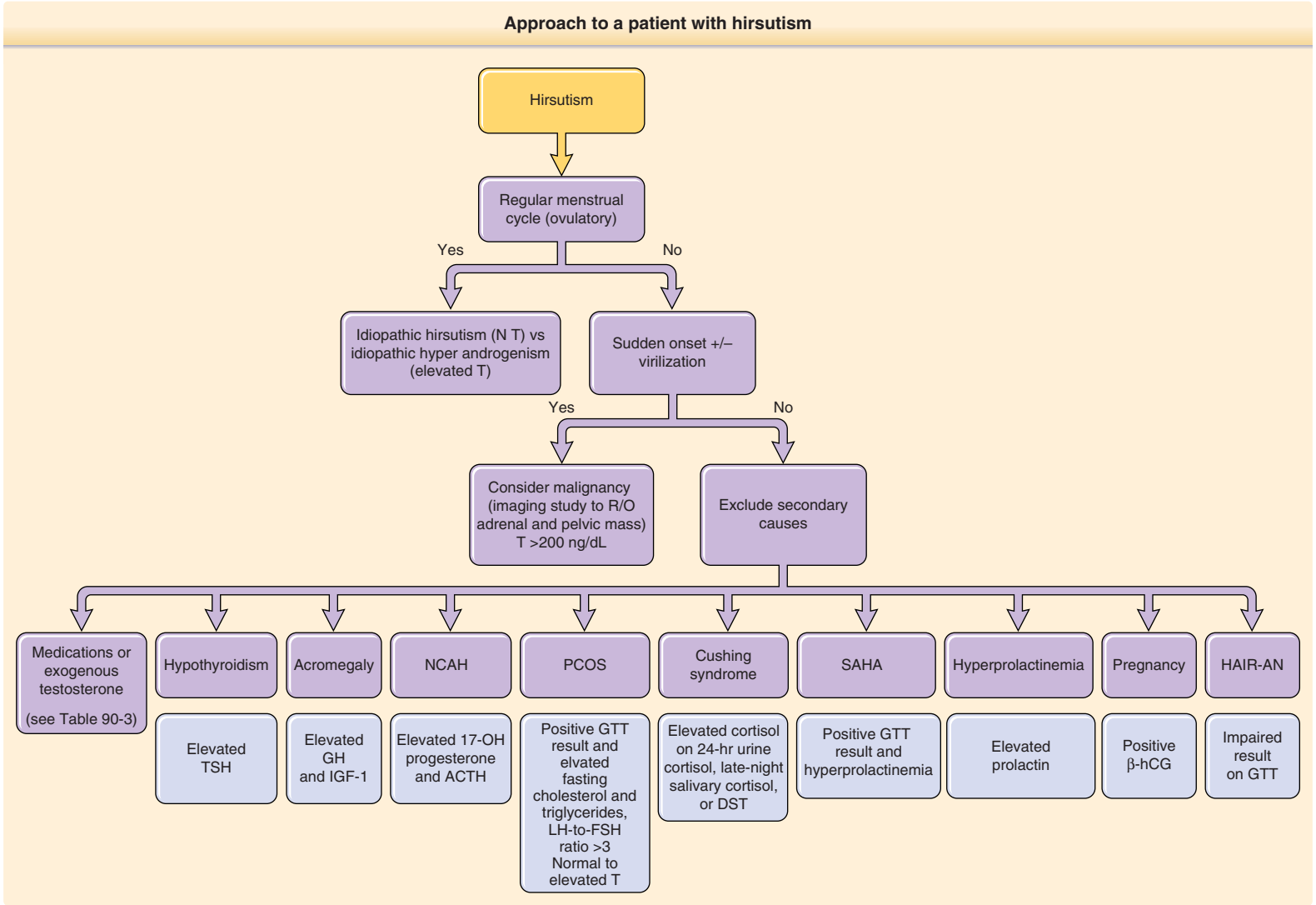

Figure 90-5 Approach to a patient with hirsutism. ACTH, adrenocorticotropic hormone; DST, dexamethasone suppression test; FSH, follicle-stimulating hormone; GH, growth hormone; GTT, glucose tolerance test; HCG, human chorionic gonadotropin; IGF, insulin-like growth factor; LH, luteinizing hormone; NCAH, non-classical adrenal hyperplasia; NT, normal testosterone; PCOS, polycystic ovarian syndrome; R/O, rule out; SAHA, seborrhea, acne, hirsutism, and androgenetic alopecia; 17-OH, 17-hydroxyprogesterone; T, testosterone; TSH, thyroid-stimulating hormone. (Source: References 36 to 38.)

excess is not suppressible by dexamethasone, the presence of Cushing syndrome, neoplasm, and PCOS must be considered. If androgen excess is dexamethasone suppressible, an ACTH test for CAH is indicated. A serum testosterone level greater than 200 ng/dL is highly suggestive of adrenal or ovarian tumor, and further imaging studies may be warranted, such as abdominal computed tomography for adrenal or ovarian neoplasm.

TREATMENTS

The cultural norm of absence of hair as being more desirable in females has driven hirsute women to seek various methods of removing excess body and facial hair. Patients affected by hirsutism have lower quality of life and symptoms of both anxiety and depression.[39] Along with treatment options directed at excess unwanted hair, patients should be evaluated for their social support, and psychological treatment should be offered when necessary.[39,40] Before the onset of therapy, it is important to advise patients that treatment will never be curative, and the effects of any drug or treatment will not likely become evident for several months; thus, chronic treatment will be necessary.[7]

The major treatment options can be categorized as physical modalities that are patient administered, such as shaving and depilation, versus physician- or aesthetician-directed therapy such as oral medications, electrolysis, and laser therapy (Table 90-2). The pharmacologic strategies aim to control the dermatologic symptoms by both lowering androgen levels and controlling the effect of androgens at the tissue level. Lifestyle modification with weight loss and diet changes in patients with PCOS may improve insulin resistance,[44] menstrual regularity, and hirsutism score.[45]

Direct hair removal can be achieved with nonpermanent techniques such as shaving, depilatories (last 12 hours to a few days), waxing, threading and sugaring (last up to 4 weeks), and photoepilation (intense pulsed light), or permanent hair reduction techniques such as electrolysis and laser (photodestruction). Bleaching hair in the affected areas to a similar color as the skin is a form of camouflage used to make hair less obvious. In patients with moderate to severe hirsutism and women with androgen excess, additional medical therapy may be necessary.

There is only one prescription medication that is approved for the treatment of unwanted facial hair in women. This drug, topical eflornithine, has been shown to slow down the hair growth cycle and can be used in combination with other hair removal techniques. Eflornithine works through inhibiting ornithine decarboxylase, which results in a shortening of the anagen phase of the hair growth cycle. The major adverse effects of topical eflornithine are burning or tingling of the treated area.

First-line medical therapy of hirsutism is oral contraceptives (OCPs), usually in combination with antiandrogens, such as spironolactone and flutamide. Studies with oral ethinyl-estradiol plus cyproterone acetate showed this combination to be superior at control of hyperandrogenism and for the restoration of menstrual regularity in patients with PCOS compared with metformin alone in PCOS patients.[46] In studies in which various forms of oral antiandrogens were compared, the effectiveness of finasteride, cyproterone acetate, and flutamide were shown to be equally effective in decreasing hirsutism.[47] Glucocorticoids can be considered for women with hirsutism caused by nonclassic CAH who have a suboptimal response to or cannot tolerate oral contraceptives or antiandrogens or who are seeking ovulation induction. In women with severe forms of hyperandrogenemia, such as ovarian hyperthecosis, who have a suboptimal response to oral contraceptives and antiandrogens, gonadotropin-releasing hormone (GnRH) agonists can also be considered. Although the benefit of such therapy can be maintained long term, the initial response may not be evident until 6 to 12 months after the start of therapy. Therefore, to manage patient expectations and to emphasize the importance of maintaining chronic long-term treatment, patients must be made aware of slow clinical response of oral therapies and be followed closely by trained physicians.[35]

ANDROGEN SUPPRESSION

The androgenic symptoms that may be attenuated by OCPs treatment include hirsutism and acne, primarily through the ability of OCPs to raise sex hormone–binding globulin and lower free testosterone levels. When treating mild to moderate alopecia or hirsutism, combination with an androgen antagonist should be considered as OCPs as monotherapy are not very effective. OCPs containing the second-generation progestin levonorgestrel have been associated with lower venous thromboembolic risk than those containing other progestins.[48] When combined with estrogen, Leuprolide, a long-acting GnRH analog, has been shown to decrease hirsutism significantly over OCPs alone,[49] and this benefit was greater in PCOS than in idiopathic hirsutism.[36]

The biological activity of androgens can also be inhibited by androgen receptor blockers. Antiandrogens (cyproterone acetate, chlormadinone acetate, drospirenone, spironolactone, flutamide, and bicalutamide) prevent androgen cellular action by blocking intracellular androgen receptors.[50,51] Cyproterone acetate and chlormadinone acetate block androgen receptors in target organs (ovaries and adrenal gland) but also reduce 5α-reductase, which converts testosterone to 5α-dihydrotestosterone, a more potent androgen. Cyproterone acetate has steroidal side effects and can cause abnormalities in liver function and menstrual irregularity. Because of its progestin activity, it needs to be combined with estrogens in women who have a uterus.

Spironolactone, a potassium-sparing diuretic that acts as an aldosterone antagonist, is the most studied of the androgen receptor blockers for hirsutism. Because of its androgen-antagonizing activity, it is also

TABLE 90-2
Pharmacologic Treatment of Hirsutism

	MECHANISM OF ACTION	DOSAGE	ADVERSE EFFECTS	COMMENTS
Oral contraceptive pills (OCPs)	Suppress ovarian androgen synthesis Increase SHBG	Single pill a day	Headaches Migraines Risk of VTE Melasma Alopecia (upon discontinuation)	First-line therapy (in women not seeking to conceive) Contradictions: ▪ Uncontrolled HTN ▪ Thromboembolic disorder ▪ Breast cancer ▪ Active smoker (absolutely if older than 35 yr) ▪ Cardiovascular disease
Spironolactone	Competitive inhibitor of AR and 5α-reductase Increases SHBG Decreases androgen synthesis	Starting dosage is 50 mg twice daily and may be increased to a total daily dose of 200 mg	Polyuria Hypotension Headaches Fatigue Syncope Hyperkalemia Irregular menses Teratogen Decreased libido	Avoid combination with other potassium-sparing diuretics and thiazides Contraindicated in patients with renal failure Recommend combination with OCPs Pregnancy Category C
Cyproterone acetate	Competes with DHT for binding to the androgen receptor	Low dose (2 mg) in OCPs 12.5–100 mg as monotherapy or with estrogen	Fluid retention Depression Menstrual irregularities Teratogen Increased risk of liver dysfunction	Not available in the United States Contraindicated during pregnancy and breastfeeding and with liver diseases
Flutamide and bicalutamide	Nonsteroidal competitive inhibitor of androgen receptor binding	Flutamide: 62.5–250mg, twice daily Bicalutamide: 25 mg/day	Teratogen Hepatotoxicity Diarrhea Nausea Vomiting	Recommend combination with OCPs Pregnancy Category D
Glucocorticoids	Suppress adrenal function	Prednisone: 5-7.5 mg by mouth at bedtime Dexamethasone: 0.5 mg at bedtime	Hyperglycemia Hypertension Cushingoid changes Esophageal reflux and peptic ulcer disease Psychosis and agitation Increased risk of infections Adrenal suppression	Indicated for hirsutism secondary to CAH Not recommended in patients with uncontrolled diabetes and hypertension When used as monotherapy, does not significantly improve hirsutism Pregnancy Category C
GnRH agonist (Leuprolide acetate, depot suspension)	Suppresses gonadotropin and ovarian androgen secretion	7.5 mg monthly intramuscularly, with 25–50 ug of transdermal estradiol	Osteoporosis if not combined with estrogen–progestin	Pregnancy Category X
Ketoconazole	Cytochrome P450 enzyme inhibitor and decreases adrenal steroid production	400–600 mg by mouth daily	Headache Nausea Hair loss	Pregnancy Category C
Finasteride	Inhibits 5α-reductase	1–5 mg by mouth	Headaches Decreased libido	Pregnancy Category X
Metformin	Insulin-sensitizing agent	850 mg twice a day or 500 mg three times a day	Rare lactic acidosis GI distress	Must ensure normal renal function before starting Pregnancy Category B

AR, androgen receptor; CAH, congenital adrenal hyperplasia; GI, gastrointestinal; GnRH, gonadotropin-releasing hormone; HTN, hypertension; SHBG, sex hormone–binding globulin; VTE, venous thromboembolic event.
Data from Refs. 38 and 41 to 43.

used as a therapeutic modality in androgenetic alopecia in postmenopausal women. It is usually administered in conjunction with OCPs to help to minimize the dysfunctional uterine bleeding that is one of the major side effects of this medication. The beneficial effect may take up to 6 months to observe.

Flutamide is used in dosages of 62.5 to 500 mg/day. Because liver toxicity is a potential side effect, serum transaminases should be measured frequently. Other side effects that have been reported include dry skin, diarrhea, nausea, and vomiting.

Bicalutamide (a dosage of 25 mg/day) is a new and potent, well-tolerated nonsteroidal pure antiandrogen. It was developed for treating prostate cancer. It has been shown effective in the treatment of patients with PCOS-induced and idiopathic hirsutism.[52] However, hepatotoxic effects in the treatment of prostate cancer have been reported starting at doses of 50 mg/day.[53]

The oral medications finasteride and dutasteride, both 5α-reductase inhibitors, may improve hirsutism by antagonizing the production or biological activity of DHT.

ELECTROLYSIS AND LASERS

Electrolysis and laser hair reduction are the only hair removal methods that may provide permanent hair reduction or long-lasting results. Electrolysis uses a fine needle insertion into individual follicles to destroy the hair follicle via current (galvanic electrolysis), a high-frequency alternating current (thermolysis), or a blend of the two.[54] Major disadvantages of this technique include potential scarring, follicular hyperpigmentation, and pain. Because this technique is time consuming, especially with extensive hair growth, and requires a well-trained operator, it can become costly. The regrowth rate of hair with this technique is approximately 40%.[50]

There have recently been major advances in the field of laser hair removal. Laser treatments remove dark hair quickly through photothermolysis by selectively damaging the pigmented part of the hair follicle. It may take 3 to 6 months before regrowth is evident. Several treatment cycles are required with the spacing between treatments depending on the body area being treated. The most commonly used devices are 755-nm alexandrite laser, 800-nm diode laser, and 1064-nm Nd:YAG (neodymium-doped yttrium aluminum garnet) laser and intense pulsed light sources.[55] Laser treatments are less painful and much quicker than electrolysis. Electrolysis is the favored method of treatment for lightly pigmented hair because only anagen hair follicles with dark bulb areas can be destroyed by the light source of laser. The major adverse effects of laser and intense pulsed light include postinflammatory pigmentary change, folliculitis, reactivation of herpes simplex, and paradoxical hypertrichosis, although these are all rare complications when laser is performed by properly trained providers.

HYPERTRICHOSIS

AT-A-GLANCE

- Hypertrichosis is defined as hair growth that is excessive in a localized or diffuse pattern not considered to be in a male pattern distribution.
- The hair growth in hypertrichosis can be lanugo, vellus, or terminal.
- Many genetic syndromes have hypertrichosis as a common finding.
- Metabolic disorders and medications can contribute to the development of hypertrichosis.
- Therapy should always consist of direct hair removal with or without medical therapy.

INTRODUCTION

Hypertrichosis is defined as hair growth that is considered excessive for age, sex, or ethnicity in areas of the body not considered to be in a pattern of male secondary characteristic. However, it can be seen in both sexual and nonsexual areas.[56] Hypertrichosis can be congenital or acquired, and causes include familial factors, medications, and metabolic disorders.[57] The hair types seen in hypertrichosis can be lanugo, vellus, or terminal.

CONGENITAL FORMS OF HYPERTRICHOSIS

Congenital forms of hypertrichosis can be localized or diffuse (Table 90-3). The generalized (diffuse) forms tend to occur as a secondary characteristic in a number of well-described syndromes except in the four cases in which the syndrome is defined by the condition of hypertrichosis. The hypertrichosis-defined conditions are congenital hypertrichosis lanuginosa (CHL) and congenital generalized hypertrichosis, osteochondrodysplasia with hypertrichosis (also known as Cantú syndrome), and gingival fibromatosis with hypertrichosis.

Congenital hypertrichosis lanuginosa, at times controversially referred to as Ambras syndrome, is a rare, inherited disorder in which an excess of lanugo hair remains over the entire body after birth or may develop in the first few months of life.[58] Only the palms, soles, mucous membranes, and glans penis are spared. Some of these patients lose the hair during childhood, but others retain the excess body hair. The disease is very rare with the first reports appearing in the German literature in the 1870s, approximately 50 cases reported in the current world literature, and an estimated incidence of 1 in 10,000,000.[59,60] CHL is associated with genetic abnormalities in chromosome 8q

TABLE 90-3
Causes of Hypertrichosis

ETIOLOGY	SPECIFIC DISORDERS
Congenital Disorders	
Diffuse	Congenital hypertrichosis lanuginosa
	Congenital generalized hypertrichosis
	Cantú syndrome
	Gingival fibromatosis with hypertrichosis
	Congenital syndromes with secondary hypertrichosis
	▪ Cornelia de Lange syndrome
	▪ Mucopolysaccharidosis disorders
	▪ Hurler Syndrome
	▪ Hunter Syndrome
	▪ Sanfilippo Syndrome
	▪ Stiff skin syndrome
Localized	▪ Winchester syndrome
	▪ Rubinstein-Taybi syndrome
	▪ Schinzel-Giedion syndrome
	▪ Barber-Say syndrome
	▪ Coffin-Siris syndrome
	▪ Lawrence-Seip syndrome
	▪ Hemimaxillofacial dysplasia
	▪ Craniofacial dysostosis
	▪ Hypomelanosis of Ito
	Spinal dysraphism
	Faun tail deformity
	Congenital nevocellular nevus
	Congenital Becker nevus
	Smooth muscle hamartoma
	Nevoid hypertrichosis
	Underlying neurofibroma
	Hypertrichosis cubiti
	Hemihypertrophy
	Hairy congenital malformation of palms and soles
	Hairy pinnae
	Anterior cervical hypertrichosis
Metabolic Disorders	Thyroid disorders
	Anorexia nervosa
	Porphyria
	Malignancy
	Fetal alcohol syndrome
	Malnutrition
Medications	Dilantin
	Cyclosporine
	Glucocorticoids
	Minoxidil
	Diazoxide
	Phenytoin
	Anabolic steroids
	Danazol
	Penicillamine
	Psoralens
	Streptomycin
	Isotretinoin
	Cetuximab
	Testosterone
	Valproic acid.
	Topical prostaglandin inhibitors
Other Acquired	Post-laser hair removal
	Local pressure or inflammation: casts, lichen simplex, biting, insect bites
	Human immunodeficiency virus: trichomegaly
	Acrodynia
	Infection
	Dermatomyositis

(insertion 8q23-24 and deletion 8q23), although other chromosomal abnormalities have been reported.[61]

Congenital generalized hypertrichosis is similar to CHL in presentation but with terminal hair growth on the body instead of lanugo hair. Only one family has been reported in the literature with this disorder, which is thought to be X-linked with gene mapping to X24-q27.1.[62,63]

Osteochondrodysplasia with hypertrichosis (Cantú syndrome) is an autosomal dominant disorder characterized by newborns with thick scalp hair and excessive hair growth on the forehead, face, back, and extremities. Some have thick or curly eyelashes. The hypertrichosis usually persists over time. Associated findings include skeletal abnormalities and a variety of cardiac abnormalities.[64] The diagnosis is established based on clinical findings and confirmed by detection of a heterozygous pathogenic variant in *ABCC9* or *KCNJ8*.[65,66]

Gingival fibromatosis with hypertrichosis is a rare genetic syndrome characterized by severe overgrowth of the hair and gums.[67,68] Seizures have been reported as part of the syndrome.[69] Overlap of the characteristics of this condition with other syndromes have been reported, making the diagnosis of this form of hypertrichosis complicated.[70]

Of the syndromes in which hypertrichosis is a secondary characteristic, the most commonly reported is Cornelia de Lange syndrome, also known as Brachmann-de Lange syndrome. It is characterized by severe mental retardation, cutis marmorata, frequent limb abnormalities, and characteristic facial features (micrognathia, high palate, low frontal hair line) with the hypertrichosis most prominent as thickened convergent (synophrys) eyebrows with hypertrichotic eyelashes.[71,72]

The most commonly reported genetic cause of Cornelia De Lange syndrome is a mutation in *NIPBL*, which accounts for up to 80% of cases, although other gene mutations have been reported to account for the rest of the cases. All the causative genes for this disorder are thought to encode proteins related to cohesion complex function.[73,74]

The mucopolysaccharidoses (MPS) are a constellation of disorders that result from a deficiency of lysosomal enzymes responsible for glycosaminoglycan metabolism. Several of the MPS are considered to have associated hypertrichosis: Hurler syndrome, Hunter syndrome, and Sanfilippo syndrome.[75]

Other less common syndromes with the secondary characteristic of diffuse hypertrichosis are listed in Table 90-3.

LOCALIZED CONGENITAL HYPERTRICHOSIS

Congenital hypertrichoses localized to a single body part include hypertrichosis cubiti (hairy elbows), hairy pinna, anterior cervical hypertrichosis, hairy polythelia (hair tufts along the mammary line), overlying plexiform neurofibromas with spinal dysraphism (when

presenting over the sacral midline, it is called "faun tail deformity") in association with congenital nevi, and occasionally in association with Becker nevi.[76] They can be present at birth or soon thereafter, but many of these disorders present later in childhood.[77] When any of these disorders are found in the midline, it is imperative to look for underlying neurologic deficits and spinal deformities.[78]

OTHER ACQUIRED FORMS OF HYPERTRICHOSIS

There is a long list of medications that can cause hypertrichosis (see Table 90-3), so a full medical history can easily identify the culprit (Fig. 90-6). Porphyria and other metabolic disorders are important forms of acquired hypertrichosis. The most common porphyrias to cause hypertrichosis are porphyria cutanea tarda and erythropoietic porphyria (Gunther disease), but hereditary coproporphyria and variegate porphyria may produce excessive hair growth as well.[79]

TREATMENT

The treatment of hypertrichosis mirrors that of hirsutism. The general approach to treatment will differ based on the patient age, ethnicity, and extent of hair.[80] For situations when there is an underlying metabolic process or a medication is involved, the underlying cause should be addressed. For other conditions in which the hair is persistent, treatments can be divided into depilatory methods (removal of hair along the hair shaft) and epilatory methods (removal of the entire hair shaft including the hair bulb).[75] Depilatory methods include mechanical and chemical methods of removal, such as shaving, waxing, sugaring, threading, tweezing, and chemical depilation. These methods are all temporizing and can produce mild to moderate pain or irritation of the treated skin.

Figure 90-6 Hypertrichosis of the forehead in a patient applying topical minoxidil to the scalp.

For more permanent hair removal, electrolysis and laser can be used. Although permanent hair reduction has improved in efficacy over the past 2 decades, the achievement of complete permanent hair removal remains elusive. Electrolysis for extensive cases can be time consuming, and appropriately trained operators can be difficult to find.[81]

Laser hair reduction has been used successfully in treating various forms of hypertrichosis but can also be time consuming and expensive.[82,83]

Laser hair epilation can rarely lead to paradoxical hypertrichosis, so this must be considered as well.[84]

When considering recommendations for hair removal, it is important to underscore the possibility of injury with both in-the-home and professionally performed treatments. Between the years 1994 and 2014, there were nearly 300,000 hair removal–related injuries seen in U.S. emergency departments. There were nearly equal numbers of men and women presenting for injuries, with 60% of the injuries occurring at home. Because this study only examined the injuries severe enough to present for treatment and tabulated only injuries caused by scissors, clippers, and razors, it is likely that hair-removal injury rates are actually much higher than reported.[85]

REFERENCES

1. Lipton MG, Sherr L, Elford J, et al. Women living with facial hair: the psychological and behavioral burden. *J Psychosom Res*. 2006;61(2):161-168.
2. Keegan A, Liao LM, Boyle M. "Hirsutism": a psychological analysis. *J Health Psychol*. 2003;8(3):327-345.
3. Pasch L, He SY, Huddleston H, et al. Clinician vs self-ratings of hirsutism in patients with polycystic ovarian syndrome: associations with quality of life and depression. *JAMA Dermatol*. 2016;152(7):783-738.
4. Knochenhauer ES, Key TJ, Kahsar-Miller M, et al. Prevalence of the polycystic ovary syndrome in unselected black and white women of the southeastern United States: a prospective study. *J Clin Endocrinol Metab*. 1998;83(9):3078-3082.
5. Azziz R. The evaluation and management of hirsutism. *Obstet Gynecol*. 2003;101(5 Pt 1):995-1007.
6. Cheewadhanaraks S, Peeyananjarassri K, Choksuchat C. Clinical diagnosis of hirsutism in Thai women. *J Med Assoc Thai*. 2004;87(5):459-463.
7. Escobar-Morreale HF, Carmina E, Dewailly D, et al. Epidemiology, diagnosis and management of hirsutism: a consensus statement by the Androgen Excess and Polycystic Ovary Syndrome Society. *Hum Reprod Update*. 2012;18(2):146-170.
8. Javorsky E, Perkins AC, Hillebrand G, et al. Race, rather than skin pigmentation, predicts facial hair growth in women. *J Clin Aesthet Dermatol*. 2014;7(5):24-26.
9. DeUgarte CM, Woods KS, Bartolucci AA, et al. Degree of facial and body terminal hair growth in unselected black and white women: toward a populational definition of hirsutism. *J Clin Endocrinol Metab*. 2006;91(4):1345-1350.

10. Li R, Qiao J, Yang D, et al. Epidemiology of hirsutism among women of reproductive age in the community: a simplified scoring system. *Eur J Obstet Gynecol Reprod Biol*. 2012;163(2):165-169.
11. Breitkopf T, Leung G, Yu M, et al. The basic science of hair biology: what are the causal mechanisms for the disordered hair follicle? *Dermatol Clin*. 2013;31(1):1-19.
12. Azziz R, Carmina E, Sawaya ME. Idiopathic hirsutism. *Endocr Rev*. 2000;21(4):347-362.
13. Azziz R, Sanchez LA, Knochenhauer ES, et al. Androgen excess in women: experience with over 1000 consecutive patients. *J Clin Endocrinol Metab*. 2004; 89(2):453-462.
14. Wong M, Zhao X, Hong Y, et al. Semiquantitative assessment of hirsutism in 850 PCOS patients and 2,988 controls in China. *Endokrynol Pol*. 2014;65(5):365-370.
15. Ferriman D, Gallwey JD. Clinical assessment of body hair growth in women. *J Clin Endocrinol Metab*. 1961; 21:1440-1447.
16. Hatch R, Rosenfield RL, Kim MH, et al. Hirsutism: implications, etiology, and management. *Am J Obstet Gynecol*. 1981;140(7):815-830.
17. Minooee S, Ramezani Tehrani F, Azizi F. Hirsutism region and the likelihood of metabolic syndrome: is there a link? *Endocrine*. 2016;53(2):607-609.
18. Bode D, Seehusen DA, Baird D. Hirsutism in women. *Am Fam Physician*. 2012;85(4):373-380.
19. Cook H, Brennan K, Azziz R. Reanalyzing the modified Ferriman-Gallwey score: is there a simpler method for assessing the extent of hirsutism? *Fertil Steril*. 2011; 96(5):1266-1270.e1261.
20. Huang Z, Yong EL. Ethnic differences: is there an Asian phenotype for polycystic ovarian syndrome? *Best Pract Res Clin Obstet Gynaecol*. 2016;37:46-55.
21. Carmina E, Rosato F, Janni A, et al. Extensive clinical experience: relative prevalence of different androgen excess disorders in 950 women referred because of clinical hyperandrogenism. *J Clin Endocrinol Metab*. 2006;91(1):2-6.
22. Taheri S, Zararsiz G, Karaburgu S, et al. Is idiopathic hirsutism (IH) really idiopathic? mRNA expressions of skin steroidogenic enzymes in women with IH. *Eur J Endocrinol*. 2015;173(4):447-454.
23. Housman E, Reynolds RV. Polycystic ovary syndrome: a review for dermatologists: part I. Diagnosis and manifestations. *J Am Acad Dermatol*. 2014;71(5): 847, e841-847, e810; quiz 857-848.
24. Falsetti L, Gambera A, Andrico S, et al. Acne and hirsutism in polycystic ovary syndrome: clinical, endocrine-metabolic and ultrasonographic differences. *Gynecol Endocrinol*. 2002;16(4):275-284.
25. Lee AT, Zane LT. Dermatologic manifestations of polycystic ovary syndrome. *Am J Clin Dermatol*. 2007; 8(4):201-219.
26. Schmidt TH, Khanijow K, Cedars MI, et al. Cutaneous findings and systemic associations in women with polycystic ovary syndrome. *JAMA Dermatol*. 2016; 152(4):391-398.
27. Carmina E, Koyama T, Chang L, et al. Does ethnicity influence the prevalence of adrenal hyperandrogenism and insulin resistance in polycystic ovary syndrome? *Am J Obstet Gynecol*. 1992;167(6):1807-1812.
28. Jayasena CN, Franks S. The management of patients with polycystic ovary syndrome. *Nat Rev Endocrinol*. 2014;10(10):624-636.
29. Amesse LS, Ding X, Pfaff-Amesse T. From HAIR-AN to eternity. *J Pediatr Adolesc Gynecol*. 2002;15(4):235-240.
30. Elmer KB, George RM. HAIR-AN syndrome: a multisystem challenge. *Am Fam Physician*. 2001;63(12): 2385-2390.
31. Chen W, Obermayer-Pietsch B, Hong JB, et al. Acne-associated syndromes: models for better understanding of acne pathogenesis. *J Eur Acad Dermatol Venereol*. 2011;25(6):637-646.
32. Orfanos CE, Adler YD, Zouboulis CC. The SAHA syndrome. *Horm Res*. 2000;54(5-6):251-258.
33. Dalamaga M, Papadavid E, Basios G, et al. Ovarian SAHA syndrome is associated with a more insulin-resistant profile and represents an independent risk factor for glucose abnormalities in women with polycystic ovary syndrome: a prospective controlled study. *J Am Acad Dermatol*. 2013;69(6):922-930.
34. Bidet M, Bellanne-Chantelot C, Galand-Portier MB, et al. Clinical and molecular characterization of a cohort of 161 unrelated women with nonclassical congenital adrenal hyperplasia due to 21-hydroxylase deficiency and 330 family members. *J Clin Endocrinol Metab*. 2009;94(5):1570-1578.
35. Escobar-Morreale HF. Diagnosis and management of hirsutism. *Ann N Y Acad Sci*. 2010;1205:166-174.
36. Falsetti L, Pasinetti E. Treatment of moderate and severe hirsutism by gonadotropin-releasing hormone agonists in women with polycystic ovary syndrome and idiopathic hirsutism. *Fertil Steril*. 1994;61(5): 817-822.
37. Ramezani Tehrani F, Behboudi-Gandevani S, Simbar M, et al. A population-based study of the relationship between idiopathic hirsutism and metabolic disturbances. *J Endocrinol Invest*. 2015;38(2):155-162.
38. Rosenfield RL. Clinical practice. Hirsutism. *N Engl J Med*. 2005;353(24):2578-2588.
39. Ekback MP, Lindberg M, Benzein E, et al. Health-related quality of life, depression and anxiety correlate with the degree of hirsutism. *Dermatology*. 2013; 227(3):278-284.
40. Ekback MP, Lindberg M, Benzein E, et al. Social support: an important factor for quality of life in women with hirsutism. *Health Qual Life Outcomes*. 2014;12:183.
41. Schmidt TH, Shinkai K. Evidence-based approach to cutaneous hyperandrogenism in women. *J Am Acad Dermatol*. 2015;73(4):672-690.
42. Akalin S. Effects of ketoconazole in hirsute women. *Acta Endocrinol*. 1991;124(1):19-22.
43. Isik AZ, Gokmen O, Zeyneloglu HB, et al. Low dose ketoconazole is an effective and a relatively safe alternative in the treatment of hirsutism. *Aust N Z J Obstet Gynaecol.* 1996;36(4):487-489.
44. Lizneva D, Gavrilova-Jordan L, Walker W, et al. Androgen excess: investigations and management. *Best Pract Res Clin Obstet Gynaecol*. 2016;37:98-118.
45. Marzouk TM, Sayed Ahmed WA. Effect of dietary weight loss on menstrual regularity in obese young adult women with polycystic ovary syndrome. *J Pediatr Adolesc Gynecol*. 2015;28(6):457-461.
46. Luque-Ramirez M, Alvarez-Blasco F, Botella-Carretero JI, et al. Comparison of ethinyl-estradiol plus cyproterone acetate versus metformin effects on classic metabolic cardiovascular risk factors in women with the polycystic ovary syndrome. *J Clin Endocrinol Metab*. 2007;92(7):2453-2461.
47. Fruzzetti F, Bersi C, Parrini D, et al. Treatment of hirsutism: comparisons between different antiandrogens with central and peripheral effects. *Fertil Steril*. 1999;71(3):445-451.

48. Evans G, Sutton EL. Oral contraception. *Med Clin North Am*. 2015;99(3):479-503.
49. Azziz R, Ochoa TM, Bradley EL Jr, et al. Leuprolide and estrogen versus oral contraceptive pills for the treatment of hirsutism: a prospective randomized study. *J Clin Endocrinol Metab*. 1995;80(12):3406-3411.
50. Blume-Peytavi U. How to diagnose and treat medically women with excessive hair. *Dermatol Clin*. 2013; 31(1):57-65.
51. Blume-Peytavi U, Hahn S. Medical treatment of hirsutism. *Dermatol Ther*. 2008;21:329-339.
52. Muderris II, Bayram F, Ozcelik B, et al. New alternative treatment in hirsutism: bicalutamide 25 mg/day. *Gynecol Endocrinol*. 2002;16(1):63-66.
53. Hussain S, Haider A, Bloom RE, et al. Bicalutamide-induced hepatotoxicity: a rare adverse effect. *Am J Case Rep*. 2014;15:266-270.
54. Kercher KR, McMichael AJ. Hirsutism and hypertrichosis. In: McMichael A, Hordinsky MK, eds. Hair and Scalp Diseases: Medical, Surgical, and Cosmetic Treatments.: New York: Informa Healthcare; 2008:218.
55. Gan SD, Graber EM. Laser hair removal: a review. *Dermatol Surg*. 2013;39(6):823-838.
56. Deplewski D, Rosenfield RL. Role of hormones in pilosebaceous unit development. *Endocr Rev*. 2000; 21(4):363.
57. Pavone P, Practico AD, Falsaperla R, et al. Congenital generalized hypertrichosis: the skin as a clue to complex malformation syndromes. *Ital J Pediatr*. 2015; 41-55.
58. Chen W, Ring J, Happle R. Congenital generalized hypertrichosis terminalis:a proposed classification and a plea to avoid the ambiguous term "Ambras syndrome." *Eur J Dermatol*. 2015;25(3):223-227.
59. Silveira LM, Ramos AN, Amaral IR, et al. Do you know this syndrome? *An Bras Dermatol*. 2013;88(3):473-475.
60. Shah IH, Zeerak S, Sajad P, et al. Congenital hypertrichosis lanuginose. *Indian J Dermatol Venereol Leprol*. 2018;84:248.
61. Tadin M, Braverman E, Cianfarani S, et al. Complex cytogenetic rearrangement of chromosome 8q in a case of Ambras syndrome. *Am J Med Genet*. 2001;102:100-104.
62. Tadin-Strapps M, Salas-Alanis JC, Moreno L, et al. Congenital universal hypertrichosis with deafness and dental anomalies inherited as an X-linked trait. *Clin Genet*. 2003;63(5):418-22.
63. DeStefano GM, Fantauzzo KA, Petukhova L, et al. Position effect on FGF13 associated with X-linked congenital generalized hypertrichosis. *Proc Natl Acad Sci U S A*. 2013;110(19):7790-5.
64. Grange DK, Nichols CG, Singh GK. Cantú syndrome and related disorders. In: Adam MP, Ardinger HH, Pagon RA, et al, eds. *GeneReviews*. Seattle, University of Washington, Seattle; 2014.
65. van Bon BW, Gilissen C, Grange DK, et al. Cantú syndrome is caused by mutations in ABCC9. *Am J Hum Genet*. 2012;90(6):1094-1101.
66. Cooper PE, Reutter H, Woelfle J, et al. Cantú syndrome resulting from activating mutation in the KCNJ8 gene. *Human Mutat*. 2014;35(7):809-813.
67. Balaji P, Balaji SM. Gingival fibromatosis with hypertrichosis syndrome: case series of rare syndrome. *Indian J Dent Res*. 2017;28(4):457-460.
68. Ishita A, Sujatha GP, Pramod GV, et al. Ambras syndrome: a rare case report. *J Indian Soc Pedod Prev Dent*. 2016;34:189-189.
69. Snyder CH. Syndrome of gingival hyperplasia, hirsutism, and convulsions. *J Pediatr*. 1965;67:499-502.
70. Lacombe D, Bioulac-Sage P, Sibout M, et al. Congenital marked hypertrichosis and Laband syndrome in a child: overlap between the gingival fibromatosis-hypertrichosis and Laband syndromes. *Genet Couns*. 1994;5(3):251-256.
71. De Lange C. Sur un type nouveau de generation (Typus amstelodamensis). *Arch Med Enfant*. 1933;36:713.
72. Salazar FN. Dermatological manifestations of the Cornelia de Lange syndrome. *Arch Dermatol*. 1966; 94(1):38-43.
74. Krantz ID, McCallum J, DeScipio C, et al. Cornelia de Lange syndrome is caused by mutations in NIBPL, the human homolog of *Drosophila melanogaster* Nipped-B. *Nat Genet*. 2004;36(6):631-635
74. Huisman SA, Redeker EJW, Maas SM, et al. High rate of mosaicism in individuals with Cornelia de Lange syndrome. *J Med Genet*. 2013;50(5):339-344.
75. Wendelin DS, Pope DN, Mallory S. Hypertrichosis. *J Am Acad Dermatol* 2003;48:161-179.
76. Guggisberg D, Hadj-Rabia S, Viney C, et al. Skin markers of occult spinal dysraphism in children: a review of 54 cases. *Arch Dermatol*. 2004;140(9):1109-1115.
77. Vashi RA, Mancini AJ, Paller AS. Primary generalized and localized hypertrichosis in children. *Arch Dermatol*. 2001;137(7):877-884.
78. Olsen E. Hypertrichosis. In: Olsen E, ed. Disorders of Hair Growth: Diagnosis and Treatment. New York: McGraw-Hill;1993:326-329.
79. Grossman ME, Bickers DR, Poh-Fitzpatrick MB, et al. Porphyria cutea tarda. Clinical features and laboratory findings in 40 patients. *Am J Med*. 1979;67(2):277-286.
80. Vachiramon V, McMichael AJ. Laser hair removal in ethnic skin: principles and practical aspects. *J Drugs Dermatol*. 2011;10(12 suppl):S17-S19.
81. Ellis FA. Electrolysis versus high frequency currents in the treatment of hypertrichosis: a comparative histologic and clinical study. *Arch Derm Syphilol*. 1947;56(3):291-305.
82. Salas-Alanis JC, Lopez-Cepeda LD, Elizondo-Rodriguez A, et al. Hypertrichosis lanuginose congenita treated with diode laser epilation during infancy. *Pediatr Dermatol*. 2014;31(4):529-530.
83. Benmously MR, Ben Hamida M, Hammami H, et al. Long-pulsed Nd:YAG laser in the treatment of facial hypertrichosis during topical minoxidil therapy. *J Cosmet Laser Ther*. 2013;15(4):217-218.
84. Alajlan A, Shapiro J, Rivers JK, et al. Paradoxical hypertrichosis after laser epilation. *J Am Acad Dermatol*. 2005;53(1):85-88.
85. Swain TA, Tully AS, Redford T, et al. Hair removal-related injuries in the United States, 1991-2014. *J Cosmet Dermatol*. 2016;15(4)444-451.

Chapter 91 :: Nail Disorders

:: Eckart Haneke

The diagnosis and treatment of nail diseases require an in-depth knowledge of the anatomy, physiology, and pathology of the nail unit (see Chap. 8). It is an integral part of the tip of the digit, and its anatomy, growth characteristics, and functions vary between the different fingers and toes, which have to be considered when faced with a diseased nail. There are different ways to classify nail disorders and a compromise between a scientifically based etiologic classification and a more clinico-morphologically based one appears to be a practical approach to nail disorders. This chapter discusses specific nail changes either resulting from particular nail disorders or from dermatologic or systemic diseases, the peculiarities, including etiopathogenetic aspects, of which are not repeated here if they are not specific for the nail lesions.

NAIL SIGNS AND NAIL-SPECIFIC CONDITIONS

ANONYCHIA, HYPONYCHIA, AND DOUBLE NAIL

Complete or almost complete lack of the nail is called anonychia, severe hypoplasia, or hyponychia. The condition is usually inborn, may be a genetic trait or the result of drug or toxin-induced lack of nail formation during embryogenesis. Several different types are known, ranging from a round tip of the digit without any visible change of the skin to an area that may correspond to the nail field, or a hyperkeratosis. When there is no terminal phalanx and no nail growth this is called Cooks syndrome or atelephalangia with anonychia. Hyponychia may be on all or several digits and is more common. A particular form with half-side index fingernail hypoplasia and a Y-shaped radiologic alteration of the distal phalanx is characteristic for Iso-Kikuchi syndrome.

Micronychia may be a sign of phenytoin and alcohol fetopathy and is a constant feature of congenital onychodysplasia of Iso-Kikuchi (COIF [congenital onychodysplasia of index finger] syndrome).

Racket nail is a short wide nail, mostly of the thumb, which develops from the age of 12 years on and is the result of a premature ossification of the epiphysis of the distal phalanx. The bone cannot grow longitudinally but continues to get broader because of apposition on the sides. This condition is autosomal dominant with variable expression and penetrance.

Very short nails (brachyonychia) may develop in patients under chronic hemodialysis who develop a tertiary hyperparathyroidism with resorption of the bone of the terminal phalanx.

A rudimentary double nail of the fifth toe is a relatively frequent finding in subjects of all races. The nail may be slightly wider and have a slight longitudinal indentation or be discernable as a complete accessory nail (Fig. 91-1).[1]

CHROMONYCHIA

The nail may show a variety of color changes that may be caused by true coloration of the nail plate or alterations of the matrix and nail bed shining through the nail plate (Table 91-1).

Leukonychia is the most common color change. It is caused by alterations in the keratinization of the nail plate with the nail cells being parakeratotic and/or having an eosinophilic cytoplasm in histologic sections. Often, these changes slowly disappear so that the free margin of the nail plate appears normal. Morphologically, there may be small patches or transverse bands, mainly seen in children and youngsters, probably the result of an overzealous manicure (Fig. 91-2). Total diffuse leukonychia (Fig. 91-3) is inborn in most cases. Subtotal diffuse leukonychia is sometimes seen in chronic liver disease. Many longitudinal white bands are characteristic for Hailey-Hailey disease.

Apparent leukonychia is a result of nail bed pallor. It may disappear with temperature change or pressure. Muehrcke lines are a pair of 2 whitish transverse lines and are said to be a sign of hypalbuminemia (Fig. 91-4).

Pseudoleukonychia is the white surface of the nail, which is infected by fungi. It was also termed (pseudo) leukonychia trichophytica although nondermatophyte molds also may be causative (Fig. 91-5).

Erythronychia is the term for red nails. It may appear as red spots in the matrix (Fig. 91-6),[2] one or more longitudinal streaks in the distal matrix and nail bed (Figs. 91-7 and 91-8). Multiple red bands are commonly caused by inflammatory conditions such as lichen planus, whereas a single red band may represent specific tumors such as onychopapilloma (Fig. 91-7) or Bowen disease; hence a biopsy is indicated. Alternating narrow white and red bands are seen in Darier disease.

Chloronychia is the term for green nails. In almost all cases, it is caused by a colonization of the nail by *Pseudomonas aeruginosa*. Often, 1 margin of the nail is involved with circumscribed swelling and detachment of the proximal nailfold, lack of the cuticle, and lateral onycholysis (Fig. 91-9). However, it is also seen in distal onycholysis and onycholysis over subungual tumors. Although *Pseudomonas* colonization is harmless for the patient, it may pose a risk for immunosuppressed individuals and these patients should not work in kitchens, bakeries, other food industry jobs, or

Figure 91-1 Rudimentary double nail of the little toe.

in surgery, premature, and newborn wards and intensive care units. The treatment of choice of *P. aeruginosa* colonization is soaking in diluted white vinegar, 2 or 3 times daily for 10 minutes, then brushing the fingers dry. Household bleach for fingertip baths can be used undiluted or 1:1 diluted in water. Other disinfective agents may be used in addition. Topical antibiotics such as gentamycin are sometimes used, but are no more efficacious. Systemic antibiotics do not reach the site of infection because *Pseudomonas* mainly colonizes an onycholytic nail. In rare cases, systemic treatment with ciprofloxacin may be indicated.

Blue nails were seen developing in persons swimming in water with copper sulfate as a disinfective agent.

Slate-gray to bluish nail matrix is a sign of *argyria*.[3]

Melanonychia denotes brown-to-black nail pigmentation. Although this term is generally used for melanin pigmentation of the nail, many other agents may stain the nail brown, such as potassium permanganate or tobacco smoke. Silver nitrate makes the nail jet-black (Fig. 91-10). Some bacteria cause dirty grayish discoloration (Fig. 91-11). Melanonychia may be diffuse and total, transverse or longitudinal. Usually, a brown-to-black band develops in the nail running from the proximal nailfold into the free margin of the nail plate. It is caused by melanocyte activation, a lentigo, nevus,

Figure 91-2 Leukonychia punctata.

TABLE 91-1
Nail Discolorations (Chromonychia)

White–Leukonychia
- **True leukonychia:** hereditary, acquired; punctate, striate, diffuse (total, subtotal), multiple narrow white longitudinal lines: Hailey-Hailey disease, Darier disease
- **Causes:** idiopathic, microtrauma, manicure induced, liver disease, renal insufficiency
- **Apparent leukonychia:** pale nail bed in anemia, Raynaud syndrome, scleroderma
- **Pseudoleukonychia:** superficial white onychomycosis

Brown to Black–Melanonychia
- **Melanin:** activation of matrix melanocytes (functional melanonychia), matrix lentigo, nevus, melanoma
- **Microbial pigments:** *Proteus* spp, *Klebsiella* spp, melanin-producing fungi
- **Exogenous:** silver nitrate, potassium permanganate, heavy smoking, dirt
- **Blood:** acute or chronic trauma, friction

Green–Chloronychia
- *Pseudomonas aeruginosa* (pyocyanin)

Red–Erythronychia
- **Red lunula:** spotted or diffuse: acute nail involvement in several dermatoses such as erythema multiforme, alopecia areata, psoriasis, lupus erythematosus
- **Longitudinal erythronychia:** onychopapilloma, Bowen disease; multiple narrow red lines: dyskeratosis follicularis of Darier (often with some white lines in between).

Yellow–Xanthonychia
- All very thick nails appear yellow, often also onycholytic nails are yellow
- Yellow nail syndrome (triad of chronic bronchopulmonary infection, edema of the distal extremities, and extremely slow-growing yellow nails)

Blue–Azure Nail (Glauconychia)
- Copper sulfate; gray-blue lunulae: ingestion of silver nitrate

Figure 91-3 Diffuse leukonychia.

or melanoma of the matrix. Multiple melanonychias in several or all digits are common in dark-skinned individuals and Asians and are a physiologic phenomenon seen in almost all African Americans (Fig. 91-12). Pregnancy, a variety of drugs, vitamin B_{12} deficiency, Addison disease, HIV infection, some dermatoses such as ungual lichen planus, and Bowen disease of the nail (particularly when associated with human papillomavirus [HPV] Type 56) may exhibit melanonychias. The

Figure 91-4 Muehrcke lines in hypoalbuminemia after more than 7 weeks of high fever.

Figure 91-5 Pseudoleukonychia in superficial white onychomycosis; the white spots are on the surface of the nail plate.

association of lenticular labial, oral, and genital mucosal brown spots with melanonychias is characteristic for Laugier-Hunziker-Baran syndrome. Friction from rubbing shoes may cause longitudinal melanonychia of the little or big toenail, and onychophagia may cause melanocyte activation with subsequent melanonychia. Longitudinal nail pigmentation is the most frequent sign of nail melanoma and requires a meticulous evaluation. Single-digit melanonychia in an adult requires a biopsy.

SUBUNGUAL HEMATOMA

A single, heavy trauma that is usually well-remembered because of its intense pain, or repeated microtraumas, most commonly from ill-fitting shoes or

Figure 91-6 Red spot in the lunula of a patient with acute nail psoriasis.

Figure 91-7 Longitudinal erythronychia caused by an onychopapilloma.

particular sports activities, lead to bleeding under the nail (Fig. 91-13). The blood is located between the overlying nail and the underlying matrix and nail bed

Figure 91-9 Green nail caused by *Pseudomonas* abscess under the nail.

epithelium and is therefore not degraded to hemosiderin by macrophages; consequently, it remains Prussian blue–negative or Perls stain–negative. With time it is included into the newly formed nail. It takes some months to slowly grow out but, in contrast to melanonychia, it never reaches into the free margin of the nail plate; this is one of the most reliable criteria for differential diagnosis. It also does not form a regular longitudinal band and when growing out a normal nail reappears. Dermatoscopy shows round red to dark-brown globules. Acute subungual hematoma can be drained by drilling a small hole into the nail plate to release the blood. Hematomas occupying more than 50% of the nail field are commonly associated with a fracture of the distal phalanx.

SPLINTER HEMORRHAGES

Splinter hemorrhages are narrow red to almost black longitudinal lines in the distal nail bed and are caused by blood that is enclosed in the subungual keratin (Fig. 91-14). They develop either from thrombosed or ruptured capillaries that run longitudinally in the nail

Figure 91-8 Multiple red lines in dyskeratosis follicularis Darier (**A**) and white lines in Hailey-Hailey disease (**B**).

Figure 91-10 Jet-black nail surface stain from 5% silver nitrate solution used to etch what was thought to be granulation tissue protruding from under the proximal nailfold.

bed. They are characteristic for trauma, psoriasis, and some other inflammatory nail and systemic diseases, such as scleroderma, systemic lupus erythematosus, rheumatoid arthritis, antiphospholipid syndrome, and hematologic malignancies. Splinter hemorrhages also are characteristic for bacterial endocarditis with subsepsis lenta (39%) where they may occur together with Osler nodes (6.7%), Janeway lesions (2.2%), and retinal hemorrhages called Roth spots (3%). Oblique splinter hemorrhages may be a sign of trichinosis.

ONYCHOLYSIS

Detachment of the nail from the distal nail bed is called onycholysis. All conditions with abnormal subungual hyperkeratosis will eventually cause onycholysis. These may be inflammatory nail diseases such as psoriasis (Fig. 91-15), lichen planus (Fig. 91-16), atopic dermatitis, and pityriasis rubra pilaris, or infections such as onychomycoses, or tumors of the nail bed. Direct trauma resulting from overzealous nail cleaning is the

Figure 91-11 Dirty grayish nail discoloration caused by *Proteus* spp.

Figure 91-12 Melanonychia caused by melanin production in the matrix of a dark-skinned person.

cause of onycholysis semilunaris (Fig. 91-17). This is characterized by sharply delimited proximal margins that may look like a half moon. Repeated frictional trauma is another cause, particularly in the asymmetric gait nail unit syndrome (see below). Onycholysis is usually colonized by a variety of microorganisms, both bacteria and fungi. Treatment is the avoiding of moisture, cutting the nail back to the adherent part, brushing the nail bed twice daily with a disinfective solution, and applying an antimicrobial cream. Approximately one-half of the regrowing nail will remain attached to the nail bed; however, once having been onycholytic, a nail remains susceptible to reoccurrence of onycholysis.

SUBUNGUAL HYPERKERATOSIS AND ONYCHOGRYPOSIS

Hyperkeratosis of the nail bed is a frequent event (Fig. 91-18). It is characteristic for onychomycoses

Figure 91-13 Subungual hematoma in a little boy with congenital malalignment of the big toenail. This condition is often associated with large subungual hematomas from minor trauma. The figure shows that the hematoma grows out with its proximal border being parallel to the presumed lunula border and free nail end.

Figure 91-14 Splinter hemorrhages in a patient with chronic diarrhea.

where it contains most of the fungi, and for psoriasis. Other frequent causes are trauma, allergic and toxic contact, and atopic dermatitis. It is virtually always associated with onycholysis, except in pachyonychia congenita, where the nail covers an excessive nail bed hyperkeratosis in a horseshoe-like fashion.

Onychogryposis (the common spelling, *onychogryphosis*, is etymologically incorrect as *gryphos* means a mythical animal that is half bird–half lion, whereas *grypos* means horn, hence it should be written *onychogryposis*) is an exaggeration of nail bed and matrix hyperkeratosis. It consists of innumerable stacks of keratin layers piled up one over the other, grows upward, is opaque and often has the shape of a ram's horn. There is usually no contact with the nail bed anymore and the nail pocket is extremely short. It is mainly seen in elderly, neglected, and debilitated individuals (Fig. 91-19). Treatment is by nail avulsion, often completed by nail matrix cauterization to prevent regrowth of a grypotic nail.

Figure 91-15 Psoriatic onycholysis.

Figure 91-16 Lichen planus of the nail bed causing onycholysis.

PTERYGIUM

Pterygium (from Greek for wing formation) is the bridging of the nail pocket by connective tissue, in most cases scars. It is very common in lichen planus (Fig. 91-20), but is occasionally seen in other conditions, such as bullous pemphigoid, but particularly also after trauma. It first divides the nail into 2 parts, but may lead to complete nail destruction when it occupies almost the entire nail pocket.

PTERYGIUM INVERSUM

When the nail plate does not separate correctly from the nail plate at the hyponychium and remains attached, a painful hyperkeratosis obliterates the distal groove. This is quite common in acral scleroderma and Raynaud syndrome, but also may be idiopathic (Fig. 91-21). Nail trimming can be very difficult and painful.

Figure 91-17 Onycholysis semilunaris induced by overzealous manicure.

Figure 91-18 Hyperkeratosis of the nail bed.

BEAU LINES AND ONYCHOMADESIS

A temporary slowdown or even arrest of nail formation results in a transverse groove that runs parallel to the lunula border (Fig. 91-22). It may be shallow at the lateral portions and deeper centrally. Onychomadesis is the result of a longer-lasting arrest of nail matrix proliferation that eventually results in a proximal gap in the nail and proximal onycholysis (Fig. 91-23). It may end up in loss of the nail. The faster a nail grows the more pronounced the lesion; hence Beau lines and onychomadesis are much more common in fingernails than in toenails. Repeated Beau lines indicate repeated trauma, such as chemotherapy cycles. Equally distributed Beau lines hint at a general cause, whereas one-sided lines are seen after surgery of the extremity or a single-digit line at previous finger or toe surgery. A great many different causes are known, ranging from high fever to other serious diseases. Localized Beau lines and onychomadesis were also seen several weeks after hand-foot-and-mouth disease (coxcackievirus infection). Trauma, cosmetic manipulations, onychophagia, and onychotillomania are other causes and explain why the fingernails are predominantly affected (Table 91-2).

Figure 91-19 Onychogryphosis in a 63-year-old woman.

Figure 91-20 Pterygium in nail lichen planus.

PITTING AND TRACHYONYCHIA

Pits are small depressions in the nail surface resulting from minute foci of abnormal keratinization in the apical matrix. This produces small mounds of parakeratosis that tend to break away from the nail when this emerges from under the proximal nailfold. Sometimes, the parakeratosis is not shed and small ivory-colored spots are seen. Pits are the most frequent sign of nail psoriasis (Fig. 91-24) where they are deep and of regular size, whereas those developing in alopecia areata and atopic dermatitis are more shallow and less-well delimited. Large surface defects are typical for pustular psoriasis and are called elkonyxis (Table 91-3).

Trachyonychia is the term for rough nails (Fig. 91-25). In addition to multiple pits, longitudinal striations and ridges such as seen in ungual lichen planus may cause

Figure 91-21 Pterygium inversum in a 54-year-old patient with Guillain-Barré syndrome.

Figure 91-22 Multiple Beau lines in a patient under cyclic chemotherapy. (Used with permission from Dr. Patricia Chang, Guatemala.)

this condition. When many nails are affected the diagnosis of 20-nail syndrome can be made.

Longitudinal grooves are the result of pressure on the nail matrix, which is usually the result of a small tumor in the proximal nailfold (Fig. 91-26).

BRITTLE NAILS

Brittle nails are a very common complaint in daily practice, particularly by women. Multiple longitudinal fissures, often associated with nail thinning and ridges, are the hallmark of *onychorrhexis* (Fig. 91-27). Defective keratinization is thought to be one of the causes.

Onychoschizia is the lamellar splitting of the nail at its free end (Fig. 91-28). It is usually confined to fingernails and occurs much more often in women than in men, pointing to the importance of environmental factors, such as frequent water contact that results in hydration and dehydration of the nail, which leaks cementing lipoproteins out. In babies with koilonychia of the big toenail, onychoschizia is common. Other causes are some dermatoses, onychomycosis, peripheral

Figure 91-23 Onychomadesis after hand-foot-and-mouth disease.

TABLE 91-2
Causes of Beau lines and Onychomadesis

- **Generalized:** Acute severe diseases, high fever, some drugs (retinoids), zinc deficiency, autoimmune bullous diseases, menstruation (often repeated)
- **One extremity:** carpal tunnel syndrome (hand), surgery with extremity tourniquet, reflex sympathetic dystrophy (regional pain syndrome)
- **One or several digits:** nail surgery, hand-foot-and-mouth disease, trauma

Figure 91-24 Psoriatic pitting.

TABLE 91-3
Causes of Pitting and Trachyonychia

- Psoriasis
- Eczema
- Alopecia areata
- Lichen planus
- Graft-versus-host disease
- Rheumatoid arthritis

Figure 91-25 Trachyonychia in an 11-year-old boy with atopic dermatitis.

Figure 91-26 Longitudinal groove in a patient with a myxoid pseudocyst.

neuropathies and vascular disease, occupational traumas, and a variety of drugs, particularly those interfering with nail growth (Table 91-4). The role of nutrition is frequently overestimated.[4]

INGROWN NAILS

Ingrown nails also affect adults and the elderly, but to a much lesser degree in terms of frequency. The most common type is distal–lateral ingrowing of the edge of the big toenail (Fig. 91-29), rarely of neighboring toes, and even less frequently of fingers (Fig. 91-30). There are many theories as to why and how ingrown nails develop and several are not exclusive of another one. Commonly, there is a discrepancy between too wide a nail plate and too narrow a nail bed. Usually, this is true for the distal portion where most pressure from shoes acts on the toes. The tip is compressed, it hurts, and the patient tries to cut the edge away, thereby leaving a kind of a spicule behind that pierces into the soft tissue of the distal portion of the nail sulcus causing pain, suppuration, granulation tissue, swelling, and,

Figure 91-27 Onychorrhexis.

Figure 91-28 Onychoschizia.

with time, fibrosis of the nailfold.[5] Further etiologic factors are tight socks, hyperhidrosis, and overcurvature of the nails. Treatment is either conservative with insertion of a wisp of cotton between the offending nail and the nail sulcus, taping to pull the soft tissue away from the nail, or protection of the soft tissue from the nail margin by a gutter, which requires a local anesthesia. There are many more conservative approaches; however, all require consistent compliance from both the physician and the patient. Surgery is either to narrow the nail or to remove the swollen soft tissue (see Chap. 205).

RETRONYCHIA

Proximal ingrowing of the nail is called retronychia. It is caused by a single strong or repeated minor trauma to the nail that eventually results in a backward movement of the nail plate. Most patients are children, adolescents, and young adults with 1 or 2 swollen, bluish, proximal nailfolds of their big toes (Fig. 91-31). The lunula is no longer present. On pressure, granulation tissue may emerge from under the nailfold. Careful clinical examination reveals that there is a major onycholysis of the nail that allows the plate to be pushed backward. This leads to a horizontal split in the matrix. As the nail bed is mainly responsible for the forward growth

TABLE 91-4
Causes of Brittle Nails

Note: General disorders tend to affect all nails; fingernail-only involvement points at an etiology linked to wet work. Single-digit nail splitting is most likely a circumscribed disease or tumor.

- Chronic anemia; iron deficiency; zinc deficiency; vitamins A, B_6, and C deficiencies; hypervitaminosis A; genetic diseases with disturbance of keratin formation
- Local damage from trauma, alkalis, detergents, overzealous manicure

Figure 91-29 Ingrown nail of the big toe.

of the nail, this mechanism may no longer function and 1 or more new nails will be formed under the old proximal nail portion lifting this up. Its margin is very hard and sharp so that it cuts into the undersurface of the proximal nailfold with each step. The Y-shaped, W-shaped, or serrated proximal nail margin is well seen when the nail is avulsed, which is the treatment of choice.[6]

Figure 91-30 Ingrown nail of the finger in a patient under targeted anticancer treatment with cetuximab.

Figure 91-31 Retronychia of the big toe in a 17-year-old girl. **A,** Dorsal view. **B,** Oblique view.

PINCER NAILS (NAIL OVERCURVATURE)

Overcurvature of the nails is commonly called pincer nails, tubed nails, trumpet nails, and the like. The most common variant shows a distally increasing curvature (Fig. 91-32), but it may also remain at the same degree (tile nail) or exhibit sharp lateral bends. Half-side overcurvature is quite common. There are 2 types: *acquired* as a result of foot deformation, degenerative distal interphalangeal osteoarthritis (mainly in fingers), and some dermatoses, and *hereditary* with symmetrical involvement of the big toenails and often some, but very rarely all, lesser toenails. The big toenails show lateral deviation, the affected lesser nails are medially deviated. The base of the distal phalanx is widened, which can be felt by sliding palpation of the toe. Systematic radiographic examinations of the toes show that the distal phalanx is asymmetrical and often shows distally pointing exophytes that may correspond to the insertion of the interosseous ligament; they are much more pronounced medially than laterally, which explains in part the increasing lateral deviation of the nail plate. Furthermore, a distal dorsal traction osteophyte is commonly seen, which has to be removed when surgically flattening and spreading out the nail bed. In the distal portion,

Figure 91-32 **A,** Pincer nails of the thumbs in a 53-year-old woman. **B,** Pincer nails of the toes in a 38-year-old woman.

the overcurved nail pinches the nail bed and heaps it up, resulting in a reactive subungual hyperkeratosis.[7] Treatment is by long-term application of nail braces to decrease the curvature, or a surgical procedure.

EFFECTS OF NAIL TREATMENT

The nails are not only subject to many environmental and traumatic influences, but also the target of cosmetic and medical treatments that often have a profound effect on the integrity of the nail. Nail hardeners are frequently prescribed for brittle nails. They contain formaldehyde that renders the nails harder and decreases their elasticity. Nail varnish is usually well tolerated but the tosyl formaldehyde resin may be the cause of allergic contact dermatitis. Artificial nails made from acrylics or cyanoacrylates may also cause contact dermatitis, often in the face and neck, less frequently of the nails; here, the reaction may persist for a long time, even after removal of the artificial nails, and be associated with long-lasting or even persisting pain. Gel nails are presently very popular. They are very hard and their removal requires harsh treatment with a coarse file that thins the nail plate and thus damages it. Chemical peels of the nail with 70% glycolic acid to improve their surface have been described[8]; their rationale remains to be clarified. Overzealous manicure is the cause of many untoward effects such as onycholysis semilunaris, wavy nail surface, loss of the cuticle with penetration of foreign substances under the proximal nailfold and subsequent paronychia, and bacterial colonization and infection. Urea in high concentrations is used to soften mycotic nails; urea 40% paste under occlusion for 3 to 5 days makes the infected nail portions soft enough to allow them to be scraped off.

INFLAMMATORY NAIL DISORDERS

PSORIASIS

AT-A-GLANCE

- Psoriasis is the dermatosis with the most frequent nail involvement.
- Approximately 50% of all psoriatics have nail changes at a given time, but 90% will have nail alterations at least once in their life.
- Nail involvement is even more frequent in psoriatic arthritis.
- The most frequent nail changes are pits, subungual hyperkeratosis, onycholysis, salmon spots, red lunulae, splinter hemorrhages, leukoplakia, and psoriatic paronychia.
- Infection with pathogenic fungi is frequent and should be treated first.

Psoriasis is the skin disease with the most frequent nail involvement. At the time of consultation, approximately 50% of the patients present with nail changes. Over their lifetime, up to 90% of all psoriatics will develop nail alterations. The prevalence is even higher in psoriatic arthritis.

ETIOLOGY AND PATHOGENESIS

There appears to be neither a gender nor race predilection. In contrast to skin, there is no association of human leukocyte antigen (HLA)-C0602 with nail and joint involvement, and nail psoriasis is often associated with inflammation at the insertion points of tendons and ligaments, giving rise to enthesitis. The nail lesions were thought to represent an aberrant response to tissue stressing of the integrated nail–joint apparatus, rather than being the result of an autoimmunity. The nail-and-joint disease may be linked to tissue-specific factors, including tissue biomechanical stressing and microtrauma that lead to activation of aberrant innate immune responses.[9]

CLINICAL FEATURES

Psoriasis causes both very specific and ambiguous nail lesions (Figs. 91-33 to 91-35). The most characteristic and most frequent signs are pits representing small, sharply delimited depressions in the nail surface of remarkably even size and depth. They may be haphazardly arranged or sometimes show parallel transverse or short longitudinal lines (Fig. 91-33). They are thought to arise from tiny psoriatic lesions in the apical matrix leading to parakeratosis that breaks off leaving these hole-like lesions. When the parakeratosis remains it is seen as an ivory-colored spot in the proximal third of the nail plate (Fig. 91-34). Pits may be single, which is not yet psoriasis specific, or multiple. Ten pits per nail or more than 50 pits on all nails are seen as proof of nail psoriasis. Rarely, red spots are seen in the lunula usually representing a very active psoriasis lesion with dilation of the capillaries and thinning of the suprapapillary plate.[10] Complete nail destruction following crumbling of the plate is a sign of total matrix affection (Fig. 91-35). Leukonychia is seen when the psoriatic lesion is in the mid to distal matrix and parakeratotic cells are incorporated into the nail plate, making it optically appear white. It is commonly an ill-defined white transverse band, but other morphologies are possible. Splinter hemorrhages are some millimeters long, reddish–dark-brown to black streaks of barely 1 mm in diameter. They are analogous to the Auspitz phenomenon on the skin and result from damage to the dilated capillaries in the nail bed causing the blood to clot in these longitudinally arranged small vessels. Salmon spots are frequent. They represent psoriatic plaques in the distal matrix

Figure 91-34 Nail psoriasis with pits and spots on the surface.

Figure 91-33 Nail psoriasis with pits arranged in a line.

Figure 91-35 Nail psoriasis destroying the entire nail.

and the nail bed. The nail looks like paper on which a drop of oil has fallen: A yellowish-brownish spot with a red margin shines through the plate. The reason for this is that the squames of the psoriasis lesion are imbibed with serum and compressed under the nail. When such a salmon spot reaches the hyponychium, part of the parakeratosis breaks out and psoriatic onycholysis develops, which typically has a reddish proximal margin differentiating it from most other causes of onycholysis. In addition, there is often subungual hyperparakeratosis without oil-drop phenomenon causing onycholysis. Psoriatic hyperkeratosis may be marked and sometimes so extreme that it resembles pachyonychia congenita. Psoriasis involving both the dorsal and ventral surface of the proximal nailfold causes thickening and rounding of its free edge, which, in turn, are associated with loss of the cuticle, thus giving the pattern of chronic paronychia.

In *psoriatic arthritis*, nail involvement is often severe with psoriatic paronychia, complete nail destruction, and swelling of the distal interphalangeal joint.

Psoriatic pachydermoperiostosis is a condition closely related to psoriatic arthritis but usually without obvious nail changes. Mainly the big toe is considerably thickened and often painful.

Pustular psoriasis occurs in 3 different forms, all of which also involve the nail. In the *palmar plantar pustular psoriasis of Barber-Königsbeck*, all nail changes described above as well as larger surface defects called elkonyxis, plus subungual yellow spots representing large Munro abscesses may be seen (Fig. 91-36). *Generalized pustular psoriasis of von Zumbusch* occasionally causes red areas with a rim of small pustules that may affect the nail. Subungual abscesses are frequent. The most notorious form of pustular psoriasis is *acrodermatitis continua suppurativa of Hallopeau*. Often beginning with a single digit, the skin of the distal phalanx becomes red, develops some pustules that migrate under the nail and cause nail dystrophy, which, with time, may lead to complete disappearance of the nail unit so that only a red smooth digit tip is left until the disease slowly wanes off. However, acrodermatitis continua suppurativa may also initially involve several fingers and toes and run a very severe course

Figure 91-36 Nail involvement in pustular psoriasis of Barber-Königsbeck.

Figure 91-37 Acrodermatitis continua suppurativa of Hallopeau.

(Fig. 91-37). A mutation in the gene for the interleukin-36 receptor antagonist leading to a defect in interleukin-36 receptor antagonist was found in generalized pustular psoriasis and acrodermatitis continua suppurativa, supporting the assumption that these conditions belong to the group of autoinflammatory diseases.[11,12]

Reiter disease, also known as reactive arthritis, is a systemic condition with characteristic joint, mucosal, eye, genitourinary, skin, and nail changes. The latter are very similar to pustular psoriasis although they usually have a more brownish tint because of the content of erythrocytes in the pustules (Fig. 91-38). Histopathology also shows spongiform pustules.

Figure 91-38 Nail changes in Reiter disease. (Used with permission from Dr. Robert Baran, France.)

TABLE 91-5
Differential Diagnosis of Nail Psoriasis and Onychomycosis

	PSORIASIS	ONYCHOMYCOSIS
Frequency	High, most common dermatosis with nail involvement	Very high: up to 30% to 40% of all nail diseases
Course	Chronic, often recurrent	Chronic, often progressive
Symptoms	Usually embarrassing cosmetically and functionally	Embarrassing, sometimes pain
Signs	Variable, depending on nail structure involved	Variable, depending on severity and type of onychomycosis
▪ Pits	▪ Very common, regular	▪ Rare, irregular
▪ Onycholysis	▪ Common	▪ Common
▪ Discoloration	▪ None to yellow	▪ Yellow to brown
▪ Spores and hyphae	▪ Rarely spores	▪ Very frequent
▪ Transverse furrows	▪ Rare	▪ Rare
▪ Skin lesions elsewhere	▪ Very common	▪ Often tinea
Trauma	May induce Köbner phenomenon	Important predisposing factor
Heredity	Strong hereditary component, particularly in juvenile onset psoriasis	Autosomal dominant susceptibility to develop onychomycosis

DIAGNOSIS

In most cases, nail psoriasis is diagnosed on clinical grounds. Skin lesions elsewhere plus 1 or several psoriatic nail features suggest the correct diagnosis. Histopathology is usually pathognomonic and helps to delineate nail psoriasis from other conditions, particularly onychomycosis. Reiter disease requires additional laboratory examinations.

DIFFERENTIAL DIAGNOSIS

Table 91-5 outlines the differential diagnosis of nail psoriasis and onychomycosis.

ASSOCIATIONS

Psoriasis is a frequent skin disease. Hence co-occurrence with other dermatoses that may also involve the nail is not exceptional. The most important association is that with onychomycosis as both conditions may look very similar, but a psoriatic nail may be colonized with pathogenic fungi and a true infection of the psoriatic nail is not infrequent (see Table 91-1).

COURSE

Why nail psoriasis often improves and worsens is unknown, although trauma may play an important role in the exacerbation of nail psoriasis. There may be periods without any nail alterations.

TREATMENT

Nail psoriasis is very resistant to almost all topical treatments whereas systemic therapies clearing the skin are usually also effective in nail psoriasis. The problem of all topical treatments is the penetration of the drug to the diseased tissue: through the nail plate in nail bed psoriasis, through all layers of the proximal nailfold plus the underlying nail in matrix lesions. Hence, pits, even though often being rather inconspicuous, are the most resistant to treatment. Nevertheless, a 3-month trial of a combination of a vitamin D_3 derivative with a potent corticosteroid is warranted. The less of the nail is present, the easier is penetration of the drug to the very psoriatic lesion. The list of other drugs tried is long and mostly comprises anecdotal reports and small case series. Injections of triamcinolone acetonide crystal suspension, 10 mg/mL every 6 weeks, into the proximal nailfold often improves nail psoriasis, but is painful and cumbersome for the patient. Methotrexate injections were also given with some success; however, this cytostatic drug may slow down nail growth and make an improvement visible only very late. The best treatment results are those with systemic antipsoriatic therapies, including biologics (see Chap. 28 for details).[13]

ECZEMA

AT-A-GLANCE

- *Eczema* is a traditional dermatologic term denoting a frequent reaction of the epidermis to a large variety of different stimuli; it is often used synonymously with "dermatitis."
- Virtually all nail components may show eczematous changes: matrix, nail bed, periungual skin.
- Allergic contact dermatitis may be the result of nail cosmetics, particularly acrylic nails; this type of contact dermatitis may last longer than the actual duration of exposition.

(Continued)

AT-A-GLANCE (*Continued*)

- Toxic contact dermatitis may be indistinguishable from allergic dermatitis and psoriasis.
- Atopic dermatitis may cause rough nails when the matrix is involved, or very shiny nails when they are used to rub the itchy skin.
- Nummular eczema is occasionally seen on the proximal nailfold.

In this context, the term *eczema* is used as a collective one comprising allergic contact dermatitis, toxic/irritant contact dermatitis, atopic dermatitis, and nummular eczema; seborrheic eczema does not occur in the nail unit. They have a common denominator, the so-called spongiotic dermatitis.

CLINICAL FEATURES

Although differing in typical cases the clinical features may be similar between the different forms of eczema (Fig. 91-39), particularly in chronic eczema. *Acute allergic contact dermatitis* exhibits redness of the periungual skin with tiny vesicles that tend to break and ooze. Serous crusts follow. Secondary infection with pyogenic micrococci leads to impetiginization. With time, oozing disappears, the redness decreases, and desquamation develops followed by cracking, particularly of the volar aspects and transition to the hyponychium and lateral nailfolds. The nails may become grossly deformed with deep asymmetric transverse furrows and ridges. Matrix and nail bed involvement is rather rare, but when present, for example, in patients with an allergy to artificial nails, may be painful. The nail itself loses its transparency as the spongiotic dermatitis of the matrix leads to inclusion of serum in the plate. The nail bed appears to be hyperkeratotic, even though this is a mixture of subungual keratin with serum inclusions. Chronic allergic contact dermatitis of the proximal nailfold leads to swelling, loss of the acute angle of its free margin with disappearance of the cuticle and separation of the underlying nail plate.

Figure 91-39 Nail eczema in a gardener handling tulips.

Toxic contact dermatitis rarely begins acute with erythema, vesicle formation, and oozing, such as from certain plants like garlic. Chronic irritant contact dermatitis is characterized by redness, scaling, fissures, and paronychia. It is often indistinguishable from chronic allergic dermatitis.

Nummular eczema of the nail region mainly involves the proximal nailfold with round red infiltrated plaques exhibiting tiny papules that are covered with a small serosanguinolent crust.

Atopic dermatitis may affect the nail in different ways. Shiny nails are characteristic in chronic itchy atopic dermatitis of children and young and middle-aged adults. These individuals "learned" not to harm their skin by scratching with the free margin of the nails and to relieve the itch by rubbing with the back of the distal phalanx. The use of emollients may enhance the polishing action of this habit. Atopic pulpitis sicca demonstrates desquamation and cracking of the finger and toe tips and is often also a feature of atopic winter feet. Painful cracks starting in the lateral nail groove of the thumbs and extending to pulp are often seen in elderly atopics. Frank "eczematous" changes are exceptional.

Trachyonychia is the term for rough nails and a hallmark of the so-called 20-nail dystrophy. In author's experience, most cases are caused by atopic dermatitis, although psoriasis, alopecia areata, and nail lichen planus were also found as the underlying disorder.[14] Many nails, rarely all 20 nails, are affected, but often 1 or more nails remain normal despite progression of the alterations. The nails become very rough, lose their shine and transparence, often turn partly koilocytotic, and the cuticles become thickened and ragged. Most cases are children between 6 and 10 years of age, sometimes younger. The condition usually runs a protracted course until, in many cases, the nails become normal from age of 14 to 16 years on.

ETIOLOGY AND PATHOGENESIS

The rare occurrence of allergic and irritant contact dermatitis on toenails as compared to fingernails points at the importance of nail cosmetics as well as a number of household allergens. The household allergens are complicated by the fact that (immediate-type) contact allergy to food may be chronic and superimposed by chronic irritation as well as colonization with yeasts.[15] Painful matrix and nail bed dermatitis is characteristic for acrylate allergy. The exact etiopathogenesis of nummular eczema is not yet fully elucidated.

DIAGNOSIS

Acute allergic contact dermatitis is usually diagnostic, although rare cases of acute irritant contact dermatitis may look identical. Skin tests are commonly applied both to make the diagnosis as well as find out the responsible allergen. In acrylate allergy, ectopic skin

lesions may characteristically be found on the neck, décolleté, and around the eyes, a result of vapors of the acrylic monomer. Atopic dermatitis almost invariably demonstrates lesions on other body sites that may vary according to the age of the patient. In nummular eczema, lesions are commonly seen on the forearms and lower legs. Twenty-nail dystrophy is diagnosed in children when more than 10 nails are involved.

Histopathology shows a spongiotic dermatitis in acute cases, but a more psoriasiform epidermal hyperplasia in chronic eczema. Persistent allergic contact dermatitis caused by acrylates exhibits a dense, often band-like lymphocytic infiltrate, exocytosis, and spongiosis with massive acanthosis of the matrix and nail bed epithelium as well as lymphocytes and serum in the nail plate. Nummular lesions show spongiotic vesicles in the upper half of the epidermis with clotted serum on top. In trachyonychia, there is a very severe spongiotic inflammation with strong exocytosis of T lymphocytes that migrate upward and become part of the nail plate.

DIFFERENTIAL DIAGNOSIS

Chronic allergic and irritative contact dermatitis are difficult to distinguish from each other, as well as from psoriasis, ungual lichen planus, and alopecia areata. Careful examination of the entire skin is a must for each dermatologist. Chronic paronychia occurs in all contact dermatitides. Parakeratosis pustulosa is a rare condition that mainly occurs in young girls and exhibits vesiculopustular lesions of the hyponychium extending into the distal nail bed. After some weeks the condition resembles an eczema or psoriasis. Twenty-nail dystrophy usually represents an eczematous reaction.

CLINICAL COURSE, PROGNOSIS, AND MANAGEMENT

Except for acute allergic contact dermatitis, all other eczemas usually run a protracted course. However, even grossly distorted nails may become completely normal when the cause is found and eliminated and the condition adequately treated, which may be difficult in persons who have to handle food and/or expose their hands to a harsh environment. In addition, smoking and nail cosmetics, as well as particular habits, often complicate treatment. Twenty-nail dystrophy is a disease of children and said to disappear spontaneously at the age of approximately 16 years.

Periungual eczematous lesions respond to topical steroids, but chronic paronychia may require intralesional steroid injections. Very severe and painful lesions may have to be treated systemically as transungual penetration is insufficient for matrix and nail bed involvement. Very recalcitrant paronychia can be treated surgically by a beveled excision of the thickened part of the proximal nailfold.

ALOPECIA AREATA

AT-A-GLANCE

- Nail involvement in alopecia areata is frequent: the more severe the alopecia areata, the more frequent the nail involvement.
- The nails are rough, as if sandpapered, with innumerable small pits.
- The surface may keep its shine or have lost it.
- The nails often lose their transparence due to inclusion of serum globules, this makes them also brittle.

CLINICAL FEATURES

Alopecia areata (AA) affects between 6 and 7 million individuals in the United States. The prevalence of nail abnormalities varies between 10% and 65%. They may precede, occur concurrently with, or follow hair loss activity. There is no known age, race, or ethnic preponderance. In contrast to other autoimmune diseases, the hair follicle does not usually sustain permanent injury and maintains its potential to regrow hair.

AA often affects the nails; the more severe the AA, the more likely is nail involvement. Thus nail changes are rare in the most frequent mild type of AA with only a few bald patches and a high rate of spontaneous resolution, whereas nail changes are rather the rule in AA universalis. However, it is generally accepted that there may be nail AA without hair loss. Two types of nail alterations are seen: rough nails that have lost their shine and pitted nails with surface shine (Fig. 91-40). The nails may lose their transparence, get thicker, become brittle and split distally. The cuticles may become ragged. Koilonychia is a sign of very severe nail involvement.

ETIOLOGY AND PATHOGENESIS

AA is an autoimmune disease mediated by natural-killer group 2 member D expressing CD8+ lymphocytes and it can be assumed that the etiology of nail AA is not different from that of hairy skin. However, the pathogenesis appears to be variable as nails do not fall off in contrast to hair, and the histopathologic pattern of inflammation in hair follicles and nails are different; exact data are not yet known. AA preferentially affects pigmented hairs, and the hair of AA patients frequently shows a change in color when it regrows following an acute episode of AA. Although this might indicate a relationship between AA, pigmentation, and melanin-concentrating hormone signaling nails are usually not pigmented in light-skinned individuals. Whether or not duplications in *MCHR2*[16] are important for the involvement in nail AA pathogenesis remains to be elucidated.

Figure 91-40 Alopecia areata of the nail.

DIAGNOSIS

In the typical case, the diagnosis is self-evident. However, AA is a relatively frequent disorder and associations with other conditions potentially affecting the nail are possible. Thus, ruling out atopic dermatitis, psoriasis, lichen planus, or onychomycosis may be warranted. The real problem is to make the diagnosis of isolated nail AA. Nail biopsy shows a spongiotic dermatitis with lymphocyte exocytosis involving the matrix; thus the histopathologic pattern is different from that of the scalp. The nail surface is wavy and often serum inclusions are seen in the nail plate.[17] There are no laboratory examinations that help make the diagnosis of nail AA.

DIFFERENTIAL DIAGNOSIS

In the presence of round bald spots on the scalp, the diagnosis of a pitted nail is obvious. However, pits were also observed in different eczemas, lichen planus, ichthyosis vulgaris, and, above all, psoriasis. In psoriasis, the pits are deeper and a bit larger.[18]

DISEASE ASSOCIATIONS

Asthma, allergic rhinitis, atopic dermatitis, thyroid disease, and autoimmune diseases, such as thyroiditis and vitiligo are common associated diseases.

CLINICAL COURSE, PROGNOSIS, AND MANAGEMENT

Occurring more commonly in severe AA, the nail changes usually run a protracted course over years. Successful systemic treatments will greatly improve the nails. Tofacitinib is a Janus kinase inhibitor with a good effect on hair loss and nail changes in nail AA. It is assumed that other Janus kinase inhibitors also might be beneficial for the treatment of nail changes in AA.[19] Apremilast did not induce hair regrowth in severe AA. Topical treatments with steroids or steroid–calcipotriol combinations are often tried, but mostly in vain. Injections of triamcinolone acetonide crystal suspension, 0.5 to 1 mg per proximal nailfold, have to be repeated every 4 to 6 weeks, but are cumbersome and painful.

The prognosis of nail AA is linked to that of AA in general. The nail lesions may persist longer than the hair loss. Permanent nail dystrophy after resolution of the AA is not observed.

The patient has to be counseled concerning the nature of the disorder and the chronicity of nail lesions in AA. This is particularly important in children where the parents require detailed information as to the natural course of AA and its nail alterations.

LICHEN PLANUS OF THE NAILS

AT-A-GLANCE

- Lichen planus rarely affects the periungual skin, most commonly the proximal matrix and less frequently the nail bed.
- Matrix involvement leads to longitudinal ridging and splitting until the distal nail plate breaks away and a pterygium develops.
- Nail bed affection causes subungual hyperkeratosis with onycholysis.
- Postlichen atrophy is the end stage of ungual lichen planus.
- Variants of ungual lichen planus include pigmented lichen planus, ulcerated lichen planus, and bullous lichen planus.

CLINICAL FEATURES

Nail lichen planus is a chronic disease that usually occurs in association with typical skin lesions (Figs. 91-41 and 91-42). Depending on the particular structure of the nail apparatus affected, variable clinical alterations develop. Most commonly, the apical matrix is involved leading to ridging, rough nails, loss of nail shine, longitudinal

Figure 91-41 Lichen planus of the nails.

Figure 91-42 Lichen planus of the nails.

surface defects, and splits. Nail bed lichen planus is rare; it may cause subungual orthokeratosis with subsequent onycholysis. Even bullous lichen planus of the nails is possible.[20] Involvement of the proximal nailfold results in a bluish-red discoloration, sometimes associated with swelling. Longstanding nail lichen planus may lead to nail thinning and obliteration of the nail pocket with pterygium formation. The nail edge may look frayed. As the apical matrix is the site of the nail stem cells,[21] scarring with permanent nail dystrophy may occur. Ulcerating nail lichen planus is very rare. Finally, a progressive nail atrophy may develop characterized by nail thinning and extreme fragility thus very similar to nails in amyloidosis.

ETIOLOGY AND PATHOGENESIS

The similarity of clinical and histopathologic nail alterations in graft-versus-host disease with those of lichen planus has supported the view that it is an autoimmune disorder. Nonwhites appear to have nail lichen planus more frequently. There is a high frequency of HLA-A3, HLA-A5, HLA-B7, HLA-DR1, and HLA-DR10.

The histopathology of nail lichen planus is characteristic. There is a dense epitheliotropic lymphocytic infiltrate around the apical matrix leading to vacuolar basal cell degeneration with thinning of the epithelium and impaired nail substance formation. As this is not evenly distributed over the width of the matrix longitudinal furrows and splits develop. Severe infiltration causes epithelial consumption and, finally, deficient nail formation, obliteration of the nail cul-de-sac, and pterygium.

DIAGNOSIS

Nail lichen planus is usually diagnosed clinically. There are no blood tests. Lichen planus lesions on the skin, oral, and genital mucosa should be looked for. Ultimately, a nail biopsy can confirm the diagnosis. Bullous nail lichen planus may mimic yellow nail syndrome.

DIFFERENTIAL DIAGNOSIS

All nail conditions causing rough nails with longitudinal ridging and surface defects have to be considered. The diagnosis is more obvious with fingernail than toenail lesions. Amyloidosis involving the nails looks very similar.

DISEASE ASSOCIATIONS

These are the same as with cutaneous lichen planus: AA, vitiligo, localized scleroderma, Castleman tumor with pemphigus vulgaris, and chronic liver disease.

CLINICAL COURSE, PROGNOSIS, AND MANAGEMENT

Nail lichen planus is particularly chronic and stubbornly resistant to almost all topical treatments. Slight variations in the disease intensity may be observed. Some patients have mild disease with almost no progression whereas others may experience rapid exacerbation with cicatricial nail dystrophy. Once a pterygium has developed, nail lichen planus is no longer amenable to treatment. Furthermore, there may be a Koebner phenomenon when using harsh treatment methods. Despite the lack of controlled studies for topical treatment modalities, the combination of a steroid with calcipotriol is recommended, which may induce some improvement or stop disease progression. Perimatricial injections of triamcinolone acetonide every 4 to 8 weeks, either with or without a needle, are often successful and may be continued by IM injections, 0.5 to 1 mg/kg bodyweight. However, up to 50% of the responders may experience a recurrence.[22] Biologics are highly effective in recalcitrant cases.[23]

AUTOIMMUNE BULLOUS DISEASES

AT-A-GLANCE

- Even though all autoimmune bullous disease can affect the nail unit, the clinical changes are nonspecific and do not permit a conclusive diagnosis.
- Chronic paronychia, hyperkeratosis, and oozing with crusting are common to all autoimmune bullous diseases.

Among the autoimmune bullous diseases, pemphigus vulgaris, pemphigus vegetans, bullous pemphigoid, cicatricial pemphigoid, and epidermolysis bullosa acquisita may affect the nails. However, nail lesions are rarely specific enough as to allow the exact diagnosis to be made. Associated skin lesions may suggest a blistering disease.

CLINICAL FEATURES

Chronic paronychia with oozing and crust formation are the most common initial signs (Fig. 91-43), followed by onychomadesis (see Fig. 91-23) and sometimes by loss of the nail, of nail involvement. Pterygium formation and permanent nail loss were observed in bullous pemphigoid, cicatricial pemphigoid, and acquired epidermolysis bullosa. Large clear periungual blisters are occasionally seen in bullous pemphigoid. They may be followed by erosions with crusting and sometimes superficial impetiginization. Pemphigus vegetans of the distal phalanx may resemble a very severe form of acrodermatitis continua suppurativa of Hallopeau with extensive pustulation and often a markedly pronounced pustular margin.

Figure 91-43 Bullous pemphigoid of the nail.

ETIOLOGY AND PATHOGENESIS

They are dealt with in the chapters on autoimmune bullous disorders. It was once thought that nail involvement in pemphigus vulgaris might be a sign of a particularly aggressive course or even a special subtype; however, this has not been substantiated.

DIAGNOSIS

The diagnosis may be suspected in case of a longstanding oozing and crusting paronychia with development of onychomadesis and even nail loss. However, serologic investigations including enzyme-linked immunosorbent assay tests and indirect immunofluorescence, and in case of skin lesions, a biopsy, are usually necessary to make the diagnosis.

DIFFERENTIAL DIAGNOSIS

The various autoimmune bullous diseases require immunoserologic and histopathologic examinations for their differentiation.

DISEASE ASSOCIATIONS

Other autoimmune phenomena and diseases may be associated.

CLINICAL COURSE, PROGNOSIS, AND MANAGEMENT

The course of the nail lesions is linked to that of the cutaneous and mucous membrane lesions. Their efficacious therapy will also control the nail alterations albeit with some delay. Nail lesions take between 6 and 18 months to grow out. Pterygium is permanent.

SO-CALLED CONNECTIVE TISSUE DISEASES

Lupus erythematosus and its particular form of chilblain lupus, dermatomyositis, and scleroderma may affect the nail unit.

CLINICAL FEATURES

All these disorders may cause alterations of the nailfold capillaries. They may be reduced in number, dilated, tortuous, shorter, and show aneurysms and bleeding. This is easily seen when using a fluorescent dye that gives evidence of vessel leakage. However, even though often stressed in the rheumatologic literature, most of these changes do not allow a safe distinction to be made between them. Some changes are more typical for dermatomyositis, which is also characterized by Gottron papules of the dorsal aspect of phalanx, less frequently on the distal phalanx (Fig. 91-44). Periungual erythema and red lunula may be seen in acute lupus erythematosus whereas in chilblain lupus the changes reach from pernio-like nonspecific violaceous-blue hue with some telangiectasias to ulceration of the tip of the toe and the nail unit. Chronic discoid lupus erythematosus may cause red streaks in the nail bed, ridging of the nail, and dystrophy. White bands were seen in the diffusely brown nail of a black patient who had leukoderma of the head as a result of chronic discoid lupus erythematosus. Onycholysis, pterygium, and clubbing are nonspecific signs.[24]

Scleroderma with its acral variant often shows ulceration of the pulp and narrowing of the tip of the finger. The nail insidiously bends volarly giving the aspect of a parrot beak. The nail surface is dull and may show pronounced ridging. The plate is often nontransparent.

Figure 91-44 Dermatomyositis. **A,** Capillary microscopy shows avascular areas and aneurysms. **B,** Gottron papules on the distal phalanges.

ETIOLOGY AND PATHOGENESIS

The etiology is that of the cutaneous involvement. Infarctions of the nailfold capillaries may lead to necrosis and scars. The degree of matrix affection determines that of the nail changes. Most sclerodermatous nail alterations are said to be secondary to the associated vascular damage.

DIAGNOSIS

As isolated nail changes in these connective tissue diseases are exceptional, the diagnosis is usually made by their skin lesions and immunoserologically (Fig. 91-45). Capillary alterations are easily seen by dermatoscopy and laser scanning confocal microscopy; the latter also permits the blood flow to be observed.

DIFFERENTIAL DIAGNOSIS

Capillary microscopy of the nailfold may give a hint at the diagnosis of an autoimmune disease; however, despite many claims, it is very difficult to differentiate them purely on capillary microscopy. Nail plate changes may have to be distinguished from lichen planus. Red lunulae are seen in acute AA of the nail and some other diseases, as well as in drug reactions. Periungual erythema may be caused by HIV infection or treatment with cytotoxic agents.

Figure 91-45 Chilblain lupus of the toes.

DISEASE ASSOCIATIONS

Mixed connective tissue disease exhibits features of lupus erythematosus plus dermatomyositis and sometimes even scleroderma. Other immune disorders may be associated. The association with erythema multiforme is called Rowell syndrome. Vasculitis accompanies systemic lupus erythematosus in 10% to 20% of patients.

CLINICAL COURSE, PROGNOSIS, AND MANAGEMENT

The clinical course, prognosis and management are those of the skin lesions, however, the nail alterations usually take longer to respond.

VASCULITIS AND VASCULOPATHIES

Nail changes of the "true" vasculitides, as well as of occlusive and infectious vasculopathies, are mentioned.

CLINICAL FEATURES

Leukocytoclastic vasculitis may affect the distal phalanx with the nail unit, particularly of the toes. Dark red small palpable spots develop both on the proximal nailfold and the pulp, which have a tendency to leave small necroses and tiny scars. Under the nail, they are seen as dark red spots and may be painful.

In "benign" gonococcal sepsis, small hemorrhagic papules may develop on the distal phalanx, involving also the proximal nailfold. Similar lesions were also observed in pneumococcal and meningococcal sepsis; however, these are very serious diseases that are not diagnosed by their nail involvement.

Livedoid vasculopathy, also called livedo reticularis, is a typical disorder of the legs that causes painful torpid ulcers. It is often called atrophie blanche when located in the ankle region.[25] It may affect the free margin of the proximal nailfold of toes, exhibiting lichenoid papules with reddening and white lines (Fig. 91-46).

ETIOLOGY AND PATHOGENESIS

The etiology and pathogenesis of the vasculitides and vasculopathies are not different from those of the skin lesions. Hypercoagulability in association with stasis are assumed to underlie livedoid vasculopathy. In infectious vasculitides, microbial thrombi are said to be responsible, but a general toxic response has also to be discussed.

DIAGNOSIS

The diagnosis of the nail lesions depends on that of the skin disease.

Figure 91-46 Livedoid vasculopathy involving the proximal nailfold.

DIFFERENTIAL DIAGNOSIS

Osler nodules are small painful nodules and bleedings in the fingertips in bacterial endocarditis.

DISEASE ASSOCIATIONS

Vasculitis is often seen in conjunction with systemic lupus erythematosus, but may also occur in a variety of infections and as a drug reaction.

CLINICAL COURSE, PROGNOSIS, AND MANAGEMENT

The clinical course depends on whether or not the cause of the vasculitis is found and removed. Large necrotic lesions heal with scars that may distort the nail.

INFECTIOUS NAIL DISEASES

AT-A-GLANCE

- Otherwise banal infections are often disproportionately painful, for instance digital herpes simplex.
- Subungual warts may be very painful because of pressure on the bone; those under the proximal nailfold mimic chronic paronychia.
- In hand-foot-and-mouth disease, small oval blisters may occur around the nail, and possibly also in the matrix region, causing late onychomadesis.
- Bullous impetigo presents as a blister with a stable roof that may extend around the nail.

(Continued)

AT-A-GLANCE (*Continued*)

- Deep bacterial infections may reach down to the bone; these whitlows (felons) cause pain and require surgical exploration.
- Syphilis may occur as a primary chancre, which also may be atypically painful, or as a subungual papular exanthem causing onycholysis.
- Both tuberculosis, leprosy and atypical mycobacterioses occur in the nail unit and cannot be diagnosed on clinical grounds alone.
- Fungal nail infections are extremely common. Independent of the pathogen, the clinical types look similar; hence cultural identification is warranted.
- Leishmaniasis can present as ulcerating paronychia.
- Nail infestation by *Sarcoptes scabiei* is very often overlooked as it may mimic psoriasis or acrokeratosis paraneoplastica of Bazex; it is refractory if not treated correctly and often the source of reinfection and small institutional epidemics.

VIRAL INFECTIONS

A variety of viruses may infect the nail and periungual skin and cause skin lesions that are sometimes different from what is seen on normal skin.

HERPES VIRUS INFECTIONS

The most important Herpesviridae affecting the nail are herpes simplex virus Type 1 (HHV1), Type 2 (HHV2), varicella-zoster virus (HHV3), and HHV8 found in Kaposi sarcoma.

Herpes Simplex of the Nail Apparatus—Clinical Features: The primary herpes simplex infection rarely causes nail lesions although virus inoculation may take place during the disease in finger-sucking babies. Recurrent digital herpes simplex is occasionally seen in children, adolescents, and in certain professions, such as dentists (before they started routinely wearing gloves). Small vesicles are seen to develop that first have a clear content, which, after some days, becomes yellowish while the blisters tend to merge (Fig. 91-47). From the beginning, a visible red streak is commonly seen extending from the finger to the arm; this lymphangitis is usually associated with pain. After 7 to 10 days, the tenderness decreases, and the blister content may turn hemorrhagic and finally dry. After 2 to 3 weeks, the blister roof sheds.

Herpes Simplex of the Nail Apparatus—Etiology and Pathogenesis: In children, recurrent digital herpes simplex is usually caused by HHV1 whereas in adults, HHV1 and HHV2 are the causative agents, with each being the cause in approximately 50% of patients.

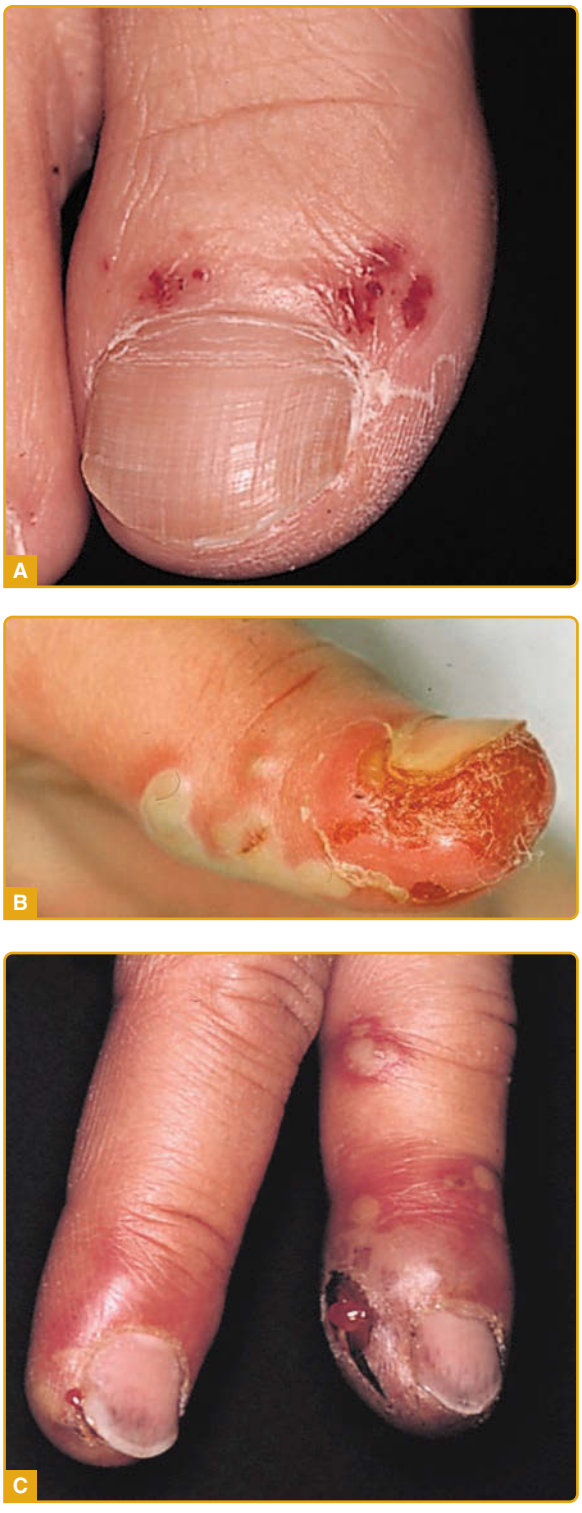

Figure 91-47 Recurrent herpes simplex of the toe (**A**), thumb (**B**), and fingers (**C**).

Herpes Simplex of the Nail Apparatus—Diagnosis: The diagnosis is made clinically by an experienced dermatologist. A classical Tzanck smear is helpful in the early stage. Immunofluorescence

with specific HHV antibodies not only confirms the diagnosis but may also distinguish infections caused by HHV1 from those caused by HHV2. Immunohistochemistry with HHV1 and HHV2 antibodies on histologic sections is also positive. Polymerase chain reaction is another option. However, when the lesion is too old, all tests may fail.

Herpes Simplex of the Nail Apparatus—Differential Diagnosis: Acute paronychia, bullous impetigo (runaround), whitlow (felon), and other bacterial infections have to be considered as part of the differential diagnosis. However, the repetitive nature of digital herpes simplex and its painful course are typical.

Herpes Simplex of the Nail Apparatus—Disease Associations: Severe and even ulcerative herpes simplex is seen in immunocompromised individuals.

Herpes Simplex of the Nail Apparatus—Clinical Course, Prognosis, and Management: Recurrent digital herpes simplex is frequently misdiagnosed as an acute paronychia. The patients consult their family physician or a surgeon who treat it as an acute whitlow by opening the blisters, disinfection, antiseptic baths, systemic antibiotics and splinting of the digit. Only after repeated recurrences may the patient be referred to a dermatologist who can make the diagnosis from the clinical course. Recurrences may come in waves: several waves in relatively short intervals that then become longer and finally turn into a herpes-free period for several months or even some years until the recurrences restart. There are no controlled studies proving the value of long-term antiviral prophylaxis.

Varicella and Herpes Zoster: Varicella may involve the nail region with a few characteristic vesicles, and herpes zoster may, although rarely, extend to the distal digits. The diagnosis is made from the skin lesions (Fig. 91-48). However, onychomadesis was observed in children several weeks after chickenpox; it may be assumed that unnoticed viral blisters of the matrix were the cause. Treatment follows the general rules of HHV3 therapy.

Figure 91-48 Generalized verrucous herpes zoster in a patient with advanced Hodgkin disease.

HUMAN PAPILLOMAVIRUS INFECTIONS

Clinical Features: Common warts belong to the most frequent infections of humans. On the proximal nailfold, they are round papules with a rough keratotic surface; on the lateral folds they are often oval (Fig. 91-49). Subungual warts have an unspecific appearance often lifting the nail up and they are commonly painful. Under the proximal nailfold they raise it from the underlying nail and cause a marked swelling. At the hyponychium there may just be a rim-like thickening of the keratin that swells after 5 minutes in water.

Etiology and Pathogenesis: Infection with HPV types 1, 2, 3, 4, and 7 is the most common cause for viral warts of the nail unit. It is believed that infectious virus particles get into the epidermis via microwounds; however, how this exactly happens is still not fully understood.

Diagnosis: The diagnosis of viral warts is clinical. Histopathology is characteristic in young warts, but may be very inconspicuous in old ones. Immunohistochemistry with an antibody against a common papillomavirus antigen can be helpful. Serologic studies do not help. Polymerase chain reaction and in situ hybridization help to identify the HPV type.

Differential Diagnosis: The differential diagnosis of ungual warts is extensive and depends also on the localization within the nail unit. Subungual warts, particularly when painful, may be mistaken for a subungual exostosis. Other subungual tumors and inflammatory processes may have to be considered.

Figure 91-49 Viral warts of the hyponychium and nailfolds.

Disease Associations: Periungual warts are common in children and adolescents. However, severe immunodeficiency states and iatrogenic immunosuppression may be associated with innumerable warts in many locations.

Clinical Course, Prognosis, and Management: It is said that the average life span of a banal wart is approximately 2 years. However, clinical experience shows that periungual warts—like palmar and plantar ones—often exist much longer and may give rise to new ones during this period. They often grow very fast to a certain size and then remain stable for many months or years. The prognosis is good as the no-risk HPV types do not progress to carcinoma.

Management of periungual and subungual warts is difficult. There are surprisingly few randomized controlled studies, but they all show that aggressive keratolysis with salicylic acid is superior to wait-and-see. Salicylic acid plus cryotherapy is more efficacious than cryosurgery alone. Second-line treatments are laser, either ablative with CO_2 laser or with nonablative lasers. One regimen using the pulsed-dye laser to coagulate the vessels to the wart has been shown to be efficacious in more than two-thirds of cases. A variety of immune therapies, such as contact allergens and different vaccines, have been used with variable effect. Imiquimod may be tried off-label after aggressive keratolysis; however, the 3-times weekly regimen recommended for condylomata acuminata is not enough for ungual warts. Here, a daily treatment under occlusion is necessary, eliciting a marked inflammatory reaction. Third-line treatments comprise compounded cidofovir as a topical therapy; however, cidofovir is very expensive and therefore rarely used except in cases of an excessively large number of ungual warts.

ENTEROVIRUS INFECTIONS

A variety of different enteroviruses may cause periungual erythema; however, this is not specific enough to allow a particular diagnosis to be made. The most characteristic infection is hand-foot-and-mouth disease.

Clinical Features: Hand-foot-and-mouth disease is a vesicular disease characterized by intraoral aphthoid lesions that cause less discomfort than common aphthous ulcers, with small vesicles on the palms, soles, and around the nails (Fig. 91-50). They are usually oval in shape, the covering epidermis is gray from necrosis, and surrounded by a narrow erythematous rim. In ridged skin, the long axis of the vesicles is along the dermatoglyphics. Mild fever may be present in the beginning. Small outbreaks of this infection typically occur in spring and autumn. Many infections remain virtually asymptomatic and escape notice.

After approximately 6 weeks, some patients develop onychomadesis of single nails, probably as a sign of direct matrix involvement.[26]

Etiology and Pathogenesis: In most cases, the cause of hand-foot-and-mouth disease is an infection with enterovirus Type 71 and Coxsackieviruses, mainly Types A5 and A16, and rarely B or other enteroviruses. The infected cells swell, necrose, form a reticular, and, finally, a multilocular vesicle. After some days, this dries out and leaves a dry scab of necrotic epidermis and serum.

Figure 91-50 Hand-foot-and-mouth disease.

Diagnosis: The characteristic slightly oval vesicles with a gray blister roof and a narrow red margin, together with oral lesions reminiscent of aphthous ulcers, permit the diagnosis to be made. Serology may confirm the serotype.

Differential Diagnosis: As skin vesicles may be scarce the oral mucosal lesions may be mistaken for viral lesions of other enteroviruses, for example, herpangina.

Disease Associations: There are no characteristic disease associations.

Clinical Course, Prognosis, and Management: The clinical course is self-limited. The vesicles usually disappear within 7 to 10 days. The prognosis is good. There is no specific antiviral therapy.

BACTERIAL INFECTIONS

Most bacterial infections are caused by streptococci or staphylococci. Enterobacteria are mainly seen in toes. Clinical variants of impetigo are the most common bacterial infections. Paronychias and whitlows are also seen.

COCCAL INFECTIONS

Clinical Features: The most characteristic bacterial infection is a bullous impetigo (Fig. 91-51) that runs around the proximal part of the nail, hence the common term *runaround*. It starts with a clear blister of the proximal and lateral nailfold that soon becomes putrid and often also hemorrhagic. Pain is usually mild. Extension under the nail is exceptional in adults, but may occur in children and is seen as a yellowish lake of pus under the nail. It is commonly painful.

Figure 91-51 Bullous impetigo of the nailfold, so-called runaround.

When the infection occurs primarily under the nail it is called a subungual whitlow. It exhibits the features of an abscess. Deep soft-tissue infections cause considerable pain and are usually treated by surgeons with incisions and pus evacuation.

Etiology and Pathogenesis: Most of these infections are caused by staphylococci, rarely by streptococci. Subungual *P. aeruginosa* infections are rare. Small lacerations often from hangnails and other minor wounds are the portal of entry.

Diagnosis: The course of the infections is sufficiently characteristic to make the correct diagnosis. Bacterial swabs may confirm the infection.

Differential Diagnosis: The main differential diagnosis is recurrent digital herpes simplex, which is more painful, develops a lymphangitis, and starts with a group of small clear blisters that coalesce and later becomes putrid.

Disease Associations: There are no specific disease associations.

Clinical Course, Prognosis, and Management: When treated early the lesions disappear within 1 to 2 weeks. The prognosis of most cases is excellent. Uncomplicated bullous impetigo of the nail is treated with opening of the blister, disinfective baths twice a day, and antimicrobial creams. However, extension under the nail, particularly in children, should immediately prompt institution of systemic *Staphylococcus*-fast antibiotics that may be changed according to the sensitivity profile of the bacteria cultured from a swab. This is essential as the matrix in children may be permanently damaged within 24 to 48 hours in a subungual whitlow.

PSEUDOMONAS INFECTION

Clinical Features: *P. aeruginosa* is a ubiquitous pathogen quite frequently seen in the nail apparatus. Most cases are colonizations causing a green to brownish-black nail and often a localized marginal paronychia as evidenced by circumscribed swelling and loss of the cuticle (Fig. 91-52). Deep infections are rare in immunocompetent subjects.

Etiology and Pathogenesis: The dorsal and ventral surfaces of the nails may be severely colonized by *P. aeruginosa,* which can form a bacterial biofilm.

Diagnosis: The greenish color of the nail is very characteristic so that bacterial cultures are usually not needed to make the diagnosis. The color can be scraped off in most cases, but soon returns if the bacteria are not addressed.

Differential Diagnosis: Both exogenous and other enterobacteria causing a grayish discoloration, particularly *Klebsiella* spp. and *Proteus* spp., may have to be considered.

Disease Associations: It appears that coinfection with yeasts and/or dermatophytes makes the nails more susceptible to *Pseudomonas* colonization.

Clinical Course, Prognosis, and Management: The clinical course is chronic with insidious aggravation. The prognosis for the immunocompetent is very good. However, these individuals should not work as doctors or nurses in newborn, cancer, or gnotobiotic units, or as scrub nurses in the surgical theater as they can spread their infection. It is also advisable that they do not work in the food industry, in bakeries, butcheries, or other professions with direct contact with foods, such as chefs. The management is usually not complicated. Baths with diluted white vinegar 2 or 3 times a day for 5 to 10 minutes, then brushing the digits dry, are often sufficient. This may be completed with a topical antimicrobial drug or

Figure 91-52 *Pseudomonas aeruginosa* colonization of the nail in a patient with an onychomatricoma.

disinfective. Topical antibiotics like gentamycin may be used in addition. Systemic antibiotics are not the first choice for 2 reasons: (a) the bacterial biofilm is approximately 1000 times less sensitive to antibiotics than isolated bacteria of the same species, and (b) the green nail is almost always onycholytic, thus not in contact with the nail bed so that the antibiotic cannot reach the biofilm. Ciprofloxacin, levofloxacin, and polymyxin B show the highest activity against *Pseudomonas*, followed by gentamicin and ofloxacin, whereas the bactericidal antibiotic cefuroxime and the bacteriostatic antibiotic chloramphenicol are less active.

FUNGAL INFECTIONS

The nail apparatus is an extremely frequent site of infection for a great variety of different fungi. They may cause various acute, subacute and chronic infections. Fungal infections may be classified according to their pathogens into dermatophyte, yeast, and nondermatophyte mold infections, according to their time course (acute, subacute, subchronic, chronic), and, above all, according to their mechanism of infection (Table 91-6).

Onychomycoses affect toenails 7 to 10 times more frequently than they affect fingernails, which is thought to be attributable to the 3 times faster growth of fingernails as compared to toenails.

CLINICAL FEATURES

Onychomycoses are often seen as the most frequent nail disorders making up approximately 40% to 50% of all nail diseases. The vast majority are distal or distal–lateral subungual onychomycoses (Fig. 91-53). In the beginning, there is a distal subungual keratosis with an irregular border toward the nail bed. This slowly and insidiously progresses proximally while the nail may become discolored, nontransparent, and break distally. After some months or years, there is often no more progression but

TABLE 91-6
Onychomycosis Facts

Onychomycoses According to Pathogens
- Dermatophytes
- Yeasts
- Nondermatophyte molds

Onychomycosis According to the Entry of the Fungi
- Distal and distal–lateral subungual onychomycosis
- Proximal white subungual onychomycosis: with/without paronychia
- Superficial white/black onychomycosis: superficial form, deep form
- Endonyx onychomycosis
- Total dystrophic onychomycosis: secondary to any of the above forms, primary in chronic mucocutaneous candidiasis

Most Important Differential Diagnoses
- Nail psoriasis, asymmetric gait nail unit syndrome, chronic nail dystrophy in the elderly, in chronic venous insufficiency, in impaired arterial circulation, ungual lichen planus, eczema

Figure 91-53 Distal–lateral subungual onychomycosis.

the subungual hyperkeratosis may continue to thicken. Often, there is a mild and inconspicuous desquamation around the nail or even an obvious tinea pedis is observed. Sometimes, a yellow streak develops that is formed like a narrow wedge in proximal direction. The lateral edge of the nail is frequently onycholytic.

Superficial white onychomycosis is a condition mostly seen on the toenails as chalky-white patches with no shine of the nail surface (Fig. 91-54). When

Figure 91-54 White superficial onychomycosis, caused by *Fusarium* spp, of the toe in an immunocompetent person.

Figure 91-55 Superficial white onychomycosis caused by *Trichophyton rubrum* in an AIDS patient.

occurring on fingernails, the white discoloration is inhomogeneous and more cloudy, but the nail surface remains shiny; this is the typical form of HIV infections (Fig. 91-55).

Proximal subungual onychomycosis is also rare. Clinically, it is seen as a white to yellowish discoloration of the nail that grows out from under the proximal nailfold (Fig. 91-56). The plate may be onycholytic under the whitish area. Repeated arched white lines are seen as recurrences from an internal focus.

Endonyx onychomycosis is a rare form in which the fungus only grows in the nail plate without affecting the subungual tissue. The nail is nontransparent, discolored, and dermatoscopy may show air-filled channels in the nail plate.

All these different onychomycoses may lead to total dystrophic onychomycosis where the nail is substituted by irregular keratotic debris full of fungi. Primary total dystrophic onychomycosis is characteristic for chronic mucocutaneous candidiasis (Fig. 91-57), which represents a group of immune defects with impaired defense against *Candida albicans*. Chronic oral lesions, involvement of the scalp and other regions, and granulomatous lesions coexist.

Figure 91-56 Proximal white subungual onychomycosis.

Figure 91-57 Total dystrophic onychomycosis in a 10-year-old boy with chronic mucocutaneous candidiasis.

ETIOLOGY AND PATHOGENESIS

The most common causes of onychomycoses are dermatophytes, particularly *Trichophyton rubrum*, *Trichophyton mentagrophytes* var *interdigitale*, much more rarely *Epidermophyton floccosum*, *Trichophyton violaceum*, and *Trichophyton soudanense*. In warm climates, *C. albicans* can cause a clinically identical nail infection as it has enzymes that also degrade keratin. Other yeasts may be found, but their pathogenic role is often not clear. Nondermatophyte molds were mainly seen in tropical climates but are now emerging pathogens in Central Europe.

The pathogenesis is characteristic for each of the onychomycosis forms described. The pathogenic fungus grows from the tip of the digit through the hyponychium toward the nail bed in *distal–lateral subungual onychomycosis*. The nail bed reacts with a hyperkeratosis that harbors the vast majority of the fungi, whereas the overlying nail plate is a barrier for the fungi rather than their site of infection. When the fungus advances proximally, an inflammatory infiltrate develops in the nail bed and epithelium with accumulations of neutrophils very similar to Munro microabscesses; however, there is much less parakeratosis in onychomycosis. Often, a yellow streak or narrow wedge is seen under the nail extending from the distal nail bed proximally. Here, huge amounts of compressed, mostly very thick-walled fungi are seen; this phenomenon is called *dermatophytoma*. In *proximal subungual (white) onychomycosis*, the fungus infects first the undersurface of the proximal nailfold via the cuticle and grows toward the matrix. When this is reached, the fungi are included into the newly formed nail substance and can be found in all layers of the nail plate. *Superficial white onychomycosis* is a rare form of infection of the dorsal surface of the nail plate. In temperate climates, it is mainly caused by *T. mentagrophytes*. Histologically, chains of small spores and, rarely, short slender hyphae are seen on the nail. When this infection extends under the proximal nailfold it may invade deeper layers of the nail plate. In HIV patients, fungi are seen directly under

the surface, showing both spores and short hyphae; they are commonly *T. rubrum*. *Endonyx onychomycosis* is a rare infection, mainly caused by *T. soudanense* or *T. violaceum* that are exclusively found within the nail plate. All these forms may progress to *total dystrophic onychomycosis*, although in a variable frequency. The nail is completely destroyed and substituted by irregular keratotic debris. The nail bed and matrix often show papillomatosis and acanthosis. Rarely, this is found as an acute infection.

DIAGNOSIS

Although most onychomycoses can be diagnosed clinically they should be confirmed by direct microscopy, after clearing of the subungual keratotic debris with 10% to 20% potassium hydroxide, culture, and histopathology. The rate of false-negative results, particularly for cultures, is very high, commonly between 30% and 60%, but histopathology has proved to be doubly sensitive. Furthermore, it can distinguish between colonization and true infection; however, species identification is not possible. Modern methods to confirm a fungal infection comprise polymerase chain reaction and matrix-assisted laser desorption/ionization–time-of-flight spectroscopy. These methods are expensive and require reference DNA and proteins, respectively.

DIFFERENTIAL DIAGNOSIS

Onychomycosis make up approximately 40% to 60% of all nail diseases. Consequently, it is frequently diagnosed without laboratory proof, risking that roughly 50% of the diagnoses are not correct. The most important differential diagnosis is nail psoriasis. Both are frequent, may involve the nails only, cause discoloration, loss of nail transparency, brittle nails, and subungual hyperkeratosis; however, the most frequent sign of nail psoriasis, the pits, are rare in onychomycoses. Onycholysis in psoriasis often has a brownish-reddish proximal margin corresponding to the salmon spot, which is not seen in onychomycosis. Dermatoscopy of this margin exhibits a proximal border that is irregularly serrated and was called the "aurora borealis" sign. Histologically, subungual hyperkeratosis and neutrophil accumulations in the subungual hyperkeratosis are seen in both conditions and called Munro microabscesses; in psoriasis, there is more parakeratosis around them, which is mostly arranged as obliquely ascending columns.

The "asymmetric gait nail unit syndrome" is a condition of toenails,[27] in which onycholysis usually affects 1 corner of the big toenail. It is a result of orthopedic abnormalities leading to rubbing and pressure against shoes. It is very often confounded with onychomycosis, but regularly negative for fungi in all laboratory tests. Additional important differential diagnoses are nail lichen planus, nail eczema, trachyonychia, pityriasis rubra pilaris, nail changes in cutaneous lymphomas, and, above all, nonspecific nail dystrophy in the elderly, persons with chronic venous and lymphatic stasis, peripheral neuropathy, impaired arterial blood supply, and repeated trauma in sportsmen like soccer players, particularly when the big toenails are involved.

DISEASE ASSOCIATIONS

Onychomycoses are usually associated with tinea of the hand and/or feet. They are more frequent in patients with nail psoriasis. Particularly severe and fast progressing onychomycoses are observed in immunosuppression. Peripheral neuropathy, arterial and venous insufficiency, and traumatically damaged nails are risk factors for onychomycoses and hence often associated. Onychomycoses are more frequently seen in diabetic patients. In the two-feet-one-hand syndrome, the tinea of both soles and 1 palm is very often accompanied by onychomycosis, most frequently *T. rubrum*. It is thought that scratching habits are the cause of the unilateral hand involvement.[28]

CLINICAL COURSE, PROGNOSIS, AND MANAGEMENT

Most onychomycoses run a chronic protracted course. For unknown reasons, they may stop progressing after years and remain virtually unchanged for decades if not treated. The prognosis as to the nail destruction is good in more than 90% of patients, and complete recovery, even after severe total dystrophic onychomycosis, is possible. In contrast to this, the management of most onychomycoses is still challenging. Any associated fungal skin infection has to be treated. Hygienic measures, such as regular disinfection of shoes and socks, wearing open shoes whenever possible, changing the footwear daily, and washing socks at 60°C (140°F) are of paramount importance. Infected nail material and subungual keratosis should be removed as much as possible. This can be accomplished with a nail clipper and later with the application of 40% urea paste under occlusion for 3 to 5 days. This softens the infected keratin and allows it to be scraped off atraumatically. Usually, this procedure has to be repeated 2 or 3 times. Surgical nail avulsion should be abandoned as it represents a severe iatrogenic trauma to the nail apparatus, rendering it more susceptible to fungal infection. In cases of less than 50% involvement of the nail or when the matrix is not affected, topical treatment with 8% ciclopirox lacquer (Penlac), 10% efinaconazole (Jublia) and 5% tavaborole (Kerydin) solution or 5% amorolfine (Loceryl, not marketed in the United States) follows for many months, including some months beyond clinically visible clearing. However, even the new antifungal drugs have complete cure rates lower than 20%. When more than 50% of the nail is affected or the infection reaches the matrix at any point, systemic treatment is indicated. Dermatophytes respond best to terbinafine (Lamisil) 250 mg daily, whereas yeasts and some nondermatophyte molds are better treated with itraconazole 400 mg/day for 1 week

TABLE 91-7

Onychomycosis Treatments Approved by the U.S. Food and Drug Administration and Their Response Rates

TREATMENT MODALITY	INDICATION	MYCOLOGIC CURE	COMPLETE CURE
Ciclopirox 8% lacquer	*Trichophyton rubrum* onychomycosis	29%, 36%	6%, 9%
Efinaconazole 5% solution	Dermatophyte onychomycosis	55%, 53%	18%, 15%
Tavaborole 8% solution	Dermatophyte onychomycosis	31%, 36%	7%, 9%
Itraconazole	Dermatophyte onychomycosis	63%, 66%	22%, 22%
Terbinafine	Dermatophyte onychomycosis	60%	46%, 44%
Neodymium:yttrium-aluminum-garnet (Nd:YAG) laser	Temporary increase in clear nail	11%	–

Compiled from Gupta AK, Versteeg SG, Shear NH. Onychomycosis in the 21st century: an update on diagnosis, epidemiology, and treatment. *J Cutan Med Surg*. 2017;21:525-39.

every 4 weeks. This pulse therapy has been shown to be at least as efficacious as continuous itraconazole 200 mg/day. Fluconazole was given once at 150 mg per week, but this dose appears to be too low for individuals weighing more than 70 kg (154 lbs). Controlled trials have shown that the combination of topical plus systemic treatment can reduce the failure rate of systemic therapy alone by 50%.[29] Nevertheless, even combined treatments have cure rates not better than 70% to 75%. Results of combined treatment with systemic and the new antifungals are not yet available. Lasers were approved by the U.S. Food and Drug Administration for the temporary increase in clear nail. Their mycologic cure rate was 11% with no complete cure rates given. Photodynamic treatment of onychomycoses is still in an experimental phase (Table 91-7).

Recurrences are very frequent. The reasons may be the persisting risk factors including the hereditary susceptibility to fungal nail infection and the potential to reinfect in the own household and public sports facilities.

NAILS IN GENERAL DISEASE

Nail alterations in systemic diseases usually affect all digits but they may vary in intensity according to the growth characteristics of the individual nails.

CARDIOVASCULAR AND PULMONARY DISEASES

Clubbing is a characteristic sign of chronic hypoxemia and thus frequently indicates a cor pulmonale. The finger tips and often also the toe tips are enlarged, giving the look of a drumstick. The nail size is increased and both the longitudinal and transverse curvatures are more pronounced so that the nail is round like a watch glass (Fig. 91-58). Quite often, the lunula is very big. Nail bed and lunula are cyanotic. The angle between the proximal nailfold and the nail plate (angle of Lovibond) is greater than 180 degrees. When the 2 opposite fingers are held together, there is a narrow lozenge space between the proximal nail areas in normal persons whereas this diamond-shaped window is absent in clubbed nails, and the angle between the free nail margins is greater than 30 degrees (Schamroth sign). In addition, many other conditions are associated with clubbing (Table 91-8). Unilateral clubbing may hint at arterial insufficiency of this extremity. The cause of clubbing is still not known, but the prevailing hypothesis is that megakaryocytes are incompletely degraded to normal-size platelets in the lungs and may strand in the capillary network of the digits where they disintegrate and release their various growth factors.

Splinter hemorrhages were once seen as an indicator of bacterial endocarditis. However, there is a plethora of other associations.

Yellow nail syndrome (YNS) is a characteristic triad of signs: yellow, thick, extremely slow-growing nails with onycholysis, often also spontaneous nail loss and complete disappearance of the cuticle (Fig. 91-59), chronic sinus-bronchopulmonary infection and edema of the distal extremities. Chronic GI diseases and a variety of internal cancers also have been observed in association with the yellow nail syndrome.

Figure 91-58 Clubbing in a patient with trisomy 21 and Eisenmenger complex.

TABLE 91-8
Causes of Digit Clubbing

Cardiovascular
- Cor pulmonale
- Cardiac insufficiency
- Open foramen ovale, Eisenmenger complex
- Aortic aneurysm

Bronchopulmonary
- Chronic obstructive and suppurative pulmonary diseases
- Intrathoracic tumors
- Hypertrophic pulmonary osteoarthropathy

Gastrointestinal
- Hepatic disorders
- Inflammatory bowel diseases
- Polyposis intestini
- GI neoplasms
- Bacillary and amebic dysentery

Blood Dyscrasias
- Chronic methemoglobinemia (eg, in heavy smokers)

INTESTINAL AND HEPATIC DISEASES

Most nail changes seen in malnutrition, anorexia nervosa, bulimia, or kwashiorkor are nonspecific: the nails may be thin, brittle, and have lost their shine. In acrodermatitis enteropathica and acquired zinc deficiency there are often periungual erosions with crusting, the nail edges may break through the epidermis of the nail grooves and cause granulation tissue (Fig. 91-60). Very similar lesions are seen in glucagonoma dermatitis.

In severe liver disease, the nails may turn white and opaque. In Terry nails, a distal normal-colored band remains. Muehrcke lines are 2 parallel white bands in the middle of the nail bed that do not move out and are seen in severe hypoalbuminemia.

The nails may turn bluish in Wilson disease.

Figure 91-59 Yellow nail syndrome.

Figure 91-60 Acrodermatitis enteropathica with blisters and erosions on the periungual skin.

UROGENITAL DISEASES

So-called half-and-half nails are seen in chronic renal insufficiency and under long-term hemodialysis. The proximal half of the nail is whitish, the distal half tends to be brownish (Fig. 91-61).

AMYLOIDOSIS

Systemic amyloidosis may have profound effects on the cutaneous appendages including the nails. They insidiously become thinner, fragile, ridged, and lose their shine, resembling late ungual lichen planus (Fig. 91-62). Subungual hemorrhage may occur.

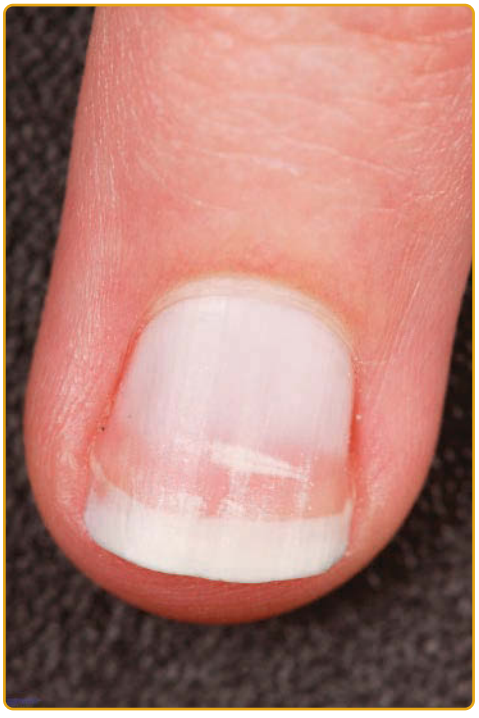

Figure 91-61 Half-and-half nail in a patient with renal insufficiency.

Figure 91-62 Severely dystrophic nails in systemic amyloidosis.

PSYCHOLOGICAL DISORDERS

A number of autoaggressive nail conditions are known that are commonly described as psychological disorders. Some are extremely frequent, such as chewing of the nails (onychophagia), picking of the periungual skin (perionychotillomania) and habitual pushing back of the cuticle and pressing on the lunula with another fingernail. *Onychophagia* is frequent in children, but it often lasts into adulthood (Fig. 91-63). *Perionychotillomania* is more a condition of adults who continuously pull off hangnails and other tiny skin tags. This habit tic results in a central depression of the nail with a washboard aspect, an unusually long lunula and loss of the cuticle (Fig. 91-64). This must not be confused with the *Heller's median canaliform dystrophy* of the thumb nails, which is characterized by a median split in the nail plate that starts in the proximal portion, extends distally, and typically shows oblique furrows running proximally on both sides, thus giving the aspect of a Christmas tree (Fig. 91-65). Trauma is also the main cause. More-severe autoaggressive behaviors are *onychoteiromania* where the nails are virtually rubbed away, *onychotillomania* where the nail is pulled out in pieces (Fig. 91-66), and *onychotemnomania* where a cutting device is used to remove all the nail. *Onychodaknomania* is a frankly psychotic behavior; the patients bite on their nails in the lunula or proximal nail bed region to produce pain. Many of these patients have a deprivation syndrome.[30] All these behavioral abnormalities are difficult to treat. Psychological support may be necessary. *N*-acetyl cysteine in a dose of 1800 to 2400 mg/day has been successfully used in a number of obsessive-compulsive disorders, including autoaggressive nail conditions. Nail chewing may spread periungual warts and lead to melanocyte activation with the development of brown streaks in the nails.

Figure 91-63 Onychophagia.

INTOXICATIONS

High doses of arsenic cause transverse white nail discoloration. The high arsenic content is important for medicolegal reasons. Cadmium and other heavy metals, as well as many drugs, can be recovered from nails many months after their intake. Toxic doses of vitamin A are destructive of the nail.

DRUG REACTIONS

Some drugs cause characteristic, although rarely specific, nail alterations (Table 91-9). They are most often observed under the treatment with cytostatic drugs. They may cause white lines, Beau lines, or onychomadesis, with the white lines being the least-severe and onychomadesis being the most-severe form of a similar reaction pattern, namely, growth retardation. Brown nail pigmentation may occur and represents an activation of matrix melanocytes. Taxanes cause painful subungual hemorrhagic abscesses that may require withdrawal of the drug. The use of frozen gloves and socks may partially prevent these adverse effects. Targeted anticancer therapies, particularly with epidermal growth factor receptor inhibitors and multiple kinase inhibitors, render the skin very fragile, leading the nail edge to break through and cause granulation tissue that looks similar to pyogenic granulomas.

Figure 91-64 Perionychotillomania (habit tic): habitual pushing back of the proximal nailfold.

This phenomenon is also seen under therapy with indinavir, a reverse transcriptase inhibitor, and retinoids. Retinoids are also associated with fragile nails and paronychia. Beta-blockers induce acral ischemia. Bleomycin may also lead to digital ischemia, and permanent nail loss was repeatedly seen after bleomycin treatment of periungual warts. Photochemotherapy with psoralens and ultraviolet A can induce multiple longitudinal brown streaks in several nails. Photoonycholysis is rarely seen during administration of some tetracyclines and fluoroquinolones, as it is painful,

Figure 91-65 The Heller's median canaliform dystrophy of the thumbnail.

may be hemorrhagic, and occurs in the central nail bed of 1 or more nails. Its pathomechanism remains dubious as the nail plate absorbs almost all ultraviolet B and more than 95% of ultraviolet A light, and the skin is often not affected. Acyclovir does induce longitudinal melanonychias.

GENODERMATOSES AFFECTING THE NAIL

Nail involvement in hereditary and congenital disorders is very frequent. Some are highly specific and characterize the genodermatosis, others are frequently seen, many may accompany other severe diseases.

PACHYONYCHIA CONGENITA

Pachyonychia congenita is a group of 5 molecular biologically well-defined diseases of cytokeratins *KRT6a*, *KRT6b*, *KRT6c*, *KRT16*, and *KRT17*. Its traditional

Figure 91-66 Onychotillomania.

TABLE 91-9
Drug-Induced Nail Alterations

Cytostatic and Targeted Therapies
- White lines
- Beau lines
- Onychomadesis
- Muehrcke lines
- Hemorrhagic onycholysis and subungual abscesses
- Melanonychia
- Granulation tissue

Bleomycin
- Permanent nail loss

Reverse Transcriptase Inhibitors
- Granulation tissue

Acyclovir
- Melanonychia

β-Blockers
- Digital ischemia
- Lichenoid-psoriasiform changes

Retinoids and High-Dose Vitamin A
- Brittle nails
- Paronychia
- Granulation tissue

Photochemotherapy with Psoralens and Ultraviolet A
- Melanonychia
- Photoonycholysis

classification into Type 1 Jadassohn-Lewandowsky syndrome and Type 2 Jackson-Lawler syndrome has now been abandoned as there were too many overlaps. Clinically, pachyonychia congenita shows painful callus-like palmar and plantar hyperkeratoses, monstrous thickening of the subungual hyperkeratosis that is covered by a horseshoe-like nail usually of normal thickness (Fig. 91-67), oral leukokeratosis with no potential for malignant degeneration, natal teeth, and vellus hair cysts. These cysts are mainly seen in *KRT17* and *KRT6a* mutations. Nail changes occur in more than 80% of the patients and develop during infancy. Whether a late-onset pachyonychia congenita exists is not yet clear. Virtually all nails are affected. They are dark, appear thick (although this is the subungual keratosis), and the nail itself is overcurved and difficult to trim.

Figure 91-67 Pachyonychia congenita.

ECTODERMAL DYSPLASIAS

By definition, any hereditary disorder involving at least 2 of the cutaneous adnexa—hair, nails, sweat glands, and teeth—are ectodermal dysplasias. Roughly 30 of the more than 200 ectodermal dysplasias are now molecular biologically defined. For clinical convenience, the ectodermal dysplasias are subdivided into hidrotic and hypohidrotic ectodermal dysplasias. The most frequent ectodermal dysplasias are characterized by hair and nail involvement with normal sweat gland function and normal teeth, particularly the Clouston type, with dysplastic nails that often exhibit distally increasing plications, and are short, thickened, or brittle (Fig. 91-68). Three types of hypohidrotic ectodermal dysplasias are known, autosomal recessive, X-linked recessive, and autosomal dominant. Clinically, they

Figure 91-68 Hidrotic ectodermal dysplasia with folded nails.

present with hypoplastic nails, hypodontia, hypotrichosis, and inability to sweat adequately, which renders the babies at risk for hyperthermia when they are kept too warm. Frontal bossing and the characteristic midface hypoplasia give the affected individuals a very similar appearance, even when they belong to different races.

BULLOUS EPIDERMOLYSIS GROUP

There are 3 distinct, large groups of hereditary bullous epidermolyses: simplex, junctional, and dystrophic. Nail lesions in the simplex types are rare, but are quite common in the course of the junctional and dystrophic bullous epidermolyses. Anonychia is the consequence of repeated blistering of the nail organ and leaves smooth digit tips covered with a shiny epidermis. One dystrophic epidermolysis bullosa is characterized by predominant nail lesions and hence called the nail type (Fig. 91-69). It may be identical with epidermolysis bullosa pruriginosa and pretibial epidermolysis bullosa. The big toenails are dystrophic and thickened; later the other toenails may follow. A pretibial reticular hyperkeratosis with tendency to develop blisters, and often itch, may be seen.

Figure 91-69 Epidermolysis bullosa hereditaria dystrophica ("epidermolysis pruriginosa").

NAIL-PATELLA SYNDROME

Nail-patella syndrome is caused by a mutation in the homeobox gene *LMXB1*, which is necessary for the anterior–posterior orientation during organogenesis. In nail-patella syndrome, nail involvement is characterized by hypoplasia, which is more marked on the thumbs, decreasing toward the fifth digit, and on the medial side of the nail. The lunula exhibits a triangular shape. The patella is hypoplastic or may be absent. Radiographs often show iliac horns. There may be eye involvement and a severe membranous glomerulopathy with protein loss.

DYSKERATOSIS CONGENITA

Dyskeratosis congenita is characterized by pigmentary abnormalities of the skin, nail dystrophy, oral leukoplakias with a tendency to malignant degeneration and severe immune deficiency that is similar, but not identical, to Fanconi anemia.

DISEASES OF CORNIFICATION

The group of *ichthyoses* is now called mendelian disorders of cornification. Nail changes are rare and not specific, such as rough nails and loss of surface shine.

Severe subungual hyperkeratoses similar to those of pachyonychia congenita were observed in a case of *epidermolytic palmar plantar keratosis*; however, the affected nail also exhibited a fungal infection, which might have triggered the hyperkeratosis (Fig. 91-70).

Figure 91-70 Epidermolytic keratosis palmaris et plantaris with nail involvement.

CONGENITAL MALALIGNMENT OF THE BIG TOENAIL

Congenital malalignment of the hallux nail, first described as congenital nail dystrophy, is a fairly common condition. The child may be born with normal nails and develop the condition later, or the nails may be abnormal at birth. Apparently, the disorder can also appear later in life, precipitated by a trauma in an individual with lateral deviation of the distal phalanx of the hallux. Sometimes only one side is affected. Identical twins may have identical unilateral involvement. In classical cases, the affected nail is triangular, thickened, oyster shell–like, discolored, and onycholytic. There is a false distal nailfold and a considerably shortened nail bed (Fig. 91-71). The degree of onycholysis and nail bed shrinkage determine the chances of spontaneous resolution and also of any type of treatment. If resolution has not started by the age of 2 years, it will likely not occur. Symptoms are rare and the children are often only presented to the dermatologist around puberty when the ugly nails are seen as an esthetic problem. Systematic radiographic examinations in more than 40 of our patients have shown that there is virtually always a lateral deviation of the distal phalanx called *hallux valgus interphalangeus*, a lateral deviation of the proximal great toe phalanx leading to classical hallux valgus, and a medial deviation of the first metatarsal bone because of an oblique distal surface of the first cuneiform bone. This forms an arch of the first ray, which self-perpetuates as a result of the action of the flexor and extensor hallux tendons. Early treatment by taping of this orthopedic abnormality is beneficial in those cases where the nail bed shrinkage, onycholysis, and distal nailfold are not too pronounced.

Figure 91-71 Congenital malalignment of the big toenail.

NAIL TUMORS

Tumors of the nail apparatus may originate from all tissue components present in the distal phalanx. Hence, more than 130 different tumors and tumor-like lesions under and around the nail unit have been described. Most of them are rare and their clinical appearance is often not pathognomonic. Analogous to the hair follicle, a few tumors are nail-specific, but these neoplasms have only been described since 30 years.

Tumors of the nail unit exhibit certain growth patterns that allow some of their components to be diagnosed. Tumors in the proximal nailfold exert pressure on the matrix, resulting in a furrow in the nail plate. Lesions under the matrix may cause bulging with increased curvature of one half of the nail. Nail bed neoplasms may cause onycholysis and elevation of the nail plate from the bed. Slow-growing benign tumors usually alter the nail shape, whereas fast-growing tumors may destroy the nail.

BENIGN NAIL TUMORS

Only the most important nail tumors are dealt with here.

EPITHELIAL AND FIBROEPITHELIAL TUMORS

Onychocytic Matricoma: First described under the name *subungual seborrheic keratosis*, this name has now been abandoned in favor of *onychocytic matricoma*.[31] Clinically, there is a longitudinal brownish to dirty-yellow lesion under the nail that shines through the plate. Looking under the free margin of the nail reveals a thickening of keratotic material (Fig. 91-72). Surgical removal demonstrates an acanthoma histologically made up of mainly basaloid cells. Round keratin inclusions are similar to squamous eddies but their keratinization mode is via a keratogenous zone like normal nail formation.

Figure 91-72 Onychocytic matricoma.

Onychomatricoma: More than 200 cases of onychomatricoma have been reported since its first description in 1992.[32] It is a fibroepithelial neoplasm originating from the matrix. The nail is thickened, funnel-shaped, yellow, striated, and may show splinter hemorrhages (Fig. 91-73). At the free end of the plate, small holes can be recognized. Dermatoscopy shows that the tunnels contain capillaries that may run a long distance distally in the nail; in rare cases they remain patent, and may cause bleeding upon nail trimming. This clinical appearance is caused by a densely cellular fibrous stroma with long filiform projections that are all covered with normal matrix epithelium extending into the nail. Thus the surface of nail-producing matrix is massively enlarged causing the nail thickening. Variants of this tumor are myxoid onychomatricoma and pigmented onychomatricoma, with pigmented onychomatricoma being an important differential diagnosis of subungual melanoma.

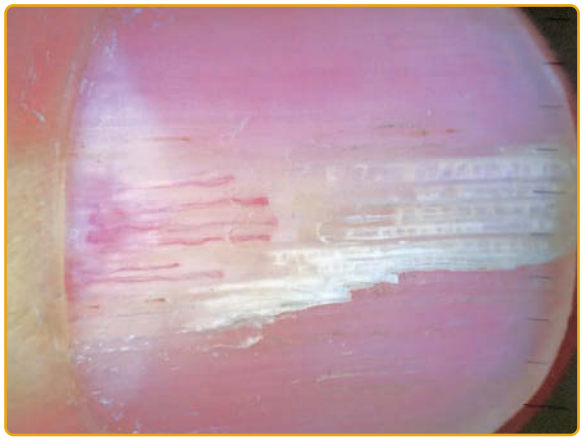

Figure 91-73 Onychomatricoma.

Figure 91-74 Onychopapilloma.

Onychopapilloma: This is another recently described nail-specific tumor that arises from the distal matrix and produces a thread of abnormal keratin. Clinically, it is seen as a whitish, ivory-colored, yellowish, reddish, or light-brown band of 4 to 8 mm in width in the nail, similar to onychocytic matricoma (Fig. 91-74). End-on dermatoscopy of the nail shows, however, a circumscribed thinning of the nail plate over the keratotic distal end of the onychopapilloma. Often, the nail tends to break here and a V-shaped onycholysis develops in the distal nail bed. Treatment is by tangential excision of the entire lesion from the hyponychium to the mid-matrix.[33]

Subungual Filamentous Tumor: Subungual filamentous tumor is clinically seen as a whitish to yellowish line of 1 to 2 mm that does not widen with time. The nail may show a short longitudinal fissure at its free margin. A tiny round keratotic tip is seen under the nail. Its relation to onychopapilloma is not clear.

Ungual Fibrokeratoma: Fibrokeratomas of the nail unit are quite common. They are sausage-like lesions with a keratotic tip. Most arise from under the proximal nailfold and remain lying on it causing a longitudinal groove (Fig. 91-75). When a fibrokeratoma originates from the mid-matrix, it grows within the nail

Figure 91-75 Fibrokeratoma of the nail.

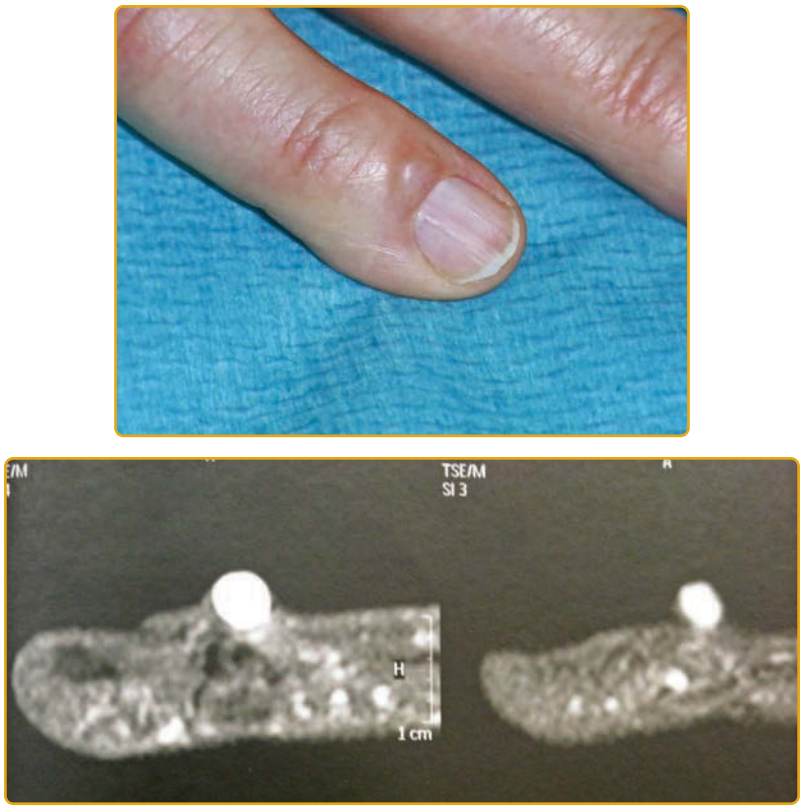

Figure 91-76 Myxoid pseudocyst in the proximal nailfold causing a longitudinal groove in the nail. In the magnetic resonance tomography, the content of the myxoid pseudocyst stands out due to its high water content. A connecting stalk is seen as a sinuous narrow band extending from the lesion to the joint.

plate until the overlying nail lamella breaks away and a sharply delimited groove remains. Subungual fibrokeratomas arise from the most distal matrix or nail bed and cause a ridge. Multiple ungual fibrokeratomas, so-called Koenen tumors, are a sign of the tuberous sclerosis complex and occur in approximately 50% of these patients after the age of 12 years. Treatment is by incision around the tumor down to the bone and extirpation.

Myxoid Pseudocysts: These lesions are very common pseudotumors of middle-aged and elderly individuals and were known as "dorsal finger cysts." Most occur in the proximal nailfold of the fingers, rarely on toes, where they exert pressure on the underlying matrix, resulting in a regular longitudinal groove (Fig. 91-76). When the lesion drains into the nail pocket the groove is very irregular, mirroring the periods of increased and released pressure. Subungual localization is rare and often seen as a violaceous lesion on one side of the matrix associated with hemi-overcurvature. Women are more frequently affected. Degenerative distal interphalangeal osteoarthritis with Heberden nodes is usually seen. Treatments vary from repeated punctures and expression of the viscous gelatinous mucin, to injection of steroids or sclerosants, infrared or laser coagulation, cryotherapy, and surgery. The recurrence rate is high except for the technique with intraarticular injection of methylene blue to visualize a potential connecting stalk to the joint, ligation of it, and meticulous extirpation of the myxoid material.

Glomus Tumor: Although rare, this is the best-known nail tumor because of its highly characteristic symptoms. Patients usually present with the complaint of an extremely painful digit tip. Clinical examination reveals a violaceous red spot under the nail of a finger, from which a reddish line may sometimes extend distally (Fig. 91-77). The slightest shock and cold precipitate the pain that radiates into the arm. Probing allows to exactly locate the tumor, but variable high-frequency ultrasound and magnetic resonance tomography may sometimes be needed. Treatment is by meticulous enucleation of the tumor and repair of the matrix and nail bed.

Figure 91-77 Glomus tumor.

Figure 91-78 Subungual exostosis of the big toe.

Figure 91-79 Bowen disease' of the nail.

Subungual Exostosis and Subungual Osteochondroma: Both lesions are often seen as being the same condition and are confounded, although there are important differences. Osteochondromas arise from the epiphysis region of the distal phalanx and have a hyaline cartilage cap, whereas subungual exostoses originate from the corona unguicularis, are thus more distal, and have a fibrous cap. The nail plate is lifted up by a stone-hard nodule that, in case of exostosis, has a characteristic collarette-like margin representing the former border of the hyponychium (Fig. 91-78). Most subungual exostoses occur in children and young adults, commonly the big toe. Trauma was thought to be the cause. The recent finding of a chromosome translocation suggests a true tumor nature; however, it is not clear whether the examined lesions were exostoses or osteochondromas. A radiograph confirms the diagnosis and helps to preoperatively estimate the extent of surgery.

MALIGNANT NAIL TUMORS

SQUAMOUS CELL CARCINOMA

Squamous cell carcinoma is the most frequent malignant neoplasm of the nail. Its in situ form is Bowen disease. Most commonly seen around fingernails, Bowen disease may clinically resemble a flat agglomeration of warts (Fig. 91-79). Paronychia may be associated. Melanonychia is a feature in dark-skinned persons and association with HPV56. Other high-risk HPV are HPV16, HPV18, and HPV35, but many more were found, hinting at a possible genitodigital transmission. Bowen disease is slowly and insidiously growing and may result in large irregular periungual areas of velvety, red and scaling skin. Extension under the nail to the nail bed and matrix are common, and leukonychia is characteristic for matrix involvement. Ulceration and crust formation indicate invasive growth (Fig. 91-80), which is, however, a late event. Bone invasion and metastases are rare in the Bowen type of squamous cell carcinoma, but occur in the common squamous cell carcinoma type. Treatment of choice is Mohs surgery, but amputation is required in case of bone invasion.

OTHER MALIGNANT NAIL TUMORS

Basal cell carcinoma is exceedingly rare in the nail unit.

Onycholemmal carcinoma is a very slow-growing subungual tumor that clinically presents as a longstanding oozing mass. The diagnosis is made by histopathology.

THE MELANONYCHIA PROBLEM

The challenging problem of brown nail pigmentation is dealt with here. This is important as nail melanoma is the most serious nail condition and the rate of misdiagnoses and diagnostic delays is very high.

BENIGN MELANONYCHIAS

A brown streaky pigmentation of the nail is called *longitudinal melanonychia* (LM). LM does not primarily

Figure 91-80 Bowen disease' of the nail with an invasive component.

TABLE 91-10
Differential Diagnosis of Longitudinal Melanonychia

Age at Onset
- Babies—benign
- Children—mostly benign
- Adolescents—probably benign
- Adults until age 30 to 35 years—suspicious
- Adults older than age 40 years—highly suspicious
- Adults older than age 50 years—probably melanoma

Color and Internal Structure of the Brown Band
- Regular light-brown band on a gray background—functional LM
- Regular brown band on a brown background—lentigo
- Regular brown band with dark brown spots on brown background—nevus
- Irregular brown band with asymmetric, unevenly spaced lines of variable length, proximal widening of the band—melanoma

include the type of pigment responsible for it. Bacterial, fungal, blood, and various exogenous pigments can cause band-like or diffuse brown to black nail pigmentations. It is the color itself, not its intensity, that is important; the internal architecture of a pigmented streak, its extension in the nail, whether it is associated with nail dystrophy or onycholysis, its time course and development, the patient's age, gender, skin type, and profession are all important for the evaluation of LM (Table 91-10).

Four lesion types can induce a true LM: *melanocyte activation* in the matrix results in functional melanonychia. This is the rule for LM in pigmented persons, including many children (Fig. 91-81), because of repeated trauma, such as friction or onychophagia, during pregnancy, under chemotherapy, and a variety of other drugs. A *matrix lentigo* is a numerical increase in melanin-producing cells (Fig. 91-82). A *matrix nevus* is characterized by the nest-like agglomeration of melanocytes in the matrix; most are seen in children and are junctional (Fig. 91-83). Pigmented *melanoma* of the matrix also causes LM (Fig. 91-84). None of the underlying pathologic processes can be safely distinguished on clinical grounds alone although dermatoscopy may help in certain respects. An LM with regular color and banding, symmetrical diameter, and no nail dystrophy is most likely benign. Periungual pigmentation in children may be a sign of a congenital nevus. LM in children and adolescents is commonly regarded as being benign. Particularly in children, an LM may fade with age, but rarely may become darker, particularly in children with skin types IV to VI. Although childhood nail melanoma is extremely rare, a single rapidly increasing LM in a light-skinned child is best excised. The tangential excision technique can prevent postsurgical nail dystrophy. It is recommended to tangentially excise all acquired matrix melanocyte proliferations in adults, and if parents insist, also in children. This approach and the growing awareness of nail melanomas among dermatologists have now led to fewer advanced nail melanomas among the author's patients.

Figure 91-81 **A,** Functional melanonychia in a dark skinned person. **B,** due to friction. **C,** drug-induced functional melanonychia.

UNGUAL MELANOMA

Nail melanoma is a subtype of acral melanoma. It makes up 1.5% to 2.5% of all melanomas in light-skinned individuals, 10% to 20% in Asians, and up to 25% in Africans, although the absolute numbers are very similar. With nails representing less than 1% of the body surface area the nail is overrepresented as a site for melanomas.[34] In fact, as subungual melanomas with melanonychia derive from the matrix, which represents only one-quarter to one-third of the nail field,

Figure 91-82 Melanonychia caused by a matrix lentigo.

this is a particular area of concentration of melanoma development.

The peak incidence of nail melanoma is from the fifth to seventh decades of life, but nail melanomas may occur in children and in the very old. There is no clear-cut gender predominance. Thumbs, big toes, index fingers, and middle fingers are the most common sites.

Figure 91-83 Melanonychia caused by a matrix nevus.

Figure 91-84 Matrix melanoma causing longitudinal melanonychia with irregular outline.

Periungual pigmentation is called the Hutchinson sign and represents periungual spread of the in situ component (Fig. 91-85). Most subungual melanomas are pigmented and start with an LM, which is irregular in contrast to benign LMs (see Table 91-10). Proximal widening indicates rapid growth of the lesion. Nail dystrophy is a sign of an advanced melanoma. Dermatoscopy helps to determine the internal structure of the LM and allows a micro-Hutchinson sign to be seen. Approximately 25% to 33% of nail melanomas are amelanotic and pose great diagnostic challenges (Fig. 91-86). They usually arise from the nail bed, cause onycholysis that may ooze, and are frequently misdiagnosed as a pyogenic granuloma, ingrown nail, or wart, or even onychomycosis. Unfortunately, even pigmented nail melanomas are usually diagnosed very late with a diagnostic delay of years to decades. This is why the prognosis of nail melanomas is so poor, with 5-year survival rates of 15% to 20% for invasive nail melanomas.

Diagnosis: A diagnostic algorithm considering several factors was proposed to facilitate the diagnosis of pigmented melanoma (Table 91-11); it is not useful for amelanotic melanomas and LM in children.[35]

Figure 91-85 Subungual melanoma with Hutchinson sign.

Figure 91-86 Amelanotic melanoma of the nail bed.

Treatment: Treatment of nail melanoma is by surgery. In situ and early invasive melanomas can be removed by wide local excision with preservation of the digit,[36,37] whereas distal amputation is recommended for advanced melanomas. Hutchinson sign responds to topical immunotherapy with imiquimod.[38]

Disease Associations: Ungual melanomas occur more frequently in those subjects with a personal or family history of melanoma. Ultraviolet exposure is not associated with nail melanoma. Histopathologically, there is a frequent association with multiple subungual onycholemmal cysts, which must not be mistaken for subungual squamous cell carcinoma.[39,40]

Clinical Course, Prognosis, and Management: As the diagnostic delay is often years or even decades many melanoma patients come late with advanced tumors, although this is exceptional in the author's practice. The list of misdiagnoses is long and often incomprehensible for an experienced dermatologist.

In situ and early invasive melanomas have a very good prognosis; however, advanced and metastatic melanomas have a 5-year survival rate of 15% to 24%.

TABLE 91-11

Diagnostic Algorithm for Nail Melanomas—The ABCDEF Rule

A—**A**ge: most ungual melanomas occur between 40 and 70 years of age; **A**frican **A**mericans, native **A**mericans, **A**sians: a higher percentage of nail melanomas

B—**B**rown to **b**lack **b**and in the nail, **b**readth over 3 mm, irregular or blurred **b**order

C—**C**hange: Rapid increase in width and growth rate, nail dystrophy does not improve despite adequate therapy; **c**olor

D—**D**igit: thumb > big toe > index finger; single-digit involvement; very rarely more affected

E—**E**xtension of pigmentation: Hutchinson sign

F—**F**amily or personal history of melanoma or so-called dysplastic nevi

There are no controlled studies concerning the efficacy of new targeted and immune checkpoint inhibitor therapies on nail melanoma, although there is no reason not to assume that they will have a similar activity.

Postoperatively, patients are seen for followup examinations at regular intervals, depending on tumor thickness and stage. It has to be stressed that ungual melanomas are not particularly aggressive and that it is the delay in diagnosis and treatment that makes their prognosis so poor.

REFERENCES

1. Haneke E. The double nail of the little toe. *Skin Appendage Disord*. 2015;1:163-167.
2. Peña-Romero AG, Domínguez-Cherit J, Guzmán-Abrego AC. Under-reported finding in acral erythema multiforme. *Indian J Dermatol*. 2015;60:636.
3. Molina-Hernandez AI, Diaz-Gonzalez JM, Saeb-Lima M, et al. Argyria after silver nitrate intake: case report and brief review of literature. *Indian J Dermatol*. 2015;60:520.
4. van de Kerkhof PC, Pasch MC, Scher RK, et al. Brittle nail syndrome: a pathogenesis-based approach with a proposed grading system. *J Am Acad Dermatol*. 2005;53:644-651.
5. Haneke E. Controversies in the treatment of ingrown nails. *Dermatol Res Pract*. 2012;2012:1-12.
6. Baumgartner M, Haneke E. Retronychia: diagnosis and treatment. *Dermatol Surg*. 2010;36:1610-1613.
7. Haneke E. Etiopathogénie et traitement de l'hypercourbure transversale de l'ongle du gros orteil. *J Méd Esth Chir Dermatol*. 1992;19:123-127.
8. Banga G, Patel K. Glycolic acid peels for nail rejuvenation. *J Cutan Aesthet Surg*. 2014;7:198-201.
9. McGonagle D, Tan AL, Benjamin M. The nail as a musculoskeletal appendage-implications for an improved understanding of the link between psoriasis and arthritis. *Dermatology*. 2009;218:97-102.
10. Morrissey KA, Rubin AI. Histopathology of the red lunula: new histologic features and clinical correlations of a rare type of erythronychia. *J Cutan Pathol*. 2013;40:972-975.
11. Marrakchi S, Guigue P, Renshaw BR, et al. Interleukin-36-receptor antagonist deficiency and generalized pustular psoriasis. *N Engl J Med*. 2011;365:620-628.
12. Abbas O, Itani S, Ghosn S, et al. Acrodermatitis continua of Hallopeau is a clinical phenotype of DITRA: evidence that it is a variant of pustular psoriasis. *Dermatology*. 2013;226:28-31.
13. Baran R, Rigopoulos D. *Nail Therapies*. London, UK: Informa Healthcare; 2012.
14. Scheinfeld NS. Trachyonychia: a case report and review of manifestations, associations, and treatments. *Cutis*. 2003;71:299-302.
15. Tosti Piraccini BM, Ghetti E, Colombo MD. Topical steroids versus systemic antifungals in the treatment of chronic paronychia: an open, randomized double-blind and double dummy study. *J Am Acad Dermatol*. 2002;47:73-76.
16. Fischer J, Degenhardt F, Hofmann A, et al. Genome-wide analysis of copy number variants in alopecia areata in a Central European cohort reveals association with MCHR2. *Exp Dermatol*. 2017;26(6):536-541.

17. Haneke E. Non-infectious inflammatory disorders of the nail apparatus. *J Dtsch Dermatol Ges.* 2009;7: 787-797.
18. Baran R, Haneke E. *The Nail in Differential Diagnosis*. Abingdon, UK: Informa Healthcare, 2007.
19. Dhayalan A, King BA. Tofacitinib citrate for the treatment of nail dystrophy associated with alopecia universalis. *JAMA Dermatol.* 2016;152:492-493.
20. Haneke E. Isolated bullous lichen planus of the nails mimicking yellow nail syndrome. *Clin Exp Dermatol.* 1983;8:425-428.
21. Sellheyer K, Nelson P. The ventral proximal nail fold: stem cell niche of the nail and equivalent to the follicular bulge–a study on developing human skin. *J Cutan Pathol.* 2012;39:835-843.
22. Piraccini BM, Saccani E, Starace M, et al. Nail lichen planus: response to treatment and long term follow-up. *Eur J Dermatol.* 2010;20:489-496.
23. Irla N, Schneiter T, Haneke E, et al. Nail lichen planus: successful treatment with etanercept. *Case Rep Dermatol.* 2010;2:173-176.
24. Bouaziz JD, Barete S, Le Pelletier F, et al. Cutaneous lesions of the digits in systemic lupus erythematosus: 50 cases. *Lupus.* 2007;16:163-167.
25. Obermoser G, Sontheimer RD, Zelger B. Overview of common, rare and atypical manifestations of cutaneous lupus erythematosus and histopathological correlates. *Lupus.* 2010;19:1050-1070.
26. Haneke E. Onychomadesis and hand, foot and mouth disease—is there a connection? *Euro Surveill.* 2010;15(37).
27. Zaias N, Rebell G, Escovar S. Asymmetric gait nail unit syndrome: the most common worldwide toenail abnormality and onychomycosis. *Skinmed.* 2014;12:217-223.
28. Zhan P, Ge YP, Lu XL, et al. A case-control analysis and laboratory study of the two feet-one hand syndrome in two dermatology hospitals in China. *Clin Exp Dermatol.* 2010;35:468-472.
29. Baran R, Feuilhade M, Combemale P, et al. A randomized trial of amorolfine 5% solution nail lacquer combined with oral terbinafine compared with terbinafine alone in the treatment of dermatophytic toenail onychomycoses affecting the matrix region. *Br J Dermatol.* 2000;142:1177-1183.
30. Haneke E. Autoaggressive nail disorders. *Dermatol Rev Mex*. 2013;57:225-234.
31. Perrin C, Cannata GE, Bossard C, et al. Onychocytic matricoma presenting as pachymelanonychia longitudinal. A new entity (report of five cases). *Am J Dermatopathol.* 2012;34:54-59.
32. Baran R, Kint A. Onychomatrixoma. Filamentous tufted tumour in the matrix of a funnel-shaped nail: a new entity. *Br J Dermatol.* 1992;126:510-515.
33. Jellinek NJ. Longitudinal erythronychia: suggestions for evaluation and management. *J Am Acad Dermatol.* 2011;64:167.e1-.e11.
34. Haneke E. Ungual melanoma—controversies in diagnosis and treatment. *Dermatol Ther.* 2012;25: 510-524.
35. Levit EK, Kagen MH, Scher RK, et al. The ABC rule for clinical detection of subungual melanoma. *J Am Acad Dermatol.* 2000;42:269-274.
36. Haneke E, Binder D. Subunguales Melanom mit streifiger Nagelpigmentierung [in German]. *Hautarzt.* 1978;29:389-391.
37. Moehrle M, Metzger S, Schippert W, et al. "Functional" surgery in subungual melanoma. *Dermatol Surg.* 2003;29:366-374.
38. Ocampo-Garza J, Gioia Di Chiacchio N, Haneke E, et al. Subungual melanoma in situ treated with imiquimod 5% cream after conservative surgery recurrence. *J Drugs Dermatol.* 2017;16:268-270.
39. Boespflug A, Debarbieux S, Depaepe L, et al. Association of subungual melanoma and subungual squamous cell carcinoma: a case series. *J Am Acad Dermatol.* 2018;78(4):760-768.
40. Haneke E. *Histopathology of the nail - Onychopathology.* CRC Press Boca Raton 2018.

This page intentionally left blank

Disorders Due to the Environment

PART 17

Chapter 92 :: Polymorphic Light Eruption

:: Alexandra Gruber-Wackernagel & Peter Wolf

AT-A-GLANCE

- Polymorphic light eruption is the most common photodermatosis with a female preponderance typically presenting in the spring.
- *Clinical presentation:* A pruritic, erythematous, symmetrically distributed, eruption of variable interindividual morphology (in most cases papular) on sun-exposed skin areas, within hours to days of exposure, with full resolution in several days.
- *Histopathology:* Epidermal spongiosis with a superficial and deep dermal, perivascular, mixed-cell infiltrate and papillary dermal edema.
- *Etiology and Pathogenesis:* A resistance to ultraviolet (UV)-induced immune suppression with subsequent delayed-type hypersensitivity reaction against UV-induced antigen(s).
- *Prevention and Therapy:* Responds to broad-spectrum sunscreen use, oral or topical steroids, and prophylactic low-dose immunosuppressive phototherapy.

DEFINITIONS

Polymorphic light eruption (PMLE) is the most common photodermatosis, with a high prevalence, particularly among young women, in temperate climates. As the name of the condition implies, itchy lesions of variable morphology appear on sun-exposed skin after the first exposure to an intense dose of sunlight in spring or early summer. The exact etiology and pathogenesis of PMLE is unknown, but a resistance to ultraviolet (UV)-induced immune suppression (a physiologic phenomenon in healthy individuals) and a subsequent immune reaction to UV-modified elements in the skin are suggested.

HISTORICAL PERSPECTIVE

Clinical symptoms of PMLE were first described under the term of *Prurigo aestivalis* in 1888 by Hutchinson.[1,2] In 1942, Epstein suggested a photoallergic pathophysiology for photodermatoses.[2] In 1984, Moncada and colleagues found a predominance of T-helper (Th) cells and cells expressing high levels of Ia antigens in the dermal cell infiltrate of PMLE, suggesting that an abnormal immune response is responsible for the pathophysiology of the disease.[3] Consistently, histologic features with an early influx of CD4+ T lymphocytes, followed by CD8+ T cells in established lesions, were described in PMLE by Norris and colleagues, pointing to a cellular-mediated immune response.[4]

EPIDEMIOLOGY

PMLE has a wide geographic distribution, but is described as being seen more frequently in temperate latitudes and rarely in equatorial latitudes. The incidence rate of PMLE in the United Kingdom has been described as being approximately 15%, compared with less than 5% in Australia.[5] However, a recent large-scale cross-sectional study with individuals residing from the Mediterranean to Scandinavia found no correlation between PMLE incidence and increasing latitude, with an average prevalence of PMLE in 18% of Europeans.[6] PMLE occurs in all skin types and racial groups.[7,8] Similar to many autoimmune disorders PMLE usually has its onset within the first 3 decades of life and affects females approximately 4 times more often than males.[8-10] Symptoms also may begin in early childhood or late adulthood, but onset during childhood is less

commonly seen in PMLE than for instance in other photodermatoses like actinic prurigo.[7] Fitzpatrick skin type is described to influence the risk of developing PMLE. In a pan-European study of PMLE patients with skin types I to IV, PMLE had the highest prevalence in individuals with skin type I and the lowest prevalence in people with skin type IV.[6] However, a specific variant of PMLE (pinpoint papular variant) has been linked to the African American population of the northern states of the United States (Michigan)[11,12] and dark-skinned individuals in Asia (eg, Singapore, Taiwan, and India).[13,14]

CLINICAL FEATURES

CUTANEOUS FINDINGS

Within several hours to days, but usually not less than 30 minutes, after the first exposure to an intense dose of sunlight, usually in spring or early summer, itchy skin lesions of variable morphology appear on sun-exposed skin. Many patients also suffer from flares during summer holidays.[6] Once UV exposure ceases, all lesions gradually resolve fully without scarring over several days, occasionally taking 7 to 10 days. As summer progresses, following repetitive exposures to sunlight, many individuals show a hardening effect. Skin lesions are then less likely to occur or are less severe, permitting the individual to tolerate prolonged sun exposure. PMLE can also occur after recreational sunbed use. It is rare in winter except after extended outdoor recreational activities. Sufficient exposure may also occur through window glass. Sunburn is not mandatory for the development of a PMLE skin rash. Itching may be noted as the first sign of an impending PMLE eruption.

In any given patient, PMLE outbreaks tend to affect the same exposed sites. The distribution is generally symmetric. Only some areas of the exposed skin are usually affected and large areas may be spared. Particularly sun-exposed areas that are normally covered during winter such as the upper chest and the extensor aspects of the arms are most affected (Figs. 92-1 through 92-6). In contrast, the face and the hands of patients with PMLE are typically spared, presumably because of continuous natural hardening resulting from daily sun exposure.

Figure 92-1 Macular polymorphic light eruption on the back of a middle-aged woman.

As the name of the condition implies, PMLE has many morphologic forms of skin lesions, all probably with similar pathogenesis and prognosis. The term *polymorphous* describes the variability in lesion morphology observed among different patients with the eruption. In general, in an individual patient the lesions are usually quite monomorphous. Macular, papular, papulovesicular, vesiculobullous, urticarial, plaque, insect bite, and erythema multiforme–like forms have been described (see Figs. 92-1 to 92-6). The papular form, characterized by large or small separate or confluent erythematous and edematous papules that may form clusters, is most common. Papulovesicular and plaque variants occur less frequently, and the other forms are rare. A pinpoint papular variant (Fig. 92-7) of PMLE has been described in people with skin phototypes IV to VI, which is characterized by the development of very small papules on sun-exposed areas, including the face.[15] The existence of a localized variant of PMLE, with erythematous–edematous papules and plaques, located on both elbows, has been suggested.[16] Another potential localized subtype of PMLE may be juvenile spring eruption,[17] which tends to affect boys in the spring and is characterized by pruritic papules and vesicles on their ear helices (Fig. 92-8), although typical features of PMLE sometimes coexist. Another potential rare variant of PMLE with manifestation predominantly on the lower legs is solar purpura (Fig. 92-9).[8] Benign summer light eruption and PMLE sine eruption, with extensive pruritus on sun-exposed skin but without visible skin changes are other potential variants of PMLE.[18,19]

CAUSING WAVEBANDS

UVA radiation (320 to 400 nm) usually seems more causative than UVB (290 to 320 nm) at initiating PMLE, but lesions also can be induced with UVB alone and sometimes with both waveband ranges.[8] Even visible light may be responsible on rare occasions.[20] The role of UVA in triggering the eruption is substantiated by phototest findings and the observation that most patients with PMLE exhibit sensitivity to sunlight through window glass,[8] and by the lack of protection from pure UVB-absorbing sunscreens.[21] As a result, paradoxically, some patients may note that the use of sunscreens, which tend preferentially to remove UVB while transmitting some UVA and all visible light, may have a PMLE-enhancing effect if exposure times are lengthened.

NONCUTANEOUS FINDINGS

Systemic symptoms in PMLE are rare, but headache, fever, chills, malaise, and nausea may occur.[7,22] These systemic symptoms may result from UV-induced release of cytokines with pyrogenic activity related to an accompanying sunburn reaction.[23,24]

Figure 92-2 Maculopapular polymorphic light eruption on the back of a young man undergoing ultraviolet B broadband hardening after several exposures. **A,** Overview image. **B** and **C,** Details of lesions.

COMPLICATIONS

Patients with PMLE may experience significant disease-related psychosocial morbidity. The rate of both anxiety and depression in patients with PMLE are twice that of the general population, and these rates are similar to those observed in patients with psoriasis and atopic dermatitis.[25] A shared pathogenesis for lupus erythematosus and PMLE has been suggested.[26-28] PMLE lesions may precede the development of lupus,[27] and progression of PMLE to lupus has been proposed in some cases, but long-term followup studies have not shown a general increased rate of lupus in PMLE patients.[29,30] A resistance to UV-induced immune suppression in PMLE

Figure 92-3 Papular polymorphic light eruption in a young woman on the trunk and arms. **A,** Overview image. **B** and **C,** Details of lesions.

may be responsible for the photoaggravation of other diseases, such as coexisting psoriasis, commonly responding beneficial to UV radiation from sunlight or artificial sources.[31] In an epidemiologic study, 43% of all patients suffering from photosensitive psoriasis were concluded to have a history of PMLE with secondary exacerbation of psoriatic lesions.[32] PMLE patients with coexisting psoriasis may not experience the beneficial antipsoriatic effects of UV, but rather induction and/or worsening of psoriatic disease after UV exposure. UV radiation may induce innate immunity in these patients, resulting in

Figure 92-4 Papulovesicular polymorphic light eruption in a young woman on the trunk and extremities. Typical lesions (**A**) in the V-neck, (**B**) on the left arm, and (**C**) on the extensor sites of the legs.

psoriatic lesions when there is simultaneous resistance against UV-induced suppression of the adaptive immune response (like in PMLE) that would otherwise counteract.[31]

ETIOLOGY AND PATHOGENESIS

IMMUNOLOGIC ASPECTS

The exact etiology and pathogenesis of PMLE are unknown, but a resistance to UV-induced immune suppression and a subsequent delayed-type hypersensitivity response to UV-modified elements of the skin have been suggested.[8] A photoallergic response to a sunlight-induced antigen in the skin was first suggested in 1942.[2] Histologic features with an initial influx of CD4+ T lymphocytes for up to 72 hours in early PMLE lesions, followed by CD8+ T cells in established lesions, are consistent with a cellular-mediated immune response.[4] Increased numbers of Langerhans cells and dermal macrophages are also present in lesions of PMLE. An immunologic basis of the pathophysiology of the disease is also supported by immunohistologic findings, showing similarities to delayed-type hypersensitivity in the expression of adhesion molecules, comparing UVB-induced erythema, delayed-type hypersensitivity response, and PMLE lesions.[33,34]

UVB irradiation of the skin modifies cellular organic molecules such as proteins and DNA, creating antigens that the immune system may recognize as foreign and that may provoke (auto)immunoreactivity.[35,36] Such adverse immune reactions are prevented in

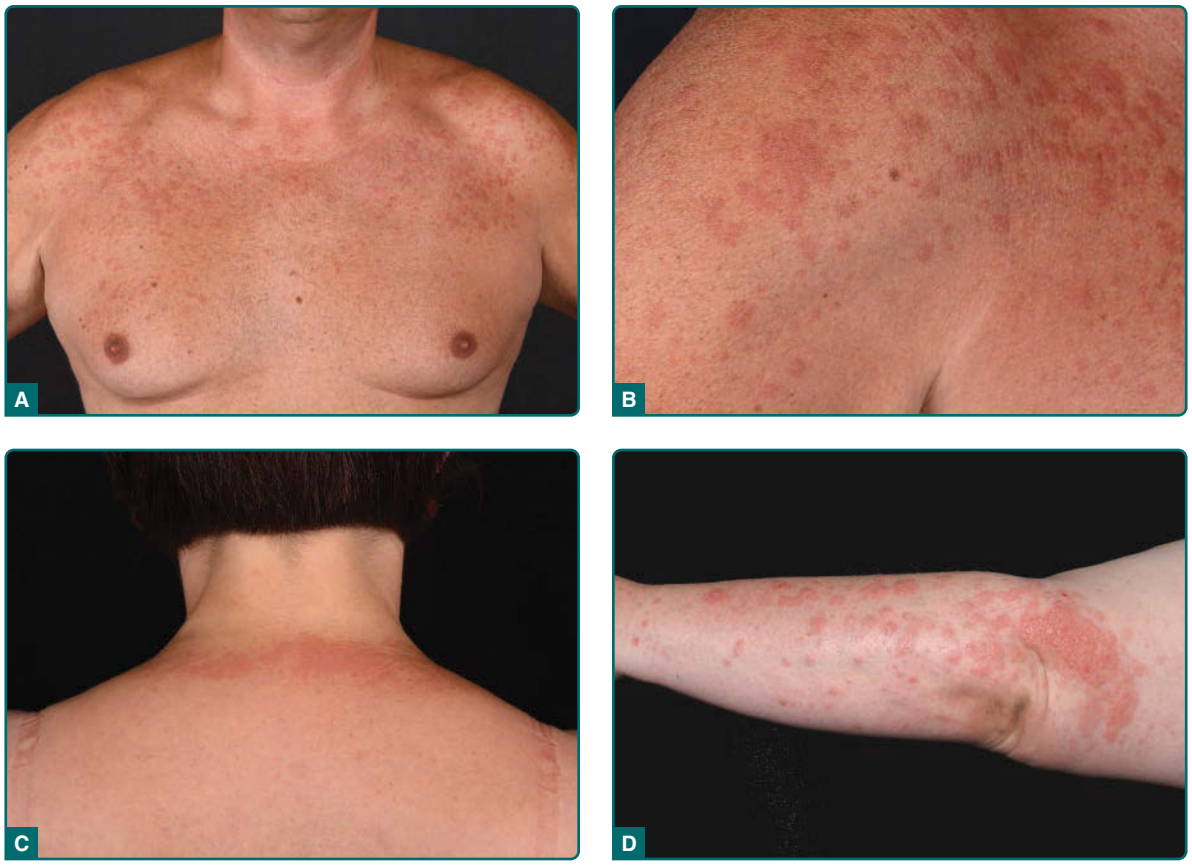

Figure 92-5 Plaque type of polymorphic light eruption (PMLE). **A,** Typical urticarial plaques and papules on the chest and shoulders occurring during a summer holiday in a young man. **B,** Detail of these lesions. **C,** Band-like PMLE lesions on the sun-exposed neck of a young woman. **D,** Elevated thick plaques on the sun-exposed extensor site of the arm in another woman. Note the involvement of the elbow.

UV-exposed healthy skin by the immunosuppressive properties of UV radiation, inducing an immunosuppressive Th2 micromilieu in UV-exposed healthy skin, accompanied by depletion of epidermal Langerhans cells,[37] neutrophilic infiltration, and the release of immunosuppressive cytokines, including interleukin (IL)-4 and IL-10.[38,39] Immune suppression after UV exposure is clinically demonstrated in studies, showing suppression of the induction of contact hypersensitivity in UV-exposed healthy skin and the induction of hapten-specific tolerance.[40-42]

However, in models of contact hypersensitivity, patients with PMLE show a resistance to UV-induced immune suppression, favoring immune response to potential UV-induced antigens under certain circumstances.[43,44] Additionally, the UV-induced tolerance to a contact allergen is impaired in PMLE.[45] On the other hand, the elicitation phase of allergic contact responses to dinitrochlorobenzene in previously sensitized PMLE patients and normal persons were equally suppressed by UV irradiation.[46]

Whereas an immunosuppressive Th2 cytokine (IL4+, IL10+) milieu is induced in normal skin following irradiation, in patients with PMLE a Th1 cytokine profile is favored.[47] In UV-exposed PMLE skin cell migration is deficient, with persistence of CD1a+ Langerhans cells[48] and impaired neutrophilic infiltration,[47,49] leading to reduced IL-4 and IL-10 release. It is thought that this creates an environment in which hypersensitivity responses to 1 or more photoinduced antigens are permissible. Photohardening therapy or desensitization, a frequently performed therapeutic approach in PMLE, is said to work by restoring the impaired UV-induced Langerhans cells depletion and neutrophil influx in PMLE.[50] Additionally, the impaired neutrophil responsiveness to chemoattractants in PMLE was found to be restored after photohardening.[51] Overall, abnormal baseline levels of proinflammatory cytokines, such as IL-1 family members, have been reported in PMLE.[52,53]

POSSIBLE PHOTOANTIGENS

The suggested photo-induced skin antigens that initiate PMLE have not been identified, but evidence for the existence of these antigens comes from experiments, in which UV-irradiated epidermal cells derived from the skin of PMLE patients stimulated strongly autologous peripheral blood mononuclear cells, suggesting that an immune-sensitizing agent is induced by UV exposure in PMLE skin.[54] As a possible photoantigen, expression

Figure 92-6 Insect bite polymorphic light eruption lesion in a young woman undergoing ultraviolet B 311-nm hardening therapy after a few exposures. **A,** Typical lesions in the V-neck and **(B)** on the arm. **C,** Detail of lesions. (Part A was taken from Gruber-Wackernagel A, Byrne S N, Wolf P. Polymorphous light eruption: clinic aspects and pathogenesis. *Dermatol Clin*. 2014;32:315-334, viii, Fig. 6. Copyright © Elsevier.)

of heat shock protein (HSP65), related to autoimmune processes such as lupus erythematosus, is described in experimentally induced PMLE lesions.[55] A recent study described a genetic deficiency in clearing apoptotic keratinocytes, resulting in a possible autoantigen source as well as altered immune function, both promoting PMLE.[56] Moreover, the hypothesis has been proposed, that microbial elements are the initial

Figure 92-7 Pinpoint variant of PMLE in dark skin. (Used with permission from Henry W. Lim, MD. Department of Dermatology, Henry Ford Hospital, Detroit, Michigan, USA.)

triggers of PMLE.[57] Direct UV-induced DNA damage to the microbiome[58] and a specific pattern of expression of antimicrobial peptides may be involved.[59]

RELATION TO SKIN CARCINOGENESIS

Skin cancer patients show a higher susceptibility to the immunosuppressive effects of UV radiation as a potential risk factor for skin cancer.[42] Consistent with

Figure 92-8 Juvenile spring eruption on the ear of a young boy.

Figure 92-9 Purpura solaris on the extensor sites of a middle-aged woman. **A,** Overview image. **B,** Detail of lesions.

the reported resistance to UV-induced immune suppression in PMLE, its prevalence has been found to be lower in patients with skin cancer.[60] In addition, a trend for decreased skin cancer prevalence was observed in PMLE patients compared to matched controls.[60] Together, this makes PMLE a potential skin cancer protective condition.

GENETICS

Genetic factors seem to play a role in PMLE, as a polygenic model indicated PMLE inheritance.[61,62] Familial clustering is evident as family history of PMLE in first-degree relatives is present in 12% of affected twins, compared with 4% in unaffected twins.[62] A positive family history is present in approximately 20% of patients.[61] Across the pedigrees of 23 PMLE patients a 21% prevalence of photosensitivity was observed among first-degree relatives.[61]

HORMONAL FACTORS

Regarding the disproportionate incidence observed in females, the role of hormonal factors was investigated. Compared to males, females are described to be relatively resistant to the immunosuppressive effects of UV radiation, requiring more than 3 times the amount to achieve the same level of immune suppression as men.[63] This may explain the higher incidence of PMLE in women. The female hormone 17β-estradiol, which can prevent UV radiation-induced immune suppression by limiting the release of IL-10 from keratinocytes, is likely to be involved.[64,65] However, the role of oral hormonal contraceptives is controversial,[66,67] and there is no clear relationship between their use and PMLE.

ANTIMICROBIAL PEPTIDES

In addition to their potent antimicrobial activity, antimicrobial peptides, guarding the body environment interface as part of the innate immune system, can also modulate inflammatory and immune responses by modulating the production and release of cytokines and chemokines and the induction of regulatory T cells.[8] In PMLE, skin UV induction of antimicrobial peptides occurred in an atypical manner, with greater upregulation and altered expression of antimicrobial peptides, particularly in the early stages of the development of PMLE lesions.[68] Dysregulated expression of antimicrobial peptides such as cathelicidin peptide LL-37 following UV radiation may play a particular role in the described failure of immune suppression in PMLE.[31]

DIAGNOSIS

PATIENT HISTORY

An exact anamnesis, especially concerning the time of occurrence of skin rash after UV exposure, the persistence and the described morphology of skin lesions, and the affected body sites is a relevant diagnostic tool. Diagnostic criteria are the delayed occurrence of skin lesions after UV exposure (within hours to days, but not less than 30 minutes), the persistence of the skin lesions for several days (up to 10 days) and the monomorphous clinical presentation on predilection sites (Table 92-1).

LABORATORY TESTING

Assessment for circulating antinuclear antibodies and antibodies against extractable nuclear antigens, including anti double-stranded DNA and anti-SSA/Ro or anti-SSB/La antibodies is advisable to exclude subacute cutaneous or other forms of lupus erythematosus. In one study, 11% of patients with PMLE were antinuclear antibody–positive, with the vast majority having insignificant titers of less than 1:160.[69] An even smaller fraction (less than 1%) of patients with PMLE had anti-Ro antibodies.[69] In certain cases, assessment of red blood cell protoporphyrins can help to exclude erythropoietic protoporphyria.

PATHOLOGY

The histologic features of PMLE are characteristic but not pathognomonic and they vary with clinical presentation.[70] There is generally a moderate to dense mixed perivascular infiltrate in the upper and mid dermis in all forms (Fig. 92-10). The infiltrate consists predominantly of T cells, with neutrophils and infrequent eosinophils. Other common features are papillary, dermal, and perivascular edema with endothelial cell swelling. Epidermal change, which is not always present, may include variable spongiosis and occasional dyskeratosis, exocytosis, and basal cell vacuolization.

TABLE 92-1

Diagnostic Criteria for Polymorphic Light Eruption

1. Delayed occurrence of skin lesions after ultraviolet (UV) exposure (within hours to days; but not <30 minutes).
2. Lesions persist for several days after exposure (up to 10 days after cessation of UV exposure).
3. *Monomorphous* clinical presentation on sites of predilection (upper chest, extensor arms, with sparing of the face and hands).

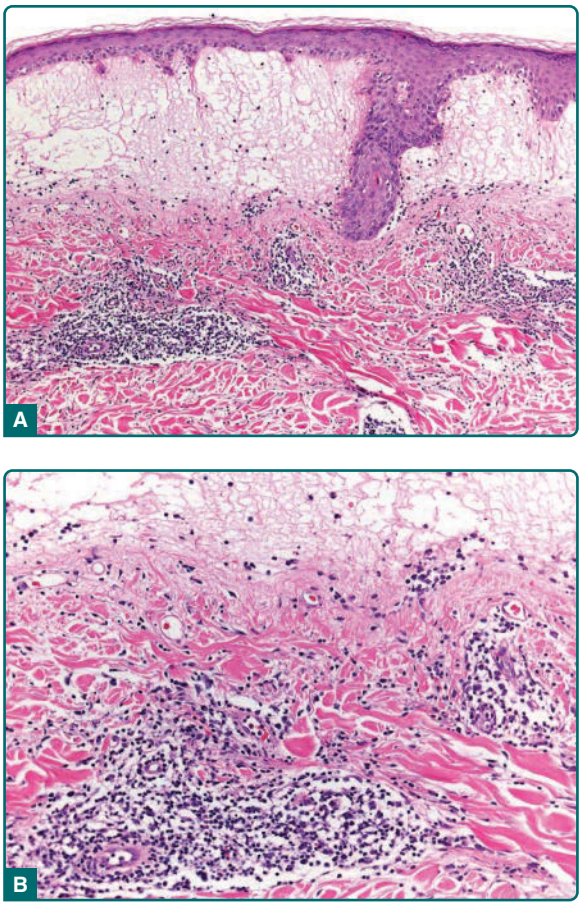

Figure 92-10 Histology of polymorphic light eruption. **A,** Hematoxylin and eosin staining shows a pronounced edema in the papillary dermis, leading to just beginning subepidermal vesiculation. **B,** Higher magnification illustrates rather dense, predominantly perivascular superficial mixed-cell infiltrates.

PHOTOTESTING AND PHOTOPROVOCATION

Patients with PMLE do not exhibit an abnormal sensitivity to develop (physiologic) erythema upon UV exposure. When tested for their UVB-induced or UVA-induced minimal erythema dose, they show normal values (Fig. 92-11). To confirm the diagnosis when the history and clinical features are not diagnostic, photoprovocation is performed in clinical practice to reproduce PMLE lesions, allowing also a subsequent skin biopsy. Repeated daily suberythemal exposures of the same skin area (at a predilection site) to UVA or UVB are necessary to provoke PMLE lesions in situ (Fig. 92-12).[71] In addition to the site of photoprovocation, the time of season of photoprovocation is critical. Photoprovocation is best performed before the beginning of the sunny summer season, preferentially in early spring, to avoid the false-negative results that may occur when the test is done too late in the season (ie, late spring or summer) because of tolerance induction through

Figure 92-11 **A,** Normal physiologic minimal erythema dose response in a polymorphic light eruption (PMLE) patient tested with an ultraviolet (UV) solar-simulated radiation ladder of 6 fields at 24 hours after exposure. Note the irregular dark erythematous small macules representing early PMLE lesions inside the erythematous test field exposed to the highest UV dose of the ladder (*arrow*). **B,** Detail of this test field. (Part A was taken from Gruber-Wackernagel A, Bambach I, Legat FJ, et al. Randomized double-blinded placebo-controlled intra-individual trial on topical treatment with a 1,25-dihydroxyvitamin D analogue in polymorphic light eruption. *Br J Dermatol*. 2011;165:152-163, Fig. 3. Used with permission. Copyright © 2011 John Wiley & Sons.)

Figure 92-12 Positive photoprovocation result in a man with a history of recurrent sun-exposure–related skin rash. **A,** Typical papular lesions occurring after 4 days of suberythemal ultraviolet B exposure within the test field, clinically consistent with polymorphic light eruption. **B,** Detail of lesions.

natural photohardening.[7] In general, the principles of photoprovocation are as follows: 2 symmetrically located test areas at predilection sites, preferably on previously involved skin, are exposed daily for 4 to 5 days to increasing suberythemal or near-erythemal doses of UVA or UVB radiation (or solar-simulated UV radiation). Depending on the method, PMLE lesions can be reproduced in 60% to 90% of affected subjects, most of them exhibiting sensitivity to UVA, and some to UVB or both wavebands.[7-9] Negative test areas of photoprovocation should be evaluated and monitored up to several weeks for a delayed eruption of possible lupus lesions, most often evolving 10 to 14 days after start of provocation. Additionally, phototesting can be performed with visible light (single irradiation of a single test area), in particular to exclude solar urticaria. Photopatch test can be used to exclude chronic actinic dermatitis or photoaggravated eczema.

DIAGNOSTIC ALGORITHM

Sometimes patients present with a manifested rash of skin lesions. Then primary diagnostic tools are patient history, clinical evaluation and in selected cases a skin biopsy. If the patient presents without (typical) skin rash, an exact patient history (concerning time of occurrence and persistence of skin lesions after UV exposure, morphology of skin lesions, and affected body sites) is most relevant and in many cases

sufficient for diagnosis. In certain cases photoprovocation is needed, also allowing a skin biopsy if there is any doubt in the clinical diagnosis of eventually provoked lesions. In all cases of not unambiguous clinical diagnosis laboratory tests (antinuclear antibodies, extractable nuclear antigens) should be done.

DIFFERENTIAL DIAGNOSIS

Table 92-2 and Fig. 92-13 outline the most important differential diagnoses of PMLE and their characteristics.

Other photosensitive conditions can be usually differentiated from PMLE by clinical features and morphology of skin lesions. Mallorca acne (acne aestivalis), characterized by long-persisting acneiform, follicular papules on sun-exposed neck and shoulder belt area[72] may represent a separate entity (Fig. 92-14). This condition occurs within or follows a summer holiday with long and intensive sun exposure and sunscreen use. A link to the use of too oily vehicles of sunscreen has been suggested. Prurigo actinica shows prurigo lesions in chronic UV-exposed skin areas, mainly in the face, associated with cheilitis, most often starting in childhood. Whereas in childhood the disease shows a seasonal character, later in adulthood the lesions may persist perennially with occurrence also on non-exposed skin.[73] Hydroa vacciniforme usually is easily differentiated from PMLE by its early onset in childhood and intermittent occurrence of papulovesicular or bullous hemorrhagic skin lesions, which are most commonly located on the face, ears, and dorsum of the hands.[74,75] Residual vacciniform scarring is typical and association with Epstein-Barr virus has been reported in some cases.[74]

Persistent erythematous plaques, mostly on the face, may be lesions of lymphocytic infiltration (Jessner-Kanof).[76] Lymphocytic infiltration typically occurs on the cheeks and earlobes, but also on the neck and upper trunk or proximal extremities of men. Lesions persist for months or years, and can resolve spontaneously without treatment, but often recur. Whether this condition is a separate entity or identical with lupus tumidus is still a matter of debate. Other forms of lupus, such as chronic discoid lupus erythematosus, can usually be easy differentiated from PMLE by its clinical morphology.

Eczematous morphology of skin lesions is atypical for PMLE and rather refers to chronic actinic dermatitis or photoaggravated atopic dermatitis.[77] Chronic actinic dermatitis[78] or photoaggravated eczema can be usually excluded in the differential diagnosis of PMLE by typical lesion morphology, patient history, and results of (photo)patch testing. An exact patient history concerning drugs can be necessary in certain cases to exclude phototoxic or photoallergic drug eruption.

TABLE 92-2

Most Important Clinical Differential Diagnoses of Polymorphic Light Eruption (Characteristics)

- Solar urticaria (occurrence of wheals at any sun-exposed body site within minutes after ultraviolet (UV) exposure and fading within hours)
- Lupus erythematosus, especially subacute cutaneous lupus erythematosus (delayed occurrence of skin lesions on exposed sites within 10-14 days or later after UV exposure and persisting for several weeks)
- Erythropoietic protoporphyria (painful skin redness and swelling within minutes of sun exposure starting in early childhood)
- Photoaggravated erythema multiforme (photodistributed erythema multiforme-like skin lesions, often associated with herpes simplex virus infection)

CLINICAL COURSE AND PROGNOSIS

PMLE is chronic in nature and in most affected patients the disease has a persistent course with a slow tendency to amelioration.[29,30] In a study with a followup time span of 7 years, 64 of 114 PMLE patients reported steadily diminishing sun sensitivity and 12 patients no further sun-precipitated rashes.[29] In another study, Hasan and colleagues found that after an average of 32 years after the onset of PMLE symptoms, 23 (24%) of 94 patients were considered cured, 48 (51%) reported alleviation of symptoms, and the remaining 23 (24%) had noticed equal or stronger symptoms than before.[30]

MANAGEMENT

PREVENTION/PROPHYLAXIS

Prophylaxis is an important therapeutic approach in PMLE, and mild cases respond well to basic photoprotective measures such as avoiding sun exposure, the use of broad-spectrum sunscreens with effective UVA protection capacity, and wearing protective clothing.[79] Whereas sunscreens with high UVA and UVB protection may prevent PMLE eruptions in photoprovocable patients,[80] sunscreens with moderate UVA protection are often ineffective. For instance, a sun protection factor 45 sunscreen with high UVA protection was able to protect most patients from the development of UV-provoked PMLE even at a low sunscreen concentration of 1 mg/cm^2.[81]

MEDICATIONS

After the eruption of PMLE lesions, topical steroids and, occasionally, oral antihistamines can be used to reduce inflammation, alleviate itch, and shorten the duration of the eruption.[7,8,82,83] Further PMLE treatment depends on the severity of the disease. Patients who have outbreaks only infrequently, such as on vacations, usually respond well to short courses of oral steroids that are prescribed to use in the event of an eruption.[84] If PMLE does develop, approximately 20 to 30 mg prednisone taken initially at the first sign of pruritus and then each morning at tapered doses until the

Figure 92-13 Algorithm of polymorphic light eruption diagnosis. HSV, herpes simplex virus.

Figure 92-14 Mallorca acne. **A,** Acneiform skin lesions in the face of a young woman. **B,** Follicular papulopustular lesions in the V-neck of this patient. **C,** Higher magnification of **B**. **D,** Acneiform skin lesions on sun-exposed upper chest of another young woman.

eruption clears usually provides relief within several days, and recurrences are then uncommon during the same vacation. This treatment, if well tolerated, may be repeated safely. Alternatively, oral prednisolone also can be given prophylactically, starting 1 to 2 days before expected sun exposure to prevent flares, when patients go to sunny locations for vacation.

PHOTOHARDENING

More-severely affected individuals, who experience repeated attacks of PMLE throughout the summer, may require prophylactic medical photohardening courses each spring before the first intense sun exposure to prevent attacks. Broadband UVB (290 to 320 nm), narrowband UVB (311 nm), or psoralen plus UVA photochemotherapy are effective in photohardening of PMLE.[8] Phototherapy, usually given 2 to 3 times per week for 4 to 6 weeks with suberythemal doses, simulates the naturally occurring phenomenon of hardening and aims to induce photoadaption. Photochemotherapy appears to be more effective than broadband UVB radiation, controlling symptoms in up to 90% of cases, compared to approximately 60% of cases,[85] respectively. Narrowband (311-nm) UVB phototherapy, effective in 70% to 80% of cases, is the treatment of choice because of ease of administration.[86] The mechanisms underlying

the photohardening effect include melanization in the skin, thickening of the stratum corneum, and restoration of immunologic susceptibility,[87-89] especially the impaired UV-induced Langerhans cells depletion, neutrophil infiltration,[50] and neutrophil responsiveness to chemoattractants.[51]

TREATMENTS FOR SEVERE CASES

In cases with severe symptoms, treatment can involve administration of azathioprin,[90] thalidomide,[91] or antimalarials, such as choloroquine or hydroxychloroquine, with immunomodulatory and antiinflammatory properties.[92-94] Efficacy of immune suppressive therapy in PMLE is consistent with the observation of reduced prevalence of PMLE in iatrogenically immunosuppressed individuals.[95]

EXPERIMENTAL APPROACHES

Oral administration of supplements (containing lycopene, beta-carotene, and *Lactobacillus johnsonii*) or extracts (*Polypodium leucotomos*, a natural extract from tropical fern leaves) with antioxidant and anti-inflammatory effects have been described to prevent eruption of PMLE and diminish PMLE symptoms.[96-98] Topical application of DNA repair enzymes incorporated in an after-sun lotion diminished PMLE symptoms in an experimental study,[99] possibly by enhancing removal of UV-induced DNA photoproducts as an antigenic immune trigger in UV-exposed PMLE skin.

ACKNOWLEDGMENTS

The current authors (Alexandra Gruber-Wackernagel and Peter Wolf) are grateful to Travis W. Vandergriff and Paul R. Bergstresser as authors of this chapter in the previous edition for leaving behind an outstanding framework that they employed as their starting point for this updated edition. The authors thank Helmut Kerl for advice and help in histology, Angelika Hofer and Franz J. Legat for support in identifying clinical images, and Werner Stieber for professional support in preparing the illustrations of this chapter.

REFERENCES

1. Sellei J, Liebner E. Über Prurigo aestivalis. *Arch Dermatol Syph.* 1926;152:19-33.
2. Epstein S. Studies in abnormal human sensitivity to light. IV. Photoallergic concept of prurigo aestivalis. *J Invest Dermatol.* 1942;5:289-298.
3. Moncada B, Gonzalez-Amaro R, Baranda ML, et al. Immunopathology of polymorphous light eruption. T lymphocytes in blood and skin. *J Am Acad Dermatol.* 1984;10(6):970-973.
4. Norris PG, Morris J, McGibbon DM, et al. Polymorphic light eruption: an immunopathological study of evolving lesions. *Br J Dermatol.* 1989;120(2):173-183.
5. Pao C, Norris PG, Corbett M, et al. Polymorphic light eruption: prevalence in Australia and England. *Br J Dermatol.* 1994;130(1):62-64.
6. Rhodes LE, Bock M, Janssens AS, et al. Polymorphic light eruption occurs in 18% of Europeans and does not show higher prevalence with increasing latitude: multicenter survey of 6,895 individuals residing from the Mediterranean to Scandinavia. *J Invest Dermatol.* 2010;130(2):626-628.
7. Stratigos AJ, Antoniou C, Katsambas AD. Polymorphous light eruption. *J Eur Acad Dermatol Venereol.* 2002;16(3):193-206.
8. Gruber-Wackernagel A, Byrne SN, Wolf P. Polymorphous light eruption: clinic aspects and pathogenesis. *Dermatol Clin.* 2014;32(3):315-334, viii.
9. Gruber-Wackernagel A, Byrne SN, Wolf P. Pathogenic mechanisms of polymorphic light eruption. *Front Biosci (Elite Ed).* 2009;1:341-354.
10. Wolf P, Byrne SN, Gruber-Wackernagel A. New insights into the mechanisms of polymorphic light eruption: resistance to ultraviolet radiation-induced immune suppression as an aetiological factor. *Exp Dermatol.* 2009;18(4):350-356.
11. Kerr HA, Lim HW. Photodermatoses in African Americans: a retrospective analysis of 135 patients over a 7-year period. *J Am Acad Dermatol.* 2007;57(4):638-643.
12. Nakamura M, Henderson M, Jacobsen G, et al. Comparison of photodermatoses in African-Americans and Caucasians: a follow-up study. *Photodermatol Photoimmunol Photomed.* 2014;30(5):231-236.
13. Wadhwani AR, Sharma VK, Ramam M, et al. A clinical study of the spectrum of photodermatoses in dark-skinned populations. *Clin Exp Dermatol.* 2013;38(8):823-829.
14. Chiam LY, Chong WS. Pinpoint papular polymorphous light eruption in Asian skin: a variant in darker-skinned individuals. *Photodermatol Photoimmunol Photomed.* 2009;25(2):71-74.
15. Isedeh P, Lim HW. Polymorphous light eruption presenting as pinhead papular eruption on the face. *J Drugs Dermatol.* 2013;12(11):1285-1286.
16. Molina-Ruiz AM, Sanmartin O, Santonja C, et al. Spring and summer eruption of the elbows: a peculiar localized variant of polymorphous light eruption. *J Am Acad Dermatol.* 2013;68(2):306-312.
17. Hawk J. Juvenile spring eruption is a variant of polymorphic light eruption. *N Z Med J.* 1996;109(1031):389.
18. Guarrera M, Cardo P, Rebora AE, et al. Polymorphous light eruption and benign summer light eruption in Italy. *Photodermatol Photoimmunol Photomed.* 2011;27(1):35-39.
19. Dover JS, Hawk JL. Polymorphic light eruption sine eruption. *Br J Dermatol.* 1988;118(1):73-76.
20. Piletta PA, Salomon D, Beani JC, et al. A pilot with an itchy rash. *Lancet.* 1996;348(9035):1142.
21. Diffey BL, Farr PM. An evaluation of sunscreens in patients with broad action-spectrum photosensitivity. *Br J Dermatol.* 1985;112(1):83-86.
22. Jansen CT. Heredity of chronic polymorphous light eruptions. *Arch Dermatol.* 1978;114(2):188-190.

23. Granstein RD, Sauder DN. Whole-body exposure to ultraviolet radiation results in increased serum interleukin-1 activity in humans. *Lymphokine Res*. 1987; 6(3):187-193.
24. Urbanski A, Schwarz T, Neuner P, et al. Ultraviolet light induces increased circulating interleukin-6 in humans. *J Invest Dermatol*. 1990;94(6):808-811.
25. Richards HL, Ling TC, Evangelou G, et al. Evidence of high levels of anxiety and depression in polymorphic light eruption and their association with clinical and demographic variables. *Br J Dermatol*. 2008;159(2):439-444.
26. Petzelbauer P, Binder M, Nikolakis P, et al. Severe sun sensitivity and the presence of antinuclear antibodies in patients with polymorphous light eruption-like lesions. A form fruste of photosensitive lupus erythematosus? *J Am Acad Dermatol*. 1992;26(1): 68-74.
27. Nyberg F, Hasan T, Puska P, et al. Occurrence of polymorphous light eruption in lupus erythematosus. *Br J Dermatol*. 1997;136(2):217-221.
28. Millard TP, Lewis CM, Khamashta MA, et al. Familial clustering of polymorphic light eruption in relatives of patients with lupus erythematosus: evidence of a shared pathogenesis. *Br J Dermatol*. 2001; 144(2):334-338.
29. Jansen CT, Karvonen J. Polymorphous light eruption. A seven-year follow-up evaluation of 114 patients. *Arch Dermatol*. 1984;120(7):862-865.
30. Hasan T, Ranki A, Jansen CT, et al. Disease associations in polymorphous light eruption. A long-term follow-up study of 94 patients. *Arch Dermatol*. 1998; 134(9):1081-1085.
31. Wolf P, Weger W, Patra V, et al. Desired response to phototherapy versus photo-aggravation in psoriasis: what makes the difference? *Exp Dermatol*. 2016; 25(12):937-944.
32. Ros AM, Eklund G. Photosensitive psoriasis. An epidemiologic study. *J Am Acad Dermatol*. 1987;17(5, pt 1): 752-758.
33. Norris PG, Barker JN, Allen MH, et al. Adhesion molecule expression in polymorphic light eruption. *J Invest Dermatol*. 1992;99(4):504-508.
34. Norris P, Poston RN, Thomas DS, et al. The expression of endothelial leukocyte adhesion molecule-1 (ELAM-1), intercellular adhesion molecule-1 (ICAM-1), and vascular cell adhesion molecule-1 (VCAM-1) in experimental cutaneous inflammation: a comparison of ultraviolet B erythema and delayed hypersensitivity. *J Invest Dermatol*. 1991;96(5):763-770.
35. de Gruijl FR. Health effects from solar UV radiation. *Radiat Prot Dosimetry*. 1997;72:177-196.
36. Jung EG, Bohnert E, Krutmann J, et al. *Photobiology of Ultraviolet Induced DNA Damage*. Vol 3. Cambridge, UK: Cambridge University Press; 1995.
37. Kolgen W, Both H, van Weelden H, et al. Epidermal Langerhans cell depletion after artificial ultraviolet B irradiation of human skin in vivo: apoptosis versus migration. *J Invest Dermatol*. 2002;118(5): 812-817.
38. Teunissen MB, Piskin G, di Nuzzo S, et al. Ultraviolet B radiation induces a transient appearance of IL-4+ neutrophils, which support the development of Th2 responses. *J Immunol*. 2002;168(8):3732-3739.
39. Piskin G, Bos JD, Teunissen MB. Neutrophils infiltrating ultraviolet B-irradiated normal human skin display high IL-10 expression. *Arch Dermatol Res*. 2005;296(7):339-342.
40. Cooper KD, Oberhelman L, Hamilton TA, et al. UV exposure reduces immunization rates and promotes tolerance to epicutaneous antigens in humans: relationship to dose, CD1a-DR+ epidermal macrophage induction, and Langerhans cell depletion. *Proc Natl Acad Sci U S A*. 1992;89(18):8497-8501.
41. Cooper KD. Cell-mediated immunosuppressive mechanisms induced by UV radiation. *Photochem Photobiol*. 1996;63(4):400-406.
42. Yoshikawa T, Rae V, Bruins-Slot W, et al. Susceptibility to effects of UVB radiation on induction of contact hypersensitivity as a risk factor for skin cancer in humans. *J Invest Dermatol*. 1990;95(5):530-536.
43. Palmer RA, Friedmann PS. Ultraviolet radiation causes less immunosuppression in patients with polymorphic light eruption than in controls. *J Invest Dermatol*. 2004;122(2):291-294.
44. van de Pas CB, Kelly DA, Seed PT, et al. Ultraviolet-radiation-induced erythema and suppression of contact hypersensitivity responses in patients with polymorphic light eruption. *J Invest Dermatol*. 2004; 122(2):295-299.
45. Koulu LM, Laihia JK, Peltoniemi HH, et al. UV-induced tolerance to a contact allergen is impaired in polymorphic light eruption. *J Invest Dermatol*. 2010; 130(11):2578-2582.
46. Palmer RA, Hawk JL, Young AR, et al. The effect of solar-simulated radiation on the elicitation phase of contact hypersensitivity does not differ between controls and patients with polymorphic light eruption. *J Invest Dermatol*. 2005;124(6):1308-1312.
47. Kolgen W, van Meurs M, Jongsma M, et al. Differential expression of cytokines in UV-B-exposed skin of patients with polymorphous light eruption: correlation with Langerhans cell migration and immunosuppression. *Arch Dermatol*. 2004;140(3): 295-302.
48. Kolgen W, Van Weelden H, Den Hengst S, et al. CD11b+ cells and ultraviolet-B-resistant CD1a+ cells in skin of patients with polymorphous light eruption. *J Invest Dermatol*. 1999;113(1):4-10.
49. Schornagel IJ, Sigurdsson V, Nijhuis EH, et al. Decreased neutrophil skin infiltration after UVB exposure in patients with polymorphous light eruption. *J Invest Dermatol*. 2004;123(1):202-206.
50. Janssens AS, Pavel S, Out-Luiting JJ, et al. Normalized ultraviolet (UV) induction of Langerhans cell depletion and neutrophil infiltrates after artificial UVB hardening of patients with polymorphic light eruption. *Br J Dermatol*. 2005;152(6):1268-1274.
51. Gruber-Wackernagel A, Heinemann A, Konya V, et al. Photohardening restores the impaired neutrophil responsiveness to chemoattractants leukotriene B4 and formyl-methionyl-leucyl-phenylalanin in patients with polymorphic light eruption. *Exp Dermatol*. 2011; 20(6):473-476.
52. Wolf P, Gruber-Wackernagel A, Rinner B, et al. Phototherapeutic hardening modulates systemic cytokine levels in patients with polymorphic light eruption. *Photochem Photobiol Sci*. 2013;12(1):166-173.
53. Lembo S, Caiazzo G, Balato N, et al. Polymorphic light eruption and IL-1 family members: any difference with allergic contact dermatitis? *Photochem Photobiol Sci*. 2017;16(9):1471-1479.
54. Gonzalez-Amaro R, Baranda L, Salazar-Gonzalez JF, et al. Immune sensitization against epidermal antigens in polymorphous light eruption. *J Am Acad Dermatol*. 1991;24(1):70-73.

55. McFadden JP, Norris PG, Cerio R, et al. Heat shock protein 65 immunoreactivity in experimentally induced polymorphic light eruption. *Acta Derm Venereol.* 1994;74(4):283-285.
56. Lembo S, Hawk JL, Murphy GM, et al. Aberrant gene expression with deficient apoptotic keratinocyte clearance may predispose to polymorphic light eruption. *Br J Dermatol.* 2017;177(5):1450-1453.
57. Patra V, Wolf P. Microbial elements as the initial triggers in the pathogenesis of polymorphic light eruption? *Exp Dermatol.* 2016;25(12):999-1001.
58. Patra V, Byrne SN, Wolf P. The skin microbiome: is it affected by UV-induced immune suppression? *Front Microbiol.* 2016;7:1235.
59. Patra V, Mayer G, Gruber-Wackernagel A, et al. Unique profile of antimicrobial peptide expression in polymorphic light eruption lesions compared to healthy skin, atopic dermatitis, and psoriasis. *Photodermatol Photoimmunol Photomed.* 2018;34(2):137-144.
60. Lembo S, Fallon J, O'Kelly P, et al. Polymorphic light eruption and skin cancer prevalence: is one protective against the other? *Br J Dermatol.* 2008; 159(6):1342-1347.
61. McGregor JM, Grabczynska S, Vaughan R, et al. Genetic modeling of abnormal photosensitivity in families with polymorphic light eruption and actinic prurigo. *J Invest Dermatol.* 2000;115(3):471-476.
62. Millard TP, Bataille V, Snieder H, et al. The heritability of polymorphic light eruption. *J Invest Dermatol.* 2000;115(3):467-470.
63. Damian DL, Patterson CR, Stapelberg M, et al. UV radiation-induced immunosuppression is greater in men and prevented by topical nicotinamide. *J Invest Dermatol.* 2008;128(2):447-454.
64. Aubin F. Why is polymorphous light eruption so common in young women? *Arch Dermatol Res.* 2004; 296(5):240-241.
65. Hiramoto K, Tanaka H, Yanagihara N, et al. Effect of 17beta-estradiol on immunosuppression induced by ultraviolet B irradiation. *Arch Dermatol Res.* 2004; 295(8-9):307-311.
66. Mentens G, Lambert J, Nijsten T. Polymorphic light eruption may be associated with cigarette smoking and alcohol consumption. *Photodermatol Photoimmunol Photomed.* 2006;22(2):87-92.
67. Neumann R. Polymorphous light eruption and oral contraceptives. *Photodermatol.* 1988;5(1):40-42.
68. Felton S, Navid F, Schwarz A, et al. Ultraviolet radiation-induced upregulation of antimicrobial proteins in health and disease. *Photochem Photobiol Sci.* 2013;12(1):29-36.
69. Tzaneva S, Volc-Platzer B, Kittler H, et al. Antinuclear antibodies in patients with polymorphic light eruption: a long-term follow-up study. *Br J Dermatol.* 2008;158(5):1050-1054.
70. Hawk JL. The photosensitive disorders. In: Elder DE, Johnson B Jr, Elenitsas R, et al, eds. *Lever's Histopathology of the Skin*. 9th ed. Baltimore, MD: Lippincott Williams & Wilkins; 2005.
71. Epstein JH. Polymorphous light eruptions; phototest technique studies. *Arch Dermatol.* 1962;85:502-504.
72. Hjorth N, Sjolin KE, Sylvest B, et al. Acne aestivalis—Mallorca acne. *Acta Derm Venereol.* 1972;52(1):61-63.
73. Grabczynska SA, McGregor JM, Kondeatis E, et al. Actinic prurigo and polymorphic light eruption: common pathogenesis and the importance of HLA-DR4/DRB1*0407. *Br J Dermatol.* 1999;140(2): 232-236.
74. Cho KH, Kim CW, Heo DS, et al. Epstein-Barr virus-associated peripheral T-cell lymphoma in adults with hydroa vacciniforme-like lesions. *Clin Exp Dermatol.* 2001;26(3):242-247.
75. Sonnex TS, Hawk JL. Hydroa vacciniforme: a review of ten cases. *Br J Dermatol.* 1988;118(1):101-108.
76. Kaatz M, Zelger B, Norgauer J, et al. Lymphocytic infiltration (Jessner-Kanof): lupus erythematosus tumidus or a manifestation of borreliosis? *Br J Dermatol.* 2007;157(2):403-405.
77. O'Gorman SM, Murphy GM. Photoaggravated disorders. *Dermatol Clin.* 2014;32(3):385-398, ix.
78. Lim HW, Paek SY. Photodermatology. *Dermatol Clin.* 2014;32(3):xiii.
79. Fesq H, Ring J, Abeck D. Management of polymorphous light eruption: clinical course, pathogenesis, diagnosis and intervention. *Am J Clin Dermatol.* 2003;4(6):399-406.
80. Schleyer V, Weber O, Yazdi A, et al. Prevention of polymorphic light eruption with a sunscreen of very high protection level against UVB and UVA radiation under standardized photodiagnostic conditions. *Acta Derm Venereol.* 2008;88(6):555-560.
81. Bissonnette R, Nigen S, Bolduc C. Influence of the quantity of sunscreen applied on the ability to protect against ultraviolet-induced polymorphous light eruption. *Photodermatol Photoimmunol Photomed.* 2012; 28(5):240-243.
82. Naleway AL. Polymorphous light eruption. *Int J Dermatol.* 2002;41(7):377-383.
83. Millard TP. Treatment of polymorphic light eruption. *J Dermatolog Treat.* 2000;11:195-199.
84. Patel DC, Bellaney GJ, Seed PT, et al. Efficacy of short-course oral prednisolone in polymorphic light eruption: a randomized controlled trial. *Br J Dermatol.* 2000;143(4):828-831.
85. Murphy GM, Logan RA, Lovell CR, et al. Prophylactic PUVA and UVB therapy in polymorphic light eruption—a controlled trial. *Br J Dermatol.* 1987;116(4):531-538.
86. Bilsland D, George SA, Gibbs NK, et al. A comparison of narrow band phototherapy (TL-01) and photochemotherapy (PUVA) in the management of polymorphic light eruption. *Br J Dermatol.* 1993;129(6):708-712.
87. Norris PG, Hawk JL. Polymorphic light eruption. *Photodermatol Photoimmunol Photomed.* 1990;7(5):186-191.
88. Wolf R, Oumeish OY. Photodermatoses. *Clin Dermatol.* 1998;16(1):41-57.
89. Ferguson J, Ibbotson S. The idiopathic photodermatoses. *Semin Cutan Med Surg.* 1999;18(4):257-273.
90. Norris PG, Hawk JL. Successful treatment of severe polymorphous light eruption with azathioprine. *Arch Dermatol.* 1989;125(10):1377-1379.
91. Saul A, Flores O, Novales J. Polymorphous light eruption: Treatment with thalidomide. *Australas J Dermatol.* 1976;17(1):17-21.
92. Holzle E, Plewig G, von Kries R, et al. Polymorphous light eruption. *J Invest Dermatol.* 1987;88(3)(suppl): 32s-38s.
93. Corbett MF, Hawk JL, Herxheimer A, et al. Controlled therapeutic trials in polymorphic light eruption. *Br J Dermatol.* 1982;107(5):571-581.
94. Murphy GM, Hawk JL, Magnus IA. Hydroxychloroquine in polymorphic light eruption: a controlled trial with drug and visual sensitivity monitoring. *Br J Dermatol.* 1987;116(3):379-386.
95. Benanni B, Bruckner T, Bock M, et al. Low incidence of polymorphous light eruption in renal transplant recipients. *Acta Derm Venereol.* 2007;87(4):372-374.

96. Marini A, Jaenicke T, Grether-Beck S, et al. Prevention of polymorphic light eruption by oral administration of a nutritional supplement containing lycopene, β-carotene and *Lactobacillus johnsonii*: results from a randomized, placebo-controlled, double-blinded study. *Photodermatol Photoimmunol Photomed.* 2014; 30(4):189-194.
97. Tanew A, Radakovic S, Gonzalez S, et al. Oral administration of a hydrophilic extract of *Polypodium leucotomos* for the prevention of polymorphic light eruption. *J Am Acad Dermatol.* 2012;66(1):58-62.
98. Caccialanza M, Percivalle S, Piccinno R, et al. Photoprotective activity of oral *Polypodium leucotomos* extract in 25 patients with idiopathic photodermatoses. *Photodermatol Photoimmunol Photomed.* 2007;23(1): 46-47.
99. Hofer A, Legat FJ, Gruber-Wackernagel A, et al. Topical liposomal DNA-repair enzymes in polymorphic light eruption. *Photochem Photobiol Sci.* 2011;10(7): 1118-1128.

Chapter 93 :: Actinic Prurigo

:: Travis Vandergriff

AT-A-GLANCE

- A rare chronic pruritic and excoriated papular or nodular eruption of sun-exposed and, to a lesser extent, nonexposed skin.
- Beginning in childhood, it may remit at puberty, exacerbate most often in summer, and fade in winter.
- Indigenous peoples of North and South America are disproportionately affected.
- Association with HLA-DR4, specifically the HLA-DRB1*0407 and DRB1*0401 variants
- Prevention through avoidance of sunlight is the first-line therapy; thalidomide or other immunosuppressive agents may be required.

INTRODUCTION

DEFINITION

Actinic prurigo (AP) is a chronic sunlight-induced pruritic eruption characterized by papules or nodules, many of which are excoriated. Lesions are distributed mostly on sun-exposed skin but may also occur in sun-protected sites. A family history of the disease may be reported by patients. Indigenous peoples of the Americas are most often affected, and strong associations with specific human leukocyte antigen (HLA) types have been identified.

HISTORICAL PERSPECTIVE

AP was first described by Hutchinson in 1878 and was designated by him as "summer prurigo." Other historical terms for the disease include solar eczema, prurigo solar, hereditary polymorphic light eruption, and hydroa aestivale.[1]

EPIDEMIOLOGY

AP occurs throughout much of the world. The indigenous populations of North and South America are particularly affected. The disease is estimated to occur in 2% of the Canadian Inuit population.[2] In Mexico, AP is seen most commonly in the indigenous and Mestizo (mixed native and European descent) populations living at altitudes greater than 1000 m.[3] Less commonly, inhabitants of Europe, United States, Australia, and Asia are reported to develop AP. In Scotland, less than 1% of all patients evaluated in a specialized photodiagnostic unit were diagnosed with AP.[4]

In most populations, females are affected more frequently than males, in a ratio ranging from 2:1 to 4:1.[5] In Asians, there is a male predominance.[6] The eruption has its onset in childhood, usually present by age 10 years.[7] The onset of disease appears to occur earliest in Native American populations, at 4 to 5 years of age.[5] A positive family history of either AP or polymorphous light eruption is present in about a fifth of patients.[8]

CLINICAL FEATURES

HISTORY

The eruption is often present all year round, but it is commonly worse in summer. About one third of patients experience symptoms in wintertime.[9] Very rarely it is worse in winter, with immunologic tolerance presumably developing during the summer. Exacerbations tend to begin gradually during sunny weather in general rather than after specific sun exposure, although PMLE-like outbreaks may also occur. Patients may not be aware that lesions are provoked by sun exposure.

Pruritus is universally present and is typically severe.[5,10] Pain or tingling sensations also may be reported, especially in patients with cheilitis.[10,11] When conjunctivitis is present, patients report pruritus, photophobia, and lacrimation.[5,12]

CUTANEOUS FINDINGS

The primary lesion of AP is a pruritic papule or nodule that occurs singly or in clusters (Fig. 93-1). Papules and nodules are often excoriated and crusted, and plaques may assume a lichenified or eczematous appearance (Fig. 93-2). Vesicles are not seen unless superinfection is present.[5] Sun-exposed areas are most often affected, particularly the forehead, chin, cheeks, ears, and forearms. There is a gradual fading toward habitually covered skin, and the sacral area and buttocks may be mildly affected. Although primary lesions of AP do not lead to scarring, healed facial lesions may leave dyspigmentation, and scarring can occur secondary to excoriations (Fig. 93-3).

NONCUTANEOUS FINDINGS

Mucosal involvement is not typically seen in Asian patients.[6] Cheilitis may be the sole manifestation in

Figure 93-1 Primary lesions are excoriated or lichenified papules or nodules, predominantly on sun-exposed skin.

more than half of Native American patients and is evident by edema, scale, crust, and fissures of lip mucosa. Conjunctivitis leads to hyperemia, pterygium, pinguecula, and Trantas dots along the limbus.[12]

Figure 93-2 Excoriated and lichenified papules and nodules on the forearms of a child with Amerindian ancestry. (Photograph used with permission from Arturo R. Dominguez, MD.)

Figure 93-3 Cheilitis of actinic prurigo seen in a Mexican landscape gardener.

COMPLICATIONS

Mild scarring, especially on the face, and hypopigmentation may result from excoriations associated with AP. Additionally, 2 cases of primary cutaneous B-cell lymphoma arising on the face in patients with AP have been reported.[14]

ETIOLOGY AND PATHOGENESIS

AP appears to be induced by ultraviolet radiation in that it is more severe in spring and summer and predominates on sun-exposed skin. Additionally, patients with AP often demonstrate abnormal skin phototest responses to UVB and/or UVA radiation.[7] UVA is implicated more often than UVB, with most patients demonstrating reduced minimal erythema doses in the UVA or combined UVA/UVB ranges.[5,15] The cytokine TNF-α is overexpressed by keratinocytes in lesions of AP, creating a proinflammatory environment.[3] There is a concomitant increase in the number of dermal dendrocytes, and lymphocytes with a TH1 phenotype are recruited to lesional skin.[3]

Sunlight exposure and solar simulating irradiation may sometimes induce an eruption resembling polymorphous light eruption (PMLE) in patients with AP, and many patients have close relatives with PMLE.[8] Therefore, AP may be a slowly evolving, chronic, and excoriated variant of PMLE, and thus also a delayed hypersensitivity reaction.

A distinct genetic predisposition to AP has been identified for patients with specific human leukocyte antigen (HLA) subtypes. HLA-DR4 is found most commonly.[16] The frequency of the HLA-DR4 allele exceeds 90% in patients from Mexico.[17] Specific

variants of HLA-DR4 are closely linked to AP, namely, DRB1*0407 and DRB1*0401. DRB1*0407 (DR4) is found in 60% to 70% of patients with AP but in only 4% to 8% of normal DR4-positive controls.[5] Additionally, HLA DRB1*0401 is found in approximately 20% of affected individuals.[5] Less frequently identified risk alleles include HLA-A24,[18] HLA-A28,[17] HLA-B39,[17] HLA-B40,[19] HLA-Cw3,[19] HLA-Cw4,[18,20] and HLA-DRB1*14.[2] These immunogenetic features may well be responsible for modulating conventional PMLE into AP. In addition, in some patients, AP appears to transform into PMLE and, in others, PMLE appears to transform into AP,[21] all of which suggests a relationship between the 2 disorders. The cutaneous UVR chromophores responsible for the eruption are not known, but they are likely to be diverse.

RISK FACTORS

Genetic risk factors for the development of AP include the aforementioned specific HLA haplotypes. Patients with these genotypes may report a family history of AP or other photosensitive disorder. Environmental risk factors have been explored, and in the Mexican population those risk factors include burning firewood, living with farm animals, and living with animals in the house.[10]

DIAGNOSIS

SUPPORTIVE STUDIES

LABORATORY TESTING

Assessment of ANA and ENA should be undertaken to exclude subacute cutaneous or other forms of cutaneous LE. The finding of HLA DR4, type DRB1*0401 or DRB1*0407 (especially the latter), supports the diagnosis of AP. Patients with moderate or severe presentations of AP may also have elevated serum immunoglobulin E (IgE) levels.[22]

PHOTOTESTING

Cutaneous phototesting with a monochromator confirms light sensitivity in up to half of cases,[7] but, as in PMLE, does not differentiate other photodermatoses. Most patients with positive monochromator testing have reduced minimal erythema doses (MEDs) in the UVA spectrum or in the combined UVA/UVB spectra.[4,5,15] Provocation testing with a solar simulator or other broadband sources induces typical lesions of AP in about two-thirds of patients.[4,5]

PATHOLOGY

Early papular lesions show changes similar to those of PMLE, namely, mild acanthosis, exocytosis of lymphocytes, spongiosis, and mild basilar vacuolar degeneration.[23] In the dermis, there is a moderate lymphohistiocytic superficial and middermal perivascular infiltrate, along with papillary dermal edema.[23] Chronic lesions of AP show more acanthosis and hyperkeratosis. Infiltrates of eosinophils may be seen (Fig. 93-4). Histopathologic findings in AP cheilitis tend to be more distinct and specific. Namely, there is a dense nodular lymphoid infiltrate in the lamina propria with formation of lymphoid follicles and expanded germinal centers[11] (Fig. 93-5). Eosinophilic spongiosis is also common.[11] In persistent lesions, however, excoriations, more acanthosis, variable lichenification, and a dense mononuclear cell infiltrate produce a nonspecific appearance.

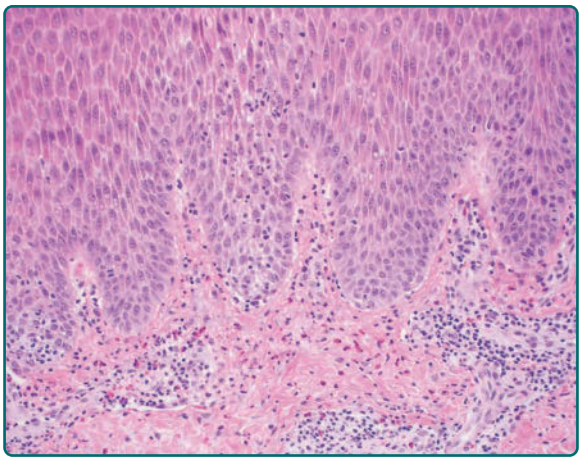

Figure 93-4 Histopathologic features are relatively nonspecific but may show acanthosis, spongiosis, exocytosis of lymphocytes, and an infiltrate of eosinophils.

DIAGNOSTIC ALGORITHM

See Fig. 93-6.

DIFFERENTIAL DIAGNOSIS

The most challenging diagnosis to distinguish from AP is PMLE, and some consider the 2 diagnoses to be chronicity variants. Some of the clinical features that

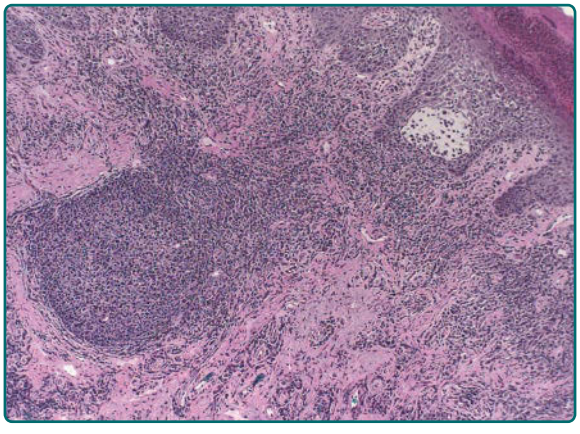

Figure 93-5 Lip biopsy from a patient with actinic prurigo shows a dense lymphohistiocytic infiltrate as well as a lymphoid follicle in the lamina propria.

suggest a diagnosis of AP rather than PMLE include disease onset in childhood, presence of lesions on both exposed and sun-protected skin, involvement of lip mucosa and conjunctiva, persistence of lesions beyond 4 weeks, occurrence in wintertime, excoriations, and scarring.[21] Previously mentioned HLA restrictions are seen in AP but not in PMLE. In a subgroup of patients, overlapping features are seen and a distinction is not possible. Diagnoses to distinguish from AP appear in Table 93-1.

TABLE 93-1
Differential Diagnosis of Actinic Prurigo

Most Likely
- Polymorphic light eruption
- Atopic eczema
- Photoexacerbated atopic or seborrheic eczema
- Insect bites
- Prurigo nodularis

Always Rule Out
- Scabies

CLINICAL COURSE AND PROGNOSIS

AP commonly arises in childhood and often improves or resolves in adolescence, although persistence into adult life is possible. When the disease begins in childhood (less than age 20 years), eruptions tend to be more severe and acute but remission in adulthood is more likely. When disease begins in adulthood, a milder but

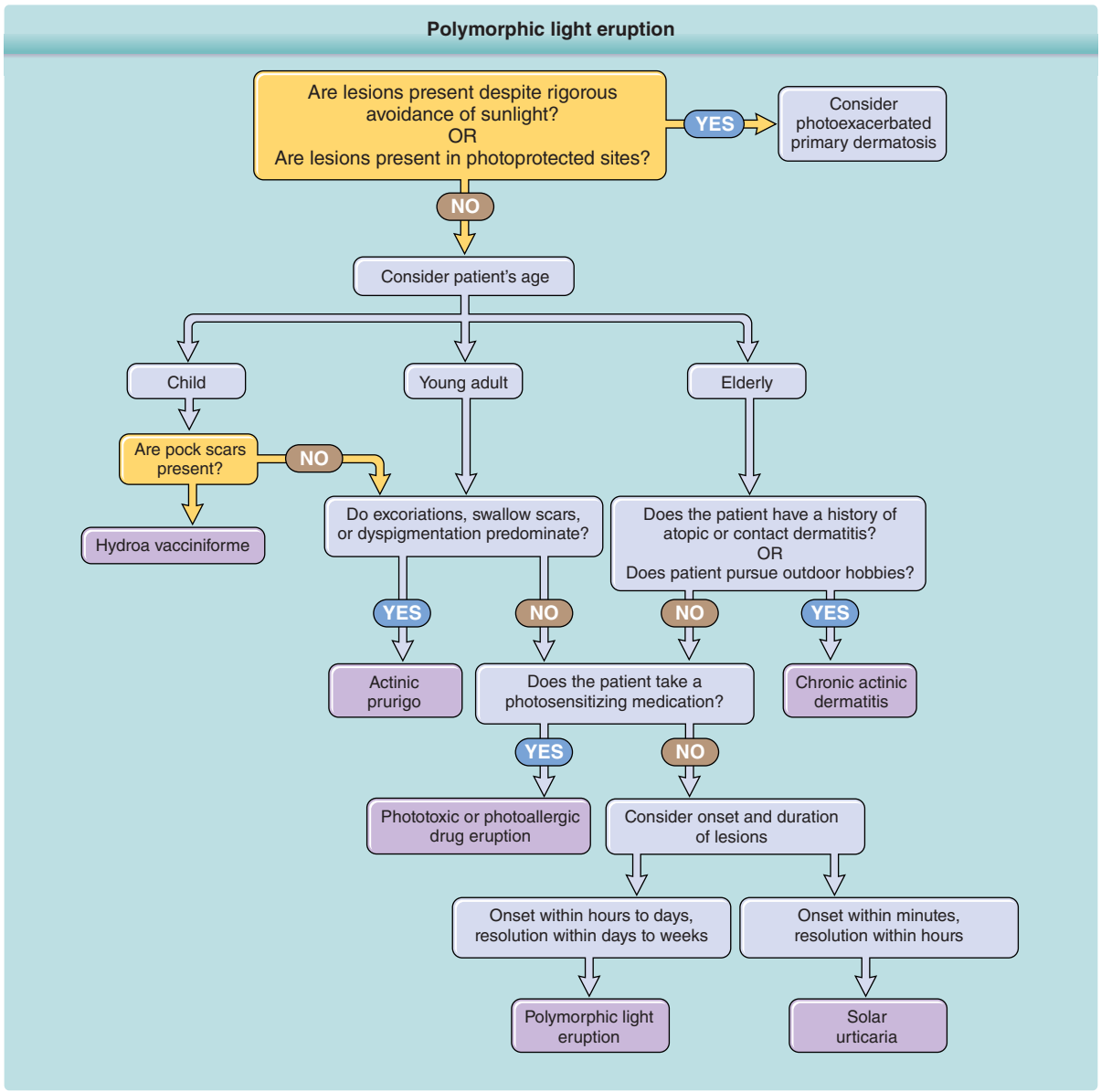

Figure 93-6 Diagnostic algorithm for abnormal responses to ultraviolet radiation.

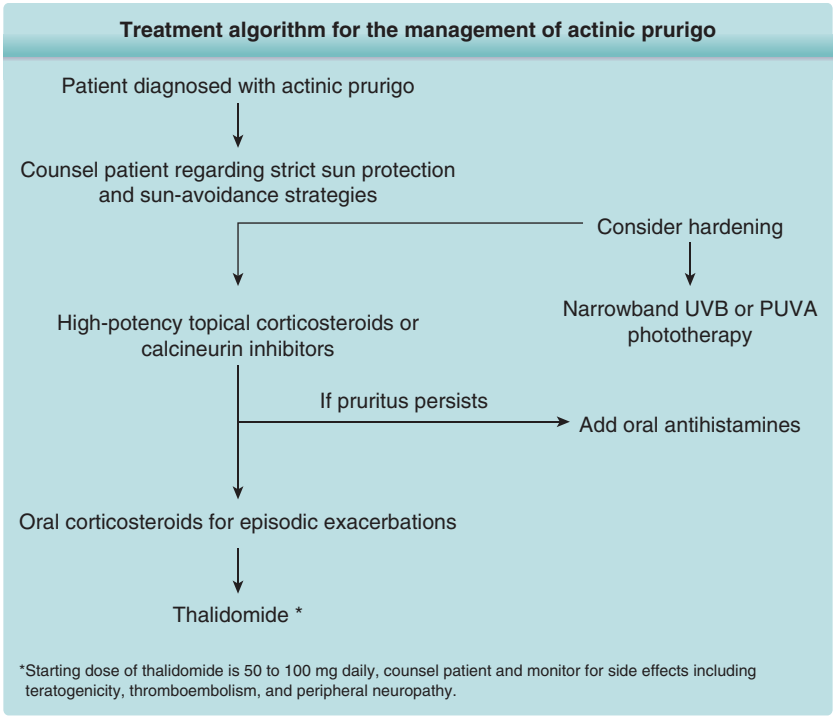

Figure 93-7 Treatment algorithm for the management of actinic prurigo.

more persistent course is seen.[9] Persistent cases may assume features of PMLE in adulthood.

MANAGEMENT

INTERVENTIONS

MEDICATIONS

Controlled clinical trials evaluating medical management of AP are lacking. Higher-potency topical corticosteroids or topical calcineurin inhibitors may be used to relieve the inflammation and pruritus associated with the disease. Oral antihistamines also may be used for treatment of pruritus. Unlike some of the other photoexacerbated dermatoses, antimalarials seem to be ineffective for AP.[5] The treatment of choice in more severe or recalcitrant cases is thalidomide, with initial doses of 50 to 100 mg daily for children and 100 to 200 mg daily for adults, preferably given intermittently.[5,24] Responses to thalidomide are evident in most patients within several weeks. The most serious complication associated with thalidomide is teratogenicity, so pregnancy must be rigorously avoided. Other potential adverse effects are typically mild, including drowsiness, headache, constipation, and weight gain. An increased risk of thromboembolism and dose-related peripheral (mostly sensory) neuropathy are other potential adverse effects of thalidomide. In cases where thalidomide is unavailable or otherwise not appropriate, oral immunosuppressive therapy with azathioprine or cyclosporine also may be considered.

PROCEDURES

Phototherapy with narrowband UVB or PUVA may occasionally help, but the treatment response is limited to exposed areas, indicating that phototherapy does not alter the underlying photosensitive process.[25]

COUNSELING

Sun protection and avoidance strategies represent the cornerstone of management for AP. In less severe cases of AP, sufficient relief may be achieved by restricting sun exposure and by using broad-spectrum, high-protection-factor sunscreens alone.[15]

TREATMENT ALGORITHM

See Fig. 93-7.

PREVENTION

Prevention of AP flares begins by restricting midday sunlight exposure, wearing sun-protective clothing, and using of broad-spectrum sunscreens. There is no known way to prevent its initial onset.

REFERENCES

1. Scheen SR 3rd, Connolly SM, Dicken CH. Actinic prurigo. *J Am Acad Dermatol.* 1981;5(2):183-190.
2. Wiseman MC, Orr PH, Macdonald SM, et al. Actinic prurigo: clinical features and HLA associations in a Canadian Inuit population. *J Am Acad Dermatol.* 2001;44(6):952-956.
3. Arrese JE, Dominguez-Soto L, Hojyo-Tomoka MT, et al. Effectors of inflammation in actinic prurigo. *J Am Acad Dermatol.* 2001;44(6):957-961.
4. Macfarlane L, Hawkey S, Naasan H, et al. Characteristics of actinic prurigo in Scotland: 24 cases seen between 2001 and 2015. *Br J Dermatol.* 2016;174(6):1411-1414.
5. Ross G, Foley P, Baker C. Actinic prurigo. *Photodermatol Photoimmunol Photomed.* 2008;24(5):272-275.
6. Ker KJ, Chong WS, Theng CT. Clinical characteristics of adult-onset actinic prurigo in Asians: a case series. *Indian J Dermatol Venereol Leprol.* 2013;79(6):783-788.
7. Lim HW, Hönigsmann H, Hawk JLM. *Photodermatology. Basic and Clinical Dermatology*. New York: Informa Healthcare USA; 2007.
8. McGregor JM, Grabczynska S, Vaughan R, et al. Genetic modeling of abnormal photosensitivity in families with polymorphic light eruption and actinic prurigo. *J Invest Dermatol.* 2000;115(3):471-476.
9. Lane PR, Hogan DJ, Martel MJ, et al. Actinic prurigo: clinical features and prognosis. *J Am Acad Dermatol.* 1992;26(5, pt 1):683-692.
10. Vera Izaguirre DS, Zuloaga Salcedo S, González Sánchez PC, et al. Actinic prurigo: a case-control study of risk factors. *Int J Dermatol.* 2014;53(9):1080-1085.
11. Plaza JA, Toussaint S, Prieto VG, et al. Actinic prurigo cheilitis: a clinicopathologic review of 75 cases. *Am J Dermatopathol.* 2016;38(6):418-422.
12. Magana M, Mendez Y, Rodriguez A, et al. The conjunctivitis of solar (actinic) prurigo. *Pediatr Dermatol.* 2000;17(6):432-435.
13. Birt AR, Davis RA. Photodermatitis in North American Indians: familial actinic prurigo. *Int J Dermatol.* 1971; 10(2):107-114.
14. Perrett CM, Harwood CA, Khorshid M, et al. Primary cutaneous B-cell lymphoma associated with actinic prurigo. *Br J Dermatol.* 2005;153(1):186-189.
15. Crouch R, Foley P, Baker C. Actinic prurigo: a retrospective analysis of 21 cases referred to an Australian photobiology clinic. *Australas J Dermatol.* 2002;43(2): 128-132.
16. Dawe RS, Collins P, Ferguson J, et al. Actinic prurigo and HLA-DR4. *J Invest Dermatol.* 1997;108(2):233-234.
17. Hojyo-Tomoka T, Granados J, Vargas-Alarcón G, et al. Further evidence of the role of HLA-DR4 in the genetic susceptibility to actinic prurigo. *J Am Acad Dermatol.* 1997;36(6, pt 1):935-937.
18. Sheridan DP, Lane PR, Irvine J, et al. HLA typing in actinic prurigo. *J Am Acad Dermatol.* 1990;22(6, pt 1): 1019-1023.
19. Bernal JE, Duran de Rueda MM, de Brigard D. Human lymphocyte antigen in actinic prurigo. *J Am Acad Dermatol.* 1988;18(2, pt 1):310-312.
20. Bernal JE, Duran de Rueda MM, Ordonez CP, et al. Actinic prurigo among the Chimila Indians in Colombia: HLA studies. *J Am Acad Dermatol.* 1990;22(6, pt 1): 1049-1051.
21. Grabczynska SA, McGregor JM, Kondeatis E, et al. Actinic prurigo and polymorphic light eruption: common pathogenesis and the importance of HLA-DR4/DRB1*0407. *Br J Dermatol.* 1999;140(2):232-236.
22. Cuevas-Gonzalez JC, Lievanos-Estrada Z, Vega-Memije ME, et al. Correlation of serum IgE levels and clinical manifestations in patients with actinic prurigo. *An Bras Dermatol.* 2016;91(1):23-26.
23. Lane PR, Murphy F, Hogan DJ, et al. Histopathology of actinic prurigo. *Am J Dermatopathol.* 1993;15(4): 326-331.
24. Lovell CR, Hawk JL, Calnan CD, et al. Thalidomide in actinic prurigo. *Br J Dermatol.* 1983;108(4):467-471.
25. Farr PM, Diffey BL. Treatment of actinic prurigo with PUVA: mechanism of action. *Br J Dermatol.* 1989;120(3):411-418.

Chapter 94 :: Hydroa Vacciniforme

:: Travis Vandergriff

AT-A-GLANCE

- A rare, chronic, scarring photodermatosis sometimes associated with Epstein-Barr virus infection.
- Characterized by recurrent sunlight-induced crops of papulovesicles and vesicles, most commonly on the face and dorsa of the hands.
- Onset commonly in childhood, remitting most often at puberty.
- May be a scarring variant of polymorphic light eruption.
- Focal intraepidermal vesiculation, reticular degeneration of the epidermis, epidermal and upper dermal necrosis, and sometimes ulceration are typical histologic changes.
- Avoidance of ultraviolet radiation including the use of broad-spectrum sunscreens is the only established therapy, but there may be a role for antivirals.
- A severe, often fatal lymphoma resembling hydroa vacciniforme is distinguished by fever, facial edema, and systemic symptoms.

DEFINITION

Hydroa vacciniforme (HV) is a rare, chronic photodermatosis with onset typically occurring in childhood and a tendency to remission in adolescence. HV is characterized by photoinduced papules and vesicles that invariably scar after healing.

HISTORICAL PERSPECTIVE

HV was first described in 1862 by Bazin.

EPIDEMIOLOGY

HV is reported most often in North America, Europe, and Japan but is known to occur globally. The disease has its onset in childhood, most often presenting before age 8 years; presentation in adulthood is unusual. Patients with light pigmentation are affected preferentially. The disease is rare, with one estimate of the prevalence of HV being 0.34 cases per 100,000 individuals with an approximately equal sex ratio.[1] There is male predominance for severe forms, whereas milder disease is more common in females.[1,2] Cases of HV are normally sporadic, and familial incidence is exceptional.

CLINICAL FEATURES

HISTORY

HV commonly develops in early childhood and resolves spontaneously by puberty, although, in some patients, it is lifelong. HV eruptions typically occur in summer,[3] often with an intense burning or stinging sensation followed by the appearance of individual or confluent papules and then vesicles, all within hours of sunlight exposure (Fig. 94-1). This is followed by umbilication, crusting, and progression to permanent pock scarring within weeks.

CUTANEOUS FINDINGS

HV is characterized initially by erythema, sometimes with swelling, followed by the eruption of tender papules and vesicles within 24 hours of sun exposure. The eruption affects the cheeks and to a lesser extent other areas of the face, as well as the backs of the hands and dorsal aspects of the arms. The distribution tends to be symmetrical. Vesicles may occasionally become confluent and hemorrhagic. Later, papules and vesicles umbilicate and develop ulceration. Within weeks to months, lesions heal leaving permanent, depressed, hypopigmented scars. These scars are invariably present and resemble those seen in vaccinia ("pock marks"), hence the "vacciniforme" nomenclature.

NONCUTANEOUS FINDINGS

Oral ulcers and eye involvement also occur in HV.[4-6] Ophthalmologic complications include conjunctival hyperemia, corneal erosions or ulcerations, iritis, keratitis, and uveitis.[6-8] Oral involvement presents as ulceration resembling aphthae or as gingivitis.[6,9]

COMPLICATIONS

Scars invariably ensue eruptions of HV. A quality-of-life study indicates that HV causes embarrassment and self-consciousness among children with the disease.[10] The negative impact of HV on quality of life exceeds previously reported indices for atopic dermatitis and psoriasis.[10]

Figure 94-1 Hydroa vacciniforme. Vesicular, bullous, and crusted facial lesions, which heal with vacciniform scars.

Patients with severe presentations of HV-like eruptions along with systemic symptoms may develop a lymphoproliferative disorder with sometimes fatal systemic lymphoma. This entity (HV-like lymphoma) is later addressed in the section "Differential Diagnosis".

ETIOLOGY AND PATHOGENESIS

The exact pathogenesis of HV is not known. No chromophores have been identified, and although ultraviolet B minimal erythema dose responses are normal in most patients, some have increased ultraviolet A sensitivity.[2] Nevertheless, its clear relationship to sunlight exposure, its distribution, and its early clinical appearances are all similar to that of polymorphous light eruption (PMLE), which suggests a relationship with that disease. On the other hand, fully developed HV eruptions are more severe than those found in PMLE, are associated with permanent scarring, and are unresponsive to treatments ordinarily effective in PMLE, apart perhaps from sunscreens and, occasionally, prophylactic phototherapy.

It is now widely recognized that chronic infection by Epstein-Barr virus (EBV) plays a role in the pathogenesis of HV in many cases,[11-13] although a relationship between EBV and HV in all populations has not been established. EBV nucleic acids are found in the cutaneous lesions of HV in 85% to 95% of patients, but not in lesional skin of control patients.[12,14] By electron microscopy, virions can be detected within lymphocytes as well as keratinocytes.[13] EBV DNA is found consistently in the peripheral blood of patients with HV, and higher levels correlate with disease activity and severity.[13,15] Patients with HV are also found to have higher percentages of circulating γδ T-cells, with demonstrable EBV infection of those cells.[15]

DIAGNOSIS

SUPPORTIVE STUDIES

LABORATORY TESTING

Blood, urine, and stool porphyrin concentrations should be assessed to exclude cutaneous porphyria, and an antinuclear antibody and extractable nuclear antibody to exclude the small possibility of cutaneous lupus erythematosus. Evidence of EBV viremia may support the diagnosis or indicate disease activity.

PHOTOTESTING

Phototesting may show increased sensitivity to short-wavelength ultraviolet A in some patients.[2,16,17] However, phototesting usually does not discriminate HV from other photodermatoses. Simulated solar irradiation may also induce erythema at reduced doses or occasionally provoke the typical vesiculation of HV (Fig. 94-2).

PATHOLOGY

Early histologic changes include intraepidermal vesicle formation with spongiosis and subsequent focal epidermal keratinocyte necrosis. There is a dermal perivascular neutrophil and lymphocyte infiltrate. The lymphocytes are predominantly T cells, and approximately 5% to 20% of infiltrating lymphocytes may show evidence of EBV integration on in situ hybridization.[15] Older lesions show necrosis, ulceration, and scarring. Vasculitic features have been reported.[2] In some cases, there also may be a septal or lobular panniculitis. Healed pock-like lesions show dermal fibrosis in the pattern of a scar.

Figure 94-2 Hydroa vacciniforme. Induction of papulovesicles by ultraviolet A exposure.

OTHER TESTS

Viral studies for herpes infection or other viral disorders should be undertaken if photoexacerbation or photoinduction of these other disorders seems at all possible.

DIAGNOSTIC ALGORITHM

Figure 94-3 shows an algorithm for abnormal responses to ultraviolet radiation.

DIFFERENTIAL DIAGNOSIS

Table 94-1 outlines the differential diagnosis of HV. Importantly, HV must be distinguished from a similar entity designated by the World Health Organization as hydroa vacciniforme–like lymphoma (HVLL).[18] The nomenclature of this entity is somewhat controversial, as some reports in the literature describe a "severe HV-like eruption" occurring in patients with chronic EBV infection and other associated disorders, such as hypersensitivity to mosquito bites and the

TABLE 94-1
Differential Diagnosis of Hydroa Vacciniforme

- Photoexacerbated viral dermatoses such as herpes simplex
- Erythropoietic protoporphyria
- Polymorphic light eruption
- Actinic prurigo
- Subacute cutaneous lupus
- Xeroderma pigmentosum
- Hydroa vacciniforme-like lymphoma

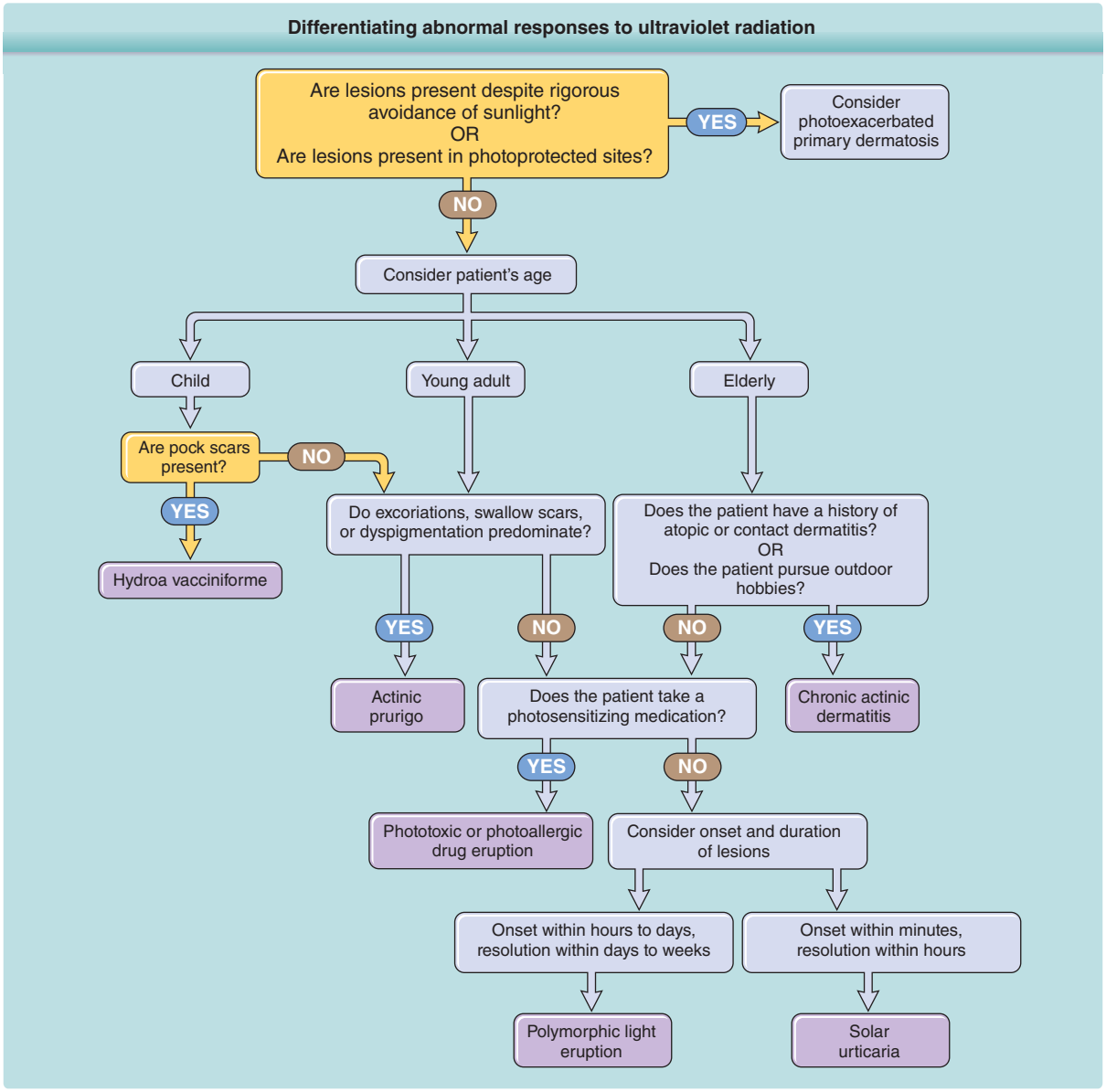

Figure 94-3 Diagnostic algorithm for abnormal responses to ultraviolet radiation.

hemophagocytic syndrome. HVLL has been identified mostly in children and young adults from Latin America and Asia.[19] HVLL eruptions are distinguished from true HV by the development of lesions in both exposed and sun-protected skin and by the presence of systemic symptoms such as fever, hepatosplenomegaly, and lymphadenopathy.[12,18,20] Facial edema with swelling of the lips and nose is common in HVLL, as is an eruption of papulovesicles on the legs.[19,21] Histologically, HVLL is distinguished by an angiocentric/angiodestructive infiltrate of atypical cytotoxic lymphocytes.[18,19,21] Clonal rearrangement of the T-cell receptor gene typifies HVLL but not HV.[18] The distinction between an HVLL and true HV is important because patients with a HVLL have a grave prognosis, with the possibility of fulminant and rapidly fatal disease.[19,21,22]

CLINICAL COURSE AND PROGNOSIS

HV often resolves in adolescence but may occasionally persist into adult life. Males have a later onset and longer duration of the disorder than females.[1] Age of onset appears to have prognostic value. Isolated cutaneous HV tends to present in early childhood, with a median age of onset around age 5 years.[23] Conversely, "severe" variants of HV and HVLL have their onset later in the first or second decade of life,[19,21,23] with one study identifying onset at age 9 years or later as significantly associated with mortality.[23]

MANAGEMENT

INTERVENTIONS

MEDICATIONS

HV often proves to be a refractory disease. Controlled clinical trials evaluating medical management of HV have not been performed. Occasionally, antimalarials appear to have helped, but their true value has not been established. Topical steroids, topical calcineurin inhibitors, and oral immunosuppressive medication tend to prove ineffective. In patients with chronic EBV infection, antiviral therapy with acyclovir and valacyclovir was reported in a small series of patients to reduce the frequency and severity of eruptions.[24] Improvement also has been reported in isolated cases with administration of dietary fish oil.[25,26]

PROCEDURES

As with PMLE, prophylactic phototherapy with narrowband ultraviolet B or psoralen and ultraviolet A, particularly psoralen and ultraviolet A, may be helpful but must be administered with care to avoid disease exacerbation.[2,13,27]

COUNSELING

The mainstay of treatment of patients with HV relates to counseling regarding strict sun protection and avoidance strategies, including the use of broad-spectrum sunscreens.

PREVENTION

In mild cases of HV, sun avoidance and sunscreen use prevent HV eruptions.

REFERENCES

1. Gupta G, Man I, Kemmett D. Hydroa vacciniforme: a clinical and follow-up study of 17 cases. *J Am Acad Dermatol*. 2000;42(2, pt 1):208-213.
2. Sonnex TS, Hawk, JL. Hydroa vacciniforme: a review of ten cases. *Br J Dermatol*. 1988;118(1):101-108.
3. Lim HW, Hönigsmann H, Hawk JLM. *Photodermatology. Basic and Clinical Dermatology*. New York, NY: Informa Healthcare USA; 2007.
4. Yesudian PD, Sharpe GR. Hydroa vacciniforme with oral mucosal involvement. *Pediatr Dermatol*. 2004; 21(5):555-557.
5. Jeng BH, Margolis TP, Chandra NS, et al. Ocular findings as a presenting sign of hydroa vacciniforme. *Br J Ophthalmol*. 2004;88(11):1478-1479.
6. Yamamoto T, Hirai Y, Miyake T, et al. Oculomucosal and gastrointestinal involvement in Epstein-Barr virus-associated hydroa vacciniforme. *Eur J Dermatol*. 2012; 22(3):380-383.
7. Bennion SD, Johnson C, Weston WL. Hydroa vacciniforme with inflammatory keratitis and secondary anterior uveitis. *Pediatr Dermatol*. 1987;4(4):320-324.
8. Mortazavi H, Hejazi P, Aghazadeh N, et al., Hydroa vacciniforme with eye involvement: report of two cases. *Pediatr Dermatol*. 2015;32(1):e39-e41.
9. Wierzbicka E, Malthieu F, Villers A, et al. Oral involvement in hydroa vacciniforme. *Arch Dermatol*. 2006; 142(5):651.
10. Huggins RH, Leithauser LA, Eide MJ, et al. Quality of life assessment and disease experience of patient members of a web-based hydroa vacciniforme support group. *Photodermatol Photoimmunol Photomed*. 2009;25(4):209-215.
11. Iwatsuki K, Xu Z, Takata M, et al. The association of latent Epstein-Barr virus infection with hydroa vacciniforme. *Br J Dermatol*. 1999;140(4):715-721.
12. Iwatsuki K, Satoh M, Yamamoto T, et al. Pathogenic link between hydroa vacciniforme and Epstein-Barr virus-associated hematologic disorders. *Arch Dermatol*. 2006;142(5):587-595.
13. Verneuil L, Gouarin S, Comoz F, et al. Epstein-Barr virus involvement in the pathogenesis of hydroa vacciniforme: an assessment of seven adult patients with long-term follow-up. *Br J Dermatol*. 2010;163(1): 174-182.
14. Yamamoto T, Tsuji K, Suzuki D, et al. A novel, noninvasive diagnostic probe for hydroa vacciniforme and related disorders: detection of latency-associated Epstein-Barr virus transcripts in the crusts. *J Microbiol Methods*. 2007;68(2):403-407.

15. Hirai Y, Yamamoto T, Kimura H, et al. Hydroa vacciniforme is associated with increased numbers of Epstein-Barr virus-infected gammadeltaT cells. *J Invest Dermatol*. 2012;132(5):1401-1408.
16. Halasz CL, Leach EE, Walther RR, et al. Hydroa vacciniforme: induction of lesions with ultraviolet A. *J Am Acad Dermatol*. 1983;8(2):171-176.
17. Sunohara A, Mizuno N, Sakai M, et al. Action spectrum for UV erythema and reproduction of the skin lesions in hydroa vacciniforme. *Photodermatol*. 1988;5(3): 139-145.
18. Quintanilla-Martinez L, Ridaura C, Nagl F, et al. Hydroa vacciniforme-like lymphoma: a chronic EBV+ lymphoproliferative disorder with risk to develop a systemic lymphoma. *Blood*. 2013;122(18):3101-3110.
19. Sangueza M, Plaza JA. Hydroa vacciniforme-like cutaneous T-cell lymphoma: clinicopathologic and immunohistochemical study of 12 cases. *J Am Acad Dermatol*. 2013;69(1):112-119.
20. Cho KH, Lee SH, Kim CW, et al. Epstein-Barr virus-associated lymphoproliferative lesions presenting as a hydroa vacciniforme-like eruption: an analysis of six cases. *Br J Dermatol*. 2004;151(2):372-380.
21. Magaña M, Massone C, Magaña P, et al. Clinicopathologic features of hydroa vacciniforme-like lymphoma: a series of 9 patients. *Am J Dermatopathol*. 2016;38(1):20-25.
22. Cho KH, Kim CW, Heo DS, et al. Epstein-Barr virus-associated peripheral T-cell lymphoma in adults with hydroa vacciniforme-like lesions. *Clin Exp Dermatol*. 2001;26(3):242-247.
23. Miyake T, Yamamoto T, Hirai Y, et al. Survival rates and prognostic factors of Epstein-Barr virus-associated hydroa vacciniforme and hypersensitivity to mosquito bites. *Br J Dermatol*. 2015;172(1):56-63.
24. Lysell J, Wiegleb Edström D, Annika L, et al. Antiviral therapy in children with hydroa vacciniforme. *Acta Derm Venereol*. 2009;89(4):393-397.
25. Durbec F, Reguiaï Z, Léonard F, et al. Efficacy of omega-3 polyunsaturated fatty acids for the treatment of refractory hydroa vacciniforme. *Pediatr Dermatol*. 2012;29(1):118-119.
26. Rhodes LE, White SI. Dietary fish oil as a photoprotective agent in hydroa vacciniforme. *Br J Dermatol*. 1998;138(1):173-178.
27. Jaschke E, Honigsmann H. Hydroa vacciniforme-action spectrum. UV-tolerance following photochemotherapy [in German]. *Hautarzt*. 1981;32(7):350-353.

Chapter 95 :: Actinic Dermatitis

:: Robert S. Dawe

Many diseases are caused by abnormal responses to ultraviolet radiation (UVR) and visible light exposure. This textbook includes separate chapters on other idiopathic (usually presumed immune-mediated) photodermatoses, including polymorphic light eruption/polymorphous light eruption (PLE/PMLE), actinic prurigo, hydroa vacciniforme (HV), and solar urticaria, and photodermatoses as a manifestation of metabolic diseases such as the cutaneous porphyrias. This chapter discusses conditions with a dermatitis on exposed sites, whether or not covered sites are also affected. These conditions include chronic actinic dermatitis, photoallergic contact dermatitis, drug-induced photosensitivity, and manifest as a dermatitis (eg, caused by thiazides) and photoaggravation of other dermatitides (atopic eczema, seborrheic dermatitis, and, often when caused by an airborne allergen, allergic contact dermatitis). Frequently, clinical assessment alone is insufficient to distinguish between true abnormal cutaneous photosensitivity (as in chronic actinic dermatitis) and photoaggravation, not true photosensitivity, of another dermatitis, and investigation with some form of phototesting can be necessary for definitive diagnosis, with important implications for management.

CHRONIC ACTINIC DERMATITIS

AT-A-GLANCE

- Chronic actinic dermatitis is a rare, acquired, persistent eczematous eruption of exposed skin, sometimes having pseudolymphomatous (reticuloid) features.
- It commonly affects older men, but is increasingly recognized in women and in younger people, including children.
- Histologic features are eczematous, but pseudolymphomatous forms may be virtually indistinguishable from cutaneous T-cell lymphoma.
- It usually involves severe ultraviolet B sensitivity but often also involves ultraviolet A sensitivity and sometimes sensitivity to visible light.
- Persistent light reaction, actinic reticuloid, photosensitive eczema, and photosensitivity dermatitis are all considered either clinical variants or old diagnostic terms.
- It is likely the result of a delayed-type hypersensitivity reaction against an endogenous photoinduced epidermal antigen(s).
- Therapy consists of strict avoidance of the relevant ultraviolet and visible rays, along with topical and intermittent oral steroids, and topical calcineurin inhibitors. Occasionally, phototherapy (ultraviolet B, broadband ultraviolet A, ultraviolet A1, or psoralen-ultraviolet A photochemotherapy) can be used, guided by the findings of investigation, particularly phototesting. If these measures are insufficient, or cause too much disruption to quality of life, then systemic immunosuppression (such as azathioprine or methotrexate) is required.

EPIDEMIOLOGY

Chronic actinic dermatitis (CAD),[1] formerly called the photosensitivity dermatitis/actinic reticuloid syndrome,[2] occurs across the world.[3-5] As it is frequently impossible to definitively diagnose CAD without some form of phototesting, it is likely that some persons with this condition are being labeled as having photoaggravated atopic eczema. CAD is possibly more common in people of darker-skin phototypes, but can be found in all peoples.[4,6] Perhaps, melanin plays a part in causing this condition. CAD has not been reported in people with albinism.

ETIOLOGY AND PATHOGENESIS

Studies of the clinical, histologic, and immunohistochemical features of CAD all show it to resemble the delayed-type hypersensitivity reaction of allergic contact dermatitis,[7,8] even in its severe pseudolymphomatous form (formerly called *actinic reticuloid*), in which the clinical and histologic features duplicate those seen in longstanding allergic contact dermatitis. It is highly probable that CAD is an allergic reaction. In addition to hypersensitivity to cutaneous photoantigens, patients with CAD often have concomitant allergic contact dermatitis to airborne and other ubiquitous allergens, including plant compounds, fragrances, and medicaments.[8-18] Commonly implicated allergens include sesquiterpene lactones from plants of the Compositae family and sunscreens.[16] The percentages with contact allergy as part of CAD vary according to the report; it seems likely that the relevant allergens will differ in different parts of the world and that the more locally relevant patch test agents are tested the higher will be the percentages with identified contact allergy.

Although photopatch testing is impossible in some persons with CAD (because the ultraviolet A photosensitivity can be too severe to allow irradiation of a photopatch test series), it can sometimes be done using an ultraviolet A minimal erythema dose assessment to determine a safe dose of ultraviolet A for this testing. This can be performed in those in whom it is helpful to determine whether or not there is photoallergy.[4]

When CAD occurs in the absence of an obvious contact allergen, the relevant novel antigen must be either directly radiation-induced or formed indirectly as a result of secondary oxidative metabolism. Important support for the latter possibility comes from the fact that albumin can become antigenic in vitro through photooxidation of its histidine moieties. There is no evidence for a genetic susceptibility to CAD; however, one stimulus for the acquisition of skin reactivity may be concurrent allergic contact dermatitis to recognized exogenous sensitizers or photosensitizers. These sensitizers are often airborne and may predispose by altering cutaneous immunity, and thus permit immunologic recognition of an endogenous photoantigen. Longstanding endogenous eczema, drug-induced photosensitivity, HIV infection,[19] and *possibly* PLE/PMLE also may play similar roles. On the other hand, in addition or instead, chronic photodamage in frequently sun-exposed elderly outdoor enthusiasts may impair normal UVR-induced skin immunosuppression sufficiently for endogenous UVR-induced photoantigens to be recognized, as apparently also occurs for genetic reasons in PLE/PMLE.[20] There is much work left to be done to identify the immunologic mechanisms that account for CAD.

Determining the action spectrum for CAD should theoretically help identify the postulated antigens, and the action spectra for CAD have been shown to resemble that of sunburn in many patients.[21] However, the eruption in CAD is eczematous, and much lower doses of UVR are required to evoke CAD than to produce erythema. In any event, the ultraviolet chromophore for some patients may be the same as that of sunburn, namely DNA,[21] with UVR-damaged DNA serving directly as an antigen in CAD. In other patients with CAD, however, the photoallergen must be different, because a few patients react only to ultraviolet A (UVA) radiation,[22] and some patients react only to visible light.[23]

In summary, CAD appears to be an allergic contact dermatitis-like reaction against UVR-altered DNA or similar or associated molecules, perhaps as a result of enhanced immune reactivity resulting from concomitant airborne contact dermatitis, or other longstanding preexisting dermatitis, or a reduced immunosuppressive capacity in ultraviolet-exposed skin.

CLINICAL FEATURES

HISTORY

CAD may arise de novo in apparently normal skin or in the skin of patients with previous endogenous eczema (often atopic or seborrheic eczema), photoallergic or allergic contact dermatitis, or, rarely, PLE/PMLE. Concurrent allergic contact sensitivity to plant allergens, fragrances, or sunscreens is common. The condition classically affects middle-aged and elderly men; however, CAD is increasingly recognized in younger people, particularly in those with atopic eczema,[24-27] although it is rarely present in children. The disorder is usually worse in summer in countries with marked seasonal variations, developing within minutes to hours after sunlight exposure and producing an itchy confluent erythematous eruption that occasionally remits over several days with scaling as long as exposure ceases and the reaction is mild. However, severely affected patients sometimes do not recognize that exacerbations are related to sunlight exposure, especially when affected all year round and when the wavelengths of sensitivity extend to longer UVA or visible wavelengths not associated with normal sunburn.

CUTANEOUS LESIONS

The lesions of CAD are eczematous, patchy or confluent, and acute, subacute, or chronic (Figs. 95-1 and 95-2). In severe cases, lichenification is common. Less commonly, scattered or widespread erythematous, shiny, infiltrated pseudolymphomatous papules or plaques are present on a background of erythematous, eczematous, or normal skin. Habitually exposed areas are most often affected, commonly with sharp cutoff at clothing lines. There is sparing of deep skin creases, upper eyelids, finger webs, and skin behind the earlobes. In severe disease, eczema of the palms and soles also may be found. Eyebrows, eyelashes, and scalp hair may be stubbly or altogether lost from constant rubbing and scratching. Erythroderma, usually accentuated on exposed sites, rarely supervenes. Variable,

Figure 95-1 Chronic actinic dermatitis: infiltrated eczematous eruption on the face.

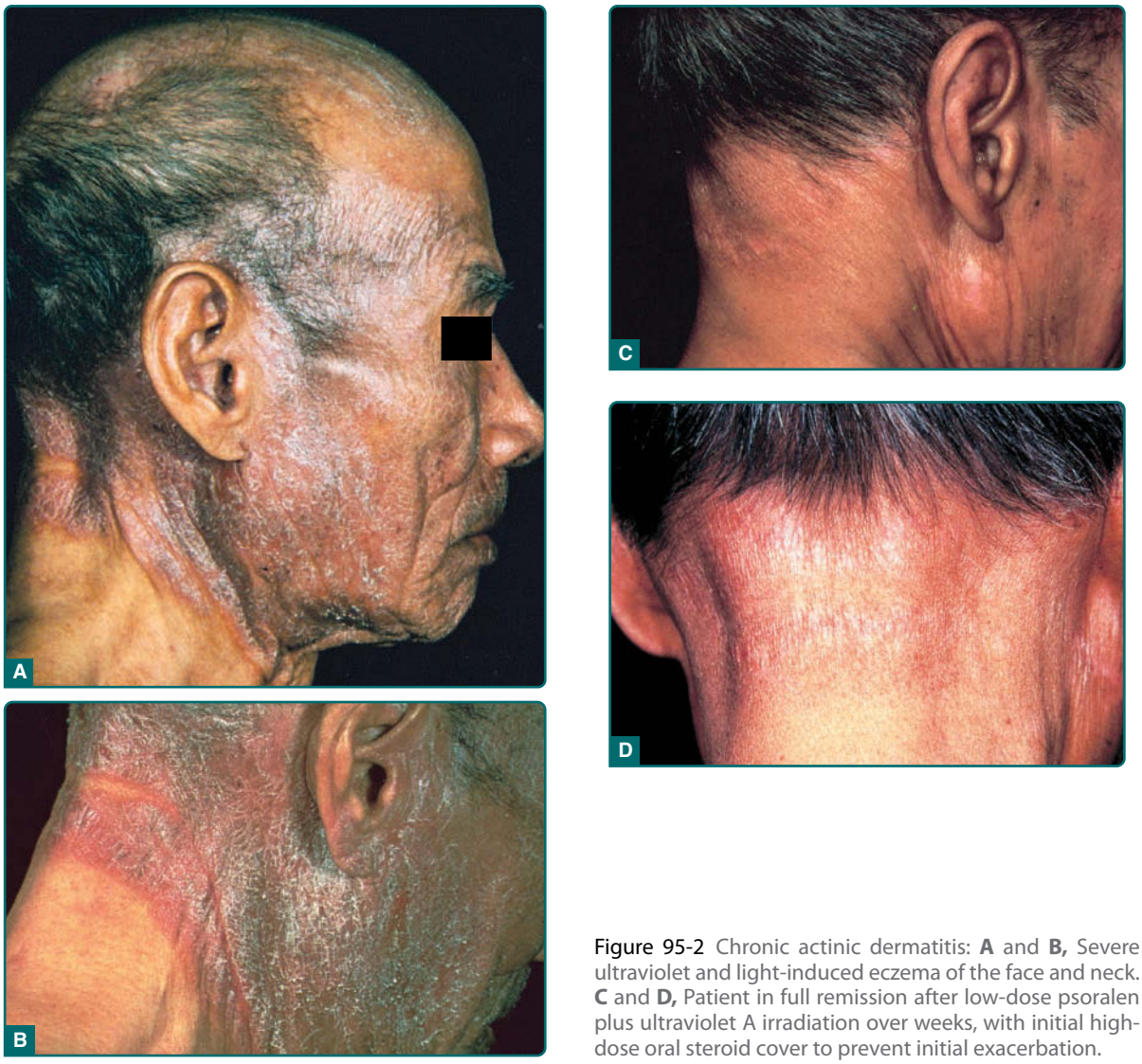

Figure 95-2 Chronic actinic dermatitis: **A** and **B,** Severe ultraviolet and light-induced eczema of the face and neck. **C** and **D,** Patient in full remission after low-dose psoralen plus ultraviolet A irradiation over weeks, with initial high-dose oral steroid cover to prevent initial exacerbation.

sometimes geographic, sparing of exposed areas of the face or elsewhere, as well as irregular hyperpigmentation and hypopigmentation, sometimes vitiligo-like, may also occasionally be found.

LABORATORY TESTS

HISTOLOGY

Histologic features include epidermal spongiosis and acanthosis, sometimes with hyperplasia. There is usually a predominantly perivascular lymphocytic cellular infiltrate confined to the upper dermis that in milder cases may resemble chronic eczema.[28] CAD cannot be diagnosed on histopathology but a biopsy of the eruption, whether naturally occurring or provoked on phototesting, can be helpful in confirming an eczema and not another pattern of inflammation. Severe CAD, however, may mimic cutaneous T-cell lymphoma (CTCL), on occasion being virtually indistinguishable. Features mimicking CTCL include epidermal Pautrier-like microabscesses and deep, dense epidermotropic mononuclear cell infiltration, sometimes with atypia. Typically, there is no marked increase in mitoses. T-cell receptor gene rearrangement studies are normally done if there is suspicion of CTCL. However, T-cell receptor clonality also may be observed in benign dermatoses, so even identification of a clone does not completely rule out CAD, rather than lymphoma, as the diagnosis.

BLOOD TESTS

Assessment of lupus autoantibodies is usually done to exclude the unlikely possibility of cutaneous lupus erythematosus. In severe or erythrodermic CAD, there may be large numbers of circulating CD8+ Sézary cells without other suggestions of malignancy.[29] HIV status should be assessed if there is suspicion that this may be a predisposing or associated factor. Serum

immunoglobulin E may be elevated (even among those whose CAD has not supervened upon atopic eczema), with higher levels of immunoglobulin E correlating with more-severe disease.

PHOTOTESTING

Phototesting is essential to make the diagnosis of CAD. Almost invariably one finds low erythemal thresholds and eczematous or pseudolymphomatous responses after irradiation with ultraviolet B (UVB), usually with UVA, and frequently also with visible wavelengths (accounting for presentations such as described after a tungsten light was used when ear cleaning).[30] A small number of patients genuinely seem to react only to UVA (although the possibility of another diagnosis such as drug reaction must be revisited if only UVA sensitivity is found), and fewer still only to visible light, in which case, drug photosensitivity must also be considered. Testing should be done on uninvolved skin of the back with no topical or systemic steroid therapy for at least the preceding few days to avoid false-negative results.[31,32] Various sources can be used for phototesting, including the irradiation monochromator, which allows the delivery of different doses of different ultraviolet and visible wavebands (which can be fairly narrow but which are not truly monochromatic).[33-36] If an irradiation monochromator is not available, then a series of different sources with filters can be used to sample through at least UVB and UVA (for which phototherapy treatment sources can be used) and visible light (such as using a slide projector). When such fairly elaborate equipment is not available, sunlight can be used (at least in warmer parts of the world) with a template devised to allow small areas of skin to have different durations of exposure and using a piece of window glass to filter out UVB, which enables testing with whole-spectrum sunlight and sunlight minus UVB. The output from the sun can be very variable, but the severity of abnormal photosensitivity in CAD is usually severe, so as long as a control population has been tested to establish what is normal, then such relatively crude testing is useful.

Monochromatic and broad-spectrum sources both induce abnormal responses, with monochromatic sources determining the action spectrum for disease induction and broad-spectrum sources tending to demonstrate acute eczema.

PATCH AND PHOTOPATCH TESTING

Patch testing and photopatch testing (when possible; sometimes the sensitivity to UVA on its own precludes irradiating with even a tiny dose of UVA for photopatch testing) are also important in suspected CAD, because contact sensitivity, including to airborne allergens such as Compositae oleoresins (including, where it occurs, parthenium),[16,37-39] colophony,[40,41] and methylisothiazolinone (the airborne dermatitis of which can be photoaggravated),[42,43] alone may resemble CAD or even coexist with CAD. In addition, occasional secondary contact or photocontact sensitivity to sunscreens or other topical therapies may complicate the clinical picture.[44]

TABLE 95-1
Differential Diagnosis of Chronic Actinic Dermatitis

- Photoexacerbated atopic or seborrheic eczema
- Drug or chemical photosensitivity
- Cutaneous T-cell lymphoma
- Eczematized actinic prurigo
- Photoallergic contact dermatitis
- Photoaggravated airborne contact allergic dermatitis

Note: The other conditions described in the text as capable of causing an exposed-site dermatosis do not cause a dermatitis unless the dermatitis is superimposed, such as someone who has PLE/PMLE but develops superimposed dermatitis changes perhaps because of having atopic eczema.

DIFFERENTIAL DIAGNOSIS

Table 95-1 outlines the differential diagnosis of CAD.

COMPLICATIONS

A relationship to CTCL was considered a possibility.[45] However, when this was studied at a population level (and misclassifications in diagnostic databases were corrected) it was found that CTCL and CAD did not coexist more than would be expected by chance.[46] Results of T-cell receptor, immunoglobulin gene rearrangement, and other studies are usually negative in CAD.[47] In addition, CAD gradually resolves in many patients, there is no higher incidence of malignancies, and life expectancies are thought to be normal.[48] However, CTCL itself may present very rarely with severe CAD-like photosensitivity, and careful investigation to exclude CTCL is necessary when the disease suspected.[49-51]

PROGNOSIS AND CLINICAL COURSE

Once established, CAD usually persists for years before resolving gradually (Dawe et al).[48] Particularly severe phototest sensitivity and a number of completely separate contact allergens seem to be predictors of a poorer prognosis for resolution. In that study, young age and female sex were also associated with a poorer prognosis for resolution but when that study was done, CAD was considered to be a disease of old men so was likely more often not diagnosed in younger people and in women (and only diagnosed in the more severely affected young people and women).[48]

TREATMENT

Treatment of CAD is often difficult and not fully effective. Rigorous avoidance of UVR and exacerbating contact allergens is essential, along with regular application of high-protection-factor broad-spectrum topical sunscreens of low irritancy and allergenic potential. Ideally, sunscreen photoprotection should be guided by knowledge of the wavelengths (UVB, UVB and UVA, or UVB, UVA, and visible) implicated in each individual. Strong topical corticosteroids, such as clobetasol propionate 0.05%, are also often needed and frequently produce marked symptomatic relief without adverse effects, even after long-term use, if confined to affected skin. Occasional oral steroid use is often helpful for disease flares. In more-resistant disease, the topical calcineurin inhibitors—tacrolimus and pimecrolimus—sometimes produce good results if tolerated.[52-58] For refractory CAD, however, oral immunosuppressive therapy is often necessary and generally helpful if tolerated. Azathioprine 1.5 to 2.5 mg/kg/day can produce remission in months,[59-65] after which it may be reduced in dosage, or perhaps discontinued in the winter. While less studied for this indication, methotrexate is also used, especially when CAD has arisen on a background of atopic eczema. Cyclosporine 3.5 to 5 mg/kg/day can be rapidly effective,[66,67] but is more likely to produce adverse effects, and so is generally not a good long-term treatment. Mycophenolate mofetil is less often used.[68,69] More localized skin immunosuppression by psoralen activated by UVA treatment also can be effective,[70,71] and is often initially accompanied by oral and topical corticosteroid therapy to reduce disease flares.[71]

PREVENTION

The risk of CAD can *possibly* be reduced by moderating outdoor pursuits, especially those associated with plant allergen exposure, such as gardening, even more so for individuals who already have a tendency to develop eczematous eruptions in exposed areas. In those persons who are already developing CAD, avoidance of UVR is critical, and patients should be aware that indoor lighting with fluorescent lamps, including compact fluorescent energy-saving lamps, is also a source of UVA and UVB. [72,73]

PHOTOEXACERBATED DERMATITIS

Several dermatoses that are not caused by UVR may be worsened by it (Table 95-2). Mechanisms of this phenomenon, termed *photoexacerbation*, have rarely been studied. The initial condition may be severely worsened even if it was originally only mild or subclinical. These disorders are relatively common. Such conditions, especially the eczemas, psoriasis, and acne, improve with sunlight exposure in most patients, perhaps because cutaneous reactivity is reduced, but in a small proportion of individuals, it is instead aggravated. If photoexacerbation does occur, the new eruption generally develops or worsens initially at sites typical of the basic disorder (Fig. 95-3), followed at times by extension to other areas. In photoexacerbated seborrheic eczema, however, an unpleasant sensation at the exposed sites may be the first or only feature.

TABLE 95-2
Selection of Diseases Sometimes Exacerbated by Ultraviolet Irradiation

- Acne
- Atopic eczema
- Carcinoid syndrome
- Cutaneous T-cell lymphoma
- Dermatomyositis
- Disseminated superficial actinic porokeratosis
- Erythema multiforme
- Familial benign chronic pemphigus (Hailey-Hailey disease)
- Keratosis follicularis (Darier disease)
- Lichen planus
- Lupus erythematosus
- Pellagra
- Pemphigus foliaceus (erythematosus)
- Pityriasis rubra pilaris
- Psoriasis
- Reticulate erythematous mucinosis syndrome
- Rosacea
- Seborrheic eczema
- Transient acantholytic dermatosis (Grover disease)
- Viral infections

Figure 95-3 Photoexacerbated seborrheic dermatitis, affecting the face only at sites of predilection for the seborrheic eruption.

Treatment consists of minimizing sunlight exposure, protection with suitable clothing, application of high-protection-factor broad-spectrum sunscreens, and careful treatment of the underlying disorder. Taking these steps alone often improves the problem. If these actions are inadequate, phototherapy often helps, for example, in seborrheic or atopic eczema and psoriasis. Often a particular value in distinguishing between photoaggravation and true photosensitivity in these conditions is to decide whether or not phototherapy can be used. Phototherapy is contraindicated in cutaneous lupus erythematosus or dermatomyositis becauseaggravation of the systemic disease is a risk. Photoexacerbated acne commonly requires treatment with oral isotretinoin.

APPROACH TO THE PATIENT WITH A DERMATOSIS ON PHOTOEXPOSED SITES

CLINICAL FEATURES

Patients with abnormal photosensitivity present in 3 ways: (a) sporadic or (b) persistent eruptions in sunlight-exposed areas (Fig. 95-4), or, infrequently, (c) erythroderma. When sporadic, the patient usually considers sunlight exposure to be responsible; when persistent, the physician often must identify the association. Careful history taking is essential, first to confirm that sunlight exposure is responsible and then to make a diagnosis. Information of considerable importance are age at disease onset, gender, family history, previous sunlight sensitivity, occupation, leisure pursuits, and systemic and topical drug (or chemical) use. Additional relevant details include distribution of lesions; effects of season; exposure times required for induction; time between exposure and the appearance of lesions; duration of the eruption after exposure ceases; effects of sunlight received through window glass (implicating UVA and visible light); presence of systemic symptoms; and patient-assessed morphologies (progression of the disease before the clinic visit).

In terms of age and sex, young women are more likely to develop PLE/PMLE; women or girls more commonly develop actinic prurigo; children of either gender may have HV, xeroderma pigmentosum, or erythropoietic protoporphyria; elderly men or younger individuals with a history of eczema most often develop CAD.

A family history of sunlight sensitivity may be present in patients with PMLE/PLE, actinic prurigo, xeroderma pigmentosum, and the porphyrias. CAD is common in outdoor enthusiasts exposed to both sunlight and airborne allergens (it is important to also consider it in patients from other demographics), although exacerbations of disease, despite sunscreen use, invoke the possibility of sunscreen allergy. An eruption appearing in minutes and remitting within 2 hours suggests solar urticaria or, occasionally, photosensitivity to drugs, such as amiodarone. Onset within 20 minutes to several hours, with resolution over days suggests PLE/PMLE, HV, erythropoietic protoporphyria, cutaneous lupus erythematosus, or other photoexacerbated dermatoses, or other drug photosensitivities, such as to thiazides. Systemic malaise is uncommon, but well recognized, in PMLE/PLE, HV, and solar urticaria. Development of lesions after exposure through window glass suggests an inducing spectrum that includes UVA and/or visible light.

The eruption described by patients with PMLE/PLE is generally that of small or large, elevated, pruritic, red or skin-colored, and often clumped spots of papules, sometimes confluent, that usually involve several, but not all exposed sites. In HV, blistering with scar formation occurs, and in solar urticaria, elevated pruritic wheals are often confluent. In erythropoietic protoporphyria and amiodarone drug photosensitivity, a marked burning sensation, without visible change, has been reported. In erythropoietic protoporphyria, relatively lengthy exposure may lead to firm, colorless or pink, diffuse swelling. In most drug photosensitivity reactions and in xeroderma pigmentosum, an exaggerated sunburn-like reaction is possible, which in many forms of xeroderma pigmentosum is maximal at 2 to 3 days. Finally, in photoexacerbated dermatoses, the eruption resembles that of the primary disorder.

Photosensitivity eruptions are usually present on some, and occasionally all, of the forehead; nose; upper cheeks; tip of the chin; rims of the pinnae; back and sides of the neck; upper chest; backs of the hands and feet; and extensor aspects of the limbs. Covered areas also may be involved, but to a lesser extent. On the other hand, portions of the face protected by hair or customarily in shadow, such as upper eyelids, finger webs, skin creases, and skin under the nose, lower lip, chin, and backs of earlobes, are frequently unaffected, except when there is associated airborne contact dermatitis. Excoriated papules suggest actinic prurigo, whereas eczematous lesions or, very rarely, light-associated erythrodermas suggest CAD, photoexacerbated atopic, or seborrheic eczema. Finally, skin fragility, bulla formation, and atrophic superficial scarring suggest hepatic porphyria or pseudoporphyria, especially if there has been drug or excessive alcohol intake.

Clinical appraisal along with the history usually results in a diagnosis, although for complete certainty, several of the studies listed below may be appropriate.

LABORATORY STUDIES

If the diagnosis is not certain, appropriate additional studies include an assessment of the antinuclear antibody and extractable nuclear antibody panel. If

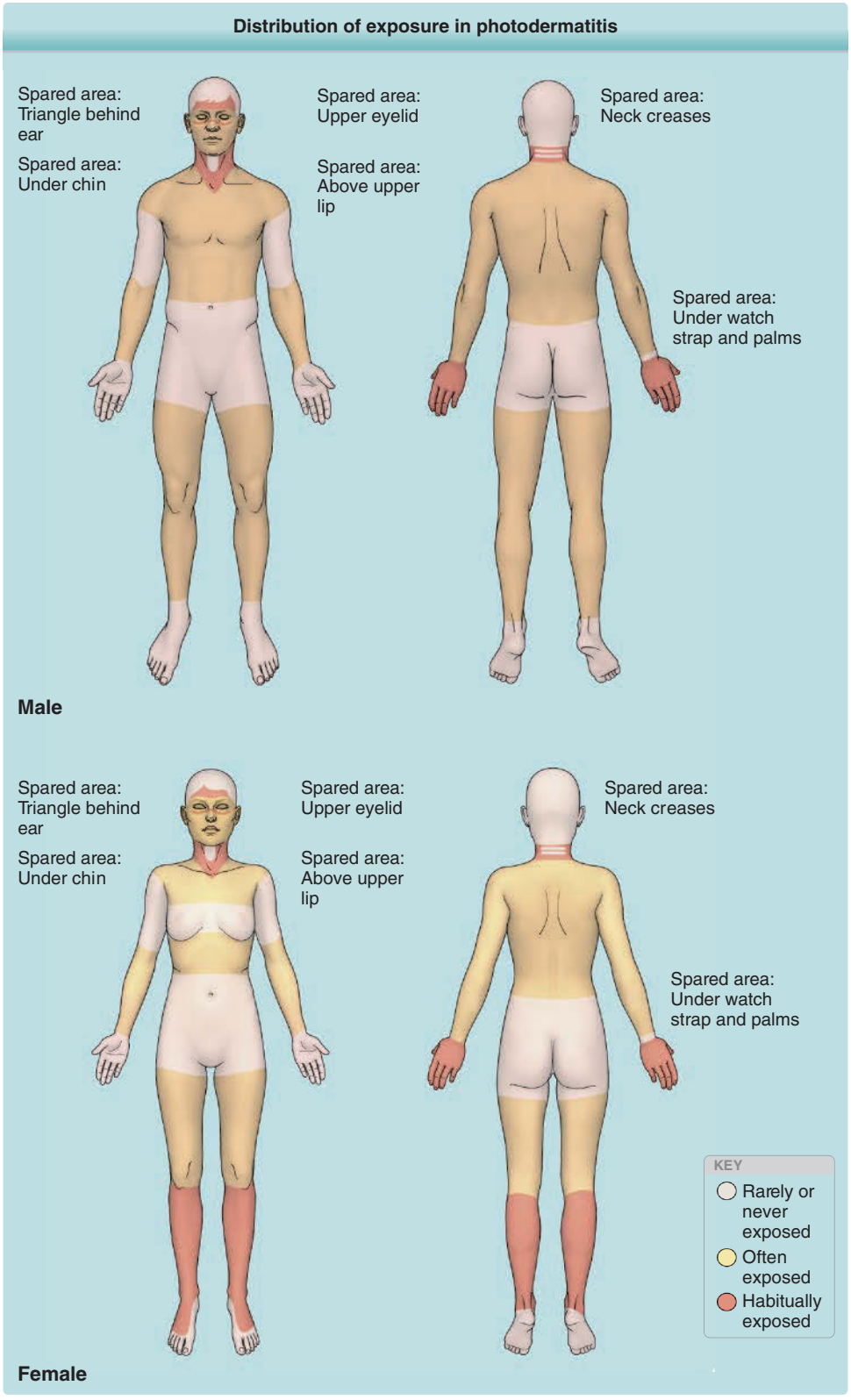

Figure 95-4 Distribution of exposure in photodermatitis. (From Wolff K, Johnson RA, Saavedra AP, et al. *Fitzpatrick's Color Atlas and Synopsis of Clinical Dermatology*, 8th ed. New York, NY: McGraw-Hill; 2017, with permission.)

present at significant titers, cutaneous lupus erythematosus should be considered. In addition, examination of blood, urine, and stools for porphyrins should be considered.

Biopsies may be helpful. Lesional histologic features are characteristic in several photodermatoses, especially PMLE, HV, and CAD. However, with the exception of HV, histopathologic changes in

TABLE 95-3

Usual Monochromatic Phototest Responses in Idiopathic, Probably Immunologic, Photodermatoses

DISEASE	ACTION SPECTRUM	FREQUENCY OF ABNORMAL FINDINGS
Polymorphic light eruption	UVA more often than UVB	Only sometimes
Actinic prurigo	UVA more often than UVB	Only sometimes
Hydroa vacciniforme	More often UVA	Only sometimes
Chronic actinic dermatitis	UVB ± UVA ± visible light	Virtually always
Solar urticaria	UVB, UVA, or visible, or combination	Usual
Xeroderma pigmentosum	UVB	Usual
Photoexacerbated dermatoses	UVB, UVA, or combination	Rare

UVA, ultraviolet A radiation; UVB, ultraviolet B radiation.

photodermatoses are rarely entirely diagnostic. These are reviewed in the preceding disease descriptions.

Phototesting of normal back skin with a monochromator in CAD and solar urticaria often produces the papules or wheals of the condition itself, frequently at low irradiation doses, and this also may identify the action spectrum. Phototesting also helps to confirm xeroderma pigmentosum through the delayed development of erythema over 2 to 3 days, with an abnormally low-dose threshold, often eventuating in blister formation (Table 95-3). In eczematous photosensitivity, patch and photopatch testing are also essential to identify relevant allergens. Finally, special techniques, such as the assessment of DNA excision repair or of RNA synthesis recovery rate in cultured fibroblasts after UVR exposure, are essential for the diagnoses of certain genophotodermatoses.

PHOTOTESTING

Techniques of phototesting vary greatly from country to country and from center to center. Although it is the investigational technique of choice for photodermatoses when the diagnosis is uncertain or when details of the inducting action spectrum are required, phototesting remains unavailable in many clinical centers. The cost of the equipment and its infrequent use in most clinical practices means that patients should be referred for consultation to such centers whenever indicated.

Phototesting falls into 2 categories: (a) monochromator phototesting (testing to wavebands, it is not strictly monochromatic, produced by an irradiation monochromator),[35] usually of the upper back with selected wavebands and selected doses to identify the action spectrum for the disorder and to provoke the eruption (frequently responses at 24 hours and later after irradiating small circles of back skin with a monochromator look eczematous in CAD), and (b) photoprovocation with a broad-spectrum source to induce the eruption for its clinical appearance and subsequent biopsy if indicated. Table 95-3 lists the disorders for which monochromatic testing may be helpful.

For precise characterization of the wavelength dependency of a disorder, monochromator testing, preferably with a xenon arc irradiation monochromator, should be employed. For photoprovocation, the favored device is often a solar simulator, usually a xenon arc-filtered source that produces a spectrum that resembles the terrestrial sunlight spectrum at noon at sea level on a cloudless midsummer's day in temperate regions of the world. Keep in mind that the terrestrial spectrum at noon in June varies considerably between Iceland and Kenya, as it also does between high elevations and sea level. So, a solar simulator is only ever a simulator of a certain "type" of sunlight. Several suitable protocols also have been described for using simple broad-spectrum metal halide or fluorescent light sources with filters if necessary. In some parts of the world, sunlight with filters also has been used, although this method is generally too unpredictable for clinical use.

The mainstay of phototesting is a monochromator. It is composed of a high-pressure xenon arc source that emits radiation along a pathway incorporating a diffraction grating angled to produce the required waveband at the exit slit. Such equipment needs regular calibration of output and wavelength. Because even large centers cannot always afford such equipment, lesser alternatives have been created, such as metal halide or fluorescent light sources of sufficient output intensity. With such sources, the UVB, UVA, and visible light components of patient photosensitivity can be studied, based on deviation from normal erythemal reactions throughout the UVR spectrum.

Monochromator phototesting is preferably performed on unaffected skin of the upper back, lateral to the paravertebral groove whereas lesion induction, except when done relatively easily with the monochromator, as in solar urticaria and CAD, is best undertaken using broadband sources with output directed over larger areas of skin known to be susceptible to the eruption. PLE/PMLE, actinic prurigo, and HV are conditions in which repeated irradiation with UVA-emitting or UVB-emitting or combined sources is often required to reproduce the disease.

It is important that the use of potent topical and systemic steroids be avoided when possible for at least several days before phototesting to prevent false-negative results.[31,32] It is not certain how much the other oral immunosuppressive agents affect testing (and in CAD severe abnormal sensitivity can still be seen in those on azathioprine, methotrexate, or ciclosporin), but they should be stopped whenever possible as well. False-positive results may also occur in patients with widespread disease (with the possibility of photoaggravation of an underlying process being

mistaken for true photosensitivity), and the eruption should first be well-controlled whenever possible, if necessary by keeping the patient in a reduced-light environment. However, it is often difficult to fulfill these requirements if the eruption is active, and in such circumstances, testing may need to be undertaken with knowledge of its limitations.

All phototesting should be undertaken at carefully standardized sequential doses (often a geometric series) and wavelengths, and the results read at consistent times after exposure in carefully controlled conditions of light and temperature. Furthermore, because testing involves UVR exposure, potentially harmful to both skin and eyes, the patient and the investigator should be protected with appropriate clothing, shielding and goggles.

PHOTOPATCH TESTING

Chapter 97 discusses photopatch testing in greater detail. Photopatch testing is an established investigational tool designed to identify photoallergic contact dermatitis, although it also can be employed to help identify phototoxic agents. It is essentially a more complex version of patch testing, and it is used in patients with exposed-site eczema, whether or not they also have another photodermatosis, to determine whether photoallergy is also present.

The methodology of photopatch testing has received less attention than allergen testing or phototesting, as it resides between the 2 specialty areas of photodermatology and contact dermatology. However, consensus methodology is now available.[74-78]

Using this approach, test materials (usually sunscreens, topical nonsteroidal, and antiinflammatory agents in Europe and North America—it is important to consider what might be locally relevant, eg, some antiseptics still used in soap in parts of the world—and other possible causative agents) are applied in duplicate for 24 to 48 hours to normal skin. One set of test sites is then uncovered and irradiated with a broad-spectrum UVA source, usually at 5 J/cm^2 from fluorescent UVA lamps (as used for psoralen activated by UVA), and the results read 24 and 48 hours later. Ideally, at the time of application of the patch tests (if 24 hours before planned irradiation), irradiations to determine the minimal erythemal dose with the planned UVA source should be conducted, especially if severe photosensitivity such as in CAD is possible. Sometimes if the minimal erythemal dose is extremely low the results preclude irradiation with any UVA, but sometimes they allow photopatch testing to proceed using a dose lower than the standard 5 J/cm^2. Strongly positive reactions at sites exposed to both chemical agent and UVA, with no reactions at the covered control sites, confirms a diagnosis of photoallergy. Occasionally, however, contact irritation or contact allergy occurs in both sites, making a diagnosis of photoallergy uncertain. One should also be alert to the possibility that all irradiated sites may become positive (especially if the patient is photosensitive and a UVA minimal erythemal dose was not done), suggesting that underlying widespread UVA photosensitivity is responsible. Furthermore, the identification of potential photoallergens is still primitive, often with separation of phototoxicity from photoallergy uncertain. Once again, testing for photoallergy is best conducted in regional centers or by physicians with appropriate experience.

ACKNOWLEDGMENTS

The author is grateful to the previous authors for the earlier versions of this chapter, Travis W. Vandergriff, Paul R. Bergstresser, John L. M. Hawk, and James Ferguson. I have not made changes for "changes sake," but I have added to or changed the text where new knowledge is available, where extra information might be useful, and to make this chapter as useful as possible in all parts of the world.

REFERENCES

1. Hawk JL, Magnus IA. Chronic actinic dermatitis—an idiopathic photosensitivity syndrome including actinic reticuloid and photosensitive eczema [proceedings]. *Br J Dermatol.* 1979;101(suppl 17):24.
2. Frain-Bell W, Lakshmipathi T, Rogers J, et al. The syndrome of chronic photosensitivity dermatitis and actinic reticuloid. *Br J Dermatol.* 1974;91:617-634.
3. Khoo SW, Tay YK, Tham SN. Photodermatoses in a Singapore skin referral centre. *Clin Exp Dermatol.* 1996;21:263-268.
4. Tan KW, Haylett AK, Ling TC, et al. Comparison of demographic and photobiological features of chronic actinic dermatitis in patients with lighter vs darker skin types. *JAMA Dermatol.* 2017;153:427-435.
5. Que SK, Brauer JA, Soter NA, et al. Chronic actinic dermatitis: an analysis at a single institution over 25 years. *Dermatitis.* 2011;22:147-154.
6. Kerr HA, Lim HW. Photodermatoses in African Americans: a retrospective analysis of 135 patients over a 7-year period. *J Am Acad Dermatol.* 2007;57:638-643.
7. Fujita M, Miyachi Y, Horio T, et al. Immunohistochemical comparison of actinic reticuloid with allergic contact dermatitis. *J Dermatol Sci.* 1990;1:289-296.
8. Hannuksela M, Suhonen R, Forstrom L. Delayed contact allergies in patients with photosensitivity dermatitis. *Acta Derm Venereol.* 1981;61:303-306.
9. Schauder S, Schroder W, Geier J. Olaquindox-induced airborne photoallergic contact dermatitis followed by transient or persistent light reactions in 15 pig breeders. *Contact Dermatitis.* 1996;35:344-354.
10. Thune P. Contact and photocontact allergy to sunscreens. *Photodermatol.* 1984;1:5-9.
11. Thune P. Photosensitivity and allergy to cosmetics. *Contact Dermatitis.* 1981;7:54-55.
12. Wahlberg JE, Wennersten G. Light sensitivity and chromium dermatitis. *Br J Dermatol.* 1977;97:411-416.
13. Thune P. Contact allergy due to lichens in patients with a history of photosensitivity. *Contact Dermatitis.* 1977;3:267-272.
14. du P Menagé H, Hawk JL, White IR. Sesquiterpene lactone mix contact sensitivity and its relationship to chronic actinic dermatitis: a follow-up study. *Contact Dermatitis.* 1998;39:119-122.

15. Frain-Bell W. Photosensitivity and compositae dermatitis. *Clin Dermatol.* 1986;4:122-126.
16. Addo HA, Sharma SC, Ferguson J, et al. A study of compositae plant extract reactions in photosensitivity dermatitis. *Photodermatol.* 1985;2:68-79.
17. Addo HA, Ferguson J, Johnson BE, et al. The relationship between exposure to fragrance materials and persistent light reaction in the photosensitivity dermatitis with actinic reticuloid syndrome. *Br J Dermatol.* 1982;107:261-274.
18. Frain-Bell W, Johnson BE. Contact allergic sensitivity to plants and the photosensitivity dermatitis and actinic reticuloid syndrome. *Br J Dermatol.* 1979;101:503-512.
19. Vin-Christian K, Epstein JH, Maurer TA, et al. Photosensitivity in HIV-infected individuals. *J Dermatol.* 2000; 27:361-369.
20. Palmer RA, Friedmann PS. Ultraviolet radiation causes less immunosuppression in patients with polymorphic light eruption than in controls. *J Invest Dermatol.* 2004;122:291-294.
21. Menage HD, Harrison GI, Potten CS, et al. The action spectrum for induction of chronic actinic dermatitis is similar to that for sunburn inflammation. *Photochem Photobiol.* 1995;62:976-979.
22. ten Berge O, van Weelden H, Bruijnzeel-Koomen CA, et al. Throwing a light on photosensitivity in atopic dermatitis: a retrospective study. *Am J Clin Dermatol.* 2009;10:119-123.
23. Healy E, Rogers S. Photosensitivity dermatitis/actinic reticuloid syndrome in an Irish population: a review and some unusual features. *Acta Derm Venereol.* 1995;75:72-74.
24. Russell SC, Dawe RS, Collins P, et al. The photosensitivity dermatitis and actinic reticuloid syndrome (chronic actinic dermatitis) occurring in seven young atopic dermatitis patients. *Br J Dermatol.* 1998;138:496-501.
25. Ogboli MI, Rhodes LE. Chronic actinic dermatitis in young atopic dermatitis sufferers. *Br J Dermatol.* 2000;142:845.
26. Creamer D, McGregor JM, Hawk JL. Chronic actinic dermatitis occurring in young patients with atopic dermatitis. *Br J Dermatol.* 1998;139:1112-1113.
27. Kurumaji Y, Kondo S, Fukuro S, et al. Chronic actinic dermatitis in a young patient with atopic dermatitis. *J Am Acad Dermatol.* 1994;31:667-669.
28. Sidiropoulos M, Deonizio J, Martinez-Escala ME, et al. Chronic actinic dermatitis/actinic reticuloid: a clinicopathologic and immunohistochemical analysis of 37 cases. *Am J Dermatopathol.* 2014;36:875-881.
29. Zugerman C, Beeaff D, Roenigk HH Jr. Photosensitivity and Sezary syndrome. *Cutis.* 1980;25:495-499.
30. Hu SC, Lan CE. Tungsten lamp and chronic actinic dermatitis. *Australas J Dermatol.* 2017;58:e14-e16.
31. Ferguson J, Ibbotson SH. A case of false-negative monochromator phototesting in a patient with chronic actinic dermatitis taking prednisolone. *Br J Dermatol.* 2012;167:214-215.
32. Kerr AC, Dawe RS, Lowe G, et al. False-negative monochromator phototesting in chronic actinic dermatitis. *Br J Dermatol.* 2010;162:1406-1408.
33. Cripps DJ. Instrumentation and action spectra in light-associated diseases. *J Invest Dermatol.* 1981;77:20-31.
34. DeLeo V, Gonzalez E, Kim J, et al. Phototesting and photopatch testing: when to do it and when not to do it. *Am J Contact Dermat.* 2000;11:57-61.
35. Bilsland D, Diffey BL, Farr PM, et al. Diagnostic phototesting in the United Kingdom. British Photodermatology Group. *Br J Dermatol.* 1992;127:297-299.
36. MacKenzie LA, Frain-Bell W. The construction and development of a grating monochromator and its application to the study of the reaction of the skin to light. *Br J Dermatol.* 1973;89:251-264.
37. Agarwal KK, D'Souza M. Airborne contact dermatitis induced by parthenium: a study of 50 cases in South India. *Clin Exp Dermatol.* 2009;34:e4-e6.
38. Ross JS, du Peloux Menage H, Hawk JL, et al. Sesquiterpene lactone contact sensitivity: clinical patterns of Compositae dermatitis and relationship to chronic actinic dermatitis. *Contact Dermatitis.* 1993;29:84-87.
39. Dawe RS, Green CM, MacLeod TM, et al. Daisy, dandelion and thistle contact allergy in the photosensitivity dermatitis and actinic reticuloid syndrome. *Contact Dermatitis.* 1996;35:109-110.
40. Kuno Y, Kato M. Photosensitivity from colophony in a case of chronic actinic dermatitis associated with contact allergy from colophony. *Acta Derm Venereol.* 2001;81:442-443.
41. Krutmann J, Rzany B, Schopf E, et al. Airborne contact dermatitis from colophony: phototoxic reaction? *Contact Dermatitis.* 1989;21:275-276.
42. Pirmez R, Fernandes AL, Melo MG. Photoaggravated contact dermatitis to Kathon CG (methylchloroisothiazolinone/methylisothiazolinone): a novel pattern of involvement in a growing epidemic? *Br J Dermatol.* 2015;173:1343-1344.
43. Trokoudes D, Banerjee P, Fityan A, et al. Photoaggravated contact dermatitis caused by methylisothiazolinone. *Contact Dermatitis.* 2017;76:303-304.
44. Bilsland D, Ferguson J. Contact allergy to sunscreen chemicals in photosensitivity dermatitis/actinic reticuloid syndrome (PD/AR) and polymorphic light eruption (PLE). *Contact Dermatitis.* 1993;29:70-73.
45. Jensen NE, Sneddon IB. Actinic reticuloid with lymphoma. *Br J Dermatol.* 1970;82:287-291.
46. Bilsland D, Crombie IK, Ferguson J. The photosensitivity dermatitis and actinic reticuloid syndrome: no association with lymphoreticular malignancy. *Br J Dermatol.* 1994;131:209-214.
47. Bakels V, van Oostveen JW, Preesman AH, et al. Differentiation between actinic reticuloid and cutaneous T cell lymphoma by T cell receptor gamma gene rearrangement analysis and immunophenotyping. *J Clin Pathol.* 1998;51:154-158.
48. Dawe RS, Crombie IK, Ferguson J. The natural history of chronic actinic dermatitis. *Arch Dermatol.* 2000;136:1215-1220.
49. Neill SM, Du Vivier A. A case of mycosis fungoides mimicking actinic reticuloid. *Br J Dermatol.* 1985;113:497-500.
50. Volden G. A study of the photosensitive factor in relation to skin lesions of mycosis fungoides patients. *Dermatologica.* 1980;161:89-92.
51. Agar N, Morris S, Russell-Jones R, et al. Case report of four patients with erythrodermic cutaneous T-cell lymphoma and severe photosensitivity mimicking chronic actinic dermatitis. *Br J Dermatol.* 2009;160:698-703.
52. Bhari N, Gupta S. Tacrolimus 0.1% ointment applied under occlusion using cling film clears chronic actinic dermatitis resistant to systemic treatment. *Int J Dermatol.* 2017;56:e139-e141.
53. Ma Y, Lu Z. Treatment with topical tacrolimus favors chronic actinic dermatitis: a clinical and immunopathological study. *J Dermatolog Treat.* 2010;21:171-177.
54. Larangeira de Almeida H Jr. Successful treatment of chronic actinic dermatitis with topical pimecrolimus. *Int J Dermatol.* 2005;44:343-344.

55. Baldo A, Prizio E, Mansueto G, et al. A case of chronic actinic dermatitis treated with topical tacrolimus. *J Dermatolog Treat*. 2005;16:245-248.
56. McCall CO. Treatment of chronic actinic dermatitis with tacrolimus ointment. *J Am Acad Dermatol*. 2003;49:775; author reply 775-776.
57. Suga Y, Hashimoto Y, Matsuba S, et al. Topical tacrolimus for chronic actinic dermatitis. *J Am Acad Dermatol*. 2002;46:321-323.
58. Abe R, Shimizu T, Tsuji A, et al. Severe refractory chronic actinic dermatitis successfully treated with tacrolimus ointment. *Br J Dermatol*. 2002;147:1273-1275.
59. Dawe RS. Chronic actinic dermatitis in the elderly: recognition and treatment. *Drugs Aging*. 2005;22:201-207.
60. Yap LM, Foley P, Crouch R, et al. Chronic actinic dermatitis: a retrospective analysis of 44 cases referred to an Australian photobiology clinic. *Australas J Dermatol*. 2003;44:256-262.
61. Lim HW, Morison WL, Kamide R, et al. Chronic actinic dermatitis. An analysis of 51 patients evaluated in the United States and Japan. *Arch Dermatol*. 1994;130:1284-1289.
62. Murphy GM, Maurice PD, Norris PG, et al. Azathioprine treatment in chronic actinic dermatitis: a double-blind controlled trial with monitoring of exposure to ultraviolet radiation. *Br J Dermatol*. 1989;121:639-646.
63. Kingston TP, Lowe NJ, Sofen HL, et al. Actinic reticuloid in a black man: successful therapy with azathioprine. *J Am Acad Dermatol*. 1987;16:1079-1083.
64. Leigh IM, Hawk JL. Treatment of chronic actinic dermatitis with azathioprine. *Br J Dermatol*. 1984;110:691-695.
65. Haynes HA, Bernhard JD, Gange RW. Actinic reticuloid. Response to combination treatment with azathioprine, hydroxychloroquine, and prednisone. *J Am Acad Dermatol*. 1984;10:947-952.
66. Norris PG, Camp RD, Hawk JL. Actinic reticuloid: response to cyclosporine. *J Am Acad Dermatol*. 1989;21:307-309.
67. Duschet P, Schwarz T, Oppolzer G, et al. Persistent light reaction. Successful treatment with cyclosporin A. *Acta Derm Venereol*. 1988;68:176-178.
68. Thomson MA, Stewart DG, Lewis HM. Chronic actinic dermatitis treated with mycophenolate mofetil. *Br J Dermatol*. 2005;152:784-786.
69. Nousari HC, Anhalt GJ, Morison WL. Mycophenolate in psoralen-UV-A desensitization therapy for chronic actinic dermatitis. *Arch Dermatol*. 1999;135:1128-1129.
70. Hindson C, Spiro J, Downey A. PUVA therapy of chronic actinic dermatitis. *Br J Dermatol*. 1985;113:157-160.
71. Chee SN, Novakovic L, Fassihi H, et al. Chronic actinic dermatitis: successful treatment with PUVA photochemotherapy. *Br J Dermatol*. 2018;178(3):e189-e190.
72. Fenton L, Ferguson J, Ibbotson S, et al. Energy-saving lamps and their impact on photosensitive and normal individuals. *Br J Dermatol*. 2013;169:910-915.
73. Eadie E, Ferguson J, Moseley H. A preliminary investigation into the effect of exposure of photosensitive individuals to light from compact fluorescent lamps. *Br J Dermatol*. 2009;160:659-664.
74. European Multicentre Photopatch Test Study (EMCPPTS) Taskforce. A European multicentre photopatch test study. *Br J Dermatol*. 2012;166:1002-1009.
75. Bryden AM, Moseley H, Ibbotson SH, et al. Photopatch testing of 1155 patients: results of the U.K. multicentre photopatch study group. *Br J Dermatol*. 2006;155:737-747.
76. Chuah SY, Leow YH, Goon AT, et al. Photopatch testing in Asians: a 5-year experience in Singapore. *Photodermatol Photoimmunol Photomed*. 2013;29:116-120.
77. Jindal N, Sharma NL, Mahajan VK, et al. Evaluation of photopatch test allergens for Indian patients of photodermatitis: preliminary results. *Indian J Dermatol Venereol Leprol*. 2011;77:148-155.
78. Sharma VK, Sethuraman G, Bansal A. Evaluation of photopatch test series in India. *Contact Dermatitis*. 2007;56:168-169.

Chapter 96 :: Solar Urticaria

:: Marcus Maurer, Joachim W. Fluhr, & Karsten Weller

AT-A-GLANCE

- An uncommon form of chronic inducible urticaria
- Erythema and itchy wheals occur within minutes of sunlight exposure and resolve within hours.
- May be disabling and, rarely, life threatening.
- Phototesting confirms the diagnosis, determines the trigger threshold, and identifies the eliciting wave lengths.
- Sensitivity may be to ultraviolet B, ultraviolet A, visible light, and/or any combination, but most commonly to ultraviolet A and visible light.
- Sunlight avoidance, high–protection factor broad-spectrum sunscreens, and antihistamines may help.
- Omalizumab may be a helpful second-line treatment
- Phototherapy may also help but is usually not feasible as long-term treatment

INTRODUCTION

DEFINITIONS

Solar urticaria (SolU) is defined by the appearance of a whealing response within minutes of exposure to sunlight.[1] SolU is a rare type of physical urticaria. Physical urticarias, together with cholinergic urticaria, contact urticaria, and aquagenic urticaria, are subforms of chronic inducible urticaria, one of the 2 forms of chronic urticaria, the other one being chronic spontaneous urticaria. SolU usually is primary, where the cause is unknown. Very rarely, SolU is linked to cutaneous porphyria or systemic lupus erythematosus (SLE) and is then termed secondary SolU.

HISTORICAL PERSPECTIVE

Chronic inducible urticaria and their characteristic features, that is, wheal responses at skin sites exposed to urticariogenic triggers, were first described by Hippocrates.[2] The first reports of SolU are from the 18th century, and in 1887, SolU was identified as being sunlight-dependent.[3,4]

EPIDEMIOLOGY

The prevalence of SolU is low, but conclusive prevalence data are missing. It has been estimated that 3 in 100,000 are affected.[5] SolU reportedly accounts for 7% of all photodermatoses[6] and for less than 0.5% of all chronic urticaria cases.[7] SolU predominantly affects women in the third decade of life. Most patients show symptoms perennially, some only during spring to autumn.[5]

CLINICAL FEATURES

CUTANEOUS FINDINGS

SolU is characterized by erythema and itchy wheals that develop rapidly at skin sites exposed to sun or artificial light (Fig. 96-1). Light-exposed skin first shows diffuse erythema, followed by whealing associated with itch and/or, less frequently, burning and stinging. Wheals in SolU generally develop within a few minutes up to 1 hour of exposure and disappear usually within 1 hour and after a maximum of 24 hours of cessation of exposure, without leaving visible changes of the skin. SolU typically affects skin areas that are normally shielded by clothing and it spares skin sites that are frequently exposed to light such as the hands and the face, presumably because chronically sun-exposed areas show "hardening" or tolerance. SolU patients typically experience their first signs and symptoms after prolonged sun exposure on the first sunny days in spring. Rare variants include fixed SolU, which is characterized by the reoccurrence of light-induced whealing in the same location[8] and delayed SolU, where the onset of signs and symptoms after UV exposure is delayed by up to several hours. In some SolU patients, bruised skin is more sensitive to light.[9] Light-induced angioedema may occur.

NONCUTANEOUS FINDINGS AND COMPLICATIONS

Systemic involvement is rare and only occurs when large areas of skin are affected. Generalized signs and symptoms include malaise, nausea, dizziness, headaches, wheezing, dyspnea, loss of consciousness, and even anaphylactic shock, which is rarely fatal.

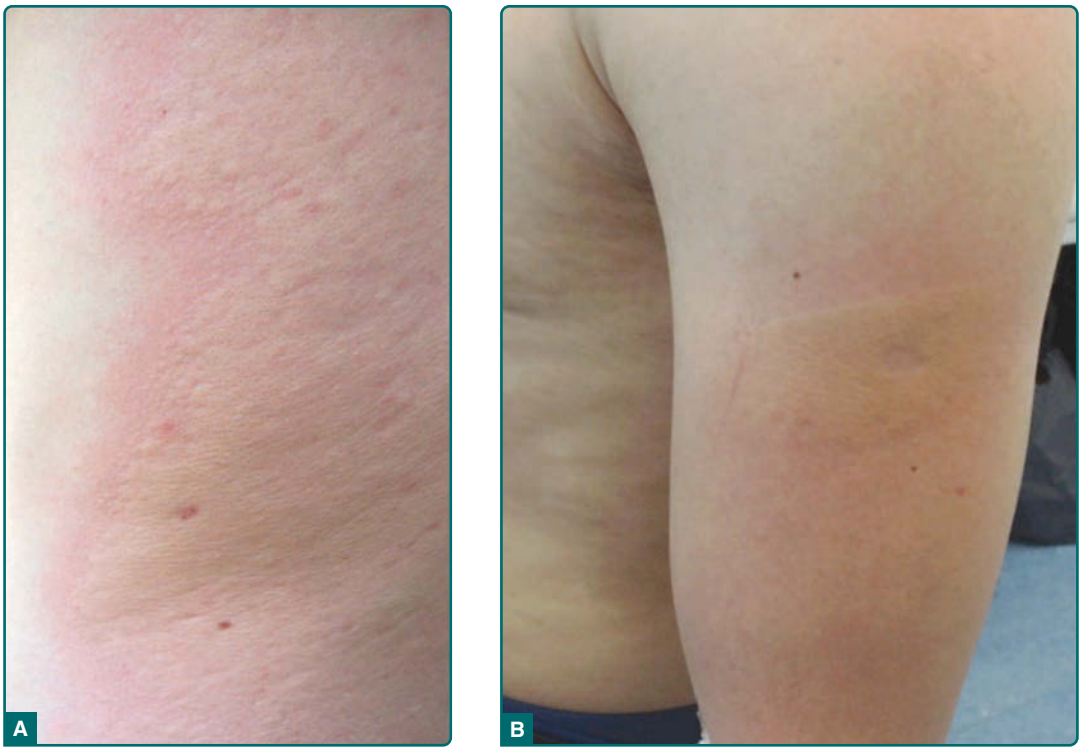

Figure 96-1 Solar urticaria. Pruritic wheals with a surrounding flare occurring 20 minutes after outdoor sun exposure at the arm. **A,** Close-up of the wheal. **B,** Lateral arm overview.

ETIOLOGY AND PATHOGENESIS

The signs and symptoms of SolU are due to the degranulation of skin mast cells and their subsequent release of histamine and other proinflammatory mediators. These mediators cause vasodilation (erythema) and increased extravasation (wheals, angioedema) and activate sensory nerves of the skin (itch). Widespread light-induced whealing in SolU patients can result in transiently increased blood levels of histamine.[10]

Skin mast cell degranulation in SolU is due to exposure of the skin to UVA (320 to 400 nm), visible (400 to 600 nm), less commonly UVB (280 to 320 nm), and, rarely, infrared (>600 nm) radiation. The underlying mechanism of mast cell degranulation has not been characterized in detail but is held to involve IgE that is specific for photo-induced neoantigens that act as autoallergens. This IgE is bound to the high-affinity IgE-receptor, FceRI, on cutaneous mast cells, which get activated by neoantigen-mediated crosslinking of IgE and FceRI. The wide range of relevant wavelengths is explained by the contribution of several different neoantigens/photoautoallergens with unique action spectra.[11,12] The range of eliciting wavelengths can narrow or broaden during the course of the disease, suggesting that the relevant neoantigens may vary over time. In some patients, skin exposure to distinct wavelength radiation, the so-called inhibition spectrum, can inhibit whealing in response to the eliciting wavelength spectrum.

RISK FACTORS

Specific risk factors for SolU or predictors for the severity or course of the disease have not yet been identified. SolU affects both genders and shows a female preponderance. The peak age of onset of symptoms is 20 to 40 years. There appears to be no influence of the skin type on the occurrence or severity of SolU.[13,14]

DIAGNOSIS

SUPPORTIVE STUDIES

The diagnosis of SolU is based on a thorough history. All patients who present with a history of rapid development of itching and whealing after exposure to light, should be investigated for SolU. Patients who report the occurrence of recurring itchy wheals should be asked if whealing can be induced, for example, by sun exposure. Patients who report the development of sunlight-induced skin lesions should be asked if these lesions resemble wheals, for example, if they are itchy, accompanied by erythema, short-lived, and transient.

Photodocumentation including self-documentation with smartphone cameras of skin lesions at the time of occurrence is helpful.

LABORATORY TESTING

In SolU, routine laboratory tests are all within normal limits and not helpful for diagnosing the disease. Porphyria and SLE should be excluded by tests for antinuclear antibody (ANA) / extractable antinuclear antibody (ENA) and blood, urine and stool testing for porphyrins, respectively.

PATHOLOGY

SolU skin lesions, within the first hours after elicitation by irradiation, show vasodilation, edema, and perivascular neutrophils and eosinophils in the upper dermis. After 24 hours, mononuclear cells are the dominating infiltrating cells.[15] The histopathologic features of SolU do not allow for its distinction from other forms of urticaria.

PHOTOTESTING

Phototesting is essential for confirming the diagnosis of SolU. It also assesses disease activity by determining trigger thresholds and defines individual eliciting and inhibition spectra. Phototesting is performed by exposing patients to ultraviolet radiation and visible light at skin sites that have been protected from light for several days, most commonly the buttocks. No sunscreens, photoactive medications, or urticaria treatments should be used before phototesting, and the washout phase for antihistaminic and immunosuppressive medication prior to test needs to be adequate.

Phototesting is done with the help of solar simulators with filters (UVA and UVB) or monochromators (UVA and UVB, visible light) separately for UVA at 6 J/cm,^{2} UVB at 60 mJ/cm,^{2} and visible light. The test is considered positive if the test site exhibits a palpable and clearly visible itchy wheal and flare reaction at 10 minutes after phototesting. In patients with a positive phototest reaction, threshold testing is done with a range of doses of the eliciting wavelengths, for example, with UVA at 2.4, 3.3, 4.2, 5.1, and 6.0 J/cm^2 and with UVB at 24, 33, 42, 51, and 60 mJ/cm^2 (Fig. 96-2). Threshold testing determines the minimal urticarial dose, a marker of disease activity and response to therapy. In patients with a negative phototest and convincing history of light-induced whealing, SolU should not be excluded, and sunlight phototesting is recommended. Reasons for a negative phototest in patients with SolU include mild disease activity, with variable occurrence of signs and symptoms limited to erythema in some patients, prior intake of antihistamines or other medications that inhibit the development of wheals, and/or refractoriness of the skin due to previous light exposure of the test site.

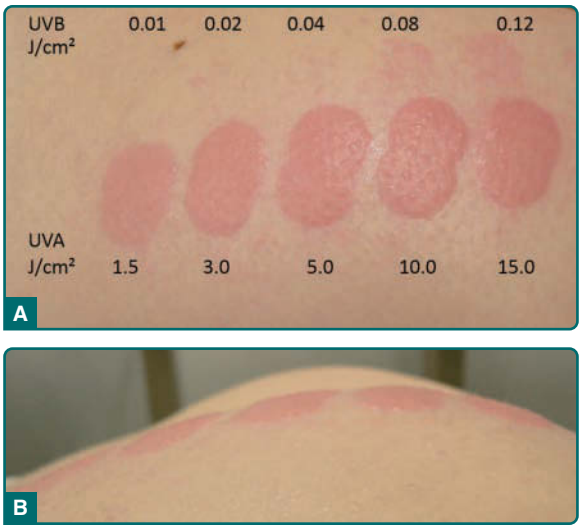

Figure 96-2 UVA and UVB testing with a solar simulator. **A,** Overview. **B,** lateral photography to demonstrate the elevation of the wheals.

DIAGNOSTIC ALGORITHM

See Fig. 96-3.

DIFFERENTIAL DIAGNOSIS

See Table 96-1.

CLINICAL COURSE AND PROGNOSIS

The mean duration of SolU is 5 to 7 years, but cases with disease duration of up to 50 years have been reported.[16] In a recent study, the median duration from disease onset to disease resolution was 63 months, and 50% of patients experienced complete spontaneous remission within 5 years of disease onset.[17] In contrast, older studies found rates of resolution of 12%, 26%, and 46% after 5, 10, and 15 years, respectively.[5,18]

MANAGEMENT

AVOIDANCE OF THE TRIGGER

All SolU patients should avoid the sun, wear protective clothing, and use high-protection broad-spectrum sunscreens, especially when the threshold is in the ultraviolet spectrum.

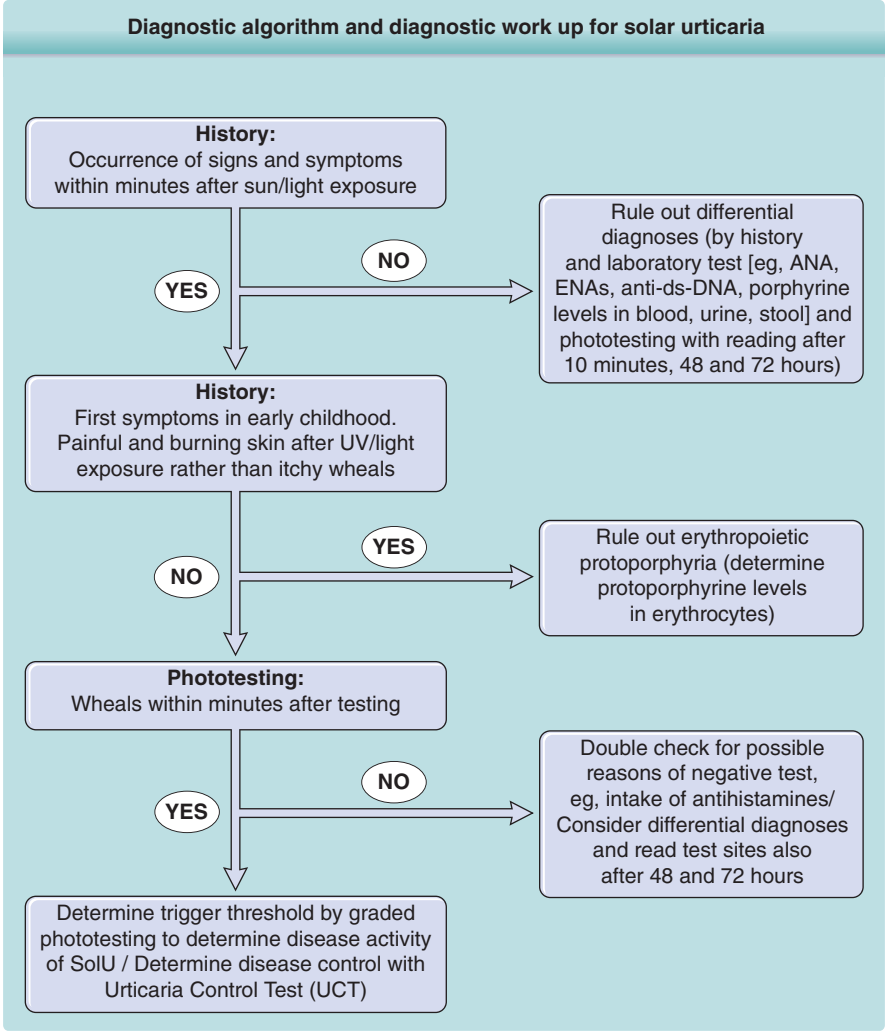

Figure 96-3 Diagnostic algorithm and diagnostic workup for solar urticaria.

MEDICATIONS

Treatment with nonsedating H1 antihistamines at standard dose is the recommended first-line treatment. Evidence for the efficacy and safety of antihistamine treatment in SolU comes from controlled and uncontrolled studies,[19,20] case series and reports, as well as clinical experience. In case of insufficient response to treatment with a standard-dosed nonsedating second-generation antihistamine, doses should be increased up to 4-fold. This recommendation is largely based on the results of studies of other forms of inducible urticaria. Antihistamines work, but not in all patients. Updosing is needed in many.

Treatment with omalizumab, a monoclonal antibody directed against IgE, is recommended in patients who do not achieve sufficient control with the combined use of sunscreens and antihistamine treatment. For omalizumab, a complete or partial response in doses of up to 450 mg every 4 to 8 weeks has been reported in several case studies.[21-30] The best evidence comes from a recent open-label French multicentric Phase II study with 10 patients[31] that shows that omalizumab, at 300 mg every 4 weeks, is of benefit in half of the treated patients. Two reports showed no improvement.[32,33]

Other therapies that have been reported to be effective in some but not all patients include ciclosporin[34] and intravenous high-dose immunoglobins.[35,36] Afamelanotide, an alpha-MSH analog and melanocortin receptor agonist recently licensed for the treatment of erythropoietic protoporphyria, was shown to protect SolU patients from the development of signs and symptoms in a small open-label study.[37]

PROCEDURES

Tolerance to UV light can be achieved by desensitization achieved by phototherapy. This treatment is

TABLE 96-1
Differential Diagnosis of Solar Urticaria

DISORDER	DISTINGUISHING FEATURES	COMMON FEATURES
Polymorphic light eruption	Skin lesions: Papules, papulovesicles, eczematous appearance; occur within hours to days after UV exposure (not within minutes); resolve within several days (not minutes to hours).	May spare face and hands (hardening).
Lupus erythematosus	Skin lesions: Occur within days to weeks after UV exposure (not within minutes); resolve within weeks (not minutes to hours). ANAs are positive.	Skin lesions with wheallike appearance.
Photoexacerbated eczema (atopic, seborrheic)	Skin lesions: No wheals; occur within hours to days after UV exposure (not within minutes); resolve within several days (not minutes to hours).	
Photoallergic/phototoxic contact dermatitis	Skin lesions: No wheals; occur within hours to days after UV exposure (not within minutes); resolve within several days (not minutes to hours). Photoallergic contact dermatitis: Photopatchtest is positive.	
Erythropoietic protoporphyria	First symptoms in early childhood and lifelong persistence. Skin (lesions) is/are painful/burning but not itchy. The pain/burning often persists for hours to days. Elevated levels of protoporphyrin in erythrocytes.	Onset within minutes after UV exposure. Skin lesions may be wheallike.
Porphyria cutanea tarda	Increased skin vulnerability in UV-exposed areas. Skin lesions comprise blisters, erosions, scars, milia, hyper- and hypopigmentation, hypertrichosis, elastosis (but not wheals). Elevated porphyrin levels in urine. Liver enzymes frequently elevated.	
Drug or chemical photosensitivity	Patient uses medication. Skin lesions: Occur within hours to days after UV exposure (not within minutes); resolve within several days (not minutes to hours).	
Heat urticaria	Phototesting is negative; heat testing is positive.	Signs/symptoms identical to SolU.

cumbersome and requires high patient compliance.[38] Phototherapy needs to be continued to maintain its effect. Discontinuation of phototherapy, in virtually all patients, results in the loss of protection from light-induced whealing.[39]

Phototherapy carries the usual risks of long-term phototherapy and should be done with caution because of the risk of anaphylaxis, particularly in severely affected individuals. So-called rush hardening protocols have been described (multiple UVA

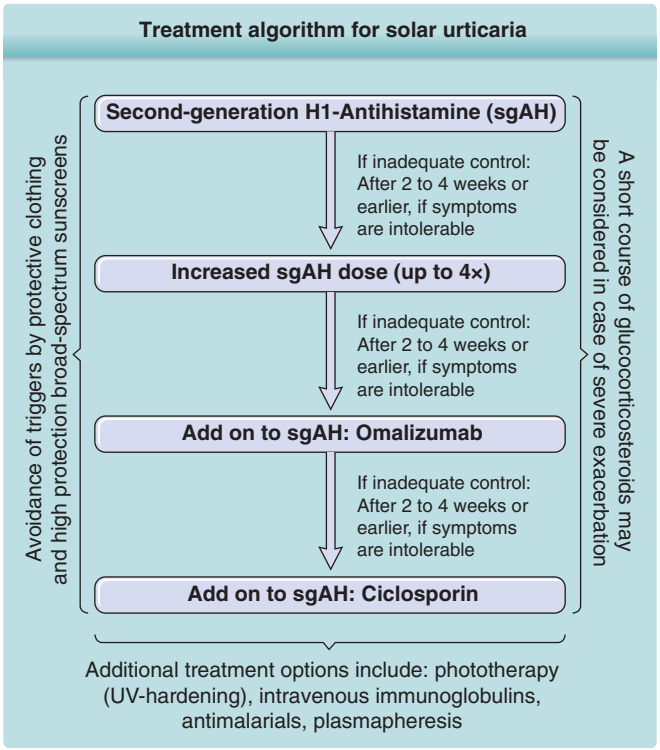

Figure 96-4 Treatment algorithm for solar urticarial.

exposures with increasing doses during the same day) and may help some patients.[40,41]

COUNSELING

Avoidance of sun exposure and the use of high–protection factor broad-spectrum sunscreens and appropriate clothing can help to prevent the development of SolU signs and symptoms.

MONITORING OF TREATMENT RESPONSES AND DISEASE ACTIVITY

Disease activity and control as well as response to treatment should be assessed at every patient visits. Suitable ways to do so include the urticaria control test (UCT) and trigger threshold phototesting.[42,43]

TREATMENT ALGORITHM

See Fig. 96-4.

ACKNOWLEDGMENTS

The authors acknowledge that this contribution is based, in part, on some of the content of the chapter by Travis W. Vandergriff and Paul R. Bergstresser on "Abnormal Responses to Ultraviolet Radiation: Idiopathic, Presumed Immunologic, and Photoexacerbated" in the 8th edition of *Fitzpatrick's Dermatology in General Medicine*.

REFERENCES

1. Magerl M, Altrichter S, Borzova E, et al. The definition, diagnostic testing, and management of chronic inducible urticarias—The EAACI/GA(2) LEN/EDF/UNEV consensus recommendations 2016 update and revision. *Allergy.* 2016;71(6):780-802.
2. Maurer M. Urticaria and angioedema. *Chem Immunol Allergy.* 2014;100:101-104.
3. Borsch JF. De purpura urticata, quam vocant "die Nesselsucht"; med diss, Halle. 1719.
4. Veiel T. Über einen Fall von Eczema solare. *Arch Derm Syph (Berlin).* 1887;19(1113).
5. Beattie PE, Dawe RS, Ibbotson SH, et al. Characteristics and prognosis of idiopathic solar urticaria: a cohort of 87 cases. *Arch Dermatol.* 2003;139(9):1149-1154.
6. Chong WS, Khoo SW. Solar urticaria in Singapore: an uncommon photodermatosis seen in a tertiary dermatology center over a 10-year period. *Photodermatol Photoimmunol Photomed.* 2004;20(2):101-104.
7. Champion RH. Urticaria: then and now. *Br J Dermatol.* 1988;119(4):427-436.
8. Reinauer S, Leenutaphong V, Holzle E. Fixed solar urticaria. *J Am Acad Dermatol.* 1993;29(2, pt 1):161-165.
9. Norris PG, Hawk JL. Bruising and susceptibility to solar urticaria. *Br J Dermatol.* 1991;124(4):393.
10. Hawk JL, Eady RA, Challoner AV, et al. Elevated blood histamine levels and mast cell degranulation in solar urticaria. *Br J Clin Pharmacol.* 1980;9(2):183-186.
11. Kojima M, Horiko T, Nakamura Y, et al. Solar urticaria. The relationship of photoallergen and action spectrum. *Arch Dermatol.* 1986;122(5):550-555.
12. Miyauchi H, Horio T. Detection of action, inhibition and augmentation spectra in solar urticaria. *Dermatology.* 1995;191(4):286-291.
13. Du-Thanh A, Debu A, Lalheve P, et al. Solar urticaria: a time-extended retrospective series of 61 patients and review of literature. *Eur J Dermatol.* 2013;23(2):202-207.
14. Pérez-Ferriols A, Barnadas M, Gardeazábal J, et al. Solar urticaria: epidemiology and clinical phenotypes in a Spanish series of 224 patients [in Spanish]. *Actas Dermosifiliogr.* 2017;108(2):132-139.
15. Norris PG, Murphy GM, Hawk JL, et al. A histological study of the evolution of solar urticaria. *Arch Dermatol.* 1988;124(1):80-83.
16. Ive H, Lloyd J, Magnus IA. Action spectra in idiopathic solar urticaria. A study of 17 cases with a monochromator. *Br J Dermatol.* 1965;77:229-243.
17. Silpa-Archa N, Wongpraparut C, Leenutaphong V. Analysis of solar urticaria in Thai patients. *Asian Pac J Allergy Immunol.* 2016;34(2):146-152.
18. Botto NC, Warshaw EM. Solar urticaria. *J Am Acad Dermatol.* 2008;59(6):909-920; quiz 921-922.
19. Bilsland D, Ferguson J. A comparison of cetirizine and terfenadine in the management of solar urticaria. *Photodermatol Photoimmunol Photomed.* 1991;8(2):62-64.
20. Monfrecola G, Masturzo E, Riccardo AM, et al. Cetirizine for solar urticaria in the visible spectrum. *Dermatology.* 2000;200(4):334-335.
21. Guzelbey O, Ardelean E, Magerl M, et al. Successful treatment of solar urticaria with anti-immunoglobulin E therapy. *Allergy.* 2008;63(11):1563-1565.
22. Levi A, Tal Y, Dranitzki Z, et al. Successful omalizumab treatment of severe solar urticaria in a 6-year-old child. *Pediatr Allergy Immunol.* 2015;26(6):588-590.
23. Metz M, Ohanyan T, Church MK, et al. Omalizumab is an effective and rapidly acting therapy in difficult-to-treat chronic urticaria: a retrospective clinical analysis. *J Dermatol Sci.* 2014;73(1):57-62.
24. Waibel KH, Reese DA, Hamilton RG, et al. Partial improvement of solar urticaria after omalizumab. *J Allergy Clin Immunol.* 2010;125(2):490-491.
25. Baliu-Pique C, Aguilera Peiro P. Three cases of solar urticaria successfully treated with omalizumab. *J Eur Acad Dermatol Venereol.* 2016;30(4):704-706.
26. Arasi S, Crisafulli G, Caminiti L, et al. Treatment with omalizumab in a 16-year-old Caucasian girl with refractory solar urticaria. *Pediatr Allergy Immunol.* 2015;26(6):583-585.
27. Kowalzick L, Thiel W, Bielfeld C, et al. Partial response of solar urticaria to omalizumab therapy [in German]. *Hautarzt.* 2017;68(6):492-496.
28. Brüning JH, Ziemer M, Pemler S, et al. Successful treatment of solar urticaria with omalizumab. *J Dtsch Dermatol Ges.* 2016;14(9):936-937.
29. de Dios-Velázquez Á, González-de Arriba M, Beteta-Gorriti V, et al. Effectiveness of omalizumab in

severe solar urticaria. *Ann Allergy Asthma Immunol.* 2016;116(3):260-262.
30. Terrani I, Bircher AJ, Scherer Hofmeier K. Solar urticaria induced by visible light: successful treatment with omalizumab. *Clin Exp Dermatol.* 2016;41(8):890-892.
31. Aubin F, Avenel-Audran M, Jeanmougin M, et al. Omalizumab in patients with severe and refractory solar urticaria: a phase II multicentric study. *J Am Acad Dermatol.* 2016;74(3):574-575.
32. Muller S, Schempp CM, Jakob T. Failure of omalizumab in the treatment of solar urticaria. *J Eur Acad Dermatol Venereol.* 2016;30(3):524-525.
33. Duchini G, Bäumler W, Bircher AJ, et al. Failure of omalizumab (Xolair(R)) in the treatment of a case of solar urticaria caused by ultraviolet A and visible light. *Photodermatol Photoimmunol Photomed.* 2011; 27(6):336-337.
34. Hurabielle C, Bedane C, Avenel-Audran M, et al. No major effect of cyclosporin A in patients with severe solar urticaria: a French retrospective case series. *Acta Derm Venereol.* 2015;95(8):1030-1031.
35. Correia I, Silva J, Filipe P, et al. Solar urticaria treated successfully with intravenous high-dose immunoglobulin: a case report. *Photodermatol Photoimmunol Photomed.* 2008;24(6):330-331.
36. Aubin F, Porcher R, Jeanmougin M, et al. Severe and refractory solar urticaria treated with intravenous immunoglobulins: a phase II multicenter study. *J Am Acad Dermatol.* 2014;71(5):948-953.e1.
37. Haylett AK, Nie Z, Brownrigg M, et al. Systemic photoprotection in solar urticaria with alpha-melanocyte-stimulating hormone analogue [Nle4-D-Phe7]-alpha-MSH. *Br J Dermatol.* 2011;164(2):407-414.
38. Dawe RS, Ferguson J. Prolonged benefit following ultraviolet A phototherapy for solar urticaria. *Br J Dermatol.* 1997;137(1):144-148.
39. Wolf R, Herzinger T, Grahovac M, et al. Solar urticaria: long-term rush hardening by inhibition spectrum narrow-band UVB 311 nm. *Clin Exp Dermatol.* 2013;38(4):446-447.
40. Beissert S, Stander H, Schwarz T. UVA rush hardening for the treatment of solar urticaria. *J Am Acad Dermatol.* 2000;42(6):1030-1032.
41. Masuoka E, Fukunaga A, Kishigami K, et al. Successful and long-lasting treatment of solar urticaria with ultraviolet A rush hardening therapy. *Br J Dermatol.* 2012;167(1):198-201.
42. Kulthanan K, Chularojanamontri L, Tuchinda P, et al. Validity, reliability and interpretability of the Thai version of the urticaria control test (UCT). *Health Qual Life Outcomes.* 2016;14:61.
43. Weller K, Groffik A, Church MK, et al. Development and validation of the Urticaria Control Test: a patient-reported outcome instrument for assessing urticaria control. *J Allergy Clin Immunol.* 2014;133(5):1365-1372, 1372.e1-1372.e6.

Chapter 97 :: Phototoxicity and Photoallergy

:: Henry W. Lim

AT-A-GLANCE

- Photosensitivity to exogenous agents is broadly divided into phototoxicity and photoallergy; it is caused by topical or systemic agents that absorb ultraviolet A (UVA) radiation.
- Phototoxicity occurs in anyone exposed to sufficient doses of phototoxic agent and UV radiation; it usually manifests as an exaggerated sunburn reaction.
- Photoallergy is an immune reaction to a UVA-modified chemical, commonly topical sunscreen agents and antimicrobials in the United States and the United Kingdom, and topical nonsteroidal antiinflammatory agents in Europe. It presents as eczematous eruption on sun-exposed areas.
- Phototoxicity and photoallergy do occur in patients with skin of color, frequently resulting in postinflammatory hyperpigmentation.
- History taking is an important part of the evaluation; phototesting and photopatch testing are sometimes helpful.
- Differential diagnosis includes contact allergic or contact irritant dermatitis, airborne contact dermatitis, and other photodermatoses.
- Management consists of identification and avoidance of the precipitating agent, photoprotection, and symptomatic therapy.

Photosensitivity may be caused by exogenous or endogenous agents. It occurs when a compound, classically one with unsaturated double bonds in a 6-carbon ring, absorbs radiation energy in its action spectrum, usually ultraviolet A (UVA) wavelengths. Exogenous photosensitizers can be agents administered systemically or applied topically. Well-characterized examples of photosensitivity induced by endogenous photosensitizers are the cutaneous porphyrias, which are associated with enzymatic defects in heme biosynthetic pathways that result in elevated levels of porphyrins, known phototoxic agents. This is covered in Chap. 124.

This chapter focuses on photosensitivity induced by exogenous agents, which can be divided into phototoxicity and photoallergy. Phototoxicity is the result of direct tissue injury caused by the phototoxic agent and radiation. It can occur in all individuals exposed to adequate doses of the agent and the activating wavelengths of radiation (Table 97-1). In contrast, photoallergy is a type IV delayed hypersensitivity response to a molecule that has been modified by absorption of photons. It has a sensitization phase, occurs only in sensitized individuals, and requires only a minimal concentration of the photoallergen (Table 97-1).

PREVALENCE

Even though hundreds of medications in the United States are reported to cause photosensitivity, only a small number of them induce reactions frequently or have been well studied (Tables 97-2 to 97-5).[1] In evaluations performed at photodermatology centers in New York City, Melbourne, Singapore, and Detroit, photosensitivity induced by systemic drugs was documented in 5% to 16% of the referred patients.[2-5] These data from different parts of the world indicate that photoallergy and phototoxicity do occur in patients with skin of color, frequently resulting in postinflammatory hyperpigmentation. Studies on photopatch testing published between 2011 and 2016 from different parts of the world showed from 1.5% to 74% of patients who had photopatch testing performed had positive response.[6-12]

Most of the photosensitivity induced by systemic medications are phototoxicity, whereas those induced by topical agents are photoallergy. However, it should be noted that clinically, it is not always possible to clearly differentiate between phototoxicity and photoallergy. Because many drug-induced photosensitivity has not been well-studied, it is possible that it is underestimated.[1,13]

PHOTOTOXICITY

CLINICAL FEATURES

ACUTE PHOTOTOXICITY

This occurs within hours of exposure to the phototoxic agent and UV radiation. Symptoms are drug-dose and UV-dose dependent; at sufficient doses, the patient complains of a burning and stinging sensation on exposed areas, such as forehead, nose, V area of the neck, and dorsa of the hands (Fig. 97-1). Erythema and edema may appear within hours of exposure; in severe cases, vesicles and bullae may develop accompanied by pruritus. Protected areas, such as nasolabial folds, postauricular and submental areas, and areas covered by clothing, are spared. A notable exception to these kinetics is psoralen-induced phototoxicity, in which the acute response first appears after 24 hours, and peaks at 48 to 72 hours; this is the rationale for administering psoralen plus UVA (PUVA) photochemotherapy treatments 48 to 72 hours

TABLE 97-1
Characteristics of Phototoxicity and Photoallergy

	PHOTOTOXICITY	PHOTOALLERGY
Clinical presentation	Exaggerated sunburn reaction: erythema, edema, vesicles, and bullae; burning, stinging; frequently resolves with hyperpigmentation	Eczematous lesions; usually pruritic
Histologic features	Eosinophilic keratinocytes, epidermal necrosis, dermal edema, sparse dermal infiltrate of lymphocytes, macrophages, and neutrophils	Spongiotic dermatitis, dermal lymphohistiocytic infiltrate
Pathophysiology	Direct tissue injury	Type IV delayed hypersensitivity response
Occurrence after first exposure	Yes	No
Onset after exposure	Minutes to hours	24-48 hours
Dose of agent needed for reaction	Large	Small
Cross-reactivity with other agents	None	Common
Diagnosis		
Topical agent	Clinical	Photopatch tests
Systemic agent	Clinical + phototests	Clinical + phototests; possibly photopatch tests

apart. The phototoxic response resolves with a varying degree of hyperpigmentation, which may last for months. At lower drug/UV doses, gradual tanning only, without preceding sunburn-like reaction, can be seen.

PHOTOONYCHOLYSIS

Separation of the distal nail from the nail bed, which could be asymptomatic, is a manifestation of acute phototoxicity, with the nail plate serving as a lens to focus UV energy on the nail bed. It has been reported with doxycycline and other tetracyclines,[13] fluoroquinolones, psoralens, benoxaprofen, clorazepate dipotassium, olanzapine, aripiprazole, indapamide, and quinine (Fig. 97-2).

TABLE 97-2
Topical Phototoxic and Photosensitizing Agents

AGENT	EXPOSURE
Phototoxic Agents	
Fluorescein	Used topically to visualize the anterior surface of the eye
Furocoumarins	Occur naturally in plants (especially *Compositae* species), including fruits and vegetables (lime, lemon, celery, fig, parsley, and parsnip); used in topical photochemotherapy
Rose bengal	Used in ophthalmologic examinations
Tar	Used as topical therapeutic agent; found in roofing materials
Photosensitizing Agent[a]	
Fluorouracil[a]	Topical treatment of actinic keratoses
Retinoids[a]	For treatment of acne and photoaging

[a]Induces exaggerated ultraviolet response because of skin irritancy.

SLATE-GRAY PIGMENTATION

Asymptomatic blue-gray pigmentation on sun-exposed areas is associated with exposure to several agents.[14-16] These agents include amiodarone, chlorpromazine, clozapine, imipramine and, less commonly, desipramine. A drug metabolite–melanin complex is postulated to be the cause of this alteration. Minocycline can induce blue-gray pigmentation on sun-exposed areas such as face (Fig. 97-3), frequently on sites of acne scars, forearms, and shins; however, it also has been reported in non–sun-exposed sites such as mucosal surface, trachea, tympanic membrane, teeth, and cartilage. Chronic exposure to diltiazem, a benzothiazepine calcium channel blocker, has resulted in photodistributed, reticulated, slate-gray pigmentation. Slate-gray pigmentation seen in argyria involves the nail lunulae, mucous membranes, and sclerae. A photochemical reaction, in which silver granules are deposited in the dermis, results in these pigmentary alterations.

PSEUDOPORPHYRIA

The development of porphyria cutanea tarda–like cutaneous changes of skin fragility, vesicles, and subepidermal blisters is associated with several phototoxic agents (Fig. 97-4). In contrast to porphyria cutanea tarda, the porphyrin profile is normal or in the upper range of normal in these patients. Naproxen is the most commonly reported causative agent. Other drugs and treatment modality incriminated include amiodarone, β-lactam antibiotics, celecoxib, ciprofloxacin, cyclosporine, diflunisal, etretinate, furosemide, imatinib, nabumetone, nalidixic acid, narrowband UVB, oral contraceptives, oxaprozin, ketoprofen, mefenamic acid, the tetracyclines, tiaprofenic acid, torsemide, and voriconazole.[17,18]

TABLE 97-3
Systemic Phototoxic Agents

CLASS	GENERIC NAME (COMMON U.S. TRADE NAMES)[a]
Antiandrogen	Bicalutamide (Casodex)
	Flutamide (Eulexin)
Antifibrotic agent	Pirfenidone (Esbriet)
Antifungal agents	Griseofulvin (Fulvicin, Grifulvin V, Gris-PEG)[b]
	Voriconazole (Vfend)[c]
Antimalarials	Chloroquine (Aralen)
	Quinine[b]
Antimicrobials	Sulfonamides
	Tetracyclines
	Demeclocycline (Declomycin)[c]
	Doxycycline (Adoxa, Doryx, Monodox, Periostat, Vibra-Tabs, Vibramycin)[c]
	Minocycline (Arestin, Dynacin, Minocin)
	Tetracycline (Helidac, Sumycin)
	Trimethoprim (Bactrim, Polytrim, Primsol, Septra)[c]
	Quinolones
	Ciprofloxacin (Cipro)
	Enoxacin (Penetrex)[b]
	Gemifloxacin (Factive)
	Lomefloxacin (Maxaquin, Okacyn, Uniquin)[b,c]
	Moxifloxacin (Avelox, Moxeza, Vigamox)
	Nalidixic acid (NegGram)[b,c]
	Norfloxacin (Noroxin, Chibroxin–ophthalmic solution)
	Ofloxacin (Floxin, Ocuflox–ophthalmic solution)
	Sparfloxacin (Zagam)[c,d]
Cardiac drugs	Amiodarone (Cordarone, Nexterone, Pacerone)[c]
	Quinidine (Quinaglute, Quinidex)[b]
Diuretics	Furosemide (Lasix)[c]
	Thiazides
	Bendroflumethiazide (Aprinox, Naturetin)
	Bendroflumethiazide/Nadolol (Corzide)
	Chlorothiazide (Diuril)[c]
	Hydrochlorothiazide (Apo-Hydro, Aquazide, BPZide, Dichlotride, Esidrex, Hydrochlorot, HydroDIURIL, HydroSaluric, Hypothiazid, Microzide, Oretic, and others; frequently used as a fixed dose combination with other classes of hypertensive drugs)[c]
Dyes	Fluorescein (Ful-Glo, Fluorescite, AK-Fluor)
	Methylene blue
Furocoumarins	Psoralens
	5-Methoxypsoralen[c]
	8-Methoxypsoralen (Oxsoralen-Ultra)[c]
Hypoglycemics	Sulfonylureas
	Chlorpropamide (Diabinese)
	Glipizide (Glucotrol)
	Glipizide/Metformin (Metaglip)
	Glyburide (DiaBeta, Glynase, Micronase)
	Glyburide/Metformin (Glucovance)
	Tolazamide (Tolinase)
	Tolbutamide (Orinase)[c]
Immunosuppressant	Azathioprine (Azasan, Imuran)
	Acetic acid derivative
Nonsteroidal antiinflammatory drugs	Diclofenac (Cambia, Cataflam, Flector, Pennsaid, Solaraze, Voltaren, Zipsor)
	Alkanone derivative
	Nabumetone (Relafen)[c,d]
	Anthranilic acid derivative
	Mefenamic acid (Ponstel)
	Cyclooxygenase-2 inhibitor
	Celecoxib (Celebrex)
	Enolic acid derivative
	Piroxicam (Feldene)[b,c]
	Propionic acid derivatives
	Ibuprofen (Advil, Medipren, Motrin, Nuprin)
	Ketoprofen[b]
	Naproxen (Aleve, Anaprox, Naprelan, Midol, Naprosyn, Rugby, Select)[c]
	Oxaprozin (Daypro)
	Tiaprofenic acid (Surgam, Surgamyl, Tiaprofen)
	Salicylic acid derivative
	Diflunisal (Dolobid)
	Capecitabine (Xeloda)
Oncologic drugs	Crizotinib (Xalkori)
	Dacarbazine (DTIC, DTIC-Dome)
	Dabrafenib (Tafinlar)
	Docetaxel (Docefrez, Taxotere)
	Fluorouracil (Adrucil)
	Methotrexate (Rheumatrex)[e]
	Paclitaxel (Abraxane, Onxol, Taxol)
	Vemurafenib (Zelboraf)[c]
	Vinblastine (Velban)
Photodynamic therapy agents	Porfimer (Photofrin)[c]
	Verteporfin (Visudyne)[c]
Psychotropic drugs	Alprazolam (Niravam, Xanax)
	Chlordiazepoxide (Librium)
	Clozapine (Clozaril, FazaClo)
	Phenothiazines
	Chlorpromazine (Largactil, Thorazine)[c]
	Perphenazine (Trilafon)
	Prochlorperazine (Compazine, Compro)[c]
	Thioridazine (Mellaril)
	Trifluoperazine (Stelazine)
	Tricyclics
	Amitriptyline (Elavil)
	Amitriptyline/Perphenazine (Duo-Vil, Etrafon, Triavil, Triptafen)
	Desipramine (Norpramin)
	Imipramine (Tofranil)
	Dapsone
Other	Hypericin (St John's wort)
	Pyridoxine (vitamin B_6)
	Ranitidine (Zantac)

[a]Although it is the policy not to use trade names in this book, exceptions are made in cases in which we consider this information to be highly useful.
[b]Also reported as a systemic photoallergen.
[c]Commonly reported.
[d]Withdrawn from the United States market.
[e]Induces erythema on previously ultraviolet-exposed sites.

TABLE 97-4
Topical Photoallergens

GROUP	CHEMICAL NAME (TRADE NAME)[a]
Sunscreens (see Chap. 197)	Benzophenones Benzophenone-3 (oxybenzone)[b] Benzophenone-4 (sulisobenzone) Para-aminobenzoic acid (PABA) derivatives Ethylhexyl dimethyl PABA (padimate O)[b] PABA[b] Cinnamates Ethylhexyl methoxycinnamate (octinoxate)[b] Ethoxyethyl methoxycinnamate (cinoxate) Others Butyl methoxydibenzoylmethane (avobenzone, Parsol 1789)[b] Octocrylene (octocrylene)[b] Octyl triazone Phenylbenzimidazole sulfonic acid (ensulizole)
Fragrances	6-Methylcoumarin[b] Musk ambrette[b] Sandalwood oil
Antiinfective agents	Surface disinfectants: halogenated salicylanilides Dibromosalicylanilide (dibromsalan, DBS)[b] Tetrochlorosalicylanilide (Irgasan BS200)[b] Tribromosalicylanilide (tribromsalan, TBS)[b] Skin cleansers Chlorhexidine (Hibiclens) Hexachlorophene (pHisoHex) Pesticides Bithionol (thiobis-dichlorophenol)[b] Dichlorophene (G4, Korium, Teniatol) Dimethylol dimethyl hydantoin Fenticlor (*bis*-hydroxy-chlorophenyl sulfide)[b] Personal care products Triclosan (Irgasan DP300, Microban, Lexol 300) Topical antifungals Buclosamide (Jadit, butylchlorosalicylamide) Multifungin (bromochlorosalicylanilide, BCSA)
Others	Antibiotic for cattle Olaquindox[b] Nonsteroidal antiinflammatory agents (topical) Etofenamate Fepradinol Flufenamic acid Ketoprofen (Oruvail gel, Powergel, Tiloket gel)[b] Phenothiazines Chlorpromazine (Thorazine)[b] Promethazine (Phenergan)[b] Miscellaneous Acyclovir cream (Zovirax) Clioquinol (Vioform, iodochlorhydroxyquin) Cadmium sulfide Cinchocaine (Dibucaine) Thiourea (thiocarbamide, sulfourea)

[a]Although it is the policy not to use trade names in this book, exceptions are made in cases in which we consider this information to be highly useful.

[b]Commonly reported to be photoallergens.

TABLE 97-5
Systemic Photoallergens

PROPERTY	GENERIC NAME (U.S. TRADE NAME[a])
Antifungal	Griseofulvin (Fulvicin, Grifulvin V, Gris-PEG)
Antimalarial	Quinine
Antimicrobials	Quinolone Enoxacin (Penetrex)
Cardiac medication	Quinidine (Quinaglute, Quinidex)
Nonsteroidal antiinflammatory drugs	Ketoprofen Piroxicam (Feldene)
Vitamin	Pyridoxine hydrochloride (vitamin B_6)

[a]Although it is the policy not to use trade names in this book, exceptions are made in cases in which we consider this information to be highly useful.

Figure 97-1 Sulfamethoxazole-trimethoprim–induced phototoxicity. Note the resolving erythema and fine scales on dorsum hand and forearm, and sparing of area covered by watch on the wrist.

Figure 97-2 Distal onycholysis in a patient receiving psoralen plus ultraviolet A therapy.

Figure 97-3 Minocycline-induced blue-gray pigmentation on cheeks and upper lip.

ACCELERATED PHOTO-INDUCED CHANGES

This has been uniquely described with voriconazole, a broad-spectrum antifungal agent.[18] Immunosuppressed patients receiving voriconazole for longer than 12 weeks can develop photosensitivity, pseudoporphyria, photoaging, lentigines, or premature dermatoheliosis; in addition, squamous cell carcinoma and melanoma have been described in patients who were on voriconazole for longer than 12 months.

PHOTODISTRIBUTED TELANGIECTASIA

This has been reported with calcium channel blockers, including nifedipine, amlodipine, felodipine, and diltiazem, with the antibiotic cefotaxime, and with the antidepressants venlafaxine and escitalopram.[19]

Figure 97-4 Pseudoporphyria. Crusted erosion and healed hypopigmented scar on dorsum of hand.

LICHENOID PHOTOSENSITIVE ERUPTION

This has been reported with doxycycline, capecitabine,[20] and other agents.

PERSISTENCE OF PHOTOSENSITIVITY AND EVOLUTION TO CHRONIC ACTINIC DERMATITIS

Phototoxicity usually resolves after discontinuation of the causative agent; however, persistence of photosensitivity for many years after the cessation of exposure, resulting in the development of chronic actinic dermatitis has been reported (Fig. 97-5). This has been reported with thiazides, quinidine, quinine, and amiodarone.

CHRONIC EFFECTS

These are best exemplified by the manifestations in patients who have received long-term PUVA photochemotherapy. These effects include premature aging of the skin, lentigines, squamous cell and basal cell carcinomas, and melanoma.

PHOTOTOXIC AGENTS

TOPICAL AGENTS

Table 97-2 lists the major topical phototoxic and photosensitizing agents. It should be noted that *fluorouracil*

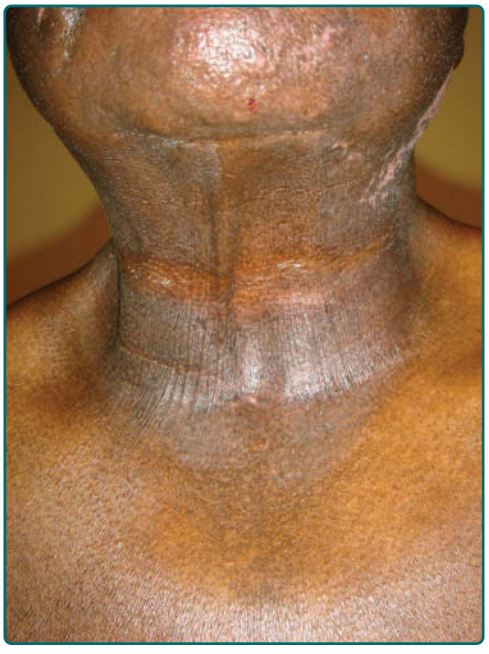

Figure 97-5 Chronic actinic dermatitis. Note the lichenification and hyperpigmentation on sun-exposed areas, and sparing of skin folds.

and *retinoids* induce exaggerated UV response as a result of their irritant effect on the skin, although systemically administered fluorouracil can induce phototoxicity. Topical exposures to *furocoumarins*, which are present in limes, celery, figs, and parsnips, may occur in individuals coming into regular contact with them (bartenders, salad chefs, gardeners) and in patients receiving topical photochemotherapy with psoralens. *Crude coal tar*, although no longer commonly used in dermatologic therapy, is well documented to produce a burning and stinging sensation on exposure to UVA (known as "tar smarts").

SYSTEMIC AGENTS

Table 97-3 lists the major systemic phototoxic agents.[1,21] The most commonly reported drugs are vemurafenib, voriconazole, doxycycline, hydrochlorothiazide, amiodarone, and chlorpromazine.[1] These agents produce an exaggerated sunburn reaction, but may also induce an eczematous response in a small percentage of users, especially after topical exposure. As a rule, the action spectra are in the UVA range; notable exceptions are the porphyrins, fluorescein, and other dyes, whose action spectra are in the visible light range.

PATHOPHYSIOLOGY

Several pathways eventuate in the development of phototoxic tissue damage, and for many phototoxic agents more than one pathway is responsible.[21]

PHOTODYNAMIC PROCESSES

This involves absorption of radiation energy by the photosensitizer and formation of an excited molecule. Subsequent generation of reactive oxygen species result in tissue injury. Phototoxicities induced by porphyrins, quinolones, nonsteroidal antiinflammatory agents, tetracyclines, amitriptyline, imipramine, sulfonylureas, hydrochlorothiazide, furosemide, and chlorpromazine are examples of photodynamic phototoxic reactions.

GENERATION OF PHOTOPRODUCTS

Stable photoproducts induced by exposure to radiation can be responsible for tissue injury. Phototoxic products have been demonstrated on irradiation of phenothiazines, chlorpromazine, tetracyclines, quinolones, and nonsteroidal antiinflammatory agents.

BINDING TO SUBSTRATE

An example of this mechanism is the covalent binding of 8-methoxypsoralen to pyrimidine bases of the DNA molecules upon exposure to UVA, which results in the formation of a crosslink between the DNA strands.

INFLAMMATORY MEDIATORS

Mediators of inflammation and inflammatory cells participate in phototoxic tissue injury. Biologically active products of complement activation, mast cell-derived mediators, eicosanoids, proteases, and polymorphonuclear leukocytes contribute to the development of phototoxicity induced by porphyrins, demeclocycline, and chlorpromazine.

APOPTOSIS

In addition to generating reactive oxygen species, photodynamic therapy also is a potent inducer of apoptosis.[22] This is discussed in detail in Chap. 199.

HISTOPATHOLOGY

Acute phototoxicity is characterized by individual necrotic keratinocytes and, in severe cases, epidermal necrosis (see Table 97-1). There may be epidermal spongiosis, dermal edema, and a mild infiltrate consisting of neutrophils, lymphocytes, and macrophages. Slate-gray pigmentation is associated with increased dermal melanin and dermal deposits of the drug or its metabolite.[23] Histologic features of lichenoid eruptions are similar to those of idiopathic lichen planus; however, there may be a greater degree of spongiosis and dermal eosinophilic and plasma cell infiltrates, and a larger number of necrotic keratinocytes and cytoid bodies. In pseudoporphyria, as in porphyria cutanea tarda, there is dermal–epidermal separation at the lamina lucida and deposits of immunoglobulins at the dermal–epidermal junction and surrounding blood vessel walls.

MANAGEMENT

Identification and avoidance of the causative phototoxic agent, along with rigorous photoprotection, are the most important steps in management.

Photoprotection includes seeking shade when outdoors, wearing photoprotective clothing, a wide-brimmed hat, sunglasses, and applying sunscreen to exposed areas.[24] Because the action spectrum for most agents is in the UVA range, high sun protection factor, broad-spectrum sunscreens should be used (see Chap. 197). Acute phototoxicity can be managed with topical corticosteroids and compresses; systemic corticosteroids can be used for the most severely affected patients. Management of patients with slate-gray pigmentation, lichenoid eruption, pseudoporphyria, and photodistributed telangiectasia is symptomatic only, and patients should be advised that it will take months after the discontinuation of the offending agent for the condition to resolve. For patients with slate-gray pigmentation, hydroquinone or hydroquinone-containing

combination products can be used; however, because the location of pigments is in the dermis, these products are not completely effective. Patients with nonsteroidal antiinflammatory drug-induced pseudoporphyria who require nonsteroidal antiinflammatory drugs should be switched to a different class of agents or to those that are less photosensitizing, such as indomethacin or sulindac.[17]

PHOTOALLERGY

CLINICAL MANIFESTATIONS

In sensitized individuals, exposure to the photoallergen and sunlight results in the development of a pruritic, eczematous eruption within 24 to 48 hours after exposure (see Table 97-1). Although the morphology is clinically indistinguishable from that of allergic contact dermatitis, the distribution of the eruption in photoallergy is predominantly confined to sun-exposed areas; however, in severe cases, it may spread to the covered areas, albeit at a lower intensity. Unlike the lesions in phototoxicity in fair-skinned individuals, those in photoallergy usually resolve without significant postinflammatory hyperpigmentation. Lichenoid eruption also has been reported.

As with phototoxicity, persistence of photosensitivity and evolution to chronic actinic dermatitis (see Chap. 95) have been reported after exposure to photoallergens, including chlorpromazine, dioxopromethazine, halogenated salicylanilides, ketoprofen, musk ambrette, olaquindox, and quinidine.[25] A proposed mechanism is that UV radiation alters the carrier protein that originally binds the photoallergen; this results in the formation of a neoantigen that stimulates the immune system over the long term. This hypothesis is supported by the observation that the histidine moiety in albumin can undergo oxidation in the presence of salicylanilide, which binds to albumin.

PHOTOALLERGENS

TOPICAL AGENTS

In the United States, Canada, Europe, and the United Kingdom, common photoallergens include UV filters (benzophenone-3, octocrylene, avobenzone, octinoxate), and topical nonsteroidal antiinflammatory drugs (ketoprofen, etofenamate).[7-11,26] In China, chlorpromazine and para-aminobenzoic acid were the most common photoallergens in a 10-year study.[12] Table 97-4 lists the common photoallergens.

SYSTEMIC AGENTS

These are listed in Table 97-5. Photoallergy caused by systemic agents is not as well documented nor studied. All but one of the photoallergens (pyridoxine) are also phototoxic and were discussed earlier in this chapter (see "Phototoxic Agents: Systemic Agents" and Table 97-3).

HISTOPATHOLOGY

The histologic features are similar to those of allergic contact dermatitis. There is epidermal spongiosis associated with infiltrate of mononuclear cells in the dermis (see Table 97-1).

PATHOPHYSIOLOGY

Photoallergy is a type IV delayed hypersensitivity response requiring the presence of both photoallergen and the activating wavelengths of radiation (UVA)[27]; this is the reason that photopatch testing is done using UVA as a light source. After the absorption of UV energy, a photoallergen may be converted to an excited state molecule, which subsequently reverts to ground state by releasing the energy. In this process, the molecule may conjugate with a carrier protein to form a complete antigen. This is thought to be the mechanism of photoallergy induced by halogenated salicylanilides, chlorpromazine, and para-aminobenzoic acid. Alternatively, a photoallergen may form a stable photoproduct on exposure to radiation, which in turn may conjugate with a carrier protein to form a complete antigen. Sulfanilamide and chlorpromazine have both been shown to participate in this reaction.

Once the complete antigen is formed, the mechanism of photoallergy is identical to that of contact allergy. The antigen is taken up and processed by epidermal Langerhans cells, which then migrate to regional lymph nodes to present the antigen to T lymphocytes. Cutaneous lesions develop when the activated T lymphocytes circulate to the exposed site to initiate an inflammatory response.

MANAGEMENT

Management is identical to that of phototoxicity: identification and avoidance of the photoallergen, sunprotective measures, and symptomatic therapy.

EVALUATION OF PATIENTS WITH PHOTOTOXICITY AND PHOTOALLERGY

The evaluation of patients with phototoxicity and photoallergy is similar to the evaluation of patients with other photosensitivity disorders. A history of exposure to known photosensitizers is most important. It is also helpful to ascertain whether window glass-filtered sunlight can induce the cutaneous eruption, because UVB is filtered out by window glass. Distribution of

the cutaneous eruption is a helpful clue to the type of photosensitizer responsible. Widespread eruption suggests systemic photosensitizers, whereas topical photosensitizers produce lesions only in areas that have been exposed to both sensitizers and radiation. Vesicular and bullous eruptions are most commonly associated with phototoxicity, whereas eczematous eruptions strongly suggest photoallergy; usually, phototoxicity is associated with a burning sensation, and photoallergy with pruritus. Skin biopsy findings also may be helpful in differentiating these 2 conditions: necrotic keratinocytes are commonly seen in phototoxicity, whereas spongiotic dermatitis is associated with photoallergy (see Table 97-1).

Phototests and photopatch tests are an integral part of the evaluation of photosensitivity when history and physical examination alone are insufficient to determine the responsible agent. Approximately 10% to 20% of patients who undergo photopatch testing have clinically relevant positive results, which leads to the diagnosis of photoallergic contact dermatitis.[2,9]

The procedures for phototesting and photopatch testing are generally as follows, although there are variations in testing methods. On day 1, exposure to UVB and UVA to determine minimal erythema doses is carried out, and duplicate sets of photoallergens are applied symmetrically to different sites on the back and covered by an opaque tape. On day 2, the minimal erythema doses are determined. One of the duplicate set of photoallergens is exposed to 10 J/cm^2 of UVA or 50% of the minimal erythema dose to UVA, whichever is lower. After irradiation, the exposed site is covered again with an opaque tape. On day 3, both irradiated and nonirradiated test sites are uncovered, and the reactions are graded. On day 5 or day 8, the irradiated and nonirradiated sites are evaluated for delayed reactions. Reaction only at an irradiated site indicates photoallergy. Reaction of equal intensity at both irradiated and covered sites indicates allergic contact dermatitis. Reaction at both sites, but with higher intensity at the irradiated site, signifies both photoallergy and allergic contact dermatitis. Well-defined erythema that resolves promptly indicates an irritant dermatitis.

DIFFERENTIAL DIAGNOSIS OF PHOTOTOXICITY AND PHOTOALLERGY

Airborne allergic contact dermatitis is characterized by involvement of skinfolds on exposed areas, such as the nasolabial folds and the eyelids that receive minimal direct sunlight. It also involves exposed areas that are relatively sun protected, such as the postauricular areas and area under the chin. Allergic contact dermatitis and irritant contact dermatitis occur at sites of contact, in both sun-exposed and sun-protected areas.

Other photodermatoses can be differentiated from phototoxicity and photoallergy by their characteristic time course and morphology and lack of exposure to photosensitizers. Polymorphous light eruption manifests itself within a few hours of sun exposure as pruritic papules, plaques, and, uncommonly, vesicles on sun-exposed sites and resolves in a few days. Chronic actinic dermatitis presents as chronically lichenified plaques on sun-exposed areas. Lesions of solar urticaria appear within minutes of sun exposure as mildly pruritic urticaria and resolve within a few hours.

REFERENCES

1. Kim WB, Shelley AJ, Novice K, et al. Drug-Induced Phototoxicity: A Systematic Review. *J Am Acad Dermatol*. 2018 Jul 9. [Epub ahead of print]
2. Fotiades J, Soter NA, Lim HW. Results of evaluation of 203 patients for photosensitivity in a 7.3-year period. *J Am Acad Dermatol*. 1995;33:597-602.
3. Crouch RB, Foley PA, Baker CS. Analysis of patients with suspected photosensitivity referred for Investigation to an Australian photodermatology clinic. *J Am Acad Dermatol*. 2003;48(5):714-720.
4. Wong SN, Khoo LS. Analysis of photodermatoses seen in a predominantly Asian population at a photodermatology clinic in Singapore. *Photodermatol Photoimmunol Photomed*. 2005;21:40-44.
5. Nakamura M, Henderson M, Jacobsen G, et al. Comparison of photodermatoses in African-Americans and Caucasians: a follow-up study. *Photodermatol Photoimmunol Photomed*. 2014;30(5):231-236.
6. Sharma VK, Bhari N, Wadhwani AR, et al. Photo-patch and patch tests in patients with dermatitis over the photo-exposed areas: a study of 101 cases from a tertiary care centre in India. *Australas J Dermatol*. 2018;59(1):e1-e5.
7. Greenspoon J, Ahluwalia R, Juma N, et al. Allergic and photoallergic contact dermatitis: a 10-year experience. *Dermatitis*. 2013;24(1):29-32.
8. Chuah SY, Leow YH, Goon AT, et al. Photopatch testing in Asians: a 5-year experience in Singapore. *Photodermatol Photoimmunol Photomed*. 2013;29(3):116-120.
9. European Multicentre Photopatch Test Study (EMCPPTS) Taskforce. A European multicentre photopatch test study. *Br J Dermatol*. 2012;166(5):1002-1009.
10. Haylett AK, Chiang YZ, Nie Z, et al. Sunscreen photopatch testing: a series of 157 children. *Br J Dermatol*. 2014;171(2):370-375.
11. Valbuena Mesa MC, Hoyos Jiménez EV. Photopatch testing in Bogota (Colombia): 2011-2013. *Contact Dermatitis*. 2016;74(1):11-17.
12. Hu Y, Wang D, Shen Y, et al. Photopatch testing in Chinese patients over 10 years. *Dermatitis*. 2016;27(3):137-142.
13. Wlodek C, Narayan S. A reminder about photo-onycholysis induced by tetracycline, and the first report of a case induced by lymecycline. *Clin Exp Dermatol*. 2014;39(6):746-747.
14. D'Agostino ML, Risser J, Robinson-Bostom L. Imipramine-induced hyperpigmentation: a case report and review of the literature. *J Cutan Pathol*. 2009;36(7):799-803.
15. Campbell M, Ahluwalia J, Watson AC. Diltiazem-associated hyperpigmentation. *J Gen Intern Med*. 2013;28(12):1676.
16. Imafuku K, Natsuga K, Aoyagi S, et al. Mucosal hyperpigmentation from prophylactic minocycline

for EGFR inhibitor. *J Eur Acad Dermatol Venereol*. 2016;30(4):690-692.
17. Markova A, Lester J, Wang J, et al. Diagnosis of common dermopathies in dialysis patients: a review and update. *Semin Dial*. 2012;25(4):408-418.
18. Alberdi Soto M, Aguado Gil L, Pretel Irazabal M, et al. Accelerated photoaging induced by voriconazole treated with Q-switched Nd:YAG laser: case report and review of the literature. *J Cosmet Laser Ther*. 2014;16(6):314-316.
19. Bakkour W, Haylett AK, Gibbs NK, et al. Photodistributed telangiectasia induced by calcium channel blockers: case report and review of the literature. *Photodermatol Photoimmunol Photomed*. 2013;29(5):272-275.
20. Walker G, Lane N, Parekh P. Photosensitive lichenoid drug eruption to capecitabine. *J Am Acad Dermatol*. 2014;71(2):e52-e53.
21. Dawe RS, Ibbotson SH. Drug-induced photosensitivity. *Dermatol Clin*. 2014;32(3):363-368.
22. Ozog DM, Rkein AM, Fabi SG, et al. Photodynamic therapy: a clinical consensus guide. *Dermatol Surg*. 2016;42(7):804-827.
23. Eichenfield DZ, Cohen P. Amitriptyline-induced cutaneous hyperpigmentation: case report and review of psychotropic drug-associated mucocutaneous hyperpigmentation. *Dermatol Online J*. 2016;22(2).
24. Jansen R, Osterwalder U, Wang SQ, et al. Photoprotection: part II. Sunscreen: development, efficacy, and controversies. *J Am Acad Dermatol*. 2013;69(6):867-882.
25. Emmert B, Schauder S, Palm H, et al. Disabling work-related persistent photosensitivity following photoallergic contact dermatitis from chlorpromazine and olaquindox in a pig breeder. *Ann Agric Environ Med*. 2007;14(2):329-333.
26. Heurung AR, Raju SI, Warshaw EM. Adverse reactions to sunscreen agents: epidemiology, responsible irritants and allergens, clinical characteristics, and management. *Dermatitis*. 2014;25(6):289-326.
27. Kerr A, Ferguson J. Photoallergic contact dermatitis. *Photodermatol Photoimmunol Photomed*. 2010;26(2):56-65.

Chapter 98 :: Cold Injuries

:: Ashley N. Millard, Clayton B. Green, & Erik J. Stratman

AT-A-GLANCE

- Skin is important for maintaining core body temperature within a narrow physiologic range.
- Cold weather, wind, humidity, dampness, and altitude combine to inflict skin damage.
- Freezing and nonfreezing conditions can both produce cold injuries.
- Frostbite occurs after exposure to intensely cold air, liquids, or metals. Several degrees of frostbite are recognized.
- Self-inflicted freeze injuries from inhalant abuse and peer challenges are emerging.
- Winter xerosis and acrocyanosis are common consequences of prolonged exposure to cold.
- Pernio is an acral eruption of edematous violaceous papules occurring in cool rather than freezing exposures, and seen more frequently in lean persons.
- Cold urticaria is rare and occurs at the sites of localized cooling.
- Cold panniculitis typically occurs on legs and cheeks.

Many physiologic, behavioral, and environmental factors predispose to cold injuries. Marked increases in convective, conductive, or radiant heat loss are responsible for the immediate effects of cold exposure. A cold environment can be a threat to the skin, and can lead to subsequent fall in core body temperature. Cold injuries are becoming more prevalent among the general population.[1] Outdoor work, winter sports, windy conditions, humidity, altitude, and skin contact with cold objects are environmental factors that may predispose an individual to cold damage.[2] Insulation from clothing is insufficient when garments are too light, wet, tight, permeable to wind, or inadequate to cover the cold sensitive body parts. Frostbite prevails among winter sport enthusiasts, such as cross-country skiers and backpackers, who get lost or trapped in a snowstorm.[3-8] Accidental exposure to liquefied gas is an emerging cause of severe cold injuries.[9]

The human capacity for physiologic adaptation to cold is minimal. This deficiency may cause problems because seasonal changes in the outdoor environment can be quite dramatic, even in the temperate zones of the world. Skin is important in thermoregulation. Cutaneous blood flow and the resulting skin temperature may vary widely to preserve the core body temperature.[10,11] In fact, the body can maintain a constant core temperature of approximately 37°C (98.6°F) over a range of external temperatures between 15°C and 54°C (59°F and 129.2°F). In addition to external temperature, physiologic, behavioral, and environmental factors modulate skin responses to cold exposure.

THERMOREGULATION AND PHYSIOLOGIC RESPONSE TO COLD

Cutaneous thermoregulation is complex. As external temperature decreases, central thermoregulation centers in the hypothalamus signal other hypothalamic control centers to generate or conserve heat. Core body temperature is prioritized and maintained largely by controlling cutaneous blood flow. Arteriovenous anastomoses are abundant in acral areas, and they regulate the volume of blood passing through the skin. When the skin is cooled, there is usually an immediate vasoconstrictive response to reduce the amount of blood flowing at the skin surface. Without this vasoconstriction there would be significant heat transfer from the blood flowing in the skin to the environment, leading eventually to core temperature drop. The parallel arrangement of large arteries and veins in the limbs allows countercurrent exchange of heat. Vasoconstriction caused by cold results in shunting of blood from the superficial to the deep venous system, and heat is transferred from arteries to veins. Thus, the venous blood returning to the heart has already received heat transferred from the arteries before the heat can be lost to the environment.

In prolonged cold exposures, the skin experiences a paradoxical cyclic vasodilation known as the *hunting reaction of Lewis*, to protect against skin necrosis from prolonged vasoconstriction.[12,13] If cold exposure continues, there is an eventual reflex constriction of the arteries and veins in the extremities resulting in increased venous pressure, decreased capillary perfusion, sludging, hypoxia, microvascular thrombus formation, and surrounding tissue damage.[14] Segmental vascular necrosis ensues in areas of erythrostasis.

The rate of tissue freezing impacts the nature of cold injury.[15] Slow freezing results in extracellular formation of ice whereas fast freezing tends to produce intracellular ice. Extracellular ice crystals alter the osmotic properties of tissues and disturb the flow of water and electrolytes across the cell membranes. Thawing may

be as damaging as the freezing itself, and repeated freeze and thaw cycles, as may occur in accidental injury, compound the damage. The rewarming rate is also important. In slow rewarming, ice crystals become larger and more destructive.

Other biologic factors influence vasoconstriction and tissue damage besides temperature. Painful stimuli, mental stress, arousal stimuli, deep breaths, and other stimuli of the autonomic nervous system can produce cutaneous vasoconstriction in warm subjects.[16,17] Increased blood viscosity (vascular sludging) also influences the negative effects of cold on the skin. Blood viscosity is strongly influenced by blood flow rates, hematocrit, platelet adhesiveness, concentrations of proteins, and the presence of abnormal proteins, such as fibrinogen.

Individual factors predisposing to cold injuries include skin conditions with transepidermal water loss (eg, atopic dermatitis), physical injuries, leanness, low physical fitness level, fatigue, dehydration, previous cold injuries, sickness, trauma, poor peripheral circulation, poor clothing insulation, and old age.[2] Newborns, the elderly, and individuals with acute or chronic impaired mental faculties remain the most vulnerable (Fig. 98-1). Many cases are associated with alcohol consumption, homelessness in urban centers, and car breakdown. Smoking and psychotropic drug use can also increase injury.

Given the presence of many cold-adapted enzymes, the skin may function more effectively when slightly cooled. In the case of adipose tissue, mild long-term exposure to cooling may lead to progressively better insulation. Consequently, overweight persons are more likely to survive prolonged accidental cold exposure.[18] Habitually cold-exposed skin also develops a more efficient system for shunting blood away from the surface. These adaptive mechanisms are most flexible during the first years of life. Tissues in the aged are less able to develop new shunts. In contrast, individuals who have experienced previous severe cold injury may have a profoundly delayed or absent hunting reaction in the affected limbs, making them more susceptible to recurrent cold injury with pain, hyperesthesia, or paresthesia.[19,20] Some of these individuals also have chronically cool skin.

Figure 98-1 Reticulate appearance of cooled skin in a newborn resulting from the anatomic pattern of the blood supply and factors influencing flow, such as arteriolar vasoconstriction and the increased viscosity of cooled blood.

CLASSIFICATION OF SKIN COLD INJURIES

Skin cold injuries can be divided into freezing and nonfreezing cold injuries. Although freezing injuries typically have clear associations with cold exposure by patient history, exposures that cause nonfreezing skin conditions are less likely to be associated or recounted by patients. Some of these conditions involve many variables other than temperature. Clinical recognition is generally easy, but awareness of potential uncommon associated disorders is important.

Table 98-1 outlines the classification of nonfreezing cold injuries. Treatment, both physical and pharmacologic, is aimed at keeping the body warm and maintaining vasodilation.

FROSTBITE

Frostbite occurs when tissue freezes after exposure to extremely cold air, liquids, or metals. The clinical effects of accidental injury that lead to the death of tissues are similar to those caused by cryosurgery.[21] Tissue injury results from initial vasoconstriction followed by intracellular and extracellular ice crystal formation.[10] This causes metabolic derangements in cells, electrolyte imbalances, membrane lysis, and cell death. Thawing can further exacerbate tissue damage through ischemia–reperfusion and increasing inflammation. Vascular stasis then occurs, followed lastly by a late ischemic phase that results in the eventual infarction of tissues, largely from damage to microcirculation.

TABLE 98-1

Classification of Nonfreezing Cold Injuries to the Skin

- Vasoconstriction
- Hunting reaction
- Immersion foot
- Pulling-boat hands
- Acrocyanosis
- Chilblains
- Cold urticaria
- Cold panniculitis
- Erythromelalgia
- Raynaud phenomenon
- Sclerema neonatorum
- Subcutaneous fat necrosis of the newborn
- Livedo reticularis
- Cryoglobulinemia
- Cold agglutinins
- Cryofibrinogenemia

Figure 98-2 Bullous frostbite following contact with a cold steel sheet.

Frostbite commonly affects fingers, toes, ears, nose, and cheeks.[22,23] Extreme and often conductive heat loss at a given body site freezes the tissues and results in localized blistering and necrosis (Fig. 98-2). The clinical presentation of frostbite falls into 3 categories that correspond to frostnip (mild frostbite), superficial frostbite, and deep frostbite with tissue loss.

Frostnip involves only the skin and damage is reversible (Fig. 98-3). There is a sensation of severe cold progressing to numbness followed by pain. Erythema is usually present on the cheeks, ears, nose, fingers, and toes. There is no edema or bleb formation. Frostnip is the only form of frostbite that can be treated safely in the field with first aid measures.

Superficial frostbite involves the skin and immediately subcutaneous tissues. It includes the previously described signs but with the pain subsiding to feelings of warmth. This is a sign of severe involvement. The skin has a waxy appearance, but deeper tissues remain soft and resilient. Clear blebs form, accompanied by edema and erythema within 24 to 36 hours after thawing. Lesions may become eroded (Fig. 98-4).

Deep frostbite extends to the deep subcutaneous tissue. The injured skin becomes white or bluish

Figure 98-3 Frostnip.

Figure 98-4 Superficial frostbite.

white with a variable degree of anesthesia. Most often the affected skin becomes deceptively pain free, and the discomfort of feeling cold vanishes. The tissue is totally numb, indurated with immobility of joints and extremities. Muscles may be paralyzed. Nerves, large blood vessels, and even bone may be damaged. Large blisters form 1 to 2 days after rewarming, and they can be classified according to depth, as in heat-induced burns (Fig. 98-5). Frostbite blister fluid contains high amounts of prostaglandins, including prostaglandin $F_{2\alpha}$ and thromboxane A_2. These mediators may contribute to increased vasoconstriction, platelet aggregation, leukocyte adhesiveness, and, ultimately, progressive tissue injury. The blister fluid begins to be resorbed within 5 to 10 days, which leads to the formation of

Figure 98-5 Deep frostbite after rewarming. Large blisters have formed. Note cyanosis of the toes as a sign of impending necrosis. This cold injury occurred in a homeless person who was found on the street after heavy alcohol consumption and overnight snowfall.

Figure 98-6 Dry gangrene of all fingers in a mountain climber 5 weeks after being caught in a snowstorm.

hard, black gangrene. Weeks later, a line of demarcation occurs, and the tissues distal to the line undergo autoamputation (Fig. 98-6).

Prevention is key to protecting individuals from the effects of cold weather; frostbite, frostnip, and hypothermia always should be taken seriously. Table 98-2 lists prognostic factors.[7,8,24-26] Wearing protective clothing, a warm hat, earflaps, and scarf, together with preventive behavior, such as turning bare areas away from the wind, are the most important procedures for preventing frostbite. Nonmedicated waterless ointments are traditionally used for protection against facial frostbite, but their benefit is undocumented. The thermal insulation they provide is indeed minimal.[22,23] The use of protective emollients may lead to a false sense of safety and increased risk of frostbite, probably through neglect of other, more efficient protective measures.[27-29] In less-extreme conditions, however, some specific topical formulations bring beneficial effects.[30] The most effective products are those reducing transepidermal water loss and perspiration because these biologic functions cause emission of body thermal energy and further cool the skin.

TABLE 98-2
Prognostic Signs of Frostbite

Good prognostic signs	Large, clear blebs extending to the tips of the digits
	Rapid return of sensation
	Rapid return of normal (warm) temperature to the injured area
	Rapid capillary filling time after pressure blanching
	Pink skin after rewarming
Poor prognostic signs	Hard, white, cold, insensitive skin
	Cold and cyanotic skin without blebs after rewarming
	Dark hemorrhagic blebs
	Early evidence of mummification
	Constitutional signs of tissue necrosis, such as fever and tachycardia
	Cyanotic or dark red skin persisting after pressure
	Freeze–thaw–refreeze injury

The first consideration in frostbite treatment is to be aware that the victim may be suffering from hypothermia.[7,14,31,32] Prompt recognition and treatment are of paramount importance, because many hypothermia victims can recover from very low body temperatures. Treatment in an adequate medical facility can make the difference between full recovery and lifelong problems. Even if the victim appears to be dead from exposure to cold, resuscitative efforts should be started and continued until the proper core body temperature is reached.[14]

Because of the difficulty in assessing the depth of frostbite injury, conservative waiting after the frostbite episode is often encouraged in an attempt to delineate the extent of tissue loss. Care providers should avoid trauma, friction, pressure, massaging with snow, and refreezing. Slow rewarming increases tissue damage, making rapid rewarming the keystone of treatment.[33] Rewarming should be performed in a water bath between 37°C and 39°C (98.6°F and 102.2°F) until the most distal parts of the body are flushed.[29,34,35] Large amounts of analgesics may be required. The damaged part should be elevated, and blisters should be left intact. Surgical debridement is often best delayed until 1 to 3 months after demarcation. However, triple-phase bone scans, MRI, and magnetic resonance angiography can be used to predict ultimate tissue loss and to assess the possibility of earlier surgical intervention.[36-38]

There is no uniformly accepted protocol for other measures allegedly beneficial in the treatment of frostbite injury.[32] Intraarterial reserpine and sympathectomy have been used to reverse vasospasm, which may contribute to tissue loss. Their role is controversial, although some patients have benefited from this therapy. To counteract vasoconstriction caused by local release of inflammatory mediators, the use of topical aloe vera, which inhibits thromboxane synthetase, and oral ibuprofen, which inhibits cyclooxygenase, has been advocated. Oxpentifylline has been presented as an advanced therapy.[39] In addition, several adjunctive therapies, including vasodilators, thrombolysis, and hyperbaric oxygen, are sometimes useful.[40] Tetanus toxoid should be given in the case of open wounds. Surgery and amputation remain the ultimate strategies to help the victims.[41]

Sequelae of frostbite include permanent hypersensitivity to cold and, less often, hyperhidrosis.[42] Squamous cell carcinoma is a rare outcome, usually occurring on the heel 20 to 30 years later.[43] Epiphyseal plate damage or premature fusion may occur in children. Premature fusion can result in shortened digits, joint deviation, and dystrophic nails. In addition, frostbite arthritis,

resembling osteoarthritis, may occur weeks to years later. Frostbite may also lead to ossification of one or both ears.[44]

IATROGENIC COLD INJURY

The most common in-office procedure performed in dermatology in the United States is cryodestruction using liquid nitrogen.[45] This destructive therapy causes localized cutaneous tissue freezing in a series of freeze–thaw cycles, leading to cell death in the targeted lesions, similar to a localized frostbite reaction. Vigorous tissue responses and overly aggressive treatments may lead to significant reactions, pain, and patient concern in the days following treatment. Vesicles and even large bullae, including hemorrhagic bullae, can occur acutely (Fig. 98-7). This can be followed by hemorrhagic crusting, hypopigmentation, and even scarring.

Figure 98-7 Iatrogenic bullae from liquid nitrogen treatment. Blister fluid may range from clear (**A**) to hemorrhagic (**B**) in appearance.

SELF-INFLICTED COLD INJURY

While accidental or incidental exposure to cool, cold, or freezing temperatures is the cause of many cold injuries and dermatoses, such injuries also may be self-inflicted by patients. Intentional and unintentional contact with cold substances, often through the misuse of household and industrial chemicals, can induce damage to the skin. Chemicals that are capable of cold-induced skin injury include the fluorinated hydrocarbons in propellants, refrigerants, and liquefied petroleum gases (eg, propane, butane), which are used as solvents and fuels.[46,47] Although these compounds can cause injury through accidental spray or drip exposures from pressurized canisters, such as occupational exposure to liquid nitrogen or pressurized ammonia,[48] they also may be intentionally abused for the purpose of achieving an altered mental state.

Inhalant abuse, which involves deliberately breathing volatile substances through the nose or mouth to achieve "a high" has been an emerging problem since the 1960s.[49] Slang terms for inhalant abuse include huffing, sniffing, snorting, dusting, glading, and bagging, depending on the substance involved and mode of inhalation.[50] The peak ages of inhalant abuse has been reported to be 14 to 15 years.[50] Individuals at increased risk include persons of low socioeconomic status and those with a history of criminal behavior, incarceration, depression, suicidal ideation, antisocial personality traits, unstable home life, or other drug use. The problem has been particularly widespread among Native American and Alaskan Native youth. Inhalation of amyl nitrite or butyl nitrite to augment sexual pleasure, referred to as "popping" or "snapping," also has been a practice among certain cultural groups, including men who have sex with men.[51]

Because of the low temperatures of inhalants, frostbite has been observed on the face, fingers, forearms, oral, laryngeal, and tracheal surfaces (Fig. 98-8A).[46-49] This may present as well-demarcated edema, erythema, cyanosis, and vesiculation concentrated around the nose, mouth, or even periorbital area (Fig. 98-8B).[49] Other skin findings may include a perioral or perinasal dermatitis with pyoderma ("huffer's rash"), contact dermatitis, yellow-stained facial dermatitis caused by nitrites,[52] and ichthyosis-like dermatitis from paradichlorobenzene in mothballs.[53] Extracutaneous manifestations of inhalant abuse can include conjunctival injection, headache, drowsiness, slurred speech, ataxia, disorientation, arrhythmia, vomiting, increased secretions, respiratory difficulty, and syncope.[50]

Pressurized gasses are not the only source of self-inflicted cold injury. Around 2012, a social media fad emerged in which teens applied table salt and ice cubes to the skin, challenging each other to see who could withstand the painful contact the longest.[54] Similar to salting an icy winter road, the salt rapidly decreases the freezing point of water to below 0°C (32°F), enhancing the ability to induce local frostbite.[55,56] A series of

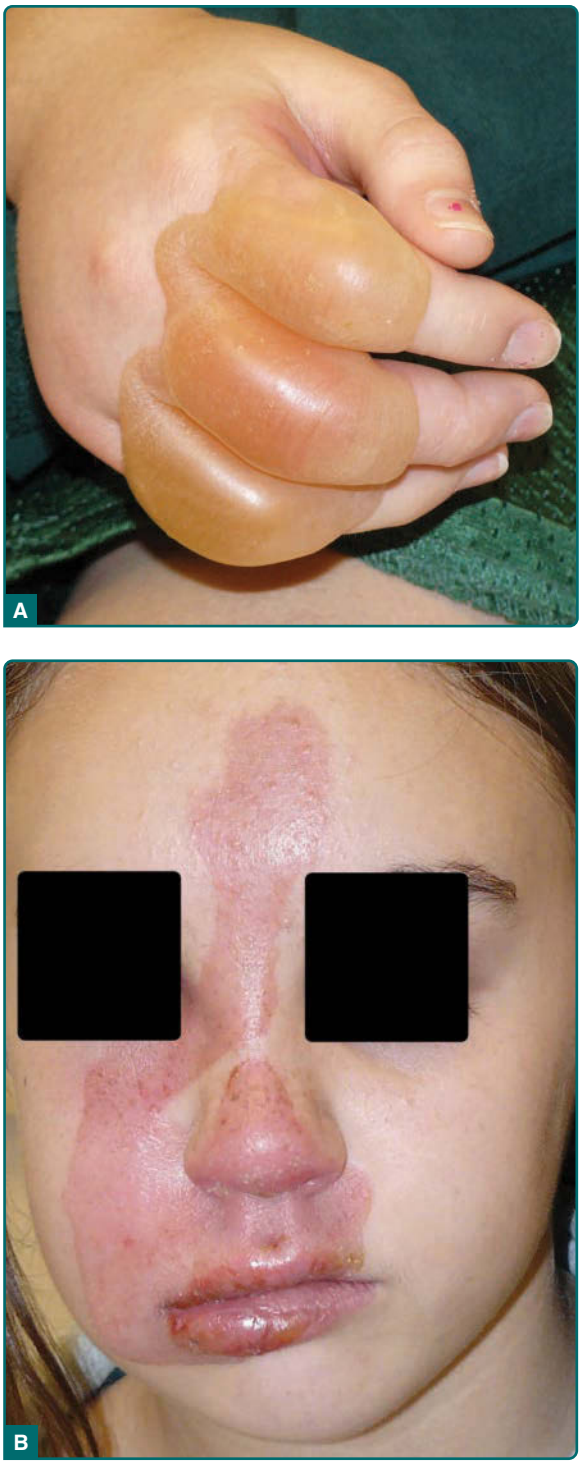

Figure 98-8 **A,** Dorsal hand frostbite and **(B)** "huffer rash" from inhalant abuse.

Figure 98-9 **A** and **B,** Acute, subacute, and chronic lesions inflicted by the "salt-and-ice challenge."

case reports have emerged in the literature in which teenage patients have presented to clinicians with factitial skin damage from the "salt-and-ice challenge." Lesions consist of painful, sharply demarcated, geometric or drip pattern, dusky erythematous patches, which may become bullous (Fig. 98-9).[54,56] Common locations include the palmar hands, forearms, and back.[54-56] Pathology on hematoxylin-and-eosin stain shows an interface dermatitis with extensive epidermal necrosis.[56] When confronted about possible self-infliction, patients frequently deny such behaviors, especially in the presence of parents or family members.

NONFREEZING COLD INJURY AND DAMPNESS

Nonfreezing cold injury occurs when tissues are cooled to temperatures between 0°C and 15°C (32°F and 59°F) for hours to days.[35] This type of injury, historically known as "trench foot," is exacerbated by dampness and has claimed numerous casualties in warfare. Cold, wet conditions at temperatures above freezing and limb dependency resulting from immobility and constrictive footwear are important pathogenic factors. Although classically thought to affect feet, nonfreezing cold injury can occur in other areas of the body.[35] Persistent erythema of the face and the hands is not a rare finding (Fig. 98-10).

WINTER XEROSIS

Minor but long-term cold exposure combined with environmental desiccation may have profound effects on the biology of the epidermis, leading, for example, to winter xerosis.[57,58] Many individuals present with dryness of the skin, particularly on the lower extremities, during wintertime (Fig. 98-11). The hands, forearms, cheeks, lips, and trunk also may be affected. Itching, a dry appearance, chapping, and cracking of the stratum corneum can be prominent. The condition is markedly influenced by cold environments, especially in combination with low humidity.[42,59] Predisposing factors include atopic dermatitis, ichthyosis, and increasing age. Excessive washing exacerbates winter xerosis. Indeed, irritant dermatitis of the hands worsens in a cold and dry environment.[60] Emollients and improvement in the environmental temperature and humidity are helpful in controlling this condition.

Figure 98-10 Facial redness in a person exposed to cold winters in a temperate climate.

Figure 98-11 Xerosis of the legs of an elderly man in winter.

ACROCYANOSIS

Vasoconstriction can alter both skin temperature and skin color, resulting in a blue to violaceous acrocyanosis, a bilateral dusky mottled or confluent red to blue discoloration of the hands, feet, nailbeds, and sometimes the face (Fig. 98-12). It is persistent and accentuated by cold exposure. When the temperature is very low, the skin may be bright red. Trophic changes and pain do not occur, and pulses are present. This condition must be distinguished from obstructive arterial disease (see Chap. 148) and Raynaud phenomenon (see Chap. 145), which is clearly episodic, often segmental, and painful.

Acrocyanosis is genetically determined and usually starts in adolescence. Chronic vasospasm of small cutaneous arterioles or venules with a secondary dilation of the capillaries and subpapillary venous plexus has been postulated. Stasis in the papillary loops with aneurysmal dilation at the tips redistributes blood flow to the subpapillary venous plexus. The blood flow may be compromised by altered erythrocyte flexibility, increased platelet adhesiveness, and other plasma viscosity factors. Cold agglutinins may exacerbate the acrocyanosis manifestations.[61,62] The "puffy hand syndrome" is defined by the presence of hand edema superposed on acrocyanosis.[63]

Figure 98-12 Acrocyanosis of the toes of an elderly woman with peripheral vascular disease. Note the contrast with the examiner's palmar skin in the background.

Tissues are less sclerotic in acrocyanosis than in Raynaud phenomenon. In cases developing for the first time late in life, an underlying myeloproliferative disorder should be excluded. Remittent necrotizing acrocyanosis is associated with enhanced susceptibility to cooling and pain, as well as ulceration and gangrene of the fingers. Arteriolar occlusion by thrombi or intimal proliferation may occur. Cold pain should be distinguished from cold allodynia and cold hyperalgesia.

There is no effective treatment for acrocyanosis. Supportive measures to keep the skin warm are helpful.

PERNIO (CHILBLAINS)

Pernio, also called *perniosis* or *chilblains*, is a condition of localized inflammatory lesions caused by continued exposure to cool temperatures (above freezing).[64,65] Dampness and wind contribute to disease flares by increasing thermal conductivity and convection. Absolute temperature is less important than the cooling of nonadapted tissue. Abnormal vascular response to cold and minor trauma are believed to play a role.[66] The condition shows a genetic predisposition. It has been described most often in temperate regions, where winters are commonly cold and damp. Pernio is seen less often in very cold climates, where well-heated houses and warm clothing are available. When occurring in these colder regions, it is more common to occur during the cool early spring season rather than winter. Pernio is more common in children, women, and persons with low body mass index. Spontaneous remission is common when spring arrives, and relapse is frequent during the following winters.

Pernio develops acutely as single or multiple, burning, erythematous to violaceous macules, edematous papules, plaques, and nodules (Fig. 98-13). Patients may complain of itching, burning, or pain. In severe cases, blisters, pustules, and ulceration may occur. Characteristic locations include the dorsal and plantar surfaces of the toes, but the fingers, heels, nose, ears, and other sites, like the calves and thighs, can be affected.[67,68] Lesions usually resolve in 1 to 3 weeks but may become chronic in elderly people with venous stasis. A papular form of pernio resembling erythema multiforme can occur at all times of the year, usually in crops on the sides of the fingers,[69] often superimposed on a background of acrocyanosis.

Idiopathic perniosis is characterized histologically by edema of the papillary dermis and by the presence of superficial and deep perivascular lymphocytic infiltrates. Necrotic keratinocytes and lymphocytic vasculitis also have been reported. Thickening of blood vessel walls with intimal proliferation may lead to obliteration of the vascular lumen.[70-72]

A peculiar clinical presentation may occur in young women riding horses for several hours daily during winter.[73,74] Indurated red-to-violet tender plaques develop on the lateral calves and thighs (see Fig. 98-13D). The condition is quite similar to the nodular perniotic lesions described in adolescent girls with erythrocyanosis. For prophylaxis, experienced riders usually wear baggy riding pants that provide insulation and are not tight enough to compromise the circulation.

Perniotic lesions have been described in association with myeloproliferative disorders,[75] probably as a consequence of blood flow changes, presence of cold agglutinins, and altered inflammatory response on cooling. Chilblains lupus is a distinct disease in which lesions occur as a variant of chronic cutaneous lupus or in the setting of systemic lupus erythematosus.[72] Additional associations reported in cases of secondary pernio include connective tissue diseases other than lupus, monoclonal gammopathies, hyperviscosity syndromes, cryoglobulinemia, antiphospholipid positivity, and viral infections.[72,76] Of note, lupus pernio is a variant of sarcoidosis (see Chap. 35) and is unrelated to cold injuries.

The unfamiliarity of physicians with pernio sometimes gives rise to unnecessary hospital admissions with expensive laboratory and radiologic evaluations and, at times, hazardous therapy. All patients with pernio should undergo a detailed history, review of systems, and physical examination with or without a skin biopsy based on the degree of clinical certainty.[76] Laboratory workup (eg, complete blood count with peripheral smear, serum protein electrophoresis, antinuclear and extractable nuclear antigen antibodies, rheumatoid factor, cold agglutinins, and antiphospholipid antibodies) should be conducted only if the history and physical suggest a possible underlying systemic disease. Pernio demonstrating a chronic course (continuous for at least 4 weeks and, in some cases, 8 weeks or longer, or episodic in nature), persistence into warm weather months, and onset in the elderly may be suggestive of an associated connective tissue disease, hematologic malignancy, or other systemic condition.[66,72,76,77]

The most important point in management of pernio is prevention through the use of adequate, loose, insulating clothing and appropriate warm housing and workplace. Tight garments, such as gloves, stockings, and shoes, are especially to be avoided in cases in which there is concomitant peripheral vascular disease. Instead, mittens can be useful for the hands. Minimizing moisture and maintaining blood circulation by avoiding immobility are also helpful.

Once pernio occurs, treatment is symptomatic with rest and warmth. Other conservative measures include smoking cessation and application of a midpotency topical steroid up to twice daily until lesions resolve. Associated systemic diseases, if present, should be treated. Second-line therapy for pernio consists of the addition of a calcium channel blocker, such as nifedipine 20 to 60 mg/day. Third-line and alternative management options include aspirin, pentoxifylline, nicotinamide, topical minoxidil, topical nitroglycerin, and tacrolimus ointment.

A related condition known as *pulling-boat hands* has been described, characterized by the presence of erythematous macules and plaques on the dorsum of the hands and fingers of sailors aboard rowboats.[78] Small vesicles developed later, accompanied by itching, burning, and tenderness. These individuals were exposed to long periods of high humidity, cool air, and

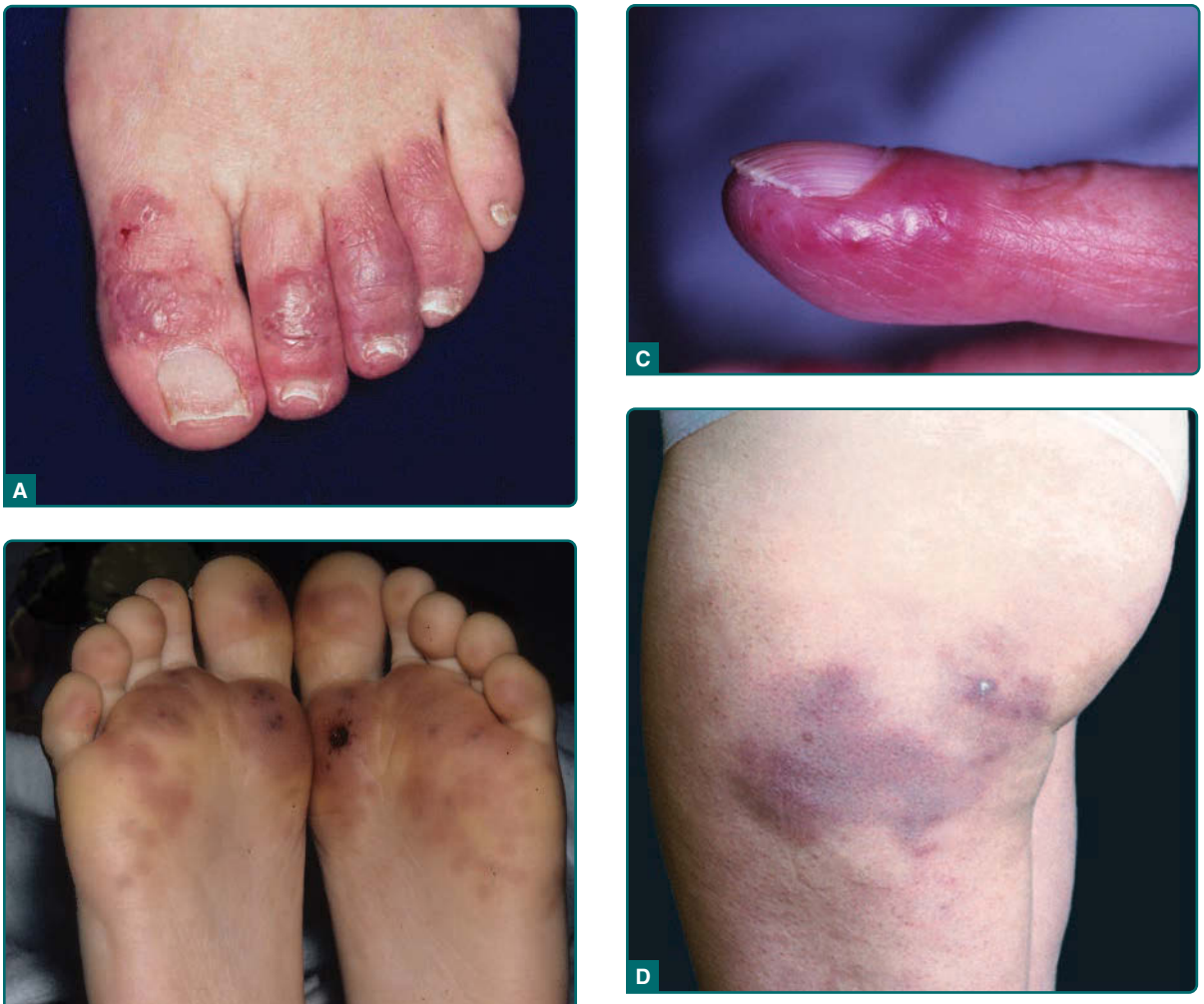

Figure 98-13 Pernio is common at sites such as the hands and feet when they are exposed to cooling, moisture, and tight garments. **A,** Pernio of the dorsal toes. **B,** Pernio of the plantar feet. **C,** Pernio of the fingertip. **D,** Equestrian chilblains from horse riding on a cold morning with inadequate clothing.

wind, an ideal setting for the development of nonfreezing cold injury. In addition, hours of vigorous rowing daily produced repetitive hand trauma.

COLD URTICARIA AND POLYMORPHOUS COLD ERUPTION

Acquired cold urticaria is a form of physical urticaria. Lesions occur at sites of localized cooling, usually when the area is rewarmed. The disease is recognized by wheal and flare-type reactions and/or angioedema. Its morphology is indistinguishable from other forms of urticaria. The condition may be idiopathic or associated with some serologic abnormality.[79-83] It accounts for approximately 2% of cases of urticaria (see Chap. 41). Immunoglobulin E and, more rarely, immunoglobulin M have been implicated in the pathogenesis. Histamine from mast cell degranulation is one of the most important mediators, but leukotrienes, platelet-activating factor, and others also have been implicated.

Familial cold urticaria is a rare autosomal dominant condition with onset at an early age and persistence throughout life.[84-86] Urticaria develops when the patient is exposed to generalized cooling, particularly chilling

wind, rather than local cold application. In addition to urticaria, headache, fever, arthralgia, leukocytosis, and swelling of the oral mucosa and esophagus can occur. The delayed type of familial cold urticaria is characterized by localized angioedema developing 24 to 72 hours after cold exposure. Coexistence with dermatographism or cholinergic urticaria is common. Alarming signs resembling histamine shock may lead to loss of consciousness. Death while swimming in cold water has been reported. A mutation in the CIAS1 gene, which is responsible for cold-induced autoinflammatory syndrome, has been identified.[85]

Cold urticaria may occur in 3% to 4% of patients with cryoglobulinemia, and it also may be associated with cold agglutinins, cryofibrinogens, and cold hemolysins. It has been reported in cases of infectious mononucleosis in association with either cryoglobulins or cold agglutinins, but such occurrences are rare. Cold urticaria also may be a sign of the Muckle-Wells syndrome that associates urticaria, deafness, and amyloidosis.[87] In this rare genetic disorder, recurrent bouts of urticaria, fever, chills, and malaise may occur from birth and persist throughout life. *Helicobacter pylori* has been suggested as a causative agent in some cases of acquired cold urticaria.[88]

Diagnosis of cold urticaria is confirmed by a cold challenge induced by an ice cube wrapped in a plastic bag placed on the skin of the forearm for periods varying from 30 seconds to 10 minutes (Fig. 98-14). Wheals form on rewarming. Sometimes water at 7°C (44.6°F) is more effective, presumably because it causes less-severe vasoconstriction. Peltier effect-based temperature challenge appears to be an improved method for diagnosis.[89] The Peltier effect relies on using 2 different sufficiently cold, microprocessor-controlled heat-transferring metals to generate a precise skin surface temperature to induce lesions.

Figure 98-14 Cold urticaria induced by the application of ice to the skin.

Avoiding cold wind exposure and swimming in cold water are important preventive measures in cold urticaria. In the acquired form, 50% of cases improve or resolve within 5 to 6 years.[86] Second-generation H_1 antihistamines, up to 4 times the standard dose, are first-line for treatment.[86] Adjunctive agents and therapies for refractory cases include sedating antihistamines, H_2 blockers, montelukast, omalizumab, cyclosporine, and other immunosuppressives. Patients should also be considered for epinephrine pen prescription because of the anaphylaxis risk. Desensitization to cold is possible by immersing 1 arm into water at 15°C (59°F) for 5 minutes daily.

Cold erythema seems to be a related disorder with erythema and pain but without urticaria. Familial polymorphous cold eruption is a rare autosomal dominant disease characterized by childhood onset of nonpruritic, erythematous patches often accompanied by influenza-like symptoms and leukocytosis after generalized exposure to cold. Results of the ice cube test are negative. The pathogenesis remains unknown. The disease frequently has been referred to as *familial cold urticaria*, although the skin lesions are not urticarial.[90]

COLD PANNICULITIS AND RELATED ENTITIES

Nonfreezing injuries also can lead to inflammatory reactions in the subcutaneous fat layers, a condition called *cold panniculitis*. This condition is more common in children than in adults. It most commonly affects the cheeks and legs. Eating popsicles is a common trigger in children who develop the condition on the cheeks, so this entity is sometimes referred to as "popsicle panniculitis." Tender erythematous subcutaneous nodules appear 1 to 3 days after exposure. Delayed presentation in an adult has been reported 10 days after initiation of post–surgical procedure cold therapy.[91] Because of the adipocyte apoptosis that can result from the cold temperature, mild subcutaneous atrophy in the form of dimpling can occasionally follow cold panniculitis. Cosmetic device manufacturers have capitalized on this fat loss effect to manufacture and market fat-cooling devices to reduce fat layers for improved cosmetic contouring.[92] When suspecting cold panniculitis, an ice cube challenge to the patient's skin for 10 minutes should result in the development of an erythematous subcutaneous plaque 12 to 18 hours later.

A perivascular mixed infiltrate with neutrophils, lymphocytes, and histiocytes is present at the dermal–subcutaneous junction after 24 hours, followed by a well-developed, primarily lobular panniculitis at 48 to 72 hours. An overlying superficial and deep perivascular dermal lymphocytic infiltrate also may be seen. Some adipocytes are necrotic and rupture to form cystic spaces.

Infants have a higher content of saturated fatty acids in adipose tissue than do adults, and this may result in

solidification at less-cold temperatures.[93,94] Cold panniculitis should be distinguished from other related disorders, including erythrocyanosis with nodules, sclerema neonatorum, and subcutaneous fat necrosis of the newborn. When the diagnosis is clear from history, biopsy to confirm cold panniculitis is not usually necessary, and care usually consists of reassurance and supportive analgesia as necessary. Lesions typically subside spontaneously within 2 to 3 weeks.

SCLEREMA NEONATORUM AND SUBCUTANEOUS FAT NECROSIS OF THE NEWBORN

See Chaps. 64 and 103.

RAYNAUD PHENOMENON

See Chap. 145.

CRYOGLOBULINEMIA

See Chap. 144.

LIVEDO RETICULARIS

See Chap. 148.

ERYTHROMELALGIA

See Chap. 148.

ACKNOWLEDGMENTS

We would like to thank Gérald E. Piérard, Pascale Quatresooz, and Claudine Piérard-Franchimont, the authors of the previous version of this chapter.

REFERENCES

1. Imray CH, Oakley EH. Cold still kills: cold-related illnesses in military practice freezing and nonfreezing cold injury. *J R Army Med Corps.* 2005;151:218.
2. Rintamaki H. Predisposing factors and prevention of frostbite. *Int J Circumpolar Health.* 2000;59:114.
3. Claes G, Henry F, Letawe C, et al. Skin, cold and winter sports [in French]. *Rev Med Liege.* 2001;56:257.
4. Long WB 3rd, Edlich RF, Winters KL, et al. Cold injuries. *J Long Term Eff Med Implants.* 2005;15:67.
5. Schindera ST, Triller J, Steinbach LS, et al. Spectrum of injuries from glacial sports. *Wilderness Environ Med.* 2005;16:33.
6. Miller BJ, Chasmar LR. Frostbite in Saskatoon: a review of 10 winters. *Can J Surg.* 1980;23:423.
7. Fritz RL, Perrin DH. Cold exposure injuries: prevention and treatment. *Clin Sports Med.* 1989;8:111.
8. Harirchi I, Arvin A, Vash JH, et al. Frostbite: Incidence and predisposing factors in mountaineers. *Br J Sports Med.* 2005;39:898.
9. Wright TC, Kim JB, Currie LJ, et al. Leakage of liquefied petroleum gas during motor vehicle refuelling—a new cause of cold injury. *Burns.* 2006;32:132.
10. Page EH, Shear NH. Temperature-dependent skin disorders. *J Am Acad Dermatol.* 1988;18:1003.
11. Quatresooz P, Piérard-Franchimont C, Paquet P, et al. It's a bit chilly, cold is stinging and skin is going to suffer [in French]. *Rev Med Liege.* 2008;63:18.
12. Dana AS Jr, Rex IH Jr, Samitz MH. The hunting reaction. *Arch Dermatol.* 1969;99:441.
13. O'Brien C. Reproducibility of the cold-induced vasodilation response in the human finger. *J Appl Physiol.* 2005;98:1334.
14. Arvesen A, Rosén L, Eltvik LP, et al. Skin microcirculation in patients with sequelae from local cold injuries. *Int J Microcirc Clin Exp.* 1994;14:335.
15. Gage AA. What temperature is lethal for cells? *J Dermatol Surg Oncol.* 1979;5:459.
16. Oberle J, Elam M, Karlsson T, et al. Temperature-dependent interaction between vasoconstrictor and vasodilator mechanisms in human skin. *Acta Physiol Scand.* 1988;132:149.
17. Hornstein OP, Heyer G. Responses of skin temperature to different thermic stimuli. *Acta Derm Venereol Suppl (Stockh).* 1989;144(suppl):149.
18. Keatinge WR, Coleshaw SR, Millard CE, et al. Exceptional case of survival in cold water. *Br Med J (Clin Res Ed).* 1986;292:171.
19. Foray J. Mountain frostbite: current trends in prognosis and treatment (from results concerning 1261 cases). *Int J Sports Med.* 1992;13(suppl 1):193.
20. Burge S, Shepherd JP, Dawber RP. Effect of freezing the helix and rim or edge of the human and pig ear. *J Dermatol Surg Oncol.* 1984;10:816.
21. Dawber R. Cold kills. *Clin Exp Dermatol.* 1988;13:137.
22. Lehmuskallio E, Anttonen H. Thermophysical effects of ointments in cold: an experimental study with a skin model. *Acta Derm Venereol.* 1999;79:33.
23. Lehmuskallio E. Cold protecting ointments and frostbite. A questionnaire study of 830 conscripts in Finland. *Acta Derm Venereol.* 1999;79:67.
24. Hamlet MP. Prevention and treatment of cold injury. *Int J Circumpolar Health.* 2000;59:108.
25. Ervasti O, Juopperi K, Kettunen P, et al. The occurrence of frostbite and its risk factors in young men. *Int J Circumpolar Health.* 2004;63:71.
26. Daanen HA, van der Struijs NR. Resistance index of frostbite as a predictor of cold injury in arctic operations. *Aviat Space Environ Med.* 2005;76:1119.
27. Lehmuskallio E. Emollients in the prevention of frostbite. *Int J Circumpolar Health.* 2000;59:122.
28. Lehmuskallio E, Rintamäki H, Anttonen H. Thermal effects of emollients on facial skin in the cold. *Acta Derm Venereol.* 2000;80:203.
29. De Buck E. BET 1: does the use of emollients prevent frostbite to the face? *Emerg Med J.* 2017;34:763.
30. Claes G, Piérard GE. Biometrological assessment of skin protectors against moderate cold threat. *Exog Dermatol.* 2002;1:92.
31. Hirvonen J. Some aspects on death in the cold and concomitant frostbites. *Int J Circumpolar Health.* 2000;59:131.

32. Koljonen V, Andersson K, Mikkonen K, et al. Frostbite injuries treated in the Helsinki area from 1995 to 2002. *J Trauma.* 2004;57:1315.
33. Murphy JV, Banwell PE, Roberts AH, et al. Frostbite: pathogenesis and treatment. *J Trauma.* 2000;48:171.
34. McIntosh SE, Opacic M, Freer L, et al. Wilderness Medical Society practice guidelines for the prevention and treatment of frostbite: 2014 Update. *Wilderness Environ Med.* 2014;25(4 suppl):S43.
35. Heil K, Thomas R, Robertson G, et al. Freezing and non-freezing cold weather injuries: a systematic review. *Br Med Bull.* 2016;117:79.
36. Kibbi AG, Tannous Z. Skin diseases caused by heat and cold. *Clin Dermatol.* 1998;16:91.
37. Mehta RC, Wilson MA. Frostbite injury: prediction of tissue viability with triple-phase bone scanning. *Radiology.* 1989;170:511.
38. Barker JR, Haws MJ, Brown RE, et al. Magnetic resonance imaging of severe frostbite injuries. *Ann Plast Surg.* 1997;38:275.
39. Probst F, Cox N, Anderson M. Oxpentifylline: an advance in the treatment of frostbite. *Emerg Nurse*. 2003;11:22.
40. Twomey JA, Peltier GL, Zera RT. An open-label study to evaluate the safety and efficacy of tissue plasminogen activator in treatment of severe frostbite. *J Trauma.* 2005;59:1350.
41. Petrone P, Kuncir EJ, Asensio JA. Surgical management and strategies in the treatment of hypothermia and cold injury. *Emerg Med Clin North Am.* 2003; 21:1165.
42. Irwin MS, Sanders R, Green CJ, et al. Neuropathy in non-freezing cold injury (trench foot). *J R Soc Med.* 1997;90:433.
43. Uysal A, Koçer U, Sungur N, et al. Marjolin's ulcer on frostbite. *Burns.* 2005;31:792.
44. Manni JJ, Berénos-Riley LC. Ossification of the external ear: a case report and review of the literature. *Eur Arch Otorhinolaryngol.* 2005;262:961.
45. Tan SY, Tsoucas D, Mostaghimi A. Association of dermatologist density with the volume and costs of dermatology procedures among Medicare beneficiaries. *JAMA Dermatol.* 2018;154:73.
46. Bonamonte D, Profeta G, Conserva A, et al. Cold burn from contact with a propane and butane gas blend inside a spray canister used as a hooter. *Contact Dermatitis.* 2008;59:61.
47. Kuspis DA, Krenzelok EP. Oral frostbite injury from intentional abuse of a fluorinated hydrocarbon. *J Toxicol Clin Toxicol.* 1999;37:873.
48. Stefanutti G, Yee J, Sparnon AL. Cryogenic burns from intentional use of aerosol spray in children: an emerging phenomenon. *Burns.* 2010;36:e65.
49. Kurbat RS, Pollack CV. Facial injury and airway threat from inhalant abuse: a case report. *J Emerg Med.* 1998;16:167.
50. Williams JF, Storck M. Inhalant abuse. *Pediatrics.* 2007;119:1009.
51. Fischer AA. "Poppers" or "snappers" dermatitis in homosexual men. *Cutis.* 1984;34:118.
52. Fregert S, Poulsen J, Trulsson L. Yellow stained skin from sodium nitrite in etching agent. *Contact Dermatitis.* 1980;6:296.
53. Feuillet L, Mallet S, Spadari M. Twin girls with neurocutaneous symptoms caused by mothball intoxication. *N Engl J Med.* 2016;355:423.
54. Templeton D. Boy, 12, badly injured in 'salt-and-ice' challenge. *Pittsburg Post-Gazette*. June 29, 2012: http://www.post-gazette.com/local/city/2012/06/29/Boy-12-badly-injured-in-salt-and-ice-challenge/stories/201206290188. Accessed February 28, 2018.
55. Vosbikian MM, Ty JM. The ice and salt challenge: an atypical presentation of a cold injury: a case report. *JBJS Case Connect*. 2015;5:e11.
56. Zack JM, Fults M, Saxena H, et al. Factitial dermatitis due to the "salt and ice challenge". *Pediatr Dermatol.* 2014;31:252.
57. Middleton JB, Allen BM. The influence of temperature and humidity on stratum corneum and its relation to skin chapping. *J Soc Cosmet Chem*. 1974;24:239.
58. Piérard-Franchimont C, Piérard GE. Beyond a glimpse at seasonal dry skin: a review. *Exog Dermatol*. 2002;1:3.
59. Ervasti O, Hassi J, Rintamäki H, et al. Sequelae of moderate finger frostbite as assessed by subjective sensations, clinical signs, and thermophysiological responses. *Int J Circumpolar Health.* 2000;59:137.
60. Uter W, Gefeller O, Schwanitz HJ. An epidemiological study of the influence of season (cold and dry air) on the occurrence of irritant skin changes of the hands. *Br J Dermatol.* 1998;138:266.
61. Cholongitas E, Ioannidou D. Acrocyanosis due to cold agglutinins in a patient with rheumatoid arthritis. *J Clin Rheumatol.* 2009;15:375.
62. Shirafuji Y, Maeda Y, Iwatsuki K. Cold agglutinin-induced acrocyanosis in a patient with subclinical chronic lymphocytic leukemia; a beneficial response to rituximab. *Eur J Dermatol.* 2010;20:394.
63. Del Giudice P, Durant J, Dellamonica P. Hand edema and acrocyanosis: "puffy hand syndrome". *Arch Dermatol.* 2006;142:1084.
64. Goette DK. Chilbain (perniosis). *J Am Acad Dermatol.* 1990;23:257.
65. Simon TD, Soep JB, Hollister JR. Pernio in pediatrics. *Pediatrics.* 2005;116:472.
66. Guadagni M, Nazzari G. Acute perniosis in elderly people: a predictive sign of systemic disease? *Acta Derm Venereol.* 2010;90:544.
67. Price RD, Murdoch DR. Perniosis (chilblains) of the thigh: report of five cases, including four following river crossings. *High Alt Med Biol.* 2001;2:535.
68. Brown PJ, Zirwas MJ, English JC 3rd. The purple digit: an algorithmic approach to diagnosis. *Am J Clin Dermatol.* 2010;11:103.
69. Wessagowit P, Asawanonda P, Noppakun N. Papular perniosis mimicking erythema multiforme: the first case report in Thailand. *Int J Dermatol.* 2000;39:527.
70. Wall LM, Smith NP. Perniosis: a histopathological review. *Clin Exp Dermatol.* 1981;6:263.
71. Cribier B, Djeridi N, Peltre B, et al. A histologic and immunohistochemical study of chilblains. *J Am Acad Dermatol.* 2001;45:924.
72. Viguier M, Pinquier L, Cavelier-Balloy B, et al. Clinical and histopathologic features and immunologic variables in patients with severe chilblains. A study of the relationship to lupus erythematosus. *Medicine (Baltimore)*. 2001;80:180.
73. Dowd PM, Rustin MH, Lanigan S, et al. Nifedipine in the treatment of chilblains. *Br Med J (Clin Res Ed).* 1986;293:923.
74. Beacham BE, Cooper PH, Buchanan CS, et al. Equestrian cold panniculitis in women. *Arch Dermatol.* 1980;116:1025.
75. Kelly JW, Dowling JP. Pernio: a possible association with chronic myelomonocytic leukemia. *Arch Dermatol.* 1985;121:1048.

76. Cappel JA, Wetter DA. Clinical characteristics, etiologic associations, laboratory findings, treatment, and proposal of diagnostic criteria of pernio (chilblains) in a series of 104 patients at Mayo Clinic, 2000 to 2011. *Mayo Clinic Proc*. 2014;89(2):207-215.
77. Takci Z, Vahaboglu G, Eksioglu H. Epidemiological patterns of perniosis, and its association with systemic disorder. *Clin Exp Dermatol.* 2012;37:844.
78. Toback AC, Korson R, Krusinski PA. Pulling boat hands: a unique dermatosis from coastal New England. *J Am Acad Dermatol.* 1985;12:649.
79. Wanderer AA. Cold urticaria syndromes: historical background, diagnostic classification, clinical and laboratory characteristics, pathogenesis, and management. *J Allergy Clin Immunol.* 1990;85:965.
80. Alangari AA, Twarog FJ, Shih MC, et al. Clinical features and anaphylaxis in children with cold urticaria. *Pediatrics.* 2004;113:e313.
81. Kozel MM, Sabroe RA. Chronic urticaria: aetiology, management and current and future treatment options. *Drugs.* 2004;64:2515.
82. La Shell MS, Tankersley MS, Kobayashi M. Cold urticaria: a case report and review of the literature. *Cutis.* 2005;76:257.
83. Buss YL, Sticherling M. Cold urticaria; disease course and outcome—an investigation of 85 patients before and after therapy. *Br J Dermatol.* 2005;153:440.
84. Hoffman HM, Rosengren S, Boyle DL, et al. Prevention of cold-associated acute inflammation in familial cold autoinflammatory syndrome by interleukin-1 receptor antagonist. *Lancet.* 2004;364:1779.
85. Shpall RL, Jeffes EW, Hoffman HM. A case of familial cold autoinflammatory syndrome confirmed by the presence of a CIAS1 mutation. *Br J Dermatol.* 2004;150:1029.
86. Singleton R, Halverstam C. Diagnosis and management of cold urticaria. *Cutis.* 2016;97:59.
87. Haas N, Küster W, Zuberbier T, et al. Muckle-Wells syndrome: clinical and histological skin findings compatible with cold air urticaria in a large kindred. *Br J Dermatol.* 2004;151:99.
88. Kränke B, Mayr-Kanhäuser S, Aberer W. *Helicobacter pylori* in acquired cold urticaria. *Contact Dermatitis.* 2001;44:57.
89. Siebenhaar F, Staubach P, Metz M, et al. Peltier effect-based temperature challenge: an improved method for diagnosing cold urticaria. *J Allergy Clin Immunol.* 2004;114:1224.
90. Urano Y, Shikiji T, Sasaki S, et al. An unusual reaction to cold: a sporadic case of familial polymorphous cold eruption? *Br J Dermatol.* 1998;139:504.
91. Lipke MM, Cutlan JE, Smith AC. Cold panniculitis: delayed onset in an adult. *Cutis.* 2015;95:21.
92. Garibyan L, Sipprell WH 3rd, Jalian HR, et al. Three-dimensional volumetric quantification of fat loss following cryolipolysis. *Lasers Surg Med.* 2014;46:75.
93. Requena L. Normal subcutaneous fat, necrosis of adipocytes and classification of the panniculitides. *Semin Cutan Med Surg.* 2007;26:66.
94. Quesada-Cortés A, Campos-Muñoz L, Díaz-Díaz RM, et al. Cold panniculitis. *Dermatol Clin.* 2008;26:485.

Chapter 99 :: Burns

:: Benjamin Levi & Stewart Wang

AT-A-GLANCE

- Burns are common in adults and kids; most are small and managed in the outpatient setting with dressing changes.
- Serious burns require inpatient care, ideally in a verified burn center.
- Large burns are managed in 4 general phases:
  - Initial evaluation and resuscitation.
  - Wound debridement and biologic closure.
  - Rehabilitation and reconstruction.
  - Long-term outcome quality tends to be very good in patients surviving large burns.

EPIDEMIOLOGY

In the year 2016, 486,000 patients in the United States received medical care for burns. In other words, 3 of every 3000 persons in the United States sustained a burn injury requiring medical attention.[1] Although the incidence of burn injury appears large, it has actually decreased by 60% since the early 1990s as the result of safety implementations, reduction in tobacco use and alcohol abuse, prevention education programs, change in home cooking practices, and decreased industrial employment.[2] Although some professions carry an increased risk of burn injury, the majority of burns occur at home. Males sustain the majority of burn injuries, and are twice as likely as females to require admission to a specialized burn center. Sadly, almost every 2.5 hours someone dies as a result of a fire, making the likelihood of fire-related death in the United States 1.5:1000.[1]

Of all United States patients receiving medical care for burns, only 5% to 10% are hospitalized for burn care, illustrating the tremendous role of outpatient care in the management of disease burden.[1,3] While not all of the other 90% to 95% patients receiving medical care for burns will require outpatient followup, of those who do, 30% will ultimately be admitted to the hospital for pain management or surgery (thus the importance of educating outpatient providers). Outpatient providers are most familiar with scald burns, as this is the most common mechanism of injury in the outpatient setting, whereas flame burns are the majority of inpatient burns.[4] Only 60% of hospitalized burn patients receive care at one of the 128 burn centers in the United States, which average about 200 patients per burn center each year. The organization of specialized, accredited burn centers has been arguably the most effective intervention in improving mortality of burn patients in the last half-century, with burn center survival rates now higher than 96%.[1,5]

Worldwide, burn injury poses a far more dramatic societal burden with much less optimistic outcomes. Yearly, 11 million people require treatment for burn injuries—more than the combined incidence of tuberculosis and HIV, and slightly less than the incidence of all combined malignant neoplasms—with 300,000 deaths annually. Socioeconomic disparities in treatment are vast, with 90% of all burn deaths sustained in low- to middle-income countries. Worldwide, injury is the cause of death in 1 in 10 persons, with burns as the fourth leading cause of injury-related death. For children who survive burn injury, 15% sustain long-term temporary disability, and 8% permanent disability—rates only superseded by near-drowning. In low- to middle-income countries, the prevalence of permanent disability attributable to burn injury is 12.5 times higher than in high-income countries. The aforementioned disparities likely arise from a mixture of inadequate safety measures, limited prevention outreach, lack of specialized burn centers, and deficiencies in training and resources necessary to provide impactful burn care.

CLINICAL FEATURES

Clinical manifestations of burn injury are determined by depth and breadth of tissue destruction (Table 99-1). Two independent systems of describing the depth of burn injury exist: that of "degrees" and of "thickness." Patients tend to be more familiar with the degrees system, whereas most medical and surgical providers will communicate using the thickness system. Both are interchangeable and should be used with awareness of one's audience.

SUPERFICIAL BURN (FIRST-DEGREE BURN)

Superficial burns involve only the epidermis. Like a sunburn, the skin is warm, erythematous, painful, blanching, and dry without blisters or eschar (Fig. 99-1). The epithelium remains intact, but will begin to slough within 7 to 14 days. They are self-limited and have no potential for scar.

PARTIAL-THICKNESS BURN (SECOND-DEGREE BURN)

Partial thickness burns involve the epidermis and penetrate to the dermis, but do not completely penetrate

TABLE 99-1
Clinical Manifestations of Burn Injury Are Determined by Depth and Breadth of Tissue Destruction

		FIRST-DEGREE BURN (SUPERFICIAL)	SECOND-DEGREE BURN (SUPERFICIAL PARTIAL THICKNESS)	SECOND-DEGREE BURN (DEEP PARTIAL THICKNESS)	THIRD-DEGREE BURN (FULL THICKNESS)
Clinical appearance		Painful, dry burn with no blisters or eschar formation, blanching	Exquisitely painful, wet, weeping burn, blanching	Less painful, pale, nonblanching	Insensate, dry, waxy, nonblanching with eschar formation
Epidermis		+	+	+	+
Dermis	Papillary	–	+	+	+
	Reticular	–	–	+	+
Subcutaneous tissue		–	–	–	+
Prognosis		Self-limited with sloughing within 7-14 days; no risk of scarring	Heals in 2 weeks with proper wound care; low risk of scarring	>3 weeks to heal; debridement and grafting may be necessary; high risk for scarring and pigmentary changes	Surgical excision with skin grafting necessary for healing; contractures, hypertrophic scars are common

through the dermis or down to the subcutaneous tissue. These burns appear wet, weeping, and erythematous, and are exquisitely painful, with blisters or sloughing epidermal remnant (Fig. 99-2). They are further divided into 2 categories:

- *Superficial partial thickness burn:* blanching, more painful, hyperemic and erythematous, typically heal in approximately 2 weeks with appropriate wound care, low risk of scar and pigment change. Involves epidermis and papillary dermis. These can be managed conservatively with dressing changes or xenograft.
- *Deep partial-thickness burn:* nonblanching, less painful, pink or pale, require more than 3 weeks to heal, high risk of hypertrophic scar and pigment change, outcomes may be improved by excision and grafting. Involves epidermis, papillary dermis, and reticular dermis. These typically require debridement and grafting.

Figure 99-1 Superficial burn to the right aspect of the neck, in this case superficial area largely on the perimeter of the burn. Blistering represents partial-thickness burn of central area.

FULL-THICKNESS BURN (THIRD-DEGREE BURN)

Full-thickness burns penetrate to the subcutaneous tissue and beyond, affecting all dermal layers. These burns are dry, leathery, waxy, nonblanching, insensate, and eschar is frequently shades of brown, white, gray, or black. The transition from adjacent partial-thickness

Figure 99-2 Partial-thickness burn of the left arm with blistering. Blisters are flaccid and contain serous fluid; burns of this degree are the most painful.

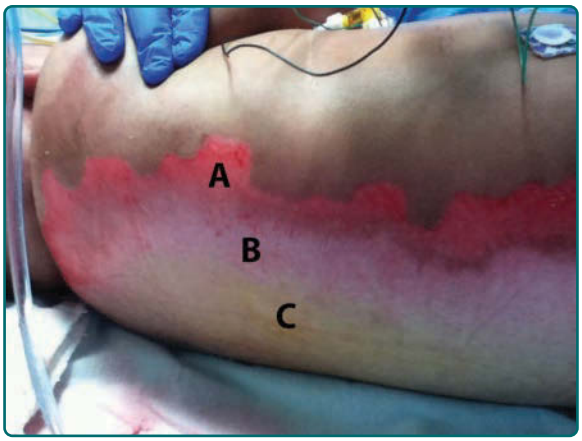

Figure 99-3 Full-thickness burn of the back demonstrating zones of injury according to Jackson's thermal wound theory. **A,** Zone of hyperemia (cells that will recover from injury); **B,** zone of stasis (cell injury that can either recover or transform into zone of coagulation); **C,** zone of coagulation (cell death).

burn is clear by the lack of tissue edema. They will not heal without surgical excision with skin grafting or tissue transposition. Sequela, such as contractures and hypertrophic scars, are common.[6,7] Of note, "fourth-degree burn" has been used to refer to burn injuries that penetrate to and/or expose deep structures (eg, bone, muscle, tendon) (Fig. 99-3). Skin grafting alone is not adequate treatment for burns of this severity, and limb loss may occur.[8]

Breadth of injury is described as a percentage of total body surface area (TBSA) that is affected; its measurement is addressed in section "Fluid Resuscitation". Damaged tissues in burn wounds are almost always heterogeneous. Characterization of different regions of burns also can be described as the zone of coagulation (cell death), zone of stasis (cell injury that can either recover or transform into zone of coagulation), or zone of hyperemia (cells that will recover from injury) (Fig. 99-4). Despite multiple classifications for burn depth, no objective measure of burn depth exists, leaving clinicians to rely on subjective assessments. Third-degree burns should be debrided within the first 3 to 5 days to avoid cellulitis and wound infections.

Figure 99-4 Fourth-degree burn of ankle with exposed tendon and muscle.

COMPLICATIONS

While it may appear that the sequelae of burn injury are limited to the integumentary system, there are many other systemic and local sequelae that must be considered when evaluating burn patients. Burns sustained in structural fires have a high incidence of smoke inhalation injury, wherein the pulmonary epithelium sustains direct thermal injury with ensuing edema and airway obstruction. Perioral burns and the presence of ashes and soot around or within the mouth and oropharynx are highly suspicious for inhalation injury and require emergent intervention to protect the airway. Carbon monoxide and cyanide toxicity are also associated with smoke inhalation injury, and the presence of inhalation injury alone doubles the mortality rate of burn injury.[9] Circumferential burns of the extremities are at risk for the development of compartment syndrome as the underlying tissues becomes increasingly swollen and edematous and constricted by the eschar. If untreated, pressures can cause nerve impingement and vascular compromise. In electrical injuries, the muscle tissues swell and become restricted by the overlying fascia at which point the fascia muscle be surgically released. Similarly, full-thickness burns of the trunk restrict and compromise respiratory function, particularly in children, necessitating escharotomy of the chest to improve ventilation. Finally, excess resuscitation can cause abdominal compartment syndrome, which is defined as bladder pressure over 30 mm Hg. Patients often present with oliguria and abdominal distension. In these patients, first steps include escharotomy of the abdominal full-thickness burns, as well as paralysis and laying the patient flat. Fluids should be immediately decreased and diuresis or continuous renal replacement therapy should be considered to avoid a decompressive laparotomy. If these noninvasive measures fail to relieve the abdominal compartment syndrome, then a laparotomy might be required.

Acute stress gastritis (Curling ulcer) with accompanying bleeding may develop in the gastric or duodenal mucosa as a result of intravascular volume depletion. Acute renal failure may occur following inadequate resuscitation or thermal injury to muscle as a consequence of massive myoglobinuria, particularly in electrical burns. Ectopic bone formation known as heterotopic ossification may develop in patients with large TBSA burns causing severe pain, contractures, and restricting range of motion.[10] This most commonly occurs in the elbow and is more frequent if the burn injury includes the upper extremity.[11-13] Burns induce a hypermetabolic state which is proportional to the size of burn injury, leading to muscle catabolism, hyperglycemia, and increased lipid liberalization with consequent steatosis. Finally, infection and sepsis are the most common cause of death in burn patients.[14]

ETIOLOGY AND PATHOGENESIS

BURN PATHOPHYSIOLOGY

The pathophysiology of burn injury can be appreciated by considering 2 paradigms: loss of skin organ function and production of an inflammatory response.

First, skin as an organ serves many functional purposes, not the least of which includes barrier protection against microbes, absorption and mitigation of mutagenic electromagnetic radiation, water and vapor impermeability, body thermoregulation, sensory perception, and motion-enabling elasticity balanced with sheer-resistant tensile strength. When skin is burned, these functions are lost. Microbe translocation into tissue or blood is unimpeded, leading to cellulitis, bacteremia, and sepsis. Unprotected from ultraviolet radiation, melanin-deficient burn scars are prone to squamous cell carcinoma development (eg, Marjolin ulcer). Loss of both the lamellar bodies of the stratum granulosum and the keratin-rich epidermal stratum lucidum and stratum corneum permits unregulated insensible vapor losses from transudates and interstitial fluid, causing intravascular volume depletion. Destruction of the dermal papillary plexus and eccrine sweat glands hinders autonomic hypothalamic regulation of body temperature and increased sensitivity to temperature fluctuations, especially in patients with high TBSA burns. Mechanoreceptor damage leads to long-term sensory loss, even in mild partial-thickness burns.[15] Destruction of native tissue elastin and migration and proliferation of fibroblasts in the wound site, with subsequent myofibroblast differentiation and deposition of irregular collagen bundles, produce function-limiting contractures and inelastic scar with only 80% tensile strength of native tissue.

Second, the inflammatory response to burn injury is profound and biphasic; an initial insult of inflammatory mediator release from necrotic tissue is followed by bacterial eschar invasion and establishment of a nidus. Local inflammatory response causes vasodilation and increased capillary permeability, promoting transudate production and insensible fluid losses. In burns greater than 20% TBSA, the initial insult from inflammatory mediator release triggers a systemic inflammatory response, manifesting as fever, hyperdynamic circulation, increased basal metabolic rate, and muscle catabolism.[7] Depending on the severity of insult, in some patients this state will persist for 1 or 2 years postburn.[16] Initially, burn wounds are sterile, but during the first week after injury, eschar becomes colonized and toxin exposure increases. In burns greater than 40% TBSA, bacterial load becomes so large that without intervention, sepsis and death are imminent. Beyond the colonization of the eschar, the excess dead tissue stimulates a massive inflammatory response which can lead to cardiovascular collapse.

FLAME BURN

Thermal injuries, caused by fire or flames, are the most common burn etiology reported over the past decade.[1] Thermal injuries are associated with the highest risk of death and complications compared to all other burn etiologies. Flame burns most commonly occur at home (64%), while work fires and recreational fire burns account for 12% and 6% of flame burns, respectively. When considering thermal injuries, it is important to consider smoke inhalation as it significantly impacts the morbidity and mortality of patients recovering from flame burns. The majority of inhalation injuries occur while the patient was indoors or in an enclosed space, and very few occur in patients who were burned while outside. Inhalation injury is present in 17% of patients with flame burns. The presence of smoke inhalation in burn patients is associated with an overall mortality rate of 24%, compared to the mortality rate of 4% in those patients without smoke inhalation damage.

SCALD BURN

Scalds are the second leading cause of burn injuries and are the most common mechanism of burns in the pediatric population. More than 50% of scalds are associated with food preparation or consumption, with a smaller proportion associated with bathing.[17,18] Common mechanisms, including pulling a tablecloth, reaching up and tipping a container near the edge of a counter, pulling electric cords attached to kitchen appliances, and carrying containers with hot liquids.[19,20] Contact burns from touching a hot object are extremely common in the pediatric population as well. Overall, contact burns make up 9% of burns reported, but they are the third leading cause of burns in children. Scald burns tend to cause a greater inflammatory response than flame burns.

ELECTRICAL BURN

Although only 4% of burns admitted to burn centers are caused by electricity, they pose the greatest diagnostic, therapeutic, and prognostic challenge among burn mechanisms. Notably, TBSA is an unreliable surrogate for burn severity, as it does not reflect the degree of internal tissue and organ damage caused after skin penetration by electrical current. To pass through dry human skin, a current must either surmount a huge amount of resistance, gain access to internal tissues through skin deficits such as cuts or burns, or induce skin breakdown (common above 500 volts [V]). Electrocution injuries are traditionally classified as low voltage (<1000 V) or high voltage (>1000 V), but ultimately it is the current (amperage) of the electricity and its direction of travel that ultimately determine ensuing tissue damage and lethality. For example,

only 20 milliamperes (mA) are required to paralyze respiratory muscles, and only 100 mA to induce ventricular fibrillation. Typical North American alternating current outlets have an average amperage of 15 to 20 amperes.[21] Although TBSA does not represent burn severity, duration of contact with electrical source is proportional to tissue destruction. During electric shock by alternating current, both flexor and extensor muscles are stimulated, but the strength of flexors is greater than that of extensors, causing the "no let-go" phenomenon, and increasing contact time and tissue destruction.

Primary electrical tissue injury is greatest in areas with the least cross-sectional area, such as digits, wrist, and toes. Burn injuries will often be present at the entrance and exit sites of the current, indicating a general path through the internal structures. For example, electrical shocks that cross the thorax are more likely to induce ventricular fibrillation, and limbs with entrance and exit sites are those at risk for compartment syndrome. Current will pass through highly conducting soft tissues, contact bone, and then continue along bone until exit. Bone has the greatest resistance of all body tissues, and therefore generates the most heat as current flows through it. Bone heating leads to severe thermal injury of deep invested muscles and tendon insertions which can cause swelling and compartment syndrome. All compartments between the entrance and exit wound should be monitored closely by examination and direct measurement of compartment pressures if concern for compartment syndrome exists. If compartment pressures are greater than 30 mm Hg, then fasciotomies should be performed. Massive myoglobinuria may result, necessitating renal protective fluid resuscitation. Damaged endothelium in major vessels leads to thrombosis. Cataracts may also develop. Apart from current flow, electrical burns are also caused by electrical arcs (temperatures upwards of 4000°C [7232°F]) and flame injury from ignited clothing. Secondary electrical injury can result from explosive shock waves generated by electric arcs, causing blunt trauma and tympanic membrane rupture. Long-term complications of high-voltage electrical injury also includes cataracts, and these patients should followup with ophthalmology as an outpatient. Lightning strike is exceedingly rare but can be catastrophic. Typically, patients who survive a lightning strike are at high risk for arrhythmias and compartment syndrome between the entry and exit points.[22]

CHEMICAL BURN

Slightly more than 3% of burn center admissions are chemical burns, and with equal proportions occurring at work and at home. According to the Centers for Disease Control and Prevention, carbon monoxide, ammonia, chlorine, hydrochloric acid, and sulfuric acid are the chemicals with the highest frequency of associated injury, although carbon monoxide is likely not directly burn related.[23] Important clinical categories of chemical burns include alkali, acid, hydrofluoric acid, phenol, and white phosphorous. Acids induce burn damage through binding of hydrogen ions to proteins, inducing coagulation. Alkali burns are typically deeper and more serious than acid burns, as hydroxide ion saponification of fats induces liquefactive necrosis and permits further depth of chemical penetration. Mortality from chemical injury is low, and treatment cost is small relative to other injury mechanisms.

Chemical burns are unique in that they will continue to progress after the initial insult until the offending agent is eliminated. Initiating immediate treatment in the field is associated with reduced injury severity and shorter hospital stay. Great care must be taken to protect health care personnel from exposure upon intake of patients, wherein clothing and accessories should be removed. It is advisable for solids or powders to be removed by brushes or dusting, as wetting with irrigation may provoke injuries in some cases (eg, calcium oxide, alkali metals). Otherwise, irrigation of the wound with copious amounts of water or saline should be initiated immediately. Attempts at neutralizing pH with a complementary chemical should not be undertaken, as heat from the consequent exothermic reaction can worsen the severity of the burn.[24] Management of certain chemical exposures, such as hydrofluoric acid, white phosphorous, and phenol, require specialized therapy, and toxicology should be consulted. Although chemicals should not be neutralized, certain chemicals require specific treatments. Hydrofluoric acid is toxic because of the fluoride ion that binds calcium, but can be neutralized with topical calcium gel (1 ampule of calcium gluconate in 100 g of lubricating jelly). If symptoms persist, you can consider intraarterial calcium infusion (10 mL calcium gluconate diluted in 80 mL of saline, infused over 4 hours) and/or subeschar injection of dilute (10%) calcium gluconate solution. Phenol is commonly used in disinfectants and chemical solvents with poor water solubility. Phenol causes protein disruption and denaturation that result in coagulation necrosis. Treatment of phenol exposure includes copious water irrigation and cleansing with 30% polyethylene glycol or ethyl alcohol.[22]

STEVENS-JOHNSON SYNDROME AND TOXIC EPIDERMAL NECROLYSIS

Given the expertise of burn teams taking care of large body surface area burns, patients with desquamating skin processes, such as Stevens-Johnson syndrome (SJS) and toxic epidermal necrolysis (TEN), are often transferred to the burn unit. These are acquired blistering disorders of cutaneous and mucosal surfaces that are differentiated only by the affected TBSA: SJS less than 20% often with mucosal involvement, and TEN greater than 40%. Through an unknown mechanism of presumed immunologic origin, the epidermal–dermal

junction begins to separate after starting new medications (particularly antiepileptic drugs or nonsteroidal antiinflammatory agents). The combined incidence of SJS and TEN in the United States is approximately 3800 per year, or 12 cases per million persons per year.[25] Diagnosis should be made by biopsy as analyzed by dermatology or a dermatopathologist. Steroids and IV immunoglobulin are controversial for SJS and TEN, and much of the burn literature does not support its use. Treatment is supportive and patients should have a robust airway assessment and should be flagged as "difficult airway" patients. Severe intraoral swelling may require intubation. If there is ocular involvement, ophthalmology should examine these patients and any vaginal mucosal involvement warrants evaluation by an obstetrician-gynecologist. For wound care, a nonadherent antimicrobial gauze such as Acticoat is preferred and mineral oil should be used on the skin to keep it from shearing off.

DIAGNOSIS

ASSESSING THE BURN

The initial care of a burn patient can be likened to that of any trauma patient. Over time, guidelines such as Advanced Trauma Life Support and Advanced Burn Life Support have standardized the care of trauma patients and have improved overall patient outcomes. Thus, given the extent of injuries that a burn patient may present with, it is important to follow a standard algorithm. A complete history and physical should be performed with specific focus placed on the cause and timing of the injury, concomitant injuries, and treatments received prior to arrival. The ultimate goal is to stabilize the patient and ensure a proper assessment of the burn so that further care can be transitioned to a burn center, if necessary.

AIRWAY ASSESSMENT

Assessment should begin with evaluation of the airway, breathing, and circulation. Inhalation injuries can occur in approximately 10% of all burn patients, but are notably present in 70% of those who eventually die of their burn.[26] Thus, it is important to specifically note such findings as soon as the patient presents with nasal passage or posterior pharynx blockage, facial burns, changes in voice quality, shortness of breath, and carbonaceous sputum in the nasal or oral passages. If there is any concern that the airway is compromised, a nasopharyngeal scope or bronchoscope can be used to directly visualize the airway. Some clinicians consider the use of these tools to be mandatory in any patient who presents with facial burns no matter the extent of the burn itself. Although patients may not present with obvious airway compromise by manifesting the symptoms as stated above, airway edema can progress very quickly making an intubation that would have been easily performed on initial presentation very difficult because of progressive swelling and obliteration of anatomic landmarks. Endotracheal intubation may be required for several days until edema subsides as the mucosal slough and secretions accumulate, obstructing the airway and atelectasis progresses. In these patients, frequent bronchoscopic suctioning should be performed until soot no longer exists. Although the data are inconclusive, most centers also recommend inhaled heparin-albuterol-Mucomyst to treat airway swelling and clots. Systemic steroids can be considered if there are no other burns outside of the inhalation injury. If inhalation injury progresses to acute respiratory distress syndrome, typical acute respiratory distress syndrome protocols should be followed, including lung-protective ventilation (keeping keep pressures less than 30 mm Hg) with permissive hypercapnia.

In some instances, identifying both the causative agent and the extent of the injury may aid in the recovery process. In particular, the possibility of carbon monoxide (CO) poisoning must also be assessed. Given the increased affinity of CO for hemoglobin molecules, oxygen ($O_{2)}$ becomes displaced which creates a hypoxic environment in the body. Formal diagnosis of CO poisoning is based on CO levels in the blood. Symptoms of CO poisoning typically begin with headaches at levels of approximately 10%, whereas CO in the blood becomes toxic at levels of approximately 50% to 70%. While the half-life of CO is normally 4 hours at room air, its half-life is shortened with treatment. It is recommended to treat CO poisoning empirically, especially in those patients presenting with agitation, reddish appearance of mucous membranes, and altered consciousness, given that delivery of 100% O_2 (fraction of inspired O_2 [FiO_2] 100%) reduces the half-life of CO to 30 to 90 minutes. In patients with toxic levels of CO in the blood, more extreme measures are necessary, including the use of hyperbaric O_2 at 2.5 atmospheres with 100% O_2. Hyperbaric O_2 will reduce the half-life of CO to 15 to 23 minutes. Consequently, prompt and aggressive evaluation and maintenance of the airway is the most important initial step in management of a burn patient. Finally, cyanide poisoning can cause severe complications and Cyanokit can be given in the field by paramedics as prophylaxis.

FLUID RESUSCITATION

After initial stabilization of the patient has been performed, the next step is to determine the extent of the burn injury. For superficial burns, treatment of the burn wound oftentimes requires both topical antimicrobial agents and corticosteroids to minimize inflammation.[27] Microorganisms proliferate rapidly in burn wounds, particularly in patients with impaired immune function caused by the burn. Topical antimicrobial agents delay the interval between injury and colonization and maintain low levels of wound flora. The specific

antibiotics and antiseptics for topical therapy in minor burns were discussed earlier in section "Wound Care". Antibiotics, however, should not be given unless signs of infection exist.

For full-thickness burns and some deep partial-thickness burns, identifying the extent of the burn injury is crucial. TBSA is used to design fluid administration regimens and defines overall prognosis of patients. Criteria for transfer to a burn center are also based on this concept.[28] Only partial-thickness and full-thickness burns are totaled to calculate TBSA. If small areas in various distributions are affected, it may be easier to use the patient as a ruler with one palm size representing 1% TBSA. Most emergency departments and burn units also have body surface charts available for use (the Lund & Browder Chart), but also follow the "rule of nines," wherein the body is partitioned into areas and each region constitutes 9% of the TBSA (Fig. 99-5). Regions on the adult that constitutes 9% of the TBSA include the head and arms, while the legs, anterior trunk, and posterior trunk account for 18% of TBSA each. In children, the arms each account for 9% of the TBSA, while the legs account for 14%. The head and neck region, the anterior trunk, and the posterior trunk each account for 18% in children. Careful estimation of TBSA is essential for proper early management of burn patients, as patients who have burns of more than 20% TBSA commonly require IV fluid resuscitation.

The Parkland Formula (Table 99-2; 4 mL × % TBSA × weight [kg]) is most commonly used to calculate fluid requirements within the first 24 hours.[29] It is extremely important to note that the original timing of the injury is what is used in the calculation, not the time of initial presentation. Half of this volume is administered in the first 8 hours after the injury and the second half is administered over the next 16 hours. For example, if a 70-kg (154-lb) patient with 10% TBSA burns sustained at 10 AM presents at 12 PM, the fluid to be administered in the first 8 hours is calculated using the following formula: [(4 mL × 10% × 70 kg)/2]/6 hours. Lactated Ringer solution is recommended to avoid complications associated with metabolic acidosis with normal saline or abnormal fluid shifts with colloid fluids.[29] Then, dextrose 5% in lactated Ringer solution is commonly used as maintenance fluids. Although such formulas exist, it is important to note that proper resuscitation is based on overall fluid status as represented by urine output, with the goal of 0.5 mL/kg/h in adults and 1 mL/kg/h in children, and fluids should

TABLE 99-2
Parkland Formula for Fluid Administration in the First 24 Hours

(4 mL × % TBSA × weight [kg])/2
= first half to be administered in the first 8 hours
= second half to be administered over the following 16 hours

TBSA, total body surface area.

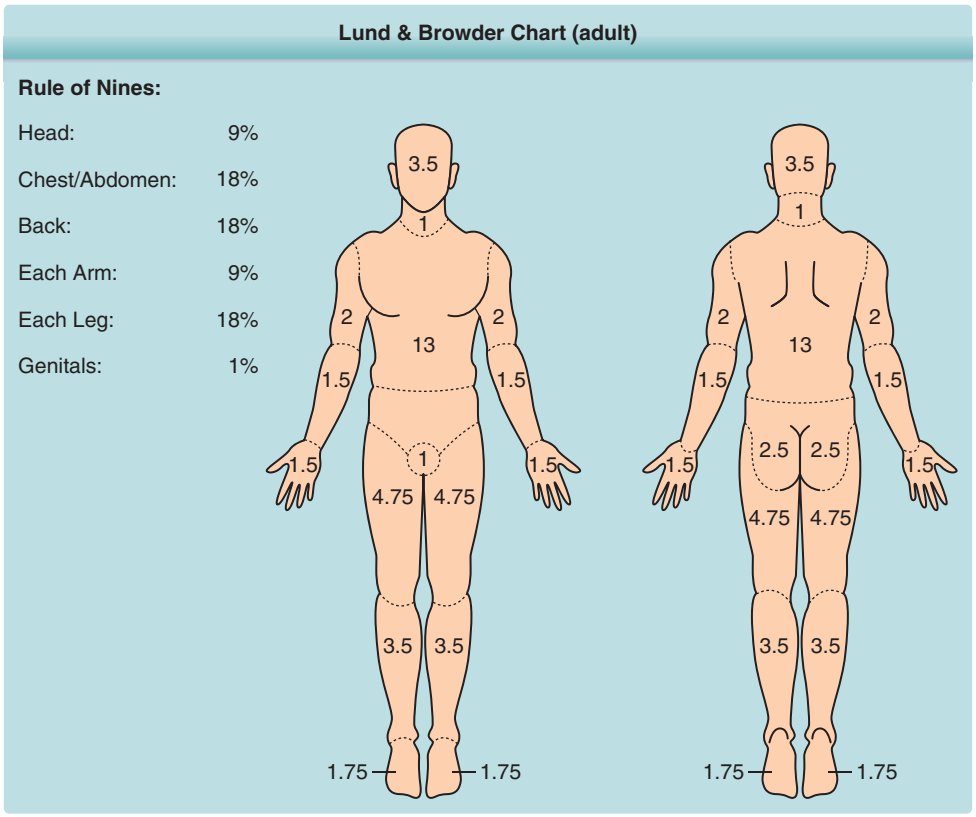

Figure 99-5 Rule of nines and the Lund & Browder Chart are methods commonly employed to estimate the total body surface area (TBSA) of a burn. Numbers in Lund & Browder Chart indicate percent TBSA of body region.

be adjusted accordingly. Given the immobility associated with severe burn injuries and the abnormal fluid shifts that occur, aggressive hydration also accounts for potential rhabdomyolysis, leading to acute kidney injury that can occur in this setting. Pulmonary status is also an indicator of fluid status but in more of a delayed fashion. Complications such as pulmonary edema result from fluid overload and necessitate daily evaluation of O_2 requirements and ventilator settings.

Once the Parkland Formula (see Table 99-2) is begun, the patient's vital signs and urine output should be closely monitored and laboratory studies should be drawn frequently. Fluids should be increased or decreased based on the response of the patient. Although the urine output is considered a "gold standard," early urine output can be slow while the patient is in shock and if tailoring fluids only to urine output, overresuscitation may occur. In addition, close monitoring of the patient's laboratories are necessary to determine the trend in organ perfusion. Laboratory values that might help assess organ perfusion include lactate, base deficit, central venous O_2, and/or pH. Although any one of these values alone does not provide a sensitive marker of the patient status, trending these values during resuscitation can help direct if the current fluid rate is causing a positive trend. If the organs are perfused, decreases in lactate and base deficit as well as increases in central venous O_2 and normalization of pH should be observed. Finally, a monitor of cardiac output during large resuscitations can help guide fluid and assess for early cardiac failure. Such cardiac output monitors include esophageal Doppler monitors, pulse pressure variation monitors (FloTrac) and thermodilution monitors (PiCCO).

In large burns that involve the face, an ophthalmologic consultation should be obtained. As the patient becomes edematous from the resuscitation, it is imperative that the globe is kept moisturized with a lubricant. Ophthalmologic consultants can help assess globe pressure, injury to the cornea and glaucoma, which often occur in electrical injury.

Thus, even though burn injuries may initially appear to be a focal area of trauma, the assessment of all systematic manifestations is paramount and must be stabilized before the burn itself is addressed.

WOUND CARE ASSESSMENT AND TREATMENT

As previously discussed, the depth, location, size, and duration of the burn injury are the most important factors to consider in the assessment of a burn. Burns can present for reconstruction in the acute or chronic phase, and reconstructive options are very different depending upon when a patient presents.

Acute burn injuries require prompt intervention and serial examinations. On initial evaluation, it is important to rule out and prevent the development of circumferential burns that can lead to tissue ischemia and subsequent necrosis by limiting perfusion to the distal tissues.[26] The overarching concept, however, in acute burn reconstruction is early debridement and grafting. All blisters and nonviable tissue must be debrided upon presentation. After the initial debridement, dressing changes are initiated while the patient is stabilized from a systemic standpoint.

There are a variety of options for dressing materials (Table 99-3), and the appearance of the burn is mainly what dictates this choice. Although the indications for systemic antibiotic therapy have not been clearly defined within the literature, use of antimicrobial dressings is recommended. Silvadene is a silver-containing cream that has broad-spectrum coverage against both Gram-negative and Gram-positive bacteria that needs to be changed on a daily basis. Although

TABLE 99-3
Wound Dressing Options

	INDICATIONS	MECHANISM OF ACTION	PRECAUTIONS
Silvadene	Partial- and full-thickness injuries	Broad-spectrum coverage vs Gram-positive and Gram-negative bacteria	Contraindicated in sulfa-allergic patients; avoid use near eyes Leukopenia known side effect
Sulfamylon	Burns over cartilaginous areas; for open burn wound therapy	Broad-spectrum coverage vs Gram-positive and Gram-negative bacteria	Associated with increased pain; risk for hyperchloremic metabolic acidosis; chronic use at risk for fungal infection
Silver nitrate	Soaking dressings, 2-4 times a day	Antifungal coverage	Hyponatremia Stains skin, adjacent surfaces
Bacitracin	Facial burns Dressings changed daily or every other day	Antibacterial	Daily dressing change required
Xeroform	Partial-thickness skin graft donor sites Dressings changed daily or every other day	Antibacterial	Daily dressing change required
Acticoat	Partial-thickness injuries with low risk for infection Dressings changed every 5 days	Antimicrobial silver impregnated dressings	

its use is contraindicated in patients with sulfa allergies and over wounds near the eyes, Silvadene is commonly used over both partial-thickness and full-thickness injuries.[30] Laboratory values, including complete blood counts, must be followed while patients are using this medication in the acute phase because of possible leukopenia, which is a known side effect of this medication. If leukopenia develops, Silvadene should be stopped; however, patients rarely develop any serious complications. Additionally, Gram-negative infections can cause leukopenia and should be ruled out if this arises. Sulfamylon is an analogous agent that is used over cartilaginous areas such as the nose or ear because of increased penetration of this dressing over these areas as compared to other dressing types. As topical Sulfamylon cream can be used without dressings, it can be used for open burn wound therapy and regular examination of the burn wound surface. However, both the cream and a 5% solution of Sulfamylon are equally effective.[31] Sulfamylon has better penetration than Silvadene but may also cause increased pain. Patients should be monitored for complications such as hyperchloremic metabolic acidosis that can occur with use of this dressing as a result of its mechanism of action. Finally, chronic Sulfamylon can lead to fungal infection given that it does not cover any fungal species. This can be avoided by mixing with amphotericin.

Silver nitrate also can be used by soaking dressings in 0.5% to 1% concentration and applied 3 to 4 times a day. Unlike Sulfamylon, silver nitrate does cover fungal species and thus may be preferable postoperatively if concern for infection exists. Typically, silver nitrate is applied as a soak to a dressing 2 to 3 times per day. It can cause leaching of cations causing hyponatremia. Additionally, it stains the skin as well as the floor and any equipment it comes in contact with.

Bacitracin and Xeroform are additional examples of antimicrobial-type dressing regimens and should be changed every day or every other day. Even though both can be used anywhere on the body, bacitracin is commonly used for facial burns, whereas Xeroform is often used for partial-thickness skin graft donor sites. Regardless of the type of dressing used, wounds should be examined daily, given the predisposition of this wound niche to become infected.

For patients who are at lower risk of infection based on the appearance of wounds, dressings may be changed with less frequency to achieve a balance between pain control and the need for wound coverage. Acticoat is one such option that is mainly used in partial-thickness injuries. This dressing consists of silver-impregnated sheets that have antimicrobial properties and can be changed less frequently, reducing pain and cutting cost and only needs to be changed every 5 days.[32] The nanocrystalline particles in Acticoat are able to reduce wound infection and promote wound healing compared to older silver products, including silver nitrate.[33] When using Acticoat, it is important to remember to activate it with water and not normal saline as the sodium can leech out the silver.

While dressing changes are sometimes used to nourish and optimize a wound before and after operative interventions, dressings also have the potential to completely heal a wound without the need for surgical intervention depending on the overall appearance of the burn and patient as a whole. Thus, a proper wound care team must not only include a critical care physician and surgeon, but it must also include a specialized wound care nurse to appropriately address this central modality of care for any burn patient.

MANAGEMENT

Table 99-4 outlines the essentials of burn management.

TRIAGE

Upon presentation for care, a primary and secondary trauma survey should be performed, with special attention paid to signs of airway involvement and injury. Examination should be performed looking for intraoral swelling, hoarse voice, soot or singed nasal hairs. Nasopharyngeal scope examination can be performed in the emergency department for confirmation of airway involvement. Early intubation is recommended for patients with severe airway involvement or patients with large TBSA burns (>20% deep partial or full thickness) that will require Parkland large fluid resuscitation. Large-bore IV access should also be obtained in nonburned regions and arterial access, central line access and Foley catheter should be established to help guide resuscitation. Access to a burn center is crucial to optimize outcomes given the intricacies of airway management and complex resuscitative strategies.

OUTPATIENT CARE

In outpatient setting or prior to transfer, the clinician must ensure the burn process has stopped by

TABLE 99-4
Essentials of Burn Management

- Burn location, size, extent, depth, and circumferential components influence decisions regarding outpatient care, hospitalization, or transfer.
- Burn percentage is best estimated using the Lund & Browder diagram that compensates for the changes in body proportions with age. An alternative is a "rule-of-nines" for adults and children.
- In the adult rule-of-nines, the head and neck is given 9%, each lower extremity is given 18%, each upper extremity is given 9%, and the anterior and posterior torso are each given 18%.
- In the pediatric rule-of-nines, the head and neck is given 18%, each lower extremity is given 15%, each upper extremity is given 10%, and the anterior and posterior torso are each given 16%.
- For scattered or irregular burns, the entire palmar surface of the patient's hand represents approximately 1% of the body surface over all ages.

removing all potentially hot or constricting items such as clothes, rings, or belts. Patient should also undergo decontamination and steps to ensure all chemicals are sufficiently diluted. Once at a burn center, the burns should be scrubbed with antimicrobial soap and subsequently wrapped in an antimicrobial dressing for transport. Practice patterns vary between centers but certain characteristics are universal. The wound should be kept clean and inspected for infection. Desiccated exudates and topical medications should be cleansed at least once daily. Burns selected for outpatient management are small and superficial with a corresponding low risk of infection, so clean rather than sterile technique is reasonable. If topical agents rather than membrane dressings are used, wounds may be cleansed with lukewarm tap water and a bland antimicrobial soap. Soaking adherent dressings prior to change will decrease the pain associated with daily wound care. It is important to instruct each patient to return promptly if erythema, swelling, increased tenderness, lymphangitis, odor, or drainage develops so that infectious complications can be addressed early. Pain and anxiety can be an issue for many. Some will benefit from pain medicine given 30 to 60 minutes prior to a planned dressing change. Increasing pain and anxiety associated with dressing changes; inability to keep scheduled followup appointments; delayed healing; signs of infection or a wound that appears deeper than appreciated at the time of the initial examination should prompt early return and specialty evaluation. Finally, wounds of the face, ears, hands, genitals, and feet have functional and cosmetic importance. Early specialty evaluation may be warranted, as initial care can have an impact on long-term outcome.

VACCINATION

A tetanus toxoid vaccine should be given to all burn patients with partial-thickness or full-thickness burns.[34] In very young children and persons with high-risk tetanus wounds (ie, burn older than 6 hours at presentation, immunodeficiency, or soil contamination in wound), tetanus immunoglobulin should also be administered (tetanus toxoid is not given in children younger than age 4 years).[35]

PAIN

Burn pain is multifactorial and frequently severe, particularly in patients with partial-thickness burns. As burn wounds heal, they initially become increasingly painful. Scheduled narcotics are first-line medications for the management of outpatient burn pain, and acetaminophen and nonsteroidal antiinflammatory drugs should play a secondary role in management. Scheduled dosing of narcotics provides superior pain control in burn patients as compared to as needed dosing, and allows for tapering down as the healing process progresses.

Despite this, some patients may have inadequate control on short-acting narcotics. In this case, the patient should be interrogated about the nature of their pain. Frequently, pain intolerance is associated with wound dressing changes, which often occur daily. Anticipatory administration of narcotics before dressing changes can improve pain. Silver-coated dressings require less-frequent dressing changes, and if available, may aid in pain management. Furthermore, anxiety or acute stress disorders associated with dressing changes exacerbates pain, and scheduled administration of low-dose anxiolytics may manage pain without increased narcotic dosages. Pulsing or throbbing pain accompanied by warmth at the wound site may be associated with inflammatory progression, and in this case nonsteroidal antiinflammatory drugs may be appropriate. Otherwise, therapy may be escalated to long-acting scheduled narcotics. If pain cannot be controlled at home, the patient should be admitted for pain management.[36,37]

INFECTION

The infection rate of burns managed in the outpatient setting is 5%, which increases to 11% to 15% in diabetic patients. Usually these infections develop in the first 7 to 10 days, and normal flora organisms, such as *Staphylococcus*, are usually the culprits. Wound culture or quantitative culture is not necessary, as these infections present as cellulitis and may be reliably diagnosed clinically, with good response to first-generation cephalosporins. Infections occurring after the first 10 days, however, are more likely caused by Gram-negative rods, and patients benefit from wound culture and empiric coverage with ciprofloxacin. If symptoms progress to a combination of fever, chills, weakness, nausea, and/or vomiting, inpatient admission should be considered. Although burn wound infection looms as a feared complication, antibiotic prophylaxis is not appropriate and evidence does not support its use.[36]

Patients should be instructed to measure temperatures once or twice daily, with a measurement above 38°C (100.4°F) warranting urgent clinical evaluation. The wound should be well dressed with limited exposure to the environment. An antimicrobial barrier at the burn site should be maintained through application of silver-impregnated dressings or antimicrobial creams and ointments. Patients should avoid swimming in rivers, lakes, oceans, and even hot-tubs in order to avoid possible exposure to more virulent bacteria such as *Pseudomonas*. Tissue edema creates a nidus for infection, a risk factor easily managed by extremity elevation or a compression wrap (eg, ACE bandage). Patients should be educated about signs of infection, and if black or gray spots develop on the healing wound they should present immediately for evaluation. If undergoing treatment

for infection, followup must be frequent (multiple visits weekly), and if hindered by provider availability, patient availability or travel, or suspected patient adherence, then admission for inpatient care may be appropriate.

PRURITUS

The majority of burn patients with both deep and superficial burns will experience clinically significant pruritus during their recovery. Regardless of severity, 90% of patients will experience pruritus during the first month after being burned. In 40% of patients, it will persist for at least 2 years, and roughly half of these chronic pruritus patients will experience consequent sleep disturbance. Risk factors for developing chronic pruritus include female gender, young age, skin grafting, raised or thick scars, and dry skin.[38]

The differentiation between transient and chronic postinjury pruritus can be understood by their distinguishable pathophysiologies. Mast cells produce and release histamine in response to the acute inflammatory burn reaction immediately following injury. As healing ensues, mast cell degranulation frequency decreases, and the majority of patients experience resolution. In full-thickness or grafted burns, however, afferent pathways have been destroyed, leading to general hypoesthesia. Despite this, such injuries predispose patients to the highest risk for chronic pruritus. Experts suggest that a neuropathic state of effective nociceptive hyperinnervation may develop in the setting of deafferentation because of release of selective neuropeptides from healing burn scar and degeneration of central inhibitory pathways regulating nociception.[39] Exact pathophysiologic mechanisms of chronic pruritus, however, remain unknown.

Evidence for treatment of burn pruritus is limited to 3 categories: topicals, antihistamines, and neuropathic agents. Selection of therapy generally follows aforementioned pathophysiologic reasoning. Nonetheless, the contribution of dry skin to pruritus should not be underestimated, and care should be taken for topical, bland, nonfragranced moisturizers to be applied to healed wound sites. Frequency of application is more important to achieve therapeutic effect than the product type, and patients should be advised to apply the moisturizer multiple times daily. When combined with antihistamines such as diphenhydramine, cetirizine, and hydroxyzine, early pruritus can be effectively managed. Cetirizine, a selective H_1-blocker, is more effective than general antihistamines such as diphenhydramine.[40] In patients with chronic pruritus, therapy with gabapentin and pregabalin is indicated—therapy that aligns with presumed neuropathic mechanisms. Similar to pain management, both antihistamines and neuropathic agents exhibit superior clinical benefits when doses are scheduled.[6]

SCAR

Thermal burn injures can cause tremendous morbidity, leaving the patient with not only cosmetic but also functional impairments. Hypertrophic scarring is a major complication after burn injury with a prevalence of 32% to 72%. Several risk factors have been identified that contribute to its development, including the localization of the burn injury, burn depth, time to heal, and skin color.[41,42] Although the precise mechanism by which hypertrophic scarring occurs remains unclear, strong and persistent expression of transforming growth factor-β and its receptors is associated with postburn hypertrophic scarring. Furthermore, a critical step in the healing process that is altered is the transition from granulation tissue into normal scarring. During this remodeling process, wound epithelization and scar collagen is formed, but accompany a gradual decrease in cellularity as a result of apoptosis. However, early immature hypertrophic scars caused by burns are hypercellular and during the process of remodeling and maturing, fibroblast density does not resemble that of normal healing.[43] More specifically, apoptosis of myofibroblasts occurs 12 days after injury in normal wound healing, but in hypertrophic scar tissue, the maximum apoptosis occurs much later—at 19 to 30 months.[44] These events result in a significantly higher percentage of myofibroblasts and the hypertrophy of the scar tissue following severe burn injuries.

Although hypertrophic scarring often cannot be avoided, there are several steps that can optimize a burn scar:

1. Wound closure of a burn that is likely not to heal on its own in 3 weeks;
2. Avoidance of sun contact of the scar during the first 6 months;
3. Compression garments for those who can tolerate treatment for up to 1 year; and
4. Keeping the scar moist.

One of the key pathologic factors that needs to be addressed in any hypertrophic scar is tension. A new concept of "scar rejuvenation" has emerged with the key idea being to improve the environment of the scar without actual excision of the scar. The most important step in rejuvenating the scar is release of the tension. Rather than excising, the scar, this involves just releasing the area of greatest tension. Despite not removing any tissue, a large defect is often created once the tension is released. This defect can then be treated by adding new tissue such as a full-thickness skin graft or a thick split-thickness skin graft. Additional ways to relieve tension involve the use of tissue rearrangements such as a Z-plasty. A Z-plasty lengthens the scar at the expense of width, thereby alleviating tension along the central access of the hypertrophic scar. In general, Z-plasty rearrangements are made with 60-degree angles to maximize tissue gain without causing excess tension on the donor-site closure. The corner can be made at 90 degrees and then the rest of

the limb at 60 degrees to improve blood flow to the tip of the flap and to avoid flap necrosis. Additionally, flaps should be kept thick to avoid flap ischemia. Alternative V-Y advancements are useful if there is healthy surrounding tissue and a combination of Z-plasty and V-Y advancement flaps, as in a 5-flap jumping man, are helpful for web spaces.[45]

Current treatment strategies for hypertrophic scars include surgical manipulation, intralesional corticosteroid injections, cryotherapy, and laser therapy. Surgical manipulation to remove the excess skin remains the traditional treatment for hypertrophic scar. Newer studies investigating the role of fat grafting into scars have shown promise to further improve function and appearance.[46] Patients who have undergone fat transfer report satisfactory results 6 months after the procedure, indicating considerable improvement in the features of the skin, skin texture, and thickness. Histologic examination demonstrated new collagen deposition, neovascularization, and dermal hyperplasia in regions treated with fat grafting, which mimicked surrounding undamaged skin. Additionally, intralesional corticosteroids suppress the inflammatory process in wounds, diminish collagen synthesis, and enhance collagen degradation.[47] Conversely, cryotherapy induces vascular damage that leads to anoxia and, ultimately, tissue necrosis, and has yielded marked improvement of hypertrophic scars.[48] However, its efficacy is limited to the management of small scars. Lastly, since the introduction of laser treatment in the mid-1980s, the therapeutic use of additional lasers with different wavelengths have been employed. The most encouraging results have been obtained with the 585-nm wavelength pulsed-dye laser, which has been recognized as an excellent therapeutic option for the treatment of younger hypertrophic scars.[49] Pulsed-dye laser induces the dissociation of disulfide bonds in collagen fibers and leads to collagen fiber realignment, decreased fibroblast proliferation, and neocollagenesis. However, it is necessary for repeated treatments, generally between 2 and 6 treatments, for optimal resolution.

Newer, exciting research has demonstrated the benefit of fractional photothermolysis in the treatment of hypertrophic scarring. Although the exact mechanism is unknown, this concept uses a CO_2 laser, which is an ablative laser that targets water in the underlying tissues (10,600 nm). The laser creates columns of tissue destruction, which stimulates collagen production in adjacent uninjured columns of tissue. The adjacent uninjured tissue allows for more rapid tissue regeneration from their follicles and sweat glands. Overall, this creates a smoother appearance and enables meshed grafts to appear less obvious.[10] Patients have described less tightness as well as decreased pruritus.[50] The key to this treatment modality is the fractionated nature of the laser, which allows for remodeling of the disorganized collagen without undue thermal injury to the surface. Different strategies are used for fractional CO_2 lasers with some clinicians preferring high density and low energy and others preferring low density and high energy.

ACKNOWLEDGMENTS

We would like to thank Dr. Joshua Peterson, MD for his assistance and guidance in figure and textual development of this chapter.

REFERENCES

1. American Burn Association. *Burn Incidence Fact Sheet: Burn Incidence and Treatment in the United States: 2016*. http://ameriburn.org/resources_factsheet.php. Accessed November 16, 2017.
2. Brigham P, McLoughlin E. Burn incidence and medical care use in the US: estimates, trends, and data souces. *J Burn Care Rehabil.* 1996;17(2):95-107.
3. Peck MD. Epidemiology of burns throughout the world. Part I: distribution and risk factors. *Burns.* 2011;37(7):1087-1100.
4. Kahn SA, Bell DE, Hutchins P, et al. Outpatient burn data: an untapped resource. *Burns.* 2013;39(7): 1351-1354.
5. Tompkins RG. Survival from burns in the new millennium: 70 years' experience from a single institution. *Ann Surg*. 2015;261(2):263-268.
6. Lloyd EC, Rodgers BC, Michener M, et al. Outpatient burns: prevention and care. *Am Fam Physician*. 2012; 85(1):25-32.
7. Grunwald TB, Garner WL. Acute burns. *Plast Reconstr Surg.* 2008;121(5):311e-319e.
8. U.S. Department of Health and Human Services, Radiation Emergency Medical Management. *Burn Triage and Treatment: Thermal Injuries—Diagnosis of Burns*. https://www.remm.nlm.gov/burns.htm#diagnosis. Accessed July 25, 2018.
9. Colohan SM. Predicting prognosis in thermal burns with associated inhalational injury: a systematic review of prognostic factors in adult burn victims. *J Burn Care Res.* 2010;31(4):529-539.
10. Agarwal S, Sorkin M, Levi B. Heterotopic ossification and hypertrophic scars. *Clin Plast Surg.* 2017;44(4):749-755.
11. Levi B, Jayakumar P, Giladi A, et al. Risk factors for the development of heterotopic ossification in seriously burned adults: a National Institute on Disability, Independent Living and Rehabilitation Research burn model system database analysis. *J Trauma Acute Care Surg.* 2015;79(5):870-876.
12. Ranganathan K, Loder S, Agarwal S, et al. Heterotopic ossification: basic-science principles and clinical correlates. *J Bone Joint Surg Am.* 2015;97(13):1101-1111.
13. Agarwal S, Loder S, Levi B. Heterotopic ossification following upper extremity injury. *Hand Clin.* 2017;33(2):363-373.
14. Williams FN, Herndon DN, Hawkins HK, et al. The leading causes of death after burn injury in a single pediatric burn center. *Crit Care.* 2009;13(6):R183.
15. Lim JY, Lum CH, Tan AJ, et al. Long term sensory function after minor partial thickness burn: a pilot study to determine if recovery is complete or incomplete. *Burns.* 2014;40(8):1538-1543.
16. Abu-Sittah GS, Sarhane KA, Dibo SA, et al. Cardiovascular dysfunction in burns: review of the literature. *Ann Burns Fire Disasters*. 2012;25(1):26-37.
17. Lowell G, Quinlan K, Gottlieb LJ. Preventing unintentional scald burns: moving beyond tap water. *Pediatrics.* 2008;122(4):799-804.

18. Rimmer RB, Weigand S, Foster KN, et al. Scald burns in young children—a review of Arizona Burn Center pediatric patients and a proposal for prevention in the Hispanic community. *J Burn Care Res.* 2008;29(4): 595-605.
19. Dissanaike S, Boshart K, Coleman A, et al. Cooking-related pediatric burns: risk factors and the role of differential cooling rates among commonly implicated substances. *J Burn Care Res.* 2009;30(4):593-598.
20. Drago DA. Kitchen scalds and thermal burns in children five years and younger. *Pediatrics.* 2005;115(1):10-16.
21. Fish RM, Geddes LA. Conduction of electrical current to and through the human body: a review. *Eplasty.* 2009;9:e44.
22. Friedstat J, Brown DA, Levi B. Chemical, electrical, and radiation injuries. *Clin Plast Surg.* 2017;44(3):657-669.
23. Orr MF, Wu J, Sloop SL; Centers for Disease Control and Prevention (CDC). Acute chemical incidents surveillance—Hazardous Substances Emergency Events Surveillance, nine states, 1999-2008. *MMWR Suppl.* 2015;64(2):1-9.
24. Palao R, Monge I, Ruiz M, et al. Chemical burns: pathophysiology and treatment. *Burns.* 2010;36(3): 295-304.
25. White ML, Chodosh J, Jang J, et al. Incidence of Stevens-Johnson syndrome and chemical burns to the eye. *Cornea.* 2015;34(12):1527-1533.
26. Bezuhly M, Fish JS. Acute burn care. *Plast Reconstr Surg.* 2012;130(2):349e-358e.
27. Posluszny JA, Conrad P, Halerz M, et al. Surgical burn wound infections and their clinical implications. *J Burn Care Res.* 2011;32(2):324-333.
28. Brown DL, Borschel GH, Levi B. *Michigan Manual of Plastic Surgery*. 2nd ed. Philadelphia, PA: Lippincott Williams & Wilkins; 2014.
29. Thorne CH, Chung KC, Gosain AK, et al, eds. *Grabb and Smith's Plastic Surgery.* 7th ed. Philadelphia, PA: Lippincott Williams & Wilkins; 2014.
30. Atiyeh BS, Costagliola M, Hayek SN, et al. Effect of silver on burn wound infection control and healing: review of the literature. *Burns.* 2007;33(2):139-148.
31. Falcone P, Harrison H, Sowemimo G, et al. Mafenide acetate concentrations and bacteriostasis in experimental burn wounds treated with a three-layered laminated famenide-saline dressing. *Ann Plast Surg.* 1980;5(4):226-229.
32. Fong J, Wood F. Nanocrystalline silver dressings in wound management: a review. *Int J Nanomedicine*. 2006;1(4):441-449.
33. Gravante G, Caruso R, Sorge R, et al. Nanocrystalline silver: a systematic review of randomized trials conducted on burned patients and an evidence-based assessment of potential advantages over older silver formulations. *Ann Plast Surg.* 2009;63(2):201-205.
34. Riddick-Grisham S, Deming L. *Pediatric Life Care Planning and Case Management*. 2nd ed. New York, NY: Routledge; 2011:993.
35. EMed. *Tetanus Prophylaxis*. http://www.emed.ie/Trauma/Wounds/Tetanus.php. Accessed July 25, 2018.
36. Warner PM, Coffee TL, Yowler CJ. Outpatient burn management. *Surg Clin North Am.* 2014;94(4):879-892.
37. Griggs C, Goverman J, Bittner EA, et al. Sedation and pain management in burn patients. *Clin Plast Surg.* 2017;44(3):535-540.
38. Carrougher GJ, Martinez EM, McMullen KS, et al. Pruritus in adult burn survivors. *J Burn Care Res.* 2013;34(1):94-101.
39. Goutos I. Neuropathic mechanisms in the pathophysiology of burns pruritus: redefining directions for therapy and research. *J Burn Care Res.* 2013;34(1):82-93.
40. Bell P, Gabriel V. Evidence based review for the treatment of post-burn pruritus. *J Burn Care Res.* 2009;30(1):55-61.
41. Lawrence JW, Mason ST, Schomer K, et al. Epidemiology and impact of scarring after burn injury. *J Burn Care Res.* 2012;33(1):136-146.
42. Gangemi EN, Gregori D, Berchialla P, et al. Epidemiology and risk factors for pathologic scarring after burn wounds. *Arch Facial Plast Surg.* 2008;10(2):93-102.
43. Nedelec B, Shankowsky H, Scott PG, et al. Myofibroblasts and apoptosis in human hypertrophic scars: the effect of interferon-α2b. *Surgery.* 2001; 130(5):798-808.
44. Armour A, Scott PG, Tredget EE. Cellular and molecular pathology of HTS: basis for treatment. *Wound Repair Regen.* 2007;15(s1):S6-S17.
45. Sorkin M, Cholok D, Levi B. Scar management of the burned hand. *Hand Clin.* 2017;33(2):305-315.
46. Parnell LK, Nedelec B, Rachelska G, et al. Assessment of pruritus characteristics and impact on burn survivors. *J Burn Care Res.* 2012;33(3):407-418.
47. Reish RG, Eriksson E. Scar treatments: preclinical and clinical studies. *J Am Coll Surg.* 2008;206(4):719-730.
48. Zouboulis CC, Blume U, Büttner P, et al. Outcomes of cryosurgery in keloids and hypertrophic scars. A prospective consecutive trial of case series. *Arch Dermatol.* 1993;129(9):1146-1151.
49. Alster TS, Handrick C. Laser treatment of hypertrophic scars, keloids, and striae. *Semin Cutan Med Surg.* 2000;19(4):287-292.
50. Manstein D, Herron GS, Sink RK, et al. Fractional photothermolysis: a new concept for cutaneous remodeling using microscopic patterns of thermal injury. *Lasers Surg Med.* 2004;34(5):426-438.

This page intentionally left blank

Psychosocial Skin Disease

PART 18

Chapter 100 :: Delusional, Obsessive-Compulsive, and Factitious Skin Diseases

:: Mio Nakamura, Josie Howard, & John Y. M. Koo

MORGELLONS PSYCHODERMATOLOGY

It is estimated that approximately one-third of patients seeking treatment of skin complaints have associated psychological stress or psychiatric disease.[1] The field of psychodermatology studies the overlap of psychology/psychiatry and dermatology.[2] Psychophysiologic skin disorders are primary skin diseases that can be precipitated or exacerbated by psychosocial stress, such as psoriasis, atopic dermatitis, and acne. Such skin diseases are also known to lead to and/or exacerbate psychiatric disorders such as anxiety and depression,[3-5] which are referred to as secondary psychiatric disorders. On the other hand, in primary psychiatric skin disorders, there is an underlying psychiatric component that causes self-induced physical findings on the skin.[6] Underlying psychiatric issues, such as anxiety, depression, obsessive-compulsive disorder (OCD), and psychosis, result in destructive manipulation of the skin, hair, or nails, often as an expression of highly dysregulated emotions.[7] Lastly, cutaneous sensory disorders are conditions in which the patient has various abnormal sensations on the skin, such as itching, burning, stinging, biting, and crawling, in the absence of any diagnosable dermatologic, neurologic, medical, or psychiatric diagnosis.[8] Table 100-1 shows the categorization of psychodermatologic disorders. Although these categories are extremely useful in conceptualizing psychodermatologic disorders, it is important to note that there can be considerable overlap or coexistence of these conditions. This chapter focuses on primary psychiatric skin disease, which broadly includes delusional, obsessive-compulsive, and factitious skin disorders (Table 100-2).

DELUSIONAL SKIN DISORDERS

AT-A-GLANCE

- Monosymptomatic hypochondriacal diseases are characterized by the presence of usually 1 fixed, false belief, which includes delusions of parasitosis, Morgellons disease, and other rare types of hypochondriacal delusional ideations.
- Secondary skin findings of excoriation and manipulation of the skin, hair, or nails are seen in delusions of parasitosis and Morgellons disease.
- Treatment and management are challenging as patients often have low to absent levels of insight and, consequently, are not open to psychiatric treatment or referral. Establishing rapport is key.
- Treatment of choice for delusions of parasitosis is pimozide, followed by atypical antipsychotics.

Delusional skin disorders are characterized by the presence of usually one fixed, false belief. Delusional patients by definition lack insight; consequently, they primarily seek care from a dermatologist rather than a psychiatrist. Delusional patients are among the most difficult cases to manage successfully as they can be distrusting and unaccepting of treatments and psychiatric referral, which makes it critical to establish therapeutic rapport with these patients.

TABLE 100-1
Psychodermatology: Categorization of Psychodermatologic Disorders[2]

PSYCHOPHYSIOLOGIC SKIN DISORDERS	PRIMARY PSYCHIATRIC SKIN DISORDERS	SECONDARY PSYCHIATRIC DISORDERS	CUTANEOUS SENSORY DISORDERS
▪ Psoriasis ▪ Atopic dermatitis ▪ Acne vulgaris ▪ Seborrheic dermatitis ▪ Hyperhidrosis ▪ Lichen simplex chronicus	Delusional disorders ▪ Delusions of parasitosis ▪ Morgellons disease Obsessive-compulsive and related disorders ▪ Body dysmorphic disorder ▪ Trichotillomania ▪ Excoriation disorder ▪ Other body-focused repetitive behavior disorders Factitious disorders ▪ Dermatitis artefacta	▪ Anxiety ▪ Depression ▪ Social phobia	▪ Cutaneous dysesthesia ▪ "Central" pruritus ▪ Formication

DELUSIONS OF PARASITOSIS (DELUSIONS OF INFESTATIONS, MORGELLONS DISEASE)

Delusions of parasitosis, also known as delusions of infestation, is a type of monosymptomatic hypochondriacal psychosis characterized by a false, fixed belief that one is infested with living organisms or inanimate materials in the absence of objective proof. Morgellons disease is a variant of delusions of parasitosis characterized by a fixed belief that there are fibers or solid material extruding from the skin.

CLINICAL FEATURES

Patients with delusions of parasitosis and Morgellons disease experience sensations of formication, including crawling, biting, and stinging, which they believe are symptoms caused by cutaneous infestation by parasites (parasitosis) or emergence of fibers from the skin (Morgellons disease). They may attempt to pick the "parasites" or "fibers" out of their skin. They frequently collect specimens they claim to have extracted from their skin, which may include scabs, skin flakes, hair, clothing fibers, and even real insects that actually have nothing to do with their symptoms. The specimens are brought in various containers, such as in an empty matchbox or Ziploc bags, which is referred to as the *matchbox sign, Ziploc sign,* or *specimen sign*.[9] In the age of the smartphone, it is also becoming increasingly common for patients to bring in what they believe to be photographic evidence of their infestation, often with an exhaustive photographic account of their skin and miscellaneous debris, which they interpret to be insects or fibers infiltrating their skin. Patients have often tried many courses of antiparasitic therapies such as permethrin and ivermectin. Many have had their homes exterminated, gotten rid of all of their belongings and pets, or moved out of their homes in an attempt to eradicate the parasites with only short-lasting relief or no improvement at all. A family member or friend may come in with the patient to confirm the patient's delusion. Physical examination often reveals evidence of self-mutilation, which can vary from minor excoriations to deep, gouged-out, irregular appearing ulcers. The skin lesions typically spare areas out of reach for the patients such as the interscapular region.

ETIOLOGY AND PATHOGENESIS

Delusions of parasitosis originates from a fixed, false belief that is encapsulated, meaning that the patient is otherwise seemingly "normal" aside from the delusion that they are infested by parasites. This is quite different from schizophrenia and other delusional disorders, which involve multiple functional defects, including auditory hallucinations, social isolation, flat or inappropriate affect, in addition to delusional ideation.

DIAGNOSIS

The diagnosis of delusions of parasitosis is a diagnosis of exclusion, meaning it cannot be diagnosed if the condition is better explained by a different disorder. It can only be made when the patient has an encapsulated delusion of infestation without presence of any organic cause. All other psychiatric disorders must also be ruled out prior to making the diagnosis of delusions of parasitosis. If the delusional ideation is part of a broader underlying psychosis such as schizophrenia or psychotic depression, then a separate diagnosis of delusions of parasitosis cannot be

TABLE 100-2
Primary Psychiatric Skin Disorders

	CHARACTERISTICS	UNDERLYING PSYCHOPATHOLOGY	DIFFERENTIAL DIAGNOSES	TREATMENTS
Delusions of parasitosis, Morgellons disease	▪ Formication (crawling, biting, stinging) attributed to infestation by parasites or fibers emerging from the skin ▪ Specimens collected and brought in ▪ Impervious to rational explanation ▪ Absent to low level of insight	▪ "Encapsulated" delusion of infestation (otherwise functional or "normal-appearing")	▪ Real infestations scabies, arthropod bites, etc. ▪ Endocrine: diabetes, thyroid disease ▪ Renal: uremia ▪ Nutritional deficiencies: vitamin B_1/B_{12}, niacin, folate, iron ▪ Neurologic: multiple sclerosis, neuropathy ▪ Infections: syphilis ▪ Drug use: cocaine, amphetamines, opiates ▪ Medication-induced: opioids, psychostimulants ▪ Psychiatric: schizophrenia, psychotic depression, psychosis with florid mania, and drug-induced psychosis	▪ Pimozide ▪ Atypical antipsychotics (eg, risperidone, aripiprazole, olanzapine)
Body dysmorphic disorder	▪ Preoccupation with an imagined or minor physical flaw ▪ Excessive time spent attempting to fix or conceal the "flaw" ▪ Significant distress and dysfunction ▪ None to low level of insight	▪ Obsession about a physical flaw ▪ Comorbid depression, anxiety, or OCD	▪ Concern about a real physical defect ▪ Anorexia nervosa ▪ Bulimia nervosa ▪ Primary psychiatric disease (depression anxiety, psychosis) ▪ Somatic delusion	▪ SSRIs ▪ CBT
Trichotillomania	▪ Repetitive action of hair-pulling ▪ Irregular, nonscarring alopecia with excoriations ▪ May acknowledge self-inflicted nature, relatively high level of insight	▪ OCD ▪ Comorbid anxiety, depression, psychosis	▪ Alopecia areata, androgenic alopecia, alopecia mucinosa ▪ Tinea capitis ▪ Lichen planopilaris ▪ Folliculitis decalvans ▪ Discoid lupus erythematosus	▪ SSRIs ▪ TCAs (eg, clomipramine) ▪ HRT
Neurotic excoriations	▪ Self-induced scratching, picking, or rubbing of the skin ▪ May acknowledge self-inflicted nature of skin lesions, relatively high level of insight and associated shame	▪ Psychosocial stressor ▪ Comorbid depression, anxiety, OCD, BPD, or psychosis	▪ Medical causes of pruritus: cutaneous dysesthesia, urticaria, uremia, hepatitis, xerosis, thyroid disease, etc ▪ Delusions of parasitosis ▪ Dermatitis artefacta ▪ Malingering	▪ Wound care ▪ SSRIs ▪ TCAs (eg, doxepin) ▪ HRT ▪ Psychotherapy
Dermatitis artefacta	▪ Self-induced injury using instruments (sharp objects, lighters, cigarettes, corrosive chemicals) ▪ Deny self-inflicted nature of skin lesions	▪ Psychosocial stressor ▪ History of physical, emotional, or sexual abuse ▪ Outlet of anger ▪ Comorbid depression, anxiety, OCD, or BPD	▪ Malingering ▪ Delusions of parasitosis ▪ Neurotic excoriation ▪ Psychiatric: OCD, depression, suicide, Munchausen syndrome ▪ Primary dermatologic diseases: pyoderma gangrenosum, collagen vascular diseases, vasculitis, arthropod bites	▪ Wound care ▪ SSRIs ▪ Antipsychotics ▪ Psychotherapy (including DBT)

BPD, borderline personality disorder; CBT, cognitive behavioral therapy; DBT, dialectical behavioral therapy; HRT, habit reversal therapy; OCD, obsessive-compulsive disorder; SSRI, selective serotonin reuptake inhibitor; TCA, tricyclic antidepressant.

made. The diagnosis can be made by history, physical examination, and appropriate laboratory testing or imaging to rule out other causes of the patient's symptoms and skin findings (see section "Differential Diagnosis"). Even though a biopsy is likely to be nondiagnostic, there is merit in using a biopsy as a means of providing further objective evidence against an infestation and to optimize trust and therapeutic rapport with the patient.

DIFFERENTIAL DIAGNOSIS

First, a real infestation with parasites, such as scabies, must be excluded.[10] Second, any organic causes

of symptoms of formication should be ruled out. Medical conditions associated with formication, pruritus, or paresthesia include endocrine disorders (diabetes mellitus, hyperthyroidism or hypothyroidism), renal disease (uremic pruritus), nutritional deficiencies (B_1, niacin, folic acid, B_{12}, iron), neurologic disorders (neuropathy, multiple sclerosis), and infections (syphilis). Laboratory tests, including comprehensive metabolic panel, thyroid function, serum vitamin levels, and ferritin level, can effectively rule out many of these medical etiologies. For cases in which there is suspicion of an underlying neurologic disease, a referral to a neurologist with appropriate workup, such as CT or MRI of the brain or spine, may be necessary. Infectious workup may be indicated in some cases. The patient's medication list should also be reviewed for pruritus-inducing medications such as opiates and stimulants. Third, recreational drug use must also be ruled out as substances such as cocaine, methamphetamine, and narcotics can cause formication. Therefore, a urine toxicology screen may be helpful.

Lastly, underlying, more global psychiatric diseases must be ruled out. The psychiatric differential diagnosis includes schizophrenia, psychotic depression, psychosis with florid mania, and drug-induced psychosis. In some patients, there is no ideation of infestation, in which case the patient has a diagnosis of simply "formication" rather than delusions of parasitosis.

CLINICAL COURSE, PROGNOSIS, AND MANAGEMENT

Early intervention is important in delusions of parasitosis, as patients with a shorter duration of active delusion have an increased probability of achieving remission following treatment.[11] On the other hand, when untreated, patients tend to further isolate themselves and subsequently progress into a more severe delusional state.[12,13]

Management of patients with delusions of parasitosis is challenging. Ultimately, the only therapy that consistently works is antipsychotic medications. However, when the patient presents to the dermatologist's office, it is highly likely that the patient has already been seen by other physicians and is disillusioned with the care received. This negativity is often projected to the new provider. Patients are often hesitant to start antipsychotic therapy and may not be willing to see a psychiatrist for the presumed skin disease. Therefore, it is extremely important to first establish rapport with the patient. Until rapport is established, interactions should be focused on support, empathy, and validation before the patient comes to trust the dermatologist, thereby making it possible to begin discussing therapeutic options. Furthermore, the desperation to be relieved from symptoms may override the need for validation; therefore, the patient may eventually be receptive to pharmacologic treatment.

The antipsychotic agent pimozide (Orap) is the most studied pharmacologic agent for the treatment of delusions of parasitosis. In a review of 53 patients with delusions of parasitosis who received pimozide, 50 (94%) achieved partial or complete remission from delusional symptoms.[14] It is believed that at low doses, the dopamine-blocking effects of pimozide address psychotic symptoms, while its opioid antagonism effects alleviate cutaneous sensations.[15] Notable adverse effects of pimozide include extrapyramidal symptoms such as akathisia (restlessness) and pseudoparkinsonian symptoms. Patients should be educated on these symptoms, which can be treated with as-needed diphenhydramine (Benadryl) or benztropine (Cogentin). Another adverse effect of pimozide is QT prolongation. Obtaining a baseline EKG and medical clearance is recommended in patients who are older or have a cardiac history.

Risperidone (Risperdal) is both the most-studied atypical antipsychotic agent for delusions of parasitosis and efficacious. In a study of 35 patients receiving risperidone, 24 (69%) achieved partial or complete remission.[16] Risperidone is less likely to induce extrapyramidal symptoms than pimozide, but is associated with other side effects, such as galactorrhea, and periodic monitoring of prolactin levels may be indicated. Other reportedly efficacious antipsychotic medications include olanzapine (Zyprexa) and aripiprazole (Abilify).[16,17] Adverse effects to be aware of include significant weight gain with olanzapine and akathisia or agitation with aripiprazole. Table 100-3 shows the dosing and common adverse effects of various antipsychotic medications that can be used to treat delusions of parasitosis. When the patient begins to experience the clinical benefit of an antipsychotic, adherence to the medication generally increases. Most patients can be treated on an episodic basis and can be tapered off of the antipsychotic after several months while maintaining remission. However, there are some patients who require long-term, low-dose maintenance treatment.

OTHER DELUSIONAL DISORDERS

Other types of monosymptomatic hypochondriacal diseases are uncommon and include olfactory reference syndrome or delusion of bromosis, a preoccupation with body odor that is not perceived by others, leading to the substantial distress and disability.[18]

TABLE 100-3

Summary of Psychopharmacologic Agents Used for the Management of Primary Psychodermatologic Conditions

		COMMON DERMATOLOGIC DOSAGE				
	CLASS	STARTING	TITRATION	MAXIMUM	ADVERSE REACTIONS	RECOMMENDED MONITORING
Pimozide (Orap)	Typical antipsychotic	0.5 mg/day	0.5-1 mg every 2-4 weeks	5 mg/day[a]	Sedation, arrhythmia (QT prolongation), orthostatic hypotension, seizure, EPS, NMS, leukopenia, neutropenia	EKG, potassium and magnesium levels
Risperidone (Risperdal)	Atypical antipsychotic	0.5 mg/day	0.5 mg every 2-4 weeks	4-6 mg/day	Sedation, QT prolongation, weight gain, hyperglycemia, galactorrhea, seizures, EPS, NMS, leukopenia	EKG, weight, fasting glucose, prolactin, CBC
Olanzapine (Zyprexa)	Atypical antipsychotic	2.5 mg/day	5 mg/day PRN	20 mg/day	Weight gain, diabetes, hyperglycemia, hyperlipidemia, galactorrhea, seizures, EPS, NMS, neutropenia, anemia	Weight, fasting glucose, lipids, prolactin, CBC
Aripiprazole (Abilify)	Atypical antipsychotic	2-5 mg/day	up to 5 mg/day qweek	30 mg/day	Akathisia, agitation, weight gain, headache, seizures, diabetes, hypertension, neutropenia	Weight, fasting glucose, CBC
Sertraline (Zoloft)	SSRI[c]	25 mg/day	25-50 mg/day qweek	200 mg/day	Nausea, diarrhea, dyspepsia, headache, sexual dysfunction, suicidality[b], hyponatremia	Clinical signs of suicidality
Paroxetine (Paxil)	SSRI[c]	20 mg/day	10 mg/day qweek	60 mg/day	Nausea, diarrhea, constipation, headache, dizziness, insomnia, sexual dysfunction, suicidality[b]	Clinical signs of suicidality
Fluoxetine (Prozac)	SSRI[c]	10 mg/day	Up to 80 mg/day	80 mg/day	Nausea, diarrhea, dyspepsia, headache, sexual dysfunction, suicidality[b], QT prolongation	Clinical signs of suicidality, EKG
Fluvoxamine (Luvox)	SSRI[c]	50 mg/day	50 mg/day q4-7 days	300 mg/day	Nausea, diarrhea, dyspepsia, headache, sexual dysfunction, suicidality[b], hyponatremia	Clinical signs of suicidality
Doxepin (Sinequan)	TCA	10 mg/day	q5-7 days up to lowest effective therapeutic dose	300 mg/day	Sedation, anticholinergic effects, QT prolongation, seizures, xerostomia, increased appetite, suicidality[b]	Clinical signs of suicidality, EKG
Clomipramine (Anafranil)	TCA	25 mg/day	25 mg/day q4-7 days	100 mg/day in first 2 weeks, 250 mg/day for maintenance tx	Headache, constipation, orthostatic hypotension, anticholinergic effects, QT prolongation, seizures, suicidality[b]	Clinical signs of suicidality, EKG, LFT

[a]This is the usual maximum, not the absolute maximum.

[b]The reported increased risk of suicidality appears situational and mostly in patients younger than 18 years of age.[53]

[c]Note that before starting an SSRI, underlying bipolar illness should be ruled out as SSRIs can unmask or precipitate a manic episode in bipolar patients. Signs of bipolar illness include periods of increased energy, risk-taking behaviors, and decreased need for sleep. Monitoring is recommended in high-risk or symptomatic patients.

CBC, complete blood count; EPS, extrapyramidal symptoms; LFT, liver function tests; NMS, neuroleptic malignant syndrome; SSRI, selective serotonin reuptake inhibitor; TCA, tricyclic antidepressant.

OBSESSIVE-COMPULSIVE AND RELATED DISORDERS

AT-A-GLANCE

- OCDs include intrusive, unwanted urges, often necessitating repetitive compulsive behaviors.
- Body dysmorphic disorder (BDD) is characterized by preoccupation with an imagined defect with excessive time spent attempting to conceal or fix the defect. Treatment of choice for BDD is high-dose selective serotonin reuptake inhibitors (SSRIs) and cognitive behavioral therapy (CBT).
- Hair pulling disorder is the repetitive action of pulling out hair, resulting in significant hair loss, which appears as nonscarring, patchy alopecia. The most effective treatment for this disorder is habit-reversal training (HRT). SSRIs can also be effective.
- Neurotic excoriations or psychogenic excoriations is a disorder characterized by self-induced cutaneous lesions resulting from the uncontrollable impulse to excessively pick, rub, or scratch normal skin or skin with minor surface irregularities. Treatment includes addressing the underlying psychiatric illness.

OCDs and related disorders are characterized by obsessive preoccupations and/or repetitive, compulsive behaviors. OCDs include intrusive thoughts or urges that are experienced as unwanted (obsession), often necessitating repetitive behaviors or rituals to help alleviate the otherwise intolerable anxiety (compulsion).[19] In the *Diagnostic and Statistical Manual of Mental Disorders*, 5th edition (DSM-5), the presence of either one or both obsessions and compulsions is necessary to make the diagnosis. OCDs and related skin disorders include body dysmorphic disorder (BDD), excoriations, and hair pulling disorder.

BODY DYSMORPHIC DISORDER

BDD is a somatoform disorder characterized by preoccupation with a nonexistent or minor physical flaw, estimated to affect 1.8% to 2.4% of the general population, which is likely an underestimate as patients with BDD often experience embarrassment and deliberately avoid confiding in the provider.[20,21] There is a slightly higher prevalence of this disease in women compared to men, and BDD can appear as early as childhood with a mean age of onset of 16 years old.[22]

CLINICAL FEATURES

Patients with BDD fixate on a specific aspect of their appearance that they find to be unattractive or "deformed." The face is commonly involved; however, body parts such as the hips, breasts, abdomen and buttocks can also be the focus of concern. Patients will present to a dermatologist or plastic surgeon with a complaint regarding the skin (wrinkles, scarring, color), hair (excessive facial or body hair, loss of hair), or part of the body (breasts, hips, abdomen, buttocks). While the alleged defects cause overwhelming anxiety and distress to the patient, the site of complaint is unremarkable in appearance to others, and thus the defect appears to be a perceptual distortion or imagined by the patient. The distress manifests as excessive time spent thinking about the defect and attempting to conceal it. Patients with BDD often perform repetitive behaviors such as mirror checking, excessive grooming, and skin picking. Seeking repeated reassurance, but receiving little to no relief from that reassurance, is also common.

ETIOLOGY AND PATHOGENESIS

The etiology of BDD is poorly understood. Some psychoanalysts believe that there may be an underlying emotional conflict that is reflected to a particular body part, as patients can have comorbid anxiety, depression, and OCD.[22] Others believe that the disease originates from social and cultural pressures to look a certain way.[23] Studies also show that patients with BDD may have neurochemical alterations responsible for visual processing in the frontostriatal system of the brain.[24]

DIAGNOSIS

BDD is diagnosed clinically and is a diagnosis of exclusion, meaning it cannot be diagnosed if the condition is better explained by a different disorder.

DIFFERENTIAL DIAGNOSES

In BDD, the defect of concern must not be a genuinely significant defect in appearance. Psychiatric differential diagnoses also include anorexia nervosa or bulimia nervosa if body weight is the concern.[25] Primary psychiatric conditions such as anxiety, depression, and psychosis may be the cause and must be ruled out prior to diagnosing BDD.

CLINICAL COURSE, PROGNOSIS, AND MANAGEMENT

Many patients with BDD seek cosmetic correction for their perceived physical flaws. Unfortunately, cosmetic intervention generally does not result in patient satisfaction. In a cross-sectional survey study of BDD, 81% of patients reported dissatisfaction with the outcome of the consultation or surgery.[26] It is possible for

a patient's delusional state to spontaneously lessen or even remit, as disordered thinking can fluctuate in severity. Therefore, it is best if unnecessary procedures are not performed in order to avoid a situation in which the patient is more dissatisfied following the intervention compared to before. High-dose selective serotonin reuptake inhibitors (SSRIs) (see Table 100-3) and cognitive behavioral therapy, alone and in combination, are 2 efficacious treatments in BDD.[27] The poor insight that is characteristic of BDD leads to poor adherence to the aforementioned interventions, making treatment and management, as well as psychiatric referral of these patients difficult.

HAIR PULLING DISORDER

Hair pulling disorder (formerly known as trichotillomania) is the repetitive action of pulling out hair, resulting in significant hair loss. Any region of the body with hair can be involved, with the scalp, eyebrows, and eyelashes comprising the most common sites. The reported prevalence of hair pulling disorder varies, with survey studies reporting prevalence rates ranging from 0.6% to 13.3%.[28,29] It is predominantly observed in females, with an early age of onset (averaging between 10.7 and 13 years).[30,31]

CLINICAL FEATURES

Patients with hair pulling disorder present with alopecia that is generally irregular and nonscarring. Broken, sparse hair on a background of excoriations is often observed. Hairs are broken at different lengths on the scalp (Fig. 100-1). Patients often endorse a history of hair pulling; however, some patients will not acknowledge the self-inflicted nature of their skin findings because of the profound shame that often accompanies the disorder. Furthermore, many sufferers engage in the behavior unconsciously at least part of the time, so they are not aware of their own contribution to the hair loss.

In rare cases, the patient may also eat the hair root (trichorhizophagia) as a secretive activity, and in even rarer cases the whole hair is eaten (trichophagia). It is possible to develop GI hairballs (trichobezoars), which have a high morbidity and can also be fatal. Children with hair pulling disorder who present with episodes of obscure abdominal pain, weight loss, nausea, vomiting, anorexia, and foul breath should be investigated for gastric trichobezoars, which may cause intestinal bleeding, pancreatitis, or obstructive symptoms.

Figure 100-1 Trichotillomania. This extensive alopecia resulted from pulling and plucking hairs by the 17-year-old patient. Hairs are broken at different lengths throughout the scalp. (From Wolff K, Johnson R, Saavedra AP, et al. *Fitzpatrick's Color Atlas and Synopsis of Clinical Dermatology*, 8th ed. New York, NY: McGraw-Hill; 2017, with permission.)

ETIOLOGY AND PATHOGENESIS

In DSM-5, hair pulling disorder is placed under the category of "obsessive compulsive disorder," which is a change from the previous editions of DSM where the condition was previously called trichotillomania and categorized under "impulse disorders." In hair pulling disorder, the patient's obsession can be characterized by building up of tension prior to pulling hair, and the compulsion is characterized by feeling of pleasure, relief, or gratification following hair removal. Many patients with hair pulling disorder have psychiatric comorbidities. In a recent, large, population-based study, psychiatric disorder was seen in 75.5% of patients presenting to a medical facility with diagnosis of hair pulling disorder, with depressive disorder being the most common comorbidity observed in approximately 40% of these patients.[32]

DIAGNOSIS

The diagnosis of hair pulling disorder can be made on a clinical basis with careful examination of the scalp. The use of dermoscopy can be useful to detect irregularly broken hairs, V-sign (2 or more hairs emerging from 1 follicular unit are broken at the same length), flame hairs (semitransparent, wavy, cone-shaped hair residues), hair powder (sprinkled hair residue), and coiled hairs.[33] Dermoscopy findings such as exclamation point hairs, which are rare in hair pulling disorder, can overlap with other causes of alopecia such as alopecia areata; consequently, a skin biopsy may be indicated in some cases. Hair pulling disorder presents histologically as an increased number of catagen hairs, traumatized hair bulbs in the absence of perifollicular inflammation (trichomalacia), empty follicles, follicular keratin debris, and melanin pigment casts.[34]

DIFFERENTIAL DIAGNOSIS

Dermatologic differential diagnoses include alopecia areata, androgenic alopecia, alopecia mucinosa, tinea

capitis, lichen planopilaris, folliculitis decalvans, syphilis-related alopecia, and discoid lupus erythematosus. Tinea capitis may be ruled out by the absence of scaling and negative fungal culture.

CLINICAL COURSE, PROGNOSIS, AND MANAGEMENT

Hair pulling disorder can cause significant social isolation and psychological disability, making treatment of this disorder important to restore the patient's quality of life. The most effective treatment is behavioral therapy, specifically habit reversal therapy. Habit reversal training is a form of behavioral therapy that focuses on 4 key aspects: awareness (increase awareness of hair-pulling behavior), competing response training (perform a specific action when there is an urge to pull hair), social support or contingency management (a person who reinforces the former), and stimulus control (minimize the influence of environmental factors on pulling behavior).[35] Children can benefit from behavioral therapy to prevent worsening of their disease into adulthood.[36] Habit reversal training does decrease repetitive, self-inflicted behaviors.[37]

Effective pharmacologic treatments involve treating the underlying psychiatric disease, and the first-line pharmaceutical approach depends on the nature of the involved underlying psychopathology. Frequently, these patients are treated with an antidepressant, such as tricyclic antidepressants (TCAs) or SSRIs (see Table 100-1). The TCA clomipramine (Anafranil), also indicated for OCD, is the most-studied medication for hair pulling disorder, and it reduces the frequency of hair-pulling urges.[38] SSRIs, such as sertraline (Zoloft), paroxetine (Paxil), and fluoxetine (Prozac), are also commonly used, although their effectiveness for the treatment of hair pulling disorder is unclear. The combination of pharmacotherapy and habit reversal training is effective in decreasing the frequency of hair pulling.[39,40]

NEUROTIC EXCORIATION

Neurotic excoriations, also called *psychogenic excoriations*,[2] is a disorder characterized by self-induced cutaneous lesions resulting from the uncontrollable impulse to excessively pick, rub, or scratch normal skin or skin with minor surface irregularities. Neurotic excoriations is estimated to occur in 2% of dermatology patients, although the disease is underreported.[41] The patient population is predominantly female, with the typical age of onset ranging from 15 to 45 years.[42]

CLINICAL FEATURES

Neurotic excoriations cause self-inflicted ulcers, abscesses, or scars that can ultimately become disfiguring (Figs. 100-2 and 100-3). There also may be atrophic, hyperpigmented or hypopigmented scars and lichenification, characteristics of older, healing lesions.

Figure 100-2 Neurotic excoriations: back. Excoriations of the upper and midback and linear areas of postinflammatory hyperpigmentation, crusting, and scarring in a 66-year-old female with diabetes. There is sparing in the interscapular region of the back. (From Wolff K, Johnson R, Saavedra AP, et al. *Fitzpatrick's Color Atlas and Synopsis of Clinical Dermatology,* 8th ed. New York, NY: McGraw-Hill; 2017, with permission.)

The skin lesions are distributed in accessible areas of the body such as the face, arms, legs, and upper back. The classic "butterfly sign," in which there are characteristic areas of sparing in the unreachable areas of the interscapular area, may be present. Patients with neurotic excoriations may openly acknowledge that the lesions are self-induced.

Figure 100-3 Neurotic excoriations/acne excoriee. Several erythematous and crusted macules and erosions on the lower cheek and upper lip of a 19-year-old female with mild facial acne. No primary lesions are seen. (From Wolff K, Johnson R, Saavedra AP, et al. *Fitzpatrick's Color Atlas and Synopsis of Clinical Dermatology,* 8th ed. New York, NY: McGraw-Hill; 2017, with permission.)

ETIOLOGY AND PATHOGENESIS

Although traditionally called "neurotic excoriation," the underlying psychopathology may not be neurosis but another underlying psychiatric illness such as depression, anxiety, OCD, or even psychosis. Psychiatric comorbidity, such as mood and anxiety disorders, is commonly observed in patients with neurotic excoriations, and the skin-picking behavior is a manifestation of the underlying psychopathology.[43] There may be triggers, such as stress or anxiety, or they may occur as a result of an unconscious tendency. Other important triggers are dermatologic in nature, such as mild to moderate acne, keratosis pilaris, pruritus, and even minor textural differences on the skin surface, which causes significant distress and subsequent manipulation of the skin. In these cases, there is a notable disconnect between the severity of the dermatologic manifestation and the level of distress, and it is important to address both the skin condition and the psychological impact.

DIAGNOSIS

A thorough history and physical examination, as well as appropriate laboratory tests should be performed as needed to rule out any potential medical or psychiatric causes.

DIFFERENTIAL DIAGNOSIS

Medical explanations for pruritus may be the underlying cause, trigger, or precipitant of excoriations. The differential diagnosis is broad and includes cutaneous dysesthesia, urticaria, uremia, hepatitis, xerosis, thyroid disease, and many other conditions that can cause pruritus without primary skin lesion. Cutaneous dysesthesia, abnormal sensations on the skin such as itching, burning, stinging, biting, and crawling, in the absence of any diagnosable dermatologic, neurologic, medical, or psychiatric diagnosis, can manifest as neurotic excoriations. The psychodermatologic differential diagnosis includes dermatitis artefacta, delusions of parasitosis, and malingering. It is important to note that there is often a concurrence of a dermatologic diagnosis as well as a psychiatric condition.

CLINICAL COURSE, PROGNOSIS, AND MANAGEMENT

Skin lesions in neurotic excoriations can be managed with topical treatment, such as topical corticosteroids or antipruritic agents, if there is underlying pruritus. The lesions should be evaluated for secondary infections and treated with topical or oral antibiotics if necessary.

When managing patients with neurotic excoriations, it is important to first assess psychosocial factors and the emotional well-being of the patient. If the patient has a comorbid psychiatric disorder such as anxiety, depression, OCD, or psychosis, it should be treated accordingly. Regardless of whether the psychiatric illness is considered to be the etiology for neurotic excoriations, it can exacerbate the tendency for skin picking. Patients with neurotic excoriations frequently acknowledge that they are self-inducing the lesions and have more insight compared to those with delusional disorders; consequently, patients may be more agreeable to pharmacologic intervention or a referral to a psychiatrist.

If referral to a psychiatrist is possible, patients may benefit from psychotherapy. If the patient is receptive to pharmacologic therapy, SSRIs such as paroxetine (Paxil), fluoxetine (Prozac), sertraline (Zoloft), and fluvoxamine (Luvox), are thought to decrease the compulsive tendencies frequently associated with this disorder (see Table 100-3).The TCA doxepin (Sinequan) is useful for neurotic excoriations because of its dual antipruritic and antianxiety effects. High-dose doxepin is particularly useful if the underlying psychopathology is major depression. With higher doses there is increasing risk of cardiac arrhythmia; therefore, a periodic EKG is recommended for elderly patients or any patient with a past history of cardiac dysrhythmia.

OTHER OBSESSIVE-COMPULSIVE AND RELATED DISORDERS

With the advent of DSM-5, a new diagnostic terminology of "body-focused repetitive behavior disorders" has been introduced. Body-focused repetitive behavior disorders are characterized by repetitive, damaging, and seemingly nonfunctional habits, such as hair pulling, skin picking, and nail biting, which cause significant distress and functional impairment.[44] Although neurotic excoriations and hair pulling disorder fall under this category of disorders, onychophagia (nail biting) and onychotillomania (nail picking) are also included. The treatment and management of these conditions are similar and focus on treating the underlying psychopathology.

Although rare, there are other forms of obsessive-compulsive skin disorders, such as hypochondriacal syndrome, whereby patients believe they are afflicted by a particular disease, infected, or contaminated. Fear of contamination and acquiring disease through physical contact may lead to compulsive handwashing rituals; as a result, these patients may present with physical findings typical of irritant hand dermatitis. Another hypochondriacal syndrome is AIDS phobia, which involves irrational fear of contracting the AIDS. Patients with AIDS phobia often seek dermatologic evaluation and multiple skin biopsies of every minor blemish to rule out Kaposi sarcoma.

FACTITIOUS DISORDERS

AT-A-GLANCE

- A psychodermatologic skin disorder characterized by self-inflicted injury to the skin, hair, or nails is called *dermatitis artefacta*.
- Secondary skin findings of abnormal-appearing lacerations, excoriations, ulcerations, scarring, and other injuries in reachable areas of the body are observed.
- Treatment is largely supportive including wound care, as well as treating the underlying psychiatric illness using both pharmacologic and nonpharmacologic interventions.

Factitious disorders are characterized by self-inflicted dermatologic lesions. The primary psychocutaneous disorder of dermatitis artefacta falls under this category of psychodermatologic disorders.

DERMATITIS ARTEFACTA

Dermatitis artefacta or factitial dermatitis is characterized by self-induced injury to the skin caused by instruments such as sharp objects, cigarettes, lighters, and corrosive materials. Although the incidence of this disease is difficult to assess, in a study evaluating 35 psychodermatology patients, nearly one-third were diagnosed with factitial dermatitis.[45] Female predominance is observed.

CLINICAL FEATURES

Patients with dermatitis artefacta generally deny that their skin injuries are self-inflicted. Furthermore, there is a "hollow history," meaning that the story of how the lesions came about is often vague and lacking in sufficient detail. Lesions, which have no recognizable characteristics of primary skin disease, are found on physically reachable areas of the body such as the face, upper trunk, and extremities. The appearance of the lesions depends upon the manner in which they are created, and can range from minor cuts to large areas of trauma, but is usually characterized by abnormally shaped superficial erosions with angulated borders surrounded by normal-looking skin.[46] Chemical or thermal burns, injection of foreign materials, circulatory occlusion, and tampering with old lesions, such as existing scars or prior surgical incision sites, are also some common methods of self-injury. More serious wounds can result in abscesses, gangrene, or even life-threatening infection.

ETIOLOGY AND PATHOGENESIS

Self-injurious behavior is often triggered by a psychosocial stressor and represents an outlet for expressing anger or satisfying internal emotional needs. The motive for creating the lesions can be a conscious or unconscious psychological need to seek attention or medical care as a result of childhood feelings of abandonment or neglect. Patients often report a history of physical, emotional, or sexual abuse. Recent studies suggest that a large proportion of patients with dermatitis artefacta may also have comorbid generalized anxiety, major depression, or borderline personality disorder.[47] In fact, self-injurious behavior such as cutting is part of the diagnostic criteria for borderline personality disorder.

DIAGNOSIS

Diagnosis is based on presenting clinical features. Skin biopsies are often nonspecific. If the self-inflicting injury is due to injection of foreign material into the skin, a foreign body reaction can be seen histologically.

DIFFERENTIAL DIAGNOSIS

First, it is imperative to rule out malingering as the etiology of the skin lesions. Malingering involves the conscious motivation of secondary gain, such as obtaining disability or insurance benefits. If malingering is suspected, the case is no longer considered psychiatric in nature; rather, it is considered a criminal act that may require legal actions. Once malingering is ruled out, dermatologic differential diagnoses include pyoderma gangrenosum, collagen vascular disorder, vasculitis, and arthropod bites.[48] Psychocutaneous differential diagnoses include delusions of parasitosis and neurotic excoriations. Primary psychiatric disease such as OCD, depression, and Munchausen syndrome should also be considered.

CLINICAL COURSE, PROGNOSIS, AND MANAGEMENT

The management of patients with dermatitis artefacta is generally supportive therapy, which includes both physical and emotional aspects. Treatment of the skin lesions should largely consist of wound care, such as irrigation, debridement, and topical or oral antibiotics, as needed. Covering the wounds with occlusive dressings may also help by discouraging the patient from further self-mutilation.

Emotional support should be provided, starting with avoiding confronting the patient's physical role in producing the lesions.[49] Rather, the focus should be placed on understanding the underlying psychiatric etiology of the self-harming behavior. Adjuvant psychiatric therapy should include both pharmacologic and nonpharmacologic interventions, depending on the nature of the underlying psychiatric illness

(see Table 100-3). High-dose SSRIs may be beneficial for patients with primary or secondary depression. SSRIs can also help to decrease underlying compulsive tendencies. As dopaminergic dysfunction is believed to contribute to self-injurious behavior, antipsychotic drugs such as pimozide and risperidone may decrease the self-induced injuries.[47] Newer atypical antipsychotics, such as olanzapine and aripiprazole, have also shown benefit in a small number of cases.[50,51] Patients with more-severe presentations or comorbid borderline personality disorder could benefit from intensive psychotherapy.[52] If borderline personality disorder is diagnosed (or suspected), there is a significant body of evidence supporting the use of dialectical behavioral therapy for treatment of the disorder. Dialectical behavioral therapy involves a specially trained team of mental health practitioners using a manualized therapy specifically designed to treat borderline personality disorder.

Most patients with dermatitis artefacta will have a chronic, waxing-and-waning course of disease. Regular visits, whether or not lesions are present, will help the patient feel cared for and diminish the need for self-mutilation as a "call for help." Thus, even when the condition is under control, the physician should still follow the patient at regular intervals to ensure that the self-destructive behavior does not relapse.

REFERENCES

1. Gupta MA. Commentary: psychodermatology. *Clin Dermatol*. 2013;31(1):1-2.
2. Koo J. Psychodermatology: a practical manual for clinicians. *Curr Probl Dermatol*. 1995;7:199-234.
3. Kurd SK, Troxel AB, Crits-Christoph P, et al. The risk of depression, anxiety, and suicidality in patients with psoriasis: a population-based cohort study. *Arch Dermatol*. 2010;146:891-895.
4. Halvorsen JA, Lien L, Dalgard F, et al. Suicidal ideation, mental health problems, and social function in adolescents with eczema: a population-based study. *J Invest Dermatol*. 2014;134:1847-1854.
5. Purvis D, Robinson E, Merry S, et al. Acne, anxiety, depression and suicide in teenagers: a cross-sectional survey of New Zealand secondary school students. *J Paediatr Child Health*. 2006;42:793-796.
6. Brown GE, Malakouti M, Sorenson E, et al. Psychodermatology. *Adv Psychosom Med*. 2015;34:123-134.
7. Gupta MA. Emotional regulation, dissociation, and the self-induced dermatoses: clinical features and implications for treatment with mood stabilizers. *Clin Dermatol*. 2013;31(1):110-117.
8. Koo J, Gambla C. Cutaneous sensory disorder. *Dermatol Clin*. 1996;14(3):497-502.
9. Freudenmann RW, Lepping P. Delusional infestation. *Clin Microbiol Rev*. 2009;22:690-732.
10. Heller MM, Wong JW, Lee ES, et al. Delusional infestations: clinical presentation, diagnosis and treatment. *Int J Dermatol*. 2013;52:775-783.
11. Trabert W. 100 Years of delusional parasitosis. Metaanalysis of 1,223 case reports. *Psychopathology*. 1995;28:238-246.
12. Reichenberg JS, Magid M, Jesser CA, et al. Patients labeled with delusions of parasitosis compose a heterogeneous group: a retrospective study from a referral center. *J Am Acad Dermatol*. 2013;68:41-46, 46.e1-46.e2.
13. Brown GE, Sorenson E, Malakouti M, et al. The spectrum of ideation in patients with symptoms of infestation: from overvalued ideas to the terminal delusional state. *J Clin Exp Dermatol Res*. 2015;5(6):1-2.
14. Lepping P, Russell I, Freudenmann RW. Antipsychotic treatment of primary delusional parasitosis: systematic review. *Br J Psychiatry*. 2007;191:198-205.
15. Heller MM, Koo JYM. *Contemporary Diagnosis and Management in Psychodermatology*. Newton, PA: Handbooks in Health Care; 2011.
16. Freudenmann RW, Lepping P. Second-generation antipsychotics in primary and secondary delusional parasitosis: outcome and efficacy. *J Clin Psychopharmacol*. 2008;28:500-508.
17. Ladizinski B, Busse KL, Bhutani T, et al. Aripiprazole as a viable alternative for treating delusions of parasitosis. *J Drugs Dermatol*. 2010;9(12):1531-1532.
18. Feunser JD, Phillips KA, Stein DJ. Olfactory reference syndrome: issues for DMS-V. *Depress Anxiety*. 2010;27(6):592-599.
19. American Psychiatric Association: Obsessive-compulsive and related disorders. In: *Diagnostic and Statistical Manual of Mental Disorders: DSM-5*. 5th ed. Washington, DC: American Psychiatric Association; 2013:235-264.
20. Koran LM, Abujaoude E, Large MD, et al. The prevalence of body dysmorphic disorder in the United States adult population. *CNS Spectr*. 2008;13:316-322.
21. Conroy M, Menard W, Fleming-Ives K, et al. Prevalence and clinical characteristics of body dysmorphic disorder in an adult inpatient setting. *Gen Hosp Psychiatry*. 2008;30:67-72.
22. Phillips KA, Menard W, Fay C, et al. Demographic characteristics, phenomenology, comorbidity, and family history in 200 individuals with body dysmorphic disorder. *Psychosomatics*. 2005;46:317-325.
23. Varma A, Rastogi R. Recognizing body dysmorphic disorders (dysmorphophobia). *J Cutan Aesthet Surg*. 2015;8(3):165-168.
24. Fuesner JD, Moody T, Hembacher E, et al. Abnormalities of visual processing and frontostriatal systems in body dysmorphic disorder. *Arch Gen Psychiatry*. 2010;67:197-205.
25. Phillips KA, Kaye WH. The relationship of body dysmorphic disorder and eating disorders to obsessive-compulsive disorder. *CNS Spectr*. 2007;12:347-358.
26. Veale D, Boocock A, Gournay K, et al. Body dysmorphic disorder. A survey of fifty cases. *Br J Psychiatry*. 1996;169:196-201.
27. Wilhelm S, Otto MW, Lohr B, et al. Cognitive behavior group therapy for body dysmorphic disorder: a case series. *Behav Res Ther*. 1999;37:71-75.
28. Christenson GA, Pyle RL, Mitchell JE. Estimated lifetime prevalence of trichotillomania in college students. *J Clin Psychiatry*. 1991;52:415-417.
29. Rothbaum BO, Shaw L, Morris R, et al. Prevalence of trichotillomania in a college freshman population. *J Clin Psychiatry*. 1993;54:72-73.
30. Cohen LJ, Stein DJ, Simeon D, et al. Clinical profile, comorbidity, and treatment history in 123 hair pullers: a survey study. *J Clin Psychiatry*. 1995;56:319-326.
31. Christenson GA, MacKenzie TB, Mitchell JE. Adult men and women with trichotillomania. A comparison of

male and female characteristics. *Psychosomatics*. 1994;35:142-149.
32. Gupta MA, Gupta AK, Knapp K. Trichotillomania: demographic and clinical features from a nationally representative US sample. *Skinmed*. 2015;13(6): 455-460.
33. Rakowska A, Slowinska M, Olszewska M, et al. New trichoscopy findings in trichotillomania: flame hairs, V-sign, hook hairs, hair powder, tulip hairs. *Acta Derm Venereol*. 2014;94(3):303-306.
34. Muller SA. Trichotillomania: a histopathological study in 66 patients. *J Am Acad Dermatol*. 1990;23:56-62.
35. Snorrason I, Berlin GS, Lee HJ. Optimizing psychological interventions for trichotillomania (hair-pulling disorder): an update on current empirical status. *Psychol Res Behav Manag*. 2015;7(8):105-113.
36. Franklin ME, Edson AL, Ledley DA, et al. Behavior therapy for pediatric trichotillomania: a randomized controlled trial. *J Am Acad Child Adolesc Psychiatry*. 2011;50(8):763-771.
37. Morris SH, Zickgraf HF, Dingfelder HE, et al. Habit reversal training in trichotillomania: guide for the clinician. *Expert Rev Neurother*. 2013;13:1069-1077.
38. Swedo SE, Leonard HL, Rapoport JL, et al. A double-blind comparison of clomipramine and desipramine in the treatment of trichotillomania (hair pulling). *N Engl J Med*. 1989;321:497-501.
39. Dougherty D. Single modality versus dual modality treatment for trichotillomania. *J Clin Psychiatry*. 2006; 67:1086-1092.
40. Walsh KH, McDougle CJ. Trichotillomania. Presentation, etiology, diagnosis and therapy. *Am J Clin Dermatol*. 2001;2:327-333.
41. Arnold LM, Auchenbach MB, McElroy SL. Psychogenic excoriation. Clinical features, proposed diagnostic criteria, epidemiology and approaches to treatment. *CNS Drugs*. 2001;15:351-359.
42. Wilhelm S, Keuthen NJ, Deckersbach T, et al. Self-injurious skin picking: clinical characteristics and comorbidity. *J Clin Psychiatry*. 1999;60:454-459.
43. Arnold LM, McElroy SL, Mutasim DF, et al. Characteristics of 34 adults with psychogenic excoriation. *J Clin Psychiatry*. 1998;59:509-514.
44. Roberts S, O'Connor K, Aardema F, et al. The impact of emotions on body-focused repetitive behaviors: evidence from a nontreatment-seeking sample. *J Behav Ther Exp Psychiatry*. 2015;46:189-197.
45. Sheppard NP, O'Loughlin S, Malone JP. Psychogenic skin disease: a review of 35 cases. *Br J Psychiatry*. 1986;149:636-643.
46. Gattu S, Rashid RM, Khachemoune A. Self-induced skin lesions: a review of dermatitis artefacta. *Cutis*. 2009;84:247-251.
47. Koblenzer CS. Dermatitis artefacta. Clinical features and approaches to treatment. *Am J Clin Dermatol*. 2000;1:47-55.
48. Koblenzer CS. Neurotic excoriations and dermatitis artefacta. *Dermatol Clin*. 1996;14:447-455.
49. Nielsen K, Jeppesen M, Simmelsgaard L, et al. Self-inflicted skin diseases. A retrospective analysis of 57 patients with dermatitis artefacta seen in a dermatology department. *Acta Derm Venereol*. 2005;85:512-515.
50. Garnis-Jones S, Collins S, Rosenthal D. Treatment of self-mutilation with olanzapine. *J Cutan Med Surg*. 2000;4:161-163.
51. Koblenzer CS. The current management of delusional parasitosis and dermatitis artefacta. *Skin Therapy Lett*. 2010;15:1-3.
52. Klobenzer CS. Psychosomatic concepts in dermatology. A dermatologist-psychoanalyst's viewpoint. *Arch Dermatol*. 1983;119:501-512.
53. Umetsu R, Abe J, Ueda N, et al. Association between selective serotonin reuptake inhibitor therapy and suicidality: analysis of U.S. Food and Drug Administration adverse event reporting system data. *Biol Pharm Bull*. 2015;38(11):1689-1699.

Chapter 101 :: Drug Abuse

:: Nicholas Frank, Cara Hennings, & Jami L. Miller

AT-A-GLANCE

- Drug use is a growing problem in the United States and around the world. There are many cutaneous findings that suggest use, abuse, and addiction to drugs.
- Specific findings in affected patients include dental caries, madarosis, presence of scarring, tattooing, and staining in the skin.
- Levamisole causes a unique syndrome characterized by retiform purpura of the ears associated with neutropenia, perinuclear antineutrophil cytoplasmic antibody and anti-MPO3 antibodies.
- Less-specific findings of drug use include morbilliform eruptions, vasculitis, and formation of autoantibodies.
- Drug-use–related infections predominantly affect the skin and soft tissues. Staphylococcal species are the most common organisms, followed by streptococcal species, oral pathogens, and *Candida*.
- Other sequelae of drug use include increased risk of infections including HIV, hepatitides B and C, and syphilis.

DEFINITION

The term *drug* is defined as a medication or other substance, other than food, that has a physiologic effect when ingested or otherwise introduced into the body. Modern society is rife with medications that affect function or structure in the body, caffeine being the most widely used psychoactive substance in the world. *Drug abuse* is defined as the recurrent use of illegal drugs, or the misuse of nonprescription or prescription drugs, that results in negative consequences. *Drug addiction* is characterized by physiologic dependence and inability to consistently abstain from the drug. Tobacco and alcohol, although not illegal in the United States and most of the western world, are also considered substances of addiction and abuse.

HISTORICAL PERSPECTIVE

Drugs have been used and abused for thousands of years and all over the world. Use in religious ceremonies, for healing, or by the general population for recreation has occurred since ancient times. There is evidence that opium has been used since 5000 BC and alcohol since 3500 BC. References to those and other medications are found in the Bible and other religious and historical texts. Columbus and his crew introduced tobacco into Europe when they returned from the New World.

EPIDEMIOLOGY

Based on estimates released in the United Nations Office of Drugs and Crime's (UNODC) *2015 World Drug Report*, 246 million people worldwide—1 of 20 people between 15 and 64 years of age—used an illicit drug in the year 2015, which corresponds to a global prevalence of 5.2%.[1] With the exception of caffeine, cannabis is the most widely used drug in the world, and its' use is increasing. Amphetamines are the second most commonly used drugs worldwide, and their use is also increasing. The use of cocaine was in decline for several years but it too is now on the rise. Opiates, particularly prescription opioids cause the highest negative health impact.

Approximately 29.5 million people suffer from drug dependancy world wide, with the highest prevalence of illicit drug use is among those 18 to 25 years of age (1 in 5 persons in this age group). Marijuana was used by 8.2% of the population, making it the most commonly used illicit drug; it is commonly referred to as the "gateway drug" because marijuana use often leads to using other drugs. Prescription pain relievers were the second most commonly used drug, followed in decreasing prevalence by sedatives, stimulants, cocaine, hallucinogens, inhalants, heroin, and sedatives. Approximately 66.9 million people were current tobacco users, a decrease over previous years. An estimated 139.7 million people were current alcohol drinkers (52.7%), including 60.9 million binge alcohol users and 16.3 million heavy alcohol users.

ETIOLOGY AND PATHOGENESIS

The biologic and environmental mechanisms by which an individual comes to abuse certain licit and illicit substances is complex and studies suggest varying levels of genetic and environmental influence. Even though the biochemical changes in the brain

that lead to drug abuse are intricate, dopaminergic neural pathways involved in motivation, reward, and habit formation play a central role in many neuropsychiatric conditions, including substance addiction.[2] Twin studies suggest that at least some component of drug abuse and dependence is driven by genetic preponderance. Environmental risk factors include easy access to the drug, poor school bonding, and peer use. Trauma, both physical and psychological, parental use and family conflict in the home are associated with use. Several protective factors also have been illustrated, including religiosity and strong family support, as well as social involvement in community organizations.[3]

DIAGNOSIS

Recognition of signs and symptoms associated with drug use is crucial and potentially lifesaving. Drug testing is the gold standard for diagnosis of most legal and illegal agents. Bodily fluids, including blood, urine, saliva, and hair can be used for drug detection. Suspected infections should be cultured by swab and, when necessary, tissue specimens. Serologic evaluation for transmissible infection, such as HIV, hepatitis, and sexually transmitted diseases, should be considered in appropriate patients.

CLINICAL FEATURES OF DRUG ABUSE (TABLE 101-1)

SIGNS OF INTRAVENOUS DRUG USE

TRACK MARKS

Track marks are the result of venous thrombosis with subsequent scarring (Fig. 101-1) and pigmentation of the veins (Fig. 101-2). Damage results from repeated injections, use of blunt needles, and irritation from chemicals that are added to the injected material. Early lesions show crusting and ecchymosis along the course of a vein; linear cords form with chronic use. The most common site is the medial vein in the antecubital fossa of the nondominant arm.[4] However, many people inject in less-visible places, such as the popliteal fossa, dorsal veins of the feet, and inguinal veins.[5] As these veins scar, intravenous drug users (IDUs) find other access points and will inject into hemorrhoids, the dorsal vein of the penis, the ventral surface of the tongue, or the internal jugular vein.[6] It is important to remember that a lack of track marks does not preclude IV drug use. Scarring is usually associated with a longer

TABLE 101-1
Cutaneous Signs of Drug Use

SIGN	MOST COMMON DRUG	SPECIFIC FINDINGS
Track marks Skin popping Soot tattoos	Cocaine Heroin	Scarring along veins and skin
Madarosis	Cocaine Heroin Methamphetamine	Loss of lateral eyebrows
Hand dermatitis, puffiness, or discoloration	Cocaine Heroin Inhalants Cannabis Tobacco	Erythema, fissuring, edema, or staining
Acne	Anabolic steroids MDMA (methylenedioxymethamphetamine) Methamphetamine Cannabis	Pustules and nodules May be severe
Vasculitis	Cocaine Levamisole Cannabis Tobacco	Cocaine—urticarial vasculitis, midline nasal destruction Levamisole—retiform purpura of ears and elsewhere associated with p-ANCA (perinuclear antineutrophil cytoplasmic antibody) and MPO (myeloperoxidase) Cannabis—cannabis arteritis and thromboangiitis obliterans Tobacco—thromboangiitis obliterans and peripheral vascular disease
Formication and/or pruritus	Methamphetamine and amphetamines Cocaine Heroin/opiates Alcohol	Excoriations Prurigo nodules Ulcerations

Figure 101-1 Track marks. Examples of track marks from intravenous drug use on the upper extremity.

duration of drug use[7] and cocaine does not normally induce track marks because it does not typically contain the sclerosing chemicals that are added to other drugs such as heroin.[8]

SCARS RESULTING FROM SKIN POPPING

Sometimes drug users inject intradermally or subcutaneously. This is done accidentally or when veins can no longer be found and used. Some prefer this method of delivery instead of injecting intravenously. This is called *skin popping*. It leaves irregular, leukodermic, atrophic, punched out scars that result from irreversible tissue injury. Hypertrophic scars or keloids can develop over these areas.[9]

PANNICULITIS

Inflammation of the dermis and subcutaneous fat may occur with injection into the skin itself or with extravasation of intended IV administration. Sclerosants, particularly pentazocine, and additives, such as talc, may induce subcutaneous nodules. A lobular panniculitis is often seen on histopathology and the injected material may leave spaces in the tissue after fixation or cause birefringence on tissue polarization.[10]

HYPERPIGMENTATION

Sooting tattoos are also stigmata of drug abuse. Sooting tattoos are caused by cooking the drugs and flaming the needles with matches. Carbon and soot then deposit into the dermis. Users may cover these with commercial tattoos so they are hidden. Hyperpigmentation can also develop at tourniquet sites when placed too tightly and left on for too long, causing inflammation and subsequent hyperpigmentation.[11]

Figure 101-2 Hyperpigmentation. Intravenous drug use–induced hyperpigmentation on the dorsal forearm and hand.

SKIN AND SOFT-TISSUE INFECTIONS

Skin and soft tissue infections (SSTIs) are very common among IDUs (Fig. 101-3). SSTIs are the most common disease for which users are usually admitted to the hospital.[12] Sepsis, rather than overdose, is the usual acute complication seen in this population.

The increased risk of SSTI in IDUs is multifactorial. Independent risk factors were found to be skin popping, the use of nonsterile needles, "speedball" (mixture of heroin and cocaine) injections, and "booting" (drawing back a small amount of blood usually into a dirty syringe prior to injection).[11] Skin popping has a fivefold greater risk of infection when compared to IV injection.[13] Infections associated with skin popping tend to be multilobulated, deeper, and have more extensive necrosis than those in non-IDUs.[8] Females also have an increased risk of SSTIs as compared to male IDUs, which is most likely a consequence of their less-prominent veins leading to more sticks to gain access.[14] Any type of immunocompromised state, such as AIDS, increases the risk of SSTIs. The local anesthetic properties of many illegal drugs can also make it difficult for users to feel the injury or realize they are developing an infection.

Many different pathogens are responsible for SSTIs in IDUs. Blood cultures are often negative in SSTIs, making it harder to identify the causative organism unless a culture can be performed of an abscess

Figure 101-3 Infection. Sequelae following soft-tissue infection as a result of intravenous drug abuse.

or ulceration. One pathogen is cultured in 50% of the cases, and more than 1 is found in 33% to 45% of cases.

The etiologic organism(s) in most SSTIs appear to be from the skin or oral cavity of the user rather than from the drug or paraphernalia used.[15] This correlates with other studies demonstrating *Staphylococcus* species (particularly *Staphylococcus aureus*) as the most frequently cultured organism, followed by group A β-hemolytic *Streptococcus* and other streptococcal species and then oral or skin pathogens.[16,17] Oral pathogens, including *Eikenella corrodens*, are also a cause of infection, as IDUs sometimes "clean" their needle or skin prior to injection with their saliva. Drug dealers have also hidden drug containers in their mouths, which was the source of an outbreak of a clonal strain of *Streptococcus pyogenes*.[18] Gram-negative bacteria and anaerobes also may be a cause of infection and the classic signs of anaerobic infections, such as free air bubbles on radiograph or foul smell, may not be present.

There have been numerous reports of SSTIs caused by uncommon pathogens. Quinine, which is usually added to heroin, increases the risk of tetanus.[19] *Clostridium botulinum* and *Clostridium tetani* are unusual organisms except in IDUs who skin pop. Wound botulism most commonly occurs from injection of black tar heroin, which is cut with dirt and is ideal for the growth of botulism because of its high water content. Heating the drug prior to injection actually stimulates the spores to germinate. Wound botulism in IDUs can present with symptoms of blurred vision, diplopia, and ptosis without any mental status changes. The patient may or may not have a visible cellulitis and may only present with pain, swelling, and tenderness. Approximately 85% of the cases of wound botulism at the time of presentation had wounds that were grossly infected and 65% had *C. botulinum* isolated from the wound. The diagnostic test of choice is detecting the toxin by standard mouse bioassay of the serum. Treatment includes the antitoxin and high-dose penicillin along with surgical debridement.[20] Other *Clostridium* species, including *Clostridium novyi*, *Clostridium perfringens*, *Clostridium sordellii*, and *Clostridium histolyticum*, have been reported to be the cause of serious illness or deaths among IDUs.

Necrotizing fasciitis (Fig. 101-4) is also common among IDUs. Chen et al reported 55% cases were in IDUs. IDUs with necrotizing fasciitis most commonly present with severe pain disproportionate to the examination (94%) or an abnormal temperature (88%).[21,22] They may show the classic findings of hemorrhagic bullae, systemic toxicity, or palpable crepitans. The pain complaints may be mistaken as a "drug-seeking" behavior, which could be deadly. Surgical exploration needs to be done in IDUs with cellulitis and unexplained severe pain.[23]

Fungal infections, including dermatophytes, are commonly seen in IDUs. Disseminated candidiasis has been reported among IV heroin users who used lemon juice to dissolve the heroin. The lemon juice was contaminated with *Candida albicans* and the patients developed high fevers, myalgias, and

Figure 101-4 Necrotizing fasciitis. Photographic depiction of necrotizing fasciitis following intravenous drug use.

headaches with negative blood cultures. Painful nodules later developed on the scalp which resolved with alopecia. They also had ocular disease (*Candida endophthalmitis*), pleuritis, and costochondritis. It has been suggested that physicians should specifically ask IDUs who present with cutaneous, ophthalmologic and osteoarticular disease about a history of using lemon juice. Aspergillosis and zygomycosis also have been reported among IDUs.

In addition to SSTIs, IDUs may present with pseudoaneurysms, which may be mistaken for a cutaneous abscess, especially when they present as a nonpulsatile inflammatory mass. These usually manifest as a pulsatile mass located in the area of major arteries. They can develop if an IDU injects accidentally or purposefully into an artery. Gangrene can also develop after intraarterial injection and present as swelling cyanosis, and extreme pain.

CUTANEOUS SIGNS OF ENDOCARDITIS

A link between endocarditis and IDU has long been established. Cutaneous signs include Janeway lesions and Osler nodes. Chapter 155 provides a more detailed discussion of the link between endocarditis and IDU.

SIGNS OF INHALANT ABUSE

Euphoria and delirium can be achieved through the use of inhalants; adolescents are the most common population to abuse them. Inhalants represent a diverse group of readily vaporized chemical compounds with variable properties and have a wide range of potential clinical consequences. Common inhalants of abuse can be subdivided into 3 groups defined as: volatile solvents, fuels, and anesthetics; nitrous oxide; and volatile alkyl nitrites. These compounds can be found in readily available household products such as paint thinner, glues, lighter fluid, spray paint, and nail polish remover.[24] Inhaling these products from their original container through the nose ("sniffing"), a soaked rag ("huffing"), or a bag ("bagging") can lead to myriad clinical presentations resulting from mucous membrane irritation: rhinorrhea, epistaxis, sneezing, coughing, excess salivation, conjunctival injection, dyspnea, and wheezing, as well as dermatitic eruptions in the perioral and/or perinasal distribution. One specific condition that has been described includes "huffer's rash," which is perioral or perinasal dermatitis with pyoderma. Frostbite on the face or oral/nasal cavity can be seen following inhalation of refrigerants or coolants (eg, chlorofluorohydrocarbon propellants in computer duster spray).[25] A helpful clinical clue to inhalant-induced hand and/or face dermatitis is the appearance of a yellow crust when it is caused by nitrites.

SPECIFIC ILLEGAL DRUGS AND ADDITIVES

COCAINE (ALSO KNOWN AS "COKE," "C," "SNOW," "FLAKE," OR "BLOW")

Cocaine is a sympathomimetic that creates feelings of euphoria and causes tachycardia, altered mental status, hypertension, and mydriasis. It is extracted and refined from the *Erythroxylum coca* plant leaves in the form of a coca paste. The paste is then treated with numerous chemicals to purify it into a water-soluble cocaine hydrochloride powder that is close to 100% pure. By the time the user buys it, the street dealer has generally diluted it with inert or active substances. Cocaine sold on the streets is a fine, bitter, white, crystalline powder that can be injected, inhaled as a powder, or ingested orally, but cannot be smoked. The free base form, also called *crack*, is processed with ammonia or sodium bicarbonate (baking soda) and water, and then heated to produce a smokable substance. The feelings of euphoria are more intense when inhaled and thus crack is more addictive. Smoking crack stimulates the user in seconds as opposed to snorting cocaine, which takes approximately 15 minutes.

There are many cutaneous signs of cocaine abuse, including halitosis, frequent lip smacking, cuts and burns on the lips from broken or chipped crack pipes, madarosis (lateral loss of the eyebrow) from the hot steam rising from the crack pipe,[26] palmar and digital hyperkeratosis from holding the hot crack pipe,[27] and midline destructive lesions of the nasal septum which result from snorting the cocaine.[8] "Snorter's warts" are nasal verrucae that can develop in cocaine abusers. They are caused by the human papillomavirus transmitted on items such as dollar bills that are used to snort the cocaine. The dollars bills are passed from person to person transmitting the human papillomavirus infection.[28]

Many types of vasculitis have been described in cocaine abusers, including urticarial vasculitis,[29] Churg-Strauss vasculitis,[30] necrotizing granulomatous vasculitis,[31] palpable purpura, and Buerger disease.[32-34] Cocaine-induced midline destructive lesions may cause aggressive nasal deformity that can sometimes be misdiagnosed as Wegener granulomatosis.[35] The cause is thought to be vascular ischemia and inflammation. Anti–human neutrophil elastase antibodies are also found in most patients with cocaine-induced midline-destructive lesions.[36]

Drug eruptions also have been documented, including acute generalized exanthematous pustulosis and Stevens-Johnson syndrome.[37,38] Cocaine also has been reported to unmask or cause scleroderma[39,40] and has been implicated in the development of Raynaud phenomenon.

Cocaine abuse can cause formication, a tactile hallucination of insects crawling underneath the skin, which leads to delusions of parasitosis and/or neurotic excoriations. Cocaine abuse should be suspected

in a patient who develops these symptoms, especially if the patient has a vague medical history, labile affect, and delusional behavior.[9,41]

Levamisole: Levamisole has been discovered as a common adulterant added to cocaine. Unlike other cutting agents, levamisole is added at the onset of manufacturing in the countries of origin and is readily available and inexpensive. Levamisole adds bulk and weight to the cocaine and goes unnoticed by cocaine users because it has a similar appearance, taste, and melting point as pure cocaine. It also has its own stimulant effects and enhances the euphoric effects of cocaine.

Levamisole was used in humans as treatment of colon cancer, nephritic syndrome, and rheumatoid arthritis because of its immunomodulating effects, but it was withdrawn from the market in 2000 because of neutropenia, agranulocytosis, and vasculitis. Currently, it can only be used in veterinary medicine as an antihelminthic medication.

Side effects of levamisole-adulterated cocaine are widely reported. Most specific is ***l****evamisole-****i****nduced* ***ne****crosis* ***s****yndrome* (**LINES**), which should be considered in patients who present with a distinctive retiform purpura on the ears (Fig. 101-5) with or without lesions elsewhere (particularly on the nose, cheeks, and extremities); the retiform purpura may also present with hemorrhagic bullae or ulceration. This is usually associated with leukopenia (especially neutropenia) and high titers of perinuclear antineutrophil antibodies and anti-myeloperoxidase antibodies, which are present in more than 70% of cases. Other testing that suggests LINES includes presence of cytoplasmic antineutrophil antibodies and anti–proteinase-3 antibodies, which are present in approximately 50% of cases. Other serologic studies may be positive for antinuclear antibodies, antiphospholipid antibodies, and the lupus anticoagulant. Biopsy specimens show leukocytoclastic vasculitis, thrombotic vasculopathy, vascular occlusion, or a combination of these. Vascular deposits of immunoglobulin M, immunoglobulin A, immunoglobulin G, and complement C3 on immunofluorescence studies point toward a vasculitis caused by levamisole-adulterated cocaine.

There also have been reports of pyoderma gangrenosum in patients using levamisole-adulterated cocaine. The lesions are consistent with classic pyoderma gangrenosum, but patients have serologic profiles that are similar to those seen in LINES.[42]

Unfortunately, levamisole is difficult to detect because of its short half-life (5 to 6 hours) and requires specific testing that is not readily available. Treatment consists of removing levamisole exposure, and mild organ involvement usually is managed with corticosteroids.[43]

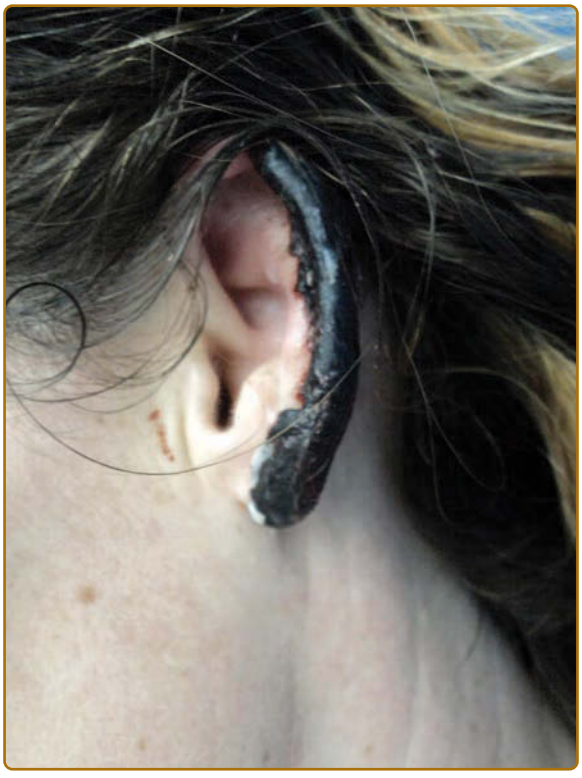

Figure 101-5 Levamisole. Characteristic purpuric eruption on the ear following levamisole toxicity. (Reproduced with permission from Hennings C, Miller J. Illicit drugs: what dermatologists need to know. *J Am Acad Dermatol.* 2013;69:135-142.)

HEROIN (ALSO KNOWN AS "SMACK," "H", "SKA", OR "JUNK")

Heroin is an opiate that causes euphoria, addiction, respiratory depression, and miosis. It is synthesized from morphine, a naturally occurring substance extracted from the seed pod of the Asian opium poppy plant. It is typically sold as a white or brownish powder or as a black sticky substance called *black tar heroin*. Heroin base (common in Europe) can only dissolve in water when mixed with an acid; the most commonly used are citric acid powder and lemon juice. Hydrochloride salt, mainly found in the United States, requires only water to dissolve. Most of the time, heroin is heated, drawn into a syringe or eyedropper through cotton, and then injected. A heroin abuser may inject up to 4 times a day. Because of decreasing prices and the increases in purity, heroin may now be snorted or smoked by inhaling its vapors, either with tobacco in a rolled cigarette or by heating the drug on aluminum foil.

There are many cutaneous signs of heroin abuse. Because it is often injected, the signs listed above for IDUs are the most common cutaneous evidence of use. Four percent of addicts develop urticaria, which can last for days. They can develop a "high pruritus," which is intense itching, especially on their genitals and on their face. "Puffy hand syndrome" (Fig. 101-6) is the condition where edema develops in the dorsal hands but not the fingers. This is mainly caused by lymphatic damage resulting from quinine, which is an adulterant that is added to heroin.[12] There have been

Figure 101-6 Puffy hand syndrome. Example of dorsal hand edema following intravenous drug use.

a few cases of penile ulcers and necrotizing cellulitis of the scrotum when heroin was injected into the dorsal vein of the penis.[44] Pemphigus vegetans,[45] fixed drug eruptions, toxic epidermal necrolysis, necrolytic migratory erythema not associated with glucagonoma, and acanthosis nigracans[11] have all been described with heroin abuse.[8] Sometimes users resort to other drugs when heroin is not available. One of the commonly used alternatives to heroin is tripelennamine with pentazocine (called *Ts and blues*). Injection causes severe ulceration with hyperkeratosis that follows a linear pattern.

"CLUB DRUGS"

Methylenedioxymethamphetamine (MDMA, Ecstasy): The main active ingredient in the popular club drug ecstasy is 3,4-methylenedioxymethamphetamine (MDMA), which is used for its ability to induce a sense of euphoria and enhance sensory perception via effects on multiple neurochemical pathways.[46] MDMA is typically ingested as a tablet. When prepared in its pure powder form it is referred to as "molly" and can be snorted or orally ingested. MDMA is often combined with a wide variety of other drugs, such as amphetamine derivatives, caffeine, and aspirin, when manufactured in tablet form for ingestion. Few cutaneous manifestations following use/abuse have been reported as its deleterious adverse effects on the kidney, liver, and neuropsychiatric systems are more commonly encountered and studied. An acneiform eruption aptly labeled "ecstasy pimples" has been described,[47] as has a widespread guttate psoriasiform eruption.

γ-Hydroxybutyrate (also known as "Liquid Ecstasy," "Liquid X," or "Fantasy"): γ-Hydroxybutyrate (GHB) is a popular "party drug" based on its euphoric and aphrodisiac properties. It is also used as a "rape drug" in the nightclub scene based on its ability to induce a reversible coma as well as short term memory loss. Specific cutaneous features following its use are not well described. However, GHB use can cause an overdose syndrome in which pale skin is prominent and should prompt immediate medical attention if use is suspected.[48]

Methamphetmine (also known as "Speed," "Meth," "Chalk," "Ice," "Crystal," "Crank," or "Glass"): Methamphetamine is made by the reduction of ephedrine or pseudoephedrine in "meth labs." It can be made in a single 2-L bottle using batteries and fertilizer, which makes meth labs more mobile and the drug more accessible. The process of making methamphetamine is very toxic and flammable. It causes euphoria, increased energy, anxiety, aggression, hallucinations, and severe withdrawal. It may be injected, smoked, or snorted.[8] Signs of methamphetamine abuse are intense pruritus, body odor, weight loss, premature aging, and hyperhidrosis. "Meth mouth", which consists of numerous dental caries and enamel erosions starting at the gum line, develops in users.[49] It is caused by a combination of xerostomia, bruxism (clenching and grinding of the teeth), and poor dental hygiene. Formication may also develop, especially on the face. Acne excoriee and lichenoid drug eruptions have been reported from methamphetamine use.[50]

Other Amphetamines and Methylphenidate—Uppers, Speed, Eye Openers, Pick Me Ups: The CNS stimulants amphetamine and methylphenidate are used for narcolepsy to improve alertness and appear to decrease abnormalities in brain structure and function found in attention deficit hyperactivity disorder.[51] Formication and obsessive skin-picking, as well as urticaria and acne, have been reported.

Hallucinogens—Lysergic Acid Diethylamide, Mushrooms: Lysergic acid diethylamide (LSD, acid) is found in ergot, a fungus cultivated from rye and other grains, which is often ingested in liquid form for its ability to alter one's sense of time and sensory perception. Psilocybin and its active metabolite psilocin (4-hydroxy-*N*,*N*- dimethyltryptamine) are the psychoactive compounds of various forms of hallucinogenic mushrooms ingested for their mind altering properties.[52] Dry mouth appears to be the main cutaneous effect.

Sedatives: Cutaneous reactions to sedatives are rare. The sedative class of drugs includes cannabis, benzodiazepines, and hydroxybutyrate. Drug reactions are rarely associated with benzodiazepines, including morbilliform hypersensitivity eruptions, erythema multiforme to clonazepam, and acute generalized exanthematous pustulosis.

CANNABIS (ALSO KNOWN AS "MARIJUANA," "POT," "WEED," OR "MARY JANE")

Cannabis is a mixture of dried shredded leaves and flowers of the *Cannabis sativa* plant. The psychoactive

chemical compound is Δ9-tetrahydrocannabinol (THC). The potency of marijuana has increased over the years and is now 5 times stronger than the marijuana used in the 1970s. Since its legalization in some states of the United States, marijuana use has increased in those states by approximately 20% according to early data. Although recreational use tends to be for its ability to produce euphoria, medicinal use is gaining acceptance. Treatment of pain, glaucoma, muscle spasm, nausea, seizures, poor appetite, and inflammation are only a few of the disorders for which cannabinoids are being used and investigated. There are topical formulations that profess to improve the appearance of aging skin.

There are 4 ways to consume marijuana: inhalation, oral, sublingual or topical application. Inhalation causes an effect within minutes, peaks at approximately 1 hour, and wanes in approximately 2 hours. Inhalation occurs via smoking or vaporization (*vaping*). Marijuana can be smoked in joints (hand-rolled cigarettes), bongs (pipes), or blunts (marijuana cigars). Other drugs, such as cocaine, may be mixed with it. Vaping (see below) is also gaining popularity. Oral ingestion is becoming more common as cannabis is used for medical purposes and is legal in several states. Onset of action for oral consumption is slower than for inhalation, with initial effects taking 30 minutes or longer and peaking at approximately 2 hours; total duration of effects can be as long as 6 hours. The effects from oral consumption have been described as more "intense" than those from inhalation. Dosage of marijuana taken orally can be difficult to titrate; irregular effects and overdose are more common with this form. Cannabis edibles include the classic brownies and cookies, as well as other formulations, including lollipops, fudge, "cannabutter," oils and tinctures, and baked in breads and pizza. Sublingual use includes product in dissolvable strips, lozenges, and sublingual sprays. Onset of action may be earlier than in oral consumption. Finally, cannabis can be delivered topically via transdermal patches, oils, salves, lotions, and bath salts. Transdermal patches may deliver enough active ingredient to cause a "high" but usually only produce local effects.

There are few cutaneous signs of cannabis use. Acne, ranging from mild to severe, has been described. Allergic reactions, including contact dermatitis, also have been reported. Cannabis arteritis is a serious vascular complication that can occur with chronic use. Cannabis arteritis is rare, with approximately 50 cases reported in the literature despite more than 5 million daily users worldwide. It presents as peripheral ischemia and necrosis, most often of the lower limbs. Cannabis arteritis is one of the most frequent causes of peripheral arterial disease in adults younger than age 50 years and is a subtype of thromboangiitis obliterans.[53] It may present with Raynaud phenomenon and digital necrosis. Cannabis arteritis is thought to be caused by the combined vasoconstrictive effects of THC and arsenic, arsenic being a common contaminant in marijuana.[54] Claudication may present before the development of ulcers or gangrene.[55] Duplex ultrasound can be used to differentiate between cannabis arteritis and atherosclerosis. Cannabis arteritis shows occlusion of peripheral arteries below the knee, whereas atherosclerosis has calcified plaques in the iliofemoral arteries. Treatment is for the patient to stop cannabis use and to take low-dose (81 mg) aspirin. For severe cases, iloprost (0.5 to 2 ng/kg/min), which is a prostaglandin analog, can be given.[56]

CUTTING AGENTS

Drugs of abuse often contain additional ingredients besides the active compound the user desires to consume. These ingredients can be added intentionally to increase the volume of the product for additional profit, or, it may be unintentionally included in the final product as a result of the chemical manufacturing process. So-called cutting agents can be divided into diluents and adulterants. Diluents, such as dirt, baking soda, talc, and mannitol, are added to expand the volume of the drug for increased distribution.[57] Adulterants, such as caffeine, hydroxyzine, diltiazem, levamisole, and phenacetin, are added to enhance the effect of the main active ingredient or facilitate administration of the drug.

Several cutting agents deserve special mention because of their potential to induce cutaneous manifestations following exposure. Most notable among these is levamisole in cocaine and arsenic in cannabis. Diluents such as talc and starch are reported to cause foreign-body granulomas after parenteral use with various drugs (Fig. 101-7).[58] Another example of an emerging adulterant leading to adverse outcomes with heroin use is clenbuterol. Although unremarkable for its skin manifestations, several case series have described dangerous cardiac events.[59]

Figure 101-7 Talc granulomas. Multiple granulomas on the bilateral legs from intravenous use of drugs containing talc as a cutting agent.

BETEL

Betel is a common drug of abuse in the Asian and Southeast Asian cultures. *Betel quid* is a combination of areca nut, betel leaf, slaked lime, and other ingredients. Psychoactive alkaloids appear to be the main stimulant. It is usually ingested by mucosal absorption similar to chewing tobacco. Chewing of the betel mixture causes maceration, erosions, and fissures of the oral commissures, which can be mistaken for other disorders such as angular cheilitis, candidiasis, or vitamin deficiencies. *Chewer's mucosa* is a brownish-red discoloration of the buccal mucosa associated with irregular desquamation. Lichenoid lesions may also appear. *Oral submucous fibrosis* is characterized by a prodrome of oral dysesthesia followed by palpable vertical fibrous bands that may require surgical interventions for opening of the mouth. Oral carcinoma can occur, usually on the buccal areas of the tongue and labial mucosa.[60]

KROKODIL

Desomorphine, a synthetic opioid derivative, manufactured using chemically altered codeine with several household ingredients, goes by the street name "Krokodil" and is reportedly ten times more potent than heroin. The drug acquired its name from the thick, scaly, green-black skin changes seen in its users.[61] The injectable drug is highly addictive and known for inducing widespread necrotizing skin lesions. It gained its popularity as a drug of abuse in Russia and cases of its adverse effects have been documented recently throughout Europe and only rarely in the United States. Besides skin color and texture change, cutaneous manifestations include swelling and pain at sites where the drug is subcutaneously injected followed by extremely aggressive necrotic ulcerations, which commonly involve muscle and cartilaginous tissue. Destructive infections often ensue and lead to extremely morbid sequelae. Alarmingly, these reactions are typically reported after short periods of use and the analgesic effects of the medicine can cause delay in the user seeking medical attention.

LEGAL DRUGS OF ABUSE

ALCOHOL

Cutaneous manifestations of alcohol consumption comprise a wide spectrum of clinical presentations. Vascular lesions are some of the most easily recognizable skin findings seen in patients who abuse alcohol; they occur secondary to alcohol's effects on the vasodilatory properties of blood vessels as well as hormonal changes induced by alterations in liver metabolism.[62] Spider angiomata, palmar erythema, and telangiectasia are examples of common cutaneous signs in alcohol abuse. More subtle findings include corkscrew scleral vessels. Other signs of liver insufficiency include dilated periumbilical veins on the abdominal wall (caput medusae) and unilateral nevoid telangiectasia, a vascular proliferative syndrome. Nevoid telangiectasias have been proposed as latent congenital nevi that present in the setting of alcohol-induced hyperestrogenism. They appear on the upper body in the C3–C4 dermatomal distribution as thread-like collections of fine telangiectasias. Systemic jaundice is typically seen after serum bilirubin levels reach greater than 2.5 mg/dL.[63] Generalized pruritus is another end-stage sequelae of liver dysfunction and may present clinically as nonspecific excoriations or as prurigo nodules if areas are chronically scratched. Several nail abnormalities to both the nail plate and nail bed have been described in the setting of alcohol abuse and concomitant liver dysfunction. The classic nail change seen in these patients are "Terry's nails" in which the proximal nail is nontranslucent white while the distal nail remains pink. One study reported that 80% of patients with cirrhosis will manifest this finding. Furthermore, nail findings previously described in the literature include transverse white bands and red lunulae in the setting of cirrhosis with congestive heart failure.

There are many chronic skin conditions that can be induced or exacerbated by alcohol abuse. One hallmark cutaneous condition associated with alcohol abuse is porphyria cutanea tarda, which is discussed in Chap. 125. Other notable alcohol-associated conditions include Dupuytren contracture, as well as Madelung disease, psoriasis, rosacea, nummular eczema, and seborrheic dermatitis, although the exact connection with these conditions is unclear.

TOBACCO (CIGARETTES, CHEWING TOBACCO, ORAL TOBACCO, SPIT OR SPITTING TOBACCO, DIP, CHEW, SNUFF, OR SNOOZE)

Tobacco is made from the leaves of plants of the genus *Nicotiana*. Tobacco is usually smoked, but can be chewed (ie, absorbed via the oral mucosa when placed between the buccal and gingival mucosa) or sniffed. "Vaping" is a relatively new phenomenon where the tobacco is inhaled through a vaporizer that infuses water into the smoke. Nicotine in tobacco in particular is known to be addictive because of its mood-boosting effects; it is also known to suppress appetite.

There are many signs and symptoms of tobacco use. Yellow-brown staining of the teeth, fingers and fingernails from nicotine is clearly visible in many smokers. One of the most-well-established effects of tobacco smoking on the skin is premature aging. Although this association has been appreciated for decades, studies in the late 20th century confirmed the link between wrinkles on tobacco and further identified that the association is proportional to the tobacco load of the patient.[64] Some of the mechanisms by which this occurs have been described. One such mechanism is the increase in elastic fiber content of the reticular

dermis along with upregulation of enzymes crucial to skin remodeling and repair essentially creating the effect of solar elastosis. Tobacco's effects on fibroblasts and the microvasculature impair wound healing.

There are more than 7000 chemicals found in cigarette smoke, more than 70 of which are known to be carcinogenic.[65] Although many studies have sought to identify a potential relationship between tobacco use and skin cancers, they have failed to identify a definitive causal relationship. One study did show an increased prevalence of keratoacanthomas in smokers compared to nonsmokers. Tobacco use also has been linked to hand dermatitis.[66]

Use of tobacco incites or worsens chronic skin conditions, including psoriasis (particularly the palmoplantar pustular variant), hidradenitis suppurativa, and subacute and chronic cutaneous lupus erythematosus. Smoking tobacco impairs the efficacy of antimalarial therapy in patients with lupus, making treatment of these patients more difficult.[67] Also, smokers should not use beta-carotene supplements because of the higher risk of lung cancer.

Chemical effects include peripheral vasoconstriction, platelet aggregation, and decrease in prostacyclin formation, which increase the risk of cardiovascular disease. Thromboangiitis obliterans (Buerger disease) is an inflammatory arteritis of the medium and small vessels of the upper and lower extremities. It typically presents with pain and necrosis of the digits in young male tobacco smokers. Carbon monoxide also increases risk of cardiovascular problems, as well as peripheral ischemia, in end organs such as the skin and digits.[68]

Both cigarette smoking and chewing are associated with several conditions of the oral mucosa. This includes *leukokeratosis nicotinica palati* (nicotine stomatitis, smoker's palate) which is characterized by uniform keratosis of the hard palate with multiple umbilicated erythematous papules that are the inflamed orifices of minor salivary glands. *Leukokeratosis nicotinica glossae* is a homogeneous white plaque that affects the anterior two-thirds of the dorsal tongue. Oral verrucous carcinoma, oral warty dyskeratoma, and oral melanosis (brown-black pigmentation of the oral mucosa) are also associated with tobacco use.[69]

PRESCRIPTION OPIATES

Hydrocodone, oxycodone, morphine, and codeine are legally prescribed analgesics that can produce euphoria. CNS depression is the most common side effect. Because they are taken orally, these medications do not produce the signs listed above for heroin. Urticaria and pruritus are the most common cutaneous effects.

ANABOLIC STEROIDS

Anabolic steroids are synthetic hormones similar to testosterone. They can be ingested or injected and have many legal indications. Illicit use is usually to build muscle and augment athletic performance. Cutaneous side effects are common and should be suspected in any patient who presents with acne vulgaris, hair growth on the body and loss on the scalp, and striae. Increased body hair, increased oil in the skin and hair, and premature androgenetic alopecia are also common.[70] Steroid acne is most commonly distributed on the face, chest, back, and shoulders. Women may demonstrate androgen-mediated effects, including androgenetic alopecia, deepening of the voice, clitoral enlargement, and menstrual irregularity. Men may experience gynecomastia, testicular atrophy, and infertility. Teenage use can induce precocious puberty and growth stunting. Side effects may not reverse upon discontinuation of the drug.[71] Striae may develop from muscle hypertrophy. Acne fulminans, psoriasis, familial angiolipomas and exacerbation of coproporphyria also have been reported. Systemic side effects also may be present, including hepatic enzyme elevations, jaundice, hypertension, and lipid abnormalities.

NONCUTANEOUS ISSUES

Noncutaneous complications and sequelae of drug use are extensive. In particular, bloodborne or sexually transmitted diseases, such as HIV and hepatitides B and C virus, are well-established comorbidities of IV drug use. There is data to suggest that illicit drug use is associated with premature mortality in young adults both from trauma and suicide.[72]

MANAGEMENT

The key to managing drug use, abuse and addiction is as early intervention as possible. The dermatologist may be able to help with recognition of the problem. Relatively recently, drug addiction has been recognized as a multifactorial disease and therapies ranging from medications, psychiatric treatment, and alternative treatments, including acupuncture and meditation, are being implemented.

REFERENCES

1. United Nations Office on Drugs and Crime. *World Drug Report 2017*. New York, NY: United Nations. http://www.unodc.org/wdr2015/.
2. Kim S, Kwok S, Mayes LC, et al. Early adverse experience and substance addiction: dopamine, oxytocin, and glucocorticoid pathways. *Ann N Y Acad Sci*. 2017;1394(1):74-91.
3. Beyers JM, Toumbourou JW, Catalano RF, et al. A cross-national comparison of risk and protective factors for adolescent substance use: the United States and Australia. *J Adolesc Health*. 2004;35:3-16.
4. Sim M, Hulse G, Khong E. Injecting drug use and skin lesions. *Aust Fam Physician*. 2004;33:519-522.
5. Hennings C, Miller J. Illicit drugs: what dermatologists need to know. *J Am Acad Dermatol*. 2013;69:135-142.

6. Bennet RG, Leyden JJ, Decherd JW. The heroin ulcer: new addition to the differential diagnosis of ulcers of the penis. *Arch Dermatol*. 1973;107:121-122.
7. Horowitz HW. Learning to recognize scarring among drug users: a tool for HIV risk reduction. *Am J Public Health*. 1997;87:1233-1234.
8. Bergstrom K. Cutaneous clues to drug addictions. *J Drugs Dermatol*. 2008;7:303-306.
9. Young AW Jr, Sweeney EW. Cutaneous clues to heroin addiction. *Am Fam Physician*. 1973;7:79-87.
10. Kathuria S, Ramesh V, Singh A. Pentazocine induced ulceration of the buttocks. *Indian J Dermatol Venereol Leprol*. 2012;78(4):521.
11. Murphy EL, DeVita D, Liu H, et al. Risk factors for skin and soft-tissue abscesses among injection drug users: a case-control study. *Clin Infect Dis*. 2001;33: 35-40.
12. Orangio GR, Pitlick SD, Della Latta P, et al. Soft tissue infections in parental drug abusers. *Ann Surg*. 1984;199:97-100.
13. Binswanger IA, Kral AH, Bultenthal RN, et al. High prevalence of abscesses and cellulitis among community-recruited injection drug users in San Francisco. *Clin Infect Dis*. 2000;30:579-581.
14. Spijkerman IJ, Langendam MW, van Ameijden EJ, et al. Gender differences in clinical manifestations before AIDS diagnosis among injecting drug users. *Eur J Epidemiol*. 1998;14(3):213-218.
15. Tuazon CU, Cardella TA, Sheagren JN. Staphylococcal endocarditis in drug users. Clinical and microbiologic aspects. *Arch Intern Med*. 1975;135(12):1555-1561.
16. Cherubin CE, Sapira JD. The medical complications of drug addiction and the medical assessment of the intravenous drug user: 25 years later. *Ann Intern Med*. 1993;119:1017-1028.
17. Brown PD, Ebright JR. Skin and soft tissue infections in injection drug users. *Curr Infect Dis Rep*. 2002;4:415-419.
18. Bohlen L, Muhlemann K, Dubuis O. Outbreak among drug users caused by a clonal strain of group A streptococcus. *Emerg Infect Dis*. 2000;6:175-179.
19. Centers for Disease Control. Tetanus among injecting-drug users—California, 1997. *MMWR Morb Mortal Wkly Rep*. 1998;47:149-151.
20. Werner SB, Passaro D, McGee J, et al. Wound botulism in California, 1951-1998: recent epidemic in heroin injectors. *Clin Infect Dis*. 2000;31:1018-1024.
21. Chen JL, Fullerton KE, Flynn NM. Necrotizing fasciitis associated with injection drug use. *Clin Infect Dis*. 2001;33:6-15.
22. Sudarsky LA, Laschinger JC, Coppa GF, et al. Improved results from a standardized approach in treating patients with necrotizing fasciitis. *Ann Surg*. 1987;206:661-665.
23. Callahan TE, Schecter WP, Horn JK. Necrotizing soft tissue infection masquerading as cutaneous abscess following illicit drug injection. *Arch Surg*. 1998;133:812-818.
24. Anderson CE, Loomis GA. Recognition and prevention of inhalant drug abuse. *Am Fam Physician*. 2003;68(5):869-874.
25. Strock M, Black L, Liddell M. Inhalant abuse and dextromethorphan. *Child Adolesc Psychiatr Clin N Am*. 2016;25:497-508.
26. Tames SM, Goldenring JM. Madarosis from cocaine use. *N Engl J Med*. 1986;314:1324.
27. Feeney CM, Briggs S. Crack hands: a dermatologic effect of smoking crack cocaine. *Cutis*. 1989;44:223-225.
28. Schuster DS. Snorters' warts. *Arch Dermatol*. 1987;123:571.
29. Hofbauer GF, Hafner J, Trueb RM. Urticarial vasculitis following cocaine use. *Br J Dermatol*. 1999;141:600-601.
30. Orriols R, Munoz X, Ferrer J, et al. Cocaine-induced Churg-Strauss vasculitis. *Eur Respir J*. 1996;9:175-177.
31. Gertner E, Hamlar D. Necrotizing granulomatous vasculitis associated with cocaine use. *J Rheumatol*. 2002;29:1795-1797.
32. Brewer J, Meves A, Bostwick M, et al. Cocaine abuse: dermatologic manifestations and therapeutic approaches. *J Am Acad Dermatol*. 2008;59:483-487.
33. Marder VJ, Mellinghoff IK. Cocaine and Buerger disease: is there a pathogenetic association? *Arch Intern Med*. 2000;13:2057-2060.
34. Bozkurt AK. The role of cocaine in the etiology of Buerger disease is questionable. *Arch Intern Med*. 2001;161:486.
35. Friedman D, Wolfsthal S. Cocaine-induced pseudovasculitis. *Mayo Clin Proc*. 2005;80:671-673.
36. Specks U. The growing complexity of the pathology associated with cocaine use. *J Clin Rheumatol*. 2011;7(4):167-168.
37. Lu LK, High WA. Acute generalized exanthematous pustulosis caused by illicit street drugs? *Arch Dermatol*. 2007;143:430-431.
38. Hofbauer GF, Burg G, Nestle FO. Cocaine-related Stevens-Johnson syndrome. *J Am Acad Dermatol*. 1994;53:97-98.
39. Kerr HD. Cocaine and scleroderma. *South Med J*. 1989;10:1275-1276.
40. Attoussi S, Faulkner ML, Oso A, et al. Cocaine-induced scleroderma and scleroderma renal crisis. *South Med J*. 1998; 91:961-963.
41. Elpern DJ. Cocaine abuse and delusions of parasitosis. *Cutis*. 1988;42:273-274.
42. Jeong HS, Layher H, Cao L, et al. Pyoderma gangrenosum (PG) associated with levamisole-adulterated cocaine: clinical, serologic, and histopathologic findings in a cohort of patients. *J Am Acad Dermatol*. 2016;74(5):892-898.
43. Strazzula L, Brown KK, Brieva JC, et al. Levamisole toxicity mimicking autoimmune disease. *J Am Acad Dermatol*. 2013;69(6):954-959.
44. Alguire PC. Necrotizing cellulitis of the scrotum: a new complication of heroin addiction. *Cutis*. 1984;43:93-95.
45. Downie J, Dicostanzo D, Cohen S. Pemphigus vegetans-Neumann variant associated with intranasal heroin abuse. *J Am Acad Dermatol*. 1998;39:872-875.
46. Gowing LR, Henry-Edwards SM, Irvine RJ, et al. The health effects of ecstasy: a literature review. *Drug Alcohol Rev*. 2002; 21:53-63.
47. Wollina U, Kammler HJ, Hesselbarth N, et al. Ecstasy pimples a new facial dermatosis. *Dermatology*. 1998; 197:171-173.
48. Stromberg MW, Knudsen K, Stomberg H, et al. Symptoms and signs in interpreting gamma-hydroxybutyrate (GHB) intoxication—an explorative study. *Scand J Trauma Resusc Emerg Med*. 2014;22:27.
49. Hamamoto DT, Rhodus NL. Methamphetamine abuse and dentistry. *Oral Dis*. 2009;15:27-37.
50. Deloach-Banta LJ. Lichenoid drug eruption: crystal methamphetamine or adulterants? *Cutis*. 1992;50: 193-194.
51. Spencer TJ, Brown A, Seidman LJ, et al. Effect of psychostimulants on brain structure and function in ADHD: a qualitative literature review of MRI-based neuroimaging studies. *J Clin Psychiatry*. 2013;74(9):902-917.

52. Dos Santos RG, Osorio FL, Crippa JA, et al. Antidepressive, anxiolytic, and antiaddictive effects of ayahuasca, psilocybin and lysergic acid diethylamide (LSD): a systematic review of clinical trials published in the last 25 years. *Ther Adv Psychopharmacol*. 2016;6(3):193-213.
52. Sauvanier M, Constans J, Skopinski S, et al. Lower limb occlusive arteriopathy: retrospective analysis of 73 patients with onset before the age of 50 years [in French]. *J Mal Vasc*. 2002;27:69-76.
54. Peyrot I, Garsaud A-M, Saint-Cyr I et al: Cannabis arteritis: a new case report and a review of literature. *J Eur Acad Dermatol Venereol*. 2007;21:388-391.
55. Cazalets C, Laurat E, Cador B, et al. Cannabis arteritis: four new cases [in French]. *Rev Med Interne*. 2003;24:127-130.
56. Noel B, Ruf I, Panizzon G. Cannabis arteritis. *J Am Acad Dermatol*. 2008;58(suppl):S65.
57. Broseus J, Gentile N, Esseiva P. The cutting of cocaine and heroin: a critical review. *Forensic Sci Int*. 2016;262:73-83.
58. Del Giudice P: Cutaneous complications of intravenous drug abuse. *Br J Dermatol*. 2004;150:1-10.
59. Hieger MA, Emswiler MP, Maskell KF, et al. A case series of clenbuterol toxicity caused by adulterated heroin. *J Emerg Med*. 2016;51(3):259-261.
60. Lee CH, Ko A, Warnakulasuriya S, et al. Population burden of betel quid abuse and its relation to oral premalignant disorders in South, Southeast, and East Asia: an Asian Betel-Quid Consortium Study. *Am J Public Health*. 2012;102(3)e17-e24.
61. Haskin A, Kim N, Aguh C. A new drug with a nasty bite: a case of krokodil-induced skin necrosis. *JAAD Case Rep*. 2016;2:174-176.
62. Smith KE, Fenske NA. Cutaneous manifestations of alcohol abuse. *J Am Acad Dermatol*. 2000;43:1-16.
63. Liu SW, Lien MH, Fenske NA. The effects of alcohol and drug abuse on the skin. *Clin Dermatol*. 2010; 28:391-399.
64. Metelitsa AI, Lauzon GJ. Tobacco and the skin. *Clin Dermatol*. 2010;28:384-390.
65. Didkowska J, Wojciechowska U, Mańczuk M, et al. Lung cancer epidemiology: contemporary and future challenges worldwide. *Ann Transl Med*. 2016;4(8):150.
66. Lai YC, Yew YW. Smoking and hand dermatitis in the United States adult population. *Ann Dermatol*. 2016;28(2):164-171.
67. Boeckler P, Cosnes A, Frances C, et al. Association of cigarette smoking but not alcohol consumption with cutaneous lupus erythematosus. *Arch Dermatol*. 2009;145(9):1012-1016.
68. Hoffman D, Hoffman I. The changing cigarette, 1950-1995. *J Toxicol Environ Health*. 1997;50(4):307-364.
69. Alkan A, Bulut E, Gunhan O, et al. Oral verrucous carcinoma: a study of 12 cases. *Eur J Dent*. 2010;4(2):202-207.
70. Yesalis CE 3rd, Herrick RT, Buckley WE, et al. Self-reported use of anabolic-androgenic steroids by elite powerlifters. *Phys Sportsmed*. 1988;16:91-99.
71. Nieschlag E, Vorona E. Doping with anabolic androgenic steroids (AAS): adverse effects on non-reproductive organs and functions. *Rev Endocr Metab Disord*. 2015;16(3):199-211.
72. Meader N, King K, Moe-Byrne T, et al. A systematic review on the clustering and co-occurrence of multiple high-risk behaviors. *BMC Public Health*. 2016;16:657.

Chapter 102 :: Physical Abuse

:: Kelly M. MacArthur & Annie Grossberg

AT-A-GLANCE

- Child abuse, elder abuse, and domestic violence are common and affect patients of all socioeconomic classes and races.
- Identifying specific cutaneous findings concerning for physical abuse allows for early intervention to impact outcomes.
- Bruising on soft padded areas of the body and patterned bruising that are multiple and in different stages of healing are suspicious of abuse.
- Burns that are bilateral and uniform are suspicious of abuse.
- Law mandates the reporting of all suspected cases of child abuse and, in some states, elder abuse.

INTRODUCTION

Abuse is a world-wide medical issue that is notoriously difficult to diagnose in those who are either not able to provide reliable histories (especially seen in pediatric, geriatric, or cognitively impaired patients) or those who fear the ramifications of reporting abuse (pertinent to any victim of abuse).

The main diagnostic challenge lies in the various manifestations of physical abuse due to great diversity of patients and range of means used to inflict trauma. Injuries can result from primary trauma (abrasions, hematomas, choke marks) or secondary effects of an initial trauma (such as in thermal injuries). Superficial cutaneous signs can also indicate the presence and extent of internal injury. Both severe penetrating and blunt trauma can cause bone fractures, torn ligaments, and joint instability. Internal organ hemorrhage can produce fatal consequences and are especially of concern in (though not exclusive to) head and abdominal injuries. Identifying specific cutaneous findings concerning for physical abuse may allow for early intervention to impact outcomes.

EPIDEMIOLOGY

Types of abuse and their respective incidence rates are listed in Table 102-1. More than 1 type of abuse can occur simultaneously.[9,10]

CHILD ABUSE

Despite potentially severe morbid and even fatal consequences, child abuse remains under-identified and thus under-reported.[1,2] In the United States, child abuse/neglect annual incidence is 700,000 to 1.25 million children, with approximately 18% of cases involving physical abuse.[3-5] Among the United States and developed countries of Europe, the prevalence of physical abuse anytime throughout childhood ranges from 5% to 16%, with only 5% of all episodes estimated to be reported to child protective services.[6,7] It is estimated that more than 300,000 children suffer from sexual abuse each year in the United States. The lifetime risk of sexual abuse is approximately 25% to 40% for girls and approximately 10% for males.

ELDER ABUSE

Elder abuse is one of the fastest-growing forms of abuse. Although statistics vary, the National Center on Elder Abuse in Washington, DC, estimates that 1 to 2 million Americans 65 years of age or older are victims of various forms of abuse each year. Abuse may affect a range of 2% to 10% of the elderly population. Those older than age 80 years are 2 to 3 times more likely to suffer abuse, and the American population in this age range continues to increase each year. True prevalence is difficult to determine as diagnoses can be often missed, with one study claiming that for every case of reported elder abuse, at least another 5 cases go undetected.[8] All segments of society are affected.

DOMESTIC ABUSE

Conservative estimates say that in the United States approximately 1 million people suffer domestic violence each year, but the actual number likely approaches 4 million. Women comprise approximately 90% to 95% of all victims, and men account for 95% of all perpetrators. Forty percent to 60% of men who abuse their partner or spouse are also abusing their children. In the United States, approximately 1 in 3 women suffers at least 1 physical assault during her life, and 1500 women are murdered by their husbands or boyfriends each year.[11,12]

CLINICAL FEATURES—CUTANEOUS FINDINGS

Because many forms of physical abuse have external manifestations, the skin examination may serve as important evidence that abuse is taking place. Implausible history can provide the first warning sign,

TABLE 102-1
Types of Elder Abuse

- Neglect: 55%
- Physical abuse: 15%
- Financial and material abuse: 12%
- Emotional or psychological abuse: 8%
- Sexual abuse: 1%
- Unspecified forms of abuse: 9%

particularly when the clinical examination and extent of injury does not match up with the proposed mechanism of trauma. Explanations for injury should be both comprehensible and coherent; providers should seek to identify congruence between history provided and physical examination findings.[13] Because of the significant heterogeneity of cutaneous clinical findings, morphology as well as traditional diagnostic criteria (localization, patterned injuries, repeated injuries, clustered injuries) helps to identify concerning lesions suspicious for abuse. In particular, morphology and localization are key features in forensic classification of abuse.[13]

MORPHOLOGY

Just as in all other facets of dermatology, morphology is key to accurate diagnosis. Examination of secondary lesions to determine concern for abuse requires inspection of size, shape (discussed in the section "Patterned Injuries"), color, and location (discussed in the section "Localization"), but also palpation to determine texture and degree of pain. These clinical features can vary based on the anatomic site, the degree of force used, the firmness of the object delivering the force, and the underlying health of the injured individual.

Although penetrating wounds develop from trauma due to sharp objects, bruises result from blunt injury. Multiple bruises of differing colors may indicate repeated trauma rather than one isolated incident. Determining time of injury based on bruise characteristics is challenging as bruise color depends on the intensity, depth, and location of the injury. However, evidence suggests that a bruise with a yellow hue is likely older than 18 hours, but a bruise may be red, blue, or purple/black throughout its life span, from onset to resolution. Bruises of identical age and cause on the same person may not appear as the same color and may not change at the same rate.[14] Faint bruising can be better appreciated with use of a Wood lamp.

CHILD ABUSE

Confounding early identification and diagnosis of abuse in this population, active children (especially toddlers) are prone to multiple accidental bruises. Although there are no absolute features to differentiate accidental bruising from intentionally inflicted bruising, location can be the most helpful for identifying abuse (see below).

ELDERLY ABUSE

Cutaneous morphologies that are more unique and specific to elderly abuse include bed sores and strangely patterned alopecia.

LOCATION

Injury distribution can vary. Although the head is a common target of physical abuse in children, centrally located injuries are more common in domestic abuse. Perpetrators in any cases of abuse may choose to injure hidden areas, such as the breast or genitals, to deter detection. Black eyes are often seen in accidental injuries but are more suspicious if they are bilateral or are unaccompanied by evidence of trauma to the nose or superior orbital ridge. Accidental bruising or other injuries to the oral mucous membranes are unusual and should be considered as suspect.

CHILD ABUSE

Because young children tend to explore in a forward direction, accidental bruises more frequently occur on the distal arms and legs, knees, elbows, and forehead. Soft, padded, posterior, and protected areas of the body are far less likely to be accidentally injured. Bruises on the trunk, buttocks (Fig. 102-1), neck folds, palms/soles, thighs, genitalia, ear lobes, neck, and cheeks are uncommon, so marks in these areas should raise concern. Trauma to the oral cavity including mucosal surfaces, posterior pharynx, teeth, and lingual/labial frenula are concerning findings that warrant abuse consideration.

Face: Subconjunctival hemorrhages can be seen in 0.5% to 13.0% of typical newborns, but a large subconjunctival hemorrhage beyond 1 and 2 weeks of life is

Figure 102-1 Purpura and erosions on the soft, padded areas of the buttock and thighs, representing very obvious abuse. (Used with permission from Paul Bellino, MD.)

suspicious of abuse. Petechiae in the periorbital region have been seen in children with abuse-related retinal hemorrhages.

Genitalia: Per the American Academy of Pediatrics, sexual abuse is the engaging of a child in sexual activities that the child cannot comprehend, for which the child is developmentally unprepared, and cannot give informed consent and that violate the social taboos of society.[15] Thus, as sexual abuse is not limited to physical abuse of genitalia, most victims of sexual abuse have no physical findings.[16,17] Although genital maltreatment (including touching, fondling, and penetration) can affect victims of all ages, the focus of sexual abuse in this chapter will be on its cutaneous manifestations in pediatric patients. Acute genital or anal injuries without plausible explanation and marked hymeneal opening enlargement with associated hymeneal disruption are very definitive signs of sexual abuse, yet these are not commonly present. The American Academy of Pediatrics Committee on Child Abuse and Neglect recommends that certain findings are consistent with, but not diagnostic of, abuse. These include chafing, abrasions, or bruising of the inner thighs and genitalia, scarring, tears or distortion of the hymen, a decreased amount or absent hymeneal tissue, scarring of the fossa navicularis, injury to or scarring of the posterior fourchette, scarring or tears of the labia minora, and enlargement of the hymeneal opening, even without disruption of the hymen.[15]

Genital warts pose a particularly difficult problem for practitioners. They certainly can be sexually transmitted to children, and the possibility of sexual abuse needs to be discussed with parents. However, there is much evidence that genital warts can be acquired perinatally from an infected mother, through autoinoculation from warts on other parts of the body, or through nonsexual contact with caretakers.[18] Children younger than 3 years of age at the onset of warts are least likely to have acquired their warts from sexual contact, whereas children with onset after 5 years of age have a much greater risk of having suffered sexual abuse. The ages in between represent a gray zone. Of note, human papillomavirus typing is not helpful.

DOMESTIC ABUSE

Unlike infants or debilitated adults, blows to a young adult may be to areas suggesting a defensive posture and might include purpura, sprains, dislocations, and fractures to the wrist or forearms, palms, and soles.

DISTRIBUTION

Injuries in particular distributions, namely those that are repeated, clustered, and/or patterned injuries are more concerning for intentional abuse. Repeated injuries pertain not only to multiple injuries in various stages of healing but also history of recurrent injuries of similar distribution. Regarding clustered injuries,

Figure 102-2 Linear purpura representing the interdigital spaces from a hand slap. Note the inferior triangular shape that corresponds to the finger web space. (Used with permission from Paul Bellino, MD.)

while the rule of 3 or more individual injuries in the same body region is a classic guideline for raising concern for abuse, one study further identified concerning clustered injuries by age. Pre-mobile children should rarely have more than one isolated bruise, whereas infants who crawl/cruise infrequently have more than 2 bruises especially in the same body region, as compared with children who walk and have commonly greater than 5 or more bruises that may or may not be clustered based on location and activity.[22]

Certain patterned injury findings can reveal method of abuse and can provide a more specific clinical indicator of abuse. Inflicted bruises often leave patterned imprints of a hand, whip, or hard object. Linear purpura, with a small triangle at the base (Fig. 102-2) representing the interdigital and finger web spaces, occurs after a slap injury. Grab or pinch marks can be recognized by their location on soft padded areas and their unusual patterning. Circumferential purpura or hemosiderin pigmentation (Fig. 102-3) suggests a ligature injury,

Figure 102-3 Linear, circumferential hyperpigmentation at the site of previous ligature. (Used with permission from Paul Bellino, MD.)

which would be difficult to explain as accidental. Tramline bruising, distinguished as 2 parallel linear bruises with appearance of preserved "normal skin" within the lines, results from trauma usually with a rectangular or round object (though an ovoid instrument can produce a variant finding). Tramline bruising results after a "high velocity" impact causes rupture of blood vasculature along the edges of the object with shunting of blood throughout the surface of contact with the skin. Withdrawal of the object allows blood from the periphery to return to the site of contact with preservation of vasculature of the center of the contact surface. Blood then extravasates from the damaged vasculature of the edges of impacted skin producing the parallel/symmetrical bruising pattern with often normal appearance of central impacted skin. Bite marks (Fig. 102-4) are always inflicted, although they are sometimes from children or pets. The shape and size of the marks can identify an adult mouth versus a bite from a child.

Inflicted burns can result from hot objects (such as iron, cigarette, spatula) applied to skin to cause shaped injuries. The most common agent involved in childhood burns (both accidental and inflicted) is hot liquid. Accidents such as inadvertently stepping into a hot tub or pulling a hot liquid off a table counter or stove leave irregular or geographic burn patterns that lack symmetry. By contrast, inflicted scalds tend to be symmetric, with sharply demarcated edges and an absence or paucity of splash marks characterized by tapered edges.

In one study, all the children whose bathtub burns were inflicted had associated features of abuse, including bruises, fractures, or evidence of neglect.[19] Stocking and glove burns result when the feet or hands are forcibly held under hot water. The uniformity of the burn indicates that the child was not able to reflexively withdraw from the scalding water as would happen with accidental immersion. A common pattern of inflicted immersion burn involves the buttocks, low back, and thighs. The child is flexed at the waist and dipped into the hot water, frequently as a punishment for a toilet training accident. The resultant pattern may give "zebra stripes" on the abdomen due to sparing of the flexural skin that is protected from the scald when bent forward. A "donut hole" pattern of sparing might be seen on the buttock if the child is pushed forcibly to the bottom of the tub that is cooler than the scalding water.[20] Inflicted splash burns are much more difficult to differentiate from accidents.

An inflicted contact burn can be recognized by the pattern that duplicates the object creating the injury. Accidental contact burns tend to be smaller, less severe, less patterned, and of irregular depth. When a patient is held against a hot object, the depth is more uniform, the pattern is more clearly defined, and the burn is more severe. Irons, curling irons, hot plates, and cigarettes are objects commonly used to inflict burns.[21] Some burns may, in fact, be accidental but represent inadequate supervision and neglect. This situation is also harmful and needs to be reported to the appropriate agencies.

ETIOLOGY AND PATHOGENESIS/RISK FACTORS

CHILD ABUSE

Victims and perpetrators span all racial, religious, and socioeconomic spectrums; however, identified factors placing children at higher risk for being victims of abuse are classified into characteristics of the patient, the provider, and the environment (society and community).[23] Typical children who suffer abuse have emotional, behavioral (including ADHD), or learning disabilities; have chronic illnesses (including failure to thrive and congenital anomalies) with special medical needs; may be premature at birth with low birth weight; have several siblings; resulted from unwanted pregnancy and/or deemed an unwanted child; live in single-parent households; or live at or below the poverty level. Girls are more likely than boys to suffer sexual abuse and the risk rises in preadolescence (Fig. 102-5). Perpetrators tend to have

Figure 102-4 Human bite marks. (Used with permission from Paul Bellino, MD.)

Figure 102-5 Sexual abuse. Perianal wound in a 3-year-old girl after anal penetration. (Used with permission from Dr. Francesca Navratil, Zurich, Switzerland.)

emotional or psychological problems, have frequently been victims of abuse themselves, abuse drugs or alcohol, are perpetrators of spousal abuse or have a history of marital discord, have marginal parental skills or knowledge, absentee mothers (extensively out of the home), and have poor self-esteem. Parents are the perpetrator 80% of the time[24]; only 10% child abuse is estimated as inflicted by strangers. Most common environmental factors seen in the setting of child abuse include poverty, social isolation, unrelated adult male in household, single-parent families, and significant family stressors. Although these profiles are helpful, it is important to remember that any child may be the victim of abuse.

ELDERLY ABUSE

Risk factors for abuse are listed in Table 102-2. Note that the risk factors have far more to do with the caretaker than the abused patient. In particular, the level of debility or health status of the patient does not predict abuse. Abuse most often occurs at the hands of caregivers or family members who have frequent close contact with patients and often may live with them. Historically, adult children of the abused patient have been the most common perpetrators, but most recent data show that spouses now account for the majority of abuse cases. Men are more likely to abuse than women. The abuser is often financially dependent on the victim, and they are usually in a shared living situation. However, financial abuse is more common among those who live alone.

DOMESTIC ABUSE

Women ages 19-29 years are the most common victims, with other risk factors being low income, mental health issues, alcohol or substance abuse by the victim or the perpetrator, pregnancy, large age difference between partners, separated or divorced status, and a family history or personal past history of abuse and violence. Women with educational or occupational levels above that of their partners may be at higher risk. Abusers are typically underachievers with occupational status below their educational level.[11,12]

TABLE 102-2
Risk Factors for Elder Abuse

- Older age
- Lack of access to resources
- Low income
- Social isolation
- Minority status
- Low level of education
- Functional impairment
- Substance abuse by elder or caregiver
- Previous history of family violence
- History of psychological problems
- Caregiver stress
- Cognitive impairment

DIAGNOSIS

CHILD ABUSE

A careful history is needed to detect inconsistencies between the proposed injury and the physical examination. Identified red flags to trigger suspicion for abuse include unexplained delay in presentation, caregiver's history provided that is inconsistent or conflicting, denial of trauma despite concerning injury, trauma secondary to in-home resuscitation attempts, and severe injury for which blame is placed on pets or young children. As fall height and ground surface have been found to be predictors of severity of injury, short fall history in a child presenting with significant injuries should trigger suspicion for abuse.[25] The history should include as much detail as possible and inconsistencies in the parent's story clearly documented in the medical record.[26]

All historical information must be very well documented and preserved with the same care as any piece of forensic evidence. It is immensely important to enlist the help of an experienced abuse team in obtaining the history and completing an appropriately thorough physical examination.

It is essential to perform a total body, skin, and mucous membrane examination. It is also important to note the child's behavior and parent-child interactions. The color of all bruises should be noted and clearly documented. This may aid in determining the age of a bruise and may point out inconsistencies in the caretaker's history. It is helpful to include a ruled measuring scale in any photographs to help forensic identification at a later date. Most importantly, the child's spoken word is a valuable piece of evidence in establishing sexual abuse.

ELDERLY ABUSE

The US National Academy of Sciences has defined *elder abuse* as:

> *(a) intentional actions that cause harm or create a serious risk of harm (whether or not harm is intended) to a vulnerable elder by a caregiver or other person who stands in a trust relationship to the elder, or (b) failure by a caregiver to satisfy the elder's basic needs or to protect the elder from harm.*

Acts of commission and omission are thus included in the definition.

Unexplained repetitive injuries or explanations by caretakers that do not match the pattern of injury are concerning. Caretakers who act withdrawn, infantilize the patient, or insist on providing the medical history should alert the clinician.

It is important to interview by directing questions to the patient rather than the caregiver, and it is prudent to try to arrange a time to confer with and examine the patient alone. Repetitive followup visits help develop a rapport with the patient and allow serial observation of past and ongoing injuries. The assurance of confidentiality facilitates garnering sensitive information.

DOMESTIC ABUSE

Domestic violence is a pattern of coercive behaviors that may include repeated battering, psychological abuse, sexual abuse, social isolation, deprivation, and intimidation perpetrated by someone who is or was involved in an intimate relationship with the victim.

Whenever possible, the patient should be interviewed alone in the absence of her or his partner. A thorough examination should be done with a nurse chaperone, but not the partner, in the room. Repeat visits may be used to document new or progressing skin findings and to build trust with the patient. For various reasons, a victim may not want to reveal abuse. Implausible explanations for an injury or a delay in seeking medical attention may be clues of abuse. Signs of depression, excessive use of sedatives, chronic pain disorders, or vague stress-related symptoms may be subtle signs of abuse.[11]

SUPPORTIVE STUDIES—LABORATORY TESTING

The advised laboratory workup is patient presentation-dependent. Although there is an argument for obtaining basic bleeding studies (to include complete blood count with differential, platelet count, prothrombin and partial thromboplastin times) in all cases of suspected child abuse, the recommendation for other laboratory studies varies based on patient presentation.

Coagulation studies are helpful in identification of coagulopathy following trauma and can help to differentiate this from an underlying preceding coagulopathy. The above basic bleeding studies can be supplemented with additional coagulation studies, though hematology should be involved in opting for this more aggressive workup approach.[23,27]

For intraabdominal trauma, transaminase (alanine aminotransferase [ALT], aspartate aminotransferase [AST]) levels are elevated in those with hepatic damage whereas serum amylase and lipase are elevated in those with pancreatic injury.[28] Even in the absence of cutaneous findings to suggest intraabdominal trauma, transaminases can be elevated (greater than 80 U/L) correlating with hepatic injury in an abused child.[23] An observational study reported 17 of 54 children with no clinical findings to have intraabdominal injury, with 14 of the 17 injured to have elevated transaminases. Thus, not all patients with abdominal trauma have cutaneous manifestations nor is serologic testing perfectly sensitive to detect intraabdominal injury following abuse. Followup study performed noted transaminase elevation to be 83% specific and 84% sensitive for detection of such occult injury.[29]

Other serologies are ordered if suspecting specific injuries including serum electrolytes and osmolality for abusive head trauma; water intoxication or dehydration; as well as serum phosphate, calcium, and alkaline phosphatase in the setting of fractures to rule out bone disease as an underlying etiology. Workup for bone fragility is controversial, with no clear guidelines for screening; thus, it is proposed to consult with a bone metabolism expert should a child present with only fractures in the absence of cutaneous findings to suggest abuse.[23,30]

Urinalysis should be considered in patients with convincing history or examination suspicious for dehydration, abdominal trauma, or concerning urinary symptoms, such as hematuria (common finding following genitourinary or abdominal injury). If heme is found in the urine in the absence of red blood cells, further workup for rhabdomyolysis would then be warranted.

Toxicology testing can be performed but should be ordered based on patient presentation and clinical suspicion for the inappropriate administration of medications and street drugs. Regional poison control centers throughout the United States are always available for consultation and should be involved in unclear clinical cases and in critically ill patients.

SUPPORTIVE STUDIES—IMAGING

Imaging studies are case-dependent and should be tailored to the patient based on age, history, and examination.[31] Radiographic studies can aid in determining the extent of injury in intentional cases, but such studies can also help to provide an alternative etiology to injuries, especially fractures.[31-33]

FRACTURES

Fractures concerning for intentional trauma include: bilateral long bone acute fractures, metaphyseal corner fractures, long bone fracture in a non-ambulatory child, epiphyseal separations, rib/sternal/spinous process/scapular fractures, fractures of variable healing stages, digital fractures in children younger than 36 months, and vertebral subluxations/fractures without high force trauma, and severe skull fractures in children younger than 18 months. Despite being widely regarded as the superior study for detection of fractures in abused children,[23,3134-36] skeletal surveys were found to rarely provide information supplemental to history and physical examination in newly diagnosed isolated skull fracture in infants, to help with determination of report to child protective services.[37]

HEAD INJURY

Neuroimaging has been proposed as indicated in all patients with suspected nonaccidental head trauma as well as all children younger than 6 months with any suspected injury.[23,34,38,39] Unenhanced CT of the head is the recommended imaging for initial workup and evaluation. Among cases of child abuse, in the absence of neurologic symptoms, patient age less than 1 year is the only key factor found to predict more thorough diagnostic evaluation. Considering history and examination to be poorly sensitive when compared with neuroimaging detected abnormalities, providers should have low threshold for neuroimaging in the setting of suspected child abuse,[40] as there are no specific physical findings to identify abusive head trauma. Although any physician can perform an eye examination, ophthalmology referral is recommended in the setting of concern for abusive head trauma, given the subjective nature of funduscopy and rendering a diagnosis of retinal hemorrhage.

VISCERAL TRAUMA

Esophageal, cardiac, pulmonary, or intraabdominal injury can be caused by many different methods of abuse with variable presenting signs and symptoms. Low threshold is warranted to perform such imaging, especially considering the need for early diagnosis of such organ injury with prompt intervention.

DIFFERENTIAL DIAGNOSIS

A broad knowledge of skin diseases provides a unique insight into those diagnoses that may mimic various forms of abuse, namely, child abuse (Tables 102-3 and 102-4) and sexual abuse (Table 102-5).

ELDERLY ABUSE

Diagnosis of abuse can be especially challenging in the elderly population because of bruising being so common in this population. Not only does the normal process of aging entail increased skin fragility, but this patient population is more likely to be on medications causing ease of bleeding, particularly blood thinners.

CLINICAL COURSE AND PROGNOSIS

Early recognition and prompt diagnosis allows for expeditious intervention to allow for appropriate medical treatment. Additionally, taking steps to provide protection from perpetrators helps to prevent recurrence and optimizes prognosis.

TABLE 102-3
Conditions Mistaken for Abusive Bruising

- True petechiae and purpura
- Disorders of coagulation
- Ehlers-Danlos syndrome
- Infections
  - Rocky Mountain spotted fever
  - Meningococcal infections
  - Group A streptococcal infections
- Palpable purpura of vasculitis
- Valsalva petechiae
- Lichen sclerosus
- Folk remedies
  - Cao gio: rubbing vigorously with a hard object such as a coin
  - Cupping: suction mark left by the cooling of a warm metal cup
- Nodular lesions mimicking deep bruises
- Neuroblastoma
- Vascular malformations
- Dermatomyositis-associated nodules
- Erythema nodosum
- Discolorations that look like bruises
- Phytophotodermatitis
- Maculae caeruleae from lice infestation
- Mongolian spots
- Dye from blue jeans
- Inflammatory conditions that mimic bruising
  - Urticaria/angioedema/urticarial vasculitis
  - Pernio
- Conditions that mimic whip marks
  - Incontinentia pigmenti
  - Striae
  - Phytophotodermatitis

CHILD ABUSE

Pediatric patients who suffer from abuse that was not initially promptly diagnosed with the first offense have up to 50% risk of a second event.[41-44] One retrospective study identified children in ED thought to have accidental traumatic injuries, reporting 13% of these patients to present for second physical abuse injury

TABLE 102-4
Conditions Mistaken for Nonaccidental Burns

- Phytophotodermatitis
- Folk remedies (Maquas, or moxibustion): burns delivered near diseased organs or therapeutic sites as in acupuncture
- Impetigo/ecthyma
- Epidermolysis bullosa
- Immunobullous diseases
- Sunburn/xeroderma pigmentosum
- Burns from objects heated by sun
- Electric burn from an enuresis blanket
- Chemical burn from use of undiluted acetic acid
- Chemical burn from Icy Hot balm
- Chemical burn from calcium chloride
- Diaper dermatitis
- Pernio
- Fixed drug eruption

TABLE 102-5
Conditions Mistaken for Sexual Abuse

- Lichen sclerosus
- Crohn disease
- Localized vulvar pemphigoid
- Langerhans cell histiocytosis
- Perianal streptococcal dermatitis
- Hemangiomas
- Urethral prolapse
- Entities that look like condylomata acuminata
  - Focal epithelial hyperplasia
  - Darier disease
  - Lymphangioma circumscriptum
  - Pigmented vulvar hamartomas
  - Pseudoverrucous papules
  - Epidermal nevus and inflammatory linear verrucous epidermal nevus
- Entities that look like herpes simplex
  - Localized varicella/zoster
  - Allergic contact dermatitis

within 5 years of first event.[45] In the United States, deaths related to child abuse/neglect incidence is estimated to reach up to 2500 deaths annually (predominantly of infants less than 1 year of age).[6] The World Health Organization (WHO) proposed that 13% of the 1.2 million deaths worldwide of children younger than 15 years to be due to child abuse/neglect.[6]

MANAGEMENT

True abuse must be reported and a thorough evaluation conducted. It is essential that practitioners develop a relationship with the institution or individual in their area who is best able to manage these difficult cases. Ideally, there should be an abuse team consisting of a dermatologist, pediatrician, social worker, medical photographer, and, when needed, pediatric subspecialists such as orthopedists, hematologists, psychologists, and gynecologists. The need for specialization in this field is highlighted by the institution in the United States of pediatric subspecialty board certification in child abuse, beginning in 2010.

It is most helpful if one's relationship is forged with the abuse team before an abuse incident and a set protocol for dealing with alleged or suspected abuse is established in the practitioner's office. Hospitalization is indicated not only for medical stabilization to workup and manage acute injuries, but also in select patients to ensure safety from his or her perpetrator. Many countries including the United States require reporting any cases of suspected abuse to appropriate government authorities. Documentation is essential and should include a recount of the (preferably quoted) spoken word (by patient and by any other involved individuals, including providers and family members) as well as detailed physical examination findings with reliance on facts. Photographs are ideal for documentation of injuries.

CHILD ABUSE

Local emergency phone numbers for reporting abuse can be obtained from the Child Welfare Information Gateway or Childhelp National Headquarters.

ELDERLY ABUSE

Information on a particular state's laws can be obtained from the National Center on Elder Abuse. The nearest medical center's social service department is well equipped to offer guidance, but the agencies listed in Table 102-6 are also helpful resources.

DOMESTIC ABUSE

The social service department at the local medical center is a good resource for information and help on domestic violence. The National Domestic Violence hotline (800-799-7233) is a 24-hour resource for women who need to find a local shelter. Other helpful organizations can be contacted (Table 102-6).

TABLE 102-6
Helpful Agencies for Information on Abuse and Domestic Violence

- Child Welfare Information Gateway, 1250 Maryland Avenue, SW, Eighth Floor, Washington, DC 20024, Ph: (800) 394-3366, email: info@childwelfare.gov, http://www.childwelfare.gov/
- Childhelp National Headquarters, 15757 N. 78th Street, Suite B, Scottsdale, AZ 85260, Ph: (480) 922-8212, http://www.childhelpusa.org
- Domestic Violence International Resources, http://www.vachss.com/help_text/domestic_violence_intl.html
- International Network for the Prevention of Elder Abuse, http://www.inpea.net, e-mail contactus@inpea.net
- International Society for Prevention of Child Abuse and Neglect, 13123 E. 16th Ave, B390, Aurora, CO 80045, Ph: (303) 864-5220, Fax: (303) 864-5222, email: ispcan@ispcan.org, http://www.ispcan.org
- National Adult Protective Services Association, 920 S. Spring Street, Suite 1200, Springfield, IL 62704, Ph: (217) 523-4431, Fax: (217) 522-6650, http://www.apsnetwork.org
- National Center on Elder Abuse, c/o Center for Community Research and Services, University of Delaware, 297 Graham Hall, Newark, DE 19716, Ph: (302) 831-3525, Fax: (302) 831-42525, e-mail ncea-info@aoa.hhs.gov, http://www.elderabusecenter.org
- National Committee for the Prevention of Elder Abuse, 1612 K Street, NW, Suite 400, Washington, DC 20006, Ph: (202) 682-4140, Fax: (202) 223-2099, email: ncpea@verizon.net, http://www.preventelderabuse.org
- National Coalition Against Domestic Violence, 1120 Lincoln Street, Suite 1603, Denver, CO 80203, Ph: (303) 839-1852, Fax: (303) 831-9251, email mainoffice@ncadv.org, http://www.ncadv.org
- National Resource Center on Domestic Violence, 6400 Flank Drive, Suite 1300, Harrisburg, PA 17112, Ph: (800) 537-2238 ext. 5, Fax (717) 545-9456, http://www.nrcdv.org

REFERENCES

1. Vandeven AM, Newton AW. Update on child physical abuse, sexual abuse, and prevention. *Curr Opin Pediatr.* 2006;18(2):201-205.
2. Flaherty EG, Sege R. Barriers to physician identification and reporting of child abuse. *Pediatr Ann.* 2005; 34(5):349-356.
3. Administration for Children and Families. *Child Maltreatment Annual Report*. http://www.acf.hhs.gov/programs/cb/pubs/cm10/cm10.pdf. Published 2010.
4. *Child Maltreatment Report*. http://www.acf.hhs.gov/sites/default/files/cb/cm11.pdf. Published 2011.
5. Sedlak AJ, Mettenberg J, Basena M, et al. *Fourth National Incidence Study of Child Abuse and Neglect (NIS–4): Report to Congress*. 2010, U.S. Department of Health and Human Services, Administration for Children and Families. Washington, DC.
6. Gilbert R, Widom CS, Browne K, et al. Burden and consequences of child maltreatment in high-income countries. *Lancet.* 2009;373(9657):68-81.
7. Finkelhor D, Turner HA, Shattuck A, et al. *Prevalence of Childhood Exposure to Violence, Crime, and Abuse: Results From the National Survey of Children's Exposure to Violence*. *JAMA Pediatr.* 2015;169(8):746-754.
8. National Research Council. Panel to Review Risk and Prevalence of Elder Abuse and Neglect. *Elder mistreatment: Abuse, Neglect, and Exploitation in an Aging America*. Washington, DC: National Academies Press; 2003.
9. Gorbien MJ, Eisenstein AR. Elder abuse and neglect: an overview. *Clin Geriatr Med.* 2005;21(2):279-292.
10. Abbey L. Elder abuse and neglect: when home is not safe. *Clin Geriatr Med.* 2009;25(1):47-60, vi.
11. Toohey JS. Domestic violence and rape. *Med Clin North Am.* 2008;92(5):1239-1252, xii.
12. Zolotor AJ, Denham AC, Weil A. Intimate partner violence. *Obstet Gynecol Clin North Am.* 2009;36(4):847-860, xi.
13. Tsokos M. Diagnostic criteria for cutaneous injuries in child abuse: classification, findings, and interpretation. *Forensic Sci Med Pathol.* 2015;11(2):235-242.
14. Maguire S, Mann MK, Sibert J, et al. Can you age bruises accurately in children? A systematic review. *Arch Dis Child.* 2005;90(2):187-189.
15. Kellogg N. American Academy of Pediatrics Committee on Child Abuse and Neglect. The evaluation of sexual abuse in children. *Pediatrics.* 2005;116(2):506-512.
16. Anderst J, Kellogg N, Jung I. Reports of repetitive penile-genital penetration often have no definitive evidence of penetration. *Pediatrics.* 2009;124(3):e403-e409.
17. Pillai M. Genital findings in prepubertal girls: what can be concluded from an examination? *J Pediatr Adolesc Gynecol.* 2008;21(4):177-185.
18. Cohen BA, Honig P, Androphy E. Anogenital warts in children. Clinical and virologic evaluation for sexual abuse. *Arch Dermatol.* 1990;126(12):1575-1580.
19. Yeoh C, Nixon JW, Dickson W, et al. Patterns of scald injuries. *Arch Dis Child.* 1994;71(2):156-158.
20. Kos L, Shwayder T. Cutaneous manifestations of child abuse. *Pediatr Dermatol.* 2006;23(4):311-320.
21. Swerdlin A, Berkowitz C, Craft N. Cutaneous signs of child abuse. *J Am Acad Dermatol.* 2007;57(3):371-392.
22. Kemp AM, et al. Patterns of bruising in preschool children—a longitudinal study. *Arch Dis Child.* 2015; 100(5): 426-31.
23. Christian CW. Committee on Child Abuse and Neglect, American Academy of Pediatrics. The evaluation of suspected child physical abuse. *Pediatrics.* 2015;135(5): e1337-e1354.
24. Child Maltreatment 2007. U.S. Department of Health and Human Services, Administration on Children, Youth and Families, Washington, DC.
25. Hettler J, Greenes DS. Can the initial history predict whether a child with a head injury has been abused? *Pediatrics.* 2003;111(3):602-607.
26. Kellogg ND. American Academy of Pediatrics Committee on Child Abuse and Neglect. Evaluation of suspected child physical abuse. *Pediatrics.* 2007;119(6):1232-1241.
27. Minford AM, Richards EM. Excluding medical and haematological conditions as a cause of bruising in suspected non-accidental injury. *Arch Dis Child Educ Pract Ed.* 2010;95(1):2-8.
28. Cameron CM, Lazoritz S, Calhoun AD. Blunt abdominal injury: simultaneously occurring liver and pancreatic injury in child abuse. *Pediatr Emerg Care.* 1997;13(5):334-336.
29. Lindberg DM, Shapiro RA, Blood EA, et al. Utility of hepatic transaminases in children with concern for abuse. *Pediatrics.* 2013;131(2):268-275.
30. Jenny C. Committee on Child Abuse and Neglect. Evaluating infants and young children with multiple fractures. *Pediatrics.* 2006;118(3):1299-1303.
31. Section on Radiology; American Academy of Pediatrics. Diagnostic imaging of child abuse. *Pediatrics.* 2009;123(5):1430-1435.
32. Merten DF, Radkowski MA, Leonidas JC. The abused child: a radiological reappraisal. *Radiology.* 1983;146(2):377-381.
33. Ablin DS, Sane SM. Non-accidental injury: confusion with temporary brittle bone disease and mild osteogenesis imperfecta. *Pediatr Radiol.* 1997;27(2):111-113.
34. Meyer JS, Gunderman R, Coley BD, et al. ACR Appropriateness Criteria((R)) on suspected physical abuse-child. *J Am Coll Radiol.* 2011;8(2):87-94.
35. Offiah A, van Rijn RR, Perez-Rossello JM, et al. Skeletal imaging of child abuse (non-accidental injury). *Pediatr Radiol.* 2009;39(5):461-470.
36. British Society of Paediatric Radiology. *Standard for skeletal surveys in suspected non-accidental injury (NAI) in children*. www.bspr.org.uk/nai.htm. Published 2009.
37. Wood JN, Christian CW, Adams CM, et al. Skeletal surveys in infants with isolated skull fractures. *Pediatrics.* 2009;123(2):e247-e252.
38. Datta S, Stoodley N, Jayawant S, et al. Neuroradiological aspects of subdural haemorrhages. *Arch Dis Child.* 2005;90(9):947-951.
39. Rubin DM, Christian CW, Bilaniuk LT, et al. Occult head injury in high-risk abused children. *Pediatrics.* 2003;111(6, pt 1):1382-1386.
40. Laskey AL, Holsti M, Runyan DK, et al. Occult head trauma in young suspected victims of physical abuse. *J Pediatr.* 2004;144(6):719-722.
41. DePanfilis D, Zuravin SJ. Predicting child maltreatment recurrences during treatment. *Child Abuse Negl.* 1999;23(8):729-743.
42. Drake B, Jonson-Reid M, Way I, et al. Substantiation and recidivism. *Child Maltreat.* 2003;8(4):248-260.
43. Connell CM, Vanderploeg JJ, Katz KH, et al. Maltreatment following reunification: predictors of subsequent Child Protective Services contact after children return home. *Child Abuse Negl.* 2009;33(4):218-228.
44. Fluke JD, Shusterman GR, Hollinshead D, et al. *Rereporting and recurrence of child maltreatment: Findings from NCANDS*. ASPE Reports 2005. http://aspe.hhs.gov/hsp/05/child-maltreat-rereporting.
45. Friedman SB, Morse CW. Child abuse: a five-year follow-up of early case finding in the emergency department. *Pediatrics.* 1974;54(4):404-410.

This page intentionally left blank

Skin Changes Across the Span of Life

PART 19

Chapter 103 :: Neonatal Dermatology

:: Raegan Hunt, Mary Wu Chang, & Kara N. Shah

AT-A-GLANCE

- Many dermatologic diseases exhibit different manifestations in newborns, infants, and children, and a subset of skin conditions are only encountered in neonates.
- Certain neonatal skin conditions require special attention as they may be a sign of a serious health condition.
- The medical history and methods of clinical examination in neonates differ from the approaches used with older children and adults. It is very important to elicit a thorough maternal and obstetric history with an emphasis on maternal health and any complications during pregnancy or delivery.
- The neonate has increased risk for systemic toxicity from topically applied substances; the risk is even greater in premature infants.

Neonatal skin diseases are a fascinating and unique spectrum of dermatologic conditions. They encompass a broad range of diagnoses, including manifestations of neonatal or maternal infection, developmental defects, cutaneous features of genetic disorders, birthmarks, malignancy, complications of prematurity, and benign transient clinical findings. An understanding of benign cutaneous conditions of newborns and an ability to identify more worrisome presentations are essential to the care of the neonate.

Appropriate care of the neonatal patient requires a thorough understanding of the maternal health history, including maternal disease as well as pregnancy complications.

NEONATES

The neonatal period is defined as the first 30 days of life. Infancy is defined as beginning after the first 30 days of life. Although this chapter focuses on conditions presenting in the neonatal period, some conditions may occur in infancy as well. Even though many neonatal skin diseases are benign and self-limiting, serious disease may occur, and cutaneous manifestations of systemic disease or an associated genetic syndrome should not be overlooked.

Full-term infants are born between 37 and 42 weeks of gestation. Preterm or premature infants are born before 37 weeks of gestation.

NEONATAL SKIN

NEONATAL SKIN PHYSIOLOGY

The skin with its associated appendages provides several important functions. It serves as a barrier against microbes and environmental and other external toxins, provides thermoregulation, prevents transepidermal water loss, and aids in sensory perception. Knowledge of normal embryologic development and the physiology of neonatal skin is helpful for understanding the adaptive changes that occur after birth and for guiding appropriate skin care in both full-term and preterm neonates.

The epidermis begins to develop around 6 weeks of gestational age as a basal cell layer and a superficial periderm layer; the periderm does not contribute to the formation of the stratified squamous epithelium and is shed during the end of the second trimester.[1] Stratification of the fetal epidermis begins in the eighth week of gestation; terminal differentiation commences first in

the skin appendages between the 11th and 15th weeks of gestation and then in the interfollicular epidermis; by 22 to 24 weeks of gestation the epidermis consists of 4 to 5 cell layers.[2,3] The dermal–epidermal junction is evident by 8 weeks of gestational age, and collagen fiber formation and organization of the papillary and reticular dermis occurs by 15 weeks of gestation; elastic fibers are noted at 22 to 24 weeks of gestation.[4,5] Hair follicles begin to develop around the 14th week of gestation; lanugo hair production begins around the 18th week of gestation and is complete by the 28th week of gestation.[6,7] Eccrine gland development is completed during the second trimester, although the eccrine glands are not functional until after birth. Apocrine gland formation occurs somewhat later in fetal development, and the apocrine glands are transiently functional during the third trimester of pregnancy. Sebaceous gland formation begins around the 16th week of gestation, and the sebaceous glands are functional shortly after formation; sebaceous gland products contribute significantly to the lipid composition of vernix caseosa.[8,9]

In utero, the skin of the fetus is protected by the vernix caseosa and is immersed in amniotic fluid. Vernix production correlates with epidermal maturation and the formation of the stratum corneum; production begins around the 36th week of gestation. Vernix caseosa is composed of water-containing corneocytes in a lipid matrix composed predominantly of nonpolar lipid such as sterol esters and triglycerides.[9,10] It provides antimicrobial, antioxidant, and barrier functions, and contains multiple antimicrobial peptides, including LL-37, cystatin A, and calgranulins.[11,12] After birth, the vernix is often manually removed and the skin exposed to room air, although some experts question the validity of this practice.

Of particular interest is the development of the epidermal barrier, including postnatal development of barrier function in term and preterm neonates.[13] After birth, the skin of the neonate undergoes a series of changes in adaptation to the extrauterine terrestrial environment. Additional maturation of the stratum corneum in neonates occurs in response to air, which contributes to the development of a functional epidermal barrier. It is generally accepted that full barrier function is achieved within 2 to 4 weeks of life in term neonates, and some experts believe that the barrier is fully developed at birth in this population.[14] In preterm infants, the epidermal barrier in immature. Barrier stabilization is a dynamic process dependent upon a balance between several biologic and environmental factors. Evaluation of parameters such as skin thickness, skin pH, transepidermal water loss (TEWL), and stratum corneum hydration indicate that neonatal skin undergoes continuous adjustment to the extrauterine environment. In full-term neonates, after drying of the skin in the first few hours after birth, TEWL is equivalent to that seen in adults, with the exception of some variability because for site and ambient temperature and/or humidity, including the diaper area, where TEWL vales are higher and contribute to impaired barrier function and risk for diaper dermatitis.[15,16]

Figure 103-1 The feet of a postterm newborn. The dry, hyperlinear, and scaly skin is typical of babies born after 40 weeks of gestation. Incidentally, pustules of transient neonatal pustular melanosis are also seen.

One of the most visible early manifestations of the adaptive process is desquamation of the upper layers of the stratum corneum, which occurs in all infants. Postterm infants born after 40 weeks of gestation have decreased amounts of vernix caseosa on the skin and more notable desquamation (Fig. 103-1). During the first 3 months of life, the thickness of the stratum corneum decreases, and epidermal thickness increases, along with the formation of dermal papillae and epidermal ridges.[17]

Normal skin pH is acidic; the acidic pH of the stratum corneum results from multiple factors, including the production of free fatty acids from phospholipids and the presence of sweat and sebum.[18] In the term and preterm neonate, skin pH is more alkaline than that of older infants and adults, and it decreases gradually over the first few weeks of life.[19-21]

Sebum production is high in the neonate, and decreases over the first few months of life.[22] Eccrine sweating is present in term neonates, but delayed in preterm neonates.[23,24]

PREMATURITY

Premature neonates, particularly those born before 34 weeks of gestation, have markedly decreased epidermal barrier function. The functional maturation of the stratum corneum begins around 24 weeks of gestational age, and in preterm neonates born before 26 weeks of gestation, functional maturation of the epidermal barrier may take longer than 4 weeks.[25,26] TEWL is significantly increased in preterm and

low-birthweight neonates, reflecting epidermal barrier immaturity, and TEWL increases with decreasing gestational age.[27] Use of radiant warmers and phototherapy also contribute to increased TEWL.[28,29] Impaired epidermal barrier function places the preterm infant at risk for electrolyte imbalances, poor thermoregulation, dehydration, increased absorption of topical agents, and infection.

Increased skin fragility is also noted in preterm infants. Epidermal and dermal injury may lead to significant cutaneous pain even with routine handling and nursing care. The premature infant is at risk for infection and sepsis from skin-associated organisms entering through breaks in the thin and fragile skin and via iatrogenic portals of entry such as indwelling venous catheters. Thermal regulation is dysfunctional because of a thin subcutaneous fat layer, decreased ability to sweat, poor autonomic control of cutaneous blood vessels, and a large surface-area-to-body-mass ratio. In the nursery, the premature infant is usually placed in a temperature- and humidity-controlled isolette until temperature and fluid regulation stabilize.

In the 1990s, researchers reported that application of petrolatum-based emollient therapy appeared to be beneficial by decreasing TEWL in hospitalized preterm infants.[30] Subsequently, many neonatal intensive care units began to implement the use of various emollients and skin-care regimens. However, while skin integrity consistently improved, a threefold increase in the incidence of systemic candidiasis was reported after emollient therapy was implemented in extremely low-birthweight (≤1000 g) premature infants in one neonatal intensive care unit.[31] Similarly, an outbreak of systemic candidiasis occurred in very-low-birthweight neonates (≤1500 g) using emollient therapy in a different neonatal intensive care unit.[32] A 2004 Cochrane review concluded that prophylactic application of topical ointments increased the risk for nosocomial infection and advised against their routine use in preterm infants. In contrast, randomized, controlled studies in a population of impoverished Bangladeshi preterm neonates have demonstrated decreased mortality rates when sunflower seed oil or Aquaphor ointment was applied by massage, compared to premature infants not receiving massage or emollients, suggesting that in certain populations, such as those without access to sophisticated neonatal intensive care practices, use of emollients may be beneficial in high-risk preterm infants.[33] A 2016 Cochrane review concluded that the use of topical emollients in preterm infants did not prevent invasive infection or death.[34] Until prospective, controlled trials are performed, neonates receiving petrolatum-based emollient therapy should be carefully monitored for infections, particularly those infants with birthweights less than 1500 g.

SKIN CARE IN THE NEONATE

Recommendations for routine skin care in the neonate, as provided by a panel of European experts, include bathing in water 2 to 3 times per week for no more than 5 to 10 minutes with use of a gentle soap-free liquid skin cleanser as opposed to a washcloth; application of an emollient after bathing is also recommended.[35] An appropriate skin-care regimen serves to minimize overbathing, maintain the epidermal barrier, minimize exposure to potential irritants or allergens, and remove fecal material.

Well-meaning parents often bathe their infants too frequently and use a multitude of products on their infant's skin. In addition to irritation and asteatosis, these practices may increase the risk of allergic contact dermatitis in infants. It has been estimated that the average newborn is exposed to approximately 10 skin care products in the first month of life, leading to exposure to more than 50 different chemicals, ranging from mildly toxic to toxic.[36] Parents should be taught that "less is best."[37] Use of a skin cleanser in healthy, term infants has been shown to have no effect on TEWL, skin surface pH, and stratum corneum hydration, as compared to bathing with water alone.[38] Skin care in full-term neonates from birth to 8 weeks of age with cleansing gel, gel plus cream, water alone, or water plus cream showed no significant differences in skin condition, microbial colonization, and sebum level.[39,40]

Neonates have an increased risk for systemic toxicity from topically applied substances. This is largely a result of the greater surface-area-to-body-mass ratio in the newborn. Preterm neonates have an even greater surface-area-to-body-mass ratio than term neonates. In addition, the metabolism, excretion, distribution, and protein binding of substances can differ significantly in neonates as compared to adults, which increases the risk of toxicity; these adverse effects may be magnified in the preterm neonate. Local or systemic toxicity can occur in the term or preterm neonate not only from topical medications, but also from soaps, lotions, and other cleansing solutions. Neonates with disorders of skin-barrier function, such as congenital ichthyosis, are at increased risk for systemic absorption of topical medications and chemicals.[41]

EXAMINATION TECHNIQUES

For the neonate, a complete medical history includes gestational and birth history as well as family history. Exposures during pregnancy, including medications, illicit drugs, and infectious diseases, such as varicella, rubella, or sexually transmitted diseases, are important to review in detail. Additionally, other complications of pregnancy and parturition and the appearance of the placenta offer useful clinical information.

Comprehensive examination of the skin of a neonate in good lighting is valuable, particularly as some skin findings are initially subtle. For example, a vasoconstricted macule or an erosion can be the presenting sign of an infantile hemangioma.[42] All congenital lesions (eg, pigmented lesions, vascular birthmarks, aplasia cutis, cutaneous nodules) warrant thorough

evaluation to help exclude associated syndromes or internal disease. Biopsy should be considered when the diagnosis is unclear and the outcome will impact management. Midline face, scalp, or spine lesions may be associated with CNS connections and should be imaged to rule out CNS communication prior to performing a skin biopsy.

The newborn is completely dependent on caretakers, and the family structure and social support network should be considered when developing treatment plans. Some new parents may feel overwhelmed or unprepared to deal with a skin condition in their infant. At times, the treatment priorities of the parents may not seem to coincide with the best interests of the newborn at this early stage in their development. Medical and surgical decision making for affected infants is typically aimed at improving function in favor of cosmesis.

DISEASES OF NEONATES

TRANSIENT DERMATOSES OF THE NEONATE

Benign skin conditions encountered in newborns that tend to resolve by 30 days of age are considered to be transient. They are very common, and the majority do not require intervention. These conditions are discussed below, and Table 103-1 lists a selected differential diagnosis based on broad categories of skin lesions encountered in neonates and infants.

CAPUT SUCCEDANEUM AND CEPHALOHEMATOMA

Trauma during delivery may induce one of several injuries to the scalp of the neonate.[43] These range from common and usually benign conditions such as caput succedaneum and cephalohematoma to subgaleal hemorrhage, which is a serious, potentially life-threatening condition.

Caput succedaneum results from subcutaneous edema over the presenting part of the head owing to pressure against the cervix and is a common occurrence in newborns. Caput succedaneum is soft to palpation with ill-defined borders. Petechiae and ecchymosis also may be noted. The edema resolves spontaneously over 7 to 10 days.

Cephalohematoma results from rupture of the diploic and/or emissary veins and subsequent subperiosteal collection of blood. It is associated with birth trauma or the use of vacuum extraction vaginal delivery. Areas of hemorrhage respect the suture lines, are well-delimited, usually unilateral, and feel firm to palpation. An underlying skull fracture may be present. Cephalohematomas usually resolve without sequelae over several weeks, but calcification may occur.

Subgaleal hemorrhage is also associated with birth trauma and occurs when there is bleeding between the periosteum of the skull and the galea as a result of damage to the emissary veins. Extensive hemorrhage may occur with either subgaleal hemorrhage or cephalohematoma, and may lead to anemia and neonatal hyperbilirubinemia. With a subgaleal hemorrhage, bleeding can be catastrophic and result in hypovolemic shock or disseminated intravascular coagulation.

TABLE 103-1
Selected Differential Diagnosis of Neonates and Infants

- Pustules
  - Erythema toxicum neonatorum
  - Transient neonatal pustular melanosis
  - Congenital candidiasis
  - Pustular psoriasis
  - Langerhans cell histiocytosis
  - Neonatal cephalic pustulosis
  - Bacterial sepsis
  - Herpes simplex infection
- Blisters
  - Sucking blisters
  - Herpes simplex virus
  - Aplasia cutis congenita
  - Cutaneous mastocytosis
  - Epidermolysis bullosa
  - Neonatal pemphigus
  - Varicella
  - Impetigo
  - Incontinentia pigmenti
  - Epidermolytic ichthyosis
- The red scaly baby
  - Physiologic scaling and redness (postdates) infant
  - Psoriasis
  - Atopic dermatitis
  - Scabies
  - Seborrheic dermatitis
  - Immunodeficiency
  - Hypohidrotic ectodermal dysplasia
  - Netherton syndrome
  - Acrodermatitis enteropathica
- The collodion baby
  - Lamellar ichthyosis
  - Congenital ichthyosiform erythroderma
  - Gaucher syndrome
  - Trichothiodystrophy
  - Neutral lipid storage disorder
- The "blueberry muffin" baby
  - TORCH infections
  - Congenital leukemia
  - Congenital self-healing reticulohistiocytosis
  - Blue rubber bleb nevus syndrome
  - Twin–twin transfusion

TORCH, toxoplasmosis, other agents, especially syphilis, but also hepatitis B, coxsackievirus, Epstein-Barr virus, varicella-zoster virus, and human parvovirus, rubella, cytomegalovirus, herpes simplex virus.

MILIA

Milia are pinpoint to 2-mm papules representing benign, superficial epidermal inclusion cysts. Usually few in number, they are seen most commonly on the

face in newborns and may be present in the oral cavity as well, where they are called *Epstein pearls*. Congenital milia en plaque also has been reported.[44] Milia generally resolve spontaneously within a few weeks of life. When persistent and/or numerous, they may be seen in association with several rare genetic disorders, including oral-facial-digital syndrome, Bazex-Dupré-Christol syndrome, and Basan syndrome.

SEBACEOUS GLAND HYPERPLASIA

At least 50% of normal newborns have sebaceous gland hyperplasia (Fig. 103-2). Minute (<1 mm) yellow macules or papules are commonly seen at the opening of pilosebaceous follicles over the nose and central forehead of term newborns. This is a benign condition thought to occur secondary to maternal androgen stimulation of the sebaceous glands; it typically resolves spontaneously by 4 to 6 months of age.

ERYTHEMA TOXICUM NEONATORUM

Erythema toxicum neonatorum is an idiopathic, common skin condition seen in up to 75% of term newborns. It is rarely seen in premature infants. Blotchy erythematous patches 1 to 3 cm in diameter with a 1- to 4-mm central vesicle or pustule are characteristic of erythema toxicum neonatorum (Fig. 103-3). The eruption usually begins at 24 to 48 hours of age, but delayed eruption as late as 10 days of age has been documented.[45] These follicular-based lesions can be located anywhere but tend to spare the palms and soles. A smear of the central vesicle or pustule contents will reveal numerous eosinophils on Wright-stained preparations. A peripheral blood eosinophilia of up to 20% may be associated, particularly in infants, with numerous lesions. Erythema toxicum neonatorum is benign and clears spontaneously by 2 to 3 weeks of age without residua.

Figure 103-2 Sebaceous hyperplasia on the nose of a 1-day-old infant.

Figure 103-3 Erythema toxicum neonatorum. Erythematous macules, some with a tiny central papule or pustule, on the arm of a 1-day-old newborn.

TRANSIENT NEONATAL PUSTULAR MELANOSIS

Transient neonatal pustular melanosis is an idiopathic pustular eruption of the newborn that resolves with hyperpigmented macules (Fig. 103-4). It is less common than erythema toxicum neonatorum and is more prevalent among newborns with darkly pigmented skin. Lesions are usually present at birth or shortly thereafter, but may appear as late as 3 weeks of age. The eruption is characterized by multiple superficial vesicles and pustules, with ruptured lesions evident as collarettes of scale. Hyperpigmented macules are also often present at birth or develop at the sites of resolving pustules or vesicles within several hours of birth or during the first days of life. Lesions can occur anywhere but are common on the forehead and mandibular area. The palms and soles may be involved. Smear of the vesicle or pustule contents will reveal a predominance of neutrophils with occasional eosinophils on Wright-stained preparations. The pustules usually disappear within 5 to 7 days; residual pigmented macules resolve over several weeks.

MILIARIA RUBRA AND CRYSTALLINA

Miliaria or "heat rash" is a common disorder of the eccrine glands that typically results from fever or overheating such as may occur when neonates are swaddled. Eccrine gland occlusion by sweat and possibly by the extracellular polysaccharides of *Staphylococcus*

Figure 103-4 Transient neonatal pustular melanosis. **A,** A newborn with congenital, thin-walled pustules that rupture easily. **B,** Hyperpigmented macules appeared by 10 hours of age.

epidermidis leads to the development of minute superficial subcorneal vesicles (miliaria crystallina). A deeper level of occlusion within the epidermis with associated inflammation leads to miliaria rubra, which manifests as 1- to 3-mm erythematous papules and/or papulopustules. The condition resolves spontaneously once the inciting factors are addressed.

MOTTLING AND CUTIS MARMORATA

Mottling is a blotchy or lace-like pattern of dusky erythema over the extremities and trunk of neonates that occurs with exposure to cold environments. Virtually all babies demonstrate mottling at some time during the newborn period as a consequence of immature autonomic control of the cutaneous vascular plexus. This physiologic mottling disappears on rewarming, differentiating it from cutis marmorata telangiectatica congenita and livedo reticularis. Physiologic mottling resolves spontaneously by 6 months of age.

HARLEQUIN COLOR CHANGE

Harlequin color change is a rare vascular phenomenon that occurs in in full-term newborns, as well as in low-birthweight and premature infants, and in infants exposed to hypoxia or systemic treatment with prostaglandins. In harlequin color change, when the neonate is placed on one side, an erythematous flush with a sharp demarcation at the midline develops on the dependent side, and the upper half of the body becomes pale. The color change usually subsides within a few seconds of placing the baby in the supine position but may persist for as long as 20 minutes. Presentation may be localized to a single body area or may be more generalized. The exact mechanism of this unusual phenomenon is not known, but it may be a result of immaturity of autonomic vasomotor control.[46] Harlequin color change is seldom seen after 10 days of age, and if noted to be persistent or to develop at an older age, may be a manifestation of an underlying neurologic disorder.

SUCKING BLISTERS

Sucking blisters may be present at birth as the result of intrauterine sucking, but are more commonly seen during the first weeks of life. Sucking blisters are usually solitary, intact, oval or linear blisters, superficial erosions, or crusts, arising on noninflamed skin on the dorsal aspect of the forearms, wrists, or fingers; a callus may be noted on the upper lip. They resolve within a few days. If the affected extremity is brought up to the infant's mouth, the infant will often commence sucking at the site, confirming the diagnosis.

BENIGN NEONATAL CEPHALIC PUSTULOSIS

Neonatal acneiform facial eruptions usually develop within the first 30 days of life and are estimated to occur in 50% of newborns (Fig. 103-5). Neonatal cephalic pustulosis is most common, and has been attributed to overgrowth of *Malassezia* spp.[47,48] Most cases resolve spontaneously, but the eruption can be treated topically with ketoconazole. True infantile acne is less common and can be distinguished by later age of onset and the presence of comedones, acneiform cysts, and scars (Fig. 103-6).

BIRTHMARKS

Birthmarks are common in newborns, and range from common, benign conditions such as nevus simplex

Figure 103-5 Benign neonatal cephalic pustulosis. Tiny papulopustules on the cheeks of a 3-week-old infant.

and dermal melanocytosis to more worrisome conditions such as large segmental hemangiomas and giant congenital melanocytic nevi. Although most birthmarks are of little medical or psychosocial consequence, the social and cultural impact of a disfiguring birthmark on both the patient and the parents should not be underestimated.[49] Table 103-2 lists common birthmarks.

PIGMENTARY BIRTHMARKS

Dermal Melanocytosis: Dermal melanocytosis (commonly called "Mongolian spots") is characterized by blue-gray patches typically located on the lumbosacral or buttock skin of infants. Collections of dermal melanocytes cause these common birthmarks, which are seen in 80% to 90% of infants of color and only 5% of white infants.[50,51]

Café-au-Lait Macules: Café-au-lait macules are well-demarcated tan macules or patches. Solitary café-au-lait macules are very common, however, the presence of multiple café-au-lait macules raises the possibility of neurofibromatosis type 1 (see Chap. 135). It is important to remember that findings of neurofibromatosis type 1 are progressive, so a potential

Figure 103-6 Infantile acne. True comedones and inflammatory papules are noted on the cheeks of a healthy 10-month-old girl.

TABLE 103-2
Common Birthmarks in the Newborn

- Dermal melanocytosis (commonly called "Mongolian spots")
- Nevus simplex (salmon patch, "stork bite," "angel's kiss")
- Port-wine stain (capillary malformation)
- Infantile hemangioma
- Epidermal nevus and nevus sebaceus
- Congenital melanocytic nevi
- Nevus depigmentosus
- Café-au-lait spots

neurofibromatosis type 1 diagnosis cannot be excluded based on neonatal examination of an infant with 1 or a few café-au-lait macules. Less-common genetic disorders are also associated with multiple café-au-lait macules. A large, geographic café-au-lait macule with a "coast-of-Maine" appearance is most likely to be an isolated skin finding but may be a marker for McCune-Albright syndrome.

Congenital Melanocytic Nevi: Melanocytic nevi that are present at birth or that appear within the first few months of life are "classic" congenital melanocytic nevi (CMN). Additionally, "late-onset" or "tardive" CMN may appear any time before age 2 years, and both are considered to be programmed from birth. CMN are typically barely elevated melanocytic papules or plaques that range in color from light brown to very dark brown or black. Some CMN have well-demarcated, geographic borders, and internal speckled patterns may be seen.

CMN enlarge proportionately as children grow. It is estimated that the size of CMN between infancy and adulthood will increase 1.7-fold on the head, whereas CMN on the lower extremities will increase 3.3-fold, and CMN of other sites will increase 2.8-fold. CMN are classified based on projected adult size into the following categories: small (<1.5 cm); medium (M1 1.5 to 10 cm, M2 >10 to 20 cm); large (L1 >20 to 30 cm, L2 >30 to 40 cm); and giant (G1 >40 to 60 cm, G2 >60 cm).[52]

Large and giant CMN are associated with an increased risk of melanoma. Additionally, individuals with large or giant CMN may be at risk for complications of neurocutaneous melanocytosis, particularly if the large or giant CMN has a posterior axial location or if more than 20 satellite nevi are present. Newborns with more than 2 medium-sized CMN are also at increased risk of neurocutaneous melanocytosis. Neurocutaneous melanocytosis results from abnormal melanocytic proliferations in the CNS, and can be complicated by obstructive hydrocephalus and primary CNS melanoma.

Pigmentary Mosaicism: Pigmentary mosaicism (patterned dyschromatosis) refers to areas of skin hypopigmentation or hyperpigmentation that are genetically determined by late somatic mosaic genetic mutations in skin cell progenitors. The dyschromia in pigmentary mosaicism tends not to cross the midline

of the body. Altered pigmentation may be curvilinear along Blaschko lines, or may manifest with checkerboard, phylloid, or patchy patterns.[53] In most cases, pigmentary mosaicism is an isolated finding, but the practitioner should maintain high suspicion for associated disease in children with widespread skin dyschromia, associated neurologic, cardiac, or musculoskeletal disease, or in children who are delayed in accomplishing expected developmental milestones.[54]

Nevus Depigmentosus: Nevus depigmentosus is a well-demarcated hypopigmented patch present from birth, which may sometimes become more visible in the first year of life as the background skin pigmentation of the newborn gradually increases. Three or more nevus depigmentosus/hypomelanotic patches in a newborn should prompt evaluation for possible tuberous sclerosis complex.[55]

Nevus Anemicus: Nevus anemicus describes a hypopigmented patch that results from focal vasoconstriction. It is attributed to skin vessel hypersensitivity to catecholamines in the affected areas. Application of pressure with a glass slide (diascopy) across the edge of a nevus depigmentosus will blanch the normal skin surrounding the nevus depigmentosus by compressing local vessels and thus blur the border. Diascopy is helpful in distinguishing nevus anemicus from nevus depigmentosus (Table 103-3), as the border of a nevus depigmentosus remains crisp despite diascopy.

VASCULAR BIRTHMARKS

Vascular tumors and malformations may present during the neonatal period, and prompt diagnosis and differentiation of those that may be associated with systemic manifestations or complications allows for early intervention when needed.

Nevus Simplex: Nevus simplex represents a superficial vascular ectasia of the capillaries. It occurs most commonly on the glabella, upper eyelids, and nuchal area, and is colloquially termed "salmon patch," "stork bite," or "angel kiss." Less-common areas include the lower back and scalp. Nevus simplex appears with high frequency in all races, occurring in 70% of white infants and in 59% of black infants. Although the majority of nevus simplex birthmarks fade over the first 2 years of life, those on the occipital scalp tend to persist. Nevus simplex should be differentiated from other capillary malformations and their associations, including nevus flammeus (port-wine stain).[56,57] Vascular malformations are discussed in detail in Chap. 147.

Infantile Hemangiomas: Infantile hemangiomas are the most common tumors of infancy. They must be differentiated from vascular malformations and other vascular anomalies. Hemangiomas are discussed in detail in Chap. 118.

Vascular Malformations: Vascular malformations are a heterogeneous group of vascular dysplasias that encompass slow-flow malformations (eg, capillary, venous, and lymphatic malformations) and fast-flow malformations (eg, arteriovenous malformations and complex combined malformations). Vascular malformations are discussed in detail in Chap. 147.

TABLE 103-3
Pathology and Diascopy of Nevus Anemicus and Nevus Depigmentosus

	NEVUS ANEMICUS	NEVUS DEPIGMENTOSUS
Pathology	Focal vasoconstriction; skin vessel hypersensitivity to catecholamines	Hypomelanosis in affected site
Diascopy	Borders of lesion disappear as a result of the blanching effect	Borders of lesion remain crisp

OTHER BIRTHMARKS

Nevus Sebaceus: Nevus sebaceus is a benign skin hamartoma comprised of numerous sebaceous glands that most often appear as yellow-hued hairless plaque on the head of newborns. Around puberty, a nevus sebaceus may thicken and develop hyperkeratotic, verrucous features. Secondary benign neoplasms, including trichoblastoma or syringocystadenoma papilliferum, sometimes develop within a nevus sebaceus, and, uncommonly, basal cell carcinoma has been reported to arise within a nevus sebaceus.[58,59] Lesions can be monitored or excised if they are symptomatic or cause disfigurement. Widespread nevus sebaceous skin lesions may be associated with increased risk of abnormalities in the central nervous, eye, or skeletal systems (Schimmelpenning or nevus sebaceus syndrome).[60]

Epidermal Nevus: Epidermal nevi appear as curvilinear arrays of tan-brown hyperkeratotic papules and/or thin, elongated rough plaques that follow the lines of Blaschko. Epidermal nevi are difficult to treat. Surgical excision may result in large scars which, in some locations, can restrict range of motion. Laser treatment and local dermal shave excision are associated with focal scarring and a high recurrence risk. Infants with widespread epidermal nevi may be at risk for epidermal nevus syndrome, and should be evaluated for associated disease of the central nervous, ocular, and skeletal systems.[60]

DEVELOPMENTAL ABNORMALITIES

Developmental anomalies of the skin and subcutaneous tissues and structures range from common, benign, minor findings, such as the supernumerary nipple, to major anomalies, such as aplasia cutis congenita, which can be markers for potentially serious underlying anomalies.

Figure 103-7 Supernumerary digit, a common minor malformation.

MINOR ANOMALIES

The supernumerary digit (Fig. 103-7), supernumerary nipple, and accessory tragus are common examples of minor anomalies of the skin and associated subcutaneous structures. Overall, single, minor congenital anomalies occur in approximately 15% of all newborns and have no functional significance. The occurrence of 2 minor congenital anomalies is less common; however, 3 or more minor congenital anomalies is unusual and warrants a complete thorough physical examination to rule out other congenital abnormalities.[61,62]

OTHER ANOMALIES

Other anomalies less frequently encountered in the neonate include dermoid cysts, aplasia cutis congenita, and branchial cleft cysts. Understanding which of these lesions imply possible risk of additional associated malformations is important for diagnosis and management.

The skin and the nervous system are both derived from the embryonic ectoderm. The neural ectoderm separates from the epithelial ectoderm during the third to fifth week of gestation, occurring simultaneously with the formation and closure of the neural tube. Hence, errors in neural tube development (ie, dysraphism [incomplete fusion]) can be associated with cutaneous anomalies. Midline facial lesions, such as dermoid cysts can be markers of cranial dysraphism, whereas cutaneous anomalies involving the lumbosacral midline may indicate underlying spinal dysraphism.

For midline nasal and facial lesions, radiologic evaluation is indicated to rule out intracranial connections before a skin biopsy is performed.[63] Radiologic imaging should also be performed in the presence of high-risk lumbosacral anomalies. The highest risk of occult spinal dysraphism occurs with the presence of 2 or more congenital midline lumbosacral skin lesions or if spinal cord dysfunction exists in the presence of 1 lumbar skin lesion.[64,65] In addition, lumbosacral lipoma, human tail, and dermal sinus (as isolated findings) are highly associated with occult spinal dysraphism, and MRI is indicated when these high-risk congenital lesions are present. An intermediate risk of occult spinal dysraphism is associated with atypical sacral dimple (≥5 mm diameter, or location ≥2.5 cm away from the anus), aplasia cutis congenita, overlying hamartoma, or deviated gluteal cleft. In the presence of any of these lesions, ultrasonography can be used to screen for occult spinal dysraphism if the infant is younger than 4 months of age. If the infant is older, MRI is needed to rule out dysraphism. Low-risk lesions that do not require imaging include small, focal infantile hemangioma, capillary malformation, mild focal hypertrichosis, congenital melanocytic nevus, dermal melanocytosis, or simple sacral dimple with a visible base (≤5 mm diameter and location ≤2.5 cm from the anus). Figure 103-8 summarizes these findings. Neurosurgical consultation is advised for infants with an intracranial or spinal anomaly.

DERMOID CYSTS

Dermoid cysts are congenital anomalies that typically arise along planes of embryonic fusion of the face and scalp. Dermoid cysts are not always apparent at birth; when appreciated, they present as a firm nodule that may adhere to the underlying periosteum. Nasal dermoid cysts may be associated with a dermal pit or sinus and carry a significant risk for intracranial extension.[66] Surgical excision is generally recommended; preoperative MRI should be considered to evaluate for deeper extension of midline dermoid cysts.[67]

NASAL GLIOMA

Nasal gliomas are composed of heterotopic neural tissue and present as firm, skin-colored to erythematous nodules on the nose (Fig. 103-9). They may distort the central facial structures. Referral to neurosurgery is indicated for surgical excision.

MENINGOCELE AND MYELOMENINGOCELE

A meningocele is formed when the meninges and cerebrospinal fluid herniate through a defect in the calvarium or vertebrae. A meningocele is a midline anomaly that may be associated with a persistent intracranial defect; as such, preoperative imaging is recommended prior to surgical excision and reconstruction. When neural tissue of the spinal cord is also present, the term *myelomeningocele* is used. Myelomeningocele is the most common presentation of spina bifida.

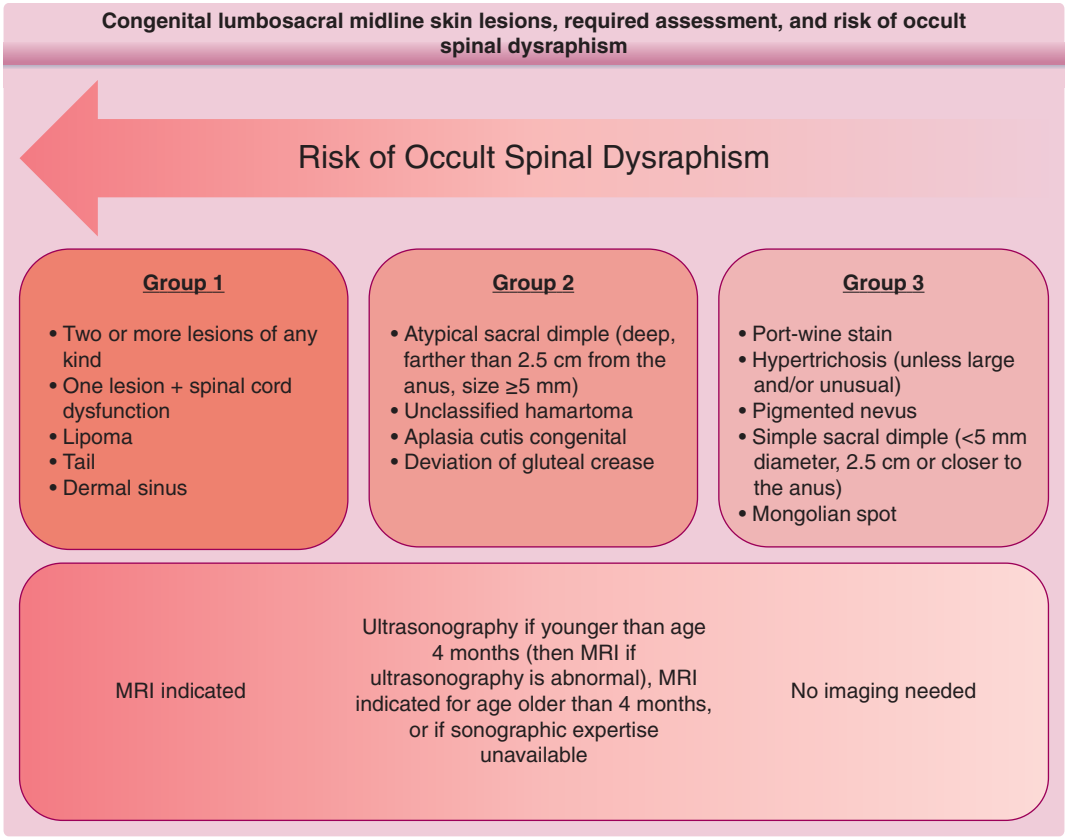

Figure 103-8 Congenital lumbosacral midline skin lesions, required assessment, and risk of occult spinal dysraphism. (Data from Guggisberg D, Hadj-Rabia S, Viney C, et al. Skin markers of occult spinal dysraphism in children: a review of 54 cases. *Arch Dermatol.* 2004;140(9):1109-1115.)

ENCEPHALOCELE

An encephalocele results from herniation of neural tissue along with the meninges and cerebrospinal fluid through a calvarial defect. As with meningoceles, preoperative imaging is recommended prior to surgical excision and reconstruction. Encephaloceles are often seen in association with other craniofacial defects, and neurodevelopmental sequelae may occur.

HUMAN TAIL

Human tails, pseudotails, and acrochordons are rare developmental anomalies. Human tails are vestigial appendages that may be composed of adipose tissue, blood vessels, muscle fibers, and nerves. Pseudotails resemble true human tails but are not related to the embryonic human tail; examples include sacrococcygeal teratomas and myelomeningoceles. True human tails, but not pseudotails, are associated with spinal dysraphism, and MRI is recommended.[68]

HYPERTRICHOSIS

Localized hypertrichosis overlying the lumbosacral, cervical, or thoracic spine may be associated with spinal dysraphism (Fig. 103-10), in particular when prominent ("faun tail").[69] Although there are only a few reported cases in the literature, the presence of a faun tail may be underestimated and mild presentations overlooked.

BRANCHIAL CLEFT ANOMALIES

Branchial cysts, clefts, and sinuses are common developmental remnants involving the neck. Presentation involves either a mass, a draining sinus, or recurrent infection.[70] Branchial cysts are the most common branchial cleft anomaly; the majority arise from the second branchial arch and present along the sternocleidomastoid muscle on the lateral aspect of the neck. The definitive treatment for branchial cleft anomalies is surgical excision.

THYROGLOSSAL DUCT CYST

Thyroglossal duct cysts are congenital neck anomalies that present as a midline mass arising anywhere from the suprasternal notch to the posterior tongue.[71] They arise from the developmental remnant of the migrational tract of the thyroid gland and, as such, may be associated with ectopic thyroid tissue. Surgical excision is the definitive treatment; preoperative verification of a normal thyroid gland is mandatory.

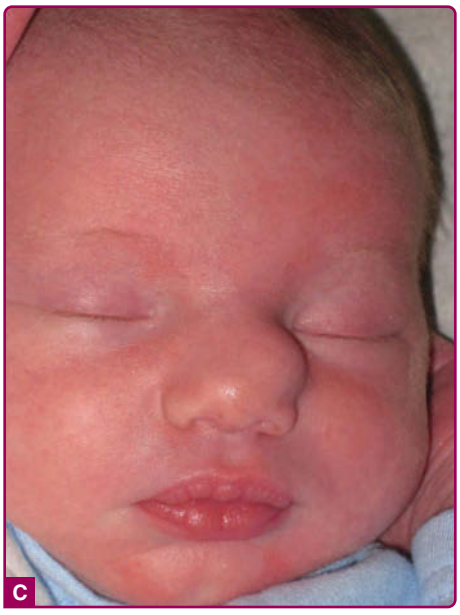

Figure 103-9 **A** and **B,** Nasal glioma initially thought to be a hemangioma of infancy. A firm, reddish, slightly pedunculated tumor was noted off of the midline of the nasal root. MRI showed no intracranial connection. **C,** Nasal glioma. Firm subcutaneous mass noted at birth.

Figure 103-10 A large, wide tuft of thick terminal hair on the lumbosacral spine noted at birth. This infant had an underlying tethered cord (note midline scar from surgical repair).

URACHAL CYSTS AND POLYPS (OMPHALOMESENTERIC DUCT CYST)

Developmental anomalies of the umbilical cord represent failure of regression of the urachus (urachal cyst or fistula between the bladder and the umbilicus) or the omphalomesenteric duct (umbilical polyp or fistula between the ileum and the umbilicus). Urachal and omphalomesenteric remnants usually present with persistent drainage from the umbilicus or with an umbilical mass.[72] Surgical repair is indicated. In contrast, umbilical granulomas are common abnormalities of the umbilicus that present with persistent friable granulation tissue involving the umbilicus noted after separation of the umbilical cord. Treatment with silver nitrate chemical cautery is typically effective.

APLASIA CUTIS CONGENITA

Aplasia cutis congenita (ACC) describes localized areas of absence of the skin and sometimes the underlying subcutaneous tissues and bone. It most often involves the scalp, but may be noted elsewhere (Fig. 103-11). ACC is often an isolated finding, but a multitude of associated conditions have been described.[73] ACC has no single underlying cause and appears to be the end result of a number of distinct pathologic processes, including a forme fruste of a neural tube defect.

In the most common form of ACC, oval, sharply marginated atrophic macules are seen on the midline of the posterior scalp; they may be ulcerated or crusted or have a thin, shiny membranous covering (membranous aplasia cutis). They are usually solitary, but may be multiple. Aplasia cutis is always hairless, and when healed, lesions are usually atrophic scars, although keloidal scarring has been observed. Superficial lesions may involve only the epidermis and superficial dermis; in more-severe cases, a full-thickness tissue defect may be present, including involvement of the calvarium. Lesions may range from a few millimeters to many centimeters in diameter. Midline lesions should not be biopsied unless cranial imaging has been performed to exclude the possibility of an intracranial connection. After a careful examination

Figure 103-11 Two infants with aplasia cutis congenita. **A,** Scalp erosions grouped at the vertex scalp. Scraping or biopsy is contraindicated. **B,** An atrophic, well-circumscribed round patch with visible capillaries on the scalp of an infant. (Image A is from Bolognia JL, Jorizzo JL, Rapini RP, eds. *Dermatology*. 2nd ed. New York: Mosby Elsevier; 2008, with permission. Copyright © Elsevier.)

to rule out associated anomalies, ACC is treated conservatively with local wound care. Surgical revision of the scar later in childhood or adolescence can be done electively to improve cosmesis.

The "hair collar sign" is a ring of darker and/or coarser terminal hairs on the scalp, typically surrounding ACC, dermoid cyst, encephalocele, meningocele, or heterotopic brain tissue.[74] The hair collar sign itself is a marker of cranial dysraphism and its presence, like aplasia cutis, mandates careful examination of the infant.

INFECTIONS OF THE NEONATE

Infants younger than 2 months of age have immature immune systems. Life-threatening sepsis can develop quickly and insidiously. Subtle clues, such as a decrease in body temperature, poor feeding, poor muscular tone, or other nonspecific signs, are taken seriously by the pediatrician, and a "rule out sepsis" admission is initiated when clinical suspicion is high. In general, blood, cerebrospinal fluid, and urine cultures are obtained, and IV antibiotic therapy is started while culture results are pending. Table 103-4 lists cutaneous infections of the neonate. Bacterial skin infections that affect neonates, including staphylococcal scalded-skin syndrome, are further discussed in Chaps. 151 and 152, and viral infections that affect neonates, such as varicella and herpes simplex virus, are discussed in Chaps. 164 and 165.

TABLE 103-4
Selected Cutaneous Infections in the Neonate

- Staphylococcal infections
  - Impetigo
  - Staphylococcal scalded-skin syndrome
  - Omphalitis
  - Breast abscess (usually caused by *Staphylococcus aureus* and Gram-negative organisms)
- Viral infections
  - Varicella
  - Herpes simplex virus
- Fungal/candidal infections
- Scabies

CONGENITAL VIRAL INFECTION

Petechiae, purpura, jaundice, hepatomegaly, splenomegaly, microcephaly, encephalopathy, ocular abnormalities, anemia, thrombocytopenia, conjugated hyperbilirubinemia, or elevated serum hepatic transaminases prompt consideration of congenital viral infection, particularly if they arise in combination with "blueberry muffin" violaceous to purpuric nodules. These findings are concerning for possible congenital TORCH (toxoplasmosis; *other* which includes syphilis, enterovirus. and HIV; rubella; cytomegalovirus; herpes) infection.

NEONATAL HERPES SIMPLEX VIRUS INFECTION

It is estimated that untreated neonatal herpes simplex virus (HSV) infection has a 50% mortality rate, with 75% of survivors suffering neurologic sequelae. The greatest risk of neonatal herpes occurs when the delivery is vaginal and the mother has active, primary genital herpes (in contrast to recurrent herpes, in which the mother provides transplacental antibodies that offer some protection to the neonate). Chapter 164 discusses HSV in detail.

The vast majority of neonatal HSV cases are caused by HSV type 2. Herpes involves the skin, eye, or mouth in most infected neonates, but some patients with CNS

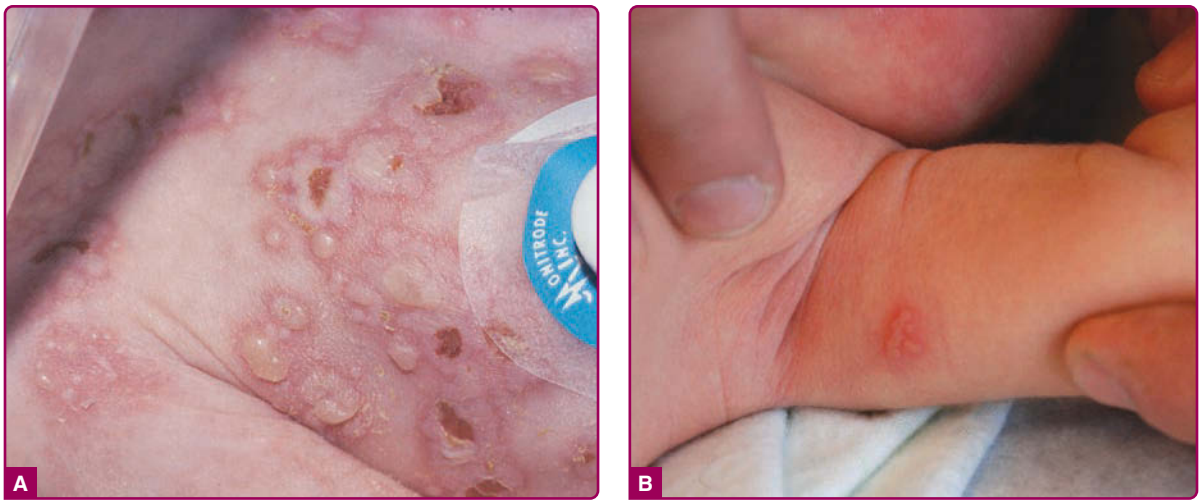

Figure 103-12 **A** and **B,** Herpes simplex infection in 2 infants. Grouped vesicles on an erythematous base. Pustules and erosions are also present. (**A** used with permission from Alvin H. Jacobs, MD.)

or disseminated disease never have skin lesions.[75] Herpetic skin lesions manifest as clusters of vesicles on an erythematous base (Fig 103-12). Vesicles that appear during the first 24 hours of life suggest in utero acquisition of HSV, but onset during the first week to 10 days of life is more common, representing exposure to the virus during the delivery.[75]

A high index of suspicion should be maintained even in the absence of maternal infection or history of genital herpes. Specimens should be obtained for direct fluorescent antibody assay and/or viral culture to detect HSV. A Tzanck smear prepared from a vesicle may provide supportive diagnostic information quickly. If available, a polymerase chain reaction test can be very helpful in rapid diagnosis. IV acyclovir should be instituted as soon as possible after specimens are collected to minimize the chance of virus replication in the CNS and systemic dissemination of HSV. Prompt recognition and early therapeutic intervention result in improved outcomes in HSV-infected infants.[75]

FUNGAL INFECTION

In full-term neonates, congenital cutaneous candidiasis typically presents with widespread erythematous macules, papules, and pustules associated with superficial desquamation, whereas preterm neonates with congenital cutaneous candidiasis may develop large, weeping erosions.[76] Angioinvasive fungal disease in the premature neonate often manifests as ulcerations or necrotic foci with eschar and surrounding erythema.

ERYTHRODERMA

Although uncommon in the neonate, erythroderma may signal a serious underlying condition. A number of genetic, infectious, inflammatory, metabolic, and immunologic disorders can present with erythroderma, and some are associated with possible death in the neonatal period. In addition, erythroderma predisposes to potentially life-threatening complications such as sepsis, dehydration, and electrolyte imbalance. In 1 retrospective case series of neonatal and infantile erythroderma, diagnostic prevalence was approximated as follows: immunodeficiency (30%), congenital ichthyosis (24%), Netherton syndrome (18%), eczematous or papulosquamous dermatitis (20%), and unknown (unspecified).[77]

Inflammatory dermatoses that may present in the first few weeks of life with generalized erythema and scaling include seborrheic dermatitis, infantile psoriasis, juvenile pityriasis rubra pilaris, and atopic or nonatopic eczema. Although seborrheic dermatitis typically presents with localized greasy scalp scaling, a more widespread inflammatory dermatitis is seen in some affected infants, typically with an onset in the first few weeks of life. Infantile psoriasis may present in the first few weeks of life as either a localized or a more widespread psoriasiform dermatitis; however, the characteristic clinical features of psoriasis may be lacking (see Chap. 28). Congenital psoriasis is an uncommon presentation that may not be associated with a family history of psoriasis.[78] In contrast, the presentation of atopic dermatitis is uncommon in the first few weeks of life, and onset of disease is usually delayed until after the first month of life (see Chap. 22). However, infantile eczema and psoriasis may coexist.[79] A family history of atopy or psoriasis and an assessment of areas of predilection and primary morphology may help to differentiate these disorders, although in some cases definitive diagnosis is only possible by observing over time.

Several inborn errors of metabolism, including holocarboxylase synthetase deficiency and biotinidase deficiency, both of which result in deficiency of the 4 biotin-dependent carboxylases (multiple carboxylase deficiency), can present with a desquamative dermatitis.[80] A collodion presentation with features of ichthyosis also has been reported.[81] Affected neonates

typically also experience lethargy, seizures, and apnea; delayed presentation may be seen in those affected with late-onset biotinidase deficiency or late-onset multiple carboxylase deficiency in which symptoms may not develop until later in infancy or childhood.[82] In the United States, depending on the state where the infant was born, these disorders may be detected through the newborn screening program before significant symptoms arise.

Essential fatty acid deficiency is an uncommon acquired nutritional deficiency that may present with an exfoliative dermatitis.[83] Risk factors for essential fatty acid deficiency include malnutrition, which may result from the implementation of specialized infant formulas, improper infant feeding or fad diets, hyperalimentation, or disorders such as cystic fibrosis that result in malabsorption. Essential fatty acid deficiency may occur in association with other nutrient deficiencies, including zinc deficiency, in which case signs of acrodermatitis also may be noted.

Several neonatal infections may result in diffuse erythema with or without scaling or other primary lesions. In term and premature neonates, staphylococcal scalded skin syndrome may present with variable erythema, erosions, scaling, and desquamation; congenital presentation has rarely been reported because of presumed intrauterine infection.[84-87] Early congenital syphilis may present as a desquamative dermatitis or a more generalized vesiculobullous dermatitis.[88-90]

The congenital ichthyoses that may present with neonatal erythroderma include Netherton syndrome, autosomal recessive congenital ichthyosis (which commonly presents with a collodion membrane), Sjögren-Larsson syndrome, keratitis-ichthyosis-deafness syndrome, and neutral lipid storage disease (Chanarin-Dorfman syndrome).[91] Other genetic disorders that may sometimes present with erythroderma or a collodion membrane include X-linked hypohidrotic ectodermal dysplasia and type 2 Gaucher disease.[92,93]

Several primary immunodeficiency syndromes are associated with neonatal erythroderma, including Omenn syndrome, severe combined immunodeficiency syndrome (SCID), hyperimmunoglobulin E syndrome, and DiGeorge syndrome. SCID is a heterogeneous group of immunodeficiency disorders characterized by combined T-cell and B-cell dysfunction; there are at least 13 different genes associated with this phenotype.[94] The presence of a diffuse eczematous dermatitis is associated with SCID, and in at least a proportion of affected infants dermatitis results from maternal engraftment and cutaneous graft-versus-host disease; diagnosis can be facilitated by skin biopsy with appropriate ancillary genetic studies.[95,96] The prognosis for affected patients is poor because of the risk for severe infection, failure to thrive, immune dysregulation, and other complications; bone marrow transplantation before 3 to 4 months of age is generally recommended and ideally is performed before infectious complications arise. Many states include screening for SCID by the T-cell receptor excision circle (TREC) assay on the newborn screen.[97] Omenn syndrome is a rare form of SCID that results from autosomal recessive mutations in the *RAG-1* or *RAG-2* gene. In addition to an exfoliative erythroderma, the characteristic features include failure to thrive, chronic diarrhea, lymphadenopathy, and hepatosplenomegaly. In the absence of bone marrow transplantation, the prognosis is poor. Hyperimmunoglobulin E syndrome associated with mutations in the *STAT3* gene may present with a diffuse eczematous dermatitis in infancy; atopy, mucocutaneous candidiasis, and recurrent staphylococcal skin infections are typical features.[98] A characteristic clinical finding of hyperimmunoglobulin E syndrome in infancy is the development of a papulopustular dermatitis of the face and scalp.[99] DiGeorge syndrome results from a deletion of chromosome 22q11.21; the key features are thymic aplasia, cardiac anomalies involving the aortic arch, hypoparathyroidism, cleft palate, and dysmorphic features. An eczematous dermatitis has been reported in some infants with DiGeorge syndrome.[100,101]

Skin biopsy may be helpful in selected diagnoses, in particular Netherton syndrome and SCID.[102]

SEBORRHEIC DERMATITIS

Seborrheic dermatitis is a common and benign inflammatory dermatosis in infancy, and may be noted as early as the first few weeks of life. The most common presentation is the development of greasy yellow scale with mild underlying erythema on the scalp ("cradle cap"). In the diaper and intertriginous areas, scaling is less prominent and erythema more well-defined, and there is clinical overlap with infantile psoriasis ("sebopsoriasis"). Less-common areas of involvement include the face, in particular the eyebrows and nasolabial folds, and the torso, where the eruption manifests as variable erythema and greasy scaling; in darker-skinned infants, postinflammatory hypopigmentation may predominate. Impetiginization or secondary candidal infection may occur.

The pathophysiology of seborrheic dermatitis is hypothesized by some experts to involve an exaggerated immune response to skin colonization with *Malassezia* species.[103] Seborrheic dermatitis typically remits spontaneously within the first 1 to 2 years of life, although there may be an association with the development of adult seborrheic dermatitis and atopic dermatitis.[104,105]

For mild cases, application of baby oil or mineral oil to the affected areas of the scalp, followed by gentle combing and shampooing to remove scales, is sufficient. For more severe involvement, use of a topical antifungal shampoo or cream or a low-potency topical corticosteroid may be necessary.

Seborrheic dermatitis must be differentiated from other inflammatory skin disorders of infancy, including infantile psoriasis, atopic and nonatopic eczema, and Langerhans cell histiocytosis. Additionally, seborrheic dermatitis-like eruptions have been reported to occur in association with immunodeficiency, and nutritional and metabolic disease. Any history of failure to thrive, developmental delay, unexplained symptoms, or recurrent infection raises concern for possible associated systemic disease.

DIAPER DERMATITIS

Diaper dermatitis (Table 103-5) is a common skin problem in infants. Multiple factors contribute to the development of diaper dermatitis. Prolonged exposure to moisture results in increased frictional damage, decreased barrier function, and increased reactivity to irritants. Interrelated etiologic factors include contact with urine and feces, fecal proteolytic and lipolytic digestive enzymes, increased skin pH, and superinfection with *Candida*.[106] Less commonly, bacterial superinfection may complicate diaper dermatitis.

IRRITANT DIAPER DERMATITIS

Irritant contact dermatitis is the most common cause of diaper dermatitis. It is characterized by erythematous, moist, and sometimes scaly patches favoring the convex surfaces of the genitalia and buttocks. The skin folds are classically spared. Barrier diaper creams and frequent diaper changes are very helpful to treat this condition.

ALLERGIC CONTACT DIAPER DERMATITIS

Allergic contact dermatitis occurs in the diaper area as well. Common contact allergens for the diaper region include preservatives, fragrances, rubber additives, and disperse dyes in diapers or baby wipes.[107]

CANDIDAL DIAPER DERMATITIS

Candidiasis (see Chap. 161) is the second most common cause of diaper dermatitis and is characterized by bright red erythematous, moist papules, patches, and plaques that tend to involve body folds as well as convex surfaces. Satellite papules and pustules are frequently observed, and oral thrush may be present. *Candida* from intestinal flora may contaminate and exacerbate any type of diaper dermatitis present for longer than 3 days.[108]

PSEUDOVERRUCOUS PAPULES AND NODULES

Pseudoverrucous papules and nodules (Fig. 103-13) are flat-topped, skin-colored papules that develop in the diaper and perianal areas in patients of any age whose skin is chronically exposed to moisture, including children with prolonged urinary or fecal incontinence.[109]

JACQUET EROSIVE DERMATITIS

Jacquet erosive dermatitis is an uncommon, severe diaper dermatitis that is characterized by well-demarcated, punched-out ulcers and erosions.

TABLE 103-5
Lesions of the Diaper Area

	DIAPER DERMATITIS	CANDIDIASIS (CANDIDAL INTERTRIGO)	LANGERHANS CELL HISTIOCYTOSIS	PSORIASIS (NAPKIN PSORIASIS)[a]	SEBORRHEIC DERMATITIS[a]
Age	Any age	Any age	1 to 3 years	Usually 3 to 6 months	First few weeks to 3 months
Affected sites	Convexities of the genitalia affected, skin folds spared	Skin folds and convexities affected	Scalp, intertriginous skin folds	Trunk, limbs, face, skin folds, and diaper area may be affected	Scalp, intertriginous skin folds, face, torso
Appearance	Scaly erythematous patches	Bright red, erythematous, moist papules, patches, and plaques with satellite papules and pustules	Tan-to-pink papulovesicles, nodules, ulcerations, and petechiae	Well-defined erythema, white scales over trunk and body, but scaling usually absent in skin folds	Greasy yellow scales with mild erythema; in diaper areas, well-defined erythema, glistening appearance, scaling not prominent
Etiology	May be irritant or allergic in origin	*Candida* sp.	Reactive vs neoplastic (see Chap. 117)	Inflammatory disease, T-cell mediated	Exaggerated immune response to *Malassezia* sp.
Treatment	Barrier creams, frequent diaper changes (see Table 103-6)	Keep intertriginous areas dry, topical antifungal agents	(See Chap. 117)	Topical steroids, topical calcineurin inhibitors	Mineral or baby oil; antifungal shampoo; low-potency topical steroid

[a]Infantile psoriasis and seborrheic dermatitis may overlap ("sebopsoriasis").

Figure 103-13 Pseudoverrucous papules and nodules in a newborn.

Prolonged contact with urine and feces under occlusion leads to this condition.[110] The availability of superabsorbent disposable diapers has made this diagnosis less common.

GRANULOMA GLUTEALE INFANTUM

Granuloma gluteale infantum is an uncommon diaper rash characterized by reddish purplish nodules of different sizes (0.5 to 3 cm) occurring on the convexities of the diaper area in 2- to 9-month-old infants. It arises within preexisting diaper dermatitis. Biopsy shows dense dermal infiltrates of lymphocytes, plasma cells, neutrophils, and eosinophils, but no true granulomas. It appears to be an unusual reaction to the usual irritant factors, *Candida* infection, and, in some cases, topical corticosteroid use in the diaper region.[110] Treatment consists of avoidance of irritants, use of a barrier ointment, and avoidance of topical corticosteroids. Resolution occurs over several months.

DERMATOSES NOT ETIOLOGICALLY RELATED TO DIAPER WEARING

Infantile seborrheic dermatitis, napkin psoriasis (Fig. 103-14), bullous impetigo, acrodermatitis enteropathica, scabies, herpes simplex infections, and Langerhans cell histiocytosis are conditions that may occur in the diaper region but are not primarily caused by the wearing of diapers. They should be considered in the differential diagnosis when evaluating diaper eruptions. Skin biopsy is indicated to rule out Langerhans cell histiocytosis (see Chap. 117) if nonhealing erosions or petechiae are seen in the diaper area (Fig. 103-15).

Figure 103-14 **A,** Infantile psoriasis with involvement in the diaper region. **B,** Infantile psoriasis. This generalized eruption responded well to topical steroids initially and topical tacrolimus later.

TREATMENT OF DIAPER DERMATITIS

Table 103-6 outlines the treatment of diaper dermatitis.[111]

HAMARTOMAS AND BENIGN TUMORS

INFANTILE MYOFIBROMATOSIS

Infantile myofibromas typically present as rubbery dermal and subcutaneous nodules. There can be a

Figure 103-15 **A** and **B,** Langerhans cell histiocytosis with petechiae and erosions of the skin. This patient also had hepatosplenomegaly.

solitary myofibroma or multiple myofibromas (myofibromatosis). In addition to skin, infantile myofibromatosis can involve bone, the GI tract, heart, lungs, and kidneys.[112] Myofibromas limited to soft tissue typically resolve spontaneously within 1 to 2 years. Thus, clinical observation is warranted.

FIBROUS HAMARTOMA OF INFANCY

Fibrous hamartoma of infancy is an uncommon infantile mass. Most cases appear as a solitary, painless, 0.5- to 10-cm skin nodule in the deep dermis or subcutis. Excision is the mainstay of treatment, and recurrence rates are low.[113,114]

TABLE 103-6
ABCs in the Treatment of Diaper Dermatitis

A = Air. The diaper should be left open as much as possible when the infant sleeps to allow drying of the skin.
B = Barrier ointments. Zinc oxide pastes, petrolatum, and other bland, unmedicated barrier preparations are mainstays of therapy. A continuous layer of barrier paste or ointment should be maintained, reapplying with every diaper change, if necessary. Baby powder on the diaper area offers no antimicrobial benefit to the infant and adds a risk of aspiration.
C = Cleansing and anticandidal treatment. Gentle cleansing with plain water, mineral oil, or unscented gentle cleanser is recommended. Avoidance of friction or rubbing is important. A topical anticandidal agent should be added for any signs of candidiasis. Oral nystatin is indicated if oral thrush is present.
D = Diapers. Diapers should be changed as frequently and as soon after soiling as possible, especially if cloth diapers are used.
E = Education of parents and caregivers.

Modified from Boiko S. Making rash decisions in the diaper area. *Pediatr Ann.* 2000;29(1):50-56.

INFANTILE DIGITAL FIBROMA

Infantile digital fibromas are smooth pink nodules that appear on the phalanges of infants. Most commonly the fingers are involved, and the thumbs and great toes are classically spared. Approximately one-third of infantile digital fibromas are present at birth. Skin biopsy is diagnostic and shows bundles of myofibroblasts with round cytoplasmic inclusions that are highlighted by the Masson trichrome or phosphotungstic acid–hematoxylin stains. Infantile digital fibromas have a high recurrence rate after surgical excision and tend to resolve spontaneously over years. Conservative observation is typically recommended.[115]

CONGENITAL SMOOTH MUSCLE HAMARTOMA

Congenital smooth muscle hamartomas (CSMHs) are benign dermal proliferations of hyperplastic smooth muscle. CSMHs most often appear as a solitary irregular dermal plaque on the trunk or proximal extremities. The overlying skin tends to be skin-toned to slightly hyperpigmented and may have associated hypertrichosis. Brisk rubbing of a CSMH results in transient piloerection and induration, which is termed the *pseudo-Darier sign*. The pseudo-Darier sign is elicited in approximately 80% of CSMHs and supports clinical diagnosis. CSMHs are benign and can be observed

with consideration of surgical excision for symptomatic or cosmetically concerning lesions.

NEOPLASTIC AND PROLIFERATIVE DISORDERS

NEUROBLASTOMA

Neuroblastoma is the second most common solid tumor of childhood, and approximately 25% of cases are congenital. Cutaneous metastatic neuroblastoma is included in the "blueberry muffin" baby differential diagnosis, owing to its purple-hued papules and nodules. Skin lesions of neuroblastoma may exhibit blanching, attributed to release of locally active catecholamines from the malignant cells, for up to 1 hour after stroking.[116] Skin biopsy is needed to determine the diagnosis of neuroblastoma and shows small, round cells with large atypical nuclei. The malignant cells may form pseudorosette structures. Immunohistochemistry for neuronal markers, particularly neuron-specific enolase, is helpful.

CONGENITAL LEUKEMIA

Congenital leukemia represents a small subset (<1%) of childhood leukemia. In the newborn, acute myeloid leukemia is more common than acute lymphocytic leukemia.[117] Signs of leukemia in newborn skin include ecchymoses, petechiae, and skin nodules. Multiple blue-to-purple skin nodules are found in approximately 60% of newborns with congenital leukemia, thus congenital leukemia is included in the differential diagnosis of the "blueberry muffin" baby. Skin biopsy shows sheets of atypical mononuclear cells infiltrating the dermis or subcutaneous fat. Complete blood counts and bone marrow biopsy help confirm the diagnosis.

LANGERHANS CELL HISTIOCYTOSIS

Langerhans cell histiocytosis (LCH) is an uncommon proliferative disorder of childhood. Approximately 5% of LCH cases are diagnosed in the newborn period. Cutaneous findings of LCH in the newborn include tan-to-pink papulovesicles, nodules, ulcerations, and petechiae that preferentially develop on the scalp and intertriginous skin folds. Cutaneous LCH may also manifest as a "blueberry muffin" baby, with blue-hued skin nodules. Red-brown skin nodules with or without ulceration are another possible presentation.

The skin lesions of congenital LCH may resolve spontaneously, which is likely responsible for the past nomenclature of congenital "self-healing" LCH. However, because of a risk for disease recurrence, even into childhood, continued monitoring for possible complications in other organ systems is required for all patients with LCH.[118] Skin biopsy of cutaneous lesions shows a histiocytic infiltrate that stains positive for CD1a and CD107 (Langerin).

CUTANEOUS MASTOCYTOSIS

Cutaneous mastocytosis refers to a spectrum of mast cell proliferative disorders that affect the skin. Infants with cutaneous mastocytosis may have a single tan-to-light brown ovoid plaque (solitary mastocytoma), many small red-brown macules and papules (urticaria pigmentosa, maculopapular cutaneous mast cell disease), or diffusely indurated, peau-de-orange textured skin (diffuse cutaneous mastocytosis). Telangiectasia macularis eruptive perstans, which manifests as small telangiectatic patches in older individuals, is an exceptionally rare form of mast cell disease in infants or children.

Of the mast cell disease spectrum entities, solitary mastocytoma and urticaria pigmentosa frequently appear in the first few months of life. Brisk stroking of affected skin will result in mast cell degranulation with a wheal and flare reaction. This useful clinical examination finding is termed *Darier sign*. Diagnosis can be made clinically in many cases, but if needed, skin biopsy demonstrates large numbers of mast cells in the dermis. Special stains, including toluidine blue, Giemsa, and c-kit (CD117), can highlight mast cell populations.

History of flushing, wheezing, vomiting, diarrhea, abdominal pain, bone pain, or shock should be elicited from patients with widespread cutaneous mast cell disease. In cases with extensive skin disease or a concerning review of symptoms, serum tryptase may be a useful clinical indicator. Based on extrapolation from adult systemic mastocytosis literature, some recommend bone marrow biopsy to rule out systemic mastocytosis in children with tryptase levels greater than 20 ng/mL, whereas others reserve bone marrow biopsy only with levels greater than 100 ng/mL. Recent work suggests that enlargement of the liver and/or spleen is a more sensitive indicator of systemic mast cell disease in children when compared to serum tryptase or history of severe mediator symptoms, and that serum tryptase levels tend to decrease over time in children.[119] In general, cutaneous mastocytosis is managed with oral antihistamines (H_1 and H_2). Parents should be counseled to avoid exposing affected children to common triggers of mast cell degranulation, which include anesthetics, other medications, and physical stimuli.

GENODERMATOSES PRESENTING IN THE NEONATAL PERIOD

Several genetic skin diseases may have the onset of characteristic cutaneous features in the neonatal period. The most common diagnoses include epidermolysis bullosa, congenital ichthyoses, and ectodermal dysplasia.

EPIDERMOLYSIS BULLOSA

Epidermolysis bullosa (EB) is a mechanobullous disease with variable presentation and prognosis (see Chap. 60). There are 4 main types: EB simplex, junctional EB, dystrophic EB, and Kindler syndrome; they are distinguished on the basis of the localization of the cleavage plane within the skin. EB should be suspected in the neonate with a bullous eruption; however, other etiologies, including infection, should also be considered.[120] Diagnosis relies on clinical examination and history, skin biopsy for transmission electron microscopy and immunoepitope mapping, and genetic testing. Prognosis for the milder forms of EB is excellent, whereas the more-severe forms (junctional EB and recessive dystrophic) are associated with significant morbidity and mortality.

CONGENITAL ICHTHYOSIS

The congenital ichthyoses or disorders of cornification are a heterogeneous group of inherited disorders which involve abnormal epidermal differentiation (see Chap. 47). The genetic basis for many of the congenital ichthyoses is known, and the current classification system differentiates syndromic from nonsyndromic forms of congenital ichthyosis.[121] Presentation in the neonatal period may include a collodion membrane, which is most commonly seen with the autosomal recessive congenital ichthyoses, such as lamellar ichthyosis and nonbullous congenital ichthyosiform erythroderma. The most extreme presentation of autosomal recessive congenital ichthyosis is harlequin ichthyosis, in which thick, plate-like hyperkeratotic scales cover the face, scalp and body, and ectropion and eclabium are present. Infants with harlequin ichthyosis may develop respiratory insufficiency and are at risk for dehydration, metabolic abnormalities, and sepsis.

ECTODERMAL DYSPLASIA

The ectodermal dysplasias are a large group of related disorders characterized by abnormalities in 1 or more ectodermal structures: the skin, hair, nails, teeth, and eccrine glands (see Chap. 131). As of this writing, there are more than 200 defined disorders, only a small proportion of which have a known genetic etiology.[122] Diagnosis of many of the forms of ectodermal dysplasia is not generally possible in the neonatal period and is delayed until features such as delayed dentition, alopecia, and nail dystrophy become more pronounced. The astute clinician, however, may suspect X-linked hypohidrotic ectodermal dysplasia, one of the more common forms of ectodermal dysplasias, by noting the characteristic facies, alopecia, and unexplained hyperpyrexia in a neonate or young infant. Other forms of ectodermal dysplasias that may present in the neonatal period include the spectrum of p63-related ectodermal dysplasias termed ankyloblepharon-ectrodactyly-clefting syndrome, which encompass the entities previously known as Hay-Wells syndrome, Rapp-Hodgkin syndrome, and ectodermal dysplasia-ectrodactyly-clefting syndrome.

INCONTINENTIA PIGMENTI

Incontinentia pigmenti is an X-linked disorder classified as a type of ectodermal dysplasia (see Chap. 131). Incontinentia pigmenti results from mutations in the nuclear factor κB essential modulator (*NEMO*) gene.[123] It is characterized by cutaneous manifestations, abnormalities of the hair, teeth and nails, ocular anomalies, and neurologic abnormalities.[124] The earliest clinical manifestations include a characteristic Blaschkoid vesicular eruption. Although more common in girls as a consequence of prenatal lethality in the majority of affected male fetuses, males may present with incontinentia pigmenti in a number of circumstances, including the presence of an XXY karyotype (Klinefelter syndrome), somatic mosaicism, or hypomorphic mutation.[125]

OTHER DERMATOSES OF THE NEONATE

SUBCUTANEOUS FAT NECROSIS OF THE NEWBORN

Subcutaneous fat necrosis of the newborn is characterized by firm, red to purple subcutaneous nodules or plaques on the back, cheeks, buttocks, arms, and thighs (Fig. 103-16; see Chap. 73). The lesions usually appear within the first 2 weeks of life and resolve spontaneously over several weeks.[126] Skin biopsy demonstrates lobular fat necrosis with needle-shaped clefts in lipocytes and mixed inflammation with lymphocytes, macrophages, and giant cells. Infants affected by subcutaneous fat necrosis of the newborn are at risk for hypercalcemia and should be monitored.

Figure 103-16 Subcutaneous fat necrosis of the newborn. This infant developed an erythematous firm mass on the back by 2 weeks of age and later developed hypercalcemia.

SCLEREMA NEONATORUM

Sclerema neonatorum describes diffuse skin hardening in a sick, premature newborn. It is thought to be exceedingly uncommon with modern neonatal care. The onset is characteristically after 24 hours of age. Critically ill premature neonates with sepsis, hypoglycemia, acidosis, or other severe metabolic abnormalities are at most risk. The skin becomes hard and appears shiny. Biopsy shows needle-like crystals within lipocytes but no associated inflammatory infiltrate or fat necrosis, differentiating it from subcutaneous fat necrosis of the newborn. The etiology of sclerema neonatorum is unknown, and infant mortality is high.

ANETODERMA OF PREMATURITY

A specific form of iatrogenic anetoderma (see Chap. 70) has been described in premature infants (born at 24 to 30 weeks of gestation) with very-low birthweights and prolonged neonatal intensive care hospitalization.[127] A retrospective review of 11 cases noted the appearance of round, flat atrophic patches on the chest and abdomen (including the periumbilical region), developing between 6 weeks and 5 months of age. Among them, eight patients had lesions at sites where adhesive monitoring leads had been removed, and 5 patients had circular ecchymotic patches from removal of adhesive monitoring leads prior to the occurrence of the anetoderma. The anetoderma did not improve with time. Given the presumed relationship of the development of anetoderma and skin trauma from adhesive leads, avoidance of pressure (placing leads on the ventral chest when the infant slept on the back, for instance) may help reduce risk.[128]

Figure 103-17 Cutis marmorata telangiectatica congenita. Note the atrophic, dusky, stellate patches with overlying telangiectasias.

CUTIS MARMORATA TELANGIECTATICA CONGENITA

Cutis marmorata telangiectatica congenita is characterized by persistent, reticulated atrophic violaceous vascular patches. It is sometimes associated with telangiectasias and ulceration (Fig. 103-17). It is a sporadic condition, and its etiology remains unknown. Theories of vascular malformation are currently favored. Diagnosis is usually evident on clinical examination. Most frequently, a lower extremity is involved, but location on the trunk or upper extremity is not uncommon. Limb asymmetry may be present. However, the majority of patients have a good prognosis, with half demonstrating improvement of the mottled appearance over the first 2 years.[129]

REFERENCES

1. Holbrook KA, Odland GF. The fine structure of developing human epidermis: light, scanning, and transmission electron microscopy of the periderm. *J Invest Dermatol.* 1975;65(1):16-38.
2. Akiyama M, Smith LT, Yoneda K, et al. Periderm cells form cornified cell envelope in their regression process during human epidermal development. *J Invest Dermatol.* 1999;112(6):903-909.

3. Dale BA, Holbrook KA, Kimball JR, et al. Expression of epidermal keratins and filaggrin during human fetal skin development. *J Cell Biol.* 1985;101(4): 1257-1269.
4. Deutsch TA, Esterly NB. Elastic fibers in fetal dermis. *J Invest Dermatol.* 1975;65(3):320-323.
5. Smith LT, Holbrook KA, Madri JA. Collagen types I, III, and V in human embryonic and fetal skin. *Am J Anat.* 1986;175(4):507-521.
6. Holbrook KA, Odland GF. Structure of the human fetal hair canal and initial hair eruption. *J Invest Dermatol.* 1978;71(6):385-390.
7. Muller M, Jasmin JR, Monteil RA, et al. Embryology of the hair follicle. *Early Hum Dev.* 1991;26(3):159-166.
8. Fujita H, Asagami C, Murota S, et al. Ultrastructural study of embryonic sebaceous cells, especially of their serum droplet formation. *Acta Derm Venereol.* 1972;52(2):99-115.
9. Rissmann R, Groenink HW, Weerheim AM, et al. New insights into ultrastructure, lipid composition and organization of vernix caseosa. *J Invest Dermatol.* 2006;126(8):1823-1833.
10. Pickens WL, Warner RR, Boissy YL, et al. Characterization of vernix caseosa: water content, morphology, and elemental analysis. *J Invest Dermatol.* 2000; 115(5):875-881.
11. Hoath SB, Pickens WL, Visscher MO. The biology of vernix caseosa. *Int J Cosmet Sci*. 2006;28(5):319-333.
12. Tollin M, Bergsson G, Kai-Larsen Y, et al. Vernix caseosa as a multi-component defence system based on polypeptides, lipids and their interactions. *Cell Mol Life Sci.* 2005;62(19-20):2390-2399.
13. Fluhr JW, Darlenski R, Taieb A, et al. Functional skin adaptation in infancy-almost complete but not fully competent. *Exp Dermatol.* 2010;19(6):483-492.
14. Fluhr JW, Darlenski R, Lachmann N, et al. Infant epidermal skin physiology: adaptation after birth. *Br J Dermatol.* 2012;166(3):483-490.
15. Rutter N, Hull D. Water loss from the skin of term and preterm babies. *Arch Dis Child.* 1979;54(11):858-868.
16. Visscher MO, Chatterjee R, Munson KA, et al. Changes in diapered and nondiapered infant skin over the first month of life. *Pediatr Dermatol.* 2000;17(1):45-51.
17. Miyauchi Y, Shimaoka Y, Fujimura T, et al. Developmental changes in neonatal and infant skin structures during the first 6 months: in vivo observation. *Pediatr Dermatol.* 2016;33(3):289-295.
18. Schmid-Wendtner MH, Korting HC. The pH of the skin surface and its impact on the barrier function. *Skin Pharmacol Physiol.* 2006;19(6):296-302.
19. Beare JM, Cheeseman EA, Gailey AA, et al. The effect of age on the pH of the skin surface in the first week of life. *Br J Dermatol.* 1960;72:62-66.
20. Hoeger PH, Enzmann CC. Skin physiology of the neonate and young infant: a prospective study of functional skin parameters during early infancy. *Pediatr Dermatol.* 2002;19(3):256-262.
21. Yosipovitch G, Maayan-Metzger A, Merlob P, et al. Skin barrier properties in different body areas in neonates. *Pediatrics.* 2000;106(1, pt 1):105-108.
22. Henderson CA, Taylor J, Cunliffe WJ. Sebum excretion rates in mothers and neonates. *Br J Dermatol.* 2000;142(1):110-111.
23. Harpin VA, Rutter N. Development of emotional sweating in the newborn infant. *Arch Dis Child.* 1982;57(9):691-695.
24. Harpin VA, Rutter N. Sweating in preterm babies. *J Pediatr.* 1982;100(4):614-619.
25. Evans NJ, Rutter N. Development of the epidermis in the newborn. *Biol Neonate.* 1986;49(2):74-80.
26. Kalia YN, Nonato LB, Lund CH, et al. Development of skin barrier function in premature infants. *J Invest Dermatol.* 1998;111(2):320-326.
27. Mathanda TR, M Bhat R, Hegde P, et al. Transepidermal water loss in neonates: baseline values using a closed-chamber system. *Pediatr Dermatol.* 2016;33(1):33-37.
28. Bertini G, Perugi S, Elia S, et al. Transepidermal water loss and cerebral hemodynamics in preterm infants: conventional versus LED phototherapy. *Eur J Pediatr.* 2008;167(1):37-42.
29. Maayan-Metzger A, Yosipovitch G, Hadad E, et al. Effect of radiant warmer on transepidermal water loss (TEWL) and skin hydration in preterm infants. *J Perinatol.* 2004;24(6):372-375.
30. Nopper AJ, Horii KA, Sookdeo-Drost S, et al. Topical ointment therapy benefits premature infants. *J Pediatr.* 1996;128(5, pt 1):660-669.
31. Campbell JR, Zaccaria E, Baker CJ. Systemic candidiasis in extremely low birth weight infants receiving topical petrolatum ointment for skin care: a case-control study. *Pediatrics.* 2000;105(5):1041-1045.
32. Edwards WH, Conner JM, Soll RF, et al. The effect of prophylactic ointment therapy on nosocomial sepsis rates and skin integrity in infants with birth weights of 501 to 1000 g. *Pediatrics.* 2004;113(5):1195-1203.
33. Darmstadt GL, Saha SK, Ahmed AS, et al. Effect of skin barrier therapy on neonatal mortality rates in preterm infants in Bangladesh: a randomized, controlled, clinical trial. *Pediatrics.* 2008;121(3):522-529.
34. Cleminson J, McGuire W. Topical emollient for preventing infection in preterm infants. *Cochrane Database Syst Rev.* 2016(1):CD001150.
35. Blume-Peytavi U, Cork MJ, Faergemann J, et al. Bathing and cleansing in newborns from day 1 to first year of life: recommendations from a European round table meeting. *J Eur Acad Dermatol Venereol.* 2009;23(7):751-759.
36. Cetta F, Lambert GH, Ros SP. Newborn chemical exposure from over-the-counter skin care products. *Clin Pediatr (Phila)*. 1991;30(5):286-289.
37. Malloy-McDonald MB, Lambert GH. Neonatal skin care. *Compr Ther.* 1993;19(6):286-290.
38. Lavender T, Bedwell C, Roberts SA, et al. Randomized, controlled trial evaluating a baby wash product on skin barrier function in healthy, term neonates. *J Obstet Gynecol Neonatal Nurs.* 2013;42(2):203-214.
39. Garcia Bartels N, Mleczko A, Schink T, et al. Influence of bathing or washing on skin barrier function in newborns during the first four weeks of life. *Skin Pharmacol Physiol.* 2009;22(5):248-257.
40. Garcia Bartels N, Scheufele R, Prosch F, et al. Effect of standardized skin care regimens on neonatal skin barrier function in different body areas. *Pediatr Dermatol.* 2010;27(1):1-8.
41. Benis MM. Newborn percutaneous absorption: hazards and therapeutic uses. *Neonatal Netw.* 1999;18(8):63-69.
42. Liang MG, Frieden IJ. Perineal and lip ulcerations as the presenting manifestation of hemangioma of infancy. *Pediatrics.* 1997;99(2):256-259.
43. Parker LA. Part 1: early recognition and treatment of birth trauma: injuries to the head and face. *Adv Neonatal Care.* 2005;5(6):288-297; quiz 298-300.
44. Wang AR, Bercovitch L. Congenital milia en plaque. *Pediatr Dermatol.* 2016;33(4):e258-e259.

45. Chang MW, Jiang SB, Orlow SJ. Atypical erythema toxicum neonatorum of delayed onset in a term infant. *Pediatr Dermatol.* 1999;16(2):137-141.
46. Januario G, Salgado M. The Harlequin phenomenon. *J Eur Acad Dermatol Venereol.* 2011;25(12):1381-1384.
47. Niamba P, Weill FX, Sarlangue J, et al. Is common neonatal cephalic pustulosis (neonatal acne) triggered by *Malassezia sympodialis*? *Arch Dermatol.* 1998;134(8):995-998.
48. Bardazzi F, Patrizi A. Transient cephalic neonatal pustulosis. *Arch Dermatol.* 1997;133(4):528-530.
49. Shaw WC. Folklore surrounding facial deformity and the origins of facial prejudice. *Br J Plast Surg.* 1981;34(3):237-246.
50. Alper JC, Holmes LB. The incidence and significance of birthmarks in a cohort of 4,641 newborns. *Pediatr Dermatol.* 1983;1(1):58-68.
51. Jacobs AH, Walton RG. The incidence of birthmarks in the neonate. *Pediatrics.* 1976;58(2):218-222.
52. Krengel S, Scope A, Dusza SW, et al. New recommendations for the categorization of cutaneous features of congenital melanocytic nevi. *J Am Acad Dermatol.* 2013;68(3):441-451.
53. Happle R. Mosaicism in human skin. Understanding the patterns and mechanisms. *Arch Dermatol.* 1993;129(11):1460-1470.
54. Treat J. Patterned pigmentation in children. *Pediatr Clin North Am.* 2010;57(5):1121-1129.
55. Northrup H, Krueger DA, International Tuberous Sclerosis Complex Consensus Group. Tuberous sclerosis complex diagnostic criteria update: recommendations of the 2012 International Tuberous Sclerosis Complex Consensus Conference. *Pediatr Neurol.* 2013;49(4):243-254.
56. Happle R. Capillary malformations: a classification using specific names for specific skin disorders. *J Eur Acad Dermatol Venereol.* 2015;29(12):2295-2305.
57. Juern AM, Glick ZR, Drolet BA, et al. Nevus simplex: a reconsideration of nomenclature, sites of involvement, and disease associations. *J Am Acad Dermatol.* 2010;63(5):805-814.
58. Kaddu S, Schaeppi H, Kerl H, et al. Basaloid neoplasms in nevus sebaceus. *J Cutan Pathol.* 2000;27(7):327-337.
59. Cribier B, Scrivener Y, Grosshans E. Tumors arising in nevus sebaceus: a study of 596 cases. *J Am Acad Dermatol.* 2000;42(2, pt 1):263-268.
60. Asch S, Sugarman JL. Epidermal nevus syndromes. *Handb Clin Neurol.* 2015;132:291-316.
61. Leppig KA, Werler MM, Cann CI, et al. Predictive value of minor anomalies. I. Association with major malformations. *J Pediatr.* 1987;110(4):531-537.
62. Marden PM, Smith DW, McDonald MJ. Congenital anomalies in the newborn infant, including minor variations. A study of 4,412 babies by surface examination for anomalies and buccal smear for sex chromatin. *J Pediatr.* 1964;64:357-371.
63. Drolet B. Birthmarks to worry about. Cutaneous markers of dysraphism. *Dermatol Clin.* 1998;16(3):447-453.
64. Guggisberg D, Hadj-Rabia S, Viney C, et al. Skin markers of occult spinal dysraphism in children: a review of 54 cases. *Arch Dermatol.* 2004;140(9):1109-1115.
65. Sewell MJ, Chiu YE, Drolet BA. Neural tube dysraphism: review of cutaneous markers and imaging. *Pediatr Dermatol.* 2015;32(2):161-170.
66. Peter JC, Sinclair-Smith C, de Villiers JC. Midline dermal sinuses and cysts and their relationship to the central nervous system. *Eur J Pediatr Surg.* 1991;1(2):73-79.
67. Golden BA, Jaskolka MS, Ruiz RL. Craniofacial and orbital dermoids in children. *Oral Maxillofac Surg Clin North Am.* 2012;24(3):417-425.
68. Tubbs RS, Malefant J, Loukas M, et al. Enigmatic human tails: a review of their history, embryology, classification, and clinical manifestations. *Clin Anat.* 2016;29(4):430-438.
69. Gupta R, Singal A, Pandhi D. Faun tail naevus: a cutaneous marker of spinal dysraphism. *Indian Pediatr.* 2005;42(1):67-69.
70. Prosser JD, Myer CM 3rd. Branchial cleft anomalies and thymic cysts. *Otolaryngol Clin North Am.* 2015;48(1):1-14.
71. Chou J, Walters A, Hage R, et al. Thyroglossal duct cysts: anatomy, embryology and treatment. *Surg Radiol Anat.* 2013;35(10):875-881.
72. Carlisle EM, Mezhir JJ, Glynn L, et al. The umbilical mass: a rare neonatal anomaly. *Pediatr Surg Int.* 2007;23(8):821-824.
73. Frieden IJ. Aplasia cutis congenita: a clinical review and proposal for classification. *J Am Acad Dermatol.* 1986;14(4):646-660.
74. Stevens CA, Galen W. The hair collar sign. *Am J Med Genet A.* 2008;146A(4):484-487.
75. Kimberlin DW, Lin CY, Jacobs RF, et al. Natural history of neonatal herpes simplex virus infections in the acyclovir era. *Pediatrics.* 2001;108(2):223-229.
76. Darmstadt GL, Dinulos JG, Miller Z. Congenital cutaneous candidiasis: clinical presentation, pathogenesis, and management guidelines. *Pediatrics.* 2000;105(2):438-444.
77. Pruszkowski A, Bodemer C, Fraitag S, et al. Neonatal and infantile erythrodermas: a retrospective study of 51 patients. *Arch Dermatol.* 2000;136(7):875-880.
78. Lehman JS, Rahil AK. Congenital psoriasis: case report and literature review. *Pediatr Dermatol.* 2008;25(3):332-338.
79. Alexopoulos A, Kakourou T, Orfanou I, et al. Retrospective analysis of the relationship between infantile seborrheic dermatitis and atopic dermatitis. *Pediatr Dermatol.* 2014;31(2):125-130.
80. Mock DM. Skin manifestations of biotin deficiency. *Semin Dermatol.* 1991;10(4):296-302.
81. Arbuckle HA, Morelli J. Holocarboxylase synthetase deficiency presenting as ichthyosis. *Pediatr Dermatol.* 2006;23(2):142-144.
82. Baumgartner ER, Suormala T. Multiple carboxylase deficiency: inherited and acquired disorders of biotin metabolism. *Int J Vitam Nutr Res.* 1997;67(5):377-384.
83. Hansen AE, Haggard ME, Boelsche AN, et al. Essential fatty acids in infant nutrition. III. Clinical manifestations of linoleic acid deficiency. *J Nutr.* 1958;66(4):565-576.
84. Haveman LM, Fleer A, de Vries LS, et al. Congenital staphylococcal scalded skin syndrome in a premature infant. *Acta Paediatr.* 2004;93(12):1661-1662.
85. Kapoor V, Travadi J, Braye S. Staphylococcal scalded skin syndrome in an extremely premature neonate: a case report with a brief review of literature. *J Paediatr Child Health.* 2008;44(6):374-376.
86. Li MY, Hua Y, Wei GH, et al. Staphylococcal scalded skin syndrome in neonates: an 8-year retrospective study in a single institution. *Pediatr Dermatol.* 2014;31(1):43-47.
87. Lo WT, Wang CC, Chu ML. Intrauterine staphylococcal scalded skin syndrome: report of a case. *Pediatr Infect Dis J.* 2000;19(5):481-482.

88. Wood VD, Rana S. Congenital syphilis presenting as desquamative dermatitis. *J Fam Pract.* 1992;35(3):327-329.
89. Kim JK, Choi SR, Lee HJ, et al. Congenital syphilis presenting with a generalized bullous and pustular eruption in a premature newborn. *Ann Dermatol.* 2011;23(suppl 1):S127-S130.
90. Lee SH, Kim JH, Kim SC. Early congenital syphilis presenting with vesicobullous eruptions beyond palmoplantar regions. *Acta Derm Venereol.* 2014;94(3):321-322.
91. Craiglow BG. Ichthyosis in the newborn. *Semin Perinatol.* 2013;37(1):26-31.
92. Stone DL, Carey WF, Christodoulou J, et al. Type 2 Gaucher disease: the collodion baby phenotype revisited. *Arch Dis Child Fetal Neonatal Ed.* 2000;82(2):F163-F166.
93. Thomas C, Suranyi E, Pride H, et al. A child with hypohidrotic ectodermal dysplasia with features of a collodion membrane. *Pediatr Dermatol.* 2006;23(3):251-254.
94. Diamond CE, Sanchez MJ, LaBelle JL. Diagnostic criteria and evaluation of severe combined immunodeficiency in the neonate. *Pediatr Ann.* 2015;44(7): e181-e187.
95. Muller SM, Ege M, Pottharst A, et al. Transplacentally acquired maternal T lymphocytes in severe combined immunodeficiency: a study of 121 patients. *Blood.* 2001;98(6):1847-1851.
96. Denianke KS, Frieden IJ, Cowan MJ, et al. Cutaneous manifestations of maternal engraftment in patients with severe combined immunodeficiency: a clinicopathologic study. *Bone Marrow Transplant.* 2001;28(3):227-233.
97. Morinishi Y, Imai K, Nakagawa N, et al. Identification of severe combined immunodeficiency by T-cell receptor excision circles quantification using neonatal Guthrie cards. *J Pediatr.* 2009;155(6):829-833.
98. Minegishi Y, Saito M. Cutaneous manifestations of hyper IgE syndrome. *Allergol Int.* 2012;61(2):191-196.
99. Chamlin SL, McCalmont TH, Cunningham BB, et al. Cutaneous manifestations of hyper-IgE syndrome in infants and children. *J Pediatr.* 2002;141(4):572-575.
100. Markert ML, Alexieff MJ, Li J, et al. Complete DiGeorge syndrome: development of rash, lymphadenopathy, and oligoclonal T cells in 5 cases. *J Allergy Clin Immunol.* 2004;113(4):734-741.
101. Selim MA, Markert ML, Burchette JL, et al. The cutaneous manifestations of atypical complete DiGeorge syndrome: a histopathologic and immunohistochemical study. *J Cutan Pathol.* 2008;35(4):380-385.
102. Leclerc-Mercier S, Bodemer C, Bourdon-Lanoy E, et al. Early skin biopsy is helpful for the diagnosis and management of neonatal and infantile erythrodermas. *J Cutan Pathol.* 2010;37(2):249-255.
103. Ruiz-Maldonado R, Lopez-Matinez R, Perez Chavarria EL, et al. *Pityrosporum ovale* in infantile seborrheic dermatitis. *Pediatr Dermatol.* 1989;6(1):16-20.
104. Mimouni K, Mukamel M, Zeharia A, et al. Prognosis of infantile seborrheic dermatitis. *J Pediatr.* 1995;127(5):744-746.
105. Menni S, Piccinno R, Baietta S, et al. Infantile seborrheic dermatitis: seven-year follow-up and some prognostic criteria. *Pediatr Dermatol.* 1989;6(1):13-15.
106. Wolf R, Wolf D, Tuzun B, et al. Diaper dermatitis. *Clin Dermatol.* 2000;18(6):657-660.
107. Smith WJ, Jacob SE. The role of allergic contact dermatitis in diaper dermatitis. *Pediatr Dermatol.* 2009;26(3):369-370.
108. Weston WL, Lane AT, Weston JA. Diaper dermatitis: current concepts. *Pediatrics.* 1980;66(4):532-536.
109. Goldberg NS, Esterly NB, Rothman KF, et al. Perianal pseudoverrucous papules and nodules in children. *Arch Dermatol.* 1992;128(2):240-242.
110. De Zeeuw R, Van Praag MC, Oranje AP. Granuloma gluteale infantum: a case report. *Pediatr Dermatol.* 2000;17(2):141-143.
111. Boiko S. Making rash decisions in the diaper area. *Pediatr Ann.* 2000;29(1):50-56.
112. Stanford D, Rogers M. Dermatological presentations of infantile myofibromatosis: a review of 27 cases. *Australas J Dermatol.* 2000;41(3):156-161.
113. Kang G, Suh YL, Han J, et al. Fibrous hamartoma of infancy: an experience of a single institute. *J Korean Surg Soc*. 2011;81(1):61-65.
114. Saab ST, McClain CM, Coffin CM. Fibrous hamartoma of infancy: a clinicopathologic analysis of 60 cases. *Am J Surg Pathol.* 2014;38(3):394-401.
115. Heymann WR. Infantile digital fibromatosis. *J Am Acad Dermatol.* 2008;59(1):122-123.
116. Hawthorne HC Jr, Nelson JS, Witzleben CL, et al. Blanching subcutaneous nodules in neonatal neuroblastoma. *J Pediatr.* 1970;77(2):297-300.
117. van der Linden MH, Creemers S, Pieters R. Diagnosis and management of neonatal leukaemia. *Semin Fetal Neonatal Med.* 2012;17(4):192-195.
118. Simko SJ, Garmezy B, Abhyankar H, et al. Differentiating skin-limited and multisystem Langerhans cell histiocytosis. *J Pediatr.* 2014;165(5):990-996.
119. Carter MC, Clayton ST, Komarow HD, et al. Assessment of clinical findings, tryptase levels, and bone marrow histopathology in the management of pediatric mastocytosis. *J Allergy Clin Immunol.* 2015;136(6): 1673-1679.e1-3.
120. Gonzalez ME. Evaluation and treatment of the newborn with epidermolysis bullosa. *Semin Perinatol.* 2013;37(1):32-39.
121. Oji V, Tadini G, Akiyama M, et al. Revised nomenclature and classification of inherited ichthyoses: results of the First Ichthyosis Consensus Conference in Soreze 2009. *J Am Acad Dermatol.* 2010;63(4):607-641.
122. Itin PH. Etiology and pathogenesis of ectodermal dysplasias. *Am J Med Genet A.* 2014;164A(10):2472-2477.
123. Smahi A, Courtois G, Vabres P, et al. Genomic rearrangement in NEMO impairs NF-kappaB activation and is a cause of incontinentia pigmenti. The International Incontinentia Pigmenti (IP) Consortium. *Nature.* 2000;405(6785):466-472.
124. Minic S, Trpinac D, Obradovic M. Incontinentia pigmenti diagnostic criteria update. *Clin Genet.* 2014;85(6):536-542.
125. Pacheco TR, Levy M, Collyer JC, et al. Incontinentia pigmenti in male patients. *J Am Acad Dermatol.* 2006;55(2):251-255.
126. Burden AD, Krafchik BR. Subcutaneous fat necrosis of the newborn: a review of 11 cases. *Pediatr Dermatol.* 1999;16(5):384-387.
127. Prizant TL, Lucky AW, Frieden IJ, et al. Spontaneous atrophic patches in extremely premature infants. Anetoderma of prematurity. *Arch Dermatol.* 1996;132(6):671-674.
128. Goujon E, Beer F, Gay S, et al. Anetoderma of prematurity: an iatrogenic consequence of neonatal intensive care. *Arch Dermatol.* 2010;146(5):565-567.
129. Amitai DB, Fichman S, Merlob P, et al. Cutis marmorata telangiectatica congenita: clinical findings in 85 patients. *Pediatr Dermatol.* 2000;17(2):100-104.

Chapter 104 :: Pediatric and Adolescent Dermatology

:: Mary Wu Chang

AT-A-GLANCE

- The infant or child is the patient, but working with the parents/caregivers and home situation is crucial in diagnosis and management.
- Obtaining a history, and methods of clinical examination in infants and children differ from the approaches chosen for adults. In adolescents, different skills are required to enhance communication and compliance.
- Many outpatient procedures in pediatric dermatology can be done with appropriate planning and age-appropriate techniques. Patch testing or biopsies should not be avoided simply because of a pediatric patient's age.
- The infant has increased risk for systemic toxicity from topically applied substances. Children with disorders of barrier function are at high risk of excess percutaneous absorption and toxicity as well.
- Drug labeling for pediatric patients is different from that in adults and most therapeutic agents are prescribed off-label.
- Autism spectrum disorders are now common. Dermatologists must be aware of special issues involved in caring for these patients.

Just as dermatology cannot be separated from internal medicine, pediatric dermatology is inseparable from general pediatrics. Most dermatologists have experience and training in internal medicine but less exposure to pediatrics, therefore an introduction to the special issues that can arise in pediatric dermatology is presented here. As it is impossible to discuss all of pediatric dermatology in a single chapter, the focus is instead on certain methods, diseases, and issues divided by age divisions: infants, children, and adolescents. This chapter discusses topics of special importance, such as pediatric medication use and biopsy pitfalls, and reviews methods to enhance success in outpatient procedures in pediatric dermatology.

Table 104-1 reviews 10 helpful tips in practicing pediatric dermatology. Successful care of the pediatric patient is best achieved via a partnership with the parents or caregivers, along with comanagement with the pediatrician or primary care physician. An awareness of the child's living situation is always relevant. For example, children living in 2 households because the parents are separated or divorced often do best with 2 sets of medications, 1 in each home, to enhance compliance. In the age of internet access, patients and caregivers will likely search online for medical information before or after the office encounter. They should be reminded that medical information on the internet is often inaccurate.[1] Instead, directing patients and families to specific internet websites, support groups, or pamphlets is valuable, but these resources should be reviewed before recommending them.

Parents are understandably very worried about their children and the office visit cannot be rushed. If conflicts arise in the office, discussions should be approached with the common goal of doing what is best for the child. At other times, the clinician must gently intervene and clarify when the parents' desire for treatment may not be in the best interest of the patient.

CONSIDERATIONS IN INFANTS

EVALUATION TECHNIQUES

A complete history for an infant includes gestational and birth history as well as family history. Exposures during pregnancy should be reviewed, including medications, illicit drugs, and infectious diseases, including sexually transmitted diseases. Inquiring about growth and development is crucial. Is the infant gaining weight along proper growth curves? Is the baby vigorous, with good tone, and feeding well with a good suck?

When examining an infant, it is crucial to be thorough. Whether the infant is examined in the lap of the parent or on the examination table, all surfaces, including the creases and valleys of body folds and the diaper region (including the genitalia), need close examination. The diaper area has its own unique set of problems and deserves examination at every visit. Even what is in the diaper (Fig. 104-1) can be useful information. An infant with atopic dermatitis and abnormal stools, for example, may have a food intolerance or allergy that must be addressed before dermatologic treatment will be successful. A vascular stain, vasoconstricted macule, or erosion can be the presenting sign of a hemangioma.[2] A stray hair may later strangulate an appendage and should be removed. Infants with digital tourniquet (pseudoainhum) and clitoral tourniquet have been described.[3,4] Cutaneous anomalies warrant closer inspection to rule out associated findings. Midline lesions on the face, scalp, or spine may have CNS connections and should not be biopsied without proper evaluation (Table 104-2).

TABLE 104-1
Ten Helpful Tips in Pediatric Dermatology

1. The child is the patient, not the parents.
2. Biopsy when indicated, regardless of age. (Refer if necessary.)
3. What is the child's living situation? Does the child live in 2 homes? Are the parents going through a divorce?
4. Be aware of the parents' perspectives of the child. Was there difficulty in conceiving? Was the child premature? Was there significant early illness? Is there chronic illness?
5. A team approach with the pediatrician, neonatologist, or family physician is best. Comanagement with a psychiatrist may be indicated (isotretinoin issues or trichotillomania, for example).
6. A chronic condition or illness in a child affects the entire family.
7. Guide parents and patients to appropriate internet resources, but always review materials for accuracy beforehand.
8. Obtain consent from parents, and assent from children, for procedures and photos.
9. An adolescent's confidentiality must be maintained unless there is a danger of harm to the patient or others. Consider interviewing the patient alone without parents for a portion of the visit. Consider having a chaperone in the room for full skin examinations.
10. First, do no harm.

Figure 104-1 Four-month-old infant with extensive eczematous dermatitis and diaper dermatitis. Opening up the diaper reveals greenish liquid stools, very abnormal at this age. Referral for pediatric allergy testing and changing the diet was indicated in this case.

BIRTHMARKS

Although the term *birthmark* implies a skin lesion that is present at birth, some cutaneous changes with congenital origins only become visible later in infancy or

TABLE 104-2
Biopsy Pitfalls in Pediatric Dermatology

AGE GROUP	LESION AND SITE	DIAGNOSIS	DANGER	PROPER MANAGEMENT
Newborn to infant	Round or oval erosion or vesicle on the scalp, less commonly on the cheek or neck	Aplasia cutis congenita (see Chap. 103); differential diagnosis includes herpes simplex, fetal scalp electrode trauma	Possible intracranial connection, risk of meningitis with biopsy or scraping	Observation for spontaneous healing; consider ultrasonography or MRI if atypical
Infant	"Hair collar" sign surrounding congenital lesion on scalp or posterior axis midline lesion	Encephalocele, spina bifida occulta, meningomyelocele	Possible intracranial connection; risk of meningitis	Preoperative imaging; consider neurosurgical consultation
Infant	Tuft of hair over midline spine	Spina bifida occulta, meningomyelocele	Possible intracranial connection; risk of meningitis	Preoperative imaging; consider neurosurgical consultation
Infant	Preauricular "tag"	Accessory tragus	Risk of chondritis if removed by shave or snip excision or if ligated with suture	Appropriate closure when excised, if cartilaginous component is present
Infant, young child	Dome-shaped mass along midline scalp, glabella, side of forehead, or other embryonic fusion plane	Dermoid cyst	Intracranial connection in up to 25% for midline dermoids; risk is higher if sinus present; dermoids near the lateral eyebrows rarely have intracranial connections	Consider MRI and neurosurgical consultation
Infant, young child	Nasal midline mass	Nasal glioma, encephalocele, or other dysraphic state; differential diagnosis: "hypertelorism," deep infantile hemangioma	Intracranial connection in 100% of encephaloceles; gliomas may extend into oropharynx or have intranasal connections	Consider MRI and neurosurgical consultation
Infant, young child	Vascular mass with greatly increased warmth, often with pulsation or bruit	Arteriovenous malformation; differential diagnosis: congenital or infantile hemangioma	Uncontrolled bleeding, problematic bony or soft-tissue hypertrophy	Consider Doppler studies, MRI, and surgical consultation

Figure 104-2 This 22-month-old child had a chronic, scaling, linear plaque extending onto 2 toes, representing linear epidermal nevus, an example of mosaicism.

childhood. For example, nevus depigmentosus in a very-pale-skinned newborn is commonly not discernable, but becomes apparent later in infancy or early childhood when the infant's normal pigmentation develops. Another birthmark that is present at birth but may not become visible until early childhood is epidermal nevus. These 2 birthmarks are examples of mosaicism (Figs. 104-2 and 104-3).

Solitary café-au-lait macules are extremely common and benign. However, the appearance of multiple café-au-lait macules during infancy and early childhood raises the possibility of neurofibromatosis Type 1 (see Chap. 135). Chapter 103 reviews birthmarks in detail.

HAIR LOSS

TELOGEN EFFLUVIUM

Telogen effluvium occurs frequently in young infants and is often overlooked. The hair loss may be gradual or sudden, and may occur as soon as the first few days after birth, with the telogen hairs shed by 3 to 4 months of age. No treatment is indicated as spontaneous resolution is the rule.

Figure 104-3 Mosaicism can be seen in nature, as demonstrated by the "birthmark" on this orange.

OCCIPITAL ALOPECIA

A transient circumscribed patch of nonscarring alopecia develops at the occiput in many infants. Thought to be caused by a combination of physiologic telogen effluvium and localized pressure from lying in the supine position, occipital alopecia spontaneously resolves.

NEVUS SEBACEUS (ORGANOID NEVUS)

This hamartoma usually occurs on the head and neck as a waxy, yellowish plaque. On the scalp, it appears hairless owing to miniaturization of hairs. The typical yellow-orange color may not develop until later in childhood (Fig. 104-4).

TRIANGULAR TEMPORAL ALOPECIA

Triangular temporal alopecia is a form of nonscarring hair loss noted at 2 to 5 years of age as a triangular-shaped, oval-shaped, or lancet-shaped area of alopecia at the frontotemporal scalp. Often, a thin row of hair separates the affected area from the forehead. The terminal hairs are replaced by vellus hair. The condition is often mistaken for alopecia areata; however, distinguishing features include the typical location and shape, the presence of vellus hairs, and the absence of exclamation point hairs or histologic findings of alopecia areata. There is no known treatment, and the condition persists unchanged. However, triangular temporal alopecia is benign and will not expand.

Figure 104-4 Nevus sebaceus (organoid nevus) appears hairless because of miniaturization of the hairs.

ALOPECIA AREATA

Alopecia areata occurs in all ages (see Chap. 87). All variants of alopecia areata occur in infants and children, with similar disease presentation and treatment challenges as in adults. Onset at younger than 2 years of age is estimated to occur in 1% to 2% of alopecia areata patients; however, it may be underrecognized. Several cases of congenital alopecia areata have been documented. Early onset is considered to be a poor prognostic marker. Total alopecia during the first year of life after having hair at birth should be distinguished from genetic disorders, such as congenital atrichia with papular lesions and vitamin D resistance.

TINEA CAPITIS

Tinea capitis can occur at any age, including infancy. Hair loss associated with scaling, broken hairs, pustules, or black dots should prompt a potassium hydroxide scraping and/or fungal culture to confirm the diagnosis. Just as in older children, *Trichophyton tonsurans* is the most common dermatophyte, and oral griseofulvin is the treatment of choice.

Scrapings for potassium hydroxide examination and fungal culture should be obtained before administration of systemic antifungal therapy. In children, collection of specimens for tinea capitis may be accomplished by the use of a toothbrush, ring curette, moistened cotton swab, a scalpel, or by collection of infected hairs. If a child is not sitting still, the blunt side of a #15 scalpel can be used rather than the sharp blade side to collect scrapings. Alternatively, a media plate with nonslanted agar may be applied directly to the infected areas of the scalp to collect material.

TRICHOTILLOMANIA

Though alarming to parents, infant hair pulling usually has a good prognosis. It is often a self-soothing mechanism for infants, and may represent a different etiology than trichotillomania in adolescents and adults, which has a much poorer prognosis (Fig. 104-5).

Figure 104-5 Irregular patches of alopecia developed in this healthy 2-year-old child. Broken hairs were noted. Trichotillomania was witnessed at home by the parents.

THE DIAPER REGION

INFANTILE PERINEAL PROTRUSION

Also known as *infantile pyramidal protrusion*, infantile perineal protrusion is a benign condition that occurs almost exclusively in female prepubertal girls. It appears as a pyramidal, soft-tissue, "tongue-like," smooth, or velvety pink protrusion. It is usually located in the midline just anterior to the anus. Infantile perineal protrusion is usually asymptomatic, but painful defecation has been reported. It occurs in 3 settings: constitutional, functional (after constipation, diarrhea, or other irritant exposure), or associated with lichen sclerosus et atrophicus. Often, infantile perineal protrusion is misdiagnosed as condyloma acuminatum, hemorrhoids, or as a sign of trauma. Conservative management is indicated. Spontaneous resolution, as well as resolution following a high-fiber diet to relieve constipation, has been noted.[5,6]

DIAPER DERMATITIS

Diaper dermatitis, like hand dermatitis, denotes a group of region-specific dermatoses. Diaper dermatitis is one of the most common dermatologic conditions in infants and children, noted in approximately 1 million pediatric outpatient visits each year.[7] With the advent of superabsorbent disposable diapers in the last decade, severe forms of diaper dermatitis have diminished in incidence. Irritant and candidal diaper dermatitis comprises the vast majority of diaper dermatitides in diaper-wearing individuals of all ages. Chap. 103 reviews diaper dermatitis and its variants. Additional considerations are presented below.

Miliaria Rubra ("Heat Rash"): Miliaria rubra tends to occur at sites where plastic components of the diaper cause occlusion of eccrine ducts of the skin. It is also seen in the folds of the neck and upper torso, and is particularly common when there is a rapid shift to warm weather, and the child is overdressed.

Infantile Granular Parakeratosis: Infantile granular parakeratosis represents an idiopathic form of retention keratosis in diaper-wearing infants. There are two clinical patterns: bilateral linear plaques in the inguinal folds and erythematous geometric plaques underlying pressure points from the diaper. A thick, flake-like scale is present in both forms and is characteristic. Therapeutic responsiveness to topical agents is ambiguous; however, spontaneous clearance after months to 1 year appears to be the rule.[8]

CONSIDERATIONS IN CHILDHOOD

EVALUATION TECHNIQUES

In addition to the themes discussed above for infants, further concepts are helpful when assessing children. Review of coexistent medical conditions and medications can lead to diagnostic clues. For example, perioral dermatitis (Fig. 104-6) can be triggered not only by topical corticosteroids, but also inhaled corticosteroids for asthma (particularly when a spacer with face mask is used), and by corticosteroid nasal sprays. Observing the play of a child allows for a quick assessment of the child's neurologic development. Interactions between caregivers and child are also informative. Early prolonged or intense eye contact with the young child should be avoided because this can be threatening to the child. If an elective biopsy or procedure is needed, it is often more acceptable for the parent or child if the procedure is scheduled for a second visit rather than for the initial visit.

If a language barrier exists between the family and the physician, one should resist the urge to have the bilingual patient serve as interpreter for the parents/caregivers. This practice places an inappropriate burden of responsibility on the child and may increase fear and anxiety in the child. In addition, inaccurate transmission of information may occur.

Examination of young children may be performed with the child on the parent's lap or while playing with toys on the examination table. If needed, examination of the perineum and genitalia can be accomplished with the child in the knee-chest position on the examination table (Fig. 104-7) or the parent's lap. Alternatively, the child may sit on the parent's lap with legs held apart by the parent. Figure 104-8 illustrates anatomic terminology of the young female genitalia for accurate documentation, and can be helpful in conditions such as lichen sclerosus. Caution must be used in interpreting the genital examination in the young female so as not to underdiagnose or overdiagnose disease or abuse. For example, the presence of labia minora adhesions is not diagnostic of trauma or abuse because they occur in as many as one-third of girls who are not abused.[9] The diastasis ani is a normal structure that can be mistaken for perianal scarring.[10] The infantile perianal pyramidal protrusion may be mistaken for condyloma acuminata but is a harmless normal finding (see above).[5,6]

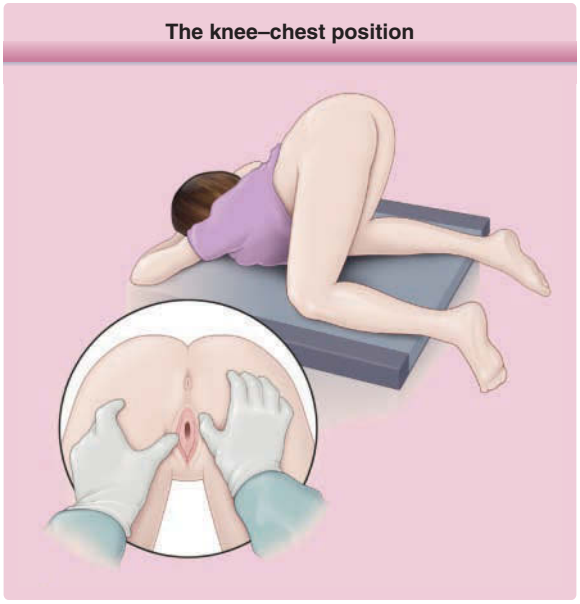

Figure 104-7 The knee–chest position allows visualization of the perineum and genitalia. (From Tintinalli JE, Stapczynski JS, Ma OJ, et al. *Tintinalli's Emergency Medicine: A Comprehensive Study Guide*. 7th ed. New York, NY: McGraw-Hill; 2010.)

Figure 104-6 Perioral dermatitis is common in children and is exacerbated by topical corticosteroid use. Inhaled corticosteroids (for asthma) or nasal corticosteroid sprays (for allergic rhinitis) can also trigger perioral dermatitis. This condition responds well to discontinuing the corticosteroid exposure, and the use of topical metronidazole cream. Oral erythromycin is helpful in severe cases.

PERFORMING PROCEDURES ON THE YOUNG CHILD

Historically, there has been a widespread reluctance to biopsy skin lesions in infants and children. This may lead to a delay in diagnosis of conditions such as childhood melanoma. In addition, many conditions in infants and children have a paucity of dermatopathologic information in the literature as a consequence of this reluctance. Parents may be anxious about causing pain or scarring, and children may be fearful because of their experience with immunizations, or an age-appropriate fear of bodily mutilation. However, with proper preparation of the parent and child, skin biopsies and other outpatient procedures are easily performed (Table 104-3). Note that there are certain situations in which a biopsy can be detrimental; Table 104-2 provides examples of these "biopsy pitfalls."

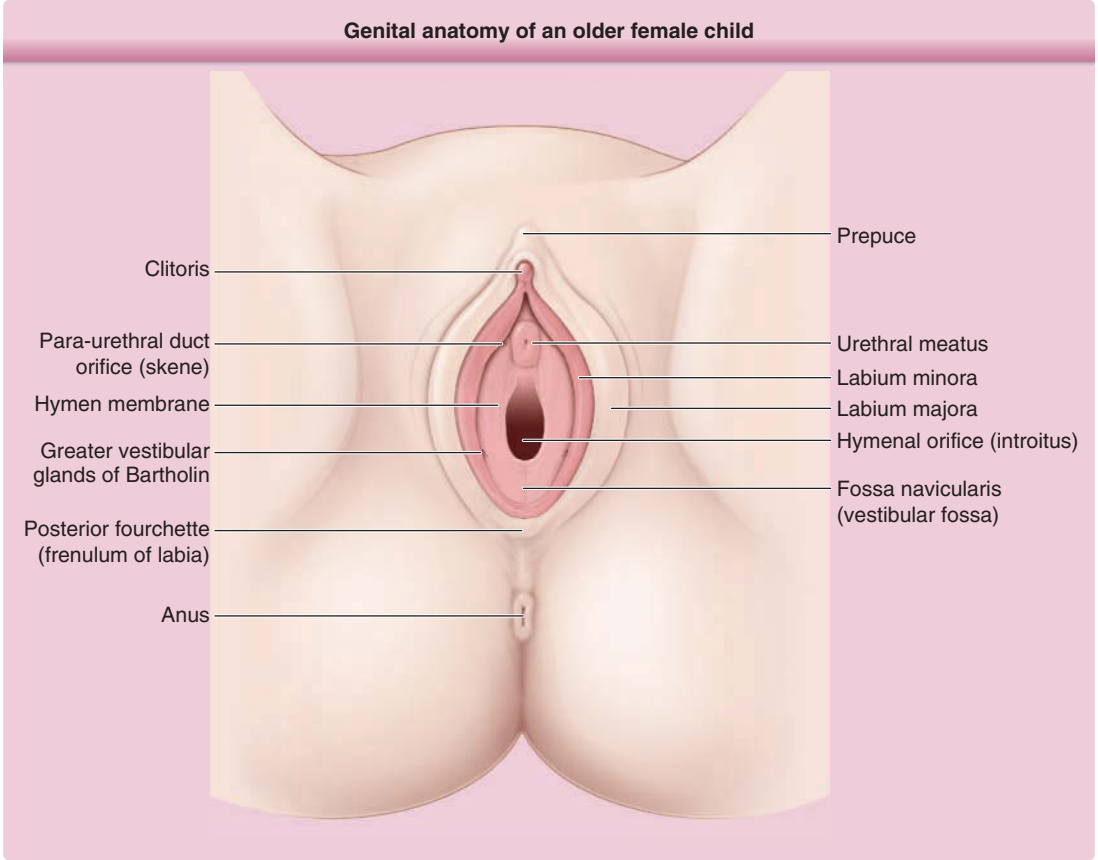

Figure 104-8 Genital anatomy of an older female child. (Redrawn from Finkel MA, DeJong AR. Medical findings in child abuse. In: Reece RM, ed. *Child Abuse: Medical Diagnosis and Management*. Philadelphia, PA: Lea & Febiger; 1994:185.)

Eutectic mixtures of lidocaine and prilocaine (EMLA cream) or plain lidocaine cream are useful in minimizing the pain of intralesional injections or local anesthetic injections for biopsies. As EMLA use has become widespread, reports of toxicity in children have resulted, including methemoglobinemia and seizures. The maximum dose, body surface area exposed to drug, and application time should not be exceeded; these parameters are age dependent: 1 g for a 1- to 3-month-old, 2 g for a 3- to 12-month-old, 10 g for a 1- to 6-year-old, and 20 g for a 7- to 12-year-old child.[11] Note that increased absorption and toxicity can occur when applied on diseased skin, even with normal dosing. Other options to numb the skin prior to injections include the application of ice or anesthetic cryospray (eg, ethylchloride). Before and during procedures, young infants can be soothed with a pacifier dipped in a sucrose solution. A randomized, controlled, double-blinded study of 201 newborns found that orally administered glucose solution was superior to topical EMLA cream in reducing pain with venipuncture.[12] Infants may be swaddled with a blanket for comfort and immobilization. The young child can be effectively immobilized and comforted with a restraining "hug" by a parent or assistant. Distraction techniques are invaluable as well. For example, instructing the child to blow a colorful toy windmill, blow soap bubbles, or "wiggle" his or her toes during an injection or procedure helps to decrease pain. Older children may be effectively soothed by listening to

TABLE 104-3
The ABCs of Successful Outpatient Procedures in Pediatric Dermatology

A: Anesthesia techniques: EMLA or ice prior to injection, buffer the lidocaine, apply vibration next to injection site, and infuse slowly. **A**ppointment times in the morning are best for procedures on young children. If they are tired, they are less able to focus and cooperate.
B: Blood: keep bloody gauze and instruments out of sight of patient and parents.
C: Calm parents = calm child. **C**onsent by parents is required if the patient is a minor.
D: Distraction techniques are essential: MP3 player, DVD player, *Where is Waldo?* books, and *I-Spy* books are all very helpful.
E: Expedite the procedure by preparing all instruments and materials before starting.
F: Four hands (minimum) are needed—have at least 1 assistant to help, preferably not the parent.
G: Go to a day surgery setting if the patient is unable to participate in local anesthesia because of age or abilities.
H: Hovering parents—keep parents seated and calm, with surgical site out of view.
I: Invest the time, do not rush.

music with headphones or by watching a movie during procedures.

Alkalinizing local anesthetics to a pH of 7.0 (0.1 mEq/mL sodium bicarbonate or a 1:10 bicarbonate-to-anesthetic ratio by volume) minimizes the pain of cutaneous infiltration without limiting anesthetic effects.[13] Alkalinization decreases the solution's shelf life to approximately 1 week[14] as a result of more rapid oxidation of epinephrine. Warming lidocaine also lessens the pain of injection.[13]

Gentle vibrational motions, applied with the surgeon's nondominant hand or a palm-sized vibrating device adjacent to the injection site while administering lidocaine, and infiltrating the anesthetic slowly are helpful to reduce the pain of anesthetic administration.

Instruments and materials laid out ahead of time ensure rapid performance of the procedure and are less frightening if kept out of sight by covering them with a drape. Needles, instruments, and blood-stained gauze should be kept out of view and out of reach of the patient.

Children sense their parents' anxiety and nervous energy. Parents who are overly anxious can be asked to sit farther away from the operating table, or sometimes are best positioned outside the procedure room.

Postoperative pain management is not necessary for the vast majority of biopsies and excisions in children. Acetaminophen, given on an as-needed basis, is usually sufficient.

GENERAL ANESTHESIA AND SEDATION

The use of general anesthesia for dermatologic procedures in healthy pediatric patients is very safe when properly performed. Fears of general anesthesia should not be a barrier to delivering necessary surgical or laser procedures to healthy children.[15]

However, for elective procedures, especially those requiring repeated or lengthy general anesthesia, the benefits of general anesthesia should be carefully weighed with the unknown risks to the developing brain in young children. Controversy exists whether repeated general anesthesia in infants and young children leads to increased risk of subsequent neurodevelopmental issues.

Obtaining an MRI study of infants and young children usually requires sedation or general anesthesia. MRI imaging typically requires the patient to lay motionless in a narrow dark space for 45 minutes or longer. Furthermore, the child must wear ear protection because the banging noises of the machine can reach sound levels of 118 to 125 decibels. Referral to a children's hospital or a radiology center that has a pediatric anesthesiologist is recommended to achieve a safe and accurate imaging study. For very young infants, sedation can sometimes be obviated by "feed and swaddle" techniques so that the infant patient sleeps deeply and remains motionless during the imaging procedure. However, this technique requires a center knowledgeable about imaging of infants.

Figure 104-9 This healthy 8-year-old girl suffered from recurrent inflammatory, fissured, eczematous dermatitis on the face, and perianal region. Patch testing revealed methylisothiazolinone contact allergy. This preservative was contained in the wet wipes that were used to cleanse these regions. The eruption promptly cleared when the wipes were discontinued.[49]

PATCH TESTING IN CHILDREN

Allergic contact dermatitis (ACD) affects all ages (Fig. 104-9), but pediatric ACD is not well studied. In children, ACD tends to be misdiagnosed, underdiagnosed, and underreported. As a consequence, the epidemiology of ACD in children is not well understood. A recent multicenter pediatric contact dermatitis registry of 1142 children demonstrated that the prevalence of sensitization among patients with suspected ACD was up to 65%. The mean age of patch-tested children was 11 years. The top allergens were nickel (22%), fragrance mix 1 (11%), cobalt (9.1%), balsam of Peru (8%), neomycin (7%), propylene glycol (7%), cocamidopropyl betaine (6%), bacitracin (6%), formaldehyde (6%), and gold (6%).[16]

Strategies to ensure successful epicutaneous patch testing in young children need to be employed. Because of the mobility and flexibility of young children, it is helpful to have the young child stand up straight during application and marking of the patches. The use of Hypafix tape or other extra dressings or tape ensures the patches stay in place. Avoiding sports or gym class may be necessary to prevent sweating and movement of the patches. Additionally, the smaller surface area of the back in children may limit the number of patches placed.

ADOLESCENT DERMATOLOGY

Dermatologic diagnoses of adolescents overlap with those of general adult dermatology. However, caring effectively for the adolescent patient requires different interviewing skills and strategies to enhance compliance.

CONFIDENTIALITY

Confidentiality is a necessary component in providing effective health care to adolescents. Confidentiality laws vary from country to country; within the United States, they vary by state. Clinicians who treat adolescents should familiarize themselves with the state and local laws that affect the rights of minors to consent to health care services, as well as federal and state confidentiality laws.

The patient's right to privacy should be respected, but the clinician should never lie to the parent/guardian. Furthermore, adolescent patients should be informed that while clinicians will respect their confidentiality, unconditional confidentiality cannot be promised. In situations where there is the potential for harm to the minor or others, such as abuse, suicidal or homicidal ideation, the physician is required by law to report the situation to the local child protective services agency. Moreover, certain sexually transmitted infections must be reported to public health departments. Finally, as most adolescents are covered by their parent/guardian's health insurance policy, the resulting explanation of benefits often discloses information to the parent/guardian.

EVALUATION TECHNIQUES

Greeting the adolescent first and the parents second, and interviewing the adolescent patient alone for a portion of the visit help to earn the patient's trust.[17] The open-ended questioning style used for adults may fail with adolescents. Phrasings using the third person and giving choices when asking questions are more effective techniques to obtain information. For example, "Many women on oral contraceptives forget to take their pill once in a while. How often do you forget to take your birth control pills: often, sometimes, or almost never?" will yield a more accurate reply than, "Do you take your birth control pills every day?"

In adolescents, long-term consequences are often less valued than immediate outcomes. Goals should be concrete, short term, and relevant to the present. Rather than using goals related to more distant benefits, such as the reduction of potentially serious disease complications (eg, smoking causes increased risk of lung cancer), emphasis should be placed on immediate and concrete effects (eg, smoking causes your clothes, hair, and breath to smell bad and your teeth to turn yellow). Body image is a more powerful motivator, and messages such as "tanning salons cause premature wrinkles and ugly skin" are more effective than future health concerns (eg, "tanning salons increase your risk of skin cancer"). Any treatment that is disfiguring or has visible side effects will be met with resistance.[17]

Physical and psychosocial development may not be congruent. Adolescents should not be expected to shoulder all medical responsibilities for themselves, or for their younger siblings. The physician's role is not to befriend, nor is it to parent the adolescent patient; instead, it is to be a trusted, valuable authority.

ACNE AND THE ADOLESCENT

Acne vulgaris is an extremely common and variable disorder that can have far-reaching detrimental effects on self-image and self-esteem. Increased unemployment has been documented among patients with a history of severe acne.[18] A streamlined treatment plan (eg, a single-drug or two-drug regimen) will optimize compliance and cost-effectiveness. Chap. 78 discusses acne in detail.

Females with treatment-resistant acne, signs of virilization (including irregular menstrual cycles, hirsutism, and/or obesity) should have evaluation for androgen excess states including polycystic ovary syndrome. However, some females with polycystic ovary syndrome lack the classic clinical features; for example, they may be slender with no overt signs of virilization ("lean polycystic ovary syndrome"). Other patients have incomplete features and may be categorized as "provisional polycystic ovary syndrome."

Several oral contraceptives (Yaz, Yazmin, and Ortho Tri-Cyclen) have Food and Drug Administration (FDA) labeling for the treatment of acne and are an important therapeutic option for adolescent females with recalcitrant acne. The effectiveness of oral contraceptives often allows discontinuation of chronic oral antibiotic therapy. Patients should be counseled that adherence to 3 months of oral contraceptives is often needed to establish treatment efficacy for acne. Oral contraceptives with a higher androgenic component and lower estrogenic component may be less effective for acne management. Topical acne medications, such as retinoids, may need to be continued for best results.

Because of its antiandrogenic effects, spironolactone, a potassium-sparing diuretic, is a valuable adjunctive therapy for adolescent females with chronic acne, particularly in conjunction with an oral contraceptive. Because spironolactone is a teratogen, concurrent use of a contraceptive is recommended. In a healthy young patient without complicating factors, repeated monitoring for hyperkalemia while on spironolactone for acne management is probably unnecessary.[19] One caveat is that some oral contraceptives contain drospirenone, which has potassium-sparing effects. Thus, female acne patients receiving both spironolactone and drospirenone may need potassium monitoring.

Isotretinoin has been a valuable, unique, and effective agent for nodulocystic acne since 1982. Isotretinoin's teratogenicity is well known. The question of psychopathology induced by isotretinoin is more controversial. The FDA's Adverse Drug Event Reporting System has received reports of depression, suicide, and other psychiatric side effects (eg, aggression, psychosis) in patients using isotretinoin. The question of isotretinoin-induced depression is complicated by the

high baseline incidence of depression and suicide in the adolescent population and by the depression and stress associated with severe acne.[20,21] Case reports, including positive cases of positive dechallenge and rechallenge, suggest that isotretinoin may induce depression and other psychiatric adverse effects, but larger retrospective and prospective studies do not demonstrate causation.[22] In some studies, depression scores improved when patients' acne improved with isotretinoin therapy.[23] Double-blind, placebo-controlled studies about isotretinoin and depression have not yet been done, and as of this writing, animal studies show conflicting results. Although a causal link has not been established between isotretinoin and depression/suicide at this time, it is likely that uncommon idiosyncratic psychiatric reactions to isotretinoin may occur in predisposed individuals. Pretreatment evaluation and, if cleared to proceed, subsequent comanagement by a psychiatrist or psychologist should be considered for vulnerable patients. If mood changes arise, the drug should be stopped until the patient is evaluated by the pediatrician or psychiatrist. If deemed appropriate, a rechallenge can be done cautiously.

A second unanswered question is whether the risk of inflammatory bowel disease increases with isotretinoin use. Studies show conflicting results thus far. It is possible that isotretinoin may trigger inflammatory bowel disease in predisposed individuals. Until we have better data, patients and parents should be counseled that a rare but potentially real risk might exist. If bowel symptoms develop, discontinuation of isotretinoin is advisable until the patient is evaluated by a gastroenterologist.[24,25]

Routine monthly laboratory monitoring during isotretinoin therapy is most important during the early months of therapy for healthy individuals receiving no other medications. If no abnormalities appear in the first 2 months, then reduced frequency of monitoring or forgoing laboratory monitoring is appropriate.[26] However, adolescents should be asked if they are taking medications or supplements, including nutritional, "energy," or "recovery" supplements. These supplements, as well as frequent or high-dose nonsteroidal antiinflammatory drug usage (eg, in athletes) may affect liver function, especially during isotretinoin therapy. More frequent laboratory monitoring of these patients may be needed if they decline to avoid supplements.

AXILLARY HYPERHIDROSIS

Idiopathic focal hyperhidrosis is a common condition that has been long been underrecognized. Axillary hyperhidrosis is the most common complaint, but palmar, plantar, and/or facial sites can be affected as well. It can be familial or sporadic. Although all ages may be affected, patients commonly present during adolescence when the condition becomes socially troubling and significantly impacts quality of life. The management of focal idiopathic hyperhidrosis is similar to that of adults. If topical and oral treatments (glycopyrrolate, oxybutynin) fail, injection of botulinum toxin A should be considered. Chap. 81 reviews hyperhidrosis.

INDOOR TANNING

The World Health Organization Cancer Group has classified tanning beds as "carcinogenic to humans." Extensive evidence has linked sunlamp or sun bed exposure to increased risk of melanoma and nonmelanoma skin cancers. Nevertheless, approximately 50,000 tanning salons exist in the United States and tanning bed use is increasing among adolescents and young adults. In addition to the desire for tanned skin and the socialization of the tanning salon, some individuals feel more relaxed, and have improved mood following tanning. Evidence is mounting that tanning bed use is physiologically and psychologically addictive. A study demonstrated that frequent tanners developed a preference for functional ultraviolet beds compared to otherwise identical sham light beds.[27] In addition, physiologic withdrawal symptoms arose in some subjects who were given naltrexone prior to their tanning sessions, suggesting that an opioid-mediated mechanism of dependency may exist in frequent tanners.[28]

Psychiatric studies, using modified tools originally used for substance abuse screening, confirm addictive behaviors of people who frequent tanning salons. Among 229 college students who had used indoor tanning facilities, 90 (39.3%) met *Diagnostic and Statistical Manual of Mental Disorders* IV-TR criteria and 70 (30.6%) met modified CAGE (cut down, annoyed, guilty, eye-opener) criteria for addiction to indoor tanning. In addition, these students also reported greater symptoms of anxiety and greater use of alcohol, marijuana, and other substances than those who did not meet these criteria.[29]

Currently, 13 states ban the use of tanning beds for all minors (persons younger than age 18 years), and at least 42 states regulate the use of tanning facilities by minors. The fight against indoor tanning is similar to the fight against the tobacco industry. Stronger legislation banning tanning bed use in minors, control of false safety claims in advertisements, and extensive education of parents and our youth are still needed.

SPECIAL TOPICS IN PEDIATRIC DERMATOLOGY

AUTISM SPECTRUM DISORDER

BACKGROUND

Autism spectrum disorder (ASD), or autism, refers to a group of complex disorders of brain development. These disorders are characterized, in varying degrees, by difficulties in social interaction and connection, verbal and nonverbal communication, and

repetitive behaviors.[30,31] In 2013, the *Diagnostic and Statistical Manual of Mental Disorders* 5 merged autistic disorder, childhood disintegrative disorder, pervasive developmental disorder–not otherwise specified, and Asperger syndrome into 1 umbrella diagnosis of ASD. Instead of separate entities, they are considered to comprise the autism spectrum. ASDs range from mildly to profoundly disabling. ASD can be associated with intellectual disability, attention difficulties, sensory processing disorders, feeding disorders, disrupted motor coordination, sleep disorders, and GI disturbances. Some (but not all) persons with ASD excel in visual skills, music, math, and art.

Autism affects more than 3 million individuals in the United States and tens of millions worldwide. Autism occurs in all racial, ethnic, and socioeconomic groups. The Centers for Disease Control and Prevention estimates that 1 in 68 American children are on the autism spectrum—a 10-fold increase in prevalence in 40 years. This increase is only partly explained by improved diagnosis and awareness. Autism is 4 to 5 times more common among boys than girls. An estimated 1 in 42 boys and 1 in 189 girls are diagnosed with autism in the United States.[30,31]

There is no proven explanation for the rising prevalence of ASD, but the cause is likely multifactorial. Genetic predisposition exists for some individuals. Children with a sibling with autism are at higher risk of ASD, and individuals with certain genetic disorders are at much higher risk of ASD (Table 104-4). Pregnancy and environmental influences also play a role in the development of ASD. The theory that childhood immunizations cause autism, however, has been debunked.

While much of its genesis is not fully understood, ASD appears to originate in very early brain development: in utero, during, or immediately after birth.[31] The clearest signs of autism tend to emerge between 2 and 3 years of age, and, consequently, it is at this age that ASD is usually diagnosable. There is no medical diagnostic test for autism. The diagnosis depends on a constellation of developmental and clinical signs, many of which are nonspecific. Diagnosis often requires consultation with experts in developmental pediatrics, child neurology, and child psychology.

AUTISM AND THE DERMATOLOGIST

Features of ASD particularly relevant to the dermatologist include sensory processing disorders (eg, sensory dysfunction including both hypersensitivity and hyposensitivity to stimuli, tactile defensiveness, inability to tolerate topical medications or emollients), and overrepresentation of neurobehavioral dermatoses (eg, scars, callosities, and self-inflicted injury resulting from repetitive or ritualistic or stimulatory behaviors) (Table 104-5). Genodermatoses can be associated with autism (see Table 104-4), although many children do not have a diagnosable genetic condition. Nutritional disorders may develop (eg, scurvy), from either ritualized eating preferences of the child, or from imposed dietary manipulations with potential therapeutic benefits (gluten-free or casein-free diets, or ketogenic diets are often experimented with).[32,33]

A new medical consultation can be anxiety provoking for child with autism, the parent, and the physician. Some children are violent and/or self-injurious. "Antecedents," or stimuli that trigger outbursts or maladaptive behaviors should be shared with the physician before any examination occurs. Many children have much higher receptive language skills and lower verbal expressive skills. Some children prefer to be addressed directly in the examination room. Try to use the family's preferred mode of communication, such as signing, simple 1-word directives, Picture Exchange Communication System, or using an assistive technology device.

Families affected by ASD shoulder chronic stress from medical, financial, and emotional challenges, as well as acute stresses from unpredictable disruptions (eg, illness, sleep deprivation). Many, if not most, have had negative experiences with health care providers. Be gentle, quiet, flexible, nonjudgmental, and open to learning about what works for the family.

TABLE 104-4
Genodermatoses Associated with Autism Spectrum Disorder[32,33]

Genetic Condition
- *PTEN* hamartoma tumor syndromes
  - Cowden
  - Bannayan-Riley-Ruvalcaba
  - *PTEN*-related Proteus syndrome
  - Proteus-like syndrome

RAS Pathway Disorders
- Cardiofaciocutaneous syndrome
- Noonan syndrome
- Costello Syndrome
- Neurofibromatosis Type 1

Sex Chromosome Aneuploidies
- Turner syndrome (45XO)
- Klinefelter syndrome (47XXY)

Neurocutaneous Syndromes
- Tuberous sclerosis
- Neurofibromatosis 1
- Angelman syndrome
- Prader-Willi syndrome
- Segmental pigmentary disorder

TABLE 104-5
Common Skin Findings in Children with Autism Spectrum Disorder

Scars/callous formation
- Accidental (eg, hyposensitivity/low pain threshold)
- From wearing devices or equipment (eg, sound-blocking headphones)
- Past surgical procedures (comorbidities are common)
- Self-inflicted injury (eg, biting, rubbing, chewing, banging)

Xerosis and atopic dermatitis—intolerance of sensation of topical medications/emollients

Features of genodermatosis (if present)

TABLE 104-6
An Approach to Caring for Children with Autism Spectrum Disorder

Characteristics of Autism

- While every child is different, the following are commonly seen:
- Emotional dysregulation is common in this population. Often, there are predictable precursors to behavioral issues called "antecedents" that trigger the maladaptive behavior. Knowing about the child's antecedents can help everyone avoid upset.
- Difficulties in social interaction and connection. Connection with full-time caregivers and close family is more readily evident, and can be inspiring.
- Self-stimulation behaviors or repetitive movements that may emerge when stressed; these behaviors can be calming to the patient:
  - Repetitive behaviors such as flapping, rocking, tapping, or flickering fingers in front of eyes
  - Playing with string, or shiny objects
  - Tearing paper
  - Spinning objects
- Hypersensitivity—Loud sounds (the child may prefer wearing protective headphones) or bright lights may be antecedents to maladaptive behaviors. Hearing certain sounds, or certain words, or even adults speaking to one another may provoke untoward responses. Tactile defensiveness.
- Hyposensitivity—High pain threshold in some individuals.
- Limited verbal or nonverbal communication, receptive and/or expressive.
- Ritualized environment—Strong desire to keep routines and things the same, in the same order and manner.

Do

- Put the family in a patient room to wait, instead of the waiting room.
- Consider booking the patient first or last on the schedule, and with extra time for the encounter.
- Ask the caregiver what works best for interactions and examinations, and what doesn't. Find out what self-soothing strategies the child employs to calm and organize.
- Consider lowering the lights. Many find bright lights difficult. Some may find the sounds of fluorescent lights annoying.
- Initially observe the child from a distance that is nonthreatening to the child.
- Use a quiet calm voice, not a loud, boisterous voice.
- Ask for permission before touching the child.
- Ask about the child's pain threshold. Is there increased or decreased pain sensitivity?
- Ask if the child tends to self-inflict injury (rubbing, biting, picking)?
- Ask about closing the office door. A lot of children have a hard time staying in the examination room and do not like any closed doors. Some doors need to have a way to be locked from the inside so the child does not bolt from the room.
- Consider using nonverbal communication. For example, some children will mimic your movements more readily than following verbal directions (eg, during a full skin examination, show how you turn your hands over, spreading fingers wide, or raise your arms above your head).
- Having a doll to point to (to convey where they are feeling hurt or uncomfortable) can be helpful.
- Be patient with the family and with yourself. Sometimes not everything will be accomplished in 1 office visit.

Don't

- Don't be afraid to ask the parent/caregiver what strategies work best for the child.
- Don't assume that general anesthesia is needed for every skin biopsy or procedure, because many will do extremely well with local anesthesia.
- Don't talk about the child as if the child is not there.
- Don't assume the child doesn't understand what you are saying, even if no acknowledgment is evident. Many children have better receptive skills than expressive communication skills.
- Don't assume every visit will unfold in the same way. The next visit may go surprisingly easily or pose unexpected challenges.

One mother of a teenage girl with severe nonverbal autism gives this advice:

> Thinking outside of the box is critical in treating autistic patients. Making special allowances will go a long way with parents, as most are trying their best with little to no support. An example might be allowing the child to have their favorite drink or snack while waiting, even if this is not usually allowed in the office. It can help keep the child calm and focused on eating rather than on the stress of being in a medical office. Allowing the child to rip paper might provide the same soothing effect. Try to complete the examination in small increments while taking the child's mind off the task at hand, using play or finding commonality in something they are interested in.

Acceptance of how these kids present is important. They understand when someone is looking negatively at them with disdain or annoyance. They understand when someone is fearful and aversive toward them.

Table 104-6 presents a treatment approach for dermatologists caring for individuals with ASD.

DRUG LABELING FOR PEDIATRIC PATIENTS

The lack of FDA labeling for pediatric use does not imply that a drug is contraindicated or disapproved; it simply means that insufficient data are available to grant approval status. Although attempts have been made to equate off-label prescribing with recklessness in the medical malpractice arena, the American Academy of Pediatrics has stated that failure to prescribe medications for off-label uses when the medication is appropriate under the standard of care may constitute malpractice.

The thalidomide tragedy led to more stringent regulation of drugs in the early 1960s, and manufacturers began omitting drug studies in infants and children. In the 1970s, pediatric dosage information in package inserts tended to exclude children from therapeutic benefit. Performing research in healthy children is problematic because of ethical and logistic questions, medicolegal risk, and cost. It has been estimated that approximately 50% to 75% of drugs used in pediatrics have not been studied adequately to provide accurate labeling information, and the younger the patient, the more likely the lack of information.[34] Safety and effectiveness information for drug use in children younger than 2 years of age is particularly lacking. The absence of pediatric testing and labeling poses significant safety risks for children. Additionally, children may be denied the benefits from therapeutic advances because physicians choose to prescribe existing, less-effective medications in the face of insufficient pediatric information about new medications. In 1997, as part of the FDA Modernization Act, Congress enacted a law known as the *Pediatric Exclusivity Provision* that provides marketing incentives (ie, 6-month extension of patent protection) to manufacturers who conduct studies of drugs in children. This law was effective in generating pediatric studies on many drugs, and an increase in labeling information has occurred for some. Unfortunately, many studies have centered on children older than 6 years of age, and many drug studies were stimulated by market concerns rather than medical need.

Hopefully, with incentives such as the Pediatric Research Equity Act of 2003, significantly more pediatric drug research will proceed forward. Ideally in the future, physicians caring for children will no longer need to prescribe drugs "off label," and children will no longer be "therapeutic orphans."

TOPICAL MEDICATIONS

While topical medications often have excellent safety and efficacy profiles, one must be aware that infants and young children are at increased risk for toxicity from topically applied agents because of an increased surface-area-to-body-mass ratio compared to adults. In addition, at times infants and children have altered metabolism of drugs compared to adults. Patients with disorders of cornification (eg, lamellar ichthyosis) or other forms of skin barrier disruption (eg, Netherton syndrome) have a much higher risk of toxicity resulting from increased percutaneous absorption. Patients with Netherton syndrome who are treated with topical tacrolimus may develop immunosuppressive or toxic blood levels of tacrolimus, without clinical signs or symptoms of toxicity.[35] A heightened awareness of this problem is important because Netherton syndrome is often misdiagnosed as atopic dermatitis, and both conditions often improve with topical tacrolimus therapy. In addition, a patient with Netherton syndrome developed Cushing syndrome after application of hydrocortisone 1% ointment for longer than 1 year.[36] Table 104-7 lists examples of inadvertent percutaneous poisoning from topical agents.

SYSTEMIC MEDICATIONS

DRUG DOSAGES

Pediatric doses of systemic medications are calculated according to body weight (mg/kg) or body surface area to account for size variations between patients of the same age and to account for a child's growth.

TABLE 104-7
Topical Medications Reported to Cause Systemic Toxicity in Children

TOPICAL MEDICATION	COMPLICATION	REFERENCE
Tacrolimus 1% ointment	Three children with Netherton syndrome found to have blood levels of tacrolimus in the range of organ transplantation requirements	35
Hydrocortisone 1% ointment	Cushing syndrome developed in an 11-year-old boy with Netherton syndrome who received topical application to extensive areas for longer than 1 year	36
Benzocaine, 3% (Lanacane)	Methemoglobinemia in a 2-year-old child	50
Iodoquinol, clioquinol (Vioform)	Neurotoxicity when used as treatment for diaper dermatitis	51, 52
Lindane	Neurologic toxicity in children with disrupted epidermal barrier and/or excessive topical application or ingestion	53, 54
N,*N*-diethyl-*m*-toluamide (DEET)	Slurred speech, tremors, seizures, and death in children after repeated and extensive application of high concentrations of DEET	55
Povidone-iodine (Betadine)	Hypothyroidism in infants with spina bifida	56
Povidone-iodine (Betadine)	Decreased free thyroxine and elevated iodine levels in infants treated with diluted povidone-iodine during *Staphylococcus aureus* epidemic	57
Salicylic acid	A 7-year-old boy with ichthyosis vulgaris developed life-threatening salicylism with neurologic sequelae lasting 6 months	58
Saline, sodium chloride	Fatalities in infants and children following ancient Turkish custom of "salting"	59
Viscous lidocaine, 2%	Lidocaine overdose following frequent application to oral lesions	60

Prescriptions for liquid medications (syrups or suspensions) must indicate concentration (eg, milligrams per 5 mL) to avoid serious error. In addition, the appropriate measuring instrument should be dispensed, along with education on its use. Dosing cups (commonly included in nonprescription liquid medications) are a common cause of dosing errors. Dosing errors were almost 5 times more likely when parents used dosing cups rather than oral measuring syringes.[37] In addition, dosing cups tend to cause overdosing, up to 300% of the proper dose in another study.[38]

For guidelines on indications and dosing of antimicrobials and other medications, the reader is directed to excellent references including the *Red Book*,[39] published by the American Academy of Pediatrics, and *The Harriet Lane Handbook*.[40]

SYSTEMIC GLUCOCORTICOIDS

Hypothalamic–pituitary axis suppression, osteonecrosis, and other adverse effects of systemic glucocorticoid therapy affect patients of all ages and are reviewed in Chap. 184. The potential risk of growth suppression is unique to childhood. Exogenous glucocorticoids disrupt the secretion of growth hormone, causing abnormal spontaneous growth hormone secretion with reduced pulse amplitude of growth hormone release and reduced response to provocative stimuli.[41,42] There is also decreased local production of insulin-like growth factor 1. These and other effects of glucocorticoids act to cause delayed growth at the bony epiphyses, with the most noticeable reduction in growth velocity occurring during early childhood and adolescent growth spurts. There is a linear relation between the daily dose and growth suppression. Alternate-day dosing, with single morning doses, may decrease the risk of glucocorticoid growth suppression. Most children eventually will have adequate catchup growth with reduction of doses, alternate-day therapy, or cessation of therapy.[43] For the pediatric patient on long-term systemic steroid therapy, charting height and weight on a standardized growth curve is the best method for the pediatrician to screen for decreasing growth velocity.

Children taking immunosuppressive doses of systemic glucocorticoids should not be vaccinated with live-virus vaccines (eg, measles, oral polio, varicella). A dosage equivalent of 2 mg/kg/day or greater of prednisone or a total of 20 mg/day or greater for children weighing more than 10 kg, when given for more than 14 days, is sufficient to warrant withholding immunization with live-virus vaccines.[44] Systemic steroids should not be given to a healthy child if the child has had recent varicella exposure and is not varicella-immune, as varicella infection can be fatal in this situation. In addition, children with ocular herpes simplex and untreated tuberculosis should not be given systemic steroids, and patients with underlying diabetes, hypertension, peptic ulcer disease, renal insufficiency, or psychosis should be treated with great caution or with an alternative agent.[39]

ANTIMICROBIALS

Use of tetracycline family medications is contraindicated in children younger than 8 years of age because it causes brown discoloration of developing teeth and decreased bone growth. Ciprofloxacin and quinolone use in children younger than 18 years of age is restricted because the fluoroquinolones have been shown to cause cartilage damage in juvenile animal models at therapeutic doses. The mechanism is unknown. It is recommended that use of these medications be restricted to relatively serious infections for which no other oral agent is available or IV antibiotics would be impractical and for certain pathogenic infections or situations, such as multidrug resistance.[40]

Griseofulvin doses of 20 mg/kg/day of the (125 mg/5 mL) liquid and 15 mg/kg/day of the ultramicrosized tablets for 6 to 8 weeks have long been considered first-line therapy for tinea capitis. In 2007, terbinafine oral granules (sprinkled on nonacidic food) were approved for the treatment of tinea capitis in children 4 years of age and older. Currently, griseofulvin and terbinafine are the only FDA-approved agents for tinea capitis in children. Griseofulvin appears to be superior against *Microsporum canis*. Crushed generic terbinafine tablets (off-label) can be substituted for terbinafine granules if the granules are not readily available. Although further studies are needed, itraconazole also appears to be effective and to have a good safety profile. Fluconazole was not very effective against pediatric tinea capitis in a large, multicenter, double-blinded, randomized trial of 880 children.[45]

CHILD ABUSE AND NEGLECT (CHILD MALTREATMENT)

Child maltreatment is abuse or neglect by a parent (or caregiver) that results in potential, actual, or threats of harm to a child. Child maltreatment includes both acts of commission (abuse) and omission (neglect). Child maltreatment is divided into 4 categories: (a) physical abuse (eg, hitting, shaking, or burning); (b) sexual abuse (eg, rape or fondling); (c) psychological abuse (eg, terrorizing or belittling); and (d) neglect (eg, failure to meet basic physical, emotional, educational, or medical needs).

Unfortunately, child maltreatment is not rare. In the United States, 1 in 8 children are victims of maltreatment annually,[46] and the true prevalence is likely higher because of underreporting.

The Centers for Disease Control and Prevention reports that in 2014, approximately 1580 children died from abuse or neglect in the United States. The total lifetime cost of child abuse and neglect is $124 billion annually.[47]

Approximately 70% of documented child maltreatment deaths occur in children younger than age

3 years. Other risk factors for abuse include children with special needs or chronic illnesses, disabilities, and other factors that increase caregiver burden. Caregiver risk factors include stress, inadequate parenting skills, substance abuse, and depression. Other factors include poverty, unemployment, isolation from support, transient nonbiologic caregivers in the home, and intimate partner violence. Similarly, predisposing community factors include poverty, violence, and housing instability. However, it is important to note that abuse and neglect can occur in the absence of the above risk factors, and occurs within all socioeconomic classes.[46,47]

Ninety percent of all abused children are said to have suggestive or confirmative dermatologic findings.[48] In all situations, the immediate safety of the child must be ensured, removing the child from the home (eg, hospitalization) if necessary. Objective documentation of physical findings is vital. Ideally, because of the sensitive medical and legal aspects of this important problem, any case of suspected child abuse should be quickly referred to a team specializing in pediatric abuse. The appropriate evaluation should not be delayed in the absence of such a resource, however. Timely reporting to child protective services is required by law in all cases of suspected child maltreatment.

REFERENCES

1. Scullard P, Peacock C, Davies P. Googling children's health: reliability of medical advice on the internet. *Arch Dis Child.* 2010;95:580.
2. Liang MG, Frieden IJ. Perineal and lip ulcerations as the presenting manifestation of hemangioma of infancy. *Pediatrics.* 1997;99:256.
3. Poole SR. The infant with acute, unexplained, excessive crying. *Pediatrics.* 1991;88:450.
4. Press S, Schachner L, Paul P. Clitoris tourniquet syndrome. *Pediatrics.* 1980;66:781.
5. Kayashima K, Kitoh M, Ono T. Infantile perianal pyramidal protrusion. *Arch Dermatol.* 1996;132:1481.
6. Khachemoune A, Guldbakke KK, Ehrsam E. Infantile perineal protrusion. *J Am Acad Dermatol.* 2006;54:1046.
7. Ward DB, Fleischer AB Jr, Feldman SR, et al. Characterization of diaper dermatitis in the United States. *Arch Pediatr Adolesc Med.* 2000;14:943.
8. Chang MW, Kaufmann JM, Orlow SJ, et al. Infantile granular parakeratosis: recognition of two clinical patterns. *J Am Acad Dermatol.* 2004;50(5)(suppl):S93.
9. McCann J, Wells R, Simon M, et al. Genital findings in prepubertal girls selected for nonabuse: a descriptive study. *Pediatrics.* 1990;86:428.
10. Siegfried E. The spectrum of anogenital diseases in children. *Curr Probl Dermatol.* 1997;9:33.
11. EMLA cream [package insert]. Wilmington, DE: AstraZeneca; 2000. https://www.accessdata.fda.gov/drugsatfda_docs/label/2000/19941S11LBL.PDF
12. Gradin M, Eriksson M, Holmqvist G, et al. Pain reduction at venipuncture in newborns: Oral glucose compared with local anesthetic cream. *Pediatrics.* 2002;110:1053.
13. Mader TJ, Playe SJ, Garb JL. Reducing the pain of local anesthetic infiltration: warming and buffering have a synergistic effect. *Ann Emerg Med.* 1994;23:550.
14. Proudfoot J. Analgesia, anesthesia, and conscious sedation. *Emerg Med Clin North Am.* 1995;13:357.
15. Cunningham BB, Gigler V, Wang K, et al. General anesthesia for pediatric dermatologic procedures: risks and complications. *Arch Dermatol.* 2005;141:573.
16. Goldenberg A, Mousdicas N, Silverberg N, et al. Pediatric Contact Dermatitis Registry inaugural case data. *Dermatitis.* 2016;27:293.
17. Blair S, Bowes. Compliance issues in adolescence: practical strategies. *Aust Fam Physician.* 1995;24:2037.
18. Cunliffe WJ. Acne and unemployment. *Br J Dermatol.* 1986;115:386.
19. Plovanich M, Weng QY, Mostaghimi A. Low usefulness of potassium monitoring among healthy young women taking spironolactone for acne. *JAMA Dermatol.* 2015;151:941.
20. Wysowski DK, Pitts M, Beitz J. Depression and suicide in patients treated with isotretinoin. *N Engl J Med.* 2001;344:460.
21. Wysowski DK, Pitts M, Beitz J. An analysis of reports of depression and suicide in patients treated with isotretinoin. *J Am Acad Dermatol.* 2001;45:515.
22. Kontaxakis VP, Skourides D, Ferentinos P, et al. Isotretinoin and psychopathology: a review. *Ann Gen Psychiatry.* 2009;8:2.
23. Chia CY, Lane W, Chibnall J, et al. Isotretinoin therapy and mood changes in adolescents with moderate to severe acne: a cohort study. *Arch Dermatol.* 2005;141:557.
24. Crockett SD, Porter CQ, Martin CF, et al. Isotretinoin use and the risk of inflammatory bowel disease: a case-control study. *Am J Gastroenterol.* 2010;105:1986.
25. Shale M, Kaplan GG, Panaccione R, et al. Isotretinoin and intestinal inflammation: What gastroenterologists need to know. *Gut.* 2009;58:737.
26. Lee YH, Scharnitz TP, Muscat J, et al. Laboratory monitoring during isotretinoin therapy for acne: a systematic review and meta-analysis. *JAMA Dermatol.* 2016;152:35.
27. Feldman SR, Liguori A, Kucenic M, et al. Ultraviolet exposure is a reinforcing stimulus in frequent indoor tanners. *J Am Acad Dermatol.* 2004;51:45.
28. Kaur M, Liguori A, Lang W, et al. Induction of withdrawal-like symptoms in a small randomized, controlled trial of opioid blockade in frequent tanners. *J Am Acad Dermatol.* 2006;54:709.
29. Mosher CE, Danoff-Burg S. Addiction to indoor tanning: relation to anxiety, depression, and substance use. *Arch Dermatol.* 2010;145:412.
30. Christensen DL, Baio J, Van Naarden Braun K, et al. Prevalence and characteristics of autism spectrum disorder among children aged 8 years—Autism and Developmental Disabilities Monitoring Network, 11 sites, United States, 2012. *MMWR Surveill Summ.* 2016;65:1.
31. Schieve LA, Tian LH, Baio J, et al. Population attributable fractions for three perinatal risk factors for autism spectrum disorders, 2002 and 2008 Autism and Developmental Disabilities Monitoring Network. *Ann Epidemiol.* 2014;24:260.
32. Oza VS, Marco E, Frieden IJ. Improving the dermatologic care of individuals with autism: a review of relevant issues and a perspective. *Pediatr Dermatol.* 2015;32:447.
33. Accordino RE, Lucarelli J, Yan AC. Cutaneous disease in autism spectrum disorder: a review. *Pediatr Dermatol.* 2015;32:455.
34. Roberts R, Rodriguez W, Murphy D, et al. Pediatric drug labeling: improving the safety and efficacy of pediatric therapies. *JAMA.* 2003;290:905.

35. Allen A, Siegfried E, Silverman R, et al. Significant absorption of topical tacrolimus in 3 patients with Netherton syndrome. *Arch Dermatol.* 2001;137:747.
36. Halverstam CP, Vachharajani A, Mallory SB. Cushing syndrome from percutaneous absorption of 1% hydrocortisone ointment in Netherton syndrome. *Pediatr Dermatol.* 2007;24:42.
37. Yin HS, Dreyer BP, Ugboaja DC, et al. Liquid medication errors and dosing tools: a randomized controlled experiment. *Pediatrics.* 2016;138:e20160357.
38. Yin HS, Parker RM, Sanders LM, et al. Parents' medication administration errors: Role of dosing instruments and health literacy. *Arch Pediatr Adolesc Med.* 2010;164:181.
39. American Academy of Pediatrics. Section 4. Antimicrobial agents and related therapy. In: Kimberlin DW, Brady MT, Jackson MA, Long SS, eds. *Red Book 2015: Report of the Committee on Infectious Diseases*. 30th ed. Elk Grove Village, IL: American Academy of Pediatrics; 2015.
40. Engorn B, Flerlage J, eds. *The Harriet Lane Handbook*, 20th ed. Philadelphia, PA: Elsevier; 2014.
41. Book CG, Hindmarsh PC, Stanhope R. Growth and growth hormone secretion. *J Endocrinol.* 1988;119:179.
42. Fine RN. Corticosteroids and growth. *Kidney Int Suppl.* 1993;43:S59.
43. Lucky AW. Principles of the use of glucocorticosteroids in the growing child. *Pediatr Dermatol.* 1984;1:226.
44. American Academy of Pediatrics. Immunization in special clinical circumstances. In: Kimberlin DW, Brady MT, Jackson MA, Long SS, eds. *Red Book 2015: Report of the Committee on Infectious Diseases*. 30th ed. Elk Grove Village, IL: American Academy of Pediatrics; 2015.
45. Foster KW, Friedlander SF, Panzer H, et al. A randomized controlled trial assessing the efficacy of fluconazole in the treatment of pediatric tinea capitis. *J Am Acad Dermatol.* 2005;53:798.
46. Ferrara P, Guadagno C, Sbordone A, et al. Child abuse and neglect and its psycho-physical and social consequences: a review of the literature. *Curr Pediatr Rev.* 2016;12:301.
47. Saul J, Valle LA, Mercy JA, et al. CDC grand rounds: creating a healthier future through prevention of child maltreatment. *MMWR Morb Mortal Wkly Rep*. 2014;63:260.
48. Duarte AM, Pruksachatkunakorn C, Schachner LA. Life threatening dermatoses in pediatric dermatology. *Adv Dermatol.* 1995;10:329.
49. Chang MW, Nakrani R. Six children with allergic contact dermatitis to methylisothiazolinone in wet wipes (baby wipes). *Pediatrics.* 2014;133:e434.
50. Eldadah M, Fitzgerald M. Methemoglobinemia due to skin application of benzocaine. *Clin Pediatr (Phila).* 1993;32:687.
51. Singalavanija S, Frieden IJ. Diaper dermatitis. *Pediatr Rev.* 1995;16:142.
52. American Academy of Pediatrics Committee on Drugs. Clioquinol (iodochlorhydroxyquin, Vioform) and iodoquinol (diiodohydroxyquin): blindness and neuropathy. *Pediatrics.* 1990;86:797.
53. Davies JE, Dedhia HV, Morgade C, et al. Lindane poisonings. *Arch Dermatol.* 1983;199:142.
54. Friedman SJ. Lindane neurotoxic reaction in nonbullous congenital ichthyosiform erythroderma. *Arch Dermatol.* 1987;123:106.
55. Brown M, Hebert AA. Insect repellants: an overview. *J Am Acad Dermatol.* 1997;36:243.
56. Barakat M, Carson D, Hetherton AM, et al. Hypothyroidism secondary to topical iodine treatment in infants with spina bifida. *Acta Paediatr.* 1994;83:741.
57. Aihara M, Sakai M, Iwasaki M, et al. Prevention and control of nosocomial infection caused by methicillin-resistant *Staphylococcus aureus* in a premature infant ward: preventive effect of a povidone-iodine wipe of neonatal skin. *Postgrad Med J.* 1993;69(suppl 3): S117.
58. Germann R, Schindera I, Kuch M, et al. Life threatening salicylate poisoning caused by percutaneous absorption in severe ichthyosis vulgaris [in German]. *Hautarzt.* 1996;47:624.
59. Yercen N, Caglayan S, Yücel N, et al. Fatal hypernatremia in an infant due to salting of the skin. *Am J Dis Child.* 1993;147:716.
60. Gonzalez del Rey J, Wason S, Druckenbrod RW. Lidocaine overdose: another preventable case? *Pediatr Emerg Care.* 1994;10:344.

Chapter 105 :: Skin Changes and Diseases in Pregnancy

:: Lauren E. Wiznia & Miriam Keltz Pomeranz

CHANGES COMMONLY ASSOCIATED WITH PREGNANCY

AT-A-GLANCE

- Cutaneous changes result from the altered endocrine, metabolic, and immunologic milieus that characterize pregnancy.
- Pigmentary disturbances, including hyperpigmentation, darkening of the linea alba, and melasma are the changes most commonly observed.
- Significant change in nevi size is not a feature of most pregnancies.
- Structural changes known to occur during pregnancy include, most commonly, striae distensae.
- Pruritus is a common complaint during pregnancy and may be related to flare of a preexisting dermatosis or onset of a specific dermatosis of pregnancy.

Pregnancy is characterized by altered endocrine, metabolic, and immunologic milieus. These dramatic alterations result in multiple cutaneous changes, both physiologic and pathologic. Table 105-1 provides a comprehensive list of physiologic alterations within the skin and appendages.[1-4]

Pigmentary disturbances are the most common of these physiologic changes. Hyperpigmentation of the areola, axillae, and genitalia are well documented in pregnancy. *Linea nigra* refers to the typically reversible darkening of the linea alba, a hypopigmented linear patch extending from the pubis symphysis to the sternal xiphoid process (Fig. 105-1). Melasma or chloasma comprises irregular, blotchy, facial hyperpigmentation that occurs in up to 70% of pregnant women (Fig. 105-2). It is aggravated by sun exposure and by oral contraceptive intake in nonpregnant women. Melasma may regress postpartum, but oftentimes persists, posing a therapeutic challenge.[1]

Changes in melanocytic nevi were historically deemed "normal" during pregnancy. However, few studies have objectively studied whether and how nevi evolve during pregnancy. Pennoyer and colleagues[5] photographically monitored 129 melanocytic nevi throughout the pregnancies of 22 healthy white women. Only 8 nevi (6.2%) changed in diameter from the first to third trimester, with a mean change in size of zero. The authors concluded that significant change in nevus size (excluding nevi on the pregnant abdomen) does not appear to be a feature of most pregnancies.[5] Dermoscopic changes of nevi in pregnancy have included widening in diameters and structure changes, that are seen, especially on the front of the body.[6] Until further controlled studies are performed, any pigmented lesion in a pregnant woman that undergoes change in morphology (size, color, or shape) or symptoms (begins to itch, bleed, or scale) should be considered for histopathologic review.

The most common structural change during pregnancy is striae distensae, also known as *striae gravidarum* or colloquially as *stretch marks* (Fig. 105-3). Sites of predilection for striae are those areas most prone to stretch, including the abdomen, hips, buttocks, and breasts. Factors such as family history, personal history, and race are the strongest predictors of an individual's risk of developing striae distensae, surpassing pregnancy weight gain or changes in body mass index.[7] These findings strongly support a genetic predisposition to this condition. Vascular changes are also common. Spider angiomas are the most common vascular lesion to develop.

Pruritus, a common complaint during pregnancy, may be physiologic, but may herald a flare of a preexisting dermatosis or onset of a specific dermatosis of pregnancy. The remainder of this chapter outlines the relatively rare conditions that may be specific to pregnancy. Table 105-2 provides an overview of these conditions.

DERMATOSES ASSOCIATED WITH FETAL RISK IN PREGNANCY

AT-A-GLANCE

- Pemphigoid gestationis is an immunologically mediated, intensely pruritic, vesiculobullous eruption of mid- to late pregnancy associated with fetal risk.
- Intrahepatic cholestasis of pregnancy represents a reversible form of cholestasis in late pregnancy associated with biochemical abnormalities and a risk of fetal complications but lacks primary cutaneous lesions. Symptoms remit within 2 to 4 weeks of delivery, but recurrences in subsequent pregnancies are common.
- Pustular psoriasis of pregnancy is a rare, acute, pustular eruption often accompanied by fever, leukocytosis, and an elevated erythrocyte sedimentation rate. This is generally regarded as a variant of psoriasis.

TABLE 105-1
Physiologic Skin Changes During Pregnancy

Pigmentary
- Hyperpigmentation (genitalia, axillae, recent scars)
- Secondary areolae
- Linea nigra
- Melasma (chloasma, mask of pregnancy)

Hair
- Hirsutism
- Thickening of scalp hair
- Postpartum telogen effluvium
- Postpartum androgenetic alopecia

Nail
- Subungual hyperkeratosis
- Distal onycholysis
- Transverse grooving
- Brittleness
- Accelerated growth

Glandular
- Increased eccrine function (except palms) (miliaria, dyshidrotic eczema, hyperhidrosis)
- Elevated thyroid activity with resultant relative iodine deficiency
- Increased sebaceous function (growth in Montgomery tubercles)
- Decreased apocrine function

Structural Changes
- Striae distensae (striae gravidarum)
- Molluscum fibrosum gravidarum (acrochordons)

Vascular
- Spider angiomas (spider nevi, nevi aranei)
- Palmar erythema
- Nonpitting edema (hands, ankles, feet, face)
- Varicosities
- Cutis marmorata
- Vasomotor instability
- Dermographism/pruritus
- Purpura
- Gingival hyperemia or hyperplasia
- Pyogenic granuloma (granuloma gravidarum, pregnancy epulis)
- Hemorrhoids
- Hemangiomas, hemangioendotheliomas, glomangiomas
- Unilateral nevoid telangiectasia (unilateral dermatomal superficial telangiectasia)

Mucosa
- Gingivitis (marginal gingivitis, papillomatous hypertrophy of the gums)
- Jacquemier-Chadwick sign (bluish discoloration of vagina and cervix)
- Goodell sign (cervical softening)

Adapted from Elling SV, Powell FC. Physiological changes in the skin during pregnancy. *Clin Dermatol*. 1997;15:35; Kroumpouzos G, Cohen LM. Dermatoses of pregnancy. *J Am Acad Dermatol*. 2001;45:1; and Muzaffar F, Hussain I, Haroon TS. Physiologic skin changes during pregnancy: a study of 140 cases. *Int J Dermatol*. 1998;77:429.

Figure 105-1 Linea nigra. A hyperpigmented line extends from the pubis symphysis to the xiphoid process of the sternum. Hyperpigmentation is often more pronounced inferior to the umbilicus.

PEMPHIGOID (HERPES) GESTATIONIS

Pemphigoid (herpes) gestationis (PG) is an intensely pruritic, vesiculobullous eruption of mid- to late pregnancy and the immediate postpartum period. It classically begins during the second or third trimester,

Figure 105-2 Melasma. Blotchy, mottled hyperpigmentation is evident on the malar cheek and upper cutaneous lip.

Figure 105-3 Striae distensae.

and is manifest by the abrupt appearance of severely pruritic urticarial lesions on a background of normal or erythematous skin. PG is associated with an increased incidence of small-for-gestational age births and premature delivery.

EPIDEMIOLOGY

PG is rare, seen in 1 in 1700 to 1 in 50,000 pregnancies.

CLINICAL FEATURES

PG presents with urticarial followed by vesicular lesions on the trunk and extremities in mid-to-late pregnancy or the early postpartum period (Fig. 105-4). Unlike polymorphic eruption of pregnancy (see section "Dermatoses not Associated with Fetal Risk in Pregnancy"), PG includes periumbilical skin (Fig. 105-5).

ETIOLOGY AND PATHOGENESIS

PG is immunologically mediated, and linear deposition of C3, with or without immunoglobulin (Ig) G, is found at the dermal–epidermal junction by direct immunofluorescence (DIF).[8] In addition to occurring in pregnancy, PG can occur in abnormal pregnancies (hydatidiform mole, choriocarcinoma), implicating a role for paternally derived tissues in the pathogenesis of this condition.

DIAGNOSIS

Patients in whom PG is suspected usually require a biopsy for histology and DIF. Histopathologic examination reveals classic features of bullous pemphigoid. In the setting of pregnancy, DIF with C3 in a linear band at the dermal–epidermal junction is pathognomonic for PG.[8] Circulating autoantibodies are directed against the same target antigens as in bullous pemphigoid, more commonly against BP180 than BP230. Enzyme-linked immunosorbent assay (ELISA) or indirect immunofluorescence studies can be sent for the BP180 antigen. ELISA is as high as 96% specific and sensitive for PG.[9]

DIFFERENTIAL DIAGNOSIS

The differential diagnosis includes polymorphic eruption of pregnancy, drug eruptions, or urticaria (during the urticarial stage of pemphigoid gestationis). Even though DIF is the gold standard for diagnosis, the aforementioned ELISA and indirect immunofluorescence studies can be useful.

CLINICAL COURSE AND PROGNOSIS

PG is associated with premature delivery and a risk of low birth weight; the risk of these fetal complications correlates with maternal disease severity. Therefore, women with PG should be followed closely by their obstetrician.

Maternal prognosis is very good, with most cases resolving within a few months postpartum; however, it may take weeks, months, or even years until complete remission. Seventy-five percent of women flare postpartum and will require treatment. Exacerbations may occur postpartum with oral contraceptives and during the menstrual cycle.

Newborns of mothers with PG may develop bullous lesions that are transient and usually require no therapy. The development of these lesions is related to passive placental transfer of the anti–basement membrane zone antibody. If the mother has received long-term high doses of prednisolone, the infant should be evaluated for evidence of adrenal insufficiency.

MANAGEMENT

Treatment can be initiated with topical steroids and a systemic antihistamine. First-generation antihistamines are favored over second-generation antihistamines. Most patients require systemic corticosteroid treatment.[10] Many women will improve and may be tapered to lower doses or even to discontinuation of steroids. In cases that do not respond satisfactorily to prednisolone alone, or in cases where prolonged treatment with corticosteroids is contraindicated, plasmapheresis or IV immunoglobulin may be considered.[10,11]

INTRAHEPATIC CHOLESTASIS OF PREGNANCY

Intrahepatic cholestasis of pregnancy (ICP) is a rare, reversible cholestasis that typically occurs in late pregnancy, when serum concentrations of estrogen reach their peak. It was first recognized as a distinct

TABLE 105-2
A Summary of Dermatoses of Pregnancy

	MORPHOLOGY	DISTRIBUTION	USUAL ONSET	FETAL RISK	SYNONYM(S)
Pemphigoid (herpes) gestationis	Urticarial papules and plaques progress to vesicles and bullae	Begins on trunk, then progresses to generalized eruption Spares face, mucus membranes, palms, soles	Second or third trimester, or immediately postpartum	Small-for-gestational age births Preterm delivery Neonatal pemphigoid gestationis	Herpes gestationis
Intrahepatic cholestasis of pregnancy	Excoriations and excoriated papules ± jaundice	Generalized, including palms and soles	Third trimester	Preterm delivery Fetal distress Fetal death	Cholestasis of pregnancy Obstetric cholestasis Recurrent jaundice of pregnancy Cholestatic jaundice of pregnancy Idiopathic jaundice of pregnancy Prurigo gravidarum Icterus gravidarum
Pustular psoriasis of pregnancy	Erythematous patches with subcorneal pustules at their margins	Begins in flexures Generalizes demonstrating centrifugal spread	Third trimester	Placental insufficiency may lead to stillbirth or neonatal death	Impetigo herpetiformis
Pruritic urticarial papules and plaques of pregnancy	"Polymorphous" including urticarial papules and plaques ± vesicles	Begins within abdominal striae Spreads to remainder of trunk and then extremities Spares umbilicus	Third trimester or immediately postpartum	None	Polymorphic eruption of pregnancy Bourne toxemic rash of pregnancy Nurse's late onset prurigo of pregnancy Toxemic erythema of pregnancy (Holmes)
E-type atopic eruption of pregnancy	Eczematous patches and plaques	Face, neck, chest, flexural extremities	Before third trimester	None	Eczema in pregnancy[a]
P-type atopic eruption of pregnancy	Excoriated or crusted papules	Extremities, occasionally trunk	Before third trimester	None	Prurigo of pregnancy[a] Besnier prurigo gestationis Nurse's early onset prurigo of pregnancy Papular dermatitis of Spangler atopic eruption of pregnancy[a]

[a]A newly proposed classification by Ambros-Rudolph and associates[41] that combines the previously distinct entities prurigo of pregnancy and pruritic folliculitis of pregnancy into a single entity, atopic eruption of pregnancy, which also includes eczema in pregnancy.

Figure 105-4 Pemphigoid gestationis. **A,** Urticarial plaques and tense bullae are seen on the face, neck, and chest. **B,** Similar lesions on the extremity. (Images from the Fitzsimmons Army Medical Center Dermatology Archive.)

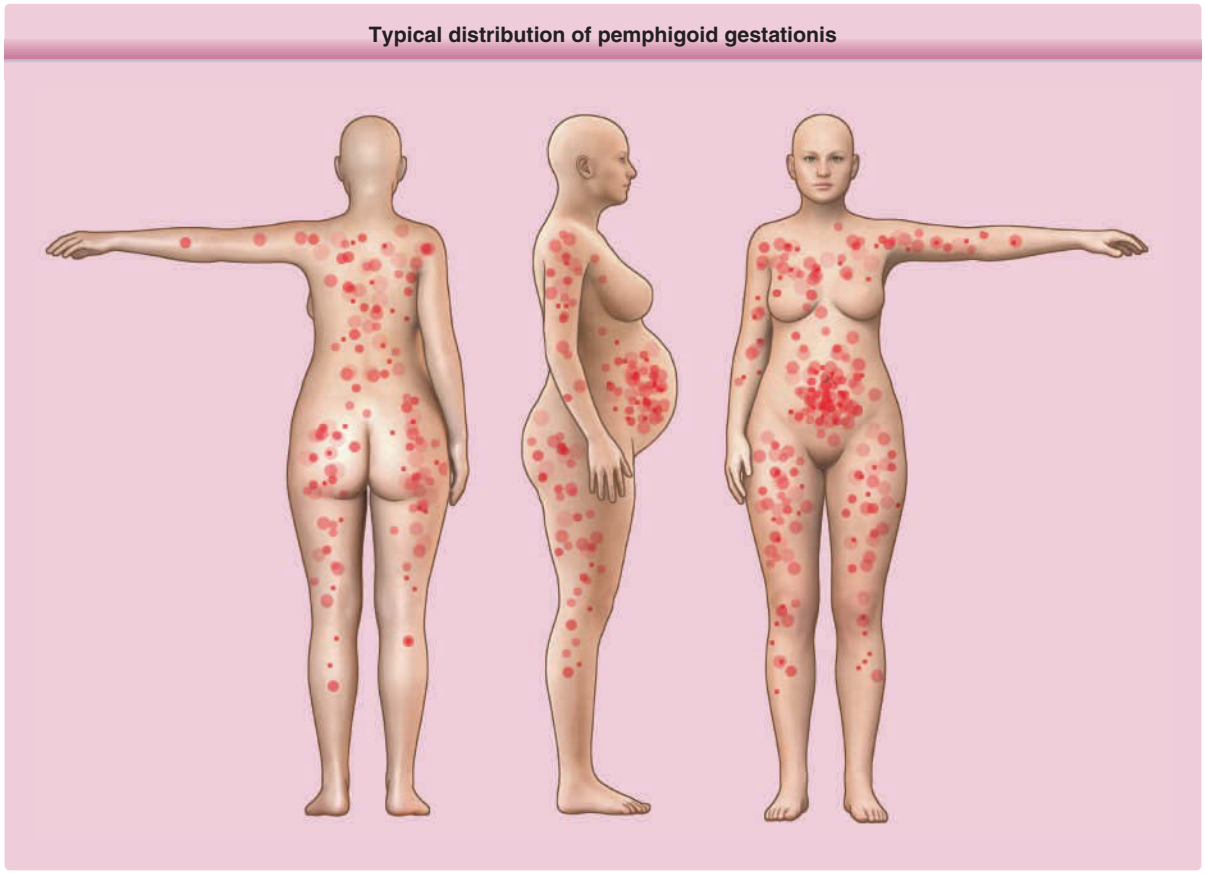

Figure 105-5 Pattern of rash in pemphigoid (herpes) gestationis.

clinical entity, separate from other forms of jaundice during pregnancy, by Svanborg and Ohlsson in 1939.[12] The terms *obstetric cholestasis*, *cholestasis of pregnancy*, *recurrent jaundice of pregnancy*, *cholestatic jaundice of pregnancy*, *idiopathic jaundice of pregnancy*, *prurigo gravidarum*, *pruritus gravidarum*, and *icterus gravidarum* all refer to this clinical entity. Mild cases of ICP, in which pruritus is not accompanied by jaundice, were previously referred to as prurigo gravidarum.

EPIDEMIOLOGY

Jaundice develops in approximately 1 in 1500 pregnant women. With an estimated incidence of 70 cases per 10,000 pregnancies in the United States, ICP ranks second only to viral hepatitis in causing jaundice in pregnant women.[13] ICP is most common in Scandinavia and South America. The highest reported incidence rates are in Chile (14% to 16%), whereas much lower rates are seen among pregnant women in the United States (less than 0.1% to 0.7%), Canada (0.1%), Australia (0.2% to 1.5%), and Central Europe (0.1% to 1.5%).[13]

CLINICAL FEATURES

ICP is the only pregnancy dermatosis that presents without primary skin lesions. Patients classically present during the third trimester with moderate-to-severe pruritus, which may be either localized to the palms and soles or generalized. Pruritus begins during the first and second trimester in 10% and 25% of cases, respectively. Intense pruritus is often associated with secondary excoriations, although primary cutaneous lesions are invariably absent. Initially, patients may complain of nocturnal pruritus only, and symptoms are generally more severe at night throughout the course of ICP.

Constitutional symptoms such as fatigue, nausea, vomiting, or anorexia may accompany the pruritus. Progression to clinical jaundice, dark urine, or lightly colored stools occurs in approximately 1 in 5 patients. Pruritus generally precedes the onset of these symptoms by 1 to 4 weeks.[13]

Harmful effects on the fetus include an increase in premature births, intrapartum fetal distress, and fetal death.

ETIOLOGY AND PATHOGENESIS

Although the precise pathogenesis remains unclear, the interplay of hormonal, genetic, environmental, and alimentary factors is thought to induce a biochemical cholestasis in susceptible individuals. A prominent role for hormonal alterations is suggested by the following observations: (a) ICP is a disease of late pregnancy, corresponding to the period of highest placental hormone levels; (b) ICP spontaneously remits at delivery when hormone concentrations normalize; (c) twin and triplet pregnancies, which are characterized by greater rises in hormone concentrations, are linked to ICP; and, (d) ICP recurs during subsequent pregnancies in an estimated 45% to 70% of patients.[13]

Geographic variation and familial clustering indicate a genetic predisposition. ICP appears to be a polygenetic condition, with candidate genes including those mutated in a variety of other forms of inherited cholestasis: *ABCB4* (multidrug resistance gene3), *ABCB11* (bile salt export pump), and *ATP8B1* (*FIC1*). A recent decline in prevalence rates in Chile, reports of higher incidence rates during the winter months, and reports of relative reductions of selenium levels in some ICP patients all point toward etiologic roles for environmental and alimentary factors.[13,14] At least 1 study confirmed a higher risk of hepatitis C virus infection for women with ICP.[15]

DIAGNOSIS

Elevation in serum bile acids is the single most sensitive indicator of ICP. Total serum bile acid levels greater than 11 μM/L are consistent with ICP. In healthy pregnant women, total bile acids are slightly elevated above baseline and levels as high as 11 are accepted as normal in late pregnancy. Clearly defined biochemical indices of ICP have not yet been established. However, Brites and colleagues[16] identified the following common features of ICP: (a) serum total bile acid concentrations greater than 11 μM (reference range: 4.6 to 8.7 μM); (b) cholic acid-to-chenodeoxycholic acid ratio greater than 1.5 (reference range: 0.7 to 1.5) or cholic acid proportion of total bile acids greater than 42%; (c) glycine conjugates-to-taurine conjugates of bile acids ratio less than 1 (reference range: 0.9 to 2) or glycocholic acid concentration greater than 2 μM (reference range: 0.6 to 1.5 μM).[16] Degree of pruritus and disease severity generally correlate with bile acid concentrations.

Mild perturbations in liver function tests, including elevated transaminases, alkaline phosphatase, 5′-nucleotidase, cholesterol, triglycerides, phospholipids, and lipoprotein X are commonly found. Among these parameters, alanine transaminase is particularly sensitive, as an elevation in this enzyme is not a feature of healthy pregnancies but is commonly seen in ICP. γ-Glutamyl transferase, which is generally low in late gestation, is typically normal or slightly elevated in ICP. Direct (or conjugated) fractions of bilirubin are most commonly elevated in ICP. Albumin may be slightly reduced, whereas α_2-globulins and β-globulins are appreciably elevated. However, routine liver tests alone are not a sufficient basis for the diagnosis of ICP.[16]

Cutaneous biopsy does not aid in the diagnosis of ICP.

DIFFERENTIAL DIAGNOSIS

Distinction from other causes of pruritus in the pregnant woman can be challenging. The presence of

primary lesions points away from a diagnosis of ICP, which lacks primary lesions. Other causes of liver derangement and jaundice, such as viral and nonviral hepatitis, medications, hepatobiliary obstruction, and other intrahepatic diseases (eg, primary biliary cirrhosis) must be ruled out. Finally, it must be remembered that hyperthyroidism, allergic reactions, polycythemia vera, lymphoma, pediculosis, and scabies may each manifest as generalized pruritus in pregnant (and nonpregnant) women.

CLINICAL COURSE AND PROGNOSIS

A hallmark of ICP is that symptoms and associated biochemical abnormalities typically resolve within 2 to 4 weeks of delivery. Recurrences during subsequent pregnancies occur in an estimated 45% to 70% of patients. Some women experience recurrent ICP after exposure to oral contraceptives or to contraceptive aids, such as synthetic estrogens and progestational agents.

Maternal outcomes are generally favorable, although women with severe cases are predisposed to postpartum hemorrhage secondary to vitamin K depletion. Additionally, affected women have a tendency toward the later development of cholelithiasis or gallbladder disease. Fetal risks in ICP include increased rates of prematurity, fetal distress, and fetal death. These complications generally correlate with higher bile acid levels and are attributed to acute placental anoxia and an increased incidence of meconium-stained amniotic fluid.

MANAGEMENT

Therapy aims to reduce serum bile acid levels and thereby prolong pregnancy, ameliorate maternal symptoms and reduce fetal risks. An interdisciplinary approach characterized by intense fetal surveillance is essential to the management of ICP.

Although in mild cases, relief can sometimes be achieved with bland emollients and topical antipruritic agents, ursodeoxycholic acid (UDCA), a naturally occurring hydrophilic bile acid, is the current treatment of choice. UDCA reduces maternal symptoms and fetal risk. UDCA exerts a hepatoprotective effect through augmentation of the excretion of hydrophobic bile acids, sulfated progesterone metabolites, and other hepatotoxic compounds. UDCA decreases bile acid levels in colostrum, cord blood, and amniotic fluid. The results of several small, randomized, placebo-controlled trials demonstrate that when administered at doses between 450 mg and 1200 mg daily, UDCA is well tolerated and highly effective in controlling the clinical and liver function abnormalities that define ICP.[17] Randomized, controlled trials comparing UDCA head-to-head with either dexamethasone[18] or cholestyramine[19] demonstrated the superior efficacy of UDCA.

There is mixed data in the literature on early delivery. A systematic review of unexplained term stillbirths associated with ICP-affected pregnancies that was completed to evaluate evidence supporting ICP as a medical indication for early delivery at less than 39 weeks of gestation found no evidence to support active management (early delivery) for ICP.[20] This article reported stillbirth rates in both groups—patients whose obstetric care did or did not include active management—similar to respective national stillbirth rate. A recent retrospective study reported that delivery at 36 weeks of gestation would reduce perinatal mortality risk as compared with expectant management.[21] Most authors recommend early induction of labor, commonly at 38 weeks of gestation or earlier.[13,21]

PUSTULAR PSORIASIS OF PREGNANCY (IMPETIGO HERPETIFORMIS)

Pustular psoriasis of pregnancy is generally regarded as a variant of pustular psoriasis attributable to hormonal alterations during pregnancy; however, some authors maintain that it is a distinct clinical entity.[22] Von Hebra first used the designation *impetigo herpetiformis* in 1872 to describe an acute pustular eruption with usual onset during the third trimester of pregnancy.

EPIDEMIOLOGY

Pustular psoriasis of pregnancy is very rare, with only approximately 350 cases described in the European and American literature as of 2000.[23]

CLINICAL FEATURES

Pustular psoriasis of pregnancy is characterized by an acute eruption occurring as early as the first trimester, but generally during the third trimester, of an otherwise uneventful pregnancy. The condition manifests as erythematous patches whose margins are studded with subcorneal pustules (Fig. 105-6). The eruption typically originates in flexural areas, spreads centrifugally and sometimes generalizes. Subungual lesions may result in onycholysis. Rarely, mucous membrane involvement may lead to painful erosions. The face, palms, and soles are commonly spared. The rash may be pruritic or painful.

Onset of the eruption is accompanied by constitutional symptoms such as fever, chills, malaise, diarrhea, nausea, and arthralgia.

Life-threatening maternal complications are infrequent but may result from profound hypocalcemia and bacterial sepsis. Rarely, tetany, delirium, and convulsions occur if hypocalcemia is severe.[1] The most feared complications are placental insufficiency and consequent stillbirth or neonatal death.

Figure 105-6 Pustular psoriasis of pregnancy. Erythematous patches are studded with subcorneal pustules.

TABLE 105-3
Differential Diagnosis of Pustular Psoriasis of Pregnancy

Most Likely
- Pustular drug eruption (acute generalized exanthematous pustulosis)
- Pemphigoid gestationis

Consider
- Pemphigus vulgaris
- Dermatitis herpetiformis
- Subcorneal pustular dermatosis
- Pustular eruption in inflammatory bowel disease

Always Rule Out
- Infectious causes of pustular eruptions

For these reasons, early induction of labor is often contemplated.[22]

ETIOLOGY AND PATHOGENESIS

Although generally regarded as a form of pustular psoriasis, absence of a positive family history, abrupt resolution of symptoms at delivery, and a tendency to recur only during subsequent pregnancies distinguish this entity from generalized pustular psoriasis. Moreover, factors known to trigger pustular psoriatic flares, such as infection, exposure to certain culprit drugs, or abrupt discontinuation of systemic corticosteroids, are lacking in most patients with pustular psoriasis of pregnancy.[1]

DIAGNOSIS

Although the clinical picture is often typical, a biopsy is helpful to confirm this diagnosis. Histopathologic examination reveals classic features of pustular psoriasis. Initial laboratory evaluation should include complete blood count and comprehensive metabolic panel with particular attention to calcium level. The most common laboratory derangements include leukocytosis, neutrophilia, an elevated erythrocyte sedimentation rate, hypoferric anemia, and hypoalbuminemia. Less commonly, calcium, phosphate, and vitamin D levels are decreased. Serum parathyroid hormone levels are rarely decreased. Cultures of pustule contents and peripheral blood are negative unless secondarily infected.[1]

DIFFERENTIAL DIAGNOSIS

Table 105-3 outlines the differential diagnosis of pustular psoriasis of pregnancy.

CLINICAL COURSE AND PROGNOSIS

Pustular psoriasis of pregnancy classically presents during the third trimester, but there are reports of cases occurring as early as the first trimester, during the puerperium, in nonpregnant women taking oral contraceptives, and in postmenopausal women. Symptoms are invariably progressive throughout pregnancy. A cardinal feature of this disorder is the rapid resolution of symptoms after delivery. Recurrences in subsequent pregnancies are common and characteristically are more severe with onset earlier in gestation.[1] Several reports of subsequent menstrual exacerbation occurring either during or immediately preceding menses exist in the literature.[24]

More widespread disease generally portends a worse prognosis.

MANAGEMENT

Resolution after delivery is the norm. However, given its consistently progressive course, treatment is indicated to reduce the risk of fetal and maternal complications during pregnancy. Topical treatments, which include wet dressings and topical corticosteroids, are rarely effective as monotherapy. Narrowband ultraviolet B combined with topical steroids has been reported to be successful in rare cases as well.[25]

Systemic corticosteroids were historically the mainstay of therapy. Now, cyclosporine and infliximab are deemed first-line therapy.[26] Cyclosporine has been successfully used at doses between 5 mg/kg and 10 mg/kg daily.[27,28] Infliximab, a tumor necrosis factor-α blocking agent, has been successfully used without adverse effect on the fetus,[29] but with the caveat that live vaccines should be delayed in newborns of mothers treated with infliximab.[30] Although careful consideration of the benefits and risks of tumor necrosis factor blockade during pregnancy must be considered, these agents (including etanercept and adalimumab) may have a role in management.[26]

In all cases, fluid status and electrolytes should be monitored with rapid correction of imbalances. Fetal monitoring is essential as decelerations in fetal heart rate may be the earliest sign of fetal hypoxemia. Maternal cardiac and renal functions may be compromised with disease progression and therefore should also be monitored. Induction of labor is an option when

symptoms do not remit despite supportive and pharmacologic therapy. The therapeutic armamentarium available after pregnancy termination or after delivery in a nonnursing mother can be extended to include oral psoralen and ultraviolet A, oral retinoids, and methotrexate.[31]

DERMATOSES NOT ASSOCIATED WITH FETAL RISK IN PREGNANCY

AT-A-GLANCE

- Polymorphic eruption of pregnancy (previously pruritic urticarial papules and plaques of pregnancy) is a common, self-limited, intensely pruritic dermatosis that occurs almost exclusively in primigravidas during late pregnancy.
- Atopic eruption of pregnancy (AEP) represents a relatively newly introduced term comprising pruritic folliculitis of pregnancy, prurigo of pregnancy, and eczema of pregnancy. Lesions typically appear before the third trimester and may resemble classic atopic dermatitis (AEP, E-type) or be papular (AEP, P-type).

POLYMORPHIC ERUPTION OF PREGNANCY (PRURITIC URTICARIAL PAPULES AND PLAQUES OF PREGNANCY)

Polymorphic eruption of pregnancy (PEP) is a common, benign, intensely pruritic dermatosis that occurs almost exclusively in primigravidas during the third trimester and immediate postpartum period. PEP (previously termed *pruritic urticarial papules and plaques of pregnancy*) is synonymous with Bourne's toxemic rash of pregnancy, Nurse's late onset prurigo of pregnancy, and toxic erythema of pregnancy.[32]

EPIDEMIOLOGY

The incidence of PEP ranges between 1 in 300 and 1 in 130 pregnancies.[33]

CLINICAL FEATURES

PEP typically occurs in primigravidas during the last trimester of pregnancy (mean onset: 35 weeks); however, cases of otherwise classic PEP have occurred earlier in pregnancy and in the immediate postpartum period. Polymorphous in nature, lesions may be urticarial (most commonly), vesicular, purpuric, polycyclic, targetoid, or eczematous in appearance (Fig. 105-7).[34] Typical lesions are 1- to 2-mm

Figure 105-7 Pruritic urticarial papules and plaques of pregnancy. **A,** The earliest lesions are 1- to 2-mm, erythematous, urticarial papules localized within and around the striae distensae and sparing the umbilicus. **B,** The papules coalesce to form erythematous plaques that spread to involve the buttocks and thighs. **C,** Urticarial plaques on the breasts. Of note, the breasts also show a "secondary areola," the physiologic darkening, and reticular expansion of the areolar pigmentation. There are also striae distensae visible on the breast as well as Montgomery tubercles on the areolae.

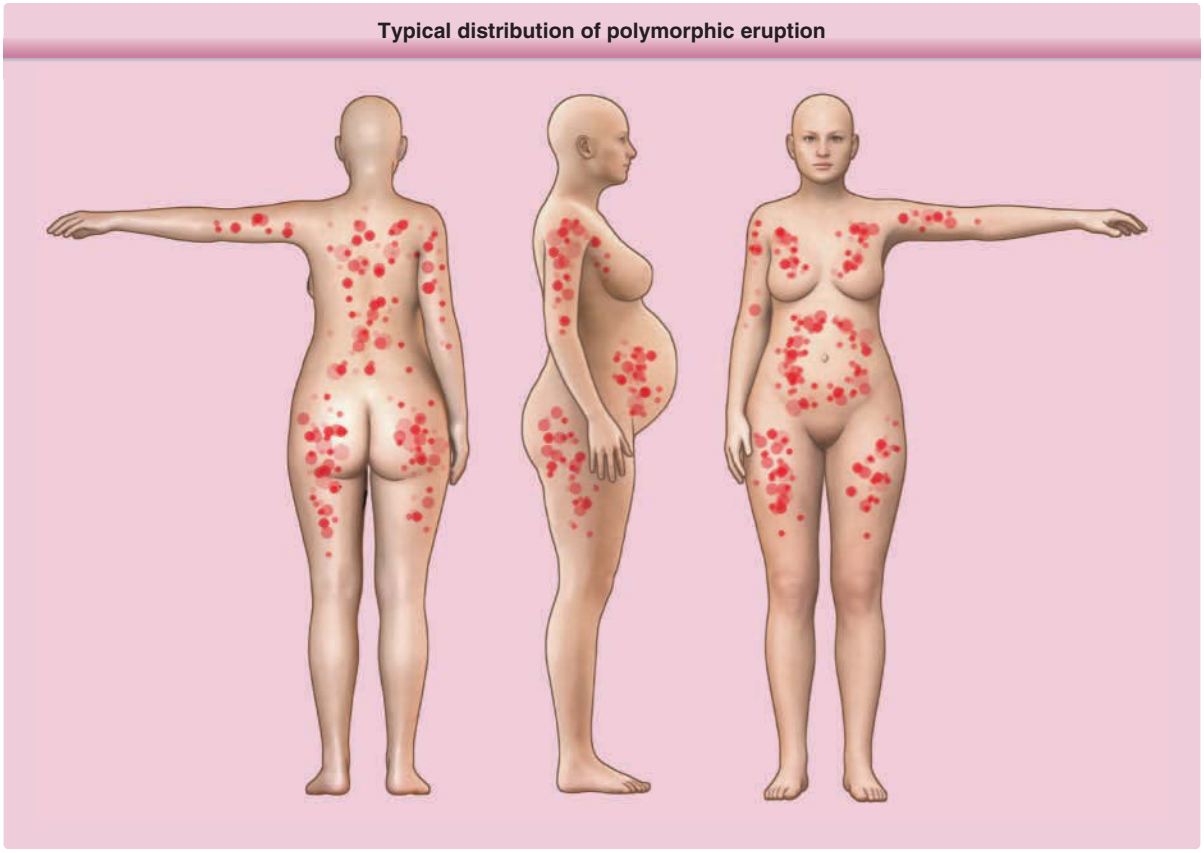

Figure 105-8 Pattern of rash in polymorphic eruption of pregnancy.

erythematous urticarial papules surrounded by a narrow pale halo. The eruption begins on the abdomen, classically within the striae gravidarum, and demonstrates periumbilical sparing (Fig. 105-8). Pruritus generally parallels the eruption and is localized to involved skin. Rapid spread to the thighs, buttocks, breasts, and arms is the norm. Involvement of the palms, soles, or skin above the breast is exceptional.[1]

Severe pruritus may disturb sleep, but no other systemic symptoms are reported.

ETIOLOGY AND PATHOGENESIS

The pathogenesis remains unknown. Some postulate that increased abdominal cutaneous distension leads to altered collagen and/or elastic tissue, thereby triggering maternal immunoreactivity to previously nonantigenic stimuli.[33] Increased progesterone receptor immunoreactivity has been detected in lesional PEP, leading some to posit a role for progesterone activation of keratinocytes.[35]

RISK FACTORS

An association between PEP and multiple gestation is suggested by the higher-than-expected rates of twin and triplet pregnancies in most published series.[33,36,37] An unexplained association with male fetuses and delivery by cesarean section has been reported, although not consistently.[33,36,37] Reports linking PEP to increased maternal–fetal weight gain[33,38] are contested.

DIAGNOSIS

The diagnosis is generally made clinically when the patient presents with the eruption in typical locations at the end of pregnancy. Biopsy should be performed if PG is being considered in the differential diagnosis. Histopathologic findings, although nonspecific, generally include parakeratosis, spongiosis, and occasional exocytosis of eosinophils (eosinophilic spongiosis). The adjacent dermis may be edematous and contains a perivascular infiltrate of lymphocytes admixed with variable numbers of eosinophils and neutrophils. DIF studies reveal either granular or absent C3, IgM, or IgA deposits at the dermoepidermal junction or around blood vessels, and indirect immunofluorescence studies are negative.[1]

DIFFERENTIAL DIAGNOSIS

Table 105-4 outlines the differential diagnosis of PEP.

CLINICAL COURSE AND PROGNOSIS

PEP mostly affects primigravidas in the last trimester, although it may occur as early as the first trimester.

TABLE 105-4
Differential Diagnosis of Polymorphic Eruption of Pregnancy

Most Likely
- Pemphigoid gestationis
- Atopic eruption of pregnancy
- Contact dermatitis

Consider
- Drug eruption
- Viral exanthem
- Pityriasis rosea
- Exfoliative or eczematous dermatitis

Always Rule Out
- Scabies

There are several reports of cases occurring in the immediate postpartum period as well. Duration of symptoms is typically brief, averaging 6 weeks. Severe symptoms rarely persist for more than 1 week. Spontaneous remission within days of delivery is the rule. Recurrences in subsequent pregnancies or with exposure to oral contraceptives are unusual. Fetal and maternal prognoses are unaltered.[1] There is a single report of involvement of a newborn.[39]

MANAGEMENT

Although harmless to the mother and fetus, pruritus is often intense and unremitting. Symptomatic relief of pruritus can usually be achieved with topical corticosteroids and/or oral antihistamines. A brief course of oral corticosteroids is rarely required, but effectively controls symptoms in most cases refractory to topical treatment. Early induction of labor was previously considered in instances in which severe pruritus is unrelenting, but has fallen out of favor given the lack of increased morbidity of the fetus or mother (other than relentless pruritus) and is generally considered unnecessary.[40] Reassurance regarding the self-limited nature of PEP can help to assuage anxiety.

ATOPIC ERUPTION OF PREGNANCY

Atopic eruption of pregnancy (AEP) is a benign pruritic condition of pregnancy characterized by an eczematous (AEP, E-type) and/or papular (AEP, P-type) eruption in individuals with a personal and/or familial atopic background and/or elevated serum IgE levels. AEP denotes the disease complex comprising the previously distinct entities prurigo of pregnancy and pruritic folliculitis of pregnancy, as well as eczema in pregnancy, which had not previously been considered a specific dermatosis of pregnancy.[41] Ambros-Rudolph and colleagues proposed this new nomenclature (AEP) in 2006. AEP includes Besnier's prurigo gestationis, Nurse's early-onset prurigo of pregnancy and papular dermatitis of Spangler.[40]

EPIDEMIOLOGY

AEP comprises approximately 50% of all pregnancy dermatoses, making it the most common pruritic disorder in pregnancy. It tends to present earlier in pregnancy than the other pregnancy-associated dermatoses.[41]

CLINICAL FEATURES

Whereas 20% of AEP patients present with a flare of preexisting atopic dermatitis, the remaining patients experience an atopic eruption for the first time ever (or after a long remission). A classic eczematous eruption primarily affecting flexural surfaces and the face occurs in two-thirds of affected individuals (AEP, E-type; Fig. 105-9). The remaining third present with papular lesions (AEP, P-type; Fig. 105-10) that would previously have been classified as prurigo of pregnancy. P-type lesions are discrete, pruritic, excoriated papules with a predilection for extensor surfaces (Fig. 105-11), with truncal involvement less common. Minor features of eczema, including xerosis or hyperlinear palms, may be noted in patients with either subtype. Distinguishing features of AEP include onset early in pregnancy (before the third trimester) and a personal and/or family history of atopy.[41]

ETIOLOGY AND PATHOGENESIS

AEP is thought to be triggered by pregnancy-related shifts in cytokine profile expression leading to preferential expression of T-helper 2 cytokines.[41]

RISK FACTORS

Risk factors for AEP include a personal and/or family history of atopy.[41]

DIAGNOSIS

The diagnosis is largely clinical as histopathologic features are nonspecific and direct and indirect immunofluorescence studies are negative.[1] Total serum IgE is elevated in 20% to 70% of individuals with AEP,[41] although the clinical relevance of testing for serum IgE is unclear. Serologic tests reveal no other abnormalities.

DIFFERENTIAL DIAGNOSIS

Other specific dermatoses of pregnancy, especially ICP and PEP, should be ruled out, as should microbial folliculitis and allergic contact dermatitis occurring in a pregnant woman.

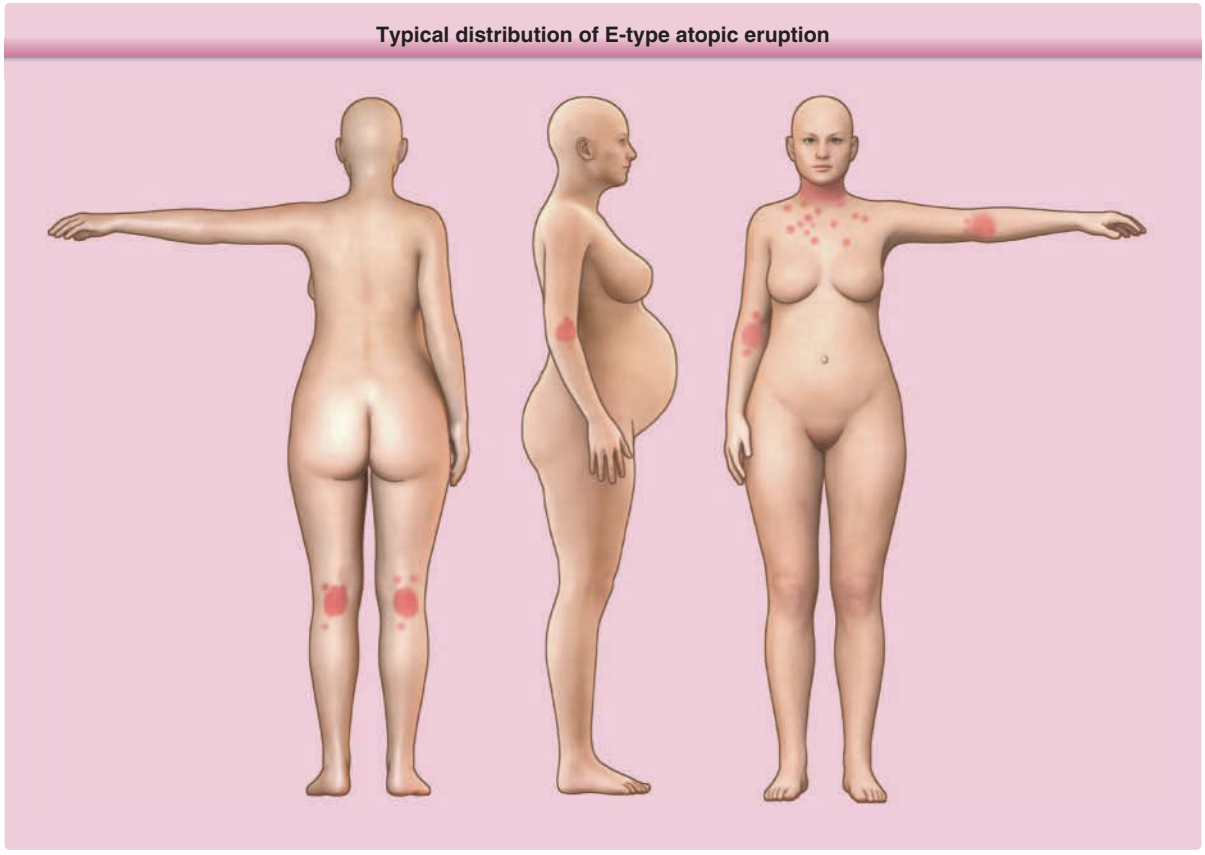

Figure 105-9 Pattern of rash for an eczematous eruption in atopic eruption of pregnancy.

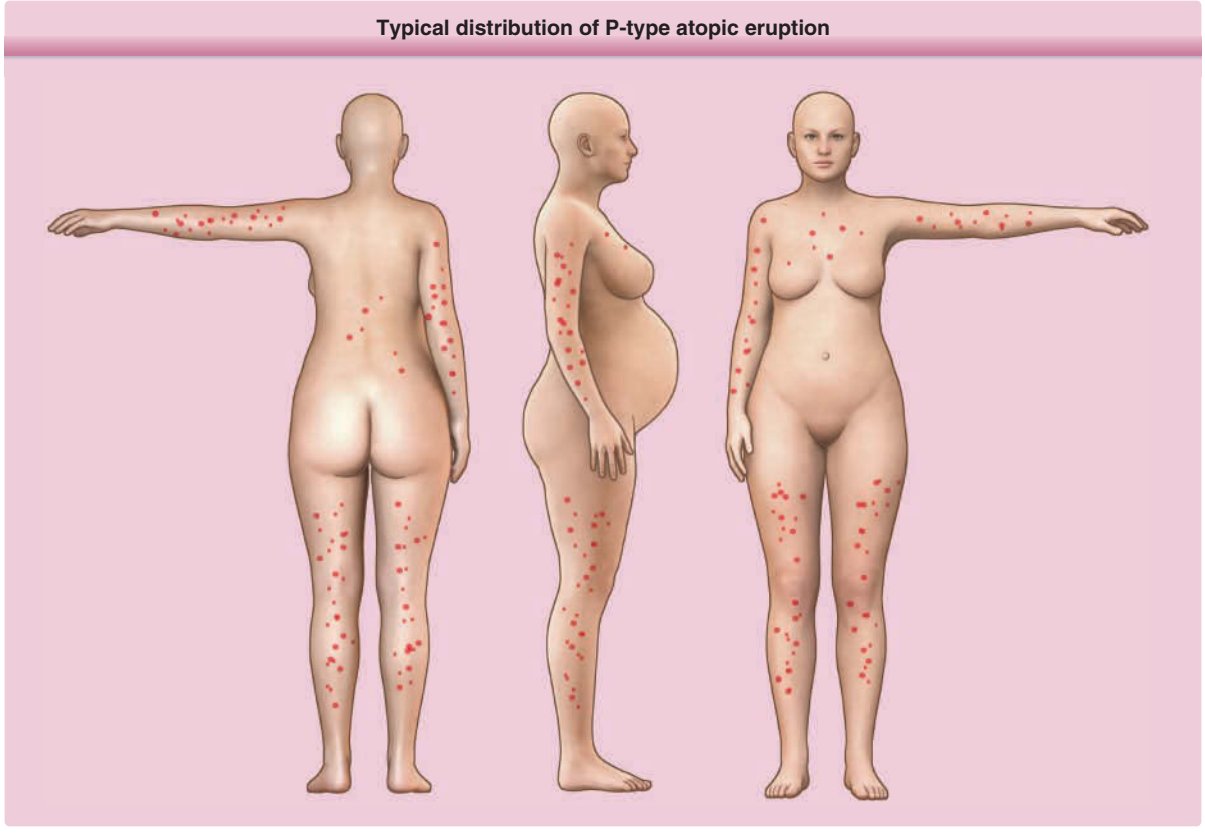

Figure 105-10 Pattern of rash for a papular eruption in atopic eruption of pregnancy.

Figure 105-11 Atopic eruption of pregnancy, P-type (previously, prurigo of pregnancy). Multiple discrete, excoriated papules demonstrate a predilection for extensor surfaces.

CLINICAL COURSE AND PROGNOSIS

Onset is typically prior to the third trimester. Lesions respond quickly to therapy; however, recurrence with subsequent pregnancies is common, consistent with an atopic diathesis. Maternal and fetal prognoses are excellent, even in severe cases.[42] In a mother with a known history of atopy, the infant will be at increased risk for atopic dermatitis. In a mother with no prior history of eczematous eruptions, her risk of recurrence outside of pregnancy is unknown.[42]

MANAGEMENT

Treatment seeks to ameliorate pruritus and includes emollients, midpotency topical corticosteroids, and antihistamines. Benzoyl peroxide may be helpful for truncal, follicular lesions, and ultraviolet B phototherapy can be used in severe cases.[1,43,44]

ACKNOWLEDGMENTS

The authors thank Dr. Julie Karen, who contributed to the previous version of this chapter in the 8th edition.

REFERENCES

1. Kroumpouzos G, Cohen LM. Dermatoses of pregnancy. *J Am Acad Dermatol.* 2001;45:1-19; quiz 19-22.
2. Geraghty LN, Pomeranz MK. Physiologic changes and dermatoses of pregnancy. *Int J Dermatol.* 2011;50:771-782.
3. Muzaffar F, Hussain I, Haroon TS. Physiologic skin changes during pregnancy: a study of 140 cases. *Int J Dermatol.* 1998;37:429-431.
4. Elling SV, Powell FC. Physiological changes in the skin during pregnancy. *Clin Dermatol.* 1997;15:35-43.
5. Pennoyer JW, Grin CM, Driscoll MS, et al. Changes in size of melanocytic nevi during pregnancy. *J Am Acad Dermatol.* 1997;36:378-382.
6. Aktürk AS, Bilen N, Bayrämgürler D, et al. Dermoscopy is a suitable method for the observation of the pregnancy-related changes in melanocytic nevi. *J Eur Acad Dermatol Venereol.* 2007;21:1086-1090.
7. Salter SA, Kimball AB. Striae gravidarum. *Clin Dermatol.* 2006;24:97-100.
8. Tani N, Kimura Y, Koga H, et al. Clinical and immunological profiles of 25 patients with pemphigoid gestationis. *Br J Dermatol.* 2015;172:120-129.
9. Powell AM, Sakuma-Oyama Y, Oyama N, et al. Usefulness of BP180 NC16a enzyme-linked immunosorbent assay in the serodiagnosis of pemphigoid gestationis and in differentiating between pemphigoid gestationis and pruritic urticarial papules and plaques of pregnancy. *Arch Dermatol.* 2005;141: 705-710.
10. Jenkins RE, Hern S, Black MM. Clinical features and management of 87 patients with pemphigoid gestationis. *Clin Exp Dermatol.* 1999;24:255-259.
11. Gan DC, Welsh B, Webster M. Successful treatment of a severe persistent case of pemphigoid gestationis with antepartum and postpartum intravenous immunoglobulin followed by azathioprine. *Australas J Dermatol.* 2012;53:66-69.
12. Svanborg A, Ohlsson S. Recurrent jaundice of pregnancy; a clinical study of twenty-two cases. *Am J Med.* 1959;27:40-49.
13. Lammert F, Marschall HU, Glantz A, et al. Intrahepatic cholestasis of pregnancy: molecular pathogenesis, diagnosis and management. *J Hepatol.* 2000;33: 1012-1021.
14. Paus TC, Schneider G, Van De Vondel P, et al. Diagnosis and therapy of intrahepatic cholestasis of pregnancy. *Z Gastroenterol.* 2004;42:623-628.
15. Paternoster DM, Fabris F, Palù G, et al. Intra-hepatic cholestasis of pregnancy in hepatitis C virus infection. *Acta Obstet Gynecol Scand.* 2002;81:99-103.
16. Brites D, Rodrigues CM, van-Zeller H, et al. Relevance of serum bile acid profile in the diagnosis of intrahepatic cholestasis of pregnancy in an high incidence area: Portugal. *Eur J Obstet Gynecol Reprod Biol.* 1998;80:31-38.
17. Kroumpouzos G. Intrahepatic cholestasis of pregnancy: what's new. *J Eur Acad Dermatol Venereol.* 2002;16:316-318.
18. Glantz A, Marschall HU, Lammert F, et al. Intrahepatic cholestasis of pregnancy: a randomized controlled trial comparing dexamethasone and ursodeoxycholic acid. *Hepatology.* 2005;42:1399-1405.
19. Kondrackiene J, Beuers U, Zalinkevicius R, et al. Predictors of premature delivery in patients with intrahepatic cholestasis of pregnancy. *World J Gastroenterol.* 2007;13:6226-6230.

20. Henderson CE, Shah RR, Gottimukkala S, et al. Primum non nocere: how active management became modus operandi for intrahepatic cholestasis of pregnancy. *Am J Obstet Gynecol.* 2014;211:189-196.
21. Puljic A, Kim E, Page J, et al. The risk of infant and fetal death by each additional week of expectant management in intrahepatic cholestasis of pregnancy by gestational age. *Am J Obstet Gynecol.* 2015;212: 667.e1-667.e5.
22. Heymann WR. Dermatoses of pregnancy update. *J Am Acad Dermatol.* 2005;52:888-889.
23. Henson TH, Tuli M, Bushore D, et al. Recurrent pustular rash in a pregnant woman. *Arch Dermatol.* 2000;136:1055-1060.
24. Chaidemenos G, Lefaki I, Tsakiri A, et al. Impetigo herpetiformis: menstrual exacerbations for 7 years postpartum. *J Eur Acad Dermatol Venereol.* 2005;19: 466-469.
25. Vun YY, Jones B, Al-Mudhaffer M, et al. Generalized pustular psoriasis of pregnancy treated with narrowband UVB and topical steroids. *J Am Acad Dermatol.* 2006;54(2)(suppl):S28-S30.
26. Robinson A, Van Voorhees AS, Hsu S, et al. Treatment of pustular psoriasis: from the Medical Board of the National Psoriasis Foundation. *J Am Acad Dermatol.* 2012;67:279-288.
27. Imai N, Watanabe R, Fujiwara H, et al. Successful treatment of impetigo herpetiformis with oral cyclosporine during pregnancy. *Arch Dermatol.* 2002;138: 128-129.
28. Kapoor R, Kapoor JR. Cyclosporine resolves generalized pustular psoriasis of pregnancy. *Arch Dermatol.* 2006;142:1373-1375.
29. Puig L, Barco D, Alomar A. Treatment of psoriasis with anti-TNF drugs during pregnancy: case report and review of the literature. *Dermatology.* 2010;220:71-76.
30. Cheent K, Nolan J, Shariq S, et al. Case report: fatal case of disseminated BCG infection in an infant born to a mother taking infliximab for Crohn's disease. *J Crohns Colitis.* 2010;4:603-605.
31. Bukhari IA. Impetigo herpetiformis in a primigravida: successful treatment with etretinate. *J Drugs Dermatol.* 2004;3:449-451.
32. Ahmadi S, Powell FC. Pruritic urticarial papules and plaques of pregnancy: current status. *Australas J Dermatol.* 2005;46:53-58; quiz 59.
33. Vaughan Jones SA, Hern S, Nelson-Piercy C, et al. A prospective study of 200 women with dermatoses of pregnancy correlating clinical findings with hormonal and immunopathological profiles. *Br J Dermatol.* 1999;141:71-81.
34. Rudolph CM, Al-Fares S, Vaughan-Jones SA, et al. Polymorphic eruption of pregnancy: clinicopathology and potential trigger factors in 181 patients. *Br J Dermatol.* 2006;154:54-60.
35. Im S, Lee ES, Kim W, et al. Expression of progesterone receptor in human keratinocytes. *J Korean Med Sci.* 2000;15:647-654.
36. Elling SV, McKenna P, Powell FC. Pruritic urticarial papules and plaques of pregnancy in twin and triplet pregnancies. *J Eur Acad Dermatol Venereol.* 2000;14:378-381.
37. Regnier S, Fermand V, Levy P, et al. A case-control study of polymorphic eruption of pregnancy. *J Am Acad Dermatol.* 2008;58:63-67.
38. Cohen LM, Capeless EL, Krusinski PA, et al. Pruritic urticarial papules and plaques of pregnancy and its relationship to maternal-fetal weight gain and twin pregnancy. *Arch Dermatol.* 1989;125:1534-1536.
39. Uhlin SR. Pruritic urticarial papules and plaques of pregnancy. Involvement in mother and infant. *Arch Dermatol.* 1981;117:238-239.
40. Kroumpouzos G, Cohen LM. Specific dermatoses of pregnancy: an evidence-based systematic review. *Am J Obstet Gynecol.* 2003;188:1083-1092.
41. Ambros-Rudolph CM, Müllegger RR, Vaughan-Jones SA, et al. The specific dermatoses of pregnancy revisited and reclassified: results of a retrospective two-center study on 505 pregnant patients. *J Am Acad Dermatol.* 2006;54:395-404.
42. Roth MM, Cristodor P, Kroumpouzos G. Prurigo, pruritic folliculitis, and atopic eruption of pregnancy: facts and controversies. *Clin Dermatol.* 2016;34:392-400.
43. Holmes RC, Black MM. The specific dermatoses of pregnancy. *J Am Acad Dermatol.* 1983;8:405-412.
44. Reed J, George S. Pruritic folliculitis of pregnancy treated with narrowband (TL-01) ultraviolet B phototherapy. *Br J Dermatol.* 1999;141:177-179.

Chapter 106 :: Skin Aging

:: Michelle L. Kerns, Anna L. Chien, & Sewon Kang

AT-A-GLANCE

- Intrinsic skin aging includes the inevitable physiologic changes of the skin that occur with time and are influenced by genetic and hormonal factors.
- Extrinsic skin aging is the preventable structural and functional changes of the skin that occur with exposure to environmental factors, the most important source being ultraviolet radiation.
- Intrinsic and extrinsic aging of the skin have distinct histologic and clinical manifestations.
- Oxidative damage is a common component of the multiple mechanisms of aging.
- Geriatric dermatoses include solar lentigines, seborrheic keratoses, senile angiomas, xerosis, asteatotic eczema, and pruritus.
- There is increased incidence of benign and malignant skin growths in the elderly population.
- Infections in the elderly often have distinctive causative organisms and increased morbidity and mortality relative to younger patients.

In Westernized countries, the chronologic age of older than 65 years is accepted as the definition of an elderly individual. By 2050, the elderly population is estimated to more than double in developing countries (World Health Organization. *Global Health and Aging.* 2011; http://www.who.int/ageing/publications/global_health/en/). This demographic transformation will present unique challenges to physicians across the medical specialties, including dermatology.

Aging is an inevitable and dynamic biologic process that is characterized by the progressive deterioration of many body systems and decline in physiologic reserve capacity. Given its location at the body's environmental interface, human skin undergoes 2 distinct types of aging: intrinsic and extrinsic. Intrinsically aged skin appears dry and pale with fine wrinkles and increased laxity; whereas, photoaged skin is darker, coarser, and often has mottled pigmentation (Fig. 106-1). Intrinsic aging encompasses a set of gradual physiologic changes that are a consequence of time and under genetic and hormonal control. Conversely, extrinsic aging, also termed *photoaging*, includes dramatic structural and functional changes that are caused by exogenous factors, the primary one being unprotected sun exposure.

OXIDATIVE STRESS AND AGING

One theory of aging involves cellular senescence or apoptosis secondary to oxidative damage.[1] The generation of reactive oxygen species is a normal consequence of aerobic metabolism. Accordingly, a complex antioxidant system of enzymatic and nonenzymatic effectors has evolved to counteract the endogenously and exogenously produced free radicals in the skin (Table 106-1). However, the skin's antioxidant defenses tend to weaken with age,[2] and the resultant oxidative stress contributes to intrinsic aging.

Oxidative damage leads to the upregulation of stress-related factors, which can then trigger downstream events enabling the aging process. For example, stress-induced factors, such as hypoxia-inducible factors and nuclear factor κB, induce the expression of cytokines. Some of these cytokines, like interleukin-1, interleukin-6, vascular endothelial growth factor and tumor necrosis factor-α, have been shown to be proinflammatory regulators of cell survival and modulators of matrix-degrading metalloproteins.[3-5] Additionally, oxidative damage to cellular proteins combined with the age-related deterioration of proteasome activity results in the accumulation of damaged proteins that interfere with normal cellular function.

Oxidative stress also modifies telomeres, the terminal portions of linear chromosomes that defend against degradation or fusion. Telomeres consist of hundreds of tandem DNA sequence repeats that are shortened with each somatic cell division. The shortening of telomeres is a result of the inability of DNA polymerase to replicate the final base pairs of a chromosome. When the telomeres reach a "critically short" threshold, the cell undergoes proliferative senescence or apoptosis, depending on the cell type. In addition to shortened telomeres secondary to serial cellular division, oxidative insult appears to trigger telomere signaling. Kosmadaki and Gilchrest have proposed a common final pathway for intrinsic and photoaging leading to the disruption of the normal loop structure at the end of telomeres. The exposure of the normally buried TTAGGG tandem repeat of the 3' overhang strand then activates p53 signaling leading to downstream events that include proliferative senescence and apoptosis (Fig. 106-2).[6]

It has been suggested that cellular senescence is the cellular basis for aging.[7] After a finite number of cellular divisions, the cell cycle of a mammalian cell is irreversibly arrested and the cell has entered a state

Figure 106-1 Difference between photoprotected and photoexposed skin.

known as replicative senescence.[8] Cellular senescence has been described as a possible tumor-suppressor mechanism, which precludes the unregulated growth of cells that have acquired multiple genetic mutations over time. This apparent biologic trade off of increased life span and increased risk of malignant transformation is further underscored by the observation that improved DNA repair mechanisms correlate with longer life spans in mammalian species.[9]

INTRINSIC SKIN AGING

Intrinsic or chronologic skin aging refers to the seemingly unavoidable physiologic changes of the skin that occur with time and are influenced by genetic and hormonal factors. These alterations include decreased collagen production, reduced blood flow, lowered amounts of lipids, and the loss of rete ridges.[10] The result is dry, pale skin with fine wrinkles, less elasticity, and impaired reparative capacity (Fig. 106-3). Intrinsically aged skin is also characterized by the development of a range of benign neoplasms, resulting from impaired regulation of cellular proliferation.[11]

EXTRINSIC SKIN AGING

Extrinsic skin aging entails the physiologic and histologic changes caused by environmental factors. The most powerful source of extrinsic aging is ultraviolet radiation. The ultraviolet radiation–mediated

TABLE 106-1
The Antioxidant Systems of the Skin

ENZYMATIC	NONENZYMATIC
Glutathione peroxidase	Vitamin C (ascorbic acid)
Catalase	Vitamin E
Superoxide dismutase	Glutathione Thioredoxin system Carotenoids Flavonoids

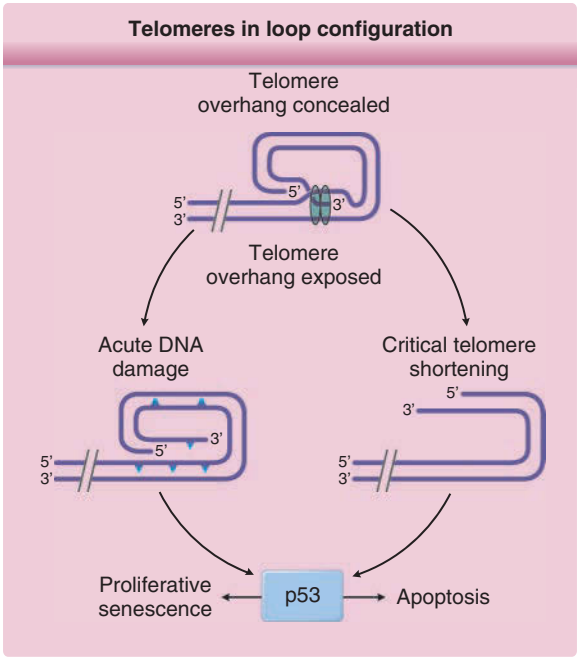

Figure 106-2 Schematic of cellular responses induced by exposure of the telomere repeat sequence. (From Yaar M. Clinical and histological features of intrinsic versus extrinsic skin aging. In: Gilchrest BA, Krutmann J, eds. *Skin Aging*. New York, NY: Springer; 2006:9-21, with permission. Copyright © 2006.)

structural and functional changes of the skin are known as photoaging, which is described in "Photoaging" section in more detail below. Other exogenous factors that contribute to extrinsic skin aging include cigarette

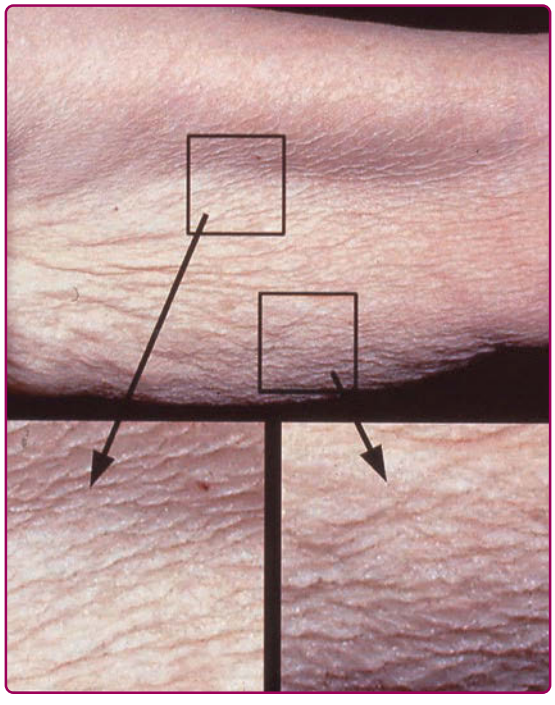

Figure 106-3 *Intrinsic aging (upper inner arm):* Intrinsic aging is characterized by fine wrinkling, increased skin laxity, and sagging.

smoking, diet, chemical exposure, trauma, and air pollutants (eg, particulate matter, CO_2, CO, SO_2, NO, and NO_2). In fact, an intense interest in the effects of air pollution on skin physiology has developed in recent years, giving rise to several mechanistic and epidemiologic studies.[12] The initial link between airborne particle exposure and extrinsic skin aging was established by a cross-sectional study in Germany that found an association between exposure to chronic traffic-related particulate matter and premature skin aging with pigment spot formation.[13] Indoor air pollution, such as cooking with fossil fuels, also has been associated with accelerated aging in Chinese populations.[14] Activation of the aryl hydrocarbon receptor by exogenous factors like tobacco smoke extract and airborne particulate matter has been identified as a potential contributor to extrinsic aging.[15,16] Ozone also causes skin inflammation and disrupts barrier function by inducing lipid peroxidation and protein oxidation in the stratum corneum.[16]

Unlike intrinsic aging, extrinsic aging is more amenable to intervention and preventive measures. Typical clinical features of extrinsically aged skin, which are mostly ultraviolet radiation–mediated, include deep wrinkles, laxity, coarseness, increased fragility, and multiple telangiectases. Moreover, photodamaged skin may appear darker and have mottled pigmentation (Fig. 106-4). Extrinsically aged skin has an increased tendency to develop benign and malignant growths.[11] Table 106-2 summarizes the histologic and clinical features that are typical of intrinsically and extrinsically aged skin.

Figure 106-4 *Photoaging aging (face):* The photograph highlights salient features of photoaging including fine and coarse wrinkles, discrete tan-brown macules, mottled pigmentation, telangiectasias, loss of translucency and elasticity, xerosis, and sallow color.

TABLE 106-2
The Typical Histologic and Clinical Features of Intrinsic and Extrinsic Skin Aging

	INTRINSIC AGING	EXTRINSIC AGING
Histologic features	Epidermal thinning Loss of rete ridges Decreased number of collagen and elastin fibers	Solar elastosis Reduced number of fibroblasts Reduced amount of extracellular matrix
Clinical features	Xerosis Pallor Fine wrinkles Decreased elasticity Fragility	Xerosis Multiple telangiectases Deep wrinkles Decreased elasticity Fragility Dyspigmentation

PHOTOAGING

At the earth's surface, sunlight is composed of infrared, visible, and ultraviolet (UV) light, with most of the UV blocked by the earth's atmosphere. Of the UV radiation that reaches the earth's surface, more than 95% is UVA (320 to 400 nm) and approximately 5% is UVB (280 to 320 nm). Both UVA and UVB contribute to skin aging. UVB, which only penetrates into the epidermis and upper dermis, is a chief source of direct DNA damage, inflammation, and immunosuppression.[17] Conversely, UVA deeply penetrates the skin down to the lower dermis. UVA is considered a larger contributor to skin aging than UVB because of its greater depth of penetration and its higher percentage of surface sunlight.

In addition to the mechanisms of aging discussed before, photodamage contributes to extrinsic aging through other mechanisms. UV damage impacts collagen degradation and synthesis, as well as causes the production of elastotic material in the skin, both of which are further described in section "Dermis". Photodamaged skin is also associated with a higher frequency of mitochondrial DNA mutations that result in decreased mitochondrial function and the generation of reactive oxygen species.[16] The basement membrane at the dermal–epidermal junction is also damaged in sun-exposed skin. Following UV radiation exposure, the basement membrane becomes multilayered and partially disrupted. Additionally, matrix metalloproteinases (MMPs) and urinary plasminogen activator are increased in photodamaged skin.[18]

Recently, there has been a growing interest in the impact of non-UV solar radiation on skin physiology and aging. Approximately 50% of the total solar spectrum is visible light (400 to 700 nm), which is able to penetrate down to the hypodermis.[19] Visible light generates reactive oxygen species in human skin[20] and induces the formation of oxidized DNA bases.[21] Additionally, irradiation of human skin equivalents with visible light results in increased production of proinflammatory cytokines and MMP-1.[22] Nearly 45% of the

solar spectrum reaching human skin is infrared, which is composed of infrared A (700 to 1400 nm), infrared B (1400 to 3000 nm), and infrared C (3000 nm to 1 mm). Infrared B and infrared C do not penetrate the skin well, but infrared A can reach down to the hypodermis, increase reactive oxygen species production, and impact mitochondrial integrity.[19]

ESTROGEN AND SKIN AGING

In addition to their reproductive roles, estrogens are important regulators of skin physiology and wound healing (Table 106-3). Estrogens exert their effects through specific estrogen receptors, which can act as ligand-activated transcription factors. Estrogen receptor signaling is a critical modulator of redox (reduction–oxidation) balance and oxidative stress, which is central to many of the mechanisms of skin aging. Recently, estrogens have been shown to have nongenomic effects that occur through estrogen receptor–independent mechanisms, including interactions with membrane-associated G-coupled protein receptors and subsequent activation of signal transduction pathways.[23] Both genomic and nongenomic effects of estrogen appear to be critical mediators of skin physiology and may impact skin aging.

As the population of menopausal women increases, the profound impact of changes in estrogen levels on aging grows in clinical relevance. In premenopausal women, the predominant form of estrogen is estradiol, which is produced by the ovaries. After menopause, the levels of estradiol drop dramatically and women may experience a rapid onset of skin aging. Postmenopausal changes that have been reported include decreased collagen content, thinner skin, reduced elasticity, dryness, and increased wrinkling. These changes reflect the loss of the protective effects of estrogen and can be ameliorated with estrogen replacement.[24]

TABLE 106-3
Impact of Estrogens on Skin Physiology

SKIN COMPONENT	EFFECT OF ESTROGENS
Epidermis	Increase in mitotic activity of epidermal cells Stimulation of epidermal melanocytes
Dermis	Increase in collagen synthesis, maturation, and turnover Morphologic improvement of collagen and elastic fibers
Glands	Reduction in activity of sebaceous and apocrine glands
Hair follicle	Influences hair follicle cycle May inhibit activity of follicular melanocytes

Data from Thornton MJ. The biological actions of estrogens on skin. *Exp Dermatol*. 2002;11(6):487-502.

Several studies have examined the effect of topical estrogens on human skin. Treatment of photoaged facial skin with a conjugated estrogen cream increased skin thickness and decreased fine wrinkles.[25] Several studies have found that topical administration of estradiol induces procollagen in sun-protected skin of postmenopausal women and age-matched men.[26,27] Despite the similar expression of estrogen receptors in photoaged and intrinsically aged skin, topical estradiol did not alter procollagen production in photoaged skin, suggesting that changes that result from long-term sun exposure impede the ability of topical estrogen to stimulate collagen synthesis. Furthermore, these findings indicate that the estradiol-mediated effect on collagen production is indirect, that is, independent of estrogen receptor signaling.

EPIDERMIS

The human epidermis undergoes several structural and functional age-related alterations. Between the third and eighth decades of life, the epidermal turnover rate decreases by 30% to 50%,[28] coinciding with a deterioration of wound repair capacity. During this time period, there is also an overall thinning of unexposed epidermis by 10% to 50%. The spinous cell layer appears to be the most greatly impacted by epidermal atrophy, whereas the stratum corneum and stratum granulosum are largely unaffected.[29] The most pronounced and consistent histologic change of aged skin is flattening of the dermal–epidermal junction and loss of rete ridges, resulting in decreased surface contact area and presumably less nutritional support of the avascular epidermis by the vascularized dermis.[11] These alterations account for the increased fragility of aged skin to minor trauma as well as propensity to blister.

Although the average thickness of the stratum corneum does not change with age, older skin has a greater susceptibility to irritant contact dermatitis and severe xerosis. Aged skin also has altered drug permeability with reduced absorption of hydrophilic substances observed in older skin relative to younger controls.[30] Taken together, these observations suggest a compromise of the aged epidermal permeability barrier. Indeed, intrinsically aged skin has impaired barrier recovery following challenge. This may be partly because of a global decline of stratum corneum lipids, leading to diminished lamellar bilayers in the stratum corneum interstices.[31] Moreover, between the ages of 50 and 80 years, abnormal stratum corneum acidification results in impaired lipid-processing enzymatic activity,[32] as well as abnormal permeability barrier homeostasis and stratum corneum integrity.[33] An age-related decrease in epidermal filaggrin also has been proposed to impact barrier function and to account for the increased dryness and scaliness of older skin.[34]

At the cellular level, a number of important age-related changes occur in epidermal keratinocytes. Cellular heterogeneity—for example, differences in cellular shape, size, and staining characteristics—results

TABLE 106-4
Age-Related Changes in the Various Epidermal Cell Types

CELL TYPE	STRUCTURAL CHANGES	FUNCTIONAL CHANGES
Epidermal keratinocytes	Epidermal dyscrasia	Reduced mitotic activity Increased migration time Increased senescence
Melanocytes	Atypia Decreased number of functional melanocytes Increased number in photodamaged skin	Decreased melanin production
Langerhans cells	Decreased number Fewer and shorter dendrites	Decreased antigen presentation capability

in epidermal dyscrasia, a mild actinic keratosis that is particularly accentuated in photoaged skin. Epidermal dyscrasia is associated with reduced mitotic activity, lengthened cell cycle, and increased migration time from the basal cell layer to the stratum corneum.[35] It has been shown in vitro that human keratinocytes approach replicative senescence after 50 to 100 doublings and arrest in G_1 phase.[36] Because senescent cells are resistant to apoptosis, they may accumulate DNA mutations and protein damage over time. The buildup of senescent keratinocytes over time may provide the mechanistic link between aging and epidermal carcinogenesis.[35]

In addition to keratinocytes, the other resident cells of the epidermis—melanocytes and Langerhans cells—experience age-associated changes. Although the density of melanocytes doubles in photodamaged skin, the number of functional melanocytes in the basal layer declines by up to 20% per decade.[37] This decrease of melanocytes is associated with a decrease in protective melanin, which in addition to the age-related impairment of DNA repair mechanisms, contributes to an elevated risk of skin cancer in the elderly. The incidence of melanocytic nevi also declines with age.[38] In aged epidermis, there is also a reduction of the number and the responsiveness of Langerhans cells,[39] the dendritic cells of the skin. Langerhans cells of older skin undergo structural changes, for example, fewer and shorter dendrites, and have diminished antigen presenting capacity,[40] which likely contributes to weakened cutaneous immunity in the elderly. Table 106-4 summarizes the age-related changes in the various epidermal cell types.

DERMIS

Age-related biochemical changes in collagen, the main component of the dermis and the structural scaffold of the skin, may account for many of the characteristics of older skin, including increased rigidity and impaired wound healing.[41] There is a reduction of collagen types I and III in intrinsically aged skin that is enhanced by photodamage.[42] There is a significant downregulation of collagen synthesis in the skin with age[43] and photodamage.[44] An age-dependent difference in the collagen-synthetic capacity of aging fibroblasts partially accounts for the lower collagen synthesis in intrinsically aged skin.[45] Collagen fragmentation also contributes to the downregulation of collagen synthesis in both intrinsically aged and photoaged skin. Collagen-degrading MMPs gradually increase with age.[43] Acute UV irradiation transiently upregulates 3 MMPs (MMP-1, MMP-3, and MMP-9) in the skin, with the epidermis being the major source.[46,47] In contrast, chronically photodamaged skin has been shown to constitutively express higher levels of 7 MMPs (MMP-1, MMP-2, MMP-3, MMP-9, MMP-11, MMP-17, and MMP-27), which are primarily derived from dermal fibroblasts.[48] The resulting fragmentation of collagen is unable to produce an amount of mechanical tension on the fibroblasts to stimulate collagen synthesis.[45] Thus, elevated MMP activity in the dermis of photodamaged skin creates a microenvironment of fragmented collagen that impairs fibroblast function leading to abnormal collagen homeostasis with increased degradation and decreased production of collagen.

Elastin, the dermal element that provides elasticity and resilience, is also altered with aging. Solar elastosis, the most striking histologic alteration of photodamaged dermis, is characterized by the replacement of normal elastic fibers with a disordered mass of elastotic material (ie, degraded elastic fibers, tropoelastin, and fibrillin) that is localized near the dermal–epidermal junction.[49] Even in sun-protected chronologically older (>70 years old) skin, elastin fibers are reduced in number and diameter, appear fragmented, and exhibit increased crosslinkage and calcification.[50,51] These structural abnormalities in elastin translate into impaired function, namely a fall off of elastic recovery and resilience in aged skin.

Aging also affects the ground substance of the skin, which is composed of proteoglycans and glycosaminoglycans leading to decreased interaction of proteins with water. Although glycosaminoglycans are increased in photoaged skin, their deposition in the abnormal elastotic material prevents the normal attraction of water molecules, resulting in tetrahedron water.[52,53] In contrast, in intrinsically aged skin there is a progressive decline of hyaluronic acid, possibly secondary to decreased secretion or extractability.[54,55] All of these changes in the ground substance of the skin may contribute to age-related declines in skin hydration and turgor. Table 106-5 summarizes the consequences of the age-dependent alterations of the dermal components.

SKIN APPENDAGES

HAIR

With aging, there are striking spatially dependent and hormonally influenced changes in overall hair density and texture. Elderly men commonly have a drop in the density of chest, axillary, and pubic hair, but an

TABLE 106-5
Age-Associated Changes in the Dermal Components of the Skin

DERMAL COMPONENT	STRUCTURAL CHANGES	FUNCTIONAL CHANGES
Collagen	Increased rigidity Reduction of types I and III collagen Increased fragmentation	Impaired wound healing Decreased mechanical stress on fibroblasts (→ decreased collagen synthesis)
Elastin	Reduced number and diameter of elastin fibers Solar elastosis (photodamage)	Decreased elasticity
Ground substance	Abnormal deposition of glycosaminoglycans preventing normal interaction with water Reduced hyaluronic acid	Decreased skin hydration

increase of hair in other body sites, especially the nostrils, external auditory meatus, and eyebrows. Elderly women typically experience a new growth of coarse hair on the chin and upper lip, likely resulting from the unopposed influence of testosterone secondary to falling estrogen levels.[11]

Both men and women are affected by age-related alopecia. Senescent alopecia is the age-related thinning of hair, whereas androgenetic alopecia (or male pattern hair loss) is a distinct entity that can occur at an earlier age and results from the effect of dihydrotestosterone on hair follicles.[56] Conversely, only a small portion of female pattern hair loss may actually be androgenic.[57]

By the age of 60 years, nearly half of the population has at least 50% gray scalp hair, with everyone experiencing some amount of graying.[58] Hair graying is a result of the progressive depletion of melanocytes specifically in the hair bulb. The reasons for the vulnerability of this specific melanocyte stem cell population is not completely understood, but may be related to the high lifetime proliferative rate and relative sensitivity to oxidative stressors.[59,60] Recently, a sublineage of hair shaft progenitors in the hair matrix that are differentiated from follicular epithelial cells expressing the transcription factor KROX2 have been identified and shown to be a source of stem cell factor, which is critical for the maintenance of differentiated follicular melanocytes and hair pigmentation.[61] Whether this stem cell factor–dependent niche for follicular melanocytes is impaired in aging remains to be seen.

NAILS

Until approximately the age of 25 years, the rate of linear nail growth steadily increases, then drops off.[62] The texture of the nails also changes with age. In elderly individuals, nails are typically more brittle. Older nails may also exhibit ridging as a consequence of variation in lipid composition.[63]

CUTANEOUS GLANDS AND NERVES

There are striking age-related alterations in all of the glands of the skin. Both the number and output of eccrine glands decline with age.[64] The resulting decrease in spontaneous sweating renders the elderly more vulnerable to heat stroke. There is also a reduction in the size and function of apocrine glands in older skin.[65] Although the size and number of sebaceous glands appear constant, there is a drop of sebum production that is likely associated with hormonal changes.[66]

With aging, tactile thresholds are increased.[67] The decrease in the size and density of Pacinian and Meissner corpuscles may account for this finding.[68,69] There is also an increase in thermal pain thresholds in the elderly.[70] An age-associated decline in the spatial acuity (ability to discriminate between 2 points, light touch, and vibration) of the skin also occurs.[71,72]

GERIATRIC DERMATOSES

BENIGN SKIN LESIONS

Benign proliferative growths commonly occur in aging skin. Solar lentigines, also known as senile lentigines and liver spots, are well-defined patches of hyperpigmentation that are associated with UV exposure and especially common in fair-skinned individuals (Fig. 106-5). The reported average prevalence of solar lentigines ranges from 10% to 90% in older subjects.[73] Solar lentigines do not require any treatment; however, lentigo maligna and lentigo maligna melanoma, which are more serious malignant conditions, should be excluded. The role of repeated UV exposure in the pathogenesis of solar lentigines is not completely

Figure 106-5 *Solar lentigo:* discrete tan, brown macules on photoexposed site. (Image from the Graham Library of Wake Forest Department of Dermatology, with permission.)

understood, but appears to involve increased melanin production and abnormal proliferation and differentiation of keratinocytes.[74]

Another common skin disorder in the elderly are seborrheic keratoses (Fig. 106-6A), which are benign papules or plaques that are highly variable in color, may have a waxy or wart-like appearance, and can arise as a single lesion or as multiple growths. Reported prevalences of seborrheic keratoses have ranged between 8% and 54% in elderly subjects.[73] Similar to senile lentigines, seborrheic keratoses have no malignant potential and do not require therapy beyond cosmetic reasons. Unlike senile lentigines, the development of seborrheic keratoses is independent of UV exposure and is likely a result of impaired focal epidermal homeostasis resulting in the clonal expansion of melanocytes and keratinocytes.[75] The pathogenesis of seborrheic keratoses is currently under investigation (see Chap. 108). Interestingly, keratinocyte-derived endothelin-1, which is a regulator of melanocyte function, has been implicated.[76]

Senile angiomas (Fig. 106-6B), also known as cherry angiomas, are another skin disorder that afflicts elderly subjects. They are small circular or oval red papules resulting from the proliferation of blood vessels that tend to increase in size and number with age and may bleed with minor trauma. The prevalence of senile angiomas has been reported as 50% to 75% in older individuals.[73] Treatment for senile angiomas is not needed unless for cosmetic reasons or repeated bleeding.

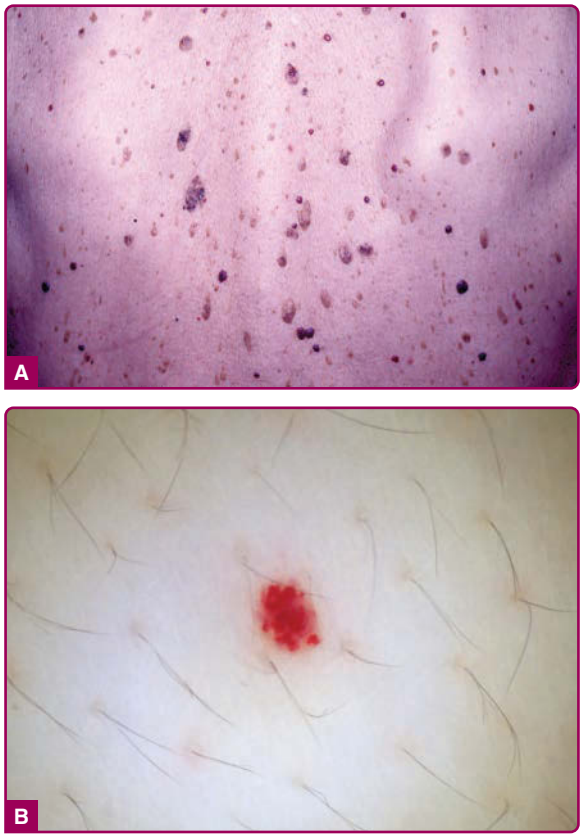

Figure 106-6 **A,** *Seborrheic keratoses:* brown, waxy, stuck-on papules and plaques and **B,** *Senile angioma:* erythematous to violaceous lobulated papules. (Image **B,** used with permission from Dr. Willy Huang.)

MALIGNANT SKIN LESIONS

The incidence of skin cancer, both melanoma and nonmelanoma skin cancers increases exponentially over a lifetime. In elderly populations, skin cancers represent approximately 40% of diagnosed malignant neoplasms. Older individuals with skin cancer are also at increased risk for poor outcomes. In particular, elderly males present with thicker melanomas and have increased mortality when compared to age-matched women and younger men.[77] The vast majority of skin cancer cases is basal cell cancer; however, squamous cell cancers are associated with greater nonmelanoma skin cancer–related morbidity and mortality.[78]

As one ages, the constant exposure to carcinogens, especially UV irradiation, leads to an accumulation of mutations. Compounding this risk is an age-related impairment of DNA repair capacity in response to UV exposure and decline in immune function.[79] There is a relationship between the risk of the type of skin cancer and the nature of the UV exposure. Squamous cell cancer and its precursor lesion, actinic keratosis, are associated with habitual sun exposure, whereas basal cell cancer and malignant melanoma correlate with a history of habitual or intense intermittent sun exposure.[80]

Merkel cell carcinoma (MCC, see Chap. 113) is a rare and aggressive type of cutaneous cancer that presents as a painless rapidly growing nodule that may be flesh-colored or bluish-red and typically occurs in sun-exposed areas of the body. Ninety percent of all cases of Merkel cell carcinoma occur in patients older than 50.[81] It is also associated with immunosuppression.[82] Merkel cell carcinoma is considered a neuroendocrine tumor of the skin that arises from a 2-step process: the integration of the Merkel polyomavirus genome into the host genome and development of T-antigen mutations that prevent autonomous replication of the viral genome. The result is an avoidance of DNA damage responses or recognition of the viral T-antigen by the immune system leading to tumor growth.[83] The clinical characteristics of Merkel cell carcinoma have been summarized in an acronym: AEIOU (*a*symptomatic/lack of tenderness, *e*xpanding rapidly, *i*mmune compromised, *o*lder than 50 years, and *U*V-exposed site on a person of fair skin).[84] These characteristics have been shown to be highly sensitive for Merkel cell carcinoma and can aid in the decision to biopsy and improve early detection of this aggressive cancer.

Angiosarcoma, a cancer of the inner lining of blood vessels, most commonly occurs in the elderly. It can affect any area of the body, but the majority present on the head and neck (Fig. 106-7). Rapidly proliferating and invasive anaplastic cells are characteristic of angiosarcoma. This aggressive and highly metastatic cancer is associated with a high mortality and often leads to death within 2 years of initial diagnosis.[85] These vascular tumors have been shown to express

Figure 106-7 *Angiosarcoma:* Angiosarcomas in the elderly typically occur on head and neck, characterized by enlarging nonblanching violaceous patch or deeply violaceous nodule with ulceration and tenderness.

high levels of vascular endothelial growth factor and vascular endothelial growth factor receptor-2, which have emerged as potential therapeutic targets.[86]

Kaposi sarcoma (KS) is a lymphoangioproliferative disease that is associated with human herpesvirus-8. There are 4 variants of KS: classic KS (CKS), AIDS-associated KS, iatrogenic posttransplantation KS, and endemic African KS. Only CKS is reviewed here. CKS primarily affects individuals of Eastern European Jewish or Mediterranean descent, and males more than females. CKS lesions are purple, red, or brown macules, plaques, and nodules that typically affect the face or lower extremities, often producing pain and debilitation. CKS lesions can also occur in the lungs, liver, and digestive tract, potentially causing life-threatening obstruction and bleeding. CKS is a rare disorder and its risk factors include increasing age, corticosteroid use, and diabetes. Treatment for localized disease entails observation, radiotherapy, surgery, or intralesional injections of vincristine or interferon alfa-2. However, the efficacy of the various therapies for CKS has not been validated, and standardized treatment guidelines are still needed.[87]

XEROSIS

Xerosis, or dry skin, is an extremely common skin disorder in the elderly and frequently affects the legs. The causes of xerosis are multifactorial. The age-associated reduction in the activity of sebaceous and sweat glands may contribute to its development. Alterations in lipid composition,[31] impaired filaggrin production,[34] and intrinsic changes in keratinization[88] are also potential etiologic factors. Xerosis is also associated with chronic renal failure, liver disorders, lower-leg atherosclerosis, autoimmune diseases, and hepatitis C virus infections.[73] Treatment options involve environmental changes and application of emollients.[88]

An associated skin condition is asteatotic eczema (Fig. 106-8), also known as winter itch, eczema craquelé,

Figure 106-8 *Asteatotic eczema ("eczema craquelé"):* minimally erythematous scaly plaques with fissures on background of xerosis. (Image from the Graham Library of Wake Forest Department of Dermatology, with permission.)

and desiccation dermatitis. Asteatotic eczema is xerosis complicated by dermatitis and is characterized by dry, extremely pruritic, fissured skin with scales. It typically presents in the elderly during the winter seasons and is often associated with low humidity in heated environments. Therapies are similar to those for xerosis, for example, behavior and environmental adaptions and topical emollients.[89]

PRURITUS

Pruritus, or itchy skin, is a common complaint of elderly patients that has a significant adverse effect on quality of life.[90] Pruritus can be caused by xerosis, but also can be a sign of an underlying systemic disease or malignancy. Pruritus has been associated with diabetes mellitus, thyroid disorders, and renal and liver failure. Malignant neoplasms, such as lymphoma or leukemia, can also present as pruritus. Pruritus is also a defining characteristic of the myeloproliferative neoplasm polycythemia vera. Infections such as scabies and tinea pedis are also typical causes of pruritus. Symptomatic treatment and addressing any underlying conditions are the mainstays of pruritus therapy.

INFECTIONS

There are many infections of medical significance that can produce both skin lesions and systemic disease in the elderly. Older individuals may be susceptible to aggressive and life-threatening infections that are rare in younger populations. In devising the appropriate medical intervention, it is important to be aware of the types of bacterial, parasitic, fungal, and viral pathogens that more frequently occur in the elderly. Given the increased likelihood of comorbidities and polypharmacy, differences in drug metabolism, atypical symptomology, and elevated risk of a poor outcome, the geriatric patient with an infection may present unique challenges relative to their younger counterparts.

BACTERIAL

Bacterial infections in elderly populations often have distinctive causative organisms and increased morbidity and mortality relative to younger patients. In elderly patients, infection with staphylococci is frequently the cause of impetigo (infection of the superficial layers of the epidermis) and folliculitis (inflammation of the hair follicles).[91] Cellulitis, an infection of the dermis and subcutaneous fat, is usually caused by streptococci or staphylococci and may present more subtly in elderly individuals. Risk factors for cellulitis, such as diabetes mellitus, immunodeficiency, lymphedema, and chronic venous insufficiency, are also more prevalent in the elderly. Older patients are particularly vulnerable to certain rare and aggressive forms of cellulitis. Orbital cellulitis can be caused by the contiguous spread of infections of the paranasal sinuses or metastatic spread from a systemic focus. In contrast to preseptal orbital cellulitis, orbital cellulitis involves the soft tissues posterior to the orbital septum. In the absence of adequate treatment, orbital cellulitis can lead to blindness and death from intracranial spread. In older individuals, the cause of orbital cellulitis is typically polymicrobial and may be a mix of aerobic and anaerobic bacteria. Elderly persons with diabetes are more likely to develop *Pseudomonas* cellulitis of the ear than are other populations.[91]

In addition to cellulitis, other rare cutaneous infections occur more frequently in the elderly. Erysipelas, a β-hemolytic streptococcal infection of the upper dermis that spreads to the lymphatics, is more common in older individuals and more likely to result in sepsis and other life-threatening complications. It can be distinguished from cellulitis by its demarcated borders. Necrotizing fasciitis, which is often caused by *Streptococcus*, is associated with increased morbidity and mortality in the elderly. Risk factors for necrotizing fasciitis, such as immunosuppression, diabetes, chronic systemic illnesses, and malignancies, are more prevalent in older individuals. The elderly population also has been identified as being at risk for carriage for methicillin-resistant *Staphylococcus aureus*,[92] which is often implicated in cases of necrotizing fasciitis.

PARASITIC[93]

Scabies is one of the most clinically significant parasitic infections in the geriatric population. Residents of nursing homes, like other communal living arrangements, are at increased risk for this highly contagious infestation. To complicate the clinical picture, the elderly, similar to other immunosuppressed groups, may present with less-severe pruritus and inflammation. Furthermore, given the common occurrence of xerosis in the elderly, pruritus in an older patient may fail to raise any alarm in the practitioner. Early detection and treatment with topical scabicides and oral ivermectin will help to limit the spread of the infestation. Another parasitic cause of pruritus in the elderly is pediculosis, or infestation with lice. Pediculosis can be treated with malathion, lindane, or permethrin. Less-frequent parasitic infections in the geriatric population include cutaneous larva migrans and cutaneous leishmaniasis.

FUNGAL[94]

There are several risk factors that predispose the geriatric population to cutaneous fungal infections, including age-associated decrease in immunity, vitamin deficiency, peripheral vascular disease, broad-spectrum antibiotic use for other infections, lymphoproliferative disorders, and malignancies. Dermatophytes, a type of fungi that requires keratin for growth, can cause superficial infections such as tinea capitis, tinea corporis, tinea pedis, and tinea unguium. Tinea pedis affects approximately 80% of patients older than 60 years age and in elderly persons with diabetes, it is often complicated by ulceration and cellulitis.[95] *Candida albicans*, a type of yeast that is part of the body's normal flora, is another frequent source of cutaneous infections in the elderly. *Pityrosporum ovale* may cause seborrheic dermatitis, tinea versicolor, and Pityrosporum folliculitis, conditions that frequently affect older patients. Antifungals are effective for the geriatric population, but have to be used with caution because of possible drug interactions and underlying disorders.

VIRAL[96]

Herpes zoster, commonly known as shingles, is a cutaneous viral disease that primarily affects elderly patients. It is characterized by painful vesicular rash in a dermatomal distribution and is often preceded by pain in the affected area. Herpes zoster is caused by the reactivation in adults of the varicella-zoster virus (VZV), which is the virus that causes chickenpox in children. Age-related changes in immunity may be responsible for the failed suppression of VZV in the elderly. Current treatment includes antivirals like acyclovir, famciclovir, and valacyclovir. There is also a live, attenuated VZV vaccine and a recently approved recombinant zoster vaccine available.[97] Pain can persist following an acute attack of herpes zoster. This is known as postherpetic neuralgia and is treated with topical anesthetics, analgesics, tricyclic antidepressants, and anticonvulsants. The VZV vaccine provides protection against herpes zoster for at least 3 years and reduce the incidence of postherpetic neuralgia by 66.5%.[98]

Infections caused by herpes simplex virus, which are characterized by vesicular eruptions in the genital and perioral regions, are also of clinical importance for the geriatric population. The vermilion border of the lip is the most frequent site of herpes simplex virus infection in older individuals. Recurrent herpes labialis in the geriatric patient can result in autoinoculation of the eye and genital area and subsequent spread of

the disease. Similar to VZV infections, herpes simplex virus infections can be treated with antivirals including acyclovir, famciclovir, and valacyclovir.

ULCERS

Compromised wound repair capacity and comorbidities like diabetes mellitus and atherosclerotic peripheral vascular disease predispose the geriatric population to the development of chronic ulcers, particularly leg ulcers. Chronic venous insufficiency can lead to venous hypertension, resulting in the leakage of fibrinogen and other macromolecules into the dermis that can block the normal flow of oxygen, nutrients, growth factors, and cytokines, all of which are vital to tissue health and wound healing. Lipodermatosclerosis, a type of lower-extremity panniculitis, can develop and further impede wound repair. It is characterized by indurated skin with brownish-red pigmentation and is associated with tissue hypoxia, cytokine activation, and interstitial protein exudates.[99] The elderly are also more prone to develop decubitus ulcers than younger patients. This is because of age-related skin atrophy from constitutive elevation in MMPs and concomitant decline in collagen synthesis by dermal fibroblasts.[48] Furthermore, decline in physical mobility, urinary and fecal incontinence, and malnutrition all contribute to the ulcer formation in the elderly.[100]

SENILE PURPURA (BATEMAN PURPURA)

Senile purpura is the recurrent formation of ecchymoses on the sun-exposed extensor surfaces of the arms or hands of elderly patients. Age-related skin thinning and sun-induced damage of the connective tissue of the dermis results in inadequate support and increased fragility of the microvasculature. As a result, minor trauma of aged photodamaged skin can lead to vessel rupture and extravasation of blood into the dermal tissues.[38] This condition can be exacerbated with the use of aspirin and other anticoagulants, medications that are common in the elderly population. Blood is typically resorbed within 2 weeks, but postinflammatory hyperpigmentation may occur. Although benign and self-resolving, senile purpura is of great cosmetic concern with a significant impact on patient well-being.

BULLOUS PEMPHIGOID

Bullous pemphigoid is an autoimmune blistering disorder that primarily affects patients older than 60 years of age. The initial manifestation can be urticarial papules and plaques with significant pruritus that subsequently progress into large tense bullae. The formation of autoantibodies that target the basement membrane leads to the separation of the dermal–epidermal junction. Certain risk factors for bullous pemphigoid have been identified and include neurologic disorders (eg, dementia and Parkinson disease), psychiatric disorders, bedridden condition, and chronic polypharmacy.[101] Mortality in bullous pemphigoid cases is associated with increased disease severity and can occur as a result of therapies.[102]

DRUG ERUPTIONS

Adverse cutaneous drug reactions, such as morbilliform and urticarial eruptions, are frequent in the elderly and can have a significant impact on quality of life. Furthermore, older patients are more likely to develop drug-induced autoimmune reactions, like bullous pemphigoid (described before), lupus erythematosus, and pemphigus. One reason for increased risk of drug eruptions is polypharmacy. Additionally, renal, cardiac, and liver functions decline with age, which negatively impact drug metabolism and excretion. Thus, appropriate consideration and follow up when prescribing new medications, as well as frequent evaluation of existing medications is advised for the geriatric population.[103]

REFERENCES

1. Harman D. Free radical theory of aging: an update: increasing the functional life span. *Ann N Y Acad Sci*. 2006;1067:10-21.
2. Chung J, Cho S, Kang S. Why does the skin age? Intrinsic aging, photoaging, and their pathophysiology. In: Rigel DS, Weiss RA, Lim HW, Dover JS, eds. *Photoaging*. New York, NY: Marcel Dekker; 2004:1-13.
3. Ahmad A, Banerjee S, Wang Z, et al. Aging and inflammation: etiological culprits of cancer. *Curr Aging Sci*. 2009;2(3):174-186.
4. Ruland J, Mak TW. Transducing signals from antigen receptors to nuclear factor kappa B. *Immunol Rev*. 2003;193:93-100.
5. Kang S, Fisher GJ, Voorhees JJ. Photoaging: pathogenesis, prevention, and treatment. *Clin Geriatr Med*. 2001;17(4):643-659, v-vi.
6. Kosmadaki MG, Gilchrest BA. The role of telomeres in skin aging/photoaging. *Micron*. 2004;35(3):155-159.
7. Campisi J. Replicative senescence: an old lives' tale? *Cell*. 1996;84(4):497-500.
8. Hayflick L. The limited in vitro lifetime of human diploid cell strains. *Exp Cell Res*. 1965;37:614-636.
9. Hart RW, Setlow RB. Correlation between deoxyribonucleic acid excision-repair and life-span in a number of mammalian species. *Proc Natl Acad Sci U S A*. 1974;71(6):2169-2173.
10. Montagna W, Kirchner S, Carlisle K. Histology of sun-damaged human skin. *J Am Acad Dermatol*. 1989; 21(5, pt 1):907-918.
11. Tobin DJ. Introduction to skin aging. *J Tissue Viability*. 2017;26(1):37-46.
12. Krutmann J, Berneburg M. Photodamage: pathophysiology-new concepts. *Eur J Dermatol*. 2002;12(6):XV-XVI.
13. Vierkotter A, Schikowski T, Ranft U, et al. Airborne particle exposure and extrinsic skin aging. *J Invest Dermatol*. 2010;130(12):2719-2726.
14. Li M, Vierkötter A, Schikowski T, et al. Epidemiological evidence that indoor air pollution from cooking with

solid fuels accelerates skin aging in Chinese women. *J Dermatol Sci.* 2015;79(2):148-154.
15. Ono Y, Torii K, Fritsche E, et al. Role of the aryl hydrocarbon receptor in tobacco smoke extract-induced matrix metalloproteinase-1 expression. *Exp Dermatol.* 2013;22(5):349-353.
16. Krutmann J, Liu W, Li L, et al. Pollution and skin: from epidemiological and mechanistic studies to clinical implications. *J Dermatol Sci.* 2014;76(3):163-168.
17. Kochevar I. Molecular and cellular effects of UV radiation relevant to chronic photodamage. In: Gilchrest BA, ed. *Photodamage*. Cambridge, MA: Blackwell Science, 1995.
18. Amano S. Possible Involvement of basement membrane damage in skin photoaging. *J Investig Dermatol Symp Proc.* 2009;14(1):2-7.
19. Dupont E, Gomez J, Bilodeau D. Beyond UV radiation: a skin under challenge. *Int J Cosmet Sci.* 2013; 35(3):224-232.
20. Zastrow L, Groth N, Klein F, et al. The missing link—light-induced (280-1,600 nm) free radical formation in human skin. *Skin Pharmacol Physiol.* 2009;22(1):31-44.
21. Cadet J, Berger M, Douki T, et al. Effects of UV and visible radiation on DNA-final base damage. *Biol Chem.* 1997;378(11):1275-1286.
22. Liebel F, Kaur S, Ruvolo E, et al. Irradiation of skin with visible light induces reactive oxygen species and matrix-degrading enzymes. *J Invest Dermatol.* 2012;132(7):1901-1907.
23. Maran A, Zhang M, Kennedy AM, et al. ER-independent actions of estrogen and estrogen metabolites in bone cells. *J Musculoskelet Neuronal Interact.* 2003;3(4): 367-369; discussion 381.
24. Thornton MJ. Estrogens and aging skin. *Dermatoendocrinol.* 2013;5(2):264-270.
25. Creidi P, Faivre B, Agache P, et al. Effect of a conjugated oestrogen (Premarin) cream on ageing facial skin. A comparative study with a placebo cream. *Maturitas.* 1994;19(3):211-223.
26. Son ED, Lee JY, Lee S, et al. Topical application of 17beta-estradiol increases extracellular matrix protein synthesis by stimulating TGF-beta signaling in aged human skin in vivo. *J Invest Dermatol.* 2005;124(6):1149-1161.
27. Rittié L, Kang S, Voorhees JJ, et al. Induction of collagen by estradiol: difference between sun-protected and photodamaged human skin in vivo. *Arch Dermatol.* 2008;144(9):1129-1140.
28. Grove GL, Kligman AM. Age-associated changes in human epidermal cell renewal. *J Gerontol.* 1983; 38(2):137-142.
29. Moragas A, Castells C, Sans M. Mathematical morphologic analysis of aging-related epidermal changes. *Anal Quant Cytol Histol.* 1993;15(2):75-82.
30. Roskos KV, Bircher AJ, Maibach HI, et al. Pharmacodynamic measurements of methyl nicotinate percutaneous absorption: the effect of aging on microcirculation. *Br J Dermatol.* 1990;122(2):165-171.
31. Ghadially R, Brown BE, Sequeira-Martin SM, et al. The aged epidermal permeability barrier. Structural, functional, and lipid biochemical abnormalities in humans and a senescent murine model. *J Clin Invest.* 1995;95(5):2281-2290.
32. Choi EH, Man MQ, Xu P, et al. Stratum corneum acidification is impaired in moderately aged human and murine skin. *J Invest Dermatol.* 2007; 127(12):2847-2856.
33. Hachem JP, Crumrine D, Fluhr J, et al. pH directly regulates epidermal permeability barrier homeostasis, and stratum corneum integrity/cohesion. *J Invest Dermatol.* 2003;121(2):345-353.
34. Tezuka T, Qing J, Saheki M, et al. Terminal differentiation of facial epidermis of the aged: immunohistochemical studies. *Dermatology.* 1994;188(1):21-24.
35. Wu J, Williams D, Walter GA, et al. Estrogen increases Nrf2 activity through activation of the PI3K pathway in MCF-7 breast cancer cells. *Exp Cell Res.* 2014; 328(2):351-360.
36. Rheinwald JG, Hahn WC, Ramsey MR, et al. A two-stage, p16(INK4A)- and p53-dependent keratinocyte senescence mechanism that limits replicative potential independent of telomere status. *Mol Cell Biol.* 2002;22(14):5157-5172.
37. Lavker RM. Structural alterations in exposed and unexposed aged skin. *J Invest Dermatol.* 1979;73(1):59-66.
38. Fenske NA, Lober CW. Structural and functional changes of normal aging skin. *J Am Acad Dermatol.* 1986;15(4, pt 1):571-585.
39. Kurban RS, Bhawan J. Histologic changes in skin associated with aging. *J Dermatol Surg Oncol.* 1990; 16(10):908-914.
40. Plowden J, Renshaw-Hoelscher M, Engleman C, et al. Innate immunity in aging: impact on macrophage function. *Aging Cell.* 2004;3(4):161-167.
41. Gerstein AD, Phillips TJ, Rogers GS, et al. Wound healing and aging. *Dermatol Clin.* 1993;11(4):749-757.
42. Fligiel SE, Varani J, Datta SC, et al. Collagen degradation in aged/photodamaged skin in vivo and after exposure to matrix metalloproteinase-1 in vitro. *J Invest Dermatol.* 2003;120(5):842-848.
43. Varani J, Warner RL, Gharaee-Kermani M, et al. Vitamin A antagonizes decreased cell growth and elevated collagen-degrading matrix metalloproteinases and stimulates collagen accumulation in naturally aged human skin. *J Invest Dermatol.* 2000;114(3): 480-486.
44. Griffiths CE, Russman AN, Majmudar G, et al. Restoration of collagen formation in photodamaged human skin by Tretinoin (retinoic acid). *N Engl J Med.* 1993;329(8):530-535.
45. Varani J, Dame MK, Rittie L, et al. Decreased collagen production in chronologically aged skin: roles of Age-dependent alteration in fibroblast function and defective mechanical stimulation. *Am J Pathol.* 2006;168(6):1861-1868.
46. Fisher GJ, Datta SC, Talwar HS, et al. Molecular basis of sun-induced premature skin ageing and retinoid antagonism. *Nature.* 1996;379(6563):335-339.
47. Fisher GJ, Wang ZQ, Datta SC. Pathophysiology of premature skin aging induced by ultraviolet light. *N Engl J Med.* 1997;337(20):1419-1428.
48. Quan T, Little E, Quan H, et al. Elevated matrix metalloproteinases and collagen fragmentation in photodamaged skin: impact of altered extracellular matrix microenvironment on dermal fibroblast function. *J Invest Dermatol.* 2013;133(5):1362-1366.
49. Yaar M, Gilchrest BA. Photoageing: mechanism, prevention and therapy. *Br J Dermatol.* 2007;157(5): 874-887.
50. Braverman IM, Fonferko E. Studies in cutaneous aging: I. The elastic fiber network. *J Invest Dermatol.* 1982;78(5):434-443.
51. Tsuji T, Hamada T. Age-related changes in human dermal elastic fibres. *Br J Dermatol.* 1981;105(1):57-63.
52. Gniadecka M, Nielsen OF, Wessel S, et al. Water and protein structure in photoaged and chronically aged skin. *J Invest Dermatol.* 1998;111(6):1129-1133.

53. Bernstein EF, Underhill CB, Hahn PJ, et al. Chronic sun exposure alters both the content and distribution of dermal glycosaminoglycans. *Br J Dermatol.* 1996; 135(2):255-262.
54. Ghersetich I, Lotti T, Campanile G, et al. Hyaluronic acid in cutaneous intrinsic aging. *Int J Dermatol.* 1994; 33(2):119-122.
55. Meyer LJ, Stern R. Age-dependent changes of hyaluronan in human skin. *J Invest Dermatol.* 1994; 102(3):385-389.
56. Karnik P, Shah S, Dvorkin-Wininger Y, et al. Microarray analysis of androgenetic and senescent alopecia: comparison of gene expression shows two distinct profiles. *J Dermatol Sci.* 2013;72(2):183-186.
57. Olsen EA, Hordinsky M, Roberts JL, et al. Dermatologic Consortium for Women's Health. Female pattern hair loss. *J Am Acad Dermatol.* 2002;47(5):795.
58. Tobin DJ, Paus R. Graying: gerontobiology of the hair follicle pigmentary unit. *Exp Gerontol.* 2001;36(1): 29-54.
59. Kauser S, Westgate GE, Green MR, et al. Human hair follicle and epidermal melanocytes exhibit striking differences in their aging profile which involves catalase. *J Invest Dermatol.* 2011;131(4):979-982.
60. Nishimura EK, Granter SR, Fisher DE. Mechanisms of hair graying: incomplete melanocyte stem cell maintenance in the niche. *Science.* 2005;307(5710): 720-724.
61. Liao CP, Booker RC, Morrison SJ, et al. Identification of hair shaft progenitors that create a niche for hair pigmentation. *Genes Dev.* 2017;31(8):744-756.
62. Orentreich N, Markofsky J, Vogelman JH. The effect of aging on the rate of linear nail growth. *J Invest Dermatol.* 1979;73(1):126-130.
63. Helmdach M, Thielitz A, Röpke EM, et al. Age and sex variation in lipid composition of human fingernail plates. *Skin Pharmacol Appl Skin Physiol.* 2000;13(2):111-119.
64. Oberste-Lehn H. The number of sweat glands and aging in man. *Arch Klin Exp Dermatol.* 1966;227(1): 342-346.
65. Rees J, Shuster S. Pubertal induction of sweat gland activity. *Clin Sci (Lond).* 1981;60(6):689-692.
66. Jacobsen E, Billings JK, Frantz RA, et al. Age-related changes in sebaceous wax ester secretion rates in men and women. *J Invest Dermatol.* 1985;85(5):483-485.
67. Thornbury JM, Mistretta CM. Tactile sensitivity as a function of age. *J Gerontol.* 1981;36(1):34-39.
68. Schimrigk K, Rüttinger H. The touch corpuscles of the plantar surface of the big toe. Histological and histometrical investigations with respect to age. *Eur Neurol.* 1980;19(1):49-60.
69. Bolton CF, Winkelmann RK, Dyck PJ. A quantitative study of Meissner's corpuscles in man. *Neurology.* 1966;16(1):1-9.
70. Sherman ED, Robillard E. Sensitivity to pain in relationship to age. *J Am Geriatr Soc.* 1964;12:1037-1044.
71. Stevens JC, Cruz LA, Hoffman JM, et al. Taste sensitivity and aging: high incidence of decline revealed by repeated threshold measures. *Chem Senses.* 1995;20(4):451-459.
72. Shimokata H, Kuzuya F. Two-point discrimination test of the skin as an index of sensory aging. *Gerontology.* 1995;41(5):267-272.
73. Reszke R, Pełka D, Walasek A, et al. Skin disorders in elderly subjects. *Int J Dermatol.* 2015;54(9):e332-e338.
74. Aoki H, Moro O, Tagami H, et al. Gene Expression profiling analysis of solar lentigo in relation to immunohistochemical characteristics. *Br J Dermatol.* 2007;156(6):1214-1223.
75. Nakamura H, Hirota S, Adachi S, et al. Clonal nature of seborrheic keratosis demonstrated by using the polymorphism of the human androgen receptor locus as a marker. *J Invest Dermatol.* 2001;116(4):506-510.
76. Manaka L, Kadono S, Kawashima M, et al. The mechanism of hyperpigmentation in seborrhoeic keratosis involves the high expression of endothelin-converting enzyme-1alpha and TNF-alpha, which stimulate secretion of endothelin 1. *Br J Dermatol.* 2001;145(6): 895-903.
77. Geller AC, Miller DR, Annas GD, et al. Melanoma incidence and mortality among US whites, 1969-1999. *JAMA.* 2002;288(14):1719-1720.
78. Syrigos KN, Tzannou I, Katirtzoglou N, et al. Skin cancer in the elderly. *In Vivo.* 2005;19(3):643-652.
79. Moriwaki S, Takahashi Y. Photoaging and DNA repair. *J Dermatol Sci.* 2008;50(3):169-176.
80. Armstrong BK, Kricker A. Epidemiology of sun exposure and skin cancer. *Cancer Surv.* 1996;26:133-153.
81. Feng H, Shuda M, Chang Y, et al. Clonal integration of a polyomavirus in human Merkel cell carcinoma. *Science.* 2008;319(5866):1096-1100.
82. Engels EA, Frisch M, Goedert JJ, et al. Merkel cell carcinoma and HIV infection. *Lancet.* 2002; 359(9305):497-498.
83. Shuda M, Feng H, Kwun HJ, et al. T antigen mutations are a human tumor-specific signature for Merkel cell polyomavirus. *Proc Natl Acad Sci U S A.* 2008;105(42):16272-16277.
84. Heath M, Jaimes N, Lemos B, et al. Clinical characteristics of Merkel cell carcinoma at diagnosis in 195 patients: the AEIOU features. *J Am Acad Dermatol.* 2008;58(3):375-381.
85. Fedok FG, Levin RJ, Maloney ME, et al. Angiosarcoma: current review. *Am J Otolaryngol.* 1999; 20(4):223-231.
86. Young RJ, Woll PJ, Staton CA, et al. Vascular-targeted agents for the treatment of angiosarcoma. *Cancer Chemother Pharmacol.* 2014;73(2):259-270.
87. Regnier-Rosencher E, Guillot B, Dupin N. Treatments for classic Kaposi sarcoma: a systematic review of the literature. *J Am Acad Dermatol.* 2013;68(2):313-331.
88. White-Chu EF, Reddy M. Dry skin in the elderly: complexities of a common problem. *Clin Dermatol.* 2011;29(1):37-42.
89. Gutman AB, Kligman AM, Sciacca J, et al. Soak and smear: a standard technique revisited. *Arch Dermatol.* 2005;141(12):1556-1559.
90. Kini SP, DeLong LK, Veledar E, et al. The impact of pruritus on quality of life: the skin equivalent of pain. *Arch Dermatol.* 2011;147(10):1153-1156.
91. Elgart ML. Skin infections and infestations in geriatric patients. *Clin Geriatr Med.* 2002;18(1):89-101, vi.
92. Eveillard M, Mortier E, Lancien E, et al. Consideration of age at admission for selective screening to identify methicillin-resistant *Staphylococcus aureus* carriers to control dissemination in a medical ward. *Am J Infect Control.* 2006;34(3):108-113.
93. Tan HH, Goh CL. Parasitic skin infections in the elderly: recognition and drug treatment. *Drugs Aging.* 2001;18(3):165-176.
94. Varade RS, Burkemper NM. Cutaneous fungal infections in the elderly. *Clin Geriatr Med.* 2013;29(2): 461-478.
95. Martin ES, Elewski BE. Cutaneous fungal infections in the elderly. *Clin Geriatr Med.* 2002;18(1):59-75.

96. Bansal R, Tutrone WD, Weinberg JM. Viral skin infections in the elderly: diagnosis and management. *Drugs Aging.* 2002;19(7):503-514.
97. Oxman MN, Levin MJ, Johnson GR, et al. A vaccine to prevent herpes zoster and postherpetic neuralgia in older adults. *N Engl J Med.* 2005;352(22):2271-2284.
98. Shapiro M, Kvern B, Watson P, et al. Update on herpes zoster vaccination: a family practitioner's guide. *Can Fam Physician.* 2011;57(10):1127-1131.
99. Paquette D, Falanga V. Leg ulcers. *Clin Geriatr Med.* 2002;18(1):77-88, vi.
100. Baumgarten M, Margolis DJ, Localio AR, et al. Pressure ulcers among elderly patients early in the hospital stay. *J Gerontol A Biol Sci Med Sci.* 2006;61(7):749-754.
101. Bastuji-Garin S, Joly P, Lemordant P, et al. Risk factors for bullous pemphigoid in the elderly: a prospective case-control study. *J Invest Dermatol.* 2011; 131(3):637-643.
102. Patton T, Korman N. Role of methotrexate in the treatment of bullous pemphigoid in the elderly. *Drugs Aging.* 2008;25(8):623-629.
103. Carneiro SC, Azevedo-e-Silva MC, Ramos-e-Silva M. Drug eruptions in the elderly. *Clin Dermatol.* 2011; 29(1):43-48.

Chapter 107 :: Caring for LGBT Persons in Dermatology

:: Howa Yeung, Matthew D. Mansh, Suephy C. Chen, & Kenneth A. Katz

AT-A-GLANCE

- Lesbian, gay, bisexual, and transgender persons face health disparities and experience unique health issues relevant to dermatologists.
- Dermatologists should follow guidelines for men who have sex with men from the Centers for Disease Control and Prevention and other public health agencies for HIV and other sexually transmitted diseases screening; HIV preexposure prophylaxis and HIV postexposure prophylaxis; and human papillomavirus, hepatitis A and B viruses, and meningococcal vaccination.
- Gender-affirming hormone treatments for transgender persons have distinct dermatologic effects.
- Eliciting a patient's sexual history and gender identity can facilitate diagnosis and management of dermatologically relevant diseases.

Lesbian, gay, bisexual, and transgender (LGBT) is an umbrella term referring to broad communities of individuals with diverse sexual orientations and behaviors, gender identities, and/or gender expressions, and distinct health needs.[1] Over 30 years into an ongoing HIV epidemic that disproportionately impacts LGBT persons, which dermatologists were among the first to recognize by helping to identify an epidemic of Kaposi sarcoma among gay men,[2] LGBT persons continue to face substantial health disparities related to both infectious and noninfectious diseases. These include higher rates of HIV and other sexually transmitted diseases (STDs), substance use, body image disorder, obesity, violence and victimization, mental health issues, and suicidality.[1,3] LGBT patients also encounter barriers in accessing health care that result from disparities in health insurance coverage, real or perceived discrimination by health care providers, and delayed or inappropriate care from providers unfamiliar with their specific health concerns.[4]

Improving the health of LGBT persons has become a priority, not only of clinicians, but also of educators,[5] researchers,[1] public health officials,[3] regulators,[4] and legislators.[6] Dermatologists should familiarize themselves with LGBT health issues, which have been rarely discussed in the dermatology literature, to provide patients with medically appropriate and patient-centered care.[7] For example, eliciting a patient's sexual history and gender identity can influence the assessment of the probability of diseases with higher prevalence among LGBT patients. Physicians can then recommend screening tests, vaccinations, and HIV prophylaxis appropriate for LGBT patients that might not apply to non-LGBT patients. This chapter reviews terminology and demographics related to LGBT health; health disparities faced by LGBT persons; dermatologic issues relevant to men who have sex with men (MSM), women who have sex with women (WSW), and transgender persons; and approaches to providing culturally competent and patient-centered care to LGBT persons.

TERMINOLOGY AND DEMOGRAPHICS

Terminology related to LGBT health is complex, evolves over time, and may not be accepted by all LGBT persons. Table 107-1 shows selected terminology and concepts.[8] Familiarity and openness with the use of appropriate and patient-preferred terminologies are essential in eliciting relevant sexual history and gender identity, discussing risk behaviors and contraception, and demonstrating respect and affirmation to patients.[4,5]

Sexual orientation, sexual behavior, and gender identity are separate concepts. Lesbian, gay, bisexual, and straight are terms that refer to sexual orientation, or one's characterization of emotional and/or sexual attraction to others. In this chapter, we use *LGBT* as an umbrella term to include MSM and WSW who engage in same-sex sexual behaviors; however, some MSM or WSW may not necessarily identify as LGBT. Sexual orientation does not dictate sexual behavior. For example, a self-identified straight person may engage in same-sex sexual behaviors, and a self-identified gay person may not be sexually active.[4,8]

MSM and WSW are terms that describe same-sex sexual behaviors, regardless of self-identified sexual orientation. Researchers and others use these terms to describe sexual behaviors (rather than sexual orientation) that can relate to disease risk, but people themselves rarely, if ever, identify as MSM or WSW. Homosexual is a term that used to refer to same-sex sexual behaviors, attraction, and/or identity; many LGBT persons consider it an outdated and derogatory term.[4,8]

Gender identity refers to one's basic internal sense of gender, such as being a man or a woman. It is fluid concept, with some persons identifying somewhere

TABLE 107-1
Selected Terminology and Concepts in LGBT Health[8]

CONCEPT	DEFINITION	EXAMPLES
Sex (sex assigned at birth, natal sex, biologic sex)	Sex assigned to a person at birth, commonly based on natal external genital anatomy, and less commonly by internal genital anatomy and/or chromosomal analysis	Male, female, intersex (differences of sex development such as congenital atypical chromosomal, gonadal, and/or anatomic sex)
Sexual orientation	A person's characterization of emotional and/or sexual attraction to others	Gay, lesbian, bisexual, straight
Gender identity	A person's basic internal sense of being a man, woman, or other gender	Man, woman, gender nonconforming
Gender expression	A person's method of communicating gender through appearance, personality, or behavior	Masculine, feminine, androgynous, gender nonconforming
Sexual behavior	Terms used by clinicians and researchers to describe same-sex sexual behaviors regardless of self-identified sexual orientation; rarely used by patients themselves	Men who have sex with men (MSM); women who have sex with women (WSW)
Transgender	An umbrella term describing persons whose gender identity or expression, to varying degrees, diverges from sex assigned at birth	Female-to-male (FTM) transgender person, transgender man; male-to-female (MTF) transgender person, transgender woman
Gender dysphoria	Distress from marked and persistent incongruence between one's gender identity and sex assigned at birth	
Gender affirmation /transition	Process of recognizing, accepting, and expressing one's gender identity, which may include behavioral, social, legal changes, medical or surgical treatments	

along the spectrum between man and woman, and others identifying as both, neither, or other genders. Gender identity may not always correspond to biologic sex, or the sex to which a person was assigned at birth based on their anatomy. For example, a transgender woman (also known as "male-to-female" transgender person or "trans woman") is a person whose sex assigned at birth was male but who identifies as a female. Some transgender persons experience gender dysphoria, defined as distress from a marked and persistent incongruence between one's assigned and experienced gender.[9] Some, but not all, transgender persons may seek medical or surgical gender-affirming treatments. Gender identity also does not dictate sexual orientation or sexual behavior.[4,8]

Demographics of LGBT persons depend on whether one is assessing sexual orientation, sexual behavior, or gender identity[10]:

- By sexual orientation, more than 8 million or an estimated 3.5% (range: 1.7% to 5.6%) of Americans identify as lesbian, gay, or bisexual.
- By sexual behavior, more than 19 million or an estimated 8.2% of Americans have ever engaged in same-sex sexual behaviors.
- By gender identity, approximately 700,000 or an estimated 0.3% of Americans identify as transgender.

MEN WHO HAVE SEX WITH MEN

MSM in the United States are disproportionately impacted by numerous dermatologically relevant conditions, including HIV, STDs, and other infectious and noninfectious diseases (Table 107-2). Recommendations from the Centers for Disease Control and Prevention and other public health agencies regarding HIV and STD screening, sexual health-related vaccinations, and HIV preexposure prophylaxis (PrEP) are different for MSM than for non-MSM men or for women regardless of sexual orientation (Table 107-3), as follows:

- More frequent screenings for HIV and additional STDs are indicated, including syphilis,[11] urethral and rectal gonorrhea and *Chlamydia*, and pharyngeal gonorrhea.[12] (MSM in mutually monogamous relationships might not require more frequent screening.) Hepatitis B screening is recommended for all MSM, and hepatitis C screening is recommended for HIV-positive MSM.[12]
- Data are insufficient to recommend anal cancer screening via anal Papanicolaou smears in MSM.[12]
- Human papillomavirus (HPV) vaccination is indicated for MSM and for women through age 26 years; for non-MSM men, HPV vaccination is indicated through age 21 years (but permissible through age 26 years).[13,14]
- PrEP is indicated for HIV-negative MSM who are at high risk of acquiring HIV (see Table 107-3).[15] Nearly a quarter of HIV-negative MSM ages 18 to 59 years meet the specific indications.[16] PrEP with daily emtricitabine-tenofovir disoproxil fumarate can reduce HIV incidence in MSM (and transgender women) by up to 92%.[17]

Dermatologists should also be aware of nonoccupational HIV postexposure prophylaxis (nPEP), which is indicated in settings of substantial risk exposure

TABLE 107-2
Selected Dermatologically Relevant Conditions Important in Caring for Men Who Have Sex with Men

Viral Infections	
HIV	▪ 27,771 (70%) of 38,782 new HIV infections in the U.S. in 2016 occurred in MSM[33] ▪ 10,477 (38%) of new HIV infections in MSM in the U.S. in 2016 occurred in Black/African-American MSM[33]
Genital herpes simplex virus (HSV)	▪ Seroprevalence of HSV Type 2 was 18.4% in 206 MSM, compared with 12.5% in 4,113 non-MSM ($P = 0.096$)[34]
Human papillomavirus (HPV)	▪ A systematic review and meta-analysis indicated that 74% of HIV-positive and 37% of HIV-negative MSM have anal infection of high-risk HPV (Types 16 and 18)[35] ▪ Higher rates of anal intraepithelial neoplasia and anal cancer occur in MSM, particularly HIV-positive MSM[35]
Kaposi sarcoma	▪ Kaposi sarcoma may develop in HIV-positive MSM with a high CD4 count and viral suppression and in HIV-negative MSM, in addition to patients with AIDS[36,37]
Bacterial Infections	
Syphilis	▪ 16,155 (58%) of 27,814 primary and secondary syphilis cases reported in 2016 occurred in MSM[38]
Gonorrhea and *Chlamydia*	▪ Higher prevalence of *Chlamydia* and gonorrhea in MSM, with more oropharynx and rectal infections independent of urethral infections[38,39] ▪ Lymphogranuloma venereum can cause classical genital ulcer disease and outbreaks of proctocolitis in MSM[40]
Community-associated methicillin-resistant *Staphylococcus aureus* (MRSA)	▪ Clusters of multidrug-resistant, community acquired MRSA skin and soft-tissue infections among MSM have occurred from the USA3000 clone[41]
Invasive meningococcal disease	▪ Outbreaks of *Neisseria* meningitis and invasive meningococcal disease with a high fatality rate have occurred in MSM living with and without HIV in urban cities in the United States and Europe[42,43]
Noninfectious Dermatoses	
Skin cancer risk factors	▪ Twice as many gay and bisexual men compared with straight men report a history of skin cancer[44] ▪ Gay and bisexual men report using indoor tanning 2 to 6 times more often than straight men[44-46]
"Poppers" dermatitis	▪ Alkyl nitrites, commonly known as "poppers" and sold as "video head cleaners" and "room odorisers," are sometimes used by MSM to enhance sexual pleasure ▪ Irritant or allergic contact dermatitis, chemical leukoderma in the perinasal and perioral region, acrocyanosis, and methemoglobinemia have been linked with poppers use[47,48]
Acne and depression	▪ Sexual minority adults with acne are 4.2 times more likely to report a history of depression and 8.1 times more likely to report suicidal ideation in the past 12 months as compared with heterosexual adults with acne[49]

to HIV transmission; for MSM, a relevant exposure would be unprotected receptive anal intercourse with an untreated HIV-positive person. A 28-day antiretroviral treatment course to prevent HIV acquisition must begin within 72 hours of exposure.[18]

WOMEN WHO HAVE SEX WITH WOMEN

Few data are available on the sexual and skin health of WSW.[11] WSW are at risk of acquiring STDs from current and prior female and/or male partners.[19] Transmissions of genital HPV, herpes simplex virus, syphilis, and HIV between female sexual partners have been described.[19] Seroprevalence of herpes simplex virus Type 2 is higher among women with same-sex partners in the past year (30%) or in their lifetime (36%) than women with no lifetime same-sex behaviors (24%).[20] Prevalence of HPV and HPV-related premalignant lesions is similar among WSW and women who do not have sex with women.[12] Guidelines for HIV, syphilis, *Chlamydia*, and gonorrhea screening, as well as cervical cancer screening and HPV vaccination, do not differ for WSW and women who do not have sex with women.[12]

TRANSGENDER PERSONS

Dermatologists may have increasing roles in the skin and sexual health of transgender persons. Some transgender persons undergo gender-affirming treatments, which may include psychological counseling, hormone therapy to alter secondary sex characteristics, and/or surgical interventions (eg, facial feminizing procedures, "top" surgery such as masculinizing chest surgery for transgender men or augmentation mammoplasty for transgender women, and "bottom" surgery such as hysterectomy and oophorectomy and/or phalloplasty for transgender men or orchiectomy and/or vaginoplasty for transgender women).[21] Dermatologists' involvement in in transgender health can include helping manage cutaneous adverse effects of hormonal treatments and surgical treatments, including keloids; performing safe and effective procedures that contribute to gender-affirming physical transformation through aesthetic procedures; and facilitating screening and preventive care.[22]

TABLE 107-3

Screening, Vaccination, and HIV Preexposure and Postexposure Prophylaxis Indications and Recommendations for Men Who Have Sex with Men from the Centers for Disease Control and Prevention and Other Public Health Agencies[12,14,15,18]

SCREENING	INDICATIONS	RECOMMENDATIONS
HIV	Sexually active men who have sex with men (MSM), if HIV status is unknown or negative	Screen at least annually; every 3-6 months if risk behaviors persist or if the patient or his sexual partner(s) have multiple partners
Syphilis	Sexually active MSM	
Gonorrhea and *Chlamydia*		
Urethra	Any insertive oral or anal intercourse in the past year, regardless of reported condom use	Screen at least annually; every 3-6 months if risk behaviors persist or if the patient or his sexual partner(s) have multiple partners
Rectum	Any receptive anal intercourse in the past year, regardless of reported condom use	
Oropharynx	Any receptive oral intercourse in the past year, regardless of reported condom use[a]	
Hepatitis B virus	All MSM	One-time screening
Hepatitis C virus	HIV-positive MSM	Screen at least annually
Human papillomavirus (HPV), genital warts, herpes simplex virus (HSV), or anal cancer	Centers for Disease Control and Prevention (CDC) does not recommend routine screening	No recommended screening
VACCINATIONS	**INDICATIONS**	**RECOMMENDATIONS**
HPV (nonavalent or quadrivalent)	MSM through age 26 years, regardless of prior or current HPV infection status	Refer for vaccination
Hepatitis A virus and hepatitis B virus	MSM with no known prior viral hepatitis A or hepatitis B infection or vaccination	
Meningococcal	MSM in urban areas where state or local public health authorities have recommended vaccination (such as during serogroup C meningococcal disease outbreaks in New York, Chicago, and Los Angeles[50])[b]	
HIV PROPHYLAXIS	**INDICATIONS**	**RECOMMENDATIONS**
Preexposure prophylaxis (PrEP)	Adult man: ▪ Without acute or established HIV infection ▪ With any male sex partners in past 6 months ▪ Not in a monogamous relationship with a recently tested, HIV-negative man *AND* at least 1 of the following: ▪ Any anal sex without condoms (receptive or insertive) in past 6 months ▪ A bacterial STI (syphilis, gonorrhea, or chlamydia) diagnosed or reported in past 6 months	Refer to primary care physician or infectious disease specialist for consideration of HIV PrEP, in addition to behavioral counseling on safer sex to decrease risk of HIV acquisition
Nonoccupational postexposure prophylaxis (nPEP)	Exposure to substantial risk for HIV acquisition within 72 hours from a source known to be HIV-positive; if source is of unknown HIV status, nPEP can be considered on case-by-case basis	Refer immediately for evaluation and treatment

[a]Centers for Disease Control and Prevention (CDC) recommends oropharyngeal testing for gonorrhea only, but many available tests screen for both gonorrhea and *Chlamydia*.

[b]CDC does not recommend routine meningococcal vaccination for all MSM; some state and local jurisdictions have recommended it, in response to outbreaks.

TRANSGENDER MEN

Transgender men seeking masculinizing hormone therapy may receive testosterone, which can cause cutaneous effects including increased facial and body hair, redistribution of subcutaneous fat, and changes in sweat and odor patterns.[21] Acne is a common adverse effect of testosterone and develops in 88% to 94% of transgender men within 4 to 6 months of testosterone initiation, typically with decreasing severity beyond 12 months of treatment.[23] Many cases can be managed effectively with topical acne treatments and/or oral antibiotics, without needing to adjust hormone therapy. Severe testosterone-induced acne in transgender men has been successfully treated with isotretinoin.[24] To receive isotretinoin in the United States, patients must register with the U.S. Food and Drug

Administration's iPLEDGE system, a risk management program that aims to minimize fetal exposure to the teratogenic medicine.[25] Contraception counseling is important because transgender men who retain female natal reproductive organs can become pregnant, even while taking testosterone. Unfortunately, iPLEDGE requires transgender men to register in the program according to their sex assigned at birth (ie, female), which is unacceptable to some patients.[26] Physicians failing to register transgender men as female risk sanction from iPLEDGE, and transgender men refusing to register as female in iPLEDGE lack isotretinoin access. Some have advocated that iPLEDGE change this registration requirement.[26,27] When caring for transgender men taking testosterone who might become pregnant, recommended practices are to explain iPLEDGE program requirements and noncompliance risks to physicians; inform patients that dermatologists have made the Food and Drug Administration aware of this issue; express empathy with patients for having to register in iPLEDGE as female; and offer to order serum rather than urine pregnancy tests to decrease awkwardness in laboratory encounters.[27]

Male pattern alopecia is associated with duration of testosterone treatment: 33% develop mild alopecia and 31% develop moderate to severe alopecia with long-term use.[23] It may be considered desirable for some who consider it as a masculine feature, but undesirable for others. Minoxidil or finasteride for testosterone-induced alopecia in transgender men has not been well studied; hair transplantation may be considered for severe cases.[23]

TRANSGENDER WOMEN

Transgender women who seek feminizing hormone therapy may receive estrogens as well as antiandrogens, including medroxyprogesterone acetate, oral progesterone, spironolactone, finasteride, and dutasteride.[21] Desired effects include breast development, reduction of body and facial hair, redistribution of subcutaneous fat, change in sweat and odor pattern, arrest or reversal of hair loss, decreased sebum production, improvement in acne vulgaris, and reduction in gender dysphoria.[21] Facial hair growth and density is often resistant to hormonal therapy.[21] Topical eflornithine, electrolysis, photoepilation, or laser treatments may reduce the need for shaving or depilatory use.[21]

Facial feminization and body contouring procedures are prevalent among transgender women. Lack of treatment access has led many transgender women—up to 16% in San Francisco, 40% in Lima, and 68% in Thailand—to receive "silicone" or "filler" injections to buttocks, hips, breasts, face, and calves from unlicensed low-cost "pumpers."[21,28] While purportedly consisting of medical-grade silicone, various substances, including food- or industrial-grade silicone, paraffin, petroleum jelly, lanolin, beeswax, various oils, tire sealant, cement glue, or automobile transmission fluid, have been injected in volumes ranging from 2 ounces to 8 liters.[28] Serious complications, including foreign-body granulomatous dermatitis, bacterial or atypical mycobacterial infections, bleeding, pain, scarring, ulceration, fistula formation, gross disfiguration, lymphedema, silicone migration or embolism, sepsis, hypersensitivity pneumonitis, and death have occurred hours to decades later.[21,28] Treatment of silicone granulomas includes intralesional corticosteroid, topical imiquimod or tacrolimus, oral doxycycline or minocycline, isotretinoin, etanercept, carbon dioxide ablative laser, or surgical excision.[29] Transgender persons who inject "fillers" from unlicensed low-cost "pumpers" should be screened for hepatitis C.[21]

Dermatologists can make tremendous differences for transgender women by providing safe, effective gender-affirming injectable treatments, particularly for those who prefer noninvasive or nonpermanent treatments or are not surgical candidates.[22] Facial contouring may be achieved by botulinum toxin neuromodulation to lift, shape, or flatten the forehead and eyebrows, reduce appearance of periorbital rhytides, or reduce masseter hypertrophy for lower face contouring.[30] Soft-tissue augmentation can also add volume to the cheeks, lips, or chin.[30]

Transgender persons face a range of sexual health risks and should receive appropriate HIV and STD screening and prevention services, including vaccination, PrEP,[21] and nPEP, based on their sexual behaviors and the gender(s) of their sex partners.[21] In the United States, 28% of transgender women, and 56% of black transgender women tested HIV-positive.[31]

APPROACHES TO CARE

Like all clinicians, dermatologists should strive to provide culturally competent care for all patients. For LGBT patients, culturally competent care includes use of inclusive language and demonstration of equality and respect. Eliciting relevant information on sex anatomy, gender identity, sexual orientation and sexual behaviors in an effective and sensitive manner can facilitate the delivery of appropriate medical care and cultivate the physician–patient relationship.

Patients may or may not expect dermatologists to inquire about their sexual history or gender identity. When sexual health is relevant to one's skin and medical care, dermatologists can normalize the discussion by explaining that it is routine to ask patients with similar signs and/or symptoms about sexual history and/or gender identity. Depending on the context, persons accompanying the patient may be asked to leave the examination room before initiating that conversation. If discussing sexual history and/or gender identity is deemed acceptable to the patient, respectfully ask relevant questions, such as whether the patient is sexually active, and, if so, with men or women or both, followed by any appropriate questions relevant to establishing a diagnosis. Beyond making a diagnosis, sexual history or gender identity may be elicited if that information contributes, for example, to medical decision-making screening or vaccination recommendations, or PrEP or nPEP considerations. Clinicians should bear in mind

that patients might not be comfortable disclosing sensitive information, especially during a first visit. Those who may be apprehensive in asking about sexual orientation and gender identity should know that the collection of these data is highly acceptable to LGBT and non-LGBT patients across diverse clinical settings in the United States.[32]

An inclusive care environment can also improve health care for LGBT persons.[4,5,21] Physicians and staff should appreciate the wide diversity of identities and experiences that patients may have; be aware of terminologies used by LGBT persons, asking respectfully for clarification when needed; respect each patient's preferences on name, pronoun and gender identity; avoid stereotypes about sexual orientation or gender identity based on appearance or other factors. When encountering patients whose name or gender identity might not match the sex or gender indicated on legal or insurance documents, patients should be asked how they would prefer to be addressed. Intake forms, electronic health records, and documentation should reflect such diversity and normalize disclosure of gender identity and sexual orientation. Information regarding patients' sex, gender, and sexuality should be kept confidential. Patients should be able to use restrooms of their choice; ideally, gender-neutral or unisex restrooms should be available. By incorporating patient-centered, culturally competent care into practice, dermatologists can contribute to improving the health of LGBT persons.

REFERENCES

1. The Institute of Medicine, Committee on Lesbian, Gay, Bisexual, and Transgender Health Issues and Research Gaps and Opportunities. *The Health of Lesbian, Gay, Bisexual, and Transgender People: Building a Foundation for Better Understanding*. Washington, DC: Institute of Medicine; 2011.
2. Bayer R, Oppenheimer GM. *AIDS Doctors: Voices from the Epidemic*. New York, NY: Oxford University Press; 2000.
3. U.S. Department of Human and Health Services, Office of Disease Prevention and Health Promotion. Lesbian, Gay, Bisexual and Transgender Health. 2014. https://www.healthypeople.gov/2020/topics-objectives/topic/lesbian-gay-bisexual-and-transgender-health. Accessed August 25, 2016.
4. The Joint Commission. *Advancing Effective Communication, Cultural Competence, and Patient- and Family-Centered Care for the Lesbian, Gay, Bisexual, and Transgender (LGBT) Community: A Field Guide*. Oak Brook, IL: The Joint Commission; 2011.
5. American Association of Medical Colleges. *Implementing Curricular and Institutional Climate Changes to Improve Health Care for Individuals Who Are LGBT, Gender Nonconforming, or Born with DSD: A Resource for Medical Educators*. Washington, DC: American Association of Medical Colleges; 2014.
6. LGBTQ Cultural Competency Continuing Education Amendment Act of 2015, 2015 DC B12-0168(2015). http://lims.dccouncil.us/Download/33671/B21-0168-SignedAct.pdf. Accessed August 25, 2016.
7. Katz KA, Furnish TJ. Dermatology-related epidemiologic and clinical concerns of men who have sex with men, women who have sex with women, and transgender individuals. *Arch Dermatol*. 2005; 141(10):1303-1310.
8. National LGBT Health Education Center. Glossary of LGBT Terms for Health Care Teams. 2016. http://www.lgbthealtheducation.org/wp-content/uploads/LGBT-Glossary_March2016.pdf. Accessed August 20, 2016.
9. American Psychiatric Association. Gender Dysphoria. In: *Diagnostic and Statistical Manual of Mental Disorders*. 5th ed. Arlington, VA: American Psychiatric Association; 2013:451-459.
10. Gates GJ. How many people are lesbian, gay, bisexual and transgender? Los Angeles, CA: The Williams Institute, UCLA School of Law; 2011. http://williamsinstitute.law.ucla.edu/wp-content/uploads/Gates-How-Many-People-LGBT-Apr-2011.pdf. Accessed on February 4, 2016.
11. US Preventive Services Task Force (USPSTF). Screening for syphilis infection in nonpregnant adults and adolescents: US Preventive Services Task Force recommendation statement. *JAMA*. 2016;315(21):2321-2327.
12. Workowski KA, Bolan GA; Centers for Disease Control and Prevention. Sexually transmitted diseases treatment guidelines, 2015. *MMWR Recomm Rep*. 2015;64(RR-03):1-137. Available at: http://www.cdc.gov/std/tg2015/tg-2015-print.pdf. Accessed on July 17, 2016.
13. Giuliano AR, Palefsky JM, Goldstone S, et al. Efficacy of quadrivalent HPV vaccine against HPV Infection and disease in males. *N Engl J Med*. 2011;364(5):401-411.
14. Centers for Disease Control and Prevention. Recommended Immunization Schedule for Adults Aged 19 Years or Older by Medical Conditions and Other Indications, United States, 2018. https://www.cdc.gov/vaccines/schedules/hcp/imz/adult-conditions.html. Accessed May 8, 2018.
15. Centers for Disease Control and Prevention. Preexposure Prophylaxis for the Prevention of HIV Infection in the United States—2017 Update. 2017. https://www.cdc.gov/hiv/pdf/risk/prep/cdc-hiv-prep-guidelines-2017.pdf Accessed May 14, 2018.
16. Smith DK, Van Handel M, Wolitski RJ, et al. Vital signs: estimated percentages and numbers of adults with indications for preexposure prophylaxis to prevent HIV acquisition—United States, 2015. *MMWR Morb Mortal Wkly Rep*. 2015;64(46):1291-1295.
17. Grant RM, Lama JR, Anderson PL, et al. Preexposure chemoprophylaxis for HIV prevention in men who have sex with men. *N Engl J Med*. 2010;363(27):2587-2599.
18. Announcement: updated guidelines for antiretroviral postexposure prophylaxis after sexual, injection-drug use, or other nonoccupational exposure to HIV-United States, 2016. *MMWR Morb Mortal Wkly Rep*. 2016;65(17):458.
19. Gorgos LM, Marrazzo JM. Sexually transmitted infections among women who have sex with women. *Clin Infect Dis*. 2011;53(suppl 3):S84-S91.
20. Xu F, Sternberg MR, Markowitz LE. Women who have sex with women in the United States: prevalence, sexual behavior and prevalence of herpes simplex virus type 2 infection-results from national health and nutrition examination survey 2001-2006. *Sex Transm Dis*. 2010;37(7):407-413.
21. Deutsch MB, ed. *Guidelines for the Primary and Gender-Affirming Care of Transgender and Gender Nonbinary People*. 2nd ed. San Francisco, CA: UCSF Center of

Excellence for Transgender Health, Department of Family and Community Medicine; 2016. http://www.transhealth.ucsf.edu/guidelines. Accessed August 11, 2016.
22. Ginsberg BA, Calderon M, Seminara NM, et al. A potential role for the dermatologist in the physical transformation of transgender people: a survey of attitudes and practices within the transgender community. *J Am Acad Dermatol*. 2016;74(2):303-308.
23. Irwig MS. Testosterone therapy for transgender men. *Lancet Diabetes Endocrinol*. 2017;5(4):301-311.
24. Turrion-Merino L, Urech-Garcia-de-la-Vega M, Miguel-Gomez L, et al. Severe acne in female-to-male transgender patients. *JAMA Dermatol*. 2015;151(11):1260-1261.
25. U.S. Food and Drug Administration. The iPLEDGE Program. Prescriber Isotretinoin Educational Kit. 2017. Available at: https://www.ipledgeprogram.com/iPledgeUI/rems/pdf/resources/Prescriber%20Isotretinoin%20Educational%20Kit.pdf. Accessed May 8, 2018.
26. Katz KA. Transgender patients, isotretinoin, and US Food and Drug Administration–mandated risk evaluation and mitigation strategies: a prescription for inclusion. *JAMA Dermatol*. 2016;152(5):513-514.
27. Yeung H, Chen SC, Katz KA, et al. Prescribing isotretinoin in the United States for transgender individuals: ethical considerations. *J Am Acad Dermatol*. 2016;75(3):648-651.
28. Wilson E, Rapues J, Jin H, et al. The use and correlates of illicit silicone or "fillers" in a population-based sample of transwomen, San Francisco, 2013. *J Sex Med*. 2014;11(7):1717-1724.
29. Paul S, Goyal A, Duncan LM, et al. Granulomatous reaction to liquid injectable silicone for gluteal enhancement: review of management options and success of doxycycline. *Dermatol Ther*. 2015;28(2):98-101.
30. Ginsberg BA. Dermatology. In: Eckstrand KL, Ehrenfeld JM, eds. *Lesbian, Gay, Bisexual, and Transgender Healthcare: A Clinical Guide to Preventive, Primary, and Specialist Care*. Cham, Switzerland: Springer International Publishing; 2016:263-288.
31. Herbst JH, Jacobs ED, Finlayson TJ, et al. Estimating HIV prevalence and risk behaviors of transgender persons in the United States: a systematic review. *AIDS Behav*. 2008;12(1):1-17.
32. Cahill S, Singal R, Grasso C, et al. Do ask, do tell: high levels of acceptability by patients of routine collection of sexual orientation and gender identity data in four diverse American community health centers. *PLoS One*. 2014;9(9):e107104.
33. National Center for HIV/AIDS, Viral Hepatitis, STD, and TB Prevention, Centers for Disease Control and Prevention. Diagnoses of HIV Infection in the United States and Dependent Areas, 2016. Vol. 28. https://www.cdc.gov/hiv/pdf/library/reports/surveillance/cdc-hiv-surveillance-report-2016-vol-28.pdf Published November 2017. Accessed May 8, 2018.
34. Xu F, Sternberg MR, Markowitz LE. Men who have sex with men in the United States: demographic and behavioral characteristics and prevalence of HIV and HSV-2 infection: results from National Health and Nutrition Examination Survey 2001-2006. *Sex Transm Dis*. 2010;37(6):399-405.
35. Machalek DA, Poynten M, Jin F, et al. Anal human papillomavirus infection and associated neoplastic lesions in men who have sex with men: a systematic review and meta-analysis. *Lancet Oncol*. 2012;13(5):487-500.
36. Lanternier F, Lebbe C, Schartz N, et al. Kaposi's sarcoma in HIV-negative men having sex with men. *AIDS*. 2008;22(10):1163-1168.
37. Maurer T, Ponte M, Leslie K. HIV-associated Kaposi's sarcoma with a high CD4 count and a low viral load. *N Engl J Med*. 2007;357(13):1352-1353.
38. Centers for Disease Control and Prevention. Sexually Transmitted Disease Surveillance 2016. https://www.cdc.gov/std/stats16/CDC_2016_STDS_Report-for508WebSep21_2017_1644.pdf. Published September 2017. Accessed May 8, 2018.
39. Patton ME, Kidd S, Llata E, et al. Extragenital gonorrhea and chlamydia testing and infection among men who have sex with men—STD Surveillance Network, United States, 2010-2012. *Clin Infect Dis*. 2014;58(11):1564-1570.
40. de Vries HJ, Zingoni A, Kreuter A, et al. 2013 European guideline on the management of lymphogranuloma venereum. *J Eur Acad Dermatol Venereol*. 2015;29(1):1-6.
41. David MZ, Daum RS. Community-associated methicillin-resistant *Staphylococcus aureus*: epidemiology and clinical consequences of an emerging epidemic. *Clin Microbiol Rev*. 2010;23(3):616-687.
42. Simon MS, Weiss D, Gulick RM. Invasive meningococcal disease in men who have sex with men. *Ann Intern Med*. 2013;159(4):300-301.
43. Janda WM, Bohnoff M, Morello JA, et al. Prevalence and site-pathogen studies of *Neisseria meningitidis* and *N gonorrhoeae* in homosexual men. *JAMA*. 1980;244(18):2060-2064.
44. Mansh M, Katz KA, Linos E, et al. Association of skin cancer and indoor tanning in sexual minority men and women. *JAMA Dermatol*. 2015;151(12):1308-1316.
45. Yeung H, Chen SC. Sexual orientation and indoor tanning device use: a population-based study. *JAMA Dermatol*. 2016;152(1):99-101.
46. Yeung H, Chen SC. Disparities in sunburns, photoprotection, indoor tanning, and skin cancer screening among U.S. men and women in same- and opposite-sex relationships [abstract]. *J Invest Dermatol*. 2015;135(suppl 1):S49.
47. Schauber J, Herzinger T. "Poppers" dermatitis. *Clin Exp Dermatol*. 2012;37(5):587-588.
48. Vine K, Meulener M, Shieh S, et al. Vitiliginous lesions induced by amyl nitrite exposure. *Cutis*. 2013;91(3):129-136.
49. Gao Y, Wei EK, Arron ST, Linos E, Margolis DJ, Mansh MD. Acne, sexual orientation, and mental health among young adults in the United States: A population-based, cross-sectional study. *J Am Acad Dermatol*. 2017 Nov;77(5):971-973.
50. Kamiya H, MacNeil J, Blain A, et al. Meningococcal disease among men who have sex with men—United States, January 2012-June 2015. *MMWR Morb Mortal Wkly Rep*. 2015;64(44):1256-1257.

Neoplasia PART 20

Chapter 108 :: Benign Epithelial Tumors, Hamartomas, and Hyperplasias

:: Jonathan D. Cuda, Sophia Rangwala, & Janis M. Taube

This chapter discusses clinical and pathologic features of benign epithelial tumors, hamartomas, and hyperplasias of the skin. A review of relevant systemic and syndromic associations is provided when applicable.

SEBORRHEIC KERATOSIS

AT-A-GLANCE

- Seborrheic keratosis is the most common benign epidermal tumor.
- They usually begin as well-circumscribed tan brown patches or thin plaques with pseudo-horn cysts (keratotic invaginations).
- Rapidly growing, symptomatic, or atypical lesions should be biopsied to rule out malignancy.
- Clinical and histologic variants include common seborrheic keratosis (SK), reticulated SK, stucco keratosis, melanoacanthoma, dermatosis papulosa nigra, clonal SK, and irritated SK.
- Hallmark histopathologic findings: acanthosis, papillomatosis, pseudo-horn cysts, and hyperkeratosis
- Multiple eruptive seborrheic keratoses may be indicative of internal malignancy (Leser-Trélat sign). Gastrointestinal malignancy is most common followed by lymphoproliferative disease.

EPIDEMIOLOGY AND CLINICAL FEATURES

Seborrheic keratoses (SKs) are the most common acquired benign epithelial tumor of the skin. They can occur anywhere on the cutaneous surface, with the exception of the palms and soles. They are common in middle-aged and older adults and have a range of clinical appearances. Differences in clinical morphology often correspond with different microscopic variations.

SKs begin as circumscribed tan brown patches or thin plaques. Over time, they may become more papular or verrucous with a greasy scale and a stuck-on appearance (Figs. 108-1 and 108-2). Hallmark histologic findings include hyperkeratosis, acanthosis, papillomatosis, and pseudohorn cysts.

Multiple SKs may be patterned along the lines of skin cleavage or Blaschko lines.[1,2] Eruptive lesions may be a sign of internal malignancy (Leser-Trélat sign).[3] The most common associated malignancy is gastrointestinal, followed by lymphoproliferative disease. Eruptive SKs have been reported in other clinical settings, including erythroderma and HIV infection.[4,5] Chemotherapeutic agents, such as cytarabine, may cause inflammation of preexisting SKs, which then become more clinically apparent ("pseudo-sign of Leser-Trélat").[6]

On occasion, cutaneous malignancies arise from or adjacent to SKs, highlighting the importance of close

Figure 108-1 Seborrheic keratosis showing a rough surface and stuck-on appearance.

examination and tissue biopsy of atypical, symptomatic, or changing lesions.[7,8]

ETIOLOGY AND PATHOGENESIS

Although the precise cause of SKs is unknown, most are sporadic. Interestingly, a family history of SKs is attainable in some instances, suggesting a genetic predisposition. Sun exposure may also contribute to their pathogenesis.[9] The monoclonal nature of these neoplasms was established in 2001.[10] By tracking polymorphisms in a human androgen receptor, researchers found that more than half of the 38 SKs sampled, regardless of subtype, were clonal in nature. Multiple oncogenic mutations have been reported in these keratinocyte-derived tumors (Table 108-1). The most frequently detected are activating mutations in the *FGFR3* and *PIK3CA* genes.[11] Activating mutations of *EGFR*, *HRAS*, and *KRAS* likely also contribute to their pathogenesis, albeit at a lower frequency.[12] Hyperpigmentation of SKs is related to increased expression of tumor necrosis factor-α and endothelin-converting enzyme -1α, thereby stimulating secretion of endothelin 1, a potent melanogenic cytokine.[13]

Figure 108-2 Multiple small seborrheic keratoses.

TABLE 108-1
Genetic Alterations Reported in Association with Seborrheic Keratosis[12]

GENETIC ALTERATION	PREVALENCE (%)
FGFR3 and *PIK3CA*	42
FGFR3	38
PIK3CA	15
FGFR3 and *AKT*	2
HRAS	2
PIK3CA and *HRAS*	1

There is not a clear etiologic relationship between human papillomavirus (HPV) infection and SKs. However, strains of HPV have been detected in SKs at both extragenital and genital sites.[14,15] There is some evidence to suggest a bystander effect, whereby lesions are colonized on their surface by regional HPV infection without an etiologic association.

SKs on genital skin may also share histologic characteristics with condyloma acuminata. Tissue in situ hybridization or PCR analysis may be used to make the distinction in equivocal cases. In one study of genital SKs, 28 of 40 (70%) were positive for HPV.[15] The overwhelming majority contained HPV6, also the most common subtype detected in condylomata. HPV was detected in only 2 of 20 (10%) extragenital SKs. These findings highlight the morphologic plasticity of HPV-related keratoses on genital skin, ranging from SK-like histology to typical condyloma acuminatum.

CLINICOPATHOLOGIC VARIANTS

There are several variants of SK. Although distinction among variants is usually unnecessary, histologic variations often correlate with clinical features.

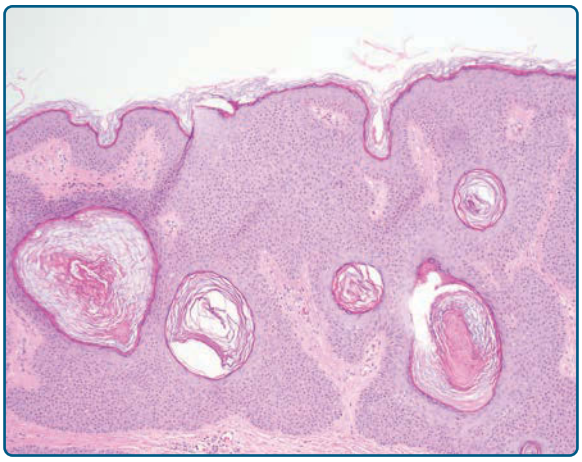

Figure 108-3 Seborrheic keratosis showing a papillomatous acanthotic epidermis consisting of small uniform basaloid keratinocytes with pseudohorn cysts.

COMMON SEBORRHEIC KERATOSIS

Common SKs are classically described as verrucous stuck-on papules or plaques (see Figs. 108-1 and 108-2). They are characterized by an acanthotic proliferation of epidermal keratinocytes with hyperkeratosis, papillomatosis, and pseudohorn cysts (Fig. 108-3). An increased number of melanocytes and pigment may be present, resulting in a tan or dark brown coloration.

RETICULATED SEBORRHEIC KERATOSIS

Reticulated (adenoid) SKs clinically present as pigmented patches or thin papules. Histologically, these epidermal tumors are composed of interconnected delicate downgrowths of pigmented basilar epithelial cells with horn cysts (Fig. 108-4). In some instances, they may arise from a solar lentigo.

STUCCO KERATOSIS

Stucco keratoses present as multiple small 1- to 3-mm white to tan keratotic papules with predilection for the distal extremities, particularly the lower legs. Histologically, they show orthokeratosis, papillomatosis, and acanthosis with fusion of rete pegs.

MELANOACANTHOMA

Melanoacanthoma is considered a variant of pigmented SK. Clinically, this lesion may resemble melanoma and is commonly seen on the head and neck or trunk of older adults. It is characterized by an acanthotic proliferation of basaloid and spinous keratinocytes, often with horn cysts. Between keratinocytes, there are sporadically distributed pigmented dendritic melanocytes. Melanin-laden histiocytes are often present in the dermis.

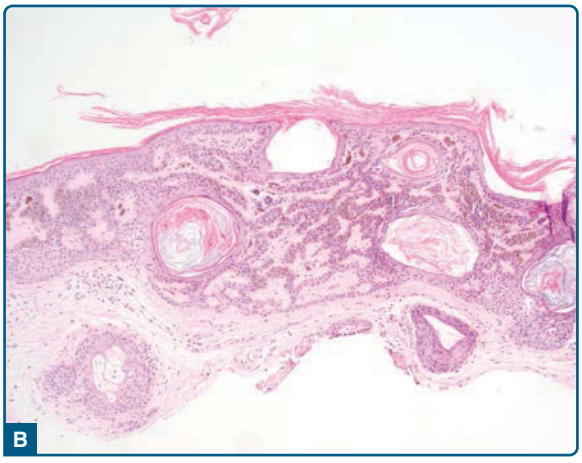

Figure 108-4 **A,** Multiple reticulated seborrheic keratoses. **B,** Reticulated seborrheic keratosis showing elongated interconnected downgrowths of pigmented basilar keratinocytes with horn cysts.

DERMATOSIS PAPULOSA NIGRA

Dermatosis papulosa nigra most commonly presents as multiple small dark brown to black keratotic papules on the malar region of individuals with Fitzpatrick skin Type IV or greater (Fig. 108-5). They may also occur on the neck and upper chest. Histologically, they show orthokeratosis, acanthosis, papillomatosis, and interconnected rete with basal layer hyperpigmentation.

POLYPOID SEBORRHEIC KERATOSIS

Similar to skin tags, SKs may assume a polypoid configuration, particularly on the neck or intertriginous areas.

Figure 108-5 Dermatosis papulosa nigra.

HISTOLOGIC VARIANTS

CLONAL SEBORRHEIC KERATOSIS

Clonal SK is a histologic term used to describe intraepithelial whorls of banal keratinocytes (Fig. 108-6).

IRRITATED SEBORRHEIC KERATOSIS

SKs may become irritated by mechanical or chemical means, or spontaneous inflammation may occur. This variant of SK is characterized by a dense inflammatory infiltrate, typically lymphocytic and sometimes lichenoid. Small whorled collections of glassy keratinocytes or squamous eddies may be seen in this variant. Lesions with surrounding eczematous changes (Meyerson phenomenon) are also seen.[16]

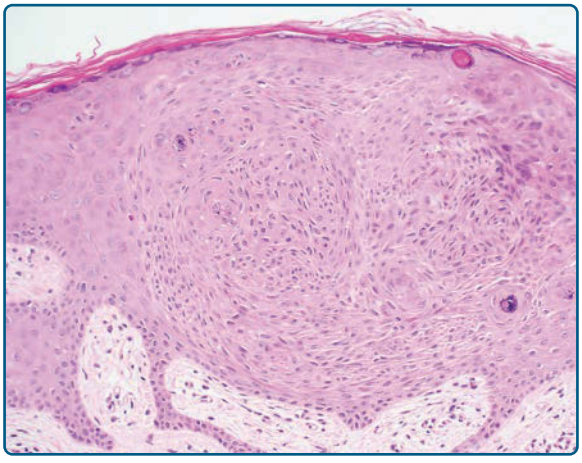

Figure 108-6 Clonal seborrheic keratosis with intraepidermal whorls of bland keratinocytes.

MALIGNANT TRANSFORMATION OR COLLISION LESIONS

Varying degrees of squamous atypia may be seen in SKs. In most instances, the atypia is reactive because of intense inflammation or irritation. However, bowenoid transformation to squamous cell carcinoma (SCC) in situ may occur. Other cutaneous malignancies, including basal cell carcinoma (BCC), invasive SCC, and melanoma, rarely arise from or collide with SKs[7,8] In a retrospective study of 813 lesions histologically diagnosed as SKs, 5.3% were associated with nonmelanoma skin cancer. In this study, the most common malignancy was SCC in situ followed by BCC and invasive SCC; no melanomas were observed in this study.[8] Rapidly growing, symptomatic, or changing lesions should be biopsied to exclude malignancy.

TREATMENT

When evaluating SKs, care should be taken not to destroy lesions that may harbor malignancy. A history of rapid growth, symptomatology, color change, atypical morphology, or unusual location should prompt strong consideration for tissue biopsy and histologic examination.

For clearly benign lesions that are irritated or cosmetically undesirable, destructive techniques such as cryotherapy, electrodesiccation followed by curettage, or laser ablation have all been shown to be effective. There are reports of giant SKs effectively treated with either dermabrasion or topical fluorouracil.[17,18] Complications of these destructive measures include scarring, pigmentary alteration, incomplete removal, or recurrence. Multiple treatments may be required to ensure lesional eradication. Care should be taken to minimize the risk of scarring.

LICHEN STRIATUS

AT-A-GLANCE

- Lichen striatus is a rare, idiopathic, papular eruption that usually resolves in 1 to 2 years.
- It occurs most commonly on the limbs of children and adolescents with a female predilection.
- Eruption is characterized by the sudden onset of flat-topped, 1- to 3-mm, pink, tan, or hypopigmented papules in a linear or blaschkoid distribution.
- Differential diagnosis: lichen planus, "linear variants" of psoriasis, linear porokeratosis, lichen nitidus, "linear variants" of Darier disease, and inflammatory linear verrucous epidermal nevus

ETIOLOGY AND EPIDEMIOLOGY

Lichen striatus is a type of "BLAISE," described as *Blaschko linear acquired inflammatory skin eruption* (adult blaschkitis is another form), most commonly affects children and adolescents 5 to 15 years of age. The cause is unknown, and the disease is self-limiting. The limbs of females are most often affected, although involvement of the trunk and less frequently the face have been reported.[19] Nail changes are rare but can occur.[20] An association with atopic dermatitis has also been suggested.[21]

CLINICAL FEATURES

Lichen striatus is an eruption characterized by the sudden onset of flat-topped, 1- to 3-mm, pink, tan, or hypopigmented papules in a linear configuration or blaschkoid distribution (Fig. 108-7). The eruption is most commonly unilateral (Fig. 108-8), although bilateral eruptions sometimes occur. Nail changes include longitudinal ridging and nail plate thinning. The eruption is self-limited, with spontaneous regression within a few months to 2 years.

Figure 108-8 Lichen striatus. Linear configuration of slightly scaling papules in a blaschkoid distribution on the leg.

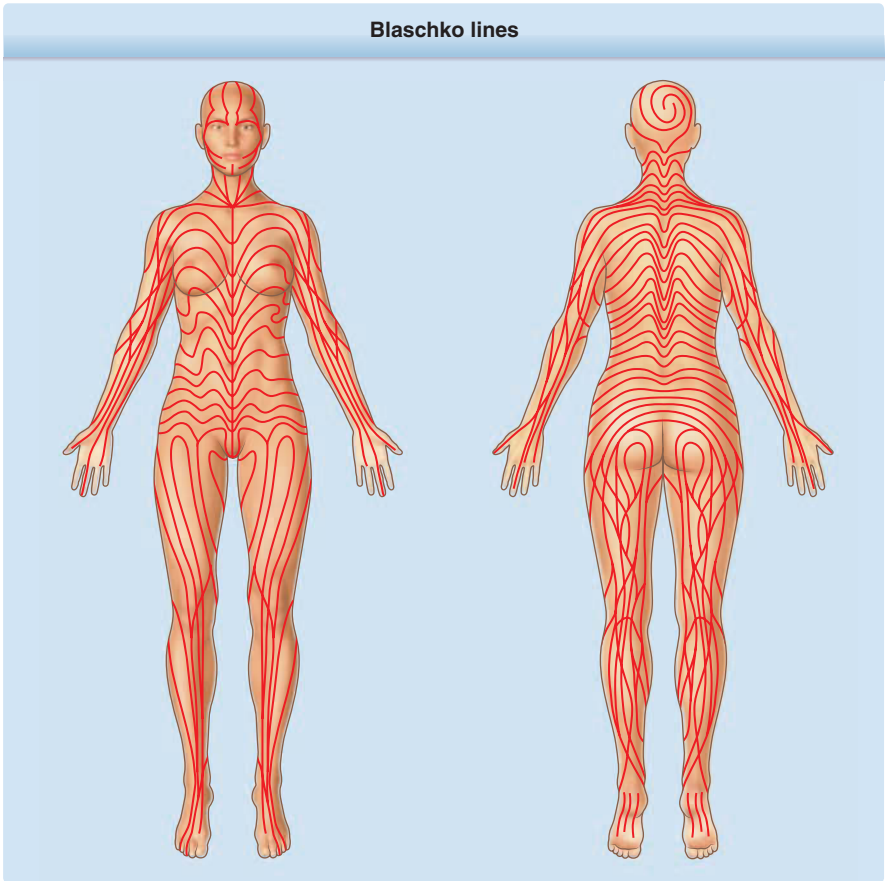

Figure 108-7 Blaschko lines. These lines represent pathways of epidermal cell migration and proliferation during fetal development and are the basis for the pattern distribution seen in cutaneous mosaicism.

DIFFERENTIAL DIAGNOSIS

Lichen planus, psoriasis, linear porokeratosis, lichen nitidus, Darier disease, and inflammatory linear verrucous epidermal nevus (ILVEN) can have similar clinical morphology and distribution to lichen striatus.

HISTOPATHOLOGY

Lichen striatus is characterized by a lichenoid lymphocytic infiltrate with overlying epidermal acanthosis, dyskeratosis, hyperkeratosis, and focal parakeratosis. There is concomitant mild epidermal spongiosis with exocytosis of inflammatory cells. Intraepidermal Langerhans cell clusters may be seen. The dermal lymphocytic infiltrate may extend into the deep dermis in a perivascular and periadnexal pattern, with characteristic accentuation around eccrine coils.

TREATMENT

Because the disease is usually asymptomatic and self-limited, treatment is not required. However, pruritic lesions may be offered symptomatic relief with topical steroids. Topical tacrolimus and pimecrolimus cream have also been reported to be effective.[22,23]

CLEAR CELL ACANTHOMA

AT-A-GLANCE

- Clear cell acanthoma is a tumor of epidermal origin.
- Solitary, shiny, erythematous or orange to brown, blanching, well-demarcated papule or nodule with collarette of scale
- Composed of distinctive, glycogen-rich keratinocytes
- Differential diagnosis: eccrine poroma, pyogenic granuloma, BCC, SCC, lichenoid keratosis

ETIOLOGY AND EPIDEMIOLOGY

Clear cell acanthoma is a benign epithelial tumor that occurs equally in men and women, with a predilection for the lower legs of middle-aged to older individuals.

The cause of clear cell acanthoma is unknown. It was first described by Degos et al. in 1962 as a benign tumor of epithelial origin.[24] Interestingly, the cytokeratin expression profile of these lesions has revealed similar staining patterns to those commonly found in inflammatory dermatoses such as lichen planus, psoriasis, and discoid lupus.[25] The occasional association of clear cell acanthoma with other cutaneous inflammatory conditions also suggests a possible role for inflammation in their development.[26]

CLINICAL FEATURES

Clear cell acanthoma presents as a solitary, shiny, erythematous to brown, well-demarcated papule or nodule that blanches almost fully with pressure (Fig. 108-9A). There is a surrounding collarette of scale. Lesions range from 5 mm to 2 cm, although rarely giant variants can measure greater than 5 cm.[27] They are most commonly found on the lower part of the legs but can be seen on the trunk or face. Rarely, lesions are multiple. They show dermatoscopic features similar to psoriasis, with prominent vascular puncta.[28] Like psoriasis, they may bleed easily with trauma.

DIFFERENTIAL DIAGNOSIS

Eccrine poroma, pyogenic granuloma, BCC, SCC, and lichenoid keratosis are within the differential diagnosis for clear cell acanthoma.

HISTOPATHOLOGY

Clear cell acanthoma is characterized by a sharply demarcated zone of pale staining epidermal keratinocytes with psoriasiform epidermal hyperplasia and a parakeratotic scale (Fig. 108-9B). Keratinocyte pallor is because of heavy cytoplasmic glycogen, as evidenced by periodic acid–Schiff positivity, which can be digested with diastase. Neutrophils commonly migrate through the epidermis to accumulate in the surface scale. There are thinning of suprapapillary plates and sparing of adnexal epithelium. The papillary dermis shows mild edema with increased vessels and a mixed inflammatory infiltrate.

TREATMENT

Cryotherapy, curettage and electrodesiccation, laser ablation, and surgical excision have been used to successfully treat this lesion.

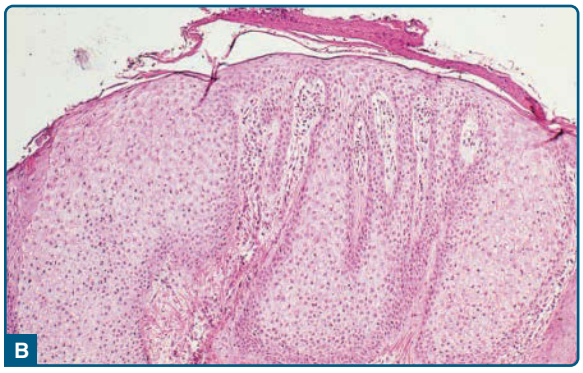

Figure 108-9 **A,** Clear cell acanthoma presenting as a flat red nodule on the sole. **B,** Histology showing a circumscribed sharply demarcated epidermal tumor composed of clear (glycogen rich) cells without cytologic atypia.

CHRONDRODERMATITIS NODULARIS HELICIS

AT-A-GLANCE

- A chronic tender solitary nodule, often ulcerated on the helix of the ear
- Histology: ulceration with underlying degeneration of dermal collagen, increased fibroblasts, and chronic inflammatory cell infiltrate; perichondrium and cartilage also with degenerative changes
- Differential diagnosis: BCC, SCC, keratoacanthoma, verruca, tophus
- Treatment: conservative treatment, including pressure-relieving pillows and steroid injection; curettage and cautery or surgical excision if necessary

ETIOLOGY AND EPIDEMIOLOGY

Chondrodermatitis nodularis helicis (CNH) is thought to be a disease of collagen degeneration with subsequent transepidermal elimination.[29] Vascular insufficiency and local ischemia are thought to play inciting roles. Other possible associations include systemic microvascular disease and pressure related to cell phone use.[30,31] The presence of solar elastosis at the periphery of lesions and prevalence of CNH in lightly pigmented populations raises the possibility that chronic actinic damage may also play a role.[32]

CLINICAL FEATURES

CNH is a chronic tender nodule that develops most commonly on the helix of the ear in men older than 50 years of age.[32] Lesions may also occur on the antihelix, particularly in women. CNH most often occurs on the helix as a small, 4 to 6 mm in diameter, nodular, tender lesion (Fig. 108-10A). Rarely, multiple lesions are present. Ulceration or scale crust are often evident. Lesions are persistent and do not typically regress spontaneously.

DIFFERENTIAL DIAGNOSIS

BCC, SCC, keratoacanthoma, warts, and tophi are within the differential diagnosis of CNH.

HISTOPATHOLOGY

There is often epidermal ulceration flanked by zones of epidermal hyperplasia. Beneath the ulcer, there are degenerative changes of dermal collagen with an increase in fibroblasts and capillary-sized blood vessels. A mild to moderate chronic inflammatory infiltrate is often present. Degenerative changes are also found within the underlying perichondrium and helical cartilage (Fig. 108-10B).

TREATMENT

Treatment is generally conservative aimed at reducing pain and improving clinical appearance. Pressure-relieving devices such as doughnut-shaped pillows can be effective. Other methods include intralesional steroids, laser therapy, curettage, and surgical excision if necessary.[33]

Figure 108-10. **A,** Chondrodermatitis nodularis helicis presenting as a painful nodule on the ear. **B,** Histology showing surface ulceration with fibrin, vascular proliferation, and cartilage with degenerative changes.

WARTY DYSKERATOMA

AT-A-GLANCE

- Solitary focus of acantholytic dyskeratosis
- Skin-colored, umbilicated papule on the head or neck of middle-aged and older individuals
- Histology: cup-shaped epidermal invagination with acantholysis and dyskeratosis filled with keratinaceous plug; may involve folliculosebaceous units
- Differential diagnosis: actinic keratosis, SCC
- Treatment: Excision is curative.

ACANTHOMA FISSURATUM (GRANULOMA FISSURATUM)

AT-A-GLANCE

- Fissured or ulcerated, firm, flesh-colored nodule, usually retroauricular, that appears in areas of friction, as with ill-fitting eyeglasses
- Histology: benign epidermal hyperplasia, hypergranulosis, and hyperparakeratosis; vascular telangiectasia, mild fibrosis, and chronic inflammatory cell infiltrate
- Differential diagnosis: BCC, SCC, CNH
- Treatment: Usually resolves after correction of the ill-fitting appliance.

EPIDERMAL NEVUS

INTRODUCTION

Epidermal nevi are benign hamartomatous proliferations of the epithelium and adnexae that present at birth or early childhood. Subtypes demonstrate varying degrees of proliferation of the squamous epithelium, sweat glands (sebaceous, apocrine, eccrine), smooth muscle, or hair follicle. Epidermal nevi are a product of cutaneous mosaicism, defined as a postzygotic genetic mutation or alteration occurring at the level of skin development.[34] This results in linear or whorled lesions that mirror the embryonic pathways of epidermal cell migration, termed the *lines of Blaschko* (Fig. 108-7). The blaschkoid distribution pattern has been described in multiple disease states, examples of which are listed in Table 108-2. Epidermal nevus syndromes are a heterogeneous group of disorders in which epidermal nevi are associated with extracutaneous anomalies and are thereby believed to represent a mosaic alteration occurring earlier in embryonic development.[35] In recent years, there have been major breakthroughs in our genetic understanding of these lesions.

KERATINOCYTIC EPIDERMAL NEVUS

AT-A-GLANCE

- The most common variant of epidermal nevi, usually presenting at birth or before adolescence
- Clinical examination: Verrucous papules coalesce to form linear or swirled plaques along the lines of Blaschko.

(Continued)

TABLE 108-2
Skin Diseases that May Occur Along Blaschko Lines

Verrucous plaques	Keratinocytic epidermal nevi, nevus sebaceous, incontinentia pigmenti stage 2
Inflammatory plaques	ILVEN, lichen striatus, linear lichen planus, blaschkitis, linear psoriasis, linear porokeratosis, incontinentia pigmenti stages 1 and 2
Spiny or comedonal plaques	Nevus comedonicus, porokeratotic eccrine ostial and dermal duct nevus, linear lichen planopilaris
Atrophic plaques	Linear lichen sclerosus, linear atrophoderma of Moulin, Goltz syndrome (focal dermal hypoplasia), incontinentia pigmenti stage 4
Hyperpigmented patches	Linear and whorled nevoid hypermelanosis, incontinentia pigmenti stage 3
Hypopigmented patches	Linear nevoid hypopigmentation, hypomelanosis of Ito

ILVEN, inflammatory linear verrucous epidermal nevus.

AT-A-GLANCE (*Continued*)

- Histology: epidermal acanthosis, papillomatosis, and hyperkeratosis
- Differential diagnosis: SK, verruca, nevus sebaceous, lichen striatus, linear psoriasis
- Treatment: Full-thickness excision is regarded as the most definitive.

EPIDEMIOLOGY

Keratinocytic epidermal nevi (linear epidermal nevi, linear verrucous epidermal nevi) are the most common variant of epidermal nevi. They occur in 1 in 1000 live births, without sexual predilection. Most cases are sporadic, but familial cases have been documented.[34]

CLINICAL FEATURES

Keratinocytic epidermal nevi are skin-colored to hyperpigmented verrucous or velvety papules that coalesce to form plaques in a blaschkoid distribution. These lesions occur most commonly on the neck, trunk, and extremities and can appear more pronounced when present on flexural skin (Fig. 108-11). Eighty percent appear at birth or by the first year of life; the rest usually manifest by adolescence. The rare reports of adult onset may represent lesions that were present subclinically, with recent growth having resulted in clinical recognition.

A systematized epidermal nevus refers to a more extensively distributed variant of keratinocytic epidermal nevi. The unilateral subtype is termed nevus unius lateris (Fig. 108-12), but the bilateral subtype is known as ichthyosis hystrix.

Figure 108-11 Keratinocytic epidermal nevus presenting as brown verrucous plaques arranged along Blaschko lines on the lateral cheek (**A**) and flexural neck (**B**). (Image **B** used with permission from Bernard Cohen, MD.)

ILVEN is a variant that clinically appears psoriasiform (erythematous with thick scale) and can be very pruritic (Fig. 108-13).[34,36] Keratinocytic epidermal nevi can also occur in the context of epidermal nevus syndromes (see section "Epidermal Nevus Syndromes").

ETIOLOGY AND PATHOGENESIS

Keratinocytic epidermal nevi are derived from pluripotent cells in the basal layer of the embryonic epidermis. Although keratinocytes are the predominant affected cell type, there is accompanying overgrowth of the papillary dermis as well. These lesions result from cutaneous mosaicism, particularly postzygotic

Figure 108-12 Nevus unius lateris, a more extensive variant of keratinocytic epidermal nevi that is limited to one side of the body.

activating mutations. Hafner and coworkers demonstrated that 40% of keratinocytic epidermal nevi harbor RAS mutations (usually *HRAS*), and another 40% have an *FGFR3* or *PIK3CA* mutation.[37-39] Up to 10% have a mutation in *KRT1* or *KRT10* and characteristically exhibit epidermolytic hyperkeratosis on pathology.[40]

Figure 108-13 Inflammatory linear verrucous epidermal nevus, a rare variant characterized by recalcitrant pruritus, erythema, and scaling.

DIAGNOSIS

These hamartomas are usually diagnosed clinically based on the combination of linear morphology, verrucous texture, and young age of the patient. If the diagnosis is in question, a skin biopsy can be done for histopathologic evaluation. Large or extensive epidermal nevi should trigger clinical workup to evaluate for involvement of other organ systems (see section "Epidermal Nevus Syndromes").

HISTOPATHOLOGY

The epidermis shows acanthosis, papillomatosis, and hyperkeratosis (Fig. 108-14). The epidermolytic variant demonstrates marked orthokeratosis with vacuolization and coarse keratohyalin granule deposition within the granular layer, defined as epidermolytic hyperkeratosis. ILVEN displays chronic dermal inflammatory infiltrate, psoriasiform epidermal hyperplasia, and alternating bands of ortho- and parakeratosis in which the granular layer is generally absent under the areas of parakeratosis.

DIFFERENTIAL DIAGNOSIS

The individual papules that make up a plaque may clinically and pathologically resemble a SK or verruca if viewed in isolation. Very early and subtle lesions of keratinocytic epidermal nevi may be macular and can thus resemble linear and whorled nevoid hypermelanosis. Nevus sebaceous may mimic keratinocytic epidermal nevi on clinical examination, but helpful features include their propensity for the head and neck and the characteristic waxy yellow-orange coloration.

ILVEN can be clinically mistaken for lichen striatus, but the latter typically has an abrupt onset, is self-limited, and has a lichenoid reaction pattern on biopsy.[41] Unlike linear psoriasis, ILVEN tends to be treatment resistant.[42] Cases of linear psoriasis may also

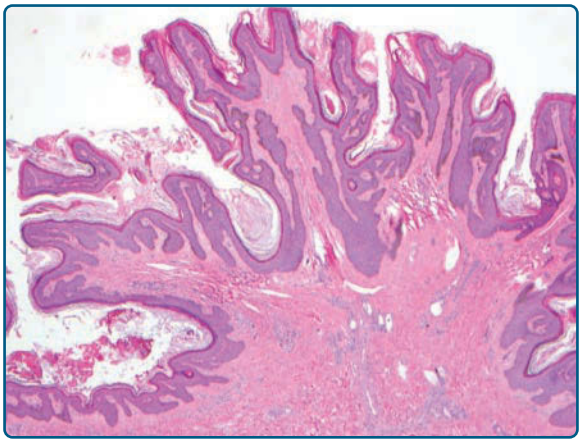

Figure 108-14 Keratinocytic epidermal nevus showing hyperkeratosis, acanthosis, and papillomatosis.

be accompanied by a family history of psoriasis, late onset, and features of traditional psoriasis elsewhere on examination. Histologically, linear psoriasis may have more confluent parakeratosis as would be seen in plaque psoriasis.

COURSE AND COMPLICATIONS

Although congenital lesions tend to be quiescent, those that present after birth can enlarge before stabilizing in size around puberty.[34] Intertriginous lesions may become macerated and secondarily infected, but the majority remain unaffected after adolescence. Rarely, cutaneous malignancies such as BCC or SCC have been reported to arise within keratinocytic epidermal nevi during adulthood.[43]

If histopathologic evaluation of an epidermal nevus reveals features of epidermolytic hyperkeratosis, the patient is at risk of having a child with epidermolytic ichthyosis if the postzygotic mutation for K1 or K10 is also present in gonadal tissue. Prenatal counseling is therefore important for this subset of patients.

TREATMENT

If the patient desires removal, full-thickness surgical excision is considered the most definitive form of treatment. The low recurrence rate with this procedure is likely due to removal of the superficial dermal component of the lesion.[44] Destructive modalities such as laser ablation, electrofulguration, cryotherapy, and medium- to full-depth chemical peels may offer partial or full clearance. Like psoriasis, ILVEN may be treated with topical steroids, topical retinoids, or calcipotriene, but these medications usually provide little relief.[36]

NEVUS SEBACEOUS

AT-A-GLANCE

- Clinical examination: hairless waxy yellow linear plaque presenting on the head and neck between birth and adolescence
- Histology: epidermal hyperplasia, immature hair follicles, and increased sebaceous and/or apocrine glands
- Various benign and malignant neoplasms can arise within nevus sebaceous, such as trichoblastoma, syringocystadenoma papilliferum, or BCC.
- Differential diagnosis: epidermal nevus, syringocystadenoma papilliferum, SK, juvenile xanthogranuloma, cutaneous mastocytoma
- Treatment: Full-thickness excision should be considered on a case-by-case basis.
- Rapidly growing papules or nodules require pathologic evaluation to rule out malignancy.

EPIDEMIOLOGY

Nevus sebaceous (nevus sebaceus of Jadassohn, organoid nevus) is a variant of epidermal nevus characterized by epidermal hyperplasia, immature hair follicles, and sweat gland overgrowth. These lesions occur in 0.1% to 0.3% of live births and have an equal male–female prevalence.[45] Cases are typically sporadic, but familial cases have been described.

CLINICAL FEATURES

Nevus sebaceous presents as hairless, yellow, waxy and verrucous plaques following a blaschkoid pattern (Fig. 108-15). These lesions can be subtle at birth, later becoming more elevated and verrucous under the hormonal influences of puberty.[46] They present most commonly on the scalp and can rarely occur elsewhere on the head and neck.

ETIOLOGY AND PATHOGENESIS

Like keratinocytic epidermal nevi, nevus sebaceous is a product of an activating postzygotic mutation. More than 90% are believed to harbor an *HRAS* mutation and less frequently a *KRAS* mutation.[47-49] The same genes appear to be affected in nevus sebaceous syndrome, also called Schimmelpenning syndrome (see section "Epidermal Nevus Syndrome").

DIAGNOSIS

Nevus sebaceous is usually diagnosed clinically based on the combination of linear morphology, waxy yellow coloration, location on the scalp, and young age of the patient. If the diagnosis is not certain, a skin biopsy can be performed.

Figure 108-15 Nevus sebaceous appearing as a waxy yellow-orange linear verrucous plaque.

Figure 108-16 Nevus sebaceous showing hyperkeratosis, acanthosis, papillomatosis and increased sebaceous glands in the superficial dermis. A deeper sample may reveal the presence of ectopic apocrine glands.

HISTOPATHOLOGY

Histologic findings consist of epidermal hyperplasia, immature and vellus hair follicles, ectopic apocrine glands, and sebaceous glands located in the superficial dermis (Fig. 108-16). In prepubescent patients, the sebaceous glands usually appear immature and decreased in number.

DIFFERENTIAL DIAGNOSIS

Epidermal nevi are clinically similar to nevus sebaceous but tend to be uncommon on the scalp and face. A skin biopsy can be done to distinguish between these entities. Syringocystadenoma papilliferum is a rare benign tumor that is usually located on the scalp, either in isolation or within a nevus sebaceous. The papillomatous architecture resembles a nevus sebaceous on clinical examination but can be easily differentiated on histology. Less linear lesions of nevus sebaceous can mimic a SK in adults or a juvenile xanthogranuloma or solitary mastocytoma in children. Abrupt growth seen within a nevus sebaceous should alert the clinician to evaluate for a possible secondary malignancy.

COURSE AND COMPLICATIONS

After puberty, nevus sebaceous become more thickened and verrucous because of hormonal influences. About 25% of affected individuals will go on to develop benign or malignant (or both) secondary neoplasms within their nevus sebaceous.[45,46] Malignant growths are usually seen in older individuals but have occasionally been reported in children.[50]

The most common benign and malignant tumors found within nevus sebaceous are listed in Table 108-3.[50] Of those listed, the most common are trichoblastoma (7% of nevus sebaceous cases) and syringocystadenoma papilliferum (5%).[50] It was previously believed that individuals with nevus sebaceous were at a significantly elevated risk for BCC, but subsequent reviews have concluded that many diagnoses of trichoblastoma may have been overdiagnosed as BCC.[46,51] The risk for developing true BCCs is currently believed to be closer to 1%.[46,51]

TABLE 108-3
Neoplasms Associated with Nevus Sebaceous[a]

BENIGN NEOPLASMS	MALIGNANT NEOPLASMS
Trichoblastoma	Basal cell carcinoma
Syringocystadenoma papilliferum	Sebaceous carcinoma
Apocrine/eccrine adenoma	Squamous cell carcinoma
Trichilemmoma	Keratoacanthoma
Benign melanocytic nevus	Apocrine carcinoma
Sebaceoma	Eccrine porocarcinoma

[a]Within each column, the tumors are listed in decreasing order of frequency.

TREATMENT

Like other epidermal nevi, nevus sebaceous can be definitively treated with full-thickness surgical excision if there are cosmetic or psychosocial concerns. It is still debated whether these lesions' association with cutaneous malignancy warrant prophylactic removal, and if so, the appropriate timing for excision.[46,51] Watchful waiting is currently considered an acceptable option.[35] Alternatives to surgical excision include laser resurfacing and dermabrasion; however, these modalities only partially remove the lesion and do not curb the risk of future neoplasms.[52] Whenever a rapidly growing papule or nodule is observed within a nevus sebaceous, biopsy or excision should be conducted for pathologic evaluation.

NEVUS COMEDONICUS

AT-A-GLANCE

- Clinical examination: localized linear plaque composed of comedones and occasionally inflammatory acne lesions
- Histology: keratin-filled epidermal invaginations associated with atrophic pilosebaceous units
- Differential diagnosis: acne vulgaris, milia, acne neonatorum, nevus sebaceous, linear Darier disease
- Treatment: Full-thickness excision is regarded as the most definitive.

Figure 108-17 Nevus comedonicus presenting as a localized linear plaque composed of open and closed comedones. The two associated tan papules may correspond to areas of keratinocytic epidermal nevus-like changes.

CLINICAL FEATURES

Nevus comedonicus (acneiform nevus) are rare hamartomas of the pilosebaceous unit that appear as localized plaques of comedonal acne at the time of birth or early childhood (Fig. 108-17). The lesions have an either clustered or linear distribution and most commonly occur on the face, chest, or upper arms. Although the noninflammatory variant is usually asymptomatic, the inflammatory form can result in significant suppuration and pain. Nevus comedonicus syndrome is the association of nevus comedonicus with noncutaneous findings such as skeletal defects, cerebral abnormalities, and cataracts.[53]

ETIOLOGY AND PATHOGENESIS

NEK9 kinase, a potential regulator of follicular homeostasis, has been postulated to be defective in nevus comedonicus.[49]

DIAGNOSIS

The diagnosis is usually made clinically.

HISTOPATHOLOGY

The hallmark histologic findings are keratin-filled epidermal invaginations in association with atrophic sebaceous glands or follicles.

DIFFERENTIAL DIAGNOSIS

The differential diagnosis includes acne vulgaris, milia, acne neonatorum, nevus sebaceous, and linear Darier disease.

COURSE AND COMPLICATIONS

Nevus comedonicus are persistent lesions. Some cases may develop inflammatory acne cysts, which can subsequently result in scarring. Malignant transformation of these lesions is extremely rare.[53] On initial clinical examination, the patient should be evaluated for features of nevus comedonicus syndrome. There seems to be no correlation between the size or extent of the lesion with risk for systemic anomalies.[53]

TREATMENT

Treatment can be reserved for cosmetically bothersome or symptomatic cases. Mild improvement can be achieved with emollients, keratolytics, topical steroids (for inflammatory lesions), and topical retinoids. Oral retinoids or destructive modalities have shown only limited efficacy, with best results being achieved with laser resurfacing. Full-thickness surgical excision is regarded as the most definitive option.

EPIDERMAL NEVUS SYNDROME

AT-A-GLANCE

- *Epidermal nevus syndrome* is a term collectively describing several distinct syndromes that all demonstrate an epidermal nevus occurring in the context of other developmental abnormalities.
- Patients with extensive epidermal nevi and those with epidermal nevi and any systemic abnormalities should be screened for these syndromes.
- The most common extracutaneous features involve the ocular, neurologic, and skeletal systems.
- Management requires a multidisciplinary approach involving a dermatologist, pediatrician, ophthalmologist, neurologist, plastic surgeon, and orthopedic services.

Epidermal nevus syndrome is loosely defined as the association of an epidermal nevus with any of various extracutaneous anomalies, most commonly of the ocular, neurologic, and skeletal systems (Table 108-4). These patients may exhibit other cutaneous abnormalities in addition to epidermal nevi. The above clinical phenotype is now known to encompass distinct diseases with differing genetic profiles of postzygotic mosaicism. Some of the well-characterized variants and their corresponding epidermal nevi are summarized in Table 108-5.[35,54-56]

TABLE 108-4
Systemic Manifestations Seen in Syndromes Associated with Epidermal Nevi

SYSTEM	SYSTEMIC MANIFESTATIONS
Skeletal	Craniofacial defects, frontal bossing, kyphoscoliosis, limb deformities, vertebral defects, hypophosphatemic rickets
Neurologic	Mental retardation, seizures, hemiparesis, sensorymotor neuropathy, cortical atrophy, hypoplasia of corpus callosum, spinal dysraphism
Ocular	Optic nerve deformities, corneal defects
Cutaneous	Lipomas, angiomas, soft tissue overgrowth

Becker nevus syndrome is another well-known variant characterized by a segmental smooth muscle hamartoma in association with musculoskeletal defects such as ipsilateral breast hypoplasia.[35] Angora hair nevus syndrome consists of an epidermal hamartoma with long, fine white hair in addition to ocular, neurologic, and skeletal deficiencies.

TABLE 108-5
Variants of Epidermal Nevi and Their Associated Syndromes

EPIDERMAL NEVI TYPE	SYNDROMIC ASSOCIATIONS
Keratinocytic epidermal nevi (nonepidermolytic)	*HRAS/FGFR3* mutation: craniofacial, skeletal, and CNS anomalies (eg, mental retardation, seizures) Proteus syndrome (*AKT1* mutation): palmoplantar cerebriform hyperplasia, asymmetrical macrodactyly, soft tissue overgrowth; epidermal nevi characteristically soft and flat Type 2 segmental Cowden disease (*PTEN* mutation): focal segmental glomerulosclerosis, soft tissue overgrowth, colon polyps; epidermal nevi characteristically thick and papillomatous (also called linear Cowden nevi)
ILVEN	CHILD syndrome (*NSDHL* mutation): ipsilateral bone, visceral, and neurologic defects; epidermal nevi lateralized with flexural affinity
Nevus sebaceous	Schimmelpenning syndrome (*HRAS/KRAS* mutation): ocular (eg, lipodermoid, coloboma), cerebral, and skeletal anomalies Phakomatosis pigmentokeratotica (*HRAS* mutation): CNS anomalies; speckled lentiginous nevi and epidermal nevi following checkerboard pattern
Nevus comedonicus	Nevus comedonicus syndrome: ocular (eg, ipsilateral cataract, corneal erosion), skeletal, and CNS anomalies

CHILD, congenital hemidysplasia with ichthyosiform nevus and limb defects; CNS, central nervous system; ILVEN, inflammatory linear verrucous epidermal nevus.

DIAGNOSIS, COURSE AND COMPLICATIONS, AND TREATMENT

Patients with extensive epidermal nevi or those with concurrent systemic abnormalities should be promptly evaluated for an underlying epidermal nevus syndrome.[35] Evaluation and management of patients with an epidermal nevus syndrome requires a multidisciplinary approach involving a dermatologist, pediatrician, ophthalmologist, neurologist, plastic surgeon, and orthopedic services. These patients require a careful history with particular attention to developmental history, attainment of milestones, and abnormalities of the bones and eyes. Thorough mucocutaneous, neurologic, ophthalmologic, and orthopedic examinations are necessary, and a regular follow-up program should be planned for the patient.

CYSTS OF EPIDERMAL ORIGIN

AT-A-GLANCE

- Many common cysts result from a plugged pilosebaceous unit.
  - Epidermoid cysts: derived from the infundibular portion of hair follicle and thus show flattened surface epithelium and keratohyaline granules
  - Trichilemmal cysts: lining resembles the isthmic portion of hair follicle and thus show a scalloped surface epithelium lacking a granular layer
  - Milia: thought to be the result of plugging of a vellus hair follicle or eccrine sweat duct; resemble small epidermal cysts
  - Steatocystoma: a sebaceous duct cyst characterized by a waxy, eosinophilic cuticle lining the cyst and characteristic sebaceous glands in the cyst walls
- Developmental cysts are much less common.
  - Dermoid cysts: collections of epidermis located along embryologic fusion planes, most commonly on the forehead, lateral eye, or neck
  - Branchial cysts: asymptomatic cysts caused by occlusion of branchial cleft sinuses that are located along the angle of the mandible if arising from the first branchial cleft and the middle to lower third of the anterior border of the sternocleidomastoid in cases arising from the second branchial cleft
  - Preauricular cysts or sinuses: epithelial invaginations located in the preauricular area that arise from the incomplete fusion of the first and second branchial arches in the preauricular area
  - Removal of the entire cyst wall is required to prevent cyst recurrence.

EPIDERMOID CYST

ETIOLOGY AND PATHOGENESIS

Epidermoid cysts (follicular cyst-infundibular type, keratin cyst, epidermal cyst, epidermal inclusion cyst, or epithelial cyst) are most commonly the result of plugged pilosebaceous units. The term *sebaceous cyst* is a misnomer and should be avoided because these cysts do not involve sebaceous glands, nor do they contain sebum. These cysts are lined by epithelium resembling the infundibulum of the hair follicle and express the same cytokeratin profile[57] and thus are thought to be derived from this structure. On non–hair-bearing sites such as the palms and soles, epidermoid cysts are thought to be the result of traumatic implantation of epidermal cells into deeper tissues or by cyst formation in an eccrine duct.[58,59] HPV types 57 and 60 DNA have been detected in palmoplantar epidermoid cysts.[60,61]

CLINICAL FEATURES

Epidermoid cysts are classically dermal or subcutaneous mobile nodules with a central punctum (Fig. 108-18). The punctum, when present, represents the plugged pilosebaceous unit from which foul-smelling cheesy debris may be expressed. They are most commonly found on the upper chest, upper back, neck, or head. The lesions thought to be traumatic in origin are most often seen on the palms, soles, or buttocks. Cysts are usually slow growing and asymptomatic. Cyst rupture is common. Although the clinical course of epidermoid cysts is benign, rarely, BCC, SCC, epithelioid carcinoma, and other malignancies have been reported to occur in conjunction with these cysts.[62-64]

Figure 108-18 Epidermoid cyst presenting as a dome-shaped protuberance of the cheek.

EPIDEMIOLOGY

Epidermoid cysts are found most commonly in adults, both men and women. Genetic disorders, such as Gorlin syndrome (nevoid BCC syndrome), pachyonychia congenita type 2 (Jackson-Lawler type), and Gardner syndrome, may predispose individuals to having this type of cyst.

DIFFERENTIAL DIAGNOSIS

Steatocystomas, pilar cysts, and lipomas can all mimic epidermoid cysts. However, clinically, steatocystomas usually express a liquid rather than a cheesy material. Pilar cysts are most commonly on the scalp, and lipomas are softer and deeper and lack a punctum. Histopathology also distinguishes among these lesions.

HISTOPATHOLOGY

An epidermoid cyst has a stratified, squamous lining with an intact granular layer (Fig. 108-19). These cysts contain orthokeratotic debris. When released into the dermis and surrounding tissues, the keratin can incite a foreign-body reaction of multinucleated giant cells and histiocytes.

TREATMENT

Complete excision or destruction of the cyst lining is the definitive treatment and is required to prevent cyst recurrence. If a cyst becomes inflamed, painful, or purulent, incision and drainage should be performed, and infection must be considered. Common microbes associated with cyst infection include *Staphylococcus aureus*, group A streptococcus, *Escherichia coli*, *Peptostreptococcus* spp., and *Bacteroides* spp. Polymicrobial infection is most common. Wound cultures with directed therapy may be indicated based on the clinical presentation of the lesion. If the cyst has ruptured or has become infected, excision of the lesion should be deferred until the inflammation has decreased, which will decrease the likelihood of wound dehiscence.

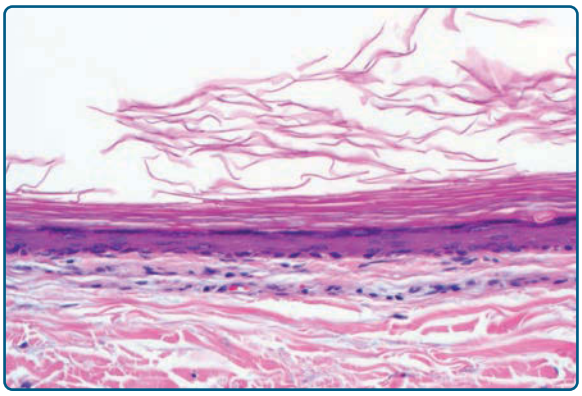

Figure 108-19 Epidermoid cyst lined by stratified epithelium with a granular layer. Within the cyst, the keratinous material is arranged in laminated layers.

For small, inflamed, symptomatic lesions, intralesional steroids may be considered.

TRICHILEMMAL CYST (PILAR CYST)

ETIOLOGY AND PATHOGENESIS

Pilar cysts arise from the epithelium located between the orifice of the sebaceous gland and the arrector pili muscle. This squamous epithelium undergoes rapid keratinization, resulting in a cyst wall without a granular layer.

CLINICAL FEATURES

Pilar cysts are mobile, firm, well-circumscribed nodules located overwhelmingly in the scalp (Fig. 108-20). These lesions can also be found on the face, head, and neck. Although these lesions largely remain asymptomatic, rupture and infection can occur. Most patients have more than one lesion, with 10% of people having more than 10 lesions. Rapid growth is abnormal and can be a sign of infection or malignant transformation.[65]

EPIDEMIOLOGY

Trichilemmal cysts can be found in 5% to 10% of the population, most commonly in middle-aged women.

DIFFERENTIAL DIAGNOSIS

See section "Differential Diagnosis" under Epidermoid Cyst.

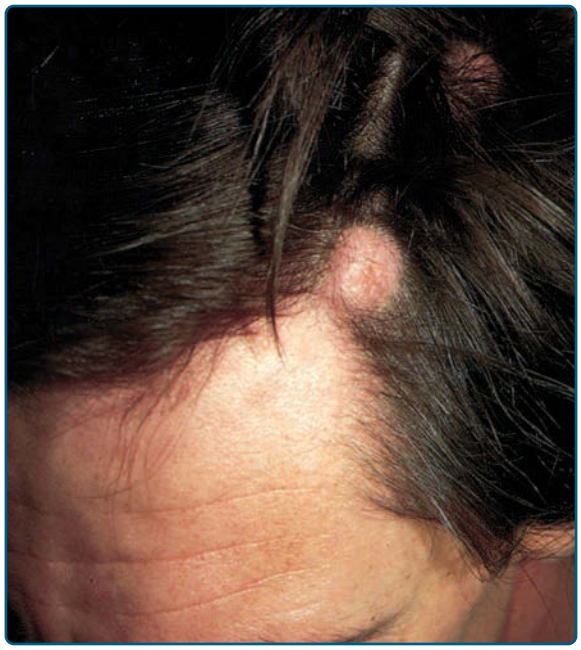

Figure 108-20 A trichilemmal (pilar) cyst on the scalp.

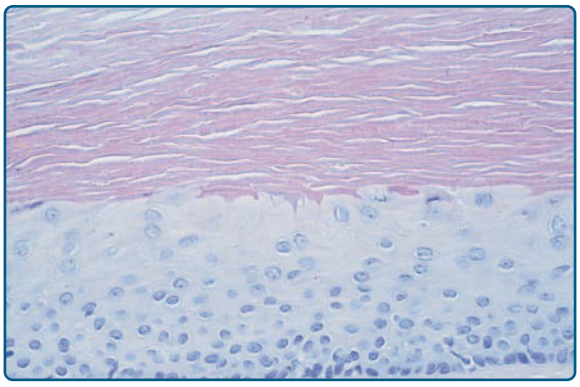

Figure 108-21 Trichilemmal cysts showing an epithelial lining that lacks a granular layer.

HISTOPATHOLOGY

Trichilemmal cysts arise from the outer root sheath of the hair follicle, and thus are characterized by the absence of a granular layer and eosinophilic keratin contents (Fig. 108-21). If abundant folds and lobules of squamous epithelium are seen in the walls of the lesion, it is most likely a proliferating trichilemmal cyst. Extensive cellular atypia and invasion of the cyst lining into the surrounding tissue are indicative of a malignant proliferating pilar tumor.

TREATMENT

The treatment is the same as with epidermoid cysts. Because the cyst wall of these tumors is typically less adherent to the surrounding stroma than epidermoid cysts, it is possible to extract the lesion through a small incision made with a dermal punch trephine.

MILIUM

ETIOLOGY AND PATHOGENESIS

Milia are thought to result from pilosebaceous or eccrine sweat duct plugging. These superficial lesions can be primary or secondary, with the latter resulting from injury to the basement membrane of the skin. Secondary lesions are common in patients with burns, in subepidermal blistering diseases such as epidermolysis bullosa and porphyria, after dermabrasion or ablative laser resurfacing, or in conjunction with topical therapy such as glucocorticoid therapy or 5-fluorouracil treatment.[66-69]

CLINICAL FEATURES

Milia are 1- to 2-mm, white, domed papules commonly located on the cheeks and eyelids of adults (Fig. 108-22). In infants, milia are common on the face and the mucosa. Epstein pearls are milia on the palate. Eruptive milia have been reported, though this is a rare

Figure 108-22 Primary milium. A 3-mm, hard, seedlike white papule.

occurrence.[69] Milia en plaque is a plaque-type, inflammatory variant of milia that is commonly located on the ear.[70] Acquired milia can be located anywhere the predisposing trauma or other factors have occurred.

EPIDEMIOLOGY

Milia are common congenital and acquired lesions in both infants and adults. Men and women are affected equally.

DIFFERENTIAL DIAGNOSIS

Closed comedones may appear clinically similarly in isolation, but comedones are more likely to contain a mixture of bacteria, keratinaceous debris, and hair shaft fragments.

HISTOPATHOLOGY

Milia are minute epidermoid cysts, lined by stratified squamous epithelium and filled with keratin. Occasionally, a connection to eccrine ducts or vellus hair follicles may be observed. Bacteria are not usually present.

TREATMENT

Congenital milia tend to spontaneously resolve. Acquired milia can resolve spontaneously as well but can also be removed by disrupting the overlying epidermis with light electro-desiccation or incision followed by expression of the keratin contents.

STEATOCYSTOMA

ETIOLOGY AND PATHOGENESIS

Steatocystoma multiplex (sebocystomatosis, epidermal polycystic disease) can be a sporadic or autosomal-dominant disorder. These lesions can also be found in syndromes such as Alagille syndrome and pachyonychia congenita type II. In the latter, lesions are associated with mutations in K17. Sporadic solitary lesions are termed *steatocystoma simplex*.

CLINICAL FEATURES

These lesions present as asymptomatic, yellow or skin-colored dermal papules or cysts located most commonly on the trunk, upper arms, scrotum, or chest (Fig. 108-23). Oily material can be expressed from these lesions when incised. These lesions can become infected and suppurate, resulting in sinus formation and scarring.

EPIDEMIOLOGY

It is relatively rare, and the true incidence is unknown. The average age of onset is 26 years old, with no sex predilection.[71]

DIFFERENTIAL DIAGNOSIS

Eruptive vellus hair cysts can mimic steatocystoma multiplex clinically. They may have a tuft of hairs protruding from the cyst centrally, with findings of vellus hairs in the lumen with follicles in the wall. Epidermal inclusion cysts also have to be excluded. The pathogenesis of steatocystoma, epidermal inclusion cysts, and eruptive vellus hair cysts may be similar.[72]

HISTOPATHOLOGY

The cyst walls of steatocystoma multiplex are composed of stratified, squamous epithelium with an

Figure 108-23 Steatocystoma multiplex. Multiple skin-colored cystic lesions on the trunk.

absent granular layer and an eosinophilic cuticle on the luminal side. Sebaceous glands are characteristically located in the cyst wall, and keratin, oil, and hairs are typically found in the lumen.

TREATMENT

Simple excision or drainage with manual removal of the cyst wall may facilitate the clinical resolution of lesions.[73,74] Inflamed lesions have been reported to respond to intralesional steroids, carbon dioxide laser, oral retinoids, or cryotherapy.[75]

DERMOID CYST

ETIOLOGY AND PATHOGENESIS

Dermoid cysts are epithelial-lined cysts containing various appendageal structures resulting from retained epithelium along embryonic fusion planes. These cysts are either congenital or develop in childhood.

CLINICAL FEATURES

Dermoid cysts are smooth, can occur in the midline, and commonly possess a deep sinus tract that connects to the epidermis. They can measure between 1 cm and 4 cm and are most commonly located on the forehead, lateral eye, or neck.[76,77] A superficial dermoid cyst located on the dorsal nose is referred to as fistula of the dorsum of the nose and is characterized by a central tuft of hair or communication intracranially. Dermoid cysts can be located deep in the subcutaneous tissue, intracranially, or intraorbitally.[78] Infections, rupture, and abscess formation from the manipulation of these cysts can potentially lead to serious complications.

EPIDEMIOLOGY

The prevalence is equal in men and women.

DIFFERENTIAL DIAGNOSIS

The differential diagnosis of dermoid cysts includes gliomas, encephaloceles, hemangiomas, soft tissue sarcomas, and other epidermal cysts such as branchial cleft cysts and thyroglossal duct cysts.

HISTOPATHOLOGY

Cysts are lined by stratified squamous epithelium and typically contain keratin and hairs. Adnexal structures are characteristically present in the cyst walls and may include pilosebaceous units, apocrine or eccrine glands, smooth muscle bundles, or goblet cells.

TREATMENT

Imaging studies that help to characterize the extent of the tumor are necessary before excision is undertaken. Consultation with neurosurgery, otolaryngology, or plastic surgery may be indicated.

BRANCHIAL CYST (BRANCHIAL CLEFT CYST)

ETIOLOGY AND PATHOGENESIS

Sequestration of first or second branchial cleft membranes results in these cysts, sinuses, or tags.

CLINICAL FEATURES

These asymptomatic lesions are often located along the angle of the mandible if arising from the first branchial cleft and the middle to lower third of the anterior border of the sternocleidomastoid in cases arising from the second branchial cleft. They may present after an upper respiratory infection as a painful mass. These lesions tend to drain internally, but communication with the epidermis can occur. Branchial cysts may become complicated by infection.

EPIDEMIOLOGY

Branchial cleft cysts are largely sporadic, but autosomal-dominant cases have been reported. There is no gender predominance. Ten percent of lesions are bilateral.

DIFFERENTIAL DIAGNOSIS

Branchial cleft cysts are can be distinguished from bronchogenic cysts by their lateral location and by histologic features, namely the presence of lymphoid follicles and the lack of smooth muscle in the cyst walls.

HISTOPATHOLOGY

Branchial cleft cysts are lined with epithelium containing a lymphocytic infiltrate and lymphoid follicles are common. Mucous glands may be found in the walls, and in these cases, the cyst contents are often mucinous.

TREATMENT

Excision is the treatment of choice. Infected cysts may require incision and drainage or antibiotic therapy.

PREAURICULAR CYST AND SINUS (CONGENITAL AURICULAR FISTULA, EAR PITS)

ETIOLOGY AND PATHOGENESIS

Preauricular cysts or sinuses are congenital epithelial invaginations. They are thought to reflect a local defect in embryonic fusion planes. They are often sporadic but may also be inherited as an autosomal-dominant trait with variable expression. They have been associated with branchial cleft anomalies and hearing and renal abnormalities.[79]

CLINICAL FEATURES

Ear pits are located in the preauricular area near the ascending limb of the helix. They can be unilateral or bilateral and are more common on the right side.

EPIDEMIOLOGY

They occur in approximately 1% of infants, with a higher incidence in certain African regions.[79]

HISTOPATHOLOGY

Ear pits are lined by stratified squamous epithelium and often show overlying hyperkeratosis.

TREATMENT

Assessment for hearing loss or associated syndromes should be completed. Simple excision may be performed if eradication of the pit is desired.

ACKNOWLEDGMENTS

This chapter was revised and updated from the former version written by Valencia D. Thomas, Nicholas R. Snavely, Ken K. Lee, and Neil A. Swanson, and we thank them for their contribution.

REFERENCES

1. Li X, Zhu W. A case of seborrheic keratosis distributed along skin cleavage lines. *J Dermatol*. 1998;25(4):272-274.
2. Mabuchi T, Akasaka E, Kondoh A, et al. Seborrheic keratosis that follows Blaschko's lines. *J Dermatol*. 2008;35(5):301-303.
3. Schwartz RA. Sign of Leser-Trelat. *J Am Acad Dermatol*. 1996;35(1):88-95.
4. Schwengle LE, Rampen FH. Eruptive seborrheic keratoses associated with erythrodermic pityriasis rubra pilaris. Possible role of retinoid therapy. *Acta Derm Venereol*. 1988;68(5):443-445.
5. Inamadar AC, Palit A. Eruptive seborrhoeic keratosis in human immunodeficiency virus infection: a coincidence or "the sign of Leser-Trelat"? *Br J Dermatol*. 2003;149(2):435-436.
6. Patton T, Zirwas M, Nieland-Fisher N, et al. Inflammation of seborrheic keratoses caused by cytarabine: a pseudo sign of Leser-Trelat. *J Drugs Dermatol*. 2004;3(5):565-566.
7. Cascajo CD, Reichel M, Sanchez JL. Malignant neoplasms associated with seborrheic keratoses. An analysis of 54 cases. *Am J Dermatopathol*. 1996;18(3):278-282.
8. Vun Y, De'Ambrosis B, Spelman L, et al. Seborrhoeic keratosis and malignancy: collision tumour or malignant transformation? *Australas J Dermatol*. 2006;47(2):106-108.
9. Yeatman JM, Kilkenny M, Marks R. The prevalence of seborrhoeic keratoses in an Australian population: does exposure to sunlight play a part in their frequency? *Br J Dermatol*. 1997;137(3):411-414.
10. Nakamura H, Hirota S, Adachi S, et al. Clonal nature of seborrheic keratosis demonstrated by using the polymorphism of the human androgen receptor locus as a marker. *J Invest Dermatol*. 2001;116(4):506-510.
11. Hafner C, Lopez-Knowles E, Luis NM, et al. Oncogenic PIK3CA mutations occur in epidermal nevi and seborrheic keratoses with a characteristic mutation pattern. *Proc Natl Acad Sci U S A*. 2007;104(33):13450-13454.
12. Hafner C, Toll A, Fernández-Casado A, et al. Multiple oncogenic mutations and clonal relationship in spatially distinct benign human epidermal tumors. *Proc Natl Acad Sci U S A*. 2010;107(48):20780-5.
13. Manaka L, Kadono S, Kawashima M, et al. The mechanism of hyperpigmentation in seborrhoeic keratosis involves the high expression of endothelin-converting enzyme-1alpha and TNF-alpha, which stimulate secretion of endothelin 1. *Br J Dermatol*. 2001;145(6):895-903.
14. Li YH, Chen G, Dong XP, et al. Detection of epidermodysplasia verruciformis-associated human papillomavirus DNA in nongenital seborrhoeic keratosis. *Br J Dermatol*. 2004;151(5):1060-1065.
15. Tardio JC, Bancalari E, Moreno A, et al. Genital seborrheic keratoses are human papillomavirus-related lesions. A linear array genotyping test study. *APMIS*. 2012;120(6):477-483.
16. Meyerson LB. A peculiar papulosquamous eruption involving pigmented nevi. *Arch Dermatol*. 1971;103(5):510-512.
17. Tsuji T, Morita A. Giant seborrheic keratosis on the frontal scalp treated with topical fluorouracil. *J Dermatol*. 1995;22(1):74-75.
18. Pepper E. Dermabrasion for the treatment of a giant seborrheic keratosis. *J Dermatol Surg Oncol*. 1985;11(6):646-647.
19. Valerio E, Giordano C, Mameli S, et al. Facial lichen striatus. *Arch Dis Child*. 2016;101(12):1148.
20. Tosti A, Peluso AM, Misciali C, et al. Nail lichen striatus: clinical features and long-term follow-up of five patients. *J Am Acad Dermatol*. 1997;36(6 Pt 1):908-913.
21. Patrizi A, Neri I, Fiorentini C, et al. Lichen striatus: clinical and laboratory features of 115 children. *Pediatr Dermatol*. 2004;21(3):197-204.
22. Kus S, Ince U. Lichen striatus in an adult patient treated with pimecrolimus. *J Eur Acad Dermatol Venereol*. 2006;20(3):360-361.

23. Sorgentini C, Allevato MA, Dahbar M, et al. Lichen striatus in an adult: successful treatment with tacrolimus. *Br J Dermatol*. 2004;150(4):776-777.
24. Degos R, Delort J, Civatte J, et al. Epidermal tumor with an unusual appearance: clear cell acanthoma. *Ann Dermatol Syphiligr (Paris)*. 1962;89:361-371.
25. Ohnishi T, Watanabe S. Immunohistochemical characterization of keratin expression in clear cell acanthoma. *Br J Dermatol*. 1995;133(2):186-193.
26. Finch TM, Tan CY. Clear cell acanthoma developing on a psoriatic plaque: further evidence of an inflammatory aetiology? *Br J Dermatol*. 2000;142(4):842-844.
27. Murphy R, Kesseler ME, Slater DN. Giant clear cell acanthoma. *Br J Dermatol*. 2000;143(5):1114-1115.
28. Blum A, Metzler G, Bauer J, et al. The dermatoscopic pattern of clear-cell acanthoma resembles psoriasis vulgaris. *Dermatology*. 2001;203(1):50-52.
29. Santa Cruz DJ. Chondrodermatitis nodularis helicis: a transepidermal perforating disorder. *J Cutan Pathol*. 1980;7(2):70-76.
30. Magro CM, Frambach GE, Crowson AN. Chondrodermatitis nodularis helicis as a marker of internal disease [corrected] associated with microvascular injury. *J Cutan Pathol*. 2005;32(5):329-333.
31. Elgart ML. Cell phone chondrodermatitis. *Arch Dermatol*. 2000;136(12):1568.
32. Goette DK. Chondrodermatitis nodularis chronica helicis: a perforating necrobiotic granuloma. *J Am Acad Dermatol*. 1980;2(2):148-154.
33. Shah S, Fiala KH. Chondrodermatitis nodularis helicis: a review of current therapies. *Dermatol Ther*. 2017;30(1).
34. Brandling-Bennett HA, Morel KD. Epidermal nevi. *Pediatr Clin North Am*. 2010;57(5):1177-1198.
35. Happle R. The group of epidermal nevus syndromes Part I. Well defined phenotypes. *J Am Acad Dermatol*. 2010;63(1):1-22; quiz 23-24.
36. Khachemoune A, Janjua SA, Guldbakke KK. Inflammatory linear verrucous epidermal nevus: a case report and short review of the literature. *Cutis*. 2006;78(4):261-267.
37. Hafner C, Toll A, Gantner S, et al. Keratinocytic epidermal nevi are associated with mosaic RAS mutations. *J Med Genet*. 2012;49(4):249-253.
38. Hafner C, van Oers JM, Vogt T, et al. Mosaicism of activating FGFR3 mutations in human skin causes epidermal nevi. *J Clin Invest*. 2006;116(8):2201-2207.
39. Toll A, Fernandez LC, Pons T, et al. Somatic embryonic FGFR2 mutations in keratinocytic epidermal nevi. *J Invest Dermatol*. 2016;136(8):1718-1721.
40. Paller AS, Syder AJ, Chan YM, et al. Genetic and clinical mosaicism in a type of epidermal nevus. *N Engl J Med*. 1994;331(21):1408-1415.
41. Muller CS, Schmaltz R, Vogt T, et al. Lichen striatus and blaschkitis: reappraisal of the concept of blaschkolinear dermatoses. *Br J Dermatol*. 2011;164(2):257-262.
42. Happle R. Linear psoriasis and ILVEN: is lumping or splitting appropriate? *Dermatology*. 2006;212(2):101-102.
43. Messerschmidt A, Wolter M, Ter-Nedden J, et al. Multiple basal cell carcinomas arising in an epidermal nevus. *J Dtsch Dermatol Ges*. 2016;14(11):1133-1135.
44. Kim R, Marmon S, Kaplan J, et al. Verrucous epidermal nevus. *Dermatol Online J*. 2013;19(12):20707.
45. Aslam A, Salam A, Griffiths CE, et al. Naevus sebaceus: a mosaic RASopathy. *Clin Exp Dermatol*. 2014;39(1):1-6.
46. Moody MN, Landau JM, Goldberg LH. Nevus sebaceous revisited. *Pediatr Dermatol*. 2012;29(1):15-23.
47. Groesser L, Herschberger E, Ruetten A, et al. Postzygotic HRAS and KRAS mutations cause nevus sebaceous and Schimmelpenning syndrome. *Nat Genet*. 2012;44(7):783-787.
48. Happle R. Nevus sebaceus is a mosaic RASopathy. *J Invest Dermatol*. 2013;133(3):597-600.
49. Levinsohn JL, Tian LC, Boyden LM, et al. Whole-exome sequencing reveals somatic mutations in HRAS and KRAS, which cause nevus sebaceus. *J Invest Dermatol*. 2013;133(3):827-830.
50. Idriss MH, Elston DM. Secondary neoplasms associated with nevus sebaceus of Jadassohn: a study of 707 cases. *J Am Acad Dermatol*. 2014;70(2):332-337.
51. Rosen H, Schmidt B, Lam HP, et al. Management of nevus sebaceous and the risk of Basal cell carcinoma: an 18-year review. *Pediatr Dermatol*. 2009;26(6):676-681.
52. Patel P, Malik K, Khachemoune A. Sebaceus and Becker's nevus: overview of their presentation, pathogenesis, associations, and treatment. *Am J Clin Dermatol*. 2015;16(3):197-204.
53. Ferrari B, Taliercio V, Restrepo P, et al. Nevus comedonicus: a case series. *Pediatr Dermatol*. 2015;32(2):216-219.
54. Lindhurst MJ, Sapp JC, Teer JK, et al. A mosaic activating mutation in AKT1 associated with the Proteus syndrome. *N Engl J Med*. 2011;365(7):611-619.
55. Happle R. Type 2 segmental Cowden disease vs. proteus syndrome. *Br J Dermatol*. 2007;156(5):1089-1090.
56. Martinez-Lopez A, Blasco-Morente G, Perez-Lopez I, et al. CLOVES syndrome: review of a PIK3CA-related overgrowth spectrum (PROS). *Clin Genet*. 2017;91(1):14-21.
57. Ohnishi T, Watanabe S. Immunohistochemical analysis of cytokeratin expression in multiple eccrine hidrocystoma. *J Cutan Pathol*. 1999;26(2):91-94.
58. Baker BR, Mitchell DF. The Pathogenesis of Epidermoid Implantation Cysts. *Oral Surg Oral Med Oral Pathol*. 1965;19:494-501.
59. Smirniotopoulos JG, Chiechi MV. Teratomas, dermoids, and epidermoids of the head and neck. *Radiographics*. 1995;15(6):1437-1455.
60. Lee S, Lee W, Chung S, et al. Detection of human papillomavirus 60 in epidermal cysts of nonpalmoplantar location. *Am J Dermatopathol*. 2003;25(3):243-247.
61. Kashima M, Takahama H, Baba T, et al. Detection of human papillomavirus type 57 in the tissue of a plantar epidermoid cyst. *Dermatology*. 2003;207(2):185-187.
62. Delacretaz J. Keratotic basal-cell carcinoma arising from an epidermoid cyst. *J Dermatol Surg Oncol*. 1977;3(3):310-311.
63. Shelley WB, Wood MG. Occult Bowen's disease in keratinous cysts. *Br J Dermatol*. 1981;105(1):105-108.
64. Lopez-Rios F, Rodriguez-Peralto JL, Castano E, et al. Squamous cell carcinoma arising in a cutaneous epidermal cyst: case report and literature review. *Am J Dermatopathol*. 1999;21(2):174-177.
65. Leppard BJ, Sanderson KV. The natural history of trichilemmal cysts. *Br J Dermatol*. 1976;94(4):379-390.
66. Hisa T, Goto Y, Taniguchi S, et al. Post-bullous milia. *Australas J Dermatol*. 1996;37(3):153-154.
67. Iacobelli D, Hashimoto K, Kato I, et al. Clobetasol-induced milia. *J Am Acad Dermatol*. 1989;21(2 Pt 1):215-217.
68. Tsuji T, Kadoya A, Tanaka R, et al. Milia induced by corticosteroids. *Arch Dermatol*. 1986;122(2):139-140.
69. Diba VC, Al-Izzi M, Green T. A case of eruptive milia. *Clin Exp Dermatol*. 2005;30(6):677-678.
70. Stefanidou MP, Panayotides JG, Tosca AD. Milia en plaque: a case report and review of the literature. *Dermatol Surg*. 2002;28(3):291-295.

71. Cho S, Chang SE, Choi JH, et al. Clinical and histologic features of 64 cases of steatocystoma multiplex. *J Dermatol*. 2002;29(3):152-156.
72. Yamada A, Saga K, Jimbow K. Acquired multiple pilosebaceous cysts on the face having the histopathological features of steatocystoma multiplex and eruptive vellus hair cysts. *Int J Dermatol*. 2005;44(10):861-863.
73. Keefe M, Leppard BJ, Royle G. Successful treatment of steatocystoma multiplex by simple surgery. *Br J Dermatol*. 1992;127(1):41-44.
74. Krahenbuhl A, Eichmann A, Pfaltz M. CO2 laser therapy for steatocystoma multiplex. *Dermatologica*. 1991;183(4):294-296.
75. Apaydin R, Bilen N, Bayramgurler D, et al. Steatocystoma multiplex suppurativum: oral isotretinoin treatment combined with cryotherapy. *Australas J Dermatol*. 2000;41(2):98-100.
76. Pryor SG, Lewis JE, Weaver AL, et al. Pediatric dermoid cysts of the head and neck. *Otolaryngol Head Neck Surg*. 2005;132(6):938-942.
77. Weedon D, Strutton G. *Skin Pathology*. 2nd ed. London: Churchill Livingstone; 2002.
78. Golden BA, Zide MF. Cutaneous cysts of the head and neck. *J Oral Maxillofac Surg*. 2005;63(11):1613-1619.
79. Scheinfeld NS, Silverberg NB, Weinberg JM, et al. The preauricular sinus: a review of its clinical presentation, treatment, and associations. *Pediatr Dermatol*. 2004;21(3):191-196.

Chapter 109 :: Appendage Tumors of the Skin

:: Ruth K. Foreman & Lyn McDivitt Duncan

AT-A-GLANCE

- Cutaneous appendage tumors are classified into eccrine, apocrine, follicular, and sebaceous entities, and can be benign or malignant.
- Clinically, appendage tumors are dermally based, usually with minimal epidermal change, and histopathologic evaluation is necessary to make a diagnosis.
- Certain appendage tumors can serve as markers for genetic diseases and syndromes.

Cutaneous appendage (adnexal) tumors encompass both benign and malignant neoplasms and have been traditionally classified by their line of differentiation toward normal adnexal structures of the skin: eccrine, apocrine, follicular, and sebaceous (Table 109-1).[1-3] Many specific types of appendage tumors have been described, and rather than providing an exhaustive list, this chapter focuses on the more common and/or clinically significant tumors. In general, with some exceptions, appendage tumors are relatively rare. Benign appendage tumors have no potential to metastasize, whereas malignant appendage tumors do. There is also a subset of tumors that may be locally aggressive but are not associated with metastasis. Appendage tumors may occur sporadically or may serve as markers of rare genetic syndromes, including Muir-Torre syndrome, Cowden syndrome, Birt-Hogg-Dubé syndrome, and Brooke-Spiegler syndrome. We describe the clinical and histopathologic features with an emphasis on differential diagnosis and tumor biology.

The clinical presentation of appendage tumors is most commonly that of solitary or multiple dermal papule(s) or nodule(s), with minimal overlying epidermal changes. The tumors may appear skin-colored, pink, or with a bluish hue. The presence of a hair follicle orifice or other central punctum may be seen. Some appendage tumors have specific site or age predilections, which may help in the differential diagnosis. Although the patient's age, gender, site of presentation, and clinical morphology may lead one to suspect an appendage tumor, biopsy with subsequent histopathology is usually required for diagnosis. Careful review of routinely processed hematoxylin-and-eosin–stained slides is often the most important part in making the diagnosis of an appendage tumor. An adequate sample is necessary given the heterogeneity of many tumors and the histologic overlap between appendage neoplasms. Furthermore, analysis of the architecture is often necessary in diagnosing appendage tumors, especially when distinguishing between benign and malignant neoplasms. Immunohistochemistry is used sparingly, only in certain instances, and often as a panel, as the cell types that compose these neoplasms are closely related and often express the same markers. Molecular testing (including cytogenetics, fluorescence in situ hybridization, and sequence analysis), is currently used primarily for research purposes, but its use in diagnosis may be become more important in the future. Some tumors are associated with specific genetic abnormalities that may assist in identifying tumors in the setting of a clinical syndrome.[4] Table 109-2 lists appendage neoplasms that are associated with genetic syndromes.

Eccrine and apocrine tumors display a range of secretory and ductal differentiation, follicular tumors show differentiation toward different components of the hair follicle, and sebaceous neoplasms display sebaceous differentiation.[1-3] Although eccrine, apocrine, and sebaceous tumors may all display ductal differentiation, this is most commonly observed in eccrine tumors, perhaps because the normal eccrine duct is much longer, extending from the eccrine coil to the epidermis, in contrast to the apocrine and sebaceous ducts which are rather short and merely connect these adnexal units to the adjacent hair follicle. The folliculosebaceous apocrine unit develops separately from the eccrine unit during embryonic development (see Chaps. 6 and 7 for detailed descriptions of the biology of normal sweat glands and hair follicles). While this may imply that eccrine neoplasms share no features of follicular, sebaceous, or apocrine differentiation, this is not always true, and some appendage tumors can show mixed differentiation and metaplasia.

In some cases, the histopathologic diagnosis of appendage tumors is straightforward, but many factors can make it difficult to precisely classify them[5]: (a) their relative rarity means that clinicians are not always familiar with them; (b) histopathologically similar appendage tumors may have many synonyms, being reported by distinct observers who have used divergent descriptive terminology; (c) tumor heterogeneity/mixed differentiation of some tumors can make it impossible to assign a tumor to a specific line of differentiation; (d) small biopsies can hamper the ability to visualize the majority of the tumor; and (e) there is significant histopathologic and immunophenotypic overlap, making it difficult, in some cases, to place the tumor in a specific diagnostic category. Because appendage tumors are neoplasms that form as aberrant proliferations derived from normal adnexal structures, there is understandably a spectrum of tumors, including a subset that will be impossible to definitively classify. Fortunately, most can be specifically

TABLE 109-1

Classification of Cutaneous Appendage Tumors

DIFFERENTIATION	BENIGN	MALIGNANT
Eccrine 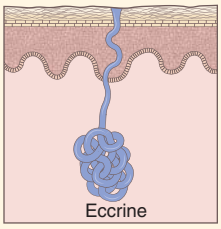	▪ Hidradenoma ▪ Poroma ▪ Cylindroma ▪ Spiradenoma ▪ Syringoma	▪ Hidradenocarcinoma ▪ Porocarcinoma ▪ Cylindrocarcinoma/spiradenocarcinoma ▪ Digital papillary adenocarcinoma ▪ Microcystic adnexal carcinoma
Apocrine 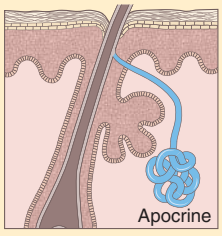	▪ Hidrocystoma ▪ Apocrine mixed tumor ▪ Syringocystadenoma papilliferum ▪ Tubular adenoma ▪ Hidradenoma papilliferum ▪ Nipple adenoma	▪ Adenoid cystic carcinoma ▪ Apocrine adenocarcinoma ▪ Mucinous carcinoma
Follicular 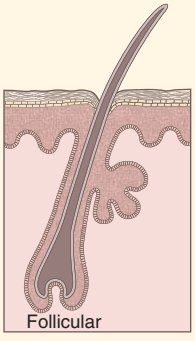		
Pan-follicular	▪ Trichofolliculoma	
Follicular germinative cells		▪ Basal cell carcinoma (see Chap. 111)
Follicular germinative and follicular stromal cells	▪ Trichoblastoma ▪ Trichoepithelioma ▪ Desmoplastic trichoepithelioma	
Follicular mesenchymal differentiation	▪ Trichodiscoma (fibrofolliculoma)	
Matrical	▪ Pilomatricoma (pilomatrixoma)	▪ Pilomatrical carcinoma
Bulb/stem outer root sheath differentiation	▪ Trichilemmoma	
Isthmic outer root sheath	▪ Tumor of follicular infundibulum ▪ Pilar sheath acanthoma ▪ Proliferating pilar tumor	
Infundibular	▪ Trichoadenoma ▪ Dilated pore (of Winer)	
Sebaceous 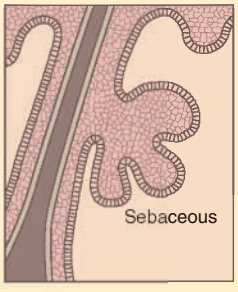	▪ Sebaceous adenoma ▪ Sebaceoma/sebaceous epithelioma	▪ Sebaceous carcinoma

TABLE 109-2
Genetic Syndromes Associated with Appendage Neoplasms

GENETIC SYNDROME	APPENDAGE NEOPLASM (S)	GENE (S)	LOCATION
Brooke-Spiegler	Cylindroma, Spiradenoma, Cylindrocarcinoma/ Spiradenocarcinoma	*CYLD1*	16q12-13
Multiple familial trichoepitheliomas	Multiple trichoepitheliomas, Cylindroma	*CYLD1*	16q12-13
Rombo	Multiple trichoepitheliomas	Unknown	Unknown
Bazex-Dupré-Christol	Multiple trichoepitheliomas	Unknown	Xq24-q27
Schöpf-Schulz-Passarge	Multiple hidrocystomas	*WNT10A*	2q35
Goltz-Gorlin	Multiple hidrocystomas	*PORCN*	Xp11
Birt-Hogg-Dubé	Trichodiscoma/fibrofolliculoma	*FLCN* (folliculin)	17p11
Gardner	Pilomatricoma	*CTNNB1* (β-catenin)	3p21
Myotonic muscular dystrophy	Pilomatricoma	*DMPK or CNBP*	19q13, 3q21
Rubinstein-Taybi	Pilomatricoma	*CREBBP, EP300*	16p13, 22q13
Cowden	Trichilemmoma (with mucosal involvement)	*PTEN*	10q23
Keratitis, ichthyosis, and deafness (KID)	Proliferating pilar tumor	*GJB2* (connexin 26)	13q12
Muir-Torre	Sebaceous adenoma (especially at sites other than head and neck), sebaceoma, sebaceous carcinoma	*MLH1, MSH2, MSH6, PMS2*	3p21, 2p21, 2p16, 7p22

diagnosed according to the patterns of appendage differentiation displayed by the neoplasm.

The histopathologic diagnosis of appendage tumors is important not only to distinguish the benign from the malignant, but also to identify those that are associated with genetic syndromes that have significant clinical implications for the patient, even if the tumor itself is benign. In addition to arriving at a specific diagnosis, the aim of histopathologic evaluation is to identify the line(s) of differentiation and determine whether the tumor is benign or malignant, and either low or high grade. This can help to further guide treatment.

Benign appendage tumors can be carefully monitored clinically, surgically excised or treated with ablative therapies, such as electrodessication and cryotherapy. Malignant tumors are usually surgically excised, typically by conventional or Mohs micrographic techniques.

TUMORS WITH ECCRINE DIFFERENTIATION

Normal eccrine glands are found everywhere in the body, but are present in larger numbers on the palms and soles. The normal eccrine unit is composed of a secretory coil located in the deep reticular dermis, and a duct that connects the secretory coil to the overlying epidermis and provides an exit path for eccrine secretions to the skin surface. The ductal portion is divided into the straight dermal portion and the spiraled, intraepidermal portion termed the acrosyringium.[1,2] (See Chap. 6 for a full discussion of normal sweat glands.) The secretory coil is composed of eccrine glands with luminal cells surrounded by myoepithelial cells, whereas the ductal structure is manifest by cuboidal epithelial cells. Eccrine tumors show a range of differentiation from the clear cell patterns derived from the secretory component to more keratinized structures derived from the ductal portion, often with obvious duct formation. These tumors also characteristically are surrounded by eosinophilic stromal deposits of basement membrane-like material. Table 109-3 lists appendage tumors with eccrine differentiation.

BENIGN

HIDRADENOMA

Hidradenoma has historically been referred to by multiple names, including nodular hidradenoma, eccrine acrospiroma, and clear-cell hidradenoma. The largest initial series of hidradenomas was published by Johnson and Helwig in 1969, which detailed clinical and histologic features of 319 tumors.[6]

TABLE 109-3
Eccrine Appendage Neoplasms

BENIGN	MALIGNANT
Hidradenoma	Hidradenocarcinoma
Poroma	Porocarcinoma
Cylindroma	Cylindrocarcinoma
Spiradenoma	Spiradenocarcinoma
Syringoma	Digital papillary adenocarcinoma
	Microcystic adnexal carcinoma

Epidemiology and Clinical Features: Hidradenomas are relatively common, benign appendage neoplasms that occur in patients over a wide age range, with an average age in the fifth decade.[1,6] They present in women and men, and while hidradenomas can occur at all anatomic sites, the head and neck region and trunk are involved in approximately 50% of cases.[1,6] Hidradenoma presents as a solitary dermal nodule that can be solid and/or cystic, and ranges from flesh-colored to red to bluish in color (Fig. 109-1A). Hidradenomas are reported to be between 0.5 and 10.5 cm, with a median of 1 cm.[6]

Etiology and Pathogenesis: Recent studies have found that 50% of hidradenomas carry a t(11;19) translocation resulting in a fusion between the *MECT1 (TORC1, CRTC1)* gene at chromosome 19p13 and the *MAML2* gene located at chromosome 11q21.[7,8] This is the same translocation identified in salivary gland mucoepidermoid carcinomas and is hypothesized to promote tumorigenesis by inducing *cAMP/CREB* target genes.

Histopathology: Microscopically, hidradenoma is a circumscribed, unencapsulated dermal neoplasm that displays solid and solid/cystic growth patterns with ductal differentiation (see Fig. 109-1B, C). Numerous cells types can be observed within hidradenomas, including clear, epidermoid (squamoid), mucinous, oncocytic, and eosinophilic polyhedral cells.[1,6] Sclerotic or hyalinized stroma also can be seen, but is usually focal. Atypical hidradenomas have been documented and, as their name implies, show focal areas of atypia, including lack of circumscription, nuclear pleomorphism, focal necrosis, and increased mitotic activity.[9]

Differential Diagnosis: The clinical differential diagnosis of hidradenoma includes cysts and other dermal cutaneous neoplasms. Histologically, hidradenoma with prominent squamous differentiation can be confused with conventional squamous cell carcinoma, although squamous cell carcinoma does not display ductal differentiation. Ductal differentiation and sclerotic stroma can be confused with invasive adenocarcinoma, although they are usually focally present within hidradenomas. Hidradenoma with prominent clear cells can imitate metastatic renal cell carcinoma.

Clinical Course and Prognosis: Hidradenoma is a benign neoplasm. Local recurrence is approximately 10% if not completely excised,[2] and more frequently occurs in atypical hidradenomas.[9] Malignant transformation to hidradenocarcinoma is a rare event, but can occur (see the section "Hidradenocarcinoma").

Management: Complete excision with clear margins is recommended, given the risk of recurrence.

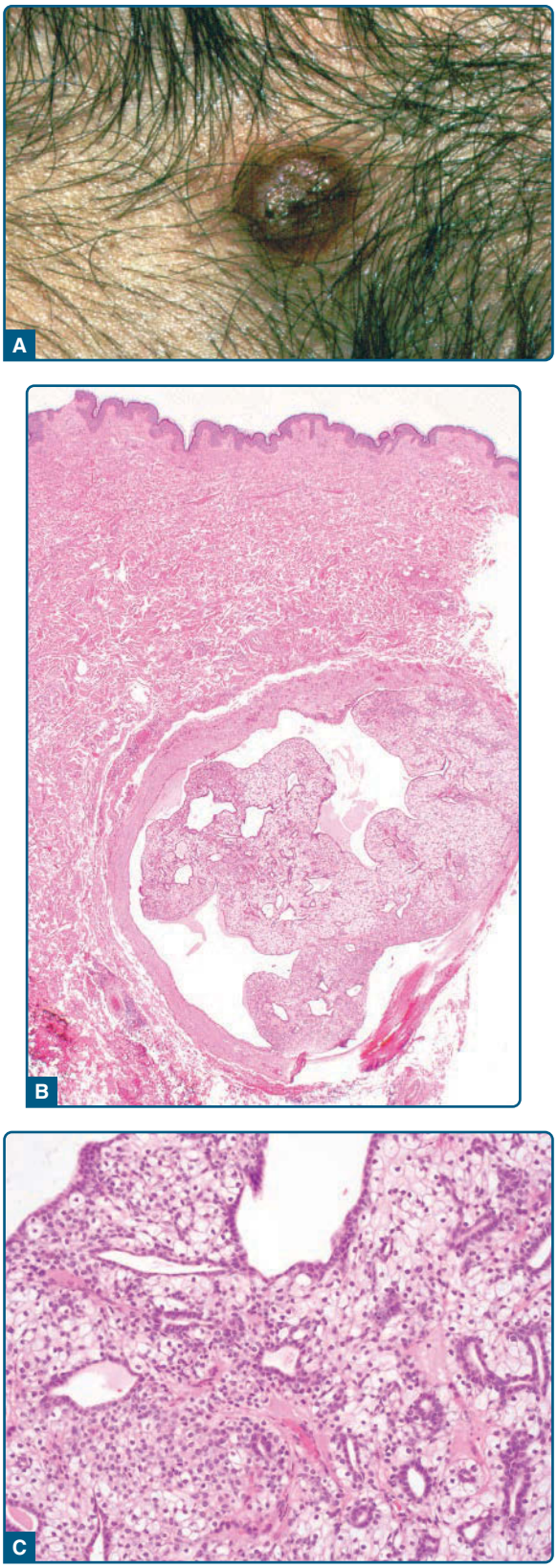

Figure 109-1 **A,** Hidradenoma is a solitary, indistinct dermal nodule. **B,** The tumor is a circumscribed, nonencapsulated, solid and cystic dermal neoplasm. **C,** Hidradenoma is composed of clear cells and cells with ductal and glandular differentiation. (Image **A,** used with permission from Dr. Ernesto Gonzalez, MD, Boston, MA, USA.)

POROMA

Poroma is a benign eccrine neoplasm initially described by Pinkus and colleagues in 1956,[10] and is further subclassified into a group of 4 entities: poroma,

hidroacanthoma simplex, dermal duct tumor, and poroid hidradenoma.[1,2]

Epidemiology and Clinical Features: Poroma affects middle-aged to elderly patients, with an average age of 55 to 57 years, and with an equal sex predilection. Hidroacanthoma simplex more commonly affects patients in their sixth decade. Classic poroma presents as a single, flesh-colored to red papule or nodule, sometimes surrounded by an epidermal rim (Fig. 109-2A). It occurs most commonly on acral surfaces, but also has been documented at other anatomic sites. Hidroacanthoma simplex presents as a verrucous or flat plaque most commonly on the trunk. Dermal duct tumor is a flesh-colored dermal papule and also occurs commonly on the trunk. Poroid hidradenoma presents as a dermal or subcutaneous nodule with pink, red, or blue coloration and is frequently found on the trunk. By dermoscopy, poromas can show a leaf-and-flower–like vascular pattern with interlacing white cords.[11]

Histopathology: Microscopically, classic poromas are relatively well-circumscribed endophytic proliferations of cuboidal cells with basophilic round nuclei and eosinophilic cytoplasm with extension from the epidermis into the dermis (see Fig. 109-2B). Ductal differentiation is variably present and is lined by an eosinophilic cuticle (see Fig. 109-2C). Epithelial membrane antigen (EMA) and carcinoembryonic antigen (CEA) immunostains can be used to highlight duct formation within the tumor. The other poroma variants are categorized based on their location in the skin. Hidroacanthoma simplex is located intraepidermally.

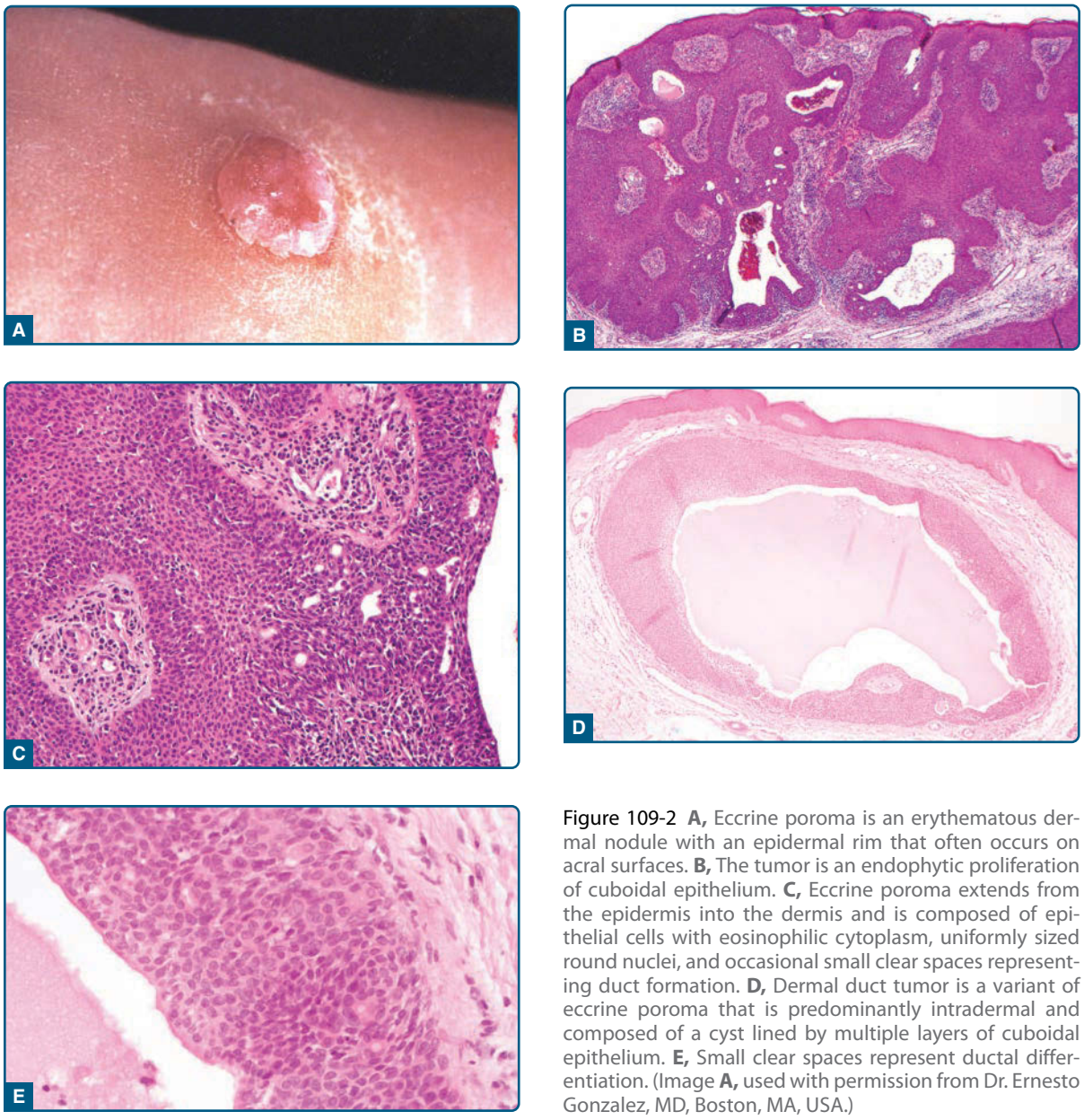

Figure 109-2 **A,** Eccrine poroma is an erythematous dermal nodule with an epidermal rim that often occurs on acral surfaces. **B,** The tumor is an endophytic proliferation of cuboidal epithelium. **C,** Eccrine poroma extends from the epidermis into the dermis and is composed of epithelial cells with eosinophilic cytoplasm, uniformly sized round nuclei, and occasional small clear spaces representing duct formation. **D,** Dermal duct tumor is a variant of eccrine poroma that is predominantly intradermal and composed of a cyst lined by multiple layers of cuboidal epithelium. **E,** Small clear spaces represent ductal differentiation. (Image **A,** used with permission from Dr. Ernesto Gonzalez, MD, Boston, MA, USA.)

Dermal duct tumor is composed of intradermal clusters with duct formation (see Fig. 109-2D, E). Poroid hidradenoma is an intradermal proliferation with both solid and cystic areas.

Differential Diagnosis: The histologic differential diagnosis of poroma can include seborrheic keratosis. Trichilemmoma can be considered if there are prominent clear cells. Hidradenoma is in the histologic differential diagnosis of poroid hidradenoma.

Clinical Course and Prognosis: Poromas are benign tumors, but malignant transformation to porocarcinoma can occur. (See the section "Porocarcinoma").

Management: Simple excision is curative, but they also can be treated with electrodessication.[11]

CYLINDROMA

Cylindromas are benign neoplasms of uncertain origin. While they have been historically classified as eccrine tumors,[12] more recent immunohistochemical studies showing expression of follicular stem cell markers in cylindromas suggest a folliculosebaceous-apocrine origin for these tumors.[13,14] Some also consider cylindroma and spiradenoma to be related entities that occur on a histologic spectrum.[1,15]

Epidemiology and Clinical Features: Cylindromas occur in adult patients, with a female predilection.[2,16] Cylindromas typically present singly as a smooth, flesh-colored to red nodule in the head and neck region in adults (Fig. 109-3A). Multiple lesions are seen in patients with Brooke-Spiegler and multiple familial trichoepitheliomas syndromes (see Table 109-2).[17] Multiple lesions can coalesce into a single, large mass.

Etiology and Pathogenesis: As mentioned before, multiple cylindromas manifest in Brooke-Spiegler syndrome, an autosomal dominant condition caused by mutations in the *CYLD* tumor-suppressor gene located on chromosome 16q.[17,18] In addition to multiple cylindromas, patients with Brooke-Spiegler syndrome also present with spiradenomas and trichoepitheliomas.[18] *CYLD* encodes an ubiquitin hydrolase and mutations in the gene lead to misregulation of nuclear factor-κB signaling.[17,18] Sporadic cylindromas have been shown to harbor *MYB-NFIB* gene fusions, similar to adenoid cystic carcinoma.[19] Interestingly, familial cylindromas with *CYLD* mutations do not contain these translocations. *MYB* expression is increased in many sporadic, as well as inherited, cylindromas, and is thought to drive proliferation in the tumors.[20]

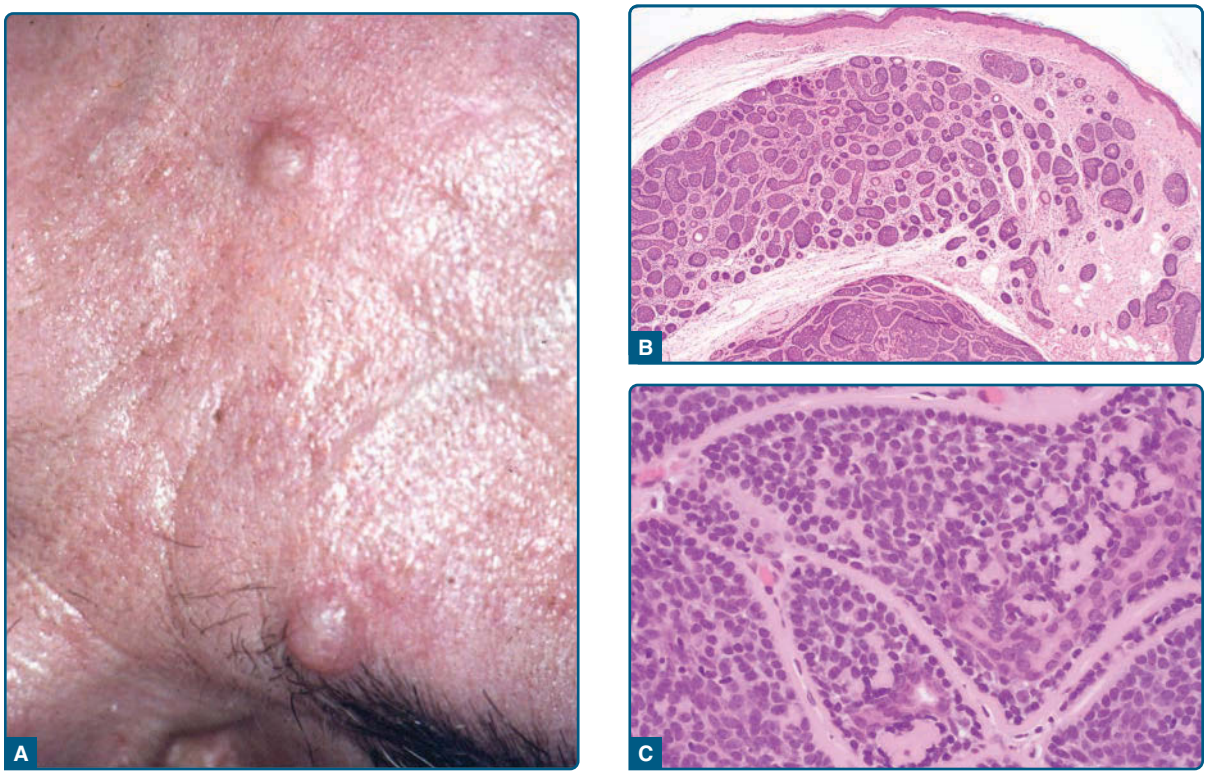

Figure 109-3 **A,** Cylindroma is a smooth, flesh-colored papule, often presenting on the head and neck. **B,** The tumor is a dermally based proliferation of islands of basaloid epithelium, arranged in a pattern similar to that seen in a jigsaw puzzle. **C,** An eosinophilic zone of basement membrane material separates the interlocking nests of tumor cells. Within the tumor nests, central cells have vesicular nuclei and eosinophilic cytoplasm, while peripheral cells have round basophilic nuclei with scant cytoplasm. (Image **A,** used with permission from Dr. Ernesto Gonzalez, MD, Boston, MA, USA.)

Histopathology: Cylindroma has a characteristic histologic appearance with islands of basaloid cells arranged in a "jigsaw puzzle"–like arrangement in the dermis surrounded by eosinophilic basement membrane material (see Fig. 109-3B). Within the islands there are centrally located larger cells and peripheral, smaller cells with palisading (see Fig. 109-3C). Extension into the subcutaneous fat is sometimes seen.

Clinical Course and Prognosis: Cylindroma is a benign tumor. Malignant transformation is rare, but has been documented in both sporadic and inherited cylindromas (see the section "Cylindrocarcinoma/Spiradenocarcinoma").

Management: Surgical excision is the treatment of choice for cylindromas.[16] For solitary lesions this is straightforward, but for patients with multiple lesions, this can be a complex undertaking. Complete scalp excision was used in the past, but is no longer favored as it is not curative and has high morbidity.[17] Tumor enucleation with secondary intention healing and other scalp-sparing surgical techniques are currently employed. Some studies have looked at the use of aspirin, both topical and systemic, in the treatment of patients with multiple cylindromas, but the outcomes were not favorable.[17]

SPIRADENOMA

Spiradenomas are benign neoplasms of uncertain origin. It was originally hypothesized that spiradenomas derive from the intradermal portion of the eccrine duct.[21] However, recent immunohistochemical studies show that spiradenomas express follicular stem cell markers, suggesting a folliculosebaceous-apocrine origin.[13,14] To some, cylindroma and spiradenoma are related entities that occur on a morphologic spectrum.[1,15]

Epidemiology and Clinical Features: Spiradenoma presents as a single, pink, gray, or blue, dermal nodule located on the trunk in young to middle-aged adults (Fig. 109-4A). Rarely, multiple spiradenomas occur in patients with Brooke-Spiegler syndrome (see Table 109-2).[18]

Histopathology: Histologically, spiradenoma has a characteristic appearance and is a multinodular, unencapsulated dermal neoplasm composed of basaloid cells arranged in cords in a trabecular pattern (see Fig. 109-4B). Two cell types are seen in spiradenomas: (a) small basaloid cells with hyperchromatic nuclei and scant cytoplasm located at the periphery of the nodules, and (b) larger basaloid cells with vesicular nuclei and pale cytoplasm located in the center of the nodules (see Fig. 109-4C). Scattered lymphocytes are seen throughout the tumor and deposits of periodic acid–Schiff (PAS)-positive hyaline basement membrane material are present in the tumor lobules.

Clinical Course and Prognosis: Malignant transformation of spiradenoma is described in rare cases (see the section "Cylindrocarcinoma/Spiradenocarcinoma").

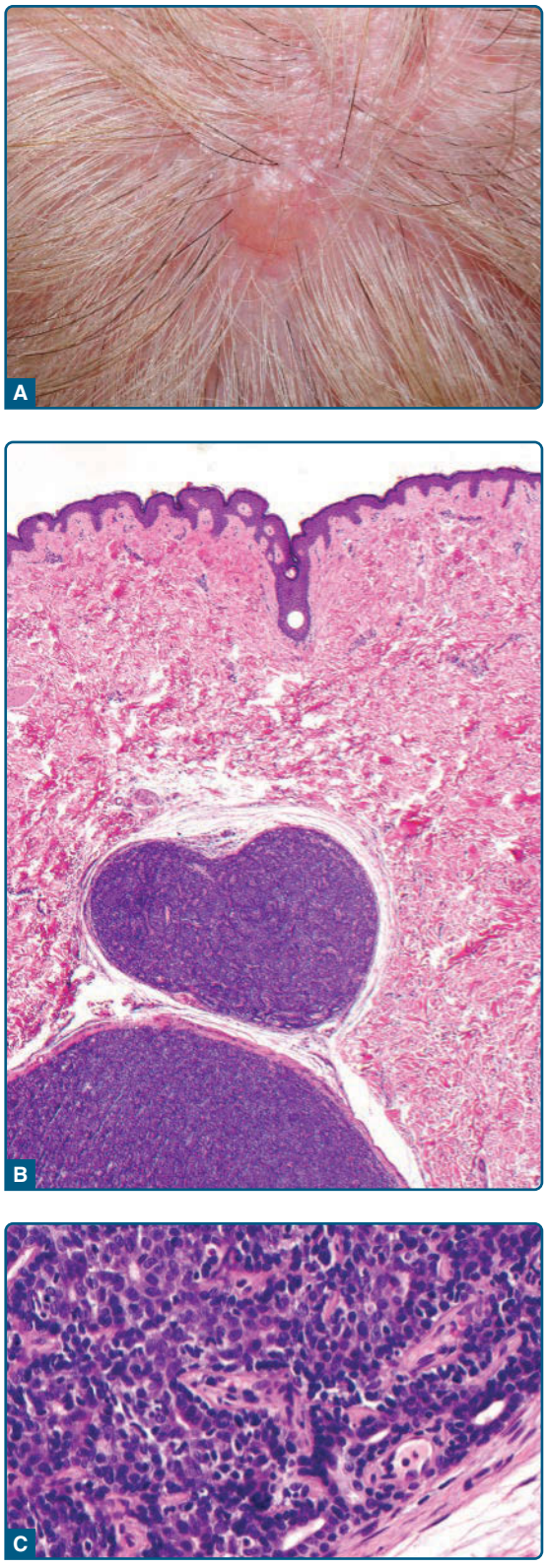

Figure 109-4 **A,** Spiradenoma is a flesh-colored nodule. **B,** It is usually a multinodular nonencapsulated dermal tumor wherein the basaloid nodules resemble blue balls in the dermis. **C,** The central tumor cells have vesicular nuclei and eosinophilic cytoplasm, and the peripheral cells have smaller, round, basophilic nuclei with scant cytoplasm. (Image **A,** used with permission from Dr. Ryan Trowbridge MD, Boston, MA, USA.)

Management: Surgical excision with clear margins is the treatment of choice for spiradenomas.

SYRINGOMA

Epidemiology and Clinical Features: Syringoma is a benign appendage tumor typically seen in adolescent and young, adult females.[22] Syringomas often present as multiple, 1- to 3-mm, flesh-colored, sometimes yellow, papules commonly on the face in a periorbital distribution (Fig. 109-5A). They can also present on the scalp, vulva, penis, chest, and axillae. An eruptive form, often affecting the chest and trunk, can be seen. Syringomas have been reported in association with Down syndrome.[22]

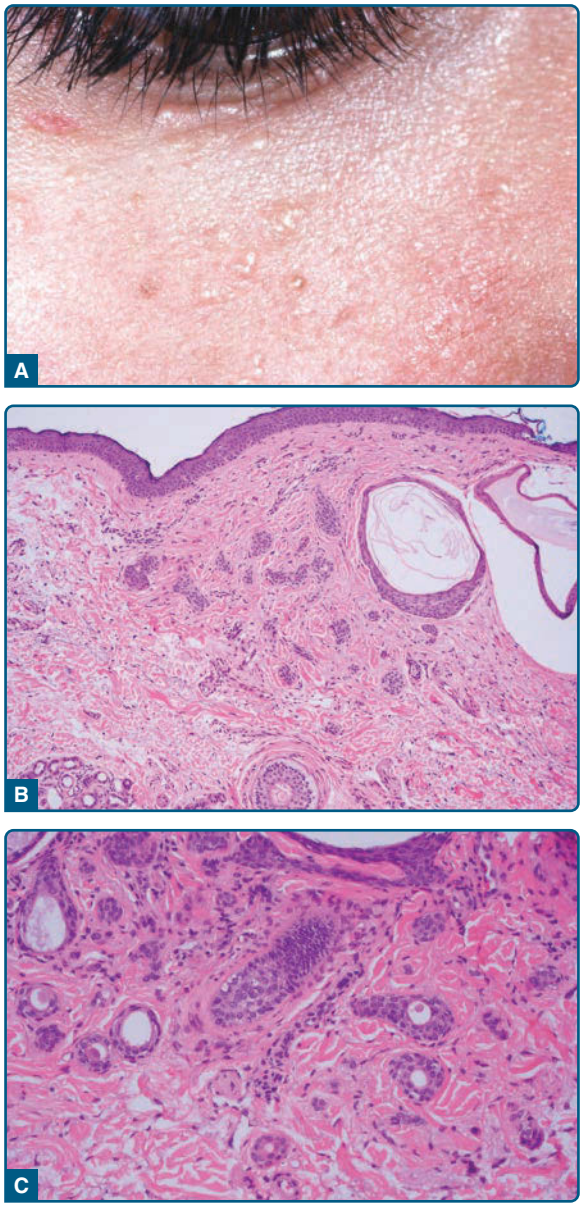

Figure 109-5 **A,** Syringoma presents as multiple, small, flesh-colored papules, often in a periorbital distribution. **B,** The tumor is composed of a dermal proliferation of cords and nests of tumor cells in the upper dermis. **C,** Small ductal structures are present in a sclerotic stroma forming tadpole-shaped and comma-shaped epithelial structures. (Image **A,** used with permission from Dr. Ernesto Gonzalez, MD, Boston, MA, USA.)

Etiology and Pathogenesis: Syringomas are thought to derive from the intraepidermal eccrine ducts.

Histopathology: Microscopically, syringomas are well-circumscribed and composed of epithelial cells arranged in cords, nests, and small ductal structures within a sclerotic stroma in the upper dermis (see Fig. 109-5B). The ductal structures classically have a "tadpole"-shaped or "comma"-shaped tail (see Fig. 109-5C). The lumina of the cells can contain PAS-positive material.

Differential Diagnosis: Clinically, milia, xanthelasma, and angiofibroma are in the differential diagnosis with syringoma.[22] Histologically, the diagnosis of syringoma is usually straightforward, but must be distinguished from microcystic adnexal carcinoma. This distinction can be challenging in superficial biopsies, as the hallmark of microcystic adnexal carcinoma is banal cytomorphology with a deeply invasive growth pattern. Clinicopathologic correlation can aid in the diagnosis in some cases.[5]

Management: As syringomas are benign neoplasms, treatment is focused on cosmesis. Destructive methods, such as laser, chemical peels, and electrodessication, and surgical excision have been used with varying results, and can have adverse side effects, such as scarring.[22] Medical therapies, such as retinoids, have been employed in small cases series without significant effectiveness.[22]

MALIGNANT

HIDRADENOCARCINOMA

Hidradenocarcinoma is a rare adnexal neoplasm that is the malignant counterpart of hidradenoma. Other terms used in the literature for hidradenocarcinoma include clear-cell eccrine hidradenocarcinoma, clear-cell hidradenocarcinoma, and cutaneous mucoepidermoid carcinoma.[23] Published reports of hidradenocarcinoma are predominantly from case reports and small case series.

Epidemiology and Clinical Features: Hidradenocarcinoma presents in adult patients with an average age in the sixth decade.[23,24] Tumors are often seen in the head and neck region, but any part of the body can be involved. Hidradenocarcinoma presents as a solitary mass averaging 2 to 2.5 cm.

Histopathology: Histologically, hidradenocarcinoma has a similar composition of cell types as hidradenoma, including clear, eosinophilic polyhedral, epidermoid (squamoid), oncocytic, and mucinous, but with malignant cytomorphology and architecture. Hidradenocarcinomas are reported to show deep extension, large areas of comedo necrosis, infiltrative

growth, nuclear pleomorphism, and 4 or more mitoses per 10 high-power fields.[24] These features can help distinguish hidradenocarcinoma from an atypical hidradenoma. Residual benign hidradenoma is seen in association with hidradenocarcinoma in approximately one-third of cases.[1]

Etiology and Pathogenesis: One case of hidradenocarcinoma with *HER2/neu* gene amplification has been described,[25] but the *HER2/neu* gene amplification has not been demonstrated in subsequently tested cases.[24] The t(11;19) translocation resulting in *MECT1 (TORC1, CRTC1)-MAML2* gene fusion has been rarely detected in hidradenocarcinomas, this translocation occurs at a lower rate than hidradenomas.[26]

Differential Diagnosis: Atypical hidradenomas can be difficult to distinguish from hidradenocarcinoma in small biopsy specimens. Pattern of growth, cytology, presence of necrosis, and mitotic activity can help to differentiate the 2 entities (see "Histopathology" before).[24]

Clinical Course and Prognosis: Local recurrence and locoregional and distant metastases are not uncommon in hidradenocarcinoma.[23]

Management: Hidradenocarcinoma is treated mainly with wide local excision. There are case reports of patients with metastatic hidradenocarcinoma treated with chemotherapy, but it is unclear if this can be extrapolated to all patients.[23] Similarly, sentinel lymph node sampling has been proposed for hidradenocarcinoma, but currently has no proven therapeutic or survival benefits.[23]

POROCARCINOMA

Porocarcinoma was first described by Coburn and Smith in 1956,[27] and again in 1963 as a single case report.[28] A metaanalysis of 105 cases was reported in 1992,[29] followed by the largest single series of 69 cases in 2001.[30]

Epidemiology and Clinical Features: Porocarcinoma typically affects adult patients in their sixth and seventh decades, although there is a wide age range.[29,30] Some reports have found it occurs more frequently in males,[29] whereas others have found a female predilection.[30] Porocarcinoma presents as a nodular or verrucous growth, most frequently affecting the lower extremities. The trunk and head are also common sites of involvement. A clinical history of recent ulceration or rapid growth from an existing lesion is sometimes reported.

Etiology and Pathogenesis: Porocarcinoma is thought to derive from the acrosyringium. Next-generation sequencing of porocarcinoma has found mutations in *HRAS* and *EGFR* genes, as well as mutations in common tumor-suppressor genes, such as *TP53*.[31]

Histopathology: Histologically, porocarcinoma is composed of malignant basaloid epithelial cells with attachment to the epidermis. The presence of ductal formation is variable, and although the majority of tumors do display duct formation, more poorly differentiated tumors may not. Both in situ and invasive forms of porocarcinoma have been described. Invasive porocarcinoma can show an infiltrative or pushing border. Approximately 20% of porocarcinomas arise in association with a benign poroma.[30] Duct formation should be distinguished from cellular dropout and can be highlighted by PAS staining or by EMA or CEA immunohistochemistry. Clear-cell change and squamous differentiation can be seen in porocarcinoma.

Differential Diagnosis: Distinguishing porocarcinoma from squamous cell carcinoma histologically can be difficult, especially in poorly differentiated tumors or in tumors with significant squamous differentiation. Demonstration of ductal differentiation is important in this distinction and can be augmented by EMA or CEA immunohistochemistry. One study found that immunohistochemistry for cytokeratin 19 (CK19) can be useful in distinguishing porocarcinoma (positive staining for CK19) from squamous cell carcinoma (negative for CK19), with a specificity of 82% and sensitivity of 67%.[32] It is important to note, however, that porocarcinomas can show focal, positive CK19 staining and that 18% of squamous cell carcinomas also showed focal, positive staining for CK19 (Table 109-4). A more recent report using CD117 (cKIT) immunohistochemistry showed positive staining in 100% of porocarcinomas, with approximately 20% of squamous cell carcinomas displaying only focal staining.[33]

TABLE 109-4

Summary of Immunohistochemical Stains in the Distinction between Squamous Cell Carcinoma and Select Appendage Neoplasms

	SCC	POROCARCINOMA	PROLIFERATING PILAR TUMOR	DESMOPLASTIC TRICHILEMMOMA
CEA	+	+ (highlights ducts)	ND	ND
CK19	–	+	ND	ND
CD34	–	ND	+	+
AE13	–	ND	+	ND
AE14	–	ND	+	ND

–, Negative; +, positive; ND, no robust data; SCC, squamous cell carcinoma.

Clinical Course and Prognosis: Porocarcinoma has a propensity for recurrence and regional lymph node metastasis (at a rate of approximately 20% each) and distant metastatic disease occurs in approximately 10% of cases.[29,30,34] High mitotic activity (>14 mitoses per high-power field), tumor thickness greater than 7 mm, and lymphovascular invasion are histologic features associated with a poorer prognosis.[30]

Management: Treatment is focused on surgical excision, by both conventional and Mohs micrographic techniques.[34] Overall, current chemotherapeutic regimens appear to have little therapeutic value in metastatic disease.[35]

CYLINDROCARCINOMA/ SPIRADENOCARCINOMA

Malignant neoplasms arising from cylindromas and spiradenomas are rare, with case reports and small case series published in the literature.[36-38] These neoplasms have been referred to by numerous names, including malignant spiradenoma, malignant cylindroma, carcinoma ex spiradenoma, and carcinoma ex cylindroma. As discussed in the "Spiradenoma" and "Cylindroma" sections before, many consider these entities to be related and to exist on a morphologic spectrum. Given their similarities and their rarity, we consider them in a single section.

Epidemiology and Clinical Features: Malignant transformation of cylindroma and spiradenoma can occur sporadically in solitary lesions or as part of the Brook-Spiegler syndrome (see Table 109-2). They arise in elderly adults without apparent sex predilection. Cylindrocarcinoma and spiradenocarcinoma present as solitary nodules, and can be quite large in size, measuring up to 17.5 cm with a median size of 4 cm.[37] There are reports of recent increases in size in preexisting tumors, as well as ulceration, which could suggest malignant transformation of existing benign neoplasms. Regions in the head and neck are the most frequently affected sites, with lower-extremity and trunk involvement also reported.[36-38]

Histopathology: Histopathologic diagnosis requires adequate sampling and recognition of a benign cylindroma or spiradenoma component within the tumor. Transition between the benign and malignant components can be gradual or abrupt.[37,38] Malignant transformation is typified by high mitotic rate, nuclear pleomorphism, sheet-like and/or infiltrative growth patterns, and necrosis. Adenocarcinoma in situ has been described and manifests as proliferations of atypical cells with a preserved myoepithelial cell layer.[37] Adenocarcinoma in situ can be difficult to distinguish from benign cylindroma and spiradenoma. A wide range of morphologies is seen in cylindrocarcinoma and spiradenocarcinoma. A study of 24 cylindrospiradenocarcinomas reported 4 main patterns seen in these tumors[37]:

1. Salivary gland–type basal cell adenocarcinoma–like pattern, low grade;
2. Salivary gland–type basal cell adenocarcinoma–like pattern, high grade;
3. Invasive adenocarcinoma, not otherwise specified; and
4. Sarcomatoid carcinoma.

As the name implies, the salivary gland–type basal cell adenocarcinoma–like pattern closely resembles basal cell adenocarcinoma of the salivary gland with either low-grade or high-grade morphology. The adenocarcinoma, not otherwise specified (or NOS), pattern is poorly differentiated and does not resemble any particular tumor. The sarcomatoid pattern shows biphasic morphologies, with both epithelial and sarcomatous components. The sarcomatous component typically resembles an unspecified pleomorphic sarcoma.

Differential Diagnosis: Depending on the morphology of the tumor cells, the histologic differential diagnosis can include squamous cell carcinoma and metastasis from salivary gland or breast tissue. In cases of in situ adenocarcinoma, a benign cylindroma or spiradenoma is in the differential diagnosis.

Clinical Course and Prognosis: Cylindrocarcinoma and spiradenocarcinoma have been documented to metastasize and associated deaths are reported, although with varying frequency.[39] Poor prognosis seems to be associated with high-grade morphology, either salivary gland–type basal cell adenocarcinoma-like, high grade, or adenocarcinoma pattern.[37] Similarly, patients with Brooke-Spiegler syndrome who undergo malignant transformation appear to have poor overall outcomes.[17]

Management: Surgical excision remains the mainstay treatment of cylindrocarcinoma and spiradenocarcinoma.[38] The role of chemotherapy and radiation therapy is unclear and not currently recommended.

DIGITAL PAPILLARY ADENOCARCINOMA

An initial case series of digital papillary adenocarcinoma from the Armed Forces Institute of Pathology files was published in 1987 and included 57 cases, with tumors classified as either adenomas or adenocarcinomas.[40] A followup study of that same cohort revealed that tumors originally classified as adenomas had recurred or developed metastases.[41] Based on these findings, the authors proposed that all such lesions be classified as adenocarcinoma regardless of their histologic features. An additional series of 31 cases was published more recently in 2012, and included immunohistochemical findings.[42]

Epidemiology and Clinical Features: Digital papillary adenocarcinoma predominantly affects males in middle age and presents as a solitary 1- to 4-cm mass. It often presents on the distal aspect

of a finger or, sometimes, a toe. The palms and soles are rarely affected. Digital papillary adenocarcinoma is slow growing and is often present for years prior to excision. Rarely, patients are found to have metastatic disease at the time of clinical presentation.[42]

Histopathology: Microscopically, digital papillary adenocarcinoma is a multinodular, poorly circumscribed dermal tumor. Extension into the subcutis is not uncommon. Tumors contain solid and cystic areas with papillary projections. The papillary structures include both true papillae with fibrovascular cores, as well as pseudopapillary structures without fibrovascular cores. Areas of ductal differentiation and cribriform growth can be seen. By immunohistochemistry, myoepithelial cells are present to varying degrees within the tumor and their presence does not portend improved patient outcomes.[42]

Differential Diagnosis: The clinical differential diagnosis for digital papillary adenocarcinoma includes a cyst, giant cell tumor, and vascular tumor. Histologically, the differential diagnosis of digital papillary adenocarcinoma includes hidradenoma, tubular adenoma, and metastatic disease from thyroid, breast, and GI primaries.[39]

Clinical Course and Prognosis: Tumors have the propensity to recur and have late metastases, with lung being the most common site of metastatic disease.[41,42]

Management: Wide excision or digital amputation of the primary lesion is recommended. Close clinical followup is recommended as metastases have been reported up to 20 years following initial presentation.[41,42]

MICROCYSTIC ADNEXAL CARCINOMA

Microcystic adnexal carcinoma is a rare, malignant adnexal tumor originally described in 1982.[43] Synonyms for microcystic adnexal carcinoma include sclerosing sweat duct carcinoma and malignant syringoma.

Epidemiology and Clinical Features: Microcystic adnexal carcinoma affects adult patients over a wide age range with an equal sex distribution.[44,45] It clinically presents as a firm, indurated plaque, typically affecting the central face, and classically described in perioral or periocular areas.

Etiology and Pathogenesis: There are reports of microcystic adnexal carcinoma occurring following radiation therapy.[44,45] Additionally, in the United States, microcystic adnexal carcinoma often presents on the left side of the face, suggesting a role for ultraviolet exposure in tumor development.[44,45] Originally believed to be of eccrine derivation, follicular differentiation can be observed within microcystic adnexal carcinoma, and suggests either metaplasia within the tumor or a possible folliculosebaceous origin.

Histopathology: Microscopically, microcystic adnexal carcinoma displays an infiltrative growth pattern with frequent extension beyond the dermis into subcutaneous tissues (Fig. 109-6A, B). The tumor is composed of strands, cords, and cysts of epithelial tumor cells embedded in a sclerotic stroma. There is often zonation within the tumor, with keratocysts observed mainly in the superficial dermis, strands and

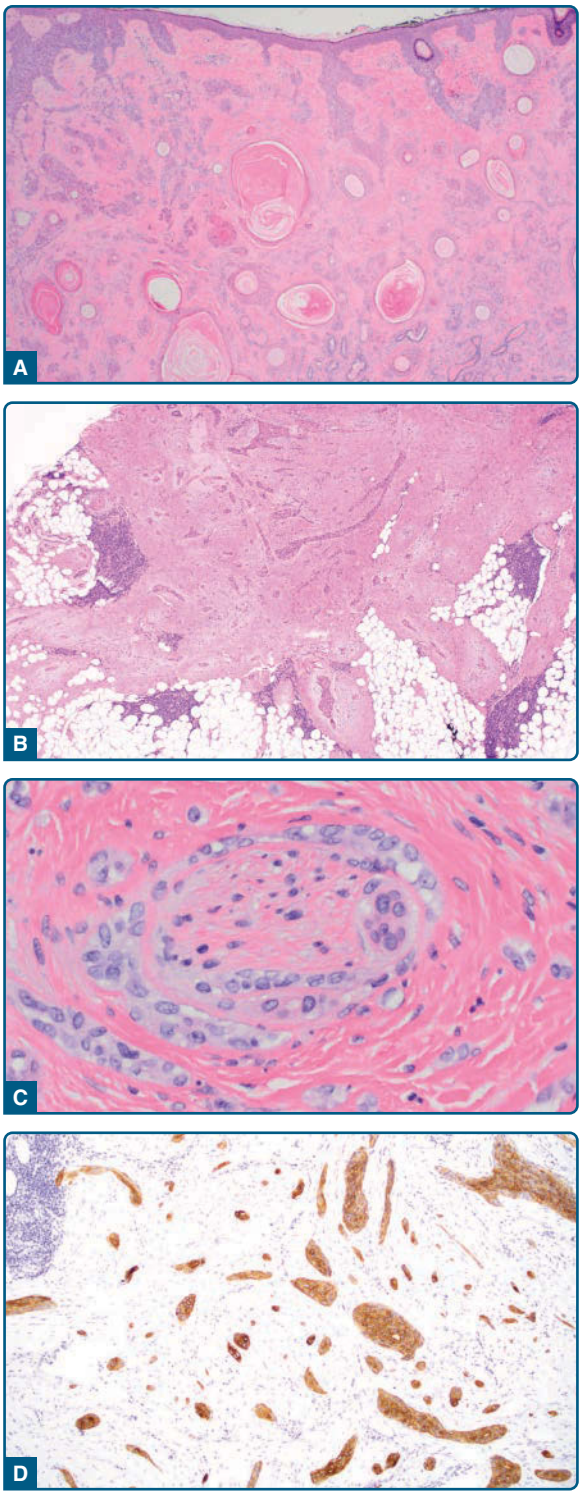

Figure 109-6 **A,** Microcystic adnexal carcinoma is an infiltrative tumor composed of cords and cysts of varying sizes and shapes. **B,** The tumor extends through the dermis to involve the subcutaneous fat. **C,** Perineural invasion is often seen. **D,** The tumor cells may be positive for CK7.

cords of tumor cells in the mid dermis, and duct-like structures in the deep dermis and subcutaneous tissues. Cytologically, microcystic adnexal carcinoma is deceptively bland, and superficial biopsies do not convey the infiltrative growth pattern. Perineural invasion is a frequent finding (Fig. 109-6C).

Tumor cells stain for cytokeratins and ductal formation is positive for EMA and CEA immunostaining (see Fig. 109-6D). Immunohistochemistry is of relatively little use in making a definitive diagnosis of microcystic adnexal carcinoma. Numerous studies have tried to use an immunohistochemical approach to distinguish microcystic adnexal carcinoma from its histologic mimics, and have produced variable results, especially when considering small biopsy specimens (see "Differential Diagnosis" below).[1,5,45] Accurate diagnosis relies most heavily on reviewing hematoxylin-and-eosin–stained slides of an adequately deep biopsy.

Differential Diagnosis: Clinically and histologically, morpheaform basal cell carcinoma mimics microcystic adnexal carcinoma, although basal cell carcinoma lacks ductal differentiation. Immunohistochemistry for cytokeratin 15 (CK15) and CEA (or EMA, highlighting duct formation) may be helpful in distinguishing microcystic adnexal carcinoma from morpheaform basal cell carcinoma, with positivity for CK15 and the presence of ductal structures supporting a diagnosis of microcystic adnexal carcinoma (Table 109-5).[46] Desmoplastic trichoepithelioma is also in the histologic differential diagnosis of microcystic adnexal carcinoma, as both can have superficial dermal keratocysts. Desmoplastic trichoepithelioma, however, does not display the infiltrative growth pattern of microcystic adnexal carcinoma. Immunohistochemistry is not particularly useful in distinguishing between microcystic adnexal carcinoma and desmoplastic trichoepithelioma.[5] Syringoma can have a similar histologic appearance to microcystic adnexal carcinoma, but does not display a deep, infiltrative pattern of growth.

Clinical Course and Prognosis: Microcystic adnexal carcinoma is a slow-growing tumor, but is locally aggressive with significant morbidity, possibly because of the frequent perineural involvement associated with this tumor. Metastatic disease is exceedingly rare.[44,45]

Management: Microcystic adnexal carcinoma is treated with surgical excision, with reports suggesting that Mohs micrographic surgery has lower recurrence rates than conventional surgical techniques.[44,45] Radiation therapy is not recommended as a first-line treatment of microcystic adnexal carcinoma, but can be considered in patients who are poor surgical candidates.[44] Chemotherapy has no role in treating microcystic adnexal carcinoma. For patients with recurrent disease in the periocular area, a study showed that review of paraffin sections (either by slow Mohs or traditional surgical excision) can be of benefit in detecting residual, small tumor foci.[47]

TUMORS WITH APOCRINE DIFFERENTIATION

Normal apocrine glands develop in association with the hair follicle and have a more limited anatomic distribution than eccrine glands, being found in the axillary, groin, and perineal regions. (See Chap. 6 for a full discussion of normal sweat glands.) Apocrine glands are composed of a secretory coil, located in the deep dermis or subcutis, and a ductal portion. The secretory portion is composed of glands lined by cuboidal epithelium with intracytoplasmic zymogen granules and characteristic decapitation secretion with apical "snouting." These luminal cells are surrounded by myoepithelial cells. Tumors with apocrine differentiation are classically composed of cells that show this decapitation secretion. Table 109-6 lists appendage tumors with apocrine differentiation.

BENIGN

HIDROCYSTOMA

Hidrocystomas are described in both apocrine and eccrine forms and have been referred to by numerous

TABLE 109-5
Summary of Immunohistochemical Stains in the Distinction Between Basal Cell Carcinoma, Microcystic Adnexal Carcinoma, and Adenoid Cystic Carcinoma

	BCC	MAC	ADCC
CK7	+/–	–	+
CK15	–	+	+
S100	–	ND	+ (myoepithelial cells)
CD117 (cKIT)	–	ND	+

–, Negative; +, positive; AdCC, adenoid cystic carcinoma; BCC, basal cell carcinoma; MAC, microcystic adnexal carcinoma; ND, no data.

TABLE 109-6
Apocrine Appendage Neoplasms

BENIGN	MALIGNANT
Hidrocystoma	Adenoid cystic carcinoma
Tubular adenoma (tubular apocrine adenoma/papillary eccrine adenoma)	Apocrine adenocarcinoma (including cribriform carcinoma)
Syringocystadenoma papilliferum	Mucinous carcinoma
Apocrine mixed tumor	
Hidradenoma papilliferum	
Nipple adenoma	

Figure 109-7 Hidrocystoma is a translucent papule, frequently seen in a periorbital distribution. (Image used with permission from Dr. Ernesto Gonzalez, MD, Boston, MA, USA.)

names, including apocrine cystadenoma, apocrine gland cyst, and eccrine cyst.[1]

Epidemiology and Clinical Features: Hidrocystomas present in adults of middle age with a slight predilection for females.[48] A hidrocystoma presents as a tan to bluish-black, translucent papule, often in the periorbital area of the face (Fig. 109-7). Other locations, including the axilla and groin, can be affected. Multiple lesions are sometimes seen.

Etiology and Pathogenesis: Apocrine hidrocystomas are considered adenomas arising from the apocrine secretory coil. Eccrine hidrocystomas are considered retention cysts of the eccrine duct.[1] Multiple hidrocystomas are associated with Schöpf-Schulz-Passarge syndrome and Goltz-Gorlin syndrome (see Table 109-2).[48] Schöpf-Schulz-Passarge syndrome is an autosomal recessive condition with ectodermal dysplasia, manifesting as multiple hidrocystomas (often involving the bilateral eyelid margins), palmoplantar keratoderma, nail dystrophy, hypodontia, and hypotrichosis.[48] Goltz-Gorlin syndrome is a sporadic condition with microcephaly, facial hypoplasia, multiple hidrocystomas, papillomas (of the lip, tongue, anus, and axilla), mental retardation, and skeletal abnormalities.[48] A relationship between multiple eccrine hidrocystomas and hyperthyroidism and warm temperatures has been suggested.[48]

Histopathology: Microscopically, hidrocystomas are epithelial-lined unilocular or multilocular cysts, present in the dermis. The epithelium is typically bilayered with an outer myoepithelial cell layer. Apocrine hidrocystomas display characteristic decapitation secretion. Flattening of the epithelium can occur, and sometimes makes the distinction between apocrine and eccrine differentiation difficult. There are claims that apocrine epithelium stains positively for HMFG (human milk fat globule)-1 and GCDFP (gross cystic disease fluid protein)-15 immunohistochemical stains, while eccrine epithelium is negative for these markers.[1] More complex epithelial proliferations, such as micropapillary projections, have been noted in apocrine hidrocystomas.

Differential Diagnosis: The clinical differential diagnosis includes epidermoid cyst, basal cell carcinoma, and, sometimes, melanoma, depending on the color of the lesion. Histologically, dacryops, a cyst of the lacrimal gland, can resemble hidrocystoma, but dacryops can be distinguished by the presence of lacrimal gland tissue.[1]

Clinical Course and Prognosis: Hidrocystomas are benign adnexal lesions.

Management: As hidrocystomas are benign, treatment is focused on cosmesis. Solitary lesions can be punctured or surgically excised. The presence of multiple hidrocystomas is more difficult to treat, with numerous treatment strategies described in the literature, including botulinum toxin, electrodessication and curettage, laser treatment, and topical atropine.[48]

APOCRINE MIXED TUMOR

Mixed tumor of the skin, also referred to historically as chondroid syringoma, is a benign myoepithelial neoplasm with tubuloductal/glandular differentiation. It can be classified as either apocrine or eccrine, although the apocrine variant is more commonly seen than the eccrine variant.[1] As follicular and sebaceous differentiation can be observed in apocrine mixed tumors (as befitting the embryologic origin of the folliculosebaceous-apocrine unit), some authors prefer the term *mixed tumor of the pilosebaceous–apocrine complex*.[49] Apocrine mixed tumor is morphologically identical to pleomorphic adenoma of the salivary gland.

Epidemiology and Clinical Features: Apocrine mixed tumor is seen in middle-aged adult patients with a male predominance.[49] Eccrine mixed tumor also affects adult patients, but has a slight female predominance.[50] Cutaneous mixed tumor typically arises in the head and neck area as a firm, flesh-colored, slow-growing nodule. Subcutaneous lesions can also present on the extremities.

Etiology and Pathogenesis: As it is a homolog of pleomorphic adenoma, mixed tumors show *PLAG1* gene rearrangements as well as PLAG1 protein expression by immunohistochemistry.[51]

Histopathology: Histologically, mixed tumors are unencapsulated, multinodular, dermal neoplasms with frequent infiltration into the surrounding tissue (Fig. 109-8A). The tumor is composed of epithelial, myoepithelial, and stromal elements, which are present in varying amounts (Fig. 109-8B). The epithelial component, by definition, is gland forming, even if focal (Fig. 109-8C). The glandular epithelium in apocrine mixed tumors displays decapitation secretion (Fig. 109-8D); in the eccrine variant, this feature is absent. Follicular and sebaceous differentiation can be observed in apocrine mixed tumors.[49] Heterologous differentiation of the stromal component can be seen, often as cartilaginous, osseous, or adipocytic differentiation.

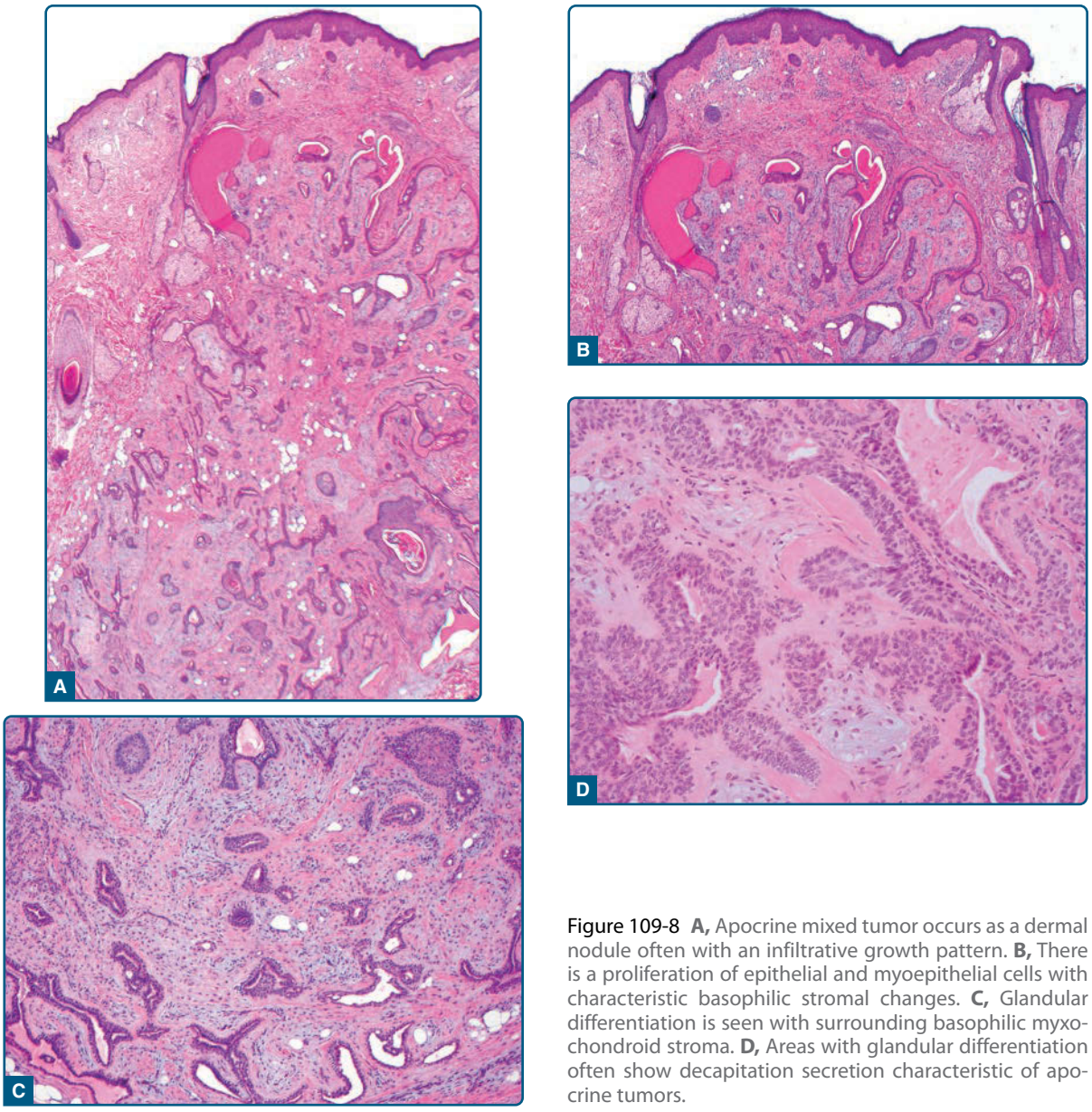

Figure 109-8 **A,** Apocrine mixed tumor occurs as a dermal nodule often with an infiltrative growth pattern. **B,** There is a proliferation of epithelial and myoepithelial cells with characteristic basophilic stromal changes. **C,** Glandular differentiation is seen with surrounding basophilic myxochondroid stroma. **D,** Areas with glandular differentiation often show decapitation secretion characteristic of apocrine tumors.

Immunohistochemistry can be used to highlight the cellular components of the tumor, but is not typically needed for diagnosis in an adequate biopsy sample. Epithelial ductal structures stain positively for cytokeratins and EMA. Myoepithelial markers include S100, p63, calponin, GFAP (glial fibrillary acidic protein), and actins. True chondroid and adipocytic differentiation will be positive for S100.

Differential Diagnosis: In the head and neck region, extension from or recurrence resulting from an incompletely excised salivary gland pleomorphic adenoma must be ruled out before making a diagnosis of mixed tumor.[51] Mixed tumor typically has a characteristic histologic appearance, but if tubuloductal differentiation is focal, a myoepithelial neoplasm could be considered.[51] Likewise, if there is significant metaplasia, including follicular, chondroid, or adipocytic, additional neoplasms, such as trichoblastoma, chondroma, or adenolipoma, could be included in the histologic differential diagnosis.

Clinical Course and Prognosis: Mixed tumors of the skin are benign and typically follow an indolent clinical course. Malignant transformation is extremely rare.

Management: Complete surgical excision is recommended to prevent recurrence, which can occur in up to 18% of benign myoepithelial neoplasms.[51]

SYRINGOCYSTADENOMA PAPILLIFERUM

Epidemiology and Clinical Features: Syringocystadenoma papilliferum is a rare, benign neoplasm that presents in children and young adults.[52]

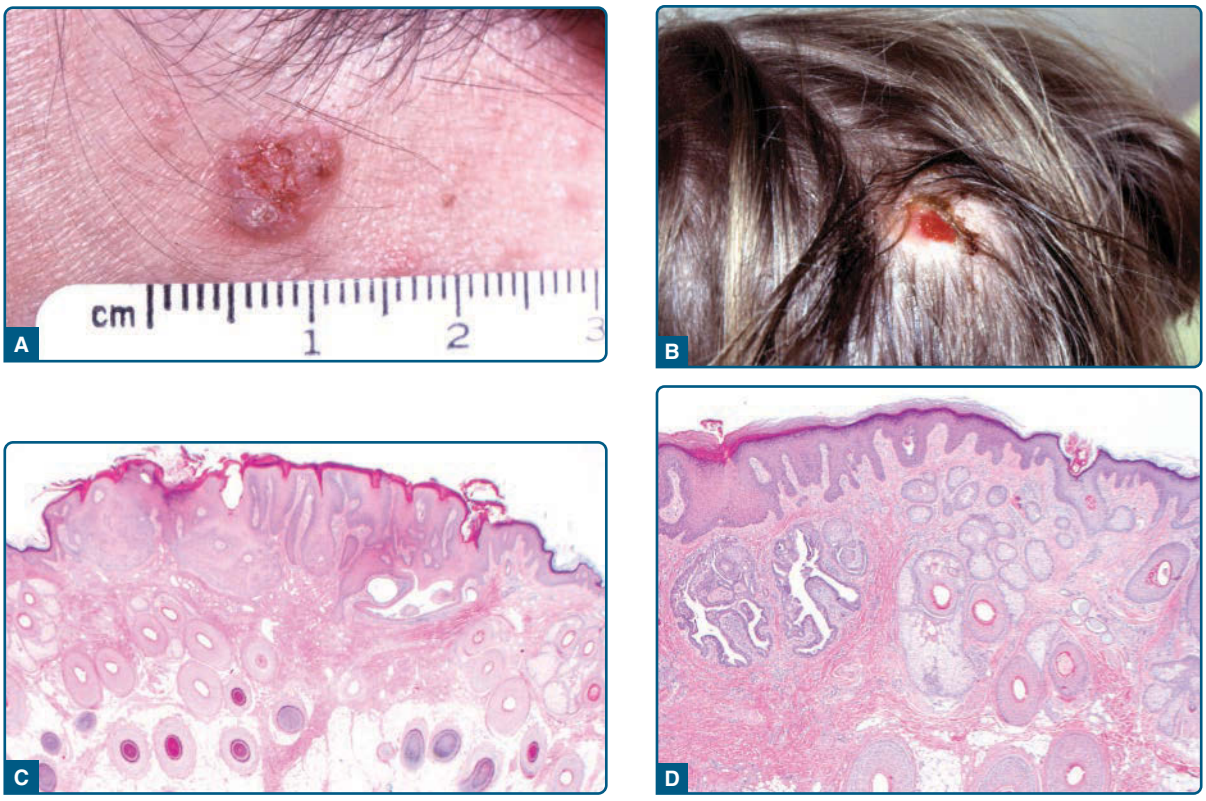

Figure 109-9 **A,** Syringocystadenoma papilliferum can present as a crusted verrucous plaque on the scalp. **B,** Serous drainage is not an uncommon finding. **C,** The tumor occurs as an invagination of papillomatous projections in the epidermis. **D,** On the left side of this image a papillary projection is seen, composed of an inner layer of columnar epithelium with decapitation secretion and an outer layer of myoepithelial cells. (Clinical images **A** and **B,** Used with permission from Dr. Ernesto Gonzalez, MD, Boston, MA, USA.)

Syringocystadenoma papilliferum presents as a single, brown to red plaque, typically on the scalp, and can have a wart-like appearance (Fig. 109-9A). Serosanguinous drainage and ulceration are not uncommon (Fig. 109-9B). Alternatively, it can also present as small papules, be distributed linearly, and occur in association with nevus sebaceus. Syringocystadenoma papilliferum can occur in other areas of the head and neck, and have rarely been reported at other sites, including the trunk and extremities.

Etiology and Pathogenesis: Some cases of syringocystadenoma papilliferum have shown deletion at 9p22 (*PTCH*) or at 9p21 (*p16*).[53] Mutations in *BRAF* (V600E), *NRAS*, and *HRAS* also have been reported in syringocystadenoma papilliferum.[54] The role these genetic alterations play, if any, in tumor pathogenesis remains unclear.

Histopathology: Syringocystadenoma papilliferum has a characteristic histologic appearance and is composed of an invagination of papillations that connect to the surface squamous epithelium (see Fig. 109-9C). The epithelium covering the papillae consists of 2 layers. The lining layer is columnar to cuboidal, often with conspicuous decapitation secretion, and the outer layer is composed of basal/myoepithelial cells (see Fig. 109-9D). The fibrous cores of the papillae frequently contain a plasma cell infiltrate. The epithelial cells express cytokeratins, including CK7, as well as EMA and CEA. The inner, myoepithelial layer is positive for smooth muscle actin.

Clinical Course and Prognosis: Syringocystadenoma papilliferum is a benign adnexal neoplasm. Very rare cases of adenocarcinoma (syringocystadenocarcinoma papilliferum) are reported arising from syringocystadenoma papilliferum, mainly in older adults with a history of rapid growth of a preexisting nodule.[55,56] Histologically, syringocystadenocarcinoma papilliferum has a malignant appearance, with epithelial multilayering, an infiltrative growth pattern, nuclear atypia, and high mitotic activity.[56]

Management: Surgical excision of syringocystadenoma papilliferum is recommended even though malignant transformation is rare. Syringocystadenocarcinoma papilliferum is treated surgically, either by conventional or Mohs micrographic techniques.

TUBULAR ADENOMA

Tubular apocrine adenoma, also referred to as tubulopapillary hidradenoma and tubular syringoadenoma, was first reported by Landry and Winkelmann in 1972.[57] Papillary eccrine adenoma was reported by

Rulon and Helwig in 1977.[58] There can be morphologic overlap between the lesions, with some preferring to separate the 2 entities, and others considering them 1 entity that exists on a morphologic spectrum.[1] Because they are rare, we discuss them in 1 section.

Epidemiology and Clinical Features: Tubular adenomas affect adult patients with a mean age in the fifth decade.[1] Tubular adenoma presents as a single, flesh-colored nodule between 1 and 3 cm in size. Tubular apocrine adenomas are described as typically occurring on the scalp, whereas papillary eccrine adenomas often present on the distal extremities.

Etiology and Pathogenesis: Tubular adenomas are rare, benign appendage neoplasms with apocrine and/or eccrine differentiation.

Histopathology: Microscopically, tubular adenoma is a relatively well-circumscribed, unencapsulated dermal nodule composed of tubules embedded in a fibrotic stroma. The epithelium lining the tubules is composed of single to multiple layers of cuboidal cells with an outer layer of myoepithelial cells. The luminal cells stain for cytokeratins, such as CK7, CEA, and EMA. Myoepithelial markers (calponin, p63, smooth muscle actin) stain the myoepithelial cell layer. Of note, myoepithelial markers can be lost with distension of the tubules and should not be interpreted as invasive carcinoma.[1] Complex architecture within the tubules, such as micropapillae and cribriforming, can be seen.

Differential Diagnosis: Histologically, tubular adenoma can sometimes display overlapping features with syringocystadenoma papilliferum.

Clinical Course and Prognosis: Tubular adenomas are benign and have an indolent clinical course.

Management: Treatment focuses on surgical methods of excision, including Mohs micrographic surgery.

HIDRADENOMA PAPILLIFERUM

Epidemiology and Clinical Features: Hidradenoma papilliferum occurs in the anogenital region in females and is typically located on the vulva.[59] It presents clinically as a flesh-colored to red nodule, often less than 1 cm in size.

Etiology and Pathogenesis: Hidradenoma papilliferum is considered an adenoma of the mammary-like anogenital glands and is morphologically similar to mammary intraductal papilloma.[59] A recent study showed that hidradenoma papilliferum contains activating mutations in *PIK3CA*, similar to those found in mammary ductal papillomas, further highlighting the similarities between these 2 entities.[60]

Histopathology: Histologically, hidradenoma papilliferum is a well-circumscribed, unencapsulated, solid-cystic dermal nodule (Fig. 109-10A).[59] Hidradenoma papilliferum displays a complex pattern of interconnected tubules and glands, often arranged in a labyrinth-like appearance. Papillae formation is common. The bilayered epithelium lining the tubules and papillary structures is composed of a luminal layer of cuboidal to columnar cells surrounded by a layer of myoepithelial cells (Fig. 109-10B). Decapitation secretion is frequently seen in the luminal layer. Oxyphilic metaplasia is not an uncommon finding. Other morphologic changes, such as sclerosing adenosis–like changes and ductal hyperplasia, also can be seen. Mitotic figures can be observed and the overall proliferative index can be variable. Adjacent remnants of mammary-like anogenital glands are seen in approximately one-third of hidradenoma papilliferum cases.[59] Connection to the overlying epidermis is rare, but when seen, is often accompanied by a plasma cell-rich infiltrate.

The luminal epithelial cells stain for cytokeratins (CK5/CK6, AE1/AE3) and GCDFP-15, as well as estrogen receptors.[1] The myoepithelial cells stain for typical myoepithelial markers, including S100, actins, calponin, and p63.

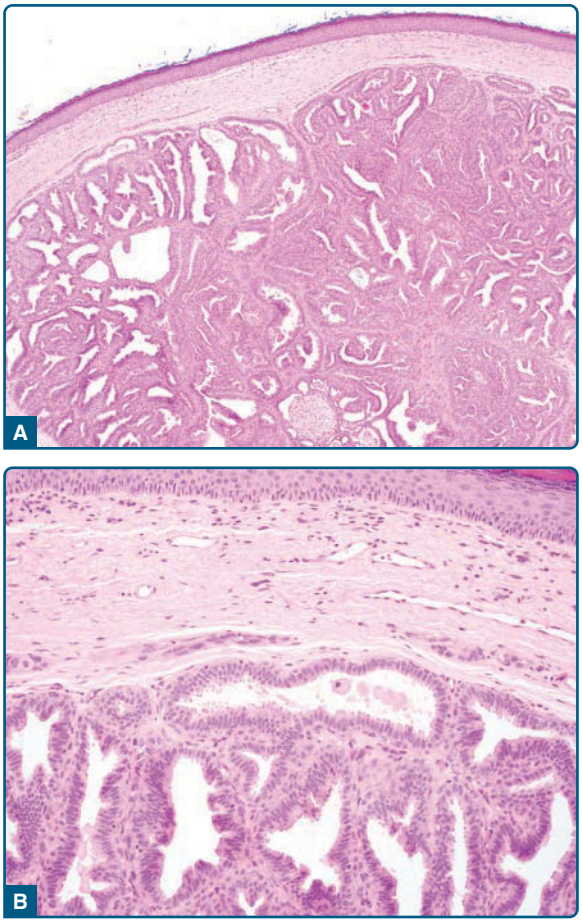

Figure 109-10 **A,** Hidradenoma papilliferum occurs as a well-circumscribed solid and cystic dermally based nodule, with interconnected glands that form labyrinth-like arrangements of tumor cells. **B,** The projections are composed of cuboidal and columnar epithelium with decapitation secretion and a basal layer of myoepithelial cells.

Differential Diagnosis: Hidradenoma papilliferum is often confused clinically with a cyst. Histologically, if there is connection with the epidermis, syringocystadenoma papilliferum can be considered in the differential diagnosis.

Clinical Course and Prognosis: Hidradenoma papilliferum is benign, but there are rare reports of ductal carcinoma in situ arising in hidradenoma papilliferum, manifested by increased cellularity, nuclear atypia, and abnormal mitotic figures.[1] Adenocarcinoma arising in hidradenoma papilliferum (hidradenocarcinoma papilliferum) is a controversial diagnosis.[1] Loss of the myoepithelial cell layer should allow differentiation between ductal carcinoma in situ (with a retained myoepithelial layer) and invasive adenocarcinoma. Extremely rare cases of extramammary Paget disease associated with hidradenoma papilliferum have been reported.[1]

Management: Surgical excision is the treatment of choice for hidradenoma papilliferum.

NIPPLE ADENOMA

Nipple adenoma is a benign proliferation in the breast. It has been described using many names, including florid papillomatosis, erosive adenomatosis, and papillary adenoma, among others, likely reflecting the differing clinical and histologic appearances this entity can have.[61,62]

Epidemiology and Clinical Features: Nipple adenoma affects females in their fourth and fifth decades and presents unilaterally as a serous or bloody nipple discharge, as well as crusting or ulceration of the nipple.[61,62] A dermal nodule is identified in some cases.

Etiology and Pathogenesis: Nipple adenoma is a benign proliferation of the lactiferous ducts in the nipple.

Histopathology: Microscopically, nipple adenoma appears as an endophytic, well-circumscribed proliferation of glandular structures.[61] The glands, or tubules, are lined by a bilayered epithelium, with an inner (luminal) apocrine secretory epithelium and an outer myoepithelial layer. Solid, papillary, and cystic areas can be seen. Sclerosis can impart the appearance of an irregular border or infiltration. Epidermal erosion or ulceration with an associated inflammatory infiltrate is not uncommon. Cytologically, the tumor cells are banal. Focal necrosis can be seen, but should not be florid in nipple adenoma.[61]

Differential Diagnosis: Depending on the clinical presentation, the clinical differential diagnosis includes Paget disease, mammary carcinoma, and eczema. Microscopically, the presence of sclerosis can simulate an invasive carcinoma, but the lack of atypia and the presence of myoepithelial cells (confirmed by immunohistochemistry) allows for a diagnosis of nipple adenoma.[61] Focal necrosis may raise the possibility of mammary ductal carcinoma in situ; however, cytological atypia should be absent in nipple adenoma.[61]

Clinical Course and Prognosis: Nipple adenoma is a benign proliferation, although coincidental mammary carcinoma has been reported.[61,62]

Management: Surgical excision is the treatment of choice to evaluate the entirety of the lesion. Recurrence can occur following incomplete excision.[62]

MALIGNANT

ADENOID CYSTIC CARCINOMA

Adenoid cystic carcinoma is a malignant adnexal neoplasm that rarely occurs as a primary skin disease, and more frequently arises in salivary gland tissues.

Epidemiology and Clinical Features: Primary cutaneous adenoid cystic carcinoma occurs in adults over a wide age range, with a median age in the sixth decade, and a slight female predominance.[63,64] It presents as a slow-growing nodule, averaging between 2 and 3 cm in size, on the head and neck, and, frequently, on the scalp. Adenoid cystic carcinoma can sometimes present on the trunk or extremities.

Etiology and Pathogenesis: Salivary gland adenoid cystic carcinoma has been shown to harbor a t(6;9)(q22-23;p23-24) translocation, resulting in a *MYB-NFIB* gene fusion.[65] This is considered a driving oncogenic event in the development of salivary gland adenoid cystic carcinoma. A recent study showed that the majority of primary cutaneous adenoid cystic carcinomas either harbored the *MYB-NFIB* fusion gene or showed overexpression of MYB by immunohistochemistry, suggesting a shared pathway in the development of salivary and primary cutaneous adenoid cystic carcinoma.[65]

Histopathology: Adenoid cystic carcinoma has a classic histologic appearance and is composed of dermal islands of basaloid cells arranged in a cribriform pattern with "punched-out" pseudocysts filled with mucin (Fig. 109-11A, B). The mucin is sialomucin, detected by an Alcian blue stain (pH 2.5).[63] The islands of basaloid cells are present in a hyalinized stroma and eosinophilic basement membrane material within the clusters of cells is often seen. Tubular and solid growth patterns also can be evident. Histologic grading for adenoid cystic carcinoma is defined as: grade 1, tubular and cribriform patterns; grade 2, less than 30% solid pattern; and grade 3, more than 30% solid pattern.[66] Perineural invasion is seen in a majority of cases.

True ductal differentiation can be seen in adenoid cystic carcinoma and highlighted by immunohistochemistry for EMA and CEA.[63,64] Adenoid cystic carcinoma tumor cells are reported to be positive for

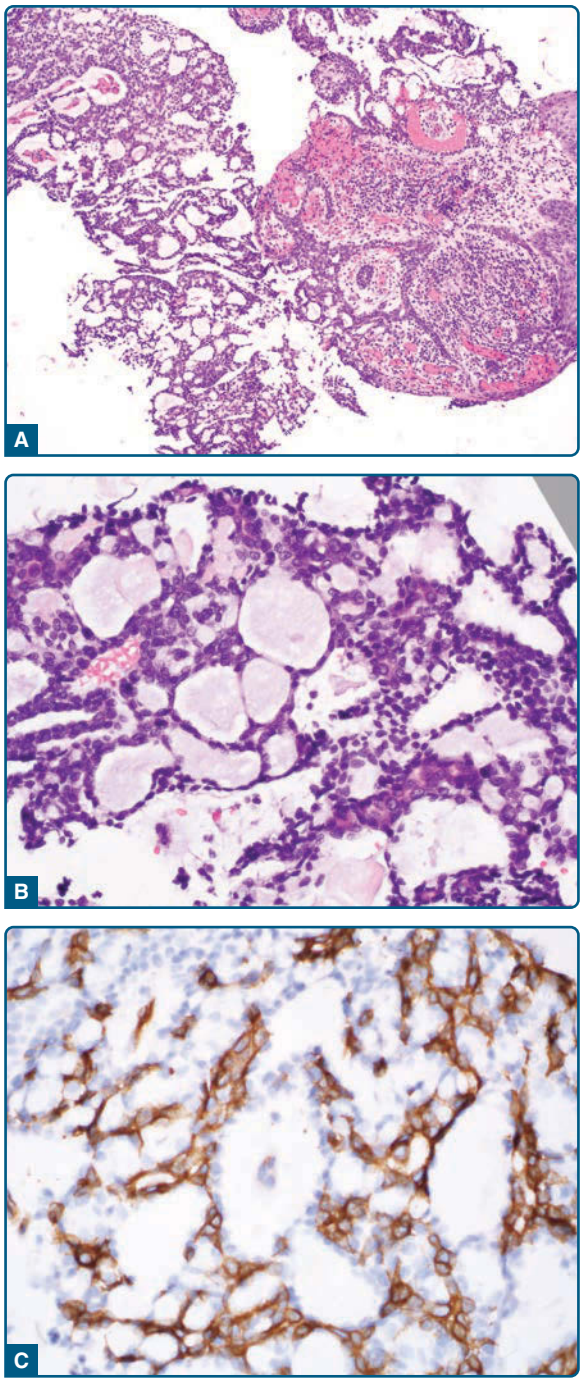

Figure 109-11 **A,** Adenoid cystic carcinoma is composed of dermal islands of basaloid cells. **B,** The tumor cells have a characteristic cribriform arrangement, with punched out pseudocysts filled with mucin. **C,** The tumor cells usually stain positively for CD117 (cKIT).

cytokeratins (including CK7), CD117 (cKIT), CK15, and SOX-10 (see Fig. 109-11C).[63-65,67] There is a myoepithelial component in adenoid cystic carcinoma, with those cells staining for typical myoepithelial markers, including smooth muscle actin, S100, and p63.[63,65]

Differential Diagnosis: Because primary cutaneous adenoid cystic carcinoma frequently occurs in the head and neck region, a salivary gland metastasis must be excluded, especially given the relative rarity of primary cutaneous adenoid cystic carcinoma compared to its salivary gland counterpart. There is significant histologic overlap between primary cutaneous and salivary gland adenoid cystic carcinoma, but reports suggest using differing immunohistochemical profiles to distinguish between them. CK15 and CK7 positivity are reported to favor primary cutaneous adenoid cystic carcinoma; CK15, however, has a high specificity and low sensitivity, whereas CK7 lacks specificity.[65] Prior reports of using CK5/CK6 and p63 to distinguish between primary cutaneous and salivary gland adenoid cystic carcinoma could not be validated in subsequent studies.[65]

Also in the histologic differential diagnosis of adenoid cystic carcinoma is basal cell carcinoma, which should be negative for CD117, EMA, CEA, or S100 immunostains (see Table 109-5).[63]

Clinical Course and Prognosis: Primary cutaneous adenoid cystic carcinoma follows an indolent clinical course, but recurrence is a frequent event, perhaps secondary to the high rates of perineural invasion.[63,64] Metastases are a rare event, but have been documented.[63-65] The prognosis for primary cutaneous adenoid cystic carcinoma is better than its salivary gland counterpart, which has an overall poor long-term survival rate. Unlike in the salivary gland, where histologic grade influences prognosis, no significant difference in recurrence has been seen between low-grade and high-grade cutaneous adenoid cystic carcinomas.[63]

Management: Wide local surgical excision is the treatment of choice, given the tendency to recur. Chemotherapy has been used to treat metastatic pulmonary disease.[64]

APOCRINE ADENOCARCINOMA

Cutaneous apocrine adenocarcinoma is a rare, malignant appendage neoplasm with apocrine differentiation.

Epidemiology and Clinical Features: Cutaneous apocrine adenocarcinoma affects elderly adults, typically in their sixth decade of life. It presents as a dermal nodule, ranging in size from 0.5 to 7.5 cm.[68] Cutaneous apocrine adenocarcinoma presents in areas of the body with a high distribution of apocrine glands, with the most frequent site being the axilla. Involvement of the anogenital region and scalp by apocrine adenocarcinoma also has been reported.

Etiology and Pathogenesis: Cutaneous apocrine adenocarcinoma is hypothesized to arise from normal or modified apocrine glands.

Histopathology: Histologically, cutaneous apocrine adenocarcinoma is a dermal tumor that displays apocrine differentiation with decapitation secretion and overt malignant features, including atypical architecture and cytological atypia. The tumor has irregular

or infiltrative borders with frequent extension into the subcutaneous fat.[68] Tubular, tubulopapillary, and solid growth patterns can be seen and there is heterogeneity between tumors. An in situ component is often identified and can help to distinguish primary disease from a metastasis.

By immunohistochemistry, apocrine adenocarcinoma expresses cytokeratins (including CK7 and CK5/CK6), as well as GCDFP-15, CEA, EMA, ER (estrogen receptor), PR (progesterone receptor), and androgen receptor.[68]

Differential Diagnosis: Given the relative frequency of mammary adenocarcinoma, metastasis of a breast primary to the skin must be excluded to make the diagnosis of cutaneous apocrine adenocarcinoma. This requires predominantly clinicopathologic correlation, although identification of an in situ component can aid in the diagnosis of primary disease. A more recent study suggests using an immunohistochemical panel, including adipophilin, ER, PR, HER2 (human epidermal growth receptor 2), CK5/CK6, and mammaglobin to distinguish cutaneous apocrine carcinoma (adipophilin−, ER+, PR+/−, HER2−, CK5/CK6+, mammaglobin+) from mammary apocrine carcinoma (adipophilin+, ER−, PR−, HER2 3+).[69]

Clinical Course and Prognosis: As cutaneous apocrine carcinoma is rare, prognostic factors are difficult to assess. In their series, Robson and colleagues, classified tumors similarly to mammary carcinomas using the modified Bloom-Richardson method, assigning scores based on histologic criteria.[68] Patients with high-grade tumors (grade 3) had statistically significant poorer survival rates than those with lower-grade tumors (grades 1 and 2). Aggressive behavior, including local recurrence, lymph node metastasis, and distant metastases, has been reported in cases of cutaneous apocrine adenocarcinoma. Patients with metastatic disease (locoregional and distant) have a poor prognosis with reduced survival rates.[70]

Management: Cutaneous apocrine adenocarcinoma is treated surgically by wide excision. Given the risk of metastatic disease and its associated poorer prognosis, some advocate for sentinel lymph node biopsy at the time of excision.[70]

Primary Cutaneous Cribriform Carcinoma: There is a more recently described variant of cutaneous apocrine carcinoma, primary cutaneous cribriform carcinoma.[71,72] Cutaneous cribriform carcinoma is a rare appendage tumor that affects adults and commonly presents on the limbs. Histologically, it is a relatively well-circumscribed, dermal neoplasm composed of connected, solid aggregates of basaloid cells with characteristic "punched out" cribriform spaces. These tumors have an indolent behavior with no recurrences or metastases reported as of this writing.

MUCINOUS CARCINOMA

Epidemiology and Clinical Features: Primary cutaneous mucinous carcinoma is a rare, malignant appendage neoplasm that primarily affects adult women in their sixth decade.[73] It presents as a solitary, flesh-colored nodule, often on the head, and can involve the scalp, eyelids, and face.

Histopathology: Mucinous carcinoma is classically composed of nests of epithelial cells floating within pools of mucin, although heterogeneity between tumors can be observed, including the presence of in situ and invasive ductal components.

Differential Diagnosis: Primary cutaneous mucinous carcinoma is a diagnosis of exclusion and the possibility of metastatic mucinous carcinoma, including from the breast or GI tract, must be evaluated. Clinical history, imaging, and site of involvement are crucial aspects in the workup of the patient. Immunohistochemistry plays a limited role, including in the evaluation of metastatic disease, but CK20 and CDX-2 can be helpful in evaluating for metastatic disease from a colonic primary.[5,73]

Clinical Course and Prognosis: Local recurrence of primary cutaneous mucinous carcinoma is a common occurrence at a reported rate between 30% and 43%, but clinically aggressive behavior is extremely rare.[74]

Management: Treatment of primary cutaneous mucinous carcinoma is surgical excision.

TUMORS WITH FOLLICULAR DIFFERENTIATION

The hair follicle is a complex miniorgan that cycles through different phases, including anagen, telogen, and catagen. (See Chap. 7 for a detailed discussion on normal hair follicles.) A mature hair follicle is composed of different horizontal portions: bulb, stem, isthmus, and infundibulum. Additionally, there is an inner root sheath and an outer root sheath that encompasses the hair shaft. Follicular neoplasms show differentiation toward these different portions of the hair follicle, as well as follicular mesenchyme and developmental stages of hair growth.[3,75] Table 109-7 lists appendage tumors with follicular differentiation. Differentiation toward follicular germinative cells recapitulates embryonic follicular hair germ and shows basaloid differentiation with peripheral palisading. Differentiation toward the perifollicular sheath (or mesenchyme) is typified by thin collagen fibrils, mucinous matrix, fibroblasts, and blood vessels. Differentiation toward the hair bulb displays matrical cell differentiation. Differentiation toward the outer root sheath shows clear cells, whereas differentiation toward the inner root sheath shows eosinophilic cells. Infundibular differentiation is similar to normal epidermal differentiation with basal, spinous, granular, and corneal layers represented.

TABLE 109-7
Classification of Follicular Appendage Neoplasms

TYPE (LINEAGE) OF FOLLICULAR DIFFERENTIATION	BENIGN	MALIGNANT
Pan-follicular	Trichofolliculoma	
Germinative cells		Basal cell carcinoma
Biphasic (Epithelial-Mesenchymal)	Trichoblastoma Trichoepithelioma Desmoplastic trichoepithelioma	
Mesenchymal	Trichodiscoma/ Fibrofolliculoma	
Matrical	Pilomatricoma	Pilomatrical carcinoma
Outer root sheath at the level of bulb/ stem	Trichilemmoma (including desmoplastic)	Trichilemmal carcinoma
Outer root sheath at the level of the isthmus	Tumor of follicular infundibulum Pilar sheath acanthoma Proliferating pilar tumor	
Infundibulum	Trichoadenoma Dilated pore (of Winer)	

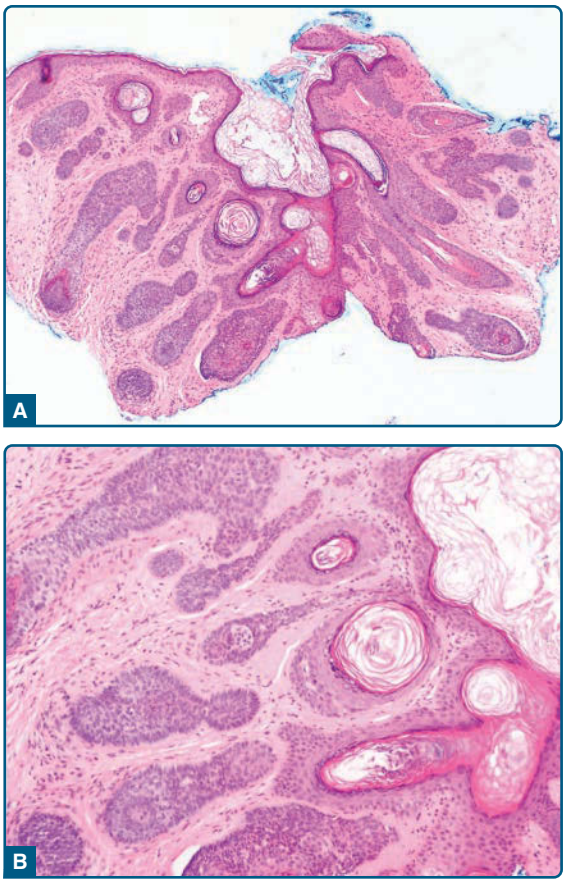

Figure 109-12 **A,** Trichofolliculoma is characterized by numerous small hair follicles radiating from a central pore. **B,** The follicles vary in stages of differentiation.

NEOPLASM WITH PAN-FOLLICULAR DIFFERENTIATION

TRICHOFOLLICULOMA

Epidemiology and Clinical Features: Trichofolliculoma is a rare, benign entity that typically presents as a single, flesh-colored papule in the head and neck region in adults.[76] The nose is the most commonly affected site. Classically, a central dell with protruding vellus hairs is seen.

Etiology and Pathogenesis: Trichofolliculoma is a benign follicular hamartoma that shows differentiation toward all portions of the hair follicle.[1,3]

Histopathology: Trichofolliculoma displays characteristic histopathologic findings, with a central dilated or cystic infundibulum and secondary hair follicles radiating into the dermis (Fig. 109-12A).[3,75,76] The secondary hair follicles are surrounded by connective tissue. The hair follicles can display different stages of differentiation, from immature hair germ to mature hair follicles to vellus hairs (Fig. 109-12B). Similarly, the abundance of connective tissue can vary between lesions. Sebaceous differentiation can be observed.

Differential Diagnosis: The histologic differential diagnosis for trichofolliculoma can include folliculosebaceous cystic hamartoma, especially if there is sebaceous differentiation. In contrast to trichofolliculoma, folliculosebaceous cystic hamartoma typically has mesenchymal differentiation (eg, into adipose tissue) and prominent sebaceous differentiation.

Clinical Course and Prognosis: Trichofolliculoma is a benign entity.

Management: The treatment of choice for trichofolliculoma is surgical excision, with an emphasis on cosmesis.

NEOPLASM OF FOLLICULAR GERMINATIVE CELLS

BASAL CELL CARCINOMA

Basal cell carcinoma is a malignant neoplasm of follicular germinative differentiation and is discussed in detail in Chap. 111.

BIPHASIC (EPITHELIAL–MESENCHYMAL) NEOPLASMS OF FOLLICULAR GERMINATIVE AND FOLLICULAR STROMAL CELLS

TRICHOBLASTOMA

Trichoblastoma is a benign neoplasm, showing differentiation toward both follicular germinative and follicular stromal cells. Trichoepithelioma (cribriform trichoblastoma) and desmoplastic trichoepithelioma (columnar trichoblastoma) are considered variants of trichoblastoma (see the section "Trichoepithelioma").[1,75]

Epidemiology and Clinical Features: Trichoblastoma (Fig. 109-13A) affects adults and presents as a flesh-colored to red, dermal nodule on the head and neck, with reported involvement of the trunk and extremities as well.[1,3]

Etiology and Pathogenesis: Trichoblastoma shows differentiation toward both follicular germinative and follicular stromal cells.

Histopathology: Microscopically, trichoblastoma is a well-circumscribed dermal tumor composed of nests of basaloid cells in a cellular stroma (see Fig. 109-13B). The basaloid nests can be arranged in a variety of patterns, including nodular and trabecular. The stromal component consists of collagen fibrils and fibroblasts. Clefting within the stroma is common (but not between the basaloid nests and the stroma, as in basal cell carcinoma; see Fig. 109-13C). Abortive follicular structures, so-called papillary mesenchymal bodies, can be seen, as can more advanced follicular differentiation.

Cutaneous lymphadenoma is considered the adamantoid form of trichoblastoma, and is composed of nests of basaloid germinative cells with peripheral palisading and epithelioid cells with pale cytoplasm in the center of the nests. The tumor is infiltrated by small lymphocytes.

Differential Diagnosis: The main differential diagnosis for trichoblastoma is basal cell carcinoma. Trichoblastoma should show little cytologic atypia, a low mitotic rate, absent necrosis (although single-cell apoptosis can be seen), and clefting within the stroma. Basal cell carcinoma often displays cytologic atypia, frequent mitoses, necrosis, stromal mucinosis, and clefting between the epithelial nests and the tumor stroma. However, there can be overlap, and distinction on small biopsies can be difficult.

Studies have reported the usefulness of immunohistochemistry in distinguishing basal cell carcinoma from trichoblastoma. CK20+ Merkel cells tend to be absent in basal cell carcinoma, but are commonly found in trichoblastoma.[77] Another study showed that CD10 stains the stromal cells in trichoblastoma, but highlights the epithelial cells in basal cell carcinoma.[78] CK17 staining has been reported to distinguish basal cell carcinoma from lymphadenoma, with strong, diffuse staining in basal cell carcinoma, and weak, peripheral staining in lymphadenoma.[79] Drebin shows strong expression in basal cell carcinoma, with weak staining in both trichoblastoma and trichoepithelioma.[80] (Table 109-8 summarizes these immunohistochemical findings.)

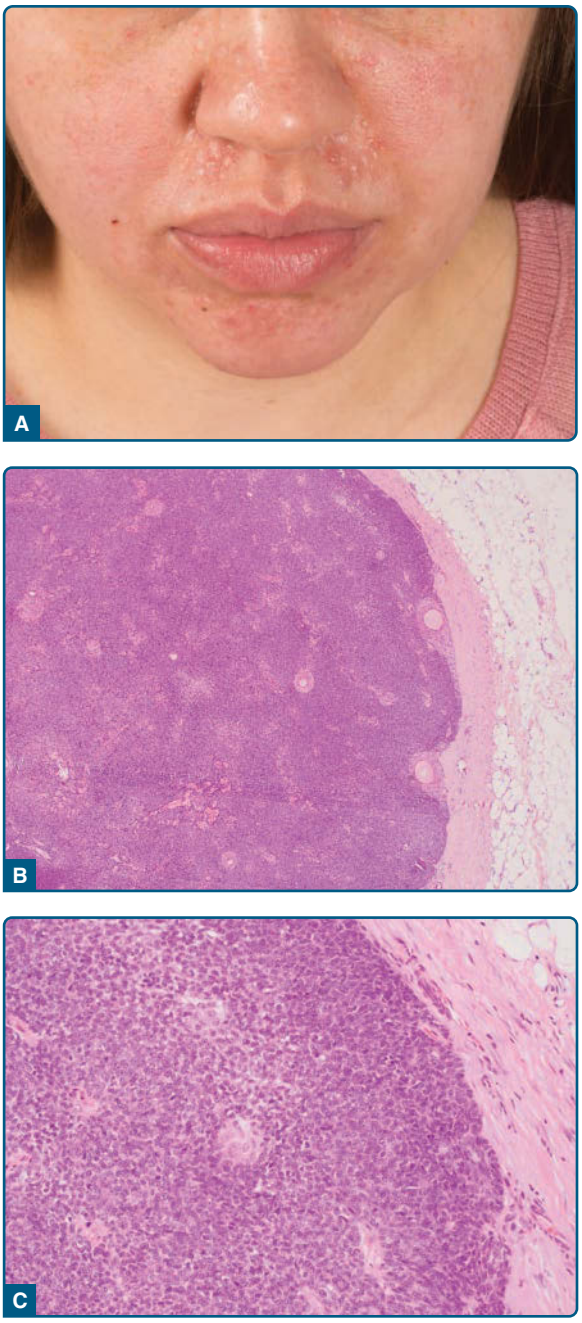

Figure 109-13 **A,** Trichoblastoma present as red to flesh-colored dermal nodules, often on the face. **B,** The tumor is a circumscribed dermal nodule composed predominantly of basaloid cells. **C,** The basaloid epithelioid structures may resemble basal cell carcinoma; however, the characteristic mucin-containing clefts separating basal cell carcinoma from the stroma are not a feature of trichoblastoma.

TABLE 109-8
Summary of Immunohistochemical Stains in the Distinction between Basal Cell Carcinoma, Trichoblastoma, and Trichoepithelioma

	BCC	TRICHOBLASTOMA	TRICHOEPITHELIOMA	DESMOPLASTIC TRICHOEPITHELIOMA
CK15	–	ND	+	+
BerEP4	+	+/–	–	+/–
CK20	–	+ (Merkel cells)	+ (Merkel cells)	+ (Merkel cells)
CD10	+ (epithelial cells)	+ (stromal cells)	ND	ND
CD34	– (stromal cells)	ND	+ (stromal cells)	– (stromal cells)
Drebin	+	–	ND	ND
PHLDA1	–	ND	+	+

–, Negative; +, positive; BCC, basal cell carcinoma; ND, no data.

Clinical Course and Prognosis: Malignant transformation from trichoblastoma to trichoblastic carcinoma or sarcoma is extremely rare.[81]

Management: Although it is a benign neoplasm, complete surgical excision of trichoblastoma is recommended, given the low risk of malignant transformation and the difficulty in distinguishing it from basal cell carcinoma on small biopsies.

TRICHOEPITHELIOMA AND DESMOPLASTIC TRICHOEPITHELIOMA

Trichoepithelioma is considered the cribriform variant of trichoblastoma with infundibulocystic differentiation. Solitary (sporadic), multiple, and desmoplastic types occur.[3,75] Desmoplastic trichoepithelioma is also known as the columnar variant of trichoblastoma.[1]

Epidemiology and Clinical Features: Both solitary and desmoplastic trichoepitheliomas affect middle-aged adults with a female predilection.[82,83] Multiple trichoepitheliomas typically affect a younger patient population in their 20s.[18] Solitary trichoepithelioma presents as a single, flesh-colored papule on the face, measuring approximately 5 mm in size, and is often located on the nose or cheek. Desmoplastic trichoepithelioma presents as a single, white to yellow, firm papule or plaque with a central depression. Desmoplastic trichoepithelioma is frequently found on the face, with the cheek and nose the most common locations. Multiple trichoepitheliomas present as multiple small papules on the face, often involving the nasolabial folds and sometimes occurring in an X-like pattern.

Etiology and Pathogenesis: Multiple trichoepitheliomas are observed with an autosomal dominant inheritance pattern and are associated with mutations in the *CYLD* gene on chromosome 16, similar to Brooke-Spiegler syndrome (see Table 109-2).[18] Multiple trichoepitheliomas are also seen in Rombo syndrome and Bazex-Dupré-Christol syndrome,[75] where patients have atrophoderma, milia, basal cell carcinomas, and hypotrichosis. Deletions of the *PTCH1* gene locus at 9q22 have been found in some trichoepitheliomas.[84]

Histopathology: Trichoepithelioma is a well-circumscribed, dermal tumor composed of basaloid germinative epithelial cells arranged in a cribriform pattern within a fibrous stroma (Fig. 109-14A). Retiform and small nodular patterns also can be seen. Desmoplastic trichoepithelioma is located in the upper dermis and composed of strands and small nests of basaloid cells in a sclerotic stroma. Like other variants of trichoblastoma, varying degrees of follicular differentiation can be seen in trichoepitheliomas. Papillary mesenchymal bodies are a characteristic finding (Fig. 109-14B). Infundibulocystic changes can be seen in both trichoepithelioma and desmoplastic trichoepithelioma.

Differential Diagnosis: If it has a classic appearance, the diagnosis of trichoepithelioma can be suggested clinically, prior to histologic evaluation. For trichoepithelioma, the main differential diagnosis is a basal cell carcinoma (see Fig. 109-14C), and like trichoblastoma, can be difficult to discern on small biopsies. Similarly, for desmoplastic trichoepithelioma, the differential diagnosis includes basal cell carcinoma, microcystic adnexal carcinoma, and, sometimes, syringoma.

Trichoepithelioma and desmoplastic trichoepithelioma, in contrast to basal cell carcinoma, tend to have symmetric growth, lack of invasion into the surrounding dermis, follicular-type stroma, and clefting within the stroma. Expression of PHLDA1 has been suggested as an immunohistochemical tool to distinguish basal cell carcinoma (PHLDA1–) from trichoepithelioma and desmoplastic trichoepithelioma (PHLDA1+).[85-87] CK20+ Merkel cells are also more prevalent in desmoplastic trichoepithelioma than in basal cell carcinoma or microcystic adnexal carcinoma (see Fig. 109-14D).[88] Although androgen receptor (AR) expression has been suggested as a way to differentiate desmoplastic trichoepithelioma (AR–) from basal cell carcinoma (AR+),[89] subsequent studies

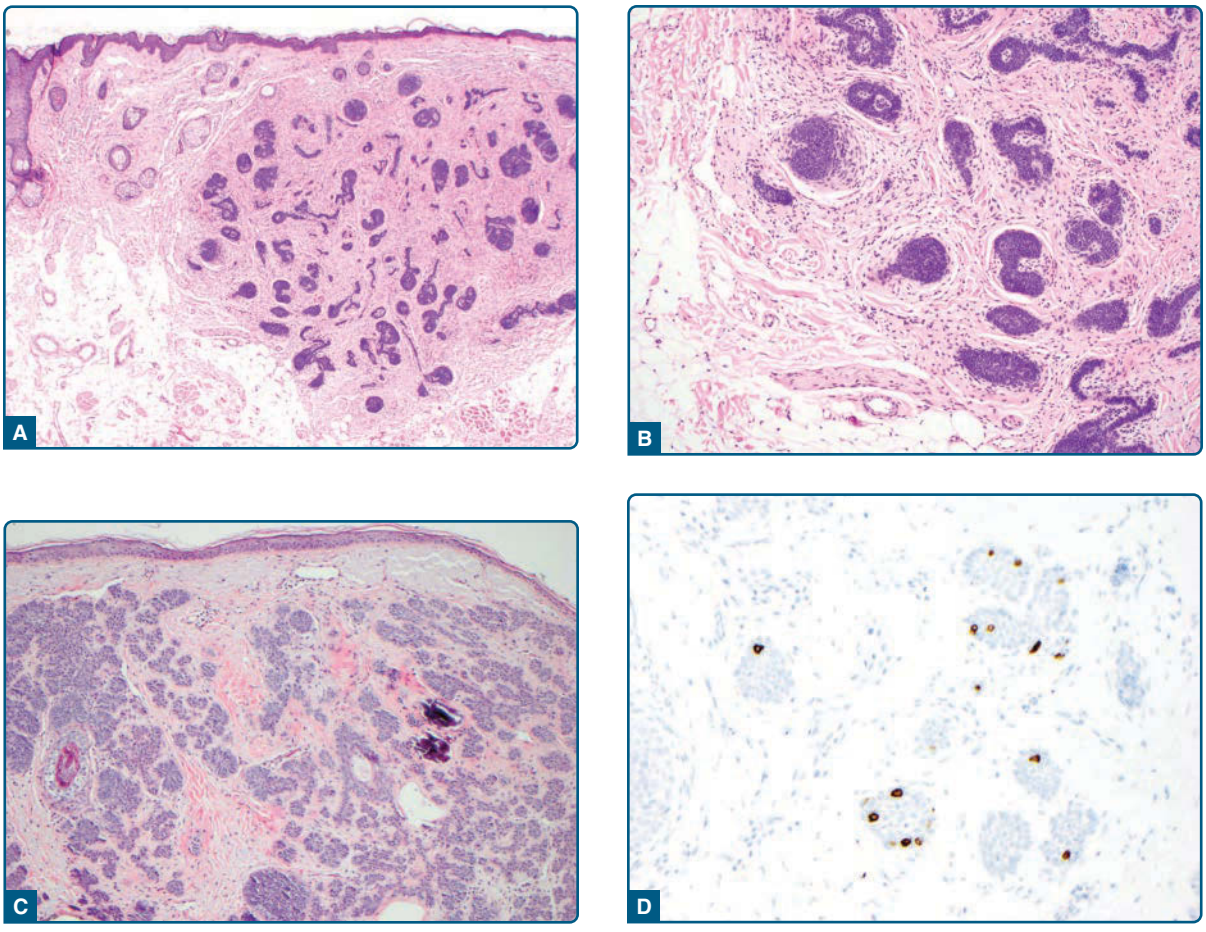

Figure 109-14 **A,** Trichoepithelioma is a well-circumscribed, superficial, dermal tumor. **B,** The tumor is composed of basaloid germinative epithelial cells that form papillary mesenchymal bodies, which are composed of a cup-shaped arrangement of basaloid epithelium with a central cellular fibroblastic core. **C,** In tumors with a predominance of basaloid cells the differential diagnosis includes basal cell carcinoma. **D,** CK20+ Merkel cells are often present.

have been less supportive.[90] Trichoepithelioma may have staining of the tumor cells and the surrounding stromal cells for CD34[91]; the tumor is usually without staining for BerEP4. In contrast, basal cell carcinoma is usually BerEP4+ without CD34+ surrounding stromal cells.[91] Desmoplastic trichoepithelioma, conversely, can show positive staining for BerEP4 and the peritumoral stromal cells are negative for CD34 staining.[5] (Table 109-8 summarizes these immunohistochemical findings.)

Clinical Course and Prognosis: Trichoepithelioma and desmoplastic trichoepithelioma are benign appendage neoplasms.

Management: Surgical excision, including by Mohs micrographic surgery, can be considered for solitary lesions, especially if the histologic diagnosis is in doubt. Treatment of multiple facial trichoepitheliomas is focused on cosmesis and can be challenging. Ablative methods, such as electrosurgery, cryosurgery, and laser treatment have been employed in the treatment of multiple trichoepitheliomas, as have topical treatments, such as imiquimod.[82]

NEOPLASMS WITH FOLLICULAR MESENCHYMAL DIFFERENTIATION

TRICHODISCOMA/ FIBROFOLLICULOMA

Historically, trichodiscoma and fibrofolliculoma were considered separate entities. They are now thought to be a single entity that exists on a morphologic spectrum, in part because they can coexist in the same patient, and because individual lesions can contain features characteristic of each entity.[1,75,92] We include trichodiscoma/fibrofolliculoma in the follicular neoplasm section, given the abundant follicular-type mesenchyme present in the tumor. Others, however, regard trichodiscoma/fibrofolliculoma as a sebaceous neoplasm, as it shows differentiation toward the

mantle.[1,92] The mantle is an immature sebaceous gland with shrunken lobules that corresponds to the state of the gland between infancy and puberty when circulating androgens are absent.

Epidemiology and Clinical Features: Trichodiscoma/fibrofolliculoma occurs in adult patients over a wide age range.[92] It presents as a firm, white to flesh-colored papule, measuring between 1 and 3 mm in size. Trichodiscoma/fibrofolliculoma is typically observed on the face, but they can be present on the trunk. Multiple lesions are associated with Birt-Hogg-Dubé syndrome (see "Etiology and Pathogenesis" below).

Etiology and Pathogenesis: Multiple trichodiscomas/fibrofolliculomas are manifestations of Birt-Hogg-Dubé syndrome, an autosomal dominant syndrome caused by mutations in the *folliculin (FLCN)* gene on chromosome 17 (see Table 109-2).[93] Patients with Birt-Hogg-Dubé syndrome have an increased risk of renal tumors, lung cysts, and recurrent pneumothoraces.[93]

Histopathology: Trichodiscomas classically are dermal neoplasms composed predominantly of fibrous stromal elements with islands of mature sebaceous lobules at the periphery. Fibrofolliculomas classically are described with a central follicular infundibulum in the dermis with radially oriented thin epithelial cords, which may or may not contain mature sebocytes (Fig. 109-15A, B). As previously mentioned, lesions may contain one or both histologic patterns with morphologic variability.[92] The stromal cells show positivity for CD34 and Nestin by immunohistochemistry, while the cellular cords are positive for CK15, suggesting the neoplastic cells are derived from the follicular bulge stem cell.[92]

Differential Diagnosis: When stromal differentiation predominates, neural tumors enter into the histologic differential diagnosis, but can be easily distinguished by S100 immunohistochemistry, which is negative in trichodiscoma/fibrofolliculoma.

Clinical Course and Prognosis: Trichodiscoma/fibrofolliculoma is benign, but given its association with Birt-Hogg-Dubé syndrome, genetic screening should be considered for patients with the neoplasm.

Management: Laser ablation of multiple trichodiscomas/fibrofolliculomas results in short-term improvement with eventual regrowth.[93]

NEOPLASMS WITH MATRICAL DIFFERENTIATION

PILOMATRICOMA (PILOMATRIXOMA)

Pilomatricoma (or pilomatrixoma) is a benign neoplasm with follicular differentiation. It was initially

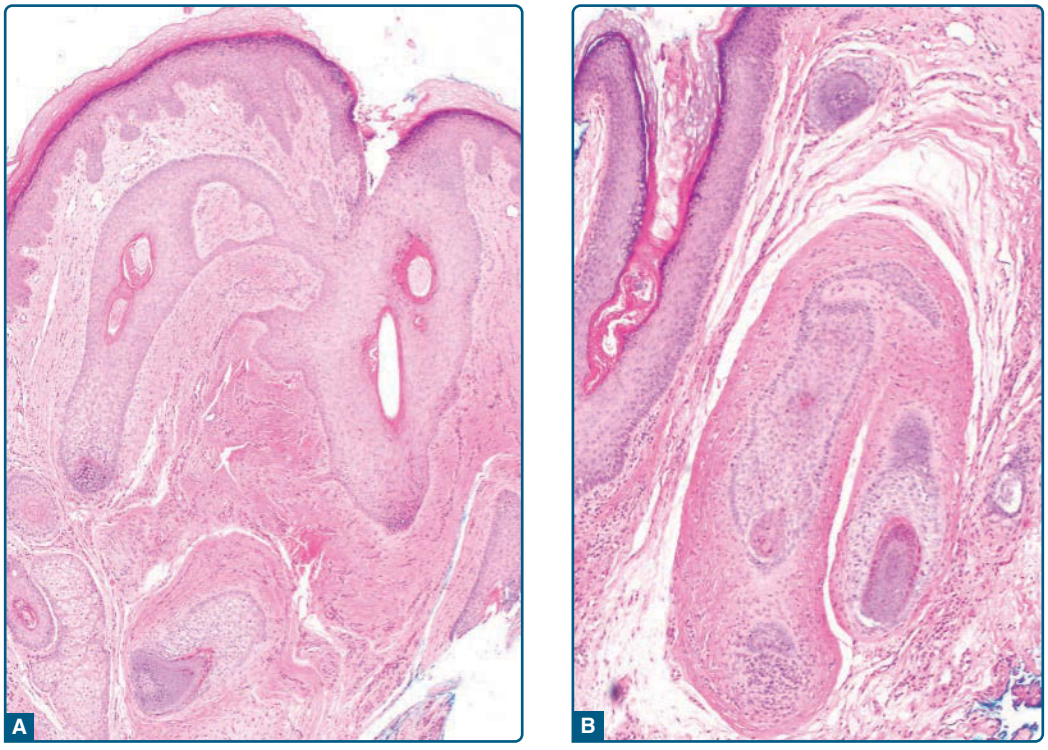

Figure 109-15 **A,** Fibrofolliculoma is composed of pilar and stromal elements. **B,** Irregularly shaped follicles with delicate fronds extend into a densely fibrotic perifollicular stroma.

described as "calcifying epithelioma of Malherbe" in 1880 and was thought to arise from sebaceous glands.[94-96]

Epidemiology and Clinical Features: Pilomatricoma (Fig. 109-16A) affects a wide age range, but is most common in children and young adults, and is the most common appendage tumor in children.[94-96] One series reported a bimodal age distribution in the first and sixth decades.[94] Some studies report a female predilection.[94,96] It presents clinically as a firm, asymptomatic, slow-growing nodule between 1 and 1.5 cm in size. The head and neck region is the most common site of involvement, followed by the upper extremities.[94-96]

Etiology and Pathogenesis: Pilomatricoma displays differentiation toward the follicular matrix. Pilomatricoma can be associated with a variety of genetic syndromes, including Gardner syndrome, myotonic muscular dystrophy, and Rubinstein-Taybi syndrome (see Table 109-2).[75] Most pilomatricomas harbor mutations in the gene encoding the β-catenin protein, *CTNNB1*, implicating WNT signaling in tumor pathogenesis.[97]

Histopathology: Pilomatricoma has a characteristic histologic appearance and is a well-circumscribed dermal nodule with peripheral, nucleated basaloid cells and central, enucleated eosinophilic "ghost" cells (see Fig. 109-16B, C). The basaloid cells have hyperchromatic, round nuclei and scant cytoplasm and resemble the matrical cells of the normal hair follicle. Tumors are initially cystic with relatively few numbers of ghost cells, but with increasing age of the lesion, ghost cells increase in number until they predominate. Calcification of pilomatricomas is not uncommon (see Fig. 109-16D).

Differential Diagnosis: Pilomatricoma can clinically resemble a cyst. Given its characteristic histologic appearance, pilomatricoma is rarely confused with other entities in an adequate biopsy specimen.

Clinical Course and Prognosis: Pilomatricoma is a benign neoplasm with rare malignant transformation (see "Pilomatrical Carcinoma" below). Local recurrences following surgery are also uncommon.[94,95]

Management: Wide local surgical excision is the treatment of choice for pilomatricoma.

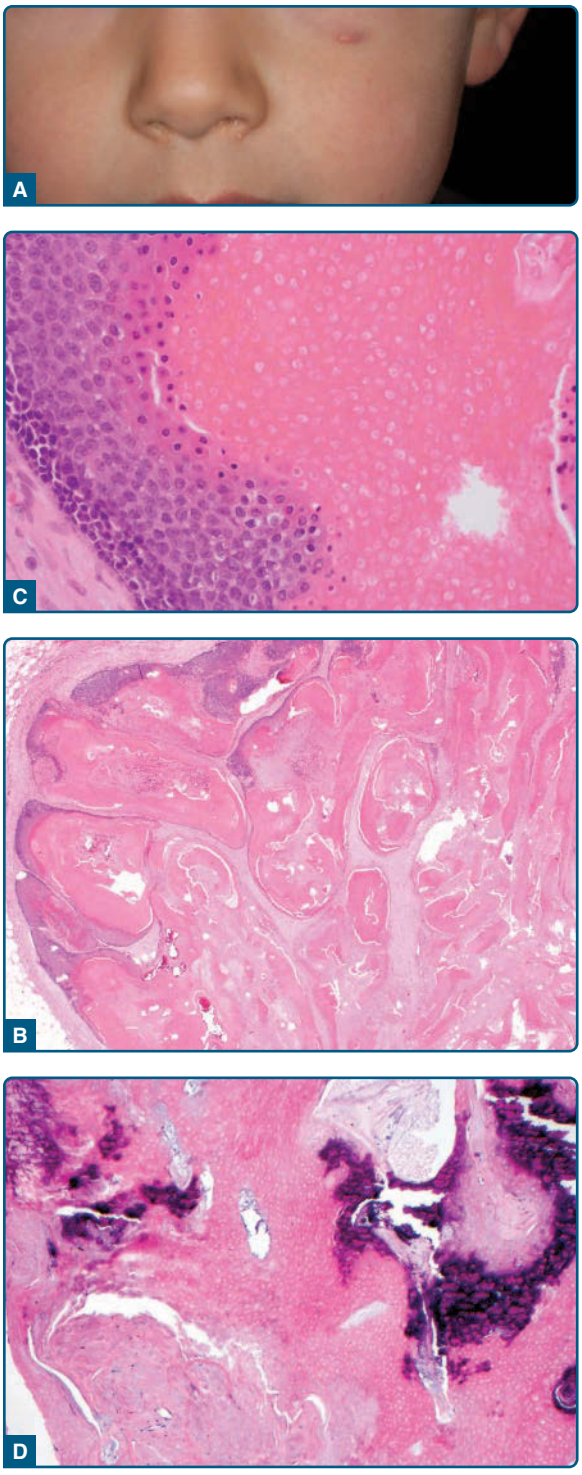

Figure 109-16 **A,** Pilomatricoma is a circumscribed dermal nodule, with (**B**) peripheral nucleated basaloid cells and central eosinophilic shadow cells (ghost cells). **C,** The basaloid cells have round nuclei resembling pilar matrical cells, whereas shadow cells are composed of eosinophilic cellular material with a faint outline of nuclear membrane. **D,** In some cases basaloid cells are inconspicuous and there is prominent calcification, in which event, the tumor also has been known as calcifying epithelioma of Malherbe.

PILOMATRICAL CARCINOMA

Pilomatrical carcinoma is a rare, malignant appendage neoplasm. It also has been referred to as pilomatrix carcinoma, malignant pilomatricoma, and matrical carcinoma.[98]

Epidemiology and Clinical Features: Pilomatrical carcinoma occurs in middle-aged to elderly patients, most often presenting in white males.[98] Pilomatrical carcinoma presents as a dermal nodule, frequently arising in the head and neck

region. "Rapid growth" is cited as a common reason for biopsy.

Etiology and Pathogenesis: Histologic evaluation can reveal areas of benign pilomatricoma with transition to malignancy; however, pilomatrical carcinoma rarely develops at the site of a previously biopsied or excised pilomatricoma.[98] Both benign pilomatricoma and malignant pilomatrical carcinoma harbor mutations in the gene encoding β-catenin, suggesting at least some role for the WNT signaling pathway in the tumorigenesis of matrical follicular tumors, but also implying that additional mutations be acquired to achieve malignant transformation.[98]

Histopathology: Histologically, pilomatrical carcinoma is a poorly circumscribed, nodular, dermal tumor, with infiltrative borders and central necrosis.[98] A desmoplastic stroma surrounds the tumor. The tumor is composed of pleomorphic, basaloid cells with frequent mitoses. "Ghost" cells can be present, but do not predominate. Lymphovascular invasion is not common.

Differential Diagnosis: Clinically, the differential diagnosis of a rapidly growing dermal nodule is broad and includes other malignant appendage neoplasms, cutaneous metastases, soft-tissue tumors, and benign cysts. Histologically, follicular matrical differentiation should be conspicuous and cytological pleomorphism, infiltrative growth, and necrosis all favor malignancy.

Clinical Course and Prognosis: Local recurrence is common and is a risk factor for locoregional metastasis.[98] Distant metastatic disease and death have been reported in association with pilomatrical carcinoma.[98]

Management: Wide local excision is the current recommended treatment for pilomatrical carcinoma, with close clinical followup given the risk of recurrence and metastasis.[98] Limited data is available for using radiation therapy either as the sole therapy or as adjuvant therapy.[98] Chemotherapy currently plays no role in the treatment of pilomatrical carcinoma.

NEOPLASMS WITH BULB/STEM OUTER ROOT SHEATH DIFFERENTIATION

TRICHILEMMOMA

Epidemiology and Clinical Features: Trichilemmoma is a benign neoplasm that presents in adults over a wide age range.[99] Clinically, it can present singly or as multiple lesions. Trichilemmomas are flesh-colored papules and can have a verrucous surface. They typically present on the head and neck and have a predilection for the nose. Multiple trichilemmomas, including involvement of the oral mucosa, are associated with Cowden syndrome (multiple hamartoma syndrome).[100] Desmoplastic trichilemmoma is a histologic variant.

Etiology and Pathogenesis: Trichilemmoma is a follicular neoplasm with differentiation toward the outer root sheath at the level of the hair bulb and stem ("trichilemmal"). Some consider trichilemmoma to be a viral wart, but studies looking at the presence of human papillomavirus DNA in trichilemmomas have produced conflicting results.[1,75] Multiple trichilemmomas with involvement of mucocutaneous sites are associated with Cowden syndrome (multiple hamartoma syndrome), an autosomal dominant syndrome caused by mutations in the tumor-suppressor gene *PTEN* (see Table 109-2).[100] Patients with Cowden syndrome have hamartomas affecting multiple organ systems, including the skin, breast, thyroid, endometrium, and GI tract, and have an increased risk of malignancy in those affected organs, especially the breast. Other clinical manifestations of Cowden syndrome include oral papillomatosis and acral and palmoplantar keratosis.[100] Expression of PTEN protein, as measured by immunohistochemistry, is lost in most Cowden syndrome–associated trichilemmomas, but is retained in sporadic trichilemmomas.[100] A recent study found *HRAS* activating mutations in 60% of sporadic trichilemmomas.[101]

Histopathology: Microscopically, trichilemmoma is a well-circumscribed tumor with endophytic lobules extending from the epidermis into the dermis (Fig. 109-17A).[99] Surface verrucous changes are often present. The lobules are composed of pale, eosinophilic keratinocytes with peripheral palisading and are surrounded by a thick, PAS-positive, hyaline membrane (Fig. 109-17B).

Desmoplastic trichilemmoma is a histologic variant and is composed of central strands of pale eosinophilic keratinocytes in a fibrotic stroma (Fig. 109-18A). The periphery of desmoplastic trichilemmoma typically has a more classic, circumscribed appearance with a PAS-positive hyaline membrane (Fig. 109-18B).

Differential Diagnosis: Clinically, trichilemmoma can resemble a wart or basal cell carcinoma. Histologically, the diagnosis of trichilemmoma is straightforward, unless a partial biopsy is received, and then the differential can include wart, seborrheic keratosis, clear-cell poroma, and clear-cell acanthoma.

Infiltrative carcinoma, including squamous cell carcinoma and basal cell carcinoma, is in the histologic differential diagnosis of desmoplastic trichilemmoma. Trichilemmoma, including the desmoplastic variant, is positive for CD34 (see Fig. 109-18C), and should not show cytologic atypia, as would be seen in a carcinoma (see Table 109-4).[2,75] Areas of conventional trichilemmoma with clear cells and surrounding hyaline membrane can aid in the diagnosis.

Clinical Course and Prognosis: Trichilemmoma is a benign follicular neoplasm. Trichilemmal carcinoma is considered the malignant counterpart,

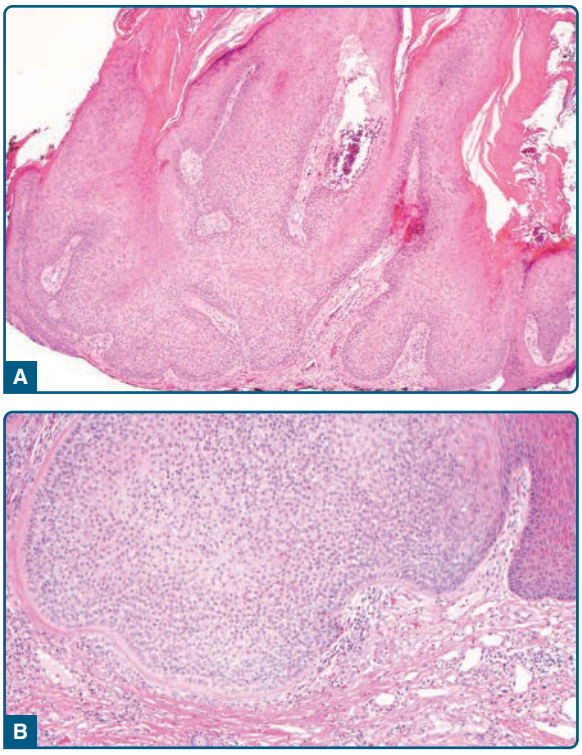

Figure 109-17 **A,** Trichilemmoma is an endophytic proliferation of epithelial cells with clear cytoplasm resembling the hair follicle outer root sheath; the surface may have a verrucous appearance. **B,** There is a palisaded proliferation of basaloid cells, surrounded by a variably dense eosinophilic hyaline membrane; the clear cells have round to oval nuclei without cellular atypia.

and appears to be a rare entity.[102] Trichilemmal carcinoma was originally described by Headington in 1976, and some now question whether entities originally diagnosed as trichilemmal carcinomas are instead clear-cell squamous carcinomas or even desmoplastic trichilemmomas.[1,102]

Management: Trichilemmomas are benign neoplasms and can be treated with surgical excision. Cases of desmoplastic trichilemmomas treated with Mohs micrographic surgery have been reported.[103] Trichilemmoma also can be treated by laser ablation. Trichilemmal carcinoma is treated by surgical excision using either conventional or Mohs micrographic techniques.[104]

NEOPLASMS WITH ISTHMIC OUTER ROOT SHEATH DIFFERENTIATION

TUMOR OF FOLLICULAR INFUNDIBULUM

Tumor of follicular infundibulum is a rare, benign appendage neoplasm originally described by Mehregan and Butler in 1961.[105]

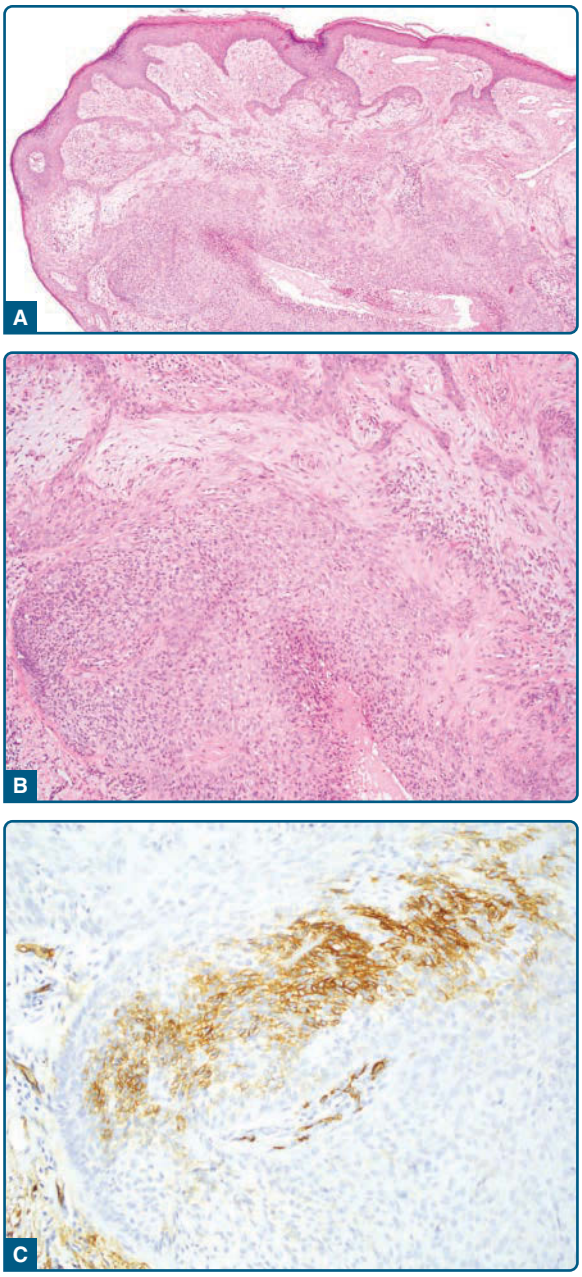

Figure 109-18 **A,** Desmoplastic trichilemmoma has features similar to trichilemmoma but with a central zone of stromal sclerosis entrapping cords of epithelium. **B,** The top of this image shows areas of desmoplastic change with cords of tumor cells; the bottom of this image shows clear cells and a thick hyaline membrane characteristic of trichilemmoma. **C,** The tumor cells may stain positively for CD34.

Epidemiology and Clinical Features: Tumor of follicular infundibulum presents in adult patients with an average age in the sixth decade. There is no apparent sex predilection, with different reports showing varying results.[1,106] Tumor of follicular infundibulum often presents as a solitary keratotic papule on the head and neck.[106] Multiple tumors of follicular infundibulum can present as hypopigmented macules, also located on the head and neck.

Etiology and Pathogenesis: Despite its name, tumor of follicular infundibulum displays follicular isthmic differentiation, rather than infundibular, and its pathogenesis is still unclear. Although most regard tumor of follicular infundibulum as a benign appendage neoplasm, some regard it as a type of basal cell carcinoma.[106]

Histopathology: Microscopically, tumor of follicular infundibulum is composed of strands of eosinophilic, isthmic keratinocytes that extend from the epidermis into the superficial dermis in a reticular pattern. Special stains reveal a "brush-like" network of elastic fibers that surround the base of the tumor.[75,106] Tumor cells are negative for BerEP4 and show scattered CK20+ Merkel cells, in contrast to basal cell carcinoma.[106] Rarely, tumor of follicular infundibulum can be associated with other entities, such as basal cell carcinoma, squamous cell carcinoma, and melanoma in situ.[106]

Differential Diagnosis: The clinical differential diagnosis includes basal cell carcinoma and seborrheic keratosis.

Clinical Course and Prognosis: Tumor of follicular infundibulum is a benign entity, but can be associated with malignancies. Transformation to basal cell carcinoma also has been reported in a patient with numerous tumors of follicular infundibulum.[107]

Management: Follicular infundibulum tumor treatments include topical steroids, retinoids, cryotherapy, curettage, and surgery, with all showing limited results, especially in patients with multiple tumors.[108]

PILAR SHEATH ACANTHOMA

Pilar sheath acanthoma is a rare, benign appendage neoplasm that was first described in 1978.[109]

Epidemiology and Clinical Features: Pilar sheath acanthoma affects adult patients over a wide age range without apparent sex predilection.[110] Clinically, it presents as a single, flesh-colored nodule with a central keratotic plug, often on the upper lip or central face.

Etiology and Pathogenesis: Pilar sheath acanthoma shows differentiation toward both infundibular and isthmic portions of the normal hair follicle.[75]

Histopathology: Microscopically, pilar sheath acanthoma is a well-circumscribed cystic epithelial proliferation with superficial/central infundibulocystic differentiation and peripheral isthmic differentiation. Lobules composed of eosinophilic, pale keratinocytes (showing isthmic differentiation at the level of the outer root sheath) emanate radially from the central cystic cavity. Horn cysts, sebocytes, and sebaceous ducts can be observed within the lobules.

Differential Diagnosis: Histologically, dilated pore and trichofolliculoma are in the differential diagnosis of pilar sheath acanthoma.[75,110] The radial projections are more lobular in pilar sheath acanthoma, as compared to dilated pore, and the radial projections in trichofolliculoma contain vellus hairs. Dilated pore does not show isthmic differentiation.

Clinical Course and Prognosis: Pilar sheath acanthoma is a benign entity.

Management: Surgical excision of pilar sheath acanthoma can be performed for cosmetic purposes.

PROLIFERATING PILAR TUMOR

Proliferating pilar tumor was first described by Jones in 1966 as "proliferating epidermoid cyst."[111] Other names used for this entity include proliferating pilar cyst, proliferating trichilemmal cyst, pilar tumor of the scalp, and invasive hair matrix tumor.[112,113]

Epidemiology and Clinical Features: Proliferating pilar tumor occurs in adult patients typically in their sixth decade or older; there is a marked female predilection.[112,113] The tumor presents as a dermal nodule on the scalp with a mean size of 3 cm, but sizes up to 25 cm have been documented.[112] Tumors can present singly or as multiple lesions.

Etiology and Pathogenesis: Proliferating pilar tumor is a follicular neoplasm with differentiation toward the outer root sheath at the level of the isthmus. Consequently, it displays characteristic trichilemmal keratinization with abrupt transition from squamous epithelium to glassy, compact keratin without a granular cell layer. Proliferating pilar tumor is thought to derive from existing pilar (trichilemmal) cysts.[113] Proliferating pilar tumors have been reported in patients with keratitis, ichthyosis, and deafness (KID) syndrome, which is caused by mutations in the gene encoding connexin-26 (see Table 109-2).[114,115]

Histopathology: Microscopically, proliferating pilar tumors are well-circumscribed dermal neoplasms with a lobular architecture (Fig. 109-19A). They are composed of eosinophilic keratinocytes with central trichilemmal keratinization and peripheral palisading. Squamous eddies and calcifications within the neoplasm are common findings (Fig. 109-19C). The basement membrane surrounding the tumor can be eosinophilic and prominent.

Differential Diagnosis: The clinical differential diagnosis includes a cyst, either epidermoid or pilar. Histologically, proliferating pilar tumor can be difficult to distinguish from squamous cell carcinoma, especially in areas of solid growth or in limited biopsies (see Fig. 109-19B). Identification of squamous eddies, trichilemmal keratinization, or possibly the remnant of a pilar cyst can be instrumental in the distinction between proliferating pilar tumor and squamous cell carcinoma. Immunohistochemistry has been proposed to distinguish proliferating pilar tumor and squamous cell carcinoma. Proliferating pilar tumor cells show

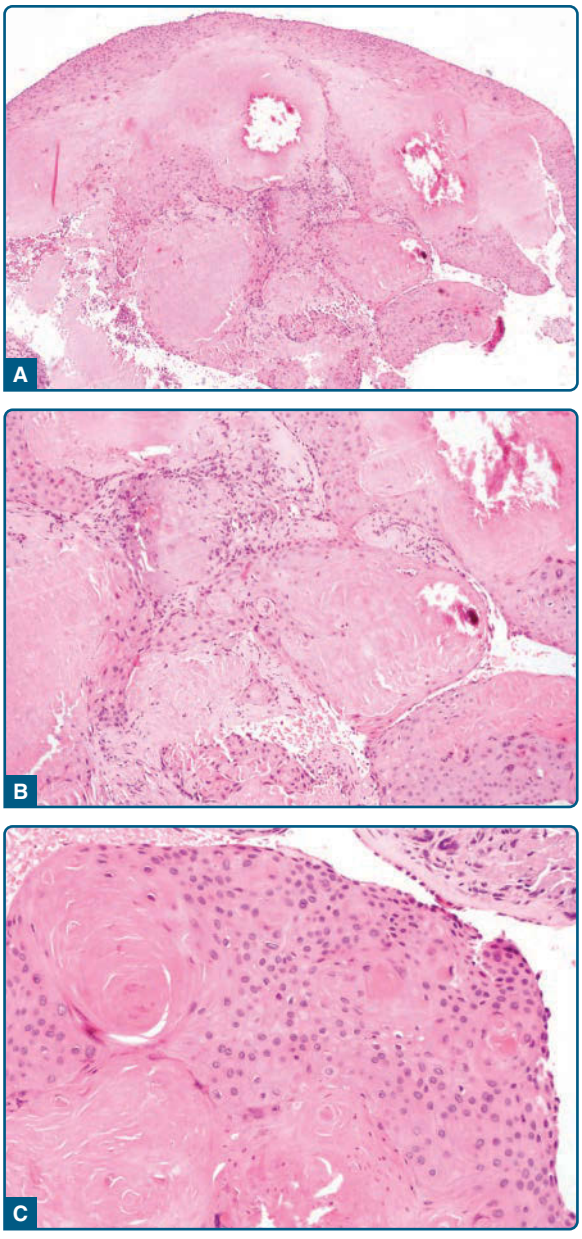

Figure 109-19 **A,** Proliferating pilar tumor occurs as a lobular proliferation of keratinocytes with pilar keratinization. **B,** The tumor forms multiple whorled nodules of keratinizing epithelium that may resemble well differentiated carcinoma. **C,** Squamous eddies resemble those observed in irritated seborrheic keratosis and inverted follicular keratosis and may be prominent.

positive staining for AE13, AE14, and CD34, whereas squamous cell carcinoma tumor cells show negative staining for these markers (see Table 109-4).[5,112]

Clinical Course and Prognosis: The majority of proliferating pilar tumors follow a benign clinical course, but malignant transformation and even metastatic disease have been described. In a study by Ye and colleagues, a 3-tier grading system of benign, low-grade malignant, and high-grade malignant proliferating pilar tumors was proposed based on histologic features and with followup clinical data.[112] Benign proliferating pilar tumors showed good circumscription, minimal cytologic atypia, and had no known recurrences. Low-grade malignant proliferating pilar tumors showed invasion into surrounding tissues, had moderate cytologic atypia and did not have local disease recurrence. High-grade malignant proliferating pilar tumors were invasive, displayed anaplastic cytologic atypia, and on clinical followup had recurrences and cases of metastatic disease. Overall, the recurrence rate for all proliferating pilar tumors is 3.7% and the rate of metastasis is 1.2%.[112,113] The metastatic rate for high-grade proliferating pilar tumors, however, is estimated at 25%, based on small series.[113]

Management: Treatment for proliferating pilar tumor is complete surgical excision.[113] Both conventional and Mohs micrographic surgical techniques have been utilized. Chemotherapy and radiotherapy in patients with malignant proliferating pilar tumor has been of limited therapeutic benefit.[113]

NEOPLASMS WITH INFUNDIBULAR DIFFERENTIATION

TRICHOADENOMA

Trichoadenoma was first described in the German literature by Nikolowski in 1958.[116] The first series published in the English literature was in 1977.[117]

Epidemiology and Clinical Features: Trichoadenoma presents in adult patients as a flesh-colored papule on the face or buttock, without apparent gender predilection.[75,118]

Etiology and Pathogenesis: Trichoadenoma is a benign follicular neoplasm with differentiation toward the infundibulum.

Histopathology: Trichoadenoma is a well-circumscribed, dermal nodule composed of infundibulocystic structures (keratin cysts) within a fibrotic stroma. Scattered cords and strands of epithelial cells can be seen.

Differential Diagnosis: The histologic features are typically characteristic for trichoadenoma. Other neoplasms with infundibulocystic structures include trichoepithelioma, desmoplastic trichoepithelioma, and microcystic adnexal carcinoma. Distinction between trichoadenoma and these other neoplasms is generally straightforward in an adequate biopsy.

Clinical Course and Prognosis: Trichoadenoma is a benign neoplasm.

Management: Excision of trichoadenoma can be performed for cosmetic purposes.

DILATED PORE (OF WINER)

Winer originally described the dilated pore in a series of 10 cases in 1954.[119]

Epidemiology and Clinical Features: Dilated pore presents in adult patients as a single papule most frequently on the head and neck, but involvement on the back also has been noted.[1,75,120] Keratinaceous material can sometimes be expressed from the lesion.

Etiology and Pathogenesis: Some have regarded dilated pore as a variant of infundibular cyst, while others consider it as a unique follicular neoplasm.[1,75,120] Dilated pore shows differentiation toward the follicular infundibulum.

Histopathology: Histologically, dilated pore shows a dilated infundibulum oriented perpendicularly to the epidermal surface. Epithelial projections resembling rete ridges radiate from the central pore. There is epithelial atrophy at the ostium of the pore and it is filled with lamellar orthokeratosis.

Differential Diagnosis: Clinically and histologically, a dilated pore can mimic a comedo. Also in the histologically differential diagnosis is a pilar sheath acanthoma. Dilated pore shows infundibular differentiation, rather than isthmic differentiation with eosinophilic or clear cytoplasm seen in pilar sheath acanthoma. The epithelial projections in dilated pore are less bulbous than those in pilar sheath acanthoma.

Clinical Course and Prognosis: Dilated pore is a benign entity.

Management: Dilated pore can be treated cosmetically by excision.

TUMORS WITH SEBACEOUS DIFFERENTIATION

Normal sebaceous glands develop from the hair sheath and are located throughout the body, except the palms and soles. They are most abundant in the head and neck. (See Chap. 6 for a thorough discussion of normal sebaceous glands.) Sebaceous neoplasms show sebaceous differentiation and are typified by mature sebocytes with characteristic vacuolated cytoplasm and scalloped nuclei. Table 109-9 lists appendage tumors with sebaceous differentiation.

TABLE 109-9
Sebaceous Appendage Neoplasms

BENIGN	MALIGNANT
Sebaceous adenoma	Sebaceous carcinoma
Sebaceoma	

BENIGN

SEBACEOUS ADENOMA

Sebaceous adenomas are benign neoplasms with sebaceous differentiation.

Epidemiology and Clinical Features: Sebaceous adenomas (Fig. 109-20A) typically occur in the head and neck region of adult patients and present as single or multiple tan, pink, or yellow papules, typically around 0.5 cm.[3,121]

Etiology and Pathogenesis: Sebaceous adenomas, as well as other sebaceous neoplasms, are associated with Muir-Torre syndrome, a variant of Lynch (hereditary nonpolyposis colorectal carcinoma) syndrome (see Table 109-2).[122] It is an autosomal dominant cancer predisposition syndrome caused by mutations in genes encoding DNA mismatch repair proteins (MLH1, MSH2, MSH6, and PMS2). Visceral malignancies, such as colon and endometrial cancer, are also associated with the syndrome. In addition to DNA mismatch repair pathways, WNT/β-catenin, Hedgehog, and p53 signaling pathways have been implicated in the development of sebaceous neoplasms.[1,121]

Histopathology: Histologically, sebaceous adenomas display a lobular architecture with central mature sebocytes with vacuolated cytoplasm and peripheral basaloid germinative cells (see Fig. 109-20B). Connection to the epidermis is often seen. Basaloid germinative cells comprise less than 50% of the tumor volume in sebaceous adenomas (see Fig. 109-20B).

Differential Diagnosis: Clinically, sebaceous adenoma may be confused with basal cell carcinoma. Histologically, the identification of mature sebocytes, basaloid epithelial cells, and lobular architecture in an adequate biopsy make the diagnosis straightforward, although clear-cell neoplasms, such as metastatic renal cell carcinoma and clear-cell squamous cell carcinoma, may enter into the differential diagnosis.

Clinical Course and Prognosis: Sebaceous adenomas are benign, but can be associated with Muir-Torre syndrome. In fact, sebaceous adenomas found at sites other than the head and neck have been found to be more highly associated with Muir-Torre syndrome.[122]

Management: Although they are benign, modest, complete excision of sebaceous adenomas is recommended.[121] Patients with sebaceous adenomas should be screened for Muir-Torre syndrome, as they can be the presenting feature.[122,123] This can be performed, at least initially, by immunohistochemistry for the mismatch repair proteins on the biopsy material. Loss of expression correlates with microsatellite instability and suggests involvement by Muir-Torre syndrome.[122] DNA microsatellite analysis also can be

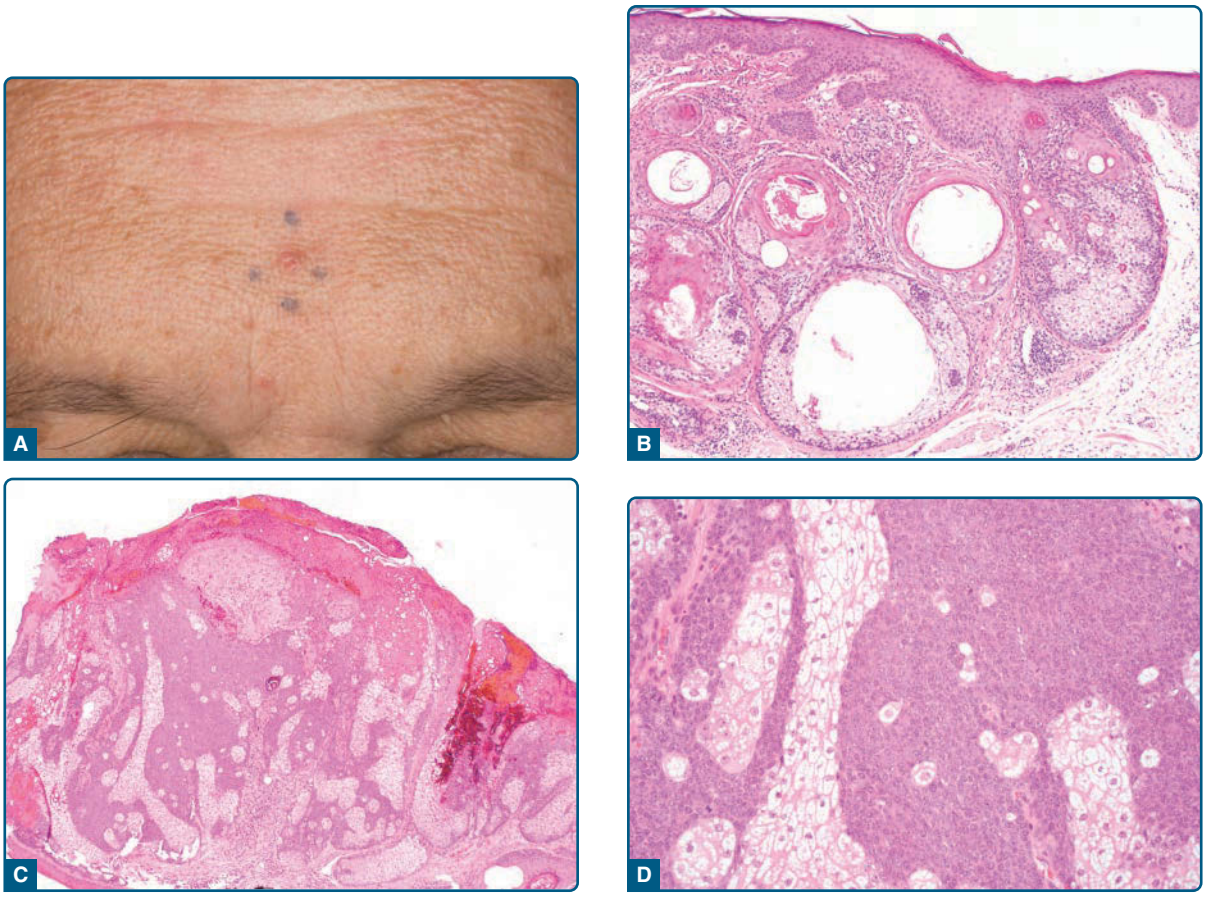

Figure 109-20 **A,** Sebaceous adenoma presents as a pink or orange-yellow papule, often in the head and neck region. **B,** Sebaceous adenoma is a lobular proliferation of basaloid epithelial cells and mature sebaceous elements that extends from the epidermis into the dermis. **C,** There is a prominent basaloid component, however it comprises less than half of the tumor cells. **D,** The sebaceous and basaloid cells have uniform round nuclei without significant atypia or mitotic activity.

performed on sebaceous neoplasms to assess for the presence of microsatellite instability.

SEBACEOMA/SEBACEOUS EPITHELIOMA

Epidemiology and Clinical Features: Sebaceoma presents as an orange-yellow papule, ranging between 0.5 and 1 cm in the head and neck region of adult patients in their fifth and sixth decades.[3,121]

Etiology and Pathogenesis: Sebaceomas are benign sebaceous neoplasms and are associated with Muir-Torre syndrome, although the association occurs with less frequency than with sebaceous adenomas (see Table 109-2).[122]

Histopathology: Histologically, sebaceoma is a well-circumscribed dermal nodule composed of greater than 50% basaloid germinative cells (Fig. 109-21A to C). Mature sebocytes can be conspicuous (but less than 50% of the neoplasm) or focal/rare. Cytologic atypia is rare and focal when present (Fig. 109-21D).

Differential Diagnosis: In small and/or superficial biopsies, the distinction between sebaceoma and sebaceous carcinoma may be difficult, and a differential diagnosis may be made. Difficulty in making the diagnosis of sebaceoma can occur when mature sebaceous differentiation is scant, with basal cell carcinoma entering the histologic differential diagnosis. Immunohistochemical stains for BerEP4 and EMA have been proposed to distinguish between basal cell carcinoma (BerEP4+, EMA−) and sebaceoma (BerEP4−, EMA+), keeping in mind that EMA staining can be weak to absent in the basaloid germinative cells of sebaceoma.[124] Immunohistochemical staining for adipophilin in a vesicular cytoplasmic pattern may confirm the presence of sebaceous differentiation (see Fig. 109-21E). (Table 109-10 summarizes the immunohistochemical stains used to distinguish between sebaceous neoplasms and basal cell carcinoma and squamous cell carcinoma.)

Clinical Course and Prognosis: Sebaceomas are benign neoplasms without an aggressive clinical course.

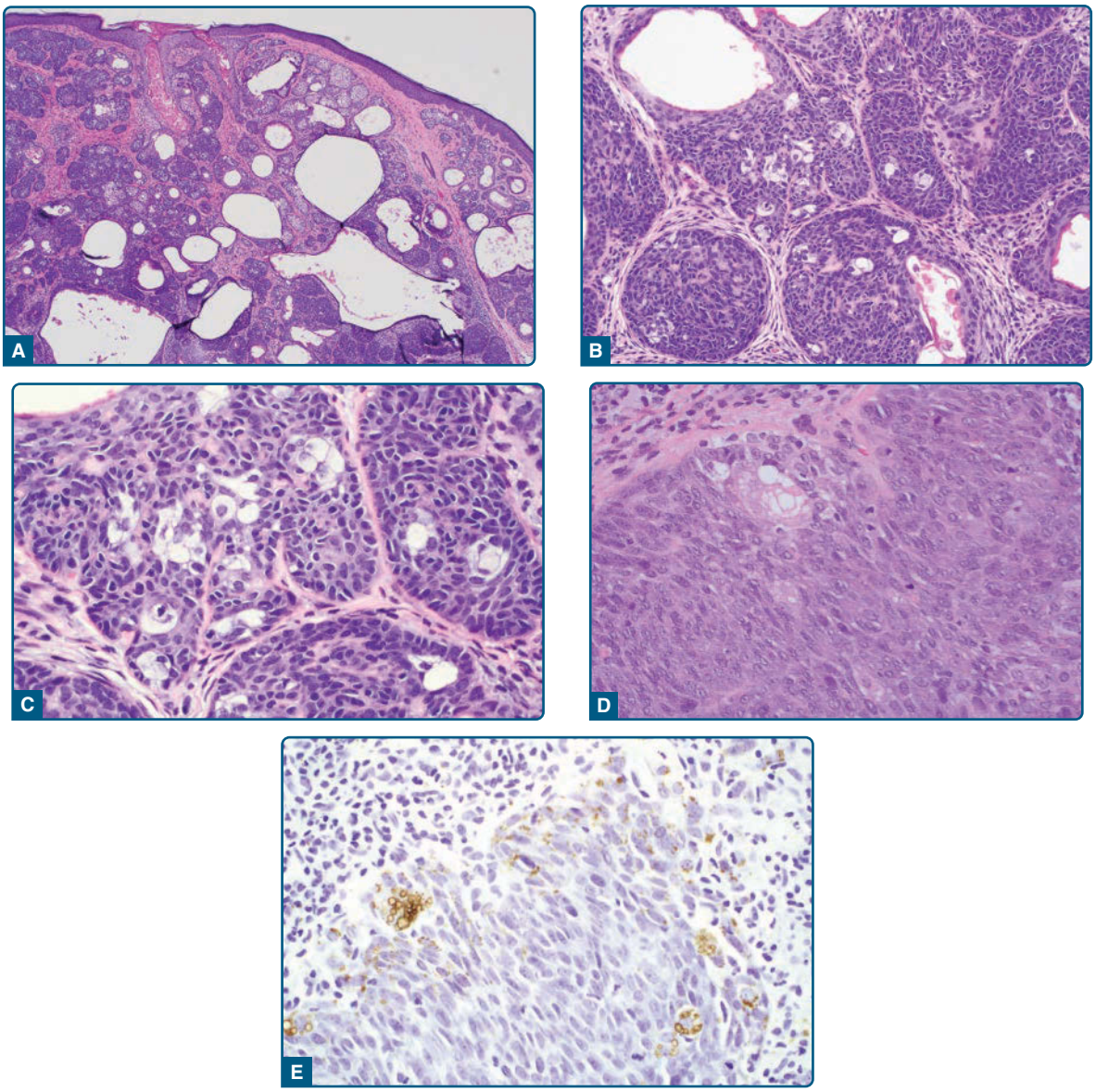

Figure 109-21 **A,** Sebaceoma occurs as a dermal nodule that usually shows connection to the epidermis. **B,** Less than half of the tumor is composed of mature sebaceous cells. **C,** The basaloid germinative cells have small round nuclei and are intermixed with small nests of mature sebocytes with prominent multivacuolated cytoplasm. **D,** In some cases there may be focal cytological atypia with nuclear pleomorphism. **E,** Immunohistochemistry for adipophilin reveals intracytoplasmic droplets of lipid.

Management: Sebaceomas are treated with surgical excision.[121,122] Screening of patients with sebaceoma(s) for Muir-Torre syndrome should be performed given their association with the syndrome.[122]

MALIGNANT

SEBACEOUS CARCINOMA

Sebaceous carcinoma is a rare, malignant sebaceous neoplasm traditionally separated into ocular (involving the orbit, conjunctiva, and eyelid) and extraocular counterparts, in part because the prognosis was considered worse for ocular sebaceous carcinoma in comparison to extraocular sites. A more recent retrospective study analyzing data from the National Cancer Institute's Surveillance, Epidemiology, and End Results (SEER) database suggest similar overall survival rates, although the regional metastatic rate is higher for orbital sebaceous carcinoma.[125,126] Categorization does appear to be important, however, as sebaceous carcinoma occurring in extraocular sites is more frequently associated with Muir-Torre syndrome (see Table 109-2).[127]

Epidemiology and Clinical Features: Both ocular and extraocular sebaceous carcinoma present in elderly patients.[126] Although previous reports suggest an increased incidence in females, the SEER study found a nearly equal incidence in men (54%)

TABLE 109-10

Summary of Immunohistochemical Stains in the Distinction between Sebaceous Neoplasms and Basal Cell Carcinoma and Squamous Cell Carcinoma

	SEBACEOMA	SEBACEOUS CARCINOMA	BCC	SCC
EMA	+	+	–	+
CK7	+	+	+/–	+/–
BerEP4	–	+/–	+	–
Adipophilin	+ (vesicular)	+ (vesicular)	–	–
Androgen receptor	+	+	–	–
Factor XIIIa (clone AC-1A1)	+ (nuclear)	+	–	–

–, Negative; +, positive; BCC, basal cell carcinoma; SCC, squamous cell carcinoma.

and women (46%).[125] Clinically, sebaceous carcinoma presents as a painless, slow-growing nodule (Fig. 109-22A, B). Ocular sebaceous carcinoma occurs more frequently than extraocular sebaceous carcinoma, but the most common extraocular site is the head and neck region (face, lip, ear).[125]

Etiology and Pathogenesis: Ocular sebaceous carcinoma arises in association with the sebaceous glands of the eyelid (the Meibomian glands and glands of Zeis).[126] Sebaceous carcinoma, especially the extraocular form, is associated with Muir-Torre syndrome, indicating a role for DNA repair mechanisms in its pathogenesis.[121,122,126] HER2/neu amplification has been identified in ocular sebaceous carcinoma.[128] A more recent study shows mutations in sebaceous carcinomas that converge on the PI3K (phosphatidylinositol 3'-kinase) signaling pathway.[129]

Histopathology: Histologically, sebaceous carcinoma is composed of poorly differentiated basaloid cells growing in sheets with an infiltrative growth pattern. The cells are cytologically malignant with atypia and frequent mitoses. Mature sebocytes are variably present and may be focal. Epidermal involvement with pagetoid spread is more common in ocular sebaceous carcinoma (see Fig. 109-22C, D).[121,126]

Differential Diagnosis: Benign lesions, such as chalazion and blepharitis, as well as malignancies, such as basal cell carcinoma, are in the clinical differential diagnosis.[126] Histologically, other poorly differentiated carcinomas, such as basal cell carcinoma, squamous cell carcinoma, and metastatic carcinoma, can enter into the differential diagnosis if sebaceous differentiation is not conspicuous. Melanoma in situ can be

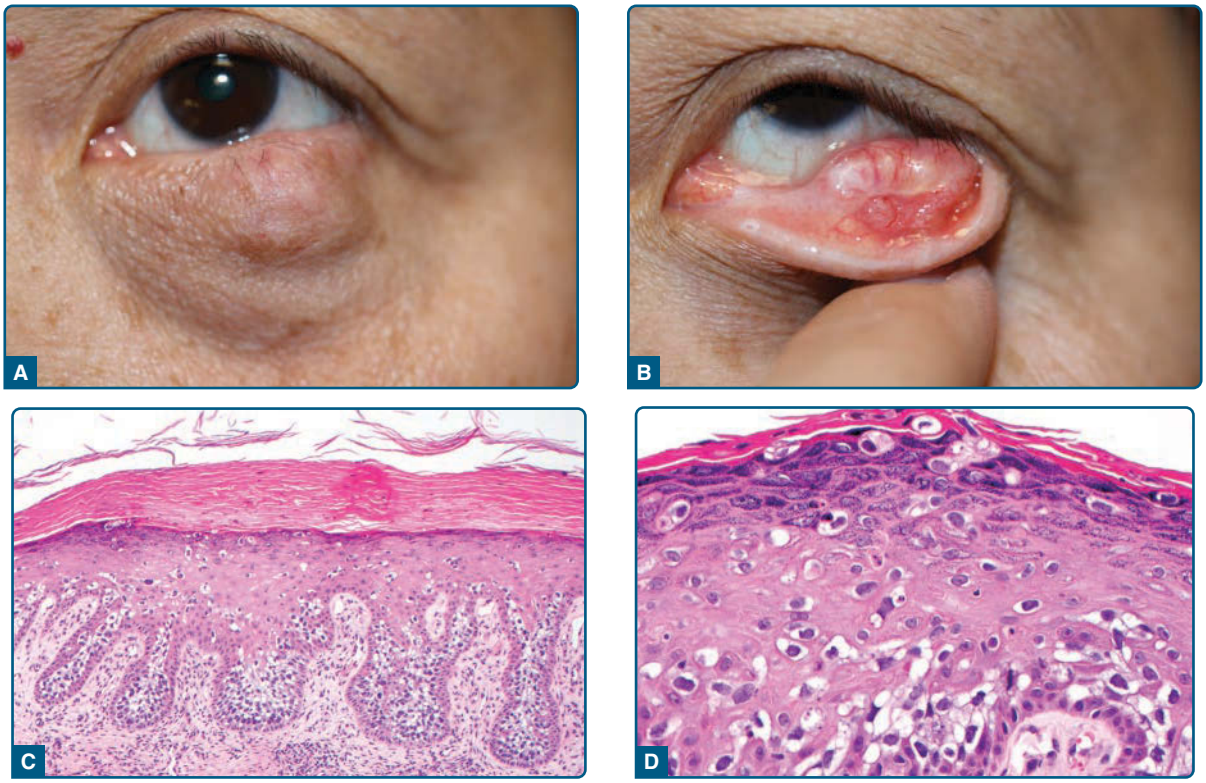

Figure 109-22 **A,** Sebaceous carcinoma can present as a discrete nodule and can clinically mimic a chalazion; however, accompanying lash loss is seen in sebaceous carcinoma. **B,** Everting the eyelid reveals a yellow-white nodule. **C,** Sebaceous carcinoma in situ occurs as an intraepidermal proliferation of cytologically atypical cells with varying degrees of sebaceous differentiation. **D,** Pagetoid growth pattern maybe prominent. (Clinical images **A** and **B,** Used with permission from Drs. Nahyoung Grace Lee, MD, and Fouad R. Zakka, MD, Boston, MA, USA.)

in the differential diagnosis of sebaceous carcinoma in situ. Immunohistochemistry has been proposed as a method to distinguish sebaceous carcinoma from its mimics. Sebaceous carcinomas have been shown to have positive staining for adipophilin and androgen receptor, while squamous cell carcinoma and basal cell carcinoma are negative.[5,130,131] Positive adipophilin staining should be membranous and vesicular, rather than the granular staining that can be seen in clear cell carcinomas.[5] EMA is positive in both sebaceous carcinoma and squamous cell carcinoma, but negative in basal cell carcinoma.[5,130] While some have found BerEP4 to be a marker to distinguish between basal cell carcinoma (BerEP4+) and sebaceous carcinoma (BerEP4–), others have found positive BerEP4 staining in up to 80% of sebaceous carcinomas.[5] Recently, nuclear factor XIIIa staining was found to highly sensitive for sebaceous differentiation compared to clear-cell carcinomas.[132,133] Sebaceous carcinoma is negative for melanocytic markers. (Table 109-10 summarizes these immunohistochemical findings.)

Clinical Course and Prognosis: Sebaceous carcinoma was historically thought to have a very poor prognosis.[121] The more recent SEER study suggests a less-aggressive course, with a 92% 5-year and a 79% 10-year age-matched relative survival rates.[125] Metastatic disease is not uncommon, with a reported range of regional metastases between 2.4% and 28%.[126] Poor clinical prognostic factors include delayed diagnosis and size of tumor greater than 1 cm.[126] Poor histologic factors include poor differentiation, pagetoid spread, multicentricity, size greater than 1 cm, and lymphovascular or perineural invasion.[126]

Management: Sebaceous carcinoma is treated with wide excision, using both conventional and Mohs micrographic surgical techniques.[121,122,126] Adjuvant radiation is used if regional lymph node metastases are detected at the time of diagnosis. Use of radiation as the sole treatment has increased rates of recurrence, but can be considered for poor surgical candidates.[126] Radiation also has been used for recurrences and for palliation.[126] Data on the role of sentinel lymph node biopsy are currently limited, but it is recommended for ocular sebaceous carcinomas greater than 1 cm.[126] Chemotherapy plays a limited role in the treatment of sebaceous carcinoma. Patients diagnosed with sebaceous carcinoma should be screened for Muir-Torre syndrome, particularly if they are younger than 50 years old and/or the tumor arises in a site other than the head and neck.[122,126]

REFERENCES

1. Kazakov DV, Kacerovska D, Michal M, et al. *Cutaneous Adnexal Tumors*. Philadelphia, PA: Lippincott Williams and Wilkins; 2012.
2. Obaidat NA, Alsaad KO, Ghazarian D. Skin adnexal neoplasms—part 2: an approach to tumours of cutaneous sweat glands. *J Clin Pathol*. 2007;60(2): 145-159.
3. Alsaad KO, Obaidat NA, Ghazarian D. Skin adnexal neoplasms—part 1: an approach to tumours of the pilosebaceous unit. *J Clin Pathol*. 2007;60(2): 129-144.
4. Kraft S, Granter SR. Molecular pathology of skin neoplasms of the head and neck. *Arch Pathol Lab Med*. 2014;138(6):759-787.
5. Danialan R, Mutyambizi K, Aung P, et al. Challenges in the diagnosis of cutaneous adnexal tumours. *J Clin Pathol*. 2015;68(12):992-1002.
6. Johnson BL, Helwig EB. Eccrine acrospiroma. A clinicopathologic study. *Cancer*. 1969;23(3):641-657.
7. Behboudi A, Winnes M, Gorunova L, et al. Clear cell hidradenoma of the skin-a third tumor type with a t(11;19)—associated TORC1-MAML2 gene fusion. *Genes Chromosomes Cancer*. 2005;43(2):202-205.
8. Winnes M, Molne L, Suurkula M, et al. Frequent fusion of the CRTCI and MAML2 genes in clear cell variants of cutaneous hidradenomas. *Genes Chromosomes Cancer*. 2007;46(6):559-563.
9. Mambo NC. The significance of atypical nuclear changes in benign eccrine acrospiromas: a clinical and pathological study of 18 cases. *J Cutan Pathol*. 1984;11(1):35-44.
10. Pinkus H, Rogin J, Goldman P. Eccrine poroma: tumors exhibiting features of the epidermal sweat duct unit. *AMA Arch Derm*. 1956;74(5):511-521.
11. Sawaya JL, Khachemoune A. Poroma: a review of eccrine, apocrine, and malignant forms. *Int J Dermatol*. 2014;53(9):1053-1061.
12. Crain RC, Helwig EB. Dermal cylindroma (dermal eccrine cylindroma). *Am J Clin Pathol*. 1961;35: 504-515.
13. Mahalingam M, Srivastava A, Hoang MP. Expression of stem-cell markers (cytokeratin 15 and nestin) in primary adnexal neoplasms—clues to etiopathogenesis. *Am J Dermatopathol*. 2010;32(8):774-779.
14. Sellheyer K. Spiradenoma and cylindroma originate from the hair follicle bulge and not from the eccrine sweat gland: an immunohistochemical study with CD200 and other stem cell markers. *J Cutan Pathol*. 2015;42(2):90-101.
15. Michal M, Lamovec J, Mukenšnabl P, et al. Spiradenocylindromas of the skin: tumors with morphological features of spiradenoma and cylindroma in the same lesion: report of 12 cases. *Pathol Int*. 1999;49(5):419-425.
16. Jordao C, de Magalhaes TC, Cuzzi T, et al. Cylindroma: an update. *Int J Dermatol*. 2015;54(3):275-278.
17. Rajan N, Ashworth A. Inherited cylindromas: lessons from a rare tumour. *Lancet Oncol*. 2015;16(9):e460 -e469.
18. Kazakov DV. Brooke-Spiegler syndrome and phenotypic variants: an update. *Head Neck Pathol*. 2016;10(2):125-130.
19. Fehr A, Kovacs A, Loning T, et al. The MYB-NFIB gene fusion-a novel genetic link between adenoid cystic carcinoma and dermal cylindroma. *J Pathol*. 2011;224(3):322-327.
20. Rajan N, Andersson MK, Sinclair N, et al. Overexpression of MYB drives proliferation of CYLD-defective cylindroma cells. *J Pathol*. 2016;239(2):197-205.
21. Kersting DW, Helwig EB. Eccrine spiradenoma. *AMA Arch Derm*. 1956;73(3):199-227.
22. Williams K, Shinkai K. Evaluation and management of the patient with multiple syringomas: a systematic review of the literature. *J Am Acad Dermatol*. 2016;74(6):1234-1240.e9.

23. Gauerke S, Driscoll JJ. Hidradenocarcinomas: a brief review and future directions. *Arch Pathol Lab Med*. 2010;134(5):781-785.
24. Nazarian RM, Kapur P, Rakheja D, et al. Atypical and malignant hidradenomas: a histological and immunohistochemical study. *Mod Pathol*. 2009;22(4): 600-610.
25. Nash JW, Barrett TL, Kies M, et al. Metastatic hidradenocarcinoma with demonstration of Her-2/neu gene amplification by fluorescence in situ hybridization: Potential treatment implications. *J Cutan Pathol*. 2007;34(1):49-54.
26. Kazakov DV, Ivan D, Kutzner H, et al. Cutaneous hidradenocarcinoma: a clinicopathological, immunohistochemical, and molecular biologic study of 14 cases, including Her2/neu gene expression/amplification, TP53 gene mutation analysis, and t(11;19) translocation. *Am J Dermatopathol*. 2009;31(3): 236-247.
27. Coburn JG, Smith JL. Hidroacanthoma simplex; an assessment of a selected group of intraepidermal basal cell epitheliomata and of their malignant homologues. *Br J Dermatol*. 1956;68(12):400-418.
28. Pinkus H, Mehregan AH. Epidermotropic eccrine carcinoma: a case combining features of eccrine poroma and Paget's dermatosis. *Arch Dermatol*. 1963;88:597-606.
29. Snow SN, Reizner GT. Eccrine porocarcinoma of the face. *J Am Acad Dermatol*. 1992;27(2, pt 2):306-311.
30. Robson A, Greene J, Ansari N, et al. Eccrine porocarcinoma (malignant eccrine poroma): a clinicopathologic study of 69 cases. *Am J Surg Pathol*. 2001;25(6):710-720.
31. Harms PW, Hovelson DH, Cani AK, et al. Porocarcinomas harbor recurrent HRAS-activating mutations and tumor suppressor inactivating mutations. *Hum Pathol*. 2016;51:25-31.
32. Mahalingam M, Richards JE, Selim MA, et al. An immunohistochemical comparison of cytokeratin 7, cytokeratin 15, cytokeratin 19, CAM 5.2, carcinoembryonic antigen, and nestin in differentiating porocarcinoma from squamous cell carcinoma. *Hum Pathol*. 2012;43(8):1265-1272.
33. Goto K, Takai T, Fukumoto T, et al. CD117 (KIT) is a useful immunohistochemical marker for differentiating porocarcinoma from squamous cell carcinoma. *J Cutan Pathol*. 2016;43(3):219-226.
34. Brown CW Jr, Dy LC. Eccrine porocarcinoma. *Dermatol Ther*. 2008;21(6):433-438.
35. De Iuliis F, Amoroso L, Taglieri L, et al. Chemotherapy of rare skin adnexal tumors: a review of literature. *Anticancer Res*. 2014;34(10):5263-5268.
36. Granter SR, Seeger K, Calonje E, et al. Malignant eccrine spiradenoma (spiradenocarcinoma): a clinicopathologic study of 12 cases. *Am J Dermatopathol*. 2000;22(2):97-103.
37. Kazakov DV, Zelger B, Rutten A, et al. Morphologic diversity of malignant neoplasms arising in preexisting spiradenoma, cylindroma, and spiradenocylindroma based on the study of 24 cases, sporadic or occurring in the setting of Brooke-Spiegler syndrome. *Am J Surg Pathol*. 2009;33(5):705-719.
38. Dai B, Kong YY, Cai X, et al. Spiradenocarcinoma, cylindrocarcinoma and spiradenocylindrocarcinoma: a clinicopathological study of nine cases. *Histopathology*. 2014;65(5):658-666.
39. Cardoso JC, Calonje E. Malignant sweat gland tumours: an update. *Histopathology*. 2015;67(5):589-606.
40. Kao GF, Helwig EB, Graham JH. Aggressive digital papillary adenoma and adenocarcinoma. A clinicopathological study of 57 patients, with histochemical, immunopathological, and ultrastructural observations. *J Cutan Pathol*. 1987;14(3):129-146.
41. Duke WH, Sherrod TT, Lupton GP. Aggressive digital papillary adenocarcinoma (aggressive digital papillary adenoma and adenocarcinoma revisited). *Am J Surg Pathol*. 2000;24(6):775-784.
42. Suchak R, Wang W, Prieto VG, et al. Cutaneous digital papillary adenocarcinoma: a clinicopathologic study of 31 cases of a rare neoplasm with new observations. *Am J Surg Pathol*. 2012;36(12):1883-1891.
43. Goldstein DJ, Barr RJ, Santa Cruz DJ. Microcystic adnexal carcinoma: a distinct clinicopathologic entity. *Cancer*. 1982;50(3):566-572.
44. Wetter R, Goldstein GD. Microcystic adnexal carcinoma: a diagnostic and therapeutic challenge. *Dermatol Ther*. 2008;21(6):452-458.
45. Gordon S, Fischer C, Martin A, et al. Microcystic adnexal carcinoma: a review of the literature. *Dermatol Surg*. 2017;43(8):1012-1016.
46. Hoang MP, Dresser KA, Kapur P, et al. Microcystic adnexal carcinoma: an immunohistochemical reappraisal. *Mod Pathol*. 2008;21(10):178-185.
47. Palamaras I, McKenna JD, Robson A, et al. Microcystic adnexal carcinoma: a case series treated with Mohs micrographic surgery and identification of patients in whom paraffin sections may be preferable. *Dermatol Surg*. 2010;36(4):446-452.
48. Sarabi K, Khachemoune A. Hidrocystomas—a brief review. *MedGenMed*. 2006;8(3):57.
49. Kazakov DV, Belousova IE, Bisceglia M, et al. Apocrine mixed tumor of the skin ("mixed tumor of the folliculosebaceous-apocrine complex"). Spectrum of differentiations and metaplastic changes in the epithelial, myoepithelial, and stromal components based on a histopathologic study of 244 cases. *J Am Acad Dermatol*. 2007;57(3):467-483.
50. Kazakov DV, Kacerovska D, Hantschke M, et al. Cutaneous mixed tumor, eccrine variant: a clinicopathologic and immunohistochemical study of 50 cases, with emphasis on unusual histopathologic features. *Am J Dermatopathol*. 2011;33(6):557-568.
51. Jo VY. Myoepithelial tumors: an update. *Surg Pathol Clin*. 2015;8(3):445-466.
52. Mammino JJ, Vidmar DA. Syringocystadenoma papilliferum. *Int J Dermatol*. 1991;30(11):763-766.
53. Boni R, Xin H, Hohl D, et al. Syringocystadenoma papilliferum: a study of potential tumor suppressor genes. *Am J Dermatopathol*. 2001;23(2):87-89.
54. Levinsohn JL, Sugarman JL, Bilguvar K, et al. Somatic V600E BRAF mutation in linear and sporadic syringocystadenoma papilliferum. *J Invest Dermatol*. 2015;135(10):2536-2538.
55. Zhang YH, Wang W-L, Rapini RP, et al. Syringocystadenocarcinoma papilliferum with transition to areas of squamous differentiation. *Am J Dermatopathol*. 2012;34(4):428-433.
56. Kazakov DV, Requena L, Kutzner H, et al. Morphologic diversity of syringocystadenocarcinoma papilliferum based on a clinicopathologic study of 6 cases and review of the literature. *Am J Dermatopathol*. 2010;32(4):340-347.
57. Landry M, Winkelmann RK. An unusual tubular apocrine adenoma. *Arch Dermatol*. 1972;105(6):869-879.
58. Rulon DB, Helwig EB. Papillary eccrine adenoma. *Arch Dermatol*. 1977;113(5):596-598.

59. Konstantinova AM, Michal M, Kacerovska D, et al. Hidradenoma papilliferum: a clinicopathologic study of 264 tumors from 261 patients, with emphasis on mammary-type alterations. *Am J Dermatopathol*. 2016;38(8):598-607.
60. Liau J-Y, Lan J, Hong J-B, et al. Frequent PIK3CA activating mutations in hidradenoma papilliferums. *Hum Pathol*. 2016;55:57-62.
61. Dillon DA, Lester SC. Lesions of the nipple. *Surg Pathol Clin*. 2009;2(2):391-412.
62. Salemis NS. Florid papillomatosis of the nipple: a rare presentation and review of the literature. *Breast Dis*. 2015;35(2):153-156.
63. Ramakrishnan R, Chaudhry IH, Ramdial P, et al. Primary cutaneous adenoid cystic carcinoma: a clinicopathologic and immunohistochemical study of 27 cases. *Am J Surg Pathol*. 2013;37(10):1603-1611.
64. Naylor E, Sarkar P, Perlis CS, et al. Primary cutaneous adenoid cystic carcinoma. *J Am Acad Dermatol*. 2008;58(4):636-641.
65. North JP, McCalmont TH, Fehr A, et al. Detection of MYB alterations and other immunohistochemical markers in primary cutaneous adenoid cystic carcinoma. *Am J Surg Pathol*. 2015;39(10):1347-1356.
66. Batsakis JG, Luna MA, El-Naggar A. Histopathologic grading of salivary gland neoplasms: III. Adenoid cystic carcinomas. *Ann Otol Rhinol Laryngol*. 1990;99(12):1007-1009.
67. Mino M, Pilch BZ, Faquin WC. Expression of KIT (CD117) in neoplasms of the head and neck: an ancillary marker for adenoid cystic carcinoma. *Mod Pathol*. 2003;16(12):1224-1231.
68. Robson A, Lazar AJF, Ben Nagi J, et al. Primary cutaneous apocrine carcinoma: a clinico-pathologic analysis of 24 cases. *Am J Surg Pathol*. 2008;32(5):682-690.
69. Piris A, Peng Y, Boussahmain C, et al. Cutaneous and mammary apocrine carcinomas have different immunoprofiles. *Hum Pathol*. 2014;45(2):320-326.
70. Hollowell KL, Agle SC, Zervos EE, et al. Cutaneous apocrine adenocarcinoma: defining epidemiology, outcomes, and optimal therapy for a rare neoplasm. *J Surg Oncol*. 2012;105(4):415-419.
71. Rutten A, Kutzner H, Mentzel T, et al. Primary cutaneous cribriform apocrine carcinoma: a clinicopathologic and immunohistochemical study of 26 cases of an under-recognized cutaneous adnexal neoplasm. *J Am Acad Dermatol*. 2009;61(4):644-651.
72. Arps DP, Chan MP, Patel RM, et al. Primary cutaneous cribriform carcinoma: report of six cases with clinicopathologic data and immunohistochemical profile. *J Cutan Pathol*. 2015;42(6):379-387.
73. Kazakov DV, Suster S, LeBoit PE, et al. Mucinous carcinoma of the skin, primary, and secondary: a clinicopathologic study of 63 cases with emphasis on the morphologic spectrum of primary cutaneous forms: homologies with mucinous lesions in the breast. *Am J Surg Pathol*. 2005;29(6):764-782.
74. Jih MH, Friedman PM, Kimyai-Asadi A, et al. A rare case of fatal primary cutaneous mucinous carcinoma of the scalp with multiple in-transit and pulmonary metastases. *J Am Acad Dermatol*. 2005;52(5)(suppl 1):S76-S80.
75. Tellechea O, Reis JP, Gameiro AR, et al. Benign follicular tumors. *An Bras Dermatol*. 2006;90(6):780-798.
76. Misago N, Kimura T, Toda S, et al. A revaluation of trichofolliculoma: the histopathological and immunohistochemical features. *Am J Dermatopathol*. 2010; 32(1):35-43.
77. Schulz T, Hartschuh W. Merkel cells are absent in basal cell carcinomas but frequently found in trichoblastomas. An immunohistochemical study. *J Cutan Pathol*. 1997;24(1):14-24.
78. Cordoba A, Guerrero D, Larrinaga B, et al. Bcl-2 and CD10 expression in the differential diagnosis of trichoblastoma, basal cell carcinoma, and basal cell carcinoma with follicular differentiation. *Int J Dermatol*. 2009;48(7):713-717.
79. Goyal A, Solus JF, Chan MP, et al. Cytokeratin 17 is highly sensitive in discriminating cutaneous lymphadenoma (a distinct trichoblastoma variant) from basal cell carcinoma. *J Cutan Pathol*. 2016;43(5):422-429.
80. Mizutani Y, Iwamoto I, Kanoh H, et al. Expression of drebrin, an actin binding protein, in basal cell carcinoma, trichoblastoma and trichoepithelioma. *Histol Histopathol*. 2014;29(6):757-766.
81. Rosso R, Lucioni M, Savio T, et al. Trichoblastic sarcoma: a high-grade stromal tumor arising in trichoblastoma. *Am J Dermatopathol*. 2007;29(1):79-83.
82. du Toit JP, Derm FC, Schneider JW, et al. The clinicopathological spectrum of trichoepitheliomas: a retrospective descriptive study. *Int J Dermatol*. 2016;55(3): 270-277.
83. Mamelak AJ, Goldberg LH, Katz TM, et al. Desmoplastic trichoepithelioma. *J Am Acad Dermatol*. 2010;62(1): 102-106.
84. Matt D, Xin H, Vortmeyer AO, et al. Sporadic trichoepithelioma demonstrates deletions at 9q22.3. *Arch Dermatol*. 2000;136(5):657-660.
85. Sellheyer K, Krahl D. PHLDA1 (TDAG51) is a follicular stem cell marker and differentiates between morphoeic basal cell carcinoma and desmoplastic trichoepithelioma. *Br J Dermatol*. 2011;164(1):141-147.
86. Sellheyer K, Nelson P. Follicular stem cell marker PHLDA1 (TDAG51) is superior to cytokeratin-20 in differentiating between trichoepithelioma and basal cell carcinoma in small biopsy specimens. *J Cutan Pathol*. 2011;38(7):542-550.
87. Yeh I, McCalmont TH, LeBoit PE. Differential expression of PHLDA1 (TDAG51) in basal cell carcinoma and trichoepithelioma. *Br J Dermatol*. 2012;167(5):1106-1110.
88. Abesamis-Cubillan E, El-Shabrawi-Caelen L, LeBoit PE. Merkel cells and sclerosing epithelial neoplasms. *Am J Dermatopathol*. 2000;22(4):311-315.
89. Arits AH, Van Marion AM, Lohman BG, et al. Differentiation between basal cell carcinoma and trichoepithelioma by immunohistochemical staining of the androgen receptor: an overview. *Eur J Dermatol*. 2011;21(6):870-873.
90. Astarci HM, Gurbuz GA, Sengul D, et al. Significance of androgen receptor and CD10 expression in cutaneous basal cell carcinoma and trichoepithelioma. *Oncol Lett*. 2015;10(6):3466-3470.
91. Tebcherani AJ, de Andrade HF, Sotto MN. Diagnostic utility of immunohistochemistry in distinguishing trichoepithelioma and basal cell carcinoma: evaluation using tissue microarray samples. *Mod Pathol*. 2012;25(10):1345-1353.
92. Lopez-Garcia DR, Teague D, Landis ET, et al. Morphological diversity of trichodiscomas and fibrofolliculomas. *Am J Dermatopathol*. 2014;36(9):734-740.
93. Toro J. Birt-Hogg-Dubé Syndrome. In: Adam MP, Ardinger HH, Pagon RA, et al, eds. GeneReviews [Internet]. Seattle, WA: University of Washington, Seattle; 1993-2018 February 27, 2006 (updated August 7, 2014). https://www.ncbi.nlm.nih.gov/books/NBK1522/#bhd.Summary.

94. Julian CG, Bowers PW. A clinical review of 209 pilomatricomas. *J Am Acad Dermatol*. 1998;39(2):191-195.
95. Lan M-Y, Lan M-C, Ho C-Y, et al. Pilomatricoma of the head and neck: a retrospective review of 179 cases. *Arch Otolaryngol Head Neck Surg*. 2003;129(12):1327-1330.
96. Moehlenbeck FW. Pilomatrixoma (calcifying epithelioma): a statistical study. *Arch Dermatol*. 1973;108(4):532-534.
97. Chan EF, Gat U, McNiff JM, et al. A common human skin tumour is caused by activating mutations in beta-catenin. *Nat Genet*. 1999;21(4):410-413.
98. Herrmann JL, Allan A, Trapp KM, et al. Pilomatrix carcinoma: 13 new cases and review of the literature with emphasis on predictors of metastasis. *J Am Acad Dermatol*. 2014;71(1):38-43.e2.
99. Brownstein MH, Shapiro L. Trichilemmoma. Analysis of 40 new cases. *Arch Dermatol*. 1973;107(6):866-869.
100. Al-Zaid T, Ditelberg JS, Prieto VG, et al. Trichilemmomas show loss of PTEN in Cowden syndrome but only rarely in sporadic tumors. *J Cutan Pathol*. 2012;39(5):493-499.
101. Tsai J-H, Huang W-C, Jhuang J-Y, et al. Frequent activating HRAS mutations in trichilemmoma. *Br J Dermatol*. 2014;171(5):1073-1077.
102. Dalton SR, LeBoit PE. Squamous cell carcinoma with clear cells: how often is there evidence of tricholemmal differentiation? *Am J Dermatopathol*. 2008;30(4):333-339.
103. Afshar M, Lee RA, Jiang SIB. Desmoplastic trichilemmoma—a report of successful treatment with Mohs micrographic surgery and a review and update of the literature. *Dermatol Surg*. 2012;38(11):1867-1871.
104. Hamman MS, Brian Jiang SI. Management of trichilemmal carcinoma: an update and comprehensive review of the literature. *Dermatol Surg*. 2014;40(7):711-717.
105. Mehregan AH, Butler JD. A tumor of follicular infundibulum. Report of a case. *Arch Dermatol*. 1961;83:924-927.
106. Alomari A, Subtil A, Owen CE, et al. Solitary and multiple tumors of follicular infundibulum: a review of 168 cases with emphasis on staining patterns and clinical variants. *J Cutan Pathol*. 2013;40(6):532-537.
107. Schnitzler L, Civatte J, Robin F, et al. Multiple tumors of the follicular infundibulum with basocellular degeneration. Apropos of a case [in French]. *Ann Dermatol Venereol*. 1987;114(4):551-556.
108. Cheng AC, Chang YL, Wu YY, et al. Multiple tumors of the follicular infundibulum. *Dermatol Surg*. 2004;30(9):1246-1248.
109. Mehregan AH, Brownstein MH. Pilar sheath acanthoma. *Arch Dermatol*. 1978;114(10):1495-1497.
110. Choi YS, Park SH, Bang D. Pilar sheath acanthoma—report of a case with review of the literature. *Yonsei Med J*. 1989;30(4):392-395.
111. Jones EW. Proliferating epidermoid cysts. *Arch Dermatol*. 1966;94(1):11-19.
112. Ye J, Nappi O, Swanson PE, et al. Proliferating pilar tumors: a clinicopathologic study of 76 cases with a proposal for definition of benign and malignant variants. *Am J Clin Pathol*. 2004;122(4):566-574.
113. Satyaprakash AK, Sheehan DJ, Sangueza OP. Proliferating trichilemmal tumors: a review of the literature. *Dermatol Surg*. 2007;33(9):1102-1108.
114. Nyquist GG, Mumm C, Grau R, et al. Malignant proliferating pilar tumors arising in KID syndrome: a report of two patients. *Am J Med Genet A*. 2007;143A(7):734-741.
115. Kim K-H, Kim J-S, Piao Y-J, et al. Keratitis, ichthyosis and deafness syndrome with development of multiple hair follicle tumours. *Br J Dermatol*. 2002;147(1):139-143.
116. Nikolowski W. Trichoadenoma (organoid follicular hamartoma) [in German]. *Arch Klin Exp Dermatol*. 1958;207(1):34-45.
117. Rahbari H, Mehregan A, Pinkus H. Trichoadenoma of Nikolowski. *J Cutan Pathol*. 1977;4(2):90-98.
118. Shimanovich I, Krahl D, Rose C. Trichoadenoma of Nikolowski is a distinct neoplasm within the spectrum of follicular tumors. *J Am Acad Dermatol*. 2010;62(2):277-283.
119. Winer LH. The dilated pore, a tricho-epithelioma. *J Invest Dermatol*. 1954;23(3):181-188.
120. Steffen C. Winer's dilated pore: the infundibuloma. *Am J Dermatopathol*. 2001;23(3):246-253.
121. Shalin SC, Lyle S, Calonje E, et al. Sebaceous neoplasia and the Muir-Torre syndrome: important connections with clinical implications. *Histopathology*. 2010;56(1):133-147.
122. John AM, Schwartz RA. Muir-Torre syndrome (MTS): an update and approach to diagnosis and management. *J Am Acad Dermatol*. 2016;74(3):558-566.
123. Jessup CJ, Redston M, Tilton E, et al. Importance of universal mismatch repair protein immunohistochemistry in patients with sebaceous neoplasia as an initial screening tool for Muir-Torre syndrome. *Hum Pathol*. 2016;49:1-9.
124. Fan YS, Carr RA, Sanders DS, et al. Characteristic Ber-EP4 and EMA expression in sebaceoma is immunohistochemically distinct from basal cell carcinoma. *Histopathology*. 2007;51(1):80-86.
125. Dasgupta T, Wilson LD, Yu JB. A retrospective review of 1349 cases of sebaceous carcinoma. *Cancer*. 2009;115(1):158-165.
126. Kyllo RL, Brady KL, Hurst EA. Sebaceous carcinoma: review of the literature. *Dermatol Surg*. 2015;41(1):1-15.
127. Dores GM, Curtis RE, Toro JR, et al. Incidence of cutaneous sebaceous carcinoma and risk of associated neoplasms: insight into Muir-Torre syndrome. *Cancer*. 2008;113(12):3372-3381.
128. Kwon MJ, Shin HS, Nam ES, et al. Comparison of HER2 gene amplification and KRAS alteration in eyelid sebaceous carcinomas with that in other eyelid tumors. *Pathol Res Pract*. 2015;211(5):349-355.
129. Tetzlaff MT, Singh RR, Seviour EG, et al. Next-generation sequencing identifies high frequency of mutations in potentially clinically actionable genes in sebaceous carcinoma. *J Pathol*. 2016;240(1):84-95.
130. Plaza JA, Mackinnon A, Carrillo L, et al. Role of immunohistochemistry in the diagnosis of sebaceous carcinoma: a clinicopathologic and immunohistochemical study. *Am J Dermatopathol*. 2015;37(11):809-821.
131. Ansai S, Takeichi H, Arase S, et al. Sebaceous carcinoma: an immunohistochemical reappraisal. *Am J Dermatopathol*. 2011;33(6):579-587.
132. Uhlenhake EE, Clark LN, Smoller BR, et al. Nuclear factor XIIIa staining (clone AC-1A1 mouse monoclonal) is a sensitive and specific marker to discriminate sebaceous proliferations from other cutaneous clear cell neoplasms. *J Cutan Pathol*. 2016;43(8):649-656.
133. Clark LN, Elwood HR, Uhlenhake EE, et al. Nuclear factor XIIIa staining (clone AC-1A1 mouse monoclonal) is a highly sensitive marker of sebaceous differentiation in normal and neoplastic sebocytes. *J Cutan Pathol*. 2016;43(8):657-662.

Chapter 110 :: Epithelial Precancerous Lesions

:: Markus V. Heppt, Gabriel Schlager, & Carola Berking

ACTINIC KERATOSES

AT-A-GLANCE

- Precursor lesions of cutaneous squamous cell carcinoma (SCC).
- Long-term and cumulative ultraviolet (UV) radiation exposure is the most important etiologic factor in the development of actinic keratoses.
- Risk factors include fair skin, age, cumulative UV radiation exposure, immunosuppression, prior history of non-melanoma skin cancer.
- The overall risk of progression to invasive SCC is estimated as 5% to 10%.
- Treatment is recommended to reduce the risk of SCC formation and to improve patients' quality of life.
- Treatment modalities include cryosurgery, shave excision, curettage, dermabrasion, ablative lasers, topical drugs (diclofenac + hyaluronic acid, 5-fluorouracil ± salicylic acid, imiquimod, ingenol mebutate), chemical peelings, and photodynamic therapy.

Actinic keratoses (AKs, also known as solar keratoses or senile keratoses) are cutaneous lesions that consist of proliferations of atypical epidermal keratinocytes that may progress to invasive squamous cell carcinoma (SCC). The concept of a precancerous keratosis was first presented by Dubreuilh in the late 1800s. AKs were first identified and named keratoma senilis by Freudenthal in 1926. In 1958, Pinkus further characterized these lesions and coined the term *actinic keratosis*. It literally means a condition (*-osis*) of excessive horny (*kerat-*) tissue induced by a ray of light (*aktis*), presumably ultraviolet (UV) light. AKs have historically been considered precancerous or premalignant lesions with a potential for developing into SCCs. However, there is a debate at what grade of atypia AKs should be considered carcinoma in situ because not all AKs progress to SCCs and some lesions may spontaneously regress. Attempts have been made to coin AK as "keratinocytic intraepidermal neoplasia" grades I to III according to the degree of atypia.[1] This concept is analogous to the grading of other precancerous lesions such as the classification of cervical intraepithelial neoplasia or vulvar intraepithelial neoplasia (VIN) as precursor lesions of cervical and vulvar carcinoma, respectively.

Regardless of the clinical course of single lesions, AKs are a strong indicator of chronic exposure to UV radiation with actinic skin damage and identify patients who are at high risk to develop nonmelanoma skin cancer. In an increasingly aging society with generations that poorly used sun protection measures and sunscreen, AKs are nowadays rated among the most common reasons to consult a dermatologist in regions with predominantly white populations such as the United States, Australia, and Europe.[2] The high prevalence and the uncertainty of the clinical course of the precancerous lesions make AKs an important challenge for patients and physicians, and an economic burden for health-care providers.

EPIDEMIOLOGY

In European countries, such as Spain and Austria, the prevalence of AKs in adult dermatology outpatients was reported to be approximately 30% in 2011. In the Netherlands, a total of 23.5% of the general population older than 50 years of age was estimated to be affected in 2011.[3] Similar numbers were reported in the United States, where AK is the most common diagnosis among dermatology patients 45 years of age and older. The disease is estimated to account for more than 5 million physician visits in the United States per year. The highest prevalence of AK was shown in Australia, it being up to 59% in the general population older than age 40 years in the 1980s. In contrast, only 0.52% of dermatology patients in China were diagnosed with AK from 2008-2012. The prevalence in other geographical regions is widely unknown.

Various risk factors for the development of AKs exist. The most important ones include skin phenotype, cumulative UV exposure, age, and gender. AKs occur most commonly in individuals with fair skin, red or blond hair, and blue eyes (Fitzpatrick type 1). People with darker skin (Fitzpatrick types 2 to 6), brown eyes, and dark hair are less likely to develop AKs.[3] The risk of AK is strongly associated with high cumulative UV exposure. Workers with a long history of outdoor occupation, such as farmers, construction workers, or fishermen, have an up to 2.5-fold increased risk compared to indoor workers.[4,5] This also accounts for individuals with predominantly outdoor hobbies.[4,5] Evidence that sun exposure plays a role in the development of AKs is reflected by their distribution on the body. They typically develop on sun-exposed areas, such as the balding scalp, head, neck, forearms, dorsal hands, and in women, additionally the dorsal legs (Fig. 110-1).

Figure 110-1 Multiple scaly and erythematous plaques on the dorsal hands of a 71-year-old male patient with a history of significant ultraviolet exposure. The lesions were grade II to grade III actinic keratoses.

Age is another major risk factor. The number of sunburns during childhood is associated with a higher likelihood of developing AKs in the future.[5] Therefore, the age at which a person received the greatest amount and intensity of sun exposure appears to be important. The risk of AK steadily increases with lifetime exposure to UV radiation, as seen in the significantly higher prevalence of AK in elderly people.[2,3] In Austria, for instance, 1.1% of female and 2.4% of male dermatology outpatients from 30 to 39 years of age are affected by AKs, compared to 68.1% of females and 89.7% of males older than 90 years of age.[2] The prevalence increases with age in both sexes. However, men are more likely to develop AK than women. This presumably reflects greater cumulative sun exposure in males than in females, and less protection on the bald scalp.[3,5,6]

Immunosuppressed patients, such as organ transplant recipients, are at increased risk of developing AKs. In addition, immunosuppression is associated with both developing AKs earlier in life and with a more rapid malignant transformation.[7] Furthermore, persons with certain genetic syndromes, namely albinism and xeroderma pigmentosum, are more likely to develop AKs. There are case reports of patients with Rothmund or Kindler syndrome who developed AKs early in life.

CLINICAL FEATURES

The typical patient with AKs is an older, fair-skinned, light-eyed individual, who has a history of significant sun exposure, who burns and freckles rather than tans, and who has significant solar elastosis on examination. AKs can be seen in younger individuals if they had sustained sufficient sun exposure over their lives. Eighty percent of AKs are found on chronically sun-exposed sites of the body, such as the bald scalp, face, ears, neck, forearms, and dorsal hands. They are mostly asymptomatic, but may come along with pruritus, burning or stinging pain, bleeding, and crusting.

CLINICAL SUBTYPES

The typical AK lesion, sometimes called the erythematous AK, presents most commonly as a 2- to 6-mm, erythematous, flat, rough, gritty or scaly papule (Fig. 110-2). It is usually more easily felt than seen. AKs can vary in size and sometimes reach to several centimeters in diameter. They are most often found against a background of photodamaged skin (dermatoheliosis), with solar elastosis, dyspigmentation, yellow discoloration, ephelides and lentigines, telangiectasias, and sagging skin notably prominent. At times, the number and confluence of AKs are so great that the patient appears to have a rash.

In some cases, multiple AKs may affect a large area of the sun-exposed skin. In addition, alongside clinically detectable AKs, multiple subclinical lesions may be present (Fig. 110-3). This concept is known as *field cancerization* and is crucial for the therapeutic approach. Various definitions of field cancerization have been proposed including (a) more than 2 AKs within 1 skin area with signs of solar damage, (b) at least 3 AKs within 25 cm^2 of skin, or (c) more than 5 AKs in 1 body region or field and contiguous areas of chronic actinic sun damage and hyperkeratosis.[8]

In addition to the typical erythematous AK, there are several other clinical subtypes. Some AKs have a pigmented brownish appearance and may be difficult to distinguish from other dermatoses of the elderly, such as seborrheic keratosis. If such lesions are ill defined,

Figure 110-2 Mild actinic keratoses on the face of a fair-skinned woman (grade I). The lesions appear as erythematous patches with a rough texture on palpation. Note other signs of actinic skin damage such as perioral wrinkling and the presence of solar lentigines.

Figure 110-3 Field cancerization. There are several ill-defined erythematous and scaly plaques, crusts, and ulcerations affecting a large area ("field") of the balding scalp. Further alterations, such as mottled hypopigmentation and hyperpigmentation, are present and indicate actinic damage.

Figure 110-4 **A,** Multiple well-defined hypertrophic actinic keratoses on the decollete of a middle-aged female. **B,** A higher magnification reveals the rough and hyperkeratotic texture of some lesions.

some authors have proposed the term *spreading pigmented actinic keratosis*. A hypertrophic AK presents as a thicker, scaly, rough papule or plaque that is skin-colored, gray-white, or erythematous (Fig. 110-4). It can be found on any chronically sun-exposed body site, but has a propensity for dorsal hands, arms, and scalp. A typical erythematous AK can progress into an hypertrophic AK. It can be difficult to distinguish an hypertrophic AK from an SCC, clinically necessitating a biopsy. Biopsies must be taken to a level deep enough to ensure that the dermal extent of the keratinocytic proliferation can be evaluated in order to obtain an unequivocal histopathologic diagnosis. Induration, inflammation, pain, and ulceration are the main clues to the transition of AK to SCC.

Cutaneous horn, also known as cornu cutaneum, refers to a reaction pattern and not a particular lesion. In reference to AKs, a cutaneous horn is a type of hypertrophic AK that presents with a conical hypertrophic protuberance emanating from a skin-colored to erythematous papular base (Fig. 110-5). Classical definitions of a cutaneous horn maintain that the height is at least one-half of the largest diameter. Approximately 21% of all cutaneous horns represent AKs. The pathology underlying a cutaneous horn can be a number of different lesions, such as AK, SCC, seborrheic keratosis, filiform verruca vulgaris, trichilemmoma, and keratoacanthoma.

Actinic cheilitis represents confluent AKs on the lips, most often the lower lip. Persons with this condition have red, scaly, chapped lips, and at times erosions or fissures may be present (Fig. 110-6). The vermilion border of the lip is often indistinct, and focal hyperkeratosis and leukoplakia also may be seen. Individuals with this condition often complain of persistent dryness and cracking of the lips. The diagnosis of actinic cheilitis should always be suspected in patients with photodamaged skin and such complaints. Biopsy is then necessary to confirm the diagnosis. Persistent ulcerations or indurated areas on the lip are suspicious for SCC.

CLASSIFICATION

The widely accepted Olsen classification suggests 3 grades of clinical severity of AK.[8,9] It is based on the palpable thickness of AK lesions. According to this classification, grade 1 includes lesions that are mild, slightly palpable, and are better seen than felt. Grade 2 represents lesions that are moderately thick and easily seen and felt. Grade 3 lesions are severe, very thick and/or obvious AKs (Table 110-1).[9]

On a histologic level, a recommended scheme for grading AK severity is the Roewert-Huber classification.[8,10] This scheme distinguishes 3 types of AK based

Figure 110-5 **A,** Cutaneous horn of the ear. Only biopsy will confirm whether this is an actinic keratosis or a squamous cell carcinoma. **B,** Cutaneous horn of the cheek.

on the extent of atypical keratinocytes in the epidermis. In type AK I, atypical keratinocytes are restricted to the lower third of the epidermis and are only found within the basal and suprabasal layers. In type AK II, atypical keratinocytes are found within the lower two-thirds of the epidermis, alternating with zones of normal epidermis. In the upper papillary dermis buds of keratinocytes can be found. In type AK III, atypical keratinocytes extend to the lower two-thirds of the full thickness of the epidermis. They can also involve the epithelia of the hair follicle, infundibula, and acrosyringium. As in type AK II, buds of keratinocytes can be found in the upper papillary dermis. If a biopsied AK lesion shows different histologic types, the classification suggests that the highest type defines the

Figure 110-6 Actinic cheilitis. Reddish to yellow crusts and erosions on the lower lip are typical features of actinic damage along the vermilion border. The patient complained of a persistent dryness of the lip.

lesion. Histologically, type I and type II AK represent the same severity grade as the former term "early in situ SCC." Type AK III has been proposed to be equivalent to the previous term "in situ SCC".[10]

In daily practice, AK is a clinical diagnosis. However, it was shown that the clinical classification following Olsen and the histologic classification of Roewert-Huber do not match in all cases. In a systematic study of 892 AK lesions, a correlation between both classification systems was found in 480 lesions (54%) only. Whereas 21 out of 259 lesions (8%) that were clinically graded as mild (Olsen grade 1) were histologically severe (Roewert-Huber type AK III), 36 out of 101 lesions (36%) that were clinically severe (Olsen grade 3) were histologically mild (Roewert-Huber type AK I).[11]

TABLE 110-1
Classification of Actinic Keratosis

Clinical Classification (Olsen et al.[9])
Grade 1 (Mild)
▪ Slight palpability
▪ AK better felt than seen
Grade 2 (Moderate)
▪ Moderately thick AK
▪ Easily seen and felt
Grade 3 (Severe)
▪ Very thick or obvious AK
Histologic Classification (Roewert-Huber et al.[10])
Early in situ SCC (type AK I)
▪ Involvement of basal and suprabasal layers of the epidermis
▪ Nuclei hyperchromatic and variable in size
▪ Loss of nuclear polarity
Early in situ SCC (type AK II)
▪ Involvement of the lower two-thirds of the epidermis
▪ Alternation with zones of normal epidermis
▪ Buds of keratinocytes in the upper papillary dermis
In situ SCC (type AK III)
▪ Involvement of more than two-thirds of the full epidermal thickness
▪ Involvement of hair follicle, infundibula, and acrosyringium
▪ Buds of keratinocytes in the upper papillary dermis

ETIOLOGY AND PATHOGENESIS

ETIOLOGIC FACTORS

Fair skin and exposure to UV radiation are the most important contributing factors for the formation of AKs. The majority of lesions develop in areas with chronic exposure to sunlight, such as the balding scalp, nose, ears, lips, and dorsal hands and forearms. A high extent of cumulative UV exposure, frequent sunburns in patient history, poor use of sun protection, and outdoor activities or occupations have been consistently associated with AK formation. Other risk factors include male sex, advancing age, and immunosuppression. It is currently under debate whether infection with human papillomavirus (HPV; particularly HPV types 5, 8, 21, and 38) contributes to the development of AK. Although HPV was detected in several epithelial tumors of the skin, it is uncertain if there is a causal relationship or only random coincidence as a result of the high prevalence of HPV infection. Rare exogenous risk factors comprise ionizing radiation and radiant heat. Rare endogenous predisposing conditions are genetic disorders with impaired DNA damage repair mechanisms after exposure to UV like xeroderma pigmentosum, Bloom syndrome, and Rothmund-Thompson syndrome.

PATHOGENESIS

Chronic UVB radiation induces genetic alterations of the keratinocytes residing at the basal layer of the epidermis. On a molecular level, UV light induces the formation of cyclobutane pyrimidine dimers which modify the structure of the DNA (photomutagenesis). Inactivating mutations of the tumor-suppressor gene *p53* occur as early and common events (Fig. 110-7). *p53* has a critical role in cell-cycle progression and DNA damage repair. If the gene is inactivated, *p53*-mutant keratinocytes show unrestricted cell growth and acquire cellular and morphologic atypia. Somatic UV signature mutations of *p53* are present in more than 50% of all AKs and SCCs. In contrast, activating mutations of the oncogene H-ras lead to constitutive activation of the extracellular signal-regulated kinase signaling pathway and uncontrolled proliferation of affected cells. Other UV-induced mutations may affect the genes *p16*, *K-ras*, telomerase, *CDKN2A*, nuclear factor κB, or tumor necrosis factor α.[11] Photodamaged transformed keratinocytes escape apoptosis and immunosurveillance and proliferate into clinically and histologically evident premalignant lesions.

Notch 1 regulates numerous processes in keratinocytes such as proliferation, differentiation, and apoptosis. Proper expression of Notch 1 within the epidermis appears to be tumor suppressive and to prevent the progression to invasive SCC, which may show decreased levels of the protein. In addition to epidermal tissue alterations, there is growing evidence that mesenchymal factors within the dermis such as the Notch/CSL signaling pathway have a significant role in the establishment of epithelial lesions.[12]

DIAGNOSIS

The diagnosis of AK is usually made clinically by touch and visual inspection recognizing the typical clinical features. Some lesions present as visually discreet macules or patches that are diagnosed best by feeling their rough texture. If the diagnosis is uncertain or if SCC cannot be excluded clinically, a histologic examination is obligatory. Common indications for a biopsy are rapidly enlarging lesions, bleeding or ulceration, evidence of inflammation, strong induration, lesions extending beyond 1 cm of size, or resistance to treatment.

HISTOPATHOLOGY

A punch or shave biopsy should be performed to confirm the diagnosis. The depth of the biopsy needs to reach the mid-reticular dermis to allow for the assessment of invasiveness of a given lesion. Initially, a compact packing of basal and suprabasal atypic keratinocytes with hyperchromatic and pleomorphic nuclei can be seen. Atypic mitotic figures, apoptotic cells and dyskeratosis may be present. The architecture is increasingly lost in the basal layers, but not the full thickness of the epidermis (Fig. 110-8). The alternation of hyperorthokeratosis and hyperparakeratosis is common in later stages, a feature that is referred to as "flag sign" or "pink and blue." Per definition, the lesion is confined to the epidermis. The underlying dermis often shows solar elastosis and a superficial inflammatory infiltrate. Immunohistochemically, AK lesions show increased expression of p53, proliferating cell nuclear antigen, Ki-67 (MiB-1), and cyclin E. Histologic variants comprise lichenoid, bowenoid, and, rarely, acantholytic forms.

DERMOSCOPY

If it is difficult to recognize the clinical features by naked eye, dermoscopic evaluation may help to facilitate the correct diagnosis. Common features of nonpigmented lesions are scales that appear as whitish or yellowish crystalline structures and a reddish pseudonetwork with erythema and wavy configuration of telangiectasias between enlarged hair follicles. The follicles may show a perifollicular halo, resulting in a "strawberry pattern." Hyperkeratotic AK lesions on the face may have prominent keratotic plugs within the hair follicles (targetoid-like pattern). The rosette sign consists of white dots localized inside the follicular openings, which may reflect alternating orthokeratosis and parakeratosis. Pigmented lesions may show brown dots and globules surrounding the follicular openings.

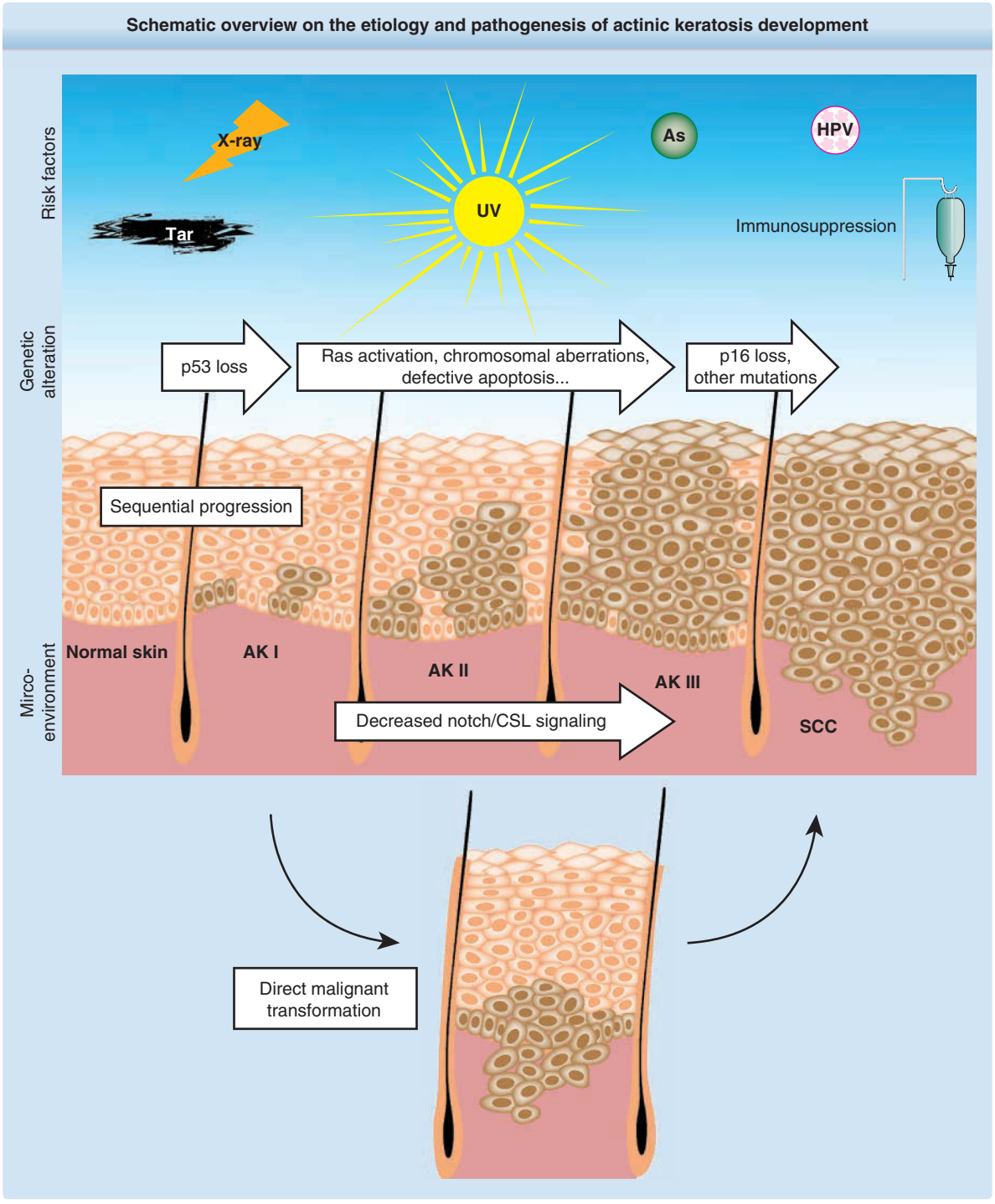

Figure 110-7 Schematic overview on the etiology and pathogenesis of actinic keratosis (AK) development. The most important etiologic factors are fair skin, ultraviolet (UV) radiation, immunosuppression, human papillomavirus (HPV) infection or exposure to tar, arsenic, and X-rays. The classic pathway (*upper panel*) assumes a stepwise progression from early lesions confined to the basal layers of the epidermis (AK I) toward intermediate (AK II) and late AK lesions (AK III), which may progress to invasive squamous cell carcinoma (SCC). A common and early molecular event is loss or inactivation of the tumor-suppressor gene *p53*. Recent evidence suggests decreased Notch signaling in underlying dermis may contribute to the formation and progression of AK. The alternative pathway (*lower panel*) assumes that any AK, including low-grade lesions, bears the potential to directly progress to invasive SCC. Abbreviation: As, arsenic; HPV, human papillomavirus.

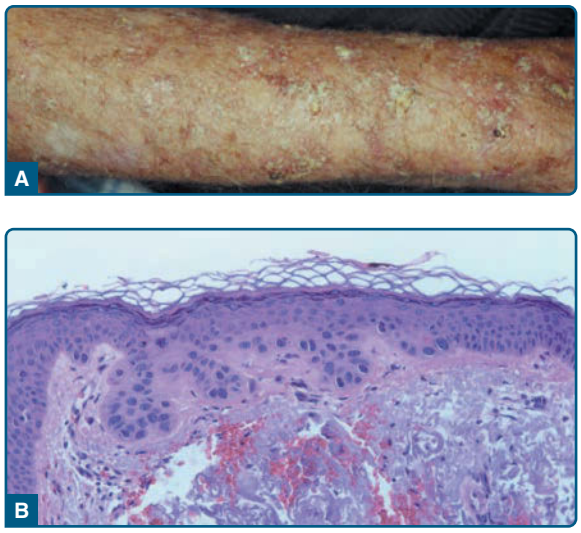

Figure 110-8 **A,** Severe solar damage of the dorsal arm demonstrating hypertrophic actinic keratoses. **B,** Histopathologic preparation of actinic keratosis demonstrates atypical cells along the basal layer with sparing of adnexal epithelium and a sparse lymphocytic infiltrate with marked actinic elastosis in the upper dermis underlying the lesion.

DIFFERENTIAL DIAGNOSIS

There are various dermatoses that may be difficult to differentiate from AKs. Spreading pigmented AK may mimic seborrheic keratosis or facial lentigo maligna. In contrast to spreading pigmented AKs, seborrheic keratoses have a velvety to finely verrucous surface that usually feels soft and greasy on palpation. In addition, seborrheic keratoses are also found on the trunk and other body surfaces that are rarely exposed to sunlight. Dermoscopy can help to distinguish pigmented AK from facial lentigo maligna. Dermoscopic findings of pigmented AK are white and evident follicles, scales, and red color. Intense pigmentation and gray rhomboidal lines are diagnostic clues for lentigo maligna.[13] In rare cases, disseminated superficial actinic porokeratoses may affect the face and be confused with AK. The flat lesions are normally asymptomatic and surrounded by a ridge-like border. Besides other precancerous (eg, arsenical keratosis) or malignant (eg, SCC) lesions, differential diagnoses include melanocytic nevi, senile lentigo, and cutaneous lupus erythematosus.

CLINICAL COURSE AND PROGNOSIS

Established AKs usually take a chronic course and lesions may persist, spontaneously regress, or progress to invasive SCCs. The likelihood for these events was investigated in a panel of studies, but revealed inconsistent and varying results. Most investigations show major methodologic limitations with a follow up period of less than 12 months and are of low quality. Thus, reliable estimates for the clinical course and prognosis of AK lesions remain uncertain to date.

PROGRESSION TO INVASIVE SQUAMOUS CELL CARCINOMA

Although atypical keratinocytes may penetrate the basement membrane and become invasive, the annual progression rate of a single lesion to SCC is supposedly below 1%, ranging from 0 to 0.53% in individuals without a history of nonmelanoma skin cancer and without immunosuppression. Currently, there is an intense debate on how the progression from AK to SCC occurs. One model assumes that low-grade AKs successively progress toward high-grade AKs and ultimately invade the epidermal–dermal junction (classic pathway of progression). However, there is evidence that not all SCCs develop from high-grade AKs, but that the majority of invasive carcinomas have their origin from AK type I. These findings suggest that each AK per se bears the potential to progress into SCC regardless of the grade of histologic atypia, and that a direct cancerous invasive transformation of basaloid atypical keratinocytes is the most common mechanism of disease progression (differentiated pathway of progression). Overall, it is estimated that only 5% to 10% of all AKs progress to invasive SCC (see Fig. 110-7). The risk for progression of AK to SCC reported in the literature varies from less than 1% to 20%. The risk for SCC formation increases with the duration of presence, total lesion count (>5), and individual patient characteristics, such as suppressed immune status. Conversely, more than 60% of cutaneous SCCs are believed to develop from preexisting AKs. Several histopathologic studies examined invasive SCC specimens and determined the percentage of associated or contiguous AKs. Premalignant AK-like areas were detected at the periphery or within the invasive parts of SCC in 60% to 100% of cases.[14-19] A lesion may become tender or painful and show signs of inflammation prior to progression, requiring a biopsy to rule out SCC formation.

REGRESSION

Spontaneous resolution without treatment may occur. The annual regression rates for single AK lesions identified in cohort studies generally range from 20% to 30% with a large variation, depending on the presence and maintenance of risk factors. For instance, limiting sun exposure and the use of sunscreen may promote regression. The resolution rates of complete fields on face and scalp are lower and have been estimated to be 0 to 7.2%.[8] Lesions that have regressed can eventually relapse, with recurrence rates ranging from 15% to 53%.[8] However, it is often not entirely clear if these lesions are true local relapses or if they have developed de novo. The presence of AKs indicates long-term sun damage and identifies individuals who are at high risk for developing actinic skin lesions. Thus, AKs are sometimes considered a chronic skin condition where lesions come and go.

TREATMENT

It is not possible to reliably predict which lesions will persist, regress, or become SCCs based on clinical and histologic features. Thus, despite the relatively low risk of transformation and high rates of spontaneous resolution, early and consequent therapy is warranted. Furthermore, treatment can help minimize symptoms like scaling, pain, or pruritus, improve the cosmetic appearance and ultimately improve the quality of lives of the patients. A plethora of treatment options exists and more agents and procedures are constantly being launched and approved by regulatory agencies. Treatment modalities for AKs can be broadly divided into lesion-targeted therapies and field-targeted therapies (Table 110-2).

LESION-TARGETED THERAPIES

The majority of lesion-targeted therapies are mechanically destructive, such as cryosurgery, surgical approaches, or ablative lasers. Other lesion-directed approaches include medical treatment with 5-fluorouracil (5-FU) plus salicylic acid and lesion-directed photodynamic therapy (PDT).

Cryosurgery: Liquid nitrogen cryosurgery is a commonly performed destructive procedure that is typically administered with a spray device, cotton swab, or probe. The freezing procedure leads to the formation of extracellular and intracellular ice crystals. With subsequent thawing, destruction of atypical keratinocytes occurs through cell dehydration and rupture of cell membranes and organelles. Cryosurgery is easy to administer, cheap, and efficient in clearing single lesions. More benefits include the lack of need for local anesthesia and simple posttreatment care. Frequent short-term complications are procedure-related discomfort with pain and hemorrhage, accompanied by, in many cases, the formation of a blister. Further drawbacks include the danger of nerve damage, pigmentary changes resulting from the destruction of adjacent melanocytes, and scarring. The application procedure of cryosurgery for AK is little standardized with varying durations of freeze–thaw cycles, number of freeze–thaw repetitions, or duration of freezing. Cryosurgery is suitable to treat a limited number of clinically perceptible or symptomatic lesions.

Surgical Approaches: Surgical approaches generally have the advantage of obtaining specimens for further histopathologic assessment. Conventional surgical

TABLE 110-2
Treatment of Actinic Keratoses

	ADVANTAGES	DISADVANTAGES
Lesion-Targeted Therapies		
Liquid nitrogen cryosurgery	▪ Short treatment duration (sec-min) ▪ No need for local anesthesia	▪ Little standardized ▪ Frequent blister formation ▪ Hypopigmentation
Surgical approaches (conventional excision, shave excision with/without electrodessication)	▪ Histopathologic assessment ▪ Low recurrence rates	▪ Local anesthesia needed ▪ Surgery-related complications ▪ Hypopigmentation/hyperpigmentation ▪ Scarring
Ablative lasers	▪ Short treatment duration	▪ Dyspigmentation ▪ Risk of scarring ▪ High equipment costs
Topical therapy (5-fluorouracil plus salicylic acid)	▪ Easy application by the patient ▪ No need for local anesthesia	▪ Long treatment duration (6-12 weeks) ▪ Local inflammation
Lesion-directed photodynamic therapy (PDT) ("patch" PDT)	▪ No need for local anesthesia ▪ Cosmetic outcome	▪ Local pain and adverse events (eg, erythema, edema, erosion) ▪ Lamp device needed
Field-Targeted Therapies		
Topical/Medical		
5-fluorouracil Imiquimod Diclofenac-Na Ingenol mebutate	▪ Application by the patient ▪ Cosmetic outcome	▪ Potential of contact hypersensitivity ▪ Treatment duration (3-90 days) ▪ Local adverse events (eg, erythema, edema, erosion) ▪ Rarely systemic adverse events
Procedural		
Conventional PDT (with blue light or red light)	▪ Cosmetic outcome	▪ Local adverse events (eg, erythema, edema) ▪ Local pain/burning sensation ▪ Lamp device needed
Natural daylight PDT	▪ Cosmetic outcome	▪ Local adverse events (eg, erythema, edema) ▪ Dependent on weather condition (<10°C [50°F], no rain)

excision is not a routine procedure for AK. It can be considered for clinically atypical lesions that warrant further histologic evaluation or to rule out invasive SCCs. Shave excisions are commonly performed for single hyperkeratotic lesions. However, the pathologic evaluation after shave excision may be problematic if the biopsy is taken too superficially to determine if the lesion is confined to the epidermis or invasive. Curettage takes advantage of a curette to mechanically scrape away the atypical keratinocytes. It may either be applied as single technique or in combination with shave excision, electrodessication, or cryosurgery. It is useful for single, hypertrophic AKs on the extremities, and is technically easy to perform in an office-based setting. Yet, the quality of specimens obtained with curettage is usually poor and histologic evaluation may be equivocal. Some studies suggest that surgical therapies show lower rates of recurrence than other destructive treatments. Nevertheless, disadvantages of all surgical procedures include the need for local anesthesia, potentially prolonged wound healing, infection, bleeding, dyspigmentation, scarring, and rather poor cosmetic outcomes.

Laser Therapies: Laser devices are increasingly used for the treatment of AKs. Most experience and evidence has been collected for ablative resurfacing with the carbon dioxide (CO_2) and erbium:yttrium aluminium garnet (Er:YAG)-laser. Both devices ablate the epidermis at varying depths, allowing for reepithelialization with adnexal or lesion-adjacent keratinocytes that are less actinically damaged. The CO_2 laser has a higher penetration depth than the Er:YAG laser and may offer advantages when treating thicker and hyperkeratotic lesions. Adverse events comprise hypopigmentation and atrophic scarring. Although lesion clearance rates were promising in a panel of studies, AKs can relapse after laser treatment. Laser resurfacing is probably best reserved for use by specially trained and experienced physicians and for patients with more cosmetic concerns. The efficacy of nonablative fractional photothermolysis is currently unclear and well-designed trials are lacking.

Lesion-Directed Photodynamic Therapy: PDT is increasingly used for the treatment of both single AK lesions and field cancerization with superb cosmetic outcomes. It is based on the topical application of a photosensitizing agent followed by exposure to a specific wavelength of light. 5-Aminolevulinic acid (ALA) and methyl aminolevulinate (MAL) are the 2 substances that are used in PDT for AKs. They are absorbed by the epidermis and preferentially accumulate in atypical cells where they are further processed to protoporphyrin IX. Subsequent exposure to a specific wavelength light source activates protoporphyrin IX, resulting in a phototoxic reaction with release of reactive oxygen species and, ultimately, in destruction of target cells by necrosis and apoptosis.

Although PDT is predominantly perceived as field therapy (see section "Field-targeted Therapies"), 5-ALA can be applied with a patch to isolated lesions to spare and protect healthy skin. This targeted application of the photosensitizer can help minimize local adverse events like erythema, crusting, blister formation and is usually well tolerated by patients. The efficacy of the patch PDT is high and results in excellent cosmetic outcomes. In particular, hypopigmentation which is observed in many cases with destructive lesion-directed approaches is not seen with this technique.

FIELD-TARGETED THERAPIES

Field-centered approaches do not target at single lesions, but treat entire actinically damaged areas ("fields"). This strategy is applicable if several ill-defined AK lesions exist within 1 field or if subclinical lesions are suspected and field cancerization is present. Field therapies can be further categorized into topical and procedural treatments (see Table 110-2).

Topical Treatment: A variety of topical agents exist for the treatment of AKs such as diclofenac, 5-FU, imiquimod, and ingenol mebutate (Table 110-3).

Diclofenac is an inhibitor of cyclooxygenase and belongs to the nonsteroidal antiinflammatory drugs. Topical therapy with 3% diclofenac in 2.5% hyaluronic acid gel is a widely used effective treatment option for patients with multiple AKs or field cancerization.[20] It was shown to be protective against the appearance of new AKs, as it also acts against subclinical lesions.[21] Diclofenac is well tolerated, but may lead to local adverse events, such as erythema, scaling, burning

TABLE 110-3
Topical Treatments for Actinic Keratoses

DRUG	PREPARATION	DOSAGE/APPLICATION
Diclofenac-Na	3% gel	Twice daily for 90 days
5-Fluorouracil (5-FU)	0.5% cream	Once daily for up to 4 weeks
	1% cream	Twice daily for 2-6 weeks
	4% cream	Once daily for 4 weeks
	5% cream	Twice daily for 2-4 weeks
	2% solution	Twice daily for 2-4 weeks
	5% solution	Twice daily for 2-4 weeks
5-FU plus salicylic acid (SA)	0.5% (5-FU) and 10% (SA) solution	Once daily up to 12 weeks
Imiquimod	5% cream	Three times per week for 4 weeks
	3.75% cream	Once daily for 2 weeks
	2.5% cream	Once daily for 2 weeks
Ingenol mebutate	0.015% gel	Once daily for 3 days
	0.05% gel	Once daily for 2 days

sensation or pruritus. The recommended treatment duration of 90 days with twice daily application is relatively long. This may have a negative impact on practicability and patient adherence.[22]

5-FU is a pyrimidine analog and acts as an antimetabolite and via inhibition of the thymidylate synthetase as a cytostatic drug. In a cream formulation, 5-FU is a well-established topical treatment option for AK. 5-FU is available in numerous preparations, most commonly as 0.5% cream once daily or 5% cream twice daily. Both are effective and similarly safe, but patients may prefer the 0.5% preparation as it is applied only once daily.[23] Typical adverse events are erythema, erosion and discomfort at the site of application. Treatment duration is usually 2 to 4 weeks.

Another formulation is a combination of 0.5% 5-FU with 10% salicylic acid.[24,25] It is applied once daily for up to 12 weeks on an area not larger than 25 cm^2. It may be more suited for hypertrophic lesions than 5-FU alone because salicylic acid has a keratolytic effect and improves the penetration of 5-FU.

Imiquimod is a Toll-like receptor 7 agonist and activates innate immune cells to produce interferon-α and other cytokines. Topical imiquimod is an effective treatment option for AK and available as 2.5%, 3.75%, and 5% cream.[26,27] Application frequency depends on which concentration is used. Imiquimod at 2.5% and 3.75% concentration is usually applied once daily for 14 consecutive days. The 5% formulation is applied 3 times per week during a 4-week period. Adverse events are usually limited to the site of application including local irritation, pain, pruritus and swelling. In some cases, systemic events, like cardiovascular disorders, myalgia, arthralgia, and flu-like symptoms, may occur. In the light of long-term experience and better tolerability, 3.75% imiquimod is commonly preferred for the treatment of single AK lesions as well as for field-directed therapy.[8] In immunosuppressed patients, 5% imiquimod cream was shown to be safe.

Ingenol mebutate is a hydrophobic triterpene ester that is extracted from the sap of the plant *Euphorbia peplus*. It is effective against AK by chemoablative and immunostimulatory properties.[28,29] Ingenol mebutate is available as a 0.015% gel for scalp and face and a 0.05% gel for the trunk and extremities. In contrast to other topical treatments for AK, 0.015% and 0.05% ingenol mebutate are only applied for 3 and 2 consecutive days, respectively. Local adverse events are virtually obligatory and are irritation, pruritus, and inflammatory changes, including erythema, blister, edema, erosion, scaling, and crusting. All these reactions appear early and usually subside within 14 days.[30] However, because of the short treatment duration and good efficacy, ingenol mebutate was shown to increase treatment satisfaction and the quality of life of patients.[31]

Cryopeeling: This procedure refers to the extensive application of liquid nitrogen not only to single lesions, but to a complete field of manifest and subclinical AK. Cryopeeling is relatively easy to apply and was found effective for hypertrophic AK. Compared to conventional cryosurgery, it may help to reduce recurrence rates, although it bears a higher risk for hypopigmentation of treated areas.

Chemical Peelings: Medium-depth chemical peels using Jessner solution and 35% trichloroacetic acid, 70% glycolic acid, or solid CO_2 are moderately effective in treating diffuse nonhypertrophic AKs, especially when a series of such peelings is repeated over time. They cause skin damage in the superficial papillary dermis and induce a wound reaction with exfoliation of the atypical keratinocytes and reepithelialization. Common side effects are stinging, burning sensation, erythema, and scaling.

Deep chemical peelings using phenol or higher concentrations of trichloroacetic acid are more effective in treating hyperkeratotic AK or AK with appendageal epithelial atypia. However, they are rarely used because of the potential cardiac and renal toxicity of phenol and a higher risk of scarring, infection, and hypopigmentation.

Dermabrasion: Dermabrasion (also known as surgical skin planing) is an older technique that is nowadays rarely used for AK treatment. It is based on physical ablation of lesions with superficial abrasion of the epidermis at the level of the epidermis. Devices for dermabrasion are either drywall sanding sheets or diamond fraises that are powered or handheld. The procedure is painful and should be performed under sedation or general anesthesia. It may be applied for field therapy for an actinically damaged bald scalp or forehead.

Field-Targeted Photodynamic Therapy: Field-targeted PDT is usually performed with 5-ALA cream or MAL nanoemulsion as photosensitizing substances in combination with visible light (ie, blue, green or red light). Randomized, placebo-controlled studies demonstrated the efficacy of both ALA-PDT and MAL-PDT. They are equally effective, with lesion clearance rates ranging from 70% to 90%. A common adverse event is local discomfort ranging from burning or stinging to intolerable pain during exposure to the light source. Allergic reactions to ALA and MAL have been rarely reported. One to 2 days after treatment, local erythema, edema, blistering, sterile pustule formation, and crusting are commonly observed as clinical correlates for the phototoxic reaction. The cosmetic outcome of PDT is excellent and the term *photorejuvenation* has been coined. The effect is characterized by collagen remodeling and a decrease of small wrinkles, telangiectasias, and lentigines.

An alternative to conventional PDT is the so-called natural daylight PDT, using much shorter incubation times of MAL/ALA and exposing the affected skin to sunlight instead of artificial visible light. Within 30 minutes after topical application of MAL/ALA patients are advised to stay outdoors for 2 hours. Natural daylight PDT is significantly less painful than conventional PDT, while the other local side effects are comparable. For the treatment of mild to moderate AKs, the effectiveness of natural daylight PDT was noninferior to conventional PDT in several trials.

APPROACH TO INDIVIDUAL MANAGEMENT

As described above, there are a number of effective lesion-targeted and field treatments available to choose from to decrease the burden of AKs. The individual patient's needs and expectations, the physician's skills, the mechanisms of action of the various treatments and their side-effect profiles, and the costs of the agents and procedures should all be considered when choosing a treatment strategy. To help physicians in their choice several national and international guidelines for the management of AKs have been proposed.[8,32]

PREVENTION

Measures of primary prevention are primarily based on the avoidance of exposure to UV, because it is the main risk factor for the development of AKs. Educational and preventive efforts should be directed toward all patients, including children and high-risk populations such as organ transplant recipients or outdoor workers. Minimizing UV radiation is the single most effective means of decreasing the risk of AKs. Because complete avoidance of the sun is impractical, the next best preventive measures are to avoid exposure to intense midday sun; consistently apply and reapply broad-spectrum sunscreens; wear UV-protective clothing, hats, and sunglasses; install UV-protective windows where indicated; and make sure to take an oral vitamin D supplement if necessary to avoid vitamin D insufficiency or deficiency. Tanning beds should be avoided. Newborns should not be exposed to sun.

USE OF SUNSCREENS

Numerous randomized studies show that the use of sunscreen can decrease the incidence and prevalence of AKs, reduce the number of AK lesions, and increase their rate of regression. There is also evidence that sunscreen use can prevent certain types of skin cancer, mostly SCC. Broad-spectrum sunscreen against UVB and UVA radiation with a minimum sun protection factor of 30 should be applied to areas that cannot be protected by physical measures like UV-protective clothes or UV avoidance. It is important to apply sunscreen in sufficient amounts at least 20 minutes before going outside and to reapply it every 2 to 3 hours especially when excessive sweating or swimming.

CHEMOPREVENTION

Some agents or dietary interventions can prevent or delay the development of AKs in high-risk populations. There is limited evidence that adhering to a low-fat diet may decrease the incidence of AKs and nonmelanoma skin cancer. Nutritional supplements, like vitamin A, selenium, and carotenes, are currently not recommended for prevention. Topical imiquimod also has been safely used in organ transplant recipients to prevent development of cutaneous SCC.

Retinoids: There is a debate on whether the application of topical retinoids is effective in the prevention of AKs because prevention trials have yielded discordant results. Unlike the controversy with topical retinoids, there is strong evidence for the use of systemic retinoids in preventing nonmelanoma skin cancer and AKs, especially in high-risk populations, such as organ transplant recipients, patients with xeroderma pigmentosum, and other chronically immunosuppressed patients.[33] However, systemic retinoids are only effective while taking them. Their use is also limited by the frequent occurrence of systemic toxicities, including hypercholesterolemia, hypertriglyceridemia, mucocutaneous xerosis, musculoskeletal abnormalities, and alteration in liver function. Thus, when considering the use of systemic retinoids as chemoprevention one must weigh the risks and benefits.

Nicotinamide: Oral nicotinamide (vitamin B_3) was reported safe and effective in reducing the rates of new nonmelanoma skin cancer and AK in high-risk patients in a recent phase III trial. Specifically, the number of AKs was reduced by 13% in patients who took 500 mg of nicotinamide twice daily for 12 months compared to placebo.[34] However, the beneficial effects disappeared when the treatment was discontinued. Furthermore, it is unclear if nicotinamide is associated with an increased risk for infectious adverse events.

BOWEN DISEASE

AT-A-GLANCE

- Bowen disease (BD) is squamous cell carcinoma (SCC) in situ.
- It can progress to Bowen carcinoma (invasive SCC) in up to 5% of cases.
- Etiologic factors include UV radiation, arsenic, previous therapy with psoralen and UVA radiation, immunosuppression, exposure to ionizing radiation, and infection with human papillomavirus.
- Clinical variants are pigmented, intertriginous, periungual, and subungual BD.
- Histopathologic features include full-thickness epidermal atypia with large, round cells and possible adnexal involvement.
- Therapeutic options include surgical, topical, and ablative interventions.
- Surgical treatment methods include excision and Mohs micrographic surgery, which permit histopathologic evaluation to exclude invasive SCC.
- Topical therapy may be used in areas that are difficult to treat with other methods.

Bowen disease (BD) is a distinct type of SCC in situ and was originally described in 1912 by John T. Bowen, a Boston dermatologist. It may affect both skin and mucous membranes and has the potential to progress to Bowen carcinoma, that is, an invasive SCC.

EPIDEMIOLOGY

The exact incidence of BD in the United States is unknown. The incidence was estimated at 142 per 100,000 persons in Hawaii. BD usually occurs in adults, and is typically seen in individuals older than age 60 years. It affects both sexes with a preponderance in men.[35] BD mostly affects sun-exposed areas, such as head and neck, as well as the upper and lower limbs. Men are more likely to have BD on the balding scalp, ear, and anterior trunk. In contrast, women commonly have BD on the cheeks and lower legs. Immunocompromised patients are more likely to develop BD at a younger age. It also affects more often the trunk, limbs, and neck, and recurrence rates are higher compared to immunocompetent patients.[35]

CLINICAL FEATURES

BD lesions grow slowly and may be accompanied by pruritus, but are usually asymptomatic. Lesions typically present as erythematous plaques with irregular, clearly demarcated borders. The surface may be scaling, crusting, or hyperkeratotic (Fig. 110-9A). Over time, lesions may grow in size and measure up to several centimeters. The flat plaque may transform to a nodular or verrucous form. BD usually appears pink or reddish, whereas crusty or hyperkeratotic lesions may take a gray or brownish color. In very few cases, lesions are pigmented. Lesions of BD are usually solitary, but may be multiple in up to 20% of individuals. Sites of predilection include sun-exposed areas such as the head and neck and lower legs, although any site of the body may be affected.

There are a few clinical variants of BD. In the periungual region BD may appear as an erythematous, scaly, thin plaque around the cuticular margin or as a verrucous plaque. It may lead to nail discoloration, onycholysis, or destruction of the nail plate (see Fig. 110-9B). In intertriginous areas, BD can present as an oozing,

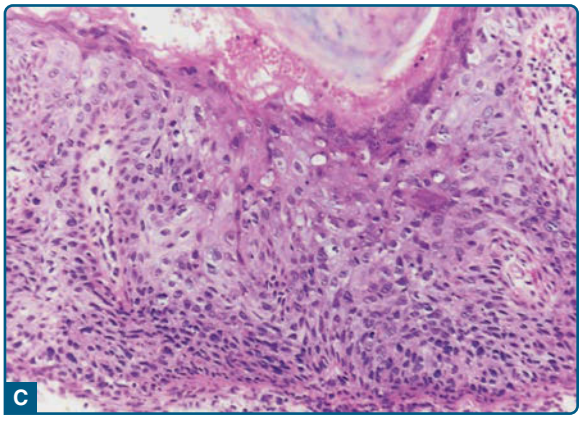

Figure 110-9 **A,** Large plaque of Bowen disease of the leg. **B,** Bowen disease of the nail unit resulting in onycholysis. **C,** Typical histopathologic features of Bowen disease include full-thickness epidermal atypia with loss of the stratified architecture. Involvement of adnexal structures is commonly seen.

erythematous, or pigmented patch or plaque. BD of the mucosal surfaces may appear as verrucous or polypoid papules and plaques, erythroplakia, or a velvety erythematous plaque. These variants are discussed in the sections on precancerous lesions of the oral cavity (see section "Potentially Malignant Disorders of the Oral Cavity,") and the lower anogenital tract (see section "Precancerous Lesions of the Lower Anogenital Tract"), respectively.

ETIOLOGY AND PATHOGENESIS

The most important etiologic factors for the development of BD include a long history of significant UV exposure and infection with HPV. BD has been described with increased frequency in patients undergoing psoralen plus UVA therapy. In contrast, it is rarely seen in stronger-pigmented individuals. Up to 30% of extragenital BD lesions have been found to harbor HPV DNA. Several HPV subtypes, such as HPV types 16, 18, 31, 34, 35, 54, 58, 61, 62, and 73 have been detected in BD lesions.[36] Infection with high-risk HPV subtypes such as HPV 16 may be responsible for BD lesions on hands or fingers after anodigital infection in patients that simultaneously have anal and genital lesions. However, the prevalence of HPV-associated BD lesions is higher on sun-protected than on sun-exposed body areas.[37] Organ transplant recipients, HIV patients and other patients with long-term immunosuppression are at higher risk of developing BD. Other etiologic factors include arsenic exposure and ionizing radiation.

DIAGNOSIS

The clinical picture together with the typical history of a slowly growing, mostly asymptomatic lesion that remains resistant to topical corticosteroid treatment is highly suspicious for BD. However, final diagnosis requires biopsy and histologic examination.

On a histologic level, BD lesions display full-thickness epidermal atypia with loss of the stratified epidermal architecture that is clearly demarcated from the surrounding physiologic structures (see Fig. 110-9C). Abnormal mitoses, acanthosis, and hyperkeratosis are further characteristics. Toward the upper epidermal layers parakeratosis is usually present. The degree of cytologic atypia may be variable. Typical are hyperchromatic, pleomorphic, and enlarged nuclei. The cells show a pale staining and eosinophilic cytoplasm. Vacuoles may be present within the keratinocytes. Atypical cells can be seen throughout the epidermal thickness alongside with mitotic figures and apoptotic cells. Intraepidermal portions of adnexal structures, such as the pilosebaceous units, may be affected as well.[14] As the basement membrane remains intact, atypia does not affect subepidermal structures. The upper dermis is usually infiltrated by numerous inflammatory cells, including lymphocytes, plasma cells, and histiocytes.

Several histopathologic subtypes, such as psoriasiform, atrophic, acantholytic, and epidermolytic BD can be distinguished. Psoriasiform BD displays parakeratosis and marked acanthosis with broad, sometimes fused, epidermal rete ridges. Atrophic BD is characterized by a thinned epidermis. Acantholytic BD shows acantholysis in the epidermis. Epidermolytic BD has changes of incidental epidermolytic hyperkeratosis present. The phenomenon of intraepidermal epithelioma of Borst-Jadassohn—namely, nesting of the atypical cells within the epidermis, or so-called pagetoid BD—can also be seen. Furthermore, verrucous-hyperkeratotic and papillomatous variants have been described.

DIFFERENTIAL DIAGNOSIS

Clinically and histologically, BD may be difficult to distinguish from other dermatoses (Tables 110-4 and 110-5).

TABLE 110-4
Clinical Differential Diagnosis of Bowen Disease

- Erythematous Bowen disease
  - Superficial basal cell carcinoma
  - Dermatitis, eczema
  - Psoriasis
  - Seborrheic dermatitis
  - Lichen planus
  - Benign lichenoid keratosis
  - Irritated or inflamed seborrheic keratosis
  - Actinic keratosis
  - Squamous cell carcinoma
  - Amelanotic melanoma
- Hyperkeratotic Bowen disease
  - Verruca vulgaris
  - Seborrheic keratosis
  - Discoid lupus erythematosus
  - Hypertrophic lichen planus
  - Squamous cell carcinoma
- Pigmented Bowen disease
  - Melanoma
  - Bowenoid papulosis
- Intertriginous Bowen disease
  - Inverse psoriasis
  - Seborrheic dermatitis
  - Candidiasis
  - Paget disease
  - Hailey-Hailey disease
- Subungual or periungual Bowen disease
  - Nail dystrophy
  - Onychomycosis
  - Squamous cell carcinoma
  - Amelanotic melanoma

TABLE 110-5
Histopathologic Differential Diagnosis of Bowen Disease

- Paget disease
- Pagetoid melanoma in situ
- Intraepidermal eccrine carcinoma
- Intraepidermal Merkel cell carcinoma
- Intraepidermal sebaceous carcinoma
- Bowenoid papulosis
- Hidroacanthoma simplex
- Podophyllin-induced changes in a wart

CLINICAL DIFFERENTIAL DIAGNOSIS

Superficial basal cell carcinoma may mimic BD but can be distinguished by its elevated, subtle and translucent border. Patches of psoriasis, atopic dermatitis or lichen planus are typically accompanied by itching and located on their sites of predilection together with other lesions. In addition, they usually respond to topical corticosteroid therapy. Hyperkeratotic or verrucous lesions of BD can be misinterpreted as viral warts, seborrheic keratosis, and SCC. For both pigmented and unpigmented BD lesions, it is important to consider melanoma and amelanotic melanoma as differential diagnoses, respectively. Because of their very similar histologic picture, the clinical setting is crucial in differentiating BD from sexually transmitted bowenoid papulosis.

HISTOPATHOLOGIC DIFFERENTIAL DIAGNOSIS

BD may be confused with (extramammary) Paget disease. Both entities show atypical cells with pleomorphic, hyperchromatic nucleus, clear cytoplasm, and mitotic figures. While BD affects the full-thickness of the epidermis, Paget cells typically form nest-like or glandular-like patterns with a central lumen that are most abundant in the basal layers. Immunohistochemistry is essential for diagnosis, as Paget cells stain positive for carcinoembryonic antigen, mucin, Alcian blue, aldehyde fuchsin, and periodic acid-Schiff and are diastase resistant. In addition, unlike BD, Paget disease overexpresses low-weight cytokeratins, such as cytokeratin 7, and gross cystic disease fluid protein 15 (GCDFP-15).[38,39]

Similar to BD, AK type III (bowenoid AK) displays cell atypia throughout the entire thickness of the epidermis. In contrast to BD, they do not have a clear border, but show a diffuse transition into the surrounding epidermis. In addition, mitotic figures are less prominent. Finally, lumican, a small leucine-rich proteoglycan, is expressed in most BD lesions, but not in AK.[40] In hidroacanthoma simplex, Lumican staining is also observed, but atypical mitoses cannot be seen.[15]

Pagetoid melanoma in situ can be difficult at times to distinguish histopathologically from BD. In BD, the intercellular desmosomal bridges should be identifiable between the atypical keratinocytes. Additionally, melanocyte-specific immunoperoxidase staining gives positive results in melanoma cells, but negative results in BD and Paget disease cells. The other rare pagetoid neoplasms are usually recognizable, but erroneous diagnoses can be made by the unwary.

Bowenoid papulosis may lack the full-thickness epidermal atypia present in BD, but the clinical setting is paramount. Podophyllin applied topically to skin lesions induces metaphase arrest, leading to bizarre keratinocyte formation, architectural disturbance, vacuolation, and sometimes a pattern of pseudoepitheliomatous hyperplasia that can be mistaken for BD. These changes typically resolve after a few days to a week.

CLINICAL COURSE AND PROGNOSIS

In general, recurrence of BD is rare and estimated to be approximately 6% within 5 years after sufficient treatment. The theory that persistent BD within the deep portion of the follicle is mainly responsible for recurrence could not be confirmed.[14] In fact, recurrent BD may be more likely caused by subclinical lateral spread, as excision with narrower lateral margin is associated with a higher risk of recurrence.[16]

The overall risk that untreated BD will progress to invasive carcinoma is estimated at approximately 5%. Immunocompromised individuals, such as organ transplant recipients, are at particular risk of recurrence, multiple BD lesions and transformation into invasive SCC.[7,35]

Once BD occurs, the risk of developing subsequent nonmelanoma skin cancer is particularly higher. There is no evidence, however, that BD is associated with a higher risk for internal malignancies. One exception is in cases of BD related to previous arsenic exposure, where the occurrence of an internal malignancy is possible. Also, BD involving the vulvar region in females and the perianal region in males may be associated with an increased risk of uterine, cervical, vaginal, and anal cancer, most likely as a consequence of HPV infection.[36]

TREATMENT

There are various treatment approaches for BD. Such therapies can be divided into 3 main categories: surgical or destructive therapies, topical therapies, and radiation therapy (Table 110-6). The evidence on efficacy and safety is strongly limited and mostly restricted to PDT.[17] However, this does not necessarily imply that other treatments lack efficacy. The choice on which treatment is best rather depends on several individual aspects, such as availability, patient or clinician's preference, affected body area, and treatment costs. Surgical and destructive therapies include excision, Mohs micrographic surgery, curettage with or without electrosurgery, chemoablation with trichloroacetic acid, and cryosurgery. These

TABLE 110-6
Treatment of Bowen Disease

	ADVANTAGE	DISADVANTAGE
Surgical and Destructive Therapies		
▪ Excision ▪ Mohs micrographic surgery ▪ Curettage with or without electrosurgery ▪ Cryosurgery	▪ Histopathologic assessment (not for cryosurgery) ▪ Short treatment duration	▪ Surgery-related complications ▪ Scarring ▪ Cryosurgery: hypopigmentation, blister formation
Topical Therapies		
▪ 5-Fluorouracil	▪ Application by the patient ▪ Cosmetic outcome ▪ No need for local anesthesia	▪ Long treatment duration ▪ Local adverse events (eg, erythema, edema, erosion) ▪ Toxic for eyes
Nonsurgical Ablative Therapies		
▪ Photodynamic therapy (PDT) ▪ Laser ablation ▪ Chemoablation (trichloroacetic acid) ▪ Radiation therapy	▪ Cosmetic outcome (PDT)	▪ Local adverse events ▪ Dyspigmentation ▪ Chronic radiation dermatitis

interventions are widely available and relatively cheap, and surgical approaches permit histopathologic evaluation. They are simple, rapid, and suitable for small BD lesions on easily accessible body areas. In particular for BD affecting the periungual region, local excision or Mohs micrographic surgery are commonly used. The most preferred topical therapies are 5-FU and 5% imiquimod cream, but others, such as ingenol mebutate, have been tried as well.[18] Like surgical interventions, they are effective and widely available and therefore suitable for the outpatient setting. In addition, they can be used in individuals who refuse surgery, have significant comorbidities or impaired healing capability. Nonsurgical ablative therapies include PDT, laser ablation, and radiation therapy. There is good evidence for the use of PDT with MAL and ALA. One major advantage of PDT is an excellent cosmetic outcome. Combination therapies using PDT, CO_2-laser, surgery, imiquimod 5% cream, and radiation have been described.[19,41,42] If previous nonsurgical therapies have failed, BD warrants surgical intervention to exclude invasiveness and involvement of large surface areas.

VIRAL-ASSOCIATED EPITHELIAL PRECANCEROUS LESIONS

It has been suggested that some epithelial precancerous lesions are associated with HPV infection. HPVs are

TABLE 110–7
Association of Human Papillomavirus Types with Epithelial Precancerous Lesions

PRECANCEROUS LESION	ASSOCIATED HUMAN PAPILLOMAVIRUS TYPES[a]
Bowenoid papulosis (BP)	**16, 18,** 31-35, 39, 42, 48, 51-54
Epidermodysplasia verruciformis (EV)	**2, 3, 5, 8,** 9, 12, 14, 15, 17, 19, 25, 26, 38, 47, 50
Anal and perianal intraepithelial lesions (AIN, PaIN)	**16, 18, 31, 33**
Vulvar intraepithelial lesions (VIN)	**16, 18, 31, 33**
Penile intraepithelial lesions (PIN)	**16, 18, 31, 33**
Digital/periungual Bowen disease	**16**

[a]The most common associations are highlighted in bold.

double-stranded DNA viruses belonging to the Papillomaviridae family. More than 100 different types have been identified so far. According to their oncogenic potential, one distinguishes high-risk types from low-risk types. They can further be subdivided according to their tissue tropism into cutaneous and mucosal categories. Chapter 167 discusses HPV infections and HPV-associated diseases in more detail. The conditions bowenoid papulosis (BP), epidermodysplasia verruciformis (EV), and precancerous lesions of the lower anogenital tract (anal intraepithelial neoplasia [AIN], perianal intraepithelial neoplasia [PaIN], VIN, penile intraepithelial neoplasia [PIN]) are reviewed here (Table 110-7).

BOWENOID PAPULOSIS

AT-A-GLANCE

- Synonyms: Bowenoid papulosis (BP) of the genitalia, pigmented penile papules with carcinoma in situ changes, genital keratinocytic dysplasia, penile carcinoma in situ associated with human papillomavirus (HPV) infection.
- BP is a precancerous condition of the genitalia caused by infection with high-risk HPV, most commonly with types 16, 18, and 33.
- BP most commonly affects young to middle-aged males.
- BP typically presents with multiple red to brownish flat papules on the penis or vulva.
- BP rarely transforms into Bowen disease or invasive squamous cell carcinoma.
- Treatment options include topical imiquimod, curettage, excision, and laser vaporization.
- Vaccination may help to reduce the prevalence of BP among young adults.

Figure 110-10 Bowenoid papulosis of the penis. Multiple erythematous to brownish papules can be seen on the dorsum of the penis of this sexually active young male. (Used with permission from James E. Fitzpatrick, MD.)

Genital lesions that histopathologically resembled SCC in situ were first described by Lloyd in 1970 as multicentric pigmented BD of the groin. In 1977, Kopf and Bart described multiple bowenoid papules of the penis, which were thereafte referred to as BP. Its association with high-risk HPV, most commonly with HPV types 16 and 18, was discovered only later. To date, numerous other mucosal HPV types have been associated with the condition, including types 31 to 35, 39, 42, 48, and 51 to 54.

BP typically presents with multiple flat verrucous papules and plaques with a red-to-brownish color (Fig. 110-10). It is most common among young to middle-aged sexually active individuals with a male predominance. Lesions are multiple, pigmented. and typically located on the glans penis, prepuce, and penis shaft in males, and around the labia minora and majora in females. Depending on sexual practices lesions may be found in the perineal and anal area. Involvement of other sites such as oral cavity, neck, and periungual area is rarely seen. BP lesions may be confused with genital warts, lichen planus, condylomata acuminata, erythroplasia, molluscum contagiosum, and seborrheic keratoses. The multiplicity of the lesions is an important distinctive feature of BP compared to BD. Patients often report condylomata acuminata in their history.

Histopathologically, BP is characterized by the presence of SCC in situ–like changes. The epidermis is usually hyperplastic and shows acanthosis, hyperorthokeratosis, and focal parakeratosis. Keratinocytes show signs of cellular atypia and disordered maturation. Dyskeratotic and pyknotic keratinocytes with scattered mitotic figures are commonly seen. HPV infection and identification of high-risk types can be achieved with polymerase chain reaction from lesional material.

BP is perceived as transitional state between genital warts and in situ SCC. It has a variable, but mostly benign, clinical course, ranging from spontaneous regression to persistence of lesions to, rarely, transformation into BD and invasive SCC. It is estimated that the risk of malignant transformation is rather low, ranging from less than 1% to 2.6%. BP is highly contagious and patients with BP and their sexual partners should be followed and examined periodically, because of the increased risk of developing SCC or cervical or vulvar neoplasia. Patients with persistent disease should probably undergo testing for altered immune status.

Despite the low risk for malignant transformation, treatment of BP is recommended. It typically responds well to local therapy, although recurrences are common. Therapeutic options include local destructive measures such as curettage with or without electrosurgery, CO_2-laser, neodymium:YAG laser, cryosurgery, and excision. Topical tretinoin, topical 5-FU, and topical cidofovir have been used in anecdotally reported cases with mixed results. Imiquimod 5% cream 3 times per week for up to 12 weeks showed high lesion clearance rates in several studies and is a valid treatment option in clinical practice. Also, the efficacy of PDT in the treatment of BP has been demonstrated. Whether HPV-specific vaccination for types 6, 11, 16, and 18 can help reduce the prevalence and incidence of BP in which HPV types 16 and 18 have frequently been identified is currently under investigation.

EPIDERMODYSPLASIA VERRUCIFORMIS

AT-A-GLANCE

- Epidermodysplasia verruciformis (EV) is an inherited skin condition with a high local susceptibility to infection with human papillomavirus (HPV), most commonly with HPV types 5 and 8.
- Sporadic and familial cases of EV may occur.
- Loss-of-function mutations of the genes *EVER1* and *EVER2* are associated with EV.
- The clinical presentation is with either widespread, flat, wart-like papules and plaques, or hypopigmented scaly patches in childhood.
- Patients with EV are at high risk to develop actinic keratosis, Bowen disease, or invasive squamous cell carcinoma in the further course of the disease.
- Late-onset EV may occur in patients with cellular immunodeficiency (HIV, organ transplant recipients).
- Sun avoidance, sun-protective measures, regular dermatologic follow up, and screening of family members for the disease are recommended.

EV is a rare inherited skin condition that is characterized by a high susceptibility to infection with some types of HPV, in particular types 5 and 8 (termed

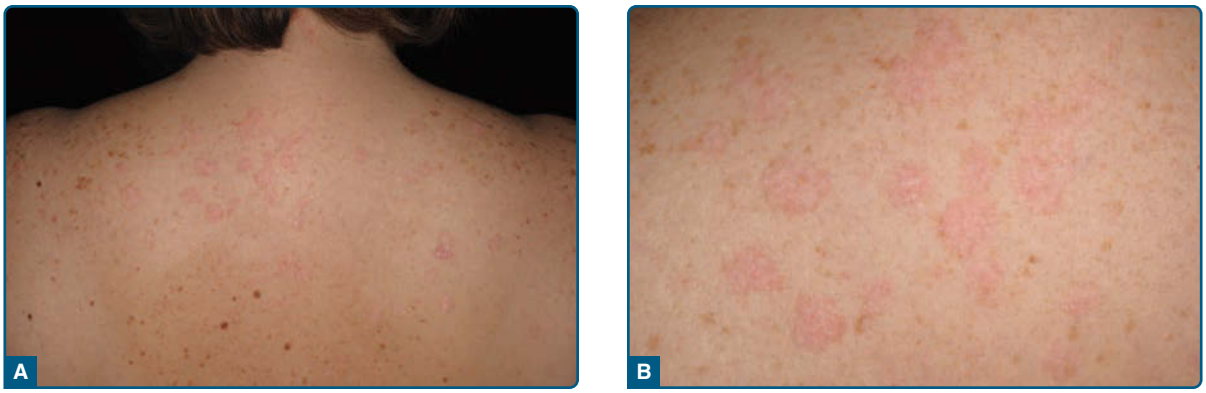

Figure 110-11 **A,** Scaly and erythematous plaques on the back of a female patient with epidermodysplasia verruciformis. **B,** The plaques are slightly elevated above skin surface level and may show areas of ill-defined hypopigmentation. These lesions may be confused with tinea corporis or tinea versicolor.

EV-HPV). In addition to the host genetic background and HPV infection, UV exposure and immunosuppression contribute to the pathogenesis of the disease.[43]

The exact prevalence of EV is not known. Sporadic and familial cases of EV have been reported in the literature. It is probably inherited as an autosomal recessive or X-chromosomal recessive disorder with 2 gene loci: EV1 (located on chromosome 17q25.3) and EV2 (located on chromosome 2p21-24). The genes *TMC6* (*EVER1*) and *TMC8* (*EVER2*) have been identified within the locus EV1.[44,45] Even though loss-of-function mutations of both genes have been linked with EV, approximately 25% of all patients do not show mutations in either gene. The *EVER* genes belong to a transmembrane-like channel protein family and are thought to be involved in zinc homeostasis of the endoplasmic reticulum and transcriptional regulation within the nucleus of keratinocytes. Cells deficient for *EVER1* or *EVER2* are unable to prevent the replication of certain HPV types, mostly beta-HPV. Thus, EV patients develop a selective immunodeficiency for HPV infection. Most commonly, HPV 5 and HPV 8 can be found in EV, but also HPV types 9, 12, 14, 15, 17, 19, 25, 36, 38, 47, and 50 have been reported.

Patients with EV develop skin lesions early in life as infection with HPV typically occurs during infancy. Skin findings comprise 2 different morphologies. First, numerous thin, pink, flat-topped papules and plaques that resemble flat warts (verrucae planae) may be seen. Therefore, these papules are sometimes referred to as *EV-plane warts*. Sites of predilection for these warts are knees, elbows, and trunk. Second, patients can present with widespread scaly, erythematous, or hypopigmented macules and flat papules that appear similar to tinea versicolor (Fig. 110-11). The mucosal membranes are usually not affected. Histopathologically, the EV-plane warts share features with plane warts not associated with EV. Dyskeratosis and pyknosis are observed more commonly in EV. However, the diagnosis is made based on a combination of the clinical image, histopathologic findings, plus viral and genetic testing.

The clinical course of EV is not entirely known and variable. It is estimated that more than 60% of patients affected by EV develop cutaneous malignancies in the wart-like lesions, most often in the fourth to fifth decades of life and usually on sun-exposed or acral areas of the skin. Patients may develop AK, BD, and invasive SCC. Some patients with immunodeficiency, such as organ transplant recipients and HIV-positive patients, can have a late-onset of EV (called *acquired EV*). Thus, older patients suspected of having EV should also be tested for HIV and other conditions with impaired cell-mediated immunity.

No specific or successful treatments exist for EV lesions. Mixed results have been achieved with topical 5% imiquimod cream and retinoids. Patients with EV should undergo a regular and thorough follow up to detect precancerous and invasive lesions as early as possible. UV radiation should be avoided because it increases the risk of malignant transformation. Single EV-plane warts can be treated successfully with excision, curettage, cryosurgery, or ablative lasers.

PRECANCEROUS LESIONS OF THE LOWER ANOGENITAL TRACT

ANAL INTRAEPITHELIAL NEOPLASIA

AT-A-GLANCE

- Synonyms: anal squamous intraepithelial neoplasia or anal dysplasia.
- Anal intraepithelial neoplasia (AIN) is associated with high-grade human papillomavirus (HPV) types, most commonly with types 16, 18, 31, and 33.
- AIN shows biologic and clinical analogy to cervical intraepithelial neoplasia.

(Continued)

AT-A-GLANCE (*Continued*)

- Major risk factors for AIN are HPV infection, high-risk sexual behavior (anal intercourse), HIV infection with low levels of CD4+ T cells, smoking, immunosuppression, a history of genital warts, and a history of cervical cancer in females.
- AIN is commonly localized within the transitional zone of squamous epithelium of the anus and columnar epithelium of the rectum, which is highly susceptible to HPV infection (dentate line).
- AIN is usually asymptomatic, but may occasionally cause local symptoms like pruritus, pain, bleeding, tenesmus, or rectal discharge.
- The diagnosis of AIN is made by anal cytology, high-resolution anoscopy, and histopathologic examination of biopsy specimens.
- AIN 1 is a low-grade squamous intraepithelial lesion (LSIL) with a low risk of progression to anal cancer.
- AIN 2 and AIN 3 are precursor high-grade squamous intraepithelial lesions (HSILs) of anal squamous cell carcinoma and histopathologically display moderate and severe dysplasia, respectively.
- It is currently under debate whether screening for AIN should be performed in high-risk populations.
- HPV vaccination with a quadruple vaccine against HPV types 6, 11, 16, and 18 may reduce the incidence of AIN.
- Patients with HSIL (AIN 2 or AIN 3) should receive treatment; treatment is optional for LSIL (AIN 1).
- Therapy options include topical treatment with trichloroacetic acid, infrared coagulation, 5-FU, intraanal imiquimod, or electrocauterization.

PERIANAL INTRAEPITHELIAL NEOPLASIA

AT-A-GLANCE

- Synonyms: genital Bowen disease (GBD).
- Perianal intraepithelial neoplasia (PaIN) is less likely than AIN to be associated with human papillomavirus than anal intraepithelial neoplasia.
- Only 5% of patients with PaIN may progress to invasive squamous cell carcinoma.
- PaIN may present with a variety of clinical patterns, including well-demarcated erythematous, or variably pigmented plaques.
- Dermatologists play a role in high-risk patients by examining the perianal skin and clinically diagnosing PaIN.
- Treatment options for PaIN include wide local excision, Mohs micrographic surgery, and various topical agents.

VULVAR INTRAEPITHELIAL NEOPLASIA

AT-A-GLANCE

- The term *vulvar intraepithelial neoplasia* (VIN) should be restricted to high-grade precancerous lesions of the vulva (formerly VIN 2 and VIN 3) that may progress to vulvar squamous cell carcinoma.
- VIN grade 1 (formerly VIN 1) is similar to vulvar condyloma acuminatum with a low oncogenic potential and not considered VIN in the nomenclature of the Vulvar Oncology Subcommittee of the International Society for the Study of Vulvar Diseases (ISSVD).
- VIN is primarily a disease of younger, sexually active females (75% of all cases) with rising incidence and prevalence.
- Three categories of VIN are distinguished: (a) usual type, (b) differentiated (simplex) type, and (c) unclassified type.
  - VIN usual type is associated with high-risk human papillomavirus (HPV) (types 16, 18, 31), occurs in younger premenopausal females, and presents with multifocal and multicentric lesions; in up to 50% of cases associations with cervical intraepithelial neoplasia can be found.
  - VIN differentiated type is less common than usual type and usually not associated with HPV; it affects postmenopausal females with a unifocal presentation and has a significant association with lichen sclerosus.

(Continued)

AT-A-GLANCE (*Continued*)

- Risk factors for VIN (usual type) are smoking, sexual promiscuity, HPV infection, and immunosuppression.
- The clinical presentation of VIN ranges from reddish patches to gray-white plaques and verrucous wart-like papules.
- The differential diagnosis of VIN includes lichen sclerosus, lichen planus, condyloma acuminatum, and other vulvar neoplasias like SCC and melanoma.
- VIN is asymptomatic in many cases, but may cause vulvodynia, vulvar pain and burning sensation, dysuria, or pruritus.
- The diagnosis of VIN is made by physical examination, biopsy, and optionally colposcopy.
- Treatment modalities include surgical excision and ablative laser therapy for single lesions, while topical treatment with 5-FU or imiquimod is more suited for multicentric VIN.
- A diagnosis of VIN mandates referral to a gynecologist to look for synchronous vaginal and cervical intraepithelial neoplasia.
- Quadrivalent HPV vaccination (HPV types 6, 11, 16, 18) may reduce the risk for VIN usual type in young females.

PENILE INTRAEPITHELIAL NEOPLASIA

AT-A-GLANCE

- Penile intraepithelial neoplasia (PIN) is an umbrella term for precursor lesions of the male genital to penile squamous cell carcinoma (SCC).
- Two clinical variants of PIN are the genital Bowen disease (GBD) and erythroplasia of Queyrat (EQ) (Fig. 110-12).
- PIN and penile SCC mainly affect older, uncircumcised males.
- Risk factors for PIN are poor genital hygiene, smegma retention, phimosis, chronic inflammatory and infectious conditions of the penis, lichen sclerosus, lichen planus, immunosuppression (HIV infection, organ transplant recipients), smoking, and preceding psoralen plus ultraviolet A or ultraviolet exposure.
- Approximately 40% to 45% of PIN cases are associated with HPV, mainly with high-risk types such as types 16, 18, 31, and 33; low-risk types 6 and 11 may be present in low-grade PIN.
- PIN associated with HPV infection are supposedly more aggressive and may develop to warty and basaloid subtypes of penile SCC.
- PIN without HPV infection is morphologically associated with the usual or differentiated type of penile SCC.
- EQ is a common type of PIN usually associated with HPV 8 and HPV 16 infection; it presents as a well-demarcated, glistening, erythematous, velvety plaque or plaques on the mucosal surfaces of the penis (Fig. 110-12A).
- The GBD variant of PIN is less common than the EQ variant; it presents as a well-demarcated, erythematous to variably pigmented plaque on the shaft of the penis (Fig. 110-12B).
- Both variants have histopathologic features of SCC in situ; EQ shows prominent epithelial hypoplasia and plasma cells in the dermal infiltrate.
- The EQ variant of PIN has a higher risk of progression to invasive SCC (~30%) than the GBD variant (3% to 6%).
- Treatment options include local excision, cryosurgery, ablative lasers (CO_2-laser), imiquimod, or topical cidofovir.
- Preventive measures comprise circumcision, proper hygiene, stopping smoking, and avoiding genital UV exposure.
- It is currently under investigation if immunization of young males with HPV vaccines can reduce the risk of PIN; however, HPV-unrelated lesions are not affected by this approach.

Figure 110-12 Penile intraepithelial neoplasia (PIN) in a male patient. **A,** The erythroplasia of Queyrat (EQ) variant clinically presents with well-demarcated, erythematous plaques on the mucosal surface of the penis. **B,** In contrast, the genital Bowen disease (GBD) variant shows variably pigmented and erythematous papules, mainly located on the shaft of the penis. This condition is at times difficult to distinguish from typical condylomata acuminata (**C**).

POTENTIALLY MALIGNANT DISORDERS OF THE ORAL CAVITY

In a World Health Organization (WHO) workshop held in 2005, the terminology, definitions, and classification of oral lesions with a predisposition to malignant transformation were discussed.[46] The term *potentially malignant* was preferred over *premalignant* or *precancerous*. In addition, it was recommended that the traditional distinction between potentially malignant lesions and potentially malignant conditions be abandoned and that the term *potentially malignant disorders* be used instead. Here, the focus will be on oral leukoplakia and erythroplakia.

LEUKOPLAKIA

Leukoplakia is a clinical term that refers to a predominantly white lesion of the oral mucosa that cannot be rubbed off or characterized by any other definable lesion or known disease. Leukoplakia is the most common potential malignant lesion of the oral mucosa, with the potential to become oral SCC. It is in the same clinical spectrum of disease as oral erythroplakia, but

leukoplakia is more common and the likelihood of malignant transformation is lower.

AT-A-GLANCE

- Leukoplakia is a clinical diagnosis of exclusion for a fixed white lesion in the oral cavity that does not resolve spontaneously.
- Oral leukoplakia is the most common potentially malignant lesion of the oral mucosa, with the potential to become oral squamous cell carcinoma (SCC).
- The prevalence is 0.2% to 3.4%.
- Approximately 50% of oral SCCs are associated with potentially malignant lesions.
- Leukoplakia and erythroplakia are markers for increased risk for additional oral or upper aerodigestive tract malignancies.
- Risk factors for leukoplakia are the use of any tobacco product, alcohol abuse, history of previous or premalignant lesions, and infection with certain human papillomavirus subtypes.
- No consensus exists on how best to treat leukoplakia.

EPIDEMIOLOGY

The prevalence of leukoplakia varies significantly by geographical region and demographic group. Estimates for global prevalence vary from 0.5% to 3.4%. Individuals 40 years of age and older are at higher risk. Males are affected more often than females with an estimated male-to-female ratio of 2:1. This may be explained by a higher exposure to certain risk factors. For instance, leukoplakia is 6 times more common among smokers than among nonsmokers.

CLINICAL FINDINGS

Leukoplakia is clinically divided into a homogeneous and nonhomogeneous form. Homogeneous leukoplakia has been defined as a mostly white, flat, uniform lesion. It may have shallow cracks and a smooth, wrinkled, or corrugated surface (Fig. 110-13). Nonhomogeneous leukoplakia is defined as a mostly white or white-reddish lesion ("erythroleukoplakia") that may be irregular and flat, nodular, ulcerative, or verrucous. Nonhomogeneous leukoplakia has a significant higher risk of malignancy than does homogeneous leukoplakia. Proliferative verrucous leukoplakia represents a rare form, which is most often found in patients who do not use tobacco products. It has a high rate of malignant transformation and recurrence after treatment.

ETIOLOGY AND PATHOGENESIS

Etiologic factors for leukoplakia include chronic chemotoxic exposure, mechanical trauma, and HPV infection. Tobacco is probably the strongest risk factor for the development of leukoplakia. It was shown that most patients with leukoplakia consumed tobacco, either as smoke or by chewing. In addition, tobacco-related white lesions of the oral mucosa may disappear once the tobacco use has been discontinued. The combination of tobacco use and alcohol consumption has a strong synergistic effect in the development of leukoplakia. However, alcohol consumption was also identified as an independent risk factor, regardless of beverage type or drinking pattern. Typical causes for chronic mechanical trauma of the oral mucosa are ill-fitting prosthesis, chronic cheek biting, and reduced dental status with poor oral hygiene.

Figure 110-13 Oral leukoplakia of the left cheek in a 65-year-old male with chronic HIV infection and a history of smoking. Note the irregular and verrucous surface (nonhomogeneous variant).

HPV represents another etiologic factor for leukoplakia. It was detected in up to 22% of leukoplakia lesions and its prevalence compared to normal mucosa is significantly higher. High-risk oncogenic subtypes, such as HPV types 16 and 18, were isolated more frequently than low-risk HPV (type 6 or type 11). For this reason, HPV is widely believed to be an independent risk factor in the development of leukoplakia, or at least an intensifier of other carcinogenic effects. However, the specific role of HPV in carcinogenesis remains controversial, as no correlation between mucosal dysplasia and HPV infection was found. Persons with a previous malignancy or premalignancy of the upper aerodigestive tract are at greater risk for the development of leukoplakia.

DIAGNOSIS AND DIFFERENTIAL DIAGNOSIS

Leukoplakia is a clinical diagnosis. Whitish lesions in the oral mucosa that cannot be rubbed off are suspicious for leukoplakia. If causative agents, such as tobacco or mechanical irritation, are detected, it is recommended to eliminate these factors for a period of 2 to 6 weeks. If regression does not occur during this observational period, biopsy and histologic examination should be performed. If upon initial examination

TABLE 110-8
Clinical Differential Diagnosis of Oral Leukoplakia

- Tobacco-associated lesion
- *Candida*-associated lesion
- Leukoedema
- Lichen planus
- Lupus erythematosus
- Linea alba
- Habitual cheek biting
- Frictional lesion
- Aspirin burn
- Oral white sponge nevus
- Oral hairy leukoplakia
- Verrucous carcinoma
- Squamous cell carcinoma

no causative agent can be identified, biopsy should be performed directly. This is particularly important for symptomatic leukoplakia. In this case, malignant transformation into invasive SCC should be ruled out.[46] Further important differential diagnoses include Epstein-Barr virus–induced hairy leukoplakia in HIV patients, lichen planus, and lupus erythematosus, among others (Table 110-8).

HISTOPATHOLOGY

On a histologic level, characteristic findings are hyperkeratosis, epithelial hyperplasia, and dysplasia. The latter includes atypical mitosis, polymorphic cells, as well as hyperchromatic and polymorphic nuclei. Epithelial hyperplasia and hyperkeratosis give the lesion the characteristic whitish appearance. The degree of dysplasia varies from lesions showing only hyperkeratosis with no dysplasia toward lesions with moderate dysplasia and those with severe dysplasia resembling SCC in situ. There are different growing patterns, which include clinically flat, papillary endophytic and papillary exophytic, verrucous proliferation. Transformation into invasive SCC occurs as dysplastic cells break through the basement membrane.

CLINICAL COURSE AND PROGNOSIS

Once a definitive diagnosis of leukoplakia has been made, the risk of malignant transformation should be evaluated. The rate of all clinical subtypes of leukoplakia is estimated to be approximately 2% to 3% per year.[46,47] Table 110-9 lists the numerous identified risk factors for malignant transformation. Of these factors, epithelial dysplasia and nonhomogeneous clinical subtype are the most important indicators for malignant transformation. However, it should be recognized that not all dysplastic lesions progress to malignancy.

TABLE 110-9
Risk Factors for the Conversion of Oral Leukoplakia into Oral Squamous Cell Carcinoma

Main risk factors
- Presence of epithelial dysplasia
- Nonhomogeneous clinical subtype
- Large size
- Location on the tongue or the floor of the mouth

Other risk factors
- Female gender
- Long duration of oral leukoplakia
- Leukoplakia in nonsmokers

Adapted and modified from van der Waal.[47,52]

Some remain clinically unchanged and others may regress spontaneously or after elimination of the causative agent, such as cessation of smoking. In addition, malignant transformation may also occur in nondysplastic leukoplakia.

TREATMENT AND PREVENTION

There is a chance of spontaneous remission of leukoplakia. However, the risk of malignant transformation warrants treatment if remission does not occur within a short period of observation. In general, any possible causative agent or risk factor such as consumption of tobacco products, alcohol, bethel nuts, or chronic mechanical trauma should be omitted. There are numerous therapeutic approaches for leukoplakia, but evidence remains strongly limited and recurrence rates for all interventions are high. Usually, surgical excision is the first treatment of choice. In contrast to other therapies, surgery allows histologic workup and unexpected carcinomas may be identified.[48] However, adequate surgical excision may be limited as field cancerization may be present and normal-appearing surrounding mucosa may harbor clones of cancer stigmatized cells. In the case of recurrence after surgical excision, cryotherapy or CO_2-laser represent useful treatment options. Other therapies include PDT, herbal extracts, beta-carotene supplements, antiinflammatory drugs, and vitamin A, among others.[49-51] Independent of the treatment, the patient should be followed closely.

ERYTHROPLAKIA

Erythroplakia (or erythroplasia) is a clinical term used to describe a red macule or patch on a mucosal surface that cannot be categorized as any other known disease entity caused by inflammatory, vascular, or traumatic factors. It is commonly seen in association with leukoplakia, a condition termed *erythroleukoplakia*.

AT-A-GLANCE

- Erythroplakia is a clinical diagnosis of exclusion for a persistent fixed red patch in the oral cavity.
- It is the least common of all oral potentially malignant lesions but has the greatest potential to harbor or become oral squamous cell carcinoma.
- Risk factors are use of tobacco products and alcohol consumption.
- Early and effective treatment is important.

EPIDEMIOLOGY

Erythroplakia is rare and the least-frequent potentially malignant lesion in the oral cavity. The prevalence depends on the geographical area and varies between 0.02% and 0.83%. Erythroplakia mainly occurs in middle-aged individuals. Males are affected more often than females, which may be explained by a higher exposure to certain risk factors, such as tobacco consumption. Erythroplakia has been well described in the chutta smokers (reverse cigar smokers) of India.

CLINICAL FINDINGS

Erythroplakia usually presents as an asymptomatic, solitary, subtle, erythematous macule or patch. It is sharply demarcated from the surrounding pink mucosa, and its surface is most often smooth and homogeneous in color. However, some lesions may have a pebbled or stippled surface and feel soft and velvety on palpation. Induration is highly suspicious for transformation into invasive SCC. The most common areas in the oral cavity are the soft palate, the floor of the mouth, and the buccal mucosa. Most often it is less than 1.5 cm in its widest diameter, but lesions up to 4 cm in diameter have been described.

ETIOLOGY AND PATHOGENESIS

The underlying etiology of erythroplakia is unknown. Risk factors are equal to those of other potentially malignant lesions in the oral cavity: consumption of tobacco products, alcohol and chewing nuts that contain carcinogenic substances, such as areca nuts. Genetic analyses have shown a high mutation rate of the tumor-suppressor gene *p53* in erythroplakia lesions, reflecting their high potential to malignant transformation.

DIAGNOSIS

Erythroplakia is a diagnosis of exclusion. Table 110-10 outlines differential diagnoses. On a histologic level, erythroplakia typically displays moderate to severe dysplasia. Frequently, SCC in situ and focal areas of invasive SCC are present.

TABLE 110-10
Clinical Differential Diagnosis of Oral Erythroplakia

- Erythematous candidiasis
- Atrophic lichen planus
- Lupus erythematosus
- Pemphigus
- Cicatricial pemphigoid
- Kaposi sarcoma
- Chronic contact or allergic contact dermatitis
- Chronic mechanical trauma
- Thermal or mechanical injury
- Squamous cell carcinoma
- Amelanotic melanoma

CLINICAL COURSE AND PROGNOSIS

Of all potentially malignant lesions in the oral cavity, erythroplakia is considered to be the most dangerous and carries the greatest risk of progressing to or harboring invasive carcinoma. In erythroleukoplakia, the red patches are most prone for malignant transformation. After excision, lesions that exceed 80 mm^2 have a significant higher risk of recurrence.

TREATMENT

The high potential for malignant transformation warrants early treatment. Surgery or excision with CO_2-laser is the treatment of choice. Any risk factors, such as consumption of tobacco or alcohol, should be avoided.

ARSENICAL KERATOSES

AT-A-GLANCE

- Arsenical keratoses (ArKs) result from chronic exposure to arsenic.
- ArKs have the potential to become squamous cell carcinoma (SCC), although reliable estimates of progression rates are unknown.
- Clinical appearance comprises punctuate, keratotic, yellow papules overlying pressure points on palms and soles.
- Further arsenic-related skin diseases are superficial basal cell carcinoma, SCC, Bowen disease, and diffuse hyperpigmentation.
- No standard recommendations for treatment exist and most lesions are followed clinically or treated symptomatically.

Arsenical keratoses (ArKs) result from chronic intake or intoxication with arsenic. Arsenic is a ubiquitous element that has no color, taste, or odor. It has the

Figure 110-14 Disseminated arsenic keratoses in a male patient who had been exposed to arsenic therapeutically for many years in the past to treat his psoriasis. The lesions were found on the entire skin including trunk, arms, and legs. Keratoses of the chest are shown.

potential to cause characteristic acute and chronic symptoms in persons exposed to it. Arsenic exposures are typically obscure and medicinal, occupational, and environmental sources still exist. ArKs are considered precancerous lesions because they have the potential to progress into invasive SCC.

ArKs are localized most commonly on the palms and soles. Clinically, they appear as gray-to-yellow keratotic papules. If lesions are large, they may acquire a verruciform look (Fig. 110-14). Further signs of a chronic exposure to arsenic are diffuse hyperpigmentation and the presence of superficial basal cell carcinoma or BD. Histopathologically, ArKs resemble hypertrophic AKs with a more cellular atypia and prominent vacuolization of keratinocytes. The diagnosis may be difficult. Taking a thorough history is an important clue and the first step toward the correct diagnosis. ArKs may be confused with vulgar warts, hypertrophic lichen planus, keratosis palmaris, and plantaris dissipata or diffusa, or AKs in sun-exposed areas. Although ArKs and arsenic-induced skin disorders tend to persist for many years, progression to invasive SCC is believed to be a relatively rare event. However, reliable estimates for progression rates are lacking as a consequence of the rarity of the disease. Some evidence exists that invasive SCCs that arise from ArKs are more locally aggressive and have a greater chance of metastasis than SCCs arising from AKs.

If ArKs are suspected, a thorough skin examination and physical examination are obligatory. The sources of exposure to arsenic should be identified and discontinued. The exact incidence of internal malignancies associated with chronic arsenism is unknown, so there is no standard protocol for the evaluation of potential internal malignancies. Exhaustive evaluations to detect such malignancies have not been recommended. Biannual detailed history taking and physical examination, yearly chest radiography, and selective testing when clinically indicated are probably reasonable recommendations.

Single lesions can be treated with surgical excision, cryosurgery, or curettage. Ablative resurfacing with the CO_2-laser and Er:YAG-laser were successfully applied in some cases. If diffuse hyperkeratosis or disseminated ArK lesions are present, topical and systemic retinoids are a valuable option, although lesion clearance is generally lower compared to treatment of AKs. Patients with verified ArKs should be followed-up and monitored regularly, possibly every 6 to 12 months.

THERMAL KERATOSES

AT-A-GLANCE

- Precancerous lesions that result from long-term exposure to infrared radiation; can progress to squamous cell carcinoma (SCC).
- Sources of infrared radiation include open fires, railway engines, wood-burning stoves, heating pads and blankets, and laptop computers.
- Precursor lesion is erythema ab igne; biopsy should be performed on any hyperkeratotic papule or plaque within such a patch.
- Risk of progression of thermal keratosis to SCC is unknown.

HYDROCARBON KERATOSES

AT-A-GLANCE

- Synonyms: pitch keratoses, tar keratoses, tar warts.
- Precancerous lesions resulting from prolonged exposure to tar.
- Tar contains highly cancerogenic polycyclic aromatic hydrocarbons such as benzpyrene, dibenzanthracene, or methylcholanthrene.
- May be present in patients with occupational exposure to tar; occupations at risk include tar distiller, shale extractor, roofer, asphalt worker, road paver, highway maintenance worker, brick mason, diesel engineer, and chimney sweep.
- Ultraviolet exposure is a cofactor in the establishment of tar keratosis.
- Hydrocarbon keratosis can progress to squamous cell carcinoma (SCC), but the rate of progression and risk are unknown.
- Latency periods between exposure and development of hydrocarbon keratosis or SCC range from 2.5 years to 45 years.
- Lesions typically present as hyperkeratotic papules with a verruciform surface; sites of predilection are face, neck, forearms, and scrotal skin.

(Continued)

AT-A-GLANCE (*Continued*)

- Other skin findings include patchy hyperpigmentation, acne, and telangiectasias.
- Therapeutic options include excision, curettage, and ablative lasers (CO_2, Er:YAG).

CHRONIC RADIATION KERATOSES

AT-A-GLANCE

- Chronic radiation keratoses are precancerous lesions that may arise at irradiated sites years after such exposure and may progress to squamous cell carcinoma.
- Ionizing radiation sources include X-rays, grenz rays, and contaminated gold rings.
- Common sites are the palms, soles, and mucosal surfaces.
- They most commonly present as hyperkeratotic papules or plaques within areas of chronic radiation dermatitis and occasionally on clinically normal skin.
- Latency for the development of lesions can be up to 50 years after exposure.
- Patients with ionizing radiation exposure and chronic radiation keratoses are also at risk for internal malignancies.

CHRONIC SCAR KERATOSES

AT-A-GLANCE

- Synonym: cicatrix keratoses.
- Chronic scar keratoses are precancerous lesions that arise in longstanding scars from various causes.
- Common conditions comprise burn scars, chronic wounds, sinuses, and leg ulcers.
- Approximately 2% of burn scars will undergo malignant changes.
- Marjolin ulcer is an umbrella term covering malignant changes within a scar from any cause.
- Acute Marjolin ulcer develops within 1 year of the time of injury; chronic Marjolin ulcer develops more than 1 year after an injury.
- Most invasive carcinomas are squamous cell carcinomas (SCCs), but basal cell carcinomas, melanomas, sarcomas, and malignant fibrous histiocytomas also have been described.
- SCCs deriving from scar keratoses show an aggressive growth pattern with a high propensity to metastasize.
- Sites of predilection are the extremities and overlying joints.
- Any persistent lesion, erosion, or ulceration within a scar requires biopsy.
- Prevention includes wound care, early skin grafting, avoidance of contractures, and early excision of any tissue showing degenerative changes.

ACKNOWLEDGMENTS

We thank Saskia A. Graf for her support with Fig. 110-1 and Karynne O. Duncan, John K. Geisse, and David J. Leffell who are the authors of the previous version of this chapter.

REFERENCES

1. Cockerell CJ. Histopathology of incipient intraepidermal squamous cell carcinoma ("actinic keratosis"). *J Am Acad Dermatol*. 2000;42(1, pt 2):11-17.
2. Eder J, Prillinger K, Korn A, et al. Prevalence of actinic keratosis among dermatology outpatients in Austria. *Br J Dermatol*. 2014;171(6):1415-1421.
3. Flohil SC, van der Leest RJ, Dowlatshahi EA, et al. Prevalence of actinic keratosis and its risk factors in the general population: the Rotterdam Study. *J Invest Dermatol*. 2013;133(8):1971-1978.
4. Trakatelli M, Barkitzi K, Apap C, et al. Skin cancer risk in outdoor workers: a European multicenter case-control study. *J Eur Acad Dermatol Venereol*. 2016;30(suppl 3):5-11.
5. Traianou A, Ulrich M, Apalla Z, et al. Risk factors for actinic keratosis in eight European centres: a case-control study. *Br J Dermatol*. 2012;167(suppl 2):36-42.
6. Memon AA, Tomenson JA, Bothwell J, et al. Prevalence of solar damage and actinic keratosis in a Merseyside population. *Br J Dermatol*. 2000;142(6):1154-1159.
7. Iannacone MR, Sinnya S, Pandeya N, et al. Prevalence of skin cancer and related skin tumors in high-risk kidney and liver transplant recipients in Queensland, Australia. *J Invest Dermatol*. 2016;136(7):1382-1386.
8. Werner RN, Stockfleth E, Connolly SM, et al. Evidence- and consensus-based (S3) guidelines for the treatment of actinic keratosis—International League of Dermatological Societies in cooperation with the European Dermatology Forum—short version. *J Eur Acad Dermatol Venereol*. 2015;29(11):2069-2079.

9. Olsen EA, Abernethy ML, Kulp-Shorten C, et al. A double-blind, vehicle-controlled study evaluating masoprocol cream in the treatment of actinic keratoses on the head and neck. *J Am Acad Dermatol*. 1991;24(5, pt 1):738-743.
10. Rowert-Huber J, Patel MJ, Forschner T, et al. Actinic keratosis is an early in situ squamous cell carcinoma: a proposal for reclassification. *Br J Dermatol*. 2007;156(suppl 3):8-12.
11. Schmitz L, Kahl P, Majores M, et al. Actinic keratosis: correlation between clinical and histological classification systems. *J Eur Acad Dermatol Venereol*. 2016;30(8):1303-1307.
12. Hu B, Castillo E, Harewood L, et al. Multifocal epithelial tumors and field cancerization from loss of mesenchymal CSL signaling. *Cell*. 2012;149(6):1207-1220.
13. Lallas A, Tschandl P, Kyrgidis A, et al. Dermoscopic clues to differentiate facial lentigo maligna from pigmented actinic keratosis. *Br J Dermatol*. 2016;174(5):1079-1085.
14. Christensen SR, McNiff JM, Cool AJ, et al. Histopathologic assessment of depth of follicular invasion of squamous cell carcinoma (SCC) in situ (SCCis): implications for treatment approach. *J Am Acad Dermatol*. 2016;74(2):356-362.
15. Niiyama S, Oharaseki T, Mukai H: Giant hidroacanthoma simplex mimicking Bowen's disease. *Case Rep Dermatol*. 2015;7(3):241-244.
16. Westers-Attema A, van den Heijkant F, Lohman BG, et al. Bowen's disease: a six-year retrospective study of treatment with emphasis on resection margins. *Acta Derm Venereol*. 2014;94(4):431-435.
17. Bath-Hextall FJ, Matin RN, Wilkinson D, et al. Interventions for cutaneous Bowen's disease. *Cochrane Database Syst Rev*. 2013;(6):CD007281.
18. Lee JH, Lee JH, Bae JM, et al. Successful treatment of Bowen's disease with ingenol mebutate 0.05% gel. *J Dermatol*. 2015;42(9):920-921.
19. Cai H, Wang YX, Zheng JC, et al. Photodynamic therapy in combination with CO_2 laser for the treatment of Bowen's disease. *Lasers Med Sci*. 2015;30(5):1505-1510.
20. Pflugfelder A, Welter AK, Leiter U, et al. Open label randomized study comparing 3 months vs. 6 months treatment of actinic keratoses with 3% diclofenac in 2.5% hyaluronic acid gel: a trial of the German Dermatologic Cooperative Oncology Group. *J Eur Acad Dermatol Venereol*. 2012;26(1):48-53.
21. Malvehy J, Roldan-Marin R, Iglesias-Garcia P, et al. Monitoring treatment of field cancerisation with 3% diclofenac sodium 2.5% hyaluronic acid by reflectance confocal microscopy: a histologic correlation. *Acta Derm Venereol*. 2015;95(1):45-50.
22. Shergill B, Zokaie S, Carr AJ. Non-adherence to topical treatments for actinic keratosis. *Patient Prefer Adherence*. 2013;8:35-41.
23. Pomerantz H, Hogan D, Eilers D, et al. Long-term efficacy of topical fluorouracil cream, 5%, for treating actinic keratosis: a randomized clinical trial. *JAMA Dermatol*. 2015;151(9):952-960.
24. Stockfleth E, Kerl H, Zwingers T, et al. Low-dose 5-fluorouracil in combination with salicylic acid as a new lesion-directed option to treat topically actinic keratoses: histological and clinical study results. *Br J Dermatol*. 2011;165(5):1101-1108.
25. Herranz P, Morton C, Dirschka T, et al. Low-dose 0.5% 5-fluorouracil/10% salicylic acid topical solution in the treatment of actinic keratoses. *J Cutan Med Surg*. 2016;20(6):555-561.
26. Swanson N, Abramovits W, Berman B, et al. Imiquimod 2.5% and 3.75% for the treatment of actinic keratoses: results of two placebo-controlled studies of daily application to the face and balding scalp for two 2-week cycles. *J Am Acad Dermatol*. 2010;62(4):582-590.
27. Gebauer K, Shumack S, Cowen PS. Effect of dosing frequency on the safety and efficacy of imiquimod 5% cream for treatment of actinic keratosis on the forearms and hands: a phase II, randomized placebo-controlled trial. *Br J Dermatol*. 2009;161(4):897-903.
28. Lebwohl M, Swanson N, Anderson LL, et al. Ingenol mebutate gel for actinic keratosis. *N Engl J Med*. 2012;366(11):1010-1019.
29. Garbe C, Basset-Seguin N, Poulin Y, et al. Efficacy and safety of follow-up field treatment of actinic keratosis with ingenol mebutate 0.015% gel: a randomized, controlled 12-month study. *Br J Dermatol*. 2016;174(3):505-513.
30. Samorano LP, Torezan LA, Sanches JA. Evaluation of the tolerability and safety of a 0.015% ingenol mebutate gel compared to 5% 5-fluorouracil cream for the treatment of facial actinic keratosis: a prospective randomized trial. *J Eur Acad Dermatol Venereol*. 2015;29(9):1822-1827.
31. Augustin M, Tu JH, Knudsen KM, et al. Ingenol mebutate gel for actinic keratosis: the link between quality of life, treatment satisfaction, and clinical outcomes. *J Am Acad Dermatol*. 2015;72(5):816-821.
32. Peris K, Calzavara-Pinton PG, Neri L, et al. Italian expert consensus for the management of actinic keratosis in immunocompetent patients. *J Eur Acad Dermatol Venereol*. 2016;30(7):1077-1084.
33. Ianhez M, Fleury LF Jr, Miot HA, Bagatin E. Retinoids for prevention and treatment of actinic keratosis. *An Bras Dermatol*. 2013;88(4):585-593.
34. Chen AC, Martin AJ, Choy B, et al. A phase 3 randomized trial of nicotinamide for skin-cancer chemoprevention. *N Engl J Med*. 2015;373(17):1618-1626.
35. Drake AL, Walling HW. Variations in presentation of squamous cell carcinoma in situ (Bowen's disease) in immunocompromised patients. *J Am Acad Dermatol*. 2008;59(1):68-71.
36. Murao K, Yoshioka R, Kubo Y. Human papillomavirus infection in Bowen disease: negative p53 expression, not p16(INK4a) overexpression, is correlated with human papillomavirus-associated Bowen disease. *J Dermatol*. 2014;41(10):878-884.
37. Svajdler M Jr, Mezencev R, Kaspirkova J, et al. Human papillomavirus infection and p16 expression in extragenital/extraungual Bowen disease in immunocompromised patients. *Am J Dermatopathol*. 2016;38(10):751-757.
38. Shu B, Shen XX, Chen P, et al. Primary invasive extramammary Paget disease on penoscrotum: a clinicopathological analysis of 41 cases. *Hum Pathol*. 2016;47(1):70-77.
39. Lopes Filho LL, Lopes IM, Lopes LR, et al. Mammary and extramammary Paget's disease. *An Bras Dermatol*. 2015;90(2):225-231.
40. Takayama R, Ishiwata T, Ansai S, et al. Lumican as a novel marker for differential diagnosis of Bowen disease and actinic keratosis. *Am J Dermatopathol*. 2013;35(8):827-832.
41. MacFarlane DF, El Tal AK. Cryoimmunotherapy: superficial basal cell cancer and squamous cell carcinoma in situ treated with liquid nitrogen followed by imiquimod. *Arch Dermatol*. 2011;147(11):1326-1327.

42. Sotiriou E, Lallas A, Apalla Z, et al. Treatment of giant Bowen's disease with sequential use of photodynamic therapy and imiquimod cream. *Photodermatol Photoimmunol Photomed*. 2011;27(3):164-166.
43. Burger B, Itin PH. Epidermodysplasia verruciformis. *Curr Probl Dermatol*. 2014;45:123-131.
44. Ramoz N, Rueda LA, Bouadjar B, et al. Mutations in two adjacent novel genes are associated with epidermodysplasia verruciformis. *Nat Genet*. 2002;32(4):579-581.
45. Ramoz N, Taieb A, Rueda LA, et al. Evidence for a nonallelic heterogeneity of epidermodysplasia verruciformis with two susceptibility loci mapped to chromosome regions 2p21-p24 and 17q25. *J Invest Dermatol*. 2000;114(6):1148-1153.
46. van der Waal I. Oral leukoplakia, the ongoing discussion on definition and terminology. *Med Oral Patol Oral Cir Bucal*. 2015;20(6):e685-e692.
47. van der Waal I. Oral potentially malignant disorders: is malignant transformation predictable and preventable? *Med Oral Patol Oral Cir Bucal*. 2014;19(4):e386-e390.
48. Holmstrup P, Dabelsteen E. Oral leukoplakia-to treat or not to treat. *Oral Dis*. 2016;22(6):494-497.
49. Kumar A, Cascarini L, McCaul JA, et al. How should we manage oral leukoplakia? *Br J Oral Maxillofac Surg*. 2013;51(5):377-383.
50. Vohra F, Al-Kheraif AA, Qadri T, et al. Efficacy of photodynamic therapy in the management of oral premalignant lesions. A systematic review. *Photodiagnosis Photodyn Ther*. 2015;12(1):150-159.
51. Lodi G, Franchini R, Warnakulasuriya S, et al. Interventions for treating oral leukoplakia to prevent oral cancer. *Cochrane Database Syst Rev*. 2016;7:CD001829.
52. van der Waal I. Potentially malignant disorders of the oral and oropharyngeal mucosa; terminology, classification and present concepts of management. *Oral Oncol*. 2009;45(4-5):317-323.

Chapter 111 :: Basal Cell Carcinoma and Basal Cell Nevus Syndrome

:: Jean Y. Tang, Ervin H. Epstein, Jr., & Anthony E. Oro

BASAL CELL CARCINOMA

AT-A-GLANCE

- Basal cell carcinomas (BCCs) are the most common cancers in humans. All BCCs have mutations activating the Hedgehog signaling pathway.
- BCCs are caused by exposure to ultraviolet light and are associated with *PTCH1* gene mutation in most cases.
- BCCs are locally destructive and rarely metastatic.
- BCCs are primarily treated by surgical excision, electrodesiccation and curettage, Mohs micrographic surgery, and topical agents.

EPIDEMIOLOGY

Basal cell carcinoma (BCC) is the most common cancer in humans. It is estimated that more than 3 million new cases occur each year in the United States.[1] The malignancy accounts for approximately 75% of all nonmelanoma skin cancers (NMSCs) and almost 25% of all cancers diagnosed in the United States.[2] Epidemiological data indicate that the overall incidence is increasing worldwide significantly by 3% to 10% per year.[3]

BCC is more common in older individuals but is becoming increasingly frequent in people younger than 50 years of age. Christenson and coworkers noted a disproportionate increase in BCC in women younger than age 40 years.[3] Men are affected slightly more often than are women. Tumors were more frequent in patients older than 60 years of age, and 57% were in men. The vast majority of BCCs were located on the head and neck.[2]

BCC tumors most typically develop on sun-exposed skin of lighter skinned individuals. Incidence rates of BCC in Asians living in Singapore increased from 1968 to 2006, especially among the older, fair-skinned Chinese patients.[4] BCC is rare in dark skin because of the inherent photoprotection of melanin and melanosomal dispersion. An estimated 1.8% of BCCs occur in blacks, and BCC is approximately 19 times more common in whites than blacks.[5]

Risk factors for BCC have been well characterized and include ultraviolet radiation (UVR) exposure, light hair and eye color, northern European ancestry, and inability to tan.[2]

ETIOLOGY AND PATHOGENESIS

The pathogenesis of BCC involves exposure to UVR, particularly the ultraviolet (UV) B spectrum (290–320 nm) that induces mutations in tumor suppressor genes.[6] UVB radiation damages DNA, leading to genetic alterations and neoplasms. UV-induced mutations in the *p53* tumor suppressor gene have been found in about 50% of BCC cases.[7,8]

Malignant activation of the sonic hedgehog (SHH) signaling pathway, a developmental signaling pathway, is the pivotal abnormality in all BCCs.[7] Common mutations that activate the aberrant HH signaling pathway are loss of PTCH1 or Suppressor of Fused (SUFU) and activation of Smoothened (SMO) (Fig. 111-1, discussed more in the basal cell nevus syndrome [BCNS] section of this chapter). Approximately 90% of sporadic BCCs have identifiable mutations in at least one allele of *PTCH1*, and an additional 10% have activating mutations in the downstream SMO protein.[9] The most frequently identified mutations in PTCH1 and SMO are of a type consistent with UV-induced damage.[10,11]

Based on genetic profiling of 293 BCCs, the majority of BCCs were found to have mutations in HH pathway genes: *PTCH1* (73%), *SMO* (20%), and *SUFU* (8%) (Table 111-1). Sporadic BCCs also commonly harbor mutations in TP53 (61%) (see Table 111-1).[12]

The contribution of high-intensity sunlight exposure to BCC development in the general population is well established.[13] A latency period of 20 to 50 years is typical between the time of UV damage and the clinical onset of BCC. Therefore, in most cases, BCC develops on sun-exposed skin in older adults, most commonly on the head and neck.[13] Other factors that appear to be involved in the pathogenesis include mutations in regulatory genes. exposure to ionizing radiation,[14] and alterations in immunosurveillance.[15,16] A recent genome-wide association study (GWAS) identified 14 new single nucleotide polymorphisms and new candidate genes and noncoding RNAs involved in telomere maintenance, immune regulation, and tumour progression, providing deeper insight into the pathogenesis of BCC.[17]

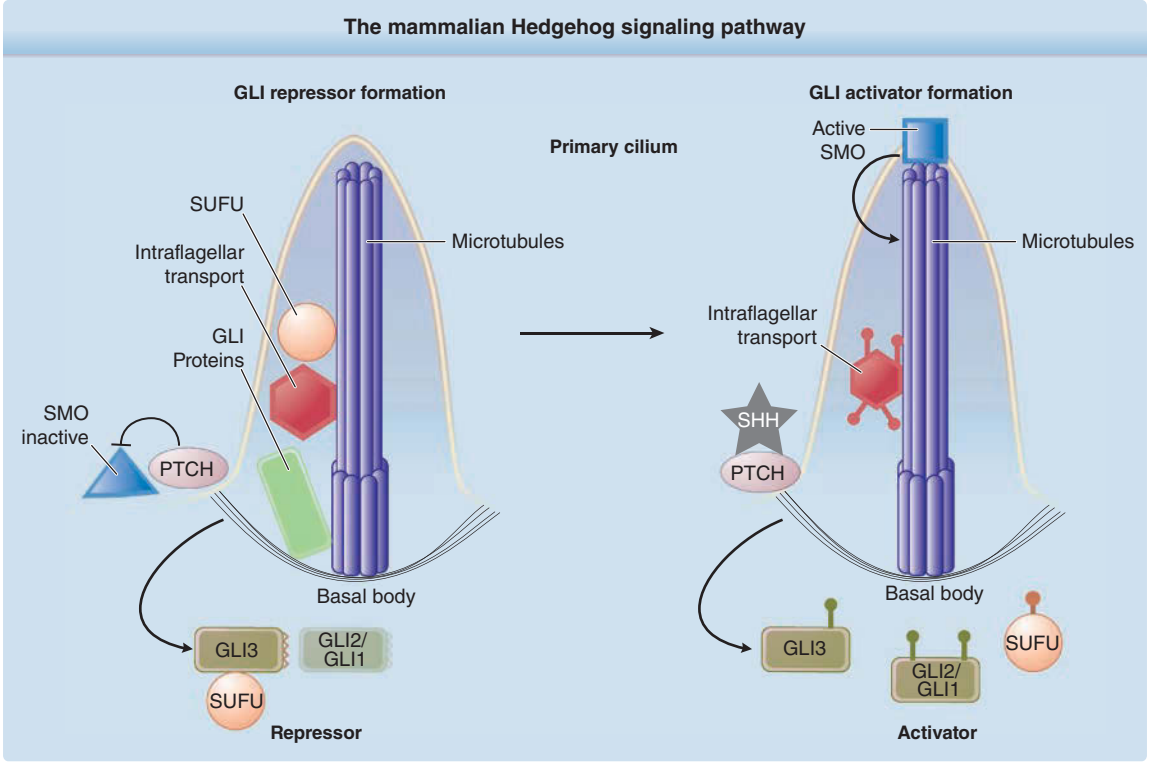

Figure 111-1 The mammalian Hedgehog signaling pathway. PTCH1 is the receptor for the growth factor Hedgehog and inhibits the function of Smoothened (SMO) by sequestering it in an inactive state outside of the microtubule-based organelle, the primary cilium. Sonic Hedgehog (SHH) inhibits PTCH1, allowing activation of SMO in the cilium. SMO inhibits Suppressor of Fused (SUFU), which in turn inhibits the GLI transcription factors GLI1, GLI2, GLI3. Intraflagellar transport proteins help mediate GLI processing.

CLINICAL AND HISTOLOGIC MANIFESTATIONS

The presence of any nonhealing lesion should raise the suspicion of skin cancer. BCC usually develops on sun-exposed areas of the head and neck but can occur anywhere on the body. Commonly seen features include translucency, ulceration, telangiectasias, and the presence of a rolled border. Characteristics may vary for different clinical subtypes, which include nodular, superficial, morpheaform, and pigmented BCCs and fibroepithelioma of Pinkus (FEP).[18] The anatomic location of BCC may favor the development of a particular subtype.

The histopathologic features vary somewhat with subtype, but most BCCs share some common histologic characteristics. The malignant basal cells have large nuclei and relatively little cytoplasm. Although the nuclei are large, they may not appear atypical. Usually, mitotic figures are absent. Frequently, slit-like retraction of stroma from tumor islands is present, creating peritumoral lacunae that are helpful in histopathologic diagnosis.[19] The most common form of BCC is nodular followed by superficial and then morpheaform. Also, nodular and morpheaform are most commonly found on the head and neck, and superficial is most often found on the trunk region.[19]

TABLE 111-1
Most Common Genes Mutated in Sporadic Basal Cell Carcinoma

GENE	PREVALENCE (%)
PTCH1 (tumor suppressor gene, part of the Hedgehog signaling pathway)	73
SMO (oncogene, part of the Hedgehog signaling pathway)	20
SUFU (tumor suppressor gene, part of the Hedgehog signaling pathway)	8
TP53 (also known as p53)	61

DIAGNOSIS

Diagnosis of BCC is accomplished by accurate interpretation of the skin biopsy results (Table 111-2). The preferred biopsy methods are shave biopsy, which is often sufficient, and punch biopsy. A punch biopsy may be useful for flat lesions of morpheaform BCC or for recurrent BCC occurring in a scar. When biopsying a lesion, adequate tissue should be taken. Small, fragmented tissue samples may make diagnosis difficult, potentially compromising the ability to accurately

TABLE 111-2
Common Basal Cell Carcinoma Subtypes with Corresponding Kodachrome

TYPE OF BASAL CELL CARCINOMA (BCC)	CLINICAL DESCRIPTION	CLINICAL PHOTOGRAPHS	HISTOLOGIC DESCRIPTION	HISTOLOGY
Nodular BCC	Translucent papule or nodule, with telangiectasis and rolled border; may ulcerate		Nodules of basophilic nests with stromal retraction	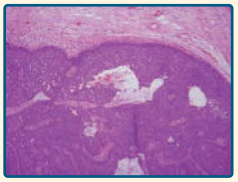
Pigmented BCC	Hyperpigmented translucent papule		Nodules of basophilic nests with melanocytes interspersed between tumor cells; melanophages within stroma	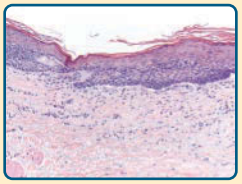
Superficial BCC	Well-demarcated, erythematous patch		Buds of malignant cells extending into the dermis from the basal layer of the epidermis. Minimal dermal involvement.	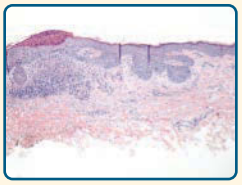
Morpheaform (sclerosing, infiltrative) BCC	Scarlike in appearance; ivory-white		Strands of tumor cells within a dense fibrous stroma	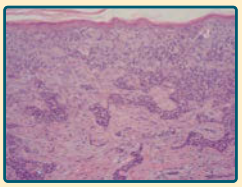

assess BCC subtype and thickness, which can affect treatment choice.

BASAL CELL CARCINOMA SUBTYPES

NODULAR BASAL CELL CARCINOMA

Nodular BCC is the most common clinical subtype of BCC (Fig. 111-2).[20,21] It occurs most often on the sun-exposed areas of the head and neck and appears as a translucent papule or nodule. There are usually telangiectasias and often a rolled border. Larger lesions with central necrosis are referred to by the historical term *rodent ulcer* (Fig. 111-3). The differential diagnosis of nodular BCC includes traumatized intradermal nevus, irritated seborrheic keratosis, and amelanotic melanoma. Nodular BCCs are characterized by nodules of large basophilic cells and stromal retraction. The term *micronodular BCC* is used to describe tumors with multiple microscopic nodules smaller than 15 µm.

PIGMENTED BASAL CELL CARCINOMA

Pigmented BCC is a subtype of nodular BCC that exhibits increased melanization. Pigmented BCC appears as a hyperpigmented, translucent papule. The differential diagnosis includes nodular melanoma and seborrheic keratosis. Approximately 75% of BCCs contain melanocytes, but only 25% contain large amounts of melanin. The melanocytes are interspersed between tumor cells and contain numerous melanin granules in their cytoplasm and dendrites. Although the tumor cells contain little melanin, numerous melanophages populate the stroma surrounding the tumor.[19]

SUPERFICIAL BASAL CELL CARCINOMA

Superficial BCC occurs most commonly on the trunk and appears as an often well-demarcated erythematous patch (Fig. 111-4).[20,21] The differential diagnosis includes SCC, lichenoid keratosis, and nummular

Figure 111-2 Basal cell carcinoma, nodular type.

dermatitis. An isolated patch of "eczema" that does not respond to treatment should raise suspicion for superficial BCC. Superficial BCC is characterized microscopically by buds of malignant cells extending into the dermis from the basal layer of the epidermis. The peripheral layer shows palisading cells. There may be epidermal atrophy, and dermal invasion is usually minimal. There may be a chronic inflammatory infiltrate in the upper dermis. This histologic subtype is encountered most often on the trunk and extremities but may also appear on the head and neck.

MORPHEAFORM (SCLEROSING, INFILTRATIVE) BASAL CELL CARCINOMA

Morpheaform BCC is an aggressive growth variant of BCC with a distinct clinical and histologic appearance.

Figure 111-3 Basal cell carcinoma, rodent ulcer type.

Figure 111-4 Superficial basal cell carcinoma. The well-demarcated plaque with a rolled edge characteristically occurs on the trunk.

Lesions of morpheaform BCC may have an ivory-white appearance and may resemble a scar or a small lesion of morphea (Fig. 111-5). Thus, the appearance of scar tissue in the absence of trauma or previous surgical procedure or the appearance of atypical-appearing scar tissue at the site of a previously treated skin lesion should alert the clinician to the possibility of morpheaform BCC and the need for biopsy. Morpheaform BCC consists of strands of tumor cells embedded within a dense fibrous stroma.[19] Tumor cells are closely packed columns, and in some cases, only one to two cells thick enmeshed in a densely collagenized fibrous stroma. Strands of tumor extend deeply into the dermis. The cancer is often larger than the clinical appearance indicates. Recurrent BCC may also demonstrate infiltrating bands and nests of cancer cells embedded within the dense fibrous stroma of scar.

BASOSQUAMOUS CARCINOMA

Basosquamous carcinoma is a form of aggressive growth BCC. It can be confused with squamous cell carcinoma (SCC) and promotes controversy

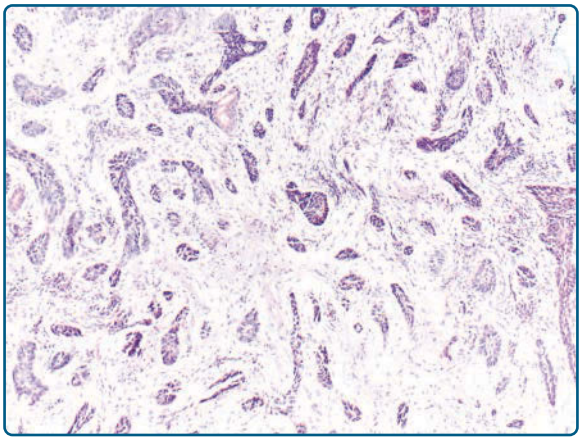

Figure 111-5 Basal cell carcinoma.

considering its precise histologic classification as it shows both basal cell and SCC differentiation in a continuous fashion. Histologically, basosquamous carcinoma shows infiltrating jagged tongues of tumor cells admixed with other areas that show squamous intercellular bridge formation and cytoplasmic keratinization.

FIBROEPITHELIOMA OF PINKUS

FEP classically presents as a pink papule, usually on the lower back. It may be difficult to distinguish from an acrochordon or skin tag. In FEP, long strands of interwoven basiloma cells are embedded in fibrous stroma with abundant collagen.[18]

TREATMENT

Management of BCC is guided by anatomic location and histological features. Approaches include standard surgical excision or destruction by various other physical modalities, Mohs micrographic surgery (MMS), and topical chemotherapy. The Cochrane Collaboration found surgery and radiotherapy to appear the most effective treatments for BCC, with the best overall results being obtained with surgery.[22] Table 111-3 outlines situations when therapies other than surgery should be considered.

The best chance to achieve cure is through adequate initial treatment because recurrent tumors are more likely to be relatively resistant to further treatments and to cause further local destruction. An algorithmic approach to management is summarized in Fig. 111-6. Although most trials have only evaluated BCCs in low-risk locations, surgery and radiotherapy appear to be the most effective treatments with surgery showing the lowest failure rates. Although cosmetic outcomes appear good with PDT (see later), long-term follow-up data are needed. Overall, removal of the tumor with clear margins remains the gold standard for treating BCC.

TABLE 111-3
When to Consider Nonsurgical Treatment

TYPE OF BASAL CELL CARCINOMA (BCC)	FDA-APPROVED THERAPIES	OTHER THERAPIES
Metastatic BCC	Vismodegib	Platinum-based chemotherapy
Locally advanced BCC (defined as BCC that is unable to be treated with surgery or radiation without significant morbidity)	Vismodegib, sonidegib	Platinum-based chemotherapy

FDA, Food and Drug Administration.

MOHS MICROGRAPHIC SURGERY

MMS offers superior histologic analysis of tumor margins while permitting maximal conservation of tissue compared with standard excisional surgery.[23,24] Rowe and coworkers report a recurrence rate of 1% for primary BCCs treated by MMS. This was superior to the rate for other modalities, including standard excision (10%), curettage and desiccation (C&D) (7.7%), radiation therapy (XRT) (8.7%), and cryotherapy (7.5%).[24] Leibovitch and coworkers found that after 5 years, MMS-treated BCCs recurred in 1.4% of primary and 4% of recurrent tumors. This low 5-year recurrence rate of BCC with MMS emphasizes the importance of margin-controlled excision over other modalities.[25] MMS is the treatment of choice for morpheaform, poorly delineated, incompletely removed, and otherwise high-risk primary BCCs as per National Comprehensive Cancer Network Guidelines.[26] It is the preferred treatment for recurrent BCC and for any BCC that occurs at a site where tissue conservation is desired. MMS is particularly useful in treating BCCs at high-risk anatomic sites, including the embryonic fusion planes represented by the nasofacial junction and retroauricular sulcus. Based on the fact that MMS provides the lowest recurrence

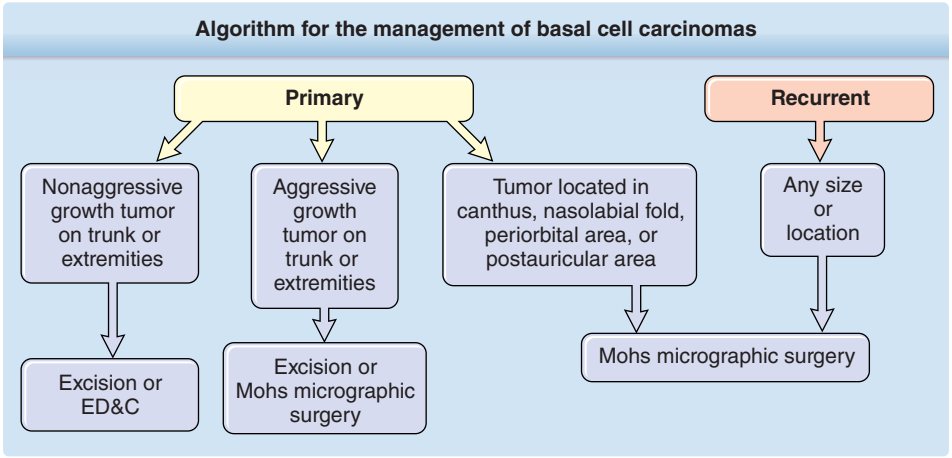

Figure 111-6 Algorithm for the management of basal cell carcinomas. ED&C, electrodesiccation and curettage.

rates, it is the treatment of first choice for primary facial BCCs with an aggressive histopathological subtype and for recurrent facial BCCs.[27] MMS has shown greater efficacy than surgical excision for the treatment of recurrent facial BCCs.[28] Recurrent BCCs treated by MMS reappeared at a rate of 5.6%, which was again superior to the rate for other modalities, including excision (17.6%), XRT (9.8%), and C&D (40%).[29] Mosterd and coworkers also found that treatment with MMS leads to a significantly lower number of recurrences than treatment with surgical excision in recurrent facial BCCs.[23] From a patient perspective, one needs to consider whether MMS is necessary in older patients with limited life expectancy or other serious medical comorbidities versus patient preference.[30,31]

STANDARD EXCISION

Compared with nonexcisional techniques, standard surgical excision offers the advantage of histologic evaluation of the removed specimen; however, depending on the sectioning method used (eg, breadloafing), areas of margin involvement can be missed during routine histologic evaluation.[32] The authors of a recent Cochrane review by Bath-Hextall and coworkers in 2007 concluded that based on the available published work, surgery is the standard treatment of choice for BCC.[22] Although standard excision is appropriate for many BCCs, cure rates for standard excisional surgery are inferior to those for MMS in cases of primary morpheaform BCCs, recurrent BCCs, and tumors located in high-risk anatomic sites.[25] This is discussed further in Chap. 204 and 206.

CURETTAGE AND DESICCATION

C&D is one of the most frequently used treatment modalities for BCC.[33] That C&D is operator dependent was shown by Kopf and coworkers, who identified a significant difference in cure rate between patients treated by private practitioners (94.3%) and those treated by residents (81.2%). High 5-year cure rates of up to 98.8% have been obtained after C&D of primary, nonfibrosing BCCs of medium- and high-risk areas of the face when performed by a skilled operator.[34] Cure rates decreased as a function of primary lesion size: for lesions smaller than 1.0 cm, the cure rate was 98.8%; for lesions between 1.0 cm and 2.0 cm, 95.5%; and for lesions larger than 2.0 cm, 84%. Therefore, C&D is not recommended for large primary BCCs nor for morpheaform or recurrent BCCs.[35] For appropriately selected lesions and locations, C&D remains an efficacious and cost-effective treatment modality.

CRYOSURGERY

Cryosurgery is another destructive modality that has been used in the treatment of BCC. Two freeze–thaw cycles with a tissue temperature of −50°C (−58°F) are required to destroy BCC. In addition, a margin of clinically normal tissue must be destroyed to eradicate subclinical extension. A systematic review of recurrence rates published between 1970 and 1997 indicated that cryotherapy in the treatment of primary BCC resulted in a 5-year recurrence rate from 4% to 17%.[35] Kuflik and Gage reported 99% cure rates in 628 patients followed for 5 years.[36] Possible complications of cryosurgery include hypertrophic scarring and postinflammatory pigmentary changes.[37] Any recent change in a cryosurgery scar after normal healing is completed should raise the suspicion of recurrent BCC.

TOPICAL TREATMENT

(Discussed more in Chap. 192).

Imiquimod: Imiquimod (5% cream) has been used in the treatment of skin cancers.[38,39] Approved in 2004 by the U.S. Food and Drug Administration (FDA) for the topical treatment of biopsy-confirmed, small (<2 cm), primary superficial BCC, imiquimod is a Toll-like receptor 7 agonist believed to induce interferon-α, tumor necrosis factor-α, and other cytokines to boost T helper 1 type immunity. In two double-blind, randomized, vehicle-controlled trials, clinical and histological clearance rates for dosing five and seven times per week were 75% and 73%, respectively, for superficial BCC.[38-40] In another study, 10 of 19 nodular BCCs (approximately 53%) cleared after treatment with imiquimod.[40] In general, adverse side effects are limited to local skin reactions; however, researchers have noted the significant correlation between the severity of the local skin reaction (erythema, erosion, and crusting) and the histologic clearance rate. Imiquimod is FDA approved for only for superficial BCCs limited to small tumors in low-risk locations in patients.[41] The safety and effectiveness of imiquimod for other types of BCC have not been established, with up to 25% of treated patients failing therapy.

5-Fluorouracil: 5-Fluorouracil (5-FU), a topically applied chemotherapeutic agent used in the treatment of actinic keratoses, has also been used to treat superficial BCCs. In one series, Epstein showed a 5-year recurrence rate of 21% for thin BCCs after 5-FU treatment, which was reduced to 6% when curettage was performed initially.[42] Gross and coworkers observed a 90% histologic clearance rate 3 weeks after 5-FU treatment but with no long-term follow-up.[43] The use of 5-FU to treat BCC should be considered carefully and should include an evaluation of the risk of recurrence and treatment failure.

PHOTODYNAMIC THERAPY

Photodynamic therapy (PDT) (discussed more in Chap. 199) involves the activation of a photosensitizing drug by visible light to produce activated oxygen species that destroy the constituent cancer cells. Exogenous δ-aminolevulinic acid increases intracellular production of the endogenous photosensitizer protoporphyrin type IX, which preferentially accumulates

in tumor cells.[44] Basset-Seguin and coworkers reported complete response rates for superficial BCCs from 85% to 93% at 3 months and a response rate on par with cryosurgery at 60 months (75% vs. 74%).[44] Marmur and coworkers reviewed PDT for NMSC and reported recurrence rates ranging from 0% to 31% for BCC.[45] The long-term cure rates for superficial BCC with PDT remains around 75%, and because of the appreciable nonresponse and recurrence rates, patients should be monitored closely during the first 2 to 3 years after PDT, which is when most lesion recurrences are seen.[45,46] The Cochrane Collaboration found that cosmetic outcome for PDT was significantly better than surgery.[22] However, there were also comparatively high failure rates associated with PDT when compared with surgery, radiotherapy, and cryotherapy. For superficial BCC, one randomized trial showed that 5-FU and imiquimod were superior to PDT. There was no difference between 5-FU and imiquimod at 3- and 12-month follow-up.[47]

RADIATION THERAPY

XRT (discussed more in Chap. 200) may be useful in cases of primary BCC or in cases in which postsurgical margins are positive for cancer. Advantages include minimal patient discomfort and avoidance of an invasive procedure for a patient unwilling or unable to undergo surgery. XRT may be a very useful modality as adjunct treatment for BCC when margins are positive after excision or for extensive perineural or large nerve involvement.[28] Good control rates of 93% to 97% have been reported; however, long-term randomized results suggest XRT remains inferior to surgery both in recurrence rate and cosmesis. The 4-year failure rate was 0.7% in the surgery group compared with 7.5% in the radiotherapy group.[48]

SPECIAL MANAGEMENT ISSUES

Perineural Invasion: In one series, Niazi and Lamberty identified perineural invasion (PNI) in fewer than 0.2% of cases. Defined as the observation of malignant cells in the perineural space of nerves, when PNI is detected, every effort should be made to clear the tumor, preferably by MMS.[49] Patients with gross PNI manifested by neurologic symptoms would benefit from preoperative magnetic resonance imaging to assess extent of tumor spread. Perineural spread may manifest as pain, paresthesias, weakness, or paralysis.

Locally Advanced Basal Cell Carcinoma: The greatest danger of BCC results from local invasion. In general, BCC is a slow-growing tumor that invades locally rather than metastasizes.[50] If left untreated, the tumor will progress to invade subcutaneous tissue, muscle, and even bone. Anatomic fusion planes appear to provide a low-resistance path for tumor progression. Metastases are rare and are correlated to the size (>7.5 cm) and a long delay in seeking treatment for the tumor.[51] The term *locally advanced BCCs* is applied to BCCs that cannot be adequately excised without significant functional impairment or tumors that cannot be treated with radiotherapy.[52] Inhibitors of the Hedgehog signaling pathway (vismodegib, sonidegib) have been FDA approved for the treatment of locally advanced BCCs.[52-54]

Metastatic Basal Cell Carcinoma: Metastasis of BCC occurs only rarely, with rates varying from 0.0028% to 0.55%.[55] If nodal disease is suspected on surgical examination, lymph node biopsy and imaging studies, as well as evaluation by medical and surgical oncologists, are indicated.[56] The most common sites of metastasis are the regional lymph nodes, lungs, and bone.[51] Aggressive histologic characteristics, including morpheaform features, squamous metaplasia, and PNI, have been identified as risk factors for metastasis.[55] The median survival period of patients with metastatic BCC is 10 months.[51] Platinum-based chemotherapy has been used with modest results in treatment of metastatic BCC; however, rapid clinical response was reported using a combination of cisplatin and paclitaxel.[57] Complete response to carboplatin and paclitaxel has been reported in case series.

Hedgehog Inhibitors: Studies have now identified a natural antagonist of the Hedgehog signaling pathway derived from the *Veratrum californicum* plant called *cyclopamine*. This substance binds and antagonizes SMO and has been shown to be effective in animal models of BCCs. Other small-molecule Hedgehog pathway antagonists with similar properties have been identified and are currently being tested for their clinical efficacy.[58] In a phase 1 trial of the first of these specific Hedgehog inhibitors, vismodegib, 33 patients with locally advanced or metastatic BCCs showed significant shrinkage of metastatic and advanced cutaneous BCCs with relatively mild systemic toxicity.[53]

Vismodegib was approved by the FDA in 2012 for patients with locally advanced or metastatic BCC.[52] In 104 patients enrolled in the ERIVANCE multicenter clinical response trial, vismodegib (150 mg/day) led to an objective response rate (complete plus partial response) of 33.3% in patients with metastatic disease and 47.6% in patients with the locally advanced form. The median duration of response in patients with metastatic disease was 7.6 months and in patients with locally advanced BCC was 9.5 months.[52]

Sonidegib, another inhibitor of SMO in the SHH pathway, has similar efficacy and is approved for locally advanced BCCs.[54] Unfortunately, as has been the case with several other such molecularly targeted anticancer drugs, about 30% of treated tumors either do not respond or develop resistance to treatment and relapse through mutations in SMO or a combination of SUFU inactivation and GLI2 amplification.[12,59] Mutations in SMO (the drug target) have been identified in 50% of resistant tumors; these mutations maintain Hedgehog signaling in the presence of SMO inhibitors.[60-62]

COURSE AND PROGNOSIS

With appropriate treatment, the prognosis for most patients with BCC is excellent. Control rates as high as 99% have been achieved by MMS. Although tumor control rates for primary tumors are high, patients must be monitored for recurrence and development of new primary BCCs. The risk for development of a second primary BCC ranges from 36% to 50%.[63] Periodic full-body skin examinations and counseling about sun protection are recommended for any patient with a history of BCC. This is especially important because patients with a history of BCC are at increased risk for melanoma. The prognosis for patients with recurrent BCC is favorable, although recurrent tumors are more likely to appear again and to behave aggressively. Patients with a history of recurrent disease must be monitored more frequently for the development of further recurrences and new primary tumors. An estimated 40% to 50% of patients with primary BCC will develop at least one or more further BCCs within 5 years.[2] For the rare patient with metastatic disease, the prognosis is poor, with a mean survival time of 8 to 10 months without treatment from the time of diagnosis. Recent clinical trials have highlighted a potential role of nicotinamide 500 mg twice a day[64] and of the nonsteroidal antiinflammatory drug celecoxib[65] in producing some decrease in BCC risk.

BASAL CELL NEVUS SYNDROME

- Patients with basal cell nevus syndrome (BCNS, Gorlin syndrome) inherit an inactivating mutation in the *PTCH1* gene.
- BCNS is a rare autosomal-dominant disorder with phenotypic abnormalities that include developmental anomalies and postnatal tumors, especially BCCs.
- In BCNS, the three most characteristic abnormalities are tumors such as medulloblastomas or BCCs, pits of the palms and soles, and odontogenic cysts of the jaw.
- Inhibitors of the Hedgehog signaling pathway (SMO inhibitors such as vismodegib, sonidegib) are FDA approved for advanced or metastatic BCCs.

Basal cell nevus syndrome, also known as *nevoid basal cell carcinoma syndrome* and *Gorlin syndrome* (Online Mendelian Inheritance in Man [OMIM] #109400), is a rare autosomal-dominant disorder associated with a panoply of phenotypic abnormalities that can be divided into developmental anomalies and postnatal tumors, especially BCCs.[66] Although individual aspects had been reported previously, their syndromic association was first appreciated widely in the late 1950s.[67,68]

EPIDEMIOLOGY

The prevalence of BCNS is variously estimated to be 1 in 31,000 to 1 in 60,000 persons.[69-71] The syndrome affects both sexes and occurs in a wide variety of cultural groups and therefore does not have a predilection for a particular skin type. The condition appears to have complete penetrance but variable expressivity of traits, such that their clinical presentation among families is nonuniform. Furthermore, as with many dominantly inherited conditions, new mutations are common. As a result, in many cases, patients may have no apparent affected ancestors or siblings.

ETIOLOGY AND PATHOGENESIS

GENETIC ABNORMALITY

Almost all known BCNS patients thus far carry mutations in the *PATCHED1* (*PTCH1*, UniGene Hs.494538) gene residing on the long arm of chromosome 9.[72,73] PTCH1 plays a central role in the Hedgehog signaling pathway that is essential for the establishment of normal body and limb patterning.[74] The *PTCH1* locus behaves like a classic tumor suppressor gene (see Fig. 111-1). The appearance of BCCs in small numbers at an older age in sporadic cases and in larger numbers at a younger age in patients with BCNS is reminiscent of differences in sporadic and hereditary cases of retinoblastoma.[75] BCNS, like other tumor susceptibility syndromes, is inherited in an autosomal-dominant manner, with inheritance of a loss-of-function allele followed by somatic loss of the remaining copy before tumor formation.

Identification of the gene mutation responsible for BCNS facilitated a molecular verification of the tumor suppressor prediction.[72,73] In BCNS, patients inherit one defective *PTCH1* allele, but their tumors contain an additional somatic mutation. As with some other tumor suppressor genes, *PTCH1* mutations have also been found in older adults with sporadic BCCs and other sporadic tumors known to be overrepresented in patients with BCNS (eg, medulloblastomas and meningiomas), which supports the idea that two somatic "hits" are required in sporadic tumors.

In contrast, the two-hit genetic model proposed for *PTCH1*-dependent tumor development may not fully explain the developmental abnormalities seen in BCNS, which occur earlier. *PTCH1* heterozygote mice display many of the developmental abnormalities seen in patients with BCNS despite a wild-type copy of the nonaffected allele.[76-78] This argues that certain tissues (skeleton, limb, neural tube) require higher levels of PTCH1 to regulate tissue development and that heterozygotes cannot compensate for loss of the other allele (haploinsufficiency).

Are *PTCH1* mutations the only cause of BCNS? Despite direct sequencing of *PTCH1* exons in patients, somatic mutations are found in fewer than half of BCCs and germline mutations in fewer than 100% of BCNS patients.[79,80] On the one hand, this suggests that mutations in other unidentified genes may underlie the disease. On the other hand, early linkage studies found strong association with the *PTCH1* locus. Moreover, although mutations are not found in PTCH1 exons in some patients, Hedgehog signaling pathway abnormalities are still present in these tumors. One family with BCNS and atypical features (medulloblastoma and plantar pits but no BCCs) was found to have germline mutations in SUFU, a tumor suppressor gene and negative regulator of SHH signaling (see Fig. 111-1).[81,82] This suggests that mutations may be found in other members of the signaling pathway in rare cases.

PTCH1 FUNCTION

PTCH1 protein plays a critical role in the hedgehog signaling pathway (see Fig. 111-1). Genetic and biochemical studies in *Drosophila* and mammals indicate that PTCH1 protein inhibits this signaling pathway by inhibiting the function of the central G protein–coupled receptor SMO and that the extracellular ligand hedgehog abrogates this inhibition. Signaling by SMO results in the activation of the GLI family of zinc finger proteins that mediate all the transcriptional effects of Hedgehog signaling. Three GLI proteins mediate activation and suppression of Hedgehog target genes, with GLI1 and GLI2 acting as activators and GLI2 and GLI3 as suppressors. SMO signaling tips the balance toward activation and away from target gene suppression. In mammals, GLI activity is controlled by the novel cytoplasmic protein SUFU, which promotes the transcriptional repression and inhibits activation.[83] SMO inhibits SUFU activity, thus releasing GLI proteins to become transcriptional activators. When Hedgehog binds to PTCH1, PTCH1 inhibition of SMO is relieved, and the pathway is activated. Thus, loss of PTCH1 function allows unregulated SMO activity and initiates tumor formation.

How PTCH1 functions as a tumor suppressor is still under investigation. A significant aspect of PTCH1 function is inhibition of SMO, although how PTCH1 accomplishes this is unknown. PTCH1 acts in an enzymatic manner as only a few molecules are necessary able to inhibit SMO by severalfold.[84] Moreover, PTCH1 and SMO are thought to exist in distinct endosomes and thought not to physically interact. Components of the Hedgehog pathway are localized to a novel microtubule-based organelle called the primary cilium (see Fig. 111-1). Mutations that affect the structure and function of the cilium, known collectively as the human ciliopathies, are also known to disrupt maximal Hedgehog signaling and have some similarities to BCNS. SMO accumulation through the actions of intraflagellar transport proteins within this organelle is correlated with pathway activation. PTCH1 is localized at the base of the organelle and appears to prevent SMO entry. Loss of PTCH1 or mutations that allow SMO to move into the cilium result in increased pathway activity.[85]

MUTATIONS IN SONIC HEDGEHOG PATHWAY IN BASAL CELL CARCINOMAS

Supporting the central role of SHH target gene induction in BCC pathogenesis is the finding of mutations in members of the SHH pathway in both BCNS patients and in sporadic BCCs. Identified mutations involving PTCH1 are by far the most common in BCNS tumors.[9] The particular type of mutation found in PTCH is consistent with mutation caused by UV light, which provides additional evidence for PTCH and sunlight in cancer development.[86]

Mutations of SMO protein have been identified in approximately 10% of BCCs, and these mutations appear to render SMO protein resistant to PTCH1 inhibition.[87] Indeed, experimental transfection of cells with mutant SMO sequences can transform them to a malignant phenotype. This finding that BCCs may have upregulation of Hedgehog target gene expression caused by mutations in either PTCH1 or SMO argues that it is the upregulation of Hedgehog signaling rather than the specific mutation that is crucial to BCC formation. Consistent with this is the finding that mutations in the gene encoding SUFU have been reported to underlie formation of medulloblastomas and BCNS.[81,88]

CLINICAL FINDINGS

CUTANEOUS LESIONS

Hedgehog signaling plays a critical role in the expansion of progenitor cells in a wide variety of tissues in both invertebrate and vertebrate organisms. PTCH1 normally is expressed both during development and in adults, which suggests an ongoing postnatal role. Patients with BCNS show multiple abnormalities, none of which is unique to this syndrome.[70,79,80] The three abnormalities considered to be most characteristic of the syndrome are tumors such as medulloblastomas or BCCs, pits of the palms and soles, and keratocystic odontogenic tumors (odontogenic cysts) of the jaw.

Individual BCCs from patients with BCNS cannot be distinguished from those in sporadic cases, which is not surprising in view of the similar pathogenesis in familial and sporadic cases. What is distinguishing is their appearance in large numbers starting at an early age. They may be banal appearing and confused grossly with nevocytic nevi, hence the name *basal cell nevus*. They may also have a translucent, papulonodular appearance more characteristic of

Figure 111-7 Face of a man with severe scarring from growth and treatment of multiple basal cell carcinomas (BCCs). Note multiple outlined new BCCs despite extensive and frequent surgery.

sporadic BCCs and may invade locally. In rare cases, they may even metastasize, causing the patient's death. Although the ratio of sun-protected to sun-exposed BCCs may be higher in BCNS than in sporadic cases, sunlight and ionizing radiation (thus making ionizing radiation a very poor choice for treatment of most BCCs in BCNS patients) clearly accelerate BCC formation in BCNS patients, and darkly pigmented BCNS patients may have few to no BCCs (Figs. 111-7 and 111-8).

Palmoplantar pits are small defects in the stratum corneum and may be pink or, if dirt has accumulated, dark in color (Fig. 111-9). They appear early in life and can be a valuable aid in diagnosis in addition to jaw cysts or medulloblastoma. Their basis is poorly understood, but they are thought to be caused by aborted attempts to generate hair follicles in the palms. They are also seen in mouse PTCH1 heterozygotes.[89]

Figure 111-8 Upper back of man with basal cell nevus syndrome with innumerable basal cell carcinomas, some of which are nodular and most of which are flat, erythematous patches.

Figure 111-9 **A,** Unusually florid palmar pits in a patient with basal cell nevus syndrome (BCNS). **B,** Larger magnification showing that these lesions in BCNS are really punched-out pits.

RELATED PHYSICAL FINDINGS

Tissue overgrowth, which is also a feature of Hedgehog signaling pathway activation in *Drosophila*, often is

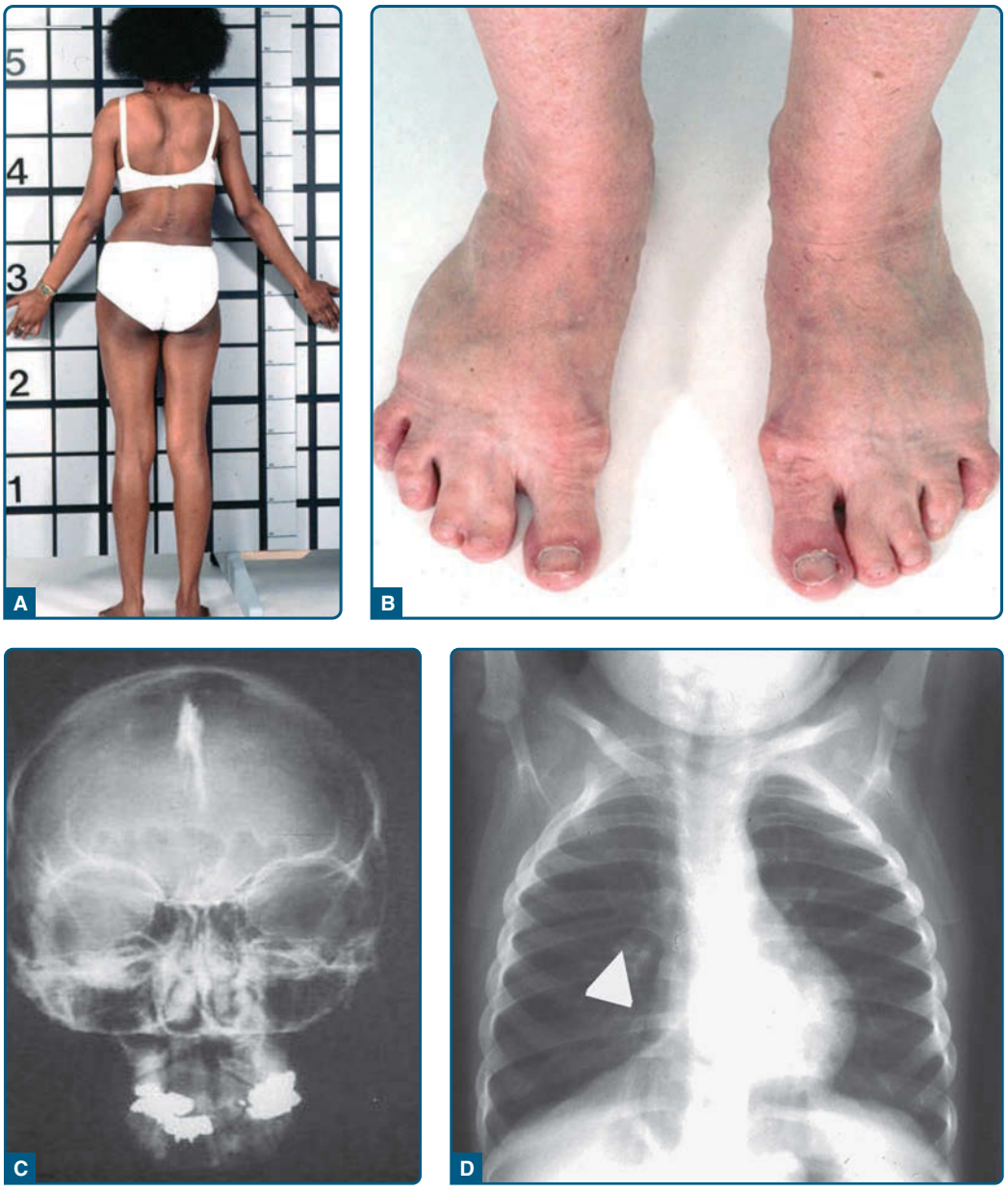

Figure 111-10 Skeletal and radiographic findings in basal cell nevus syndrome. **A,** Unusually large body habitus and extremities. **B,** Syndactyly in the digits. **C,** Calcification of the falx cerebri. **D,** Rib development abnormalities, including rib fusion (*arrowhead*).

manifested by an overall body size larger than that of other family members. Limbs may be particularly long, giving a marfanoid appearance (see Fig. 111-10), and a large head circumference (at least in probands) and frontal bossing are often described.

Jaw cysts often are the first detectable abnormality[70,79,80] (Fig. 111-11). They may be asymptomatic and therefore diagnosed only radiologically. However, they also may erode enough bone to cause pain, swelling, and loss of teeth. They occur more often in the mandibular jaw than in the maxillary jaw.[90] These jaw cysts presumably form from inappropriate SHH induction of dental epithelium and can recur often and be the most debilitating aspect of the syndrome.[91]

DIAGNOSIS

Because the individual abnormalities are not unique to patients with BCNS, it is possible to diagnose BCNS clinically only when multiple typical defects are present. The severity of abnormalities may differ markedly among members of a single kindred, and diagnostic certainty may be difficult for specific individuals even if they belong to a kindred with known BCNS.[92] Generally, the diagnosis is suggested to the dermatologist when multiple BCCs arise in a patient at an unexpectedly early age and in unexpectedly large numbers, with the average age of onset in the early 20s.

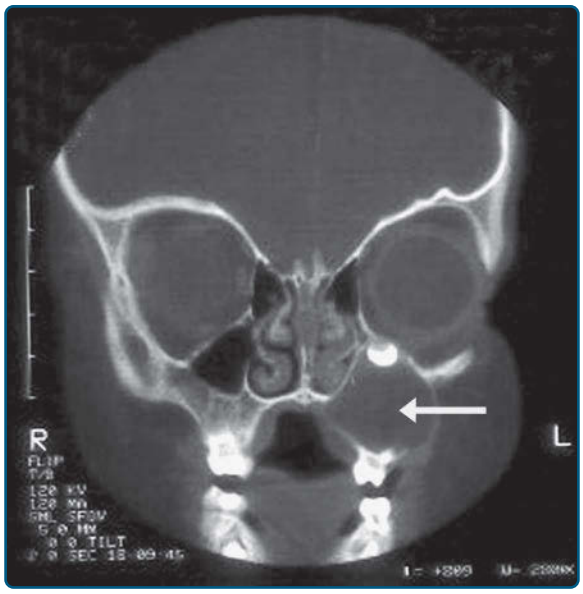

Figure 111-11 Radiographic findings of odontogenic keratocyst (*arrow*).

TABLE 111-4
Diagnostic Criteria for Basal Cell Nevus Syndrome (BCNS, Gorlin Syndrome)

Major Criteria

1. Basal cell carcinoma before age 20 yr
2. Odontogenic keratocysts before age 15 yr
3. Three or more palmar or plantar pits
4. Bilamellar calcification of the falx cerebri (if younger than 20 yr)
5. Fused, bifid, or markedly splayed ribs
6. First-degree relative with BCNS
7. *PTCH* gene mutation in normal tissue

Minor Criteria

1. Macrocephaly determined after adjustment for height
2. Congenital malformations: cleft lip or palate, frontal bossing, "coarse face," moderate or severe hypertelorism
3. Skeletal abnormalities: Sprengel deformity, marked pectus deformity, or marked syndactyly of the digits
4. Radiologic abnormalities: bridging of the sella turcica; rib anomalies such as bifid or splayed ribs; vertebral anomalies such as hemivertebrae, fusion, or elongation of the vertebral bodies; modeling defects of the hands and feet; or flame-shaped lucencies of the hands or feet
5. Ovarian fibroma
6. Medulloblastoma

Further evaluation should include (1) questions about whether other family members have had abnormalities consistent with BCNS (although perhaps 30% of patients with BCNS have no affected ancestors) and whether the patient is taller and heavier than his or her relatives; (2) examination for palmoplantar pits and skin cysts and assessment of body and head size; and (3) radiologic evaluation for jaw cysts (which often appear around the start of the second decade), calcification of the falx (which occurs in nearly all adults with BCNS and may be present in early childhood in patients with BCNS, thus suggesting the diagnosis of BCNS in those patients with early-onset medulloblastomas), and abnormalities of the ribs, spine, and phalanges (flame-shaped lucencies), each of which is present in one-third to one-half of BCNS patients.[70,71,79,80] Kimonis and colleagues proposed a set of major and minor criteria for presumptive diagnosis of BCNS (Table 111-4), which has since been modified.[79] For cases in which the diagnosis is in doubt or for genotyping of other family members, identification of *PTCH1* gene mutations is now available commercially through GeneDX (Gaithersburg, MD).

DIFFERENTIAL DIAGNOSIS

Other syndromes exist that are characterized by the development of multiple BCCs. These include Bazex syndrome (OMIM 301845),[93] Rombo syndrome (OMIM 180730),[94] and a syndrome observed in a family with BCCs, milia, and coarse, sparse hair.[95] Hair abnormalities are present in all three syndromes, which is a finding of interest in view of the often-repeated suggestion that BCCs arise from hair follicles rather than from interfollicular epidermis. The exact nosologic relationships among these three syndromes are uncertain, but patients with BCNS have normal hair, and all three syndromes seem quite different from BCNS.

Two other syndromes that have been described include multiple hereditary infundibulocystic basal cell carcinoma (MHIBCC)[96] and generalized basaloid follicular hamartoma (GBFH).[97] Both demonstrate histologic variants of BCCs, with more hamartomatous lesions, and are characterized by palmar pits and milia. Recent molecular characterization of MHIBCC suggest that loss of SUFU underlies many of these cases, consistent with the well-differentiated nature of the tumors.[98,99] GBFH is acquired and associated with autoimmune disease, which suggests an immunologic stimulation of the hedgehog pathway.

Patients with long-term arsenic ingestion may have multiple BCCs. Their dyschromia and lack of other phenotypic abnormalities differentiate them from BCNS patients. Patients with xeroderma pigmentosum develop multiple BCCs but are readily differentiated from BCNS patients by their severe photosensitivity and other phenotypic abnormalities (see Chap. 130).

The most challenging patients are those who have a marked propensity to develop multiple BCCs throughout life, sometimes sporadically or in rare cases after therapeutic irradiation (eg, for Hodgkin disease) without showing any of the other signs of BCNS. These patients resemble BCNS patients with many BCCs, but do not have mutations in *PTCH1* alleles and are called High-Frequency (HF-BCC) patients.[100,101]

COMPLICATIONS, PROGNOSIS, AND CLINICAL COURSE

Although disease pathogenesis involves abnormalities in SHH signaling, the wide variability in clinical course among families and even between generations of the same family make prediction of the clinical course difficult. If BCNS is suspected or confirmed, physicians should also screen for the most frequent sequelae of the disease during childhood or adolescence (Table 111-5). No large-scale survival studies have been performed to determine whether BCNS patients die earlier because of their disease.[79,102] The major complications are developmental delay, physical impairment in children, and the childhood tumors that arise, such as medulloblastoma. The latter often occur within the first 5 years of life and are frequently the initial sign of BCNS. Complications arising from medulloblastoma treatment (radiation, shunt placement) are relatively common, and multidisciplinary teams of physicians are required to optimally treat these patients.

In the skin, BCCs that arise are locally aggressive but very rarely metastasize.[103] No reports document an increased risk for metastatic BCCs, which suggests that the basic character of the tumor is similar to that seen in sporadic BCC cases. However, because of the high numbers and wide distribution of the tumor, even in the absence of sun exposure, involvement of key epithelial surfaces or membranes is likely and can be disfiguring for the patient.

TABLE 111-5

Approach to the Patient with Known or Suspected Basal Cell Nevus Syndrome (BCNS)

Pediatric Patients

- Baseline MRI of brain; repeat yearly (if asymptomatic) until age 8 yr
- Baseline dermatologic examination; repeat yearly until first BCC develops and then every 6 months (or more frequently as needed) throughout life
- Digital Panorex of jaw at age 3 or 4 hr (or as soon as tolerated) and then yearly until the first jaw cyst develops. Repeat yearly (or more frequently as needed) until age 21 yr
- Pelvic ultrasonography in girls at menarche (or earlier if symptomatic)
- Molecular diagnosis (if desired) for patients with family history and known mutation
- Baseline scoliosis assessment at one year of age and then annually for progression if present
- Routine developmental screening and referral for all children who do not meet developmental milestones

Adult Patients

- Baseline MRI of brain (if not done at age 8 yr or later)
- Dermatologic examination at 4 mo (or more frequently if new lesions present at each examination)
- Digital Panorex of jaw twice yearly until cyst free for 2 years and then yearly or less frequently (depending on patient's concern about radiation)
- Prenatal or preconception counseling if desired

BCC, basal cell carcinoma; MRI, magnetic resonance imaging.

Data from Kimonis VE, Goldstein AM, Pastakia B, et al. Clinical manifestations in 105 persons with nevoid basal cell carcinoma syndrome. *Am J Med Genet*. 1997;69(3):299-308.

TREATMENT

Therapy must be directed at the individual lesions as they arise, and the most important aspects of management are frequent examination, counseling about avoidance of sun exposure, and early treatment of small tumors. In animal models of BCNS, small, clinically undetectable tumors arise throughout the skin. This suggests that many more tumors form than are detectable visibly by the clinician.[89,104] This has several therapeutic ramifications. One is that clinicians caring for patients with BCNS should become confident in their clinical acumen so that they can diagnose and treat tiny BCCs without histopathologic confirmation. This would eliminate multiple scar-inducing biopsies in addition to potentially disfiguring treatments. Another is that invasive treatments should be focused on lesions that are potentially the most harmful, such as those invading mucous membranes or adjacent structures. Repetitive surgical treatments run the risk of severe disfigurement for the patient. Finally, clear surgical margins may be difficult to achieve when using Mohs surgery, so aggressive pursuit of a clear margin needs to be balanced against other factors in treating these patients.

Nonsurgical approaches to BCC treatment should be used aggressively in patients with BCNS when possible. Because the key is to convince the patient to accept frequent treatments, minimization of discomfort and scarring is a major goal. Approaches that may be of benefit are topical treatment with 5-FU (with or without occlusion, depending on the degree of inflammation produced),[105] the Toll-like receptor agonist imiquimod,[106] and PDT.[107] Oral therapy with retinoids also may be of value but often only at a dosage that generally causes severe side effects. There are several agents for BCC prevention in BCNS patients, including PDT, celecoxib, topical retinoids, and topical 5-FU, each with some suggestion of efficacy. The most effective agent appears to be oral vismodegib 150 mg/day, which dramatically shrank existing BCCs and prevented new BCCs (30 BCC/year in placebo vs 1 BCC/year on drug) in a 3-year randomized, double-blinded controlled trial in patients with BCNS.[108,109] Unfortunately, the mild to moderate side effects of muscle cramps, taste loss, and hair loss precluded most patients with BCNS from taking vismodegib long term (>3 years).[107,109] In contrast to advanced and metastatic BCCs, resistance to SMO inhibitors is rare in patients with BCNS; few SMO mutations have been detected in tumors, and BCCs shrink when systemic HH inhibitor treatment is resumed.[12,108]

The X-irradiation of BCCs has been advocated in otherwise normal patients who are not surgical candidates. However, excessive radiation should be avoided if possible because enhanced radiation-induced carcinogenesis (eg, in the skin of the portals of irradiation for childhood medulloblastomas) is characteristic of BCNS. Patients with BCNS who receive radiation have developed an unusually large number of basal cell tumors in the irradiated area a short time after exposure.

Genetic counseling is appropriate. With the availability of direct sequencing of the PTCH1 locus, genotyping for prenatal diagnosis is potentially achievable for interested families. Because PTCH1 is transmitted with complete penetrance, half of the children of affected individuals are expected to develop BCNS.

ACKNOWLEDGMENTS

The authors acknowledge the contributions of John A. Carucci, David J. Leffell, and Julia S. Pettersen, the former authors of this chapter.

REFERENCES

1. Asgari MM, Moffet HH, Ray GT, et al. Trends in basal cell carcinoma incidence and identification of high-risk subgroups, 1998-2012. *JAMA Dermatol*. 2015;151(9):976-981.
2. Rubin AI, Chen EH, Ratner D. Basal-cell carcinoma. *N Engl J Med*. 2005;353:2262-2269.
3. Christenson LJ, Borrowman TA, Vachon CM, et al. Incidence of basal cell and squamous cell carcinomas in a population younger than 40 years. *JAMA*. 2005; 294(6):681-690.
4. Sng J, Koh D, Siong WC, et al. Skin cancer trends among Asians living in Singapore from 1968 to 2006. *J Am Acad Dermatol*. 2009;61(3):426-432.
5. Gloster HM Jr, Neal K. Skin cancer in skin of color. *J Am Acad Dermatol*. 2006;55(5):741-760; quiz 761-764.
6. Gailani MR, Leffell DJ, Ziegler A, et al. Relationship between sunlight exposure and a key genetic alteration in basal cell carcinoma. *J Natl Cancer Inst*. 1996; 88(6):349-354.
7. Epstein EH. Basal cell carcinomas: attack of the hedgehog. *Nat Rev Cancer*. 2008;8(10):743-754.
8. Benjamin CL, Ananthaswamy HN. p53 and the pathogenesis of skin cancer. *Toxicol Appl Pharmacol*. 2007; 224(3):241-248.
9. Reifenberger J, Wolter M, Knobbe CB, et al. Somatic mutations in the PTCH, SMOH, SUFUH and TP53 genes in sporadic basal cell carcinomas. *Br J Dermatol*. 2005;152(1):43-51.
10. Lindström E, Shimokawa T, Toftgård R, et al. PTCH mutations: distribution and analyses. *Hum Mutat*. 2006;27(3):215-219.
11. Heitzer E, Lassacher A, Quehenberger F, et al. UV fingerprints predominate in the PTCH mutation spectra of basal cell carcinomas independent of clinical phenotype. *J Invest Dermatol*. 2007;127(12):2872-2881.
12. Bonilla X, Parmentier L, King B, et al. Genomic analysis identifies new drivers and progression pathways in skin basal cell carcinoma. *Nat Genet*. 2016;48(4):398-406.
13. Pelucchi C, Di Landro A, Naldi L, et al. Risk factors for histological types and anatomic sites of cutaneous basal-cell carcinoma: an Italian case-control study. *J Invest Dermatol*. 2007;127(4):935-944.
14. Karagas MR, Nelson HH, Zens MS, et al. Squamous cell and basal cell carcinoma of the skin in relation to radiation therapy and potential modification of risk by sun exposure. *Epidemiology*. 2007;18(6):776-784.
15. Berg D, Otley CC. Skin cancer in organ transplant recipients: epidemiology, pathogenesis, and management. *J Am Acad Dermatol*. 2002;47(1):p. 1-17; quiz 18-20.
16. Brewer JD, Colegio OR, Phillips PK, et al. Incidence of and risk factors for skin cancer after heart transplant. *Arch Dermatol*. 2009;145(12):1391-1396.
17. Chahal HS, Wu W, Ransohoff KJ, et al. Genome-wide association study identifies 14 novel risk alleles associated with basal cell carcinoma. *Nat Commun*. 2016;7:12510.
18. Pinkus H. Epithelial and fibroepithelial tumors. *Arch Dermatol*. 1965;91:24-37.
19. Scrivener Y, Grosshans E, Cribier B. Variations of basal cell carcinomas according to gender, age, location and histopathological subtype. *Br J Dermatol*. 2002;147(1):41-47.
20. Raasch BA, Buettner PG, Garbe C. Basal cell carcinoma: histological classification and body-site distribution. *Br J Dermatol*. 2006;155(2):401-407.
21. McCormack CJ, Kelly JW, Dorevitch AP. Differences in age and body site distribution of the histological subtypes of basal cell carcinoma. A possible indicator of differing causes. *Arch Dermatol*. 1997;133(5):593-596.
22. Bath-Hextall FJ, Perkins W, Bong J, et al. Interventions for basal cell carcinoma of the skin. *Cochrane Database Syst Rev*. 2007(1):CD003412.
23. Mosterd K, Krekels GA, Nieman FH, et al. Surgical excision versus Mohs' micrographic surgery for primary and recurrent basal-cell carcinoma of the face: a prospective randomised controlled trial with 5-years' follow-up. *Lancet Oncol*. 2008;9(12):1149-1156.
24. Rowe DE, Carroll RJ, Day CL Jr. Long-term recurrence rates in previously untreated (primary) basal cell carcinoma: implications for patient follow-up. *J Dermatol Surg Oncol*. 1989;15(3):315-328.
25. Leibovitch I, Huilgol SC, Selva D, et al. Basal cell carcinoma treated with Mohs surgery in Australia II. Outcome at 5-year follow-up. *J Am Acad Dermatol*. 2005;53(3):452-457.
26. NCCN.org. *NCCN Clinical Practice Guidelines in Oncology (NCCN Guidelines) Basal Cell and Squamous Cell Skin Cancers*. Version 2.2014.
27. Smeets NW, Kuijpers DI, Nelemans P, et al. Mohs' micrographic surgery for treatment of basal cell carcinoma of the face—results of a retrospective study and review of the literature. *Br J Dermatol*. 2004;151(1):141-147.
28. Ceilley RI, Del Rosso JQ. Current modalities and new advances in the treatment of basal cell carcinoma. *Int J Dermatol*. 2006;45(5):489-498.
29. Rowe DE, Carroll RJ, Day CL Jr. Mohs surgery is the treatment of choice for recurrent (previously treated) basal cell carcinoma. *J Dermatol Surg Oncol*. 1989;15(4):424-431.
30. Linos E, Parvataneni R, Stuart SE, et al. Treatment of nonfatal conditions at the end of life: nonmelanoma skin cancer. *JAMA Intern Med*. 2013;173(11): 1006-1012.

31. Asgari MM, Bertenthal D, Sen S, et al. Patient satisfaction after treatment of nonmelanoma skin cancer. *Dermatol Surg*. 2009;35(7):1041-1049.
32. Fernandes JD, de Lorenzo Messina MC, de Almeida Pimentel ER, et al. Presence of residual basal cell carcinoma in re-excised specimens is more probable when deep and lateral margins were positive. *J Eur Acad Dermatol Venereol*. 2008;22(6):704-706.
33. Kopf AW, Bart RS, Schrager D, et al. Curettage-electrodesiccation treatment of basal cell carcinomas. *Arch Dermatol*. 1977;113(4):439-443.
34. Rodriguez-Vigil T, Vazquez-Lopez F, Perez-Oliva N. Recurrence rates of primary basal cell carcinoma in facial risk areas treated with curettage and electrodesiccation. *J Am Acad Dermatol*. 2007. 56(1):91-95.
35. Thissen MR, Neumann MH, Schouten LJ. A systematic review of treatment modalities for primary basal cell carcinomas. *Arch Dermatol*. 1999;135(10):1177-1183.
36. Kuflik EG, Gage AA. The five-year cure rate achieved by cryosurgery for skin cancer. *J Am Acad Dermatol*. 1991;24(6 Pt 1):1002-1004.
37. Thissen MR, Nieman FH, Ideler AH, et al. Cosmetic results of cryosurgery versus surgical excision for primary uncomplicated basal cell carcinomas of the head and neck. *Dermatol Surg*. 2000;26(8):759-764.
38. Geisse J, Caro I, Lindholm J, et al. Imiquimod 5% cream for the treatment of superficial basal cell carcinoma: results from two phase III, randomized, vehicle-controlled studies. *J Am Acad Dermatol*. 2004;50(5):722-733.
39. Geisse JK, Rich P, Pandya A, et al. Imiquimod 5% cream for the treatment of superficial basal cell carcinoma: a double-blind, randomized, vehicle-controlled study. *J Am Acad Dermatol*. 2002;47(3):390-398.
40. Peri K, Campione E, Micantonio T, et al. Imiquimod treatment of superficial and nodular basal cell carcinoma: 12-week open-label trial. *Dermatol Surg*. 2005;31(3):318-323.
41. Murphy ME, Brodland DG, Zitelli JA. Definitive surgical treatment of 24 skin cancers not cured by prior imiquimod therapy: a case series. *Dermatol Surg*. 2008;34(9):1258-1263.
42. Epstein E. Fluorouracil paste treatment of thin basal cell carcinomas. *Arch Dermatol*. 1985;121(2):207-213.
43. Gross K, Kircik L, Kricorian G. 5% 5-Fluorouracil cream for the treatment of small superficial Basal cell carcinoma: efficacy, tolerability, cosmetic outcome, and patient satisfaction. *Dermatol Surg*. 2007;33(4):433-439; discussion 440.
44. Basset-Seguin N, Ibbotson SH, Emtestam L, et al. Topical methyl aminolaevulinate photodynamic therapy versus cryotherapy for superficial basal cell carcinoma: a 5 year randomized trial. *Eur J Dermatol*. 2008;18(5):547-553.
45. Marmur ES, Schmults CD, Goldberg DJ. A review of laser and photodynamic therapy for the treatment of nonmelanoma skin cancer. *Dermatol Surg*. 2004;30(2 Pt 2):264-271.
46. Szeimies RM. Methyl aminolevulinate-photodynamic therapy for basal cell carcinoma. *Dermatol Clin*. 2007;25(1):89-94.
47. Arits AH, Mosterd K, Essers BA, et al. Photodynamic therapy versus topical imiquimod versus topical fluorouracil for treatment of superficial basal-cell carcinoma: a single blind, non-inferiority, randomised controlled trial. *Lancet Oncol*. 2013;14(7):647-654.
48. Avril MF, Auperin A, Margulis A, et al. Basal cell carcinoma of the face: surgery or radiotherapy? Results of a randomized study. *Br J Cancer*. 1997;76(1):100-106.
49. Dunn M, Morgan MB, Beer TW. Perineural invasion: identification, significance, and a standardized definition. *Dermatol Surg*. 2009;35(2):214-221.
50. Sherman JE, Talmor M. Slow progression and sequential documentation of a giant basal cell carcinoma of the face. *Surgery*. 2001;130(1):90-92.
51. Wysong A, Aasi SZ, Tang JY. Update on metastatic basal cell carcinoma: a summary of published cases from 1981 through 2011. *JAMA Dermatol*. 2013;149(5):615-616.
52. Sekulic A, Migden MR, Lewis K, et al. Pivotal ERIVANCE basal cell carcinoma (BCC) study: 12-month update of efficacy and safety of vismodegib in advanced BCC. *J Am Acad Dermatol*. 2015;72(6):1021-6;e8.
53. Von Hoff DD, LoRusso PM, Rudin CM, et al. Inhibition of the hedgehog pathway in advanced basal-cell carcinoma. *N Engl J Med*. 2009;361(12):1164-1172.
54. Migden MR, Guminski A, Gutzmer R, et al. Treatment with two different doses of sonidegib in patients with locally advanced or metastatic basal cell carcinoma (BOLT): a multicentre, randomised, double-blind phase 2 trial. *Lancet Oncol*. 2015;16(6):716-728.
55. von Domarus H, Stevens PJ. Metastatic basal cell carcinoma. Report of five cases and review of 170 cases in the literature. *J Am Acad Dermatol*. 1984;10(6):1043-1060.
56. Elghissassi I, Mikou A, Inrhaoun H, et al. Metastatic basal cell carcinoma to the bone and bone marrow. *Int J Dermatol*. 2009;48(5):481-483.
57. Carneiro BA, Watkin WG, Mehta UK, et al. Metastatic basal cell carcinoma: complete response to chemotherapy and associated pure red cell aplasia. *Cancer Invest*. 2006;24(4):396-400.
58. Williams JA, Guicherit OM, Zaharian BI, et al. Identification of a small molecule inhibitor of the hedgehog signaling pathway: effects on basal cell carcinoma-like lesions. *Proc Natl Acad Sci UA*. 2003;100(8):4616-4621.
59. Rudin CM, Hann CL, Laterra J, et al. Treatment of medulloblastoma with hedgehog pathway inhibitor GDC-0449. *N Engl J Med*. 2009;361(12):1173-1178.
60. Atwood SX, Sarin KY, Whitson RJ, et al. Smoothened variants explain the majority of drug resistance in basal cell carcinoma. *Cancer Cell*. 2015;27(3):342-353.
61. Atwood SX, Chang AL, Oro AE. Hedgehog pathway inhibition and the race against tumor evolution. *J Cell Biol*. 2012;199(2):193-197.
62. Sharpe HJ, Pau G, Dijkgraaf GJ, et al. Genomic analysis of smoothened inhibitor resistance in basal cell carcinoma. *Cancer Cell*. 2015;27(3):327-341.
63. Madan V, Lear JT, Szeimies RM. Non-melanoma skin cancer. *Lancet*. 2010;375(9715):673-685.
64. Chen AC, Martin AJ, Damian DL. Nicotinamide for skin-cancer chemoprevention. *N Engl J Med*. 2016;374(8):790.
65. Elmets CA, Viner JL, Pentland AP, et al. Chemoprevention of nonmelanoma skin cancer with celecoxib: a randomized, double-blind, placebo-controlled trial. *J Natl Cancer Inst*. 2010;102(24):1835-1844.
66. Gorlin RJ. Nevoid basal-cell carcinoma syndrome. *Medicine (Baltimore)*. 1987;66(2):98-113.
67. Gorlin RJ, Goltz RW. Multiple nevoid basal-cell epithelioma, jaw cysts and bifid rib. A syndrome. *N Engl J Med*. 1960;262:908-912.

68. Howell JB, Caro MR. The basal-cell nevus: its relationship to multiple cutaneous cancers and associated anomalies of development. *AMA Arch Derm*. 1959;79(1):67-77; discussion 77-80.
69. Farndon PA, Morris DJ, Hardy C, et al. Analysis of 133 meioses places the genes for nevoid basal cell carcinoma (Gorlin) syndrome and Fanconi anemia group C in a 2.6-cM interval and contributes to the fine map of 9q22.3. *Genomics*. 1994;23(2): 486-489.
70. Shanley S, Ratcliffe J, Hockey A, et al. Nevoid basal cell carcinoma syndrome: review of 118 affected individuals. *Am J Med Genet*. 1994;50(3):282-290.
71. Evans DG, Ladusans EJ, Rimmer S, et al. Complications of the naevoid basal cell carcinoma syndrome: results of a population based study. *J Med Genet*. 1993;30(6):460-464.
72. Hahn H, Wicking C, Zaphiropoulous PG, et al. Mutations of the human homolog of Drosophila patched in the nevoid basal cell carcinoma syndrome. *Cell*. 1996;85:841-851.
73. Johnson RL, Rothman AL, Xie J, et al. Human homolog of patched, a candidate gene for the basal cell nevus syndrome. *Science*. 1996;272(5268): 1668-1671.
74. Ingham PW. Hedgehog signalling. *Curr Biol*. 2008; 18(6):R238-R241.
75. Howell JB. Nevoid basal cell carcinoma syndrome. Profile of genetic and environmental factors in oncogenesis. *J Am Acad Dermatol*. 1984;11(1):98-104.
76. Goodrich LV, Milenković L, Higgins KM, et al. Altered neural cell fates and medulloblastoma in mouse patched mutants. *Science*. 1997;277(5329): 1109-1113.
77. Hahn H, Wicking C, Zaphiropoulous PG, et al. Mutations of the human homolog of Drosophila patched in the nevoid basal cell carcinoma syndrome. *Cell*. 1996;85(6):841-851.
78. Hahn H, Wojnowski L, Zimmer AM, et al. Rhabdomyosarcomas and radiation hypersensitivity in a mouse model of Gorlin syndrome. *Nat Med*. 1998; 4(5):619-622.
79. Kimonis VE, Goldstein AM, Pastakia B, et al. Clinical manifestations in 105 persons with nevoid basal cell carcinoma syndrome. *Am J Med Genet*. 1997; 69(3):299-308.
80. Pruvost-Balland C, Gorry P, Boutet N, et al. Etude clinique et recherche de mutations germinales du gene PTCH1 dans le syndrome des harmartomaes basocellulaires. *Ann Dermatol Venereol*. 2006;113: 117-123.
81. Pastorino L, Ghiorzo P, Nasti S, et al. Identification of a SUFU germline mutation in a family with Gorlin syndrome. *Am J Med Genet A*. 2009;149A(7): 1539-1543.
82. Smith MJ, Beetz C, Williams SG, et al. Germline mutations in SUFU cause Gorlin syndrome–associated childhood medulloblastoma and redefine the risk associated with PTCH1 mutations. *J Clin Oncol*. 2014; 32(36):4155-4161.
83. Oro AE. Mammalian variations on a theme: a Smo and Sufu surprise. *Dev Cell*. 2006;10(2):156-158.
84. Taipale J, Cooper MK, Maiti T, et al. Patched acts catalytically to suppress the activity of Smoothened. *Nature*. 2002;418(6900):892-897.
85. Rohatgi R, Milenkovic L, Scott MP. Patched1 regulates hedgehog signaling at the primary cilium. *Science*. 2007;317(5836):372-376.
86. Ling G, Ahmadian A, Persson A, et al. PATCHED and p53 gene alterations in sporadic and hereditary basal cell cancer. *Oncogene*. 2001;20(53):7770-7778.
87. Xie J, Murone M, Luoh SM, et al. Activating Smoothened mutations in sporadic basal-cell carcinoma. *Nature*. 1998;391(6662):90-92.
88. Taylor MD, Liu L, Raffel C, et al. Mutations in SUFU predispose to medulloblastoma. *Nat Genet*. 2002; 31(3):306-310.
89. Aszterbaum M, Epstein J, Oro A, et al. Ultraviolet and ionizing radiation enhance the growth of BCCs and trichoblastomas in patched heterozygous knockout mice. *Nat Med*. 1999;5(11):1285-1291.
90. Sun LS, Li XF, Li TJ. PTCH1 and SMO gene alterations in keratocystic odontogenic tumors. *J Dent Res*. 2008; 87(6):575-579.
91. Shear M. The aggressive nature of the odontogenic keratocyst: is it a benign cystic neoplasm? Part 2. Proliferation and genetic studies. *Oral Oncol*. 2002; 38(4):323-331.
92. Wicking C, Shanley S, Smyth I, et al. Most germline mutations in the nevoid basal cell carcinoma syndrome lead to a premature termination of the PATCHED protein, and no genotype-phenotype correlations are evident. *Am J Hum Genet*. 1997; 60(1):21-26.
93. Goeteyn M, Geerts ML, Kint A, et al. The Bazex-Dupre-Christol syndrome. *Arch Dermatol*. 1994;130(3): 337-342.
94. Ashinoff R, Jacobson M, Belsito DV. Rombo syndrome: a second case report and review. *J Am Acad Dermatol*. 1993;28(6):1011-1014.
95. Oley CA, Sharpe H, Chenevix-Trench G. Basal cell carcinomas, coarse sparse hair, and milia. *Am J Med Genet*. 1992;43(5):799-804.
96. Requena L, Fariña MC, Robledo M, et al. Multiple hereditary infundibulocystic basal cell carcinomas: a genodermatosis different from nevoid basal cell carcinoma syndrome. *Arch Dermatol*. 1999; 135(10):1227-1235.
97. Jih DM, Shapiro M, James WD, et al. Familial basaloid follicular hamartoma: lesional characterization and review of the literature. *Am J Dermatopathol*. 2003;25(2):130-137.
98. Schulman JM, Oh DH, Sanborn JZ, et al. Multiple hereditary infundibulocystic basal cell carcinoma syndrome associated with a germline SUFU mutation. *JAMA Dermatol*. 2016;152(3):323-327.
99. Mann K, Magee J, Guillaud-Bataille M, et al. Multiple skin hamartomata: a possible novel clinical presentation of SUFU neoplasia syndrome. *Fam Cancer*. 2015;14(1):151-155.
100. Cho HG, Kuo KY, Epstein E, et al. Inherited cancer susceptibility mutations in individuals who develop high frequency of basal cell carcinomas [abstract]. Portland, OR, Society of Investigative Dermatology, April 26-29, 2017.
101. Cho HG, Kuo KY, Li S, et al. Frequent basal cell cancer development is a clinical marker for inherited cancer susceptibility. *JCI Insight*. 2018;3(15):e122744.
102. Kimonis VE, Mehta SG, Digiovanna JJ, et al. Radiological features in 82 patients with nevoid basal cell carcinoma (NBCC or Gorlin) syndrome. *Genet Med*. 2004;6(6):495-502.
103. Ionescu DN, Arida M, Jukic DM. Metastatic basal cell carcinoma: four case reports, review of literature, and immunohistochemical evaluation. *Arch Pathol Lab Med*. 2006;130(1):45-51.

104. Oro AE, Higgins KM. Hair cycle regulation of Hedgehog signal reception. *Dev Biol*. 2003;255(2): 238-248.
105. Reymann F. Treatment of basal cell carcinoma of the skin with 5-fluorouracil ointment. A 10-year follow-up study. *Dermatologica*. 1979;158(5):368-372.
106. Stockfleth E, Ulrich C, Hauschild A, et al. Successful treatment of basal cell carcinomas in a nevoid basal cell carcinoma syndrome with topical 5% imiquimod. *Eur J Dermatol*. 2002;12(6):569-572.
107. Wilson BD, Mang TS, Stoll H, et al. Photodynamic therapy for the treatment of basal cell carcinoma. *Arch Dermatol*. 1992;128(12):1597-1601.
108. Tang JY, Mackay-Wiggan JM, Aszterbaum M, et al. Inhibiting the hedgehog pathway in patients with the basal-cell nevus syndrome. *N Engl J Med*. 2012; 366(23):2180-2188.
109. Tang JY, Ally MS, Chanana AM, et al. Inhibiting the hedgehog pathway in patients with basal-cell nevus syndrome: final results from the 36-month trial. *Lancet Oncol*. 2016;17(12):1720-1731.

Chapter 112 :: Squamous Cell Carcinoma and Keratoacanthoma

:: Anke S. Lonsdorf & Eva N. Hadaschik

AT-A-GLANCE

- Squamous cell carcinoma (SCC) is the second most common skin cancer, after basal cell carcinoma, in immunocompetent white individuals, and the most common skin cancer in immunosuppressed organ transplantation recipients worldwide.
- SCC development in the skin is considered a multistep process, most invasive SCCs develop from preinvasive lesions or in situ tumors such as actinic keratosis or Bowen disease.
- Risk factors for SCC include ultraviolet (UV) radiation, genetic predisposition, physical and chemical carcinogens, immunosuppression, drugs, viral infection, chronic inflammation, and chronic injury of the skin.
- Diagnosis of SCC is established histologically. Histologic subtypes include spindle-cell, acantholytic, verrucous, and desmoplastic SCCs, and keratoacanthoma.
- High-risk features for local recurrence and the development of metastatic disease include >2 mm thickness; Clark level higher than IV; perineural invasion; lip or ear as primary site; poorly or undifferentiated tumor.
- The primary mode of therapy for localized SCC is complete surgical excision, preferentially microscopically controlled surgery (Mohs surgery). Nonsurgical interventions include topical therapy, and for locally advanced, unresectable or metastatic SCC, radiation therapy and systemic treatment with chemotherapy or targeted therapy.
- Primary prevention for the development of SCC is based on decreasing UV radiation exposure and concomitant risk factors, and the effective treatment of precursor lesions. Systemic retinoids, niacinamide, as well as change of the immunosuppressive regimen in solid-organ transplantation recipients may be options for the secondary prevention of SCC in high-risk patients.

EPIDEMIOLOGY AND DEMOGRAPHICS

An accurate incidence of squamous cell carcinoma (SCC) is unknown, but the cancer is among the most common and costly malignancies in populations of European ancestry.[1] The morbidity and mortality of SCC seem to be rather underestimated public health issues,[2] and the health burden is considerable, particularly when considering high-risk populations, such as immunosuppressed patients, in which a 65-fold to 250-fold increased incidence of SCC has been reported.[3,4]

INCIDENCE

The accurate incidence of SCC is unknown as the majority of cancer registries in most countries do not generally document nonmelanoma skin cancers (NMSCs) and statistics frequently fail to include any subsequent tumors after the first SCC and to discriminate between cutaneous and mucosal SCC. However, assuming that 20% of NMSCs are SCCs,[5,6] the estimated annual incidence of SCC in the United States is 700,000 cases. Therefore, SCC is, after basal cell carcinoma (BCC), the second most common skin cancer in immunocompetent white individuals and the most common skin cancer in immunosuppressed organ transplantation recipients worldwide.[7] The incidence of SCC is steadily rising, with reported increases of 50% to 200% over the past 3 decades; this rise is largely attributed to a greater lifetime ultraviolet radiation (UVR) exposure as a result of greater longevity, ozone depletion, and increased voluntary exposure to UVR.[8]

MORBIDITY AND MORTALITY

The vast majority of SCC patients present with early-stage disease, and prognosis is excellent in the majority of cases. Most SCCs are readily treated and cured with surgery. However, after a diagnosis of SCC, patients have an increased risk of developing secondary NMSC.

The risk of developing metastasis from SCC is generally low, with a 5-year metastatic rate of 5%.[9] Metastases are predominantly nodal.[10] However, depending on patient and tumor characteristics, certain subgroups of patients are at significantly higher

risk for metastasis, with metastatic rates of up to 30% in some subgroups (see 'Prognosis').[9] Outcome is particularly poor for metastatic disease, and SCC accounts for the vast majority of deaths attributed to NMSC.[5]

GEOGRAPHIC FACTORS

Geographic variation in the incidence of SCC is largely attributed to ambient UV irradiation as suggested by the reported inverse association with latitude.[5,7] Ethnicity and skin type have an effect on incidence rates and therefore reported incidence rates worldwide may somewhat reflect the geographical distribution of ethnicity and skin type; however, within countries, the closer to the equator the higher the incidence of SCC in white individuals with similar gradients for both genders and all ages.[5,7] With a reported rate of 387 per 100,000 person-years, Australians, exposed to very high, long-term UVR levels, are more likely to develop SCC than other populations in countries with more intermittent UVR exposure such as the United Kingdom.[7,11] Altitude also has an effect on SCC incidence; Switzerland has the highest altitude of all mainland Europe and reportedly the highest SCC incidence rates, as well as showing the fastest increase.[7]

AGE

SCC incidence increases with age and mostly affects individuals 60 years of age and older.[12] As the cumulative lifetime exposure to UVR is thought to be the predominant etiologic risk factor for skin carcinogenesis, the age shift in the population along with lifestyle changes (ie, increased voluntary exposure to UVR) during the past decades have been suggested to be major causes of the overall increase in total numbers of SCC in most countries.[5]

SEX

The incidence of SCC is higher in men than in women[5] and is attributed to a greater lifetime UVR exposure in men. However, studies on the role of functional polymorphisms in UV-induced immunosuppression pathways have suggested the existence of a gender-based differential genetic susceptibility to UV-induced immunosuppression and the risk for SCC.[13]

RACE

Sun-sensitive individuals with red hair, blue eyes, and fair complexion are at higher risk for developing SCC than individuals with darker pigmentation. Even though SCC is the most common skin cancer phenotype in American blacks, the incidence of SCC is decreased by 30-fold compared to whites, with SCC typically arising on non–sun-exposed skin at sites of predisposing skin conditions.[14] Albinism is associated with a high risk for SCC, even in black individuals, which provides further evidence for the relationships between skin carcinogenesis and sun-exposure and the protective effect of eumelanin in the skin.[15]

ETIOLOGY AND PATHOGENESIS

Figure 112-1 is a schematic of SCC etiology/pathophysiology. Table 112-1 outlines the syndromes and genes associated with a predisposition for SCC and/or keratoacanthoma (KA).

PRECURSOR LESIONS

SCCs are thought to typically arise from basal keratinocytes of the interfollicular epidermis. SCC development in the skin is considered a multistep process, and most invasive SCCs develop from preinvasive lesions or in situ tumors, such as actinic keratosis (AK) or Bowen disease (see Chap. 110).[16] Although the cumulative risk depends on the number of lesions and the length of time they persist, estimates of the annual rate per AK of progression into invasive disease range from 0.025% to 20%.[17,18] The estimated cumulative lifetime risk among patients with multiple AK is approximately 6% to 10%.[19]

Other noninvasive, precancerous conditions that may evolve into SCC include bowenoid papulosis and erythroplasia of Queyrat.

KA is a squamous neoplasm characterized by a rapid growth phase and subsequent slow spontaneous regression and is controversially discussed in the classical sequence of skin carcinogenesis.[20]

RISK FACTORS

The risk for SCC development is attributed to genotypic, phenotypic, and environmental factors. UVR is classified by the IARC (International Agency for Research on Cancer) as a class I carcinogen, sufficient for the initiation, promotion, and progression of squamous carcinogenesis of the skin,[21] and the most important environmental risk factor for SCC. Other major risk factors predisposing for SCC include exposure to physical and chemical carcinogens, genetic predisposition and immunosuppression (Table 112-2).

ULTRAVIOLET RADIATION

Exposure to UVR (both UVB and UVA) has been recognized as the most important environmental risk factor for the development of SCC with a strong dose–response association,[5,22] as suggested by the preferential localization of AK and SCC on sun-exposed and

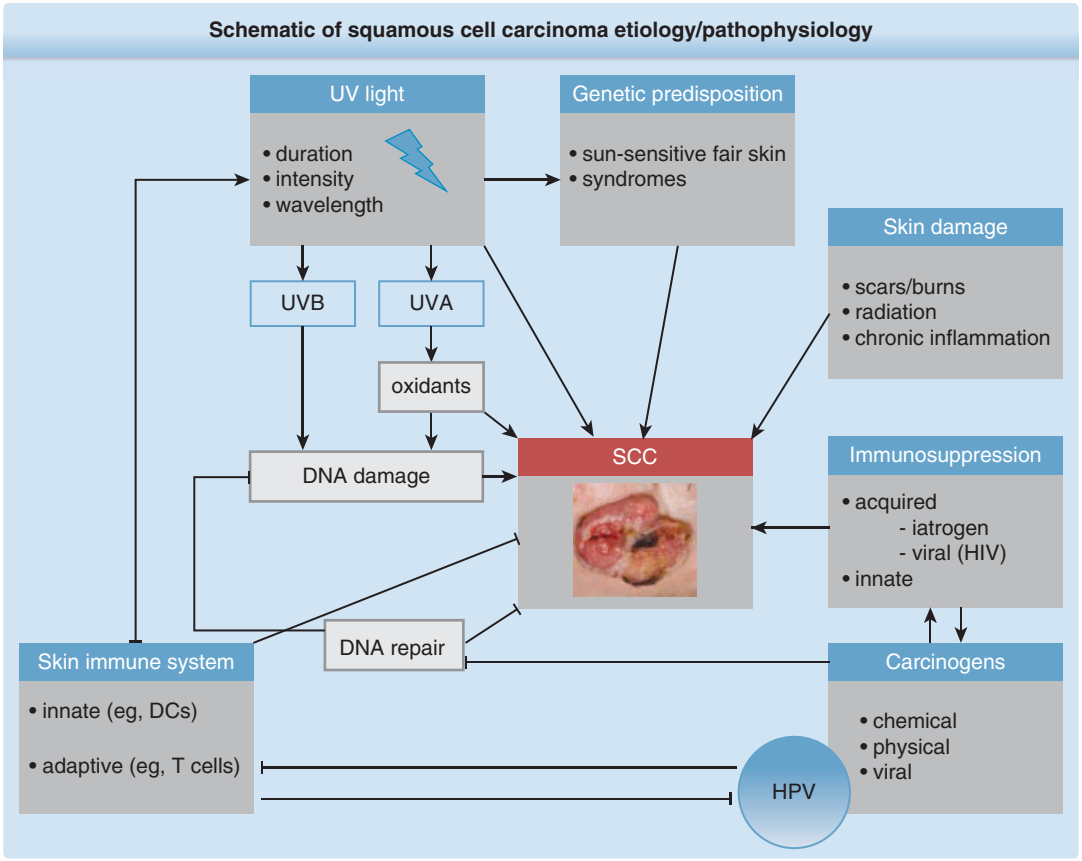

Figure 112-1 Schematic of squamous cell carcinoma (SCC) etiology/pathophysiology.

chronically photodamaged sites and in sun-sensitive phenotypes (ie, patients with fair complexions) with increasing age and high cumulative UV irradiation.

UVB-induced mutagenesis of the skin gives rise to specific UV signature mutations (ie, characteristic C-T and CC-TT dipyrimidine transitions), which constitute the majority of mutations found in SCC.[23] Genotoxicity of UVA radiation seems mostly to indirectly add to the risk, primarily by photooxidative stress-mediated mechanisms such as the induction of reactive oxygen species in the skin.[24,25]

In addition to the mutagenic effects, UVR is thought to promote SCC development by its immunosuppressive and immunomodulatory properties, such as depletion of Langerhans cells from the epidermis, improper antigen presentation in skin-draining lymph nodes, and hindered tumor surveillance by the expansion of tumor antigen-specific regulatory T cells and a shift toward T-helper cell type 2 responses in UV-irradiated skin.[13]

GENETIC PREDISPOSITION

Genetic factors may critically potentiate the risk conveyed by environmental risk factors such as UVR. Clinical skin phenotype is defined by constitutive and facultative pigmentation, which are controlled by more than 150 genes.[23] Light skin complexion (as in skin photo types I and II) and the underlying genetic variations in the melanocortin-1 receptor, predispose for UV sensitivity of the skin and are associated with a high incidence of SCC.[26] Single-nucleotide polymorphisms in pigmentation genes, such as *tyrosinase (TYR)* required for melanization in melanosomes, are significantly associated with SCC risk.[13,27,28]

Oculocutaneous albinism, which is characterized by impaired melanin biosynthesis, is the most common inherited pigmentary disorder of the skin and is associated with an increased risk of developing SCC, particularly in sun-exposed skin areas.[15] Black albinos in sub-Saharan Africa are at approximately a 1000-fold higher risk of developing SCC of the skin than the general population.[15]

The incidence of SCC is also highly elevated in other genetic skin disorders.[10] Patients with recessive dystrophic epidermolysis bullosa (RDEB), a skin fragility disorder caused by mutations in the *COL7A1* gene encoding collagen VII, are at high risk for developing aggressive SCC. In the most-severe form of RDEB, the cumulative risk of SCC is greater than 90% by age 55 years and 80% of RDEB patients die from metastasis within 5 years after their first SCC.[29]

A genetic predisposition to SCC is well recognized in certain family cancer syndromes, and inherited defects in DNA repair and genomic stability, such as aberrations in nucleotide excision repair genes *XPA-G* and *XP-V* (xeroderma pigmentosum), *PTEN* (Cowden

TABLE 112-1

Syndromes and Genes Associated with a Predisposition for Squamous Cell Carcinoma and/or Keratoacanthoma

DISEASE/SYNDROME	GENE(S)	MAIN FUNCTION
Squamous Cell Carcinoma		
Bloom syndrome	*BLM/RECQL3*	Maintenance of chromosomal stability
Dyskeratosis congenita (Zinsser-Cole-Engman syndrome)	*DKC1, TERC, TINF2, NHP2/NOLA2*	Telomere homeostasis and trafficking of telomerase
Epidermodysplasia verruciformis (EV)	*EVER1/TMC6, EVER2/TMC8*	Regulation of zinc homeostasis, signal transduction in endoplasmic reticulum
Epidermolysis bullosa (EB) (a) Dystrophic EB (DEB) (b) Junctional EB (JEB)	(a) *COL7A1* (b) *LAMA3, LAMB3, LAMC2, COL17A1*	(a) Anchoring of basement membrane to dermis (b) Anchoring of epidermis to basement membrane, connective tissue
Fanconi anemia	*FANCA, FANCB, FANCC, FANCD1/BRCA2, FANCD2, FANCE, FANCF, FANCG/XRCC9, FANCI, FANCJ/BACH1, FANCL/PHF9, FANCM, FANCN/PALB2, FANCO/RAD51C, FANKP/SLX4, FANCQ/ERCC4, FANCS*	DNA crosslink repair
Oculocutaneous albinism (OCA)	*TYR, OCA2, MATP/OCA4, TYRP1*, Locus 4q24, *SLC24A5, C10Orf11*	Melanin synthesis
Other syndromes associated with albinism/decreased pigmentation of the skin: (a) Chediak-Higashi syndrome (b) Elejalde disease (c) Griscelli syndrome (d) Hermansky-Pudlak syndrome	(a) *LYST* (b) *MYO5A* (c) *MYO5A, RAB27A, MLPH* (d) *HPS1, HPS3, HPS4, HPS5, HPS6, HPS7/DTNBP1, HPS8/BLOC1S3*	(a) Regulation of lysosomal transport (b) Transport of pigment granule (c) Transport of pigment granule (d) Melanosomal and lysosomal storage
Rothmund-Thomson syndrome	*RECQL4, C16orf57*	Maintenance of chromosomal stability
Werner syndrome	*WRN/RECQL2*	Maintenance of chromosomal stability
Xeroderma pigmentosum (XP)	*XPA, XPB/ERCC3, XPC, XPD/ERCC2, XPE/DDB2, XPF/ERCC4, XPG/ERCC5, XPG*	Nucleotide excision repair
XP variant	*POLH/XPV*	Error-prone DNA polymerase
Keratoacanthoma		
Muir-Torre syndrome	*MSH1, MSH2*	DNA mismatch repair
Multiple self-healing squamous epithelioma (Ferguson–Smith syndrome)	*TGFBR1*	Transforming growth factor β–receptor 1 signaling

Information adapted from the National Cancer Institute Database, available at http://www.cancer.gov.

syndrome), *FANCA-N* (Fanconi anemia), *TP53* (Li-Fraumeni syndrome), *RECQL4* (Rothmund-Thomson syndrome), *WRN* (Werner syndrome), telomere maintenance (dyskeratosis congenita), and mammalian mismatch repair (Muir-Torre syndrome).[23]

A 40-year followup found that patients with xeroderma pigmentosum before age 20 years had a more than 10,000-fold increase in NMSC, especially at UV-exposed sites.[30]

PHYSICAL AND CHEMICAL CARCINOGENS

Historically, the exposure to occupational and environmental carcinogenic agents has been a major cause of SCC.[9] Arsenic, used in various medications, tainted wine, and unprocessed well water may stimulate skin carcinogenesis.[31] Cutting oils constitute a risk of SCC development in certain industrial occupations and the high incidence of SCC on the scrotum of chimney sweeps is attributed to chronic exposure to ash and polycyclic aromatic hydrocarbons derived from carbon compounds such as coal tar.[9]

In addition to the significant contribution of UVR, ionizing irradiation also is implicated in the pathogenesis of SCC, based on studies on ionizing irradiation being used for the treatment of acne, hemangiomas, and other skin conditions, and workers in certain medical or industrial fields who may be exposed to ionizing irradiation. The latency period for SCC development in patients with chronic radiation dermatitis is typically long (approximately 30 years).[32] The risk for SCC is reported to be directly related to the cumulative dose of ionizing radiation.[9]

IMMUNOSUPPRESSION

Innate and acquired immunosuppression dramatically increases the risk of developing SCC.[33] Immunosuppression is reported as a risk factor for high tumor

TABLE 112-2
Risk Factors for the Development of Squamous Cell Carcinoma

RISK FACTOR	EXAMPLES
Carcinoma in situ and precursor lesions	▪ Actinic keratoses ▪ Bowen disease ▪ Erythroplasia of Queyrat ▪ Bowenoid papulosis
Physical and chemical carcinogens	▪ Ultraviolet (UV) radiation (UVA and UVB) ▪ Ionizing irradiation ▪ Arsenic ▪ Polycyclic aromatic hydrocarbons
Genetic predisposition	▪ Skin phenotype (sun-sensitive, fair skin complexion) ▪ Oculocutaneous albinism ▪ Xeroderma pigmentosum (XP) ▪ Epidermodysplasia verruciformis (EV) ▪ Recessive dystrophic epidermolysis bullosa (RDEB)
Immunosuppression	▪ Iatrogenic immunosuppression (eg, solid-organ transplantation recipients, patients with autoimmune or rheumatoid disease) ▪ Hematopoietic stem cell transplantation ▪ Infection with HIV/AIDS ▪ Chronic lymphatic leukemia (CLL)
Drugs	▪ Immunosuppressive drugs (eg, azathioprine, cyclosporine) ▪ Photosensitizing drugs (eg, doxycycline, fluoroquinolone, triazole antifungals) ▪ Targeted therapies (eg, BRAF [v-raf murine sarcoma viral oncogene homolog B] inhibitors vemurafenib and dabrafenib; tyrosine kinase inhibitor sorafenib; hedgehog pathway inhibitor vismodegib)
Chronic inflammation and chronic injury of the skin	▪ Chronic ulcers ▪ Burn scars ▪ Discoid lupus erythematodes ▪ Lichen ruber mucosae ▪ Lichen sclerosus ▪ Lupus vulgaris ▪ Infection with human papillomavirus (HPV) ▪ RDEB

burden,[34] metastatic disease,[35] and disease-specific death from SCC.[36]

Long-term immunosuppressed patients, such as in solid-organ transplantation recipients (OTRs),[33] hematopoietic stem-cell transplant recipients,[37] and patients with HIV or a history of autoimmune or rheumatoid disease,[38] are at increased risk for SCC of the skin. In OTRs, the most frequent malignancy is skin cancers, 95% of which are NMSC, mostly SCC.[33] The ratio of SCC to basal cell carcinoma (BCC) reverses in immunosuppressed patients, with SCC being the most frequent NMSC; in the general population, BCC occurs 6 times more frequently than SCC.[3,33] SCC in OTRs occur predominantly in sun-exposed skin in areas of field cancerization and appear an average of 2 to 4 years after transplantation.[39] OTRs have been reported to have an up to 65-fold increase in the incidence of SCC,[3] an increased risk for high tumor burden[34] and developing multiple and aggressive, high-risk histologic subtypes of SCC, and a poorer outcome in advanced disease compared with the general population.[22,39] The incidence of SCC in OTRs in the United States and western Europe increases from 10% to 27% at 10 years after transplantation to 40% to 60% at 20 years after transplantation, compared to the highest incidence in Australia, which is 80% at 20 years after transplantation.[40] Type, duration, and intensity of the immunosuppressive regimen, as well as the age at transplantation, cumulative exposure to UVR, and skin type affect the risk for posttransplantation skin cancer.[40,41] Heart and lung transplantation recipients have a higher risk of SCC development than renal transplantation or liver transplantation recipients because of generally more intensive immunosuppressive regimens and older age at time of transplantation.[41] Revision of the immunosuppressive regimen, strict sun-protection measures, the early treatment of preinvasive and invasive NMSC, and close dermatologic surveillance is crucial in the management of high-risk immunosuppressed patients.[41]

DRUGS

The chronic use of photosensitizing drugs (eg, antibiotics, fluoroquinolone, triazole antifungals) and long-term therapy with psoralen plus UVA radiation for chronic inflammatory skin diseases increases the risk for SCC, particularly in patients with sun-sensitive skin types[42,43] and immunosuppressed patients such as OTRs.[41]

Substance-specific effects of immunosuppressive drugs are reported to affect the skin cancer risk independent of host immunity. Interference with cellular DNA repair, induction of oxidative stress, and upregulation of the *p53* oncogene are reported mechanisms by which commonly used immunosuppressants may contribute to the elevated risk for SCC. Azathioprine, in particular, may drive photocarcinogenesis in the skin by synergizing with mutagenic UV(A)-induced DNA-damage and DNA repair.[44,45]

Conversely, a multicenter, randomized, controlled trial indicated that the mammalian target of rapamycin (mTOR) inhibitor sirolimus decreases the risk of developing secondary posttransplantation SCC and delays the occurrence of lesions in kidney transplantation recipients compared to cyclosporine-based immunosuppressive therapy.[46] Although the exact mechanisms for the antineoplastic properties of mTOR inhibitors in SCCs are unknown, mTOR inhibitors are reported to interrupt the phosphatidylinositide 3′-kinase (PI3K)–AKT pathway, which plays a critical role in the regulation of cell proliferation, survival, mobility, and angiogenesis, and may attenuate the pathway downstream of epidermal growth factor receptor (EGFR) signaling, which is frequently dysregulated in SCC.[23]

Although the conversion to a sirolimus-based immunosuppressive regimen may be limited by adverse side effects in some patients, it provides a strategy for the secondary skin cancer prevention in high-risk patients, such as OTRs.[46]

Drugs influencing the cell cycle, including v-raf murine sarcoma viral oncogene homolog B (BRAF)-inhibitors such as vemurafenib and dabrafenib, approved for the treatment of metastatic melanoma, and the kinase inhibitor sorafenib, are associated with the induction of rapidly developing well-differentiated SCC and/or eruptive KA as a side effect in up to 25% of patients.[47] A contribution of beta-human papillomavirus (HPV) infection and additional preexisting UV-induced somatic genetic alterations to the rapid-onset of SCC during BRAF-inhibition therapy has been suggested.[48,49] Likewise, the hedgehog pathway inhibitor vismodegib, approved for the targeted therapy for unresectable BCC, is reported to increase the risk for SCC with a hazard ratio of 8.12, accounting for age and basal cell nevus syndrome status,[50] highlighting the importance of continued skin surveillance after initiation of these therapies.

VIRAL INFECTION

Even though the exact role for HPVs in SCC pathogenesis remains poorly defined, HPVs have proposed to be a possible cocarcinogen in the development of SCC with environmental factors such as UVR. Epidemiologic studies suggest a link between these 2 factors in skin carcinogenesis[51,52] as a high prevalence of HPV DNA has been reported in sun-exposed skin in immunocompetent individuals.[51] Also, HPV prevalence and viral load are reportedly higher in AK compared to invasive SCC and normal-appearing skin, and HPVs, particularly of genus type beta, are believed to play a role in the initiation of SCC but may not be necessary for tumor maintenance.[53,54]

The oncogenic potential of HPV infection in SCC has been studied in epidermodysplasia verruciformis, an autosomal-recessive genodermatosis characterized by a high susceptibility for infection with predominantly beta-genus HPV-5 and HPV-8, and at high risk for developing SCC in chronically HPV-infected skin, particularly in sun-exposed areas.[51,55]

While the significance of specific types of alpha-genus HPV is well recognized in cervical and anogenital SCC, no specific cutaneous HPV subtypes have been clearly identified to be associated with cutaneous SCC because of the very high frequency of multiple infections.[1,52] Unlike the mucosal cancer–associated alpha-genus HPV, cutaneous beta-HPV is unable to integrate into the cellular DNA and is thought to convey its oncogenic potential indirectly by disturbing cellular DNA repair or apoptosis mechanisms, resulting in higher susceptibility for UV-induced damage in keratinocytes.[56-58] The oncogenicity of beta-HPV is largely attributed to a synergistic role between UV-induced DNA damage and the oncogenic potential of the viral proteins E6 and E7 to impair the tumor-suppressor function of p53 in keratinocytes (see section "Molecular Aspects").[53] The E6 proteins of certain HPV types of the beta genus are thought to prevent UV-induced apoptosis by degrading the proapoptotic protein Bak,[57,59] and some of the beta-HPV E6 proteins extend the life span of keratinocytes by activation of telomerase.[60] Conversely, UV light may have a transient immunosuppressive effect on skin predisposing for HPV infection and HPV viral immune evasion.[54] An increase in HPV prevalence was found in SCC from immunosuppressed patients compared with immunocompetent patients.[55]

KA, as a highly differentiated subtype of SCC has been proposed to represent a midpoint between a viral acanthoma and SCC.[61]

Even though its etiologic role remains to be elucidated, MCPyV polyoma virus, originally discovered in Merkel cell carcinoma, is reported to be associated with SCC arising in patients treated with BRAF inhibitors for metastatic melanoma.[62,63]

CHRONIC INFLAMMATION AND CHRONIC INJURY OF THE SKIN

SCCs are more likely to develop in chronically diseased or injured skin, including skin affected by chronic ulcers, burn scars, and radiation dermatitis. Chronic inflammatory disorders of the skin and mucosal tissue may also predispose for SCC development; these diseases include discoid lupus erythematodes, lichen ruber mucosae, lichen sclerosus, and dystrophic epidermolysis bullosa.[9] SCCs in RDEB most commonly occur in chronic, nonhealing ulcers with minimal UV exposure and chronic injury-driven stiffening of the dermal tumor microenvironment is a major contributing factor for rapid carcinoma progression in RDEB.[64]

MOLECULAR ASPECTS

The sequence of events in which normal keratinocytes transform into SCCs, referred to as *skin carcinogenesis*, is thought to be a multistep process of progressive and accumulating genetic and epigenetic alterations in key signaling pathways regulating cell survival, cell cycle, and genome maintenance.[16,65] The genomic instability and very high burden of mutations in SCC, which is significantly greater than in other solid tumors, impedes the identification of critical driver mutations, and it is increasingly apparent that multiple genes and pathways may be involved (reviewed in Harwood et al[23]).

TP53

Mutations in the tumor-suppressor gene p53 (*TP53*) are the most prominent and best studied aberrations in skin cancers,[20] and are likely to be a cause of the marked genomic instability observed in SCCs.[16] *TP53* exerts a central tumor-suppressor function in the response to UV damage through mechanisms such as induction of apoptosis and cell-cycle arrest. The protective role of p53 and the significance of p53-dependent apoptosis in response to UV-damage is emphasized by the high susceptibility of p53-deficient mice to UV-induced SCCs.[66]

Supporting the contribution of cumulative UV exposure in the pathogenesis of SCCs, clones of mutated

TP53 are highly prevalent in AK and in fields of chronically sun-damaged skin, and their expansion seems to be driven by continuing UVB exposure.[23] The loss of p53 provides a survival advantage for UV-damaged keratinocytes as the induction of apoptosis following UV-mediated DNA damage is hampered.[67] In this concept, UVR acts as a major initiator and promoter of skin carcinogenesis by inducing the accumulation of genetic alterations, such as p53 mutations in the skin, that allow for uncontrolled proliferation of keratinocytes and create a selective growth advantage as compared to normal cells. The loss of the second p53 allele is commonly found at later stages of SCC development and may be a critical event for the transition from AK and in situ carcinomas to invasive SCC.[23]

Of note, the E6 and E7 viral proteins of certain HPV types dysregulate the UV-activated cell-cycle checkpoints by inhibiting p53-mediated transcription of genes, which suggests a synergistic role between UV-induced DNA damage and the oncogenic potential of HPV.[68]

THE *RAS* PROTOONCOGENE AND EPIDERMAL GROWTH FACTOR RECEPTOR SIGNALING

The protooncogene *RAS* has been implicated in the initiation of SCC in murine chemical carcinogenesis models.[69] Data from the Catalog of Somatic Mutations in Cancer (COSMIC) indicates that 21% of SCCs harbor activating mutations in a least 1 of the 3 Ras genes (9% Hras, 7% Nras, 5% Kras).[70] UV-induced mutations in Ras genes also are found in AK and postulated to play a role during early stages of human UV-induced SCC development.[16,71] In an experimental setting, oncogenic *RAS* was insufficient to drive SCC formation in human keratinocytes alone, but did trigger epidermal tumorigenesis in the presence of additional blockade of nuclear factor κB, which is important for growth inhibition in keratinocytes.[72]

Interestingly, an increase in RAS mutations has been detected in rapidly developing, well-differentiated SCCs arising in patients receiving the BRAF-inhibitor vemurafenib for the treatment of advanced melanoma.[73]

Although the frequency of RAS mutations in most sporadic human SCCs is relatively low, an increase in levels of activated RAS in non-RAS mutant tumors and a consecutive upregulation of the downstream mitogen-activated protein kinase and the mTOR signaling pathways has been observed in human SCC.[72] It is postulated that in non-*RAS* mutant SCC the aberrant expression of the EGFR may contribute to the downstream activation of mitogen-activated protein kinase and mTOR signaling pathways.[23] EGFR (HER-1) is a member of the human epidermal growth receptor family of receptor tyrosine kinases on the surface of keratinocytes and persistently activated in SCC.[74] Although there is a high level of EGFR expression in SCC, the overall incidence of EGFR mutations is low and advanced SCC often shows a dysregulated EGFR expression in the absence of EGFR or RAS mutation.[74-76] Treatment with sirolimus, the mTOR inhibitor, is associated with a reduced rate of secondary SCCs in OTRs,[46] possibly in part by attenuating the downstream EGFR pathway, EGFR blockade, by employing either small molecules (eg, erlotinib) or antibodies (eg, cetuximab), may represent a therapeutic option for advanced or metastatic SCC.[77,78]

CLINICAL PRESENTATION

CLASSICAL PRESENTATION

The clinical presentation of SCC is variable and depends on the histologic subtype and location of the tumor. Typically, SCCs arise on sun-exposed areas, especially the face, head, and neck region, and the forearms and dorsum of the hands.[9] In UV-exposed skin, SCCs usually develop on a background of AK or Bowen disease as precursor lesions (see Chap. 110). Field cancerization with numerous precursor lesions on UV-damaged skin (Fig. 112-2) constitutes a high risk for progression to SCC; de novo formation on undamaged skin rarely occurs. The typical clinical finding of SCC includes slowly enlarging, firm, skin-colored to erythematous plaques or nodules (Fig. 112-2) with marked hyperkeratosis. Ulceration, exophytic (Fig. 112-3), or infiltrative growth patterns are seen.

SPECIAL LOCATIONS

ORAL SQUAMOUS CELL CARCINOMA

Oral SCC may arise on apparently normal mucosa but are usually preceded by leukoplakia, erythroplakia, or leukoerythroplakia, which are localization-specific

Figure 112-2 Classical clinical presentation of cutaneous squamous cell carcinoma (SCC). Two nodular SCCs and several actinic keratoses as precursor lesions are present on the forehead in the setting of field cancerization on heavily sun-damaged skin.

Figure 112-3 Large, exophytic squamous cell carcinoma with erosion on the left cheek.

precursor lesions.[79] The typical clinical presentation of oral SCC is tumors with whitish surface or ulcers with elevated indurated borders. Exophytic or endophytic growth patterns with subsequent ulcer formation occur.

SQUAMOUS CELL CARCINOMA OF THE LOWER LIP

SCC of the lip occurs on the lower lip (Fig. 112-4) more often than on the upper lip, because the lower lip, along with the nose and cheeks, is regarded as one of the typical "sun terraces."[80] Because SCCs on the lip and ear show higher rates of metastasis, tumors at these locations require special attention.

VERRUCOUS SQUAMOUS CELL CARCINOMA

Verrucous SCC clinically presents as a slowly growing ulcerated plaque or an exophytic cauliflower-like slowly growing tumor. Typical locations of verrucous SCC include the oral cavity (oral florid papillomatosis), the genitoanal region (often referred to as *giant condyloma acuminatum Buschke-Löwenstein*), plantar

Figure 112-4 Hyperkeratotic squamous cell carcinoma located centrally on the lower lip.

Figure 112-5 Typical clinical presentation of a keratoacanthoma on the forehead as a sharply circumscribed symmetric nodule with the characteristic horn-filled crater in the middle.

skin (in this location it is commonly named *epithelioma cuniculatum*), and amputation stumps. Verrucous SCC is less common than other forms of invasive SCC.[81]

KERATOACANTHOMA

KA commonly is regarded as a subtype of highly differentiated SCC with typical clinical and histopathologic features. KA usually erupts rapidly within a few weeks and has the ability to spontaneously regress. KA clinically presents as a sharply circumscribed firm nodule with a central horn-filled crater that typically arises on the head and sun-exposed areas of the extremities (Fig. 112-5). There are several distinct clinical variants, including grouped KA, subungual KA, intraoral KA, giant KA, KA centrifugum marginatum, multiple KA of the Ferguson-Smith type, eruptive KA of Grzybowski, and KA associated with Muir-Torre syndrome.

DIAGNOSIS

The standard histopathology report of SCC should include the following: histologic subtype (acantholytic, spindle cell, verrucous, or desmoplastic type); grade of differentiation (G1 to G4); maximum vertical tumor diameter in millimeters; extent of dermal invasion (Clark level); and presence or absence of perineural, vascular, or lymphatic invasion. To facilitate correct management of SCC, information about whether the margins are free or do not have the minimum distance required between the tumor and the resection margin also should be included in the histopathology report (Table 112-3).

GENERAL CONSIDERATIONS IN HISTOPATHOLOGY

The hallmark of invasive SCC is the growth of atypical keratinocytes beyond the basement membrane into the

TABLE 112-3

Basic Features of Histopathology Report of Cutaneous Squamous Cell Carcinoma Diagnosis

Histopathology Report	
Histologic subtype	Common Verrucous Desmoplastic Acantholytic Spindle-cell Other
Grading	Well differentiated Moderately differentiated Poorly differentiated Undifferentiated Cannot be assessed
Maximum tumor thickness	_____ mm
Clark level	>IV <IV
Perineural invasion	No Yes
Vascular/lymphatic invasion	No Yes
Complete excision	No Yes
Minimum lateral margin	_____ mm
Minimum deep margin	_____ mm

Modified from Bonerandi JJ, Beauvillain C, Caquant L, et al. Guidelines for the diagnosis and treatment of cutaneous squamous cell carcinoma and precursor lesions. *J Eur Acad Dermatol Venereol.* 2011;25(suppl 5):1-51.

dermis. The diagnosis of SCC is established histologically. All clinically suspicious lesions should be subjected to a skin biopsy or excision biopsy followed by histologic examination. Depending on the size of the tumor, its localization, and treatment options, different biopsy techniques are available, including incisional biopsy, punch biopsy, shave biopsy, or an excisional biopsy of the entire lesion. The diagnosis is confirmed by histologic examination using routine hematoxylin and eosin stains and additional immunohistochemical markers, such as cytokeratins or molecular markers in the case of uncertain diagnosis, especially in tumors with little or no keratinization.

BASIC HISTOPATHOLOGIC FEATURES OF SQUAMOUS CELL CARCINOMA

The typical histopathologic picture of SCC shows atypical keratinocytes originating in the epidermis and infiltrating into the dermis (Fig. 112-6). The degree of differentiation is variable among SCCs. It ranges from well-differentiated SCC with minimal pleomorphism, prominent keratinization as represented morphologically by parakeratosis, individual cell dyskeratosis, and horn pearl formation (Fig. 112-7A) to poorly differentiated SCCs showing pleomorphic nuclei with a high degree of atypia, frequent mitoses, and very few areas of keratinization.

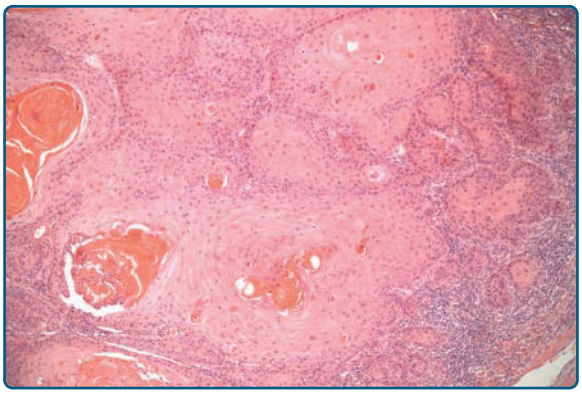

Figure 112-6 Typical histopathologic picture of a well-differentiated squamous cell carcinoma (grade 1) with atypical keratinocytes originating in the epidermis and infiltrating into the dermis with minimal pleomorphism and prominent keratinization (hematoxylin and eosin stain, ×50 magnification).

HISTOPATHOLOGIC VARIANTS OF SQUAMOUS CELL CARCINOMA WITH DIFFERENTIAL DIAGNOSIS

In addition to the typical histopathologic picture of SCC described above, there are distinct histologic subtypes, some of which account for classification of the tumor as high risk. To facilitate the prognostic classification and correct management of SCC, the following well-established histologic subtypes should be distinguished:

SPINDLE-CELL SQUAMOUS CELL CARCINOMA

Spindle-cell SCC is a relatively rare form of SCC. It is characterized by spindled morphology of the atypical keratinocytes and lack of keratinization (see Fig. 112-7B). It typically arises in sun-exposed areas of skin of elderly patients, and sometimes in the setting of radiation therapy. The histologic differential diagnoses include other spindle-cell neoplasms like atypical fibroxanthoma, spindle-cell melanoma, and sarcoma. Immunohistochemical staining, including cytokeratins, often is necessary to confirm the diagnosis.[82]

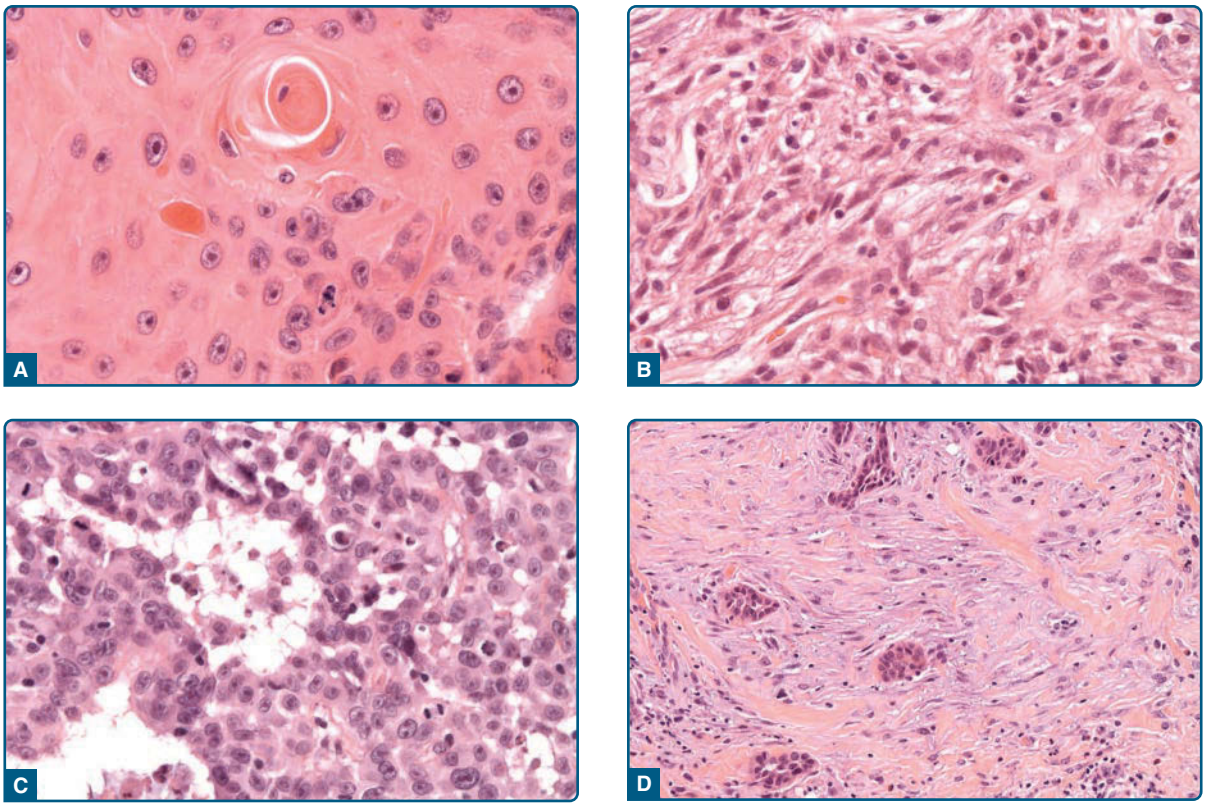

Figure 112-7 Histopathologic variants of squamous cell carcinoma (SCC). **A,** Well-differentiated SCC with minimal pleomorphism and individual cell dyskeratosis with horn pearl formation (hematoxylin and eosin stain [H&E], ×400 magnification). **B,** Spindle-cell SCC revealing spindled morphology of the atypical keratinocytes and lack of keratinization (H&E, ×400 magnification). **C,** Acantholytic SCC with extensive acantholysis of the atypical keratinocytes leading to pseudoglandular structures within the tumor (H&E, ×400 magnification). **D,** Desmoplastic SCC showing infiltrative growth pattern with abundant mucinous stroma surrounding the tumor cells (H&E, ×200 magnification).

ACANTHOLYTIC (ADENOID) SQUAMOUS CELL CARCINOMA

Acantholytic SCC comprises less than 5% of all SCCs and bears an increased propensity for metastasis as shown in 1 study that reported metastatic disease in 19% of acantholytic SCCs.[83] The main histologic characteristic of acantholytic SCC is extensive acantholysis of the atypical keratinocytes leading to pseudoglandular structures within the tumor area (see Fig. 112-7C).

VERRUCOUS SQUAMOUS CELL CARCINOMA

Verrucous SCC is a well-differentiated variant of SCC that slowly grows and is locally destructive, but with only low metastatic potential.[81] For the histopathologic diagnosis of verrucous SCC, a large, deep incisional biopsy is necessary. The superficial parts resemble verrucae with parakeratosis, acanthosis, and a prominent stratum granulosum. In the deeper parts, monomorphic well-differentiated keratinocytes with small nuclei form broad, deep, downward proliferations of light eosinophilic tumor cells. The tumor areas show noninvasive pushing borders, and even in the deeper areas, nuclear atypia is rare. Keratinization, individual cell dyskeratosis, and horn pearl formation are absent.

DESMOPLASTIC SQUAMOUS CELL CARCINOMA

Desmoplastic SCC is a distinct variant of SCC that shows a highly infiltrative growth pattern with abundant mucinous stroma surrounding the tumor cells (see Fig. 112-7D). Desmoplastic SCC often is associated with perineural (Fig. 112-8) or perivascular infiltration, and reveals a high rate of recurrence and metastases.[84]

KERATOACANTHOMA

KA is commonly regarded as a highly differentiated variant of SCC with distinct clinical and histomorphologic characteristics. KA has an overall symmetric aspect at scanning magnification (Fig. 112-9). Cytomorphologically, KAs are built of large strands of monomorphic keratinocytes with eosinophilic cytoplasm and small nuclei; a surrounding inflammatory infiltrate containing lymphocytes, eosinophils, and neutrophils is commonly observed (Fig. 112-9, insert). The final histomorphologic diagnosis needs the entire lesion because

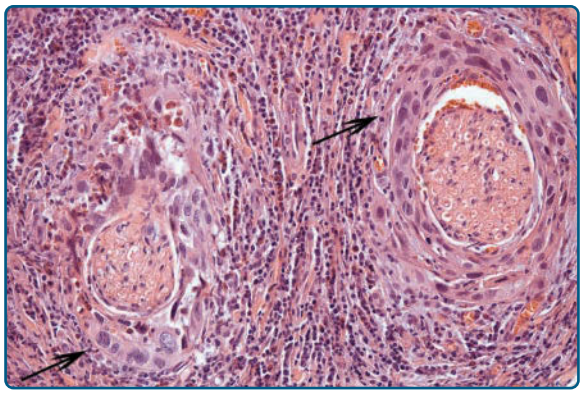

Figure 112-8 Histopathologic picture of perineural invasion of squamous cell carcinoma showing the atypical keratinocytes (*black arrows*) growing around a central nerve fiber (hematoxylin and eosin staining, ×200 magnification).

there is a characteristic growth pattern and the histopathologic diagnosis of KA relies mainly on the silhouette of the tumor as assessed at scanning magnification. The histopathologic features of KA vary depending on the evolutionary stage of the tumor: The epithelium of early lesions is markedly hyperplastic and the central keratotic plug is not as pronounced as in later stages. Fully developed lesions are characterized by a large central core of keratin surrounded by a well-differentiated proliferation of squamous epithelium (Fig. 112-9). In regressing lesions, the epithelium is rather hypoplastic; epithelial hyperplasia and atypical cells are no longer present, but the central crater can still be recognized.

GRADING

In addition to the subtyping of cutaneous SCC, histologic grading of SCC is very important with respect to recurrences and risk of metastasis. The classification system of the American Joint Committee on Cancer (AJCC) includes histologic grading in consideration of so-called high-risk features for staging. Histologic grading of SCC based on the degree of cellular differentiation was introduced in 1932 by Broders and is still commonly used today.[85] Tumors are graded on a scale of 1 to 4 based on increasing percentages of undifferentiated cells: G1 = well differentiated; G2 = moderately differentiated; G3 = poorly differentiated; G4 = undifferentiated grade; and Gx = grade cannot be assessed.

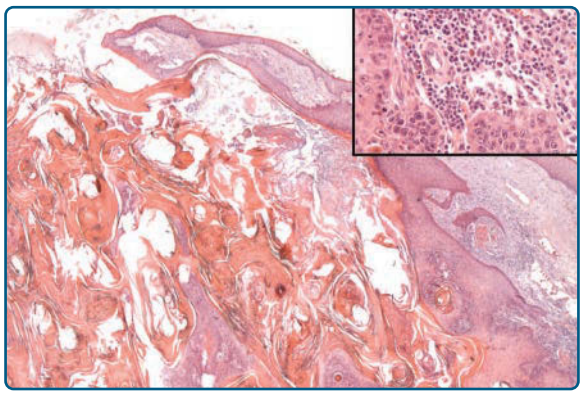

Figure 112-9 Histopathologic picture of keratoacanthoma as a fully developed lesion with a central core of keratin surrounded by a well-differentiated proliferation of squamous epithelium (hematoxylin and eosin staining [H&E], ×25 magnification). The insert shows the surrounding inflammatory infiltrate containing lymphocytes, eosinophils, and neutrophils (H&E, ×400 magnification).

STAGING

If a SCC is suspected, a complete examination of the entire skin should be performed followed by assessment for nodal involvement of the regional lymph nodes by palpation and/or ultrasound examination.

The current classification and staging of cutaneous SCC is based on the most recent TNM (tumor, node, metastasis) system of the Union International Contre le Cancer (UICC, 2009)[86] and the AJCC (2010).[87] *T1* defines "low-risk" tumors smaller than 2 cm in diameter in greatest dimension and fewer than 2 high-risk features (high-risk features include >2 mm thickness, Clark level >IV, perineural invasion, primary site being the lip or ear, and poorly or undifferentiated tumor). *T2* includes "high-risk" tumors larger than 2 cm in diameter in greatest dimension and tumors of any size with 2 or more high-risk features. *T3* is used for tumors that invade muscle, bone, or cartilage of maxilla, mandible or orbit, and *T4* includes tumors that invade the skull base or axial skeleton (Table 112-4).

Lymph node involvement of cutaneous SCC significantly increases the risk of recurrence and mortality, especially in high-risk tumors. If evaluation for nodal involvement of the regional lymph nodes by palpation and/or ultrasound examination is suspicious, histologic confirmation should be sought by fine-needle aspiration or lymph node biopsy. The TNM/UICC classifies lymph node involvement in 3 groups (N1, N2, N3) depending on size and number of involved nodes, whereas the AJCC uses 5 categories (N1, N2a, N2b, N2c, N3) based on number, localization and size (see Table 112-4).

Concerning distant metastases, both TNM/UICC and AJCC distinguish no distant metastases (M0) from distant metastases (M1) (see Table 112-4).

DIFFERENTIAL DIAGNOSES

Depending on the localization and type of SCC there are different differential diagnoses to be ruled out, including SCC with a classical clinical presentation of hyperkeratotic seborrheic keratoses; viral acanthoma; viral warts; and acanthoma fissuratum. For SCCs with ulcerative or infiltrative growth, scars, chronic discoid lupus erythematodes, lichen planus, and morpheaform BCC are to be considered. SCCs at special

TABLE 112-4
Staging of Primary Tumor (T) of the TNM Staging Classification for Cutaneous Squamous Cell Carcinoma According to the American Joint Committee on Cancer (2010)

Tx	Primary tumor cannot be assessed
T0	No evidence of primary tumor
Tis	Carcinoma in situ
T1	Tumor ≤2 cm or less in greatest dimension with fewer than 2 high-risk features[a]
T2	Tumor >2 cm in greatest dimension or tumor any size with 2 or more high-risk features[a]
T3	Tumor with invasion of maxilla, mandible, orbit, or temporal bone
T4	Tumor with invasion of skeleton (axial, appendicular) or perineural invasion of skull base
Nx	Regional lymph nodes cannot be assessed
N0	No regional lymph node metastases
N1	Metastasis in a single ipsilateral lymph node, 3 cm or less in greatest dimension
N2a	Metastasis in a single ipsilateral lymph node, more than 3 cm but not more than 6 cm in greatest dimension
N2b	Metastasis in multiple ipsilateral lymph nodes, none more than 6 cm in greatest dimension
N2c	Metastasis in bilateral or contralateral lymph nodes, none more than 6 cm in greatest dimension
N3	Metastasis in a lymph node, more than 6 cm in greatest dimension
M0	No distant metastases
M1	Distant metastases

[a]High-risk features include >2 mm thickness, Clark level >IV, perineural invasion, primary site being the lip or ear, and poorly or undifferentiated tumor.

locations require exclusion of site-specific differential diagnoses such as chondrodermatitis nodularis chronica helicis for SCC on the ear.

MANAGEMENT

As the treatment modality for the primary lesion is a major determinant for the risk of local recurrence, the ideal management of SCC is predicated on local tumor control along with maximal preservation of function and cosmetics. In cases of clinical uncertainty about invasiveness, surgical resection or a biopsy followed by histologic evaluation is recommended before employing any therapeutic intervention other than surgery.[77]

SURGERY

Surgical excision, preferably microscopically controlled surgery (Mohs surgery), is regarded as the primary mode of therapy for localized SCC and has a cure rate of 95%.[78,88,89] Full histopathologic characterization of the tumor and its margins allows for the adequate management of the patient[77,88] and is particularly important for recurring and deeply infiltrating tumors, that is, tumors with histologic risk factors such as perineural invasion, tumors in immunosuppressed patients, and at sites where tissue preservation is essential (ie, eyelid, nasal tip, ear). Conventional standard excision with 4- to 6-mm margins may be acceptable as primary treatment of local, low-risk SCCs.[78]

SCC may give rise to local in-transit metastasis, which may be removed by wide surgical excision or treated by irradiation of a wide field around the primary lesion. Treatment of nodal metastasis may involve lymph node dissection, radiation, or a combination of both.

NONSURGICAL INTERVENTION

TOPICAL THERAPY

Topical therapeutic treatments such as topical imiquimod, topical or intralesional 5-fluoruracil, cryotherapy, and photodynamic therapy for SCC have been reported.[90-92] As evidence for the efficacy of these treatments is lacking and limited to case reports, topical therapy is generally not regarded an appropriate treatment modality for invasive SCC.

RADIATION THERAPY

While surgery is regarded the primary mode of local therapy for the vast majority of SCCs, patient preference and other factors, such as problematic locations for surgery, may lead to the selection of radiation therapy as the treatment modality. In any case, appropriate confirmation of the diagnosis by histologic evaluation is mandatory prior to radiotherapy. Radiation therapy may serve as an alternative to surgery in the primary treatment of superficially invasive, small SCCs in low-risk areas, and may be discussed for inoperable, local in-transit metastasis, and in the adjuvant setting for patients with potentially aggressive local tumors, such as histopathologically confirmed, extensive, perineural involvement.[77] Patients treated with Mohs surgery (microscopically controlled surgery) should be considered for postoperative adjuvant radiation if clear margins cannot be achieved.[77,78]

ELECTIVE PROPHYLACTIC LYMPH NODE DISSECTION AND SENTINEL LYMPH NODE BIOPSY

Sentinel lymph node biopsy and elective prophylactic lymph node dissection have been proposed in SCC patients at high risk for metastatic disease, but there is no conclusive evidence of its prognostic or therapeutic value.[77,93]

SYSTEMIC TREATMENT OF LOCALLY ADVANCED AND METASTATIC SQUAMOUS CELL CARCINOMA

Locally advanced, unresectable or metastatic SCC is a therapeutic challenge because of the scarce amount of available prospective data on systemic therapy. In addition, only approximately 30% of patients are reported as responsive to any type of standard treatment.[94] In patients undergoing iatrogenic immunosuppression, such as OTRs, dose reduction of the immunosuppressive agents and minimizing the doses of calcineurin inhibitors and/or antimetabolites in favor of mTOR inhibitors should be the goal.[41,78]

CHEMOTHERAPY

Although there are limited data on the efficacy of chemotherapy for metastatic SCC, standard options in metastatic or unresectable SCC include systemic platinum-based chemotherapeutic regimens, 5-fluorouracil/capecitabine, or monotherapy/chemotherapy with methotrexate.[77,78,88,89] However, besides a limited effect on overall survival, currently available therapy for locally advanced or metastatic disease is frequently restricted by comorbidities and advanced age of the patient.

TARGETED THERAPY

Using therapeutic strategies targeting the EGFR either by small molecules (ie, erlotinib and gefitinib) or antibodies (ie, cetuximab and panitumumab) may be nonsurgical, off-label options for advanced SCC beyond radiotherapy and conventional chemotherapy. A prospective Phase II trial has demonstrated the efficacy of monotherapy with cetuximab as a first-line treatment of unresectable SCC (a 29% response rate).[95] Although mostly in case reports, the use of cetuximab also has been reported in SCC in neoadjuvant and adjuvant therapy settings and as radiosensitizer combined with radiation therapy.[23]

Recent evidence suggest that, immune inhibitory pathways such as the programmed death protein 1 (PD-1)/PD-1 ligand pathway may control skin carcinogenesis. Although not yet explored sufficiently in either an independent or a combined therapeutic setting, preclinical studies reveal that the overexpression of the PD-1 ligand in keratinocytes of transgenic mice results in accelerated SCC formation,[96] and therapeutic checkpoint blockade of the immune inhibitory PD-1 pathway has resulted in a notable antitumor response in a case of unresectable SCC.[97]

PROGNOSIS

The majority of SCCs are low risk and present with early stage disease, resulting in a high cure rate and excellent prognosis.

Prognosis for locally advanced SCC at the time of diagnosis and patients with progressive disease after first-line surgical therapy is generally poor.[94] A retrospective study of patients with unresectable SCC reported a poor overall survival of only 10.9 months and unresponsiveness to the majority of available treatments.[94]

A poorer outcome of immunosuppressed patients with advanced disease compared with the general population has been reported.[22,39] Immunosuppression is a risk factor for a greater tumor burden, more aggressive tumor behavior, metastatic disease,[35,98] and disease-specific death from SCC.[36] SCCs in immunosuppressed patients are designated as high-risk tumors per the National Comprehensive Cancer Network (NCCN). SCC accounts for more than 60% of deaths from all skin malignancies in OTRs with a death rate of approximately 5%.[7,41]

LOCAL RECURRENCE

Table 112-5 outlines the NCCN's guidelines regarding risk factors for local recurrence. Local recurrence may result from a failure to completely treat the primary tumor or from local metastasis. Local recurrence at the site of the primary lesion often precedes metastasis and is frequently found to be the first indicator of aggressive biologic behavior in SCC.[9,99] Local recurrence rates are considerably lower with microscopically controlled surgery (Mohs surgery) as compared to other local treatment modalities.[99,100]

METASTASIS

Table 112-5 outlines the NCCN's guidelines regarding risk factors for metastases. The risk of developing metastasis from SCC is generally low, with a 5-year metastatic rate of 5%, and 85% of metastatic cases are nodal disease.[9,10] However, depending on patient and tumor characteristics, certain subgroups of patients are at significantly higher risk for metastasis, with metastatic rates of up to 30%.[9] The incidence of metastatic SCC in OTRs is significantly higher than in the general population (8% vs. 0.5% to 5%), with metastasis developing rapidly after diagnosis of the primary tumor in a mean of only 1.4 years and a poor prognosis.[22]

HIGH-RISK LESIONS AND PROGNOSTIC RISK FACTORS FOR SQUAMOUS CELL CARCINOMA

Histopathologic and clinical features, as well as host-dependent factors, considerably influence the metastatic potential and prognosis of SCC.

TABLE 112-5

NCCN Clinical Practice Guidelines in Oncology (NCCN Guidelines®): Risk Factors for Local Recurrence or Metastases

National Comprehensive Cancer Network®

NCCN Guidelines Version 2.2019
Squamous Cell Skin Cancer

NCCN Guidelines Index
Table of Contents
Discussion

RISK FACTORS FOR LOCAL RECURRENCE OR METASTASES

H&P	Low Risk	High Risk
Location/size[1]	Area L <20 mm	Area L ≥20 mm
	Area M <10 mm[4]	Area M ≥10 mm
		Area H[5]
Borders	Well-defined	Poorly defined
Primary vs. recurrent	Primary	Recurrent
Immunosuppression	(–)	(+)
Site of prior RT or chronic inflammatory process	(–)	(+)
Rapidly growing tumor	(–)	(+)
Neurologic symptoms	(–)	(+)
Pathology (See SCC-A)		
Degree of differentiation	Well or moderately differentiated	Poorly differentiated
Acantholytic (adenoid), adenosquamous (showing mucin production), desmoplastic, or metaplastic (carcinosarcomatous) subtypes	(–)	(+)
Depth[2,3]: Thickness or level of invasion	≤6 mm and no invasion beyond subcutaneous fat	>6 mm or invasion beyond subcutaneous fat
Perineural, lymphatic, or vascular involvement	(–)	(+)

[1]Must include peripheral rim of erythema.
[2]If clinical evaluation of incisional biopsy suggests that microstaging is inadequate, consider narrow margin excisional biopsy.
[3]Deep invasion is defined as invasion beyond the subcutaneous fat OR >6 mm (as measured from the granular layer of adjacent normal epidermis to the base of the tumor, consistent with AJCC 8th edition.)
[4]Location independent of size may constitute high risk.
[5]Area H constitutes high risk based on location, independent of size, narrow excision margins due to anatomic and functional constraints are associated with increased recurrence rates with standard histologic processing. Complete margin assessment such as with Mohs micrographic surgery is recommended for optimal tumor clearance and maximal tissue conservation. For tumors <6 mm in size, without other high risk features, other treatment modalities may be considered if at least 4-mm clinically tumor-free margins can be obtained without significant anatomic or functional distortions.

Area H = "mask areas" of face (central face, eyelids, eyebrows, periorbital, nose, lips [cutaneous and vermilion], chin, mandible, preauricular and postauricular skin/sulci, temple, ear), genitalia, hands, and feet.
Area M = cheeks, forehead, scalp, neck, and pretibia.
Area L = trunk and extremities (excluding pretibia, hands, feet, nail units, and ankles).

Note: All recommendations are category 2A unless otherwise indicated.
Clinical Trials: NCCN believes that the best management of any patient with cancer is in a clinical trial. Participation in clinical trials is especially encouraged.

SCC-B

Reproduced with permission from the NCCN Clinical Practice Guidelines in Oncology (NCCN Guidelines®) for Squamous Cell Skin Cancer V.2.2019. © 2018 National Comprehensive Cancer Network, Inc. All rights reserved. The NCCN Guidelines® and illustrations herein may not be reproduced in any form for any purpose without the express written permission of NCCN. To view the most recent and complete version of the NCCN Guidelines, go online to NCCN.org. The NCCN Guidelines are a work in progress that may be refined as often as new significant data becomes available.
NCCN makes no warranties of any kind whatsoever regarding their content, use or application and disclaims any responsibility for their application or use in any way.

A metaanalysis and systematic review on all published data found that tumor depth (ie, Breslow thickness exceeding 2 mm and invasion beyond subcutaneous fat) is associated with the highest relative risk of local recurrence and metastasis of SCC.[35] A tumor diameter exceeding 20 mm is associated with the highest relative risk for disease-specific death of SCC (relative risk 19.10, confidence interval 95%). Additional risk factors for local recurrence and/or metastasis are clinical and histopathologic features. A prospective study investigated potential risk factors for metastasis or local recurrence of SCC in a large cohort of patients and found that only SCCs thicker than 2 mm are associated with a significant risk of metastasis. Tumors larger than 6 mm are associated with a high risk of metastasis and local recurrence. Desmoplastic growth is an independent risk factor for local recurrence. Additional key prognostic factors for metastasis besides increased horizontal size are immunosuppression and localization at the ear.[101] Another prospective study found that lesion size equal to or greater than 4 cm and histologic evidence of perineural invasion and deep invasion beyond subcutaneous structures were the factors most significantly associated with disease-specific mortality in cutaneous SCC.[102]

AFTERCARE

As standardized followup schedules for patients with SCC generally do not exist, it is recommended to follow patients closely based on risk assessment for the development of new lesions, local recurrence, and metastatic spread.[77] The significant tumor burden and high incidence of SCC in immunosuppressed patients such as OTRs highlight the importance of dermatologic surveillance, skin cancer prevention strategies, and the timely treatment of precancerous and in situ lesions in this high-risk population.

Early detection and treatment improves survival of patients with recurrent and progressive disease.

Of locally recurring and metastatic SCCs, 70% to 80% are detected within 2 years after primary diagnosis.

SECONDARY SKIN CANCER

After diagnosis of SCC, all patients should be considered to be at risk for the development of additional secondary SCC as well as BCC. Overall, the 3-year cumulative risk of a subsequent SCC after an index SCC is 18%, at least a 10-fold increase in incidence compared with the incidence of first tumors in a comparable general population.[103]

Compared to the general population, immunosuppressed OTRs are at particularly high risk of developing subsequent secondary SCC after the initial diagnosis of NMSC, with 25% of patients developing another NMSC within 13 months, and 50% developing another cancer within 3.5 years.[8]

PREVENTION

NMSCs, including SCC, are largely preventable.[9] Prevention can be emphasized through education for skin cancer risk factors, effective UV protection measures, and regular self-examination. Sun avoidance and close dermatologic surveillance of high-risk individuals are key factors for the prevention of SCC.

SUN PROTECTION

In general, sun avoidance and sun protection (protective clothing, sunscreens) are cost-effective measures to prevent the development of cutaneous SCC.[104] The preventive effect of sunscreens with high sun protection factor and broad UVA/UVB coverage is well established and there is evidence that sun protection throughout life can prevent the development of both SCC precursor lesions and invasive SCC.[105]

TREATMENT OF PRECURSOR LESIONS

Effective treatment of AK and Bowen disease or areas of field cancerization in photodamaged skin is expected to reduce the incidence of SCC, because cutaneous SCC develop from these precursor lesions. Several treatment options are available and need to be chosen and adapted to the individual patient's situation (see Chap. 110). Regular complete skin examination incorporated in a structured dermatooncologic concept of primary and secondary prevention represents an important measure in the prevention of the development of SCC.

OTHER PREVENTIVE MEASURES

Chemoprevention of skin tumors represents an innovative new preventive concept. The general idea of chemoprevention is to prevent progression of clinically undiscovered precursor lesions into invasive carcinoma, reducing, in particular, the risk of the occurrence of secondary tumors for patients at risk.

NIACINAMIDE

Niacinamide (vitamin B_3) is suitable for chemoprevention of NMSC, as supported by animal studies and data from a large, randomized Phase III clinical study.[106] Compared with placebo, the administration of niacinamide 500 mg twice daily resulted in a 23% lower rate of newly formed NMSC (similar for SCC and BCC) during an intervention period of 12 months.[106] In addition, the safety profile was favorable. Niacinamide constitutes a part of nicotinamide adenine dinucleotide, which, in turn, is an essential cofactor for the production of nicotinamide adenine trinucleotide. Consequently, niacinamide can prevent nicotinamide adenine trinucleotide deficiency, which occurs in the epidermis under the action of UV light and prevents repair of DNA damage. Consequently, vitamin B_3 protects keratinocytes against UV-induced cellular nicotinamide adenine trinucleotide loss,[107] promotes epidermal differentiation in photodamaged skin, and inhibits UV-induced immunosuppression and photocarcinogenesis as shown in different mouse models.[108-110]

VITAMIN A

Systemic retinoids have a transient preventive effect for secondary SCC in both immunocompetent and immunosuppressed patients.[111-113] Some years ago, data from small, randomized trials, especially in OTRs[114] and other high-risk patients,[115] suggested a role for prophylactic administration of systemic retinoids for chemoprevention of NMSC. One study assessed the prevention of new skin cancers in xeroderma pigmentosum patients using vitamin A derivatives.[115] Vitamin A derivatives are associated with promotion of normal differentiation. Five xeroderma pigmentosum patients with a high frequency of new primary skin cancers were selected. Their cancers were cataloged and surgically removed over a period of 2 years. Patients were then treated for 2 years with high-dose oral 13-*cis* retinoic acid (isotretinoin). During the treatment interval there was a 63% reduction in frequency of new skin cancers. Although there were numerous side effects, this treatment was the first demonstration of effective chemoprevention of cancer in humans.[115] A future indication of retinoids as a chemopreventive agent may include patients on BRAF inhibitors who are at

risk of developing multiple cutaneous SCC. However, significant side effects, mainly affecting quality of life, but also including teratogenesis in female patients of child-bearing age, need to be taken considered.

CHANGE OF IMMUNOSUPPRESSIVE REGIMEN IN SOLID ORGAN TRANSPLANTATION RECIPIENTS

For an OTR, a change of the immunosuppressive regimen may be an important preventive measure, especially if the immunosuppressed OTR has a life-threatening SCC or multiple, rapidly developing tumors.[41] In this situation, either a dose reduction of the immunosuppressive agent and/or a change from calcineurin inhibitors or antimetabolites to mTOR inhibitors is recommended.[46]

REFERENCES

1. Housman TS, Feldman SR, Williford PM, et al. Skin cancer is among the most costly of all cancers to treat for the Medicare population. *J Am Acad Dermatol*. 2003;48(3):425-429.
2. Carucci JA. Press for an underestimated nemesis. *JAMA Dermatol*. 2013;149(10):1147-1148.
3. Berg D, Otley CC. Skin cancer in organ transplant recipients: epidemiology, pathogenesis, and management. *J Am Acad Dermatol*. 2002;47(1):1-17; quiz 18-20.
4. Lindelof B, Sigurgeirsson B, Gabel H, et al. Incidence of skin cancer in 5356 patients following organ transplantation. *Br J Dermatol*. 2000;143(3):513-519.
5. Madan V, Lear JT, Szeimies RM. Non-melanoma skin cancer. *Lancet*. 2010;375(9715):673-685.
6. Rogers HW, Weinstock MA, Harris AR, et al. Incidence estimate of nonmelanoma skin cancer in the United States, 2006. *Arch Dermatol*. 2010;146(3):283-287.
7. Lomas A, Leonardi-Bee J, Bath-Hextall F. A systematic review of worldwide incidence of nonmelanoma skin cancer. *Br J Dermatol*. 2012;166(5):1069-1080.
8. Karia PS, Han J, Schmults CD. Cutaneous squamous cell carcinoma: estimated incidence of disease, nodal metastasis, and deaths from disease in the United States, 2012. *J Am Acad Dermatol*. 2013;68(6):957-966.
9. Alam M, Ratner D. Cutaneous squamous-cell carcinoma. *N Engl J Med*. 2001;344(13):975-983.
10. Kivisaari A, Kahari VM. Squamous cell carcinoma of the skin: Emerging need for novel biomarkers. *World J Clin Oncol*. 2013;4(4):85-90.
11. Staples MP, Elwood M, Burton RC, et al. Non-melanoma skin cancer in Australia: the 2002 national survey and trends since 1985. *Med J Aust*. 2006;184(1):6-10.
12. Diffey BL, Langtry JA. Skin cancer incidence and the ageing population. *Br J Dermatol*. 2005;153(3):679-680.
13. Welsh MM, Karagas MR, Kuriger JK, et al. Genetic determinants of UV-susceptibility in non-melanoma skin cancer. *PLoS One*. 2011;6(7):e20019.
14. Mora RG, Perniciaro C. Cancer of the skin in blacks. I. A review of 163 black patients with cutaneous squamous cell carcinoma. *J Am Acad Dermatol*. 1981;5(5):535-543.
15. Lekalakala PT, Khammissa RA, Kramer B, et al. Oculocutaneous albinism and squamous cell carcinoma of the skin of the head and neck in sub-Saharan Africa. *J Skin Cancer*. 2015;2015:167847.
16. Ratushny V, Gober MD, Hick R, et al. From keratinocyte to cancer: the pathogenesis and modeling of cutaneous squamous cell carcinoma. *J Clin Invest*. 2012;122(2):464-472.
17. Callen JP, Bickers DR, Moy RL. Actinic keratoses. *J Am Acad Dermatol*. 1997;36(4):650-653.
18. Glogau RG. The risk of progression to invasive disease. *J Am Acad Dermatol*. 2000;42(1, pt 2):23-24.
19. Salasche SJ. Epidemiology of actinic keratoses and squamous cell carcinoma. *J Am Acad Dermatol*. 2000;42(1, pt 2):4-7.
20. Boukamp P. Non-melanoma skin cancer: what drives tumor development and progression? *Carcinogenesis*. 2005;26(10):1657-1667.
21. IARC Working Group on the Evaluation of Carcinogenic Risks in Humans. Monographs on the evaluation of carcinogenic risks in humans. A review of human carcinogens: radiation. *IARC Monogr Eval Carcinog Risks Hum*. 2012:100D.
22. Martinez JC, Otley CC, Stasko T, et al. Defining the clinical course of metastatic skin cancer in organ transplant recipients: a multicenter collaborative study. *Arch Dermatol*. 2003;139(3):301-306. Available at http://monographs.iarc.fr/ENG/Monographs/vol100D/index.php.
23. Harwood CA, Proby CM, Inman GJ, et al. The promise of genomics and the development of targeted therapies for cutaneous squamous cell carcinoma. *Acta Derm Venereol*. 2016;96(1):3-16.
24. Nishigori C, Hattori Y, Toyokuni S. Role of reactive oxygen species in skin carcinogenesis. *Antioxid Redox Signal*. 2004;6(3):561-570.
25. Hussein MR. Ultraviolet radiation and skin cancer: molecular mechanisms. *J Cutan Pathol*. 2005;32(3):191-205.
26. Box NF, Duffy DL, Irving RE, et al. Melanocortin-1 receptor genotype is a risk factor for basal and squamous cell carcinoma. *J Invest Dermatol*. 2001;116(2):224-229.
27. Asgari MM, Wang W, Ioannidis NM, et al. Identification of susceptibility loci for cutaneous squamous cell carcinoma. *J Invest Dermatol*. 2016;136(5):930-937.
28. Nan H, Kraft P, Hunter DJ, et al. Genetic variants in pigmentation genes, pigmentary phenotypes, and risk of skin cancer in Caucasians. *Int J Cancer*. 2009;125(4):909-917.
29. Fine JD, Johnson LB, Weiner M, et al. Epidermolysis bullosa and the risk of life-threatening cancers: the National EB Registry experience, 1986-2006. *J Am Acad Dermatol*. 2009;60(2):203-211.
30. Bradford PT, Goldstein AM, Tamura D, et al. Cancer and neurologic degeneration in xeroderma pigmentosum: long term follow-up characterises the role of DNA repair. *J Med Genet*. 2011;48(3):168-176.
31. Yu HS, Liao WT, Chai CY. Arsenic carcinogenesis in the skin. *J Biomed Sci*. 2006;13(5):657-666.
32. Davis MM, Hanke CW, Zollinger TW, et al. Skin cancer in patients with chronic radiation dermatitis. *J Am Acad Dermatol*. 1989;20(4):608-616.
33. Euvrard S, Kanitakis J, Claudy A. Skin cancers after organ transplantation. *N Engl J Med*. 2003;348(17):1681-1691.
34. Harwood CA, Mesher D, McGregor JM, et al. A surveillance model for skin cancer in organ transplant recipients: a 22-year prospective study in an ethnically diverse population. *Am J Transplant*. 2013;13(1):119-129.

35. Thompson AK, Kelley BF, Prokop LJ, et al. Risk factors for cutaneous squamous cell carcinoma recurrence, metastasis, and disease-specific death: a systematic review and meta-analysis. *JAMA Dermatol*. 2016;152(4):419-428.
36. Karia PS, Jambusaria-Pahlajani A, Harrington DP, et al. Evaluation of American Joint Committee on Cancer, International Union Against Cancer, and Brigham and Women's Hospital tumor staging for cutaneous squamous cell carcinoma. *J Clin Oncol*. 2014;32(4):327-334.
37. Omland SH, Gniadecki R, Haedersdal M, et al. Skin cancer risk in hematopoietic stem-cell transplant recipients compared with background population and renal transplant recipients: a population-based cohort study. *JAMA Dermatol*. 2016;152(2):177-183.
38. Scott FI, Mamtani R, Brensinger CM, et al. Risk of nonmelanoma skin cancer associated with the use of immunosuppressant and biologic agents in patients with a history of autoimmune disease and nonmelanoma skin cancer. *JAMA Dermatol*. 2016;152(2):164-172.
39. Jensen P, Hansen S, Moller B, et al. Skin cancer in kidney and heart transplant recipients and different long-term immunosuppressive therapy regimens. *J Am Acad Dermatol*. 1999;40(2, pt 1):177-186.
40. Zwald FO, Brown M. Skin cancer in solid organ transplant recipients: advances in therapy and management: part I. Epidemiology of skin cancer in solid organ transplant recipients. *J Am Acad Dermatol*. 2011;65(2):253-261; quiz 262.
41. Zwald FO, Brown M. Skin cancer in solid organ transplant recipients: advances in therapy and management: part II. Management of skin cancer in solid organ transplant recipients. *J Am Acad Dermatol*. 2011; 65(2):263-279; quiz 280.
42. Karagas MR, Stukel TA, Umland V, et al. Reported use of photosensitizing medications and basal cell and squamous cell carcinoma of the skin: results of a population-based case-control study. *J Invest Dermatol*. 2007;127(12):2901-2903.
43. Lindelof B, Sigurgeirsson B, Tegner E, et al. PUVA and cancer: a large-scale epidemiological study. *Lancet*. 1991;338(8759):91-93.
44. O'Donovan P, Perrett CM, Zhang X, et al. Azathioprine and UVA light generate mutagenic oxidative DNA damage. *Science*. 2005;309(5742):1871-1874.
45. Brem R, Li F, Montaner B, et al. DNA breakage and cell cycle checkpoint abrogation induced by a therapeutic thiopurine and UVA radiation. *Oncogene*. 2010;29(27):3953-3963.
46. Euvrard S, Morelon E, Rostaing L, et al. Sirolimus and secondary skin-cancer prevention in kidney transplantation. *N Engl J Med*. 2012;367(4):329-339.
47. Kwiek B, Schwartz RA. Keratoacanthoma (KA): an update and review. *J Am Acad Dermatol*. 2016;74(6): 1220-1233.
48. Cohen DN, Lawson SK, Shaver AC, et al. Contribution of beta-HPV infection and UV damage to rapid-onset cutaneous squamous cell carcinoma during BRAF-inhibition therapy. *Clin Cancer Res*. 2015;21(11): 2624-2634.
49. Arnault JP, Mateus C, Escudier B, et al. Skin tumors induced by sorafenib; paradoxic RAS-RAF pathway activation and oncogenic mutations of *HRAS*, *TP53*, and *TGFBR1*. *Clin Cancer Res*. 2012;18(1):263-272.
50. Mohan SV, Chang J, Li S, et al. Increased risk of cutaneous squamous cell carcinoma after vismodegib therapy for basal cell carcinoma. *JAMA Dermatol*. 2016;152(5):527-532.
51. Asgari MM, Kiviat NB, Critchlow CW, et al. Detection of human papillomavirus DNA in cutaneous squamous cell carcinoma among immunocompetent individuals. *J Invest Dermatol*. 2008;128(6):1409-1417.
52. Karagas MR, Nelson HH, Sehr P, et al. Human papillomavirus infection and incidence of squamous cell and basal cell carcinomas of the skin. *J Natl Cancer Inst*. 2006;98(6):389-395.
53. Chockalingam R, Downing C, Tyring SK. Cutaneous squamous cell carcinomas in organ transplant recipients. *J Clin Med*. 2015;4(6):1229-1239.
54. Wang J, Aldabagh B, Yu J, et al. Role of human papillomavirus in cutaneous squamous cell carcinoma: a meta-analysis. *J Am Acad Dermatol*. 2014;70(4):621-629.
55. Harwood CA, McGregor JM, Proby CM, et al. Human papillomavirus and the development of non-melanoma skin cancer. *J Clin Pathol*. 1999;52(4):249-253.
56. Akgul B, Cooke JC, Storey A. HPV-associated skin disease. *J Pathol*. 2006;208(2):165-175.
57. Jackson S, Storey A. E6 proteins from diverse cutaneous HPV types inhibit apoptosis in response to UV damage. *Oncogene*. 2000;19(4):592-598.
58. Jackson S, Harwood C, Thomas M, et al. Role of Bak in UV-induced apoptosis in skin cancer and abrogation by HPV E6 proteins. *Genes Dev*. 2000;14(23):3065-3073.
59. Howley PM, Pfister HJ. Beta genus papillomaviruses and skin cancer. *Virology*. 2015;479-480:290-296.
60. Gabet AS, Accardi R, Bellopede A, et al. Impairment of the telomere/telomerase system and genomic instability are associated with keratinocyte immortalization induced by the skin human papillomavirus type 38. *FASEB J*. 2008;22(2):622-632.
61. LeBoit PE. Can we understand keratoacanthoma? *Am J Dermatopathol*. 2002;24(2):166-168.
62. Falchook GS, Rady P, Hymes S, et al. Merkel cell polyomavirus and HPV-17 associated with cutaneous squamous cell carcinoma arising in a patient with melanoma treated with the BRAF inhibitor dabrafenib. *JAMA Dermatol*. 2013;149(3):322-326.
63. Falchook GS, Rady P, Konopinski JC, et al. Merkel cell polyomavirus and human papilloma virus in proliferative skin lesions arising in patients treated with BRAF inhibitors. *Arch Dermatol Res*. 2016;308(5):357-365.
64. Mittapalli VR, Madl J, Loffek S, et al. Injury-driven stiffening of the dermis expedites skin carcinoma progression. *Cancer Res*. 2016;76(4):940-951.
65. Vogelstein B, Papadopoulos N, Velculescu VE, et al. Cancer genome landscapes. *Science*. 2013;339(6127): 1546-1558.
66. Jiang W, Ananthaswamy HN, Muller HK, et al. p53 protects against skin cancer induction by UV-B radiation. *Oncogene*. 1999;18(29):4247-4253.
67. Ziegler A, Jonason AS, Leffell DJ, et al. Sunburn and p53 in the onset of skin cancer. *Nature*. 1994;372(6508): 773-776.
68. Dong W, Arpin C, Accardi R, et al. Loss of p53 or p73 in human papillomavirus type 38 E6 and E7 transgenic mice partially restores the UV-activated cell cycle checkpoints. *Oncogene*. 2008;27(20):2923-2928.
69. Balmain A, Ramsden M, Bowden GT, et al. Activation of the mouse cellular Harvey-ras gene in chemically induced benign skin papillomas. *Nature*. 1984;307(5952):658-660.
70. Bamford S, Dawson E, Forbes S, et al. The COSMIC (Catalogue of Somatic Mutations in Cancer) database and website. *Br J Cancer*. 2004;91(2):355-358.
71. Tsai KY, Tsao H. The genetics of skin cancer. *Am J Med Genet C Semin Med Genet*. 2004;131C(1):82-92.

72. Dajee M, Lazarov M, Zhang JY, et al. NF-kappaB blockade and oncogenic Ras trigger invasive human epidermal neoplasia. *Nature*. 2003;421(6923):639-643.
73. Su F, Viros A, Milagre C, et al. RAS mutations in cutaneous squamous-cell carcinomas in patients treated with BRAF inhibitors. *N Engl J Med*. 2012;366(3): 207-215.
74. Uribe P, Gonzalez S. Epidermal growth factor receptor (EGFR) and squamous cell carcinoma of the skin: molecular bases for EGFR-targeted therapy. *Pathol Res Pract*. 2011;207(6):337-342.
75. Ridd K, Bastian BC. Somatic mutation of epidermal growth factor receptor in a small subset of cutaneous squamous cell carcinoma. *J Invest Dermatol*. 2010; 130(3):901-903.
76. Mauerer A, Herschberger E, Dietmaier W, et al. Low incidence of EGFR and HRAS mutations in cutaneous squamous cell carcinomas of a German cohort. *Exp Dermatol*. 2011;20(10):848-850.
77. Stratigos A, Garbe C, Lebbe C, et al. Diagnosis and treatment of invasive squamous cell carcinoma of the skin: European consensus-based interdisciplinary guideline. *Eur J Cancer*. 2015;51(14):1989-2007.
78. National Comprehensive Cancer Network. NCCN Guidelines Version 1.2016. Squamous Cell Skin Cancer. http://www.nccn.org. 2016.
79. Chi AC, Day TA, Neville BW. Oral cavity and oropharyngeal squamous cell carcinoma—an update. *CA Cancer J Clin*. 2015;65(5):401-421.
80. Biasoli ER, Valente VB, Mantovan B, et al. Lip cancer: a clinicopathological study and treatment outcomes in a 25-year experience. *J Oral Maxillofac Surg*. 2016;74(7):1360-1367.
81. Rinker MH, Fenske NA, Scalf LA, et al. Histologic variants of squamous cell carcinoma of the skin. *Cancer Control*. 2001;8(4):354-363.
82. Kanner WA, Brill LB 2nd, Patterson JW, et al. CD10, p63 and CD99 expression in the differential diagnosis of atypical fibroxanthoma, spindle cell squamous cell carcinoma and desmoplastic melanoma. *J Cutan Pathol*. 2010;37(7):744-750.
83. Nappi O, Wick MR, Pettinato G, et al. Pseudovascular adenoid squamous cell carcinoma of the skin. A neoplasm that may be mistaken for angiosarcoma. *Am J Surg Pathol*. 1992;16(5):429-438.
84. Breuninger H, Schaumburg-Lever G, Holzschuh J, et al. Desmoplastic squamous cell carcinoma of skin and vermilion surface: a highly malignant subtype of skin cancer. *Cancer*. 1997;79(5):915-919.
85. Goyanna R, Torres ET, Broders AC. Histological grading of malignant tumors; Broder's method [in undetermined language]. *Hospital (Rio J)*. 1951;39(6): 791-818.
86. Greene FL, Sobin LH. A worldwide approach to the TNM staging system: collaborative efforts of the AJCC and UICC. *J Surg Oncol*. 2009;99(5):269-272.
87. Edge SB, Compton CC. The American Joint Committee on Cancer: the 7th edition of the AJCC cancer staging manual and the future of TNM. *Ann Surg Oncol*. 2010;17(6):1471-1474.
88. Breuninger H, Eigentler T, Bootz F, et al. Brief S2k guidelines—cutaneous squamous cell carcinoma. *J Dtsch Dermatol Ges*. 2013;11(suppl 3):37-45, 39-47.
89. Bonerandi JJ, Beauvillain C, Caquant L, et al. Guidelines for the diagnosis and treatment of cutaneous squamous cell carcinoma and precursor lesions. *J Eur Acad Dermatol Venereol*. 2011;25(suppl 5):1-51.
90. Oster-Schmidt C. Two cases of squamous cell carcinoma treated with topical imiquimod 5%. *J Eur Acad Dermatol Venereol*. 2004;18(1):93-95.
91. Morse LG, Kendrick C, Hooper D, et al. Treatment of squamous cell carcinoma with intralesional 5-fluorouracil. *Dermatol Surg*. 2003;29(11):1150-1153; discussion 1153.
92. Marmur ES, Schmults CD, Goldberg DJ. A review of laser and photodynamic therapy for the treatment of nonmelanoma skin cancer. *Dermatol Surg*. 2004;30(2, pt 2):264-271.
93. Krediet JT, Beyer M, Lenz K, et al. Sentinel lymph node biopsy and risk factors for predicting metastasis in cutaneous squamous cell carcinoma. *Br J Dermatol*. 2015;172(4):1029-1036.
94. Jarkowski A 3rd, Hare R, Loud P, et al. Systemic therapy in advanced cutaneous squamous cell carcinoma (CSCC): the Roswell Park experience and a review of the literature. *Am J Clin Oncol*. 2016;39(6):545-548.
95. Maubec E, Petrow P, Scheer-Senyarich I, et al. Phase II study of cetuximab as first-line single-drug therapy in patients with unresectable squamous cell carcinoma of the skin. *J Clin Oncol*. 2011;29(25):3419-3426.
96. Ritprajak P, Azuma M. Intrinsic and extrinsic control of expression of the immunoregulatory molecule PD-L1 in epithelial cells and squamous cell carcinoma. *Oral Oncol*. 2015;51(3):221-228.
97. Chang AL, Kim J, Luciano R, et al. A case report of unresectable cutaneous squamous cell carcinoma responsive to pembrolizumab, a programmed cell death protein 1 inhibitor. *JAMA Dermatol*. 2016;152(1): 106-108.
98. Lott DG, Manz R, Koch C, et al. Aggressive behavior of nonmelanotic skin cancers in solid organ transplant recipients. *Transplantation*. 2010;90(6):683-687.
99. Rowe DE, Carroll RJ, Day CL Jr. Prognostic factors for local recurrence, metastasis, and survival rates in squamous cell carcinoma of the skin, ear, and lip. Implications for treatment modality selection. *J Am Acad Dermatol*. 1992;26(6):976-990.
100. Rapini RP. Comparison of methods for checking surgical margins. *J Am Acad Dermatol*. 1990;23(2, pt 1):288-294.
101. Brantsch KD, Meisner C, Schonfisch B, et al. Analysis of risk factors determining prognosis of cutaneous squamous-cell carcinoma: a prospective study. *Lancet Oncol*. 2008;9(8):713-720.
102. Clayman GL, Lee JJ, Holsinger FC, et al. Mortality risk from squamous cell skin cancer. *J Clin Oncol*. 2005;23(4):759-765.
103. Marcil I, Stern RS. Risk of developing a subsequent nonmelanoma skin cancer in patients with a history of nonmelanoma skin cancer: a critical review of the literature and meta-analysis. *Arch Dermatol*. 2000;136(12):1524-1530.
104. Lautenschlager S, Wulf HC, Pittelkow MR. Photoprotection. *Lancet*. 2007;370(9586):528-537.
105. Gordon LG, Scuffham PA, van der Pols JC, et al. Regular sunscreen use is a cost-effective approach to skin cancer prevention in subtropical settings. *J Invest Dermatol*. 2009;129(12):2766-2771.
106. Chen AC, Martin AJ, Choy B, et al. A phase 3 randomized trial of nicotinamide for skin-cancer chemoprevention. *N Engl J Med*. 2015;373(17):1618-1626.
107. Surjana D, Halliday GM, Damian DL. Nicotinamide enhances repair of ultraviolet radiation-induced DNA

damage in human keratinocytes and ex vivo skin. *Carcinogenesis*. 2013;34(5):1144-1149.
108. Oblong JE. The evolving role of the NAD+/nicotinamide metabolome in skin homeostasis, cellular bioenergetics, and aging. *DNA Repair (Amst)*. 2014;23:59-63.
109. Gensler HL. Prevention of photoimmunosuppression and photocarcinogenesis by topical nicotinamide. *Nutr Cancer*. 1997;29(2):157-162.
110. Kuchel JM, Barnetson RS, Halliday GM. Cyclobutane pyrimidine dimer formation is a molecular trigger for solar-simulated ultraviolet radiation-induced suppression of memory immunity in humans. *Photochem Photobiol Sci*. 2005;4(8):577-582.
111. Shimizu M, Suzui M, Deguchi A, et al. Effects of acyclic retinoid on growth, cell cycle control, epidermal growth factor receptor signaling, and gene expression in human squamous cell carcinoma cells. *Clin Cancer Res*. 2004;10(3):1130-1140.
112. Amini S, Viera MH, Valins W, et al. Nonsurgical innovations in the treatment of nonmelanoma skin cancer. *J Clin Aesthet Dermatol*. 2010;3(6):20-34.
113. Bavinck JN, Tieben LM, Van der Woude FJ, et al. Prevention of skin cancer and reduction of keratotic skin lesions during acitretin therapy in renal transplant recipients: a double-blind, placebo-controlled study. *J Clin Oncol*. 1995;13(8):1933-1938.
114. Chen K, Craig JC, Shumack S. Oral retinoids for the prevention of skin cancers in solid organ transplant recipients: a systematic review of randomized controlled trials. *Br J Dermatol*. 2005;152(3):518-523.
115. Kraemer KH, DiGiovanna JJ, Moshell AN, et al. Prevention of skin cancer in xeroderma pigmentosum with the use of oral isotretinoin. *N Engl J Med*. 1988;318(25):1633-1637.

Chapter 113 :: Merkel Cell Carcinoma

:: Aubriana McEvoy & Paul Nghiem

AT-A-GLANCE

- The risk of death from Merkel cell carcinoma (MCC) is 2 to 3 times higher than from melanoma.
- Reported incidence of MCC quadrupled from 1986 to 2006.
- Risk factors for MCC include advanced age, immune suppression, and fair skin.
- Merkel cell polyomavirus (MCPyV) is integrated in 80% of MCC cases.
- Consider MCC in the differential diagnosis of any rapidly growing, nontender nodule on a sun-exposed area.
- Management is challenging as therapy is unique and controversial.
- Sentinel lymph node biopsy, surgery, and radiation are indicated in many cases.
- Imaging (CT, MRI, positron emission tomography) has poor sensitivity and specificity in early stages of MCC, but can be useful in assessment of and surveillance for metastatic disease.
- MCC is an especially radiosensitive tumor. Adjuvant radiation therapy is highly effective, and overaggressive surgery should be avoided. Radiation monotherapy is an important and effective option for managing disease in patients who are not candidates for surgery.
- Immune therapies, including checkpoint inhibition and T-cell therapies are now the treatment of choice for advanced disease.
- Chemotherapy has very limited utility in treating MCC, and adjuvant chemotherapy is not beneficial. Adjuvant immune therapy is an area of new research.
- Optimal care includes multidisciplinary coordination between dermatologists, surgeons, radiologists, and medical oncologists with reference to the National Comprehensive Cancer Network (NCCN) guidelines.

Merkel cell carcinoma (MCC) is an increasingly common neuroendocrine skin cancer that is associated with ultraviolet (UV) light exposure, advanced age, immune suppression, and the Merkel cell polyomavirus (MCPyV). The reported incidence of MCC has more than tripled in the past 20 years[1] to approximately 1500 U.S. cases/year,[2] and is expected to grow with the aging population. Although it is 40 times less common than malignant melanoma, it carries a markedly poorer prognosis, with disease-associated mortality at 5 years of 46%[3] as compared with 9% for invasive melanoma.[4] Management of MCC is controversial as optimal therapy is rapidly evolving with promising immune therapy options.

HISTORICAL PERSPECTIVE

MCC is a relatively recently described entity, although the Merkel cell was identified more than 100 years ago. In 1875, human Merkel cells were first described by Friedrich S. Merkel (1845-1919). He named these cells *Tastzellen* (touch cells) assuming that they had a sensory touch function within the skin because of their association with nerves. In 2009, a series of studies using mouse models resolved several longstanding debates by conclusively establishing that (a) Merkel cells are essential for light touch responses,[5] (b) Merkel cells have an epidermal origin,[5,6] and (c) Merkel cells do not divide, but are renewed by a reservoir of epidermal progenitor cells.[6]

In 1972, Toker described 5 cases of "trabecular cell carcinoma of the skin," consistent with what we now call MCC. In 1978, Tang and Toker found that cells from these tumors contained dense core granules on electron microscopy that were typical of Merkel cells and other neuroendocrine cells. In 1980, the name *Merkel cell carcinoma* was first applied to this tumor because of the characteristic ultrastructural features it shares with normal Merkel cells. In 1992, it was found that antibodies to cytokeratin-20 stain normal skin Merkel cells as well as the vast majority of MCC tumors. This critical finding enables specific and relatively easy diagnosis of MCC to be made through immunohistochemistry. Since that time, electron microscopy is no longer used to make this diagnosis. Of note, it is unlikely that MCC is derived from normal Merkel cells within the skin (these cells are postmitotic and it has proven impossible to coax them to divide). Even though it is more likely that MCC derives from epidermal precursor cells, the phenotypic similarities between the normal Merkel cells and MCC are striking and informative.

EPIDEMIOLOGY

Between 1986 and 2006, the reported incidence of MCC quadrupled from 0.15 per 100,000[1] to 0.6 per 100,000 persons.[7] This increase in reported incidence is more rapid than any other type of skin cancer, and can be attributed to two factors. One factor is an increase in the accurate diagnosis of this malignancy through the routine use of cytokeratin-20 immunohistochemistry and the improved recognition of this malignancy by dermatopathologists. In the past, MCCs were often

mischaracterized as lymphoma, melanoma, or undifferentiated carcinoma in the era before immunohistochemistry. A second likely factor is an increase in the prevalence of MCC risk factors: a growing population older than age 65 years with extensive sun exposure history, and more individuals living with prolonged immune suppression. Risk factors for MCC are discussed in section "Etiology and Pathogenesis".

There are approximately 2500 MCC cases per year in the United States.[2] It is far more common in white individuals than in black individuals, which is consistent with a known role for UV radiation in MCC pathogenesis. Specifically, the MCC rates for white individuals have been reported as 0.23 per 100,000 as compared to 0.01 per 100,000 for black individuals.[8] Although not specifically reported, rates in Latino and Asian populations are likely intermediate between those in populations of black and white individuals. MCC is more common in men than in women (2:1 ratio).[9] Furthermore, men also tend to have a worse prognosis than women, with reported 10-year disease-associated survival rates of 51% for men and 65% for women.[7]

CLINICAL PRESENTATION

CUTANEOUS FINDINGS

In a 2008 systematic analysis of 195 MCC patients, clinical features of MCC were characterized.[10] The most significant features can be summarized in an acronym: AEIOU (asymptomatic/lack of tenderness, expanding rapidly, immune suppression, older than age 50 years, and UV-exposed site on a person with fair skin; Table 113-1). This study found that 89% of MCC cases exhibited at least 3 of the 5 features listed below in Table 113-1. If a lesion exhibits at least 3 of these features, suspicion of MCC should increase, and biopsy of the lesion is indicated. In particular, a lesion that is red or purple, rapidly growing, and nontender should be concerning.

Strikingly, in more than one-half of MCC cases, the clinician listed a benign diagnosis as the initial clinical impression. In particular, a cyst or acneiform lesion were the most common diagnoses (Table 113-2 and Figs. 113-1A and 113-1B), and nonmelanoma skin cancer was also a relatively frequent presumptive diagnosis (Fig. 113-1C).

TABLE 113-1
Clinical Features of Merkel Cell Carcinoma

- ***A***symptomatic (nontender, firm, red, purple, or skin-colored papule or nodule; ulceration is rare; see Figs. 113-1A and 113-1B)
- ***E***xpanding rapidly (significant growth noted within 1-3 months of diagnosis, but most lesions are <2 cm at time of diagnosis)
- ***I***mmune suppression (eg, HIV/AIDS, chronic lymphocytic leukemia, solid organ transplant)
- ***O***lder than 50 years of age
- ***U***ltraviolet-exposed site on a person with fair skin (most likely presentation, but can also occur in sun-protected areas; see Fig. 113-2)

TABLE 113-2
Differential Diagnosis of Merkel Cell Carcinoma

Most Likely
- Cyst
- Basal cell carcinoma
- Squamous cell carcinoma (see Fig. 113-1C)
- Amelanotic melanoma
- Cutaneous lymphoma
- Adnexal tumor

Consider
- Metastasis
- Dermatofibrosarcoma protuberans
- Keratoacanthoma
- Neuroblastoma

NONCUTANEOUS FINDINGS

MCC may present with regional lymph node or distant metastatic disease, with or without a known primary cutaneous lesion. Reports indicate that MCC patients presenting without an identifiable primary lesion—"unknown primary"—have better outcomes than similarly staged patients with known primary tumors.[11] It is possible that primary lesion regression is immune mediated, and that the immune system of a patient with an unknown primary lesion is able to recognize and respond to the disease. This underlines the importance of developments in immune therapy such as T-cell therapy and checkpoint therapy as systemic treatment options.

Recurrent or metastatic MCC is generally detectable via positron emission tomography–CT scan and/or clinical examination, and frequently includes noncutaneous sites. One study demonstrated that about half of patients with local or nodal disease at presentation recurred after primary treatment. For patients who experienced a recurrence, the site of first recurrence was: local (21% of first recurrences), nodal (27% of first recurrences presented as regional lymphadenopathy), and distant (52% of first recurrences occurred at sites beyond the regional draining lymph nodes).[12] In the past, MCC metastases to the viscera indicated incurable disease. However, immune therapy trials have reported a high percentage of positive, durable responses of advanced MCC as detailed in section "Immune Therapy".

CLINICAL COURSE AND COMPLICATIONS

In more than 90% of cases, MCC is an unanticipated diagnosis before the pathology results become known. Most commonly, the lesion in question was thought to

Figure 113-1 Clinical appearance of Merkel cell carcinoma (MCC). **A,** MCC frequently has a "cyst-like" appearance. This is reflected in the differential diagnoses given by clinicians at the time of the biopsy, with cyst/acneiform lesion being the most common clinical impression. **B,** MCC on the knee of a 70-year-old woman with chronic lymphocytic leukemia. For 6 months this lesion was thought to be a "cyst"; consequently, diagnosis and treatment were delayed. Pen marks indicate palpable satellite metastases that developed several months after the primary lesion, presumably tracking via lymphatics. **C,** MCC on the ear of an 87-year-old woman. The lesion grew rapidly and was nontender. After approximately 3 months, it was biopsied by a clinician who listed squamous cell carcinoma as the presumptive diagnosis.

be a cyst or acneiform lesion. Although most patients and many physicians are not familiar with this disease or its specific management, MCC can be lethal and it is important to initiate therapy promptly. In one Australian study, a high fraction of patients (45%) developed progressive disease while waiting for adjuvant radiation therapy to begin (median wait time: 41 days).[13]

The patterns of MCC local, regional, and distant recurrences differ from melanoma. Among patients who experience a recurrence of their MCC, approximately 80% recur within 2 years of diagnosis.[14] MCC patients who have had no recurrences for 3 to 5 years, have a greatly reduced risk of recurrence.

The complications for those who do not experience a metastasis depend very much on the therapy they received. We believe that treatment with surgical excision, radiation therapy, and possibly systemic therapy as outlined in this chapter has relatively minimal complication rates and the best possible chance of cure based on current literature. Furthermore, for those who receive very aggressive surgical excision, amputation, or chemotherapy for low-risk disease, complication rates tend to be higher without improved outcomes.

ETIOLOGY AND PATHOGENESIS

There are several known risk factors for MCC that have led to an increase in the incidence of this disease.

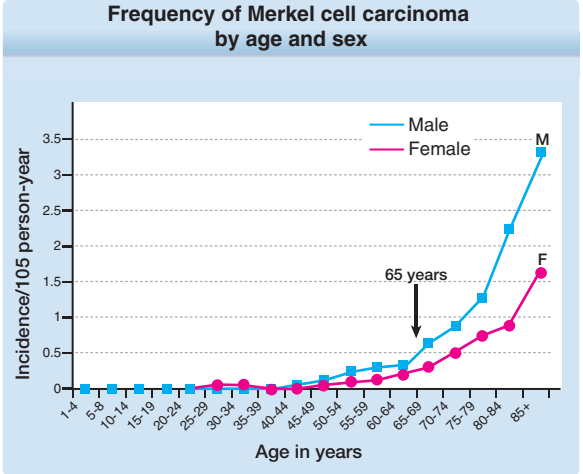

Figure 113-2 Frequency of Merkel cell carcinoma by age and sex. The most significant risk factor for Merkel cell carcinoma is age. M, male (■); F, female (●). (Reprinted from Agelli M, Clegg LX. Epidemiology of primary Merkel cell carcinoma in the United States. *J Am Acad Dermatol.* 2003;49:832, with permission. Copyright © American Academy of Dermatology.)

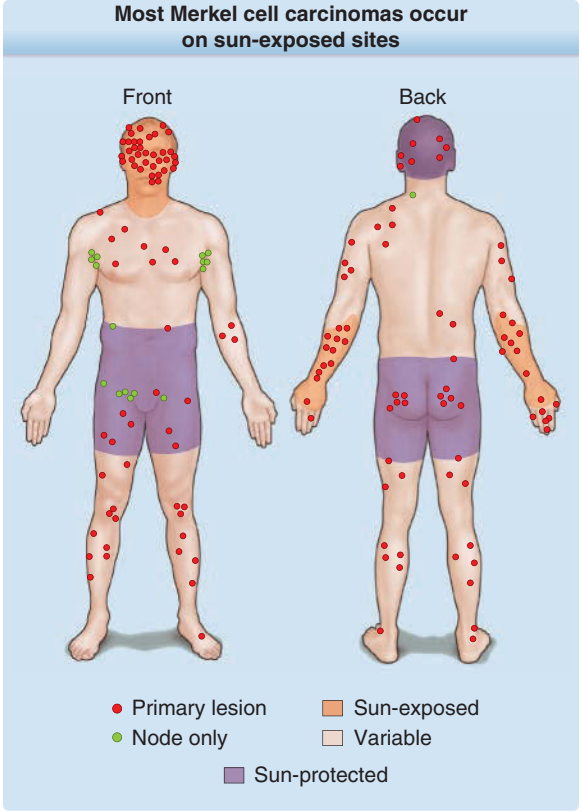

Figure 113-3 Merkel cell carcinomas (MCCs) occur frequently, but not exclusively, on sun-exposed sites. This diagram shows the locations of tumor presentation for 195 MCC patients. For the 168 patients with a known primary lesion, 96 of them (57%) presented with a primary tumor located on the heavily sun-exposed face, neck, or arm (*brown shading*). 62 patients (37%) of patients presented with MCC in partially sun-protected skin (*skin tone*), and 10 patients (~6%) presented with tumors in completely sun-protected skin areas (*purple shading*). (Adapted from Heath M, Jaimes N, Lemos B, et al. Clinical characteristics of Merkel cell carcinoma at diagnosis in 195 patients: the AEIOU features. *J Am Acad Dermatol.* 2008;58:375-381.)

RISK FACTORS

AGE GREATER THAN 65 YEARS

The median age for diagnosis of MCC is 70 years, and there is a 5- to 10-fold increase in incidence after age 70 years, compared with age younger than 60 years (Fig. 113-2). Furthermore, only approximately 10% of MCC cases present in patients younger than age 50 years, and it is extremely rare in childhood.[10]

SUN EXPOSURE

Sunlight, prolonged UV exposure, and photochemotherapy are all associated with an increased risk of MCC. As Fig. 113-3 illustrates, the majority of MCC tumors present on sun-exposed skin.[10] However, it is clear that sun exposure is not required for MCC to develop. MCC cases can occur on sun-protected skin, including buttocks and the inguinal/groin/genital regions, as well as portions of the scalp that are covered by hair.

IMMUNE SUPPRESSION

MCC is strongly associated with immune suppression. Approximately 8% of MCC patients are profoundly immune suppressed, which is a 16-fold overrepresentation compared with what is expected.[10] Multiple forms of immune suppression are associated with an increased risk for MCC, including HIV/AIDS,[15] non-Hodgkin lymphoma including chronic lymphocytic leukemia,[10] immune suppressive regimens associated with solid-organ transplantation, and chronic treatment of autoimmune disease.[9]

Additionally, there are 19 reported cases of complete spontaneous regression in the MCC literature—a far greater number than expected for its rarity—suggesting immune recognition and clearance of MCC.[8,16]

MERKEL CELL POLYOMAVIRUS

In 2008, the MCPyV was discovered by extensive sequencing of MCC tumor RNA. MCPyV was reported to be present in 80% of MCC tumors compared to only 7% of skin controls.[17] Numerous groups across several continents (more than 25 literature citations) have verified a strong association between MCPyV and MCC.

MCPyV is a small, circular, double-stranded DNA virus related to other known polyomaviruses

(including SV40, BK, JC, KI, and WU). MCPyV is unique among the human polyomaviruses as it is the only one proven to integrate into and be causal for human cancer.[17] Monoclonal integration of MCPyV into MCC tumors suggests that the virus is present prior to or very early in tumorigenesis.

In an analysis of exome sequencing of 49 MCCs, each tumor was grouped into 1 of 2 mutational profiles: one group of MCC tumors with relatively low mutational burden (relatively few single-nucleotide variants, *MCC-LO*, on the left side of Fig. 113-4), and the other group included tumors with relatively high mutational burden (*MCC-HI*, on the far right of Fig. 113-4).[18] Analysis demonstrated strong relationships between the mutational burden and presence of either MCPyV integration or UV-induced mutations. A vast majority of the MCC-LO tumors contained MCPyV (virus-positive), whereas virtually all of the MCC-HI tumors were virus-negative. Furthermore, the mutations in the MCC-HI tumors were almost entirely UV-induced. Simply put, it appears that generation of a MCC tumor requires either integration of the Merkel polyomavirus, or extensive UV-induced mutations—even a higher number than for melanoma (*SKCM* in Fig. 113-4).

A large fraction of the population has been exposed to the MCPyV. Accurate data about prior exposure to polyomaviruses can be derived by determining the prevalence of MCPyV capsid antibodies, which are easily differentiated from other polyomaviruses. The capsid proteins are very specific to MCPyV. By the age of 5 years, the prevalence of individuals who produce antibodies to the MCPyV capsid protein is approximately 35%; it increases to 50% by the age of 15 years.[19] Interestingly, among MCC patients, the prevalence of individuals that produce capsid antibodies is significantly higher (88%) than age-matched and sex-matched controls (53%).[20]

Despite the nearly ubiquitous exposure to this virus in the general population, the incidence of MCC is very low. For MCPyV to cause cancer, the virus must integrate into the host's DNA and evade the host's immune system. A key portion of the MCPyV—the "oncoprotein" or T-antigen—is present in approximately 80% of all MCC tumors. This protein is critical for most MCC tumors to grow.

Antibodies to the MCPyV oncoprotein can be detected and measured using a clinically available serology test. Determining the oncoprotein antibody status is clinically useful for newly diagnosed MCC patients, whether or not they are antibody producers. For patients who produce oncoprotein antibodies, tracking their antibody titer can be used to detect early MCC recurrence. Patients who do not produce detectable oncoprotein antibodies are at higher risk of recurrence and will need to be followed more closely with surveillance, consisting of clinical and radiologic examinations (more details in section "Surveillance").

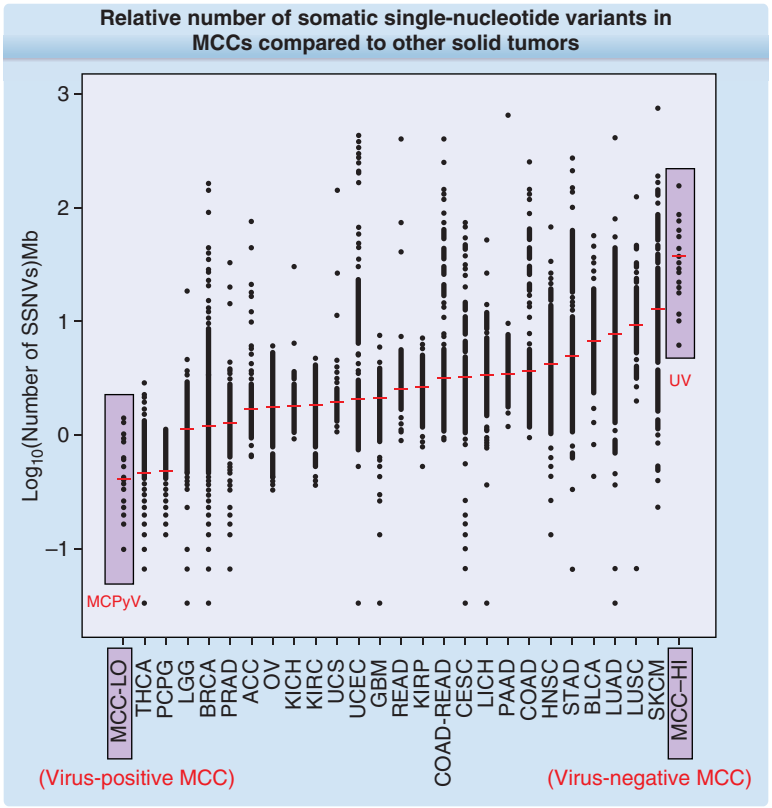

Figure 113-4 Relative number of somatic single-nucleotide variants (SSNVs) in MCCs compared to other solid tumors sequenced by The Cancer Genome Atlas. The red lines reflect the median number of SSNVs in each group. (Reproduced from Goh G, Walradt T, Markarov V, et al: Mutational landscape of MCPyV-positive and MCPyV-negative Merkel cell carcinomas with implications for immunotherapy. *Oncotarget.* 2016;7(3):3403-3415, with permission.)

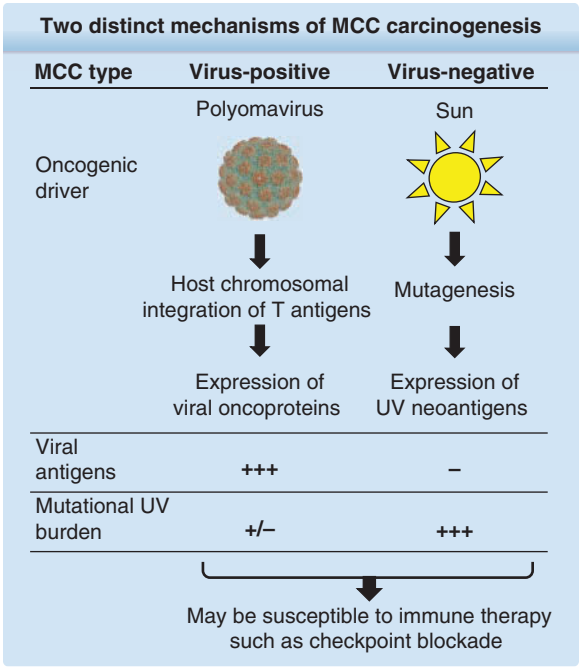

Figure 113-5 Merkel cell carcinoma (MCC) carcinogenesis: 2 distinct mechanisms. Virus-negative MCCs harbor extremely large numbers of UV-induced mutations, which can serve as neoantigens for tumor recognition by the immune system. Merkel polyomavirus-positive MCCs persistently express viral proteins that drive the cancer cells to divide. These viral oncoproteins can be used to track disease progression (via antibodies in the blood that indicate tumor recurrence) and serve as nonself proteins that can be recognized by the immune system.

The MCPyV and UV radiation play distinct roles in MCC tumorigenesis. In the 80% of MCC tumors that contain MCPyV, viral oncoproteins are expressed through clonal integration of viral DNA into the host genome. In the 20% of MCCs that are virus-negative, UV-induced mutations are present at extremely high levels (on average, several times higher even than in malignant melanoma). A portion of these UV-induced mutations represent neoantigens that are visible to the immune system. In either case, expression of viral oncoproteins or UV-induced neoantigens means the tumor must develop effective mechanisms of immune evasion for the tumor to survive. Figure 113-5 summarizes these oncogenic mechanisms and their relevance to the immune-based therapies that are increasingly available to treat advanced MCC. (Immune therapy is discussed further in section "Management".)

DIAGNOSIS

PATHOLOGY

As Figure 113-6A shows, the classic histologic features of MCC include sheets of small basophilic cells with scant cytoplasm, fine chromatin, and no nucleoli. There are numerous mitotic figures and occasional individual necrotic cells. Lymphovascular invasion is a very common feature and often can be found when it is specifically searched for, even in a "negative" margin. This helps to explain the high local recurrence rate in MCC for narrow or even relatively wide margin excision when adjuvant radiation therapy is not given.

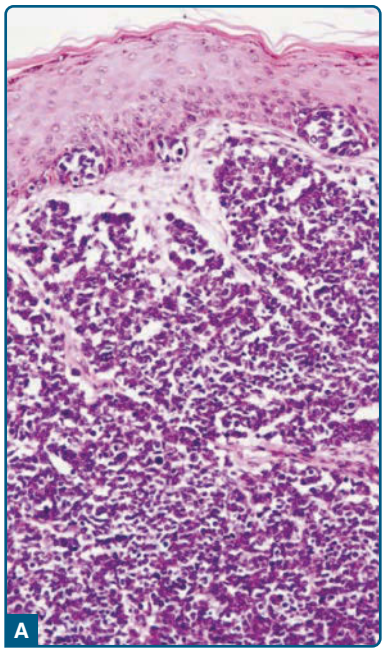

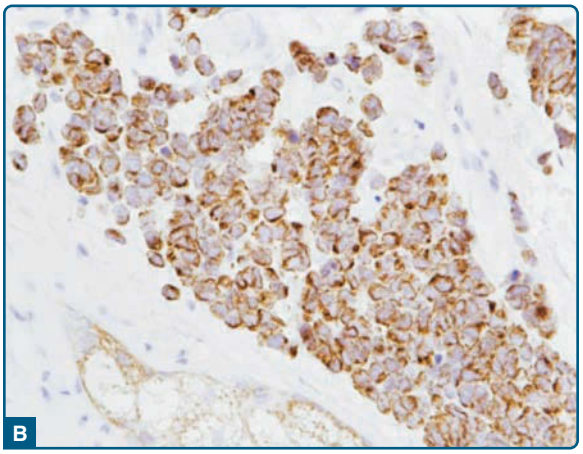

Figure 113-6 Merkel cell carcinoma pathology. **A,** Hematoxylin and eosin. There is diffuse dermal as well as intraepidermal involvement with Merkel cell carcinoma. This case was seen in consultation, with an initial diagnosis of cutaneous T-cell lymphoma. **B,** Cytokeratin-20. Showing the pathognomonic "perinuclear pattern" of cytokeratins (CAM5.2). (Reprinted from Nghiem P, Mckee P, Haynes H. Merkel cell [cutaneous neuroendocrine] carcinoma. In: Sober A, Haluska F, eds. *Skin Cancer, Atlas of Clinical Oncology.* Atlanta, GA:, American Cancer Society; 2001, with permission.)

HEMATOXYLIN AND EOSIN STAIN

Three histologic patterns have been described up to now and none is clearly associated with a better or worse prognosis. The most common type is

the "intermediate type." This type features uniform small cells with minimal cytoplasm, pale nuclei, and a dispersed chromatin appearance. On hematoxylin and eosin staining, the differential diagnosis for this presentation is that of the small, blue-cell tumors, including melanoma and lymphoma. The second most common pattern is the "small cell type." This takes its name from small-cell lung carcinoma, which is the principal differential diagnosis for this pattern. It shows irregular, hyperchromatic cells with scant cytoplasm and malignant cells that are arranged in linear patterns infiltrating stromal structures. The least common, but perhaps most histologically distinctive type, is the "trabecular" type. This is the pattern originally described by Toker in 1972. It has a lattice-like, or network appearance, and the differential diagnosis includes metastatic carcinoid tumor.

IMMUNOHISTOCHEMICAL STAINS

The use of antibody-based stains has greatly facilitated the ease and specificity of MCC diagnosis (Table 113-3). The single most useful of these stains is cytokeratin-20.

CYTOKERATIN-20

This intermediate filament protein is expressed in MCC as well as in adenocarcinomas of the colon, stomach, and pancreas. However, within the skin, the expression of cytokeratin-20 is limited to Merkel cells. A "perinuclear dot" pattern of cytokeratin is essentially pathognomonic for MCC (see Fig. 113-6B). However, 10% to 20% of MCCs are cytokeratin-20–negative.

ANTIBODIES TO CAM5.2

CAM5.2, a cocktail of antibodies that detects multiple human cytokeratin epitopes, typically reacts with both MCC and small-cell lung carcinoma. Although it is useful as an initial screening tool to detect tumors of squamous origin, its lack of selectivity relative to cytokeratin-20 means that it cannot be used to definitively diagnose MCC.

THYROID TRANSCRIPTION FACTOR-1

Thyroid transcription factor-1 is negative in MCC and positive in small-cell lung cancer. Consequently, it is useful for the differential diagnosis between these 2 tumors that can look identical by routine histology.

CYTOKERATIN-7

Cytokeratin-7 has the same staining pattern as thyroid transcription factor-1, that is, typically negative in MCC and positive in small-cell lung carcinoma. It is also expressed in epithelial cells of the lung, ovary, and breast.

MERKEL CELL POLYOMAVIRUS ONCOPROTEIN

MCC tumor tissue may be tested for the MCPyV oncoprotein using the CM2B4 antibody. The CM2B4 antibody is specific for MCC, rather than other tumors, and is an excellent tool for determining if an MCC is virally induced or not. MCC tumors induced only by UV radiation (no virus) would be negative for CM2B4, and approximately 20% of MCCs would thus be negative for this antibody. The relationship between CM2B4 antibody presence and prognosis is controversial, but viral positivity is likely associated with moderately decreased risk of MCC recurrence.

DIFFERENTIAL DIAGNOSIS

Table 113-2 outlines the differential diagnosis of MCC.

STAGING AND PROGNOSIS

Survival after a diagnosis of MCC is highly dependent on the stage at presentation, and decreases markedly with nodal involvement and metastatic disease.

TABLE 113-3
Immunohistochemistry Panel

	CYTOKERATIN-20	CYTOKERATIN-7 AND THYROID TRANSCRIPTION FACTOR-1	LEUKOCYTE COMMON ANTIGEN	S-100	ONCOPROTEIN ANTIBODY CM2B4
Merkel cell carcinoma	+	–	–	–	+ (In Merkel cell polyomavirus-induced Merkel cell carcinomas)
Small-cell lung carcinoma	–	+	–	–	–
Lymphoma	–	–	+	–	–
Melanoma	–	–	–	+	–

In 2010, the American Joint Committee on Cancer (AJCC) adopted the 7th edition staging system for MCC that replaced 5 existing—and conflicting—staging systems.[19] The AJCC's 8th edition staging system for MCC was adopted in 2018. As with other staging systems, the 8th edition system uses the TNM (tumor, node, metastasis) staging system, with information from clinical examinations, imaging studies, and pathologic evaluation of the primary tumor, lymph nodes, and metastatic lesions. A major change with this new staging system is that patients with clinically apparent lymph node involvement are split into 2 groups based on whether or not they have a detectable/known primary lesion. Those without a known primary lesion have significantly better survival and are now included in stage IIIA, while those with a known primary lesion are stage IIIB.[20] Table 113-4 summarizes this staging system.

MCC-specific survival and progression-free survival are important analyses for estimating prognosis by stage. An online resource, http://www.merkelcell.org, is devoted to aiding patients and physicians by presenting current data, including stage-specific prognostic information, and referral center availability. Figure 113-7 details overall survival by stage.

SENTINEL LYMPH NODE BIOPSY

In addition to its established role in managing higher risk melanoma, several studies have indicated that sentinel lymph node biopsy (SLNB) is also a sensitive test for detecting MCC spread to the lymph nodes.[21-23] Interestingly, MCC is far more likely to have occult lymph node involvement (approximately 30% for the average 1.7-cm MCC) than melanoma (~1% for melanomas with the average Breslow thickness of 0.63 mm).[23,24] SLNB (typically involving 1 to 3 nodes) clearly has less morbidity than an elective lymph node

TABLE 113-4
Outline of American Joint Committee on Cancer 8th Edition Staging System for Merkel Cell Carcinoma

STAGE	PRIMARY TUMOR	LYMPH NODE	METASTASIS
0	In situ (within epidermis only)	No regional lymph node metastasis	No distant metastasis
I Clinical[a]	≤2 cm maximum tumor dimension	Nodes negative by clinical examination (no pathologic examination performed)	No distant metastasis
I Pathologic[b]	≤2 cm maximum tumor dimension	Nodes negative by pathologic examination	No distant metastasis
IIA Clinical	>2 cm tumor dimension	Nodes negative by clinical examination (no pathologic examination performed)	No distant metastasis
IIA Pathologic	>2 cm tumor dimension	Nodes negative by pathologic examination	No distant metastasis
IIB Clinical	Primary tumor invades bone, muscle, fascia, or cartilage	Nodes negative by clinical examination (no pathologic examination performed)	No distant metastasis
IIB Pathologic	Primary tumor invades bone, muscle, fascia, or cartilage	Nodes negative by pathologic examination	No distant metastasis
III Clinical	Any size/depth tumor	Nodes positive by clinical examination (no pathologic examination performed)	No distant metastasis
IIIA Pathologic	Any size/depth tumor	Nodes positive by pathologic examination only (nodal disease not apparent on clinical examination)	No distant metastasis
	Not detected ("unknown primary")	Nodes positive by clinical examination, and confirmed via pathologic examination	No distant metastasis
IIIB Pathologic	Any size/depth tumor	Nodes positive by clinical examination, and confirmed via pathologic examination OR in-transit metastasis[c]	No distant metastasis
IV Clinical	Any	+/– Regional nodal involvement	Distant metastasis detected via clinical examination
IV Pathologic	Any	+/– Regional nodal involvement	Distant metastasis confirmed via pathologic examination

[a]Clinical detection of nodal or metastatic disease may be via inspection, palpation, and/or imaging

[b]Pathologic detection/confirmation of nodal disease may be via sentinel lymph node biopsy, lymphadenectomy, or fine-needle biopsy; and pathologic confirmation of metastatic disease may be via biopsy of the suspected metastasis

[c]In transit metastasis: a tumor distinct from the primary lesion and located either (a) between the primary lesion and the draining regional lymph nodes or (b) distal to the primary lesion

Note: In this staging system updated for 2017, it is necessary to specify whether staging was determined by clinical evaluation or microscopic/pathologic evaluation.

Adapted by Aubriana McEvoy and Dr. Paul Nghiem with permission of Springer: Harms KL, Healy MA, Nghiem P, et al. Analysis of prognostic factors from 9387 Merkel cell carcinoma cases forms the basis for the new 8th edition AJCC staging system. *Ann Surg Oncol*. 2016;23(11):3564-3571. Copyright © Society of Surgical Oncology 2016. See www.merkelcell.org/staging for more information.

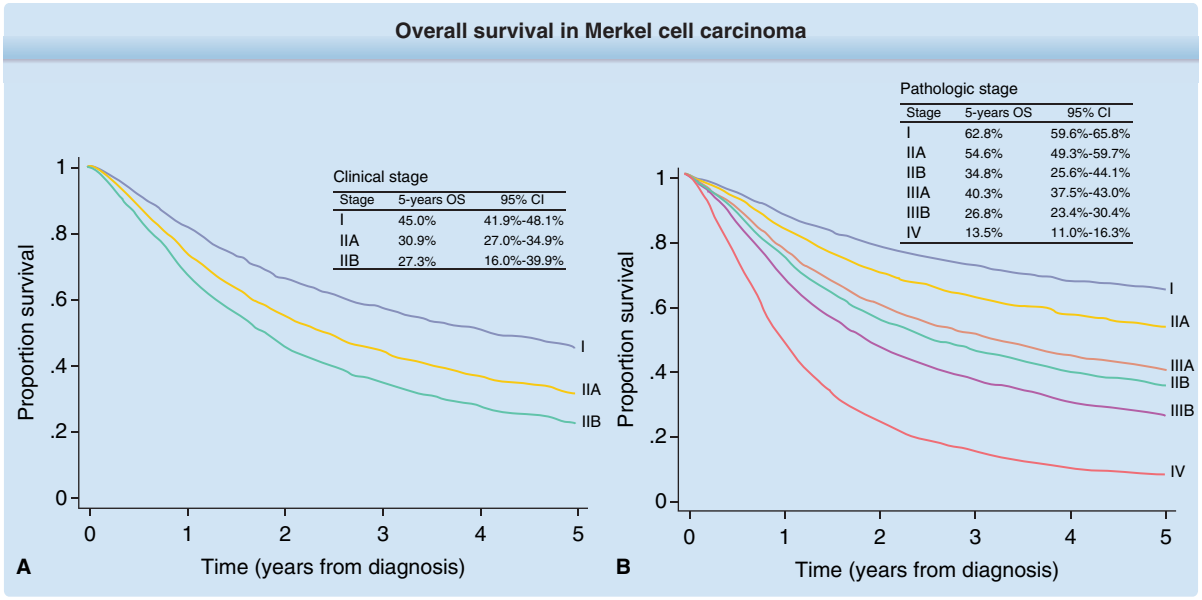

Figure 113-7 Overall survival in Merkel cell carcinoma (MCC). Prognosis of MCC depends on stage at diagnosis. This figure shows overall survival curves for 9387 Merkel cell carcinoma patients by "Clinical Stage" (see Fig. 113-6A) and "Pathologic Stage" (see Fig. 113-6B). Particularly for low-risk (stage I) MCC, most deaths are not from MCC in this older population. (Reprinted with permission of Springer: Harms KL, Healy MA, Nghiem P, et al. Analysis of prognostic factors from 9387 Merkel cell carcinoma cases forms the basis for the new 8th edition AJCC staging system. *Ann Surg Oncol*. 2016;23(11): 3564-3571. Copyright © Society of Surgical Oncology 2016.)

dissection (typically involving more than 20 nodes). Ideally, an SLNB should be performed at the time of the wide resection, as opposed to after the wide excision when local lymphatics have been disturbed.

The SLNB is critical for detecting microscopic lymph node disease, which is not apparent on clinical examination. It has been demonstrated that one-third of patients with local-only disease based on clinical examination, in fact, have occult nodal disease that very much affects their subsequent survival (see Fig. 113-7).[23] Specifically, one-third of patients would be understaged by clinical examination only, and would shift to stage III disease with microscopic evaluation. Identification of microscopic nodal disease also importantly alters therapy for the node bed, as discussed in subsequent sections.

RADIOLOGIC IMAGING

In the era of immune therapy, there is a potentially stronger rationale for more frequent imaging studies. New therapies are sometimes curative and are more likely to be effective in earlier stages of MCC, which correspond to lower disease burdens. Thus, baseline scans are indicated in most patients except those with very-low-risk disease (eg, primary ≤1 cm and negative SLNB), or those who would not be candidates for systemic treatment because of advanced age or comorbidities. Although in some situations, positron emission tomography/CT may have better sensitivity and is often performed at diagnosis for baseline imaging, CT scans are typically performed for ongoing surveillance because of cost.

PROGNOSTIC FINDINGS ON HISTOLOGY

There are 6 histologic findings that may be associated with MCC outcomes. Each histologic feature and its correlation to survival is discussed below.

LYMPHOVASCULAR INVASION

Lymphovascular invasion can be defined as tumor emboli within vascular spaces. One study found that the tumors of MCC patients with detectable lymphovascular invasion had a worse overall survival as compared to those with tumors without lymphovascular invasion (hazard ratio: 3.84; P = 0.007).[25] However, the clinical correlation of lymphovascular invasion evaluation awaits independent validation.

TUMOR GROWTH PATTERN

MCC growth pattern is described as nodular (well-circumscribed interface between tumor and surrounding tissue) or infiltrative (rows, trabeculae, or single cells that penetrate the dermis). Tumors that exhibited both features were considered infiltrative. An infiltrative tumor growth pattern was associated with poor outcomes as compared to MCC tumors with a nodular growth pattern (hazard ratio: 6.85; P = 0.001).[25] Tumor growth pattern and its association with outcomes has not been independently validated and clinically utility is controversial.

MERKEL CELL POLYOMAVIRUS ONCOPROTEIN EXPRESSION

The monoclonal antibody, CM2B4, recognizes the large T-antigen of MCPyV in MCC tissue specimens. As discussed in section "Merkel Cell Polyomavirus" above, MCC tumors can be classified into 1 of 2 subgroups depending on their MCPyV involvement. Although controversial, MCPyV positivity tends to be associated with better outcomes.[26]

P63

Transformation-related/tumor protein 63 can be identified in approximately one-third to one-half of MCC cases. In 2 studies, cases that were positive for p63 demonstrated a more aggressive clinical course than those that were negative, although the strength of the association has been questioned.[27] Clinical significance is controversial.

CD8 INFILTRATION

One 2013 study investigated whether specific mechanisms of T-cell migration may be commonly disrupted in MCC tumors with poor CD8 lymphocyte infiltration. Intratumoral vascular E-selectin, critical for T-cell entry into skin, was downregulated in the majority (52%) of MCCs and its loss was associated with poor intratumoral CD8 lymphocyte infiltration (p <0.05; n = 45). Importantly, survival was improved in MCC patients whose tumors had higher vascular E-selectin expression (p <0.05). These data suggest that one mechanism of immune evasion in MCC may be restriction of T-cell entry into the tumor.[28] Further investigation demonstrated a reliable method for evaluating CD8 lymphocyte infiltration via paraffin-embedded tissue examination, and that infiltration is independently associated with improved MCC-specific survival.[29,30]

MANAGEMENT

In the past 10 years, the optimal therapy for MCC has evolved with exciting advances in treatment options. Furthermore, the expanding availability of clinical trials is allowing for more data collection to support optimization of treatment. These developments have provided an especially improved outlook for stage IV patients, whose disease was previously only viewed as treatable with palliation.

The best summary of consensus treatment of MCC is available through the National Comprehensive Cancer Network (http://www.nccn.org) and is updated annually (these guidelines and other useful information can also be found at http://www.merkelcell.org/usefulInfo/). The best outcome for MCC is clearly obtained when multidisciplinary management is carried out by an experienced team. Each major treatment modality is summarized next.

SURGERY AT THE PRIMARY SITE

The initial management in most cases of MCC is surgical excision of the tumor. When carried out without subsequent adjuvant radiation, patients treated with surgery only may have a relatively high recurrence rate depending on the margins chosen and the risk profile for the tumor. For Mohs surgical excision, the local recurrence rate was 16% for surgery alone and 0% in patients who also had adjuvant radiation therapy, although this difference was not statistically significant.[31] There are no data to suggest that extremely wide excision margins improve overall survival. Depending on the location of the tumor, significant morbidity can result when 2- to 3-cm margins are taken. Numerous studies show that if surgery is the sole treatment, recurrence rates are significantly higher than if radiation therapy is added to the regimen. Excision with narrow but clear margins (carried out at the time of SLNB) followed by adjuvant radiation therapy is a reasonable approach to management in many cases. Overly aggressive surgery, including amputation, or very wide margins in cosmetically sensitive areas, decreases quality of life, increases morbidity, delays time to initiation of adjuvant radiation, and does not appear to improve survival or local control rates.

SURGERY AT THE DRAINING NODE BED

Completion lymphadenectomy is typically carried out if there is clinically apparent involvement of the draining node bed. However, the role of completion lymphadenectomy in MCC is controversial. For example, a 2010 study suggests that patients with nodal MCC disease who underwent complete lymphadenectomy had comparable outcomes as those patients who only underwent radiation therapy to the nodal bed.[32] These 2 options have similar and excellent control rates for node-positive disease. Although either surgery or radiation can be chosen, depending on the clinical situation, it is clear that for microscopic nodal disease, only 1 of these 2 modalities should be performed. This is because regional control rates were 100% for each modality and the combination of radiation and surgery to the lymph node bed greatly increases risk of chronic lymphedema.

RADIATION THERAPY

MCC is an unusually radiosensitive tumor.[33-36] There are several case series of successful treatment of MCC with radiation as monotherapy. One study of 43 patients with MCC, for whom surgical excision was not possible, demonstrated an excellent infield

control rate (75%) after treatment with radiation therapy alone.[32] In a separate cohort, there were no recurrences among 9 patients treated with radiation monotherapy.[37] Figure 113-8 shows one of our cases treated with radiation monotherapy. In most of these cases, the lesion was thought to be inoperable and radiation was given for palliation, but typically resulted in long-lasting local control.

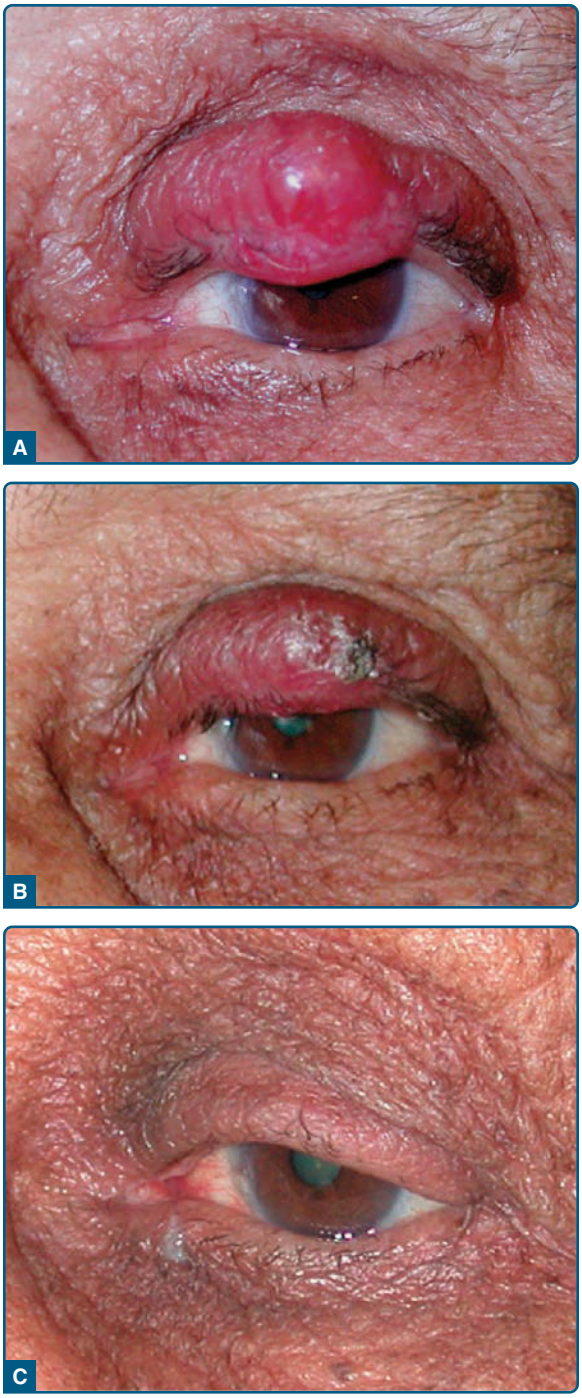

Figure 113-8 **A,** Merkel cell carcinoma on the eyelid arising 3 months before biopsy. The lesion was initially presumed to be a chalazion or cyst. **B,** Using a thin lead shield to protect the globe, the eyelid, the surrounding tissues, and the draining lymph node bed were treated with radiation monotherapy. **C,** The patient remained recurrence-free at 4.5 years after diagnosis, and thus had a greater than 97% chance of cure.

More commonly, radiation is used as an adjuvant treatment to surgery. Adjuvant radiation is critical if surgical margins are positive or if microscopic margins are relatively narrow (<0.5 cm). There is a statistically significant improved local and nodal rate of control of MCC if radiation is added.[38] A cancer registry-based study also indicates improved survival in patients with adjuvant radiation therapy.[39] The typical doses of radiation for MCC are 50 Gy to 56 Gy for a primary site with negative excision margins. Detailed dosing regimens can be found in the National Comprehensive Cancer Network's MCC guidelines. Radiation doses are typically given in 2-Gy fractions, 5 times per week over 4 to 6 weeks. Acute side effects from radiation therapy include erythema at the site and mild-to-moderate fatigue that peaks toward the end of radiation and usually resolves within 1 to 2 months of completing a 5-week course. Chronic radiation skin changes include temporary or permanent alopecia within the irradiated field, epidermal atrophy, loss of adnexal structures leading to skin or mucosal dryness, and risk of subsequent secondary skin cancers in the irradiated region in patients with a life expectancy of greater than 20 years after the radiation treatment. Perhaps the most significant potential side effect is lymphedema. This is more commonly an issue in lower extremities, when radiation therapy is given to the inguinal lymph nodes, especially after surgery also has been done in that region. Early referral to a physical therapist trained in lymphedema management is indicated to minimize the severity and incidence of this potential complication in higher risk cases.

Single-fraction radiotherapy is a viable option for treatment and palliation in some cases of MCC. In one 2015 study, 26 patients received single-fraction radiotherapy (8 Gy) to 93 MCC tumors. The responses were generally excellent, demonstrating infield control and durable responses with minimal toxicity.[33] Single-fraction radiotherapy may represent a convenient and appealing alternative to systemic chemotherapy for palliation, for which most patients with 1 or few metastatic MCC lesions are eligible.

IMMUNE THERAPY

As detailed in section "Etiology and Pathogenesis" above, MCC virus-positive and virus-negative subtypes are both immunogenic, and certain immune evasion mechanisms are now targetable for MCC therapy. Immune therapies are rapidly evolving and, in a subset of patients, are associated with a durable, if not curative, response, even in tumors resistant to standard chemotherapy.

Multiple inhibitors of immune checkpoints, such as programmed death ligand 1 or its receptor, programmed death 1, are the subjects of clinical trials.

In a Phase II clinical trial published in 2016, pembrolizumab, an anti–programmed death 1 antibody, elicited a complete or partial response in more than half of MCC patients treated.[34] Several other clinical trials have demonstrated promising results, and National Comprehensive Cancer Network guidelines indicate that patient participation in clinical trials is recommended, whenever possible.

CHEMOTHERAPY

The most commonly used chemotherapeutic regimen for MCC is the combination of etoposide and either cisplatin (perhaps more clinically effective) or carboplatin (less nephrotoxic). Chemotherapy is often useful in palliation for symptomatic disease that is otherwise inoperable. MCC patients receiving chemotherapy for the first time usually have a significant response with shrinkage of the tumor. Unfortunately, in almost all cases, the tumor grows back and is resistant to chemotherapy, even if entirely different agents are used on a subsequent round of chemotherapy. After careful analysis of the literature, we currently do not recommend adjuvant chemotherapy for patients whose MCC has been treated with surgery, radiation therapy, or both. There are 6 reasons why we do not recommend adjuvant chemotherapy:

1. *Mortality:* There is a 4% to 7% acute death rate from adjuvant chemotherapy in MCC partly because these patients are often elderly.[12,35]
2. *Morbidity:* Neutropenia is reported to occur in 60% of patients with fever, and sepsis in 40%.[36]
3. *Decreased quality of life:* This can be quite severe in this older population, including fatigue, hair loss, nausea, and vomiting.
4. *Resistance to chemotherapy:* MCC that recurs after chemotherapy is less responsive to later palliative chemotherapy.

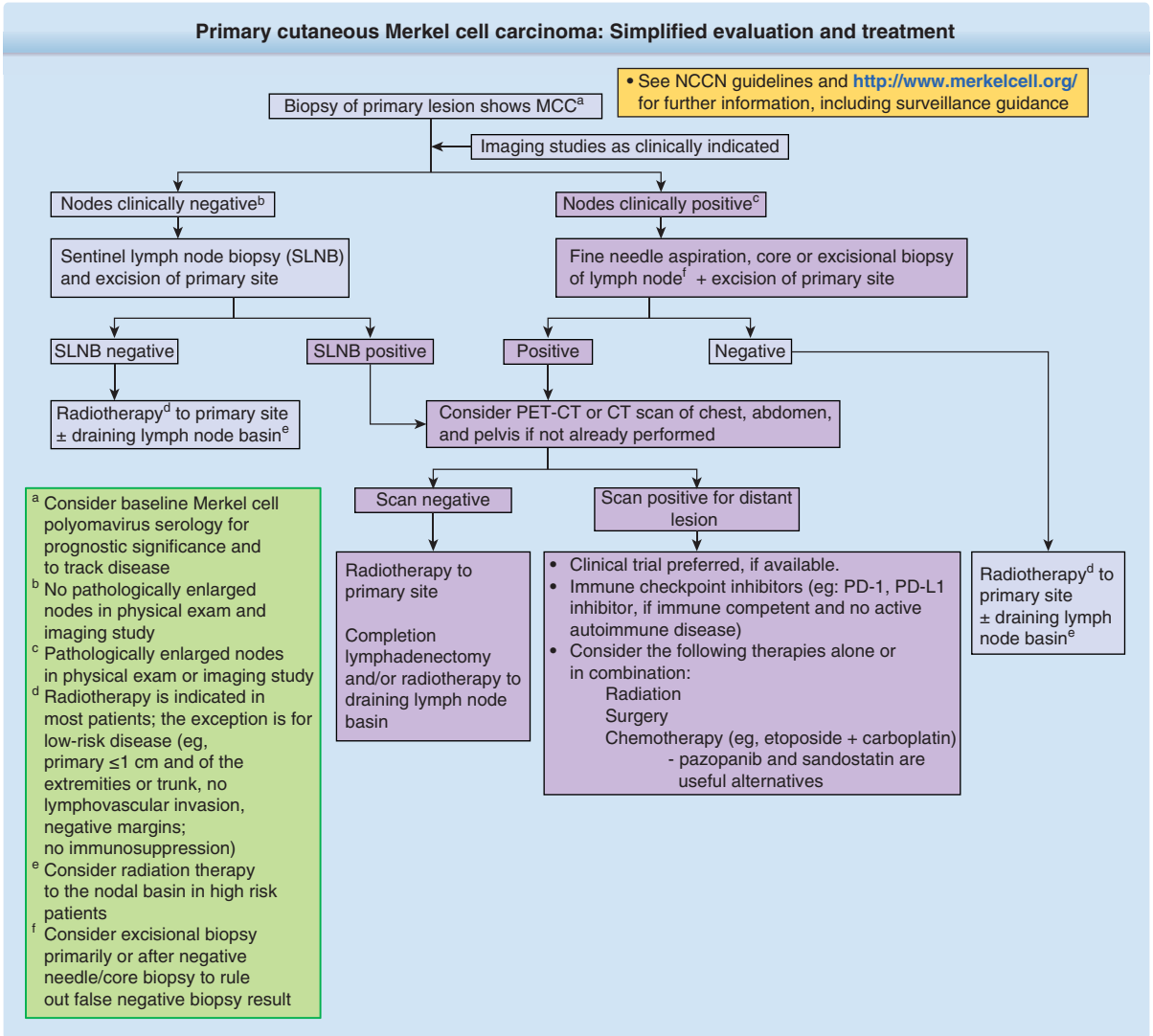

Figure 113-9 Simplified evaluation and treatment diagram for primary cutaneous Merkel cell carcinoma (MCC). NCCN, National Comprehensive Cancer Network; PD-1, programmed death 1; PD-L1, programmed death ligand 1; PET, positron emission tomography; SLNB, sentinel lymph node biopsy.

5. *Immunity:* Chemotherapy suppresses immune function, and this is known in general to be very important in preventing and controlling MCC.
6. *Outcomes are not improved:* A large analysis of 6908 patients from the National Cancer Database demonstrated no survival benefit among node-positive patients who received chemotherapy as compared to those who did not. Even though this was a not randomized study, the results certainly do not suggest a clinically meaningful benefit for adjuvant chemotherapy.[40]

SURVEILLANCE

Currently, there is a paucity of data on which to develop national guidelines for surveillance of MCC patients. Current guidelines include relatively general recommendations for clinical examination every 3 to 6 months for the first 2 years after diagnosis, and every 6 to 12 months thereafter. Imaging studies are recommended "as clinically indicated."[41] Disease-specific and progression-free survival data available at www.merkelcell.org/prognosis can be useful for guiding surveillance/imaging decisions. Given the lower risk of progression in early stage disease, surveillance can be tapered more rapidly (by year 3 or 4), than for patients with higher-risk disease at presentation. Additionally, in patients who produce antibodies to the Merkel polyomavirus oncoprotein, surveillance via serology may be an approach to monitoring disease burden with less cost and less exposure to radiation (see "Merkel Cell Polyomavirus" above for more details).[26]

OPTIMAL TREATMENT

In general, optimal treatment of MCC should involve obtaining pathologically clear margins by surgery, typically with 1- to 2-cm margins if possible, depending on the site. Narrower margins or even positive margins can often be effectively treated by local radiation, typically extending 3 to 5 cm beyond the tumor bed. We also recommend treating the draining lymph node bed, likely with radiation therapy, for patients with high-risk disease including a positive SLNB, immune suppression, or a tumor greater than 2 cm in diameter. Although still controversial, we currently do not recommend adjuvant radiation therapy for MCC patients with all of the following 5 good prognostic features: (a) primary tumor diameter ≤1 cm; (b) microscopic margins that are confidently negative following surgery; (c) no lymphovascular invasion noted in the tumor; (d) no profound immune suppression (eg, HIV, chronic lymphocytic leukemia); and (e) SLNB that was negative with proper immunohistochemistry studies.

Figure 113-9 provides a flow chart for evaluation and treatment of primary MCC.

REFERENCES

1. Hodgson NC. Merkel cell carcinoma: changing incidence trends. *J Surg Oncol*. 2005;89:1-4.
2. Paulson KG, Park SY, Vandeven NA et al. Merkel cell carcinoma: Current US incidence and projected increases based on changing demographics. *J Am Acad Dermatol*. 2018;78(3):457-463;e452.
3. Lemos BD, Storer BE, Iyer JG, et al. Pathologic nodal evaluation improves prognostic accuracy in Merkel cell carcinoma: analysis of 5823 cases as the basis of the first consensus staging system. *J Am Acad Dermatol*. 2010;63:751-761.
4. U.S. National Cancer Institute Surveillance, Epidemiology, and End Results (SEER) Program. *SEER Cancer Statistics Review, 1973-1993*. Bethesda, MD: National Institutes of Health; 1993. Available at: https://seer.cancer.gov/archive/csr/1973_1993/
5. Maricich SM, Wellnitz SA, Nelson AM, et al. Merkel cells are essential for light-touch responses. *Science*. 2009;324:1580-1582.
6. Van Keymeulen A, Mascre G, Youseff KK, et al. Epidermal progenitors give rise to Merkel cells during embryonic development and adult homeostasis. *J Cell Biol*. 2009;187:91-100.
7. Albores-Saavedra J, Batich K, Chable-Montero F, et al. Merkel cell carcinoma demographics, morphology, and survival based on 3870 cases: a population based study. *J Cutan Pathol*. 2010;37:20-27.
8. Miller RW, Rabkin CS. Merkel cell carcinoma and melanoma: etiological similarities and differences. *Cancer Epidemiol Biomarkers Prev*. 1999;8:153-158.
9. Agelli M, Clegg LX. Epidemiology of primary Merkel cell carcinoma in the United States. *J Am Acad Dermatol*. 2003;49:832-841.
10. Heath M, Jaimes N, Lemos B, et al. Clinical characteristics of Merkel cell carcinoma at diagnosis in 195 patients: the AEIOU features. *J Am Acad Dermatol*. 2008;58:375-381.
11. Kotteas EA, Pavlidis N. Neuroendocrine Merkel cell nodal carcinoma of unknown primary site: management and outcomes of a rare entity. *Crit Rev Oncol Hematol*. 2015;94:116-121.
12. Santamaria-Barria JA, Boland GM, Yeap BY, et al. Merkel cell carcinoma: 30-year experience from a single institution. *Ann Surg Oncol*. 2013;20(4):1365-1373.
13. Tsang G, O'Brien P, Robertson R, et al. All delays before radiotherapy risk progression of Merkel cell carcinoma. *Australas Radiol*. 2004;48:371-375.
14. Allen PJ, Bowne WB, Jaques DP, et al. Merkel cell carcinoma: prognosis and treatment of patients from a single institution. *J Clin Oncol*. 2005;23:2300-2309.
15. Engels EA, Frisch M, Goedert JJ, et al. Merkel cell carcinoma and HIV infection. *Lancet*. 2002;359:497-498.
16. Pan D, Narayan D, Ariyan S. Merkel cell carcinoma: five case reports using sentinel lymph node biopsy and a review of 110 new cases. *Plast Reconstr Surg*. 2002;110:1259-1265.
17. Feng H, Shuda M, Chang Y, et al. Clonal integration of a polyomavirus in human Merkel cell carcinoma. *Science*. 2008;319:1096-1100.
18. Goh G, Walradt T, Markarov V, et al. Mutational landscape of MCPyV-positive and MCPyV-negative Merkel cell carcinomas with implications for immunotherapy. *Oncotarget*. 2016;7:3403-3415.

19. Edge SB, Compton CC. The American Joint Committee on Cancer: the 7th edition of the AJCC cancer staging manual and the future of TNM. *Ann Surg Oncol*. 2010;17:1471-1474.
20. Harms KL, Healy MA, Nghiem P, et al. Analysis of prognostic factors from 9387 Merkel cell carcinoma cases forms the basis for the new 8th edition AJCC staging system. *Ann Surg Oncol*. 2016;23(11):3564-3571.
21. Messina JL, Reintgen DS, Cruse CW, et al. Selective lymphadenectomy in patients with Merkel cell (cutaneous neuroendocrine) carcinoma. *Ann Surg Oncol*. 1997;4:389-395.
22. Hill AD, Brady MS, Coit DG. Intraoperative lymphatic mapping and sentinel lymph node biopsy for Merkel cell carcinoma. *Br J Surg*. 1999;86:518-521.
23. Gupta SG, Wang LC, Peñas PF, et al. Sentinel lymph node biopsy for evaluation and treatment of patients with Merkel cell carcinoma: the Dana-Farber experience and metaanalysis of the literature. *Arch Dermatol*. 2006;142:685-690.
24. Lens MB, Dawes M, Newton-Bishop JA, et al. Tumour thickness as a predictor of occult lymph node metastases in patients with stage I and II melanoma undergoing sentinel lymph node biopsy. *Br J Surg*. 2002;89:1223-1227.
25. Andea AA, Coit DG, Amin B, et al. Merkel cell carcinoma: histologic features and prognosis. *Cancer*. 2008;113:2549-2558.
26. Paulson KG, Carter JJ, Johnson LG, et al. Antibodies to Merkel cell polyomavirus T antigen oncoproteins reflect tumor burden in Merkel cell carcinoma patients. *Cancer Res*. 2010;70:8388-8397.
27. Stetsenko GY, Malekirad J, Paulson KG, et al. p63 expression in Merkel cell carcinoma predicts poorer survival yet may have limited clinical utility. *Am J Clin Pathol*. 2013;140:838-844.
28. Afanasiev OK, Nagase K, Simonson W, et al. Vascular E-selectin expression correlates with CD8 lymphocyte infiltration and improved outcome in Merkel cell carcinoma. *J Invest Dermatol*. 2013;133:2065-2073.
29. Paulson KG, Iyer JG, Tegeder AR, et al. Transcriptome-wide studies of Merkel cell carcinoma and validation of intratumoral CD8+ lymphocyte invasion as an independent predictor of survival. *J Clin Oncol*. 2011;29:1539-1546.
30. Paulson KG, Iyer JG, Simonson WT, et al. CD8+ lymphocyte intratumoral infiltration as a stage-independent predictor of Merkel cell carcinoma survival: a population-based study. *Am J Clin Pathol*. 2014;142:452-458.
31. Boyer JD, Zitelli JA, Brodland DG, et al. Local control of primary Merkel cell carcinoma: review of 45 cases treated with Mohs micrographic surgery with and without adjuvant radiation. *J Am Acad Dermatol*. 2002;47:885-892.
32. Fang LC, Lemos B, Douglas J, et al. Radiation monotherapy as regional treatment for lymph node-positive Merkel cell carcinoma. *Cancer*. 2010;116:1783-1790.
33. Iyer JG, Parvathaneni U, Gooley T, et al. Single-fraction radiation therapy in patients with metastatic Merkel cell carcinoma. *Cancer Med*. 2015;4:1161-1170.
34. Nghiem PT, Bhatia S, Lipson EJ, et al. PD-1 blockade with pembrolizumab in advanced Merkel-cell carcinoma. *N Engl J Med*. 2016;374:2542-2552.
35. Tai PT, Yu E, Winquist E, et al. Chemotherapy in neuroendocrine/Merkel cell carcinoma of the skin: case series and review of 204 cases. *J Clin Oncol*. 2000;18:2493-2499.
36. Poulsen M, Rischin D, Walpole E, et al. Analysis of toxicity of Merkel cell carcinoma of the skin treated with synchronous carboplatin/etoposide and radiation: a Trans-Tasman Radiation Oncology Group study. *Int J Radiat Oncol Biol Phys*. 2001;51:156-163.
37. Mortier L, Mirabel X, Fournier C, et al. Radiotherapy alone for primary Merkel cell carcinoma. *Arch Dermatol*. 2003;139:1587-1590.
38. Longo MI, Nghiem P. Merkel cell carcinoma treatment with radiation: a good case despite no prospective studies. *Arch Dermatol*. 2003;139:1641-1643.
39. Mojica P, Smith D, Ellenhorn JD. Adjuvant radiation therapy is associated with improved survival in Merkel cell carcinoma of the skin. *J Clin Oncol*. 2007;25:1043-1047.
40. Bhatia S, Storer BE, Iyer JG, et al. Adjuvant radiation therapy and chemotherapy in Merkel cell carcinoma: survival analyses of 6908 cases from the national cancer data base. *J Natl Cancer Inst*. 2016;108(9).
41. Bichakjian CK, Olencki T, Alam M, et al. Merkel cell carcinoma, version 1.2014. *J Natl Compr Canc Netw*. 2014;12:410-424.

Chapter 114 :: Paget's Disease

:: Conroy Chow, Isaac M. Neuhaus, & Roy C. Grekin

AT-A-GLANCE

- Uncommon intraepithelial adenocarcinoma occurring in apocrine gland-bearing skin in patients older than age 50 years.
- Erythematous, scaly plaque frequently misdiagnosed as inflammatory or infectious dermatitis.
- Most commonly affected sites: unilateral nipple/areola (mammary Paget's disease [MPD]); vulva, perianal skin, scrotum, and penis (extramammary Paget's disease [EMPD]).
- Nearly all cases of MPD are associated with underlying breast carcinoma; EMPD is associated with underlying cancer in a minority (20% to 30%) of cases.

DEFINITIONS

Mammary Paget's disease (MPD; also called Paget's disease of the breast) is an intraepidermal adenocarcinoma of the nipple and/or areola, typically associated with underlying breast carcinoma. Extramammary Paget's disease (EMPD) is a clinically distinct condition that affects extramammary sites, such as the vulva, penis, scrotum, perineum, and anus. Even though both MPD and EMPD may appear similar clinically and histologically, they differ in their pathogenesis and frequency of associations with underlying malignancies.

HISTORICAL PERSPECTIVE

In 1874, Sir James Paget first reported MPD in a series of 15 women with chronic dermatitis of the nipple and areola who were subsequently diagnosed with underlying breast carcinoma.[1] In 1889, English dermatologist Henry Racliffe Crocker first described EMPD as a condition on the scrotum and penis with histopathology similar to MPD.[2]

EPIDEMIOLOGY

MPD represents approximately 1% to 3% of breast cancers.[3] The peak incidence is between 50 and 60 years of age, with most reported cases occurring in women. In various studies, between 82% and 100% of MPD cases are associated with an underlying in situ or invasive ductal carcinoma.[3]

EMPD is a rare malignancy of the anogenital region, with various studies citing incidence rates ranging from 0.6 per 1,000,000 person-years to 0.11 per 100,000 person-years.[4,5] The majority of cases occur in the sixth through eighth decades of life, with women more commonly affected than men.[6-8] In contrast to MPD, most cases of EMPD are not associated with an underlying adnexal carcinoma or visceral malignancy, with most studies reporting approximately a 20% to 30% risk.[7]

CLINICAL FEATURES

HISTORY

Both MPD and EMPD present with a longstanding history of erythematous, scaly, or velvety patches or plaques on the breast and anogenital skin, respectively. The most commonly reported symptom is pruritus. Other symptoms may include pain, bleeding, a burning sensation, and serosanguinous discharge. Because of the rather nondescript appearance, there is often a several-month delay in diagnosis as initial treatment frequently involves topical steroids (for presumed inflammatory dermatitis) or antifungal agents (for presumed infectious dermatitis).

CUTANEOUS FINDINGS

MPD frequently presents as a unilateral, erythematous, scaly plaque involving the nipple and/or the areola (Fig. 114-1). The associated pruritus may lead to lichenification and excoriations. Ulceration, weeping, and crusting are often present. Nipple erosion and discharge may occur. Retraction of the nipple and areola may be seen in advanced disease.

Lesions of EMPD are clinically similar to MPD and often present as well-defined, moist, erythematous, scaly plaques, usually involving apocrine gland-bearing skin (eg, in the genitoperineal region and axilla). Hypopigmentation and hyperpigmentation may occur. Lichenification and excoriations of the involved area are commonly found because of pruritus. The vulva is the most commonly affected area, representing 65% of EMPD cases but less than 2% of all vulvar neoplasms.[3,9] EMPD in other sites, such as the perineum, scrotum (Fig. 114-2), perianal skin (Fig. 114-3), and penis, is less common. In rare cases, ectopic EMPD has been reported in areas that are relatively free of apocrine glands, such as the chest, abdomen, thigh, eyelids, face, and external auditory canal.[10-14]

Figure 114-1 Paget's disease of the nipple. Erythematous and scaly plaque involving the nipple and areola.

Figure 114-2 Scrotal extramammary Paget's disease. Moist, eroded, oozing plaque on the scrotum of an older man.

Figure 114-3 Perianal extramammary Paget's disease presenting as moist, superficially eroded plaque.

Table 114-1 outlines the differential diagnoses of MPD and EMPD.

NONCUTANEOUS FINDINGS

Patients may present with symptoms and physical findings of an underlying carcinoma or metastatic disease. Complete physical examination including thorough full-body skin examination is required in all cases of MPD and EMPD, as approximately one-half of patients presenting with MPD are found concurrently to have a palpable underlying breast mass.[15,16] Of these patients, one-half to two-thirds have axillary lymph node metastases.[16]

Given the less-established association with underlying carcinoma in EMPD as compared to MPD, a palpable mass or lymph node is much less frequently found on physical examination in EMPD. EMPD of the external male and female genitalia may be associated with tumors of the bladder and urethra and of the prostate in men.[17] Perianal EMPD may be associated with colorectal cancer.[17]

Failure to identify and adequately treat MPD and EMPD can lead to progression and metastasis, with a poor prognosis.

ETIOLOGY AND PATHOGENESIS

MAMMARY PAGET'S DISEASE

Historically, 2 contrasting theories, known as the *epidermotropic* and *transformation* theories, attempted to explain the pathogenesis of MPD.

In the epidermotropic theory, malignant Paget cells arise from an underlying breast adenocarcinoma and directly extend into the epidermis via the lactiferous ducts and ductules (epidermotropism).[9] These malignant cells then invade the epidermis of the nipple and areola, leading to the clinical manifestations detailed above. In multiple reports, immunohistochemical studies showed significant similarities between the Paget cells and the underlying breast carcinoma in a majority of cases, further suggesting that MPD arose from intraepidermal extension of the ductal carcinoma.[9,18,19] In contrast, epidermal keratinocytes expressed a different immunohistochemical staining pattern.

In one study, overexpression of the heregulin receptor HER2/neu (also known as cluster of differentiation 340 [CD340], c-erbB-2, and human epidermal growth factor receptor 2) was identified in 80% of MPD cases. In all these cases, there was complete concordance between HER2/neu overexpression in both the Paget cells and the underlying ductal carcinoma.[20] Normal epidermis does not show overexpression of HER2/neu. Another study suggested that movement of Paget

TABLE 114-1
Differential Diagnosis of Mammary and Extramammary Paget's Disease

	MOST COMMON	CONSIDER	ALWAYS RULE OUT
Mammary Paget's disease	Nipple dermatitis	Hailey-Hailey disease	Bowen disease
	Erosive adenomatosis	Pemphigus	Melanoma
	Contact dermatitis	Lichen simplex chronicus	
	Dermatophyte infection		
Extramammary Paget's disease	Candidiasis	Lichen sclerosus et atrophicus	Bowen disease
	Tinea cruris	Pemphigus	Erythroplasia of Queyrat
	Inverse psoriasis	Lichen simplex chronicus	Melanoma
	Contact dermatitis	Lichen planus	
	Intertrigo	Symmetrical drug-related intertriginous and flexural exanthema	

cells is induced by the action of the heregulin-alpha motility factor, which is produced by normal epidermal keratinocytes, on HER2/neu receptors on the Paget cells, leading to chemotaxis to the overlying nipple epidermis.[21] These studies suggest that a common mutation or progenitor cell leads to the development of both MPD and the underlying breast carcinoma.

The transformation theory suggests that epidermal keratinocytes on the nipple transform or degenerate into malignant Paget cells that are distinct from any underlying breast carcinoma.[15,22] Therefore, MPD originates as an in situ carcinoma that may subsequently progress.

The epidermotropic theory is supported by the presence of an underlying breast carcinoma in nearly all cases of MPD, but the transformation theory is supported by the small fraction of cases without an underlying ductal carcinoma.[15] Although both theories are possible, the literature currently favors the epidermotropic theory for the very reason that almost all cases of MPD are associated with underlying breast carcinoma.

EXTRAMAMMARY PAGET'S DISEASE

Unlike MPD, which, in most cases, has a documented underlying carcinoma, EMPD more commonly occurs in the absence of underlying malignancy and accounts for the majority of EMPD cases. Known as primary EMPD, this form of EMPD represents malignant cells that are believed to originate from the intraepidermal parts of apocrine glands or from pluripotent cells in the epidermis.[7] Primary EMPD is thought to start as an in situ carcinoma that can progress by invading the dermis and subsequently metastasizing via lymphatic spread.[7] In contrast, secondary EMPD arises from an underlying adnexal carcinoma or internal malignancy in approximately 20% to 30% of cases. These cases are caused by epidermotropic spread of malignant cells from the underlying tumor.[7] Common visceral malignancies associated with EMPD are carcinomas of the colon, rectum, bladder, urethra, cervix, and prostate.[9]

DIAGNOSIS

Diagnosis of MPD and EMPD requires a high index of suspicion, with full-thickness punch, wedge, or excisional biopsy of the skin for histopathologic confirmation. A complete review of systems and full-body skin examination, including palpation of lymph nodes, should be performed in all patients. A complete workup for both MPD and EMPD should also include a thorough search for underlying malignancy.

MAMMARY PAGET'S DISEASE

Punch, wedge, or excisional biopsy of lesional skin is necessary to confirm the diagnosis by histopathology. A few studies in the past suggested a role for nipple scrapings for cytologic evaluation, but this method has not gained widespread acceptance because of the potential for false-positives and false-negatives results that occur from processing artifact.[23,24]

Bilateral mammography is required in all cases, with biopsy of any detectable breast mass. Various studies have shown approximately 35% to 65% of patients with biopsy-proven MPD show findings on mammography that are concerning for underlying breast carcinoma.[25,26] However, because nearly all patients with MPD have underlying breast carcinoma, a negative mammogram does rule out this possibility.

Although the likelihood of an invasive breast carcinoma is low (~5%) in patients without a clinically palpable breast mass and with a negative mammogram, ductal carcinoma in situ may be present and not detected by mammography.[27] In one particular study, 68% of patients without a palpable breast mass and with negative mammography were found to have ductal carcinoma in situ.[27]

Because of the limitations of mammography, a few newer studies have suggested use of MRI in patients

with biopsy-proven MPD and negative mammogram to help identify occult breast malignancy.[25,28] However, despite the increased sensitivity of MRI compared to mammography, this imaging modality has limitations because there remains a small possibility of an underlying cancer that was not visualized with MRI (potential for a false negative). In addition, because MRI is very sensitive but not very specific, it may detect findings that lead to unnecessary diagnostic testing, so patients should be counseled to the possibility of a false-positive result.

EXTRAMAMMARY PAGET'S DISEASE

As in MPD, histopathologic confirmation from a punch or excisional biopsy of lesional skin is necessary. As a consequence of the low incidence of EMPD, there is currently no standardized diagnostic algorithm once EMPD is diagnosed, but workup (Table 114-2) is directed to the possibility of an underlying GI or genitourinary neoplasm. Colonoscopy, cystoscopy, and, in female patients, pelvic examination with Papanicolaou test and colposcopy should all be considered as first-line studies to evaluate underlying malignancy.

Further imaging studies should be guided by the results of the initial studies, sex of the patient, and anatomic areas of involvement. Other imaging studies to consider, as clinically indicated, include pelvic ultrasound, positron emission tomography, chest radiography, MRI, mammography, and intravenous pyelogram.

The clinical utility of other laboratory tests and imaging remain unclear. In 2 reports, patients with significantly elevated serum carcinoembryonic antigen (CEA) levels had a greater risk of death from EMPD compared to patients with normal serum CEA, and the level of CEA paralleled disease course.[8,29] Other studies suggest that positron emission tomography (PET)-CT scans may be useful for cases of invasive EMPD to evaluate for lymph node involvement and metastases.[29-31] However, even PET-CT scans may not detect microscopic metastases.

The role of sentinel lymph node biopsy (SLNB) for patients with EMPD is discussed in section "Management Extramammary Paget's Disease".

TABLE 114-2

Suggested Laboratory Workup for Extramammary Paget's Disease[a]

- Sigmoidoscopy
- Cystoscopy
- Papanicolaou test
- Colposcopy
- Pelvic ultrasound
- Positron emission tomography
- Chest radiography
- MRI
- Mammogram
- Intravenous pyelogram
- Serum carcinoembryonic antigen
- Positron emission tomography–CT scans

[a]These should be guided by the results of the initial studies, sex of the patient, and anatomic areas involved.

PATHOLOGY

The intraepidermal adenocarcinoma of EMPD and MPD has a similar histologic appearance. There are groups, clusters, or single cells within the epidermis that show nuclear enlargement with atypia, prominent nucleoli, and well-defined ample cytoplasm (Fig. 114-4).[32] Intercellular bridges are absent. The cells may be in all levels of the epidermis, and compress, but preserve, the basal layer without junctional nest formation. The cells may extend into the contiguous epithelium of hair follicles and sweat gland ducts. Acanthosis, hyperkeratosis, and parakeratosis are often present. These cells have a "pagetoid" appearance and simulate other intraepidermal malignancies, such as melanoma, pagetoid squamous cell carcinoma, mycosis fungoides, cutaneous adnexal carcinomas (eg, sebaceous carcinoma, porocarcinoma, and others), Merkel cell carcinoma, Langerhans cell histiocytosis, and other epidermotropic cutaneous metastases. The cells of MPD and EMPD can be pigmented, which does not necessarily indicate that they are melanocytic.

Paget cells have intracellular mucopolysaccharides, with EMPD having a greater amount of mucin compared to MPD. As a result, cells stain positive for periodic acid-Schiff, mucicarmine, Alcian blue, and colloidal iron, and are diastase resistant. There may be focal "skip areas" that are devoid of mucin, resulting in sections of negative staining.

Immunohistochemistry is invaluable in confirming the diagnosis (Table 114-3). Low-molecular-weight cytokeratin stains cytokeratin 7 (CK7) and anticytokeratin (CAM 5.2) are sensitive markers for both MPD and EMPD (Fig. 114-5), as they stain Paget cells but do

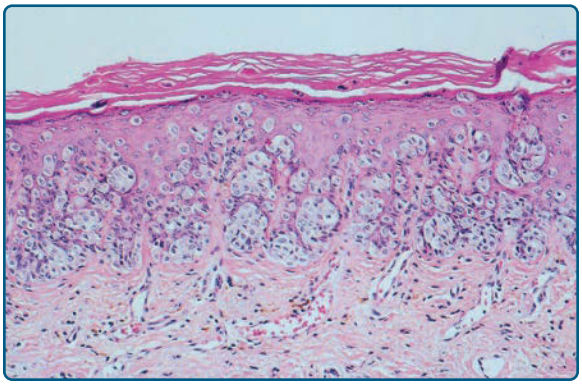

Figure 114-4 Paget's disease, hematoxylin and eosin stain. Paget cells have distinctive pale-staining cytoplasm and are usually randomly dispersed throughout the epidermis.

TABLE 114-3
Immunohistochemistry Markers for Mammary and Extramammary Paget's Disease

	S100	CK7	CAM 5.2	CEA	CK20	EMA	GCDFP-15	MUC1	MUC2	HER2/NEU
MPD	–	+	+	+	–	+		+		+
1° EMPD	–	+	+	+	–	+	+	+	–	+/–
2° EMPD	–	+			+		–		+[a]	

[a]Positivity in underlying colorectal adenocarcinoma.
1°, primary; 2°, secondary; CAM 5.2, anticytokeratin; CEA, carcinoembryonic antigen; CK, cytokeratin; EMA, epithelial membrane antigen; EMPD, extramammary Paget's disease; GCDFP-15, gross cystic disease fluid protein-15; HER2, human epidermal growth factor receptor 2 (also known as cluster of differentiation 340 [CD340], c-erbB-2, and neu); MPD, mammary Paget's disease; MUC, mucin core protein.

not typically react with epidermal or mucosal keratinocytes, helping to distinguish MPD and EMPD from pagetoid squamous cell carcinoma.[33] These cytokeratin stains are not completely specific, however; for example, both Toker and Merkel cells also exhibit CK7 positivity. The cells of MPD and EMPD also commonly stain with CEA and epithelial membrane antigen, but these stains also are not specific for these entities.[33] HER2/neu has been used in select studies and is more often positive in MPD than in EMPD.[34] S100, Melan-A (also known as MART-1), and HMB-45 are useful markers to exclude melanoma and are typically negative in MPD and EMPD. Cytokeratin 20 (CK20) positivity has been found more frequently in cases of secondary EMPD with underlying carcinoma as compared to cases of primary EMPD (CK7+/CK20–).[35] Gross cystic disease fluid protein-15 (GCDFP-15) is a marker for apocrine epithelium and is more commonly positive in primary EMPD and negative in cases of secondary EMPD with an associated malignancy.[36]

Mucin core protein (MUC) expression is useful in the diagnosis of MPD and EMPD.[37] MUC1 positivity is noted in both MPD and EMPD. MUC2 expression is generally negative in primary EMPD but may be expressed in cases of secondary EMPD with an associated underlying colorectal adenocarcinoma.[38] MUC5AC is more frequently positive in invasive and metastatic EMPD than in noninvasive EMPD.[39]

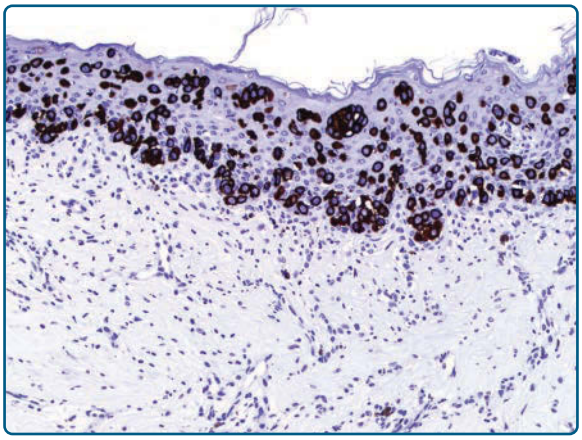

Figure 114-5 Anticytokeratin (CAM 5.2) is a sensitive marker for both mammary and extramammary Paget's disease on histopathology. (Image used with permission from Thaddeus Mully, MD, UCSF.)

A study investigating a relationship between expression of androgen receptor on Paget cells in EMPD and 5α-reductase levels showed an elevated 5α-reductase level more frequently in invasive (81%) compared with purely intraepidermal (45%) cases of EMPD.[40] For invasive cases, men had a significantly higher level of androgen receptor and 5α-reductase positivity than women (70% vs 17%), suggesting the possibility of autocrine synthesis of androgens in EMPD and gender-specific microenvironments that may contribute to invasiveness of the disease.[40] In a related study, Ki-67 and cyclin D1 were expressed more frequently in cases of invasive EMPD than in intraepidermal EMPD. When both Ki-67 and cyclin D1 were expressed, the likelihood of invasive disease was higher than when either was expressed alone.[41] This study raised the question of whether androgens may be associated with cell-cycle regulation and invasiveness of EMPD.[41]

DIFFERENTIAL DIAGNOSIS

Table 114-1 outlines the differential diagnosis of EMPD and MPD.

CLINICAL COURSE AND PROGNOSIS

The prognosis in patients with MPD depends on the presence or absence of a clinically palpable breast mass and nodal metastases. Patients with MPD who present with a palpable breast mass tend to have more advanced disease than patients without a palpable breast mass. In these 2 groups, the rates of metastases to the lymph nodes were 57% to 63% (with a palpable breast mass) versus 11% to 21% (without a palpable breast mass).[42-44] In addition, patients with MPD who also present with a palpable mass were more likely to have invasive, rather than in situ, and multifocal ductal carcinoma.[44] The median survival of patients with a palpable breast mass was 42 months compared to 126 months for patients without a palpable breast mass, and the 5-year overall survival rates of patients with a palpable breast mass were 35% to 43% versus 75% to 93% for patients without a palpable breast mass.[43,45]

As a result of the limited number of longitudinal studies, heterogeneity in disease stage, and variability in management of MPD, recurrence rates are extremely variable across studies. One study found about one-third of the underlying breast carcinomas were located more than 2 cm beyond the areolar margin. Thus, with limited excision of the MPD and the underlying breast carcinoma, rather than mastectomy, a significant number of underlying breast carcinomas may be inadequately treated, which may help explain why some studies show higher recurrence rates.[43] See "Management: Mammary Paget's Disease" below for a full discussion of treatment of MPD.

The prognosis for primary EMPD is excellent with appropriate treatment, with 5-year overall survival rates ranging between 72% and 91% across several studies.[4,5,8] Risk factors that appear to carry a worse prognosis include lymphovascular invasion and increasing depth of tumor invasion, with one study suggesting that a dermal invasion greater than 1 mm confers a worse prognosis.[7] The presence of lymph node metastases markedly reduces overall survival and indicates a very poor prognosis, with 5-year survival rates ranging from 0 to approximately 20% in case series.[8,17] Two studies noted that patients with elevated serum CEA levels were more likely to have a worse prognosis, with 1 study noting that all the patients with elevated CEA levels had metastatic disease, but not all patients with metastatic disease had elevated CEA levels.[8,29] The usefulness of measuring CEA levels in the serum at this time is unclear; however, this particular study suggested that, for the subset of patients with a history of metastatic disease and elevated serum CEA, trending the serum CEA values over time may be useful in surveillance of the disease.[29] Nevertheless, regular surveillance for early detection of local recurrence is critical given the multifocal pattern often present in EMPD.

The prognosis for secondary EMPD caused by an underlying adnexal carcinoma or visceral malignancy is generally worse than for primary EMPD and depends on the prognosis of the underlying cancer.[17]

MANAGEMENT

MAMMARY PAGET'S DISEASE

Figure 114-6 outlines an approach to treatment of MPD. Historically, the standard of care for MPD has been mastectomy, but emerging evidence suggests that select cases of MPD may be treated with breast-conserving therapy (BCT) plus radiotherapy with excellent results and low rates of recurrences.[45-47] However, standardized, evidence-based treatment recommendations for MPD are not available because of the lack of studies directly comparing outcomes for mastectomy versus BCT plus radiotherapy. Most of the current treatment recommendations are based on small studies with variable treatment techniques and followup periods, making comparisons among different studies difficult.

For patients with MPD with a clinically palpable breast mass, most studies recommend mastectomy versus BCT (resection of the nipple and areola with wide local excision of the breast mass) followed by whole-breast radiotherapy.[43,45-47] In patients with an underlying invasive ductal carcinoma, SLNB is typically recommended at the time of excision if no clinically palpable pathologic nodes are identified. However, for patients with underlying invasive ductal carcinoma

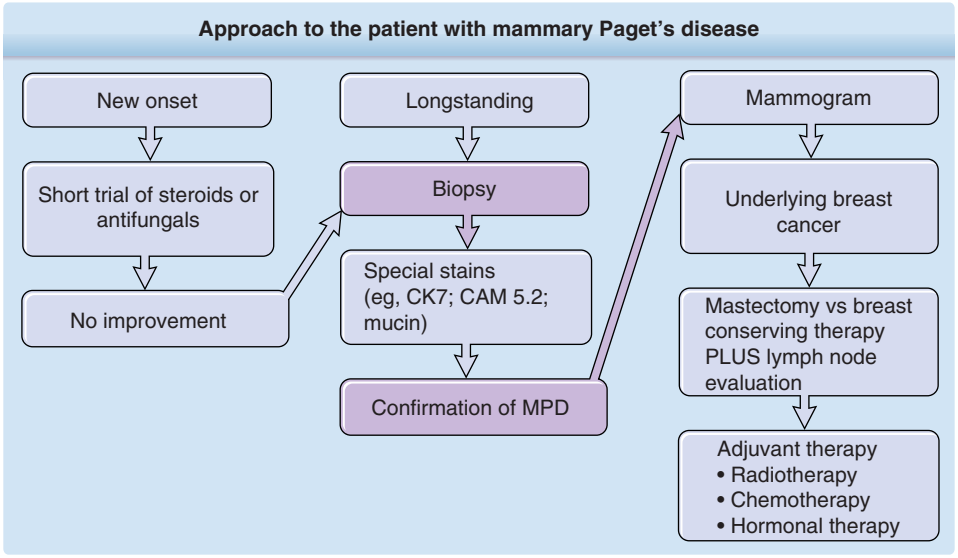

Figure 114-6 Approach to the patient with mammary Paget's disease (MPD). CAM 5.2, anticytokeratin stain; CK7, cytokeratin 7 stain.

and clinically pathologic lymph nodes, biopsy of the lymph nodes should be performed prior to surgery. If lymph node biopsy confirms metastatic disease, axillary lymph node dissection should be considered. If pathology is negative for metastatic disease on lymph node biopsy, SLNB should be considered at the time of wide local excision.

In patients with MPD with negative mammography and without a palpable breast mass, most studies recommend mastectomy versus BCT followed by whole-breast radiotherapy.[43,45-47] Most of these patients have ductal carcinoma in situ, rather than invasive ductal carcinoma, so many studies do not routinely recommend SLNB in these patients. However, 1 study found that approximately 20% of patients without an associated breast mass had metastases to the axillary lymph nodes and suggested consideration of SLNB even in cases of ductal carcinoma in situ.[43] Another study in patients with MPD without any identified underlying breast carcinoma found that 11% had metastases to the axilla and, thus, recommended SLNB for all patients.[48] Because all diagnoses of MPD require management by a surgical oncologist with expertise in breast cancer, a thorough discussion regarding the pros and cons of these various surgical approaches is warranted before proceeding with treatment.

EXTRAMAMMARY PAGET'S DISEASE

Figure 114-7 outlines an approach to treatment of EMPD. EMPD has been treated with a variety of modalities. The condition is most frequently managed with surgery, but other treatments have a role for poor surgical candidates and as adjuvant therapy.

SURGERY

Surgery is generally considered the standard treatment for EMPD. However, local recurrences are common, even when wide excision margins are used, with studies reporting rates ranging from approximately 30% to 60%.[7,49] Invasive disease has a higher recurrence rate than in situ disease, with one study reporting rates of 67% and 35%, respectively.[7,49] The high recurrence rates are likely the result of the clinical characteristics of EMPD: the ill-defined clinical margins, multifocal nature of the tumor, and involvement of clinically normal-appearing adjacent skin.[6] More extensive procedures are associated with lower rates of recurrence, but also may be more technically difficult and

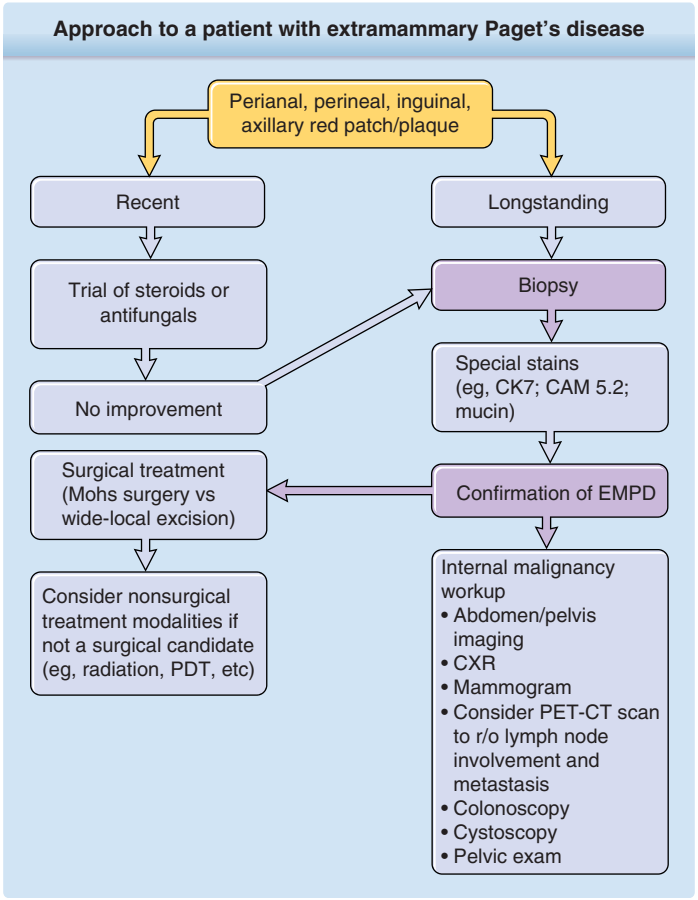

Figure 114-7 Approach to a patient with extramammary Paget's disease (EMPD). CAM 5.2, anticytokeratin stain; CK7, cytokeratin 7 stain; CXR, chest radiography; PDT, photodynamic therapy; PET-CT, positron emission tomography–computed tomography; r/o, rule out.

disfiguring for patients. In one study, patients with primary vulvar EMPD treated with radical vulvectomy, radical hemivulvectomy, and wide local excision had recurrence rates of 15%, 20%, and 43%, respectively.[7]

A few studies have attempted to decrease recurrences of EMPD using adjuvant techniques for surgery. Intraoperative frozen-section analysis reduced recurrences in some studies but not in others.[50,51] Multiple scouting biopsies performed prior to surgery have been reported to be helpful in delineating the extent of disease and surgical planning.[52,53] Intraoperative CK7 immunostaining during Mohs micrographic surgery also has been reported to be helpful in delineating tumor margins.[53]

SLNB has been described in the treatment of EMPD.[54] This technique has been limited to a small number of reported patients, and most cases of EMPD have in situ disease. However, SLNB may prove beneficial for the prognosis and management of patients with increased risk of metastatic disease, such as those with invasive disease or elevated serum CEA levels.[55] A study involving patients with in situ, microinvasive (to the papillary dermis), or deeply invasive (to the reticular dermis or deeper) EMPD found that the incidence of sentinel lymph node metastasis was 16.9%. Stratified by depth of invasion, the rates were 0% for intraepidermal lesions, 4.1% for microinvasive disease, and 42.8% for deeply invasive disease.[56] Thus, some advocate the use of SLNB and/or regional lymph node dissection in all high-risk EMPD cases, despite negative findings on PET-CT, as micrometastases are undetectable with this form of imaging.[29]

With the high rates of local recurrence and the significant morbidity associated with radical and repeated surgical procedures, Mohs micrographic surgery has been used to improve cure rates and for tissue sparing of critical genitourinary anatomic structures.[6,7,57] The recurrence rate with Mohs micrographic surgery has ranged from 16% to 28% for primary EMPD in recent studies, and 50% for recurrent EMPD.[6,57] It was also reported that 97% of the cases treated with Mohs micrographic surgery required margins of 5 cm from the clinical margin for tumor clearance.[57] The same study found that surgical margins of 2 cm would clear only 59% of the cases, which is consistent with reported recurrence rates of approximately 40% with wide local excision. This further suggests a potential benefit of frozen horizontal sectioning for complete peripheral and deep margin mapping to reduce the possibility of residual tumor.

RADIOTHERAPY

Radiotherapy may be indicated in patients who are poor surgical candidates or are concerned with the risk of compromising genitourinary function as a consequence of the extensive surgery required for curative treatment.[7] Although initial studies indicated poor success with radiotherapy as a primary treatment modality, subsequent case series reported acceptable outcomes, with recurrence rates of less than 35%.[58-60] Even though these results may appear more favorable than some of the surgical modalities, it is important to note that the sample sizes in these reports were several patients, making generalizations difficult. In addition, one of the studies reported no recurrences in a subset of 7 patients with intraepidermal disease but had a recurrence in 1 of 2 patients with invasive disease.[59]

Moreover, radiotherapy is beneficial for local recurrences after surgery or as an adjuvant therapy in those patients with a high risk of recurrence.[61,62] No randomized controlled studies comparing surgery to radiotherapy have been performed as of this writing.

TOPICAL CHEMOTHERAPY AND IMMUNOMODULATOR

Topical 5-fluorouracil (5-FU) and imiquimod have been used to treat EMPD with varying degrees of success.

5-FU has been used as a neoadjuvant modality prior to surgery to delineate clinical margins and for early postoperative detection of recurrence.[63,64] However, topical 5-FU has not proven to be a reliably curative agent in the treatment of EMPD because of the limited penetration of the drug and the inability to reach the deeper epidermal layers and adnexal structures that are frequently involved in EMPD.[7,64]

Imiquimod has been reported to result in clinical and histologic clearance in a few case series involving primary and recurrent EMPD.[65,66] In one study of 8 patients with recurrent primary intraepidermal EMPD, 6 patients initially experienced complete clinical and histologic response, but 4 patients subsequently developed recurrences during the followup period (median: 35 months).[67] All the patients with recurrences did not have progression to invasive disease, declined further surgery for their recurrences, and chose to retreat with imiquimod.[67]

As a result of the limited number of patients treated with these topical agents, the ideal duration and frequency of application is unknown. Further studies and long-term followup in a larger cohort are necessary.

PHOTODYNAMIC THERAPY

Photodynamic therapy has been used as an adjuvant to chemoradiotherapy, neoadjuvant prior to surgery, and as a primary modality with reasonable success.[7] However, as in the case of other topical treatment modalities, the ideal duration and frequency of application is unknown. Further studies and long-term followup in a larger cohort are necessary.

SYSTEMIC CHEMOTHERAPY

Systemic chemotherapy has been used to treat patients with invasive and metastatic disease and may be considered in rare cases in which surgery and radiotherapy are contraindicated. Limited reports of systemic chemotherapy for the treatment of EMPD have been described, including a combination of low-dose 5-FU and cisplatin[68]; a combination of 5-FU, carboplatin/cisplatin, mitomycin C, epirubicin, and vincristine[69,70]; docetaxel[71-73]; and combination trastuzumab, docetaxel, and carboplatin followed by lapatinib.[74]

REFERENCES

1. Paget J. On disease of the mammary areola preceding cancer of the mammary gland. *St Bartholomew Hosp Res Lond*. 1874;10:87-89.
2. Crocker HR. Paget's disease affecting the scrotum and penis. *Trans Pathol Soc London*. 1889;40:187-191.
3. Caliskan M, Gatti G, Sosnovskikh I, et al. Paget's disease of the breast: the experience of the European Institute of Oncology and review of the literature. *Breast Cancer Res Treat*. 2008;112(3):513-521.
4. van der Zwan JM, Siesling S, Blokx WA, et al. Invasive extramammary Paget's disease and the risk for secondary tumours in Europe. *Eur J Surg Oncol*. 2012;38(3):214-221.
5. Siesling S, Elferink MA, van Dijck JA, et al. Epidemiology and treatment of extramammary Paget disease in the Netherlands. *Eur J Surg Oncol*. 2007;33(8):951-955.
6. Zollo JD, Zeitouni NC. The Roswell Park Cancer Institute experience with extramammary Paget's disease. *Br J Dermatol*. 2000;142(1):59-65.
7. Shepherd V, Davidson EJ, Davies-Humphreys J. Extramammary Paget's disease. *BJOG*. 2005;112(3):273-279.
8. Hatta N, Yamada M, Hirano T, et al. Extramammary Paget's disease: treatment, prognostic factors and outcome in 76 patients. *Br J Dermatol*. 2008;158(2):313-318.
9. Lopes Filho LL, Lopes IM, Lopes LR, et al. Mammary and extramammary Paget's disease. *An Bras Dermatol*. 2015;90(2):225-231.
10. Saida T, Iwata M. "Ectopic" extramammary Paget's disease affecting the lower anterior aspect of the chest. *J Am Acad Dermatol*. 1987;17(5, pt 2):910-913.
11. Nagai Y, Ishibuchi H, Takahashi M, et al. Extramammary Paget's disease with bowenoid histologic features accompanied by an ectopic lesion on the upper abdomen. *J Dermatol*. 2005;32(8):670-673.
12. Cohen MA, Hanly A, Poulos E, et al. Extramammary Paget's disease presenting on the face. *Dermatol Surg*. 2004;30(10):1361-1363.
13. Chilukuri S, Page R, Reed JA, et al. Ectopic extramammary Paget's disease arising on the cheek. *Dermatol Surg*. 2002;28(5):430-433.
14. Gonzalez-Castro J, Iranzo P, Palou J, et al. Extramammary Paget's disease involving the external ear. *Br J Dermatol*. 1998;138(5):914-915.
15. Günhan-Bilgen I, Oktay A. Paget's disease of the breast: clinical, mammographic, sonographic and pathologic findings in 52 cases. *Eur J Radiol*. 2006;60(2):256-263.
16. Sakorafas GH, Blanchard K, Sarr MG, et al. Paget's disease of the breast. *Cancer Treat Rev*. 2001;27(1):9-18.
17. Lloyd J, Flanagan AM. Mammary and extramammary Paget's disease. *J Clin Pathol*. 2000;53(10):742-749.
18. Fu W, Lobocki CA, Silberberg BK, et al. Molecular markers in Paget disease of the breast. *J Surg Oncol*. 2001;77(3):171-178.
19. Cohen C, Guarner J, DeRose PB. Mammary Paget's disease and associated carcinoma. An immunohistochemical study. *Arch Pathol Lab Med*. 1993;117:291-294.
20. Anderson JM, Ariga R, Govil H, et al. Assessment of Her-2/Neu status by immunohistochemistry and fluorescence in situ hybridization in mammary Paget disease and underlying carcinoma. *Appl Immunohistochem Mol Morphol*. 2003;11(2):120-124.
21. Schelfhout VR, Coene ED, Delaey B, et al. Pathogenesis of Paget's disease: epidermal heregulin-alpha, motility factor, and the HER receptor family. *J Natl Cancer Inst*. 2000;92(8):622-628.
22. Lagios MD, Westdahl PR, Rose MR, et al. Paget's disease of the nipple. Alternative management in cases without or with minimal extent of underlying breast carcinoma. *Cancer*. 1984;54:545-551.
23. Gupta RK, Simpson J, Dowle C. The role of cytology in the diagnosis of Paget's disease of the nipple. *Pathology*. 1996;28(3):248-250.
24. Lucarotti ME, Dunn JM, Webb AJ. Scrape cytology in the diagnosis of Paget's disease of the breast. *Cytopathology*. 1994;5(5):301-305.
25. Morrogh M, Morris EA, Liberman L, et al. MRI identifies otherwise occult disease in select patients with Paget disease of the nipple. *J Am Coll Surg*. 2008;206(2):316-321.
26. Ikeda DM, Helvie MA, Frank TS, et al. Paget disease of the nipple: radiologic-pathologic correlation. *Radiology*. 1993;189(1):89-94.
27. Zakaria S, Pantvaidya G, Ghosh K, et al. Paget's disease of the breast: accuracy of preoperative assessment. *Breast Cancer Res Treat*. 2007;102(2):137-142.
28. Frei KA, Bonel HM, Pelte MF, et al. Paget disease of the breast: findings at magnetic resonance imaging and histopathologic correlation. *Invest Radiol*. 2005;40(6):363-367.
29. Zhu Y, Ye DW, Yao XD, et al. Clinicopathological characteristics, management and outcome of metastatic penoscrotal extramammary Paget's disease. *Br J Dermatol*. 2009;161(3):577-582.
30. Cho SB, Yun M, Lee MG, et al. Variable patterns of positron emission tomography in the assessment of patients with extramammary Paget's disease. *J Am Acad Dermatol*. 2005;52(2):353-355.
31. Aoyagi S, Sato-Matsumura KC, Shimizu H. Staging and assessment of lymph node involvement by 18F-fluorodeoxyglucose-positron emission tomography in invasive extramammary Paget's disease. *Dermatol Surg*. 2005;31(5):595-598.
32. Requena L, Kutzner H, Hurt MA, et al. Malignant tumours with apocrine and eccrine differentiation. In: LeBoit PE, Burg G, Weedon D, et al, eds. *World Health Organization Classification of Tumours of Skin*. Lyon, France: IARC Press; 2006:125-138.
33. Lau J, Kohler S. Keratin profile of intraepidermal cells in Paget's disease, extramammary Paget's disease, and pagetoid squamous cell carcinoma in situ. *J Cutan Pathol*. 2003;30(7):449-454.
34. Plaza JA, Torres-Cabala C, Ivan D, et al. HER-2/neu expression in extramammary Paget disease: aclinicopathologic and immunohistochemistry study of 47 cases with and without underlying malignancy. *J Cutan Pathol*. 2009;36(7):729-733.
35. Ohnishi T, Watanabe S. The use of cytokeratins 7 and 20 in the diagnosis of primary and secondary extramammary Paget's disease. *Br J Dermatol*. 2000;142(2):243-247.
36. Kohler S, Smoller BR. Gross cystic disease fluid protein-15 reactivity in extramammary Paget's disease with and without associated internal malignancy. *Am J Dermatopathol*. 1996;18(2):118-123.
37. Yoshii N, Kitajima S, Yonezawa S, et al. Expression of mucin core proteins in extramammary Paget's disease. *Pathol Int*. 2002;52(5-6):390-399.
38. Kuan SF, Montag AG, Hart J, et al. Differential expression of mucin genes in mammary and extramammary Paget's disease. *Am J Surg Pathol*. 2001;25(12):1469-1477.
39. Hata H, Abe R, Hoshina D, et al. MUC5AC expression correlates with invasiveness and progression of

extramammary Paget's disease. *J Eur Acad Dermatol Venereol*. 2014;28(6):727-732.
40. Kasashima S, Ozaki S, Kawashima A, et al. Androgen receptor and 5alpha-reductase immunohistochemical profiles in extramammary Paget disease. *Br J Dermatol*. 2010;162(5):1098-1102.
41. Aoyagi S, Akiyama M, Shimizu H. High expression of Ki-67 and cyclin D1 in invasive extramammary Paget's disease. *J Dermatol Sci*. 2008;50(3):177-184.
42. Fu W, Mittel VK, Young SC. Paget disease of the breast: analysis of 41 patients. *Am J Clin Oncol*. 2001; 24(4):397-400.
43. Kollmorgen DR, Varanasi JS, Edge SB, et al. Paget's disease of the breast: a 33-year experience. *J Am Coll Surg*. 1998;187(2):171-177.
44. Yim JH, Wick MR, Philpott GW, et al. Underlying pathology in mammary Paget's disease. *Ann Surg Oncol*. 1997;4(4):287-292.
45. Marshall JK, Griffith KA, Haffty BG, et al. Conservative management of Paget disease of the breast with radiotherapy: 10- and 15-year results. *Cancer*. 2003;97(9):2142-2149.
46. Bijker N, Rutgers EJ, Duchateau L, et al. Breast-conserving therapy for Paget disease of the nipple: a prospective European Organization for Research and Treatment of Cancer study of 61 patients. *Cancer*. 2001;91(3):472-477.
47. Pierce LJ, Haffty BG, Solin LJ, et al. The conservative management of Paget's disease of the breast with radiotherapy. *Cancer*. 1997;80(6):1065-1072.
48. Sukumvanich P, Bentrem DJ, Cody HS 3rd, et al. The role of sentinel lymph node biopsy in Paget's disease of the breast. *Ann Surg Oncol*. 2007;14(3):1020-1023.
49. Fanning J, Lambert HC, Hale TM, et al. Paget's disease of the vulva: prevalence of associated vulvar adenocarcinoma, invasive Paget's disease, and recurrence after surgical excision. *Am J Obstet Gynecol*. 1999;180(1, pt 1): 24-27.
50. Kodama S, Kaneko T, Saito M, et al. A clinicopathologic study of 30 patients with Paget's disease of the vulva. *Gynecol Oncol*. 1995;56(1):63-70.
51. Fishman DA, Chambers SK, Schwartz PE, et al. Extramammary Paget's disease of the vulva. *Gynecol Oncol*. 1995;56(2):266-270.
52. Appert DL, Otley CC, Phillips PK, et al. Role of multiple scouting biopsies before Mohs micrographic surgery for extramammary Paget's disease. *Dermatol Surg*. 2005;31(11, pt 1):1417-1422.
53. O'Connor WJ, Lim KK, Zalla MJ, et al. Comparison of Mohs micrographic surgery and wide excision for extramammary Paget's disease. *Dermatol Surg*. 2003;29(7):723-727.
54. Hatta N, Morita R, Yamada M, et al. Sentinel lymph node biopsy in patients with extramammary Paget's disease. *Dermatol Surg*. 2004;30(10):1329-1334.
55. Tsutsumida A, Yamamoto Y, Minakawa H, et al. Indications for lymph node dissection in the treatment of extramammary Paget's disease. *Dermatol Surg*. 2003;29(1):21-24.
56. Ogata D, Kiyohara Y, Yoshikawa S, et al. Usefulness of sentinel lymph node biopsy for prognostic prediction in extramammary Paget's disease. *Eur J Dermatol*. 2016;26(3):254-259.
57. Hendi A, Brodland DG, Zitelli JA. Extramammary Paget's disease: surgical treatment with Mohs micrographic surgery. *J Am Acad Dermatol*. 2004;51(5):767-773.
58. Brierley JD, Stockdale AD. Radiotherapy: an effective treatment for extramammary Paget's disease. *Clin Oncol (R Coll Radiol)*. 1991;3(1):3-5.
59. Besa P, Rich TA, Delclos L, et al. Extramammary Paget's disease of the perineal skin: role of radiotherapy. *Int J Radiat Oncol Biol Phys*. 1992;24(1):73-78.
60. Moreno-Arias GA, Conill C, Castells-Mas A, et al. Radiotherapy for genital extramammary Paget's disease in situ. *Dermatol Surg*. 2001;27(6):587-590.
61. Luk NM, Yu KH, Yeung WK, et al. Extramammary Paget's disease: outcome of radiotherapy with curative intent. *Clin Exp Dermatol*. 2003;28(4):360-363.
62. Guerrieri M, Back MF. Extramammary Paget's disease: role of radiation therapy. *Australas Radiol*. 2002; 46(2):204-208.
63. Bewley AP, Bracka A, Staughton RC, et al. Extramammary Paget's disease of the scrotum: treatment with topical 5-fluorouracil and plastic surgery. *Br J Dermatol*. 1994;131(3):445-446.
64. Del Castillo LF, Garcia C, Schoendorff C, et al. Spontaneous apparent clinical resolution with histologic persistence of a case of extramammary Paget's disease: response to topical 5-fluorouracil. *Cutis*. 2000;65(5):331-333.
65. Sendagorta E, Herranz P, Feito M, et al. Successful treatment of three cases of primary extramammary Paget's disease of the vulva with imiquimod-proposal of a therapeutic schedule. *J Eur Acad Dermatol Venereol*. 2010;24(4):490-492.
66. Marchitelli C, Perematteu MS, Sluga MC, et al. Treatment of primary vulvar paget disease with 5% imiquimod cream. *J Low Genit Tract Dis*. 2014;18(4):347-350.
67. Cowan RA, Black DR, Hoang LN, et al. A pilot study of topical imiquimod therapy for the treatment of recurrent extramammary Paget's disease. *Gynecol Oncol*. 2016;142(1):139-143.
68. Kariya K, Tsuji T, Schwartz RA. Trial of low-dose 5-fluorouracil/cisplatin therapy for advanced extramammary Paget's disease. *Dermatol Surg*. 2004;30(2, pt 2): 341-344.
69. Mochitomi Y, Sakamoto R, Gushi A, et al. Extramammary Paget's disease/carcinoma successfully treated with a combination chemotherapy: report of two cases. *J Dermatol*. 2005;32(8):632-637.
70. Oashi K, Tsutsumida A, Namikawa K, et al. Combination chemotherapy for metastatic extramammary Paget disease. *Br J Dermatol*. 2014;170(6):1354-1357.
71. Yoshino K, Fujisawa Y, Kiyohara Y, et al. Usefulness of docetaxel as first-line chemotherapy for metastatic extramammary Paget's disease. *J Dermatol*. 2016;43(6): 633-637.
72. Fujisawa Y, Umebayashi Y, Otsuka F. Metastatic extramammary Paget's disease successfully controlled with tumour dormancy therapy using docetaxel. *Br J Dermatol*. 2006;154(2):375-376.
73. Oguchi S, Kaneko M, Uhara H, et al. Docetaxel induced durable response in advanced extramammary Paget's disease: a case report. *J Dermatol*. 2002;29(1):33-37.
74. Shin DS, Sherry T, Kallen ME, et al. Human epidermal growth factor receptor 2 (HER-2/neu)-directed therapy for rare metastatic epithelial tumors with HER-2 amplification. *Case Rep Oncol*. 2016;9(2):298-304.

Chapter 115 :: Melanocytic Nevi

:: Jonathan D. Cuda, Robert F. Moore, & Klaus J. Busam

INTRODUCTION

This chapter discusses melanocytic nevi, defined as benign neoplasms of melanocytes, most of which manifest themselves as cutaneous pigmented lesions. They are characterized by the presence of banal melanocytic cells in nests (defined as three or more melanocytes in direct contact [also known as *thèque*]), within the epidermis, dermis, or in other tissues. The melanocytic cells forming these nevi are referred to as *nevomelanocytes*. The term *melanocytic hyperplasia* is a descriptive term used to indicate increased melanocytes confined to the basal layer of the epidermis in the absence of nest formation.

Simplistically, melanocytic nevi can be divided into those that arise from junctional melanocytes (often termed *acquired nevi*) and those that arise from neural-crest derived melanocytic precursors that migrate along neurovascular bundles, stop before they reach the epidermis, and proliferate at those sites. The latter are termed *congenital melanocytic nevi* (CMNs).

Dysplastic nevi are defined as those that display atypical architectural and cytologic features. Historically, the nomenclature associated with these lesions includes B-K moles (recognizing the first two families described with such lesions whose surnames began with the letters B and K),[1] familial atypical multiple mole and melanoma syndrome,[2] atypical mole syndrome,[3] Clark nevus,[4] atypical moles, and nevus with architectural disorder and (varying degrees of) cytologic atypia.[5] Although the nomenclature for these lesions remains contentious, the term *dysplastic nevus* (DN) is most frequently utilized[5,6] and is the term that will be used in this chapter. It is also important to note that in practice, the terms *dysplastic* and *atypical* are sometimes used as a modifier for other melanocytic neoplasias (eg, Spitz nevi) or hyperplasias to indicate a variation from a typical pattern or to recognize an increased concern for malignant biologic potential.

The nevi described in this chapter include CMNs, nevus spilus, common acquired melanocytic nevi, blue nevi, Spitz nevi, pigmented spindle cell nevi (PSCN), dysplastic nevi, and nodal nevi. Benign melanocytic hyperplasias include lentigo simplex and solar lentigo.

CONGENITAL MELANOCYTIC NEVI

AT-A-GLANCE

- Pigmented neoplasms of melanocytes that are evident at birth or shortly thereafter.
- Lesions may be small, medium-sized, or large and cover substantial body surface area.
- Large or giant lesions have a significant risk for melanoma development. Cranial or midline congenital melanocytic nevi and those with satellite lesions have an increased risk of leptomeningeal involvement.
- Histology shows extensive nevomelanocytic infiltration of the dermis, accentuation along the adventitia of skin adnexa and nerves, single-filing between collagen bundles, often with involvement of subcutaneous tissues.

EPIDEMIOLOGY

CMNs are found in approximately 1% to 3% of neonates across ethnicities.[7] The majority of lesions are small to medium in size and are present at birth; however, there are also congenital nevi (>1.5 cm) that appear for the first time between 1 month and 2 years of life (termed *tardive congenital nevi*). A significant gender predilection has not been demonstrated. CMNs occur most commonly on the trunk and extremities, although scalp and facial involvement are seen. Giant CMNs are uncommon. CMNs that attain 99 mm or more in diameter occur in approximately 1 of every 20,000 newborns, and those with a garment distribution affect 1 of every 500,000 newborns.[8]

CLINICAL FEATURES

Nevi of congenital onset have traditionally been grouped based on diameter into small, medium, and

large sizes. The size limits of each type are arbitrary because the diameter of these lesions lies on a continuum. There is some rationale for standardizing congenital nevi by size because there is increased risk of melanoma associated with large and giant CMNs.[9,10] The most accepted system is based on the expected size of the nevus in adult life[11] because CMNs have been shown to grow in proportion with the affected anatomic region.[12] Small CMNs are less than 1.5 cm in diameter (projected adult size), medium ones are divided into two groups—M1, 1.5 to 10 cm and M2, >10 to 20 cm—as are large ones—L1, >20 to 30 cm and L2, >30 to 40 cm. Last, giant CMNs are categorized as G1, >40 to 60 cm and G2, >60 cm (Fig. 115-1). This classification scheme also rates the number of satellite nevi (S1: <20, S2: >20–50, S3: >50).

CUTANEOUS FINDINGS

Although CMNs are on average larger than acquired nevi, there is no specific size limitation that can be used to reliably predict whether a given nevus is congenital or acquired. Pigmented lesions attaining a diameter of 1.5 cm or more are likely to be CMN, dysplastic nevi, or melanoma.

Most CMNs present as flat brown patches or plaques with smooth or slightly uneven borders. Many show hypertrichosis compared to surrounding unaffected skin. Hair growth may be present at birth or commence in the years thereafter. Most congenital nevi begin with even pigmentation, but some variability of pigmentation and irregularity of surface texture eventuates in most medium- and large-sized lesions over time. Lesions may have a pebbly, rugose, verrucous, or lobular appearance.

Dermoscopic features are variable and include a reticular, globular, homogeneous, and cobblestone pattern or a combination thereof. Dermoscopic findings in dysplastic nevi sometimes overlap with those of CMN. In one study, most of the features related to dysplastic nevi, including atypical dots and globules, focal hypopigmentation, and perifollicular hypopigmentation, were observed in CMN.[13] Therefore, eliciting a history with regards to the time of lesion onset is important. In large CMN, there can be significant variability in pigmentation and structure, and melanomas may develop in the deep components, potentially limiting the utility of dermoscopy in such lesions.

Some CMNs show an atypical clinical appearance, including significant color variegation and irregularities in outline and surface contour. Color variations include dark brown, black, or hues of blue. These features often correlate with atypical histopathologic findings. Loss of pigmentation, halo depigmentation, and regression can also occur.

Figure 115-1 Giant congenital pigmented nevus in the bathing trunk distribution. Note the satellite nevi.

RELATED PHYSICAL CONDITIONS

One of the most important related physical conditions in patients with CMNs on the head, neck, or posterior midline is neurocutaneous melanosis (NCM). In this condition, the cells of the congenital nevus involve the meninges or even the parenchymal cells of the brain. Most patients with NCM have many cutaneous congenital nevi, either in the form of a giant nevus with many satellites or in the form of many medium-sized lesions.

Symptomatic NCM presents with seizures and hydrocephalus in the first few years of life when melanocytes are diffusely distributed along the meninges. There may be neurologic deficits and vomiting from increased intracranial pressure. When an intracranial mass is present, symptoms may present later in life.[14] The prognosis is poor if neurologic symptoms develop. Patients often die within 3 years of symptom onset.

COMPLICATIONS

The most important complication of congenital nevi is that they can give rise to melanoma. The overall incidence of this complication is approximately 1% to 2%.[9] The risk of melanoma appears to be proportionate to the number of melanocytes that comprise the nevus. This in turn is closely related to its size. Thus, small- and medium-sized lesions have a low risk of developing melanoma, but large- and giant-sized lesions have greater risk. Additionally, satellite nevi are associated with increased risk of melanoma. In one systematic literature review, melanoma arising from CMN exceeded 40 cm in 74% of 52 cases studied and 94% of those had satellite nevi.[15] The lifetime risk of melanoma development in lesions exceeding 40 cm (projected adult size) with satellite nevi has been estimated at 10% to 15%.[9]

Although melanoma arising from CMN may occur at the dermal–epidermal junction (DEJ) (as they do in acquired nevi), they show a tendency to arise in deeper dermal and subcutaneous components of the nevus. These tumors are highly aggressive in part because of

their greater Breslow thickness at presentation. They present with the sudden appearance of a dermal or subcutaneous nodule. Sometimes lymph node metastasis precedes clinical detection of the primary melanoma. Other clinical features that should raise concern for melanoma include very dark pigmentation, ulceration, bleeding, or onset of other sensory symptoms. There is no ethnic predilection for melanoma developing in CMN.

For cranial, midline, or CMN with multiple satellite lesions, there is a risk of leptomeningeal involvement (NCM). Symptomatic NCM carries a poor prognosis, even in the absence of malignant degeneration (central nervous system [CNS] melanoma). A recent literature review revealed that 37% of 178 melanomas arising in patients with congenital nevi were primary CNS melanomas rather than of cutaneous origin, and most of these (53.9%) developed in patients with multiple medium-sized CMNs.[16]

Proliferative nodules also constitute a significant complication of congenital nevi because they need to be removed. They typically present as a lightly pigmented or flesh-colored nodule developing in a preexisting congenital nevus. Although they almost always behave in a benign fashion, histopathologic examination of a lesion that is clinically indistinguishable from a proliferative nodule may show the findings of a clear-cut melanoma.

RISK FACTORS

There are rare reports of familial clustering of congenital nevi (Fig. 115-2).[17] Patients with neurofibromatosis type 1 appear to have an increased incidence of giant CMNs.[18]

ETIOLOGY AND PATHOGENESIS

CMN result from postzygotic somatic mutations of proteins involved in the mitogen-activated protein kinase (MAPK) pathway within the embryonic melanocyte. These primarily include mutations of *NRAS*, resulting in abnormal accumulation of melanocytic cells along migration pathways during normal development. Whereas *NRAS* mutations are most prevalent in large- and giant-sized CMNs, small- and medium-sized lesions have been reported to have either *NRAS* mutations or in a small number of cases, activating mutations in *BRAF*.

It should be noted that the proportion of cases with *NRAS* or *BRAF* mutations vary between studies in the literature, which probably reflects the different methodologies used (ie, whether CMN was defined as historically being present at birth, the exact measurements that were used, whether both genes were sequenced, and so on).[19] In one study of 32 congenital nevi confirmed to be present at birth, the authors found that 81% of cases had mutations in *NRAS*, but no *BRAF* mutations were detected; furthermore, 7 of the 10 proliferating nodules that developed within the congenital nevi also harbored mutations in *NRAS* rather than *BRAF*. In contrast, 20 of 28 nevi studied that had a congenital pattern histologically but were not confirmed to be present since birth harbored *BRAF* mutations (similar to acquired nevi); only 7 had mutations of *NRAS*.[20]

Clinical findings such as a congenital divided nevus of the eyelid can give us insight into when these mutational events may occur (Fig. 115-3). The palpebral buds develop during the 7th week of gestation and

Figure 115-2 Familial aggregation of small congenital nevomelanocytic nevi. Note the small congenital nevus on the thigh of a 3-year-old Caucasian boy and on the back of his 5-year-old brother.

Figure 115-3 Congenital divided nevomelanocytic nevus of the eyelid. The nevus is contiguous when the eyelids are closed, suggesting that the lesion was formed in the developing fetus before the eyelids split (ie, before 24 weeks).

the upper and lower eyelids fuse by week 9 or 10. The eyelids then begin to separate during the 20th week, and complete separation commences between weeks 28 and 30.[21] Because of the contiguous nature of the lesion on the upper and lower eyelids, it may be presumed that the nevus cells migrated into this location sometime during or after eyelid fusion but before the eyelids separated.

DIAGNOSIS

The diagnosis of a congenital nevus is usually straightforward. The more challenging problem is whether the nevus contains any areas that necessitate biopsy. For patients with congenital nevi on the head or axial midline, an important question is whether there is subjacent NCM. This is best addressed by imaging studies (see later).

PATHOLOGY

Although there are histopathologic features that are suggestive of a congenital nevus, there are no criteria with absolute sensitivity and specificity for predicting whether a lesion is of congenital onset.

Prototypical large- or medium-sized CMNs involve the entire skin from the junctional zone to the subcutis (Fig. 115-4). Small, round melanocytes are present in subcutaneous septae and to a lesser extent in lobules, with progressively (slightly) larger cells in the upper levels of the dermis and along the junctional zone. Some lesions are densely cellular, and there is a propensity for the cells to surround neurovascular bundles, appendageal structures, and folliculosebaceous units. Subendothelial protrusion by nevomelanocytes within lymphovascular spaces is sometimes prominent. The junctional zone may be involved by cells distributed singly and in small nests. These are often separated from the upper dermal part of the lesion by a zone of uninvolved papillary dermis. The junctional cells are usually larger than those beneath them, and basilar hyperpigmentation is common. A rim of pigmented melanocytes is often present along the upper border of the dermal component, which often extends along the innermost perifollicular melanocytes.

In some large and in most small congenital nevi, the subcutis is not involved. In such cases, at the base of the lesion, melanocytes splay between collagen bundles in cords and strands within the deep or mid reticular dermis.

Congenital nevi that undergo neurotization show areas where schwannian differentiation occurs. Instead of small round melanocytes, one sees small S-shaped spindle cells. These can form thin, wavy fascicles with clefts in between them containing mucin. Admixed adipocytes are commonly seen. Collections of neuroid cells can form pseudomeissnerian corpuscles, a palisaded arrangement of cells around a cellular mass of homogeneous material, simulating native Wagner-Meissner corpuscles. In highly neurotized lesions, one may not be able to morphologically distinguish between nevus and neurofibroma. Neural differentiation is sometimes responsible for the lobulation and redundancy of tissue corresponding clinically with soft rugose areas of the nevus.

Other histologic variations seen include cells with a combined epithelioid cell (Spitz) phenotype, which are often admixed with more conventional round cell and neuroid elements. CMNs may also have elements of blue nevus (either common or cellular type) with heavily pigmented spindle-shaped melanocytic cells or show features of inverted type-A or deep penetrating nevus. In a recent series of 197 congenital nevi in children younger than 3 years of age, 74% of patients studied had atypical histopathologic features. These included cytologic atypia (mostly mild or moderate),

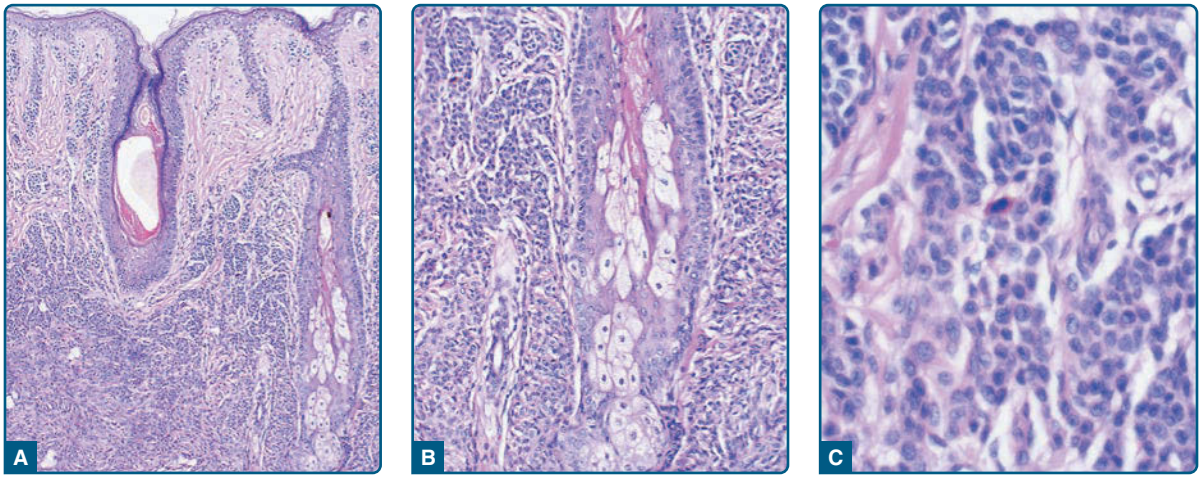

Figure 115-4 Histopathologic features of congenital nevomelanocytic nevus. Nevomelanocytes in the low-magnification image (**A**) reveal dense accumulation in the lower two-thirds of the dermis; at medium magnification (**B**), these cells encroach on dermal adnexal structures (follicular, sebaceous, and eccrine); and higher magnification (**C**) reveals dense collections of small nevomelanocytic cells.

architectural disorder (mostly mild or moderate), and pagetoid scatter; no cases of melanoma were identified in these patients with a mean follow-up period of 7.3 years.[22]

Proliferative nodules feature large, round hypercellular aggregates of melanocytes that appear discrete on scanning magnification but tend to blend in with the background nevus cells. True to their name, they often contain mitotic figures. The melanocytes in these nodules may have a range of appearances, including cells with small to moderately enlarged nuclei, cells with epithelioid cytology, spindled cells, and blue nevus–like features. Proliferative nodules tend to have lower mitotic counts than melanoma and are less likely to show ulceration or the cytogenetic or epigenetic aberrations detected in melanoma.[23,24]

SPECIAL TESTS

Imaging studies to detect NCM include magnetic resonance imaging of the brain or spinal cord concordant with the anatomic location of the nevus.

DIFFERENTIAL DIAGNOSIS

See Table 115-1.

CLINICAL COURSE AND PROGNOSIS

CMNs have a dynamic evolution during body growth. CMNs at birth usually distort the skin surface at least slightly when assessed by oblique lighting and may become more elevated over time. Surface pigmentation also may change. Lightly pigmented CMNs may become more darkly pigmented, and darkly pigmented CMNs eventually may become less pigmented. CMNs may also develop a halo of depigmentation, potentially heralding spontaneous regression. Relatively hairless CMNs at birth may develop long, dark, coarse hair or may maintain a relatively normal hair density. CMNs generally expand in direct proportion to growth of a given anatomic region.[12] Proliferative nodules present as flesh-colored or lightly pigmented nodules that develop and then stabilize. CMNs in fully grown individuals should remain stable. The prognosis is excellent unless complicated by NCM or melanoma.

TABLE 115-1

Differential Diagnosis of Congenital Melanocytic Nevus

- Café-au-lait macule
- Nevus spilus
- Lentigo simplex
- Nevus of Ota/Ito
- Dermal melanocytosis (Mongolian spot)
- Becker melanosis
- Arrector pili (smooth muscle) hamartoma
- Epidermal nevus
- Nevus sebaceous
- Solitary mastocytoma

MANAGEMENT

TREATMENT

The treatment of CMN depends on the perceived risk of melanoma plus cosmetic and functional considerations. The risk of developing melanoma is related to its size, and melanoma may arise in large CMNs even in the first few years of life. Therefore, debulking of large nevi and excision of smaller or medium-sized ones is desirable when feasible. This can be done for large nevi in serial stages.

It is probably prudent to delay treatment until after the first 6 months of life to reduce surgical and anesthetic risks. Management of patients with large and giant CMNs must be individualized. Extensive involvement of the body surface, with little or no normal skin available for graft sites, may necessitate abandoning efforts at prophylactic excision and accepting lifelong surveillance to detect the earliest signs of malignant change. It may be impossible to remove every nevomelanocyte in large CMN, particularly when there is involvement of vital structures or deep anatomic zones. The treatment goal is to remove as much of the nevus as possible while preserving function and improving cosmetic appearance.

Other indications for surgical excision include symptomatology (ie, chronic pruritus, pain, ulceration). Unlike surgical excision, dermabrasion, lasers, and other modes of destructive therapy do not address the malignant potential of CMN; nevomelanocytes will still be left behind in the dermis, and the cosmetic results associated with destructive therapy are not always predictable.

Although atypical-appearing CMN should be considered for immediate excision, careful surveillance without excision may be an option for clinically benign lesions depending on gross appearance, size, location, cosmetic and functional deficits (or improvement) resulting from excision, and general health issues. Given the risk of general anesthesia, for lesions perceived to be at low risk during the first decade of life, it is appropriate to consider waiting until the child is old enough to tolerate local anesthesia.

All CMNs should be documented at birth, preferably in the form of high-quality photographs that can be used to aid follow-up by parents and physicians. Follow-up is complicated by the natural evolutionary changes that take place in a nevus during body growth (ie, surface, size, color, and hair), and periodic updates of photographs may be warranted. Suspicious changes in color, surface, or size require urgent evaluation.

PREVENTION AND COUNSELING

There is no known preventive approach to avoid the development of CMNs. UV radiation (UVR)–induced mutations play no role in the initial development of lesions already present at birth. The issues around body image and social adjustment raised by large and giant congenital nevi may benefit from counseling and support groups, including Nevus Network (www.nevusnetwork.org) and Nevus Outreach, Inc. (www.nevus.org).

NEVUS SPILUS

AT-A-GLANCE

- Nevus spilus (derived from Greek *spilos*, meaning *spot*)—spotted nevus
- Synonyms: speckled lentiginous nevus, zosteriform lentiginous nevus
- Pigmented neoplasm of melanocytes that develops during infancy or early childhood.
- Lesion presents with two components, a light brown patch (café-au-lait) containing speckled dark macules or papules.
- Risk for melanoma is low but may occur.
- Histology shows localized collections of nevus elements forming in the background of mild melanocytic hyperplasia.

EPIDEMIOLOGY

Nevus spilus occurs in approximately 1% to 2% of the population. They are present either at birth or in the first years of life and have therefore been regarded as a variant of congenital nevus. There does not appear to be gender or ethnic predilection.

CLINICAL FEATURES

Darkly pigmented flat macules or papules are usually present within the nevus spilus on presentation. New pigmented elements may evolve within the lesion over time.

CUTANEOUS FINDINGS

The background pigmentation of a nevus spilus is circumscribed and similar in appearance to a café-au-lait macule in hue, with even light pigmentation. There are scattered superimposed more darkly pigmented macules or papules. The tan macular background pigmentation can range in size from less than 1 cm to larger than 10 cm in diameter (Fig. 115-5).

Figure 115-5 Nevus spilus. **A,** Nevus spilus appearing first at age 3 years on the ankle and foot of a 25-year-old white woman. **B,** Congenital nevus spilus on the arm of a 10-year-old white boy.

Lesions are most commonly found on the trunk and extremities, although any cutaneous site may be affected. Multiple lesions may be present and have a segmental distribution. There are rare reports of a divided nevus spilus of the eyelid[25] as well as a report of one in the oral cavity.[26]

Dermoscopy reveals dark speckled foci with a reticuloglobular pattern in a background light brown and reticular pattern. Mixed patterns may occur that include combinations of homogeneous, reticular, globular, granular, and spitzoid patterns.[27] Dermoscopy and reflectance confocal microscopy have been used for early detection of melanoma, a rare complication of nevus spilus.[28]

RELATED PHYSICAL CONDITIONS

Nevus spilus has been associated with other anomalies of vascular, CNS, or connective tissue origin. It has

been proposed by Vidaurri-de la Cruz and Happle that two distinct forms of nevus spilus exist, those with macular and those with papular speckles.[29] Whereas macular varieties are more commonly associated with phakomatosis spilorosea (previously classified as pigmentovascularis type III), the papular variant is typically seen in phakomatosis pigmentokeratotica. Phakomatosis spilorosea constitutes presentation of both nevus flammeus and nevus spilus with or without nevus anemicus. Systemic disease may or may not be present, which include vascular anomalies, ocular abnormalities, limb hemihypertrophy, or development of multiple granular cell tumors. Phakomatosis pigmentokeratotica includes nevus spilus plus organoid nevus with or without systemic symptoms, which include neurologic deficits and skeletal abnormalities.

COMPLICATIONS

The main concern that prompts a biopsy is a changing lesion, where one may see enlargement of dark macules or papules within the nevus spilus. One can see larger, irregularly shaped macules, sometimes with a central papule in so-called *dysplastic nevus spilus*. In such cases, the lesion can show any of the changes seen in dysplastic nevi. Rare cases of melanoma arise in nevus spilus and are recognizable as larger, irregularly shaped areas with variegated pigmentation. It is likely the risk of melanoma increases to some degree with the size of the nevus spilus, particularly with larger segmental lesions greater than 40 cm.[30]

RISK FACTORS

There are no known risk factors for nevus spilus, aside from the association with phakomatosis spilorosea and pigmentokeratotica.

ETIOLOGY AND PATHOGENESIS

Nevus spilus is believed to develop secondary to a postzygotic mutational event initiating a clonal field of melanocytes susceptible of creating multiple melanocytic tumors within. These arise likely secondary to additional mutational or epigenetic events. Sarin and coworkers identified an activating HRAS mutation (c.37G->C, p.Gly13Arg) in eight of eight nevi spili studied, implicating this gene locus as the predominant causative mutation in sporadic nevi spili.[31] The same author previously described a nevus spilus giving rise to agminated Spitz nevi with the same mutation.[32]

Kinsler and coworkers performed next-generation sequencing on three nevi spili with a distinct phenotype, large background café-au-lait–type patches with superimposed multiple medium or large pigmented patches indistinguishable from CMN.[33] This phenotype was termed *nevus spilus-type congenital melanocytic nevus*. In contrast to the activating HRAS mutations seen in small sporadic nevi spili,[30] nevus spilus–type CMNs displayed activating mutations of NRAS in all three patients (two with c.183A->Cp.Q61H, one with c.37G->Cp.G13R). Targeted exon capture of two skin samples from an additional patient also showed the same NRAS mutation (p.Q61H) in both the background pigmentation and the superimposed nevus.[33]

DIAGNOSIS

The diagnosis of nevus spilus is usually straightforward. Small lesions are sometimes mistaken for dysplastic nevi and large lesions for conventional CMN.

PATHOLOGY

Histologic sections reveal that the tan background corresponds to a diffuse area where there is slight epidermal hyperplasia with basilar hyperpigmentation, from no perceptible increase in melanocytes to a slight increase in singular melanocytes along the basal layer. The dark spots correspond to small lentiginous junctional and compound nevi featuring increased numbers of single melanocytes and small nests along the DEJ and small, round melanocytes in the superficial dermis, in cases of compound nevi. Rarely agminated nevi within a nevus spilus may have the phenotype of a blue nevus (pigmented dendritic melanocytes) or Spitz nevus (epithelioid and spindled melanocytes).

SPECIAL TESTS

There are no other diagnostic tests at present.

DIFFERENTIAL DIAGNOSIS

See Table 115-2.

CLINICAL COURSE AND PROGNOSIS

Nevus spilus is a benign lesion that may develop more spotted nevoid elements over time. After

TABLE 115-2
Differential Diagnosis of Nevus Spilus

- Agminated nevomelanocytic nevi
- Agminated lentigines
- Becker melanosis
- Congenital nevomelanocytic nevus with heterogeneous pigmentation
- Café-au-lait macule

developing, they are presumed to persist throughout life, although it is possible that some elements within the nevus spilus or rarely the entire nevus spilus itself could regress with time. The prognosis is excellent with the exception of rare cases complicated by melanoma.

MANAGEMENT

TREATMENT

No standard guidelines exist for the management of patients with nevus spilus. Clinical appearance (typical or atypical), history of stability or instability of pigmented elements, congenital or noncongenital onset, perceived risk of developing melanoma, and cosmetic concerns are considerations when determining whether to excise or recommend periodic clinical evaluation for life. Documentation with high-quality photographs can be used to aid follow-up by parents and physicians. Atypical-appearing new or unstable elements in nevus spilus should be evaluated by histopathologic examination to exclude melanoma.

PREVENTION AND COUNSELING

There are no preventive measures for nevus spilus. UV protection is theoretically prudent in light of the propensity for melanocytic neoplasms to develop within nevi spili, as well as the rare reported cases complicated by melanoma.

COMMON ACQUIRED MELANOCYTIC NEVUS

AT-A-GLANCE

- Synonyms: nevocellular nevus, common nevus, melanocytic nevus
- Lesions are pigmented or skin-colored macules or papules which tend to be uniform in appearance and relatively small in size.
- They primarily develop during childhood or early adulthood.
- Increased numbers of acquired nevi impart an increased risk for melanoma development.
- Common nevi are subcategorized based on location of cells: cells in the epidermis (junctional), dermis (intradermal), or both areas (compound). Pathologically, the cells mature becoming smaller in size within the deeper dermis and express melanocytic antigen HMB-45 at lower levels.

EPIDEMIOLOGY

Common acquired melanocytic nevi develop after birth, slowly enlarge symmetrically, stabilize, and regress after a period of time. The number of nevi peaks in the third decade of life and declines thereafter. A number of studies have quantified the number of acquired nevi in different age groups. In a study of 432 European with white skin between the ages of 4 days and 96 years, nevi that were 3 mm in diameter or larger were detected in females and males, respectively, at median numbers of 0 and 2 in the first decade, 10 and 16 in the second decade, 16 and 24 in the third decade, 10 and 19 in the fourth decade, 12 and 15 in the fifth decade, 4 and 12 in the sixth decade, and 2.0 and 3.5 in the seventh through the ninth decades.[34] Numbers of nevi vary among study populations, but a similar age-related trend has been documented in most other large epidemiologic studies.

The prevalence of acquired nevi also varies according to ethnicity. In a longitudinal study of children in Colorado, non-Hispanic white children showed significantly more nevi than all other ethnic groups, developing an average of four to six new nevi per year from ages 3 to 8 years.[35] Nevi tend to be increased in individuals with light skin tone and those who have a tendency to sunburn.

CLINICAL FEATURES

Acquired common nevi develop over the first 3 decades of life and can persist in a stable state for decades, and many regress thereafter. In later adult years, nevus counts are significantly less and the rate of new or growing nevi declines, but melanoma incidence increases. Therefore, a new, growing, or changing pigmented lesion in an adult assumes a greater risk of being melanoma.

CUTANEOUS FINDINGS

The majority of common acquired nevi are less than 6 mm in diameter. Individual lesions have a homogeneous surface and coloration pattern, are round to oval in shape, and have sharply demarcated borders (Fig. 115-6). Most are skin colored, pink, or brown. Very dark brown or black nevi are unusual for people with light skin tones and should be viewed with suspicion. On the other hand, darkly colored nevi are common in those with dark skin tones. Blue, gray, red, and white areas are not typical for common acquired nevi and should raise concern for melanoma.

Lesions that are papillomatous or dome shaped tend to be lighter in color and display a more dominant intradermal component, but flat lesions tend to show more pigmentation and a more robust junctional component. Similar to congenital nevi, acquired nevi sometimes show hypertrichosis compared with the surrounding skin.

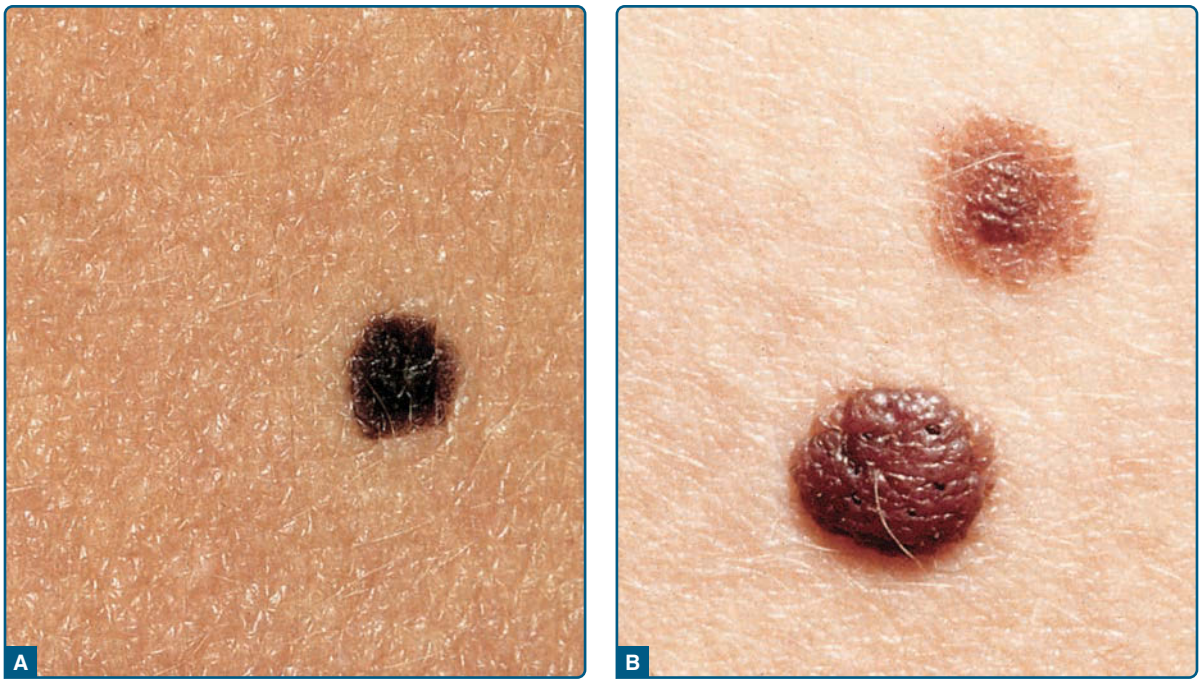

Figure 115-6 Typical acquired nevomelanocytic nevi. **A,** Junctional nevus. A uniformly dark brown macule, round in shape, with a smooth, regular border. **B,** Two compound nevi. A uniformly pigmented papule and domed nodule. The upper lesion is flatter and tan with slight central elevation. The lower lesion is older and is uniformly elevated because of an increased intradermal component.

Common acquired nevi occur anywhere on the skin surface. However, compared with light-skinned individuals, those with dark skin more commonly develop nevi on the palms, soles, nail apparatus, and mucous membranes. Nevi on the palms and soles tend to be flat and may not distort the skin surface because of the thickness of the stratum corneum. Nevi of the nail apparatus commonly present as a linear longitudinal streak of dark or light-brown pigment from the nail matrix extending to the distal edge of the nail plate. Extension of pigment onto the proximal nail fold or beyond the distal nail groove should be considered suspicious for melanoma.

Dermoscopy can reveal a number of patterns, but a reticular or globular pattern is commonly seen in acquired nevi. Nevi on the palms and soles can show a parallel-furrow pattern, lattice-like, or fibrillar pattern. Nonuniform patterns and parallel-ridge patterns are worrisome for melanoma. Nail matrix nevi show regular lines on a brown background. A recent comparative analysis of the dermoscopic features of benign nail matrix nevi in adults and children revealed that those in children more often showed atypical melanoma-associated dermoscopic features.[36]

Halo nevi are usually asymptomatic, often multiple, and most commonly affect the trunk of teenagers (Fig. 115-7). The halo phenomenon signifies self-immunologic regression of a preexisting melanocytic nevus. Lesions present with a central pink or brown nevus

Figure 115-7 Halo nevomelanocytic nevus. **A,** Acquired halo nevus on the chest of a 16-year-old Caucasian boy whose maternal grandmother had melanoma. **B,** Acquired halo nevi on the back of a 6-year-old Caucasian boy. Scale in millimeters. **C,** Halo congenital nevomelanocytic nevus on the neck of a 4-year-old girl. This child also had scattered areas of vitiligo-like depigmentation in other sites. A 3-year follow-up after excision of the nevus revealed almost total repigmentation of the widely scattered previously depigmented areas.

centrally, surrounded by a symmetric round or oval halo of depigmented skin. The central nevus may be small and typical of common acquired nevi or be large in dysplastic or congenital nevi. The radial zone of depigmented skin around the nevus ranges from less than 5 mm to 5 cm. Over time, the central nevus may lose its pigmentation and disappear followed by gradual repigmentation of the entire area.

Other names for the halo phenomenon include *leukoderma acquisitum centrifugum*, *Sutton nevus*, *leukopigmentary nevus*, *perinevoid vitiligo*, and *perinevoid leukoderma*. An atypical gross appearance of the central lesion or an asymmetric halo of depigmentation, particularly in adults, should raise suspicion for a DN or melanoma.

The Meyerson's nevus presents as an asymptomatic or slightly pruritic, red, and slightly scaly eczematous halo around a central nevus. Lesions occur most often on the trunk and proximal extremities and may be multiple. Unlike halo nevi, the skin does not depigment, and regression of the nevus does not occur. Eczematous changes often self-resolve over the course of months.

The spontaneous and concurrent development of multiple nevi, often similar in appearance, is termed eruptive nevi. This phenomenon has been described in the context of blistering diseases of the skin (immunobullous as well as erythema multiforme–Stevens-Johnson syndrome–toxic epidermal necrolysis spectrum), immunosuppression, neoplasia, and drugs (particularly chemotherapeutic and immune-modulating agents). Eruptive nevi may be of the common acquired type, Spitz, or blue nevus varieties.

RELATED PHYSICAL CONDITIONS

There is a general increased risk of melanoma in patients with multiple nevi. This risk is further increased in the setting of multiple atypical nevi or a personal or family history of melanoma. In patients with eruptive nevi, there may be findings of bullous disease or immunosuppression. Halo nevi, particularly when multiple, may be associated with concurrent or subsequent development of vitiligo or other autoimmune disease.[37] Halo nevi are also more frequent in patients with Turner syndrome.[38]

COMPLICATIONS

Several studies demonstrate that increased numbers of nevi indicate an increased risk for melanoma development. In one large meta-analysis, the relative risk for people with high nevus counts (101–120 nevi) was 6.89 compared with those with low nevus counts (0–15 nevi).[39] In addition, those with five atypical nevi had a relative risk of 6.52 compared with those with no atypical nevi.[39] Other risk factors such as skin color, freckling, and patterns of sun exposure may be multiplicative to the number of nevi in increasing melanoma risk.

Most melanoma arise from normal skin and thus increased number of nevi are associated with a general melanoma risk. However, approximately 20% of melanomas are reported to have associated nevus elements suggesting a precursor pathway. In one study of 131 melanomas, a history of frequent sunburns predicted the greatest risk for nevus-associated melanoma.[40]

RISK FACTORS

Environmental exposure to UV radiation appears to be the most critical risk factor for the development of acquired nevi. In a US population-based longitudinal study of nevi in children (n = 443), spending 5 to 6 hours per week outside between 10 AM and 4 PM, painful sunburn(s), decreased UV barrier protection, and male gender were significantly associated with increased number of nevi.[41] Intermittent intense sun exposure appears to impose greatest risk for nevus development. A randomized trial assessing sunscreen use on nevi development in white school-aged children also demonstrated a significant reduction in the number of nevi on intermittently sun-exposed body sites compared with control participants.[42]

Genetic factors appear to play a role in their development. The size, frequency, and distribution patterns of acquired nevi tend to aggregate in families. This observation is also well documented for atypical nevi in the setting of DN and melanoma syndromes (see dysplastic nevi).

ETIOLOGY AND PATHOGENESIS

Common acquired nevi are clonal neoplasms, the majority of which demonstrate activating *BRAF* mutations. It is likely that this mutation is an early or initiating event in melanocytic neoplasia. All cells within common nevi have been shown to be fully clonal and contain the same heterozygous *BRAF* mutation by droplet digital polymerase chain reaction.[43]

Eruptive nevi occur in the setting of immunosuppression or chemotherapy. *BRAF* mutations have been identified in eruptive melanocytic nevi associated with 6-mercaptopurine therapy.[44] However in one case, eruptive nevi of the Spitz type showed absence of *BRAF* and *HRAS* mutations in 39 nevi analyzed.[45] This is not surprising because of the diverse molecular pathways that have been implicated in Spitz nevus development (see Spitz nevi).

Halo nevi are nevi in which the body attempts an immune-mediated attack on nevus cells orchestrated by effector CD8+ cytotoxic T-lymphocytes. In this phenomenon, increased levels of interferon—γ–inducible chemokine pair CXCL10–CXCR3 have been demonstrated, similar to that seen in vitiligo.[46] The precise trigger for this immunologic phenomenon in the absence of disease remains unclear. In patients with Turner syndrome, there was a significantly higher

association of HLA-CW6 in those who developed halo nevi, suggesting a genetic predisposition.[38]

DIAGNOSIS

The diagnosis of common acquired nevi is usually made by clinical inspection, assessing that the lesion is relatively small, symmetrical, has even borders, is not ulcerated, and has a limited variety of colors and normal pigment network.

PATHOLOGY

The common junctional nevus is circumscribed and mostly nested at the basal layer of the epidermis (Figs. 115-8 and 115-9). Junctional melanocytes have pale or pigmented cytoplasm and small, monomorphous nuclei with inconspicuous nucleoli. In some common junctional nevi, the nests of melanocytes are positioned toward the bases of rete ridges, but in others, the rete ridge pattern is unrelated. Epidermal melanocytes between junctional nests are disposed as single typical cells along the basal layer, with overall numbers equal to or slightly greater than that in adjacent skin. The epidermis is often hyperpigmented with lentiginous architecture (elongated and club-shaped rete pegs).

In compound nevi (see Fig. 115-9), the epidermis may be normal or hyperplastic, with an appearance similar to seborrheic keratosis complete with horn cysts or epidermal verrucous hyperplasia similar to epidermal nevus. The dermal component of compound and intradermal nevi has an orderly progression from top to bottom, with larger epithelioid cells above (within the epidermis and superficial dermis) blending into a pattern of smaller round and spindled cells in the deeper dermis. This orderly progression of larger, more epithelioid cells in the superficial aspect of the nevus to smaller cells in its deep aspect is known as maturation.

In the epidermis and superficial dermis, nevomelanocytes frequently contain melanin pigment. With

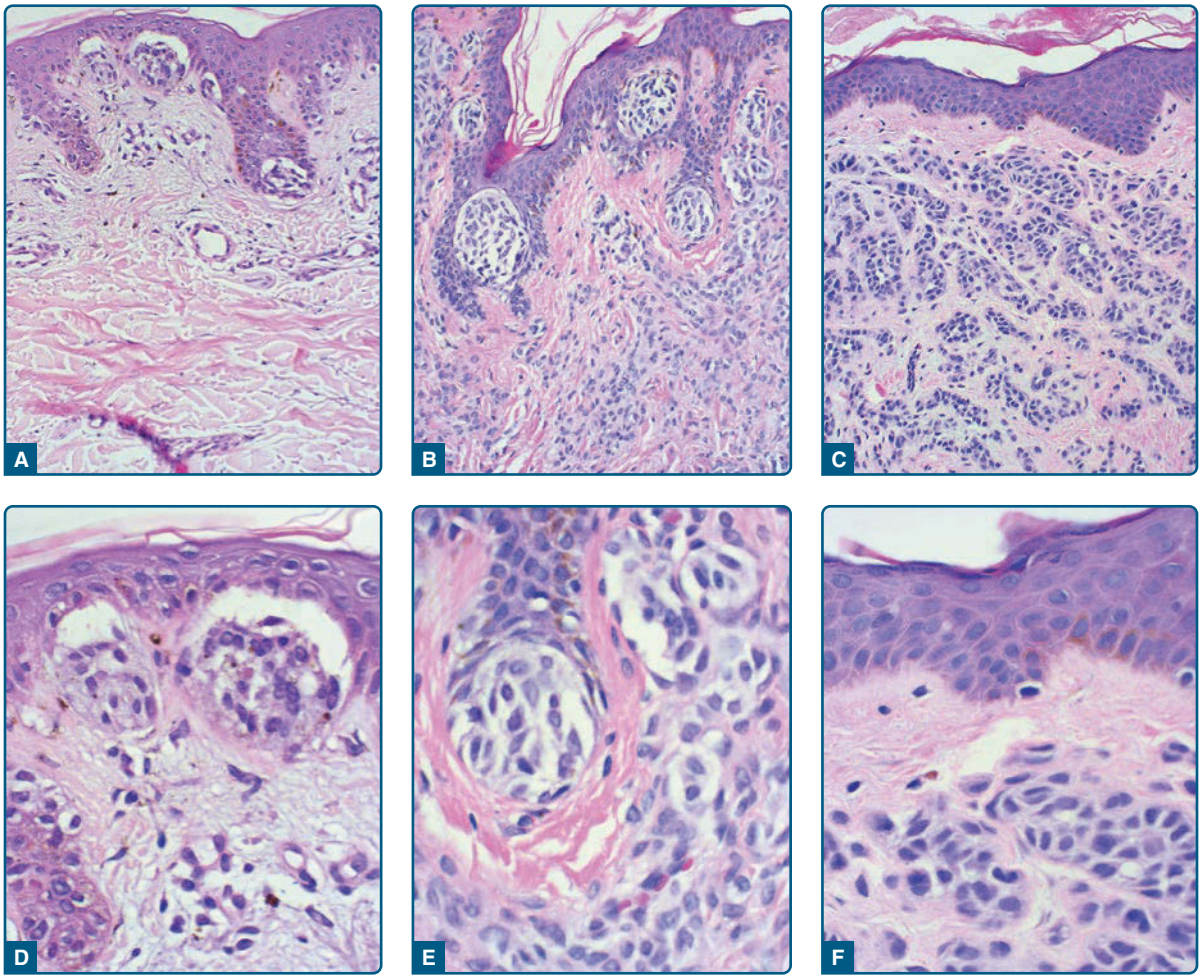

Figure 115-8 Histopathologic features of acquired nevi. Junctional nevus (**A**) and higher magnification (**D**). Compound nevus (**B**) and higher magnification (**E**). Intradermal nevus (**C**) and higher magnification (**F**). Well-formed nests of nevomelanocytes are present in the junctional and compound nevi. Sheets and cords of nevocytes are present in the dermis of the compound and intradermal nevi. A grenz zone free of nevomelanocytes is present just below the epidermis in the intradermal nevus (**C** and **F**).

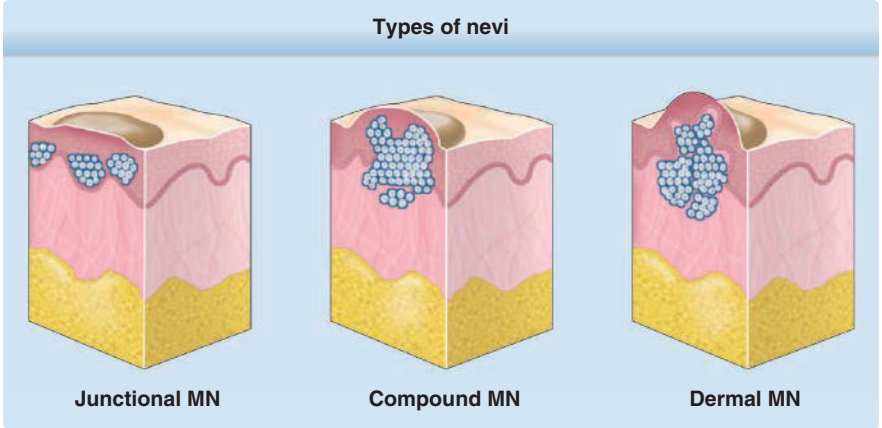

Figure 115-9 Types of nevi. MN, melanocytic nevi.

descent into the dermis (see Fig. 115-9), nevus cells become smaller and lose their pigmentation. Nevomelanocytes in the dermis have a monotonous similarity to one another within the same anatomic level and an overall symmetry of architecture from top to bottom and side to side.

Multinucleated nevomelanocytes occur occasionally within the superficial and mid-dermal portions of the nevus. Nevomelanocytes in the deep dermis may be disposed as spindle cells within a collagenous framework that is loose, pale, and wavy in formations similar to a neurofibroma or sometimes disposed in concentrically arranged whorls resembling Meissner tactile corpuscles. The term *neural nevus* is used when the vast majority of the nevus demonstrates a neural phenotype.

Sometimes dermal nevus cells aggregate around epithelial adnexal structures or lie as cords and strands in the superficial reticular dermis, making these "congenital pattern nevi" or "congenital-like nevi." Such histologic features are not limited to nevi that were present since birth.

Other findings identified in nevi include fibrous, mucinous, and fatty degeneration.

Inflammatory cellular infiltrates in typical, stable acquired nevi are usually scanty or absent. Melanin-laden macrophages are usually apparent in the superficial papillary dermis of nevi; their number usually proportional to the degree of melanin production. Asymmetry between the junctional and dermal elements, poor circumscription, and lamellar fibroplasia (features frequently seen in dysplastic nevi) are usually not prominent in common acquired nevi.

Histopathologic artifacts include shrinkage clefts, which may resemble lymphatics or vascular spaces, may be prominent in the midportion of nevi and in areas with hemorrhage. Separation of sheets of nevomelanocytes into parallel rows may be caused by improper cutting. Local anesthesia injection directly into the nevus also may be associated with artifactual changes.

The *balloon cell nevus* is a histopathologic variant of common acquired nevus, composed of peculiar foam cells comprising a portion or all of a given lesion. In addition to clear cells with a single central basophilic nucleus, multinucleated balloon cells may be seen. Electron microscopy suggests that vacuolization of nevomelanocytes in balloon cell nevi is a degenerative change, with melanosome swelling, microvacuole formation in nevus granules, and loss of particulate martrix.[47] In contrast to balloon cell melanoma, a maturation pattern is evident, and no cytologic atypia or significant mitotic activity is present.

The *combined nevus* refers to the intermingling of two different nevus types in one lesion. Most such lesions are composed of either an acquired or congenital nevus and blue nevus.

Recurrent melanocytic nevus is the name given to recurrent lesions after incomplete removal of a benign nevus. A markedly atypical clinical and histopathologic appearance may accompany this recurrence, making these lesions worrisome for possible melanoma. Clinically, the recurrent nevus is confined to the scar but may be markedly irregular in appearance. Recurrent nevi demonstrate melanocytic hyperplasia in a lentiginous and junctional pattern (often to a greater extent than the original nevus). Junctional melanocytes are frequently hyperpigmented and may display moderate cytologic atypia, significant architectural disorganization, and pagetoid growth, raising concern for melanoma. However, such features do not extend beyond the scar, and banal-appearing nevus cells may be seen within the underlying dermis. It is important to review the original histopathologic specimen to ensure that the findings can be solely attributed to nevus regeneration when making determinations for reexcision.

No distinguishing histopathologic features have been described for eruptive nevi.

In halo nevi, the usual histopathologic findings are a central nevus associated with an obscuring dermal lymphohistiocytic infiltrate and a surrounding depigmented zone totally or almost devoid of epidermal melanocytes. Immunohistochemical staining with melanocytic markers such as Melan-A or Sox-10 may help to identify residual epidermal melanocytes or residual dermal melanocytes obscured by the inflammatory infiltrate. Lymphocytes in halo nevi are mostly of the $CD8^+$ subset.

Normal-growing nevi in childhood and adolescence may show histologically alarming features, including more prominent epithelioid cell change of melanocytes and architectural variability of junctional melanocytic nests. Rare mitotic figures may also be evident.

Site-related changes also influence the histopathology of common acquired nevi. These are known as *special site nevi* because of their unconventional histopathologic appearances. Special site locations include the scalp, ear, nipple, abdominal milk line, umbilicus, anogenital region, and acral surfaces. At these locations, there is often more architectural variability of junctional nests, some of which may be larger and discohesive. Limited pagetoid scatter can be seen in the central portions of some lesions, particularly on acral surfaces or in areas with frequent friction. Anogenital nevi commonly share architectural features with dysplastic nevi, including lamellar fibroplasia, bridging of rete by junctional nests, and lymphocytic infiltrates.

Worrisome features for possible melanoma include pagetoid upward migration of cells in the epidermis, cytologic atypia of melanocytes (including irregularity of size and shape of cells and nuclear hyperchromasia), failure of the cells to "mature" in the deeper dermis, persistence of pigment production in the deep dermis, lack of symmetry, increased or deep dermal mitotic figures, focal areas of necrosis, and desmoplasia or fibroplasia.

SPECIAL TESTS

Special tests are not usually required in the gross and microscopic assessment of melanocytic or nevomelanocytic nevi. However, for patients who have eruptive nevi, given the association with immunosuppression, immunologic tests may be in order. Immunohistochemical profiles may be of value for difficult to diagnose lesions. Low Ki67 activity and loss of HMB45 in deeper dermal cells may help support a benign diagnosis. Compared with melanoma, common acquired nevi are genomically stable.[48] Fluorescence in situ hybridization (café-au-lait) or comparative genomic hybridization (CGH) analysis may be useful in discriminating a nevus from nevoid melanoma.

DIFFERENTIAL DIAGNOSIS

See Table 115-3.

TABLE 115-3
Differential Diagnosis of Common Acquired Nevomelanocytic Nevus

Pigmented Lesions
- Solar lentigo
- Lentigo simplex
- Café-au-lait macule
- Blue nevus
- Pigmented fibrous histiocytoma (dermatofibroma)
- Kaposi sarcoma
- Pigmented basal cell carcinoma
- Pigmented actinic keratoses
- Mastocytoma
- Seborrheic keratoses
- Epidermal nevus
- Subungual hematoma
- Supernumerary nipple
- Pigmented spindle cell nevus
- Spitz nevus
- Sclerosing hemangioma
- Pyogenic granuloma
- Dysplastic (atypical) melanocytic nevus
- Cutaneous melanoma
- Nonpigmented or pink lesion
- Basal cell carcinoma
- Fibrous papule
- Verruca vulgaris
- Molluscum contagiosum
- Dermal mucinosis
- Spitz nevus (epithelioid cell nevus)
- Appendageal tumors
- Clear cell acanthoma
- Large cell acanthoma
- Other lesions with halo phenomenon
- Congenital nevomelanocytic nevus
- Melanoma
- Histiocytoma
- Molluscum contagiosum
- Flat wart
- Acrochordon
- Basal cell epithelioma
- Neurofibroma
- Congenital dermal melanocytosis (mongolian spot)
- Blue nevus
- Lichen planus
- Sarcoidosis
- Psoriasis
- Angioma
- Angiokeratoma

CLINICAL COURSE AND PROGNOSIS

There may be relatively sudden changes in nevi that are unrelated to malignant transformation. Any single nevus that is noted to suddenly change or become symptomatic independently should be cause for concern. Causes of sudden changes in a nevus (color, surface, or size, with or without pain, itching, ulceration, or bleeding) over days or weeks include cystic dilation of a hair follicle, folliculitis, abscess, trauma, hemorrhage, and, in the case of a pedunculated nevus, strangulation and thrombosis. These benign causes of sudden change may require close observation for several weeks until resolution occurs or removal for histopathologic examination.

The vast majority of acquired nevi are harmless. New nevi may continue to appear and disappear throughout life, but most develop during childhood and early adulthood. New or growing nevi in older individuals are more worrisome. Melanoma risk

appears to be related to the number and size of nevi; patients with numerous nevi, dysplastic nevi, and a personal or family history of melanoma should be closely monitored with periodic surveillance examinations for life.

MANAGEMENT

TREATMENT

The vast majority of acquired common nevi require no treatment. Indications for removal of benign-appearing lesions may include cosmetic concerns or continual irritation. Lesions with worrisome clinical features need to be excised for histopathologic examination. Dermoscopy may be used to differentiate benign from potentially malignant features. Photographic surveillance can play a critical role in identifying change, or lack of change, in suspicious nevi.

Although a benign-appearing nevus associated with halo depigmentation does not require excision, it is reasonable to recommend periodic examination of affected individuals for dysplastic nevi, vitiligo, and melanoma. Atypical-appearing central nevi, presence of an asymmetric halo, eccentric placement of a melanocytic lesion within a halo, or in the setting of dysplastic nevi or melanoma (personal or family history) suggest the need for histopathologic examination for melanoma. Cover-ups or sunscreens should be recommended for sun-exposed areas of depigmentation to prevent acute burn, chronic actinic damage, and UVR-induced carcinogenesis.

Complete removal of nevi is best accomplished by excision. Leaving a partially excised nevus, regardless of the initial pathology, is fraught with potentially concerning consequences of repigmentation, regrowth, or both (see *recurrent melanocytic nevus*). Incisional biopsy is necessary at times, particularly for lesions that cannot be excised easily but require histopathologic diagnosis. Destructive modes of therapy (electrodesiccation, cryotherapy, dermabrasion, and laser) should be avoided. These destructive modes of therapy preclude histopathologic assessment of the treated nevi. They have the disadvantage of not providing tissue for histopathology. Although dermabrasion may eliminate pigmentation of nevi, residual nevomelanocytes in the dermis are to be expected, cosmetic outcome is often unpredictable, and recurrence with worrisome clinical features may complicate future management.

PREVENTION AND COUNSELING

There appears to be a direct relationship between the number of acquired nevi and sun exposure and a decrease with sunscreen use. Patients should be encouraged to minimize UVR overexposure without impeding day-to-day activities. Sensible UVR exposure includes confining outdoor activities to the early morning or late afternoon or evening and avoiding the most intense UVR exposure occurring 2 hours on either side of noon. Cover-up clothing that blocks light transmission should be worn during intense UVR exposure. Clothing is often easier to put on than sunscreen and does not rapidly wear off with swimming or sweating. Effective sunscreens should be used as part of a comprehensive sun-protection program. Vitamin D supplementation should be recommended for patients who diligently practice UVR avoidance and protection.

BLUE NEVUS

AT-A-GLANCE

- A group of lesions composed of deeply pigmented spindle or epithelioid melanocytes in the dermis; includes common blue, cellular blue, combined blue, and atypical cellular blue lesions
- Lesions appear as blue, blue-gray, or blue-black papules, nodules, or plaques.
- Lesions are generally acquired but may be congenital.
- Cellular blue nevi may have an elevated risk for development of melanoma.
- Related lesions include nevus of Ota/Ito, Mongolian spot, dermal dendritic hamartoma.
- Initiating mutations in *GNAQ* or *GNA11* are present in most blue nevi.

EPIDEMIOLOGY

Blue nevi are present in approximately 1% to 2% of white adults and in 3% to 5% of Japanese adults. Women are more often affected than men. The vast majority of blue nevi present in the second decade of life and are single, small, deep-blue macules or papules less than 1 cm in diameter. Common blue nevi arise most often in adolescence and cellular blue nevi before age 40 years. Congenital onset or those that appear in the first few years of life are less common.

CLINICAL FEATURES

The most frequent sites for blue nevi are on the dorsal hands and feet, scalp, and buttocks or sacral skin. The blue hue seen in many lesions comes from the *Tyndall effect*, the result of the refraction of light reflected from the nevus by the overlying dermis.

Blue nevi have been reported to rarely occur in the oral mucosa, uterine cervix, vagina, spermatic cord, prostate, and lymph nodes, and several clinical variants have been described: eruptive, plaquelike,

linear, agminate, disseminated, satellite, familial, and targetoid.[49]

CUTANEOUS FINDINGS

Most blue nevi are blue, blue-gray, or blue-black smooth surfaced papules or nodules (Fig. 115-10). Common blue nevi are deeply pigmented small lesions, usually less than 1 cm in diameter. Cellular blue nevi have a similar color but are often larger plaques or nodules greater than 1 cm.

Blue nevi tend to be firm, reflecting their dermal location and often fibrotic stroma. *Hypomelanotic blue nevus* is a rare variant in which not much melanin pigment is produced. The resultant lesions are flattish skin-colored firm papules or plaques.

Many group the dermal melanocytoses, conditions in which there are pigmented dendritic melanocytes, in the blue nevus family. Nevus of Ota and Ito share similar underlying defects to blue nevi and are also commonly acquired (in early childhood, often before age 1 year or around puberty) but are far more extensive, encompassing a portion of the trigeminal (ophthalmic and maxillary) and brachial (posterior supraclavicular and lateral cutaneous) nerve distributions, respectively. Dermal melanocyte hamartoma presents at birth as coalescing macules, resulting in diffuse blue-gray pigmentation. Mongolian spot is usually present at birth or within the first few weeks of life

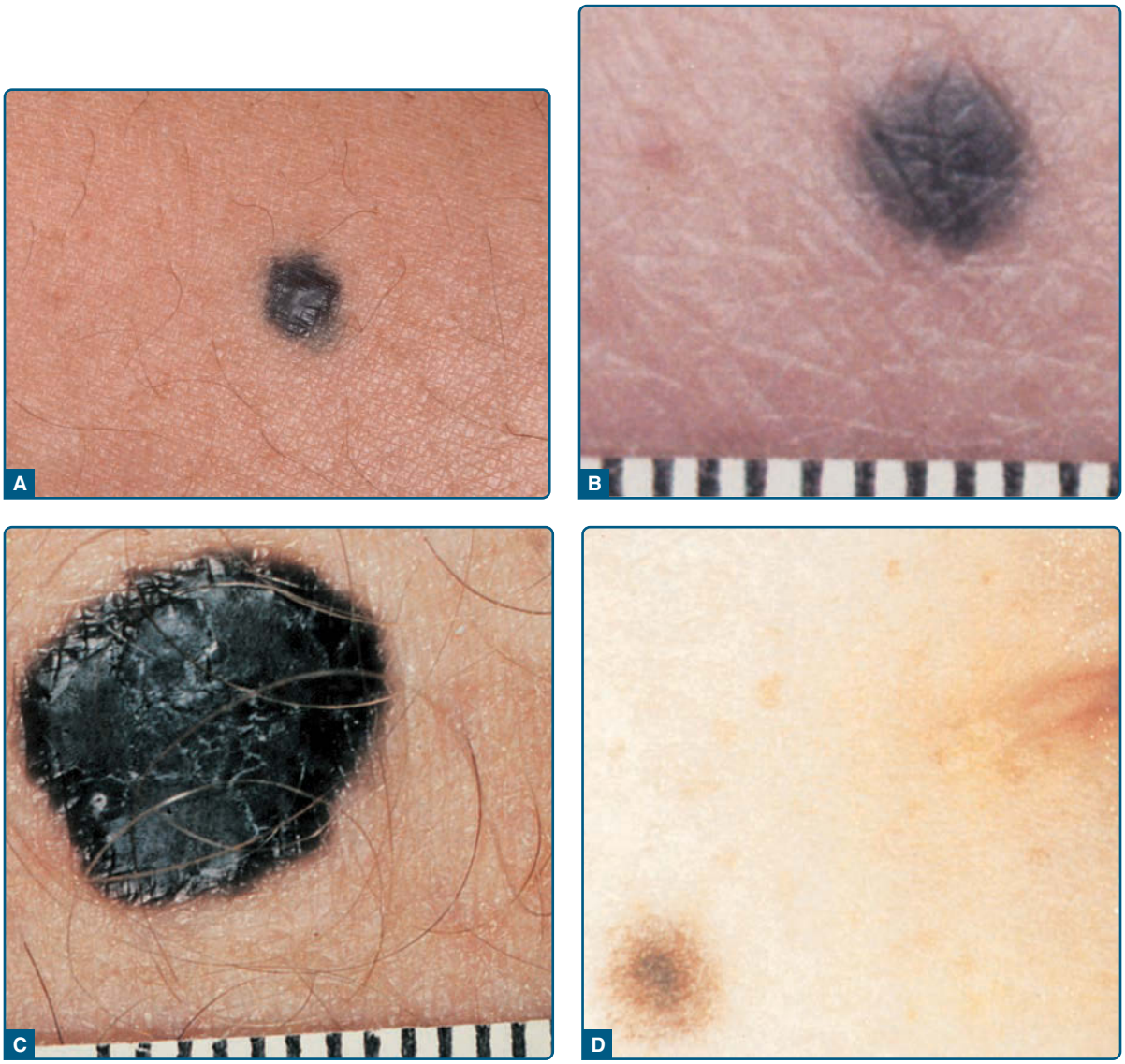

Figure 115-10 Blue nevus. **A,** Common blue nevus appearing as an acquired blue–gray papule on an adult male. **B,** Common blue nevus appearing as an acquired blue-gray papule on the buttock of a 62-year-old white man. **C,** Cellular blue nevus appearing as a congenital blue papule on the low back of a 30-year-old white man. **D,** Combined common blue nevus–nevomelanocytic nevus appearing as a brown papule with a blue-gray center on the cheek of a 12-year-old white boy, beginning as a pinpoint dot at age 1 year and enlarging slowly over time. Scale in millimeters. (Part A used with permission from Logical Images, Inc., Rochester, NY.)

and centered over the lumbosacral area. Mongolian spots typically regress in early childhood but may persist in approximately 10% of cases. Nevus of Ota/Ito typically persist into adulthood. Acquired adult variants of dermal melanocytosis rarely occur.

RELATED PHYSICAL CONDITIONS

Multiple blue nevi and epithelioid blue nevi may be associated with lentigines, cardiac myxoma, and mucocutaneous myxomas (Carney complex/LAMB syndrome [*l*entigines, *a*trial myxomas, *m*ucocutaneous myxomas, and *b*lue nevi]). Extensive dermal melanocytosis may be associated with phakomatosis pigmentovascularis.

COMPLICATIONS

Malignant blue nevus (melanoma) may arise de novo but more often arises in contiguity with a cellular blue nevus. Rarely, there is malignant transformation of a dermal melanocytosis.[50] This event may present as an expanding dermal or subcutaneous nodule with or without ulceration.

RISK FACTORS

Other than Carney complex/LAMB syndrome and phakomatosis pigmentovascularis, there are no known risk factors for blue nevi. The risk of UVR in the development of blue nevi is unknown.

ETIOLOGY AND PATHOGENESIS

Most blue nevi have initiating mutations in *GNAQ* and to a lesser extent *GNA11*. These mutations result in loss of GTPase activity and constitutive activation of the MAPK pathway, resulting in increased cellular proliferation. Although the frequency of these mutations varies among studies, mutation in the *GNAQ* gene has been identified in up to 87% of blue nevi, almost all of them in codon 209.[51]

The distribution of blue nevi is thought to parallel sites of colonization by active non-neoplastic pigmented bipolar dermal melanocytes during embryogenesis.[19] These cells typically migrate and disappear during embryonic life, but occasionally incidental pigmented dendritic cells can be seen in biopsies from the scalp, upper face, dorsal hands or feet, and sacrum.

GNAQ mutations have been reported in nevus of Ota,[52] and more recently mosaic activating mutations in *GNA11* and *GNAQ* were discovered in the pigmented lesions of phakomatosis pigmentovascularis with extensive dermal melanocytosis.[53] Thus, the molecular mutational profile of dermal melanocytoses appears to parallel that of blue nevi.

In contrast, neither *GNAQ* nor *GNA11* mutations have been documented in deep penetrating nevi; rather, *HRAS* mutations were seen in 6% of lesions in one study, implicating that these lesions may be more related to Spitz nevi.[51] Recently, deep penetrating nevi have been found to harbor activating mutations in both the MAPK and β-catenin pathways.[54] There is also a subgroup of lesions with mixed morphologic features of blue nevus and Spitz nevus. Evidence mounts that such "Blitz" nevi are best classified as blue melanocytic neoplasms because of their high frequency (57%) of *GNAQ* and *GNA11* mutations.[55]

Pigmented epithelioid melanocytoma is indistinguishable from epithelioid blue nevus of Carney complex. In the sporadic setting, it is considered an intermediate-grade melanocytic tumor that demonstrates a propensity to spread to regional lymph nodes but has a favorable long-term clinical course.[56] Those that occur in the setting of Carney complex behave in an entirely benign fashion. In both settings, such lesions are linked to mutations of protein kinase A regulatory subunit type 1 α (*PRKAR1α*) gene.[57] Protein kinase C alpha isoform (PRKCA) fusion genes have also been recently reported in pigmented epithelioid melanocytoma.[58]

DIAGNOSIS

The diagnosis of blue nevus is sometimes made clinically when a small, very dark or blue lesion is found in a typical location for a common blue nevus. For larger lesions and those in less typical locations, it is customary to confirm the diagnosis by biopsy.

PATHOLOGY

All types of blue nevus have components that include some of the following: deeply pigmented dendritic melanocytes, spindled and less pigmented melanocytes, oval melanocytes, melanophages, and fibrotic stroma (Fig. 115-11). Nevus cells may show perivascular or periadnexal accentuation. Almost all blue nevi lack a junctional component. Very occasionally, one can see single dendritic melanocytes in increased number along the DEJ (so-called compound blue nevus). Another exception is combined blue nevus, in which another form of nevus is contiguous and a junctional component occurs (eg, common or congenital nevus).

The stereotypic common blue nevus is an inverted dermal wedge-shaped mass in which pigmented dendritic melanocytes are admixed with melanophages within a fibrotic stroma.

The prototypical cellular blue nevus has vertically oriented dumbbell-shaped masses of melanocytes that protrude into the subcutis. The superficial dermis often contains a fibrotic stroma in which there are dendritic melanocytes and melanophages, but the definitional component is the presence of larger streaming aggregates of oval melanocytes. These cells usually have only scant melanin. Multinucleated melanocytes

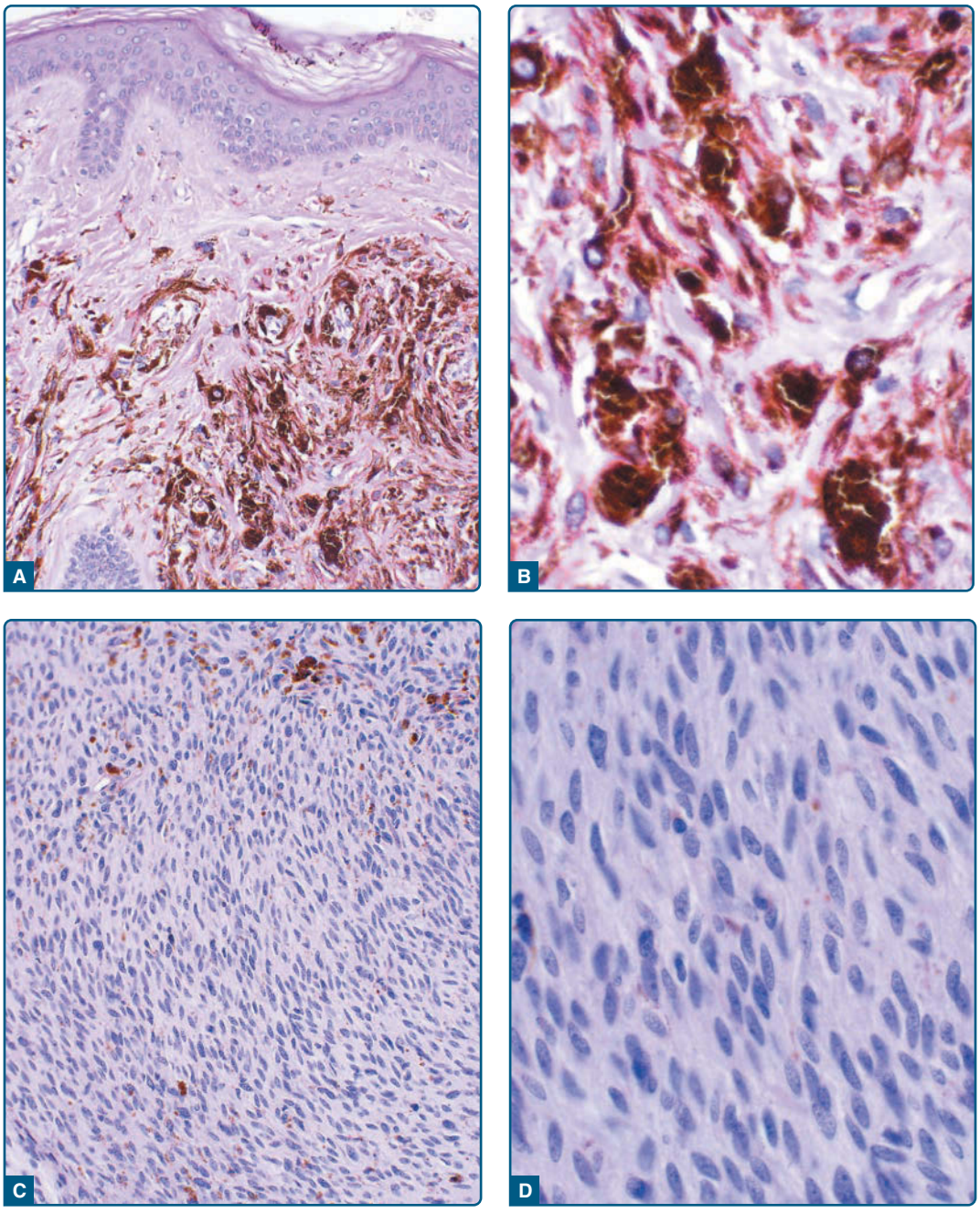

Figure 115-11 Histopathologic features of common and cellular blue nevi. Common blue nevus (**A**) and higher magnification of the dermal component (**B**) revealing heavily pigmented, elongated melanocytes. Cellular blue nevus (**C**) and higher magnification (**D**) revealing sheets of melanocytes with ovoid nuclei.

are sometimes present within aggregates. The presence of cells with large central nucleoli, more than a few mitotic figures per section, atypical mitotic figures, necrosis, or lymphocytic infiltrates evokes concern for melanoma.

Sparsely scattered mid and deep dermal dendritic melanocytes oriented parallel to the skin surface typify the dermal melanocytoses.

The cells of blue nevus are usually positive with S100 immunohistochemistry, stain strongly with Melan-A/Mart-1, and are positive for HMB-45. They have a low proliferation rate.

Deep penetrating nevi may clinically simulate a blue nevus but can be distinguished histopathologically. They are named for their tendency to extend through most of the thickness of the dermis, and some lesions reach the superficial subcutis. They are usually wedge shaped, with the apex sometimes surrounding a folliculosebaceous unit. They are composed of nests of large, oval melanocytes with abundant, pale vacuolated cytoplasm with dusty melanin and moderately enlarged nuclei. Mitoses are few, although two or three can occur in a single section. Combined deep penetrating nevi have a component of common

nevus or congenital-like nevus to the side, above, or both. The criteria for distinguishing deep penetrating nevi from intermediate-grade lesions, in which metastases are rare, and higher grade lesions are still being developed.

Benign epithelioid blue nevi of Carney complex are histologically indistinguishable from pigmented epithelioid melanocytoma, which occurs in the sporadic setting.[56] It is characterized by a mostly dermal nodular and sheetlike proliferation of enlarged epithelioid melanocytes with round nuclei, conspicuous nucleoli, and heavily pigmented cytoplasm. Numerous admixed melanophages are present. Some melanocytes show a spindled morphology, particularly at the periphery of the lesion. Occasional mitotic figures may be evident in some lesions. No morphologic criteria have been determined to reliably predict metastatic potential in sporadically occurring pigmented epithelioid melanocytoma.

SPECIAL TESTS

Imaging tests of the heart may be required if there is concern for Carney complex/myxoma syndrome/LAMB syndrome. Mutation analysis can be helpful diagnostically for distinguishing cellular blue nevi or atypical blue nevi from blue nevus–like melanoma.

DIFFERENTIAL DIAGNOSIS

See Table 115-4.

CLINICAL COURSE AND PROGNOSIS

Blue nevi are benign lesions, and their only adverse prognostic event is the development of melanoma within one. This more frequently occurs in cellular blue nevi. Melanomas associated with or mimicking cellular blue nevi have been demonstrated to have a propensity for the scalp and a high frequency of *GNA11* mutations with loss of BAP1 expression.[59]

TABLE 115-4
Differential Diagnosis of Blue Nevus

- Pigmented spindle cell nevus
- Tattoo (traumatic, radiation port marker)
- Primary or metastatic melanoma
- Glomus tumor
- Pyogenic granuloma
- Sclerosing hemangioma
- Dermatofibroma
- Ochronosis

MANAGEMENT

TREATMENT

Stable common blue nevi usually do not require therapy. However, clinical change of a blue nevus, such as sudden appearance of a new nodule, enlargement of an existing nevus, or a large or atypical clinical appearance should prompt histopathologic examination. Cellular blue nevi, particularly in adults, should be evaluated for excision because of the small risk of malignant transformation. Excision should include subcutaneous fat to ensure removal of the deeper melanocytic components that are often present in cellular blue nevi.

The prognosis for deep penetrating nevi is excellent, although there may be a very low conversion rate to deep penetrating-like melanoma for lesions that are not completely removed. What this rate is and how much higher it is than for other forms of nevus are unknown. Some dermatopathologists advocate complete removal of deep penetrating nevi, but others regard clinical removal as sufficient.

Pigmented epithelioid melanocytoma occurring in the sporadic setting are typically treated similar to melanoma, with wide excision and sentinel lymph node biopsy.

PREVENTION AND COUNSELING

There are no known preventative measures. As with other nevi, it is reasonable to minimize excessive UVR exposure.

PIGMENTED SPINDLE CELL NEVUS

AT-A-GLANCE

- Synonym: Reed nevus
- Acquired, benign melanocytic tumor composed of heavily pigmented spindle-shaped melanocytes in nests confined primarily to the epidermis
- Lesions are jet black often with "starburst" appearance on dermoscopy.
- They may develop quickly and then stabilize.
- Malignant degeneration is thought to be rare.

EPIDEMIOLOGY

The pigmented spindle cell nevus (PSCN) presents most commonly in the third decade of life. The mean age at presentation has been reported to be 25.3 years,

ranging from 2.5 to 56.0 years of age.[60] Similar age ranges have been reported in other studies.[61] Female patients outnumber male patients with reported ratios of up to 2:1.[60,62] The majority of these lesions are found on the extremities with reported frequencies of 67.0%,[60] 69.6%,[62] and 75.0%.[61] There is a preference for the lower extremity, particularly the thigh.[61]

CLINICAL FEATURES

PSCN was first described by Reed in 1975.[63] Many authors consider it a variant of Spitz nevus, but others define it as a distinct entity. At presentation, patients often note that the lesion has increased in size, prompting biopsy.[61,62] If allowed to fully develop, they are thought to generally remain stable over time.

CUTANEOUS FINDINGS

PSCN classically presents as a sharply circumscribed darkly pigmented papule, usually less than 7 mm in diameter. They are jet-black but may have shades of blue, gray, or brown (Fig. 115-12). Dermoscopically, most have streaks or pseudopods, giving the lesion a starburst appearance; others may have a globular pattern with reticular depigmentation.[64]

RELATED PHYSICAL CONDITIONS

There are no known associations.

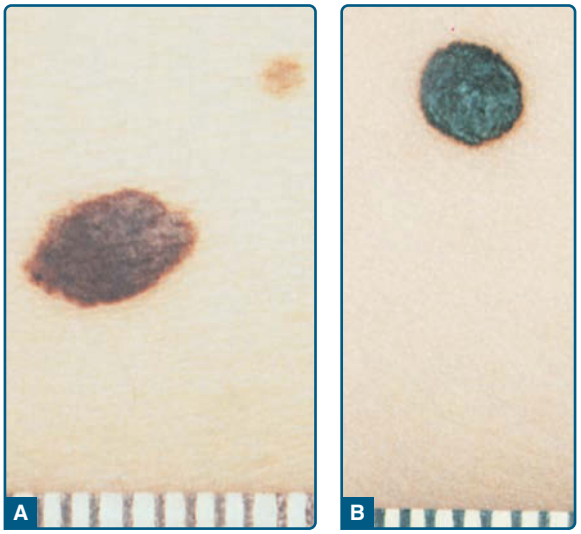

Figure 115-12 Pigmented spindle cell nevus. **A,** Very dark brown plaque appearing over several weeks on the posterior thigh of a 22-year-old white woman. **B,** Very dark-bluish plaque appearing de novo 3 months previously on the back of an 8-month-old white (Hispanic) boy. Scale in millimeters.

COMPLICATIONS

There are no reported complications, but misinterpretation as a melanoma may result in overtreatment.

RISK FACTORS

There are no known risk factors.

ETIOLOGY AND PATHOGENESIS

Although *BRAF* mutation and gene fusions have been detected, these changes are also present in other types of acquired and Spitz nevi, respectively. No known specific mutation has been identified for PSCN.

DIAGNOSIS

The diagnosis may be suspected given the clinical scenario and supportive dermoscopic features. However, the diagnosis should be confirmed by biopsy.

PATHOLOGY

The PSCN is a sharply circumscribed lesion composed of fascicles of uniform pigment-synthesizing melanocytes with spindled appearance along the junction and to a lesser extent the superficial dermis (Fig. 115-13). Melanocytes have uniform nuclei and small nucleoli. Occasionally, there is an admixture of epithelioid appearing cells. Pagetoid cells may be seen but are usually limited to the central portion of the nevus. Extension of the spindle cells along skin adnexal structures is relatively common. There are invariably pigment-laden macrophages in the papillary dermis with a mild perivascular infiltrate of lymphocytes. Atypical variants of PSCN exist in which there are architectural alterations and striking cellular atypia, raising a differential diagnosis of melanoma.[62]

SPECIAL TESTS

In cases with atypical histologic features, immunohistochemical markers (Ki-67, cyclin-D1, survivin) and FISH have shown utility in distinguishing PSCN from melanoma.[65]

DIFFERENTIAL DIAGNOSIS

See Table 115-5.

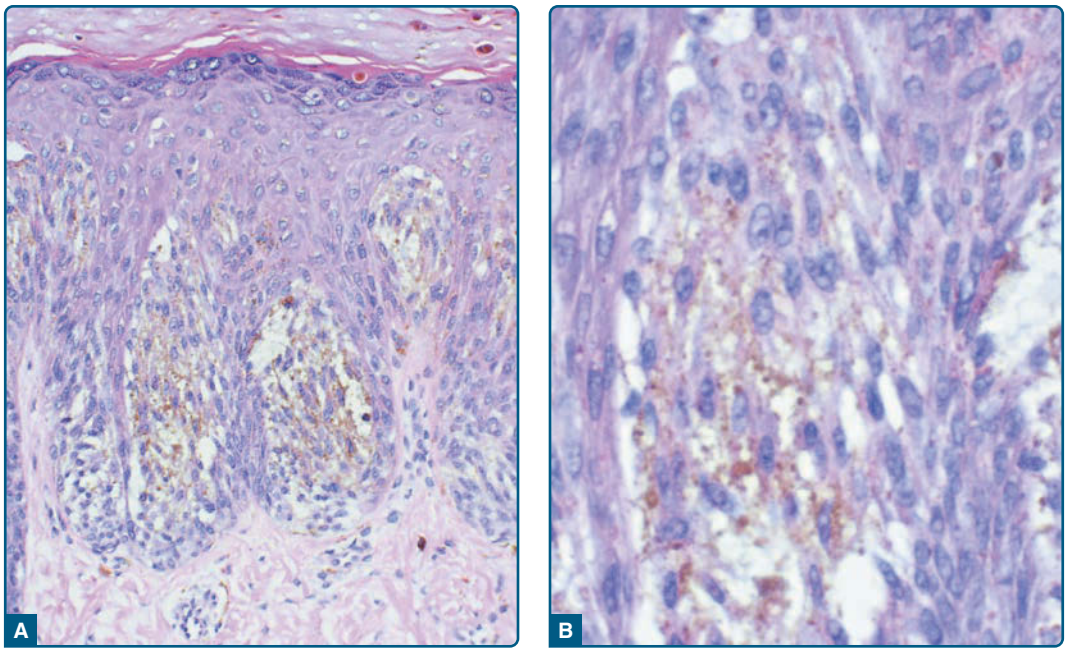

Figure 115-13 Histopathologic features of pigmented spindle cell nevus (**A**) and higher magnification of the intraepidermal component (**B**) revealing pigmented spindle-shaped cells.

CLINICAL COURSE AND PROGNOSIS

PSCN is considered benign. No local recurrence or distant spread was noted for 38 patients followed for an average of 14 months.[60] In another study, 57 patients were followed for an average of 6 years, and again no local recurrence or metastasis was noted.[61]

MANAGEMENT

TREATMENT

Given the difficulties in the histopathologic differentiation from melanoma in some cases, these lesions should be considered for excision to attain histologically free margins.

TABLE 115-5
Differential Diagnosis of Pigmented Spindle Cell Nevus

- Spitz tumor
- Blue nevus
- Hematoma
- Dysplastic junctional nevus
- Hypermelanotic nevomelanocytic nevus
- Combined nevomelanocytic/blue nevus
- Melanoma

PREVENTION AND COUNSELING

There are no known preventative measures. The role of UVR exposure in the development of PSCN is unknown.

SPITZ NEVUS

AT-A-GLANCE

- Spitz nevi represent a spectrum of unique, usually acquired lesions, exhibiting epithelioid and often spindle-shaped melanocytic cells with abundant eosinophilic cytoplasm, large nuclei, and often prominent nucleoli. The often develop in the epidermis and dermis or may be purely intradermal and even desmoplastic. Atypical variants exist.
- Clinically, they often present as red, dome-shaped papules. Some have varying degrees of pigmentation.
- Spitz nevi are thought to develop quickly and then stabilize. Their clinical presentation and histopathology can cause diagnostic confusion for melanoma.
- Synonyms: spindle and epithelioid cell nevus

EPIDEMIOLOGY

The annual incidence rate of Spitz nevi is approximately 1.4 to 1.6 cases per 100,000 individuals.[66] In a

series reported by Weedon and Little, 70% of 211 Spitz nevi occurred in patients younger than 20 years of age.[67] This higher pediatric prevalence of Spitz nevi is confirmed in most large epidemiologic studies. There appears to be no gender predilection for Spitz nevi in children. Whites are more commonly affected than other ethnicities.

CLINICAL FEATURES

Spitz nevi typically begin with an initial phase of growth, with either gradual or relatively rapid enlargement followed by a stable quiescent period. The presence of a new or growing lesion in the pediatric population often prompts tissue biopsy.

CUTANEOUS FINDINGS

The most common variety of Spitz nevus is solitary, asymptomatic, pink or red, hairless, firm, and dome shaped (Fig. 115-14). Some Spitz nevi may resemble a keloid or pyogenic granuloma when eroded. The surface is commonly smooth, and the borders may fade into surrounding skin. Verrucous, scaly, stippled, and crusted lesions may occur. Spitz nevi are usually asymptomatic, but pruritus, tenderness, or bleeding is sometimes noted. The halo phenomenon may occur in Spitz nevi as they do in common acquired nevi.

Spitz nevi can also present as widespread eruptive lesions or in a grouped manner as multiple agminated lesions consisting of red, red-brown, brown, or dark-brown papules or nodules, with a fine stippled surface. Agminated Spitz nevi often occur in the early years of life within a background of congenital (sometimes acquired) macular pigmentation (nevus spilus) or occasionally within a hypopigmented plaque. Spitz nevi may also develop as single or multiple lesions in a large CMN.

The diameter of Spitz nevi ranges from several millimeters to several centimeters. They have a predilection for the head and neck and extremities, although truncal lesions are not uncommon. Spitz nevi tend to spare the palms, soles, and mucous membranes.

RELATED PHYSICAL FINDINGS

Multiple epithelioid Spitz nevi with loss of BAP-1 expression may occur as part of a familial cancer syndrome.[68,69]

COMPLICATIONS

Misinterpretation of benign or malignant behavior of the lesion could result in unnecessary or insufficient treatment, respectively. Spitz nevi rarely acquire more mutational aberrations over time and thus may attain metastatic (atypical Spitz tumor) or malignant potential (Spitzoid melanoma).

ETIOLOGY AND PATHOGENESIS

Unlike common acquired nevi, congenital nevi, and melanoma, which frequently harbor *BRAF* or *NRAS* mutations, Spitz tumors often either harbor *HRAS* mutations or demonstrate genomic rearrangements involving kinase genes (*ALK, ROS1, NTRK1, BRAF, RET, MET*).[70] The combination of *BAP1* loss and *BRAF* mutation has been shown to be characteristic of a subset of atypical Spitz tumors that display distinct histopathologic features.[69] Such lesions often occur sporadically via somatic mutation, although a subset of *BAP1*-deficient melanocytic neoplasms arises in the setting of a familial germline mutation, resulting in *BAP1*-associated cancer susceptibility syndrome. Affected individuals are at increased risk for cutaneous and uveal melanoma, mesothelioma,

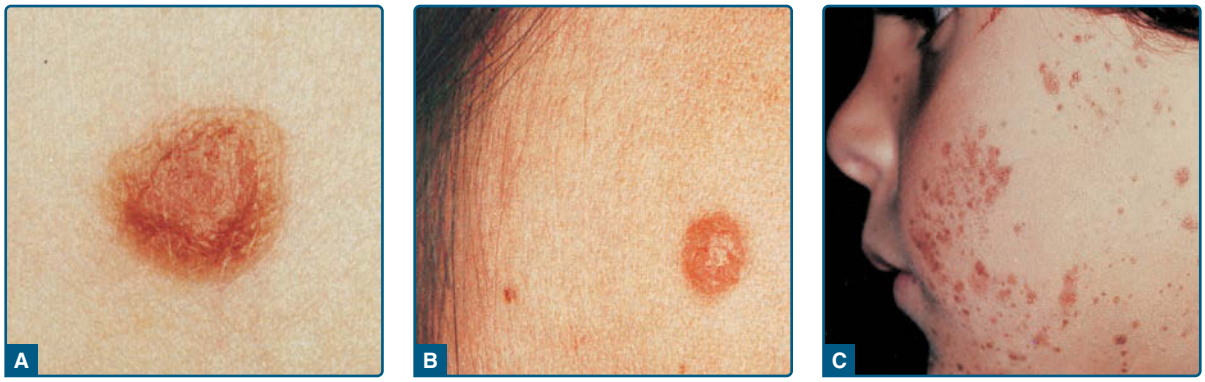

Figure 115-14 Spitz nevi. **A,** Pink plaque, which appeared de novo over an 8-week period, becoming more elevated with time, in the preauricular area of a 4-year-old white boy. **B,** Dome-shaped pink papule, which appeared de novo over a 2-week interval 4 months before, on the forehead of a 5-year-old white boy. **C,** Agminated Spitz tumors. Numerous grouped pink papules and plaques, appearing at age 6 months, on the face of a 4-year-old white boy.

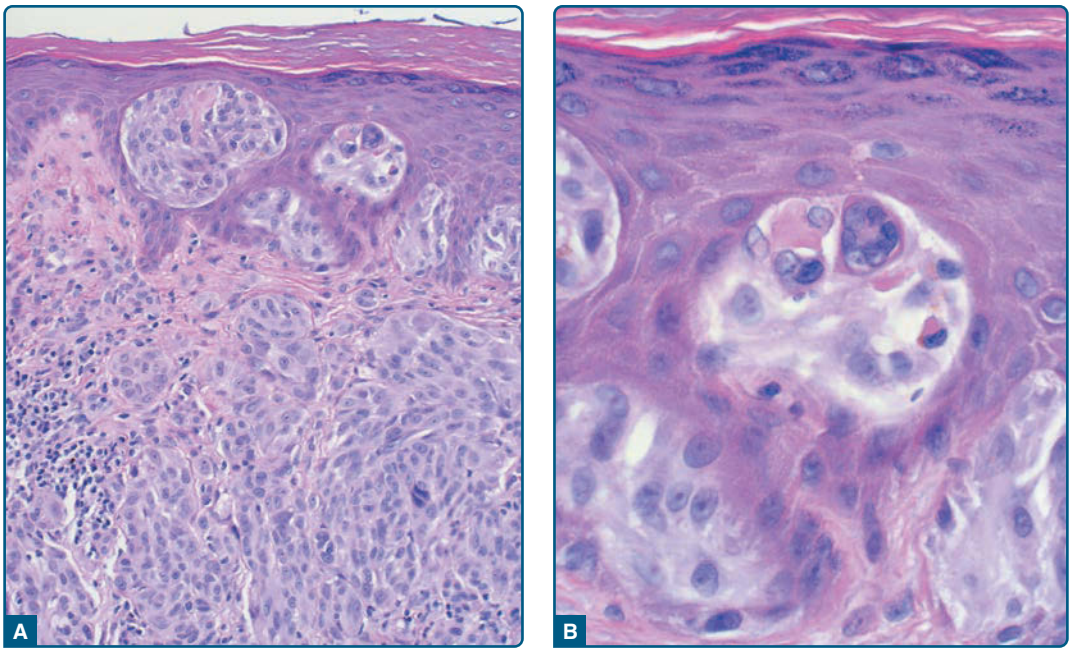

Figure 115-15 Histopathologic features of Spitz tumor (**A**) and higher magnification of the intraepidermal component revealing eosinophilic globules (Kamino bodies) adjacent to junctional nests (**B**).

renal cell carcinoma, cholangiocarcinoma, and other malignancies.[71]

DIAGNOSIS

PATHOLOGY

Spitz nevi are characterized by melanocytic cells with large epithelioid nuclei, often with prominent nucleoli and surrounded by a rim of eosinophilic cytoplasm with "ground-glass" appearance (Fig. 115-15). These lesions are well-circumscribed and symmetric from side to side and from top to bottom. In contrast to melanoma, the melanocytic cells in Spitz nevi show progressive maturation with increasing depth, becoming smaller with the overall distribution of cells in the dermis being wedge shaped, with narrowing of the wedge toward the subcutaneous fat. Purely junctional and dermal lesions also occur.

When there is a junctional component, there is often epidermal hyperplasia. Small intraepidermal eosinophilic globules (Kamino bodies), which are positive for periodic acid–Schiff and diastase resistant (resembling colloid bodies), may be seen. Melanocytic elements are usually well nested, although there may be permeation of the epidermis by single cells or small groups of cells. Pagetoid cells are more commonly encountered in the center of the lesion. There are often artifactual clefts between melanocytic nests and the epidermis. Ovoid junctional nests often show vertical streaming of the constituent cells.

In most cases, dermal inflammation is mild and confined to a sparse perivascular lymphocytic infiltrate. However, more intense infiltrates including a halo may occur. Atypical features including nuclear pleomorphism, increased or atypical or deep mitoses, asymmetry, and lack of maturation should raise concern for an atypical Spitz tumor or melanoma.

SPECIAL TESTING

Immunohistochemical studies may be helpful when the differential diagnosis includes Spitzoid melanoma. In most Spitz nevi, there is full or partial retention of p16 staining, but Spitzoid melanomas tend to lose p16 expression. Ki-67 proliferation marker is low in nevi but elevated in melanoma. In difficult cases, CGH or FISH studies may help better define the biologic potential of a given lesion.

DIFFERENTIAL DIAGNOSIS

See Table 115-6.

CLINICAL COURSE AND PROGNOSIS

The natural history of the Spitz nevus is that most have an initial growth phase and then remain stable over time. However, a small subset may show atypical

TABLE 115-6
Differential Diagnosis of Spitz Nevi

Nonpigmented or Red
- Amelanotic melanoma
- Juvenile xanthogranuloma
- Hemangioma
- Pyogenic granuloma
- Molluscum contagiosum
- Intradermal nevus
- Solitary mastocytoma
- Granuloma
- Clear cell acanthoma
- Insect bite reaction
- Dermatofibroma
- Appendageal tumor
- Keloid

Pigmented
- Blue nevus
- Deep penetrating nevus
- Hypermelanotic intradermal nevus
- Melanoma
- Hematoma

Warty Variants
- Verruca vulgaris
- Seborrheic keratoses
- Epidermal nevus
- Epidermolytic acanthoma

histopathologic features corresponding with accrual of additional genomic aberrations (atypical Spitz tumor or Spitzoid melanoma). Spitz tumors in the adult population should be viewed with suspicion, particularly if they are new or changing.

MANAGEMENT

TREATMENT

Complete excision with histologically clear margins is generally sufficient treatment for benign Spitz nevi. Given the difficulty of confidently excluding the possibility of melanoma in certain cases, such as those with atypical histopathologic features, an even wider margin of normal skin may be prudent for worrisome lesions. The role of sentinel lymph node biopsies for atypical Spitz tumors is controversial because tumor cells may be present in the regional lymph nodes but not have the biologic significance or poor prognosis associated with metastatic melanoma. Management of patients who have numerous Spitz nevi requires individual judgment and periodic surveillance for new or unstable lesions.

PREVENTION

There are no known preventative measures for the development of Spitz nevus.

NODAL NEVI

AT-A-GLANCE

- Benign melanocytic neoplasia present in a lymph node. Nevomelanocytes are characteristically located in the capsule.
- They are generally asymptomatic and found incidentally as a result of lymph node removal.
- Cells may be deposited passively into the node from a cutaneous melanocytic lesion. It is also possible that abnormal migration pathways result in the nevomelanocytes taking up residence in lymph nodes during embryonic development.
- The presence of melanocytic cells in nodal tissue may create difficulties for pathologists evaluating sentinel node biopsies in patients with cutaneous melanoma.

EPIDEMIOLOGY

Nevomelanocytes can be identified in lymph nodes with a frequency ranging from 0.3% to 7.3% in lymphadenectomies not related to melanoma and up to 22% in regional nodes removed because of melanoma.[72] A significant association has also been noted for the presence of cutaneous nevomelanocytic nevi in the zones of skin drained by lymph nodes that were found to include nevomelanocytes.[73] This association was strongest with congenital nevi. In most cases, nodal nevomelanocytes phenotypically resemble common acquired nevomelanocytic nevi, but nevi with congenital features, blue nevi, cellular blue, and Spitz nevi have all also been reported to involve regional lymph nodes.[74]

CLINICAL FEATURES

HISTORY

Generally, nodal nevi are identified in lymph nodes that are removed for other reasons, usually melanoma or breast cancer, but these benign cells are also identified in nodes removed for other reasons. Patients do not note symptoms related to nodal nevi.

CUTANEOUS FINDINGS

Melanocytic neoplasia in the form of melanoma or melanocytic nevi may be present at the cutaneous site corresponding to the draining lymph node basin.

RELATED PHYSICAL FINDINGS

Lymph nodes harboring benign nodal nevi are most commonly seen in patients undergoing lymphadenectomy for melanoma but are also seen in lymphadenectomy specimens for breast carcinoma and other causes.

COMPLICATIONS

Complications, such as scarring or lymphedema, may be the consequence of lymphadenectomy. Misinterpretation of benign nodal deposits as malignant could result in unnecessary regional lymph node dissection and treatment with systemic agents. Misinterpretation of malignant melanocytes as benign in lymph nodes may lead to under treatment.

ETIOLOGY AND PATHOGENESIS

There are two prevailing theories as to the mechanism by which nevomelanocytes appear in regional lymph nodes.

The first theory is that during development, melanoblasts get trapped in developing nodal tissues. Some support for this theory could be based on the fact that nodal nevi can be found in association with CMN. This observation suggests that there is an opportunity for nevomelanocytes to be deposited during development. Furthermore, blue nevus cells can be found in tissues such as prostate, cervix, vagina, spermatic cord, and seminal vesicles.[74] Thus, aberrant migration and differentiation of melanocytic cells does occur.

The second theory suggests that there may be passive transfer from the cutaneous lesion to the lymph node. Substances such as carbon, tattoo ink, and radioactive colloid are readily transferred to the draining lymph node. It is reasonable to assume that loosely adherent nevomelanocytes could also traverse the same path. In fact, nevomelanocytes have been noted in lymph channels.[74] In the lymph node, nevomelanocytes are generally identified in the capsule, but they can also be found in the parenchyma.[72] It is not known how nevomelanocytes get into the capsule, but it is reasonable to assume that these cells migrate from the parenchyma into the capsule. It is important to note that melanoma cells can also be found in the capsule, so it is rational to assume that entry into the capsule is not limited to a developmental event. The fact that nevomelanocytes in regional lymph nodes are highly correlated with the presence of nevomelanocytic nevi in the skin supports the concept that these cells may arrive in lymph nodes via dissemination from benign cutaneous lesions.[75]

TABLE 115-7
Differential Diagnosis of Nodal Nevi

- Melanoma
- Cells from another neoplastic source
- Foreign body deposit (tattoo ink, carbon)

DIAGNOSIS

PATHOLOGY

Pathology often reveals nevomelanocytes largely confined to the nodal capsule or trabeculae. However, cells may also be noted in the parenchyma. Nodal nevi should lack cellular atypia and mitotic activity.

SPECIAL TESTING

The use of standard immunohistochemical tests may help identify the location and cellular features of nevomelanocytes in lymph node tissue sections. Weak or negative staining for HMB-45, lack of proliferative markers (Ki67), and strong p16 expression support a benign diagnosis.[76,77] A recent study determined that fatty acid synthase and acetyl-CoA carboxylase are not expressed in intracapular nodal nevi but are expressed in metastatic melanoma.[78]

DIFFERENTIAL DIAGNOSIS

See Table 115-7.

CLINICAL COURSE AND PROGNOSIS

If the lymph node deposits are determined to be benign, no further treatment is warranted.

TREATMENT

None required for benign nodal nevi.

LENTIGO SIMPLEX

AT-A-GLANCE

- Clinically, lesions are hyperpigmented macules, occurring alone, in focal clusters (agminated), or have a generalized distribution. They occur on the skin, conjunctivae and mucous membranes.

(Continued)

AT-A-GLANCE (*Continued*)

- They commonly develop in early childhood.
- Multiple lentigines may be associated with somatic abnormalities.
- Synonyms: simple lentigo, melanotic macule, lentiginosis. Other names for agminated lentigines include unilateral lentigines, partial unilateral lentiginosis, lentiginous mosaicism, and segmental lentiginosis.
- Other lesions in which epidermal melanocytic hyperplasia may be noted, where overlap may exist with simple lentigines, include café-au-lait macules, melanoacanthoma, labial melanotic macule, melasma, and inflammatory/cytokine-induced proliferation.

EPIDEMIOLOGY

Lentigo simplex is a very common melanocytic lesion, present either at birth or developing later in childhood or adulthood. Although acral lentigo is more prevalent in blacks, lentigo simplex does not have a racial or gender predilection. The incidence of agminated and generalized lentiginosis is rare.

CLINICAL FEATURES

Lentigo simplex occurs on the skin, conjunctivae, and mucocutaneous surfaces. They may develop as early as the first decade of life (juvenile lentigo) and arise on both sun-exposed and sun-protected sites. Lentigines may develop in a unilateral, agminated (partial or segmental lentigines), or generalized distribution (lentigines profuse) and may occur as an isolated phenomenon or in associated with a number of inherited disorders, including LEOPARD (lentigines, electrocardiographic conduction abnormalities, ocular hypertelorism, pulmonary valve stenosis, abnormalities of genitalia, growth retardation, and sensorineural deafness) syndrome, Carney syndrome, Peutz-Jeghers syndrome, Laugier-Hunziker syndrome (idiopathic lenticular mucocutaneous pigmentation), and centrofacial lentiginosis.

CUTANEOUS FINDINGS

Lentigo simplex are usually sharply circumscribed macules, measuring 1 to 5 mm in size, with uniform light brown to black pigmentation. If partial or generalized lentiginosis is present, the specific pattern and clinical course of lesions may be suggestive of a specific inherited syndrome.

In LEOPARD syndrome, lentigines are often absent during the first years of life; patients subsequently may develop hundreds of lentigines during childhood, including on the genitalia, conjunctiva, oral cavity, palms, and soles.

In Peutz-Jeghers syndrome, lentigines are commonly present on the buccal mucosa, lips, perioral skin, and ventral surfaces of the hands and feet. Although cutaneous lesions may fade at puberty, oral lentigines usually persist into adulthood.

In centrofacial lentiginosis, lentigines are characteristically distributed in a horizontal band across the face.

In Laugier-Hunziker syndrome, lentigines predominantly occur on the lips, hard and soft palates, fingers, nail matrix and palms, and infrequently at other sites, including conjunctivae and genitalia.

In LAMB (lentigines, atrial myxoma, mucocutaneous myxomas and blue nevi) syndrome, lentigines mainly occur on the face, trunk, and genitalia as tan to black macules (Fig. 115-16).

Agminated lentigines are congenital or develop shortly after birth and often are confined to a localized area of the skin, often in a segmental distribution and frequently demonstrate a curvilinear or swirled pattern (Fig. 115-17).

Figure 115-16 Lentigo simplex. **A,** Acquired darkly pigmented lentigines on the vulva of a 13-year-old white girl who has *l*entigines, *a*trial myxomas, *m*ucocutaneous myxomas, and *b*lue nevi (LAMB, myxoma syndrome, Carney complex). **B,** Multiple lentigines on the lips of the same patient. This patient died in her mid-20s of a malignant schwannoma.

Figure 115-17 Agminated lentigines. **A,** Grouping of small light brown macules, present since age 14 years, on the right side of the shaft and glans penis of a 17-year-old healthy white male patient. **B,** Grouping of small, light brown macules, present for at least 6 years, on the right cheek of a healthy 10-year-old African American male patient. **C,** Grouping of small, light-brown macules, present since age 2 years, on the right neck and supraclavicular area of a 13-year-old healthy white female patient.

RELATED PHYSICAL FINDINGS

In addition to several inherited syndromes, lentigines may be associated with Addison disease; topical immunosuppressive calcineurin inhibitors, such as tacrolimus; and type 1 hereditary punctate palmoplantar keratoderma.[79,80] Eruptive acral lentigines have been reported with synchronous malignancies, including gastric adenocarcinoma, mammary carcinoma, large-cell lymphoma, non-Hogkin lymphoma, melanoma, and AIDS.[81-84]

COMPLICATIONS

Complications may arise from associated syndromes; however, lentigines are benign without any direct complications.

ETIOLOGY AND PATHOGENESIS

The mechanisms underlying lentigo simplex formation are not well understood. An increased density of melanocytes suggests that melanocyte homeostasis is disrupted in lentigo simplex. Additionally, the presence of melanin macroglobules in melanocytes suggests that melanization is dysregulated and may contribute to the formation of lentigines. The presence of lentigines in association with various inherited syndromes underscores the likelihood that lentigo development may be influenced by a variety of different genetic and developmental factors.

Interestingly, lentigo simplex does not harbor characteristic mutations found in solar lentigo, psoralen UVA (PUVA) lentigines, and common acquired nevi. In a study by Hafner and coworkers, lentiginous junctional nevi, compound, and intradermal nevi harbored *BRAF*^{V600E} mutations in 17%, 55%, and 78% of cases, respectively, but lentigo simplex was shown to lack *BRAF*^{V600E} mutation.[85] Likewise, lentigo simplex lacks *FGFR3* and *PIK3CA* mutations, which are frequently present in solar lentigo and PUVA lentigines.[85,86]

DIAGNOSIS

PATHOLOGY

Histologic sections of lentigo simplex show slight to moderate elongation of rete ridges, basilar melanocytic hyperplasia, and increased pigmentation within the epidermis and melanophages in the papillary dermis. Melanocytes lack atypia. Rarely, giant pigment granules (melanin macroglobules) may be present. Frequently, a lymphohistiocytic infiltrate is present within the superficial dermis. Commonly, a junctional nevus and lentigo may coexist (lentiginous junctional nevus). Solar lentigo characteristically shows greater elongation of rete ridges and prominent solar elastosis with the papillary dermis.

LABORATORY TESTING

Immunohistochemistry to highlight melanocyte density with the epidermis (MITF, Mart-1, Sox10) is typically not necessary for histologic diagnosis.

DIFFERENTIAL DIAGNOSIS

See Table 115-8.

TABLE 115-8
Differential Diagnosis of Lentigo Simplex

Solitary
- Solar lentigo
- Ephelis
- Junctional nevomelanocytic nevus
- Dysplastic (atypical) melanocytic nevus
- Café-au-lait macule
- Melanoma (lentigo maligna)

Grouped
- Agminated nevomelanocytic nevi or lentigines
- Nevus spilus

CLINICAL COURSE AND PROGNOSIS

Generally, when present, lentigo simplex are relatively stable. During pregnancy, lentigines may become more conspicuous. There is not an association with progression to nevomelanocytic nevus or increased risk of malignant transformation to melanoma.

MANAGEMENT

TREATMENT

Treatment is not necessary for lentigo simplex. Cosmetic removal has been completed with cryotherapy or other approaches, including Q-switched laser.

PREVENTION

There are no known preventive measures for lentigo simplex. Avoidance of sun exposure and UVR does not reduce the risk of development of lentigo simplex.

SOLAR LENTIGO

AT-A-GLANCE

- Solar lentigines are hyperpigmented macules that occur on photodamaged skin, singly or as multiple lesions.
- They predominantly develop in older individuals. Children with xeroderma pigmentosum develop solar lentigines during the first year of life because of increased susceptibility to UV radiation.
- Histology shows elongation of rete ridges with budlike processes, hyperpigmentation, normal or slightly increased melanocytes, and dermal solar elastosis.
- Solar lentigines are benign. Development is associated with increased risk of UV-related cutaneous malignancies, including squamous cell carcinoma, basal cell carcinoma, and melanoma.
- Synonyms: actinic lentigo, sun-induced freckle, liver spot, lentigo senilis, senile lentigo

EPIDEMIOLOGY

The prevalence of solar lentigines is strongly associated with older age and photodamage. They mainly arise on sun-exposed skin of those with white skin and Asians. More than 90% of those with white skin develop a solar lentigo by the age of 50 years.[87] Multiple lentigines on the face appear to be associated with dark skin (types III and IV).[88,89] In addition to age and sun exposure, they are associated with history of facial ephelides (freckles), tanning capacity, and concurrent use of oral contraceptive therapy.[88]

Chronic psoralen photochemotherapy may induce lentigines, termed PUVA lentigines. A study of 1380 adults undergoing PUVA treatment for psoriasis observed buttock lentigines in 53% of patients, arising an average of 5.7 years after initiating treatment (Fig. 115-18).[90] PUVA lentigines are associated with total number of treatments, male gender, fair-skin, and older age.[90] Additionally, lentigines are associated with UVA exposure from artificial sunbed use.[91]

CLINICAL FEATURES

Solar lentigines are acquired hyperpigmented lesions that generally arise on sun-exposed sites on light-skinned individuals. They most commonly occur on the face and dorsal surfaces of the forearm and hand.

CUTANEOUS FINDINGS

Solar lentigines arise on skin exposed to natural sunlight or artificial sources of UV radiation. They have well-defined, irregular borders, with a tendency to coalesce at sites of severe sun damage where multiple lesions may be present (Fig. 115-19). They range in size from less than 1 mm to several centimeters in greatest dimension. Lesions are light to dark brown in color. Ink spot lentigo (reticulated black solar lentigo) is a variant with black pigmentation.

Unlike solar lentigo, PUVA lentigines commonly develop on sun-protected sites, including the buttocks and genitalia (see Fig. 115-18), in addition to sun-exposed areas. They often have brown-black pigmentation and are irregular.

An ephelis (freckle) is a small, uniformly pigmented macule that may be clinically distinct from a solar lentigo. Freckles are most common on the central face. Typically, they develop in early childhood, increase

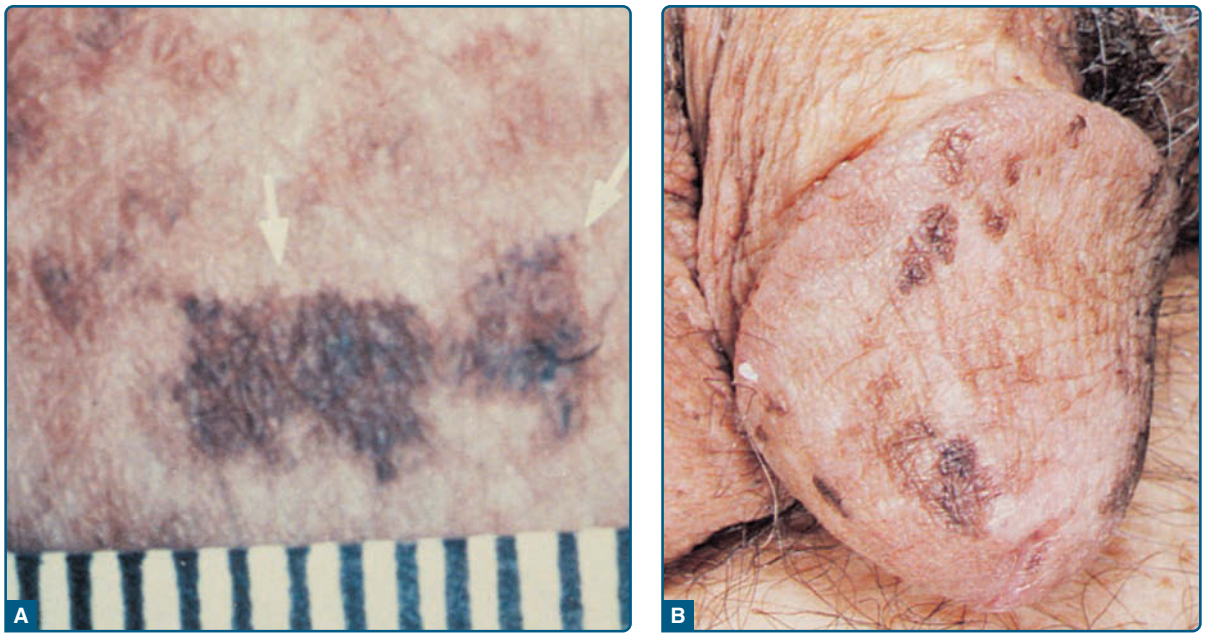

Figure 115-18 Photochemotherapy (psoralen and ultraviolet A light [PUVA])-induced lentigines (*arrow*) on the buttock (**A**) and penis (**B**) of a 57-year-old white man who had received PUVA for psoriasis several times per week for 5 years. The PUVA lentigines appeared between 1 and 2 years after PUVA therapy was begun. The current recommendation is to shield the male genitalia during PUVA therapy to prevent squamous cell carcinoma of the penis and scrotum.

in adulthood, and may regress in the elderly or in the absence of continued sun-exposure.

RELATED PHYSICAL FINDINGS

Given that solar lentigines occur on photodamaged skin, they are associated with actinic keratosis, squamous cell carcinoma, basal cell carcinoma, and melanoma. Type 2 diabetes has been shown to be independently associated with solar lentigo.[92]

COMPLICATIONS

Although solar lentigines may sometimes show melanocytic atypia on sun-damaged skin, they are benign. However, in lesions where significant atypia is present, distinction between atypical solar lentigo and melanoma in situ, lentigo maligna type may be challenging.

ETIOLOGY AND PATHOGENESIS

Solar lentigines arise from proliferation of basal melanocytes and increased melanin production. The relationship between UVR and development of lentigines is well-recognized. The cumulative effects of photodamage produce genetic and epigenetic changes in gene expression within both keratinocytes and melanocytes. Interestingly, keratinocytes are more sensitive to UVR than melanocytes.[93,94]

In response to UVR exposure, keratinocytes upregulate multiple ligands and produce reactive oxygen species (ROS), ultimately leading to MC1R and subsequently MITF activation in melanocytes through direct cell-to-cell communication and paracrine signaling.[95] MITF is a key transcription factor for melanin production in melanocytes.

Studies have reported the association of solar lentigo with loss of function MC1R alleles, MC1R promoter polymorphisms, and SLC45A2 allele variants.[96-98] Hafner and coworkers observed FGFR3 and PIK3CA mutations in 17% and 7% of solar lentigos, respectively. Kadono and coworkers demonstrated increased expression of endothelin B receptor and endothelin 1 in solar lentigo, which are key factors for melanocyte development and melanogenesis.[99] Additionally, fibroblast-derived growth factors, including keratinocyte growth factor, hepatocyte growth factor, and stem cell factor, may contribute to formation of solar lentigo.[100,101] T1799A *BRAF* mutation are detected in 33% of PUVA lentigines.[102]

DIAGNOSIS

PATHOLOGY

Histologic sections of solar lentigo show elongated rete ridges, extending into the papillary dermis with club-shaped or budlike endings. The epidermis between the rete ridges may be atrophic and have minimal overlying hyperkeratosis. The rete ridges may branch and become fused, creating a reticular pattern, caused by

Figure 115-19 Solar lentigo. **A,** Uncountable solar lentigines on the back of a 30-year-old white man, appearing initially during early childhood after multiple sunburns. **B,** High magnification of lentigines in (**A**) showing light-brown macules with markedly irregular outlines (*arrowheads*). **C,** Solar lentigines on sun-damaged dorsal hand skin (hypopigmentation, wrinkling, and telangiectasia) of an older white man.

epidermal proliferation. Within the lesion, melanocytes may be normal in number or slightly increased and are hyperactive with markedly increased melanin production. Both within the lesion and background adjacent skin, melanocytes may have mild nuclear atypia, likely because of actinic changes. Occasionally, small horn cysts form, resulting in histologic overlap with seborrheic keratosis. The dermis characteristically shows solar elastosis. A scant to moderate perivascular chronic inflammatory infiltrate is usually present within the dermis, along with melanin-laden macrophages.

PUVA lentigines show a variety of histologic features, ranging from predominantly basal cell hyperpigmentation with normal melanocyte count to markedly elongated rete ridges with melanocyte hyperplasia. In a subset of cases, melanocytes show cellular atypia, including nuclear pleomorphism, pseudoinclusions, multinucleation, irregular nuclear contours and melanin macroglobules.[103]

In electron microscopy studies of solar lentigo, melanosome complexes were greatly enlarged within keratinocytes compared with background adjacent skin.[104] PUVA lentigines had more dendrites and more active melanogenesis.[103]

LABORATORY TESTING

Immunohistochemistry to highlight melanocyte density is generally not required for histologic diagnosis.

DIFFERENTIAL DIAGNOSIS

See Table 115-9.

TABLE 115-9
Differential Diagnosis of Solar Lentigo

- Reticulated seborrheic keratoses
- Lentigo simplex
- Ephelis
- Junctional nevomelanocytic nevus
- Pigmented actinic keratoses
- Large cell acanthoma
- Lentigo maligna

CLINICAL COURSE AND PROGNOSIS

Over time, solar lentigines may enlarge or darken, persist as a stable lesion, or regress. They may evolve into lichenoid keratoses.[105] Subsequent resolution of the lichenoid keratosis ultimately may cause complete resolution of the prior lentigo. Recent molecular studies support this pathway of solar lentigo regression. Benign lichenoid keratoses have been shown to harbor *FGFR3*, *PIK3CA*, and *RAS* mutations, which are known to be involved in the pathogenesis of solar lentigo.[106]

Some authors have suggested that solar lentigo may evolve into large cell acanthoma or that large cell acanthoma is a variant with cellular hypertrophy.[107] Although the lesions share similar morphological features, differences in immunophenotype, including keratin 10 and BCL-2 expression, have been observed. Higher expression of keratin 10 and lower expression of BCL-2 suggests large cell acanthoma to have advanced maturation compared with solar lentigo.[107]

PUVA lentigines may persist years after treatment discontinuation.[90] Long-term follow-up of a large cohort of patients treated with PUVA demonstrated increased risk of melanoma, which emerged 15 years after initial therapy and continued to increase as time progressed.[108] Solar lentigines are similarly associated with increased risk of cutaneous malignancies.

MANAGEMENT

TREATMENT

Solar lentigines are benign lesions that do not require therapy. If desired, cosmetic removal may be completed with cryotherapy or other techniques, including Q-switched laser.

PREVENTION

Avoidance of UVR exposure may decrease the risk of developing additional solar lentigines.

DYSPLASTIC MELANOCYTIC NEVI

AT-A-GLANCE

- Commonly occur in Caucasians; prevalence varies by population
- Flat or raised with smooth or "pebbly" surface, irregular shape, indistinct borders, variable pigmentation, and measure at least 5 mm in diameter
- Identify population at risk for melanoma
- Most frequent on sun-exposed areas, especially intermittently exposed, including the upper back
- Associated with large numbers of common acquired nevi
- May persist or involute; subset undergoes malignant transformation to melanoma
- Histologic features include lentiginous melanocytic hyperplasia with architectural and cytologic atypia and stromal response.

EPIDEMIOLOGY

Dysplastic nevi are common melanocytic lesions, predominantly occurring in Caucasians. The prevalence of dysplastic nevi varies by population. Individuals from melanoma-prone families have the highest incidence of dysplastic nevi. In a study by Rhodes and coworkers, dysplastic nevi were present in 30.4% of patients with melanoma compared with 1.8% of the control group.[109] Studies involving populations of northern European descent have reported variable ranges for clinically atypical nevi from 7% to 18%, with histologic-proven dysplastic nevi estimated near 10%.[6] Some support a more accurate frequency to be between 2% to 8% in this population. Dysplastic nevi are uncommon in Japanese.[110] Individuals with dysplastic nevus syndrome (DNS) may develop more than 100 clinically atypical nevi by adolescence.

CLINICAL FINDINGS

CUTANEOUS FINDINGS

Clinically, dysplastic nevi often measure at least 5 mm in diameter and characteristically have irregular, indistinct borders and variable pigmentation (Fig. 115-20). Color is typically a mixture of tan and brown, with some lesions showing pink-red coloration.

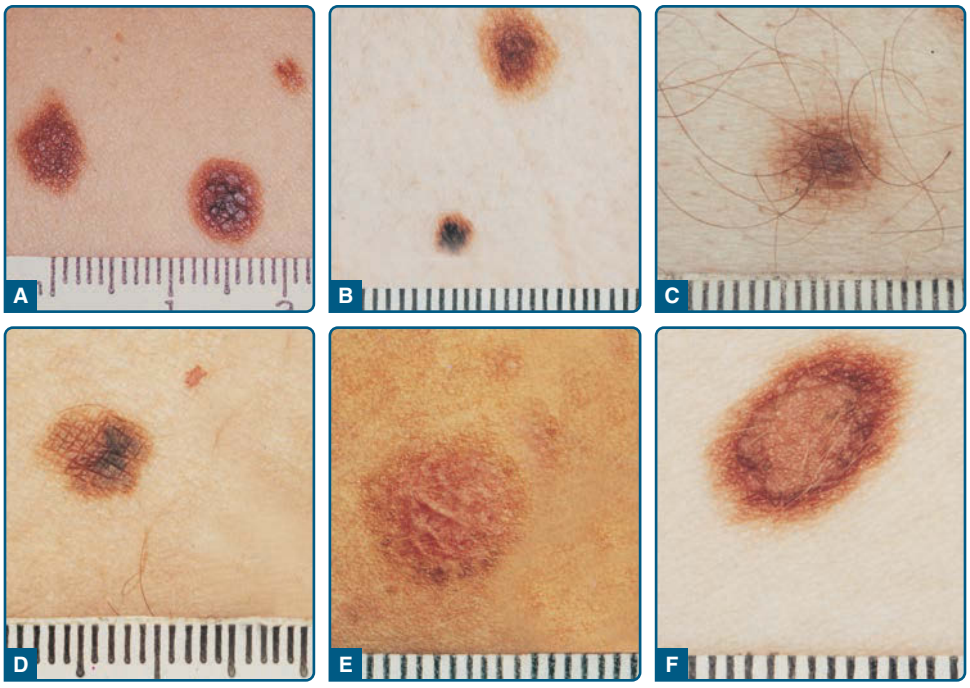

Figure 115-20 **A–F,** Atypical nevi typically have a diameter (diameter in one dimension at least 5 mm and a prominent flat component) and two of three other features (irregular asymmetric outline, indistinct borders, and variable pigmentation).

Black pigmentation is more commonly associated with melanoma.[111] Rarely, nonpigmented dysplastic nevi may develop. Additionally, dysplastic nevi frequently have a flat macular component, which corresponds to a 'shoulder' or junctional component of a compound lesion. Absence of a macular component and lesional symmetry are clinically suggestive of benignity. A study by Barnhill and Roush found that nevus size and irregular borders are the most significant clinical features that had the highest correlation to histologically proven dysplastic nevi.[112] Notably, nevi that are clinically atypical may be recognized on microscopy as benign. Moreover, site-specific changes should be well-known to dermatopathologists. For instance, acral and flexural site nevi may display atypia both clinically and histologically but lack diagnostic criteria for frank dysplasia on histologic examination.

Dysplastic nevi are often slightly raised and have a "pebbly" or smooth texture. They predominate on intermediate sun-exposed skin sites, such as the trunk and especially the upper back (Fig. 115-21). To a lesser extent, they occur on sun-protected sites, such as the chest and buttocks, and less commonly the scalp. Skin creases are usually unaffected. Patients may have solitary or numerous dysplastic nevi. Agminated lesions are rarely described.

In DNS, more than 100 nevi may develop. In affected individuals, large numbers of common acquired nevi develop during childhood and subsequently acquire dysplastic features at or around puberty. Patients tend to develop melanoma at an earlier age, often in the mid-30s, and may have multiple sites of malignancy. The trunk is the most common site of malignant transformation in DNS.

RELATED PHYSICAL FINDINGS

Patients with DN may develop melanoma. A subset of melanoma cases directly progress from dysplastic nevi, and histologic evidence of an associated nevus may be apparent on microscopy. However, the majority of melanomas arise from normal skin. Several physical and environmental factors, independent of dysplastic nevi, are known to increase the risk of melanoma, including cutaneous phenotype, solar injury, and presence of ephelides (freckles). Cases of eruptive dysplastic nevi have been described in patients with AIDS, renal transplantation, chronic myeloid leukemia, and after chemotherapy for pre–B-cell acute leukemia.[113-115] Individuals with dysplastic nevi have higher numbers of common acquired nevi.

COMPLICATIONS

Melanoma is the most clinically concerning complication, associated with dysplastic nevi. Its relative risk increases with the number of dysplastic nevi on an individual and the presence of personal or family history of melanoma. A large meta-analysis found that sporadic dysplastic nevi are associated with a 10-fold increased risk for melanoma.[39] If family history of melanoma is present in at least two relatives, there is an associated 200-fold increased risk of melanoma.[116]

Figure 115-21 **A,** A back view showing the distribution of dysplastic nevus (DN) and lesion-to-lesion variability, with an increased number of common acquired nevi also. **B,** A closer view of a cluster of lesions marked as #2 on the back. The lesions are of different sizes, colors, and shapes with differing amounts of asymmetry and indistinct borders. The largest lesion meets all of the criteria for a clinical DN.

ETIOLOGY AND PATHOGENESIS

The pathogenesis of dysplastic nevi is not well understood. DNS can be sporadic or inherited as an autosomal-dominant trait with variable expressivity and incomplete penetrance.[117] Recently, genetic variants in *CDK6* and *XRCC1* were found to be associated with dysplastic nevi in melanoma-prone families, independent of melanoma status. Mutations on 9p21-22 (*CDKN2A*) are present in approximately 40% of cases of DNS and are associated with melanoma; however, they are not frequently detected in dysplastic nevi.[118,119] *CDKN2A* encodes tumor suppressor gene products p16INK4a and p14ARK. Microsatellite instability at chromosome 1p and 9p is frequently identified in dysplastic nevi and melanoma.[120] Similar to common acquired nevi, dysplastic nevi have a similar rate of *BRAF* mutation and can show loss of PTEN expression and altered p53 expression.[121,122] Studies have demonstrated that dysplastic nevi may have higher levels of reactive oxidative species and a higher proliferative rate than common nevi, but less than melanoma.[123]

Additionally, UVR exposure is important for the development of dysplastic nevi. Dysplastic nevi are more likely to develop on sun-exposed sites compared with doubly covered locations such as the buttocks. Sun exposure and sunburns, especially before the age of 20 years, have been shown to be associated with dysplastic nevi.[124] In melanoma-prone families, sun-protective measures in childhood reduce the number of nevi that occur. Additionally, the dysplastic and common nevi are more likely to involute in this population with adherence to sun-protective measures.[118]

DIAGNOSIS

PATHOLOGY

The histological features of dysplastic nevi characteristically show an intraepidermal lentiginous melanocytic hyperplasia with cytologic and architectural atypia and dermal stromal response (Fig. 115-22). Melanocytes are irregular in shape and distribution. In a common acquired nevus, nests of melanocytes are confined to the tips of the rete ridges. Dysplastic nevi show melanocytes distributed singly and in nests located at the tips and sides and between rete ridges. Pagetoid spread, especially atypical melanocytes at the level of the granular layer, are more commonly seen in severely dysplastic nevi and melanoma. Additional features of architectural atypia include bridging of melanocytic nests at the tips of the rete ridges, and a "shouldering" junctional component of atypical melanocytes, extending at least three rete ridges beyond a dermal nevomelanocytic component. Confluence of atypical melanocytes along the epidermis is suggestive of melanoma in situ. The epidermis usually shows elongated rete ridges and a normal epidermal thickness. Although effacement of the rete ridges and attenuation of the epidermis, may occur, regressive features are more common in melanoma. A range of cytologic atypia is present in melanocytes, including dusty cytoplasm,

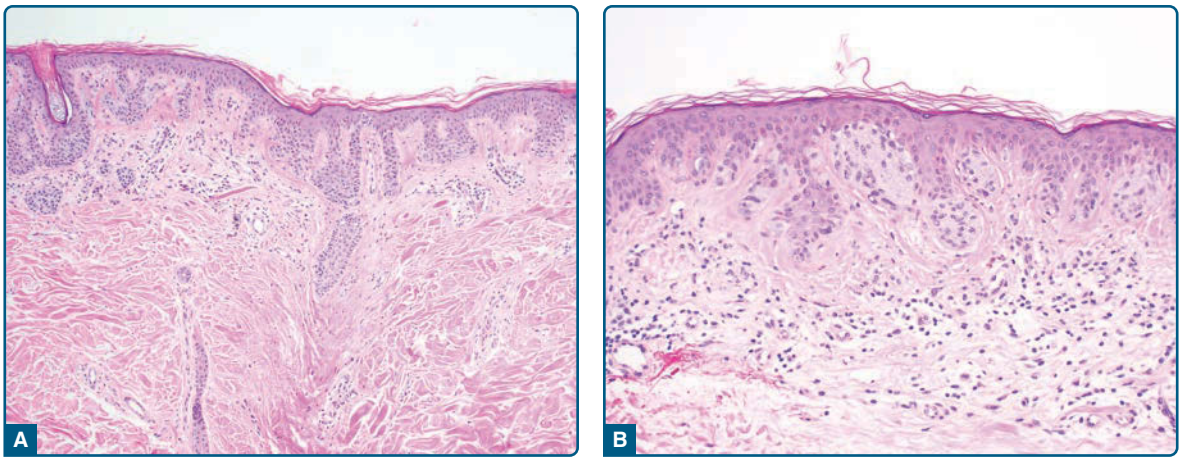

Figure 115-22 Dysplastic nevus. **A,** Compound dysplastic nevus with architecturally disordered junctional nests extending well beyond the dermal component (100× magnification). **B,** Junctional melanocytic nests are situated along the tips and sides of rete and display random cytologic atypia. There is underlying papillary dermal fibroplasia, lymphocytic infiltrate, and pigment incontinence (200× magnification).

nuclear enlargement, nuclear membrane irregularity, prominent nucleoli, and nuclear pleomorphism. If present, the dermal nevomelanocytic component is usually bland. Dermal fibroplasia is commonly seen directly under the epidermal component in the papillary dermis. A superficial lymphocytic infiltrate and melanin-laden macrophages may be present in the papillary dermis.

The overall degree of dysplasia should be scored by a dermatopathologist. Studies examining diagnostic accuracy and reproducibility for melanocytic lesions, including dysplastic nevi, have demonstrated variable results. Multiple studies have moderate to good interobserver agreement, but others have yielded limited to fair concordance.[125-128] A recent well-designed study demonstrated poor interobserver accuracy and reproducibility.[129] It should be noted that although grading systems have been proposed by multiple groups, consensus amongst dermatopathologists is lacking. Site- and gender-specific differences in DN are well described.[111] Additionally, margin status should be noted, particularly in cases of moderate and severe dysplasia.

SPECIAL TESTING

Dermoscopy (dermatoscopy or epiluminescence microscopy) is recommended during the evaluation of melanocytic neoplasia. Dermoscopy increases the diagnostic accuracy of melanoma detection.[130]

Digital imaging may be beneficial for clinical and histologic evaluation of pigmented lesions. Total-body photography, or mole mapping, is recommended for patients with multiple pigmented lesions or DNS. Total body photography has been shown to detect melanomas at earlier stages and reduce biopsies of benign lesions.[131] Other noninvasive and objective imaging techniques are being developing and include Raman spectroscopy, confocal microscopy, and multispectral imaging.

Recent work has focused on the development of a clinically validated molecular test to classify challenging melanocytic lesions as benign or malignant. Several panels have shown some promise differentiating benign nevi from melanoma with respectable sensitivity and specificity. Gene expression profiling may have additional utility in predicting responses to specific treatments or understanding treatment resistance. Further validation of gene-expression signatures in diagnostically challenging melanocytic lesions is critical.

DIFFERENTIAL DIAGNOSIS

See Table 115-10.

CLINICAL COURSE AND PROGNOSIS

The majority of dysplastic nevi do not progress to melanoma. Most studies support that only about 20% of melanoma arise from dysplastic nevi.[132,133] The risk of developing melanoma is dependent on a combination of factors, including number of dysplastic

TABLE 115-10
Differential Diagnosis of Dysplastic Nevi

- Common acquired nevus
- Congenital or congenital-type nevus
- Combined nevus
- Spitz nevus or /Spitz variant
- Pigmented spindle cell nevus
- Recurrent nevus
- Melanoma

nevi, personal history of melanoma or nonmelanoma skin cancer, family history of melanoma, and UVR exposure. Given that early diagnosis of melanoma improves prognosis, periodic dermatologic follow-up is recommended and should be based on the perceived risk of malignancy and competency in self-examination. For high-risk patients, intensive surveillance is initially recommended at 4- to 6-month intervals. For patients with a family history of melanoma and multiple dysplastic nevi, annual surveillance may be appropriate. Surveillance should be initiated at 10 years of age for high-risk individuals with a family history of melanoma in at least two family members and a history of dysplastic nevi in the patient or a family member. Of patients who subsequently develop melanoma, those followed in pigmented lesion clinics usually are diagnosed and treated at earlier stages.[131] If performed, the patient should receive a copy of his or her total-body photography. Sun-protective measures, self-examination, and family screening are recommended.

MANAGEMENT

TREATMENT

Biopsy should be performed of clinically suspicious, changing, or symptomatic lesions. If melanoma is of significant concern, excision is appropriate. For patients with DNS, wholesale removal of dysplastic nevi does not significantly reduce the lifetime risk of melanoma. Lesions suspicious for melanoma should be identified as early as possible and completely excised. Reexcision may be necessary to obtain a 5-mm margin if a dysplastic nevi with severe atypia is identified on histology.

Patients should be educated on the warning signs of melanoma, including changing pigmented lesions and the ABCD rule (asymmetry, border irregularity, color variation, diameter >6 mm). Sun-protective measures, such as use of sun-protective clothing, sunglasses, sunscreens, and avoidance of overexposure, should be recommended.

PREVENTION

Sun-protective measures reduce the incidence of dysplastic and common acquired nevi.

ACKNOWLEDGMENTS

We acknowledge and extend our thanks to the contributions contained herein by Dr. Philip LeBoit as well as the prior authors of the corresponding chapters in the eighth edition. The former authors are James M. Grichnik, Arthur R. Rhodes, and Arthur J. Sober ("Benign Neoplasias and Hyperplasias of Melanocytes") and James M. Grichnik and Margaret A. Tucker ("Atypical [Dysplastic] Melanocytic Nevi").

REFERENCES

1. Clark WH Jr, Reimer RR, Greene M, et al. Origin of familial malignant melanomas from heritable melanocytic lesions. "The B-K mole syndrome." *Arch Dermatol*. 1978;114(5):732-738.
2. Lynch HT, Frichot BC 3rd, Lynch JF. Familial atypical multiple mole-melanoma syndrome. *J Med Genet*. 1978;15(5):352-356.
3. Slade J, Marghoob AA, Salopek TG, et al. Atypical mole syndrome: risk factor for cutaneous malignant melanoma and implications for management. *J Am Acad Dermatol*. 1995;32(3):479-494.
4. Ackerman AB, Magana-Garcia M. Naming acquired melanocytic nevi. Unna's, Miescher's, Spitz's Clark's. *Am J Dermatopathol*. 1990;12(2):193-209.
5. Shapiro M, Chren MM, Levy RM, et al. Variability in nomenclature used for nevi with architectural disorder and cytologic atypia (microscopically dysplastic nevi) by dermatologists and dermatopathologists. *J Cutan Pathol*. 2004;31(8):523-530.
6. Naeyaert JM, Brochez L. Clinical practice. Dysplastic nevi. *N Engl J Med*. 2003;349(23):2233-2240.
7. Kanada KN, Merin MR, Munden A, et al. A prospective study of cutaneous findings in newborns in the United States: correlation with race, ethnicity, and gestational status using updated classification and nomenclature. *J Pediatr*. 2012;161(2):240-245.
8. Castilla EE, da Graca Dutra M, Orioli-Parreiras IM. Epidemiology of congenital pigmented naevi: I. Incidence rates and relative frequencies. *Br J Dermatol*. 1981;104(3):307-315.
9. Kinsler VA, O'Hare P, Bulstrode N, et al. Melanoma in congenital melanocytic naevi. *Br J Dermatol*. 2017;176(5):1131-1143.
10. Turkeltaub AE, Pezzi TA, Pezzi CM, et al. Characteristics, treatment, and survival of invasive malignant melanoma (MM) in giant pigmented nevi (GPN) in adults: 976 cases from the National Cancer Data Base (NCDB). *J Am Acad Dermatol*. 2016;74(6):1128-1134.
11. Krengel S, Scope A, Dusza SW, et al. New recommendations for the categorization of cutaneous features of congenital melanocytic nevi. *J Am Acad Dermatol*. 2013;68(3):441-451.
12. Rhodes AR, Albert LS, Weinstock MA. Congenital nevomelanocytic nevi: proportionate area expansion during infancy and early childhood. *J Am Acad Dermatol*. 1996;34(1):51-62.
13. Cengiz FP, Emiroglu N, Ozkaya DB, et al. Dermoscopic features of small, medium, and large-sized congenital melanocytic nevi. *Ann Dermatol*. 2017;29(1):26-32.
14. Monica I, Kumar LP, Uppin MS, et al. Neurocutaneous melanocytosis presenting in a teenager: a case report and review of the literature. *J Cancer Res Ther*. 2015;11(3):649.
15. Vourc'h-Jourdain M, Martin L, Barbarot S. aRED Large congenital melanocytic nevi: therapeutic management and melanoma risk: a systematic review. *J Am Acad Dermatol*. 2013;68(3):493-498, e491-414.
16. Neuhold JC, Friesenhahn J, Gerdes N, et al. Case reports of fatal or metastasizing melanoma in children and adolescents: a systematic analysis of the literature. *Pediatr Dermatol*. 2015;32(1):13-22.
17. de Wijn RS, Zaal LH, Hennekam RC, et al. Familial clustering of giant congenital melanocytic nevi. *J Plast Reconstr Aesthet Surg*. 2010;63(6):906-913.

18. Silfen R, Skoll PJ, Hudson DA. Congenital giant hairy nevi and neurofibromatosis: the significance of their common origin. *Plast Reconstr Surg*. 2002; 110(5):1364-1365.
19. Roh MR, Eliades P, Gupta S, et al. Genetics of melanocytic nevi. *Pigment Cell Melanoma Res*. 2015;28(6): 661-672.
20. Bauer J, Curtin JA, Pinkel D, et al. Congenital melanocytic nevi frequently harbor NRAS mutations but no BRAF mutations. *J Invest Dermatol*. 2007;127(1): 179-182.
21. Desai SC, Walen S, Holds JB, et al. Divided nevus of the eyelid: review of embryology, pathology and treatment. *Am J Otolaryngol*. 2013;34(3):223-229.
22. Simons EA, Huang JT, Schmidt B. Congenital melanocytic nevi in young children: Histopathologic features and clinical outcomes. *J Am Acad Dermatol*. 2017; 76(5):941-947.
23. Yelamos O, Arva NC, Obregon R, et al. A comparative study of proliferative nodules and lethal melanomas in congenital nevi from children. *Am J Surg Pathol*. 2015;39(3):405-415.
24. Busam KJ, Shah KN, Gerami P, et al. Reduced H3K27me3 expression is common in nodular melanomas of childhood associated with congenital melanocytic nevi but not in proliferative nodules. *Am J Surg Pathol*. 2017;41(3):396-404.
25. Sato S, Kato H, Hidano A. Divided nevus spilus and divided form of spotted grouped pigmented nevus. *J Cutan Pathol*. 1979;6(6):507-512.
26. Torres KG, Carle L, Royer M. Nevus spilus (speckled lentiginous nevus) in the oral cavity: report of a case and review of the literature. *Am J Dermatopathol*. 2017;39(1):e8-e12.
27. Kaminska-Winciorek G. Dermoscopy of nevus spilus. *Dermatol Surg*. 2013;39(10):1550-1554.
28. Tavoloni Braga JC, Gomes E, Macedo MP, et al. Early detection of melanoma arising within nevus spilus. *J Am Acad Dermatol*. 2014;70(2):e31-32.
29. Vidaurri-de la Cruz H, Happle R. Two distinct types of speckled lentiginous nevi characterized by macular versus papular speckles. *Dermatology*. 2006; 212(1):53-58.
30. Boot-Bloemen MCT, de Kort WJA, van der Spek-Keijser LMT, et al. Melanoma in segmental naevus spilus: a case series and literature review. *Acta Derm Venereol*. 2017;97(6):749-750.
31. Sarin KY, McNiff JM, Kwok S, et al. Activating HRAS mutation in nevus spilus. *J Invest Dermatol*. 2014;134(6):1766-1768.
32. Sarin KY, Sun BK, Bangs CD, et al. Activating HRAS mutation in agminated Spitz nevi arising in a nevus spilus. *JAMA Dermatol*. 2013;149(9):1077-1081.
33. Kinsler VA, Krengel S, Riviere JB, et al. Next-generation sequencing of nevus spilus-type congenital melanocytic nevus: exquisite genotype-phenotype correlation in mosaic RASopathies. *J Invest Dermatol*. 2014;134(10):2658-2660.
34. MacKie RM, English J, Aitchison TC, et al. The number and distribution of benign pigmented moles (melanocytic naevi) in a healthy British population. *Br J Dermatol*. 1985;113(2):167-174.
35. Crane LA, Mokrohisky ST, Dellavalle RP, et al. Melanocytic nevus development in Colorado children born in 1998: a longitudinal study. *Arch Dermatol*. 2009;145(2):148-156.
36. Ohn J, Choe YS, Mun JH. Dermoscopic features of nail matrix nevus (NMN) in adults and children: a comparative analysis. *J Am Acad Dermatol*. 2016; 75(3):535-540.
37. Patrizi A, Bentivogli M, Raone B, et al. Association of halo nevus/i and vitiligo in childhood: a retrospective observational study. *J Eur Acad Dermatol Venereol*. 2013;27(2):e148-152.
38. Brazzelli V, Larizza D, Martinetti M, et al. Halo nevus, rather than vitiligo, is a typical dermatologic finding of Turner's syndrome: clinical, genetic, and immunogenetic study in 72 patients. *J Am Acad Dermatol*. 2004;51(3):354-358.
39. Gandini S, Sera F, Cattaruzza MS, et al. Meta-analysis of risk factors for cutaneous melanoma: I. Common and atypical naevi. *Eur J Cancer*. 2005;41(1):28-44.
40. Carli P, Massi D, Santucci M, et al. Cutaneous melanoma histologically associated with a nevus and melanoma de novo have a different profile of risk: results from a case-control study. *J Am Acad Dermatol*. 1999;40(4):549-557.
41. Oliveria SA, Satagopan JM, Geller AC, et al. Study of Nevi in Children (SONIC): baseline findings and predictors of nevus count. *Am J Epidemiol*. 2009;169(1):41-53.
42. Crane LA, Mokrohisky ST, Dellavalle RP, et al. Melanocytic nevus development in Colorado children born in 1998: a longitudinal study. *Arch Dermatol*. 2009;145(2):148-156.
43. Yeh I, von Deimling A, Bastian BC. Clonal BRAF mutations in melanocytic nevi and initiating role of BRAF in melanocytic neoplasia. *J Natl Cancer Inst*. 2013;105(12):917-919.
44. Sekulic A, Colgan MB, Davis MD, et al. Activating BRAF mutations in eruptive melanocytic naevi. *Br J Dermatol*. 2010;163(5):1095-1098.
45. Gantner S, Wiesner T, Cerroni L, et al. Absence of BRAF and HRAS mutations in eruptive Spitz naevi. *Br J Dermatol*. 2011;164(4):873-877.
46. Yang Y, Li S, Zhu G, et al. A similar local immune and oxidative stress phenotype in vitiligo and halo nevus. *J Dermatol Sci*. 2017;87(1):50-59.
47. Okun MR, Donnellan B, Edelstein L. An ultrastructural study of balloon cell nevus. Relationship of mast cells to nevus cells. *Cancer*. 1974;34(3):615-625.
48. Bastian BC, Olshen AB, LeBoit PE, et al. Classifying melanocytic tumors based on DNA copy number changes. *Am J Pathol*. 2003;163(5):1765-1770.
49. Phadke PA, Zembowicz A. Blue nevi and related tumors. *Clin Lab Med*. 2011;31(2):345-358.
50. Tse JY, Walls BE, Pomerantz H, et al. Melanoma arising in a nevus of Ito: novel genetic mutations and a review of the literature on cutaneous malignant transformation of dermal melanocytosis. *J Cutan Pathol*. 2016;43(1):57-63.
51. Bender RP, McGinniss MJ, Esmay P, et al. Identification of HRAS mutations and absence of GNAQ or GNA11 mutations in deep penetrating nevi. *Mod Pathol*. 2013;26(10):1320-1328.
52. Van Raamsdonk CD, Bezrookove V, Green G, et al. Frequent somatic mutations of GNAQ in uveal melanoma and blue naevi. *Nature*. 2009;457(7229):599-602.
53. Thomas AC, Zeng Z, Riviere JB, et al. Mosaic activating mutations in GNA11 and GNAQ are associated with phakomatosis pigmentovascularis and extensive dermal melanocytosis. *J Invest Dermatol*. 2016;136(4):770-778.
54. Yeh I, Lang UE, Durieux E, et al. Combined activation of MAP kinase pathway and beta-catenin signaling cause deep penetrating nevi. *Nat Commun*. 2017;8(1):644.

55. Isales MC, Haugh AM, Bubley J, et al. Genomic assessment of blitz nevi suggests classification as a subset of blue nevus rather than Spitz nevus: clinical, histopathologic, and molecular analysis of 18 cases. *Am J Dermatopathol*. 2017.
56. Mandal RV, Murali R, Lundquist KF, et al. Pigmented epithelioid melanocytoma: favorable outcome after 5-year follow-up. *Am J Surg Pathol*. 2009;33(12): 1778-1782.
57. Zembowicz A, Knoepp SM, Bei T, et al. Loss of expression of protein kinase a regulatory subunit 1alpha in pigmented epithelioid melanocytoma but not in melanoma or other melanocytic lesions. *Am J Surg Pathol*. 2007;31(11):1764-1775.
58. Cohen JN, Joseph NM, North JP, et al. Genomic Analysis of Pigmented Epithelioid Melanocytomas Reveals Recurrent Alterations in PRKAR1A, and PRKCA Genes. *Am J Surg Pathol*. 2017;41(10):1333-1346.
59. Costa S, Byrne M, Pissaloux D, et al. Melanomas associated with blue nevi or mimicking cellular blue nevi: clinical, pathologic, and molecular study of 11 cases displaying a high frequency of GNA11 mutations, BAP1 expression loss, and a predilection for the scalp. *Am J Surg Pathol*. 2016;40(3):368-377.
60. Sagebiel RW, Chinn EK, Egbert BM. Pigmented spindle cell nevus. Clinical and histologic review of 90 cases. *Am J Surg Pathol*. 1984;8(9):645-653.
61. Sau P, Graham JH, Helwig EB. Pigmented spindle cell nevus: a clinicopathologic analysis of ninety-five cases. *J Am Acad Dermatol*. 1993;28(4):565-571.
62. Barnhill RL, Barnhill MA, Berwick M, et al. The histologic spectrum of pigmented spindle cell nevus: a review of 120 cases with emphasis on atypical variants. *Hum Pathol*. 1991;22(1):52-58.
63. Reed RJ, Ichinose H, Clark WH Jr, et al. Common and uncommon melanocytic nevi and borderline melanomas. *Semin Oncol*. 1975;2(2):119-147.
64. Lallas A, Apalla Z, Ioannides D, et al. Update on dermoscopy of Spitz/Reed naevi and management guidelines by the International Dermoscopy Society. *Br J Dermatol*. 2017;177(3):645-655.
65. Diaz A, Valera A, Carrera C, et al. Pigmented spindle cell nevus: clues for differentiating it from spindle cell malignant melanoma. A comprehensive survey including clinicopathologic, immunohistochemical, and FISH studies. *Am J Surg Pathol*. 2011;35(11):1733-1742.
66. Sepehr A, Chao E, Trefrey B, et al. Long-term outcome of Spitz-type melanocytic tumors. *Arch Dermatol*. 2011;147(10):1173-1179.
67. Weedon D, Little JH. Spindle and epithelioid cell nevi in children and adults. A review of 211 cases of the Spitz nevus. *Cancer*. 1977;40(1):217-225.
68. Busam KJ, Wanna M, Wiesner T. Multiple epithelioid Spitz nevi or tumors with loss of BAP1 expression: a clue to a hereditary tumor syndrome. *JAMA Dermatol*. 2013;149(3):335-339.
69. Wiesner T, Murali R, Fried I, et al. A distinct subset of atypical Spitz tumors is characterized by BRAF mutation and loss of BAP1 expression. *Am J Surg Pathol*. 2012;36(6):818-830.
70. Wiesner T, Kutzner H, Cerroni L, et al. Genomic aberrations in spitzoid melanocytic tumours and their implications for diagnosis, prognosis and therapy. *Pathology*. 2016;48(2):113-131.
71. Marusic Z, Buljan M, Busam KJ. Histomorphologic spectrum of BAP1 negative melanocytic neoplasms in a family with BAP1-associated cancer susceptibility syndrome. *J Cutan Pathol*. 2015;42(6):406-412.
72. Biddle DA, Evans HL, Kemp BL, et al. Intraparenchymal nevus cell aggregates in lymph nodes: a possible diagnostic pitfall with malignant melanoma and carcinoma. *Am J Surg Pathol*. 2003;27(5):673-681.
73. Fontaine D, Parkhill W, Greer W, et al. Nevus cells in lymph nodes: an association with congenital cutaneous nevi. *Am J Dermatopathol*. 2002;24(1):1-5.
74. Patterson JW. Nevus cell aggregates in lymph nodes. *Am J Clin Pathol*. 2004;121(1):13-15.
75. Howell BG, Lipa JE, Ghazarian DM. Intracapsular melanoma: a new pitfall for sentinel lymph node biopsy. *J Clin Pathol*. 2006;59(8):891-892.
76. Piana S, Tagliavini E, Ragazzi M, et al. Lymph node melanocytic nevi: pathogenesis and differential diagnoses, with special reference to p16 reactivity. *Pathol Res Pract*. 2015;211(5):381-388.
77. Mihic-Probst D, Saremaslani P, Komminoth P, et al. Immunostaining for the tumour suppressor gene p16 product is a useful marker to differentiate melanoma metastasis from lymph-node nevus. *Virchows Arch*. 2003;443(6):745-751.
78. Saab J, Santos-Zabala ML, Loda M, et al. Fatty acid synthase and acetyl-CoA carboxylase are expressed in nodal metastatic melanoma but not in benign intracapsular nodal nevi. *Am J Dermatopathol*. 2018;40(4):259-264.
79. Erkek E, Erdogan S, Tuncez F, et al. Type I hereditary punctate keratoderma associated with widespread lentigo simplex and successfully treated with low-dose oral acitretin. *Arch Dermatol*. 2006; 142(8):1076-1077.
80. Castelo-Soccio L, Di Marcantonio D, Shah P, et al. Induced lentiginosis with use of topical calcineurin inhibitors. *Arch Dermatol*. 2012;148(6):766-768.
81. Mohizea SA, Al-Balbeesi A. Acral lentigines, is it a paraneoplastic syndrome? *Int J Health Sci (Qassim)*. 2009;3(1):89-92.
82. Wolf R, Lipozencic J, Segal Z, et al. Eruptive acral lentigines—a new paraneoplastic sign? *Acta Dermatovenerol Croat*. 2008;16(3):130-132.
83. Wolf R, Orion E, Davidovici B. Acral lentigines: a new paraneoplastic syndrome. *Int J Dermatol*. 2008;47(2): 168-170.
84. Gallais V, Lacour JP, Perrin C, et al. Acral hyperpigmented macules and longitudinal melanonychia in AIDS patients. *Br J Dermatol*. 1992;126(4):387-391.
85. Hafner C, Stoehr R, van Oers JM, et al. The absence of BRAF, FGFR3, and PIK3CA mutations differentiates lentigo simplex from melanocytic nevus and solar lentigo. *J Invest Dermatol*. 2009;129(11):2730-2735.
86. Hafner C, Stoehr R, van Oers JM, et al. FGFR3 and PIK3CA mutations are involved in the molecular pathogenesis of solar lentigo. *Br J Dermatol*. 2009;160(3):546-551.
87. Ortonne JP. Pigmentary changes of the ageing skin. *Br J Dermatol*. 1990;122(suppl 35):21-28.
88. Ezzedine K, Mauger E, Latreille J, et al. Freckles and solar lentigines have different risk factors in Caucasian women. *J Eur Acad Dermatol Venereol*. 2013;27(3):e345-356.
89. Monestier S, Gaudy C, Gouvernet J, et al. Multiple senile lentigos of the face, a skin ageing pattern resulting from a life excess of intermittent sun exposure in dark-skinned Caucasians: a case-control study. *Br J Dermatol*. 2006;154(3):438-444.
90. Rhodes AR, Stern RS, Melski JW. The PUVA lentigo: an analysis of predisposing factors. *J Invest Dermatol*. 1983;81(5):459-463.

91. Kadunce DP, Piepkorn MW, Zone JJ. Persistent melanocytic lesions associated with cosmetic tanning bed use: "sunbed lentigines." *J Am Acad Dermatol*. 1990;23(5 Pt 2):1029-1031.
92. Moazzami B, Razavi N, Babaei M, et al. The association between solar lentigines and type-2 diabetes. *Caspian J Intern Med*. 2017;8(4):317-320.
93. Cui R, Widlund HR, Feige E, et al. Central role of p53 in the suntan response and pathologic hyperpigmentation. *Cell*. 2007;128(5):853-864.
94. Gordon PR, Mansur CP, Gilchrest BA. Regulation of human melanocyte growth, dendricity, and melanization by keratinocyte derived factors. *J Invest Dermatol*. 1989;92(4):565-572.
95. Praetorius C, Sturm RA, Steingrimsson E. Sun-induced freckling: ephelides and solar lentigines. *Pigment Cell Melanoma Res*. 2014;27(3):339-350.
96. Vierkotter A, Kramer U, Sugiri D, et al. Development of lentigines in German and Japanese women correlates with variants in the SLC45A2 gene. *J Invest Dermatol*. 2012;132(3 Pt 1):733-736.
97. Motokawa T, Kato T, Hashimoto Y, et al. Polymorphism patterns in the promoter region of the MC1R gene are associated with development of freckles and solar lentigines. *J Invest Dermatol*. 2008;128(6):1588-1591.
98. Motokawa T, Kato T, Hashimoto Y, et al. Effect of Val92Met and Arg163Gln variants of the MC1R gene on freckles and solar lentigines in Japanese. *Pigment Cell Res*. 2007;20(2):140-143.
99. Kadono S, Manaka I, Kawashima M, et al. The role of the epidermal endothelin cascade in the hyperpigmentation mechanism of lentigo senilis. *J Invest Dermatol*. 2001;116(4):571-577.
100. Chen N, Hu Y, Li WH, et al. The role of keratinocyte growth factor in melanogenesis: a possible mechanism for the initiation of solar lentigines. *Exp Dermatol*. 2010;19(10):865-872.
101. Kovacs D, Cardinali G, Aspite N, et al. Role of fibroblast-derived growth factors in regulating hyperpigmentation of solar lentigo. *Br J Dermatol*. 2010; 163(5):1020-1027.
102. Lassacher A, Worda M, Kaddu S, et al. T1799A BRAF mutation is common in PUVA lentigines. *J Invest Dermatol*. 2006;126(8):1915-1917.
103. Nakagawa H, Rhodes AR, Momtaz TK, et al. Morphologic alterations of epidermal melanocytes and melanosomes in PUVA lentigines: a comparative ultrastructural investigation of lentigines induced by PUVA and sunlight. *J Invest Dermatol*. 1984;82(1):101-107.
104. Montagna W, Hu F, Carlisle K. A reinvestigation of solar lentigines. *Arch Dermatol*. 1980;116(10):1151-1154.
105. Goldenhersh MA, Barnhill RL, Rosenbaum HM, et al. Documented evolution of a solar lentigo into a solitary lichen planus-like keratosis. *J Cutan Pathol*. 1986;13(4):308-311.
106. Groesser L, Herschberger E, Landthaler M, et al. FGFR3, PIK3CA and RAS mutations in benign lichenoid keratosis. *Br J Dermatol*. 2012;166(4):784-788.
107. Fraga GR, Amin SM. Large cell acanthoma: a variant of solar lentigo with cellular hypertrophy. *J Cutan Pathol*. 2014;41(9):733-739.
108. Stern RS, PUVA Follow up Study. The risk of melanoma in association with long-term exposure to PUVA. *J Am Acad Dermatol*. 2001;44(5):755-761.
109. Rhodes AR, Seki Y, Fitzpatrick TB, et al. Melanosomal alterations in dysplastic melanocytic nevi. A quantitative, ultrastructural investigation. *Cancer*. 1988;61(2): 358-369.
110. Hara K, Nitta Y, Ikeya T. Dysplastic nevus syndrome among Japanese. A case study and review of the Japanese literature. *Am J Dermatopathol*. 1992;14(1):24-31.
111. Elder DE. Precursors to melanoma and their mimics: nevi of special sites. *Mod Pathol*. 2006;19(suppl 2): S4-S20.
112. Barnhill RL, Roush GC. Correlation of clinical and histopathologic features in clinically atypical melanocytic nevi. *Cancer*. 1991;67(12):3157-3164.
113. Lozeau DF, Farber MJ, Lee JB. A nongrading histologic approach to Clark (dysplastic) nevi: a potential to decrease the excision rate. *J Am Acad Dermatol*. 2016;74(1):68-74.
114. Reutter JC, Long EM, Morrell DS, et al. Eruptive postchemotherapy in situ melanomas and dysplastic nevi. *Pediatr Dermatol*. 2007;24(2):135-137.
115. Duvic M, Lowe L, Rapini RP, et al. Eruptive dysplastic nevi associated with human immunodeficiency virus infection. *Arch Dermatol*. 1989;125(3):397-401.
116. Halpern AC, Guerry Dt, Elder DE, et al. A cohort study of melanoma in patients with dysplastic nevi. *J Invest Dermatol*. 1993;100(3):346S-349S.
117. Celebi JT, Ward KM, Wanner M, et al. Evaluation of germline CDKN2A, ARF, CDK4, PTEN, and BRAF alterations in atypical mole syndrome. *Clin Exp Dermatol*. 2005;30(1):68-70.
118. Tucker MA, Fraser MC, Goldstein AM, et al. A natural history of melanomas and dysplastic nevi: an atlas of lesions in melanoma-prone families. *Cancer*. 2002;94(12):3192-3209.
119. Piepkorn M. Whither the atypical (dysplastic) nevus? *Am J Clin Pathol*. 2001;115(2):177-179.
120. Hussein MR, Sun M, Tuthill RJ, et al. Comprehensive analysis of 112 melanocytic skin lesions demonstrates microsatellite instability in melanomas and dysplastic nevi, but not in benign nevi. *J Cutan Pathol*. 2001;28(7):343-350.
121. Uribe P, Andrade L, Gonzalez S. Lack of association between BRAF mutation and MAPK ERK activation in melanocytic nevi. *J Invest Dermatol*. 2006; 126(1):161-166.
122. Tsao H, Mihm MC, Jr, Sheehan C. PTEN expression in normal skin, acquired melanocytic nevi, and cutaneous melanoma. *J Am Acad Dermatol*. 2003;49(5):865-872.
123. Duffy K, Grossman D. The dysplastic nevus: from historical perspective to management in the modern era: part II. Molecular aspects and clinical management. *J Am Acad Dermatol*. 2012;67(1):19 e11-12; quiz 31-32.
124. Titus-Ernstoff L, Ernstoff MS, Duray PH, et al. A relation between childhood sun exposure and dysplastic nevus syndrome among patients with nonfamilial melanoma. *Epidemiology*. 1991;2(3):210-214.
125. Clemente C, Cochran AJ, Elder DE, et al. Histopathologic diagnosis of dysplastic nevi: concordance among pathologists convened by the World Health Organization Melanoma Programme. *Hum Pathol*. 1991;22(4):313-319.
126. Piepkorn MW, Barnhill RL, Cannon-Albright LA, et al. A multiobserver, population-based analysis of histologic dysplasia in melanocytic nevi. *J Am Acad Dermatol*. 1994;30(5 Pt 1):707-714.
127. Nobre AB, Pineiro-Maceira J, Luiz RR. Analysis of interobserver reproducibility in grading histological patterns of dysplastic nevi. *An Bras Dermatol*. 2013;88(1):23-31.

128. de Wit PE, van't Hof-Grootenboer B, Ruiter DJ, et al. Validity of the histopathological criteria used for diagnosing dysplastic naevi. An interobserver study by the pathology subgroup of the EORTC Malignant Melanoma Cooperative Group. *Eur J Cancer*. 1993;29A(6):831-839.
129. Elmore JG, Barnhill RL, Elder DE, et al. Pathologists' diagnosis of invasive melanoma and melanocytic proliferations: observer accuracy and reproducibility study. *BMJ*. 2017;357:j2813.
130. Vestergaard ME, Macaskill P, Holt PE, et al. Dermoscopy compared with naked eye examination for the diagnosis of primary melanoma: a meta-analysis of studies performed in a clinical setting. *Br J Dermatol*. 2008;159(3):669-676.
131. Banky JP, Kelly JW, English DR, et al. Incidence of new and changed nevi and melanomas detected using baseline images and dermoscopy in patients at high risk for melanoma. *Arch Dermatol*. 2005;141(8):998-1006.
132. Ko JS, Matharoo-Ball B, Billings SD, et al. Diagnostic distinction of malignant melanoma and benign nevi by a gene expression signature and correlation to clinical outcomes. *Cancer Epidemiol Biomarkers Prev*. 2017;26(7):1107-1113.
133. Duffy K, Grossman D. The dysplastic nevus: from historical perspective to management in the modern era: part I. Historical, histologic, and clinical aspects. *J Am Acad Dermatol*. 2012;67(1):1 e1-16; quiz 17-18.

Chapter 116 :: Melanoma

:: Jessica C. Hassel & Alexander H. Enk

AT-A-GLANCE

- Rising incidence worldwide in countries with white inhabitants, with highest incidence rates in Australia (35 new cases per year per 100,000 population), followed by North America (21.8 new cases per 100,000 population) and Europe (13.5 new cases per 100,000 population).
- Risk factors include history of sunburns and/or heavy sun exposure, blue or green eyes, blonde or red hair, fair complexion, >100 typical nevi, any atypical nevi, prior personal or family history of melanoma, or *p16* mutation.
- Mean age of diagnosis is 63 years, with 15% being younger than 45 years.
- Most common location is the back for men, and lower extremities followed by trunk for women, but can occur anywhere on the skin surface.
- Features used for melanoma recognition: A (*a*symmetry), B (*b*order), C (*c*olor), D (*d*iameter, >5 mm in most common use), and E (*e*volution).
- Follows a highly variable course and represents a heterogeneous disorder; surgically curable if diagnosed and treated in early phase, but potentially lethal with increased risk when diagnosed and treated late.
- In the last decades, completely new and effective treatment options for metastatic melanoma approved with immunotherapies such as the immune checkpoint blockade (anti-CTLA4, anti-PD-1 antibodies) and targeted therapies like BRAF/MEK inhibitors leading to a median overall survival of 2 years in stage IV melanoma and the chance for a long-term tumor control.

INTRODUCTION

DEFINITIONS

Melanoma (a word derived from the greek *melas* [dark] and *oma* [tumor]) is a malignant tumor arising from melanocytic cells and hence can occur anywhere where these cells are found. The most frequent type is cutaneous melanoma but melanomas develop also at the mucosal, the uveal, or even the meningeal membrane. Ten percent of melanomas are detected by lymph node metastases with so-called "unknown primary" and are likely to develop in the lymph node from preexisting nodal nevi.[1]

HISTORICAL PERSPECTIVE

Cancer is a disease that probably accompanied human life from the very beginning. The earliest physical evidence of melanoma comes from diffuse melanotic metastases found in skeletons of Pre-Colombian mummies from Chancay and Chingas in Peru, dated to be about 2400 years old (radiocarbon). However, the first descriptions of the disease can be found in the writings of Hippocrates of Cos in the 5th century BC.[2]

Until a few years ago, the only cure was by surgery in the early stages. The first documented operation of a melanoma was done by the Scottish surgeon John Hunter in 1787. The preserved tumor is still housed in the Hunterian Museum at Lincolns Inn Fields in London.[2] Until recently, in the unresectable metastatic setting, no treatment was available that could prolong patients' survival. This was revolutionized in the last decade by the approval of immunotherapies, the so-called immune checkpoint blockers, and targeted treatments to the frequently found *BRAF* mutations.

EPIDEMIOLOGY

The incidence of melanoma has increased significantly worldwide over the last several decades. It is mainly a tumor of people with fair skin from more developed regions. There is a low annual incidence in the whole world population of 3.0 new cases per 100,000 population—thus, it is not one of the top 10 cancers worldwide.[3] The highest incidence of melanoma is reported for Australia/New Zealand with about 35 new cases per year and 100,000 population, followed by Northern Europe and Northern America (Fig. 116-1). In the year 2016, an estimated 76,380 new cases of melanoma will be diagnosed in the United States of America translating to an annual incidence of 21.8 new cases per 100,000 population.[4] In Europe, incidence rates are lower, with an annual incidence of 13.5 new cases per 100,000 population and large differences between European countries, with the highest incidence in Switzerland for men and in Denmark for women.[5] Central and Eastern European countries have the lowest reported incidence rates in Europe. In the United States, incidence rises about 2.6% per year, leading to an increase of 33% for men and 23% for women between 2002 and 2006.[6] Across all cancers, melanoma incidence is the most rapidly increasing in men and is only second to lung cancer in women. Invasive melanoma of the skin is the fourth most frequent site for cancer to occur in men and the sixth most frequent site in women.

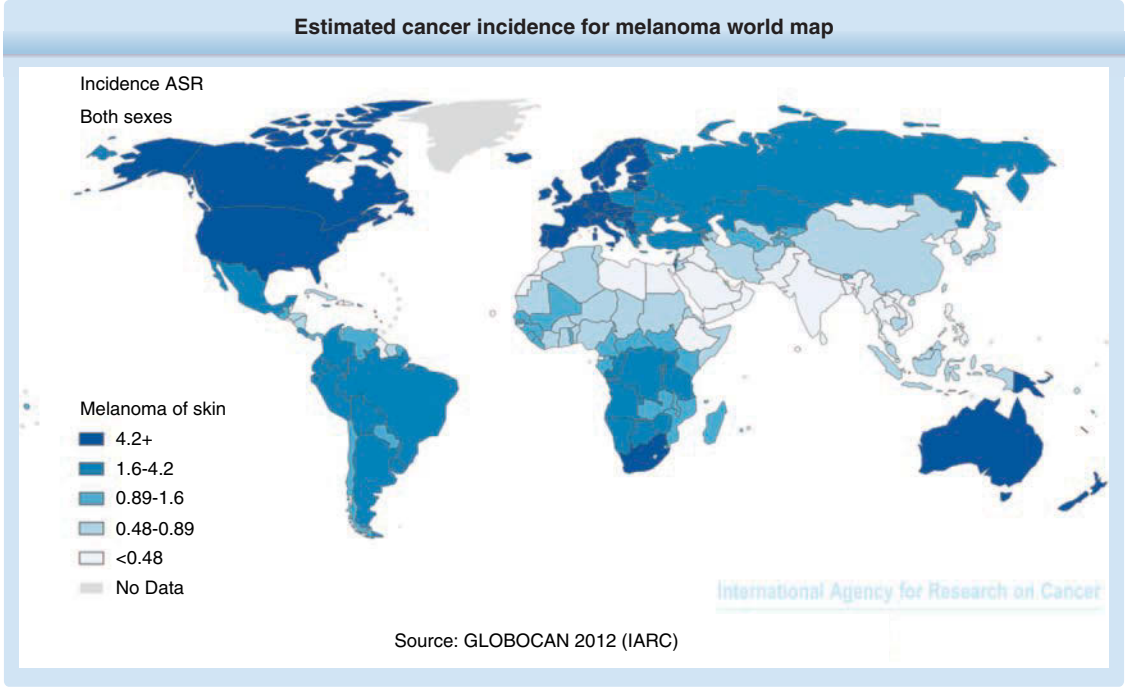

Figure 116-1 Estimated cancer incidence for melanoma world map. ASR = age-standardized rate. (Reproduced with permission from Ferlay J, Soerjomataram I, Ervik M, et al. GLOBOCAN 2012 v1.0, Cancer Incidence and Mortality Worldwide: IARC CancerBase No. 11 [Internet]. Lyon, France: International Agency for Research on Cancer; 2013. Available from: http://globocan.iarc.fr, accessed 13 September 2016.)

By 2015, it is estimated that 1 in 50 Americans will develop melanoma in their lifetime.[6]

The median age for a melanoma diagnosis is 63 years with 15% being younger than 45 years. Incidence rises with age to a maximum between 55 and 74 years. Mortality data parallel incidence data, with a median age at death of 69 years.[4] Even though melanoma accounts for only 4% of all skin cancer diagnoses each year in the United States, it is responsible for 75% of skin cancer deaths. Currently, one US citizen dies from a melanoma every hour. However, even though melanoma incidence is rising rapidly with a tripling from 1980 to 2003, it is not associated with a corresponding increase in melanoma deaths. This is probably based on earlier detection and hence better prognosis of the melanoma.[6]

CLINICAL FEATURES

CUTANEOUS FINDINGS

The different subtypes of cutaneous melanoma can be distinguished clinically. However, these subtypes are not of prognostic significance itself, for example, a nodular or amelanotic melanoma might have a poorer prognosis compared to a superficial spreading melanoma but this is most likely based on a higher tumor thickness because of a later diagnosis.[7] However, clinical heterogeneity of melanomas might be explained by genetically distinct types of melanoma with different susceptibility to ultraviolet light.[8]

SUPERFICIAL SPREADING MELANOMA (SSM)

SSM is the most common subtype, accounting for approximately 70% of all cutaneous melanomas. It is diagnosed most commonly on intermittently sun-exposed areas, most frequently the lower extremity of women, and the upper back of men. Its classic clinical appearance best fits into the ABCD criteria (see section "Making a Diagnosis"), with irregular borders and irregular pigmentation, but it may present subtly as a discrete focal area of darkening within a preexisting nevus. The range of appearance of SSM is broad (Figs. 116-2A,B, and Fig. 116-3). Although varying shades of brown typify most melanocytic lesions, striking aspects of dark brown to black, blue-gray, red, and gray-white (which may represent regression) may be found in melanoma. SSM is the subtype of melanoma most commonly associated with preexisting nevi. The history of SSM is often of a lesion slowly changing over months to years. It may be mistaken for an atypical nevus or seborrheic keratosis.

NODULAR MELANOMA (NM)

NM is the second most common melanoma subtype and accounts for approximately 15% to 30% of all melanomas. The trunk is the most common site. NM is remarkable for rapid evolution, often arising over several weeks to months. NM more often lacks an apparent radial growth phase. It is more common

Figure 116-2 Clinical subtypes of melanoma: **A, B,** Superficial spreading melanoma, in **A** with extensive signs of regression (whole center of the lesion); **C,** ulcerated amelanotic nodular melanoma; **D,** pigmented nodular melanoma; **E,** lentigo maligna melanoma; **F,** acral lentiginous melanoma; **G,** subungual melanoma with melanonychia striata; **H,** ulcerated desmoplastic melanoma.

Figure 116-2 (*Continued*)

for NM to begin de novo than to arise in a preexisting nevus. NM typically appears as a uniformly dark blue-black or bluish-red raised lesion, but 5% are amelanotic (Fig. 116-2C,D). Early lesions often lack asymmetry, have regular borders, and are a uniform color. Amelanotic lesions may be mistaken for basal cell carcinoma, pyogenic granuloma, or hemangioma, whereas pigmented lesions may be mistaken for blue nevi or pigmented basal cell carcinomas. SSM and NM have the highest rate of mutations in the *BRAF* gene, with up to 56% of the melanomas harboring this alteration.[8] There is also an association with multiple melanocytic nevi.

LENTIGO MALIGNA (LM) AND LENTIGO MALIGNA MELANOMA (LMM)

LM is a melanoma in situ with a prolonged radial growth phase that eventually becomes invasive and is then called LMM. LMM constitutes 10% to 15% of cutaneous melanomas. LM and LMM are diagnosed most commonly in the seventh to eighth decades in an older population than other types of melanoma—uncommon before the age 40. The most common location is on the chronically sun-exposed face, on the cheeks and

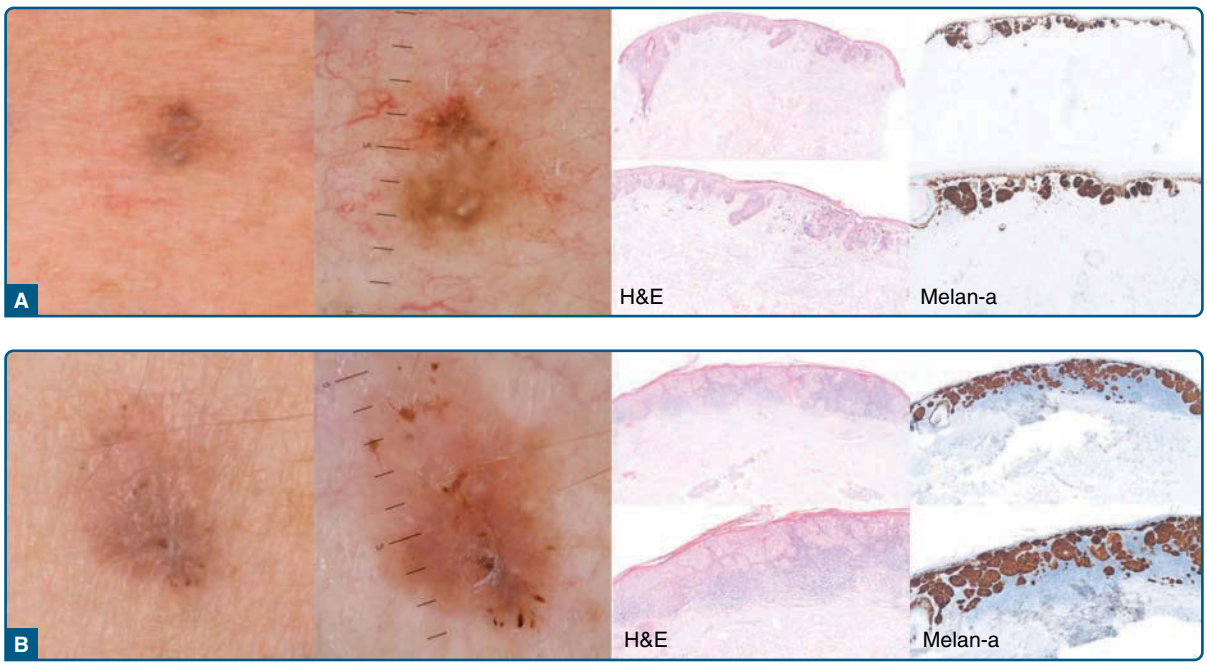

Figure 116-3 Clinical, dermoscopic and histologic presentation of 2 superficial spreading melanomas (**A, B**).

nose in particular; the neck, scalp, and ears in men. Its pathogenesis is thought to be related to cumulative sun exposure rather than intermittent exposure. Clinical appearance is an initially flat, slowly enlarging, brown, frecklelike macule with irregular shape and differing shades of brown and tan, usually arising in a background of photodamage (Fig. 116-2E). Both LM and LMM often have clinically ill-defined borders, which may be obscured by background actinic damage consisting of lentigines, pigmented actinic keratoses, or ephelides. LM and LMM are associated with significantly higher rates of extensive subclinical lateral growth, resulting in higher recurrence rates with standard recommended margins and failure to completely excise the lesion. LM and LMM have the least common association with nevi, at 3% of cases, but the highest rate of association with desmoplastic melanoma (DM, see below). Molecularly, melanomas occurring in sun-damaged skin carry *c-KIT* aberrations (mutations and copy number changes) more frequently than *BRAF* mutations, with up to 28% versus 6%.[9]

ACRAL LENTIGINOUS MELANOMA (ALM)

ALM is a subtype of melanoma with distinct differences in frequencies seen between ethnic groups. ALM constitutes only 2% to 8% of melanomas in whites but represents the most common form in darker-pigmented individuals (60% to 72% in African Americans and 29% to 46% in Asians). Although the proportion of ALM seen in darker-pigmented individuals is higher, the incidence of ALM is similar between whites and other ethnicities. ALM is diagnosed more often in an older population, with the median age of onset of 65. The most common site for ALM is the sole, with the palm and subungual locations following (Fig. 116-2F). The clinical appearance of ALM is mainly brown to black, but red with variegations in color and irregular borders can occur. Often ALM are misdiagnosed first as a plantar wart or hematoma, leading to a more advanced lesion upon diagnosis associated with poorer outcomes. ALM is not thought to be associated with sun exposure.

Subungual melanoma, considered a variant of ALM, generally arises from the nail matrix, most commonly on the great toe or thumb (Fig. 116-2G). It appears as a brown to black discoloration or growth in the nail bed (Table 116-1). A widening, dark, or irregularly pigmented longitudinal nail streak (melanonychia striata) with or without nail dystrophy and nail plate elevation may be seen. Hutchinson sign, the finding of pigmentation on the proximal nail fold, may be noted with subungual melanoma. Benign lesions that mimic subungual melanoma include benign longitudinal melanonychia, subungual hematoma, pyogenic granuloma, or even onychomycosis with pigmentation or hemorrhage.

In acral melanoma, the most frequent targetable mutation is the *BRAF* mutation (21%), followed by a *c-KIT* mutation (13%)[10]—*c-KIT* aberrations including copy number changes are higher, with up to 36% but with questionable clinical significance.[9]

TABLE 116-1
When to Consider Malignancy in Pigmented Nail Lesions

- Lesion is isolated on a single digit
- Occurrence in the fourth to sixth decade
- Abrupt pigmentation in a previously normal nail plate
- Pigmentation appears darker, larger, or blurred towards the nail matrix (proximally)
- Acquired pigmentation of the thumb, index finger, or large toe
- Pigmentation occurring after a history of trauma, after ruling out subungual hematoma
- Individual with a history of melanoma
- Pigmentation associated with nail dystrophy, or absence of nail plate
- Pigmentation extending to the periungual skin (Hutchinson sign)

Braun R, Baran R, Frederique A, et al. Diagnosis and management of nail pigmentations. *J Am Acad Dermatol.* 2007;56(5):835-847.

DESMOPLASTIC MELANOMA (DM)

DM most commonly develops in the sixth or seventh decade on sun-exposed head and neck regions. The lesions typically have a firm, sclerotic, or indurated quality, and one-half are amelanotic (Fig. 116-2H). Approximately half of the lesions arise in association with the LM histologic subtype. Although often deeply invasive at the time of diagnosis with a tendency to perineural growth, DM is associated with higher local recurrence but lower nodal metastatic rates than other subtypes of melanoma when matched for depth of invasion. Results from a small study that involved 10 samples that investigated gene expression profiling demonstrated a molecular distinction between DM and nondesmoplastic melanoma.[11] DMs reveal a high mutation burden most likely induced by UV radiation. *BRAF* and *NRAS* mutations are not found; instead, other genetic alteration known to activate the MAPK signaling cascade were identified, for example, mutations in neurofibromin (NF1) in more than 90% of cases.[12,13]

MUCOSAL MELANOMA

Melanoma can infrequently (1.3% of melanomas) arise on mucosal surfaces on the head and neck (conjunctival, intranasal, sinus, and oral cavities), genital, anorectal, or even urethral mucosa (Fig. 116-4).[14] With the exception of the conjunctiva, patients present most often with delayed detection and a deeply pigmented, irregular lesion, often tumorous with signs of bleeding. As most of these lesions present initially with a radial growth phase manifesting a macular pigmentation, any suspicious area in these sites should be biopsied. Lesions of the conjunctiva are visible and appear increased in patients with atypical nevi.[15] Mucosal melanomas are more frequent in women, especially

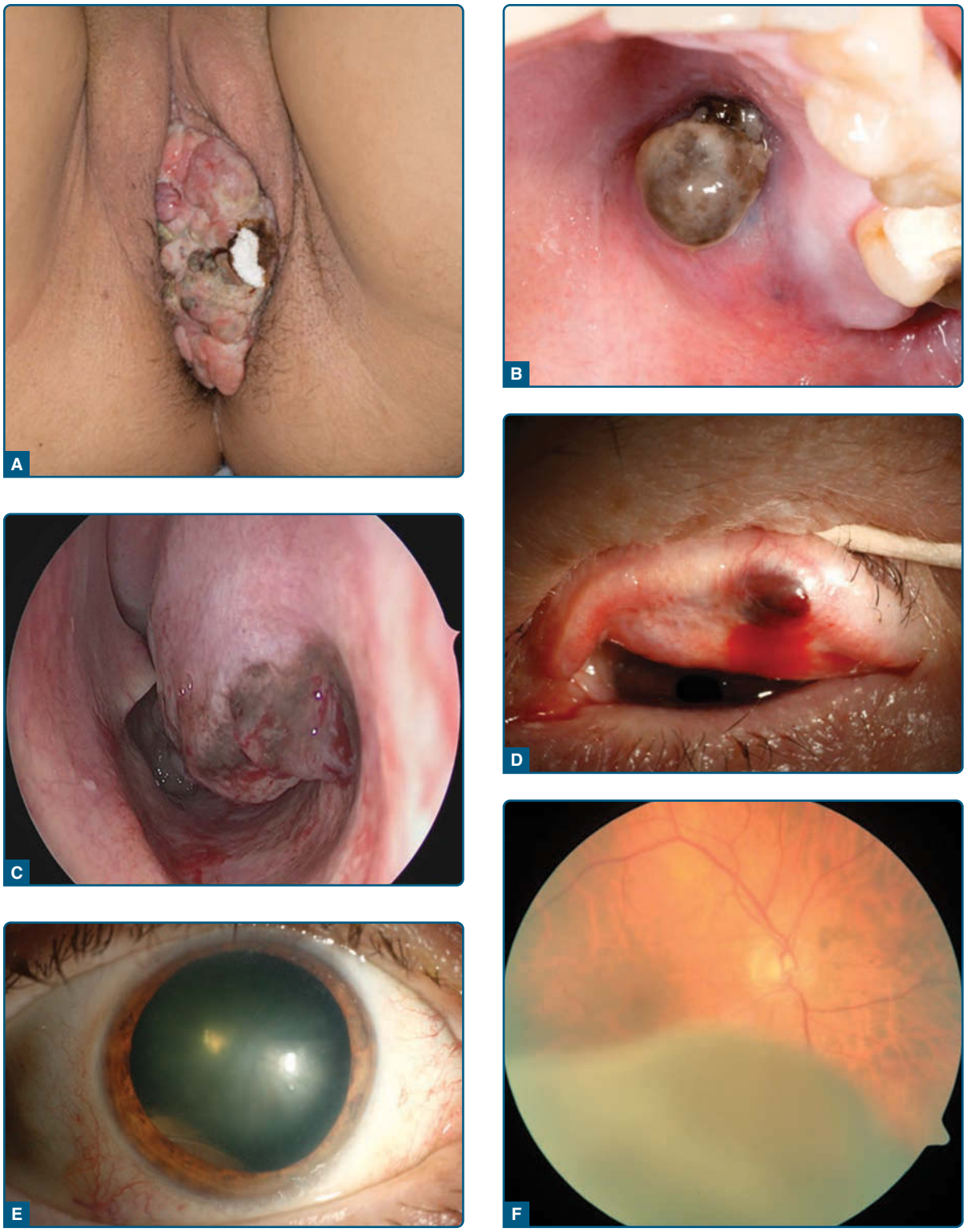

Figure 116-4 Mucosal melanomas: **A,** Introitus vaginae; **B,** gingiva; **C,** intranasal; **D,** conjunctiva; **E, F** uveal melanoma. (**A-C,** With friendly permission to publish from J. Thierauf, Department of ENT, University Hospital Heidelberg; **D-F,** Permission to publish from A. Scheuerle, Department of Ophthalmology, University Hospital Heidelberg.)

based on the genital tract melanomas. Melanomas on vulva and vagina account for about 50% of the mucosal melanomas among women. In both genders, the nasal cavity was otherwise the most frequent location for mucosal melanomas. Anorectal melanomas account for only 16.5% of mucosal melanomas.[14]

Mucosal melanoma differs from cutaneous melanoma on the molecular level. Besides NF1, the most

frequently occurring driver mutations are RAS alterations, consisting of *NRAS* and *KRAS* mutations with a frequency between 5% and 30% that lead to an activation of the MAPK pathway similar to BRAF mutations. Less than 10% of mucosal melanomas harbor *BRAF* mutations.[16-18] Only in mucosal melanomas of vulvovaginal origin, the mutation frequency is higher, with up to 26% for BRAF and lower for RAS.[19] More frequent than in cutaneous melanoma, mutations of the receptor tyrosine kinase c-kit can be found with varying frequencies in between 5% and 20% of mucosal melanomas.[9,16,17] Here, frequency again seems to be higher in tumors of vulvovaginal or anorectal origin, compared with other sites.[19,20] This mutation is targetable with multi-kinase inhibitors such as imatinib[21]; however, the mutation status of the tumors showed no association with patients' survival outcomes.[17]

NEVOID MELANOMA

Nevoid melanoma describes a heterogeneous group of rare lesions that histologically resemble benign nevi by their symmetry and apparent maturation with descent in the dermis, thus with greater potential for misdiagnosis. Clues to their histologic diagnosis include marked hyperchromasia of the nuclei of the tumor cells, the presence of mitoses, and expansive growth of the dermal cells. Clinically, this may correspond to a tan papule or nodule, more often >1 cm in diameter on a young adult.[22]

SPITZOID MELANOMA

Spitzoid melanoma is a subtype of melanoma that clinically and histologically resembles a Spitz nevus, but tends to be larger and have asymmetry and irregular coloration. Features that favor the diagnosis of a Spitzoid melanoma over a benign Spitz nevus are large size (greater than 1 cm in greatest dimension); lesions with a thick invasive component (>2 mm Breslow thickness); lesions with numerous mitoses (especially any atypical forms), many cytologically atypical cells, and lesions that have a clinically concerning course such as very rapid growth in size or satellitosis. Clinical and histologic distinction between the two is often extremely difficult, and tumors with overlapping features of Spitz nevi and melanoma are classified as atypical Spitz tumors of uncertain biologic behavior (AST).[23]

Whereas common acquired nevi and melanoma often harbor *BRAF* mutations, *NRAS* mutations, or inactivation of NF1, Spitz tumors show *HRAS* mutations, inactivation of *BAP1*, or genomic rearrangements involving kinases like ALK, ROS1 and others. Additional genomic aberrations may abrogate various tumor-suppressive mechanisms and lead to atypia and malignant transformation. Comparative genomic hybridization (CGH) is generally able to differentiate Spitz tumors of benign or malignant behavior and may help classify the histologically ambiguous tumors, that is, the AST.[24]

OTHER RARE TYPES

Several other rare and unusual types of melanoma are beyond the scope of this chapter, but previously reported in a comprehensive review, which include metaplastic melanoma, balloon cell melanoma, signet-ring cell melanoma, myxoid melanoma, rhabdoid melanoma, animal-type melanoma, and malignant blue nevus.[22,25]

NONCUTANEOUS FINDINGS

Although most melanomas develop on the skin, there are rarer types of noncutaneous melanomas arising from extracutaneous melanocytes, for example, in the choroidea. In addition, mucosal melanomas (see before) are defined as noncutaneous melanomas as they can occur at mucosa of the ear, nose, and throat (ENT) region, intestine, or urinary tract. Melanomas of unknown primary that most often are diagnosed with lymph node metastases might develop from nodal nevi.[1] As nodal nevi only occur in skin draining lymph nodes, the precursor lesion here might be nevus cells that escaped from melanocytic nevi of the skin.[26,27]

UVEAL MELANOMAS

Uveal melanomas account for about 5% of all melanomas and develop mainly in the choroid, followed by ciliary body and iris of the eye.[28] Nevertheless, uveal melanoma is the most common primary intraocular malignancy. The median age at diagnosis is 58 years. Risk factors include the presence of a choroidal nevus, a nevus of Ota, and dysplastic nevus syndrome. There is an 8 times higher incidence rate in whites as compared to the black population, leading to the hypothesis that UV exposure increases the risk for uveal melanoma, but this has not been definitely proven.[14] Clinically most patients present with painless loss or distortion of vision or the tumor is diagnosed in asymptomatic patients in routine ophthalmic screening. The risk of metastases could be linked to chromosomal aberrations. Patients with monosomy 3 (about 50% of patients) had a much poorer clinical outcome, with a disease-specific mortality of 75.1% for patients with monosomy 3 and 13.2% for patients with disomy 3 after 5 years, respectively.[29] Patients usually die from liver metastases, the primary metastatic site in uveal melanoma probably based on the microenvironment in the liver that seems to support growth of the metastases there, for example, by secretion of the hepatocyte growth factor (HGF).[30]

COMPLICATIONS

If complications occur with melanoma, they are usually based on *metastatic disease* within organs leading to symptoms associated with the affected organ.

These include pain (any metastases), convulsion (brain metastases), instabilities (bone metastases), etc and later on all the symptoms associated with progression of the disease and death in the palliative setting.

Relatively frequent *cutaneous changes* associated with melanoma are localized or diffuse hypo- or hyperpigmentation. The development of a melanoma-associated vitiligo as an accompanying autoimmune disease against melanocytes is reported to occur in up to 4% of patients and is associated with a better prognosis.[31] Vitiligo has become especially frequent in patients treated with immune checkpoint blockers, and is also correlated with a better treatment response.[32] In highly advanced patients, a diffuse cutaneous melanosis can occur that is characterized by a slate-grey pigmentation over the entire skin surface, mucosal membranes, and internal organs, with accentuation in photo-exposed areas. Such cases are often associated with melanuria, a darkening of the urine. Histopathologically, melanin deposits in the connective tissue and within macrophages in a perivascular distribution can be found. These most likely come from ischemic metastases distributed through the body via the blood.[31]

Rare complications based on *paraneoplastic mechanisms* described like dermatomyositis (Chap. 62)[31] and autoimmune retinopathies also occur.[33] Melanoma-associated retinopathies (MAR) present after the melanoma has been diagnosed as metastatic and are more frequent in men. Patients may develop vision problems years later, leading to latency from melanoma diagnosis to recognition of MAR on average after 3.6 years. Pathophysiologically, antiretinal antibodies against different structures like the bipolar cells, transducing, rhodopsin, and others can be found.

ETIOLOGY AND PATHOGENESIS

There are several risk factors for melanoma, with sun exposure and genetics being the 2 most important ones. Risk prediction models reveal in detail that the number of nevi, presence of freckles, history of sunburn, hair color, and skin color are the best measures to estimate melanoma risk.[34,35] All these factors are influenced by the genetic background leading to a certain photosensitivity.

SUN EXPOSURE

There is clear convincing evidence that sun exposure, and more specifically ultraviolet (UV) exposure, is a major environmental cause of melanoma, especially in high-risk populations. However, certainly not all melanomas are sun related. Bastian and others suggested a molecular classification for melanoma based on the hypothesis that clinical heterogeneity is explained by genetically distinct types of melanoma with different susceptibility to ultraviolet light.[8] Epidemiologic studies suggest that periodic, intense sun exposure (particularly during the critical time period of childhood and adolescence) rather than long, continued, heavy sun exposure is most important in melanoma causation, termed the *intermittent exposure* hypothesis. Sunburn history, notably blistering and peeling burns, serves as a surrogate measure of intermittent intense sun exposure. In most melanoma risk prediction models, the history of sunburns is an important risk factor, not just in childhood,[34-36] that is, the more sunburns in a lifetime, the higher the melanoma risk. One blistering sunburn in childhood more than doubles a person's chances of developing melanoma later in life.[37]

The anatomic distribution of melanoma by body site demonstrates that intermittently exposed skin areas have the highest rates of developing melanoma. In men, the trunk, particularly the upper back, is the most common site for melanoma. In women, the lower legs, followed by the trunk, are the most common sites.[38] These intermittently exposed areas are the most common areas to develop melanoma in younger persons. In older persons, there is a greater incidence of melanomas located on chronically exposed areas with maximal cumulative sun exposure. The face is the most common location for melanoma in older persons, with the addition of the neck, scalp, and ears as well, in older men.[39]

Several forms of artificial light have been associated with the development of melanoma, particularly psoralen and UVA light (PUVA) and UVB as well as tanning booths. The so-called *PUVA Follow-up Study* demonstrated increased rates of melanoma after PUVA exposure, with an incidence rate ratio of 9.3 approximately 20 years after PUVA therapy; these rates increase over time and are higher in patients exposed to high cumulative doses of PUVA.[40] However, in 2 European cohorts of PUVA-treated patients, there was no increased risk for melanoma detected in contrast to nonmelanoma skin cancers such as squamous and basal cell carcinomas.[41] There is also rising concern over tanning beds and melanoma risk, especially because exposure to the artificial UV radiation is intermittent in nature. Any exposure to artificial tanning devices significantly increases the risk of cutaneous melanoma, and longer duration of bed use, younger age at first exposure, and higher frequency of use are associated with a significantly elevated risk (odds ratio 1.69).[42] Moreover, indoor tanning also has been associated with accelerated skin aging and ocular melanoma.[43]

Pathophysiologically, DNA-damaging, carcinogenic, inflammatory, and immunosuppressive properties of UV radiation contribute to initiation, progression, and metastasis of primary melanoma.[37,44] UV-A (320 to 400 nm) and UV-B (280 to 320 nm) have a significant impact, with UV-B directly damaging the DNA and UV-A mainly by the production of reactive oxygen species (ROS). The final proof of the carcinogenic property of UV on melanoma development was given by a large Australian clinical trial. In 1992, a total of 1621 randomly selected residents from Queensland between

25 and 75 years of age were randomly assigned to daily or discretionary sunscreen use to head and arms until 2006. Ten years after trial cessation, the rate of primary melanomas was halved in the daily sunscreen group, with 11 new primary melanomas instead of 22 in the discretionary sunscreen group.[45]

SKIN PHENOTYPE

Light skin pigmentation, blond or red hair, blue or green eyes, prominent freckling tendency, and tendency to sunburn with Fitzpatrick skin phototype I–II are phenotypic features associated with an increased risk of melanoma of 2- to 3-fold.[34,46] Melanoma occurs much less frequently in Type V–VI skin, suggesting that skin pigment plays a protective role. This is explained of course by different photosensitivity and ability to tan.

MELANOCYTIC NEVI

There is an increased risk of melanoma associated with nevi, both in a quantitative (ie, number of nevi) and qualitative (ie, typical vs atypical nevi) manner.[34,47] Adults with more than 100 clinically typical-appearing nevi, children with more than 50 typical-appearing nevi, and any patient with atypical nevi are at risk. The presence of a solitary dysplastic nevus doubles the risk of melanoma, while having 10 or more atypical nevi is associated with a 12-fold elevation of risk.[48] Nevi more often serve as a genetic marker of increased risk rather than a premalignant lesion, as most melanomas arise de novo. In a study of 1606 patients with melanoma, only 26% of the melanomas were histologically associated with nevi (43% of these atypical nevi, 57% other nevi).[49] However, sun exposure plays an important role to acquire melanocytic nevi, particularly in early childhood. Hence, the amount of melanocytic nevi as a risk factor for melanoma development is influenced by genetic as well as environmental factors.[47]

There is a recognized risk of melanoma development in large congenital nevi, which varies depending on the size of the lesion.[50,51] Many series define large congenital nevi as greater than 20 cm in diameter in adulthood, and lifetime risks for developing melanoma are generally accepted to be in the 2% to 10% range. In a large review of more than 2500 patients with a large congenital melanocytic nevus, 2% developed a melanoma at a median age of 12.6 years (range birth to 58 years). In 74% of patients, the melanocytic nevus was greater than 40 cm in diameter, and 94% had satellite nevi.[51] Patients with large congenital nevi located on the posterior axis (paraspinal, head, and neck regions) or in conjunction with multiple satellite lesions are at risk for neurocutaneous melanosis, with an increased risk of developing melanoma in the CNS. Melanomas developing on large congenital nevi are usually detected late and hence have a bad prognosis, with more than 50% of them being fatal.[51] For small- to medium-sized congenital nevi, the melanoma risk is similar to any other area of skin.[50] Thus, prophylactic excision of small- and medium-sized congenital nevi is usually unwarranted.

TABLE 116-2
Genes Associated with Melanoma

CDKN2A
p16
CDK4
POT1
TERT
BAP1
BRAF
NRAS
HRAS
NF1
c-KIT

FAMILY HISTORY

Patients with familial melanoma are estimated to account for approximately 5% to 12% of all patients with melanoma.[46] Having one first-degree relative with melanoma doubles the risk of melanoma, whereas having 3 or more first-degree relatives with melanoma increases the risk 35- to 70-fold.[52] Some of this risk may be attributed to shared risk factors such as skin phenotype, multiple nevi, and excessive sun exposure. The association between familial melanoma and multiple atypical nevi has historically been given various names, including *B-K mole* syndrome*, *familial atypical multiple mole-melanoma syndrome*, and *dysplastic nevus syndrome*. Patients with familial melanoma typically have earlier-onset melanoma and multiple primaries as well as atypical nevi. In addition, patients with familial melanoma have an increased risk of internal cancers, such as pancreatic cancer or CNS tumors.[46]

Different genes are responsible for the development of inherited melanoma (Table 116-2) and genetic alterations typically increase cancer risk via 3 major mechanisms: the activation of oncogenes, the loss of tumor suppressor genes, or increased chromosomal instability. Inherited mutations in *CDKN2A*, *CDK4*, *POT1*, and *TERT* confer a 60% to 90% lifetime risk of melanoma.

CDKN2A-CDK4-TP53 PATHWAY MUTATIONS

Germline mutations in the chromosome 9p21 tumor suppressor gene, cyclin-dependent kinase inhibitor 2A (*CDKN2A*), account for approximately 40% of hereditary melanoma cases (≥3 melanomas in one lineage). In countries with high levels of UV exposure, the lifetime melanoma risk in carriers of the *CDKN2A* mutation

*B-K=initials of the first 2 described related patients.

is 76% (United States) and 91% (Australia), whereas the risk is lower in countries with low levels of UV exposure (58%, United Kingdom).[46] Individuals with germline *CDKN2A* mutations also exhibit a higher risk of pancreatic cancer; an estimated 15% of individuals with a mutant allele will develop pancreatic cancer in their lifetime.[53] Bona fide deleterious point mutations in *CDKN2A* are relatively uncommon in primary melanoma tumors although homozygous deletions of this gene may obscure the true rate of somatic loss in melanoma. *CDKN2A* encodes 2 gene products: p16 (also known as *INK4a*, inhibitor of kinase 4a) and $p14^{ARF}$ (alternative reading frame). p16 is a cell-cycle regulator that binds and inhibits cyclin-dependent kinases Cdk4 or Cdk6, thereby inhibiting progression of cells through the G1 phase of the cell cycle (Fig. 116-5). If p16 function is absent or inactivated by mutation, unrestrained Cdk4 activity phosphorylates the retinoblastoma protein, thereby releasing the transcription factor E2-F and inducing S-phase entry. This sequence culminates in enhanced cellular proliferation, which, in the absence of checkpoint regulation, results in unrestrained growth and neoplasia.

The binding partner of the p16 protein is Cdk4. Only a handful of families worldwide thus far have been reported to carry hereditary mutations in *CDK4*, while somatic mutations in this gene also have been detected in some melanoma cell lines. Functional studies suggest that mutations in Cdk4 render the cyclin-dependent protein kinase resistant to p16 inhibition, resulting in a phenotype identical to that from p16 loss.

The $p14^{ARF}$ protein from *CDKN2A* inhibits a cellular oncogene Hdm2, which in turn accelerates the destruction of the p53 tumor-suppressor gene.[54] Complete loss of *CDKN2A* also leads to abrogation of $p14^{ARF}$ and loss of p53 function. Thus, this single locus can inactivate both the retinoblastoma protein and p53 pathways and probably explains the low rate of direct *TP53* mutagenesis in melanoma.

GENES INVOLVED IN TELOMERE MAINTENANCE

POT1 and TERT mutations are prevalent in 9% of patients with hereditary melanoma and, when normally functioning, contribute to protection of exposed chromosomal ends.[46] Increased TERT activity may allow unlimited cell division and subsequently promote cancer progression.

DIAGNOSIS

Early detection is the key to improving prognosis in melanoma, as the risk of metastases increases with infiltration depth of the primary. Although melanoma may have a characteristic appearance, there is no single clinical feature that ensures or excludes a diagnosis of melanoma. Change in color and increase in size (or a new lesion) are the 2 most common early characteristics noticed by patients that may be useful in discriminating between melanoma and other benign lesions.[55]

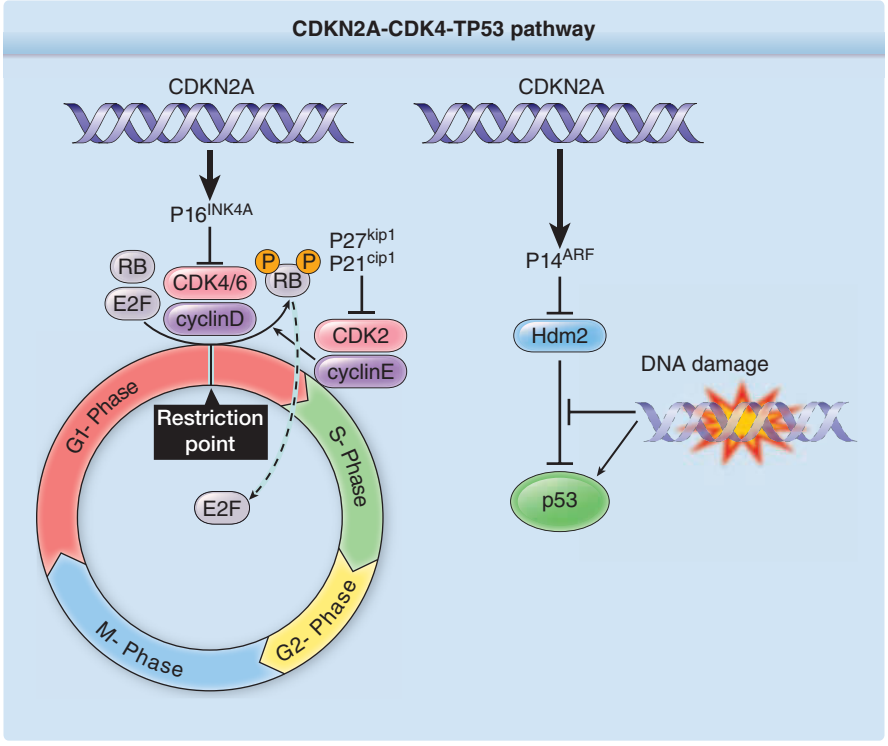

Figure 116-5 Mutations in the tumor suppressor gene *CDKN2A* account for approximately 40% of hereditary melanoma cases and lead to a loss of cell cycle control (**A**) and antiapoptosis (**B**).

PHYSICAL EXAMINATION

The skin examination should be conducted under optimal lighting and encompass the entire skin integument, including the scalp, external ocular/conjunctivae, oral mucosa, groin, buttocks, and palms/soles/web spaces. Melanomas in hidden anatomic sites are associated with thicker tumors at diagnosis, often as a result of later detection.[56] Clinical diagnosis of melanoma can be made in about 80% to 90% of cases. The well-known *ABCDE acronym* for melanoma detection continues to be a useful tool for the lay public and physicians.[57,58] *A* stands for asymmetry (one half is not identical to the other half), *B* for border (irregular, notched, scalloped, ragged, or poorly defined borders as opposed to smooth and straight edges), *C* for color (having varying shades from one area to another), *D* for diameter (ie, greater than 5 mm), and *E* for evolution (changes in the lesion over time). Lesions having these characteristics may potentially represent melanoma. Studies have found the sensitivity of the ABCDE checklist (Table 116-3) to be very high, but the specificity much lower.[59]

Another diagnostic aid that is useful in detecting melanoma is the "ugly duckling" sign.[60] A pigmented lesion that is different from other pigmented lesions on a particular individual should be approached with a high index of suspicion. This is based on the premise that within an individual, nevi should globally share a common appearance or family resemblance. Even in an individual with multiple atypical nevi, the nevi should be morphologically similar.

DERMOSCOPY

Dermoscopy (also known as *epiluminescence microscopy, dermatoscopy, incident light microscopy*, and *surface microscopy*) is a noninvasive technique in which a handheld device is used to examine a lesion through a film of liquid (eg, immersion oil), using nonpolarized light (contact dermoscopy), or the lesion is examined under polarized light without a contact medium (noncontact dermoscopy). In experienced hands, it may improve both the sensitivity and specificity for the clinical diagnosis of melanoma and other pigmented and nonpigmented lesions.[61,62] Morphologic features (Table 116-4) that are otherwise not visible to the naked eye are observed using this technique that allows visualization of microstructures of the epidermis, the dermoepidermal junction, and the papillary dermis (Fig.116-3).

Different diagnostic algorithms using dermoscopic findings have been developed for melanoma, including the ABCD rule, the 7-point checklist, pattern analysis, Menzies method, modified ABC-point list, and CASH (color, architecture, symmetry, and homogeneity).[63-66] Several studies have compared these methods to determine the most effective method for dermoscopic detection of melanoma.[63,64] Pattern analysis, which provides an overall impression of multiple dermoscopic patterns without rigid rules, based primarily on a subjective, simultaneous evaluation of a number of different criteria, is the most widely used method among experienced users of dermoscopy for evaluating pigmented lesions.[67]

Digital dermoscopy or digital epiluminescent microscopy permits computerized digital dermoscopic images to be retrieved and examined at a later date so that comparisons can be made and changes detected over time. There are also a number of commercially available automated computer image analysis programs, devices that incorporate image analysis algorithms to digital dermoscopic images, providing objective measurement of changes over time. Sequential digital dermoscopy was shown to improve early diagnosis of melanoma compared to standard dermoscopy.[68,69]

The use of body or lesional photography can help to monitor minor changes in melanocytic lesions, particularly in patients with many nevi. Finally, confocal scanning laser microscopy and multispectral digital dermoscopy are among a number of new imaging techniques being evaluated for early detection of melanomas.[70,71]

TABLE 116-3
ABCDE Checklist[a]

- A = Asymmetry
- B = Border
- C = Color
- D = Diameter
- E = Evolution

[a]Does not apply to nodular or desmoplastic melanoma.

TABLE 116-4
Dermoscopic Features of Melanoma

- Atypical pigment network
- Negative network
- Atypical dots or globules
- Irregular streaks
- Regression structures
- Blue-white veil
- Shiny white lines
- Atypical blotch
- Polymorphous vessels

Data from Wolner Z, Yelamos O, Liopyris K, et al. Enhancing skin cancer diagnosis with dermoscopy. *Dermatol Clin*. 2017;35(4):417-37.

HISTOLOGY

Patients with lesions clinically suspicious for melanoma should, whenever possible, undergo prompt excisional biopsy with narrow margins. A wider margin should be avoided to permit the most accurate

subsequent SLNB if indicated.[72] However, if the lesion is large and/or located on anatomic areas such as the palm/sole, digit, face, or ear, an incisional skin biopsy may be performed in the most elevated or darkest area of the lesion, with a strong appreciation that the clinically most suspicious area may not always correlate with the thickest portion of the lesion. There is no evidence that biopsy or incision of a primary melanoma leads to "seeding" of tissue and adversely affects survival.[73] Excisional biopsy performed after incisional biopsy of melanoma with ≥50% of the lesion remaining resulted in significant upstaging in 21% of patients, and change in SLNB consideration in 10% of patients in one large study.[74] Hence, a wider margin should be taken after complete excision with narrow margins and histologic evaluation of the whole lesion.

Excisional biopsy, if possible, is important because symmetry of the whole lesion is one major criterion in differentiating a benign melanocytic nevus from melanoma. The histologic diagnosis of melanoma is based on the assessment of a constellation of findings, including both architectural and cytologic features. No single feature is diagnostic. The major architectural features of melanoma include asymmetry, poor circumscription (cells at the edge of the lesion tend to be small, single, and scattered rather than nested), and large size (>5 to 6 mm). Nests of melanocytes in the lower epidermis and dermis tend to vary in size and shape, and to become confluent. There is a lack of maturation of nests with descent into the dermis. In addition, single melanocytes dominate over nests and show an aberrant distribution (Fig. 116-3).[75] The presence of melanocytes above the basal layer (pagetoid spread), usually considered diagnostic of melanoma in situ, should be assessed cautiously in the context of other findings, as pagetoid spread may be seen in benign lesions including Spitz nevi and nevi in special anatomic regions (vulvar nevi, acral nevi). The different subtypes of melanoma may also have histopathologic differences (Fig. 116-6), especially DM, which is composed of strands of elongated, spindle-shaped cells that often infiltrate deeply in a sarcomatoid pattern.

Immunohistochemistry may be useful for the diagnosis of melanoma, especially in poorly differentiated neoplasms with little or no pigment (ie, amelanotic melanomas), spindle cell tumors, or tumors with pagetoid spread that are not obviously melanoma. S100 and Sox10 proteins are expressed by almost all melanomas,

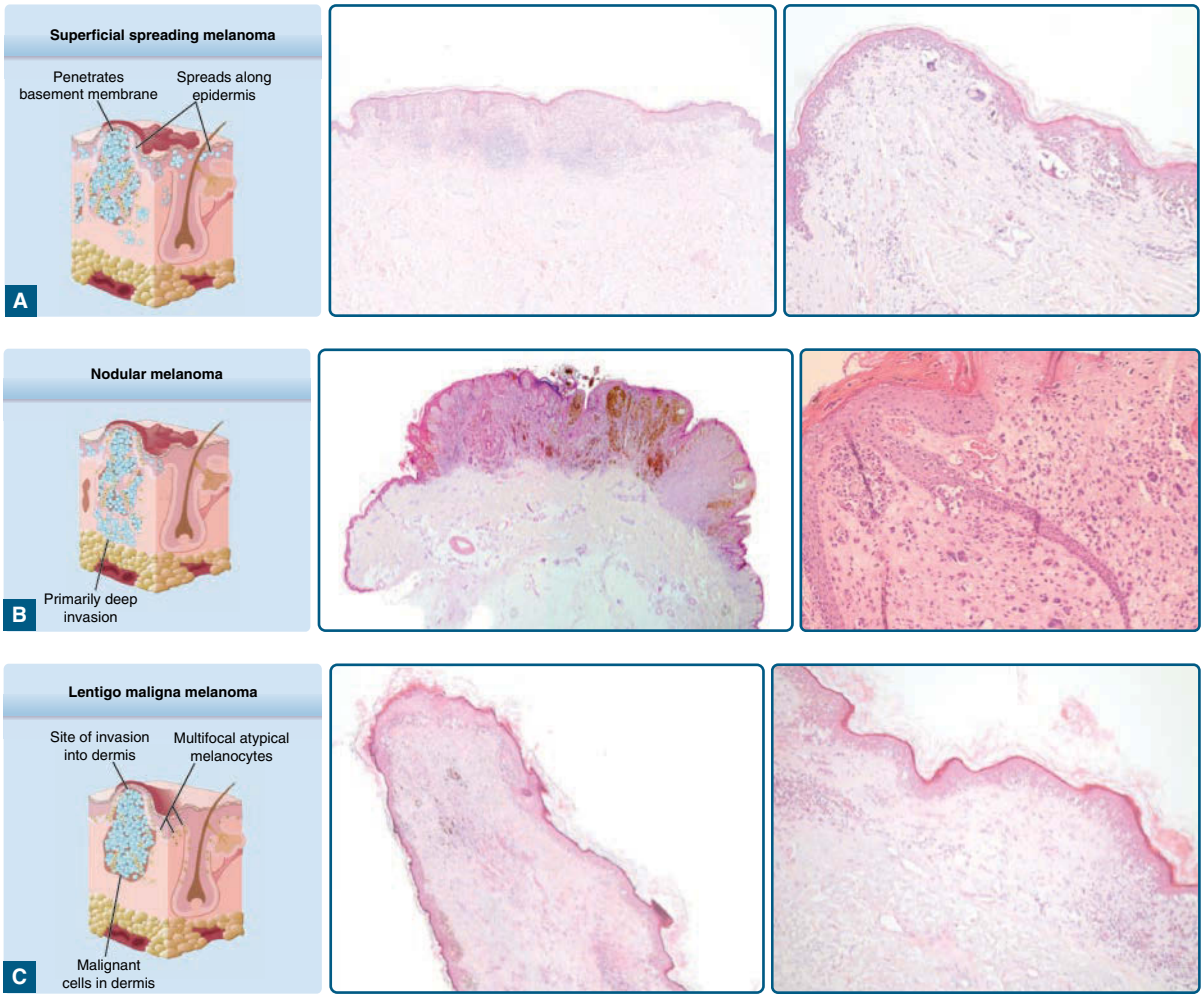

Figure 116-6 Histologic appearance (schematic, histopathologic overview, and close-up) of superficial spreading melanoma (**A**), nodular melanoma (**B**), and lentigo maligna melanoma (**C**).

but also by melanocytic nevi, and other tumor types, including cutaneous neural tumors. HMB-45 is a monoclonal antibody with high specificity for melanoma cells. Melan-A and MART-1 (melanoma antigen recognized by T cells) are the names given independently to the same gene encoding a melanocytic differentiation antigen expressed in the skin and retina. Melan-A is broadly expressed in benign and malignant melanocytic lesions. It is more sensitive than HMB-45 and more specific than S100 for melanoma. Search for the microphthalmia-associated transcription factor (MiTF) may be useful, especially in amelanotic melanomas, as it is a marker in the nucleus, whereas all other markers are mainly intracytoplasmic.[76] Immunohistochemically, DMs commonly express only S100 and Sox10[77] and lack other melanocytic markers like HMB-45, Melan-A, and MiTF.

In nevoid melanomas staining for the proliferation rate, for example, with Ki-67, might be helpful to uncover malignancy.

In addition to diagnosis, histology gives further clinically important information on the infiltration depth (Breslow thickness) and ulceration status—features needed for AJCC (American Academy of Dermatology) classification and prognostic evaluation.[78] Further diagnostic investigations are stage dependent as the risk to metastasize increases with tumor stage.[78]

LABORATORY TESTING

As early as in 1954, increased levels of lactate dehydrogenase (LDH) were detected in the serum of melanoma patients.[79] Ever since, the value of LDH as a tumor marker for melanoma has been discussed. S100B in the serum is a bit more specific than LDH but lacks sensitivity. For that reason, S100B can be detected and monitored in clinical followup as an additional marker to detect progression of the disease.[80] Hence, blood investigations to measure for tumor markers play a minor role in the diagnosis of melanoma, but are mainly used to monitor the clinical course. Testing of the nonspecific tumor marker LDH is indicated only for patients with distant metastatic disease as it is needed for AJCC classification and prognostic evaluation.[78,81]

Other tumor markers like melanoma-inhibiting activity (MIA), tumor-associated antigen 90 immune complex (TA90IC), and YKL-40 are under investigation and not used in routine clinical practice. It is not clear as of this writing if they add a benefit to S100B and LDH.[79]

IMAGING

REGIONAL SKIN AND LYMPH NODE ULTRASOUND

Patients should be evaluated for regional spread by careful palpation of lymph nodes first, particularly the primary echelon nodal basin(s). The concepts of aberrant lymphatic drainage pathways to unexpected nodal basins and interval nodes located between the primary site and the expected regional nodal basin have taught physicians to search for clinically detectable nodal disease in unexpected locations.[82] Skin and lymph node ultrasonography is perhaps the most sensitive noninvasive method to detect small nodal metastases and is much more sensitive than clinical examination.[83] Lymph node metastases are characterized by a ballooned shape, loss of central echo, and peripheral perfusion.[84] If a lymph node or a dermal/subcutaneous nodule in the regional area of the primary is found, an excisional biopsy should be performed if possible.

TOMOGRAPHY

Routine imaging and hematologic tests in asymptomatic patients rarely identifies occult systemic disease.[85] Tomographic investigations like computed tomography (CT), magnet resonance imaging (MRI) and positron emission tomography (PET) are generally not recommended at the stage of primary melanoma.[86,87] The rate of false positive findings is far too high (8%-15%), for example, unspecific lung lesions,[88] which leads to additional cost of followup studies and possibly invasive procedures, as well as increased patient anxiety. Unfortunately, there are no data demonstrating improved survival rates if metastases are detected when clinically asymptomatic versus early symptomatic stage IV disease. However, especially in high-risk melanomas (>4 mm Breslow thickness), the risk for hematologic spread increases, and tomographic imaging can be justified. Distant metastases are more likely in patients with regional metastases. However, in a retrospective analysis of 185 patients with a positive sentinel lymph node (SLN), only 1 patient (0.5%) had detectable metastatic disease on the imaging. Hence, imaging with CT, MRI, or PET is indicated only in high-risk and known metastatic melanoma and recommended to be performed as clinically indicated. This further emphasizes the importance of a thorough melanoma-focused review of systems and physical examination.

SENTINEL LYMPH NODE BIOPSY (SLNB)

The SLN is per definition the first draining lymph node in the lymphatic draining system of the primary tumor. SLNB is a powerful staging and prognostic tool which may be used to detect occult micrometastases in regional lymph nodes,[89] and represents the best baseline staging test for detection of occult nodal metastasis in the subset of melanoma patients where it is indicated. SLNB is far more sensitive and accurate at detecting microscopic metastases than PET scan, CT scans, or ultrasonographic imaging combined with

lymph node fine-needle aspiration.[85] In a meta-analysis of 34 studies, a Breslow thickness of <1 mm was associated with a positive SLN in 5.6% of patients.[90] This rate was higher (19.5%) in patients younger than 40 years and a tumor with 0.75 to 1 mm thickness as well as in ulcerated primary melanomas and melanomas with detectable mitoses.[91-93] For patients with lesions of a Breslow thickness between 1 and 4 mm Breslow, 25.2% had a positive SLN, whereas those with lesions >4 mm in thickness had a 50% likelihood of SLN positivity.[92,94] Based on this risk stratification, SLNB is recommended in patients with a melanoma ≥1 mm Breslow thickness.[89,90] In addition, it can be offered for patients with thinner melanomas (0.8-1 mm) or even <0.8 mm if additional risk factors such as high mitotic index or lymphovascular invasion exists, especially in the setting of young age.[91]

In current practice, technetium-99–labeled radiocolloid solution, often complemented with vital blue dye, allows for detection of the SLN >98% of the time in skilled hands.[95] Ideally, the procedure should be performed at the same time as wide local excision (WLE) of the primary melanoma for greatest accuracy. SLNB may not be accurate if performed after WLE in areas of ambiguous or surgically altered lymphatic drainage or following a local skin flap due to radiocolloid and dye injection location away from the true primary site.[96] Once removed, the SLN(s) must be assessed with serial sectioning, using standard hematoxylin and eosin (H&E) techniques often combined with immunohistochemical stains such as S100, HMB-45, and/or Melan-A. The use of immunostains increases sensitivity for melanoma and has resulted in the upstaging of up to 10% to 20% of patients.[97] In melanoma, even single melanoma cells in the immunostains of the sentinel define the lymph node as sentinel positive (N1a). In 2006, Morton et al published the third interim analysis of the multicenter sentinel lymphadenectomy trial (MSLT)–I, the first prospective randomized controlled clinical trial of SLNB in melanoma.[98] In this analysis, 1269 clinically node-negative patients with newly diagnosed melanoma 1.2 to 3.5 mm in depth were randomized to wide excision and nodal basin observation versus wide excision and SLNB. Patients with a positive SLN received an immediate complete lymph node dissection (CLND), and patients in the observation arm also received CLND if they developed regional lymph node metastasis. SLN status was demonstrated to be a powerful predictor of survival, as those with a negative SLN had a 5-year survival of 90.2%, versus 72.3% 5-year survival for those with a positive SLN. Recently, results of the DECOG-SLT trial have been published. In this German trial, almost 500 patients with a positive SLN with an at least 1-mm metastasis were randomized to obtain CLND or observation. This led to an improvement in local recurrence rate but did not lead to a survival benefit.[99] Final analysis of both trials confirm these results with no significant benefit of an immediate CLND. Hence, this procedure is not recommended any more in patients with only microscopic nodal disease. However, Sentinel positive patients might be selected for adjuvant therapy.

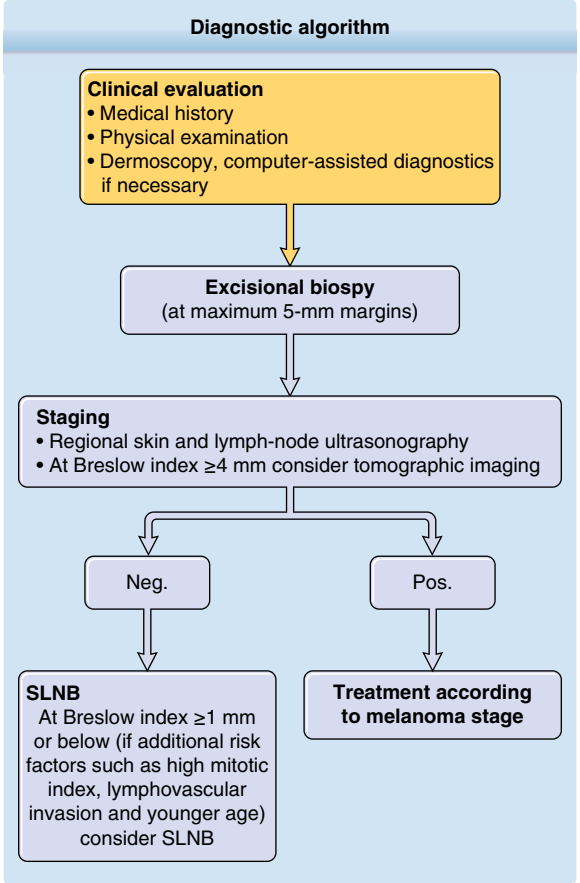

Figure 116-7 Diagnostic algorithm.

DIAGNOSTIC ALGORITHM

See Fig. 116-7.

DIFFERENTIAL DIAGNOSIS

See Table 116-5.

TABLE 116-5
Differential Diagnosis of Melanoma

- Atypical nevus: ABCD criteria help to differentiate
- Seborrheic keratosis: no pigment net in dermoscopy
- Basal cell carcinoma, especially if pigmented: more black than brown, prominent vasculature
- Hemangioma: can be difficult to distinguish from amelanotic melanoma
- Pyogenic granuloma: especially difficult to distinguish from amelanotic acral melanoma
- Solar lentigo, pigmented actinic keratosis, flat seborrheic keratosis: can mimic lentigo maligna melanoma
- Plantar wart: might be hard to distinguish from acral melanoma
- Hematoma: especially acral or subungual hematoma
- Longitudinal melanonychia: look for Hutchinson sign

CLINICAL COURSE AND PROGNOSIS

Melanoma can progress to different stages of the disease, starting with the primary (stage I/II), regional metastases (stage III) and distant metastases (stage IV) (Fig. 116-8). In general, prognosis and survival rates worsen with increasing stage. At initial presentation, approximately 85% of patients have localized disease, 10% have regional metastatic disease, and 5% have distant metastatic disease already.[78]

STAGES I AND II MELANOMA

In general, the 5- to 10-year survival for patients with localized thin primary melanoma <1 mm in Breslow depth is more than 90%. Melanoma typically recurs in a predictable fashion, first in a local and regional distribution, then to distant sites. It is also recognized that melanoma may bypass the regional nodes with direct hematogenous dissemination. The majority of recurrences manifest in the first 5 years after diagnosis and treatment, depending on tumor thickness and other prognostic features of the primary lesion. However, melanoma can recur at any time, and the incidence of late recurrence 10 or more years after initial diagnosis is approximately 1% to 5%.[100]

STAGE III MELANOMA

Stage III melanoma represents a broad range of patients with a diverse clinical outcome, from patients with microscopic nodal disease (IIIA) to patients with bulky clinical nodes or in-transit metastases (IIIC) (Fig. 116-8). The general overall 5-year survival range of 38% to 78% is wide, primarily related to several variables such as the number of positive lymph nodes (most important); tumor burden within a lymph node (microscopic vs macroscopic); age; and ulceration status as well as Breslow thickness of the primary melanoma (Table 116-6).[78] There is a significant decline in survival in melanoma patients who present with clinically evident macroscopic nodal disease versus those with microscopic nodal disease identified via SLNB.

STAGE IV MELANOMA

Melanoma is known for its propensity to metastasize to virtually any organ and also for its highly variable clinical course. Melanoma metastasizes to nonvisceral sites: distant skin/subcutaneous tissue and distant lymph nodes in approximately half of the stage IV cases (42% to 57%) (Fig. 116-8). The most

Figure 116-8 **A,** Patient with stage III disease (primary melanoma with bulky lymph node metastases). **B,** Patient with in-transit metastases. **C,** Patient with stage IV disease and extensive cutaneous metastases.

TABLE 116-6
Melanoma TNM Classifications (AJCC 2017)

T CLASSIFICATION	THICKNESS (mm)	ULCERATION STATUS
T1	≤1.0	a: <0.8 mm without ulceration b: <0.8 mm with ulceration or 0.8-1 mm (with or without ulceration)
T2	1.01-2.0	a: without ulceration b: with ulceration
T3	2.01-4.0	a: without ulceration b: with ulceration
T4	>4.0	a: without ulceration b: with ulceration
N CLASSIFICATION	**NUMBER OF METASTATIC NODES**	**NODAL METASTATIC MASS**
n1	1	a: clinically occult b: clinically apparent c: pure in-transit met(s)/satellite(s) without metastatic nodes
N2	2-3	a: only occult metastases b: at least one clinically apparent metastasis c: in-transit met(s)/satellite(s) with 1 metastatic node (clinically occult or apparent)
N3	≥4	a: only clinically occult metastases b: at least one clinically apparent metastasis c: in-transit met(s)/satellite(s) with at least 2 metastatic nodes (clinically occult or apparent)
M CLASSIFICATION	**SITE**	**SERUM LACTATE DEHYDROGENASE**
m1a	Distant skin or soft tissue including muscles, or nodal metastases	M1a(0): Normal M1a(1): Elevated
M1b	Lung metastases (with or without M1a involvement)	M1b(0): Normal M1b(1): Elevated
M1c	All other visceral metastases without CNS metastases (with or without M1a or M1b involvement)	M1c(0): Normal M1c(1): Elevated
M1d	CNS metastasis (with or without M1a, M1b, or M1c involvement	M1d(0): Normal M1d(1): Elevated

common visceral sites are the lungs (18%-36%), liver (14%-20%), brain (12%-20%), bone (11%-17%), and GI tract (1%-7%). Once metastases to distant sites have been detected, median survival without any treatment is approximately 6 to 9 months. With the help of targeted and immunotherapies this can be increased to 2 years, and even long-term tumor control can be achieved.[101,102]

METASTATIC MELANOMA OF UNKNOWN PRIMARY (MUP)

Metastatic melanoma of unknown primary (MUP) is defined as the presence of histologically confirmed melanoma in a lymph node, visceral site, or distant skin/subcutaneous tissues without a history or evidence of a primary cutaneous, mucosal, or ocular melanoma. This situation occurs in 2% to 5% of all cases of melanoma. Approximately 60% of these involve the lymph nodes and might have developed from nodal nevi.[1] The remaining involve distant sites, typically skin/subcutaneous tissue, and less commonly lung, brain, or GI tract. MUP has similar survival rates compared to equivalently staged cutaneous melanomas of known primary origin. MUP metastatic to lymph nodes had 5- and 10-year survival rates of 46% and 41%, which is comparable to the equivalent stage III melanoma of known primary.[103] Melanoma of unknown primary metastatic to viscera had a median survival of 6 months.[104]

Evaluation of melanoma of unknown primary should involve a complete skin examination looking for a primary site. Wood lamp may be used to identify subclinical hypopigmented areas, which may suggest a regressed primary lesion. In melanoma of unknown primary metastatic to a lymph node, particular attention should be focused on the skin areas that drain to the nodal basin involved. A complete history of previously excised skin lesions should be reviewed. The patient should be referred for proctoscopic, gynecologic, ocular, and nasal mucosal examinations, when warranted. However, only rarely a primary tumor is detectable, and hence more invasive procedures like gastroscopy/colonoscopy should be avoided without any clinical hints for a melanoma at these locations. Staging workup and treatment should be performed as for the equivalent clinical stage of known primary.

THE AJCC CLASSIFICATION

Accurate staging forms the basis for prognosis and treatment, which is invaluable for the majority of patients in their informed decision-making process. The American Joint Committee on Cancer (AJCC) published a revised staging system for melanoma in 2017

TABLE 116-7
Stage Groupings for Cutaneous Melanoma

	CLINICAL STAGING[a]			PATHOLOGIC STAGING[b]		
	T	N	M	T	N	M
0	Tis	N0	M0	Tis	N0	M0
IA	T1a	N0	M0	T1a/b	N0	M0
IB	T1b T2a	N0 N0	M0 M0	T2a	N0	M0
IIA	T2b T3a	N0 N0	M0 M0	T2b T3a	N0 N0	M0 M0
IIB	T3b T4a	N0 N0	M0 M0	T3b T4a	N0 N0	M0 M0
IIC	T4b	N0	M0	T4b	N0	M0
III[c]	Any T	N1 N2 N3	M0			
IIIA				T1a/b– T2a	N1a or N2a N1a or N2a	M0 M0
IIIB				T0 T1a/b–T2a T2b/T3a	N1b/c N1b/c or N2b N1a-N2b	M0 M0 M0
IIIC				T0 T1a–T3a T3b/T4a T4b	N2b/c or N3b/c N2c or N3a/b/c Any N N1a-N2c	M0 M0 M0 M0
IIID				T4b	N3a/b/c	M0
IV	Any T	Any N	Any M1	Any T	Any N	Any M1

[a]Clinical staging includes microstaging of the primary melanoma and clinical/radiologic evaluation for metastases. By convention, it should be used after complete excision of the primary melanoma with clinical assessment for regional and distant metastases.

[b]Pathologic staging includes microstaging of the primary melanoma and pathologic information about the regional lymph nodes after partial or complete lymphadenectomy. Pathologic stage 0 or stage IA patients are the exception; they do not require pathologic evaluation of their lymph nodes.

[c]There are no stage III subgroups for clinical staging.

M, metastasis classification; N, node status; T, tumor size.

From Amin MB et al. *AJCC Cancer Staging Manual*, 8th ed. 2016.

(Tables 116-6 and 116-7).[78,105,106] The 2017 melanoma staging system was obtained from a data set of >46,000 melanoma patients from 10 centers worldwide. This represents the largest body of AJCC melanoma data analyzed in an evidence-based approach and incorporates many patients more accurately staged using SLNB. The *t*umor size, *n*ode status, *m*etastasis classification (TNM) system continues to form the backbone of the staging system, in which T describes the extent or thickness of the primary tumor, N the extent of lymph node metastases, and M the extent of distant metastases. Table 116-6 presents the TNM categories, and Table 116-7 lists the Stage groupings.

CLINICAL PROGNOSTIC FACTORS

GENDER AND AGE

A large number of studies have reported that women have better survival rates than men, even after adjustment for tumor thickness and anatomic site.[107] In addition, increasing patient age portends a worse prognosis with respect to overall survival rates. Males more than 60 years of age have the highest mortality rates from melanoma. Older patients have thicker primaries and a higher proportion of ulcerated melanomas, but even after adjusting for these factors, age appears to be an independent prognostic factor.[108,109] It has been postulated that age may serve as a surrogate for declining host immune defense mechanisms.

PROGNOSTIC FACTORS OF THE PRIMARY MELANOMA

TUMOR THICKNESS (BRESLOW INDEX)

The single most important prognostic factor for survival and clinical management in localized stage I and II cutaneous melanoma is tumor thickness.[78] As originally described by Breslow, thickness is measured from the top of the granular layer of the epidermis to the greatest depth of tumor invasion using an ocular micrometer measured in millimeters. Survival decreases with increasing Breslow thickness. Clark level is an alternate, less accurate method of measuring tumor thickness by the anatomic level of invasion. Clark level of invasion is no longer used in routine staging of melanoma.

ULCERATION

Ulceration correlates with tumor thickness; it occurs infrequently in thin melanomas (6% for melanomas <1 mm) and frequently in thick melanomas (63% for melanomas >4 mm). However, patients with an ulcerated melanoma do much worse than patients with a non-ulcerated melanoma with the same Breslow thickness.[110] Ulceration is an independent prognostic factor for localized melanoma.[78] The presence of ulceration in the primary confers a higher risk of developing advanced disease and lower survival rate and upstages all patients with localized and regional disease (ie, stages I to III [Table 116-6]). The worse prognosis of ulcerated melanoma might be due to the

fact that ulceration may be indicative of a melanoma with different biologic potential.[111] Ulcerated melanomas tend to have increased vascularity and lymphatic and angiogenic metastatic rates, immunosuppressive features, and a gene profile that differs from nonulcerated melanoma. In 2 large European Organization for Research and Treatment of Cancer (EORTC) trials with adjuvant interferon, ulceration was found to be an independent predictive factor for the beneficial effect of the immunotherapy.[111-113] The same was seen for ipilimumab adjuvant in stage III disease.[111]

MITOTIC RATE

Several studies reported the importance of tumor mitotic rate as an independent predictor of survival, with an increasing mitotic rate correlating with decreasing survival.[114] Among patients with clinically localized melanoma, a mitotic rate of 1/mm^2 or greater was described as the second most powerful predictor of survival, after tumor thickness.[78] In the 2009 revised AJCC staging system, the mitotic rate had replaced Clark level of invasion in defining T1b melanomas because when ulceration, tumor thickness, and mitotic rate are accounted for, Clark level was no longer an independent predictor of survival. Mitotic rate may also correlate with SLNB positivity, especially in younger patients.[115] However, in the new classification system based on >46,000 patients the mitotic rate was not an independent prognostic factor any more and hence, does not define clinical staging (Tables 116-6 and 116-7).

ANGIOLYMPHATIC INVASION

Vascular involvement denotes the invasion of tumor cells into the microvasculature in the dermis. Some reports note that vascular invasion significantly increases the risk of relapse, lymph node involvement, distant metastases, and death.[108,115]

MICROSCOPIC SATELLITES

The presence of microscopic satellitosis, in particular, has been consistently reported to correlate with a poorer outcome, and this has been retained in the current AJCC melanoma staging system (Tables 116-6 and 116-7).[78,105] Patients with any satellite metastases, including microsatellite metastases, are considered to have stage III disease even in the absence of nodal metastases (N1c, satellite metastases without nodal metastases).

TUMOR INFILTRATING LYMPHOCYTES (TILs)

TILs in primary melanomas are thought to represent the host antitumor immune response. In the radial growth phase, a brisk host response is commonly present, and this feature may be associated with the appearance of areas of partial regression (Fig. 116-2A).[116] However, signs of regression itself play no role for the risk of nodal involvement nor in survival of patients with melanoma.[107] In contrast to this, TIL in the vertical growth phase of the melanoma are less frequent and might be relevant for prognosis of the patient. They have been characterized as brisk (a dense band of lymphocytes among tumor cells across the entire base or throughout the tumor), nonbrisk, or absent, and a direct relationship between the TIL grade and prolonged survival was observed.[116] In 2 large studies, up to 3330 and 1241 primary melanomas were investigated for TIL infiltration. TILs were classified as absent in 21% and 31%, nonbrisk in 64% and 27%, and brisk in 15% and 42%, respectively.[117,118] Patients with a higher TIL grade of the primary melanoma were associated with a lower risk of melanoma-specific death, independent of tumor characteristics by AJCC tumor stage.[117] Patients with brisk TIL had improved recurrence-free and overall survival compared to patients with non-brisk and absent TILs.[118]

PROGNOSTIC FACTORS IN REGIONAL METASTASES

The status of the regional lymph nodes is the most powerful prognostic factor for survival in melanoma, with regional lymph node metastasis portending a worse prognosis. The number of lymph nodes involved (independent of tumor deposit size) is the most significant risk factor in patients with stage III melanoma.[78] The second most important risk factor is tumor burden, stratified into micro-metastatic disease (determined by SLNB) or macro-metastatic disease (clinically palpable nodes). In clinically node-negative stage I or II patients, SLN status is the most significant prognostic factor with respect to disease-free and disease-specific survival.[98,119] As such, consideration of SLNB to search for micro-metastatic disease has become the standard of care for most clinically node-negative patients with melanomas 1 mm and greater in thickness, and for a subset of thinner melanomas, with additional risk factors such as high mitotic rate and lymphovascular invasion, especially in younger patients. SLNB is a powerful tool for accurately staging clinically node-negative patients and as such, use of this technique continues to play a central role in the AJCC staging classification system for melanoma.[78] Ulceration of the primary lesion indicates a worse prognosis in regional stage III disease. Mitotic rate of the primary lesion strongly correlates with a worse prognosis for microscopic regional stage III disease. Satellite metastases, both clinical and microscopic, around a primary melanoma and in-transit metastases between the primary and its nodal basin represent intra-lymphatic disease (N1c, N2c, N3c) and portend the worst prognosis for regional metastases (stage IIIB/C disease) with a 5-year survival rate less than 50%.[78]

PROGNOSTIC FACTORS IN DISTANT METASTASES

The presence of distant metastases is associated with the worst prognosis, with mean survival rates measured in months rather than years—at least till a few years ago. Site of metastasis continues to be an important prognostic factor in the AJCC melanoma staging; with visceral metastases having a relatively poorer prognosis than nonvisceral (skin, subcutaneous tissue, and distant lymph nodes) sites.[78] Other variables of prognostic significance are the number of metastatic sites and surgical resectability. Solitary metastases resected after radiologic demonstration of stability over 3 to 6 months have been associated with prolonged survival in some patients, but no strong evidence exists that asymptomatic detection is associated with significant overall survival as of this writing.[120] Elevated serum LDH levels are associated with a worse prognosis, regardless of the site of metastatic disease (Table 116-6).

MANAGEMENT

SURGICAL TREATMENT OF PRIMARY MELANOMA

The standard of therapy for primary cutaneous melanoma is wide local excision (WLE). The purpose of the wider excision is to prevent local recurrence due to subclinical persistent disease—whether there is a minor influence on overall survival is not clear as of this writing.[121,122] The risk of satellite metastases is directly related to primary melanoma thickness.[123] Hence, current recommendations on the clinical margins differ depending on the Breslow thickness of the primary and are based on several large randomized trials comparing different-sized margins.[121] For melanoma in situ, a 0.5- to 1-cm margin, for melanoma <1 mm Breslow depth a 1-cm margin, for melanoma 1 to 2 mm thick a 1- to 2-cm margin, and for melanoma >2 mm thick a 2-cm margin is recommended. Wider excisions with up to 5-cm margins have not shown a benefit for local recurrence rate.[124]

Ultimately, each patient should be evaluated individually, taking into account current surgical guidelines as well as anatomic site (ie, location near a vital structure), the possibility of primary closure versus need for skin graft, and the presence or lack of adverse prognostic factors from micro-staging. Melanoma excision at special sites, such as the digits, soles, ears, vagina, or anus, also requires separate surgical and functional considerations. When anatomically in a difficult location, for example, lentigo maligna on the face or acral melanoma on the hands/feet, an excision with histopathologically confirmed free margins can be done instead after informed consent of the patient.[125] Still, the fundamental oncologic principle should always be tumor clearance first, reconstruction second.

SURGICAL TREATMENT OF REGIONAL METASTASES

MICROSCOPIC NODAL DISEASE

Elective lymph node dissection (ELND) is the removal of regional lymph nodes draining the site of a primary cutaneous melanoma in the absence of any palpable or clinically evident metastatic disease. Historically, before the advent of SLNB, ELND was advocated for melanomas at higher risk of regional spread to eradicate occult micro-metastases in a potentially curative manner. Multiple prospective randomized controlled trials failed to demonstrate a significant benefit from ELND for melanoma.[126] Thus, there is no role for ELND today, especially in light of the development and availability of SLNB.

As mentioned previously, the SLNB procedure is a powerful staging tool that identifies micro-metastatic nodal disease.[127] After positive SLNB, up to 15% to 20% of patients have evidence of non-SLN metastases found during CLND.[128-130] For the entire group, patients in the randomized MSLT-I trial who received an SLNB did not have an improved melanoma specific survival when compared to patients who did not receive an SLNB, and thus SLNB cannot be classified as therapeutic as of this writing based on interim data. Importantly, the study is underpowered to answer that question, with approximately 80% of subjects not harboring nodal deposits. Nevertheless, in the group of patients with melanoma metastatic to the lymph nodes, the 5-year survival was significantly higher among patients with a positive SLNB and immediate CLND compared to patients in the observation followed by CLND for clinical nodal disease arm (72% vs 52%).[98] Critics accurately point to the fact that this trial component was not randomized and data are not mature.

In the DECOG-SLT trial where patients with a positive SLN were randomized to CLND or observation (followed by CLND in the case of local recurrence) no benefit in overall survival was found for the CLND group.[99] Three-year overall survival was 81.2% in the CLND group and 81.7% in the observation group (hazard ratio [HR] 0.96; P = .87). The only difference detected between the groups was the rate in regional lymph node recurrences, with 8.3% in the CLND arm and 14.6% in the observation arm (P = .029). This finding did not translate into a benefit in recurrence-free survival, with a 3-year recurrence-free survival of 66.8% in the CLND arm and 67.4% in the observation arm (P = .75). Hence, CLND is not recommended any more for patients with a positive Sentinel node. Recent data from the MSLT-II trial with a similar scientific objective of

assessing the impact of SLNB on survival support this recommendation.

MACROSCOPIC NODAL DISEASE

The current standard of therapy for macroscopic (stage IIIB or IIIC) melanoma in lymph nodes is CLND of the involved regional basin. Uncontrolled nodal disease is a cause of melanoma-related morbidity with a significant high negative impact on quality of life. CLND for regional metastatic melanoma has been associated with long-term survival in a proportion of patients.[131]

ADJUVANT TREATMENT

Adjuvant therapy is treatment for patients with surgically resected disease who are at high risk for relapse, such as those with thick primary melanomas or nodal disease. For decades, treatment with interferon-α was the only adjuvant option outside clinical trials for these patients. Recently, the immune checkpoint blockers used to treat stage IV disease like the anticytotoxic T-lymphocyte–associated protein 4 (CTLA-4) antibody ipilimumab and the anti-PD-1 antibodies nivolumab and pembrolizumab have been studied in the adjuvant setting for stage III disease, leading to FDA approval of ipilimumab and nivolumab already.[111]

INTERFERON-α

Interferons (IFNs) are cytokines that are usually released by cells in response to the presence of several pathogens such as viruses, bacteria, parasites, and also tumor cells. Typically, IFNs lead to a protection of neighboring cells from virus infection. But they have various other functions like the activation of natural killer cells and macrophages and enhancing immune recognition by upregulation of MHC class I and II molecules. In addition, IFN-α has direct antineoplastic activity leading to the inhibition of tumor cell proliferation likely via activation of STAT1[132-134] and a possible antimetastatic effect.[135] However, in the treatment of melanoma, IFN-α only has moderate activity and the survival advantage associated with this treatment is unclear. Two different dosage regimens were routinely used: high-dose (HDI) and low-dose interferon (LDI) treatment. The high-dose regimen consists of 20 million units per square meter of body surface area per day given intravenously 5 days a week for 4 weeks (induction phase), followed by 10 million units per square meter per day given subcutaneously 3 times a week for 48 weeks (maintenance phase). The low-dose regimen uses 3 million units 3 times a week given subcutaneously for 1.5 years. In a Cochrane data review, 18 randomized controlled trials were included, with a total of 10,499 patients.[136] This analysis showed that adjuvant interferon was associated with significantly improved disease-free survival (HR 0.83; $P < .00001$) and overall survival (OS) (HR 0.91; $P = .003$). The authors state that considering a 5-year OS rate for TNM stage II to III is 60%, the number needed to treat to prevent 1 death is 35. However, the patients treated with IFN have very different prognoses worsening from stage I to III. Unfortunately, even though so many patients were included, subgroup analysis failed to answer the question of whether some treatment features like dosage or treatment duration might have an impact on interferon efficacy or whether subgroups (eg, stage II vs stage III) might benefit.

In another meta-analyses of more than 6000 patients, survival benefit was 7% for progression-free survival (PFS) and 3% for OS after 5 years with no significant differences between HDI and LDI treatment.[137] A subgroup analysis of 2 EORTC trials revealed that patients with an ulcerated primary melanoma and/or a positive SLN might benefit more from IFN.[112] The effect on ulcerated primary melanoma is currently being validated by another prospective EORTC trial (NCT01502696) in SLN-negative melanoma patients. For patients with a positive SLN, the Sunbelt Melanoma Trial showed that they do not benefit from HDI treatment after CLND.[138] However, patient numbers were too small to answer this question.

There are significant toxicities associated with IFN treatment, the most frequent being flulike symptoms in almost all patients (ie, fatigue, anorexia, weight loss, myalgias, fever, nausea, and headache). Other side effects include depression, hepatotoxicity (elevated transaminases), and myelosuppression.[132] The toxicities may require dose modification, especially in HDI treatment, and if the patient makes it through the first 3 months of therapy, most are able to complete at least 80% of the scheduled dosing and are able to finish treatment.[139] Interestingly, the appearance of autoantibodies or clinical manifestations of autoimmunity such as vitiligo during treatment with IFN may be associated with a significant improvement in relapse-free survival and overall survival in melanoma patients undergoing adjuvant IFN.[140]

Importantly, HDI treatment is not recommended any more as more effective treatments are now approved for stage III disease.

IMMUNE CHECKPOINT BLOCKERS

For patients with stage III disease in the USA, treatment with the anti-CTLA-4 antibody ipilimumab is FDA approved. CTLA-4 (or CD152) is a so-called immune checkpoint molecule that is expressed on the surface of activated T cells and leads to their deactivation on binding to CD80 or CD86 on the surface of antigen-presenting cells. This mechanism seems to be in place to downregulate an immune response after activation and thereby prevent autoimmunity. In a randomized double-blind phase 3 trial, 951 stage III melanoma patients were included after complete resection of nodal metastases of at least 1 mm diameter to receive either 10 mg/kg ipilimumab or placebo every 3 weeks for 4 doses and then every 3 months for up to

3 years.[111] Ipilimumab treatment led to an improvement of the median recurrence-free survival by 9 months from 17.1 months in the placebo group to 26.1 months in the ipilimumab group. Three-year recurrence-free survival was 34.8% in the placebo group and 46.5% in the ipilimumab group. Whether this approach leads to a benefit in overall survival is still under analysis. In addition, the ipilimumab treatment is also being compared to HDI in clinical trials to assess relative effectivity.

Side effects with ipilimumab are mainly of autoimmune nature and can be severe but are manageable (see below). However, treatment with less toxic immune checkpoint blockers nivolumab or pembrolizumab directed against programmed cell death protein 1 (PD-1) have just been reported to be even more effective with a better tolerability -reducing the relative risk for recurrence by half (Checkmate 238, Keynote-054).

ADJUVANT RADIOTHERAPY

Adjuvant radiotherapy after CLND can help to control metastases in the nodal basin of stage III melanoma patients. Recommendations are based on retrospective analyses focusing on the likelihood of nodal recurrence as a function of different risk factors.[141-143] These investigations revealed 3 main risk factors for relapse: ≥3 lymph node metastases, lymph nodes with extracapsular spread, or lymph nodes >3 cm in diameter. In addition, adjuvant radiotherapy should be considered in the case of nodal recurrence. A small randomized controlled trial with patients at high risk for lymph node relapse judged on these criteria confirmed data from the retrospective analyses and demonstrated a significantly higher loco-regional control rate for patients with adjuvant radiotherapy but no effect on relapse-free or overall survival.[144] If this stays right under adjuvant immunotherapies with immune checkpoint blockers needs to be verified.

MANAGEMENT OF SATELLITE OR IN-TRANSIT METASTASES

In general, regional in-transit or satellite disease should be surgically excised whenever possible with curative intent. However, if multiple lesions make surgery unreasonable, other treatment options should be considered. In locally limited disease, radiation can be a good option, especially in multiple small metastases.[145] Additional application of hyperthermia can increase the ratio for complete responses.[146] Small and superficial metastases respond very well to intralesional interleukin-2. For bigger metastases, intralesional injections with the oncolytic virus Talimogene Laherparepvec (T-VEC) or electrochemotherapy (ECT) are therapeutic options. In a meta-analysis, 47 trials on skin-directed treatment approaches were compared.[147] In these trials, 915 patients with 4313 metastases received different treatments such as ECT, photodynamic therapy, radiotherapy, intralesional, or topical treatments. Patients showed an overall response rate of 60.2%, a complete remission rate of 35.5%, and a recurrence rate of 9.2%. If local treatments do not lead to local control, patients with extensive disease in the extremities can benefit from locally applied chemotherapy by isolated limb perfusion. All systemic treatment options are also available for nonresectable stage III disease.

INTRALESIONAL INTERLEUKIN-2

This is a very effective approach especially for small and superficial metastases, with a response rate of more than 80% if applied 2 to 3 times a week over multiple weeks (Fig. 116-9). Unexpectedly long survival times and good responses to subsequent chemotherapies were noted in a retrospective analysis, suggesting that a systemic effect may accompany such intralesional administration.[148] In a systemic review, 140 patients with 2182 metastases from 6 publications were evaluated and showed a complete response rate of 50%.[149] Treatment is tolerated well, with local pain and swelling and mild flu-like symptoms as main side effects.

TALIMOGENE LAHERPAREPVEC (T-VEC)

Intralesional application of an oncolytic virus is a new treatment option for patients with unresectable stage III or stage IV M1a disease. T-VEC is a transgenic herpes virus (Type 1) that is selectively replicated in the tumor and produces granulocyte macrophage colony-stimulating factor (GM-CSF) to augment local and potentially distant immune responses. In a randomized phase 3 trial versus GM-CSF monotherapy, the best durable response with T-VEC was found in patients with stage IIIB/C or M1a disease without systemic pretreatment.[150] Also, this treatment is tolerated relatively well, with fatigue and fever being the most frequent side effects.

ELECTROCHEMOTHERAPY (ECT)

ECT is an effective and tolerable treatment option for patients with in-transit metastases, but needs special technical equipment. ECT is a combination of a local or systemic chemotherapy (usually bleomycin or cisplatin) with intralesionally applied electrical pulses. As these lead to painful muscle contractions the procedure should be done in general anaesthesia or local anaesthesia with sedation and is hence usually done in the operating room. Theoretically, the electric pulses increase the permeability of the tumor cell membranes (electroporation) and thereby sensitize them to the chemotherapy. In a systematic review and meta-analysis, data from 44 trials with altogether

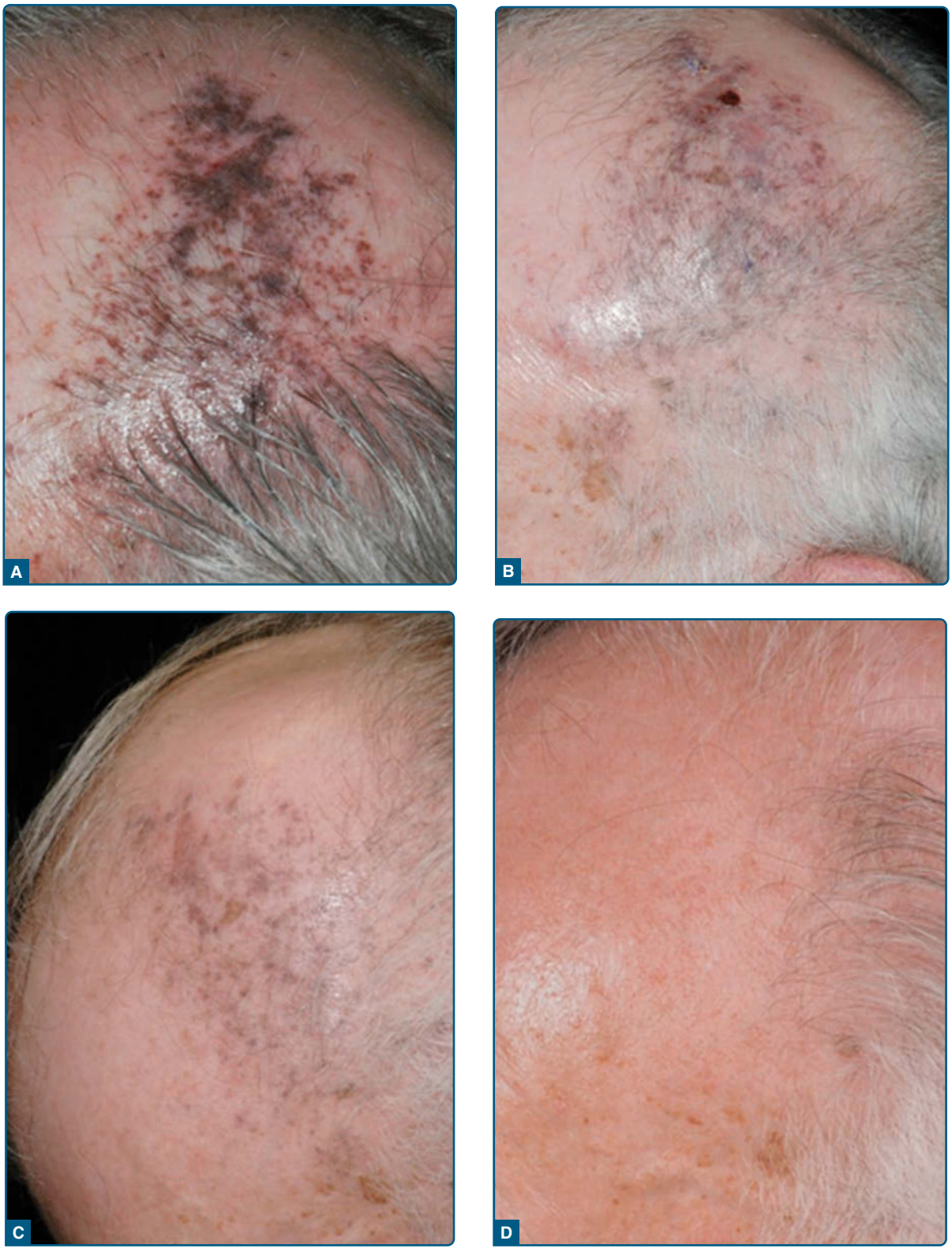

Figure 116-9 Treatment of satellite metastases with intralesional interleukin-2: **A,** before treatment; **B,** after 6 weeks of treatment; **C,** 4 weeks later without any further treatment; **D,** 2 years later without any further treatment.

431 patients and 1894 metastases were pooled.[151] The response rate of single metastases was 80.6%, complete remissions were observed in 56.8%. Even though intralesional injections of the chemotherapy were associated with a higher response rate compared to systemic chemotherapy, because of practical reasons systemic chemotherapy is preferred in routine clinical practice.

ISOLATED LIMB PERFUSION (ILP)

Isolated limb perfusion (ILP) may be considered for loco-regional disease control limited to an extremity. ILP is a form of regional chemotherapy that delivers higher doses of chemotherapeutic agents to the limb with less systemic toxicities. The technique involves perfusing an isolated extremity under hyperthermic conditions with cytotoxic agents, conventionally melphalan. ILP with melphalan is an effective form of regional therapy in some cases with an associated considerable morbidity, producing partial or complete regional responses in up to 80%.[152] The benefit is aimed at loco-regional control, not overall survival. The ILP procedure may be associated with serious local morbidities, including significant tissue damage or compartment syndrome. Elderly age and serious medical comorbidities are generally considered exclusion criteria. Isolated limb infusion (ILI) is a, simpler, less-invasive technique. Early studies of ILI with melphalan and actinomycin D demonstrate efficacy comparable to that of ILP with melphalan.[153] ILI may be considered for patients ineligible for ILP.

LOCAL HEPATIC THERAPY FOR UVEAL MELANOMA WITH LIVER METASTASES

As uveal melanomas metastasize preferentially into the liver, local treatments to the liver can be a treatment option. Different procedures have been established from surgery or ablation of isolated metastases to chemoperfusion/embolization or radio-embolization. In a phase 3 trial, hepatic intraarterial infusion of fotemustine was compared with fotemustine applied intravenously. The trial was stopped early, as interim analysis revealed that the local application of fotemustine did not improve overall survival compared to the IV arm despite having a better response rate and better PFS.[154] In another randomized phase 3 trial of percutaneous hepatic perfusion with melphalan (chemosaturation) versus best available care, a highly significant difference was found concerning hepatic PFS (7.0 vs 1.6 months; $P < .0001$) and overall PFS (5.4 vs 1.6 months; $P < .0001$). However, overall survival again was not significantly different—though this might be influenced by the crossover design of the trial.[155] All procedures can achieve responses but have not been shown to prolong survival of the patients. Additionally, the procedure is laborious and has a significant risk of complications. As such, randomized controlled trials are rarely performed.

TREATMENT OF UNRESECTABLE METASTATIC DISEASE

Until a few years ago, treatment of stage IV melanoma was purely palliative with the intention to potentially increase length of survival and palliation of symptoms. Recently, significant progress was achieved and treatment modalities are available now that substantially improve patient survival from a median of 6 to 9 months to 2 years with the chance to achieve long-term tumor control.[101,102,156]

SURGERY AND RADIOTHERAPY

Even though hematologic spread should be defined as unresectable in general, surgical excision of isolated visceral metastases (ie, metastasectomy) can be considered and may be performed with long-term disease-free intervals in some patients. In addition, surgery also may be palliative, for example, to treat isolated brain metastases or relieve obstruction from GI metastases. Surgical excision of skin/subcutis or distant lymph node metastases may result in improved loco-regional control and decreased morbidity.[157] Radiotherapy is an option and preferably used to treat brain metastases, especially using stereotactic radiation for limited brain disease. Palliative radiation may be indicated for spinal cord compression and painful bone metastases.

IMMUNOTHERAPIES

The importance of the immune system in cancer control was nicely shown in a mouse experiment where sarcomas can be induced by chemical carcinogenesis with 3′-methylcholanthrene (MCA).[158] Mice with clinically stable tumors were either injected with depleting antibodies against T cells (CD4/CD8/IFN-γ) or a control antibody. Mice receiving the control antibody remained stable but mice with a T-cell depletion developed growing sarcomas in 60% of cases. Hence, tumors can be controlled by the immune system. This is suggested to work via the so-called Cancer-Immunity-Cycle[159] where the release of cancer cell antigens by cancer cell death leads to presentation of the antigens by dendritic cells. These prime and activate T cells in the lymph nodes, which then traffic through the blood vessels to the tumor and infiltrate it. Finally, recognition of cancer cells by these T cells lead to cancer killing and elimination.

A known phenomenon in primary melanomas is the tendency for regression (Fig. 116-2). When observed in melanoma metastases it is often associated with a favorable outcome.[160] This has been linked to an effective immune defense, and the number of TILs in the primary melanoma could be correlated with patients' survival.[117,118] In addition, it is well known that immunosuppressed patients, for example, transplant recipients have an increased risk for developing melanoma and show an aggressive clinical course of the disease.[161] Hence, treatments that stimulate the immune response and aim to overcome immune escape mechanisms of the tumor have a potential to effectively fight cancer.

Historically, several approaches have been studied starting with William Coley, an American surgeon, who tried to elicit a therapeutic immune response through injection of bacterial broth (later called Coley toxin) into soft-tissue tumors. In the following decades

cytokines like interleukin-2 and interferon-α have been used in the clinic. In addition, multiple attempts have been made to develop a therapeutic vaccine—all with limited success.[162] The scientific turning point for cancer immunotherapy came with the understanding that T-cell immune responses are controlled through on and off switches, the so-called immune checkpoints that protect the body from possibly damaging immune responses.

Immune Checkpoint Blockade: T-cell activation relies on 2 stimulating signals mediated via several surface receptors: one is the T-cell receptor (TCR) recognition of antigens associated with MHC antigen–presenting molecules, the second is binding of a costimulatory molecule like CD28, CD27, GITR, OX40, or ICOS. On activation, T cells express coinhibitory receptors like CTLA-4, PD-1, TIM-3, and LAG-3, the so-called immune checkpoints that lead to downregulation of the T-cell response and T-cell anergy. Ipilimumab is a monoclonal blocking antibody against CTLA-4 and hence stops inhibition of the T-cell response (Fig. 116-10). Ipilimumab is particularly remarkable because it was the first drug to show a significant benefit for OS in patients with stage IV melanoma.[163] In addition, despite a response rate of only about 10%, more than 20% of patients reach a long-term tumor control of more than 3 years.[156]

These results were improved even further by the use of blocking antibodies against PD-1, namely, nivolumab and pembrolizumab. PD-1 on the surface of activated T cells binds to PD-L1 and PD-L2, which are expressed in peripheral tissues and different cancer types, including melanoma. The PD-1/PD-L1 pathway plays a critical role in tumor escape as binding leads to downregulation of tumor-associated T cells. In some tumors, surface expression of PD-L1 has been reported to be an independent predictor of adverse clinical outcome,[164] although it appears to be a positive prognostic feature in patients with melanoma.[165-167]

In melanoma, PD-1 blockage leads to significant tumor reduction in 30% to 40% of patients and was shown to prolong PFS and OS with a 2-year OS of roughly 60%.[102,168] Patients with a PD-L1 tumor expression of at least 5% might have a better objective response to the treatment (odds ratio 2.52) ranging from 46% for PD-L1-positive and 27% for PD-L1-negative tumors.[164] Two-year OS rates differ too, with 57.2% of patients alive with a PD-L1-positive tumor and 32.6% with a PD-L1-negative tumor in the Keynote 001 trial.[169] Hence, patients with a PD-L1-negative tumor can still respond to treatment. This might be partly based on the fact that PD-L1 expression is focal and dynamic, leading to potential sampling error on smaller biopsies. Additionally, numerous immunohistochemical assays with potentially different scoring systems of positivity as well as sensitivity for PD-L1 detection are currently being used to test specimens. For patients with melanoma, testing for PD-L1 expression is not required for anti-PD-1 administration, as it is for some other tumor types.

The combination of both ipilimumab and nivolumab lead to remarkable responses in melanoma in the Checkmate 067 trial. Response rates of 58% and

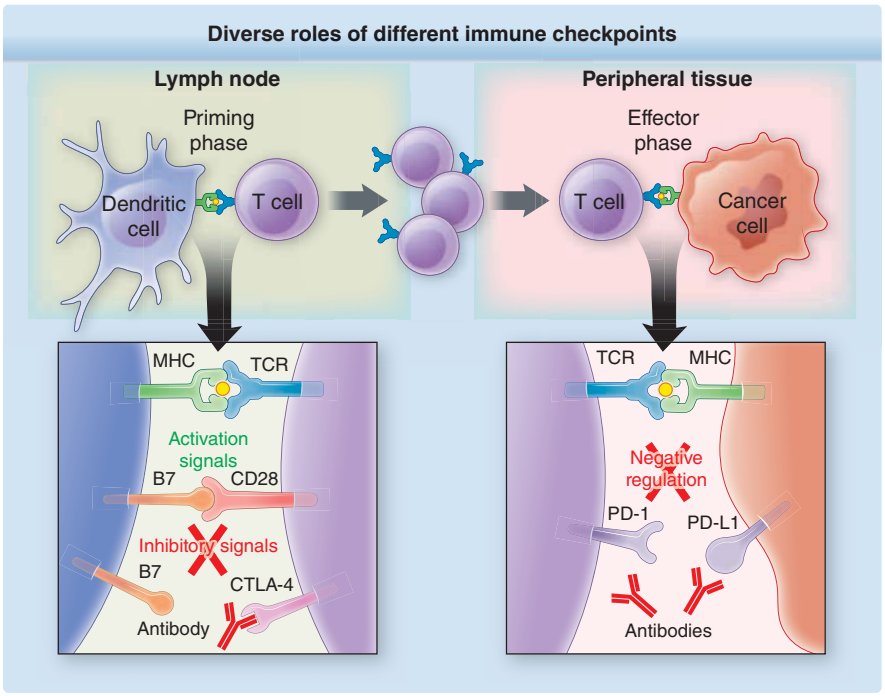

Figure 116-10 Mechanism of action of immune checkpoint blockage: The anti-CTLA-4 antibodies block the downregulation of T cells in their priming phase in the lymph nodes whereas the anti-PD-1 antibodies block the downregulation of activated T cells in their effector phase in the tumor microenvironment.

a median PFS of 11.5 months were seen with the combination compared to a 19.0% response rate and a median PFS of 2.9 months with ipilimumab monotherapy.[170] In addition, responses to the combination immunotherapy seem to occur faster, including potentially in patients with highly advanced disease. Concerning OS, median OS had not been reached yet for the ipilimumab plus nivolumab combination at a minimum followup of 36 months, it was 37.5 months in the nivolumab and 19.9 months in the ipilimumab monotherapy group. The overall survival rate at 3 years was 58% for ipilimumab plus nivolumab, 52% for nivolumab, and 34% for ipilimumab.[171] Unfortunately, in the treatment of metastasized ocular melanoma immunotherapies have been of limited success with no responses and a median OS of 6.8 months in a Phase II trial.[172] Responses to PD-1 directed treatment are rarely observed. Reported response rates range from 3% to 30% and may be higher in patients with extrahepatic disease.[173-175]

Side effects from these treatments can be severe to life-threatening. These consist of mainly autoimmune effects, so-called immune-related adverse events (irAEs), against different organs secondary to immune stimulation. The most frequent side effects affect the skin, the liver, the GI tract, and the endocrine system (hypophysis, thyroid) (Table 116-8).[176] The dermatitis is typically mild in degree. IrAEs affecting other organ systems such as colitis, however, can be severe and require high-dose immunosuppressant treatment to prevent complications like bowel perforations.

Even though the character of these side effects is similar between the anti-CTLA-4 antibodies, the PD-1 antibodies, and a combination of both, the frequency differs considerably. Side effects can be nicely compared within the CheckMate 067 trial.[170] Here, severe side effects (grade 3 or higher according to the common toxicity criteria for adverse events [CTC-AE]) occurred in only 16% of patients receiving treatment with nivolumab, 27% in those receiving ipilimumab, and 55% of those receiving nivolumab plus ipilimumab. In addition to experiencing a higher frequency of side effects with combination therapy, patients receiving combination treatment tended to have several organs affected, for example, one patient experiencing colitis, hepatitis, thyroiditis, and pancreatitis. An increasing familiarity with this new class of side effects led to the development of special treatment algorithms that can be used to effectively treat patients experiencing irAEs (see Fig. 116-11). In general, side effects should be treated quickly, with the choice of the immunosuppressive treatment dependent on the severity of symptoms. The relationship between the side effects and response to therapy is still under discussion, though a number of reports have suggested that there might be a relationship with an improved clinical outcome.[32,177-181]

Adoptive T-Cell Therapy: Adoptive T-cell therapy (ACT), in particular, autologous in vitro expanded TIL therapy, is another promising approach in immunotherapy of cancer but is only established in a few cancer centers worldwide. TILs from melanoma metastases are expanded under GMP conditions and reinfused into the patient after lymphoablative chemotherapy followed by high-dose interleukin-2 treatment. Several clinical trials demonstrated durable clinical responses for more than 50% of patients.[182,183] However, not much is known on the nature of expanded T cells. Recent findings suggest that a crucial component of the therapeutic T-cell response targets patient- and tumor-specific neoantigens resulting from somatic mutations and that only a minority of TILs respond to defined melanoma-associated antigens like differentiation (MART-a, gp100, tyrosinase) or cancer/testis antigens (MAGE, NY-Eso).[184] Newer approaches attempt to genetically modify the T cells with expression of TCRs or chimeric antigen receptors (CARs) against known antigens before re-infusion.

TABLE 116-8

Common Side Effects from Immune Checkpoint Blocker Treatment (Treatment-Related Adverse Events from CheckMate 067 Trial)

IMMUNE CHECKPOINT BLOCKER	IPILIMUMAB		NIVOLUMAB		IPILIMUMAB + NIVOLUMAB	
SEVERITY (CTC-AE) OF EVENT	ANY	3 OR 4	ANY	3 OR 4	ANY	3 OR 4
All treatment-related events (in %)	86	27	82	16	96	55
GI (lower tract: Diarrhea, Colitis)	37	12	22	3	48	15
GI (upper tract: Nausea, decreased appetite)	29	1	24	0	44	3.5
Dermatologic (Rash, Pruritus)	55	3	44	2	60	6
Hepatic (elevated transaminases)	7	2	7	3	32	20
Endocrine (Hypo-/hyperthyroidism)	12	3	16	2	32	6
Pulmonary (Pneumonitis)	2	<1	2	<1	7	1
Renal (elevated creatinine)	3	<1	1	<1	6	2
Fatigue	28	1	34	1	35	4
Arthralgia	6	0	8	0	11	<1

Algorithm to treat side effects from immune checkpoint blockers

Severity	Examinations	Management
CTC Grade 1	**Monitor clinical course** • Blood draws (especially in hepatitis, thyroiditis, pancreatitis, nephritis) • Exclude other cause (eg, stool test on pathogens in colitis, CMV/EBV reactivation in hepatitis)	**Symptomatic treatment** eg, • Topical steroids for exanthema • Loperamide for diarrhea
CTC Grade 2	**Monitor clinical course** as Grade 1 plus • Consider colonoscopy in colitis • Consider bronchoscopy in pneumonitis • Consider renal biopsy in nephritis • Consider liver biopsy in hepatitis	**Oral corticosteroid treatment** • Interrupt treatment with immune checkpoint blocker • 1 mg/kg prednisolone (or equivalent) orally once a day
CTC Grade 3/4	**Hospital admission** • As Grade 2 but examinations strongly recommended if possible on day of admission • Don't delay corticosteroid treatment • Daily monitoring for symptoms and blood values where applicable	**IV corticosteroid treatment** • Discontinue treatment with immune checkpoint blocker • 2 mg/kg methylprednisolone (or equivalent) IV once a day • If no improvement within 2 days add another immunosuppressive agent, eg, mycophenolate mofetil 3 g orally daily (hepatitis) or infliximab 5 mg/kg IV (colitis)

Figure 116-11 Algorithm to treat side effects from immune checkpoint blockers.

High-Dose Interleukin-2 (IL-2): Before the era of immune checkpoint inhibition, high-dose bolus IL-2 was the only FDA-approved immunologic treatment for metastatic melanoma that was recognized to produce rare but durable complete responses. It has been shown as a single agent to induce a 16% overall response rate with durable response in up to 5% to 8% of patients.[185] High-dose IL-2 is associated with significant toxicity, for example, a capillary-leak syndrome. Following FDA approval of immune checkpoint blocking agents, IL-2 is generally not used systemically in routine clinical use.

TARGETED THERAPIES

Melanoma is characterized by a high genetic instability that leads to a high mutation rate and molecular heterogeneity attributed to the mutagenic effects of UV irradiation. In a 2002 genomewide screen, *BRAF* point mutations were discovered at high frequency in melanomas relative to other cancers such as those of the thyroid and colon.[186] Most oncogenic *BRAF* mutations cause valine-to-glutamic acid substitutions at codon 600 (V600E) that constitutively activate the kinase domain and thereby the mitogen-activated protein kinase (MAPK) signaling pathway. Further sequencing studies identified numerous novel melanoma genes involved in regulation of the MAPK and other signaling pathways. BRAF and NRAS mutations are found in two-thirds of melanomas (other genetic alterations include amplification of AKT3 and loss of PTEN), leading to an activation of the phosphatidylinositol 3-kinase (PI3K) pathway. In addition, these pathways can be hyperactivated by overexpression or mutation of growth factor receptors such as c-Kit, Met and EGF-R or inactivating mutation in neurofibromin 1 (NF1).[187]

BRAF/MEK Inhibition: The BRAF V600 mutation is most common in melanomas of sun-exposed skin[8] and can be detected in about 50% of melanomas. The first BRAF inhibitor used was sorafenib which is an orally available unspecific RAF inhibitor that inhibits B-raf and C-raf in addition to other kinases. Sorafenib demonstrated little activity in patients with unresectable stage III or stage IV melanoma.[187,188] The observed clinical benefit was substantially different with the development of the selective BRAF inhibitors such as vemurafenib and dabrafenib (Fig. 116-12), both of which are FDA approved. Approximately 50% of patients with a BRAF V600-mutated melanoma respond, and those who do tend to demonstrate incredibly fast responses.[189,190] Treatment prolongs survival, with a median PFS of 7 to 8 months and a median OS of 16 to 18 months.[101,191] Because patients do tend to respond quickly, these agents can specifically benefit those with a high tumor load (Fig. 116-13) and provide symptom relief. Unfortunately, most patients develop later resistance to the treatment.[192] Mutational analysis of resistant metastases revealed several genes known to reactivate the MAPK pathway by bypassing BRAF. These include somatic mutations in *NRAS*, amplifications of BRAF and mutation in *MAP2K1/K2*, *MITF*, and *NF1*. Additional alterations with less clear of a relationship to resistance were observed in the PI3K pathway,

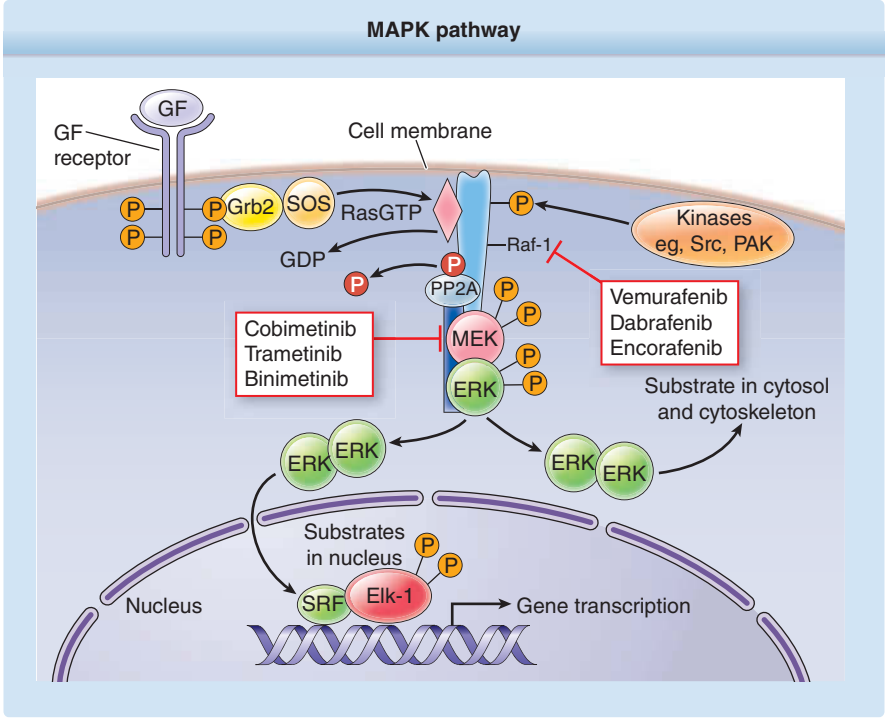

Figure 116-12 The BRAF and MEK inhibitors block the activity of the respective kinases in the MAPK signaling pathway and hence block cell proliferation and facilitate apoptosis.

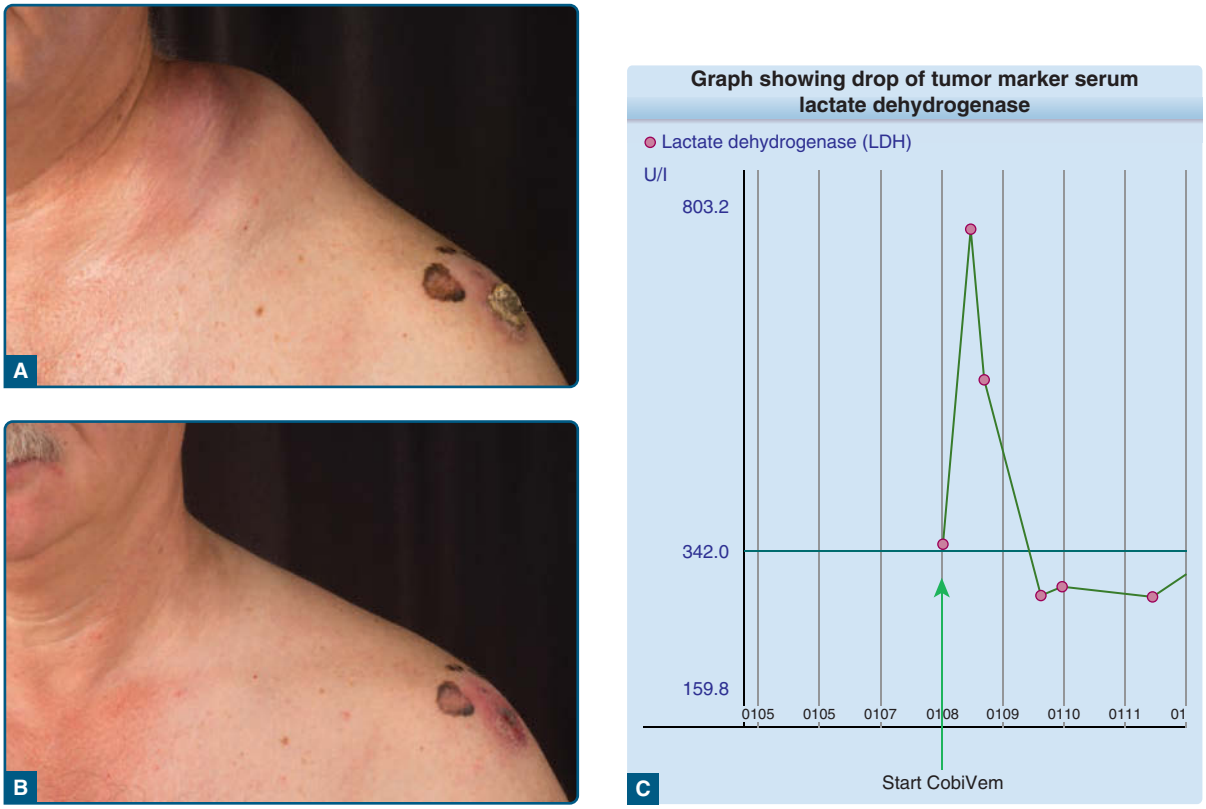

Figure 116-13 A 62-year-old patient with a superficial spreading melanoma on the left shoulder that metastasized to the regional lymph nodes already and was unresectable at the time of diagnosis (**A**). As a BRAF V600E mutation was detected, he received a combination treatment with the BRAF inhibitor dabrafenib and the MEK inhibitor trametinib. After 2 months of treatment, the lymph node conglomerates decreased in size significantly (**B**), accompanied by a drop of the tumor marker serum lactate dehydrogenase (**C**).

including *PIK3CA/R1*, *PTEN*, and *HOXD8* or *RAC1*. Reactivation of the MAPK pathway is the most frequent mechanism of acquired therapeutic resistance; thus, BRAF inhibitors have been combined with MEK inhibitors such as trametinib and cobimetinib. Combination treatment leads to even higher response rates of up to 70%, a median PFS of 10 to 11 months, and a median OS of about 2 years. Hence, combination treatment with a BRAF and a MEK inhibitor is standard of care for patients with *BRAF* mutant melanoma in addition to the immunotherapeutic options.

Treatment is generally well tolerated, with fatigue, nausea, diarrhea, arthralgia, and skin side effects as most common.[101] Skin side effects include exanthemas, hyperkeratosis, verrucous lesions, and secondary malignancies (cutaneous squamous cell carcinoma and even melanoma). The squamous lesions are explained by a paradoxical activation of MAPK signaling during treatment with BRAF inhibitors in BRAF wildtype keratinocytes. In most of the lesions, an *RAS* mutation can be found.[193,194] Such lesions are less frequent in the combination of BRAF and MEK inhibition.

Some side effects are not class but substance specific such as photosensitivity by vemurafenib and fever by dabrafenib. MEK inhibitors can worsen a preexisting heart insufficiency and lead to eye side effects like retinal vein occlusions and retinopathies. Hence, patients need surveillance by a cardiologist and an ophthalmologist under treatment.

In patients with NRAS mutations, the MEK inhibitor binimetinib was tested in a phase 3 trial against dacarbazine. It revealed limited efficacy, with an overall response rate of 15% and a median PFS of 2.8 months,[195] and hence will at best be a treatment after failure of immunotherapy.

c-KIT Inhibition: Melanomas from acral and mucosal sites are genetically distinct from other melanomas.[8] Most melanomas from acral and mucosal sites do not demonstrate mutations in *BRAF*, but a subset has activating mutations or amplification of the tyrosine kinase receptor *KIT*. These oncogenic lesions occur mostly in the juxtamembrane domain (*KIT* exons 11, 13, and 17)—a region that is frequently targeted in other cancers, including GI stromal tumors. Early studies with the tyrosine kinase inhibitor imatinib have demonstrated significant responses in patients with metastatic melanoma harboring activating mutations in c-KIT.[196,197] In several Phase II trials, imatinib and other KIT inhibitors such as nilotinib were tested in patients with KIT mutations and amplifications. Responses were observed in 16% to 23% of patients.[198,199] In both studies, certain mutations in exon 11 and 13 of c-KIT (particularly L576P mutation in exon 11) were associated with the highest response rate. Thus, sensitivity to KIT inhibition exists in metastatic melanoma but it is confined to a subset of this already small subpopulation of patients.

CHEMOTHERAPIES

The alkylating agent dacarbazine (DTIC) is the only FDA-approved chemotherapy for metastatic melanoma and is generally tolerated very well. However, response rates are only in the 10% range, with a median response duration of 4 to 6 months.[200] There is no difference in terms of response rates and duration of response between the various dosing schedules used. The major side effects are nausea and vomiting, which can be controlled by antiemetics. Temozolomide (TMZ) is an alkylating agent with the same active metabolite as DTIC, but it is absorbed orally and can be taken as a capsule. TMZ has been shown in a randomized Phase III study to have efficacy equal to DTIC.[201] Combination chemotherapies, for example, carboplatin/paclitaxel, might reveal higher response rates but have no survival benefit compared with monochemotherapy.[187,202] Toxicity is generally remarkably higher.

With the approval of immune checkpoint blocker and BRAF/MEK inhibitors, the use of chemotherapies has faded into the background. They might be used in a later line though it is important to keep in mind that an advantage in patient survival has not been shown. No randomized clinical trial exists where chemotherapy was compared to best supportive care.

TREATMENT ALGORITHM

See Fig. 116-14.

FUTURE DIRECTIONS

First results are available for the combination of targeted therapies with immune checkpoint blockade. The combination is enticing as the fast response to targeted therapies might be combined with a higher rate of long-term remissions, especially in patients with highly advanced disease. Combination of vemurafenib and ipilimumab demonstrated apparent success in a case series.[203] However, a significant hepatotoxicity was seen in a Phase I trial testing this combination.[204] Combination of BRAF/MEK inhibitors with PD-1/PD-L1–directed therapy seems to be less toxic.[205] Randomized phase 3 trials are recruiting patients, and data are pending.

Other combination strategies combine different immunotherapeutic approaches, for example, the combination of the PD-1 antibody pembrolizumab with the oncolytic virus T-VEC (Masterkey-265; NCT02263508)[206] or the indolamin-2,3-dioxygenase (IDO) inhibitor indoximod (NCT02073123) (Table 116-9). IDO is a negative immune modulator that may be expressed by antigen-presenting cells in the tumor microenvironment. Other inhibitory checkpoint molecules that could be targeted to modulate the immune response include LAG-3 and TIM-3, both of which are being targeted in early clinical trials for a number of indications. In addition, costimulatory TCR signals could be elicited, eg, by targeting CD137, OX40, CD27 or GITR. The complexity of the immune system and tumor microenvironment gives an idea of possible future treatment

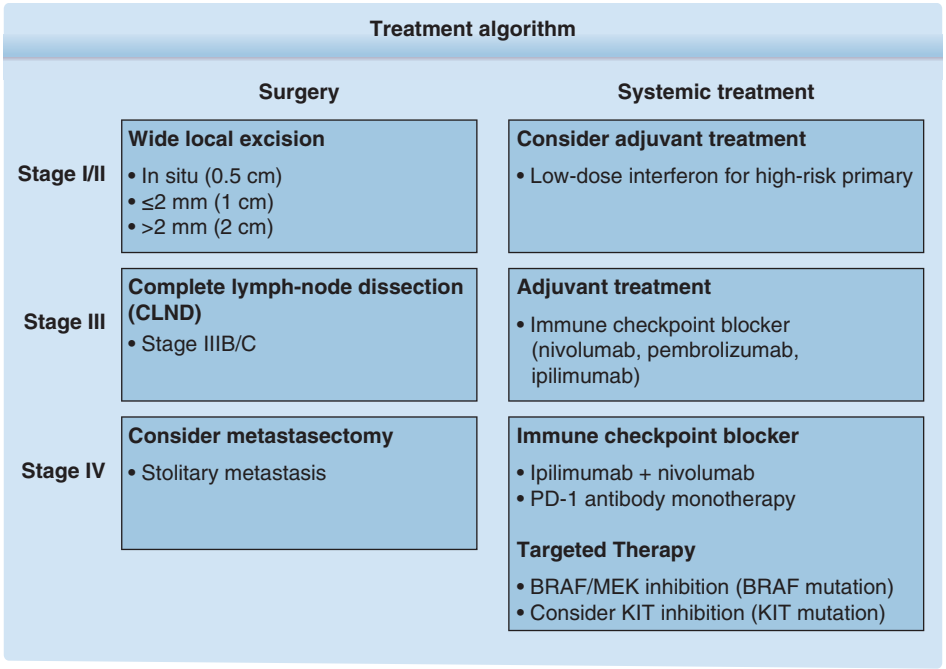

Figure 116-14 Treatment algorithm.

strategies and the challenge will be to find the best suitable targets and combinations.

The best treatment option might differ considerably between patients eg, it is known already that tumor characteristics like the mutational load (number of mutations) correlates with response to treatment with immune checkpoint blockers.[207,208] This is probably based on an increased chance for the immune system

TABLE 116-9
New Developments in Immunotherapy of Stage IV Melanoma

SUBSTANCE	TARGET	CLINICAL TRIALS	NCT NUMBER
Epacadostat	IDO inhibitor	Phase 3, in combination with pembrolizumab	NCT02752074
Indoximod	IDO inhibitor	Phase I/2 in combination with either ipilimumab, nivolumab or pembrolizumab	NCT02073123
Immune Checkpoint Blockers			
IMP321	LAG-3Ig Fusion Protein	Phase I, in combination with pembrolizumab	NCT02676869
Costimulatory TCR Signals			
BMS-663513	CD137 (4-1BB) antibody	Phase II, monotherapy	NCT00612664
Varlilumab	CD27 antibody	Phase I/2, in combination with ipilimumab +/- CDX-1401 (NY-ESO vaccine)	NCT02413827
TRX518-001	GITR antibody	Phase I, monotherapy	NCT01239134
Other Costimulatory Signals			
APX005M	CD40 antibody	Phase I/2 in combination with pembrolizumab	NCT02706353
Vaccinations			
Lipo-Merit	RNA vaccine encoding for 4 shared tumor antigens	Phase I, first in human	NCT02410733
IVAC Mutanome	Individual RNA vaccine encoding neoantigens	Phase I, first in human	NCT02035956
Other Mechanisms			
RFT-5-dgA	Immunotoxin against CD25+ T cells	Phase II, monotherapy	NCT00314093
IMCgp100	Bispecific soluble gp100-specific TCR fused to anti-CD3protein	Phase1b/2 monotherapy and combination with either durvalumab (PD-L1 Ab) or tremilimumab (CTLA-4 Ab) Phase I in uveal melanoma	NCT02535078 NCT02570308

to detect neo-antigens of the tumor by specific T-cell clones and hence a cancer-specific immune attack. In addition, other patient characteristics such as composition and responsiveness of the immune system are likely to influence treatment efficacy. Hence, it is very likely that several individual patient characteristics beyond the BRAF status will direct treatment choice to an individualized treatment in the near future—including analysis of tumor mutations, expression of immunoactive proteins such as PD-L1, and studies on the composition and geography of tumor-infiltrating immune cells. The understanding of the tumor immune defense can lead to new therapeutic strategies, for example, vaccination approaches not only against tumor-associated antigens[209] but individualized vaccines targeting the tumor mutanome of the patient.

In addition to combination with other systemic treatments, combination of immune checkpoint blockers with radiotherapy likely enhances tumor immune response by release of tumor antigens and proinflammatory cytokines as well as enhanced antigen presentation by upregulation of MHC molecule expression.[210] After radiation of single metastases, responses have been seen in metastases outside the radiation field, so-called abscopal responses.[211] Clinical trials will be necessary to evaluate fully the efficacy of this combination.

PREVENTION/SCREENING

Public awareness and knowledge of melanoma and UV exposure is improving, but still a substantial gap exists between knowledge and behavior. Primary prevention strategy should focus on safe sun exposure, including limited UV exposure and sunburn prevention, especially in childhood and adolescence when the risk is greatest. Avoidance of peak sunlight hours and use of wide-brimmed hats, clothing, and sunscreen are recommended. In addition, early detection by regular self-skin examinations, skin awareness, and knowledge of the early signs and symptoms of melanomas should also be emphasized to patient, partners, and family members. The goal of secondary prevention is early diagnosis, which greatly reduces melanoma-related morbidity and mortality.

FOLLOWUP

Patients with melanoma are at risk for local, regional, and distant recurrence, with the level of risk dependent on the stage at initial diagnosis and workup. Followup visits are an opportunity to review how to perform monthly skin and lymph node self-examinations, address any psychosocial emotional distress issues, obtain a melanoma-focused review of systems, and provide continuing patient education regarding early detection signs and symptoms and sun-protection/prevention strategies. Regular followup is indicated for all patients with melanoma. Current NCCN and national melanoma center guidelines call for at least annual followup visits for life, with followup intervals generally ranging from every 3 to 6 months for 1 to 3 years after diagnosis and annually thereafter, depending primarily on stage of disease.[212] Patients with other risk factors, such as a positive family history of melanoma, numerous nevi, or difficulty with self-examination, may require more frequent followup. A referral to a genetics counselor is warranted if there is a strong family history of melanoma, or a family history of pancreatic cancer.

The followup visit should consist of a thorough complete skin examination for additional primary lesions and cutaneous/subcutaneous metastases, particularly in the regional distribution of the primary, palpation of lymph nodes preferably accompanied by lymph node ultrasound with particular attention to the regional nodal basin, and thorough history taking. The review of systems is the foundation for detecting symptomatology possibly attributable to melanoma, and directs additional testing or imaging. The yield and value of routine imaging to restage asymptomatic patients as part of standard melanoma followup are low and, thus, internationally recommendation concerning followup procedures based on imaging and hematologic tests differ substantially.

ACKNOWLEGDMENTS

This chapter was revised and updated from the former version, composed by Evans C. Bailey, Arthur J. Sober, Hensin Tsao, Martin C. Mihm Jr, and Timothy M. Johnson, and we thank them for their contribution. We thank Nina Reuter, Media Center, University Hospital Heidelberg for photograph search.

REFERENCES

1. Shain AH, Bastian BC. From melanocytes to melanomas. *Nat Rev Cancer.* 2016;16(6):345-358.
2. Rebecca VW, Sondak VK, Smalley KSM. A brief history of melanoma: from mummies to mutations. *Melanoma Res.* 2012;22(2):114-122.
3. Ferlay J, Soerjomataram I, Ervik M, et al. GLOBOCAN 2012 v1.0, Cancer Incidence and Mortality Worldwide: IARC CancerBase No. 11 [Internet]. Lyon, France: International Agency for Research on Cancer; 2013. http://globocan.iarc.fr. Accessed day/month/year.
4. Howlader N, Noone AM, Krapcho M, et al. SEER Cancer Statistics Review, 1975-2013, National Cancer Institute. Bethesda, MD, http://seer.cancer.gov/csr/1975_2013/, based on November 2015 SEER data submission, posted to the SEER web site, April 2016.
5. Svedman FC, Pillas D, Taylor A, et al. Stage-specific survival and recurrence in patients with cutaneous malignant melanoma in Europe—a systematic review of the literature. *Clin Epidemiol.* 2016;8:109-122.
6. Arrangoiz R, Dorantes J, Cordera F, et al. Melanoma review: epidemiology, risk factors, diagnosis and staging. *J Cancer Treat Res.* 2016;4(1):1-15.
7. Thomas NE, Kricker A, Waxweiler WT, et al; Genes, Environment, and Melanoma (GEM) Study Group.

Comparison of clinicopathologic features and survival of histopathologically amelanotic and pigmented melanomas: a population-based study. *JAMA Dermatol.* 2014;150(12):1306-1314.
8. Curtin JA, Fridlyand J, Kageshita T, et al. Distinct sets of genetic alterations in melanoma. *N Engl J Med.* 2005;353(20):2135-2147.
9. Curtin JA, Busam K, Pinkel D, et al. Somatic activation of KIT in distinct subtypes of melanoma. *J Clin Oncol.* 2006;24(26):4340-4346.
10. Torres-Cabala CA, Wang WL, Trent J, et al. Correlation between KIT expression and KIT mutation in melanoma: a study of 173 cases with emphasis on the acral-lentiginous/mucosal type. *Mod Pathol.* 2009;22(11):1446-1456.
11. Busam KJ, Zhao H, Coit DG, et al. Distinction of desmoplastic melanoma from non-desmoplastic melanoma by gene expression profiling. *J Invest Dermatol.* 2005;124(2):412-418.
12. Shain AH, Garrido M, Botton T, et al. Exome sequencing of desmoplastic melanoma identifies recurrent NFKBIE promoter mutations and diverse activating mutations in the MAPK pathway. *Nat Genet.* 2015;47(10):1194-1199.
13. Wiesner T, Kiuru M, Scott SN, et al. NF1 Mutations are common in desmoplastic melanoma. *Am J Surg Pathol.* 2015;39(10):1357-1362.
14. McLaughlin CC, Wu XC, Jemal A, et al. Incidence of noncutaneous melanomas in the U.S. *Cancer.* 2005;103(5):1000-1007.
15. Rodriguez-Sains RS. Pigmented conjunctival neoplasms. *Orbit.* 2002;21(3):231-238.
16. Cosgarea I, Ugurel S, Sucker A, et al. Targeted next generation sequencing of mucosal melanomas identifies frequent NF1 and RAS mutations. *Oncotarget.* 2017;8(25):40683-40692.
17. Amit M, Tam S, Abdelmeguid AS, et al. Mutation status among patients with sinonasal mucosal melanoma and its impact on survival. *Br J Cancer.* 2017;116(12):1564-1571.
18. Öztürk Sari Ş, Yilmaz İ, Taşkin OÇ, et al. BRAF, NRAS, KIT, TERT, GNAQ/GNA11 mutation profile analysis of head and neck mucosal melanomas: a study of 42 cases. *Pathology.* 2017;49(1):55-61.
19. Hou JY, Baptiste C, Hombalegowda RB, et al. Vulvar and vaginal melanoma: a unique subclass of mucosal melanoma based on a comprehensive molecular analysis of 51 cases compared with 2253 cases of nongynecologic melanoma. *Cancer.* 2017;123(8):1333-1344.
20. Yang HM, Hsiao SJ, Schaeffer DF, et al. Identification of recurrent mutational events in anorectal melanoma. *Mod Pathol.* 2017;30(2):286-296.
21. Kim KB, Alrwas A. Treatment of KIT-mutated metastatic mucosal melanoma. *Chin Clin Oncol.* 2014;3(3):35.
22. Magro CM, Crowson AN, Mihm MC. Unusual variants of malignant melanoma. *Mod Pathol.* 2006;19(suppl 2):S41-S70.
23. Ludgate MW, Fullen DR, Lee J, et al. The atypical Spitz tumor of uncertain biologic potential: a series of 67 patients from a single institution. *Cancer.* 2009;115(3):631-641.
24. Wiesner T, Kutzner H, Cerroni L, et al. Genomic aberrations in spitzoid melanocytic tumours and their implications for diagnosis, prognosis and therapy. *Pathology.* 2016;48(2):113-131.
25. Ludgate MW, Fullen DR, Lee J, et al. Animal-type melanoma: a clinical and histopathological study of 22 cases from a single institution. *Br J Dermatol.* 2010;162(1):129-136.
26. Dutton-Regester K, Kakavand H, Aoude LG, et al. Melanomas of unknown primary have a mutation profile consistent with cutaneous sun-exposed melanoma. *Pigment Cell Melanoma Res.* 2013;26(6):852-860.
27. Carson KF, Wen DR, Li PX, et al. Nodal nevi and cutaneous melanomas. *Am J Surg Pathol.* 1996;20(7):834-840.
28. Chattopadhyay C, Kim DW, Gombos DS, et al. Uveal melanoma: from diagnosis to treatment and the science in between. *Cancer.* 2016;122(15):2299-2312.
29. Thomas S, Pütter C, Weber S, et al. Prognostic significance of chromosome 3 alterations determined by microsatellite analysis in uveal melanoma: a long-term follow-up study. *Br J Cancer.* 2012;106(6):1171-1176.
30. Woodward JK, Elshaw SR, Murray AK, et al. Stimulation and inhibition of uveal melanoma invasion by HGF, GRO, IL-1alpha and TGF-beta. *Invest Ophthalmol Vis Sci.* 2002;43(10):3144-3152.
31. Vyas R, Selph J, Gerstenblith MR. Cutaneous manifestations associated with melanoma. *Semin Oncol.* 2016;43(3):384-389.
32. Hua C, Boussemart L, Mateus C, et al. Association of vitiligo with tumor response in patients with metastatic melanoma treated with pembrolizumab. *JAMA Dermatol.* 2016;152(1):45-51.
33. Grewal DS, Fishman GA, Jampol LM. Autoimmune retinopathy and antiretinal antibodies: a review. *Retina.* 2014;34(5):827-845.
34. Usher-Smith JA, Emery J, Kassianos AP, et al. Risk prediction models for melanoma: a systematic review. *Cancer Epidemiol Biomarkers Prev.* 2014;23(8):1450-1463.
35. Vuong K, McGeechan K, Armstrong BK, et al. Risk prediction models for incident primary cutaneous melanoma: a systematic review. *JAMA Dermatol.* 2014;150(4):434-444.
36. Elwood JM, Jopson J. Melanoma and sun exposure: an overview of published studies. *Int J Cancer.* 1997;73(2):198-203.
37. Volkovova K, Bilanicova D, Bartonova A, et al. Associations between environmental factors and incidence of cutaneous melanoma. *Environ Health.* 2012;11(suppl 1):S12.
38. Gillgren P, Brattström G, Djureen Mårtensson E, et al. A new computerized methodology to analyse tumour site in relation to phenotypic traits and epidemiological characteristics of cutaneous malignant melanoma. *Br J Dermatol.* 2002;146(6):1023-1030.
39. Elwood JM, Gallagher RP. Body site distribution of cutaneous malignant melanoma in relationship to patterns of sun exposure. *Int J Cancer.* 1998;78(3):276-280.
40. Stern RS. The risk of melanoma in association with long-term exposure to PUVA. *J Am Acad Dermatol.* 2001;44(5):755-761.
41. Pouplard C, Brenaut E, Horreau C, et al. Risk of cancer in psoriasis: a systematic review and meta-analysis of epidemiological studies. *J Eur Acad Dermatol Venereol.* 2013;27(suppl 3):36-46.
42. Gallagher RP, Spinelli JJ, Lee TK. Tanning beds, sunlamps, and risk of cutaneous malignant melanoma. *Cancer Epidemiol Biomarkers Prev.* 2005;14(3):562-566.
43. Le Clair MZ, Cockburn MG. Tanning bed use and melanoma: establishing risk and improving prevention interventions. *Prev Med Rep.* 2016;3:139-144.

44. Bald T, Quast T, Landsberg J, et al. Ultraviolet-radiation-induced inflammation promotes angiotropism and metastasis in melanoma. *Nature.* 2014; 507(7490):109-113.
45. Green AC, Williams GM, Logan V, et al. Reduced melanoma after regular sunscreen use: randomized trial follow-up. *J Clin Oncol.* 2011;29(3):257-263.
46. Ransohoff KJ, Jaju PD, Tang JY, et al. Familial skin cancer syndromes: increased melanoma risk. *J Am Acad Dermatol.* 2016;74(3):423-434.
47. Bauer J, Garbe C. Acquired melanocytic nevi as risk factor for melanoma development. A comprehensive review of epidemiological data. *Pigment Cell Res.* 2003;16(3):297-306.
48. Tucker MA, Halpern A, Holly EA, et al. Clinically recognized dysplastic nevi. A central risk factor for cutaneous melanoma. *JAMA.* 1997;277(18):1439-1444.
49. Bevona C, Goggins W, Quinn T, et al. Cutaneous melanomas associated with nevi. *Arch Dermatol.* 2003;139(12):1620-1624.
50. Tromberg J, Bauer B, Benvenuto-Andrade C, et al. Congenital melanocytic nevi needing treatment. *Dermatol Ther.* 2005;18(2):136-150.
51. Vourc'h-Jourdain M, Martin L, Barbarot S, et al. Large congenital melanocytic nevi: therapeutic management and melanoma risk: a systematic review. *J Am Acad Dermatol.* 2013;68(3):493-498,e1-e14.
52. Niendorf KB, Tsao H. Cutaneous melanoma: family screening and genetic testing. *Dermatol Ther.* 2006; 19(1):1-8.
53. Hansen CB, Wadge LM, Lowstuter K, et al. Clinical germline genetic testing for melanoma. *Lancet Oncol.* 2004;5(5):314-319.
54. Sharpless E, Chin L. The INK4a/ARF locus and melanoma. *Oncogene.* 2003;22(20):3092-3098.
55. Liu W, Hill D, Gibbs AF, et al. What features do patients notice that help to distinguish between benign pigmented lesions and melanomas? The ABCD(E) rule versus the seven-point checklist. *Melanoma Res.* 2005;15(6):549-554.
56. Nagore E, Oliver V, Moreno-Picot S, et al. Primary cutaneous melanoma in hidden sites is associated with thicker tumours—A study of 829 patients. *Eur J Cancer.* 2001;37(1):79-82.
57. Friedman RJ, Rigel DS, Kopf AW. Early detection of malignant melanoma: the role of physician examination and self-examination of the skin. *CA Cancer J Clin.* 1985;35(3):130-151.
58. Abbasi NR, Shaw HM, Rigel DS, et al. Early diagnosis of cutaneous melanoma: revisiting the ABCD criteria. *JAMA.* 2004;292(22):2771-2776.
59. Whited JD, Grichnik JM. The rational clinical examination. Does this patient have a mole or a melanoma? *JAMA.* 1998;279(9):696-701.
60. Gachon J, Beaulieu P, Sei JF, et al. First prospective study of the recognition process of melanoma in dermatological practice. *Arch Dermatol.* 2005;141(4):434-438.
61. Vestergaard ME, Macaskill P, Holt PE, et al. Dermoscopy compared with naked eye examination for the diagnosis of primary melanoma: a meta-analysis of studies performed in a clinical setting. *Br J Dermatol.* 2008;159(3):669-676.
62. Bafounta ML, Beauchet A, Aegerter P, et al. Is dermoscopy (epiluminescence microscopy) useful for the diagnosis of melanoma? Results of a meta-analysis using techniques adapted to the evaluation of diagnostic tests. *Arch Dermatol.* 2001;137(10):1343-1350.
63. Annessi G, Bono R, Sampogna F, et al. Sensitivity, specificity, and diagnostic accuracy of three dermoscopic algorithmic methods in the diagnosis of doubtful melanocytic lesions: the importance of light brown structureless areas in differentiating atypical melanocytic nevi from thin melanomas. *J Am Acad Dermatol.* 2007;56(5):759-767.
64. Dolianitis C, Kelly J, Wolfe R, et al. Comparative performance of 4 dermoscopic algorithms by nonexperts for the diagnosis of melanocytic lesions. *Arch Dermatol.* 2005;141(8):1008-1014.
65. Blum A, Rassner G, Garbe C. Modified ABC-point list of dermoscopy: a simplified and highly accurate dermoscopic algorithm for the diagnosis of cutaneous melanocytic lesions. *J Am Acad Dermatol.* 2003;48(5):672-678.
66. Henning JS, Dusza SW, Wang SQ, et al. The CASH (color, architecture, symmetry, and homogeneity) algorithm for dermoscopy. *J Am Acad Dermatol.* 2007;56(1):45-52.
67. Noor O 2nd, Nanda A, Rao BK. A dermoscopy survey to assess who is using it and why it is or is not being used. *Int J Dermatol.* 2009;48(9):951-952.
68. Haenssle HA, Krueger U, Vente C, et al. Results from an observational trial: digital epiluminescence microscopy follow-up of atypical nevi increases the sensitivity and the chance of success of conventional dermoscopy in detecting melanoma. *J Invest Dermatol.* 2006;126(5):980-985.
69. Kittler H, Guitera P, Riedl E, et al. Identification of clinically featureless incipient melanoma using sequential dermoscopy imaging. *Arch Dermatol.* 2006;142(9): 1113-1139.
70. Goodson AG, Grossman D. Strategies for early melanoma detection: approaches to the patient with nevi. *J Am Acad Dermatol.* 2009;60(5):719-735.
71. Lien MH, Sondak VK. Diagnostic techniques for primary cutaneous melanoma [review]. *G Ital Dermatol Venereol.* 2009;144(2):187-194.
72. Tran KT, Wright NA, Cockerell CJ. Biopsy of the pigmented lesion—when and how. *J Am Acad Dermatol.* 2008;59(5):852-871.
73. Martin RC 2nd, Scoggins CR, Ross MI, et al. Is incisional biopsy of melanoma harmful? *Am J Surg.* 2005;190(6):913-917.
74. Karimipour DJ, Schwartz JL, Wang TS, et al. Microstaging accuracy after subtotal incisional biopsy of cutaneous melanoma. *J Am Acad Dermatol.* 2005; 52(5):798-802.
75. Smoller BR. Histologic criteria for diagnosing primary cutaneous malignant melanoma. *Mod Pathol.* 2006;19(suppl 2):S34-S40.
76. Davis IJ, Kim JJ, Ozsolak F. Oncogenic MITF dysregulation in clear cell sarcoma: defining the MiT family of human cancers. *Cancer Cell.* 2006;9(6):473-484.
77. Ramos-Herberth FI, Karamchandani J, Kim J, et al. SOX10 immunostaining distinguishes desmoplastic melanoma from excision scar. *J Cutan Pathol.* 2010;37(9):944-952.
78. Balch CM, Gershenwald JE, Soong SJ, et al. Final version of 2009 AJCC melanoma staging and classification. *J Clin Oncol.* 2009;27(36):6199-6206.
79. Gogas H, Eggermont AM, Hauschild A, et al. Biomarkers in melanoma. *Ann Oncol.* 2009;20(suppl 6):vi8-vi13.
80. Mocellin S, Zavagno G, Nitti D. The prognostic value of serum S100B in patients with cutaneous melanoma: a meta-analysis. *Int J Cancer.* 2008;123(10):2370-2376.

81. Wang TS, Johnson TM, Cascade PN, et al. Evaluation of staging chest radiographs and serum lactate dehydrogenase for localized melanoma. *J Am Acad Dermatol.* 2004;51(3):399-405.
82. Uren RF, Howman-Giles R, Thompson JF. Patterns of lymphatic drainage from the skin in patients with melanoma. *J Nucl Med.* 2003;44(4):570-582.
83. Bafounta ML, Beauchet A, Chagnon S, et al. Ultrasonography or palpation for detection of melanoma nodal invasion: a meta-analysis. *Lancet Oncol.* 2004;5(11):673-680.
84. Voit C, Van Akkooi AC, Schäfer-Hesterberg G, et al. Ultrasound morphology criteria predict metastatic disease of the sentinel nodes in patients with melanoma. *J Clin Oncol.* 2010;28(5):847-852.
85. Sabel MS, Wong SL. Review of evidence-based support for pretreatment imaging in melanoma. *J Natl Compr Canc Netw.* 2009;7(3):281-289.
86. Sawyer A, McGoldrick RB, Mackey SP, et al. Does staging computed tomography change management in thick malignant melanoma? *J Plast Reconstr Aesthet Surg.* 2009;62(4):453-456.
87. Vereecken P, Laporte M, Petein M, et al. Evaluation of extensive initial staging procedure in intermediate/high-risk melanoma patients. *J Eur Acad Dermatol Venereol.* 2005;19(1):66-73.
88. Johnson TM, Bradford CR, Gruber SB, et al. Staging workup, sentinel node biopsy, and follow-up tests for melanoma: update of current concepts. *Arch Dermatol.* 2004;140(1):107-113.
89. Valsecchi ME, Silbermins D, de Rosa N, et al. Lymphatic mapping and sentinel lymph node biopsy in patients with melanoma: a meta-analysis. *J Clin Oncol.* 2011;29(11):1479-1487.
90. Warycha M, Zakrzewski J, Ni Q, et al. Metaanalysis of sentinel lymph node positivity in thin melanoma (≤1 mm). *Cancer.* 2009;115(4):869-879.
91. Kretschmer L, Starz H, Thoms KM, et al. Age as a key factor influencing metastasizing patterns and disease-specific survival after sentinel lymph node biopsy for cutaneous melanoma. *Int J Cancer.* 2011;129(6):1435-1442.
92. Kunte C, Geimer T, Baumert J, et al. Prognostic factors associated with sentinel lymph node positivity and effect of sentinel status on survival: an analysis of 1049 patients with cutaneous melanoma. *Melanoma Res.* 2010;20(4):330-337.
93. McMasters KM, Reintgen DS, Ross MI, et al. Factors that predict the presence of sentinel lymph node metastasis in patients with melanoma. *Surgery.* 2001;130(2):151-156.
94. Gutzmer R, Satzger I, Thoms KM, et al. Sentinel lymph node status is the most important prognostic factor for thick (> or = 4 mm) melanomas. *J Dtsch Dermatol Ges.* 2008;6(3):198-203.
95. Morton DL, Wen DR, Wong JH, et al. Technical details of intraoperative lymphatic mapping for early stage melanoma. *Arch Surg.* 1992;127(4):392-399.
96. McCready DR, Ghazarian DM, Hershkop MS, et al. Sentinel lymph-node biopsy after previous wide local excision for melanoma. *Can J Surg.* 2001;44(6):432-434.
97. Thompson JF, Shaw HM, Hersey P, et al. The history and future of melanoma staging. *J Surg Oncol.* 2004;86(4):224-235.
98. Morton DL, Thompson JF, Cochran AJ, et al. Sentinel-node biopsy or nodal observation in melanoma. *N Engl J Med.* 2006;355(13):1307-1317.
99. Leiter U, Stadler R, Mauch C, et al. German Dermatologic Cooperative Oncology Group (DeCOG): complete lymph node dissection versus no dissection in patients with sentinel lymph node biopsy positive melanoma (DeCOG-SLT): a multicentre, randomised, phase 3 trial. *Lancet Oncol.* 2016;17(6):757-767.
100. Crowley NJ, Seigler HF. Late recurrence of malignant melanoma. Analysis of 168 patients. *Ann Surg.* 1990;212(2):173-177.
101. Long GV, Stroyakovskiy D, Gogas H, et al. Dabrafenib and trametinib versus dabrafenib and placebo for Val600 BRAF-mutant melanoma: a multicentre, double-blind, phase 3 randomised controlled trial. *Lancet.* 2015;386(9992):444-451.
102. Robert C, Ribas A, Hamid O, et al. Three-year overall survival for patients with advanced melanoma treated with pembrolizumab in Keynote-001 [abstract 9503]. *J Clin Oncol.* 2016;34(suppl).
103. Chang P, Knapper WH. Metastatic melanoma of unknown primary. *Cancer.* 1982;49(6):1106-1111.
104. Schlagenhauff B, Stroebel W, Ellwanger U, et al. Metastatic melanoma of unknown primary origin shows prognostic similarities to regional metastatic melanoma: recommendations for initial staging examinations. *Cancer.* 1997;80(1):60-65.
105. Edge SB, Compton CC. The American Joint Committee on Cancer: the 7th edition of the AJCC cancer staging manual and the future of TNM. *Ann Surg Oncol.* 2010;17(6):1471-1474.
106. Gershenwald JE, Scolyer RA, Hess KR, et al. Melanoma staging: evidence-based changes in the American Joint Committee on Cancer eighth edition cancer staging manual. *CA Cancer J Clin.* 2017;67(6):472-492.
107. Tas F, Erturk K. Presence of histological regression as a prognostic factor in cutaneous melanoma patients. *Melanoma Res.* 2016;26(5):492-496.
108. Stucky CC, Gray RJ, Dueck AC, et al. Risk factors associated with local and in-transit recurrence of cutaneous melanoma. *Am J Surg.* 2010;200(6):770-774.
109. Homsi J, Kashani-Sabet M, Messina JL, et al. Cutaneous melanoma: prognostic factors. *Cancer Control.* 2005;12(4):223-229.
110. Balch CM, Soong SJ, Gershenwald JE, et al. Prognostic factors analysis of 17,600 melanoma patients: validation of the American Joint Committee on Cancer melanoma staging system. *J Clin Oncol.* 2001;19(16):3622-3634.
111. Eggermont AM, Chiarion-Sileni V, Grob JJ, et al. Adjuvant ipilimumab versus placebo after complete resection of high-risk stage III melanoma (EORTC 18071): a randomised, double-blind, phase 3 trial. *Lancet Oncol.* 2015;16(5):522-530.
112. Eggermont AM, Suciu S, Rutkowski P, et al. EORTC Melanoma group: long term follow up of the EORTC 18952 trial of adjuvant therapy in resected stage IIB-III cutaneous melanoma patients comparing intermediate doses of interferon-alpha-2b (IFN) with observation: ulceration of primary is key determinant for IFN-sensitivity. *Eur J Cancer.* 2016;55:111-121.
113. Eggermont AM, Spatz A, Lazar V, et al. Is ulceration in cutaneous melanoma just a prognostic and predictive factor or is ulcerated melanoma a distinct biologic entity? *Curr Opin Oncol.* 2012;24(2):137-140.
114. Azzola MF, Shaw HM, Thompson JF, et al. Tumor mitotic rate is a more powerful prognostic indicator than ulceration in patients with primary cutaneous melanoma: an analysis of 3661 patients from a single center. *Cancer.* 2003;97(6):1488-1498.

115. Paek SC, Griffith KA, Johnson TM, et al. The impact of factors beyond Breslow depth on predicting sentinel lymph node positivity in melanoma. *Cancer.* 2007;109(1):100-108.
116. Elder DE, Gimotty PA, Guerry D. Cutaneous melanoma: estimating survival and recurrence risk based on histopathologic features. *Dermatol Ther.* 2005; 18(5):369-385.
117. Thomas NE, Busam KJ, From L, et al. Tumor-infiltrating lymphocyte grade in primary melanomas is independently associated with melanoma-specific survival in the population-based genes, environment and melanoma study. *J Clin Oncol.* 2013;31(33):4252-4259.
118. Weiss SA, Han SW, Lui K, et al. Immunologic heterogeneity of tumor infiltrating lymphocyte composition in primary melanoma. *Hum Pathol.* 2016;57:116-125.
119. Gershenwald JE, Thompson W, Mansfield PF, et al. Multi-institutional melanoma lymphatic mapping experience: the prognostic value of sentinel lymph node status in 612 stage I or II melanoma patients. *J Clin Oncol.* 1999;17(3):976-983.
120. Tsao H, Feldman M, Fullerton JE, et al. Early detection of asymptomatic pulmonary melanoma metastases by routine chest radiographs is not associated with improved survival. *Arch Dermatol.* 2004;140(1):67-70.
121. Sladden MJ, Balch C, Barzilai DA, et al. Surgical excision margins for primary cutaneous melanoma. *Cochrane Database Syst Rev.* 2009;(4):CD004835.
122. Hayes AJ, Maynard L, Coombes G, et al; UK Melanoma Study Group; British Association of Plastic, Reconstructive and Aesthetic Surgeons; Scottish Cancer Therapy Network: wide versus narrow excision margins for high-risk, primary cutaneous melanomas: long-term follow-up of survival in a randomised trial. *Lancet Oncol.* 2016;17(2):184-192.
123. Veronesi U, Cascinelli N. Narrow excision (1-cm margin). A safe procedure for thin cutaneous melanoma. *Arch Surg.* 1991;126(4):438-441.
124. Cohn-Cedermark G, Rutqvist LE, Andersson R, et al. Long term results of a randomized study by the Swedish Melanoma Study Group on 2-cm versus 5-cm resection margins for patients with cutaneous melanoma with a tumor thickness of 0.8-2.0 mm. *Cancer.* 2000;89(7):1495-1501.
125. McLeod M, Choudhary S, Giannakakis G, et al. Surgical treatments for lentigo maligna: a review. *Dermatol Surg.* 2011;37(9):1210-1228.
126. Lens MB, Dawes M, Goodacre T, et al. Elective lymph node dissection in patients with melanoma: systematic review and meta-analysis of randomized controlled trials. *Arch Surg.* 2002;137(4):458-461.
127. Morton DL, Cochran AJ, Thompson JF, et al. Sentinel node biopsy for early-stage melanoma: accuracy and morbidity in MSLT-I, an international multicenter trial. *Ann Surg.* 2005;242(3):302-311.
128. Sabel MS, Griffith K, Sondak VK, et al. Predictors of nonsentinel lymph node positivity in patients with a positive sentinel node for melanoma. *J Am Coll Surg.* 2005;201(1):37- 47.
129. Ghaferi AA, Wong SL, Johnson TM, et al. Prognostic significance of a positive nonsentinel lymph node in cutaneous melanoma. *Ann Surg Oncol.* 2009;16(11):2978-2984.
130. Sabel MS, Griffith KA, Arora A, et al. Inguinal node dissection for melanoma in the era of sentinel lymph node biopsy. *Surgery.* 2007;141(6):728-735.
131. Young SE, Martinez SR, Faries MB, et al. Can surgical therapy alone achieve long-term cure of melanoma metastatic to regional nodes? *Cancer J.* 2006;12(3):207-211.
132. Bender C, Hassel JC, Enk A. Immunotherapy of melanoma. *Oncol Res Treat.* 2016;39(6):369-376.
133. Hassel JC, Winnemöller D, Schartl M, et al. STAT5 contributes to antiapoptosis in melanoma. *Melanoma Res.* 2008;18(6):378-385.
134. Wellbrock C, Weisser C, Hassel JC, et al. STAT5 contributes to interferon resistance of melanoma cells. *Curr Biol.* 2005;15(18):1629-1639.
135. Ortiz A, Fuchs SY. Anti-metastatic functions of type 1 interferons: Foundation for the Adjuvant Therapy of Cancer. *Cytokine.* 2016;S1043-4666(16)30010-2.
136. Mocellin S, Lens MB, Pasquali S, et al. Interferon alpha for the adjuvant treatment of cutaneous melanoma. *Cochrane Database Syst Rev.* 2013;18(6):CD008955.
137. Wheatley K, Ives N, Eggermont A, et al. Interferon-alpha as adjuvant therapy for melanoma: an individual patient data meta-analysis of randomized trials [abstract 8526]. *J Clin Oncol.* 2007;25(suppl).
138. McMasters KM, Egger ME, Edwards MJ, et al. Final results of the sunbelt melanoma trial: a multi-institutional prospective randomized phase III study evaluating the role of adjuvant high-dose interferon alfa-2b and completion lymph node dissection for patients staged by sentinel lymph node biopsy. *J Clin Oncol.* 2016;34(10):1079-1086.
139. Kirkwood JM, Ibrahim JG, Sondak VK, et al. High- and low-dose interferon alfa-2b in high-risk melanoma: first analysis of intergroup trial E1690/S9111/C9190. *J Clin Oncol.* 2000;18(12):2444-2458.
140. Gogas H, Ioannovich J, Dafni U, et al. Prognostic significance of autoimmunity during treatment of melanoma with interferon. *N Engl J Med.* 2006;354(7):709-718.
141. Agrawal S, Kane JM 3rd, Guadagnolo BA, et al. The benefits of adjuvant radiation therapy after therapeutic lymphadenectomy for clinically advanced, high-risk, lymph node-metastatic melanoma. *Cancer.* 2009;115(24):5836-5844.
142. Bibault JE, Dewas S, Mirabel X, et al. Adjuvant radiation therapy in metastatic lymph nodes from melanoma. *Radiat Oncol.* 2011;6(Web Page):12.
143. Strojan P, Jancar B, Cemazar M, et al. Melanoma metastases to the neck nodes: role of adjuvant irradiation. *Int J Radiat Oncol Biol Phys*. 2010;77(4):1039-1045.
144. Burmeister BH, Henderson MA, Ainslie J, et al. Adjuvant radiotherapy versus observation alone for patients at risk of lymph-node field relapse after therapeutic lymphadenectomy for melanoma: a randomised trial. *Lancet Oncol.* 2012;13(6):589-597.
145. Chadha M, Hilaris B, Nori D, et al. Role of brachytherapy in malignant melanoma: a preliminary report. *J Surg Oncol.* 1990;43(4):223-227.
146. Overgaard J, Gonzalez Gonzalez D, Hulshof MC, et al. Hyperthermia as an adjuvant to radiation therapy of recurrent or metastatic malignant melanoma. A multicentre randomized trial by the European Society for Hyperthermic Oncology. *Int J Hyperthermia.* 2009; 25(Web Page):323-334.
147. Spratt DE, Gordon Spratt EA, Wu S, et al. Efficacy of skin-directed therapy for cutaneous metastases from advanced cancer: a meta-analysis. *J Clin Oncol.* 2014;32(28):3144-3155.
148. Weide B, Eigentler TK, Pflugfelder A, et al. Survival after intratumoral interleukin-2 treatment of 72 melanoma patients and response upon the first chemotherapy during follow-up. *Cancer Immunol Immunother.* 2011;60(4):487-493.

149. Byers BA, Temple-Oberle CF, Hurdle V, et al. Treatment of in-transit melanoma with intra-lesional interleukin-2: a systematic review. *J Surg Oncol.* 2014;110(6):770-775.
150. Andtbacka RH, Kaufman HL, Collichio F, et al. Talimogene laherparepvec improves durable response rate in patients with advanced melanoma. *J Clin Oncol.* 2015;33(25):2780-2788.
151. Mali B, Jarm T, Snoj M, et al. Antitumor effectiveness of electrochemotherapy: a systematic review and meta-analysis. *Eur J Surg Oncol.* 2013;39(1):4-16.
152. Grunhagen DJ, de Wilt JH, van Geel AN, et al. Isolated limb perfusion for melanoma patients—a review of its indications and the role of tumour necrosis factor-alpha. *Eur J Surg Oncol.* 2006;32(4):371-380.
153. Thompson JF, Kam PC. Isolated limb infusion for melanoma: a simple but effective alternative to isolated limb perfusion. *J Surg Oncol.* 2004;88(1):1-3.
154. Leyvraz S, Piperno-Neumann S, Suciu S, et al. Hepatic intra-arterial versus intravenous fotemustine in patients with liver metastases from uveal melanoma (EORTC 18021): a multicentric randomized trial. *Ann Oncol.* 2014;25(3):742-746.
155. Hughes MS, Zager J, Faries M, et al. Results of a randomized controlled multicenter phase III trial of percutaneous hepatic perfusion compared with best available care for patients with melanoma liver metastases. *Ann Surg Oncol.* 2016;23(4):1309-1319.
156. Schadendorf D, Hodi FS, Robert C, et al. Pooled analysis of long-term survival data from phase II and phase III trials of ipilimumab in unresectable or metastatic melanoma. *J Clin Oncol.* 2015;33(17):1889-1894.
157. Tagawa ST, Cheung E, Banta W, et al. Survival analysis after resection of metastatic disease followed by peptide vaccines in patients with Stage IV melanoma. *Cancer.* 2006;106(6):1353-1357.
158. Koebel CM, Vermi W, Swann JB, et al. Adaptive immunity maintains occult cancer in an equilibrium state. *Nature.* 2007;450(7171):903-907.
159. Chen DS, Mellman I. Oncology meets immunology: the cancer-immunity cycle. *Immunity.* 2013;39(1):1-10.
160. Kalialis LV, Drzewiecki KT, Klyver H. Spontaneous regression of metastases from melanoma: review of the literature. *Melanoma Res.* 2009;19(5):275-282.
161. Robbins HA, Clarke CA, Arron ST, et al. Melanoma risk and survival among organ transplant recipients. *J Invest Dermatol.* 2015;135(11):2657-2665.
162. Hoos A. Development of immuno-oncology drugs-from CTLA4 to PD1 to the next generations. *Nat Rev Drug Discov.* 2016;15(4):235-247.
163. Hodi FS, O'Day SJ, McDermott DF, et al. Improved survival with ipilimumab in patients with metastatic melanoma. *N Engl J Med.* 2010;363(8):711-723.
164. Gandini S, Massi D, Mandalà M. PD-L1 expression in cancer patients receiving anti PD-1/PD-L1 antibodies: a systematic review and meta-analysis. *Crit Rev Oncol Hematol.* 2016;100:88-98.
165. Taube JM, Anders RA, Young GD, et al. Colocalization of inflammatory response with B7-h1 expression in human melanocytic lesions supports an adaptive resistance mechanism of immune escape. *Sci Transl Med.* 2012;4(127):127ra37.
166. Obeid JM, Erdag G, Smolkin ME, et al. PD-L1, PD-L2 and PD-1 expression in metastatic melanoma: correlation with tumor-infiltrating immune cells and clinical outcome. *Oncoimmunology.* 2016;5(11):e1235107.
167. Danilova L, Wang H, Sunshine J, et al. Association of PD-1/PD-L axis expression with cytolytic activity, mutational load, and prognosis in melanoma and other solid tumors. *Proc Natl Acad Sci U S A.* 2016;113(48):e7769-e7777.
168. Robert C, Long GV, Brady B, et al. Nivolumab in previously untreated melanoma without BRAF mutation. *N Engl J Med.* 2015;372(4):320-330.
169. Daud A, Hamid O, Robert C, et al. Relationship between PD-L1 expression and efficacy in 655 patients with melanoma treated with pembrolizumab (MK-3475). Society for Melanoma Research Annual Meeting; San Francisco, CA; November 18-21, 2015.
170. Larkin J, Chiarion-Sileni V, Gonzalez R, et al. Combined nivolumab and ipilimumab or monotherapy in untreated melanoma. *N Engl J Med.* 2015;373(13):1270-1271.
171. Wolchok JD, Rollin L, Larkin J. Nivolumab and ipilimumab in advanced melanoma. *N Engl J Med.* 2017;377(25):2503-2504.
172. Zimmer L, Vaubel J, Mohr P, et al. Phase II DeCOG-study of ipilimumab in pretreated and treatment-naïve patients with metastatic uveal melanoma. *PLoS One.* 2015;10(3):e0118564.
173. Algazi AP, Tsai KK, Shoushtari AN, et al. Clinical outcomes in metastatic uveal melanoma treated with PD-1 and PD-L1 antibodies. *Cancer.* 2016;122(21):3344-3353.
174. Karydis I, Chan PY, Wheater M, et al. Clinical activity and safety of pembrolizumab in ipilimumab pre-treated patients with uveal melanoma. *Oncoimmunology.* 2016;5(5):e1143997.
175. Kottschade LA, McWilliams RR, Markovic SN, et al. The use of pembrolizumab for the treatment of metastatic uveal melanoma. *Melanoma Res.* 2016;26(3):300-303.
176. Hassel JC, Heinzerling L, Aberle J, et al. Combined immune checkpoint blockade (anti-PD-1/anti-CTLA-4): evaluation and management of adverse drug reactions. *Cancer Treat Rev.* 2017;57:36-49.
177. Sanlorenzo M, Vujic I, Daud A, et al. Pembrolizumab cutaneous adverse events and their association with disease progression. *JAMA Dermatol.* 2015;151(11):1206-1212.
178. Weber JS, Hodi FS, Wolchok JD, et al. Safety profile of nivolumab monotherapy: a pooled analysis of patients with advanced melanoma. *J Clin Oncol.* 2017;35(7):785-792.
179. Dick J, Lang N, Slynko A, et al. Use of LDH and autoimmune side effects to predict response to ipilimumab treatment. *Immunotherapy.* 2016;8(9):1033-1044.
180. Buder-Bakhaya K, Benesova K, Schulz C, et al. Characterization of arthralgia induced by PD-1 antibody treatment in patients with metastasized cutaneous malignancies. *Cancer Immunol Immunother.* 2017;41(10):1381-1389.
181. Kaunitz GJ, Loss M, Rizvi H, et al. Cutaneous eruptions in patients receiving immune checkpoint blockade: clinicopathologic analysis of the nonlichenoid histologic pattern. *Am J Surg Pathol.* 2017;41(10):1381-1389.
182. Dudley ME, Yang JC, Sherry R, et al. Adoptive cell therapy for patients with metastatic melanoma: evaluation of intensive myeloablative chemoradiation preparative regimens. *J Clin Oncol.* 2008;26(32):5233-5239.

183. Besser MJ, Shapira-Frommer R, Treves AJ, et al. Clinical responses in a phase II study using adoptive transfer of short-term cultured tumor infiltration lymphocytes in metastatic melanoma patients. *Clin Cancer Res.* 2010;16(9):2646-2655.
184. Lu YC, Yao X, Crystal JS, et al. Efficient identification of mutated cancer antigens recognized by T cells associated with durable tumor regressions. *Clin Cancer Res.* 2014;20(13):3401-3410.
185. Atkins MB, Lotze MT, Dutcher JP, et al. High-dose recombinant interleukin 2 therapy for patients with metastatic melanoma: analysis of 270 patients treated between 1985 and 1993. *J Clin Oncol.* 1999;17(7):2105-2116.
186. Lo JA, Fisher DE. The melanoma revolution: from UV carcinogenesis to a new era in therapeutics. *Science.* 2014;346(6212):945-949.
187. Hauschild A, Agarwala SS, Trefzer U, et al. Results of a phase III, randomized, placebo-controlled study of sorafenib in combination with carboplatin and paclitaxel as second-line treatment in patients with unresectable stage III or stage IV melanoma. *J Clin Oncol.* 2009;27(17):2823-2830.
188. Egberts F, Gutzmer R, Ugurel S, et al. Sorafenib and pegylated interferon-α2b in advanced metastatic melanoma: a multicenter phase II DeCOG trial. *Ann Oncol.* 2011;22(7):1667-1674.
189. Chapman PB, Hauschild A, Robert C, et al. BRIM-3 Study Group: improved survival with vemurafenib in melanoma with BRAF V600E mutation. *N Engl J Med.* 2011;364(26):2507-2516.
190. Hauschild A, Grob JJ, Demidov LV, et al. Dabrafenib in BRAF-mutated metastatic melanoma: a multicentre, open-label, phase 3 randomised controlled trial. *Lancet.* 2012;380(9839):358-365.
191. Sosman JA, Kim KB, Schuchter L, et al. Survival in BRAF V600-mutant advanced melanoma treated with vemurafenib. *N Engl J Med.* 2012;366:707-714.
192. Van Allen EM, Wagle N, Sucker A, et al. Dermatologic Cooperative Oncology Group of Germany (DeCOG): the genetic landscape of clinical resistance to RAF inhibition in metastatic melanoma. *Cancer Discov.* 2014;4(1):94-109.
193. Su F, Viros A, Milagre C, et al. RAS mutations in cutaneous squamous-cell carcinomas in patients treated with BRAF inhibitors. *N Engl J Med.* 2012; 366(3):207-215.
194. Hassel JC, Groesser L, Herschberger E, et al. RAS mutations in benign epithelial tumors associated with BRAF inhibitor treatment of melanoma. *J Invest Dermatol.* 2015;135(2):636-639.
195. Dummer R, Schadendorf D, Ascierto PA, et al. Results of NEMO: a phase II trial of binimetinib vs dacarbazine in NRAS-mutant cutaneous melanoma [abstract 9500]. *J Clin Oncol.* 2016;34(suppl).
196. Lutzky J, Bauer J, Bastian BC. Dose-dependent, complete response to imatinib of a metastatic mucosal melanoma with a K642E KIT mutation. *Pigment Cell Melanoma Res.* 2008;21(4):492-493.
197. Hodi FS, Friedlander P, Corless CL, et al. Major response to imatinib mesylate in KIT-mutated melanoma. *J Clin Oncol.* 2008;26(12):2046-2051.
198. Guo J, Si L, Kong Y. Phase II, open-label, single-arm trial of imatinib mesylate in patients with metastatic melanoma harboring c-Kit mutation or amplification. *J Clin Oncol.* 2011;29(21):2904-2909.
199. Lee SJ, Kim TM, Kim YJ, et al. Phase II trial of nilotinib in patients with metastatic malignant melanoma harboring KIT gene aberration: a multicenter trial of Korean Cancer Study Group (UN10-06). *Oncologist.* 2015;20(11):1312-1319.
200. Tarhini AA, Agarwala SS. Cutaneous melanoma: available therapy for metastatic disease. *Dermatol Ther.* 2006;19(1):19-25.
201. Middleton MR, Grob JJ, Aaronson N, et al. Randomized phase III study of temozolomide versus dacarbazine in the treatment of patients with advanced metastatic malignant melanoma. *J Clin Oncol.* 2000; 18(1):158-166.
202. Eigentler TK, Caroli UM, Radny P, et al. Palliative therapy of disseminated malignant melanoma: a systematic review of 41 randomised clinical trials. *Lancet Oncol.* 2003;4(12):748-759.
203. Hassel JC, Lee SB, Meiss F, et al. Vemurafenib and ipilimumab: a promising combination? Results of a case series. *Oncoimmunology.* 2015;5(4):e1101207.
204. Ribas A, Hodi FS, Callahan M, et al. Hepatotoxicity with combination of vemurafenib and ipilimumab. *N Engl J Med.* 2013;368(14):1365-1366.
205. Ribas A, Hodi FS, Lawrence DP, et al. Pembrolizumab (pembro) in combination with dabrafenib (D) and trametinib (T) for BRAF-mutant advanced melanoma: phase 1 KEYNOTE-022 study [abstract 3014]. *J Clin Oncol.* 2016;34(suppl).
206. Ribas A, Dummer R, Puzanov I, et al. Oncolytic virotherapy promotes intratumoral T cell infiltration and improves anti-PD-1 immunotherapy. *Cell.* 2017;170(6):1109.e10-1119.e10.
207. Van Allen EM, Miao D, Schilling B, et al. Genomic correlates of response to CTLA-4 blockade in metastatic melanoma. *Science.* 2015;350(6257):207-211.
208. Snyder A, Makarov V, Merghoub T, et al. Genetic basis for clinical response to CTLA-4 blockade in melanoma. *N Engl J Med.* 2014;371(23):2189-2199.
209. Kranz LM, Diken M, Haas H, et al. Systemic RNA delivery to dendritic cells exploits antiviral defence for cancer immunotherapy. *Nature.* 2016;534(7607):396-401.
210. Shahabi V, Postow MA, Tuck D, et al. Immune-priming of the tumor microenvironment by radiotherapy: rationale for combination with immunotherapy to improve anticancer efficacy. *Am J Clin Oncol.* 2015; 38(1):90-97.
211. Postow MA, Callahan MK, Barker CA, et al. Immunologic correlates of the abscopal effect in a patient with melanoma. *N Engl J Med.* 2012;366(10):925-931.
212. Coit DG, Andtbacka R, Bichakjian CK, et al. Melanoma. *J Natl Compr Canc Netw.* 2009;7(3):250-275.

Chapter 117 :: Histiocytosis

:: Astrid Schmieder, Sergij Goerdt, & Jochen Utikal

CUTANEOUS CLINICAL FEATURES OF HISTIOCYTOSIS

AT-A-GLANCE

- *Langerhans cell histiocytosis*: Translucent, rose-yellowish, crusted papules or papulovesicles, eczematous lesions, hemorrhagic papules and nodules, petechiae, noduloulcerative mucosal lesions, and nail involvement
- *Rosai-Dorfman disease*: Lymphadenopathy, cutaneous nodules, and plaques
- *Hemophagocytic lymphohistiocytosis*: Various cutaneous manifestations such as erythroderma, generalized purpuric macules and papules, and morbilliform eruptions
- *Juvenile xanthogranuloma*: Solitary as well as multiple (oligolesional) papules or nodules—early lesions show a reddish-brown color; mature lesions have a reddish-yellow appearance
- *Benign cephalic histiocytosis*: Like juvenile xanthogranuloma; ultrastructural presence of worm-like bodies
- *Generalized eruptive histiocytoma of childhood*: Widespread, erythematous, essentially symmetrical papules
- *Adult xanthogranuloma*: Oligolesional, yellow-orange papules that usually appear on the face, neck, and lower arms
- *Papular xanthoma*: Solitary yellowish papule
- *Generalized eruptive histiocytoma*: Multiple asymptomatic and symmetrically distributed brownish erythematous papules, particularly involving the axial regions such as the trunk, face, and proximal extremities, frequently flares
- *Xanthoma disseminatum*: Small, yellow-red to brown papules and nodules that are discrete and are disseminated with a predilection for the flexural and intertriginous areas, as well as for mucous membranes
- *Multicentric reticulohistiocytosis*: Firm, yellow-brownish papules or nodules that reach a size of several centimeters and progress slowly in size; lesions over the joints of fingers and wrists are typical; often involvement of mucosae and conjunctivae
- *Erdheim-Chester disease*: Xanthelasma and xanthoma are present in one-sixth of cases; long bone and other extracutaneous involvement
- *Necrobiotic xanthogranuloma*: Yellowish plaques and nodules that can ulcerate
- *Hereditary progressive mucinous histiocytosis*: Skin-colored to red-brown papules that usually develop in the first decade on the nose, hands, forearms, and thighs that can later develop into persistent and progressive erythematous papules
- *Progressive nodular histiocytosis*: Generalized, discrete yellow to red-brown papules and nodules measuring a few centimeters in size with prominent facial involvement

Langerhans cell histiocytoses (LCHs) and non–Langerhans cell histiocytoses (N-LCHs) present a rare group of neoplastic and reactive diseases characterized by the proliferation of myeloid cells in various organ sites with a predilection to the skin. As shown in Table 117-1, they are categorized in different subgroups.

TABLE 117-1

Classification of Langerhans and Non–Langerhans Cell Histiocytosis

Langerhans Cell Histiocytosis

1. Single system
2. Multisystem

Non–Langerhans Cell Histiocytosis

1. Systemic non–Langerhans cell histiocytosis
   - Rosai-Dorfman disease
   - Hemophagocytic lymphohistiocytosis
2. Cutaneous non–Langerhans cell histiocytosis
   - Juvenile xanthogranuloma
     - Juvenile xanthogranuloma
     - Benign cephalic histiocytosis
     - Generalized eruptive histiocytoma of childhood
   - Adult xanthogranuloma
     - Oligolesional
       - Adult xanthogranuloma
       - Papular xanthoma
     - Disseminated
       - Generalized eruptive histiocytoma
       - Xanthoma disseminatum
       - Multicentric reticulohistiocytosis
       - Erdheim-Chester disease
   - Necrobiotic xanthogranuloma
   - Spindle-cell non–Langerhans cell histiocytosis
     - Hereditary progressive mucinous histiocytosis
     - Progressive nodular histiocytosis

LANGERHANS CELL HISTIOCYTOSIS

AT-A-GLANCE

- New definition of Langerhans cell histiocytosis (LCH) as rare, inflammatory neoplasia of myeloid-dendritic (mostly clonal) cells with heterogeneous clinical manifestation
- Histopathology:
  - Infiltration of the organs with immature, morphologically rounded myeloid dendritic cells with bean-shaped nuclei; shared characteristics of cell surface antigens (CD1a/S100B/CD207-positive) with mature skin Langerhans cells
  - 60% of LCH biopsy specimens bear the V600E mutation in cell-growth-directing oncogene *BRAF* (v-Raf murine sarcoma viral oncogene homolog B)
  - Highly variable clinical manifestations ranging from single, osteolytic bone lesions to an aggressive, life-threatening multisystem disease affecting risk organs such as the spleen, the liver, and the hematopoietic system
  - Skin involvement in 39% (crucial for early diagnosis)
- New (clinical) classification according to the extent of organ involvement:
  - Single-organ system LCH
  - Multisystem LCH
- Treatment:
  - Close monitoring for single-organ system LCH ("watch and wait")
  - Topical or systemic treatments include topical nitrogen mustard, narrowband ultraviolet light-B, photochemotherapy, methotrexate, 6-mercaptopurine, and chemotherapy, depending on the extent of the disease

HISTORICAL PERSPECTIVE

LCH is newly defined as a rare, heterogeneous neoplasm of dendritic cells. Characteristically, CD1a/S100B/CD207-positive mononuclear cells with bean-shaped nuclei infiltrate single-organ systems, most commonly the bone, but also the skin, or multiple-organ systems.

A long-term controversy regarding the neoplastic nature of this disease exists as there are some arguments in support of a reactive condition resulting from an immunologic dysregulation such as a regulatory T-cell expansion found in LCH and the lack of mutations in tumor-suppressor genes.[1] Another argument is the broad spectrum of clinical manifestations of LCH, ranging from a self-healing single bone lesion to aggressive multiorgan involvement with a lethal outcome. Thus, in the past, patients were divided into 4 main clinical types: Hashimoto-Pritzker disease, eosinophilic granuloma, Hand-Schüller-Christian disease, and Letterer-Siwe disease (Table 117-2 outlines the traditional classification of LCH).

Hashimoto-Pritzker disease, first described in 1973, is the benign clinical variant typically presenting with multiple firm red-brown nodules with an elevated border or papulovesicular and papulocrusted lesions mostly on the scalp and face in the first few months and years of life, with no signs of systemic involvement. These lesions usually heal within 2 to 3 months and occasionally leave whitish atrophic scars.

Eosinophilic granuloma is also a mainly benign isolated or multifocal osteolytic bone LCH, which sometimes affects the skin and mucous membranes. Consequently, skin lesions often resemble those seen in Hand-Schüller-Christian (HSC) disease with nodulo-ulcerative lesions in the mouth and yellowish-brown papules and plaques on the scalp or in the perineal or perivulvar region. The first publication by Thomas Smith describing this disease can be found in the 1865 edition of the *American Journal of Pathology*.

HSC disease is the chronic variant of a multisystem LCH mostly found in children 2 to 5 years old, but the age-range is wide. It was first described by Alfred Hand in 1893, followed by Arthur Schüller in 1915

TABLE 117-2
Variants of Langerhans Cell Histiocytosis (LCH)[a]

	AGE AT ONSET	CLINICAL CHARACTERISTICS	COURSE OF DISEASE	PROGNOSIS
Hashimoto-Pritzker disease	First months to years of age	Multiple firm, red-brown nodules with an elevated border; papulovesicular and crusted lesions on scalp and face	Self-healing with resolution in 2-3 months and occasional atrophic scarring	No systemic involvement; excellent prognosis
Eosinophilic granuloma[b] (unifocal LCH)	Most commonly childhood	Skin not always involved; when present, lesions are nodulo-ulcerative on mouth, yellowish-brown papules and plaques on scalp or perineal or perivulvar region; swelling over bony lesions	Benign isolated or multifocal osteolytic bone LCH	No systemic involvement; good prognosis; may have complications with tissue destruction
Hand-Schüller-Christian disease[b]	2-5 years old (age range is wide)	Triad of diabetes insipidus, bone lesions, and exophthalmos; seborrheic dermatitis-like lesions, with small reddish-brown crusted papules, vesicles, and pustules on scalp, face, and intertriginous areas Nodulo-ulcerative lesions may affect the gingiva, perioral, and genital area; xanthomatous plaques may be present	Chronic, progressive, multifocal form of LCH with systemic involvement	Progressive; prognosis poorer at extremes of age and with extrapulmonary involvement
Letterer-Siwe disease[b]	Mostly younger than 2 years of age	Lung, bone marrow, and brain commonly affected; cutaneous lesions consist of yellow-brown to translucent papules, occasionally with a hemorrhagic or ulcerative aspect; purpura is a poor prognostic sign	Most aggressive, multisystem variant	Lethal, if untreated

[a]This table represents the traditional classification of LCH for reader reference; newer classifications (see Fig. 117-1) have greater implications for treatment and prognosis.
[b]These variants fall under a single nosologic entity called histiocytosis X.

and Henry Christian in 1920. It is characterized by the triad of diabetes insipidus, bone lesions, and exophthalmos and affects the skin in approximately 30% of cases. Patients frequently complain about a chronic otitis media that is the result of an involvement of the mastoid or the petrous temporal bones. Cutaneous lesions can resemble seborrheic dermatitis with small reddish-brown crusted papules, but also vesicles and pustules on the scalp and face and in intertriginous areas. Also, nodulo-ulcerative lesions can develop in mucous membranes, especially in the gingiva and the perioral and genital areas. Xanthomatous yellowish-brown or yellowish-red papules and plaques also have been described.

Letterer-Siwe disease is the most aggressive acute LCH multisystem variant with apparent systemic symptoms such as fever, hepatosplenomegaly, polylymphadenopathy, anemia, arthralgia, malaise, and weight loss. Letterer first described the disease in 1924, followed by Siwe in 1933. Frequently affected organs are the lung, the bone marrow, and the brain. Skin lesions are common and consist of yellow-brown, sometimes translucent papules, which can have a hemorrhagic aspect and ulcerate similar to the ones seen in HSC disease. Also, purpura is frequently found and is a poor prognostic sign. Untreated, Letterer-Siwe disease is lethal.

Although these LCH types show a distinct clinical course, the cellular infiltrate in the affected organs is the same. Thus, in 1953, Lichtenstein proposed to combine eosinophilic granuloma, HSC, and Letterer-Siwe disease into a single nosologic entity called *histiocytosis X*. In 1973, Nezelof termed the lesional cell as a "Langerhans-like" cell based on the presence of Birbeck granules found with the help of the electron microscope. In 1987, the Histiocyte Society published the classification of the histiocytic disorders, which finally consolidated the strenghtened position that all the above-mentioned diseases are part of a single entity. Since then there has been a vivid dispute about whether LCH should be classified as a neoplastic or a reactive disease. This was finally resolved in 2010 with the discovery of the *BRAF-V600E* somatic point mutation in approximately 60% of patients with LCH,[2] which led to the conclusion that LCH is a clonal neoplastic disorder. The resolution of this controversy is important as it will significantly accelerate research in this field and progress in treatment.

EPIDEMIOLOGY

Because LCH is a rare neoplastic disease, exact epidemiologic data is missing. In children younger than 15 years of age, the annual incidence is approximately 0.7 to 4.1 cases per 1 million population with a median age at diagnosis of 30.2 months to 5.9 years.[3] In adults, the incidence is lower with only 1 to 2 cases per 1 million adults of all ethnicities per year reported.

A lower incidence has been observed in black patients, whereas the Hispanic population shows a slightly higher incidence. Other risk factors include living in crowded conditions and lower education level as well as exposure to metal, granite, wood dust, or solvents in parents, a family history of thyroid disease and cancer, and perinatal infections, but these risk factors should be interpreted with caution.[3,4]

ETIOLOGY AND PATHOGENESIS

From an etiologic point of view, LCH is an inflammatory myeloid neoplasm characterized by infiltrations of different organ systems with CD1a/S100B/CD207-positive mononuclear cells, which morphologically and immunohistochemically resemble specialized dendritic cells of the skin known as Langerhans cells. Gene expression arrays revealed that these cells are different from resident mature Langerhans cells of the skin as they express immature myeloid markers and are more closely related to a myeloid-derived precursor dendritic cell.[5] Also, approximately 60% of LCH-cells bear a V600E mutation in the *BRAF* (v-Raf murine sarcoma viral oncogene homolog B) oncogene, and 33% of BRAF wild-type lesions harbor mutations in the *MAP2K1* (mitogen-activated protein kinase kinase1)geneleadingtouniversalMEK(mitogenactivated protein/extracellular signal-related kinase kinase) and ERK (extracellular signal-regulated kinase) activation (Fig. 117-1A). Based on these results the "Misguided Myeloid Dendritic Cell Precursor Model," in which precursor bone marrow–derived myeloid dendritic cells acquire a pathologic ERK activation and express antigens typically found in mature Langerhans cells such as CD207 and CD1a (Fig. 117-1B), has been proposed. These cells secrete factors such as osteopontin, vanin, and different proinflammatory factors, as well as transforming growth factor-β and attract, among other inflammatory cells such as macrophages and eosinophils, activated T cells, especially activated regulatory FOXP3/CTLA4, and SPP-positive T cells.[5] The severity and the extent of the organ involvement is supposed to depend on the stage of differentiation in which ERK gets activated: whereas an activation in a hematopoietic stem cell or an undifferentiated myeloid dendritic cell leads to multisystem disease, ERK activation in more differentiated myeloid precursors only results in multifocal or unifocal disease.[1] More studies are needed to gain further insights into the pathogenesis of LCH as there are still many open questions, including: Why is it that in adult pulmonary LCH, unlike in the other organs, the infiltrating mononuclear cells seem to be mostly nonclonal mature dendritic cells? Another interesting question is whether a high expression of PD-L1 (programmed death ligand 1) immune checkpoint protein in LCH could serve as a new therapeutic target[6]; as of this writing, it is still too early to tell.

CLINICAL FEATURES

CLASSIFICATION

The traditional classification of LCH in Hashimoto-Pritzker disease, eosinophilic granuloma, HSC, and Letterer-Siwe disease has been abandoned because the disease spectrum is broader than that of the traditional classification and many patients do not fit into these clinical subtypes. Also, the clinical course can change with time. The new classification considers the extent of organ involvement as this has significant implications for treatment and prognosis (see Fig. 117-1). In addition, LCH might best be described as a continuum as illustrated in Figure 117-2. Patients are divided into:

- Single-system LCH: Approximately 55% to 65% of the LCH patients present with single-system LCH, in which only 1 organ system is involved. Organ systems most commonly affected are bone, skin, lymph nodes, lungs, and the CNS.[7]
- Multisystem LCH: In multisystem LCH, more than 1 organ system is affected by the disease. It is important to distinguish whether high-risk organs are involved.

At-risk organs include the hematopoietic system, the liver, and the spleen. The lung is no longer regarded as a high-risk organ, as recent studies could not confirm lung involvement as a negative prognostic factor. Table 117-1 provides an overview of the currently accepted classification.

CUTANEOUS FINDINGS

Cutaneous findings in LCH can be identified in more than one-third of LCH. It is the second most common organ involved after bone lesions and can be the earliest sign of disease. Only 12% of children with single-system disease and 53% of patients affected by multisystem LCH show a skin involvement.[7] Consequently, age is an important risk factor as children younger than the age of 1 year more frequently show a true skin-only LCH, while those older than the age of 18 months have a higher risk for multisystem LCH. The role of the dermatologist in making an early diagnosis is, therefore, crucial.

Patients can present with a broad variety of skin manifestations. The most typical ones are small, translucent rose-yellowish crusted papules or papulovesicles on the trunk, in the intertriginous areas and the scalp, associated with eczematous scaling which resembles "candida intertrigo" or "seborrheic dermatitis" (Figs. 117-3, 117-4, and 117-5). Lesions can also present as hemorrhagic papules and nodules associated with petechiae reminiscent of vascular lesions or "varicella-like eruptions" (Fig. 117-6). Vesicles, pustules, and nail involvement have been described. Nail involvement can present as paronychia, nailfold destruction, onycholysis, subungual hyperkeratosis, longitudinal grooving, and

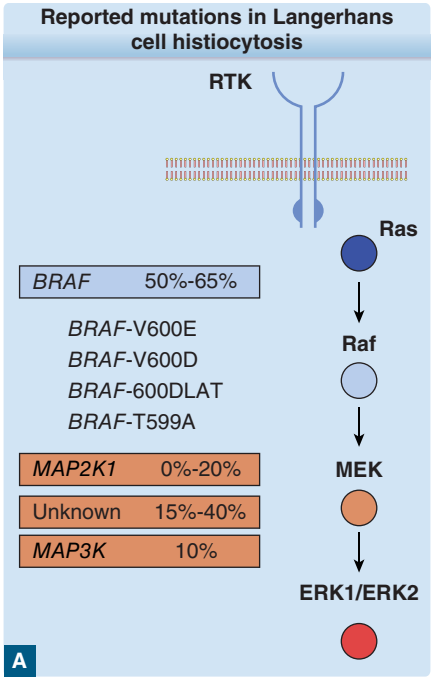

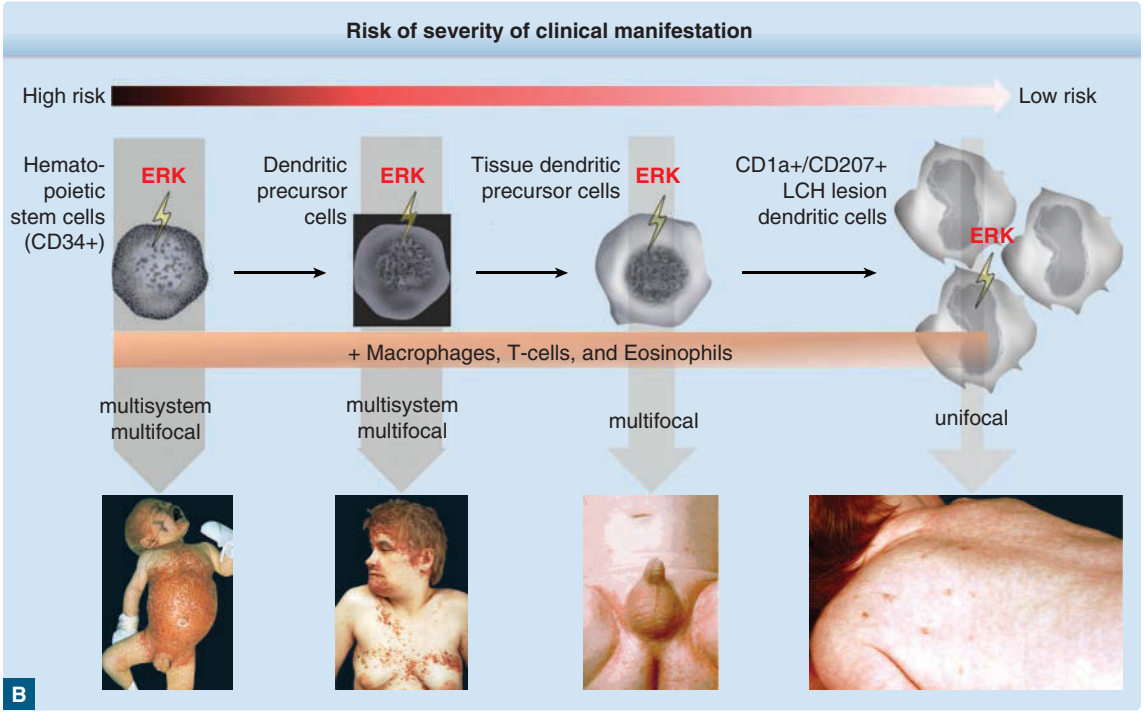

Figure 117-1 **A,** Reported mutations in Langerhans cell histiocytosis (LCH). This figure illustrates the frequency of identified mutations in LCH, leading to a downstream activation of the transcription factor ERK (extracellular signal-regulated kinase). In 50% to 65% of LCH cases, a mutation in the *BRAF* (v-Raf murine sarcoma viral oncogene homolog B) gene was found. The *BRAF-V600E* mutation was by far the most common mutation found, but *BRAF-V600D*, *BRAF-600DLAT*, and *BRAF-T599A* mutations also have been described. MAP2K1, mitogen-activated protein kinase kinase 1; MAP3K, mitogen-activated protein kinase kinase kinase; MEK, mitogen-activated protein/extracellular signal-related kinase kinase; RTK, receptor tyrosine kinase. **B,** The "Misguided Myeloid Dendritic Cell Model." Based on the "Misguided Myeloid Dendritic Cell Model," the clinical manifestation depends on the stage of differentiation of the hematopoietic cell in which the ERK activation takes place. ERK activation in the hematopoietic stem cell and the dendritic precursor cell leads to an extensive LCH, whereas ERK activation in the tissue dendritic precursor cell and the CD1a+/CD207+ LCH lesion dendritic cell leads to a single-system LCH.

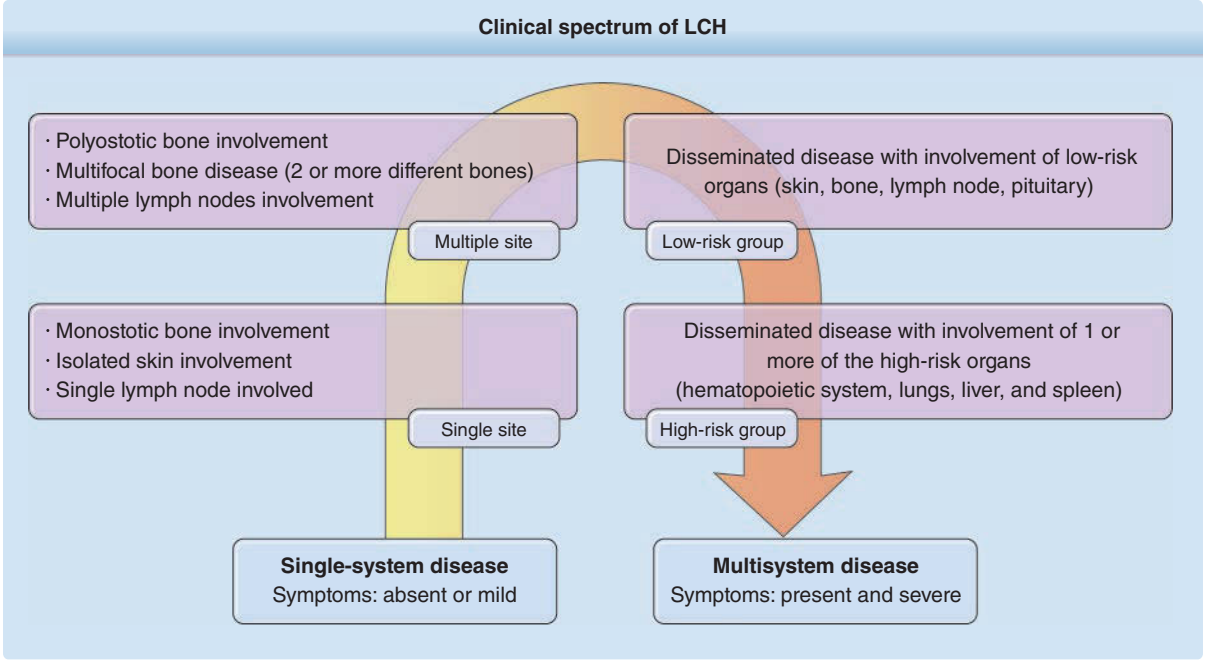

Figure 117-2 Clinical spectrum of Langerhans cell histiocytosis (LCH). Any single patient affected by LCH can be situated in a given point on the arrow.

pigmented and purpuric striae of the nail bed. Mucosal lesions most commonly are nodulo-ulcerative and involve the perioral, the perigenital, and the perianal areas as well as the gingiva. Mucosal lesions and external otitis media seem to be associated with a higher risk for multisystem LCH.[7] Purpura with nail involvement might be a poor prognostic sign, but this should be evaluated in larger clinical trials. This broad variety of skin and mucosal manifestations frequently leads to a delayed diagnosis as skin lesions are misinterpreted as eczema, miliaria, scabies, varicella, seborrheic dermatitis, folliculitis, or candidiasis. LCH should be kept in mind as a rare, but important, differential diagnosis when the above-mentioned lesions are seen, especially if they are resistant to therapy and are spreading.

Figure 117-3 Rose-yellowish papules on the abdominal area of an infant suffering from extensive Langerhans cell histiocytosis.

NONCUTANEOUS FINDINGS

The most common noncutaneous organ involved in LCH is bone (77% of cases), followed by lymph nodes (19%), liver (16%), spleen (13%), lung (10%), and the CNS (6%). In aggressive manifestations

Figure 117-4 "*Candida* intertrigo"–like eruptions in the genital area of an infant with Langerhans cell histiocytosis.

Figure 117-5 "Seborrheic dermatitis"–like eruptions on the scalp of an infant with Langerhans cell histiocytosis.

Figure 117-6 Hemorrhagic papules and nodules on the abdominal area of a patient who has Langerhans cell histiocytosis.

of the disease, patients present with a variety of clinical symptoms such as malaise, fever, nausea, weight loss, myalgia and arthralgia, and memory problems.

Bone Lesions: Although LCH can affect any bone in the body, it most frequently affects the skull, jaw, femur, rib, vertebra, and humerus. Patients complain about tender masses, and the radiologic workup shows lytic areas in affected bones with a "punched out" appearance. Particularly in children, the cervical vertebrae are commonly involved, which can lead to vertebra plana. In adults, an asymmetric collapse of the vertebrae is more common, which can provoke neurologic defects. Involvement of the jaw can cause loose teeth. Vertebral collapse can be one of the most prominent diagnostic hints for LCH. Involvement of the base of the skull might result in hearing loss, recurrent otitis externa, diabetes insipidus, or cranial nerve palsies. Lesions of the facial bones and anterior or middle cranial fossae classify as "CNS-risk" lesions as they are associated with a 3-fold increased risk for developing CNS diseases such as diabetes insipidus, which at diagnosis is mostly an irreversible condition.

Lymph Nodes: Cervical lymph nodes are the most frequently affected by LCH, but LCH can also involve lymph nodes of the mediastinum, which could be misdiagnosed as lymphoma, and can cause asthma-like symptoms because of airway system compression. A biopsy for proper diagnosis is mandatory.

Bone Marrow: Bone marrow involvement frequently affects young children when other risk organs, such as liver and spleen, are involved. In the past, bone marrow involvement was suspected only if significant anemia, thrombocytopenia, or neutropenia was present. A recent study found CD1a+ cells in the bone marrow in single-system LCH even if no hematologic abnormalities could be detected. When thrombocytopenia and anemia, especially in combination with hypoalbuminemia, are present, LCH was associated with a poor outcome.[8]

Liver and Spleen: Cholestasis and sclerosing cholangitis induced by hepatic involvement of LCH are among the most serious complications of LCH. In most cases, sclerosing cholangitis will not respond to chemotherapy and liver transplantation remains the only possible treatment option. Clinically, patients present with hepatosplenomegaly and elevated liver enzymes such as elevated liver transaminases, γ-glutamyltransferase, and/or alkaline phosphatase. Also, hypoalbuminemia with ascites and clotting deficiencies can appear. Involvement of the spleen with massive splenomegaly can significantly worsen the clinical outcome because of hypersplenism with resulting cytopenias and respiratory compromise.

Lungs: Involvement of the lungs is more frequently seen in adults than in children, and smoking has been identified as a major risk factor. LCH induces a cystic and/or nodular destruction of lung tissue of the upper

and middle lung fields and can result in a spontaneous pneumothorax, tachypnea, and/or dyspnea,[9] ultimately leading to severe pulmonary insufficiency.

Central Nervous System: LCH can directly affect any part of the brain. A risk factor for CNS involvement (25% risk) is LCH lesions of the facial bones or bones of the anterior or middle cranial fossae ("CNS-risk" lesions). The most common manifestations of CNS involvement include endocrine abnormalities resulting from large pituitary tumors, most frequently diabetes insipidus, and neurodegenerative symptoms such as ataxia, dysarthria, cognitive dysfunction, and behavior changes. Radiologic changes can precede these symptoms by many years. Interestingly, histologically in neurodegenerative lesions, no CD1a+ cells are found; instead, lymphocytes and activated microglia cells are found, which leads to the speculation that it could be a paraneoplastic inflammatory response.

Endocrinopathies: Diabetes insipidus is the most common endocrinopathy encountered in LCH. Patients present with polyuria, polydipsia, and nocturia. This is a sign of damage to the antidiuretic hormone-secreting cells of the posterior pituitary. In approximately 4% of patients, idiopathic diabetes insipidus can precede the diagnosis of LCH.[10] In patients with diagnosed LCH, the risk of developing diabetes insipidus is approximately 24%. In most cases, diabetes insipidus persists despite treatment.

Other endocrine abnormalities associated with the anterior pituitary, such as hypogonadism, growth failure, thyroid hormone dysfunctions, and abnormalities in glucose metabolism, can manifest. Therefore, a complete endocrine work-up is recommended.

Gastrointestinal System: Patients with GI involvement can present clinically with diarrhea, hematochezia, perianal fistulas, and/or malabsorption, but this organ system is rarely affected. If patients present with GI symptoms, multiple biopsies are required, as in most cases GI involvement is patchy.

DIAGNOSIS

The diagnosis of LCH is based on clinicopathologic and radiologic features of affected organs.

COMPLETE HISTORY

Nature and duration of symptoms should be assessed. In addition based on the recommendations of the Histiocyte Society, a complete history should include questions regarding pain, swelling, skin rash, otorrhea, irritability, fever, loss of appetite, diarrhea, weight loss, growth failure, polydipsia, polyuria, changes in activity level, dyspnea, smoke exposure, and behavioral and neurologic changes.

COMPLETE PHYSICAL EXAMINATION

Temperature, height, and weight should be measured. In addition, the Histiocyte Society recommends assessment of pubertal status; for thorough skin and mucous membrane evaluation, for presence of jaundice, pallor, edema, lymphadenopathy, ear discharge, orbital abnormalities, abnormal mucosal lesions, abnornal dentation, and soft-tissue swelling, as well as evaluation of any tachypnea, intercostal retractions, and ascites; and evaluation of liver and spleen size evaluation. Also, a complete neurologic evaluation is mandatory.

LABORATORY TESTING AND IMAGING STUDIES

Table 117-3 lists the recommended laboratory investigations and imaging studies for patients suffering from LCH. Table 117-4 identifies the recommendations for specific clinical scenarios.

HISTOPATHOLOGY

A histopathologic diagnosis is by far the most reliable and accurate diagnostic tool for a definitive diagnosis of LCH and should always be performed if it doesn't put the patient at an increased risk. Histopathologically, typical findings in a skin biopsy show a dense and band-like infiltration of the papillary dermis with LCH cells (Fig. 117-7). These cells are oval shaped

TABLE 117-3

Recommended Baseline Laboratory Tests and Imaging Studies of Patients Suffering from Langerhans Cell Histiocytosis

Full blood count
- Hemoglobin, white blood cell and differential count, and platelet count

Blood chemistry
- Total protein, albumin, bilirubin, alanine aminotransferase (serum glutamic-pyruvic transaminase), aspartate aminotransferase (serum glutamic-oxaloacetic transaminase), alkaline phosphatase, γ-glutamyl transpeptidase
- Blood urea nitrogen, creatinine, electrolytes
- Ferritin
- Fasting glucose level
- Serum protein electrophoresis

Coagulation studies
- International normalized ratio/prothrombin time, activated partial thromboplastin time/partial thromboplastin time, fibrinogen

Early morning urine sample
- Specific gravity and osmolarity

Abdominal ultrasound

Chest radiography

Bone scans, skeletal survey, or fluorodeoxyglucose positron emission tomography

Adapted from the recommendations of the Histiocyte Society (https://histiocytesociety.org/).

TABLE 117-4

Specific Clinical Scenarios and Recommended Additional Laboratory, Imaging, and Specialized Clinical Assessments

Skin lesions
- Skin biopsy

Bicytopenia, pancytopenia, or persistent unexplained single cytopenia
- Bone marrow aspirate and trephine biopsy to exclude causes other than Langerhans cell histiocytosis (LCH)

Liver dysfunction
- Liver biopsy only recommended if there is clinically significant liver involvement and the result will alter treatment (ie, to differentiate between active LCH and sclerosing cholangitis)

Lung involvement
- Lung high-resolution computed tomography
- Lung function test

Abnormal lung CT *and* findings not characteristic for LCH or suspicious for atypical infection
- Bronchoalveolar lavage (BAL): >5% CD1a+ cells in BAL fluid is diagnostic in nonsmokers
- Lung biopsy (if BAL is not diagnostic)

Suspected craniofacial bone lesions, including maxilla and mandible
- MRI of head

Suspected vertebral lesions
- MRI of spine

Visual or neurologic abnormalities
- MRI of head
- Neurology assessment
- Neuropsychometric assessment

Suspected endocrine abnormality (eg, growth failure, polyuria, polydipsia, hypothalamic syndromes, precocious or delayed puberty)
- Endocrine assessment (including water deprivation test and dynamic tests of the anterior pituitary and thyroid)
- MRI of the head

Aural discharge or suspected hearing impairment/mastoid involvement
- Formal hearing assessment
- MRI of head
- High-resolution CT of temporal bone

Unexplained chronic diarrhea, failure to thrive, or evidence of malabsorption
- Endoscopy and biopsy

Adapted from the recommendations of the Histiocyte Society (https://histiocytesociety.org/).

with an eosinophilic cytoplasm and typically display an irregular, vesicular, and infolded (kidney-shaped) nucleus (Fig. 117-8). In some cases, longitudinal nuclear grooves, which confer onto these cells a coffee bean-like appearance, can be seen. Conspicuously, LCH cells are 4 to 5 times larger than lymphocytes and are admixed with variable numbers of neutrophils, eosinophils, lymphocytes, plasma cells, and histiocytes, especially in early lesions. In later lesions, foamy histiocytes and a prominent fibrosis of the dermis prevail. LCH cells often show a marked epidermotropism with the formation of intraepidermal microabscesses and a periappendageal distribution (Figs. 117-7 and 117-9). The epidermotropism can be so marked that the dermoepidermal junction gets obscured and the epidermis gets thinned and even destroyed. Also, edema

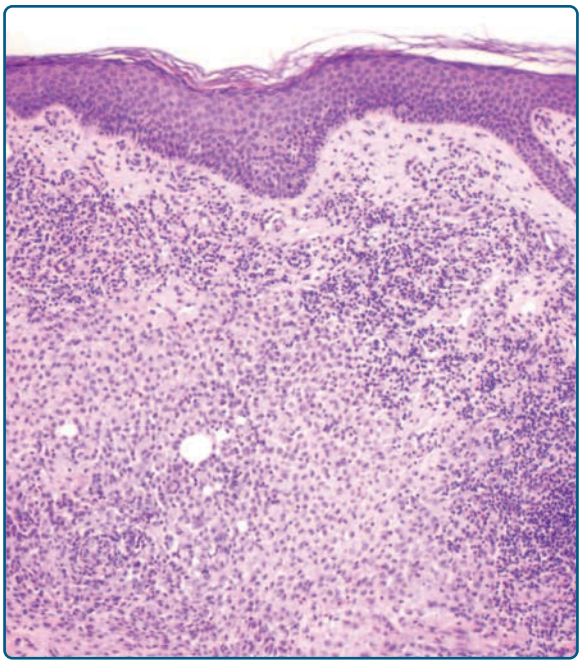

Figure 117-7 Histology of Langerhans cell histiocytosis (LCH) showing a dense mononuclear infiltrate of the dermis with oval to rounded LCH cell and lymphocytes as well as some eosinophils with epidermal involvement.

in the papillary dermis and multinucleated giant cells can be found on occasion. Typical immunohistochemical markers of LCH cells are CD1a (Fig. 117-9), S100B, CD207 (Langerin), and fascin. Stabilin-1 and CD34 are not expressed (Table 117-5). A typical finding in LCH cells is the presence of Birbeck granules in the cytoplasm, as identified by electron microscopy. They are organelles, which resemble a tennis racquet and have a zipper-like appearance along the "handle" (Fig. 117-10). In the past, the detection of Birbeck granules by electron microscopy was the diagnostic gold standard for LCH. Nowadays however, immunohistochemical staining with CD207, an antibody that recognizes a C-type lectin associated with Birbeck granules, is the most sensitive marker. Electron microscopy is no longer needed for a specific diagnosis.

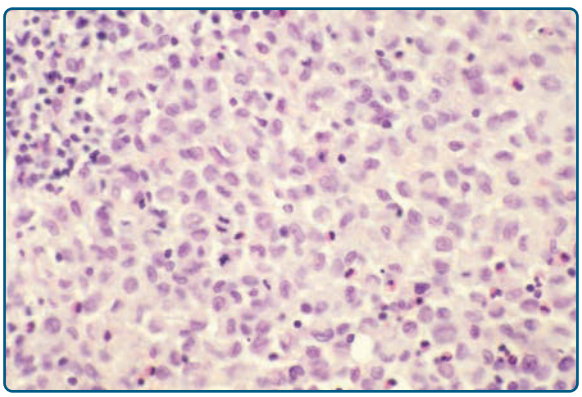

Figure 117-8 Histology of Langerhans cell histiocytosis (LCH). LCH cells have a kidney-shaped nucleus.

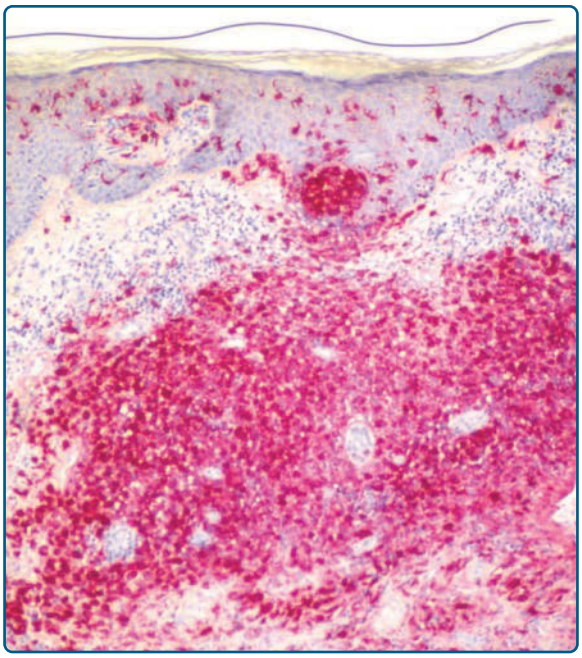

Figure 117-9 Histology of Langerhans cell histiocytosis (LCH). The LCH cells stain for CD1a (red) and show a marked epidermotropism.

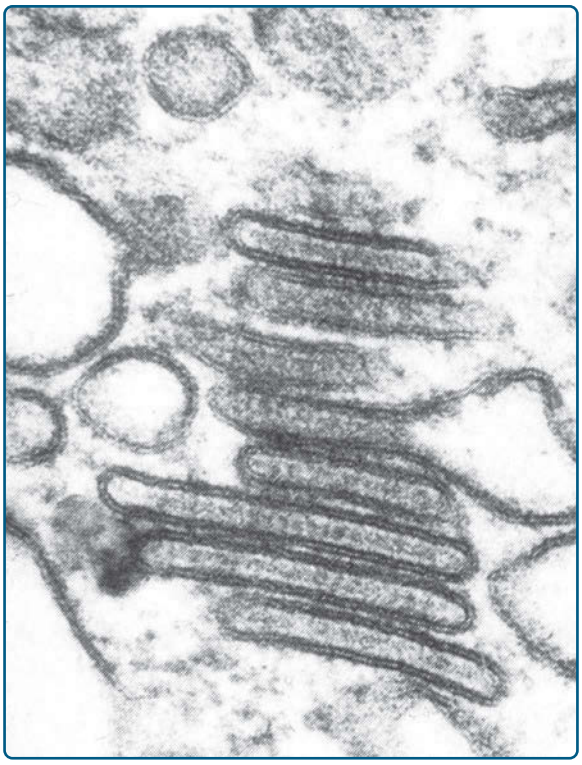

Figure 117-10 Electron microscope picture of a Langerhans cell histiocytosis cell shows typical Birbeck granules.

DIFFERENTIAL DIAGNOSIS

Table 117-6 lists possible differential diagnoses for different clinical manifestations of LCH in the skin.

CLINICAL COURSE AND PROGNOSIS

LCH is a heterogeneous disease. Patients can present with lesions confined to a single-organ system with an indolent self-healing course or with multiple lesions in different organs—especially in at-risk organs—with a fatal outcome. Consequently, risk stratification is crucial to delivering the optimal treatment regimen to each patient. The prognosis depends on a variety of factors. A recent multicenter LCH Phase III trial investigated a 12-month treatment with vinblastine and prednisolone demonstrating 5-year survival rates of 95%, 83%, and 57%, respectively, in patients who showed a complete resolution of disease, intermediate response to treatment, and progression of the disease after the 6-week induction phase.[11] Therefore, one of the most important predictors of outcome in patients with multiorgan involvement is how the disease responds to systemic treatment in the first 6 weeks.[11] Other predictors previously associated with a poor outcome, such as age younger than 2 years or lung involvement, are now no longer regarded as risk factors for a poor outcome. Involvement of at-risk organs such as the liver, the spleen, and the bone marrow is also associated with a poor outcome. Enlargement of the liver by more than 3 cm below the costal margins at the midclavicular line; hyperbilirubinemia greater than 3 times normal; hypoalbuminemia less than 30 g/dL; γ-glutamyl transpeptidase increased by more than 2 times normal; alanine aminotransferase and aspartate aminotransferase greater than 3 times normal; ascites; edema; or an intrahepatic nodular mass are signs for liver involvement and need to be confirmed by ultrasound and, if possible, by biopsy. Involvement of the spleen should be suspected if the organ can be palpated by more than 3 cm below the costal margin at the midclavicular line. Hematopoietic involvement can be divided into a mild form with hemoglobin between 10 and 7 g/dL, not the result of other causes, and/or a thrombocytopenia

TABLE 117-5

Marker Expression of Langerhans and Non–Langerhans Cell Histiocytosis

Langerhans cell histiocytosis
- Positive: CD1a, CD2, CD11b, CD11c, CD13, CD66c, CD68, CD207 (Langerin), CD300LF, S100B, fascin
- Negative: stabilin-1

Non–Langerhans cell histiocytosis
1. Systemic non–Langerhans cell histiocytosis
   - Positive: CD68
   - Negative: *CD1a*
2. Cutaneous non–Langerhans cell histiocytosis:
   - Positive: CD68, stabilin-1
   - Negative: *S100B, CD1a*

TABLE 117-6
Differential Diagnosis of Langerhans Cell Histiocytosis (Lesion Specific)

	TYPE OF LESION			
	PAPULAR	**VESICOPUSTULAR**	**XANTHOMATOUS**	**NODULOULCERATIVE**
Most likely	Seborrheic dermatitis	Scabies	Papular xanthoma	Juvenile xanthogranuloma
	Lichen nitidus	Miliaria	Xanthoma disseminatum	Urticaria pigmentosa
	Generalized eruptive histiocytosis	Varicella	Juvenile xanthogranuloma	Diffuse neonatal hemangiomatosis
	Benign cephalic histiocytosis	Intertrigo	Urticaria pigmentosa	Blueberry muffin baby
	Darier disease	Candidiasis		Hidradenitis
	Lichen planus	Rosacea Folliculitis decalvans		Tuberculosis
Consider	Leukemia	Dermatitis	Hyperlipidemic xanthomatosis	Leukemia
	Pityriasis lichenoides chronica	Pityriasis lichenoides et varioliformis acuta	Granuloma annulare disseminatum	Pyoderma gangrenosum
	Hidradenitis suppurativa	Granuloma faciale		Cherry angioma
	Psoriasis, guttate	Perioral dermatitis		
	Tinea corporis, tinea capitis	Lupus miliaris faciei		

with platelets between 20,000 and 100,000/mm^3, and a severe form with hemoglobin below 7 g/dL and platelets less than 20,000/mm^3.[12] To date, no data has demonstrated diabetes insipidus to be a predictor of poor outcome. Small numbers of lesions, a prompt resolution of lesions, and single-organ involvement are usually associated with a good outcome.

The prognosis is, however, not only dependent on the disease itself, but also on associated findings. LCH patients tend to suffer from intercurrent infections, mostly mild ones, such as candidiasis and dermatophytosis, but they are also prone to more severe systemic infections, which can lead to sepsis and death. Also, LCH is associated with other malignancies, which may precede, occur concurrently with, or follow the diagnosis of LCH. Described associated malignant neoplasms are solid tumors (lung tumors, celiomesenteric neuroblastoma), malignant lymphomas, and leukemias, in particular, acute lymphoblastic leukemia and myeloid leukemias. Some of these malignancies may be related to alkylating chemotherapeutic regimens and radiotherapy used for LCH. These possible complications and/or associations should be considered at every clinical visit.

MANAGEMENT

Treatment strategies depend on the extent and localization of the disease and the age of the patient. Patients with more limited disease confined to bone or skin are usually not treated systemically, except for "special site" lesions such as the odontoid peg, vertebral lesions with intraspinal soft-tissue extension, and anatomically functionally critical sites. All treatment recommendations are based on the recommendations of the Histiocyte Society. Systemic treatment also can be considered for multifocal bone lesions and "CNS-risk" lesions. In children with LCH confined to the skin, a watch-and-wait strategy is the best approach. Topical treatment can be tried with corticosteroid ointments, but topical steroids have shown little efficacy. A skin rash that does not respond to topical steroids is considered a clue for LCH. Other topical treatment options include imiquimod and tacrolimus as well as intralesional corticosteroid injections, CO_2 laser therapy, or excision of single LCH nodules. Nitrogen mustard ointment can be applied to treat skin lesions in adults. Several case reports exist that show a significant improvement after narrowband ultraviolet B irradiation in adults and children. This treatment might work well with papules and eczematous lesions, but not when nodules are present. Photochemotherapy is effective in some adult patients. In case of ineffective local therapy, systemic glucocorticoids, thalidomide, or antimitotic drugs, such as low-dose methotrexate, can be tried. Thalidomide can ameliorate skin lesions, but the treatment is associated with neurologic toxicity and fatigue. Thalidomide should not be used in women with child-bearing potential if the skin is the only organ affected. There is 1 case report in which a patient went into complete remission after oral isotretinoin therapy (1.5 mg/day for 8 months). Table 117-7 outlines some treatment options.

Also for single-bone lesions a watch-and-wait strategy can be used. Other options include simple curettage, complete excision of small lesions (lesions <2 cm diameter) and intralesional steroid injections of steroids (see Table 117-7).

Thanks to the efforts of the Histiocyte Society, which was founded 1985, the scientific evidence for

TABLE 117-7
Treatment Options for Patients Suffering from Single-System Langerhans Cell Histiocytosis

SKIN	BONE
▪ Observation	▪ Observation
▪ Nitrogen mustard	▪ Biopsy or curettage
▪ Tacrolimus	▪ Surgery
▪ Imiquimod	▪ Steroid injections
▪ Intralesional steroids	▪ Vinblastine/prednisolone (multiple bone lesions *or* "special site" lesions)
▪ Narrowband ultraviolet B	
▪ Photochemotherapy	
▪ CO_2 laser	
▪ Methotrexate	
▪ Systemic steroids	
▪ Thalidomide	
▪ Isotretinoin	
▪ Excision (single lesions)	

the treatment of LCH multisystem disease is far better than that for single-system LCH based on the reported results of multicenter trials (LCH-I, LCH-II, LCH-III).

Based on the results of the most recent LCH-III trial, patients should be treated systemically for 12 months because patients treated for only 6 months have an increased frequency of early relapse. The treatment protocol consists of a 6-week induction chemotherapy phase with vinblastine (6 mg/m^2 weekly intravenous bolus) combined with prednisolone (40 mg/m^2/day orally for 4 weeks and then tapered over 2 weeks) and a subsequent therapy with vinblastine/prednisolone with or without mercaptopurine, depending on the treatment response after 6 weeks and the involvement of at-risk organs (Fig. 117-11). With this treatment regimen, 86% of patients without risk-organ involvement and 66% with risk-organ involvement show a response to therapy after 6 weeks—an important prognostic factor for outcome. Still, 50% of patients in this study did not respond to treatment,[11] illustrating the need for additional therapeutic strategies. Other chemotherapeutic agents used as salvage strategies with proven efficacy for multisystem LCH, albeit with serious side effects, are cytarabine, cladribine, and clofarabine. Allogeneic bone marrow transplantation has been attempted in 87 patients with high-risk LCH. Among patients transplanted, 77% survived after 3 years following myeloablative and reduced-intensity conditioning regimens.[13] Based on recent research results, which provided evidence for a strong ERK activation arising from somatic mutations in the mitogen-activated protein kinase (MAPK) signaling pathway in LCH, novel therapeutic options include BRAF and MAPK inhibitors. Although limited data exist for these treatment regimens, first reports are promising.[14,15] Also, a high programmed death ligand 1 expression in LCH has been described,[6] which suggests that anti–programmed death 1 and anti–programmed death ligand 1 treatments might be successful.

NON–LANGERHANS CELL HISTIOCYTOSIS

AT-A-GLANCE

- Non–Langerhans cell histiocytosis (N-LCH) represents a group of different disorders characterized by the proliferation of histiocytes that do not meet criteria to be diagnosed as Langerhans cells
- N-LCH are immunohistochemically positive for CD68 and negative for S100B and CD1a
- Stabilin-1 (formerly MS-1 antigen or MS-1-HMWP) can discriminate N-LCH from LCH and other granulomatous diseases
- Systemic manifestations, such as diabetes insipidus, or ocular involvement, as well as an association with malignancies can occur in N-LCH
- Local skin manifestations of the disease can be treated by excision, laser therapy, or intralesional steroid injection. Radiotherapy also is used for the treatment of skin lesions and cerebral lesions. For the treatment of patients with visceral lesions, systemic glucocorticoids and chemotherapy, and in some cases targeted therapies, such as imatinib mesylate or BRAF and MEK inhibitors, are useful.

N-LCH is a group of different disorders characterized by the proliferation of histiocytes other than Langerhans cells. N-LCH can be classified as systemic or cutaneous N-LCH (see Table 117-1). Cutaneous N-LCH can be subclassified as juvenile, adult, and necrobiotic xanthogranulomas, as well as spindle-cell N-LCH.

ETIOLOGY AND PATHOGENESIS

Systemic forms of N-LCH are regarded as an accumulation of classically activated macrophages (Mϕ1). In contrast, the lesions of cutaneous N-LCH are characterized by the presence of alternatively activated macrophages (Mϕ2).

In forms with single lesions, local trauma might play a pathogenetic role. In diffuse forms an association with malignancies and autoimmune diseases suggests an immunologic cause.

Mϕ1 are known to develop in response to proinflammatory stimuli such as T-helper (Th) 1 cytokines (interferon-γ or bacterial products [lipopolysaccharides]). They are characterized by secretion of proinflammatory cytokines, such as interleukin (IL)-1,

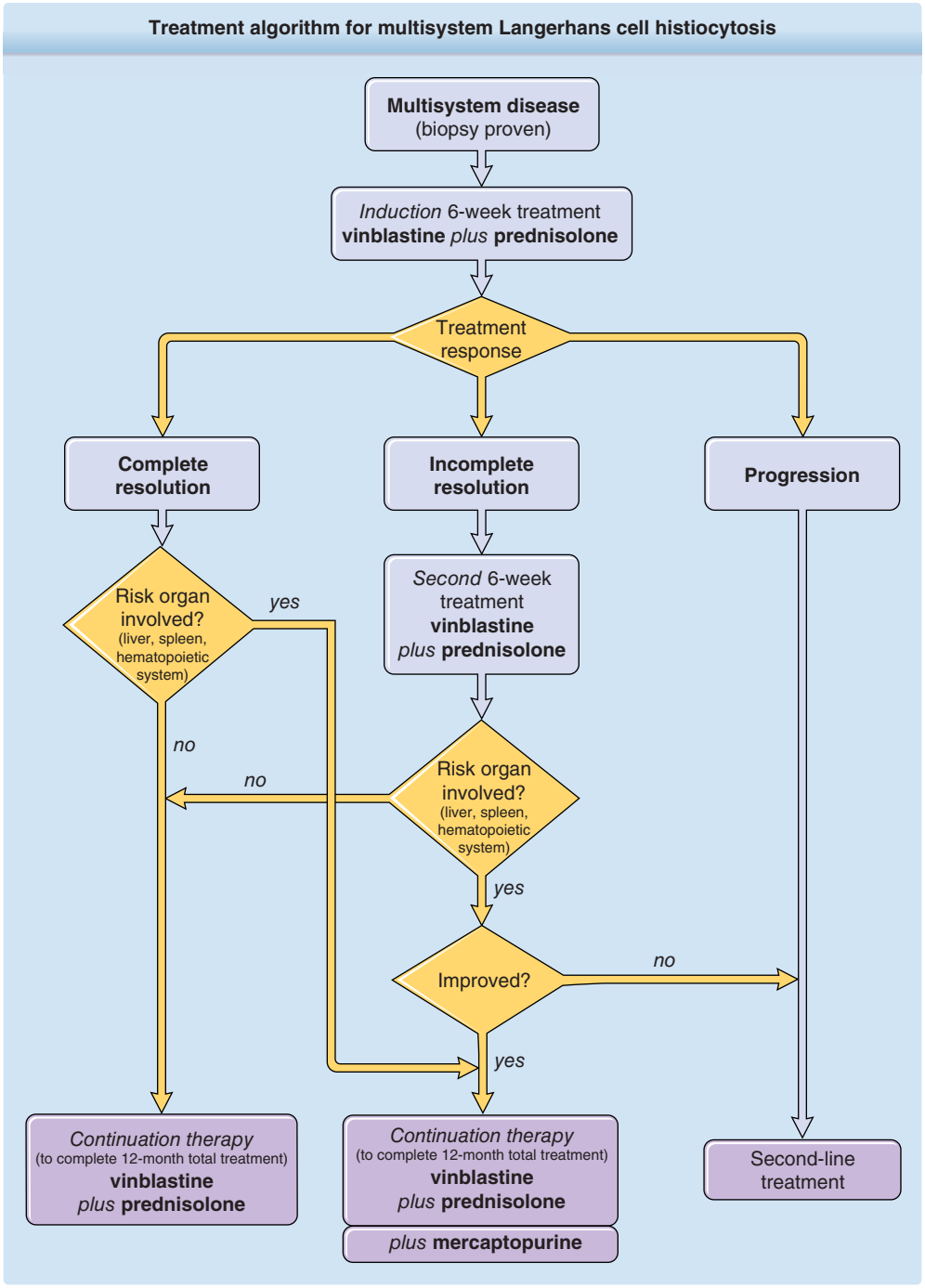

Figure 117-11 Treatment algorithm for multisystem Langerhans cell histiocytosis.

IL-6, IL-1, and tumor necrosis factor-α, and possess a strong oxidative burst and a profound antimicrobial activity.

In contrast to systemic N-LCHs, the lesions of cutaneous N-LCHs show alternatively activated effector macrophages (Mϕ2). Mϕ2 are induced by Th2 cytokines, including IL-4, IL-10, IL-13, and transforming growth factor-β, or by antiinflammatory mediators such as glucocorticoids. They express antiinflammatory cytokines such as IL-1R antagonist and IL-10, chemokine receptor antagonists such as AMAC-1, broad-spectrum receptors of innate immunity, such as macrophage mannose receptor and the haptoglobin receptor CD163.

N-LCHs are positive for CD68 but negative for CD1a. Stabilin-1 (formerly MS-1 antigen or MS-1-HMWP) is expressed on some N-LCH. Because of its specific expression in N-LCH, it can be used as one marker to discriminate N-LCH from LCH or granulomatous diseases (see Table 117-5).

ROSAI-DORFMAN DISEASE (SINUS HISTIOCYTOSIS WITH MASSIVE LYMPHADENOPATHY)

PATHOPHYSIOLOGIC ASPECTS AND CLINICAL FEATURES

In 1969, sinus histiocytosis with massive lymphadenopathy was described by Juan Rosai and Ronald Dorfman. Rosai-Dorfman disease (RDD) is an idiopathic disease, but its occurrence has frequently been observed after infectious disease. A possible viral etiology, such as Epstein-Barr virus, human herpesvirus 6, parvovirus B19, and polyomavirus, has been suggested by several authors.[16,17] Lymphadenopathy is the main clinical manifestation. The neck lymph nodes are the most common place of histiocyte accumulation, although accumulation outside of lymph nodes may occur. Here, the skin (Fig. 117-12) and other organs, such as the breast, kidney, thyroid, testis, and CNS, may be affected.[17] Similar to other regional tumors, the symptoms of this disease vary with the site of accumulation. Despite the rarity of RDD, the co-occurrence with LCH, lymphomas, or autoimmune disorders has been reported.[17] Because of the expression of S100B by histiocytes, S100B can be used as a serum marker to monitor disease progression or therapy response.

HISTOPATHOLOGIC FINDINGS

RDD cells are characteristically S100B+ (Fig. 117-13A) and CD1a–. The RDD cells are also positive for CD68, CD163, α_1-antitrypsin, α_1-antichymotrypsin, fascin, HAM-56 (human alveolar macrophage 56), and stabilin-1 (Fig. 117-13B). The hallmark of RDD is emperipolesis, in which different types of bone marrow cells, such as lymphocytes or neutrophils, are found in the cytoplasm of histiocytes with a background of mature lymphocytes and plasma cells.[17]

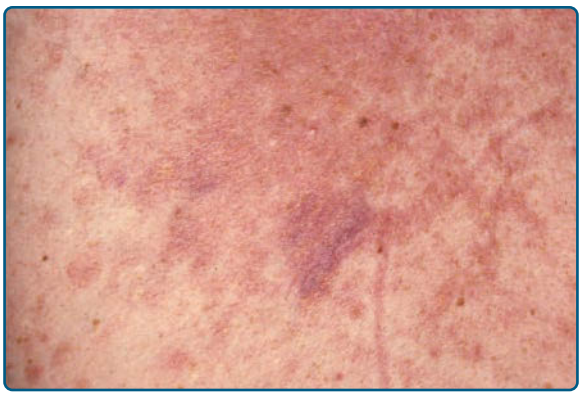

Figure 117-12 Rosai-Dorfman disease.

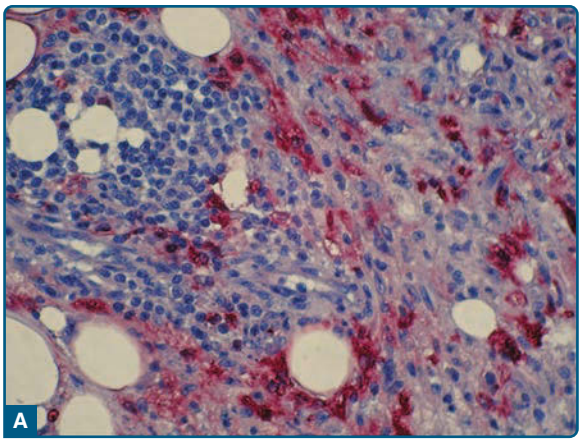

S100B

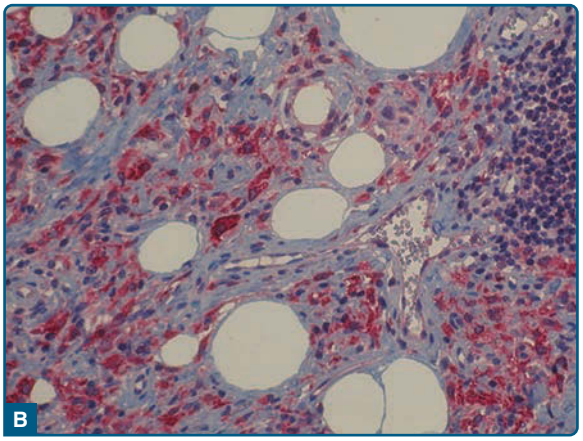

Stabilin 1

Figure 117-13 Photomicrographs of a lesion of Rosai-Dorfman disease. Histiocytes are positive for S100B (**A**) and stabilin-1 (**B**).

DIFFERENTIAL DIAGNOSIS

Because enlarged and massive unilateral or bilateral lymph nodes are a frequent manifestation in isolated or multiple regions, lymphoma or abscesses may be clinically suspected. Extranodal RDD can also mimic other diseases, such as meningioma.[17]

CLINICAL COURSE AND PROGNOSIS

Spontaneous resolution in patients with RDD was reported. There are reports that surgical resection as well as radiotherapy for affected lymph nodes or skin lesions has resulted in the complete disappearance of RDD. Oral prednisone can have a remarkably favorable response, mainly in patients with lymph node involvement. However, intralesional corticosteroid or oral prednisone does not always result in resolution of cutaneous lesions. Treatment with chemotherapeutic agents has been disappointing in general. There are reports, however, that some patients could benefit from a combination of methotrexate/6-mercaptopurine/vinblastine/6-thioguanine.[17]

Tyrosine kinase inhibitors such as imatinib mesylate are effective in some patients with RDD.[18]

HEMOPHAGOCYTIC LYMPHOHISTIOCYTOSIS

CLINICAL FEATURES

Hemophagocytic lymphohistiocytosis (HLH) was first described in 1952 by Farquhar and Claireaux and is a rare disease. The 70% of HLH cases are children younger than the age of 1 year. HLH is characterized by persistent fever, splenomegaly with cytopenia, hypertriglyceridemia, and hypofibrinogenemia. The infiltration of histiocytes is usually observed in reticuloendothelial systems, including the bone marrow and CNS. Various cutaneous manifestations, such as erythroderma, generalized purpuric macules and papules, and morbilliform eruptions, have been described in up to 65% of HLH patients. HLH is classified as one of the cytokine storm syndromes because high amounts of inflammatory cytokines are secreted.

There are 2 major forms: primary and secondary. Primary HLH includes familial HLH and several primary immunodeficiencies, which exhibit genetic inheritance and usually occur in infancy. Several genetic defects in primary HLH—particularly familial HLH genes such as *HPLH1*, perforin, *UNC13D*, *STX11*, and *STXBP2*—have been identified. Secondary HLH is associated with infections (eg, Epstein-Barr virus), autoimmune disorders (eg, juvenile idiopathic arthritis), and malignancies (mainly non-Hodgkin lymphoma). Increased levels of various cytokines and soluble IL-2 receptor are biologic markers of HLH.[19]

DIFFERENTIAL DIAGNOSIS

The differential diagnosis of HLH includes autoimmune lymphoproliferative syndrome, Griscelli syndrome, macrophage activation syndrome, and other primary immunodeficiencies that present with HLH, such as X-linked lymphoproliferative disease.[19]

CLINICAL COURSE AND PROGNOSIS

The prognosis is guarded with an overall mortality of 50%. It is a poor prognostic factor if HLH is associated with malignancy.[20] In some individuals, secondary HLH may be self-limited.

Therapeutic options include high-dose corticosteroids, cyclosporine, etoposide, methotrexate, and vincristine. Use of intravenous immunoglobulin also has been described. An aggressive therapeutic approach is warranted in most cases, including immunochemotherapy and hematopoietic stem cell transplantation.[19]

JUVENILE XANTHOGRANULOMA

CLINICAL FEATURES

Juvenile xanthogranuloma (JXG) was first described in 1905 by Adamson. It is a benign, self-healing skin disorder that primarily affects infants younger than 1 year of age, but also can be found in older children. At birth, 5% to 17% of children already have cutaneous lesions. In 40% to 70% of children who are affected by JXG, the disorder presents during the first year of life.

JXG usually manifests with both solitary and multiple (oligolesional) papules or nodules that are usually located on the face, neck, and upper trunk, and on other body parts, including lungs, bone, heart, and GI tract. Early lesions show a reddish-brown color (Fig. 117-14A). Mature lesions have a reddish-yellow appearance (Fig. 117-14B). Telangiectasia can be present. Ocular lesions occur in up to 10% of children with JXG and may affect their vision. JXG is often accompanied with other disorders, such as neurofibromatosis Type 1 and juvenile chronic myelogenous leukemia.[21]

HISTOPATHOLOGIC FINDINGS

In early lesions, microscopic examination shows monomorphous, non–lipid-containing histiocytic infiltrates in the dermis (Fig. 117-15A). In contrast mature lesions are characterized by foam cells, Touton giant cells, and foreign-body giant cells in the superficial dermis and on the border of infiltrates (Fig. 117-15B). Also, fibrosis can be appreciated. Lesional histiocytes are positive for stabilin-1. Cells stain for macrophage markers such as CD163, CD11b, CD11c, CD36, CD68, factor XIIIa, and vimentin. S100B and CD1a are not expressed.

DIFFERENTIAL DIAGNOSIS

JXG can be distinguished from LCH by the expression of stabilin-1 and the absence of CD1a and CD207. Other differential diagnoses include, for example, molluscum contagiosum, hemangioma, and neurofibroma (Table 117-8).

CLINICAL COURSE AND PROGNOSIS

JXG usually resolves spontaneously over 1 to 5 years. Ocular lesions, however, rarely improve spontaneously and require treatment. Treatments include surgical excision, CO_2 laser treatment, intralesional steroid injection, cryotherapy, and low-dose radiotherapy. In the case of a resistant or recurring lesion, chemotherapy should be considered.[21]

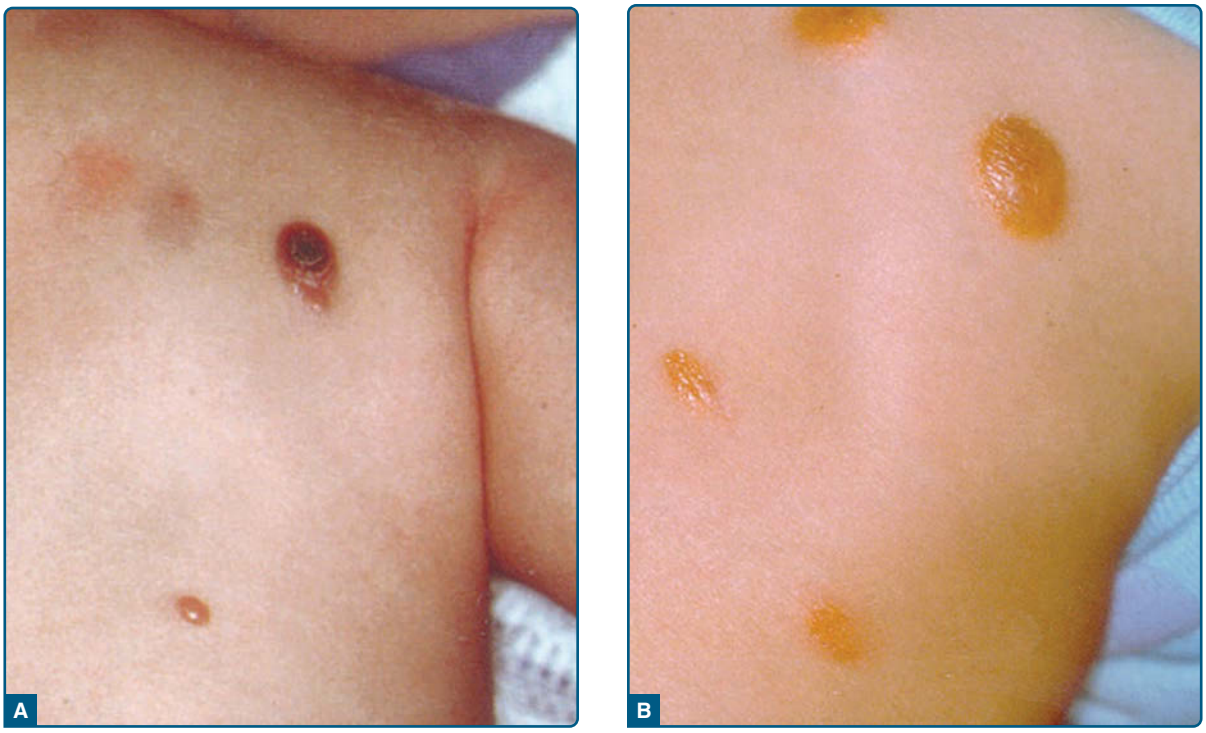

Figure 117-14 Juvenile xanthogranuloma. **A,** Early stage presents with reddish papules. **B,** Mature stage shows a reddish-yellow shade of color.

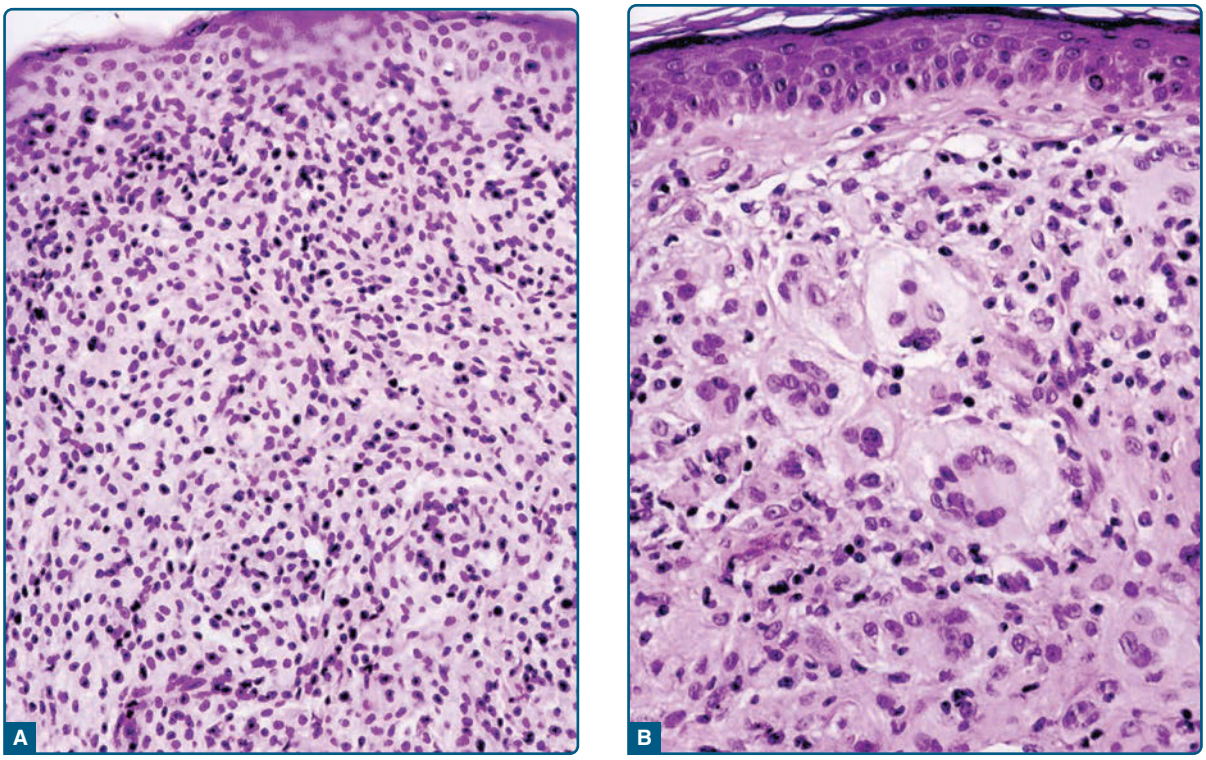

Figure 117-15 Photomicrographs of lesions of juvenile xanthogranuloma. **A,** The early stage is characterized by small, mostly mononuclear histiocytes with a small cytoplasm and less lipid reaching the epidermis without any Grenz zone. **B,** The mature stage shows big, cytoplasm-rich, lipidized histiocytes, big foam cells, and typical Touton giant cells.

TABLE 117-8
Differential Diagnosis of Juvenile Xanthogranuloma

- Xanthoma
- Neurofibroma
- Hemangioma
- Molluscum contagiosum
- Spitz nevus
- Papular mastocytosis
- Sarcoidosis
- Dermatofibroma
- Cutaneous leukemia
- Other forms of non–Langerhans cell histiocytosis and Langerhans cell histiocytosis

BENIGN CEPHALIC HISTIOCYTOSIS

CLINICAL FEATURES

Benign cephalic histiocytosis was reported initially by Gianotti in 1971 and was separated from JXG. Because of the ultrastructural presence of worm-like bodies, it also has been called "histiocytosis with intracytoplasmic worm-like bodies." However, these bodies can be found in other forms of N-LCH. An overlap with other forms of N-LCH, especially with JXG, has been reported.

Benign cephalic histiocytosis usually presents with small, yellow-red or yellow-brown, asymptomatic papules, located on the head and neck of young children with a tendency toward spontaneous remission.[22]

HISTOPATHOLOGIC FINDINGS

Histologic examination of skin samples reveals an infiltrate of histiocytes, which closely approach the epidermis, accompanied by scattered lymphocytes and eosinophils. The histiocytes express the typical macrophage marker CD68, whereas immunostaining for Langerhans cell markers such as CD1a and CD207 is negative.[22] Ultrastructural presence of worm-like bodies is typical.

DIFFERENTIAL DIAGNOSIS

It is difficult to separate benign cephalic histiocytosis from other forms of N-LCH, especially JXG. Therefore, it can be discussed as a variant of JXG.

CLINICAL COURSE AND PROGNOSIS

Benign cephalic histiocytosis usually resolves spontaneously. Therapeutic options include CO_2 laser therapies.

GENERALIZED ERUPTIVE HISTIOCYTOMA OF CHILDHOOD

CLINICAL FEATURES

Generalized eruptive histiocytoma (GEH) (also known as "eruptive histiocytoma" or "generalized eruptive histiocytosis") was initially reported by Winkelmann and Muller in 1963. This rare disease is characterized by widespread, erythematous, essentially symmetrical papules, particularly involving proximal extremities as well as the trunk. Unlike in JXG, brownish papules and nodules do not develop; mucosal membranes, however, can be affected. Cutaneous lesions resolve spontaneously with remaining hyperpigmented maculae. There is also a report associating GEH with rheumatic fever. GEH can be seen as a variant of JXG.

ADULT XANTHOGRANULOMA

CLINICAL FEATURES

Adult xanthogranuloma was originally described by Gartmann and Tritsch in 1963. Both solitary and oligolesional yellow-orange papules usually appear on the face, neck, and lower arms. In contrast to JXG, adult xanthogranuloma does not show a spontaneous remission. No association with systemic diseases such as neurofibromatosis or leukemia has been reported. Histologic findings of adult and juvenile forms of the disease are almost identical. Usually in adult xanthogranuloma there are more giant cells. Therapeutic options include excisions of lesions or CO_2 laser therapies.

PAPULAR XANTHOMA

CLINICAL FEATURES

Papular xanthoma was reported for the first time in 1981 by Winkelmann. It is a rare disease in normolipemic patients who present clinically. It appears mainly as a solitary yellowish papule, and seems to appear more often in males. It shows a biphasic occurrence in young adolescents and in persons of middle age. A congenital form has been reported. Mucous membranes were affected in some cases but there is no systemic involvement. A plaque-like form of papular xanthoma can be seen as a variant.[23,24]

HISTOPATHOLOGIC FINDINGS

Histology shows a normal epidermis and a dense infiltration of xanthomatized macrophages interspersed by numerous Touton-type giant cells. Immunohistochemically mononucleated and multinucleated macrophages are positive for KiM1p. Only giant cells are positive for CD68. Up to 50% of the xanthomatized cells are positive for the lectin peanut agglutinin. Stainings for factor XIIIa and CD1a are negative.

DIFFERENTIAL DIAGNOSIS

Differential diagnoses include xanthoma, atheroma, keloid, histiocytoma, Spitz nevus, clear cell acanthoma, and other benign and malignant cutaneous tumors.

CLINICAL COURSE AND PROGNOSIS

Papular xanthoma usually resolves spontaneously. Therapeutic options include surgical excision and CO_2 laser therapy.[22,23]

GENERALIZED ERUPTIVE HISTIOCYTOMA

CLINICAL FEATURES

GEH was first described by Winkelmann and Muller in 1963. There are fewer than 50 case reports worldwide and it affects mainly adults.[25] GEH is characterized by multiple asymptomatic and symmetrically distributed brownish erythematous papules that involve the axial regions—trunk, face, and proximal extremities—that frequently evolve to flares. The big flexures are spared (Fig. 117-16). Mucous membranes were reported to be affected in some cases.[26] Although the disorder usually follows a benign clinical course, there are 2 reports of an atypical form associated with acute monocytic leukemia.

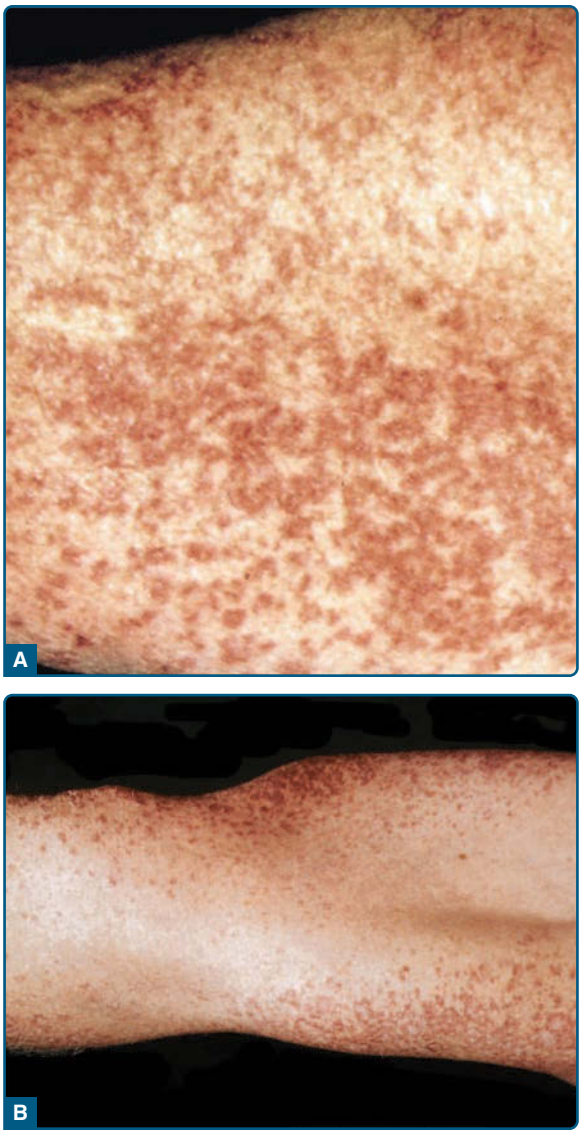

Figure 117-16 Generalized eruptive histiocytoma. Note that the big flexures are spared, as seen in part B of the figure.

HISTOPATHOLOGIC FINDINGS

Skin biopsies show a normal epidermis. The papillary dermis is infiltrated by mostly small, nonlipidized cells and few lymphocytes underneath a Grenz zone, which is characteristic for GEH (Fig. 117-17). Giant cells are missing. Macrophages are positive for CD68 and stabilin-1, and negative for CD1a, CD34, and S100B.

DIFFERENTIAL DIAGNOSIS

Differential diagnosis includes LCH, other forms of N-LCH, and urticaria pigmentosa. Other N-LCHs are easily distinguished by histology.

CLINICAL COURSE AND PROGNOSIS

GEH usually resolves spontaneously. Therapeutic options include surgical excision and CO_2 laser therapy. Systemic psoralen and ultraviolet A therapy was reported to produce rapid regression of the skin lesions. Given the potential development of acute monocytic leukemia, close follow-up of patients with GEH is recommended.[25,26]

XANTHOMA DISSEMINATUM

CLINICAL FEATURES

Xanthoma disseminatum was described by Montgomery in 1938. It preferentially affects male children. The disease is characterized by the sudden appearance of small, yellow-red to brown papules and nodules that are discrete and disseminated with a predilection for the flexural and intertriginous areas as well as mucous

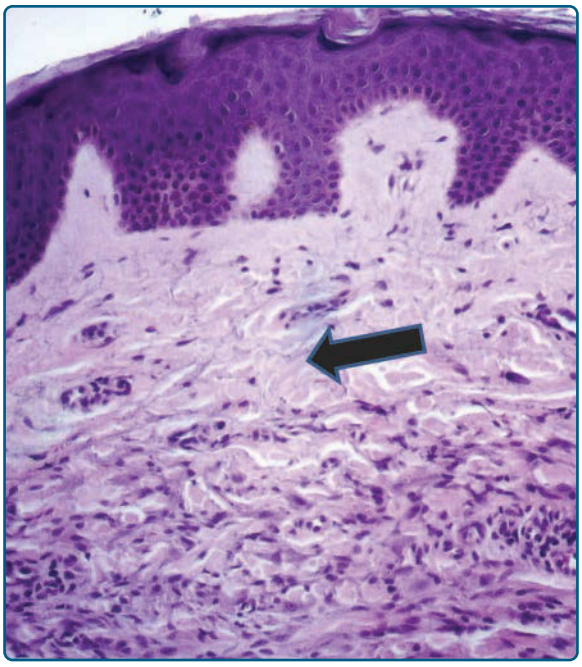

Figure 117-17 Photomicrographs of a lesion of generalized eruptive histiocytoma. In the papillary dermis an infiltration of mostly small, nonlipidized cells and of few lymphocytes underneath a Grenz zone (*arrow*) can be seen. This is a typical sign for generalized eruptive histiocytoma. Giant cells are missing.

membranes (Fig. 117-18). Involvement of mucosae and a variety of internal organs can result in significant morbidity and mortality. Systemic associations include central diabetes insipidus owing to involvement of the pituitary stalk and paraproteinemias, such as multiple myeloma.[27]

Variants of xanthoma disseminatum include disseminated xanthosiderohistiocytosis, which was described by Halprin and Lorincz in 1960 and is associated with multiple myeloma. In 1998, Ferrando described a case of systemic xanthohistiocytoma that can be also seen as a variant of xanthoma disseminatum.

Figure 117-18 Xanthoma disseminatum.

HISTOPATHOLOGIC FINDINGS

Histopathologic examination of early lesions of xanthoma disseminatum shows a predominance of scalloped histiocytes, whereas more established lesions consist mainly of foamy histiocytes with few scalloped cells. In the most established or mature lesions, a mixture of scalloped cells, foam cells, lymphocytes, and Touton giant cells is seen. These cells are positive for stabilin-1, HAM-56, HHF35, KP1, KiM1P, factor XIIIa, and vimentin, and negative for S100B and CD1a (Fig. 117-19).[27]

DIFFERENTIAL DIAGNOSIS

The main differential diagnosis includes eruptive xanthomas, other N-LCH, and LCH.

CLINICAL COURSE AND PROGNOSIS

Xanthoma disseminatum is a slowly progressing disease. Cutaneous lesions can be treated, for example, by CO_2 laser therapy. Lesions are not very radiosensitive. Several medications, including statins, fibrates, glitazones, prednisolone, azathioprine, cyclophosphamide, and thalidomide, have been tried with variable results. A successful therapeutic approach seems to be the administration of 2-chlorodeoxyadenosine.[27,28]

MULTICENTRIC RETICULOHISTIOCYTOSIS

CLINICAL FEATURES

Multicentric reticulohistiocytosis (MRH) was first reported by Weber and Freudenthal in 1937. The term was coined by Goltz and Laymon in 1954. It is a rare, multisystem inflammatory disease that usually appears around the age of 50 years, but there are a few reports of its occurrence during childhood. It is twice as common in females. Cutaneous lesions are firm, yellow-brownish papules or nodules that reach a size of several centimeters and progress slowly in size. The occurrence of lesions over the joints of fingers and wrist is typical (Figs. 117-20 and 117-21). Leonine facies can occur via confluence of facial lesions. Involvement of mucosae and conjunctivae can be appreciated in every second patient. MRH can affect any organ. However, the most common clinical manifestations are cutaneous eruptions and symmetric inflammatory polyarthritis. Internal organs, such as the lungs (resulting in pleural effusion) and heart (pericardial effusion and congestive heart failure), have been described as affected by MRH. In addition, mesenteric lymphadenopathy and

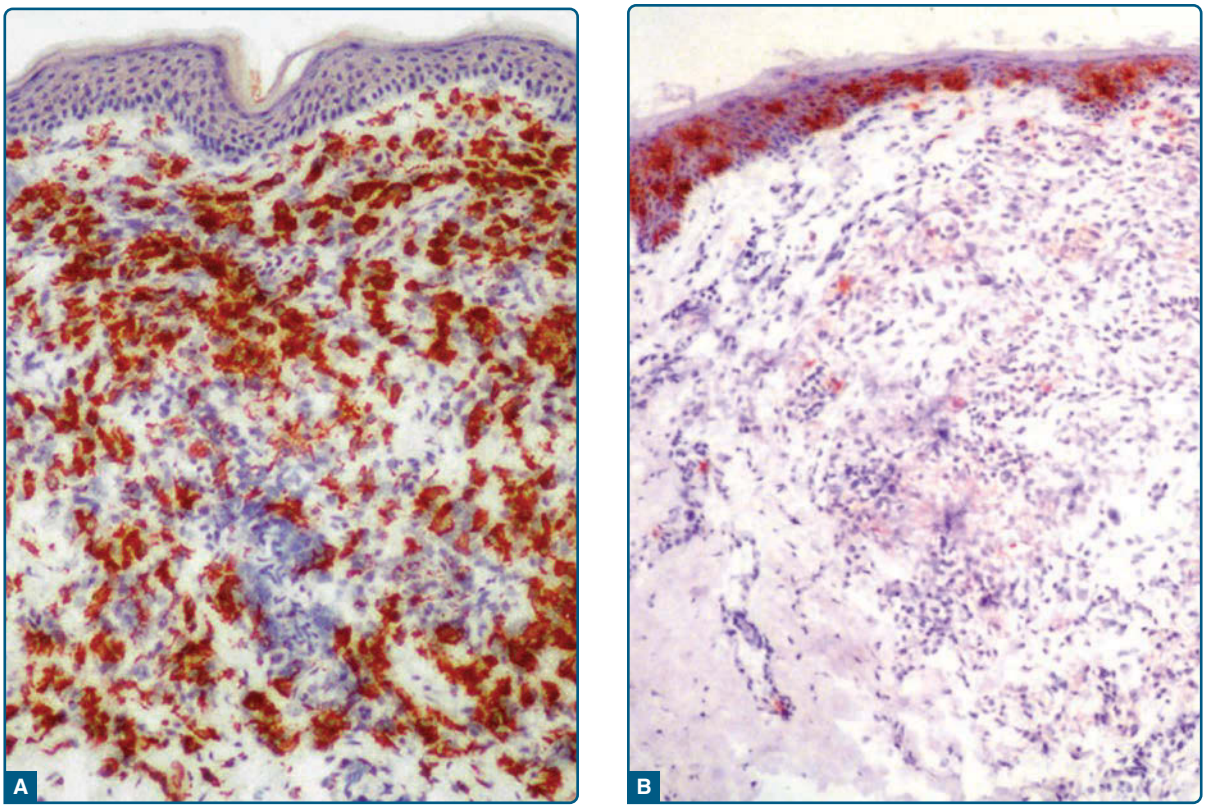

Figure 117-19 Photomicrographs of an early-stage lesion of xanthoma disseminatum. **A,** Stabilin-1 shows strong expression in lesional histiocytes. **B,** CD1a staining is limited mainly to the epidermal Langerhans cells.

Figure 117-20 Multicentric reticulohistiocytosis.

Figure 117-21 Multicentric reticulohistiocytosis.

urogenital lesions have been reported.[29] Constitutional symptoms such as fever, weight loss, and malaise can be observed.[30] A malignancy rate of 33 (25%) in 133 cases of MRH has been reported in the literature. The malignancies were most commonly hematologic, breast, or stomach carcinomas.[31]

HISTOPATHOLOGIC FINDINGS

Histology reveals mid-dermal infiltrates of mononuclear histiocytes and multinucleated histiocytes with a ground-glass appearance and a variable number of vacuolated, spindle-shaped, and xanthomatized mononuclear histiocytes. In the case of MRH, immunohistochemical analyses are usually positive for CD45, CD68 and HLA-DR (human leukocyte antigen-D related), but are negative for S100B, CD1a, or HHF-35 actin.[29,30]

DIFFERENTIAL DIAGNOSIS

Differential diagnosis includes François syndrome (dermochondrocorneal dystrophy), Morbus Farber (lipogranulomatosis disseminata) as well as different metabolic diseases such as gout.

CLINICAL COURSE AND PROGNOSIS

The disease can be self-limited. However, severe joint destruction usually results. Surgical excision, pulsed-dye laser, oral corticosteroids, methotrexate, cyclophosphamide, and tocilizumab have shown success in treating extensive MRH lesions. A systematic review of 17 cases of MRH treated with tumor necrosis factor antagonists showed an efficacy of anti–tumor necrosis factor treatment in MRH.[30]

ERDHEIM-CHESTER DISEASE

CLINICAL FEATURES

The first report of the disease was by Chester who cooperated with Erdheim in 1930. In 1972, Jaffe reported on a similar case and named the disease Erdheim-Chester disease.

Erdheim-Chester disease is a rare disease with onset in middle age. Long bone involvement is almost universal in Erdheim-Chester disease patients, and is bilateral and symmetrical in nature. It encompasses a spectrum of disorders, ranging from asymptomatic bone lesions to multisystem, life-threatening variants.

More than 50% of cases have some sort of extraskeletal involvement. This can include kidney, skin, brain, and lung involvement; less frequently, retro-orbital tissue, pituitary gland, and heart involvement is observed.[32,33] On the skin, xanthelasma and xanthoma are present in one-sixth of cases. Yellow-brown papular and widespread infiltrated lesions have been described in some patients. Newer studies demonstrate that approximately 50% of Erdheim-Chester disease patients have *BRAF* mutations in early multipotent myelomonocytic precursors or in tissue-resident histiocytes. Rarely, other genes involved in the MAPK signaling pathway also mutate.[32]

HISTOPATHOLOGIC FINDINGS

Tissue samples show a xanthomatous or xanthogranulomatous infiltration by lipid-laden or foamy histiocytes that are usually surrounded by fibrosis, especially in longer-standing lesions. Bone biopsies show infiltration of lipid-laden macrophages, multinucleated giant cells, inflammatory infiltrates of lymphocytes, and histiocytes as well as a generalized sclerosis of the long bones.

DIFFERENTIAL DIAGNOSIS

Differential diagnosis mainly includes LCH.

CLINICAL COURSE AND PROGNOSIS

Interferon-α is the first-line treatment in Erdheim-Chester disease, as it has been clearly demonstrated to increase overall survival. Anakinra and infliximab have also led to encouraging results and should be considered when treatment with interferon-α fails. More recently, BRAF inhibitors have been shown to be efficient in all treated cases.[33]

NECROBIOTIC XANTHOGRANULOMA

CLINICAL FEATURES

Necrobiotic xanthogranuloma was first reported by Kossard and Winkelmann in 1980. However, a necrobiosis with xanthogranulomas associated with paraproteinemia was already observed in the 1960s. It is a multisystem disease that affects older adults and it manifests as yellowish plaques and nodules that can ulcerate. Necrobiotic xanthogranuloma is predominantly located on the trunk, the extremities, and the face (periorbital lesions). Extracutaneous involvement also has been described, such as of the eyes, heart, skeletal muscle, larynx, spleen, and ovaries. A systemic association in the form of serum monoclonal gammopathy usually of immunoglobulin G κ and λ type is seen in 80% of necrobiotic xanthogranuloma patients. There is an increased risk for concomitant hematologic and lymphoproliferative malignancies.[34]

HISTOPATHOLOGIC FINDINGS

Necrobiotic xanthogranuloma is characterized by typical necrobiotic areas surrounded by granulomas

composed of lymphocytes, Touton giant cells, foamy histiocytes and foreign body-type multinucleated giant cells in the dermis as well as subcutis. As with other N-LCHs, there is no expression of CD1a antigen or CD207. There are no Birbeck granules.

DIFFERENTIAL DIAGNOSIS

Necrobiosis lipoidica, subcutaneous granuloma annulare, and noduli rheumatica can be considered as differential diagnoses. In cases with only a modest necrobiosis, xanthoma that is associated with paraproteinemia and lymphomas should be considered. In cases with periorbital skin lesions, xanthelasma can be a differential diagnosis.

CLINICAL COURSE AND PROGNOSIS

The prognosis is poor with several treatments showing variable results. Neither treatment nor nontreatment of monoclonal gammopathy with alkylating agents necessarily influences the activity of the skin disease. There are no randomized controlled trials and studies on long-term outcomes do not exist. Treatment options are mainly described in case reports and include topical and systemic corticosteroids, thalidomide, high-dose intravenous immunoglobulin, chlorambucil, cyclophosphamide, fludarabine, rituximab, melphalan, infliximab, interferon-α, cladribine, hydroxychloroquine, azathioprine, and methotrexate. In addition, laser therapy, radiotherapy, surgery, psoralen and ultraviolet A, plasmapheresis, and extracorporeal photopheresis are described (systematically reviewed in Miguel et al[35]).

HEREDITARY PROGRESSIVE MUCINOUS HISTIOCYTOSIS

CLINICAL FEATURES

Hereditary progressive mucinous histiocytosis was described by Bork and Hoede in 1988. It is a rare, potentially autosomal dominant inherited disease. Progressive eruptions of self-resolving skin-colored to red-brown papules usually develop in the first decade on the nose, hands, forearms, and thighs (Fig. 117-22). These lesions can later develop into persistent and progressive erythematous papules. Visceral involvement has not yet been reported.

HISTOPATHOLOGIC FINDINGS

Collections of epithelioid S100B/CD1a– and CD68 as well as weak stabilin-1+ histiocytes and telangiectatic vessels in the upper dermis of early lesions can be seen. In the mid-dermis of early and well-developed lesions, nodular aggregates of tightly packed spindle-shaped cells are present. Moderate to extensive mucin production was demonstrated in epithelioid histiocytes and spindle-shaped cells (Fig. 117-23).[36]

Figure 117-22 Hereditary progressive mucinous histiocytosis.

DIFFERENTIAL DIAGNOSIS

Acral persistent papular mucinosis, scleromyxedema, granuloma annulare, dermatofibroma, and GEH can be distinguished by histology.

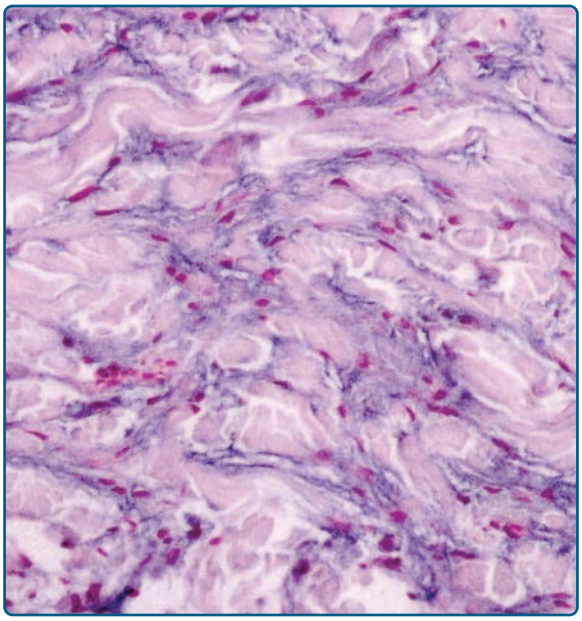

Figure 117-23 Photomicrographs of a lesion of hereditary progressive mucinous histiocytosis. Production of mucin by histiocytes in the dermis is a typical feature of the disease.

CLINICAL COURSE AND PROGNOSIS

Ablative laser therapy for single lesions is an option.

PROGRESSIVE NODULAR HISTIOCYTOSIS

CLINICAL FEATURES

Progressive nodular histiocytosis was described by Taunton and colleagues in 1978. The disease is characterized by generalized, discrete yellow to red-brown papules and nodules measuring a few centimeters in size. A prominent facial involvement has been described. Other organs are not affected. There is an association with chronic myeloid leukemia as well as with tumors of the hypothalamus.[37]

HISTOPATHOLOGIC FINDINGS

The dermis contains abundant spindle-shaped histiocytes, some with foamy cytoplasm. Cells are positive for CD68, CD163, vimentin, and fascin, while negative for CD1a and S100B.

DIFFERENTIAL DIAGNOSIS

MRH, which usually shows an involvement of other organ sites, is a differential diagnosis.

CLINICAL COURSE AND PROGNOSIS

Surgical ablation, for example, with a CO_2 laser, of all visible lesions is a therapeutic option.

REFERENCES

1. Zinn DJ, Chakraborty R, Allen CE. Langerhans cell histiocytosis: emerging insights and clinical implications. *Oncology (Williston Park)*. 2016;30:122-132, 139.
2. Badalian-Very G, Vergilio JA, Degar BA, et al. Recurrent BRAF mutations in Langerhans cell histiocytosis. *Blood*. 2010;116:1919-1923.
3. Ribeiro KB, Degar B, Antoneli CB, et al. Ethnicity, race, and socioeconomic status influence incidence of Langerhans cell histiocytosis. *Pediatr Blood Cancer*. 2015;62:982-987.
4. Venkatramani R, Rosenberg S, Indramohan G, et al. An exploratory epidemiological study of Langerhans cell histiocytosis. *Pediatr Blood Cancer*. 2012;59:1324-1326.
5. Allen CE, Li L, Peters TL, et al. Cell-specific gene expression in Langerhans cell histiocytosis lesions reveals a distinct profile compared with epidermal Langerhans cells. *J Immunol*. 2010;184:4557-4567.
6. Gatalica Z, Bilalovic N, Palazzo JP, et al. Disseminated histiocytoses biomarkers beyond BRAFV600E: frequent expression of PD-L1. *Oncotarget*. 2015;6:19819-19825.
7. Morren MA, Vanden Broecke K, Vangeebergen L, et al. Diverse cutaneous presentations of Langerhans cell histiocytosis in children: a retrospective cohort study. *Pediatr Blood Cancer*. 2016;63:486-492.
8. Braier JL, Rosso D, Latella A, et al. Importance of multi-lineage hematologic involvement and hypoalbuminemia at diagnosis in patients with "risk-organ" multi-system Langerhans cell histiocytosis. *J Pediatr Hematol Oncol*. 2010;32:e122-e125.
9. Abbritti M, Mazzei MA, Bargagli E, et al. Utility of spiral CAT scan in the follow-up of patients with pulmonary Langerhans cell histiocytosis. *Eur J Radiol*. 2012;81:1907-1912.
10. Richards GE, Thomsett MJ, Boston BA, et al. Natural history of idiopathic diabetes insipidus. *J Pediatr*. 2011;159:566-570.
11. Gadner H, Minkov M, Grois N, et al. Therapy prolongation improves outcome in multisystem Langerhans cell histiocytosis. *Blood*. 2013;121:5006-5014.
12. Haupt R, Minkov M, Astigarraga I, et al. Langerhans cell histiocytosis (LCH): guidelines for diagnosis, clinical work-up, and treatment for patients till the age of 18 years. *Pediatr Blood Cancer*. 2013;60:175-184.
13. Veys PA, Nanduri V, Baker KS, et al. Haematopoietic stem cell transplantation for refractory Langerhans cell histiocytosis: outcome by intensity of conditioning. *Br J Haematol*. 2015;169:711-718.
14. Heritier S, Jehanne M, Leverger G, et al. Vemurafenib use in an infant for high-risk Langerhans cell histiocytosis. *JAMA Oncol*. 2015;1:836-838.
15. Haroche J, Cohen-Aubart F, Emile JF, et al. Dramatic efficacy of vemurafenib in both multisystemic and refractory Erdheim-Chester disease and Langerhans cell histiocytosis harboring the BRAF V600E mutation. *Blood*. 2013;121:1495-1500.
16. Al-Daraji W, Anandan A, Klassen-Fischer M, et al. Soft tissue Rosai-Dorfman disease: 29 new lesions in 18 patients, with detection of polyomavirus antigen in 3 abdominal cases. *Ann Diagn Pathol*. 2010;14:309-316.
17. Maia RC, de Meis E, Romano S, et al. Rosai-Dorfman disease: a report of eight cases in a tertiary care center and a review of the literature. *Braz J Med Biol Res*. 2015;48:6-12.
18. Dalia S, Sagatys E, Sokol L, et al. Rosai-Dorfman disease: tumor biology, clinical features, pathology, and treatment. *Cancer Control*. 2014;21:322-327.
19. Ishii E. Hemophagocytic lymphohistiocytosis in children: pathogenesis and treatment. *Front Pediatr*. 2016;4:47.
20. Parikh SA, Kapoor P, Letendre L, et al. Prognostic factors and outcomes of adults with hemophagocytic lymphohistiocytosis. *Mayo Clin Proc*. 2014;89:484-492.
21. Kim MS, Kim SA, Sa HS. Old-age-onset subconjunctival juvenile xanthogranuloma without limbal involvement. *BMC Ophthalmol*. 2014;14:24.
22. Lange M, Izycka-Swieszewska E, Michajlowski I, et al. Benign cephalic histiocytosis. *Cutis*. 2015;95:E15-E17.
23. Emberger M, Zelger BW, Laimer M, et al. Plaque-like papular xanthoma, an unusual, localized variant of non-Langerhans cell disease. *Eur J Dermatol*. 2013;23:278-279.
24. Coutinho I, Moreira S, Ramos L, et al. Plaque-like papular xanthoma: a new variant of non-Langerhans cell disease. *J Eur Acad Dermatol Venereol*. 2016;30:332-333.
25. Hansel G, Schonlebe J, Tchernev G, et al. Generalized eruptive histiocytoma in adult patient. *J Biol Regul Homeost Agents*. 2015;29:15-17.
26. Cardoso F, Serafini NB, Reis BD, et al. Generalized eruptive histiocytoma: a rare disease in an elderly patient. *An Bras Dermatol*. 2013;88:105-108.

27. Krishna CV, Parmar NV, Ganguly S, et al. Xanthoma disseminatum with extensive koebnerization associated with familial hypertriglyceridemia. *JAAD Case Rep*. 2016;2:253-256.
28. Khezri F, Gibson LE, Tefferi A. Xanthoma disseminatum: effective therapy with 2-chlorodeoxyadenosine in a case series. *Arch Dermatol*. 2011;147:459-464.
29. Tariq S, Hugenberg ST, Hirano-Ali SA, et al. Multicentric reticulohistiocytosis (MRH): case report with review of literature between 1991 and 2014 with in depth analysis of various treatment regimens and outcomes. *Springerplus*. 2016;5:180.
30. Zhao H, Wu C, Wu M, et al. Tumor necrosis factor antagonists in the treatment of multicentric reticulohistiocytosis: current clinical evidence. *Mol Med Rep*. 2016;14:209-217.
31. Han L, Huang Q, Liao KH, et al. Multicentric reticulohistiocytosis associated with liver carcinoma: report of a case. *Case Rep Dermatol*. 2012;4:163-169.
32. Cives M, Simone V, Rizzo FM, et al. Erdheim-Chester disease: a systematic review. *Crit Rev Oncol Hematol*. 2015;95:1-11.
33. Campochiaro C, Tomelleri A, Cavalli G, et al. Erdheim-Chester disease. *Eur J Intern Med*. 2015;26:223-229.
34. Girisha BS, Holla AP, Fernandes M, et al. Necrobiotic xanthogranuloma. *J Cutan Aesthet Surg*. 2012;5:43-45.
35. Miguel D, Lukacs J, Illing T, et al. Treatment of necrobiotic xanthogranuloma—a systematic review. *J Eur Acad Dermatol Venereol*. 2017;31(2):221-235.
36. Nguyen NV, Prok L, Burgos A, et al. Hereditary progressive mucinous histiocytosis: new insights into a rare disease. *Pediatr Dermatol*. 2015;32:e273-e276.
37. Hilker O, Kovneristy A, Varga R, et al. Progressive nodular histiocytosis. *J Dtsch Dermatol Ges*. 2013;11:301-307.

Chapter 118 :: Vascular Tumors

:: Kelly M. MacArthur & Katherine Püttgen

Vascular anomalies commonly present as birthmarks.[1] Their classification has historically been problematic, with contradictory and confusing terminology and nomenclature. Although several classification schemes exist, the most widely accepted and comprehensive is the International Society for the Study of Vascular Anomalies (ISSVA) classification, updated in 2014, to incorporate clinical, imaging, histologic and (where known) genetic characteristics.[1,2] Vascular anomalies are broadly divided into vascular malformations and vascular tumors.[3] Vascular malformations (see Chap. 147) are errors of vascular morphogenesis whereas infantile hemangiomas and other vascular tumors are proliferative. Vascular tumors in the current ISSVA classification are subdivided into (a) benign, (b) locally aggressive or borderline, and (c) malignant; each has unique features based upon histology, biology, clinical appearance, behavior, prognosis, and treatment (Table 118-1).

There are several types of vascular tumors, many of which occur in childhood. These tumors also have confusing nosology,[4] with descriptive but imprecise terminology such as *strawberry*, *capillary*, and *cavernous*. The nonspecific term *hemangioma* should be avoided as a standalone term without a qualifying descriptor (eg, infantile, rapidly involuting congenital, lobular capillary, spindle cell).

INFANTILE HEMANGIOMAS

AT-A-GLANCE

- Infantile hemangiomas are the most common tumor of infancy.
- Infantile hemangiomas in high-risk anatomic sites are likely to require further workup and treatment.
- Segmental infantile hemangiomas are associated with greater morbidity than localized infantile hemangiomas.
- Kasabach-Merritt syndrome does not occur with infantile hemangiomas.

EPIDEMIOLOGY

Infantile hemangiomas (IHs) are the most common benign tumors of childhood, occurring in approximately 4% to 5% of children.[4-7] IHs are distinguished from other vascular tumors and malformations by their unique growth pattern (rapid proliferative phase with subsequent slower involution.) They are more common in girls (2 to 3:1 ratio), in white, non-Hispanic infants,[6,8,9] and infants with low birth weight, and affect up to 30% of premature infants,[5,10] especially those weighing less than 2500 g.[8,11] Low birth weight appears to be the most significant risk factor for IH development, conferring greater risk than prematurity alone, with a 40% risk increase for every 500 g decrease in birth weight,[11] which complements earlier data showing that nearly 1 in 4 infants whose birth weight is less than 1000 g develops IH. Prenatal risk factors include advanced maternal age (older than 30 years of age), preeclampsia, placenta previa, and other placental anomalies.[8,12] Preterm infants are more likely to have multiple IHs. IH in the setting of prematurity is less-strongly associated with female predominance.[8,13] Complicated IHs are more common in girls; the cause is unknown.[14] Chorionic villus sampling is no longer accepted as a significant risk factor.[8,11,13]

CLINICAL FEATURES

CUTANEOUS FINDINGS

A clinical history of a life cycle marked by characteristic proliferation and involution is critical in the diagnosis of IH (Table 118-2).[15]

Growth Characteristics—Proliferation: Absence at birth or presence of a nascent IH, often an area of pallor, telangiectasias, or duskiness is characteristic. A fully formed soft-tissue mass at birth is almost certainly another vascular anomaly or other disease process. Most IHs occur on the head and neck, but His can be found at any cutaneous or mucosal site and can, less commonly, involve internal organs (see section "Noncutaneous Findings and Complications").

Almost all IHs with a superficial component become apparent in the first month of life, and most will at least double in size within the first 2 months of life. The early proliferative phase is associated with rapid nonlinear growth with the peak IH growth period occurring between 5.5 weeks and 7.5 weeks of age.[16] While 80% of growth has occurred by 3 months of age, 80% of IHs have completed all growth by 5 months of age (Fig. 118-1).[17] The late proliferative stage of ongoing slower growth that occurs after peak rapid growth typically ends by 9 months of age; only 3% of IHs have clinically documented growth beyond this age.[17] Deep IHs are more likely to have a longer proliferative phase. Large, segmental and parotid gland IHs may also continue to enlarge slowly for months to, rarely, years, which is longer than other IHs.[17-19]

TABLE 118-1
International Society for the Study of Vascular Anomalies Classification

VASCULAR ANOMALIES				
VASCULAR TUMORS			VASCULAR MALFORMATIONS	
BENIGN	LOCALLY AGGRESSIVE	MALIGNANT	SIMPLE	COMBINED
Infantile hemangioma	Kaposiform hemangioendothelioma	Angiosarcoma	Capillary malformation (C)	CVM, CLM
Congenital hemangioma	Retiform hemangioendothelioma	Epithelioid hemangioendothelioma	Lymphatic malformation (LM)	LVM, CLVM
Tufted hemangioma	PILA, Dabska tumor		Venous malformation (VM)	CAVM
Spindle-cell hemangioma	Composite hemangioendothelioma		Arteriovenous malformation (AVM)	CLAVM
Epithelioid hemangioma	Kaposi sarcoma		Arteriovenous fistula	
Pyogenic granuloma				

CAVM, capillary arteriovenous malformation; CLAVM, capillary lymphatic arteriovenous malformation; CLM, capillary lymphatic malformation; CLVM, capillary lymphatic venous malformation; CVM, capillary venous malformation; LVM, venous malformation; PILA, papillary intralymphatic angioendothelioma.
Abbreviated ISSVA classification for Vascular Anomalies by International Society for the Study of Vascular Anomalies is licensed under a Creative Commons Attribution 4.0 International License.

Growth Characteristics—Involution: The rapid and late proliferative growth phases are followed by a slower involution phase that is more variable in length, lasting for months to years (Fig. 118-2). Evidence of involution, often referred to as *graying*, involves change to a dull red, then gray or milky-white color, followed by flattening and softening. The change is usually apparent by 1 year of age.[17] Smaller hemangiomas typically involute sooner than very large ones.[17] More than 90% of IHs have completed involution by 3.5 to 4 years of age.[20,21] It is important to recognize that complete involution does not equate with complete resolution of the IH. More than half of children with hemangiomas will be left with residual telangiectasias, fibrofatty tissue, or anetodermic skin. Superficial IHs are more likely to develop residual skin changes following involution compared with deep IHs (odds ratio: 8.4).[22] Combined IH and those with a steep border or a cobblestoned surface have a significantly higher risk of permanent scarring.[21]

TABLE 118-2
History

- Birth history
  - Was the child of low birth weight and/or premature?
  - Part of a multiple gestational birth?
  - Placental abnormalities?
- Overall health and past medical history
  - Is the child feeding well and gaining weight appropriately?
  - Have there been any hospitalizations or major illnesses?
- History of "birthmark"
  - Was it visible at the time of birth?
  - Has it changed since birth?
  - Growth: Is the birthmark growing proportionately or disproportionately with child's somatic growth? Is it still growing, stable, or shrinking in size? (Serial photographs are helpful.)
  - Any complications such as ulceration, pain or bleeding?
  - Any prior treatments?
- Family history
  - Is there a family history of infantile hemangiomas or other vascular birthmarks?

Classification[8]: Cutaneous IH morphology can be classified based on tumor depth (superficial, deep, combined/mixed) and distribution (localized, segmental, indeterminate, multifocal).[23,24] This morphologic distinction can guide expectations as natural history, prognosis, and possible complications vary based on these classification features.

Superficial IHs are the most common of the morphologic subtypes, presenting as bright fuchsia pink to "strawberry" red vascular plaques or nodules; they involve the papillary dermis. In contrast, deep IHs present as a partially compressible, localized subcutaneous tumors with variable prominence depending upon depth in the skin, and either appear with a slight blue hue or the same color as the surrounding skin; they may be noted, on average, 1 month later than superficial IHs. Less frequently, deep IHs are not appreciated until the infant is a few months of age. Deep IHs are more likely to have a longer proliferative phase, rarely growing for months to years beyond the growth phase of other IHs, and later onset of involution compared with their superficial counterparts.[17,18] Combined (also called *mixed*) IHs have clinical features of both deep and superficial IHs. A less-common subtype of IH is distinguished by its minimal-to-absent proliferation and telangiectatic surface, referred to as IH with minimal or abortive growth,[25] has been described (Fig. 118-3). Found most commonly on the lower body, especially at acral sites, these IHs express the same histologic markers (eg, GLUT1) as typical proliferative IHs, but for unclear reasons fail to undergo the usual IH trajectory of growth.[25,26]

In addition to their individual morphology, IHs can be classified based on their distribution on the

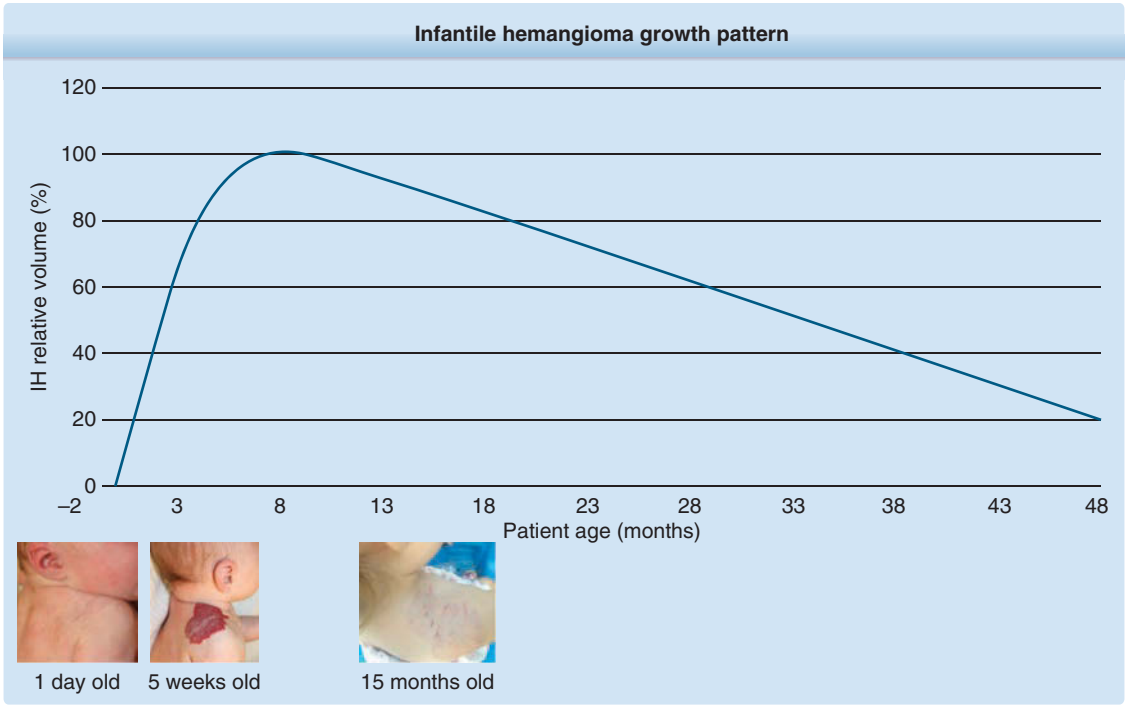

Figure 118-1 Growth characteristics of infantile hemangioma.

Figure 118-2 Natural history of segmental infantile hemangioma. Note the plaque-like, geographic configuration. **A,** Age 11 months, peak of proliferative phase. **B,** Age 2 years, involuting phase. **C,** Age 4 years, majority of natural involution has occurred.

Figure 118-3 An infantile hemangioma with minimal or abortive growth on the right arm and hand of an infant.

body as localized (focal), segmental, indeterminate, or multifocal, which provides valuable prognostic information.[23,24] Approximately two-thirds of IHs are localized (focal) and exhibit clear spatial containment as if arising from one central focus (Fig. 118-4).[27] On the face, localized IHs tend to present near lines of mesenchymal and ectodermal embryonic fusion.[23] Segmental hemangiomas—similar to other segmental dermatologic disease such as vitiligo and neurofibromatosis—are often plaque-like and correspond to a portion of a developmental segment or broad geographic anatomic territory (Fig. 118-5).[28] In a large study, 13.1%

Figure 118-4 Localized infantile hemangioma on the cheek of an infant.

of IHs were segmental.[29] The patterns of facial segmental IH have been suggested to correspond to neural crest–derived facial prominences and their presence is associated with risk of PHACE (posterior fossa brain malformations, hemangiomas of the face, arterial anomalies, cardiac anomalies, and eye abnormalities).[29] Segmental IHs on the lower body confer risk of myelopathy and genitourinary anomalies in LUMBAR (lower body hemangioma and other cutaneous defects, urogenital anomalies, ulceration, myelopathy, bony deformities, anorectal malformations, arterial anomalies, and renal anomalies) syndrome (see section "Lumbar Syndrome"). Indeterminate IHs are those that are not clearly identifiable as localized or segmental; some authors consider them to be "subsegmental" (Fig. 118-6). Multifocal (multiple localized) IHs are less common, with fewer than 3% of infants presenting with 6 or more IHs.[27]

Figure 118-5 Segmental infantile hemangioma on the face, scalp, and neck of a newborn with PHACE.

Figure 118-6 Indeterminate infantile hemangioma on the cheek of an infant 14 months of age.

Classification of hemangiomas by subtype not only facilitates communication, but also helps predict risk of complications and need for treatment. A prospective study of more than 1000 children with IHs showed that segmental hemangiomas are 11 times more likely to experience complications and 8 times more likely to receive treatment than localized hemangiomas, even when controlled for size.[27]

NONCUTANEOUS FINDINGS AND COMPLICATIONS

Certain IHs have a known risk of associated complications and congenital anomalies (Table 118-3). The presence of multifocal or segmental IH is associated with a greater risk of extracutaneous disease.[15] Anatomic location is one of the most important factors affecting risk. Involvement of the central face (especially the nose and perioral skin), periocular area, neck, mandibular region, and perineum should alert clinicians to possible increased risk of complications. Even though the vast majority of IHs remain asymptomatic and uncomplicated with no intervention required, complications can include ulceration, severe bleeding (less than 1% of cases), scarring, pain, and infection, with additional complications found in certain sites of involvement (eg, airway obstruction, congestive heart failure, and visual compromise). Approximately 12% of all IHs are complex, requiring specialist referral. Outcomes are greatly dependent upon timing of referral and intervention.

TABLE 118-3
High-risk Infantile Hemangioma Features

ANATOMIC LOCATION/ MORPHOLOGY	ASSOCIATED RISK
Facial, large segmental	PHACE (posterior fossa malformations, hemangiomas, arterial anomalies, cardiac defects, eye abnormalities, sternal clefting) syndrome
Nasal tip, ear, large facial (especially with prominent deep component)	Permanent scarring, cartilage destruction, disfigurement
Periorbital and retrobulbar	Ocular axis occlusion, astigmatism, amblyopia, tear-duct obstruction
Segmental (S3)/"beard area," central neck	Airway infantile hemangioma
Perioral	Ulceration, disfigurement, feeding difficulties
Segmental overlying lumbosacral spine	Myelopathy, genitourinary anomalies
Perineal, axilla, neck, perioral	Ulceration
Multifocal	Visceral involvement (especially liver, GI tract)

SYNDROMES AND ASSOCIATIONS WITH SEGMENTAL INFANTILE HEMANGIOMAS

As described above, facial segmental IH patterns correspond to developmental units and have been labeled as 4 segments (S1 to S4): frontotemporal (S1), maxillary (S2), mandibular (S3), and frontonasal (S4).[27] The frontotemporal segment (S1) is associated with cerebral, cerebrovascular, and ocular anomalies; the maxillary segment (S2) is less-frequently associated with extracutaneous involvement; the mandibular segment (S3) is correlated with airway IH, ventral developmental defects, and cardiovascular abnormalities; and the frontonasal segment (S4) encompasses the high-risk territory of the nose, including the nasal tip,[30] and confers risk of cerebral and cerebrovascular involvement (Fig. 118-7).

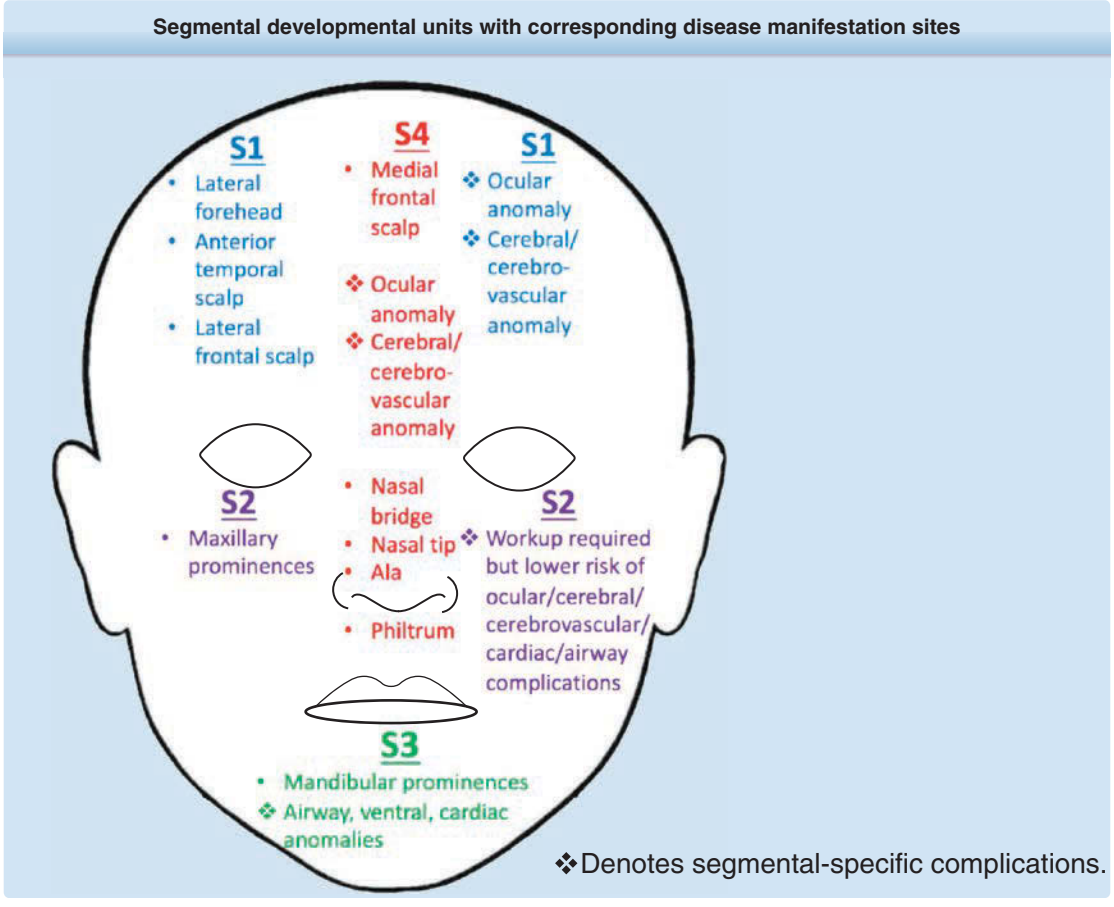

Figure 118-7 Segmental developmental units with corresponding disease manifestation sites. (Data from Haggstrom AN, Lammer EJ, Schneider RA, et al. Patterns of infantile hemangiomas: new clues to hemangioma pathogenesis and embryonic facial development. *Pediatrics.* 2006;117(3):698-703.)

PHACE

Facial segmental IHs confer a risk of PHACE,[31] which is a neurocutaneous association. It is sometimes referred to as PHACES to denote the additional association of *S*ternal defects (ie, sternal clefting or supraumbilical raphe).[32] For unclear reasons, up to 90% of PHACE cases are in girls.—In addition, up to one-third of patients with facial segmental IHs with a surface area equal to or greater than 22 cm^2 have been reported to meet criteria for PHACE syndrome.[33-35] The frontotemporal (S1) and mandibular (S3) segments are the segments most highly associated with PHACE. There are infants with extracutaneous features of PHACE who have segmental IHs on the back of the head, upper trunk, or arm, as well as infants who have small IHs or who lack cutaneous IHs entirely.[36-39] Diagnostic criteria have been revised (Table 118-4).[40]

Congenital vascular anomalies of are the most common extracutaneous features in PHACE. Cerebral vascular anomalies occur in greater than 90% of cases, and cardiac abnormalities occur in up to 67% of cases.[30,32,33,35,41] Dysplasia, stenosis, hypoplasia, and agenesis of major cerebral and cervical vessels can occur. Coarctation of the aorta has been reported in 19% to 30% of PHACE cases, and aortic arch anomalies are uniquely complex when associated with PHACE, frequently involving long segment of the transversa and/or descending aorta.[40,42] Notably, aortic coarctation in PHACE is frequently associated with aberrant origin of both subclavian arteries arising distal to the coarctation, rendering the blood pressures of the 4 extremities

TABLE 118-4
PHACE Diagnostic Criteria

ORGAN SYSTEM	MAJOR CRITERIA	MINOR CRITERIA
Arterial anomalies	Anomaly of major cerebral or cervical arteries[a] Dysplasia[b] of the large cerebral arteries Arterial stenosis or occlusion with or without moyamoya collaterals Absence or moderate-severe hypoplasia of the large cerebral and cervical arteries Aberrant origin or course of the large cerebral or cervical arteries except common arch variants such as bovine arch Persistent carotid-vertebrobasilar anastomosis (proatlantal segmental, hypoglossal, otic, and/or trigeminal arteries)	Aneurysm of any of the cerebral arteries
Structural brain	Posterior fossa brain anomalies Dandy-Walker complex Other hypoplasia/dysplasia of the mid and/or hind brain	Midline brain anomalies Malformation of cortical development
Cardiovascular	Aortic arch anomalies Coarctation of the aorta Dysplasia[a] Aneurysm Aberrant origin of the subclavian artery with or without a vascular ring	Ventricular septal defect Right aortic arch/double aortic arch Systemic venous anomalies
Ocular	Posterior segment abnormalities Persistent hyperplastic primary vitreous Persistent fetal vasculature Retinal vascular anomalies Morning glory disc anomaly Optic nerve hypoplasia Peripapillary staphyloma	Anterior segment abnormalities Microphthalmia Sclerocornea Coloboma Cataracts
Ventral/midline	Anomaly of the midline chest and abdomen Sternal defect Sternal pit Sternal cleft Supraumbilical raphe	Ectopic thyroid hypopituitarism Midline sternal papule/hamartoma
Definite PHACE		
IH >5 cm diameter of the head (including scalp) *plus* 1 major criterion or 2 minor criteria	IH of the neck, upper trunk, or trunk, and proximal upper extremity *plus* 2 major criteria	
Possible PHACE		
IH >5 cm diameter of the head (including scalp) *plus* 1 minor criterion	IH of the neck, upper trunk, or trunk, and proximal upper extremity *plus* 1 major criterion or 2 minor criteria	No IH *plus* 2 major criteria

[a]Internal carotid artery, middle cerebral artery, anterior cerebral artery, posterior cerebral artery, or vertebrobasilar system.
[b]Includes kinking, looping, tortuosity, and/or dolichoectasia.
From Garzon MC, Epstein LG, Heyer GL, et al. PHACE syndrome: consensus-derived diagnosis and care recommendations. *J Pediatr*. 2016;178:24-33.e2. With permission. Copyright © Elsevier.

incapable of demonstrating a gradient reflective of the coarctation on physical examination. Structural brain anomalies occur in approximately 40% of PHACE patients,[43] with estimates ranging widely from 30% to greater than 80%.[40] Arterial ischemic stroke is known to occur in PHACE, and often presents with seizure or hemiparesis.[44] Although the degree of risk for most infants with PHACE is unclear, risk appears highest in the setting of occlusion or significant narrowing of a major cerebral artery within or above the circle of Willis, especially with concomitant aortic coarctation.[40] Ocular anomalies are less common and typically manifest as posterior segment anomalies (eg, morning glory disc anomaly, optic nerve hypoplasia, persistent fetal vasculature, or retinal vascular anomalies) or microphthalmia. Endocrine abnormalities, including hypothyroidism and hypopituitarism, with subsequent growth hormone deficiency, as well as headaches, and speech and language delays can also occur.[40,45]

LUMBAR SYNDROME

Similar to PHACE, segmental IHs on the lower body involving the perineum or lumbosacral area are risk factors for associated spinal, bony, and genitourinary anomalies (Fig. 118-8). LUMBAR syndrome describes the constellation of lower body hemangioma and other cutaneous defects, urogenital anomalies, ulceration, myelopathy, bony deformities, anorectal malformations, arterial anomalies, and renal anomalies.[46] Similar groups of patients have been described with the acronyms PELVIS (perineal hemangioma, external genitalia malformations, lipomyelomeningocele, vesicorenal abnormalities, imperforate anus, skin tag) and SACRAL (spinal dysraphism, anogenital anomalies, cutaneous anomalies, renal and urologic anomalies, associated with angioma of lumbosacral localization).[47,48] Myelopathy is the most commonly associated extracutaneous abnormality, presenting as tethered cord or lipomyelo(meningo)cele.[46] MRI is strongly recommended in this setting as lumbosacral ultrasound is reported to result in false-negative findings given its poor sensitivity.[49,50] IHs in the setting of LUMBAR are more likely to be IHs with minimal or abortive growth morphology and carry a notable risk of ulceration. Underlying arterial anomalies and limb hypotrophy can occur.[46]

Figure 118-8 A segmental infantile hemangioma of the lower body in an infant with LUMBAR syndrome complicated by painful ulceration.

PERIOCULAR HEMANGIOMAS

Infants with periocular hemangiomas are at risk for anisometropia and amblyopia, which, if untreated, can lead to permanent visual loss (Fig. 118-9).[51,52] Amblyopia is the most common ocular complication, occurring in 40% to 60% of infants with untreated periocular IH.[53,54] IHs larger than 1 cm in diameter confer greater risk of amblyopia, significantly lowering the threshold to initiate treatment.[52] Direct pressure on the cornea can produce astigmatism or myopia, and the mass effect of the tumor itself can cause ptosis, proptosis, visual axis occlusion, or strabismus. Any patient with a hemangioma in the periocular area should have a prompt formal ophthalmologic evaluation with repeat visits during the rapid and late proliferative phases. In the setting of ophthalmologic complications, treatment should be initiated urgently to prevent long-term effects, including permanent blindness. Standard evaluation with an ophthalmologist trained in the care of infants should include refraction via retinoscopy following cycloplegia. Serial examinations are especially important with involvement of upper eyelid or supraorbital region. Long-term morbidity can include optic atrophy, blepharoptosis, and ocular proptosis.[55] Between 40% and 80% of periorbital IHs have permanent residual changes following involution.[56] The most favorable prognostic sign to herald normal vision following involution is the absence of asymmetrical refractive error.[54] In certain cases, MRI may be necessary to determine the presence of retrobulbar involvement.

"BEARD AREA" HEMANGIOMAS

Segment 3 IHs involving the preauricular, mandibular, chin, and neck skin (or so-called *beard area*) carry a 60% risk of causing symptomatic airway disease.[57] Airway hemangiomas often present with the insidious onset of biphasic stridor between weeks 4 and 12 of life and are often mistakenly diagnosed as tracheomalacia, upper respiratory tract infection, or croup. Without intervention, respiratory distress can ensue and become life-threatening. Prompt evaluation by a pediatric otolaryngologist and treatment is essential.[58] Parotid gland IH may have an unusually prolonged growth phase and may require treatment because of

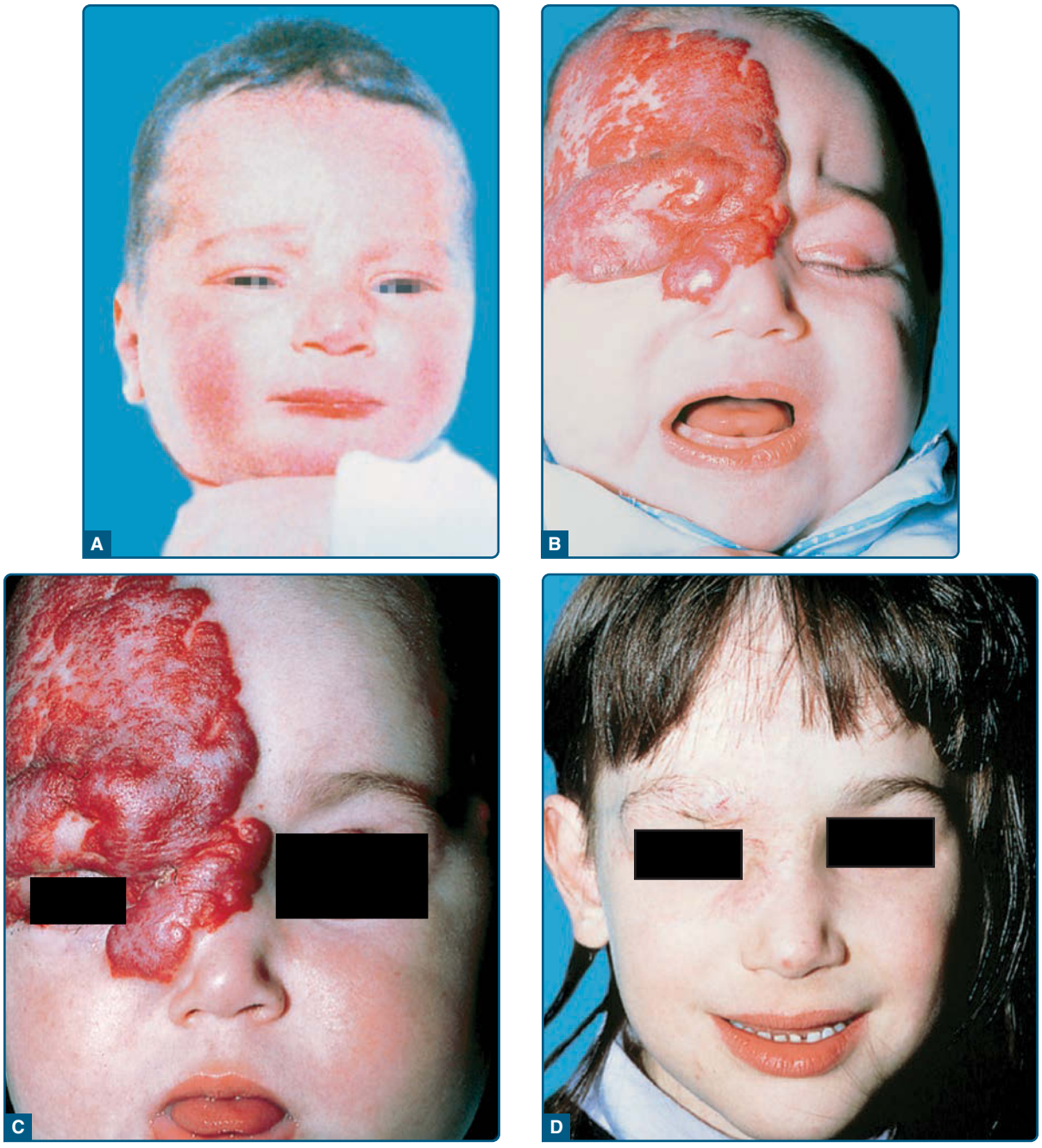

Figure 118-9 Vision-endangering segmental infantile hemangioma treated with systemic glucocorticoids. **A,** No premonitory signs of tumor seen on infant's photograph. **B,** By age 3 months, extensive infantile hemangioma infiltrating the upper lid and surrounding tissue, causing blocked vision. **C,** Eyelid opened within 2 weeks of glucocorticoid therapy. **D,** Involuted tumor at age 6 years with residual scarring.

massive growth of the IH and deformity of adjacent structures. High-output congestive heart failure has been reported, although rarely.[59,60]

MULTIFOCAL HEMANGIOMAS

Approximately 15% of infants will have more than 1 hemangioma. Infants with multifocal IH have an increased risk of noncutaneous IH. Screening hepatic and abdominal ultrasound is recommended for infants presenting with 5 or more cutaneous IHs (Fig. 118-10).[61,62] In rare cases, infants can have hundreds of lesions. The term *multifocal IH with or without extracutaneous disease* has been suggested to replace the older term *diffuse neonatal hemangiomatosis*, given that it is now understood that cases reported in the older literature confused IH with multifocal lymphangioendotheliomatosis with thrombocytopenia (MLT) and other non-IH multifocal tumors. Other sites of visceral involvement are very rare in true IH. Visceral hemangiomas, including those affecting the liver,

Figure 118-10 Multifocal infantile hemangiomas in an infant. There are multiple, small, superficial, pink papules on the trunk and extremities.

GI tract, and brain, also have been reported with solitary segmental hemangiomas.[63]

HEPATIC HEMANGIOMAS

The liver is the most common extracutaneous site for IH. Even when present, hepatic IHs are frequently asymptomatic. A minority of hepatic IHs cause morbidity, and, in rare cases, can be life threatening, causing high-output congestive heart failure, hypothyroidism, or hepatic failure. Hepatic hemangiomas can be focal, multifocal, or diffuse.[64] Focal hepatic hemangiomas are not true IHs, but are analogous to rapidly involuting congenital hemangioma (RICH) occurring in the liver. They are fully formed at birth, present without cutaneous IHs, and can cause moderately severe thrombocytopenia and coagulopathy, although not as severe as the consumptive coagulopathy of Kasabach-Merritt phenomenon. Multifocal and diffuse hepatic hemangiomas are true IHs. Multifocal infantile hepatic hemangiomas are often asymptomatic but can cause high-output congestive heart failure if arteriovenous or portovenous shunting occurs. Diffuse infantile hepatic hemangiomas are less common and associated with high morbidity and mortality. In this setting, the majority of the liver parenchyma is replaced by tumor and can cause abdominal compartment syndrome and severe hypothyroidism as a consequence of tumor-related overproduction of Type III iodothyronine deiodinase. Systemic β-blocker therapy and, in severe cases, concomitant systemic corticosteroids or embolization may be required.[65,66] Aggressive thyroid hormone replacement is needed in cases with hypothyroidism.[67] In life-threatening cases, liver transplantation may be considered.

Figure 118-11 A painful ulcerated infantile hemangioma on the neck that required treatment with wound care, pulsed-dye laser, and propranolol.

ULCERATION

Ulceration is the most common complication of IH, occurring in greater than 20% of infants in a referral setting, typically during the proliferative phase, with a median age of onset of 4 months.[27,68] It occurs most commonly in large or segmental IHs and at sites that are exposed to moisture and friction, such as the perioral, perianal, and intertriginous areas (Fig. 118-11).[68,69] Early gray-white discoloration in patients younger than 3 months is a sensitive marker of impending ulceration.[70] Secondary infection can occur, but polymicrobial colonization is more typical.[71] Treatment of the ulceration (Table 118-5) is often successful in the absence of antibiotic therapy, although localized colonization versus infection can improve with the topical mupirocin or metronidazole. If deep or persistent

TABLE 118-5
Management of Ulcerations

- Local wound care and barrier protection
- Compresses (wet to dry saline compresses, Burow solution) for exudative ulcers
- Occlusive dressings
- Absorbent nonstick dressings, foam dressings
- Alginate dressings (exudative ulcers)
- Petrolatum-based ointments; petroleum jelly-impregnated gauze
- Zinc oxide paste, hydrophilic petrolatum
- Pain control
- Topical lidocaine (very small amount)
- Acetaminophen with or without codeine
- Topical antibiotics (if secondary infection is suspected)
- Mupirocin ointment
- Metronidazole gel
- Aggressive therapy in ulcers that are unhealed after 2 to 3 weeks of wound care
- Systemic β-blocker therapy
- Topical β-blocker (timolol maleate)
- Pulsed-dye laser
- Becaplermin 0.01% gel
- Intralesional and systemic corticosteroids
- Early excision

infection is suspected, systemic antibiotics should be prescribed.

Local wound care, barrier protection, and pain control are essential for treatment. Bio-occlusive dressings may be helpful but their usefulness is often limited by location because they do not adhere well near the mouth or in diaper area.[72,73] In these areas, thick applications of petrolatum-based ointments can be helpful. Pain can be a major issue in management. It can be minimized with an occlusive dressing, oral acetaminophen with or without codeine, and the use of very small amounts of topical lidocaine ointment no more than a few times a day.[69] Severe ulcers or those that remain unhealed after 2 to 3 weeks of appropriate wound care warrant more aggressive therapy. Options include systemic β-blocker therapy, topical β-blocker (eg, topical timolol maleate), and pulsed-dye laser (PDL). Other options less frequently employed in the β-blocker era include becaplermin 0.01% gel,[74,75] intralesional and systemic corticosteroids, and early excision.

ETIOLOGY AND PATHOGENESIS

IHs occur exclusively in humans and are primarily composed of endothelial cells. IHs also contain fibroblasts, pericytes, interstitial cells, and mast cells. The patterns found in segmental IHs suggest at least some IHs occur as the result of a developmental error as early as 4 to 6 weeks of gestation.[29] The pathogenesis of their development and evolution remains elusive, in part hampered by the lack of a strong in vitro system or in vivo animal model (Fig. 118-12). Research continues to highlight the complex pathophysiology[56,76-79] by which these tumors proliferate and involute. Current understanding suggests that both angiogenesis, the development of new blood vessels from existing blood vessels, and vasculogenesis, the de novo development of blood vessels, are important in IH development. Studies show IHs to be of fetal, rather than maternal, origin,[80] and demonstrate immature mesenchymal features with similarities to the cardinal vein, an early embryologic vascular structure.[81]

The recognition that GLUT1, a red blood cell glucose transporter protein and the most reliable histologic marker of IH, which is expressed in all stages of IH, prompted new hypotheses on the pathogenesis of IH.[82,83] GLUT1 expression is absent in the normal cutaneous vasculature but is found in placental blood vessels as well as in other so-called barrier tissues, such as the blood–brain barrier. This, together with other immunohistochemical markers shared by IH and human placenta (Lewis Y antigen, merosin, Fc-γ receptor-IIb, indoleamine 2,3-deoxygenase, and Type III iodothyronine deiodinase), and the similar gene expression profiles found on DNA-based microarrays led to speculation that these tumors are of placental origin from invading angioblasts that have differentiated toward a placental phenotype.[83,84] Earlier theories of embolic placental tissue as the trigger for IH have been discredited given that both placental trophoblastic marker expression and villous architecture are absent in IH.[85]

Proliferation is differentiated by the expression of the primitive cell marker, CD133+,[86,87] found in pluripotent

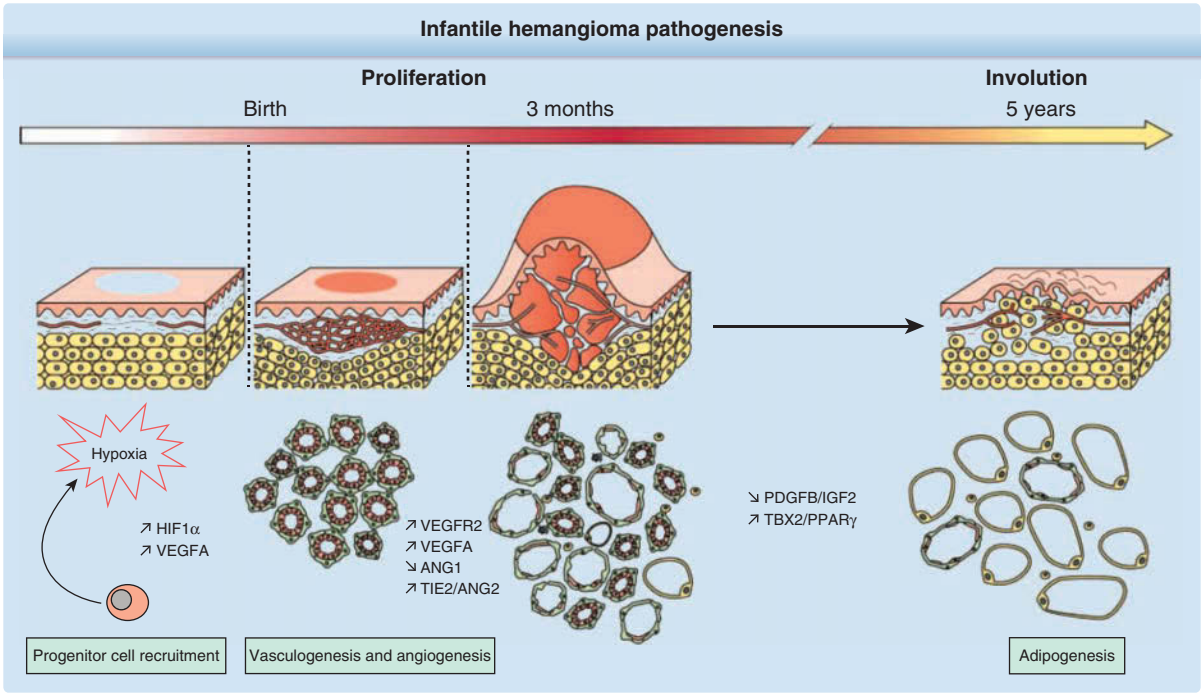

Figure 118-12 Infantile hemangioma pathogenesis. (Figure reprinted from Léauté-Labrèze C, Harper JI, Hoeger PH. Infantile haemangioma. *The Lancet*. 2017;390(10089):85-94, with permission. Copyright © Elsevier.)

stem cells known as HemSCs, with demonstration of the presence of endothelial progenitor cells (CD31+, CD34+, CD133+ stem cells) (HemEPCs) in proliferative IH but absent in the involution phase.[88,89] Translational studies involving implantation of HemSCs isolated from human IH into immunodeficient mice resulted in mimicry of the IH life cycle, with development of GLUT1+ vessels and subsequent adipocyte replacement.[88] HemSCs are precursors for adipocytes, and the presence of adipocytes in involuted IH is well known. Vasculogenesis in IH is theorized to occur from the clonal expansion of circulating endothelial progenitor cells and circulating endothelial progenitor cells may be the progenitor of the endothelial cells lining IH vessels.[35] Other studies demonstrate increased amounts of angiogenic factors in proliferating IH, including basic fibroblast growth factor, vascular endothelial growth factor A, insulin-like growth factor, and matrix metalloprotease 9.[90] These angiogenic factors are downregulated during involution.

Increasing evidence supports the role of hypoxia in IH development and hypoxia is postulated to trigger neovasculogenesis in infants. Low birth weight, the most significant risk factor for IH, is known to be associated with hypoxia.[8,12] GLUT1 is upregulated in the setting of hypoxia.[35,91] Translational studies performed on proliferating IH have identified presence of multiple markers of hypoxia in addition to GLUT1, including insulin-like growth factor-2 and vascular endothelial growth factor A.[92] Histologic features differentiate between the proliferative and involuting phases of IH and shed light on the pathogenesis as well. During proliferation, the clonal nature and histologic features of endothelial cell proliferation[93,94] suggest the process to be secondary to vasculogenesis,[95] whereas involution is marked by apoptosis and capillary lumina fibrosis.[96] However, the definitive pathogenesis to explain trajectory of IH initiation, proliferation, and involution remain controversial. At present, the most supported explanation suggests that hypoxia (in utero or in local tissue) is key[97] to stimulation of circulating endothelial progenitor cells (CD34+, CD133+ stem cells), subsequent vasculogenesis[98] with ensuing proliferation to maintain tissue oxygenation homeostasis,[97] and eventual increased apoptosis (beginning by end of first year of life) to initiate involution.[96]

DIAGNOSIS

With the exception of unusually challenging cases, the diagnosis of IH is almost exclusively clinical, based on the physical examination and clinical history.

SUPPORTIVE STUDIES

Supportive studies may be warranted in certain clinical contexts (Fig. 118-13). When necessary, ultrasound imaging offers the advantages of lack of need for sedation, lack of ionizing radiation and relatively low cost. On Doppler ultrasound, IH is a high-flow lesion and appears as a well-defined solid mass with increased vascular flow within the mass. Arterial feeder and venous drainage can be visualized. The use of MRI offers the benefit of additional anatomic detail, but its use must be weighed against both the risk of exposure to inhaled anesthesia in young infants and increased cost. The current weight of evidence does support the use of MRI and magnetic

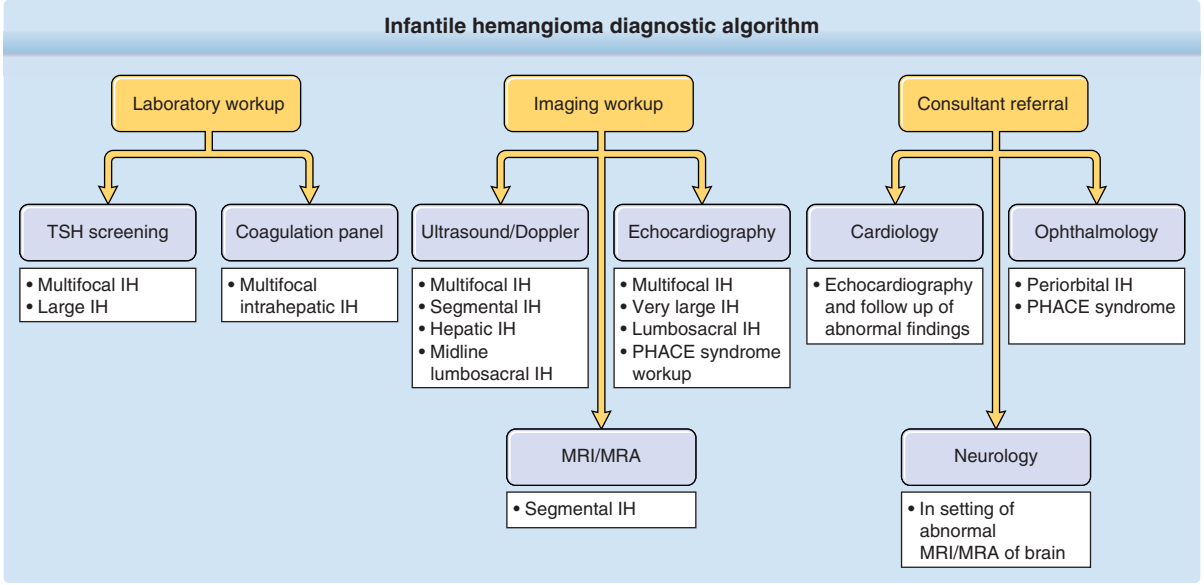

Figure 118-13 Infantile hemangioma (IH) diagnostic algorithm. PHACE, posterior fossa brain malformations, hemangiomas of the face, arterial anomalies, cardiac anomalies, and eye abnormalities; TSH, thyroid-stimulating hormone. (Adapted from Léauté-Labrèze C, Harper JI, Hoeger PH. Infantile haemangioma. *Lancet*. 2017;390(10089):85-94.)

resonance angiography (MRA) in the workup of PHACE syndrome in early life.[40] Some centers experienced in the imaging of infants may be able to successfully complete an MRI in the neonatal period after feeding and swaddling ("feed-and-wrap" technique); the likelihood of compromising image quality by motion artifact increases with the age of the infant and the duration of the study. On MRI, IH appears as a T2 bright, T1 isointense mass with homogeneous, avid contrast enhancement. Internal serpiginous flow voids, indicative of arterial feeding vessels, are visible on T2-weighted imaging. MRA demonstrates early arterial enhancement.[99]

LABORATORY TESTS

Thyroid Function Tests: Hypothyroidism is a rare complication in infants with diffuse infantile hepatic hemangiomas.[100,101] The liver tumor demonstrates high levels of Type III iodothyronine deiodinase activity, which accelerates the degradation of thyroid hormone.[67,102] Infants with significant hepatic hemangiomas should have thyroid function evaluated, including triiodothyronine (T3) (the hormone consumed) and thyroid-stimulating hormone, because thyroxine (T4) levels may initially remain normal. Conversely, screening hepatic ultrasound should be performed in infants with hypothyroidism of unknown etiology even in the absence of cutaneous hemangiomas. Hypothyroidism and other endocrine abnormalities also have been reported with PHACE syndrome.

PATHOLOGY

The histopathologic appearance of IH varies markedly over the course of its life cycle. In all but the earliest phase of growth and the very end of involution, features of proliferation and involution are comingled. As a complement to radiologic imaging, IH in the rapid proliferative phase are made up of unencapsulated but well-defined mass of capillaries arranged in lobules divided by fine septae or normal surrounding soft tissue, comprised of endothelial cells, pericytes, mast cells and interstitial dendritic cells. The vessels are lined with plump endothelial cells with enlarged nuclei and abundant cytoplasm with a surrounding rim of similarly plump pericytes in the absence of smooth muscle cells.[35] The appearance is somewhat similar to young pyogenic granulomas (lobular capillary hemangiomas). In early IH, markers of cellular proliferation such as Ki-67 denotes proliferation of endothelium and pericytes and normal appearing mitotic figures appear abundant. Thick-walled draining veins may be visible. In involuting IH specimens, capillaries begin to be regress and are replaced with adipocytes; mast cells are increased and apoptosis is notable. The basement membranes vessels within the IH thicken and hyalinize. At the end of involution, fibrofatty stroma is prominent and apoptotic debris in the remaining "ghost" capillaries remains.[60,64] When necessary to confirm the diagnosis on histopathologic specimen, GLUT1 immunostaining is positive in the endothelial cells lining IH capillaries at all stages of IH growth, distinguishing IH from other vascular tumors and all vascular malformations.[65,66,76,82] IHs are also CD31+ and CD34+, as noted above.

IMAGING

Presence of a segmental IH of the head, neck, and/or scalp warrants evaluation for possible PHACE to include MRI and MRA of the head/neck/chest,[40] formal ophthalmologic evaluation, and echocardiogram. Likewise, workup of possible LUMBAR syndrome includes MRI/MRA of the lumbosacral spine, pelvis, and/or lower extremity. Initial evaluation for potential hepatic IHs in the setting of multifocal IHs requires hepatic/abdominal ultrasound with Doppler flow and spectral analysis (baseline ultrasound ± serial imaging.)

DIFFERENTIAL DIAGNOSIS

Table 118-6 discusses the differential diagnosis of IH.[103]

CLINICAL COURSE AND PROGNOSIS

The prognosis of most IHs is excellent, with spontaneous involution and little to no sequelae, but a significant minority of IH result in permanent disfigurement or medical sequelae. Following involution, approximately half of all treated patients will attain normal skin, while the other half can have residual atrophy, scarring, telangiectasias, or fibrofatty soft-tissue remnant. One study of 97 untreated patients demonstrated residual skin changes in more than 68 (70%) of patients.[22] Specific IH characteristics (as previously outlined by each subclassification) are associated with increased rates of complications.[17,104] The most important factor to affect prognosis in complicated IH is timing of specialist referral for management, including initiation of therapy and workup as necessary. Certain characteristics are associated with an increased risk of complications and need for treatment (see Table 118-3).[17,104] Consideration of early treatment should be given to IH with these characteristics, depending on the specific clinical setting.

MANAGEMENT

INTERVENTIONS

The decision to initiate treatment is based on many factors, including size and location, psychosocial implications, and risks and benefits of the proposed therapy (Fig. 118-14). For the majority of small IH,

TABLE 118-6
Differential Diagnosis of Infantile Hemangioma

DISORDER	AGE OF ONSET	CLINICAL EXAMINATION	DISTINGUISHING FEATURES
Vascular Anomalies			
Kaposiform hemangioendothelioma (KHE)	Congenital to infancy or later	Firm, reddish-brown to violaceous, plaque or nodule	May be associated with Kasabach-Merritt phenomenon: increased D-dimer, low fibrinogen, severe thrombocytopenia
Tufted angioma	As for KHE	Similar to KHE ± associated hair	Similar to KHE, although considered less severe on spectrum
Rapidly involuting congenital hemangiomas	Congenital; full size at birth	Often symmetric blue nodule with coarse telangiectasia; rim of pallor	High flow
Noninvoluting congenital hemangiomas	Congenital; full size at birth or minimal postnatal growth	Similar to rapidly involuting congenital hemangioma (RICH)	High flow
Pyogenic granuloma	Infancy or childhood (more commonly)	Friable vascular papule with brisk intermittent bleeding	Rarely may be multiple and congenital
Multifocal lymphangioendotheliomatosis	Congenital	Varied appearance of papules, plaques, or nodules	Thrombocytopenia (waxing and waning), potentially severe GI bleeding
Blue rubber bleb nevus syndrome	Congenital, infancy or later	Small, compressible, blue to purple papulonodules	May be confused for multifocal infantile hemangioma (IH); associated with GI bleeding ± larger venous malformation, often in thigh or pelvis
Capillary malformation (port-wine stain)	Congenital	Confluent pink to dusky pink; possibly reticulated	Reticulated may appear similar to minimal growth IH
Venous malformation	Congenital; may not be noted until later	Blue-purple compressible; growth gradual and progressive	Low flow; may be confused with deep IH
Glomuvenous malformation	Congenital in segmental plaque presentation; multifocal present later	Segmental thin plaque pink to violaceous; papules/nodules firm ± tender	Autosomal dominant; limited to skin and soft tissue
Lymphatic malformation	Macrocystic cervicofacial present at birth; microcystic often noted later	Deep, skin-colored nodule ± vascular appearing pink to purple blebs	Low flow; may be confused with deep IH
Verrucous hemangioma	Congenital	Plaque, papule, or nodule with keratotic change over time	A subtype of lymphatic malformation
Cutis marmorata telangiectatica congenita	Congenital	Reticulated, marbled pink to dusky purple ± ulceration ± limb undergrowth	May be confused with minimal growth IH or reticulated port-wine stain
Nonvascular Lesions			
Myofibroma	Congenital to infancy	Small to large plaques and nodules	May ulcerate and mimick ulcerated IH
Spitz nevus	Infancy rarely; childhood commonly	Pink to red-brown papule	Typically solitary although may have agminated presentation
Juvenile xanthogranuloma	Congenital to infancy	Pink to red-brown papules or nodules	Become yellow with time; central ulceration possible in larger lesions
Dermoid cyst	Congenital	Skin colored to slightly bluish; firm; typically mobile nodule face and scalp at sites of suture closure/embryonic fusion	May be confused with deep IH
Encephalocele	Congenital	Bluish nodule, may transilluminate in midline frontal or occipital scalp	Consider with midline deep blue nodule
Rhabdomyosarcoma	Congenital to first year in most	Firm tumoral nodule with overlying telangiectasias; embryonal rhabdomyosarcoma is multifocal and congenital	May be confused with deep or mixed IH

(*Continued*)

TABLE 118-6
Differential Diagnosis of Infantile Hemangioma (*Continued*)

DISORDER	AGE OF ONSET	CLINICAL EXAMINATION	DISTINGUISHING FEATURES
Infantile fibrosarcoma	Congenital to first 2 years	Red to blue; firm and fixed to underlying tissue	May be confused with mixed IH, but more often KHE/tufted angioma or RICH/noninvoluting congenital hemangioma
Langerhans cell histiocytosis	Congenital, infancy or later	Seborrheic distribution in scalp and diaper area especially; red to brown papules, nodules, petechial papules	Congenital presentation has a more-favorable prognosis than presentation in infancy or later; presentation with larger nodule, often on scalp, possible
Neuroblastoma	Congenital to early infancy	Blue to violaceous nodule	Increased urine homovanillic ± vanillylmandelic acid
Congenital leukemia cutis	Congenital to neonatal	Pink, blue, or violaceous firm plaques and nodules	May be confused with multifocal IH

Adapted from Püttgen KB. Diagnosis and management of infantile hemangiomas. *Pediatr Clin North Am*. 2014;61(2):383-402.

active nonintervention with close observation and followup is the most appropriate approach. Especially during the first few months of life and during the rapid proliferative phase, visits should be more frequent, as often as every 1 to 2 weeks in the youngest infants.[105] Visits with parents and caregivers should emphasize education about the natural course and prognosis of IH, addressing both parental anxiety[106] and psychosocial impact on the patient and family.[107-109] Photographs of the likely outcome for a similar lesion are often helpful. Many parents experience anxiety and may find themselves subject to comments from complete strangers about their child's hemangioma.[106] Most parents of young children do not think their child is deeply affected by these reactions, but facial IHs, in particular, can cause psychological suffering once the child reaches school-age.[107,108] Potential treatment options should be discussed well ahead of entrance to elementary school.

For those IHs warranting intervention, options include pharmacologic, laser, and surgical interventions.

MEDICATIONS

Beta Blockers: With widely established efficacy in IH treatment and a more favorable risk profile compared with prior systemic treatment options, propranolol is the only medication approved by the United States Food and Drug Administration (FDA) for the treatment of complicated IH. Propranolol is the clear first-line systemic pharmacologic therapy for most moderate to severe IHs at risk for significant morbidity.[110-112] Unlike corticosteroids, which stabilize IH growth but do not cause involution, propranolol

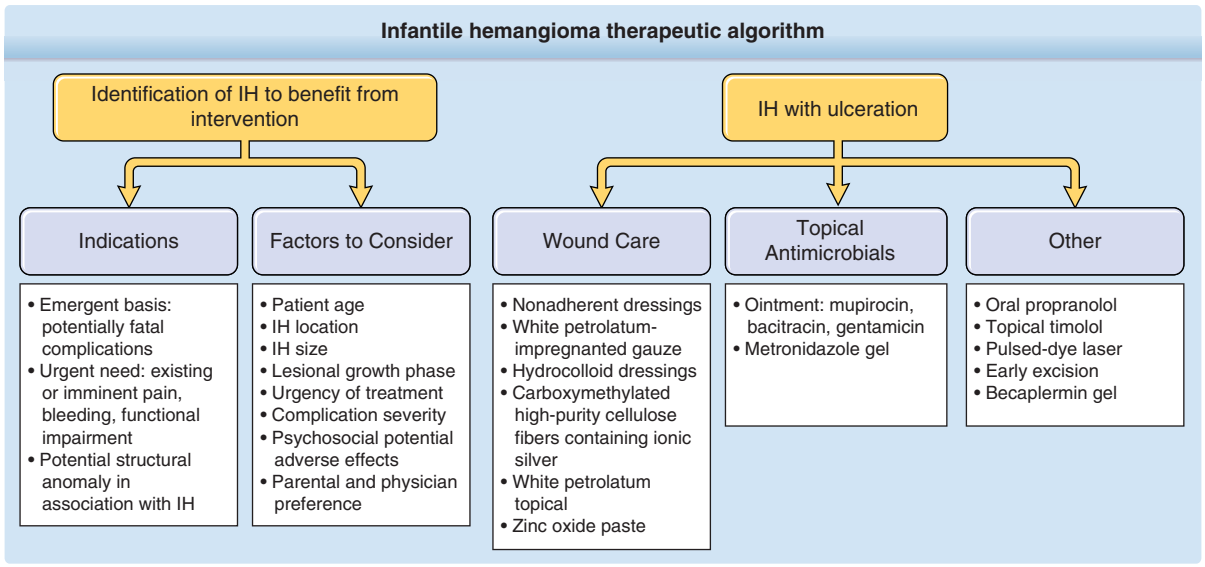

Figure 118-14 Infantile hemangioma (IH) therapeutic algorithm. (Data from Darrow DH, Greene AK, Mancini AJ, et al. Diagnosis and management of infantile hemangioma. *Pediatrics*. 2015;136(4):e1060-e1104.)

causes regression in the vast majority of cases. Rebound growth after cessation of therapy can occur, but usually responds well to retreatment.[111,112] Key criteria to warrant consideration of beta-blocker treatment initiation for IH include facial deformity, active or impending functional impairment, early prevention of anticipated permanent sequelae, and mitigation of the need for surgery.[113] Positive results also have been reported in other settings, including fully proliferated IHs and airway, liver, and orbital hemangiomas.[111,114-116] Despite early controversy, most patients with PHACE can safely tolerate propranolol, although it is recommended to use the lowest effective dose, consider a slower dose titration, and to give the medication in 3 divided doses, rather than the standard twice-daily dosing, to avoid significant alterations in peak blood levels.[40] Molecular mechanisms of propranolol in effectively treating IH include lesional capillary vasoconstriction (visible IH color change within first 48 hours of use), angiogenesis inhibition (arresting growth), and induction of apoptosis (bringing about IH regression).[117] Common side effects of propranolol include sleep disturbance, acrocyanosis, and asymptomatic transient decrease in blood pressure or heart rate. Rarely observed potential important adverse effects include hypoglycemia, symptomatic hypotension or bradycardia, wheezing, bronchospasm, and diarrhea. Propranolol's efficacy has been documented in a large, international, placebo-controlled, randomized trial and numerous smaller prospective and retrospective case series and case reports, including a small multicenter randomized trial comparing oral corticosteroids to propranolol and several comparative retrospective studies.[111,112,118] A multicenter, randomized, double-blind, Phase II-III trial comprised of 456 patients investigating the efficacy of oral propranolol in IH involved 5 treatment arms (1 mg/kg/day for 3 months vs 6 months' duration, 3 mg/kg/day for 3 months vs 6 months' duration, and placebo). Dosing of 3 mg/kg/day for 6 months was found to have the highest benefit-to-risk ratio with 88% of patients on this daily dose demonstrating improvement by the fifth week of treatment. In this study, side effects included a decrease in heart rate (by a mean of 7 beats per minute with observed change of heart rate within 1 hour of dose with minimal change thereafter) and a decrease in mean systolic blood pressure (by 3 mm Hg). Serious adverse events (n = 33) included: bronchospasm, diarrhea (3 mg/kg/day > 1 mg/kg/day), and sleep disorder (73 propranolol vs 7 placebo).[119] A study cohort involving 39 European centers with nearly 1100 total patients, reported the use patterns of propranolol in IH, with 91.4% of patients demonstrating clinically significant improvement regardless of daily maintenance dose (less than 2 mg/kg/day, 2 mg/kg/day, greater than 2 mg/kg/day) with risk of adverse events to be based upon daily maintenance dosing.[120] With report of overall IH response rate of 98% and 0.9% resistance rate in IH, propranolol has reduced the need for surgery in nasal-site-specific IH.[121-123] Given propranolol's lipophilic nature with ease of crossing the blood–brain barrier, sleep disorder can manifest in several ways (fatigue, restlessness, nightmares, insomnia), affecting 11.4% of patients, with a reported 3.7% of patients experiencing nightmares. Theoretical risks of propranolol extrapolated from adult volunteer studies in the psychology literature include impaired short-term and long-term memory, sleep quality, mood, and psychomotor function. Fatigue associated with pediatric hypertension improves over time.[124,125]

Propranolol initiation can take place in the inpatient or outpatient setting (Fig. 118-15). In determining a patient's candidacy for propranolol, family history must be obtained to ensure absence of congenital heart disease, arrhythmia, and maternal connective tissue disease. Uniformly accepted standard monitoring procedures for patients on propranolol for IH have not yet been established. However, current proposed factors favoring inpatient initiation include young age (the study on which FDA approval of propranolol was granted included infants as young as 5 weeks of age with outpatient initiation), comorbid medical conditions (eg, respiratory or cardiovascular), inadequate social support, or any preexisting concerns for blood glucose. In the outpatient setting, hypoglycemia can be prevented with anticipatory guidance, dosing propranolol with feedings, frequent feedings, and either decreasing or holding the dose in the setting of decreased oral intake.[126,127] Outpatient initiation is suitable for most otherwise healthy children beyond the neonatal period. Current published guidelines and many, but not all, physicians advocate 2-hour monitoring in the ambulatory setting for heart rate and blood pressure with first dose administered. Dosing is typically started at 1 mg/kg/day in 2 divided doses and increased by 0.5 mg/kg/day increments every 3 to 7 days to a target dose between 2 and 3 mg/kg/day. Most practitioners use 2 mg/kg/day. Slower dose escalation or lower target dose may be warranted in the setting of PHACE syndrome, ulceration or other comorbid conditions. Atenolol, a β_1-selective antagonist, and nadolol, a nonselective β-antagonist, have been used in infants for IH treatment but neither is available in liquid formulation in the United States. The main benefit of atenolol is the lack of bronchial reactivity; nadolol's advantage is its inability to cross the blood–brain barrier, thereby decreasing concerns for any potential neurocognitive side effects compared with propranolol. Only few international publications reporting the use of atenolol and nadolol in IH are available as of this writing; further studies are warranted. Likewise, further studies investigating any neurocognitive effects of propranolol are ongoing. Early evidence does not demonstrate adverse effects on neurodevelopment with use of propranolol, but comprehensive neurocognitive testing in this population has not been reported.[128]

In light of the proved efficacy of systemic beta blockers, the efficacy of topical beta blockers in IH treatment were evaluated in an effort to even further decrease side effects. Topical timolol is a nonselective beta blocker available in an ophthalmic preparation approved for the treatment of pediatric glaucoma.[129] Eight to 10 times more potent than propranolol, topical

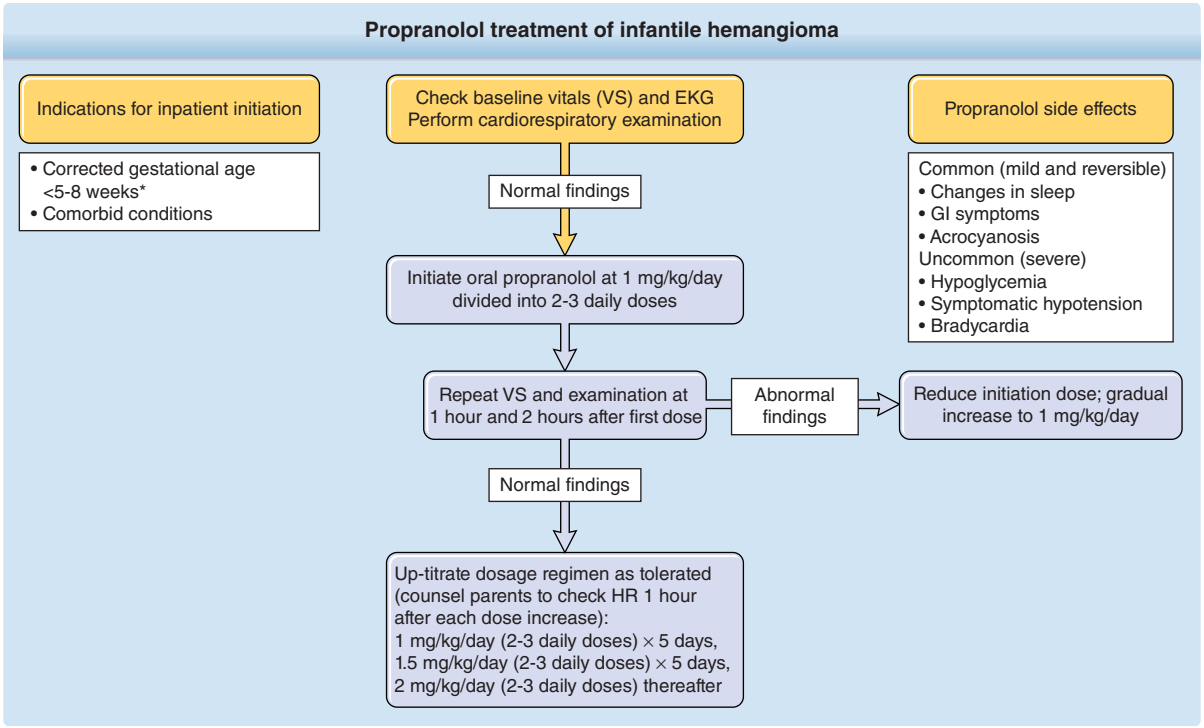

Figure 118-15 Propranolol treatment of infantile hemangioma. *Drolet BA, Frommelt PC, Chamlin SL, et al. Initiation and use of propranolol for infantile hemangioma: report of a consensus conference. *Pediatrics.* 2013;131(1):128-140; Léauté-Labrèze C, Hoeger P, Mazereeuw-Hautier J, et al. A randomized controlled trial of oral propranolol in infantile hemangioma. *N Engl J Med.* 2015;372:735-746. (Data from Drolet BA, Frommelt PC, Chamlin SL, et al. Initiation and use of propranolol for infantile hemangioma: report of a consensus conference. *Pediatrics*. 2013;131(1):128-140.)

timolol was first reported as an effective option for IH treatment in 2010,[130] and continues to gain increasing acceptance and application. The systemic bioavailability of 1 intraocular drop of timolol 0.5% solution ranged from 39% to 98%, with a mean value of 78.3±24.5%.[131] Additional research on topical timolol demonstrated differences in systemic absorption based upon vehicle preparation. Compared to aqueous timolol solution (0.25% to 0.5%) with average plasma concentration of 0.46 to 1.72 ng/mL, timolol gel-forming solution (0.1% to 0.5%) was developed to decrease systemic absorption with average plasma concentration rage of 0.13 to 0.71 ng/mL. Little is known about the absorption across IH-affected skin. Several contributing factors can impact systemic absorption independent of vehicle, including application site (mucosa, ulceration, and areas under occlusion increase absorption), application size, and size of patients (neonates and especially premature infants with greater absorption as a result of increased surface-area-to-volume ratios). Timolol is metabolized by cytochrome P450 CYP2D6; poor metabolizers are likely at greater risk for adverse effects. Changes in heart rate correlate with plasma levels in timolol, thus less-significant heart rate changes were found in hydrogel formulation. Topical timolol in either vehicle had negligible pulmonary or blood pressure effects.[132] The largest powered multicenter retrospective topical (0.05%) timolol (85% gel foaming solution) study (n = 731) with a 9.5-month mean duration of treatment (83.5% of participants dosed at 1 drop twice daily) reported 3.4% adverse events (half of these noted to be local irritation at application site with 3 cases of bronchospasm and 4 cases of ulceration development). The retrospective endeavor concluded timolol was most effective in thinner IH and with longer duration of treatment. Color improved more than overall volume, extent, and size with topical timolol use.[133]

Corticosteroids: Systemic corticosteroids, previously considered first-line treatment of deforming, endangering, or life-threatening IH, are now used rarely given the efficacy, safety and improved tolerability of beta blockers.[134] Corticosteroids are most effective during the proliferative phase, causing slowing or cessation of growth in up to 90% of cases, with actual shrinkage in approximately one-third. Although the mechanism of action is not well understood, prior studies suggest the upregulation of mitochondrial cytochrome b, clusterin/ApoJ (possible apoptotic markers), and/or interleukin-6 as markers of corticosteroid-induced cessation of IH growth.[135-137] When used, prednisone or prednisolone is given at a dose of 2 to 3 mg/kg/day, typically for 4-8 weeks followed by a tapering of varying length, depending on the age of the child and indication for treatment. A metaanalysis showed an 84% response rate with an average dose of 2.9 mg/kg for a mean of 1.8 months before tapering. Although 3 mg/kg/day

is more effective (94% response) than 2 mg/kg/day (75% response), greater adverse events occur at higher doses.[138]

Short-term complications of systemic corticosteroids include cushingoid faces (71%), personality changes (irritability/fussiness) (29%), gastric irritation (21%), fungal infection (oral or perineal, 6%), and diminished gain of height (35%) and weight (42%) during treatment. More than 90% of children with diminished gain of height return to their pretreatment growth curve by 24 months of age.[139,140] Other complications include hypertension, steroid-induced myopathy, immunosuppression, and transient adrenal insufficiency.[140,141] Blood pressure should be closely monitored by the treating physician.[142] Children taking more than 2 mg/kg/day of prednisone for longer than 14 days are considered to have a deficit in cell-mediated immunity. Live viral vaccinations should be deferred in infants receiving high-dose corticosteroids. Rare cases of *Pneumocystis carinii* pneumonia has been reported in this setting, leading some physicians to use trimethoprim-sulfamethoxazole prophylaxis during treatment.[143,144]

Intralesional corticosteroids can be an effective treatment for select, relatively small, localized IHs located in high-risk sites such as the lip, nasal tip, cheek, and ear. Current use of this modality for IH is maintained by a minority of physicians with expertise in its use. Injections for periocular hemangiomas are not recommended. If used, it should only be performed by experienced ophthalmologists, given reports of retinal artery embolization and blindness.[145,146] The largest published case series of intralesional steroids found that the majority showed a greater than 50% reduction in volume, with the best results occurring in relatively superficial IHs. Adverse events occurred in 6.4% of patients and included cushingoid appearance, cutaneous atrophy and anaphylactic shock.[147]

Only few case series have reported on the efficacy of Class 1 topical corticosteroids, namely for small, superficial hemangiomas.[110,148,149]

Medications of Historical Importance (Interferon-α, Vincristine, Imiquimod): Interferon-α, vincristine, and imiquimod were previously regarded as second-line or third-line therapeutic options for IH. Their use is no longer advocated in light of the established efficacy and more favorable side-effect profile of beta blockers. Interferon-α carries the notable risk of potential neurotoxicity, specifically spastic diplegia. A metaanalysis of 441 patients showed 11 developed irreversible spastic diplegia and 16 developed motor disturbances that were reversible on discontinuation of the drug.[150] All affected patients were younger than 1 year of age at initiation of therapy. Vincristine's use in the treatment of vascular tumors is now reserved for complicated kaposiform hemangioendothelioma (KHE) and tufted angioma (TA); its use for this indication may be eclipsed by sirolimus in future years, but further study is warranted.[151-153]

PROCEDURES

Laser Therapy: PDL, originally designed to treat port-wine stains (ie, capillary malformations), has been used to treat IH with varying results.[154] PDL was used more frequently in the treatment of IH before the discovery of propranolol. Its usefulness is primarily limited by its minimal depth of penetration (less than 2 mm).[35] Several reports have shown improvement in treating associated ulceration[155,156]; its use in diminishing residual telangiectasias and erythema after involution is well accepted. Its use in the treatment of proliferating IHs is controversial.[157] In a prospective, randomized, controlled study, 22 infants treated with either observation or PDL with epidermal cooling demonstrated significant color improvement in the PDL group, but unchanged total surface area and echo depth by 12 months' followup.[158] Another prospective study randomized children to PDL without epidermal cooling (n = 60) and observation (n = 61) groups with comparable results of (near-) complete resolution between groups at age 1 year, with a trend toward increased hypopigmentation and textural change in the PDL group. Outcomes between groups were similar at the 5-year followup of 117 children.[155] Other studies have shown good results with either the 585-nm PDL or 595-nm PDL, with varying fluencies (total energy per unit area), but several have emphasized that treatments work best for more superficial hemangiomas and are unable to halt growth of deeper components.[159-162] Severe ulceration and scarring, particularly in treating segmental hemangiomas during the proliferative phase, have been reported.[163] Although comparative studies are lacking, the same IHs that are reasonable candidates in the proliferative phase for PDL are similarly good candidates for topical timolol treatment. Expert opinion and rudimentary cost analysis support the use of medical therapy with timolol in superficial IHs over the use of PDL in most cases.[133] A conservative approach is to reserve PDL primarily for treating ulceration and for hastening resolution of erythema in IH after the proliferative phase is completed.[164]

Surgical Therapy: Surgical excision may be indicated at any time during the life cycle of an IH, but elective excision in infancy is typically neither necessary nor advocated. Proposed indications for surgical intervention of IH during infancy include an anatomically favorable site amenable to resection, a contraindication or failure of pharmacotherapy, or a high risk of ultimately necessary resection with similar scar regardless of timing of surgery. Timing of surgical intervention depends upon evolution of tumor (whether it continues to regress), anatomic location, degree of deformity, and the age of the child. Certain anatomic locations, such as the nasal tip and lip, often require surgery.[165-170] Even earlier excision may be indicated in cases where clinical characteristics, such as pedunculated IH, severe, recalcitrant ulceration, or extremely thick dermal involvement dictate that scarring will inevitably occur. In most instances, it is best

to wait until regression is well under way and a more accurate assessment can be made regarding whether scarring and textural changes have occurred. Surgery during and after involution can allow reconstruction of affected adjacent structures, resection of residual excess skin or fibrofatty tissue, or scar revision. Decisions regarding this can often be made between 3 and 5 years of age, even if involution is not complete.[171] Four years serves an appropriate threshold age as most IHs have completed involution and children develop self-awareness, long-term memory, and self-esteem.[35] A standard elliptical excision is often performed; however, circular excision followed by a purse-string closure may leave a smaller scar.[172] A second stage following purse-string closure may or may not be necessary.

SCREENING

Screening for PHACE is recommended in the setting of segmental IH on the head, in infants without classic segmental IH or with a small IH who have a major anomaly seen in PHACE (eg, coarctation of the aorta or supraumbilical raphe) and in infants with 2 major criteria for PHACE as outlined in consensus guidelines from 2016.[40]

OTHER VASCULAR TUMORS

AT-A-GLANCE

- Vascular tumors in the current International Society for the Study of Vascular Anomalies classification are subdivided into (a) benign, (b) locally aggressive or borderline, or (c) malignant.
- Congenital hemangiomas are fully formed at birth. Rapidly involuting, noninvoluting, and partially involuting congenital hemangiomas are recognized subtypes.
- Tufted angiomas represent subtle pink or dusky-red patches and may evolve into plaques or nodules and have a characteristic histology.
- Kaposiform hemangioendothelioma is a locally aggressive vascular tumor, morphologically similar to but etiologically distinct from Kaposi sarcoma and can be associated with Kasabach-Merritt phenomenon. Kaposiform hemangioendothelioma exists on a spectrum with tufted angioma.
- Multifocal lymphangiomatosis with thrombocytopenia consists of cutaneous vascular papules and plaques associated with intermittent thrombocytopenia, often with GI bleeding.
- Spindle-cell hemangioma usually occurs in the extremities most often associated with Maffucci syndrome.
- Pyogenic granuloma, a rapidly growing papule or nodule with a collarette of scale or eroded surface, is very common. Treatment is excision or electrocautery.
- Congenital eccrine angiomatous hamartoma is a rare ill-defined plaque associated with increased lanugo hair and sweating.

Many other benign vascular neoplasms occur in both children and adults.[173] This section highlights selected important vascular tumors according to the 2014 ISSVA classification, which classifies vascular tumors as (a) benign, (b) locally aggressive or borderline, or (c) malignant. More comprehensive reviews of this subject can be found elsewhere.[2,173,174]

CONGENITAL HEMANGIOMAS

Hemangiomas that are fully formed tumors at the time of birth and do not proliferate in postnatal life are referred to as *congenital hemangiomas*. They are benign and much less common than IH. There are now 3 major subtypes recognized on the basis of their natural history: the rapidly involuting (RICH), noninvoluting (NICH), and partially involuting congenital hemangioma.[175,176] Recognition of the partially involuting congenital hemangioma subtype in recent years highlights that these tumors exist on a spectrum. Definitive categorization is often challenging in the immediate newborn period and can often only be made with confidence in retrospect after observation of the clinical behavior. Congenital hemangiomas have similar anatomic sites of predilection, including the head, neck, and extremities, but can occur elsewhere. They are equally common in boys and girls.[176]

RICH often appears as a raised, violaceous tumor with large, radiating veins or with overlying telangiectasia and a halo of pallor (Fig. 118-16). Central ulceration may be present. Most RICHs involute spontaneously by or before 14 months of age and usually leave residual atrophic anetodermic scar tissue.[177] A presumed RICH noted on prenatal ultrasound that involuted before birth has been reported, leaving a scar tissue at the site of the lesion.[178]

RICHs can be associated with mild to moderate thrombocytopenia and a coagulopathy characterized by elevated fibrin degradation products and low fibrinogen in the neonatal period. In contrast to Kasabach-Merritt phenomenon (discussed in section "Kaposiform Hemangioendothelioma"), the laboratory findings of cutaneous RICHs are often self-limited and uncomplicated with only supportive care generally required.[179]

Figure 118-16 Rapidly involuting congenital hemangioma on left scalp. **A,** Infant with overlying coarse telangiectasias at 1 month of age. **B,** Early regression at age 5 months. **C,** Continued rapid involution at age 8 months.

Hepatic RICHs, which are the focal subtype of hepatic hemangioma, are rare, but at greater risk of complications, with associations with marked thrombocytopenia as well as severe progressive hepatic dysfunction and resultant heart failure.

NICHs are less common than RICHs and also present at birth. They are usually flatter than RICHs, presenting as a well-circumscribed round to oval, somewhat indurated or raised soft-tissue mass with overlying telangiectasias and a rim of pallor (Fig. 118-17).

Figure 118-17 Noninvoluting congenital hemangioma on right mandible. Note the overlying telangiectasias and rim of pallor.

Partially involuting congenital hemangioma was introduced into the vascular anomalies lexicon in 2014 and fewer than 20 cases have been reported. Partial involution occurs over the first 12 to 30 months of life (mean: 18 months) before stabilization occurs (Fig. 118-18).[176]

Somatic activating missense mutations in the genes *GNAQ* and *GNA11* are reported to cause RICH and NICH. The mutational change, alteration of glutamine at amino acid 209 (Gln209), was the same in both tumors, so does not explain their varied clinical courses.[180] The same Gln209 missense mutation is common in uveal melanoma, and postzygotic mosaic mutations in *GNAQ* and *GNA11* codons 183 or 209 have been reported in association with phakomatosis pigmentovascularis and extensive dermal melanocytosis.[181]

Indications for treatment of congenital hemangiomas are similar to those for IH, including ulceration, impairment of vital function and congestive heart failure. Excision, with or without preoperative embolization, should definitely be considered for ulceration, which can lead to severe hemorrhage, and for postinvolutional skin changes if disfiguring.[175] NICH do not go away, but are often asymptomatic; decisions regarding their removal must weigh risks and benefits of the proposed treatment.

The distinguishing pathologic features of congenital hemangiomas are lobules of capillaries with plump endothelial cells and pericytes set within densely fibrotic stroma containing hemosiderin deposits, focal lobular thrombosis, and sclerosis.[182] They are GLUT1 negative, unlike IH.[183] On ultrasound, congenital hemangiomas heterogenous with scattered calcifications possible and are generally confined to the subcutaneous fat. They are high-flow vascular tumors, often showing arteriovenous microfistulas, more common seen in NICH, on Doppler interrogation.[184]

Figure 118-18 Partially involuting congenital hemangioma on the right thigh. Note the overlying telangiectasias and rim of pallor. **A,** First day of life. **B,** Early decrease in size at 6 weeks of age. **C,** At 13 months of age it is broad but flat. **D,** At 5 years of age no further involution has occurred and there is renewed prominence of superficial vessels.

TUFTED ANGIOMA

EPIDEMIOLOGY

TA is a rare benign vascular tumor that also has been called *angioblastoma of Nakagawa*. Although adult cases have been reported, most cases occur early in childhood and may have a protracted course. Approximately 25% of TA are congenital and 50% appear in the first year of life. There is no sex predilection.

CLINICAL FEATURES

TA display various clinical patterns and are most commonly seen on the neck, trunk, and extremities. They may present as a subtle stain-like area that later thickens, as a large, plaque-like, infiltrated, red or dusky blue-purple lesion, or as an exophytic, firm, rubbery, violaceous, cutaneous nodule (Fig. 118-19). Tenderness and overlying hyperhidrosis may occur.[185] TA are usually solitary, but multifocal cases have been reported.[186]

COMPLICATIONS

Kasabach-Merritt phenomenon (KMP) may develop in TA but this is more common with KHE (see section "Kaposiform Hemangioendothelioma").

ETIOLOGY AND PATHOGENESIS

Its etiology and pathogenesis are uncertain, although based on its immunostaining pattern, a lymphatic

Figure 118-19 Tufted angioma (confirmed by biopsy) of the left leg, buttocks, lower abdomen in an 18-month-old child. Laboratory evaluation revealed elevated D-dimers.

origin is likely. Unlike IH, there are no known gender or gestational age correlates.

DIAGNOSIS

Histologically, both acquired and congenital TAs demonstrate vascular tufts of tightly packed capillaries, randomly dispersed throughout the dermis in a typical "cannonball distribution" with crescentic spaces surrounding the vascular tufts, and lymphatic-like spaces within the tumor stroma.[187,188] Unlike IH, TA does not stain with GLUT1.[82] It is CD31+; D2-40, LYVE1, and PROX1 lymphatic markers, are only partially positive in surrounding vessels, helping distinguish TA from KHE.[189]

CLINICAL COURSE AND PROGNOSIS

TAs may persist unchanged or regress completely within a few years.[190] TAs that are present at birth or in the first year of life have a greater tendency to spontaneously regress than do those that appear later in life.[191] Of those TAs that regress, 95% are reported to do so within 2 years.[187]

MANAGEMENT

No widely accepted treatment guidelines exist for management of TA. Recommended therapies for TA, with and without KMP, include excision, compression, laser, topical or systemic corticosteroids, propranolol and chemotherapy. See "Kaposiform Hemangioendothelioma" below for a fuller discussion of therapy.

KAPOSIFORM HEMANGIOENDOTHELIOMA

EPIDEMIOLOGY

KHE is a rare vascular tumor with an estimated prevalence of 0.91 cases per 100,000 children.[192] It may be present at birth or develop in early childhood. A series of more than 100 patients reported that 60% present as neonates and 93% in infancy. Rare adult cases have been reported. Three-quarters involve the skin. It is usually reported in association with KMP, which occurs in more than 70% of cases.[192]

CLINICAL FEATURES

KHE is an infiltrative, aggressive tumor classified as locally aggressive or borderline in the ISSVA classification. It may present as a brown-red stain at birth which begins to thicken and become purpuric, or as plaques or deep-seated nodules and bulky tumors. Most cases involve the skin and musculature. KHE can occur on the extremities, especially overlying joints, trunk, head, neck. Deeper viscera including cervicothoracic, abdominal, and the retroperitoneum can be affected. Notably, KHE does not occur in the liver. Locoregional lymph node involvement may occur and likely represents multifocal disease. Distant metastases do not occur. Mediastinal or retroperitoneal disease may present with hemothorax and ascites.[141] Spontaneous involution is rare. Most reported cases have had associated KMP, but KHE can occur in the absence of a coagulopathy.[192-195] KHE may resolve with atrophic or stain-like areas, infiltrated plaques and papules, or nodules. Residual fibrosis is not rare and can result in considerable morbidity.[196]

COMPLICATIONS

Kasabach-Merritt Phenomenon: KMP refers to the presence of platelet trapping within a vascular tumor resulting in profoundly severe thrombocytopenia (typically less than 30000/μL) and associated microangiopathic hemolytic anemia and consumption of clotting factors resulting in low fibrinogen, elevated D-dimers, and varying degrees of decreased coagulation factors (Fig. 118-20). It was long considered to be a complication of "hemangioma," but it is now recognized to be a complication almost exclusively of TA and KHE, not IH.[14,197] KMP must be differentiated from the coagulopathy that can arise in association with venous and mixed venous-lymphatic malformations (sometimes erroneously called KMP) as a result of chronic clotting and consumption of clotting factors, but not primarily by platelet trapping,[198] which is more likely to be either localized or disseminated intravascular coagulopathy.

ETIOLOGY AND PATHOGENESIS

The pathogenesis of KHE and KMP is unknown. KHE and TA are thought to exist on a spectrum of severity.[192]

Figure 118-20 Kasabach-Merritt phenomenon secondary to kaposiform hemangioendothelioma (KHE). An indurated, purpuric tumor appeared at age 3 months and is seen here at age 8 months. KHE confirmed by MRI and biopsy. Platelet count <5000/mm^3.

RISK FACTORS

Involvement across more than 1 anatomic region increases the risk of developing KMP, while KHE presenting at a later age, with superficial tumors or tumors involving only bone, appears to have a lower risk of KMP.[192]

DIAGNOSIS

Diagnosis is based upon clinical and histologic features and laboratory abnormalities, including severe thrombocytopenia, consumption of fibrinogen, elevated D-dimers, decreased coagulation factors to varying degrees, and microangiopathic hemolytic anemia.

The histology of KHE is characterized by infiltrative nodules and sheets of spindled endothelial cells with minimal atypia and infrequent mitoses lining slit-like or crescentic vessels containing hemosiderin. Edema, microthrombi, fibrosis and atypical appearing lymphatic vessels can be seen. The tumor is GLUT1 negative. Similar to TA, increased lymphatic spaces reactive with the lymphatic markers including vascular endothelial growth factor receptor-3 and D2-40 suggest a lymphatic origin, similar to that of Kaposi sarcoma.[199,200]

CLINICAL COURSE AND PROGNOSIS

The prognosis and management of KHE varies with extent and location of the tumor, in addition to the presence of KMP. Although the KHE and TA may persist, the coagulopathy of KMP usually abates by 1 year of age or sooner with treatment.

MANAGEMENT

No one treatment is uniformly effective nor are there widely accepted treatment guidelines for KHE management. KHE complicated by KMP requires more aggressive intervention than KHE in the absence of coagulopathy. Complete surgical excision, when possible, is curative, but is often not feasible given the infiltrative nature of the tumor. Systemic corticosteroids are considered first-line treatment and are often used in combination with vincristine, especially in the setting of KMP. Ticlopidine and aspirin are reported as adjunctive therapies with variable benefit. Arterial embolization may be adjunctive before planned surgery to decrease bleeding risk and may result in temporary improvement of coagulopathy and lesion size but is rarely effective as monotherapy.[201] Reports on the use of oral sirolimus, a mammalian target of rapamycin inhibitor, in this condition are promising[202,203] showing rapid reversal of the coagulopathy; results from prospective clinical trials are pending. Older literature reports use of radiation therapy, cyclophosphamide, interferon-α, actinomycin-D, and methotrexate, but these are all considered third-line therapies to be used only in the setting of failure of other agents. Platelet transfusions should be avoided unless active bleeding occurs or before surgical procedures.[204-208] The use of other blood transfusion products has proved ineffective in correction of the coagulopathy.

SPINDLE-CELL HEMANGIOMA

Spindle-cell hemangioma, also called *spindle-cell hemangioendothelioma*, is a rare benign vascular tumor most often seen with Maffucci syndrome. While the genetic mutation associated with this syndrome has been identified (IDH1 and IDH2, which produce isocitrate dehydrogenases to convert isocitrate to 2-ketoglutarate) and detected in associated cutaneous findings of this condition, the relationship of the mutations and the manifestations of this disorder remains unclear. It can occur at any age and site but the extremities are the most commonly affected. The histology is of a nodular, dense, spindle cell proliferation associated with dilated dysplastic veins. Lesions can be locally aggressive and may recur even after excision.[209]

PYOGENIC GRANULOMA (LOBULAR CAPILLARY HEMANGIOMA)

Pyogenic granuloma (PG) is also known by its correct histopathologic description *lobular capillary hemangioma.* It is one of the most common vascular tumors of infants and children and can also occur in adults, particularly in pregnant women. PG usually presents as a solitary, red, rapidly growing papule or nodule, often with a subtle collarette of scale (Fig. 118-21). Typical locations include the cheek or forehead, but virtually any body site including the mucous membranes may be affected. The rapid growth of PGs usually presents at a later age than that associated with the proliferative phase of IH, but in very young infants can cause confusion.[210] They often develop an eroded surface, with subsequent bleeding which can be profuse, resulting in the

Figure 118-21 Large pyogenic granuloma on left cheek.

moniker *the Band-Aid disease*. Solitary and agminated PG-like lesions have rarely been reported in association with vascular anomalies including arteriovenous malformations and congenital hemangioma.[211,212]

PG does not typically involute spontaneously. Even after definitive treatment, recurrence and even satellite lesions surrounding the original PG have been reported.[213,214] Simple curettage with electrocautery is usually curative. Other options include excision, laser surgery (carbon dioxide or pulsed-dye laser), and cryotherapy. Imiquimod and timolol have been suggested as effective topical treatment options.[215,216]

MULTIFOCAL LYMPHANGIOENDOTHELIOMATOSIS WITH THROMBOCYTOPENIA

MLT—also known as *cutaneovisceral angiomatosis with thrombocytopenia*—is a rare condition that was initially described in 2004, and is characterized by multiple cutaneous vascular papules and plaques that are usually congenital with development of new lesions over time.[217] It is currently unclear whether it is a vascular tumor or a vascular malformation. Some patients have prominent exophytic cutaneous vascular tumors, whereas others have subtle blueberry muffin-like papules.[218] Most affected infants have intermittent thrombocytopenia and lesions in the GI tract, leading to GI bleeding. Other reported sites of involvement include bones, synovium, lungs, liver, spleen, and brain. It is now understood that many patients previously diagnosed with "diffuse neonatal hemangiomatosis" actually had MLT.[219] Skin biopsy specimens demonstrate thin-walled vessels, some hobnailed endothelial cells, and intraluminal papillary projections similar to Dabska tumor.[217,220] Endothelial cells stain positively for CD31, CD34, and LYVE1, variably for D2-40, and are negative for GLUT1.[186,218] Prognosis varies based on extent of disease and bleeding complications. A metaanalysis reported a 65% mortality rate.[219] Effective therapy has been challenging but early experience with sirolimus has been positive, with some authors recommending it as first-line treatment.[221,222] A variety of other systemic medications have been reported with variable benefit including corticosteroids, vincristine, thalidomide, interferon-α2a, propranolol, and bevacizumab.[218,223]

PAPILLARY INTRALYMPHATIC ANGIOENDOTHELIOMA

Papillary intralymphatic angioendothelioma (PILA), also known as Dabska tumor, is a dermal nodule or a diffuse violaceous swelling on the head, neck, or extremities that is seen almost exclusively in the pediatric-age group. PILA/Dabska tumor is a low-grade vascular tumor whose rarity has made study of its long-term prognosis and optimal treatment difficult. Histopathology shows enlarged vessels with thick walls surrounded with lymphoid aggregates and smaller lymphatic vessels. The presence of "hobnail" endothelial cells inside tumoral vessels is the sine qua non of PILA/Dabska tumor.[185]

RETIFORM HEMANGIOENDOTHELIOMA

Retiform hemangioendothelioma occurs primarily in adults and has significant overlap with PILA/Dabska tumor. There is no noted sex predilection and development occurs in the second to fourth decades of life (mean age: 36 years). Histopathology demonstrates presence of retiform pattern of long, arborizing blood vessels lined by monomorphic hobnail endothelial cells. Most cases noted to have prominent lymphocytic infiltrate with focal presence of hyaline collagenous core comprising papillae, similar to PILA/Dabska tumor. Recurrence is frequent but metastatic rate is low.[224]

COMPOSITE HEMANGIOENDOTHELIOMA

Composite hemangioendothelioma is a low- to intermediate-grade malignant vascular tumor comprised of a variable combination of benign and malignant vascular components. Identification of at least 2 hemangioendothelioma variants is necessary to render this diagnosis. Epithelioid and retiform variants are most commonly observed, although foci of spindle-cell hemangioma and/or angiosarcoma-like foci can also be present.[225]

TARGETOID HEMOSIDEROTIC HEMANGIOMA

Targetoid hemosiderotic hemangioma is a benign lesion presenting as a violaceous papule, often surrounded by a pale rim and peripheral ecchymotic halo, which fades with time. Lesions usually present on the trunk or extremities and histologically consist of dilated vascular channels within intraluminal papillary projections dissecting into collagen bundles in the subcutis. Extravasated erythrocytes and hemosiderin are present, hence the designation.

CONGENITAL ECCRINE ANGIOMATOUS HAMARTOMA (SUDORIPAROUS ANGIOMA)

Congenital eccrine angiomatous hamartoma is a rare condition characterized by ill-defined plaques with increased lanugo hair and sweating at the site of the lesion. They are usually located on the extremities or abdomen. Diagnosis is established on the basis of characteristic histologic findings: closely packed eccrine sweat glands associated with dilated capillaries, a few dysplastic venous channels, and a dense collagenous matrix.[226]

REFERENCES

1. Wassef M, Blei F, Adams D, et al. Vascular anomalies classification: recommendations from the International Society for the Study of Vascular Anomalies. *Pediatrics*. 2015;136(1):e203-e214.
2. ISSVA classification of vascular anomalies. 2014. International Society for the Study of Vascular Anomalies. Available at http://www.issva.org/classification. Accessed December 2016.
3. Enjolras O, Mulliken JB. Vascular tumors and vascular malformations (new issues). *Adv Dermatol*. 1997;13:375-423.
4. Hand JL, Frieden IJ. Vascular birthmarks of infancy: resolving nosologic confusion. *Am J Med Genet A*. 2002;108(4):257-264.
5. Frieden IJ, Haggstrom AN, Drolet BA, et al. Infantile hemangiomas: current knowledge, future directions. Proceedings of a research workshop on infantile hemangiomas, April 7-9, 2005, Bethesda, Maryland, USA. *Pediatr Dermatol*. 2005;22(5):383-406.
6. Jacobs AH, Walton RG. The incidence of birthmarks in the neonate. *Pediatrics*. 1976;58(2):218-222.
7. Alper JC, Holmes LB. The incidence and significance of birthmarks in a cohort of 4,641 newborns. *Pediatr Dermatol*. 1983;1(1):58-68.
8. Hemangioma Investigator Group, Haggstrom AN, Drolet BA, et al. Prospective study of infantile hemangiomas: demographic, prenatal, and perinatal characteristics. *J Pediatr*. 2007;150(3):291-294.
9. Finn MC, Glowacki J, Mulliken JB. Congenital vascular lesions: clinical application of a new classification. *J Pediatr Surg*. 1983;18(6):894-900.
10. Kilcline C, Frieden IJ. Infantile hemangiomas: how common are they? A systematic review of the medical literature. *Pediatr Dermatol*. 2008;25(2):168-173.
11. Drolet BA, Swanson EA, Frieden IJ; Hemangioma Investigator Group. Infantile hemangiomas: an emerging health issue linked to an increased rate of low birth weight infants. *J Pediatr*. 2008;153(5):712-715, 715e1.
12. Munden A, Butschek R, Tom WL, et al. Prospective study of infantile haemangiomas: incidence, clinical characteristics and association with placental anomalies. *Br J Dermatol*. 2014;170(4):907-913.
13. Garzon MC, Drolet BA, Baselga E, et al. Comparison of infantile hemangiomas in preterm and term infants: a prospective study. *Arch Dermatol*. 2008; 144(9):1231-1232.
14. Enjolras O, Gelbert F. Superficial hemangiomas: associations and management. *Pediatr Dermatol*. 1997;14(3):173-179.
15. Bruckner AL, Frieden IJ. Hemangiomas of infancy. *J Am Acad Dermatol*. 2003;48(4):477-493; quiz 494-496.
16. Tollefson MM, Frieden IJ. Early growth of infantile hemangiomas: what parents' photographs tell us. *Pediatrics*. 2012;130(2):e314-e320.
17. Chang LC, Haggstrom AN, Drolet BA, et al. Growth characteristics of infantile hemangiomas: implications for management. *Pediatrics*. 2008;122(2):360-367.
18. Ritter MR, Reinisch J, Friedlander SF, et al. Myeloid cells in infantile hemangioma. *Am J Pathol*. 2006;168(2): 621-628.
19. Brandling-Bennett HA, Metry DW, Baselga E, et al. Infantile hemangiomas with unusually prolonged growth phase: a case series. *Arch Dermatol*. 2008;144(12):1632-1637.
20. Couto RA, Maclellan RA, Zurakowski D, et al. Infantile hemangioma: clinical assessment of the involuting phase and implications for management. *Plast Reconstr Surg,* 2012;130(3):619-624.
21. Baselga E, Roe E, Coulie J, et al. Risk factors for degree and type of sequelae after involution of untreated hemangiomas of infancy. *JAMA Dermatol*. 2016;152(11):1239-1243.
22. Bauland CG, Luning TH, Smit JM, et al. Untreated hemangiomas: growth pattern and residual lesions. *Plast Reconstr Surg*. 2011;127(4):1643-1648.
23. Waner M, North PE, Scherer KA, et al. The nonrandom distribution of facial hemangiomas. *Arch Dermatol*. 2003;139(7):869-875.
24. Chiller KG, Passaro D, Frieden IJ. Hemangiomas of infancy: clinical characteristics, morphologic subtypes, and their relationship to race, ethnicity, and sex. *Arch Dermatol*. 2002;138(12):1567-1576.
25. Suh KY, Frieden IJ. Infantile hemangiomas with minimal or arrested growth: a retrospective case series. *Arch Dermatol*. 2010;146(9):971-976.
26. Corella F, Garcia-Navarro X, Ribe A, et al. Abortive or minimal-growth hemangiomas: Immunohistochemical evidence that they represent true infantile hemangiomas. *J Am Acad Dermatol*. 2008;58(4): 685-690.
27. Haggstrom AN, Drolet BA, Baselga E, et al. Prospective study of infantile hemangiomas: clinical characteristics predicting complications and treatment. *Pediatrics*. 2006;118(3):882-887.
28. Happle R. Superimposed segmental hemangioma of infancy. *Dermatology*. 2010;220(2):180-182.
29. Haggstrom AN, Lammer EJ, Schneider RA, et al. Patterns of infantile hemangiomas: new clues to hemangioma pathogenesis and embryonic facial development. *Pediatrics*. 2006;117(3):698-703.
30. Metry D, Heyer G, Hess C, et al. Consensus statement on diagnostic criteria for PHACE syndrome. *Pediatrics*. 2009;124(5):1447-1456.
31. PHACE Association.
32. Frieden IJ, Reese V, Cohen D. PHACE syndrome. The association of posterior fossa brain malformations, hemangiomas, arterial anomalies, coarctation of the aorta and cardiac defects, and eye abnormalities. *Arch Dermatol*. 1996;132(3):307-311.
33. Metry DW, Garzon MC, Drolet BA, et al. PHACE syndrome: current knowledge, future directions. *Pediatr Dermatol*. 2009;26(4):381-398.

34. Haggstrom AN, Garzon MC, Baselga E, et al. Risk for PHACE syndrome in infants with large facial hemangiomas. *Pediatrics*. 2010;126(2):e418-e426.
35. Darrow DH, Greene AK, Mancini AJ, et al. Diagnosis and management of infantile hemangioma. *Pediatrics*. 2015;136(4):e1060-e1104.
36. Brandon K, Burrows P, Hess C, et al. Arteriovenous malformation: a rare manifestation of PHACE syndrome. *Pediatr Dermatol*. 2011;28(2):180-184.
37. Chan YC, Eichenfield LF, Malchiodi J, et al. Small facial haemangioma and supraumbilical raphe—a forme fruste of PHACES syndrome? *Br J Dermatol*. 2005;153(5):1053-1057.
38. Nabatian AS, Milgraum SS, Hess CP, et al. PHACE without face? Infantile hemangiomas of the upper body region with minimal or absent facial hemangiomas and associated structural malformations. *Pediatr Dermatol*. 2011;28(3):235-241.
39. Antonov NK, Spence-Shishido A, Marathe KS, et al. Orbital hemangioma with intracranial vascular anomalies and hemangiomas: a new presentation of PHACE syndrome? *Pediatr Dermatol*. 2015;32(6):e267-e272.
40. Garzon MC, Epstein LG, Heyer GL, et al. PHACE syndrome: consensus-derived diagnosis and care recommendations. *J Pediatr*. 2016;178:24-33,e2.
41. Metry DW, Dowd CF, Barkovich AJ, et al. The many faces of PHACE syndrome. *J Pediatr*. 2001;139(1):117-123.
42. Bayer ML, Frommelt PC, Blei F, et al. Congenital cardiac, aortic arch, and vascular bed anomalies in PHACE syndrome (from the International PHACE Syndrome Registry). *Am J Cardiol*. 2013;112(12):1948-1952.
43. Hess CP, Fullerton HJ, Metry DW, et al. Cervical and intracranial arterial anomalies in 70 patients with PHACE syndrome. *AJNR Am J Neuroradiol*. 2010;31(10):1980-1986.
44. Siegel DH, Tefft KA, Kelly T, et al. Stroke in children with posterior fossa brain malformations, hemangiomas, arterial anomalies, coarctation of the aorta and cardiac defects, and eye abnormalities (PHACE) syndrome: a systematic review of the literature. *Stroke*. 2012;43(6):1672-1674.
45. Goddard DS, Liang MG, Chamlin SL, et al. Hypopituitarism in PHACES association. *Pediatr Dermatol*. 2006;23(5):476-480.
46. Iacobas I, Burrows PE, Frieden IJ, et al. LUMBAR: association between cutaneous infantile hemangiomas of the lower body and regional congenital anomalies. *J Pediatr*. 2010;157(5):795-801.e1-7.
47. Girard C, Bigorre M, Guillot B, et al. PELVIS syndrome. *Arch Dermatol*. 2006;142(7):884-888.
48. Stockman A, Boralevi F, Taieb A, et al. SACRAL syndrome: spinal dysraphism, anogenital, cutaneous, renal and urologic anomalies, associated with an angioma of lumbosacral localization. *Dermatology*. 2007;214(1):40-45.
49. Drolet BA, Chamlin SL, Garzon MC, et al. Prospective study of spinal anomalies in children with infantile hemangiomas of the lumbosacral skin. *J Pediatr*. 2010;157(5):789-794.
50. Tubbs RS, Wellons JC 3rd, Iskandar BJ, et al. Isolated flat capillary midline lumbosacral hemangiomas as indicators of occult spinal dysraphism. *J Neurosurg* 2004;100(2, suppl pediatrics):86-89.
51. Ceisler EJ, Santos L, Blei F. Periocular hemangiomas: what every physician should know. *Pediatr Dermatol*. 2004;21(1):1-9.
52. Schwartz SR, Blei F, Ceisler E, et al. Risk factors for amblyopia in children with capillary hemangiomas of the eyelids and orbit. *J AAPOS*. 2006;10(3):262-268.
53. Haik BG, Jakobiec FA, Ellsworth RM, et al. Capillary hemangioma of the lids and orbit: an analysis of the clinical features and therapeutic results in 101 cases. *Ophthalmology*. 1979;86(5):760-792.
54. Robb RM. Refractive errors associated with hemangiomas of the eyelids and orbit in infancy. *Am J Ophthalmol*. 1977;83(1):52-58.
55. Stigmar G, Crawford JS, Ward CM, et al. Ophthalmic sequelae of infantile hemangiomas of the eyelids and orbit. *Am J Ophthalmol*. 1978;85(6):806-813.
56. Boscolo E, Bischoff J. Vasculogenesis in infantile hemangioma. *Angiogenesis*. 2009;12(2):197-207.
57. Orlow SJ, Isakoff MS, Blei F. Increased risk of symptomatic hemangiomas of the airway in association with cutaneous hemangiomas in a "beard" distribution. *J Pediatr*. 1997;131(4):643-646.
58. Rahbar R, Nicollas R, Roger G, et al. The biology and management of subglottic hemangioma: past, present, future. *Laryngoscope*. 2004;114(11):1880-1891.
59. Reinisch JF, Kim RY, Harshbarger RJ, et al. Surgical management of parotid hemangioma. *Plast Reconstr Surg*. 2004;113(7):1940-1948.
60. Greene AK, Rogers GF, Mulliken JB. Management of parotid hemangioma in 100 children. *Plast Reconstr Surg*. 2004;113(1):53-60.
61. Hughes JA, Hill V, Patel K, et al. Cutaneous haemangioma: prevalence and sonographic characteristics of associated hepatic haemangioma. *Clin Radiol*. 2004;59(3):273-280.
62. Horii KA, Drolet BA, Frieden IJ, et al. Prospective study of the frequency of hepatic hemangiomas in infants with multiple cutaneous infantile hemangiomas. *Pediatr Dermatol*. 2011;28(3):245-253.
63. Metry DW, Hawrot A, Altman C, et al. Association of solitary, segmental hemangiomas of the skin with visceral hemangiomatosis. *Arch Dermatol*. 2004;140(5):591-596.
64. Christison-Lagay ER, Burrows PE, Alomari A, et al. Hepatic hemangiomas: subtype classification and development of a clinical practice algorithm and registry. *J Pediatr Surg*. 2007;42(1):62-67; discussion 67-68.
65. Kassarjian A, Dubois J, Burrows PE. Angiographic classification of hepatic hemangiomas in infants. *Radiology*. 2002;222(3):693-698.
66. Kassarjian A, Zurakowski D, Dubois J, et al. Infantile hepatic hemangiomas: clinical and imaging findings and their correlation with therapy. *AJR Am J Roentgenol*. 2004;182(3):785-795.
67. Ho J, Kendrick V, Dewey D, et al. New insight into the pathophysiology of severe hypothyroidism in an infant with multiple hepatic hemangiomas. *J Pediatr Endocrinol Metab*. 2005;18(5):511-514.
68. Chamlin SL, Haggstrom AN, Drolet BA, et al. Multicenter prospective study of ulcerated hemangiomas. *J Pediatr*. 2007;151(6):684-689, 689.e1.
69. Kim HJ, Colombo M, Frieden IJ. Ulcerated hemangiomas: clinical characteristics and response to therapy. *J Am Acad Dermatol*. 2001;44(6):962-972.
70. Maguiness SM, Hoffman WY, McCalmont TH, et al. Early white discoloration of infantile hemangioma: a sign of impending ulceration. *Arch Dermatol*. 2010;146(11):1235-1239.
71. Brook I. Microbiology of infected hemangiomas in children. *Pediatr Dermatol*. 2004;21(2):113-116.

72. Yan AC. Pain management for ulcerated hemangiomas. *Pediatr Dermatol*. 2008;25(6):586-589.
73. Oranje AP, de Waard-van der Spek FB, Devillers AC, et al. Treatment and pain relief of ulcerative hemangiomas with a polyurethane film. *Dermatology*. 2000;200(1):31-34.
74. Metz BJ, Rubenstein MC, Levy ML, et al. Response of ulcerated perineal hemangiomas of infancy to becaplermin gel, a recombinant human platelet-derived growth factor. *Arch Dermatol*. 2004;140(7):867-870.
75. Sugarman JL, Mauro TM, Frieden IJ. Treatment of an ulcerated hemangioma with recombinant platelet-derived growth factor. *Arch Dermatol*. 2002;138(3):314-316.
76. Boye E, Jinnin M, Olsen BR. Infantile hemangioma: challenges, new insights, and therapeutic promise. *J Craniofac Surg*. 2009;20(suppl 1):678-684.
77. Bischoff J. Progenitor cells in infantile hemangioma. *J Craniofac Surg*. 2009;20(suppl 1):695-697.
78. Chang EI, Chang EI, Thangarajah H, et al. Hypoxia, hormones, and endothelial progenitor cells in hemangioma. *Lymphat Res Biol*. 2007;5(4):237-243.
79. Barnes CM, Christison-Lagay EA, Folkman J. The placenta theory and the origin of infantile hemangioma. *Lymphat Res Biol*. 2007;5(4):245-255.
80. Pittman KM, Losken HW, Kleinman ME, et al. No evidence for maternal-fetal microchimerism in infantile hemangioma: a molecular genetic investigation. *J Invest Dermatol*. 2006;126(11):2533-2538.
81. Dadras SS, North PE, Bertoncini J, et al. Infantile hemangiomas are arrested in an early developmental vascular differentiation state. *Mod Pathol*. 2004;17(9):1068-1079.
82. North PE, Waner M, Mizeracki A, et al. GLUT1: a newly discovered immunohistochemical marker for juvenile hemangiomas. *Hum Pathol*. 2000;31(1):11-22.
83. North PE, Waner M, Mizeracki A, et al. A unique microvascular phenotype shared by juvenile hemangiomas and human placenta. *Arch Dermatol*. 2001;137(5):559-570.
84. Barnes CM, Huang S, Kaipainen A, et al. Evidence by molecular profiling for a placental origin of infantile hemangioma. *Proc Natl Acad Sci U S A*. 2005;102(52):19097-19102.
85. Bree AF, Siegfried E, Sotelo-Avila C, et al. Infantile hemangiomas: speculation on placental trophoblastic origin. *Arch Dermatol*. 2001;137(5):573-577.
86. Kleinman ME, Greives MR, Churgin SS, et al. Hypoxia-induced mediators of stem/progenitor cell trafficking are increased in children with hemangioma. *Arterioscler Thromb Vasc Biol*. 2007;27(12):2664-2670.
87. Yu Y, Flint AF, Mulliken JB, et al. Endothelial progenitor cells in infantile hemangioma. *Blood*. 2004;103(4):1373-1375.
88. Khan ZA, Boscolo E, Picard A, et al. Multipotential stem cells recapitulate human infantile hemangioma in immunodeficient mice. *J Clin Invest*. 2008;118(7):2592-2599.
89. Chen TS, Eichenfield LF, Friedlander SF. Infantile hemangiomas: an update on pathogenesis and therapy. *Pediatrics*. 2013;131(1):99-108.
90. Mihm MC Jr, Nelson JS. Hypothesis: the metastatic niche theory can elucidate infantile hemangioma development. *J Cutan Pathol*. 2010;37(suppl 1):83-87.
91. Ahrens WA, Ridenour RV 3rd, Caron BL, et al. GLUT-1 expression in mesenchymal tumors: an immunohistochemical study of 247 soft tissue and bone neoplasms. *Hum Pathol*. 2008;39(10):1519-1526.
92. Ritter MR, Dorrell MI, Edmonds J, et al. Insulin-like growth factor 2 and potential regulators of hemangioma growth and involution identified by large-scale expression analysis. *Proc Natl Acad Sci U S A*. 2002;99(11):7455-7460.
93. Boye E, Yu Y, Paranya G, et al. Clonality and altered behavior of endothelial cells from hemangiomas. *J Clin Invest*. 2001;107(6):745-752.
94. Walter JW, North PE, Waner M, et al. Somatic mutation of vascular endothelial growth factor receptors in juvenile hemangioma. *Genes Chromosomes Cancer*. 2002;33(3):295-303.
95. Nguyen VA, Furhapter C, Romani N, et al. Infantile hemangioma is a proliferation of beta 4-negative endothelial cells adjacent to HLA-DR-positive cells with dendritic cell morphology. *Hum Pathol*. 2004;35(6):739-744.
96. Razon MJ, Kraling BM, Mulliken JB, et al. Increased apoptosis coincides with onset of involution in infantile hemangioma. *Microcirculation*. 1998;5(2-3):189-195.
97. Drolet BA, Frieden IJ. Characteristics of infantile hemangiomas as clues to pathogenesis: does hypoxia connect the dots? *Arch Dermatol*. 2010;146(11):1295-1299.
98. Bielenberg DR, Bucana CD, Sanchez R, et al. Progressive growth of infantile cutaneous hemangiomas is directly correlated with hyperplasia and angiogenesis of adjacent epidermis and inversely correlated with expression of the endogenous angiogenesis inhibitor, IFN-beta. *Int J Oncol*. 1999;14(3):401-408.
99. Tekes A, Koshy J, Kalayci TO, et al. S.E. Mitchell Vascular Anomalies Flow Chart (SEMVAFC): a visual pathway combining clinical and imaging findings for classification of soft-tissue vascular anomalies. *Clin Radiol*. 2014;69(5):443-457.
100. Konrad D, Ellis G, Perlman K. Spontaneous regression of severe acquired infantile hypothyroidism associated with multiple liver hemangiomas. *Pediatrics*. 2003;112(6, pt 1):1424-1426.
101. Ayling RM, Davenport M, Hadzic N, et al. Hepatic hemangioendothelioma associated with production of humoral thyrotropin-like factor. *J Pediatr*. 2001;138(6):932-935.
102. Huang SA, Tu HM, Harney JW, et al. Severe hypothyroidism caused by type 3 iodothyronine deiodinase in infantile hemangiomas. *N Engl J Med*. 2000;343(3):185-189.
103. Puttgen KB. Diagnosis and management of infantile hemangiomas. *Pediatr Clin North Am*. 2014;61(2):383-402.
104. Metry DW. Potential complications of segmental hemangiomas of infancy. *Semin Cutan Med Surg*. 2004;23(2):107-115.
105. Hoeger PH, Harper JI, Baselga E, et al. Treatment of infantile haemangiomas: recommendations of a European expert group. *Eur J Pediatr*. 2015;174(7):855-865.
106. Williams EF 3rd, Hochman M, Rodgers BJ, et al. A psychological profile of children with hemangiomas and their families. *Arch Facial Plast Surg*. 2003;5(3):229-234.
107. Gleason T. Summer's strawberry. *J Am Acad Dermatol*. 2004;51(1)(suppl):S53-S54.
108. Greig AV, Harris DL. A study of perceptions of facial hemangiomas in professionals involved in child abuse surveillance. *Pediatr Dermatol*. 2003;20(1):1-4.
109. Tanner JL, Dechert MP, Frieden IJ. Growing up with a facial hemangioma: parent and child coping and adaptation. *Pediatrics*. 1998;101(3, pt 1):446-452.

110. Leaute-Labreze C, Dumas de la Roque E, Hubiche T, et al. Propranolol for severe hemangiomas of infancy. *N Engl J Med*. 2008;358(24):2649-2651.
111. Hogeling M, Adams S, Wargon O. A randomized controlled trial of propranolol for infantile hemangiomas. *Pediatrics*. 2011;128(2):e259-e266.
112. Price CJ, Lattouf C, Baum B, et al. Propranolol vs corticosteroids for infantile hemangiomas: a multicenter retrospective analysis. *Arch Dermatol*. 2011;147(12): 1371-1376.
113. Hermans DJ, Bauland CG, Zweegers J, et al. Propranolol in a case series of 174 patients with complicated infantile haemangioma: indications, safety and future directions. *Br J Dermatol*. 2013;168(4):837-843.
114. Marsciani A, Pericoli R, Alaggio R, et al. Massive response of severe infantile hepatic hemangioma to propranolol. *Pediatr Blood Cancer*. 2010;54(1):176.
115. Fay A, Nguyen J, Jakobiec FA, et al. Propranolol for isolated orbital infantile hemangioma. *Arch Ophthalmol*. 2010;128(2):256-258.
116. Buckmiller L, Dyamenahalli U, Richter GT. Propranolol for airway hemangiomas: case report of novel treatment. *Laryngoscope*. 2009;119(10):2051-2054.
117. Storch CH, Hoeger PH. Propranolol for infantile haemangiomas: insights into the molecular mechanisms of action. *Br J Dermatol*. 2010;163(2):269-274.
118. Bauman NM, McCarter RJ, Guzzetta PC, et al. Propranolol vs prednisolone for symptomatic proliferating infantile hemangiomas: a randomized clinical trial. *JAMA Otolaryngol Head Neck Surg*. 2014;140(4):323-330.
119. Leaute-Labreze C, Hoeger P, Mazereeuw-Hautier J, et al. A randomized, controlled trial of oral propranolol in infantile hemangioma. *N Engl J Med*. 2015;372(8): 735-746.
120. Wedgeworth E, Glover M, Irvine AD, et al. Propranolol in the treatment of infantile haemangiomas: lessons from the European Propranolol In the Treatment of Complicated Haemangiomas (PITCH) Taskforce survey. *Br J Dermatol*. 2016;174(3):594-601.
121. Marqueling AL, Oza V, Frieden IJ, et al. Propranolol and infantile hemangiomas four years later: a systematic review. *Pediatr Dermatol*. 2013;30(2):182-191.
122. Causse S, Aubert H, Saint-Jean M, et al. Propranolol-resistant infantile haemangiomas. *Br J Dermatol*. 2013;169(1):125-129.
123. Perkins JA, Chen BS, Saltzman B, et al. Propranolol therapy for reducing the number of nasal infantile hemangioma invasive procedures. *JAMA Otolaryngol Head Neck Surg*. 2014;140(3):220-227.
124. Langley A, Pope E. Propranolol and central nervous system function: potential implications for paediatric patients with infantile haemangiomas. *Br J Dermatol*. 2015;172(1):13-23.
125. Drolet BA, Frommelt PC, Chamlin SL, et al. Initiation and use of propranolol for infantile hemangioma: report of a consensus conference. *Pediatrics*. 2013;131(1):128-140.
126. Lawley LP, Siegfried E, Todd JL. Propranolol treatment for hemangioma of infancy: risks and recommendations. *Pediatr Dermatol*. 2009;26(5):610-614.
127. Frieden IJ, Drolet BA. Propranolol for infantile hemangiomas: promise, peril, pathogenesis. *Pediatr Dermatol*. 2009;26(5):642-644.
128. Moyakine AV, Kerstjens JM, Spillekom-van Koulil S, et al. Propranolol treatment of infantile hemangioma (IH) is not associated with developmental risk or growth impairment at age 4 years. *J Am Acad Dermatol*. 2016;75(1):59-63 e1.
129. Singh BN, Williams FM, Whitlock RM, et al. Plasma timolol levels and systolic time intervals. *Clin Pharmacol Ther*. 1980;28(2):159-166.
130. Guo S, Ni N. Topical treatment for capillary hemangioma of the eyelid using beta-blocker solution. *Arch Ophthalmol*. 2010;128(2):255-256.
131. Korte JM, Kaila T, Saari KM. Systemic bioavailability and cardiopulmonary effects of 0.5% timolol eyedrops. *Graefes Arch Clin Exp Ophthalmol*. 2002;240(6):430-435.
132. Nieminen T, Lehtimaki T, Maenpaa J, et al. Ophthalmic timolol: plasma concentration and systemic cardiopulmonary effects. *Scand J Clin Lab Invest*. 2007;67(2):237-245.
133. Puttgen K, Lucky A, Adams D, et al. Topical timolol maleate treatment of infantile hemangiomas. *Pediatrics*. 2016;138(3).
134. Al-Sebeih K, Manoukian J. Systemic steroids for the management of obstructive subglottic hemangioma. *J Otolaryngol*. 2000;29(6):361-366.
135. Hasan Q, Tan ST, Gush J, et al. Steroid therapy of a proliferating hemangioma: histochemical and molecular changes. *Pediatrics*. 2000;105(1, pt 1): 117-120.
136. Hasan Q, Tan ST, Gush J, et al. Altered mitochondrial cytochrome b gene expression during the regression of hemangioma. *Plast Reconstr Surg*. 2001;108(6):1471-1476; discussion 1477-1478.
137. Hasan Q, Tan ST, Xu B, et al. Effects of five commonly used glucocorticoids on haemangioma in vitro. *Clin Exp Pharmacol Physiol*. 2003;30(3):140-144.
138. Bennett ML, Fleischer AB Jr, Chamlin SL, et al. Oral corticosteroid use is effective for cutaneous hemangiomas: an evidence-based evaluation. *Arch Dermatol*. 2001;137(9):1208-1213.
139. Boon LM, MacDonald DM, Mulliken JB. Complications of systemic corticosteroid therapy for problematic hemangioma. *Plast Reconstr Surg*. 1999;104(6): 1616-1623.
140. Lomenick JP, Backeljauw PF, Lucky AW. Growth, bone mineral accretion, and adrenal function in glucocorticoid-treated infants with hemangiomas—a retrospective study. *Pediatr Dermatol*. 2006;23(2): 169-174.
141. Lomenick JP, Reifschneider KL, Lucky AW, et al. Prevalence of adrenal insufficiency following systemic glucocorticoid therapy in infants with hemangiomas. *Arch Dermatol*. 2009;145(3):262-266.
142. George ME, Sharma V, Jacobson J, et al. Adverse effects of systemic glucocorticosteroid therapy in infants with hemangiomas. *Arch Dermatol*. 2004;140(8):963-969.
143. Aviles R, Boyce TG, Thompson DM. *Pneumocystis carinii* pneumonia in a 3-month-old infant receiving high-dose corticosteroid therapy for airway hemangiomas. *Mayo Clin Proc*. 2004;79(2):243-245.
144. Maronn ML, Corden T, Drolet BA. *Pneumocystis carinii* pneumonia in infant treated with oral steroids for hemangioma. *Arch Dermatol*. 2007;143(9): 1224-1225.
145. O'Keefe M, Lanigan B, Byrne SA. Capillary haemangioma of the eyelids and orbit: a clinical review of the safety and efficacy of intralesional steroid. *Acta Ophthalmol Scand*. 2003;81(3):294-298.
146. Egbert JE, Paul S, Engel WK, et al. High injection pressure during intralesional injection of corticosteroids into capillary hemangiomas. *Arch Ophthalmol*. 2001;119(5):677-683.

147. Chen MT, Yeong EK, Horng SY. Intralesional corticosteroid therapy in proliferating head and neck hemangiomas: a review of 155 cases. *J Pediatr Surg*. 2000;35(3):420-423.
148. Cruz OA, Zarnegar SR, Myers SE. Treatment of periocular capillary hemangioma with topical clobetasol propionate. *Ophthalmology*. 1995;102(12):2012-2015.
149. Garzon MC, Lucky AW, Hawrot A, et al. Ultrapotent topical corticosteroid treatment of hemangiomas of infancy. *J Am Acad Dermatol*. 2005;52(2):281-286.
150. Michaud AP, Bauman NM, Burke DK, et al. Spastic diplegia and other motor disturbances in infants receiving interferon-alpha. *Laryngoscope*. 2004;114(7):1231-1236.
151. Perez J, Pardo J, Gomez C. Vincristine—an effective treatment of corticoid-resistant life-threatening infantile hemangiomas. *Acta Oncol*. 2002;41(2):197-199.
152. Fawcett SL, Grant I, Hall PN, et al. Vincristine as a treatment for a large haemangioma threatening vital functions. *Br J Plast Surg*. 2004;57(2):168-171.
153. Moore J, Lee M, Garzon M, et al. Effective therapy of a vascular tumor of infancy with vincristine. *J Pediatr Surg*. 2001;36(8):1273-1276.
154. Morelli JG, Tan OT, Yohn JJ, et al. Treatment of ulcerated hemangiomas infancy. *Arch Pediatr Adolesc Med*. 1994;148(10):1104-1105.
155. Batta K, Goodyear HM, Moss C, et al. Randomised controlled study of early pulsed dye laser treatment of uncomplicated childhood haemangiomas: results of a 1-year analysis. *Lancet*. 2002;360(9332):521-527.
156. David LR, Malek MM, Argenta LC. Efficacy of pulse dye laser therapy for the treatment of ulcerated haemangiomas: a review of 78 patients. *Br J Plast Surg*. 2003;56(4):317-327.
157. Michel JL. Treatment of hemangiomas with 595 nm pulsed dye laser dermobeam. *Eur J Dermatol*. 2003;13(2):136-141.
158. Kessels JP, Hamers ET, Ostertag JU. Superficial hemangioma: pulsed dye laser versus wait-and-see. *Dermatol Surg*. 2013;39(3, pt 1):414-421.
159. Hohenleutner U, Landthaler M. Laser treatment of childhood haemangioma: progress or not? *Lancet*. 2002;360(9332):502-503.
160. Kolde G. Early pulsed-dye laser treatment of childhood haemangiomas. *Lancet*. 2003;361(9354):348-349; author reply 349.
161. Kono T, Sakurai H, Groff WF, et al. Comparison study of a traditional pulsed dye laser versus a long-pulsed dye laser in the treatment of early childhood hemangiomas. *Lasers Surg Med*. 2006;38(2):112-115.
162. Rizzo C, Brightman L, Chapas AM, et al. Outcomes of childhood hemangiomas treated with the pulsed-dye laser with dynamic cooling: a retrospective chart analysis. *Dermatol Surg*. 2009;35(12):1947-1954.
163. Witman PM, Wagner AM, Scherer K, et al. Complications following pulsed dye laser treatment of superficial hemangiomas. *Lasers Surg Med*. 2006;38(2):116-123.
164. Anderson RR. Infant hemangiomas: a controversy worth solving. *Lasers Surg Med*. 2006;38(2):92-93.
165. Demiri EC, Pelissier P, Genin-Etcheberry T, et al. Treatment of facial haemangiomas: the present status of surgery. *Br J Plast Surg*. 2001;54(8):665-674.
166. Denk MJ, Ajkay N, Yuan X, et al. Surgical treatment of nasal hemangiomas. *Ann Plast Surg*. 2002;48(5):489-494; discussion 494-495.
167. Hochman M, Mascareno A. Management of nasal hemangiomas. *Arch Facial Plast Surg*. 2005;7(5):295-300.
168. Faguer K, Dompmartin A, Labbe D, et al. Early surgical treatment of Cyrano-nose haemangiomas with Rethi incision. *Br J Plast Surg*. 2002;55(6):498-503.
169. McCarthy JG, Borud LJ, Schreiber JS. Hemangiomas of the nasal tip. *Plast Reconstr Surg*. 2002;109(1):31-40.
170. Warren SM, Longaker MT, Zide BM. The subunit approach to nasal tip hemangiomas. *Plast Reconstr Surg*. 2002;109(1):25-30.
171. McHeik JN, Renauld V, Duport G, et al. Surgical treatment of haemangioma in infants. *Br J Plast Surg*. 2005;58(8):1067-1072.
172. Mulliken JB, Rogers GF, Marler JJ. Circular excision of hemangioma and purse-string closure: the smallest possible scar. *Plast Reconstr Surg*. 2002;109(5):1544-1554; discussion 1555.
173. Requena L, Sangueza OP. Cutaneous vascular proliferation. Part II. Hyperplasias and benign neoplasms. *J Am Acad Dermatol*. 1997;37(6):887-919; quiz 920-922.
174. Weiss SW, Goldblum JR. *Enzinger and Weiss's Soft Tissue Tumors*. 4th ed. St Louis, MO: Mosby; 2001.
175. Krol A, MacArthur CJ. Congenital hemangiomas: rapidly involuting and noninvoluting congenital hemangiomas. *Arch Facial Plast Surg*. 2005;7(5):307-311.
176. Nasseri E, Piram M, McCuaig CC, et al. Partially involuting congenital hemangiomas: a report of 8 cases and review of the literature. *J Am Acad Dermatol*. 2014;70(1):75-79.
177. Boon LM, Enjolras O, Mulliken JB. Congenital hemangioma: evidence of accelerated involution. *J Pediatr*. 1996;128(3):329-335.
178. Ozcan UA. Rapidly involuting congenital hemangioma: a case of complete prenatal involution. *J Clin Ultrasound*. 2010;38(2):85-88.
179. Baselga E, Cordisco MR, Garzon M, et al. Rapidly involuting congenital haemangioma associated with transient thrombocytopenia and coagulopathy: a case series. *Br J Dermatol*. 2008;158(6):1363-1370.
180. Ayturk UM, Couto JA, Hann S, et al. Somatic activating mutations in GNAQ and GNA11 are associated with congenital hemangioma. *Am J Hum Genet*. 2016;98(6):1271.
181. Thomas AC, Zeng Z, Riviere JB, et al. Mosaic activating mutations in GNA11 and GNAQ are associated with phakomatosis pigmentovascularis and extensive dermal melanocytosis. *J Invest Dermatol*. 2016;136(4):770-778.
182. Berenguer B, Mulliken JB, Enjolras O, et al. Rapidly involuting congenital hemangioma: clinical and histopathologic features. *Pediatr Dev Pathol*. 2003;6(6):495-510.
183. North PE, Waner M, James CA, et al. Congenital nonprogressive hemangioma: a distinct clinicopathologic entity unlike infantile hemangioma. *Arch Dermatol*. 2001;137(12):1607-1620.
184. Gorincour G, Kokta V, Rypens F, et al. Imaging characteristics of two subtypes of congenital hemangiomas: rapidly involuting congenital hemangiomas and non-involuting congenital hemangiomas. *Pediatr Radiol*. 2005;35(12):1178-1185.
185. Colmenero I, Hoeger PH. Vascular tumours in infants. Part II: vascular tumours of intermediate malignancy [corrected] and malignant tumours. *Br J Dermatol*. 2014;171(3):474-484.
186. Maronn M, Chamlin S, Metry D. Multifocal tufted angiomas in 2 infants. *Arch Dermatol*. 2009;145(7):847-848.
187. Ishikawa K, Hatano Y, Ichikawa H, et al. The spontaneous regression of tufted angioma. A case of regression after two recurrences and a review of

27 cases reported in the literature. *Dermatology*. 2005;210(4):346-348.
188. Jones EW, Orkin M. Tufted angioma (angioblastoma). A benign progressive angioma, not to be confused with Kaposi's sarcoma or low-grade angiosarcoma. *J Am Acad Dermatol*. 1989;20(2, pt 1):214-225.
189. Arai E, Kuramochi A, Tsuchida T, et al. Usefulness of D2-40 immunohistochemistry for differentiation between kaposiform hemangioendothelioma and tufted angioma. *J Cutan Pathol*. 2006;33(7):492-497.
190. Browning J, Frieden I, Baselga E, et al. Congenital, self-regressing tufted angioma. *Arch Dermatol*. 2006;142(6):749-751.
191. Okada E, Tamura A, Ishikawa O, et al. Tufted angioma (angioblastoma): case report and review of 41 cases in the Japanese literature. *Clin Exp Dermatol*. 2000;25(8):627-630.
192. Croteau SE, Liang MG, Kozakewich HP, et al. Kaposiform hemangioendothelioma: atypical features and risks of Kasabach-Merritt phenomenon in 107 referrals. *J Pediatr*. 2013;162(1):142-147.
193. Lyons LL, North PE, Mac-Moune Lai F, et al. Kaposiform hemangioendothelioma: a study of 33 cases emphasizing its pathologic, immunophenotypic, and biologic uniqueness from juvenile hemangioma. *Am J Surg Pathol*. 2004;28(5):559-568.
194. Gruman A, Liang MG, Mulliken JB, et al. Kaposiform hemangioendothelioma without Kasabach-Merritt phenomenon. *J Am Acad Dermatol*. 2005;52(4):616-622.
195. Adams DM, Trenor CC 3rd, Hammill AM, et al. Efficacy and safety of sirolimus in the treatment of complicated vascular anomalies. *Pediatrics*. 2016;137(2): e20153257.
196. Enjolras O, Mulliken JB, Wassef M, et al. Residual lesions after Kasabach-Merritt phenomenon in 41 patients. *J Am Acad Dermatol*. 2000;42(2, pt 1):225-235.
197. Sarkar M, Mulliken JB, Kozakewich HP, et al. Thrombocytopenic coagulopathy (Kasabach-Merritt phenomenon) is associated with Kaposiform hemangioendothelioma and not with common infantile hemangioma. *Plast Reconstr Surg*. 1997;100(6):1377-1386.
198. Mazoyer E, Enjolras O, Laurian C, et al. Coagulation abnormalities associated with extensive venous malformations of the limbs: differentiation from Kasabach-Merritt syndrome. *Clin Lab Haematol*. 2002;24(4):243-251.
199. Debelenko LV, Perez-Atayde AR, Mulliken JB, et al. D2-40 immunohistochemical analysis of pediatric vascular tumors reveals positivity in kaposiform hemangioendothelioma. *Mod Pathol*. 2005;18(11): 1454-1460.
200. Folpe AL, Veikkola T, Valtola R, et al. Vascular endothelial growth factor receptor-3 (VEGFR-3): a marker of vascular tumors with presumed lymphatic differentiation, including Kaposi's sarcoma, kaposiform and Dabska-type hemangioendotheliomas, and a subset of angiosarcomas. *Mod Pathol*. 2000;13(2):180-185.
201. Drolet BA, Trenor CC 3rd, Brandao LR, et al. Consensus-derived practice standards plan for complicated Kaposiform hemangioendothelioma. *J Pediatr*. 2013;163(1): 285-291.
202. Blatt J, Stavas J, Moats-Staats B, et al. Treatment of childhood kaposiform hemangioendothelioma with sirolimus. *Pediatr Blood Cancer*. 2010;55(7):1396-1398.
203. Wang Z, Li K, Dong K, et al. Successful treatment of Kasabach-Merritt phenomenon arising from Kaposiform hemangioendothelioma by sirolimus. *J Pediatr Hematol Oncol*. 2015;37(1):72-73.
204. Hauer J, Graubner U, Konstantopoulos N, et al. Effective treatment of kaposiform hemangioendotheliomas associated with Kasabach-Merritt phenomenon using four-drug regimen. *Pediatr Blood Cancer*. 2007;49(6):852-854.
205. Haisley-Royster C, Enjolras O, Frieden IJ, et al. Kasabach-Merritt phenomenon: a retrospective study of treatment with vincristine. *J Pediatr Hematol Oncol*. 2002;24(6):459-462.
206. Drucker AM, Pope E, Mahant S, et al. Vincristine and corticosteroids as first-line treatment of Kasabach-Merritt syndrome in kaposiform hemangioendothelioma. *J Cutan Med Surg*. 2009;13(3):155-159.
207. Lopez V, Marti N, Pereda C, et al. Successful management of Kaposiform hemangioendothelioma with Kasabach-Merritt phenomenon using vincristine and ticlopidine. *Pediatr Dermatol*. 2009;26(3):365-366.
208. Rodriguez V, Lee A, Witman PM, et al. Kasabach-Merritt phenomenon: case series and retrospective review of the Mayo Clinic experience. *J Pediatr Hematol Oncol*. 2009;31(7):522-526.
209. Perkins P, Weiss SW. Spindle cell hemangioendothelioma. An analysis of 78 cases with reassessment of its pathogenesis and biologic behavior. *Am J Surg Pathol*. 1996;20(10):1196-1204.
210. Frieden IJ, Esterly NB. Pyogenic granulomas of infancy masquerading as strawberry hemangiomas. *Pediatrics*. 1992;90(6):989-991.
211. Barrick B, Lehman J, Tollefson M. Agminated pyogenic granuloma-like growth arising in a congenital hemangioma. *JAMA Dermatol*. 2014;150(7):781-783.
212. Baselga E, Wassef M, Lopez S, et al. Agminated, eruptive pyogenic granuloma-like lesions developing over congenital vascular stains. *Pediatr Dermatol*. 2012;29(2):186-190.
213. Patrice SJ, Wiss K, Mulliken JB. Pyogenic granuloma (lobular capillary hemangioma): a clinicopathologic study of 178 cases. *Pediatr Dermatol*. 1991;8(4):267-276.
214. Pagliai KA, Cohen BA. Pyogenic granuloma in children. *Pediatr Dermatol*. 2004;21(1):10-13.
215. Tritton SM, Smith S, Wong LC, et al. Pyogenic granuloma in ten children treated with topical imiquimod. *Pediatr Dermatol*. 2009;26(3):269-272.
216. Malik M, Murphy R. A pyogenic granuloma treated with topical timolol. *Br J Dermatol*. 2014;171(6):1537-1538.
217. North PE, Kahn T, Cordisco MR, et al. Multifocal lymphangioendotheliomatosis with thrombocytopenia: a newly recognized clinicopathological entity. *Arch Dermatol*. 2004;140(5):599-606.
218. Maronn M, Catrine K, North P, et al. Expanding the phenotype of multifocal lymphangioendotheliomatosis with thrombocytopenia. *Pediatr Blood Cancer*. 2009;52(4):531-534.
219. Glick ZR, Frieden IJ, Garzon MC, et al. Diffuse neonatal hemangiomatosis: an evidence-based review of case reports in the literature. *J Am Acad Dermatol*. 2012;67(5):898-903.
220. Prasad V, Fishman SJ, Mulliken JB, et al. Cutaneovisceral angiomatosis with thrombocytopenia. *Pediatr Dev Pathol*. 2005;8(4):407-419.
221. Droitcourt C, Boccara O, Fraitag S, et al. Multifocal lymphangioendotheliomatosis with thrombocytopenia: clinical features and response to sirolimus. *Pediatrics*. 2015;136(2):e517-e522.
222. Lanoel A, Torres Huamani AN, Feliu A, et al. Multifocal lymphangioendotheliomatosis with thrombocytopenia: presentation of two cases treated with sirolimus. *Pediatr Dermatol*. 2016;33(4):e235-e239.

223. Kline RM, Buck LM. Bevacizumab treatment in multifocal lymphangioendotheliomatosis with thrombocytopenia. *Pediatr Blood Cancer*. 2009;52(4):534-536.
224. Calonje E, Fletcher CD, Wilson-Jones E, et al. Retiform hemangioendothelioma. A distinctive form of low-grade angiosarcoma delineated in a series of 15 cases. *Am J Surg Pathol*. 1994;18(2):115-125.
225. Nayler SJ, Rubin BP, Calonje E, et al. Composite hemangioendothelioma: a complex, low-grade vascular lesion mimicking angiosarcoma. *Am J Surg Pathol*. 2000;24(3):352-361.
226. Nakatsui TC, Schloss E, Krol A, et al. Eccrine angiomatous hamartoma: report of a case and literature review. *J Am Acad Dermatol*. 1999;41(1):109-111.

Chapter 119 :: Cutaneous Lymphoma

:: Martine Bagot & Rudolf Stadler

Primary cutaneous lymphomas are a heterogeneous group of extranodal non-Hodgkin lymphomas arising from malignant clonal transformation of skin homing or/and skin resident T cells or B lymphocytes and hematodermic precursor neoplasias (plasmacytoid dendritic cell neoplasias). Cutaneous lymphomas (Fig. 119-1) are defined as a heterogeneous group with distinct variability in clinical presentation, histopathology, immunophenotyping, and prognosis.

Primary cutaneous lymphomas are defined entities with a completely different clinical behavior and prognosis as nodal non-Hodgkin lymphomas and require different treatment approaches.

For this reason the European Organization for Research and Treatment of Cancer (EORTC) and World Health Organization (WHO) published a consensus classification for cutaneous lymphomas in 2005.[1] This first common classification (WHO-EORTC) categorizes the entities according to lineage and then according to a combination of morphology, immunophenotype, genetic features, and clinical syndromes, and constitutes the basis for the classification of cutaneous lymphomas in the WHO classification 2008 and the revised classification of lymphoid neoplasias in 2016.[2,3] This chapter discusses the most frequent cutaneous T-cell lymphomas (CTCLs)—mycosis fungoides (MF), Sézary syndrome, primary cutaneous anaplastic large-cell lymphoma, and lymphomatoid papulosis—and the most frequent cutaneous B-cell lymphomas (CBCLs)—primary cutaneous follicle center lymphoma (PCFCL), primary cutaneous marginal zone lymphoma (PCMZL), and primary cutaneous diffuse large B-cell lymphoma (PCLBCL), leg type. These 7 types of cutaneous lymphoma represent nearly 90% of all cutaneous lymphomas. Rare entities occurring primary in the skin are also described.

EPIDEMIOLOGY

CTCLs represent the second most common group of extranodal lymphomas after the primary GI lymphomas. The incidence of CTCLs has been increasing and is currently, in the United States, estimated to be 6.4 cases/million people between 1993 and 2002 or 7.7 cases/million people between 2001 and 2005. The incidence of CTCL increases significantly with age, with a median age at diagnosis in the mid-50s and a fourfold increase in incidence appreciated in patients older than age 70 years.[4-6]

PRIMARY CUTANEOUS T-CELL LYMPHOMAS

CTCLs are non-Hodgkin lymphomas characterized by clonal expansion of activated T-cells expressing the E-selectin ligand cutaneous lymphocyte antigen and chemokine receptors (eg, CCR4, CCR8, CCR10) that are required for their subsequent trafficking to the skin.[7-9] Clonal expansion is followed by differentiation into multiple subsets of effector and memory cells. Human skin is protected by 4 functionally-distinct populations of T cells, 2 resident and 2 recirculating, with differing territories of migration and distinct functional activities. Central memory cells (T_{CM}) retain the ability to access the peripheral blood and lymph nodes. Effector memory cells (T_{EM}), in contrast, migrate into extranodal sites, including the skin, where a subset will remain as tissue-resident memory cells (T_{RM}). The majority of T cells in the skin are T_{RM}, express a high affinity antigen receptor, and have a distinct gene expression profile. Clonal T cells in MF are commonly T_{RM}-derived, which explains their tendency to be confined to the skin. In contrast, in patients with leukemic CTCL variants (Sézary syndrome and MF with secondary leukemic involvement), tumor cells express CCR7 and L-selectin, resembling T_{CM}. This fundamental difference in the putative cell origin between Sézary syndrome (T_{CM}-derived) and MF (T_{RM}-derived) is consistent with the distinct clinical behavior. Among the recirculating cells 2 distinct populations were observed, CCR7+/L-selectin+ T_{CM} and CCR7+/L-selectin– T cells termed *migratory memory T cells* (T_{MM}). A subset of MF patients with secondary leukemic involvement, poorly demarcated patches/plaques, dermal involvement, and lymphadenopathy most probably harbor a T_{MM} clone.[10,11]

The most common forms, representing approximately 65% of CTCL, are MF and Sézary syndrome, with an annual incidence of 7.7 cases/million people. CTCL encompasses skin-limited variants such as MF and leukemic forms of the disease, including Sézary syndrome.

After MF and Sézary syndrome, the primary cutaneous CD30+ lymphoproliferative disorders, comprising lymphomatoid papulosis and cutaneous anaplastic large-cell lymphoma, represent the second most common group of CTCLs (approximately 27%).[12] Table 119-1 outlines the WHO classification of primary cutaneous lymphomas.

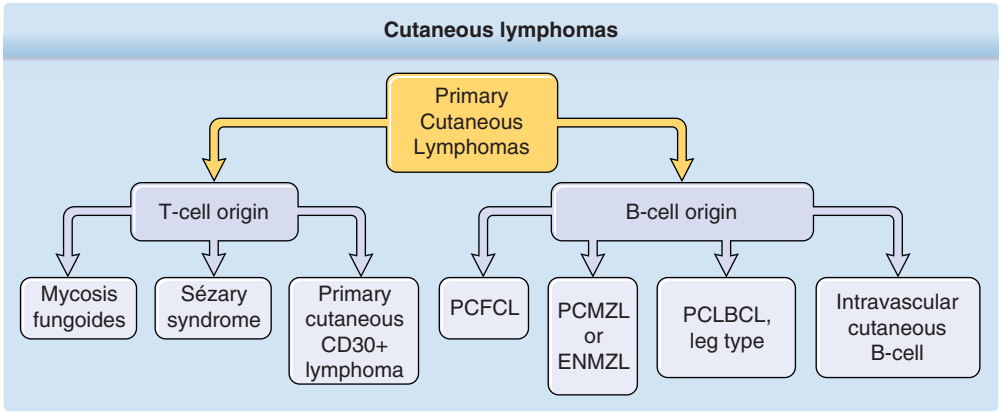

Figure 119-1 Cutaneous lymphomas. ENMZL, extranodal marginal zone lymphoma; PCFCL, primary cutaneous follicle center lymphoma; PCLBCL, primary cutaneous diffuse large B-cell lymphoma; PCMZL, primary cutaneous marginal zone lymphoma.

ETIOLOGY

The skin of a human adult contains approximately 20 billion memory T cells. Despite major advances in cellular and molecular biology revealing many details about lymphocytes, including the incredible diversity of T-cell antigen receptors, their characterization as T_{CM} or T_{EM} or T_{RM}, and the role of environmental and host genetic factors for the pathogenesis in CTCL remains unclear. In general, long-term antigen stimulation is thought to induce an inflammatory response with T-cell proliferation leading to clonal malignant T cells with continuous expansion. However, recent advances in the understanding of the molecular pathogenesis, signal transduction pathways, and disease-associated immune dysregulation helped to understand the complex pathogenesis to advance the treatment in CTCL.[10-19]

TABLE 119-1
World Health Organization Classification of Primary Cutaneous Lymphomas

Cutaneous T-Cell and Natural Killer (NK)-Cell Lymphomas
- Mycosis fungoides
- Mycosis fungoides variants and subtypes
  - Folliculotropic mycosis fungoides
  - Pagetoid reticulosis
  - Granulomatous slack skin
- Sézary syndrome
- Adult T-cell leukemia/lymphoma
- Primary cutaneous CD30+ T-cell lymphoproliferative disorders
  - Primary cutaneous anaplastic large-cell lymphoma
  - Lymphomatoid papulosis
- Subcutaneous panniculitis-like T-cell lymphoma
- Extranodal NK/T-cell lymphoma, nasal type
- Primary cutaneous peripheral T-cell lymphoma, not otherwise specified
  - Primary cutaneous γ/δ T-cell lymphoma
  - Primary cutaneous CD8+ aggressive epidermotropic cytotoxic T-cell lymphoma
  - Primary cutaneous acral CD8+ T-cell lymphoma
  - Primary cutaneous CD4+ small–medium T-cell lymphoproliferative disorder

Cutaneous B-Cell Lymphomas
- Primary cutaneous marginal zone B-cell lymphoma
- Primary cutaneous follicle center lymphoma
- Primary cutaneous diffuse large B-cell lymphoma, leg type
- Primary cutaneous diffuse large B-cell lymphoma, other
  - Intravascular large B-cell lymphoma
- Epstein-Barr virus–positive, mucocutaneous ulcer
- Precursor hematologic neoplasm
- CD4+/CD56+ hematodermic neoplasm (plasmacytoid dendritic cell neoplasia)

ENDOGENOUS FACTORS

As a result of the above-mentioned hypothesis of antigen stimulation, several studies have analyzed the human leukocyte antigen (HLA) background of affected individuals. Two independent studies showed an association of distinct HLA class II molecules and MF or Sézary syndrome; that is, the alleles HLA-DRB1*11 and DQB1*03 are significantly overrepresented in these patients (Fig. 119-2).

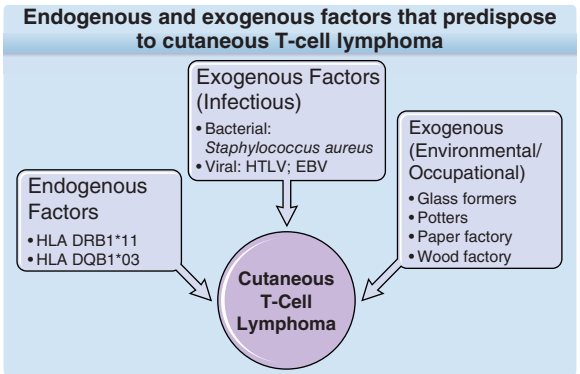

Figure 119-2 Endogenous and exogenous factors that predispose to cutaneous T-cell lymphoma. EBV, Epstein-Barr virus; HTLV, human T-cell lymphotropic virus.

EXOGENOUS FACTORS

Viruses have been identified as etiologic factors in at least 2 cutaneous lymphomas (human T-cell lymphotropic virus-1 [HTLV-1]-associated adult T-cell lymphoma/leukemia, and Epstein-Barr virus [EBV]-associated natural killer [NK]/T-cell lymphoma), whereas no such relation has been confirmed for MF or Sézary syndrome. All these data suggest that HTLV does not play an important role in the etiology of CTCLs, outside of HTLV-1 endemic regions, and that the only reason to screen patients for antibodies is the suspicion that the diagnosis is adult T-cell lymphoma/leukemia rather than MF. EBV as well as cytomegalovirus have been discussed as causative pathogens. EBV is associated with CD30 lymphoproliferation and with immunosuppression. Several studies show that EBV is detectable only in a minor percentage of CTCL lesions. In these studies, EBV detection was related to a poor prognosis and its presence is more likely related to immunosuppression caused by either the disease or the therapy, rather than to the etiology of CTCL. However, a strong association of EBV in a rare cutaneous lymphoproliferative disease with a hydroa vacciniforme–like appearance, which occurs mostly in people of Asian origin, has been observed.

Bacterial infections also have been implicated in the etiology of CTCLs. Of special interest has been the hypothesis that superantigens from *Staphylococcus aureus* may be responsible for chronic antigenic stimulation. In several studies, *S. aureus* has been detected in a high percentage on the skin of CTCL patients with a high tumor burden, while patients in early stage disease did not show significant differences to control groups. Although these studies conclusively demonstrate the involvement of *S. aureus* in disease exacerbation and clinical improvement following antibiotic treatment, the missing difference in *S. aureus* colonization in early stages of CTCL and control groups questions the involvement of *S. aureus* or superantigens produced by these bacteria in initiation of CTCLs.

However, *S. aureus* enterotoxin A stimulates signal transducer and activator of transcription (STAT) 3 activation, and interleukin (IL)-17 expression in cutaneous T-cell lymphoma and may play a direct role in the progression of the disease.

Besides infectious pathogens, it also has been suggested that environmental and occupational risk factors play a causative role in CTCL (see Fig. 119-2), because an indolent dermatitis often precedes the diagnosis. Exposure to carcinogens in the work environment could provide the suspected long-term antigenic stimulation for the initiation of the clonal expansion. In epidemiologic studies, several occupations, such as glass formers, potters, and paper and wood industry workers, have been associated with a higher risk for development of MF. However, the results of the different studies were not consistent, and a common denominator, like exposure to known carcinogens, could not be identified. With regard to chronic antigenic stimulation by occupational contact allergens, it has to be considered that MF arises typically on body areas like the lateral trunk that are protected by clothes during working time. Also, other environmental risk factors, like consumption of alcohol, smoking, or exposure to ultraviolet (UV) radiation, were not consistently observed in association with an increased risk for CTCLs.[20-31]

PATHOGENESIS

Cutaneous T-cell lymphoma is a malignancy of skin-homing T-cells. Patients typically present with localized patches and plaques in sun-protected skin. Lymphoma cells extend from these lesions to uninvolved skin and accumulate in the superficial dermis, leading to patches/plaques and tumors. In advanced disease, malignant T cells disseminate to blood, lymph nodes and viscera. In leukemic CTCL (Sézary syndrome), malignant T-cells can comprise greater than 99% of the circulating T lymphocytes. Loss of the normal T-cell receptor (TCR) and the disappearance of normal lymphocytes lead to immunosuppression and opportunistic infections, which are the most common disease-related causes of death.

The clinical entities encompassed by the term *cutaneous T-cell lymphoma* share several components: the epidermal and/or dermal microenvironment, a clonal T-cell population, and a modulated antitumor response. A spectral karyotyping and comparative genomic hybridization studies combined with TCRγ polymerase chain reaction have demonstrated that genetically-damaged malignant T cells are present in even the earliest stages of MF, confirming that MF is a lymphoma of genetically-damaged malignant T cells even in its earliest manifestation. There is emerging evidence that the distinct clinical presentation of CTCLs may represent their derivation from different subsets of skin-homing T cells. Malignant T cells in MF have the surface phenotype of nonrecirculating T_{RM} and classic erythrodermic Sézary syndrome has malignant T cells with a surface phenotype of T_{CM}, consistent with their tendency to form stable inflammatory skin lesions versus transitory erythroderma, respectively. However, the phenotype of Sézary cells is more heterogeneous than initially reported, and Sézary cells can also present phenotypic plasticity.[10,32-37]

T_{MM} are novel skin-homing T cells. These cells express CCR7 but lack L-selectin, are present in the blood and skin of healthy individuals, and recirculate more slowly out of skin than do T_{CM}. In CTCL patients, malignant T_{MM} give rise to discrete skin lesions with ill-defined borders and peripheral blood disease, which, in the current classification, is referred to as MF with peripheral blood disease.

The fundamental difference in the putative cell of origin between Sézary syndrome (T_{CM} derived) and MF (T_{RM} derived) is consistent with their distinct clinical behaviors, as T_{CM} may be found in both, in the peripheral blood, lymph node, and skin, and are resistant to apoptosis, whereas resident T_{RM} cells remain fixed within the skin. In addition, a population

of recirculating CCR7+ L-selectin– T_{MM} has been described in the skin. The contention that MF subtypes and Sézary syndrome originate from different T-cell subsets is consistent with comparative genomic hybridization (CGH), a gene expression profiling data demonstrating that these CTCL subtypes are genetically distinct. Detection of these malignant T-cell clones is critical in making the diagnosis of CTCL.[10,11]

Emerging with new molecular technology using high-throughput TCR sequencing, it has been demonstrated that the malignant T-cell clones in MF and leukemic CTCL localized to different anatomic compartments in the skin could be discriminated from benign inflammatory skin diseases.

Regulatory T cells expressing the transcription factor FOX-P3 are important in the maintenance of self-tolerance and form a minor subset of skin-resident T cells. It is discussed that a subset of Sézary patients harbor a clone that is derived from resident regulatory T cells. However, regulatory T cells represent only a minority of skin-resident T cells; the majority of T cells in the skin produce cytokines characteristic of distinct effector T-cell subsets, including T-helper (Th) 1, Th2, and Th17 cells. MF and Sézary syndrome are associated with the expression of Th2-associated genes (eg, GATA-3) and the production of Th2-associated cytokines (eg, IL-4, IL-5, IL-13), raising the possibility that a significant subset of patients may harbor Th2-derived clones.[38-44]

Alternatively, recurrence mutations activating specific signaling pathways (nuclear factor of activated T cells [NFAT], nuclear factor κB [NFκB], Janus kinase [JAK]/STAT) may provoke the acquisition of a particular phenotype independent of the cell of origin.[37]

Recent molecular studies have advanced our understanding of the molecular pathogenesis of CTCL. Recurrent deletions of 10q and 17p and amplification of 8q and 17q have been identified with robust evidence implicating deletions of TP53 und CDKN2a and amplifications of 8q containing MYC. In a recent study of the genomic landscape of cutaneous lymphomas, somatic mutations in 17 genes in CTCL were described. Frequent deletion and damaging somatic copy number variants in chromatin-modifying genes (*ARID1A* [62.5%], *CTCF* [12.5%], and *DNNT3A* [42.5%]) were found. Many genes mutated in CTCL contribute to other T-cell neoplasms, including peripheral T-cell lymphoma (*CD28*, *DNMT3A*, and *RHOA*), underscoring the importance of these genes for the malignant transformation of T cells. Consistent with this notion, mutations were found in multiple components of the TCR signaling pathway, including CD28 and the genes for TCR-associated enzymes (*PLCG1*, *PRKCQ*, and *TNFAIP3*) and transcription factors (*NFκB2*, *STAT5B*, and *ZEB1*). These genes drive the Th2 differentiation (*ZEB1*) that facilitates escape from transforming growth factor-β–mediated growth suppression (*ZEB1*) and facilitates resistance to tumor necrosis factor receptor superfamily–mediated apoptosis (*FAS* and *ARID1A*).[45,46]

In CTCL, several cytokines play a role in disease manifestation as well as in the progression of this disease. In early stages of CTCL, signaling of IL-2, IL-7, and IL-15, which all are γc-chain cytokines using JAK1/JAK3, drives the activation of STAT5 and STAT3. As a result of downstream processes of STAT3 and STAT5, a shift from Th1 toward a Th2 phenotype of the malignant T cells can be observed. This is achieved by the transcriptional activation of the micro-RNA (miRNA)-155 by STAT5. In turn, miRNA-155 targets STAT4, leading to the downregulation of Th1 genes. In addition, STAT5 activates IL-4 expression, fostering the Th2 phenotype. This shift is associated with the progression of CTCL as Th2 responses (IL-4, IL-10) are well known mechanisms of tumor-induced immunosuppression.

Furthermore, the activation of JAK3, STAT3, and STAT5 leads to a transcriptional repression of miRNA-22, a known tumor suppressor. For CTCL, malignant T cells—CTCL cell lines as well as peripheral blood Sézary CD4+ T cells—demonstrate a reduced expression of miRNA-22. The miRNA-22 normally inhibits tumor growth and metastasis because it targets the transcription of a number of putative oncogenic genes (eg, *MYCB*, *HDAC4*, *HDAC6*, *CDK6*, and *NcoA1*). But in CTCL, a loss of these tumor-suppressive activities by miRNA-22 is observed, as the expression of miRNA-22 is directly downregulated by STAT5, leading to a faster progression of the malignant state of the T cells. These findings suggest that JAK/STAT signaling plays another key role in the pathogenesis and progression of CTCL and that JAK-inhibition could mediate a direct suppressive effect on tumor growth and metastasis (Fig. 119-3).

In addition to this, the activation of STAT3 is a critical mediator of the transformation of malignant CTCL T cells, as well as an important mediator of plasticity.[1,7] STAT3 activation leads to IL-17 production of CTCL T cells as demonstrated in vitro with CTCL cell lines, as well as by expression of IL-17 in neoplastic lymphocytes in CTCL skin lesions ex vivo. Receptors for IL-17 are expressed by various cells in the skin microenvironment of CTCL lesions, such as fibroblast, keratinocytes, and epithelial cells. Upon stimulation with IL-17 these cells produce other proinflammatory cytokines, chemokines, and angiogenic factors. It was shown that CTCL lesions exhibit increased angiogenesis, providing the suggestion that IL-17 of neoplastic T cells in CTCL influences tumorigenesis by modulating inflammation and angiogenesis in CTCL skin lesions. Therefore, targeting the initial STAT3 activation by JAK inhibition would also have beneficial effects on these indirect effects of aberrant T cells of the Th17 phenotype.

STAT3 transcriptional activity also leads to the expression of IL-21 in the aberrant T cells, which drives an autocrine signaling loop, leading to constitutive signaling via JAK1/JAK3 and the activation of STAT3. This constitutive activation of STAT3 driven by IL-21 is essential for the progression of CTCL by several mechanisms: (a) it promotes the expression of antiapoptotic proteins like bcl-2, leading to survival of malignant T cells[1]; (b) STAT3 is involved in

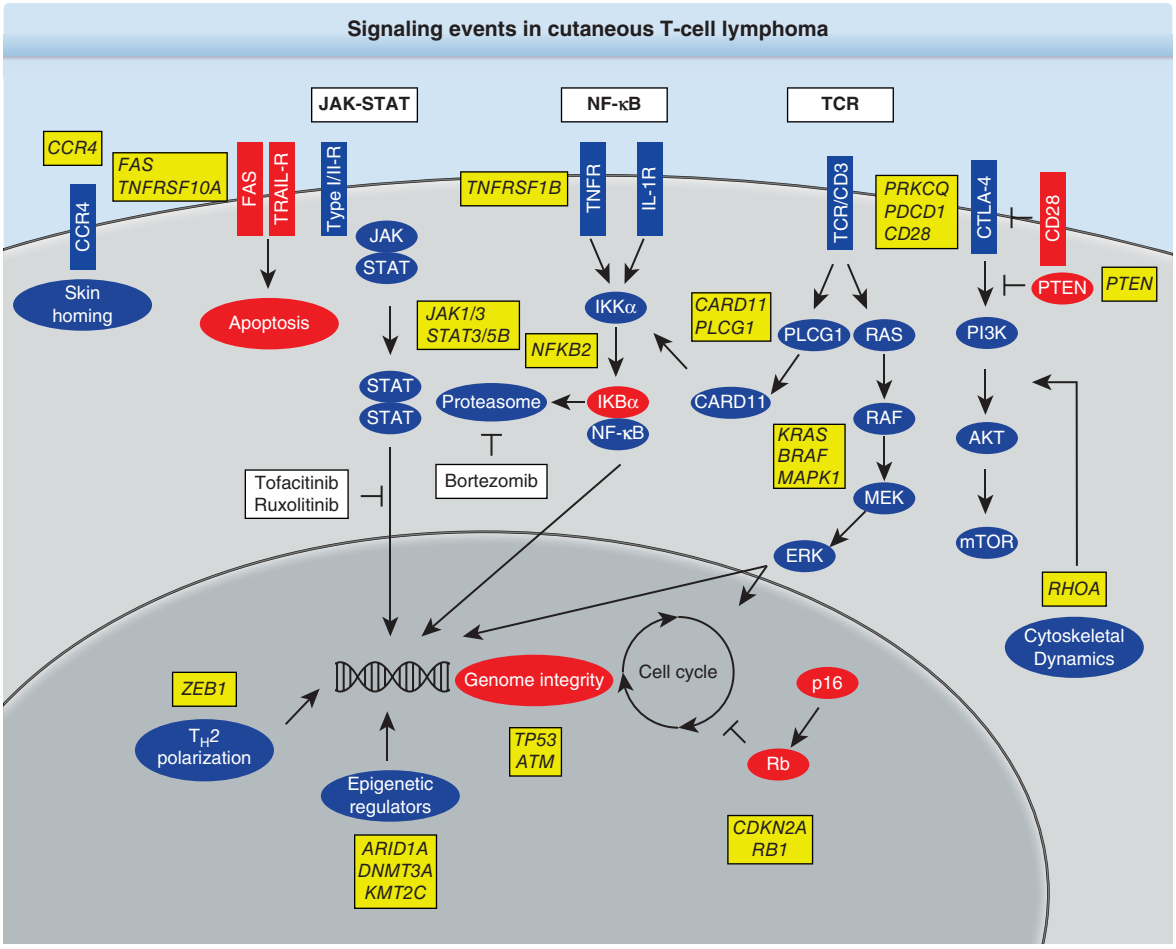

Figure 119-3 Signaling events in cutaneous T-cell lymphoma. (From Damsky WE, Choi J. Genetics of cutaneous T cell lymphoma: from bench to bedside. *Curr Treat Options Oncol*. 2016;17(7):33, with permission from Springer. Copyright © 2016.)

the upregulation of the transcription of the angiogenic factor vascular endothelial growth factor; (c) it induces the expression of IL-5 and other cytokines involved in erythroderma and eosinophilia; (d) STAT3 transcriptional activities are involved in driving the plasticity of the T cells (Th2 and Th17 phenotypes) observed in advanced stages of CTCL; and (e) it induces the expression of an oncogenic miRNA, miRNA-21. The miRNA-21 is involved in the survival of malignant T cells due to antiapoptotic activities. All these reasons provide a strong rationale for targeting JAK/STAT pathways in CTCL.

Other cytokines in the microenvironment of CTCL are also involved, like IL-13, a cytokine related to the γc-chain cytokines sharing the IL-4 receptor α subunit (IL-4Rα). IL-13 belongs, therefore, to the IL-4 family and is secreted by the transformed malignant Th2 cells in CTCL, as IL-13 is highly expressed in clinically involved skin of CTCL patients. IL-13 acts as an autocrine growth factor of CTCL cells, especially in the Sézary syndrome variant of CTCL. Blockade of JAK1/JAK3 would also block IL-13 cytokine signaling, leading to the inhibition of tumor cell proliferation.[47-60]

In recent years, it has become evident that cytokine signaling plays a critical role in the pathogenesis of CTCL.

In addition to multiple defects in apoptosis, aberrant cell-cycle regulation, including inactivation of the CDKN2A-CDKN2B locus, is frequently observed in CTCL. Cyclin upregulation, including cyclin D_1, and loss of RB1 also have been described. As gene expression profiling and next-generation sequencing technologies are employed, additional pathogenic pathways, including those involved in transcription factors regulating T-cell differentiation and C-MYC, RAS, BRAF, and MEK signaling, are being identified in subsets of CTCL.[13,34]

In summary, recent research into CTCL has significantly advanced our knowledge of molecular pathogenesis, cellular origin, migratory behavior, and death signaling. As for other malignancies, the major challenge now will be to define meaningful molecular and/or phenotypic subgroups that relate to clinical behavior and/or treatment response to drugs that specifically interfere with disease-promoting signaling cascades or cellular interactions. As a result, promising treatment approaches will be based on our increasing knowledge about the molecular pathogenesis of CTCL.

MYCOSIS FUNGOIDES

DEFINITION

MF is the most common form of primary cutaneous lymphoma, accounting for approximately 40% of all cutaneous lymphomas, usually arising in mid to late adulthood (median age at diagnosis: 55-60 years) with a male predominance of 2:1. According to the WHO classification, MF is defined by its classic form, that is, by patches and plaques or variants.

CLINICAL FINDINGS

Skin Signs: Clinically, MF is categorized as patch, plaque, or tumor stage, but patients may simultaneously have more than 1 type of lesion. In early patch stage MF (Figs. 119-4 and 119-5), there are single or multiple erythematous, scaly macules and patches that vary in size and are usually well defined. The color of the lesions may vary from orange to a dusky violet-red. The distribution classically favors non–sun-exposed sites, with the "bathing trunk" and intertriginous areas predominant early in the course of the disease. The eruption may be intensely pruritic or asymptomatic, and occasionally may be transitory, disappearing spontaneously without scarring. Diagnosis at this stage may be difficult. Often a patient will recall a preceding "chronic dermatitis" for 10 to 20 years that may have been considered to be therapeutically-resistant contact dermatitis, atopic dermatitis, psoriasis, or eczema. In any patient with a dermatosis that is refractory to the usual modalities of treatment, multiple biopsy specimens should be taken to pursue a diagnosis.

Figure 119-4 Patch lesions of mycosis fungoides in typical locations on the lateral trunk.

Figure 119-5 Large patch lesions of mycosis fungoides surrounding areas of uninvolved skin.

Patches may last for months or years before progressing to plaque stage (Fig. 119-6), or plaques may arise de novo. Plaques appear as sharply demarcated, scaly, elevated lesions that are dusky red to violaceous and variably indurated (Figs. 119-6 and 119-7). Lesions in this stage may regress spontaneously or may coalesce to form large plaques with annular, arcuate, or serpiginous borders, and may clear centrally with disease activity remaining at the periphery of the lesion. There may be purpuric hyperpigmentation or hypopigmentation and poikiloderma.

Tumors may occur anywhere on the body, but have a predilection for the face (Figs. 119-8 and 119-9) and body folds: axillae, groin, antecubital fossae, and, in

Figure 119-6 Polymorphic nature of mycosis fungoides. Patches and a plaque with a developing nodule on the left buttock.

Figure 119-7 Multiple patches and plaques of mycosis fungoides on the lateral trunk. In this patient, the plaques developed rapidly and show partial central necrosis.

Figure 119-9 Tumor lesions of mycosis fungoides on the right arm, which are partially eroded and ulcerated.

women, the inframammary area. These usually occur in preexisting plaques or patches of MF; this coincides with an extension of these lesions in the vertical dimension (see Fig. 119-6). At this point, the neoplastic cells behave in a biologically-more aggressive manner, with pronounced tumor cell accumulation that leads to the clinical appearance of an expanding dermal nodule (see Fig. 119-9). De novo occurrence suggests metastatic spread by cells of a malignant T-cell clone. The nodules are reddish brown or purplish red and smooth surfaced, but they often ulcerate and may become secondarily infected. Growth rate is variable. Patients with tumors tend to have a more aggressive form of the disease than patients with patch and plaque disease.

Figure 119-8 Leonine facies characterized by infiltrated plaques and tumors of cutaneous T-cell lymphoma.

Erythroderma (Fig. 119-10A) may start de novo or develop in MF. The nomenclature for erythrodermic phases of CTCL varies. It has been proposed that erythroderma be defined as the involvement of 80% of body surface area with lesions of ill-defined borders and that patients with a history of preexisting MF be defined as having a separate syndrome of "erythrodermic MF."

The skin is diffusely bright red with readily apparent scaling, but there may be characteristic islands of uninvolved skin. There may be sparing of the areas of skin that are frequently folded, such as the abdomen and antecubital and axillary areas. This sparing produces a finding often called the *deck chair* or *folded luggage* sign. Some patients with the erythrodermic form of CTCL develop tumors.

Other Symptoms: Patients may complain of fever, chills, weight loss, malaise, insomnia secondary to the overwhelming pruritus, and poor body temperature homeostasis. There may be hyperkeratosis, scaling and fissuring of the palms and soles, alopecia, ectropion, nail dystrophy, and ankle edema, with the integument being shiny and hidebound. These changes result in pain on walking and extreme difficulty with tasks requiring manual dexterity. Such patients experience severe restrictions by the extent and localization of their skin manifestations. Pruritus is often intense, which results in excoriation, exudation, and secondary infection that may dominate the clinical picture.

Figure 119-10 Sézary syndrome patient with erythroderma (**A**), palmar fissuring (**B**), and plantar hyperkeratosis (**C**).

Hypopigmentated Mycosis Fungoides: Patients with dark skin develop hypopigmented MF, a variant (Table 119-2) of patch MF. This form of MF must be differentiated from vitiligo. In darker-skinned individuals, this may be the most common presentation of the disease. Patients respond to therapy with repigmentation, and the reappearance of hypopigmented lesions often indicates a relapse.

HISTOPATHOLOGY

Figure 119-11 shows the characteristic histology of MF. In the patch, plaque, and also in the erythrodermic stage, there is a band-like infiltrate in the upper dermis composed of reactive T cells and neoplastic T lymphocytes, which are characterized by hyperconvoluted cerebriform nuclei. The neoplastic T cells show an epidermotropism with formation of intraepidermal Pautrier microabscesses (Figs. 119-12 and 119-13). In the tumor stage, a nodular infiltrate in the dermis is found, and the epidermal component is much less pronounced (Fig. 119-14). Immunohistologically, the malignant cells express a mature peripheral T-cell (CD4+) phenotype. Partial loss of pan–T-cell antigens such as CD7 and CD3 may be a feature of MF, but is not pathognomonic of the disease. Analysis of TCR genes typically shows a clonal rearrangement as demonstrated by polymerase chain reaction or Southern blot techniques. However, a T-cell clone is only found in half the biopsies in early stages of disease.

Thus, neither molecular tests for T-cell clonality nor phenotypic marker are of significant diagnostic value in early MF. Maybe in the near future modern molecular diagnostics, such as high-throughput technology, will be capable of detecting T-cell clones even in early MF.

Table 119-3 presents an algorithm for diagnosis of early MF.

TOX (thymocyte selection-associated high-mobility group box factor) is associated with development of CD4+, CD8– T cells in the thymus, but is suppressed in mature CD4+ T cells. It is aberrantly expressed in MF and Sézary syndrome. It was thought to help in discriminating between early MF lesions and biopsy from inflammatory skin disorders. According to recent data it could contribute the diagnosis of CTCL; however, TOX expression is not restricted to CD4+, CD8– neoplastic T cells.[61]

Table 119-4 summarizes the recommended evaluation/initial staging of the patient with MF/Sézary syndrome.

TABLE 119-2
Subtypes and Variants of Mycosis Fungoides

SUBTYPES	
Erythrodermic mycosis fungoides (MF)	Develops de novo or as a progression of MF; > 80% involvement of skin surface
Hypopigmented mycosis fungoides	Common in darkly pigmented individuals; response to therapy characterized by repigmentation. Vitiligo is a differential diagnosis

DIFFERENTIAL DIAGNOSIS

Table 119-5 summarizes the differential diagnosis of MF.

TREATMENT AND PROGNOSIS

Treatment should be stage adapted. In early disease stages, treatment should be based on skin-directed

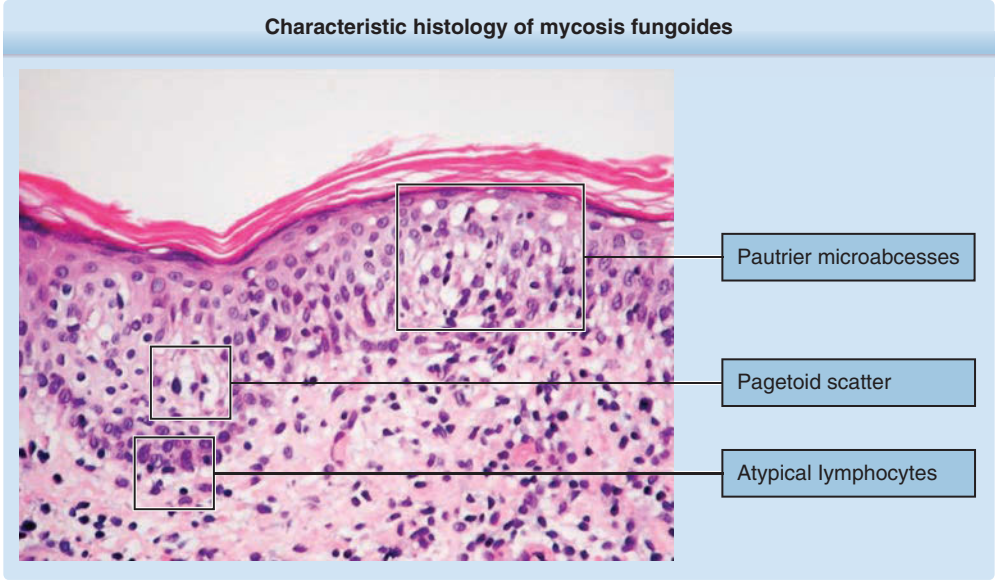

Figure 119-11 Characteristic histology of mycosis fungoides.

therapies alone or combined with systemic biologic response modifiers (eg, interferon α or γ, retinoids). Targeted therapies and small molecules are gaining favor as ways to debulk tumors and blood compartments as an alternative for chemotherapy approaches (see sections "Staging of Cutaneous T-Cell Lymphoma" and "Principles of Treatment of Cutaneous T-Cell Lymphoma"). Prognosis depends on the type and extent of skin involvement (plaque, tumor, or erythroderma), the presence of lymph node involvement, and the presence of visceral disease. Among early stage patients, 25% will progress to advanced stage. Overall, patients with MF limited to the skin have a 5-year survival rate of 80% to 100%. In contrast, patients with lymph node involvement show a 5-year survival rate of 40%.[62]

The Cutaneous Lymphoma International Consortium study published survival data and analysis based on 1275 patients with advanced MF and Sézary syndrome. The median overall survival was 63 months with 2-year and 5-year survival rates of 77% and 52%, respectively. The median overall survival for patients with Stage IIB disease was 86 months, but patients diagnosed with Stage III disease have slightly improved survival compared with patients with Stage IIB disease. Patients

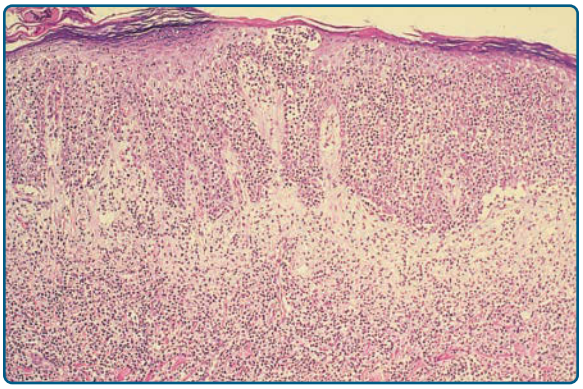

Figure 119-12 Dense mononuclear cell infiltrate extending from the papillary dermis into the epidermis. The epidermis is completely permeated by these cells, which form a Pautrier abscess.

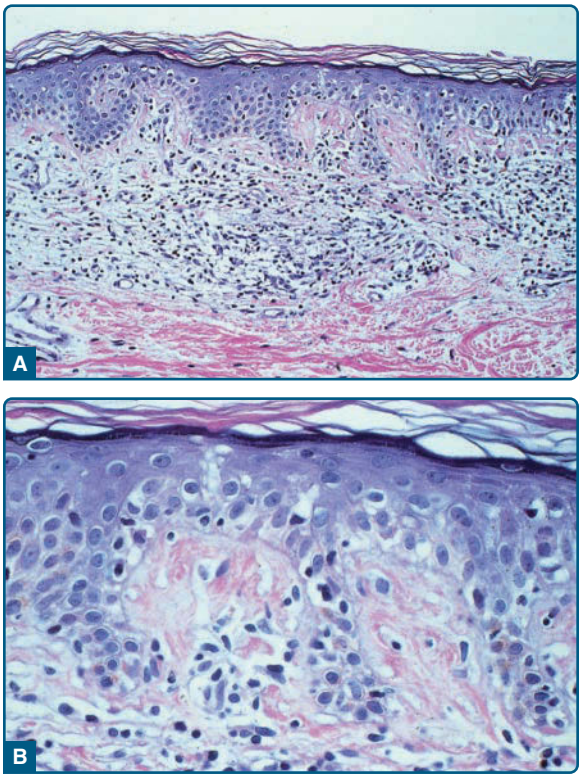

Figure 119-13 Patch stage of mycosis fungoides. **A,** Single atypical mononuclear cells in epidermis with sparse superficial perivascular infiltrate in the papillary dermis. (Hematoxylin and eosin-stained section.) **B,** High-power view of atypical cells in epidermis of same section.

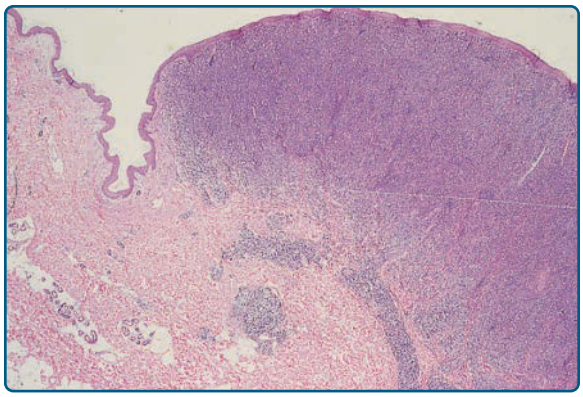

Figure 119-14 Low-power view of a mycosis fungoides tumor. The dense infiltrate extends deep into the dermis.

diagnosed with Stage IV disease had a significantly worse survival (48 months for Stage IVA and 33 months for Stage IVB). Of 10 variables tested, 4 (Stage IV, age >60 years, large-cell transformation, and increased lactate dehydrogenase) were independent prognostic markers for worse survival. Combining these 4 factors for a prognostic index model led to the identification of 3 risk groups across stages, with significantly different 5-year survival rates: low risk (0-1) 68%, intermediate risk (2) 44%, and high risk (3-4) 28%.[63]

TABLE 119-3

Algorithm for Diagnosis of Early Mycosis Fungoides

CRITERIA SCORING SYSTEM

- Clinical
  - Basic 2 points for basic criteria and 2 additional criteria
  - Persistent and/or progressive patches/thin plaques 1 point for basic criteria and 1 additional criterion
  - Additional
    - Non–sun-exposed location
    - Size/shape variation
    - Poikiloderma
- Histopathologic
  - Basic 2 points for basic criteria and 2 additional criteria
  - Superficial lymphoid infiltrate 1 point for basic criteria and 1 additional criterion
  - Additional
    - Epidermotropism without spongiosis
    - Lymphoid atypia
- Molecular biological
  - Clonal TCR gene rearrangement 1 point for clonality
- Immunopathologic
  - <50% CD2+, CD3+, and/or CD5+ T cells 1 point for 1 or more criteria
  - <10% CD7+ T cells
  - Epidermal/dermal discordance of CD2, CD3, CD5, or CD7

A total of 4 points is required for the diagnosis of MF based on any combination of points from the clinical, histopathologic, molecular biologic, and immunopathologic criteria

From Pimpinelli N, Olsen EA, Santucci M, et al. Defining early mycosis fungoides. *J Am Acad Dermatol.* 2005;53:1053-1063, with permission. Copyright © American Academy of Dermatology.

TABLE 119-4

Recommended Evaluation/Initial Staging of the Patient with Mycosis Fungoides/Sézary Syndrome

- Evaluation of skin lesions; measure of the percentages of body surface area of patches, plaques, and tumors
- Evaluation of localization and measures of lymph nodes
- Clinical identification of visceral disease
- Histology and immunohistology of skin lesions, and evaluation for T-cell clonality
- Histology and immunohistology of enlarged lymph nodes, and evaluation for T-cell clonality
- Blood cell count, lactate dehydrogenase, liver function tests
- Blood T-cell clonality
- Sézary cell count by cytomorphology and/or flow cytometric analysis of T-cell blood subpopulations (CD4+/CD7– and CD4+CD26–)
- Early-stage patients: chest radiograph and ultrasound of abdomen
- Late-stage patients: CT scan of chest, abdomen, and pelvis

MYCOSIS FUNGOIDES VARIANTS

Table 119-6 outlines the clinical findings and prognosis for MF and variants.

FOLLICULOTROPIC MYCOSIS FUNGOIDES

Compared to classic MF, follicular or folliculotropic MF has classically been considered to carry a worse prognosis with 5-year survival rates of approximately 60% (follicular MF) and 41% (folliculotropic MF) by 15 years.

TABLE 119-5

Differential Diagnosis of Mycosis Fungoides

Patch/Plaque Stage

- "Chronic dermatitis"
- Psoriasis
- Contact dermatitis
- Eczema
- Tinea corporis
- Vitiligo

Tumor Stage

- B-cell lymphoma
- Carcinoma cutis
- Sarcoidosis
- Deep fungal infection
- Atypical mycobacterial infection
- Leprosy
- Leishmaniasis
- Erythroderma
- Pityriasis rubra pilaris
- Psoriasis
- Atopic dermatitis
- Drug eruption
- Seborrheic dermatitis

TABLE 119-6
Clinical Findings and Prognosis for Mycosis Fungoides and Variants

	CLINICAL FINDINGS	PROGNOSIS (5-YEAR SURVIVAL RATE)
Mycosis fungoides (skin limited)	Single-to-multiple erythematous scaly macules and patches on non–sun-exposed sites; plaques appear sharply demarcated, scaly, violaceous, and indurated; tumors have a predilection for the face and body folds	80%-100%
Mycosis fungoides (lymph node involvement)		40%
Folliculotropic mycosis fungoides	Characterized by patches, plaques, and hair loss within lesions; preferential involvement of head and neck	More aggressive than early mycosis fungoides; 60%
Pagetoid reticulosis	A solitary, hyperkeratotic plaque, usually on an extremity	Generally indolent behavior, recurrences and relapses may occur[a,b]
Granulomatous slack skin	Localized areas of bulky folding of the skin, on axillae and groins	Indolent course, slowly progressive with rare nodal involvement[a]
Sézary syndrome	Diffuse erythroderma, generalized lymphadenopathy, presence of circulating Sézary cells	24%-43%

[a]Martinez-Escala ME, Gonzales BR, Guitart J. Mycosis fungoides variants. *Surg Pathol Clin*. 2014;7(2):169-89.
[b]Haghighi B, Smoller B, LeBoit P, et al. Pagetoid reticulosis (Woringer-Kolopp disease): an immunophenotypic, molecular and clinicopathologic study. *Mod Pathol*. 2000;13(5):502-10.

Clinically, folliculotropic MF presents with patches, plaques, and unusual hair loss within the lesions; occasionally, the disease may manifest with predominantly papular lesions. Folliculotropic MF preferentially involves the head and neck region and is characterized by folliculotropic T-cell infiltrates, with or without mucinous degeneration of the hair follicles. Previously, this variant was called *follicular mucinosis* or *alopecia mucinosa*. Folliculotropic MF affects mostly adults and is rarely observed in children and adolescents. Patients may have grouped follicular papules (Fig. 119-15A), acneiform lesions, indurated plaques, and, sometimes, tumors, which usually involve the head and neck region. The occurrence of hair loss within the lesions, most conspicuous on the eyebrows, an intense pruritus, and secondary bacterial infection are common.

It is important to mention that 2 newer studies show that it is possible to distinguish 2 different types of folliculotropic MF, including a subtype with a favorable prognosis.[64,65]

Distinction of folliculotropic MF-associated follicular mucinosis from benign (idiopathic follicular mucinosis) remains challenging. Although folliculotropic MF more probably displays a dense lymphocytic infiltrate with slight nuclear atypia, increased CD4-to-CD8 ratio, and a clonal rearrangement of TCR genes, the histologic or phenotypic features do not allow separating the 2 entities with certainty.

PAGETOID RETICULOSIS

Patients with pagetoid reticulosis present with a solitary psoriasiform or hyperkeratotic patch or plaque, which is usually localized on the extremities (Fig. 119-16) and is slowly progressive. Unlike in classic MF, extracutaneous dissemination has not been observed.

Pagetoid reticulosis, listed as an MF subtype in the WHO classification, shows more prominent epidermotropism and nuclear pleomorphism compared with unilesional MF, and more commonly shows a CD8+ phenotype. Furthermore, pagetoid reticulosis manifests more often as a hyperkeratotic lesion.

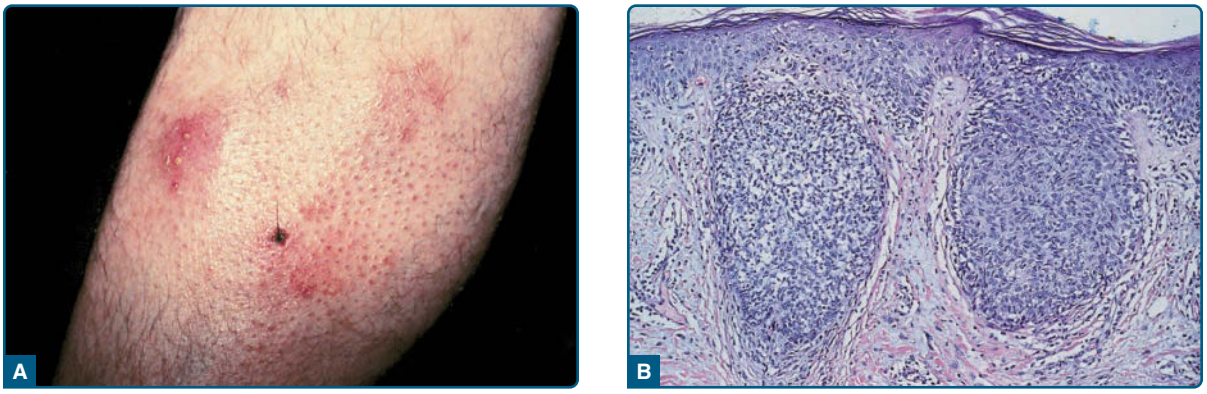

Figure 119-15 **A,** Folliculotropic mycosis fungoides. Note follicular localization and resulting hair loss. **B,** Outer root sheath of hair follicle is disrupted by T cells and mucin deposition, which leads to small cystic spaces.

Figure 119-16 Pagetoid reticulosis. Hyperkeratotic plaque localized on the leg of a male patient.

GRANULOMATOUS SLACK SKIN

Granulomatous slack skin is a rare subtype of MF characterized by localized areas of bulky folding of skin, with a predilection for the axillae and groin (Fig. 119-17). Light microscopy reveals a dense granulomatous infiltrate in the entire dermis. In addition to small, atypical cells with cerebriform nuclei, one finds macrophages and multinucleated giant cells and loss of elastic fibres. The neoplastic cells express a CD3+CD4+CD8− phenotype.

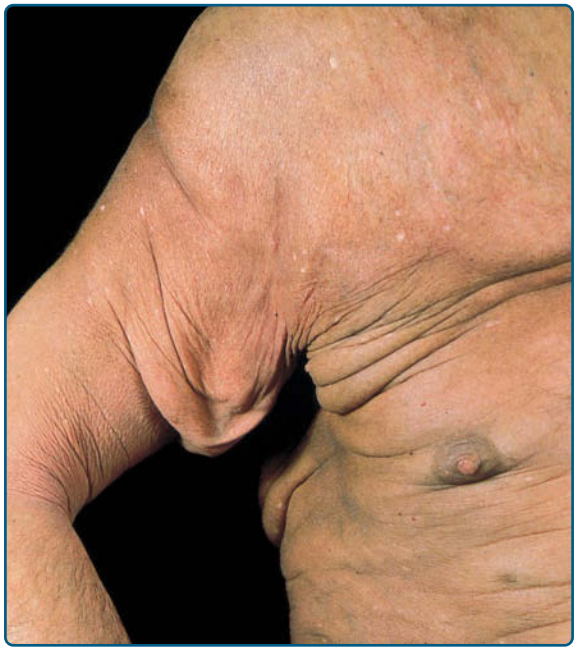

Figure 119-17 Granulomatous slack skin. Note skinfolds caused by secondary elastolysis.

SÉZARY SYNDROME

DEFINITION

Sézary syndrome is characterized by the triad of diffuse erythroderma, generalized lymphadenopathy, and circulating malignant T cells with cerebriform nuclei, so-called Sézary cells.

Sézary syndrome is a rare form of CTCL, accounting for 3% of all cutaneous lymphomas. In contrast to MF, Sézary syndrome carries an unfavorable prognosis, with a 5-year overall survival varying from 24% to 43%.[1,63]

CLINICAL FINDINGS

The erythroderma is often accompanied by severe scaling or fissuring of the palms and soles (see Fig. 119-10), alopecia, and onychodystrophy, and may be associated with marked exfoliation, edema, lichenification, and intense pruritus. In rare cases, hyperpigmentation occurs.

LABORATORY FINDINGS

Sézary syndrome demonstrates histologic features similar to those of MF, but repeated biopsies may be necessary as specimens often show nondiagnostic findings. The clonal T cells are generally CD3+, CD4+, and CD8− by multicolor flow cytometry. As in MF, the aberrant loss of T-cell antigens, including CD2, CD3, CD4, CD5, and CD7, is frequently observed. Of these, loss of CD7 expression is observed in approximately two-thirds of cases. Loss of CD26 expression, observed in the majority of cases, is also useful in the identification of Sézary cells. The aberrant expression of the major histocompatibility complex class I-binding, immunoglobulin-like receptor (KIR) CD158k/KIR3DL2, normally expressed by NK cells, was described in the majority of patients with Sézary syndrome. In the current International Society for Cutaneous Lymphomas (ISCL)/EORTC TNMB staging classification, the diagnosis of Sézary syndrome requires an erythroderma with a positive T-cell clone in the peripheral blood associated with at least one B2 criterion, such as identification of more than 1000 Sézary cells/mm^3 in the blood. Sézary cells were first described in 1938 by Sézary as large, atypical, mononuclear cells with lobulated, cerebriform nuclei. However, detection of Sézary cells by cytomorphology lacks specificity for the diagnosis of Sézary syndrome as they can be found in other inflammatory erythrodermas. Other diagnosis criteria include an expanded CD4+ T-cell population resulting in a CD4-to-CD8 ratio of more than 10; loss of any or all of the T-cell antigens CD2, CD3, CD4, or CD5; and lack of CD7 and CD26.[66,67]

TREATMENT AND PROGNOSIS

Compared with patients with patch/plaque-stage MF, patients with Sézary syndrome have a markedly decreased 5-year survival rate. By the time the Sézary syndrome appears, there is very little normal immunity left. Indeed, Sézary syndrome patients often die because of infectious complications.

PRIMARY CUTANEOUS CD30+ LYMPHOPROLIFERATIVE DISORDERS

Primary cutaneous CD30+ lymphoproliferative disorders are the second most common form (20%-25%) of cutaneous lymphomas (CTCL). Primary cutaneous CD30+ lymphoproliferative disorders represent a spectrum of diseases, including lymphomatoid papulosis and primary cutaneous anaplastic large-cell lymphoma (ALCL).

LYMPHOMATOID PAPULOSIS

Definition: Lymphomatoid papulosis was first described by Macaulay in 1968. It is an uncommon chronic disorder (prevalence of 1.2-1.9 cases per 1,000,000 persons) characterized by recurrent, self-healing crops of papules and nodules.

Clinical Findings: Lymphomatoid papulosis is a chronic, recurrent, and self-healing papulonecrotic or papulonodular skin eruption (Fig. 119-18). The lesions typically involve the trunk and extremities, and lesions in various stages of evolution may be present concurrently.

Histopathology: Lymphomatoid papulosis is a clinically diverse disorder; in recent years a number of new pathologic and clinical variants have been described. The atypical cells express one or more T-cell antigens as well as the lymphoid activation antigen CD30 (Fig. 119-19).

The WHO 2016 classification recognizes the original variants Types A, B, and C, as well as the more recently described Type D (mimics primary cutaneous aggressive epidermotropic CD8+ cytotoxic T-cell lymphoma) and the angioinvasive, angiocentric Type E.

Lymphomatoid papulosis with chromosome 6p25 rearrangement (IRF4/DUSPP locus) was described by Karai et al, clinically characterized by localized papules and nodules, and histologically characterized by epidermotropic and nodular CD30+ cells. Appreciation of these variants is important, as histologically they can mimic very aggressive T-cell lymphomas, but they are clinically similar to other forms of lymphomatoid papulosis.[68,69]

Treatment and Prognosis: Because a curative therapy is not available and none of the available treatment modalities affects the natural course of the disease, the short-term benefits of active treatment should be balanced carefully against the potential side effects. Low-dose methotrexate (5-10 mg/week) is the most effective therapy to suppress development of new

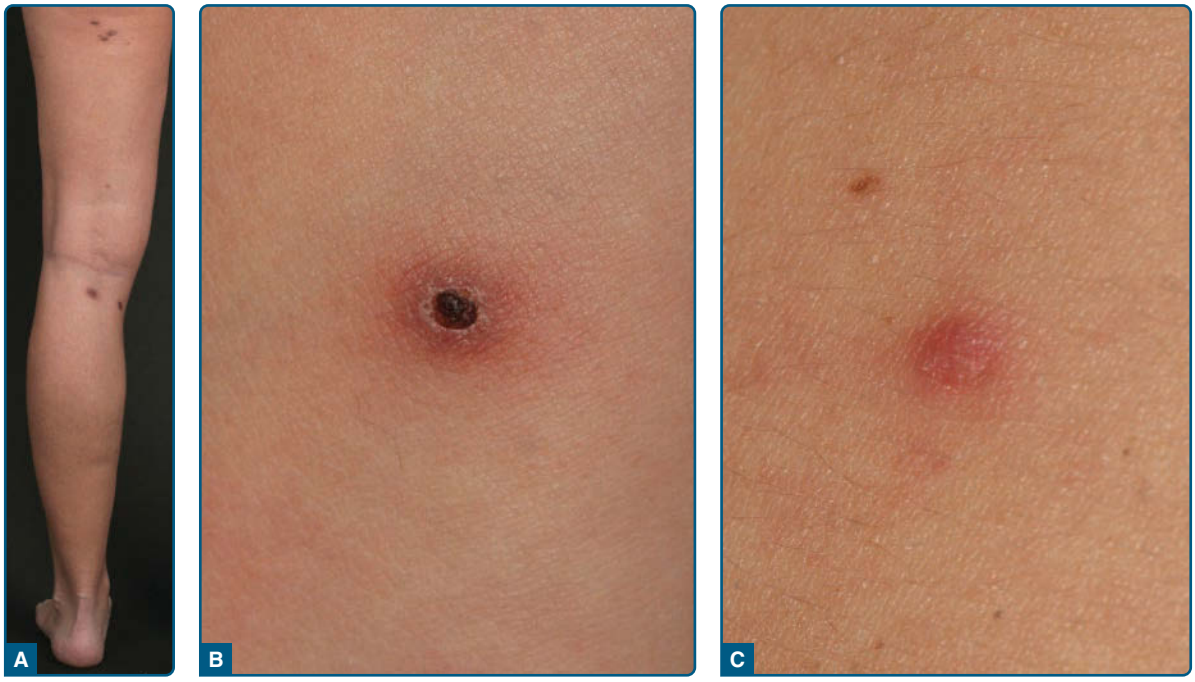

Figure 119-18 Lymphomatoid papulosis. **A,** Papular skin lesions on the right leg. The lesions may appear disseminated and grouped. **B,** Lymphomatoid papulosis papulonecrotic lesion. **C,** Lymphomatoid papulosis erythematous papulonodule.

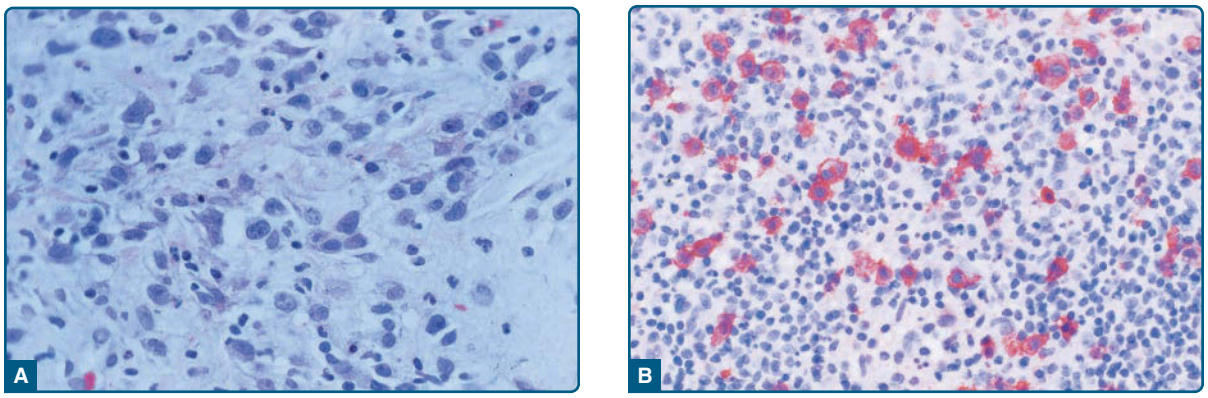

Figure 119-19 **A,** Lymphomatoid papulosis. Dermal infiltrate contains several large lymphoid cells with nuclei showing evenly dispersed chromatin and variably prominent nucleoli (so-called Type A cells). **B,** Type A with large CD30+ T cells (*red*) among admixed inflammatory cells.

skin lesions. Treatment with PUVA has been reported to yield beneficial effects, but duration of response is often short-lived after discontinuation of treatment. Therefore, in patients with few, nonscarring lesions, long-term followup without active treatment should be considered.[70]

In general, lymphomatoid papulosis shows a benign clinical course and a favorable 10-year survival rate of nearly 100%. However, in a proportion of patients, estimated at 10% to 20% of cases, lymphomatoid papulosis can precede, coexist with, or follow malignant lymphoma, especially MF, Hodgkin lymphoma, and nodal ALCL. In many of these cases, the same clonal TCR rearrangements have been found in the lymphomatoid papulosis, as well as in the associated lymphoma. In the majority of lymphomatoid papulosis cases, despite the sometimes extremely long course of the disease, there is no evolution of a secondary lymphoma. Nevertheless, patients suffering from lymphomatoid papulosis should be monitored lifelong. In patients with lymphomatoid papulosis, monoclonal TCR rearrangement or histologic mixed-type may be prognostic for disease more likely to develop lymphomatoid papulosis–associated lymphomas.

CUTANEOUS ANAPLASTIC LARGE-CELL LYMPHOMA

Definition: Cutaneous ALCL is characterized by large tumor cells, of which the majority express the CD30 antigen, with no evidence or history of MF or other type of primary CTCL. Regardless of the morphology of the tumor cells (eg. anaplastic, immunoblastic, or pleomorphic large cells), the clinical presentation and behavior are identical.

Clinical Findings: CD30+ cutaneous large-cell lymphomas occur in adults and rarely in children and adolescents, with a male-to-female ratio of 1.5:1. The clinical picture is characterized by the solitary or locoregional occurrence of reddish-to-brownish nodules and tumors, which frequently ulcerate (Fig. 119-20A). Cutaneous lesions may regress spontaneously. Although secondary involvement of regional lymph nodes is observed in roughly 10% of patients, it is not necessarily associated with an unfavorable prognosis.

Histopathology: A nodular or diffuse non-epidermotropic infiltrate of large cells is seen in the dermis (see Fig. 119-20B). In the majority of cases, the neoplastic cells show an anaplastic morphology with oval or irregularly-shaped nuclei, prominent nucleoli, and an abundant cytoplasm. Less commonly, a pleomorphic or immunoblastic appearance is observed. Atypical mitotic figures are frequent. In the periphery of the lesions, inflammatory cells (eg. lymphocytes, eosinophils, and neutrophils) are present, sometimes mimicking the histologic picture seen in lymphomatoid papulosis.

The most common phenotype in primary cutaneous ALCL is that of a CD4+ T-helper phenotype. In rare cases, tumor cells express CD8+, which does not seem to be associated with an impaired prognosis. By definition, more than 75% of the tumor cells express CD30 in cohesive sheets. In contrast to nodal ALCL, which expresses anaplastic lymphoma kinase (ALK) in approximately 60% of cases, primary cutaneous ALCLs are usually negative for this marker and lack the translocation t(2;5). Unusual cases of ALK+ primary cutaneous ALCL that are associated with a translocation variant and cytoplasmic staining for ALK have been reported.

Improved criteria now exist for the recognition of ALK– ALCL in daily practice, and the actual WHO 2016 classification no longer considers this type provisional. Gene expression profiling studies show that ALK– ALCL has a signature quite close to that of ALK+ ALCL and distinct from NK/T-cell lymphomas. Newer studies illuminating the genetic landscape of ALK– ALCL have shown convergent mutations and kinase fusions that lead to constitutive activation of the JAK/STAT3 pathways. These studies provide a genetic rationale for the morphologic and phenotypic similarities between ALK+ and ALK– ALCL. However, not all cases of ALK– ALCL are created equal. A subset with rearrangements at the locus

Figure 119-20 Primary cutaneous anaplastic large-cell lymphoma. **A,** Localized nodules, some with ulcerations. **B,** Pleomorphic large-cell lymphoma T-cell infiltrate.

containing DUSP22-IRF4 in chromosome 6p25 tends to be relatively monomorphic, usually lacks cytotoxic granules, and is reported to have a better prognosis, whereas a small subset with TP63 rearrangement is very aggressive. Interestingly, the same locus in 6p25 is also implicated in lymphomatoid papulosis and primary cutaneous ALCL.[3,69,71,72]

Treatment and Prognosis: In cases of solitary or localized skin lesions, excision or radiotherapy is the treatment of choice. A successful treatment with PUVA in combination with interferon-α has been reported. If skin lesions are generalized, systemic therapy with methotrexate (20 mg/week) is preferred; vinblastine is an alternative option.

In the case of extracutaneous dissemination, treatment with cyclophosphamide, doxorubicin, vincristine, and prednisone (CHOP) is the most frequently chosen option. Brentuximab vedotin can also be regarded as a therapy of choice. This immunoconjugate is an anti-CD30 monoclonal antibody linked to monomethyl auristatin, a spindle-cell toxin that induces cell-cycle arrest. A 100% response of primary cutaneous ALCL was observed with this treatment.

In contrast to nodal ALCL, cutaneous CD30+ large-cell lymphomas have a favorable prognosis, with a disease-related 5-year survival rate of 90%.

SUBCUTANEOUS PANNICULITIS-LIKE T-CELL LYMPHOMA

Definition: Subcutaneous panniculitis-like T-cell lymphoma is defined as a cytotoxic T-cell lymphoma characterized by the presence of primarily subcutaneous infiltrates of small, medium, or large pleomorphic αβ T cells and many macrophages that predominantly affect the legs and are occasionally complicated by a hemophagocytic syndrome. Subcutaneous lymphomas with a γδ phenotype of the TCR show a more aggressive course and are classified within the cutaneous γδ T-cell lymphomas.

Clinical Findings: This lymphoma accounts for 1% of all cutaneous lymphoma and for 75% of all subcutaneous forms of T-cell lymphoma. In the revised WHO 2016 classification, this term is, by definition, restricted to cases expressing a TCR α/β phenotype.

Subcutaneous panniculitis-like T-cell lymphoma is characterized by subcutaneous nodules and plaques, which usually involve the extremities, the trunk, and, less commonly, the face. Patients may present with "B" symptoms, that is, weight loss, fever, and fatigue.

Histopathology: Histologic examination shows subcutaneous infiltrates simulating a lobular panniculitis. Infiltrates contain a mixture of neoplastic pleomorphic cells of various sizes and macrophages. Rimming of individual fat cells by neoplastic T cells is a helpful diagnostic feature.

Immunophenotyping shows that the neoplastic cells express CD3+, CD4–, CD8+, CD56–, TIA-1+, granzyme-β+, and βF1+. The expression of βF1 (TCR α/β) by immunohistochemistry is a pivotal diagnostic marker for this entity.

Treatment and Prognosis: The α/β type of the subcutaneous panniculitis-like T-cell lymphoma responds well to systemic corticosteroids with an excellent prognosis (a 5-year survival rate of 85%), which justifies an initial treatment approach with corticosteroids alone.[73-75]

EXTRANODAL NATURAL KILLER/ T-CELL LYMPHOMA, NASAL TYPE

Definition: Extranodal NK/T-cell lymphoma, nasal type, is a rare, aggressive form of primary cutaneous lymphoma that shares immunophenotypical characteristics with normal NK cells and characteristically displays a strong expression of CD56 and cytotoxic proteins, such as perforin, granzyme B, and TIA-1. This lymphoma is nearly always EBV+. The tumor cells are small, medium, or large, and usually have an NK cell or, more rarely, a cytotoxic T-cell phenotype.

The skin is the second most common site of presentation after the nasal cavity.

Clinical Findings: Extranodal NK/T-cell lymphoma either affects the nasopharynx, which leads to destruction of the nasal region (formerly described as lethal midline granuloma), or manifests in skin, subcutis, lungs, viscera, and testes. Skin lesions comprise subcutaneous tumors, erythematous plaques, ulcers, or an exanthematous eruption with macules and papules (Fig. 119-21). The clinical course is often worsened by a hemophagocytic syndrome with pancytopenia.

Histopathology: This type of lymphoma shows dense infiltrates involving the dermis and often the subcutis. Epidermotropism may be present. Prominent angiocentricity and angiodestruction are often accompanied by extensive necrosis (Fig. 119-22). Immunophenotypically, the neoplastic cells express CD56 and cytotoxic proteins (TIA-1, granzyme B, perforin), and are characteristically positive for EBV. The TCR–CD3 complex is not expressed on the surface. Clonal episome presence of EBV is typically found. TCR genes are usually in germline configuration.[3,76]

Figure 119-21 Extranodal natural killer/T-cell lymphoma, nasal type. Infiltrated and ulcerated plaque.

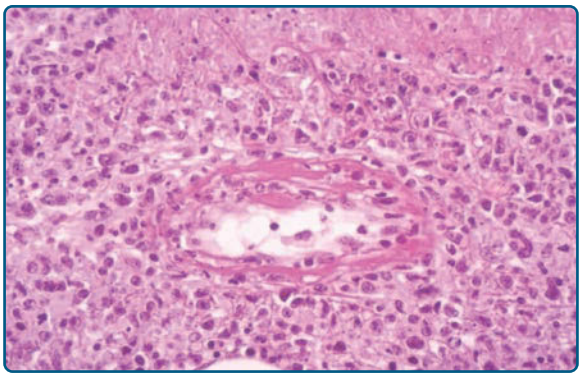

Figure 119-22 Extranodal natural killer/T-cell lymphoma, nasal type. Dense angiocentric infiltrate.

Treatment and Prognosis: Even with aggressive polychemotherapy, the disease is often lethal within months. A study of the EORTC cutaneous lymphoma group suggested that bone marrow transplantation may be the treatment of choice.

PROVISIONAL ENTITIES OF CUTANEOUS T-CELL LYMPHOMA

DEFINITION

In addition to the diseases discussed in preceding sections, a number of provisional entities are included in the revised WHO classification system. These primary CTCLs display characteristic clinical and histologic features, but the series reported remain limited and do not allow definition of a precise outcome.

PRIMARY CUTANEOUS CD4+ SMALL AND MEDIUM T-CELL LYMPHOPROLIFERATIVE DISORDER

Definition: This entity is defined clinically by papules and nodules, and histologically by a skin infiltrate composed of pleomorphic, small- and medium-sized T cells. The outcome is usually favorable but limited series have been reported.

Clinical Findings: Patients have one or several red-purplish papules or nodules with a predilection for the head and neck area. Because histologic differentiation from MF and MF-associated follicular mucinosis can raise problems, the absence of patches and plaques in pleomorphic small- and medium-sized CTCL is an important criterion.

Histopathology: Histologically, a dense, diffuse or nodular infiltrate containing small- to medium-sized pleomorphic cells is observed within the dermis and, sometimes, the subcutis. Epidermotropism may

be present. The neoplastic cells express a T-helper cell phenotype with frequent loss of pan–T-cell markers. Demonstration of an aberrant phenotype and of T-cell clonality, as well as predominance of pleomorphic T cells in the infiltrate, serve as useful criteria for the exclusion of pseudolymphomas, which often show an identical histologic pattern. MF is excluded by the absence of a dominant cerebriform tumor cell population.

Treatment and Prognosis: Solitary lesions are often excised for diagnostic purposes. If excision is not possible or lesions are localized, radiotherapy is the preferred mode of treatment. PUVA therapy, possibly in combination with interferon (IFN)-α, is useful in cases with disseminated lesions.

A 5-year survival rate between 60% and 90% is reported for this type of lymphoma.[77-79]

PRIMARY CUTANEOUS AGGRESSIVE EPIDERMOTROPIC CD8+ CYTOTOXIC T-CELL LYMPHOMA

Definition: Primary cutaneous aggressive epidermotropic CD8+ cytotoxic T-cell lymphoma is a CTCL characterized by a proliferation of CD8+ cytotoxic T cells that exhibit a strong epidermotropism and aggressive clinical behavior. Differentiation from other types of CTCL expressing a CD8+ cytotoxic T-cell phenotype, as observed in pagetoid reticulosis and rare cases of MF, lymphomatoid papulosis, and cutaneous ALCL, is based on clinical presentation, histopathology, and clinical behavior.

Clinical Findings: Primary cutaneous aggressive epidermotropic CD8+ T-cell lymphoma presents with hyperkeratotic patches and plaques, well-demarcated papules and tumors, or ulcerations. A metastatic spread to unusual sites, such as the lung, testis, CNS, and oral cavity, but not to the lymph nodes, is often observed.

Histopathology: Histologically, band-like infiltrates consisting of pleomorphic lymphocytes or immunoblasts are observed, displaying diffuse infiltration of the epidermis with variable degrees of spongiosis, intraepidermal blistering, and necrosis. The neoplastic cells express the Ki67 antigen at high frequency and are positive for CD3, CD8, CD45RA, and TIA, whereas CD2 and CD5 are frequently lost. Expression of TIA identifies these lymphomas derived from a cytotoxic T-cell subset.

Treatment and Prognosis: Even with multiagent chemotherapy, the disease shows an aggressive course and median survival is 32 months.[76,79,80]

CUTANEOUS γ/δ T-CELL LYMPHOMA

Definition: Cutaneous γ/δ T-cell lymphoma comprises the peripheral T-cell lymphomas with a clonal proliferation of mature, activated γ/δ T cells with a cytotoxic phenotype. This group includes cases previously termed *subcutaneous panniculitis-like T-cell lymphoma with a γ/δ phenotype*.[3]

Clinical Findings: Patients have disseminated ulceronecrotic nodules or tumors, particularly on the extremities, but other sites also may be affected. Involvement of mucosal and other extranodal sites is frequent, but involvement of lymph nodes, spleen, or bone marrow is uncommon. A hemophagocytic syndrome may occur.

Histopathology: Histologically, 3 major patterns of involvement can be present in the skin: epidermotropic, dermal, and subcutaneous. The neoplastic cells are generally medium to large with coarsely clumped chromatin. Large blastic cells with vesicular nuclei and prominent nucleoli are infrequent. Apoptosis and necrosis are common, often with vessel invasion. Immunohistologically, the tumor cells have a βF1−, CD3+, CD2+, CD5−, CD7+/−, CD56+ phenotype with strong expression of cytotoxic proteins. Most cases are CD4 or lack both CD4 and CD8, although CD8 may be expressed in some cases. In frozen sections, the cells are strongly positive for TCRδ (antibody testing is not available for paraffin sections). If only paraffin sections are available, the absence of βF1 may be used to conclude a γ/δ origin.[74,75]

Treatment and Prognosis: Most patients have aggressive disease resistant to multiagent chemotherapy and/or radiation therapy. Median survival is 15 months.

PRIMARY CUTANEOUS ACRAL CD8+ T-CELL LYMPHOPROLIFERATION

Definition: This entity is characterized by indolent cutaneous, CD8+ lymphoid proliferation originating predominately in the ear, with a favorable prognosis.

Clinical Features: Indolent cutaneous, CD8+ lymphoid proliferation, typically presents with solitary skin lesions on the face or at acral sites. Solitary papules or, in some cases, bilateral plaques, have been described on the feet.

Histopathology: Histologically, indolent CD8+ lymphoid proliferations are characterized by a dense dermal infiltrate of nonepidermotropic, medium-sized pleomorphic clonal CD8+ T cells, mostly of the nonactivated cytotoxic phenotype, showing, in the majority of cases, a clear cut grenz zone and a low proliferation index.

Differentiation from otherwise aggressive T-cell lymphomas bearing a cytotoxic CD8+ phenotype is fundamental to avoid unnecessary anxiety for the patient and unwarranted aggressive treatment that would be considered as part of the therapeutic algorithm for the CD8+ phenotype.

It has recently been suggested that CD68 could be a new discriminative marker, helpful in distinguishing

indolent CD8+ lymphoid proliferation from other CD8+ cutaneous lymphomas in ambiguous cases.

Treatment and Prognosis: Treatment is based on local excision or radiation therapy. Complete remission lasts for years and the prognosis is excellent.[81]

STAGING OF CUTANEOUS T-CELL LYMPHOMA

After establishing the diagnosis of a CTCL, appropriate staging investigations are mandatory to exclude secondary involvement of the skin by an extracutaneous lymphoma and to determine the extent of disease. The first classification and staging system of CTCLs was published in 1979 by the MF Cooperative Group. It is recognized that this staging system does not apply to all CTCL types listed in the current WHO classification. Furthermore, the Ann Arbor system, commonly used for staging of nodal non-Hodgkin lymphomas, is not suitable for all CTCL types. Because of these facts and new data on prognostic factors, both revisions of the staging and classification for MF and Sézary syndrome and a TNM (tumor, node, metastasis) classification system for cutaneous lymphomas other than MF and Sézary syndrome have been proposed by the EORTC and the ISCL. It has to be mentioned that staging according to the TNM system has been proven to be useful for choosing an appropriate therapy for patients with MF and Sézary syndrome, but data correlating results of the TNM staging and prognosis are missing for some types of CTCLs. Staging examination for all types of CTCLs includes examination of the entire skin, chest radiography, and ultrasonography of abdominal organs and peripheral lymph nodes (cervical, axillary, and inguinal). Blood investigations should include complete blood cell count, clinical chemistry with liver enzymes, kidney function tests, and lactate dehydrogenase level, as well as T-cell clonality. Staging may be completed by CT scan and/or histologic and molecular (TCR rearrangement) investigations of suspicious lymph nodes and/or visceral organs. Staging examination should be repeated at relapse or progression of disease. A bone marrow examination is only recommended at a B2 blood rating (Table 119-7) or where there are unexplained hematologic abnormalities. However, this procedure is not of direct clinical relevance, as detection of atypical cells in the bone marrow is not an independent prognostic factor.

The aforementioned investigations allow for classification according to the TNM system (see Tables 119-4 and 119-7). Although the prognostic value and applicability of TNM staging for different CTCLs is controversial, the TNM scheme directs the decision-making process toward an appropriate therapeutic regimen for most CTCLs.

TABLE 119-7
Staging System for Mycosis Fungoides and Sézary Syndrome

STAGE	T (TUMOR)	N (LYMPH NODE)	M (METASTASES)	B (BLOOD)
IA	T1	N0	M0	B0 or B1
IB	T2	N0	M0	B0 or B1
IIA	T1 or T2	N1 or N2	M0	B0 or B1
IIB	T3	N0-N2	M0	B0 or B1
III	T4	N0-N2	M0	B0 or B1
IIIA	T4	N0-N2	M0	B0
IIIB	T4	N0-N2	M0	B1
IVA1	T1-T4	N0-N2	M0	B2
IVA2	T1-T4	N3	M0	B0-B2
IVB	T1-T4	N0-N3	M1	B0-B2

T1, patch/plaque on ≤10% of body surface; T2, patch/plaque on ≥10% of body surface; T3, skin tumor(s); T4, erythroderma; N0, normal nodes; N1, palpable nodes without clear histologic evidence of lymphoma (for N1 and N2, "a" or "b" may be added for either no [a] or detection [b] of a T-cell clone by Southern blot or polymerase chain reaction [PCR] analysis); N2, palpable nodes, histologic evidence of lymphoma, node architecture preserved; N3, palpable nodes with histologic evidence of lymphoma, effacement of node architecture; M0, no visceral involvement; M1, histologically confirmed visceral involvement. B0, ≤5% Sézary cells (for B0 and B1, "a" or "b" may be added for either no [a] or detection [b] of a T-cell clone by Southern blot or PCR analysis); B1, >5% Sézary cells but either less than 1.0 K/μL absolute Sézary cells or absence of a clonal rearrangement of the TCR or both; clonal rearrangement of the TCR in the blood and either 1.0 K/μL or more Sézary cells or one of the following 2: (a) increased CD4+ or CD3+ cells with CD4/CD8 of 10 or more or (b) increase in CD4+ cells with an abnormal phenotype (>40% CD4+/CD7− or >30% CD4+/CD26−).

PRINCIPLES OF TREATMENT OF CUTANEOUS T-CELL LYMPHOMA

Every successful strategy in managing CTCL begins with the correct diagnosis and staging. The prognosis and survival of patients does not only vary based on the type of cutaneous lymphoma but also on the stage; each lymphoma has its own best treatment to date, which is primarily stage based. Current staging is based on the proposal of the ISCL and the Cutaneous Lymphoma Task Force of the EORTC as published in the journal *Blood* in 2007.[66]

Table 119-8 outlines the international staging system for cutaneous lymphomas other than MF and Sézary syndrome.

Once the individual classification of TNMB (tumor, node, metastasis, blood) has been determined, then these cases can be rolled into the staging system for MF and Sézary syndrome.

To assess the response to a given treatment, a consensus statement of criteria was established by the International Society of Cutaneous T-cell Lymphomas, the United States Cutaneous Lymphoma Consortium, and

TABLE 119-8

Staging System for Cutaneous Lymphomas Other Than Mycosis Fungoides and Sézary Syndrome

T (Tumor)

- T1: solitary skin involvement
  - T1a: a solitary lesion with a diameter <5 cm
  - T1b: a solitary lesion with a diameter >5 cm
- T2: regional skin involvement: multiple lesions limited to 1 body region or 2 contiguous body regions[a]
  - T2a: all-disease-encompassing in a circular area with a diameter <15 cm
  - T2b: all-disease-encompassing in a circular area with a diameter >15 but <30 cm
  - T2c: all-disease-encompassing in a circular area with a diameter >30 cm
- T3: generalized skin involvement
  - T3a: multiple lesions involving 2 noncontiguous body regions
  - T3b: multiple lesions involving ≥3 body regions

N (Lymph Node)

- N0: No clinical or pathologic lymph node involvement
- N1: Involvement of 1 peripheral lymph node region[b] that drains an area of current or prior skin involvement
- N2: Involvement of 2 or more peripheral lymph node regions[b] or involvement of any lymph node region that does not drain an area of current or prior skin involvement
- N3: Involvement of central lymph nodes

M (Metastases)

- M0: No evidence of extracutaneous non–lymph node disease
- M1: Extracutaneous non–lymph node disease present

[a]Definition of body regions.[61]

[b]Definition of lymph node regions is consistent with the Ann Arbor system: Peripheral sites: antecubital, cervical, supraclavicular, axillary, inguinal-femoral, and popliteal. Central sites: mediastinal, pulmonary hilar, paraortic, iliac.

the Cutaneous Lymphoma Task Force of the EORTC, and published in 2011.[82] A global response score for MF and Sézary syndrome was established that addresses the entire TNMB spectrum, not only the response in the skin. However, as of this writing, there are still some problems regarding staging and prediction of survival. Indeed, survival does not always correlate with conventional staging: there is an overlap between Stages IIB versus III, and IB with folliculotropic MF.

Many prognostic factors are still outside the staging system and have to be evaluated in prognostic trials.

As of this writing, the most valid prognostic factors are age older than 60 years, tumor burden, and large-cell transformation. A prognostic index model was published by Scarisbrick et al.[63]

The chronic disease course of the most frequently occurring CTCL subtypes, MF and Sézary syndrome, makes surrogate markers necessary and tumor burden is still the best surrogate marker for survival. Additional measures of symptoms, like pruritus or quality-of-life assessments, are commonly used; skin scores provide a measure of objective responses to therapy; and questionnaires guide the assessment of subjective responses to therapy. It has not been shown that reducing disease in a patient from T3 to T1 is accompanied by any survival benefit, yet it is also recognized that a cure is unattainable unless the patient is first in remission with a skin score of 0 by whatever skin scoring system is used. Thus, remission is the first step toward cure.

Treatment of CTCL ideally requires a multidisciplinary team that includes dermatologists, radiation oncologists, and hematological-medical oncologists. The National Comprehensive Cancer Network, the EORTC, and the European Medical Society of Oncology have developed treatment guidelines that might be helpful in guiding therapeutic strategies. With a chronic disease like CTCL, supportive care, addressing quality of life, and reducing symptoms like pruritus and skin infections are mandatory for improving the quality of life of patients with CTCL.[83,84]

Table 119-9 outlines treatment algorithms for MF and Sézary syndrome.

TREATMENT OF EARLY STAGE MYCOSIS FUNGOIDES

Treatment of early stage MF usually involves skin-directed therapy, with or without systemic therapy. Established skin-directed therapy approaches consist of UVB phototherapy, PUVA phototherapy, topical corticosteroids, topical chlormethine, topical retinoids (eg, bexarotene), and radiation (eg, external beam radiotherapy and total skin electron beam therapy).

IMIQUIMOD AND RESIQUIMOD

Imiquimod and resiquimod are novel topical immune response modifiers belonging to the imidazoquinoline family of drugs. They are Toll-like receptor agonists that, when used topically or injected into lesions or tumors, may cause systemic effects. Both imiquimod and resiquimod induce synthesis and release of the cytokines IFN-α, tumor necrosis factor-α, IL-6, and IL-12 that all activate the adaptive immune response toward Th1 or the cell-mediated pathway, while inhibiting the Th2 pathway. Promising results have been reported with resiquimod.[85,86]

LOCAL AND TOTAL SKIN ELECTRON BEAM THERAPY

Total skin electron beam is perhaps the most effective of all skin-directed therapies. It is often used locally in patients with skin-limited disease, especially resistant plaques and tumors. Combined initial data of 11,065 patients with total skin electron beam therapy showed complete response rates close to 70%. Complete response rates are higher in patients with T1-limited disease where use of early, low-dose radiation toward solitary lesions may lead to a cure. However, total skin electron beam is usually reserved for patients with greater skin involvement than IA, especially

TABLE 119-9
Treatment Algorithms for Mycosis Fungoides and Sézary Syndrome

		LEVEL OF EVIDENCE
Recommendations for First-Line Treatment of Mycosis Fungoides (MF) Stages IA, IB, and IIA		
Expectant policy (mainly T1a)		Level 4
SDT[a]	Topical corticosteroids (mainly T1a and T2a)	Level 3
	UVB (ultraviolet B) (mainly T1a and T2a)	Level 2
	PUVA (psoralen and ultraviolet A)	Level 2
	Localized radiotherapy (RT) (for localized MF including pagetoid reticulosis)	Level 4
Recommendations for Second-Line Treatment of MF Stages IA, IB, and IIA		
Systemic therapies[b]		
	Retinoids[c]	Level 2
	Interferon (IFN)-α	Level 2
Total skin electron beam (TSEB) (mainly T2b)		Level 2
Low-dose methotrexate (MTX)		Level 4
Recommendations for First-Line Treatment of MF Stage IIB		
Systemic therapies[b]		
	Retinoids[c]	Level 2
	IFN-α	Level 2
TSEB		Level 2
Monochemotherapy (gemcitabine, pegylated liposomal doxorubicin)		Level 4
Low-dose MTX		Level 4
Localized RT[d]		Level 4
Recommendations for Second-Line Treatment of MF Stage IIB		
Polychemotherapy[e]		Level 3
Allogeneic stem cell transplantation[f]		Level 3
Recommendations for First-Line Treatment of MF Stages IIIA and IIIB		
Systemic therapies[b]		
	Retinoids[c]	Level 2
	IFN-α	Level 2
Extracorporeal photochemotherapy (ECP)[g]		Level 3
Low-dose MTX		Level 4
TSEB		Level 2
Recommendations for Second-Line Treatment of MF Stages IIIA and IIIB		
Monochemotherapy (gemcitabine, pegylated liposomal doxorubicin)		Level 3
Allogeneic stem cell transplantation[h]		Level 3
Recommendations for Treatment of MF Stages IVA and IVB[i]		
Chemotherapy (gemcitabine, pegylated liposomal doxorubicin, CHOP, and CHOP-like polychemotherapy)[j]		Level 3
Radiotherapy (TSEB and localized)[k]		Level 4
Alemtuzumab (mainly in B2)		Level 4
Allogeneic stem cell transplantation		Level 3
Recommendations for First-Line Treatment of Sézary Syndrome		
ECP[p]		Level 3
Chlorambucil + prednisone		Level 3
Systemic therapies in combination with ECP or PUVA		
	Retinoids[c]	Level 3
	IFN-α	Level 3
Low-dose MTX		Level 4

(*Continued*)

TABLE 119-9
Treatment Algorithms for Mycosis Fungoides and Sézary Syndrome (*Continued*)

	LEVEL OF EVIDENCE
Recommendations for Second-Line Treatment of Sézary Syndrome	
Chemotherapy (gemcitabine, pegylated liposomal doxorubicin, CHOP, and CHOP-like polychemotherapy)	Level 3
Alemtuzumab	Level 4
Allogeneic stem cell transplantation[h]	Level 3
Agents That Can Be Used for Maintenance After Remission Has Been Achieved in MF and Sézary Syndrome[i]	
ECP	
IFN-α	
Low-dose MTX	
Mechlorethamine	
PUVA	
Retinoids	
Topical corticosteroids	
UVB	

[a]Skin-directed therapy.
[b]The following agents are most commonly combined with PUVA; combinations with other modalities and with each other are also widely used.
[c]Including retinoic acid receptor (RAR) and retinoid X receptor (RXR) agonists.
[d]Used as add-on treatment in combination with systemic and other SDTs.
[e]CHOP (cyclophosphamide, doxorubicin, vincristine, and prednisone) is the most widely used regimen with a number of variants and other combinations available.
[f]Should be restricted to exceptional patients, see text for details.
[g]ECP can be used alone or in combination with skin-directed and other systemic therapies.
[h]Should be restricted to exceptional patients.
[i]For treatment of MF Stage IVA1, recommendations for Sézary syndrome might apply.
[j]Monochemotherapy should be preferentially used.
[k]Used alone or in combination with systemic therapies.
[l]Options are listed alphabetically and should be chosen to be effective, tolerable, easy to use, and efficient. Oxford Center for Evidence-Based Medicine levels are generally 5.
Adapted from Trautinger F, Eder J, Assaf C, et al. EORTC consensus recommendations for the treatment of mycosis fungoides/Sézary syndrome—update 2017. *Eur J Cancer*. 2017;77:57-74.

for extensive plaques or for palliation of Sézary syndrome or prior to nonablative allogeneic stem cell transplantation.

In solitary nodules in Stage IIB disease, control may be achieved using a lower dose of 4 to 8 Gy administered for single refractory lesions or using low-dose 12 Gy total-body administration. Lower doses are effective and provide an opportunity for multiple treatments to be given without undue toxicity.[87-89]

MAINTENANCE THERAPY AND TOPICAL STEROID THERAPY

The concept of treating normal skin evolved from the clinical experiences with skin-directed therapies. There are 2 components to this approach: the treatment of normal skin during remission-induction skin-directed therapy and the treatment of normal skin during the remission-maintenance phase. Topical chemotherapy, PUVA, and total skin electron beam radiation all involve the exposure of normal skin as an integral component of their success in achieving remission. This success reflects the ability of the therapy to interrupt the critical skin-based phase of the lifecycle of a recirculating CTCL cell. Once remission has been achieved, normal skin can be maintained with lower doses and frequencies of the therapies used to clear it. Maintenance therapies have been described with PUVA, total skin application of nitrogen mustard, extracorporeal photochemotherapy (ECP), and IFN. The most commonly used maintenance therapy is PUVA or UVB irradiation. As a maintenance therapy, PUVA is initially administered at once-weekly intervals for 1 year. Beginning with the second year of treatment, the schedule is changed to every other week for another year, to every third week for the following year, and, finally, to every fourth week for 2 years. At this point, the patient should have been in remission for 5 years. Consideration should be given to stopping therapy at this point. A cure is defined as freedom from

disease for 8 years off all therapy. This definition arose from the experience with nitrogen mustard treatment and total skin electron beam radiotherapy showing that after a patient achieves a remission off therapy for 5 to 8 years, late relapse is extremely rare. This would imply that malignant cutaneous T cells recirculate without causing lesions for up to 5 years. With 5 years of intermittent PUVA, it is less likely that one of these cells will survive, but it is still possible. After therapy has been discontinued, patients should not be considered cured unless they remain clear of disease for 8 years.[88,89]

The management of suspected relapse often includes the use of topical glucocorticoids and reflects the critical role this modality can play in the treatment of suspicious lesions. Early in the course of CTCL and in a relapse of the disease in a patient in remission, the T-cell activation process can be blunted by the aggressive use of topical glucocorticoids. Indeed, most patients have a history of using these agents before a firm diagnosis is made. A regimen for treating early lesions of MF is twice-daily applications of a class I topical glucocorticoid for 8 weeks. This regimen is one of the first-line modalities for suspected relapse, and it can help to identify those patients who need to undergo a 4-week "washout" before repeated biopsies are performed.

ERYTHRODERMA

In erythrodermic CTCLs, immune dysfunction and inflammatory processes initiated by the malignant cells result in total skin redness, scaling, and discomfort. It is not surprising that immune-based therapies take the forefront in the management of these disorders. The 3 major biologic response modifiers (BRMs) used in the treatment of erythrodermic CTCLs are (a) oral retinoids, (b) ECP via an intravenous route, and (c) subcutaneous injections of IFN-α (Table 119-10). In the clinical trials of these agents, patients have undergone monotherapy for what has usually been heavily pretreated refractory disease. In practice, these treatments are often used as first-line monotherapy in erythroderma, and other agents are incorporated for combination therapies if the response is incomplete. With these agents, partial responses are more common than complete responses. Thus, if the goal is remission, combination therapy is used more commonly than monotherapy. If the goal is palliation, monotherapy with a BRM is often sufficient. The BRMs differ in terms of their administration, side effects, interactions with other therapy modalities, and availability.[83]

RETINOID THERAPY

First-generation retinoids, such as isotretinoin, have limited effect on CTCL. The synthetic retinoid bexarotene binds the retinoid X receptor with high selectivity, whereas the other available retinoids have less-specific binding patterns. In monotherapy trials, bexarotene was used at 300 mg/m^2. Responses were seen in patients in all stages of the disease: plaques, erythroderma, and tumors. Responses paralleled the secondary end points: decreases in overall body surface area involved and in overall tumor aggregate area, and improvement in pruritus. Erythrodermic patients may experience increased desquamation during the first few weeks of oral bexarotene therapy. Improvement typically starts by week 12 of therapy.

Although there appeared to be a dose–response relationship with respect to efficacy, the higher dosages were also associated with a higher rate of adverse events and dose-limiting toxicities. Of these, hypertriglyceridemia, hypercholesterolemia, neutropenia, and

TABLE 119-10
Biologic Response Modifiers for the Treatment of Erythrodermic Cutaneous T-cell Lymphomas

		DOSE OPTIONS	TIME TO EXPECTED CLINICAL RESPONSE	SIDE EFFECTS AND ADVERSE REACTIONS
Retinoid therapy		Bexarotene, 300 mg/m^2	12 weeks	Hypertriglyceridemia, hypercholesterolemia, neutropenia, central hypothyroidism, pancreatitis (reversible)
Extracorporeal photochemotherapy		Photopheresis, with 8-methoxypsoralen and ultraviolet A, on 2 consecutive days every 4 weeks	4-6 months	See Chap. 198 ("Phototherapy")
Interferon-α therapy		3 million units, 3×/week, increasing to a maximally tolerated dose (~9 million units/day)	3-6 months	Flu-like symptoms, chronic fatigue; risk for long-term neurologic toxicity (depression, neuropathy, dementia, and myelopathy); thyroiditis, liver, bone marrow toxicity
Targeted monoclonal antibodies	Alemtuzumab	Varies, according to protocol (see text)		Cytomegalovirus reactivation, opportunistic infections at higher doses
	Brentuximab vedotin	1.2-1.8 mg/kg every 3 weeks	12 weeks	Peripheral neuropathy (reversible in most)

central hypothyroidism were most common. Elevations in lipid levels occurred rapidly, within 2 to 4 weeks, and were associated with serious, but reversible, pancreatitis. Monitoring of lipids and the use of lipid-lowering drugs were helpful in controlling the lipid levels. Dosage reduction of bexarotene capsules was also required in some patients. Drug interactions of oral bexarotene with gemfibrozil and warfarin have been observed.

Patients started on bexarotene therapy develop central hypothyroidism with low levels of thyroid-stimulating hormone and free thyroxine within weeks of starting the medication. Symptoms of hypothyroidism may be subtle and include feeling fatigued and feeling cold, which may wrongly be attributed to the disease itself. Supplementation with levothyroxine while taking bexarotene alleviates the symptoms and improves tolerance of treatment. The condition is reversible within weeks of stopping therapy. There is no immunosuppression with bexarotene therapy. Patients taking bexarotene typically have monthly monitoring visits to follow lipid, liver, and thyroid parameters.[90-94]

EXTRACORPOREAL PHOTOCHEMOTHERAPY

Refer to Chap. 199, "Photochemotherapy and Photodynamic Therapy" for an in-depth discussion of ECP.

ECP involves the treatment of a portion of a patient's lymphocyte compartment with 8-methoxypsoralen in the presence of UVA light, followed by reinfusion of these cells. The treatment is performed via an intravenous line that feeds into an UVA-radiation device, and the procedure typically requires the patient to remain recumbent for 3 hours. Treatments are conducted on 2 consecutive days every 4 weeks. Erythrodermic CTCLs can be managed with ECP monotherapy, but treatment of other disease stages with monotherapy has not been rigorously studied. In a multicenter study involving erythrodermic CTCL patients, approximately one-fourth had a complete response, one-fourth had no response, and the remainder had partial responses. However, it is clear that even a partial response can improve the quality of life of these patients. Improvement sometimes began as early as 6 weeks into therapy, but some patients did not show complete lesion clearance until 12 months after starting therapy. There were occasional temporary responses immediately after a 2-day cycle of therapy. On average, after 4 to 6 months there was typically a gradual and permanent decrease in erythema, scaling, and pruritus. Patients often notice more subtle changes, such as the return of body hair, loss of rigors, and a return of the ability to sweat. Partial responses may also decrease the morbidity these patients experience in terms of infectious complications. More heavily involved and inflamed skin is more readily colonized, providing both a reservoir and access point for microbes to invade the host. Thus, cutaneous improvement can also minimize complications of CTCLs.

The clinical experiences with ECP for erythrodermic MF and Sézary syndrome suggest that the therapeutic response may well be based in the immune system. One feature is that when less than 5% of the malignant lymphocyte pool is photoinactivated with 8-methoxypsoralen and UVA light, clinical responses can be seen, with more than 95% of the malignant lymphocytes disappearing over time. It also appears that most immunocompetent patients respond. Patients, who were heavily pretreated, with longer disease durations, were less responsive. Also, patients with normal or only slightly decreased CD8+ lymphocyte levels were responsive to ECP. In one study, total skin electron beam radiotherapy was combined with ECP in patients with Stage T3 and Stage T4 disease. Comparison of patients receiving skin-directed radiotherapy plus BRM with historic controls who underwent electron beam radiotherapy at the same institution demonstrated the impact of ECP, because patients in the skin-directed therapy plus BRM group showed significantly longer survival.[95,96]

INTERFERON-α THERAPY

In the treatment of CTCLs, the most-studied IFN is IFN-α; however, clinical studies regarding the use of IFN-β and IFN-γ in the treatment of CTCLs have also been conducted. The initial studies using IFN-α as monotherapy showed rates of complete responses that varied from 10% to 27% with treatment durations of less than 6 months. Again, the heterogeneity of the disease and the pretreatments patients underwent before may affect outcomes and make comparisons with other modalities impossible. IFN-α is typically started at 3 million units, 3 times a week, and can be increased to a maximally tolerated dose, typically in the range of 9 million units/day. As with the other BRMs, the response to IFN is gradual, and 3 to 6 months are needed to determine the maximal response. After patients achieve a maximal response, IFN dosage can be lowered to a maintenance level.

All IFNs have similar toxicities. Initially IFN therapy is complicated by a flu-like illness that is characterized by fever, headache, myalgia, and fatigue. As this wears off, patients are often left with a slight feeling of chronic fatigue. The long-term toxicity that causes most concern is neurologic: depression, neuropathy, dementia, and myelopathy. Autoimmune phenomena, such as thyroiditis, may occur. Furthermore, toxic effects of the liver and bone marrow may occur. Monitoring of IFN therapy includes blood counts along with questionnaires assessing the impact on the patient's quality of life.[97]

TARGETED MONOCLONAL ANTIBODIES

Alemtuzumab: Alemtuzumab is a humanized monoclonal antibody that targets CD52, expressed on most T and B lymphocytes and NK cells. Lundin et al[97A] reported a response rate of 50% to 70% in patients with CTCL. Because of prolonged depression of T, B, and NK cells in the original dosage schedule and

immunosuppression, this treatment led to reactivation of cytomegalovirus and other opportunistic infections.

Alternative dosage schedules with lower doses and subcutaneous administration have been investigated. Querfeld et al[97B] reported a favorable response when intravenous alemtuzumab was followed with lower-dose subcutaneous antibody. A different schedule was proposed by Bernengo et al[99]; 4 patients received 3 mg alemtuzumab on day 1, 10 mg on day 3, and then 15 mg on alternate days. Bernengo et al reported 86% response rates in 12 of 14 refractory Sézary syndrome patients, including 3 complete remissions.

However, Rei Watanabe[98] showed that low-dose alemtuzumab is a highly effective and generally well tolerated therapy for refractory CTCL (ie, CTCL patients with peripheral blood disease).

Low-dose alemtuzumab is effective in patients with blood involvement (leukemic disease) but ineffective in MF, reflecting the fact that MF derives from distinct T-cell subsets. Patients with malignant T cells with blood disease have the phenotype of CCR7+ L-selectin+ T_{CM} that are migratory and recirculate between skin, blood, and lymph nodes, whereas MF T cells are derived from nonmigratory skin-resident T_{RM}. Low-dose alemtuzumab depletes all circulating T cells and depletes skin in recirculating malignant T cells, leading to complete, and often durable, remissions in 50% of patients while sparing benign T cells in skin. Based on the clinical experience of Rachael Clark,[98A] alemtuzumab should be used in patients with or without adjuvant skin-directed therapy and in patients with diffuse cutaneous erythema, but some investigators caution against its use in patients with preexisting plaques and/or tumors.[98,99]

Brentuximab Vedotin: The antibody drug conjugate brentuximab vedotin is an anti-CD30 monoclonal antibody conjugated via a highly stable protease cleavable linker with monomethyl auristatin E, an antitubulin agent. It is U.S. Food and Drug Administration approved for the treatment of relapsed-refractory Hodgkin lymphoma and ALCL.

In the past, CD30 has been identified as an excellent therapeutic target in lymphomas that express CD30. Histologically it is uniquely expressed in Hodgkin lymphoma, ALCL, and normal activated T, B, and NK cells, but is not expressed in normal tissues. Monoclonal antibodies that interact with CD30 are thought to induce apoptosis by initiating CD30 signaling.

CD30 is highly expressed on the surface of primary cutaneous ALCL and subtypes of lymphomatoid papulosis and variably expressed in MF morphologic subtypes, including large-cell transformed MF. The first results of Phase II clinical trials in CTCL were published recently. In the Phase II trial of brentuximab vedotin in MF or Sézary syndrome by Kim et al,[101] the overall global response was 70% among the 30 evaluable patients. CD30 expression assessed by immunohistochemistry was highly variable with a median CD30 maximum expression of 13% (range: 0%-100%); those with less than 5% CD30 expression had a lower likelihood of global response than those with greater than or equal to 5% CD30 expression. The detection of abundant macrophages CD163+ M2 type in the tumor milieu suggested that brentuximab may target these macrophages in addition to the malignant T cells and disrupt their tumor-promoting function. The detection also suggested that these CD30-bearing macrophages may offer an additional source of monomethyl auristatin E to the nearby malignant T cells.

The other Phase II study was published by Duvic et al[100] in patients with CD30 lymphoproliferative disorder or CD30 MF/Sézary syndrome. The evaluable 48 patients showed an overall response rate of 73% and a complete response rate of 35%. The median time to response was 12 weeks, and duration of response was 32 weeks (range: 3-93 weeks). All patients with lymphomatoid papulosis or primary cutaneous ALCL responded.

The most common side effect is the induction of peripheral neuropathy. Although reversible in most of the cases, some experienced irreversible neuropathy. The recommended dose of brentuximab vedotin is 1.8 mg/kg every 3 weeks; to overcome its side effects, a lower dosage of 1.2 mg/kg is recommended or prolongation of the interval between doses.

Currently, brentuximab vedotin in the treatment of CTCL is being studied in an open-label Phase III ALCANZA Study Group trial,[100A] which is comparing brentuximab vedotin with physicians' choices, either bexarotene or methotrexate, in patients with relapsed CD30+ MF or primary cutaneous ALCL.[100,101]

Mogamulizumab: Mogamulizumab is a defucosylated anti-CCR4 monoclonal antibody. It targets CCR4, a chemokine receptor that is preferentially expressed by Th2 and regulatory T cells in MF and Sézary syndrome patients. In response to its ligands, CCL17 (TARC) and CCL22 (MDC), CCR4 promotes T-cell migration to the skin. These CCR4 ligands are produced by keratinocytes, dendritic cells, and macrophages, and are abundant within MF/Sézary syndrome–involved skin. A recently described subset of peripheral T-cell lymphoma expresses CCR4 as part of the transcriptional repertoire of GATA-3, the master transcriptional regulator driving Th2 differentiation. GATA-3 is not only expressed by regulatory T cells, residing within various sites such as the skin, but also by MF/Sézary syndrome cells, and may drive CCR4 expression in these cells.

In addition to its role in regulating cell homing and trafficking, CCR4 engagement may also promote cell growth and survival. However, cells can become desensitized to CCR4 through receptor internalization, a homeostatic regulatory mechanism. Clearly, CCR4 has a pathogenic role in MF/Sézary syndrome and other T-cell lymphoproliferative disorders and is an attractive therapeutic target.

Mogamulizumab depletes CCR4-expressing cells by antibody-dependent cell-mediated cytotoxicity. Targeting the chemokine receptor CCR4, Duvic et al demonstrated that mogamulizumab is well tolerated and has significant clinical activity, with an overall response rate of 36% and a median duration of time to response of 1.4 months in heavily pretreated patients with MF

and Sézary syndrome. The same group showed that in addition to antibody-dependent cell-mediated cytotoxicity, mogamulizumab depletes regulatory T cells, an important therapeutic target in many human cancers because of the role of regulatory T cells in suppressing host antitumor immunity.

Mogamulizumab is currently being evaluated worldwide in a Phase III trial comparing mogamulizumab with the histone deacetylase inhibitor vorinostat.[102,102A]

SINGLE-AGENT CHEMOTHERAPY

More than 20 years ago, Bunn et al[103] at the National Institutes of Health concluded that multiagent chemotherapy was not superior to sequential conservative therapies with respect to overall survival in advanced CTCL. Therefore, the therapeutic approach was more concentrated to reduce systemic side effects to a single-agent chemotherapy shown to be as effective. Choice of therapy is based on stage, concomitant medical condition, and prior treatment, as each agent has unique side effects and efficacy profile.

Methotrexate, pegylated liposomal doxorubicin, gemcitabine, and pentostatin have all been studied in Phase II trials of CTCL patients.[84]

Gemcitabine: Gemcitabine hydrochloride, a nucleoside analog of deoxycytidine that inhibits DNA synthesis has shown activity against solid tumors as well as hematologic malignancies. In a number of small studies, gemcitabine, given as a dosage of 1200 mg/m^2 administered for 3 or 4 weeks for 3 courses, has shown overall response rates of 70.5% with a median duration of 15 months. Duvic et al demonstrated that a lower dose of gemcitabine (1000 mg/m^2 once per week for 3 weekly cycles) produced an overall response rate of 68% in 25 patients with advanced stage and refractory MF. It was especially active in MF patients with cutaneous tumors. Gemcitabine can be used in combination with bexarotene maintenance therapy to manage the plaques and patches of MF. It can also be alternated with liposomal doxorubicin infusion to prolong the duration of chemotherapy. The adverse effects of gemcitabine have most frequently involved bone marrow suppression (leukopenia), anemia, and, especially, thrombocytopenia.[104,105]

Pegylated Liposomal Doxorubicin: Pegylated liposomal doxorubicin is a new formulation of doxorubicin in which the drug is encapsulated in liposomes and stabilized by the attachment of polyethylene glycol (ie, pegylation) to the liposomal surface, resulting in increased half-life and improved accumulation in tumor tissues. Toxicity profile is characterized by dose-limiting mucosal and cutaneous adverse effects, in particular palmar-plantar erythrodysesthesia syndrome reporting up to 20% of treated patients.

In a prospective multicenter controlled trial by the EORTC, patients with Stage IIB, IIIB, or IVA MF, refractory or recurrent after at least 2 previous systemic therapies, were treated with 6 cycles of pegylated liposomal doxorubicin 20 mg/m^2 on days 1 and 15 over a single 28-day cycle. The primary end point was response rate. Among the 49 patients, the overall response rate was 48% with 6.1% complete remission. The median progression-free survival was 6.2 months. Toxicity (grades III to IV) was observed in 20% of the treated patients.[106]

The trial has produced benchmark data in a defined population of patients with MF in need of cytotoxic therapy. The efficacy is reasonable, and patients are allowed to use liposomal encapsulated doxorubicin as a debulking agent.

Pralatrexate: Pralatrexate, a novel antifolate with a high affinity for the reduced folate carrier (RFC-1), a novel mechanism of resistance when compared with methotrexate, was associated with an overall response rate of 29% in patients with relapsed or refractory peripheral T-cell lymphoma. A total of 12 patients with transformed MF were included in the study. Many of these patients had received more than 5 prior systemic therapies, including CHOP or CHOP-like regimens. However, results of a dose-finding study were reported in a larger cohort of CTCL patients. In this study, published by Horwitz et al,[106A] the optimal dose was identified as 15 mg/m^2, given weekly 3 weeks out of 4, and was associated with an overall response rate of 43%. In an effort to reduce the incidence of mucositis, folic acid and vitamin B_{12} supplementation was routinely provided to these patients. However, pralatrexate has not been studied in a randomized trial against established compounds in CTCL.[107]

ALLOGENEIC STEM CELL TRANSPLANTATION

Younger patients with advanced stage CTCL (Stage IIB or greater) who fail to respond to first-line therapy are now being considered for nonablative allogeneic hematopoietic stem cell transplantation.

Patients need to have a related or unrelated matched donor and be physically and emotionally able to undergo the procedure. The therapeutic concept is based on the existence of a graft-versus-T-cell-lymphoma effect particularly using nonmyeloablative conditions. Selected patients have achieved long-term remission and curative responses.

Duarte et al reported on the long-term outcome of allogeneic hematopoietic stem cell transplantation for patients with MF and Sézary syndrome. These data show that patients with advanced stage MF and Sézary syndrome continue to benefit from allogenic hematopoietic cell transplantation over time, with an overall survival of 46% at 5 years and 44% at 7 years, and progression-free survival of 32% at 5 years and 30% at 7 years. Disease-relapse progression is a main cause of posttransplantation failure; a total of 45% of patients experience relapse progression at a medium of 3.8 months after hematopoietic stem cell transplantation. In a multivariable analysis, a number of disease and transplantation factors showed an independent impact on patient outcomes. The analysis focused on nonrelapse mortality, which was borderline associated with transplants from unrelated donors. Relapse

was highly significantly associated with myeloablative conditioning versus nonmyeloablative and with a poor performance score at hematopoietic cell transplantation (Karnofsky score <70). Patients must be treated with allogeneic transplantation after having achieved complete or nearly complete remission.[108,109]

PRIMARY CUTANEOUS B-CELL LYMPHOMAS

Primary CBCLs (Table 119-11) are B-lymphocyte–derived malignancies that develop in the skin without extracutaneous involvement at the time of diagnosis and account for 20% to 25% of primary cutaneous lymphomas. The incidence of CBCL is estimated at 3 cases per 1,000,000 persons per year based on surveillance epidemiology and end results registry data.[110]

The PCMZL/extranodal marginal zone lymphoma and the PCFCL are indolent subtypes, whereas the PCLBCL, leg type has an intermediate to aggressive clinical behavior.

These 3 entities (ie, PCMZL, PCFCL, and PCLBCL) together comprise 97% of the CBCL.[111-113]

ETIOLOGY

As for CTCL, an infectious trigger has been hypothesized to be involved in the etiology of CBCL. A strong association of gastric extranodal marginal zone lymphomas and *Helicobacter pylori* infection is well known. In a minority of PCMZLs from European patients, but not in American or Asian patients, *Borrelia burgdorferi* has been detected. A newer study suggests that, based on immunoglobulin expression, 2 types of PCMZLs can be distinguished. In the most frequent PCMZL subtype, B cells expressing class-switched immunoglobulin (Ig) heavy chains, including IgG and to a lesser extend IgA or IgE, are observed. In a majority of cases, diffuse proliferation of IgM+ MCXCR3-expressing B cells is observed, which is associated with fewer infiltrating T cells and a skewed CD4-to-CD8 ratio toward an increased number of CD4+ T cells. In IgM+ cases, extracutaneous localization of disease is frequently observed, suggesting that cutaneous localizations of extranodal mucosal-associated lymphoid tissue from class-switched and non–class-switched immunoglobulin heavy chains result from distinct pathologic processes.

Detailed studies on immunoglobulin heavy-chain expression showed that PCMZL showed IgG_4 expression in 39% of cases. There was no evidence of IgG_4-related disease in any of these patients pointing to a localized immunologic IgG_4-driven process. In clinical management, these observations are helpful, as the marginal zone lymphomas presenting skin that expresses IgG_4 will invariably be PCMZL.

A viral agent, in particular hepatitis C virus, also is suspected to be relevant in the etiology of CBCL, but the results of the studies are contradictory.[110-116]

TABLE 119-11
Summary of Cutaneous B-Cell Lymphomas

	AGE AT DIAGNOSIS	NATURE OF DISEASE	CLINICAL FINDINGS	CELL OF ORIGIN	IMMUNOHISTOCHEMICAL CHARACTERISTICS	TREATMENT
Primary cutaneous follicle center lymphoma (PCFCL)	Median age at diagnosis is 58 years	Indolent	Solitary or grouped firm, painless erythematous plaques and tumors, head and trunk commonly affected	Clonal centrocytes and centroblasts	CD19+, CD20+, CD79a, CD10, Bcl6+[a]	Radiotherapy; immune therapy for disseminated lesions
Extranodal marginal zone lymphoma (EMZL)/primary cutaneous marginal zone lymphoma (PCMZL)	Median age at diagnosis is 55 years; female predominant	Indolent	Violaceous papules, plaques, or nodules; occur on multiple locations	Small B lymphocytes, marginal zone cells, lymphoplasmacytoid cells, plasma cells	CD20, CD79a, Bcl2+; plasma cells may express CD138, CD79a	Radiotherapy; systemic antibiotics if *Borrelia burgdorferi* associated; chlorambucil, rituximab, intralesional interferon
Primary cutaneous diffuse large B-cell lymphoma, leg type	Median age at diagnosis is 65 years; female predominant	Intermediate to aggressive	Solitary or clustered bluish erythematous plaques and tumors located on 1 or both legs	Large B cells	CD20+, CD79a, IRF4-MUM-1+, FOXP1+, cytoplasmic immunoglobulin M ± D, Bcl2+, Bcl6+	Rituximab, cyclophosphamide, hydroxydaunorubicin, Oncovin, prednisolone, bendamustine + rituximab regimen

[a]May be Bcl2+ with nodal disease.

PATHOGENESIS

Because of the rarity of the CBCL subtypes, studies investigating pathogenetic events in CBCL have been mainly conducted on a small number of cases. However, in recent years, considerable progress in understanding the pathogenesis of CBCL has been made.

A phenomenon called *aberrant somatic hypermutation*, which has been reported in nodal B-cell lymphomas, has been detected in the 3 main types of CBCL. This term describes the activity of the enzyme activation–induced deaminase, which contributes to the process of affinity maturation of immunoglobulins by somatic hypermutation, in regions of the genome that do not encode immunoglobulin genes. If this process occurs in oncogene-containing gene loci, in association with the loss of the physiologically high-fidelity DNA repair mechanisms, tumorigenic mutations may occur and contribute to lymphomagenesis.[79]

Furthermore, genetic investigations demonstrated distinct differences of CBCL subtypes. A genetic basis for differentiation of histologic skin PCFCL with a diffuse growth pattern of large cells and PCLBCL, leg type, was shown. The gene expression profiles of these entities were consistent with either germinal center B cells for PCFCL or activated B cells for PCLBCL, leg type. Similar results were found in a study focusing on proapoptotic and antiapoptotic genes. While PCLBCL, leg type with a poor prognosis had a genetic profile called *activate apoptosis cascade*, PCFCL and cases of PCLBCL, leg type with a favorable prognosis had a high expression level for genes that are associated with an antitumoral cytotoxic immune response. These findings also explain why PCFCL has a more favorable prognosis than PCLBCL, leg type.

Furthermore, PCMZLs were found to arise in a different pathogenetic background than extranodal marginal zone lymphomas. The main differences were the high percentage of CXCR3– PCMZLs, which also, in contrast to other extranodal marginal zone lymphoma, exhibited an immunoglobulin class switch and a Th2 cytokine milieu. It remains to be investigated how this relates to the presence of plasmacytoid dendritic cells in PCMZL, which were also found in cutaneous pseudolymphomas, but not in diffuse large B-cell lymphomas and only rarely in PCFCL.[113,117-124]

PRIMARY CUTANEOUS FOLLICULAR CENTER LYMPHOMA

DEFINITION

PCFCL can be defined as a neoplasm of clonal centrocytes (small and large cleaved follicle center cells) and centroblasts (large follicle center cells with prominent nucleoli) with or without formation of follicles.

CLINICAL FINDINGS

PCFCL usually presents with solitary or grouped firm, painless, erythematous plaques and tumors that are preferentially located on the head and trunk, and rarely present on the leg. Patients with PCFCL have a median age of 58 years at diagnosis, and adult males are affected nearly twice as often as adult females. Occasionally, an annular erythema can be observed in the surrounding area (Fig. 119-23A). A typical finding is the occurrence of lesions in a circumscribed area of the head and neck region or the trunk, but rarely on the legs.

HISTOPATHOLOGY

These tumors are composed of medium to large follicle center cells containing a mixture of centrocytes and centroblasts arranged in a follicular or diffuse

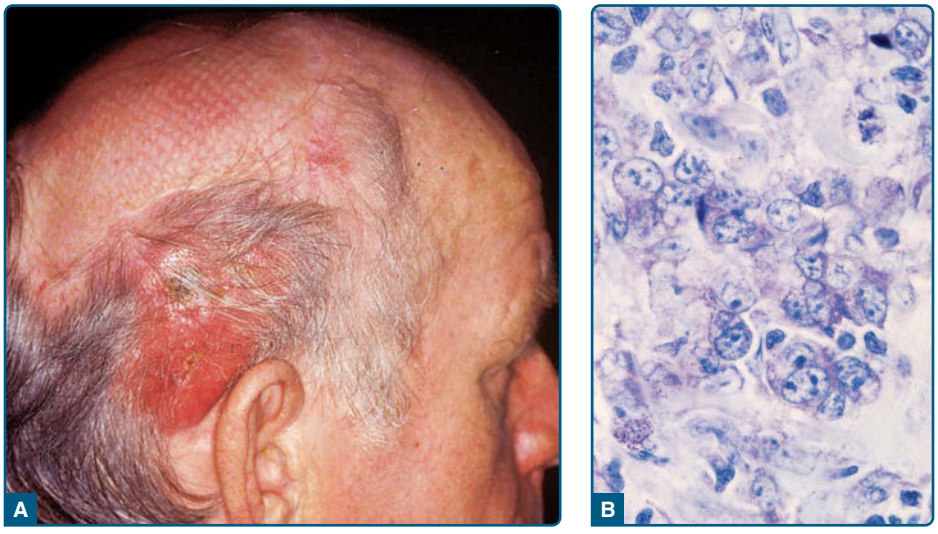

Figure 119-23 Primary cutaneous follicle center lymphoma. **A,** Tumor in the head area surrounded by erythema. **B,** The cellular infiltrate consists of a mixture of centrocytes, a number of centroblasts, and reactive T cells.

growth pattern (see Fig. 119-23B). The neoplastic cells express the pan–B-cell markers CD19, CD20, and CD79a, and express the germinal center marker Bcl6. Expression of CD10 is particularly observed in cases with a follicular growth pattern. Unlike primary cutaneous B-cell lymphoma, leg type, expression of IRF4-MUM-1, FOXP1, and cytoplasmic immunoglobulin is generally not observed. In contrast to nodal follicular center lymphomas, in most studies PCFCLs uncommonly express Bcl2 and generally do not contain the translocation t(14;18). Gene expression studies demonstrate that PCFCLs have a gene expression profile resembling germinal center B-cell–like diffuse large B-cell lymphomas. Genomic studies found c-REL amplification in 63% of cases and deletions of 14q32.33 in 68% of cases.

TREATMENT AND PROGNOSIS

PCFCLs are indolent lymphomas that rarely metastasize to extracutaneous localizations and their prognosis is excellent with a 5-year survival of greater than 95%. Approximately 5% of PCFCLs develop on the legs and these cases have a more aggressive behavior. Radiotherapy (30 Gy) is the preferred treatment for PCFCL (Table 119-12). Relapses are observed in 30% of cases, but these do not herald an adverse prognosis and can be retreated with radiotherapy. For relapses a palliative dose of 4 Gy can be used, which will result in effective local control in 90% of cases. Immune therapy, such as administration of IFN-α or monoclonal antibodies against CD20, may be beneficial in cases with disseminated lesions.[124,125]

TABLE 119-12
Treatment Algorithms for Cutaneous B-Cell Lymphomas

DISEASE TYPE AND EXTENT	FIRST-LINE THERAPY	ALTERNATIVE THERAPIES
Primary Cutaneous Marginal Zone Lymphoma		
Solitary/localized	Local radiotherapy	Interferon (IFN)-α intralesional
	Excision	Rituximab intralesional
	Antibiotics[a]	Intralesional steroids
Multifocal	Wait-and-see	IFN-α intralesional
	Local radiotherapy	Rituximab intralesional
	Chlorambucil[b]	Topical or intralesional steroids
	Rituximab IV	
	Antibiotics[a]	
Primary Cutaneous Follicle Center Lymphoma		
Solitary/localized	Local radiotherapy	IFN-α intralesional
	Excision	Rituximab intralesional
Multifocal	Wait-and-see	R-CVP/CHOP[c]
	Local radiotherapy	
	Rituximab IV	
Primary Cutaneous Diffuse Large B-Cell Lymphoma, Leg Type		
Solitary/localized	R-CHOP ± IFRT	Local radiotherapy
		Rituximab IV
Multifocal	R-CHOP	Rituximab IV

Abbreviations: CHOP, cyclophosphamide, doxorubicin, vincristine, and prednisone; IFRT, involved-field radiotherapy; R-CHOP, rituximab, cyclophosphamide, doxorubicin, vincristine, and prednisone; R-CVP, rituximab, cyclophosphamide, vincristine, and prednisone.

[a]In case of evidence for *Borrelia burgdorferi* infection.

[b]Or other single or combination regimens appropriate for low-grade B-cell lymphomas.

[c]In exceptional cases or for patients developing extracutaneous disease.

Adapted from Senff NJ, Noordijk EM, Kim YH, et al. European Organization for Research and Treatment of Cancer and International Society for Cutaneous Lymphoma consensus recommendations for the management of cutaneous B-cell lymphomas. *Blood*. 2008;112(5):1600-09, with permission.

EXTRANODAL MARGINAL ZONE B-CELL LYMPHOMA

DEFINITION

PCMZL or extranodal marginal zone lymphoma is an indolent B-cell lymphoma composed of small B lymphocytes, marginal zone cells, lymphoplasmacytoid cells, and plasma cells, which are initially localized in the marginal zone of a follicular center. In the current WHO classification, it is classified within the extranodal marginal zone lymphoma of mucosa-associated lymphatic tissue. In a subgroup of PCMZL, *B. burgdorferi* is thought to have an etiologic role.

CLINICAL FINDINGS

PCMZLs are seen most commonly on the upper extremities or the trunk and occur at a median age of 55 years; they predominate in females. Patients have small red-to-violaceous papules, plaques, or nodules that, in contrast to the lesions of PCFCL, frequently occur in multiple locations. PCMZL accounts for 25% of primary CBCLs.

HISTOPATHOLOGY

The histologic infiltrate includes marginal zone (centrocyte-like) cells, plasmacytoid cells, and plasma cells. Typically, the marginal zone cells express CD20, CD79a, and Bcl2, but are negative for CD5, CD10, and Bcl6. Plasma cells express CD138 and CD79a, and show monotypic cytoplasmic immunoglobulin light-chain expression on paraffin sections.[118,119,126,127]

TREATMENT AND PROGNOSIS

PCMZLs have been described in relation to tick bites and antigen injection, which suggests that chronic antigenic stimulation may play a role in the

pathogenesis of these lymphomas. PCMZLs are indolent lymphomas and scattered lesions can be treated with radiotherapy (see Table 119-12). In case of detection of *B. burgdorferi,* a systemic antibiotic treatment should be given first. For widespread lesions a wait-and-see approach can be adopted and symptomatic lesions can be treated with surgery, topical or intralesional steroids, or low-dose radiotherapy. In addition, systemic therapy with chlorambucil or rituximab and intralesional treatment with IFN-α or rituximab are reported to lead to complete responses in a majority of patients.[117]

PRIMARY CUTANEOUS DIFFUSE LARGE B-CELL LYMPHOMA, LEG TYPE

DEFINITION

PCLBCL, leg type, has been identified as a distinct clinical entity because of its perceived poor outcome compared with the indolent subtypes described above. This entity shows an intermediate, and in some patients aggressive, clinical course. It is defined by tumors composed of large B cells that present in the overwhelming majority of cases on the legs, but can also arise at other locations. The majority of patients with PCLBCL, leg type, have aberrations on chromosome 9p21, and loss of this region, which contains the *CDKN2A* gene, is associated with a worse prognosis.[128,129]

CLINICAL FINDINGS

PCLBCL, leg type affects elderly patients (older than age 65 years), with a predominance in females. Typically, patients have solitary or clustered bluish erythematous plaques and tumors located on one or, sometimes, both legs (Fig. 119-24A); approximately 10% of patients present with lesions at other sites than the legs. Ulceration is common and sometimes leads to the misdiagnosis of an ulcer from chronic venous insufficiency.

HISTOPATHOLOGY

The diffuse infiltrate shows sheets of immunoblasts and centroblasts with few mixed reactive cells (see Fig. 119-24B). The neoplastic cells express CD20 and CD79a, and, unlike PCFCL, are strongly positive for Bcl2, IRF4-MUM1, and FOXP1, and have cytoplasmic expression of IgM ± IgD. Bcl6 is expressed in most cases, whereas CD10 is generally absent. In line with the immunophenotypic profile, PCLBCL, leg type has a gene expression profile resembling activated B cells diffuse large B-cell lymphoma. In addition, PCLBCL, leg type expresses activation-induced cytidine desaminase, solves thermotic hypermutation of the immunoglobulin genes, and harbors mutations in the *Bcl6*, *Myc*, *Rho-TTF*, and *PAX5* genes, which are indicative of ectopic somatic hypermutation. Translocations have been observed for Myc in up to 43% of PCLBCL, leg type cases, and Bcl6 in up to 46% of PCLBCL, leg type cases. Studies on copy number alterations describe high-level amplifications for the *Bcl2* gene in 67% of cases and loss of CDKN2a in 23% to 42% of patients.

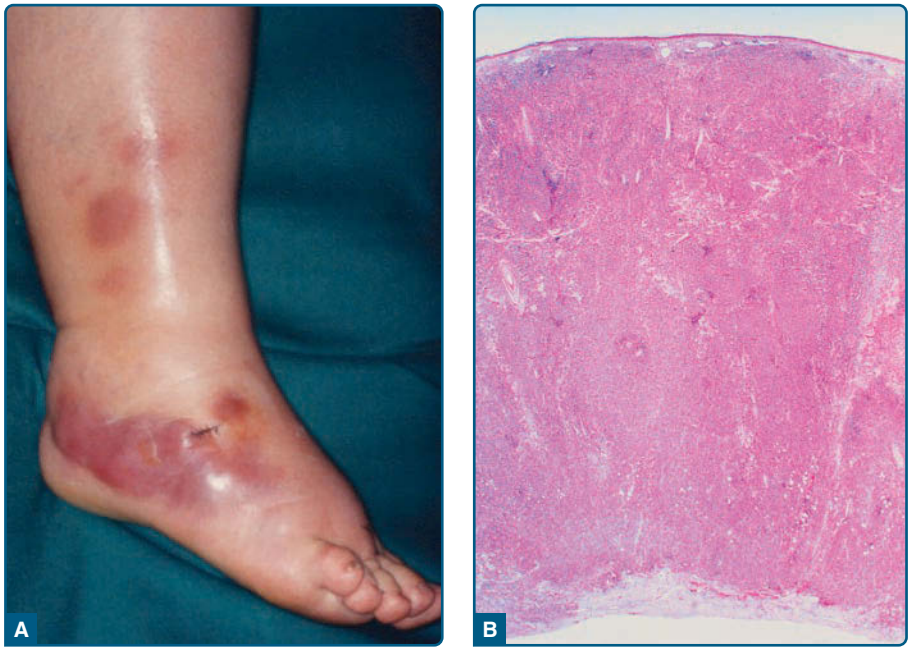

Figure 119-24 Primary cutaneous diffuse large B-cell lymphoma, leg type. **A,** Nodules and tumors on the right leg. **B,** Histology shows a diffuse infiltrate of large B cells with centroblasts, large centrocytes, and numerous immunoblasts.

Loss of CDKN2a expression either by gene deletion or promoter methylation correlates with an adverse prognosis.

TREATMENT AND PROGNOSIS

PCLBCL, leg type, belongs to the intermediate-aggressive group of CBCLs and should preferentially be treated with rituximab, cyclophosphamide, hydroxydaunorubicin, Oncovin (vincristine), and prednisolone (R-CHOP) (see Table 119-12). In general, age-adapted polychemotherapy combined with rituximab showed a better outcome than polychemotherapy regimens alone.[125] Because PCLBCL, leg type, occurs in elderly women (older than age 80 years), less-toxic regimens like bendamustine combined with rituximab could also be recommended. Despite this treatment, recurrences are observed in the majority of patients, and disease-related 5-year survival is approximately 50%.

PRIMARY CUTANEOUS DIFFUSE LARGE B-CELL LYMPHOMA, OTHER

PCLBCL, other, covers diffuse large B-cell lymphomas that do not belong to either PCLBCL, leg type, or PCFCL. These cases may represent a skin manifestation of systemic lymphomas. T-cell/histocyte-rich B-cell lymphomas with skin lesions only are also included; these cases show, in contrast to their nodal counterparts, an excellent prognosis.

INTRAVASCULAR CUTANEOUS B-CELL LYMPHOMA

Intravascular CBCL is characterized by clusters of large neoplastic B cells within dermal and subcutaneous blood vessels. Occasionally, slight extravascular infiltrates of atypical cells are observed. Clinically, red to bluish, indurated plaques occur on the legs or trunk. Sometimes, a panniculitis-like pattern can be seen. Multiagent chemotherapy is the preferred mode of treatment.[130,131]

STAGING OF CUTANEOUS B-CELL LYMPHOMA

The International Society for Cutaneous Lymphoma and the Cutaneous Lymphoma Task Force of the EORTC developed a proposal for a tumor-node-metastases (TNM) classification for cutaneous lymphomas, other than MF and Sézary syndrome (see Table 119-4). Recommended staging procedures for primary cutaneous B-cell lymphomas (PCBL) included thorough physical examination, laboratory studies, including a complete blood cell count, blood chemistry, including lactate dehydrogenase level, and, if indicated, a serum electrophoresis to exclude monoclonal gammopathy and/or flow cytometry on peripheral blood.

In endemic regions, *Borrelia* serologic testing and polymerase chain reaction of skin biopsy specimens should be performed.

Imaging studies include a contrast-enhanced CT scan with or without positron emission tomography, for chest, abdomen, and pelvis, and if lesions arose on the head and neck area, of the neck. Bone marrow biopsy and aspirate are required in PCFCL and PCLBCL, leg type, but are not required in patients presenting with a B-cell lymphoma in the skin with histologic features suggesting a follicular center lymphoma or marginal zone lymphoma, unless indicated by other staging assessments. However, a study by Senff et al[131A] demonstrated bone marrow involvement at diagnosis in 22 (11%) of 193 PCFCLs in 9 patients. Bone marrow involvement was the only extracutaneous localization. Because these patients with skin and bone marrow localization had significantly worse prognoses than patients with only skin lesions, it was suggested that bone marrow examination should be considered in these patients.

The proposed staging system for CBCL has been investigated in retrospective studies, demonstrating that the TNM system is a useful tool when documenting the extent of disease in CBCLs and for providing prognostic information in PCLBCL, leg type.

PRINCIPLES OF TREATMENT OF CUTANEOUS B-CELL LYMPHOMA

Treatment of primary CBCLs (see Table 119-12) should be adapted to the favorable prognosis of these lymphomas, in particular of PCFCL and PCMZL. Because no curative regimen has been defined as of this writing, therapy depends on the lymphoma and the dissemination of cutaneous lesions. In the case of solitary lesions, complete excision of the tumor may be proposed. Alternatively, or in the case of few localized lesions, local irradiation (a single dose of 3-4 Gy; total dose of 30-40 Gy) by X-ray or electron beam is effective. When this regimen is used, long-lasting remissions can be achieved.[125,132]

Systemic treatment is recommended for disseminated PCMZL or PCFCL with anti-CD20 antibodies. For relapse of indolent CBCLs with disseminated lesions a wait-and-see strategy combined with treatment of symptomatic lesions may be followed.

Systemic treatment regimens are recommended in cases of PCLBCL, leg type, and in PCFCL with localization on the legs, as these PCFCLs have a worse

prognosis, as well as when secondary extracutaneous manifestations are present. Polychemotherapy (6 cycles of CHOP or COP [cyclophosphamide, vincristine, and prednisone]) in combination with an anti-CD20 antibody is recommended. In patients who would not tolerate such an aggressive treatment, local radiotherapy or rituximab monotherapy may be considered.

PRECURSOR NEOPLASMS

BLASTIC PLASMACYTOID DENDRITIC CELL NEOPLASM

DEFINITION

According to the current WHO classification, blastic plasmacytoid dendritic cell neoplasm (BPDCN) is classified as an acute myeloid leukemia–related precursor neoplasm that derives from precursors of plasmacytoid dendritic cells. BPDCN is an orphan disease with a very aggressive clinical course that results in median survival times of 12 to 14 months.

CLINICAL FINDINGS

BPDCN usually occurs in elderly patients with a median age between 60 and 70 years. However, BPDCN can present at any age, even in children. More often BPDCN occurs in men (male-to-female ratio: 3:1) but has no known racial or ethnic predilection. Patients typically present with asymptomatic solitary or multiple skin lesions, such as nodules, plaques, or bruise-like lesions that can range in size from a few millimeters to 10 cm (Fig. 119-25). The skin lesions can be associated with erythema, hyperpigmentation, purpura, or ulceration. Extracutaneous disease is present in most patients at diagnosis, often involving the regional lymph nodes. As the disease continues to progress, the peripheral blood and bone marrow become involved.

Figure 119-25 Blastic plasmacytoid dendritic cell neoplasm. Multiple lesions on the back. The large tumor was the initial site of manifestation (centrally located is the scar of a biopsy). The multiple small lesions developed in a short period of time.

In 10% to 20% of patients with BPDCN, coincident myelodysplasia that can subsequently lead to the development of acute myelomonocytic leukemia is identified.

HISTOPATHOLOGY

In cutaneous lesions, BPDCN typically infiltrates the dermis but spares the epidermis. As the disease progresses, it frequently extends into the subcutaneous fat. The neoplastic cells tend to aggregate in the superficial to mid dermis in a perivascular and/or periadnexal distribution, although, less frequently, they may be seen as a lichenoid infiltrate in the superficial dermis. At high magnification, BPDCN is characterized by a monotonous population of small to medium cells with irregular nuclear contours, fine to evenly dispersed chromatin, 1 to 3 small nucleoli, and scant to moderate amounts of cytoplasm.

By immunohistochemistry, the BPDCN cells typically express CD56, CD4, CD123, and T-cell leukemia/lymphoma 1 (TCL1). They can also express other plasmacytoid dendritic cell–associated antigens, such as blood dendritic cell antigen 2 (BDCA-2)/CD303 and the IFN-α–dependent molecule MxA.

PATHOGENESIS

BPDCN cells demonstrate a recurrent recombination of deletions in several tumor-suppressor genes, including *RB1*, *CDKN1B*, *CDKN2A*, and tumor protein P53 (*TP53*). The *TET2* gene (ten-eleven translocation-2) located on band 4q24 is mutated in BPDCN, myelodysplastic syndromes, chronic myelomonocytic leukemia, and acute myelomonocytic leukemia, which provides addition evidence that BPDCN is a myeloid-related neoplasm.

Targeted ultradeep sequencing revealed recurrent and mutually exclusive mutation of cancer genes in BPDCN. In 33 BPDCN samples, point mutations in *NRAS* (27.3%), *ATM* (21.2%), *MET*, *KRAS*, *IDH2*, and *KIT* (9.1% each) occurred. Moreover, *NRAS*, *KRAS*, and *ATM* mutations were found to be mutually exclusive. *CDKN2A* deletions were detected in 27.3% of the cases, followed by deletion of *RB1* (9.1%). The mutual exclusive distribution of some mutations may point to different subgroups of BPDCN, the biologic significance of which remains to be explored.[131,133,134]

TREATMENT AND PROGNOSIS

BPDCN is associated with a highly aggressive clinical course and thus a poor prognosis (median survival of 14 months). Although systemic chemotherapy is the first choice for treatment of this disease, gemcitabine may be useful to control the initial disease so that the patient can be referred as fast as possible for bone marrow transplantation.[135,136]

Another possibly promising approach is to address the IL-3 receptor CD123 by an immunoconjugate.[137]

REFERENCES

1. Willemze R, Jaffe ES, Burg G, et al. WHO-EORTC classification for cutaneous lymphomas. *Blood*. 2005;105:3768-3785.
2. Swerdlow SH, Campo E, Harris NL, et al. *WHO Classification of Tumours of Hematopoetic and Lymphoid Tissues*. 4th ed. Lyon, France: IARC Press; 2008.
3. Swerdlow SH, Campo E, Harris NL, et al. The 2016 revision of the World Health Organization classification of lymphoid neoplasms. *Blood*. 2016;127:2375-2390.
4. Weinstock MA, Gardstein B. Twenty-year trends in the reported incidence of mycosis fungoides and associated mortality. *Am J Public Health*. 1999;89:1240-1244.
5. Bradford PT, Devesa SS, Anderson WF, et al. Cutaneous lymphoma incidence pattern in the United States: a population-based study of 3884 cases. *Blood*. 2009;113:5064-5073.
6. Korgavkar K, Xiong M, Weinstock MA. Changing incidence trends in cutaneous lymphoma. *JAMA Dermatol*. 2013;149:1295-1299.
7. Clark RA, Chong B, Mirchandani N, et al. The vast majority of CLA+ T cells are resident in normal skin. *J Immunol*. 2006;176:4431-4439.
8. Reiss Y, Proudfoot AE, Power CA, et al. CC chemokine receptor (CCR)4 and the CCR 10 ligand cutaneous T cell-attracting chemokine (CTACK) in lymphocyte trafficking in inflamed skin. *J Exp Med*. 2001;194:1541-1547.
9. Homey B, Alenius H, Muller A, et al. CCL27-CCR10 interactions regulate T cell-mediated skin inflammation. *Nat Med*. 2002;8:157-165.
10. Kirsch IR, Watanabe R, O'Malley JT, et al. TCR sequencing facilitates diagnoses and identifies mature T cells as the cell of origin in CTCL. *Sci Transl Med*. 2015;7:308ra158.
11. Watanabe R, Gehad A, Yang C, et al. Human skin is protected by four functionally and phenotypically discrete populations of resident and recirculating memory T cells. *Sci Transl Med*. 2015;7:279ra39.
12. Assaf CGS, Steinhoff M, Nashan D, et al. Cutaneous lymphomas in Germany: an analysis of the central cutaneous lymphoma registry of the German Society of Dermatology (DDG). *J Dtsch Dermatol Ges*. 2007;5:662-668.
13. Wilcox RA. Cutaneous T-cell lymphoma: 2016 Update on diagnosis, risk-stratification, and management. *Am J Hematol*. 2016;91:152-165.
14. Tan RS, Butterworth CM, McLaughlin H, et al. Mycosis fungoides—a disease of antigen persistence. *Br J Dermatol*. 1974;91:607-616.
15. Jackow CM, McHam JB, Friss A, et al. HLA-DR5 and DQB1*03 class II alleles are associated with cutaneous T-cell lymphoma. *J Invest Dermatol*. 1996;107:373-376.
16. Hodak E, Lapidoth M, Kohn K, et al. Mycosis fungoides: HLA class II associations among Ashkenazi and non-Ashkenazi Jewish patients. *Br J Dermatol*. 2001;145:974-980.
17. Pancake BA, Zucker-Franklin D, Coutavas EE. The cutaneous T cell lymphoma, mycosis fungoides, is a human T cell lymphotropic virus-associated disease. A study of 50 patients. *J Clin Invest*. 1995;95:547-550.
18. Zendri E, Pilotti E, Perez M, et al. The HTLV tax-like sequences in cutaneous T-cell lymphoma patients. *J Invest Dermatol*. 2008;128:489-492.
19. Courgnaud V, Duthanh A, Guillot B, et al. Absence of HTLV-related sequences in skin lesions and peripheral blood of cutaneous T-cell lymphomas. *J Invest Dermatol*. 2009;129:2520-2522.
20. Pawlaczyk M, Filas V, Sobieska M, et al. No evidence of HTLV-I infection in patients with mycosis fungoides and Sezary syndrome. *Neoplasma*. 2005;52:52-55.
21. Bazarbachi A, Soriano V, Pawson R, et al. Mycosis fungoides and Sezary syndrome are not associated with HTLV-I infection: an international study. *Br J Haematol*. 1997;98:927-933.
22. De Francesco MA, Gargiulo F, Esteban P, et al. Polymorphism analysis of Epstein-Barr virus isolates of lymphoblastoid cell lines from patients with mycosis fungoides. *J Med Microbiol*. 2004;53:381-387.
23. Novelli M, Merlino C, Ponti R, et al. Epstein-Barr virus in cutaneous T- cell lymphomas: evaluation of the viral presence and significance in skin and peripheral blood. *J Invest Dermatol*. 2009;129:1556-1561.
24. Quintanilla-Martinez L, Kimura H, Jaffe ES. EBV-positive T-cell lymphoproliferative disorders of childhood. In: Swerdlow SH, Campo E, Harris NL, et al, eds. *WHO Classification of Tumours of Haematopoetic and Lymphoid Tissues*. 4th ed. Lyon, France: IARC Press; 2008:278.
25. Vonderheid EC, Bigler RD, Hou JS. On the possible relationship between staphylococcal superantigens and increased Vbeta5.1 usage in cutaneous T-cell lymphoma. *Br J Dermatol*. 2005;152:825-826.
26. Jackow CM, Cather JC, Hearne V, et al. Association of erythrodermic cutaneous T-cell lymphoma, superantigen-positive *Staphylococcus aureus*, and oligoclonal T-cell receptor V beta gene expansion. *Blood*. 1997;89:32-40.
27. Tokura Y, Yagi H, Ohshima A, et al. Cutaneous colonization with staphylococci influences the disease activity of Sézary syndrome: a potential role for bacterial superantigens. *Br J Dermatol*. 1995;133:6-12.
28. Talpur R, Bassett R, Duvic M. Prevalence and treatment of *Staphylococcus aureus* colonization in patients with mycosis fungoides and Sézary syndrome. *Br J Dermatol*. 2008;159:105-112.
29. Willerslev-Olsen A, Krejsgaard T, Lindahl LM, et al. *Staphylococcus aureus* enterotoxin A (SEA) stimulates STAT3 activation and IL-17 expression in cutaneous T-cell lymphoma. *Blood*. 2016;127:1287-1296.
30. Whittemore AS, Holly EA, Lee IM, et al. Mycosis fungoides in relation to environmental exposures and immune response: a case-control study. *J Natl Cancer Inst*. 1989;81:1560-1567.
31. Morales-Suárez-Varela MM, Olsen J, Johansen P, et al. Occupational risk factors for mycosis fungoides: a European multicenter case-control study. *J Occup Environ Med*. 2004;46:205-211.
32. Girardi M, Heald PW, Wilson LD. The pathogenesis of mycosis fungoides. *N Engl J Med*. 2004;350:1978-1988.
33. Dummer R, Willers J, Kamarashev J, et al. Pathogenesis of cutaneous lymphomas. *Semin Cutan Med Surg*. 2000;19:78-86.
34. Chung GC, Poligone B. Cutaneous T cell lymphoma: an update on pathogenesis and systemic therapy. *Curr Hematol Malig Rep*. 2015;10:468-476.

35. Moins-Teisserenc H, Daubord M, Clave E, et al. CD158k is a reliable marker for diagnosis of Sézary syndrome and reveals an unprecedented heterogeneity of circulating malignant cells. *J Invest Dermatol*. 2015;135:247-257.
36. van Doorn R, van Kester MS, Dijkman R, et al. Oncogenomic analysis of mycosis fungoides reveals major differences with Sezary syndrome. *Blood*. 2009;113:127-136.
37. Vaque JP, Gomez-Lopez G, Monsalvez V, et al. PLCG1 mutations in cutaneous T-cell lymphomas. *Blood*. 2014;123:2034-2043.
38. Heid JB, Schmidt A, Oberle N, et al. FOXP31CD25- tumor cells with regulator function in Sezary syndrome. *J Invest Dermatol*. 2009;129:2875-2885.
39. Krejsgaard T, Odum N, Geisler C, et al. Regulator T cells and immunodeficiency in mycosis fungoides and Sezary syndrome. *Leukemia*. 2012;26: 424-432.
40. Wilcox RA, Wada DA, Ziesmer SC, et al. Monocytes promote tumor cell survival in T cell lymphoproliferative disorders and are impaired in their ability to differentiate into mature dendritic cells. *Blood*. 2009;114:2936-2944.
41. Berger CL, Tigelaar R, Cohen J, et al. Cutaneous T-cell lymphoma: malignant proliferation of T-regulatory cells. *Blood*. 2005;105:1640-1647.
42. Clark RA. Skin-resident T cells: the ups and downs of on-site immunity. *J Invest Dermatol*. 2010;130: 362-370.
43. Wang T, Feldman AL, Wada DA, et al. GATA-3 expression identifies a high-risk subset of PTCL, NOS with distinct molecular and clinical features. *Blood*. 2014;123:3007-3015.
44. Vowels BR, Lessin SR, Cassin M, et al. Th2 cytokine mRNA expression in skin in cutaneous T-cell lymphoma. *J Invest Dermatol*. 1994;103:669-673.
45. Choi J, Goh G, Walradt T, et al. Genomic landscape of cutaneous T cell lymphoma. *Nat Genet*. 2015;47:1011-1011.
46. McGirt LY, Jia P, Baerenwald DA, et al. Whole-genome sequencing reveals oncogenic mutations in mycosis fungoides. *Blood*. 2015;126:508-519.
47. Netchiporouk E, Litvinov IV, Moreau L, et al. Deregulation in STAT signaling is important for cutaneous T-cell lymphoma (CTCL) pathogenesis and cancer progression. *Cell Cycle*. 2014;13:3331-3335.
48. Kim YH, Liu HL, Mraz-Gernhard S, et al. Long-term outcome of 525 patients with mycosis fungoides and Sezary syndrome: clinical prognostic factors and risk for disease progression. *Arch Dermatol*. 2003;139:857-866.
49. Wasik MA. IL-13 as a novel growth factor in CTCL. *Blood*. 2015;125:2737-2738.
50. Rubio Gonzalez B, Zain J, Rosen ST, et al. Tumor microenvironment in mycosis fungoides and Sézary syndrome. *Curr Opin Oncol*. 2016;28:88-96.
51. Sibbesen NA, Kopp KL, Litvinov IV, et al. JAK3, STAT3, and STAT5 inhibit expression of MiR-22, a novel tumor suppressor microRNA, in cutaneous T-cell lymphoma. *Oncotarget*. 2015;6:20555-20569.
52. Ballabio E, Mitchell T, van Kester MS, et al. MicroRNA expression in Sezary syndrome: identification, function, and diagnostic. *Blood*. 2010;116:1105-1113.
53. Abraham RM, Zhang Q, Odum N, et al. The role of cytokine signaling in the pathogenesis of cutaneous T-cell lymphoma. *Cancer Biol Ther*. 2011;12: 1019-1022.
54. Krejsgaard T, Ralfkiaer U, Clasen-Linde E, et al. Malignant cutaneous T-cell lymphoma cells express IL-17 utilizing the JAK3/Stat3 signaling pathway. *J Invest Dermatol*. 2011;131:1331-1338.
55. van der Fits L, Out-Luiting JJ, van Leeuwen MA, et al. Autocrine IL-12 stimulation is involved in the maintenance of constitutive STAT3 activation in Sézary syndrome. *J Invest Dermatol*. 2012;132:440-447.
56. Krejsgaard T, Vetter-Kauczok CS, Woetmann A, et al. JAK3- and JNK-dependent vascular endothelial growth factor expression in cutaneous T-cell lymphoma. *Leukemia*. 2006;20:1759-1766.
57. van der Fits L, van Kester MS, Qin Y, et al. MicroRNA-21 expression in CD4+ T cells is regulated by STAT 3 and is pathologically involved in Sézary syndrome. *J Invest Dermatol*. 2011;131:762-768.
58. Geskin LJ, Viragova S, Stolz DB, et al. Interleukin-13 is overexpressed in cutaneous T-cell lymphoma cells and regulates their proliferation. *Blood*. 2015;125:2798-2805.
59. Schwartz DM, Bonelli M, Gadina M, et al. Type I/II cytokines, JAKs, and new strategies for treating autoimmune diseases. *Nat Rev Rheumatol*. 2016;12:25-36.
60. Chung GC, Poligone B. Cutaneous T cell lymphoma: an update on pathogenesis and systemic treatment. *Curr Hematol Malig Rep*. 2015;10:468-476.
61. Schrader AM, Jansen PM, Willemze R. TOX expression in cutaneous T-cell lymphomas: an adjunctive diagnostic marker that is not tumor specific and not restricted to the CD4(+) CD8(-) phenotype. *Br J Dermatol*. 2016;175:382-386.
62. Scarisbrick JJ, Kim YH, Whittaker SJ, et al. Prognostic factors, prognostic indices and staging in mycosis fungoides and Sézary syndrome: where are we now? *Br J Dermatol*. 2014;170:1226-1236.
63. Scarisbrick JJ, Prince HM, Vermeer MH, et al. Cutaneous Lymphoma International Consortium study of outcome in advanced stages of mycosis fungoides and Sézary syndrome: effect of specific prognostic markers on survival and development of a prognostic model. *J Clin Oncol*. 2015;33:3766-3773.
64. van Santen S, Roach RE, van Doorn R, et al. Clinical staging and prognostic factors in folliculotropic mycosis fungoides. *JAMA Dermatol*. 2016;1;152(9):992-1000.
65. Hodak E, Amitay-Laish I, Atzmony L, et al. New insights into folliculotropic mycosis fungoides (FMF): a single-center experience. *J Am Acad Dermatol*. 2016;75:347-355.
66. Olsen, E., Vonderheid E, Pimpinelli N, et al. Revisions to the staging and classification of mycosis fungoides and Sezary syndrome: a proposal of International Society for Cutaneous Lymphomas (ISCL) and the Cutaneous Lymphoma Task Force of the European Organization of Research and Treatment of Cancer (EORTC). *Blood*. 2007;110: 1713-1722.
67. Kim YH, Willemze R, Pimpinelli N, et al. TNM classification system for primary cutaneous lymphomas other than mycosis fungoides and Sezary syndrome: a proposal of the International Society for Cutaneous Lymphomas (ISCL) and the Cutaneous Lymphoma Task Force of the European Organization of Research and Treatment of Cancer (EORTC). *Blood*. 2007;110:479-484.
68. Burg G, Kempf W, Cozzio A, et al. WHO/EORTC classification of cutaneous lymphomas 2005:

histological and molecular aspects. *J Cutan Pathol*. 2005;32:647-674.
69. Kempf W. Cutaneous CD30-positive lymphoproliferative disorders. *Surg Pathol Clin*. 2014;7:203-228.
70. Kempf W, Pfaltz K, Vermeer MH, et al. European Organization for Research and Treatment of Cancer (EORTC), International Society of Cutaneous Lymphoma (ISCL) and United States Cutaneous Lymphoma Consortium (USCLC) consensus recommendations for the treatment of primary cutaneous CD30-positive lymphoproliferative disorders: lymphomatoid papulosis and primary cutaneous anaplastic large-cell lymphoma. *Blood*. 2011;118:4024-4035.
71. Kadin ME, Carpenter C. Systemic and primary cutaneous anaplastic large cell lymphomas. *Semin Hematol*. 2003;40:244-256.
72. Massone C, El-Shabrawi-Caelen L, Kerl H, et al. The morphologic spectrum of primary cutaneous anaplastic large T-cell lymphoma: a histopathologic study on 66 biopsy specimens from 47 patients with report of rare variants. *J Cutan Pathol*. 2008;35:46-53.
73. Kempf W, Mitteldorf C. Pathologic diagnosis of cutaneous lymphomas. *Dermatol Clin*. 2015;33:655-681.
74. Willemze R, Jansen PM, Cerroni L, et al. Subcutaneous panniculitis-like T-cell lymphoma: definition, classification, and prognostic factors: an EORTC Cutaneous Lymphoma Group Study of 83 cases. *Blood*. 2008;111:838-845.
75. Guitart J, Weisenburger DD, Subtil A, et al. Cutaneous gamma delta T-cell lymphomas: a spectrum of presentations with overlap with other cytotoxic lymphomas. *Am J Surg Pathol*. 2012;36:1656-1665.
76. Kempf W, Kazakov D, Kerl K. Cutaneous lymphomas an update part 1: T-cell and natural killer/T-cell lymphomas and related conditions. *Am J Dermatopathol*. 2014;36:105-123.
77. Garcia-Herrera A, Colomo L, Camos M, et al. Primary cutaneous small/medium CD4+ T-cell lymphomas: a heterogeneous group of tumors with different clinicopathologic features and outcome. *J Clin Oncol*. 2008;26:3364-3371.
78. James E, Sokhn JK, Gibson JF, et al. CD4+ primary cutaneous small/medium-sized pleomorphic T-cell lymphoma: a retrospective case series and review of the literature. *Leuk Lymphoma*. 2015;56:951-957.
79. Beltraminelli H, Leinweber B, Kerl H, et al. Primary cutaneous CD4+ small-/medium-sized pleomorphic T-cell lymphoma: a cutaneous nodular proliferation of pleomorphic T lymphocytes of undetermined significance? A study of 136 cases. *Am J Dermatopathol*. 2009;31:317-322.
80. Berti E, Tomasini D, Vermeer MH, et al. Primary cutaneous CD8-positive epidermotropic cytotoxic T cell lymphomas. A distinct clinicopathological entity with an aggressive clinical behavior. *Am J Pathol*. 1999;155:483-492.
81. Kluk J, Kai A, Koch D, et al. Indolent CD8-positive lymphoid proliferation of acral sites: three further cases of a rare entity and an update on a unique patient. *J Cutan Pathol*. 2016;43:125-136.
82. Olsen EA, Whittaker S, Kim YH, et al. Clinical end points and response criteria in mycosis fungoides and Sézary syndrome: a consensus statement of the International Society for Cutaneous Lymphomas, the United States Cutaneous Lymphoma Consortium, and the Cutaneous Lymphoma Task Force of the European Organisation for Research and Treatment of Cancer. *J Clin Oncol*. 2011;29:2598-2607.
83. Trautinger F, Knobler R, Willemze R, et al. EORTC consensus recommendations for the treatment of mycosis fungoides/Sézary syndrome. *Eur J Cancer*. 2006;42:1014-1030.
84. Duvic M. Choosing a systemic treatment for advanced stage cutaneous T-cell lymphoma: mycosis fungoides and Sézary syndrome. *Hematology Am Soc Hematol Educ Program*. 2015;2015:529-544.
85. Martinez-Gonzalez MC, Verea-Hernando MM, Yebra-Pimental MT, et al. Imiquimod in mycosis fungoides. *Eur J Dermatol*. 2008;18:148-152.
86. Rook AH, Gelfand JC, Wysocka M, et al. Topical resiquimod can induce disease regression and enhance T-cell effector functions in cutaneous T-cell lymphoma. *Blood*. 2015;126:1452-1461.
87. Kamstrup, MR, Lindahl LM, Gniadecki R, et al. Low-dose total skin electron beam therapy as a debulking agent for cutaneous T-cell lymphoma: an open-label prospective phase II study. *Br J Dermatol*. 2012;166:399-404.
88. Hoppe, RT, Harrison C, Travallaee M, et al. Low-dose total skin electron beam therapy as an effective modality to reduce disease burden in patients with mycosis fungoides: results of a pooled analysis from 3 phase-II clinical trials. *J Am Acad Dermatol*. 2015;72:286-292.
89. Stadler R. Optimal combination with PUVA: rationale and clinical trial update. *Oncology (Williston Park)*. 2007;21(2)(suppl 1):29-32.
90. Duvic M, Hymes K, Heald P, et al. Bexarotene is effective and safe for treatment of refractory advanced-stage cutaneous T-cell lymphoma: multinational phase II-III trial results. *J Clin Oncol*. 2001;19:2456-2471.
91. Duvic M, Martin AG, Kim Y, et al. Phase 2 and 3 clinical trial of oral bexarotene (Targretin capsules) for the treatment of refractory or persistent early-stage cutaneous T-cell lymphoma. *Arch Dermatol*. 2001;137:581-593.
92. Whittaker S, Ortiz P, Dummer R, et al. Efficacy and safety of bexarotene combined with psoralen-ultraviolet A (PUVA) compared with PUVA treatment alone in stage IB-IIA mycosis fungoides: final results from the EORTC Cutaneous Lymphoma Task Force phase III randomized clinical trial (NCT00056056). *Br J Dermatol*. 2012;167:678-687.
93. Assaf C, Bagot M, Dummer R, et al. Minimizing adverse side-effects of oral bexarotene in cutaneous T-cell lymphoma: an expert opinion. *Br J Dermatol*. 2006;155:261-266.
94. Gniadecki R, Assaf C, Bagot M, et al. The optimal use of bexarotene in cutaneous T-cell lymphoma. *Br J Dermatol*. 2007;157:433-440.
95. Knobler R, Berlin G, Calzavara-Pinton P, et al. Guidelines on the use of extracorporeal photopheresis. *J Eur Acad Dermatol Venereol*. 2014;28(suppl 1):1-37.
96. Dippel E, Schrag H, Goerdt S, et al. Extracorporeal photopheresis and interferon-alpha in advanced cutaneous T-cell lymphoma. *Lancet*. 1997;350:32-33.
97. Stadler R, Otte HG, Luger T, et al. Prospective randomized multicenter clinical trial on the use of interferon-2a plus acitretin versus interferon-2a plus PUVA in patients with cutaneous T-cell lymphoma stages I and II. *Blood*. 1998;92:3578-3581.
97A. Lundin J, Hagberg H, Repp R, et al. Phase 2 study of alemtuzumab (anti-CD52 monoclonal antibody) in

patients with advanced mycosis fungoides/Sezary syndrome. *Blood*. 2003;101(11):4267-4272.

97B. Querfeld C, Mehta N, Rosen ST, et al. Alemtuzumab for relapsed and refractory erythrodermic cutaneous T-cell lymphoma: a single institution experience from the Robert H. Lurie Comprehensive Cancer Center. *Leuk Lymphoma*. 2009;50(12):1969-1976.

98. Watanabe R, Teague JE, Fisher DC, et al. Alemtuzumab therapy for leukemic cutaneous T-cell lymphoma: diffuse erythema as a positive predictor of complete remission. *JAMA Dermatol*. 2014;150:776-779.

98A. Clark RA, Watanabe R, Teague JE, et al. Skin effector memory T cells do not recirculate and provide immune protection in alemtuzumab-treated CTCL patients. *Sci Transl Med*. 2012 Jan 18;4(117):117ra7.

99. Bernengo MG, Quaglino P, Comessatti A, et al. Low-dose intermittent alemtuzumab in the treatment of Sézary syndrome: clinical and immunological findings in 14 patients. *Haematologica*. 2007;92:784-794.

100. Duvic M, Tetzlaff MT, Gangar P, et al. Results of a phase II trial of brentuximab vedotin for CD30+ cutaneous T-cell lymphoma and lymphomatoid papulosis. *J Clin Oncol*. 2015;33:3759-3765.

100A. Prince HM, Kim YH, Horwitz SM, et al; ALCANZA Study Group. Brentuximab vedotin or physician's choice in CD30-positive cutaneous T-cell lymphoma (ALCANZA): an international, open-label, randomised, phase 3, multicentre trial. *Lancet*. 2017 Aug 5;390(10094):555-566.

101. Kim YH, Tavallaee M, Sundram U, et al. Phase II investigator-initiated study of brentuximab vedotin in mycosis fungoides and Sézary syndrome with variable CD30 expression level: a multi-institution collaborative project. *J Clin Oncol*. 2015;33:2750-2758.

102. Duvic M, Pinter-Brown LC, Foss FM, et al. Phase 1/2 study of mogamulizumab, a defucosylated anti-CCR4 antibody, in previously treated patients with cutaneous T-cell lymphoma. *Blood*. 2015;125: 1883-1889.

102A. Kim YH, Bagot M, Pinter-Brown L, et al. Anti-CCR4 monoclonal antibody mogamulizumab versus vorinostat in previously treated cutaneous T-cell lymphoma (MAVORIC): an international, randomized, phase 3 trial. *Lancet Oncol,* in press.

103. Bunn PA, Hoffmann SJ, Norris D, et al. Systemic therapy of cutaneous T-cell lymphomas (mycosis fungoides and the Sézary syndrome). *Ann Intern Med*. 1994;121: 592-602.

104. Marchi E, Alinari L, Tani M, et al. Gemcitabine as frontline treatment for cutaneous T-cell lymphoma: phase II study of 32 patients. *Cancer*. 2005;104:2437-2441.

105. Duvic M, Talpur R, Wen S, et al. Phase II evaluation of gemcitabine monotherapy for cutaneous T-cell lymphoma. *Clin Lymphoma Myeloma*. 2006;7:51-58.

106. Dummer R, Quaglino P, Becker JC, et al. Prospective international multicenter phase II trial of intravenous pegylated liposomal doxorubicin monochemotherapy in patients with stage IIB, IVA, or IVB advanced mycosis fungoides: final results from EORTC 21012. *J Clin Oncol*. 2012;30:4891-4897.

106A. Horwitz SM, Kim YH, Foss F, et al. Identification of an active, well-tolerated dose of pralatrexate in patients with relapsed or refractory cutaneous T-cell lymphoma. *Blood*. 2012;119(18):4115-4122.

107. O'Connor OA, Pro B, Pinter-Brown L, et al. Pralatrexate in patients with relapsed or refractory peripheral T-cell lymphoma: results from the pivotal PROPEL study. *J Clin Oncol*. 2011;29:1182-1189.

108. Lechowicz MJ, Lazarus HM, Carreras J, et al. Allogeneic hematopoietic cell transplantation for mycosis fungoides and Sezary syndrome. *Bone Marrow Transplant*. 2014;49:1360-1365.

109. Duarte RF, Boumendil A, Gabriel I, et al. Long-term outcome of allogeneic hematopoietic cell transplantation for patients with mycosis fungoides and Sézary syndrome: a European Society for Blood and Marrow Transplantation Lymphoma Working Party extended analysis. *J Clin Oncol*. 2014;32:3347-3348.

110. Smith BD, Smith GL, Cooper DL, et al. The cutaneous B-cell lymphoma prognostic index: a novel prognostic index derived from a population-based registry. *J Clin Oncol*. 2005;23:3390-3395.

111. Zinzani PL, Quaglino P, Pimpinelli N, et al.; Italian Study Group for Cutaneous Lymphomas. Prognostic factors in primary cutaneous B-cell lymphoma: the Italian Study Group for Cutaneous Lymphomas. *J Clin Oncol*. 2006;24:1376-1382.

112. Senff NJ, Hoefnagel JJ, Jansen PM, et al. Reclassification of 300 primary cutaneous B-cell lymphomas according to the new WHO-EORTC classification for cutaneous lymphomas: comparison with previous classifications and identification of prognostic markers. *J Clin Oncol*. 2007;25:1381-1387.

113. Kerl H, Kodama K, Cerroni L. Diagnostic principles and new developments in primary cutaneous B-cell lymphomas. *J Dermatol Sci*. 2004;34:167-175.

114. Hallermann C, Kaune KM, Gesk S, et al. Molecular cytogenetic analysis of chromosomal breakpoints in the IGH, MYC, BCL6, and MALT1 gene loci in primary cutaneous B-cell lymphomas. *J Invest Dermatol*. 2004;123:213-219.

115. Vermeer MH, Willemze R. Recent advances in primary cutaneous B-cell Lymphoma. *Curr Opin Oncol*. 2014;26:230-236.

116. Kodama K, Massone C, Chott A, et al. Primary cutaneous large B-cell lymphomas: clinicopathologic features, classification, and prognostic factors in a large series of patients. *Blood*. 2005;106: 2491-2497.

117. Golling P, Cozzio A, Dummer R, et al. Primary cutaneous B-cell lymphomas—clinicopathological, prognostic and therapeutic characterisation of 54 cases according to the WHO-EORTC classification and the ISCL/EORTC TNM classification system for primary cutaneous lymphomas other than mycosis fungoides and Sézary syndrome. *Leuk Lymphoma*. 2008;49:1094-1103.

118. Servitje O, Estrach T, Pujol RM, et al. Primary cutaneous marginal zone B-cell lymphoma: a clinical, histopathological, immunophenotypic and molecular genetic study of 22 cases. *Br J Dermatol*. 2002;147:1147-1158.

119. Hoefnagel JJ, Vermeer MH, Jansen PM, et al. Primary cutaneous marginal zone B-cell lymphoma: clinical and therapeutic features in 50 cases. *Arch Dermatol*. 2005;141:1139-1145.

120. Dijkman R, Tensen CP, Buettner M, et al. Primary cutaneous follicle center lymphoma and primary cutaneous large B-cell lymphoma, leg type, are both targeted by aberrant somatic hypermutation but demonstrate differential expression of AID. *Blood*. 2006;107:4926-4929.

121. Deutsch AJ, Frühwirth M, Aigelsreiter A, et al. Primary cutaneous marginal zone B-cell lymphomas are targeted by aberrant somatic hypermutation. *J Invest Dermatol*. 2009;129:476-479.
122. Liu M, Schatz DG. Balancing AID and DNA repair during somatic hypermutation. *Trends Immunol*. 2009;30:173-181.
123. Hoefnagel JJ, Dijkman R, Basso K, et al. Distinct types of primary cutaneous large B-cell lymphoma identified by gene expression profiling. *Blood*. 2005;105:3671-3678.
124. Senff NJ, Zoutman WH, Vermeer MH, et al. Fine-mapping chromosomal loss at 9p21: correlation with prognosis in primary cutaneous diffuse large B-cell lymphoma, leg type. *J Invest Dermatol*. 2009;129:1149-1155.
125. Grange F, Joly P, Barbe C, et al. Improvement of survival in patients with primary cutaneous diffuse large B-cell lymphoma, leg type, in France. *JAMA Dermatol*. 2014;150:535-541.
126. van Maldegem F, van Dijk R, Wormhoudt TA, et al. The majority of cutaneous marginal zone B-cell lymphomas expresses class-switched immunoglobulins and develops in a T-helper type 2 inflammatory environment. *Blood*. 2008;112:3355-3361.
127. Kutzner H, Kerl H, Pfaltz MC, et al. CD123-positive plasmacytoid dendritic cells in primary cutaneous marginal zone B-cell lymphoma: diagnostic and pathogenetic implications. *Am J Surg Pathol*. 2009;33:1307-1313.
128. van Galen JC, Hoefnagel JJ, Vermeer MH, et al. Profiling of apoptosis genes identifies distinct types of primary cutaneous large B cell lymphoma. *J Pathol*. 2008;215:340-346.
129. Senff NJ, Hoefnagel JJ, Jansen PM, et al. Reclassification of 300 primary cutaneous B-cell lymphomas according to the new WHO-EORTC classification for cutaneous lymphomas: comparison with previous classifications and identification of prognostic markers. *J Clin Oncol*. 2007;25:1581-1587.
130. Brandenburg A, Humme D, Terhorst D, et al. Long-term outcome of intravenous therapy with rituximab in patients with primary cutaneous B-cell lymphomas. *Br J Dermatol*. 2013;169:1126-1132.
131. Stenzinger A, Endris V, Pfarr N, et al. Targeted ultra-deep sequencing reveals recurrent and mutually exclusive mutations of cancer genes in blastic plasmacytoid dendritic cell neoplasm. *Oncotarget*. 2014;5:6404-6412.
131A. Senff NJ, Kluin-Nelemans HC, Willemze R. Results of bone marrow examination in 275 patients with histological features that suggest an indolent type of cutaneous B-cell lymphoma. *Br J Haematol*. 2008 Jul;142(1):52-56.
132. Neelis KJ, Schimmel EV. Vermeer MH, et al. Low-dose palliative radiotherapy for cutaneous B- and T-cell lymphomas. *Int J Radiat Oncol Biol Phys*. 2009;74:154-158.
133. Shi Y, Wang E. Blastic plasmacytoid dendritic cell neoplasm. A clinicopathologic review. *Arch Pathol Lab Med*. 2014;138:564-569.
134. Julia F, Dalle S, Duru G, et al. Blastic plasmacytoid dendritic cell neoplasms. Clinico-immunohistochemical correlations in a series of 91 patients. *Am J Surg Pathol*. 2014;38:673-680.
135. Aoki T, Suzuki R, Kuwatsuka Y, et al. Long-term survival following autologous and allogeneic stem cell transplantation for blastic plasmacytoid dendritic cell neoplasm. *Blood*. 2015;125:3559-3562.
136. Julia F, Petrella T, Beylot-Barry M, et al. Blastic plasmacytoid dendritic cell neoplasm: clinical features in 90 patients. *Br J Dermatol*. 2013;169:579-586.
137. Frankel AE, Woo JH, Ahn C, et al. Activity of SL401, a targeted therapy directed to interleukin-3 receptor in blastic plasmacytoid dendritic cell neoplasm patients. *Blood*. 2014;124:385-392.

Chapter 120 :: Cutaneous Pseudolymphoma

:: Werner Kempf, Rudolf Stadler, & Martine Bagot

AT-A-GLANCE

- Cutaneous pseudolymphomas are benign lymphoproliferations that clinically and/or histologically simulate cutaneous lymphomas.
- They exhibit a wide range of clinical, histological, and immunophenotypic features and can be triggered by different infectious and non-infectious agents.
- Clinicopathological correlation plays an important role in the differentiation from cutaneous lymphomas.
- Therapy includes avoidance of exposure to the causative agent, immunomodulating agents or ablative approaches.

DEFINITION

The term *cutaneous pseudolymphoma* refers to a group of skin diseases that can be defined as benign lymphoproliferative processes that clinically and/or histologically simulate cutaneous lymphomas. These diseases differ in their clinical, histologic, and immunophenotypic presentation, and are of different etiologies (Table 120-1).

A broad spectrum of causative factors known to induce cutaneous pseudolymphomas (PSLs) have been identified. Infectious agents, such as spirochetal bacteria (*Borrelia burgdorferi* sp., *Treponema pallidum*), viruses (eg, parapoxviruses), infestations (eg, scabies), insect bites, injection of vaccines or antigens for hyposensitization, foreign bodies such as tattoos and metals, and drugs have been identified as causative factors for PSL. All cases without identifiable cause are referred to as an idiopathic form of PSL.

HISTORICAL ASPECTS

Various synonyms have been introduced and several terms are still nowadays used to describe PSLs of the skin. For the first time the concept of PSL (pseudomalignancy) had been introduced by M. Kaposi in 1891 (Table 120-2).[1] In 1923, Biberstein coined the term *lymphocytoma cutis*.[2] Subsequently, in 1943, Bäfverstedt used the designation *lymphadenosis benigna cutis*.[3] Lever introduced the term *pseudolymphoma of Spiegler and Fendt* in 1967, and in 1969, Caro and Helwig employed the term *cutaneous lymphoid hyperplasia*.[4] Many other terms were proposed and referred mostly to B-cell PSLs. Among T-cell PSLs, actinic reticuloid was first described in 1969.[5] In the 1980s the designation cutaneous PSL for B-cell–dominated and T-cell–dominated processes became more widely used and accepted.[6] Synonymously, the term *atypical lymphoid proliferation* is often employed by pathologists and dermatopathologists.

CLASSIFICATION

Various approaches have been proposed to categorize cutaneous PSL. For example, according to the etiology, the predominant lymphocytic component (T, B, or mixed cells) or distinct clinical features (eg, acral papular angiokeratoma of childhood).[7-9]

Categorization of PSL according to etiology or histology and phenotype into T-cell and B-cell PSL is widely used in textbooks. In daily work, clinicians or pathologists encountering infiltrates suspicious of being a PSL cannot recognize the etiology and the phenotype at first glance; further diagnostic workup is needed. Moreover, it has to be emphasized that the composition of the infiltrate is determined mostly by genetic and immunologic factors of the host rather than the causative agent per se, as the same agents can, in many instances, induce B-cell PSL and T-cell PSL as well.

From a practical point of view, cutaneous PSL presenting as a solitary or multiple nodule(s), which clinically and histologically simulate lymphoma, can be distinguished from other forms of PSL, which mimic cutaneous T-cell lymphoma on histologic grounds alone, and are summarized under the term *pseudo–mycosis fungoides* (pseudo-MF). In addition, there are numerous infectious and noninfectious conditions that are characterized by a lymphocyte-rich infiltrate and are prone to be misinterpreted as cutaneous lymphoma primarily on histologic grounds.

Thus, this chapter is divided into the following sections: (a) nodular PSL simulating clinically and histologically T-cell or B-cell lymphoma; (b) PSLs mimicking histologically mycosis fungoides (so called pseudo-MF); (c) other skin disorders with lymphocyte-rich infiltrates; and (d) benign intravascular proliferation of lymphocytes (simulating intravascular lymphoma) (see Table 120-1).

DIAGNOSTIC APPROACH

The clinical presentation of cutaneous PSL ranges from a solitary nodule to clustered or disseminated papules to erythroderma.[8,10] The histologic analysis plays a crucial role in the diagnostic approach to cutaneous PSLs. Different infiltrate patterns (nodular infiltrate vs epidermotropic infiltrates), the size of the lymphocytes (mostly small cells; occasionally medium and large cells), immunophenotype (T-cell vs B-cell; CD4 vs CD8; CD30) can be distinguished. Molecular studies

TABLE 120-1
Spectrum of Cutaneous Pseudolymphoma

1. Nodular pseudolymphoma
B-cell pseudolymphoma (PSL)
T-cell PSL
CD30+ T-cell PSL
Mixed PSL
Pseudolymphomatous folliculitis
Causes:
Infections: *Borrelia burgdorferi*
Treponema pallidum
α-Herpesviruses
Parapoxviruses
Molluscum contagiosum virus
Drugs: Anticonvulsants, vaccines
Arthropod bites, infestations, leeches (*Hirudo medicinalis*)
Lymphomatoid reaction to tattoo and metals
2. PSLs—histologic simulators of mycosis fungoides ("pseudo-MF")
Lymphomatoid contact dermatitis
Lymphomatoid drug reaction
Actinic reticuloid
Immunodeficiency-associated cutaneous CD8+ infiltrates
B. burgdorferi–associated T-cell infiltrates
Papuloerythroderma Ofuji
Clonal dermatitis
3. Other disorders with lymphocyte-rich infiltrates
Acral persistent angiokeratoma
Lymphoplasmacytic plaque
Cutaneous plasmacytosis
Cutaneous inflammatory pseudotumor
Angiolymphoid hyperplasia with eosinophilia
T-cell–rich angiomatoid polypoid pseudolymphoma of the skin
Castleman disease
Lymphocytic infiltration of the skin
Palpable arciforme migratory erythema
Lichen sclerosus, pityriasis lichenoides, vitiligo
Pigmented purpuric dermatoses
Morphea (inflammatory stage)
Lupus tumidus, lupus panniculitis
4. Benign intravascular proliferation of lymphocytes
Benign intravascular proliferation of lymphoid blasts
Benign atypical intravascular CD30+ T-cell proliferation

for clonality and infectious agents, especially *Borrelia burgdorferi*, are adjunctive diagnostic tools. It is important to emphasize that the detection of a clonal T-cell or B-cell population per se does not indicate the presence of malignant lymphoma. Moreover some PSL cases have been reported to harbor clonal T or B cells.[11-14] Thus, both the histologic and the molecular findings always need to be interpreted in synopsis with the clinical context; that is, the clinicopathologic correlation is essential to achieve the final diagnosis.

The diagnostic workup includes the medical history (particularly exposure to arthropods, allergens, and drugs) and physical examination including palpatory evaluation of lymph nodes, examination of peripheral blood (lymphocytosis, eosinophilia, serology for infectious agents, especially *B. burgdorferi*, syphilis, HIV). Because PSLs represent benign lymphocytic proliferations without the potential for extracutaneous spread, staging examinations are usually not indicated. In cases with unusual clinical manifestations and multiple nodular lesions, monotypic expression of immunoglobulin light chains, detection of T-cell or B-cell clonality, or other inconsistent or unexpected histologic or phenotypic findings, radiologic staging (computed tomography or positron emission tomography-computed tomography) should be considered to exclude primary or secondary cutaneous lymphoma mimicking PSL.

TABLE 120-2
Terminology of Cutaneous Pseudolymphoma—Historical Aspect

1891	Sarcomatosis cutis (M. Kaposi)[1]
1910	Sarcoid Spiegler-Fendt (Darier)[1,14]
1923	Lymphocytoma cutis (Biberstein)[2]
1943	Lymphadenosis benigna cutis (Bäfverstedt)[3]
1969	Cutaneous lymphoid hyperplasia (Caro and Helwig)[4]
1982	Cutaneous pseudolymphoma (Burg et al)[6]

COURSE

The course of cutaneous PSLs is highly variable. Resolution may occur after biopsy, but some lesions may persist over several months or even years. Recurrences can be observed particularly after reexposure to the inducing agent in cases that are caused by drugs or allergens. Progression of PSL has been reported, but is a very rare event, if it exists at all.[15] It remains unclear whether PSL in fact progressed to overt lymphoma (eg, by acquisition of chromosomal aberrations or persisting antigenic stimulus resulting in permanent proliferation of lymphocytes) or whether those cases represent cutaneous lymphomas from the very beginning, but could not be recognized as such by histologic, phenotypic, or molecular findings in their very early disease stages.

NODULAR PSEUDOLYMPHOMA

PSLs that present with a solitary nodule or with multiple nodules simulate cutaneous T-cell and B-cell lymphomas on clinical and histologic grounds. They represent one of the most common forms of PSL, but no detailed data on the overall prevalence of B-cell PSLs have been reported. Histologically they can be classified according to the predominant lymphocytic subset into B-cell, T-cell, and mixed (T-cell/B-cell) PSL.[8,10] This classification is rather artificial as B-cell PSL always contains T cells and vice versa. T-cell PSL often harbors a variable number of B cells. Nevertheless, the distinction into the 3 histologic and phenotypic subtypes of nodular PSL remains useful for the differential diagnosis, which also has to be considered for the potential cause of the pseudolymphomatous reaction.

TABLE 120-3
Treatment of Nodular Pseudolymphoma

1. Avoidance or elimination of the causative agent (eg, contact allergen)
2. Antibiotic treatment for infection-associated pseudolymphoma (eg, *Borrelia*-associated-cell pseudolymphoma)
3. Surgical excision, cryotherapy, laser treatment
4. Topical/intralesional steroids or interferon-α
5. Systemic steroids, hydroxychloroquine

Avoidance of reexposure to the inducing agent (eg, vaccines, allergen injection, other drugs, *Hirudo medicinalis* treatment, acupuncture, and tattoo) is the most important step to prevent persistence and recurrence of nodular PSL. Solitary lesions can be treated by complete surgical excision, topical or intralesional corticosteroids, cryotherapy, or laser therapy (Table 120-3). If those therapeutic approaches are not successful, radiation therapy may be considered. In patients with multiple PSL lesions, particularly those with idiopathic multifocal PSL, systemic corticosteroids, intralesional interferon-α, or hydroxychloroquine may be therapeutic options. Hydroxychloroquine inhibits the activity of plasmacytoid dendritic cells, which are found in the majority of B-cell PSLs as clusters in close vicinity to T cells and plasma cells, and may represent the driving force in induction and maintenance of the PSLs.[16,17]

CUTANEOUS B-CELL PSEUDOLYMPHOMA

B-cell PSL is often also referred as lymphocytoma cutis or cutaneous lymphoid hyperplasia.

CLINICAL FEATURES

B-cell PSL most commonly presents with a nodule or plaque. The face, especially the nose and the cheeks, the upper trunk, and the arms are the most commonly involved sites. A male-to-female ratio of 2:1 has been described.[18] Approximately 67% of the patients with B-cell PSLs are younger than age 40 years and less than 10% are children and adolescents.[4]

The localized form of B-cell PSL that presents with a solitary nodule measuring up to 4 cm, is the most common presentation. One-third of patients develop multiple nodules or a miliarial form in which the lesions are papules measuring only a few millimeters in diameter.[19]

HISTOLOGY

All nodular B-cell PSLs essentially share the same growth pattern and composition of the infiltrate. There is a dense nodular infiltrate, predominantly located in the reticular dermis and occasionally extending into the superficial parts of the subcutis. The infiltrate is mostly composed of small lymphocytes with chromatin dense nuclei and reactive germinal centers containing tingible body macrophages. The lymphocytes do not show nuclear atypia. There is an admixture of plasma cells, which usually do not form aggregates but are rather diffusely scattered throughout the infiltrate. Eosinophils and a granulomatous component can be observed in some cases. There is an admixture of a variable number of T cells, which usually account for less than 30% of the infiltrate. Immunophenotyping reveals that the majority of the infiltrate is represented by CD19+, CD20+, and CD79a+ B cells. The cells in the reactive follicles express bcl-6, but are negative for bcl-2, whereas the small B cells in the interfollicular area express bcl-2, but are negative for bcl-6. The networks of CD21+ follicular dendritic cells are sharply demarcated and regularly structured. Polytypic expression of immunoglobulin (Ig) light chains κ and λ by plasma cells is found by immunohistochemistry or in situ hybridization. Molecular studies demonstrate lack of monoclonal rearrangement of Ig heavy-chain genes by polymerase chain reaction (PCR) or Southern blot analysis.

DIFFERENTIAL DIAGNOSES

The differential diagnosis of B-cell PSLs primarily includes other B-cell infiltrates with a follicular pattern; that is, primary cutaneous marginal zone lymphoma (PCMZL) and primary cutaneous follicle center lymphoma (PCFCL) or their nodal or other extranodal counterparts presenting with secondary cutaneous infiltrates (Table 120-4). The architecture and composition of the infiltrate in PCMZL is very similar to that of B-cell PSL as both present with nodular infiltrates in the reticular dermis and superficial subcutis.[20] In comparison with B-cell PSL, the plasma cells in PCMZL are usually more prominent and found in sheets, particularly at the periphery of the infiltrates. The most important histopathologic diagnostic finding is the monotypic expression of Ig light chains in PCMZL with a ratio of at least 5:1 and ranging up to 10:1 for the expression of 1 of the 2 Ig light chains. The presence and number of eosinophils are not a useful finding for discrimination between B-cell PSL and PCMZL. Detection of a clonal B-cell population can be used as an additional diagnostic hint for PCMZL, but such deletion is only found in 50% to 70% of PCMZL cases, thereby limiting its diagnostic value for distinguishing between B-cell PSL and PCMZL. The other important differential diagnosis to be considered is PCFCL, which is characterized by the predominance of centrocyte-like differentiated tumor cells arranged in large neoplastic follicles. In addition, tingible body macrophages are only found in a small minority of PCFCLs compared to those found in B-cell PSLs with readily identifiable tingible body macrophages as part of the reactive follices.[21] Furthermore, a low proliferative activity in the neoplastic follicles of PCFCL is a characteristic finding, which contrasts with the high proliferative activity in the reactive germinal

TABLE 120-4
Comparison of B-Cell Pseudolymphoma and Cutaneous B-Cell Lymphomas

	B-CELL PSEUDOLYMPHOMA	PRIMARY CUTANEOUS MARGINAL ZONE LYMPHOMA	PRIMARY CUTANEOUS FOLLICLE CENTER LYMPHOMA
Gender (male-to-female ratio)	3:1	1:2	1:1.5
Age	<40 years	30-50 years	>50 years
Localization	Face > upper trunk > arms	Upper trunk > arms > face/head	Head/neck > upper trunk
Clinical features	Solitary nodule	Solitary or multiple nodules	Solitary or multiple nodules and plaques
Histology	Nodular infiltrate	Nodular infiltrate	Nodular infiltrate
	Reactive germinal centers with tingible body macrophages	Reactive germinal centers with tingible body macrophages	Neoplastic germinal centers; lack of polarization
	Small lymphocytes	Tumor cells with lymphoplasmacytoid (or, rarely, with monocytoid) differentiation	Tumor cells with centrocyte-like differentiation
	Plasma cells scattered	Plasma cells in small sheets	Few plasma cells
Phenotype	Small lymphocytes: CD20+ B cells > CD3+ T cells	Tumor cells: CD20+, bcl-2+, bcl-6–	Tumor cells: CD20+, bcl-2–, bcl-6+
	Germinal centers: bcl-2–, bcl-6+; high proliferative activity; sharply demarcated networks of follicular dendritic cells	Germinal centers: bcl-2–, bcl-6+; high proliferative activity; sharply demarcated networks of follicular dendritic cells	Germinal centers: bcl-2–, bcl-6+; low proliferative activity; irregular networks of follicular dendritic cells
	Polytypic expression of immunoglobulin light chains	Monotypic expression of immunoglobulin light chains	Usually no significant expression of immunoglobulin light chains
Molecular findings	Polyclonal	Monoclonal (70% to 80%)	Monoclonal (80% to 90%)

centers of B-cell PSLs. The networks of CD21+ follicular dendritic cells in PCFCL are irregular and disrupted in contrast to the sharply demarcated and regularly structured networks in B-cell PSLs. A clonal B-cell population can be detected in the majority of PCFCL detected by PCR or Southern blot analysis. It should be mentioned that the vast majority of PCFCL do not express bcl-2 by the neoplastic centrocyte-like differentiated cells. Consequently, the expression of bcl-2 is not of diagnostic value for distinguishing PCFCL from B-cell PSL. In cases with expression of bcl-2 by the centrocyte-like tumor cells, secondary cutaneous infiltration by a nodal follicle center lymphoma has to be considered because nodal follicle center lymphoma exhibits expression of bcl-2 by the neoplastic cells as the result of an underlying t(14;18) translocation in the majority of the cases. Other differential diagnoses include cutaneous infiltrates of B-cell chronic lymphocytic leukemia or small cell lymphocytic lymphoma, although the cutaneous infiltrates of small cell lymphocytic lymphoma usually do not show reactive germinal centers.

Clonality studies in B-cell PSLs are of limited value in distinguishing B-cell PSLs from cutaneous B-cell lymphomas as approximately 10% to 20% of PSLs harbor a clonal B-cell population.[12,22] In some studies, an even higher percentage of cases with clonal B cells were detected in nodular PSL.[23] In lesions with rather subtle infiltrates, pseudoclonality should always be ruled out as it represents a diagnostic pitfall.[24]

ETIOLOGY

A broad range of causes for B-cell PSLs has been identified. In addition to B-cell PSLs being caused by *Borrelia burgdorferi* sp. infection, insect bites, or injection of vaccines or antigens for hyposensitization, B-cell PSLs can be caused by acupuncture treatment, tattoos, metals in piercing rings and earrings, and drugs.

BORRELIA-ASSOCIATED B-CELL PSEUDOLYMPHOMA

EPIDEMIOLOGY

The terms *lymphocytoma cutis* and *lymphadenosis cutis benigna* are used synonymously for cases caused by *B. burgdorferi* infection. Approximately 1% of clinically apparent *Borrelia burgdorferi* sp. infections manifest as B-cell PSLs. A female preponderance (male-to-female ratio: 2:1) is observed in some, but not all, studies. This form of B-cell PSLs has more often been reported in whites than in African Americans. *Borrelia*-associated B-cell PSLs affects typically children and occurs in early adulthood, but may be seen in all age groups, with most patients being younger than age 40 years.

Figure 120-1 *Borrelia*-associated nodular B-cell lymphoma (lymphocytoma cutis, lymphadenosis cutis benigna): violaceous nodule on the earlobe.

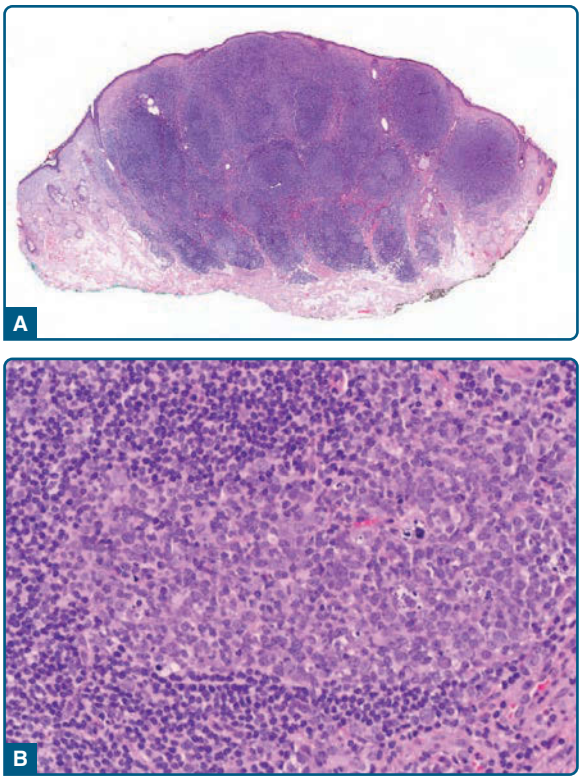

Figure 120-2 *Borrelia*-associated B-cell pseudolymphoma, histology: nodular lymphocytic infiltrate (**A**) with reactive germinal centers containing tingible body macrophages (**B**).

CLINICAL FINDINGS

A solitary red to violaceous dome-shaped nodule usually develops in *Borrelia*-induced B-cell PSLs, but in approximately 10% to 15% of patients, multifocal skin lesions can be observed. The face and scalp, and especially the earlobes, nipples, and scrotum, are the preferred sites for *Borrelia*-induced B-cell PSLs, but the trunk and extremities also may be involved (Fig. 120-1). Regional lymphadenopathy can be present.

LABORATORY TESTS

Histologically, the archetypic pattern of a dense dermal nodular infiltrate of small B cells and reactive germinal centers is found (Fig. 120-2).[14] In *Borrelia*-associated B-cell PSL, the germinal centers tend to be larger and confluent with only a small mantle zone, and in some cases there is a lack of polarization.[14,22] Because of the confluence of the large germinal centers, the lesions resemble the neoplastic follicles in PCFCL (follicular growth pattern).[22] Plasma cells are almost always present and are found particularly at the periphery of the infiltrates.

In rare cases of so-called large cell lymphocytoma associated with *Borrelia* infection, a predominance of blasts, resembling centroblasts and immunoblasts, are found simulating the findings in large B-cell lymphoma.[25] Those cases are prone to be misdiagnosed as diffuse large B-cell lymphoma.

In the vast majority of the cases of *Borrelia*-associated B-cell PSLs, molecular studies show a polyclonal rearrangement of IgH genes, but detection of monoclonal B cells has been observed and thus does not exclude the diagnosis of *Borrelia*-induced B-cell PSL.[14]

Serology shows antibodies against *B. burgdorferi* with variable pattern; that is, IgG and IgM or only 1 class of antibodies may be detectable and elevated. Nevertheless, cases with negative serologic findings can be seen[14]; consequently, negative serology does not exclude *Borrelia*-induced B-cell PSL. Molecular studies for the detection of *B. burgdorferi* DNA by PCR are a helpful adjunctive diagnostic tool with a sensitivity of approximately 70%.[26]

Diagnosis is based on histology, the clinical context (history of tick bite, localization at predilection site), serologic findings and/or detection of *B. burgdorferi* DNA in the tissue by PCR.

CLINICAL COURSE, PROGNOSIS, AND TREATMENT

In *Borrelia*-associated B-cell PSLs, antibiotics (see Table 120-3) are the first-line therapy and prevent other complications from *Borrelia* infection, such as arthritis and carditis.

CUTANEOUS T-CELL AND MIXED PSEUDOLYMPHOMA

Nodular T-cell PSL is characterized by a dense dermal T-cell–rich nodular infiltrate, which is accompanied by variable number of B cells, which can reach up to 30% of the entire infiltrate.[27] Mixed forms of PSL contain an equal number of T-cells and B-cells.

EPIDEMIOLOGY

There are no detailed epidemiologic data on the prevalence of T-cell or mixed PSL. They affect patients of both genders and all age and ethnic groups.

ETIOLOGY AND PATHOGENESIS

All causes identified in B-cell PSLs also can be found as underlying stimuli in T-cell and mixed PSLs. In approximately 5% of cases, drugs are identified as the causative stimulus in T-cell PSL. Most cases, however, are without known cause and therefore referred to as idiopathic T-cell PSL or mixed PSL.

CLINICAL FEATURES

T-cell and mixed PSL usually presents with a solitary or multiple red to violaceous nodules similar to B-cell PSL (Fig. 120-3).

LABORATORY TESTS

Histologically, T-cell and mixed PSL present in most cases with a dense nodular infiltrate extending throughout the entire dermis and into the superficial parts of the subcutis (Fig. 120-4). The infiltrates

Figure 120-3 Nodular T-cell pseudolymphoma: erythematous nodule on the nose.

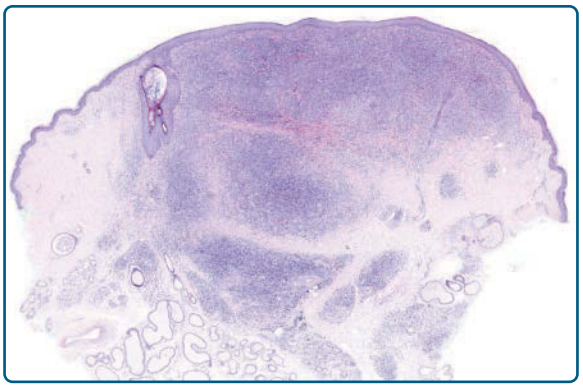

Figure 120-4 Nodular T-cell pseudolymphoma, histology: nodular infiltrate composed mostly of small lymphocytes. No follicles are present.

are predominantly composed of small lymphocytes with chromatin-dense nuclei, but a variable number of slightly enlarged (up to medium-sized) lymphocytes with chromatin-dense nuclei can be found. There is an admixture of a variable number of eosinophils, histiocytes, plasma cells (ranging from a few up to small clusters). The B cells can be arranged in small aggregates, but, rarely, germinal centers are found. Granuloma formation can be observed. There may be exocytosis of T lymphocytes into the epithelia of the hair follicles, but usually there is no significant exocytosis of lymphocytes into the overlying interfollicular epidermis (lack of epidermotropism).

Immunohistochemistry shows that, in most cases, the majority of the small lymphocytes are CD4+ CD30– T cells. There may be an admixture of a few CD30+ blasts representing activated lymphocytes.

Clonality studies reveal a polyclonal infiltrate in the majority of T-cell PSLs, but PSLs with clonal T cells have been reported and are referred to as *clonal PSL*s. Some of those cases may progress to overt lymphoma and may rather represent very early stages of lymphomagenesis than real PSLs.

DIFFERENTIAL DIAGNOSIS

Differential diagnosis of nodular T-cell and mixed PSLs includes cutaneous CD4+ small-/medium-sized T-cell lymphoma/lymphoproliferative disorder (CD4+ SMT-LPD) according to the World Health Organization (WHO) 2008 classification and the revised WHO 2016 classification, which show overlapping histologic and immunophenotypic features.[28,29] The CD4+ SMT-LPD also presents usually with a solitary lesion located mostly on the head and neck area and shows an indolent course (Fig. 120-5). Because nodular T-cell PSL and cutaneous CD4+ SMT-LPD cannot be distinguished with certainty based on clinical or histopathologic or phenotypic features, some authors consider them to represent the same process. Therefore, the encompassing term *cutaneous CD4+ small/medium T-cell lymphoproliferative disorder* has been introduced in the updated WHO 2016 classification to emphasize the indolent

Figure 120-5 Cutaneous CD4+ small-/medium-sized T-cell lymphoproliferative disorder: nodular lesion on the chin.

nature of this process. The expression of programmed cell death protein 1 (PD-1), originally thought to be a discriminative marker, is not of diagnostic value.

Nodular T-cell PSLs should be differentiated from mycosis fungoides (MF) in tumor stage because MF tumor stage may rarely present with small to medium-sized T cells without a significant number of large cells. In MF, however, the small and medium-sized cells show a higher degree of nuclear atypia than in CD4+ SMT-LPD. The distinction between MF, CD4+ SMT-LPD, and T-cell PSL has to be based on the clinical presentation with patches and plaques preceding the tumors in MF in contrast to the mostly solitary nodule without preceding patch(es) and plaque(s) in T-cell PSL. The differential diagnosis further includes secondary cutaneous infiltrates of angioimmunoblastic T-cell lymphoma (AITL), in which the small CD4+ and PD-1+ T cells are accompanied by a significant number of B cells. The clinical context with B symptoms, serologic findings, the nodal involvement shown by radiologic staging examinations, a high proliferation rate in AITL infiltrates, and the association with Epstein-Barr virus in some of the cases of AITL, are useful findings for distinguishing AITL from nodular T-cell PSL.

Among inflammatory skin disorders, lupus erythematosus (particularly the tumidus type) has to be considered, which also can present with dense dermal lymphocytic infiltrates. In those cases, however, vacuolization at the interface of the hair follicle epithelium and interstitial mucin deposits are present. In addition, the clinical presentation allows differentiation from nodular T-cell PSLs.

CLINICAL COURSE, PROGNOSIS, AND TREATMENT

T-cell and mixed PSL can resolve spontaneously after withdrawal of the underlying cause, but may persist for longer periods (months or years). If no spontaneous regression is observed after biopsy, surgical excision, cryotherapy, laser treatment, topical/intralesional steroids, or interferon represent therapeutic options.[30] T-cell PSL usually does not recur unless the underlying stimulus persists (eg, a drug). As in B-cell PSL, avoidance of the underlying stimulus is the effective preventive measure to avoid recurrence.

CD30+ T-CELL PSEUDOLYMPHOMA

CD30+ PSL represents a histologic subtype of T-cell PSL of the skin that is characterized by the presence of medium-sized to large atypical CD30+ T cells.[31,32] T-cell–rich pseudolymphomatous infiltrates with admixture of CD30+ cells have been reported in the context of lymphomatoid drug eruptions, nodular scabies, and arthropod bite reactions, as well as viral infections, particularly parapoxvirus-associated disorders such as Orf disease[33] and milker nodule, as well as molluscum contagiosum and herpes virus infections (for a review see reference 31). Among noninfectious disorders, CD30+ pseudolymphomatous infiltrates have been described in drug eruptions, hidradenitis, and injuries by corals.[34]

In CD30+ PSL, immunohistochemistry shows enlarged, that is, medium-sized to even large, CD30+ blast-like cells that are usually found as single units scattered throughout the infiltrate, which is otherwise dominated by small T cells (Fig. 120-6). In contrast to CD30+ lymphomas, CD30+ PSLs do not, in most of the cases, harbor a clonal T-cell population. Because of the presence of enlarged CD30+ cells, lymphomatoid papulosis (particularly histologic Type A) and cutaneous anaplastic large cell lymphoma (ALCL) have to be considered as differential diagnoses. In contrast to lymphomatoid papulosis and ALCL, the CD30+ cells in CD30+ PSL are usually not arranged in aggregates. Moreover, the significant number of B cells and plasma cells argues for a reactive process, that is, PSL, as they are usually absent or only present in a small number in lymphomatoid papulosis and ALCL. In addition, in contrast to lymphomatoid papulosis, expression of 5hmC in the CD30+ cells in CD30+ PSL is preserved and can serve as an additional diagnostic marker.[35]

Treatment of CD30+ PSL is directed against the underlying cause of the disease.

PSEUDOLYMPHOMATOUS FOLLICULITIS

This PSL variant was first described in 1988 by Kibbi and coworkers.[36] It presents with a solitary nodule located on the face that measures less than 1.5 cm and is similar or identical identical to the clinical manifestation found in cutaneous CD4+ SMT-LPD.[37] A miliarial

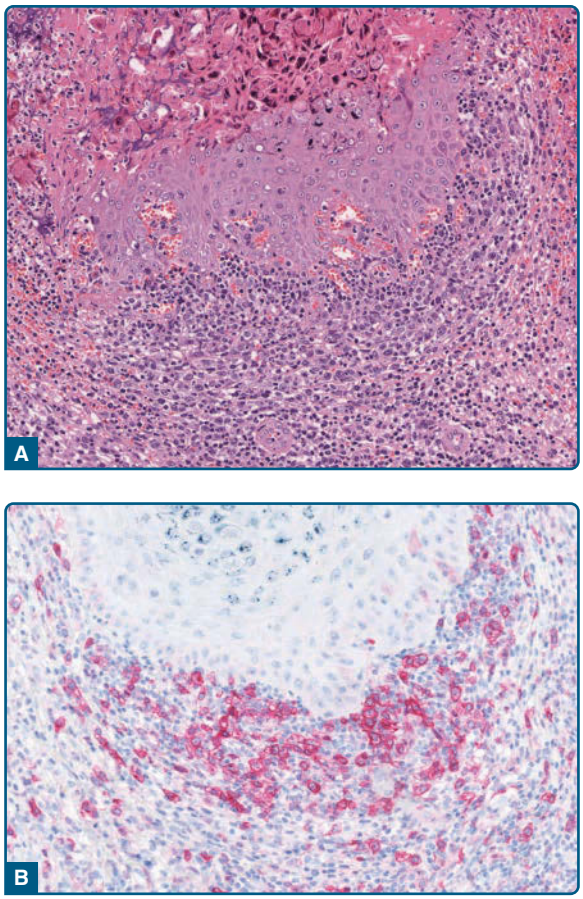

Figure 120-6 CD30+ pseudolymphoma. **A,** Infiltrates of atypical lymphocytes in molluscum contagiosum. **B,** Expression of CD30 by the medium-sized to large atypical lymphocytes.

form of B-cell pseudolymphomatous folliculitis has been described.[19] Histologically, half of the cases carry the features of nodular B-cell PSLs and the remaining cases carry the features of nodular T-cell PSLs. The lymphocytic infiltrates are located throughout the entire dermis and may extend into the subcutis and are arranged around the hair follicles (Fig. 120-7). A Grenz zone may be present. There is exocytosis of lymphocytes into the hair follicles often showing broadened epithelia.[38] In half of the cases, atypical lymphocytes are found. Half of the cases harbor aggregates of histiocytes. An admixture of numerous dendritic cells with expression of CD1a and S-100 was identified in all cases.[37] The course and treatment is similar to other forms of nodular PSL and CD4+ SMT-LPD.

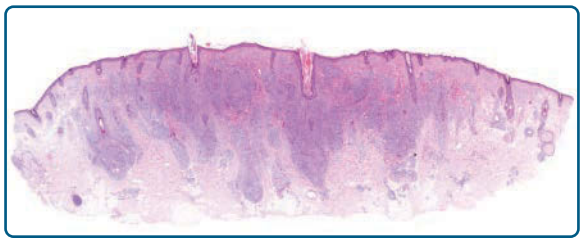

Figure 120-7 Pseudolymphomatous folliculitis, histology: dense dermal lymphocytic infiltrates with perifollicular accentuation.

OTHER FORMS OF NODULAR PSEUDOLYMPHOMA

On clinical grounds alone T-cell, B-cell, or mixed PSL cannot be discerned. In addition, some agents may induce T-cell and B-cell PSL so that an unequivocal correlation between the causative factor and the composition of the PSL is not possible. Nevertheless, the clinical context may provide essential information regarding the etiology of PSL, especially for those cases resulting from tattoos or metals (piercing, earrings), or PSL caused by exposure to leaches and acupuncture.

PERSISTENT NODULAR ARTHROPOD BITE REACTIONS AND NODULAR SCABIES

In both conditions longstanding pruritic papules and nodules are found with a predilection for the elbows, trunk, genitalia, and axillary, as well as inguinal folds. The lesions tend to be red-brown and may be excoriated. Mites or scybala are rarely found in the epidermis overlying the dense dermal lymphocytic infiltrates. A delayed-type hypersensitivity reaction is considered to be the underlying trigger factor for the formation of the T-cell–rich infiltrates.

Histologically the epidermis often shows features of pruriginous reaction with acanthosis and hyperparakeratosis. There is a wedge-shaped dermal infiltrate predominantly composed of small lymphocytes with admixture of eosinophils and occasional plasma cells (Fig. 120-8). Formation of flame figures can be seen particularly in cases with numerous eosinophils. In the center of the infiltrates, hypereosinophilic collagen bundles are found. The vessels show plump endothelia. In the majority of nodular arthropod bite

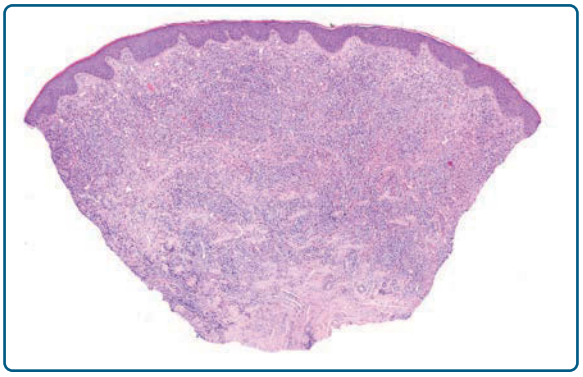

Figure 120-8 Nodular arthropod bite reaction, histology: wedge-shaped dermal infiltrate composed of lymphocytes and numerous eosinophils.

reactions, the infiltrate is dominated by T cells. Rarely, B-cell–rich forms with germinal centers may be seen. There can be an admixture of medium to even large atypical-appearing CD30+ lymphocytes (see section "CD30+ pseudolymphomas").[31,32,39] In those cases, distinguishing CD30+ pseudolymphomas from lymphomatoid papulosis can be challenging. There is no clonal rearrangement of T cells in nodular arthropod bite reactions and nodular scabies.

Persistent arthropod bite reactions have to be differentiated from exaggerated bite reactions, which can occur in patients with B-cell chronic lymphocytic leukemia and other leukemias.[40] In those patients, hematologic examination may be considered. Moreover, lymphomatoid papulosis (Type A), Hodgkin lymphoma, and nodular secondary syphilis are histologically differential diagnoses.

The lesions in nodular arthropod bite reactions and nodular scabies may be longstanding and persist for several months. Antiscabietic treatment is ineffective. Excision, intralesional corticosteroids, or topical immunomodulators may be considered if spontaneous regression does not occur or topical steroids are ineffective.[41]

PSEUDOLYMPHOMA CAUSED BY LEECHES (*HIRUDO MEDICINALIS*) THERAPY

The distribution of the lesions corresponds to the exposure to leeches (*H. medicinalis*) which are commonly found on the lower back or over areas that have been treated for hematoma after trauma or surgery (Fig. 120-9).[42] A diffuse form has been described.[43] Both T-cell and B-cell predominant forms were observed. Hypothetically bacteria residing in the leeches are transferred to the host during the blood meal and induce the pseudolymphomatous reaction.

NODULAR PSEUDOLYMPHOMA CAUSED BY DRUGS

PSL caused by drugs show a variety of clinical, histologic, and phenotypic manifestations. Some of the drugs, like anticonvulsants, may induce nodular PSL (Fig. 120-10), as well as other histologic manifestations (see below).[27,44,45] Clinically, drug-related nodular PSL may present with a solitary or multiple nodules.[44]

Figure 120-9 Pseudolymphoma caused by leeches (*Hirudo medicinalis*): characteristic localization of the pseudolymphoma.

Figure 120-10 Nodular T-cell pseudolymphoma caused by anticonvulsant (phenytoin): erythematous nodule on the right breast.

Histologically, nodular drug-related PSL presents with the typical histologic features of nodular T-cell or B-cell PSL.[46,47] The lymphocytes in nodular T-cell PSLs may show subtle nuclear atypia. Proliferation rate is low, approximately 10%. In B-cell PSLs, the typical immunophenotypic features as outlined above are found. In T-cell PSLs, immunohistochemistry reveals a predominance of CD4 lymphocytes and admixture of a variable number of CD30+ lymphocytes.[48] Loss of pan–T-cell markers is not observed. In most cases, there is no monoclonal rearrangement of T-cell receptor γ genes or IgH genes.

Diagnosis of lymphomatoid drug eruption is challenging, particularly as the latency between onset of medication and development of drug eruption can be very long (several months up to years).

Differential diagnosis depends on the phenotype. In B-cell nodular PSL, differential diagnosis includes cutaneous marginal zone lymphoma and follicle center lymphoma. In CD4+ T-cell rich forms of drug-related nodular PSL, the differential diagnoses include cutaneous CD4+ SMT-LPD, MF, and Sézary syndrome.

Withdrawal of the drug is the first step in the management of drug-related PSL. Surgical excision or intralesional injection of corticosteroids may be considered, if spontaneous regression is delayed. One has to be aware that drug-related nodular PSL may persist for several months even after withdrawal of the causative drug. Reexposure to the drug may elicit a relapse of the PSL.

PSEUDOLYMPHOMA AT DRUG AND VACCINE INJECTION SITES

Solitary or multiple PSL may also develop after injection of vaccines to prevent infectious diseases

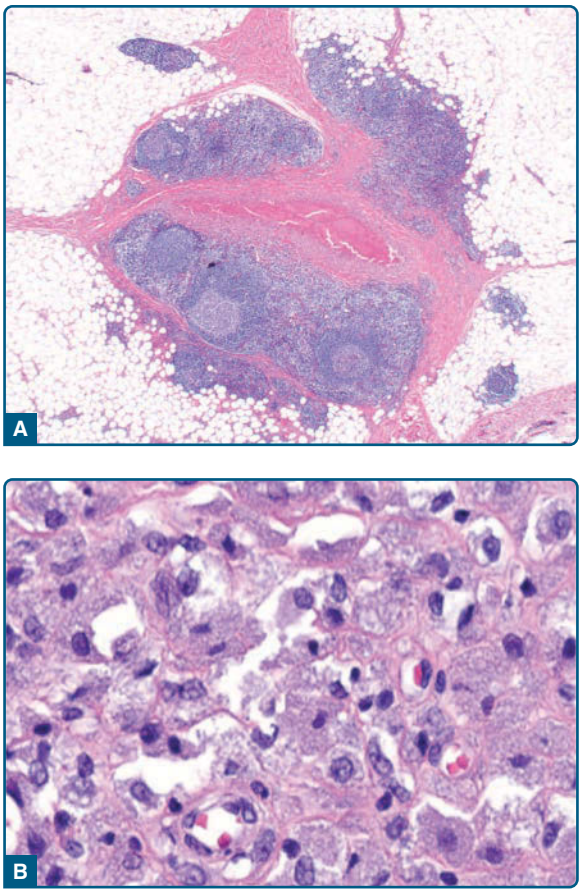

Figure 120-11 Pseudolymphoma caused by allergen injection: **A,** Subcutaneous B-cell–rich infiltrate with formation of follicles. Note the central area with the histiocyte-rich infiltrate. **B,** The histiocytes show a grayish granular cytoplasm containing aluminum hydroxide–bound vaccine.

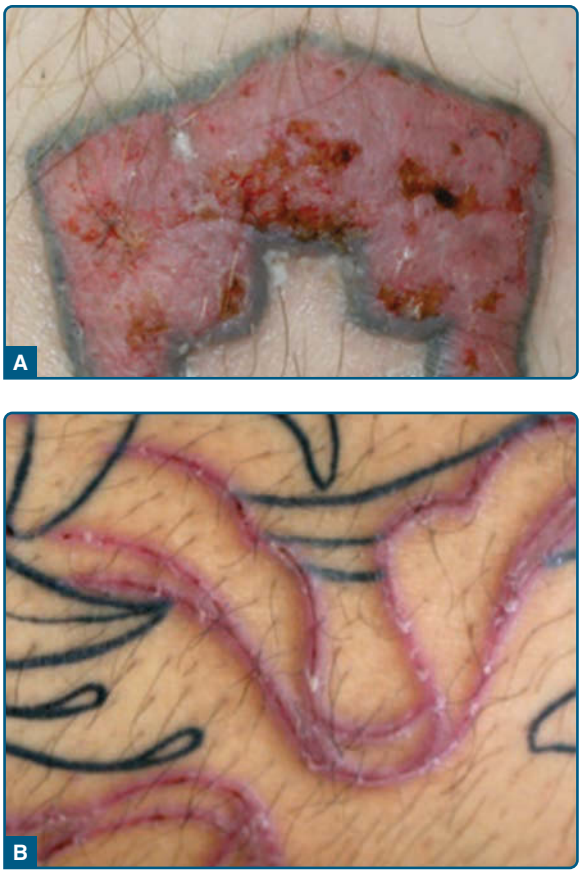

Figure 120-12 **A** and **B,** Pseudolymphoma in association with tattoo: Infiltration within the area of red tattoo component.

or after injection of allergens for hyposensitization. They are typically found in the subcutaneous tissue at the injection site.[49] The histologic features show B-cell–rich infiltrates with reactive germinal centers. In the center of the infiltrates, an accumulation of histiocytes can be seen (Fig. 120-11).[50,51] The histiocytes show a cytoplasm with a granular gray-blue aspect, which seems to represent aluminium hydroxide–bound vaccines.[52]

PSEUDOLYMPHOMA IN ASSOCIATION WITH TATTOOS OR METALS

Pseudolymphomatous infiltrates arising in tattoos and caused by metals in earrings or piercings share similar features.[53,54] In tattoos, the lymphocytic infiltrates mostly arise and remain limited to areas with red tattoo dye (Fig. 120-12). Cinnabar, a mercuric sulfide, is the most commonly used dye for red tattoos. In addition, PSLs also have been observed in blue or green tattoos, for which cobalt and chrome salts are employed. The PSL to the tattoo dye can be regarded as a delayed-type hypersensitivity reaction. Clinically, mostly papules, nodules, or plaque-like infiltrates develop within 1 compartment of the tattoo. They are usually asymptomatic. The latency between application of the tattoo dye and occurrence of the PSL is highly variable, ranging from months to years.[55] Histologically, a lichenoid component with a band-like superficial infiltrate, interface changes, and exocytosis of lymphocytes, as well as a deeper lymphocytic infiltrate in the mid and deep dermis with admixture of eosinophils, is present leading to a pseudolymphomatous appearance.[56] The lymphocytes are small and do not display significant nuclear atypia. Patch test to mercury or other substances in the tattoo dyes may reveal delayed type hypersensitivity, but the test also may be negative.[55] Therapy is challenging and includes intralesional injections of corticosteroids, laser therapy, or excision if small papulonodular lesions are present.

INFECTIONS WITH LYMPHOCYTE-RICH INFILTRATES SIMULATING LYMPHOMA

Various infections, particularly those caused by viruses and parasites, may show dense lymphocyte-rich

infiltrates, thereby simulating a lymphoma. Among infections with parasites, cutaneous leishmaniasis histologically simulates lymphoma by its nodular infiltrate composed of numerous lymphocytes, including plasma cells and histiocytes. The lack of nuclear atypia and detection of the parasite either by special stains, immunohistochemistry or by molecular techniques enables cutaneous leishmaniasis to be differentiated from cutaneous lymphoma. Not only histologic can findings in cutaneous leishmaniasis simulate lymphoma, but the clinical aspects occasionally can resemble B-cell PSL.[57,58]

In infections with herpes simplex virus and varicella zoster virus, occasionally lymphocyte-rich infiltrates without the pathognomonic epithelial changes can be observed and have been referred to as *herpes incognito*. Both lymphocytes with slightly enlarged and atypical-appearing chromatin-dense nuclei and enlarged CD30+ lymphocytes may be found in herpes incognito, making those infiltrates subject to being mistaken for lymphoma infiltrates. Detection of viral antigens by immunohistochemistry and/or detection of viral DNA by PCR enable identification of those infiltrates as herpes virus–related T-cell reactions.

Parapoxvirus infection may induce cytomorphologic changes and expression of CD30 by the infiltrating T cells, which makes distinguishing them from pleomorphic lymphocytes in the context of anaplastic large-cell lymphoma challenging (see Fig. 120-6).[31,32] The presence of epithelial changes with inclusion bodies typical for parapoxvirus infection, the absence of loss of T-cell markers, and the lack of monoclonal rearrangement of T-cell receptor–γ genes help to distinguish those infiltrates from cutaneous T-cell lymphoma. However, the diagnosis is based on the detection of the virus by immunohistochemistry, electron microscopy, or PCR.

PSEUDOLYMPHOMAS-HISTOLOGIC MYCOSIS FUNGOIDES SIMULATORS

The term *pseudo-MF* describes a group of disorders of different etiologies that histologically mimic MF. Because the histologic evaluation suggests MF or another form of epidermotropic cutaneous T-cell lymphoma, the clinicopathologic correlation is crucial to avoid misinterpreting the histologic findings as a lymphoma and for assigning the findings to a distinct reactive skin disease, such as PSL.

Histologically, the diseases described in this section have in common a dermal, either band-like or perivascular, infiltrate of mostly small lymphocytes, which show exocytosis into the epidermis and may exhibit subtle nuclear atypia, thereby simulating epidermotropic cutaneous T-cell lymphoma (CTCL). Phenotyping reveals either a predominance of CD4+ or CD8+ cells. In addition, a variable expression of CD30 can be seen in some cases of pseudo-MF. As in other forms of PSL, the lymphocytes are polyclonal in the majority of cases. In some diseases, such as pityriasis lichenoides et varioliformis acuta, a significant percentage of clonal T cells is found, but does not indicate malignancy or a risk of progression to lymphoma.

Differential diagnoses include primarily MF or Sézary syndrome. In cases with a predominantly CD8+ infiltrate, differential diagnosie include CD8+ MF, Sézary syndrome, cutaneous CD8+ aggressive epidermotropic cytotoxic T-cell lymphoma, and lymphomatoid papulosis (Types D and E). Profound nuclear atypia, predominance of medium-sized to large cells, loss of pan T-cell markers, and monoclonal rearrangement of T-cell receptor genes, are findings in favor of CTCL.

As in other forms of PSL, the treatment focuses on avoiding exposure to the causative agents, such as allergens in lymphomatoid contact dermatitis and drugs in lymphomatoid drug eruption. In addition, topical corticosteroids or immunomodulators and ultraviolet (UV) light therapy are used. Systemic steroids and immunosuppressive drugs, such as cyclosporine, may be indicated in severe forms of PSL.

LYMPHOMATOID CONTACT DERMATITIS

Lymphomatoid contact dermatitis (LCD) is a chronic contact dermatitis that histologically simulates MF.[59] Various antigens, including nickel sulfate, gold, zinc, paraphenylenediamine, textile dye, and several other antigens, have been identified as culprits.[60] LCD occurs mostly in adults and affects both genders.

Clinically, LCD manifests with eczematous erythematous and scaly papules, patches, plaques, and, in rare cases, erythroderma (Fig. 120-13). The lesions are pruritic.

Histopathologically there is a superficial band-like infiltrate with variable exocytosis of lymphocytes into the epidermis, which may show spongiosis or spongiotic vesicles. Intraepidermal accumulations of Langerhans cells (so-called pseudo Pautrier collections) can be found. Some of the lymphocytes can show slightly convoluted nuclei, but nuclear atypia is not prominent.

Figure 120-13 Lymphomatoid contact dermatitis: eczematous lesions in both axillae caused by contact allergy to fragrance components.

There is an admixture of eosinophils. The ratio of CD4+ to CD8+ lymphocytes is inconspicuous, but there can be an admixture of slightly enlarged CD30+ cells representing activated lymphocytes.

Differentiation of LCD from MF is based on the presence of variable degree of spongiosis, the lack of significant atypia of lymphocytes, an inconspicuous CD4-to-CD8 ratio, and the absence of loss of T-cell markers in LCD. Monoclonal T cells have been reported in LCD and do not indicate lymphoma. Sensitization against the allergen(s) is documented by patch test and is an essential diagnostic criterion for proving a diagnosis of LCD.[61]

The course of LCD is chronic, particularly if exposure to the allergen cannot be avoided. The treatment follows the general recommendation for the treatment of other forms of contact dermatitis with avoidance of exposure to the allergen and suppression of the immunologic reaction against the allergen mostly by topical corticosteroids or topical immunomodulators. In addition, UV light–based strategies or systemic immunosuppression may be effective.

LYMPHOMATOID DRUG REACTION

Apart from its nodular form, drug-related PSL commonly presents with maculopapular or papular eruptions. A large number of drug classes that induce various forms of lymphomatoid drug eruptions have been described.[8,62]

In this form of lymphomatoid drug reaction, a band-like infiltrate in the upper dermis, with variable degrees of exocytosis of lymphocytes, is found.[63] Vacuolar alteration at the dermoepidermal junction and apoptotic keratinocytes may be present. The lymphocytes may show an irregular nuclear contour (ie, nuclear atypia) (Fig. 120-14 A, B). Eosinophils are commonly found, but also may be absent. Immunohistochemistry reveals either a predominance of CD4+ or CD8+ lymphocytes and an admixture of a variable number of CD30+ lymphocytes (Fig. 120-14C).[48] Loss of pan T-cell markers is not observed.

Differential diagnosis includes epidermotropic CTCL, particularly MF and Sézary syndrome. Lining up of lymphocytes along the junctional zone, nuclear atypia of the lymphocytes, loss of pan T-cell markers, and monoclonal rearrangement of T-cell receptor-γ genes favor MF or Sézary syndrome. Moreover, expression of PD-1 and TOX (thymocyte selection-associated high-mobility group box factor) by the majority of the lymphocytes was found in Sézary syndrome, but not in inflammatory erythrodermas.[64] Cases with CD8+ infiltrates showing exocytosis of lymphocytes have to be distinguished from CD8+ MF (patches and plaques), CD8+ lymphomatoid papulosis (especially Type D or Type E), and pityriasis lichenoides et varioliformis acuta (PLEVA). Drug-related CD30+ PSL simulates lymphomatoid papulosis (Type A or Type B).[65] Occasionally,

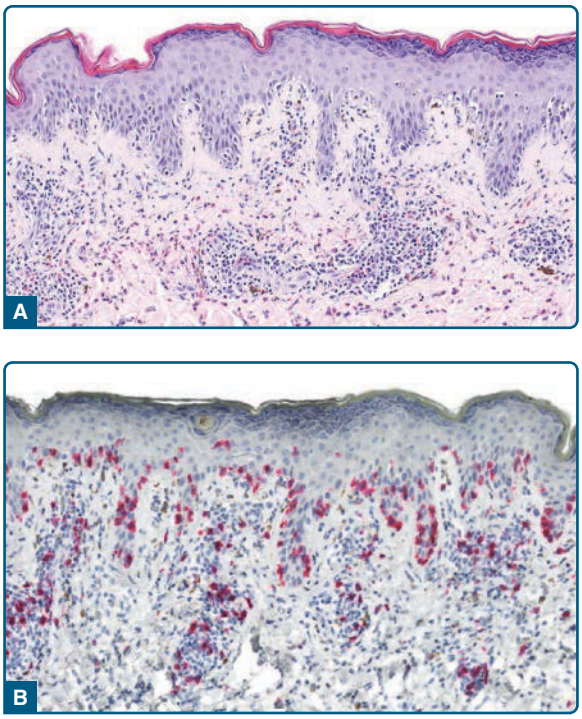

Figure 120-14 Lymphomatoid drug reaction, histology: lymphocytic infiltrate with exocytosis of lymphocytes into the epidermis and nuclear atypia of the lymphocytes **(A)** with expression of CD8 (**B**).

the lymphocytes in lymphomatoid drug eruptions exhibit remarkable nuclear atypia so that distinction from lymphoma is very challenging or even impossible by histology alone. Clinicopathologic correlation and history are mandatory to reach the final diagnosis in drug-related PSL.

As in the nodular form of drug-related PSL, withdrawal of the drug is the essential step in the management. Lymphomatoid drug eruption can persist for several months and reexposure to the drug may elicit a relapse of the PSL. Systemic, intralesional, or topical steroids are used for treatment.

ACTINIC RETICULOID

Actinic reticuloid represents a chronic multifactorial dermatitis with severe photosensitivity to a broad spectrum of wavelengths, which histologically mimics epidermotropic CTCL.[5]

CLINICAL FINDINGS

It affects mostly middle-aged and older men.[66] It presents with persistent erythematous lichenoid papules and plaques on light-exposed skin areas, particularly on the face and neck. In some patients infiltration on the face leads to a facies leonina-like aspect (Fig. 120-15). Progression into erythroderma can be observed. Lichenification and erosions usually occur

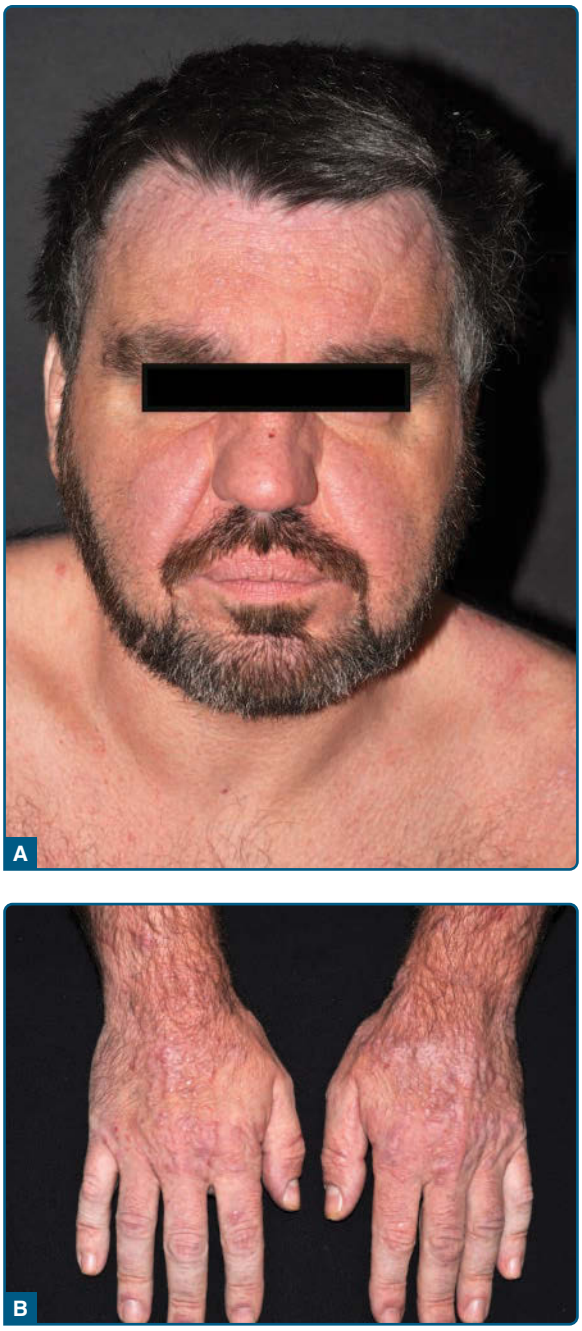

Figure 120-15 Actinic reticuloid: diffuse infiltration and erythema and papules on the face (**A**) and papules on the back of the hands (**B**).

over time. The skin lesions are accompanied by intense pruritus.

LABORATORY TESTS

Histologically, there is psoriasiform hyperplasia of the epidermis, slight spongiosis, and compact orthokeratosis with focal parakeratosis. In the upper dermis there is an infiltrate arranged in a perivascular, but also interstitial, distribution and composed of small lymphocytes, eosinophils, and plasma cells. Coarse bundles of collagen arranged in vertical streaks are found in the papillary dermis. Multinucleated fibroblasts may be present. The lymphocytes may show slightly atypical nuclei and exocytosis into the overlying epidermis. Immunohistochemistry reveals a predominance of CD8+ T cells.[67]

In the peripheral blood, an increased number of CD8+ T cells (reversed CD4-to-CD8 ratio) is characteristic for actinic reticuloid, particularly in erythrodermic patients.[66] The atypical circulating lymphocytes show indented nuclei. Phototesting, including positive photo patch tests, reveals sensitization to 1 or multiple allergens.

DIAGNOSIS AND DIFFERENTIAL DIAGNOSIS

The diagnosis of actinic reticuloid is based on the presence of persistent infiltrated plaques and papules on light-exposed skin areas, photo sensitivity to a broad spectrum of wavelengths, and histologic findings with a predominance of CD8+ slightly atypical lymphocytes and variable degree of exocytosis, as well as the presence of circulating CD8+ lymphocytes in the peripheral blood.[67]

Based on clinical and/or histologic grounds, MF and/or Sézary syndrome have to be considered. CD8+ MF shows a more pronounced epidermotropism and nuclear atypia of the lymphocytes. Moreover, CD8+ MF is usually located on UV-protected body regions in contrast to actinic reticuloid displaying a distribution in light-exposed areas. Particularly in patients with actinic reticuloid presenting with erythroderma, Sézary syndrome represents an important differential diagnosis. In contrast to actinic reticuloid with a predominance of CD8+ lymphocytes, Sézary syndrome is characterized by clonal CD4+ atypical lymphocytes in the skin and the peripheral blood, lymphadenopathy, alopecia, and palmoplantar hyperkeratosis.

CLINICAL COURSE, PROGNOSIS, AND TREATMENT

Actinic reticuloid shows a longstanding highly chronic course. In addition to UV light protection with sunscreens, topical steroids and topical immunomodulators can be used, but show variable efficacy. Among systemic drugs, cyclosporine may be effective. Photo hardening with UV-B irradiation to induce photo tolerance was reported to produce a good response in one series.[67]

CD8+ T-CELL PSEUDOLYMPHOMA IN IMMUNODEFICIENCY

In patients with immunodeficiency, in particular HIV infection, infiltrates of CD8+ lymphocytes mimicking MF may develop. Fewer than 50 cases of CD8+

infiltrates in HIV-infected patients have been reported as of this writing. The etiology and pathogenesis of these infiltrates is largely unknown, but may be related to severe immunodeficiency as the cutaneous CD8+ infiltrates occur in advanced HIV infection with low numbers of CD4+ cells. A variety of clinical presentations have been described, including disseminated, often pruritic papules, or a diffuse, mildly pruritic papular eruption.[68,69] In addition, palmoplantar hyperkeratosis and erythroderma were observed. The dermal infiltrates of CD8+ lymphocytes are accompanied by exocytosis of CD8+ lymphocytes into the epidermis. The lymphocytes may show subtle nuclear atypia. Molecular studies revealed a polyclonal nature.

The course of the cutaneous CD8+ infiltrates per se is indolent in most patients, but is considered as a sign for bad overall prognosis, which is mostly determined by the severe lymphopenia of CD4+ T cells. In most patients remission was achieved when receiving highly active antiretroviral therapy, and in moderately immunosuppressed patients methotrexate was shown to be effective.[70,71]

This condition seems not to be exclusively limited to patients with HIV infection, as similar features were recently described in a renal transplant recipient.[72]

BORRELIA-ASSOCIATED T-CELL PSEUDOLYMPHOMA

With the exception of erythema migrans, *Borrelia* infection of the skin most commonly manifests with B-cell–predominant infiltrates, including plasma cells, such as lymphocytoma cutis. Recently *B. burgdorferi* infections with T-cell–rich infiltrates have been reported.[73,74] The dermal T-cell infiltrate was either band-like or diffuse and displayed focal epidermotropism with lining-up of lymphocytes along the junctional zone. The lymphocytes show slight nuclear atypia. In addition, a minor interstitial histiocytic component of the infiltrate can be observed. Both the histologic features that mimic MF and the clinical aspect with patches resembling MF represent a diagnostic pitfall in some of the affected individuals. Other clinical presentations included the typical findings of erythema migrans or acrodermatitis chronica atrophicans. Treatment with antibiotics results in remission.

PAPULOERYTHRODERMA OFUJI

Papuloerythroderma Ofuji is a rare pruritic erythrodermic dermatosis that clinically can simulate CTCL.[75] Association with drugs, Hodgkin lymphoma, visceral malignancies, and immunodeficiency syndromes have been reported. In some patients,[76,77] papuloerythroderma Ofuji was described as a manifestation of MF, in others as a disease accompanying MF.[78]

Figure 120-16 Papuloerythroderma Ofuji: papules with confluence to plaques and spared areas.

Papuloerythroderma Ofuji was originally described in Japanese patients, but similar cases have been reported from other geographic regions. The median age is 70 years. It occurs more frequently in males than in females. Clinically, papuloerythroderma Ofuji manifests with disseminated solid papules. The coalescing brownish papules are flat-topped and observed mainly on the flexor surfaces of the extremities. The axillae, inguinal regions, antecubital and popliteal fossae, and big furrows on the abdomen are spared ("deckchair" sign; Fig. 120-16).[79]

Histology shows eczematous features with acanthosis, spongiosis and hyperparakeratosis, and a dermal lymphocytic infiltrate with admixture of plasma cells, eosinophils, and neutrophils is found. Exocytosis of neutrophils and eosinophils may be observed.[80] Immunohistochemistry shows numerous dendritic cells and mature T cells in the dermis. The most common abnormal laboratory findings were eosinophilia and an elevated serum IgE level. There should be a search for immunodeficiency, especially HIV infection.

The clinical differential diagnoses include Sézary syndrome. Papuloerythroderma Ofuji can be distinguished from Sézary syndrome because, unlike Sézary syndrome, papuloerythroderma Ofuji lacks nuclear atypia of the lymphocytes and circulating atypical lymphocytes.

The prognosis of papuloerythroderma Ofuji is good, if there is no underlying malignancy. UV light treatment including psoralen and ultraviolet A (PUVA), bath PUVA, UV-B in combination with topical steroids, etretinate, Re-PUVA, oral steroids, and cyclosporine have been described as effective therapeutic approaches.[11-14]

INFLAMMATORY DISORDERS AS CTCL AND CLONAL DERMATITIS

Various disorders, which are discussed in other chapters, are characterized by a T-cell–rich infiltrate and exocytosis of lymphocytes into the epidermis, making

the disorders prone to be misinterpreted as epidermotropic CTCL. These disorders include lichen planus, lichen sclerosus et atrophicans, pigmented purpuric dermatitis, and pityriasis lichenoides.[65,81-83] Furthermore, inflammatory diseases with lymphocyte-rich dermal and/or subcutaneous infiltrates, such as lupus erythematosus (particularly the tumid type) and lupus panniculitis, have to be differentiated from other forms of CTCL including subcutaneous panniculitis-like T-cell lymphoma.

DETECTION OF T-CELL CLONES IN INFLAMMATORY SKIN DISEASES

Highly sensitive methods to assess clonality, such as PCR combined with temperature gradient gel electrophoresis or denaturing gradient gel electrophoresis and automated high-resolution fragment analysis, allow detection of clonal T cells, which may comprise as little as 1% of all infiltrating cells. Clonal T-cell populations have been found in some cases in the above mentioned inflammatory skin conditions, for example, in lichen planus and lichen sclerosus et atrophicans, in which clonal T cells were found in 6% (lichen planus) and 13% (lichen sclerosus et atrophicans) of the cases. Remarkably, a monoclonal rearrangement of *TCR* genes is commonly found in pityriasis lichenoides harboring clonal T cells in up to 60% of cases.[82,84] The significance of these T-cell clones is unclear. As a consequence for the diagnostic workup of lymphocyte-rich infiltrates, detection of a clonal T-cell population cannot be used as a sufficient finding to diagnose CTCL.[13] The presence of clonal T cells within an infiltrate may merely represent a predominance of 1 or more T-cell clones in the context of an immunologic reaction that may be induced and maintained by certain antigens. In contrast to cutaneous lymphomas with persistence of a single T-cell clone during disease evolution, the T-cell clones in inflammatory skin disorders are transient and change over time. As a consequence the detection of clonal T-cells in inflammatory disorders underlines the necessity to correlate the results of clonality assays with the clinical, histologic, and immunophenotypic findings to achieve the final diagnosis.[85]

CLONAL DERMATITIS

Apart from the above-mentioned well-characterized and distinct inflammatory skin diseases that may harbor clonal T cells in some cases, clonality studies employing PCR techniques led to the identification of cases with chronic, nonspecific dermatitis harboring T-cell clones. Those cases have been referred to as "clonal dermatitis."[86] Approximately 25% of clonal dermatitis cases progress to overt CTCL within 5 years.[86] These observations indicate that at least some cases of "clonal dermatitis" may represent CTCL precursor lesions. Clonal dermatitis would thus be one of the earliest manifestations of CTCL, harboring a dominant T-cell clone but lacking histologic features diagnostic for CTCL.

LYMPHOCYTIC INFILTRATION OF THE SKIN AND PALPABLE ARCIFORME MIGRATORY ERYTHEMA

Lymphocytic infiltration of the skin Jessner-Kanof (LIS) and palpable arciform migratory erythema of Clark (PAME) have been regarded by some authors as T-cell PSLs, and by others as lupus-like eruptions.

The clinical presentation in PAME led to its designation with infiltrated annular erythema developing into large migrating lesions.[87] The trunk is the predilection site. Histology shows dense perivascular and periadnexal predominantly lymphocytic infiltrate. There is no admixture of plasma cells and interstitial mucin deposits such as in lupus erythematosus are absent. Immunohistochemistry reveals an infiltrate dominated by T cells with admixture of B cells and histiocytes. The lymphocytes are polyclonal. The histology is very similar to the findings in LIS.[88] Phenotypically, the infiltrate in LIS is mostly composed of CD8+ lymphocytes.[89] We consider PAME and LIS to represent the same process because of the similarities in clinical presentation, histology, and course. Both processes may respond to topical steroids, oral antibiotics, and UV-A1.[88] There is a tendency for relapses.

OTHER DISORDERS WITH LYMPHOCYTE-RICH INFILTRATES

ACRAL PSEUDOLYMPHOMATOUS ANGIOKERATOMA

Acral pseudolymphomatous angiokeratoma (APA) was originally described as occurring in children (hence the original name *acral pseudolymphomatous angiokeratoma of childhood* [APACHE]), but it has been shown that it also affects adults.[90-92] Some authors consider the lesions to represent persistent arthropod bite reactions, whereas others categorize APA as a benign vascular process with a prominent lymphocytic infiltrate, that is, a form of cutaneous PSL.[90,92] Consequently, the term *papular pseudolymphoma* has been proposed.[92]

Clinically, APA manifests as a unilateral eruption of clustered red to violaceous angiomatous papules (diameter: 1 to 5 mm) on acral sites, that is, hands and

Figure 120-17 Acral pseudolymphomatous angiokeratoma of childhood (APACHE): grouped papules on the hand of an 8-year old girl. (Used with permission from Prof. Dr. S. Lautenschlager, Zurich, Switzerland.)

feet (Fig. 120-17).[90] Coalescence of the lesions can be seen. Longitudinal splitting of the nails, onycholysis, and nail deformities may occur.

The histology of APA shows a dense infiltrate of small lymphocytes, eosinophils, plasma cells, and histiocytes. Within the infiltrate there are thick-walled vessels lined by plump endothelia. Diagnosis is based on clinicopathologic correlation. The accompanying infiltrate is composed of small, well-differentiated lymphocytes admixed with a few plasma cells and histiocytes, including histiocytic giant cells. In some instances, a few eosinophils may be present. Immunohistochemistry demonstrates that the lymphocytes are polyclonal T cells and B cells, with B cells occasionally forming small aggregates. The histologic differential diagnoses of APACHE include lymphomatoid drug eruptions and arthropod bite reaction.

Similar histologic findings, but clinically manifesting as a solitary, polypoid, erythematous papule, was described under the term T-cell–rich angiomatoid polypoid PSL of the skin.[93] Its nosologic relationship to APACHE remains to be determined.

APACHE is a benign process. No reoccurrences have been reported following treatment. When left untreated, the lesions can regress, show a waning-and-waxing course, or remain unchanged for months or years.

Destruction of the lesions by curettage, intralesional corticosteroids, or high-potency topical corticosteroids under occlusion has been used for treatment and resulted in complete remission.[91]

LYMPHOPLASMACYTIC PLAQUE

Lymphoplasmacytic plaque (LPP) is a recently described rare skin disease that is considered to be a form of PSL of unknown etiology. Originally it was reported in children with the pretibial region as predilection site, and referred to as isolated primary cutaneous plasmacytosis in children and pretibial LPP.[94,95] A recent study indicates that LPP can also affect adults and involve the trunk and arms. Consequently, we prefer the term *lymphoplasmacytic plaque*.[96] There is a female preponderance.

Clinically, LPP shows a distinct presentation characterized by a longstanding plaque or circumscribed, often linear arranged, reddish and brownish papules and plaques (Fig. 120-18).[96,97] Histology reveals a dense dermal lymphohistiocytic infiltrate with numerous polyclonal plasma cells accounting for up to 25% of the entire infiltrate. The infiltrate is superficial, band-like, or deep nodular and interstitial, often accentuated around adnexal structures or blood vessels (Fig. 120-19). Interstitial histiocytic granulomas around sclerotic collagen bundles (so-called pseudorosettes) with histiocytic giant cells and an increased number of vessels can be seen.[96]

LPP have to be differentiated from other conditions containing plasma cells and histiocytes, such

Figure 120-18 Lymphoplasmacytoid plaque: longstanding erythematous plaque on the lateral aspect of the left upper arm.

as primary cutaneous plasmocytosis, lymphocytoma cutis, cutaneous marginal zone lymphoma, primary and secondary cutaneous plasmocytoma, and infections (eg, fungal, mycobacterial, treponemal). An infectious process should always be ruled out by serology, special stains, and molecular pathologic techniques. The diagnosis of LPP is based on clinicopathologic correlation.

LPP and APA show overlapping clinical and histologic features, such as female predominance and a predilection for the extremities, especially the legs, as well as a lymphohistiocytic infiltrate and polyclonal plasma cells. It has been postulated that both entities (APACHE and LPP) belong to the same spectrum of diseases and represent a plasma cell–rich PSL with a prominent vascular component.

The course of LPP is longstanding up to several years. Surgical excision is the first-line treatment, especially as other therapies are not effective.[96]

CUTANEOUS PLASMOCYTOSIS

Cutaneous plasmocytosis is a rare disease that has been reported in Asian countries, especially Japan. It mostly affects adults.[98,99] It is characterized by multiple, brownish, small plaques and nodules occurring all over the body. Histology shows dermal infiltrates composed predominantly of mature polyclonal plasma cells.[98,99] In some patients, signs of a systemic involvement (eg, lymphadenopathy, hepatosplenomegaly, hypergammaglobulinemia, increased levels of interleukin-6 in the serum, and elevated erythrocyte sedimentation rate) can be found. Treatment includes PUVA, steroids, and chemotherapeutic approaches.

CUTANEOUS INFLAMMATORY PSEUDOTUMOR

The term *inflammatory pseudotumor* has been used to describe 2 conditions that today are considered to be distinct entities, namely, plasma cell granuloma and inflammatory myofibroblastic tumor.[100] Inflammatory pseudotumor is a benign process of unknown etiology. Clinically, it manifests as longstanding dermal or subcutaneous nodules of firm consistency. Histologically, a circumscribed nodular infiltrate of small lymphocytes, numerous plasma cells arranged in sheets, and histiocytes is found in plasma cell granuloma. Reactive germinal centers may be found. In inflammatory myofibroblastic tumor, a prominent spindle-cell component of myofibroblasts with expression of ALK (anaplastic lymphoma kinase) and a lymphocytic infiltrate with plasma cells are the characteristic findings. Surgical excision results in complete remission.

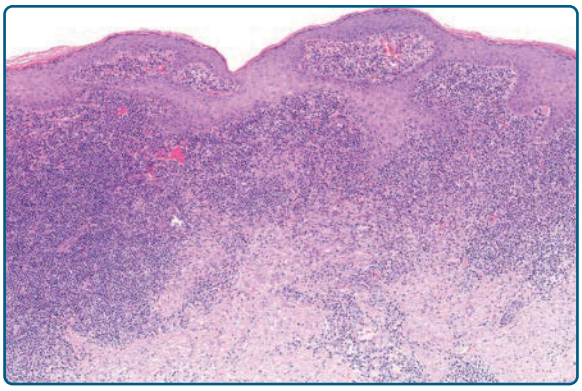

Figure 120-19 Lymphoplasmacytoid plaque, histology: epidermal hyperplasia and dense dermal infiltrate of lymphocytes and histiocytes.

ANGIOLYMPHOID HYPERPLASIA WITH EOSINOPHILIA

Angiolymphoid hyperplasia with eosinophilia (ALHE) represents a proliferation of blood vessels with prominent endothelia accompanied by a dense infiltrate of T-cells and B-cells in conjunction with eosinophils. It was first described in 1969 by Wells and Whimster.[101] Nowadays ALHE is commonly regarded to be an angioproliferative process resulting from the presence of prominent, bizarrely shaped blood vessels and epithelioid endothelia leading to its alternative synonymous designation as epithelioid hemangioma.[102,103] Most authors consider ALHE as a hyperplastic process in response to tissue damage and formation of vascular shunts.

The relationship of ALHE to Kimura disease is a matter of debate, but most experts consider them as distinct clinicopathologic entities. The lesions in Kimura disease tend to be larger and deeper and are accompanied by peripheral blood eosinophilia as well as enlarged lymph nodes.

EPIDEMIOLOGY AND PATHOGENESIS

ALHE and Kimura disease affect both genders without sex predominance.[103] Most patients are in the third or fourth decade of life. Arteriovenous shunts may underlie the formation of blood vessels seen in ALHE and Kimura disease.

CLINICAL FEATURES

ALHE presents as angiomatous pink to red-brown papules or nodule(s) most commonly found on the head and neck, especially on the face and ears, but also occurring at the extremities and genital area (Fig. 120-20). The lesions may be asymptomatic or be associated with pruritus, pain, or bleeding.

Figure 120-20 Angiolymphoid hyperplasia with eosinophilia: nodular infiltrate on the left forehead.

HISTOPATHOLOGY, IMMUNOPHENOTYPING, AND MOLECULAR TESTS

The dermal and/or subcutaneous nodules are composed of a proliferation of postcapillary vessels and a dense lymphocytic infiltrate (Fig. 120-21). The vessels are lined by prominent endothelial cells with a round or oval nucleus, an abundant eosinophilic cytoplasm, and an epithelioid or hobnail appearance. The infiltrate contains small lymphocytes, reactive germinal centers, and eosinophils.[104] Immunohistochemistry shows expression of CD31 and ERG by the endothelia, but no reactivity for podoplanin/D2-40. Immunohistochemical studies demonstrate that the majority of lymphocytes are of T-cell lineage. Admixed B cells may form lymphoid follicles. In Kimura disease the lymphoid component with germinal centers predominates over the proliferation of vessels. Clonal T cells have been detected in both ALHE and in Kimura disease.[105,106] In ALHE, the majority of those cases showed a protracted and therapy-resistant course with recurrences.

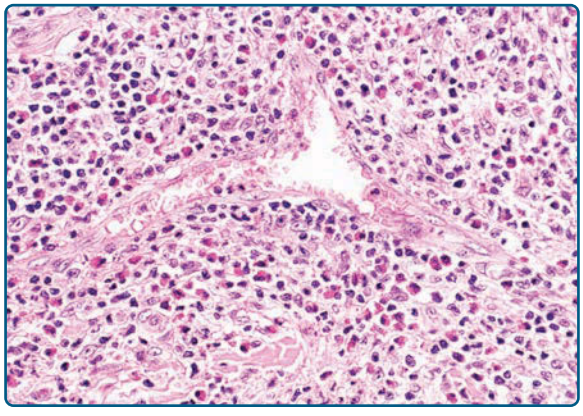

Figure 120-21 Angiolymphoid hyperplasia with eosinophilia, histology: vessels with prominent endothelia embedded in a dense infiltrate of lymphocytes and eosinophils.

DIFFERENTIAL DIAGNOSIS

Differential diagnosis includes pyogenic granuloma, which shows lobularly proliferation of vessels accompanied by a mixed-cellular infiltrate. Among lymphomas, specific infiltrates of adult T-cell lymphoma/leukemia (AITL) should be considered as they also show an increased number of vessels as well as an infiltrate composed of T cells and B cells with slight nuclear atypia. The T cells in AITL, however, are atypical, proliferatively active, and express markers of follicular helper T cells such as PD-1, ICOS, bcl-6, CD10, and CXCL-13.

CLINICAL COURSE, PROGNOSIS, AND TREATMENT

There is no spontaneous regression of ALHE lesions. Recurrences are common, particularly after surgical resection.[103,107] Surgery, cryotherapy, and laser ablation, as well as methotrexate and interferon-α, have been used to treat ALHE.[108] If an arteriovenous shunt can be identified as an underlying triggering factor, the shunt should be removed by, for example, embolization.

CASTLEMAN DISEASE

Castleman disease is a benign lymphoproliferative disorder with 2 variants: the hyaline vascular type and the plasma cell variant. The plasma cell variant can be associated with POEMS syndrome (*p*olyneuropathy, *o*rganomegaly, *e*ndocrinopathy, *m* protein, and *s*kin changes).[109] Castleman disease most commonly is located in the lymph nodes (mediastinal or generalized) and rarely affects the skin.[110] Histologically, the hyaline vascular type is more common with small lymphocytes that surround the germinal centers in a concentrically whorled pattern. This type is more common in younger patients. The plasma cell type shows large follicles and an interfollicular zone rich in blood vessels and plasma cells. The prognosis of Castleman disease with localized extranodal lesions is favorable. Therapy depends on the extent of the disease and includes surgical excision, radiation, and chemotherapy.

BENIGN INTRAVASCULAR PROLIFERATION OF LYMPHOCYTES

Recently, benign intravascular proliferation of lymphoid blasts with or without expression of CD30 has been reported. This condition arises in areas with inflammatory skin diseases or trauma of the skin.[111-113] Pathogenetically, obstruction of lymphatics by lichen sclerosus with disrupted immune cell trafficking may result in the accumulation of activated CD30+ lymphocytes. The lymphocytes are large and have

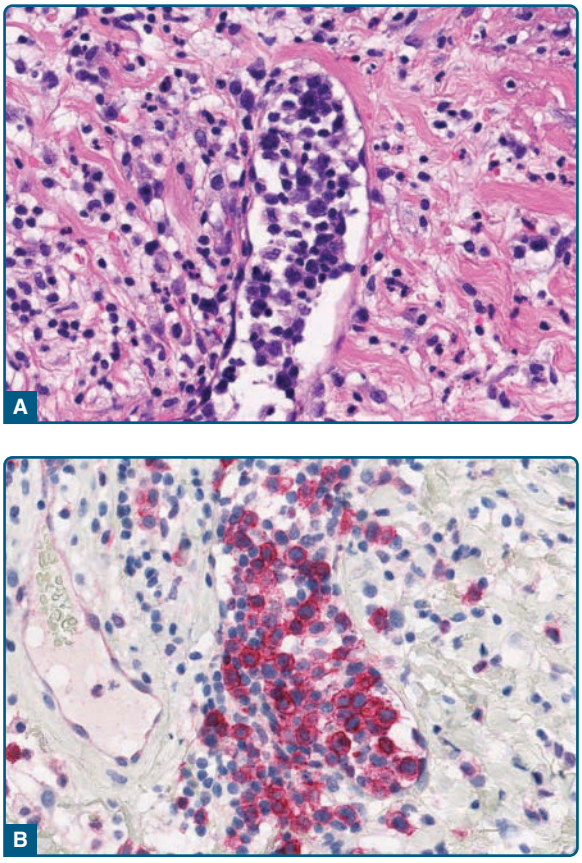

Figure 120-22 Intravascular lymphoid proliferation, histology: Intralymphatic accumulation of blast-like lymphoid cells (**A**) with expression of CD30 (**B**).

a blast-like morphology (Fig. 120-22). They express T-cell markers (CD3, CD4) and, in some cases, CD30. There is no association with Epstein-Barr virus infection. Clonality studies reveal the polyclonal nature of the process. Intravascular lymphoma is the most important differential diagnosis as it is an aggressive lymphoma with various phenotypic forms (B cell, T cell, or natural killer/T cell). In addition, benign intravascular proliferation of lymphoid cells needs to be distinguished from intralymphatic histiocytosis representing a reactive proliferation of histiocytes in the lumina of lymphatics in patients with rheumatoid arthritis or orthopedic metal implants.

SUMMARY

Cutaneous PSL refers to a group of lymphocyte-rich infiltrates that clinically and/or histologically simulate cutaneous lymphomas.[115] Clinicopathologic correlation is essential to achieve the final diagnosis in cutaneous PSL and to differentiate it from cutaneous lymphomas. Elimination of infectious agents (eg, by antibiotics or antiviral drugs) or avoidance of exposure to the causative agent (eg, LCD and drug reactions) are the first step in the management in addition to immunomodulating agents (eg, corticosteroids, UV light treatment) or ablative approaches (eg, surgical excision, cryotherapy).

REFERENCES

1. Kaposi M. *Pathologie und Therapie der Hautkrankheiten*. 4th ed. Vienna, Austria: Urban und Schwartzenberg; 1893.
2. Biberstein H. Lymphozytom. *Z Haut Geschlechtskr*. 1923;6:70-71.
3. Bäfverstedt B. Ueber lymphadenosis benigna cutis. Eine klinische pathologisch-anatomische Studie. *Acta Derm Venereol Suppl (Stockh)*. 1944;24(suppl XI):1-102.
4. Caro WA, Helwig HB. Cutaneous lymphoid hyperplasia. *Cancer*. 1969;24:487-502.
5. Ive FA, Magnus IA, Warin RP, et al. "Actinic reticuloid"; a chronic dermatosis associated with severe photosensitivity and the histological resemblance to lymphoma. *Br J Dermatol*. 1969;81(7):469-485.
6. Burg G, Braun-Falco O. *Cutaneous Lymphomas, Pseudolymphomas and Related Disorders*. Berlin, Germany: Springer-Verlag; 1983.
7. Rijlaarsdam JU, Willemze R. Cutaneous pseudolymphomas: classification and differential diagnosis. *Semin Dermatol*. 1994;13(3):187-196.
8. Ploysangam T, Breneman DL, Mutasim DF. Cutaneous pseudolymphomas. *J Am Acad Dermatol*. 1998;38(6, pt 1):877-895.
9. Gilliam AC, Wood GS. Cutaneous lymphoid hyperplasias. *Semin Cutan Med Surg*. 2000;19(2):133-141.
10. van Vloten WA, Willemze R. The many faces of lymphocytoma cutis. *J Eur Acad Dermatol Venereol*. 2003;17(1):3-6.
11. Hammer E, Sangueza O, Suwanjindar P, et al. Immunophenotypic and genotypic analysis in cutaneous lymphoid hyperplasias. *J Am Acad Dermatol*. 1993;28(3):426-433.
12. Bouloc A, Delfau-Larue MH, Lenormand B, et al. Polymerase chain reaction analysis of immunoglobulin gene rearrangement in cutaneous lymphoid hyperplasias. French Study Group for Cutaneous Lymphomas. *Arch Dermatol*. 1999;135(2):168-172.
13. Holm N, Flaig MJ, Yazdi AS, et al. The value of molecular analysis by PCR in the diagnosis of cutaneous lymphocytic infiltrates. *J Cutan Pathol*. 2002;29(8):447-452.
14. Colli C, Leinweber B, Mullegger R, et al. *Borrelia burgdorferi*-associated lymphocytoma cutis: clinicopathologic, immunophenotypic, and molecular study of 106 cases. *J Cutan Pathol*. 2004;31(3):232-240.
15. Goodlad JR, Davidson MM, Hollowood K, et al. *Borrelia burgdorferi*-associated cutaneous marginal zone lymphoma: a clinicopathological study of two cases illustrating the temporal progression of *B. burgdorferi*-associated B-cell proliferation in the skin. *Histopathology*. 2000;37(6):501-508.
16. Kempf W, Kerl H, Kutzner H. CD123-positive plasmacytoid dendritic cells in primary cutaneous marginal zone B-cell lymphoma: a crucial role and a new lymphoma paradigm. *Am J Dermatopathol*. 2009;32(2):194-196.
17. Kutzner H, Kerl H, Pfaltz MC, et al. CD123-positive plasmacytoid dendritic cells in primary cutaneous marginal zone B-cell lymphoma: diagnostic and pathogenetic implications. *Am J Surg Pathol*. 2009;33(9):1307-1313.
18. Brodell RT, Santa Cruz DJ. Cutaneous pseudolymphomas. *Dermatol Clin*. 1985;3(4):719-734.
19. Moulonguet I, Ghnassia M, Molina T, et al. Miliarial-type perifollicular B-cell pseudolymphoma (lymphocytoma cutis): a misleading eruption in two women. *J Cutan Pathol*. 2012;39(11):1016-1021.
20. Baldassano MF, Bailey EM, Ferry JA, et al. Cutaneous lymphoid hyperplasia and cutaneous marginal

zone lymphoma: comparison of morphologic and immunophenotypic features. *Am J Surg Pathol*. 1999;23(1):88-96.
21. Leinweber B, Colli C, Chott A, et al. Differential diagnosis of cutaneous infiltrates of B lymphocytes with follicular growth pattern. *Am J Dermatopathol*. 2004;26(1):4-13.
22. Boudova L, Kazakov DV, Sima R, et al. Cutaneous lymphoid hyperplasia and other lymphoid infiltrates of the breast nipple: a retrospective clinicopathologic study of fifty-six patients. *Am J Dermatopathol*. 2005;27(5):375-386.
23. Nihal M, Mikkola D, Horvath N, et al. Cutaneous lymphoid hyperplasia: a lymphoproliferative continuum with lymphomatous potential. *Hum Pathol*. 2003;34(6):617-622.
24. Boer A, Tirumalae R, Bresch M, et al. Pseudoclonality in cutaneous pseudolymphomas: a pitfall in interpretation of rearrangement studies. *Br J Dermatol*. 2008;159(2):394-402.
25. Grange F, Wechsler J, Guillaume JC, et al. *Borrelia burgdorferi*-associated lymphocytoma cutis simulating a primary cutaneous large B-cell lymphoma. *J Am Acad Dermatol*. 2002;47(4):530-534.
26. Kempf W, Flaig MJ, Kutzner H. Molecular diagnostics in infectious skin diseases. *J Dtsch Dermatol Ges*. 2013;11(suppl 4):50-58.
27. Rijlaarsdam JU, Scheffer E, Meijer CJ, et al. Cutaneous pseudo-T-cell lymphomas. A clinicopathologic study of 20 patients. *Cancer*. 1992;69(3):717-724.
28. Bergman R, Khamaysi Z, Sahar D, et al. Cutaneous lymphoid hyperplasia presenting as a solitary facial nodule: clinical, histopathological, immunophenotypical, and molecular studies. *Arch Dermatol*. 2006;142(12):1561-1566.
29. Leinweber B, Beltraminelli H, Kerl H, et al. Solitary small- to medium-sized pleomorphic T-cell nodules of undetermined significance: clinical, histopathological, immunohistochemical and molecular analysis of 26 cases. *Dermatology*. 2009;219(1):42-47.
30. Tomar S, Stoll HL, Grassi MA, et al. Treatment of cutaneous pseudolymphoma with interferon alfa-2b. *J Am Acad Dermatol*. 2009;60(1):172-174.
31. Kempf W. CD30+ lymphoproliferative disorders: histopathology, differential diagnosis, new variants, and simulators. *J Cutan Pathol*. 2006;33(suppl 1):58-70.
32. Werner B, Massone C, Kerl H, et al. Large CD30-positive cells in benign, atypical lymphoid infiltrates of the skin. *J Cutan Pathol*. 2008;35(12):1100-1107.
33. Gonzalez LC, Murua MA, Perez RG, et al. CD30+ lymphoma simulating Orf. *Int J Dermatol*. 2010;49(6):690-692.
34. Fukamachi S, Sugita K, Sawada Y, et al. Drug-induced CD30+ T cell pseudolymphoma. *Eur J Dermatol*. 2009;19(3):292-294.
35. De Souza A, Tinguely M, Pfaltz M, et al. Loss of expression of 5-hydroxymethylcytosine in CD30-positive cutaneous lymphoproliferative disorders. *J Cutan Pathol*. 2014;41(12):901-906.
36. Kibbi AG, Scrimenti RJ, Koenig RR, et al. A solitary nodule of the left cheek. Pseudolymphomatous folliculitis. *Arch Dermatol*. 1988;124(8):1272-1273, 1276.
37. Arai E, Okubo H, Tsuchida T, et al. Pseudolymphomatous folliculitis: a clinicopathologic study of 15 cases of cutaneous pseudolymphoma with follicular invasion. *Am J Surg Pathol*. 1999;23(11):1313-1319.
38. Petersson F. Pseudolymphomatous folliculitis with marked lymphocytic folliculo- and focal epidermotropism—expanding the morphologic spectrum. *Am J Dermatopathol*. 2011;33(3):323-325.
39. Gallardo F, Barranco C, Toll A, et al. CD30 antigen expression in cutaneous inflammatory infiltrates of scabies: a dynamic immunophenotypic pattern that should be distinguished from lymphomatoid papulosis. *J Cutan Pathol*. 2002;29(6):368-373.
40. Liu KC, Hsu CK, Lee JY. Insect bite-like reaction in association with chronic lymphocytic leukemia. *Int J Dermatol*. 2015;54(10):1191-1193.
41. Almeida HL Jr. Treatment of steroid-resistant nodular scabies with topical pimecrolimus. *J Am Acad Dermatol*. 2005;53(2):357-358.
42. Smolle J, Cerroni L, Kerl H. Multiple pseudolymphomas caused by *Hirudo medicinalis* therapy. *J Am Acad Dermatol*. 2000;43(5, pt 1):867-869.
43. Altamura D, Calonje E, Liau J, et al. Diffuse cutaneous pseudolymphoma due to therapy with medicinal leeches. *JAMA Dermatol*. 2014;150(7):783-784.
44. Braddock SW, Harrington D, Vose J. Generalized nodular cutaneous pseudolymphoma associated with phenytoin therapy. Use of T-cell receptor gene rearrangement in diagnosis and clinical review of cutaneous reactions to phenytoin. *J Am Acad Dermatol*. 1992;27(2, pt 2):337-340.
45. Albrecht J, Fine LA, Piette W. Drug-associated lymphoma and pseudolymphoma: recognition and management. *Dermatol Clin*. 2007;25(2):233-244, vii.
46. Kardaun SH, Scheffer E, Vermeer BJ. Drug-induced pseudolymphomatous skin reactions. *Br J Dermatol*. 1988;118(4):545-552.
47. Magro CM, Crowson AN. Drugs with antihistaminic properties as a cause of atypical cutaneous lymphoid hyperplasia. *J Am Acad Dermatol*. 1995;32(3):419-428.
48. Pulitzer MP, Nolan KA, Oshman RG, et al. CD30+ lymphomatoid drug reactions. *Am J Dermatopathol*. 2013;35(3):343-350.
49. Goerdt S, Spieker T, Wolffer LU. Multiple cutaneous B-cell pseudolymphomas after allergen injections. *J Am Acad Dermatol*. 1996;34(6):1072-1074.
50. Maubec E, Pinquier L, Viguier M, et al. Vaccination-induced cutaneous pseudolymphoma. *J Am Acad Dermatol*. 2005;52(4):623-629.
51. Chong H, Brady K, Metze D, et al. Persistent nodules at injection sites (aluminium granuloma)—clinicopathological study of 14 cases with a diverse range of histological reaction patterns. *Histopathology*. 2006;48(2):182-188.
52. Cerroni L, Borroni RG, Massone C, et al. Cutaneous B-cell pseudolymphoma at the site of vaccination. *Am J Dermatopathol*. 2007;29(6):538-542.
53. Blumental G, Okun MR, Ponitch JA. Pseudolymphomatous reaction to tattoos. Report of three cases. *J Am Acad Dermatol*. 1982;6(4, pt 1):485-488.
54. Iwatsuki K, Yamada M, Takigawa M, et al. Benign lymphoplasia of the earlobes induced by gold earrings: immunohistologic study on the cellular infiltrates. *J Am Acad Dermatol*. 1987;16(1, pt 1):83-88.
55. Lubach D, Hinz E. A pseudolymphomatous reaction in tattooing [in German]. *Hautarzt*. 1986;37(10):573-575.
56. Amann U, Luger TA, Metze D. Lichenoid pseudolymphomatous tattooing reaction [in German]. *Hautarzt*. 1997;48(6):410-413.
57. Yavuzer R, Akyurek N, Ozmen S, et al. Leishmania cutis with B-cell cutaneous hyperplasia. *Plast Reconstr Surg*. 2001;108(7):2177-2178.
58. Flaig MJ, Rupec RA. Cutaneous pseudolymphoma in association with *Leishmania donovani*. *Br J Dermatol*. 2007;157(5):1042-1043.
59. Gomez-Orbaneja J, Diez LI, Lozano JL, et al. Lymphomatoid contact dermatitis: a syndrome produced by

epicutaneous hypersensitivity with clinical features and a histopathologic picture similar to that of mycosis fungoides. *Contact Dermatitis*. 1976;2(3):139-143.
60. Uzuncakmak TK, Akdeniz N, Ozkanli S, et al. Lymphomatoid contact dermatitis associated with textile dye at an unusual location. *Indian Dermatol Online J*. 2015;6(suppl 1):S24-S26.
61. Martinez-Moran C, Sanz-Munoz C, Morales-Callaghan AM, et al. Lymphomatoid contact dermatitis. *Contact Dermatitis*. 2009;60(1):53-55.
62. Wolf IH, Cerroni L, Fink-Puches R, et al. The morphologic spectrum of cutaneous pseudolymphomas [in German]. *J Dtsch Dermatol Ges*. 2005;3(9):710-720; quiz 721.
63. Souteyrand P, d'Incan M. Drug-induced mycosis fungoides-like lesions. *Curr Probl Dermatol*. 1990;19:176-182.
64. Klemke CD, Booken N, Weiss C, et al. Histopathological and immunophenotypical criteria for the diagnosis of Sezary syndrome in differentiation from other erythrodermic skin diseases: a European Organisation for Research and Treatment of Cancer (EORTC) Cutaneous Lymphoma Task Force Study of 97 cases. *Br J Dermatol*. 2015;173(1):93-105.
65. Kempf W, Kazakov DV, Palmedo G, et al. Pityriasis lichenoides et varioliformis acuta with numerous CD30+ cells: A variant mimicking lymphomatoid papulosis and other cutaneous lymphomas. A clinicopathologic, immunohistochemical, and molecular biological study of 13 cases. *Am J Surg Pathol*. 2012;36(7):1021-1029.
66. Toonstra J, Henquet CJ, van Weelden H, et al. Actinic reticuloid. A clinical photobiologic, histopathologic, and follow-up study of 16 patients. *J Am Acad Dermatol*. 1989;21(2, pt 1):205-214.
67. Toonstra J. Actinic reticuloid. *Semin Diagn Pathol*. 1991;8(2):109-116.
68. Longacre TA, Foucar K, Koster F, et al. Atypical cutaneous lymphoproliferative disorder resembling mycosis fungoides in AIDS. Report of a case with concurrent Kaposi's sarcoma. *Am J Dermatopathol*. 1989;11(5):451-456.
69. Egbers RG, Do TT, Su L, et al. Rapid clinical change in lesions of atypical cutaneous lymphoproliferative disorder in an HIV patient: a case report and review of the literature. *Dermatol Online J*. 2011;17(9):4.
70. Sbidian E, Battistella M, Rivet J, et al. Remission of severe CD8(+) cytotoxic T cell skin infiltrative disease in human immunodeficiency virus-infected patients receiving highly active antiretroviral therapy. *Clin Infect Dis*. 2010;51(6):741-748.
71. Ingen-Housz-Oro S, Sbidian E, Ortonne N, et al. HIV-related CD8+ cutaneous pseudolymphoma: efficacy of methotrexate. *Dermatology*. 2013;226(1):15-18.
72. Bayal C, Büyükbani N, Seckin D, et al. Cutaneous atypical papular CD8+ lymphoproliferative disorder at acral sites in a renal transplant patient. *Clin Exp Dermatol*. 2017;42(8):902-905.
73. Tee SI, Martinez-Escaname M, Zuriel D, et al. Acrodermatitis chronica atrophicans with pseudolymphomatous infiltrates. *Am J Dermatopathol*. 2013;35(3):338-342.
74. Kempf W, Kazakov DV, Hubscher E, et al. Cutaneous borreliosis associated with T cell-predominant infiltrates: a diagnostic challenge. *J Am Acad Dermatol*. 2015;72(4):683-689.
75. Ofuji S, Furukawa F, Miyachi Y, et al. Papuloerythroderma. *Dermatologica*. 1984;169(3):125-130.
76. Sugita K, Kabashima K, Nakamura M, et al. Drug-induced papuloerythroderma: analysis of T-cell populations and a literature review. *Acta Derm Venereol*. 2009;89(6):618-622.
77. Torchia D, Miteva M, Hu S, et al. Papuloerythroderma 2009: two new cases and systematic review of the worldwide literature 25 years after its identification by Ofuji et al. *Dermatology*. 2010;220(4):311-320.
78. Shah M, Reid WA, Layton AM. Cutaneous T-cell lymphoma presenting as papuloerythroderma—a case and review of the literature. *Clin Exp Dermatol*. 1995;20(2):161-163.
79. Aste N, Fumo G, Conti B, et al. Ofuji papuloerythroderma. *J Eur Acad Dermatol Venereol*. 2000;14(1):55-57.
80. Bech-Thomsen N, Thomsen K. Ofuji's papuloerythroderma: a study of 17 cases. *Clin Exp Dermatol*. 1998;23(2):79-83.
81. Toro JR, Sander CA, LeBoit PE. Persistent pigmented purpuric dermatitis and mycosis fungoides: simulant, precursor, or both? A study by light microscopy and molecular methods. *Am J Dermatopathol*. 1997;19(2):108-118.
82. Magro C, Crowson AN, Kovatich A, et al. Pityriasis lichenoides: a clonal T-cell lymphoproliferative disorder. *Hum Pathol*. 2002;33(8):788-795.
83. Citarella L, Massone C, Kerl H, et al. Lichen sclerosus with histopathologic features simulating early mycosis fungoides. *Am J Dermatopathol*. 2003;25(6):463-465.
84. Dereure O, Levi E, Kadin ME. T-Cell clonality in pityriasis lichenoides et varioliformis acuta: a heteroduplex analysis of 20 cases. *Arch Dermatol*. 2000;136(12):1483-1486.
85. Lor P, Krueger U, Kempf W, et al. Monoclonal rearrangement of the T cell receptor gamma-chain in lichenoid pigmented purpuric dermatitis of Gougerot-Blum responding to topical corticosteroid therapy. *Dermatology*. 2002;205(2):191-193.
86. Wood GS. Analysis of clonality in cutaneous T cell lymphoma and associated diseases. *Ann N Y Acad Sci*. 2001;941:26-30.
87. Abeck D, Ollert MW, Eckert F, et al. Palpable migratory arciform erythema. Clinical morphology, histopathology, immunohistochemistry, and response to treatment. *Arch Dermatol*. 1997;133(6):763-766.
88. Wagner G, Bartsch S, Rose C, et al. Palpable arciforme migratory erythema [in German]. *Hautarzt*. 2012;63(12):965-968.
89. Poenitz N, Dippel E, Klemke CD, et al. Jessner's lymphocytic infiltration of the skin: a CD8+ polyclonal reactive skin condition. *Dermatology*. 2003;207(3):276-284.
90. Kaddu S, Cerroni L, Pilatti A, et al. Acral pseudolymphomatous angiokeratoma. A variant of the cutaneous pseudolymphomas. *Am J Dermatopathol*. 1994;16(2):130-133.
91. Okada M, Funayama M, Tanita M, et al. Acral angiokeratoma-like pseudolymphoma: one adolescent and two adults. *J Am Acad Dermatol*. 2001;45(6)(suppl):S209-S211.
92. Wagner G, Rose C, Sachse MM. Papular pseudolymphoma of adults as a variant of acral pseudolymphomatous angiokeratoma of children (APACHE). *J Dtsch Dermatol Ges*. 2014;12(5):423-424.
93. Dayrit JF, Wang WL, Goh SG, et al. T-cell-rich angiomatoid polypoid pseudolymphoma of the skin: a clinicopathologic study of 17 cases and a proposed nomenclature. *J Cutan Pathol*. 2011;38(6):475-482.
94. Gilliam AC, Mullen RH, Oviedo G, et al. Isolated benign primary cutaneous plasmacytosis in children: two illustrative cases. *Arch Dermatol*. 2009;145(3):299-302.
95. Fried I, Wiesner T, Cerroni L. Pretibial lymphoplasmacytic plaque in children. *Arch Dermatol*. 2010;146(1):95-96.

96. Mitteldorf C, Palmedo G, Kutzner H, et al. Diagnostic approach in lymphoplasmacytic plaque. *J Eur Acad Dermatol Venereol*. 2015;29(11):2206-2215.
97. Moulonguet I, Hadj-Rabia S, Gounod N, et al. Tibial lymphoplasmacytic plaque: a new, illustrative case of a recently and poorly recognized benign lesion in children. *Dermatology*. 2012;225(1):27-30.
98. Uhara H, Saida T, Ikegawa S, et al. Primary cutaneous plasmacytosis: report of three cases and review of the literature. *Dermatology*. 1994;189(3):251-255.
99. Honda R, Cerroni L, Tanikawa A, et al. Cutaneous plasmacytosis: report of 6 cases with or without systemic involvement. *J Am Acad Dermatol*. 2013;68(6):978-985.
100. El Shabrawi-Caelen L, Kerl K, Cerroni L, et al. Cutaneous inflammatory pseudotumor—a spectrum of various diseases? *J Cutan Pathol*. 2004;31(9):605-611.
101. Wells GC, Whimster IW. Subcutaneous angiolymphoid hyperplasia with eosinophilia. *Br J Dermatol*. 1969;81(1):1-14.
102. Requena L, Sangueza OP. Cutaneous vascular proliferation. Part II. Hyperplasias and benign neoplasms. *J Am Acad Dermatol*. 1997;37(6):887-919; quiz 920-922.
103. Adler BL, Krausz AE, Minuti A, et al. Epidemiology and treatment of angiolymphoid hyperplasia with eosinophilia (ALHE): a systematic review. *J Am Acad Dermatol*. 2016;74(3):506-512.e11.
104. Olsen TG, Helwig EB. Angiolymphoid hyperplasia with eosinophilia. A clinicopathologic study of 116 patients. *J Am Acad Dermatol*. 1985;12(5, pt 1):781-796.
105. Chim CS, Fung A, Shek TW, et al. Analysis of clonality in Kimura's disease. *Am J Surg Pathol*. 2002;26(8):1083-1086.
106. Kempf W, Haeffner AC, Zepter K, et al. Angiolymphoid hyperplasia with eosinophilia: evidence for a T-cell lymphoproliferative origin. *Hum Pathol*. 2002;33(10):1023-1029.
107. Al-Jitawi S, Oumeish OY. Angiolymphoid hyperplasia with tissue eosinophilia. *Int J Dermatol*. 1989;28(2):114-118.
108. Sagi L, Halachmi S, Levi A, et al. Combined pulsed dye and CO_2 lasers in the treatment of angiolymphoid hyperplasia with eosinophilia. *Lasers Med Sci*. 2016;31(6):1093-1096..
109. Dispenzieri A. POEMS syndrome: 2014 update on diagnosis, risk-stratification, and management. *Am J Hematol*. 2014;89(2):214-223.
110. Skelton HG, Smith KJ. Extranodal multicentric Castleman's disease with cutaneous involvement. *Mod Pathol*. 1998;11(1):93-98.
111. Riveiro-Falkenbach E, Fernandez-Figueras MT, Rodriguez-Peralto JL. Benign atypical intravascular CD30(+) T-cell proliferation: a reactive condition mimicking intravascular lymphoma. *Am J Dermatopathol*. 2013;35(2):143-150.
112. Kempf W, Keller K, John H, et al. Benign atypical intravascular CD30+ T-cell proliferation: a recently described reactive lymphoproliferative process and simulator of intravascular lymphoma: report of a case associated with lichen sclerosus and review of the literature. *Am J Clin Pathol*. 2014;142(5):694-699.
113. Calamaro P, Cerroni L. Intralymphatic proliferation of T-cell lymphoid blasts in the setting of hidradenitis suppurativa. *Am J Dermatopathol*. 2016;38(7):536-540.
114. Darier J. Die cutanen und subcutanen Sarkoide. Ihre Beziehungen zum Sarkom, zum Lymphodermie, zur Tuberkulose usw. *Monatschr Prakt Dermatol*. 1910;50:419-451.
115. Mitteldorf C, Kempf W. Cutaneous pseudolymphoma. *Surg Pathol Clin*. 2017;10:455-476.

Chapter 121 :: Neoplasias and Hyperplasias of Muscular and Neural Origin

:: Hansgeorg Müller & Heinz Kutzner

TUMORS OF SMOOTH MUSCLE

Cutaneous tumors with smooth muscle differentiation Table 121-1) can be categorized according to their microanatomical origin: (a) arrector pili muscles, (b) smooth muscle of genital skin, including scrotum (dartos muscle), vulva, nipple and areolar region, and (c) walls of blood vessels. Each of these sources of smooth muscle can give rise to benign superficial smooth muscle tumors (leiomyomas) as well as their malignant counterparts (leiomyosarcomas).[1] Anecdotally, smooth muscle also has been reported in organoid and blue nevi.[2] Of note, smooth muscle tumors arising in deep soft tissues (eg, abdominal cavity, pelvis, retroperitoneum), and visceral organs (including uterine tumors) often show overlapping morphologic and immunohistochemical features with cutaneous tumors, but form different clinicopathologic categories because biologic potential, clinical prognosis, and criteria for malignancy depend primarily on location.[3,4] Histologically, the constituent cells of smooth muscle lesions are spindled and contain abundant brightly eosinophilic cytoplasm as well as blunt-ended (cigar-shaped) nuclei. Smooth muscle antigens, including α-smooth muscle actin (α-SMA), muscle-specific actin, desmin, and h-caldesmon are readily identified by immunohistochemistry. Atypical intradermal smooth muscle neoplasms and leiomyosarcomas often at least focally express epithelial markers, and sporadic cases may express S-100 protein.[5,6] Figure 121-1 provides an overview of the diagnosis of cutaneous tumors with smooth muscle differentiation. The spectrum of cutaneous smooth muscle lesions includes leiomyomas, leiomyosarcomas, and smooth muscle hamartomas.

LEIOMYOMA

AT-A-GLANCE

- Synonyms: superficial leiomyoma; leiomyoma cutis; superficial benign smooth muscle tumor.
- Benign neoplasm of the skin with smooth muscle differentiation occurring in 3 categories: piloleiomyoma (synonym: pilar leiomyoma), solitary genital (including dartoic, vulvar, nipple and areolar) leiomyoma, and angioleiomyoma.
- Commonly presents as solitary or multiple, firm, reddish-brown papulonodule with a predilection for the face, back, and extensor surfaces of the extremities.
- Multiple piloleiomyomas usually develop during adolescence in the setting of a multiple cutaneous and uterine leiomyomatosis syndrome resulting from a germline mutation in the fumarate hydratase (*FH*) gene.

EPIDEMIOLOGY

Cutaneous leiomyomas are reported to be relatively uncommon. In the experience of Orellana-Diaz and associates, based on surgical material, the incidence was 34 out of 85,349 pathology specimens (0.04%).[7] This study probably underestimates the large number of asymptomatic, usually unrecognized lesions. The relative incidence of the various leiomyoma subtypes is unknown. Although formerly considered to represent the more common subgroup, pilar leiomyomas are probably less frequent than previously thought and are potentially outnumbered by those originating from genital sites.[8]

ETIOLOGY AND PATHOGENESIS

Superficial benign smooth muscle tumors segregate into (a) piloleiomyomas (Fig. 121-2) deriving from the arrector pili muscles, (b) leiomyomas of genital sites (Fig. 121-3) and the nipple and the areola (Fig. 121-4), deriving from specialized smooth muscle of genital skin (dartoic, vulvar, mammillary, areolar), and (c) angioleiomyomas (Fig. 121-2), deriving from smooth muscle tissue of vessel walls. Pilar leiomyoma usually afflicts adolescents, although rare cases are present at birth or appear during early childhood.[9] Lesions are more often multiple than solitary. Up to several hundred lesions may develop. A positive family history with an autosomal dominant inheritance pattern can be detected in a minority of patients.[10] Recent evidence implies that most patients presenting with multiple cutaneous leiomyomas have a germline loss-of-function mutation in the fumarate hydratase gene (*FH*), mapped to chromosome 1q42.3-43 and encoding an enzyme that functions as part of the Krebs cycle by converting fumarate to malate.[11-13] The gene may also act as tumor suppressor gene. The vast majority of women

TABLE 121-1

Tumors of Muscular Differentation Involving the Skin Comprise 2 Large Subgroups

	TUMORS OF SMOOTH MUSCLE					TUMORS OF STRIATED MUSCLE			
	PILAR LEIOMYOMA	**GENITAL LEIOMYOMA**	**ANGIOLEIOMYOMA**	**LEIOMYSARCOMA**	**SMOOTH MUSCLE HAMARTOMA**	**RHABDOMYOMA**	**RHABDOMYOSARCOMA**	**RHABDOMYOMATOUS MESENCHYMAL HAMARTOMA**	**NEUROMUSCULAR HAMARTOMA**
Incidence	Uncommom	Uncommon	Uncommon	Rare	Very rare	Very rare	Very rare	Extremely rare	Extremely rare
Age & gender	Adolescence M:F = 1:1	Adolescence M:F = 1:1	Adults (30 to 50 years of age) M:F = 1:2	Adults (40 to 60 years of age) M>F	Birth M:F = 1:1	Children to adults M>F	Neonates to adults M>F	Neonate M>F	Children <2 years of age and adults
Location	Back, extensor sites of upper extremities, face, etc	Tunica dartos, labium majus, nipple, areola	Strong predilection for extremities, particularly lower leg	Hair-bearing areas of lower extremities, scalp, trunk	Trunk or extremities	Head and neck region, vulva	Most commonly on the head and neck region or the extremities	Midline region of the skin in the head and neck region, most frequently on the chin	Large nerve trunks (brachial and sciatic), cranial nerves
Size	0.5 to 2 cm	0.5 to 14 cm	0.5 to 2 cm	1 to 4 cm	1 to 10 cm	0.5 to 10 cm	1 to 15 cm	0.5 to 2 cm	
Clinical presentation	Brown-red to pearly, firm papulonodule, solitary or multiple lesions	Firm nodule	Firm, slowly growing, subcutaneous mass	Firm nodule with hyperpigmentation and erythema of the involved skin	Skin-colored or lightly pigmented patch or plaque, may show hyperpigmentation and/or hypertrichosis	Round or polypoid mass (adult rhabdomyoma), subcutaneous mass (fetal rhabdomyoma)	Rapidly growing, subcutaneous or ulcerated mass; "blueberry muffin baby"	Small dome-shaped papule or polypoid pedunculated lesion	Solitary mass
Symptoms	Episodic pain	Usually painless	Pain or tenderness in 50% of cases	Pain or tenderness occasionally present	Pseudo-Darier sign	Usually painless	May limit range of motion	Usually painless	Neurologic symptoms
Genetics	Hereditary variant (multiple lesions): loss-of-function germline mutation in the fumarate hydratase gene (*FH*), chromosome 1q42.3-43			May develop as secondary malignancy in the setting of hereditary retinoblastoma, alterations of the retinoblastoma 1 (Rb1) locus		*PTCH* (patched hedgehog gene) mutations for fetal rhabdomyomas in the setting of nevoid basal cell carcinoma syndrome	80% of adult-type rhabdomyosarcomas have the *PAX3-FOXO1A* or *PAX7-FOXO1A* fusion gene		

(*Continued*)

TABLE 121-1

Tumors of Muscular Differentation Involving the Skin Comprise 2 Large Subgroups (*Continued*)

	TUMORS OF SMOOTH MUSCLE					TUMORS OF STRIATED MUSCLE			
	PILAR LEIOMYOMA	**GENITAL LEIOMYOMA**	**ANGIOLEIOMYOMA**	**LEIOMYSARCOMA**	**SMOOTH MUSCLE HAMARTOMA**	**RHABDOMYOMA**	**RHABDOMYOSARCOMA**	**RHABDOMYOMATOUS MESENCHYMAL HAMARTOMA**	**NEUROMUSCULAR HAMARTOMA**
Histopathologic features	Dermal tumor, interweaving fascicles of spindle cells containing blunt-ended, cigar-shaped nuclei with brightly eosinophilic cytoplasm	Ill-defined fascicles of spindle cells containing blunt-ended, cigar-shaped nuclei with brightly eosinophilic cytoplasm	Well-demarcated nodule of smooth muscle tissue punctuated with thick-walled vessels with partially open lumina	Intersecting fascicles of large, atypical spindle cells, nuclear atypia, mitosis, necrosis	Well-defined and thickened smooth muscle fibers haphazardly oriented in reticular dermis; some fibers are attached to hair follicles	Adult rhabdomyoma: eosinophilic polygonal cells with small, peripherally placed nuclei and intracellular vacuoles	Rhabdomyoblasts, multinucleated giant cells, areas of necrosis, high mitotic index	Mixture of mature-appearing adipose and skeletal muscle tissue, adnexal structures, blood vessels, and nerves	Bundles of perpendicularly oriented skeletal muscles intermingled with small nerve fascicles
Immunohistochemical features	h-Caldesmon, desmin, α-smooth muscle actin (SMA), muscle-specific actin (MSA)	h-Caldesmon, desmin, α-SMA, MSA	h-Caldesmon, desmin, α-SMA, MSA	h-Caldesmon, desmin, α-SMA, MSA	h-Caldesmon, desmin, α-SMA, MSA	Desmin, MSA	Myogenin (myogenic factor 4) and MyoD1 (myogenic differentiation 1)	Myogenin and MyoD1	Myogenin and MyoD1
Management	Surgical excision	Surgical excision	Surgical excision	Wide surgical excision with >3 cm margins	Surgical excision	Surgical excision	Multidisciplinary approach	Surgical excision	Surgical excision
Associated syndromes	HLRCC (hereditary leiomyomatosis and renal cell cancer)				Michelin tire baby syndrome	Nevoid basal cell carcinoma syndrome			
Other	Early-onset uterine leiomyomas, 15% lifetime risk for renal cell cancer (!) HLRCC (early-onset uterine leiomyomas, 10%-16% life time risk for renal cell cancer)		Symptoms may be paroxysmal with worsening by light touch, temperature, or hormonal change	Dermal leiomyomas ("intradermal smooth muscle neoplasms") have an excellent prognosis	Overlapping features with Becker melanosis	Cardiac rhabdomyomas are associated with tuberous sclerosis		Multiple lesions occur in the setting of associated congenital abnormalities	

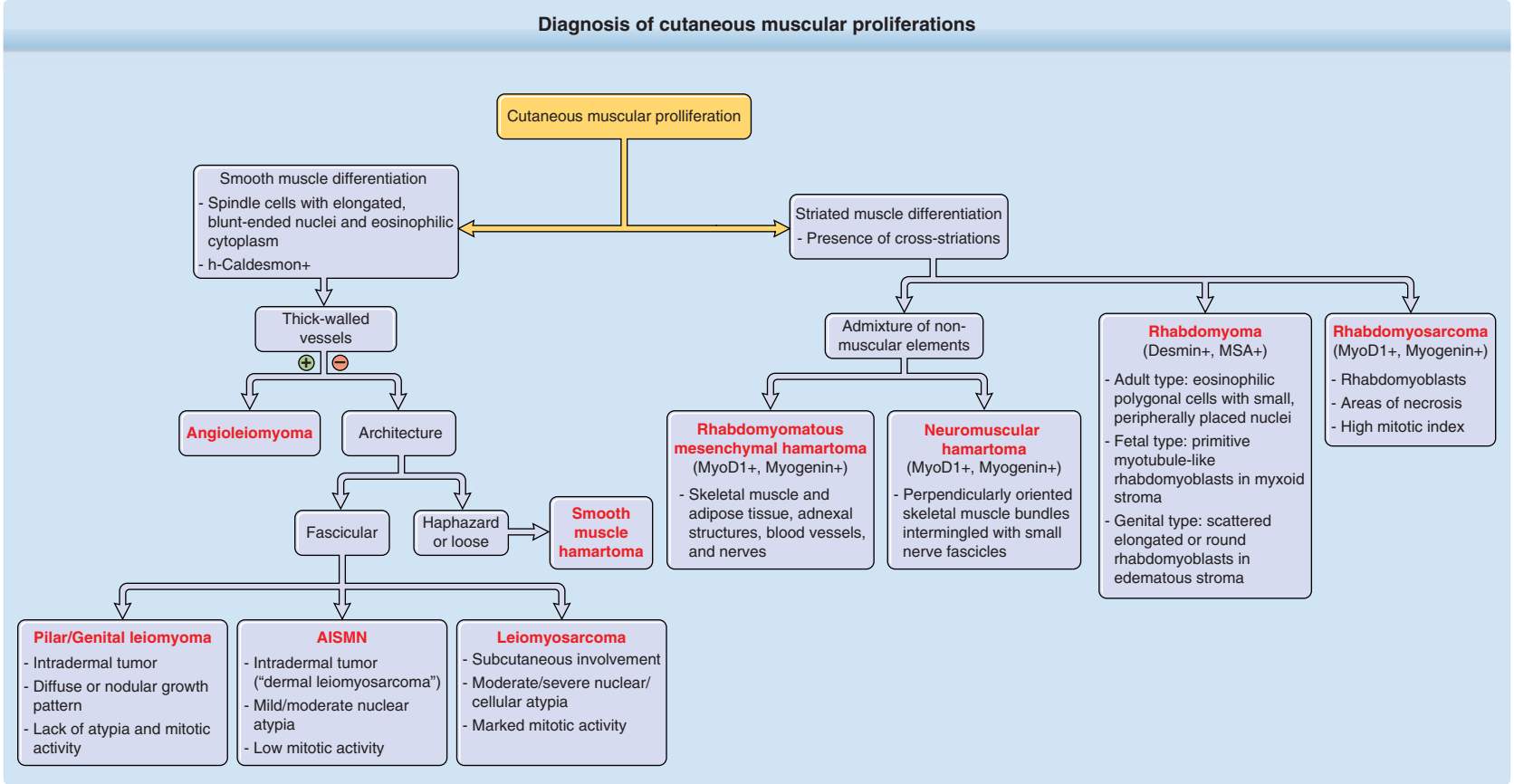

Figure 121-1 Diagnosis of cutaneous muscular proliferations. AISMN, atypical intradermal smooth muscle neoplasm; MSA, muscle-specific actin; MyoD1, myogenic differentiation 1.

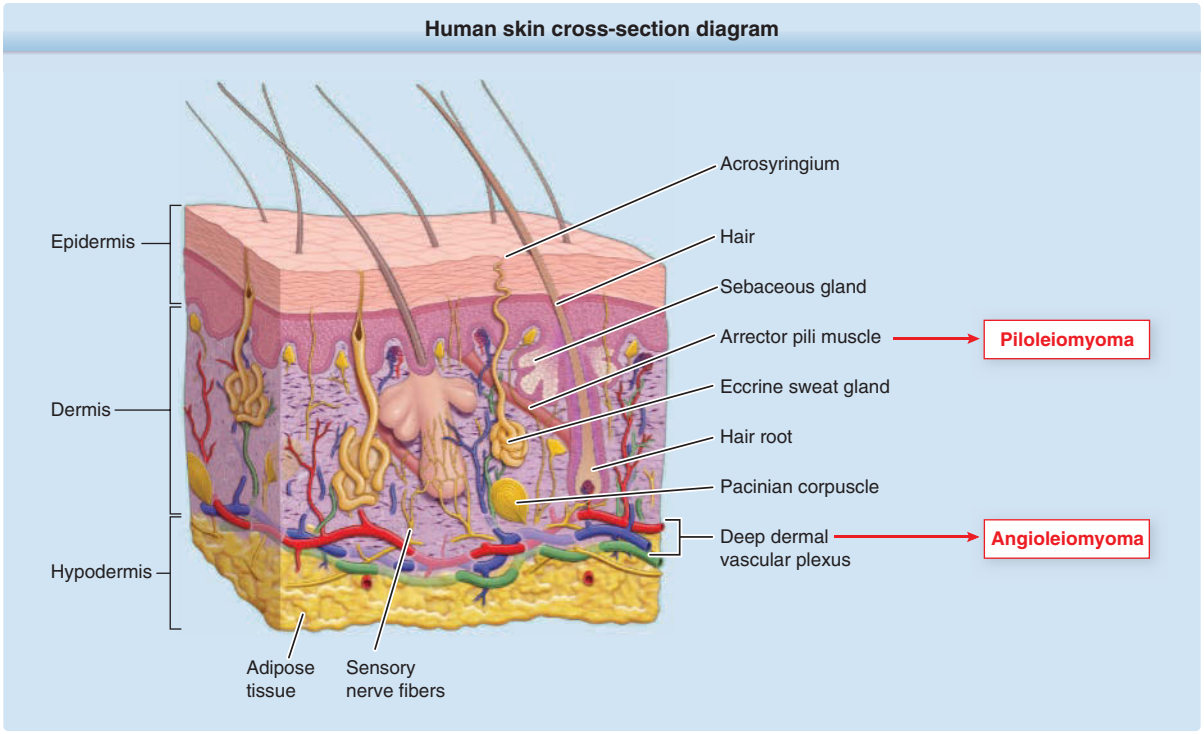

Figure 121-2 Piloleiomyomas, deriving from the arrector pili muscles, and angioleiomyomas, deriving from smooth muscle tissue of vessel walls.

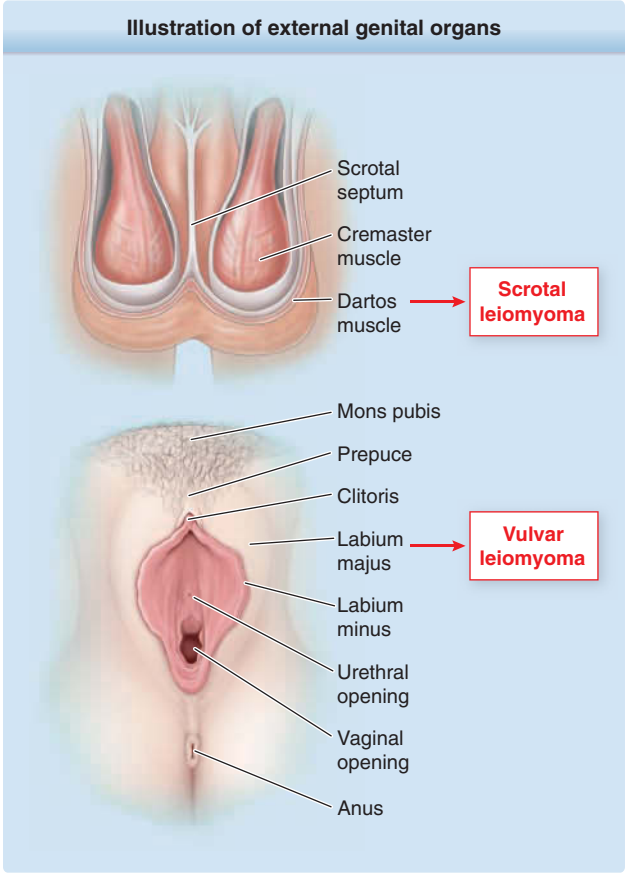

Figure 121-3 Leiomyomas of genital sites, deriving from specialized smooth muscle of genital skin (dartoic, vulvar). **Top**, Scrotal leiomyomas. **Bottom**, Vulvar leiomyomas.

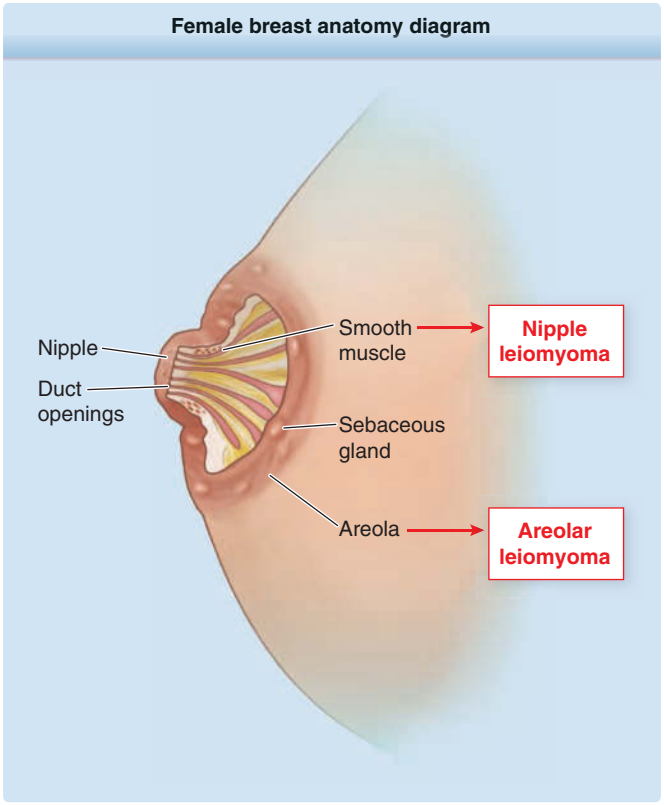

Figure 121-4 Leiomyomas of the nipple and the areola, deriving from specialized smooth muscle of skin (mammillary, areolar).

with multiple cutaneous leiomyomas develop early-onset uterine leiomyomas with the cutaneous tumors typically occurring in the late second or third decade of life prior to the diagnosis of uterine lesions.[14] This syndrome, known as multiple cutaneous and uterine leiomyomatosis (Reed syndrome, multiple leiomyomatosis, familial leiomyomatosis cutis et uteri),[15] also can be associated with early-onset renal cell carcinoma of the papillary Type II, the tubule-papillary type, and the collecting duct type, a condition referred to as hereditary leiomyomatosis and renal cell cancer Table 121-2.[16] Renal tumors present at relatively advanced stages in approximately 10% to 16% of individuals with hereditary leiomyomatosis and renal cell cancer and tend to occur more commonly in adult females than in adult males with this syndrome.[17,18] The specific risk to women with hereditary leiomyomatosis and renal cell cancer of developing uterine leiomyosarcoma is unknown.

TABLE 121-2
Diagnostic Criteria for Hereditary Leiomyomatosis and Renal Cell Carcinoma

Major Criteria (High Likelihood of HLRCC)
▪ Multiple cutaneous leiomyomata with at least 1 biopsy proven/histologically confirmed
Minor Criteria (Suspicious for HLRCC)
▪ Solitary cutaneous leiomyoma and family history of HLRCC
▪ Early-onset renal tumors of Type 2 papillary histology
▪ Multiple early-onset (<40 years of age) symptomatic uterine fibroids
Definitive Diagnosis
▪ Positive germline *FH*-mutation test

HLRCC, hereditary leiomyomatosis and renal cell cancer.

CLINICAL FINDINGS

Piloleiomyomas typically appear as multiple, firm, brown-red to pearly discrete papulonodules that in the nascent stage are more easily palpable than visible. Sites of predilection include the face and back, and the extensor sites of the extremities. Solitary piloleiomyomas are commonly slightly larger than the tumors in individuals presenting with multiple lesions, reaching 2 cm or greater in diameter.[19] Lesions on the trunk are typically multiple ("cutaneous leiomyomatosis"; Fig. 121-5) and can be arranged in a diffuse (disseminated), blaschkoid, segmental (zosteriform), or, rarely, symmetrical distribution.[9,20] They may coalesce to form plaques or display an agminated, clustered, or linear pattern.[21] Anecdotal cases of Type 2 segmental manifestations of hereditary cutaneous leiomyomatosis have been reported.[22] The tumors are frequently associated with spontaneous or secondary pain, particularly by exposure to cold. It is unclear whether the produced pain results from a contraction of the muscle fibers, local compression of nearby located nerves, or an increased number of nerve bundles.[1] Genital

Figure 121-5 Clinical photograph showing multiple leiomyomas involving the shoulder area. (Image from the collection of Sonja Radakovic, MD, and Teresa Valero, MD, Department of Dermatology, Medical University of Vienna, Austria. Used with permission.)

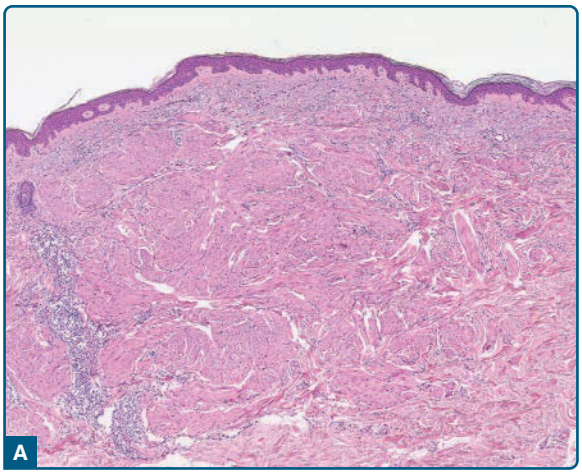

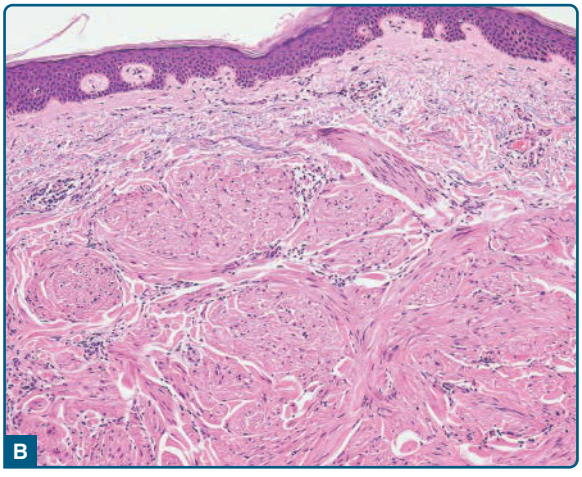

Figure 121-6 **A,** Photomicrograph of a pilar leiomyoma showing an ill-defined dermal-based tumor composed of interweaving fascicles of spindle cells (hematoxylin-and-eosin [H&E], ×20 magnification). **B,** Well-differentiated elongated spindle cells with blunt-ended, cigar-shaped nuclei and abundant fibrillary eosinophilic cytoplasm (H&E, ×100 magnification).

leiomyomas of the nipple–areolar region are rare and usually small, seldom exceeding 2 cm in diameter. Scrotal leiomyomas present as firm nodules. Vulval tumors, typically arising in the labia majora, and scrotal tumors tend to be larger, measuring 1 to 5 cm and 1 to 14 cm in diameter, respectively.[23] Angioleiomyomas occur preferentially as slowly enlarging nodules of several years' duration on the extremities, particularly the lower leg. They are more frequent in females, except for those tumors in the oral cavity where the opposite holds true.[24]

HISTOPATHOLOGY

Pilar leiomyoma is a dermal-based tumor, but focal involvement of the superficial subcutis may occasionally be present. The cellular neoplasms are ill defined and composed of bland-appearing spindle cells containing blunt-ended, cigar-shaped nuclei with eosinophilic cytoplasm arranged in interweaving fascicles (Fig. 121-6). In contrast to angioleiomyomas, the lesions blend in an irregular fashion with the surrounding dermal collagen and adjacent pilar muscle. The central tumor parts are usually devoid of connective tissue and consist of densely packed bundles of smooth muscle fibers. A nodular and well-circumscribed growth pattern is infrequently encountered. Neither atypia nor mitotic activity is seen in piloleiomyomas. In contrast to leiomyomas of the uterus and deep soft tissue, cutaneous tumors with cellular atypia but without mitotic activity can be comfortably labeled "symplastic leiomyomas." α-Smooth muscle actin (Fig. 121-7B), desmin (Fig. 121-7C), muscle-specific actin, and h-caldesmon are strongly and diffusely expressed in virtually all piloleiomyomas. *FH* mutation carriers have FH-deficient cutaneous and uterine leiomyomas defined as negative FH staining by immunohistochemistry (Fig. 121-7D), but loss of FH protein expression also may be observed in sporadic cases.[25,26] The presence of multiple FH-deficient cutaneous piloleiomyomas in adolescents should raise the suspicion for an underlying Reed syndrome and prompt for a detailed family history assessment. Genital leiomyomas display a greater range of histologic appearance (eg, spindle-cell or epithelioid cell type, myxoid variants), tend to be more cellular, and often have ill-defined or focally infiltrative margins.[27] Angioleiomyomas are well-demarcated nodules of smooth muscle tissue punctuated with thick-walled vessels with partially open lumina (Fig. 121-8A). The inner layers of smooth muscle of the vessel are arranged circumferentially, and the outer layers blend with the less-well-ordered peripheral smooth fibers (Fig. 121-8B).

DIFFERENTIAL DIAGNOSIS

The clinical differential diagnosis of cutaneous leiomyomas comprises a broad spectrum of solitary, agminated, and widespread dermal-centered papulonodular lesions, including dermatofibromas (fibrous

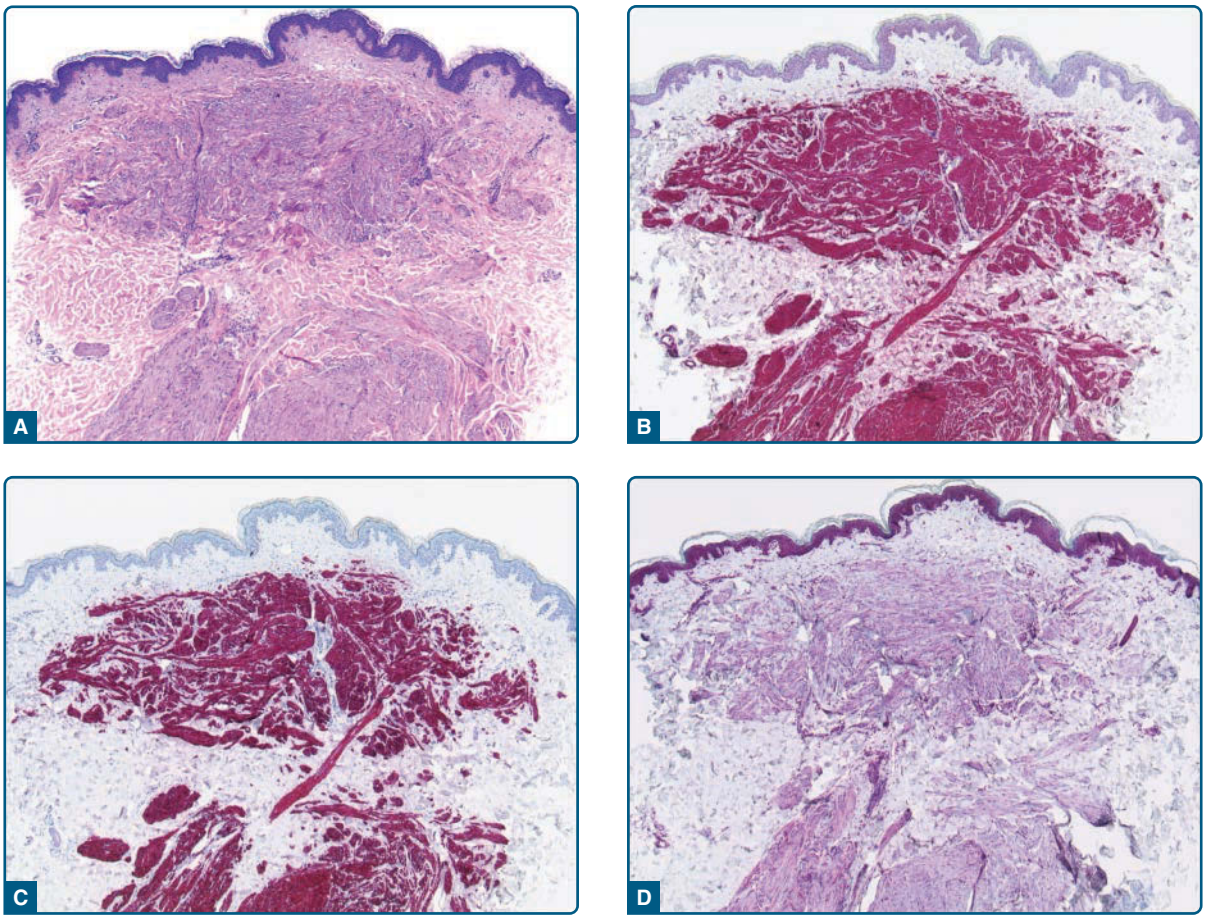

Figure 121-7 **A**, Photomicrograph of a pilar leiomyoma from a *FH*-mutation carrier (hematoxylin-and-eosin [H&E], ×40 magnification). Diffuse and strong expression of α-smooth muscle actin **(B**; anti–α-smooth muscle actin, ×40 magnification) and desmin (**C**; anti-desmin, ×40 magnification) accompanied by an almost complete loss of FH expression **(D**; anti-FH, ×40 magnification).

histiocytomas), dermal melanocytic nevi, neurofibromas, schwannomas, (angio)lipomas, adnexal tumors, and metastases. Cellular and atypical dermatofibroma variants are in the main histopathologic differential diagnosis with the constituent cells being slenderer and less-well-ordered, and lacking myofibrils. The differential diagnosis with leiomyosarcoma and smooth muscle hamartoma is discussed in sections "Etiology and Pathogenesis (for leiomyosarcoma)" and "Etiology and Pathogenesis (for smooth muscle hamartoma)".

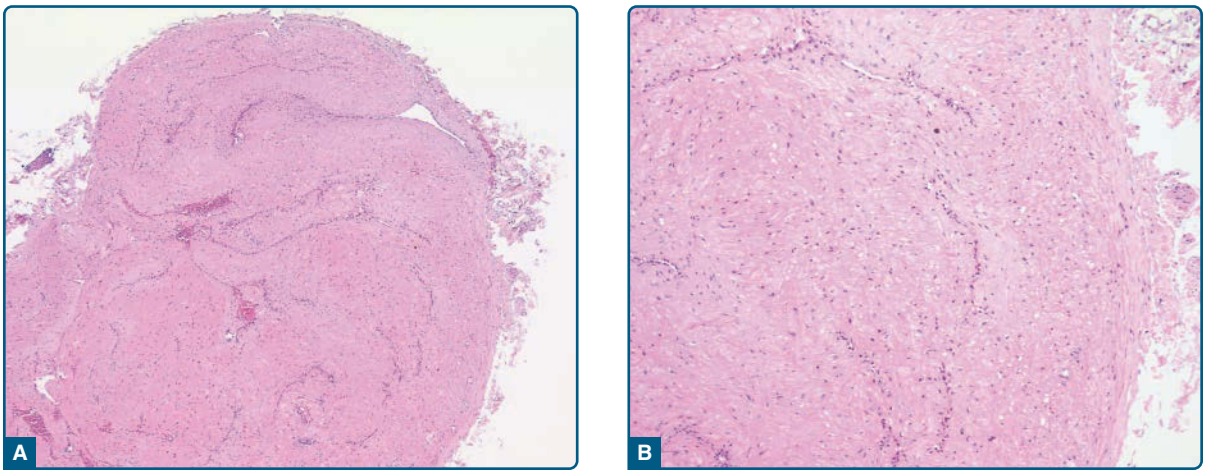

Figure 121-8 Histologic appearance of an angioleiomyoma. **A,** Sharply circumscribed nodular smooth muscle cell proliferation within which multiple vascular channels are present (hematoxylin-and-eosin [H&E], ×20 magnification). **B,** Densely packed fascicles of bland smooth muscle cells surrounding vascular channels (H&E, ×100 magnification).

CLINICAL COURSE AND PROGNOSIS

At present, cutaneous leiomyomas are generally considered not to undergo malignant transformation. Recurrence after complete excision is unusual. The genetic predisposition of females with hereditary leiomyomatosis and renal cell cancer to early-onset uterine leiomyomas and of affected individuals of both sexes to early-onset renal cell cancer requires adequate screening. The lifetime renal cancer risk for *FH* mutation carriers is estimated to be 15%.[28]

MANAGEMENT

Simple excision is curative and the appropriate treatment for those tumors that are symptomatic or of cosmetic concern and amenable to surgical treatment. CO_2 laser ablation, cryotherapy, and electrosurgery are alternative treatment modalities that have been used for cutaneous leiomyomatosis, where surgical excision is not feasible.[29] Symptomatic treatment options include nitroglycerin, nifedipine, phenoxybenzamine, gabapentin, intralesional botulinum toxin, and topical analgesics.[30-34]

LEIOMYOSARCOMA

AT-A-GLANCE

- Malignant smooth muscle tumor comprising 2 subtypes with respect to location and prognosis: *dermal* leiomyosarcomas arising from the arrector pili or genital smooth muscle and *subcutaneous* leiomyosarcomas (synonym: superficial leiomyosarcomas) probably arising from vascular smooth muscle.
- Most commonly presents in males between the fifth and seventh decades as solitary tumors on the scalp or hair-bearing areas of the lower extremities.
- Leiomyosarcomas confined to the dermis are considered to have no metastatic potential and are referred to as *atypical intradermal smooth muscle neoplasms.*
- Tumors involving the subcutaneous adipose tissue warrant the designation leiomyosarcoma and metastasize in approximately 30% to 40% of cases. Wide local excision is required.

EPIDEMIOLOGY

Leiomyosarcomas account for 5% to 10% of soft-tissue sarcomas. They are principally tumors of adults, but occur in all age groups, and no gender predilection is known. Atypical intradermal smooth muscle neoplasms (see section "Etiology and Pathogenesis") affect middle-aged to elderly adults, with a male-to-female ratio of nearly 5:1.[35,36]

ETIOLOGY AND PATHOGENESIS

It is useful to divide superficial leiomyosarcomas into 2 site-related subgroups because of their significant clinical and biologic differences: (a) dermal leiomyosarcomas deriving from arrector pili muscles or smooth muscle at genital sites, and (b) subcutaneous leiomyosarcomas probably deriving from vascular smooth muscle. Although the designation *cutaneous leiomyosarcoma* in the past referred to neoplasms originating in the dermis or subcutis, this term should be restricted to tumors that arise from the dermis and only secondarily involve the subcutis. When limited to the dermis, the tumors may recur locally but, to the best of our knowledge, have no metastatic potential; as a result, the "leiomyosarcoma" designation has been recently challenged. Consequently, it has been proposed that dermal tumors with smooth muscle differentiation displaying atypia and mitotic activity (1 to 2 mitosis/10 high-power field [HPF]) be termed *atypical intradermal smooth muscle neoplasms (AISMN)*, although this designation has not been universally accepted.[35] At present, these tumors are continued to be diagnosed as leiomyosarcoma. Tumors arising from the dermis and displaying invasion into the subcutaneous tissue warrant the designation *cutaneous leiomyosarcoma* and rarely metastasize. The vast majority of leiomyosarcomas that are centered in the subcutis arise from vessels and thus resemble leiomyosarcomas of soft tissue with respect to biologic and clinical behavior, and ultimate prognosis. Those tumors are termed *subcutaneous leiomyosarcomas* (synonym: superficial leiomyosarcomas) and carry a substantial risk of metastasis. Leiomyosarcomas rarely occur in radiation fields or following trauma but may develop as a second malignancy in the setting of hereditary retinoblastoma.[37,38] Alterations of the retinoblastoma 1 locus can be identified in a minority of sporadic leiomyosarcomas as well.[39] Even though well-differentiated areas mimicking leiomyoma are frequently present in a leiomyosarcoma, this is not regarded as evidence of malignant transformation. Moreover, the predilection of leiomyosarcomas to the subcutis, in contrast to the predominantly intradermal location of leiomyomas, is indicative of the contrary. Cutaneous leiomyosarcomas arise de novo, whereas cutaneous leiomyomas, to the best of our knowledge, are not thought to undergo malignant transformation.

CLINICAL FINDINGS

Cutaneous leiomyosarcomas typically present as solitary lesions and have a predilection for hair-bearing areas of lower extremities, and to a lesser extent, to the scalp and trunk, but can occur ubiquitously. There is a male predominance, and most tumors appear between the fifth and seventh decades of life.[40] The tumors usually present as deep-seated, firm nodules with occasional ulceration and hyperplasia of the epidermis. Dermal tumors are typically fixed to the epidermis and rarely exceed 3 cm in diameter, whereas subcutaneous

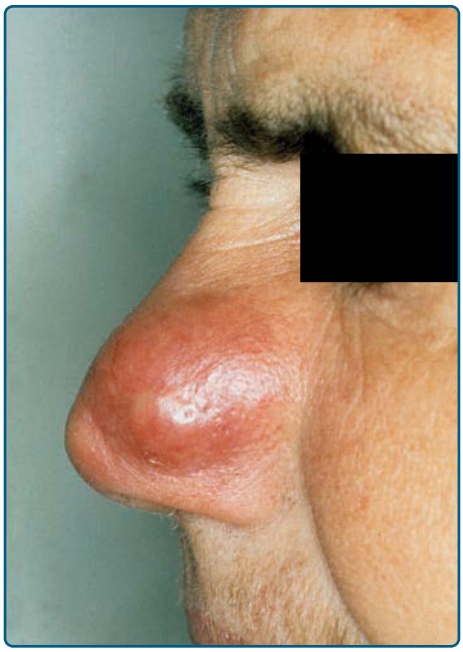

Figure 121-9 Cutaneous leiomyosarcoma on the nose. A firm nodule with erythema and hyperpigmentation of the involved skin is seen. (Image from the collection of Arno Rütten, MD, Dermatopathology Friedrichshafen. Used with permission.)

lesions may rapidly develop into larger, well-circumscribed tumor nodules. Hyperpigmentation and erythema of the involved skin is common (Fig. 121-9). Leiomyosarcomas arising from uterine and retroperitoneal uterine primary tumors rarely present as "secondary leiomyosarcomas" with multiple dermal or subcutaneous nodules in the skin.

HISTOPATHOLOGY

Leiomyosarcomas are composed of intersecting fascicles of atypical spindle cells (Fig. 121-10). Dermal-based tumors appear ill-defined, with tumor fascicles ramifying through the surrounding collagen and pilar arrector muscle. Tumors with involvement of the subcutis appear more circumscribed because of the pseudocapsule that is generated by compression of the adjacent collagenous tissue. Most tumors are well-differentiated (low-grade) or moderately differentiated (intermediate grade) tumors and the tumor cells demonstrate the characteristic cytomorphology indicative of smooth muscle differentiation; that is, large, elongated fusiform cells with abundant brightly eosinophilic cytoplasm, variably blunt-ended nuclei, and well-defined cell borders. Intratumoral hemorrhage, necrosis, and hyalinization are rarely observed. Tumor giant cells may be detected. Poorly differentiated (high-grade) tumors exhibit marked nuclear pleomorphism and a high mitotic rate (>10 mitosis/10 HPF). Identification of cells with pathognomonic nuclear features is essential for correct diagnosis. Myxoid, epithelioid cell, granular cell, and sclerosing/desmoplastic variants have been reported.[41] Tumors that are

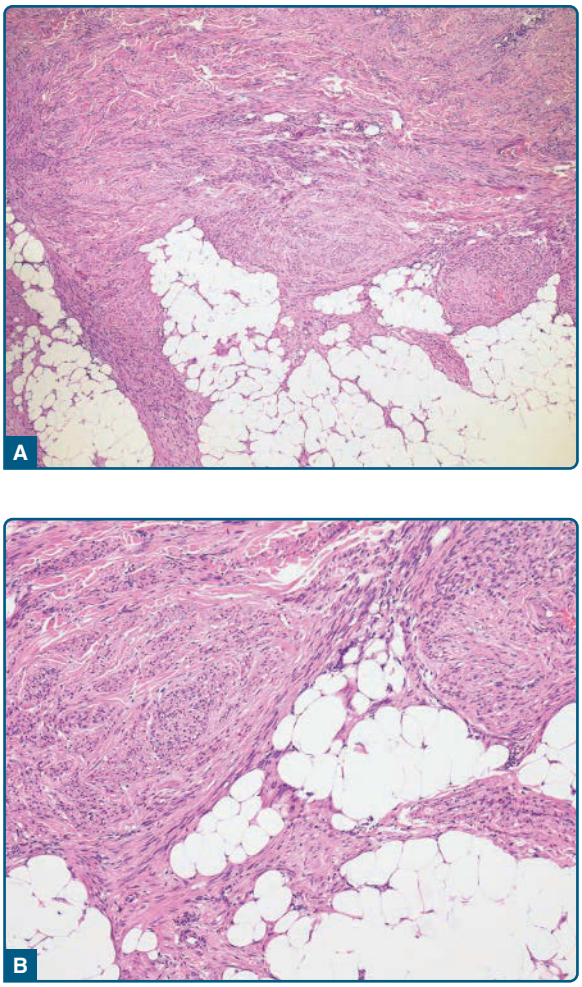

Figure 121-10 Histologic examination of a cutaneous leiomyosarcoma. **A,** Ill-defined atypical dermal spindle-cell tumor displaying a diffusely infiltrative growth pattern (hematoxylin-and-eosin [H&E], ×20 magnification). **B,** Fascicles of atypical spindle cells with hyperchromatic, pleomorphic nuclei infiltrate the surrounding collagen and the subcutaneous fatty tissue (H&E, ×100 magnification).

predominantly composed of pleomorphic cells are known as pleomorphic leiomyosarcoma. AISMN (see "Etiology and Pathogenesis" above) are limited to the dermis and typically display a mixed nodular and infiltrative growth pattern (Fig. 121-11A). Only minimal involvement of the superficial subcutaneous fat with a pushing border is allowed for the designation AISMN. The constituent cells display a typical smooth muscle cell morphology and, in contrast to pilar leiomyoma, mild to moderate atypia and mitotic activity (1 to 2 mitoses/10 HPF; Fig. 121-11B). Recurrent tumors often present with a nodular growth pattern, marked nuclear atypia, and a higher mitotic rate. AISMN are usually positive for α-SMA, muscle-specific actin, desmin, and h-caldesmon. Approximately 50% of cases show focal cytokeratin expression. Detection of smooth muscle antigens is particularly important for the diagnosis of poorly differentiated (high-grade) leiomyosarcomas. α-SMA and muscle-specific actin

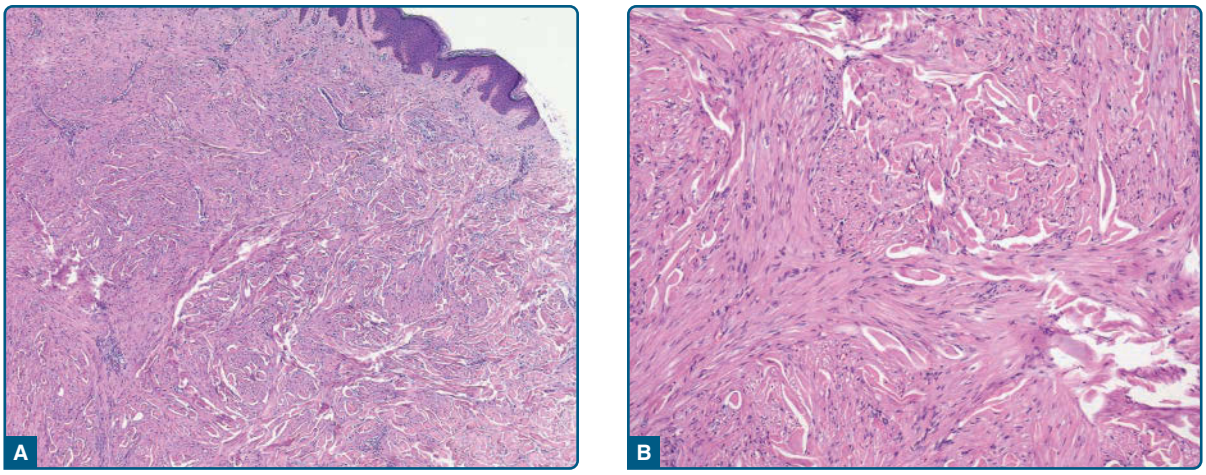

Figure 121-11 Photomicrograph of an atypical intradermal smooth muscle neoplasm. **A,** The tumor is confined to the dermis and fascicles of tumor cells ramify through dermal collagen bundles (hematoxylin-and-eosin [H&E], ×20 magnification). **B,** The tumor cells show mild nuclear atypia and mitotic activity (H&E, ×100 magnification).

are present in most leiomyosarcomas. h-Caldesmon is a specific, but less-sensitive (approximately 40%) smooth muscle antigen.[42] Desmin expression is variable, and if present, only focally, or even absent in high-grade tumors. Expression of epithelial membrane antigen (EMA) and cytokeratin is seen in 30% to 40% of leiomyosarcomas.[43]

DIFFERENTIAL DIAGNOSIS

The clinical differential diagnosis comprises all lesions appearing as solitary, growing, dermal or subcutaneous nodule: dermatofibroma, dermatofibrosarcoma, neurofibroma, squamous cell carcinoma (SCC), atypical fibroxanthoma, pleomorphic dermal sarcoma, melanoma, adnexal tumors, and cysts. Definitive diagnosis requires histopathologic confirmation. On histology, the differential diagnosis for leiomyosarcoma includes both nonpleomorphic spindle-cell tumors, such as cellular dermatofibroma, cellular schwannoma, malignant peripheral nerve sheath tumor (MPNST), myopericytoma, myofibroma, as well as various pleomorphic spindle-cell tumors. In addition, well-differentiated leiomyosarcoma must be delineated from cutaneous leiomyoma. The differential diagnosis versus non–smooth muscle tumors requires immunophenotyping. It must be noted, however, that the distribution and intensity of muscle markers in dedifferentiated tumor areas are strikingly diminished compared to well-differentiated and moderately differentiated areas. Moreover, focal expression of actin or desmin is not necessarily indicative of myoid differentiation, because myofibroblasts also display these phenotypes. Tumors arising from vascular smooth muscle, such as subcutaneous leiomyosarcoma, often show a desmin-negative/h-caldesmon–positive phenotype.[44] In contrast to AISMN, cellular dermatofibroma lacks the well-defined tumor bundles, blunt-ended nuclei, nuclear atypia, and bright eosinophilic appearance. α-SMA and desmin (myofibroblasts) can be focally positive, but h-caldesmon is consistently negative. Atypical dermatofibroma is composed of pleomorphic, plump and spindled fibrohistiocytic cells displaying marked nuclear atypia including bizarre multinucleated giant cells. α-SMA, desmin, and CD34 are sometimes focally positive. It can be distinguished from AISMN by its mixed fascicular and storiform architecture, the heterogeneous tumor cells, and absence of h-caldesmon expression. Cellular schwannoma is an encapsulated neoplasm composed of spindle cells that form a compact fascicular growth pattern and show diffuse expression of S-100 protein. MPNST shows loss of SOX10, neurofibromin, and p16 expression. Myopericytoma/myofibroma typically display a whorled perivascular arrangement of tumor cells with less-abundant eosinophilic cytoplasm and areas with dilated blood vessels. Immunohistochemical staining for α-SMA and h-caldesmon is positive in almost all cases, but desmin expression is restricted to approximately 10% of cases. Leiomyosarcomas that arise on the head and neck must be distinguished from pleomorphic spindle-cell neoplasms arising in sun-damaged skin such as spindle-cell (sarcomatoid) SCC, melanoma, spindle-cell angiosarcoma, atypical fibroxanthoma, and pleomorphic dermal sarcoma. Similar to spindle-cell SCC cell carcinoma, AISMN and leiomyosarcomas are often focally positive for keratin, but desmin and h-caldesmon are not expressed in SCC. The presence of an overlying atypical lentiginous melanocytic hyperplasia and/or a junctional tumor component as well as expression of S-100 protein, HMB-45, MART-1, MITF, SOX10, and NGFR/p75(NTR) should be excluded to distinguish high-grade leiomyosarcoma occurring in severely sun-damaged skin from malignant melanoma. Spindle-cell angiosarcoma can be delineated by search for classical morphologic features (multilayering, papillary structures, irregular anastomosing blood vessels) and immunophenotyping for ERG, a marker expressed in benign and malignant vascular

endothelial cells. Spindle-cell variants of atypical fibroxanthoma and pleomorphic dermal sarcoma may pose a significant diagnostic challenge and both are diagnoses of exclusion. The tumors arise almost exclusively in actinically damaged skin of the head and neck area of older adults. Focal areas with scattered epithelioid and histiocytic tumor cells, multinucleated giant cells, and brisk mitotic activity are usually present. Weak positivity for α-SMA may be present and atypical fibroxanthoma is frequently positive for CD10, while tumor cells stain negative for S-100 protein, melanocytic differentiation antigens, cytokeratins, desmin, h-caldesmon, and ERG. The presence of epithelial-like areas or an in situ component facilitates the diagnosis of spindle-cell SCC (sarcomatoid SCC), but both components may be completely absent. By immunohistochemistry, spindled tumor cells in sarcomatoid SCC often at least focally express broad-spectrum keratins (eg, clone MNF116 and/or AE1/AE3), as well as nuclear p63.

CLINICAL COURSE AND PROGNOSIS

The prognosis of cutaneous leiomyosarcomas is almost always favorable, with the majority of tumors cured with a timely wide surgical excision. This is, in part, contributable to the fact that most tumors are small (<2 cm) and highly-differentiated (low-grade). AISMN have an a particularly excellent prognosis but incompletely excised tumors bear a recurrence rate of 20% to 30% with margin status representing the only predictor of local recurrence.[35] Although quantification of risk of metastatic spread in cutaneous leiomyosarcoma is difficult, tumor size, degree of subcutaneous involvement, high histologic grade, and previous local reoccurrence are considered as risk factors. In general, leiomyosarcomas confined to the dermis do not metastasize, whereas those with subcutaneous involvement metastasize in approximately 30% to 40% of cases.[45-47] Metastatic dissemination occurs commonly hematogenously to the lung, and regional lymph may be occasionally involved.

MANAGEMENT

As the overwhelming majority of cutaneous leiomyosarcomas are potentially curable, initial eradication of the tumors by wide surgical excision with at least 3-cm margins and careful histologic examination of surgical margins is the treatment of choice. Given its substantial risk for local recurrence, complete excision with negative margins is also the appropriate therapy for AISMN. Recurrent leiomyosarcomas confer an increased risk of eventual metastasis because of their distinct propensity for a larger tumor size at diagnosis and infiltration of deeper structures. Mohs micrographic surgery has been used as an alternative treatment modality with a reported recurrence rate of 14%.[48]

SMOOTH MUSCLE HAMARTOMA

AT-A-GLANCE

- Hyperplasia of dermal smooth muscles fibers giving rise to a rare hamartoma.
- Solitary flesh-colored patch or plaque typically occurring in the lumbar region during childhood or early adolescence.
- Follicular prominence, hypertrichosis, and variable pigmentation are frequent.
- Clinical and histopathologic association with the nevus of Becker.

EPIDEMIOLOGY

Smooth muscle hamartoma was initially described by Stokes in 1923.[49] The lesions are usually present from birth, but exceptional cases of an acquired variant have been reported. The estimated prevalence is approximately 1 in 2600 live births.[50]

ETIOLOGY AND PATHOGENESIS

Smooth muscle hamartoma of the skin is a benign hamartomatous proliferation consisting of well-defined smooth muscle located in the dermis. The etiology is unknown. Familial occurrence has been reported. Some of the acquired cases appear to represent acquired smooth muscle secondary to chronic lymphedema.

CLINICAL FINDINGS

Smooth muscle hamartoma typically presents as skin-colored or lightly pigmented patch or plaque measuring up to 10 cm in diameter with a predilection for the lumbar region of the trunk, the buttocks, and the proximal extremities (Fig. 121-12). The spectrum of clinical presentations comprises solitary lesions, agminated lesions, and a generalized variant with excess symmetrical skin folds (known as *Michelin tire baby syndrome*), as well as occasional hypertrichosis and follicular dimpling.[51,52] All forms can display variable hyperpigmentation and hypertrichosis. Small papules may be detectable within the lesions and sensitive to transient piloerection following rubbing (pseudo-Darier sign). Smooth muscle bundles may also occur in the nevus of Becker, a pigmentary hamartoma with its onset in adolescence, characterized by invariable hyperpigmentation and hypertrichosis. Given their overlapping histologic and clinical features, smooth muscle hamartoma and Becker melanosis can be regarded as varying

Figure 121-12 Congenital smooth muscle hamartoma on the lower back of an infant. The tumor presents as a skin-colored patch with hypertrichosis. (Image from the collection of Antonio Torrelo, MD, Department of Pediatric Dermatology, Hospital del Niño Jesús, Madrid, Spain. Used with permission.)

morphologic expressions of the same hamartomatous process involving the pilar unit and the arrector pili muscles.[53]

HISTOPATHOLOGY

There are well-defined and thickened smooth muscle fibers haphazardly oriented in reticular dermis (Fig. 121-13). Some surround or are attached to hair follicles. Commonly, there are thin retractions spaces separating the muscle bundles from the adjacent collagen. The overlying epidermis may show mild hyperpigmentation of the basal layer, acanthosis and papillomatosis. The constituent cells express α-SMA and desmin. The surrounding stroma may contain a high number of cells positive for CD34.

DIFFERENTIAL DIAGNOSIS

Differential diagnosis of cutaneous smooth muscle hamartoma includes leiomyoma, Becker nevus,

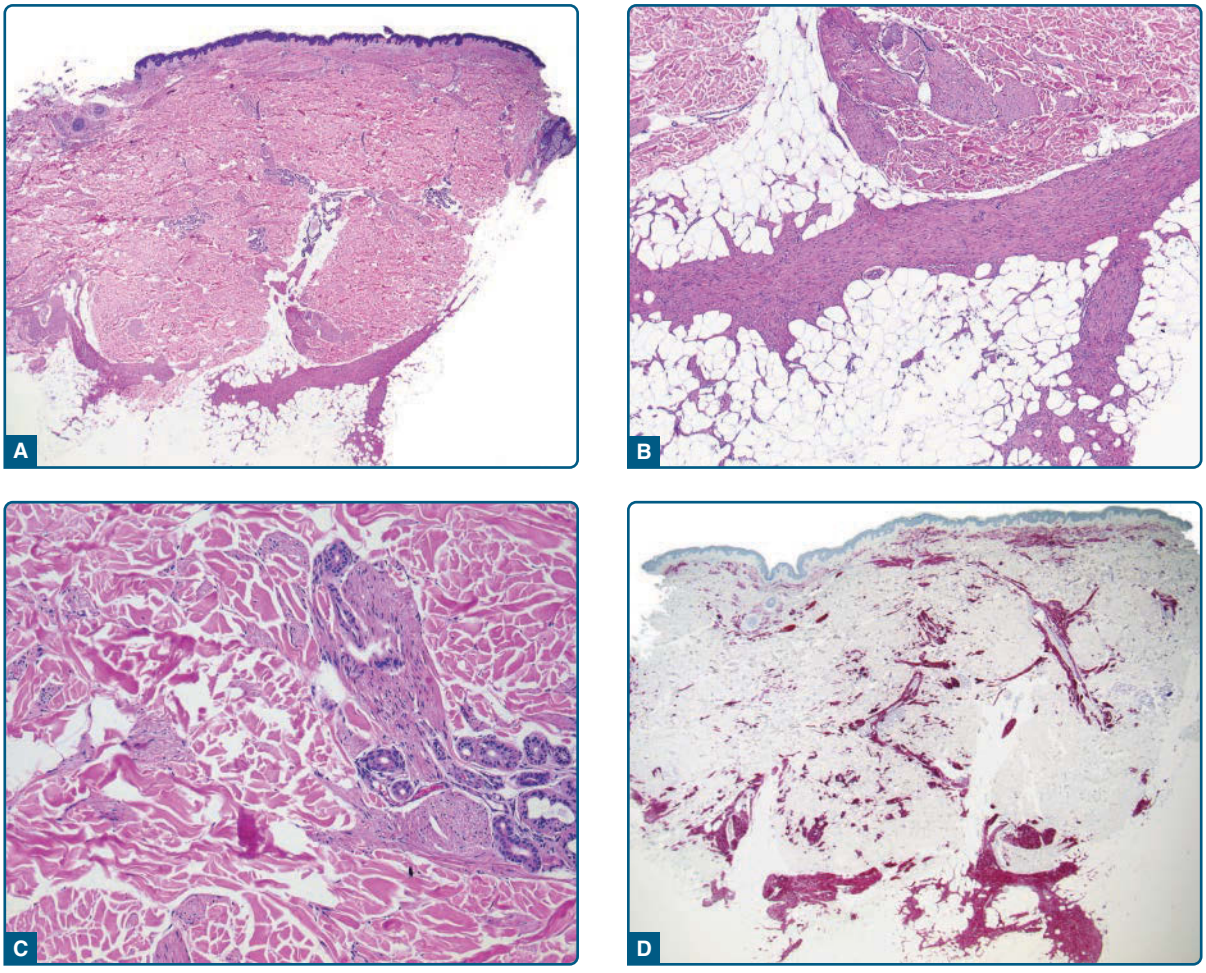

Figure 121-13 Photomicrograph of a congenital smooth muscle hamartoma. Proliferation of scattered, well-demarcated, haphazardly arranged bundles of smooth muscle throughout the dermis (**A**; hematoxylin-and-eosin [H&E], ×4 magnification) and the superficial subcutaneous fatty tissue (**B**; H&E, ×10 magnification). **C,** Short fascicles of smooth muscle cells with characteristic elongated, spindle-shaped to blunt-ended nuclei (H&E, ×100 magnification). **D,** The constituent cells are immunoreactive for desmin (anti-desmin, ×4 magnification).

congenital melanocytic nevus, neurofibroma, connective tissue nevus, and solitary mastocytoma. Leiomyomas usually appear as papulonodules rather than as plaques. Histologic distinction of cutaneous leiomyomas from smooth muscle hamartomas of the skin is not always clearcut and may substantially relate more to differences in clinical presentation than histologic features. The smooth muscle fibers in leiomyomas are arranged in interweaving fascicles that blend with the adjacent dermal collagen fibers whereas smooth muscle hamartomas are composed of discrete smooth muscle fibers set in dermal collagen.

CLINICAL COURSE AND PROGNOSIS

To the best of our knowledge, smooth muscle hamartomas do not undergo malignant transformation. A melanocytic nevus has been reported in association with a smooth muscle hamartoma. A naevus flammeus also was present in 1 case. Individuals presenting with the generalized form may have variety of congenital anomalies that have been reported in babies with multiple symmetric circumferential rings of folded skin ("Michelin tire baby syndrome").[54]

MANAGEMENT

Treatment may be indicated for cosmetic purposes. Lesions may be amenable for surgical excision.

TUMORS OF STRIATED MUSCLE

Tumors of striated muscle (see Table 121-1) segregate into genuine neoplasms with striated muscle differentiation (rhabdomyoma and rhabdomyosarcoma) and nonneoplastic hamartomas (rhabdomyomatous mesenchymal hamartoma and neuromuscular hamartoma). Figure 121-1 provides an overview of the diagnosis of cutaneous tumors with striated muscle differentiation.

RHABDOMYOMA

AT-A-GLANCE

- Benign neoplasm of striated muscle presenting as adult, fetal, or genital type.
- Most commonly located on the head and neck of males.
- Fetal rhabdomyoma may be associated with nevoid basal cell carcinoma syndrome.
- Surgical removal is the treatment of choice.

EPIDEMIOLOGY

Rhabdomyomas are much less common than rhabdomyosarcomas and account for no more than 2% all of striated muscle neoplasms.[55] There are 2 main categories of rhabdomyomas: cardiac and extracardiac. For practical reasons extracardiac rhabdomyomas are further subcategorized into 3 clinical and morphologic subtypes: adult-type, fetal-type, and genital-type rhabdomyomas. Fetal-type and adult-type rhabdomyomas affect mostly men (male-to-female ratio is 3:1). In 20% to 30% cases of adult-type rhabdomyomas, multiple lesions develop in the same patient.

ETIOLOGY AND PATHOGENESIS

Rhabdomyomas are benign neoplasms of striated muscle differentiation. Cardiac tumors are associated with tuberous sclerosis. The prevalence rates of cardiac rhabdomyomas in patients with tuberous sclerosis range from 47% to 67%, as assessed by repeated echocardiography, whereas extracardiac rhabdomyomas do not occur in the setting of tuberous sclerosis.[56,57] There are repeated reports in the literature documenting an association of fetal rhabdomyoma with the nevoid basal cell carcinoma syndrome.[58] Mutations in the *PTCH1* tumor-suppressor gene have been identified in this syndrome.

CLINICAL FINDINGS

Among the group of extracardiac rhabdomyomas, 3 clinically and morphologically different subtypes can be defined: (a) the *adult type*, a slowly enlarging mass that is almost always arising in the head and neck area of middle-aged and elderly adults (mean age: 60 years) that causes neither tenderness nor pain; (b) the *fetal type*, an exceptionally rare tumor that also principally occurs in the head and neck region in both children and adults; and (c) the *genital type*, a small polypoid lesion detected nearly always in the vagina or vulva of middle-aged women. The designation as *adult* or *fetal* refers to the tumor's resemblance to adult or fetal skeletal muscle, not to the age of the patient.

HISTOPATHOLOGY

Microscopically, adult rhabdomyoma is composed of variously sized, deeply eosinophilic polygonal cells with small, peripherally placed nuclei and occasional intracellular vacuoles (Fig. 121-14). The histologic spectrum of fetal rhabdomyoma recapitulates fetal skeletal muscle: "Classic" or "myxoid" fetal rhabdomyoma is chiefly composed of primitive oval or spindle-shaped cells and a richly myxoid stroma. "Intermediate" or "cellular" fetal rhabdomyoma consists of intersecting bundles of differentiated eosinophilic myofibrils containing cross-striations, fewer or absent spindle-shaped mesenchymal cells, and sparse or no myxoid stroma. Irrespective of cellularity, the nuclei are bland and lack atypia, pleomorphism, and anaplasia; in addition, most cases lack mitosis.

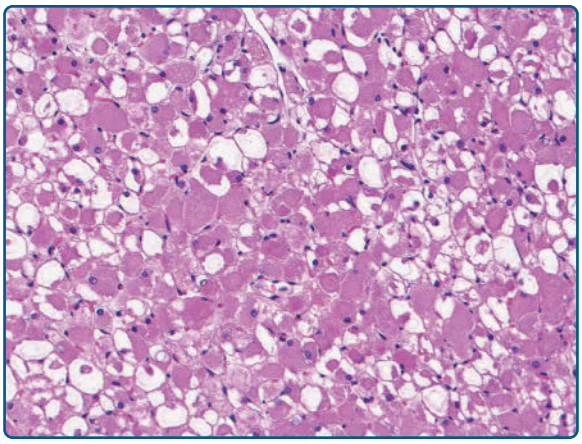

Figure 121-14 Histologic appearance of an adult rhabdomyoma. There are round and polygonal cells with small, peripherally placed nuclei and deeply eosinophilic, finely granular cytoplasm arranged in solid sheets (hematoxylin-and-eosin [H&E] ×100 magnification).

DIFFERENTIAL DIAGNOSIS

Differential diagnosis of rhabdomyomas includes granular cell tumor, hibernoma, paraganglioma, and embryonal rhabdomyosarcoma.

CLINICAL COURSE AND PROGNOSIS

Cardiac rhabdomyomas often regress spontaneously by age, but this has not been observed for extracardiac rhabdomyomas. Adult-type rhabdomyoma carries an estimated 42% risk of local recurrence following incomplete excision, while only rare reports of local recurrences of fetal rhabdomyomas exist.[59,60] As of this writing, there is no valid evidence for the concept that fetal rhabdomyoma represents an early stage in the development of adult rhabdomyoma.

MANAGEMENT

Extracardiac rhabdomyomas are readily curable by surgical excision.

RHABDOMYOSARCOMA

AT-A-GLANCE

- Malignant soft-tissue neoplasm with primitive skeletal muscle differentiation.
- Most common soft-tissue sarcoma in children and adolescents.
- Presents as subcutaneous or ulcerated mass on the head and neck or the extremities; rare cause of "blueberry muffin baby."
- Highly variable prognosis, with 5-year survival rates ranging from 30% to 95%.
- Multidisciplinary therapeutic approach of surgery and chemotherapy ± radiotherapy is needed.

EPIDEMIOLOGY

Rhabdomyosarcoma (RMS) is the most frequent soft-tissue sarcoma in children and adolescents and one of the most common soft-tissue sarcomas in young adults. The estimated annual incidence in children is approximately 4.3 cases per million children per year, accounting for approximately 5% of all pediatric cancers and approximately 50% of soft-tissue sarcomas in children younger than age 15 years.[61] The tumor rarely occurs in individuals older than 45 years of age and has been estimated to account for 3% of all sarcomas in adults.[62] There is a slight male predominance.

ETIOLOGY AND PATHOGENESIS

RMS is a primitive malignant soft-tissue sarcoma that shows some differentiation toward skeletal muscle. Because the tumor often arises in at sites in which skeletal muscle tissue is normally absent or scant, it is not suggested to arise from skeletal muscle cells. Embryonal RMS appears to arise from the undifferentiated mesoderm. Genetic factors are implicated by the rare occurrence in siblings, the association of the tumor with other neoplasms, and the infrequent presentation at birth. In one study, approximately 30% of children with RMS had a congenital anomaly.[63] Based on histologic criteria, RMS can be generally divided into 3 broad subsets: *embryonal* rhabdomyosarcoma (ERMS), *alveolar* rhabdomyosarcoma (ARMS), and *anaplastic* (*undifferentiated*) RMS (also known as *pleomorphic* RMS). Within the ERMS subtype, there are 2 histopathologic variants with superior outcome, botryoid and spindle cell. Sclerosing RMS and epithelioid RMS represent other proposed variants. ERMS is the most common (60%) followed by ARMS (20%). ERMS is associated with an 11p15.5 loss of heterozygosity.[64] Approximately 60% of tumors diagnosed histologically as ARMS have a $t^{2;13}$(q35;q14) translocation and approximately 20% carry a $t^{1;13}$(p36;q14) translocation, resulting in a *PAX3-FOXO1A* and a *PAX7-FOXO1A* fusion, respectively.[65,66]

CLINICAL FINDINGS

RMS can occur at various anatomic sites throughout the body. The most common primary tumor sites include the head and neck region, followed by the genitourinary tract, the retroperitoneum, and the extremities. primaries. Cutaneous manifestation is rare and usually recognizable as a rapidly growing mass of several months' duration that results from expansion of an underlying soft-tissue lesion and may eventually

Figure 121-15 Rhabdomyosarcoma presenting as a subcutaneous mass on the shoulder of an infant. (Image from the collection of Antonio Torrelo, MD, Department of Pediatric Dermatology, Hospital del Niño Jesús, Madrid, Spain. Used with permission.)

become ulcerated (Fig. 121-15). RMS is often palpable and limits motion. The tumor also may be encountered in areas where the expanding neoplasm reaches the body surface (eg, eyelid, anal region). Primary cutaneous origin is very rare. Neonatal ARMS presenting with cutaneous and subcutaneous metastases is a very rare cause of "blueberry muffin baby."

HISTOPATHOLOGY

The presence of rhabdomyoblasts is essential for the diagnosis of RMS. Rhabdomyoblasts are large round, spindle-shaped, or elongated ("strap"-shaped) cells with deeply eosinophilic granular cytoplasm rich in thick and thin filaments that may show cross-striations, reflecting sarcomere formation and advancement of differentiation. The cells in RMS may exhibit a marked primitive ovoid or primitive spindle-shaped, small, round, pleomorphic, clear, or even elongated-fusiform cytomorphology with cigar-shaped nuclei and prominent nucleoli resembling smooth muscle cells. Multinucleated giant cells and areas of necrosis may be present. In rare cases of ARMS, viable cells are virtually absent. Mitotic index is high. ERMS typically consists of small, round or spindle-shaped cells with alternating cellular and myxoid zones. ARMS displays a characteristic alveolar growth pattern with central loss of cellular cohesion in cellular nests and adherence of the peripheral cell layer to fibrovascular septa. Various immunohistochemical markers have been applied to the diagnosis of RMS. However, diagnostic accuracy is variable in routine practice and of limited utility. Given their high sensitivity and specificity for RMS, the myogenic markers myogenin (myogenic factor 4) and myogenic differentiation 1 (MyoD1) have the highest diagnostic value in the setting of pediatric "small, blue, round-cell tumor"(see section "Epidemiology, Etiology, and Pathogenesis").[67] Approximately 80% of ARMS have the *PAX3-FOXO1A* or *PAX7-FOXO1A* fusion.

DIFFERENTIAL DIAGNOSIS

Differential diagnosis of RMS includes other malignant neoplasms composed of primitive cells with minimal or no differentiation ("small, blue, round-cell tumors of childhood") and poorly differentiated spindle-cell sarcomas in children and young adults. Immunohistochemical analysis using a panel of stains is basically indispensable to delineate RMS from its histologic mimickers, including neuroblastoma, Ewing sarcoma, lymphoma, melanoma, poorly differentiated angiosarcoma, granulocytic sarcoma, synovial sarcoma, pleomorphic leiomyosarcoma, and undifferentiated pleomorphic sarcoma. Pleomorphic RMS and pleomorphic leiomyosarcoma may exhibit a quite similar cytomorphology. As desmin is positive in both tumors, specific skeletal muscle markers, including monoclonal myoglobin and MyoD1 and/or myogenin, must be included in the antibody panel. Of note, CD99, a highly sensitive marker of Ewing sarcoma, is sometimes detectable in ERMS and ARMS.[68]

CLINICAL COURSE AND PROGNOSIS

Although generally considered as poor, the prognosis of RMS is highly variable among affected individuals and has improved dramatically in the recent decades. The International Classification of RMS distinguishes 4 main categories with respect to prognosis: (a) superior prognosis (botryoid RMS, spindle-cell RMS), (b) intermediate prognosis (ERMS), (c) poor prognosis (ARMS, undifferentiated sarcoma), and (d) subtypes whose prognosis is not presently evaluable (RMS with rhabdoid features).[69] Notably, the prognosis of RMS has improved substantially since 1970 with 5-year-survival rates ranging from approximately 20% to 30% for undifferentiated sarcoma to 90% to 95% for botryoid RMS.

MANAGEMENT

Treatment of RMS requires a multidisciplinary approach including a biopsy or surgical removal of the tumor and chemotherapy with or without radiotherapy.

RHABDOMYOMATOUS MESENCHYMAL HAMARTOMA

First described in 1986 by Hendrick and associates as *striated muscle hamartoma* and renamed in 1989 by Mills as *rhabdomyomatous mesenchymal hamartoma*, this extremely rare cutaneous entity usually presents in the midline of newborns (synonym: *congenital midline hamartoma*).[70,71] It may arise as a solitary lesion in an otherwise healthy neonates or occur as multiple lesions in the setting of uncommon ectodermal/mesodermal abnormalities. Anecdotal cases have been diagnosed

in adults. Rhabdomyomatous mesenchymal hamartoma clinically presents as a small dome-shaped papule or polypoid pedunculated lesion in the midline region of the skin in the head and neck region, most frequently on the chin. Unusual sites include the oral cavity, nasal vestibule, vagina, and the anal region. Histologically, the lesion is composed of disordered mixture of mature-appearing adipose and skeletal muscle tissue, adnexal structures and sometimes blood vessels and nerves (synonym: *hamartoma of cutaneous adnexa and mesenchyma*). The differential diagnosis includes nevus lipomatosus superficialis and fibrous hamartoma of infancy, both of which lack skeletal muscle fibers. Moreover, rhabdomyomatous mesenchymal hamartoma must also be distinguished from cutaneous ERMS and neuromuscular hamartoma (see "Neuromuscular Hamartoma" below). Rare cases of rhabdomyomatous mesenchymal hamartoma may undergo spontaneous regression. Local excision is an adequate treatment option.

NEUROMUSCULAR HAMARTOMA

Neuromuscular hamartoma, also called *benign Triton tumor* or *neuromuscular choristoma*, is a rare developmental lesion composed of skeletal muscle and nerve muscle elements. Of the fewer than 50 cases reported in the literature, the majority presented in children younger than 2 years of age as solitary masses involving large nerve trunks, principally the brachial plexus and the sciatic nerve.[72] Tumors arising from intracranial nerves are typically detected during adult life (Fig. 121-16). Owing to their locations, neuromuscular hamartomas commonly cause neurologic symptoms. Cutaneous manifestation without major nerve involvement is exceedingly rare, with only a few reported cases in the literature. The histogenesis of this entity remains controversial. Histologic appearance is characterized by bundles of perpendicularly oriented skeletal muscles intermingled with multiple small nerve fascicles. Total excision of neuromuscular hamartoma is often challenging because of its association with a major nerve. Given its benignity, treatment should thus be aimed at amelioration of symptoms and maintaining the integrity of the nerve.

Figure 121-16 Neuromuscular hamartoma on the forehead of a teenager. (Image from the collection of Antonio Torrelo, MD, Department of Pediatric Dermatology, Hospital del Niño Jesús, Madrid, Spain. Used with permission.)

PERIPHERAL NERVE SHEATH TUMORS

Peripheral nerve sheath tumors constitute the vast majority of neural proliferations presenting in the skin and the subcutis Table 121-3). These tumors arise from, or differentiate toward, one or more elements of the peripheral nervous system. The entire spectrum can be broadly subdivided for practical purposes into genuine nerve sheath neoplasms and nonneoplastic proliferations, including hamartomatous tumors.[73] From a clinical perspective, peripheral nerve sheath tumors often resemble each other and most tumors are benign. However, some neoplasms may occur in the setting of an underlying clinical syndrome, and their correct diagnosis can therefore facilitate the recognition of an important genetic disorder and, ultimately, better patient management. In addition, malignant transformation of neurofibromas is an acknowledged phenomenon in a subset of patients with neurofibromatosis 1 (NF-1). The sheath of peripheral nerves is composed by 3 different cell types: (a) Schwann cells, which give rise to the 3 main entities of cutaneous peripheral nerve sheath tumors: neuromas, schwannomas (neurilemomas), neurofibromas, and their variants; (b) perineurial cells, which are considered specific fibroblasts that give rise to perineuriomas and differ from Schwann cells by lacking a basement membrane; and (c) nonspecific mesenchymal cells (eg, fibroblasts, mast cells), which are predominantly located in the endoneurium, that is, the space between the individual nerve fibers. The various types of peripheral nerve sheath tumors contain the same principal constituents of a peripheral nerve—Schwann cells, axons, fibroblasts, and stroma tissue. However, the proportion and architectural arrangement of these basic units varies according to the tumor type. Schwann cells are considered as neural crest–derived cells and express S-100 protein but not EMA, whereas perineurial cells are generally viewed as mesodermal derived cells and express EMA, GLUT1 (glucose transporter 1), and claudin-1, but not S-100 protein.[74] Axons contain the specific intermediate filament type designated neurofilament, and myelinated axons contain myelin basic protein. Figure 121-17

TABLE 121-3

Cutaneous Proliferations with Neural Differentiation

	TRAUMATIC NEUROMA	PALISADED ENCAPSULATED NEUROMA	SCHWANNOMA	NEUROFIBROMA	NERVE SHEATH MYXOMA	PERINEURIOMA	GRANULAR CELL TUMOR	MPNST
Incidence	Uncommon	Rare	Uncommon	Very common	Rare	Rare	Rare	Very rare
Age & gender	Any M:F = 1:1	Adults (20 to 50 years of age) M:F = 1:1	Adults (20 to 60 years of age) M:F = 1:1	Adults (20 to 80 years of age) M:F = 1:1	Any (mean age: 36 years) Males > Females	Any (mean age: 46 years) M:F = 1:2	Adults (20 to 80 years of age) M:F = 1:3	Adults (20 to 50 years of age) Males > Females
Location	Trauma sites, amputation stumps, scars	90% Face (nose, lip, cheek), 10% extrafacial	Head and neck area, flexural aspects of extremities	Localized type: trunk, head Diffuse type: head, neck Plexiform type: anywhere	Extremities (hand/fingers, knee/pretibial region, ankle/foot)	Sclerosing type: digits and palms Deep soft-tissue type: trunk, legs	65% Head and neck area (mainly tongue, oral mucosa, hard palate), 35% elsewhere	Proximal extremities and trunk
Size	0.5 to 2 cm	0.2 to 0.6 cm	1 to 4 cm	0.2 to 2 cm (localized type)	0.5 to 2.5 cm	0.5 to 1.5 cm	0.2 to 3 cm	>5 cm
Clinical presentation	Oval, firm, flesh-colored papule or nodule	Small, immobile, firm, rubbery, skin-colored or pink, dome-shaped papule or nodule	Soft, slowly growing, skin-colored to yellowish, dermal or subcutaneous nodule	Soft, skin-colored, dome-shaped or pedunculated papule or nodule	Soft, skin-colored, multinodular mass	Firm, flesh-colored, superficial papule or nodule	Flesh-colored or brownish-red, firm nodule with a smooth, rough, or verrucous surface	Enlarging palpable mass
Symptoms	Itching, prickling, pain in 10% to 30% of cases	Asymptomatic	Asymptomatic; pain, tenderness, neurologic symptoms may occur	Asymptomatic; positive "button-hole" sign	Asymptomatic	Usually asymptomatic	Asymptomatic; pruritus or tenderness may occur	Radicular pain, paresthesia, motor weakness
Genetics		MEN2B: gain-of-function germline mutations in *RET* (10q11.21)	Sporadic and NF-2–associated tumors: inactivation of *NF2* (22q12.2); Schwannomatosis: inactivation of *SMARCB1/INI1*, (22q11.23)	Sporadic and NF-1–associated tumors: inactivation of *NF1* (17q11.2); genetic heterogeneity (eg, loss-of-function variants, gene deletions)		Often mutations or deletions of the *NF2* gene	LEOPARD syndrome: germline missense mutations in *PTPN11* (12q24.13)	Sporadic, radiotherapy- and NF-1–associated tumors: inactivation of *NF1* (17q11.2), *CDKN2A* (9p21.3), *PRC2* (EED or SUZ12)

(*Continued*)

TABLE 121-3
Cutaneous Proliferations with Neural Differentiation (*Continued*)

	TRAUMATIC NEUROMA	PALISADED ENCAPSULATED NEUROMA	SCHWANNOMA	NEUROFIBROMA	NERVE SHEATH MYXOMA	PERINEURIOMA	GRANULAR CELL TUMOR	MPNST
Histopathologic features	Haphazard proliferation of nerve fascicles including myelinated axons, Schwann cells, fibroblasts, and perineural cells; collagenous stroma	Well-circumscribed tumor with partial encapsulation; multiple closely packed Schwann cell fascicles and abundant axons; interfascicular clefting	Well-circumscribed encapsulated tumor; parenchyma composed of Schwann cells; hypercellular areas with nuclear palisades alternate with hypocellular areas	Poorly circumscribed to well-circumscribed, usually nonencapsulated, haphazard proliferation of Schwann cells with slender, wavy nuclei, fibroblasts, perineurial cells, mast cells	Nonencapsulated multilobulated or multinodular tumor with abundant myxoid matrix; epithelioid, stellate-shaped, multipolar, spindled Schwann cells	Well-circumscribed nonencapsulated tumor with whorled, storiform, or lamellar growth pattern; spindle cells with elongated, bipolar cytoplasmic processes; usually collagenous stroma	Poorly circumscribed nodule; polygonal cells with abundant, fine to coarsely granular cytoplasm and round, dark nuclei; pseudoepitheliomatous hyperplasia	Poorly circumscribed unencapsulated tumor with fibrosarcoma-like appearance; cells arranged in sweeping fascicles; cellular and myxoid areas alternate ("marbleized" pattern), mitotic activity
Immunohistochemical features	NF+, EMA+/–, S-100+	NF+, EMA+, S-100+	NF–, EMA+, S-100+	NF+/–, S-100+, EMA–	S-100+, GFAP+, NSE+	EMA+, GLUT1+, claudin-1+	S-100+, NSE+, CD68+	S-100+/–, H3K27me3+/–
Management	Reapposition, surgical excision	Surgical excision	Surgical excision	Surgical excision	Surgical excision	Surgical excision	Surgical excision	Surgical excision, radiotherapy and/or chemotherapy
Associated syndromes		Multiple mucosal neuromas occur in the setting of MEN2B	5% with multiple meningiomas; 3% with NF-2; 2% with multiple schwannomas	Plexiform type almost unique to NF-1; diffuse type usually associated with NF-1			Multiple granular cell tumors are an associated feature of LEOPARD syndrome	Approximately 50% of MPNSTs occur in the setting of NF-1; 8% to 13% lifetime risk of MPNST in NF-1
Other	"Rudimentary polydactyly" is regarded as a variant		Multiple schwannomas ("schwannomatosis"): multiple cranial, spinal and peripheral schwannomas without vestibular tumors	Malignant transformation of plexiform type into MPNST occurs in approximately 4% of cases		Malignant transformation of soft-tissue perineurioma into malignant perineurioma is very uncommon	Malignant granular cell tumors are very rare	1-Year local reoccurrence rate of 40%; 1-year distant metastasis rate of 50%

EMA, epithelial membrane antigen; GFAP, glial fibrillary acidic protein; GLUT1, glucose transporter 1; LEOPARD, lentigines, electrocardiographic abnormalities, ocular hypertelorism, pulmonary stenosis, abnormalities of genitalia, retardation of growth, and deafness; M:F, male-to-female ratio; MEN, multiple endocrine neoplasia; MPNST, malignant peripheral nerve sheath tumor; NF, neurofibromatosis; NSE, neuron-specific enolase.

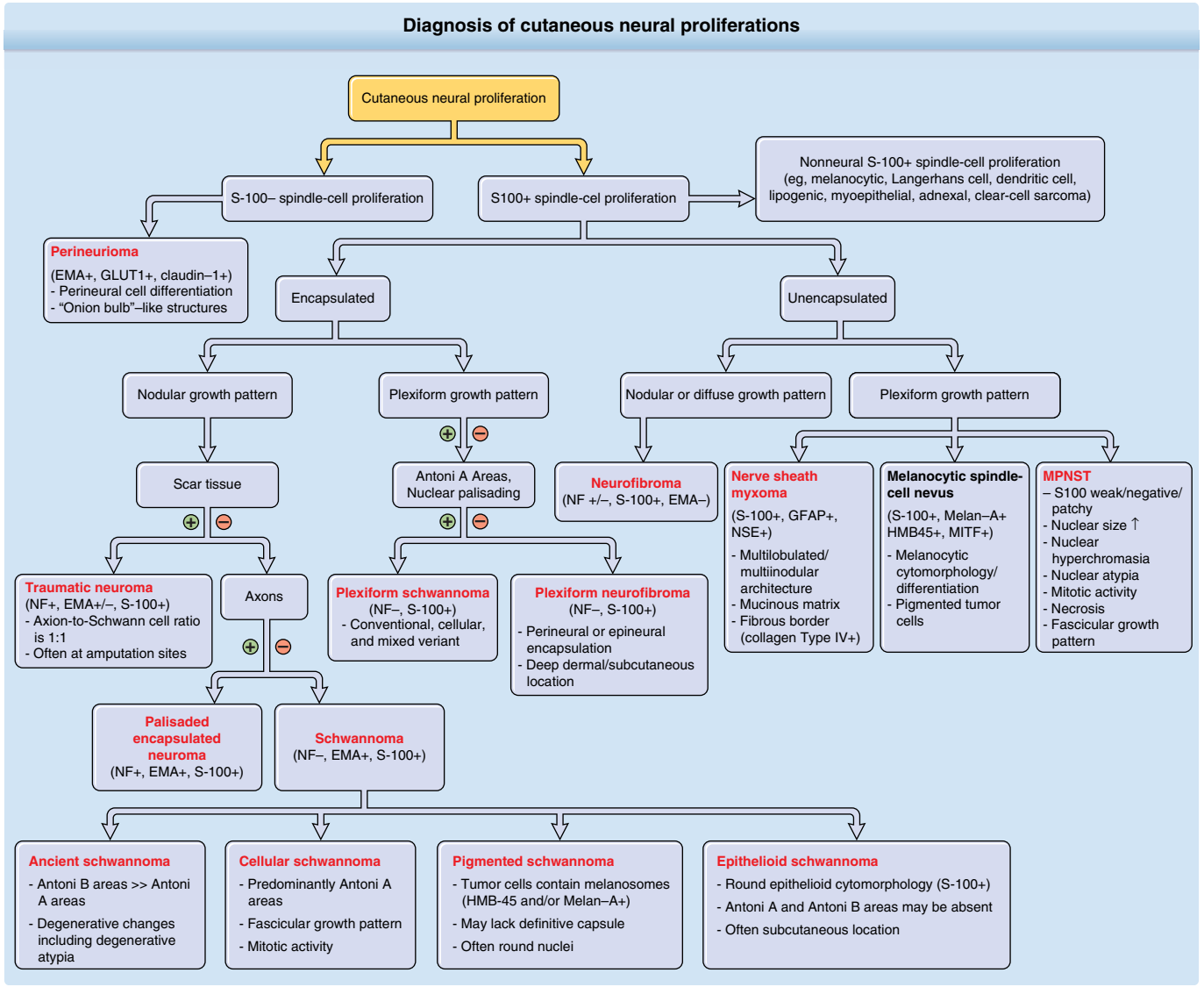

Figure 121-17 Diagnosis of cutaneous neural proliferations. –, Negative; +, positive; EMA, epithelial membrane antigen; GLUT1, glucose transporter 1; HMB45, melanocytic differentiation antigen; Melan-A, melanocytic differentiation antigen; MITF, microphthalmia-associated transcription factor; NF, neurofilament; NSE, neuron-specific enolase; S-100, S-100 protein.

provides an overview of the diagnosis of cutaneous neural proliferations.

BENIGN NERVE SHEATH TUMORS (NEUROMAS)

AT-A-GLANCE

- Nonneoplastic nerve sheath proliferations occurring in distinct clinicopathologic settings.
- Consist of both axons and Schwann cells at a ratio of approximately 1:1.
- Presents as flesh-colored papules or nodules; occasionally painful.
- Treatment is excision.

TRAUMATIC (AMPUTATION) NEUROMA

EPIDEMIOLOGY

The incidence of traumatic neuromas varies widely in the literature, with a reported range of 10% to 30% for symptomatic traumatic neuromas.[75,76] They can present at any age.

ETIOLOGY AND PATHOGENESIS

Traumatic neuromas are regenerative proliferations that result after sectioning or traumatization of a nerve in any way so that its continuity cannot be reestablished. As a result, a guided growth of axons in a proximal–distal axis through tubes of proliferating Schwann cells is not possible and the disorganized proliferation of the proximal nerve gives rise to a *traumatic neuroma*.[77] They may be painful as a result of abnormal synapse formation and signaling within the tangle of nerve fascicles.

CLINICAL FINDINGS

Traumatic neuromas present as firm, oval, flesh-colored, occasionally painful papules or nodules in the subcutis or deeper soft tissues. They occur at sites of previous trauma, in amputation stumps, and in scars.[78]

HISTOPATHOLOGY

Histologically, traumatic neuromas are composed of a haphazard proliferation of nerve fascicles, including axons with their myelin sheaths, Schwann cells, and fibroblasts embedded in a collagenous stroma. Concentric condensations of fibrous tissue around individual fascicles may be present. Perineurial cells, expressing EMA, surround each fascicle Table 121-4).

DIFFERENTIAL DIAGNOSIS

Differential diagnosis of traumatic neuromas includes granuloma, dermatofibroma, neurofibroma, schwannoma, and hypertrophic scar.

MANAGEMENT

Effective treatment of painful traumatic neuroma remains a challenge. Following nerve injury, an attempt should thus be made to reappose the disconnected

TABLE 121-4
Immunohistochemical Staining of Neural Hyperplasias and Neoplasms

NEURAL PROLIFERATION	S-100 PROTEIN	NEUROFILAMENT	EPITHELIAL MEMBRANE ANTIGEN	OTHER
Traumatic neuroma	+	+	+	Neuron-specific enolase positive
Palisaded encapsulated neuroma	+	+	+ for the capsule	
Schwannoma	+	–	+ for the capsule only	Vimentin positive
Neurofibroma	+	Variable	–	CD34 positive
Plexiform neurofibroma	+	+	–	
Nerve sheath myxoma	+	–	+ in adjacent dense collagen	GFAP positive; CD57 positive; collagen Type IV pericellular positive
Perineurioma	–	–	+	Claudin-1 positive; GLUT1 positive
Malignant peripheral nerve sheath tumor	+	+	Variable	Vimentin variable; cytokeratin negative; neuron-specific enolase positive
Primitive neuroectodermal tumor	+ if differentiated	–	–	Neuron-specific enolase positive; CD99 positive
Granular cell tumor	+	–	–	Neuron-specific enolase positive

–, Negative; +, positive; GFAP, glial fibrillary acidic protein; GLUT1, glucose transporter 1.

nerve ends to enable regeneration in an orderly fashion. Once a neuroma has developed, a nerve block provides temporary pain relief. Surgical excision of the lesion and reposition of the proximal nerve stump into a scar-free area is the conventional therapy.[79]

RUDIMENTARY POLYDACTYLY

EPIDEMIOLOGY

The vast majority of cases presents in newborns or in early childhood. Recognition in adult life is rare.[80]

ETIOLOGY AND PATHOGENESIS

The designation "rudimentary polydactyly" is applied to a nodular tumor that rarely appears on the ulnar surface of the proximal fifth finger and contains a disordered proliferation of nerve fascicles analogous to a classical conventional neuroma. The lesion has been traditionally viewed as a variant of amputation neuroma at the site of a supernumerary sixth digit that has undergone autoamputation in utero. This concept has been challenged and it has been suggested that such proliferations are neural malformations unrelated to a supernumerary digit.[81]

CLINICAL FINDINGS

Raised nodule on the ulnar border of the proximal fifth finger (Fig. 121-18).

Figure 121-18 Rudimentary polydactyly on the left hand. The lesion was excised because of paresthesia. (Image from the collection of Mar Llamas-Velasco, MD, Hospital Universitario de La Princesa, Madrid, Spain. Used with permission.)

HISTOPATHOLOGY

Multiple bundles of nerve fibers embedded in connective tissue in the upper dermis, and in dermal papillae. Numerous Meissner corpuscles are present.

DIFFERENTIAL DIAGNOSIS

The diagnosis is usually suspected by the history of a solitary nodular lesion at the ulnar site of the fifth finger since birth or early childhood.

MANAGEMENT

Primary suture ligation of accessory digits in infancy may lead to the subsequent development of a genuine traumatic neuroma. Primary surgical excision with high transection and retraction of the accessory digital nerve prevents postoperative neuroma formation.[82]

PALISADED ENCAPSULATED NEUROMA

EPIDEMIOLOGY

Palisaded encapsulated neuromas (PENs), also described as "solitary circumscribed neuromas," appear during adulthood, mostly in the third to fifth decade. Males and females are equally affected.[83] PENs account for approximately 25% of all cutaneous nerve sheath tumors.[84]

ETIOLOGY AND PATHOGENESIS

PEN can be conceptualized as a morphologically distinctive hamartomatous overgrowth of Schwann cells and axons of a cutaneous peripheral nerve.[83] It is not associated with trauma, multiple endocrine neoplasia syndrome Type 2B (MEN2B), or neurofibromatosis. The etiology is unknown.

CLINICAL FINDINGS

PENs commonly appear as small, asymptomatic, flesh-colored, firm papules or nodules (Fig. 121-19). They may arise at any location, but approximately 90% of cases are diagnosed in the area of the face, primarily around the nose and lips.[84] Rare cases on the distal extremities have been described.[85]

HISTOPATHOLOGY

PENs usually present as nodular or polypoid, well-circumscribed, dermal-based tumors that are surrounded by a thin perineurial connective tissue capsule (Fig. 121-20A). Multinodular and plexiform growth patterns are described.[86] The solid proliferations are composed of multiple closely packed fascicles of Schwann cells and abundant axons. The variably oriented fascicles are commonly separated

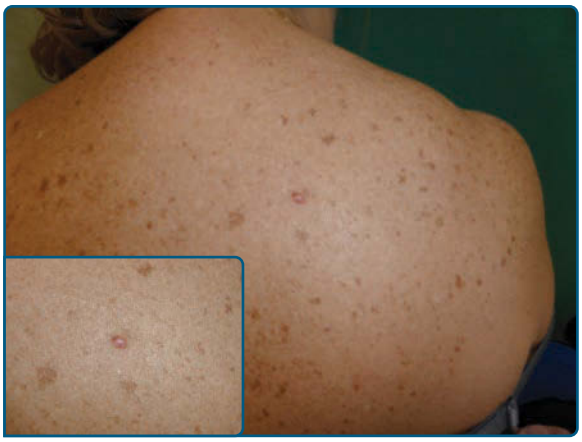

Figure 121-19 Palisaded encapsulated neuroma on the upper back. (Image from the collection of Mar Llamas-Velasco, MD, Hospital Universitario de La Princesa, Madrid, Spain. Used with permission.)

by clefts (Fig. 121-20B). Parallel arrangement of nuclei ("nuclear palisading") may occasionally be found, but distinct Verocay body formation is rare. The perineurial cell-rich capsule stains for EMA (Fig. 121-20C). The spindle-shaped tumor cells stain for S-100 protein (Fig. 121-20D), and numerous axons can be readily identified by staining for neurofilament protein (Fig. 121-20E) (see Table 121-4).[87,88]

DIFFERENTIAL DIAGNOSIS

Differential diagnosis of PEN includes dermal melanocytic nevus, basal cell carcinoma, adnexal tumor, and neurofibroma. Schwannoma and neurofibroma are in the main histopathologic differential diagnosis. PENs typically lack the variety of stromal changes that are frequently encountered in these tumors. Focal hypercellularity and minor degrees of nuclear palisading reminiscent of schwannoma may be found in PENs, but they differ by the absence of Verocay bodies and the presence of axons. Occasionally, the spindle cells in PEN lack a fascicular pattern, as seen in neurofibroma. In contrast to PEN, neurofibroma is not encapsulated in the dermis.

MANAGEMENT

Complete surgical excision of the tumor is curative.

MUCOSAL NEUROMAS AND MULTIPLE ENDOCRINE NEOPLASIA SYNDROME TYPE 2B

EPIDEMIOLOGY

The exact incidence of mucosal neuromas is not clear. Lesions occurring in the setting of MEN2B manifest during the first few decades in life. The prevalence of MEN2B has been derived from epidemiologic studies as 1 in 600,000 patients[89] to 1 in 4,000,000 patients.[90]

ETIOLOGY AND PATHOGENESIS

MEN2B is an autosomal dominant condition caused by gain-of-function germline mutations of the RET protooncogene, which encodes a receptor tyrosine kinase and maps to chromosome 10q11.2. At least 95% of MEN2B cases are the result of a point mutation in exon 16 (M918/T).[90]

CLINICAL FINDINGS

MEN2B is characterized by the early development of medullary thyroid carcinoma in all affected individuals and the occurrence of pheochromocytomas in approximately 50% of individuals. In contrast to MEN2A, clinically significant parathyroid disease is absent, but patients with MEN2B have additional malformations (Marfanoid habitus, facial dysmorphism), as well as mucosal neuromas and diffuse ganglioneuromatosis of the GI tract.

Multiple mucosal neuromas are the most consistent and distinctive clinical manifestation of MEN2B, occurring in 100% of patients.[91] As they may represent the initial manifestation of this life-threatening syndrome, early recognition of these marker lesions is essential for establishing a timely diagnosis. Neuromas appear by the age of 2 years as pink, pedunculated, painless papules on the mucosal surfaces of the eyelids, lips, tongue, and intestines. The lips become diffusely hypertrophied and bulging (or "blubbery") over time, and submucosal nodules may be present on the vermilion border of the lips. Neuromas of the eyelids may cause thickening and eversion of the upper eyelid margins. Other cutaneous signs of MEN2B include café-au-lait spots, facial lentigines, and hyperpigmentation of the hands and feet. Mucocutaneous neuromas also have been reported in association with the spectrum of genetic disorders caused by *PTEN* (phosphatase and tensin homolog) mutations, that is, the PTEN hamartoma–tumor syndrome.[92]

HISTOPATHOLOGY

Histologically, lesions are composed of irregular, tortuous, hyperplastic nerves with a prominent perineurium lying in the submucosal tissue.

DIFFERENTIAL DIAGNOSIS

Differential diagnosis of mucosal neuromas and MEN2B includes mucosal neuromas occurring in PTEN hamartoma–tumor syndrome, mucocele, and PEN.

MANAGEMENT

In MEN2B, management should be aimed at (a) identification of individuals with germline gain-of-function

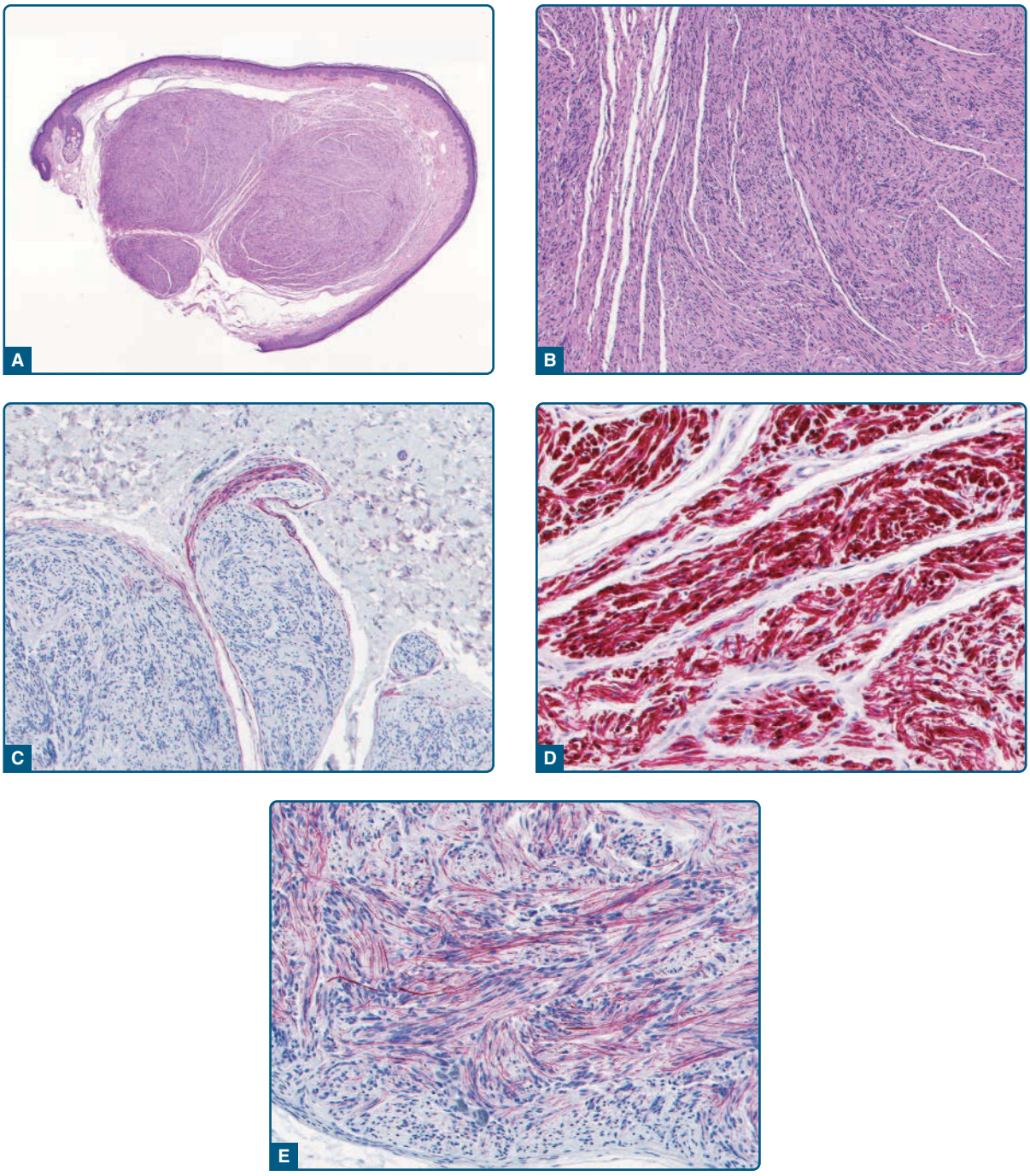

Figure 121-20 Photomicrograph of a palisaded encapsulated neuroma. **A,** Presentation as a dermal-based tumor that is partially surrounded by a thin connective tissue capsule is typical (hematoxylin-and-eosin [H&E], ×20 magnification). **B,** Short fascicles of closely packed Schwann cells that are separated by clefts (H&E, ×100 magnification). The capsule stains for epithelial membrane antigen (EMA) (**C**; anti-EMA, ×100 magnification), the tumor cells stain diffusely positive for S-100 protein (**D**; anti–S-100 protein, ×100 magnification), and numerous intratumoral axons can be identified with staining for neurofilament protein (**E**; anti-neurofilament protein, ×100 magnification).

mutations of the *RET* gene associated with MEN2B and (b) reduction of morbidity and mortality in high-risk individuals via either prophylactic thyroidectomy or screening for medullary thyroid cancer (catecholamine urine testing, serum calcium and parathyroid hormone levels). Patients with clinical evidence of MEN2B as well as all at-risk members of kindreds in which a germline RET pathogenic variant has been identified should undergo genetic analysis of the *RET* gene. Relatives who do not carry the genetic mutation are not at risk for developing the disease. Prophylactic thyroidectomy during the first 6 to 12 months of life is advised for individuals with an identified germline RET pathogenic variant, because

medullary thyroid cancer develops at an early age in affects individuals.[92]

BENIGN NERVE SHEATH NEOPLASMS

AT-A-GLANCE

- Schwannomas are benign encapsulated nerve sheaths neoplasms derived from the proliferation of Schwann cells and lack axons.
- Neurofibromas are benign nonencapsulated nerve sheath tumors composed of all elements of a peripheral nerve. Plexiform neurofibroma is linked to NF-1 and has a potential for malignant transformation.
- Usually presents as isolated lesions, but multiple neurofibromas are found in neurofibromatosis Type 1 and multiple schwannomas found in neurofibromatosis Type 2, in schwannomatosis, or in association with multiple meningiomas.
- Treatment is simple excision of schwannomas and localized neurofibromas is curative. Resection of diffuse and plexiform neurofibromas is performed when tumors are severely disfiguring or severely compromise functionality.

SCHWANNOMA

EPIDEMIOLOGY

Schwannomas occur at all ages but mostly between the ages of 20 and 60 years. Women are slightly more affected than men.[73] According to a population-based study by Antinheimo and associates approximately 90% of schwannomas arise sporadically, 5% in individuals with multiple meningiomas (with or without NF-2), 3% in those with NF-2 (detailed in Chap. 135), and 2% in individuals with multiple schwannomas.[93] In contrast to plexiform neurofibromas, which are considered a clinical hallmark of NF-1, the association of plexiform schwannomas with neurofibromatosis Type 2 and with schwannomatosis is approximately 5% each.[94]

ETIOLOGY AND PATHOGENESIS

Schwannomas are genuine true nerve sheath neoplasms that are derived the proliferation of Schwann cells within nerve sheaths and are thus surrounded by a true capsule consisting of epineurium. Historically, they have been termed *neurinomas*, *neurolem(m)omas*, or *neurilem(m)omas*. Approximately 60% of sporadic and NF-2–associated schwannomas harbor inactivating mutations of the *NF2* gene located at 22q12.2, and in approximately one-third of schwannomas there is chromosomal loss of 22q. All schwannomas, including sporadic and syndromic tumors, lack merlin, the protein product of *NF2*, suggesting the presence of either undetectable mutations or epigenetic modification in the remaining tumors.[95,96] The tumors grow within a capsule and are almost entirely composed of Schwann cells. They remain attached to the parent nerve, which, on pathologic exanimation, may occasionally be detected at the periphery. Sites of predilection include the peripheral nerves at the flexor sites of the upper and lower extremities, followed by the cranial and cervical nerves, particularly the division of the eighth cranial nerve, which gives rise to vestibular schwannomas (formerly known as *acoustic neuromas*).[97] They also occur in spinal roots and on the tongue. Deeply seated schwannomas are mostly found in the retroperitoneum and in the posterior mediastinum.

CLINICAL FINDINGS

Cutaneous schwannomas (Fig. 121-21) present as soft, slowly growing, skin-colored to yellowish dermal or subcutaneous nodules. They are usually solitary and measure 1 to 4 cm in diameter.[78] When attached to a small nerve, the tumors are highly movable in several axes. Small tumors are usually asymptomatic, but pain, tenderness, and neurologic symptoms may occur in larger lesions and as a consequence of forceful displacement of tumors.[97] Plexiform schwannomas, which represent approximately 15% of all cutaneous schwannomas, may be clinically recognizable as intradermal multinodular masses.

Multiple Schwannomas: Schwannomatosis, also known as neurilemmomatosis, is a genetic disorder characterized by multiple cranial, spinal and peripheral schwannomas, without vestibular schwannomas or other signs of NF-1 or NF-2. The reported incidence of this recently recognized entity ranges from 1.40,000 to 1.7 million, with most studies suggesting an incidence analogous to that of NF-2.[93] The genetics

Figure 121-21 Schwannoma on the scalp of a child with neurofibromatosis Type II. (Image from the collection of Marta Feito-Rodríguez, MD, Department of Dermatology, Hospital Universitario La Paz, Spain. Used with permission.)

of schwannomatosis is complex. Schwannomatosis occurs mostly sporadically, likely representing new mutations, but cases of autosomal dominant transmission have been reported. Sporadic cases may occasionally show mosaicism for the *NF2* mutation, reflecting the phenotype overlap between patients with NF-2 and patients with sporadic schwannomatosis. Somatic mutations of the *NF2* gene are frequently detected in schwannomas of schwannomatosis patients, but germline transmission of schwannomatosis occurs by involvement of the tumor-suppressor gene *SMARCB1*, also known as *INI1*.[98] The vast majority of schwannomatosis patients harbor somatic *SMARCB1* and *NF2* mutations in affected tissues. Notably, SMARCB1 has been reported not to play a role in solitary sporadic schwannomas.[99]

HISTOPATHOLOGY

Schwannomas are well-circumscribed, encapsulated, nodular true nerve sheath proliferations, usually limited to the subcutis. The tumor parenchyma is exclusively composed of Schwann cells. Neither axons nor perineurial cells are detectable. The surrounding fibrous capsule consists of epineurium and residual nerve fibers. Schwannomas commonly grow as uninodular eccentric masses, resulting in displacement of the nerve of origin. Apart from plexiform schwannomas, intradermal occurrence is rare and has been mostly reported in the setting of schwannomatosis or NF-2. The constituent tumor cells show a typical Schwann cell appearance with elongated slender nuclei and elongated eosinophilic cytoplasmic processes. The hallmark of schwannomas is the pattern of 2 alternating tissue areas (Fig. 121-22A). In the areas of high cellularity (called *Antoni A*), compact spindle-shaped Schwann cells are arranged in short bundles or interlacing fascicles. The tumor cells have indistinct cytoplasmic borders and their nuclei are frequently twisted. The nuclei of adjacent cells may be tightly aligned, creating stacks of nuclear *palisades*. A *Verocay body* is formed by a horizontal arrangement of 2 rows of elongated palisading nuclei that are separated by acellular zones made up of stacked cytoplasmic processes of the tumor cells (Fig. 121-22B).[100] The areas of low cellularity (called *Antoni B*) consist of widely separated and haphazardly arranged spindle or oval tumor cells in a loosely textured myxoid matrix with delicate collagen fibers and large, irregularly spaced, partially thrombosed blood wells with thickened walls caused by dense fibrosis. Antoni B tissue may represent degenerated Antoni A tissue and typically shows varying changes indicative of degeneration, such as hyalinization, cyst formation, hemorrhage, fibrosis, and, occasionally, calcification. The relative proportions of Antoni A and Antoni B areas vary considerably, and they may blend indiscernibly or change abruptly. Tumors of long duration may develop substantial degenerative changes in association with marked nuclear atypia. The nuclei are large and hyperchromatic, but lack mitotic figures. Numerous inflammatory cells are commonly present. These

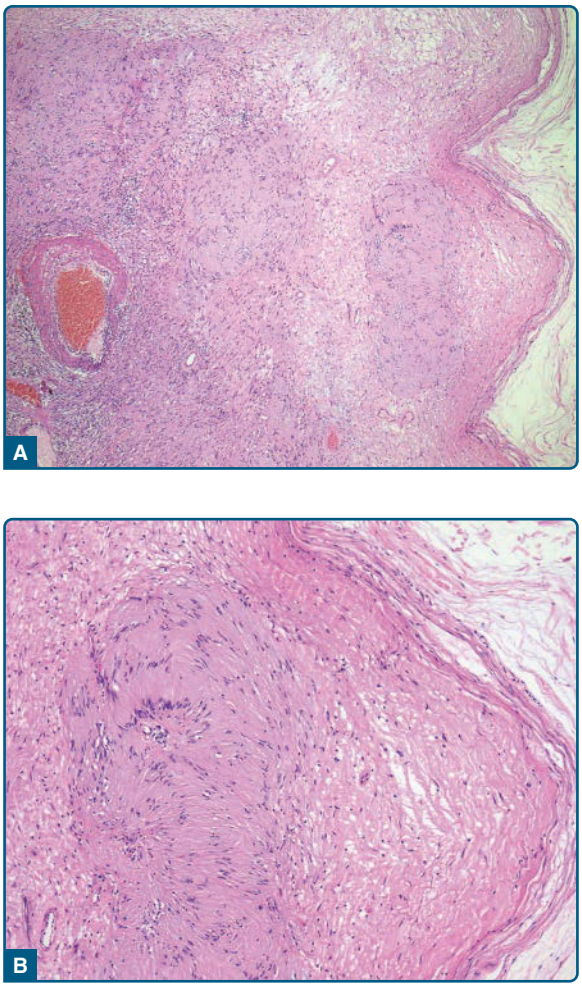

Figure 121-22 Photomicrograph of a schwannoma. **A,** Nodular, well-circumsribed, encapsulated tumor composed of fascicles of plump spindle cells. Characteristic zonation of alternating hypercellular areas (Antoni A) and hypocellular areas (Antoni B), and hyalinized, thick-walled blood vessels are seen. **B,** Foci of nuclear palisades surrounding aggregates of cytoplasmic processes (Verocay bodies) are present.

tumors behave as classic schwannomas and are thus comfortably termed *ancient schwannomas*.[101] *Cellular schwannomas* are defined as tumors composed exclusively or predominantly of Antoni A areas (ie, Antoni B areas not exceeding 10%) that lack Verocay bodies. Low mitotic activity and focal areas of necrosis may be present. *Plexiform schwannomas* are characterized by a plexiform pattern (Fig. 121-23) that is often associated with multinodularity. They have a propensity for the skin and may present in the dermis and or in the subcutis, and infrequently in deep soft tissues. Similar to classic schwannomas, they are encapsulated and often cellular, thus frequently qualifying as cellular schwannomas. Schwannomas composed predominantly or exclusively of small rounded Schwann cells arranged singly, in cohesive nests, or in cords within a collagenous or partially myxoid stroma have been referred to as *epithelioid schwannomas.* In *melanotic (pigmented)*

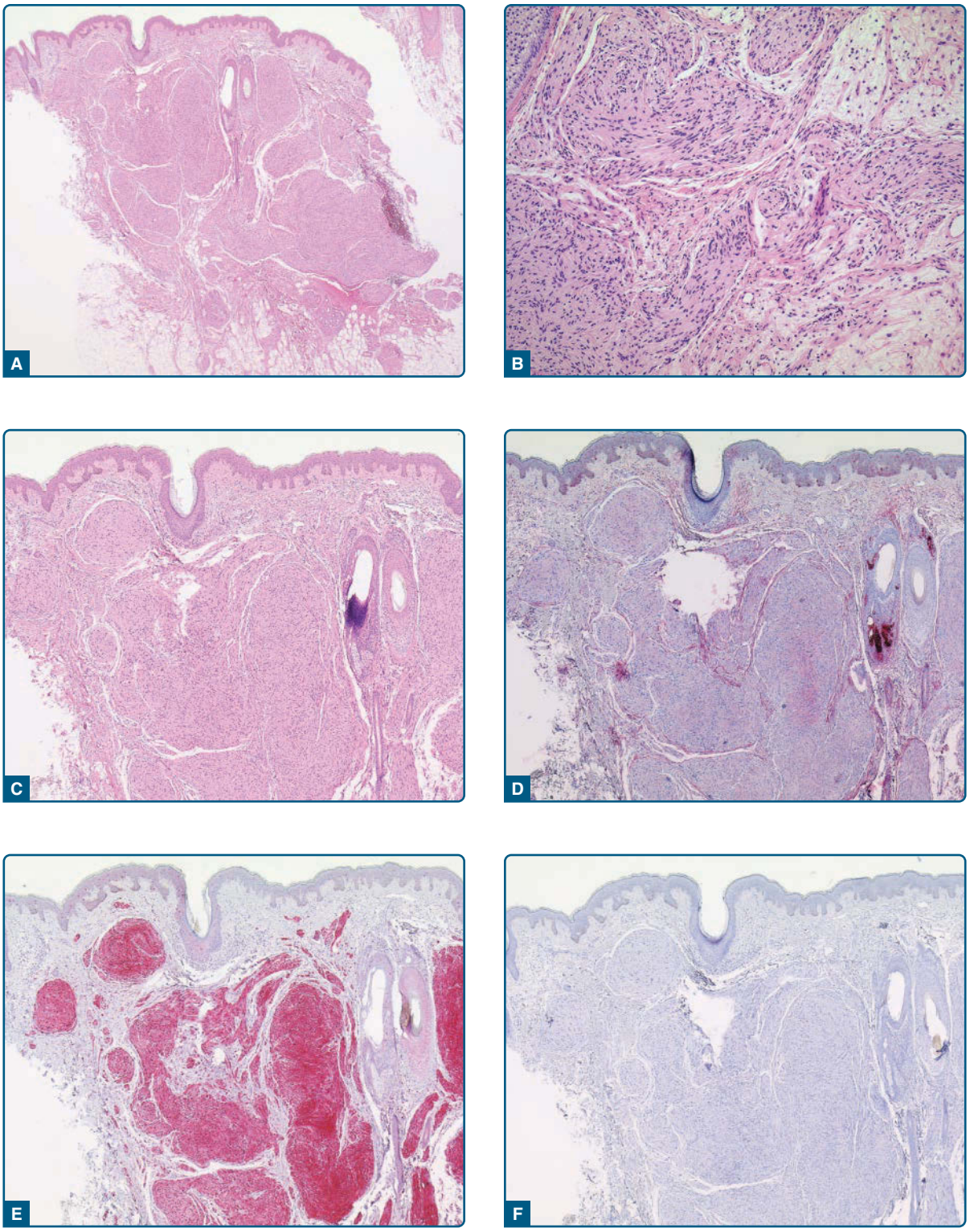

Figure 121-23 Photomicrograph of a plexiform schwannoma in a child with neurofibromatosis-2. **A,** Multinodular, well-circumscribed, encapsulated tumor composed of uniform spindle cells in a plexiform pattern (hematoxylin-and-eosin [H&E], ×4 magnification). **B,** Characteristic cellular Antoni A areas with vague nuclear palisades are present (H&E, ×100 magnification). Tumor masses (**C**; H&E, ×10 magnification) are surrounded by an epithelial membrane antigen (EMA)-positive perineurial capsule (**D**; anti-EMA, ×10 magnification**)**, the tumor cells stain diffusely positive for S-100 protein (**E**; anti–S-100 protein, ×10 magnification). **F,** Neurofilament protein expression is negative because of an absence of axons (anti-neurofilament protein, ×10 magnification). (Image from the collection of Elena Ruíz Bravo-Burguillos, MD, Department of Pathology, Hospital Universitario La Paz, Madrid, Spain. Used with permission.)

schwannomas, Schwann cells contain melanosomes and are immunoreactive with melanocytic markers (eg, HMB-45). The highly cellular tumors are composed of spindled and epithelioid cells and carry a 10% risk of malignant transformation. The psammomatous subvariant (*psammomatous melanotic schwannomas*) is associated with the Carney complex in half of the cases.[102] Additional rare variants include the (pseudo) glandular, neuroblastoma-like, and the microcystic-reticular variant. Schwannomas stain strongly and diffusely positive for S-100 protein (see Table 121-4).

DIFFERENTIAL DIAGNOSIS

Clinical differential diagnosis of schwannomas includes lipoma, cyst, leiomyoma, adnexal tumors, and MPNST. Histologically, schwannomas must be distinguished from PEN (see "Palisaded Encapsulated Neuroma" before) and neurofibromas by their growth pattern and cellular composition. In contrast to PEN, most schwannomas are composed of both hypercellular and hypocellular areas, and are without intervening clefts. Verocay bodies are usually present, but are rare in PEN. Neurofibromas are noncapsulated and differ from schwannomas with respect to cellular composition (see "Neurofibroma" below). Cellular schwannomas may occasionally exhibit Antoni A areas with broad, long, sweeping tumor fascicles arranged in a herringbone pattern and may thus partially mimic leiomyosarcoma, fibrosarcomatous dermatofibrosarcoma protuberans or fibrosarcoma. Plexiform schwannoma must be critically distinguished from plexiform neurofibroma (see section "Epidemiology"), which is pathognomonic for NF-1 and has a propensity for malignant transformation, as well as from plexiform MPNST, plexiform fibrohistiocytic tumor, plexiform granular cell tumor, and traumatic neuroma.

CLINICAL COURSE AND PROGNOSIS

Malignant transformation of classic schwannomas is exceedingly rare but has been observed. The biologic behavior of melanotic schwannomas is difficult to predict and slightly more than 10% of melanotic schwannomas undergo malignant transformation[73]; 50% of the psammomatous variant are associated with the Carney syndrome.[102]

MANAGEMENT

Simple excision is the treatment of choice. Plexiform schwannomas have been associated with an increased risk of local recurrence following incomplete excision.

NEUROFIBROMA

EPIDEMIOLOGY

Localized sporadic neurofibromas are common benign tumors that, like their inherited counterparts, have no gender predilection. Most lesions arise in individuals between the ages of 20 and 30 years. Multiple neurofibromas that arise in a segmental or widespread distribution should raise suspicion for one of several types of NF.[103] Plexiform neurofibromas are pathognomonic of NF-1.

ETIOLOGY AND PATHOGENESIS

Neurofibromas are benign nerve sheath proliferations that are composed of all elements of a peripheral nerve.[73] In contrast to neuromas, the relative ratio of axons to Schwann cells is less than 1:1. Neurofibromas can occur sporadically or in the context of NF-1, which is covered in detail in Chap. 135. NF-1 is inherited as an autosomal dominant trait with a high rate of penetrance. Only half of the patients with this trait have affected family members, with the remainder of affected individuals representing de novo mutations.[104] The *NF-1* gene maps to the long arm of chromosome 17 (17q11.2). More than 1000 pathogenic allelic variants have been identified. The *NF1* gene product is a cytoplasmic protein called *neurofibromin 1*, which is considered to have diverse functions in many different tissues. Although not all functional aspects of neurofibromin 1 are understood, it regulates activation of the Ras intracellular signaling pathway in Schwann cells.[105,106]

CLINICAL FINDINGS

There are 3 main subtypes of neurofibromas based on architectural growth patterns: (a) localized neurofibromas, (b) diffuse neurofibromas, and (c) plexiform neurofibromas. The localized form is by far the most common type, representing 90% of all tumors.[107] The majority are solitary lesions that are not associated with NF-1. Multiple tumors arise in patients with NF-1 (Fig. 121-24). *Localized neurofibromas* present as slowly growing, skin-colored, soft or rubbery, papules or nodules. They may enlarge to protuberant or pedunculated tumors, but rarely exceed 5 cm in diameter. The tumors tend to invaginate on pressure (the *buttonhole sign*). They are usually asymptomatic, but may be pruritic. *Diffuse neurofibromas* mainly affect children and young adults and are most frequently located within the subcutaneous tissues of the head and neck; 90% are solitary lesions and not associated with NF-1. Clinically, the diffuse variant typically causes a plaque-like elevation of the skin with thickening of the entire subcutis. *Plexiform neurofibromas* are characterized by diffuse involvement of a long nerve segment and its branches, forming bag-like or pedunculated rope-like masses that feel similar to a "bag of worms" on palpation. These tumors can be associated with massive soft-tissue overgrowth, resulting in functional impairment. They usually occur in early childhood and are pathognomonic of NF-1. A subset of plexiform neurofibromas presents with hyperpigmentation and hypertrichosis of the overlying skin and has been termed *pigmented neurofibroma* (Fig. 121-25).[108]

Figure 121-24 Clinical photograph showing multiple neurofibromas on the back of a patient with neurofibromatosis Type I ("NF1 microdeletion syndrome"). (Image from the collection of Robert Gruber, MD, Dermatology, Venereology and Allergology, Medical University of Innsbruck, Innsbruck, Austria. Used with permission.)

Figure 121-25 Pigmented neurofibroma, a variant of plexiform neurofibroma with hyperpigmentation and hypertrichosis of the overlying skin, on the upper arm. (Image from the collection of Robert Gruber, MD, Dermatology, Venereology and Allergology, Medical University of Innsbruck, Innsbruck, Austria. Used with permission.)

HISTOPATHOLOGY

Localized solitary neurofibromas are dermal-centered, nonencapsulated, loosely textured proliferations composed of Schwann cells, perineurial cells, mast cells, and plump fibroblasts arranged haphazardly in a variably collagenous and myxoid matrix (Fig. 121-26A). The delicate tumor cell fascicles are usually only a single-layer thick and the cells contain oval or "wavy," spindle-shaped nuclei and a scant, indefinite cytoplasm (Fig. 121-26B). The matrix can be variably mucinous, sclerosing or hyalinized. Occasionally nuclear palisades can occur, but true Verocay formation is exceedingly rare. Nuclear pleomorphism may be present, but mitoses are rare. Diffuse neurofibromas demonstrate a similar cytomorphology but display a diffusely infiltrative growth pattern with involvement of adjacent structures such as the skin appendages and considerable subcutaneous extension along connective tissue septa. The correct diagnosis of plexiform neurofibromas is crucial for

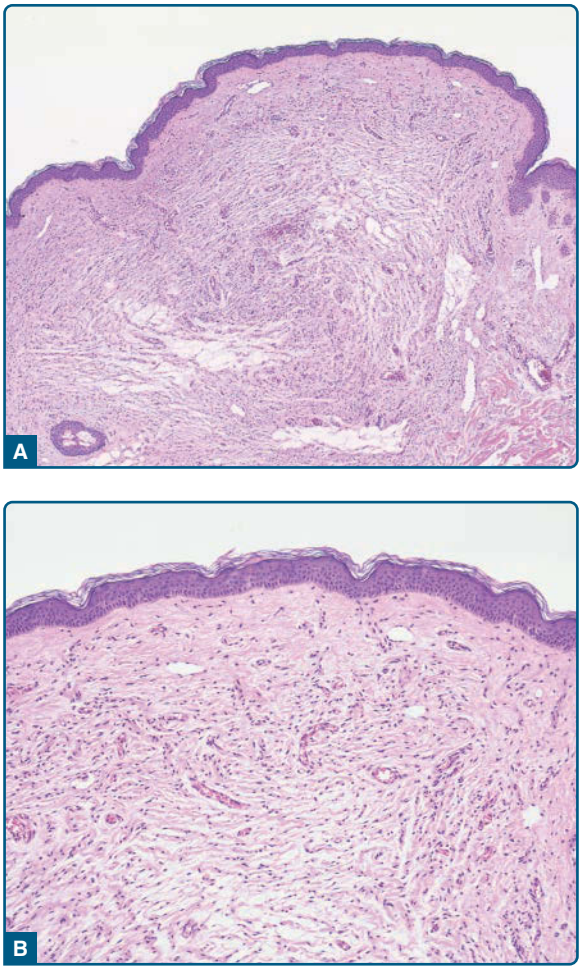

Figure 121-26 Histologic appearance of localized neurofibroma. **A,** Nonencapsulated, loosely textured, dermal proliferation of spindle cells in a variably collagenous and myxoid matrix (hematoxylin-and-eosin [H&E], ×20 magnification). **B,** Delicate tumor cell fascicles composed of short to more elongated spindle cells elongated, "wavy" nuclei and scant indefinite cytoplasm (H&E, ×100 magnification).

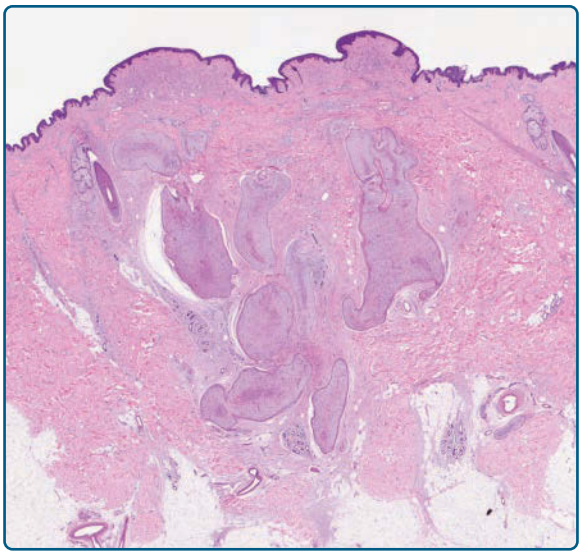

Figure 121-27 Photomicrograph of a plexiform neurofibroma. The tumor consists of multiple tortuous nodules and cords that result from irregular replacement and expansion of peripheral nerve fascicles. In contrast to localized neurofibroma, this neurofibroma variant is more circumscribed (hematoxylin-and-eosin [H&E], ×40 magnification).

establishing the diagnosis of NF-1. The tumors rarely arise in the dermis and consist of a tortuous mass of numerous large nerve fascicles embedded in a matrix composed of collagen, mucin, fibroblasts, and Schwann cells (Fig. 121-27). Initially, the tumor is confined to the epineurium. Upon continued growth, tumor cells spill out into soft tissue. These areas may mimic areas of diffuse neurofibroma, and tumors in NF-1 patients can show both plexiform and diffuse areas. Plexiform neurofibromas may display nuclear atypia. Because this neurofibroma type carries the highest risk of malignant transformation, careful evaluation of areas with high cellularity and severe atypia is crucial. In pigmented plexiform neurofibroma, there is melanocytic hyperplasia at the dermoepidermal junction and a proliferation of single pigmented melanocytes with occasional small nests in the papillary dermis, and scattered within underlying neurofibromatous tissue.[109] A variant characterized by 2 distinct cell types and pseudorosette formation has been described as *dendritic cell neurofibroma with pseudorosettes* (Fig. 121-28).[110]

DIFFERENTIAL DIAGNOSIS

Clinical differential diagnosis of neurofibroma includes dermal melanocytic nevus, soft fibroma, neuroma, lipoma, dermatofibroma, and MPNST. Histopathologic differential diagnosis includes dermatofibroma, neural nevus, neuroma, plexiform schwannoma, MPNST, desmoplastic melanoma, and dermatofibrosarcoma protuberans. Plexiform schwannomas, in contrast to plexiform neurofibromas, are encapsulated tumors that consist exclusively of Schwann cells presenting a plexiform arrangement. The histopathologic delineation

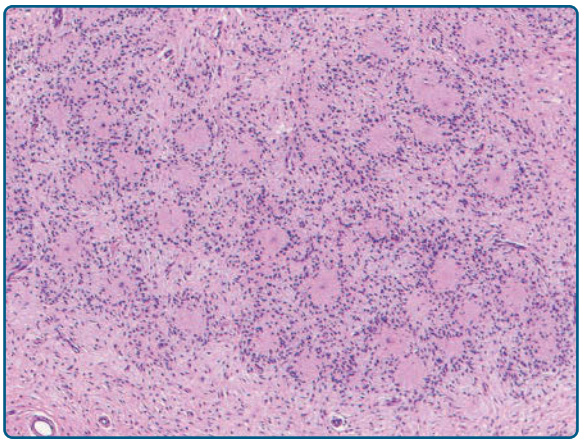

Figure 121-28 Histologic appearance of a dendritic cell neurofibroma with pseudorosettes (hematoxylin-and-eosin [H&E], ×100 magnification). Small, dark, lymphocyte-like cells are grouped concentrically around cells with larger pale-staining nuclei and clear eosinophilic cytoplasm.

of a neurofibroma with atypical histologic features from a low-grade MPNST is challenging because these lesions represent a histologic continuum (see section "Histopathology"). Desmoplastic malignant melanoma may be composed of deceptively bland cells with wavy nuclei, virtually mimicking neurofibroma. Important clues to the diagnosis of melanoma include the presence of significant solar elastosis, atypical junctional melanocytic hyperplasia and/or an in situ component, the presence of very long, hyperchromatic cells, a "packeted" growth pattern, dense fibrosis, and deep nodular lymphoid aggregates. Immunohistochemistry is of limited value in this situation, as both tumors express S-100 protein, and more specific melanocytic differentiation antigens (eg, Melan-A, HMB-45, MITF [microphthalmia-associated transcription factor]) are essentially never positive in desmoplastic melanoma. CD34 immunoreactivity in a "fingerprint" pattern has been reported to be more typical of neurofibroma than desmoplastic melanoma.[111] Pigmented neurofibromas can be distinguished from pigmented forms of dermatofibrosarcoma protuberans (Bednar tumor), formerly known as *storiform pigmented neurofibroma*. The Bednar tumor is characterized by a repetitive storiform pattern and uniform fibroblastic tumor cells that express CD34 and lack expression of S-100 protein.

CLINICAL COURSE AND PROGNOSIS

Plexiform neurofibroma has a potential for malignant transformation, and is a recognized precursor for MPNST in NF-1 patients.[112] The clinical course, prognosis, and management of patients NF-1 are discussed in Chap. 135.

MANAGEMENT

Simple excision of sporadic neurofibromas is curative. Surgical intervention is currently the best treatment

option for plexiform neurofibromas, but complete tumor resection is not always possible. Treatment with arterial embolization and surgical resection has been reported in a patient with a giant plexiform neurofibroma.[113] Treatment of large tumors should be aimed at resection of rapidly enlarging masses, symptomatic and functional improvement, and enhancement of cosmesis in disfiguring disease.[114] Recurrence of plexiform neurofibromas is common.

NERVE SHEATH MYXOMA

EPIDEMIOLOGY

Nerve sheath myxoma is an uncommon benign nerve sheath tumor. It occurs at all ages, but the peak incidence is in the fourth decade. Both sexes are roughly equally affected. Almost 90% of cases arise on the extremity, particularly the fingers and the knee/pretibial region.[115]

ETIOLOGY AND PATHOGENESIS

Nerve sheath myxoma, first described in 1969 by Harkin and Reed, has been a controversial entity for decades. In 1980, Gallagher and Helwig used the term *neurothekeoma* to describe the same tumor.[115] Because some neurothekeomas have a myxoid stroma, both entities were for many years regarded as neural tumors at either end of a histopathologic spectrum. In 2005, Fetsch and associates characterized nerve sheath myxomas as distinct true nerve sheath tumors perhaps related to schwannoma and unrelated to cellular and mixed-type neurothekeomas.[116] This concept was further substantiated by differential gene expression profiling of nerve sheath myxomas and neurothekeomas that confirm a peripheral nerve sheath origin for dermal nerve sheath myxomas and suggest a fibrohistiocytic origin for neurothekeomas.[117]

CLINICAL FINDINGS

The tumors are solitary, superficial, slow growing, and usually painless. The size ranges from 0.5 cm to 2.5 cm in diameter.

HISTOPATHOLOGY

Histologically, the nonencapsulated tumors form distinct multilobulated or multinodular masses with abundant myxoid matrix and a peripheral fibrous border (Fig. 121-29A). They are dermal centered but frequently extend into the superficial subcutaneous tissue.[118] The tumors are composed of small epithelioid Schwann cells arranged in cords, nests or syncytial-like aggregates (Fig. 121-29B). In addition, a variable amount of multipolar Schwann cells with a ring-like appearance, and scattered spindled and stellate-shaped Schwann cells are present. Nuclear hyperchromatism

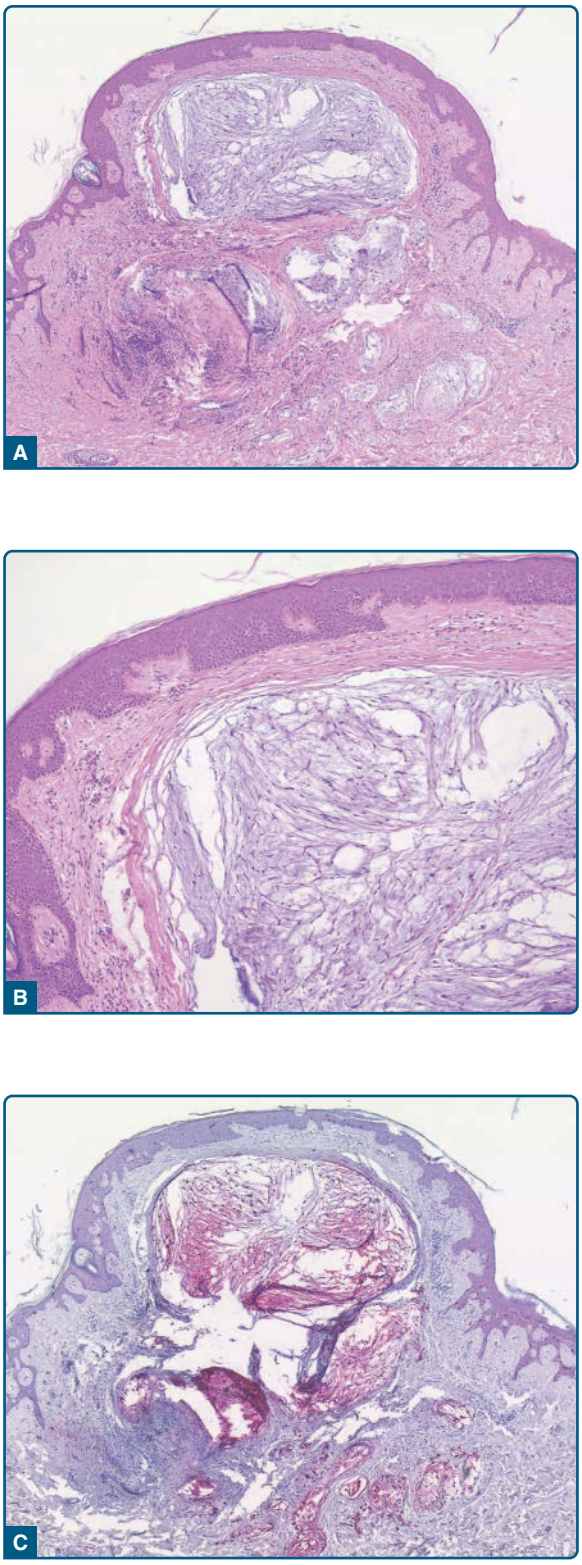

Figure 121-29 Photomicrograph of a nerve sheath myxoma. **A,** Well-circumscribed, nonencapsulated, multinodular, dermal tumor with a myxoid stroma and a peripheral fibrous border (hematoxylin-and-eosin [H&E], ×20 magnification). **B,** Spindled, stellate-shaped, multipolar, and epithelioid Schwann cells arranged in syncytial-like aggregates are seen (H&E, ×100 magnification). **C,** The tumor cells strongly express S-100 protein (anti–S-100 protein, ×100 magnification).

and nuclear atypia are occasionally present. Mitotic figures are rare. The tumor cells strongly express S-100 protein (Fig. 121-29C), glial fibrillary acidic protein, neuron specific enolase, and CD57 (see Table 121-4). They are bordered by collagen IV. EMA-positive perineurial cells are typically present in small numbers, primarily in the fibrous tissue directly adjacent to the myxoid nodules.

DIFFERENTIAL DIAGNOSIS

Clinical differential diagnosis includes myxoid or ganglion cyst, adnexal tumor, dermal melanocytic nevus, and neurothekeoma. Histopathologic differential diagnosis of nerve sheath myxoma includes schwannoma, neuroma, and myxoid neurofibroma, as well as cellular and mixed-type neurothekeoma. *Cellular neurothekeoma*, first described by Rosati and associates in 1986,[119] is a dermal neoplasm of presumed fibrohistiocytic lineage.[120] It commonly occurs on the head, neck, and upper body of young adults, with a slight female predominance. On histology, these tumors are poorly circumscribed, typically being composed of nests and fascicles of epithelioid and spindle-shaped cells. The tumor cells do not express S-100 protein, but are essentially always positive for NK1-C3 antibody. The marker PGP9.5 (protein gene product 9.5) is frequently expressed. Immunoreactivity for CD10, MITF (microphthalmia-associated transcription factor), α-SMA, vimentin, and CD86 has been reported. The *mixed type* of neurothekeomas shows overlapping features of nerve sheath myxoma and cellular neurothekeoma.

CLINICAL COURSE AND PROGNOSIS

Nerve sheath myxomas are benign but recur in almost 50% of cases, often after incomplete excisions.[116]

MANAGEMENT

Nerve sheath myxomas are managed by simple excision.

PERINEURIOMA

EPIDEMIOLOGY

Perineuriomas are uncommon benign tumors that comprise less than 1% of nerve sheath tumors. Epidemiologic data are scarce. Cutaneous and soft-tissue perineuriomas have a male-to-female ratio of 1:2.

ETIOLOGY AND PATHOGENESIS

Perineurial cells are of mesenchymal origin and form a sheath for peripheral nerves. A perineurioma is a benign peripheral nerve sheath tumor composed exclusively of perineurial cells that occurs in the dermis, subcutis, or soft tissue. Neither intraneural nor extraneural perineuriomas appear to be associated with NF-1 or NF-2, but chromosome 22 deletions have been seen.[121,122]

CLINICAL FINDINGS

There are 2 forms of perineurioma: One form is intraneural and presents as a fusiform swelling of a major nerve, often with signs of mononeuropathy.

The other form of perineurioma is extraneural. It usually arises in soft tissue, but cutaneous examples are increasingly being reported. Cutaneous perineuriomas present as firm, flesh-colored, superficial nodules, usually ranging from 0.5 to 1.5 cm in diameter. Larger variants have been reported, usually in soft tissues.[121] Perineuriomas are most commonly reported on the leg or trunk. The sclerosing perineurioma is a distinctive variant that most commonly presents on fingers and palms of young adults.

HISTOPATHOLOGY

Histologically, intraneural perineuriomas are circumscribed nonencapsulated proliferations of delicate spindle cells with elongated, bipolar cytoplasmic processes (Fig. 121-30A). There are small aggregates and bundles with individual cells oriented either parallel to each other or forming small whorls composed of multiple concentric layers ensheathing a central axon and Schwann cell ("onion bulbs") (Fig. 121-30B).[123] The stroma can vary from densely collagenous (principally in the sclerosing variant) to myxoid in character. The "onion bulb"-like structures of concentric circles are an important clue to the diagnosis but are also a characteristic finding in *localized hypertrophic neuropathy*, with which it has no relationship at all.[124,125] The cells in perineurioma clearly differentiate along perineurial lines, as shown by ultrastructure and immunohistochemistry, whereas the "onion bulbs" of hypertrophic neuropathy are composed of Schwann cells. The *sclerosing perineurioma* shows a heavily collagenous background, whereas the *reticular (retiform) perineurioma* is composed of anastomosing cords of fusiform cells that wrap around islands of fibromyxoid stroma. The *epithelioid perineurioma* is composed of epithelioid cells with eosinophilic cytoplasm. Perineuriomas stain positive for EMA (Fig. 121-30C) and negative for S-100 and neurofilament. Most cases also express GLUT1 (Fig. 121-30D) and claudin-1 (Fig. 121-30E) (see Table 121-4).

DIFFERENTIAL DIAGNOSIS

Differential diagnosis of perineurioma includes dermal nevus, dermatofibroma, and infundibular cyst.

TREATMENT

Excision is curative.

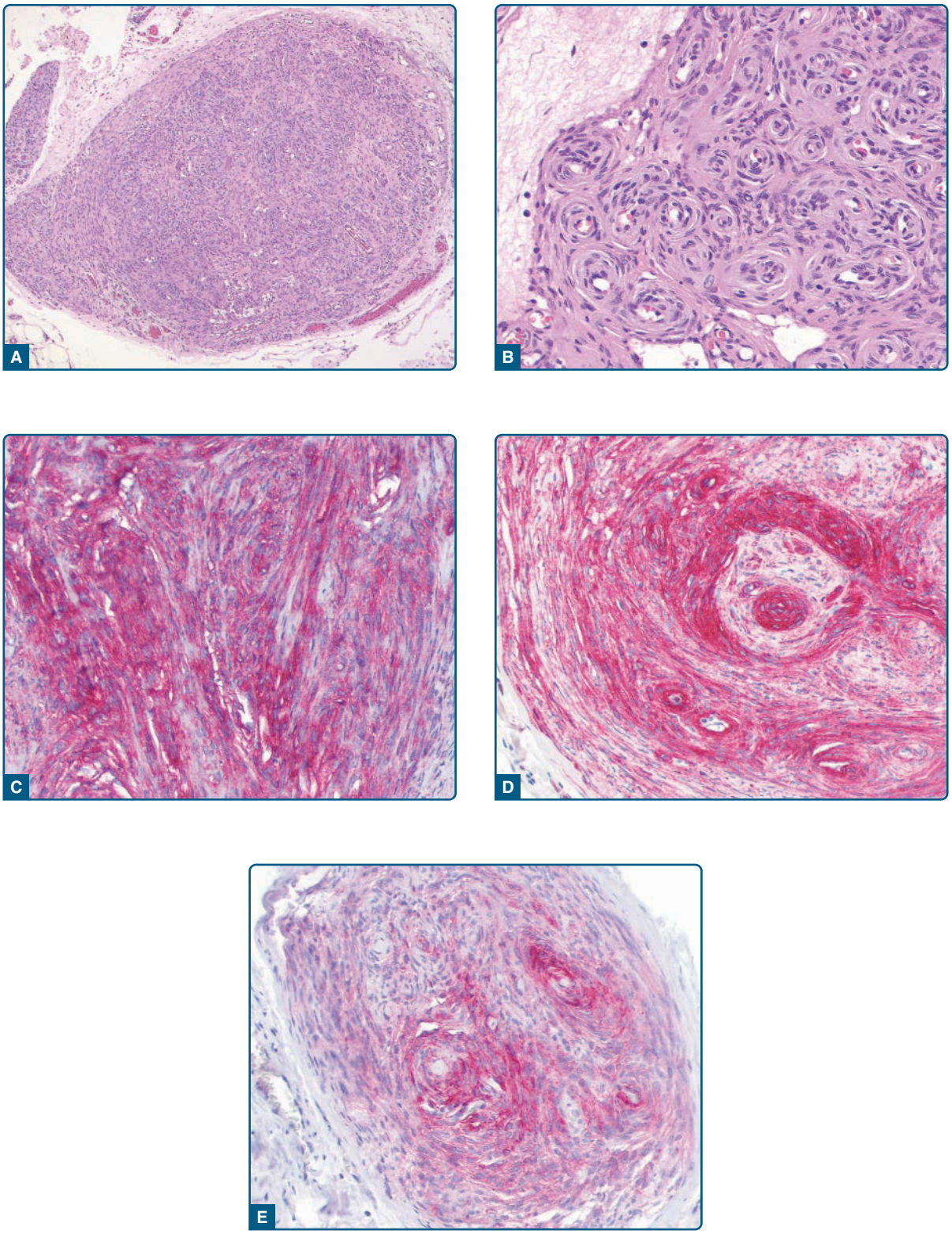

Figure 121-30 Histologic appearance of an intraneural perineurioma. **A,** Well-circumscribed, unencapsulated, dermal centered, nodular tumor composed of bland spindled perineurial cells forming characteristic "onion bulb"-like structures (hematoxylin-and-eosin [H&E], ×20 magnification). **B,** Onion-bulb formations consist of perineurial cells wrapping around individual axons and residual Schwann cells (H&E, ×100 magnification). The tumor cells stain positive for EMA (anti–epithelial membrane antigen, ×100 magnification) **(C)**, GLUT1 (anti–glucose transporter-1, ×100 magnification) **(D)**, and claudin-1 (anti–claudin-1, ×100 magnification) **(E)**.

MALIGNANT TUMORS OF NERVE

MALIGNANT NERVE SHEATH TUMORS

AT-A-GLANCE

- Malignant nerve sheath tumors are also known as neurofibrosarcoma, neurogenic sarcoma, neurosarcoma or malignant schwannoma.
- Two percent of nerve sheath tumors are malignant peripheral nerve sheath tumors (MPNSTs).
- Approximately 50% of MPNSTs occur in neurofibromatosis Type 1.
- Clinical presentation: enlarging masses in the deep soft tissues.
- Treatment is a multimodality approach.
- Outcome is poor, with 5-year survival rates of 10% to 50%.

EPIDEMIOLOGY

MPNSTs account for approximately 2% of all nerve sheath tumors. In most large studies, approximately 50% of MPNSTs occur in the context of NF-1.[126] The estimated lifetime risk of MPNST in patients with NF-1 is 8% to 13%.[127] Individuals with microdeletions of the *NF1* gene have a lifetime risk of 16% to 26%.[128] Young and middle-aged adults are most commonly affected.

ETIOLOGY AND PATHOGENESIS

MPNST is the preferred designation for a tumor arising from or showing differentiation toward the various elements of the nerve sheath. Historically, MPNST also has been called *neurofibrosarcoma*, *neurogenic sarcoma*, *neurosarcoma*, and *malignant schwannoma*. MPNST may arise (a) from a peripheral nerve, (b) from a preexisting benign nerve sheath tumor, or, rarely, (c) de novo. The main benign precursors to MPNST are plexiform neurofibroma and massive soft-tissue neurofibroma in the setting of NF-1. Approximately 10% to 20% of sporadic cases occur as postirradiation tumors after a latent period of 15 years.[126] Malignant transformation of schwannoma into MPNST is rare.[129]

CLINICAL FINDINGS

MPNSTs arise predominantly in deep soft tissues of the proximal extremities and present as enlarging masses (Fig. 121-31). Pain is more prevalent in patients with NF-1, and pain or sudden enlargement of a longstanding tumor in the setting of NF-1 should raise should raise the suspicion of malignant transformation.

Figure 121-31 Malignant peripheral nerve sheath tumor on the lower back. (Image from the collection of Arno Rütten, MD, Dermatopathology Friedrichshafen. Used with permission.)

HISTOPATHOLOGY

MPNST is a cellular tumor composed of tight wavy or interlacing fascicles of spindle cells (Fig. 121-32A). The tumor typically presents typically with

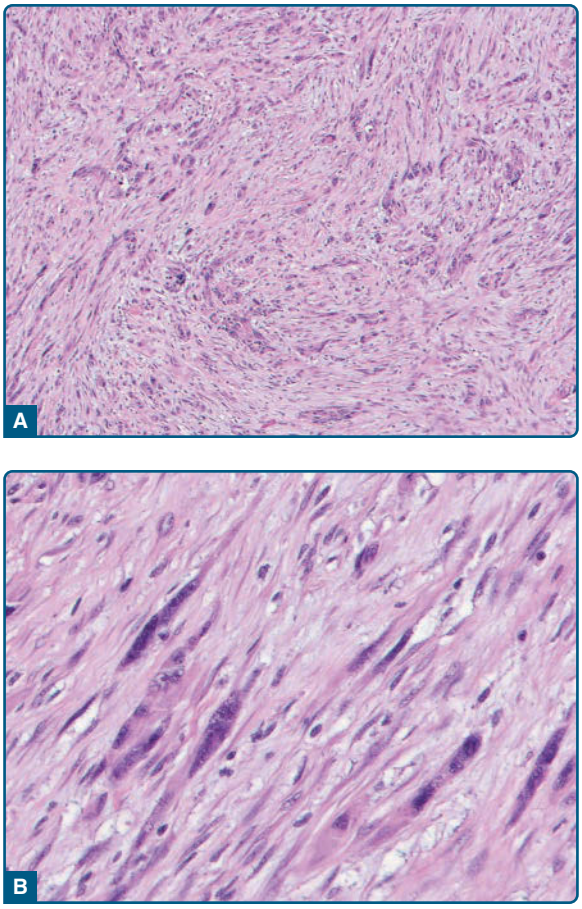

Figure 121-32 Histologic examination of a MPNST. **A,** The tumor is composed of highly cellular fascicles of atypical spindle cells (hematoxylin-and-eosin [H&E], ×20 magnification). **B,** Asymmetrically tapered spindle cells with hyperchromatic buckled nuclei and indistinct cytoplasm are seen (H&E, ×100 magnification).

fibrosarcoma-like appearance: densely cellular areas alternate with less cellular areas, creating a marble-like effect. The constituent cells exhibit a malignant Schwann cell morphology, that is, asymmetrically tapered spindle cells with hyperchromatic, wavy, buckled, or comma-shaped nuclei and a pale cytoplasm (Fig. 121-32B). However, in the majority of cases there is a mixed proliferation of Schwann cells, perineurial cells, fibroblastic cells, and primitive cells. Nuclear palisading is uncommon. A plexiform and an epithelioid variant (malignant epithelioid schwannoma) have been described. Heterologous elements occur in 10% to 15% of cases in the form of cartilage and bone, or, less commonly, skeletal muscle (so called malignant triton tumor), smooth muscle, angiosarcoma, or well-differentiated glands (MPNST with glands). A rare subset of MPNSTs with perineurial differentiation has been termed *perineurial MPNST*. This variant stains positive for EMA and negative for S-100 protein. Immunohistochemistry is of limited value in the diagnosis of MPNST. At most, 50% of tumors show a focal or patchy expression of S-100 protein. The partial or even complete loss of S-100 expression in MPNST is one of the most useful distinctions from benign Schwann cell tumors. CD34 is frequently expressed and glial fibrillary acidic protein is positive in 30% to 40% of cases (see Table 121-4).

DIFFERENTIAL DIAGNOSIS

Clinical differential diagnosis of MPNSTs includes neurofibroma, schwannoma, lipoma, and cyst. Desmoplastic melanoma, cellular schwannoma and a variety of sarcomas, primarily synovial sarcoma, leiomyosarcoma, RMS, adult-type fibrosarcoma, dedifferentiated liposarcoma, and clear-cell sarcoma, are in the main histopathologic differential diagnosis. Moreover, low-grade MPNST may demonstrate very scarce mitotic activity and thus mimic neurofibroma with atypical features (see section "Histopathology"). The minimal criteria for the delineation of a MPNST from a benign nerve sheath tumor are: (a) marked cell crowding, (b) generalized nuclear enlargement (3 times normal neurofibroma cells), (c) nuclear hyperchromasia, and (d) a mitotic rate greater than 5 per 10 HPF. In the setting of NF-1, the presence of any mitotic activity in a neurofibroma warrants the diagnosis of low-grade MPNST. Desmoplastic melanomas present as fibrosing spindle-cell melanomas in chronically sun-damaged skin, typically the head and neck area. In addition to the superficial location, there is often a junctional component of atypical melanocytes and a strong expression of S-100 protein. Complete loss of SOX10, neurofibromin, or p16 expression, or the presence of epidermal growth factor receptor immunoreactivity are helpful in differential diagnosis with cellular schwannoma.[130] Synovial sarcoma is characterized by a t(X;18) balanced translocation and shows strong nuclear staining for TLE1 as well as consistently negative staining for glial fibrillary acidic protein.

CLINICAL COURSE AND PROGNOSIS

MPNSTs are high-grade sarcomas with a high tendency of local recurrence and distant metastasis. Prognosis is poor, with local recurrences developing in approximately 40% of patients and metastases developing in 40% to 60% of patients within 12 months of surgery on average.[126] Overall 5-year survival rates range from approximately 50% in sporadic patients to 10% to 35% in NF-1 patients.

MANAGEMENT

The management of patients with MPNST involves a multimodality approach. Complete surgical resection and adjuvant radiation therapy are required for good local tumor control. The response rates to cytotoxic chemotherapy in metastatic disease are low.

PRIMITIVE NEUROECTODERMAL TUMOR

EPIDEMIOLOGY, ETIOLOGY, AND PATHOGENESIS

Primitive neuroectodermal tumors (PNETs) are a group of highly malignant tumors composed of small round cells of neuroectodermal origin. Peripheral PNET and Ewing sarcoma represent ends of a morphologic spectrum known as the Ewing family of tumors. They both express the cell surface product of the *MIC2* gene, CD99, and both carry a consistent chromosomal translocation (t11;22) (q24;q12). PNETs are primarily a disease of childhood with a median age at diagnosis of 9 years of age. PNETs represent 2.8% of all primary cerebral tumors of childhood and adolescence.

CLINICAL FINDINGS

PNETs can metastasize to the skin.[131] Most peripheral PNETs/Ewing sarcomas are located in deep soft tissue.[132] With neuroblastoma, cutaneous metastases can be very numerous and involve multiple sites. In approximately 50% of patients with such metastases, they were the initial clinical presentation. Extremely rare cases of peripheral PNETs arising as primary cutaneous or subcutaneous tumors also have been reported.

HISTOPATHOLOGY

PNETs consist of small, round, basophilic ("blue") cells. Homer Wright rosettes can be present. If the tumor is differentiated, S-100 protein, neuron-specific enolase, and CD99 are positive.

DIFFERENTIAL DIAGNOSIS

Differential diagnosis of PNET includes neurofibroma, lipoma, and cyst.

MANAGEMENT

Treatment is surgical. A wide margin of excision and a young age correlated with improved survival in a series of patients with extraskeletal Ewing sarcoma.

MISCELLANEOUS TUMORS

GRANULAR CELL TUMOR

AT-A-GLANCE

- Neural tumor composed of large granular-appearing eosinophilic cells.
- Most common single anatomic site is the tongue.
- Malignant transformation is exceedingly rare.
- Treatment is excision.

EPIDEMIOLOGY

Granular cell tumors (GCTs) are relatively rare. The major majority arise in adults with a male-to-female ratio of 1:3. Approximately 10% to 15% have multiple lesions.

ETIOLOGY AND PATHOGENESIS

Although originally considered by Abrikossoff to be a muscle tumor, the expression of S-100 protein, myelin proteins, and myelin-associated glycoprotein has resulted in the reclassification of GCT as a tumor of Schwann cell origin.

CLINICAL FINDINGS

GCTs are small, asymptomatic or occasionally tender or pruritic, skin-colored, firm nodules usually located in the dermis or subcutis. They are slow growing and rarely exceed 3 cm in diameter. GCTs may present in various anatomical sites but have a strong predilection for the tongue and the dermis of the head and neck region, and the breast. GCTs also have been reported in the genitalia, esophagus, and larynx.[133]

HISTOPATHOLOGY

GCTs are ill-defined, dermal-based, nodular proliferations composed of sheets of large polyhedral cells. The cells have distinct cell borders, small, round, central nuclei, and abundant fine to coarsely granular cytoplasm (Fig. 121-33). The cytoplasmic granules stain strongly with the periodic acid-Schiff stain and retain this characteristic after diastase digestion. The overlying epithelium often shows prominent pseudoepitheliomatous hyperplasia, a feature that can lead to a mistaken diagnosis of SCC on superficial biopsies. Dermal tumors often extent into the subcutaneous tissue. Cells infiltrate between collagen bundles and tend to grow along small nerves and muscle fibers. Rarely, a plexiform or dermatofibroma-like growth pattern is present.[134] GCTs usually express S-100 protein, CD68, NGFR-5, MITF, NK1-C3, neuron specific enolase, and PGP9.5 (see Table 121-4). Rare cases of GCT show focal Melan-A positivity.[135] Malignant GCTs are extremely rare, accounting for only 1-2% of all GTCs.[136] *Atypical GCTs* are histologically defined by the presence of 1 or 2 of the following criteria: spindling of the tumor cells, necrosis, diffuse pleomorphism, prominent nucleoli, a high nuclear-to-cytoplasmic ratio, and a mitotic activity of greater than 2 per 10 HPF. Neoplasms that meet 3 or more of these criteria are classified as *malignant GCTs*, and GCTs with focal pleomorphism but none of the other criteria are classified as benign.[137]

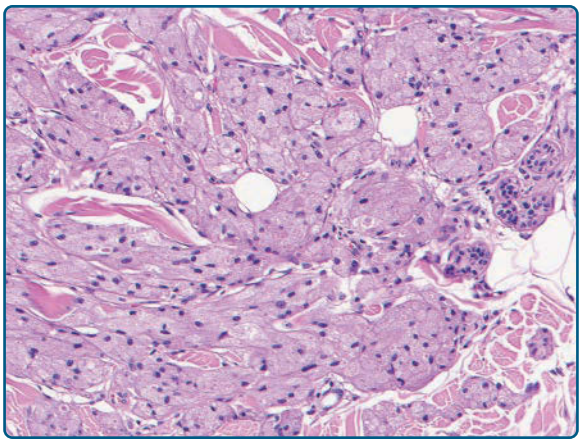

Figure 121-33 Photomicrograph of a granular cell tumor composed of sheets of polygonal cells with abundant granular eosinophilic cytoplasm, small, round, mostly central nuclei, and distinct cell borders. The present case shows a markedly collagenized stroma (hematoxylin-and-eosin [H&E], ×100 magnification).

DIFFERENTIAL DIAGNOSIS

Differential diagnosis of GCTs includes adnexal tumors, melanocytic nevi, dermatofibroma, and SCC of the tongue. On histology, various other tumor entities may present with a granular cell variant, such as dermatofibroma, leiomyosarcoma, melanoma, and angiosarcoma. Congenital granular cell tumor is a rare benign neoplastic growth affecting the gingival mucosa of neonates.

CLINICAL COURSE AND PROGNOSIS

Benign and atypical GCTs have an excellent outcome with no metastasis. Local recurrence and metastasis

are relatively common in malignant GCTs. Poor prognostic factors associated with malignant GCT include large tumor size, older patient age, increased mitotic activity, and Ki-67 greater than 10%.[137]

MANAGEMENT

Local surgical excision is the treatment of choice.

CENTRAL NERVOUS SYSTEM HETEROTOPIA

CNS heterotopias are composed of ectopic neural tissue and are divided into neuroglial heterotopia (nasal glioma) and meningeal heterotopia (MH).

NEUROGLIAL HETEROTOPIA

AT-A-GLANCE

- Rare congenital lesion commonly referred to as *nasal glioma*.
- Developmental anomaly consists of mature displaced neuroglial tissue; not a true neoplasm.
- Most often presents as a round, firm papule on the nose.
- Rarely connected to intracranial cavity.

Epidemiology: Heterotopic neuroglial tissue or nasal gliomas are rare congenital lesions.[138]

Etiology and Pathogenesis: Neuroglial heterotopias represent displaced mature neuroglial tissue that is entrapped in dural diverticula. This occurs during craniofacial development and sometimes does not regress. These lesions are now considered malformations[139] rather than neoplasms, as the designation *nasal glioma* implies.

Clinical Findings: Heterotopic neuroglial tissue occurs as a solitary, firm, papule, often vascular appearing, most commonly in or on the nose but also can be present on the face, scalp, lip, tongue, oropharynx, nasopharynx, or orbit.

Histopathology: There are various admixtures of neurons, astrocytes, oligodendrocytes, ependyma, and choroid plexus. There may be significant fibrosis, which can obscure the neuroglial component[139,140]

Differential Diagnosis: Differential diagnosis of neuroglial heterotopia includes encephalocele, dermoid cyst, hemangioma, intracranial astrocytoma or meningioma with nasal extension, lymphatic malformation, lymphoma/plasmacytoma, and carcinoid tumor.

Clinical Course and Prognosis: Neuroglial heterotopias can be connected to the intracranial cavity, and therefore CT and/or MRI of the head is imperative before biopsy or excision. In one small series, 3 of 10 patients had lesions that extended into the intracranial cavity.[141]

Management: Surgical excision is the treatment of choice.

MENINGEAL HETEROTOPIA

AT-A-GLANCE

- Rare lesion characterized by meningothelial elements in skin.
- Occurs in children secondary to developmental defect; occurs in adults secondary to extension of intracranial meningioma.
- Can be connected to intracranial cavity.

Epidemiology: Heterotopic meningeal tissue is a rare condition that presents most commonly in the neonatal period but also can be seen in adults. Rare familial cases have been reported.[142,143]

Etiology and Pathogenesis: Meningeal heterotopia is characterized by meningothelial elements present in the skin.[142] This condition is also known as *cutaneous meningioma, rudimentary meningocele, acroleic meningocele,* and *meningeal hamartoma.* In adults, these lesions usually represent cutaneous or subcutaneous extension of an aggressive intracranial meningioma and are commonly referred to as cutaneous meningiomas. In children, they are often referred to as rudimentary meningoceles and most likely represent a developmental defect related to abnormal attachment and closure of the neural tube during embryogenesis. There is evidence to suggest that rudimentary meningoceles represent an atretic form of a meningocele.[142] Some lesions may contain a central lumen and be connected to the dura by a fibrous band running through a skull or vertebral defect.

Clinical Findings: Meningeal heterotopia typically presents as a skin-colored nodule on the scalp over the midline or along the spine (Fig. 121-34). In children, they can be associated with the "hair collar" sign, in which a ring of long, dark, coarse hair surrounds a midline scalp nodule (Fig. 121-35). In adults with cutaneous meningiomas, the intracranial component itself surprisingly may cause few neurologic symptoms, and patients may actually present because of an enlarging nodule on their scalp.

Figure 121-34 Meningeal heterotopia in adulthood: Slowly enlarging nodule on the scalp of a 67-year-old woman with an evolution period of 10 years. (Image from the collection of Mar Llamas-Velasco, MD, Hospital Universitario de La Princesa, Madrid, Spain. Used with permission.)

Histopathology: Microscopic examination reveals a mass composed of meningothelial elements in the superficial and deep dermis surrounded by dense collagen bundles.[142] The meningothelial cells contain round nuclei with stippled chromatin and clear cytoplasm.[143] Occasionally, a whorled pattern can be observed. Psammoma bodies, collagen bodies, and calcification are variably present.[142,143]

Differential Diagnosis: Differential diagnosis of meningeal heterotopia includes meningocele, encephalocele, aplasia cutis, and epidermal/pilar cyst.

Clinical Course and Prognosis: These lesions can be connected to the intracranial cavity, and, therefore, radiographic imaging is necessary before any invasive procedure such as biopsy or excision.

Management: The treatment of choice is surgical excision.

Figure 121-35 Meningeal heterotopia in childhood: A hairless patch on the scalp of an infant with the "hair collar" sign, present since birth. (Image from the collection of Antonio Torrelo, MD, Department of Pediatric Dermatology, Hospital del Niño Jesús, Madrid, Spain. Used with permission.)

CUTANEOUS GANGLIONEUROMA AND GANGLION CELL TUMOR

Ganglioneuromas are neoplasms composed of mature ganglion cells, that are usually intermingled with fascicles of spindle cells of Schwann cell origin. Pure ganglion cell tumors do not contain the Schwann cell component. They are usually seen as deep-seated tumors of the autonomic nervous system. Primary cutaneous ganglioneuromas are exceedingly rare. The majority develops after birth. Clinically, they present as nondescript small papules or nodules. Of the half dozen or so reported cases,[144,145] only 1 case was congenital. These lesions have to be distinguished from cutaneous metastases from a neuroblastoma, which can mature into ganglioneuroma. Furthermore, some plexiform neurofibromas in patients with neurofibromatosis arise in autonomic ganglia and can therefore contain residual, entrapped ganglion cells.[146]

MYXOPAPILLARY EPENDYMOMA

Myxopapillary ependymoma is a peculiar variant of ependymoma that typically arises intradurally from the filum terminale of the spinal cord. However, histologically identical lesions also rarely occur as primary extradural tumors of the sacrococcygeal soft tissue, where they present as subcutaneous masses. They are thought to arise from subcutaneous ependymal rests, which are quite common in this region.[147] These tumors generally present in young patients as a sacrococcygeal or, more rarely, a gluteal mass that is asymptomatic in most cases and can reach a size of several centimeters. Histologically, they are composed of papillae covered by ependymal cells. The cores of the papillae contain abundant myxoid ground substance, hence the name. Although intradural myxopapillary ependymomas are usually benign, the subcutaneous type is more aggressive with a significant risk of local recurrence and even metastasis.[147]

REFERENCES

1. Holst VA, Junkins-Hopkins JM, Elenitsas R. Cutaneous smooth muscle neoplasms: clinical features, histologic findings, and treatment options. *J Am Acad Dermatol*. 2002;46:477-490; quiz, 491-494.
2. Burden PA, Gentry RH, Fitzpatrick JE. Piloleiomyoma arising in an organoid nevus: a case report and review of the literature. *J Dermatol Surg Oncol*. 1987;13:1213-1218.
3. Hornick JL, Fletcher CD. Criteria for malignancy in nonvisceral smooth muscle tumors. *Ann Diagn Pathol*. 2003;7:60-66.

4. Miettinen M. Smooth muscle tumors of soft tissue and non-uterine viscera: biology and prognosis. *Mod Pathol.* 2014;27(suppl 1):S17-S29.
5. Iwata J, Fletcher CD. Immunohistochemical detection of cytokeratin and epithelial membrane antigen in leiomyosarcoma: a systematic study of 100 cases. *Pathol Int.* 2000;50:7-14.
6. Swanson PE, Stanley MW, Scheithauer BW, et al. Primary cutaneous leiomyosarcoma. A histological and immunohistochemical study of 9 cases, with ultrastructural correlation. *J Cutan Pathol.* 1988;15:129-141.
7. Orellana-Diaz O, Hernandez-Perez E. Leiomyoma cutis and leiomyosarcoma: a 10-year study and a short review. *J Dermatol Surg Oncol.* 1983;9:283-287.
8. Yokoyama R, Hashimoto H, Daimaru Y, et al. Superficial leiomyomas. A clinicopathologic study of 34 cases. *Acta Pathol Jpn.* 1987;37:1415-1422.
9. Henderson CA, Ruban E, Porter DI. Multiple leiomyomata presenting in a child. *Pediatr Dermatol.* 1997;14:287-289.
10. Thyresson HN, Su WP. Familial cutaneous leiomyomatosis. *J Am Acad Dermatol.* 1981;4:430-434.
11. Tomlinson IP, Alam NA, Rowan AJ, et al. Germline mutations in FH predispose to dominantly inherited uterine fibroids, skin leiomyomata and papillary renal cell cancer. *Nat Genet.* 2002;30:406-410.
12. Martinez-Mir A, Gordon D, Horev L, et al. Multiple cutaneous and uterine leiomyomas: refinement of the genetic locus for multiple cutaneous and uterine leiomyomas on chromosome 1q42.3-43. *J Invest Dermatol.* 2002;118:876-880.
13. Chuang GS, Martinez-Mir A, Engler DE, et al. Multiple cutaneous and uterine leiomyomata resulting from missense mutations in the fumarate hydratase gene. *Clin Exp Dermatol.* 2006;31:118-121.
14. Varol A, Stapleton K, Roscioli T. The syndrome of hereditary leiomyomatosis and renal cell cancer (HLRCC): the clinical features of an individual with a fumarate hydratase gene mutation. *Australas J Dermatol.* 2006;47:274-276.
15. Reed WB, Walker R, Horowitz R. Cutaneous leiomyomata with uterine leiomyomata. *Acta Derm Venereol.* 1973;53:409-416.
16. Launonen V, Vierimaa O, Kiuru M, et al. Inherited susceptibility to uterine leiomyomas and renal cell cancer. *Proc Natl Acad Sci U S A.* 2001;98:3387-3392.
17. Toro JR, Nickerson ML, Wei MH, et al. Mutations in the fumarate hydratase gene cause hereditary leiomyomatosis and renal cell cancer in families in North America. *Am J Hum Genet.* 2003;73:95-106.
18. Alam NA, Barclay E, Rowan AJ, et al. Clinical features of multiple cutaneous and uterine leiomyomatosis: an underdiagnosed tumor syndrome. *Arch Dermatol.* 2005;141:199-206.
19. Stout AP. Solitary cutaneous and subcutaneous leiomyoma. *Am J Cancer*. 1937:435-469.
20. Agarwalla A, Thakur A, Jacob M, et al. Zosteriform and disseminated lesions in cutaneous leiomyoma. *Acta Derm Venereol.* 2000;80:446.
21. Fisher WC, Helwig EB. Leiomyomas of the skin. *Arch Dermatol.* 1963;88:510.
22. Konig A, Happle R. Type 2 segmental cutaneous leiomyomatosis. *Acta Derm Venereol.* 2001;81:383.
23. Newman PL, Fletcher CD. Smooth muscle tumours of the external genitalia: clinicopathological analysis of a series. *Histopathology.* 1991;18:523-529.
24. Gutmann J, Cifuentes C, Balzarini MA, et al. Angiomyoma of the oral cavity. *Oral Surg Oral Med Oral Pathol.* 1974;38:269-273.
25. Llamas-Velasco M, Requena L, Kutzner H, et al. Fumarate hydratase immunohistochemical staining may help to identify patients with multiple cutaneous and uterine leiomyomatosis (MCUL) and hereditary leiomyomatosis and renal cell cancer (HLRCC) syndrome. *J Cutan Pathol.* 2014;41:859-865.
26. Harrison WJ, Andrici J, Maclean F, et al. Fumarate hydratase-deficient uterine leiomyomas occur in both the syndromic and sporadic settings. *Am J Surg Pathol.* 2016;40:599-607.
27. Tavassoli FA, Norris HJ. Smooth muscle tumors of the vulva. *Obstet Gynecol.* 1979;53:213-217.
28. Menko FH, Maher ER, Schmidt LS, et al. Hereditary leiomyomatosis and renal cell cancer (HLRCC): renal cancer risk, surveillance and treatment. *Fam Cancer.* 2014;13:637-644.
29. Christenson LJ, Smith K, Arpey CJ. Treatment of multiple cutaneous leiomyomas with CO2 laser ablation. *Dermatol Surg.* 2000;26:319-322.
30. Fernandez-Pugnaire MA, Delgado-Florencio V. Familial multiple cutaneous leiomyomas. *Dermatology.* 1995; 191:295-298.
31. Tiffee JC, Budnick SD. Multiple cutaneous leiomyomas. Report of a case. *Oral Surg Oral Med Oral Pathol.* 1993;76:716-717.
32. Batchelor RJ, Lyon CC, Highet AS. Successful treatment of pain in two patients with cutaneous leiomyomata with the oral alpha-1 adrenoceptor antagonist, doxazosin. *Br J Dermatol.* 2004;150:775-776.
33. Alam M, Rabinowitz AD, Engler DE. Gabapentin treatment of multiple piloleiomyoma-related pain. *J Am Acad Dermatol.* 2002;46(2)(suppl case reports):S27-S29.
34. Onder M, Adisen E. A new indication of botulinum toxin: leiomyoma-related pain. *J Am Acad Dermatol.* 2009;60:325-328.
35. Kraft S, Fletcher CD. Atypical intradermal smooth muscle neoplasms: clinicopathologic analysis of 84 cases and a reappraisal of cutaneous "leiomyosarcoma." *Am J Surg Pathol.* 2011;35:599-607.
36. Massi D, Franchi A, Alos L, et al. Primary cutaneous leiomyosarcoma: clinicopathological analysis of 36 cases. *Histopathology.* 2010;56:251-262.
37. Laskin WB, Silverman TA, Enzinger FM. Postradiation soft tissue sarcomas. An analysis of 53 cases. *Cancer.* 1988;62:2330-2340.
38. Francis JH, Kleinerman RA, Seddon JM, Abramson DH. Increased risk of secondary uterine leiomyosarcoma in hereditary retinoblastoma. *Gynecol Oncol.* 2012;124:254-259.
39. Panelos J, Beltrami G, Scoccianti G, et al. Prognostic significance of the alterations of the G1-S checkpoint in localized leiomyosarcoma of the peripheral soft tissue. *Ann Surg Oncol.* 2011;18:566-571.
40. Kaddu S, Beham A, Cerroni L, et al. Cutaneous leiomyosarcoma. *Am J Surg Pathol.* 1997;21:979-987.
41. Diaz-Cascajo C, Borghi S, Weyers W. Desmoplastic leiomyosarcoma of the skin. *Am J Dermatopathol.* 2000;22:251-255.
42. Watanabe K, Kusakabe T, Hoshi N, et al. h-Caldesmon in leiomyosarcoma and tumors with smooth muscle cell-like differentiation: its specific expression in the smooth muscle cell tumor. *Hum Pathol.* 1999; 30:392-396.

43. Miettinen M. Immunoreactivity for cytokeratin and epithelial membrane antigen in leiomyosarcoma. *Arch Pathol Lab Med.* 1988;112:637-640.
44. Matsuyama A, Hisaoka M, Hashimoto H. Vascular leiomyosarcoma: clinicopathology and immunohistochemistry with special reference to a unique smooth muscle phenotype. *Pathol Int.* 2010;60: 212-216.
45. Fields JP, Helwig EB. Leiomyosarcoma of the skin and subcutaneous tissue. *Cancer.* 1981;47:156-169.
46. Jensen ML, Jensen OM, Michalski W, et al. Intradermal and subcutaneous leiomyosarcoma: a clinicopathological and immunohistochemical study of 41 cases. *J Cutan Pathol.* 1996;23:458-463.
47. Dahl I, Angervall L. Cutaneous and subcutaneous leiomyosarcoma. A clinicopathologic study of 47 patients. *Pathol Eur.* 1974;9:307-315.
48. Auroy S, Contesso G, Spatz A, et al. Primary cutaneous leiomyosarcoma: 32 cases [in French]. *Ann Dermatol Venereol.* 1999;126:235-242.
49. Stokes JH. Nevus pilaris with hyperplasia of nonstriated muscle. *Arch Dermatol Syph.* 1923;7:479.
50. Zvulunov A, Rotem A, Merlob P, et al. Congenital smooth muscle hamartoma. Prevalence, clinical findings, and follow-up in 15 patients. *Am J Dis Child.* 1990;144:782-784.
51. Gerdsen R, Lagarde C, Steen A, et al. Congenital smooth muscle hamartoma of the skin: clinical classification. *Acta Derm Venereol.* 1999;79:408-409.
52. Jang HS, Kim MB, Oh CK, et al. Linear congenital smooth muscle hamartoma with follicular spotted appearance. *Br J Dermatol.* 2000;142:138-142.
53. de la Espriella J, Grossin M, Marinho E, et al. Smooth muscle hamartoma: anatomoclinical characteristics and nosological limits [in French]. *Ann Dermatol Venereol.* 1993;120:879-883.
54. Schnur RE, Herzberg AJ, Spinner N, et al. Variability in the Michelin tire syndrome. A child with multiple anomalies, smooth muscle hamartoma, and familial paracentric inversion of chromosome 7q. *J Am Acad Dermatol.* 1993;28:364-370.
55. Kawada H, Kawada J, Iwahara K, et al. Multiple cutaneous rhabdomyomas in a child. *Eur J Dermatol.* 2004;14:418-420.
56. Harding CO, Pagon RA. Incidence of tuberous sclerosis in patients with cardiac rhabdomyoma. *Am J Med Genet.* 1990;37:443-446.
57. Nir A, Tajik AJ, Freeman WK, et al. Tuberous sclerosis and cardiac rhabdomyoma. *Am J Cardiol.* 1995; 76:419-421.
58. Yang S, Zhao C, Zhang Y, et al. Mediastinal fetal rhabdomyoma in nevoid basal cell carcinoma syndrome: a case report and review of the literature. *Virchows Arch.* 2011;459:235-238.
59. Kapadia SB, Meis JM, Frisman DM, et al. Adult rhabdomyoma of the head and neck: a clinicopathologic and immunophenotypic study. *Hum Pathol.* 1993;24:608-617.
60. Kapadia SB, Meis JM, Frisman DM, et al. Fetal rhabdomyoma of the head and neck: a clinicopathologic and immunophenotypic study of 24 cases. *Hum Pathol.* 1993;24:754-765.
61. Dasgupta R, Rodeberg DA. Update on rhabdomyosarcoma. *Semin Pediatr Surg.* 2012;21:68-78.
62. Hawkins WG, Hoos A, Antonescu CR, et al. Clinicopathologic analysis of patients with adult rhabdomyosarcoma. *Cancer.* 2001;91:794-803.
63. Ruymann FB, Maddux HR, Ragab A, et al. Congenital anomalies associated with rhabdomyosarcoma: an autopsy study of 115 cases. A report from the Intergroup Rhabdomyosarcoma Study Committee (representing the Children's Cancer Study Group, the Pediatric Oncology Group, the United Kingdom Children's Cancer Study Group, and the Pediatric Intergroup Statistical Center). *Med Pediatr Oncol.* 1988;16:33-39.
64. Anderson J, Gordon A, McManus A, et al. Disruption of imprinted genes at chromosome region 11p15.5 in paediatric rhabdomyosarcoma. *Neoplasia.* 1999;1:340-348.
65. Mercado GE, Barr FG. Fusions involving PAX and FOX genes in the molecular pathogenesis of alveolar rhabdomyosarcoma: recent advances. *Curr Mol Med.* 2007;7:47-61.
66. Parham DM, Qualman SJ, Teot L, et al. Correlation between histology and PAX/FKHR fusion status in alveolar rhabdomyosarcoma: a report from the Children's Oncology Group. *Am J Surg Pathol.* 2007;31:895-901.
67. Wang NP, Marx J, McNutt MA, et al. Expression of myogenic regulatory proteins (myogenin and MyoD1) in small blue round cell tumors of childhood. *Am J Pathol.* 1995;147:1799-1810.
68. Folpe AL, Hill CE, Parham DM, et al. Immunohistochemical detection of FLI-1 protein expression: a study of 132 round cell tumors with emphasis on CD99-positive mimics of Ewing's sarcoma/primitive neuroectodermal tumor. *Am J Surg Pathol.* 2000;24:1657-1662.
69. Newton WA Jr, Gehan EA, Webber BL, et al. Classification of rhabdomyosarcomas and related sarcomas. Pathologic aspects and proposal for a new classification—an Intergroup Rhabdomyosarcoma Study. *Cancer.* 1995;76:1073-1085.
70. Hendrick SJ, Sanchez RL, Blackwell SJ, et al. Striated muscle hamartoma: description of two cases. *Pediatr Dermatol.* 1986;3:153-157.
71. Mills AE. Rhabdomyomatous mesenchymal hamartoma of skin. *Am J Dermatopathol.* 1989;11:58-63.
72. Maher CO, Spinner RJ, Giannini C, et al. Neuromuscular choristoma of the sciatic nerve. Case report. *J Neurosurg.* 2002;96:1123-1126.
73. Antonescu C, Scheithauer BW, Woodruff JM. *Tumors of the Peripheral Nervous System Atlas of Tumor Pathology, 4th series, Fascicle 19.* Washington, DC: Armed Forces Institute of Pathology, 2013:1-553.
74. Pina-Oviedo S, Ortiz-Hidalgo C. The normal and neoplastic perineurium: a review. *Adv Anat Pathol.* 2008;15:147-164.
75. Schley MT, Wilms P, Toepfner S, et al. Painful and nonpainful phantom and stump sensations in acute traumatic amputees. *J Trauma.* 2008;65:858-864.
76. van der Avoort DJ, Hovius SE, Selles RW, et al. The incidence of symptomatic neuroma in amputation and neurorrhaphy patients. *J Plast Reconstr Aesthet Surg.* 2013;66:1330-1334.
77. Mathews GJ, Osterholm JL. Painful traumatic neuromas. *Surg Clin North Am.* 1972;52:1313-1324.
78. Reed ML, Jacoby RA. Cutaneous neuroanatomy and neuropathology. Normal nerves, neural-crest derivatives, and benign neural neoplasms in the skin. *Am J Dermatopathol.* 1983;5:335-362.
79. Vernadakis AJ, Koch H, Mackinnon SE. Management of neuromas. *Clin Plast Surg.* 2003;30:247-268, vii.

80. Upjohn E, Barlow R, Robson A. Rudimentary polydactyly in an adult: an unusual presentation to a dermatological surgery unit. *Australas J Dermatol.* 2006;47:206-208.
81. Brehmer-Andersson EE. Penile neuromas with multiple Meissner's corpuscles. *Histopathology.* 1999; 34:555-556.
82. Leber GE, Gosain AK. Surgical excision of pedunculated supernumerary digits prevents traumatic amputation neuromas. *Pediatr Dermatol.* 2003;20:108-112.
83. Reed RJ, Fine RM, Meltzer HD. Palisaded, encapsulated neuromas of the skin. *Arch Dermatol.* 1972; 106:865-870.
84. Dakin MC, Leppard B, Theaker JM. The palisaded, encapsulated neuroma (solitary circumscribed neuroma). *Histopathology.* 1992;20:405-410.
85. Jokinen CH, Ragsdale BD, Argenyi ZB. Expanding the clinicopathologic spectrum of palisaded encapsulated neuroma. *J Cutan Pathol.* 2010;37:43-48.
86. Argenyi ZB, Cooper PH, Santa Cruz D. Plexiform and other unusual variants of palisaded encapsulated neuroma. *J Cutan Pathol.* 1993;20:34-39.
87. Albrecht S, Kahn HJ, From L. Palisaded encapsulated neuroma: an immunohistochemical study. *Mod Pathol.* 1989;2:403-406.
88. Fletcher CD. Solitary circumscribed neuroma of the skin (so-called palisaded, encapsulated neuroma). A clinicopathologic and immunohistochemical study. *Am J Surg Pathol.* 1989;13:574-580.
89. Marx SJ. Multiple endocrine neoplasia. In Melmed S, Polonsky KS, Larson PR, Kronenberg HM, eds. *Williams Textbook of Endocrinology*. 12th ed. Philadelphia, PA: Elsevier Saunders; 2011:1728-1767.
90. Moline J, Eng C. Multiple endocrine neoplasia type 2: an overview. *Genet Med.* 2011;13:755-764.
91. Pujol RM, Matias-Guiu X, Miralles J, et al. Multiple idiopathic mucosal neuromas: a minor form of multiple endocrine neoplasia type 2B or a new entity? *J Am Acad Dermatol.* 1997;37:349-352.
92. Schaffer JV, Kamino H, Witkiewicz A, et al. Mucocutaneous neuromas: an underrecognized manifestation of PTEN hamartoma-tumor syndrome. *Arch Dermatol.* 2006;142:625-632.
93. Antinheimo J, Sankila R, Carpen O, et al. Population-based analysis of sporadic and type 2 neurofibromatosis-associated meningiomas and schwannomas. *Neurology.* 2000;54:71-76.
94. Berg JC, Scheithauer BW, Spinner RJ, et al. Plexiform schwannoma: a clinicopathologic overview with emphasis on the head and neck region. *Hum Pathol.* 2008;39:633-640.
95. Roche PH, Bouvier C, Chinot O, et al. Genesis and biology of vestibular schwannomas. *Prog Neurol Surg.* 2008;21:24-31.
96. Stemmer-Rachamimov AO, Xu L, Gonzalez-Agosti C, et al. Universal absence of merlin, but not other ERM family members, in schwannomas. *Am J Pathol.* 1997;151:1649-1654.
97. Whitaker WG, Droulias C. Benign encapsulated neurilemoma: a report of 76 cases. *Am Surg.* 1976; 42:675-678.
98. Hulsebos TJ, Plomp AS, Wolterman RA, et al. Germline mutation of INI1/SMARCB1 in familial schwannomatosis. *Am J Hum Genet.* 2007;80:805-810.
99. Patil S, Perry A, Maccollin M, et al. Immunohistochemical analysis supports a role for INI1/SMARCB1 in hereditary forms of schwannomas, but not in solitary, sporadic schwannomas. *Brain Pathol.* 2008; 18:517-519.
100. Joshi R. Learning from eponyms: Jose Verocay and Verocay bodies, Antoni A and B areas, Nils Antoni and schwannomas. *Indian Dermatol Online J.* 2012; 3:215-219.
101. Argenyi ZB, Balogh K, Abraham AA. Degenerative ("ancient") changes in benign cutaneous schwannoma. A light microscopic, histochemical and immunohistochemical study. *J Cutan Pathol.* 1993;20:148-153.
102. Carney JA. Psammomatous melanotic schwannoma. A distinctive, heritable tumor with special associations, including cardiac myxoma and the Cushing syndrome. *Am J Surg Pathol.* 1990;14:206-222.
103. Huson SM, Compston DA, Clark P, et al. A genetic study of von Recklinghausen neurofibromatosis in south east Wales. I. Prevalence, fitness, mutation rate, and effect of parental transmission on severity. *J Med Genet.* 1989;26:704-711.
104. Friedman JM. Epidemiology of neurofibromatosis type 1. *Am J Med Genet.* 1999;89:1-6.
105. Xu GF, Lin B, Tanaka K, et al. The catalytic domain of the neurofibromatosis type 1 gene product stimulates ras GTPase and complements ira mutants of *S. cerevisiae*. *Cell.* 1990;63:835-841.
106. Marchuk DA, Saulino AM, Tavakkol R, et al. cDNA cloning of the type 1 neurofibromatosis gene: complete sequence of the NF1 gene product. *Genomics.* 1991;11:931-940.
107. Murphey MD, Smith WS, Smith SE, et al. From the archives of the AFIP. Imaging of musculoskeletal neurogenic tumors: radiologic-pathologic correlation. *Radiographics.* 1999;19:1253-1280.
108. Williamson DM, Suggit RI. Pigmented neurofibroma. *Br J Dermatol.* 1977;97:685-688.
109. Schaffer JV, Chang MW, Kovich OI, et al. Pigmented plexiform neurofibroma: distinction from a large congenital melanocytic nevus. *J Am Acad Dermatol.* 2007;56:862-868.
110. Michal M, Fanburg-Smith JC, Mentzel T, et al. Dendritic cell neurofibroma with pseudorosettes: a report of 18 cases of a distinct and hitherto unrecognized neurofibroma variant. *Am J Surg Pathol.* 2001;25:587-594.
111. Yeh I, McCalmont TH. Distinguishing neurofibroma from desmoplastic melanoma: the value of the CD34 fingerprint. *J Cutan Pathol.* 2011;38:625-630.
112. McCarron KF, Goldblum JR. Plexiform neurofibroma with and without associated malignant peripheral nerve sheath tumor: a clinicopathologic and immunohistochemical analysis of 54 cases. *Mod Pathol.* 1998;11:612-617.
113. Velez R, Barrera-Ochoa S, Barastegui D, et al. Multidisciplinary management of a giant plexiform neurofibroma by double sequential preoperative embolization and surgical resection. *Case Rep Neurol Med.* 2013;2013:987623.
114. Wise JB, Cryer JE, Belasco JB, et al. Management of head and neck plexiform neurofibromas in pediatric patients with neurofibromatosis type 1. *Arch Otolaryngol Head Neck Surg.* 2005;131:712-718.
115. Gallager RL, Helwig EB. Neurothekeoma—a benign cutaneous tumor of neural origin. *Am J Clin Pathol.* 1980;74:759-764.
116. Fetsch JF, Laskin WB, Miettinen M. Nerve sheath myxoma: a clinicopathologic and immunohistochemical analysis of 57 morphologically distinctive, S-100

protein- and GFAP-positive, myxoid peripheral nerve sheath tumors with a predilection for the extremities and a high local recurrence rate. *Am J Surg Pathol.* 2005;29:1615-1624.
117. Sheth S, Li X, Binder S, et al. Differential gene expression profiles of neurothekeomas and nerve sheath myxomas by microarray analysis. *Mod Pathol.* 2011;24:343-354.
118. Goldstein J, Lifshitz T. Myxoma of the nerve sheath. Report of three cases, observations by light and electron microscopy and histochemical analysis. *Am J Dermatopathol.* 1985;7:423-429.
119. Rosati LA, Fratamico FC, Eusebi V. Cellular neurothekeoma. *Appl Pathol*. 1986;4:186-191.
120. Hornick JL, Fletcher CD. Cellular neurothekeoma: detailed characterization in a series of 133 cases. *Am J Surg Pathol.* 2007;31:329-340.
121. Robson AM, Calonje E. Cutaneous perineurioma: a poorly recognized tumour often misdiagnosed as epithelioid histiocytoma. *Histopathology.* 2000; 37:332-339.
122. Sciot R, Dal Cin P, Hagemeijer A, et al. Cutaneous sclerosing perineurioma with cryptic NF2 gene deletion. *Am J Surg Pathol.* 1999;23:849-853.
123. Emory TS, Scheithauer BW, Hirose T, et al. Intraneural perineurioma. A clonal neoplasm associated with abnormalities of chromosome 22. *Am J Clin Pathol.* 1995;103:696-704.
124. Mentzel T, Dei Tos AP, Fletcher CD. Perineurioma (storiform perineurial fibroma): clinico-pathological analysis of four cases. *Histopathology.* 1994;25:261-267.
125. Tsang WY, Chan JK, Chow LT, et al. Perineurioma: an uncommon soft tissue neoplasm distinct from localized hypertrophic neuropathy and neurofibroma. *Am J Surg Pathol.* 1992;16:756-763.
126. Goldblum JR, Folpe AL, Weiss SW, eds. *Enzinger and Weiss's Soft Tissue Tumors*. 6th ed. Philadelphia, PA: Saunders/Elsevier; 2014.
127. Evans DG, Baser ME, McGaughran J, et al. Malignant peripheral nerve sheath tumours in neurofibromatosis 1. *J Med Genet.* 2002;39:311-314.
128. De Raedt T, Brems H, Wolkenstein P, et al. Elevated risk for MPNST in NF1 microdeletion patients. *Am J Hum Genet.* 2003;72:1288-1292.
129. Woodruff JM, Selig AM, Crowley K, et al. Schwannoma (neurilemoma) with malignant transformation. A rare, distinctive peripheral nerve tumor. *Am J Surg Pathol.* 1994;18:882-895.
130. Pekmezci M, Reuss DE, Hirbe AC, et al. Morphologic and immunohistochemical features of malignant peripheral nerve sheath tumors and cellular schwannomas. *Mod Pathol.* 2015;28:187-200.
131. Wesche WA, Khare VK, Chesney TM, et al. Non-hematopoietic cutaneous metastases in children and adolescents: thirty years experience at St. Jude Children's Research Hospital. *J Cutan Pathol.* 2000;27:485-492.
132. Hashimoto H, Enjoji M, Nakajima T, et al. Malignant neuroepithelioma (peripheral neuroblastoma). A clinicopathologic study of 15 cases. *Am J Surg Pathol.* 1983;7:309-318.
133. Lack EE, Worsham GF, Callihan MD, et al. Granular cell tumor: a clinicopathologic study of 110 patients. *J Surg Oncol.* 1980;13:301-316.
134. Lee J, Bhawan J, Wax F, et al. Plexiform granular cell tumor. A report of two cases. *Am J Dermatopathol.* 1994;16:537-541.
135. Gleason BC, Nascimento AF. HMB-45 and Melan-A are useful in the differential diagnosis between granular cell tumor and malignant melanoma. *Am J Dermatopathol.* 2007;29:22-27.
136. Ordonez NG. Granular cell tumor: a review and update. *Adv Anat Pathol.* 1999;6:186-203.
137. Fanburg-Smith JC, Meis-Kindblom JM, Fante R, et al. Malignant granular cell tumor of soft tissue: diagnostic criteria and clinicopathologic correlation. *Am J Surg Pathol.* 1998;22:779-794.
138. Marina MB, Zurin AR, Muhaizan WM, et al. Heterotopic neuroglial tissue presenting as oral cavity mass with intracranial extension. *Int J Pediatr Otorhinolaryngol.* 2005;69:1587-1590.
139. Argenyi ZB. Cutaneous neural heterotopias and related tumors relevant for the dermatopathologist. *Semin Diagn Pathol.* 1996;13:60-71.
140. Amin A, Monabati A, Kumar PV, et al. Nasal glioma (neuroglial heterotopia) mimicking an astrocytoma: case report. *Ear Nose Throat J.* 2005;84:657-658.
141. Pensler JM, Ivescu AS, Ciletti SJ, et al. Craniofacial gliomas. *Plast Reconstr Surg.* 1996;98:27-30.
142. El Shabrawi-Caelen L, White WL, Soyer HP, et al. Rudimentary meningocele: remnant of a neural tube defect? *Arch Dermatol.* 2001;137:45-50.
143. Miyamoto T, Mihara M, Hagari Y, et al. Primary cutaneous meningioma on the scalp: report of two siblings. *J Dermatol.* 1995;22:611-619.
144. Gambini C, Rongioletti F. Primary congenital cutaneous ganglioneuroma. *J Am Acad Dermatol.* 1996; 35:353-354.
145. Hammond RR, Walton JC. Cutaneous ganglioneuromas: a case report and review of the literature. *Hum Pathol.* 1996;27:735-738.
146. Rios JJ, Diaz-Cano SJ, Rivera-Hueto F, et al. Cutaneous ganglion cell choristoma. Report of a case. *J Cutan Pathol.* 1991;18:469-473.
147. Kline MJ, Kays DW, Rojiani AM. Extradural myxopapillary ependymoma: report of two cases and review of the literature. *Pediatr Pathol Lab Med*. 1996;16:813-822.

Chapter 122 :: Lipogenic Neoplasms

:: Thomas Mentzel & Thomas Brenn

AT-A-GLANCE

- Lipogenic neoplasms represent the most frequent mesenchymal neoplasms.
- Lipogenic neoplasms include benign neoplasms (eg, lipoma, angiolipoma), intermediate, locally aggressive, nonmetastasizing neoplasms (eg, atypical lipomatous tumor), and clearly malignant lesions (eg, pleomorphic liposarcoma).
- Anatomic site, depth, and size are responsible for striking differences in regard to incidence, morphology, and prognosis.
- The clinical presentation of lipogenic neoplasms is usually nonspecific.
- The majority of lipogenic neoplasms is characterized by distinct cytogenetic abnormalities that may have diagnostic and therapeutic value.
- Surgical excision is the treatment of choice; in cases of malignant neoplasms not amenable for complete excision radiation therapy, however, chemotherapy or target-like therapy may be used.

Although lipogenic neoplasms represent the largest single group of mesenchymal tumors in the skin and in soft tissues, there are significant differences in regard to incidence, morphologic features, and prognosis between superficial and deep-seated lipogenic neoplasms that are important to know to avoid misdiagnosis and therapeutic errors. Whereas liposarcomas in deep soft tissues represent the most common sarcomas in adults, they are exceedingly rare in purely dermal location. Cases of spindle-cell/pleomorphic lipoma arising in the subcutis are encapsulated and occur predominantly in the neck and shoulder region of elderly male patients. In contrast, purely dermal spindle-cell/pleomorphic lipomas are ill-defined, infiltrative lesions that occur equally in both genders and show a broad anatomic distribution. The prognosis of atypical lipomatous tumor ("well-differentiated liposarcoma") is strongly related to site and size of the neoplasms. Cases of atypical lipomatous tumor, arising in the retroperitoneum, intraabdominal, in the mediastinum and in the spermatic cord are associated with a poor clinical prognosis. These neoplasms often achieve a large size, recur repeatedly, and may cause death in a high number of cases as a result of uncontrolled local effects. In striking contrast, cases of atypical lipomatous tumor arising in surgically amenable soft tissue of the extremities usually do not recur after complete excision, and in general superficially located liposarcomas have a relatively good prognosis.

LIPOMA

AT-A-GLANCE

- Lipoma is one of the most common benign mesenchymal neoplasms in adults.
- Lipomas are composed of mature white adipocytes.
- Lipomas show varying cytogenetic abnormalities.
- Although surgical excision is curative, cases of intramuscular lipoma show a higher recurrence rate.

EPIDEMIOLOGY

Lipoma is the most common benign mesenchymal neoplasm and tends to occur in adults without gender predilection. Cases in childhood and multiple lesions are rare.

CLINICAL FEATURES

Lipomas usually present as a painless, slowly growing mass involving the subcutaneous tissue of the trunk, neck, or extremities; involvement of the hands and feet is uncommon. Superficial lipomas are typically small, measuring less than 5 cm. In contrast, deep-seated intramuscular and intermuscular lipomas may reach a considerable size. Parosteal lipoma arises on the surface of bone, and so-called lipoma arborescens represents a villous lipomatous proliferation of the synovial membrane.[1] Lipomas may be seen as a manifestation of Gardner syndrome, and multiple lipomas together with macrocephaly, lymphangiomas, and hemangiomas are noted in Bannayan syndrome (Table 122-1).[2]

ETIOLOGY AND PATHOGENESIS

Lipomas are cytogenetically heterogeneous and the most common abnormalities include aberrations involving 12q13-15, rearrangements involving 6p21-23, and deletions involving 13q.[3] The *HMGA2* gene, localized at 12q14.3, plays an important role in the pathogenesis

TABLE 122-1
Syndromes Where Lipogenic Tumors Are Found

SYNDROME	ASSOCIATED TUMORS
Gardner syndrome	Familial adenomatous polyposis, desmofibromatosis, lipomas, osteomas, cysts
Bannayan-Riley-Ruvalcaba syndrome	Macrocephaly, lipomas, lymphangiomas, hamartomas, intestinal polyposis, lentigines
Cowden syndrome	Hamartomas, trichilemmomas, lipomas, oral papillomas, palmoplantar keratoses
Goldenhar-Gorlin syndrome	Intracranial lipomas, hydrocephalus, oculoauriculovertebral dysplasia
Myoclonus epilepsy and ragged-red fibers syndrome	Symmetric lipomas
CLOVE syndrome	Congenital lipomatous overgrowth, vascular malformations, epidermal nevi
Ekbom syndrome	Cervical lipomas, cerebellar ataxia, photomyoclonus, skeletal deformities

of some lipomas, and a recombination of *HMGA2* with several genes has been reported.[4]

HISTOLOGIC FEATURES

Classical subcutaneously located lipomas are well-circumscribed, encapsulated and lobulated lesions composed of mature adipocytes with thin and hypocellular fibrous septa containing thin-walled capillaries (Fig. 122-1). There is only slight variation in size and shape of adipocytes and no nuclear atypia is present. Immunohistochemically, tumor cells are negative for p16, MDM2, and CDK4. Cases of lipoma may show posttraumatic changes with fat necrosis and inflammation, and the presence of numerous histiocytes

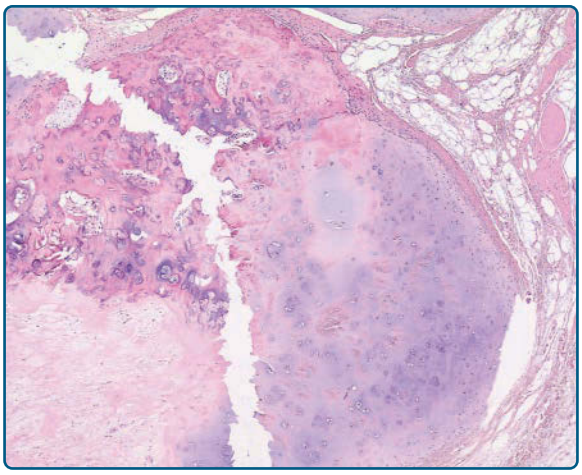

Figure 122-2 Chondrolipoma. An example of lipoma with prominent chondrous metaplasia.

containing enlarged nuclei that show a cytoplasmic staining for p16, MDM2, and CDK4 may mimic features of more aggressive atypical lipomatous tumor. Cases of lipoma may contain abundant fibrous tissue (fibrolipoma), cartilage (chondrolipoma) or bone (osteolipoma) (Fig. 122-2). Purely dermal lipomas are unencapsulated and rather ill-defined lesions (Fig. 122-3), and if sweat ducts and sweat glands are present within the lesion, the term *adenolipoma* has been used. Intramuscular and intermuscular lipomas are ill-defined, infiltrating neoplasms (Fig. 122-4) and preexisting skeletal muscle fibers often show features of atrophy.

DIFFERENTIAL DIAGNOSIS

Angiolipoma is characterized by a variable increased number of blood vessels containing fibrin thrombi, and often present as painful multiple lesions. Cases

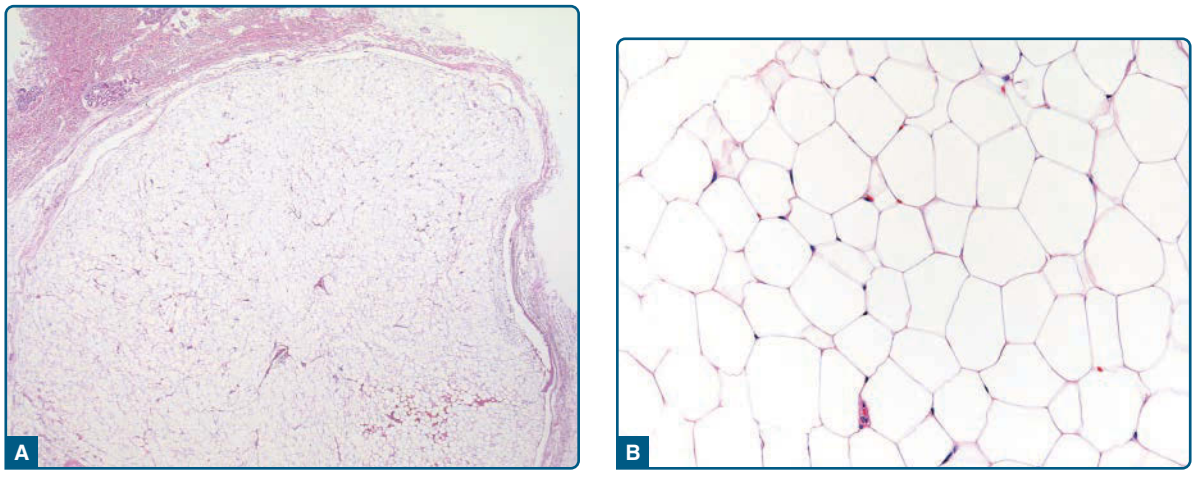

Figure 122-1 Lipoma. Subcutaneously located lipomas are well-circumscribed, often encapsulated lipogenic lesions (**A**), composed of mature univacuolated adipocytes showing only mild variation in size and shape (**B**).

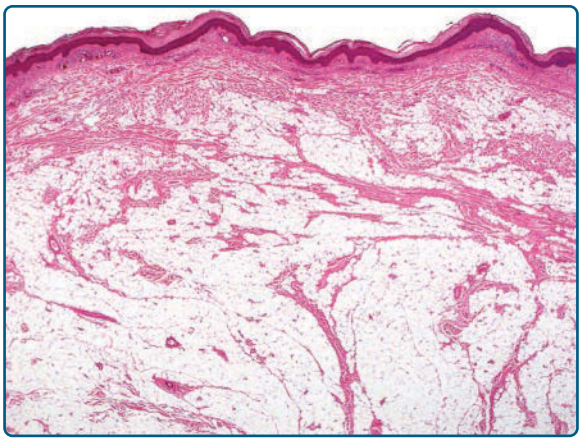

Figure 122-3 Intradermal lipoma. Mature lipogenic cells diffusely infiltrate preexisting dermal collagen bundles.

of atypical lipomatous tumor are characterized by striking variations in size and shape of lipogenic cells, and the presence of enlarged and hyperchromatic nuclei. The fibrous septa in atypical lipomatous tumor often contain atypical cells and lipoblasts may be present. Immunohistochemically, a focal expression of p16 is seen in atypical lipomatous tumor, and in a number of cases a focal nuclear staining for MDM2 and CDK4 is present. Fluorescence in situ hybridization (FISH) analysis reveals amplification of *MDM2* and *CDK4* in cases of atypical lipomatous tumor.

CLINICAL COURSE, PROGNOSIS, AND TREATMENT

Classical lipomas are entirely benign and recur only rarely; in contrast, intramuscular and intermuscular lipoma shows a higher rate of local recurrences (up to 20%).[5] The transition of a preexisting lipoma to an atypical lipomatous tumor represents an exceedingly rare phenomenon.[6] Surgical excision is curative.

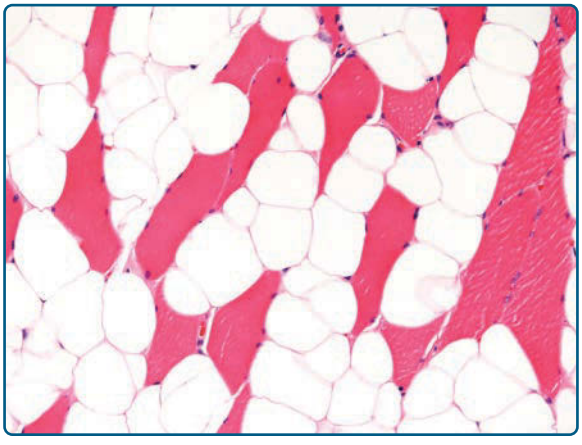

Figure 122-4 Intramuscular lipoma. Mature lipogenic cells show an infiltrative growth pattern within skeletal muscle fibers.

LIPOMATOSIS

AT-A-GLANCE

- Lipomatosis is characterized by a diffuse overgrowth of mature adipose tissue infiltrating through preexisting structures.
- Different clinical presentations are known.

EPIDEMIOLOGY AND CLINICAL FINDINGS

Diffuse lipomatosis occurs predominantly in children and rarely in adults. It is characterized by a diffuse overgrowth of mature lipogenic tissue involving subcutaneous tissue and skeletal muscle of the trunk and the extremities; in addition, osseous involvement may be seen. Pelvic lipomatosis is seen more frequently in black males, whereas symmetric lipomatosis (Madelung disease) develops in middle-aged men of Mediterranean origin and has a predilection for the neck, shoulder, and proximal upper limbs. In addition, peripheral neuropathy is a common finding in these patients. HIV-positive patients treated with protease inhibitors may develop lipodystrophy with increased fat tissue at the neck, the breast, and visceral organs, and steroid lipomatosis is seen in patients on hormonal therapy or suffering from increased endogenous production of adrenocortical steroids.

ETIOLOGY AND PATHOGENESIS

Generally, the basic mechanisms in lipomatosis are not well understood; however, an association with mitochondrial dysfunction has been reported, and multiple deletions of mitochondrial DNA, as well as point mutations in mitochondrial genes, have been found.[7]

HISTOLOGIC FEATURES

The gross appearance and the histologic features are the same for all of the different subtypes of

lipomatosis. Poorly circumscribed, infiltrating, soft, yellow, fat tissue that is identical to normal fat is seen.

CLINICAL COURSE, PROGNOSIS, AND TREATMENT

Palliative surgical excision of the fat tissue is the treatment of choice; however, all forms of lipomatosis tend to recur, and massive accumulation of fat tissue may cause considerable clinical problems.

LIPOMATOSIS OF NERVE

AT-A-GLANCE

- Lipomatosis of nerve is a rare lesion seen in infants and children.
- Lipomatosis of nerve is a growing mass with a predilection for the hand.
- Lipomatosis of nerve shows a proliferation of adipose and fibrous tissue within the epineurium and perineurium, mainly of the median nerve.

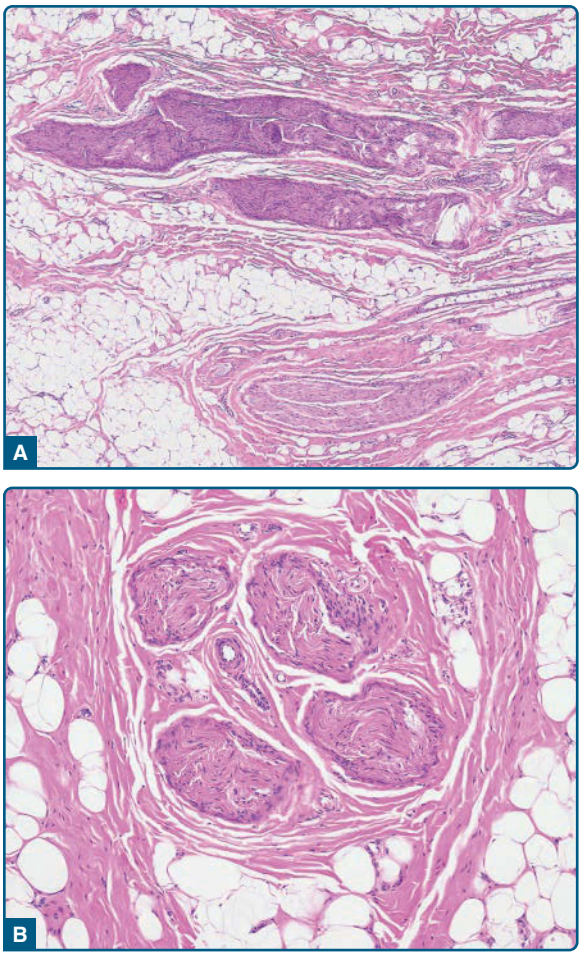

Figure 122-5 Lipomatosis of nerve. **A,** Epineural infiltration of lipogenic cells and collagenous fibrous tissue separating nerve bundles. **B,** Note the perineural fibrosis.

EPIDEMIOLOGY

Lipomatosis of nerve, also known as fibrolipomatous hamartoma of nerve, arises most frequently at birth or in early childhood, and may be associated with macrodactyly of the digits innervated by the affected nerve.[8]

CLINICAL FEATURES

Clinically, the patients present with a slowly growing mass that is often associated with pain, paresthesia, and sensor or motor deficits. The median nerve and its branches, followed by the ulnar nerve, are most commonly affected, whereas an involvement of cranial nerves and the brachial plexus is seen only rarely.[9,10]

HISTOLOGIC FEATURES

Grossly, a fusiform enlargement of the affected nerve is seen, and histologically, the epineurial and perineurial compartments of the affected nerve are infiltrated by mature adipose tissue and collagenous fibrous tissue (Fig. 122-5). Concentric perineurial fibrosis is present, and, rarely, metaplastic bone formation has been reported.[11]

CLINICAL COURSE, PROGNOSIS, AND TREATMENT

Lipomatosis of nerve is an entirely benign lesion; surgical excision may cause severe damage of the affected nerve.

NEVUS LIPOMATOSIS SUPERFICIALIS

AT-A-GLANCE

- Nevus lipomatosis superficialis (Hoffmann-Zurhelle) represents a rare type of connective tissue nevus that affects children and young adults.
- Nevus lipomatosis superficialis is usually found as a plaque-like, solitary lesion, which arises predominantly at the buttock, lumbar back, and posterior thigh.
- The lesions are composed of mature adipose tissue and connective tissue components.

EPIDEMIOLOGY

Nevus lipomatosus superficialis is a rare form of connective tissue nevus that usually affects children and young adults in the first decades of life with an equal gender distribution.

CLINICAL FEATURES

Cases of nevus lipomatosus superficialis present as plaques, papules, or solitary lesions with a predilection for the buttocks, upper posterior thighs, and lumbar back. A generalized form is extremely rare. The lesions are unilateral, and sometimes a linear or zosteriform arrangement is noted.

HISTOLOGIC FEATURES

Histologically, the ill-defined lesions are composed of mature adipose tissue that replaces the dermis. In addition, thickening of collagen bundles, as well as an increase of elastic fibers in deeper parts of the dermis and an increase of fibroblasts, may be seen. The overlying epidermis may show slight acanthosis and hyperpigmentation (Fig. 122-6).

DIFFERENTIAL DIAGNOSIS

Rare dermal spindle-cell lipoma is composed of mature adipose tissue associated with bland spindled tumor cells that stain positively for CD34, show loss of Rb-1 expression, and the often myxoid stroma contains hyalinized collagen fibers and mast cells.

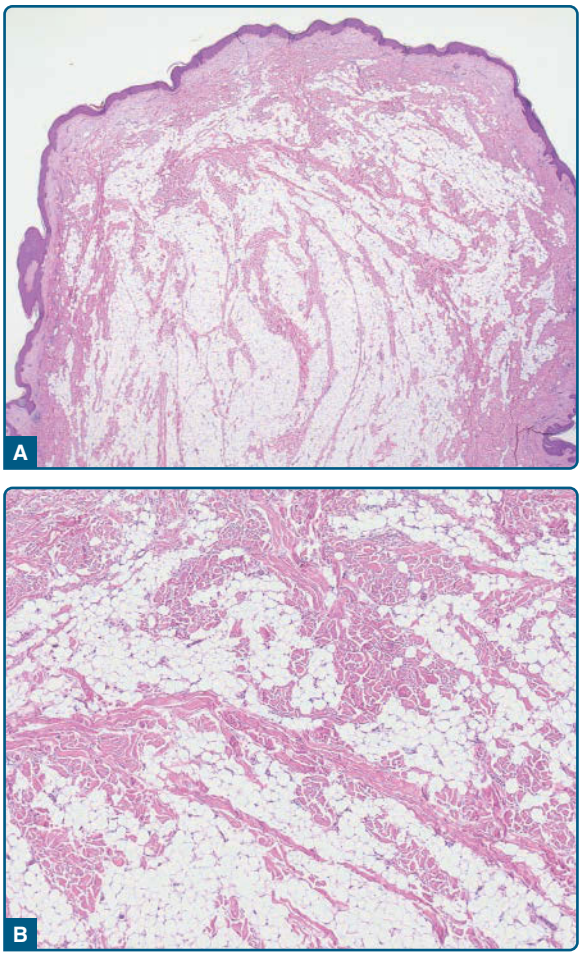

Figure 122-6 Nevus lipomatosus superficialis. Polypoid lesion with diffuse infiltration of the dermis by mature lipogenic cells (**A**), with typically hyalinized collagen bundles (**B**).

LIPOBLASTOMA/ LIPOBLASTOMATOSIS

AT-A-GLANCE

- Lipoblastomas/lipoblastomatosis are benign lipogenic neoplasms arising predominantly in infancy and early childhood.
- Lipoblastomas/lipoblastomatosis are well-circumscribed, lobulated lesions composed of lipogenic cells showing a spectrum of maturation from primitive mesenchymal cells and lipoblasts to mature adipocytes.
- Lipoblastomas/lipoblastomatosis show characteristic genetic changes.

EPIDEMIOLOGY

Lipoblastomas/lipoblastomatosis are rare, benign neoplasms of embryonal white fat arising predominantly in infants and young children, with a male predominance.[12-14] Infrequently, tumors are congenital or occur in young adults.[15]

CLINICAL FEATURES

Cases of lipoblastoma/lipoblastomatosis tend to occur on the trunk, at the extremities, and in the head and neck region, whereas visceral involvement and involvement of the retroperitoneum, pelvis, mediastinum, and the abdominal cavity is rarely seen. Most cases present as painless, slowly growing lesions. Lipoblastoma is a rather well-circumscribed neoplasm whereas lipoblastomatosis is characterized by an infiltrative growth that often extends into deeper structures. A significant number of patients have disorders of the CNS, such as seizures, autism, developmental delay, congenital anomalies, and/or Sturge-Weber syndrome.[14]

ETIOLOGY AND PATHOGENESIS

Cytogenetically, the majority of analyzed cases of lipoblastoma/lipoblastomatosis show aberrations involving chromosome 8, and a recurrent translocation involving chromosome band 8q11-13 with rearrangements of the *PLAG1* gene.[16]

HISTOLOGIC FEATURES

Lipoblastoma represents a well-circumscribed, lobulated tumor composed of an admixture of mature and immature lipogenic cells separated by fibrovascular septa (Fig. 122-7). Lobulation is less prominent in cases of lipoblastomatosis that show an infiltrative growth pattern. Lipoblasts are seen in different stages of development, and varying amounts of myxoid stroma with primitive spindled cells and a plexiform vascular pattern (reminiscent of the vascular pattern in myxoid liposarcoma) may be present (Figs. 122-8 and 122-9). Even though some tumors are predominantly composed of mature adipocytes as a manifestation of maturation, the characteristic lobular growth and the presence of fibrous septa are helpful clues for the diagnosis. A fibroblastic proliferation, chondroid metaplasia, or extramedullary hematopoiesis is seen occasionally. The lipogenic cells demonstrate an expression of S-100 protein, PLAG1, and CD34,[14] the spindled cells stain often positively for desmin.[17] Interestingly, cases of

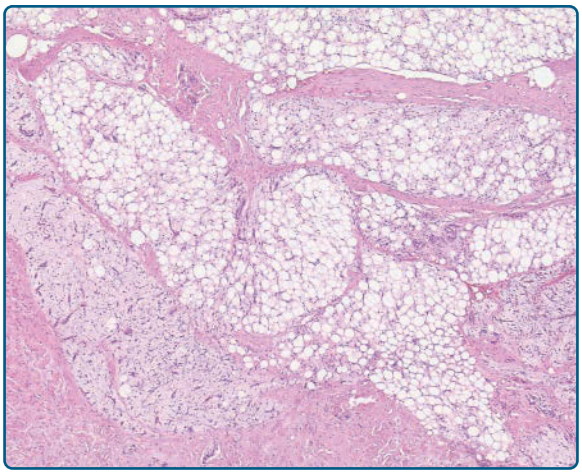

Figure 122-7 Lipoblastoma: lipoblastoma represents a well-circumscribed lipogenic neoplasm showing multilobulation and collagenous fibrous septa.

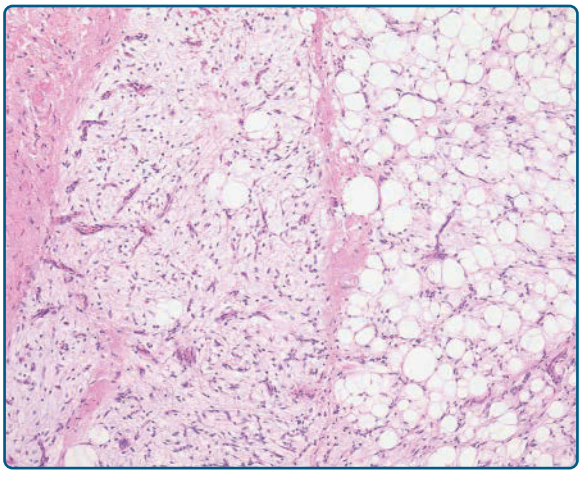

Figure 122-8 Lipoblastoma. Areas of lipogenic cells are admixed with myxoid areas showing a plexiform vascular pattern.

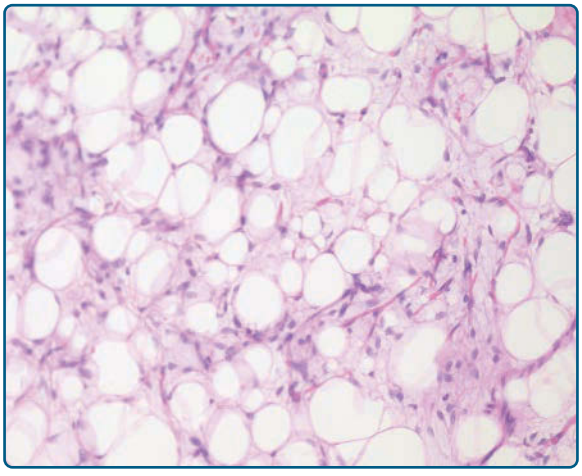

Figure 122-9 Lipoblastoma. Lipogenic cells in different stages of development are present.

lipoblastoma may stain positively for p16, which represents a diagnostic pitfall in the distinction to atypical lipomatous tumor.[18]

DIFFERENTIAL DIAGNOSIS

Myxoid liposarcoma represents one of the most important differential diagnoses of lipoblastoma/lipoblastomatosis; however, this diagnosis in patients younger than 10 years of age is exceedingly rare. In older children, adolescents, and young adults, the differentiation can be quite problematic. A striking lobulation and lack of hyperchromatic nuclei support the diagnosis of lipoblastoma/lipoblastomatosis; in addition, different molecular changes are helpful for the correct diagnosis. Further differential diagnoses include lipoma, lipofibromatosis, hibernoma, and atypical lipomatous tumor. Rare lipoblastoma-like tumor of the vulva arises in adults; the tumor lacks PLAG1 expression and shows loss of Rb-1.[19]

CLINICAL COURSE, PROGNOSIS, AND TREATMENT

Lipoblastoma/lipoblastomatosis has an excellent prognosis despite their potential to invade locally and their considerable size as seen in a number of cases. The reported rate of local recurrences is up to 46%,[14] which is caused by incomplete excision or confined to diffuse-type lesions (lipoblastomatosis). There is no risk of tumor progression, metastasis, or malignant transformation.

ANGIOLIPOMA

AT-A-GLANCE

- Angiolipoma is a common, often painful, entirely benign lipogenic lesion.
- Angiolipoma affects young adults; multiple lesions often are seen.
- Angiolipoma contains a variable number of thin-walled vessels that may contain fibrin thrombi.

EPIDEMIOLOGY

Subcutaneous angiolipomas are frequent mesenchymal tumors that occur predominantly in young males; a familial incidence has been described.[20]

CLINICAL FEATURES

Angiolipomas tend to be multifocal and often present as painful and tender subcutaneous lesions that occur predominantly on the forearm followed by the trunk, upper arm, and legs.

ETIOLOGY AND PATHOGENESIS

In contrast to lipomas, all investigated angiolipomas have had a normal karyotype, and because cases of cellular angiolipoma can be almost exclusively composed of blood vessels, it has been speculated, that these lesions represent hemangiomas instead of lipomas.[21]

HISTOLOGIC FEATURES

Histologically, angiolipomas are well-circumscribed, encapsulated nodular lesions composed of mature adipocytes, a variable number of thin-walled capillaries, which may contain fibrin thrombi, and stromal spindled cells (Figs. 122-10 and 122-11). In cases of cellular angiolipoma the vessels predominate and lipogenic cells may be absent (Fig. 122-12).

DIFFERENTIAL DIAGNOSIS

The presence of fibrin thrombi and clinical features are helpful in the distinction of angiolipoma from cases of lipoma with an increased number of vessels. Cellular angiolipoma has to be distinguished from vascular neoplasms such as Kaposi sarcoma, kaposiform hemangioendothelioma, spindle-cell hemangioma, and angiosarcoma.

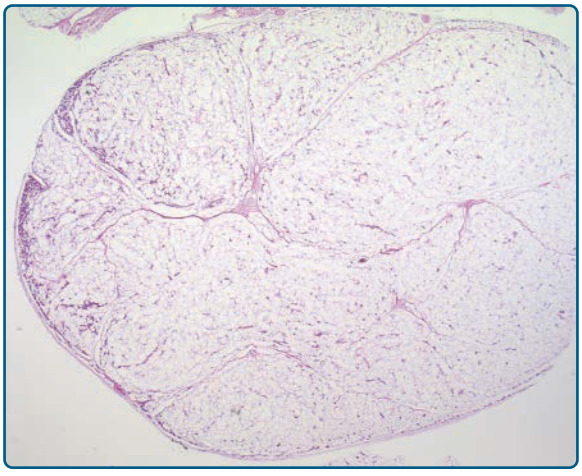

Figure 122-10 Angiolipoma. Low-power view shows an encapsulated, subcutaneously located lipogenic neoplasm with an increased number of vessels in the periphery.

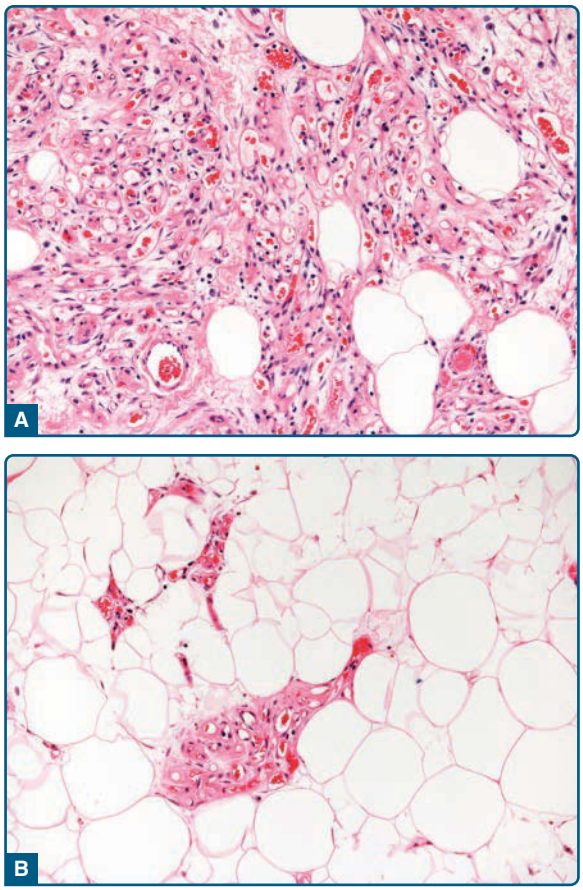

Figure 122-11 Angiolipoma. **A,** Narrow and dilated, thin-walled capillaries are admixed with mature adipocytic tissue. **B,** The adipocytic component can predominate.

CLINICAL COURSE, PROGNOSIS, AND TREATMENT

The clinical behavior of angiolipomas is entirely benign and simple resection is curative.

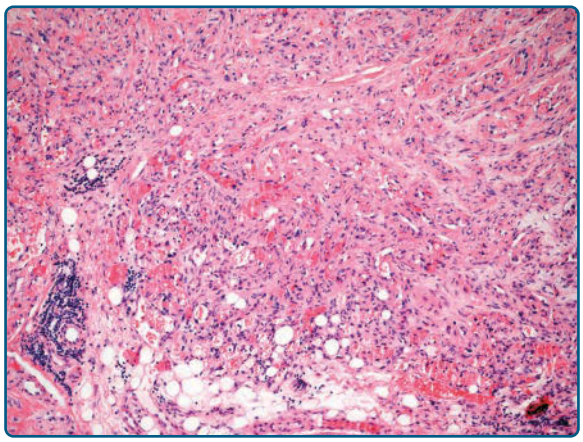

Figure 122-12 Cellular angiolipoma. Predominant vascular component mimicking a vascular neoplasm.

SPINDLE-CELL LIPOMA AND PLEOMORPHIC LIPOMA

AT-A-GLANCE

- Spindle-cell lipoma and pleomorphic lipoma represent a morphologic continuum of a single clinicopathologic entity.
- Spindle-cell lipoma and pleomorphic lipoma are related to mammary myofibroblastoma and cellular angiofibroma.
- Classical cases of spindle-cell lipoma and pleomorphic lipoma occur as encapsulated subcutaneous lesions arising predominantly on the posterior neck, shoulder, and upper back of elderly males.
- Purely dermal spindle cell lipoma and pleomorphic lipoma represent ill-defined, infiltrative lesions, show a broad anatomic distribution, and no gender preference.
- Spindle-cell lipoma is composed of mature adipocytes and CD34+, bland spindled cells; multinucleated, CD34+ giant cells are present in pleomorphic lipoma.
- Atypical spindle cell lipomatous tumor and atypical pleomorphic lipomatous tumor represent intermediate, locally aggressive, nonmetastasizing neoplasms.

EPIDEMIOLOGY

Spindle-cell lipoma and pleomorphic lipoma form a morphologic spectrum of a single clinicopathologic entity with significant clinical, morphologic, and cytogenetic overlap. The majority of these rare neoplasms are seen in elderly males; very rarely have familial spindle-cell lipomas with multiple lesions in the affected patients have been reported.[22] In contrast, purely dermal lipomas show no gender preference.[23]

CLINICAL FEATURES

Spindle-cell lipoma and pleomorphic lipoma usually present as an asymptomatic, often longstanding, mobile tumor in the subcutaneous tissue. The majority of these lesions are seen on the posterior neck, shoulder, and upper back. Infrequently, the face, oral cavity, and extremities are affected.[24,25] Purely dermal spindle-cell lipoma and pleomorphic lipoma show a broad anatomic distribution.[23]

ETIOLOGY AND PATHOGENESIS

The karyotype of spindle-cell and pleomorphic lipomas is complex and frequently hypodiploid with frequent partial losses and few balanced rearrangements. Many cases show monosomy and partial losses involving chromosomes 13 and 16.[3] Given the overlapping clinical, histologic, and molecular features between spindle-cell lipoma, cellular angiofibroma, and mammary-type myofibroblastoma, these tumors probably represent points along a spectrum of a single clinicopathologic entity.[26,27]

HISTOLOGIC FEATURES

Subcutaneous spindle-cell lipoma represents an encapsulated lesion composed of mature adipocytes and a variable number of cytologically bland spindled tumor cells set in a collagenous and myxoid stroma containing blood vessels, hyalinized rope-like collagen fibers and, often, mast cells (Fig. 122-13). Mitotic activity is virtually absent. The spindled cells can predominate, and even cases without lipogenic cells have been reported that may cause significant diagnostic problems (Fig. 122-14).[28] Occasionally, prominent myxoid stromal changes are seen, and numerous slit-like spaces resembling vascular channels are present in the so-called pseudoangiomatous variant (Fig. 122-15).[29]

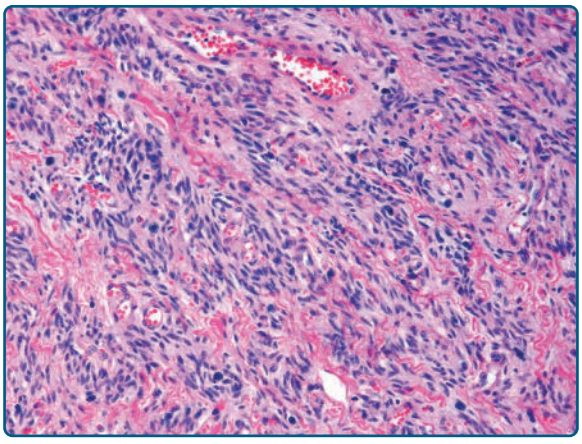

Figure 122-14 Spindle-cell lipoma. The spindled cells can predominate. Note scattered mast cells.

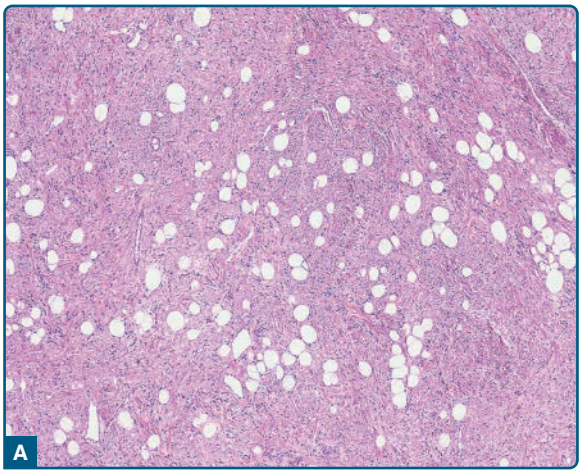

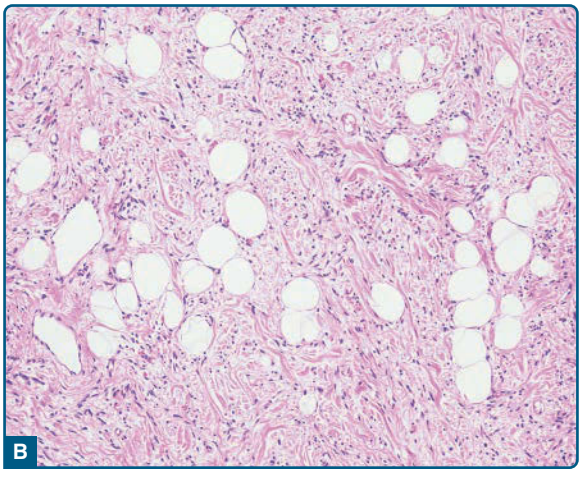

Figure 122-13 Spindle-cell lipoma. **A,** Mature adipocytes are admixed with short, loosely arranged spindled tumor cells. **B,** Hyalinized, rope-like collagen fibers are present.

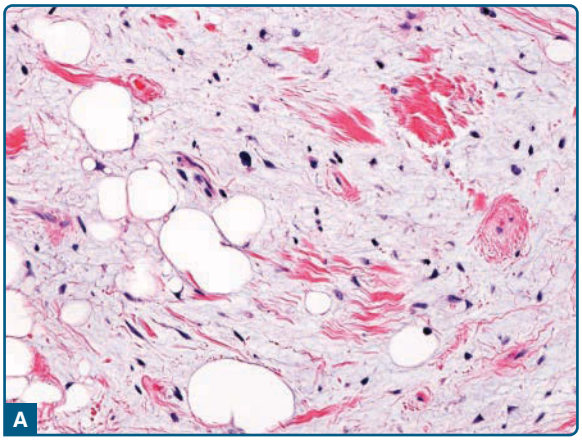

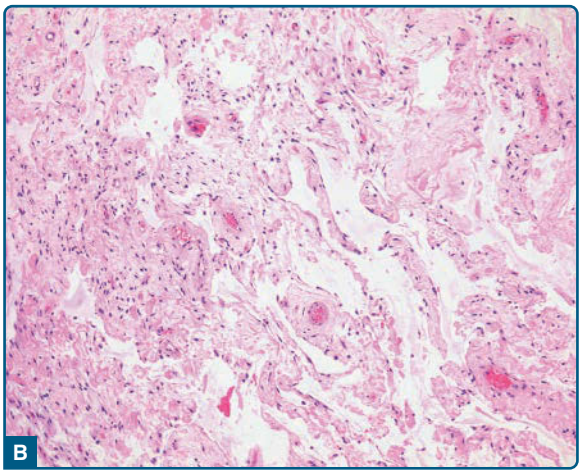

Figure 122-15 Spindle-cell lipoma. **A,** Prominent myxoid stromal changes; note that the tumor cell nuclei are slightly enlarged and hyperchromatic. **B,** Slit-like spaces are seen in the pseudoangiomatous variant.

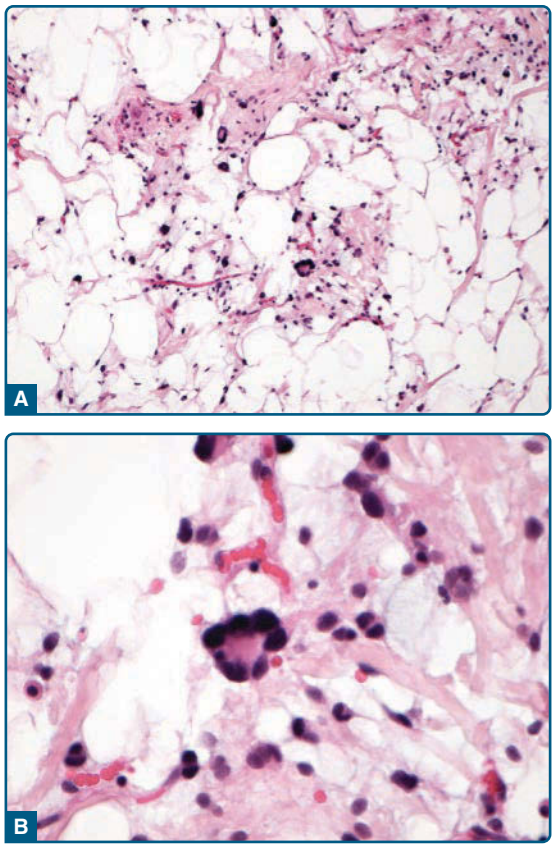

Figure 122-16 Pleomorphic lipoma. **A,** The characteristic floret-like multinucleated giant cells contain overlapping hyperchromatic nuclei in a circular or semicircular arrangement. **B,** Higher-power view of a floret-like tumor giant cell set in a myxoid stroma with scattered mast cells.

Scattered lipoblasts may be present in otherwise typical cases of spindle-cell lipoma. The characteristic feature of pleomorphic lipoma is the additional presence of multinucleated giant cells with radially arranged nuclei (floret-like giant cells; Fig. 122-16); both low-fat and fat-free pleomorphic lipomas also have been reported.[30] Purely dermal cases of spindle-cell lipoma

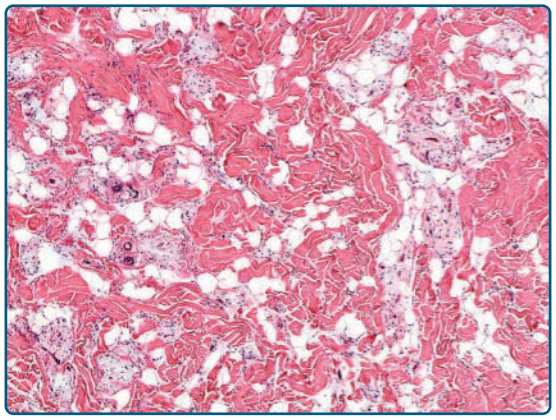

Figure 122-17 Dermal spindle-cell lipoma. Intradermal lesions are less circumscribed and show a diffuse infiltration of preexisting dermal collagen bundles.

and pleomorphic lipoma are in contrast unencapsulated and infiltrative mimicking a more aggressive neoplasm (Fig. 122-17). Infrequently, cases of spindle-cell lipoma and pleomorphic lipoma arise at unusual anatomic sites and show an infiltrative pattern and significant atypia of lipogenic cells, as well as of spindled and pleomorphic giant cells (Fig. 122-18). These cases are designated as atypical spindle cell lipomatous

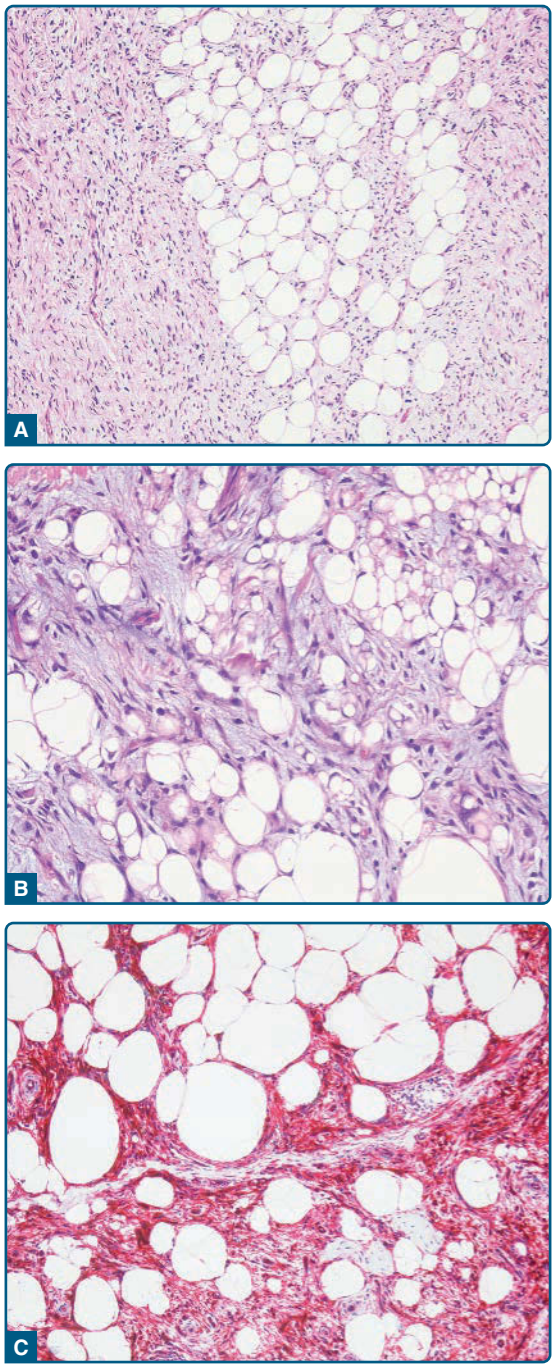

Figure 122-18 Atypical spindle cell lipoma. **A,** An irregular admixture of lipogenic cells with spindle-shaped tumor cells. **B,** Both components show at least sight nuclear atypia with enlarged and hyperchromatic nuclei; in addition lipoblastic cells are noted. **C,** Immunohistochemically, spindled cells stain positively for CD34.

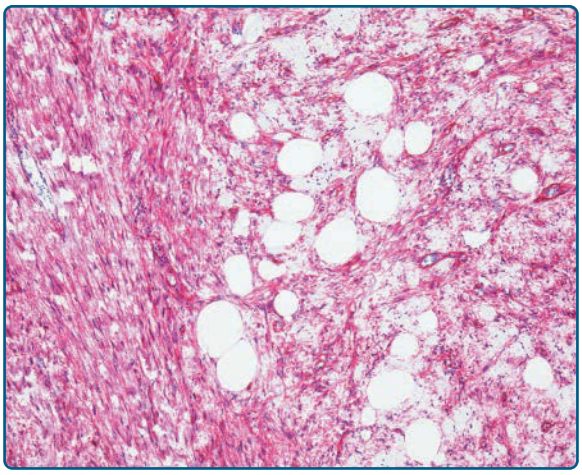

Figure 122-19 Spindle-cell lipoma Tumor cells stain positively for CD34.

tumor and atypical pleomorphic lipomatous tumor, and show a clinical behavior comparable to atypical lipomatous tumor.[31,32,32A,32B] Immunohistochemically, spindled cells and pleomorphic tumor giant cells stain positively for CD34 (Fig. 122-19), and show loss of the expression of Rb-1 (Fig. 122-20).[33] Very rarely an expression of desmin and S-100 protein by spindled cells has been reported.[34,35]

DIFFERENTIAL DIAGNOSIS

Atypical lipomatous tumor shows striking variation of size and shape of the lipogenic cells and significant atypia with the presence of enlarged and hyperchromatic nuclei. In addition, a focal nuclear expression of MDM2 and CDK4 may be seen; FISH analysis reveals *MDM2* and *CDK4* amplification. Cases of solitary fibrous tumor may contain fat cells and tumor cells stain positively for CD34 as well. However, solitary fibrous tumor is characterized by a varying cellularity,

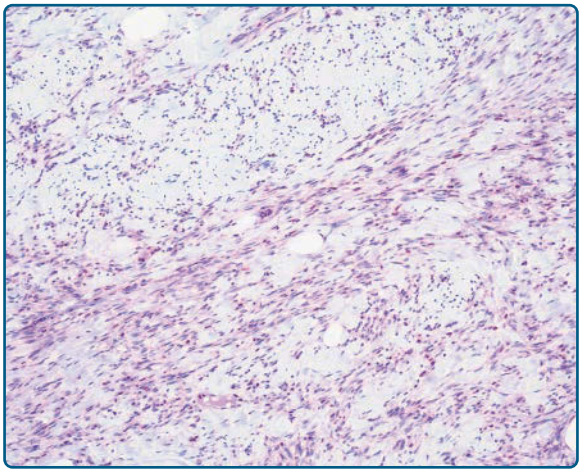

Figure 122-20 Spindle-cell lipoma. Tumor cells show loss of the expression of Rb1.

the presence of hemangiopericytoma-like blood vessels, and tumor cells that show nuclear expression of STAT6. Dermatofibrosarcoma protuberans is composed of CD34+ spindled cells, however, these neoplasms show a diffuse, honey-comb infiltration of the subcutaneous tissue and different genetic changes.

CLINICAL COURSE, PROGNOSIS, AND TREATMENT

Spindle-cell and pleomorphic lipomas are entirely benign, although local recurrences occur rarely. Cases of atypical spindle cell lipomatous tumor and pleomorphic lipomatous tumor are locally aggressive neoplasms and show an increased rate of local recurrences.[31,32]

CHONDROID LIPOMA

AT-A-GLANCE

- Chondroid lipoma represents a rare benign lipogenic neoplasm.
- Chondroid lipoma is seen more frequently in female patients.
- Chondroid lipoma arises predominantly in deep soft tissues of the extremities.
- Chondroid lipoma is composed of adipocytes, lipoblasts, and small vacuolated cells.
- Tumor cells in chondroid lipoma are set in a myxoid–chondroid matrix.
- A recurrent t(11;16)(q13;p13) is seen in cases of chondroid lipoma.

EPIDEMIOLOGY

Chondroid lipoma, first described in 1993,[36] is a very rare lipogenic neoplasm and arises predominantly in adults, with a predilection for females.

CLINICAL FEATURES

The majority of cases of chondroid lipoma presents as a painless, deep-seated mass, and may show a history of recent growth. The proximal extremities and limb girdles are the most frequently affected anatomic sites,[36,37] but the trunk and the head and neck region, including the oral cavity,[38] also may be affected. The neoplasms arise usually in deep subcutaneous tissue, fascia, and skeletal muscle.

ETIOLOGY AND PATHOGENESIS

Ultrastructural studies confirmed the lipogenic differentiation in cases of chondroid lipoma, and a spectrum of differentiation ranging from primitive mesenchymal cells, with features of prelipoblasts, to lipoblasts, preadipocytes, and mature adipocytes, has been reported.[36,39] Cytogenetically, a balanced translocation involving chromosomes 11 and 16, t(11;16)(q13;p12-13) with a *C11orf95-MKL2* fusion gene product has been found,[40] and cyclin D1 (*CCND1*) expression without abnormalities of the *CCND1* locus has been reported.[41]

HISTOLOGIC FEATURES

Chondroid lipomas are usually deep-seated, well-circumscribed, encapsulated, nodular, and lobulated neoplasms. The neoplasms are composed of a variable admixture of mature adipocytes, multivacuolated lipoblasts with enlarged and hyperchromatic nuclei, and small, round cells containing an eosinophilic and vacuolated cytoplasm displaying a range of lipoblastic differentiation and containing small lipid droplets and periodic acid–Schiff–positive glycogen (Figs. 122-21, 122-22, and 122-23). The tumor cells are set in a myxoid–chondroid stroma and positive Alcian blue stainings at low pH indicate the presence of sulfated chondroitin. The lesions contain many vessels, and areas of hemorrhage, fibrosis, and calcification may be present. Mature lipogenic cells stain positively for S-100 protein, and, occasionally, a focal expression of pancytokeratin by lipogenic cells can be seen.

DIFFERENTIAL DIAGNOSIS

Given the depth and size of the lesion associated with the presence of nuclear atypia and lipoblasts, benign chondroid lipoma has to be distinguished from more aggressive neoplasms, including atypical lipomatous tumor, myxoid liposarcoma, extraskeletal myxoid chondrosarcoma, and myoepithelioma of soft tissues.

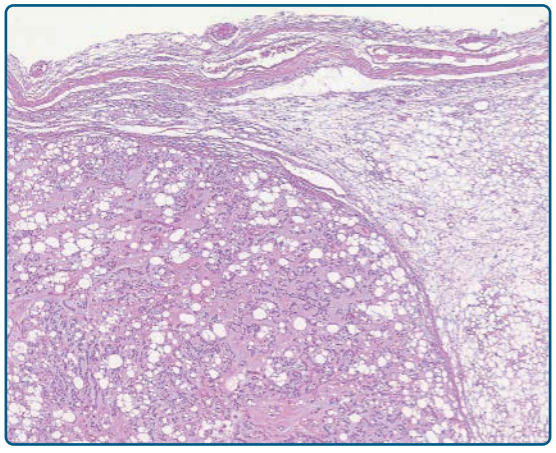

Figure 122-21 Chondroid lipoma. Encapsulated lipogenic neoplasm with a lobular growth.

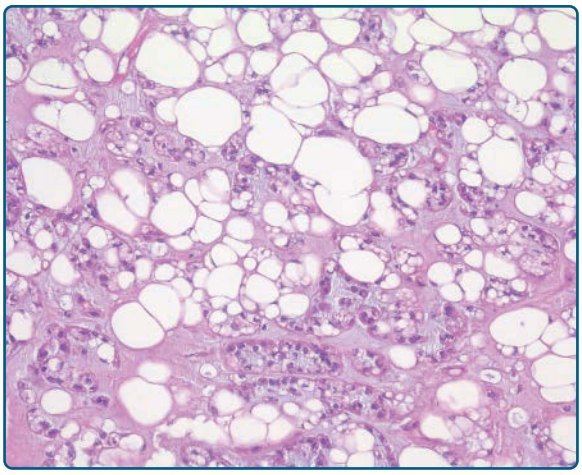

Figure 122-22 Chondroid lipoma. Univacuolated and multivacuolated lipoblasts are admixed with mature adipocytes.

CLINICAL COURSE, PROGNOSIS, AND TREATMENT

Chondroid lipoma represents an entirely benign lipogenic neoplasm and simple surgical excision is curative. Local recurrences are rare and neither malignant transformation nor metastases have been reported as of this writing.

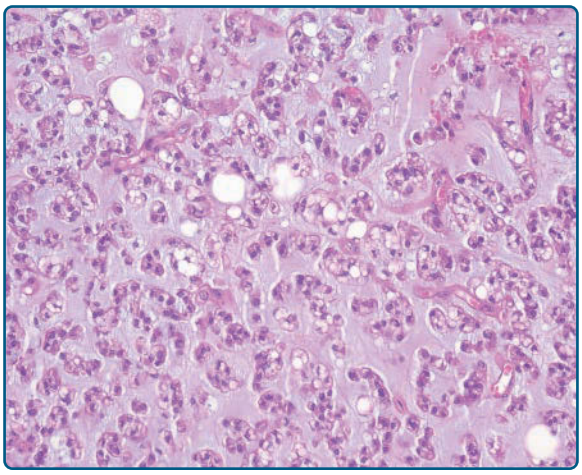

Figure 122-23 Chondroid lipoma. In addition, small, round tumor cells containing an eosinophilic and vacuolated cytoplasm are seen.

MYOLIPOMA

AT-A-GLANCE

- Myolipoma is a very rare benign mesenchymal neoplasm of deep soft tissue.
- Myolipoma occurs predominantly in females.
- Myolipoma is composed of an irregular mixture of mature adipocytes and smooth muscle cells.

EPIDEMIOLOGY

Myolipoma represents a very rare neoplasm of soft tissues occurring in adult patients with a female predominance.[42]

CLINICAL FEATURES

Cases of myolipoma tend to occur in deep soft tissue of the retroperitoneum, abdominal cavity, and inguinal region, whereas an involvement of subcutaneous tissue of the extremities and the trunk is only rarely seen.[42] Although these lesions may reach a considerable size, they are often found incidentally.

ETIOLOGY AND PATHOGENESIS

HMGA2 alterations have been reported in cases of myolipoma, and most recently a fusion of the *HMGA2* and *C9orf92* genes with t(9;12)(p22;q14) has been detected.[43]

HISTOLOGIC FEATURES

Myolipoma of soft tissues is a well-circumscribed or encapsulated lesion composed of fascicles of cytologically bland smooth muscle cells associated with a variable amount of mature fat (Fig. 122-24). No cytologic atypia, mitoses, or thick-walled vessels are present. Immunohistochemically, smooth muscle cells stain positively for alpha-smooth muscle actin, desmin, and h-caldesmon (Fig. 122-25), and an expression of estrogen and progesterone receptors has been reported.[44] No expression of HMB-45 by smooth muscle cells and no expression of MDM2 and CDK4 by lipogenic cells are noted.

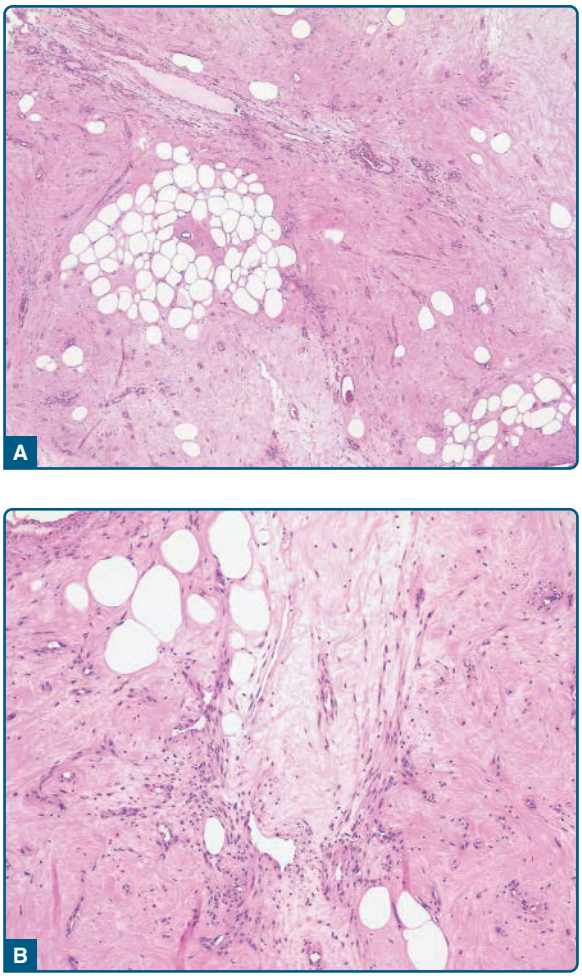

Figure 122-24 Myolipoma. **A,** Mature adipocytic cells are admixed with bland spindled cells. **B,** The myogenic spindled cells contain an eosinophilic cytoplasm and bland spindled nuclei.

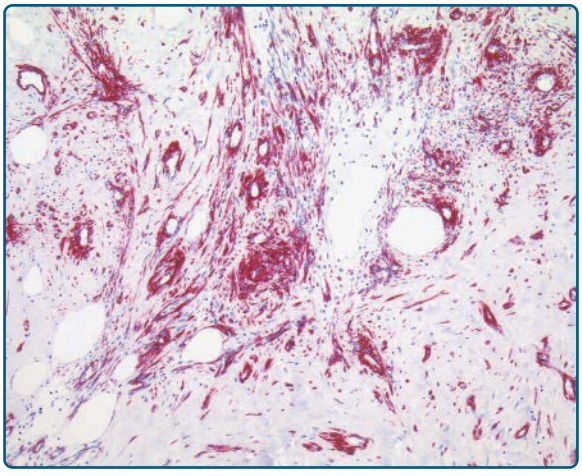

Figure 122-25 Myolipoma. Eosinophilic spindled tumor cells stain positively for h-caldesmon, confirming their smooth muscle differentiation.

DIFFERENTIAL DIAGNOSIS

The differential diagnosis for myolipoma of soft tissues includes atypical lipomatous tumor, dedifferentiated liposarcoma, well-differentiated leiomyosarcoma, and angiomyolipoma.

CLINICAL COURSE, PROGNOSIS, AND TREATMENT

Despite the large size, myolipoma of soft tissues represents an entirely benign mesenchymal neoplasm, and complete excision is curative.

HIBERNOMA

AT-A-GLANCE

- Hibernoma represents a benign neoplasm of brown fat.
- Hibernoma usually arises in adults and the most common anatomic site is the thigh.
- Cases of atypical lipomatous tumor and myxoid liposarcoma may contain hibernoma-like areas.

EPIDEMIOLOGY

Hibernoma is a rare neoplasm, and occurs predominantly in young adults, whereas it is only rarely seen in children and the elderly. Males are slightly more frequently affected than females.

CLINICAL FEATURES

Hibernoma represents a painless, slowly growing, mobile tumor arising in the subcutis or in deep soft tissues. The most common anatomic site for hibernoma is the thigh followed by the trunk, the chest wall, the shoulder area, the upper extremity, and the head and neck area.[45] Rarely, hibernoma arises intraabdominally, in the retroperitoneum, in the mediastinum, or intraosseous.[46,47]

ETIOLOGY AND PATHOGENESIS

The reported karyotypes of hibernoma appear to be more complex than those in other benign lipogenic neoplasms, and structural rearrangements involving chromosome band 11q13-21 have been detected.[48]

HISTOLOGIC FEATURES

Hibernomas are well-circumscribed, lobular neoplasms containing a capillary network and are composed of a variable number of brown fat cells admixed with white fat cells and stromal cells. Typical hibernomas are composed of large, polygonal, brown fat cells with multivacuolation, granular cytoplasm, and a small, centrally located nucleus admixed with mature white fat cells (Fig. 122-26). The eosinophilic variant is composed of predominantly brown fat cells with a deeply eosinophilic and granular cytoplasm, the pale cell variant contains mostly large brown fat cells with palely staining vacuolated cytoplasm, and the mixed subtype is intermediate between the two. In addition, myxoid, spindle-cell, and lipoma-like variants are known.[45] Prominent cytologic atypia and increased proliferative activity are not present. Immunohistochemically,

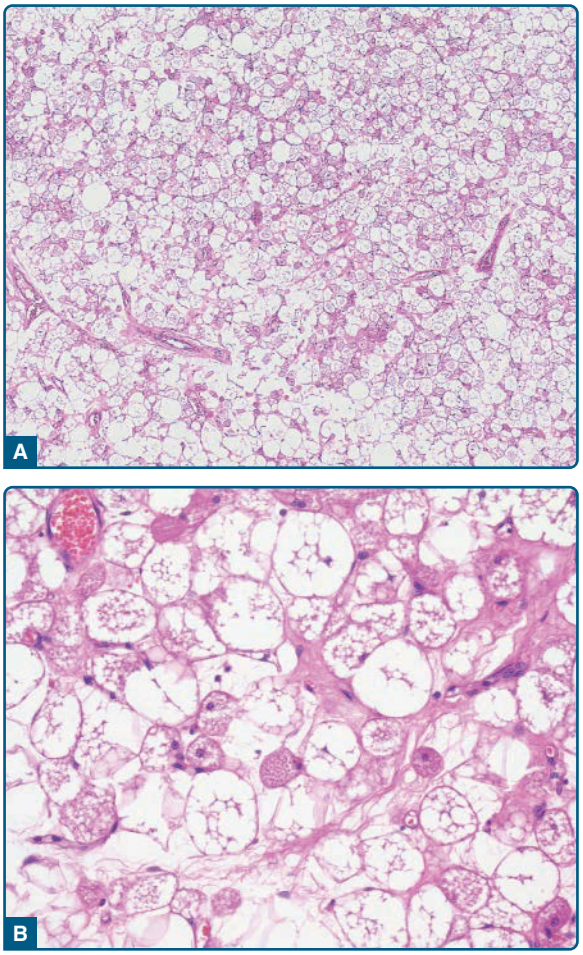

Figure 122-26 Hibernoma. **A,** Mature adipocytes are admixed with large multivacuolated cells and smaller eosinophilic cells. **B,** Vacuolated tumor cells with centrally placed nuclei and a clear or eosinophilic granular cytoplasm.

tumor cells stain positively for S-100 protein and for uncoupling protein, a protein unique to brown adipocyte mitochondria.[49] The spindled cells may express CD34.

DIFFERENTIAL DIAGNOSIS

Scattered brown fat cells as well as hibernoma-like areas may be present in cases of myxoid liposarcoma and atypical lipomatous tumor that have to be distinguished from hibernoma. Further differential diagnoses include granular cell tumor and spindle-cell lipoma.

CLINICAL COURSE, PROGNOSIS, AND TREATMENT

Hibernoma is an entirely benign lipogenic neoplasm, and complete excision is curative.

ATYPICAL LIPOMATOUS TUMOR AND WELL-DIFFERENTIATED LIPOSARCOMA

AT-A-GLANCE

- Atypical lipomatous tumor and well-differentiated liposarcoma are synonyms and describe lipogenic neoplasms with identical morphologic and cytogenetic features.
- Atypical lipomatous tumor represents a locally aggressive, nonmetastasizing neoplasm.
- Anatomic location, size, and depth of the lesions are important prognostic predictors.
- Neoplasms arising at sites amenable to surgical excision (ie, extremities) show a low rate of local recurrence, risk of dedifferentiation, and mortality.
- In striking contrast, neoplasms arising in the retroperitoneum, intraabdominal cavity, or in paratesticular location, where complete excision is difficult or not achievable, are characterized by a high rate of local recurrence, a high risk of dedifferentiation, and a poor clinical outcome.
- The known morphologic variants have no prognostic value.

EPIDEMIOLOGY

Atypical lipomatous tumor represents the largest single group of clinically aggressive lipogenic neoplasms, and liposarcomas in general are the most frequent sarcomas in adults. The majority of neoplasms occurs in middle-age adults, with a peak incidence in the sixth decade.[50-54] Cases in children are extremely rare, but have been described.[55,56]

CLINICAL FEATURES

Cases of atypical lipomatous tumor occur usually in deep soft tissues. The subcutaneous tissue may be occasionally involved, but purely dermal lesions that may present as a skin tag are extremely rare (Fig. 122-27).[57] The predominantly affected site is the musculature of the extremities, especially the thigh, followed by the

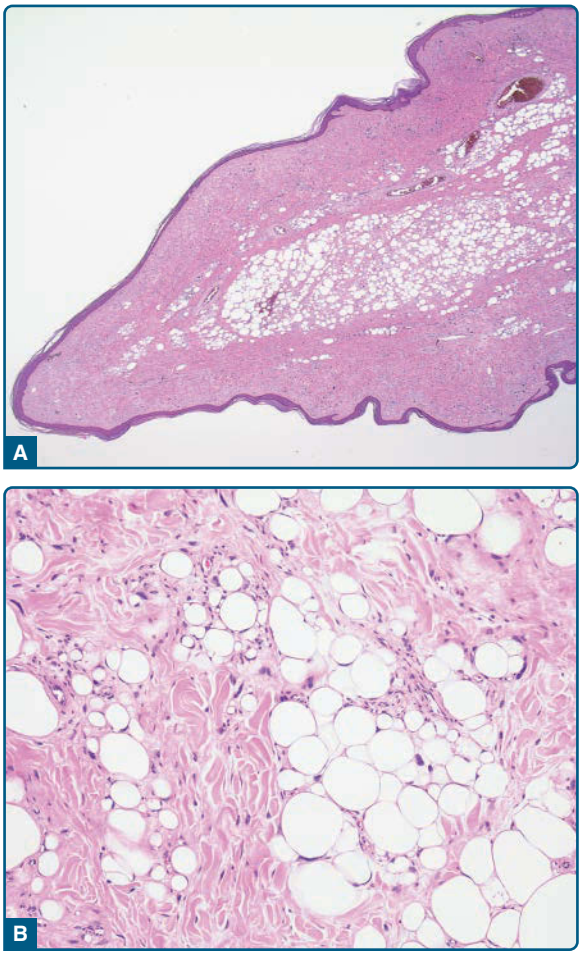

Figure 122-27 Dermal atypical lipomatous tumor. **A,** A polypoid lesion, clinically diagnosed as a skin tag, has been excised. **B,** Histologically, an atypical lipomatous tumor composed of atypical stromal cells and atypical lipogenic cells with enlarged hyperchromatic nuclei and scattered lipoblasts is seen.

retroperitoneum, the abdominal cavity, the groin, the paratesticular region, and the mediastinum. However, also other anatomic locations are rarely involved, as it is the oral cavity, the orbit, the larynx, and the vulva.[58-61] An enlarging painless mass is the typical presenting sign and tumors may grow to a very large size before becoming symptomatic, especially in retroperitoneal and intraabdominal locations.

ETIOLOGY AND PATHOGENESIS

Cases of atypical lipomatous tumor are characterized cytogenetically by supernumerary ring and giant marker chromosomes derived from the 12q13-15 region and resulting in consistent amplification of the *MDM2* and *CDK4* genes.[62,63]

HISTOLOGIC FEATURES

Atypical lipomatous tumors are typically large, well-circumscribed and lobulated lesions, and in retroperitoneal and intraabdominal locations, multiple discontinuous neoplasms may be present. Morphologically, atypical lipomatous tumor can be divided into 3 main subtypes; however, especially in large neoplasms of the retroperitoneum, more than 1 variant may be present. The most frequent adipocytic (lipoma-like) variant is composed of relatively mature adipocytic cells with marked variations in size and shape showing scattered enlarged and hyperchromatic nuclei. In addition, atypical stromal cells with enlarged nuclei located in fibrous septa, as well as multivacuolated lipoblasts, may be present; however, lipoblasts may be entirely absent (Fig. 122-28). The second most frequent sclerosing variant that is frequently seen in the retroperitoneal and paratesticular locations is characterized by the presence of enlarged stromal cells with large and hyperchromatic nuclei set in a paucicellular, fibrillary, collagenous stroma, and scattered atypical lipogenic cells and lipoblasts (Fig. 122-29). Rare, inflammatory atypical lipomatous tumors are mainly seen in retroperitoneal and intraabdominal locations, and show a prominent inflammatory infiltrate that mimics features of a lymphoma or an inflammatory pseudotumor.[64] So-called well-differentiated spindle-cell liposarcoma[65] shows a predilection for the subcutaneous tissue of the shoulder girdle and the limbs and is composed of slightly atypical spindled cells with enlarged, hyperchromatic nuclei arranged in fascicles and whorls set in a fibrous and/or myxoid stroma associated with atypical adipocytic cells. Genetic studies emphasize that these neoplasms most likely represent atypical spindle cell lipomatous tumor with a clinical behavior almost identical to atypical lipomatous tumor.[31,32,66] Very rarely, a heterologous differentiation with osseous or myogenic elements is seen. The term

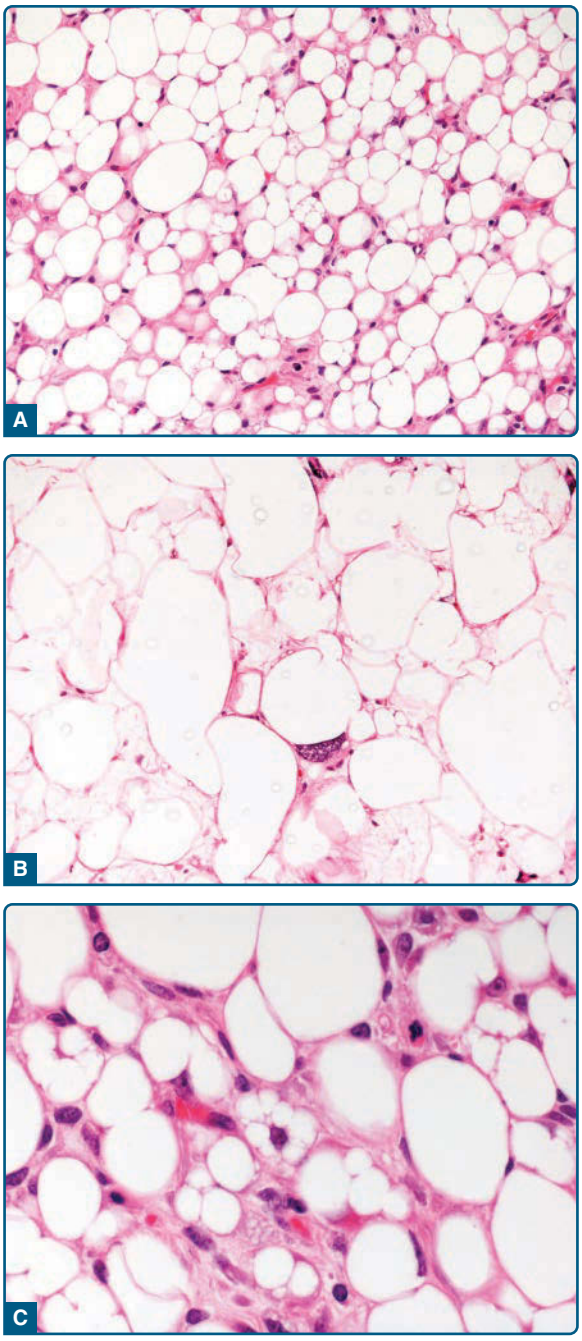

Figure 122-28 Atypical lipomatous tumor. **A,** The lipoma-like variant is composed of lipogenic cells showing marked variation in size and shape. Scattered, enlarged, hyperchromatic nuclei and vacuolated lipogenic cells are noted. Higher-power view reveals enlarged and hyperchromatic nuclei (**B**), as well as multivacuolated lipoblasts (**C**).

lipoleiomyosarcoma has been applied to lesions showing morphologic features of atypical lipomatous tumor and well-differentiated leiomyosarcoma.[67] Immunohistochemically, focal expression of p16, as well as nuclear staining for MDM2 and/or CDK4, is helpful in the differential diagnoses to other lipogenic and nonlipogenic lesions. However, especially, very well-differentiated examples of atypical lipomatous tumor

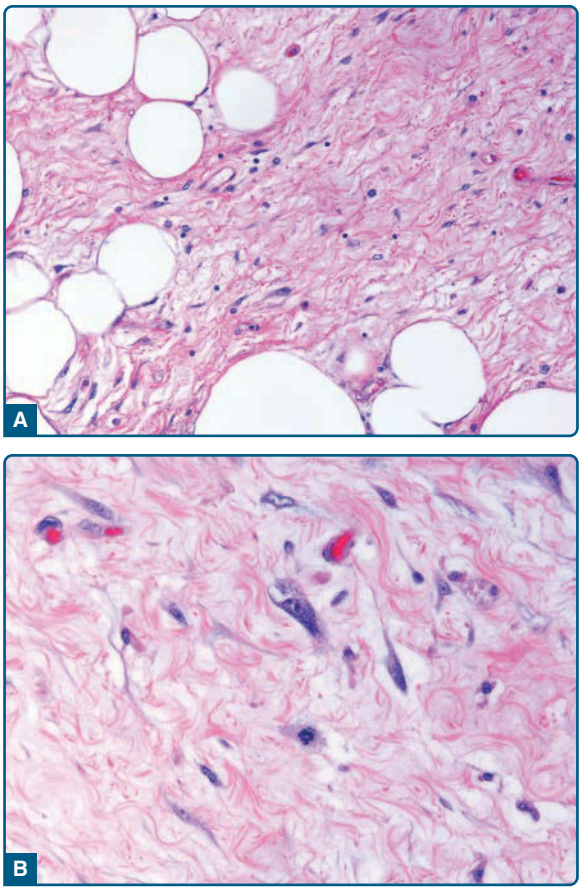

Figure 122-29 Atypical lipomatous tumor. **A,** The presence of a paucicellular stroma with admixed adipocytes characterizes the sclerosing variant. **B,** Note the presence of bizarre-appearing stromal cells set in a fibrillary stroma.

may not show MDM2 and/or CDK4 expression by immunohistochemistry. In these cases, FISH analysis may be very helpful.[68,69]

DIFFERENTIAL DIAGNOSIS

In contrast to atypical lipomatous tumor, typical cases of lipoma are composed of mature adipocytes without nuclear atypia and lipoblasts, and do not stain positively for p16, MDM2, and CDK4. However, traumatized lipomas may contain numerous histiocytes with enlarged nuclei that show a cytoplasmic staining for p16, MDM2, and CDK4, and may mimic a more aggressive neoplasm. Lipoblastoma is composed of a varying number of lipoblasts and may stain positively for p16,[18] but the presence of a lobular lesion with characteristic septa, and the lack of MDM2/CDK4 expression are of help in the differential diagnosis. Spindle-cell lipoma and pleomorphic lipoma may contain scattered lipoblasts, but lack atypia, and neoplastic cells are negative for MDM2 and/or CDK4. Dedifferentiated liposarcoma contains a nonlipogenic component with strong expression of p16, MDM2, and CDK4. Angiomyolipoma is characterized by the presence of thick-walled blood vessels and a perivascular myogenic component staining positively for myogenic marker and HMB-45. Rare cases of massive localized lymphedema simulate clinically and histologically atypical lipomatous tumor,[70] but no significant atypia and no expression of p16, MDM2, and CDK4 are noted in these lesions.

CLINICAL COURSE, PROGNOSIS, AND TREATMENT

The clinical behavior and the prognosis of atypical lipomatous tumor is strongly dependent on the anatomic site, the depth, and the size of the neoplasms. Surgical treatment is curative for lesions arising superficially, and at surgically amenable anatomic sites such as the extremities. The estimated rate of progressing to dedifferentiated liposarcoma is less than 2% with a mortality rate of virtually zero for cases arising at these anatomic locations. In striking contrast, cases of atypical lipomatous tumor arising in deep soft tissues of the retroperitoneum, the mediastinum, intraabdominal cavity, and paratesticular location, where complete surgical excision is problematic and not possible, tend to recur locally, may cause death as a result of uncontrolled local effects, and have a risk of dedifferentiation of more than 20%. The overall mortality of atypical lipomatous tumor in the retroperitoneum is more than 80%.[53,71] Surgical excision is the primary therapeutic approach in cases of atypical lipomatous tumor; adjuvant chemotherapy and radiotherapy may be used in advanced cases.

DEDIFFERENTIATED LIPOSARCOMA

AT-A-GLANCE

- Dedifferentiated liposarcoma represents the morphologic form of progression of atypical lipomatous tumor.
- Dedifferentiated liposarcoma most frequently occurs in the retroperitoneum and intraabdominal cavity as a large tumor mass.
- An abrupt or gradual transition from an atypical lipomatous tumor to a nonlipogenic sarcomatous component is seen in dedifferentiated liposarcoma.
- The nonlipogenic component shows a variable morphology, and a heterologous differentiation is seen in a significant number of cases.
- Dedifferentiated liposarcoma shows the same karyotypic changes as atypical lipomatous tumor.
- Dedifferentiated liposarcoma is best regarded as an intermediate-grade sarcoma (grade 2 of malignancy).

EPIDEMIOLOGY

Dedifferentiated liposarcoma represents the most common pleomorphic sarcoma in the retroperitoneum, and typically affects adult patients in the sixth decade.[72] Dedifferentiation as a morphologic form of tumor progression represents a time-dependent phenomenon, and occurs in approximately 90% of cases as a de novo presentation, whereas 10% develop it in a local recurrence.

CLINICAL FEATURES

The majority of dedifferentiated liposarcomas occur in the retroperitoneum, intraabdominal, and paratesticular locations, whereas an involvement of deep soft tissues of the extremities is seen more rarely. Other rare locations include the trunk, and the head and neck region, presentation in subcutaneous tissue is very rare.[73] Typically, cases of dedifferentiated liposarcoma present as a large painless mass, and are found in the retroperitoneum and intraabdominal locations by chance. A recent increase in size of a longstanding deep-seated mass in the extremities may indicate dedifferentiation in an atypical lipomatous tumor.

ETIOLOGY AND PATHOGENESIS

The karyotypic findings in dedifferentiated liposarcoma are similar to those seen in atypical lipomatous tumor; however, coamplification involving 1p32 and 6q23 with activation of the *JUN* and *ASK2* genes has been reported.[74]

HISTOLOGIC FEATURES

Histologically, an abrupt or gradual transition from areas showing features of atypical lipomatous tumor to nonlipogenic sarcoma areas is characteristic for dedifferentiated liposarcoma (Fig. 122-30). The extent and the morphology of the nonlipogenic component are variable, but in most cases, the dedifferentiated component shows features of a high-grade, undifferentiated, pleomorphic sarcoma (Fig. 122-31). Especially in the retroperitoneum and intraabdominal locations, intermediate-grade or high-grade myxofibrosarcoma areas are present. Occasionally, a low-grade dedifferentiation is noted that mimics features of low-grade fibrosarcoma or desmoid fibromatosis (Fig. 122-32). Heterologous differentiation is seen in approximately 10% of cases, and most often a myogenic or osteosarcomatous/chondrosarcomatous differentiation is detected (Fig. 122-33). More rarely angiosarcomatous

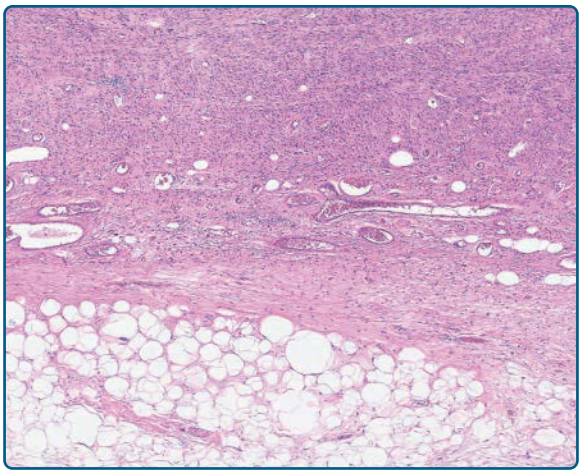

Figure 122-30 Dedifferentiated liposarcoma. A rather abrupt transition from areas showing features of an atypical lipomatous tumor (button) to a nonlipogenic sarcoma is seen.

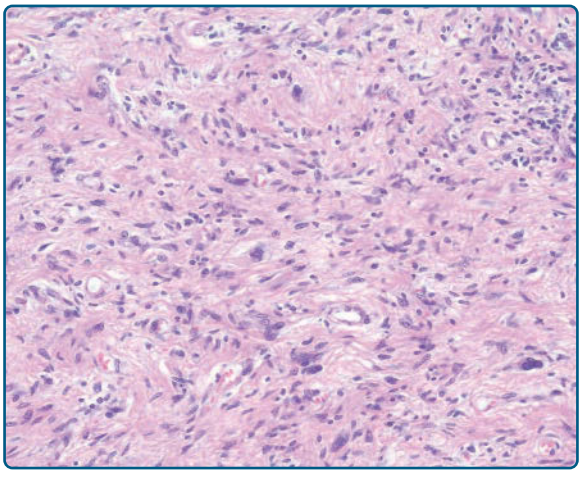

Figure 122-31 Dedifferentiated liposarcoma. The nonlipogenic component often shows features of a rather undifferentiated, pleomorphic sarcoma.

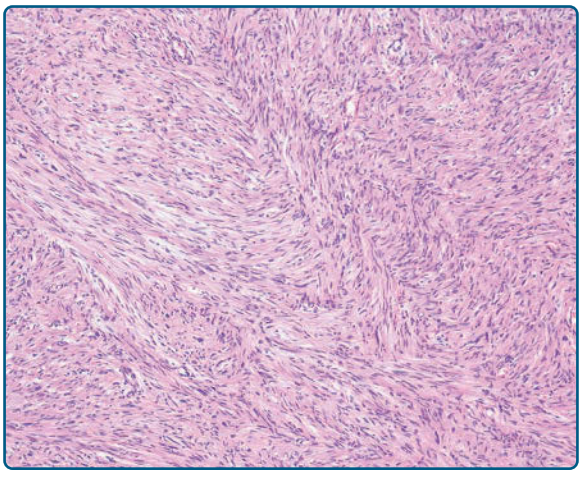

Figure 122-32 Dedifferentiated liposarcoma. Infrequently, a low-grade dedifferentiation with features of a low-grade fibroblastic sarcoma is noted.

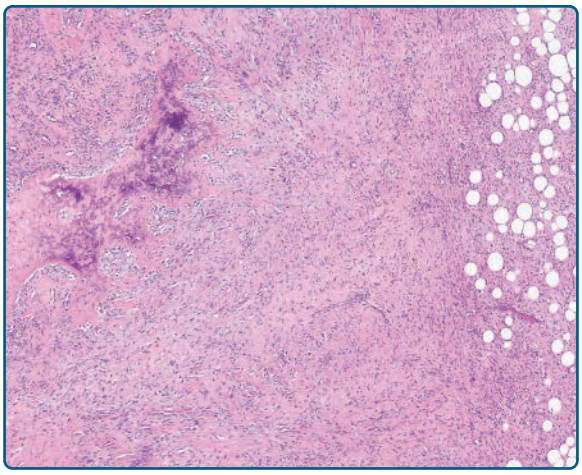

Figure 122-33 Dedifferentiated liposarcoma. A heterologous, osteosarcomatous differentiation with focal calcification is noted in this case.

and meningothelial-like whorls have been reported.[75] Interestingly, the dedifferentiated component may show a lipoblastic differentiation that resembles pleomorphic liposarcoma, but molecular changes are identical to classical dedifferentiated liposarcoma.[76] Immunohistochemically, a strong expression of p16, MDM2, and CDK4 is seen, especially in the nonlipogenic component (Fig. 122-34). Heterologous myogenic differentiation is reflected by positive staining for myogenic (actin, desmin, h-caldesmon, myogenin), osteosarcomatous (SATB2), chondrosarcomatous (S-100 protein), or angiosarcomatous (CD31, ERG) immunohistochemical markers (Fig. 122-35).

DIFFERENTIAL DIAGNOSIS

Given the variable morphology of the nonlipogenic component, the differential diagnosis of dedifferentiated liposarcoma is broad and includes pleomorphic liposarcoma, myxofibrosarcoma, GI stromal tumor, leiomyosarcoma, rhabdomyosarcoma, malignant solitary fibrous tumor, rare fibrosarcoma, and desmoid fibromatosis. In addition, large lipomas with cytologic atypia and atypical spindle cell lipomatous tumor and atypical pleomorphic lipomatous tumor have to be considered, especially when dealing with a small biopsy.

CLINICAL COURSE, PROGNOSIS, AND TREATMENT

Dedifferentiated liposarcoma is characterized by a protracted clinical course with a high risk for local recurrences and a locally aggressive growth. Almost all cases arising in the retroperitoneum and intraabdominal locations recur if followed long enough. However, in contrast to many other high-grade sarcomas, the

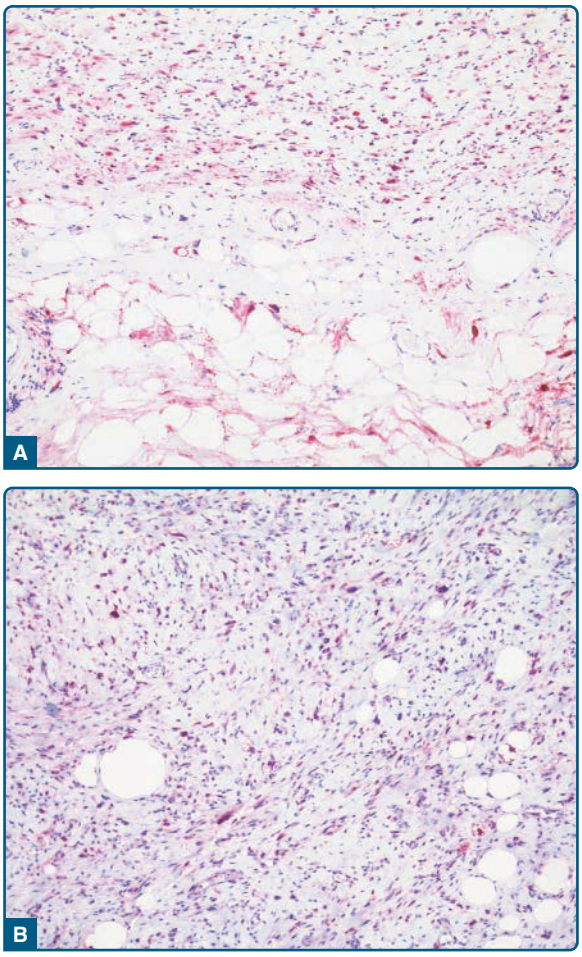

Figure 122-34 Dedifferentiated liposarcoma. Immunohistochemically, an expression of p16 (**A**) and MDM2 (**B**) is seen in the lipogenic and in the nonlipogenic component.

overall risk of distant metastatic spread is estimated at approximately 15% to 20%.[72,77] It can be speculated that the absence of complex karyotypic aberrations and the rarity of p53 mutations in cases of dedifferentiated

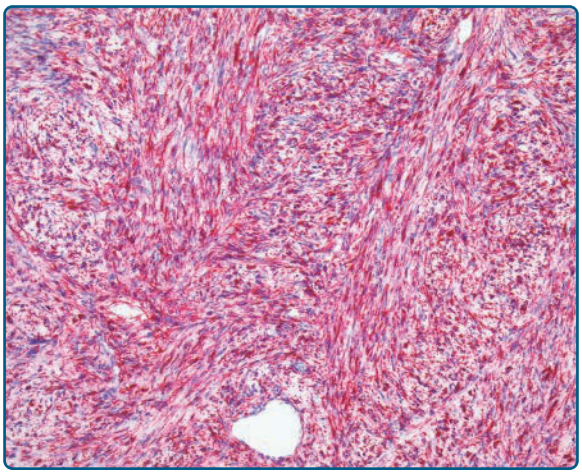

Figure 122-35 Dedifferentiated liposarcoma. Heterologous myogenic differentiation with strong expression of desmin by nonlipogenic spindled tumor cells.

liposarcoma[78] may explain the better outcome. As in cases of atypical lipomatous tumor, the anatomic location is the most important prognostic factor in dedifferentiated liposarcoma, and cases arising in retroperitoneum and intraabdominal locations are associated with a poor prognosis. It has been shown that myogenic differentiation and the histologic grade of the nonlipogenic tumor component are important prognostic parameters.[79] The extent of dedifferentiation is prognostically not predictive. Complete surgical removal represents the treatment of choice; however, especially in the retroperitoneum and in intraabdominal locations, this is often impossible. New therapeutic options targeting the gene products of chromosome 12 or inhibitors of the Akt-mTOR and MAPK (mitogen-activated protein kinase) pathways are under discussion for use in nonresectable cases.[80,81]

MYXOID LIPOSARCOMA

AT-A-GLANCE

- Myxoid liposarcoma usually occurs in deep soft tissues of the extremities, particularly the thigh, of middle-aged adults.
- Myxoid liposarcoma is composed of small, primitive, mesenchymal cells and lipoblasts in varying stages of differentiation with a characteristic vascular pattern.
- The presence of a round cell component is of adverse significant prognostic importance.
- Myxoid liposarcoma is characterized by *FUS-DDIT3* or *EWSR1-DDIT3* rearrangements.

EPIDEMIOLOGY

Myxoid liposarcoma represents the second most frequent variant of liposarcoma and approximately 5% of all soft-tissue sarcomas in adults. Most cases of myxoid liposarcoma arise in young to middle-aged adults; however, a significant number of cases are seen in children and adolescents, representing the most frequent variant of liposarcoma in this age group, and these cases may show unusual morphologic features.[82] In addition an expression of cancer testis antigens, ie, PRAME is seen.[82A]

CLINICAL FEATURES

Cases of myxoid liposarcoma present as a large, painless mass in deep soft tissues of the extremities, and the majority of neoplasms arise on the thigh. Only rarely, myxoid liposarcoma is seen in the subcutis and in the retroperitoneum or intraabdominal locations. The monoclonal origin of cases multifocal myxoid liposarcoma confirms an unusual metastatic pattern in these cases.[83]

ETIOLOGY AND PATHOGENESIS

Cytogenetically, myxoid liposarcoma is characterized by a recurrent translocation t(12;16)(q13;p11) with *FUS-DDIT3* fusion in the majority of cases; more rarely, a t(12;22)(q13:q12) with *EWSR1-DDIT3* fusion is present.[84,85]

HISTOLOGIC FEATURES

The nodular neoplasms are composed of an admixture of uniform, cytologically bland, small, oval, mesenchymal tumor cells, and small, univacuolated or bivacuolated lipoblasts set in a prominent myxoid stroma with microcystic spaces and characteristic branching, thin-walled blood vessels (Fig. 122-36). These well-differentiated neoplasms lack significant cytologic atypia, mitoses, and tumor necrosis. Myxoid/round-cell liposarcoma, and predominantly round-cell liposarcoma, is characterized by progression to more cellular areas containing enlarged round tumor cells with enlarged and overlapping round nuclei (Fig. 122-37). Rarely, myxoid liposarcoma may show prominent adipocytic differentiation mimicking morphologic features of atypical lipomatous tumor (Fig. 122-38),[86] which also has been reported in cases treated with neoadjuvant therapy.[87] In addition, cases of myxoid liposarcoma may show a prominent spindle-cell component (spindle-cell myxoid liposarcoma) or a pleomorphic component (pleomorphic myxoid liposarcoma), and these features are mainly seen in young patients.[82] Immunohistochemically, S-100 protein is variably positive in the high-grade, round-cell component.

DIFFERENTIAL DIAGNOSIS

The differential diagnosis includes benign lesions as lipoblastoma and chondroid lipoma, as well as malignant neoplasms of different lines of differentiation (myxofibrosarcoma, low-grade fibromyxoid sarcoma, extraskeletal myxoid chondrosarcoma, myxoid malignant melanoma).

CLINICAL COURSE, PROGNOSIS, AND TREATMENT

Myxoid liposarcoma tends to recur and may develop distant metastases in up to 40% of patients, and metastases at unusual locations in soft tissues or bone often are observed. Patients with "multifocal" disease at

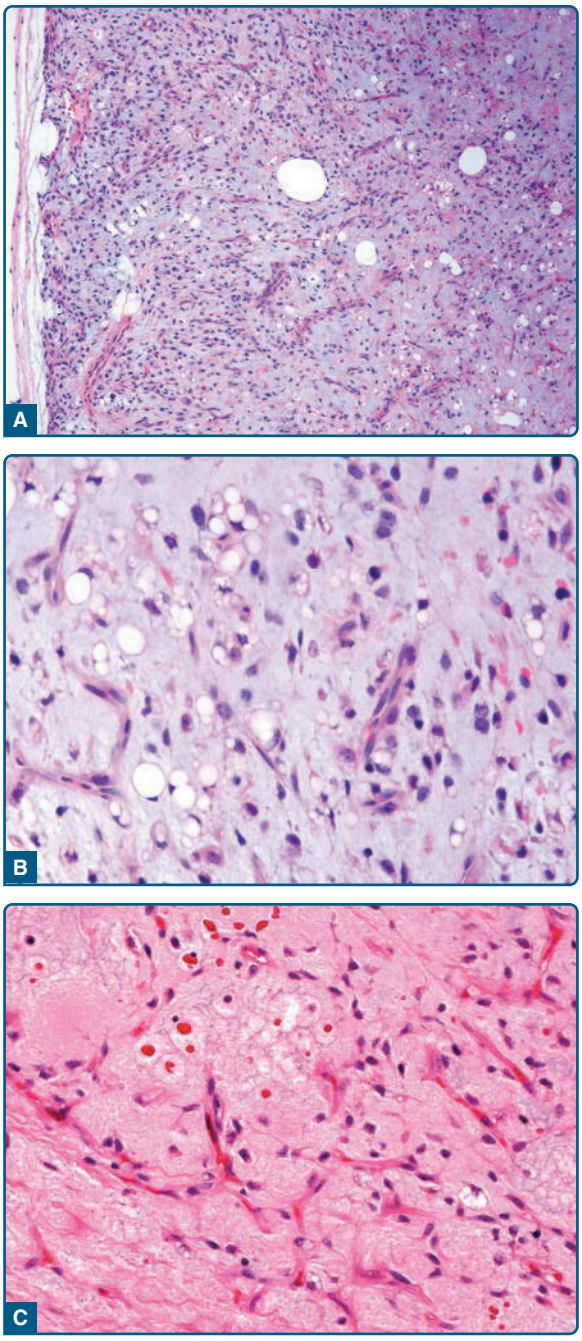

Figure 122-36 Myxoid liposarcoma. **A,** The myxoid neoplasms are lobulated and composed of immature mesenchymal cells and atypical lipogenic cells. Note the increased cellularity in the periphery. **B,** The presence of univacuolated, bivacuolated, and multivacuolated lipoblasts and cytologically bland oval-shaped cells set in a myxoid stroma is a characteristic feature. **C,** Note the delicate branching, capillary sized vessels.

presentation have a poor prognosis, and adverse histologic features include the presence of a round-cell differentiation (>5%), tumor necrosis, p53 overexpression, and *CDKN2A* aberrations.[88,89] It has been shown that advanced cases of myxoid liposarcoma can be treated successfully with trabectedin.[90-92]

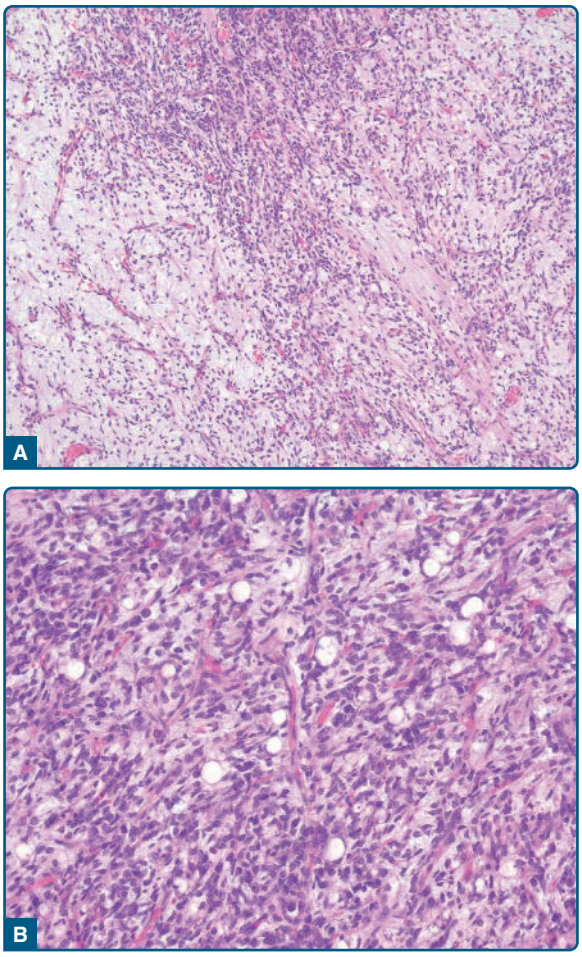

Figure 122-37 Myxoid/round cell liposarcoma. **A,** Areas of increased cellularity with slightly enlarged round tumor cells containing round nuclei are seen. **B,** High-grade round-cell liposarcoma is composed predominantly of enlarged round tumor cells without prominent pleomorphism. Note the characteristic vascular pattern and the presence of lipoblasts.

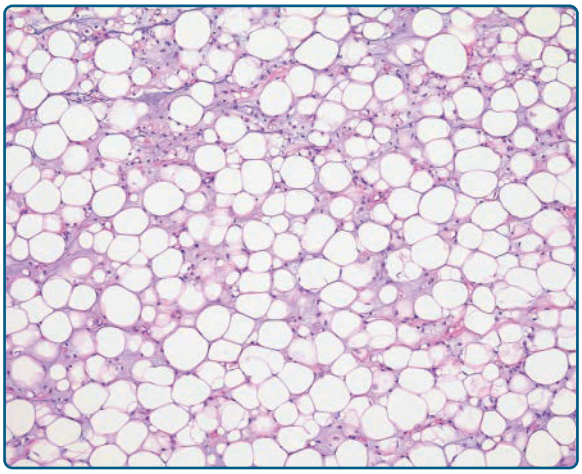

Figure 122-38 Lipogenic myxoid liposarcoma. In some cases of myxoid liposarcoma, a predominant lipogenic differentiation is seen mimicking an atypical lipomatous tumor.

PLEOMORPHIC LIPOSARCOMA

AT-A-GLANCE

- Pleomorphic liposarcoma represents a high-grade sarcoma containing a variable number of pleomorphic lipoblasts.
- Pleomorphic liposarcoma shows a predilection for the extremities of adults.
- Pleomorphic liposarcoma arises either de novo or represents the morphologic form of progression of atypical lipomatous tumor/dedifferentiated liposarcoma.

EPIDEMIOLOGY

Pleomorphic liposarcoma represents the rarest subtype of liposarcoma (5%) and arises predominantly in the elderly with a slight male predominance.[93,94]

CLINICAL FEATURES

Clinically, pleomorphic liposarcoma usually presents as a fast growing neoplasm in deep soft tissues of the extremities (lower > upper extremities), while the trunk, the retroperitoneum, the abdominal cavity, the head and neck region, and the pelvis are only rarely involved. A small but significant number of cases of pleomorphic liposarcoma arise in subcutaneous tissues, whereas purely dermal neoplasms are exceedingly rare (Fig. 122-39).[94-96]

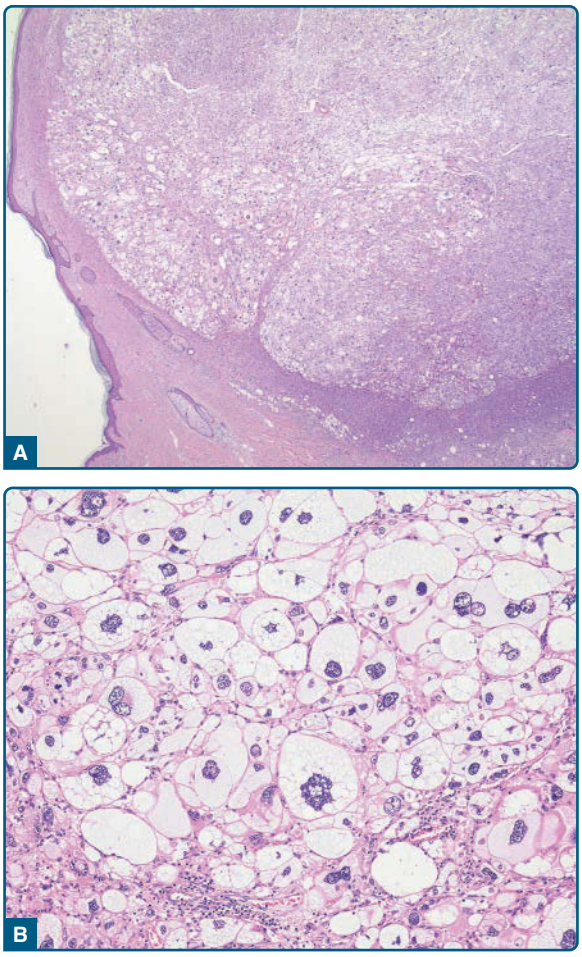

Figure 122-39 Superficial pleomorphic liposarcoma. **A,** An exophytic growing, purely dermal pleomorphic liposarcoma. **B,** Note the presence of pleomorphic lipoblasts, with bizarre, hyperchromatic nuclei.

ETIOLOGY AND PATHOGENESIS

Cytogenetically, many cases of pleomorphic liposarcoma closely resemble other pleomorphic sarcomas and show complex structural rearrangements. However, it has been shown that a small, but significant, number of cases reveal *MDM2* and *CDK4* amplifications, which suggests that these neoplasms represent a tumor progression from atypical lipomatous tumor/dedifferentiated liposarcoma.[76,97]

HISTOLOGIC FEATURES

The well-circumscribed or infiltrative neoplasms show features of a high-grade pleomorphic sarcoma (high-grade fibrosarcoma or "malignant fibrous histiocytoma") containing pleomorphic spindled cells and multinucleated tumor giant cells admixed with a variable number of pleomorphic lipoblasts. These pleomorphic lipoblasts contain enlarged and bizarre, hyperchromatic nuclei scalloped by cytoplasmic lipid droplets, and are scattered throughout the pleomorphic sarcoma or are arranged in larger sheets (Fig. 122-40). Often intracellular and extracellular eosinophilic droplets are noted. Many cases show morphologic features similar to intermediate-grade or high-grade myxofibrosarcoma with scattered pleomorphic lipoblasts (Fig. 122-41). The epithelioid variant of pleomorphic liposarcoma is characterized by large, densely packed, epithelioid tumor cells with abundant eosinophilic cytoplasm and vesicular nuclei resembling renal clear cell carcinoma or adrenal cortical carcinoma.[98] Immunohistochemically, tumor cells in pleomorphic liposarcoma may stain positively for actins, cytokeratins, CD34, and, rarely, desmin.

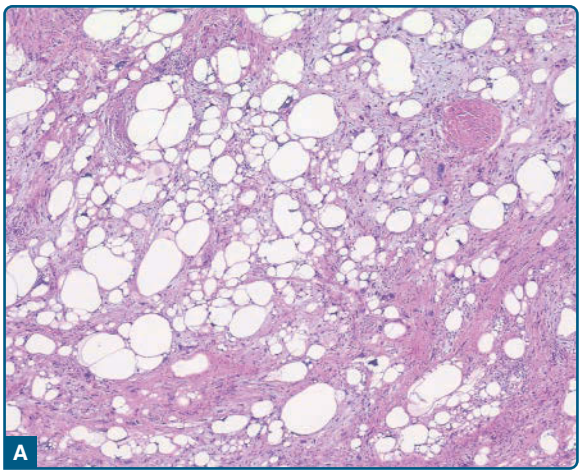

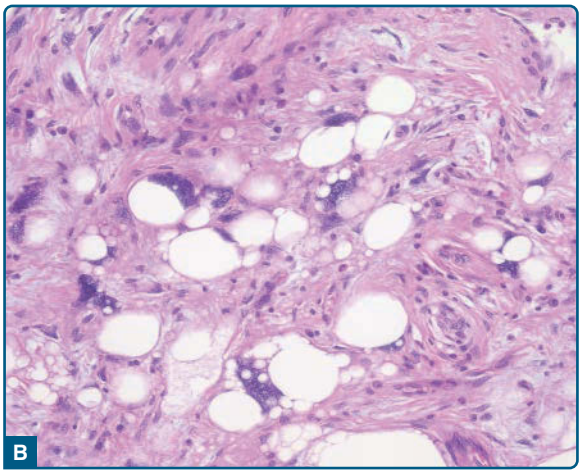

Figure 122-40 Pleomorphic liposarcoma. **A** and **B,** Pleomorphic lipoblasts and atypical lipogenic cells are irregularly admixed with sarcoma cells.

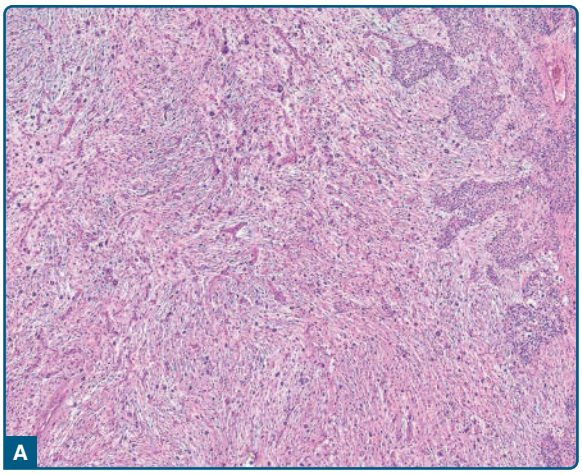

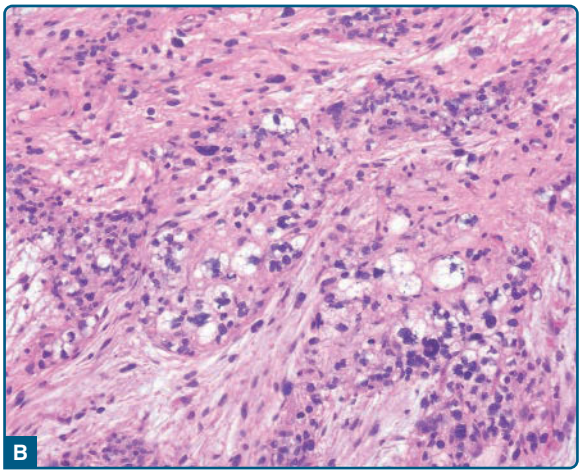

Figure 122-41 Pleomorphic liposarcoma. **A,** The neoplasm shows features of a higher grade myxofibrosarcoma. **B,** Pleomorphic lipoblasts are present at the right side.

DIFFERENTIAL DIAGNOSIS

Dedifferentiated liposarcoma contains an atypical lipomatous tumor component and no pleomorphic lipoblasts. The presence of at least scattered pleomorphic lipoblasts in pleomorphic liposarcoma is important in the differential diagnosis to other pleomorphic, high-grade sarcomas (myxofibrosarcoma, leiomyosarcoma, rhabdomyosarcoma), as well as poorly differentiated, sarcomatoid melanoma and carcinoma.

CLINICAL COURSE, PROGNOSIS, AND TREATMENT

Pleomorphic liposarcoma represents a high-grade sarcoma with a local recurrence and metastatic rate of 30-50%, and an estimated overall 5-year survival rate of 50% to 60%. The lung is the preferred metastatic site. The treatment is surgical excision with radiation and chemotherapy for advanced cases.

REFERENCES

1. Nielsen GP, Mandahl N. Lipoma. In: Fletcher CDM, Bridge JA, Hogendoorn PCW, et al. *World Health Organization Classification of Tumours of Soft Tissue and Bone*. Lyon, France: IARC; 2013.
2. Bannayan GA. Lipomatosis, angiomatosis, and macrocephalia. A previously undescribed congenital syndrome. *Arch Pathol*. 1971;92(1):1.
3. Sandberg AA. Updates on the cytogenetics and molecular genetics of bone and soft tissue tumors: lipoma. *Cancer Genet Cytogenet*. 2004;150(2):93.
4. Petit MM, Mols R, Schoenmakers ET, et al. LPP, the preferred fusion partner gene of HMGIC in lipomas, is a novel member of the LIM protein gene family. *Genomics*. 1996;36(1):118.
5. Fletcher CDM, Martin-Bates E: Intramuscular and intermuscular lipoma: neglected diagnoses. *Histopathology*. 1988;12(3):275.

6. Kuhnen C, Mentzel T, Lehnhardt M, et al. Lipoma and atypical lipomatous tumor within the same neoplasia: evidence for a continuous transition [in German]. *Pathologe*. 2010;31(2):129.
7. Klopstock T, Naumann M, Seibel P, et al. Mitochondrial DNA mutations in multiple symmetric lipomatosis. *Mol Cell Biochem*. 1997;174(1-2):271.
8. Ruppert V, Friedel R, Mentzel T, et al. Fibrolipomatous hamartoma of nerve—a rare etiology of macrodactyly. A case report [in German]. *Handchir Mikrochir Plast Chir*. 1999;31(1):53.
9. Silverman TA, Enzinger FM. Fibrolipomatous hamartoma of nerve. A clinicopathologic analysis of 26 cases. *Am J Surg Pathol*. 1985;9(1):7.
10. Price AJ, Compson JP, Calonje E. Fibrolipomatous hamartoma of nerve arising in the brachial plexus. *J Hand Surg Br*. 1995;20(1):16.
11. Drut R. Ossifying fibrolipomatous hamartoma of the ulnar nerve. *Pediatr Pathol*. 1988;8(2):179.
12. Collins MH, Chatten J. Lipoblastoma/lipoblastomatosis: a clinicopathologic study of 25 tumors. *Am J Surg Pathol*. 1997;21(1):1131.
13. Mentzel T, Calonje E, Fletcher CDM. Lipoblastoma and lipoblastomatosis: a clinicopathological study of 14 cases. *Histopathology*. 1993;23(6):527.
14. Coffin CM, Lowichik A, Putman A. Lipoblastoma (LPB): a clinicopathologic and immunohistochemical study of 59 cases. *Am J Surg Pathol*. 2009;33(11):1705.
15. de Saint Aubain Somerhausen N, Coindre JM, Debiec-Rychter M, et al. Lipoblastoma in adolescents and young adults: report of six cases with FISH analysis. *Histopathology*. 2008;52(3):294.
16. Hibbard MK, Kozakewich HP, Dal Cin P, et al. PLAG1 fusion oncogenes in lipoblastoma. *Cancer Res*. 2000; 60(17):4869.
17. Kubota F, Matsuyama A, Shibuya R, et al. Desmin positivity in spindle cells: under-recognized immunophenotype in lipoblastoma. *Pathol Int*. 2013;63(7):353.
18. Cappellesso R, d'Amore ES, Dall'Igna P, et al. Immunohistochemical expression of p16 in lipoblastomas. *Hum Pathol*. 2016;47(1):64.
19. Mirkovic J, Fletcher CDM. Lipoblastoma-like tumor of the vulva. Further characterization in 8 new cases. *Am J Surg Pathol*. 2015;39(9):1290.
20. Abbasi NR, Brownell I, Fangman W. Familial multiple angiolipomatosis. *Dermatol Online J*. 2007;13(1):3.
21. Sciot R, Akerman M, Dal Cin P, et al. Cytogenetic analysis of subcutaneous angiolipoma: further evidence supporting its difference from ordinary pure lipomas: a report of the CHAMP study group. *Am J Surg Pathol*. 1997;21(4):441.
22. Fanburg-Smith JC, Devaney KO, Miettinen M, et al. Multiple spindle cell lipomas: a report of 7 familial and 11 nonfamilial cases. *Am J Surg Pathol*. 1998;22(1):40.
23. French CA, Mentzel T, Kutzner H, et al. Intradermal spindle cell/pleomorphic lipoma. A distinct subset. *Am J Dermatopathol*. 2000;22(6):496.
24. Billings SD, Henley JD, Summerlin DJ, et al. Spindle cell lipoma of the oral cavity. *Am J Dermatopathol*. 2006;28(1):28.
25. Akaike K, Suehara Y, Takagi T, et al. Spindle cell lipoma of the wrist, occurring in a distinctly rare location. A case report with review of the literature. *Int J Clin Exp Pathol*. 2015;8(3):3299.
26. Flucke U, van Krieken JH, Mentzel T. Cellular angiofibroma: analysis of 25 cases emphasizing its relationship to spindle cell lipoma and mammary-type myofibroblastoma. *Mod Pathol*. 2011;24(1):82.
27. Howitt BE, Fletcher CDM. Mammary-type myofibroblastoma: clinicopathologic characterization in a series of 143 cases. *Am J Surg Pathol*. 2016;40(3):361.
28. Billings SD, Folpe AL. Diagnostically challenging spindle cell lipoma: a report of 34 "low-fat" and "fat-free" variants. *Am J Dermatopathol*. 2007;29(5):437.
29. Hawley IC, Krausz T, Evans DJ, et al. Spindle cell lipoma–a pseudoangiomatous variant. *Histopathology*. 1994;24(6):565.
30. Sachdeva MP, Goldblum JR, Rubin BP, et al. Low-fat and fat-free pleomorphic lipoma: a diagnostic challenge. *Am J Dermatopathol*. 2009;31(5):423.
31. Mentzel T, Palmedo G, Kuhnen C. Well-differentiated spindle cell liposarcoma ("atypical spindle cell lipomatous tumor") does not belong to the spectrum of atypical lipomatous tumor but has a close relationship to spindle cell lipoma: clinicopathologic, immunohistochemical, and molecular analysis of six cases. *Mod Pathol*. 2010;23(5):729.
32. Creytens D, van Gorp J, Savola S, et al. Atypical spindle cell lipoma: a clinicopathological, immunohistochemical, and molecular study emphasizing its relationship to classical spindle cell lipoma. *Virchows Arch*. 2014;465(1):97.

32A. Marino-Enriquez A, Nascimento AF, Logon AH, et al. Atypical spindle cell lipomatous tumor: clinicopathologic characterization of 232 cases demonstrating a morphologic spectrum. *Am J Surg Pathol*. 2017;41(2):234.

32B. Creytens D, Mentzel T, Ferdinande L, et al. "Atypical" pleomorphic lipomatous tumor: a clinicopathologic, immunohistochemical and molecular study of 21 cases, ephasizing its relationship to atypical spindle cell lipomatous tumor and suggesting a morphologic spectrum (atypical spindle cell/pleomorphic lipomatous tumor). *Am J Surg Pathol.* 2017;41(11):1443.

33. Chen BJ, Marino-Enriquez, Fletcher CDM, et al. Loss of retinoblastoma protein expression in spindle cell/pleomorphic lipomas and cytogenetically related tumors: an immunohistochemically study with diagnostic implications. *Am J Surg Pathol*. 2012;36(8):1119.
34. Tardio JC, Aramburu JA, Santonja C. Desmin expression in spindle cell lipomas: a potential diagnostic pitfall. *Virchows Arch*. 2004;445(4):354.
35. Mentzel T, Rütten A, Hantschke M, et al. S-100 protein expression of spindle cells in spindle cell lipoma: a diagnostic pitfall. *Virchows Arch*. 2016;469(4):435.
36. Meis JM, Enzinger FM. Chondroid lipoma. A unique tumor simulating liposarcoma and myxoid chondrosarcoma. *Am J Surg Pathol*. 1993;17(11):1103.
37. Mentzel T, Remmler K, Katenkamp D. Chondroid lipoma. Clinicopathological, immunohistochemical, and ultrastructural analysis of six cases of a distinct entity in the spectrum of lipomas. *Pathologe*. 1999;20(6):330.
38. Villarroel Dorrego M, Papp Y, Shelley MJ, et al. Chondroid lipoma of the tongue: a report of two cases. *Oral Maxillofac Surg*. 2014;18(2):219.
39. Nielsen GP, O'Connell JX, Dickersin GR, et al. Chondroid lipoma, a tumor of white fat cells. A brief report of two cases with ultrastructural analysis. *Am J Surg Pathol*. 1995;19(11):1272.
40. Flucke U, Tops BB, de Saint Aubain Somerhausen N, et al. Presence of *C11orf95-MKL2* fusion is a consistent finding in chondroid lipomas: a study of eight cases. *Histopathology*. 2013;62(6):925.
41. de Vreeze RS, van Coevorden F, Boerrigter L, et al. Delineation of chondroid lipoma: an immunohistochemical and molecular biological analysis. *Sarcoma*. 2011;2011:638403.

42. Meis JM, Enzinger FM. Myolipoma of soft tissue. *Am J Surg Pathol*. 1991;15(12):121.
43. Panagopoulos I, Gorunova L, Agostini A, et al. Fusion of the *HMGA2* and *C9orf92* genes in myolipoma with t(9;12)(p22;q14). *Diagn Pathol*. 2016;11(1):22.
44. Fernandez-Aguilar S, de Saint Aubain Somerhausen N, Dargent JL, et al. Myolipoma of soft tissue: an unusual tumor with expression of estrogen and progesterone receptors. Report of two cases and review of the literature. *Acta Obstet Gynecol Scand*. 2002;81(11):1088.
45. Furlong MA, Fanburg-Smith JC, Miettinen M. The morphologic spectrum of hibernoma: a clinicopathologic study of 170 cases. *Am J Surg Pathol*. 2001;25(6):809.
46. Baldi A, Santini N, Mellone P, et al. Mediastinal hibernoma: a case report. *J Clin Pathol*. 2004;57(9):993.
47. Kumar R, Deaver MT, Czerniak BA, et al. Intraosseous hibernoma. *Skeletal Radiol*. 2011;40(5):641.
48. Mertens F, Rydholm A, Brosjö O, et al. Hibernomas are characterized by rearrangements of chromosome bands 11q13-21. *Int J Cancer*. 1994;58(4):503.
49. Zancanaro C, Pelosi G, Accordini C, et al. Immunohistochemical identification of the uncoupling protein in human hibernoma. *Biol Cell*. 1994;80(1):75.
50. Enzinger FM, Winslow DJ. Liposarcoma. A study of 103 cases. *Virchows Arch Pathol Anat Physiol Klin Med*. 1962;335:367.
51. Kindblom LG, Angervall L, Svendsen P. Liposarcoma a clinicopathologic, radiographic and prognostic study. *Acta Pathol Microbiol Scand*. 1975;253:1.
52. Evans HL. Liposarcoma: a study of 55 cases with a reassessment of its classification. *Am J Surg Pathol*. 1979;3(6):507.
53. Weiss SW, Rao VK. Well-differentiated liposarcoma (atypical lipoma) of deep soft tissue of the extremities, retroperitoneum, and miscellaneous sites. A follow-up study of 92 cases with analysis of the incidence of "dedifferentiation." *Am J Surg Pathol*. 1992;16(11):1051.
54. Evans HL. Atypical lipomatous tumor, its variants, and its combined forms: a study of 61 cases, with a minimum follow-up of 10 years. *Am J Surg Pathol*. 2007;31(1):1.
55. Shmookler BM, Enzinger FM. Liposarcoma occurring in children. An analysis of 17 cases and review of the literature. *Cancer*. 1983;52(3):567.
56. Kuhnen C, Mentzel T, Fisseler-Eckhoff A, et al. Atypical lipomatous tumor in a 14-year-old patient. Distinction from lipoblastoma using FISH-analysis. *Virchows Arch*. 2002;441(3):299.
57. Paredes BE, Mentzel T. Atypical lipomatous tumor/"well-differentiated liposarcoma" of the skin clinically presenting as a skin tag: clinicopathologic, immunohistochemical, and molecular analysis of 2 cases. *Am J Dermatopathol*. 2011;33(6):603.
58. Nascimento AF, McMenamin ME, Fletcher CDM. Liposarcomas/atypical lipomatous tumors of the oral cavity: a clinicopathologic study of 23 cases. *Ann Diagn Pathol*. 2002;6(2):83.
59. Cai YC, McMenamin ME, Rose G, et al. Primary liposarcoma of the orbit: a clinicopathologic study of seven cases. *Ann Diagn Pathol*. 2001;5(5):255.
60. Wenig BM, Weiss SW, Gnepp DR. Laryngeal and hypolaryngeal liposarcoma. A clinicopathologic study of 10 cases with a comparison to soft-tissue counterparts. *Am J Surg Pathol*. 1990;14(2):134.
61. Nucci MR, Fletcher CDM. Liposarcoma (atypical lipomatous tumors) of the vulva: a clinicopathologic study of six cases. *Int J Gynecol Pathol*. 1998:17(1):17.
62. Rosai J, Akerman M, Dal Cin P, et al. Combined morphological and karyotypic study of 59 atypical lipomatous tumors. Evaluation of their relationship and differential diagnosis with other adipose tissue tumors (a report of the CHAMP study group). *Am J Surg Pathol*. 1996;20(10):1182.
63. Sandberg AA. Updates on the cytogenetics and molecular genetics of bone and soft tissue tumors: liposarcoma. *Cancer Genet Cytogenet*. 2004;155(1):1.
64. Kraus MD, Guillou L, Fletcher CDM. Well-differentiated inflammatory liposarcoma: an uncommon and easily overlooked variant of a common sarcoma. *Am J Surg Pathol*. 1997;21(5):518.
65. Dei Tos AP, Mentzel T, Newman PL, et al. Spindle cell liposarcoma, a hitherto unrecognized variant of liposarcoma. Analysis of six cases. *Am J Surg Pathol*. 1994;18(9):913.
66. Italiano A, Chambonniere ML, Attias R, et al. Monosomy 7 and absence of 12q amplification in two cases of spindle cell liposarcoma. *Cancer Genet Cytogenet*. 2008;184(2):99.
67. Folpe AL, Weiss SW. Lipoleiomyosarcoma (well-differentiated liposarcoma with leiomyosarcomatous differentiation): a clinicopathologic study of nine cases including one with dedifferentiation. *Am J Surg Pathol*. 2002;26(6):742.
68. Binh MB, Sastre-Garau X, Guillou L, et al. MDM2 and CDK4 immunostainings are useful adjuncts in diagnosing well-differentiated and dedifferentiated liposarcoma subtypes: a comparative analysis of 559 soft tissue neoplasms with genetic data. *Am J Surg Pathol*. 2005;29(10):1340.
69. Thway K, Flora R, Shah C, et al. Diagnostic utility of p16, CDK4, and MDM2 as an immunohistochemical panel in distinguishing well-differentiated and dedifferentiated liposarcomas from other adipocytic tumors. *Am J Surg Pathol*. 2012;36(3):462.
70. Farshid G, Weiss SW. Massive localized lymphedema in the morbidly obese: a histologically distinct reactive lesion simulating liposarcoma. *Am J Surg Pathol*. 1998;22(10):1277.
71. Lucas DR, Nascimento AG, Sanjay BK, et al. Well-differentiated liposarcoma. The Mayo Clinic experience with 58 cases. *Am J Clin Pathol*. 1994;102(5):677.
72. Henricks WH, Chu YC, Goldblum JR, et al. Dedifferentiated liposarcoma: a clinicopathological of 155 cases with a proposal for an expanded definition of dedifferentiation. *Am J Surg Pathol*. 1997;21(3):271.
73. Yoshikawa H, Ueda T, Mori S, et al. Dedifferentiated liposarcoma of the subcutis. *Am J Surg Pathol*. 1996;20(12):1525.
74. Chibon F, Mariani O, Derre J, et al. ASK1 (MAP3K5) as a potential therapeutic target in malignant fibrous histiocytomas with 12q14-q15 and 6q23 amplifications. *Genes Chromosomes Cancer*. 2004;40(1):32.
75. Nascimento AG, Kurtin PJ, Guillou L, et al. Dedifferentiated liposarcoma: a report of nine cases with a peculiar neurallike whorling pattern associated with metaplastic bone formation. *Am J Surg Pathol*. 1998;22(8):945.
76. Marino-Enriquez A, Fletcher CDM, Dal Cin P, et al. Dedifferentiated liposarcoma with "homologous" lipoblastic (pleomorphic liposarcoma-like) differentiation: clinicopathologic and molecular analysis of a series suggesting revised diagnostic criteria. *Am J Surg Pathol*. 2010;34(8):1122.
77. McCormick D, Mentzel T, Beham A, et al. Dedifferentiated liposarcoma. Clinicopathologic analysis of 32 cases suggesting a better prognosis subgroup among pleomorphic sarcomas. *Am J Surg Pathol*. 1994;18(12):1213.

78. Dei Tos AP, Doglioni C, Piccinin S, et al. Molecular abnormalities of the p53 pathway in dedifferentiated liposarcoma. *J Pathol*. 1997;181(1):8.
79. Gronchi A, Collini P, Miceli R, et al. Myogenic differentiation and histologic grading are major prognostic determinants in retroperitoneal liposarcoma. *Am J Surg Pathol*. 2015;39(5):383.
80. Thway K, Jones RL, Noujaim J, et al. Dedifferentiated liposarcoma: updates on morphology, genetics, and therapeutic strategies. *Adv Anat Pathol*. 2016;23(1):30.
81. Ishii T, Kohashi K, Iura K, et al. Activation of the Akt-mTOR and MAPK pathways in dedifferentiated liposarcoma. *Tumour Biol*. 2016;37(4):4767.
82. Alaggio R, Coffin CM, Weiss SW, et al. Liposarcomas in young patients: a study of 82 cases occurring in patients younger than 22 years of age. *Am J Surg Pathol*. 2009;33(5):645.
82A. Hemminger JA, Toland AE, Scharschmidt TJ, et al. Expression of cancer testis antigens MAGEA1, MAGEA3, ACRBP, PRAME, SSX2, and CTAG2 in myxoid and round cell liposarcoma. *Mod Pathol.* 2014;27(9):1238.
83. Antonescu CR, Elahi A, Healey JH, et al. Monoclonality of multifocal myxoid liposarcoma: confirmation by analysis of TLS-CHOP or EWS-CHOP rearrangements. *Clin Cancer Res*. 2000;6(7):2877.
84. Knight JC, Renwick PJ, Dal Cin P, et al. Translocation t(12;16)(q13;p11) in myxoid liposarcoma and round cell liposarcoma: molecular and genetic analysis. *Cancer Res*. 1995;55(1):24.
85. Dal Cin P, Sciot R, Panagopoulos I, et al. Additional evidence of a variant translocation t(12;22) with EWS/CHOP fusion in myxoid liposarcoma: clinicopathological features. *J Pathol*. 1997;182(4):437.
86. Iwasaki H, Ishiguro M, Nishio J, et al. Extensive lipoma-like changes of myxoid liposarcoma: morphologic, immunohistochemical, and molecular cytogenetic analyses. *Virchows Arch*. 2015;466(4):453.
87. Wang WL, Katz D, Araujo DM, et al. Extensive adipocytic maturation can be seen in myxoid liposarcomas treated with neoadjuvant doxorubicin and ifosfamide and pre-operative radiation therapy. *Clin Sarcoma Res*. 2012;2(1):25.
88. Antonescu CR, Tschernyavsky SJ, Decuseara R, et al. Prognostic impact pf p53 status, *TLS-CHOP* fusion transcript structure, and histological grade in myxoid liposarcoma: a molecular and clinicopathologic study of 82 cases. *Clin Cancer Res*. 2001;7(12):3977.
89. Haniball J, Sumathi VP, Kindblom LG, et al. Prognostic factors and metastatic patterns in primary myxoid/round cell liposarcoma. *Sarcoma*. 2011;2011:538085.
90. Gronchi A, Bui BN, Bonvalot S, et al. Phase II clinical trial of neoadjuvant trabectedin in patients with advanced localized myxoid liposarcoma. *Ann Oncol*. 2012;23(3):771.
91. Grosso F, Jones RL, Demetri GD, et al. Efficacy of trabectedin (ecteinascidin-743) in advanced pretreated myxoid liposarcoma: a retrospective study. *Lancet Oncol*. 2007;8(7):595.
92. Grosso F, Sanfilippo R, Virdis E, et al. Trabectedin in myxoid liposarcomas (MLS): a long-term analysis of a single-institution series. *Ann Oncol*. 2009;20(8):1439.
93. Gebhard S, Coindre JM, Michels JJ, et al. Pleomorphic liposarcoma: clinicopathologic, immunohistochemical, and follow-up analysis of 63 cases: a study from the French Federation of Cancer Centers Sarcoma Group. *Am J Surg Pathol*. 2002;26(5):601.
94. Hornick JL, Bosenberg MW, Mentzel T, et al. Pleomorphic liposarcoma: clinicopathologic study of 57 cases. *Am J Surg Pathol*. 2004;28(10):1257.
95. Dei Tos AP, Mentzel T, Fletcher CDM. Primary liposarcoma of the skin: a rare neoplasm with unusual high grade features. *Am J Dermatopathol*. 1998;20(4):332.
96. Gardner JM, Dandekar M, Thomas D, et al. Cutaneous and subcutaneous pleomorphic liposarcoma: a clinicopathologic study of 29 cases with evaluation of MDM2 gene amplification in 26. *Am J Surg Pathol*. 2012;36(7):1047.
97. Boland JM, Weiss SW, Oliveira AM, et al. Liposarcomas with mixed well-differentiated and pleomorphic features: a clinicopathologic study of 12 cases. *Am J Surg Pathol*. 2010;34(6):837.
98. Miettinen M, Enzinger FM. Epithelioid variant of pleomorphic liposarcoma: a study of 12 cases of a distinctive variant of high-grade liposarcoma. *Mod Pathol*. 1999;12(7):722.

This page intentionally left blank

Metabolic, Genetic, and Systemic Diseases

PART 21

Chapter 123 :: Cutaneous Changes in Nutritional Disease

:: Albert C. Yan

PROTEIN ENERGY MALNUTRITION

AT-A-GLANCE

- *Marasmus* is caused by chronic global nutrient deficiency and characterized by dry, loose, and wrinkled skin with a loss of subcutaneous fat.
- *Kwashiorkor* is caused by inadequate protein or fat in the context of ongoing carbohydrate intake and characterized by generalized edema with a "flaky paint" dermatosis.
- In modern industrialized settings, kwashiorkor may result from excessive intake of rice beverages (young children), anorexia and associated eating disorders (adolescents and young adults), and GI surgery, especially bariatric surgical procedures (adults).
- Particular attention should be given to preventing refeeding syndrome, which is characterized by electrolyte abnormalities.

Nutrition is the complex series of events by which living organisms consume and assimilate foods and other nutrients to live, grow, and maintain homeostasis. Proper nutrition involves the consumption of key macronutrients in balanced tandem with essential micronutrients. Consisting of carbohydrates, proteins, and lipids, macronutrients are those nutrients that are needed in large quantities by an organism to both fuel metabolic processes and provide the substrate for building and maintaining cellular structure. By contrast, micronutrients are vitamins and minerals, which, although necessary to good health, are required in relatively minute quantities. Because humans are unable to synthesize these molecules, clinical disease results when disturbances occur in that equilibrium—most commonly from nutrient deficiencies, but also from an unbalanced ratio of consumed nutrients, or, less commonly, from nutrient excesses.

With an improved understanding of the role of diet in health and the advent of nutritional supplements, longstanding named scourges, such as scurvy, beriberi, and pellagra, have largely become diseases of historical interest. Even so, nutritional diseases remain problematic in developing countries and in settings of war, famine, and poverty. In industrialized countries, nutritional diseases may still arise among the disenfranchised—the homeless and those suffering from alcoholism or other forms of substance abuse. Individuals at risk also include those with derangements in their normal diets, such as might be encountered with eating disorders or unusual dietary habits, as well as with parenteral nutrition. Hypercatabolic states, exemplified by those with cancer, AIDS, hepatic or renal disease, and certain disease states such as carcinoid syndrome, may develop nutrient deficiencies even in the face of normal intake as a consequence of increased metabolic requirements. Excessive nutrient losses may occur as a result of decreased absorption arising from GI diseases such as cystic fibrosis, inflammatory bowel disease, celiac disease, or following GI surgery, especially bariatric procedures. Those receiving chronic medications, such as anticonvulsants or antibiotics, may experience impaired utilization of their nutrients when their medications interfere with GI absorption and normal metabolism. Impaired utilization may derive from underlying genetic metabolic defects, enzyme deficiencies, hepatic disease, or drug–nutrient interactions. In contrast, syndromes of nutrient excess generally stem from dietary surplus or iatrogenic therapeutic intake.

Because macronutrients and micronutrients are intrinsically involved in multiple biochemical pathways, disorders of nutrition may produce extracutaneous consequences. Moreover, those at risk for one nutrient deficiency may be suffering from other concomitant deficiencies as well. Appropriate evaluation of the patient with suspected nutritional disease should commence with a detailed history of dietary and medication intake, a review of past medical and family history, and careful inspection of the skin with special attention to the status of hair, nails, and mucous membranes. Even though some skin findings may be pathognomonic for certain nutritional disorders, physical findings are more often nondiagnostic. Laboratory analysis of blood and urine nutrient levels may be useful, but poor correlation with tissue levels limits their utility. Radiologic imaging studies may also offer corroboration for diseases such as scurvy, rickets, or beriberi. Clinical improvement following replacement therapy may represent the best or only means to confirm the clinical diagnosis of some nutritional deficiencies. This chapter reviews the important clinical features observed in nutritional disease states.

MACRONUTRIENTS

PROTEIN-ENERGY MALNUTRITION

EPIDEMIOLOGY

Malnutrition is a medical concern of global significance. The United Nations estimates that more than 2 billion individuals worldwide are malnourished.[1] As of 2017, estimates are that 150 million children younger than 5 or a quarter of children in this age group, suffered from malnutrition. Approximately 5 million children younger than age 5 years die from malnutrition each year.[2] The global response to malnutrition in financial terms exceeds $3.5 billion.[1]

In developing countries, malnutrition most commonly arises as a result of inadequate dietary intake, often compounded by disease. War, famine, and poverty states often aggravate the inadequate access to food, which may arise from political unrest, natural disasters, infectious diseases, seasonal and climactic factors, insufficient food production, lack of education, poor sanitation, regional and religious practices, and the limited availability of health care.[3] The availability of food in these settings may be limited to diets of corn, rice, and sometimes beans, which provide inadequate amounts of macronutrients and micronutrients. In industrialized countries such as the United States, less than 1% of children nationally suffer from protein-energy malnutrition (PEM). When it is encountered, chronic illness, malabsorption, presumed food allergies, food aversion, nutritional ignorance, and fad diets are more typical etiologies.

ETIOLOGY AND PATHOGENESIS

PEM refers to a spectrum of disorders describing varying degrees of protein and calorie deficiency. Several subtypes of PEM have been defined on the basis of relative deficiencies in protein and total calorie intake.

Children with marasmus are defined as those with severe wasting and stunting and are at less than 60% of expected body weight for age. The term *marasmus* derives from the Greek *marasmos*, meaning wasting. These changes are the result of chronic and global nutrient deficiencies, often because of a lack of available food. Children with kwashiorkor have body weights less than 60% to 80% of that expected for age, generally as a result of being fed grain-derived foods without adequate accompanying protein or fat. This might occur in geographic areas where grains are more plentiful, but more expensive proteins and fats are not. In fact, the term *kwashiorkor* derives from the Ghanaian term for "the one who is deposed," referring to the child who is weaned off of breastmilk onto a carbohydrate-rich but often protein-poor diet when the next child is born. The exclusive use of rice beverages, so-called rice milk products, as a substitute for baby formulas—either because of their lower cost or because of their perceived hypoallergenicity—has been linked to the development of kwashiorkor among infants in the United States as well as other countries.[4-8] A hybrid form of malnutrition in which stunting is associated with edema has been termed *marasmic kwashiorkor*.

The pathophysiology of these disorders can also be conceptualized as adapted and nonadapted forms of starvation. In adapted starvation (marasmus), decreased intake of all macronutrients, particularly carbohydrates, results in suppressed insulin production. As a result, catabolic hormones act unopposed and allow the appropriate conversion of glycogen into glucose. In the early stages of adapted starvation, muscle breakdown occurs within the first 24 hours, which permits gluconeogenesis to release glucose into the systemic circulation. Later, fat breakdown creates ketone bodies, which can also be utilized by the brain and CNS. This reduces the need for further muscle breakdown and, therefore, ammonia synthesis, so that lean body mass and some protein synthesis can be spared. In prolonged states of adapted starvation, wasting occurs and lean body mass is eventually used when all other sources are expended; in the absence of additional nutrient intake, the organism dies. In nonadapted starvation states (kwashiorkor), an imbalance results when intake of carbohydrate is increased relative to decreased intake of protein and fat. In this setting, insulin production is not appropriately suppressed. Without concomitant fat and protein intake, insulin inhibits protein synthesis. Hypoproteinemia, edema, and diarrhea develop, and without protein synthesis, affected individuals are unable to manufacture lipoproteins so fats accumulate, resulting in a fatty liver; more importantly, necessary immune proteins are not produced so patients become susceptible to opportunistic infection and septicemia, which represent major causes of mortality in these patients.

Although the concepts of adapted and nonadapted starvation provide convenient explanations for why some children develop marasmus and others develop kwashiorkor, some controversy exists. For instance, aflatoxins have been detected with greater frequency in patients with kwashiorkor than in those with marasmus.[9] Also, the role of oxidative and nitrosative stress in kwashiorkor is supported by data showing that patients with edematous PEM have lower levels of erythrocyte glutathione and total plasma antioxidants than healthy controls.[10]

CLINICAL FINDINGS

Childhood is marked by periods of significant and rapid growth and development, and nutritional deprivation often manifests as alterations in these patterns of normal growth and development. Failure to thrive, a key finding in patients with PEM, may appear first as wasting in which patients have poor weight gain, and eventually, as decreased rates of linear growth (stunting). Various measurements have been recommended as markers for malnutrition, and include body weight and length/height ratio relative to age, body mass index, triceps, or middle upper arm circumference, as well as skin and hair characteristics.[11,12] Suboptimal neurodevelopmental outcomes, heightened susceptibility to infection, and increased mortality also may be observed in chronically malnourished children.

Marasmus typically affects infants younger than 1 year of age. The physical findings of marasmus include dry, thin, loose, wrinkled skin resulting from loss of subcutaneous fat with an emaciated appearance (Table 123-1 and Fig. 123-1).[13] Hair growth slows and examination may reveal easy hair loss leading to thin, fine, brittle hair and alopecia. Increased lanugo hair also may be present. Nails may also show signs of fissuring with impaired growth.[14] As the body mobilizes all endogenous energy stores to survive, both subcutaneous fat and muscle mass are lost. The loss of buccal fat pads creates the aged or wizened appearance attributed to children with marasmus that has been referred to disparagingly as "monkey facies" (Fig. 123-2). Perianal fat loss can lead to rectal prolapse and abdominal muscle hypotonia may result in abdominal distension.[15] Constipation may alternate with periods of diarrhea that may or may not be associated with concomitant GI tract infection. Angular cheilitis and mucous membrane changes also have been observed in patients with marasmus.[16] Patients often show both decreased resting body temperature and bradycardia.

The hallmark features of kwashiorkor—also known as edematous or "wet" PEM—include failure to thrive in association with edema and is primarily noted in children between 6 months and 5 years of

Figure 123-1 Marasmus. General appearance with advanced disease.

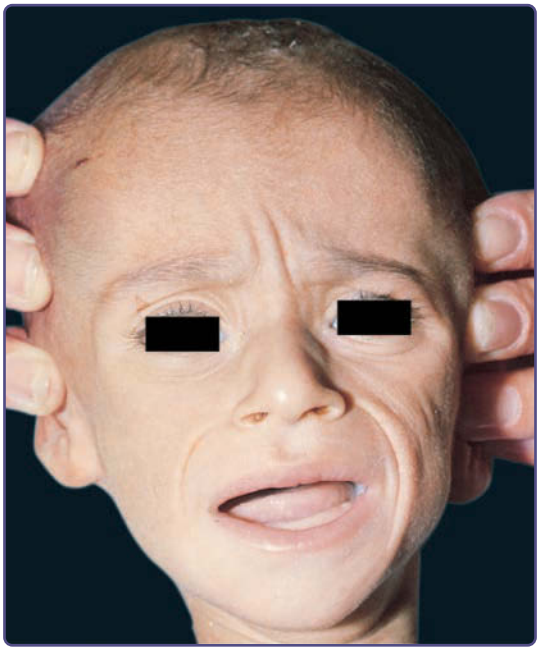

Figure 123-2 Marasmus. "Monkey facies" in an Arab infant, with wrinkled skin and loss of subcutaneous fat.

TABLE 123-1
Clinical Features of Marasmus

- Affects infants younger than age 1 year
- Failure to thrive
- Dry, thin, loose, wrinkled skin
- Hair loss; fine, brittle hair; alopecia
- Fissuring and impaired growth of nails
- Loss of subcutaneous fat and muscle mass
- Loss of buccal fat (monkey facies)
- Rectal prolapse, abdominal distension
- Diarrhea, constipation
- Angular cheilitis

TABLE 123-2
Clinical Features of Kwashiorkor

- Affects children between 6 months and 5 years of age
- Failure to thrive, edema
- Irritability, lethargy, apathy
- Generalized dermatitis likened to "flaking enamel paint," "cracked pavement"
- Increased pigmentation on arms and legs
- Hair color changes (red tint → gray-white; "flag sign")
- Distension of abdomen

age (Table 123-2). Children are often irritable, but may become lethargic and apathetic. In contrast to marasmus, skin findings are common in kwashiorkor. The generalized dermatitis in edematous PEM has been likened to flaking enamel paint, with the pattern of skin fissuring suggesting cracked or "crazy" pavement (Fig. 123-3). Increased pigmentation of skin may be observed on extensor surfaces of the arms and legs. Hair often changes from its natural color, typically developing a red tint before further pigment dilution results in light, gray-white hair (Fig. 123-4B). If a child experiences intermittent periods of kwashiorkor and improved nutrition, alternate bands of light and dark color within the hair shaft may be observed and has been referred to as the "flag sign" (Fig. 123-4A). Increased lanugo hair can also be noted in kwashiorkor. In addition to the peripheral edema, a direct consequence of hypoproteinemia, distension of the abdomen is noted as a result of fatty infiltration of the liver.

Adults also may be at risk for PEM, particularly those suffering from chronic illnesses, eating disorders such as anorexia nervosa, and the elderly. The prevalence of PEM in adult dialysis patients has been estimated at 25% to 50% and is posited to occur as a result of semistarvation with inadequate caloric and protein intake, possibly complicated by the presence of a chronic systemic inflammatory response to dialysis.[17,18] Cases of macronutrient PEM have been reported as a complication of bariatric surgery.[19-21] The manifestations of PEM

Figure 123-3 The "flaky paint" or "crazy pavement" dermatitis of kwashiorkor.

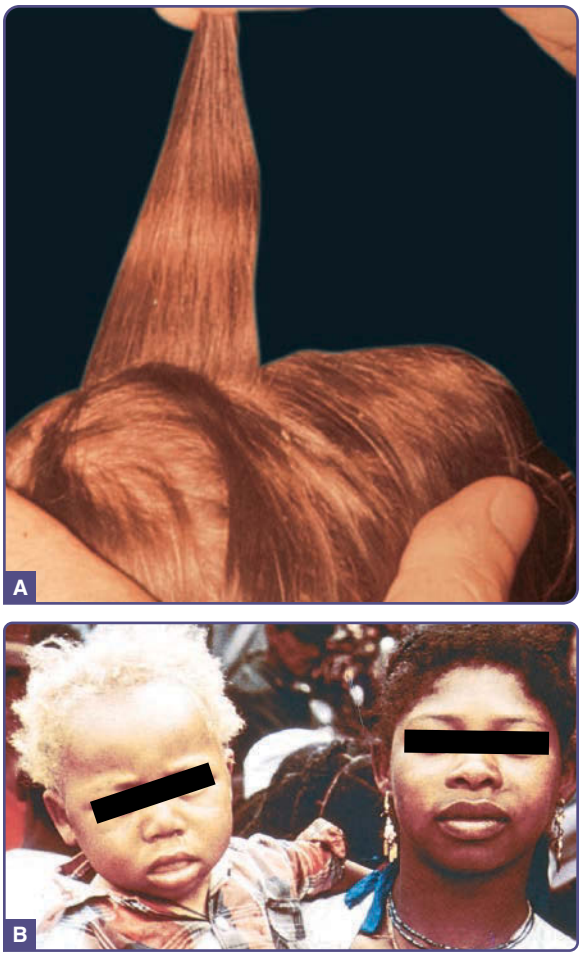

Figure 123-4 **A,** Flag sign in a Salvadoran child. **B,** Hypomelanization of the hair and skin.

in adults may be less prominent, manifesting more as xerosis or acquired ichthyosis, and may be the result of decreased sebaceous gland secretions or concurrent micronutrient deficiency.[22] Hyperpigmentation at characteristic sites also may be present, including the perioral, periocular, and malar areas. Diffuse telogen effluvium, lanugo, and thin, dry, dull hair also has been reported in adult PEM.[23]

LABORATORY TESTING

Initial laboratory testing in PEM as recommended by the World Health Organization[24] includes screening for hypoglycemia and anemia, and an investigation into potential comorbid infectious diseases. Because patients with PEM are at a significantly increased risk of serious infection, urinalysis for bacterial infection, blood smear for malaria parasites, and examination of feces for blood, ova, and parasites are essential. Skin testing for tuberculosis should be performed. Chest radiography may demonstrate concomitant signs of bacterial pneumonia, tuberculosis, heart failure, rickets, and fractures. Patients with kwashiorkor will also demonstrate hypoproteinemia, which may help guide treatment and prognosis. Evaluation of

electrolyte levels before treatment should be interpreted with caution, as refeeding will likely alter mineral balances.

Elevated soluble CD14 levels are associated with indicators of protein-energy wasting, such as low body mass index and muscle atrophy, and increased mortality in hemodialysis patients. CD14 is a coreceptor that triggers immune activation in response to various ligands, including endotoxins and bacterial products. In patients with chronic renal failure on hemodialysis, increased soluble CD14 is associated with elevated markers of systemic inflammation, such as C-reactive protein, interleukin 6, fibrinogen, and plasma pentraxin 3. This suggests a possible link between chronic inflammation, PEM, and mortality in hemodialysis patients.[25] In one recent study, C-reactive protein elevation of greater than 15 mg/L and low phosphate in the context of PEM were documented as risk factors for greater mortality.[26]

Histologic evaluation is generally unnecessary because the clinical features in association with an appropriate history are diagnostic. However, histologic evaluation of the skin reveals increased thickness of the stratum corneum, atrophy of the granular layer, increased basal layer pigmentation, reduction of collagen fibers, and crowding of elastic fibers. Atrophy of the hair appendages with sparing of the sweat gland apparatus can also be noted.[27]

DIFFERENTIAL DIAGNOSIS

Table 123-3 outlines the differential diagnosis of PEM.

TREATMENT

Patients with severe PEM often require hospitalization because of the concurrent risks of hypoglycemia, hypothermia, dehydration, and sepsis. Individuals who are not awake and responsive may require intravenous hyperalimentation during the initial stages of therapy; care must be taken to avoid excessively rapid rehydration because of the risks of congestive heart failure. Oral refeeding using oral rehydration salts containing a mixture of essential electrolytes, at least until diarrhea subsides, or fortified formulas as soon as these can be tolerated, is generally preferred. Because severely malnourished children are relatively immunocompromised, empiric antibiotic therapy may be considered on admission for suspected sepsis, and any identified infections should appropriately addressed.[24]

TABLE 123-3

Differential Diagnosis of Protein-Energy Malnutrition

- Acrodermatitis enteropathica
- Atopic dermatitis
- Seborrheic dermatitis
- Langerhans cell histiocytosis

ESSENTIAL FATTY ACIDS

AT-A-GLANCE

- *Function:* cell membrane fluidity, inflammatory mediators, and lamellar granule formation in the stratum corneum.
- *Sources:* fish oil and vegetable oil.

EPIDEMIOLOGY

Naturally occurring essential fatty acids (EFAs) deficiency states are uncommon in humans. Cases of deficiency arise, instead, from inadequate intake, malabsorption, or excessive loss. In the past, parenteral nutrition was a common cause of EFA deficiency, but with the introduction of lipid supplementation during parenteral nutrition in 1975, the incidence of EFA deficiency has decreased substantially. However, acquired EFA deficiency may arise as a result of recent attempts at lipid minimization. Neonates receiving lipid emulsions as an adjunct to parenteral nutrition for more than 21 days are at increased risk of parenteral nutrition-associated liver disease. There has been some interest in substituting soybean oil emulsions in lieu of fish oil emulsions to reduce the risk of hepatopathy, but their use has been linked to an increased incidence of EFA deficiency.[28]

Patients at risk for EFA deficiency include those with poor dietary intake, including alcoholics and patients with anorexia nervosa, and those with malabsorptive conditions such as biliary disease, inflammatory bowel disease, postgastrointestinal surgery (eg, bariatric surgery), and may represent one of the primary etiologies for the rash observed in cystic fibrosis patients.[29] Premature low-birthweight infants are born with inadequate EFA stores and are also at risk.

ETIOLOGY AND PATHOGENESIS

EFAs represent a group of 18-carbon, 20-carbon, or 22-carbon polyunsaturated fatty acids that cannot be synthesized de novo by the human body. The ω-3 series of fatty acids is found in fish oils, and is derived from α-linoleic acid. The ω-6 series is found in vegetable oils, and is derived from linoleic acid.[13] Linoleic acid and α-linoleic acid are the 2 EFAs that serve as precursors for other EFAs and thus must be obtained from dietary intake. In cell membranes, EFAs increase lipoprotein unsaturation to modulate cell membrane fluidity. Arachidonic acid, a derivative of linoleic acid, is converted into prostaglandins, eicosanoids, and leukotrienes. In the epidermis, linoleic acid contributes to lamellar granule formation in the stratum corneum. Therefore, EFAs play a number of key roles in maintaining homeostasis.

TABLE 123-4
Skin Manifestations of Essential Fatty Acid Deficiency

- Xerosis
- Scaly erythema, intertriginous erosions
- Traumatic purpura, poor wound healing
- Brittle nails, alopecia
- Hyperpigmentation and hypopigmentation of hair

CLINICAL FINDINGS

Skin manifestations of EFA deficiency include: xerosis and scaly, diffuse erythema, and associated intertriginous erosions. Poor wound healing, traumatic purpura secondary to capillary fragility, brittle nails, and alopecia may be observed. Affected individuals may also demonstrate hyperpigmentation or hypopigmentation of the hair (Table 123-4). Extracutaneous findings include fatty liver infiltration, increased susceptibility to infection, a blunted immune response, anemia, thrombocytopenia, and growth retardation.

LABORATORY TESTING

In EFA deficiency states, linoleic acid levels are low and the enzymes that normally convert linoleic acid to arachidonic acid use oleic acid to create an abnormal byproduct. Consequently, laboratory evaluation would demonstrate decreased levels of linoleic and arachidonic acids, and elevated plasma levels of an abnormal intermediary, 5,8,11-eicosatrienoic acid. Measurements documenting an increased ratio (≥0.2) of this abnormal intermediary relative to arachidonic acid are diagnostic for EFA deficiency.

TREATMENT

Although topical application of sunflower seed and safflower oils that contain linoleic acid may improve the clinical cutaneous findings of EFA deficiency,[30] topical absorption is unpredictable[31] and optimal treatment typically consists of oral or intravenous supplementation of EFA. To prevent EFA deficiency, EFA should represent 1% to 2% of total daily calories.[32]

MICRONUTRIENTS

FAT-SOLUBLE VITAMINS

AT-A-GLANCE

- Vitamins A, D, E, and K.
- Vitamin A deficiency is the most common cause of preventable childhood blindness in the world.
- Carotenemia results from excess carotene not converted to vitamin A in the intestinal mucosa deposits in stratum corneum.
- Understanding of the full function of vitamin D is still evolving.
- Vitamin D supplementation is recommended for exclusively breastfed infants, and others who have inadequate oral intake or sun exposure.
- Hemorrhagic disease of the newborn results from vitamin K deficiency and can present with a spectrum of bleeding, from ecchymoses to intracranial hemorrhage.

VITAMIN A (RETINOL)

Etiology and Pathogenesis: Vitamin A is a fat-soluble vitamin important in retinal photoreceptor function, epithelial proliferation, and keratinization. The two most clinically important metabolites of vitamin A are retinal, which is a key component of rhodopsin generation, and retinoic acid, which regulates cell differentiation.[33] Dietary intake of vitamin A derives from both plant and animal sources. Plant sources include dark, green, leafy vegetables, red palm oil, and brightly colored fruits such as papaya, mango, carrots, tomatoes, apricots, and cantaloupe. In plants, the vitamin A precursor beta-carotene can be found as a 2-molecule complex of the carotenoid known as retinal. The retinal can be later reduced to retinol in the intestinal villous cells. Animal sources of vitamin A include egg yolk, liver, fish, fortified milk, and other dairy products. In animal sources, vitamin A exists as retinyl esters, which are hydrolyzed to retinol in the intestinal lumen and absorbed into intestinal mucosal cells. All retinol vitamin A alcohol is esterified to retinyl esters within the intestinal mucosa, released into the bloodstream bound to chylomicrons, and then transported to the liver for storage. Here, retinol can be stored as retinyl esters in the liver; when needed, this storage form may be converted to retinol and bound to retinol binding protein and transthyretin and circulated throughout the body.

VITAMIN A DEFICIENCY

Epidemiology: Vitamin A deficiency (VAD) can result in both cutaneous and ocular complications. It is, in fact, the most common cause of preventable blindness in children, according to the World Health Organization. VAD also is associated with defects in immune regulation.

Etiology and Pathogenesis: The primary causes of VAD continue to be inadequate intake, fat malabsorption states, and liver disease. In the United States, inadequate intake can be seen in individuals with eating disorders, restrictive diets, and chronic illness. Because vitamin A is fat-soluble, conditions associated with malabsorption of fat, such as pancreatic

TABLE 123-5
Manifestations of Vitamin A Deficiency

- **Ocular**
  - Impaired dark adaption
  - Xerophthalmia
  - Corneal xerosis, ulceration, keratomalacia
  - Corneal perforation, blindness
- **Cutaneous, Mucocutaneous**
  - Xerosis
  - Skin fissuring (dermatomalacia)
  - Phrynoderma
  - Mucosa
  - Xerostomia
  - Hypotonia
  - Hypogeusia

or biliary tract disease, celiac disease, Crohn disease, Shwachman-Diamond syndrome, cystic fibrosis, cholestatic liver disease, chronic intestinal parasitic infection, and gastric bypass surgery, can predispose a person to VAD.

Clinical Findings: Table 123-5 outlines the manifestations of VAD. The earliest manifestations are ocular changes. Impaired dark adaptation (nyctalopia), is followed by xerophthalmia, and as corneal keratin desquamates and overgrowth of *Corynebacterium xerosis* on the sclera occurs, white patches known as *Bitot spots* develop. Severe deficiency may lead to corneal xerosis, ulceration, and keratomalacia, which may result in corneal perforation, prolapse of the iris, and blindness (Fig. 123-5).

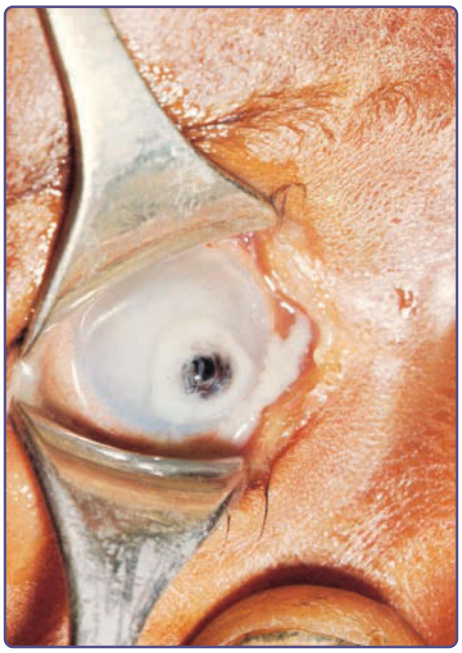

Figure 123-5 Vitamin A deficiency, advanced keratomalacia, in a 5-month-old Arab child. Note hyperkeratosis of facial skin. Serum vitamin A level was 2 mcg/dL (normal: 20-50 mcg/dL).

Figure 123-6 Vitamin A deficiency. Typical perifollicular hyperkeratosis of the chest in a Tanzanian adult male.

The cutaneous findings of VAD are the result of abnormal keratinization. Mild deficiency may manifest as xerosis and scaling, whereas more-severe deficiency may result in deep skin fissuring referred to as *dermomalacia*. Squamous metaplasia of the salivary glands, as well as of the nasal and oral mucosa, may occur, leading to xerostomia, hyposmia, and hypogeusia. Laryngeal, bronchial, and vaginal mucosa can also become involved.

Phrynoderma, "toad skin" (Greek for toad + skin), is typically associated with VAD. These keratotic follicular papules often first develop on the anterolateral thighs and posterolateral upper arms, which then spread to extensory surfaces of the extremities, shoulders, abdomen, back, buttocks, face, and posterior neck (Fig. 123-6). Lucius Nicholas noted the association between this hyperkeratotic folliculitis or phrynoderma with VAD in 1933, when he observed these cutaneous findings among East African workers who developed night blindness and xerophthalmia.[34] Although originally reported in association with VAD, phrynoderma is a nonspecific finding that can be observed with deficiencies in B-complex vitamins, vitamin C, vitamin E, EFA deficiency, PEM, and general malnutrition states.[35]

Laboratory Testing: Vitamin A levels can be measured from serum. Normal serum levels are between 20 and 50 mcg/dL (Table 123-6). Recently, assessment for the hydrolysis of retinoyl glucuronide to retinoic acid has shown promise as an adjunctive test for VAD. Retinoyl glucuronide is a water-soluble form of vitamin A that is not absorbed or hydrolyzed to retinoic acid in vitamin A–replete humans. The presence of serum retinoic acid for 4 hours after oral administration of retinoyl glucuronide is correlated with low serum retinol.[36]

Treatment: An international unit is equivalent to 0.3 mcg of retinol or 0.6 mcg of beta-carotene.[37] The recommended daily allowance (RDA) of vitamin A is between 700 mcg (adult females) to 900 mcg

TABLE 123-6
Diagnostic Tests for Vitamin Deficiency

CONDITION	LABORATORY TESTS	NORMAL VALUES[a]	DEFICIENCY[a]
Vitamin A	Serum vitamin A levels/plasma retinol	20-50 mcg/dL	<20 mcg/dL (<0.70 µmol/L)–deficiency[c]
	Relative dose–response test: serum retinoic acid in serum after oral retinoyl administration glucuronide	In normal states, oral retinoyl administration leads to a *decrease* in serum retinoic acid	Serum retinoic acid *increase* of at least 20% indicates low liver vitamin A reserves
Vitamin D (calcitriol)	Serum 25-hydroxyvitamin D levels	≥50 nmol/L (≥20 ng/mL)[d]	<30 nmol/L (<12 ng/mL)–deficiency[d] 30-50 nmol/L (12-20 ng/mL)–inadequate for bone health[d]
Vitamin K (phytonadione)	Prothrombin time (PT) Activated partial thromboplastin time (PTT) Serum vitamin K des-γ-carboxy prothrombin (DCP)	11-13 seconds[e]	>13 seconds[e]
Vitamin B_1 (thiamine)	Erythrocyte thiamine transketolase	0-15%[f]	15%-25%–marginal deficiency[f] >25%–deficiency[f]
Vitamin B_2 (riboflavin)	Erythrocyte glutathione reductase activity coefficient Total riboflavin excretion	≤1.2 120 mcg/day[g]	1.2-1.4–marginal deficiency[e] >1.4–deficiency[g] <40 mcg/day–deficiency[g]
Vitamin B_3 (niacin)	Urinary *N*-methylnicotinamide and pyridone[b]	1	≤1–deficiency
Vitamin B_6 (pyridoxine)	Plasma pyridoxal-5-phosphate	>30 nmol/L[f]	20-30 nmol/L–marginal deficiency[h] <20 nmol/L–deficiency[h]
Vitamin B_9 (folate)	Serum folic acid levels Erythrocyte folate concentration	>3 ng/mL[i] >140 ng/mL[i]	<3 ng/mL[i] <140 ng/mL[i]
Vitamin B_{12} (cobalamin)	Serum cobalamin levels	350 ng/mL or higher[j]	<350 ng/mL[j] 1000 nmol/L–deficiency[j]
	Methylmalonic acid levels	<280 nmol/L[k]	>400 nmol/L[k]
Vitamin C (ascorbic acid)	Leukocyte ascorbate levels	>11.4 µM (0.2 mg/dL)[k]	<75 mg/L; <11.4 µM or 0.2 mg/dL–deficiency[l]

[a]There may be a wide range of normal values between laboratories. Values also differ between age groups.
[b]Urinary excretion of *N*-methyl-2-pyridone-5-carboxamide decreases to a greater extent than *N*-methylnicotinamide.
[c]Data from the National Institutes of Health (NIH), Office of Dietary Supplements. Vitamin A fact sheet for health professionals. https://ods.od.nih.gov/factsheets/VitaminA-HealthProfessional/ and Ross A. Vitamin A and carotenoids. In: Shils M, Shike M, Ross A, et al, eds. *Modern Nutrition in Health and Disease*. 10th ed. Baltimore, MD: Lippincott Williams & Wilkins; 2014.
[d]Data from the NIH, Office of Dietary Supplements. Vitamin D fact sheet for health professionals. t https://ods.od.nih.gov/factsheets/VitaminD-HealthProfessional/.
[e]Data from the NIH, Office of Dietary Supplements. Vitamin K fact sheet for health professionals. https://ods.od.nih.gov/factsheets/list-all/VitaminK/.
[f]Data from the NIH, Office of Dietary Supplements. Thiamin fact sheet for health professionals. https://ods.od.nih.gov/factsheets/Thiamin-HealthProfessional/.
[g]Data from the NIH, Office of Dietary Supplements. Riboflavin fact sheet for health professionals. https://ods.od.nih.gov/factsheets/Riboflavin-HealthProfessional/.
[h]Data from the NIH, Office of Dietary Supplements. Vitamin B_6 fact sheet for health professionals. https://ods.od.nih.gov/factsheets/VitaminB6-HealthProfessional/.
[i]Data from the NIH, Office of Dietary Supplements. Folate fact sheet for health professionals. https://ods.od.nih.gov/factsheets/Folate-HealthProfessional/.
[j]Data from the NIH, Office of Dietary Supplements. Vitamin B_{12} fact sheet for health professionals. https://ods.od.nih.gov/factsheets/VitaminB12-HealthProfessional/.
[k]Data from the NIH, Office of Dietary Supplements. Vitamin C fact sheet for health professionals. https://ods.od.nih.gov/factsheets/list-all/VitaminC/.

(adult males) (Table 123-7), with younger individuals requiring a lower intake of vitamin A. Lower levels are recommended during pregnancy and higher levels are recommended during lactation. Recommended treatment of VAD is 600 to 3000 mcg of oral vitamin A daily until symptoms resolve and serum levels normalize. Repletion dosages depend on the age of the patient, and require conversion to the appropriate food-related equivalent.[38]

VITAMIN A TOXICITY

Additional information is found in Chap. 213.

Epidemiology: In 1856, Elisha Kent Kane published his 2-volume *Arctic Explorations*, which included accounts of vitamin A toxicity that resulted after his team ingested polar bear liver during his expedition. The toxic substance in polar bear liver was later identified as vitamin A. Since that time, studies have shown that animal livers contain exceptionally high amounts of vitamin A.

Vitamin A toxicity is the result of excess intake of vitamin A and can occur on an acute or chronic basis. Acute toxicity occurs when excessive amounts of vitamin A are ingested over a period of several hours or days. Toxicity typically results when intake exceeds

TABLE 123-7
Summary of Recommended Daily Allowances in Vitamin Deficiency

DEFICIENCY	RDA	TREATMENT DOSE
Vitamin A	Adult (males): 900 mcg[a] Adult (females): 700 mcg[a]	600-3000 mcg/day until symptoms resolve
Vitamin D (calcitriol)	RDA: 15 mcg[b]	200-400 mcg/day × 2-3 months
Vitamin E (tocopherol)	RDA: 15 mg/day[c]	Deficiency states rare
Vitamin K (phytonadione)	Adult (males): 120 mcg[d] Adult (females): 90 mcg[d]	Acute: Fresh-frozen plasma Parenteral or intramuscular (IM) 5-10 mg vitamin K per day
Vitamin B_1 (thiamine)	Adult (males): 1.2 mg[e,f] Adult (females): 1.1 mg[f]	Beriberi: 50-100 mg/day for 1-2 weeks, IV or IM, then oral supplementation until recovered
Vitamin B_2 (riboflavin)	Adult (males): 1.3 mg[g,h] Adult (females): 1.1 mg[h]	Infants, children: 1-3 mg/day Adults: 10-20 mg/day
Vitamin B_3 (niacin)	15-20 mg of niacin or 60 mg of exogenous tryptophan	500 mg/day of nicotinamide or nicotinic acid
Vitamin B_6 (pyridoxine)	Adult (males): 2 mg/day Adult (females): 1.6 mg/day Infants: 0.3 mg/day	Replacement therapy of 100 mg of pyridoxine per day
Vitamin B_9 (folate)	400 mcg/day[i]	1-5 mg of folic acid per day; rule out concurrent vitamin B_{12} deficiency
Vitamin B_{12} (cobalamin)	RDA: 2.4 mcg[j]	Cyanocobalamin 1 mg/week per month
Vitamin C (ascorbic acid)	Adult (males): 90 mg[k] Adult (females): 75 mg[k]	100-300 mg
Biotin	Neonate: 30 mcg Adults: 100-200 mcg	Acquired deficiency: 150 mcg/day until resolution of symptoms Holocarboxylase synthetase

[a]Data from the National Institutes of Health (NIH), Office of Dietary Supplements. Vitamin A fact sheet for health professionals. https://ods.od.nih.gov/factsheets/VitaminA-HealthProfessional/.
[b]Data from the NIH, Office of Dietary Supplements. Vitamin D fact sheet for health professionals. https://ods.od.nih.gov/factsheets/VitaminD-HealthProfessional/.
[c]Data from the NIH, Office of Dietary Supplements. Vitamin E fact sheet for health professionals. https://ods.od.nih.gov/factsheets/VitaminE-HealthProfessional/.
[d]Data from the NIH, Office of Dietary Supplements. Vitamin K fact sheet for health professionals. https://ods.od.nih.gov/factsheets/list-all/VitaminK/.
[e]Approximately 0.5 mg/1000 kcal.
[f]Data from the NIH, Office of Dietary Supplements. Thiamin fact sheet for health professionals. https://ods.od.nih.gov/factsheets/Thiamin-HealthProfessional/.
[g]Approximately 0.6 mg/1000 kcal.
[h]Data from the NIH, Office of Dietary Supplements. Riboflavin fact sheet for health professionals. https://ods.od.nih.gov/factsheets/Riboflavin-HealthProfessional/.
[i]Data from the NIH, Office of Dietary Supplements. Folate fact sheet for health professionals. https://ods.od.nih.gov/factsheets/Folate-HealthProfessional/.
[j]Data from the NIH, Office of Dietary Supplements. Vitamin B_{12} fact sheet for health professionals. https://ods.od.nih.gov/factsheets/VitaminB12-HealthProfessional/.
[k]Data from the NIH, Office of Dietary Supplements. Vitamin C fact sheet for health professionals. https://ods.od.nih.gov/factsheets/list-all/VitaminC/.

20 times the RDA in a child or 100 times the RDA in an adult. Chronic toxicity results from daily ingestion of greater than 25,000 IU (international units) for more than 6 years or greater than 100,000 IU for more than 6 months of preformed vitamin A. Children appear to be more sensitive to vitamin A intake than adults. Individuals most at risk for toxicity include patients taking systemic vitamin A derivatives for the treatment of dermatologic conditions such as acne, psoriasis, and ichthyosis. The other population at risk includes vitamin food faddists who consume large quantities of nonprescription vitamin A supplements.[39] Two notable episodes of vitamin A toxicity occurred in the 1950s when very high levels of vitamin A supplementation were added to infant formulas and the 1970s when high doses of vitamin A were used to treat a variety of dermatologic diseases.[40]

Vitamin A derivatives have been studied in chemoprevention of keratinocytic carcinomas, such as squamous cell and basal cell carcinomas. A large, blinded, randomized, controlled study of elderly men with a history of 2 keratinocytic carcinomas in the 5 years prior to initiation of the study compared topical tretinoin 0.1% cream to placebo. Surprisingly, the study was terminated 6 months early because of a statistically significant increase in all-cause mortality in the tretinoin group compared to the placebo group.[41] Analysis of this increased risk was limited by its post hoc nature and suggests that further studies are needed to clarify this association. Rare cases of iatrogenic intoxication have been reported in association with excessive use of vitamin A as a nutritional supplement.[42]

Clinical Findings: Table 123-8 outlines manifestations of vitamin A toxicity. Individuals with acute vitamin A toxicity have dry, scaly skin, with large areas of desquamation and fissuring of the lips and angles of the mouth. Other signs and symptoms include headache, fatigue, anorexia, nausea, vomiting, blurred vision, pseudotumor cerebri, myalgias, arthralgias, and bone pain and swelling. An early cutaneous sign of chronic vitamin A toxicity in adults is dryness of

TABLE 123-8
Manifestations of Vitamin A Toxicity

- Dry, scaly skin with desquamation
- Peeling of palms and soles, follicular hyperkeratosis
- Cheilitis, fissuring of lips and angles of mouth
- Alopecia
- Anorexia, nausea, vomiting
- Myalgias, arthralgias
- Blurred vision, pseudotumor cerebri
- Skeletal changes: premature closure of the epiphyses, spontaneous bone fractures

the lips, which may progress to diffuse, dry, pruritic, scaly skin with peeling of palms and soles, alopecia, follicular hyperkeratosis, and hyperpigmentation of the face and neck. Anorexia, fatigue, and weight loss may also occur. It is interesting to note that follicular hyperkeratosis may occur in the settings of both VAD and toxicity.

In children, chronic toxicity presents as coarse hair with diffuse alopecia, coarse skin with generalized exfoliation, hyperpigmentation, and exfoliative cheilitis. Associated pseudotumor cerebri with headaches and papilledema, and in infants may a bulging fontanelle may be present. Skeletal changes are common with vitamin A toxicity, and may present with growth retardation secondary to premature closure of the epiphyses and spontaneous bone fractures. Proposed mechanisms for the pathologic bone findings seen in vitamin A toxicity involves antagonism between vitamin A-mediated and vitamin D-mediated intracellular signaling pathways and interactions with calcium-regulating hormones.[23,39]

Laboratory Testing: Laboratory findings in patients with hypervitaminosis A include elevated levels of calcium and alkaline phosphatase. This alteration in calcium homeostasis can lead to calcification of tendons, ligaments, and soft tissues. Deposition of excess vitamin A in adipose tissue and perisinusoidal fibrosis of the liver, which can lead to cirrhosis, are the most significant effect of long-term vitamin A toxicity.

Treatment: Almost all of the symptoms of vitamin A toxicity subside after the excess vitamin intake is discontinued, with the exception of liver cirrhosis and consequences of pseudotumor cerebri.

CAROTENEMIA AND CAROTENODERMA

Epidemiology: While hypervitaminosis A is a disease that causes a broad spectrum of clinical findings, excessive intake of carotene results in a benign disorder characterized by yellow-orange skin pigmentation. The condition was described as "carotenemia" in 1919 by Hess and Meyers who reported a connection between yellow skin pigmentation and increased serum carotene levels.[43] During World War I and World War II, carotenemia was more commonly seen because of the dietary shift from a meat-based diet to a more plant-based diet as a result of food shortages.

As antioxidants, carotenoids also have been studied in cancer prevention. A recent metaanalysis and systematic review was concordant with other past studies showing no significant benefit in reducing the incidence of cancer or cardiovascular disease.[44]

Interestingly, beta-carotene supplementation of 20 to 30 mg per day was associated with an increased risk of lung and gastric cancers.[45,46] Beta-carotene supplementation is also associated with an increased risk of aggressive prostate cancer.[47] Animal studies suggest that excessive carotenoids may increase cyclic adenosine monophosphate signaling and cause deleterious effects on oxidative stress pathways, leading to the increased risk of malignancy.[48,49]

Etiology and Pathogenesis: Carotenes are not synthesized endogenously and are obtained through intake of carotene-rich foods. Plant carotenes are converted to vitamin A in the GI tract, but approximately one-third of carotene is directly absorbed. Several factors can affect carotene absorption, including thyroid hormone, pancreatic lipase and bile acid concentrations, processing of foods, and dietary fat and fiber content. Hypothyroid patients notice an elevation of carotene levels as a result of decreased conversion to retinol. Pancreatic lipase and bile acids digest carotene so that a deficiency of these enzymes from pancreatic or biliary or hepatic dysfunction could result in elevated carotene levels. Mashing, cooking, and pureeing fruits and vegetables increase the availability of carotene because cell membranes are ruptured in the process. Dietary fiber decreases absorption. Because carotene is fat-soluble, a high-fat meal increases absorption. Patients with conditions that lead to hyperlipidemia, like diabetes mellitus, nephrotic syndrome, and hypothyroidism, also predispose patients to carotenemia because of a linear relationship between the amount of β-lipoprotein and carotene. Impaired conversion of carotene to vitamin A in patients with hypothyroidism and liver disease further contributes to carotenemia. Some patients with anorexia nervosa can present with carotenemia because of increased intake of vegetables. Other groups at risk for carotenemia are food faddists, those with excessive intake of nutritional supplements, dried seaweed (nori), carrots, and papayas, and infants ingesting a large amount of pureed vegetables.[50-52]

Clinical Findings: Excessive ingestion of carotenes does not result in hypervitaminosis A because the slow conversion of carotene to vitamin A in the intestinal mucosa is not rapid enough to produce toxic amounts of vitamin A.

Carotene deposits in the stratum corneum because of its high lipid content. The yellow discoloration of skin secondary to carotenemia is called carotenoderma. The carotene is excreted by sebaceous glands and in sweat, so the yellow pigmentation appears first on the face, predominantly in the nasolabial folds and forehead, and then progresses to manifest diffusely, especially on the palms and soles. The pigmentation is particularly

noticeable in artificial light. Of note, carotenoderma, in contrast to jaundice, spares mucous membranes, like the sclera.

Laboratory Testing: Carotenemia does not occur until serum levels reach 3 to 4 times normal levels, greater than 250 mcg/dL, and is detectable approximately 4 to 7 weeks following initiation of a carotenoid-rich diet.

Treatment: Treatment involves discontinuation of excessive carotene intake, and carotenoderma typically fades as the intake of carotene decreases.

VITAMIN D (CALCITRIOL)

Etiology and Pathogenesis: Vitamin D is essential for regulation of calcium and phosphorus metabolism. Vitamin D acts on the GI tract to increase dietary calcium and phosphate absorption, stimulates increased bone resorption of calcium and phosphate, and stimulates the renal tubules to increase reabsorption of calcium and phosphate.

Humans obtain vitamin D from 2 sources: dietary intake and synthesis in the skin from exposure to ultraviolet light. Common dietary sources of vitamin D include fortified milk, fish oil, and fish such as salmon, sardines, herring, tuna, cod, and shrimp. Vitamin D can also be synthesized in the epidermis from the precursor molecule 7-dehydrocholesterol (provitamin D_3) by ultraviolet light in the 290 to 320 nm range. Previtamin D_3 then undergoes a spontaneous, temperature-dependent isomerization to vitamin D_3 (cholecalciferol), which enters the dermal capillaries. At this point, endogenous vitamin D_3 joins with exogenous D_2 (ergocalciferol) for hydroxylation in the liver to 25-hydroxyvitamin D. This molecule travels to the kidney where it is again hydroxylated to make mature vitamin D (1,25-hydroxyvitamin D, also known as calcitriol).

The most common disorder seen with vitamin D is vitamin D-deficient rickets related to decreased dietary intake of vitamin D. Several genetic causes of rickets also deserve mention. Two types of vitamin D-dependent rickets have been described. Type I represents an autosomal recessive defect in renal vitamin D–1α-hydroxylase, and is therefore treated with supplements of 1,25-hydroxyvitamin D. Type II, also referred to as hereditary vitamin D–resistant rickets, is associated with a rare autosomal recessive end-organ resistance to physiologic levels of 1,25-hydroxyvitamin D. Supplementation with high doses of 1,25-hydroxyvitamin D and calcium may overcome this resistance.

A surge in interest regarding the multisystem effect of vitamin D has spurred numerous studies. Evidence suggests that vitamin D deficiency is associated with increased systolic blood pressures,[53] fasting plasma glucose and insulin concentrations,[54] risk of cardiovascular disease,[55-57] risk of hip fractures in postmenopausal women,[58] and colon cancer mortality.[59] Vitamin D deficient individuals have an increased rate of all-cause mortality when compared to those who are vitamin D replete.[57,60] Studies into the function of vitamin D in the immune system have indicated that vitamin D is involved in the innate immune response. Toll-like receptor activation triggers expression of vitamin D receptor and vitamin D–1α-hydroxylase, which promotes macrophage activation.[61] A low vitamin D level is associated with an increased risk of active *Mycobacterium tuberculosis* infection.[62]

Vitamin D–deficient rickets continues to occur in modern times. Groups at risk for vitamin D deficiency include those with inadequate diet, malabsorption, and decreased exposure to sunlight. This includes the elderly or debilitated who have decreased sun exposure or decreased vitamin intake; patients on anticonvulsant therapy; those with malabsorption from GI surgery, celiac disease, or pancreatic or biliary disease; those with chronic renal failure; dark-skinned individuals living in areas with poor sun exposure; and breastfed babies who are exclusively breastfed without vitamin supplementation.

A recent resurgence in vitamin D–deficient rickets has prompted further evaluation of those at risk. A review of 166 cases of rickets in the United States between 1986 and 2003 showed that most cases presented between 4 and 54 months of age. Eighty-three percent were African American or black and 96% were breastfed.[63]

These results emphasized that exclusively breastfed infants, especially those with dark skin tones, may require vitamin supplementation. In response to the continued increase in cases of vitamin D–deficient rickets, the American Academy of Pediatrics in 2003 identified 3 populations who should be given supplemental vitamin D (200 IU): (a) all breastfed infants unless they take in 500 mL/day of fortified formula or milk; (b) all non-breastfed infants taking in less than 500 mL/day of fortified formula or milk; and (c) children and adolescents who do not obtain regular sun exposure, do not ingest at least 500 mL of fortified milk a day, or do not take a multivitamin with at least 200 IU vitamin D.[64]

Vitamin D–deficient rickets is associated with congenital ichthyoses, such as lamellar ichthyosis,[65-67] nonbullous ichthyosiform erythroderma,[68] X-linked ichthyosis,[66] and epidermolytic hyperkeratosis,[69] as well as photosensitive disorders such as xeroderma pigmentosum.[70] Factors contributing to vitamin D deficiency include avoidance of sun exposure, excessive transepidermal calcium loss, defective vitamin D synthesis in affected skin, and decreased intestinal calcium absorption secondary to systemic retinoid therapy.

There is increasing interest in the role of vitamin D and its deficiency in skin cancer risk. Vitamin D is thought to have antiproliferative properties that may influence the development of skin cancer.[71] Some emerging evidence indicates that vitamin D deficiency is associated with increased Breslow thickness of melanoma[72,73] and may correlate to some degree with nevus count. However, the exact relationship between vitamin D levels and skin cancer development remain uncertain as to whether increasing vitamin levels will

have a causal influence on reducing skin cancer at this time.

Given the movement to encourage sunscreen use, there is concern regarding secondary vitamin D deficiency. Theoretically, regular use of the recommended amount of sunscreen can decrease 25-hydroxyvitamin D levels, but with real-life application of inadequate amounts of sunscreen and the tendency for increased sun exposure in individuals wearing sunscreen, there seems to be no significant impact on the incidence of vitamin D deficiency.[74]

At the same time, it appears that only limited sunlight exposure is necessary to produce adequate amounts of vitamin D_3. For patients with Fitzpatrick skin Type II, it has been calculated that only 5 minutes of summertime noon sun 2 to 3 times a week provides adequate vitamin D production to satisfy physiologic requirements (see also Chap. 17).[75,76]

Clinical Findings: The classic manifestations of vitamin D–deficient rickets are skeletal (Table 123-9). Calcium and phosphorus deficiency leads to poor calcification of new bones, resulting in fraying and widening of the metaphysis. This can be seen at costochondral junctions of the anterior ribs, creating the well-known "rachitic rosary." Poor calcification of the skull bones results in craniotabes, a softening of the skull bones giving them a ping-pong ball feel. As the bones become weaker, they cannot support the weight of the child and progressive lateral bowing of the lower extremities occurs. Other findings can include frontal bossing, widening of the wrists, scoliosis, hypotonia, fractures, dental defects, and, rarely, hypocalcemic seizures or tetany. Early radiographic signs of rickets include widening of the epiphyseal plate and blurring of the epiphyseal and metaphyseal junction. If the disease progresses, deformities at the growth plate develop, including cupping, splaying, formation of cortical spurs, and stippling. The bone cortices appear thinner and generalized osteopenia is noted.

A potentially fatal manifestation of vitamin D deficiency is a dilated cardiomyopathy. In a report of 16 British cases, 3 infants died and 6 additional infants were successfully resuscitated from cardiopulmonary arrest.[77] Importantly, the cardiomyopathy is responsive to vitamin D supplementation and can result in complete resolution.[77-79]

Vitamin D–dependent rickets Type II also is associated with cutaneous features that are clinically indistinguishable from the syndrome of generalized atrichia

TABLE 123-9
Clinical Manifestations of Rickets

- Rachitic rosary
- Craniotabes, frontal bossing
- Lateral bowing of lower extremities
- Widening of wrists, scoliosis, fractures
- Dental defects
- Rarely hypocalcemic seizures

TABLE 123-10
Comparison of Vitamin D–Resistant Rickets and Generalized Atrichia

VITAMIN D–RESISTANT RICKETS TYPE I	GENERALIZED ATRICHIA
Chromosome 12q14	Chromosome 8p12
Mutations in vitamin D receptor (Zn finger)	Mutations in human hairless gene (Zn finger)
End-organ unresponsiveness to vitamin D	Defect in catagen remodeling
Atrichia with papules and milia; + eyebrows/eyelashes	Atrichia with papules and milia; + eyebrows/eyelashes
Alopecia by 1-3 months of age	Alopecia by 40 days to 4 months

associated with mutations in the hairless gene.[80,81] Affected patients in both conditions are born with hair. However, within a few months after birth, scalp and body hair are lost with the exception of eyebrows and eyelashes. Small papules and cysts representing abnormal, rudimentary hair structures characteristically develop on the face and scalp. These cysts typically show disintegration of the lower two-thirds of the follicular unit. While the cutaneous features—notably the alopecia and cysts—are phenotypically and histologically identical, these are distinct clinical entities (Table 123-10).

Laboratory Testing: In addition to the clinical and radiologic signs of rickets, laboratory examination may be helpful. Elevated alkaline phosphatase levels and low serum 25-hydroxyvitamin D levels are often useful laboratory indicators of vitamin D deficiency (see Table 123-6). In the early stages of rickets, parathyroid hormone levels increase to compensate, but this compensatory mechanism becomes inadequate if the deficiency continues.

Treatment: The recommended daily value of vitamin D is 5 to 10 mcg (see Table 123-7). Treatment includes oral vitamin D repletion with dihydroxyvitamin D in addition to a calcium-rich diet. Supplementation with 200 to 400 mcg vitamin D per day until resolution of symptoms, approximately 2 to 3 months, is usually adequate.[82] Additional therapy can include judicious sun exposure.

Two additional therapies can be used in cases of hepatic rickets, which is unresponsive to oral vitamin D supplementation because of decreased intraluminal bile salts. D-α-Tocopheryl polyethylene glycol-1000 succinate (TPGS), a water-soluble vitamin E that forms micelles at low concentrations, enhances vitamin D absorption and successfully treated 8 pediatric cases of hepatic rickets. These patients maintained adequate levels of vitamin D while on continued TPGS and vitamin D supplementation, without elevation of vitamin E levels.[83] Promoting cutaneous synthesis of vitamin D through ultraviolet radiation successfully treated 2 cases of hepatic rickets secondary to chronic cytomegalovirus hepatitis and to Alagille syndrome.[84]

Ultraviolet light therapy also has treated an Asian male with poor dietary intake of vitamin D.[85]

VITAMIN E (TOCOPHEROL)

Vitamin E is rarely associated with deficiency or excess states of disease. Found in oils and shortenings, as well as various fortified grains, dark-green leafy vegetables, legumes, nuts, avocado, and small fishes such as herring and sardines.[86] Because it is a fat-soluble vitamin, excessive intake may augment the effects of anticoagulant medications leading to purpura and propensity for hemorrhage.[87] Deficiency states are rare. However, ataxia with isolated vitamin E deficiency is a rare and severe spinocerebellar neurodegenerative disorder with autosomal recessive inheritance. Patients with mutations in the α-tocopherol transfer protein are unable to properly transfer α-tocopherol from lysosomes into lipoproteins that results in a predisposition to oxidative stress in affected cells.[88-90]

VITAMIN K (PHYTONADIONE)

Etiology and Pathogenesis: Vitamin K is a necessary cofactor in the carboxylation of glutamate residues on coagulation factors II, VII, IX, and X, and proteins C and S. Dietary vitamin K, phylloquinone, is found in green, leafy vegetables, certain legumes, soybeans, cereals, and beef liver. Phylloquinone is actively transported in the distal small bowel. Approximately half of the body's vitamin K is obtained though these dietary sources, and the other half is synthesized by GI flora as menaquinones, which are passively absorbed in the distal small bowel and colon.

Vitamin K is derived from the German word *Koagulationsvitamin*, which literally translates to mean "clotting vitamin." In the early 1900s, Henrik Dam of Denmark discovered an "antihemorrhagic factor" that reversed diet-induced bleeding disorders in chicks. In 1943, Edward Doisy and Henrik Dam were awarded the Nobel Prize in Physiology and Medicine for their separate work on isolating vitamin K.

Clinical Findings: Vitamin K deficiency leads to impaired coagulation and hemorrhage, which in neonates is referred to as hemorrhagic disease of the newborn (HDN). Neonates are particularly prone to vitamin K deficiency because of poor transplacental transfer, low dietary intake, and a sterile bowel. HDN is divided into early presentation and late presentation. The incidence of early HDN is 0.25% to 1.7% and causes unexpected bleeding in the first week of life in an otherwise healthy neonate. It can present as ecchymoses, cephalohematomas or nasal, subgaleal, umbilical, intestinal, or intracranial hemorrhages. Late HDN is defined by the American Academy of Pediatrics as unexpected bleeding from severe vitamin K deficiency in 2- to 12-week-old infants who are primarily breastfed and who received no or inadequate neonatal vitamin K prophylaxis.[91] Vitamin K deficiency beyond the newborn period is rare, but may result from malabsorption, liver disease, inadequate dietary intake, or medications. Fat malabsorption occurs in conditions such as regional ileitis, topical sprue, celiac disease, cystic fibrosis, pancreatic insufficiency, and biliary obstruction. Antibiotic use can result in vitamin K deficiency by altering the populations of normal bowel flora. Coumarin interferes with vitamin K epoxide reductase, an enzyme important in the recycling of inactive vitamin K into its active form. Other medications that can interfere with vitamin K metabolism include anticonvulsants (phenytoin), rifampin, isoniazid, high-dose salicylates, cholestyramine, and cephalosporins.[13,92] Vitamin K deficiency in older children and adults can present as purpura, ecchymoses, gingival bleeding, and GI, genitourinary, and retroperitoneal hemorrhage.

Laboratory Testing: Because vitamin K is a key cofactor in the coagulation pathway, deficiency of vitamin K typically manifests as elevations in both prothrombin time and activated partial thromboplastin time. Serum levels of vitamin K can also be measured (see Table 123-6).

Although des-γ-carboxy prothrombin, also known as the abnormal "protein induced by vitamin K absence," can be a sensitive indicator for vitamin K deficiency, its presence also has been strongly linked to certain malignancies, in particular, hepatocellular carcinoma. It appears that hepatocellular carcinoma cells produce des-γ-carboxy prothrombin directly rather than as a byproduct of low vitamin K levels, which may be normal in patients with hepatocellular carcinoma.[93]

Treatment: Neonatal prophylaxis is traditionally with a single intramuscular dose of 0.5 to 1.0 mg vitamin K. There have been some studies regarding the use of oral vitamin K prophylaxis, but there is no definitive data on efficacy, safety, or bioavailability.[91]

Acute treatment is with fresh-frozen plasma to replace deficient coagulation factors. Vitamin deficiency can also be treated with parenteral or intramuscular 5 to 10 mg vitamin K per day to correct severe deficiency (see Table 123-7).

WATER-SOLUBLE VITAMINS

AT-A-GLANCE

- B complex vitamins, vitamin C, biotin.
- Niacin supplementation should be given with isoniazid therapy to prevent pellagra, characterized by a photosensitive dermatitis, diarrhea, dementia, and death.
- Vitamin C is an essential cofactor in multiple biologic reactions, including collagen synthesis. Deficiency causes scurvy, which presents with follicular hyperkeratosis, curled corkscrew hairs, and a bleeding diathesis.

VITAMIN B_1 (THIAMINE)

Etiology and Pathogenesis: Disorders of thiamine may have broad-ranging implications because thiamine is an essential coenzyme for 3 separate enzymes involved in nicotinamide adenine dinucleotide phosphate synthesis, carbohydrate metabolism, and deoxyribose and ribose synthesis. Thiamine is used as a coenzyme for transketolase in the pentose phosphate pathway to produce nicotinamide adenine dinucleotide phosphate. Thiamine pyrophosphate acts as a coenzyme in pyruvate dehydrogenase and α-ketoglutarate dehydrogenase, which are involved in oxidative decarboxylation reactions in the metabolism of carbohydrates and branched-chain amino acids.

Epidemiology: Thiamine is obtained from whole grains, enriched bread products, dried peas and beans, potatoes, and fish. Polished rice eliminates the thiamine-containing husk and predisposes to thiamine deficiency.

Disorders of thiamine excess are extremely rare. Most arise as a result of intravenous administration for suspected thiamine deficiency in the context of chronic alcoholism. Local irritation at the site of intravenous administration, generalized pruritus, and anaphylactic or anaphylactoid reactions have been described.[94] Neurotoxicity can occur in experimental settings when thiamine is administered directly into the CNS.[95] In general, thiamine excess states are extremely rare in humans.

Beriberi refers to a thiamine deficiency state. The word is derived from Sinhalese meaning "extreme weakness." The symptoms of beriberi have been recognized in East Asian countries for thousands of years because polished white rice is a dietary staple. The Japanese navy observed in the 1890s that beriberi could be eradicated by adding meat, fish, and vegetables to the diet.[96] Beriberi became an epidemic in the Dutch East Indies in the late 1800s. Christiaan Eijkman was part of the medical team stationed in the Dutch East Indies to study beriberi. In 1929, Eijkman was awarded the Nobel Prize in Physiology and Medicine for his work, starting in 1886, studying the effect of polished rice and unpolished rice on the incidence of beriberi in chickens. Through a series of detailed experiments on populations of chickens fed various diets and injected with various bacteria, he concluded that there was a direct correlation between diet and beriberi, but like many, had initially misattributed the cause to a nonexistent infectious agent in polished rice. In 1926, Barend Coenraad Petrus Jansen and William Frederick Donath successfully isolated thiamine from rice polishings, and Robert Williams was able to synthesize thiamine in the 1930s.[97]

Predisposing factors for pediatric thiamine deficiency include unsupplemented parenteral nutrition, breastfed infants of thiamine-deficient mothers, congestive heart failure,[98] certain metabolic disorders,[99] and severe malnutrition. In adults, aside from chronic alcoholism, cases of thiamine deficiency are associated with bariatric surgery,[100] food refusal in severe depression,[101] renal disease,[102,103] congestive heart failure (most likely related to furosemide administration which inhibits thiamine absorption),[104,105] lymphoma,[106] bezoar,[107] and complicated obesity.[108]

Clinical Findings: Thiamine deficiency in the United States is now rare. Early signs include irritability, apathy, restlessness, and vomiting. As the disease progresses, neurologic signs of Wernicke encephalopathy may develop, such as ophthalmoplegia, ataxia, nystagmus, and characteristic laryngeal nerve paralysis resulting in aphonia, which is a classic manifestation of infantile beriberi. Other symptoms include congestive heart failure, tachycardia, dyspnea, and cyanosis. In 2003, a series of infants presenting with ophthalmoplegia as a manifestation of Wernicke encephalopathy was reported in Israel as a result of a thiamine-deficient infant soy formula. In all these cases, a prodromal illness was observed. Early symptoms included vomiting, anorexia, diarrhea, lethargy, irritability, and developmental delay. Upbeat nystagmus and ophthalmoplegia were the primary neurologic signs. Following treatment, those with early disease had complete recovery, but those with severe disease had residual neurologic complications.[109]

Adult beriberi has been categorized into dry and wet forms. Dry beriberi describes a symmetric distal peripheral neuropathy involving both sensory and motor systems. Wet beriberi includes neuropathy and signs of cardiac involvement, including cardiomegaly, cardiomyopathy, congestive heart failure, peripheral edema, and tachycardia. Rarely, wet beriberi can be associated with pulmonary hypertension that is reversible after thiamine supplementation.[110] A red, burning tongue and peripheral edema also have been observed with wet beriberi.

Laboratory Testing: Diagnosis of thiamine deficiency is made by measurement of erythrocyte thiamine transketolase or blood thiamine concentration (see Table 123-6). The more reliable measure is erythrocyte thiamine transketolase before and after thiamine pyrophosphate stimulation, represented as a percentage of thiamine pyrophosphate effect. Normal values are up to 15%.

Treatment: Because thiamine is a cofactor in a variety of metabolic pathways, daily thiamine requirements are calculated from an individual's ideal total caloric intake, with current recommendations indicating 0.5 mg per 1000 kcal.

Treatment of thiamine deficiency can be via intravenous, intramuscular, or oral routes of administration. Usually, treatment of beriberi is initiated with IV or intramuscular thiamine of 50 to 100 mg per day for 7 to 14 days; oral supplementation is then provided until full recovery is documented (see Table 123-7).

VITAMIN B_2 (RIBOFLAVIN)

Etiology and Pathogenesis: Riboflavin was discovered in 1879 as a fluorescent yellow-green substance found in milk. Its chemical structure was later

determined in 1933. Riboflavin is used in 2 coenzymes, flavin mononucleotide (FMN) and flavin-adenine dinucleotide, both of which are involved in oxidation-reduction reactions in cellular respiration and oxidative phosphorylation. These 2 enzymes are also involved in pyridoxine (vitamin B_6) metabolism. Newer studies suggest that riboflavin deficiency may contribute to increased plasma homocysteine levels, impaired handling of iron, and night blindness.[111]

Riboflavin is typically obtained through dairy products, nuts, meat, eggs, whole grain and enriched bread products, fatty fish, and green leafy vegetables. A small amount of dietary riboflavin is present as free riboflavin; most are found as flavin-adenine dinucleotide or flavin mononucleotide. Dietary flavin-adenine dinucleotide and flavin mononucleotide are hydrolyzed to riboflavin by brush-border membranes or enterocytes. Free riboflavin in the intestinal lumen is then taken up by active transport in the proximal small bowel.

Deficiency states can be caused by decreased intake, inadequate absorption, phototherapy, and underlying metabolic disorder. Alcoholics, elderly, and adolescents are groups at risk for riboflavin deficiency secondary to poor nutritional intake. Malabsorption after gastric bypass surgery can also predispose individuals to riboflavin deficiency.[112] In areas of India, China, and Iran, riboflavin deficiency is endemic because of their dependence on an unenriched cereal diet. Infants of riboflavin-deficient mothers are also at risk of deficiency because breastmilk concentrations of the vitamin are proportional to maternal concentrations. Once weaned from the breast, these infants are at additional risk if they are not transitioned to milk. When confounded by PEM, riboflavin deficiency may be worsened because the usual renal compensatory mechanism of increased riboflavin absorption is impaired in this setting. Visible light phototherapy for jaundiced neonates causes photodecomposition of riboflavin.[113] Certain drugs also affect riboflavin levels through effects on absorption or metabolic inhibition. Chlorpromazine and other tricyclic drugs inhibit transport of riboflavin in the GI tract predisposing to deficiency states.[114] Borate displaces riboflavin from binding sites, increases urinary riboflavin excretion, and inhibits riboflavin-dependent enzymes, thereby contributing to riboflavin deficiency.[115] The neurodegenerative disorder, Brown-Vialetto-Van Laere syndrome is characterized by hearing loss and pontobulbar palsy, and has been linked to mutations in RFVT2 and RFVT3, riboflavin transporter genes that result in riboflavin deficiency.[116]

Clinical Findings: Signs of acute riboflavin deficiency include a deep-red erythema, epidermal necrolysis, and mucositis. The severity of symptoms depends on the severity of deficiency (Table 123-11).[117]

Clinical signs of chronic riboflavin deficiency or ariboflavinosis begin 3 to 5 months after initiation of an inadequate diet. Skin and mucous membrane findings predominate. Initially, angular stomatitis manifests as small papules at the corners of the mouth that enlarge and ulcerate before developing into macerated fissures that extend laterally and often bleed (Fig. 123-7). Pronounced cheilosis with erythema, xerosis, and vertical fissuring of lips can occur. Early glossitis appears as prominent lingual papillae, but after these papillae are lost, the tongue becomes smooth, swollen, and magenta in color. The dermatitis of riboflavin deficiency resembles seborrheic dermatitis in that it involves the nasolabial folds, nostrils, nasal bridge, forehead, cheeks, and posterior auricular regions. Flexural areas of the limbs also may be affected. Plugging of the sebaceous glands (dyssebacia) may be observed around the nose. The dermatitis can affect the genitalia, more often to a greater extent in males than in females. A red, confluent, crusty, or lichenified dermatitis of the scrotum often spreads to involve the inner thighs. In general, the dermatitis is worse in areas of chafing or trauma. Infants frequently manifest the dermatitis in the inguinal areas. In older individuals, the dermatitis is often more pronounced in facial creases and wrinkles, and if incontinent, can involve the perianal and buttock areas. Cutaneous findings are not aggravated by light exposure, but are exacerbated by heavy physical

TABLE 123-11
Clinical Signs of Riboflavin Deficiency

Acute
- Erythema
- Epidermal necrolysis
- Mucositis

Chronic
- Angular stomatitis
- Cheilosis with erythema, xerosis, and fissuring
- Glossitis
- Seborrheic dermatitis-like dermatitis affecting typical sites and flexural areas of limbs and genitalia
- Photophobia and conjunctivitis

Figure 123-7 Riboflavin deficiency. Angular stomatitis with maceration in an Arab child. Riboflavin excretion in the urine was diminished.

activity. Ocular findings are also a prominent feature of this disorder with photophobia and conjunctivitis being most notable. *Oculo-orogenital syndrome* is the term used to describe this constellation of symptoms.

Laboratory Testing: A normochromic, normocytic anemia may be observed. Erythrocyte glutathione reductase activity can be used as a screening test (see Table 123-6), but a trial of riboflavin supplementation is often the most optimal method to confirm a riboflavin deficiency.

Treatment: The recommended daily value of riboflavin is 0.6 mg per 1000 kcal. Treatment of deficient infants and children is 1 to 3 mg per day, and for deficient adults, 10 to 20 mg per day (see Table 123-7).

VITAMIN B_3 (NIACIN)

Etiology and Pathogenesis: Niacin is a vitamin cofactor that can be obtained for the diet or synthesized endogenously from the essential amino acid tryptophan. Niacin is found in whole grains and enriched bread products, nuts, dairy products, liver, animal meat, mushrooms, and dried beans. Dietary niacin exists primarily in the form of nicotinamide-adenine dinucleotide (NAD) and nicotinamide-adenine dinucleotide phosphate (NADP). NAD and NADP are hydrolyzed in the intestinal lumen to form nicotinamide. Nicotinamide can be converted to nicotinic acid by intestinal bacteria or be absorbed into plasma. Nicotinamide and nicotinic acid then travel to the liver, kidney, enterocytes, where they are converted back to NAD and NADP. These 2 agents act as hydrogen donors and acceptors in oxidation-reduction reactions involved in the synthesis and metabolism of carbohydrates, fatty acids, and proteins.

Deficiency of niacin or vitamin B_3 results in pellagra.

Historical Background: In 1735, Gasper Casal noted poor peasants in northern Spain were particularly affected by a skin disorder referred to then as "mal de la rose," so named because of the reddish, glossy rash on the dorsum of the hands and feet. He noted that these peasants were all poor, ate mainly maize, and rarely ate fresh meat. Francois Thierty published the first description of pellagra in 1755, but it was Francesco Frapoli who coined the name *pellagra* after the Italian words "pelle," meaning skin, and "agra," meaning rough.

During the 19th century, the cause of many diseases was attributed to infectious agents, and pellagra had been thought to be related to some infectious microorganism. While working as for the United States Public Health Service, Joseph Goldberger first suggested that pellagra might be caused by an amino acid deficiency in 1922, and that a dietary "pellagra-preventive factor" existed. Pellagra was endemic in the southern United States in the early 1900s because of a ubiquitous diet consisting principally of corn bread, molasses, and pork fat. Beginning in 1914, Goldberger worked with 2 orphanages and 1 sanitarium in the South. By increasing the amount of fresh animal meat and vegetables available at the 3 institutions, Goldberger was able to significantly decrease the incidence of pellagra. He went on to investigate pellagra among male prisoners. Using 12 prisoners from the Mississippi State Penitentiary and offering prisoners pardons as an incentive to participate, he successfully demonstrated that pellagra could be induced by a monotonous cereal-based, low calorie, and protein diet. To disprove the allegation that pellagra was caused by an infectious agent, he subjected 16 volunteers to the blood, urine, feces, and epidermal scales of pellagrous patients and showed that they were not predisposed to develop pellagra.[118] Goldberger died before he identified the pellagra-preventive factor, but in 1937, Conrad Elvanhjem identified niacin as the antipellagra factor.[119]

Pellagra remains endemic in parts of the world, including South Africa, China, and India, where corn and maize continue to be a dietary mainstay. Corn and maize contain bound niacin, so without alkaline hydrolysis to release the niacin, it is unavailable for absorption. Jowar, a type of millet found in parts of India, contains adequate levels of niacin, but large quantities of leucine interfere with the conversion of tryptophan to niacin.[120] Although Mexicans have a predominantly maize-based diet, pellagra is relatively uncommon because preparation of the maize includes washing it in lime water, which releases the complexed niacin.

Because niacin is absorbed from the GI tract, GI disorders can predispose to pellagra. Impaired absorption of tryptophan and niacin occurs in patients with jejunoileitis, gastroenterostomy, prolonged diarrhea, chronic colitis, ulcerative colitis, cirrhosis, Crohn disease, and subtotal gastrectomy.[121] Patients with Hartnup disease, a rare autosomal recessive disorder, develop pellagra-like symptoms in childhood. This is caused by a defect in the neutral brush-border system, resulting in malabsorption of amino acids, including tryptophan. Alcoholics develop pellagra from a combination of poor diet and malabsorption. Overly restrictive diets from eating disorders, such as anorexia nervosa, presumed food allergies, and food faddism can also cause pellagra.

Patients with increased metabolic needs as seen in carcinoid syndrome can develop pellagra. Normally, approximately 1% of tryptophan is metabolized to serotonin, but in carcinoid syndrome, an excessive amount, approximately 60%, of tryptophan is converted to serotonin. Because of this diversion of tryptophan to serotonin production, less tryptophan is available to make niacin.

Medications can also induce pellagra symptoms. Isoniazid is a competitive inhibitor of NAD because of their similar structures, and also impairs pyridoxine functioning, which is essential for niacin synthesis from tryptophan. 5-Fluorouracil inhibits conversion of tryptophan to niacin, and 6-mercaptopurine inhibits NAD phosphorylase, which inhibits NAD production. Other implicated medications include phenytoin, chloramphenicol, azathioprine, sulfonamides, and antidepressants.[122]

Clinical Findings: Pellagra is classically described with the four Ds of (a) dermatitis, (b) diarrhea, (c) dementia, and (d) death. The characteristic dermatitis begins as painful, erythematous, pruritic patches in photodistributed areas. The skin becomes progressively more edematous, and several days later may develop vesicles and bullae, which can rupture, leaving crusted erosions, or develop into brown scales. Over time, the skin thickens into sharply demarcated, keratotic, hyperpigmented plaques. Painful fissures can develop in the palms and soles, resembling goose skin. The dorsum of the hands is the most commonly affected site, and when the rash extends proximally, more on the radial than ulnar side, it forms the "gauntlet" of pellagra (Fig. 123-8A). A butterfly distribution may be apparent on the face when it extends from the nose to the cheeks, chins, and lips. When the dermatitis affects the upper central portion of the chest and neck, it is referred to as "Casal's necklace" (Fig. 123-8B). It can sometimes extend down over the sternum to create a "cravat." Mucous membrane involvement may manifest as cheilitis, angular stomatitis, a red tongue, and ulceration of the buccal mucosa and vulva. Half and half nails also may be present (Table 123-12).[123]

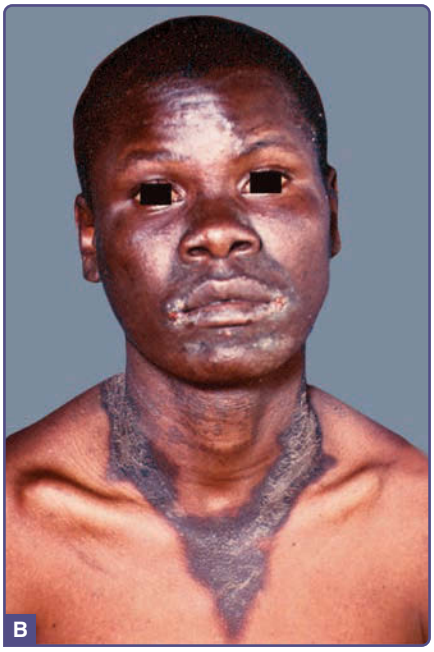

Figure 123-8 Pellagra. Acute dermatosis. **A,** "Glove" or "gauntlet" exudative and crusted lesions on the hands. **B,** "Casal's necklace" on the neck with facial involvement.

TABLE 123-12
Clinical Manifestations of Pellagra

- Painful pruritic dermatitis in photoexposed areas
- May be vesicular, crusted, and develops into scaly, keratotic plaques
- Dorsum of hands ("gauntlet"), neck ("Casal's necklace"), dorsa of feet ("gaiter" of pellagra); butterfly distribution in face
- Angular stomatitis, cheilitis, glossitis
- Diarrhea, nausea, vomiting, abdominal pain, anorexia
- Insomnia, fatigue, nervousness, apathy, impaired memory, depression, psychosis, dementia

GI symptoms may represent the earliest signs of pellagra. Diarrhea, nausea, vomiting, abdominal pain, and anorexia have been reported. Neurologic symptoms, such as insomnia, fatigue, nervousness, apathy, impaired memory, and depression, can progress to psychosis and dementia in later stages. Without treatment, pellagra leads to death from multiorgan failure.

Laboratory Testing: Diagnosis is primarily made on clinical grounds and through a rapid response to vitamin supplementation. However, measurement of urinary metabolites of niacin—*N*-methylnicotinamide and pyridone—may be used to aid in the diagnosis (see Table 123-6). Histologic examination of skin biopsies from affected skin areas may demonstrate depletion of Langerhans cells whose absence are thought to allow for more prolonged inflammation at these sites.[124]

Treatment: The recommended daily value of niacin is 15 to 20 mg of niacin (see Table 123-6), or approximately 60 mg of exogenous tryptophan. Treatment with 500 mg per day of nicotinamide or nicotinic acid is given over several weeks. Nicotinamide is preferred over nicotinic acid because nicotinic acid is frequently associated with headache and flushing. Neuropsychiatric symptoms may remit after 24 to 48 hours of treatment, but skin lesions often take 3 to 4 weeks to clear.[125]

VITAMIN B_6 (PYRIDOXINE)

Etiology and Pathogenesis: Pyridoxine deficiency was elucidated by Albert Szent-Gyorgi in 1934 while studying pellagra in rats. Esmond Snell identified the 2 other forms of vitamin B_6 and worked extensively to clarify the biochemical properties of these molecules in the mid-1900s.

Vitamin B_6 describes 3 interchangeable molecules: pyridoxine, pyridoxamine, and pyridoxal. Humans are unable to synthesize any of these molecules, but, fortunately, they are widely available in both plant and animal products. Meats, whole grains, vegetables, and

nuts are the best sources for vitamin B_6. Processing of these foods can decrease the amount of vitamin available. They are absorbed through passive diffusion in the jejunum and undergo phosphorylation to become components of active coenzymes. The most common form existing is pyridoxal-5-phosphate. Vitamin B_6 is employed in multiple pathways, including the decarboxylation and transamination of amino acids, gluconeogenesis, and conversion of tryptophan to niacin, sphingolipid synthesis, prostaglandin synthesis, and neurotransmitter synthesis. As such, clinical features of pyridoxine deficiency may overlap with those of niacin deficiency.

As a consequence of the availability of dietary vitamin B_6, deficiency is seldom caused by inadequate intake, but can occur in alcoholics as the result of poor diet. More commonly, malabsorption and medication-induced deficiency is etiologic. Small-bowel disorders, such as Crohn disease and celiac disease, can interfere with absorption and produce deficiency. Medications that are implicated in causing deficiency include isoniazid, hydralazine, penicillamine, and oral contraceptives. Isoniazid, hydralazine, and penicillamine bind to pyridoxal-5-phosphate to increase excretion or decrease activity of the coenzyme. Bariatric surgery has been reported as an infrequent cause of pyridoxine deficiency.

Clinical Findings: Vitamin B_6 toxicity from excessive intake does not typically produce skin findings, although it can be associated with peripheral neuropathy.

Vitamin B_6 deficiency classically presents as a seborrheic-like dermatitis of the face, scalp, neck, shoulders, buttocks, and perineum. Clinical features overlap those of niacin deficiency including features of photodermatitis, glossitis, and cheilitis. Glossitis appears as redness, burning, and ulceration of the tongue, leading to flattening of the filiform papillae. Other areas of oral mucosa also become red and ulcerated, resulting in angular stomatitis, cheilosis, and conjunctivitis. This condition produces an oculo-orogenital syndrome quite similar to that seen with riboflavin deficiency.[126] Neurologic signs include somnolence, peripheral neuropathy, paresthesias, weakness, and confusion. Other signs and symptoms are nonspecific, and include nausea, vomiting, depression, anorexia, and anemia. The clinical manifestations of vitamin B_6 deficiency often resemble pellagra because vitamin B_6 is needed for the conversion of tryptophan to niacin.

Laboratory Testing: Vitamin B_6 can be evaluated by mean measurement of plasma pyridoxal-5-phosphate. Low levels of plasma pyridoxal-5-phosphate indicate deficiency (see Table 123-6).

Treatment: Recommended daily values of pyridoxine depend on age and gender. Adult males require at least 2 mg per day; adult females require at least 1.6 mg per day; and infants require approximately 0.3 mg per day (see Table 123-7). Treatment involves discontinuation of inciting medication and initiating replacement therapy of 100 mg of pyridoxine per day. Oral lesions resolve in days, skin, and hematologic changes resolve in weeks and neurologic symptoms over several months.[13]

VITAMIN B_9 (FOLATE)

Etiology and Pathogenesis: Folate can be found in almost all foods, particularly in liver, wheat bran and other grains, leafy green vegetables, and dried beans. Tetrahydrofolate, the coenzyme form of folate, is used for single-carbon transfers in amino acid, purine, and pyrimidine metabolism. The poor diets of alcoholics, malabsorption, and medications can produce folate deficiency. Malabsorptive states (such as celiac disease, chronic diarrhea, following total gastrectomy) and antifolate medications (such as methotrexate, trimethoprim, oral contraceptives, and pyrimethamine) can produce folate deficiency. The antiepileptics phenobarbital and phenytoin can also lead to folate deficiency states through induction of microsomal hepatic enzymes by antiepileptics, which deplete folate stores.[127] In children, folate deficiency also can be associated with excessive boiling of milk or a goat's milk diet. Human milk has greater bioavailability of folate when compared with goat's milk.[128,129]

Clinical Findings: As with vitamin B_{12} deficiency, the primary manifestation is hematologic: hypersegmented neutrophils, followed by macrocytosis and megaloblastic anemia. Neutropenia, thrombocytopenia, diarrhea, and irritability also may be observed. In contradistinction to vitamin B_{12} deficiency, folate deficiency is not associated with neurologic symptoms.

Mucocutaneous findings include glossitis with atrophy of the filiform papillae, angular cheilitis, mucosal ulceration, perirectal ulcerations, perineal seborrheic dermatitis, and diffuse brown hyperpigmentation concentrated in the palmar creases and flexures.[130,131]

Laboratory Testing: Macrocytic and megaloblastic anemia with hypersegmentation of neutrophils is suggestive. Diagnostic confirmation can be accomplished through measurement of serum folic acid levels (see Table 123-6).

Treatment: Folic acid supplementation is typically curative. Discontinuation of antifolate agents is recommended if involved. Ruling out concurrent vitamin B_{12} deficiency is crucial before initiating treatment of folate deficiency. If vitamin B_{12} deficiency is present but not treated, the hematologic symptoms may be respond to folate, but the neurologic symptoms will progress. Treatment involves 1 to 5 mg of folic acid per day (see Table 123-7).

VITAMIN B_{12} (COBALAMIN)

Historical Background: Some controversy exists as to who documented the earliest report of pernicious anemia. Thomas Addison is often credited with the first published description in 1855, but others, like

James Combe and Antoine Biemer, also deserve some measure of credit. Pernicious anemia was a recognized entity in the late 1800s, and strides were made in the early 20th century toward a better understanding of pernicious anemia. As understanding of other diseases, such as pellagra and beriberi, began to emerge, researchers began to wonder if pernicious anemia was also caused by a dietary deficiency. In 1920, George Whipple published results from studies he had done on anemic dogs. Whipple induced anemia in dogs by bleeding them. After trials of different foods to recover the hemoglobin level, Whipple observed the greatest improvement with liver. George Minot and William Murphy won the 1934 Nobel Prize in Physiology and Medicine along with Whipple for their work in documenting that meat and liver could be employed to treat anemic patients.[132,133]

Around the same time, William Castle used controls and patients with pernicious anemia to prove that an essential interaction between meat (extrinsic factor) and a component of normal human gastric secretions (intrinsic factor) were required for resolution of anemia. Finally, in 1948, Karl Folkers and colleagues successfully crystallized vitamin B_{12} and in 1964 Philippus Hoedenmaeker showed that Castle's intrinsic factor was produced by the gastric parietal cell. The well-known Schilling test to assess intrinsic factor deficiency was described by Robert Schilling in 1953.[134]

Etiology and Pathogenesis: Vitamin B_{12} is an important coenzyme for 2 biochemical pathways in humans. The first enzyme uses methylcobalamin as a coenzyme for methyltransferase to methylate homocysteine to methionine, which is used in DNA, protein, and lipid metabolism. The second requires 5'-adenosylcobalamin to catalyze the reaction by methylmalonyl coenzyme A (CoA) mutase to convert methylmalonic acid to succinyl-CoA, which is used in fat and carbohydrate metabolism.

Vitamin B_{12} is found primarily in animal products, with liver, eggs, milk, beef, and organ meats being excellent sources. Gastric acid separates vitamin B_{12} from food proteins so it can bind to intrinsic factor in the duodenum. This complex is taken up by specific ileal receptors in the terminal ileum. In the enterocyte, vitamin B_{12} dissociates from intrinsic factor and enters the portal circulation bound to transcobalamin II for transport to tissues. Between 1% and 5% of free cobalamin is absorbed along the intestinal wall by passive diffusion. The body is able to store large amounts of vitamin B_{12}, so symptoms of deficiency often take 3 to 6 years to develop.

Epidemiology: Causes of vitamin B_{12} deficiency can be divided into 3 groups: inadequate intake, malabsorption, and other. Elderly individuals and psychiatric patients with poor diets (including those with anorexia nervosa), and strict vegetarians and their breastfed infants are most likely to become deficient from inadequate intake. Cases related to malabsorption can be further divided into 4 groups: (a) decreased gastric acid states leaving more B_{12} food-bound (chronic proton pump inhibitors and histamine H_2 receptor blockers); (b) decreased intrinsic factor (pernicious anemia, atrophic gastritis, postgastrectomy); (c) microbial competition in the gut (bacterial overgrowth, *Diphyllobothrium latum* infection); and (d) impaired absorption (Crohn disease, Whipple disease, Zollinger-Ellison syndrome, celiac disease, short-bowel syndrome). The other causes of cobalamin deficiency relate to inborn errors of transport or metabolism.[135]

Clinical Findings: Vitamin B_{12} deficiency manifests primarily in 4 systems. As with cases of folate deficiency, mucocutaneous manifestations include glossitis, angular cheilitis, hair depigmentation, and cutaneous hyperpigmentation. Glossitis is characterized by an atrophic, red, and painful tongue with atrophy of the filiform papillae, which is referred to as *Hunter glossitis*. Early vitamin B_{12} deficiency can manifest as a linear glossitis.[136] Hair depigmentation may be localized or diffuse. Hyperpigmentation can be diffuse and symmetric or few scattered macules. The greatest concentration is usually observed on the hands, nails, and face, with the most commonly affected areas being the palmar creases, flexural regions, and pressure points. This hyperpigmentation often resembles Addison disease, but patients show no evidence of adrenal insufficiency.[137-140]

Three proposed hypotheses exist regarding the pathophysiology of the hyperpigmentation. Vitamin B_{12} maintains glutathione in reduced form, which is used to regulate tyrosinase, an enzyme necessary in melanogenesis. In B_{12} deficiency, increased tyrosinase activity results in hypermelanosis. Another proposed hypothesis involves defective melanin transport between melanocytes and keratinocytes. Finally, megaloblastic changes in keratinocytes from B_{12} deficiency may affect melanin distribution.[13,23,139,140]

The importance of cobalamin deficiency lies in its association with the classically described neurologic manifestations of subacute combined degeneration of the dorsal and lateral spinal column. Generalized weakness with paresthesias progresses to ataxia and symmetric loss of vibration and proprioception, worse in the lower extremities, eventuating in severe weakness, spasticity, paraplegia, and incontinence. Other neurologic findings include apathy, somnolence irritability, memory loss, dementia, and psychosis. Early neurologic findings may present before hematologic signs.

Laboratory Testing: The hematologic findings are similar to those found in folate deficiency, namely macrocytic anemia and hypersegmented neutrophils. Bone marrow biopsy reveals a hypercellular marrow secondary to disordered maturation.

Deficiency is diagnosed by measuring serum cobalamin levels, with levels less than 200 pg/mL indicating definite B_{12} deficiency and 200 to 300 pg/mL being borderline low (see Table 123-6).

Treatment: Treatment depends on treating the cause of deficiency and supplementing with vitamin B_{12}. Oral and parenteral supplementations have both been used. Oral supplementation can even

be used in patients with pernicious anemia, but require much larger doses of enteral B_{12} than when parental as absorption has to be through the intrinsic-factor-independent mechanism. Supplementation with cyanocobalamin of some form is 1 mg per week for 1 month (see Table 123-7). If symptoms persist, or if deficiency is to be a long-term problem, as in pernicious anemia, then additional supplementation is with 1 mg of cyanocobalamin every month.

VITAMIN C (ASCORBIC ACID)

Etiology and Pathogenesis: Vitamin C is an antioxidant and essential cofactor in several biologic reactions, including collagen biosynthesis, prostaglandin metabolism, fatty acid transport, and norepinephrine synthesis. Humans are unable to synthesize ascorbic acid because they lack gulonolactone oxidase, an enzyme most other animals possess and use to convert glucose to ascorbic acid. Other organisms that require ascorbic acid include the guinea pig, the fruit bat, and certain fish and bird species.

The majority of Western dietary vitamin C is obtained from fruits and vegetables, like potatoes, tomatoes, berries, citrus fruits, and green vegetables. Vitamin C is absorbed in the distal small bowel. Most dietary vitamin C is completely absorbed, but there is a decrease in absorption as dietary intake increases. Vitamin C is found in greatest concentration in the pituitary, adrenal glands, liver, leukocytes, and eyes. Depletion of body stores occurs after 1 to 3 months of a deficient diet.

As a water-soluble vitamin, ascorbic acid excess states are not typically associated with significant clinical disease. However, vitamin C deficiency is a disease of both great clinical importance and of great historical significance. Vitamin C deficiency results in scurvy.

Historical Background: Scurvy, the disease of vitamin C deficiency, has been documented since antiquity. Ancient Greek, Roman, and Egyptian texts describe cases of scurvy. The *Ebers Papyrus*, which dates to approximately 1552 BCE, documents cases of scurvy that were successfully treated with onions. Scurvy plagued sailors for hundreds of years before its cause was fully understood. One of the earliest reports dates to the 1497 expedition of India by Vasco da Gama. On this journey, many of the crew members developed scurvy, but da Gama noted that their symptoms improved after they traded for fresh oranges with locals in East Africa. After their supply of fresh oranges were depleted, da Gama observed the symptoms returned, so at their next landfall, they again sought locals with oranges to cure their disease. Other ships were not as fortunate as da Gama's crew. George Anson's pursuit of Spanish ships in 1740-1744 began with more than 1400 crew members. By the end of the 4-year journey, he returned with only 145 of his original crew members with only four killed in enemy action and more than 1300 having died from scurvy.[141]

In 1747, James Lind devised one of the earliest clinical trials to investigate crew members from the *HMS Salisbury* who were afflicted with scurvy. Lind selected 12 seamen with severe scurvy and divided them into 6 groups of 2, and each group was assigned to receive a different dietary therapy: hard apple cider, elixir of vitriol, vinegar, sea water, two oranges and one lemon daily for 6 days, and a medicinal paste. Lind published his findings in his *Treatise of the Scurvy* in 1753 where he concluded that oranges and lemons were the most effective treatment for scurvy.[142] Although Lind's findings were published in 1753, it was not until 1793 that lemon juice became a required daily provision on long sea voyages under the advice of Gilbert Blaine.[143]

As the incidence of scurvy decreased at sea, several epidemics on land occurred. The Great Potato Famine of 1845-1848, World War I, and World War II were times of nutritional impoverishment. The armies of the Crimean War and American Civil War, Arctic explorers, and California gold rush communities suffered from scurvy in large numbers. In the late 19th and early 20th centuries, an explosion in cases of infantile scurvy occurred in the United States because of the trend toward heated milk and proprietary foods. As shown by James Lind, heating of vitamin C decreased its biologic activity. Alfred Hess reported that pasteurization of milk likewise decreases its vitamin C concentration.[144] Proprietary food at that time was of poor nutritional quality. Interestingly, most of the affected infants were from affluent families who thought they were providing superior nutrition for their children.[145] Vitamin C was isolated by Albert Szent-Gyorgyi in 1927 when he isolated a compound found in high concentrations in the adrenal cortex, oranges, cabbages, and paprika.

Etiology and Pathogenesis: Causes of scurvy include insufficient vitamin C intake, increased vitamin requirement, and increased loss. Inadequate intake is the most common cause. Elderly individuals living alone may have limited diets as a result of poverty, immobility, poor dentition, poor access to groceries, or dementia.[146,147] Alcoholics, food faddists, individuals with presumed food allergies, and cancer patients may have decreased overall dietary intake or may simply avoid fruit and vegetables.[148] Iatrogenic scurvy occurs when physicians recommend dietary restrictions for certain conditions, such as ulcerative colitis, Whipple disease, peptic ulcers, and gastroesophageal reflux, or with inadequate vitamin supplementation with parenteral nutrition. Increased vitamin C requirements are encountered with certain drugs, including aspirin, indomethacin, tetracycline, oral contraceptives, corticosteroids, and tobacco smoking. Scurvy has been reported as a complication of interleukin-2 treatment of metastatic renal cell carcinoma.[149] Peritoneal dialysis and hemodialysis can induce scurvy because the water-soluble vitamin is removed during the dialyzing process.[150] Scurvy also has been reported among patients receiving liver transplantations.[151] One series highlighted associations between scurvy and patients suffering from thalassemia, neurologic disease, and those receiving chemotherapy or bone marrow transplantations.[152]

TABLE 123-13
Clinical Manifestations of Scurvy

Skin	▪ Follicular keratotic plugging ▪ Corkscrew hairs ▪ Perifollicular purpura ▪ Lower-extremity edema with ecchymosis ▪ Poor wound healing and dehiscence
Mucosa	▪ Swelling, ecchymoses, and bleeding of gingiva ▪ Hemorrhagic gingivitis, necrosis, loss of teeth
Other organs	▪ Hemorrhagic intraarticular, subperiosteal, intramuscular, disruption of growth plates, bowing of bones, depressed sternum ▪ Epistaxis, hematuria, GI, and cerebral hemorrhage

Figure 123-9 Vitamin C deficiency in an 18-year-old girl after GI surgery. Note the "corkscrew" or "swan-neck" hairs associated with perifollicular purpura.

Impaired collagen synthesis is the basis for many cutaneous manifestation of scurvy. Ascorbic acid is required for the hydroxylation of proline residues on procollagen, allowing the formation of hydrogen–hydrogen bonding in the triple helix of mature collagen. Without ascorbic acid, the polypeptides are unstable and unable to form stable triple helices. This results in decreased collagen secretion from fibroblasts, increased collagen solubility, and unstable collage fibrils. This abnormal collagen creates pathology in skin, mucous membranes, blood vessels, and bone, leading to the 4 Hs of scurvy: hemorrhagic signs, hyperkeratosis of hair follicles, hypochondriasis, and hematologic abnormalities (Table 123-13).

Clinical Manifestations: Table 123-13 outlines the clinical manifestations of scurvy. The earliest cutaneous sign of scurvy is phrynoderma, which is the enlargement and keratosis of hair follicles, especially on the posterolateral aspect of the arms, resembling keratosis pilaris. The keratotic plugging generalizes, extending to the back, buttocks, posterior thighs, calves, and shins. The hairs within these plugged follicles become curled, resulting in corkscrew hairs. The corkscrew hair results from impaired keratin cross-links by disulfide bonds. As the disease progresses, the follicles turn red from congestion and proliferation of surrounding blood vessels, then turn purple, and finally red and hemorrhagic (Fig. 123-9). This palpable perifollicular purpura is characteristically found on the legs. Lower-extremity edema is often referred to as "woody edema," which is associated with pain and ecchymosis. Other nonspecific cutaneous findings include xerosis and acne. Poor wound healing, and even dehiscence of old wounds, involving skin and bone, can occur because vitamin C is necessary for wound healing and maintenance of healed wounds. Hemorrhage in the nail bed is noted as subungual linear (splinter) hemorrhages.

Oral manifestations are common. Gingival disease manifests as swelling, ecchymoses, bleeding, and loosening of teeth. Interdental and marginal gingivae become red, smooth, swollen, and shiny before becoming purple, black, and necrotic. This hemorrhagic gingivitis is secondary to poor osteodentin formation, which produces softer teeth that are prone to infection. Existing gingivitis and poor dentition predispose to more severe disease, but those without teeth do not develop hemorrhagic gingivitis.

Hemorrhage can occur in areas other than the skin, mouth, and nails. Bone disease is a frequent manifestation in children. Hemorrhage can be intraarticular, intramuscular, and subperiosteal. All of the above can lead to pain and disruption of the growth plates. Bowing of the long bones and a depressed sternum with and outward projection of the end of the ribs are noted on musculoskeletal examination. Metaphyseal spurs with marginal fractures (Pelkan sign), a ring of increased density surrounding the epiphysis (Wimberger sign), widening of the zone of provisional calcification (white line of Frankl), and a transverse band of radiolucency in the metaphysis (scurvy line or Trümmerfeld zone) are seen on radiographs of extremities. Periosteal bleeding may occur. Epistaxis, hematuria, intracerebral hemorrhage, subconjunctival hemorrhage, and GI hemorrhage have been reported. Weakness, fatigue, emotional lability, hypochondriasis, weight loss, arthralgias, hypotension, anorexia, and diarrhea are nonspecific findings associated with vitamin C deficiency.

The causes of a normochromic, normocytic anemia are multifactorial, including blood loss from hemorrhage, intravascular hemolysis, intracellular iron depletion, and decreased folate levels.

Laboratory Testing: Scurvy is a clinical diagnosis, but when unsure of the diagnosis, measurement of leukocyte ascorbate level can be helpful. Levels less than 75 mg/L indicate a deficient state (see Table 123-6).

Treatment: Recommended daily intake of vitamin C is 40 to 60 mg of ascorbic acid. With vitamin C supplementation, clinical symptoms rapidly improve within several days following initiation of supplementation. Therapeutic doses of 100 to 300 mg of ascorbic acid are administered daily until symptoms completely resolve (see Table 123-7).

BIOTIN

Etiology and Pathogenesis: Biotin is an essential cofactor for 4 carboxylating enzymes: (a) acetyl-CoA carboxylase in fatty acid synthesis and lipogenesis; (b) pyruvate carboxylase in gluconeogenesis; and (c) propionyl-CoA carboxylase and (d) 3-methylcrotonyl-CoA carboxylase, both of which are involved in amino acid catabolism.

Eggs, liver, milk, peanuts, mushrooms, chocolates, and hazelnuts are common sources of biotin. Release of protein-bound dietary biotin depends on pancreatic biotinidase. Free biotin diffuses across the gut to bind to plasma proteins. Because biotin is found in many dietary sources and can be synthesized by enteric bacteria, deficiency is uncommon. In 1941, Paul Gyorgy found that avidin in egg white bound and inactivated biotin. Virgil Sydenstricker took this observation and induced biotin deficiency by feeding normal volunteers raw-egg-white-rich diets. Avidin, a protein found in egg whites, binds free biotin in the bowel, thereby preventing absorption of both dietary and synthesized biotin. Although an uncommon cause of biotin deficiency, individuals following fad diets high in raw egg whites can be at risk for deficiency.[153] Biotin deficiency may arise from long-term parenteral nutrition without biotin supplementation.[154] Individuals on unsupplemented parenteral nutrition and on long-term antibiotics are particularly at risk because the antibiotics eradicate biotin-producing enteric flora.[155] Anticonvulsants, such as valproic acid, carbamazepine, and phenytoin, can increase biotin catabolism or impair liver function, leading to biotin deficiency.[156-158] A series of biotin deficiency cases were reported in Japan secondary to an elemental infant formula without supplemental biotin.[159,160]

Clinical Findings: Symptoms can develop 3 to 6 months after initiation of unsupplemented parenteral nutrition or a raw-egg-white-rich diet, but appear earlier in infants because of the greater biotin requirement for growth. The cutaneous manifestations are similar to those of acrodermatitis enteropathica (AE) and EFA deficiency (see section "Essential Fatty Acids") (Table 123-14). An erythematous, scaling, and crusting dermatitis usually begins around the eyes, nose, and mouth, and continues to involve multiple periorificial areas, including the perianal region. Alopecia, conjunctivitis, and glossitis also are associated. Neurologic findings include irritability, lethargy, paresthesias, hypotonia, developmental delay, and myalgias. Nausea and anorexia also have been described.

TABLE 123-14

Clinical Manifestations of Biotin Deficiency and Multiple Carboxylase Deficiency

- Erythematous, crusting, scaly dermatitis around eyes, nose, mouth, and other periorificial areas
- Alopecia, glossitis, conjunctivitis
- Irritability, lethargy, paresthesias, hypotonia, developmental delay

Two inborn errors of metabolism, both autosomal-recessive multiple-carboxylase deficiencies, also alter normal biotin metabolism. The neonatal (early onset) form is associated with a defect in holocarboxylase synthetase. This enzyme is used to catalyze the formation of the amide bond that links biotin to several carboxylase enzymes. Symptoms develop during the first 6 weeks of life and the condition is typically fatal. Patients present with a bright red scaling dermatosis that starts on the scalp, eyebrows, and eyelashes, which can spread to involve the perioral, perinasal, and intertriginous regions. Hair thinning can progress to patchy or total alopecia. Holocarboxylase synthetase deficiency can also present as a collodion membrane and subsequent ichthyosis.[161] Neurologic findings are common and manifest as difficulty feeding and breathing, hypotonia, ataxia, seizures, lethargy, and global developmental delay. Associated metabolic derangements are metabolic acidosis, mild-to-moderate hyperammonemia, lactic acidosis, ketoacidosis, and organic aciduria, all of which can be exacerbated by intercurrent illness.[162]

The juvenile (infantile or late-onset) form presents after 3 months of age and is caused by biotinidase deficiency. Biotinidase is found in pancreatic secretions to recycle endogenous biotin and release protein-bound dietary biotin. Because symptoms derive from a relative biotin deficiency, large supplemental doses of biotin are used to treat this disorder. In biotinidase deficiency, children present with a scaly, erythematous periorificial dermatitis. Severe cases develop lichenification, crusting, and eroded lesions, which can become infected by *Candida*. Keratoconjunctivitis, total alopecia, including eyebrows and eyelashes, and glossitis are associated mucocutaneous findings. Ataxia, developmental delay, hypotonia, seizures, optic nerve atrophy, hearing loss, and myoclonic spasms are common neurologic findings. Hypertonia does not rule out this deficiency.[163] Sensorineural hearing loss is preventable with early diagnosis of biotinidase deficiency, but once present, is irreversible.[164] In contrast, the metabolic encephalopathy is reversible once appropriate therapy is initiated.[165] Like holocarboxylase synthetase deficiency, metabolic acidosis, lactic acidosis, and organic aciduria are found. Humoral and cellular immunodeficiencies can predispose to cutaneous and systemic infections.

Laboratory Testing: If dietary history is not explanatory, consultation to evaluate for inborn errors of metabolism is recommended in children who present with findings suggestive of a biotin deficiency. Biotinidase levels, serum amino acids, urine organic acids, carnitine studies, and ammonia may be helpful in differentiating this disorder from other metabolic diseases.

Treatment: The recommended daily value increases from 30 mcg in neonates to 100 to 200 mcg in adults (see Table 123-7). Acquired deficiency is treated with 150 mcg of biotin per day until resolution of symptoms. Although holocarboxylase synthetase deficiency can be treated with 10 to 40 mg of biotin per

day to reverse cutaneous symptoms, neurologic deficits may persist. Patients with biotinidase deficiency are treated with 5 to 10 mg of biotin and have better clinical outcomes than that seen with holocarboxylase synthetase deficiency.

MINERALS

AT-A-GLANCE

- Cutaneous changes associated with iron deficiency include koilonychia, spoon-shaped nails; brittle, lusterless hair; aphthous stomatitis; and angular stomatitis.
- Acrodermatitis enteropathica is an inherited defect in the intestinal zinc transporter ZIP4.
- Zinc deficiency presents with a periorificial and acral eczematous and erosive dermatitis.
- Zinc status can be measured by serum zinc or alkaline phosphatase, a zinc-dependent enzyme.
- Menkes disease is an X-linked disorder of intestinal copper transport, and results in characteristic kinking of the hair and neurologic deficits.

COPPER

Etiology and Pathogenesis: Copper is an essential component of several metalloenzymes, including tyrosinase and lysyl oxidase. Tyrosinase is involved in melanin biosynthesis, and lysyl oxidase deaminates lysine and hydroxylysine in the first step in collagen crosslinking. Other copper enzymes are involved in catecholamine production, free radical detoxification, and oxidation-reduction reactions.

Epidemiology: Copper is found in fish, oysters, whole grains, beef and pork liver, chocolate, eggs, and raisins. Copper deficiency is uncommon, but can result from malnutrition, malabsorptive states, chronic unsupplemented parenteral nutrition, infants with a strictly cow's-milk diet, and excessive intake of antacids, zinc, iron, or vitamin C, that can interfere with absorption. Celiac disease, cystic fibrosis, gastric bypass surgery, and short-bowel syndrome lead to malabsorption of dietary copper.

Clinical Findings: Clinical manifestations in these cases include hypopigmentation of hair and skin and bony abnormalities (osteoporosis, fractures, periosteal reaction, and flaring of anterior ribs). Copper deficiency myeloneuropathy presents as a progressive and symmetric sensory loss and motor weakness of both upper and lower extremities.[166-168] All sensory modalities are affected. If untreated, optic nerve involvement may occur, with permanent vision loss.[168] Copper supplementation prevents further neurologic deterioration, but recovery of function is not guaranteed.

Laboratory Testing: Microcytic anemia, neutropenia, hypocupremia, and hypoceruloplasminemia can be observed. Neutropenia is the earliest and most common sign of copper deficiency and is a sensitive measure of treatment adequacy.

Treatment: Treatment is with supplemental copper in the diet.

COPPER AND MENKES DISEASE

Epidemiology: Menkes disease, also known as kinky hair disease, was described by John Menkes in 1962 as a multifocal degenerative disease of gray matter. The connection between copper deficiency and demyelinating disease was first suggested in the 1930s by Australian veterinarians after observing ataxia in lambs born to mothers grazing in copper-deficient pastures. Menkes described 5 male infants born into an English-Irish family who showed an X-linked syndrome of neurologic degeneration, particular hair, and failure to thrive. The incidence of Menkes disease ranges from 1 in 100,000 to 1 in 250,000 live births.

Etiology and Pathogenesis: The Menkes gene, *MNK*, was identified on chromosome Xq13 in 1993. The protein product is a copper-transporting *P*-type adenosine triphosphatase, which is expressed in almost all tissues, except the liver. Mutations in *MNK* lead to decreased concentrations of copper because of impaired intestinal absorption and consequent decreased activity of cuproenzymes.

Clinical Findings: Classically, signs of Menkes disease begin at 2 to 3 months of age, although neonatal indicators include preterm labor, large cephalohematomas, hypothermia, hypoglycemia, and jaundice. The characteristic facies of Menkes disease is a cherubic appearance with a depressed nasal bridge, ptosis, and reduced facial movements. At 2 to 3 months of age, there is loss of developmental milestones, hypotonia, seizures, and failure to thrive. Structural changes in the hair are seen, with the general appearance of short, sparse, lusterless, tangled, and depigmented hair. The eyebrows have the same steel wool appearance as scalp hair. On light microscopy, pili torti is classically seen. Monilethrix, segmental shaft narrowing, and trichorrhexis nodosa, small beaded swelling of the hair shaft with fractures at regular intervals, also may be observed. Other cutaneous findings include follicular hyperkeratosis and soft, inelastic, depigmented skin, especially at the nape of the neck, axillae, and trunk. A high-arched palate and delayed tooth eruption may be noted on oral examination (Table 123-15).

Neurologic deficits represent the major morbidity in this disorder. Profound truncal hypotonia with poor head control is typical, while appendicular tone may be increased. Deep tendon reflexes are hyperactive. Suck and cry remain strong. Optic disks are pale with impaired visual fixation and tracking. Hearing

TABLE 123-15
Clinical Features of Menkes Disease

- Depressed nasal bridge, ptosis, and reduced facial movements
- Loss of developmental milestones, hypotonia, seizures, hypothermia, and failure of thrive
- Steel wool appearance of hair: short, sparse lusterless, tangled, and depigmented. Microscopically: pili torti, trichorrhexis nodosa
- Follicular hyperkeratosis, inelastic depigmented skin at nape of neck, axillae, and trunk
- Arched palate, delayed tooth eruption
- Severe neurologic deficits
- Bony and renal changes, including bone fractures and subdural hematoma

remains normal. Developmental arrest occurs at occasional smiling and babbling. Bony changes most often involve the extremities and the skull, and less often the thorax, vertebrae, and pelvis. They include osteoporosis, metaphyseal widening and lateral spur formation, ossification of sutures, a diaphyseal periosteal reaction, and scalloping of the posterior aspects of the vertebral bodies, and subperiosteal new bone formation. Patients are at increased risk of bone fractures and subdural hematomas which may resemble those seen with nonaccidental trauma (child abuse).[169] Renal involvement as hydronephrosis, hydroureter, and diverticula of the bladder can occur. Elongation and tortuosity of many large vessels lead to severe arterial disease, a frequent cause of death by 3 to 4 years of age.

Laboratory Testing: Diagnosis is through the clinical history, physical examination, and reduced levels of serum ceruloplasmin and copper.

Treatment: Early treatment with copper histidinate has resulted in good outcomes, including normal neurodevelopmental milestones, in some patients. Initiation of therapy in older patients may be helpful in alleviation of symptoms like irritability and insomnia.[170,171]

SELENIUM

Etiology and Pathogenesis: Selenium is an essential component of glutathione peroxidase, an antioxidant. Selenium is found in seafood, red meat, egg yolks, grain products, and chicken. The amount of selenium available in cereal grains depends on the selenium content of the soil where it was grown. An area with low soil selenium is Keshan, China, where selenium deficiency in humans is endemic. Selenium-deficient soil is seen in the context of heavy erosion of the surface soil, resulting in trace mineral depletion.[172,173]

SELENIUM DEFICIENCY

Epidemiology: Selenium deficiency is primarily seen in geographic areas where low soil selenium exists, but can also occur in the context of restricted protein diets, unsupplemented parenteral nutrition, malabsorption states, and increased losses.[174,175]

Clinical Findings: Two disorders are attributed to selenium deficiency: Keshan disease and Keshin-Beck (or Kashin-Bek) disease. These diseases have only been reported in endemic areas of Asia.

Keshan disease is a multifocal myocarditis leading to fatal cardiomyopathy that is seen primarily in women and young children in endemic areas. Acute or chronic insufficiency of cardiac function, cardiomegaly, arrhythmias, and electrocardiographic abnormalities have been noted. Muscle pain and weakness with hepatic congestion, mesenteric lymphadenosis, erythrocyte macrocytosis without anemia, and pancreatic exocrine dysfunction also have been seen. Cutaneous findings in these patients have included white nail beds, similar to those of Terry's nails in hepatic cirrhosis, and hypopigmentation of skin and hair (pseudoalbinism). These findings resolve with selenium supplementation.

Keshin-Beck disease is an osteoarthropathy that affects the epiphyseal and articular cartilage and the epiphyseal growth plates, resulting in enlarged joints, and shortened fingers and toes.

Laboratory Testing: Diagnosis of selenium deficiency is through measurement of plasma selenium levels and glutathione peroxidase activity.

Treatment: Selenium supplementation is used for both acute correction and long-term maintenance.

SELENIUM EXCESS

Epidemiology: Selenium toxicity can be acutely fatal. Cases of toxicity have been associated with increased soil selenium. Marco Polo described findings consistent with selenium poisoning in Western China during his explorations in 1295. In the 1960s, reports of selenium toxicity came out of Enshi County in Hubei, China. The cause of this endemic toxicity arose from coal contaminated with selenium that was then used to fertilize the soil.[176] Sporadic cases of selenium intoxication secondary to excess supplement ingestion have been reported.[177] Additional cases of acute selenium toxicity have been documented after ingestion of glass blue (used in stained glass manufacturing),[178] selenite broth (enriched culture media used to isolate *Salmonella* bacilli), and gun bluing agent (a finishing product for firearms).[179]

Clinical Findings: Hair becomes dry and brittle in association with an exfoliative dermatitis on the scalp, often resulting in broken hairs and alopecia. Nails also become brittle with white horizontal streaking on the surface. Breaks in the wall of then nail eventually leads to nail loss. The new nail is fragile and thickened with a rough surface. Nails, hair, and teeth can all develop a reddish hue. Skin on the extremities and neck can become red, swollen, blistered, and occasionally ulcerate that heal slowly. Neurologic complaints of peripheral anesthesia, hyperreflexia, numbness, convulsions,

and paralysis have been reported. Nausea, vomiting, diarrhea, garlic or sour-milk breath odor, and hypersalivation can occur. Severe corrosive hemorrhagic gastritis can progress into a deep gastric ulcer after acute intoxication. Acute tubular necrosis of the kidneys with the potential for acute renal failure requiring dialysis may also complicate selenium toxicity.[180]

Laboratory Testing: Screening of plasma can be used to document elevation selenium levels.

Treatment: Treatment involves removal of the source of excess selenium and supportive care for complications.

MANGANESE

Etiology and Pathogenesis: Manganese activates glycosyltransferases used in the synthesis of glycosaminoglycans and glycoproteins and is used in 2 metalloenzymes (pyruvate carboxylase and superoxide dismutase). Manganese is also found in high concentrations in melanocytes. Reported cases of manganese deficiency are rare. Manganese deficiency was reported during a study of vitamin K requirements, when a study participant was accidentally placed on a manganese-deficient diet. He developed a mild dermatitis, reddening of his black hair, slowed hair and nail growth, and occasional nausea and vomiting with moderate weight loss. A subsequent study of manganese-deficient states showed no hair changes, but miliaria crystallina developed in half the subjects, and disappeared after repletion. Long-term parenteral nutrition without adequate supplementation can induce manganese-deficient states.[181] Likewise, in cases where manganese is supplemented in parenteral nutrition, hypermagnesemia can occur, which is associated with neurologic sequelae.[182] More recently, loss-of-function mutations in the manganese-zinc dication transporter gene, *SLC39A8*, are associated with glycosylation and mitochondrial disorders.[183] Affected patients demonstrated hypotonia, intellectual disability, variable short stature, strabismus, and cerebellar atrophy.[184] An exome-wide association study identified a mutation in the this transporter that is associated with dilated cardiomyopathy.[185]

IRON

Iron is used in several biologic pathways, including heme synthesis, oxidation-reduction reactions, collagen synthesis, and as a cofactor for enzymes such as succinic dehydrogenase, monoamine oxidase, and glycerophosphate oxidase. Iron is found in red meats, egg yolks, dried beans, nuts, dried fruits, green leafy vegetables, and enriched grain products.

IRON DEFICIENCY

Iron deficiency continues to be an international problem that crosses socioeconomic and ethnic divides. Deficiency states result from inadequate intake or chronic blood loss. Groups at high risk include infants, menstruating females, and individuals with chronic GI bleeding. Infants on an iron-fortified formula are at risk for deficiency 3 to 6 months after transitioning to cow's-milk formula because of the lower iron content of cow's milk.[186]

TABLE 123-16
Cutaneous Features of Iron Deficiency

Nails	▪ Fragile, longitudinally ridged ▪ Lamellated brittle nails → thinning, flattening of nail plate, koilonychia
Hair	▪ Lusterless, dry, focally narrow and split hair shafts, heterochromia of black hair; hair loss
Mucous membranes	▪ Aphthous stomatitis, angular stomatitis, glossodynia, atrophied tongue papillae
Blue sclerae	
Pruritus	

Skin changes seen in iron deficiency involve the skin, mucous membranes, hair, and nails (Table 123-16). Moderate iron deficiency causes fragile, longitudinally ridged, lamellated, or brittle nails. As deficiency progresses, the nail plate shows thinning, flattening, and a spoon-shaped convexity known as *koilonychia*. The index and third fingernails are usually the most severely involved. Even after iron replacement therapy begins, koilonychia resolves slowly.

Hair changes include a lusterless, brittle, dry, and focally narrow or split hair shafts, likely caused by impaired keratin production. Heterochromia of black scalp hair with alternating segments of dark brown, white, and liver bands have been described. Cunningham noted, in 1932, that hair loss occurred in iron deficiency, but Hard was the first to show an etiologic connection between iron-deficiency anemia and diffuse scalp hair loss.[187,188] However, the role of iron deficiency in hair loss continues to be a controversial topic.[189,190]

Mucous membrane manifestations include aphthous stomatitis, angular stomatitis, glossodynia, and absent or atrophied tongue papillae. Blue sclerae that persists after iron replacement is likely secondary to impaired collagen synthesis. Generalized pruritus of variable severity has been reported in some individuals with iron deficiency, and sometimes associated with dermatitis herpetiformis. Plummer-Vinson syndrome is an iron-deficiency-associated syndrome encountered predominantly in middle-aged women with microcytic anemia, dysphagia, glossitis, koilonychia, and angular stomatitis. This is considered to be a precancerous phenomenon, associated with carcinoma of the mouth or upper respiratory tract.

Iron deficiency in a microcytic anemia is diagnosed by measurement of serum iron levels, ferritin, total iron binding capacity, transferrin saturation, as well as free or zinc protoporphyrin levels. Treatment involves appropriate iron supplementation. Low zinc levels may aggravate iron-deficiency anemia, and if present, may require correction as well.

IRON EXCESS

Chronic iron overload, hemosiderosis, can be associated with tissue injury, which is called *hemochromatosis*. Hyperpigmentation and ichthyosis-like changes of the skin are seen. Associated findings are cirrhosis of the liver, diabetes mellitus, and cardiomyopathy.

ZINC

Zinc is an important micronutrient that is an essential component of many metalloenzymes involved in a variety of metabolic pathways and cellular functions, and is particularly important in protein and nucleic acid synthesis. Adequate zinc levels are also important for wound healing and for T-cell, neutrophil, and natural killer cell function. Zinc homeostasis depends on adequate zinc absorption and maintenance of appropriate intracellular and extracellular zinc levels, as well as its regulated transport across luminal surfaces. Dietary sources of zinc include meat, fish, shellfish, eggs, dairy products, and legumes, with the highest and most bioavailable forms of zinc found in meats, fish, and shellfish. Other vegetables, fruits, and refined carbohydrates contain very little zinc. Phytates (found in cereal grains, legumes, and nuts) and fiber interfere with intestinal zinc absorption. Human breastmilk contains very high levels of zinc during the first 1 to 2 months of lactation, averaging 3 mg/L; subsequently, zinc levels decrease. Human breastmilk also contains a zinc-binding ligand that increases the bioavailability of breastmilk zinc. Although cow's-milk formula contains higher levels of zinc, the bioavailability is significantly less than that in human breastmilk.

Enteral zinc absorption occurs in the small intestine. Zinc excretion occurs primarily via the GI tract via pancreatic and intestinal secretions, with lesser amounts excreted in the urine complexed to free amino acids. There are more than 27 genes encoding transporter proteins for zinc. Two important families of zinc transporter proteins, including *ZnT* (zinc transporter) genes and Zip (Zrt-like and Irt-like proteins) transporters, have been identified in humans.

Although total-body zinc is stored primarily in the bones, muscles, prostate, and skin, there is no free exchange of stored zinc, and metabolic needs must be met by a continual supply of dietary zinc. In plasma, approximately 50% of the total zinc is complexed with albumin, while the remainder is bound to other serum proteins, including transferrin and α_2-macroglobulin, or to free amino acids. Plasma levels may decrease transiently in response to intercurrent illness, surgery, or other stressors. Excess plasma zinc levels inhibit copper absorption, possibly through competitive inhibition of a common divalent cationic transporter. Zinc deficiency also results in impaired mobilization of hepatic retinol stores and is associated with impaired night vision (nyctalopia). Conversely, excessive calcium intake can interfere with normal zinc absorption, likely also a result of competitive inhibition.

ZINC DEFICIENCY

Epidemiology: Zinc deficiency occurs worldwide. Populations at special risk include patients with intestinal malabsorption syndromes liver disease, anorexia nervosa or food faddism, extensive cutaneous burns, and nephritic syndrome. Iatrogenic zinc deficiency may result from prolonged parenteral or enteral nutrition that contains inadequate zinc levels to meet the metabolic demands. Certain rural populations with diets high in phytates, as have been reported in certain parts of Iran, Turkey, and the former Yugoslavia, are also at risk for acquired zinc deficiency (AZD).

Etiology and Pathogenesis: Zinc deficiency may be either inherited, a form commonly referred to as AE, or acquired, and therefore referred to as AZD.

AZD may results from states associated with inadequate intake, impaired absorption, or increased excretion, including pregnancy, lactation, extensive cutaneous burns, generalized exfoliative dermatoses, food faddism, parenteral nutrition, anorexia nervosa, and even excessive sweating. Intestinal malabsorption syndromes, such as inflammatory bowel disease and cystic fibrosis, result in impaired intestinal absorption of zinc, whereas alcoholism and nephrotic syndrome result in increased renal zinc losses. Penicillamine has been reported to cause zinc deficiency in a patient with Wilson disease. Ornithine transcarbamylase deficiency also is associated with zinc deficiency.

Acute AZD secondary to impaired absorption of zinc, inadequate intake, or excessive renal or intestinal losses may result in a clinical picture that resembles AE and occurs also in adults (Fig. 123-10). This is also seen as a complication to bariatric surgery.

A chronic or subacute form of zinc deficiency is also recognized. These patients often have zinc levels in the mildly deficient range (40 to 60 mcg/dL). Clinical manifestations include growth retardation in children and adolescents, hypogonadism in males, dysgeusia, poor appetite, poor wound healing, abnormal dark adaptation, and impaired mentation. Cutaneous manifestations, when present, are usually less striking and present predominantly as a psoriasiform dermatitis involving the hands and feet and, occasionally, the knees.

AE, the inherited form of zinc deficiency, is a rare autosomal recessive disorder of zinc absorption. These infants have a defect in an intestinal zinc transporter, the human ZIP4 protein encoded on the *SLC39A4* gene. Mutations in this gene prevents appropriate enteral zinc absorption.[191-193]

AE classically presents during infancy on weaning from breastmilk to formula or cereal, which have lower zinc bioavailability than breastmilk. There is a form of AZD that may also present during infancy but, in contrast to AE, these infants become symptomatic

Figure 123-10 Zinc deficiency. **A,** There are plaques of dry, scaly, eczematous skin around the buttocks. The lesions often become secondarily infected with *Candida albicans*. **B,** Hands. The fingers are enlarged, and there are paronychia and bright erythema on the terminal phalanges.

while breastfeeding and improve after weaning to formula or table foods. Many of these reported infants were premature, but cases also have been reported in full-term infants. The mothers of these infants have a presumed defect in mammary excretion of zinc into their breastmilk, resulting in inadequate zinc intake in their infants.[194,195] In a single case evaluated by the author of this chapter (ACY), breastmilk zinc deficiency occurred as a result of excessive maternal intake of calcium that the mother was taking in the belief that calcium supplements might mitigate postpartum depression. Measured breastmilk zinc levels were significantly decreased and rebounded to normal levels upon discontinuation of maternal calcium supplementation. Measurement of breastmilk zinc levels is a useful tool and is diagnostic when less than 70 mcg/dL.

AE presents soon after weaning in affected infants or during the fourth to tenth week of life in infants who are not breastfed. The classic features of AE include alopecia, diarrhea, lethargy, and an acute eczematous and erosive dermatitis favoring periorificial (perioral, periocular, anogenital) and acral areas (hands and feet) (Table 123-17). The cutaneous findings are highly characteristic and often present initially as a nonspecific, acrally distributed, symmetric, eczematous dermatitis. Over time, bullae and erosions with a characteristic peripheral crusted border develop (Fig. 123-11). Vitiligo-like depigmented patches have been described.[196] In addition to dry and brittle hair,

TABLE 123-17
Clinical Features of Acrodermatitis Enteropathica

- Eczematous and erosive dermatitis
- Preferentially localized to periorificial and acral areas
- Alopecia
- Diarrhea
- Lethargy, irritability
- Whining and crying
- Superinfection with *Candida albicans* and *Staphylococcus aureus*

Figure 123-11 **A,** Patient with acrodermatitis enteropathica. These clinical findings resolved within 2 weeks of initiating zinc supplementation. **B,** This crusted and scaly, erosive, and sharply demarcated eruption appeared shortly after weaning. The child was highly irritable, whining and crying, and had diarrhea.

alternating dark and light bands with polarized light can be seen.[197] Patients also appear to be predisposed to systemic infections as a result of impaired cell-mediated immunity, and superinfection with *Candida albicans* and bacteria, usually *Staphylococcus aureus*, is common. Delayed wound healing, acute paronychia, conjunctivitis, blepharitis, and photophobia also may be observed. Diarrhea may be prominent but is not seen in all cases. If untreated, the disease is fatal.

Laboratory Testing: A low plasma zinc level is the gold standard for diagnosing zinc deficiency. Use of contaminated needles, catheters, and sample tubes may lead to erroneously high measured zinc levels. Contact with collection tubes with rubber stoppers should be avoided as they may contain high levels of zinc. Normal plasma zinc levels range from 70 to 250 mcg/dL. Measurement of serum alkaline phosphatase—a zinc-dependent enzyme—is another useful and rapid indicator of zinc status, as alkaline phosphatase may be low-normal; serum alkaline phosphatase will increase with zinc supplementation, thus confirming the diagnosis.

In cases in which the plasma zinc level is equivocal and the diagnosis is uncertain, skin biopsy for routine histology may be helpful. The characteristic features are variable psoriasiform hyperplasia with confluent parakeratosis, spongiosis and pallor of the upper epidermis, focal dyskeratosis, and variable epidermal atrophy. However, these findings are not specific; and may be seen in a number of other nutritional deficiencies.

Treatment: Zinc supplementation with either an enteral or parenteral formulation is appropriate. Clinical response is usually rapid, with initial improvement noted within several days. Irritability and whining disappear first, followed by improvement of skin lesions. Although several zinc formulations are available, the most commonly used enteral formulation is zinc sulfate. Zinc chloride is recommended for parenteral supplementation.

In children, 0.5 to 1.0 mg/kg of elemental zinc given as 1 to 2 daily doses is recommended for mild-to-moderate zinc deficiency. Higher doses may be required in cases of AZD caused by intestinal malabsorption. In adults, 15 to 30 mg of elemental zinc per day is usually sufficient in cases of AZD. Serum zinc levels should be monitored during therapy. Patients with AE require lifelong treatment. Patients with AZD may need variable levels of supplementation, depending on their underlying disease. Of note, excess zinc levels may interfere with copper metabolism.

ZINC TOXICITY

Zinc toxicity has been reported with exposure to zinc-containing fumes, intravenous poisoning, and ingestion of large amounts of zinc. There are no cutaneous manifestations, but patients may present with severe vomiting, nausea, lethargy, dizziness, neuropathy, and dehydration. Hypocupremia may result.

NOMA

AT-A-GLANCE

- Devastating gangrene of the soft and hard tissue of the face found in developing countries.
- Malnutrition, vitamin deficiencies, and immune dysregulation create an environment for this rapidly progressive destructive polymicrobial infection.

EPIDEMIOLOGY

Noma (necrotizing ulcerative stomatitis, stomatitis gangrenosa, or cancrum oris) is a devastating gangrenous condition that destroys soft and hard tissue of the face; predominantly, it affects children between the ages of 1 to 7 years. The word *noma* originates from the Greek word *νομη*, which means to graze or devour, which reflects the rapid progression of this condition.

In 1848, Tourdes was the first to define noma as

> a gangrenous disease affecting the mouth and face of children living in poor hygiene conditions and suffering from debilitating diseases, especially eruptive fevers. Beginning with an ulcer on the oral mucosa rapidly spreading outside and destroying the soft and hard tissues of the face—and almost always fatal.[198]

As public health initiatives improved sanitation in developed countries, the global epidemiology of noma likewise improved. In general, noma has become a rare occurrence in developed countries and is predominantly encountered now only in parts of Africa, Latin America, and Asia. Intermittent epidemics of noma were noted during World War I, the malaria epidemic in 1938, and World War II in the Belsen and Auschwitz concentration camps.[199] In response to reports from humanitarian organizations, the World Health Organization declared noma a health priority in 1994. The World Health Organization estimates the worldwide incidence of noma to be 500,000 cases per year with a 79% mortality rate. An estimated 25,000 children are affected in the developing countries bordering the Sahara every year.[200] Unfortunately, the data on the incidence of noma are likely an underestimation of the true incidence as less than 10% of affected individuals actually seek medical care.[201] The high mortality rate and rapid progression of disease means that many patients die before reaching medical attention. Moreover, many cultures perceive noma as a curse on the family, so affected children are often ignored or hidden. Finally, the nomadic lifestyles of many patients make them difficult to register and follow.

An increase in noma has been observed in developed countries since 2000, mostly in association with

immunosuppressive therapy, HIV/AIDS, and severe combined immunodeficiency.[202]

Noma neonatorum is thought to be a related but separate entity from noma. The original description by Ghosal, in 1978, described 35 premature and low-birthweight infants in India who developed gangrenous lesions on their noses, eyelids, oral cavities, anal regions, and genitalia. These infants had *Pseudomonas aeruginosa* isolated from their skin lesions and many of their blood cultures. This condition is almost uniformly fatal. Since Ghosal's description, clinical experience has shown that preterm and low-birthweight newborns, especially those with severe intrauterine growth retardation, are at highest risk. The causative organism is usually *Pseudomonas*, but *Escherichia coli*, *Klebsiella*, and staphylococci have occasionally been isolated. Because most cases of noma neonatorum are caused by *Pseudomonas*, some researchers have wondered if it is really ecthyma gangrenosum.[63] Almost all reported cases have been from India, China, Lebanon, or Israel, but there was 1 reported case in the United States in 2002.

ETIOLOGY AND PATHOGENESIS

The pathogenesis of noma is a complex, and yet undefined, interaction between infection, impaired host defense, and malnutrition. The one known risk factor for noma is poverty. There are no reported cases of noma in well-nourished African children. An epidemiologic study in a Nigerian hospital in 2002 revealed that 98% of affected children lived in very poor homes with an average of 7 children per family.[64]

Malnutrition and associated vitamin deficiencies contribute to the pathogenesis of noma. Deficiencies in vitamin A, B_6, C, and E, and the trace elements iron and zinc, and the amino acids cysteine, methionine, serine, and glycine have been identified as possible contributing factors to immune dysfunction in the malnourished. Adrenal hyperfunction in PEM also has been implicated in depression of cell-mediated immunity, and decrease in mucosal resilience. Early malnutrition and chronic infections resulting from early weaning from breastmilk may also represent predisposing factors.[203]

In the early 1940s, Albert Eckstein proposed that acute necrotizing gingivitis, a painful inflammation and necrosis of the interdental papillae, was the precursor to noma. He hypothesized that progression to necrotic stomatitis and noma occurred if appropriate dental hygiene and antibiotics were not initiated. Acute necrotizing gingivitis is associated with poor oral hygiene, stress, and malnutrition. However, any oral mucosal ulceration or trauma, including tooth eruption and viral ulcers, can develop into noma.[204]

Patients with noma frequently have a recent history of debilitating infections, with measles and malaria being the most frequent. Unfortunately, the causative link between these preceding infections and noma remains unclear. Studies in Nigeria show that the frequencies of malaria in northern and southern regions are equal, but the prevalence of noma in the north is higher than in the south. The link between measles and noma appears stronger, but still elusive. The ulcerative oral lesions in patients with measles are one proposed site of initiation of noma.[205]

Noma is a polymicrobial infection, with *Prevotella intermedia* and *Fusobacterium necrophorum* being the 2 most frequently isolated organisms.[206] Other frequently identified organisms are *Tannerella forsythensis*, *Peptostreptococcus micros*, *Campylobacter*, streptococci, and enteric Gram-negative rods. Although organisms are isolated from noma lesions, there is a low likelihood of transmissibility. There are no reports of outbreaks in families or villages after 1 child develops noma. Groupings of noma seem to be more associated with common risk factors rather than true transmission.

CLINICAL FINDINGS

The prodrome of noma is not well documented because of late presentation to medical care and rapid progression. Parents often describe fever and apathy. Early acute noma often presents with soreness of the mouth, halitosis, tenderness of the lip or cheek, cervical lymphadenopathy, and purulent oral discharge. The intraoral lesion is a necrotizing stomatitis generally starting on the alveolar margin and extending to the mucosal surface of the cheek. This evolution is rapid, taking 24 to 48 hours. Swelling and blue-black discoloration of the skin overlying the intraoral lesion develops and rapidly becomes necrotic with well-defined borders. As it becomes black, this necrotic zone expands and forms a classic cone shape, cone gangreneux, with internal destruction greater than external involvement (Fig. 123-12). Laboratory investigation

Figure 123-12 Cancrum oris (noma). Massive destruction of the face in a Tanzanian child.

TABLE 123-18
Clinical Presentation of Noma

- Rapid progression of soreness of mouth, halitosis, purulent oral discharge, tenderness of lips and cheeks
- Necrotizing stomatitis starting at alveolar margin and extending to mucosal surface of cheek
- Swelling and blue-black discoloration of cheek → cone-shaped black necrosis, tissue destruction, and ulceration

often shows severe anemia, a high white blood cell count, and hypoalbuminemia (Table 123-18).

Healing noma lesions are also difficult to manage because of the extensive fibrous scars. These scars can lead to strictures of the mouth, severe dental malposition, defective speech, and even complete closure of the mouth from contractures.

TREATMENT

Management of acute noma is geared toward minimizing damage, but invasive intraoral procedures are contraindicated. Key goals of acute management are:

- Correction of dehydration and electrolyte imbalances.
- Treatment of predisposing disease, ie, malaria, measles, HIV, tuberculosis.
- Antibiotics: Some researchers recommend broad-spectrum antibiotics, whereas others believe that metronidazole is adequate because anaerobic organisms predominate.
- Oral hygiene with chlorhexidine digluconate rinses.
- Nutritional rehabilitation—oral, enteral, or parenteral.
- Local wound care.
- Physiotherapy to reduce strictures from fibrous scarring.

Surgical intervention should not occur until the acute phase has ended, and is aimed at restoring function and improving appearance to allow patients to reintegrate into society.

CONCLUSION

Nutritional disorders arise most commonly as a result of nutrient deficiencies, but may also derive from imbalances in nutrients or at times from nutrient excess. Because macronutrients and micronutrients play roles in multiple biochemical pathways, these disorders often present with clinical features in a variety of organ systems. The key to diagnosis is in having a familiarity with the range of clinical presentations associated with these disorders and maintaining an appropriate index of suspicion for these disorders when evaluating dermatologic patients with skin findings or a history that might suggest a nutritional etiology.

ACKNOWLEDGMENTS

The author gratefully acknowledges Melinda Jen, MD, and Kara N. Shah, MD, PhD, for their contributions to this chapter in previous editions.

REFERENCES

1. WorldHealthOrganization.*MalnutritionintheCrosshairs*. http://www.who.int/nutrition/pressrelease-FAOWHO-symposium-malnutrition/en/. Accessed March 24, 2017.
2. World Health Organization. *Nutrition for Health and Development: A Global Agenda for Combating Malnutrition*. Geneva, Switzerland: World Health Organization; 2000.
3. UNICEF. *The State of the World's Children*. New York, NY: Oxford University Press; 1998.
4. Katz KA, Mahlberg MJ, Honig PJ, et al. Rice nightmare: kwashiorkor in 2 Philadelphia-area infants fed Rice Dream beverage. *J Am Acad Dermatol*. 2005;52: S69-S72.
5. Kuhl J, Davis MD, Kalaaji AN, et al. Skin signs as the presenting manifestation of severe nutritional deficiency: report of 2 cases. *Arch Dermatol*. 2004;140: 521-524.
6. Liu T, Howard RM, Mancini AJ, et al. Kwashiorkor in the United States: fad diets, perceived and true milk allergy,andnutritionalignorance.*ArchDermatol*.2001; 137:630-636.
7. Mori F, Serranti D, Barni S, et al. A kwashiorkor case due to the use of an exclusive rice milk diet to treat atopic dermatitis. *Nutr J*. 2015;14:83.
8. Fourreau D, Peretti N, Hengy B, et al. Pediatric nutrition: Severe deficiency complications by using vegetable beverages, four cases report [in French]. *Presse Med*. 2013;42(2):e37-e43.
9. Hatem NL, Hassab HM, Abd Al-Rahman EM, et al. Prevalence of aflatoxins in blood and urine of Egyptian infants with protein-energy malnutrition. *Food Nutr Bull*. 2005;26:49-56.
10. Fechner A, Böhme C, Gromer S, et al. Antioxidant status and nitric oxide in the malnutrition syndrome kwashiorkor. *Pediatr Res*. 2001;49:237-243.
11. Barness L. *Nutrition and Nutritional Disorders*. 14th ed. Philadelphia, PA: WB Saunders; 1992.
12. Mei Z, Grummer-Strawn LM, de Onis M, et al. The development of a MUAC-for-height reference, including a comparison to other nutritional status screening indicators. *Bull World Health Organ*. 1997;75:333-341.
13. Miller S. Nutritional deficiency and the skin. *J Am Acad Dermatol*. 1989;21:1-30.
14. Prendiville J, Manfredi L. Skin signs of nutritional disorders. *Semin Dermatol*. 1992;11:88-97.
15. Müller O, Krawinkel M. Malnutrition and health in developing countries. *CMAJ*. 2005;173:279-286.
16. Ruiz-Maldonado R, Orozco-Ovarrubias L. *Skin Manifestations of Nutritional Disorders*. Malden, MA: Blackwell Publishing; 2006.
17. Bistrian B, McCowen K, Chan S. Protein-energy malnutrition in dialysis patients. *Am J Kidney Dis*. 1999;33:172-175.
18. Lacquaniti A, Bolignano D, Campo S, et al. Malnutrition in the elderly patient on dialysis. *Ren Fail*. 2009;31:239-245.

19. Malinowski S. Nutritional and metabolic complications of bariatric surgery. *Am J Med Sci*. 2006;331:219-225.
20. Pitt R, Labib PL, Wolinski A, et al. Iatrogenic kwashiorkor after distal gastric bypass surgery: the consequences of receiving multinational treatment. *Eur J Clin Nutr*. 2016;70(5):635-636.
21. Boutin D, Cante V, Levillain P, et al. Adult kwashiorkor: a rare complication of bariatric surgery [in French]. *Ann Dermatol Venereol*. 2015;142(2):99-103.
22. Strumia R. Dermatologic signs in patients with eating disorders. *Am J Clin Dermatol*. 2005;6:165-173.
23. Ryan A, Goldsmith L. Nutrition and the skin. *Clin Dermatol*. 1996;14:389-406.
24. World Health Organization. *Management of Severe Malnutrition: A Manual for Physicians and Other Senior Health Workers*. Geneva, Switzerland: World Health Organization; 1999.
25. Raj DS, Carrero JJ, Shah VO, et al. Soluble CD14 levels, interleukin 6, and mortality among prevalent hemodialysis patients. *Am J Kidney Dis*. 2009;54:1072-1080.
26. Rytter MJ, Babirekere-Iriso E, Namusoke H, et al. Risk factors for death in children during inpatient treatment of severe acute malnutrition: a prospective cohort study. *Am J Clin Nutr*. 2017;105(2):494-502.
27. Thavaraj V, Sesikeran B. Histopathological changes in skin of children with clinical protein energy malnutrition before and after recovery. *J Trop Pediatr*. 1989;35:105-108.
28. Ernst KD. Essential fatty acid deficiency during parenteral soybean oil lipid minimization. *J Perinatol*. 2017;37(6):695-697.
29. Darmstadt G, McGuire J, Ziboh V. Malnutrition-associated rash of cystic fibrosis. *Pediatr Dermatol*. 2000;17:337-347.
30. Friedman Z, Shochat SJ, Maisels MJ, et al. Correction of essential fatty acid deficiency in newborn infants by cutaneous application of sunflower-seed oil. *Pediatrics*. 1976;58:650-654.
31. Hunt CE, Engel RR, Modler S, et al. Essential fatty acid deficiency in neonates: Inability to reverse deficiency by topical applications of EFA-rich oil. *J Pediatr*. 1978;92:603-607.
32. Duerksen D, McCurdy K. Essential fatty acid deficiency in a severely malnourished patient receiving parenteral nutrition. *Dig Dis Sci*. 2005;50:2386-2388.
33. Bates C. Vitamin A. *Lancet*. 1995;345:31-35.
34. Nicholls L. Phrynoderma: a condition due to vitamin deficiency. *Ind Med Gaz*. 1933;68:681.
35. Maronn M, Allen D, Esterly N. Phrynoderma: a manifestation of vitamin A deficiency?… The rest of the story. *Pediatr Dermatol*. 2005;22:60-63.
36. Sarma PC, Goswami BC, Gogoi K, et al. A new approach to the assessment of marginal vitamin A deficiency in children in suburban Guwahati, India: hydrolysis of retinoyl glucuronide to retinoic acid. *Br J Nutr*. 2009;101:794-797.
37. National Institutes of Health, Office of Dietary Supplements. Dietary Supplement Ingredient Database. https://dietarysupplementdatabase.usda.nih.gov/ingredient_calculator/help.php. Accessed March 25, 2017.
38. National Institutes of Health: Office of Dietary Supplements. Vitamin A Fact Sheet for Health Professionals. https://ods.od.nih.gov/factsheets/VitaminA-HealthProfessional/. Accessed March 25, 2017.
39. Penniston K, Tanumihardjo S. The acute and chronic toxic effects of vitamin A. *Am J Clin Nutr*. 2006;83:191-201.
40. Brooke P. Diseases of nutrition and metabolism. *Adv Dermatol*. 1993;8:155-171; discussion 172.
41. Weinstock MA, Bingham SF, Lew RA, et al. Topical tretinoin therapy and all-cause mortality. *Arch Dermatol*. 2009;145:18-24.
42. Baineni R, Gulati R, Delhi CK. Vitamin A toxicity presenting as bone pain. *Arch Dis Child*. 2017;102(6):556-558.
43. Hess A, Meyers V. Carotenemia. A new clinical picture. *JAMA*. 1919;73:1743-1745.
44. Schwingshackl L, Boeing H, Stelmach-Mardas M, et al. Dietary supplements and risk of cause-specific death, cardiovascular disease, and cancer: a systematic review and meta-analysis of primary prevention trials. *Adv Nutr*. 2017;8(1):27-39.
45. Druesne-Pecollo N, Latino-Martel P, Norat T, et al. Beta-carotene supplementation and cancer risk: A systematic review and meta-analysis of randomized controlled trials. *Int J Cancer*. 2009;127(1):172-184.
46. Satia JA, Littman A, Slatore CG, et al. Long-term use of beta-carotene, retinol, lycopene, and lutein supplements and lung cancer risk: Results from the VITamins And Lifestyle (VITAL) study. *Am J Epidemiol*. 2009;169:815-828.
47. Neuhouser ML, Barnett MJ, Kristal AR, et al. Dietary supplement use and prostate cancer risk in the Carotene and Retinol Efficacy Trial. *Cancer Epidemiol Biomarkers Prev*. 2009;18:2202-2206,
48. Al-Wadei HA, Schuller HM. Non-genomic inhibitory signaling of beta-carotene in squamous cell carcinoma of the lungs. *Int J Oncol*. 2009;34:1093-1098.
49. van Helden YG, Keijer J, Heil SG, et al. Beta-carotene affects oxidative stress-related DNA damage in lung epithelial cells and in ferret lung. *Carcinogenesis*. 2009;30:2070-2076.
50. Maharshak N, Shapiro J, Trau H. Carotenoderma—a review of the current literature. *Int J Dermatol*. 2003;42:178-181.
51. Sale T, Stratman E. Carotenemia associated with green bean ingestion. *Pediatr Dermatol*. 2004;21:657-659.
52. Takita Y, Ichimiya M, Hamamoto Y, et al. A case of carotenemia associated with ingestion of nutrient supplements. *J Dermatol*. 2006;33:132-134.
53. Judd SE, Nanes MS, Ziegler TR, et al. Optimal vitamin D status attenuates the age-associated increase in systolic blood pressure in white Americans: results from the third National Health and Nutrition Examination Survey. *Am J Clin Nutr*. 2008;87:136-141.
54. Liu E, Meigs JB, Pittas AG, et al. Plasma 25-hydroxyvitamin d is associated with markers of the insulin resistant phenotype in nondiabetic adults. *J Nutr*. 2009;139:329-334.
55. Kendrick J, Targher G, Smits G, et al. 25-Hydroxyvitamin D deficiency is independently associated with cardiovascular disease in the Third National Health and Nutrition Examination Survey. *Atherosclerosis*. 2009;205:255-260.
56. Wang TJ, Pencina MJ, Booth SL, et al. Vitamin D deficiency and risk of cardiovascular disease. *Circulation*. 2008;117:503-511.
57. Dobnig H, Pilz S, Scharnagl H, et al. Independent association of low serum 25-hydroxyvitamin D and 1,25-dihydroxyvitamin D levels with all-cause and cardiovascular mortality. *Arch Intern Med*. 2008; 168:1340-1349.
58. Cauley JA, Parimi N, Ensrud KE, et al. Serum 25 hydroxyvitamin D and the risk of hip and non-spine fractures in older men. *J Bone Miner Res*. 2010;25(3):545-553.

59. Wu K, Feskanich D, Fuchs CS, et al. A nested case control study of plasma 25-hydroxyvitamin D concentrations and risk of colorectal cancer. *J Natl Cancer Inst*. 2007;99:1120-1129.
60. Melamed ML, Michos ED, Post W, et al. 25-Hydroxyvitamin D levels and the risk of mortality in the general population. *Arch Intern Med*. 2008;168: 1629-1637.
61. Liu PT, Stenger S, Li H, et al. Toll-like receptor triggering of a vitamin D-mediated human antimicrobial response. *Science*. 2006;311:1770-1773.
62. Nnoaham K, Clarke A. Low serum vitamin D levels and tuberculosis: a systematic review and metaanalysis. *Int J Epidemiol*. 2008;37:113-119.
63. Freeman A, Mancini A, Yogev R. Is noma neonatorum a presentation of ecthyma gangrenosum in the newborn? *Pediatr Infect Dis J*. 2002;21:83-85.
64. Obiechina A, Arotiba J, Fasola A. Cancrum oris (noma). Level of education and occupation of parents of affected children in Nigeria. *Odontostomatol Trop*. 2000;23:11-14.
65. Sethuraman G, Khaitan BK, Dash SS, et al. Ichthyosiform erythroderma with rickets: report of five cases. *Br J Dermatol*. 2008;158:603-606.
66. Thacher TD, Fischer PR, Pettifor JM, et al. Nutritional rickets in ichthyosis and response to calcipotriene. *Pediatrics*. 2004;114:e119-e123.
67. Sathish Kumar T, Scott XJ, Simon A, et al. Vitamin D deficiency rickets with lamellar ichthyosis. *J Postgrad Med*. 2007;53:215-217.
68. Dayal D, Kumar L, Singh M. Non-bullous ichthyosiform erythroderma with rickets. *Indian Pediatr*. 2002; 39:207-208.
69. Nayak S, Behera SK, Acharjya B, et al. Epidermolytic hyperkeratosis with rickets. *Indian J Dermatol Venereol Leprol*. 2006;72:139-142.
70. Kuwabara A, Tsugawa N, Tanaka K, et al. High prevalence of vitamin D deficiency in patients with xeroderma pigmetosum-A under strict sun protection. *Eur J Clin Nutr*. 2015;69(6):693-6.
71. Ombra MN, Paliogiannis P, Doneddu V, et al. Vitamin D status and risk for malignant cutaneous melanoma: recent advances. *Eur J Cancer Prev*. 2017;26(6):532-541.
72. Wyatt C, Lucas RM, Hurst C, et al. Vitamin D deficiency at melanoma diagnosis is associated with higher Breslow thickness. *PLoS One*. 2015;10(5):e0126394.
73. Caini S, Boniol M, Tosti G, et al. Vitamin D and melanoma and non-melanoma skin cancer risk and prognosis: a comprehensive review and meta-analysis. *Eur J Cancer*. 2014;50(15):2649-2658.
74. Norval M, Wulf H. Does chronic sunscreen use reduce vitamin D production to insufficient levels? *Br J Dermatol*. 2009;161:732-736.
75. Holick MF. Sunlight "D"ilemma: risk of skin cancer or bone disease and muscle weakness. *Lancet*. 2001;357:4-6.
76. Lim HW, Gilchrest BA, Cooper KD, et al. Sunlight, tanning booths, and vitamin D. *J Am Acad Dermatol*. 2005;52:868-876.
77. Maiya S, Sullivan I, Allgrove J, et al. Hypocalcaemia and vitamin D deficiency: an important, but preventable, cause of life-threatening infant heart failure. *Heart*. 2008;94:581-584.
78. Amirlak I, Al Dhaheri W, Narchi H. Dilated cardiomyopathy secondary to nutritional rickets. *Ann Trop Paediatr*. 2008;28:227-230.
79. Kosecik M, Ertas T. Dilated cardiomyopathy due to nutritional vitamin D deficiency rickets. *Pediatr Int*. 2007;49:397-399.
80. Bergman R, Schein-Goldshmid R, Hochberg Z, et al. The alopecias associated with vitamin D-dependent rickets type IIA and with hairless gene mutations: a comparative clinical, histologic, and immunohistochemical study. *Arch Dermatol*. 2005;141:343-351.
81. Miller J, Djabali K, Chen T, et al. Atrichia caused by mutations in the vitamin D receptor gene is a phenocopy of generalized atrichia caused by mutations in the hairless gene. *J Invest Dermatol*. 2001;117:612-617.
82. Wagner CL, Greer FR; American Academy of Pediatrics Section on Breastfeeding; American Academy of Pediatrics Committee on Nutrition. Prevention of rickets and vitamin D deficiency in infants, children, and adolescents. *Pediatrics*. 2008;122(5):1142-1152. Erratum in: *Pediatrics*. 2009;123(1):197.
83. Argao EA, Heubi JE, Hollis BW, et al. d-Alpha-tocopheryl polyethylene glycol-1000 succinate enhances the absorption of vitamin D in chronic cholestatic liver disease of infancy and childhood. *Pediatr Res*. 1992;31:146-150.
84. Kooh SW, Roberts EA, Fraser D, et al. Ultraviolet irradiation for hepatic rickets. *Arch Dis Child*. 1989;64:617-619.
85. Dent CE, Round JM, Rowe DJ, et al. Effect of chapattis and ultraviolet irradiation on nutritional rickets in an Indian immigrant. *Lancet*. 1973;1:1282-1284.
86. U.S. Department of Health and Human Services, Department of Agriculture. *Dietary Guidelines for Americans, 2005*. 6th ed. Washington, DC: U.S. Government Printing Office; 2005.
87. Thomson C, Sarubin-Fragakis A. Vitamin, minerals, and phytochemicals. In: Hark L, Morrison G, eds. *Medical Nutrition and Disease: A Case-based Approach*. Malden, MA: Blackwell Publishing; 2003.
88. Copp RP, Wisniewski T, Hentati F, et al. Localization of alpha-tocopherol transfer protein in the brains of patients with ataxia with vitamin E deficiency and other oxidative stress related neurodegenerative disorders. *Brain Res*. 1999;822:80-87.
89. Ouahchi K, Arita M, Kayden H, et al. Ataxia with isolated vitamin E deficiency is caused by mutations in the alpha-tocopherol transfer protein. *Nat Genet*. 1995;9:141-145.
90. Qian J, Atkinson J, Manor D. Biochemical consequences of heritable mutations in the alpha-tocopherol transfer protein. *Biochemistry*. 2006;45: 8236-8242.
91. American Academy of Pediatrics Committee on Fetus and Newborn. Controversies concerning vitamin K and the newborn. *Pediatrics*. 2003;112:191-192.
92. Goskowicz M, Eichenfield L. Cutaneous findings of nutritional deficiencies in children. *Curr Opin Pediatr*. 1993;5:441-445.
93. Fujiyama S, Morishita T, Hashiguchi O, et al. Plasma abnormal prothrombin (des-gamma-carboxy prothrombin) as a marker of hepatocellular carcinoma. *Cancer*. 1988;61:1621-1628.
94. Wrenn K, Murphy F, Slovis C. A toxicity study of parenteral thiamine hydrochloride. *Ann Emerg Med*. 1989;18:867-870.
95. Snodgrass S. Vitamin neurotoxicity. *Mol Neurobiol*. 1992;6:41-73.
96. Carpenter K. *Beriberi, White Rice, and Vitamin B*. Berkeley, CA: University of California Press; 2000.
97. Hardy A. Beriberi, vitamin B1 and world food policy, 1925-1970. *Med Hist*. 1995;39:61-77.
98. Hanninen SA, Darling PB, Sole MJ, et al. The prevalence of thiamin deficiency in hospitalized patients

with congestive heart failure. *J Am Coll Cardiol*. 2006;47:354-361.
99. Kara B, Genç HM, Uyur-Yalçın E, et al. Pyruvate dehydrogenase-E1α deficiency presenting as recurrent acute proximal muscle weakness of upper and lower extremities in an 8-year-old boy. *Neuromuscul Disord*. 2017;27(1):94-97.
100. Lawton AW, Frisard NE. Visual loss, retinal hemorrhages, and optic disc edema resulting from thiamine deficiency following bariatric surgery complicated by prolonged vomiting. *Ochsner J*. 2017;17(1): 112-114.
101. Dias SP, Diogo MC, Capela C, et al. Wernicke's encephalopathy due to food refusal in a patient with severe depressive disorder. *J Neurol Sci*. 2017;375:92-93.
102. Ubukata M, Amemiya N, Nitta K, et al. Serum thiamine values in end-stage renal disease patients under maintenance hemodialysis. *Int J Vitam Nutr Res*. 2016 [Epub ahead of print].
103. Zhang F, Masania J, Anwar A, et al. The uremic toxin oxythiamine causes functional thiamine deficiency in end-stage renal disease by inhibiting transketolase activity. *Kidney Int*. 2016;90(2):396-403.
104. Teigen LM, Twernbold DD, Miller WL. Prevalence of thiamine deficiency in a stable heart failure outpatient cohort on standard loop diuretic therapy. *Clin Nutr*. 2016;35(6):1323-1327.
105. Katta N, Balla S, Alpert MA. Does long-term furosemide therapy cause thiamine deficiency in patients with heart failure? A focused review. *Am J Med*. 2016;129(7):753.e7-753.e11.
106. Masood U, Sharma A, Nijjar S, et al. B-cell lymphoma, thiamine deficiency, and lactic acidosis. *Proc (Bayl Univ Med Cent)*. 2017;30(1):69-70.
107. Huertas-González N, Hernando-Requejo V, Luciano-García Z, et al. Wernicke's encephalopathy, wet beriberi, and polyneuropathy in a patient with folate and thiamine deficiency related to gastric phytobezoar. *Case Rep Neurol Med*. 2015;2015:624807.
108. Nath A, Tran T, Shope TR, et al. Prevalence of clinical thiamine deficiency in individuals with medically complicated obesity. *Nutr Res*. 2017;37:29-36.
109. Fattal-Valevski A, Kesler A, Sela BA, et al. Outbreak of life-threatening thiamine deficiency in infants in Israel caused by a defective soy-based formula. *Pediatrics*. 2005;115:e233-e238.
110. Park JH, Lee JH, Jeong JO, et al. Thiamine deficiency as a rare cause of reversible severe pulmonary hypertension. *Int J Cardiol*. 2007;121:e1-e3.
111. Powers H. Riboflavin (vitamin B-2) and health. *Am J Clin Nutr*. 2003;77:1352-1360.
112. Clements R, Katasani VG, Palepu R, et al. Incidence of vitamin deficiency after laparoscopic Roux-en-Y gastric bypass in a university hospital setting. *Am Surg*. 2006;72:1196-1202; discussion 203-204.
113. Gromisch DS, Lopez R, Cole HS, et al. Light (phototherapy)-induced riboflavin deficiency in the neonate. *J Pediatr*. 1977;90:118-122.
114. Tomei S, Yuasa H, Inoue K, et al. Transport functions of riboflavin carriers in the rat small intestine and colon: Site difference and effects of tricyclic-type drugs. *Drug Deliv*. 2001;8:119-124.
115. Pinto J, Rivlin R. Drugs that promote renal excretion of riboflavin. *Drug Nutr Interact*. 1987;5:143-151.
116. Menezes MP, O'Brien K, Hill M, et al. Auditory neuropathy in Brown-Vialetto-Van Laere syndrome due to riboflavin transporter RFVT2 deficiency. *Dev Med Child Neurol*. 2016;58(8):848-854.
117. Roe D. Riboflavin deficiency: mucocutaneous signs of acute and chronic deficiency. *Semin Dermatol*. 1991;10:293-295.
118. Kraut A. *Goldberger's War: The Life and Work of a Public Health Crusader*. New York, NY: Hill and Wang; 2003.
119. Rajakumar K. Pellagra in the United States: a historical perspective. *South Med J*. 2000;93:272-277.
120. Karthikeyan K, Thappa D. Pellagra and skin. *Int J Dermatol*. 2002;41:476-481.
121. MacDonald A, Forsyth A. Nutritional deficiencies and the skin. *Clin Exp Dermatol*. 2005;30:388-390.
122. Kaur S, Goraya JS, Thami GP, et al. Pellagrous dermatitis induced by phenytoin. *Pediatr Dermatol*. 2002;19:93.
123. Cakmak SK, Gönül M, Aslan E, et al. Half-and-half nail in a case of pellagra. *Eur J Dermatol*. 2006;16(6): 695-696.
124. Yamaguchi S, Miyagi T, Sogabe Y, et al. Depletion of epidermal Langerhans cells in the skin lesions of pellagra patients. *Am J Dermatopathol*. 2017;39(6): 428-432.
125. Isaac S. The "gauntlet" of pellagra. *Int J Dermatol*. 1998;37:599.
126. Friedli A, Saurat J. Images in clinical medicine. Oculo-orogenital syndrome—a deficiency of vitamins B2 and B6. *N Engl J Med*. 2004;350:1130.
127. Kishi T, Fujita N, Eguchi T, et al. Mechanism for reduction of serum folate by antiepileptic drugs during prolonged therapy. *J Neurol Sci*. 1997;145:109-112.
128. Swiatlo N, O'Connor DL, Andrews J, et al. Relative folate bioavailability from diets containing human, bovine and goat milk. *J Nutr*. 1990;120:172-177.
129. Semchuk G, Allen O, O'Connor D. Folate bioavailability from milk-containing diets is affected by altered intestinal biosynthesis of folate in rats. *J Nutr*. 1994;124:1118-1125.
130. Downham T, Rehbein H, Taylor K. Letter: hyperpigmentation and folate deficiency. *Arch Dermatol*. 1976;112:562.
131. Jucgla A, Sais G, Berlanga J, et al. Hyperpigmentation of the flexures and pancytopenia during treatment with folate antagonists. *Acta Derm Venereol*. 1997;77:165-166.
132. Okuda K. Discovery of vitamin B12 in the liver and its absorption factor in the stomach: a historical review. *J Gastroenterol Hepatol*. 1999;14:301-308.
133. Rasmussen S, Fernhoff P, Scanlon K. Vitamin B12 deficiency in children and adolescents. *J Pediatr*. 2001;138:10-17.
134. Chanarin I. Historical review: a history of pernicious anaemia. *Br J Haematol*. 2000;111:407-415.
135. Oh R, Brown D. Vitamin B12 deficiency. *Am Fam Physician*. 2003;67:979-986.
136. Graells J, Ojeda RM, Muniesa C, et al. Glossitis with linear lesions: an early sign of vitamin B12 deficiency. *J Am Acad Dermatol*. 2009;60:498-500.
137. Ahuja S, Sharma R. Reversible cutaneous hyperpigmentation in vitamin B12 deficiency. *Indian Pediatr*. 2003;40:170-171.
138. Hoffman C, Palmer D, Papadopoulos D. Vitamin B12 deficiency: a case report of ongoing cutaneous hyperpigmentation. *Cutis*. 2003;71:127-130; quiz 138-140.
139. Mori K, Ando I, Kukita A. Generalized hyperpigmentation of the skin due to vitamin B12 deficiency. *J Dermatol*. 2001;28:282-285.
140. Simşek OP, Gönç N, Gümrük F, et al. A child with vitamin B12 deficiency presenting with pancytopenia

and hyperpigmentation. *J Pediatr Hematol Oncol*. 2004;26:834-836.
141. Hirschmann J, Raugi G. Adult scurvy. *J Am Acad Dermatol*. 1999;41:895-906; quiz 907-910.
142. Lind J. *A Treatise on the Scurvy in Three Parts*. 3rd ed. London, UK: S. Crowder, D. Wilson, G. Nicholls, T. Cadell, T. Becket, and Co; 1772.
143. Brown S. *Scurvy*. New York, NY: Thomas Dunne Books; 2003.
144. Hess A. *Scurvy, Past and Present*. Philadelphia, PA: JB Lippincott; 1920.
145. Rajakumar K. Infantile scurvy: a historical perspective. *Pediatrics*. 2001;108:E76.
146. Francescone M, Levitt J. Scurvy masquerading as leukocytoclastic vasculitis: a case report and review of the literature. *Cutis*. 2005;76:261-266.
147. Pimentel L. Scurvy: historical review and current diagnostic approach. *Am J Emerg Med*. 2003;21:328-332.
148. Weinstein M, Babyn P, Zlotkin S. An orange a day keeps the doctor away: scurvy in the year 2000. *Pediatrics*. 2001;108:E55.
149. Alexandrescu DT, Dasanu CA, Kauffman CL. Acute scurvy during treatment with interleukin-2. *Clin Exp Dermatol*. 2008;34(7):811-814.
150. Blumberg A, Hanck A, Sander G. Vitamin nutrition in patients on continuous ambulatory peritoneal dialysis (CAPD). *Clin Nephrol*. 1983;20:244-250.
151. Hatuel H, Buffet M, Mateus C, et al. Scurvy in liver transplant patients. *J Am Acad Dermatol*. 2006;55:154-156.
152. Golriz F, Donnelly LF, Devaraj S, et al. Modern American scurvy-experience with vitamin C deficiency at a large children's hospital. *Pediatr Radiol*. 2017;47(2):214-220.
153. Baugh C, Malone J, Butterworth CJ. Human biotin deficiency. A case history of biotin deficiency induced by raw egg consumption in a cirrhotic patient. *Am J Clin Nutr*. 1968;21:173-182.
154. Carlson GL, Williams N, Barber D, et al. Biotin deficiency complicating long-term total parenteral nutrition in an adult patient. *Clin Nutr*. 1995;14:186-190.
155. Mock DM, Baswell DL, Baker H, et al. Biotin deficiency complicating parenteral alimentation: diagnosis, metabolic repercussions, and treatment. *J Pediatr*. 1985; 106:762-769.
156. Mock D, Dyken M. Biotin catabolism is accelerated in adults receiving long-term therapy with anticonvulsants. *Neurology*. 1997;49:1444-1447.
157. Mock DM, Mock NI, Nelson RP, et al. Disturbances in biotin metabolism in children undergoing long-term anticonvulsant therapy. *J Pediatr Gastroenterol Nutr*. 1998;26:245-250.
158. Schulpis KH, Karikas GA, Tjamouranis J, et al. Low serum biotinidase activity in children with valproic acid monotherapy. *Epilepsia*. 2001;42:1359-1362.
159. Fujimoto W, Inaoki M, Fukui T, et al. Biotin deficiency in an infant fed with amino acid formula. *J Dermatol*. 2005;32:256-261.
160. Higuchi R, Noda E, Koyama Y, et al. Biotin deficiency in an infant fed with amino acid formula and hypoallergenic rice. *Acta Paediatr*. 1996;85:872-874.
161. Arbuckle H, Morelli J. Holocarboxylase synthetase deficiency presenting as ichthyosis. *Pediatr Dermatol*. 2006;23(2):142-144.
162. Seymons K, De Moor A, De Raeve H, et al. Dermatologic signs of biotin deficiency leading to the diagnosis of multiple carboxylase deficiency. *Pediatr Dermatol*. 2004;21:231-235.
163. Rathi N, Rathi M. Biotinidase deficiency with hypertonia as unusual feature. *Indian Pediatr*. 2009;46:65-67.
164. Genc GA, Sivri-Kalkanoğlu HS, Dursun A, et al. Audiologic findings in children with biotinidase deficiency in Turkey. *Int J Pediatr Otorhinolaryngol*. 2007;71:333-339.
165. Desai S, Ganesan K, Hegde A. Biotinidase deficiency: A reversible metabolic encephalopathy. Neuroimaging and MR spectroscopic findings in a series of four patients. *Pediatr Radiol*. 2008;38:848-856.
166. Goodman BP, Mistry DH, Pasha SF, et al. Copper deficiency myeloneuropathy due to occult celiac disease. *Neurologist*. 2009;15:355-356.
167. Kumar N, Low P. Myeloneuropathy and anemia due to copper malabsorption. *J Neurol*. 2004;251:747-749.
168. Naismith RT, Shepherd JB, Weihl CC, et al. Acute and bilateral blindness due to optic neuropathy associated with copper deficiency. *Arch Neurol*. 2009;66:1025-1027.
169. Droms RJ, Rork JF, McLean R, et al. Menkes disease mimicking child abuse. *Pediatr Dermatol*. 2017;34(3):e132-e134.
170. Kaler S. Diagnosis and therapy of Menkes syndrome, a genetic form of copper deficiency. *Am J Clin Nutr*. 1998;67:1029S-1034S.
171. Menkes J. Menkes disease and Wilson disease: two sides of the same copper coin. Part II: Wilson disease. *Eur J Paediatr Neurol*. 1999;3:245-253.
172. Ge K, Yang G. The epidemiology of selenium deficiency in the etiological study of endemic diseases in China. *Am J Clin Nutr*. 1993;57:259S-263S.
173. Litov R, Combs GJ. Selenium in pediatric nutrition. *Pediatrics*. 1991;87:339-351.
174. de Berranger E, Colinet S, Michaud L, et al. Severe selenium deficiency secondary to chylous loss. *JPEN J Parenter Enteral Nutr*. 2006;30:173-174.
175. Kanekura T, Yotsumoto S, Maeno N, et al. Selenium deficiency: report of a case. *Clin Exp Dermatol*. 2005;30:346-348.
176. Yang GQ, Wang SZ, Zhou RH, et al. Endemic selenium intoxication of humans in China. *Am J Clin Nutr*. 1983;37:872-881.
177. Centers for Disease Control (CDC). Selenium intoxication–New York. *MMWR Morb Mortal Wkly Rep*. 1984;33:157-158.
178. Kise Y, Yoshimura S, Akieda K, et al. Acute oral selenium intoxication with ten times the lethal dose resulting in deep gastric ulcer. *J Emerg Med*. 2004;26:183-187.
179. Hunsaker D, Spiller H, Williams D. Acute selenium poisoning: suicide by ingestion. *J Forensic Sci*. 2005;50:942-946.
180. Kamble P, Mohsin N, Jha A, et al. Selenium intoxication with selenite broth resulting in acute renal failure and severe gastritis. *Saudi J Kidney Dis Transpl*. 2009;20:106-111.
181. Dickerson R. Manganese intoxication and parenteral nutrition. *Nutrition*. 2001;17:689-693.
182. Fitzgerald K, Mikalunas V, Rubin H, et al. Hypermanganesemia in patients receiving total parenteral nutrition. *JPEN J Parenter Enteral Nutr*. 1999;23:333-336.
183. Park JH, Hogrebe M, Grüneberg M, et al. SLC39A8 deficiency: a disorder of manganese transport and glycosylation. *Am J Hum Genet*. 2015;97(6):894-903.
184. Boycott KM, Beaulieu CL, Kernohan KD, et al. Autosomal-recessive intellectual disability with cerebellar atrophy syndrome caused by mutation of the manganese and zinc transporter gene SLC39A8. *Am J Hum Genet*. 2015;97(6):886-893.
185. Esslinger U, Garnier S, Korniat A, et al. Exome-wide association study reveals novel susceptibility genes

to sporadic dilated cardiomyopathy. *PLoS One*. 2017;12(3):e0172995.
186. Balint J. Physical findings in nutritional deficiencies. *Pediatr Clin North Am*. 1998;45:245-260.
187. Rushton D. Nutritional factors and hair loss. *Clin Exp Dermatol*. 2002;27:396-404.
188. Sato S. Iron deficiency: structural and microchemical changes in hair, nails, and skin. *Semin Dermatol*. 1991;10:313-319.
189. Sinclair R. There is no clear association between low serum ferritin and chronic diffuse telogen hair loss. *Br J Dermatol*. 2002;147:982-984.
190. Trost L, Bergfeld W, Calogeras E. The diagnosis and treatment of iron deficiency and its potential relationship to hair loss. *J Am Acad Dermatol*. 2006;54:824-844.
191. Küry S, Dréno B, Bézieau S, et al. Identification of SLC39A4, a gene involved in acrodermatitis enteropathica. *Nat Genet*. 2002;31:239-240.
192. Wang K, Zhou B, Kuo YM, et al. A novel member of a zinc transporter family is defective in acrodermatitis enteropathica. *Am J Hum Genet*. 2002;71:66-73.
193. Wang K, Pugh EW, Griffen S, et al. Homozygosity mapping places the acrodermatitis enteropathica gene on chromosomal region 8q24.3. *Am J Hum Genet*. 2001;68:1055-1060.
194. Chew AL, Chan I, McGrath JA, et al. Infantile acquired zinc deficiency resembling acrodermatitis enteropathica. *Clin Exp Dermatol*. 2005;30:594-595.
195. Leverkus M, Kütt S, Bröcker EB, et al. Nutritional zinc deficiency mimicking acrodermatitis enteropathica in a fully breast-fed infant. *J Eur Acad Dermatol Venereol*. 2006;20:1380-1381.
196. Inamadar A, Palit A. Acrodermatitis enteropathica with depigmented skin lesions simulating vitiligo. *Pediatr Dermatol*. 2007;24(6):668-669.
197. Traupe H, Happle R, Gröbe H, et al. Polarization microscopy of hair in acrodermatitis enteropathica. *Pediatr Dermatol*. 1986;3:300-303.
198. Tourdes J. *Du noma ou du sphacèle de la bouche chez les enfants*. Strasbourg, France: Faculté de Médecine de Strasbourg; 1848.
199. Baratti-Mayer D, Pittet B, Montandon D, et al. Noma: an "infectious" disease of unknown aetiology. *Lancet Infect Dis*. 2003;3:419-431.
200. Fieger A, Marck KW, Busch R, et al. An estimation of the incidence of noma in north-west Nigeria. *Trop Med Int Health*. 2003;8:402-407.
201. Enwonwu C. Noma—the ulcer of extreme poverty. *N Engl J Med*. 2006;354:221-224.
202. Enwonwu C, Falkler WJ, Phillips R. Noma (cancrum oris). *Lancet*. 2006;368:147-156.
203. Enwonwu C, Phillips R, Ferrell C. Temporal relationship between the occurrence of fresh noma and the timing of linear growth retardation in Nigerian children. *Trop Med Int Health*. 2005;10:65-73.
204. Enwonwu C. Noma. A neglected scourge of children in sub-Saharan Africa. *Bull World Health Organ*. 1995;73:541-545.
205. Koźmińska-Kubarska A, Talleyrand D, Bakatubia M. Cutaneous complications during measles in Zairian children: noma-like postmeasles ulcerations. *Int J Dermatol*. 1982;21:465-469.
206. Falkler WJ, Enwonwu C, Idigbe E. Isolation of *Fusobacterium necrophorum* from cancrum oris (noma). *Am J Trop Med Hyg*. 1999;60:150-156.

Chapter 124 :: The Porphyrias

:: Eric W. Gou & Karl E. Anderson

INTRODUCTION

Porphyrias are metabolic diseases caused by abnormalities of the 8 enzymes in the heme biosynthetic pathway. All but one arise from mutation of a pathway enzyme; the exception is porphyria cutanea tarda (PCT), which develops as an acquired deficiency of the fifth enzyme in the pathway with or without a mutation. Porphyrias are classified as hepatic or erythropoietic based on whether heme precursors first accumulate in liver or bone marrow, the tissues that most actively synthesize heme. Porphyrias are categorized clinically based on their clinical features as either *cutaneous* or *acute* (Table 124-1). Cutaneous porphyrias are due to overproduction and accumulation of photosensitizing porphyrins. Most, as exemplified by PCT, cause chronic blistering and scarring on sun-exposed areas of skin, whereas protoporphyrias produce an acute, severe, and mostly nonblistering reaction to light, often leaving few if any chronic skin changes. Acute porphyrias are characterized by neurologic symptoms and elevated levels of the porphyrin precursors, δ-aminolevulinic acid (ALA) and porphobilinogen (PBG). Porphyrins also accumulate in acute porphyrias, and sometimes achieve levels in plasma sufficient to cause cutaneous blistering, as exemplified especially by variegate porphyria (VP). In some porphyrias, damage to other organs, such as liver and kidney, may also occur. Symptoms, signs, and histologic findings caused by porphyrias are nonspecific, whereas patterns of porphyrins and porphyrin precursors enable specific diagnoses and treatments (Table 124-2).

HISTORICAL PERSPECTIVE

The first known description of porphyria was in 1874 by Schultz. He described a 33-year-old man with photosensitivity since 3 months of age with associated anemia, splenomegaly, and red urine.[1,2] T. McCall Anderson in 1898 described 2 brothers with blistering of sun-exposed skin, extensive scarring of facial features, and red urine.[3] These patients are thought to have had congenital erythropoietic porphyria (CEP), a very rare and severe cutaneous porphyria. Acute porphyria was first described by Stokvis in 1888 in an elderly woman with symptoms after taking sulphonal, a sedative related to barbiturates; she developed dark red urine and later died.[4] In 1923, Archibald Garrod proposed the term *inborn errors of metabolism* to describe a number of inherited metabolic disorders, including the porphyrias.[5] Porphyrias were first classified as hepatic or erythropoietic in 1954.[6] Treatment of porphyria cutanea tarda by phlebotomy was introduced by Ippen in 1961.[7] In 1970, an inherited enzyme deficiency was first described in acute intermittent porphyria,[8] and hemin therapy was first introduced for this condition in 1971.[9] In the decades that followed, the enzymes of the pathway and their genes were characterized and multiple mutations found in each of the porphyrias. Also, regulation of heme synthesis especially in liver and bone marrow has become better understood. Based on these advances, additional treatments have been introduced and are being developed.

HEME SYNTHESIS AND FUNCTIONS

Heme, or iron protoporphyrin IX, is synthesized in eukaryotic cells in 8 steps, each catalyzed by a different enzyme (Fig. 124-1). The first and last 3 of these enzymes are in the mitochondria and the other 4 are cytosolic. The first enzyme, δ-aminolevulinic acid synthase (ALAS), combines glycine and succinyl-coenzyme A to produce the amino acid δ-aminolevulinic acid (ALA), also known as 5-aminolevulinic acid. Two molecules of ALA are then combined to form a pyrrole, porphobilinogen (PBG). Four molecules of PBG are joined to form a linear tetrapyrrole, hydroxymethylbilane (HMB). HMB is a substrate for the fourth enzyme, which inverts one of the pyrrole rings of HMB and cyclizes the molecule to create uroporphyrinogen III, the first porphyrin in the pathway. This asymmetric molecule undergoes a series of decarboxylations and an oxidation to form protoporphyrin IX. Iron is then inserted to form heme. With the exception of protoporphyrin IX, the porphyrin intermediates in this pathway are in their reduced forms (ie, porphyrinogens).[10] The end product heme consists of an iron atom in the ferrous (reduced) state (Fe^{2+}) bound to the 4 pyrrolic nitrogens of the porphyrin macrocycle (Fig. 124-1), leaving 2 unoccupied electron pairs. Heme is the prosthetic group for many essential hemoproteins. In hemoglobin, for example, one unoccupied electron pair is coordinated with a histidine residue of the globin chain while the other is available to bind molecular oxygen.

Hemin is the chemical term for the oxidized form of heme, ferric protoporphyrin IX, which has only one residual positive charge, and can be isolated from blood and other tissues in the chloride form. *Hemin* also refers generically to biologics, namely,

TABLE 124-1

Human Porphyrias: Specific Enzymes Affected by Mutations, Modes of Inheritance, Classification, and Major Types of Clinical Features

PORPHYRIA[a]	AFFECTED ENZYME	KNOWN MUTATIONS	INHERITANCE	CLASSIFICATION	PRINCIPAL CLINICAL FEATURES
X-linked protoporphyria (XLP)	δ-Aminolevulinic acid (ALA) synthase–erythroid specific form (ALAS2)	4 (gain of function)	Sex linked	Erythropoietic	Nonblistering photosensitivity
δ-Aminolevulinic acid dehydratase porphyria (ADP)	ALA dehydratase (ALAD)	10	Autosomal recessive	Hepatic[b]	Neurovisceral
Acute intermittent porphyria (AIP)	Hydroxymethylbilane synthase (HMBS)	>400	Autosomal dominant	Hepatic	Neurovisceral
Congenital erythropoietic porphyria (CEP)	Uroporphyrinogen III synthase (UROS)	48	Autosomal recessive	Erythropoietic	Neurovisceral
Porphyria cutanea tarda (PCT)	Uroporphyrinogen decarboxylase (UROD)	121 (includes HEP)	Autosomal dominant[c]	Hepatic	Blistering photosensitivity
Hepatoerythropoietic porphyria (HEP)	UROD	—	Autosomal recessive	Hepatic[b]	Blistering photosensitivity
Hereditary coproporphyria (HCP)	Coproporphyrinogen oxidase (CPOX)	64	Autosomal dominant	Hepatic	Neurovisceral; blistering photosensitivity (uncommon)
Variegate porphyria (VP)	Protoporphyrinogen oxidase (PPOX)	174	Autosomal dominant	Hepatic	Neurovisceral; blistering photosensitivity (common)
Erythropoietic protoporphyria (EPP)	Ferrochelatase (FECH)	189	Autosomal recessive	Erythropoietic	Nonblistering photosensitivity

[a]Porphyrias are listed in the order of the affected enzyme in the heme biosynthetic pathway.

[b]These porphyrias also have erythropoietic features, including increases in erythrocyte zinc protoporphyrin.

[c]UROD inhibition in PCT is mostly acquired, but an inherited deficiency of the enzyme predisposes in familial (type 2) disease.

lyophilized *hematin* (heme hydroxide) and heme arginate, which are available for treatment of acute porphyrias.

Approximately 85% of heme synthesis occurs in the bone marrow to support hemoglobin formation, with the remainder mostly in the liver, primarily for cytochrome P450 enzymes (CYPs) found in the endoplasmic reticulum.[11] All other tissues synthesize heme in smaller amounts. Examples of the numerous other vital hemoproteins include myoglobin, mitochondrial respiratory cytochromes, nitric oxide synthase, and catalase.

Heme synthesis in the liver is regulated primarily by the activity of δ-aminolevulinic acid synthase 1 (ALAS1, the housekeeping form of ALAS, the first enzyme in the pathway), with repression of synthesis of this enzyme and its import into mitochondria by heme, the end product of the pathway. In the marrow, heme and globin synthesis are closely coordinated during erythropoietin signaling. Expression of ALAS2, the erythroid-specific form of ALAS, and a number of other pathway enzymes, are stimulated by heme or iron and by erythroid-specific *cis*-acting elements including GATA-1 and NF-E2, culminating with phosphorylation of ferrochelatase (FECH), the final enzyme in heme synthesis.[12]

PORPHYRIA CUTANEA TARDA

AT-A-GLANCE

- Characterized by skin friability and blistering lesions on sun-exposed areas of skin
- Caused by inhibition of hepatic uroporphyrinogen decarboxylase (UROD) activity
- This leads to excess amounts of highly carboxylated porphyrins in liver, plasma, urine, and feces in diagnostic patterns
- Genetic factors that predispose may include mutations of UROD (heterozygous, only in ~20% of cases) and hemochromatosis (HFE)
- Acquired susceptibility factors (alcohol, smoking, secondary iron overload, chronic hepatitis C, HIV, and estrogen) are often multiple
- Responds readily to repeated phlebotomy while following serum ferritin, or low-dose hydroxychloroquine

Figure 124-1 The sequence and chemical structures of intermediates in the heme biosynthetic pathway and localization of the 8 pathway enzymes in mitochondria or the cytosol. δ-Aminolevulinic acid synthase exists as a house-keeping form (ALAS1), found in all tissues, and an erythroid-specific form (ALAS2) found only in marrow erythroid cells. As shown here, the synthesis of ALAS1 in liver is under sensitive feedback control by the end product heme.

TABLE 124-2

Major Biochemical Abnormalities (in Bold) and Other Differentiating Measurements in the Human Porphyrias[a]

PORPHYRIA	ERYTHROCYTES	PLASMA	URINE	STOOL
ADP*	▪ **Increased zinc protoporphyrin**	▪ **Increased ALA** ▪ PBG and porphyrin levels normal or slightly increased	▪ **Increased ALA** ▪ **Increased coproporphyrin III** ▪ PBG and other porphyrin levels normal or slightly increased	▪ Porphyrin levels normal or slightly increased
AIP	▪ **PBGD usually decreased**[§]	▪ **Increased ALA and PBG** ▪ Porphyrin levels normal or slightly increased ▪ Peak fluorescence ~620 nm[b]	▪ **Increased ALA, PBG, and porphyrins (often mostly uroporphyrin)**	▪ Porphyrin levels normal or slightly increased
CEP	▪ **Uroporphyrin I; coproporphyrin I**	▪ **Uroporphyrin I; coproporphyrin I** ▪ Peak fluorescence ~620 nm[b]	▪ **Uroporphyrin I; coproporphyrin I**	▪ **Coproporphyrin I**
PCT HEP	▪ Porphyrin levels normal or slightly increased ▪ **Zinc protoporphyrin**	▪ **Uroporphyrin, heptacarboxyl porphyrin** ▪ Peak fluorescence ~620 nm[b]	▪ **Uroporphyrin, heptacarboxyl porphyrin**	▪ **Uroporphyrin, heptacarboxyl porphyrin, coproporphyrin III, isocoproporphyrins**
HCP	▪ Porphyrin levels normal or slightly increased	▪ Porphyrins normal or increased[c] ▪ Peak fluorescence ~620 nm[b]	▪ **ALA, PBG,** coproporphyrin III	▪ **Coproporphyrin III**
VP	▪ Porphyrin levels normal or slightly increased	▪ Protoporphyrins usually increased ▪ **Peak fluorescence ~626 nm[b]**	▪ **ALA, PBG,** coproporphyrin III	▪ **Coproporphyrin III, protoporphyrin**
EPP and XLP	▪ **Metal-free protoporphyrin**[d]	▪ **Protoporphyrin** ▪ **Peak fluorescence ~634 nm[b]**	▪ ALA, PBG, porphyrins normal	▪ Protoporphyrin normal or modestly increased

[a]Abbreviations as in Table 124-1.

[b]Fluorescence emission peak of diluted plasma at neutral Ph.

[c]Increased in the presence of skin lesions.

[d]Metal-free protoporphyrin approximately 85%-100% of the total in EPP, and 50%-85% in XLP.

PCT is the most common porphyria, and is characterized by the development of skin friability and chronic, blistering lesions on the dorsal aspects of the hands and other sun-exposed areas of skin usually in mid- or late life.[13] The underlying cause is deficient uroporphyrinogen deaminase (UROD) activity in hepatocytes, where uroporphyrinogen and other highly carboxylated porphyrinogens accumulate and are oxidized to the corresponding porphyrins. In active cases, hepatic UROD activity is reduced to less than ~20% of normal. PCT is an iron-related disorder and develops only in the presence of normal or increased amounts of hepatic iron. Multiple susceptibility factors contribute to iron accumulation, oxidative stress, and generation of a UROD inhibitor in hepatocytes, and are important to identify in individual patients. This is the only porphyria that can develop in absence of the mutation of the affected enzyme.[14] Heterozygous *UROD* mutations are found in ~20% of patients, but these do not cause PCT in the absence of other susceptibility factors.

PCT is the most readily treated porphyria, responding well to either phlebotomy or low-dose hydroxychloroquine. But the disease must first be differentiated from other less common porphyrias that cause identical skin lesions but are unresponsive to these treatments.

CLINICAL FEATURES

PCT usually develops in the fourth or fifth decade of life, most commonly in males. Fluid-filled blisters and bullae are found especially on the dorsal hands (Fig. 124-2), the most sun-exposed areas of the body, and often arise after minor or inapparent trauma as a result of increased skin friability. Blisters may also occur on the forearms, face, ears, neck, legs, and feet. These rupture easily, leaving erosions that may become dry and crusted and heal slowly (Fig. 124-2). Eroded areas of skin are prone to bacterial infection. Residual scarring and hyper- and hypopigmentation are prominent with prolonged disease. Milia may precede or follow vesicle formation. Facial hypertrichosis and hyperpigmentation (Fig. 124-3) are common, may even occur in the absence of blistering, and are cosmetically problematic, especially in women.[16] Severe thickening of affected areas of skin, sometimes with associated calcification, can resemble systemic sclerosis and is termed *pseudoscleroderma*. Neurologic symptoms characteristic of the acute porphyrias are not seen in PCT.

Rare childhood cases have often been associated with UROD mutations and cancer chemotherapy[15] (Fig. 124-3). The disease may develop during

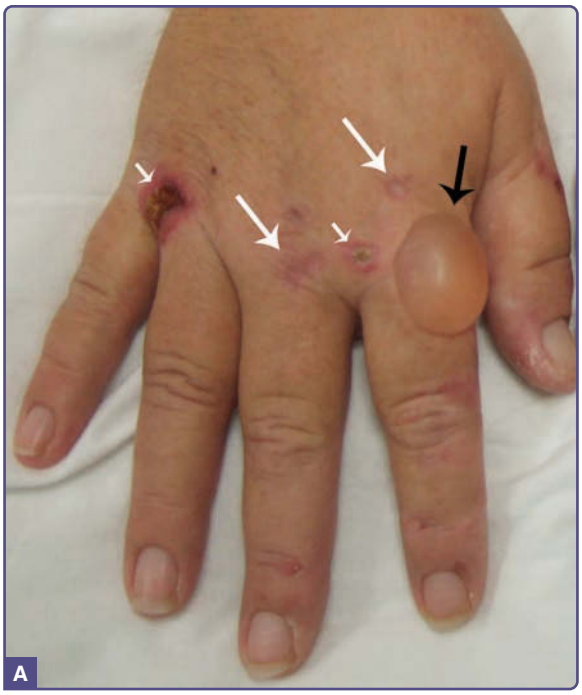

Figure 124-2 Characteristic skin lesions in PCT occur most commonly on the dorsal hands and are indistinguishable from those seen in other blistering cutaneous porphyrias (especially variegate porphyria) and pseudoporphyria. **A,** Blisters (short black arrow) often form after minor trauma, rupture to leave superficial ulcerations that may crust over (short white arrows) and leave atropic areas (long arrows) that heal slowly. **B,** Blisters are fragile, so often the only lesions present are chronic, such as erosions, crusts and scarring.

pregnancy, possibly related to effects of increased estrogen. Reported associations with cutaneous and systemic lupus erythematosus are unexplained. PCT associated with end-stage renal disease is usually more severe, because urinary excretion of porphyrins is impaired, and porphyrins are poorly dialyzed. The resulting plasma porphyrin levels can equal those seen in congenital erythropoietic porphyria (CEP) and be associated with severe bacterial infections and mutilation.[17]

Figure 124-3 Marked hypertrichosis and hyperpigmentation due to porphyria cutanea tarda that developed in a child with an inherited *UROD* mutation after chemotherapy for leukemia, as previously reported.[15]

Mild abnormalities in liver function tests are found in almost all cases. Fresh hepatic tissue exhibits strong red fluorescence on exposure to long-wave ultraviolet light (Fig. 124-4), reflecting massive accumulation of porphyrins. Liver histopathology is nonspecific and usually includes increased iron, increased fat, hepatocyte necrosis and inflammation, which in many cases reflects the effects of alcohol or hepatitis C infection. Cirrhosis is unusual at the onset of PCT. The risk of HCC is increased, especially with more prolonged disease, perhaps due partly to concomitant susceptibility factors that themselves can cause chronic liver damage and fibrosis.[18-20]

SUSCEPTIBILITY FACTORS

PCT is a multifactorial disorder, with many common susceptibility factors contributing to the disease, none of which is present in every patient. These include genetic factors, viral infections, and chemical exposures. Patients almost always possess multiple such factors, which have other health implications.[21] For example, in a large series of 143 patients with PCT in the United States, the most common susceptibility factors were ethanol use (87%), smoking (81%), chronic hepatitis C (69%), and *HFE* (hemochromatosis) mutations (53%).[22] These factors are common in the general population but do not by themselves cause PCT to develop. Additional susceptibility factors are likely to be identified in the future.

UROD MUTATIONS

Most PCT patients do not have a *UROD* mutation and are said to have sporadic (type 1) disease. Approximately 20% of patients have a heterozygous predisposing *UROD* mutation and are labeled as familial (type 2) PCT. Such mutations are inherited as autosomal

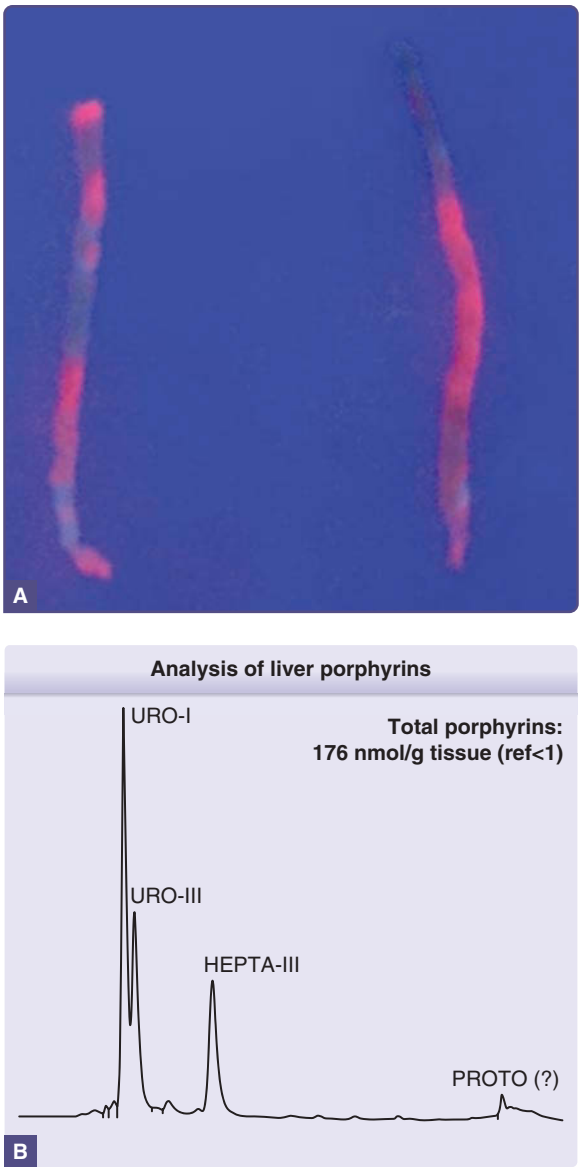

Figure 124-4 **A,** Fresh liver biopsy tissue showing bright red fluorescence under longwave ultraviolet light (Wood lamp) reflecting marked accumulation of highly carboxylated porphyrins in hepatocytes. **B,** Analysis of liver porphyrins from the same biopsy (total porphyrins 176 nmol/g tissue, ref <1) with a predominance of uroporphyrins I and III and heptacarboxyl porphyrin III on separation of porphyrins by high-performance liquid chromatography (HPLC); this pattern resembles that found in plasma and urine. (Image used with permission from Heather Stevenson-Lerner, MD, PhD; HPLC used with permission from V.M.S. Ramanujam, PhD).

dominant traits, but with low penetrance, so most type 2 patients present sporadically, having no known relatives with PCT. Having such a mutation is a susceptibility factor that does not cause PCT in the absence of other acquired or inherited susceptibility factors. HEP is the homozygous form of type 2 PCT, and resembles CEP clinically. At least 100 different mutations of the *UROD* gene, mostly missense mutations occurring in 1 or a few families, have been identified in type 2 PCT and HEP (Table 124-1). Type 3 refers to rare families with more than 1 affected individuals but no *UROD* mutation. All 3 PCT types are clinically identical, although disease onset is sometimes earlier in type 2.[23]

IRON AND HEMOCHROMATOSIS GENE (*HFE*) MUTATIONS

Iron stores are always normal or increased in PCT, whereas iron deficiency is protective. Iron provides an oxidative environment in hepatocytes and facilitates generation of a UROD inhibitor, but does not itself directly inhibit UROD. The *C282Y* mutation of the *HFE* gene, the major mutation causing hemochromatosis in whites, is more prevalent in both sporadic and familial PCT than in unaffected individuals. Up to 10% to 20% of patients may be *C282Y* homozygotes, and these may experience earlier onset of disease.[23,24] In southern Europe, where the *C282Y* is less prevalent, the *H63D* mutation is more commonly associated with PCT.[25] *HFE* mutations impair sensing of serum iron, thereby reducing hepatic hepcidin production. Because circulating levels of hepcidin are inappropriately low, downregulation of enterocyte ferroportin by hepcidin is impaired, leading to inappropriately high intestinal iron absorption. Hepatic hepcidin expression is also reduced in PCT patients without *HFE* mutations, because some other susceptibility factors reduce expression of this hormone, as noted below.[26]

ALCOHOL

PCT has long been associated with alcohol abuse. Alcohol and its metabolites may predispose to onset of PCT by inducing hepatic ALAS1 and CYPs, generating reactive oxygen species, and causing mitochondrial injury, lipid deposition, depletion of reduced glutathione and other antioxidant defenses, increasing production of endotoxin and activating Küpffer cells. Alcohol intake can also reduce hepcidin expression.[26]

SMOKING AND CYTOCHROME P450 ENZYMES

Smoking is frequently associated with alcohol use but is regarded as an independent risk factor in PCT.[21] Smoking may increase oxidative stress in hepatocytes and induces hepatic CYPs, including CYP1A2 which is important for development of uroporphyria in rodent models of PCT.[27,28] Hepatic CYPs are often increased in human PCT,[29] but it is unclear which CYPs contribute to the disease. However, a more inducible *CYP1A2* variant was found to be more common in PCT than in normal subjects.[30,31]

ESTROGENS

Estrogen use is common in women with PCT.[21,32,33] The disease has also occurred in some men treated with

estrogen for prostate cancer.[32] Female rats or males receiving estrogens are more susceptible to development of chemically-induced uroporphyria than untreated males.[34] The mechanism for this predisposition is not certain, but may be secondary to generation of reactive oxygen species.[14,35]

HEPATITIS C

Hepatitis C promotes hepatocyte steatosis, iron accumulation, mitochondrial dysfunction, oxidative stress and dysregulation of hepcidin expression.[36,37] The prevalence of chronic hepatitis C in PCT ranges from 21% to 92% in various countries, and always exceeds the prevalence of this viral infection in the general population. Only an estimated 0.05% of individuals with chronic hepatitis C develop PCT.[38] Large differences in the prevalence of this viral infection in PCT in different countries reflects the considerable geographic variation in prevalence of this infection in at-risk populations.

HIV

PCT is less commonly associated with HIV infection, which may be present with or without HCV coinfection.[39] PCT can be the initial manifestation of HIV infection. The mechanism for the association with HIV infection and possible relationships to specific antiretroviral therapies are not established.

ANTIOXIDANTS

Reduced plasma levels of ascorbate and carotenoids have been noted in some patients with PCT.[40-42] Rodents with ascorbate deficiency are more susceptible to development of uroporphyria.[43]

CHEMICAL EXPOSURE AND DRUGS

A large outbreak of PCT occurred in eastern Turkey in the 1950s during a period of food shortage when the population consumed seed wheat treated with the fungicide hexachlorobenzene.[44] Smaller outbreaks and individual cases of the disease have occurred after exposures to other chemicals such as 2,3,7,8-tetrachlorodibenzo-*p*-dioxin (TCDD, dioxin).[45] These and related chemicals cause biochemical features of PCT in laboratory animals and cultured hepatocytes.[10,14]

ETIOLOGY AND PATHOGENESIS

PCT develops when hepatic UROD activity is reduced to ~20% of normal.[14] With enzyme inhibition, the amount of UROD protein remains at its genetically determined level in the liver.[46,47] As previously discussed, about 20% of patients are heterozygous for *UROD* mutations and are more susceptible to developing PCT, because their UROD activity in the liver (as well as other tissues) is half-normal from birth. PCT does not manifest in these individuals unless further reduction of UROD activity occurs in the liver. A UROD inhibitor, characterized as a *uroporphomethene*, was identified in a mouse model that spontaneously develops biochemical features of PCT. This inhibitor is a product of partial oxidation of uroporphyrinogen, possibly generated by 1 or more CYPs (Fig. 124-5).[49]

UROD sequentially decarboxylates uroporphyrinogen I and III (each with 8 carboxyl side groups) to coproporphyrinogen I and III (each with 4 carboxyl

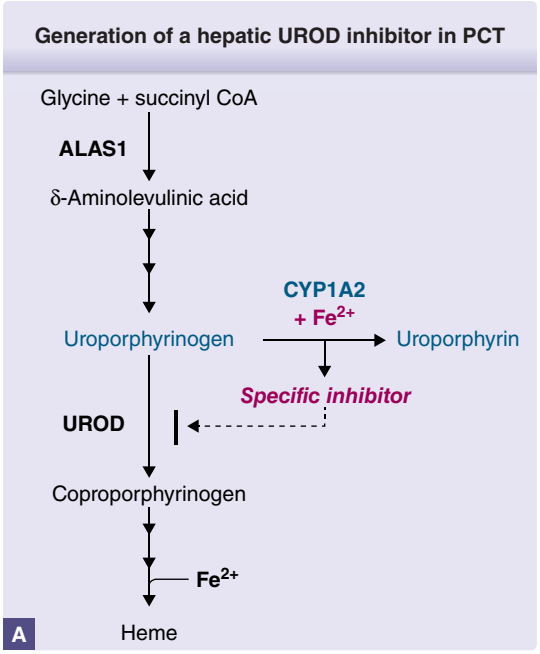

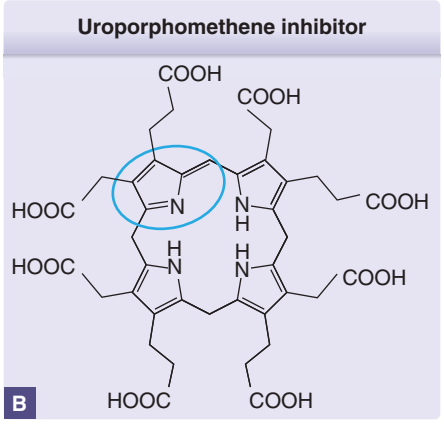

Figure 124-5 **A,** Schema for generation of a specific inhibitor of uroporphyrinogen decarboxylase in the liver in the presence of iron, cytochrome P450 enzymes (especially CYP1A2) and oxidative stress in PCT. (Modified from Anderson KE. Porphyria cutanea tarda: A possible role for ascorbic acid. *Hepatology*. 2007;45(1):6-8; with permission. Copyright © 2007, John Wiley & Sons.[48]) **B,** A UROD inhibitor has been isolated as a uroporphomethene, a uroporphyrinogen molecule that is partially oxidized at one ring (circled in blue) and its adjacent methyl bridge.

groups), respectively. Both isomers are substrates for UROD, but uroporphyrinogen III is preferred. (The next enzyme in the pathway is specific for coproporphyrinogen III as a substrate, so uroporphyrinogen I and coproporphyrin I are not heme precursors.) When hepatic UROD is inhibited, uroporphyrinogen I and III and the intermediates in the reaction (ie, I and III isomers of hepta-, hexa-, and pentacarboxyl porphyrinogen) accumulate as the corresponding oxidized porphyrins, and are eventually transported in plasma to the skin, causing photosensitivity, and to the kidneys for excretion. Biliary and fecal porphyrins are also increased. Porphyrins in their oxidized state are reddish, fluorescent, and photosensitizing, whereas porphyrinogens do not have these properties. The polycyclic aromatic structure of oxidized porphyrins contains delocalized electrons, which increase in energy level on exposure to violet light (at a wavelength of ~410 nm). This energy may be released at a higher wavelength as red fluorescent light or transferred to molecular oxygen, forming reactive singlet state oxygen and other reactive oxygen species. These may damage cutaneous cellular constituents or cause mast cell degranulation and complement activation.[50,51] Damage to the subepidermal layers of skin makes the skin friable and prone to blistering.[50,51]

DIAGNOSIS

PCT develops most commonly in adult males in association with factors such as excess alcohol use, smoking and chronic hepatitis C, and in females, particularly with estrogen use. The presentation is usually characteristic, but it must be remembered that adults with variegate porphyria (VP), hereditary coproporphyria (HCP) or pseudoporphyria, and children or adults with congenital erythropoietic porphyria (CEP) or hepatoerythropoietic porphyria (HEP) can present with identical skin lesions. Therefore, it is essential to establish a laboratory diagnosis of PCT before initiating treatment.

First-line testing (ie, screening) for PCT is measurement of total plasma or urine porphyrins. Normal results may indicate a diagnosis of pseudoporphyria. Because elevated porphyrins, especially in urine, is common in liver disease and other medical conditions, a finding of increased porphyrins and does not itself support a diagnosis of porphyria. Therefore, if first-line testing is positive, the following are suggested to establish a diagnosis and exclude other less common porphyrias that can cause similar skin manifestations and often be misdiagnosed as PCT:

- Fluorescence scanning of diluted plasma at neutral pH.[52] The porphyria most commonly misdiagnosed as PCT is VP,[53] and is rapidly and reliably recognized by plasma scanning and finding an emission peak at ~626 nm, in contrast to ~620 nm for PCT and other blistering cutaneous porphyrias.
- Fractionation of urine or plasma porphyrins, which will show a predominance of uroporphyrin, and hepta-, hexa-, and pentacarboxyl, porphyrins in PCT. This pattern of predominance of highly carboxylated porphyrins is not fully diagnostic, as it can occur in other much less common porphyrias that can be misdiagnosed as PCT especially when they present in adults.
- Total erythrocyte porphyrins, which are normal or modestly elevated in PCT, but markedly elevated in rare cases of CEP, HEP, or homozygous HCP or VP. These usually present in infancy, but can first become manifest in adults, sometimes in associated with a clonal myeloproliferative or myelodysplastic disorder.
- Fecal porphyrins may be normal or modestly increased in PCT, with a complex pattern that includes isocoproporphyrins. These atypical tetracarboxylporphyrins are formed when pentacarboxylporphyrinogen accumulates in liver as a result of UROD inhibition and undergoes premature decarboxylation by CPOX, the next enzyme in the pathway, forming dehydroisocoproporphyrinogen. The latter is excreted in bile and undergoes oxidation by intestinal bacteria to isocoproporphyrins.[54] In contrast to PCT, fecal porphyrins are markedly elevated in CEP, HCP, and VP, with a predominance of coproporphyrin I in CEP, coproporphyrin III in HCP, and both coproporphyrin III and protoporphyrin in VP.
- Urine ALA is normal or modestly increased in PCT, and PBG is always normal. Levels of these porphyrin precursors may be elevated in the acute hepatic porphyrias, AIP, HCP and VP.

An increase of plasma porphyrins and demonstration of a predominance of highly carboxylated porphyrins is essential for diagnosis of PCT in patients with advanced renal disease, although the reference range is higher in this population.[55] Advanced renal disease is commonly associated with altered erythropoiesis and resulting increases in erythrocyte zinc protoporphyrin, which should not be attributed to PCT or other porphyria. Patients with AIP and end-stage renal disease sometimes present with blistering skin lesions that resemble PCT.[56]

Although not required for diagnosis of PCT, skin biopsy reveals characteristic but nonspecific findings such as subepidermal blistering and deposition of periodic acid–Schiff-positive material around blood vessels and fine fibrillar material in the upper dermis and at the dermoepithelial junction. Deposits of immunoglobulins and complement are also found.[57] These histologic changes are also seen in other cutaneous porphyrias as well as pseudoporphyria, a poorly understood condition that presents with lesions that closely resemble PCT, but with plasma porphyrins that are not significantly increased.[58]

IDENTIFICATION OF SUSCEPTIBILITY FACTORS

All PCT patients should be questioned or examined for the following susceptibility factors, some of which

are modifiable: alcohol and estrogen use, smoking, hepatitis C and HIV infection, and *HFE* and *UROD* mutations. Use of drugs that exacerbate acute porphyrias are seldom implicated in PCT. Although familial (type 2) cases of PCT can be identified by half-normal erythrocyte UROD activity, *UROD* mutation analysis is more dependable. This full analysis of susceptibility factors helps explain the disease in individual cases and may affect management. Moreover, some of these factors also have medical implications of their own. Serum ferritin should be measured and may influence choice of treatment.

THERAPY

Treatment with phlebotomy or low-dose hydroxychloroquine is highly effective in both sporadic and familial forms of PCT. These should be initiated only after the diagnosis is certain, because they are not effective in other porphyrias. It may be reasonable to start treatment after plasma porphyrin results, including fluorescence scanning,[52] are consistent with PCT and have excluded VP and pseudoporphyria. Patients should be advised to stop smoking and alcohol consumption. Use of estrogen and drugs known to induce hepatic heme synthesis should be discontinued if possible. Estrogen replacement therapy, preferably transdermal, can be considered, if needed, after PCT is in remission.[59] Adequate intake of ascorbic acid and other nutrients should be established. Removal of 1 or more susceptibility factors can lead to improvement, but the response is slow or unpredictable.[60]

Repeated phlebotomy to reduce hepatic iron is the preferred treatment at most institutions. Removal of 450 mL blood at 2-week intervals is guided by the serum ferritin level, with a target of 15 to 20 ng/mL (ie, near the lower limit of normal). Measurement of hematocrit and ferritin at each session allows monitoring to prevent symptomatic anemia and assess progress toward the target ferritin level. Phlebotomies are stopped when the ferritin from the previous visit is 25 to 30 ng/L, and ferritin is measured to confirm that the target level was reached. At that point, porphyrin levels may not have become completely normal and skin lesions are not completely resolved. Additional iron depletion is not beneficial and leads to anemia. Most patients require 6 to 8 phlebotomies for biochemical and clinical remission, but additional sessions may be necessary, especially if the baseline serum ferritin level is markedly elevated. Decreases in plasma (or serum) porphyrin levels tend to lag behind serum ferritin, but will normalize within weeks after phlebotomies are completed.[61,62] Friability of skin may persist for some time after porphyrin levels are normal, until healing and repair of the subepidermal layer of the skin is complete. Subsequent phlebotomies are generally not needed, with the exception of patients homozygous or compound heterozygous for the *C282Y HFE* mutation, as current guidelines for hemochromatosis recommend maintaining a ferritin level between 50 and 100 ng/mL.[63] Relapse of PCT may occur, often related to resumption of alcohol use, but usually responds to retreatment. Following porphyrin levels after remission can detect recurrences early so that retreatment can be reinstituted promptly.

A low-dose regimen of hydroxychloroquine (or chloroquine) is an effective alternative to phlebotomies, and is the preferred approach at some institutions.[14,64-70] These 4-aminoquinoline antimalarials do not appear to deplete hepatic iron, but mobilize porphyrins that have accumulated in lysosomes and other intracellular organelles in hepatocytes. Full therapeutic doses of these drugs rapidly mobilize porphyrins and induce an acute hepatitis, characterized by fever, malaise, nausea, and marked increases in urinary and plasma porphyrins and photosensitivity, but followed by remission.[71] Unmasking of previously unrecognized PCT with use of chloroquine for malaria prophylaxis has been described.[72] A low-dose regimen (hydroxychloroquine 100 mg or chloroquine 125 mg [one half of a standard tablet] twice weekly) is recommended to achieve remission and avoid the side effects of full doses of these drugs.[64,67,68] Treatment is continued until plasma or urine porphyrins are normalized for at least a month. Patients who respond poorly may require alternate therapy with phlebotomy.[71] These medications are associated with a small risk of retinopathy,[73] which may be lower with hydroxychloroquine. Therefore, patients should be screened by an ophthalmologist before treatment.[74] Comparison of treatment with phlebotomy or hydroxychloroquine (100 mg twice weekly), showed that time to remission (normal plasma porphyrin levels) was comparable with these treatments.[70] Treatment with an iron chelator such as desferrioxamine is much less efficient for removal of iron than phlebotomy, but can be considered if both phlebotomy and low-dose hydroxychloroquine are contraindicated.[75]

Treatment of hepatitis C with interferon-based regimens is lengthy and often not successful. Therefore we have first treated PCT, which is usually more symptomatic, and after achieving remission, then treated coexisting hepatitis C. Interferon-based treatment regimens commonly cause anemia, which usually precludes phlebotomy for PCT, and are sometimes associated with relapse of previously treated PCT.[76] Experience with low-dose hydroxychloroquine during concurrent treatment of hepatitis C is limited. The new direct-acting antivirals can treat this infection rapidly and dependably, and studies are under way to collect evidence whether they should be used instead of phlebotomy or low-dose hydroxychloroquine as initial treatment of PCT associated with hepatitis C.[76]

PCT associated with end-stage renal disease is often difficult to treat. Phlebotomy is effective if supported, as needed, by starting or increasing the dose of erythropoietin.[17,77,78] High-flux hemodialysis may provide some benefit.[79] Renal transplantation can lead to remission presumably because of resumption of endogenous erythropoietin production and reduced hepcidin levels.[80]

Periodic screening for hepatocellular carcinoma should include liver imaging by abdominal ultrasonography or computed tomography. As in other liver

diseases, this should be guided by evidence of cirrhosis or hepatic fibrosis, which may be assessed by liver biopsy or indirectly by elastography, and the presence of other causes of liver disease.

HEPATOERYTHROPOIETIC PORPHYRIA

AT-A-GLANCE

- HEP is the homozygous form of familial (type 2) PCT, with mutation of both *UROD* alleles resulting in severely deficient UROD activity
- HEP resembles CEP, with blistering lesions on sun-exposed areas of skin, usually starting in childhood
- Biochemical findings resemble PCT, but with substantial elevation of erythrocyte zinc protoporphyrin
- Patients should avoid sunlight. Treatment with phlebotomy or low-dose hydroxychloroquine is not effective.

This very rare form of porphyria is the homozygous (or compound heterozygous) form of familial (type 2) PCT and is characterized by blistering skin lesions from chronic, severe photosensitivity.

CLINICAL FEATURES

HEP presents with onset of blistering skin lesions, hypertrichosis, scarring, hemolytic anemia, and red urine typically in early childhood. Sclerodermoid skin changes are sometimes prominent. The cutaneous manifestations resemble those found in PCT, but are usually much more severe. Unusually mild cases and onset during adult life have been reported.[81]

ETIOLOGY AND PATHOGENESIS

Patients with HEP have inherited a *UROD* mutation from each parent. Numerous *UROD* mutations associated with PCT or UROD have been identified. Erythrocyte UROD activity is 5% to 30% of normal in HEP. As homozygosity for a *UROD* null allele is lethal, at least one of the mutant *UROD* alleles must produce some enzyme protein with catalytic activity. Expression studies in eukaryotic cells suggest that some mutations may destabilize the enzyme protein in a tissue-specific manner.[82] Excess porphyrins are primarily generated in the liver. Zinc protoporphyrin accumulates in the marrow and is markedly elevated in erythrocytes.

DIAGNOSIS

Biochemical findings in HEP resemble PCT, with predominant accumulation and excretion of uroporphyrin, heptacarboxyl porphyrin, and isocoproporphyrins. In contrast to PCT, erythrocyte zinc protoporphyrin is substantially increased. Erythrocyte UROD activity is markedly diminished, and molecular studies should demonstrate mutations affecting both *UROD* alleles.

THERAPY

Patients with HEP should be advised to avoid sunlight. Phlebotomy and hydroxychloroquine have shown little or no benefit.[83] Patients should avoid susceptibility factors known to be important in PCT. Oral charcoal was helpful in a severe case associated with dyserythropoiesis, likely due to trapping of porphyrins in the intestinal lumen and preventing their enterohepatic circulation.[84] Retrovirus-mediated gene transfer studies suggest that correction of the HEP defect through gene replacement therapy may be applicable in the future.[85]

CONGENITAL ERYTHROPOIETIC PORPHYRIA

AT-A-GLANCE

- As a result of mutation of both uroporphyrinogen III synthase (UROS) alleles resulting in severe loss of activity of UROS and elevations of uroporphyrin I and coproporphyrin I
- Characterized by subepidermal scarring and bullous lesions affecting light-exposed areas
- Diagnosis is established by markedly elevated uroporphyrin I and coproporphyrin I in erythrocytes, urine, plasma, and feces and identification of causative mutations
- Hematopoietic stem cell transplantation at a young age is potentially curative
- Strict light avoidance can prevent chronic, disfiguring skin disease

Cases of CEP, also known as Günther disease, were first described in 1874 and 1898.[3] CEP is due to substantial deficiency of uroporphyrinogen III synthase (UROS), which results in accumulation of isomer I porphyrinogens, especially uroporphyrinogen I and coproporphyrinogen I, in the marrow during hemoglobin synthesis. Porphyrins are usually markedly elevated in erythrocytes, plasma and urine and cause chronic, severe photosensitivity

ETIOLOGY AND PATHOGENESIS

UROS catalyzes the formation of uroporphyrinogen III from hydroxymethylbilane (HMB) in the cytosol (Fig. 124-1). This reaction involves inverting one of the 4 pyrroles (ring D) of the linear tetrapyrrole and formation of a porphyrin macrocycle with an asymmetric arrangement of side chains. In the absence of this enzyme, HMB spontaneously cyclizes to form uroporphyrinogen I, which is symmetrical. UROD, the next enzyme in the pathway, will metabolize both uroporphyrinogen I and III to coproporphyrinogen I and III, respectively. However, coproporphyrinogen I is a dead-end product because the next enzyme in the heme biosynthetic pathway accepts only coproporphyrinogen III as a substrate.

More than 48 mutations of the *UROS* gene have been identified, and more severe mutations are associated with more severe clinical manifestations.[86] A GATA-1 mutation described in one case associated with beta-thalassemia indicates that a genetic defect outside the heme biosynthetic pathway can cause CEP.[87]

Marrow normoblasts in CEP display marked microscopic fluorescence due to porphyrin accumulation.[88] Increased porphyrin concentrations in circulating erythrocytes cause cell damage due to exposure to light in the dermal capillaries. Hemolysis and increased uptake of damaged cells by the spleen leads to splenomegaly as a common finding in CEP. Ineffective erythropoiesis in the marrow contributes to anemia. Excess porphyrins are transported in erythrocytes and plasma to the skin and lead to chronic and usually severe photosensitivity.

CLINICAL FEATURES

CEP is characterized by subepidermal bullous lesions affecting light-exposed areas such as the dorsal hands, fingers and face (Fig. 124-6), which often leads to scarring and areas of hyper- and hypopigmentation. Cutaneous lesions resemble those found in PCT, but with much higher porphyrin levels causing more prominent hyperpigmentation, scarring, contraction, and loss of fingers and facial features. Milder disease is often misdiagnosed as PCT, and rare onset in adults may be associated with myelodysplastic or myeloproliferative disorders with expansion of a clone of erythrocyte precursors carrying a *UROS* mutation.[90] The disease may be recognized in utero as a cause of fetal hydrops.[91] In most cases, photosensitivity is noted soon after birth. Erythrodontia (brown staining of the teeth) is caused by porphyrin deposition in developing teeth in utero. Porphyrins are also deposited in bone.[92] Pathologic fractures and other bony abnormalities may result from bone marrow expansion and vitamin D deficiency resulting from avoidance of sunlight.

Anemia resulting from intravascular hemolysis and ineffective erythropoiesis can be severe and require repeated red blood cell transfusions. Uncorrected anemia can further stimulate erythropoiesis and contribute to increased porphyrin production. Peripheral blood smears reveal polychromasia, poikilocytosis, anisocytosis, and basophilic stippling of erythrocytes and increases in reticulocytes and nucleated red blood cells. The liver and nervous system are not affected in CEP. A mother with CEP successfully delivered a healthy, unaffected infant with erythrodontia as a result of porphyrins crossing placenta.[93]

DIAGNOSIS

CEP can be recognized in utero by large amounts of porphyrins measured in amniotic fluid or fetal blood. CEP is often diagnosed shortly after birth when pink to brownish staining of the diapers is noted, with red fluorescence under long-wave ultraviolet light. Urinary, erythrocyte, and plasma porphyrins are markedly increased, with a predominance of uroporphyrin I and coproporphyrin I. Fecal porphyrins are markedly increased and are predominantly coproporphyrin I. Protoporphyrin IX is sometimes the predominant porphyrin in erythrocytes, especially in milder cases. DNA studies to identify causative mutations are important for confirming the diagnosis, genetic counseling, and prenatal diagnosis in subsequent pregnancies.

THERAPY

An individualized, multidisciplinary approach is required.[99] Patients should be advised to avoid sunlight, skin trauma, and infections to avoid severe scarring and loss of facial features and digits. Topical sunscreens that absorb ultraviolet A and B light are marginally beneficial because the harmful light is mostly visible; oral beta-carotene is also not effective.[94] Patients may require erythrocyte transfusions for severe anemia[95] and an iron chelator to avoid the sequelae of iron overload.[96] Hydroxyurea to reduce erythropoiesis and porphyrin production also may be considered.[97] Splenectomy may be beneficial if hypersplenism is contributing to significant anemia, leucopenia or thrombocytopenia. Ascorbic acid and α-tocopherol improved anemia in one patient.[98] Oral charcoal was reportedly beneficial in another.[84] Use of oral charcoal, splenectomy, and chronic hypertransfusion were associated with complications, without appreciable clinical benefit and negative impact on health-related quality of life in a large case series.[99]

Hematopoietic stem cell transplantation is curative and is the treatment of choice for young patients with severe disease.[100] Successful transplantation results in marked clinical improvement and reduction in porphyrin levels. Gene therapy is being explored using retroviral and lentiviral vectors and hematopoietic stem cells in patients with CEP.[101,102]

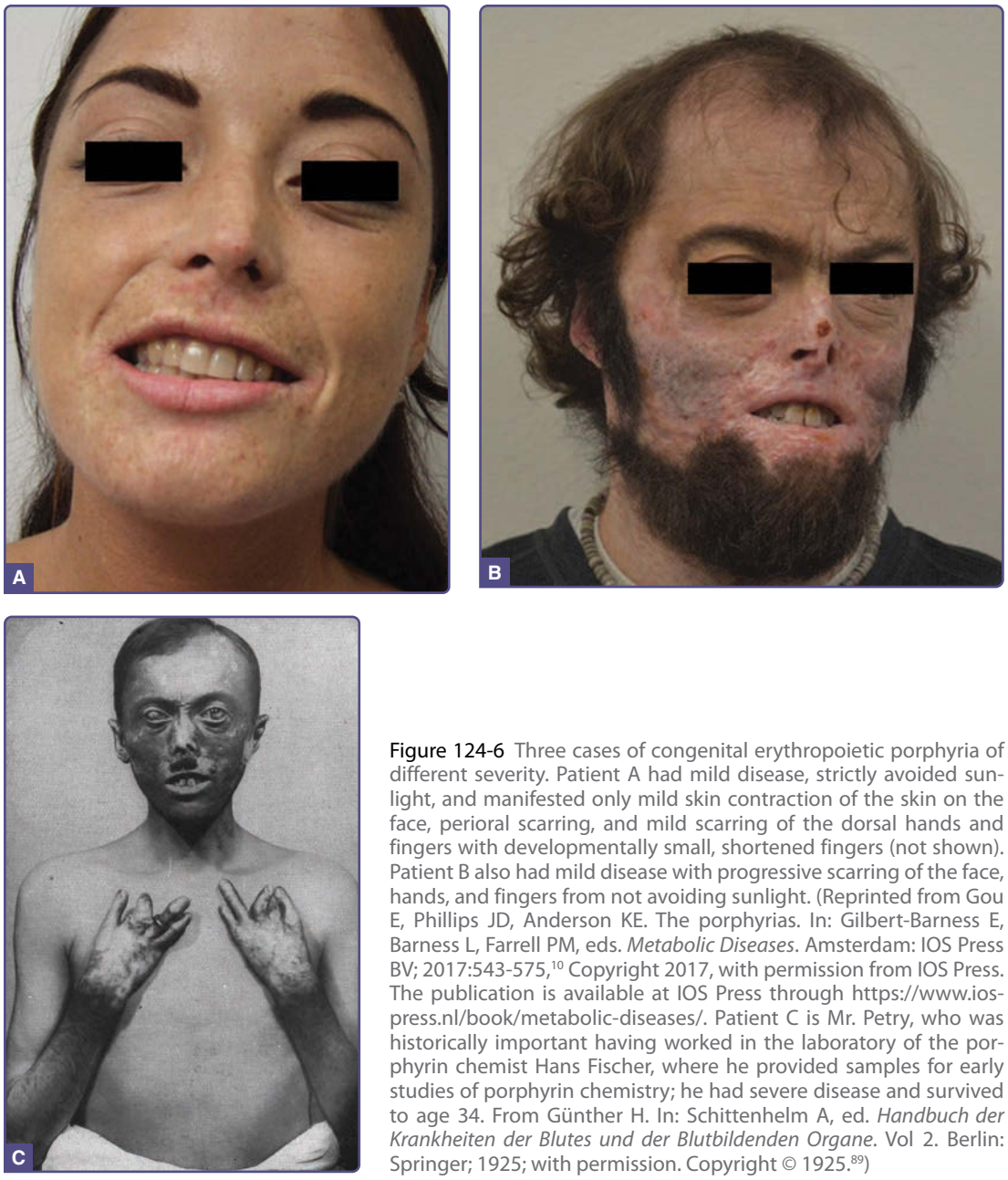

Figure 124-6 Three cases of congenital erythropoietic porphyria of different severity. Patient A had mild disease, strictly avoided sunlight, and manifested only mild skin contraction of the skin on the face, perioral scarring, and mild scarring of the dorsal hands and fingers with developmentally small, shortened fingers (not shown). Patient B also had mild disease with progressive scarring of the face, hands, and fingers from not avoiding sunlight. (Reprinted from Gou E, Phillips JD, Anderson KE. The porphyrias. In: Gilbert-Barness E, Barness L, Farrell PM, eds. *Metabolic Diseases*. Amsterdam: IOS Press BV; 2017:543-575,[10] Copyright 2017, with permission from IOS Press. The publication is available at IOS Press through https://www.iospress.nl/book/metabolic-diseases/. Patient C is Mr. Petry, who was historically important having worked in the laboratory of the porphyrin chemist Hans Fischer, where he provided samples for early studies of porphyrin chemistry; he had severe disease and survived to age 34. From Günther H. In: Schittenhelm A, ed. *Handbuch der Krankheiten der Blutes und der Blutbildenden Organe*. Vol 2. Berlin: Springer; 1925; with permission. Copyright © 1925.[89])

PROTOPORPHYRIAS

AT-A-GLANCE

- EPP is the third most common porphyria and the most common in children
- It results from mutation of both ferrochelatase (FECH) alleles; one with a severe mutation and in most families the other with a predisposing alteration that is common in the population
- XLP is less common and results from gain-of-function mutations of ALAS2
- Both are characterized by an acute, mostly nonblistering type of cutaneous photosensitivity and risk of liver damage.
- Diagnosis is established by marked elevation of erythrocyte protoporphyrin, which is predominantly metal-free protoporphyrin (not zinc protoporphyrin)
- Management emphasizes light avoidance and photoprotection

Erythropoietic protoporphyria (EPP) is the most common type of porphyria in children and the third most common in adults, with reported prevalence ranging between 0.5 and 1.5 cases per 100,000 individuals.[103-105] It results from loss-of-function mutation of ferrochelatase (FECH), the last enzyme of the heme biosynthetic pathway. But the protoporphyria phenotype can result from mutation of other genes. X-linked protoporphyria (XLP) results from gain-of-function mutation of ALAS2, the erythroid-specific form of the first enzyme in the pathway, and comprises ~5% of protoporphyria cases.[106] Protoporphyria with increased ALAS2 activity can also result from mutation of mitochondrial CLPX.[107] With rare exceptions, symptoms in all protoporphyrias begin in early childhood with an acute and nonblistering type of cutaneous photosensitivity. Protoporphyric hepatopathy is a potentially fatal complication occurring in less than 5% of patients.

ETIOLOGY AND PATHOGENESIS

EPP is caused by mutation of ferrochelatase (FECH, which catalyzes insertion of iron into protoporphyrin IX, the last step of the heme biosynthetic pathway; Fig. 124-1). FECH deficiency results in the accumulation of the substrate protoporphyrin particularly in marrow reticulocytes. Inheritance of EPP has been described as autosomal dominant with variable penetrance. But since the discovery that mutation of both FECH alleles is required, it is now best described as autosomal recessive. In most families, a severe *FECH* mutation, of which at least 189 have been described, is *trans* to a low-expression (hypomorphic) variant allele (IVS3-48C/T).[108-110] The change in DNA sequence in the low-expression allele results in increased use of an aberrant splice site that produces an mRNA more prone to degradation and a decreased steady-state level of wildtype FECH mRNA.[110] This *FECH* allele occurs in 10% of whites, and by itself has no phenotype. Its frequency varies widely in other populations; its prevalence is higher in east Asians but very low in Africa, accounting for geographic differences in the prevalence of EPP.[103-110]

Cases with 2 severe *FECH* mutations, 1 inherited from each parent, but without the low-expression allele, have been described. At least 1 allele must allow enough FECH enzyme to be synthesized for adequate synthesis of heme. These cases are sometimes associated with seasonal palmar keratoderma, neurologic symptoms, less-than-expected increases in erythrocyte protoporphyrin, and absence of liver dysfunction.[111]

Adult-onset cases of EPP have been described in patients with a myeloproliferative or myelodysplastic syndrome, in which there is expansion of a clone of hematopoietic cells carrying a *FECH* mutation.[112,113] For example, a patient with a myeloproliferative disorder developed severe EPP due to clonal expansion of erythroid precursor cells with a *FECH* deletion *trans* to a hypomorphic *FECH* allele, and died of EPP-induced liver disease.[114]

An X-linked pattern of inheritance in some patients with protoporphyria who lacked *FECH* mutations led to discovery of gain-of-function mutations of *ALAS2* (the only gene encoding an enzyme in the heme biosynthetic pathway found on the X chromosome).[106] These mutations lead to an approximately 3-fold increase in enzymatic activity of the ALAS protein and accumulation of protoporphyrin IX, which indicates that FECH activity is the next rate-limiting step in erythroid heme synthesis.[106] Two members of a family in France were recently found to have protoporphyria without mutation of *FECH* or *ALAS2*, but with a loss-of-function mutation of *CLPX* inherited as an autosomal dominant trait, resulting in decreased degradation of ALAS2 and overproduction of ALA and protoporphyrin.[107]

In EPP, the excess protoporphyrin found in circulating erythrocytes is primarily metal-free rather complexed with zinc, in contrast to many other conditions that increase erythrocyte protoporphyrin that is mostly zinc protoporphyrin (eg, lead intoxication, iron deficiency, anemia of chronic disease, hemolytic states). Excess metal-free protoporphyrin in plasma, which originates from the marrow, where hemoglobin synthesis is active, as well as from circulating erythrocytes, is taken up by hepatocytes, excreted in bile and feces, and may undergo enterohepatic recirculation. Protoporphyrin is hydrophobic as it only possesses 2 hydroxyl groups and is not excreted in urine. Erythrocytes in XLP and protoporphyria due to a CLPX mutation contain increased amounts of both metal-free and zinc-complexed protoporphyrin.

Excitation of porphyrins by ultraviolet light generates free radicals and singlet oxygen,[115] which in EPP can lead to complement activation, peroxidation of lipids,[116] crosslinking of membrane proteins,[117] and polymorphonuclear chemotaxis, resulting in skin pathology.[118] Nonspecific findings on skin histopathology include thickened capillary walls in the papillary dermis surrounded by deposition of amorphous hyalinelike and periodic acid–Schiff (PAS)-positive mucopolysaccharides, complement, and immunoglobulins.[119] Basement membrane abnormalities are less marked than in other forms of cutaneous porphyria.[120]

Protoporphyric hepatopathy occurs in less than 5% of patients. It may cause chronic abnormalities in liver function tests with progression to cirrhosis, or present acutely with rapid progression and require urgent liver transplantation. Other causes of liver damage, such as alcoholic or nonalcoholic steatohepatitis or viral hepatitis, can predispose patients to this condition by impairing protoporphyrin excretion and thereby increasing circulating protoporphyrin to levels that accelerate damage to the liver. Excess protoporphyrin is cholestatic, forms crystalline structures in hepatocytes, and impairs mitochondrial function.[121,122] Accumulated protoporphyrin may appear as brown pigment in hepatocytes, Küpffer cells, and biliary canaliculi and as doubly refractive inclusions with a "Maltese cross" appearance under polarizing microscopy.[123]

TABLE 124-3
Clinical Manifestations in a Series of 32 Cases of Erythropoietic Protoporphyria

SYMPTOMS AND FINDINGS	INCIDENCE (% OF TOTAL)
Burning	97
Edema	94
Itching	88
Erythema	69
Scarring	19
Vesicles	3
Anemia	27
Cholelithiasis	12
Abnormal liver function results	4

Data from Bloomer J, Wang Y, Singhal A, et al. Molecular studies of liver disease in erythropoietic protoporphyria. *J Clin Gastroenterol.* 2005;39(4 suppl 2):S167-S175.[124]

CLINICAL FEATURES

Disease manifestations in a series of 32 patients with EPP are summarized in Table 124-3. Acute cutaneous photosensitivity, which is seldom seen by physicians, is the most prominent symptom described as stinging, burning, or tingling pain that may develop within minutes of sunlight exposure, followed by erythema and edema (described as solar urticaria) (Fig. 124-7), and systemic manifestations that may last for several days. Petechiae or purpura may occur with prolonged exposure. Children are unable to describe these symptoms, but parents may observe crying, skin swelling, and erythema after exposure to sunlight. Hands and face are most often affected, and symptoms are worse during spring and summer. Patients are sensitive to sunlight, either direct or passing through window glass, and also to artificial light, including operating room lights.[125] Among 226 patients in North America, the mean age at symptom onset was 4.4 years, and higher protoporphyrin levels were associated with earlier age of onset, less sun tolerance, and more frequent reports of liver function abnormalities. On average, male patients with XLP had higher erythrocyte protoporphyrin levels than patients with EPP (3574 vs 1669 μg/dL; P <.001). Symptom severity and protoporphyrin levels varied markedly among female XLP patients owing to random X-chromosomal inactivation.[126]

Because patients are prompted by pain and learn to avoid sunlight, chronic skin changes are uncommon and usually subtle. These may include leathery hyperkeratotic skin on the dorsae of the hands and finger joints, mild scarring, labial grooving, and separation of the nail plate (onycholysis), developing with frequent sun exposure (Fig. 124-8). Bullae, skin fragility, hypertrichosis, hyperpigmentation, severe scarring, and mutilation, as seen in other cutaneous porphyrias, are rare. Pregnancy is reported to lower erythrocyte

Figure 124-7 Acute swelling and erythema of the face in 2 children with EPP after exposure to sunlight. In the second child, only the lower face, which was not shielded by a ski mask, was affected.

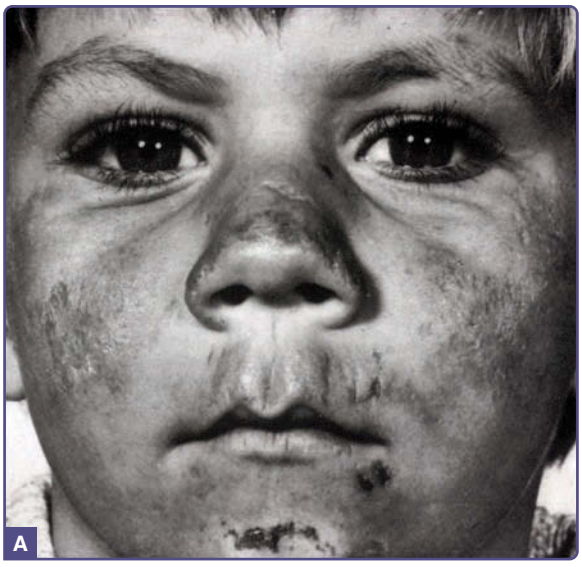

Figure 124-8 Chronic skin manifestations in a 6-year-old child with EPP resulting from repeated light reactions, including facial ulcerations and scarring, labial grooving, and thickened skin on the dorsal hands and loss of lanulae of the fingernails. (Reproduced from Schmidt H, Snitker G, Thomsen K, Lintrup J. Erythropoietic protoporphyria. A clinical study based on 29 cases in 14 families. *Arch Dermatol*. 1974;110(1):58-64; with permission. Copyright © 1974 American Medical Association. All rights reserved.[127])

protoporphyrin levels somewhat and increase tolerance to sunlight.[128]

Mild iron-deficiency anemia with microcytosis, decreased transferrin saturation, in the low part of the normal range of serum ferritin is seen in 20% to 50% of cases of EPP.[129,130] There is little evidence for impaired erythropoiesis or abnormal iron absorption or metabolism,[131-133] and hemolysis is absent or mild.

Neurovisceral manifestations are absent in uncomplicated EPP, but protoporphyric hepatopathy may be complicated by severe motor neuropathy similar to that seen in the acute porphyrias.[134] Autosomal recessive EPP associated with palmar keratoderma also has been associated with unexplained neurologic symptoms.[111]

Gallstones containing large amounts of protoporphyrin are common, and form from excretion of large amounts of water-insoluble protoporphyrin in bile. Such stones may be symptomatic and require cholecystectomy at an early age.[135] Liver function and liver protoporphyrin content are usually normal in EPP. Protoporphyric hepatopathy results from the cholestatic effects of protoporphyrin presented in excess amounts to the liver. Rarely, this is the major presenting feature of EPP.[136] Circulating protoporphyrin levels increase markedly as impairment of biliary excretion progresses. Operating room lights during liver transplantation or other prolonged surgery, especially in patients with hepatopathy, can cause marked photosensitivity with extensive burns of the skin and peritoneum, and can be avoided by use of special filters.[137,138]

DIAGNOSIS

Painful, nonblistering photosensitivity occurring at any age with few chronic skin changes should suggest a diagnosis of protoporphyria. Measurement of total erythrocyte protoporphyrin and, if elevated, measurement of the proportions of metal-free and zinc protoporphyrin will establish or exclude this diagnosis. Elevation of total erythrocyte protoporphyrin is not specific for EPP, because it is increased, with a predominance of erythrocyte zinc protoporphyrin, in many conditions such as homozygous porphyrias (other than most cases of CEP), iron deficiency, lead poisoning, anemia of chronic disease,[139] hemolytic conditions,[140] and many other erythrocyte disorders. But an increase in erythrocyte protoporphyrin comprised predominantly of metal-free protoporphyrin is a finding unique to protoporphyrias. FECH catalyzes the formation of both zinc protoporphyrin and heme (iron protoporphyrin), and when this enzyme is deficient, formation of both is impaired and the accumulating protoporphyrin remains mostly metal free. In XLP, FECH activity is normal but its capacity is exceeded by an excess amount of substrate, so the protoporphyrin that accumulates is usually mostly metal free.

Clinicians who wish to screen for EPP and XLP should be aware of major pitfalls in measuring erythrocyte protoporphyrin for this purpose and should use a laboratory that report results correctly as "total erythrocyte protoporphyrin" and "metal-free protoporphyrin." The now obsolete term "free erythrocyte protoporphyrin," abbreviated "FEP," was widely used to describe iron-free protoporphyrin before the 1970s. This was before it was discovered that this increase is due to zinc protoporphyrin in lead poisoning, iron deficiency, and the many other conditions, but to metal-free protoporphyrin in EPP. Some laboratories (Quest and LabCorp) measure erythrocyte protoporphyrin by hematofluorometry, which only measures zinc protoporphyrin and was developed for screening for lead poisoning and not protoporphyrias; their use of the misleading and obsolete terms "free protoporphyrin" and "FEP" falsely indicate that metal-free protoporphyrin was measured. ARUP measures the total amount correctly but if that is elevated does not fractionate metal-free and zinc protoporphyrin, which is essential to show that the increase is due to protoporphyrias. Testing for protoporphyrias

is carried out correctly in the United States by the Porphyria Laboratory at the University of Texas Medical Branch and Mayo Medical Laboratories.[141]

Plasma porphyrins are increased in most but not all cases of EPP and are particularly susceptible to photodegradation during sample processing.[142] A plasma fluorescence peak of diluted plasma at neutral pH near 634 nm can help confirm a diagnosis of EPP.[53] Fecal porphyrin levels are normal or somewhat increased and consist mostly of protoporphyrin. Urine porphyrins are normal, except in patients with protoporphyric hepatopathy, which causes increases in urinary coproporphyrin, as is typical for hepatic dysfunction of any cause.

THERAPY

Photoprotection, especially avoidance of sunlight exposure, is the primary therapeutic intervention in EPP. This necessitates changes in lifestyle and the working environment and other avoidance behaviors that greatly impair quality of life. Protective clothing and hats are essential for most patients when outdoors. Topical sunblocks containing zinc oxide or titanium dioxide can provide some benefit. Sunscreens that absorb UV wavelengths are not beneficial. Orally administered beta-carotene, thought to quench activated oxygen radicals,[143] can increase sunlight tolerance.[144] A daily dose of 120 to 180 mg or higher is recommended to achieve serum beta-carotene levels of 600 to 800 μg/dL, which can be assessed 3 to 4 weeks after a dose change.[125] However, skin discoloration from carotenemia may be difficult cosmetically especially for children. Oral cysteine at doses of 500 mg twice daily may also quench excited oxygen species and increase tolerance to sunlight in EPP.[145] Afamelanotide, a synthetic analog of α-melanocyte–stimulating hormone mimics the naturally occurring hormone and increases melanin production in melanocytes, resulting in increased skin pigmentation and better sunlight tolerance in patients with EPP or XLP.[146,147] Afamelanotide is currently approved for restricted use in the European Union and Switzerland and is under review by the US Food and Drug Administration for use in patients with EPP and XLP. Cimetidine, which inhibits hepatic CYPs, was reported to decrease photosensitivity in 3 children with EPP.[148] This is not recommended because the proposed inhibition of ALAS2 and lowering of protoporphyrin levels have not been documented.[149]

Mild iron deficiency in protoporphyrias is unexplained and is thought by some to be beneficial (by limiting up-regulation of ALAS2 by iron), but is also potentially detrimental (by further limiting iron incorporation into protoporphyrin). Some patients have noted that iron supplementation increases photosensitivity, but increases in erythrocyte or plasma protoporphyrin levels have not been documented, to our knowledge. On the other hand, clinical and biochemical improvement have been noted in some individual cases of EPP and XLP with iron supplementation.[150,151] The effects of iron supplementation in patients with protoporphyrias and low serum ferritin levels is currently under study by the Porphyrias Consortium in the United States.

Exposure to alcohol, hepatotoxic drugs, or drugs and hormones that increase hepatic porphyrin and heme synthesis or impair hepatic excretory function should be avoided as a precaution.[152,153] Erythrocyte and plasma porphyrin levels, liver function tests, serum ferritin, and serum vitamin D levels should be monitored yearly. Daily intake of 800 international units of vitamin D and 1000 mg of calcium is recommended because EPP patients must avoid sunlight exposure.

Protoporphyric hepatopathy may resolve spontaneously or with treatment, especially if it was triggered by a reversible cause of liver dysfunction, such as viral infection or alcohol.[120,154] This life-threatening complication is usually treated with a combination of interventions including cholestyramine,[122,155,156] ursodeoxycholic acid,[157] vitamin E, red blood cell transfusions,[158] plasma exchange, and intravenous hemin with the aim to reduce plasma and erythrocyte protoporphyrin levels and the amount of protoporphyrin delivered to the liver. This may bridge patients to liver transplantation or even spontaneous improvement.[159] Liver transplantation is as successful as in other liver diseases, although a recurrence rate in the new liver of 69% at 5 years has been reported.[160,161] Acute motor neuropathy has developed in some patients with protoporphyric liver disease after transfusion[162] or liver transplantation,[134,163] and is sometimes reversible with administration of hemin and plasmapheresis prior to transplantation.[164] Bone marrow transplantation is effective in EPP,[165] and sequential bone marrow transplantation after liver transplantation can prevent recurrence of liver disease.[166]

ACUTE HEPATIC PORPHYRIAS

AT-A-GLANCE

- The acute porphyrias are characterized by intermittent acute neurologic symptoms, but can develop chronic blistering lesions in 3 of these conditions, VP, HCP, and AIP (in advanced renal disease).
- Neurovisceral manifestations include abdominal pain, vomiting, extremity pain, seizures, and muscle weakness due to motor neuropathy.
- Urine porphobilinogen is elevated especially during acute attacks. Fluorometric scanning of plasma porphyrin and patterns of fecal porphyrins are most useful for distinguishing the specific acute porphyria.
- Cutaneous manifestations are prevented by avoidance of sunlight.
- Acute neurovisceral attacks are prevented by avoiding exacerbating factors and best treated with hemin infusion

The 4 acute porphyrias, δ-aminolevulinate dehydratase deficiency porphyria (ADP), acute intermittent porphyria (AIP), hereditary coproporphyria (HCP), and variegate porphyria (VP) result from loss-of-function mutation of the second, third, sixth, and seventh enzymes in the heme biosynthetic pathway, respectively, and are characterized by neurologic symptoms occurring mostly as intermittent acute exacerbations. However, chronic blistering skin lesions resembling PCT can occur in 3 of these conditions. They are common in VP, uncommon in HCP, in AIP occur only with advanced renal disease, and are not described in ADP.[167]

ADP is extremely rare, with only 6 cases reported; unlike the other acute porphyrias, its inheritance is autosomal recessive.[168] (It will not be discussed further in this chapter.) The enzyme deficiencies in the other acute porphyrias are inherited as autosomal dominant traits with low penetrance (see Table 124-1). AIP is the most common acute hepatic porphyria worldwide. The prevalence of AIP has been estimated to be 1 to 2 per 100,000 in Europe,[169] that of HCP was estimated to be 0.2 per 100,000 in Denmark,[170] and that of VP in Finland reported at 1.3 per 100,000.[171] VP is especially common in South Africa among whites of Dutch descent due a founder effect, with an estimated prevalence of 300 per 100,000[172], and almost all cases share the same *PPOX* mutation (R59W).

ETIOLOGY AND PATHOGENESIS

At least 400 *PBGD/HMBS* mutations have been identified in AIP, 64 *CPOX* mutations in HCP[173] and 174 *PPOX* mutations in VP[86] (Table 124-1). Mutation types include missense, nonsense, splicing, deletion, and insertion mutations. PBGD catalyzes the assembly of HMBS, a linear tetrapyrrole, from 4 molecules of PBG. CPOX catalyzes the 2-step oxidative decarboxylation at a single active site of coproporphyrinogen III to yield protoporphyrinogen IX, with intermediate formation of harderoporphyrinogen, a tricarboxyl porphyrinogen. PPOX catalyzes the dehydrogenation of protoporphyrinogen IX to form protoporphyrin IX. Neurovisceral symptoms in the acute hepatic porphyrias are associated with accumulation of the porphyrin precursors delta-aminolevulinic acid (ALA) and porphobilinogen (PBG). Symptoms may result from neurotoxic effects of ALA and/or from heme deficiency in neuronal or vascular tissue.[174] Porphyrins accumulate in all of these disorders and most commonly in sufficient amounts to cause chronic blistering skin manifestations in VP.

CLINICAL FEATURES

Typical neurovisceral manifestations of the acute porphyrias include abdominal pain, vomiting, extremity pain, seizures, and muscle weakness due to motor neuropathy. Several factors are recognized to contribute to attacks in AIP, HCP, and VP, including drugs, hormones, and dietary factors. Risk of chronic hypertension, renal disease, and hepatocellular carcinoma are increased. Very rare cases of homozygous AIP, HCP, and VP have presented with severe photosensitivity and neurologic impairment early in life but without acute attacks.[174] A variant form of homozygous HCP termed harderoporphyria is due to *CPOX* mutations that prematurely release harderoporphyrinogen from the enzyme before the second decarboxylation occurs.[175]

PRECIPITATING FACTORS

Known endogenous and exogenous factors can precipitate acute attacks in heterozygotes and are additive in individual patients. Many known factors cause induction of hepatic ALAS1, and this leads to accumulation of pathway intermediates. Some individuals remain susceptible to repeated attacks despite avoidance of known precipitants. Additional unknown factors, including undiscovered modifying genes, are likely to contribute.

DRUGS AND OTHER EXOGENOUS CHEMICALS

Most drugs that are harmful in acute porphyrias are known to induce hepatic CYPs and ALAS1. Induction of CYPs (the most abundant hemoproteins in liver) increases demand for newly synthesized heme.[176] Examples of drugs known to be harmful and safe are shown in Table 124-4. Updated drug safety databases are found at the websites of the American Porphyria Foundation (www.porphyriafoundation.com) and the European Porphyria Network (www.porphyria-europe.com). Smoking is known to increase hepatic CYPs in humans, probably from effects of inhaled polycyclic aromatic hydrocarbons, and is associated with more frequent symptoms.[177] Ethanol and other alcohols also induce ALAS1 and some CYPs, and have been implicated in causing attacks.[178,179]

ENDOCRINE FACTORS

Symptoms often develop after puberty and occur more commonly in women, suggesting that endogenous female hormones contribute to the onset of symptoms. Progesterone, synthetic progestins, and certain metabolites of testosterone are potent inducers of ALAS1 and CYPs and have been associated with acute attacks of porphyria. Increases in progesterone in the luteal phase of the menstrual cycle are most likely responsible for cyclic attacks in AIP, HCP, and VP. Estrogens have been considered harmful, but do not have the inducing effects of progestins on ALAS1 and CYPs, and reports of attacks when they are administered without a progestin are few. But as discussed

TABLE 124-4

A Partial List of Drugs Known to Be Unsafe or Safe in the Acute Porphyrias

UNSAFE		SAFE
Alcohol	Meprobamate[a] (also mebutamate,[a] tybutamate[a])	Acetaminophen
Barbiturates[a]	Methyprylon	Aspirin
Carbamazepine[a]	Metoclopramide[a]	Atropine
Carisoprodol[a]	Phenytoin[a]	Bromides
Clonazepam (high doses)	Primidone[a]	Cimetidine
Danazol[a]	Progesterone and synthetic progestins[a]	Erythropoietin[a,b]
Diclofenac[a] and possibly other NSAIDs	Pyrazinamide[a]	Gabapentin
Ergots	Pyrazolones (aminopyrine, antipyrine)	Glucocorticoids
Estrogens[a,c]	Rifampin[a]	Insulin
Ethchlorvynol[a]	Succinimides (ethosuximide, methsuximide)	Levetiracetam
Glutethimide[a]	Sulfonamide antibiotics[a]	Narcotic analgesics
Griseofulvin[a]	Valproic acid[a]	Penicillin and derivatives
Mephenytoin		Phenothiazines
		Ranitidine[a,b]
		Streptomycin
		Vigabatrin

[a]Porphyria is listed as a contraindication, warning, precaution, or adverse effect in US labeling for these drugs.

[b]Although porphyria is listed as a precaution in US labeling; these drugs are regarded as safe by other sources.

[c]Estrogens–unsafe for porphyria cutanea tarda but can be used with caution in the acute porphyrias.

Note: More complete and frequently updates sources, such as the websites of the American Porphyria Foundation (www.porphyriafoundation.com/) and the European Porphyria Initiative (www.porphyria-europe.com/), should be consulted before using drugs not listed here.

Modified from Anderson KE, Bloomer JR, Bonkovsky HL, et al. Recommendations for the diagnosis and treatment of the acute porphyrias. *Ann Intern Med*. 2005;142(6):439-450; with permission.[167]

earlier, estrogen use is a common susceptibility factor in women with PCT. Diabetes mellitus may decrease the frequency of attacks and lower porphyrin precursor levels, likely because of high glucose levels.[180]

PREGNANCY

Most women with AIP report that pregnancy is well tolerated.[181] However, attacks sometimes become more frequent during pregnancy, which may be due to harmful drugs (eg, metoclopramide)[182,183] or reduced caloric intake with hyperemesis gravidarum. Attacks during pregnancy should be treated with hemin, unless they are mild. Termination of pregnancy is rarely indicated for an acute attack of porphyria.

NUTRITION

Reduced intake of calories and carbohydrate to lose weight or during an illness or surgery can precipitate attacks. In these circumstances, peroxisomal proliferator-activated cofactor 1α (PGC-1α) is up-regulated in the liver, which induces ALAS1 and increases ALA and PBG. These effects can be prevented or reversed by administration of carbohydrate.[184,185] Starvation may also induce hepatic heme oxygenase,[186] which may deplete hepatic heme and contribute to ALAS1 induction.

DIAGNOSIS

Urinary PBG is elevated during acute attacks of AIP, HCP and VP, but often less so, and more transiently, in HCP and VP than in AIP; further testing readily differentiates these 3 conditions. Skin lesions resembling PCT are rare in AIP and occur only in the presence of advanced renal disease with increases in plasma levels of both PBG and porphyrins. In HCP and VP, urine porphyrins (especially uroporphyrin and coproporphyrin) are also elevated, but this finding by itself is nonspecific and does not readily differentiate these porphyrias from each other. Fecal porphyrin levels are markedly increased in both HCP and VP and are predominantly coproporphyrin III in HCP, and both coproporphyrin III and protoporphyrin in VP. The fecal coproporphyrin III/I ratio is sensitive for diagnosis of HCP, even in asymptomatic stages of the disease.[187]

Plasma porphyrin concentration is commonly elevated in VP and seldom increased in AIP and HCP, unless there are cutaneous manifestations. A specific feature of VP is a plasma porphyrin fluorescence maximum at neutral pH of ~626 nm, which represents protoporphyrin bound covalently to plasma proteins.[188] This fluorometric scanning method is more effective than examination of fecal porphyrins for detecting asymptomatic VP,[189] and is especially useful for rapidly differentiating VP from PCT, which displays a fluorescence peak at ~620 nm. Erythrocyte PBGD activity is decreased in most AIP patients and normal in HCP and VP. Assays for CPOX and PPOX require cells containing mitochondria and are not widely available. DNA studies are most reliable for identifying asymptomatic carriers, once the familial mutation is identified.

Homozygous cases of AIP, HCP, and VP demonstrate more severe increases in porphyrin precursors and porphyrins, including erythrocyte zinc protoporphyrin. Harderoporphyria is identified by elevations in both coproporphyrin III and harderoporphyrin III in feces and erythrocytes.[190]

THERAPY

Cutaneous manifestations of VP and HCP, though identical to the blistering skin lesions seen in PCT, do not respond to phlebotomies or low-dose hydroxychloroquine. Therefore, avoidance of sunlight and use of protective clothing is most important. Long-term avoidance of precipitating factors may lower chronically elevated porphyrin levels, but to our knowledge this has not been documented. Patients with AIP, renal failure, and associated cutaneous manifestations

should be considered for renal or combined hepatic and renal transplantation.[191]

For acute attacks, hospitalization is usually advisable for treatment of severe symptoms, intravenous therapies and monitoring of respiration, electrolytes, and nutritional status. Milder recurring attacks that respond rapidly to treatment are sometimes managed as outpatients. Precipitating factors, such as harmful drugs are removed. Pain, nausea, and vomiting usually require narcotic analgesics, chlorpromazine or another phenothiazine, or ondansetron. Short-acting benzodiazepines are given for anxiety and insomnia.[167] β-Adrenergic-blocking agents can be used to control tachycardia and hypertension, unless contraindicated by hypovolemia or heart failure.[192] Treatment for seizures should focus on correcting hyponatremia, if present. Most anticonvulsant drugs are potentially harmful in acute porphyrias. Clonazepam may be less harmful than phenytoin, barbiturates, or valproic acid.[193,194]

The identification and long-term avoidance of factors precipitating acute neurovisceral attacks is essential. Yearly screening for hepatocellular carcinoma is recommended after 50 years of age, especially in those with persistent increases in porphyrin precursors or porphyrins.

Hemin is the most effective treatment for acute attacks, and is available in the United States as lyophilized hematin (Panhematin, Recordati Rare Diseases), and as heme arginate (Normosang, Orphan Europe) in Europe and South Africa.[195,196] Intravenously infused hemin is taken up primarily by hepatocytes where it reconstitutes the regulatory heme pool and represses the synthesis of ALAS1, leading to dramatic reduction in ALA, PBG, and porphyrins, and more rapid resolution of symptoms.[197]

Hemin therapy should be initiated for moderate to severe attacks, and for mild attacks unresponsive to carbohydrate loading.[167,195,198] Infusion of 3 to 4 mg/kg daily for 4 days is standard therapy and may be extended if a response is incomplete within this time. Hemin has been administered safely during pregnancy.[167,195,196] Reconstitution of hematin with 25% human albumin is recommended, as degradation products that form when using sterile water may cause infusion site phlebitis and limit future venous access.[167,199] A transient coagulopathy with thrombocytopenia and prolongation of prothrombin and partial thromboplastin times is also prevented with use of albumin.[200,201] Side effects of hemin may include fever, aching, malaise, and rarely hemolysis, anaphylaxis, and circulatory collapse.[202,203] Hemin administered once or twice weekly is an option for preventing frequent, noncyclic attacks.[204,205]

CARBOHYDRATE LOADING

Administration of carbohydrates downregulates PGC-1α and the induction of hepatic ALAS1, thereby decreasing production of porphyrin precursors. However, this is less effective than hemin and should be used only for mild attacks (without severe pain requiring opioids, paresis, seizures or hyponatremia),[167] or until hemin becomes available. Intravenous treatment with 300 to 500 g of IV glucose is usually administered as a 10% solution, with careful monitoring to avoid hyponatremia due to administration of large volumes of free water.[167] Oral glucose polymer solutions may be given if tolerated.

REFERENCES

1. Moore M, McColl K. *Disorders of Porphyrin Metabolism*. New York, NY: Plenum; 1987.
2. Schultz J. *Ein fall von pemphigus, kompliziert durch lepra visceralis*. Greifswald: Greifswald University; 1874.
3. Anderson TM. Hydroa aestivale in two brothers, complicated with the presence of haematoporphyrin in the urine. *Br J Dermatol.* 1898;10:1.
4. Stokvis BJ. Over Twee Zeldsame Kleuerstoffen in Urine van Zicken. *Ned Tijdschr Geneeskd.* 1889;13:409.
5. Garrod AE. *Inborn Errors of Metabolism.* London: Hodder & Stoughton; 1923.
6. Schmid R, Schwartz S, Watson CJ. Porphyrin content of bone marrow and liver in the various forms of porphyria. *Arch Intern Med.* 1954;93:167-190.
7. Ippen H. Treatment of porphyria cutanea tarda by phlebotomy. *Semin Hematol.* 1977;14:253-259.
8. Strand LJ, Felsher BF, Redeker AG, et al. Heme biosynthesis in intermittent acute porphyria: decreased hepatic conversion of porphobilinogen to porphyrins and increased delta-aminolevulinic acid synthetase activity. *Proc Natl Acad Sci U S A.* 1970;67:1315-1320.
9. Bonkowsky HL, Tschudy DP, Collins A, et al. Repression of the overproduction of porphyrin precursors in acute intermittent porphyria by intravenous infusions of hematin. *Proc Natl Acad Sci U S A.* 1971; 68(11):2725-2729.
10. Gou EW, Phillips JD, Anderson KE. The porphyrias. In: Gilbert-Barness E, Barness L, Farrell P, eds. *Metabolic Diseases.* Amsterdam: IOS Press BV; 2017:543-575.
11. Granick S, Sassa S. δ-Aminolevulinic acid synthase and the control of heme and chlorophyll synthesis. In: Vogel HJ, ed. *Metabolic Regulation*. New York, NY: Academic Press; 1971:77.
12. Chung J, Wittig JG, Ghamari A, et al. Erythropoietin signaling regulates heme biosynthesis. *Elife.* 2017;6.
13. Bissell DM, Anderson KE, Bonkovsky HL. Porphyria. *N Engl J Med.* 2017;377(9):862-872.
14. Elder GH. Porphyria cutanea tarda and related disorders (Chap. 88). In: Kadish KM, Smith K, Guilard R, eds. *Porphyrin Handbook, Part II.* Vol 14. San Diego, CA: Academic Press; 2003:67-92.
15. Thawani R, Moghe A, Idhate T, et al. Porphyria cutanea tarda in a child with acute lymphoblastic leukemia. *Q J Med.* 2016;109(3):191-192.
16. Boffa MJ, Reed P, Weinkove C, et al. Hypertrichosis as the presenting feature of porphyria cutanea tarda. *Clin Exp Dermatol.* 1995;20(1):62-64.
17. Anderson KE, Goeger DE, Carson RW, et al. Erythropoietin for the treatment of porphyria cutanea tarda in a patient on long-term hemodialysis. *N Engl J Med.* 1990;322:315-317.
18. Cassiman D, Vannoote J, Roelandts R, et al. Porphyria cutanea tarda and liver disease. A retrospective analysis of 17 cases from a single centre and review of the literature. *Acta Gastroenterol Belg.* 2008; 71(2):237-242.

19. Gisbert JP, Garcia-Buey L, Alonso A, et al. Hepatocellular carcinoma risk in patients with porphyria cutanea tarda. *Eur J Gastroenterol Hepatol.* 2004;16(7):689-692.
20. Rossmann-Ringdahl I, Olsson R. Porphyria cutanea tarda in a Swedish population: risk factors and complications. *Acta Derm Venereol.* 2005;85(4):337-341.
21. Egger NG, Goeger DE, Payne DA, et al. Porphyria cutanea tarda: multiplicity of risk factors including HFE mutations, hepatitis C, and inherited uroporphyrinogen decarboxylase deficiency. *Dig Dis Sci.* 2002;47(2):419-426.
22. Jalil S, Grady JJ, Lee C, et al. Associations among behavior-related susceptibility factors in porphyria cutanea tarda. *Clin Gastroenterol Hepatol.* 2010; 8(3):297-302, 302.e1.
23. Brady JJ, Jackson HA, Roberts AG, et al. Co-inheritance of mutations in the uroporphyrinogen decarboxylase and hemochromatosis genes accelerates the onset of porphyria cutanea tarda. *J Invest Dermatol.* 2000;115(5):868-874.
24. Roberts AG, Whatley SD, Nicklin S, et al. The frequency of hemochromatosis-associated alleles is increased in British patients with sporadic porphyria cutanea tarda. *Hepatology.* 1997;25(1):159-161.
25. Dereure O, Aguilar-Martinez P, Bessis D, et al. HFE mutations and transferrin receptor polymorphism analysis in porphyria cutanea tarda: a prospective study of 36 cases from southern France. *Br J Dermatol.* 2001;144(3):533-539.
26. Ajioka RS, Phillips JD, Weiss RB, et al. Down-regulation of hepcidin in porphyria cutanea tarda. *Blood.* 2008; 112(12):4723-4728.
27. Sinclair PR, Gorman N, Walton HS, et al. CYP1A2 is essential in murine uroporphyria caused by hexachlorobenzene and iron. *Toxicol Appl Pharmacol.* 2000; 162(1):60-67.
28. Smith AG, Clothier B, Carthew P, et al. Protection of the Cyp1A2(–/–) null mouse against uroporphyria and hepatic injury following exposure to 2,3,7,8-tetrachlorodibenzo-*p*-dioxin. *Toxicol Appl Pharmacol.* 2001;173(2):89-98.
29. Blekkenhorst GH, Eales L, Pimstone NR. Activation of uroporphyrinogen decarboxylase by ferrous iron in porphyria cutanea tarda. *S Afr Med J.* 1979;56(22):918-920.
30. Christiansen L, Bygum A, Jensen A, et al. Association between CYP1A2 polymorphism and susceptibility to porphyria cutanea tarda. *Hum Genet.* 2000; 107(6):612-614.
31. Wickliffe JK, Abdel-Rahman SZ, Lee C, et al. CYP1A2*1F and GSTM1 alleles are associated with susceptibility to porphyria cutanea tarda. *Mol Med.* 2011;17(3-4):241-247.
32. Grossman ME, Bickers DR, Poh-Fitzpatrick MB, et al. Porphyria cutanea tarda. Clinical features and laboratory findings in 40 patients. *Am J Med.* 1979;67(2):277-286.
33. Sixel-Dietrich F, Doss M. Hereditary uroporphyrinogen-decarboxylase deficiency predisposing porphyria cutanea tarda (chronic hepatic porphyria) in females after oral contraceptive medication. *Arch Dermatol Res.* 1985;278(1):13-16.
34. Legault N, Sabik H, Cooper SF, et al. Effect of estradiol on the induction of porphyria by hexachlorobenzene in the rat. *Biochem Pharmacol.* 1997;54(1):19-25.
35. Liehr JG. Vitamin C reduces the incidence and severity of renal tumors induced by estradiol or diethylstilbestrol. *Am J Clin Nutr.* 1991;54(6)(suppl):S1256-S1260.
36. Fujita N, Sugimoto R, Motonishi S, et al. Patients with chronic hepatitis C achieving a sustained virological response to peginterferon and ribavirin therapy recover from impaired hepcidin secretion. *J Hepatol.* 2008;49(5):702-710.
37. Nishina S, Hino K, Korenaga M, et al. Hepatitis C virus-induced reactive oxygen species raise hepatic iron level in mice by reducing hepcidin transcription. *Gastroenterology.* 2008;134(1):226-238.
38. Younossi Z, Park H, Henry L, et al. Extrahepatic manifestations of hepatitis C: a meta-analysis of prevalence, quality of life, and economic burden. *Gastroenterology.* 2016;150(7):1599-1608.
39. Wissel PS, Sordillo P, Anderson KE, et al. Porphyria cutanea tarda associated with the acquired immune deficiency syndrome. *Am J Hematol.* 1987;25(1):107-113.
40. Percy VA, Naidoo D, Joubert SM, et al. Ascorbate status of patients with porphyria cutanea tarda symptomatica and its effect on porphyrin metabolism. *S Afr J Med Sci.* 1975;40(4):185-196.
41. Rocchi E, Casalgrandi G, Masini A, et al. Circulating pro- and antioxidant factors in iron and porphyrin metabolism disorders. *Ital J Gastroenterol Hepatol.* 1999;31(9):861-867.
42. Sinclair PR, Gorman G, Shedlofsky SI, et al. Ascorbic acid deficiency in porphyria cutanea tarda. *J Lab Clin Med.* 1997;130:197-201.
43. Gorman N, Zaharia A, Trask HS, et al. Effect of iron and ascorbate on uroporphyria in ascorbate-requiring mice as a model for porphyria cutanea tarda. *Hepatology.* 2007;45(1):187-194.
44. Schmid R. Cutaneous porphyria in Turkey. *N Engl J Med.* 1960;263:397-398.
45. Calvert GM, Sweeney MH, Fingerhut MA, et al. Evaluation of porphyria cutanea tarda in U.S. workers exposed to 2,3,7,8-tetrachlorodibenzo-*p*-dioxin. *Am J Ind Med.* 1994;25(4):559-571.
46. Elder GH, Urquhart AJ, de Salamanca RE, et al. Immunoreactive uroporphyrinogen decarboxylase in the liver in porphyria cutanea tarda. *Lancet.* 1985;2(8449):229-233.
47. Moran MJ, Fontanellas A, Brudieux E, et al. Hepatic uroporphyrinogen decarboxylase activity in porphyria cutanea tarda patients: the influence of virus C infection. *Hepatology.* 1998;27(2):584-589.
48. Anderson KE. Porphyria cutanea tarda: a possible role for ascorbic acid. *Hepatology.* 2007;45(1):6-8.
49. Phillips JD, Bergonia HA, Reilly CA, et al. A porphomethene inhibitor of uroporphyrinogen decarboxylase causes porphyria cutanea tarda. *Proc Natl Acad Sci U S A.* 2007;104(12):5079-5084.
50. Sarkany RP. Making sense of the porphyrias. *Photodermatol Photoimmunol Photomed.* 2008;24(2):102-108.
51. Pigatto PD, Polenghi MM, Altomare GF, et al. Complement cleavage products in the phototoxic reaction of porphyria cutanea tarda. *Br J Dermatol.* 1986;114(5):567-573.
52. Poh-Fitzpatrick MB. A plasma porphyrin fluorescence marker for variegate porphyria. *Arch Dermatol.* 1980;116(5):543-547.
53. Poh-Fitzpatrick MB, Lamola AA. Direct spectrophotometry of diluted erythrocytes and plasma: a rapid diagnostic method in primary and secondary porphyrinemias. *J Lab Clin Med.* 1976;87:362-370.
54. Elder GH. The metabolism of porphyrins of the isocoproporphyrin series. *Enzyme.* 1974;17(1):61-68.
55. Poh-Fitzpatrick MB, Sosin AE, Bemis J. Porphyrin levels in plasma and erythrocytes of chronic hemodialysis patients. *J Am Acad Dermatol.* 1982;7(1):100-104.
56. Sardh E, Andersson DE, Henrichson A, et al. Porphyrin precursors and porphyrins in three patients with

acute intermittent porphyria and end-stage renal disease under different therapy regimes. *Cell Mol Biol (Noisy-le-grand).* 2009;55(1):66-71.
57. Dabski C, Beutner EH. Studies of laminin and type IV collagen in blisters of porphyria cutanea tarda and drug-induced pseudoporphyria. *J Am Acad Dermatol.* 1991;25(1, pt 1):28-32.
58. Bajaj D, Pachyala A, Singal A. Porphyria cutanea tarda is a biochemical and not histological diagnosis. *Gastroenterol Hepatol Open Access.* 2016;5(8).
59. Bulaj ZJ, Franklin MR, Phillips JD, et al. Transdermal estrogen replacement therapy in postmenopausal women previously treated for porphyria cutanea tarda. *J Lab Clin Med.* 2000;136(6):482-488.
60. Topi GC, Amantea A, Griso D. Recovery from porphyria cutanea tarda with no specific therapy other than avoidance of hepatic toxins. *Br J Dermatol.* 1984;111(1):75-82.
61. Ratnaike S, Blake D, Campbell D, et al. Plasma ferritin levels as a guide to the treatment of porphyria cutanea tarda by venesection. *Australas J Dermatol.* 1988;29(1):3-7.
62. Rocchi E, Gibertini P, Cassanelli M, et al. Serum ferritin in the assessment of liver iron overload and iron removal therapy in porphyria cutanea tarda. *J Lab Clin Med.* 1986;107:36-42.
63. Bacon BR, Adams PC, Kowdley KV, et al. Diagnosis and management of hemochromatosis: 2011 practice guideline by the American Association for the Study of Liver Diseases. *Hepatology.* 2011;54(1):328-343.
64. Ashton RE, Hawk JLM, Magnus IA. Low-dose oral chloroquine in the treatment of porphyria cutanea tarda. *Br J Dermatol.* 1984;3:609-613.
65. Bruce AJ, Ahmed I. Childhood-onset porphyria cutanea tarda: successful therapy with low-dose hydroxychloroquine (Plaquenil). *J Am Acad Dermatol.* 1998;38(5, pt 2):810-814.
66. Freesemann A, Frank M, Sieg I, et al. Treatment of porphyria cutanea tarda by the effect of chloroquine on the liver. *Skin Pharmacol.* 1995;8(3):156-161.
67. Kordac V, Semradova M. Treatment of porphyria cutanea tarda with chloroquine. *Br J Dermatol.* 1974; 90:95-100.
68. Taljaard JJF, Shanley BC, Stewart-Wynne EG, et al. Studies on low dose chloroquine therapy and the action of chloroquine in symptomatic porphyria. *Br J Dermatol.* 1972;87(3):261-269.
69. Timonen K, Niemi KM, Mustajoki P. Skin morphology in porphyria cutanea tarda does not improve despite clinical remission. *Clin Exp Dermatol.* 1991;16(5): 355-358.
70. Singal AK, Kormos-Hallberg C, Lee C, et al. Low-dose hydroxychloroquine is as effective as phlebotomy in treatment of patients with porphyria cutanea tarda. *Clin Gastroenterol Hepatol.* 2012;10(12):1402-1409.
71. Sweeney GD, Jones KG. Porphyria cutanea tarda: clinical and laboratory features. *Can Med Assoc J.* 1979;120(7):803-807.
72. Thornsvard MAJCT, Guider BA, Kimball DB. An unusual reaction to chloroquine-primaquine. *JAMA.* 1976;235(16):1719-1720.
73. Malkinson FD, Levitt L. Hydroxychloroquine treatment of porphyria cutanea tarda. *Arch Dermatol.* 1980;116(10):1147-1150.
74. Marmor MF, Kellner U, Lai TY, et al. Revised recommendations on screening for chloroquine and hydroxychloroquine retinopathy. *Ophthalmology.* 2011; 118(2):415-422.
75. Rocchi E, Cassanelli M, Ventura E. High weekly intravenous doses of desferrioxamine in porphyria cutanea tarda. *Br J Dermatol.* 1987;117(3):393-396.
76. Singal AK, Venkata KVR, Jampana S, et al. Hepatitis C treatment in patients with porphyria cutanea tarda. *Am J Med Sci.* 2017;353(6):523-528.
77. Shieh S, Cohen JL, Lim HW. Management of porphyria cutanea tarda in the setting of chronic renal failure: a case report and review. *J Am Acad Dermatol.* 2000;42(4):645-652.
78. Yaqoob M, Smyth J, Ahmad R, et al. Haemodialysis-related porphyria cutanea tarda and treatment by recombinant human erythropoietin. *Nephron.* 1992;60(4):428-431.
79. Carson RW, Dunnigan EJ, DuBose TDJ, et al. Removal of plasma porphyrins with high-flux hemodialysis in porphyria cutanea tarda associated with end-stage renal disease. *J Am Soc Nephrol.* 1992;2(9): 1445-1450.
80. Stevens BR, Fleischer AB, Piering F, et al. Porphyria cutanea tarda in the setting of renal failure: response to renal transplantation. *Arch Dermatol.* 1993;129(3):337-339.
81. Armstrong DK, Sharpe PC, Chambers CR, et al. Hepatoerythropoietic porphyria: a missense mutation in the UROD gene is associated with mild disease and an unusual porphyrin excretion pattern. *Br J Dermatol.* 2004;151(4):920-923.
82. Phillips JD, Parker TL, Schubert HL, et al. Functional consequences of naturally occurring mutations in human uroporphyrinogen decarboxylase. *Blood.* 2001;98(12): 3179-3185.
83. Bundino S, Topi GC, Zina AM, et al. Hepatoerythropoietic porphyria. *Pediatr Dermatol.* 1987;4(3):229-233.
84. Pimstone NR, Gandhi SN, Mukerji SK. Therapeutic efficacy of oral charcoal in congenital erythropoietic porphyria. *N Engl J Med.* 1987;316(7):390-393.
85. Fontanellas A, Mazurier F, Moreau-Gaudry F, et al. Correction of uroporphyrinogen decarboxylase deficiency (hepatoerythropoietic porphyria) in Epstein-Barr virus-transformed B-cell lines by retrovirus-mediated gene transfer: fluorescence-based selection of transduced cells. *Blood.* 1999;94(2): 465-474.
86. Balwani M, Desnick RJ. The porphyrias: advances in diagnosis and treatment. *Blood.* 2012;120(23):4496-504. [Erratum In: *Blood.* 2013;122(17):3090.]
87. Phillips JD, Steensma DP, Pulsipher MA, et al. Congenital erythropoietic porphyria due to a mutation in *GATA1*: the first trans-acting mutation causative for a human porphyria. *Blood.* 2007;109(6):2618-2621.
88. Watson CJ, Perman V, Spurrell FA, et al. Some studies of the comparative biology of human and bovine porphyria erythropoietica. *Trans Assoc Am Physicians.* 1958;71:196-209.
89. Günther H. In: Schittenhelm A, ed. *Handbuch der Krankheiten der Blutes und der Blutbildenden Organe.* Vol 2. Berlin: Springer; 1925.
90. Sassa S, Akagi R, Nishitani C, et al. Late-onset porphyrias: what are they? *Cell Mol Biol (Noisy-le-grand).* 2002;48(1):97-101.
91. Verstraeten L, Van Regemorter N, Pardou A, et al. Biochemical diagnosis of a fatal case of Gunther's disease in a newborn with hydrops foetalis. *Eur J Clin Chem Clin Biochem.* 1993;31(3):121-124.
92. Desnick RJ, Astrin KH. Congenital erythropoietic porphyria: advances in pathogenesis and treatment. *Br J Haematol.* 2002;117(4):779-795.

93. Hallai N, Anstey A, Mendelsohn S, et al. Pregnancy in a patient with congenital erythropoietic porphyria. *N Engl J Med.* 2007;357(6):622-623.
94. Seip M, Thune PO, Eriksen L. Treatment of photosensitivity in congenital erythropoietic porphyria (CEP) with beta-carotene. *Acta Derm Venereol.* 1974;54(3): 239-240.
95. Haining RG, Cowger ML, Labbe RF, et al. Congenital erythropoietic porphyria. II. The effects of induced polycythemia. *Blood.* 1970;36(3):297-309.
96. Piomelli S, Poh-Fitzpatrick MB, Seaman C, et al. Complete suppression of the symptoms of congenital erythropoietic porphyria by long-term treatment with high-level transfusions. *N Engl J Med.* 1986;314(16):1029-1031.
97. Guarini L, Piomelli S, Poh-Fitzpatrick MB. Hydroxyurea in congenital erythropoietic porphyria [letter]. *N Engl J Med.* 1994;330(15):1091-1092.
98. Fritsch C, Bolsen K, Ruzicka T, et al. Congenital erythropoietic porphyria. *J Am Acad Dermatol.* 1997; 36(4):594-610.
99. Katugampola RP, Anstey AV, Finlay AY, et al. A management algorithm for congenital erythropoietic porphyria derived from a study of 29 cases. *Br J Dermatol.* 2012;167(4):888-900.
100. Dupuis-Girod S, Akkari V, Ged C, et al. Successful match-unrelated donor bone marrow transplantation for congenital erythropoietic porphyria (Gunther disease). *Eur J Pediatr.* 2005;164(2):104-107.
101. Geronimi F, Richard E, Lamrissi-Garcia I, et al. Lentivirus-mediated gene transfer of uroporphyrinogen III synthase fully corrects the porphyric phenotype in human cells. *J Mol Med (Berl).* 2003;81(5):310-320.
102. Kauppinen R, Glass IA, Aizencang G, et al. Congenital erythropoietic porphyria: prolonged high-level expression and correction of the heme biosynthetic defect by retroviral-mediated gene transfer into porphyric and erythroid cells. *Mol Genet Metab.* 1998; 65(1):10-17.
103. Marko PB, Miljkovic J, Gorenjak M, et al. Erythropoietic protoporphyria patients in Slovenia. *Acta Dermatovenerol Alp Pannonica Adriat.* 2007;16(3):99-102, 104.
104. Parker M, Corrigall AV, Hift RJ, et al. Molecular characterization of erythropoietic protoporphyria in South Africa. *Br J Dermatol.* 2008;159(1):182-191.
105. Holme SA, Anstey AV, Finlay AY, et al. Erythropoietic protoporphyria in the U.K.: clinical features and effect on quality of life. *Br J Dermatol.* 2006;155(3):574-581.
106. Whatley SD, Ducamp S, Gouya L, et al. C-terminal deletions in the *ALAS2* gene lead to gain of function and cause X-linked dominant protoporphyria without anemia or iron overload. *Am J Hum Genet.* 2008;83(3):408-414.
107. Yien YY, Ducamp S, van der Vorm LN, et al. Mutation in human *CLPX* elevates levels of δ-aminolevulinate synthase and protoporphyrin IX to promote erythropoietic protoporphyria. *Proc Natl Acad Sci U S A.* 2017; 114(38):E8045-E8052.
108. Gouya L, Deybach JC, Lamoril J, et al. Modulation of the phenotype in dominant erythropoietic protoporphyria by a low expression of the normal ferrochelatase allele. *Am J Hum Genet.* 1996;58(2):292-299.
109. Gouya L, Puy H, Lamoril J, et al. Inheritance in erythropoietic protoporphyria: a common wild-type ferrochelatase allelic variant with low expression accounts for clinical manifestation. *Blood.* 1999;93(6):2105-2110.
110. Gouya L, Puy H, Robreau AM, et al. The penetrance of dominant erythropoietic protoporphyria is modulated by expression of wildtype FECH. *Nat Genet.* 2002;30(1):27-28.
111. Holme SA, Whatley SD, Roberts AG, et al. Seasonal palmar keratoderma in erythropoietic protoporphyria indicates autosomal recessive inheritance. *J Invest Dermatol.* 2009;129(3):599-605.
112. Aplin C, Whatley SD, Thompson P, et al. Late-onset erythropoietic porphyria caused by a chromosome 18q deletion in erythroid cells. *J Invest Dermatol.* 2001;117(6):1647-1649.
113. Shirota T, Yamamoto H, Hayashi S, et al. Myelodysplastic syndrome terminating in erythropoietic protoporphyria after 15 years of aplastic anemia. *Int J Hematol.* 2000;72(1):44-47.
114. Goodwin RG, Kell WJ, Laidler P, et al. Photosensitivity and acute liver injury in myeloproliferative disorder secondary to late-onset protoporphyria caused by deletion of a ferrochelatase gene in hematopoietic cells. *Blood.* 2006;107(1):60-62.
115. Spikes JD. Porphyrins and related compounds as photodynamic sensitizers. *Ann N Y Acad Sci.* 1975; 244:496-508.
116. Goldstein BD, Harber LC. Erythropoietic protoporphyria: lipid peroxidation and red cell membrane damage associated with photohemolysis. *J Clin Invest.* 1972;51(4):892-902.
117. Schothorst AA, van Steveninck J, Went LN, et al. Photodynamic damage of the erythrocyte membrane caused by protoporphyrin in protoporphyria and in normal red blood cells. *Clin Chim Acta.* 1972; 39(1):161-170.
118. Lim HW, Poh-Fitzpatrick MB, Gigli I. Activation of the complement system in patients with porphyrias after irradiation in vivo. *J Clin Invest.* 1984;74(6):1961-1965.
119. Ryan EA. Histochemistry of the skin in erythropoietic protoporphyria. *Br J Dermatol.* 1966;78(10):501-518.
120. Poh-Fitzpatrick MB. The erythropoietic porphyrias. *Dermatol Clin.* 1986;4(2):291-296.
121. Berenson MM, Kimura R, Samowitz W, et al. Protoporphyrin overload in unrestrained rats: biochemical and histopathologic characterization of a new model of protoporphyric hepatopathy. *Int J Exp Pathol.* 1992;73(5):665-673.
122. Bloomer JR. The liver in protoporphyria. *Hepatol.* 1988;8(2):402-407.
123. Bloomer JR, Enriquez R. Evidence that hepatic crystalline deposits in a patient with protoporphyria are composed of protoporphyrin. *Gastroenterology.* 1982;82(3):569-573.
124. Bloomer J, Wang Y, Singhal A, et al. Molecular studies of liver disease in erythropoietic protoporphyria. *J Clin Gastroenterol.* 2005;39(4)(suppl 2):S167-S175.
125. Mathews-Roth MM. Systemic photoprotection. *Dermatol Clin.* 1986;4(2):335-339.
126. Balwani M, Naik H, Anderson KE, et al. Clinical, biochemical, and genetic characterization of North American patients with erythropoietic protoporphyria and X-linked protoporphyria. *JAMA Dermatol.* 2017;153(8):789-796.
127. Schmidt H, Snitker G, Thomsen K, et al. Erythropoietic protoporphyria. A clinical study based on 29 cases in 14 families. *Arch Dermatol.* 1974;110(1):58-64.
128. Poh-Fitzpatrick MB. Human protoporphyria: reduced cutaneous photosensitivity and lower erythrocyte porphyrin levels during pregnancy. *J Am Acad Dermatol.* 1997;36(1):40-43.
129. Balwani M, Doheny D, Bishop DF, et al. Loss-of-function ferrochelatase and gain-of-function erythroid

5-aminolevulinate synthase mutations causing erythropoietic protoporphyria and X-linked protoporphyria in North American patients reveal novel mutations and a high prevalence of X-linked protoporphyria. *Mol Med.* 2013;19:26-35.
130. Holme SA, Worwood M, Anstey AV, et al. Erythropoiesis and iron metabolism in dominant erythropoietic protoporphyria. *Blood.* 2007;110(12):4108-4110.
131. Bossi K, Lee J, Schmeltzer P, et al. Homeostasis of iron and hepcidin in erythropoietic protoporphyria. *Eur J Clin Invest.* 2015;45(10):1032-1041.
132. Risheg H, Chen FP, Bloomer JR. Genotypic determinants of phenotype in North American patients with erythropoietic protoporphyria. *Mol Genet Metab.* 2003;80(1-2):196-206.
133. Turnbull A, Baker H, Vernon-Roberts B, et al. Iron metabolism in porphyria cutanea tarda and in erythropoietic protoporphyria. *Q J Med.* 1973;42:341-355.
134. Rank JM, Carithers R, Bloomer J. Evidence for neurological dysfunction in end-stage protoporphyric liver disease. *Hepatology.* 1993;18(6):1404-1409.
135. Doss MO, Frank M. Hepatobiliary implications and complications in protoporphyria, a 20-year study. *Clin Biochem.* 1989;22(3):223-229.
136. Singer JA, Plaut AG, Kaplan MM. Hepatic failure and death from erythropoietic protoporphyria. *Gastroenterology.* 1978;74(3):588-591.
137. Key NS, Rank JM, Freese D, et al. Hemolytic anemia in protoporphyria: possible precipitating role of liver failure and photic stress. *Am J Hematol.* 1992;39(3):202-207.
138. Wahlin S, Srikanthan N, Hamre B, et al. Protection from phototoxic injury during surgery and endoscopy in erythropoietic protoporphyria. *Liver Transpl.* 2008;14(9):1340-1346.
139. Hastka J, Lasserre JJ, Schwarzbeck A, et al. Zinc protoporphyrin in anemia of chronic disorders. *Blood.* 1993;81(5):1200-1204.
140. Anderson KE, Sassa S, Peterson CM, et al. Increased erythrocyte uroporphyrinogen-I-synthetase, δ-aminolevulinic acid dehydratase and protoporphyrin in hemolytic anemias. *Am J Med.* 1977;63(3):359-364.
141. Gou EW, Balwani M, Bissell DM, et al. Pitfalls in erythrocyte protoporphyrin measurement for diagnosis and monitoring of protoporphyrias. *Clin Chem.* 2015;61(12):1453-1456.
142. Poh-Fitzpatrick MB, DeLeo VA. Rates of plasma porphyrin disappearance in fluorescent vs. red incandescent light exposure. *J Invest Dermatol.* 1977;69(6):510-512.
143. Mathews-Roth MM, Pathak MA, Fitzpatrick TB, et al. Beta carotene therapy for erythropoietic protoporphyria and other photosensitivity diseases. *Arch Dermatol.* 1977;113(9):1229-1232.
144. Minder EI, Schneider-Yin X, Steurer J, et al. A systematic review of treatment options for dermal photosensitivity in erythropoietic protoporphyria. *Cell Mol Biol (Noisy-le-grand).* 2009;55(1):84-97.
145. Mathews-Roth MM, Rosner B. Long-term treatment of erythropoietic protoporphyria with cysteine. *Photodermatol Photoimmunol Photomed.* 2002;18(6):307-309.
146. Langendonk JG, Balwani M, Anderson KE, et al. Afamelanotide for erythropoietic protoporphyria. *N Engl J Med.* 2015;373(1):48-59.
147. Lane AM, McKay JT, Bonkovsky HL. Advances in the management of erythropoietic protoporphyria-role of afamelanotide. *Appl Clin Genet.* 2016;9:179-189.
148. Tu JH, Sheu SL, Teng JM. Novel treatment using cimetidine for erythropoietic protoporphyria in children. *JAMA Dermatol.* 2016;152(11):1258-1261.
149. Langendonk JG, Wilson J. Insufficient evidence of cimetidine benefit in protoporphyria. *JAMA Dermatol.* 2017;153(2):237-237.
150. Bentley DP, Meek EM. Clinical and biochemical improvement following low-dose intravenous iron therapy in a patient with erythropoietic protoporphyria. *Br J Haematol.* 2013;163(2):289-291.
151. Landefeld C, Kentouche K, Gruhn B, et al. X-linked protoporphyria: iron supplementation improves protoporphyrin overload, liver damage and anaemia. *Br J Haematol.* 2016;173(3):482-484.
152. Gordeuk VR, Brittenham GM, Hawkins CW, et al. Iron therapy for hepatic dysfunction in erythropoietic protoporphyria. *Ann Intern Med.* 1986;105(1):27-31.
153. Mercurio MG, Prince G, Weber FL, et al. Terminal hepatic failure in erythropoietic protoporphyria. *J Am Acad Dermatol.* 1993;29(5, pt 2):829-833.
154. Bonkovsky HL, Schned AR. Fatal liver failure in protoporphyria: synergism between ethanol excess and the genetic defect. *Gastroenterology.* 1986;90(1):191-201.
155. Bloomer JR. Pathogenesis and therapy of liver disease in protoporphyria. *Yale J Biol Med.* 1979;52(1):39-48.
156. Kniffen JC. Protoporphyrin removal in intrahepatic porphyrastasis. *Gastroenterology.* 1970;58:1027.
157. Gross U, Frank M, Doss MO. Hepatic complications of erythropoietic protoporphyria. *Photodermatol Photoimmunol Photomed.* 1998;14(2):52-57.
158. Bechtel MA, Bertolone SJ, Hodge SJ. Transfusion therapy in a patient with erythropoietic protoporphyria. *Arch Dermatol.* 1981;117(2):99-101.
159. Van Wijk HJ, Van Hattum J, Delafaille HB, et al. Blood exchange and transfusion therapy for acute cholestasis in protoporphyria. *Dig Dis Sci.* 1988;33(12):1621-1625.
160. McGuire BM, Bonkovsky HL, Carithers RL Jr, et al. Liver transplantation for erythropoietic protoporphyria liver disease. *Liver Transpl.* 2005;11(12):1590-1596.
161. Wahlin S, Stal P, Adam R, et al. Liver transplantation for erythropoietic protoporphyria in Europe. *Liver Transpl.* 2011;17(9):1021-1026.
162. Todd DJ, Callender ME, Mayne EE, et al. Erythropoietic protoporphyria, transfusion therapy and liver disease. *Br J Dermatol.* 1992;127(5):534-537.
163. Nordmann Y. Erythropoietic protoporphyria and hepatic complications. *J Hepatol.* 1992;16(1-2):4-6.
164. Muley SA, Midani HA, Rank JM, et al. Neuropathy in erythropoietic protoporphyrias. *Neurology.* 1998;51(1):262-265.
165. Poh-Fitzpatrick MB, Wang X, Anderson KE, et al. Erythropoietic protoporphyria: Altered phenotype after bone marrow transplantation for myelogenous leukemia in a patient heteroallelic for ferrochelatase gene mutations. *J Am Acad Dermatol.* 2002;46(6):861-866.
166. Rand EB, Bunin N, Cochran W, et al. Sequential liver and bone marrow transplantation for treatment of erythropoietic protoporphyria. *Pediatrics.* 2006;118(6):e1896-e1899.
167. Anderson KE, Bloomer JR, Bonkovsky HL, et al. Recommendations for the diagnosis and treatment of the acute porphyrias. *Ann Intern Med.* 2005;142(6):439-450.
168. Akagi R, Kato N, Inoue R, et al. delta-Aminolevulinate dehydratase (ALAD) porphyria: the first case in

North America with two novel ALAD mutations. *Mol Genet Metab.* 2006;87(4):329-336.
169. Goldberg A, Moore MR, McColl KEL, et al. Porphyrin metabolism and the porphyrias. In: Ledingham DA, Warrell DA, Wetherall DJ, eds. *Oxford Textbook of Medicine*. Oxford: Oxford University Press; 1987:9136.
170. With TK. Hereditary coproporphyria and variegate porphyria in Denmark. *Dan Med Bull.* 1983;30(2): 106-112.
171. Mustajoki P. Variegate porphyria. Twelve years' experience in Finland. *Q J Med.* 1980;49(194):191-203.
172. Eales L, Day RS, Blekkenhorst GH. The clinical and biochemical features of variegate porphyria: an analysis of 300 cases studied at Groote Schuur Hospital, Cape Town. *Int J Biochem.* 1980;12(5-6):837-853.
173. Meyer UA, Schuurmans MM, Lindberg RLP. Acute porphyrias: pathogenesis of neurological manifestations. *Semin Liver Dis.* 1998;18(1):43-52.
174. Grandchamp B, Phung N, Nordmann Y. Homozygous case of hereditary coproporphyria. *Lancet.* 1977;2(8052-8053):1348-1349.
175. Schmitt C, Gouya L, Malonova E, et al. Mutations in human CPO gene predict clinical expression of either hepatic hereditary coproporphyria or erythropoietic harderoporphyria. *Hum Mol Genet*. 2005; 14(20):3089-3098.
176. Podvinec M, Handschin C, Looser R, et al. Identification of the xenosensors regulating human 5-aminolevulinate synthase. *Proc Natl Acad Sci U S A.* 2004;101(24):9127-9132.
177. Lip GYH, McColl KEL, Goldberg A, et al. Smoking and recurrent attacks of acute intermittent porphyria. *Br Med J.* 1991;302(6775):507.
178. Louis CA, Sinclair JF, Wood SG, et al. Synergistic induction of cytochrome-P450 by ethanol and isopentanol in cultures of chick embryo and rat hepatocytes. *Toxicol Appl Pharmacol.* 1993;118(2):169-176.
179. Thunell S, Floderus Y, Henrichson A, et al. Alcoholic beverages in acute porphyria. *J Stud Alcohol.* 1992;53(3):272-276.
180. Andersson C, Bylesjo I, Lithner F. Effects of diabetes mellitus on patients with acute intermittent porphyria. *J Intern Med.* 1999;245(2):193-197.
181. Kauppinen R. Prognosis of acute porphyrias and molecular genetics of acute intermittent porphyria in Finland. Thesis, University of Helskinki; 1992.
182. Milo R, Neuman M, Klein C, et al. Acute intermittent porphyria in pregnancy. *Obstet Gynecol.* 1989;73(3, pt 2): 450-452.
183. Shenhav S, Gemer O, Sassoon E, et al. Acute intermittent porphyria precipitated by hyperemesis and metoclopramide treatment in pregnancy. *Acta Obstet Gynecol Scand.* 1997;76(5):484-485.
184. Handschin C, Lin J, Rhee J, et al. Nutritional regulation of hepatic heme biosynthesis and porphyria through PGC-1alpha. *Cell.* 2005;122(4):505-515.
185. Welland FH, Hellman ES, Gaddis EM, et al. Factors affecting the excretion of porphyrin precursors by patients with acute intermittent porphyria. I. The effect of diet. *Metabolism.* 1964;13:232-250.
186. Thaler MM, Dawber NH. Stimulation of bilirubin formation in liver of newborn rats by fasting and glucagon. *Gastroenterology.* 1977;72(2):312-315.
187. Blake D, McManus J, Cronin V, et al. Fecal coproporphyrin isomers in hereditary coproporphyria. *Clin Chem.* 1992;38(1):96-100.
188. Longas MO, Poh-Fitzpatrick MB. A tightly bound protein-porphyrin complex isolated from the plasma of a patient with variegate porphyria. *Clin Chim Acta.* 1982;118(2-3):219-228.
189. Hift RJ, Davidson BP, van der Hooft C, et al. Plasma fluorescence scanning and fecal porphyrin analysis for the diagnosis of variegate porphyria: precise determination of sensitivity and specificity with detection of protoporphyrinogen oxidase mutations as a reference standard. *Clin Chem.* 2004;50(5):915-923.
190. Nordmann Y, Grandchamp B, De Verneuil H, et al. Harderoporphyria: a variant hereditary coproporphyria. *J Clin Invest.* 1983;72(3):1139-1149.
191. Wahlin S, Harper P, Sardh E, et al. Combined liver and kidney transplantation in acute intermittent porphyria. *Transpl Int.* 2010;23(6):e18-e21.
192. Bonkowsky HL, Tschudy DP. Hazard of propranolol in treatment of acute porphyria (letter). *Br Med J.* 1974;4(5935):47-48.
193. Bonkowsky HL, Sinclair PR, Emery S, et al. Seizure management in acute hepatic porphyria: risks of valproate and clonazepam. *Neurology.* 1980;30(6):588-592.
194. Larson AW, Wasserstrom WR, Felsher BF, et al. Posttraumatic epilepsy and acute intermittent porphyria: effects of phenytoin, carbamazepine, and clonazepam. *Neurology.* 1978;28(8):824-828.
195. Mustajoki P, Nordmann Y. Early administration of heme arginate for acute porphyric attacks. *Arch Intern Med.* 1993;153(17):2004-2008.
196. Tenhunen R, Mustajoki P. Acute porphyria: treatment with heme. *Semin Liver Dis.* 1998;18(1):53-55.
197. Bonkovsky HL, Healey JF, Lourie AN, et al. Intravenous heme-albumin in acute intermittent porphyria: evidence for repletion of hepatic hemoproteins and regulatory heme pools. *Am J Gastroenterol.* 1991;86(8): 1050-1056.
198. Harper P, Wahlin S. Treatment options in acute porphyria, porphyria cutanea tarda, and erythropoietic protoporphyria. *Curr Treat Options Gastroenterol.* 2007;10(6):444-455.
199. Anderson KE, Bonkovsky HL, Bloomer JR, et al. Reconstitution of hematin for intravenous infusion. *Ann Intern Med.* 2006;144(7):537-538.
200. Green D, Reynolds N, Klein J, et al. The inactivation of hemostatic factors by hematin. *J Lab Clin Med.* 1983;102(3):361-369.
201. Jones RL. Hematin-derived anticoagulant. Generation in vitro and in vivo. *J Exp Med.* 1986;163(3):724-439.
202. Daimon M, Susa S, Igarashi M, et al. Administration of heme arginate, but not hematin, caused anaphylactic shock. *Am J Med.* 2001;110(3):240.
203. Khanderia U. Circulatory collapse associated with hemin therapy for acute intermittent porphyria. *Clin Pharm.* 1986;5(8):690-692.
204. Marsden JT, Guppy S, Stein P, et al. Audit of the use of regular haem arginate infusions in patients with acute porphyria to prevent recurrent symptoms. *JIMD Rep.* 2015;22:57-65.
205. Anderson KE, Collins S. Open-label study of hemin for acute porphyria: clinical practice implications. *Am J Med.* 2006;119(9):801.e19-801.e24.

Chapter 125 :: Amyloidosis

:: Peter D. Gorevic & Robert G. Phelps

AT-A-GLANCE

- There are 36 types of amyloid disease, defined by the subunit proteins that constitute the fibrils in these disorders, 11 of which involve the skin.
- Cutaneous amyloidosis may reflect a systemic form of amyloid, or be localized to the skin and/or mucous membranes.
- Precursors of fibril subunit proteins may circulate in blood and/or be synthesized locally; they may be wildtype or mutant molecules that can be typed by DNA sequencing.
- Amyloid in skin may be sampled by lesional biopsy or abdominal fat pad aspiration or biopsy; it is characterized by metachromasia and apple-green birefringence after staining with Congo red, or yellow-green fluorescence after staining with thioflavin T.
- Deposits may localize to the papillary dermis (macular and lichen amyloidosis) or be characterized by congophilic angiopathy and involvement of adnexal structures (nodular amyloidosis).
- Amyloid can be typed by immunohistochemistry, immunoelectron microscopy, and/or laser capture mass spectroscopy followed by protein sequencing.
- Treatment of amyloid diseases is determined by the fibril subunit protein, associated clinical manifestations, and whether disease is systemic or localized.
- Treatment strategies include suppression of precursor protein, disruption of oligomers and/or fibrils, and/or enhanced clearance of deposits.
- Localized cutaneous amyloidoses present specific challenges and opportunities for diagnosis and therapy because of the accessibility of skin lesions, association in some cases with defined genetic abnormalities, and multifactorial etiologies for itch in pathogenesis.

DEFINITION

Amyloid is a pathologic entity characterized by the presence of mostly extracellular homogenous hyaline material that is typically metachromatic, as seen by color changes of dyes such as Congo red (actually orange in solution), crystal violet (which yields a deep red-purple color on a blue background), or sodium sulfate Alcian blue (reacts with proteoglycan in amyloid deposits to yield a green color). Other stains that can be used include cotton dyes such as Sirius red (a polyazo dye) and Pagoda red. Amyloid is further defined in tissue section as yielding apple-green birefringence by polarizing microscopy after staining with Congo red, and as having typical yellow-green fluorescence after staining with thioflavin T. Ultrastructurally, the main constituents of deposits are fibrils which are 10 to 15 nm in diameter, and variable in length, that accumulate in the extracellular space, and can be visualized by electron microscopy.

A second feature of all amyloid deposits is the presence of a pentraxin, serum amyloid P-component (SAP). In addition to the fibril and SAP, deposits are enriched in heparan sulfate proteoglycan, as well as a number of proteins that have been identified by extraction of amyloid from tissue. These other substances include several apolipoproteins, notably apoE, apoJ, and apoA4.[1] Thus the diagnosis of amyloidosis is rigorously defined by the appearance, tinctorial properties and ultrastructural features of biopsied material (Table 125-1).

AMYLOID DISEASES RELEVANT TO DERMATOLOGY

Different forms of amyloid disease are distinguished by the subunit proteins that constitute the fibril, 36 of which have been described, each associated with distinct clinical entities,[2] 11 known to involve the skin and/or have cutaneous manifestations (Table 125-2). The current list of 36 subunit proteins includes 6 different apolipoproteins, notably the high-density lipoprotein-associated serum amyloid A (apoSAA), an acute-phase reactant that forms the amyloid in reactive or secondary (AA) amyloidosis, and 2 members of the immunoglobulin gene superfamily, immunoglobulin light chain (AL), the major constituent of primary or myeloma-associated amyloidosis, and β_2-microglobulin ($A\beta_2m$), the subunit protein in patients on longstanding hemodialysis or chronic peritoneal dialysis (dialysis amyloidosis). Fibril subunit proteins arise from soluble precursors, most of which can be found in blood, but which also may be synthesized by cells contiguous to the amyloid deposits. They may be wildtype (WT) (ie, have the same amino acid sequence as the physiologic precursor), but in several forms of amyloidosis they have been found to have single nucleotide and amino acid substitutions, corresponding to point mutations in the DNA sequence. These mutations characterize familial forms of amyloidosis, in which multiple members of a kindred are affected by distinct organ-specific clinical syndromes, but may

TABLE 125-1
Histologic Criteria for the Definition of Amyloid

- Homogenous-hyaline
- Mostly extracellular
- Typical 10 to 15 nm fibrils by electron microscopy
- Metachromasia
- Congo red birefringence
- Thioflavin T yellow-green fluorescence
- Multiple chemical types

also occur in apparently sporadic cases of amyloidosis. More than 500 different mutations in subunit proteins, or in proteins strongly associated with several forms of amyloidosis, have been identified, providing diagnostic genetic markers for several important forms of amyloid disease.[3]

PATHOGENESIS

Following synthesis in the cell of origin, precursor proteins may adopt a number of configurations, some of which may be normal folding intermediates important for intracellular processing and secretion. Cellular factors that contribute to protein misfolding include membrane interactions, altered cell chemistry, post-translational modifications, crowding, and pathogenic mutations; in both the intracellular and extracellular milieu, acidification, temperature, protein concentration, and oxidative stress may be important.[4]

Prior to the formation of amyloid fibrils, precursor proteins may adopt the configuration of amorphous aggregates, oligomers, and other intermediates, which may be demonstrable in vitro, and in several cases in vivo. Aggregates have not yet accumulated cofactors, such as SAP and heparan sulfate proteoglans, but appear to be important in mediating distinct functional abnormalities that are demonstrable in association with, or preceding, amyloid deposition, as well as inducing apoptosis and cell death. In addition, several precursor proteins undergo proteolysis as part of the conversion to insoluble fibrils, with specific cleavage products being the main form of subunit protein retrieved from deposits. However, the precursor–product relationships of amorphous aggregates, oligomers, and alternative fibrillar states have yet to be fully defined (Fig. 125-1).[1,4]

SYSTEMIC FORMS OF AMYLOIDOSIS

The majority of patients seen in tertiary care centers have systemic forms of amyloidosis, most commonly AL, AA, and amyloidosis caused by transthyretin (ATTR), a thyroid transport protein also known as prealbumin. In a 2013 series from the United Kingdom, 65% of patients with systemic amyloid were AL, 18% AA, 7% WT ATTR, and 10% mutant ATTR.[5] In AL, high levels of a monoclonal immunoglobulin (Ig) light chain are produced by an aberrant plasma cell population, associated with frank or smoldering multiple myeloma in 10% to 20%. Sustained elevated levels of SAA are triggered by proinflammatory cytokines, notably interleukin (IL)-6, which may be a result of chronic infections or rheumatic or autoinflammatory diseases. In ATTR, the conversion of circulating WT or mutant TTR may be reflected in relatively low levels of precursor protein as a result of a "sink" effect in which precursor may deposit onto existing amyloid. Organ system involvement for AL is clinically diverse, with cardiac, renal and neurologic disease being particularly important; in AA amyloidosis, approximately 80% renal involvement occurs, and is the cause of morbidity and mortality, with lesser

TABLE 125-2
Nomenclature for Amyloid Fibril Proteins with Known Cutaneous Involvement, Including Precursor Proteins, Major Organ System Disease, and Skin Manifestations

FIBRIL PROTEIN	PRECURSOR PROTEIN	TARGET ORGANS	CUTANEOUS INVOLVEMENT
AL	Immunoglobulin light chain	All except CNS	Pinch/postproctoscopic purpura; nodules; waxy plaques; congophilic angiography; macroglossia
Aβ_2M	β_2-Microglobulin	Musculoskeletal	Subcutaneous and lingual nodules
AA	Serum amyloid A	All except CNS	Fat pad aspiration/biopsy
ATTR	Transthyretin	Nervous system; heart; vitreous	Periorbital purpura; nodules; fat pad aspiration/biopsy
AApoAI	Apolipoprotein AI	Heart; liver; kidney; nervous system	C-terminal variants affect larynx and skin; yellow and maculopapular squamous lesions
ALys	Lysozyme	Kidney	Variants may present with sicca, have adenopathy, petechial rash/bruising
AGel	Gelsolin	Cornea; peripheral nervous system	Cutis laxa; pruritus; ecchymoses; alopecia
ACys	Cystatin C	Cerebral hemorrhages	Asymptomatic
AGal7	Galectin 7	Localized cutaneous	Lichen/macular amyloidosis
AIns	Insulin	Iatrogenic	Injection site (insulin pump)
AEnf	Enfuvirtide	Iatrogenic (HIV medicine)	Local injection site

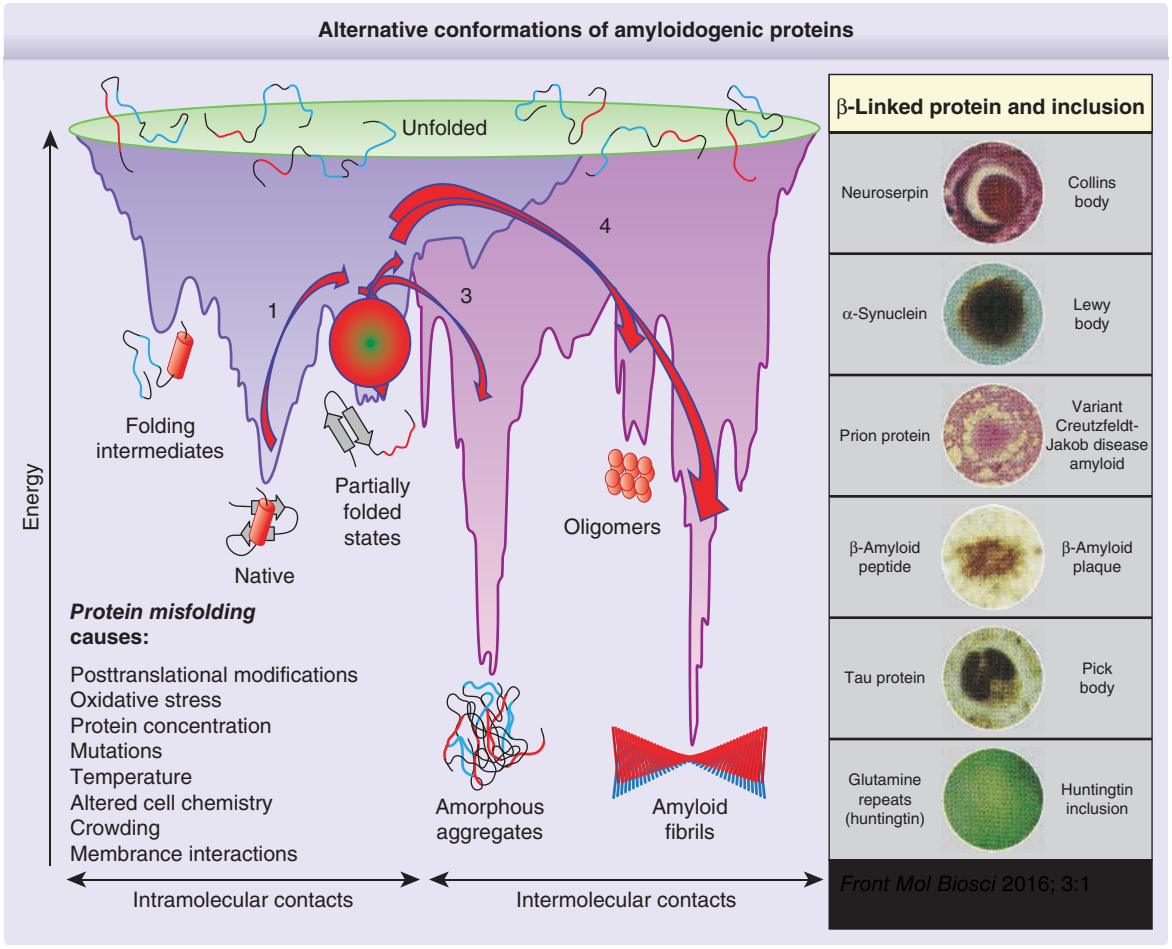

Figure 125-1 Alternative conformations of amyloidogenic proteins, including amorphous aggregates, oligomers and fibrils, and factors implicated in fibrillogenesis. Amyloidosis within the spectrum of aggregation disorders, several of which are implicated in neurodegeneration. (Adapted by permission from Springer Nature: Hartl FU, Hayer-Hartl M. Converging concepts of protein folding in vitro and in vivo. *Nat Struct Mol Biol*. 2009;16(6):574-81. Copyright © 2009.)

involvement of the GI tract (20%) and heart; ATTR may present as overlapping syndromes of neuropathy, cardiomyopathy, GI, vitreous, and occasional leptomeningeal amyloidosis.[6]

Less-common forms of systemic amyloidosis include several heredofamilial syndromes that have been prominently associated with nephropathic amyloidosis (apoA2, apoCII and apoCIII, fibrinogen, lysozyme), and lattice dystrophy, cutis laxa, and cranial neuropathy (gelsolin).[3]

Although dominant organ involvement may define clinical presentation in each of the systemic amyloidoses, there is often diffuse involvement that may become more apparent as disease progresses, or is apparent at postmortem. Organ-dominant disease may significantly influence the prognosis of patients with AL, with cardiac involvement accounting for a 1-year mortality of approximately 45% and a median survival time of 6 to 14 months compared to a subset of patients with soft-tissue (eg, macroglossia, submandibular swelling), bone, and joint disease, among whom 2- to 3-year survivals are not uncommon. In AA, most patients have glomerular disease, presenting as proteinuria/nephrotic syndrome; however, there also may be interstitial and vascular amyloid, which may present as an elevation in creatinine, or renal insufficiency, without significant proteinuria. WT and mutant ATTR may present as carpal tunnel syndrome with amyloid retrievable from the flexor retinaculum in cases that have been available for study. Although most mutant ATTR are associated with neuropathy, approximately 50% also have cardiomyopathy, which may dominate the clinical presentation in patients with specific mutations associated with late-onset disease.

SKIN DISEASE IN SYSTEMIC AMYLOIDS

All forms of systemic amyloid may be associated with occult or overt cutaneous involvement, again with variable clinical presentations. Overt presentations include pinch and periorbital purpura in approximately 10% of patients with AL (Fig. 125-2) and a smaller number with ATTR. Macroglossia, lingual nodules, or lateral ridging, are unique to AL (Fig. 125-3) and $A\beta_2m$.

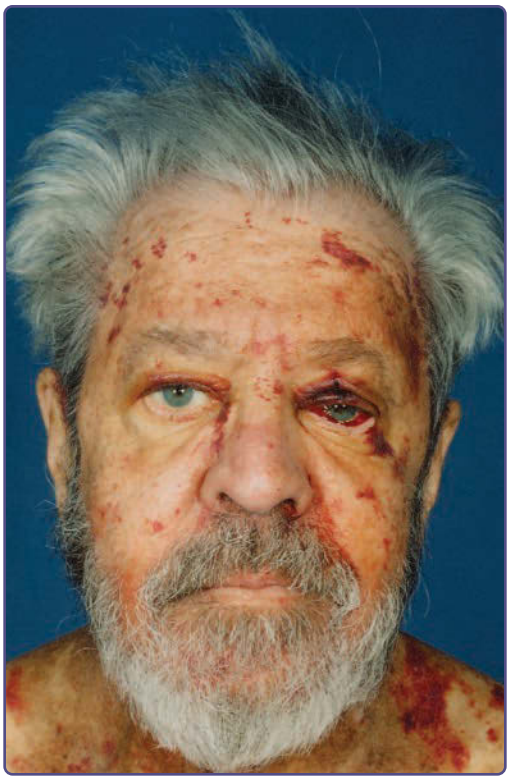

Figure 125-2 Pinch, periorbital and facial purpura in a patient with known systemic AL amyloidosis. Patient grew a beard to avoid the trauma/purpura associated with shaving.

Dermatologic signs may be found in as many as one-third of patients with AL amyloid. Almost any site has been described, including face, neck and fingers. Sclerodermoid and bullous lesions may be found rarely[7]; hair and nail changes can also occur. In AL, fissured masses may be present focally or diffusely in the papillary or reticular dermis. A common and often diagnostic

Figure 125-3 Macroglossia with lateral ridging caused by the impression of adjacent teeth in a patient with known systemic AL amyloidosis. Note the perioral macules with a waxy appearance also caused by cutaneous amyloid.

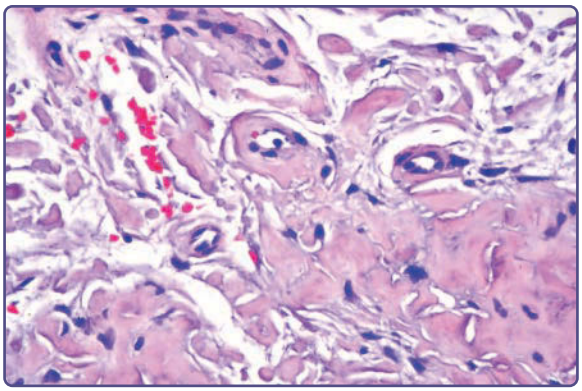

Figure 125-4 AL amyloidosis showing deposits in the dermis and walls of capillaries (hematoxylin and eosin, ×10 magnification).

feature is the presence of amyloid in the walls of small or medium-sized blood vessels (Fig. 125-4), causing vascular wall weakening and hemorrhage.

Overt cutaneous involvement is rare in AA amyloidosis; however this form of amyloid may complicate inflammatory cutaneous disorders, most notably in patients with severe inflammation complicating Hidradenitis suppurativa, pyoderma gangrenosum/inflammatory bowel disease, and some patients with severe and uncontrolled psoriatic arthritis. AA amyloidosis may also complicate autoinflammatory diseases that have distinctive skin lesions such as erysipelas-like erythema (familial Mediterranean fever), cold urticaria (some of the cryopyrinopathies), erythematous macules and papules (hyper-IgD syndrome), and migratory edematous patches or periorbital edema (tumor necrosis factor receptor-associated periodic syndrome).

Cutaneous manifestations may occasionally be found in the hereditary forms of amyloid. ATTR may be associated with eyelid and peripheral ecchymoses, atrophic scars, bullous lesions, thickened skin, and xerosis[8]; cutis laxa is a major manifestation of AGel[9]; yellow and maculopapular squamous rashes may complicate carboxyterminal variants of AApoAI[10]; and petechial rashes/easy bruising have been described in some variants of ALys[11]; asymptomatic skin deposition has been found for ALys and ACys[12] (see Table 125-2).

EPIDEMIOLOGY OF THE SYSTEMIC AMYLOIDS

The overall incidence of systemic amyloid is 5 to 12 cases per million-person years in large series reported from the Mayo Clinic, the United Kingdom amyloidosis referral center, and Scandinavia.[5,13] During the 20th century, the percent contribution of AA amyloid resulting from chronic infection decreased, correlating with an increased representation of associated rheumatologic, inflammatory bowel and autoinflammatory diseases such as familial Mediterranean

fever. There are an estimated 5000 to 10,000 cases of AA amyloid in Europe and North America. Approximately 100,000 persons are affected by familial Mediterranean fever worldwide; in Turkey, Syria, Egypt, and Israel, it is a common cause of AA, and is responsible for a significant percent of renal disease caused by amyloidosis. Each year, 1275 to 3200 new cases of AL amyloid are reported, giving an estimate of 15,000 patients in the United States and Europe. The overall incidence of familial amyloid polyneuropathy caused by ATTR is 0.3 cases per year per million persons, or 5000 to 10,000 cases worldwide. However, there are wide variations in incidence for the most common Met30 ATTR mutation, which is endemic in northern Portugal and the north of Sweden. The Ile122 ATTR mutation is carried by 4% of the African American and African Caribbean populations, and in parts of west Africa.[3,13,14]

LOCALIZED AMYLOIDOSIS

Excluding CNS amyloid associated with neurodegenerative diseases, localized forms of amyloid account for approximately 10% of patients seen in referral centers. They include nasopharyngeal (laryngeal), ocular, genitourinary, and pulmonary amyloidoses, as well as amyloidomas that may occur in a variety of locations. Symptoms reflect the specific organ system (eg, hoarseness in laryngeal amyloid, gross hematuria in genitourinary amyloid, and subconjunctival masses, often mistaken for lymphomas). The large majority of cases of localized amyloid that have been characterized biochemically appear to be AL, with evidence in some cases that the aggregates are being synthesized by clonal contiguous plasma cells. Even though patients are routinely evaluated for systemic involvement, disease may remain stable or only extend locally even with prolonged periods of observation, with cures reported if full resection is feasible.[15]

CUTANEOUS AMYLOIDOSES[16]

Table 125-3 lists common cutaneous amyloidoses and their characteristics.

Cutaneous amyloid diseases may have heterogenous manifestations, depending on the location of amyloid deposition within the dermis or epidermis. Localized cutaneous amyloidoses are often restricted to the papillary dermis, whereas in systemic disorders, the subpapillary layers, dermal appendages and blood vessels are frequently involved.[17] Vascular involvement may be apparent as congophilic angiopathy, causing petechiae, purpura, or ecchymoses, which typically occur over the upper chest wall, or in a periorbital distribution distinct from that seen in purpura from other causes (eg, vasculitis) (see Fig. 125-2). Involvement of the upper dermis may cause thickening, apparent as waxy papules and plaques, or nodules (see Fig. 125-3). Nodules may be single or multiple in systemic or localized AL amyloid, sometimes growing to a large size[18] if untreated (Fig. 125-5), and can also involve the face. Three major types of primary cutaneous amyloidosis have been described: macular (~35%), papular/lichen (~35%), and mixed/biphasic (~15%),[19] in addition to rarer disease entities.

MACULAR AMYLOIDOSIS

Macular amyloidosis commonly presents in the interscapular region as a pigmented patch of varying size. It can occur in other sites, such as the extensor surface of the arms, thighs, and shins. Typical is a rippled salt-and-pepper appearance with alternating hyperpigmentation and hypopigmentation (Fig. 125-6). It is more common in women and patients with a darker complexion. The pathology of macular amyloidosis is subtle and easily missed without clinical correlation.

TABLE 125-3
Common Cutaneous Amyloidoses

	EPIDEMIOLOGY	COMMONLY AFFECTED SITES	CLINICAL APPEARANCE	PATHOLOGIC FEATURES
Macular amyloidosis	~35% of cutaneous amyloidosis cases; women of darker complexion more commonly affected	Interscapular region, extensor surfaces of arms, thighs, and shins	"Salt-and-pepper" appearance with alternating hyper- and hypopigmentation	Mild epidermal hyperkeratosis; collections of amyloid "corpuscles" within papillary dermis; melanin-containing histiocytes encircle the deposits
Lichen amyloidosis	~35% of cutaneous amyloidosis; most common subtype; men in their fifth to sixth decades are more commonly affected	Shins and forearms, occasionally upper back	Linear rows of firm, pigmented, grouped, hyperkeratotic papules that can evolve into plaques	Epidermis is acanthotic and papillomatous with basal layer hyperpigmentation and elongated rete ridges; small collections of amphophilic material in papillary dermis surrounded by melanophages
Biphasic cutaneous amyloidosis	~15% of cases	Characteristics of both macular and lichen amyloidosis	Overlapping clinical features	Overlapping pathologic features

Figure 125-5 Multiple large and confluent nodules developed on the shin of a patient with nodular amyloidosis, noting the site of biopsy shown in Fig. 125-4. Followed over several years, the patient had no indication of systemic AL amyloid or plasma cell dyscrasia on repeated evaluations.

Within the papillary dermis are small collections of amyloid globules, or "corpuscles." These can be irregularly scattered and not found in every rete. A useful clue (as in lichen amyloidosis) is the presence of rare

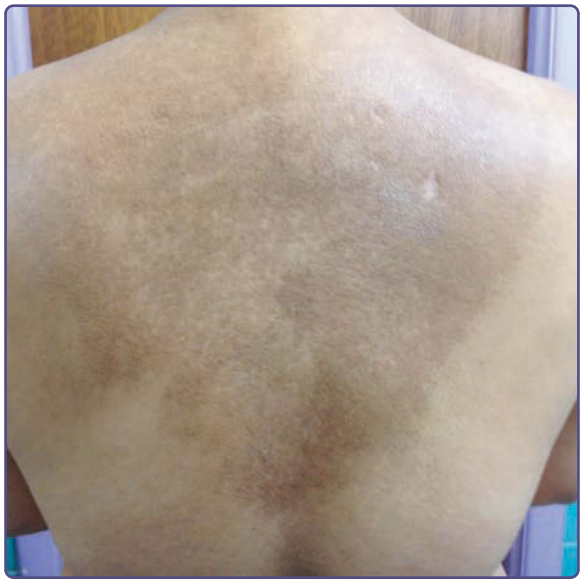

Figure 125-6 Interscapular area of a patient showing edge-shaped rippled hypopigmentation and hyperpigmentation consistent with macular amyloidosis.

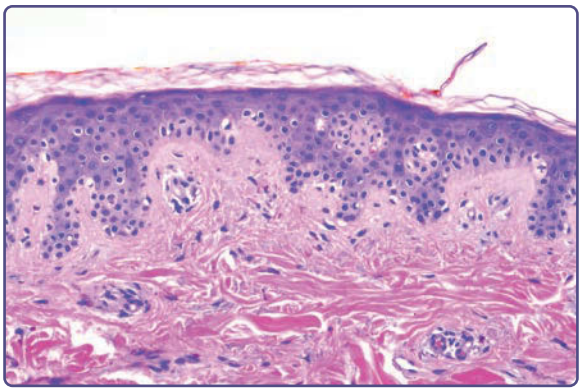

Figure 125-7 Dermis of a patient with macular amyloidosis showing scattered melanin and rare foci of amyloid (hematoxylin and eosin, ×20 magnification).

melanin-containing histiocytes encircling these deposits. Often, special stains are necessary to demonstrate the amyloid. The extent of epidermal changes is minimal with only mild hyperkeratosis (Fig. 125-7).

LICHEN AMYLOIDOSIS

Lichen amyloidosis is the most common type of cutaneous amyloidosis. It usually presents later in life, predominantly in the fifth and sixth decades, and is more common in men and patients with a higher Fitzpatrick skin type. The initial symptom of this disorder is intense pruritus that may improve with sun exposure and worsen during periods of stress. Hyperpigmented lesions are presumed to be secondary to scratching. Clinically, lesions often occur on the shins and forearms as linear rows of firm pigmented grouped hyperkeratotic papules that can evolve into large plaques (Fig. 125-8); the upper back also can be involved. As a result of the intense pruritus, the epidermis is often acanthotic and papillomatous with a compact horn; hyperkeratosis, hyperpigmentation of basal keratinocytes and elongation of rete ridges is typical. Basal cell vacuolar changes may occur with intraepidermal cytoid bodies. Within or adjacent to the lesion, changes of lichen simplex chronicus may occur. Within the broadened papillary dermis, there are small collections of amphophilic material often surrounded by melanophages (macrophages with engulfed melanin) (Figs. 125-9 and 125-10).

BIPHASIC CUTANEOUS AMYLOIDOSIS

Biphasic cutaneous amyloidosis refers to the concurrent presence of macular amyloidosis and lichen amyloidosis. This entity may also exist as a form in combination with blisters and poikilodermic skin lesions.[19]

Figure 125-8 Linear keratotic papules on the shin characteristic for lichen amyloidosis.

VARIANT FORMS OF LOCALIZED CUTANEOUS AMYLOIDOSIS

- Towel-associated amyloidosis induced by prolonged contact with nylon towels.[20]
- Anosacral amyloidosis has been described mainly in Chinese and Japanese patients presenting with brownish patches of plaques in the anosacral region. It is often associated with lichenification, and most patients report pruritus. Amyloid deposits are found in the papillary dermis with pigment incontinence.[21]
- Notalgia paresthetica amyloidosis isolated sensory neuropathy that typically occurs on the back may be associated with amyloid, likely resulting from prolonged pruritus and scratching.[22]
- Friction melanosis or amyloidosis prolonged contact with sponges, towels, plant sticks and leaves. In the opinion of the authors and others, these most likely represent variants of macular or lichen amyloidosis, with a similar pathology[23,24]
- Lichen amyloidosis of the auricular concha hyperpigmentation of the bowl of the ear; likely a variant of lichen amyloidosis.[25]

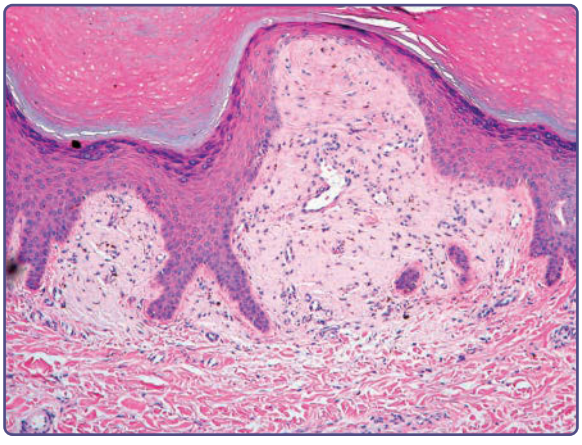

Figure 125-9 Beneath an acanthotic and papillomatous epidermis, a widened dermal papillae contains amyloid globules (hematoxylin and eosin, ×4 magnification).

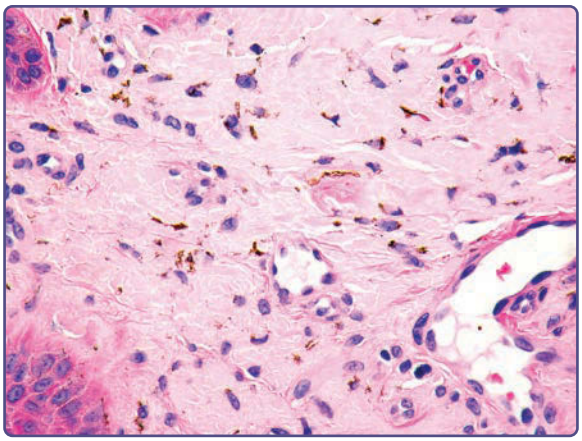

Figure 125-10 Characteristic appearance of amyloid: fissured small globules in the dermis, surrounded by melanophages, in lichen amyloidosis (hematoxylin and eosin, ×20 magnification).

NODULAR AMYLOIDOSIS

Patients present with 1 or more deep-seated lesions that have a waxy or nodular appearance. They can appear as papules, nodules, or plaques (see Fig. 125-5). Common sites include the feet and trunk.[26] Deposition may occur as discrete amorphous areas between collagen bundles. Nodular amyloidosis may be unique to the skin, although vascular involvement is common (Fig. 125-11). AL is the amyloid type of the large majority of cases that have been characterized biochemically, and the presence of monotypic plasma cells contiguous to nodules has suggested local synthesis (Fig. 125-12); nevertheless, followup for the development of a plasma cell dyscrasia or lymphoproliferative disease is indicated for these patients. In addition, up to 25% of nodular amyloidosis may be associated with primary Sjögren syndrome, a disease in which there may be an increased incidence of non-Hodgkin lymphoma of mucosa-associated lymphoid tissue.[27]

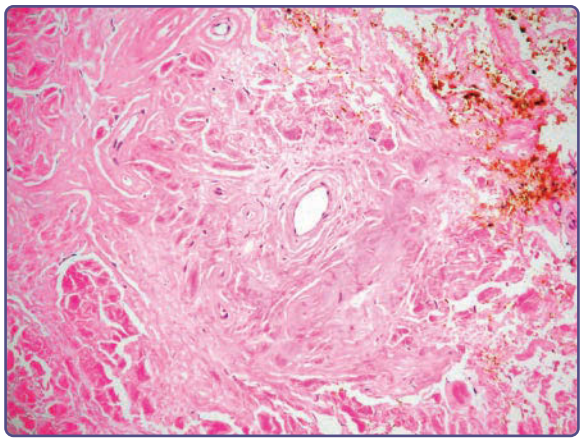

Figure 125-11 Diffuse deposits of amyloid completely replacing the dermis and surrounding blood vessels in nodular amyloidosis (hematoxylin and eosin, ×4 magnification).

Cutaneous amyloidomas of β_2-microglobulin have also rarely been described in patients with dialysis amyloidosis.[28]

AMYLOID ADJACENT TO TUMORS

Although not evident clinically, it is not uncommon to find collections of amyloid adjacent to keratocytic tumors such as basal cell carcinoma, Bowen disease, squamous cell carcinoma, or associated with more benign lesions such as seborrheic or actinic keratoses. Between 66% and 77% of basal cell carcinomas, particularly the nodular type, have been reported to have amyloid deposits within the tumor stroma.[29,30]

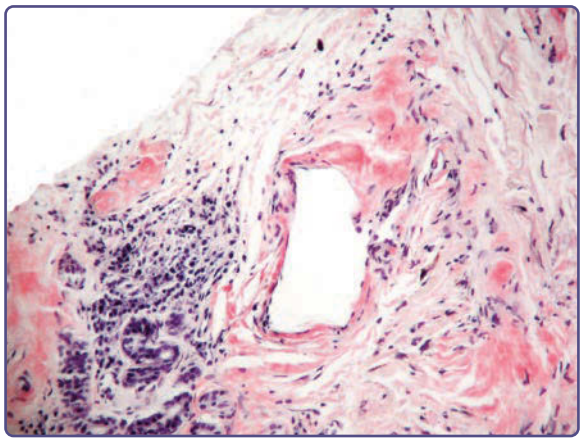

Figure 125-12 Small collection of plasma cells adjacent to nodular amyloid (Congo red, ×10 magnification). Immunohistology may reveal the same light chain in the amyloid as is produced by the adjacent plasma cells.

CUTIS LAXA IN FAMILIAL AMYLOID CAUSED BY MUTANT GELSOLIN

Originally described in Finland as Meretoja syndrome, the gelsolin mutation has a worldwide distribution and manifests as lattice corneal dystrophy, Type 4, cranial and peripheral neuropathies, and, in some families, prominent renal involvement. Cutis laxa starts on the face, usually in the fifth decade of life, and is apparent as premature aging, but then becomes more generalized. The consequences of skin atrophy may be xerosis, easy bruising with minor trauma, loss of body and scalp hair and occasional lichen amyloidosis. Gelsolin amyloid tends to deposit adjacent to basement structures, including the subdermis and eccrine sweat glands, in dermal blood vessels, and between collagen and elastic fibers.[9]

TRANSTHYRETIN AMYLOIDOSIS

Amyloid can be found in the walls of small blood vessels, freely in the dermis as small fissured collections, and diffusely in adipose tissue between adipocytes (Fig. 125-13).[8]

INJECTION-SITE AMYLOIDOSES

Localized forms of amyloid that result from therapeutics with amyloidogenic propensity have been found in association with insulin pumps and with the use of

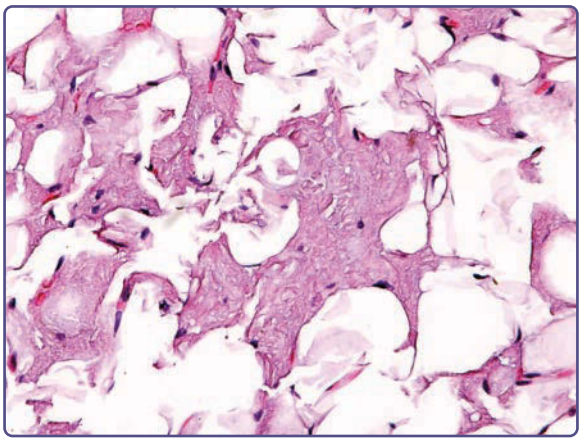

Figure 125-13 Transthyretin amyloid, late stage, apparent on abdominal fat pad biopsy, with fissured masses of amyloid replacing and surrounding adipocytes (hematoxylin and eosin, ×4 magnification).

Figure 125-14 Spotted hypopigmentation on a hyperpigmented background in a patient with amyloidosis cutis dyschromica.

enfuvirtide (Fuzeon). Enfuvirtide is a second-line antiretroviral agent used in patients with multidrug resistance to HIV. It comes in a form that is reconstituted for subcutaneous injection, which may result in large, red-yellow, subcutaneous nodules at the sites of injection. Biochemical characterization of these amyloids has been carried out by mass spectroscopy and sequence analysis, and fibrillogenesis demonstrated in vitro.[31]

AMYLOIDOSIS CUTIS DYSCHROMICA

Amyloidosis cutis dyschromica is a rare condition in which patients develop progressive diffuse hyperpigmentation and hypopigmentation and atrophy (Fig. 125-14). It usually has no other associations, though occasional patients have neurologic changes, or signs and symptoms consistent with connective tissue disease. Pathogenesis is unknown, although photosensitivity has been implicated. Amyloid is usually localized within the papillary dermis, and stains with antikeratin antibodies.[32,33]

EPIDEMIOLOGY OF CUTANEOUS AMYLOIDOSES

Macular amyloidosis has a high incidence in Asia, the Middle East, and South America, but is rarely seen in Europe and North America. Macular lesions predominate in studies from Indonesia, Turkey, and India, although papular lesions were more common in one study from Kuala Lumpur. The highest incidence has been reported from southern China and Taiwan, and in most series, the female predominance is overwhelming. Familial cases are estimated to account for up to 10% overall, and. have been associated with specific gene defects, including mutations in the oncostatin M receptor (OSMR), interleukin-31 receptor A (IL31RA), and the RET protooncogene.[17]

Cutaneous lichen amyloidosis defines a variant of the multiple endocrine neoplasia 2A syndrome, which is primarily (~95%) associated with medullary thyroid cancer (MTC), and less commonly with pheochromocytoma (30% to 50%) or primary hyperparathyroidism (20% to 30%) and mutations in the RET (rearranged during transfection) protooncogene, which causes constitutive activation of the transmembrane tyrosine kinase receptor. In this syndrome, lichen amyloidosis may occur in childhood before MTC, with most reported cases being the codon 634 mutations, which is estimated to give a 30% likelihood of developing lichen amyloidosis, with 77% affected individuals being women.[34] In one Chinese family with MTC associated with cutaneous amyloidosis, disease was associated with a RET S891A mutation coexisting with a novel OSMR variant, G513D, in 3 family members, with clinical data suggesting a synergism between the 2 mutations that may be driving the clinical phenotype.[35]

GENETICS AND PRURITUS IN CUTANEOUS AMYLOIDOSIS

Recent studies have identified receptors in skin additional to those responsible for histamine effects, including the Mas-related G-protein–coupled receptors, and the transient receptor potential vanilloid Type 1, some of which have been identified in sensory neurons and may respond to histamine, heat, or capsaicin.[36] Particular interest has been directed to OSMR, which encodes OSMRb, a component of both the OSM Type II receptor and the IL-31 receptor. IL-31 has been implicated in pruritus associated with atopic dermatitis, prurigo nodularis and cutaneous T-cell lymphoma (Sézary syndrome).[37] Thirteen heterozygous mutations in OSMRb have been described in association with familial primary cutaneous amyloidosis, most in the extracellular fibronectin III repeat domains central to receptor dimerization with gp-130 (IL-6) or IL-31RA. One heterozygous missense mutation in IL-31RA also has been reported in association with familial lichen amyloidosis.[38] Lesional skin was found to have increased apoptosis of keratinocytes, epidermal hyperinnervation, cytokeratin-5 specific antibody reactivity, increased epidermal expression of IL-31 receptors, and elevated tissue/serum IL-31 levels.[39,40]

Although keratinocyte apoptosis appears to be a central event in the pathogenesis of lichen amyloidosis, and cytokeratin immunohistology a valuable adjunct to diagnosis, recent studies provide evidence that the amyloid fibrils in this disorder may be attributed to subsequences of galectin 7 (Gal7). Early extraction studies yielded codepositing keratin epitopes, as well as P-component, actin, and apoE (enriched in apoE4 in 2 studies), and Gal7, results which could

be confirmed by immunohistology[17,41]; however, only Gal7 was found to bind thioflavin T. This protein is one of a family of β-galactoside–binding proteins, only expressed in stratified epithelia, particularly abundant in the stratum spinosum, through which postmitotic keratinocytes move from the basal layer of the epithelium and transform into flattened, enucleated cells connected by tight junctions that secrete keratins to the extracellular matrix; it is markedly induced during keratinocyte apoptosis. Subsequences of Gal7 were found to be fibrillogenic in vitro, corresponding to fragments generated by enzymes known to be active during apoptosis, and modulated by coassociated actin.[42] The exact relationship of these findings to keratinocyte apoptosis and the clinical symptoms of itch are active areas of investigation.

AN APPROACH TO THE DIAGNOSIS OF CUTANEOUS AMYLOIDOSIS

Table 125-4 outlines the diagnosis of patients with known or suspected cutaneous amyloidosis.

INITIAL EVALUATION

Patients with cutaneous amyloidosis may present to dermatologists for evaluation, or as referrals from specialists who suspect amyloid involving the skin. The specialist referral might be an individual in whom the diagnosis of systemic amyloid is suspected or known, and in whom skin lesions are to be examined and possibly studied pathologically; patients presenting to a dermatologist might include patients with cutaneous findings that include macular, lichen, or nodular amyloid in the differential diagnosis (Table 125-5).

Initial evaluation should include a cataloging of comorbid medical conditions, such as carpal tunnel syndrome or other forms of neuropathy, enquiry regarding easy bruising, petechial rash, or ecchymoses, localized areas of pruritus on the upper back or shins, a search for multiple lesions, pinch or periorbital purpura, and an evaluation for macroglossia or lateral ridging of the tongue. Macular or papular lesions should be examined for a waxy appearance suggestive of amyloidosis. Some patients may be able to volunteer a family history of amyloid diseases; others may be aware of multiple relatives known to have neuropathy, renal or cardiac disease, or affected by periodic fever syndromes. A family history of cutaneous disease may be relevant in considering a patient with suspected macular or lichen amyloidosis from Southeast Asia or South America.

TABLE 125-4
Diagnosis of Patients with Known or Suspected Cutaneous Amyloidosis

- *History:* evidence of systemic disease, and which organ systems may be involved; onset of disease in general and cutaneous lesions/pruritus in particular
- *Family history:* include ethnicity, and familial clustering of conditions known to be associated with amyloid
- *Laboratory:* immunoglobulin clonality for AL, elevated acute-phase reactants for AA, low TTR levels for ATTR
- *Genetic testing:* TTR, MEFV, RET, others in specialty laboratory test results
- *Skin lesions:* waxy deposits, macroglossia or lingual nodules; nodules, macules, lichen, and variants; single or multiple lesions; evidence of increased vascular fragility; hyperkeratosis/hyperpigmentation; cutis laxa
- *Biopsy:* lesional skin or abdominal fat pad; Congo red or thioflavin T; subpapillary amyloid or congophilic angiography/involvement of adnexa
- *Immunohistochemistry:* generic (eg, P-component), fibril subunit specific (L-chain, TTR, GAL7), or coassociating (keratin, actin)-specific antibodies; immunoelectron microscopy
- *Mass spectroscopy:* protein (AL variable; mutations) sequences and coassociating molecules

TABLE 125-5
Differential Diagnosis of Cutaneous Amyloidoses

- *Interscapular:* lichen simplex chronicus; lichen sclerosis and atrophicus; postinflammatory hyperpigmentation; dorsal macular pigmentary incontinence; fixed drug eruption; notalgia paresthetica; poikiloderma; scleroderma/morphea
- *Shins:* prurigo nodularis; atopic eczema; pretibial myxedema; hypertrophic lichen planus
- *Nodules:* cutaneous lymphomas; nevus lipomatosis; nodular cutaneous neoplasms; nodular pseudolymphomas
- *Waxy deposits:* sebaceous keratosis; xanthomas
- *Periorbital purpura:* dermatomyositis/heliotrope; posttraumatic raccoon eyes
- *Pinch purpura:* vasculitic purpura; pigmented purpuric dermatoses; thrombocytopenic purpura; trichinosis

LABORATORY

In addition to routine studies, specific laboratory testing may be suggestive for certain forms of systemic amyloidosis. For both systemic and localized AL amyloidosis, this includes a measurement of quantitative immunoglobulins (IgG, IgA, and IgM isotypes), serum and urine immunofixation, and a measurement of serum κ and λ free light chains, which will identify a clonal population of immunoglobulin light chains in more than 95% of patients with systemic AL disease, and a much lower number of patients with localized AL disease. For AA, an elevated erythrocyte sedimentation rate, as well as specific acute-phase reactants, such as C-reactive protein and fibrinogen, serve as surrogates for elevated levels of SAA protein, which can directly be measured in panels of acute-phase

reactants available for profiling rheumatoid arthritis or inflammatory bowel disease. For suspected ATTR, an assay for serum TTR levels and TTR gene-sequence analysis may serve to identify a specific mutations, although it should be noted that up to 25% of patients also are found to have monoclonal immunoglobulins as an incidental finding.

PATHOLOGY

Congo red binding to several forms of cutaneous amyloid may be weak and inferior to the use of thioflavin T or Pagoda red as diagnostic reagents; in addition, the interpretation of apple-green birefringence may be obscured by the small amount of amyloid in early lesions, and because of background white birefringence attributable to collagen in the dermis.[30] To this end, a modified Congo Red immunohistochemical overlay has been suggested to improve diagnosis,[43] and a luminescent conjugated oligothiophene, h-FTAA (heptamer formyl thiophene acetic acid), was developed to improve selectivity and sensitivity.[44] The immunohistochemistry of amyloid in tissue has proven to be a valuable adjunct to confirming proper diagnosis and guiding treatment, although its applicability to cutaneous amyloid presents certain caveats not found in other organ systems. A panel of polyclonal or monoclonal antibodies for the identification and typing of amyloid in tissue includes anti–P-component, anti-apoE, anti–κ Ig light chain, and anti–λ Ig light chain, anti-TTR, anti-AA, anti-β_2m, and generic or specific anti-keratin antibodies. In particular, the utility of antibodies to P-component as an immunohistologic surrogate marker for amyloid in tissue may be limited by the fact that this protein is an elastic fiber microfibrillar sheath-associated protein in normal skin,[45] as well as in cutis laxa associated with Meretoja syndrome,[9] and other dermal elastolytic conditions. Anti-TTR antibodies have been used to uncover amyloid in skin of patients with advanced ATTR (Fig. 125-15), and anti–keratin antibodies to type and define the distribution of localized cutaneous amyloidosis (Fig. 125-16). Among the organ-limited cutaneous amyloidoses, association with basal keratinocytes has been reflected in the identification of cytokeratin (CK)-5 as a major constituent of amyloid deposits and suggested a role of keratinocyte apoptosis in pathogenesis. In addition, other cytokeratins are positive immunochemically to varying degrees in lichen amyloidosis (CK5 > 1 > 14 > 10) and cutaneous amyloidosis associated with tumors and keratoses (CKL5 > 1 > 10 > 14).[17] For all forms of localized cutaneous amyloid, diagnosis may be improved by immunohistochemistry using pan CK antibodies, or monoclonal reagents, such as 34βE12 (anti–keratin 903), which is reactive with CK5, CK1, CK10, and CK14.[46] The identification of deposits as fibrils distinct from collagen or elastic fibers can be established by electron microscopy (Fig. 125-17). The utility of anti-κ or anti-λ antisera is limited by their specificity for determinants in the constant region of the Ig light chain, which may be lost during the proteolysis that is a concomitant of fibril

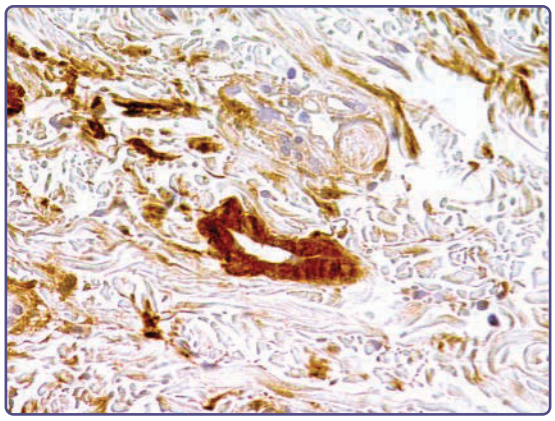

Figure 125-15 Anti-transthyretin (TTR) (prealbumin) antibodies highlighting a blood vessel in a patient with amyloidosis transthyretin (ATTR) amyloid attributable to familial amyloid polyneuropathy (hematoxylin and eosin (H&E), diaminobenzidine, ×10 magnification).

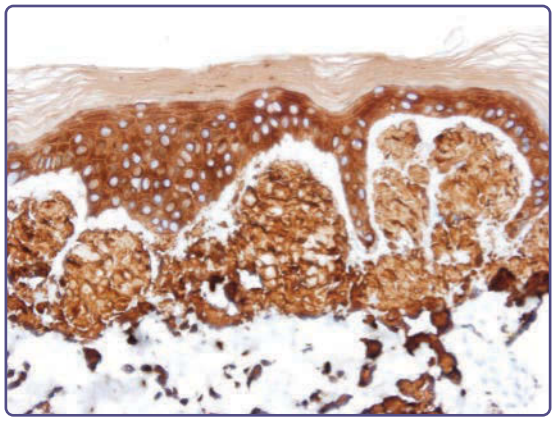

Figure 125-16 Anti–keratin 903 antibodies highlighting amyloid in expanded dermal papillae (hematoxylin and eosin (H&E), diaminobenzidine, ×4 magnification).

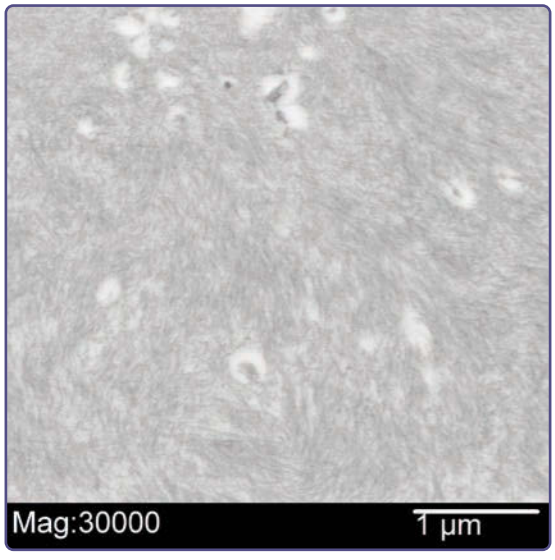

Figure 125-17 Electron micrograph showing thin filaments of amyloid in the dermis measuring 7 to 10 nm in thickness (uranyl acetate, lead citrate, ×30,000 magnification).

formation; improved specificity has been reported by immunofluorescence, using specific imaging dyes, and by immunoelectron microscopy. Treatment of tissue by autoclaving with potassium permanganate causes loss of Congo red affinity for AA and $A\beta_2m$; prolonged autoclaving affects binding of AL but not ATTR.[47] Although immunohistochemistry has been validated as a technique of typing amyloids in tissue section, antibodies specific for some forms are not yet commercially available, and the importance of in-house quality controls has been emphasized.[43]

BIOCHEMISTRY

The diagnostic value of skin biopsy as a noninvasive way to diagnose systemic amyloids was first reported in the 1970s, and has been perfected as the abdominal fat pad aspiration or fat pad biopsy, both of which are office procedures with minimal morbidity.[48] Aspiration has been used to screen for Congo red–positive material among fat globules (so-called fat rings), and can be modified for proteomic studies, quantitation of specific precursor proteins, and immunoelectron microscopy[49]; biopsy can be used to assess the morphology of amyloid in subcutaneous fat, for immunohistochemistry, and to isolate and sequence amyloid proteins by mass spectroscopy.[50] Using this technique, the diagnosis of AL can be established in 80% to 90% of cases, and AA in 75% to 80%, with a lower (~40%) yield for ATTR.[49] Laser capture microdissection of amyloid from formalin-fixed amyloidotic tissue, followed by trypsin digestion, mass spectroscopy, and direct sequence analysis of peptides, has been validated for the typing of amyloid in various tissues, including cutaneous lesions and abdominal fat pad biopsies. This methodology also has been adapted for the identification of pathogenic mutations in cases of hereditary amyloid and for the identification of Ig light chain subgroups in systemic and localized AL amyloidosis.[51] It also provides a profile of colocalizing proteins, such as P-component, keratins, and apoE, which may be important in pathogenesis.

TREATMENT STRATEGIES FOR AMYLOID DISEASES

SYSTEMIC AMYLOIDS

The onset of amyloid deposition may be preceded over many years by the presence of a mutant precursor protein, excess Ig light chain, or elevated SAA levels in blood; functional abnormalities, such as pruritus, may also anticipate the appearance of characteristic skin lesions or MTC in familial cases of lichen amyloidosis. Identification of genetic abnormalities, either reflecting fibril subunit proteins, proteolysis, or coassociating conditions, allows for the potential to identify persons at risk and initiate prophylactic therapies early in the course of disease. For the systemic amyloidoses, lowering the level of precursor protein correlates with clinical improvement and even regression of amyloid for SAA (with anticytokine therapy) and AL (with chemotherapies largely adapted from evolving myeloma protocols); in particular, the use of anti–IL-6 for AA amyloidosis, and high-dose dexamethasone, melphalan, thalidomide analogs, proteasome inhibitors, and anti-CD38 monoclonal antibodies have proven effective in reducing Ig light chain production by aberrant plasmablasts in AL amyloid.[13,52] Ongoing trials have demonstrated the ability of silencing RNAs and antisense oligonucleotides to knock down the levels of mutant and wildtype TTR in blood, and are assessing efficacy for the clinical manifestations of polyneuropathy and/or cardiomyopathy. An alternative approach that has reached licensing is to use TTR tetramer stabilizers (diflunisal/tafamidis) to prevent dissociation to the monomer stage, which is the direct precursor of oligomers, amorphous aggregates, and fibrils in ATTR.[53]

An alternative strategy is to focus on inhibiting the aggregation phenomena responsible for oligomerization or fibril formation. This may occur at the deposition phase of amyloid formation, or to interfere with formed fibrils by intercalating at the sites of intermolecular contact critical for β-pleated sheet formation. Agents that may be active as fibril disrupters that have progressed to clinical testing include (a) doxycycline (ATTR, AL, $A\beta_2m$), which disrupts fibril formation and mature fibrils, as well as inhibiting matrix metalloproteinase (MMP)-9; and the nutraceuticals[54]; (b) epigallocatechin-3-gallate (green tea) (ATTR, Aβ-Alzheimer disease; AApoA2, transforming growth factor (TGF) β_1-lattice corneal dystrophy, Type 1), which disrupts mature fibrils and suppresses markers of oxidative stress; and (c) curcumin (ATTR; Aβ), which induces oligomerization to a nontoxic "off pathway."[55] Low-molecular-weight aggregation inhibitors include β-sheet breaker peptides, Fab, scFv or single chain camelid nanobodies, and peptide inhibitors of adhesive segments.[56]

A third approach is to use immunotherapy to neutralize oligomers and facilitate the clearance of tissue amyloid. Critical to this approach is to design antibodies that are specific for shared conformational epitopes rather than the native precursor protein, accessibility to the target conformers, and the safe elicitation of macrophage-dependent clearance mechanisms. Currently, an anti-AL antibody with specificity for amyloid and oligomers is undergoing Phase III clinical trials, and antibodies to P-component are being tested as generic agents for systemic amyloids following depletion of serum, but not tissue amyloid–associated, SAP with a proline-derived small molecule that binds the pentamers together and facilitates their clearance from blood.[57,58]

THERAPY FOR CUTANEOUS AMYLOIDOSES

Currently, treatment of cutaneous manifestations associated with systemic amyloids has followed the

general strategies outlined above.[17] However, accessibility of skin amyloid allows for direct delivery to the sites of pathology. Early studies used dimethylsulfoxide (DMSO), based on a suggestion that it might be able to disaggregate AL fibrils, possible antiinflammatory effects, and deep permeability at the sites of application; general applicability, however was limited by the acrid smell and difficulty in obtaining preparations that were free of contaminants. Newer studies in patients with macular and lichen amyloidosis have reported rapid and significant improvement in pruritus and hyperpigmentation, although not resolution of amyloid on followup biopsies.[59]

The main concern for nodular amyloid is the potential for progression to systemic AL, which has been reported as up to 50%; therefore, the main therapeutic challenge is to assess for monoclonal gammopathy and for other organ involvement. More rarely, evaluation of nodular amyloidosis may reveal that a patient has primary Sjögrens disease, a syndrome characterized by dry eyes and dry mouth (sicca syndrome) sometimes associated with major hematologic, pulmonary, GI or renal involvement. This may in turn suggest the use of systemic treatments for sicca (eg, sialogogues) or Disease Modifying Agents (DMARDs) such as hydroxychloroquine or methotrexate for systemic disease. Absent any indication of systemic AL, treatment is determined by the size, location, and multiplicity of the cutaneous nodules. Lesions in locations such as the foot or temple have been effectively treated with curettage, excision, and, rarely, intralesional methotrexate or ablative laser therapy; a 9% risk of local reoccurrence has been reported, and long-term followup recommended if localized AL is documented by special studies.[17,26]

Treatment of localized cutaneous amyloidoses overlaps the spectrum of macular and papular (lichen) variants, with a specific target of interrupting the cycle of pruritus, scratching, and lichenification. Common treatments that have been used in small series include topical and intralesional steroids, topical calcineurin inhibitors, low-dose oral cyclophosphamide, dermabrasion, and cyclosporine. Small series have reported successes with carbon dioxide resurfacing surgical laser, yttrium-aluminum-garnet laser, tocoretinate (a synthetic esterified compound of tocopherol and retinoic acid), narrowband ultraviolet B light therapy, and a combination of psoralen and ultraviolet A with acitretin. Resurfacing, neodymium-doped yttrium-aluminum-garnet, and pulsed-dye laser treatments have been recommended because of the lack of scarring or pigmentary changes; in some instances, improvement in histology and resolution of amyloid have been reported.[60]

In general, antihistamines are ineffective for the treatment of pruritus in this disorder, likely reflecting the lack of generation of histamine or involvement of histamine receptors in observed pathology. An alternative focus has been on the common occurrence of dysesthesias correlating with lichenoid skin lesions, and changes in epidermal nerve fiber density that have been demonstrated on biopsies. Topical capsaicin 0.025%, which releases neuropeptides from C-fibers, and prevents their deposition, may be tried, and there may be role for inhibitors of nonhistamine pruritogens and receptors currently being considered.[36] Lastly, antagonists of IL-31 receptors or its receptor have been under development for the treatment of atopic dermatitis, and might also have relevance to ameliorating the itch of lichen amyloidosis.[37]

ACKNOWLEDGMENTS

Research support from the Seaver Foundation is gratefully acknowledged.

REFERENCES

1. Kisilevsky R, Raimondi S, Bellotti V. Historical and current concepts of fibrillogenesis and in vivo amyloidogenesis: implications of amyloid tissue targeting. *Front Mol Biosci*. 2016;3:17.
2. Sipe JD, Benson MD, Buxbaum JN, et al. Amyloid fibril proteins and amyloidosis: chemical identification and clinical classification International Society of Amyloidosis 2016 Nomenclature Guidelines. *Amyloid*. 2016;23(4):209-213.
3. Gorevic PD. Genetic factors in the amyloid diseases. *Up-To-Date*. 2016.
4. Merlini G, Bellotti V. Molecular mechanisms of amyloidosis. *N Engl J Med*. 2003;349(6):583-596.
5. Pinney JH, Smith CJ, Taube JB, et al. Systemic amyloidosis in England: an epidemiological study. *Br J Haematol*. 2013;161:525-532.
6. Wechalekar AD, Gillmore JD, Hawkins PN. Systemic amyloidosis. *Lancet*. 2016;387(10038):2641-2654.
7. Brownstein MH, Helwig EB. The cutaneous amyloidoses. II. Systemic forms. *Arch Dermatol*. 1970;102(1):20-28.
8. Lanoue J, Wei N, Gorevic P, et al. Cutaneous manifestations of familial transthyretin amyloid polyneuropathy. *Am J Dermatopathol*. 2016;38(10):719-725.
9. Kiuru-Enari S, Keski-Oja J, Haltia M. Cutis laxa in hereditary gelsolin amyloidosis. *Br J Dermatol*. 2005;152(2):250-257.
10. Muscardin L, Cota C, Donati P, et al. Hereditary apolipoprotein A1 amyloidosis with cutaneous and cardiac involvement: a long familial history. *Eur J Dermatol*. 2014;24(2):261-263.
11. Sattianayagam PT, Gibbs SD, Rowczenio D, et al. Hereditary lysozyme amyloidosis—phenotypic heterogeneity and the role of solid organ transplantation. *J Intern Med*. 2012;272(1):36-44.
12. Benedikz E, Blöndal H, Gudmundsson G. Skin deposits in hereditary cystatin C amyloidosis. *Virchows Arch A Pathol Anat Histopathol*. 1990;417(4):325-331.
13. Nienhuis HL, Bijzet J, Hazenberg BP. The prevalence and management of systemic amyloidosis in western countries. *Kidney Dis (Basel)*. 2016;2(1):10-19.
14. Jacobson DR, Alexander AA, Tagoe C, et al. The prevalence and distribution of the amyloidogenic transthyretin (TTR) V122I allele in Africa. *Mol Genet Genomic Med*. 2016;4(5):548-556.
15. Mahmood S, Bridoux F, Venner CP, et al. Natural history and outcomes in localised immunoglobulin light-chain amyloidosis: a long-term observational study. *Lancet Haematol*. 2015;2(6):e241-e250.

16. Brownstein MH, Helwig EB. The cutaneous amyloidoses. I. Localized forms. *Arch Dermatol*. 1970;102(1):8-19.
17. Schreml S, Szeimies RM, Vogt T, et al. Cutaneous amyloidoses and systemic amyloidoses with cutaneous involvement. *Eur J Dermatol*. 2010;20(2):152-160.
18. Haverkampf S, Evert K, Schröder J, et al. Nodular cutaneous amyloidosis resembling a giant tumor. *Case Rep Dermatol*. 2016;8(1):22-25.
19. Brownstein MH, Hashimoto K, Greenwald G. Biphasic amyloidosis: link between macular and lichenoid forms. *Br J Dermatol*. 1973;88(1):25-29.
20. Yoshida A, Takahashi K, Tagami H, et al. Lichen amyloidosis induced on the upper back by long-term friction with a nylon towel. *J Dermatol*. 2009;36(1):56-59.
21. Wang WJ, Huang CY, Chang YT, et al. Anosacral cutaneous amyloidosis: a study of 10 Chinese cases. *Br J Dermatol*. 2000;143(6):1266-1269.
22. Bernhard JD. Macular amyloidosis, notalgia paresthetica and pruritus: three sides of the same coin? *Dermatologica*. 1991;183(1):53-54.
23. Mysore V, Bhushnurmath SR, Muirhead DE, et al. Frictional amyloidosis in Oman—a study of ten cases. *Indian J Dermatol Venereol Leprol*. 2002;68(1):28-32.
24. Siragusa M, Ferri R, Cavallari V, et al. Friction melanosis, friction amyloidosis, macular amyloidosis, towel melanosis: many names for the same clinical entity. *Eur J Dermatol*. 2001;11(6):545-548.
25. Kandhari R, Ramesh V, Singh A. Asymptomatic conchal papules. Lichen amyloidosis of the auricular concha. *Indian J Dermatol Venereol Leprol*. 2013;79(3):445-447.
26. Konopinski JC, Seyfer SJ, Robbins KL, et al. A case of nodular cutaneous amyloidosis and review of the literature. *Dermatol Online J*. 2013;19(4):10.
27. Wey SJ, Chen YM, Lai PJ, et al. Primary Sjögren syndrome manifested as localized cutaneous nodular amyloidosis. *J Clin Rheumatol*. 2011;17(7):368-370.
28. Gargallo V, Angulo L, Hernández E, et al. Massive subcutaneous masses on the back related to β2-microglobulin amyloidosis. *JAMA Dermatol*. 2015;151(5):564-565.
29. Apaydin R, Gürbüz Y, Bayramgürler D, et al. Cytokeratin contents of basal cell carcinoma, epidermis overlying tumour, and associated stromal amyloidosis: an immunohistochemical study. *Amyloid*. 2005;12(1):41-47.
30. Westermark P. Localized amyloidoses and amyloidoses associated with aging outside the central nervous system. In: Pickens MM, Dogan A, Herrera GA, eds. *Amyloid and Related Disorders: Surgical Pathology and Clinical Correlations*. New York, NY: Humana Press; 2012:81-103.
31. D'Souza A, Theis JD, Vrana JA, et al. Pharmaceutical amyloidosis associated with subcutaneous insulin and enfuvirtide administration. *Amyloid*. 2014;21(2):71-75.
32. Fernandes, NF, Mercer SE, Kleinerman R, et al. Amyloidosis cutis dyschromica associated with atypical Parkinsonism, spasticity and motor weakness in a Pakistani female. *J Cutan Pathol*. 2011;38(10):827-831.
33. Mahon C, Oliver F, Purvis D, et al. Amyloidosis cutis dyschromica in two siblings and review of the epidemiology, clinical features and management in 48 cases. *Australas J Dermatol*. 2015. [Epub ahead of print]
34. Scapineli JO, Ceolin L, Puñales MK, et al. MEN 2A-related cutaneous lichen amyloidosis: report of three kindred and systematic literature review of clinical, biochemical and molecular characteristics. *Fam Cancer*. 2016;15(4):625-633.
35. Qi XP, Zhao JQ, Chen ZG, et al. RET mutation p.S891A in a Chinese family with familial medullary thyroid carcinoma and associated cutaneous amyloidosis binding OSMR variant p.G513D. *Oncotarget*. 2015;6(32):33993-34003.
36. Sanders KM, Nattkemper LA, Yosipovitch G. Advances in understanding itching and scratching: a new era of targeted treatments. *F1000Res*. 2016;5.
37. Cevikbas F, Kempkes C, Buhl T, et al. Role of interleukin-31 and oncostatin M in itch and neuroimmune communication. In: Carstens E, Akiyama T, eds. *Itch: Mechanisms and Treatment*. Boca Raton, FL: CRC Press; 2014.
38. Wali A, Liu L, Takeichi T, et al. Familial primary localized cutaneous amyloidosis results from either dominant or recessive mutations in OSMR. *Acta Derm Venereol*. 2015;95(8):1005-1007.
39. Tanaka A, Arita K, Lai-Cheong JE, et al. New insight into mechanisms of pruritus from molecular studies on familial primary localized cutaneous amyloidosis. *Br J Dermatol*. 2009;161(6):1217-1224.
40. Dousset L, Seneschal J, Boniface K, et al. A Th2 cytokine interleukin-31 signature in a case of sporadic lichen amyloidosis. *Acta Derm Venereol*. 2015;95(2):223-224.
41. Miura Y, Harumiya S, Ono K, et al. Galectin-7 and actin are components of amyloid deposit of localized cutaneous amyloidosis. *Exp Dermatol*. 2013;22(1):36-40.
42. Ono K, Fujimoto E, Fujimoto N, et al. In vitro amyloidogenic peptides of galectin-7: possible mechanism of amyloidogenesis of primary localized cutaneous amyloidosis. *J Biol Chem*. 2014;289(42):29195-29207.
43. Linke RP. On typing amyloidosis using immunohistochemistry. Detailed illustrations, review and a note on mass spectrometry. *Prog Histochem Cytochem*. 2012;47(2):61-132.
44. Sjölander D, Röcken C, Westermark P, et al. Establishing the fluorescent amyloid ligand h-FTAA for studying human tissues with systemic and localized amyloid. *Amyloid*. 2016;23(2):98-108.
45. Breathnach SM, Hintner H. Amyloid P-component and the skin. *Clin Dermatol*. 1990;8(2):46-54.
46. Yoneda, K. Watanabe H, Yanagihara M, et al. Immunohistochemical staining properties of amyloids with anti-keratin antibodies using formalin-fixed, paraffin-embedded sections. *J Cutan Pathol*. 1989;16(3):133-136.
47. Fernandez-Flores A. Cutaneous amyloidosis: a concept review. *Am J Dermatopathol*. 2012;34(1):1-14.
48. Westermark P. Amyloid diagnosis, subcutaneous adipose tissue, immunohistochemistry and mass spectrometry. *Amyloid*. 2011;18:175-176.
49. Brambilla F, Lavatelli F, Di Silvestre D, et al. Reliable typing of systemic amyloidoses through proteomic analysis of subcutaneous adipose tissue. *Blood*. 2012;119(8):1844-1847.
50. Vrana JA, Theis JD, Dasari S, et al. Clinical diagnosis and typing of systemic amyloidosis in subcutaneous fat aspirates by mass spectrometry-based proteomics. *Haematologica*. 2014;99(7):1239-1247.
51. Kourelis TV, Dasari S, Theis JD, et al. Clarifying immunoglobulin gene usage in systemic and localized immunoglobulin light chain amyloidosis by mass spectrometry. *Blood*. 2017;129(3):299-306.
52. Muchtar E, Buadi FK, Dispenzieri A, et al. Immunoglobulin light-chain amyloidosis: from basics to new developments in diagnosis, prognosis and therapy. *Acta Haematol*. 2016;135(3):172-190.
53. Gertz MA, Benson MD, Dyck PJ, et al. Diagnosis, prognosis, and therapy of transthyretin amyloidosis. *J Am Coll Cardiol*. 2015;66(21):2451-2466.

54. Stoilova T, Colombo L, Forloni G, et al. A new face for old antibiotics: tetracyclines in treatment of amyloidoses. *J Med Chem*. 2013;56(15):5987-6006.
55. Stefani M, Rigacci S. Beneficial properties of natural phenols: highlight on protection against pathological conditions associated with amyloid aggregation. *Biofactors*. 2014;40(5):482-493.
56. De Genst E, Messer A, Dobson CM. Antibodies and protein misfolding: from structural research tools to therapeutic strategies. *Biochim Biophys Acta*. 2014;1844(11): 1907-1919.
57. Gertz MA, Landau H, Comenzo RL, et al. First-in-human phase I/II study of NEOD001 in patients with light chain amyloidosis and persistent organ dysfunction. *J Clin Oncol*. 2016;34(10):1097-1103.
58. Richards DB, Cookson LM, Berges AC, et al. Therapeutic clearance of amyloid by antibodies to serum amyloid P component. *N Engl J Med*. 2015;373(12):1106-1114.
59. Krishna A, Nath B, Dhir GG, et al. Study on epidemiology of cutaneous amyloidosis in northern India and effectiveness of dimethylsulphoxide in cutaneous amyloidosis. *Indian Dermatol Online J*. 2012;3(3):182-186.
60. Al Yahya RS. Treatment of primary cutaneous amyloidosis with laser: a review of the literature. *Lasers Med Sci*. 2016;31(5):1027-1035.

Chapter 126 :: Xanthomas and Lipoprotein Disorders

:: Vasanth Sathiyakumar, Steven R. Jones, & Seth S. Martin

AT-A-GLANCE

- Xanthomas are plaques or nodules consisting of an abnormal excess of lipid primarily in the skin or tendons.
- Clinically, xanthomas may be divided into eruptive, tuber-eruptive or tuberous, tendinous, or planar forms. Two traditionally noninherited variations include verruciform and disseminated xanthomas, both of which have a propensity for largely noncutaneous manifestations.
- Xanthomas are not disease entities themselves but are signs of various lipoprotein disorders, which may be primary lipid disorders or secondary disorders from a variety of causes including hepatic, hematologic, and endocrine sources.
- The key pathogenesis of xanthoma formation consists of the downstream formation of foam cells, which involves an interplay of various lipoproteins including chylomicrons, very-low-density lipoproteins (VLDLs), chylomicron and VLDL remnant lipoproteins, low-density lipoproteins, and high-density lipoproteins.
- Primary dyslipidemias, designated as Types I to V, have been historically categorized into various phenotypes described by Fredrickson, Levy, and Lees, based on the elevated lipoprotein fractions found in serum.
- Diagnosis of xanthoma is based on clinical and morphologic characteristics of the lesions and identifying the underlying lipid disorder.
- Treatment of xanthoma is aimed at the underlying lipid disorder, and typically involves lifestyle changes (diet, weight loss, smoking cessation) and medications (statins, adjuvant agents, PCSK9 inhibitors).
- Young patients with xanthomas and those with suspected familial dyslipidemias should be referred for genetic testing and counseling.

DEFINITIONS

Xanthomas are plaques or nodules consisting of an accumulation of excess of lipid primarily in the skin or tendons, resulting in the formation of foam cells. Not a disease entity in themselves, xanthomas are signs of various lipoprotein disorders and are occasionally seen without underlying metabolic effects. Xanthomas may arise from primary dyslipidemias or may be the cutaneous manifestations of systemic disorders resulting in secondary dyslipidemia.

HISTORICAL PERSPECTIVE

Primary dyslipidemias have been traditionally grouped into 6 major phenotypes (Types I, IIa, IIb, III, IV, and V) classified by Fredrickson, Levy, and Lees in a series of seminal papers from the 1960s.[1] By visually assessing samples of patient serum and directly measuring cholesterol content through ultracentrifugation, precipitation, and electrophoresis techniques, Fredrickson, Levy, and Lees quantified the size, composition, and density of various lipoproteins, including chylomicrons, low-density lipoprotein (LDL), and very-low-density lipoprotein (VLDL). At the time of publication, 5 phenotypes were proposed based on the predominant lipoprotein present in serum with a sixth phenotype later added to this scheme in the 1970s by Goldstein and colleagues.[2]

The World Health Organization formally adopted the Fredrickson-Levy-Lees classification in 1972 using a biochemical phenotypic classification and incorporated clinical dyslipidemias associated with the various combinations of elevated apolipoprotein B (apoB) containing lipoproteins. Interestingly, the adoption of the Fredrickson-Levy-Lees classification occurred prior to the recognition of HDL as an important contributor to dyslipidemia. Although the basis of these definitions is rooted in which serum lipoprotein is elevated; as of this writing there is no consensus on absolute values used to define an excess state. However, after the discovery of apolipoprotein E (apoE) as a significant factor in dyslipidemia development in the 1970s, increasing use of genetic testing involving quantification and identifying mutations in apolipoproteins has helped confirm the diagnosis for many patients with primary dyslipidemias.

Since the adaptation of the World Health Organization classification, various systemic diseases have been linked to secondary dyslipidemias and xanthoma formation, including nephrotic syndrome, hepatic abnormalities, and thyroid dysfunction. These disease entities are increasingly recognized as important causes of dyslipidemia.

Yet, the recognition of clinical xanthomas predated the modern-day characterization of dyslipidemias

by decades. Planar xanthomas were first reported in the medical literature in the early 1900s. Xanthoma disseminatum was described in 1938, and diffuse normolipemic plane xanthoma was first reported in 1962.[3]

Regardless of the etiology of dyslipidemia—primary or secondary—worldwide clinical lipid guidelines emphasize the importance of monitoring dyslipidemia to initiate and intensify therapy directed at non-HDL, apoB-containing lipoproteins. The 2002 National Cholesterol Education Program guidelines focused on low-density lipoprotein cholesterol (LDL-C) as the main target for disease management.[4] The 2013 American College of Cardiology/American Heart Association joint *Guideline on the Treatment of Blood Cholesterol* recognized dyslipidemia as a modifiable risk factor in patients with known atherosclerotic cardiovascular disease, and recommended primary prevention statin-therapy for high-risk patients.[5] In 2016, the American College of Cardiology released an Expert Consensus Statement highlighting the role of nonstatin therapies for further LDL-C lowering in patients with dyslipidemia.[6]

EPIDEMIOLOGY

Because xanthomas are signs of underlying dyslipidemia, little data is available regarding the prevalence of xanthomas themselves. Xanthelasmas, a specific type of xanthoma involving the eyelids, constitute 6% of eyelid tumors according to one study.[7] There is no specific age or gender bias toward xanthoma formation, except in the rare xanthoma disseminatum variation that tends to affect younger males in a 2:1 predilection compared to younger females, and in patients with homozygous familial hypercholesterolemia in which xanthomas may be seen as early as the first decade of life.[3]

However, identifying the prevalence of underlying dyslipidemia—either primary or secondary—may serve as a surrogate predictor for possible xanthoma formation. Based on the National Health and Nutrition Examination Survey, a cross-population sample of children and adults living in the United States, an estimated 53% of all U.S. adults have some form of lipid abnormalities, with 27% of adults manifesting high LDL-C and 30% with high triglyceride levels. Nearly 21% of U.S. adults have multiple lipid abnormalities.[8] Even among children and adolescents, almost 20% were reported to have some form of dyslipidemia.[9] When assessing hyperlipidemias within the Multi-Ethnic Study of Atherosclerosis, nearly 30% were characterized with dyslipidemias. The Multi-Ethnic Study of Atherosclerosis study includes participants from 4 major race groups, namely, whites, African Americans, Hispanic Americans, and Chinese Americans. There were no significant differences in the prevalence of dyslipidemia among the races.[10]

Excluding familial hypercholesterolemia (Type IIa), which has a prevalence in the United States and in Europe in the range of 1 in 200 to 250 individuals with upwards of 34 million patients diagnosed worldwide, relatively few studies have directly assessed the prevalence of the Fredrickson-Levy-Lees phenotypes in large, modern, crosspopulation cohorts.[11,12] In a cross-population cohort from the Very Large Database of Lipids study, the prevalence of the various phenotypes were as follows: Type I <0.01%; Type IIa 4.5%; Type IIb 1.7%; Type III 0.1%; Type IV 7.5%; and Type V 0.04%. These frequencies changed depending on concomitant HDL levels, such that at lower HDL levels the frequencies of Types IIb, IV, and V increased. The opposite trend was seen with the Type IIa phenotype. Smaller studies have suggested Types IIa (7%), IV (41%), and IIb (51%) are relatively common among primary dyslipidemias, with Types I, III, and V much more uncommon.[13]

Lipoprotein lipase and apolipoprotein CII deficiencies are identified causes of the Type I phenotype yet only range from less than 1 to 1-2 per 1 million in the general population. Genetic studies suggest founder populations in Canada and the Netherlands, where prevalence is still rare but slightly increased to 20 per million in the general population. Familial combined dyslipidemia (Type IIb) is found in 0.5% to 2% of the general population and in upwards of 10% in those with known cardiovascular disease. Dysbetalipoproteinemia, or the Type III phenotype, is reported in 1 in 10,000 adults and familial hypertriglyceridemia has been reported to have a population prevalence of 0.5 to 1.0 in 10,000 adults.[14,15]

The prevalence of secondary causes of dyslipidemias is more readily apparent. Nearly 10% of Americans have diabetes; upwards of 12% of the U.S. population will develop some form of thyroid dysfunction; and nearly 14% of Americans have a form of chronic kidney disease.[16,17] However, of those who have a form of dyslipidemia or are at risk of developing dyslipidemia from a secondary cause, the direct prevalence of xanthomas is unknown.

CLINICAL FEATURES

CUTANEOUS FINDINGS

Xanthomas are clinically divided into eruptive, tuberoeruptive or tuberous, tendinous, or planar forms.[18] Two traditionally noninherited variations are verruciform and disseminated xanthomas, both of which have a propensity for largely noncutaneous manifestations.

Eruptive xanthomas are multiple, small, red-yellow papules, usually less than 5 mm in size, that may appear suddenly and are arranged in crops on the extensor surface of the extremities and the buttocks, often forming a confluent rash (Fig. 126-1).[19] They are associated with severe hypertriglyceridemia, usually resulting from accumulation of chylomicrons as in Types I and V dyslipidemia, and may be aggravated by underlying diabetes, obesity, excessive ethanol intake, and drugs such as retinoids, estrogen therapy, and protease inhibitors (Fig. 126-2). Eruptive xanthomas also

Figure 126-1 Example of eruptive xanthoma.

follow the Koebner phenomenon; that is, lesions may appear secondary to direct skin trauma.

Tuberous xanthomas are nodules that are localized to pressure areas including the extensor surfaces of the elbows, knees, knuckles, and buttocks (Figs. 126-3 and 126-4).[20] Rarely, they can be found on the face.

Figure 126-2 Example of eruptive xanthoma in a patient with severe chylomicronemia.

Figure 126-3 Examples of tuberoeruptive and tuberous xanthomas. **A,** Knee. **B,** Palm.

Tendinous xanthomas are firm, subcutaneous nodules found in fascia, ligaments, Achilles tendons, or extensor tendons of the hands, knees, and elbows (Fig. 126-5 and 126-6).[21] They may occasionally appear as tophus-like lesions over the great toe and be mistaken for gout, and may be uncovered by direct trauma.

Planar xanthomas are yellow macules, soft papules, or plaques found commonly on the upper eyelids near the inner canthus (xanthelasma palpebrarum or

Figure 126-4 Examples of tuberoeruptive xanthomas. **A, B,** Hands. **C, D,** Elbows. **E, F,** Knees. Panels **D, E,** and **F** demonstrate regression of these lesions after lipid-lowering therapy.

xanthelasma), the wrists and palms (xanthoma striatum palmare), and in intertriginous areas (Fig. 126-7 and 126-8).[22] Xanthelasmas may be found in patients with elevated LDL-C levels, but most often occur in patients with relatively normal lipid levels and the occurrence of these lesions on the eyelids is usually not associated with coronary heart disease.[23] A variation of this disorder, known as giant xanthelasma palpebrarum, may involve all 4 eyelids.

Patients with Type III dyslipidemia and accumulation of chylomicron and VLDL remnant lipoproteins may develop a characteristic variant xanthoma characterized by yellow-orange discoloration of the cutaneous creases of the palmar skin.[24-26]

NONCUTANEOUS FINDINGS

Patients with verruciform xanthoma mainly have oral mucosal involvement with lesions appearing in polypoid or sessile forms.[27] Cutaneous lesions are largely limited to the perineum and scrotum in males, and are associated with the CHILD (congenital hemidysplasia with ichthyosiform erythroderma and limb defects) syndrome or epidermolysis bullosa.

Xanthoma disseminatum involves xanthoma formation and histiocyte proliferation within common mucocutaneous sites, but also can involve visceral organs, ocular structures, the CNS, and the skeletal

Figure 126-5 Example of tendon xanthoma.

system.[28-30] Without any known familial inheritance, the disease is thought to evolve as a reactive phenomenon with only a handful of cases reported in medical literature over the past century. Variations of the disease include a persistent form, a progressive form with systemic involvement, and an uncommon self-limited disease state. Because all types of xanthoma are associated with underlying dyslipidemia, noncutaneous findings may also include atherosclerotic disease in any vascular bed. However, most clinically important lesions include coronary atherosclerosis, carotid stenosis, peripheral vascular disease, and intracranial lesions.

A subset of patients with tendinous xanthomas develop cerebrotendinous xanthomas, which manifest as intracranial lesions causing neurologic dysfunction, including dementia and cerebellar ataxia.[31] These patients have only modest elevations in plasma cholesterol levels, and are unable to convert cholesterol to chenodeoxycholate, a major bile acid, because of defects in the sterol 27-hydroxylase gene. The result of this defect is accumulation of cholestanol, which can be noted by gas chromatography.[32] The condition is inherited in an autosomal recessive pattern. Typical treatment consists of chenodeoxycholic acid in concert with statin therapy.[33,34]

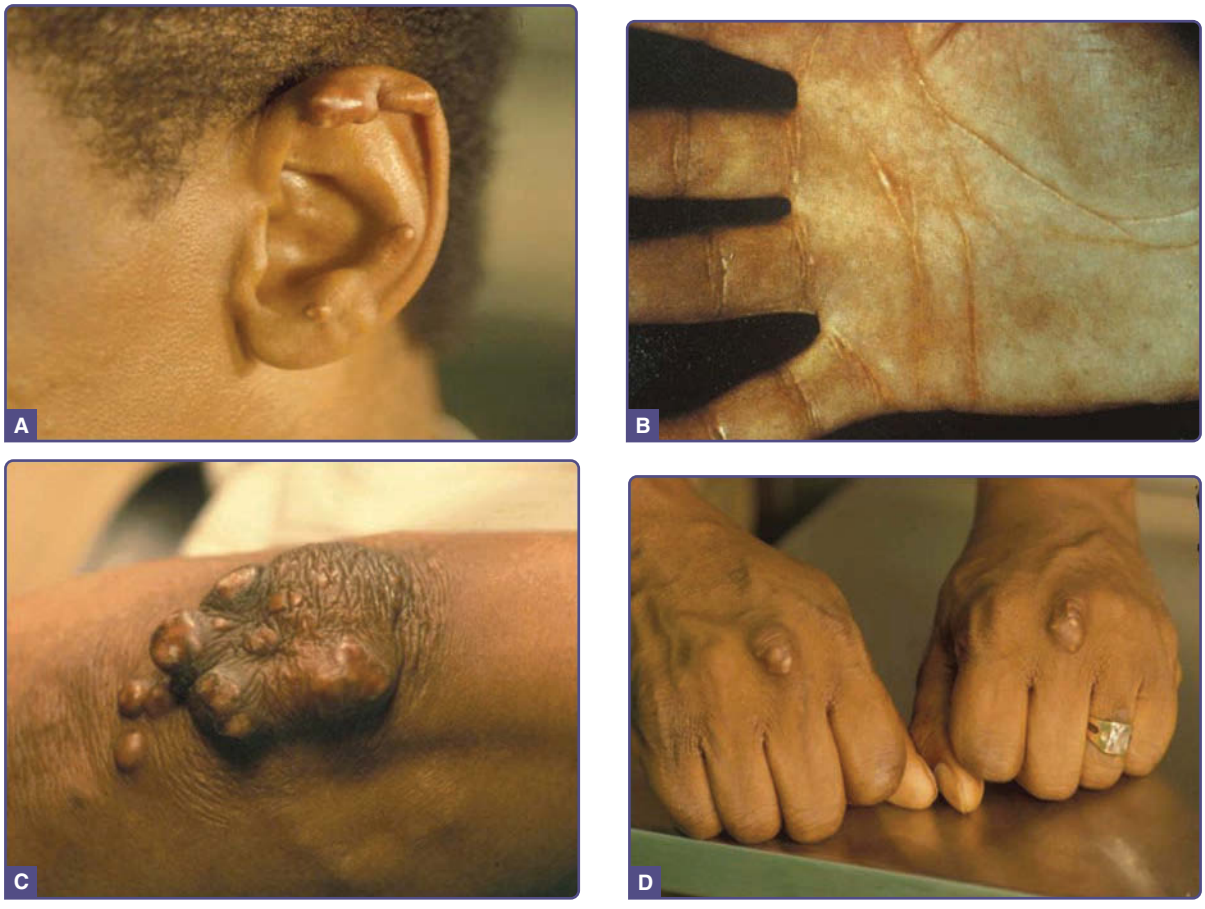

Figure 126-6 Examples of tuberoeruptive xanthomas. **A,** Ears. **C,** Elbows. **D,** Hands. **B,** An example of a palmar xanthoma is seen in the hand creases.

Figure 126-7 Examples of tuberoeruptive and palmar xanthomas in a patient with apoAI deficiency. **A,** Located in the lower back and buttocks. **B,** Palmar xanthomas.

Some patients may develop sitosterolemia, or a retention and elevation of plant-based sterols in the serum. This condition is caused by a mutation of the ABCG5/G8 transporter (discussed in "Pathogenesis" section), which is important for intestinal absorption of sterols. These patients may develop tendinous xanthomas with the overall clinical picture imitating familial hypercholesterolemia (also discussed in "Primary (Genetic) Dyslipidemias" section). Distinguishing this entity from familial hypercholesterolemia is important, as first-line therapy consists of ezetimibe, usually in combination with statin-based therapy, and sometimes bile acid sequestrants.

Figure 126-8 Example of plane xanthoma in a patient with lymphoma.

COMPLICATIONS

Morbidity from cutaneous xanthomas is largely limited to cosmetic and functional defects or localized pain depending on the site of involvement. Patients with flexural surface lesions may have restricted range of motion, whereas those with xanthelasmas may develop obstructive blindness. However, any further morbidity or mortality from isolated cutaneous lesions is rare.

Nonetheless, various case reports have linked the presence of cutaneous xanthomas to underlying systemic diseases other than primary disorders of lipid metabolism, which carry significant mortality. For example, planar xanthomas may be the first sign of underlying hematologic abnormalities and may be associated with chronic microcytic anemia or hematologic malignancies.[22,35,36]

Patients with xanthoma disseminatum are at further increased risk for morbidity. Involvement of the GI tract may result in dysphagia, whereas airway involvement may cause dyspnea. Ocular involvement may involve the cornea or conjunctiva and lead to blindness.[37] Intracranial lesions may present similarly as cerebrotendinous xanthoma and can cause a number of motor or sensory deficits secondary to hydrocephalus or epileptic episodes. Involvement of the skeletal system may result in subclinical osteolytic lesions, overt fractures, or the development of rheumatoid arthritis.[28] Rarer forms are associated with Budd-Chiari syndrome and may result in marked hepatic dysfunction.

Mortality in patients with xanthomas stems from the underlying dyslipidemia, which places patients at increased risk for clinical atherosclerotic cardiovascular disease, including obstructive atherosclerosis, myocardial infarction, and stroke. Patients with severely elevated triglycerides resulting from accumulation of chylomicrons are prone to significant morbidity from repeated episodes of acute pancreatitis.

ETIOLOGY AND PATHOGENESIS

PATHOGENESIS

The key pathogenesis of xanthoma formation results from accumulations of serum chylomicrons and lipoproteins, which eventually deposit within the skin. After diffusion of serum lipoproteins through capillary

walls and deposition in skin and tendons, monocytes incorporate LDL and other lipid subtypes through scavenger receptors. This results in the formation of foam cells, which clinically manifest as xanthomas. Foam cells may also develop secondary to in situ lipid synthesis by the macrophage itself, and lipid that has been extravasated by the capillaries may also recruit additional foam cells into an already established xanthoma by inducing vascular cellular adhesion.[38,39] Local factors, such as heat, movement, and friction, may increase lipid capillary leakage and lead to underlying inflammation and recruitment of macrophages, resulting in downstream formation of xanthomas. Because of the central role of lipids in the formation of xanthomas, an understanding of cholesterol and lipoprotein pathophysiology is essential (Fig. 126-9).

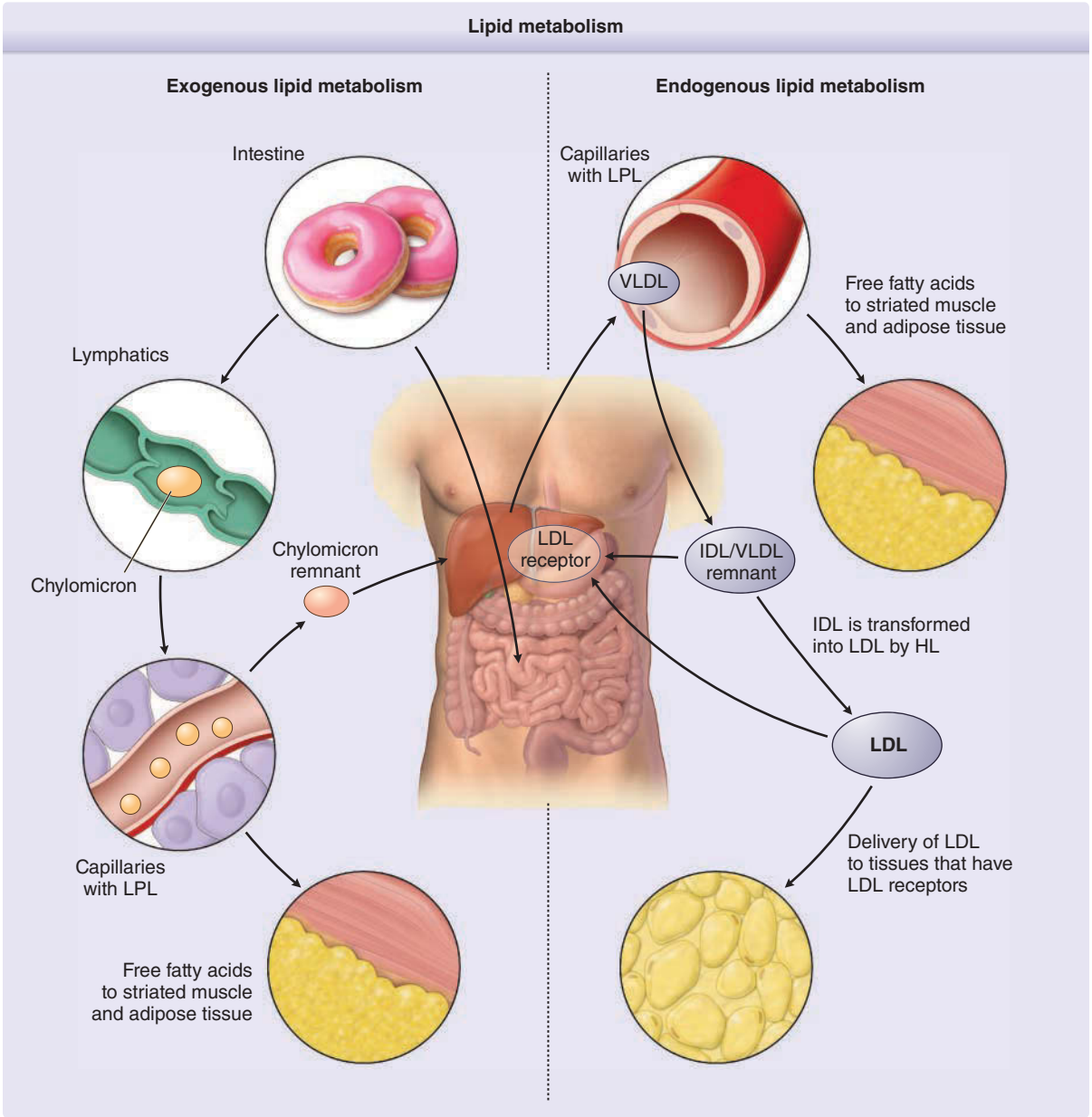

Figure 126-9 Overview of lipid metabolism with an emphasis on exogenous and endogenous pathways. The exogenous pathway consists of triglycerides in the intestines packaged into chylomicrons in the intestinal enterocytes. Capillary lipoprotein lipase (LPL), which requires apoCII as a cofactor, hydrolyzes the triglycerides and releases fatty acids for uptake by various tissues. The remaining chylomicron particle, called a *chylomicron remnant*, is recycled by the liver in a process that requires apoE as a ligand for the low-density lipoprotein (LDL) receptors in the liver. The endogenous pathway involves the hepatic production of very-low-density lipoprotein (VLDL) and the delivery of free fatty acids to peripheral tissues. Similar to chylomicron metabolism, LPL hydrolyzes triglycerides and releases fatty acids for peripheral tissue uptake. VLDL remnants are called intermediate-density lipoproteins (IDLs). IDLs may be removed from circulation via the LDL receptor or be transformed into LDL by hepatic lipase (HL) in the liver. LDL may bind to the LDL receptor for clearance or deposit within luminal walls.

Cholesterol, the most abundant sterol in plasma, is primarily produced from an endogenous pathway (ie, synthesized in cells in the body, especially the liver) or, to a lesser extent, absorbed via an exogenous pathway through intestinal uptake.[40] Cholesterol, primarily in its esterified form, linking a fatty acid moiety at the 3-hydroxy position, is a core component of lipoprotein. Cholesterol serves as a precursor for bile acids; helps form steroid hormones, including estrogen, testosterone, and cortisol; and maintains the integrity and structure of cell membranes.[39,41-43]

Dietary cholesterol through the exogenous pathway is transported from the intestine via the Niemann-Pick C-like protein 1 transporter. Cholesterol in the intestinal cell is largely packaged into chylomicrons for entry into the bloodstream, stored in the intestine as either free cholesterol or cholesteryl ester, or transported back into the intestinal lumen via the action of the 2 adenosine triphosphate–binding cassette transporters (ABCG5 and ABCG8).[44] Nearly 50% of the intestinal cholesterol and more than 95% of the intestinal β-sitosterol and campesterol are transported into the intestinal lumen and are not absorbed. Of note, patients who have defects in ABCG5 and ABCG8 have elevated plasma levels of β-sitosterol.

The endogenous pathway of cholesterol synthesis involves multiple reduction and condensation steps to form mevalonate, a key intermediate molecule. The terminal step in this pathway involves the enzyme β-hydroxy-β-methylglutaryl-coenzyme A (HMG-CoA) reductase, which is the rate limiting step in cholesterol synthesis and the target of statin-based therapies. After an additional 19 steps, mevalonate is transformed into cholesterol.[40] The endogenous pathway is regulated in a negative feedback mechanism based on the amount of exogenous cholesterol absorbed.

In plasma, lipoproteins are the transporters of lipid molecules and consist of cholesterol, triglycerides, and a surface layer of phospholipids functioning as a detergent, allowing these hydrophobic molecules to be mobilized in the aqueous environment of plasma. Lipoproteins contain specific apolipoproteins that interact with specific enzymes and receptors, and in combination with the specific lipid composition of the particle, define its class and function. The hydrophobic components of lipoproteins, including cholesteryl ester and triglyceride, are carried within the core of the spherical lipoprotein particles. Plasma lipoproteins are classified based on size and density, ranging from very large triglyceride-rich lipoproteins with a density of less than 0.94 g/mL (chylomicrons) to small HDL molecules of density up to 1.21 g/mL.[1,39,41]

Chylomicrons made in the intestine have a plasma density of less than 0.93 g/mL, and range in weight (50 to 1000 × 10^6 Da) and size (diameter: 75 to 1200 nm).[41,42,45] These particles predominantly contain triglyceride (85% by weight) and include 3% cholesteryl ester.[39] They contain fat-soluble vitamins, including vitamin A as retinyl palmitate, carotenoids, vitamin D, vitamin E as α-tocopherol or γ-tocopherol, and vitamin K. Each chylomicron particle has an apoB48, and after chylomicrons are released into the lymphatic system, they pick up additional lipoproteins including apolipoprotein AI (apoAI), apoAIV, and the C apolipoproteins (apoCI, apoCII, and apoCIII).

After chylomicrons are transported to the serum, lipoprotein lipase (LPL) on the surfaces of adipocytes and myocytes cleave free fatty acids off the glycerol backbones of trygiclerides.[46] ApoCII acts as a cofactor for LPL in this reaction, whereas apoAV promotes LPL-mediated triglyceride lipolysis. The free fatty acids are taken up by adjacent cells, or bind to albumin for transport to other tissues including the liver. In adipocytes, the free fatty acids are converted back into triglyceride as a form of energy storage. ApoCIII inhibits the process of lipolysis.

After the majority of chylomicron triglyceride has been removed, chylomicrons obtain cholesteryl ester from HDL in exchange for triglyceride via the action of HDL-specific cholesteryl ester transfer protein (CETP). The remainder of the chylomicron, now called a chylomicron remnant, is taken up by the liver through the binding of surface apoE to the hepatic LDL or lipoprotein receptor-related protein (LRP) receptor. In the process of metabolizing into remnant particles, chylomicrons transfer apoAI, apoAIV, apoAV, and the C apolipoproteins to HDL, but still retain their apoB48 and apoE. Of note, the plasma residence time of chylomicron triglyceride is roughly 5 to 10 minutes compared to 5 hours for apoB48.[39,41,45]

VLDLs, which have plasma densities of 0.93 to 1.006 g/mL, are synthesized in the liver and range in molecular weight (10 to 80 × 10^6 Da) and size (diameter: 30 to 80 nm).[1,39] These particles are abundant in triglyceride (60% by weight) and contain 10% cholesteryl ester. These lipoproteins are proteomically similar to chylomicrons but approximately one-tenth the typical chylomicron diameter at the time of secretion, contain a higher proportion of cholesterol ester, and contain the larger apoB100. Additional apolipoproteins include CI, CII, CIII, and E. In the prandial state, the average daily production of apoB100 in humans is approximately 20 mg/kg/day.[39] When VLDLs enter plasma, the particles obtain apoE from HDL. VLDL triglyceride is removed similarly to chylomicrons via LPL, with free fatty acids converted into triglyceride in adipocytes for energy storage. After the action of LPL, remnant VLDL particles are known as intermediate-density lipoproteins (IDLs), which have roughly equal amounts of cholesterol and triglyceride.[47] The liver internalizes IDL through the binding surface IDL apoE to the LDL and LRP receptors. Remaining serum IDL is converted to LDL by the enzyme hepatic lipase, found on the surface of liver cells.[39]

LDLs, the end product of VLDL catabolism, are the predominant plasma lipoproteins. These lipoproteins have molecular weights of 2 × 10^6 Da, diameters of 18 to 25 nm, and plasma densities of 1.019 to 1.063 g/mL.[1,39,41,48] These particles are rich in cholesteryl ester (40% by weight) and contain 5% triglyceride. The predominant protein in LDL is apoB100, but LDL particles may contain trace amounts of CI, CII, CIII, and apoE. In adults, LDL contains approximately

60% to 70% of total cholesterol and roughly 80% to 90% of the total apoB. LDL apoB has a plasma residence of approximately 3.5 days, and is taken up by various tissues through the LDL receptor.[39] LDL has been divided into large LDL (density 1.019 to 1.044 g/mL) and small dense LDL (density 1.044 to 1.063 g/mL). Small dense LDL is considered more atherogenic than large LDL, yet specifically measuring small dense LDL does not clearly improve risk prediction over and above total LDL particle or apoB concentrations.[49]

HDLs (density 1.063 to 1.21 g/mL) contain variable proportions of triglyceride, cholesterol, and cholesterol ester, dependent on particle size.[1,39,41,50] The major proteins of HDL are apoAI and apoAII. HDL-specific apoAI has a residence time of approximately 4.5 days. HDLs are key participants in reverse cholesterol transport, in which HDL particles obtain cholesterol from cells in peripheral tissues, and then deliver cholesterol to the liver for excretion or transfer it to triglyceride-rich lipoproteins in exchange for triglyceride via the action of CETP.[39] In HDL, the enzyme lecithin–cholesterol acyltransferase catalyzes the formation of the cholesteryl esters, which are later transferred to lipoproteins via CETP. Decreased HDL-C of less than 40 mg/dL is often considered a significant cardiovascular risk factor.

ETIOLOGIES AND RISK FACTORS

Etiologies of xanthomas may be categorized into (a) primary dyslipidemias, which may carry a heritable or familial component; (b) secondary dyslipidemias, which are typically acquired but may unmask an underlying genetic predisposition; or (c) normolipemic states in which there is no underlying dyslipidemia. The normolipemic state is much rarer compared to primary and secondary dyslipidemias.

PRIMARY (GENETIC) DYSLIPIDEMIAS

Type I hyperlipidemias are characterized by an increase in serum chylomicrons. Deficiencies or functional defects in LPL or apoCII, both of which have autosomal recessive inheritance, are common genetic mutations underlying this disorder.[51] Without the ability to cleave triglycerides in peripheral tissues, chylomicrons accumulate with triglyceride levels 10 to 100 times above normal serum triglyceride limits. Serum triglyceride levels are commonly above 1000 mg/dL, but morbidity may be seen at much lower levels. Severe hypertriglyceridemia can lead to episodic eruptive xanthomas that may quickly subside without intervention. Other clinical manifestations include frequent episodes of acute pancreatitis, neuropathy, arthralgias, hepatosplenomegaly, and lipemia retinalis, which may herald the development of eruptive xanthomas.[52] Repeated episodes of acute pancreatitis may lead to chronic pancreatitis and eventual diabetes, which itself is a risk factor for further dyslipidemia.

Type IIa hyperlipidemias are commonly caused by familial hypercholesterolemia and result in abnormally high circulating levels of LDL-C. Mutations either in the LDL receptor, which clears circulating LDL, or in apoB, which serves as a cofactor in the binding between LDL and its receptor, are common genetic defects.[11,12,53] Rarer causes of familial hypercholesterolemia include (a) the autosomal recessive form resulting from defects in LDL receptor adaptor protein 1 (LDLRAP1), which helps traffic LDL bound to LDL receptors intracellularly for degradation, and (b) mutations in proprotein convertase subtilisin/kexin type 9 (PCSK9). PCSK9 also promotes degradation of LDL receptors and therefore results in less availability of LDL receptors on the surface of hepatocytes and other cells.[54]

Familial hypercholesterolemia is typically classified into heterozygous or homozygous forms. The homozygous form manifests with cardiovascular disease and xanthoma formation at a much younger age. Familial hypercholesterolemia is further categorized into 1 of 5 classes.[55] Class I involves a complete absence of LDL receptor synthesis; Class II involves a defect in transportation of the LDL receptor from the endoplasmic reticulum to the Golgi apparatus within cells; Class III involves abnormal binding between the LDL receptor and LDL as a result of mutations in the receptor itself or in apoB; Class IV involves correct binding between the LDL receptor and LDL, with a defect in endocytosis of LDL; and Class V results from dysregulation in recycling of the LDL receptor. Patients with familial hypercholesterolemia or Type IIa hyperlipidemia in general are prone to developing tendinous xanthomas, especially over the Achilles tendon. Such xanthomas can also be seen in patients who synthesize excess cholestanol or overabsorb plant sterols. Both cholestanol and plant sterols (β-sitosterol and campesterol) are then carried in excess on LDL particles.

Type IIb hyperlipidemia is commonly caused by familial combined hyperlipidemia, resulting in elevated LDL and VLDL concentrations. Although the condition is inherited, other factors, including excessive alcohol intake, obesity, hypothyroidism, and diabetes, may exacerbate the expression of this disorder. The pathogenesis stems from an increase in hepatic VLDL production, although the exact mechanisms contributing to VLDL overproduction are still not clear. Postulated mechanisms include increased free fatty acid delivery to the liver; decreased LPL activity either from mutations, insulin resistance, or increased apoCIII concentrations; an increase in dense LDL particles from CETP overactivity or an increase in VLDL precursors; insulin resistance from the aforementioned factors (ie, obesity, alcohol intake); and defects in adipose tissue metabolism.[56,57] Elevated LDL may be a result of heterozygous mutations in LPL and possible mutations in *APOA5* and *APOC3*. Xanthomas are rarely seen with Type IIb hyperlipidemia.

The Type III phenotype, referred to as dysbetalipoproteinemia, results in elevated concentrations of remnant lipoprotein particles, either chylomicron remnants or VLDL remnants including IDL. A defect in

apoE 2/2 is a major causative factor and has implications in the development of hyperlipidemia and eventual atherosclerosis.[58] As discussed in "Pathogenesis" section, apoE plays a central role in the clearance of triglyceride-rich particles by facilitating the binding of remnant particles to the LDL and LRP receptors. Defects in this protein therefore result in elevated remnant particle concentration, which is highly atherogenic and leads to the development of characteristic palmar xanthomas. Most causes of hyperlipidemia and subsequent xanthoma formation occur with homozygous defects; those with a heterozygous defect may, paradoxically, have decreased cholesterol because of a compensatory upregulation in LDL receptor concentration, increased binding of apoB100 to the LDL-receptor instead, and decreased conversion of VLDL to LDL resulting in lower serum concentrations of LDL.[14,15] As with the aforementioned dyslipidemias, concomitant secondary causes, such as nephrosis, obesity, and diabetes, may be required for phenotypic expression in heterozygous patients. Ongoing work evaluating polymorphisms in other interacting cofactors, such as mutations in apoCIII and apoAV, continues to mold the pathophysiology underlying this genetic disorder.[59] Aside from palmar xanthomas, tuberoeruptive xanthomas are the most common xanthoma seen with Type III disorders.

The Type IV disorder, known as familial hypertriglyceridemia, results in an isolated elevation of VLDL. This phenotype is relatively common and, as a result of increased triglyceride synthesis, results in increased VLDL synthesis and secretion.[60,61] There is no concomitant increase in LDL, which distinguishes this disorder from the Type IIb hyperlipidemia; triglycerides are carried in plasma primarily by VLDL, distinguishing this disorder from the Type I hyperlipidemia where elevated triglyceride levels are a result of the accumulation of chylomicrons. Although VLDL carries apoB and is considered atherogenic, the increase in risk of cardiovascular disease with familial hypertriglyceridemia is modest in isolation given normal or even low levels of LDL and apoB.[60,61] However, the dyslipidemia is associated with obesity, diabetes, and development of insulin resistance, and these patients are at substantially elevated cardiovascular risk. The exact molecular basis underlying excess VLDL secretion is not known. As with other conditions associated with hypertriglyceridemia, eruptive xanthomas may be seen, but are rare in comparison with hyperchylomicronemic dyslipidemias. Most patients are without cutaneous manifestations of the dyslipidemia.

The Type V dyslipidemia consists of elevated VLDL and chylomicrons; consequently, patients are at increased risk of eruptive xanthomas secondary to hypertriglyceridemia. The genetic mechanisms underlying this disorder result from a combination of the aforementioned mutations, resulting in Types I and IV dyslipidemia. It is commonly seen in the setting of diabetes with underlying Type IV dyslipidemia, progressing to increasing extent of impairment in LPL activity or high dietary fat intake and chylomicron accumulation, and hyperchylomicronemia in combination with underlying excess VLDL concentration typical of common diabetic dyslipidemia.

It is important to note that the Fredrickson-Levy-Lees categories do not factor HDL-C levels or lipoprotein(A) levels into its schema. This was a limitation noted by the authors in their original papers. They specifically recognized that further genetic dyslipidemias would be discovered with more advanced genotyping and fractionation techniques. To this point, tuberoeruptive xanthomas may be observed in marked HDL deficiency. Other known genetic lipoprotein disorders not formerly classified by Fredrickson, Levy, and Lees that are associated with premature coronary heart disease include heritable lipoprotein(A) levels in excess of the 80th population percentile and seen in approximately 20% of families with premature coronary heart disease, and familial hypoalphalipoproteinemia (isolated low HDL-C <40 mg/dL), which may be seen in 5% of families.[39,62,63] Patients with disorders impairing HDL reverse cholesterol transport function occasionally develop tendinous or tuberoeruptive xanthomas, although cutaneous xanthomas are rarely attributable to elevations in lipoprotein(A).

SECONDARY (ACQUIRED) HYPERLIPIDEMIA

Many of the aforementioned genetic dyslipidemias require secondary, acquired causes of hyperlipidemia for phenotypic expressions, including xanthomas. Several categories of secondary hyperlipidemia have been identified, including hematologic, hepatic, nephrotic, endocrinologic/metabolic, and drug-induced.

Various types of xanthomas, including tuberoeruptive and planar xanthomas, have been observed in patients with hematologic and oncologic abnormalities, including monoclonal gammopathies, multiple myeloma, lymphoma, and various forms of leukemia.[64,65] Immunoglobulins may bind to plasma lipoprotein particles and, in some cases, markedly delay the clearance of chylomicron remnants or VLDL remnants, resulting in combined hyperlipidemia or dysbetalipoproteinemia. Solid tumors also have been linked to elevated LDL and triglyceride concentrations, possibly the result of a shared pathway in cellular proliferation and endogenous cholesterol formation through the mevalonate pathway, which increases the guanosine triphosphatases Ras and Rho.[66] An alternative explanation linking malignancy and dyslipidemia may be the existence of an underlying metabolic syndrome, which has been demonstrated to be a risk factor for cancer development.[67]

Hepatic causes of dyslipidemia include prolonged biliary tree obstruction leading to the accumulation of serum cholesterol,[68] which may take the form of a novel lipoprotein-like particle Lp-X.[69] Common causes of chronic biliary obstruction include primary biliary cirrhosis and secondary biliary obstruction, leading to hypercholesterolemia. Long-term hypercholesterolemia may lead to plane xanthomas (beige-orange plaques on hands, feet, and trunk), xanthelasma, and,

occasionally, tuberous xanthomas. Patients with prolonged biliary obstruction may also manifest jaundice, pruritus, and hyperpigmentation of the skin. Treatment involves relieving the underlying cause of obstruction.

Metabolic and endocrinologic causes of dyslipidemia include pregnancy, thyroid disorders, and the metabolic syndrome spectrum, which includes obesity and diabetes. Expected changes during normal pregnancy include hypertrophy of maternal adipocytes and a subsequent increase in insulin and hormonal (ie, estrogen and progesterone) secretion, which leads to a disproportionate increase in lipogenesis (especially triglyceride formation) compared to lipolysis.[70] Patients with predisposed hypertriglyceridemia are nevertheless at increased risk for eruptive xanthoma formation in pregnancy with the added stimulus of pregnancy-induced triglyceridemia.

Thyroid dysfunction is well established as a modifiable factor in dyslipidemia, with a direct, linear relationship observed between increasing thyroid-stimulating hormone levels and total cholesterol, LDL-C, and triglycerides.[71] Thyroid hormones, particularly triiodothyronine (T_3), upregulate LDL receptors by increasing LDL receptor gene expression, increasing the activity of LPL, and increasing the affinity of remnant particles to the LDL receptor. As a result, hypothyroidism may promote increased concentrations of serum lipid subfractions through the reversal of these mechanisms, but also by increasing insulin resistance, increasing overall obesity, and decreasing the function of CETP.[71] Because of the mixed effects of decreased thyroid levels on lipid metabolism, clinical hypothyroidism may mimic the Type IIa or Type III phenotypes. Patients are therefore at increased risks for tendon xanthoma formation or eruptive xanthomas.

Diabetes is perhaps the most important factor on the metabolic syndrome/obesity spectrum. Because of decreased peripheral insulin resistance and resultant lipolysis with free fatty acid delivery to hepatic cells, patients with diabetes have increased rates of production and secretion of VLDL.[72] Peripheral LPL, which is stimulated by insulin, may be decreased in patients with diabetes. Finally, postprandial chylomicrons may have defective clearance in diabetes. The combination of these mechanisms may lead to a number of lipid disorders, including chylomicronemia, hypertriglyceridemia, increased LDL, and increased VLDL.[72] Consequently, all types of xanthomas may be seen in patients prone to dyslipidemia with underlying diabetes.

Several drugs and toxins may result in dyslipidemia. Because of the extensive list of known therapeutics that affect lipid metabolism, general trends in lipid metabolism based on therapeutic category are discussed here. Drugs that increase LDL concentration include protease antineoplastic agents (ie, danazol with a 10% to 40% increase), antiretroviral therapy (ie, protease inhibitors with a 15% to 30% increase), anabolic steroids (20% increase), immunosuppressant agents (0% to 50% increase), and thiazide diuretics (5% to 10% increase).[73] Several drugs that increase serum triglyceride levels include estrogen (40% increase), antiretrovirals (15% to 200% increase), immunosuppressant agents (0 to 70% increase), thiazide diuretics (5% to 15% increase), beta-blockers (10% to 40% increase), and antipsychotics (20% to 50% increase).[73]

NORMOLIPEMIC XANTHOMAS

Interestingly, the 2 nonheritable types of xanthomas without a predilection for cutaneous manifestations are often seen in normolipemic patients. Because of the rarity of xanthoma disseminatum, few risk factors have been found. Verruciform xanthomas may be uncovered by chronic inflammatory states and local oromucosal trauma, given the propensity for mucosal lesions. Prior studies have failed to find a link to human papillomavirus or other preceding viral infections.[27,74] However, poor oral hygiene, prior dental abscesses, mechanical stimuli, tobacco abuse, alcohol exposure, dental implants, and overall immunocompromise are postulated as risk factors.

The even rarer diffuse normolipemic plane xanthoma is characterized by symmetric plaques found diffusely in the neck, flexural areas, and upper trunk.[22,23,75] This entity is associated with hematologic disorders, including multiple myeloma and monoclonal gammopathies.[75] Disorders in the reticuloendothelial system also are linked to diffuse xanthoma formation.

DIAGNOSIS

Accurate diagnosis of xanthoma is important as it can point to underlying systemic disease or hyperlipidemia. Even though the morbidity from cutaneous xanthomas is limited, pinpointing hyperlipidemia may help identify early lifestyle and treatment options that would help slow the progression of clinical atherosclerotic cardiovascular disease.

SUPPORTIVE STUDIES AND LABORATORY TESTING

For primary hyperlipidemias, the traditional methodologies used by Fredrickson, Levy, and Lees included direct lipid fractionation through electrophoresis and ultracentrifugation.[1] In modern-day medicine, the initial standard approach is to order a plasma lipid profile. This test provides a measurement of the concentration of total cholesterol, triglyceride, HDL-C, and calculated LDL-C. A total cholesterol of greater than 240 mg/dL and associated LDL-C value of greater than 160 mg/dL are classified as elevated and are associated with an increased cardiovascular risk, with cholesterol less than 200 mg/dL and LDL-C less than 100 mg/dL being classified as optimal for the majority of patients. A triglyceride level of greater than 1000 mg/dL is classified as markedly elevated and is associated with an increased risk of pancreatitis, as well as eruptive xanthomas.

Occasionally, patients will have elevated total cholesterol levels as a result of elevated levels of β-sitosterol (>225 µmol/mmol of total cholesterol) and campesterol (>270 µmol/mmol of total cholesterol) as seen in phytosterolemia, or elevated cholestanol as seen in cerebrotendinous xanthomatosis. These abnormalities may only be detected by measuring plasma sterols using gas chromatography.

Although the definition of the primary hyperlipidemia is based on which lipoprotein subfraction(s) is (are) present and elevated in concentration, as of this writing there is no formal consensus on what cutoffs should be used for these definitions. Furthermore, while total cholesterol and HDL-C are provided in the lipid panel, obtaining direct measurement of lipoprotein subfractions, including VLDL, IDL, LDL, and chylomicrons, is only possible through more complex assays such as ultracentrifugation.[76] Other methodologies are now clinically available, such as ion mobility and nuclear magnetic resonance spectroscopy, to measure lipoprotein particle concentrations.[77,78]

Recently, an algorithm proposed by Sniderman and colleagues classifies patients into one of the Fredrickson-Levy-Lees phenotypes based on 3 lipid parameters: total cholesterol, apoB concentration, and triglyceride levels.[79] This algorithm has not yet been validated in large-scale studies. Definitive classification relies on genotyping, including apoE status.

Depending on the underlying clinical suspicion, further tests may be warranted to assess secondary causes of dyslipidemia. Fasting glucose tolerance testing and hemoglobin A_{1c} values help with diagnosing diabetes. In patients with proteinuria noted on standard urinalysis, a 24-hour urine protein collection may be warranted to assess for nephrotic syndrome. Both diabetes and renal disorders are associated with elevated triglycerides and decreased HDL-C. Both hypothyroidism and obstructive liver disease (with elevated levels of alkaline phosphatase and total bilirubin) are often associated with elevated LDL-C. Hypothyroidism is associated, typically, with elevated thyroid-stimulating hormone levels, but decreased free thyroxine (T_4) levels. Hepatocellular disease or fatty liver with elevated transaminases is often observed in patients with hypertriglyceridemia. For hematologic conditions, serum and urine protein electrophoresis, serum free light chains, and immunofixation assays may help identify conditions such as multiple myeloma and monoclonal gammopathy if the clinical suspicion is high. Certain tumor markers, such as carcinoembryonic antigen, cancer antigen 19-9, and prostate-specific antigen may help identify solid malignancies if history points to one.

Serum genetic testing is described in the "Counseling and Screening" section.

PATHOLOGY

Foam cells are macrophages that contain lipid and are histopathologically characteristic of xanthomas (Fig. 126-10).

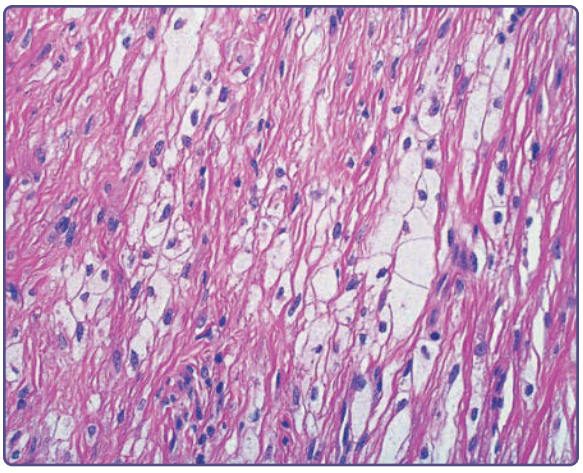

Figure 126-10 Example of foam cells seen histologically from a tuberous xanthoma.

Slight variations in associated cells and surrounding material (eg, amount of fibrosis and inflammatory cells) may be seen, depending on the type of xanthoma.[31,37,80-82] For example, eruptive xanthomas often consist of lymphoid cells, histiocytes, neutrophils, and, frequently, free lipid in the dermis.[19,81] Tuberous xanthomas contain foam cells and cholesterol clefts.[20] Cholesterol is doubly refractile, whereas other types of lipid are not. Tendon xanthomas are histopathologically similar to tuberous xanthomas; however, xanthelasmas can be differentiated by their superficial location.[31,32] Along with the foam cells, xanthelasmas may reveal striated muscle, vellus hair, and/or a thinned epidermis, indicative of the superficial location.[7] Both tuberous and tendinous xanthomas may have associated fibrosis, with greater degrees of fibrosis indicating older lesions.

Although the diagnosis of xanthomas is made clinically, certain histopathologic considerations may help differentiate similar appearing lesions. Necrobiotic xanthogranuloma, a primarily granulomatous disease that may be mistaken for planar xanthoma, largely involves degenerated collagen, granulomatous inflammation, multinucleate giant cells, cholesterol clefts, and lymphoid follicles on pathology specimens.[83] Basal cell carcinoma, which may be mistaken for xanthelasmas with a similar "waxy" appearance, involves proliferation of the basal epithelial layer, whereas sebaceous hyperplasia results in an increase in the number of sebaceous glands.[7] Eruptive xanthomas may be mistaken for granuloma annulare, which may involve histiocytes, necrobiosis, multinucleated giant cells, fibrin deposition, and perivascular and interstitial lymphocytes. Tendinous xanthomas sometimes clinically appear as rheumatoid nodules, gouty tophi, or erythema elevatum diutinum. Rheumatoid nodules appear as granulomatous tissue with multinucleated giant cells, histiocytes, plasma cells, and eosinophils, whereas gouty tophi may appear as edematous synovium with characteristic uric acid crystals under polarized light.[84] Finally, verrucous xanthomas may be confused for condylomata, which appear as vacuolated

keratinocytes and stain positive for human papillomavirus, or squamous cell carcinoma, which consists of a proliferation in the squamous epithelial layer.[74]

IMAGING

Imaging is usually unnecessary for the diagnosis of xanthomas, as clinical appearance and laboratory tests typically suffice. In cases where diagnosis is unclear, ultrasonography or MRI may be considered. In ultrasonography, xanthomas typically appear as hypoechoic nodules with an overall heterogeneous pattern. Under MRI, xanthomas appear as hyperintense lesions on T1-weighted and T2-weighted images with possible diffuse reticulate patterns.[85] The use of positron emission tomography has been reported in cases of xanthoma disseminatum to aid in prognosticating the extent of disease.[86]

Imaging may be necessary, however, to further diagnose secondary causes of dyslipidemia. For thyroid abnormalities, diagnostic algorithms involve the use of both thyroid ultrasonography and sestamibi scans. Abnormal liver function tests may involve the use of ultrasonography, triple-phase CT scans, or MRI for further characterization of possible lesions. Renal disorders typically involve the use of renal ultrasonography to assess parenchymal changes and urinary system abnormalities, including obstruction and dilation. Underlying hematologic or oncologic disorders require imaging-based staging, which is beyond the scope of this chapter.

For patients with diagnosed primary dyslipidemias, evaluating for coronary artery disease, especially with a history of chest pain, may involve noninvasive or invasive imaging. Noninvasive stress tests involve transthoracic echocardiograms, nuclear imaging, positron emission tomography, or MRI. For a global assessment of coronary artery disease without a stress test, specialized CT scans to assess for coronary artery calcium or coronary CT angiograms may be appropriate. In patients who are thought to have hemodynamically significant coronary lesions, invasive coronary arteriograms may be indicated. Intravascular ultrasonography has been used to assess for plaque burden in clinical trials, but is not considered a clinical tool aside from its use in percutaneous coronary interventional procedures.

DIFFERENTIAL DIAGNOSIS

Table 126-1 outlines the differential diagnoses of xanthelasma, planar xanthomas, eruptive xanthomas, tendinous and tuberous xanthomas, verrucous xanthomas, and xanthoma disseminatum.

MANAGEMENT

The cornerstone of xanthoma therapy involves addressing the underlying hyperlipidemia, typically through lifestyle changes and medication management. Even though xanthomas themselves have relatively benign courses and are usually treated for cosmetic purposes, the underlying dyslipidemia may progress to atherosclerotic cardiovascular disease and warrants further treatment consideration. This is especially important given the morbidity and mortality stemming from any untreated, underlying dyslipidemia.

TABLE 126-1
Differential Diagnoses

- For xanthelasma: sebaceous hyperplasia, juvenile xanthogranuloma, syringoma, nodular basal cell carcinoma
- For planar xanthomas: necrobiotic xanthogranuloma, syringeal palmar keratoderma, digital fibromatosis
- For eruptive xanthomas: generalized granuloma annulare, molluscum contagiosum, subepidermal calcified nodules, xanthoma disseminatum, sarcoidosis
- For tendinous and tuberous xanthomas: rheumatoid nodules, gouty tophi, subcutaneous granuloma annulare, erythema elevatum diutinum
- For verrucous xanthomas: condylomata, oral papilloma, verrucous carcinoma, squamous cell carcinoma
- For xanthoma disseminatum: benign cephalic histiocytosis, reticulohistiocytoma, juvenile xanthogranuloma, generalized eruptive histiocytoma, progressive nodular histiocytosis

INTERVENTIONS

LIFESTYLE–EXERCISE

Lifestyle changes represent the initial intervention for all lipid disorders, as reflected in clinical guidelines, including those from the National Cholesterol Education Program, American College of Cardiology, American Heart Association, and National Lipid Association.[87] Increased aerobic physical activity (at least 30 min/day of walking, riding on a bicycle, or some other weekly activity totaling 900 kcal of energy expenditure) as well as weight control are important for preventing diabetes, lowering total cholesterol and LDL-C by up to 3.9 mg/dL, lowering triglycerides by approximately 7.1 mg/dL, and raising HDL-C levels by 1.9 to 2.5 mg/dL.[87] Greater benefits are seen in patients with established cardiovascular disease. Physical inactivity may result in the opposite trends in lipid values.

LIFESTYLE–SMOKING

Tobacco abuse has a similar effect to physical inactivity, and may lower HDL-C levels while concomitantly increasing total cholesterol, LDL-C, and triglyceride levels.[88] Smoking cessation aids include nicotine patches and nicotine gum, while prescription medications include bupropion and varenicline. Tobacco use reduces activity of LPL and will tend to exacerbate hypertriglyceridemic dyslipidemias.

LIFESTYLE–DIET

In patients with elevated LDL-C and other high-risk patients with known atherosclerotic cardiovascular disease, referral to a nutritionist for dietary restriction is appropriate. Prior systematic reviews have shown patients referred for counseling have reductions in total cholesterol and LDL-C. Dietary management involves goals set forth by therapeutic diets such as the Mediterranean diet, which is high in monounsaturated fats and limits consumption of red meat and dairy products, and the Portfolio Diet, which is plant based and consists of soluble fiber, soy, plant sterols, and almonds. These diets may further reduce total cholesterol and LDL-C levels.[87]

Diets specifically targeted toward lowering chylomicron concentrations and triglycerides include a fat-restricted diet, typically less than 15% of total calories in hyperchylomicronemia syndromes. Furthermore, a low glycemic, carbohydrate-restricted diet is recommended in insulin-resistance states and hypertriglyceridemic disorders (eg, Types IIb and IV) where the problem is mainly excess VLDL secretion.

LIFESTYLE–WEIGHT MANAGEMENT

Excess weight or obesity is the most common "second hit" in secondary dyslipidemias and will exacerbate insulin resistance in a variety of tissues and organs, result in hypersecretion of VLDL, contribute to the formation of the metabolic syndrome and its related disorders, and reduce LPL activity. Pathogenic effects from excess adipocytes, termed *adiposopathy* or *sick fat*, may result in excess hyperlipidemia through impaired fatty acid storage and subsequent increases in circulating free fatty acids.[89] Based on recommendations from the American College of Cardiology, American Heart Association, and The Obesity Society, even sustained weight losses of 3% to 5% will result in beneficial effects on triglyceride and blood glucose levels. Overweight adults should aim for a 500 to 750 kcal/day energy deficit, which typically amounts to 1200 to 1500 kcal/day for women and 1500 to 1800 kcal/day for men.[90]

MEDICATIONS

STATIN THERAPY

Statins are the first-line pharmacotherapy for lowering LDL-C. The rate-limiting enzyme in endogenous cholesterol synthesis is HMG-CoA reductase. Statins competitively inhibit this enzyme, decreasing cellular cholesterol synthesis by up to 80%. The cells in the body respond by increasing the level and activity of surface LDL receptors, enhancing the clearance of LDL particles from the bloodstream.[91] Statins may also improve endothelial function, increase plaque stability, and prevent thrombus formation. Statins are typically categorized based on their potency, the lipid-lowering effect per unit dose of the particular statin, and intensity, which represents the overall lipid-lowering effect of the therapy. High-potency, high-intensity statin therapies include rosuvastatin 20 mg or 40 mg and atorvastatin 40 mg or 80 mg daily. Common reported side effects include an increased propensity for diabetes (particularly in those predisposed) and, rarely, hemorrhagic stroke and rhabdomyolysis.

Several trials have evaluated the efficacy and potency of statin therapy in both primary and secondary prevention. Within the context of dyslipidemia, the American College of Cardiology and American Heart Association combined guidelines strongly recommend the use of statin therapy in individuals with established atherosclerotic cardiovascular disease and 3 other "statin benefit groups" in which statins may be considered based on clinician–patient risk discussions. These groups include those with LDL-C levels equal to or greater than 190 mg/dL, those with diabetes within an age range of 40 to 75 years with LDL-C values ranging between 70 and 189 mg/dL, and those with 10-year estimated risks of 7.5% or greater of developing a clinical atherosclerotic event, including myocardial infarctions or strokes.[5] The group with LDL-C levels equal to or greater than 190 mg/dL includes patients for whom there is a high clinical suspicion of familial hypercholesterolemia.

ADJUVANT THERAPY

Second-line medication therapy often includes ezetimibe, a specific inhibitor of the Niemann-Pick C-like protein 1 transporter, which is responsible for dietary cholesterol and plant sterol absorption within intestinal cells.[92] The use of ezetimibe is supported by multiple international guidelines, including the European Society of Cardiology and the National Institute for Health and Clinical Excellence. Recently, the 2016 Consensus Statement from the American College of Cardiology suggested the use of ezetimibe in patients with LDL-C equal to or greater than 190 mg/dL who are on statin therapy for secondary prevention and who have failed to achieve at least a 50% reduction in LDL-C levels on maximally tolerated statins.[6] Side effects are few, it is usually well tolerated with rare side effects include headaches and diarrhea.

Fibrates are common agents used to help lower triglyceride levels by 40% to 60%, and are especially useful in patients with elevated VLDL and chylomicrons.[93] Through activation of nuclear peroxisome-proliferator-activated receptors (PPARs), fibrates directly induce genes responsible for triglyceride catabolism, including PPAR-mediated synthesis of apoAI and apoAII needed for HDL formation, as well as PPAR-mediated increase in LPL activity. Fibrates may consequently raise HDL-C levels by 15% to 25% dependent on triglyceride levels, and are often used as adjuvant therapy to statins to further reduce rates of cardiovascular events or as therapy to manage hyperchylomicronemia for prevention of pancreatitis. Side effects include dyspepsia and myopathy.

Other agents that may help further reduce triglycerides include niacin, which may cause triglyceride reductions of 30% to 50% and also raise HDL-C levels by 20% to 30%. The exact mechanism of niacin is not precisely known, although it may lower the release of adipose free fatty acids and increase the activity of LPL. Common side effects include flushing, pruritus, and, occasionally, GI symptoms, including nausea and vomiting.

Omega-3 fatty acids may also help reduce triglycerides by 25% to 50%, but may increase LDL-C levels by 5% to 10%.[93,94] The increase in LDL-C is usually without increase in LDL particle concentration. Omega-3 fatty acids in fish oil are thought to be anti-inflammatory mediators and direct inhibitors of hepatic VLDL secretion through decreased triglyceride synthesis among other mechanisms, including inhibition of diacylglycerol acyltransferase, which catalyzes the final step in triacylglycerol synthesis.[95]

Lomitapide was approved by the U.S. Food and Drug Administration (FDA) in 2012 for use in patients with homozygous familial hypercholesterolemia.[96] The agent inhibits microsomal triglyceride transfer protein, which is responsible for loading triglycerides onto apoB in hepatic VLDL particles. LDL-C reductions in small studies ranged from 30% to 50%. Adverse events included diarrhea, hepatic toxicity, and embryotoxicity in pregnant patients. As a result of these toxicities, the use of the drug is restricted to a subset of certified physicians. Mipomersen subsequently was approved by the FDA in 2013 in patients with homozygous familial hypercholesterolemia. The mechanism of action involves direct binding of apoB messenger RNA, leading to decreased production of apoB, a key protein in VLDL, IDL, and LDL particle constitution.[97] Small trials have demonstrated LDL-C decreases of 25% to 47%, with side effects including injection-site reactions, flu-like symptoms, and increase in transaminases.

PCSK9 INHIBITORS

The FDA has approved a new class of injectable medications, PCSK9 inhibitors, for the treatment of dyslipidemias in patients refractory to standard medical therapy. PCSK9 normally binds to LDL receptors on the surface of cells, mainly hepatocytes, and induces their clearance via phagocytosis and subsequent degradation. By blocking the action of PCSK9, these inhibitors increase the availability of surface LDL receptors, thereby helping to clear circulating LDL.[54] Currently, 2 formulations are clinically available: evolocumab and alirocumab. FDA indications currently are limited to patients with familial hypercholesterolemia or those with established atherosclerotic cardiovascular disease who are on diet therapy and maximally tolerated statin therapy, and in need of additional LDL-C lowering. Early randomized controlled trials showed robust LDL-C lowering in a variety of patient populations and that clinically approved PCSK9 inhibitor regimens reduce LDL-C by approximately 60% on average. Subsequent studies with evolocumab have shown plaque regression and the large clinical outcomes trial FOURIER (Further Cardiovascular Outcomes Research With PCSK9 Inhibition in Patients With Elevated Risk) met its primary end point for cardiovascular event reduction. Adverse effects may include myalgia, ophthalmologic complaints, headaches and neurologic dysfunction, and injection-site reactions.

FUTURE OPTIONS

Several novel medications are in clinical development, most notably CETP inhibition, which has failed to improve clinical outcomes in the first 3 large outcomes trials.[98] Other targets include adenosine triphosphate-citrate lyase and adenosine monophosphate-activated protein kinase (ETC-1002), as well as thyromimetics.

TREATMENT OF SECONDARY DYSLIPIDEMIAS

Specific medical management of secondary dyslipidemias, including, for example, hepatic, endocrinologic, and renal causes, are beyond the scope of this chapter. However, recognition of secondary causes and their associated treatments should be initiated in any patient with overt dyslipidemia.

PROCEDURES

BIOPSY

Although the diagnosis of xanthomas is made on a clinical basis, biopsies may help in the diagnosis depending on the suspicion for alternate etiologies (Table 126-2). Specific histopathologic patterns expected with xanthomas and other diseases were previously discussed in the Pathology section.

SURGERY AND RELATED OPTIONS

Definitive management and removal of xanthomas involve surgical resection, especially if they cause functional impairment, and treatment of the underlying dyslipidemia. Surgery also may be pursued for mainly cosmetic reasons, especially with xanthelasmas. Other treatment options for xanthelasmas include ablative laser therapy or cryotherapy. Lesions may improve with lipid-lowering therapy. However, lesions will usually recur if the underlying dyslipidemia is not treated. In patients with homozygous familial hypercholesterolemia, a variety of surgical options have been tried without sustained clinical response. These include ileal bypass, portacaval shunt, and, in severe cases, liver transplantation to replenish functional LDL receptors. However, with the advent of apoB lipoprotein apheresis and PCSK9 inhibitors, surgical options are considered only in refractory cases.

TABLE 126-2
Characteristics of the Fredrickson-Levy-Lees Dyslipidemias

FREDERICKSON-LEVY-LEES PHENOTYPE	DEFECT	LIPOPROTEIN EXCESS	XANTHOMA TYPE
Type I (familial lipoprotein lipase [LPL] deficiency or familial hyperchylomicronemia)	Decreased LPL or apolipoprotein CII deficiencies	Chylomicrons	Eruptive
Type IIa (familial hypercholesterolemia or familial defective apolipoprotein B100)	Low-density lipoprotein (LDL) receptor defect	LDL	Tendinous Tuberous Xanthelasma intertriginous
Type IIb (familial combined dyslipidemia)	LDL receptor defect	LDL + very-low-density lipoprotein (VLDL)	Rarely seen
Type III (dysbetalipoproteinemia)	Apoprotein E 2/2 defect	Remnant particles	Palmar Tuberous Tuberoeruptive
Type IV (familial hypertriglyceridemia)	Increased VLDL production	VLDL	Rarely eruptive
Type V	Apolipoprotein CII deficiency and increased VLDL	VLDL + chylomicrons	Eruptive Rarely palmar

ApoB LIPOPROTEIN PHERESIS AND PLASMAPHERESIS

ApoB lipoprotein apheresis has been approved by the FDA for patients who are not at LDL-C goals despite standard medical therapy. It is typically used in patients with homozygous familial hypercholesterolemia and, occasionally, in those with severe elevation in elevations in lipoprotein(A) and recurrent atherosclerotic cardiovascular events. The process involves extracorporeal removal of apoB particles, including VLDL and LDL on a weekly or biweekly basis through an apoB-avid adsorbent column.[99] Expected LDL-C reduction is 50% to 75% per session, with 30% reduction over a several-month time averaged interval. Similar to dialysis, patients often have venous access through port or through an arteriovenous fistula, and side effects include hypotension, anemia, and headaches. Small studies suggest a reduction in the progression of atherosclerosis and incidence of myocardial infarctions in patients undergoing apoB lipoprotein apheresis.

Plasmapheresis is a related procedure and is used for severe chylomicronemia to remove chylomicrons and replenish functional LPL and apoCII in the setting of severe episodes of recurrent pancreatitis.

COUNSELING AND SCREENING

In addition to nutritional and smoking cessation counseling, two other forms of counseling include individual genetic screening and family screening. The most commonly tested primary dyslipidemia is familial hypercholesterolemia, but even this may be underdiagnosed in the United States, as less than 10% of cases are recognized. More than 1500 genetic defects in the LDL receptor, as well as mutations in apoB100 and PCSK9, have been identified. If patients meet clinical criteria for familial hypercholesterolemia, it is reasonable to consider pedigree analysis of first-degree and second-degree relatives, and perform genetic testing both for the patient and first-degree family members. Cascade genetic testing involves testing second-degree family members only if first-degree members test positive.[53] Even if patients do not meet overt criteria for familial hypercholesterolemia but clinical suspicion is still high, genetic testing may still be performed as these individuals (a) still have a chance for passing mutations to offspring, (b) may have elevated cholesterol levels at a later testing period, placing them at high risk for cardiovascular disease, and (c) may not have phenotypic expression of the disease. Furthermore, knowing the specific type of mutation (eg, if there are mutations in PCSK9) may further help tailor therapy for maximum lipid-lowering effect. However, it is important to note that upward of 40% of patients meeting clinical criteria may not test positive for any known genetic mutations.[11]

Hypertriglyceridemic states are only being genetically verified in very specialized centers. The Type III phenotype is most commonly investigated with apoE genotyping[100] in patients with suspected Type III dyslipidemia.

Xanthomas in children are uncommon and must always be investigated. The differential diagnosis for xanthomas in children includes homozygous familial hypercholesterolemia, phytosterolemia/sitosterolemia, cerebrotendinous xanthomatosis, and Alagille syndrome.

Alagille syndrome is an inherited syndrome of biliary hypoplasia leading to elevated serum cholesterol.[101] Children with Alagille syndrome have a characteristic facies with a prominent forehead, hypertelorism, pointed chin, and nasal dystrophy. Serum cholesterol is elevated when patients are young, but can decrease over time. Cirrhosis develops in approximately 12% of patients. Treatment includes medical

management or, if cirrhosis develops, liver transplantation. Xanthomas have been found to resolve after liver transplantation.

ACKNOWLEDGMENTS

The authors acknowledge Dr. Ernst J. Schaefer and Dr. Raul D. Santos for their authorship in the previous edition of this chapter.

REFERENCES

1. Fredrickson DS, Levy RI, Lees RS. Fat transport in lipoproteins—an integrated approach to mechanisms and disorders. *N Engl J Med*. 1967;276(1):34-44.
2. Goldstein JL, Schrott HG, Hazzard WR, et al. Hyperlipidemia in coronary heart disease II. Genetic analysis of lipid levels in 176 families and delineation of a new inherited disorder, combined hyperlipidemia. *J Clin Invest*. 1973;52(7):1544-1568.
3. Khezri F, Gibson LE, Tefferi A. Xanthoma disseminatum: effective therapy with 2-chlorodeoxyadenosine in a case series. *Arch Dermatol*. 2011;147(4):459-464.
4. National Cholesterol Education Program (NCEP) Expert Panel on Detection, Evaluation, and Treatment of High Blood Cholesterol in Adults (Adult Treatment Panel III). Third report of the National Cholesterol Education Program (NCEP) Expert Panel on Detection, Evaluation, and Treatment of High Blood Cholesterol in Adults (Adult Treatment Panel III) final report. *Circulation*. 2002;106(25):3143-3421.
5. Stone NJ, Robinson JG, Lichtenstein AH, et al. 2013 ACC/AHA guideline on the treatment of blood cholesterol to reduce atherosclerotic cardiovascular risk in adults: a report of the American College of Cardiology/American Heart Association Task Force on Practice Guidelines. *J Am Coll Cardiol*. 2014;63(25, pt B):2889-2934.
6. Lloyd-Jones DM, Morris PB, Ballantyne CM, et al. 2016 ACC expert consensus decision pathway on the role of non-statin therapies for LDL-cholesterol lowering in the management of atherosclerotic cardiovascular disease risk: a report of the American College of Cardiology Task Force on Clinical Expert Consensus Documents. *J Am Coll Cardiol*. 2016;68(1):92-125.
7. Deprez M, Uffer S. Clinicopathological features of eyelid skin tumors. A retrospective study of 5504 cases and review of literature. *Am J Dermatopathol*. 2009;31(3):256-262.
8. Tóth PP, Potter D, Ming EE. Prevalence of lipid abnormalities in the United States: the National Health and Nutrition Examination Survey 2003-2006. *J Clin Lipidol*. 2012;6(4):325-330.
9. Kit BK, Kuklina E, Carroll MD, et al. Prevalence of and trends in dyslipidemia and blood pressure among US children and adolescents, 1999-2012. *JAMA Pediatr*. 2015;169(3):272.
10. Goff DC, Bertoni AG, Kramer H, et al. Dyslipidemia prevalence, treatment, and control in the multi-ethnic study of atherosclerosis (MESA): gender, ethnicity, and coronary artery calcium. *Circulation*. 2006;113(5):647-656.
11. Santos RD, Maranhao RC. What is new in familial hypercholesterolemia? *Curr Opin Lipidol*. 2014;25(3):183-188.
12. Nordestgaard BG, Chapman MJ, Humphries SE, et al. Familial hypercholesterolaemia is underdiagnosed and undertreated in the general population: guidance for clinicians to prevent coronary heart disease: consensus statement of the European Atherosclerosis Society. *Eur Heart J*. 2013;34(45):3478-3490a.
13. Albuquerque EM, de Faria EC, Oliveira HC, et al. High frequency of Fredrickson's phenotypes IV and IIb in Brazilians infected by human immunodeficiency virus. *BMC Infect Dis*. 2005;5(1):47.
14. Mahley RW, Huang Y, Rall SC. Pathogenesis of type III hyperlipoproteinemia (dysbetalipoproteinemia). Questions, quandaries, and paradoxes. *J Lipid Res*. 1999;40(11):1933-1949.
15. Schaefer JR. Unraveling hyperlipidemia type III (dysbetalipoproteinemia), slowly. *Eur J Hum Genet*. 2009;17(5):541-542.
16. Menke A, Casagrande S, Geiss L, et al. Prevalence of and trends in diabetes among adults in the United States, 1988-2012. *JAMA*. 2015;314(10):1021.
17. Centers for Disease Control and Prevention, National Center for Chronic Disease Prevention and Health Promotion. *National Chronic Kidney Disease Fact Sheet*, 2017. https://www.cdc.gov/diabetes/pubs/pdf/kidney_factsheet.pdf. Accessed May 29th, 2018.
18. Sprecher DL, Schaefer EJ, Kent KM, et al. Cardiovascular features of homozygous familial hypercholesterolemia: analysis of 16 patients. *Am J Cardiol*. 1984;54(1):20-30.
19. Kashif M, Kumar H, Khaja M. An unusual presentation of eruptive xanthoma. *Medicine (Baltimore)*. 2016;95(37):e4866.
20. Fujiwara S, Oka M, Kunisada M, et al. Severe xanthomatosis with prominent tuberous xanthomas on the cheeks and the nasal dorsum in a patient with type IIa hyperlipoproteinemia. *Eur J Dermatol*. 2013;23(4):517-518.
21. Terasaki F, Morita H, Harada-Shiba M, et al. Familial hypercholesterolemia with multiple large tendinous xanthomas and advanced coronary artery atherosclerosis. *Intern Med*. 2013;52(5):577-581.
22. Groszek E, Abrams JJ, Grundy SM. Normolipidemic planar xanthomatosis associated with benign monoclonal gammopathy. *Metabolism*. 1981;30(9):927-935.
23. Esmat S, Abdel-Halim MRE, Fawzy MM, et al. Are normolipidaemic patients with xanthelasma prone to atherosclerosis? *Clin Exp Dermatol*. 2015;40(4):373-378.
24. Brewer HB, Zech LA, Gregg RE, et al. NIH conference. Type III hyperlipoproteinemia: diagnosis, molecular defects, pathology, and treatment. *Ann Intern Med*. 1983;98(5, pt 1):623-640.
25. Burnside NJ, Alberta L, Robinson-Bostom L, et al. Type III hyperlipoproteinemia with xanthomas and multiple myeloma. *J Am Acad Dermatol*. 2005;53(5):S281-S284.
26. Sharma D, Thirkannad S. Palmar xanthoma—an indicator of a more sinister problem. *Hand (N Y)*. 2010;5(2):210-212.
27. Beutler BD, Cohen PR. Verruciform genital-associated (vegas) xanthoma: report of a patient with verruciform xanthoma of the scrotum and literature review. *Dermatol Online J*. 2015;21(8).
28. Gupta P, Khandpur S, Vedi K, et al. Xanthoma disseminatum associated with inflammatory arthritis and synovitis—a rare association. *Pediatr Dermatol*. 2015;32(1):e1-e4.

29. Zak IT, Altinok D, Neilsen SSF, et al. Xanthoma disseminatum of the central nervous system and cranium. *AJNR Am J Neuroradiol*. 2006;27(4):919-921.
30. Büyükavci M, Selimoglu A, Yildirim U, et al. Xanthoma disseminatum with hepatic involvement in a child. *Pediatr Dermatol*. 2005;22(6):550-553.
31. Razi SM, Gupta AK, Gupta DC, et al. Cerebrotendinous xanthomatosis (a rare lipid storage disorder): a case report. *J Med Case Rep*. 2016;10(1):103.
32. Parente F, Vesnaver M, Massie R, et al. An unusual cause of Achilles tendon xanthoma. *J Clin Lipidol*. 2016;10(4):1040-1044.
33. Bhattacharyya AK, Connor WE. β-Sitosterolemia and xanthomatosis. *J Clin Invest*. 1974;53(4):1033-1043.
34. Salen G, Starc T, Sisk CM, et al. Intestinal cholesterol absorption inhibitor ezetimibe added to cholestyramine for sitosterolemia and xanthomatosis. *Gastroenterology*. 2006;130(6):1853-1857.
35. Horne MK, Merryman P, Cullinane A, et al. In vitro characterization of a monoclonal IgG(kappa) from a patient with planar xanthomatosis. *Eur J Haematol*. 2008;80(6):495-502.
36. Guidry J, Thompson W, Sonabend M. Chronic myelomonocytic leukemia can present with diffuse planar xanthoma. *Dermatol Online J*. 2014;20(7).
37. Kim JY, Jung HD, Choe YS, et al. A case of xanthoma disseminatum accentuating over the eyelids. *Ann Dermatol*. 2010;22(3):353-357.
38. Yu X-H, Fu Y-C, Zhang D-W, et al. Foam cells in atherosclerosis. *Clin Chim Acta*. 2013;424:245-252.
39. Schaefer EJ. Lipoproteins, nutrition, and heart disease. *Am J Clin Nutr*. 2002;75(2):191-212.
40. Mazein A, Watterson S, Hsieh W-Y, et al. A comprehensive machine-readable view of the mammalian cholesterol biosynthesis pathway. *Biochem Pharmacol*. 2013;86(1):56-66.
41. Feingold KR, Grunfeld C. *Introduction to Lipids and Lipoproteins*. 2000. http://www.ncbi.nlm.nih.gov/pubmed/26247089. Accessed February 20, 2017.
42. Ramasamy I. Recent advances in physiological lipoprotein metabolism. *Clin Chem Lab Med*. 2014;52(12):1695-1727.
43. Jun KR, Park H-I, Chun S, et al. Effects of total cholesterol and triglyceride on the percentage difference between the low-density lipoprotein cholesterol concentration measured directly and calculated using the Friedewald formula. *Clin Chem Lab Med*. 2008;46(3):371-375.
44. Yu X-H, Qian K, Jiang N, et al. ABCG5/ABCG8 in cholesterol excretion and atherosclerosis. *Clin Chim Acta*. 2014;428:82-88.
45. Julve J, Martín-Campos JM, Escolà-Gil JC, et al. Chylomicrons: advances in biology, pathology, laboratory testing, and therapeutics. *Clin Chim Acta*. 2016;455:134-148.
46. Kobayashi J, Mabuchi H. Lipoprotein lipase and atherosclerosis. *Ann Clin Biochem*. 2015;52(6):632-637.
47. Ooi EM, Russell BS, Olson E, et al. Apolipoprotein B-100-containing lipoprotein metabolism in subjects with lipoprotein lipase gene mutations. *Arterioscler Thromb Vasc Biol*. 2012;32(2):459-466.
48. Gibbons GF, Wiggins D, Brown A-M, et al. Synthesis and function of hepatic very-low-density lipoprotein. *Biochem Soc Trans*. 2004;32(pt 1):59-64.
49. Jungner I, Sniderman AD, Furberg C, et al. Does low-density lipoprotein size add to atherogenic particle number in predicting the risk of fatal myocardial infarction? *Am J Cardiol*. 2006;97(7):943-946.
50. Zhou L, Li C, Gao L, et al. High-density lipoprotein synthesis and metabolism (review). *Mol Med Rep*. 2015;12(3):4015-4021.
51. Brahm AJ, Hegele RA. Chylomicronaemia—current diagnosis and future therapies. *Nat Rev Endocrinol*. 2015;11(6):352-362.
52. Gaudet D, Brisson D, Tremblay K, et al. Targeting APOC3 in the familial chylomicronemia syndrome. *N Engl J Med*. 2014;371(23):2200-2206.
53. Santos RD, Frauches TS, Chacra AP. Cascade screening in familial hypercholesterolemia: advancing forward. *J Atheroscler Thromb*. 2015;22(9):869-880.
54. Sattar N, Preiss D, Robinson JG, et al. Lipid-lowering efficacy of the PCSK9 inhibitor evolocumab (AMG 145) in patients with type 2 diabetes: a meta-analysis of individual patient data. *Lancet Diabetes Endocrinol*. 2016;4(5):403-410.
55. Marais AD. Familial hypercholesterolaemia. *Clin Biochem Rev*. 2004;25(1):49-68.
56. Gaddi A, Cicero AF, Odoo FO, et al; Atherosclerosis and Metabolic Diseases Study Group. Practical guidelines for familial combined hyperlipidemia diagnosis: an up-date. *Vasc Health Risk Manag*. 2007;3(6):877-886.
57. van Greevenbroek MM, Stalenhoef AF, de Graaf J, et al. Familial combined hyperlipidemia. *Curr Opin Lipidol*. 2014;25(3):176-182.
58. Yu J-T, Tan L, Hardy J. Apolipoprotein E in Alzheimer's disease: an update. *Annu Rev Neurosci*. 2014;37(1):79-100.
59. Evans D, Aberle J, Beil FU. Resequencing the apolipoprotein A5 (APOA5) gene in patients with various forms of hypertriglyceridemia. *Atherosclerosis*. 2011;219(2):715-720.
60. Berglund L, Brunzell JD, Goldberg AC, et al. Evaluation and treatment of hypertriglyceridemia: an Endocrine Society clinical practice guideline. *J Clin Endocrinol Metab*. 2012;97(9):2969-2989.
61. Yuan G, Al-Shali KZ, Hegele RA. Hypertriglyceridemia: its etiology, effects and treatment. *CMAJ*. 2007;176(8):1113-1120.
62. Loscalzo J. Lipoprotein(a). A unique risk factor for atherothrombotic disease. *Arteriosclerosis*. 10(5):672-679.
63. Jacobson TA. Lipoprotein(a), cardiovascular disease, and contemporary management. *Mayo Clin Proc*. 2013;88(11):1294-1311.
64. Segner S, Theate I, Poiré X, et al. Diffuse xanthomatosis as a presenting feature of multiple myeloma. *Eur J Haematol*. 2010;84(5):460-461.
65. Buezo GF, Porras JI, Fraga J, et al. Coexistence of diffuse plane normolipaemic xanthoma and amyloidosis in a patient with monoclonal gammopathy. *Br J Dermatol*. 1996;135(3):460-462.
66. Bielecka-Dąbrowa A, Hannam S, Rysz J, et al. Malignancy-associated dyslipidemia. *Open Cardiovasc Med J*. 2011;5:35-40.
67. Mozessohn L, Earle C, Spaner D, et al. The association of dyslipidemia with chronic lymphocytic leukemia: a population-based study. *J Natl Cancer Inst*. 2016;109(3).
68. Yazgan Y, Oncu K, Kaplan M, et al. Malignant biliary obstruction increases significantly serum lipid levels: a novel biochemical tumor marker? *Hepatogastroenterology*. 2012;59(119):2079-2082.
69. Seidel D, Alaupovic P, Furman RH. A lipoprotein characterizing obstructive jaundice. I. Method for quantitative separation and identification of lipoproteins in jaundiced subjects. *J Clin Invest*. 1969;48(7):1211-1223.

70. Mukherjee M; American College of Cardiology. *Dyslipidemia in Pregnancy*. 2014. http://www.acc.org/latest-in-cardiology/articles/2014/07/18/16/08/dyslipidemia-in-pregnancy. Accessed February 19, 2017.
71. Rizos CV, Elisaf MS, Liberopoulos EN. Effects of thyroid dysfunction on lipid profile. *Open Cardiovasc Med J*. 2011;5:76-84.
72. Goldberg IJ. Diabetic dyslipidemia: causes and consequences. *J Clin Endocrinol Metab*. 2001;86(3):965-971.
73. Herink M, Ito MK. *Medication Induced Changes in Lipid and Lipoproteins*. 2015. http://www.ncbi.nlm.nih.gov/pubmed/26561699. Accessed February 19, 2017.
74. Hegde U, Doddawad VG, Sreeshyla H, et al. Verruciform xanthoma: a view on the concepts of its etiopathogenesis. *J Oral Maxillofac Pathol*. 2013;17(3):392-396.
75. Cohen YK, Elpern DJ. Diffuse normolipemic plane xanthoma associated with monoclonal gammopathy. *Dermatol Pract Concept*. 2015;5(4):65-67.
76. Martin SS, Blaha MJ, Elshazly MB, et al. Comparison of a novel method vs the Friedewald equation for estimating low-density lipoprotein cholesterol levels from the standard lipid profile. *JAMA*. 2013;310(19):2061-2068.
77. Quest Diagnostics. *Your Cardio IQ Report. An in-Depth Assessment of CVD Risk to Help Individualize Treatment*. http://www.questdiagnostics.com/home/physicians/testing-services/condition/cardiovascular/cardio-iq-report.html. Accessed March 5, 2017.
78. LabCorp. *Lipid Cascade With Reflex to Lipoprotein Particle Assessment by NMR (With Graph)*. https://www.labcorp.com/test-menu/30431/lipid-cascade-with-reflex-to-lipoprotein-particle-assessment-by-nmr-with-graph. Accessed March 5, 2017.
79. Sniderman A, Couture P, de Graaf J. Diagnosis and treatment of apolipoprotein B dyslipoproteinemias. *Nat Rev Endocrinol*. 2010;6(6):335-346.
80. Yang G-Z, Li J, Wang L-P. Disseminated intracranial xanthoma disseminatum: a rare case report and review of literature. *Diagn Pathol*. 2016;11(1):78.
81. Digby M, Belli R, McGraw T, et al. Eruptive xanthomas as a cutaneous manifestation of hypertriglyceridemia: a case report. *J Clin Aesthet Dermatol*. 2011;4(1):44-46.
82. Dabski K, Winkelmann RK. Generalized granuloma annulare: histopathology and immunopathology. Systematic review of 100 cases and comparison with localized granuloma annulare. *J Am Acad Dermatol*. 1989;20(1):28-39.
83. Fernández-Herrera J, Pedraz J. Necrobiotic xanthogranuloma. *Semin Cutan Med Surg*. 2007;26(2):108-113.
84. Veys EM, De Keyser F. Rheumatoid nodules: differential diagnosis and immunohistological findings. *Ann Rheum Dis*. 1993;52(9):625-626.
85. Fernandes Ede Á, Santos EH, Tucunduva TC, et al. Achilles tendon xanthoma imaging on ultrasound and magnetic resonance imaging [in Portuguese]. *Rev Bras Reumatol*. 2015;55(3):313-316.
86. Jin S, Chae SY, Chang SE, et al. A case of xanthoma disseminatum: evaluation and monitoring by 18F-fluorodeoxyglucose positron emission tomography/computed tomography. *Br J Dermatol*. 2014;170(5):1177-1181.
87. Kelly RB. Diet and exercise in the management of hyperlipidemia. *Am Fam Physician*. 2010;81(9):1097-1102.
88. Rao Ch S, Subash YE. The effect of chronic tobacco smoking and chewing on the lipid profile. *J Clin Diagn Res*. 2013;7(1):31-34.
89. Bays HE, Toth PP, Kris-Etherton PM, et al. Obesity, adiposity, and dyslipidemia: A consensus statement from the National Lipid Association. *J Clin Lipidol*. 2013;7(4):304-383.
90. Jensen MD, Ryan DH, Apovian CM, et al. 2013 AHA/ACC/TOS guideline for the management of overweight and obesity in adults. *Circulation*. 2014;129(25)(suppl 2):S102-S138.
91. Collins R, Reith C, Emberson J, et al. Interpretation of the evidence for the efficacy and safety of statin therapy. *Lancet*. 2016;388(10059):2532-2561.
92. Battaggia A, Donzelli A, Font M, et al. Clinical efficacy and safety of ezetimibe on major cardiovascular endpoints: systematic review and meta-analysis of randomized controlled trials. *PLoS One*. 2015;10(4):e0124587.
93. Ito MK. Long-chain omega-3 fatty acids, fibrates and niacin as therapeutic options in the treatment of hypertriglyceridemia: a review of the literature. *Atherosclerosis*. 2015;242(2):647-656.
94. Weitz D, Weintraub H, Fisher E, et al. Fish oil for the treatment of cardiovascular disease. *Cardiol Rev*. 2010;18(5):258-263.
95. Barter P, Ginsberg HN. Effectiveness of combined statin plus omega-3 fatty acid therapy for mixed dyslipidemia. *Am J Cardiol*. 2008;102(8):1040-1045.
96. Blom DJ, Fayad ZA, Kastelein JJ, et al; LOWER Investigators. LOWER, a registry of lomitapide-treated patients with homozygous familial hypercholesterolemia: rationale and design. *J Clin Lipidol*. 2016;10(2):273-282.
97. Panta R, Dahal K, Kunwar S. Efficacy and safety of mipomersen in treatment of dyslipidemia: a meta-analysis of randomized controlled trials. *J Clin Lipidol*. 2015;9(2):217-225.
98. Eyvazian VA, Frishman WH. Evacetrapib. *Cardiol Rev*. 2017;25(2):1.
99. McGowan MP. Emerging low-density lipoprotein (LDL) therapies: management of severely elevated LDL cholesterol—the role of LDL-apheresis. *J Clin Lipidol*. 2013;7(3):S21-S26.
100. Evans D, Beil FU, Aberle J. Resequencing the APOE gene reveals that rare mutations are not significant contributory factors in the development of type III hyperlipidemia. *J Clin Lipidol*. 2013;7(6):671-674.
101. Turnpenny PD, Ellard S. Alagille syndrome: pathogenesis, diagnosis and management. *Eur J Hum Genet*. 2012;20(3):251-257.

Chapter 127 :: Fabry Disease

:: Atul B. Mehta & Catherine H. Orteu

AT-A-GLANCE

- Incidence estimated at 1:3200 to 1:170,000 population in all ethnicities.
- X-linked lysosomal storage disorder.
- Highly penetrant in males; female heterozygotes have variable expressivity.
- Partial or complete deficiency of α-galactosidase A with deposition of glycosphingolipids (mostly globotriaosylceramide).
- Classical variants affect predominantly skin, kidneys, heart, eyes, and brain.
- Life expectancy shortened by 20 years in males and 15 years in females.
- Later onset variants are milder and predominantly involve a single organ (eg, renal or cardiac).
- Dermatologic manifestations include angiokeratoma, telangiectases, "pseudoacromegalic" facies, hypohidrosis and hyperhidrosis, lymphoedema, and Raynaud phenomenon.
- Light microscopy shows ectatic upper dermal vessels, peripheral epidermal acanthosis, and variable hyperkeratosis.
- Electron microscopy shows intracytoplasmic, electron-dense, vacuolar "Zebra bodies."
- Treatment is symptomatic, enzyme replacement; chaperone therapy (for amenable mutations).

EPIDEMIOLOGY

Fabry disease (α-galactosidase A deficiency) is generally considered the second most prevalent lysosomal storage disorder, after Gaucher disease,[1,2] with an estimated incidence ranging between 1:40,000 and 1:170,000 persons. All ethnic groups are affected. Neonatal screening studies reveal a higher incidence of mutations in the *GLA* gene and some of the affected individuals suffer from milder variants of the disease, which are associated with significant residual enzyme activity. These may occur with much higher frequency (eg, 1:3200) as suggested by a recent survey of neonates in Northern Italy.[3] A study of more than 7000 neonates in Japan suggests an incidence of pathogenic mutations of approximately 1:7000[4] and a similar incidence has been reported from Europe.[5] These variants often have predominant involvement of a single organ (eg, heart or kidney) and have onset in adult life. A study of the Taiwan Chinese population revealed an unexpectedly high prevalence of the cardiac-variant Fabry-causing mutation IVS4+919G>A among newborns (approximately 1:1600 males), as well as patients with idiopathic hypertrophic cardiomyopathy.[6]

ETIOLOGY AND PATHOGENESIS

Fabry disease (Online Mendelian Inheritance in Man #301500) is a rare X-linked metabolic disorder caused by the partial or complete deficiency of a lysosomal enzyme, α-galactosidase A (Fig. 127-1). As a result of this enzyme deficiency, neutral sphingolipids with terminal α-galactosyl residues (predominantly globotriaosylceramide [Gb3]) accumulate in the lysosomes of different tissues and fluids (epithelial cells of glomeruli and tubules of the kidneys; cardiac myocytes; ganglion cells of the autonomic system; cornea; endothelial, perithelial, and smooth muscle cells of blood vessels; and histiocytic and reticular cells of connective tissue). Elevated levels of globotriaosylsphingosine, which is the deacylated derivative of Gb3, correlate with disease severity in males and females. Globotriaosylsphingosine inhibits the activity of α-galactosidase A and it has been suggested that elevated levels in females could be of pathogenic significance.[7] Clinical onset is variable (Fig. 127-2). Although the condition is X linked, heterozygous females are frequently affected and may be as severely affected as hemizygous males.[8] Clinical symptoms typically occur a decade or so later in females than in males and organ damage in females is usually less severe than in males. Variable expression in females is attributed to the Lyon hypothesis whereby 1 X chromosome is inactivated on a random basis in the female, while the other provides the genetic information. The mutant X chromosome is more likely to be expressed in a range of tissues in symptomatic females with Fabry disease.[9]

The gene *GLA* for α-galactosidase A is located at the Xq22.1 region. More than 600 mutations have been identified in the *GLA* gene,[10-12] including missense, nonsense mutations, and single amino acid deletions and insertions. Most of these mutations are "private," having been identified only in individual families. Some (eg, the p.N215S mutation) are associated with single-organ or late-onset variants and patients have normal levels of urinary Gb_3, despite having clinical evidence of Fabry disease.

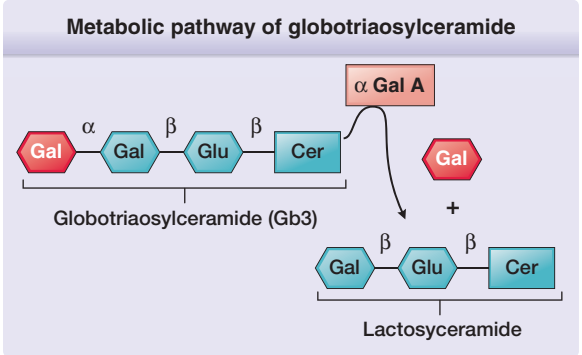

Figure 127-1 Metabolic pathway of globotriaosylceramide. α-Galactosidase A (α Gal A) metabolizes globotriaosylceramide to galactose (Gal) and lactosylceramide. Cer, ceramide; Glu, glucose.

CUTANEOUS MANIFESTATIONS

CUTANEOUS VASCULAR LESIONS

ANGIOKERATOMA

Angiokeratomas, are the cutaneous hallmark of Fabry disease.[11-13] Present in 70% of males and 39% of females,[13,14] angiokeratomas are pinpoint to 4 mm diameter, dark-red to blue-black, macular and papular lesions that do not blanch on pressure (Fig. 127-3). Overlying hyperkeratosis is variable and frequently absent at sites other than the genitalia and umbilicus.

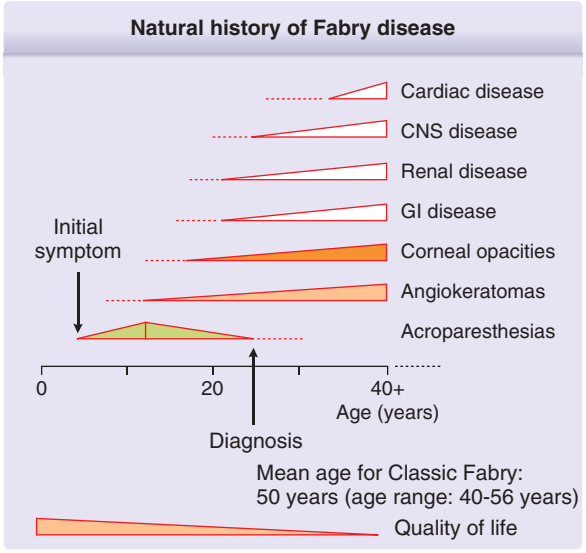

Figure 127-2 Natural history of Fabry disease. Acroparesthesias, angiokeratomas, corneal opacities, and GI symptoms are often the first manifestations. Diagnosis is usually delayed and occurs around the second decade.

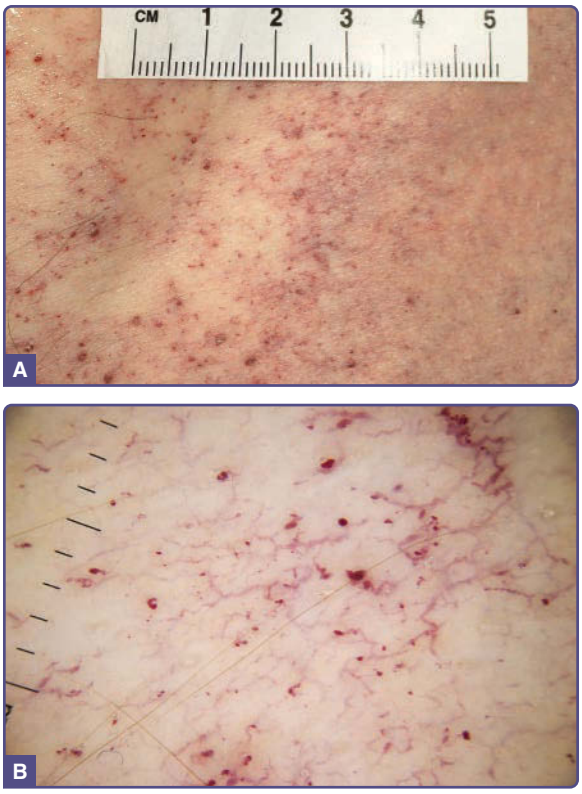

Figure 127-3 **A,** Angiokeratomas and telangiectatic vessels on the flank of a patient with angiokeratoma corporis diffusum. **B,** Dermatoscopic view showing angiokeratomas and upper dermal vessel tortuosity.

Angiokeratomas appear between the ages of 5 and 15 years in males and the ages of 8 and 25 years in females.[15-17] They were a presenting feature in 50 (14.2%) of 352 pediatric patients,[18] in 114 (31.7%) of 359 adult males (n = 359), and in 13 (11.2%) of 118 adult females (n = 118).[19] They may be widespread or grouped. In males, lesions are typically within the "bathing trunk" area (genitals, buttocks, lower abdomen, umbilicus, groins, inner thighs and sacrum). Angiokeratomas are also seen on the proximal limbs, particularly their medial aspects, the elbows and knees, the palms and soles, and over the distal phalanges of the digits (Fig. 127-4). Lesions may occur on the lips, particularly along the vermilion border, and occasionally on the mucosal surfaces (Fig. 127-5). They rarely occur elsewhere on the face. In females, angiokeratomas are usually sparsely distributed (Fig. 127-6), and may occasionally occur in a dermatomal distribution.[13] The most common sites are the trunk and proximal limbs.[13] Female genital lesions are relatively infrequent.

HISTOPATHOLOGY

Histology typically shows dilated, ectatic capillaries in the papillary dermis, a variably thinned epidermis centrally, with epidermal acanthosis at the edges of the lesion, and variable degrees of overlying focal compact

Figure 127-4 Distribution of angiokeratomas in Fabry males with complete phenotypic expression of disease. **A,** Lower abdomen; **B,** scrotum and medial thighs; **C,** umbilicus; **D,** upper limb; **E,** palms; **F,** toes.

orthohyperkeratosis (Fig. 127-7A). Endothelial, perithelial, perineural, eccrine, smooth muscle cells, and fibroblasts are filled with cytoplasmic vacuoles containing glycosphingolipid that can be visualized with toluidine blue stains.[20] Characteristic, electron-dense, lamellated, intracytoplasmic vacuolar inclusions (Zebra bodies) are typically seen on electron microscopy (Fig. 127-7B-D).[21] They exhibit a pattern of alternating light and dark 4- to 6-nm bands. These inclusions may be present in biopsies of angiokeratoma or from normal skin. They may

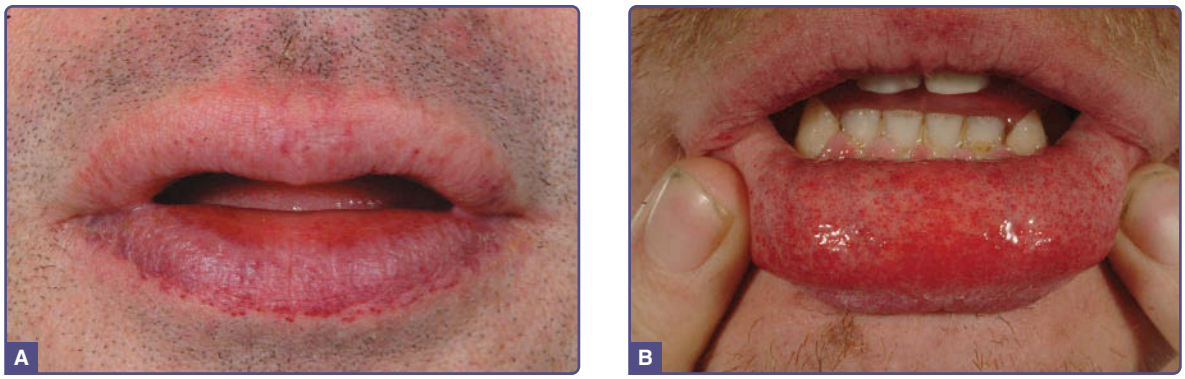

Figure 127-5 Angiomatous lesions on the lips. **A,** Concentrated along the vermilion border; **B,** on the mucosal surface of the lower lip.

be absent in the skin of heterozygous females. Electron microscopy and immunoelectron microscopy using anti-Gb3 antibodies are useful tools when other diagnostic tests are inconclusive.[22]

ANGIOMAS AND TELANGIECTASES

Up to a third of Fabry males and two-thirds of Fabry females do not have angiokeratomas.[16,17] A proportion have no cutaneous vascular lesions,[1] others have 1- to 2-mm diameter bright red macular angiomatous lesions, which could represent early angiokeratomas or macular hemangiomas clinically.[11] Patients with widespread papular angiomas, clinically and histologically in keeping with cherry angiomas, are also recognized. In one series, patients with a predominantly cardiac phenotype (N215S mutation) rarely had classical angiokeratoma, but a third of males in this group had widespread (>100) cherry angiomas.[23] Because the prevalence of cherry angiomas in the general population may be as high as 50%,[18] their significance in patients with Fabry disease is not clear. Telangiectases are also common,[13] and may be distinguished from angiokeratomas and macular and cherry angiomas by the presence of blanching on diascopic pressure. Registry data show that they are more common in males (23%) than females (9%).[13,14] Although based on patient recall, data suggest that telangiectases appear later than angiokeratomas, with a mean age at onset of 26 years in males (SD 17, range: 3-70 years) and 42 years in females (SD 22, range: 5-73 years).[13] In a majority of cases, telangiectases occur at sun-exposed sites such as the face and V of the neck, often in patients with skin Type I or Type II. Occasionally, telangiectases may be seen at unusual sites, such as the flanks, groin, and elbow and knee flexures. Dermoscopy of these areas reveals dilated, tortuous upper dermal vessels (see Fig. 127-3). This tends to occur in patients with widespread angiokeratoma and full phenotypic expression of disease.

Figure 127-6 Sparsely distributed pinpoint dark-red macular and papular lesions on the trunk of a Fabry female.

RELATIONSHIP TO DISEASE SEVERITY

In both sexes, the presence of cutaneous vascular lesions, namely telangiectases and/or angiokeratomas, is associated with higher disease severity scores and a higher prevalence of major organ involvement.[13,14] Thus, cerebrovascular involvement (stroke and transient ischemic attack) was present in 38% of females and 32% of males with cutaneous vascular lesions, but in only 12% of females and 9% of males without. Cardiac involvement occurred in 80% of females and 73% of males with cutaneous vascular lesions versus 38% of females and 49% of males without; renal involvement occurred in 62% of females and 72% of males with cutaneous vascular lesions versus 29% of females and 42% of males without. Similar differences are observed for hypertension, eye, ear, GI, and other neurologic involvement.[14] These findings demonstrate the importance of dermatologic assessment and its possible predictive value in terms of systemic morbidity.

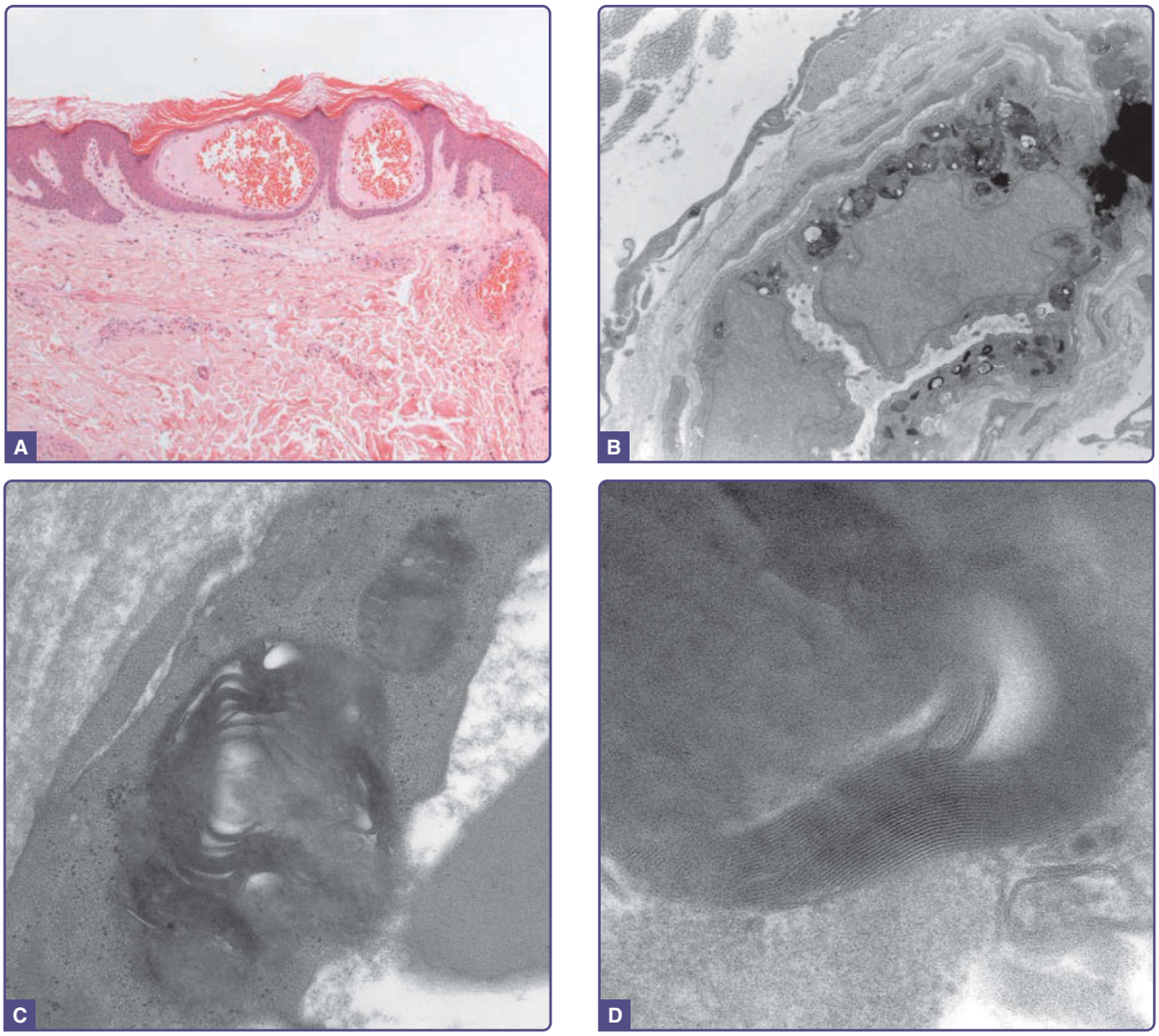

Figure 127-7 Histopathologic features of angiokeratoma. **A,** Light microscopy. Dilated capillaries in the papillary dermis with overlying epidermal thinning and mild orthohyperkeratosis. Acanthotic epidermis at the periphery. Hematoxylin and eosin (H&E) stain ×40 magnification. **B-D,** Electron microscopy. **B,** Multiple electron-dense inclusions in a cutaneous vascular endothelial cell (×9000 magnification). **C,** At higher power a lamellar or "zebra" body is seen (×63,000 magnification). **D,** At highest power (×223,000 magnification) light and dark bands with a periodicity of 4 to 6 nm are identified.

FACIAL FEATURES

A "pseudoacromegalic" facial appearance has been described in some families with Fabry disease (Fig. 127-8). This feature is documented in 2 larger studies. An assessment of 38 patients by a panel of 3 clinical geneticists was based on standardized medical photography[24] and identified (in order of decreasing frequency) periorbital fullness, prominent ear lobes, bushy eyebrows, recessed forehead, pronounced nasal angle, generous nose/bulbous nasal tip, prominent supraorbital ridges, shallow midface, full lips, prominent nasal bridge, broad alar base, coarse features, posteriorly rotated ears, and prognathism. A second study, in which facial dysmorphism was objectively assessed by three-dimensional dense surface modeling and anthropometric analysis using a three-dimensional photogrammetric camera, facial features in 20 males and 22 females with Fabry disease were compared to controls.[25] This study confirmed, in males, and less prominently in females, the presence of the facial features noted above. The presence of these facial features should prompt appropriate investigations for Fabry disease.

The Fabry face appears more common in patients with widespread angiokeratomas and classical disease at the more-severe end of the spectrum. Moderate or marked facial changes were present in 26 (63%) of 41 males with a classical disease phenotype; 16 (61%) of the 26 males had angiokeratoma corporis diffusum. In contrast, facial features were present to a very mild degree (periorbital puffiness only) in 2 (10.5%) of 19 males with a predominantly cardiac phenotype of disease.[14]

Figure 127-8 Typical facial features: prominent supraorbital ridges, periorbital fullness, large bitemporal width, bushy eyebrows, broad nasal base, full lips, and prominent chin.

LOWER-LIMB EDEMA AND LYMPHEDEMA

Edema and lymphedema, particularly affecting the limbs, is frequently observed in Fabry patients (Fig. 127-9). Lymphedema was cited in the original description of Fabry disease and is recognized in other lysosomal storage diseases such as α-*N*-acetylgalactosaminidase deficiency.[26] Case reports document it as an unusual presenting feature of the condition,[27] and some suggest that familial lymphedema and Fabry disease might be linked.[28] Registry data from the Fabry Outcome Survey on more than 700 patients confirm that reversible peripheral edema of the lower limbs was present in 25% of Fabry males and 17% of Fabry females; lymphedema was present in 16% of Fabry males and 7% of Fabry females. The mean age of onset was 37 years for males (range: 13-70 years) and a decade or so later for females.[13] This is significantly more than the documented UK community prevalence of 1.33 per 1000 population.[29] In the community it is 5 times more common in women. The mechanism underlying the changes is unclear, and the presence of the changes does not correlate with renal or cardiac involvement. Contributory factors may include glycosphingolipid accumulation,[30] recurrent edema, and primary abnormality of the lymphatics.[31,32] Using the technique of fluorescence microlymphography and measurement of lymph capillary pressure, Amann-Vesti et al demonstrated fragmentation of the microlymphatic network in 5 of 5 hemizygous males and 5 of 5 heterozygous females but in none of 12 healthy controls. Severe structural and functional changes in the initial lymphatics of the skin were present, even when lymphedema was not manifest.[32] Significantly higher serum levels of vascular endothelial growth factor (VEGF)-A, a glycoprotein known to stimulate endothelial cell migration and proliferation, and to increase microvascular permeability and vasodilation, have been identified in Fabry patients.[33]

The possibility that abnormalities in expression or function of recently identified mediators of lymphangiogenesis (VEGF-C/-D and VEGF-Rs)[34] may be involved in the development of lymphedema in Fabry disease remains to be investigated.

Figure 127-9 Bilateral lower-limb lymphedema in a 43-year-old Fabry male.

ABNORMALITIES OF SWEATING

Reduced sweating is a classical feature of Fabry disease and thought largely to be a consequence of autonomic neuropathy, although substrate accumulation within sweat glands may play a role.[35,36] Hypohidrosis was reported by 53% of males and 28% of females, with earlier onset in males (mean age: 23 vs 26 years). Anhidrosis was described by 25% of males, but only 4% of females.[8] Heat intolerance is a commonly associated and disabling symptom, resulting in reduced exercise tolerance, nausea, dyspnea, light-headedness, and headache, or complete collapse with loss of consciousness. Previous studies[36,37] demonstrated an improvement in sweating in Fabry patients undergoing enzyme replacement therapy (ERT). Hyperhidrosis may also occur, more often in females than males: 44 (11.9%) of 369 females versus 22 (6.4%) of 345 males.[38] This is higher than the

estimated prevalence of 1.0% to 2.8% of the general population in the United States.[39] In a majority of Fabry patients, hyperhidrosis affects palms and soles and is not generalized.[38]

RAYNAUD PHENOMENON

"Cold intolerance" and the development of pain in the extremities in cold environments is a frequent complaint among Fabry patients. Registry data has documented Raynaud phenomenon in 57 (8%) of 710 females and 71 (11%) of 644 males (data from Fabry Outcome Survey).[14] Two newer studies identified Raynaud phenomenon in 15.3% to 38% of Fabry patients.[40,41] This is significantly higher than the prevalence of 3% to 22% reported in the general population, in which males are less commonly affected (0.5% to 16%) than females (2.5% to 22%).[41] The reversal of the sex ratio and high prevalence in males suggest a possible causal link to the underlying Fabry disease. In a fluoroscopic nailfold capillaroscopy study[42] that examined 25 Fabry patients (17 males), significantly more bushy capillaries and clusters were identified in cases (72%) than controls (10%). Morphologic and functional abnormalities of nailfold capillaries were present. In a further capillaroscopic study of 32 Fabry patients, 25 (78%) of whom were on ERT, the only significant difference identified was an increase in ramification of capillaries.[41] Although the abnormal vasoreactivity of digital vessels could be related to autonomic dysfunction, abnormalities of nitric oxide synthetase, and increased oxidative stress in vascular endothelium and smooth muscle, might also be important triggers.[43]

NONCUTANEOUS FINDINGS

The noncutaneous findings in Fabry disease are illustrated in Figure 127-2 and listed in Table 127-1 in relation to their typical age of onset. Fabry disease is a progressive, multisystem disorder that typically results in a global reduction in quality of life for affected individuals. Symptoms in childhood typically relate to lethargy, tiredness, pain, cutaneous abnormalities, changes to sensory organs, and, often, GI disturbances. In early adulthood, patients may suffer extension of any of the above symptoms and often develop lymphedema, proteinuria and the first signs of renal, cardiac, or CNS/cerebrovascular disease. In late adulthood (age >30 years), symptoms include worsening of the above and more-severe organ dysfunction (cardiac disease, renal disease, and cerebrovascular disease).

NEUROLOGIC FINDINGS

Acroparesthesias occur in 80% to 90% of affected individuals and typically occur in the first decade.[16]

TABLE 127-1
Noncutaneous Findings

- Renal
  - Chronic renal failure
- Cardiovascular
  - Hypertension
  - Coronary vascular disease
  - Left ventricle hypertrophy
  - Valve disease
  - Arrhythmias
  - Elevated high-density lipoprotein
- Neurologic/psychiatric
  - Acroparesthesias
  - Cerebrovascular disease
  - Dementia
  - Depression
  - Increased suicide ideation
- Ocular
  - Cornea verticillata
  - Conjunctival vessel aneurysms
  - Increased tortuosity of retinal vessels
  - Fabry cataract
- GI
  - Diarrhea
  - Nausea
  - Vomiting
  - Postprandial flank pain
  - Malabsorption
- Others
  - Hearing loss and tinnitus
  - Hypothyroidism
  - Obstructive airway disease
  - Osteopenia and osteoporosis
  - Anemia

Patients describe the sensation as pain, feeling like pins and needles in hands and feet often radiating proximally. Triggers include increased body temperature, exercise, and stress. Pain typically declines over time, which may be the result of damage to nerve fibers as a result of inflammation and substrate accumulation.

SENSORY ORGAN ABNORMALITIES

The most common ocular finding is cornea verticillata (opacities in the cornea characterized by 1 or more lines radiating from near the center of the cornea), which occurs in more than 90% of Fabry males and 70% of Fabry males. Other changes include increased tortuosity of retinal vessels, optic atrophy, cataracts, and lenticular changes. The extent of ocular abnormalities correlates with the overall extent of the disease.[44] Ocular changes also correlate with the genotype, and are more severe in subjects with nonsense mutations.[45] Tinnitus and high-frequency sensorineural hearing loss are also common manifestations, occurring in more than 50% of patients.[16]

Sudden deafness and dizziness resulting from vestibular pathology can also occur.[16]

GASTROINTESTINAL CHANGES

Cramping abdominal pain, nausea, diarrhea and, occasionally, constipation are frequent, and are often the presenting symptom.[46] The pathogenesis is probably related to neurologic abnormalities.

ORGAN DAMAGE IN FABRY DISEASE

RENAL MANIFESTATIONS

Renal manifestations are seen in more than 90% of males.[16] Microalbuminuria and hyperfiltration are early features; proteinuria is typically seen in the third and fourth decades; and progressive decline in renal filtering capacity occurs. Females frequently show proteinuria, although progression to end-stage renal failure is less common. A renal variant of Fabry disease has been described in patients with decreased,[1] but not absent, α-galactosidase A activity; these patients lack other characteristic manifestations.

CARDIAC MANIFESTATIONS

Cardiac manifestations are a constant feature and increasingly recognized as the major cause of death in both male and female patients.[47] Substrate deposition can be demonstrated throughout the myocardium, valves, and conduction system, and is often accompanied by an inflammatory cell infiltrate. A common presentation is with left ventricular hypertrophy, but mitral valve prolapse, arrhythmia, and coronary artery disease can all be present. A cardiac variant[1] has been described in patients with reduced, but not absent, α-galactosidase A activity, and presents later in life (often when patient is older than age 40 years) with predominant cardiac symptoms. MRI scanning has a valuable role in detecting early involvement and in demonstrating scarring, which is a feature of advanced disease.[48]

CEREBROVASCULAR MANIFESTATIONS

Cerebrovascular manifestations include ischemic or hemorrhagic strokes occurring early in life, and transient ischemic attack and strokes affecting the posterior circulation. Stroke is often reported as the presenting feature of Fabry disease and Fabry disease should be considered in the differential diagnosis of young patients with cryptogenic stroke.[49] There is an increased prevalence of factor V Leiden among Fabry patients who have suffered stroke.[50] Cognitive impairment can be demonstrated among older males and females with Fabry disease.[51]

OTHER MANIFESTATIONS

Global manifestations of Fabry disease include lethargy, tiredness, failure to thrive in children, and anemia. Depression is frequent and often underdiagnosed, affecting up to 50% of Fabry males and females.[52] Sexual activity is often affected by the presence of angiokeratomas in the genital region and can lead to decreased self-esteem and libido. Autonomic dysfunction is underrecognized and can lead to hyperhidrosis, abnormal tear and saliva formation, abnormal cardiac reactivity, GI dysmobility, altered pain and temperature perception, and peripheral edema. Endocrine abnormalities are uncommon but osteopenia and hypothyroidism[53] are well described. Pulmonary abnormalities are underrecognized; Fabry disease can lead to an obstructive airways pattern[54] in some patients, but asthma is the presenting feature in other patients. In contrast to other lysosomal storage disorders, cognitive impairment is not generally seen; however, older patients (older than age 50 years) are increasingly seen with memory loss, global intellectual deterioration, and personality change.[51]

DIAGNOSIS

The definitive diagnosis of Fabry disease is usually delayed, with a mean time between the onset of symptoms and diagnosis of 15 years.[55] The diagnosis must be confirmed by the demonstration of deficient α-galactosidase A activity in plasma, serum, or leukocytes and the identification of the pathogenic mutation. Female patients have variable, and, occasionally, even normal levels of enzyme activity, making DNA confirmation of the diagnosis essential.

Biopsy of tissues, such as skin and kidney, demonstrates the presence of lipid deposition and multilamellated myelin bodies in electron micrographs (see Fig. 127-7). As Gb3 deposition starts in utero, prenatal diagnosis can be performed from chorionic villi or culture of amniotic cells, where low α-galactosidase A activity can be demonstrated.[1] There is an increasing recognition of the importance of late-onset mutations; and it is very important that the pathogenicity of the mutation should be confirmed. Measurement of globotriaosylsphingosine can add valuable information.[56]

DIFFERENTIAL DIAGNOSIS

The pain associated with acroparesthesia is often misdiagnosed as rheumatoid arthritis, rheumatic fever, erythromelalgia, Raynaud disease, or simply as "growing pains."[16]

TABLE 127-2
Differential Diagnosis of Angiokeratomas

LOCALIZED FORMS	ANGIOKERATOMA CORPORIS DIFFUSUM
Angiokeratoma of Fordyce	Fucosidosis
Angiokeratoma of the vulva	Aspartylglycosaminuria
Angiokeratoma of Mibelli	Galactosialidosis
Solitary papular angiokeratoma	Schindler/Kanzaki disease
Angiokeratoma circumscriptum	β-Mannosidosis GM_1-gangliosidosis/ β-galactosidase Sialidosis Idiopathic

The clinical diagnosis of angiokeratomas in Fabry disease may be difficult. Careful inspection of the skin may be required to distinguish them from purpura, petechiae, and angioma serpiginosum. They should also be distinguished from the solitary and localized forms of angiokeratoma that occur in the absence of underlying systemic disease (Tables 127-2 and 127-3).[57]

Widespread angiokeratomas occur in other lysosomal storage disorders which should be considered in the differential diagnosis. They include fucosidosis,[58] where more than 50% of patients have the changes, α-*N*-galactosaminidase deficiency and galactosialidosis (47% to 50%) (see Tables 127-2 and 127-4). In addition to the distinct enzyme deficiency in each of these storage diseases and other clinical features, angiokeratomas from Fabry disease can be differentiated by electron microscopic examination by the characteristic electron-dense, lamellar (zebra-like) inclusions within endothelial and other cell types.[59-62] Chloroquine therapy may result in storage of biochemically and ultrastructurally similar inclusions in many of the same cells as Fabry disease and may result in similar clinical manifestations, including the development of angiokeratoma.[63] Widespread angiokeratomas have also been described in association with tuberous sclerosis,[64] juvenile dermatomyositis,[65] and without an associated metabolic disorder.[66]

PROGNOSIS AND CLINICAL COURSE

Earlier studies suggested that males with Fabry disease typically die in the fourth or fifth decade, and females live perhaps 15 years longer. More recently, the life expectancy for males has been estimated as 58.2 years (compared to 74.7 in the general U.S. population) and 75.4 years for females (compared to 80 years in the general U.S. population).[67] There is also evidence that, whereas renal failure was previously the most common cause of death, cardiac disease and cerebrovascular disease are increasingly common. Some of these changes may be a result of the impact of ERT.[67,68]

TREATMENT

Table 127-5 outlines Fabry disease treatment. Fabry disease is a multisystem disorder and patients should be assessed within a multidisciplinary setting.

TABLE 127-3
Clinical Features of Different Types of Angiokeratoma

TYPE	AGE AT ONSET (YR)	SEX	CLINICAL ASPECT	BODY SITE	INHERITED	ASSOCIATION
Fabry	5-12	Both, males > females	Multiple, clustered dark-red to blue-black macules and papules; larger lesions warty (1-4 mm)	Any part of the body, especially bathing trunk area, umbilicus, lips	Yes, X-linked	Acroparesthesias, heart and renal failure, stroke, cornea verticillata, deafness, etc.
Mibelli	10-15	Both, female > males	Grouped, warty, dark-red papules (1-5 mm)	Lateral aspect and dorsa of fingers and toes, hands, and feet	Yes, autosomal dominant	Acrocyanosis and chilblains
Fordyce	>60	Male	Multiple warty, blue-black papules (1-4 mm)	Genitals, mainly scrotum	No	Local venous hypertension
Vulva	>60	Female	Grouped, warty, blue-black papules (1-4 mm)	Vulva	No	Local venous hypertension
Solitary papular	10-40	Both	Single dark-red to black keratotic papules (2-10 mm) often bleed/thrombose	Any part of the body, especially in lower extremities	No	—
Circumscriptum	Usually early onset or at birth	Both	Unilateral plaque keratotic dark-red papules, may bleed	Lower legs or foot may be zosteriform[53]	No	Cobb syndrome; vascular malformations

TABLE 127-4
Differential Diagnosis of Angiokeratoma Corporis Diffusum

GROUP	NAME	ENZYME DEFICIENCY	GENE	ELECTRON MICROSCOPY FINDINGS[55]	CLINICAL FINDINGS	DERMATOLOGIC FINDINGS
Sphingolipidoses	Fabry (OMIM #301500)	α-Galactosidase A	*Xq22*	Electron-dense lysosomal deposits	Acroparesthesias, heart and renal failure, stroke, cornea verticillata	Angiokeratoma corporis diffusum, telangiectasias, hypohidrosis/anhidrosis, lymphedema
	GM_1-gangliosidosis (OMIM #230500)	β-Galactosidase	*3p21-3pter*	Electron-lucent lysosomal dilation	Facial dysmorphism, hematologic signs, mental retardation, organomegaly	Angiokeratoma corporis diffusum
Glycoproteinoses	Aspartylglucosaminuria (OMIM #208400)	Aspartylglycosaminidase	*4q32-33*	Electron-lucent lysosomal dilation	Coarse facies, macroglossia, organomegaly, ocular findings, cardiac valve involvement	Angiokeratoma corporis diffusum, facial angiofibromas, oral fibromatosis, and leukokeratosis
	Fucosidosis (OMIM #230000)	α-Fucosidase	*1p34*	Electron-lucent lysosomal dilation	Mental retardation, coarse facies, growth retardation, recurrent respiratory tract infections, dysostosis multiplex, visceromegaly	Angiokeratoma corporis diffusum, widespread telangiectasias, acrocyanosis, purple transverse distal nail bands, increased vasculature in hands and feet, sweating abnormalities
	β-Mannosidosis (OMIM #248510)	β-Mannosidase	*4q22-q25*	Electron-lucent lysosomal dilation	Mental retardation, neuropathy, hearing loss, recurrent infections	Angiokeratoma corporis diffusum in bathing trunk area
	Sialidosis II (OMIM #256550)	Neuraminidase	*6p21.3*	Electron-lucent lysosomal dilation	Mental retardation, dysostosis multiplex, vacuolated lymphocytes, subtle coarse facial features	Angiokeratoma corporis diffusum
Multiple enzyme deficiency	Galactosialidosis (OMIM #256540)	β-Galactosidase and neuraminidase	*20q13.1*	Electron-lucent lysosomal dilation	Dwarfism, gargoyle facies, mental retardation, seizures, corneal clouding, dysostosis multiplex, and hearing loss	Angiokeratoma corporis diffusum scattered along entire body, especially knees, elbows, and bathing trunk area
	Kanzaki (OMIM #104170)	α-*N*-acetylgalactosaminidase	*22q11*	Electron-lucent lysosomal dilation	Mental retardation, coarse facial features, ocular signs, hearing loss, neuropathy	Angiokeratoma corporis diffusum of entire body, more dense on the bathing trunk area, axillae, and breasts Telangiectasias on lips and oral mucosa

OMIM, Online Mendelian Inheritance in Man.

TABLE 127-5

Treatment: A Multidisciplinary Approach Is Always Advisable

Symptomatic

Angiokeratomas
- Liquid nitrogen
- Electrocoagulation
- Surgical excision
- Laser (pulsed-dye 585 nm, neodynium YAG [Nd:YAG] 1064 nm, combined pulsed-dye and Nd:YAG) and intense pulsed light

Lymphedema
- Manual lymphatic drainage massage and compression

Hyperhidrosis
- Aluminium chloride hexahydrate
- Electrophoresis
- Botulinum toxin
- Glycopyrrolate sodium

Raynaud phenomenon
- Avoid smoking, cold and vasoconstrictor therapies
- Losartan
- Diltiazem
- Fluoxetine
- Sildenafil

Pain
- Avoid triggers
- Diphenylhydantoin
- Carbamazepine
- Gabapentin

Stroke
- Antiplatelet
- Anticoagulant

Hearing
- Hearing aid devices
- Avoid noise trauma

Lungs
- Avoid smoking
- Bronchodilators

GI
- Pancrelipase
- Metoclopramide

Cardiovascular
- Antihypertensive drugs
- Antiarrhythmia drugs
- Artificial pacemakers
- Implantable defibrillators
- Coronary bypass

Chronic renal failure
- Angiotensin converting enzyme inhibitors
- Hemodialysis
- Allograft transplant

Specific

Enzyme replacement
- α-Galactosidase B (Fabrazyme)
- α-Galactosidase A (Replagal)
- Migalastat (for patients with amenable mutations)

The advent of ERT has meant that patients and families are increasingly assessed in a specialist center, where they will have access to a physician or pediatrician, dermatologist, and possibly cardiologist/nephrologist/neurologist. Access to audiologists, ophthalmologists, gastroenterologists, and psychiatrists/counselors, as well as to genetic counselors and nurses is desirable and available at larger centers.

SYMPTOMATIC THERAPIES

Individual end-organ manifestations of disease are treated symptomatically (see Table 127-5).

SKIN-DIRECTED THERAPIES

Although clearance of Gb3 from the skin following ERT is reported,[69,70] this does not necessarily translate to clearance of angiokeratomas. The variety of vascular lesions seen in Fabry disease can, however, be treated effectively with quasicontinuous wave and pulsed lasers, and intense pulsed light systems.[71,72] Newer lasers, which combine a high-powered pulsed-dye laser and a 1064-nm long-pulse Nd:YAG laser penetrate deeper and seem to work particularly well for the larger genital angiokeratomas.[73,74]

Prophylactic therapy with grade II graduated below-knee compression hosiery can prevent the development of lymphedema in patients whose edema is still fully reversible. Once lymphedema is established, control can be maintained in up to 80% of patients by regular skin care, exercise, manual lymphatic draining and/or self-massage, and the use of appropriate specialist bandaging and hosiery for lymphedema.[75]

There is some evidence that hypohidrosis improves with ERT.

For those patients with hyperhidrosis, treatment options include the use of topical aluminium chloride hexahydrate, tap water iontophoresis and local botulinum toxin injections, oral glycopyrrolate sodium up to 2 mg three times daily (a well-tolerated anticholinergic with minimal side effects, provided there are no cardiac contraindications) and chemical or endoscopic sympathectomy.[76,77]

For patients with cold extremities, standard measures, such as stopping smoking, avoiding vasoconstricting medications such as beta-blockers, and maintaining warm hands and feet with suitable clothing during winter months are generally recommended. Drug therapies with proven efficacy for Raynaud phenomenon in other patient groups include angiotensin II receptor antagonists, calcium channel blockers, fluoxetine, and sildenafil.[78,79] Possible cardiac and renal contraindications should be taken into account before prescribing these drugs in Fabry patients.

THERAPIES DIRECTED AT OTHER ORGAN SYSTEMS

Pain is the most disturbing and early symptom, and can sometimes be partially managed with diphenylhydantoin, carbamazepine, or gabapentin. Patients

should be encouraged to identify, and try to avoid, their personal precipitating factors.

For the primary or secondary prevention of stroke and other vascular pathologies, such as retinal artery occlusion, antiplatelet and anticoagulant therapy might be needed.

Metoclopramide and pancrelipase are used to reduce GI symptoms. Hypertension must be controlled, as it significantly affects 3 of the most affected organs: the kidney, brain, and heart. Angiotensin-receptor blockade should be undertaken at the first sign of proteinuria and is an important adjunct to ERT in slowing the decline in renal function. Fabry patients are good candidates for kidney transplant in the event of end-stage renal failure and the role of ERT in this situation is to preserve the function of other organs. Ancillary care from a cardiac perspective includes consideration of antiarrhythmics, artificial pacemakers, and surgery, including septal ablation and cardiac transplantation.

SPECIFIC THERAPEUTICS: ENZYME REPLACEMENT THERAPY

Two formulations of ERT have been developed: agalsidase beta (Genzyme) and agalsidase alpha (Replagal). Only agalsidase beta is licensed in the United States, whereas both formulations are available in most other parts of the world. Agalsidase beta is administered at a dose of 1 mg/kg biweekly and is manufactured using a recombinant technology in a Chinese hamster ovary cell line. Agalsidase alpha is given at a dose of 0.2 mg/kg biweekly and is manufactured using a gene activation methodology in a human fibroblast cell line. The efficacy of both ERT formulations has been demonstrated in randomized controlled trials,[80-82] and both improve biochemical (eg, levels of Gb3 in plasma, urine, and tissue biopsy) and clinical parameters. The main clinical parameters chosen for study are renal function, pain, cardiac size and function, and quality of life.[83] Long-term effectiveness (with data over 10 years) has been demonstrated in Registry studies of both preparations.[84,85] Both preparations are considered safe and well tolerated. The main side effects are infusion related (fever, temperature) and both preparations can induce antibody formation. However, the impact of antibodies on clinical effectiveness has not been demonstrated. The 2 ERT formulations are generally considered to be of equivalent effectiveness when used at their licensed doses.[86] The optimum time for commencement of treatment has not been established. ERT is recommended for all symptomatic males and at the first sign of organ dysfunction in females. Patients receiving ERT should be regularly monitored with serial measurements of pain, quality of life, and renal and cardiac function. Their data should be entered onto Registries wherever possible.[87] ERT improves hearing and GI symptoms. Direct beneficial effects of ERT on CNS abnormalities have not been demonstrated and enzymes cannot cross the blood–brain barrier.

NEW TREATMENTS

Chaperone-based enzyme enhancement therapy consists of small molecules that rescue misfolded/mistrafficked enzymes from the lysosomes and transport them to the endoplasmic reticulum. Chaperone-based therapy can be administered orally and has demonstrated activity in subjects with amenable mutations and residual activity.[88] Migalastat has been approved by the regulatory authorities in both the United States and Europe.

Substrate deprivation (inhibition of an early step in the synthesis of glycosphingolipids) and the infusion of galactose are other therapeutic options that are still in the research stage.

Gene therapy and hematopoietic cell transplantation are still being developed.

GENETIC COUNSELING

All families that have a member with Fabry disease should have an opportunity to receive genetic counseling. Given the X-linked nature of Fabry disease, female patients have a 50% chance of transmitting the gene to both their sons and daughters, whereas male patients will have no affected sons and 100% of daughters affected. The genotype–phenotype variability should also be stressed, especially among patients with subtle manifestations.

REFERENCES

1. Mehta A, Hughes DA. Fabry disease. In: Adam, MP, Ardinger HH, Pagon RA, et al, eds. *GeneReviews*. Seattle, WA: University of Washington; 2017. https://www.ncbi.nlm.nih.gov/books/NBK1292/. Accessed January 5, 2017.
2. Meikle PJ, Hopwood JJ, Clague AE, et al. Prevalence of lysosomal storage disorders. *JAMA*. 1999;281(3): 249-254.
3. Spada M, Pagliardini S, Yasuda M, et al. High incidence of later-onset Fabry disease revealed by newborn screening. *Am J Hum Genet*. 2006;79(1):31-40.
4. Inoue T, Hattori K, Ihara K, et al. Newborn screening for Fabry disease in Japan: prevalence and genotypes of Fabry disease in a pilot study. *J Hum Genet*. 2013; 58(8):548-552.
5. Mechtler TP, Stary S, Mez TF, et al. Neonatal screening for lysosomal storage disorders; feasibility and incidence from a nationwide study in Austria. *Lancet*. 2012;379(9813):335-341.
6. Hsu TR, Sung SH, Change FP, et al. Endomyocardial biopsies in patients with left ventricular hypertrophy and a common later-onset Fabry mutation (IV54+919G>A). *Orphanet J Rare Dis*. 2014;9:96.

7. Aerts JM, Groener JE, Kuiper S, et al. Elevated globotriaosylsphingosine is a hallmark of Fabry disease. *Proc Natl Acad Sci U S A*. 2008;105:2812-2817.
8. Wilcox WR, Oliveira JP, Hopkin RJ, et al. Females with Fabry disease frequently have major organ involvement: lessons from the Fabry Registry. *Mol Genet Metab*. 2008;93(2):112-128.
9. Echevarria L, Benistan K, Toussaint A, et al. X chromosome inactivation in female patients with Fabry disease. *Clin Genet*. 2016;89::44-54.
10. Desnick RJ, Ioannou YA, Eng CM, et al. Alpha-galactosidase A deficiency: Fabry disease. In: Valle D, Beaudet AL, Vogelstein B, et al, eds. *The Online Metabolic and Molecular Bases of Inherited Disease*. New York, NY: McGraw-Hill; 2014.
11. Anderson W. A case of angiokeratoma. *Br J Dermatol*. 1898;10:113-117.
12. Fabry J. Ein Beitrag zur Kenntnis der Purpura haemorrhagica nodularis (Purpura papulosa haemorrhagica Hebrae). *Arch Dermatol Syph*. 1898;43:187-200.
13. Orteu CH, Jansen T, Lidove O, et al. Fabry disease and the skin: data from FOS the Fabry outcome survey. *Br J Dermatol*. 2007;157(2):331-337.
14. Dhoat S, Orteu CH, Navarro C, et al. Patients with Fabry disease with cutaneous vascular lesions have higher disease severity scores and more multisystem involvement: data from 1354 patients registered on FOS, the Fabry outcome survey. *Br J Dermatol*. 2009;161 (suppl 1):45.
15. Ramaswami U, Whybra C, Parini R, et al. Clinical manifestations of Fabry disease in children: data from FOS—the Fabry Outcome Survey. *Acta Paediatr*. 2006;95: 86-92.
16. MacDermott KD, Holmes A, Miners AH. Anderson-Fabry disease: clinical manifestations and impact of disease in a cohort of 98 hemizygous males. *J Med Genet*. 2001;38:750-760.
17. MacDermott KD, Holmes A, Miners AH. Anderson-Fabry disease: clinical manifestations and impact of disease in a cohort of 60 obligate carrier females. *J Med Genet*. 2001;38:769-775.
18. Hopkin RJ, Bissler J, Banikazemi M, et al. Characterization of Fabry disease in 352 pediatric patients in the Fabry Registry. *Pediatr Res*. 2008;64:550.
19. Mehta A, Ricci R, Widmer U, et al. Fabry disease defined: baseline clinical manifestations of 366 patients in the Fabry Outcome Survey. *Eur J Clin Invest*. 2004;34:236-242.
20. Larralde M, Boggio P, Amartino H, et al. Fabry disease: a study of 6 hemizygous men and 5 heterozygous women with emphasis on dermatologic manifestations. *Arch Dermatol*. 2004;140 (12):1440-1446.
21. Navarro C, Teijeira S, Dominguez C, et al. Fabry disease: an ultrastructural comparative study of skin in hemizygous and heterozygous patients. *Acta Neuropathol*. 2006;7:1-8.
22. Kanekura T, Fukushige T, Kanda A, et al. Immunoelectron-microscopic detection of globotriaosylceramide accumulated in the skin of patients with Fabry disease. *Br J Dermatol*. 2005;153(3):544-548.
23. Orteu CH, Mehta AB, Dhoat S, et al. Fabry disease and angiokeratoma corporis diffusum are not synonymous: cutaneous vascular lesions and facial features in 100 patients with Fabry disease. *Br J Dermatol*. 2009;161(suppl 1):46.
24. Ries M, Moore DF, Robinson CJ, et al. Quantitative dysmorphology assessment in Fabry disease. *Genet Med*. 2006;8(2):96-101.
25. Cox-Brinkman J, Vedder A, Hollak C, et al. Three-dimensional face shape in Fabry disease. *Eur J Hum Genet*. 2007;15(5):535-542.
26. Chabas A, Coll MJ, Aparicio M, et al. Mild phenotypic expression of alpha-N-acetylgalactosaminidase deficiency in two adult siblings. *J Inherit Metab Dis*. 1994;17(6):724-731.
27. Lozano F, Garcia-Talavera R, Gomez-Alonso A. An unusual cause of lymphoedema—confirmed by isotopic lymphangiography. *Eur J Vasc Surg*. 1988;2(2): 129-131.
28. Gemignani F, Pietrini V, Tagliavini F, et al. Fabry's disease with familial lymphedema of the lower limbs. Case report and family study. *Eur Neurol*. 1979;18(2):84-90.
29. Moffatt CJ, Franks PJ, Doherty DC, et al. Lymphoedema: an underestimated health problem. *Q J Med*. 2003;96(10):731-738.
30. Jansen T, Bechara FG, Orteu CH, et al. The significance of lymphoedema in Fabry Disease. *Acta Paediatr Suppl*. 2005;447:117.
31. Gitzelmann G, Widmer U, Bosshard NU, et al. Lymphoedema in Fabry disease: pathology and therapeutic perspectives. *Acta Paediatr Suppl*. 2006;451:122.
32. Amann-Vesti BR, Gitzelmann G, Widmer U, et al. Severe lymphatic micrangiopathy in Fabry disease. *Lymphat Res Biol*. 2003;1(3):185-189.
33. Zampetti A, Gnarra M, Borsini W, et al. Vascular endothelial growth factor (VEGF-a) in Fabry disease: association with cutaneous and systemic manifestations with vascular involvement. *Cytokine*. 2013;61(3):933-939.
34. Lohela M, Bry M, Tammela T, et al. VEGFs and receptors involved in angiogenesis versus lymphangiogenesis. *Curr Opin Cell Biol*. 2009;21(2):154-165.
35. Cable WJ, Kolodny EH, Adams RD. Fabry disease, impaired autonomic function. *Neurology*. 1982;32: 498-450.
36. Hilz MJ, Brys M, Marthol H, et al. Enzyme replacement therapy improves function of C-, Adelta-, and Abeta-nerve fibers in Fabry neuropathy. *Neurology*. 2004; 62(7):1066-1072.
37. Schiffman R, Floeter MK, Dambrosia JM, et al. Enzyme replacement therapy improves peripheral nerve and sweat function in Fabry disease. *Muscle Nerve*. 2003;28(6):703-710.
38. Lidove O, Ramaswami U, Jaussaud R, et al. Hyperhidrosis: a new and often early symptom in Fabry disease. International experience and data from the Fabry Outcome Survey. *Int J Clin Pract*. 2006;60(9):1053-1059.
39. Strutton DR, Kowalski JW, Glaser DA, et al. US prevalence of hyperhidrosis and impact on individuals with axillary hyperhidrosis: results from a national survey. *J Am Acad Dermatol*. 2004;51(2):241-248.
40. Germain DP, Atanasiu OI, Akrout-Marouene J, et al. Raynaud's phenomenon associated with Fabry disease. *J Inherit Metab Dis*. 2015;38(2):367-368.
41. Deshayes S, Auboire L, Jaussaud R, et al Prevalence of Raynaud phenomenon and nailfold capillaroscopic abnormalities in Fabry disease: a cross-sectional study. *Medicine (Baltimore)*. 2015;94(20):e780.
42. Wasik JS, Simon RW, Meier T, et al. Nailfold capillaroscopy: specific features in Fabry disease. *Clin Hemorheol Microcirc*. 2009;42(2):99-106.
43. Cooke JP, Marshall JM. Mechanisms of Raynaud's disease. *Vasc Med*. 2005;10(4):293-307.
44. Sodi A, Ioannidis AS. Mehta A, et al. Ocular manifestations of Fabry disease: data from the Fabry Outcome Survey. *Br J Ophthalmol*. 2007;91(2):210-214.

45. Pitz S, Kalkum G, Arash L, et al. Ocular signs correlate well with disease severity and genotype in Fabry disease. Data from FOS. *PLoS One*. 2015;10(3): e0120814.
46. Hoffman B, Schwarz M, Mehta A, et al. Gastrointestinal symptoms in 342 patients with Fabry disease: prevalence and response to enzyme replacement therapy. *Clin Gastroenterol Hepatol*. 2007;5(12):1447-1453.
47. Linhart A, Kampmann C, Zamorano JL, et al. Cardiac manifestations of Anderson Fabry disease: results from the International Fabry Outcome Survey. *Eur Heart J*. 2007;28(10):1228-1235.
48. Sado DM, White SK, Piechnik SK, et al. Identification and assessment of Anderson-Fabry disease by cardiovascular magnetic resonance noncontrast myocardial T1 mapping. *Circ Cardiovasc Imaging*. 2013;6(3):392-398.
49. Rolfs A, Bottcher T, Zschiesche M, et al. Prevalence of Fabry disease in patients with cryptogenic stroke: a prospective study. *Lancet*. 2005;366:1794-1796.
50. Lenders M, Karabul N, Dunting T, et al. Thromboembolic events in Fabry disease and the impact of factor V Leiden. *Neurology*. 2015;84(10):1009-1016.
51. Löhle M, Hughes D, Milligan A, et al. Clinical prodromes of neurodegeneration in Anderson Fabry disease. *Neurology*. 2015;84(14):1454-1464.
52. Cole AL, Lee PJ, Hughes DA, et al. Depression in adults with Fabry disease: a common and under-diagnosed problem. *J Inherit Metab Dis*. 2007;30:943-951.
53. Hauser AC, Gessl A, Lorenz M, et al. High prevalence of subclinical hypothyroidism in patients with Anderson-Fabry disease. *J Inherit Metab Dis*. 2005;28:715-722.
54. Magage S, Lubanda JC, Susa Z, et al. Natural history of the respiratory involvement in Anderson-Fabry disease. *J Inherit Metab Dis*. 2007;30:790-799.
55. Mehta AB, Lewis S, Laverey C. Treatment of lysosomal storage disorders. *BMJ*. 2003;327(7413):462-463.
56. Niemann M, Rolfs A, Störk S, et al. Gene mutations versus clinically relevant phenotypes: lyso-Gb3 defines Fabry disease. *Circ Cardiovasc Genet*. 2014;7:8-16.
57. Schiller PI, Itin PH. Angiokeratomas: an update. *Dermatology*. 1996;193(4):275-282.
58. Fleming C, Rennie A, Fallowfield M, et al. Cutaneous manifestations of fucosidosis. *Br J Dermatol*. 1997; 136(4):594-597.
59. Kanzaki T, Yokota M, Irie F, et al. Angiokeratoma corporis diffusum with glycopeptiduria due to deficient lysosomal alpha-N-acetylgalactosaminidase activity. Clinical, morphologic and biochemical studies. *Arch Dermatol*. 1993;129:460-465.
60. Rodriguez-Serna M, Botella-Estrada R, Chabas A, et al. Angiokeratoma corporis diffusum associated with beta-mannosidase deficiency. *Arch Dermatol*. 1996;132(10):1219-1222.
61. Paller SA. Metabolic disorders characterized by angiokeratomas and neurologic dysfunction. *Neurol Clin*. 1987;5(3):441-446.
62. Kanitakis J, Allombert C, Doebelin B, et al. Fucosidosis with angiokeratoma. Immunohistochemical & electron microscopic study of a new case and literature review. *J Cutan Pathol*. 2005;32(7):506-511.
63. Albay D, Adler SG, Philipose J, et al. Chloroquine-induced lipidosis mimicking Fabry disease. *Mod Pathol*. 2005;18(5):733-738.
64. Gil-Mateo MP, Miquel FJ, Velasco AM, et al. Widespread angiokeratomas and tuberous sclerosis. *Br J Dermatol*. 1996;135:280.
65. Shannon PL, Ford M. Angiokeratomas in juvenile dermatomyositis. *Pediatr Dermatol*. 1999;16:448.
66. Marsden J, Allen R. Widespread angiokeratomas without evidence of metabolic disease [Letter]. *Arch Dermatol*. 1987;123:1125.
67. Waldek S, Patel MR, Banikazemi M, et al. Life expectancy and cause of death in males and females with Fabry disease: findings from the Fabry Registry. *Genet Med*. 2009;11(11):1-7.
68. Mehta A, Clarke JT, Giugliani R, et al. Natural course of Fabry disease: changing pattern of causes of death in FOS–Fabry Outcome Survey. *J Med Genet*. 2009;46(8):548-552.
69. Eng CM, Banikazemi M, Gordon RE, et al. A phase 1/2 clinical trial of enzyme replacement in Fabry disease: pharmacokinetic, substrate clearance, and safety studies. *Am J Hum Genet*. 2001;68(3):711-722.
70. Thurberg BL, Randolph Byers H, Granter SR, et al. Monitoring the 3-year efficacy of enzyme replacement therapy in Fabry disease by repeated skin biopsies. *J Invest Dermatol*. 2004;122(4):900-908.
71. Ross BS, Levine VJ, Ashinoff R. Laser treatment of acquired vascular lesions. *Dermatol Clin*. 1997;15(3): 385-396.
72. Morais P, Santos AL, Baudrier T, et al. Angiokeratomas of Fabry successfully treated with intense pulsed light. *J Cosmet Laser Ther*. 2008;10(4):218-222.
73. Pfirrmann G, Raulin C, Karsai S. Angiokeratoma of the lower extremities: successful treatment with a dual-wavelength laser system (595 and 1064 nm). *J Eur Acad Dermatol Venereol*. 2009;23(2):186-187.
74. Ozdemir M, Baysal I, Engin B, et al. Treatment of angiokeratoma of Fordyce with long-pulse neodymium-doped yttrium aluminium garnet laser. *Dermatol Surg*. 2009;35(1):92-97.
75. Rockson SG. Diagnosis and management of lymphatic vascular disease. *J Am Coll Cardiol*. 2008;52(10): 799-806.
76. Ram R, Lowe NJ, Yamauchi PS. Current and emerging therapeutic modalities for hyperhidrosis, part 1: conservative and non-invasive treatments. *Cutis*. 2007;79(3):211-217.
77. Ram R, Lowe NJ, Yamauchi PS. Current and emerging therapeutic modalities for hyperhidrosis, part 2: moderately invasive and invasive procedures. *Cutis*. 2007;79(4):281-288.
78. Pope JE. The diagnosis and treatment of Raynaud's phenomenon. *Drugs*. 2007;67(4):517-525.
79. Coleiro B, Marshall SE, Denton CP, et al. Treatment of Raynaud's phenomenon with the selective serotonin reuptake inhibitor fluoxetine. *Rheumatology (Oxford)*. 2001;40(9):1038-1043.
80. Schiffmann R, Kopp JB, Austin HA 3rd, et al. Enzyme replacement therapy in Fabry disease: a randomized controlled trial. *JAMA*. 2001;285:2743-2749.
81. Eng CM, Guffon N, Wilcox WR, et al. Safety and efficacy of recombinant human alpha-galactosidase A replacement therapy in Fabry's disease. *N Engl J Med*. 2001;345:9-16.
82. Hughes DA, Elliott PM, Shah J, et al. Effects of enzyme replacement therapy on the cardiomyopathy of Anderson-Fabry disease: a randomised, double-blind, placebo-controlled clinical trial of agalsidase alfa. *Heart*. 2008;94(2):153-158.
83. Mehta AB, Beck M, Elliott P, et al. Evidence of benefit of 5 years of enzyme replacement therapy with agalsidase alfa in patients with Fabry disease—a report from the Fabry Outcome Survey (FOS) *Lancet*. 2009;374:1986-1996.
84. Germain DP, Charrow J, Desnick RJ, et al. Ten-year outcome of enzyme replacement therapy with agalsidase

beta in patients with Fabry disease. *J Med Genet*. 2015;52(5):353-358.
85. Beck M, Hughes D, Kampmann C, et al. Long term effectiveness of agalsidase alfa enzyme replacement therapy in Fabry disease: a Fabry Outcome Survey analysis. *Mol Genet Metab Rep*. 2015;3:21-27.
86. Sirrs SM, Bichet DG, Casey R, et al. Outcomes of patients treated through the Canadian Fabry Disease Initiative. *Mol Genet Metab*. 2014;11(4):499-506.
87. Biegstraaten M, Arngrímsson R, Barbey F, et al. Recommendations for initiation and cessation of enzyme replacement therapy in patients with Fabry disease: the European Fabry Working Group consensus document. *Orphanet J Rare Dis*. 2015;10:36.
88. Germain DP, Hughes DA, Nicholls K, et al. Treatment of Fabry's disease with pharmacologic chaperone migalastat. *N Engl J Med*. 2016;375:545-555.

Chapter 128 :: Calcium and Other Mineral Deposition Disorders

:: Janet A. Fairley & Adam B. Aronson

AT-A-GLANCE

- Results from the deposition of calcium salts in the dermis, subcutaneous tissue, or vascular endothelium when the local calcium concentration exceeds its solubility in the tissue.
- Clinically, it may be categorized as dystrophic, metastatic, idiopathic, or iatrogenic.
- Pathology shows aggregates of calcium that stain with Alizarin red S or von Kossa stains.
- Ossification may occur secondary to calcification or primarily in genetic syndromes.
- Treatment is often difficult.

CALCIUM

Calcium is involved in many physiologic processes. It is key to skeletal muscle and myocardial contraction, neurotransmission, and blood coagulation. In addition, it is the primary mineral in the bony skeleton. On the cellular level, its diverse functions include transmission of information into and between cells, regulation of plasma membrane potential, and exocytosis. Only over the last 20 years has its effect on skin been fully appreciated. Calcium regulates major functions in the epidermal keratinocytes including proliferation, differentiation, and cell–cell adhesion.[1-6]

REGULATORY HORMONES

At least 3 regulatory hormones control the ionic calcium concentration in serum: (1) parathyroid hormone (PTH), (2) calcitonin, and (3) 1,25-dihydroxyvitamin D_3 ($1,25(OH)_2D_3$).

PTH is an 84–amino acid, single-chain polypeptide that is synthesized in the parathyroid glands. Under normal conditions, a decrease in the serum concentration of ionized calcium results in an increase in PTH production, whereas an increase in the serum concentration of ionized calcium results in a decrease in PTH production. In the kidney, PTH increases renal tubular reabsorption of calcium and increases renal clearance of phosphate. PTH also acts directly on the bone to increase the plasma calcium concentration. It does this acutely by mobilizing calcium from bone into the extracellular fluid. Osteocytes and osteoblasts are the presumed target cells for this effect. PTH also stimulates osteoclastic bone resorption, possibly by stimulating osteoblasts to release factors that activate osteoclasts. PTH together with a decreased plasma phosphate concentration stimulates 1α-hydroxylase activity in the kidney, causing an increase in the plasma concentration of $1,25(OH)_2D_3$. $1,25(OH)_2D_3$ increases intestinal absorption of calcium.

Calcitonin is a 32–amino acid polypeptide that is produced by parafollicular or C cells of the thyroid gland. Calcium is the primary stimulant for calcitonin secretion. Calcitonin lowers the serum calcium concentration, primarily through osteoclast inhibition, but whether it plays a major role in serum calcium metabolism outside of the neonatal period in vivo is unclear.

Vitamin D_3, or cholecalciferol, is a secosteroid (steroid with a "broken" ring) formed by the opening of the β ring of 7-dehydrocholesterol. In humans, this formation occurs in the basal layer of the epidermis. First, there is an ultraviolet B-mediated conversion of 7-dehydrocholesterol to previtamin D_3. Previtamin D_3 then undergoes thermal isomerization to form vitamin D_3. To become biologically active, vitamin D_3 must first be hydroxylated at carbon position 25 in the liver and then at carbon position 1α by the enzyme 1α-hydroxylase in the kidney. 1α-Hydroxylase is tightly regulated. PTH and calcitonin increase its activity, whereas calcium, phosphate, and $1,25(OH)_2D_3$ inhibit it.[7]

$1,25(OH)_2D_3$, similarly to PTH, increases the concentration of plasma calcium. Its primary action is to stimulate the active transport of calcium across the intestine. $1,25(OH)_2D_3$ also increases the plasma calcium concentration by mobilizing calcium from bone.[8] The simultaneous presence of PTH appears to be necessary for this effect.

$1,25(OH)_2D_3$ also plays a major role in the growth and differentiation of tissues, including skin.[9] $1,25(OH)_2D_3$ acts through its nuclear receptor (vitamin D receptor [VDR]), which is a member of the superfamily of steroid/thyroid/retinoid nuclear receptors. In the skin, receptors for $1,25(OH)_2D_3$ are present on epidermal keratinocytes, pilosebaceous structures, and in the dermis.[10-13] In human keratinocyte cultures, $1,25(OH)_2D_3$ causes a dose-dependent decrease in proliferation, an increase in morphologic differentiation, and an increase in terminal differentiation markers.[14] Cultured human keratinocytes can also convert $25(OH)D_3$ to $1,25(OH)_2D_3$, suggesting that the epidermis may regulate its own growth and differentiation by endogenously produced $1,25(OH)_2D_3$.[14] The mechanism by which $1,25(OH)_2D_3$ may induce differentiation of epidermal cells may be through calcium, because calcium is required for terminal differentiation of keratinocytes. $1,25(OH)_2D_3$ may facilitate calcium entry into cells and, through induction of calcium-binding

proteins, facilitate the ability of calcium to regulate various cellular processes.

ABERRANT CALCIFICATION AND OSSIFICATION

Despite the careful regulation of serum calcium, calcification and ossification of cutaneous and subcutaneous tissues may occur.[15] Calcification is the deposition of insoluble calcium salts; when it occurs in cutaneous tissues, it is known as *calcinosis cutis*. Ossification is the formation of true bony tissue by the deposition of calcium and phosphorus in a proteinaceous matrix as hydroxyapatite crystals. Cutaneous calcification may be divided into 4 major categories: (1) dystrophic, (2) metastatic, (3) idiopathic, and (4) iatrogenic (Table 128-1). Dystrophic calcification is the most common type of calcinosis cutis and occurs as a result of local tissue injury. Although calcium and phosphate metabolism and serum levels are normal, local tissue abnormalities, such as alterations in collagen, elastin, or subcutaneous fat may trigger calcification. The internal organs usually remain unaffected. Metastatic calcification is the precipitation of calcium salts in normal tissue secondary to an underlying defect in calcium and/or phosphate metabolism. The calcification may be widespread and, in addition to the skin, affects predominantly blood vessels, kidneys, lungs, and gastric mucosa. All patients presenting with signs of cutaneous calcification should receive a calcium and phosphate metabolic evaluation. Idiopathic calcification occurs without identifiable underlying tissue abnormalities, abnormal calcium, and/or phosphate metabolism. Cutaneous calcification also may be iatrogenic. Cutaneous ossification most commonly occurs secondary to local tissue alteration or preexisting calcification. Any calcifying disorder of the skin may ossify secondarily. Rarely, primary cutaneous ossification may occur without underlying tissue abnormalities or preexisting calcification.

DYSTROPHIC CALCIFICATION

CONNECTIVE TISSUE DISEASES

Dystrophic calcification frequently occurs in connective tissue diseases.[16] Scleroderma, including the limited cutaneous form previously known as CREST syndrome (*c*alcinosis cutis, *R*aynaud phenomenon, *e*sophageal dysfunction, *s*clerodactyly, *t*elangiectasia) are notable examples that are frequently associated with calcinosis cutis (Fig. 128-1; Chap. 63). In these disorders, nodules and plaques of calcium deposits may occur in the skin, subcutaneous tissue, muscle, or tendons. The calcium deposits most commonly occur on the upper extremities, especially on the fingers and wrists, but may occur in any area subject to trauma or motion. As the calcifications enlarge, they may ulcerate and exude a chalky material.

Dystrophic calcification also occurs in dermatomyositis (Chap. 62). It is more commonly associated with juvenile rather than adult-onset dermatomyositis (formerly in about 50% to 70% of children as opposed to 20% of adults); nevertheless, the more aggressive early treatment of juvenile dermatomyositis has been associated with a decrease in the occurrence of dystrophic calcification.[17] The calcification tends to occur 2 to 3 years after disease onset and most frequently appears on the elbows, knees, shoulders, and buttocks.[18] The calcium deposits may be painful and can ulcerate. They also may exude a chalky material, form sinuses, and become chronically infected. In a condition known as calcinosis universalis, calcium salt deposition may become quite extensive, progressing along fascial planes of skin and muscle, forming an "exoskeleton," and leading to significant morbidity and mortality. Calcinosis cutis in dermatomyositis is difficult to treat; however, if the patient survives long

TABLE 128-1
Calcinosis Cutis Subtypes

CATEGORIES OF CALCINOSIS CUTIS	SERUM CALCIUM	SERUM PHOSPHATE	CAUSE	ASSOCIATED CONDITIONS
Dystrophic	Normal	Normal	Local tissue injury	Connective tissue diseases Panniculitis Inherited disorders Cutaneous neoplasms Infections
Metastatic	Elevated or normal	Elevated or normal	Precipitation of calcium salts in normal tissue due to underlying defect in calcium and/or phosphate metabolism	Chronic renal failure Hypervitaminosis D Milk-alkali syndrome Tumoral calcinosis
Idiopathic	Normal	Normal	unknown	
Iatrogenic	Normal	Normal	Local injury	IV calcium chloride IV calcium gluconate therapy

Figure 128-1 Dystrophic calcification in limited cutaneous systemic sclerosis (formerly CREST syndrome: *c*alcinosis cutis, *R*aynaud phenomenon, *e*sophageal dysfunction, sclerodactyly, *t*elangiectasia).

enough, the calcified nodules may improve spontaneously. Although uncommon, calcinosis cutis has been described in all clinical subsets of lupus erythematosus and scleroderma.[19-22]

There is no standard treatment for dystrophic calcification. A diet low in calcium and phosphate along with aluminum hydroxide has been reported to arrest or facilitate regression of the calcified nodules.[23] Disodium etidronate also has been used with some success.[24] Several series report long-term treatment with diltiazem improves the calcinosis in some patients.[25,26] Other reported treatments include warfarin, colchicine, probenecid, bisphosphonates, and sodium thiosulfate.[16,27] Occasionally, calcium deposits must be removed surgically to clear sinus tracts, ulcers, or chronic infections.

PANNICULITIS

Pancreatic enzyme panniculitis (Chap. 73) is a lobular panniculitis that commonly demonstrates dystrophic calcification. It occurs in patients with pancreatitis or pancreatic adenocarcinoma and is presumably caused by the action of liberated pancreatic enzymes on subcutaneous fat. The fatty acids formed by lipolysis may combine with calcium and form calcium soap.

In subcutaneous fat necrosis of the newborn, erythematous, well-defined nodules and plaques occur during the first few weeks of life over the cheeks, back, buttocks, and extremities.[28,29] The affected infants are generally otherwise healthy, and the nodules and plaques usually clear spontaneously. Occasionally, the lesions calcify, and in a small subset of patients symptomatic hypercalcemia may develop, sometimes several months after birth.

INHERITED DISORDERS

Dystrophic calcification occurs in patients with pseudoxanthoma elasticum (PXE; Chap. 72). PXE is a hereditary disorder of elastic tissue characterized by progressive calcification of elastin fibers, primarily within the skin, Bruch's membrane of the retina, and the cardiovascular system. Mutations in the *ABCC6* gene (ATP-binding cassette) have been found in PXE patients.[30] This gene is thought to play a critical role in transmembrane transport. These patients also have significantly reduced serum levels of fetuin-A, an antimineralization protein, which may allowed increased calcification of elastic fibers.[31] Most patients with PXE have normal calcium phosphate metabolism, but a few have been identified who have abnormal calcium, phosphate, and/or vitamin D metabolism. Patients in this subset may develop metastatic calcification in the form of calcified or ossified tumors, calcification of the falx cerebri, and arterial calcification.[32-34]

Ehlers-Danlos syndrome (EDS; Chap. 72) is a group of inherited disorders of fibrillar collagen metabolism. Mutations in the collagen genes or enzymes that regulate collagen biosynthesis have been determined to underlie a number of EDS subtypes.[35-37] The skin characteristically shows hyperelasticity and fragility with formation of pseudotumors and large gaping scars. Subcutaneous calcified nodules, termed *spheroids* or *spherules*, may appear and are thought to represent calcified ischemic fat lobules.[38,39] Calcification of healing surgical incisions also has been reported in patients with EDS.[40]

Dystrophic calcification has been observed in patients with porphyria cutanea tarda (Chap. 124).[41,42] Sclerodermoid plaques with dystrophic calcification have occurred on the preauricular area, scalp, neck, and dorsa of the hands. Ulceration with transepidermal elimination of sheets of calcium is also rarely reported. Other genetic disorders in which calcification may occur include Werner syndrome, Rothmund–Thomson syndrome, and cerebral amyloid angiopathy (Chap. 130).[43,44]

CUTANEOUS NEOPLASMS

Dystrophic calcification occurs in association with a variety of benign and malignant cutaneous neoplasms. Often the neoplasms also show ossification in the surrounding stroma.

Pilomatricomas (Chap. 109) are the most common cutaneous neoplasms that manifest calcification and ossification. Approximately 75% of pilomatricomas show calcification and 15% to 20% show ossification.[45,46] Ossification usually occurs within the connective tissue adjacent to the shadow cells, probably through metaplasia of fibroblasts into osteoblasts. High levels of the adherens junction protein β-catenin have been identified in pilomatricomas due to mutations in the APC gene or by activating mutations in b-catenin gene. B-catenin signaling is a necessary for bone morphogenic protein 2–dependent ossification.[47,48]

A large number of other neoplasms may be associated with calcification and ossification, including pilar cyst, basal cell carcinoma, intradermal nevi (probably

as a result of inflammation or folliculitis), desmoplastic malignant melanoma, atypical fibroxanthoma, pyogenic granuloma, hemangioma, neurilemmoma, trichoepithelioma, and seborrheic keratoses.[49-53] Mixed tumors (chondroid syringomas) may also show calcification and ossification. However, unlike other neoplasms, the ossification occurs within the tumor via ossification of the chondroid cells, much like endochondral bone formation occurring in the epiphyses of bones.

INFECTIONS

Infectious agents may produce enough cutaneous damage to cause dystrophic calcification. Parasitic infections that may result in calcinosis cutis include onchocerciasis (*Onchocerca volvulus*) and cysticercosis (*Taenia solium*).[54,55] Calcinosis cutis in annular plaques also has been reported as a complication of intrauterine herpes simplex infection.[56]

OTHER

Dystrophic calcification has been reported in a variety of settings where local tissue injury occurs, such as in scarring caused by burns, trauma, neonatal heel sticks, surgery, and keloids.[57-61]

METASTATIC CALCIFICATION

CHRONIC RENAL FAILURE

Metastatic calcification most commonly occurs in chronic renal failure and takes the form of either benign nodular calcification or calciphylaxis. In chronic renal failure, decreased clearance of phosphate results in hyperphosphatemia. In addition, the impaired production of $1,25(OH)_2D_3$ results in a decrease in calcium absorption from the intestine and decreased serum calcium levels. The hypocalcemia results in increased PTH production and secondary hyperparathyroidism. Elevated levels of PTH cause bone resorption and mobilization of calcium and phosphate into the serum, leading to normalization of the serum calcium concentration but marked hyperphosphatemia. If the solubility product of calcium and phosphate is exceeded, metastatic calcification may occur, resulting in benign nodular calcification or calciphylaxis. In benign nodular calcification, the calcifications typically occur at periarticular sites, and their size and number tend to correlate with the degree of hyperphosphatemia. The lesions are usually asymptomatic except for mass effect and disappear with normalization of calcium and phosphate levels, though they may require surgical removal if interfering with function. Deposition of calcium in the skin also has been reported following subcutaneous administration of low-molecular-weight heparin in 2 renal transplant patients, which resolved following cessation of nadoparin.[62]

Figure 128-2 Calciphylaxis. The lesions develop as violaceous plaques that may progress to necrotic ulcers, as shown in this patient.

Calciphylaxis is a life-threatening disorder characterized by progressive vascular calcification, soft tissue necrosis, and ischemic necrosis of the skin (Chap. 137).[63] Clinically, it presents as firm, extremely painful, reticulated violaceous plaques associated with soft tissue necrosis and ulceration (Fig. 128-2). The lesions may occur anywhere, but the lower extremities are most frequently involved. The mortality rate is estimated to be approximately 80%, usually as a result of gangrene and sepsis.

Histopathologically, there is medial calcification of small and medium-sized arteries with intimal hyperplasia, primarily in dermal and subcutaneous tissues. Calciphylaxis occurs almost exclusively in patients with a history of chronic renal failure and prolonged secondary hyperparathyroidism. However, there exist rare reports of the occurrence of calciphylaxis in the absence of renal failure.[64] Most of the patients reported are female, and there may be an association with obesity, poor nutritional status, and diabetes.[65,66]

The pathogenesis of calciphylaxis remains controversial. Experiments in a rat model suggested that calciphylaxis may be triggered by exposure to a sensitizing agent (PTH, dihydrotachysterol, or vitamin D) followed by a challenging agent (metal salts, albumin, or corticosteroids).[67] However, the clinical description and histopathology of the animal lesions differ from the human disease. Protein C dysfunction also has been described in a subset of patients with calciphylaxis, but this more likely is a marker for a coagulation defect that predisposes this group to calciphylaxis.[68] More recently, it has been proposed that conversion of vascular smooth muscle cells into osteoblast-like cells is a critical step in the development of progressive vascular calcification as is seen in calciphylaxis. This conversion may be stimulated by phosphates, substances that stimulate inflammation in the vascular wall and bone morphogenic protein (BMP)-2. Other proteins that are currently under study as potential effectors, both positive and negative, are BMP-7, osteoprotegerin, matrix Gla protein, fetuin-A, and phosphatonins.[69]

The current therapy of calciphylaxis involves a multifaceted approach. The calcium-phosphate product should be normalized by methods including low calcium dialysis, use of phosphate binders that combine calcium acetate and magnesium carbonate, sodium thiosulfate, and parathyroidectomy in those instances where medical management fails. Other possible treatments include pamidronate, cinacalcet, hyperbaric oxygen, and low-dose tissue plasminogen activator.[70,71] There is increasing evidence for the use of sodium thiosulfate for the treatment of calciphylaxis. Sodium thiosulfate has antioxidant effect and also enhances calcium chelation; however, its exact mechanism of action in calciphylaxis remains unknown.[72] Aggressive management of wound infections and judicious use of debridement may help lower the incidence of sepsis and death in these patients.

HYPERVITAMINOSIS D

Chronic ingestion of vitamin D in supraphysiologic doses (50,000–100,000 units/d) may produce hypervitaminosis D.[73] The initial signs and symptoms of hypervitaminosis D are attributable to hypercalcemia and hypercalciuria, and include weakness, lethargy, headache, nausea, and polyuria. Metastatic calcification and nephrolithiasis may also occur.

MILK–ALKALI SYNDROME

Milk–alkali syndrome is characterized by excessive ingestion of calcium-containing foods or antacids, leading to hypercalcemia.[74] Complications other than the acute manifestations of hypercalcemia include irreversible renal failure, nephrocalcinosis, and subcutaneous calcification, occurring predominantly in periarticular tissues.

TUMORAL CALCINOSIS

Tumoral calcinosis (TC) is a disorder characterized by the deposition of calcific masses around major joints, such as hips, shoulders, elbows, and knees. The masses are intramuscular or subcutaneous and may enlarge to sizes causing significant impairment of joint function. Usually, the overlying skin is normal, but associated ulceration and calcinosis cutis may occur. It generally occurs in otherwise healthy adolescents. Tumoral calcinosis may be either sporadic or familial. The familial type may be associated with hyperphosphatemia or normophosphatemia. Inactivating mutations in either the *GALNT3*, KLOTHO, or *FGF23* genes may lead to hyperphosphatemic TC.[75-77] *GALNT3* encodes a glycosyltransferase (*N*-acetylgalactosaminyltransferase 3 or ppGalNAc-T3) that initiates mucin-type *O*-glycosylation. It is hypothesized that FGF23, an important regulator of phosphate homeostasis, must be glycosylated by ppGalNAc-T3 to function properly. Normophosphatemic familial TC has been associated with mutations resulting in the absence of SAMD9, an anti-inflammatory protein that also has been suggested to be a tumor suppressor. Surgical excision is the treatment of choice, but phosphate deprivation via dietary restriction and antacids that impair phosphate absorption has met with some success.[78]

OTHER DISORDERS

Other systemic disorders associated with hypercalcemia and/or hyperphosphatemia are reported to cause metastatic calcification. These include neoplasms associated with bony destruction, such as lymphoma, leukemia, multiple myeloma, and metastatic carcinoma.[79-81] Sarcoidosis also may be associated with metastatic calcification.[82]

IDIOPATHIC CALCIFICATION

Calcified nodules characterize idiopathic calcification of the scrotum. The lesions usually appear in otherwise healthy males and tend to increase in size and number with time.[83] Eventually, they may break down and exude a chalky material. Controversy exists over the etiology of this disorder.[84-87] The largest series of patients as of this writing with calcified nodules of the scrotum (n = 100) exhibit a spectrum of histologic findings from clear-cut calcification of an epidermal cyst, to inflamed cyst with partial loss of the epithelia lining, to calcium deposits, suggesting that these nodules form from dystrophic calcification of cysts and obliteration of the cyst wall.[87] Excision of the lesions is the treatment of choice, although patients may continue to develop nodules at other sites. Idiopathic calcification of the penis, vulva, and breast also has been reported.[88,89]

Subepidermal calcified nodules appear on the exposed areas of the head and the extremities, usually in children.[90] They may be congenital or acquired and typically appear as hard, 3- to 10-mm solitary lesions, although multiple lesions may occur. Some investigators believe the lesions represent calcified sweat gland hamartomas.[91]

Reports have described the appearance of milialike idiopathic calcinosis cutis on the dorsa of hands and forearms of patients with Down syndrome.[92-94] Some of the calcifications are associated with syringomas.

IATROGENIC CALCIFICATION

Cutaneous calcification may be iatrogenic. Calcinosis cutis is a complication of IV calcium chloride and calcium gluconate therapy.[95] Calcified nodules may

appear at sites of extravasation, probably as a result of an elevated tissue concentration of calcium and tissue damage. A secondary inflammatory response results, following which calcium deposits are either absorbed or transepidermally eliminated. In a rabbit model of iatrogenic calcification, intralesional triamcinolone injection decreased inflammation and ulceration. Minor trauma and prolonged contact with calcium salts can lead to calcinosis cutis in a variety of settings.[96,97] It has occurred in patients undergoing electroencephalography with saturated calcium chloride electrode paste.[98] Cutaneous calcification of skin graft donor sites after the application of calcium alginate dressings also has been reported.[99] Transient deposits of calcium in the skin and other soft tissues also have been reported after liver transplantation.[100] It is hypothesized that these transient deposits are caused by the large amounts of calcium- and citrate-containing blood products used during surgery, combined with metabolic abnormalities in the perioperative period.

PRIMARY OSSIFICATION

Primary ossification of cutaneous and subcutaneous tissues rarely occurs without underlying tissue abnormalities or preexisting calcification. However, there are 3 well-described ossifying syndromes[101]: fibrodysplasia ossificans progressiva (FOP), and 2 GNAS-associated disorders, Albright hereditary osteodystrophy (AHO), and progressive osseous heteroplasia (POH). Other primary ossification disorders reported in the literature, such as platelike osteoma cutis (also termed primary osteoma cutis, isolated osteoma, or widespread osteoma) probably are variants of the described ossifying syndromes or represent a group of poorly described primary ossification disorders.

FIBRODYSPLASIA OSSIFICANS PROGRESSIVA

FOP is an autosomal-dominant syndrome characterized by the progressive ossification of deep connective tissues leading to significant morbidity and mortality.[102] Ossification is of the endochondral type and involvement of the skin occurs as a result of direct extension from underlying tissues; thus, it is rare for it to initially present to the dermatologist. Dysmorphic great toes are a characteristic feature of FOP. Other features include abnormal phalanges of the hands, hearing loss (both conductive and sensorineural), sparse scalp hair, cognitive impairment (usually mild), cataracts, persistence of primary teeth, and severe growth retardation.

Gain-of-function point mutations in the activin (*ACVR1/ALK2*) gene have been identified as the cause of FOP. Most cases represent spontaneous mutations but in a few families parental germ-line mosaicism has been identified.[103] Activin (also known as activinlike kinase 2 [ALK2]) is a bone morphogenic protein Type I receptor and its mutation leads to overactive BMP signaling, leading to ectopic bone formation.

ALBRIGHT HEREDITARY OSTEODYSTROPHY, PROGRESSIVE OSSEOUS HETEROPLASIA, AND PLATELIKE OSTEOMA CUTIS

AHO, and POH, are closely related syndromes that are characterized by intramembranous bone formation in skin. Heterozygous, inactivating mutations in the gene encoding for the α-subunit of the stimulatory G protein of adenyl cyclase (GNAS1), a negative regulator of bone formation, have been identified in both of these disorders.[101,104,105] In addition, some patients have been described in which features of both disorders are present.[106] Several families have demonstrated an "imprinting" effect; inheritance of an inactivating mutation in GNAS1 from the mother results in pseudohypoparathyroidism Type Ia, whereas paternal inheritance leads to POH.[107,108] In addition, different splice variants are expressed solely by maternal or paternal alleles. AHO more commonly arises from maternally inherited mutations but no clear genotype–phenotype correlation has yet been established between these disorders. Those patients described as platelike osteoma cutis appear to be formes frustes of AHO or POH.

AHO is an autosomal dominantly inherited syndrome characterized by the ossification of cutaneous and subcutaneous tissues in childhood. AHO generally follows a limited course, and significant deformity and physical impairment are rare. Patients typically have brachydactyly dimpling over the metacarpophalangeal joints (Albright sign), obesity, round or moon facies, short stature, and mental retardation. Most patients have a deficient end-organ response to PTH or "pseudohypoparathyroidism" with hypocalcemia, hyperphosphatemia, and elevated levels of PTH. Other patients have "pseudopseudohypoparathyroidism" with normal serum levels of calcium and phosphorus.

POH is characterized by progressive ossification of skin and deep tissues during infancy or childhood.[109,110] Ossification usually begins in the dermis and progresses to involve deeper tissues, such as muscle, as well as overlying skin. Skin involvement has been described as a papular eruption resembling "rice grains" and having a "gritty" consistency (Fig. 128-3). When well developed, there are weblike areas of ectopic bone formation. The bone formation is most commonly intramembranous (50%), but also may be endochondral (20%) or both (30%). To meet criteria for POH, a patient must have progressive heterotopic ossification, 2 or fewer signs of AHO, and no parathyroid hormone resistance. Secondary orthopedic problems, such as limb-length discrepancy or ankylosis of the joint, may arise if cutaneous ossification is severe enough to limit motion. Other clinical features of POH

Figure 128-3 Progressive osseous heteroplasia. The appearance of the skin in progressive osseous heteroplasia can be subtle, but the lesions have a distinctive textural change that feels like rice grains in the skin.

include low birth weight (usually at or below the 5th percentile).[111]

OTHER

Miliary osteoma cutis of the face most commonly occurs as multiple small, firm nodules on the faces of young women with a history of acne vulgaris. However, there are reports of multiple miliary osteoma cutis in older patients without acne vulgaris or other underlying skin disease.[112]

GOUT

Gout is a clinical syndrome caused by a group of heterogeneous diseases characterized by deposition of monosodium urate crystals in synovial fluid and joints with or without hyperuricemia, renal disease, or nephrolithiasis.[113,114] It occurs in both acute and chronic forms. Classically, the acute presentation is that of sudden-onset lower extremity peripheral joint inflammatory synovitis. The most commonly affected sites are the first metatarsophalangeal joint and the ankle. In the chronic form, aggregates of crystals are deposited in tissue, especially in skin and around joints. Although skin disease is often asymptomatic, periarticular and osseous deposition may lead to bone destruction.

EPIDEMIOLOGY

Gout affects over 8 million Americans and has historically been described as a disease that affects men, though it also affects women.[115] Recent epidemiologic studies demonstrate that on average, women develop gout a decade later than men, and that female patients with gout are more likely to have renal insufficiency or to be taking diuretics.[116] Obesity has been linked to gout, and both diseases have increased in incidence over the last 3 decades. Recognized risk factors for gout include consumption of alcohol and purine-rich foods such as meat and seafood. Consumption of low-fat dairy products may be protective.[117] Gouty attacks in children are so uncommon that this diagnosis should prompt an evaluation for a malignant or genetic cause.

PATHOGENESIS

Hyperuricemia is a risk factor for gout, but acute gouty arthritis may also occur in patients with normal serum uric acid levels. Patients with serum uric acid levels greater than 7 mg/dL have a 22% chance of developing gout over a 5-year period; accordingly, many patients with elevated serum uric acid levels may never develop gouty arthritis.[118]

Uric acid is the end product of purine catabolism. In most fish, amphibians, and nonprimate mammals, purine-generated uric acid is degraded through uricase (a uric acid oxidase).[114] In primates, including humans, the uricase gene is silenced by 2 mutations. The absence of uricase, along with extensive reabsorption of filtered urate, results in plasma urate levels that are 10 times that of most other mammals.[114] When plasma urate levels exceed its limit of solubility, it may precipitate in tissues.

Hyperuricemia results from either overproduction or underexcretion of uric acid. Ninety percent of patients with gout are under excreters.[118] Conversely, less than 10% of patients with hyperuricemia or gout excrete excessive quantities of uric acid in a 24-hour urine collection. Table 128-2 presents a classification of hyperuricemia. It is usually in the excessive excreters that identifiable mutations in mechanisms regulating protein nucleotide synthesis can be found. The most common mutations are in hypoxanthine-guanine phosphoribosyltransferase, glucose-6-phosphatase, or fructose-1-phosphatase, and can result in either partial or complete deficiency of these enzymes. These mutations are inherited by X-linked or autosomal recessive means (in the latter two); therefore, a family history of gout or early presentation may be a clue toward the existence of one of these mutations. The Lesch–Nyhan syndrome, well described but very rare, is an extremely severe form of hypoxanthine-guanine phosphoribosyltransferase deficiency associated with mental retardation, gout, and self-mutilation.[118]

Genetic determinants of gout in the presence of hyperuricemia are still being elucidated. Genomewide association studies have identified 28 loci of associated common genetic variants. Distinct pathways of renal and gut excretion of uric acid with glycolysis are implicated in hyperuricemia, as well as a mechanism of extrarenal uric acid underexcretion with major urate loci SLC2A9 and ABCG2, respectively.[119]

TABLE 128-2
Classification of Hyperuricemia

Overproduction of uric acid
- Primary hyperuricemia
  - Idiopathic
  - Hypoxanthine-guanine phosphoribosyltransferase deficiency
  - Phosphoribosylpyrophosphate synthetase superactivity
- Secondary hyperuricemia
  - Excessive dietary purine intake
  - Increased nucleotide turnover (eg, myeloproliferative and lymphoproliferative disorders, hemolytic disease, psoriasis)

Diminished excretion of uric acid
- Primary hyperuricemia
  - Idiopathic
- Secondary hyperuricemia
  - Diminished renal function
  - Inhibition of tubular urate secretion by competitive anions (eg, keto- and lactic acidosis)
  - Enhanced tubular urate reabsorption

Dehydration, diuretics
- Miscellaneous
  - Hypertension
  - Hyperparathyroidism
  - Certain drugs (eg, cyclosporine, pyrazinamide, ethambutol, low-dose salicylates)
  - Lead nephropathy

Uric acid underexcretion is idiopathic in patients with hyperuricemia. The anatomic appearance and physiologic function of the kidney appear normal; however, drug-induced alteration of renal tubular function in these patients can precipitate gouty attacks. These pharmacologic agents include loop diuretics, low-dose cyclosporine, and salicylates.

Precipitating causes of an acute gouty attack are not well understood. Studies have shown the presence of intracellular monosodium urate crystals in synovial fluid of asymptomatic patients, suggesting that inflammation in gout is chronic. There must be an unidentified trigger in the acute attack that incites a more robust inflammatory response. Monocytes are present and secrete cytokines, including tumor necrosis factor alpha (TNF-α), interleukin 1, interleukin 6, and interleukin 8. Neutrophils are then attracted to the site as well; they ingest the crystals and release multiple inflammatory mediators, initiating further inflammation and tissue damage.[114,118]

CLINICAL MANIFESTATIONS

Gout can be divided into 4 stages: (1) asymptomatic hyperuricemia, (2) acute gouty arthritis, (3) intercritical gout (between gouty attacks), and (4) chronic tophaceous gout.[118] Patients are often asymptomatic for years, requiring no therapeutic intervention in the absence of other evidence of disease (eg, arthritis, nephrolithiasis, or renal insufficiency).

Acute gouty arthritis usually occurs in middle age and primarily affects a single joint in the lower extremities, the first metatarsophalangeal joint being the most common site of initial involvement (podagra).[113,118] Clinically, the affected joint is erythematous and exquisitely tender to palpation. This may be confused with a sprain, a septic joint, or cellulitis. Cytokine release can lead to fever and systemic symptoms, confounding the picture further. The differential diagnosis also includes other forms of arthritis (psoriatic, reactive, rheumatoid, or osteoarthritis) and pseudogout (chondrocalcinosis).[118]

Intercritical gout describes the interval that occurs between attacks of gout, an interval of between 6 months and 2 years. As attacks continue, they tend to be polyarticular, more severe, and of longer duration. Chronic tophaceous gout describes gout where patients rarely have asymptomatic periods. Urate crystals may be found in the soft tissues, cartilage, and tendons (Fig. 128-4A).[118] Lesions that occur in the skin are referred to as tophi and are a pathognomonic sign of gout. They have been reported in a variety of unusual places as well, including the nasal dorsum.[120] They may be confused with rheumatoid nodules, calcinosis cutis, or granuloma annulare, and aspiration or biopsy may prove useful in confirming the diagnosis.

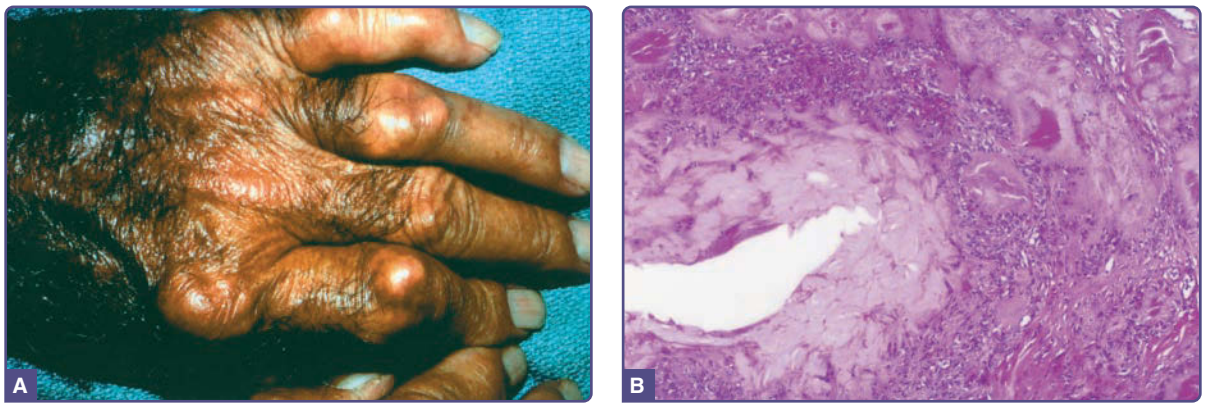

Figure 128-4 Gouty tophi. **A,** Tender nodules overlying joints and tendons, which may drain chalky white material. **B,** Histopathology shows granulomatous "fluffy" appearing infiltrate surrounding radially arranged needle-like spaces.

LABORATORY PRESENTATION AND PATHOLOGY

Laboratory analysis may reveal elevated uric acid levels, but this finding is not necessary for the diagnosis of gout. Leukocytosis and elevated sedimentation rate are often seen during acute arthritic attacks. Accurate diagnosis rests on the demonstration of intracellular, negatively birefringent, needle-shaped crystals by polarized microscopy. Histopathologic examination of a gouty tophus reveals granulomatous inflammation surrounding yellow–brown urate crystals or needlelike spaces in a radial arrangement, representing crystals dissolved during processing (see Figs. 128-4B and 128-5).[121]

TREATMENT

The goal of therapy in acute gouty attacks is analgesia and reduction in inflammation. The main options to choose from are nonsteroidal anti-inflammatory drugs, colchicine, and corticosteroids. Indomethacin has been shown in randomized controlled trials to decrease pain, as has colchicine. Colchicine may have adverse GI side effects; however, a newer dosing regimen for colchicine use in acute attacks appears to greatly reduce the incidence of GI symptoms.[121] This regimen of 1.2 mg of colchicine followed in 1 hour by 0.6 mg also reduces drug–drug interactions mediated by colchicine inhibition of *P*-glycoprotein and cytochrome 3A4 pathways. Severe adverse reaction and deaths have been reported when colchicine is combined with other strong inhibitors of one or both pathways (eg, clarithromycin, erythromycin, and cyclosporine).[122] Indomethacin can precipitate acute renal failure in patients with underlying renal disease. Corticosteroids, both oral and intraarticular, are also believed to be effective. Because patients with gout are typically older with many comorbidities, therapy should be individualized. Treatment should continue for 7 to 10 days after the acute attack, and prophylactic therapy may be continued for 3 to 6 months.[113,118]

Figure 128-5 Gouty tophi on helix.

In patients with history of only one gouty attack, a conservative management approach can be used. This includes avoidance of drugs that decrease the excretion of uric acid such as thiazide or loop diuretics, aspirin, pyrazinamide, or niacin. Patients should maintain adequate hydration, lose weight, control hypertension and hyperlipidemia, and make diet adjustments by decreasing purine intake. Effectiveness of limiting cholesterol, fat, meat, and alcohol has never been studied, but should be advocated to avoid the need for lifelong oral therapy.[118,123]

Uric acid–lowering therapy is likely necessary in patients with chronic tophaceous gout or those who have had more than one gouty attack. It is also indicated in patients with history of gout and renal calculi, extremely high values of serum uric acid, high serum uric acid levels in the setting of a known familial history of gout (eg, where there is a known deficiency of one of the relevant enzymes previously described), and as prophylaxis for patients receiving acute courses of chemotherapy.

The goal of urate-lowering drugs is to maintain the serum urate level consistently at less than 6 mg/dL (5 mg/dL in patients with tophi or frequent attacks). Uricosuric therapy is ideal in younger patients (age less than 60 years) with normal kidneys who are underexcreters of uric acid. Uricosurics include probenecid, sulfinpyrazone, and benzbromarone.[124,125] The major risks associated with these medicines include hypersensitivity reactions and increased risk of uric acid nephrolithiasis (avoided by alkalinizing the urine). Unfortunately, most patients with gout do not fit this "ideal" situation. Benzbromarone is not commercially available in the United States; though potent, it may cause severe hepatotoxicity.[125]

For all other patients, xanthine oxidase inhibitors are used. Allopurinol is the first-line drug for lowering serum urate.[123] It decreases production of uric acid, and is indicated for patients with nephrolithiasis, renal impairment, those who failed uricosuric agents, with myeloproliferative disorders on chemotherapy, and patients with hyperuricemia due to enzyme abnormalities. Dosages must be reduced in patients with renal failure. Twenty percent of patients taking allopurinol report side effects, and 5% discontinue medication as a result. Side effects include dyspepsia, headache, diarrhea, a pruritic papular eruption, thrombocytopenia, and hepatic function abnormalities. Allopurinol hypersensitivity syndrome is rare and includes fever, urticaria, leukocytosis, eosinophilia, interstitial

nephritis, acute renal failure, granulomatous hepatitis, and toxic epidermal necrolysis. A second xanthine oxidase inhibitor is febuxostat, labeled for use at 40 mg once daily.[124,125] It appears to be roughly equivalent to allopurinol. However, it does show higher efficacy in the setting of renal impairment, when allopurinol, but not febuxostate, must be reduced.[125]

Uricases are an additional class of therapeutic agents used in treating urate disorders. The nonpegylated recombinant fungal enzyme rasburicase is FDA approved for short-course therapy to prevent tumor lysis syndrome.[124] It is highly immunogenic, and its plasma half-life is less than 24 hours. IV pegloticase, another uricase, is approved in patients with refractory chronic gout. Pegylation of uricases with production of PEG multimers has decreased the immunogenicity and increased the serum half-life to days or weeks. Infusion reactions may be seen, and include flushing, urticaria, hypotension, and anaphylaxis. All uricase therapies may induce oxidative stress, which can lead to methemoglobinemia or anemia, occurring more often but not confined to glucose-6-phosphate dehydrogenase–deficient (G6PD-deficient) individuals.[124] The role of pegylated uricases in treating urate disease remains to be determined.

Lesinurad is a recently Food and Drug Administration (FDA)–approved selective uric acid reabsorption inhibitor. It inhibits URAT1, a urate transporter that is responsible for most renal reabsorption of uric acid. It also inhibits OAT4, a transporter associated with diuretic-induced hyper uricemia. Lesinurad is administered with a xanthine oxidase inhibitor in those patients who have not achieved control with the xanthine oxidase inhibitor alone.[126]

ACKNOWLEDGMENTS

The authors thank John S. Walsh, MD, and Warren W. Piette, MD, for their work on this chapter in previous editions.

REFERENCES

1. Hennings H, Michael D, Cheng C, et al. Calcium regulation on growth and differentiation of mouse epidermal cells in culture. *Cell.* 1980;19(1):245.
2. Yuspa SH. Chapter IV. In: Skerrow D, Skerrow C, eds. *Methods of Skin Research*. Sussex, UK: John Wiley; 1985:213.
3. Yuspa SH, Kilkenny AE, Steinert PM, et al. Expression of murine epidermal differentiation markers is tightly regulated by restricted extracellular calcium concentrations in vitro. *J Cell Biol.* 1989;109(3):1207.
4. Milstone LM. Calcium modulates the growth of human keratinocytes in confluent culture. *Epithelia.* 1987;1:129.
5. Hu Z, Bonifas JM, Beech J, et al. Mutations in *ATP2C1*, encoding a calcium pump, cause Hailey-Hailey disease. *Nat Genet.* 2000;24(1):61.
6. Sakuntabhai A, Burge S, Monk S, et al. Spectrum of novel *ATP2A2* mutations in patients with Darier's disease. *Hum Mol Gen.* 1999;8:1611.
7. Holick MF, MacLaughlin JA, Clark MB, et al. Photosynthesis of previtamin D_3 in human skin and the physiological consequences. *Science.* 1980;210(4466):203.
8. Deluca HF, Schnoes HK. Vitamin D. Recent advances. *Annu Rev Biochem.* 1983;52:411-439.
9. Bikle DD. Vitamin D regulated keratinocyte differentiation. *J Cellular Biochem.* 2004;92(3):436-444.
10. Clemens TL, Adams JS, Horiuchi N, et al. Interaction of 1,25 dihydroxyvitamin D with keratinocytes and fibroblasts from skin of normal subjects and a subject with vitamin D dependent Rickets, Type II: a model for the study of the mode of action of 1,25(OH)2D3. *J Clin Endocrinol Metab.* 1983;56(4):824.
11. Eli C, Marx SJ. Nuclear uptake of 1,25 dihydroxy3H cholecalciferol in dispersed fibroblasts cultured from normal human skin. *Proc Natl Acad Sci U S A.* 1981;79:2562.
12. Feldman D, Chen T, Cone C, et al. Vitamin D resistant rickets with alopecia: cultured skin fibroblasts elicit defective cytoplasmic receptors and unresponsiveness to 1,25 dihydroxyvitamin D in rat skin. *Endocrinol Metab.* 1982;55:1020.
13. Simpson RU, DeLuca HF. Characterization of a receptor like protein for 1,25 dihydroxyvitamin D in rat skin. *Proc Natl Acad Sci U S A.* 1980;77(10):5822-5826.
14. Pillai S, Bikle DD, Elias PM, et al. Vitamin D and epidermal differentiation. Evidence for a role of endogenously produced vitamin D metabolites in keratinocyte differentiation. *Skin Pharmacol.* 1988;1(3):149-160.
15. Walsh JS, Fairley JA. Calcifying disorders of the skin. *J Am Acad Dermatol.* 1995;33(5, pt 1):693-706.
16. Boulman N, Slobodin G, Rozenbaum M, et al. Calcinosis in rheumatic diseases. *Semin Arthritis Rheum.* 2005;34(6):805-812.
17. Cook DC, Rosen FS, Banker BQ. Dermatomyositis and focal scleroderma. *Pediatr Clin North Am.* 1963;10:979.
18. Bowyer SL, Blane CE, Sullivan DB, et al. Childhood dermatomyositis. Factors predicting functional outcome and development of dystrophic calcification. *J Pediatr.* 1983;103(6):882-888.
19. Rothe MJ, Grant-Kels JM, Rothfield NF, et al. Extensive calcinosis cutis with systemic lupus erythematosus. *Arch Dermatol.* 1990;126:1060.
20. Marzano AV, Kolesnikova LV, Gasparini G, et al. Dystrophic calcinosis cutis in subacute lupus. *Dermatology.* 1999;198(1):90-92.
21. Ueki H, Takei Y, Nakagawa S. Cutaneous calcinosis in localized discoid lupus erythematosus. *Arch Dermatol.* 1980;116(2):196-197.
22. Carette S, Urowitz MB. Systemic lupus erythematosus and diffuse soft tissue calcification. *J Dermatol.* 1983;22:416.
23. Wang WJ, Lo WL, Wong CK. Calcinosis cutis in juvenile dermatomyositis. Remarkable response to aluminum hydroxide therapy. *Arch Dermatol.* 1988;124(11):1721-1722.
24. Rabens SF, Bethune JE. Disodium etidronate therapy for dystrophic cutaneous calcification. *Arch Dermatol.* 1975;11:357.
25. Palmieri GM, Sebes JI, Aelion JA, et al. Treatment of calcinosis with diltiazem. *Arthritis Rheum.* 1995;38(11):1646-1654.
26. Dolan AL, Kassimos D, Gibson T, et al. Diltiazem induces remission of calcinosis in scleroderma. *Br J Rheumatol.* 1995;34(6):576-578.

27. Fuchs D, Fruchter L, Fishel B, et al. Colchicine suppression of local inflammation due to calcinosis in dermatomyositis and progressive systemic sclerosis. *Clin Rheum.* 1986;5(4):527-530.
28. Shackelford GD, Barton LL, McAlister WH. Calcified subcutaneous fat necrosis in infancy. *J Can Assoc Radiol.* 1975;26(3):203-207.
29. Martin MM, Steven EM. Subcutaneous fat necrosis of the newborn associated with subcutaneous fat necrosis and calcification. *Am J Dis Child.* 1962;104:235.
30. Struk B, Cai L, Zäch S, et al. Mutations of the gene encoding the transmembrane transporter protein ABC-C6 cause pseudoxanthoma elasticum. *J Mol Med (Berl).* 2000;78(5):282-286.
31. Hendig D, Schulz V, Arndt M, et al. Role of serum fetuin-A, a major inhibitor of systemic calcification, in pseudoxanthoma elasticum. *Clin Chem.* 2006;52(2): 227-234.
32. Choi GS, Kang DS, Chung JJ, et al. Osteoma cutis coexisting with cutis laxa-like pseudoxanthoma elasticum. *J Am Acad Dermatol.* 2000;43(2, pt 2):337-339.
33. Buka R, Wei H, Sapadin A, et al. Pseudoxanthoma elasticum and calcinosis. *J Am Acad Dermatol.* 2000;43(2, pt 1):312-315.
34. Mallette LE, Mechanick JI. Heritable syndrome of pseudoxanthoma elasticum with abnormal phosphorus and vitamin D metabolism. *Am J Med.* 1987;83(6):1157-1162.
35. Giunta C, Steinmann B. Compound heterozygosity for a disease-causing G1489D and disease-modifying G530S substitution in COL5A1 of a patient with the classical type of Ehlers-Danlos syndrome: an explanation of intrafamilial variability? *Am J Med Genet.* 2000;90(1):72-79.
36. Richards AJ, Martin S, Nicholls AC, et al. A single base mutation in *COL5A2* causes Ehlers-Danlos syndrome type II. *J Med Genet.* 1998;35(10):846-848
37. Imamura Y, Scott IC, Greenspan DS. The pro-alpha3(V) collagen chain. Complete primary structure, expression domains in adult and developing tissues, and comparison to the structures and expression domains of the other types V and XI procollagen chains. *J Biol Chem.* 2000;275(12):8749-8759.
38. Novice FM, Collison DW, Burgdorf WHC, et al. *Dysplasias and Malformations: Handbook of Genetic Skin Disorders*. Philadelphia, PA: WB Saunders; 1994:298.
39. Linnemann MP, Johnson VW. Ehlers-Danlos syndrome presenting with torsion of stomach. *Proc R Soc Med.* 1975;68:330.
40. Rees TD, Wood-Smith D, Converse J, et al. The Ehlers-Danlos syndrome. *Plast Reconstr Surg.* 1963;32:39.
41. Grossman ME, Bickers DR, Poh-Fitzpatrick MB, et al. Porphyria cutanea tarda. Clinical features and laboratory findings in 40 patients. *Am J Med.* 1979;67(2): 277-286.
42. Wilson PR. Porphyria cutanea tarda with cutaneous "scleroderma" and calcification. *Australas J Dermatol.* 1989;30(2):93-96.
43. Murata K, Nakashima H. Werner's syndrome. Twenty-four cases and review of the Japanese medical literature. *J Am Geriatr Soc.* 1982;30(5):303-308.
44. Aydemir EH, Onsun N, Ozan S, et al. Rothmund-Thomson syndrome with calcinosis universalis. *J Dermatol.* 1988;27(8):591-592.
45. Peterson WC, Hult AM. Calcifying epithelioma of Malherbe. *Arch Dermatol.* 1964;90:404.
46. Forbis R, Helwig EB. Pilomatrixoma (calcifying epithelioma). *Arch Dermatol.* 1961;83:606.
47. Chan EF. Pilomatricomas contain activating mutations in beta-catenin. *J Am Acad Dermatol.* 2000;43(4):701-702.
48. Chen Y, Whetstone HC, Youn A, et al. B-Catenin signaling pathway is crucial for bone morphogenetic protein 2 to induce new bone formation. *J Biol Chem.* 2007;282(1):526-533.
49. Leppard BJ, Sanderson KB. The natural history of trichilemmal cysts. *Br J Dermatol.* 1976;94(4):379-390.
50. Walsh JS, Perniciaro C, Randle HW. Calcifying basal cell carcinomas. *Dermatol Surg.* 1999;25(1):49-51.
51. Roth SI, Stowell Re, Helwigeb. Cutaneous ossification. Report of 120 cases and review of the literature. *Arch Pathol.* 1963;76:44.
52. Moreno A, Lamarca J, Martinez R, et al. Osteoid and bone formation in desmoplastic malignant melanoma. *J Cutan Pathol.* 1986;13(2):128-134.
53. Chen KTK. Atypical fibroxanthoma of the skin with osteoid production. *Arch Dermatol.* 1980;116(1): 113-114.
54. Browne SG. Calcinosis circumscripta of the scrotal wall. The etiological role of *Onchocerca volvulus*. *Br J Dermatol.* 1962;74:136-140.
55. Pastel A, Grupper C. Subcutaneous calcification, generalized calcinosis in nodular chains. Cysticercosis [in French]. *Bull Soc Fr Dermatol Syphligr.* 1969; 76(1):28-31.
56. Beers BB, Flowers FP, Sherertz EF, et al. Dystrophic calcinosis cutis secondary to intrauterine herpes simplex. *Pediatr Dermatol.* 1986;3(3):208-211.
57. Coskey RJ, Mehregan AH. Calcinosis cutis in a burn scar. *J Am Acad Dermatol.* 1984;11:666.
58. Ellis IO, Foster MC, Womack C. Plumber's knee. Calcinosis cutis after repeated trauma in a plumber. *Br Med J.* 1984;288(6432):1723.
59. Leung A. Calcification following heel sticks. *J Pediatr.* 1985;106(1):168.
60. Katz I, LeVine M. Bone formation in laparotomy scars. Roentgen findings. *AJR Am J Roentgenol.* 1960;84:248.
61. Redmond WJ, Baker SR. Keloidal calcification. *Arch Dermatol.* 1983;119:270.
62. van Haren FM, Ruiter DJ, Hilbrands LB. Nadoparin-induced calcinosis cutis in renal transplant recipients. *Nephron.* 2001;87(3):279-282.
63. Weenig RH, Sewell LD, Davis MD, et al. Calciphylaxis: natural history, risk factor analysis and outcome. *J Am Acad Dermatol.* 2007;56(4):569-579.
64. Fader DJ, Kang S. Calciphylaxis without renal failure. *Arch Dermatol.* 1996;132:837.
65. Walsh JS, Fairley JA. Calciphylaxis. *J Am Acad Dermatol.* 1996;35:786.
66. Bleyer AJ, Choi M, Igwemezie B, et al. A case control study of proximal calciphylaxis. *Am J Kidney Dis.* 1998;32(3):376-383.
67. Selye H. *Calciphylaxis*. Chicago: University of Chicago Press; 1962.
68. Mehta RL, Scott G, Sloand JA, et al. Skin necrosis with acquired protein C deficiency in patients with renal failure and calciphylaxis. *Am J Med.* 1990;88(3):252-257.
69. Stompor T. An overview of the pathophysiology of vascular calcification in chronic kidney disease. *Perit Dial Int.* 2007;27(suppl 2):S215-S222.
70. Hafner J, Keusch G, Wahl C, et al. Uremic small-artery disease with medial calcification and intimal hyperplasia (so-called calciphylaxis): a complication of chronic renal failure and benefit from parathyroidectomy. *J Am Acad Dermatol.* 1995;33(6):954-962.

71. Robinson MR, Augustine KK, Korman NJ. Cinacalcet for the treatment of calciphylaxis. *Arch Dermatol.* 2007;143:2.
72. Peng T, Zhuo Y, Jun M, et al. A systematic review of sodium thiosulfate in treating calciphylaxis in chronic kidney disease patients [published online ahead of print June 11, 2017]. *Nephrology (Carlton).* doi:10.111/neph.13081.
73. Wilson CW, Wingfield WL, Toone EC. Vitamin D poisoning with metastatic calcification. *Am J Med.* 1953;14(1):116-123.
74. Wermer P, Kuscher M, Riley EA. Reversible metastatic calcification associated with excessive milk and alkali intake. *Am J Med.* 1953;14:108-115.
75. Topaz O, Bergman R, Mandel U, et al. Absence of intraepidermal glycosyltransferase ppGalNAc-T3 expression in familial tumoral calcinosis. *Am J Dermatopathol.* 2005;27(3):211-215.
76. Topaz O, Shurman DL, Bergman R, et al. Mutations in GALNT3, encoding a protein involved in O-linked glycosylation, cause familial tumoral calcinosis. *Nat Genet.* 2004;36(6):579-581.
77. Kato K, Jeanneau C, Tarp MA, et al. Polypeptide GalNAc-transferase T3 and familial tumoral calcinosis. Secretion of fibroblast growth factor 23 requires O-glycosylation. *J Biol Chem.* 2006;281(27):18370-18377.
78. Sprecher E. Familial tumoral calcinosis: from characterization of a rare phenotype to the pathogenesis of ectopic calcification. *J Invest Dermatol.* 2010;130(2):652-660.
79. Panicek DM, Harty MP, Scicutella CJ, et al. Calcification in untreated mediastinal lymphoma. *Radiology.* 1988;166(3):735-736.
80. Abe M, Segami H, Wakasa H. Hypercalcemia and metastatic calcification in adult T-cell leukemia-pathogenesis of hypercalcemia. *Fukushima J Med Sci.* 1985;31(2):85-97.
81. Raper RF, Ibels LS. Osteosclerotic myeloma complicated by diffuse arteritis, vascular calcification and extensive cutaneous necrosis. *Nephron.* 1985;39(4):389-392.
82. Kroll JJ, Shapiro L, Koplon BS, et al. Subcutaneous sarcoidosis with calcification. *Arch Dermatol.* 1972;106(6):894-895.
83. Shapiro L, Plutt N, Torres-Rodriques VM. Idiopathic calcinosis of the scrotum. *Arch Dermatol.* 1970;102(2):199-204.
84. Wright S, Navsaria H, Leigh IM. Idiopathic scrotal calcinosis is idiopathic. *J Am Acad Dermatol.* 1991;24(5, pt 1):727-730.
85. Swinehart JW, Golitz LE. Scrotal calcinosis. Dystrophic calcification of epidermoid cysts. *Arch Dermatol.* 1982;118(12):985-988.
86. Bhawan J, Nalhotra R, Frank S. The so-called idiopathic calcinosis. *Arch Dermatol.* 1983;119(9):709.
87. Dubey S, Sharma R, Maheshwari V. Scrotal calcinosis: idiopathic or dystrophic. *Dermatol Online J.* 2010;16(2):5.
88. Hutchinson IF, Abel BJ, Susskind W. Idiopathic calcinosis cutis of the penis. *Br J Dermatol.* 1980;102(3):341-343.
89. Balfour PJ, Vincenti AC. Idiopathic vulvar calcinosis. *Histopathology.* 1991;18(2):183-184.
90. Woods B, Kellaway TD. Cutaneous calculi. Subepidermal calcified nodules. *Br J Dermatol.* 1963;75:1-11.
91. Shmunes E, Wood MG. Subepidermal calcified nodules. *Arch Dermatol.* 1972;105(4):593-597.
92. Schepis C, Siragusa M, Palazzo R, et al. Perforating milia-like idiopathic calcinosis cutis and periorbital syringomas in a girl with Down syndrome. *Pediatr Dermatol.* 1994;11(3):258-260.
93. Smith ML, Golitz LE, Morelli JG, et al. Milia-like idiopathic calcinosis cutis in Down's syndrome. *Arch Dermatol.* 1989;125(11):1586-1587.
94. Maroon M, Tyler W, Marks VJ. Calcinosis cutis associated with syringomas. A transepidermal elimination disorder in a patient with Down syndrome. *J Am Acad Dermatol.* 1990;23(2, pt 2):372-375.
95. Goldminz D, Barnhill R, McGuire J, et al. Calcinosis cutis following extravasation of calcium chloride. *Arch Dermatol.* 1988;124(6):922-925.
96. Wheeland RG, Roundtree JM. Calcinosis cutis resulting from percutaneous penetration and deposition of calcium. *J Am Acad Dermatol.* 1985;12(1, pt 2):172-175.
97. Clendenning WE, Auerbach R. Traumatic calcium deposition in the skin. *Arch Dermatol.* 1964;89:360-363.
98. Schoenfeld RJ, Grekin JN, Mehregan A. Calcium deposition in the skin. A report of four cases following electroencephalography. *Neurology.* 1965;15:477-480.
99. Davey RB, Sparnon AL, Byard RW. Unusual donor site reactions to calcium alginate dressings. *Burns.* 2000;26(4):393-398.
100. Munoz SJ, Nagelberg SB, Green PJ, et al. Ectopic soft tissue calcium deposition following liver transplantation. *Hepatology.* 1988;8(3):476-483.
101. Adegbite NS, Xu M, Kaplan FS, et al. Diagnosis and mutational spectrum of progressive osseous heteroplasia (POH) and other forms of GNAS-based heterotopic ossification. *Am J Med Genet.* 2008;146A(14):1788-1796.
102. Cohen RB et al. The natural history of heterotopic ossification in patients who have fibrodysplasia ossificans progressiva. A study of forty-four patients. *J Bone Joint Surg Am.* 1993;75(2):215-219.
103. Pignolo RJ, Shore EM, Kaplan FS. Fibrodysplasia ossificans progressiva: clinical and genetic aspects. *Orphanet J Rare Dis.* 2011;6:80.
104. Eddy MC, Jan De Beur SM, Yandow SM, et al. Deficiency of the alpha-subunit of the stimulatory G protein and severe extraskeletal ossification. *J Bone Miner Res.* 2000;15(11):2074-2083.
105. Yeh GL, Mathur S, Wivel A, et al. GNAS1 mutation and Cbfa1 misexpression in a child with severe congenital platelike osteoma cutis. *J Bone Miner Res.* 2000;15(11):2063-2073.
106. Bastepe M, Juppner H. Identification and characterization of two new, highly polymorphic loci adjacent to GNAS1 on chromosome 20q13.3. *Mol Cell Probes.* 2000;14(4):261-264.
107. Urtizberea JA, Testart H, Cartault F, et al. Progressive osseous heteroplasia. Report of a family. *J Bone Joint Surg Br.* 1998;80(5):768-771.
108. Shore EM, Ahn J, Jan de Beur S, et al. Paternally inherited inactivating mutations of the GNAS1 gene in progressive osseous heteroplasia. *N Engl J Med.* 2002;346(2):99-106.
109. Kaplan FS, Craver R, MacEwen GD, et al. Progressive osseous heteroplasia: a distinct developmental disorder of heterotopic ossification. *J Bone Joint Surg Am.* 1994;76(3):425-436.
110. Miller ES, Esterly NB, Fairley JA, et al. Progressive osseous heteroplasia: report of two cases. *Arch Dermatol.* 1996;132(7):787-791.

111. Pignolo RJ, Ramaswamy G, Fong JT, et al. Progressive osseous heteroplasia: diagnosis, treatment and prognosis. *Appl Clin Genet.* 2015;8:37-48.
112. Levell NJ, Lawrence CM. Multiple papules on the face. *Arch Dermatol.* 1994;130(3):373-374.
113. Wilson JF. In the clinic. Gout. *Ann Intern Med.* 2010;152(3):ITC21.
114. Choi HK, Mount DB, Reginato AM; American College of Physicians; American Physiological Society. Pathogenesis of gout. *Ann Intern Med.* 2005;143(7):499-516.
115. Zhu Y, Pandya BJ, Choi HK. Prevalence of gout and hyperuricemia in the US general population: the National Health and Nutrition Examination Survey 2007-2008. *Arthritis Rheum.* 2011;63(10):3136-3141.
116. Harrold LR, Yood RA, Mikuls TR, et al. Sex differences in gout epidemiology, evaluation, and treatment. *Ann Rheum Dis.* 2006;65(10):1368-1372.
117. Lee SJ, Terkeltaub RA, Kavanaugh A. Recent developments in diet and gout. *Curr Opin Rheumatol.* 2006;18(2):193-198.
118. Harris ED, Ruddy S, Kelley WN. *Kelley's Textbook of Rheumatology*. Philadelphia, PA: Elsevier Saunders; 2005, Chaps 65, 68, 87, and 103.
119. Merriman TR. An update on the genetic architecture of hyperuricemia and gout. *Arthritis Res Ther.* 2015;17:98.
120. Hughes JP, Di Palma S, Rowe-Jones J. Tophaceous gout presenting as a dorsal nasal lump. *J Laryngol Otol.* 2005;119(6):492-494.
121. Ackerman AB, Boer A, Benin B, et al. *Histological Diagnosis of Inflammatory Skin Disease*. 2nd ed. Philadelphia, PA: Williams and Wilkins, 1997.
122. Terkeltaub RA, Furst DE, Bennett K, et al. High versus low dosing of oral colchicine for early acute gout flare. Twenty-four-hour outcome of the first multicenter, randomized, double-blind, placebo-controlled, parallel-group, dose-comparison colchicine study. *Arthritis Rheum.* 2000;62(2):2010.
123. Sutaria S, Katbamna R, Underwood M. Effectiveness of interventions for the treatment of acute and prevention recurrent gout: a systematic review. *Rheumatology (Oxford).* 2006;45(11):1422-1431.
124. Terkeltaub R. The management of gout and hyperuricemia. In: Hochberg MC, Gavallese EM, Silman AJ, et al, eds. *Rheumatology*. Philadelphia, PA: Mosby; 2010.
125. Chohan S, Becker MA. Update on emerging urate lowering therapies. *Curr Opin Rheumatol.* 2009;21(2): 143-149.
126. Haber SL, Fente G, Fenton SN, et al. Lesinurad: a novel agent for management of chronic gout. *Ann Pharmacother.* 2018;52(7):690-696.

Chapter 129 :: Graft-Versus-Host Disease

:: Kathryn J. Martires & Edward W. Cowen

AT-A-GLANCE

- Acute graft-versus-host disease (GVHD) is a serious and potentially life-threatening sequelae of allogeneic hematopoietic stem cell transplantation. Skin manifestations range from a mild, asymptomatic morbilliform eruption to full-thickness skin loss resembling toxic epidermal necrolysis. Hepatic involvement is characterized by elevated total bilirubin. GI disease manifests as abdominal pain, nausea/vomiting, and secretory diarrhea.
- The most important risk factor for chronic GVHD is a history of acute GVHD. Other important factors include human leukocyte antigen incompatibility, older age, female donor/male recipient, and peripheral blood stem cell source (vs bone marrow).
- Chronic GVHD of the skin may resemble lichen planus, lichen sclerosus, morphea, systemic sclerosis, or eosinophilic fasciitis. The presentation can be remarkably variable, however, and may resemble folliculitis, keratosis pilaris, or psoriasis. Both epidermal and sclerotic skin manifestations may present at sites of trauma.
- Patients with chronic GVHD may manifest other autoimmune skin diseases, such as vitiligo and alopecia areata.
- The pathogenesis of chronic GVHD is poorly understood and nearly every organ system is at risk. The skin, oral mucosa, eyes, GI tract, and lungs are most frequently involved. In many cases, organ system disease resembles known autoimmune conditions.
- Topical steroids and topical calcineurin inhibitors are used to treat mild, skin-limited chronic GVHD, and systemic steroids are first line in the treatment of moderate to severe chronic GVHD.
- Optimal dermatologic management of chronic GVHD of the skin requires an understanding of other organ involvement, infection status, and cancer relapse risk. Close communication with the transplantation physician and a "team approach" to multispecialty management is needed.

EPIDEMIOLOGY

Approximately 50,000 hematopoietic stem cell transplantation (HCT) procedures are performed worldwide each year for an expanding array of hematologic malignancies and marrow failure syndromes, metabolic disorders, and immunodeficiencies. HCT may use autologous, syngeneic, or allogeneic donor hematopoietic stem cells (HCs). During autologous transplantation, the patient's own HCs are returned to the patient following preparative chemotherapy with or without radiation. Allogeneic HCT (allo-HCT) is the transfer of HCs from a related (nonidentical) or unrelated donor to a recipient. Syngeneic transplantation is the transfer of HCs between identical twins. Graft-versus-host disease (GVHD) is the primary cause of non–relapse-related morbidity and mortality in allo-HCT, and also rarely occurs following transplantation of solid organs, transfusion of blood products, and autologous transplantation.

Transplantation regimens have advanced rapidly since the first successful allo-HCT was performed in 1968.[1] Peripheral blood is now the primary source of donor HCs at many transplantation centers because of decreased risks of relapse and improved survival, although bone marrow transplantation is associated with reduced risk of GVHD.[2] Reduced intensity and nonmyeloablative conditioning permitted older patients and others who would not tolerate myeloablative chemotherapy a chance for cure with HCT.[3] Umbilical cord blood has gained prominence as a stem cell source in both pediatric and adult HCT given the low risks of GVHD and high engraftment rates.[4] Donor leukocyte infusions, the administration of additional donor HCs to the recipient weeks or even months after HCT, may be used to augment graft-versus-malignancy effect, but also may trigger GVHD activity.[5]

These evolving trends in HCT, in conjunction with other known donor/recipient risk variables (Table 129-1), contribute to a wide range of reported GVHD incidence. The degree of human leukocyte antigen (HLA) mismatch between donor and recipient remains the single most important predictor of GVHD.[6] A history of acute GVHD, in turn, confers the greatest risk of developing chronic disease.[7] Acute GVHD develops in approximately 40% of fully matched sibling donor HCTs and 80% of mismatched unrelated HCT recipients.[8] However, changing peritransplantation regimens, including use of cyclophosphamide and antithymocyte globulin has reduced the rate of acute GVHD in recent years to as low as 10%.[9] Risk estimates of chronic GVHD also vary widely from 37% to 47%,[2] but data from the Centers for International Bone Marrow Transplant Research demonstrate a gradual increase in chronic GVHD incidence over more than a decade.[10] Confounding factors, such as improved post-transplantation survival, may be influencing the apparent trend in increasing chronic GVHD incidence.[7]

Skin involvement is often the first indicator of acute GVHD (81%), followed by GI (54%) and liver disease (50%).[12] Similarly, the majority of patients who develop chronic GVHD manifest skin symptoms at some point in their disease course. Although sclerotic involvement

TABLE 129-1
Major Risk Factors for the Development of Graft-Versus-Host Disease

- Human leukocyte antigen (HLA) incompatibility
- Patient age (elderly > adult > pediatric)
- Female donor (especially multiparous)/male recipient
- Stem cell source (peripheral blood > bone marrow > cord blood)
- T-cell replete graft
- Unrelated donor
- Donor leukocyte infusion
- Interruption or rapid tapering of immunosuppression
- Total body irradiation in pretransplantation conditioning regimen[11]

is less common than "lichenoid" GVHD and tends to occur later post-HCT, sclerotic features, particularly deep-seated fascial changes, may have an insidious onset, and "lichenoid" involvement is not a prerequisite to the development of sclerotic features. The incidence of sclerosis in chronic GVHD has been reported to be between 3.6% and 22.6%.[10,11,13,14]

ETIOLOGY AND PATHOGENESIS

Table 129-2 compares acute GVHD with chronic GVHD. The fundamental concept of GVHD is encompassed by the balance between immunosuppression, induced by the conditioning regimen and GVHD prophylaxis, and immune system (graft) activation. In 1966, Billingham proposed 3 basic requirements for GVHD: (a) immunocompetent transplanted cells, (b) host antigens recognizable by the transplanted cells and lacking in the donor, and (c) a host incapable of mounting an immune response to the transplanted cells.[15] The immunocompetent cells are T cells, targeting HLAs expressed on host tissues, as well as key minor histocompatibility antigens (eg, HY, HA-3).[16] An allogeneic response to these minor antigens is thought to partially explain the development of GVHD in 40% of recipients of HLA-identical grafts.

Host autoreactive T cells may also play a role in disease pathogenesis.[17] Tissue damage, infection, and pretransplantation conditioning modifies the inflammatory response through proinflammatory cytokine production and antigen-presenting cell activation.[18] Antigen-presenting cell activation may be mediated by damage-associated molecular patterns and pathogen-associated molecular patterns released from damaged skin, gut, and vascular tissue.[19] Demonstration of lichen planus-like and sclerotic chronic GVHD at sites of injury and viral infection has highlighted a likely role for Type I interferons, which are known to play a critical role in the innate immune response to cellular damage and viral infection.[20]

Acute GVHD has traditionally been considered T-helper cell (Th) 1–mediated, while Th2 mechanisms were thought to predominate in chronic GVHD. It is now known that Th17 pathways also play a role in the pathogenesis of both disease processes.[21] Donor interleukin (IL)-17A, derived from Th17 cells, promotes skin fibrosis. There also is increased IL-17 messenger RNA in skin of chronic GVHD patients, as well as higher levels of Th17-promoting cytokines including IL-6 and IL-21, and transcription factor STAT3.[21-23]

Following activation of host antigen-presenting cells, T-cell activation and differentiation drives the response in acute GVHD. T-cell activation results in a massive release of proinflammatory cytokines, causing damage to the organs and tissues.[24] The final effector phase of acute GVHD is characterized by cell damage via cytotoxic T cells, natural killer cells, and soluble inflammatory mediators, including tumor necrosis factor (TNF), interferon-γ, and IL-1.[18]

Regulatory T cells are known to play a key role in inhibiting GVHD.[25] Acute GVHD may target secondary

TABLE 129-2
Comparison of Acute with Chronic Graft-Versus-Host Disease

	ACUTE GVHD	CHRONIC GVHD
Time to onset[a]	Usually <100 days after transplantation	Usually >100 days after transplantation
Immune pathways	T-helper (Th)-1 and Th17 mediated	Th2 and Th17 mediated
Cellular response	T cells (cytotoxic T cells) play a major role; also natural killer cells Decreased regulatory T cells	B cells play a major role; also T cells, plasma cells Tissue macrophages Decreased regulatory T cells
Inflammatory mediators	Tumor necrosis factor Interferon-γ Interleukin (IL)-1 IL-2	B-cell activating factor Platelet-derived growth factor Transforming growth factor-β IL-6 IL-21 B-cell autoantibodies (ANA, anti-dsDNA)
Histologic features *(cutaneous)*	Necrotic keratinocytes with dermal lymphocytic infiltrate Basal vacuolar interface alterations *or* subepidermal cleft formations *or* epidermal–dermal separation (depending on severity)	Vacuolar interface dermatitis with dyskeratotic keratinocytes Sclerosis of the upper dermis Epidermal atrophy, hyperkeratosis, follicular plugging

[a]Classic presentation; however, features and timing may overlap. (See revised classification in Fig. 129-1.)
ANA, anti-nuclear antibody; dsDNA, double-stranded DNA; GVHD, graft-versus-host disease.

lymphoid organs, which may result in loss of regulatory T-cell production.[17] Decreased T-regulatory cells are associated with severity of acute GVHD and poor response to GVHD treatment.[26] Although many therapies for acute GVHD target T cells, particularly IL-2 or its receptor (CD25), these approaches may have the unintended consequence of adversely impacting the CD4+CD25+ regulatory T-cell population.[27]

The pathophysiology of chronic GVHD is less-well understood, but may share the same activating and regulatory mechanisms as acute GVHD.[19] Chronic GVHD is also associated with decreased numbers of regulatory T cells.[28] Natural killer cells and regulatory B cells may also serve roles in preventing GVHD.[29,30]

Chronic GVHD is thought to be at least partly mediated through Th2 interaction with B cells and autoantibody induction. B cells may act as antigen-presenting cells, priming T cells to respond to HLA antigens in cases of partial matching, or minor histocompatibility antigens, and high-titers of antibodies directed against minor histocompatibility antigens are associated with chronic GVHD, particularly histocompatibility Y (HY) antigen.[31] Similarly, soluble levels of B-cell activating factor (BAFF), a cytokine which inhibits apoptosis of B cells and promotes differentiation into plasma cells, correlate with chronic GVHD activity.[32] B-cell autoantibodies have been shown to associate with Th17 cells in skin, and perpetuate GVHD in mice.[33]

The role of B-cell function in chronic GVHD is supported by reports of success of use of the anti-CD20 antibody rituximab in chronic GVHD.[34] Patients who respond well to rituximab have higher circulating levels of activated B cells.[35] Administration of rituximab in preparative regimens also has been associated with lower incidence and severity of acute GVHD.[36] Autoantibody formation (eg, antinuclear antibody, anti–double-stranded DNA antibody) is a frequent finding in chronic GVHD, although the antibodies lack the specificity of typical autoimmune disease.[37]

The mechanisms responsible for chronic GVHD-induced fibrosis in the skin and elsewhere (eg, bronchiolitis obliterans) remains uncertain. Platelet-derived growth factor (PDGF) may activate transforming growth factor-β, a potent profibrotic cytokine capable of stimulating collagen production, abrogating metalloproteinase activity, and sensitizing fibroblasts to a constitutive-activated state via autocrine signaling.[38-40] Stimulatory antibodies targeting the PDGF receptor have been proposed as the etiology of fibrosis in GVHD and systemic sclerosis.[39] However, the significance of these antibodies remains unclear and other studies have failed to correlate PDGFR antibody with severity of chronic GVHD.[41] Kinase inhibition of intracellular PDGF signaling is a targeted therapeutic approach in sclerotic chronic GVHD.

Macrophages are known to play a role in the tissue-repair response contributing to fibrosis,[42] and have been shown to accumulate in fibrotic lesions in chronic GVHD.[43] Macrophages in GVHD tissue are of donor origin, and may be efficient in generating antibodies that may contribute to GVHD pathogenesis, including transforming growth factor-β.[19] Macrophages may also represent potential therapeutic targets.

In recent years, genome-wide association studies have begun to define individual genetic risk factors for GVHD.[44] Studies have revealed that single-nucleotide polymorphisms in *NOD2* (nucleotide-binding oligomerization domain-2), *TNF*, and *IL-10* are associated with GVHD. Single-nucleotide polymorphisms in *BANK1*, *CD247*, and *HLA-DPA-1* are associated with development of sclerotic GVHD.[45]

CLINICAL FINDINGS

HISTORY

Accurate diagnosis of acute GVHD is challenging, and requires a thorough assessment and clinicopathologic correlation. Because the skin eruption (and histology) may be nonspecific in the context of several potential differential diagnoses, a careful history is invaluable. Key factors include assessment of the primary disease for which the patient underwent an organ transplant procedure, stem cell source (eg, peripheral blood, bone marrow, umbilical cord blood), type of transplant (eg, allogeneic, syngeneic, autologous), degree of HLA match, use of a related versus unrelated donor, and T-cell depletion of the graft. Additional factors include agents used for GVHD prophylaxis and the pretransplantation conditioning regimen. The use of particular chemotherapeutic agents such as cytarabine may render the differential diagnosis of toxic erythema of chemotherapy more likely.[46] Reduced intensity conditioning and nonmyeloablative conditioning may be associated with increased risk of sclerotic chronic GVHD,[11] and may delay the onset of acute GVHD symptoms beyond the 100-day period.[47] The timing of engraftment, new medication exposures, virus status of both the donor and recipient (eg, cytomegalovirus), and evidence of other organ involvement (eg, elevated total bilirubin, diarrhea) provide additional data for clinicopathologic correlation. Bilirubin elevation and diarrhea, however, are nonspecific, and may be related to concomitant viral infection, drug toxicity and bile duct obstruction.

Features of acute GVHD following recent blood transfusion should raise concern for transfusion-associated GVHD (TA-GVHD). TA-GVHD is an often-fatal sequelae of administration of cellular blood products to immunocompromised HCT recipients. As a result, all blood products given to HCT recipients must be irradiated. TA-GVHD may also occur following transfusion of unirradiated blood products to children with congenital immunodeficiency. TA-GVHD may also occur in the immunocompetent setting following transfusion of an unirradiated blood product that contains donor lymphocytes that are homozygous for the HLA haplotype of the recipient, typically when transfusion occurs from a relative or genetically similar person. For example, in Japan where the genetic background of the population is more homogenous, the estimated risk of randomly receiving blood from a homozygous donor is 1 in 874.[48] In this form of

TA-GVHD, the donor lymphocytes in the blood product are not recognized as foreign, leading to a GVHD reaction similar to classic acute GVHD. Beginning 10 days after transfusion, fever and skin rash (histologically consistent with GVHD) develops, followed by liver dysfunction and diarrhea. Death from pancytopenia usually occurs within several weeks.[49]

As with acute disease, a new diagnosis of chronic GVHD is best made based by history, cutaneous examination, and histology. A previous history of acute GVHD is the single greatest risk factor for chronic disease. When there is no cessation of acute GVHD prior to development of chronic GVHD, it is considered progressive, and carries the poorest prognosis. In contrast, quiescent disease is the onset of chronic disease after previous resolution of acute GVHD symptoms. Chronic GVHD is considered de novo when there is no prior history of acute GVHD. Traditionally, acute GVHD occurs within 100 days posttransplantation, while symptoms after 100 days are considered chronic GVHD. However, because acute symptoms may develop after 100 days posttransplantation and chronic symptoms may develop before then, the revised classification of acute and chronic GVHD symptoms includes additional subtypes of GVHD with overlapping features or timing of acute and chronic symptoms (Fig. 129-1).[50] Recent tapering of immunosuppressant medication or donor leukocyte infusion given to augment the graft-versus-malignancy response are potential triggers of skin activity. Donor leukocyte infusions, in particular, may present with an acute GVHD skin eruption consistent with acute GVHD rather than the eruption of chronic disease. Cutaneous or systemic infection may also induce a flare of skin GVHD, as will drug reactions, which can result in a diagnostic challenge given the clinical and histologic similarities between viral exanthem, drug eruption, and GVHD.[51] Intense ultraviolet (UV) exposure may also trigger skin GVHD. Important clues to sclerotic and fascial disease includes a new-onset edema of an extremity, muscle cramping, decreased flexibility, and complaints of skin tightness, particularly at the waistband and brassiere-line,[52] and at sites of prior injury or trauma, such as intravenous access sites or radiation fields.[53]

Although GVHD in other organ systems may not necessarily flare in synchrony with skin involvement, the presence of other organ system involvement is helpful when the cutaneous features are nondiagnostic. Therefore, a thorough review of systems should be conducted to assess for organ involvement. Common GVHD symptoms include oral and ocular sicca and oral pain, particularly with spicy foods. The presence of genital discomfort or pain also suggests GVHD. Dysphagia may indicate the presence of esophageal strictures or webbing. Bronchiolitis obliterans manifests as dry cough, wheezing, and dyspnea, but requires pulmonary function tests and CT scans to rule out infection and other etiologies. Also common, but less specific, are symptoms of fatigue, poor appetite, and weakness.[54,55]

Finally, it is important to remember that despite the phenotypic variability in chronic GVHD of the skin, not every skin manifestation in a patient after HCT is caused by GVHD, so a careful dermatologic history to detect other possible diagnoses is prudent.

CUTANEOUS PRESENTATION

The most common presentation of acute GVHD begins with erythematous-dusky macules and papules of the volar and plantar surfaces and ears that may rapidly become a diffuse morbilliform exanthem (Fig. 129-2A and B; Table 129-3). Very early

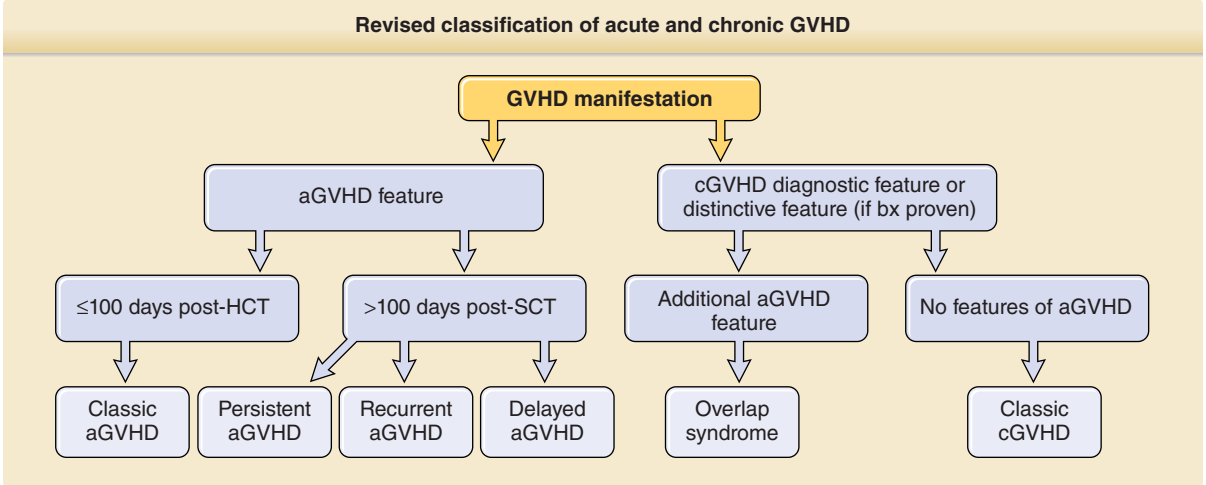

Figure 129-1 Revised classification of acute and chronic graft-versus-host disease (GVHD). aGVHD, acute graft-versus-host disease; bx, biopsy; cGVHD, chronic graft-versus-host disease; HCT, hematopoietic cell transplantation; SCT, stem cell transplantation. (Adapted from Jagasia MH, Greinix HT, Arora M, et al. National Institutes of Health consensus development project on criteria for clinical trials in chronic graft-versus-host disease: I. The 2014 Diagnosis and Staging Working Group report. *Biol Blood Marrow Transplant*. 2015;21:389-401.e1.)

Figure 129-2 Spectrum of acute graft-versus-host skin manifestations. Acute cutaneous graft-versus-host reaction. Erythematous macules involving the ears **(A)**, palms **(B)**, and soles are characteristic of early cutaneous involvement. **C,** Follicular graft-versus-host disease (GVHD). Perifollicular involvement is an early manifestation of skin involvement. **D,** GVHD-associated necrolysis. Acute GVHD with bullae formation following donor leukocyte infusion for relapsed acute lymphoblastic leukemia following allogeneic hematopoietic cell transplantation. **E,** Skin sloughing in a toxic epidermal necrolysis–like presentation of acute GVHD.

involvement may manifest as erythema limited to hair follicles (Fig. 129-2C). A predisposition for acral and perifollicular sites may help distinguish new-onset acute GVHD from other morbilliform eruptions, although these features are not always present. Pruritus is variable and is also not useful to distinguish acute GVHD from other causes. Erythroderma and, in severe cases, spontaneous bullae (Fig. 129-2D) with skin sloughing resembling toxic epidermal necrolysis may develop (Fig. 129-2E). Widespread erythrodermic

TABLE 129-3
Acute Graft-Versus-Host Disease Organ System Manifestations

Skin
- Erythema of palms, soles, ears
- Perifollicular erythema
- Generalized exanthem
- Bullae/necrolysis

Gastrointestinal
- Abdominal pain
- Anorexia
- Ileus
- Mucositis
- Vomiting
- Secretory diarrhea

Liver
- Endothelialitis
- Pericholangitis
- Cholestatic hyperbilirubinemia

involvement, particularly skin sloughing, portends a very poor prognosis. Acute GVHD is staged based on percent body surface area involvement with concordant histologic findings, as well as degree of bilirubin elevation and diarrhea (Table 129-4).[56] In contrast to chronic disease, postinflammatory pigmentary changes following acute GVHD are uncommon.

Clinical features of chronic skin GVHD are classified as *diagnostic* or *distinctive.* Diagnostic criteria establish the presence of chronic GVHD without the need for further testing or evidence of other organ involvement, while distinctive criteria warrant skin biopsy or establishment of additional organ involvement (Table 129-5). Diagnostic cutaneous features of GVHD include poikiloderma, lichen planus–like lesions, and sclerotic skin changes.[50] There is a growing appreciation of the tremendous variability in the clinical presentation of chronic skin GVHD. Previously, especially in the organ transplant community, skin findings in chronic GVHD were dichotomized as "lichenoid" or

TABLE 129-4
Acute Graft-Versus-Host Disease Staging[56]

STAGE	SKIN	HISTOLOGY	DIARRHEA (500 mL/day)	BILIRUBIN (mg/dL)
0	–	–	≤500	≤2
1	<25% body surface area (BSA)	Focal or diffuse vacuolar interface	>500 or persistent anorexia, nausea, vomiting	2 to 2.9
2	25% to 50% BSA	Dyskeratotic keratinocytes	≥1000	3 to 5.9
3	>50% BSA	Subepidermal clefting	≥1500	6 to 14.9
4	Erythroderma with bullae or desquamation	Loss of epidermis	≥2000 or severe abdominal pain ± ileus	≥15

TABLE 129-5
Clinical Features of Chronic Graft-Versus-Host Disease[50]

	DIAGNOSTIC	DISTINCTIVE	OTHER	COMMON (SEEN IN BOTH ACUTE AND CHRONIC GVHD)
Skin	▪ Poikiloderma ▪ Lichen sclerosus–like lesions ▪ Lichen planus–like eruption ▪ Morphea-like lesions ▪ Sclerotic features	▪ Depigmentation (including vitiligo) ▪ Papulosquamous lesions	▪ Sweat impairment ▪ Ichthyosis ▪ Keratosis pilaris ▪ Hypopigmentation ▪ Hyperpigmentation	▪ Erythema ▪ Maculopapular rash ▪ Pruritus
Nails	–	▪ Dystrophy ▪ Longitudinal ridging, splitting, or brittle features ▪ Onycholysis ▪ Pterygium unguis ▪ Nail loss (symmetric, most nails)	–	–
Hair	–	▪ New-onset scarring or nonscarring scalp alopecia ▪ Loss of body hair ▪ Scaling	▪ Thinning scalp hair, typically patchy ▪ Coarse or dull hair ▪ Premature gray hair	–

Figure 129-3 Lichen planus-like chronic graft-versus-host disease. Reticulate violaceous plaques with dry scale on the posterior neck and upper back.

"sclerodermoid." The term *lichenoid GVHD* had been used to denote any involvement of the skin in which erythema or scaling was present; however, "lichenoid" is a histologic pattern, not a clinical one, and, therefore, usage of it is best reserved to pathologic description. Furthermore, although chronic GVHD may resemble lichen planus (Fig. 129-3), other epidermal patterns are frequently observed, such as ichthyosis, poikiloderma (Fig. 129-4), and skin lesions resembling lupus erythematosus, keratosis pilaris, or psoriasis.[57] A linear form of chronic GVHD resembling lichen planus has been described, which may present following Blaschko lines (Fig. 129-5). Postinflammatory hyperpigmentation is common following the resolution of epidermal involvement, particularly in darkly pigmented individuals, and may persist for many months after the skin disease becomes quiescent.

The fibrosing manifestations of chronic GVHD are also remarkably variable, and the term *sclerodermoid* is an inadequate descriptor of the varied tissue abnormalities in the dermis, subcutaneous tissue, and fascia. As in systemic sclerosis, an edematous phase may herald the onset of skin fibrosis, but in contrast to systemic sclerosis, the face, fingers, and toes are usually spared,

Figure 129-4 Poikilodermic chronic graft-versus-host disease. Hypopigmentation, hyperpigmentation, and erythema on the chest and proximal arms.

Figure 129-5 Blaschkoid chronic graft-versus-host disease (GVHD). Lichen planus–like chronic GVHD presenting unilaterally in a Blaschkoid distribution of the right-side of the back. (Used with permission from Milan J. Anadkat, MD.)

and the typical acral-to-proximal progression characteristic of systemic sclerosis is not commonly seen in chronic GVHD. Certainly, many cases do involve the hands and fingers, but occur more proximal to the fingertips (Fig. 129-6).[58] Early superficial fibrotic involvement resembles lichen sclerosus. In contrast to traditional lichen sclerosus, which is much less common on the skin than the genital region, lichen sclerosis in GVHD patients often manifests on the skin as porcelain-white atrophic plaques on the upper back (Fig. 129-7A). A common pattern of GVHD-associated fibrosis involves patchy sclerotic plaques with hypopigmentation and hyperpigmentation mimicking morphea (Fig. 129-7B). Sclerosis of this type

Figure 129-6 Morphea-like hyperpigmented, shiny sclerotic plaques of the dorsal hands and fingers causing functional disability.

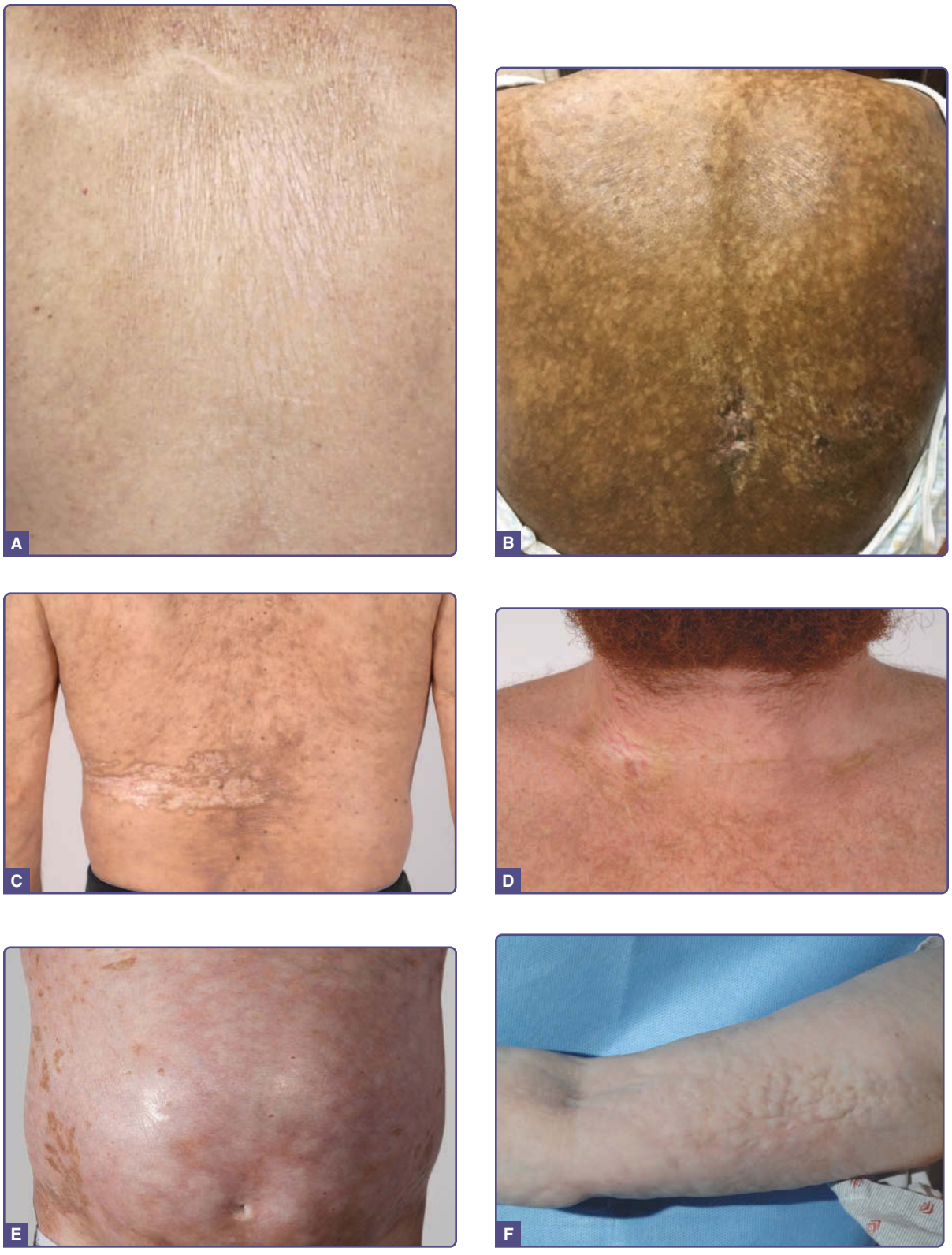

Figure 129-7 Clinical spectrum of sclerotic graft-versus-host disease (GVHD) skin manifestations. **A,** Guttate white plaques on the upper back resembling lichen sclerosus. **B,** Hypopigmentation and hyperpigmentation with extensive superficial and deep dermal sclerosis on the back. **C,** Morphea-like sclerotic plaques in the distribution of a prior zoster infection at this site of the left back and flank. **D,** Morphea-like sclerotic plaques at sites of previous indwelling line placement near the clavicle (isotopic response). **E,** Diffuse dermal sclerosis resembling scleroderma on the anterior torso with patchy hyperpigmentation. **F,** Subcutaneous fibrosis of chronic GVHD. There is prominent rippling with a firm nodular texture extending along the medial arm resembling eosinophilic fasciitis. There is associated decreased range of motion at the elbow.

may exhibit an isomorphic response, localizing to the sites of minor skin trauma, particularly the waistband area,[52] or may develop at sites of previous scar formation (Fig. 129-7C) or radiation. It also has been associated with an isotopic response, developing at sites of prior zoster infection (Fig. 129-7D).[53] Diffuse dermal involvement may result in a "pipestem" appearance of the lower extremities with marked reduction in limb volume and overlying shiny hidebound skin with loss of hair resembling scleroderma (Fig. 129-7E). Deeper involvement of the subcutaneous fat results in irregular hyperpigmented sclerotic plaques with intervening areas of edematous skin closely resembling deep morphea/morphea profunda.[59] Bullae may develop at sites of fibrosis, particularly on the lower legs, as a result of dermal edema, as has been described in bullous morphea profunda.[60] Patchy hyperpigmentation ("leopard spots") may be visible prior to the diagnosis of dermal sclerotic involvement.[61] Dermal sclerosis results in decreased ability to pinch the skin.

Primary involvement of the subcutaneous fat and fascia results in a diffuse firm, rippled pattern to the skin resembling eosinophilic fasciitis (see Fig. 129-7F).[62] Features of overlying epidermal GVHD involvement and pigmentary changes may be absent. Fascial involvement is often most visible on the medial arms and thighs and be accentuated by abduction and supination of the arm. Prominent "grooving" demarcating fascial bundles and along the path of superficial vessels may be observed. Careful palpation of the skin is helpful in detecting deep-seated irregularities in skin texture and differentiation from cellulite. Examination of patients while they are lying down on the examination table may help to reveal rippling or pseudocellulite of the abdomen.[54] Dermal fibrosis or fascial involvement without overlying dermal thickening may lead to progressive loss of joint range of motion and contracture formation. Unlike in systemic sclerosis, chronic GVHD tends to affect large joints, including the shoulders, elbows, wrists, hips, and ankles.[58] Range of motion may be assessed through simple maneuvers on physical examination including flexion/extension (arms/shoulders), abduction/adduction (thighs), and prayer sign (wrists, fingers). It may be helpful to have children sit cross-legged on the examination table to determine range-of-motion abnormalities of the hips.[54] Fasciitis may be associated with cramping, polymyositis, and arthritis.

Nail involvement in chronic GVHD typically results in longitudinal ridging and thin, easily broken nails. Partial or complete anonychia and dorsal pterygium formation may occur.[50] Other findings include onycholysis, periungual erythema, and paronychia.[63]

Other skin sequelae of chronic GVHD include milia formation, porokeratosis, often on the buttock area,[64] angiomatosis,[65] nipple hyperkeratosis,[66] vitiligo, and alopecia, either diffuse or focal areas of alopecia areata.[67] A verrucous acral keratosis form of GVHD has been described, resembling common warts on the fingers, but distinguished by the presence of vacuolar interface and dyskeratotic keratinocytes on histology.[68]

Multiple manifestations of sclerotic and nonsclerotic skin disease may be present in the same individual, making accurate quantification of disease activity challenging. A number of different instruments are currently under investigation to measure skin involvement, most commonly the National Institutes of Health (NIH) Consensus organ-specific severity scoring system, in which the skin composite score in separated into body surface area and specific skin features.[50] Other tools include the Vienna Skin Score,[69] the Hopkins skin sclerosis and fasciitis scores,[70] and the Lee symptom scale and skin subscale.[55] The modified Rodnan score, which is validated for use in systemic sclerosis,[71] has not been validated for use in sclerotic GVHD, and may be of limited value for fascial disease.

RELATED PHYSICAL FINDINGS

Acute GVHD is primarily a disorder of the skin, GI tract, and liver (see Table 129-3), typically presenting with skin rash, new-onset elevation of total bilirubin, and/or voluminous diarrhea. By contrast, chronic GVHD is remarkably diverse in its breadth of organ system manifestations (Table 129-6). The most frequently affected sites are skin and nails, oral mucosa, eyes, liver, lungs, and marrow (usually thrombocytopenia).[7] Esophageal webs/strictures, vaginovulvar disease, myositis, nephrotic syndrome, and pericarditis are less-frequent sequelae of chronic disease.

Mucosal disease is second only to skin involvement in frequency in chronic GVHD. Erythema, lichen planus–like changes with Wickham striae, erosions and ulcerations, and mucoceles are the most common manifestations. The buccal mucosa is most commonly affected, followed by the lips, tongue, and soft palate. Patients often also experience sicca symptoms, and pain from erosions may limit oral intake.[54] Dryness and violaceous erythema of the lips are common. Genital involvement significantly impairs sexual function and quality of life and may be overlooked if a specific examination and directed questions regarding genital symptoms are not undertaken. Involvement of the penis may induce phimosis. Vulvovaginal involvement presents as erythema, erosions/fissures, vestibulitis, vaginal stenosis, labial resorption, or complete agglutination of the introitus leading to hematocolpos (Fig. 129-8).[72]

The 2014 chronic GVHD NIH Consensus Development Project provided precise terminology for organ-specific diagnostic manifestations of chronic GVHD in the setting of HCT (see Table 129-6).[50]

HISTOPATHOLOGY

Table 129-4 shows the histologic grading scale for acute GVHD. The hallmark feature of acute GVHD is the

TABLE 129-6

Signs and Symptoms of Chronic Graft-Versus-Host Disease Based on National Institutes of Health Consensus Criteria

Mucosal Involvement

Oral mucosa

- Erythema
- Gingivitis
- **Lichen planus-like**[a]
- **Mucocele**
- Mucosal atrophy
- Mucositis
- Pain
- Pseudomembrane
- Ulcer
- Xerostomia

Genital mucosa

- Lichen planus–like[a]
- Lichen sclerosus–like[a]
- Phimosis or urethral meatus scarring or stenosis[a]
- Vulvar erosions/fissures/ulcers
- Vaginal scarring or clitoral/labial agglutination[a]

Muscle, Fascia, Joint Involvement

- Arthralgia or arthritis
- Edema
- Fasciitis[a]
- Joint stiffness or contractures secondary to fasciitis or sclerosis[a]
- **Muscle cramps**
- Myasthenia gravis
- Myositis or polymyositis

Other Organ System Involvement

Cardiovascular

- Pericardial effusion
- Cardiac conduction abnormality or cardiomyopathy

Ophthalmologic

- Blepharitis
- Cicatricial conjunctivitis
- Confluent punctuate keratopathy
- **Dry, gritty, or painful sensation in eyes**
- **Periorbital hyperpigmentation**
- Photophobia

GI

- **Anorexia**, nausea, vomiting, **diarrhea**, weight loss, failure to thrive
- Esophageal web[a]
- Esophageal upper third stricture/stenosis[a]
- Exocrine pancreatic insufficiency

Hematopoietic and immune

- Autoantibodies (autoimmune hemolytic anemia, immune thrombocytopenic purpura)
- Eosinophilia
- Hypogammaglobulinemia/hypergammaglobulinemia
- Lymphopenia
- **Thrombocytopenia**
- Raynaud phenomenon

Hepatic

- Elevated total bilirubin
- Elevated alkaline phosphatase
- **Elevated transaminases**

Neurologic

- Peripheral neuropathy

Pulmonary

- Air trapping and bronchiectasis on CT
- **Bronchiolitis obliterans diagnosed by biopsy**[a] or syndrome
- Cryptogenic organizing pneumonia
- Pleural effusions
- Restrictive lung disease

Renal

- Nephrotic syndrome

[a]Diagnostic features of chronic graft-versus-host disease (GVHD) based on NIH Consensus Criteria. Other signs and symptoms listed are not considered sufficient to establish a diagnosis of chronic GVHD without further testing or evidence of other organ system involvement. The most common GVHD manifestations are shown in **bold.**

Adapted from Jagasia MH, Greinix HT, Arora M, et al. National Institutes of Health consensus development project on criteria for clinical trials in chronic graft-versus-host disease: I. The 2014 Diagnosis and Staging Working Group report. *Biol Blood Marrow Transplant*. 2015;21:389-401.e1.

presence of necrotic keratinocytes accompanied by a dermal lymphocytic infiltrate (usually sparse) and basal vacuolar interface alteration (Fig. 129-9). Early GVHD involvement with follicular erythema correlates with involvement limited to the hair follicle. Subepidermal cleft formation (grade III) is indicative of more-severe involvement, whereas complete separation of epidermis from dermis (grade IV) correlates with clinical findings resembling toxic epidermal necrolysis. Grade IV involvement may be impossible to differentiate histologically from drug-induced toxic epidermal necrolysis and requires careful clinical correlation. The presence of eosinophils has been used to argue against a diagnosis of GVHD; however, it cannot be reliably used to distinguish between GVHD and drug hypersensitivity.[73] Engraftment syndrome is a poorly understood phenomenon at the time of neutrophil engraftment following autologous HCT or allo-HCT and is characterized by a nonspecific erythematous skin eruption, fever, and pulmonary edema.[74] Histologically, it may not be possible to distinguish engraftment rash from early (grade I) acute GVHD.

Epidermal changes in chronic GVHD may be indistinguishable from those of acute disease and are characterized by vacuolar interface dermatitis and epidermal dyskeratotic keratinocytes (Fig. 129-10A). Adnexal structures are often affected. Sclerotic involvement of the upper dermis may resemble lichen sclerosus, with epidermal atrophy, hyperkeratosis, follicular plugging, and a pale, homogenized appearance of the upper dermis collagen (Fig. 129-10B). Sclerotic GVHD is characterized by thickened collagen bundles, increased numbers of fibroblasts, loss of periadnexal fat, and periadnexal inflammation, and may be indistinguishable from morphea and scleroderma. Subcutaneous and fascial involvement accordingly demonstrates changes in the fat septae and fascia, including thickening, edema, and fibrosis.

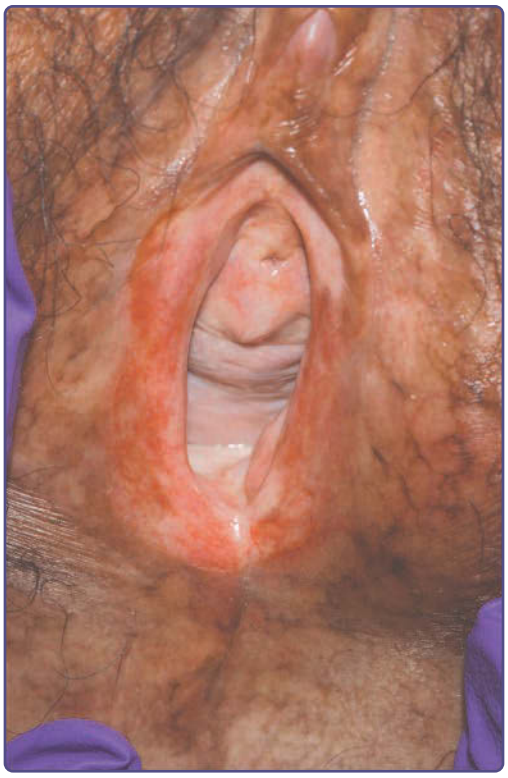

Figure 129-8 Severe chronic graft-versus-host disease (GVHD) of the vulva. The labia minora are partially resorbed with residual vulvitis and atrophic mucosa. Surrounding reticulate hyperpigmentation of the nonmucosal skin is consistent with postinflammatory changes of chronic GVHD.

An inflammatory infiltrate, consisting of variable numbers of lymphocytes, histiocytes, and eosinophils may be seen.[57,75]

Histology of oral mucosal GVHD reflects similar interface changes as those seen in epidermal GVHD, but without associated acanthosis. Lymphocytic infiltration of the salivary glands resembles changes seen in Sjögren syndrome.[75,76]

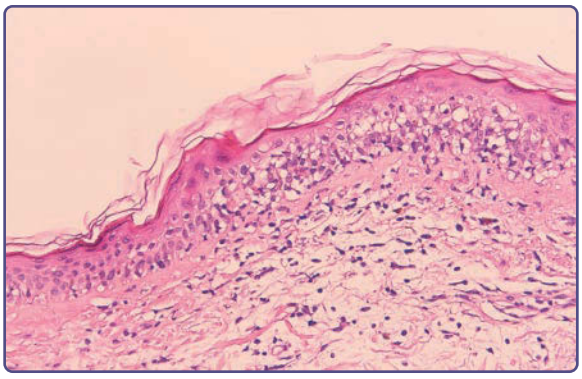

Figure 129-9 Histopathologic features of acute cutaneous graft-versus-host disease, grade II. Inflammation of the upper dermis is present, with extension of lymphocytes into the dermis and interface change.

DIAGNOSIS

LABORATORY TESTS

Diagnosis of acute GVHD skin involvement is based on clinicopathologic correlation, particularly exclusion of drugs and infectious causes. Total bilirubin levels and quantification of diarrhea volume are used in conjunction with skin disease to stage the disease (see Table 129-3). The presence of a neutrophil count greater than 0.5×10^9/L and a platelet count greater than 20×10^9/L indicates engraftment, and brings engraftment syndrome into the differential diagnosis of acute GVHD.[74]

In recent years, genome-wide association and proteomic studies have helped identify potential biomarkers in GVHD patients. Candidate markers found to

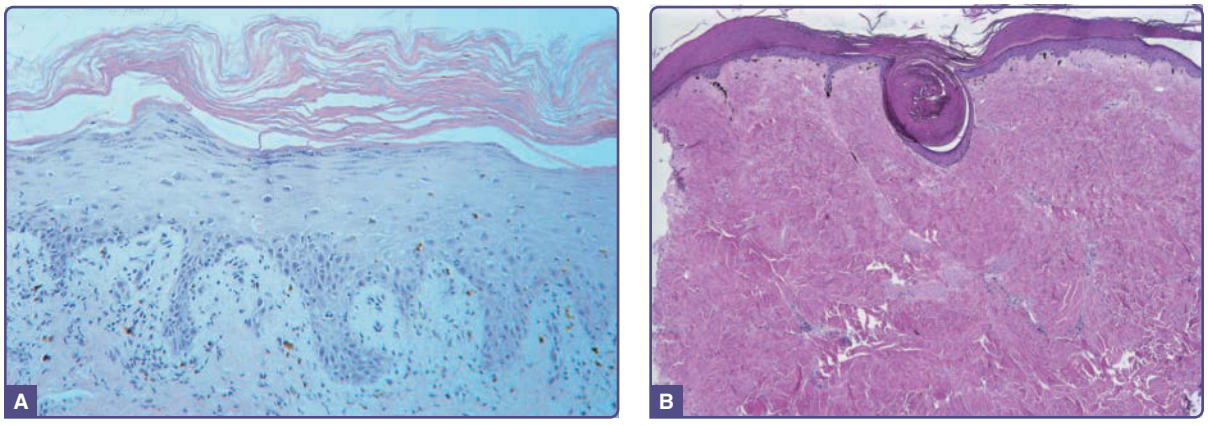

Figure 129-10 Histologic features of epidermal and sclerotic-type chronic cutaneous graft-versus-host disease. **A,** Histopathologic features of a lichen planus–like reaction. Acanthosis, hypergranulosis, hyperkeratosis, and pointed rete ridges are present. The inflammatory infiltrate is less dense than that usually seen in idiopathic lichen planus. **B,** Sclerotic-type graft-versus-host disease. There is mild, compact hyperkeratosis of the epidermis with keratin plugging. There is hyalinization of the collagen throughout the dermis with loss of appendageal structures.

have diagnostic and prognostic value for acute GVHD include TNF receptor-1, IL-2 receptor-α, IL-8, hepatocyte growth factor, and regenerating islet-derived 3α. Elevated levels of these markers have been associated with increased likelihood of nonresponse, as well as poorer survival.[77] Additional markers whose increased expressed may be associated with acute GVHD include BAFF, IL-33, CXCL-10, and CXCL-11.[78]

In chronic GVHD, circulating B-cell subsets and decreased T-regulatory cells are associated with disease.[28,37,69,79] BAFF, CXCL-9, elafin, aminopeptidase N, soluble-type IL-2 receptor-α, IL-4, IL-6, and TNF also are associated with diagnostic usefulness in chronic GVHD.[80-82] TNF has shown both diagnostic and prognostic value in chronic disease.[83] Although autoimmune markers may be seen in the majority of patients after allo-HCT, their presence is generally not specific for the development of chronic GVHD manifestations. In an NIH cohort, autoantibodies were identified in 62% of chronic GVHD patients, and multiple antibodies in 35% of patients. The most frequent antibodies were antinuclear antibody (29%) and rheumatoid factor (13%).[37] Other autoantibodies that have been reported in GVHD patients include anti–double-stranded DNA, anti-PDGF, and anti-HY.[31,39,84] Identifying specific biomarkers of disease activity is an area of research emphasis in acute and chronic GVHD.[82]

TABLE 129-7
Differential Diagnosis of Graft-Versus-Host Disease

Acute Graft-Versus-Host Disease (GVHD)
- Drug eruption
- Eruption of lymphocyte recovery
- Rash of engraftment syndrome
- Transient acantholytic dermatosis
- Toxic epidermal necrolysis (for stage IV disease)
- Toxic erythema of chemotherapy
- Viral exanthem

Chronic GVHD

Epidermal involvement
- Drug eruption
- *Demodex* folliculitis
- Eczematous drug eruption
- Lichen planus
- Pityriasis lichenoides chronica
- *Pityrosporum* folliculitis
- Psoriasis

Sclerotic involvement
- Eosinophilic fasciitis
- Lichen sclerosus
- Morphea
- Nephrogenic systemic fibrosis
- Radiation dermatitis
- Systemic sclerosis

SPECIAL TESTS (INCLUDING IMAGING STUDIES)

Suspicion of subcutaneous sclerotic and fascial disease and myositis may be confirmed by MRI, particularly in cases in which definitive sclerotic changes are not observed or when a fascial or muscle biopsy is deferred.[85]

High-frequency ultrasound,[86] digital heat mapping, and durometry also have been used to study sclerosis of the skin in GVHD, but are not widely available in clinical practice.

DIFFERENTIAL DIAGNOSIS

The differential diagnosis of acute GVHD is broad, and especially challenging as the clinical and histologic features are often indistinguishable from morbilliform drug eruption and engraftment syndrome, the latter of which follows neutrophil recovery and presents with a morbilliform eruption, fever, and pulmonary edema. It also may be accompanied by elevated total bilirubin and diarrhea, and appears histologically similar to acute GVHD.[74] Although engraftment syndrome is thought to occur sooner posttransplantation than GVHD, hyperacute GVHD can present within this window as well. Engraftment syndrome tends to be more steroid-responsive compared to acute GVHD. Toxic erythema of chemotherapy may occur up to 1 week after transplantation, and encompasses multiple skin reactions to chemotherapy. Chemotherapeutic agents commonly associated with toxic erythema of chemotherapy include cytarabine, anthracycline, 5-FU, capecitabine, taxanes, and methotrexate.[46,87] Another differential diagnosis to consider is eruption of lymphocyte recovery, which represents immune system recovery approximately 3 weeks after chemotherapy, and may be associated with fever. Viral reactivation is common post-HCT, including human herpesvirus-6 reactivation, cytomegalovirus, and Epstein-Barr virus, which may present as morbilliform eruptions.

As the presentation of chronic GVHD is quite varied, there are many other potential differential diagnoses. An important consideration is that not every cutaneous finding in the post-HCT setting represents GVHD. Biopsy can be useful in helping to distinguish nondiagnostic presentations. One important differential diagnosis in these patients is *Demodex* folliculitis, which increasingly occurs in the immunosuppressed setting in HCT recipients. Table 129-7 outlines the differential diagnosis of graft-versus-host disease.

COMPLICATIONS

Skin erosions and ulceration caused by chronic GVHD may lead to secondary infection. Wound-healing in these patients is often slow and difficult in the setting of systemic corticosteroids and certain GVHD therapies (eg, sirolimus).[88] Sclerotic changes resulting in restriction in joint function may lead to functional disability and joint contractures. Restrictive lung disease may result from sclerotic involvement of the torso.

HCT survivors are at increased risk for melanoma and nonmelanoma skin cancer because of previous exposure to ionizing radiation, GVHD-associated immune dysregulation, and immunosuppressive treatment of GVHD.[89-91] Both cutaneous squamous cell carcinoma and melanoma also may be increased by long-term treatment with voriconazole, a potent photosensitizer, which may be employed for antifungal treatment or prophylaxis.[92,93] Multiple squamous cell carcinomas also have been reported after psoralen and ultraviolet A (PUVA) therapy for GVHD.[94] Treatment of skin cancers in these patients is challenging because of the increased risk of infection and poor wound healing.

PROGNOSIS AND CLINICAL COURSE

Although the presence of GVHD is associated with a decreased risk of malignancy relapse, GVHD leads to significant morbidity, especially in patients with steroid-refractory disease. Chronic GVHD is the second leading cause of long-term mortality in HCT patients after recurrence of primary disease.[95] Extensive (>50%) skin involvement[96] and "lichenoid" skin histology also may be associated with poorer survival. The association between sclerotic skin and mortality is thought to relate to higher doses of immunosuppression required, and therefore increased risk of infection. Sclerotic skin is likely also a marker of more-severe disease, such as lung disease, which may directly impact mortality.

A number of systemic risk factors portend a poor prognosis, including a history of progressive involvement from acute to chronic GVHD,[97] thrombocytopenia (fewer than 100,000 cells/mL),[56] elevated bilirubin,[98] older age, GI symptoms, and lack of response to therapy at 6 months.[97]

PREVENTION

GVHD prevention begins prior to transplantation with selection of the most closely HLA-matched donor, the GVHD prophylaxis regimen, and, in some cases, T-cell depletion or manipulation of the graft. T-cell depletion is accomplished through ex vivo T-cell–negative selection or enrichment of the CD34+ stem cell population, or more commonly through in vivo treatment with anti–T-cell therapy, such as posttransplantation cyclophosphamide,[99] or alemtuzumab, an anti-CD52 monoclonal antibody.[100,101] Other strategies for T-cell modulation, including IL-2 and antibodies targeting IL-17 and IL-21. have been used to attempt to induce the expansion of T-regulatory cells.[102,103] Even though T-cell modulation may lead to higher rates of graft failure, cancer relapse, and infection, studies show that strategies aimed at reducing the incidence of GVHD may lead to improved overall mortality.[104,105] Prophylactic immunosuppressive therapy is initiated concomitantly with the administration of the hematopoietic graft, but, as with T-cell depletion, such therapy must be balanced with the potential for diminished graft-versus-leukemia/lymphoma effect and long-term infection risk. One of the most important strategies has been increasing use of antihuman T-lymphocyte immune globulin (or antithymocyte globulin) as part of the conditioning regimen,[106,107] which has shown efficacy in acute and chronic GVHD. Administration of antithymocyte globulin in this setting has been shown to significantly reduce the incidence of chronic GVHD at 2 years, and lead to discontinuation of immunosuppression with a trend toward improved survival.[108] Sirolimus is an mammalian target of rapamycin inhibitor that has been used in prophylactic regimens in combination with standard therapy or in place of calcineurin inhibitors, and which may have the advantage of improved tolerance compared to calcineurin inhibitors.[109,110]

Similar to solid-organ transplantation, skin cancer screening and patient education regarding photoprotective measures is a key preventive strategy in all HCT patients, especially those who develop chronic GVHD.[111] Patients are also at elevated risk of systemic infection; consequently, implementation of preventive infectious disease recommendations and careful monitoring for cutaneous infection, particularly in patients with chronic skin erosions/ulcerations, is prudent. Finally, patient education regarding early signs of skin sclerosis and fascial involvement, including skin tightness, edema, muscle cramping, and range-of-motion restriction, may facilitate early diagnosis and initiation of treatment.

TREATMENT

MANAGEMENT OF ACUTE GRAFT-VERSUS-HOST DISEASE

Treatment of acute GVHD is usually initiated in the hospital, given the proximity to the date of HCT and the need for close observation. Patients with mild (grade I) skin involvement without hepatic or GI symptoms may respond to high-potency topical steroids. However, more-severe skin involvement or the presence of internal organ involvement necessitates treatment with systemic corticosteroids. Patients with moderate-to-severe acute GVHD may warrant treatment with methylprednisone 1 to 2 mg/kg/day; however, lower doses may be adequate to control disease. Patients with skin sloughing require meticulous skin care, infection surveillance, and fluid management similar to toxic epidermal necrolysis. Approximately 50% of patients respond to systemic corticosteroids; however those who require additional therapy typically receive increased doses of their GVHD prophylaxis (most commonly tacrolimus, cyclosporine, or methotrexate) or additional therapy, including horse antithymocyte globulin, extracorporeal photopheresis (ECP), and mycophenolate mofetil.[112] Mycophenolate

mofetil is particularly helpful in patients with acute GVHD limited to the skin, with a large case series demonstrating a 92.3% response.[113] Other agents include alemtuzumab,[100] basiliximab,[114] inolimumab,[115] daclizumab,[116] etanercept,[117] infliximab,[118] denileukin diftitox, pentostatin,[119] sirolimus,[120] and mesenchymal stem cells.[121] Levine and colleagues[117] demonstrated complete remission of skin symptoms in 81% of patients treated with steroids and etanercept, compared to steroids alone (complete remission = 47%). Similarly, infliximab has also shown success in acute treatment-refractory skin GVHD (33% to 60%).[118] Immunosuppression to treat acute GVHD must always be weighed against the risk of infection and dampening of the graft-versus-leukemia effect.

Administration of ECP is sometimes preferred prior to increased immunosuppression. ECP is thought to modulate alloreactive T-cell and dendritic cell activity. During ECP, the white cell compartment of the blood is removed from the patient via pheresis, mixed with 8-methyoxypsoralen, irradiated with UVA light, and then returned to the patient. In a pooled analysis of studies examining ECP, the overall response rate was 84% for acute skin GVHD.[122] In a randomized trial, the addition of ECP to systemic steroids resulted in higher response rates, particularly for skin-only acute GVHD.[123] Limitations to ECP include the time commitment for the procedure—requiring several hours on 2 consecutive days for 1 cycle, the requirement and cost of a dedicated pheresis center, potentially prolonged vascular access, and fluid imbalance. The optimal frequency and duration of ECP treatment is unclear. Typically, 1 cycle is given weekly, followed by tapering as a response is achieved. Phototherapy (UVA1,[124] PUVA,[125] narrow band UVB[126]) also has been used for acute GVHD,[127] but is logistically challenging in the inpatient setting and should be administered cautiously to avoid inducing erythema.

In a 2008 study, 39 (71%) of 55 participants with steroid-resistant acute GVHD sustained a complete or partial response to mesenchymal stem cell infusion.[128] Responses were seen regardless of mesenchymal stem cell source (HLA-matched, haploidentical, or third-party unmatched donors), and immunogenicity was not observed. In a Phase I study, response rates of 67.5% were reported, with 27.5% experiencing a complete response.[121] The immunomodulatory mechanism of mesenchymal stem cells is unclear in GVHD, but may be through the induction of T-regulatory cells.

MANAGEMENT OF CHRONIC GRAFT-VERSUS-HOST DISEASE

The dermatologist should play a key role in the multidisciplinary approach to chronic GVHD management, beginning with careful assessment of the subtype and extent of skin involvement. Together with an understanding of other organ system activity, infection risk, relapse risk, and GVHD prognostic risk factors, a decision regarding the appropriateness of topical, physical (eg, phototherapy), and systemic therapy can then be made. If systemic therapy is prescribed by the transplant physician, periodic dermatologic monitoring is advised to differentiate adverse drug reactions or other new skin disease from GVHD, to assess cutaneous disease response, and to monitor for infection and skin malignancy.

For mild chronic skin GVHD without sclerotic features, including lichen planus–like, ichthyotic, and papulosquamous types, topical steroids may be used either alone or in conjunction with systemic steroids with close followup and screening for more significant or systemic disease.[129] Treatment typically includes mid- to high-potency topical steroids with topical calcineurin inhibitors[130] applied twice daily, potentially under occlusion for thicker or refractory lesions. Topical calcineurin inhibitors are particularly useful for treatment of areas at high risk of skin atrophy, such as the face (including the lips) and intertriginous surfaces. Extensive application of topical calcineurin inhibitors, however, can lead to systemic absorption.[131] Additional objectives of topical therapy include relief of pruritus and prevention of skin breakdown and infection. Regular moisturization to maintain skin integrity and strict photoprotection should also be employed. Pruritus without rash can be treated with low-potency topical steroids and menthol-based creams. Although systemic antihistamines at higher-than-standard dosing are often helpful, caution should be taken to avoid inducing or exacerbating oral and ocular sicca symptoms.[132]

Phototherapy may be appropriate for patients with limited epidermal or sclerotic disease in whom systemic therapy is not otherwise warranted (eg, without internal organ system involvement), or in whom systemic immunosuppressive therapy is contraindicated (eg, active infection). Data are limited to anecdotal cases and case series. Longer-wavelength UVA (340 to 400 nm; UVA-1) may be particularly beneficial for fibrosing forms of chronic GVHD.[124] UVA-1 does not require psoralen ingestion/topical, and penetrates deeper into the dermis than full-spectrum UVA. UVA-1 is thought to increase the synthesis of matrix metalloproteinases, and decrease the synthesis of procollagen though IL-1 and IL-6. It may also reduce levels of transforming growth factor-β, TNF, IL-8, and IL-10. Although UVA-1 is not yet widely available in the Unites States, it appears to be well tolerated, acceptable for pediatric use, and is not associated with persistent photosensitivity, carcinogenic risk, or potential GI issues that may occur with oral psoralen use. The largest series describes skin softening following UVA-1 treatment of sclerotic-type GVHD in 17 (70.8%) of 24 GVHD patients, with the best response rate in patients receiving high-dose UVA-1.[133] In a study of medium-dose UVA-1 phototherapy in 7 patients with lichenoid GVHD and 3 with sclerotic GVHD, all 3 patients with sclerotic GVHD demonstrated partial response or

improvement.[134] Ständer and colleagues[135] described softening of skin lesions, improved joint mobility, and healing of skin erosions in 5 adult patients with medium-dose UVA-1 and 1 child treated with low-dose UVA-1. Calzavara Pinton and colleagues[136] described 5 patients with sclerotic involvement treated with UVA-1 therapy with complete resolution in 3 patients and partial response in 2 patients. Although UVA-1 may accentuate pigmentary abnormalities, the risk of skin cancer is significantly less than the risk associated with PUVA.[137] PUVA has shown limited efficacy in treating GVHD and is associated with potential phototoxicity and risk of skin cancer.[138] Narrow band UVB also has been used, with some response in patients with primarily "lichenoid" disease.[126,139] Care must be taken in administering phototherapy, as UV radiation may trigger flares of cutaneous disease. Skin cancer risk assessment and concurrent use of photosensitizing medications should also be considered. Voriconazole therapy, in particular, is an important photosensitizer in this setting and may increase the risk of squamous cell carcinoma and melanoma.[92,93]

First-line treatment of moderate to severe GVHD is high-dose systemic steroids, usually in combination with other immunosuppressive agents.[129] Long-term systemic therapy is often required for patients with moderate-to-severe disease (3 or more organs involved, moderate or severe involvement in any organ, or lung involvement).[50] Combination therapy with azathioprine, thalidomide, mycophenolate mofetil, Plaquenil, and sirolimus have suggested no significant benefit over prednisone alone for first-line therapy.[129] Calcineurin inhibitors should be used in combination with systemic steroids, and can be particularly helpful in moderating steroid dependence.[140]

Among the myriad of systemic treatments that have been used in patients with chronic GVHD who cannot be tapered from systemic corticosteroids or who are steroid-refractory, no single treatment has demonstrated proven superiority. There are no U.S. Food and Drug Administration–approved treatments for chronic GVHD. Determination of a preferred second-line or salvage agent has been complicated by poor understanding of the disease process and a lack of high-quality clinical trials. The need to spur clinical trial development in the field of chronic GVHD was acknowledged by the chronic GVHD NIH Consensus Project, which included a standardized system of organ system assessments and recommendations for clinical trial design.[50] Unfortunately, validated measures of cutaneous disease activity still have limitations, and are not routinely implemented in clinical care.[141] Ideally, dermatologic collaboration in future therapeutic trials will permit better quantification of cutaneous disease response. Response should be assessed 8 to 12 weeks after initiation of a systemic treatment. If patients progress after 4 weeks, a new treatment option should be offered.[129] Significant sclerotic disease may require substantially longer treatment periods to determine an effect.

ECP is a major salvage therapy in steroid-refractory chronic GVHD, especially in patients with evidence of skin sclerosis at high risk of adverse effects from systemic immunosuppression. ECP has an excellent safety profile, but is limiting in that it requires sustained venous access. A pooled analysis of ECP studies for chronic GVHD found an overall response rate of 71% for cutaneous disease.[122] In a large retrospective analysis of 71 patients, response was seen in 61% with best response was seen in 44 (61%) of patients, most notably in the skin. Thrombocytopenia was associated with a lower response rate.[142] Patients with classic chronic GVHD and overlap acute and chronic GVHD demonstrated superior survival after treatment with ECP.[143] ECP may be particularly useful for patients with deep-seated sclerotic involvement of the subcutaneous tissue and fascia. Although GVHD-related fasciitis resembles eosinophilic fasciitis, in contrast to eosinophilic fasciitis, GVHD-related fasciitis does not respond well to steroid therapy and may result in significant long-term functional disability. Several case reports describe successful use of ECP for GVHD-related fasciitis.[144]

Imatinib mesylate, a multikinase inhibitor with activity against bc-abl, c-kit, PDGFR, and other kinases, has been reported to have a modest benefit at doses lower than are typically administered for treatment of chronic myeloid leukemia (adult: 400 mg daily; children 260 mg/m^2 daily) as the drug in GVHD patients is poorly tolerated. In a prospective study specifically for sclerotic skin GVHD, Baird and colleagues[145] observed a partial response in 5 of 14 patients, with an average range-of-motion improvement of 26%. The drug is generally well tolerated in the setting of treatment of chronic myelogenous leukemia; however, side effects are common in the GVHD setting and include hypophosphatemia, fatigue, nausea, diarrhea, edema, and muscle cramping. The modest effect reported is in line with a large series reporting limited efficacy,[146] despite many prior case series and other studies revealing more promising results.[147-149] Ibrutinib, a small-molecule inhibitor of Bruton tyrosine kinase, has shown preclinical efficacy in mouse models of GVHD, and clinical trials are ongoing.[150-152]

Rituximab has immunoregulatory effects in patients with chronic GVHD, and data suggesting elevated levels of BAFF in chronic GVHD patients supports this.[32] In a prospective, multicenter randomized trial, a significant clinical response in skin sclerosis and joint range of motion was seen in 27% of patients receiving rituximab, compared to 36% of patients receiving imatinib. Among rituximab patients, those with higher circulating activated B cells were more likely to have treatment success.[35]

Inhibitors of Janus kinase (JAK)/signal transducer and activator of transcription (STAT) signaling, ruxolitinib and tofacitinib, have also shown promising preclinical and early clinical results.[153,154] One study reported an 81.5% response rate in 54 patients with acute GVHD and 84.4% response rate for 41 patients with chronic GVHD treated with ruxolitinib. Cytopenias and cytomegalovirus reactivation were observed during treatment with ruxolitinib.[153]

TABLE 129-8

Other Potential Systemic Treatments of Chronic Skin Graft-Versus-Host Disease

Immunosuppressive Agents
- Mycophenolate mofetil[156]
- Calcineurin inhibitors (cyclosporine, tacrolimus)[157]

Chemotherapeutic Agents
- Thalidomide[158]
- Azathioprine[159]
- Methotrexate[160]
- Pentostatin[161]

Antimicrobial Agents
- Cyclophosphamide[162]
- Clofazimine[163]
- Hydroxychloroquine[132]

Small Molecule Inhibitors
- Imatinib,[145] dasatinib, nilotinib
- Sirolimus[155]
- Ruxolitinib,[153] tofacitinib[154]
- Vorinostat[164]
- Erlotinib[165]

Antibodies and Fusion Proteins
- Antithymocyte globulin[108]
- Rituximab[35]
- Infliximab, etanercept[166]
- Alefacept[167]
- Denileukin diftitox, basiliximab, daclizumab[116]

Cytokines
- Low-dose interleukin-2[168]

Cellular Therapies
- T-reg adoptive therapy[169]
- Mesenchymal stem cell therapy[170]

Radiation
- Total nodal irradiation[171]
- Thoracoabdominal irradiation[172]

Other
- Retinoids[173]
- Intravenous immunoglobulin[174]
- Extracorporeal photophoresis[122]
- Bortezomib[175]
- Vismodegib[176]

Sirolimus also has been used therapeutically in chronic GVHD, with a Phase II trial demonstrating clinical response in 15 (79%) of 19 patients.[155] Table 129-8 lists systemic second-line therapies for chronic GVHD.

SUPPORTIVE CARE

Supportive care including physical and occupational therapy is especially important in patients with skin sclerosis and fasciitis leading to joint contractures. Weight-bearing exercise for 30 minutes daily 5 days per week are important for preserving range of motion and bone health. Deep-tissue massage may be helpful to preserve range of motion in patients with fasciitis.[132]

TREATMENT OF CHRONIC ORAL AND VULVOVAGINAL DISEASE

Limited oral mucosal disease can be controlled with application of a high-potency topical corticosteroid gel or paste (fluocinonide gel 0.05%, clobestasol gel 0.05%, triamcinolone 0.1% dental paste). Solutions of dexamethasone 0.5 mg/mL and prednisolone 15 mg/mL also may be used as rinses, and are beneficial for widespread involvement and should be swished in the mouth for 4 to 6 minutes 4 to 6 times daily.[177] Refractory lesions may respond to intralesional triamcinolone injection. Topical application of tacrolimus 0.1% ointment also may be used in conjunction with steroids and for maintenance; however, systemic absorption has been reported. Calcineurin inhibitors also can be constituted as oral solutions. Topical antiinflammatories should be used in combination with an antiyeast wash (nystatin) as to avoid secondary *Candida* infection in the setting of oral steroids. Cyclosporine and azathioprine rinses also may be used for refractory disease, but require pharmacy compounding. Patients with salivary gland disease should avoid oral antihistamines as well as other xerogenic medications (selective serotonin reuptake inhibitors, tricyclic antidepressants). Dental hygiene is very important in patients with decreased salivary function and home fluoride treatment is frequently recommended. Salivary stimulants (eg, sugar-free gum) and sialogogue therapy (cevimeline, pilocarpine) are recommended for patients with severe salivary gland dysfunction.[132] Although sclerotic involvement of perioral skin involvement is uncommon, in this setting aggressive systemic therapy is indicated.

Genital erosions and fissures associated with chronic vulvovaginal disease may be treated with clobetasol propionate ointment nightly, which should be tapered to a maintenance level of 2 to 3 times weekly. Fluocinolone 0.025% ointment can be used in cases of mild disease or for maintenance in cases of treated severe disease. Additionally, tacrolimus ointment has been commonly employed for maintenance therapy in this area. If estrogen is not contraindicated, hormone replacement via topical cream, vaginal ring, or oral replacement may improve genital skin integrity. Limited vaginal scarring/synechiae can be treated with dilators or manual lysing; however, thick vaginal scarring may require surgical intervention.[178]

REFERENCES

1. Gatti R, Meuwissen H, Allen H, et al. Immunological reconstitution of sex-linked lymphopenic immunological deficiency. *Lancet*. 1968;292:1366-1369.
2. Stem Cell Trialists' Collaborative Group. Allogeneic peripheral blood stem-cell compared with bone marrow transplantation in the management of

hematologic malignancies: an individual patient data meta-analysis of nine randomized trials. *J Clin Oncol*. 2005;23:5074-5087.
3. Slavin S, Nagler A, Naparstek E, et al. Nonmyeloablative stem cell transplantation and cell therapy as an alternative to conventional bone marrow transplantation with lethal cytoreduction for the treatment of malignant and nonmalignant hematologic diseases. *Blood*. 1998;91:756-763.
4. Brunstein CG, Barker JN, Weisdorf DJ, et al. Umbilical cord blood transplantation after nonmyeloablative conditioning: impact on transplantation outcomes in 110 adults with hematologic disease. *Blood*. 2007;110:3064-3070.
5. Lokhorst HM, Wu K, Verdonck LF, et al. The occurrence of graft-versus-host disease is the major predictive factor for response to donor lymphocyte infusions in multiple myeloma. *Blood*. 2004;103:4362-4364.
6. Laughlin MJ, Eapen M, Rubinstein P, et al. Outcomes after transplantation of cord blood or bone marrow from unrelated donors in adults with leukemia. *N Engl J Med*. 2004;351:2265-2275.
7. Lee SJ, Vogelsang G, Flowers ME. Chronic graft-versus-host disease. *Biol Blood Marrow Transplant*. 2003;9:215-233.
8. Shlomchik WD. Graft-versus-host disease. *Nat Rev Immunol*. 2007;7:340-352.
9. Arora M, Cutler CS, Jagasia MH, et al. Late acute and chronic graft-versus-host disease after allogeneic hematopoietic cell transplantation. *Biol Blood Marrow Transplant*. 2016;22:449-455.
10. Arai S, Arora M, Wang T, et al. Increasing incidence of chronic graft-versus-host disease in allogeneic transplantation: a report from the Center for International Blood and Marrow Transplant Research. *Biol Blood Marrow Transplant*. 2015;21:266-274.
11. Martires KJ, Baird K, Steinberg SM, et al. Sclerotic-type chronic GVHD of the skin: clinical risk factors, laboratory markers, and burden of disease. *Blood*. 2011;118:4250-4257.
12. Flowers ME, Parker PM, Johnston LJ, et al. Comparison of chronic graft-versus-host disease after transplantation of peripheral blood stem cells versus bone marrow in allogeneic recipients: long-term follow-up of a randomized trial. *Blood*. 2002;100:415-419.
13. Chosidow O, Bagot M, Vernant JP, et al. Sclerodermatous chronic graft-versus-host disease. Analysis of seven cases. *J Am Acad Dermatol*. 1992;26:49-55.
14. Uhm J, Hamad N, Shin EM, et al. Incidence, risk factors, and long-term outcomes of sclerotic graft-versus-host disease after allogeneic hematopoietic cell transplantation. *Biol Blood Marrow Transplant*. 2014;20:1751-1757.
15. Billingham RE. The biology of graft-versus-host reactions. *Harvey Lect*. 1966;62:21-78.
16. Bleakley M, Riddell SR. Molecules and mechanisms of the graft-versus-leukaemia effect. *Nat Rev Cancer*. 2004;4:371-380.
17. Wu T, Young JS, Johnston H, et al. Thymic damage, impaired negative selection, and development of chronic graft-versus-host disease caused by donor CD4+ and CD8+ T cells. *J Immunol*. 2013;191:488-499.
18. Ferrara JL, Levine JE, Reddy P, et al. Graft-versus-host disease. *Lancet*. 2009;373:1550-1561.
19. MacDonald KP, Hill GR, Blazar BR. Chronic graft-versus-host disease: biological insights from pre-clinical and clinical studies. *Blood*. 2017;129(1):13-21.
20. Hakim FT, Memon S, Jin P, et al. Upregulation of IFN-inducible and damage-response pathways in chronic graft-versus-host disease. *J Immunol*. 2016;197:3490-3503.
21. Gartlan KH, Markey KA, Varelias A, et al. Tc17 cells are a proinflammatory, plastic lineage of pathogenic CD8+ T cells that induce GVHD without antileukemic effects. *Blood*. 2015;126:1609-1620.
22. Harris T, Grosso JF, Yen HR, et al. Cutting edge: an in vivo requirement for STAT3 signaling in TH17 development and TH17-dependent autoimmunity. *J Immunol*. 2007;179:4313-4317.
23. Yi T, Chen Y, Wang L, et al. Reciprocal differentiation and tissue-specific pathogenesis of Th1, Th2, and Th17 cells in graft-versus-host disease. *Blood*. 2009;114: 3101-3112.
24. Antin JH, Ferrara JL. Cytokine dysregulation and acute graft-versus-host disease. *Blood*. 1992;80:2964-2968.
25. Edinger M, Hoffmann P, Ermann J, et al. CD4+CD25+ regulatory T cells preserve graft-versus-tumor activity while inhibiting graft-versus-host disease after bone marrow transplantation. *Nat Med*. 2003;9:1144-1150.
26. Magenau JM, Qin X, Tawara I, et al. Frequency of CD4(+)CD25(hi)FOXP3(+) regulatory T cells has diagnostic and prognostic value as a biomarker for acute graft-versus-host-disease. *Biol Blood Marrow Transplant*. 2010;16:907-914.
27. Zeiser R, Nguyen VH, Beilhack A, et al. Inhibition of CD4+CD25+ regulatory T-cell function by calcineurin-dependent interleukin-2 production. *Blood*. 2006;108: 390-399.
28. Zorn E, Kim HT, Lee SJ, et al. Reduced frequency of FOXP3+ CD4+CD25+ regulatory T cells in patients with chronic graft-versus-host disease. *Blood*. 2005;106: 2903-2911.
29. Iwata Y, Matsushita T, Horikawa M, et al. Characterization of a rare IL-10-competent B-cell subset in humans that parallels mouse regulatory B10 cells. *Blood*. 2011;117:530-541.
30. Kheav VD, Busson M, Scieux C, et al. Favorable impact of natural killer cell reconstitution on chronic graft-versus-host disease and cytomegalovirus reactivation after allogeneic hematopoietic stem cell transplantation. *Haematologica*. 2014;99:1860-1867.
31. Miklos DB, Kim HT, Miller KH, et al. Antibody responses to H-Y minor histocompatibility antigens correlate with chronic graft-versus-host disease and disease remission. *Blood*. 2005;105:2973-2978.
32. Sarantopoulos S, Stevenson KE, Kim HT, et al. Altered B-cell homeostasis and excess BAFF in human chronic graft-versus-host disease. *Blood*. 2009;113:3865-3874.
33. Jin H, Ni X, Deng R, et al. Antibodies from donor B cells perpetuate cutaneous chronic graft-versus-host disease in mice. *Blood*. 2016;127:2249-2260.
34. Cutler C, Miklos D, Kim HT, et al. Rituximab for steroid-refractory chronic graft-versus-host disease. *Blood*. 2006;108:756-762.
35. Arai S, Pidala J, Pusic I, et al. A randomized phase II crossover study of imatinib or rituximab for cutaneous sclerosis after hematopoietic cell transplantation. *Clin Cancer Res*. 2016;22:319-327.
36. Nakasone H, Sahaf B, Miklos DB. Therapeutic benefits targeting B-cells in chronic graft-versus-host disease. *Int J Hematol*. 2015;101:438-451.
37. Kuzmina Z, Gounden V, Curtis L, et al. Clinical significance of autoantibodies in a large cohort of patients with chronic graft-versus-host disease defined by NIH criteria. *Am J Hematol*. 2015;90:114-119.
38. Ochs LA, Blazar BR, Roy J, et al. Cytokine expression in human cutaneous chronic graft-versus-host disease. *Bone Marrow Transplant*. 1996;17:1085-1092.

39. Svegliati S, Olivieri A, Campelli N, et al. Stimulatory autoantibodies to PDGF receptor in patients with extensive chronic graft-versus-host disease. *Blood*. 2007;110:237-241.
40. Zhang Y, McCormick LL, Desai SR, et al. Murine sclerodermatous graft-versus-host disease, a model for human scleroderma: cutaneous cytokines, chemokines, and immune cell activation. *J Immunol*. 2002;168:3088-3098.
41. Spies-Weisshart B, Schilling K, Böhmer F, et al. Lack of association of platelet-derived growth factor (PDGF) receptor autoantibodies and severity of chronic graft-versus-host disease (GvHD). *J Cancer Res Clin Oncol*. 2013;139:1397-1404.
42. Duffield JS, Forbes SJ, Constandinou CM, et al. Selective depletion of macrophages reveals distinct, opposing roles during liver injury and repair. *J Clin Invest*. 2005;115:56-65.
43. Alexander KA, Flynn R, Lineburg KE, et al. CSF-1-dependant donor-derived macrophages mediate chronic graft-versus-host disease. *J Clin Invest*. 2014;124:4266-4280.
44. Hansen JA, Chien JW, Warren EH, et al. Defining genetic risk for GVHD and mortality following allogeneic hematopoietic stem cell transplantation. *Curr Opin Hematol*. 2010;17:483-492.
45. Inamoto Y, Martin PJ, Flowers ME, et al. Genetic risk factors for sclerotic graft-versus-host disease. *Blood*. 2016;128:1516-1524.
46. Baack BR, Burgdorf WH. Chemotherapy-induced acral erythema. *J Am Acad Dermatol*. 1991;24:457-461.
47. Mielcarek M, Martin PJ, Leisenring W, et al. Graft-versus-host disease after nonmyeloablative versus conventional hematopoietic stem cell transplantation. *Blood*. 2003;102:756-762.
48. Ohto H, Yasuda H, Noguchi M, et al. Risk of transfusion-associated graft-versus-host disease as a result of directed donations from relatives. *Transfusion (Paris)*. 1992;32:691-693.
49. Rühl H, Bein G, Sachs UJ. Transfusion-associated graft-versus-host disease. *Transfus Med Rev*. 2009;23:62-71.
50. Jagasia MH, Greinix HT, Arora M, et al. National Institutes of Health consensus development project on criteria for clinical trials in chronic graft-versus-host disease: I. The 2014 Diagnosis and Staging Working Group report. *Biol Blood Marrow Transplant*. 2015;21:389-401.e1.
51. Paun O, Phillips T, Fu P, et al. Cutaneous complications in hematopoietic cell transplant recipients: impact of biopsy on patient management. *Biol Blood Marrow Transplant*. 2013;19:1204-1209.
52. Patel AR, Pavletic SZ, Turner ML, et al. The isomorphic response in morphea-like chronic graft-versus-host disease. *Arch Dermatol*. 2008;144:1229-1231.
53. Martires KJ, Baird K, Citrin DE, et al. Localization of sclerotic-type chronic graft-vs-host disease to sites of skin injury: potential insight into the mechanism of isomorphic and isotopic responses. *Arch Dermatol*. 2011;147:1081-1086.
54. Carpenter PA. How I conduct a comprehensive chronic graft-versus-host disease assessment. *Blood*. 2011;118:2679-2687.
55. Lee SK, Cook EF, Soiffer R, et al. Development and validation of a scale to measure symptoms of chronic graft-versus-host disease. *Biol Blood Marrow Transplant*. 2002;8:444-452.
56. Przepiorka D, Weisdorf D, Martin P, et al. 1994 Consensus Conference on Acute GVHD Grading. *Bone Marrow Transplant*. 1995;15:825-828.
57. Hymes SR, Turner ML, Champlin RE, et al. Cutaneous manifestations of chronic graft-versus-host disease. *Biol Blood Marrow Transplant*. 2006;12:1101-1113.
58. Hymes SR, Alousi AM, Cowen EW. Graft-versus-host disease: part I. Pathogenesis and clinical manifestations of graft-versus-host disease. *J Am Acad Dermatol*. 2012;66:515.e1-e18; quiz 533-534.
59. Fett N, Werth VP. Update on morphea: part I. Epidemiology, clinical presentation, and pathogenesis. *J Am Acad Dermatol*. 2011;64:217-228.
60. Su WP, Greene SL. Bullous morphea profunda. *Am J Dermatopathol*. 1986;8:144-147.
61. Peñas PF, Jones-Caballero M, Aragüés M, et al. Sclerodermatous graft-vs-host disease: clinical and pathological study of 17 patients. *Arch Dermatol*. 2002;138:924-934.
62. Schaffer JV, McNiff JM, Seropian S, et al. Lichen sclerosus and eosinophilic fasciitis as manifestations of chronic graft-versus-host disease: expanding the sclerodermoid spectrum. *J Am Acad Dermatol*. 2005;53:591-601.
63. Sanli H, Arat M, Oskay T, et al. Evaluation of nail involvement in patients with chronic cutaneous graft versus host disease: a single-center study from Turkey. *Int J Dermatol*. 2004;43:176-180.
64. Alexis AF, Busam K, Myskowski PL. Porokeratosis of Mibelli following bone marrow transplantation. *Int J Dermatol*. 2006;45:361-365.
65. Kaffenberger BH, Zuo RC, Gru A, et al. Graft-versus-host disease-associated angiomatosis: a clinicopathologically distinct entity. *J Am Acad Dermatol*. 2014;71:745-753.
66. Sanli H, Ekmekci P, Kusak F, et al. Hyperkeratosis of the nipple associated with chronic graft versus host disease after allogeneic haematopoietic cell transplantation. *Acta Derm Venereol*. 2003;83:385-386.
67. Zuo RC, Naik HB, Steinberg SM, et al. Risk factors and characterization of vitiligo and alopecia areata in patients with chronic graft-vs-host disease. *JAMA Dermatol*. 2015;151:23-32.
68. Park JH, Lester L, Kim J, et al. Acral verruca-like presentation of chronic graft-vs.-host disease. *J Cutan Pathol*. 2016;43:236-241.
69. Greinix HT, Pohlreich D, Maalouf J, et al. A single-center pilot validation study of a new chronic GVHD skin scoring system. *Biol Blood Marrow Transplant*. 2007;13:715-723.
70. Jacobsohn DA, Rademaker A, Kaup M, et al. Skin response using NIH consensus criteria vs Hopkins scale in a phase II study for steroid-refractory chronic GVHD. *Bone Marrow Transplant*. 2009;44:813-819.
71. Furst DE, Clements PJ, Steen VD, et al. The modified Rodnan skin score is an accurate reflection of skin biopsy thickness in systemic sclerosis. *J Rheumatol*. 1998;25:84-88.
72. Spiryda LB, Laufer MR, Soiffer RJ, et al. Graft-versus-host disease of the vulva and/or vagina: diagnosis and treatment. *Biol Blood Marrow Transplant*. 2003;9:760-765.
73. Marra DE, McKee PH, Nghiem P. Tissue eosinophils and the perils of using skin biopsy specimens to distinguish between drug hypersensitivity and cutaneous graft-versus-host disease. *J Am Acad Dermatol*. 2004;51:543-546.
74. Cornell RF, Hari P, Drobyski WR. Engraftment syndrome after autologous stem cell transplantation: an update unifying the definition and management approach. *Biol Blood Marrow Transplant*. 2015;21:2061-2068.

75. Shulman HM, Kleiner D, Lee SJ, et al. Histopathologic diagnosis of chronic graft-versus-host disease: National Institutes of Health consensus development project on criteria for clinical trials in chronic graft-versus-host disease: II. Pathology Working Group Report. *Biol Blood Marrow Transplant*. 2006;12:31-47.
76. Horn TD, Rest EB, Mirenski Y, et al. The significance of oral mucosal and salivary gland pathology after allogeneic bone marrow transplantation. *Arch Dermatol*. 1995;131:964-965.
77. Levine JE, Logan BR, Wu J, et al. Acute graft-versus-host disease biomarkers measured during therapy can predict treatment outcomes: a Blood and Marrow Transplant Clinical Trials Network study. *Blood*. 2012;119:3854-3860.
78. Ahmed SS, Wang XN, Norden J, et al. Identification and validation of biomarkers associated with acute and chronic graft versus host disease. *Bone Marrow Transplant*. 2015;50:1563-1571.
79. Miura Y, Thoburn CJ, Bright EC, et al. Association of Foxp3 regulatory gene expression with graft-versus-host disease. *Blood*. 2004;104:2187-2193.
80. Kitko CL, Levine JE, Storer BE, et al. Plasma CXCL9 elevations correlate with chronic GVHD diagnosis. *Blood*. 2014;123:786-793.
81. Tanaka J, Imamura M, Kasai M, et al. Th2 cytokines (IL-4, IL-10 and IL-13) and IL-12 mRNA expression by concanavalin A-stimulated peripheral blood mononuclear cells during chronic graft-versus-host disease. *Eur J Haematol*. 1996;57:111-113.
82. Paczesny S, Hakim FT, Pidala J, et al. National Institutes of Health consensus development project on criteria for clinical trials in chronic graft-versus-host disease: III. The 2014 Biomarker Working Group Report. *Biol Blood Marrow Transplant*. 2015;21:780-792.
83. Ritchie D, Seconi J, Wood C, et al. Prospective monitoring of tumor necrosis factor alpha and interferon gamma to predict the onset of acute and chronic graft-versus-host disease after allogeneic stem cell transplantation. *Biol Blood Marrow Transplant*. 2005;11:706-712.
84. Fujii H, Cuvelier G, She K, et al. Biomarkers in newly diagnosed pediatric-extensive chronic graft-versus-host disease: a report from the Children's Oncology Group. *Blood*. 2008;111:3276-3285.
85. Clark J, Yao L, Pavletic SZ, et al. Magnetic resonance imaging in sclerotic-type chronic graft-vs-host disease. *Arch Dermatol.Dermatology*. 2009;145:918-922.
86. Tedstone JL, Richards SM, Garman RD, et al. Ultrasound imaging accurately detects skin thickening in a mouse scleroderma model. *Ultrasound Med Biol*. 2008;34:1239-1247.
87. Bolognia JL, Cooper DL, Glusac EJ. Toxic erythema of chemotherapy: a useful clinical term. *J Am Acad Dermatol*. 2008;59:524-529.
88. Dean PG, Lund WJ, Larson TS, et al. Wound-healing complications after kidney transplantation: a prospective, randomized comparison of sirolimus and tacrolimus. *Transplantation*. 2004;77:1555-1561.
89. DePry JL, Vyas R, Lazarus HM, et al. Cutaneous malignant neoplasms in hematopoietic cell transplant recipients: a systematic review. *JAMA Dermatol*. 2015;151:775-782.
90. Curtis RE, Rowlings PA, Deeg HJ, et al. Solid cancers after bone marrow transplantation. *N Engl J Med*. 1997;336:897-904.
91. Leisenring W, Friedman DL, Flowers ME, et al. Nonmelanoma skin and mucosal cancers after hematopoietic cell transplantation. *J Clin Oncol*. 2006;24:1119-1126.
92. Cowen EW, Nguyen JC, Miller DD, et al. Chronic phototoxicity and aggressive squamous cell carcinoma of the skin in children and adults during treatment with voriconazole. *J Am Acad Dermatol*. 2010;62:31-37.
93. Miller DD, Cowen EW, Nguyen JC, et al. Melanoma associated with long-term voriconazole therapy: a new manifestation of chronic photosensitivity. *Arch Dermatol*. 2010;146:300-304.
94. Altman JS, Adler SS. Development of multiple cutaneous squamous cell carcinomas during PUVA treatment for chronic graft-versus-host disease. *J Am Acad Dermatol*. 1994;31:505-507.
95. Wingard JR, Majhail NS, Brazauskas R, et al. Long-term survival and late deaths after allogeneic hematopoietic cell transplantation. *J Clin Oncol*. 2011;29:2230-2239.
96. Akpek G, Zahurak ML, Piantadosi S, et al. Development of a prognostic model for grading chronic graft-versus-host disease. *Blood*. 2001;97:1219-1226.
97. Wingard JR, Piantadosi S, Vogelsang GB, et al. Predictors of death from chronic graft-versus-host disease after bone marrow transplantation. *Blood*. 1989;74:1428-1435.
98. Pavletic SZ, Smith LM, Bishop MR, et al. Prognostic factors of chronic graft-versus-host disease after allogeneic blood stem-cell transplantation. *Am J Hematol*. 2005;78:265-274.
99. Robinson TM, O'Donnell PV, Fuchs EJ, et al. Haploidentical bone marrow and stem cell transplantation: experience with post-transplantation cyclophosphamide. *Semin Hematol*. 2016;53:90-97.
100. Gibbs SD, Herbert KE, McCormack C, et al. Alemtuzumab: effective monotherapy for simultaneous B-cell chronic lymphocytic leukaemia and Sézary syndrome. *Eur J Haematol*. 2004;73:447-449.
101. Pérez-Simón JA, Kottaridis PD, Martino R, et al. Nonmyeloablative transplantation with or without alemtuzumab: comparison between 2 prospective studies in patients with lymphoproliferative disorders. *Blood*. 2002;100:3121-3127.
102. Kennedy-Nasser AA, Ku S, Castillo-Caro P, et al. Ultra low-dose IL-2 for GVHD prophylaxis after allogeneic hematopoietic stem cell transplantation mediates expansion of regulatory T cells without diminishing antiviral and antileukemic activity. *Clin Cancer Res*. 2014;20:2215-2225.
103. Bucher C, Koch L, Vogtenhuber C, et al. IL-21 blockade reduces graft-versus-host disease mortality by supporting inducible T regulatory cell generation. *Blood*. 2009;114:5375-5384.
104. Bacigalupo A, Lamparelli T, Barisione G, et al. Thymoglobulin prevents chronic graft-versus-host disease, chronic lung dysfunction, and late transplant-related mortality: long-term follow-up of a randomized trial in patients undergoing unrelated donor transplantation. *Biol Blood Marrow Transplant*. 2006;12:560-565.
105. MacMillan ML, Weisdorf DJ, Davies SM, et al. Early antithymocyte globulin therapy improves survival in patients with steroid-resistant acute graft-versus-host disease. *Biol Blood Marrow Transplant*. 2002;8:40-46.
106. Kröger N, Zabelina T, Krüger W, et al. In vivo T cell depletion with pretransplant anti-thymocyte globulin reduces graft-versus-host disease without increasing relapse in good risk myeloid leukemia patients after stem cell transplantation from matched related donors. *Bone Marrow Transplant*. 2002;29:683-689.

107. Kumar, A. et al. Antithymocyte globulin for acute-graft-versus-host-disease prophylaxis in patients undergoing allogeneic hematopoietic cell transplantation: a systematic review. *Leukemia*. 2012;26:582-588.
108. Kröger N, Solano C, Bonifazi F. Antilymphocyte globulin for prevention of chronic graft-versus-host disease. *N Engl J Med*. 2016;374:43-53.
109. Bejanyan N, Rogosheske J, DeFor TE, et al. Sirolimus and mycophenolate mofetil as calcineurin inhibitor-free graft-versus-host disease prophylaxis for reduced-intensity conditioning umbilical cord blood transplantation. *Biol Blood Marrow Transplant*. 2016;22: 2025-2030.
110. Armand P, Kim HT, Sainvil MM, et al. The addition of sirolimus to the graft-versus-host disease prophylaxis regimen in reduced intensity allogeneic stem cell transplantation for lymphoma: a multicentre randomized trial. *Br J Haematol*. 2016;173:96-104.
111. Inamoto Y, Shah NN, Savani BN, et al. Secondary solid cancer screening following hematopoietic cell transplantation. *Bone Marrow Transplant*. 2015;50: 1013-1023.
112. Martin PJ, Inamoto Y, Flowers ME, et al. Secondary treatment of acute graft-versus-host disease: a critical review. *Biol Blood Marrow Transplant*. 2012;18: 982-988.
113. Hattori K, Doki N, Kurosawa S, et al. Mycophenolate mofetil is effective only for involved skin in the treatment for steroid-refractory acute graft-versus-host disease after allogeneic hematopoietic stem cell transplantation. *Ann Hematol*. 2017;96(2):319-321.
114. Piñana JL, Valcárcel D, Martino R, et al. Encouraging results with inolimomab (anti-IL-2 receptor) as treatment for refractory acute graft-versus-host disease. *Biol Blood Marrow Transplant*. 2006;12:1135-1141.
115. van Groningen LF, Liefferink AM, de Haan AF, et al. Combination therapy with inolimomab and etanercept for severe steroid-refractory acute graft-versus-host disease. *Biol Blood Marrow Transplant*. 2016;22:179-182.
116. Lee SJ, Zahrieh D, Agura E, et al. Effect of up-front daclizumab when combined with steroids for the treatment of acute graft-versus-host disease: results of a randomized trial. *Blood*. 2004;104:1559-1564.
117. Levine JE, Paczesny S, Mineishi S, et al. Etanercept plus methylprednisolone as initial therapy for acute graft-versus-host disease. *Blood*. 2008;111:2470-2475.
118. Couriel DR, Saliba R, de Lima M, et al. A phase III study of infliximab and corticosteroids for the initial treatment of acute graft-versus-host disease. *Biol Blood Marrow Transplant*. 2009;15:1555-1562.
119. Alousi AM, Weisdorf DJ, Logan BR, et al. Etanercept, mycophenolate, denileukin, or pentostatin plus corticosteroids for acute graft-versus-host disease: a randomized phase 2 trial from the Blood and Marrow Transplant Clinical Trials Network. *Blood*. 2009;114:511-517.
120. Pidala J, Kim J, Anasetti C. Sirolimus as primary treatment of acute graft-versus-host disease following allogeneic hematopoietic cell transplantation. *Biol Blood Marrow Transplant*. 2009;15:881-885.
121. Introna M, Lucchini G, Dander E, et al. Treatment of graft versus host disease with mesenchymal stromal cells: a phase I study on 40 adult and pediatric patients. *Biol Blood Marrow Transplant*. 2014;20:375-381.
122. Abu-Dalle I, Reljic T, Nishihori T, et al. Extracorporeal photopheresis in steroid-refractory acute or chronic graft-versus-host disease: results of a systematic review of prospective studies. *Biol Blood Marrow Transplant*. 2014;20:1677-1686.
123. Alousi AM, Bassett R, Chen J, et al. A bayesian, phase II randomized trial of extracorporeal photopheresis (ECP) plus steroids versus steroids-alone in patients with newly diagnosed acute graft vs. host disease (GVHD): the addition of ECP improves GVHD response and the ability to taper steroids. *Blood*. 2015;126:854.
124. Schlaak M, Schwind S, Wetzig T, et al. UVA (UVA-1) therapy for the treatment of acute GVHD of the skin. *Bone Marrow Transplant*. 2010;45:1741-1748.
125. Furlong T, Leisenring W, Storb R, et al. Psoralen and ultraviolet A irradiation (PUVA) as therapy for steroid-resistant cutaneous acute graft-versus-host disease. *Biol Blood Marrow Transplant*. 2002;8:206-212.
126. Feldstein JV, Bolaños-Meade J, Anders VL, et al. Narrowband ultraviolet B phototherapy for the treatment of steroid-refractory and steroid-dependent acute graft-versus-host disease of the skin. *J Am Acad Dermatol*. 2011;65:733-738.
127. Garbutcheon-Singh KB, Fernández-Peñas P. Phototherapy for the treatment of cutaneous graft versus host disease. *Australas J Dermatol*. 2015;56: 93-99.
128. Le Blanc K, Frassoni F, Ball L, et al. Mesenchymal stem cells for treatment of steroid-resistant, severe, acute graft-versus-host disease: a phase II study. *Lancet*. 2008;371:1579-1586.
129. Wolff D, Gerbitz A, Ayuk F, et al. Consensus conference on clinical practice in chronic graft-versus-host disease (GVHD): first-line and topical treatment of chronic GVHD. *Biol Blood Marrow Transplant*. 2010;16: 1611-1628.
130. Choi CJ, Nghiem P. Tacrolimus ointment in the treatment of chronic cutaneous graft-vs-host disease: a case series of 18 patients. *Arch Dermatol*. 2001;137: 1202-1206.
131. Neuman DL, Farrar JE, Moresi JM, et al. Toxic absorption of tacrolimus [corrected] in a patient with severe acute graft-versus-host disease. *Bone Marrow Transplant*. 2005;36(10):919-920 [erratum in *Bone Marrow Transplant*. 2006;38:81].
132. Carpenter PA, Kitko CL, Elad S, et al. National Institutes of Health consensus development project on criteria for clinical trials in chronic graft-versus-host disease: V. The 2014 Ancillary Therapy and Supportive Care Working Group Report. *Biol Blood Marrow Transplant*. 2015;21:1167-1187.
133. Connolly KL, Griffith JL, McEvoy M, et al. Ultraviolet A1 phototherapy beyond morphea: experience in 83 patients. *Photodermatol Photoimmunol Photomed*. 2015;31:289-295.
134. Wetzig T, Sticherling M, Simon JC, et al. Medium dose long-wavelength ultraviolet A (UVA1) phototherapy for the treatment of acute and chronic graft-versus-host disease of the skin. *Bone Marrow Transplant*. 2005;35:515-519.
135. Ständer H, Schiller M, Schwarz T. UVA1 therapy for sclerodermic graft-versus-host disease of the skin. *J Am Acad Dermatol*. 2002;46:799-800.
136. Calzavara Pinton P, Porta F, Izzi T, et al. Prospects for ultraviolet A1 phototherapy as a treatment for chronic cutaneous graft-versus-host disease. *Haematologica*. 2003;88:1169-1175.
137. Teske NM, Jacobe HT. Phototherapy for sclerosing skin conditions. *Clin Dermatol*. 2016;34:614-622.
138. Vogelsang GB, Wolff D, Altomonte V, et al. Treatment of chronic graft-versus-host disease with ultraviolet irradiation and psoralen (PUVA). *Bone Marrow Transplant*. 1996;17:1061-1067.

139. Ballester-Sánchez R, Navarro-Mira MÁ, de Unamuno-Bustos B, et al. The role of phototherapy in cutaneous chronic graft-vs-host disease: a retrospective study and review of the literature. *Actas Dermosifiliogr*. 2015;106:651-657.
140. Koc S, Leisenring W, Flowers ME, et al. Therapy for chronic graft-versus-host disease: a randomized trial comparing cyclosporine plus prednisone versus prednisone alone. *Blood*. 2002;100:48-51.
141. Lee SJ. Classification systems for chronic graft-versus-host disease. *Blood*. 2017;129(1):30-37.
142. Couriel DR, Hosing C, Saliba R, et al. Extracorporeal photochemotherapy for the treatment of steroid-resistant chronic GVHD. *Blood*. 2006;107:3074-3080.
143. Jagasia MH, Savani BN, Stricklin G, et al. Classic and overlap chronic graft-versus-host disease (cGVHD) is associated with superior outcome after extracorporeal photopheresis (ECP). *Biol Blood Marrow Transplant*. 2009;15:1288-1295.
144. Sbano P, Rubegni P, De Aloe GB, et al. Extracorporeal photochemotherapy for treatment of fasciitis in chronic graft-versus-host disease. *Bone Marrow Transplant*. 2004;33:869-870.
145. Baird K, Comis LE, Joe GO, et al. Imatinib mesylate for the treatment of steroid-refractory sclerotic-type cutaneous chronic graft-versus-host disease. *Biol Blood Marrow Transplant*. 2015;21:1083-1090.
146. de Masson A, Bouaziz JD, Peffault de Latour R, et al. Limited efficacy and tolerance of imatinib mesylate in steroid-refractory sclerodermatous chronic GVHD. *Blood*. 2012;120:5089-5090.
147. Olivieri A, Locatelli F, Zecca M, et al. Imatinib for refractory chronic graft-versus-host disease with fibrotic features. *Blood*. 2009;114:709-718.
148. Chen GL, Arai S, Flowers ME, et al. A phase 1 study of imatinib for corticosteroid-dependent/refractory chronic graft-versus-host disease: response does not correlate with anti-PDGFRA antibodies. *Blood*. 2011;118:4070-4078.
149. Magro L, Mohty M, Catteau B, et al. Imatinib mesylate as salvage therapy for refractory sclerotic chronic graft-versus-host disease. *Blood*. 2009;114:719-722.
150. Dubovsky JA, Flynn R, Du J, et al. Ibrutinib treatment ameliorates murine chronic graft-versus-host disease. *J Clin Invest*. 2014;124:4867-4876.
151. Schutt SD, Fu J, Nguyen H, et al. Inhibition of BTK and ITK with ibrutinib is effective in the prevention of chronic graft-versus-host disease in mice. *PLoS One*. 2015;10:e0137641.
152. Xu Y, Johnston HF, Forman SJ, et al. Oral administration of ibrutinib is ineffective at preventing scleroderma in chronic GVHD in two preclinical mouse models. *Blood*. 2014;124:3818-3818.
153. Zeiser R, Burchert A, Lengerke C, et al. Ruxolitinib in corticosteroid-refractory graft-versus-host disease after allogeneic stem cell transplantation: a multicenter survey. *Leukemia*. 2015;29:2062-2068.
154. Okiyama N, Furumoto Y, Villarroel VA, et al. Reversal of CD8 T-cell-mediated mucocutaneous graft-versus-host-like disease by the JAK inhibitor tofacitinib. *J Invest Dermatol*. 2014;134:992-1000.
155. Johnston LJ, Brown J, Shizuru JA, et al. Rapamycin (sirolimus) for treatment of chronic graft-versus-host disease. *Biol Blood Marrow Transplant*. 2005;11:47-55.
156. Pidala J, Kim J, Perkins J, et al. Mycophenolate mofetil for the management of steroid-refractory acute graft vs host disease. *Bone Marrow Transplant*. 2010;45:919-924.
157. Carnevale-Schianca F, Martin P, Sullivan K, et al. Changing from cyclosporine to tacrolimus as salvage therapy for chronic graft-versus-host disease. *Biol Blood Marrow Transplant*. 2000;6:613-620.
158. Vogelsang GB, Farmer ER, Hess AD, et al. Thalidomide for the treatment of chronic graft-versus-host disease. *N Engl J Med*. 1992;326:1055-1058.
159. Sullivan KM, Witherspoon RP, Storb R, et al. Prednisone and azathioprine compared with prednisone and placebo for treatment of chronic graft-v-host disease: prognostic influence of prolonged thrombocytopenia after allogeneic marrow transplantation. *Blood*. 1988;72:546-554.
160. de Lavallade H, Mohty M, Faucher C, et al. Low-dose methotrexate as salvage therapy for refractory graft-versus-host disease after reduced-intensity conditioning allogeneic stem cell transplantation. *Haematologica*. 2006;91:1438-1440.
161. Schmitt T, Luft T, Hegenbart U, et al. Pentostatin for treatment of steroid-refractory acute GVHD: a retrospective single-center analysis. *Bone Marrow Transplant*. 2011;46:580-585.
162. Mayer J, Krejcí M, Doubek M, et al. Pulse cyclophosphamide for corticosteroid-refractory graft-versus-host disease. *Bone Marrow Transplant*. 2005;35:699-705.
163. Lee SJ, Wegner SA, McGarigle CJ, et al. Treatment of chronic graft-versus-host disease with clofazimine. *Blood*. 1997;89:2298-2302.
164. Reddy P, Sun Y, Toubai T, et al. Histone deacetylase inhibition modulates indoleamine 2,3-dioxygenase-dependent DC functions and regulates experimental graft-versus-host disease in mice. *J Clin Invest*. 2008;118:2562-2573.
165. Morin F, Kavian N, Marut W, et al. Inhibition of EGFR tyrosine kinase by erlotinib prevents sclerodermatous graft-versus-host disease in a mouse model. *J Invest Dermatol*. 2015;135:2385-2393.
166. Busca A, Locatelli F, Marmont F, et al. Recombinant human soluble tumor necrosis factor receptor fusion protein as treatment for steroid refractory graft-versus-host disease following allogeneic hematopoietic stem cell transplantation. *Am J Hematol*. 2007;82:45-52.
167. Shapira MY, Abdul-Hai A, Resnick IB, et al. Alefacept treatment for refractory chronic extensive GVHD. *Bone Marrow Transplant*. 2009;43:339-343.
168. Koreth J, Kim HT, Jones KT, et al. Efficacy, durability, and response predictors of low-dose interleukin-2 therapy for chronic graft-versus-host disease. *Blood*. 2016;128:130-137.
169. Cohen JL, Trenado A, Vasey D, et al. CD4(+)CD25(+) immunoregulatory T cells: new therapeutics for graft-versus-host disease. *J Exp Med*. 2002;196:401-406.
170. Ringden O, Keating A. Mesenchymal stromal cells as treatment for chronic GVHD. *Bone Marrow Transplant*. 2011;46:163-164.
171. Hautmann AH, Wolff D, Hilgendorf I, et al. Total nodal irradiation in patients with severe treatment-refractory chronic graft-versus-host disease after allogeneic stem cell transplantation: response rates and immunomodulatory effects. *Radiother Oncol*. 2015;116:287-293.
172. Robin M, Guardiola P, Girinsky T, et al. Low-dose thoracoabdominal irradiation for the treatment of

refractory chronic graft-versus-host disease. *Transplantation*. 2005;80:634-642.
173. Marcellus DC, Altomonte VL, Farmer ER, et al. Etretinate therapy for refractory sclerodermatous chronic graft-versus-host disease. *Blood*. 1999;93:66-70.
174. Sullivan KM, Storek J, Kopecky KJ, et al. A controlled trial of long-term administration of intravenous immunoglobulin to prevent late infection and chronic graft-vs.-host disease after marrow transplantation: clinical outcome and effect on subsequent immune recovery. *Biol Blood Marrow Transplant*. 1996;2:44-53.
175. Herrera AF, Kim HT, Bindra B, et al. A phase II study of bortezomib plus prednisone for initial therapy of chronic graft-versus-host disease. *Biol Blood Marrow Transplant*. 2014;20:1737-1743.
176. Zerr P, Palumbo-Zerr K, Distler A, et al. Inhibition of hedgehog signaling for the treatment of murine sclerodermatous chronic graft-versus-host disease. *Blood*. 2012;120:2909-2917.
177. Margaix-Muñoz M, Bagán JV, Jiménez Y, et al. Graft-versus-host disease affecting oral cavity. A review. *J Clin Exp Dent*. 2015;7:e138-e145.
178. Stratton P, Turner ML, Childs R, et al. Vulvovaginal chronic graft-versus-host disease with allogeneic hematopoietic stem cell transplantation. *Obstet Gynecol*. 2007;110:1041-1049.

Chapter 130 :: Hereditary Disorders of Genome Instability and DNA Repair

:: John J. DiGiovanna, Thomas M. Rünger, & Kenneth H. Kraemer

AT-A-GLANCE

- Genome instability characterizes a large group of inherited disorders with prominent cutaneous abnormalities; many have an increased cancer risk.
- Genome instability is caused by impaired repair and/or maintenance of DNA.
- Xeroderma pigmentosum is a prototype with impaired repair of environmentally induced DNA damage and a greatly increased frequency of sunlight-induced cancer.
- Although these disorders are rare, heterozygous carriers of affected genes, which may comprise several percent of the general population, may carry an increased cancer risk as well.

Because the genome exerts control of cellular function, maintaining genome stability is important for the continued function of cells, tissues, and organisms. DNA is the carrier of genetic information. Its structure is regularly threatened by damaging agents that include oxidative stress, ultraviolet (UV) and X radiation, and chemical agents. Although much damage is repaired, failure to maintain genomic integrity may lead to abnormal cell function or cell death. If the cell divides, progeny may accumulate additional damage and this progressive accumulation of damage can lead to malignancy.

This chapter describes the relevant skin disorders with genome instability and the underlying defective mechanisms of DNA repair or DNA maintenance (Tables 130-1 and 130-2). All of these disorders exhibit prominent cutaneous abnormalities that involve dermatologists in their diagnosis and management. Most, but not all, are also characterized by an increased risk of malignancies. This demonstrates that the maintenance of genome integrity is important for the prevention of malignant transformation. Malignant transformation requires the accumulation of several mutations in specific genes of a single cell. Thus a mutator phenotype is often regarded a prerequisite for carcinogenesis, because without genome instability it would be exceedingly unlikely that all of those mutations would occur in a single cell.[1-4] The same genes that are affected in the hereditary genome instability disorders can also confer genome instability to individual cells when impaired through acquired mutations, thereby playing an important role early in spontaneous carcinogenesis.

In addition, although these heritable diseases are rare (1 in 100,000 to 1 in 1,000,000 people), heterozygous carriers of the affected genes (with 1 mutated allele and 1 normal allele) are more common, and may comprise several percent of the general population. These individuals are usually free of clinical symptoms, as most of these disorders are characterized by autosomal recessive inheritance. However, epidemiologic studies suggest that heterozygous carriers may have an increased risk of neoplasia as well.[5,6]

Spontaneous genome instability is present in Bloom syndrome (BS), ataxia telangiectasia, and Fanconi anemia (FA) as manifested by increased chromosome breakage in primary blood or skin cells. On the other hand, genome instability is present in cells from patients with xeroderma pigmentosum (XP) only after exposure to DNA-damaging agents such as UV radiation or other carcinogens such as benzo[*a*]pyrene, which is present in cigarette smoke. In some of the disorders discussed here, genome instability is caused by an impaired ability to repair damage to DNA introduced by certain physical or chemical agents. Cells are equipped with different DNA repair pathways that repair different types of DNA damage. The nucleotide excision repair (NER) pathway, which processes bulky DNA lesions, including UV-induced DNA photoproducts, is impaired in XP, Cockayne syndrome (CS), and trichothiodystrophy (TTD). Cells from patients with these conditions are characterized by increased cell death and mutagenesis. However, only XP patients have an increased cancer risk. The reason for this difference in cancer risk is not known.

Proteins encoded by some of the affected genes in XP, CS, and TTD are not only involved in DNA repair, but also in transcription and cellular DNA damage responses. Thus, mutations affecting different functions of the same gene (such as nervous system development or immune competence) appear to play a role in various phenotypes that are not directly linked to DNA repair functions and underlie several overlap syndromes between the 3 conditions (Table 130-3). The multisystem abnormalities of TTD may be a result of failure of the transcription function of the NER pathway proteins, or other proteins involved in transcription. Multiple clinical phenotypes of DNA repair diseases have been recognized and the relationship between the clinical phenotypes and their underlying molecular abnormalities is complex and depicted

TABLE 130-1
Clinical Features of Hereditary Disorders of Genome Instability and DNA Repair

	CLINICAL FEATURES			
DISORDER	**CUTANEOUS**	**NEOPLASIA**	**OTHER**	**INHERITANCE**
Disorders of Genome Instability With Defective DNA Repair				
Xeroderma pigmentosum (XP)	Photosensitivity (burning on minimal sun exposure in some patients); freckle-like (lentiginous) macules; poikiloderma (hyperpigmentation and hypopigmentation, atrophy, telangiectasia); skin cancer	Basal cell carcinoma (BCC), squamous cell carcinoma (SCC), melanoma, CNS tumors	Sensorineural deafness, progressive neurologic degeneration, primary loss of neurons (some patients)	Autosomal recessive
Cockayne syndrome (CS)	Photosensitivity (burning on sun exposure in some patients)	No increased incidence	Typical facial features (deep-set eyes; loss of subcutaneous fat); pigmentary retinal degeneration; postnatal growth failure; sensorineural deafness; progressive neurologic degeneration; primary dysmyelination; brain calcifications	Autosomal recessive
XP/CS complex	Photosensitivity (burning on sun exposure in some patients); freckle-like (lentiginous) macules; poikiloderma (hyperpigmentation and hypopigmentation, atrophy, telangiectasia); skin cancer	BCC, SCC	Neurologic changes of CS	Autosomal recessive
Trichothiodystrophy (TTD)	Brittle hair, photosensitivity (burning on minimal sun exposure in some patients); ichthyosis; collodion membrane; "tiger tail banding" of hair with polarized microscopy	No increased incidence	Congenital cataracts; short stature developmental delay; microcephaly; brain dysmyelination (failure to develop white matter); recurrent infections	Autosomal recessive (rare X-linked)
XP/TTD	Clinical features of both TTD and XP including skin cancer	BCC, SCC, melanoma	Clinical features of both TTD and XP	Autosomal recessive
Hereditary nonpolyposis colon cancer (HNPCC)/ Muir-Torre syndrome (MTS)	Sebaceous tumors (benign and malignant), keratoacanthomas	Low-grade cancer of the colon, endometrium, stomach, small intestine, hepatobiliary system, upper urethral tract, larynx, and ovary; sebaceous carcinoma; BCC with sebaceous differentiation		Autosomal dominant
Other Disorders of Genome Instability				
Bloom syndrome (BS)	Photosensitivity (burning on sun exposure); malar erythema; café-au-lait macules	Most cancer types, particularly leukemias, lymphomas, carcinomas of the breast and GI tract	Immune deficiency; growth retardation; unusual facies; male infertility and female subfertility; Type II diabetes	Autosomal recessive
Werner syndrome (WS)	Graying of hair; skin atrophy; leg ulcers; melanomas	Sarcomas; thyroid cancer; meningiomas; melanomas (acral lentiginous and mucous membrane melanomas)	Premature aging (atherosclerosis, diabetes mellitus, osteoporosis, cataracts)	Autosomal recessive

(*Continued*)

TABLE 130-1
Clinical Features of Hereditary Disorders of Genome Instability and DNA Repair (*Continued*)

	CLINICAL FEATURES			
DISORDER	**CUTANEOUS**	**NEOPLASIA**	**OTHER**	**INHERITANCE**
Rothmund-Thomson syndrome (RTS)	Photosensitivity (burning on sun exposure); poikiloderma; alopecia	Osteosarcomas; cutaneous SCC; and others	Skeletal abnormalities; growth deficiency; juvenile cataracts; osteoporosis	Autosomal recessive
Fanconi anemia (FA)	Café-au-lait macules	Myeloid leukemia; SCC of head and neck	Aplastic anemia; pancytopenia; growth retardation; thumb and other bone abnormalities	Autosomal recessive
Dyskeratosis congenita	Lacy, reticular pigmentation of neck and upper chest; nail dystrophy; premature gray hair; hyperhidrosis; skin cancer	Mucosal leukoplakia leading to cancer of anus or mouth; Hodgkin disease; pancreatic adenocarcinoma	Stenosis of lacrimal duct; anemia; pancytopenia; immunodeficiency; learning difficulties; deafness; brain calcifications; cerebellar hypoplasia; testicular atrophy; short stature; intrauterine growth retardation; retinopathy	X-linked recessive; autosomal dominant; autosomal recessive
Ataxia telangiectasia (AT)	Telangiectasias	T-cell leukemia, lymphomas	Progressive cerebellar ataxia; immune defects; hypogonadism; increased acute toxicity of therapeutic X-ray	Autosomal recessive
AT-like disorder (ATLD)	Similar to AT	Similar to AT	Similar to AT, but no ocular telangiectasias	Autosomal recessive
Nijmegen breakage syndrome (NBS)	Café-au-lait macule; vitiligo	B-cell and T-cell lymphomas; rhabdomyosarcoma; neuroblastoma	Immune defects; growth retardation; microcephaly; mental retardation; characteristic facies	Autosomal recessive
Seckel syndrome	Café-au-lait macules	Leukemia	Proportionate dwarfism; microcephaly; mental retardation; characteristic facies (receding forehead, narrow face, large, beaked nose, micrognathia); immune deficiency; pancytopenia	Autosomal recessive

in Fig. 130-1. Mutations in different DNA repair genes can be associated with the same clinical phenotype. On the other hand, different mutations in one DNA repair gene can be associated with different clinical phenotypes. For example, mutations in the *XPD*(*ERCC2)* DNA repair/transcription gene have been associated with the following clinical phenotypes: XP, XP with neurologic abnormalities, the XP–CS complex, XP–TTD, COFS (cerebro-oculo-facio-skeletal) syndrome, or CS–TTD. In contrast to the defects in the NER pathway, XP variant, which is clinically indistinguishable from XP, is a disorder of DNA damage tolerance with mutations in the DNA polymerase eta *(POLH)*(pol η) gene. Although normal cells can bypass DNA damage during replication (translesional DNA synthesis), cells from XP-variant patients have a defect in this process. Defects in the DNA mismatch repair pathway result in hereditary nonpolyposis colon cancer (Lynch syndrome) and its subform, Muir-Torre syndrome (MTS). Muir-Torre syndrome has cutaneous features including sebaceous gland tumors.

Helicases are proteins that unwind DNA and are required for a multitude of metabolic processes involving DNA, such as transcription, replication, and repair. Two genes involved in NER are helicases that are also part of the basal transcription factor, TFIIH. The *XPB* (*ERCC3*) gene product unwinds DNA in the 3′ to 5′ direction, whereas the *XPD* (*ERCC2*) gene product unwinds DNA in the opposite direction. Defects in these genes are associated with multiple clinical phenotypes (see above). The RecQ family of DNA helicases is highly conserved in evolution from bacteria to humans.[7,8] Of the 5 known human RecQ family members, 3 (BLM, which causes BS; WRN, which causes Werner syndrome [WS]; and RECQL4, which causes Rothmund-Thomson syndrome [RTS]) are mutated in distinct clinical disorders associated with chromosomal instability, cancer predisposition, and/or premature aging.[9]

Genetic instability can also result from abnormal telomere maintenance. Telomeres are long nucleotide (TTAGGG)*n* repeats that are important for

TABLE 130-2

Mechanisms of Hereditary Disorders of Genome Instability and DNA Repair

	MECHANISMS		
DISORDER	**CELLULAR ABNORMALITIES**	**AFFECTED GENE(S)**	**IMPAIRED FUNCTION**
Disorders of Genome Instability With Defective DNA Repair			
Xeroderma pigmentosum (XP)	Increased ultraviolet (UV)-induced cell killing and mutagenesis	*XPA*, *XPB*, *XPC*, *XPD*, *XPE*, *XPF*, *XPG*, or DNA polymerase η	Nucleotide excision repair: global genome and transcription-coupled DNA repair; translesional DNA synthesis (XP-variant)
Cockayne syndrome (CS)	Increased cell killing and mutagenesis after exposure to UV and ionizing radiation	*CSA* or *CSB*	Nucleotide excision repair: transcription-coupled DNA repair only
XP/CS complex	Increased UV-induced cell killing and mutagenesis	*XPG*, *XPD*, or *XPB*	Nucleotide excision repair: global genome and transcription-coupled DNA repair
Trichothiodystrophy (TTD)	Increased UV-induced cell killing	*XPB*, *XPD*, *TTDA*, or *TTDN1*, *GTF2E2*, *RNF113A*	Nucleotide excision repair: transcription-coupled pathway of nucleotide excision repair
XP/TTD	Same as XP	*XPD*	Nucleotide excision repair: global genome and transcription-coupled DNA repair
Hereditary nonpolyposis colon cancer (HNPCC)/Muir-Torre syndrome (MTS)	High level of microsatellite instability in tumors	*hMSH2* (MTS, HNPCC1), *hMLH1* (MTS, HNPCC2), *PMS1* (HNPCC3), *hPMS2* (HNPCC4), *hMSH6* (HNPCC5), *TGFBR2* (HNPCC6), or *hMLH3* (HNPCC7)	Mismatch repair
Other Disorders of Genome Instability			
Bloom syndrome (BS)	Spontaneous chromosome breakage and rearrangements, increased sister chromatid exchanges, quadriradial chromosomes	*BLM*	A RecQ DNA helicase, recombination, replication
Werner syndrome (WS)	Chromosomal instability, accelerated telomere shortening	*WRN*	A RecQ DNA helicase, transcription, DNA repair (DSBR, SSBR, recombination), DNA replication, telomere maintenance
Rothmund-Thomson syndrome (RTS)	Chromosomal instability in response to ionizing radiation	*RECQL4* (some patients)	A RecQ DNA helicase
Fanconi anemia (FA)	Increased sensitivity to DNA crosslinking agents	*FANCA*, *FANCB*, *FANCC*, *FANCD1/BRCA2*, *FANCD2*, *FANCE*, *FANCF*, *FANCG/XRCC9*, *FANCI*, *FANCJ/BACH1/BRIP1*, *FANCL*, *FANCM*, *FANCN/PALB2*	DNA damage signaling, recombination repair
Dyskeratosis congenita	Shortened telomeres	*DKC1* X-linked; *TERC*, *TERT*, *TINF2*, autosomal dominant; *TERT*, *NOLA3*, *NOLA2* autosomal recessive	Abnormal telomere biology
Ataxia telangiectasia (AT)	Increased spontaneous and X-ray–induced chromosome breakage; increased sensitivity to killing by ionizing radiation; impaired cell-cycle arrest and/or apoptosis in response to DNA damage	*ATM*	DNA damage signaling (control of cell cycle, apoptosis), repair of DNA double-strand breaks
AT-like disorder (ATLD)	Increased spontaneous and X-ray–induced chromosome breakage; increased sensitivity to killing by ionizing radiation; impaired DNA strand break repair	*LIG4*	DNA ligase 4, strand break repair
Nijmegen breakage syndrome (NBS)	Increased spontaneous and X-ray–induced chromosome breakage; increased sensitivity to killing by ionizing radiation	*NBS1*	Nibrin (p95), which is part of the MRE11–RAD50–NBS1 complex; DNA damage signaling; recombination; DNA double-strand break repair; cell-cycle checkpoint
Seckel syndrome	Spontaneous and mitomycin C– induced chromosome instability; sensitivity to killing by ultraviolet and DNA crosslinking agents	*ATR*	AT-related and RAD3-related protein; DNA damage response; cell-cycle checkpoints

TABLE 130-3
DNA Repair Disorders and Molecular Defects

CLINICAL DISORDERS	MOLECULAR DEFECTS
Xeroderma pigmentosum	XP-C, XP variant, XP-D, XP-A, XP-F, XP-G, XP-E
Xeroderma pigmentosum with neurologic abnormalities	XP-A, XP-D, XP-B
Trichothiodystrophy	XP-D, TTD-A, XP-B, TTDN1, *GTF2E2, RNF113A*
Cockayne syndrome	CS-B, CS-A
Xeroderma pigmentosum–Cockayne syndrome complex	XP-G, XP-D, XP-B
Xeroderma pigmentosum–trichothiodystrophy complex	XP-D
Cerebro-ocular-facio-skeletal (COFS) syndrome	CS-B, XP-D

the maintenance of chromosomal integrity.[10] Some telomeric repeats are lost at each cell division and shortened telomere lengths are a feature of aged cells. Accelerated telomere shortening is a hallmark of cells from patients with the cancer-prone disorder dyskeratosis congenita. In approximately half of dyskeratosis congenita patients, mutations have been found in 1 of 6 genes involved in telomere maintenance.[11]

BASC (*B*RCA1-*a*ssociated genome *s*urveillance *c*omplex) is a multienzyme complex centered around the BRCA1 protein in the nucleus.[12] It contains important DNA damage response proteins including ATM, ATR, the MRE11-RAD50-NBS1 complex, BRCA1, BLM, FANCD2, and MLH1. These proteins physically interact with each other. Genome instability may result from a defect in any of those and cause the genome instability disorders including ataxia-telangiectasia, Seckel syndrome, Nijmegen breakage syndrome, hereditary breast cancer, BS, FA, or hereditary colon cancer. BS and FA are reviewed here.

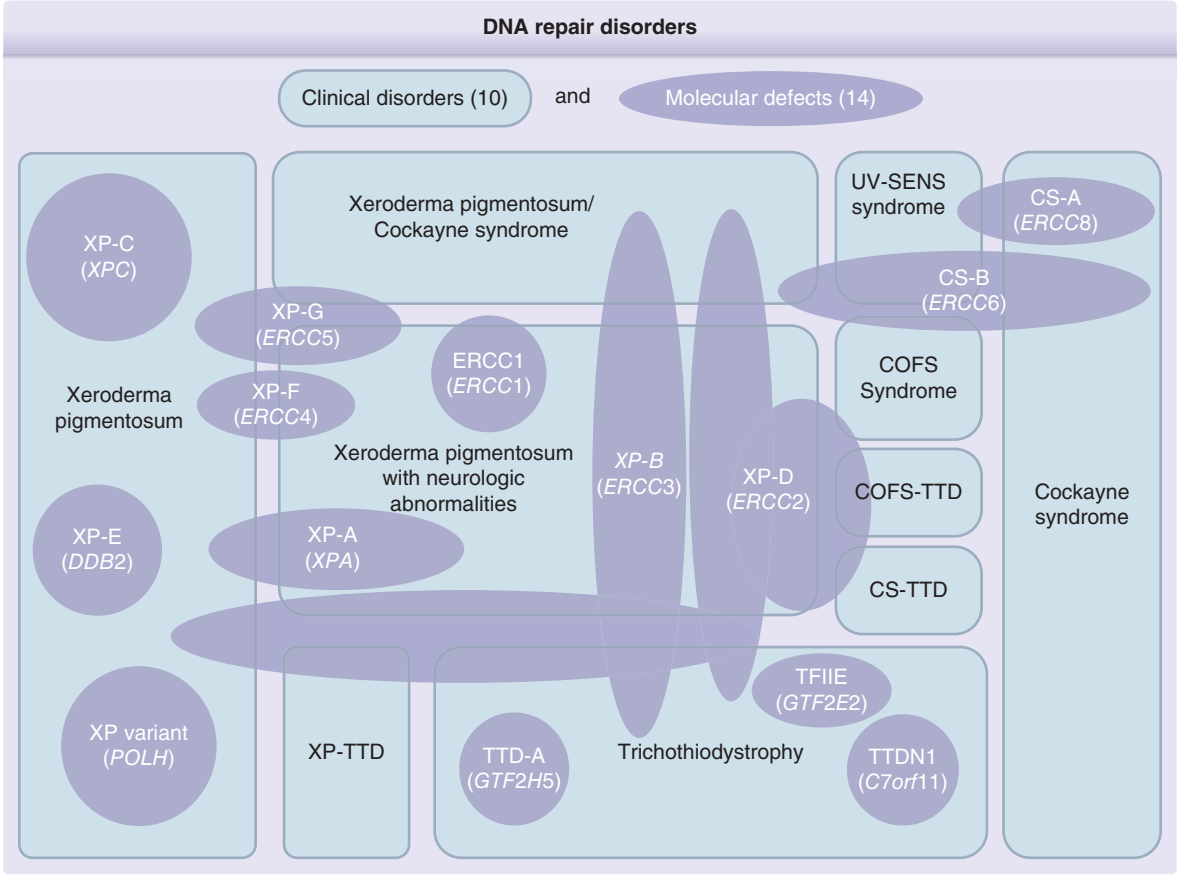

Figure 130-1 The relationship of clinical disorders (*light-blue rectangles*) to molecular defects (*dark-blue ovals*) in DNA repair disorders. A total of 10 clinical disorders and 14 molecular defects are represented. One disorder may be caused by mutations in several different genes. Conversely, different mutations in 1 gene may result in several different clinical diseases. Mutations in *RNF113A* (not shown) have been reported in 1 TTD family with X-linked inheritance. COFS syndrome, cerebro-oculo-facial-skeletal syndrome; CS, Cockayne syndrome; DDB2, double-strand DNA–binding protein 2; SENS, sensitive; TTD, trichothiodystrophy; UV, ultraviolet; XP, xeroderma pigmentosum. (Modified from DiGiovanna JJ and Kraemer KH.[13])

DISORDERS OF DNA REPAIR

XERODERMA PIGMENTOSUM

AT-A-GLANCE

- Xeroderma pigmentosum (XP) is an autosomal recessive disease characterized by sun sensitivity, with approximately 50% of patients having acute burning on minimal sun exposure.
- Onset of freckling (lentigines) on sun-exposed skin before age 2 years in most patients.
- Greatly increased risk of sunlight-induced cutaneous neoplasms (basal cell carcinoma, squamous cell carcinoma, melanoma) at an early age.
- Sunlight-induced ocular involvement (photophobia, keratitis, atrophy of lids, cancer).
- Progressive neurologic degeneration (progressive hearing loss and cognitive impairment) in approximately 25% of the patients.
- Cellular hypersensitivity to ultraviolet radiation and to certain chemicals in association with abnormal DNA repair.
- The most common causes of death are skin cancer, neurologic degeneration, and internal cancer. The median age at death of persons with XP with neurodegeneration (29 years) is younger than that of persons with XP without neurodegeneration (37 years).

XP was first described in Vienna by Moriz Kaposi in the textbook of dermatology he published in 1870 with his father-in-law, Ferdinand Hebra. The disorder was first called xeroderma or parchment skin. Subsequently, the term *pigmentosum* was added for the greatly increased freckle-like pigmentation (Fig. 130-2A, B). See discussion in DiGiovanna and Kraemer[13] and Kraemer and colleagues.[14]

In 1968, hypersensitivity of cultured XP cells to UV damage was reported by Cleaver to be the result of defective DNA repair.[15] Most XP cells have a normal response to treatment with X-rays, indicating the specificity of the DNA repair defect. The defective genes for the 7 NER-defective forms of XP and the XP variant have been cloned and their functions are being investigated.[13]

In XP, many of the severe disease manifestations, such as cancer and corneal scarring leading to blindness, are the result of the interplay between genetic risk and environmental exposure. For example, XP patients who avoid UV radiation dramatically reduce or eliminate the probability of developing skin cancer and blindness.

EPIDEMIOLOGY

Patients have been reported worldwide in all races. XP occurs with a frequency of about 1 in 1 million persons in Europe and the United States.[16] The frequency is higher in certain populations. In Japan, prevalence is estimated at 1 in 22,000 persons.[17] It is relatively more common in areas such as the Middle East where marriage of close relatives is practiced. Founder mutations have been reported in Japan, India, Tunisia, North Africa, Israel, Spain, and Brazil. A review of 106 XP patients examined at the U.S. National Institutes of Health described observations between 1971 and 2009.[18] A report of 89 patients examined at the multidisciplinary XP service in the United Kingdom in a 5-year interval described heterogeneous clinical and laboratory features.[19]

CLINICAL FEATURES

Cutaneous Findings:

Skin: Approximately 50% of the patients with XP have a history of acute burning on minimal sun exposure.[18] The other 50% of patients tan normally without excessive burning of their skin (Fig. 130-3). In all patients, numerous freckle-like hyperpigmented macules (lentigines) appear predominately on sun-exposed skin. The median age of onset of the cutaneous symptoms in XP is between 1 and 2 years.[14] These generally spare sun-protected sites, such as the buttocks (see Fig. 130-2D). However, some severely sun-exposed patients may show pigmentary abnormalities in the axillae. Continued sun exposure causes the patient's skin to become dry and parchment-like with increased pigmentation, hence the name *xeroderma pigmentosum* ("dry pigmented skin"; see Fig. 130-2A). Premalignant actinic keratosis also develop at an early age. The appearance of sun-exposed skin in children with XP is similar to that occurring in farmers and sailors after many years of extreme sun exposure.

Cancer: Patients with XP who are younger than 20 years of age have a greater than 10,000-fold increased risk of cutaneous basal cell carcinoma, squamous cell carcinoma, or melanoma.[18] The median age of onset of nonmelanoma skin cancer reported in patients with XP is 8 years. Compared to the general population, XP patients have a greater than 50-year reduction in age of onset of first nonmelanoma skin cancer (and greater than 30-year reduction in first melanoma), which indicates the importance of DNA repair in protection from skin cancer in unaffected individuals (Fig. 130-4).

Noncutaneous Findings:

Eyes: Ocular abnormalities are almost as common as the cutaneous abnormalities and are an important feature of XP (see Fig. 130-2C).[20] The posterior portion of the eye (retina) is shielded from UV radiation by the anterior portion (lids, cornea, and conjunctiva). Clinical findings are strikingly limited to these anterior, UV-exposed structures. Photophobia is often present and may be associated with prominent conjunctival injection. Schirmer testing frequently reveals reduced tearing leading to dry

Figure 130-2 Xeroderma pigmentosum. **A,** Pigmentary changes, atrophy, dryness, and cheilitis in a 16-year-old patient. **B,** Cheek of a 14-year-old patient with pigmented macules of varying size and intensity, actinic keratosis, basal cell carcinoma, and a surgical scar. **C,** Corneal clouding, prominent conjunctival blood vasculature, and loss of lashes. **D,** Myriad pigmented macules of varying sizes and intensities and scattered hypopigmented areas on the back, with marked sparing of the sun-protected buttocks of a 14-year-old patient.

Figure 130-3 Xeroderma pigmentosum (XP): different sunburning clinical phenotypes. **A,** Complementation group XP-D patient at 9 months of age with severe blistering erythema of the malar area following minimal sun exposure. Note sparing of her forehead and eyes that were protected by a hat. **B,** Patient XP358BE (XP-C) at age 2 years did not sunburn easily but developed multiple hyperpigmented macules on her face. A rapidly growing squamous cell carcinoma or keratoacanthoma grew on her upper lip and a precancerous lesion appeared on her forehead.

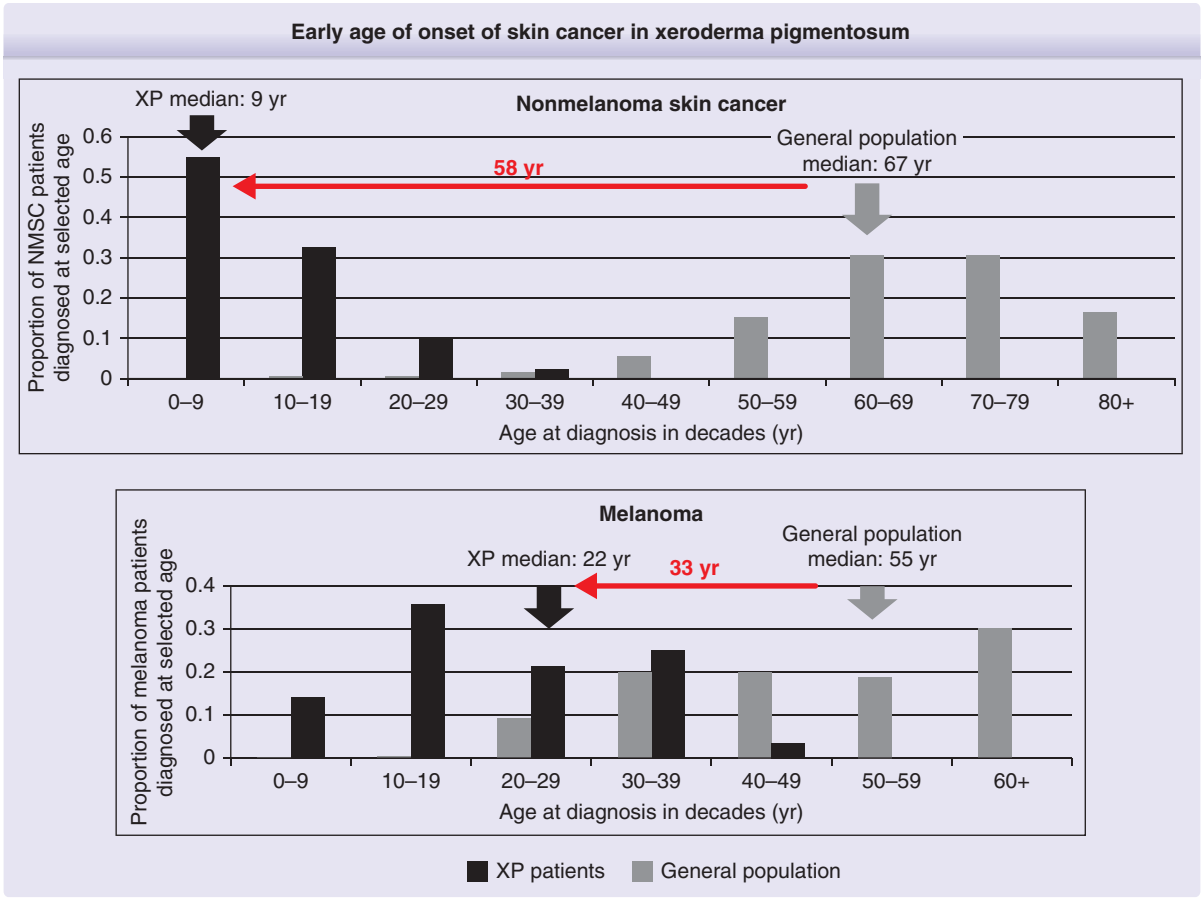

Figure 130-4 Xeroderma pigmentosum (XP) skin cancer by age at first skin cancer diagnosis and skin cancer type compared to U.S. general population. *Upper panel:* Proportion of nonmelanoma skin cancer (NMSC) patients diagnosed at selected ages. *Lower panel:* Proportion of melanoma patients diagnosed at selected ages. Compared to the U.S. general population, XP patients had a 58-year reduction in age of first NMSC, and a 33-year reduction in age of first melanoma. Individuals with both NMSC and melanoma were used for both analyses. (Adapted by permission from BMJ Publishing Group Ltd: Bradford PT, Goldstein AM, Tamura D, et al. Cancer and neurologic degeneration in xeroderma pigmentosum: long term follow-up characterises the role of DNA repair. *J Med Genet* 2011;48:168-76.[18])

eyes. Continued UV exposure of the eye may result in severe keratitis, leading to corneal opacification and vascularization. The lids develop increased pigmentation and loss of lashes. Atrophy of the skin of the lids results in ectropion, entropion, or, in severe cases, complete loss of the lids. Benign conjunctival inflammatory masses or papillomas of the lids may be present. Epithelioma, squamous cell carcinoma, and melanoma of UV-exposed portions of the eye are common. The ocular manifestations may be more severe in black patients.

Neurologic System: Neurologic abnormalities have been reported in approximately 25% of the patients.[18] The onset may be early in infancy or, in some patients, delayed until the second decade. The neurologic abnormalities may be mild (eg, isolated hyporeflexia) or severe, with progressive mental retardation, sensorineural deafness (beginning with high-frequency hearing loss), spasticity, or seizures. The most severe form, known as the *De Sanctis-Cacchione syndrome*, involves the cutaneous and ocular manifestations of classic XP plus additional neurologic and somatic abnormalities, including microcephaly, progressive mental deterioration, low intelligence, hyporeflexia or areflexia, choreoathetosis, ataxia, spasticity, Achilles tendon shortening leading to quadriparesis, dwarfism, and immature sexual development. The complete De Sanctis-Cacchione syndrome has been recognized in very few patients; however, many patients with XP have 1 or more of its neurologic features. In clinical practice, deep-tendon reflex testing and routine audiometry usually can serve as a screen for the presence of XP-associated neurologic abnormalities.[21] In cases where there is clinical evidence of early neurologic abnormalities, a brain MRI or CT scan may show enlarged ventricles.[22]

The predominant neuropathologic abnormality found at autopsy in patients with neurologic symptoms was loss (or absence) of neurons, particularly in the cerebrum and cerebellum.[23] There is evidence for a primary axonal degeneration in these patients. In a long-term followup study of 106 XP patients, those with neurodegeneration had a younger age at death (29 years) than those without neurodegeneration (37 years).[18]

Internal Cancers: Review of the world's literature on XP reveals a substantial number of cases of oral cavity neoplasms, particularly squamous cell carcinoma of the tip of the tongue, a presumed sun-exposed location.[14] Brain (sarcoma and medulloblastoma), CNS (astrocytoma of the spinal cord), lung, uterine, breast, pancreatic, gastric, renal, and testicular tumors, and leukemia have been reported in a few patients with XP. Overall, these reports suggest an approximate 10- to 20-fold increase in internal neoplasms in XP.[24,25]

ETIOLOGY AND PATHOGENESIS

Patients with XP are hypersensitive to UV radiation, as are their cultured cells. Cutaneous and ocular abnormalities are strikingly limited to UV-exposed areas and usually spare such UV-shielded locations as the axillae, buttocks, and retina. The fact that black patients with XP have an increased frequency of skin cancer suggests that a normally functioning DNA repair system provides greater protection against skin cancer than does the natural pigmentation of black skin.

Complementation Groups: Genetic heterogeneity among the XP DNA repair defects was found by fusing cultured fibroblasts from different patients and defining complementation groups. Seven such DNA excision repair-deficient complementation groups have been identified (named XP-A to XP-G) and the mutated genes have been identified (*DDB2, ERCC1, ERCC2*, *ERCC3*, *ERCC4*, *ERCC5*, *XPA*, and *XPC*; see Table 130-3).[13] Additional patients with clinical XP but normal NER are called *XP variants*. Studies of cellular hypersensitivity reveal a slightly increased sensitivity to UV-induced inhibition of cell growth that was potentiated by caffeine. Cells from XP-variant patients have a defect in an error-prone DNA polymerase *(POLH)*(pol η) that bypasses unrepaired DNA damage.[8]

There is a complex relationship among the DNA repair genes and clinical disease[13] (see Table 130-3 and Fig. 130-1; also see https://www.ncbi.nlm.nih.gov/books/NBK1397/ for review of XP). One clinical phenotype can be associated with defects in each of several genes. Conversely, mutations in one gene can be associated with several different clinical phenotypes.[18,19] These complex relationships and the roles of DNA repair genes in regulation of transcription and in immune functions are under intense investigation.

Complementation Group A: XP complementation group A (XP-A; see Table 130-3) contains patients with the most-severe neurologic and somatic abnormalities (the De Sanctis-Cacchione syndrome), as well as patients with minimal or no neurologic abnormalities. Long-term followup of these patients has revealed a relationship between the genotype and the phenotype.[18,19] Patients with the most-severe disease appear to have truncating mutations in both alleles of the *XPA* gene, leading to no detectible normal protein. In contrast, patients with minimal neurologic abnormalities have splice-site mutations that permit a small amount of normal messenger RNA (mRNA) to be made. Patients with *XPA* mutations have been reported in the United States, Europe, and the Middle East. It is the most common form of XP in Japan. Approximately 90% of Japanese XP-A patients have the same founder mutation, which is a single base substitution (see https://www.ncbi.nlm.nih.gov/books/NBK1397/). This finding has served as the basis for development of a rapid diagnostic assay for Japanese XP-A patients (including prenatal diagnosis) using polymerase chain reaction analysis of a small sample of DNA. Heterozygous carriers of this disease-causing mutation who have 1 mutated allele and 1 normal allele are estimated to comprise approximately 1% of the Japanese population.[17]

Complementation Group B: XP complementation group B (XP-B; Fig. 130-5) is composed of 5 patients in 4 kindreds who had the cutaneous abnormalities characteristic of XP (including neoplasms) in conjunction with neurologic and ocular abnormalities typical of CS. Another family had 2 adult sisters with XP but without CS who had ocular melanomas and were parents of normal children.[26] Surprisingly, a patient with TTD also was found to have a defect in the *XPB (ERCC3)* gene.

Complementation Group C: Patients in XP complementation group C (XP-C), with rare exceptions, have XP with skin and ocular involvement but without neurologic abnormalities.[13] This is the most common group in the United States, Europe, and Egypt, but is found rarely in Japan. Most patients have truncating mutations in both alleles leading to undetectable levels of *XPC* mRNA (the result of nonsense-mediated message decay).[19] However, a splice lariat branchpoint mutation resulting in as little as 3% to 5% of normal mRNA resulted in milder clinical symptoms in 1 family in Turkey.[27] XP-C patients typically do not give a history of severe blistering sunburns on minimal sun exposure and at times are first diagnosed with the appearance of skin cancer in a child.[28]

Complementation Group D: Patients in XP complementation group D (XP-D) have been described with several different clinical phenotypes. They may have cutaneous XP with late onset of neurologic abnormalities in their second decade of life or XP with no neurologic abnormalities.[18,19] Two XP-D patients have been reported with clinical symptoms of both XP and CS. Cells from patients with a photosensitive form of TTD (without XP) also were assigned to the XP-D.[29] Two patients were reported with combined symptoms of both TTD and XP (1 patient had a skin cancer and the other died of metastatic melanoma) and mutations in the *XPD (ERCC2)* gene. Finally, a patient with COFS syndrome had a mutation in the *XPD* gene.

Complementation Group E: XP complementation group E (XP-E) was found in 1 kindred in Europe and

Figure 130-5 Xeroderma pigmentosum (XP)–Cockayne syndrome (CS) complex. **A,** A 28-year-old patient (XP11BE) in XP complementation group B with cutaneous changes of XP, including pigmentary changes and atrophy. She has a beak-like nose and loss of subcutaneous tissue, which are typical of Cockayne syndrome. **B,** The patient is of short stature (less than 4 ft. tall). Her mother, an obligate heterozygote, is clinically normal.

in several kindreds in Japan. We studied adult patients from 3 kindreds from the United States and Germany who had mutations in the *XPE (DDB2)* gene. These patients had no neurologic involvement.[30]

Complementation Group F: XP complementation group F (XP-F) patients are found mainly in Japan. Most of these patients have mild clinical symptoms without neurologic abnormalities or skin cancer.[18,19] However, we recently found 2 families with adult onset of severe neurodegeneration with mutations in the *XPF (ERCC4)* gene. The residual rate of DNA repair is very low (only 10% to 20% of normal).

Complementation Group G: Thirteen patients in XP complementation group G (XP-G) have been identified in the United States, Europe, and Japan (Fig. 130-6).[18,19] There is a large variation in clinical features among these patients. Several patients with mutations in the *XPG (ERCC5)* gene had clinical features of both XP and severe CS with cachexia and death in the first decade (see Fig. 130-5). Other patients with different mutations (missense mutations) in the same gene had no neurologic abnormalities, probably because of the low level of residual activity present in cells from these patients.[31]

Xeroderma Pigmentosum Variant: XP-variant cells have normal DNA NER and thus do not fall into any of the complementation groups of cells with defective DNA excision repair. However, there is a defect in an error-prone, translesional DNA damage bypass polymerase, *POLH* (pol η). Most XP-variant patients have clinical XP with no neurologic abnormalities.[18,19] The cutaneous and ocular abnormalities have been severe in some patients and mild in others.[32]

Parents: Both parents of XP patients are asymptomatic carriers of mutations in one of these genes. They are obligate heterozygotes with 1 mutated allele and 1 normal allele. There is a 1 in 4 chance that their offspring will have inherited a mutated allele from each parent and thus have symptomatic XP.

DIAGNOSIS (LABORATORY TESTING)

Cellular Hypersensitivity: Cultured cells from patients with XP generally grow normally when not exposed to damaging agents. However, the population growth rate or single-cell colony-forming ability is reduced to a greater extent than normal cells after exposure to UV radiation. A range of post-UV exposure colony-forming abilities has been found with fibroblasts from patients, some having extremely low post-UV exposure colony-forming ability and others having nearly normal survival.[13]

XP fibroblasts are deficient in their ability to repair some UV-damaged viruses or plasmids to a functionally active state. These host cell reactivation assays have detected an abnormality in every form of XP tested.

UV-irradiated XP fibroblasts are hypermutable compared to normal fibroblasts. This post-UV irradiation hypermutability is believed to be the basis of the increased frequency of sunlight-induced somatic mutations that lead to cancer in XP patients.[33]

Chromosome Abnormalities: XP cells generally are found to have a normal karyotype without

Figure 130-6 Severe and mild xeroderma pigmentosum complementation group G (XP-G) patients. **A** and **B,** XP82DC. **C** to **F,** XP65BE. **A,** Patient XP82DC at 3 years of age has deep-set eyes, which is characteristic of Cockayne syndrome (CS), and irregular lentiginous pigmentation on her face, which is characteristic of XP, indicating XP–CS complex. **B,** Patient XP82DC at 3 years of age has characteristic XP-pigmented lesions on her forearms and dorsa of hands along with thin, translucent skin with readily visible veins. The small size of her hands is apparent in comparison with the hands of her mother. **C,** Patient XP65BE at age 6 months experienced severe sunburn on her face with minimal sun exposure. Erythema and swelling are seen on skin of forehead, cheeks, and periorbital area. **D,** Patient XP65BE at age 9 months shows erythema and peeling of skin of malar area of face after sun exposure. **E,** Patient XP65BE at age 4.5 years shows pigmentary changes on her nose, malar area, and other portions of her face. **F,** Patient XP65BE at 4.5 years shows blistering sunburn on her upper thigh. Note spared area above knee where sunscreen was applied. **G,** Patient XP65BE shows minimal pigmentary changes on face and sparing of neck and hand. She used measures to protect her skin from sun exposure. (From Emmert S, Slor H, Busch DB, et al. Relationship of neurologic degeneration to genotype in three xeroderma pigmentosum group G patients. *J Invest Dermatol* 2002;118:972, with permission. Copyright © Society for Investigative Dermatology.)

excessive chromosome breakage or increased sister chromatid exchanges (as seen in BS). However, after exposure to UV radiation, abnormally large increases in chromosome breakage and in sister chromatid exchanges have been observed. The extent of this induced abnormality varies in different patients.

DNA Repair Testing: Incorporation of nucleotides into DNA following UV exposure of living, cultured cells (unscheduled DNA synthesis) is reduced in XP cells of complementation groups A to G. Unscheduled DNA synthesis is normal in cells from XP-variant patients.[13]

Drug and Chemical Hypersensitivity: A number of DNA-damaging agents other than UV radiation have been found to yield hypersensitive responses with XP cells. These agents include drugs (psoralens, chlorpromazine), cancer chemotherapeutic agents (cisplatin, carmustine), and chemical carcinogens (benzo[*a*]pyrene derivatives). Presumably, these agents induce DNA damage whose repair involves portions of the DNA repair pathways that are defective in XP.

DNA Sequence Analysis: Sequence analysis of DNA obtained from blood, cheek cells, or cultured

cells is now available in CLIA (Clinical Laboratory Improvement Amendments)-certified laboratories. (See https://www.cms.gov/Regulations-and-Guidance/Legislation/CLIA/Laboratory_Registry.html for an updated listing of laboratories.)

Prenatal Diagnosis: In kindreds with an affected XP patient, prenatal diagnosis has been reported by measuring UV-induced unscheduled DNA synthesis in cultured amniotic fluid cells and by use of DNA diagnosis of trophoblast cells obtained early in pregnancy. DNA-based prenatal diagnoses also may be possible. (See https://www.cms.gov/Regulations-and-Guidance/Legislation/CLIA/Laboratory_Registry.html for an updated listing of laboratories.)

DIFFERENTIAL DIAGNOSIS

Other diseases with deficient NER and neurologic degeneration, such as CS (see below), may be considered. CS patients have abnormal myelin in the brain, retinal degeneration, and a low frequency of skin cancer. Other diseases with cutaneous photosensitivity, such as porphyria, RTS, and the allelic disorder Baller-Gerold syndrome, should be ruled out.

Hartnup disorder is a disorder of amino acid absorption resulting from biallelic pathogenic variants in *SLC6A19*, a nonpolar amino acid transporter. Affected individuals may have reduced levels of niacin with resulting pellagra-like symptoms of photosensitivity with dermatitis, diarrhea, and dementia. However, individuals with Hartnup disorder are not reported to have increased frequency of skin cancer.

The cutaneous findings of Carney complex may be confused with those of XP; however, Carney complex is characterized by lentigines without evidence of the usually associated signs of skin damage, such as atrophy and telangiectasia (ie, poikiloderma), and cutaneous findings are not limited to sun-exposed sites.[34]

CLINICAL COURSE AND PROGNOSIS

The most common causes of death are skin cancer, neurologic degeneration, and internal cancer. The median age at death of persons with XP with neurodegeneration (29 years) is younger than that of persons with XP without neurodegeneration (37 years).[18]

In a few families, patients who received an early diagnosis and used rigorous sun protection had fewer skin cancers and a longer life than did their affected siblings who did not use rigorous sun protection.[35]

MANAGEMENT

Management of patients with XP is based on early diagnosis, lifelong protection from UV radiation exposure, and early detection and treatment of neoplasms.[36] Diagnosis rests on recognition of the characteristic clinical features of XP and is confirmed by laboratory tests of cellular hypersensitivity to UV and defective DNA repair. Molecular determination of some of the XP disease-causing mutations is offered in a laboratory that is certified for clinical testing (see https://www.cms.gov/Regulations-and-Guidance/Legislation/CLIA/Laboratory_Registry.htmlgenetests.org for the most recent listing of CLIA-certified laboratories).

Interventions:

Sun Protection: Patients should be educated to protect all body surfaces from UV radiation by wearing protective clothing, UV-absorbing glasses, and long hair styles. They should adopt a lifestyle to minimize UV exposure and use sunscreens with high sun protective factor (SPF) ratings (minimum SPF 30) daily. Because the cells of individuals with XP are hypersensitive to UVA (found in sunlight), UVB (found in sunlight), and UVC (found in some artificial light sources), it is useful to measure UV light in an individual's home, school, or work environment with a light meter. The meter permits detection of high levels of environmental UV (such as halogen lamps) that can be eliminated. Although no standards exist for perfectly safe UV exposure in individuals with XP, the use of UV meters can alert individuals to unexpected sources of high levels of environmental UV.[36]

Patients should be examined frequently by a family member who has been instructed in recognition of cutaneous neoplasms. A set of color photographs of the entire skin surface with close-ups of lesions (including a ruler) is often extremely useful to both the patient and the physician in detecting new or changing lesions. A physician should examine patients at frequent intervals (approximately every 3 to 6 months depending on severity of skin disease). Premalignant lesions such as actinic keratoses may be treated by freezing with liquid nitrogen, or with topical 5-fluorouracil or imiquimod. Photodynamic therapy, using, for example, the topical photosensitizer 5-aminolevulinic acid followed by exposure to blue light, is an effective treatment modality for normal patients with multiple actinic keratoses. There are no data on the safety or efficacy of this treatment in XP patients. *Caution is recommended because an abnormal response to photodynamic therapy or other light-based or laser-based therapy cannot be excluded in XP cells.* Larger areas have been treated with therapeutic dermatome shaving or dermabrasion to remove the more damaged superficial epidermal layers. This procedure permits repopulation by cells from the follicles and glands, which are deeper and relatively UV-shielded.

Because cells from patients with XP are also hypersensitive to environmental mutagens such as benzo[*a*] pyrene found in cigarette smoke, prudence dictates that patients should be protected against these agents. One of our patients who smoked cigarettes for more than 10 years died of bronchogenic carcinoma of the lungs at age 37 years,[18] and another patient who smoked developed a lung cancer at age 48 years.

Thus, we recommend that XP patients refrain from smoking cigarettes and that parents should protect children with XP from being exposed to secondhand smoke.

Cancer: Cutaneous neoplasms are treated in the same manner as in patients who do not have XP. However, special consideration should be given to the extent of actinic damage in the area surrounding the tumor and to the need for tissue conservation because of the very high risk of future tumors requiring surgical intervention. Typical procedures include electrodesiccation and curettage, surgical excision, or Mohs micrographic surgery. Although actinically damaged skin in non-XP patients is characterized by laxity and wrinkling, XP skin is atrophic and taut, complicating skin closure. Because multiple surgical procedures are often necessary, removal of undamaged skin should be minimized. Extremely severe cases have been treated by excision of large portions of the facial surface and grafting with uninvolved skin.

Most patients with XP are not abnormally sensitive to therapeutic X-rays, and XP patients have responded normally to full doses of therapeutic X-radiation for treatment of inoperable neoplasms such as an astrocytoma of the spinal cord, a frontal lobe astrocytoma, or recurrent squamous cell carcinoma in the orbit.[23]

Medications: In a controlled study, oral isotretinoin was effective in preventing new neoplasms in patients with multiple skin cancers.[37] Because of its toxicity (hepatic, hyperlipidemic, teratogenic, calcification of ligaments and tendons, premature closure of the epiphyses), oral isotretinoin should be reserved for patients with XP who are actively developing large numbers of new skin cancers. We found that the effective dose varies among patients and some patients may respond to doses of oral isotretinoin as low as 0.5 mg/kg/day.

One research study has reported that a bacterial DNA repair enzyme, denV T4 endonuclease, in a topical liposome-containing preparation, reduces the frequency of new actinic keratoses and basal cell carcinomas in XP patients.[38] As of 2018, this treatment has not been approved by the U.S. Food and Drug Administration (FDA).

A study treating multiple melanoma in situ lesions with intralesional interferon-α in 1 XP patient showed localized clearing only of lesions injected with the intralesional interferon-α but not with the control diluent.[39]

There are several case reports of XP patients responding to topical treatment with the immune modulator imiquimod. However, none of these reported long-term followup.

Oral vismodegib (Erivedge), an inhibitor of the hedgehog pathway, has been approved by the FDA for treatment of metastatic basal cell carcinoma or locally advanced basal cell carcinoma that has recurred following surgery. This drug also has been approved for use in individuals with basal cell carcinoma who are not candidates for surgery or for radiation therapy (see FDA package insert). Although this treatment may be appropriate for some individuals with XP, no studies on the efficacy of this drug in those with XP have been published. Oral vismodegib is also a teratogen, leading to embryo-fetal death, midline defects, missing digits, and other birth defects in an exposed embryo or fetus; effective contraception during and after vismodegib treatment is advised for both women and men. There is concern that vismodegib treatment of skin cancers having mixed basal cell carcinoma and squamous cell carcinoma histology might result in shrinking of the basal cell carcinoma component while permitting the squamous cell carcinoma component to proliferate.

Vitamin D is produced in the skin by a reaction involving exposure to UV radiation. Active adults with XP and skin cancers received sufficient vitamin D in their diet in the past to result in normal serum concentrations of the active form (1,25-dihydroxy vitamin D).[40] However, children protected from sunlight very early in life have had low serum concentration of 25-hydroxy vitamin D; one child became susceptible to bone fractures.[41] Dietary supplementation with oral vitamin D is recommended for persons with low serum concentration of serum vitamin D.[42]

Eyes: The eyes should be protected by wearing UV-absorbing glasses with side shields. Methylcellulose eye drops can be used to keep the cornea moist. Corneal transplantation has restored vision in patients with corneal opacity from severe keratitis. However, some of these suffered graft rejection as a result of neovascularization. Neoplasms of the lids, conjunctiva, and cornea are usually treated surgically. We are examining the possibility of using a swab to obtain cytologic specimens from the surface of the eye to determine if early neoplasms can be detected or excluded without the need for performing biopsies.[20]

Hearing Loss: Hearing aids can be of great help for individuals who have sensorineural hearing loss with learning difficulties in school.[21]

Heterozygotes: XP heterozygotes (parents and some other relatives) are carriers of the gene for XP but are clinically normal. There is limited epidemiologic evidence to indicate that such persons have an increased risk of developing skin cancer. Most tests of cell function or DNA repair yield normal responses with cells from XP heterozygotes.[43]

Patient Support Groups: The XP Family Support Group provides ongoing educational and community support to families and patients living with XP (XP Family Support Group, 10259 Atlantis Drive, Elk Grove, CA 95624; Phone: (916) 628-3814; Email: contact@xpfamilysupport.org). The XP Society has a summer camp with activities designed for light-sensitive individuals (https://www.xps.org; 437 Snydertown Road, Craryville, NY 12521-5224; Phone: 518-851-3466; Email: xps@xps.org).

COCKAYNE SYNDROME (INCLUDING XERODERMA PIGMENTOSUM–COCKAYNE SYNDROME OVERLAP)

AT-A-GLANCE

- Cockayne syndrome (CS) is an autosomal recessive disease with acute burning of the skin on minimal sun exposure.
- CS patients have developmental delay, microcephaly, progressive hearing loss, cataracts, and pigmentary retinal degeneration.
- A moderate type (CS Type I) has been distinguished from the an early-onset severe form (CS Type II) and a milder, late-onset form (CS Type III).
- Cells from CS patients have a defect in transcription coupled DNA repair with approximately two-thirds having mutations in the *CSB (ERCC6)* gene and one-third with mutations in the *CSA (ERCC8)* gene.

In 1936, E. A. Cockayne described a syndrome characterized by cachectic dwarfism, deafness, and pigmentary retinal degeneration with a characteristic "salt-and-pepper" appearance of the retina.[44]

EPIDEMIOLOGY

CS is a very rare, autosomal recessive degenerative disease with cutaneous, ocular, neurologic, and somatic abnormalities (see Table 130-1).[45] A review published in 1992 described 140 cases reported in the literature.[46] A nationwide survey of CS patients in Japan, published in 2015, reported 47 patients.[47] In 2015, the Cockayne Syndrome Natural History (CoSyNH) study described clinical findings in 102 patients from Europe, North Africa/Middle East, West Asia, and East Asia.[48] The incidence of CS has been estimated as 1.8 per million persons in native West European population and 2.7 per million live births overall.[16]

CLINICAL FEATURES

Cutaneous Findings: The skin has photosensitivity without the excessive pigmentary abnormalities seen in XP. There is marked loss of subcutaneous fat, resulting in a "wizened" appearance with typical deep-set eyes and prominent ears. A systematic dermatologic examination of 14 European CS patients and 2 COFS syndrome patients (ages 1 to 28 years) reported photosensitivity in 75% with sunburn after brief sun exposure.[49] Six patients had pigmented macules on sun-exposed skin but none developed skin neoplasms. Cyanotic acral edema of the extremities was present in 12 patients, 8 had nail dystrophy, and 7 had hair abnormalities.

Noncutaneous Findings: CS is a progressive disorder and most symptoms appear and worsen with time. The eyes are small (microphthalmia) and develop a characteristic sunken appearance over time because of loss of orbital fat. The ocular abnormalities include a progressive pigmentary retinal degeneration and optic atrophy leading to eventual blindness. Other manifestations include photophobia, early cataract, and diminished tearing leading to conjunctivitis, corneal infection, and scarring. The pupils are typically small with iris atrophy and poorly reactive to light. CS patients frequently have abnormal electroretinograms.[45,50]

Birth weight and early development are usually normal. Neurologic abnormalities, in addition to deafness, include peripheral neuropathy, normal pressure hydrocephalus, microcephaly, and segmental loss of myelin "tigroid leukodystrophy."[45]

The disease onset is usually in the second year of life with slowly progressive neurologic degeneration (CS Type I). Intellectual deterioration may be nonuniform, with some functions preserved better than others. A severe infantile form has been described (CS Type II) as well as a milder form with late onset (CS Type III). COFS syndrome with microcephaly and severe mental retardation and CAMFAK syndrome of congenital *ca*taracts, *m*icrocephaly, *fa*ilure to thrive, and *k*yphoscoliosis have some similar features. A continuous spectrum of severity in CS has been proposed.[51] The most severe form is COFS syndrome, then CS Type II, CS Type I, and CS Type III. The mildest form is UVSS with photosensitivity without the systemic features of CS.

CS is not associated with an increased incidence of neoplasia.

ETIOLOGY AND PATHOGENESIS

CS is an autosomal recessive disorder caused by mutations in *CSB (ERCC6)* in approximately two-thirds of the patients, and in *CSA (ERCC8)* in approximately one-third.[51] Patients with mutations in these genes have similar clinical features. A survey in 2013 listed 78 different mutations in the *CSB* gene and 30 in the *CSA* gene from 120 genetically confirmed patients.[51] A patient with COFS syndrome was reported with a defect in *CSB* and another with a defect in *XPD*. These genes are part of the NER pathway and have a primary role in transcription coupled DNA repair.[13]

Parents: Both parents of CS patients are asymptomatic carriers of mutations in one of these genes. They are obligate heterozygotes with one mutated allele and one normal allele. There is a 1 in 4 chance that their offspring will have inherited a mutated allele from each parent and thus have symptomatic CS.

DIAGNOSIS

Diagnostic criteria for CS have been proposed[51] with mandatory major criteria of developmental delay,

progressive growth failure, and progressive microcephaly. Minor criteria (3 out of 5) are cutaneous photosensitivity, pigmentary retinopathy and/or cataracts, progressive sensorineural hearing loss, tooth enamel hypoplasia, and enophthalmia (abnormally sunken eyes). In addition, brain imaging criteria include white matter hypomyelination, cerebellar atrophy or hypoplasia, and bilateral calcifications of the putamen.

COFS syndrome is an autosomal recessive disorder with microcephaly, cataracts, microphthalmia and arthrogryposis (congenital joint contractures usually associated with curtailed joint movement before birth).[51]

Laboratory Testing: Clinical laboratory testing often shows sensorineural deafness, neuropathic electromyogram, and slow motor nerve conduction velocity.[52] The electroencephalogram may be abnormal, and X-ray examination may show thickened skull and microcephaly. CT may be diagnostically useful in the detection of normal-pressure hydrocephalus and showing calcification of the basal ganglia and other structures (Fig. 130-7). MRI of the brain shows atrophy and dysmyelination of the cerebrum and cerebellum.[53] Bone age is usually normal. Height and weight are usually well below the third percentile for the age.[48]

Cellular Hypersensitivity: As with XP, cultured cells (fibroblasts or lymphocytes) from patients with CS are hypersensitive to UV-induced inhibition of growth and colony-forming ability. Host cell reactivation of UV-damaged adenovirus or plasmids is reduced, although generally to a lesser extent than in XP. Molecular determination of the CS-causing mutations is offered in a laboratory that is CLIA-certified for clinical testing (see https://www.cms.gov/Regulations-and-Guidance/Legislation/CLIA/Laboratory_Registry.htmlgenetests.org for a current list of laboratories that provide this service).

Prenatal Diagnosis: Prenatal diagnosis of CS has been performed based on the delay in recovery of post-UV radiation RNA synthesis and the increased cell killing by UV radiation. Molecular identification of the mutations is more commonly used currently for families with an affected child where the causative mutations are known (see https://www.cms.gov/Regulations-and-Guidance/Legislation/CLIA/Laboratory_Registry.htmlgenetests.org for a current list of laboratories that provide this service).

Clinical-Laboratory Correlation: Patients with defects in *CSA* or *CSB* have similar clinical features.[48,51]

DIFFERENTIAL DIAGNOSIS

As CS patients have involvement of multiple organ systems with varying degrees of severity, some of the features may be present in other disorders (see discussion in Laugel[54]). Thus growth failure may be a common feature of many chromosomal, endocrine, or GI disorders. Calcifications in the brain are also seen in congenital infections such as rubella or toxoplasmosis,

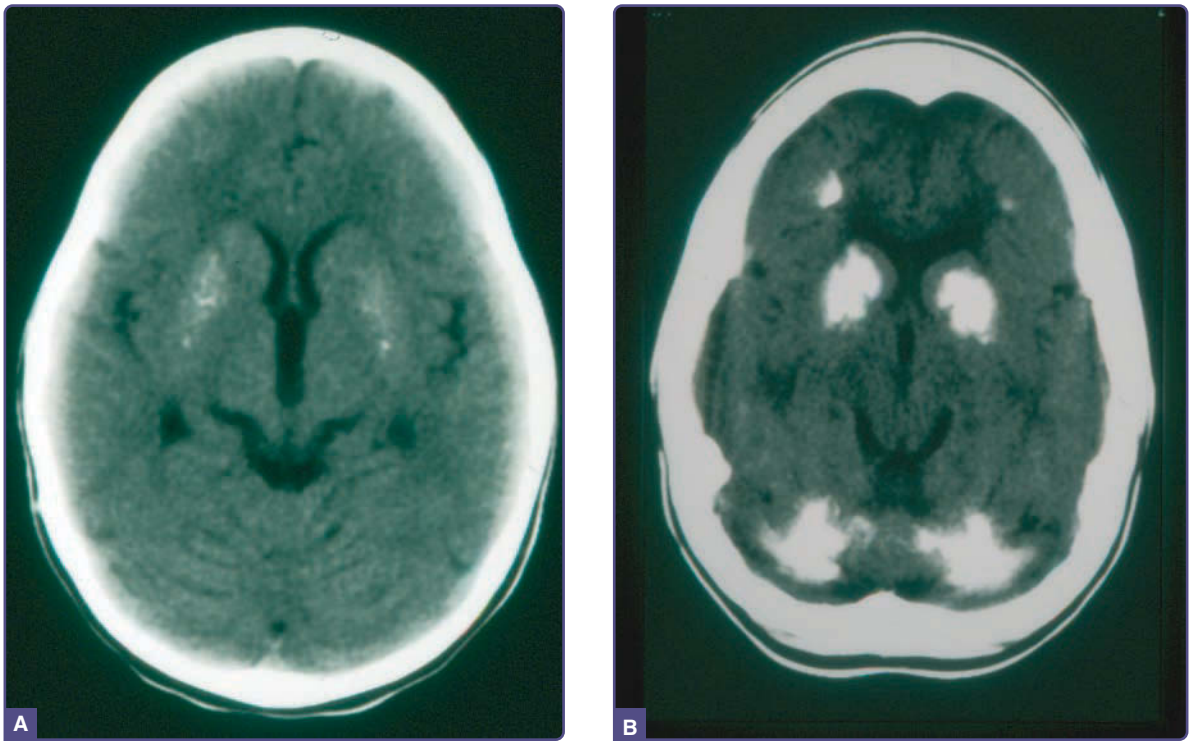

Figure 130-7 Cockayne syndrome. Calcification of brain visualized on CT scan. **A,** A 2-year-old patient with bilateral calcification of basal ganglia. **B,** A 15-year-old patient with extensive calcification involving basal ganglia, cerebellum, and cerebral hemispheres.

or in calcium or phosphate metabolism abnormalities. Cutaneous photosensitivity is also present in premature aging syndromes including XP (accompanied by early onset of freckle-like pigmentation and skin cancer), BS, progeria, WS, and RTS. Retinal pigmentary abnormalities and growth failure may be present in mitochondrial dystrophies. Other disorders with profound growth failure have characteristic physical appearance include Cornelia de Lange syndrome, Dubowitz syndrome, Hallermann-Streiff syndrome, Russell-Silver syndrome, and Seckel syndrome. Warburg MICRO syndrome has features of microcephaly, microcornea, congenital cataract, mental retardation, optic atrophy, and hypogenitalism,[55] but does not have rapidly progressive neurodegeneration or defective DNA repair.

CLINICAL COURSE AND PROGNOSIS

In the CoSyNH study of 102 patients from 81 families,[48] the mean age of the recruited individuals was 11.5 years (range: 3 months to 19 years). At the time of analysis, 28 individuals had died with a median age at death of 8.4 years (range: 17 months to 30 years). The presence of cataracts before 3 years of age was the single most important prognostic factor with a statistically significant association with reduced survival, earlier onset of hearing loss, and earlier onset of contractures.

MANAGEMENT

Recommendations for care of CS patients have been developed by the authors of the CoSyNH study of clinical findings in 102 patients.[48] These include molecular testing *(CSA [ERCC8], CSB [ERCC6]* followed by *XPG [ERCC5], XPD [ERCC2]* or *XPB [ERCC3]* if these are normal and features of XP–CS complex are present [see below]); multidisciplinary care (coordinating clinician, dietician, physiotherapist); annual surveillance (cataracts, retinal evaluation, hearing assessment, blood pressure monitoring); and laboratory testing (liver function tests, blood glucose). Supplementary feeding may be required, including use of a nasogastric tube or percutaneous gastrostomy. Hypertension, gastroesophageal reflux disease, and tremor may be treated with specific medications. Low temperature may reflect thyroid insufficiency and recurrent pneumonias may be related to swallowing difficulty.

Metronidazole for GI abnormalities was associated with acute liver failure in 8 CS patients (3 fatal within 11 days of treatment).[56] These authors state that metronidazole is contraindicated for CS patients.

Patient Support Group: The Share and Care Cockayne Syndrome Network (http://cockaynesyndrome.net or http://www.cockayne-syndrome.org) is an educational, advocacy, and support organization for CS patients and their families (Box 570618, Dallas, TX 75357).

XERODERMA PIGMENTOSUM–COCKAYNE SYNDROME COMPLEX

Approximately 12 patients with CS have been found to have, in addition to CS, clinical features of XP.[18,19,48] These features include freckle-like pigmentation on sun-exposed skin and cutaneous neoplasms (see Fig. 130-5). Cells from these XP–CS complex patients have reduced DNA excision repair, which is characteristic of XP. Clinically, these patients can be distinguished from XP patients with neurologic abnormalities by the presence of the CS features of pigmentary retinal degeneration, calcification of the basal ganglia, normal-pressure hydrocephalus, and hyperreflexia.[45,57,58] Cells from patients with this complex have been found to have mutations in 3 different XP genes: *XPG*, *XPD*, and *XPB* (see Table 130-3).

TRICHOTHIODYSTROPHY

AT-A-GLANCE

- Trichothiodystrophy is a rare genetic disorder characterized by sulfur-deficient brittle hair and a broad spectrum of clinical abnormalities.
- A diagnostic feature is tiger tail banding under polarizing microscopy with structural abnormalities of hair shafts.
- Typical clinical features include maternal pregnancy abnormalities, abnormal birth and development (collodion presentation, microcephaly, short stature, developmental delay), photosensitivity, and developmental abnormalities, such as the skin (hair and nails), brain, eyes, musculoskeletal system, and immune system (infections).

DEFINITIONS

TTD is a rare genetic disorder that is characterized by sulfur-deficient brittle hair and includes a broad spectrum of clinical abnormalities that may include photosensitivity, ichthyosis, intellectual impairment, short stature, microcephaly, characteristic facial features (protruding ears, micrognathia), recurrent infections, bilateral congenital cataracts, dystrophic nails, and other features (see Table 130-1; Fig. 130-8).[59-68] Although usually inherited as autosomal recessive, in one family an X-linked inheritance was described.[69] TTD encompasses patients who have been described as *Tay syndrome*, *Amish brittle hair syndrome*, *Sabinas brittle hair syndrome*, or *Pollitt syndrome*.

TTD is caused by different mutations in some of the same genes that cause XP. The functional defect in XP is abnormal DNA repair, whereas the abnormality in TTD is thought to be related to the transcription.

Figure 130-8 Trichothiodystrophy (TTD): clinical and microscopic hair findings. **A,** A 7-year-old boy with short, brittle scalp and eyebrow hair, and a smiling, outgoing demeanor. He had hip surgery at age 14 years, followed by a downward course and died approximately 7 months later of pneumonia. **B,** A 9-year-old girl with short stature, developmental delay, multiple infections, died 2 months after this picture of sepsis. **C, D,** and **E,** A 14-year-old boy with short brittle hair, dysmorphic facies, micrognathia, head elongation in the fronto-occipital plane (**E**). He also has ichthyosis (**C**), intellectual impairment, short stature, photosensitivity, osteosclerosis, neurologic abnormalities, recurrent infections, and nail abnormalities. **D,** Note the onychoschizias (distal nail plate split/layering at *arrows*). Light microscopy findings: **F,** TTD hair shafts displaying alternating light and dark "tiger tail" bands using polarizing microscopy. **G,** Irregular, undulating hair shaft with light microscopy **H,** Trichoschisis (*arrow*): clean, transverse cleavage fracture; marked narrowing of shaft diameter (*asterisk*). **I,** Ribboning. (Modified with permission from Liang C, Kraemer KH, Morris A, et al.[63])

HISTORICAL PERSPECTIVE

In 1968, Pollitt reported a brother and sister with mental and physical growth retardation, trichorrhexis nodosa and other hair shaft defects, and identified that their hair had low cystine content, indicating deficiency of high sulfur hair proteins.[70] In 1971, Tay described 3 children of a Chinese family with an autosomal recessive disorder characterized by growth retardation, short stature, developmental delay, ichthyosis, and hair shaft defects.[59] In 1970, Brown described alternating hair shaft patterning in hair, and later, Baden and colleagues studied the hair from an Amish kindred, identifying reduced level of cystine and observed alternating light and dark bands in their hairs when viewed under polarizing microscopy.[71] Price proposed the term *trichothiodystrophy* (derived from Greek *tricho*: hair; *thio*: sulfur; *dys*: faulty; *trophe*: nourishment)

recognizing the hair shaft sulfur deficiency as a marker for this symptom complex.[60]

EPIDEMIOLOGY

The disease is rare. A review attempting to capture all TTD cases reported up to the year 2005 only identified 112 cases worldwide. However, TTD is probably much more common and underdiagnosed because of failure to recognize the condition.

CLINICAL FEATURES

In addition to the diagnostic hair shaft features, TTD patients have a broad spectrum of multisystem abnormalities. Table 130-4 lists the clinical features seen in TTD as summarized from an extensive literature review.[66] Table 130-5 summarizes the findings in 1 patient.[72]

Cutaneous Findings: The newborn with TTD often has generalized redness or a mild collodion appearance, which typically clears over a few weeks. This may progress to ichthyosis, which is often mild and involves the trunk and scalp. Most TTD patients have short, broken hair (see Fig. 130-8A, B, and E), and some do not need to get haircuts. After an illness with fever, many have an episode of hair loss or "falling out." Under light microscopy with polarization, TTD hair shafts have a characteristic dark-and-light banding pattern that gives a "tiger tail" appearance (see Fig. 130-8F). Their hair shafts have multiple abnormalities, including undulating hair shaft surface (see Fig. 130-8G), trichoschisis (a clean transverse break through the hair; see Fig. 130-8H), trichorrhexis nodosa-like defects, and ribboning (see Fig. 130-8I).[63,64] Hair shafts are brittle because of a reduction of high-sulfur matrix proteins, and amino acid analysis of the hair demonstrates reduced levels of cysteine and cystine in hair shaft proteins. This is associated with a decrease in the ratio of strong to weak disulfide bonds within the hair shafts.[65] Approximately 50% of TTD patients have clinical photosensitivity that ranges from subtle to severe. However, in contrast to the typical clinical features of XP, patients with TTD do not develop poikilodermatous changes (hyperpigmentation, hypopigmentation, telangiectasias, and atrophy) nor skin cancer. Nails are brittle and may have onychoschizia, koilonychia (spooning) or other dystrophy. Rarely, patients may have an overlap syndrome with diluted features of both TTD and XP. They may have longer hair with some hair shaft features of TTD visible in only a portion of the hair shafts, and the pigmentary and skin cancers suggestive of XP.

Noncutaneous Findings: TTD children typically have a happy, friendly, and interactive personality but with a broad spectrum of abnormalities of growth and development. Extent of involvement varies from only hair and mild developmental impairment to severe multisystem abnormalities with a high mortality in childhood. Typical abnormalities (see Tables 130-4 and 130-5) include dysmorphic (eg, short stature, micrognathia, microcephaly), neurologic (developmental delay, intellectual impairment), ophthalmologic (congenital cataracts, nystagmus),[68] recurrent infections, musculoskeletal and bone (osteosclerosis of the axial skeleton with peripheral osteopenia, delayed bone age, contractures), and dental. Decreased red blood cell mean corpuscular volume and increased hemoglobin A_2 levels mimic β-thalassemia trait. Developmental delay may be associated with brain dysmyelination,[73]

TABLE 130-4

Most Frequent Clinical Manifestations of 112 Reported Patients with Trichothiodystrophy[a,66]

ABNORMALITY	# OF 112 PATIENTS	%
Short, brittle hair with shaft abnormalities	108	96
Developmental delay/intellectual impairment	96	86
Short stature	82	73
Facial dysmorphism (eg, microcephaly)	74	66
Ichthyosis	73	65
Ocular abnormality (eg, cataracts)	57	51
Infections	51	46
Photosensitivity	47	42

[a]Numbers may be artificially low because the presence of normal versus abnormal features are not always reported in case reports. Details of reported abnormal, reported normal, and unreported can be found in the "clinical array" in Faghri S, Tamura D, Kraemer KH, et al.[66]

TABLE 130-5

Clinical Features of a Patient with Trichothiodystrophy (TTD421BE), Showing the Broad Array of Abnormalities

- *Hair abnormalities:* tiger tail banding; brittle hair; sparse hair; other hair shaft abnormalities
- *Nail abnormalities:* brittle nails; koilonychias; soft nails
- *Skin abnormalities:* ichthyosis; photosensitivity; hypohidrosis
- *Oral abnormalities:* high-arched palate; abnormal teeth; frequent caries
- *Growth abnormalities:* short stature and poor weight gain (third percentile) and microcephaly (10th percentile)
- *Neonatal skin abnormalities:* collodion membrane; erythroderma
- *Neurologic abnormalities:* developmental delay; intellectual impairment; abnormal gait/ataxia; abnormal MRI results (diffuse dysmyelination)
- *Personality characteristics:* sociable/engaging/cheerful
- *Hematologic/immunologic abnormalities:* recurrent infections (particularly respiratory); neutropenia; elevated hemoglobin A_2; low serum immunoglobulin M
- *Maternal pregnancy and fetal abnormalities:* pregnancy-induced hypertension; spotting during pregnancy; abnormal prenatal screening (elevated maternal α-fetoprotein); premature birth; intrauterine growth restriction; birth weight low for gestational age; placental abnormalities

From Zhou X, Khan SG, Tamura D, et al.[72]

a feature similar to CS; however, patients do not have the retinal changes or brain calcifications of CS.

ETIOLOGY AND PATHOGENESIS

The majority of TTD patients have a defect in *XPD* (*ERCC2*). A few have mutations in *XPB* (*ERCC3*) or *TTDA* (*GTF2H5*) genes, which are components of TFIIH, a transcription factor that regulates both DNA repair and transcription. Mutations in the gene *GTF2E2,* which encodes the general transcription factor IIE (TF2E2), have recently been shown to cause TTD, supporting the theory that TTD is caused by impaired transcription.[74] Some TTD patients have mutations in the gene *TTDN1,*[75] and recently an X-linked form of TTD was associated with a mutation in the gene *RNF113A,*[69] but the molecular functions of these 2 genes are not yet known. It is believed that mutations that affect the repair function of the NER genes are associated with features of XP, whereas mutations affecting the transcription-related function results in features of TTD.[76] Most DNA repair disorders are inherited as autosomal recessive, requiring failure of the proteins encoded by each of 2 alleles, and different mutations in *XPD* can lead to a wide spectrum of clinical phenotypes. Some mutations in the *XPD* gene impair the repair function of the protein leading to clinical XP, while other mutations impair the transcription function leading to clinical TTD. Patients carrying mutations that impair both functions can have clinical overlap syndromes with features of both diseases.

DIAGNOSIS

The diagnosis of TTD is made on the basis of clinical features in association with characteristic hair shaft abnormalities. These include tiger tail banding under polarizing microscopy with hair shaft abnormalities and/or analysis of hair shafts for reduced sulfur content.[63] Identification of mutations known to cause TTD can confirm the diagnosis. However, because underlying genetic mutations have not been identified in all patients, failure to identify mutations does not diminish the clinical diagnosis.

A typical patient presentation in the newborn period is an infant with a preterm delivery, small for gestational age, short stature, micrognathia, congenital cataracts, and cryptorchidism, who may have erythroderma or a collodion membrane. These newborns are often in neonatal intensive care units and are at high risk for infection. Mothers frequently have a history of pregnancy difficulties, which can include hypertension, preeclampsia, or the more severe HELLP (hemolysis, elevated liver enzymes, low platelets) syndrome.[77,78]

A typical childhood presentation is a happy, outgoing child with short, brittle hair, developmental delay, short stature, microcephaly, micrognathia, abnormal myelination of the brain, recurrent infections, and feeding difficulties. Table 130-5 lists the clinical findings in 1 TTD patient, as an example of the diverse findings.[72]

Laboratory Testing: The diagnosis of TTD can be confirmed with examination of hair shafts (see Fig. 130-8F to I). TTD hair shafts display tiger tail banding under polarizing microscopy. In addition, they show a spectrum of typical hair shaft abnormalities, including trichoschisis, trichorrhexis nodosa–like fractures, surface irregularities, and ribboning.[63,64] Amino acid analysis of hair shafts can confirm reduced levels of cysteine and cystine.

Testing for mutations in the genes known to cause TTD (*XPD* [*ERCC2*]; *XPB* [*ERCC3*] or *TTDA* [*TFB5*]; *GTF2E2; TTDN; RNF113A*) can be performed. Patients with mutations in the *TTDN1* gene have a distinct TTD phenotype, are more likely to display autistic behaviors (compared to the usual socially interactive personality), and have delayed bone age and seizures; additionally, they are less likely to have low birth weight, collodion presentation, cataracts, and brain abnormal myelination.[79]

Imaging:

Brain Imaging: TTD patients fail to develop myelin in the brain and MRI can identify this dysmyelination. Rare patients can have overlap syndromes with features not only of TTD, but also of XP or CS. These patients may have features of brain atrophy (eg, dilated ventricles, loss of brain tissue volume). TTD–CS patients may have the deep-set eyes and pigmentary retinopathy of CS.

Bone Imaging: TTD patients have an unusual combination of osteosclerosis of the axial skeleton and osteopenia of the peripheral skeleton can be seen on radiographs or dual-energy x-ray absorptiometry (DEXA) scan.

Diagnostic Algorithm: Once the diagnosis is suspected because a patient has the characteristic newborn or childhood presentation described before (see "Diagnosis"), a lock of hair shafts can be cut for microscopic examination. The identification of hair shaft defects under regular light microscopy and tiger tail banding under polarizing lenses can confirm the diagnosis. Further confirmation can be obtained with amino acid analysis of hair shafts to identify low sulfur content. Mutation testing may identify a mutation in one of the associated genes, but mutations have not been identified in all patients, suggesting that there are other causative genes not yet identified.

CLINICAL COURSE AND PROGNOSIS

TTD children are prone to feeding difficulties, failure to thrive, and recurrent infections. In many children, relatively mild infections can quickly progress to systemic illness. A review of the literature identified a high mortality (>20%) in children younger than the age of 10 years, with most deaths caused by infection.[66]

MANAGEMENT

Management focuses on identification and support for individual clinical problems. Photosensitive

patients should use sun-protective measures such as sunscreen, cover with clothing, and use sun-avoidance measures. Patients with developmental delay and intellectual impairment may benefit from neurologic and developmental assessment and support. Ophthalmologic consultation can identify developmental abnormalities such as congenital cataracts. Cataracts and refraction errors that impair vision can be treated.[68] In some patients, recurrent infections have been managed with prophylactic antibiotics or intravenous immunoglobulin. Patients generally have abnormal growth and difficulty maintaining weight. The reason for this is not known and may be a result of mitochondrial dysfunction. In some cases, gastrostomy tubes (G-tubes) may help maintain adequate nutrition.[80] Several of our TTD patients in their first or second decade of life have experienced progressive inability to walk from bilateral aseptic necrosis of their hips. Rehabilitation medicine and support can address musculoskeletal abnormalities and can help to maintain walking ability. In addition, a high frequency of complications occurs during pregnancies carrying an affected fetus. These can include intrauterine growth restriction, preeclampsia, preterm delivery, HELLP syndrome, and abnormal levels of maternal serum screening markers, highlighting the role of DNA repair in normal development.[78,81]

Patient Support Group: The Foundation for Ichthyosis and Related Skin Types (FIRST, http://www.firstskinfoundation.org/, 2616 N. Broad Street, Colmar, PA 18915) is an educational, advocacy and support organization for those affected by ichthyosis and related skin types.

DISORDERS OF GENOME INSTABILITY

BLOOM SYNDROME

AT-A-GLANCE

- Bloom Syndrome (BS) is a rare chromosome instability syndrome with a predisposition to a variety of cancers and multiple infections.
- BS is caused by a mutation in *BLM*, a RecQ helicase.
- Cells demonstrate impaired DNA recombination.
- Patients present with facial erythema and telangiectasia, an usual facies, and growth deficiency.
- No specific treatment is available.

BS is a rare, autosomal recessive disorder characterized by growth deficiency, unusual facies, sun-sensitive telangiectatic erythema, immunodeficiency, and predisposition to a variety of different cancers.[7,82]

EPIDEMIOLOGY

BS is most frequent among Ashkenazi Jews, who have a carrier frequency of 1%.[83] Approximately 250 patients have been recognized worldwide.

CLINICAL FEATURES

Cutaneous Findings: Facial erythema and telangiectasia superficially resembling lupus erythematosus (Fig. 130-9) are often present within the first few weeks after birth in the malar area, on the nose, and around the ears.[82] Sun exposure accentuates these abnormalities and may induce bullae, bleeding, and crusting of the lips and eyelids. Café-au-lait spots are common, at times accompanied by adjacent depigmented areas.

Noncutaneous Findings: Patients are well proportioned but small. Adult height is usually less than 150 cm (5 feet). Patients have a long, narrow head with characteristic facies consisting of a narrow, prominent nose, relatively hypoplastic malar areas, and a receding chin.

Complications: Patients with BS are predisposed to multiple infections, as there is immune dysfunction. Fertility is decreased and diabetes mellitus is common. Approximately 20% of patients with BS develop malignancies, comprising a normal spectrum of cancer types, of which half occur before age 20 years.[82]

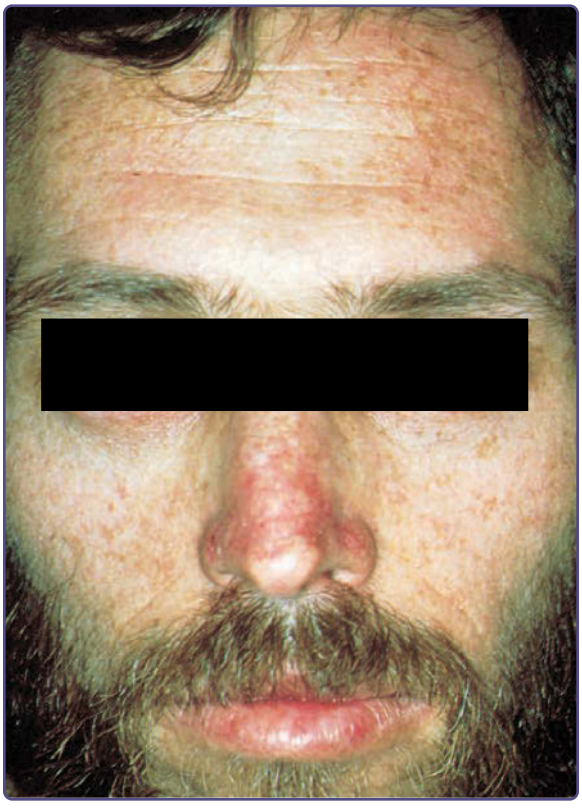

Figure 130-9 Bloom syndrome. Prominent telangiectasia in malar distribution.

ETIOLOGY AND PATHOGENESIS

BS is caused by mutations in *BLM*, which encodes a RecQ helicase.[7,9,83-85] BS cells are characterized by an increase in the frequency of spontaneous sister chromatid exchanges and in exchanges between homologous chromosomes. The latter is often visualized by quadriradial chromosomes. These are 4-arm chromosomes most likely formed by recombination between 2 chromosomes (and almost never found in unaffected individuals). These observations demonstrate that BS cells are characterized by hyperrecombination. Although the exact mechanisms of how mutations in the BLM helicase lead to hyperrecombination are still not completely understood, it has been suggested that it interacts with the Fanconi anemia D2 protein (FANCD2; see below).[86] It also has been shown to participate in telomere replication and with that maintain telomere integrity.[87-89] Hyperrecombination may result in an increased frequency of loss of heterozygosity and through that mechanism, in conjunction with increased spontaneous mutation frequency, an increased frequency of malignant transformation. The immune deficiency, characterized by diminished immunoglobulin levels, reduced cellular proliferative response to mitogens, and decreased proliferation in the mixed leukocyte reaction, may be a result of impaired recombination of immunoglobulin and lymphocyte receptor genes, and probably further contributes to the increased cancer risk.

DIAGNOSIS

The observation of quadriradial chromosomes (observed in 0.5% to 14% of lymphocytes of BS patients) and the approximately 10-fold increased frequency of spontaneous sister chromatid exchanges are used to diagnose BS.[90] A founder deletion/insertion mutation in the *BLM* gene was identified in Ashkenazi Jews at a frequency of approximately 1% (BLM^{Ash})[83,91] and can be used for DNA diagnosis of BS patients and carriers among Ashkenazi Jews.[92] Diagnostic testing for BS, including sequencing of *BLM* is offered in a number of laboratories that are CLIA-certified for clinical testing (see https://www.cms.gov/Regulations-and-Guidance/Legislation/CLIA/Laboratory_Registry.htmlgenetests.org for the most recent listing).

DIFFERENTIAL DIAGNOSIS

Table 130-1 outlines the clinical features of hereditary disorders of genome instability and DNA repair needed for the differential diagnosis. The differential diagnosis of BS includes other disorders, in that photosensitivity is seen in xeroderma pigmentosum and Rothmund-Thompson Syndrome, café-au-lait macules occur in neurofibromatosis, and early-onset telangiectasias are present in ataxia telangiectasia.

CLINICAL COURSE AND PROGNOSIS

Patients usually die before the age of 30 years from either cancer or infection.

MANAGEMENT

There is no specific treatment for BS. Early monitoring for the development of cancers is recommended.

WERNER SYNDROME (ADULT PROGERIA)

AT-A-GLANCE

- Werner syndrome (WS) is a rare disorder of premature aging (progeria) with an increased cancer risk.
- WS is caused by a mutation in WRN, a RecQ helicase.
- Cells demonstrate impaired DNA metabolism and a reduced replicative life span.
- Patients present with premature graying of hair, loss of subcutaneous fat, wrinkling of the skin, and cataracts starting in adolescence.
- Premature aging also affects other organs.
- No specific treatment is available.

WS is a rare, autosomal recessive disorder, characterized by several features of premature aging and an increased cancer risk.[93]

EPIDEMIOLOGY

More than 800 patients have been reported worldwide.[94] Most WS patients are Japanese.

CLINICAL FEATURES

Cutaneous Findings: Patients with WS are clinically normal until adolescence, when they do not show the usual growth spurt and start to prematurely develop features and diseases of aging, including graying and thinning of hair, loss of subcutaneous fat, and wrinkling of skin. Other features that are not part of the normal skin-aging process are scleroderma-like changes with subcutaneous atrophy, leg ulcers, and soft-tissue calcifications.

Noncutaneous Findings: Signs of premature aging also affect other organs and include Type 2 diabetes, osteoporosis, and cardiovascular disease secondary to atherosclerosis.[95] Often, ophthalmologists are the first to make the diagnosis of WS as cataracts develop early.[96] A feature that is not related to aging is a bird-like facies.

Complications: Although an increased incidence and early onset of cancer is related to aging, the 10:1 ratio between epithelial and mesenchymal cancer

seen in a normally aging population is shifted to 1:1 in WS patients, with mostly thyroid epithelioid carcinomas, melanomas, meningiomas, soft-tissue sarcomas, hematologic neoplasias (mostly leukemias), and osteosarcomas.[97,98] As in the Japanese general population, most of the melanomas are of the acral-lentiginous type or arise from mucous membranes, and, consequently, are not considered to be related to UV exposure. Thyroid cancer occurs at a younger age in WS patients than in the Japanese general population.

ETIOLOGY AND PATHOGENESIS

WS is caused by a mutation in *WRN*, which encodes a RecQ helicase.[7,99,100] Most mutations of *WRN* result in truncation of the protein, sometimes by only a small amount, with loss of the nuclear targeting sequence. WRN is involved in many processes of DNA metabolism and *WRN* mutations cause various defects in DNA replication, recombination, base excision repair of oxidative DNA damage, repair of DNA strand breaks, DNA damage signaling, telomere maintenance, and transcription.[88] Cells from WS patients have a reduced replicative life span in culture[101] and show altered telomere structure and accelerated telomere attrition. Genome instability in WS cells is shown by an increased frequency of nonhomologous chromosome exchanges and of large chromosomal deletions.

Atypical Werner syndrome is a term used for patients in whom WS is suspected, but who do not carry *WRN* mutations. Several candidate genes have been identified.[93]

DIAGNOSIS

For the most recent listing of CLIA-certified laboratories offering diagnostic testing, including sequencing of the *WRN* gene, see https://www.cms.gov/Regulations-and-Guidance/Legislation/CLIA/Laboratory_Registry.htmlgenetests.org.

DIFFERENTIAL DIAGNOSIS

Table 130-1 outlines the clinical features of hereditary disorders of genome instability and DNA repair needed for the differential diagnosis. In addition, there are other hereditary conditions with premature aging, including, eg, Hutchinson-Gilford Progeria.

CLINICAL COURSE AND PROGNOSIS

Death from either myocardial infarction or cancer usually occurs before the age of 50 years.

MANAGEMENT

There is no specific treatment for WS. Early monitoring for the development of cancers, management of heart disease, and avoidance of risk factors for cardiovascular disease is recommended. Several pharmacologic interventions (mammalian target of rapamycin inhibitors, p38 mitogen-activated protein kinase inhibitors, and vitamin C) and stem cell-based treatments have been explored to alleviate the phenotypes of WS, but none of these have been studied in clinical applications.[93,102]

ROTHMUND-THOMSON SYNDROME

AT-A-GLANCE

- Rothmund-Thomson syndrome (RTS) is a rare chromosomal instability syndrome with an increased cancer risk and a typical poikiloderma that starts on the face during infancy.
- In two-thirds of patients, RTS is caused by a mutation in the DNA helicase RecQL4.
- Cells demonstrate impaired DNA metabolism and chromosomal instability.
- No specific treatment is available. Photoprotection is important.

RTS is a rare autosomal recessive disorder characterized by a hallmark poikiloderma, photosensitivity, short stature, bone abnormalities, and an increased risk for cancer.

EPIDEMIOLOGY

Approximately 400 patients worldwide have been described, but many may have been overlooked owing to the highly variable clinical presentations.

CLINICAL FEATURES

Cutaneous Findings: The hallmark of RTS is poikiloderma with variegated cutaneous pigmentation, atrophy, and telangiectasias beginning in infancy on the face, later spreading to the extremities and buttocks.[103-105,119] RTS patients are photosensitive and develop prominent erythema and facial swelling upon sun exposure early in life, which may be accompanied by blister formation. They also often have sparse scalp hair, eyebrows, and eyelashes, and abnormal nails.

Noncutaneous Findings: Other clinical features include juvenile cataracts, stunted growth, dental and skeletal abnormalities including radial bone defects and osteopenia.

Complications: RTS patients have a predisposition for cancer, in particular for osteosarcomas (32% of patients). Five percent of RTS patients also develop

squamous cell carcinomas of the skin and 2% develop basal cell carcinomas.

ETIOLOGY AND PATHOGENESIS

Mutations in the helicase RecQL4 have been identified in approximately 67% of patients with RTS.[104,106,107] The gene defects of the other 33% of RTS patients remain unknown. RTS patients without *RECQL4* mutations (RTS Type 1) may not have an increased risk for osteosarcoma.[108] Two other syndromes that share many of the features of RTS, except the poikiloderma, Rapadilino syndrome and Baller-Gerold syndrome, are also caused by *RECQL4* mutations, but are now considered part of the spectrum of RecQL4 diseases.[104]

Cells from RTS patients are characterized by chromosomal instability with trisomy, aneuploidy, and chromosomal rearrangements, suggesting a role of RecQL4 in maintaining chromosome stability.[109,119] The exact function of the RecQL4 helicase remains unclear,[100,104,110,111] but likely, similar to the RecQ helicases mutated in BS and WS, includes a variety of functions involving DNA metabolism, including DNA replication, homologous recombination, DNA damage repair, and maintenance of mitochondrial and telomeric DNA integrity.

DIAGNOSIS

See https://www.cms.gov/Regulations-and-Guidance/Legislation/CLIA/Laboratory_Registry.htmlgenetests.org for the most recent listing of CLIA-certified laboratories offering diagnostic testing, including sequencing of the *RECQL4* gene.

DIFFERENTIAL DIAGNOSIS

Table 130-1 outlines the clinical features of hereditary disorders of genome instability and DNA repair needed for the differential diagnosis. Myeloblastic syndrome in childhood can also be seen in Fanconi anemia and dyskeratosis congenita.

CLINICAL COURSE AND PROGNOSIS

Life expectance is limited by cancer, but is normal in RTS patients without cancer.[111]

MANAGEMENT

There is no specific treatment for RTS. Photoprotection and regular skin checks to screen for skin cancers are recommended. The telangiectatic component of the poikiloderma can be ameliorated by photocoagulation with a pulsed-dye laser. There are various yet inconsistent reports of cellular and clinical hypersensitivity to ionizing radiation and chemotherapeutic agents,[110] which must be considered when using radiation or chemotherapy for cancer treatment.

FANCONI ANEMIA

AT-A-GLANCE

- Fanconi anemia (FA) is a rare, genetically heterogeneous condition with an increased risk for aplastic anemia and cancer.
- Proteins encoded by the FA genes act in a common DNA damage-recognition-and-repair pathway that mediates DNA recombination.
- Cells are characterized by a hypersensitivity to DNA crosslinking agents.
- Cutaneous findings include diffuse hyperpigmentations and other pigment abnormalities.
- Growth retardation and abnormalities of the limbs, heart, kidney, and nervous system.
- No specific treatment is available. Allogeneic hematopoietic stem cell transplantation is the treatment of choice for aplastic anemia/myelodysplastic syndrome and leukemia.

FA is an autosomal recessive or in the case of Fanconi anemia complementation group B X-linked disease characterized by progressive pancytopenia, growth retardation, various congenital abnormalities of the heart, kidney, and limbs, and a predisposition to cancer.[112,113]

EPIDEMIOLOGY

More than 1200 patients have been reported to the International Fanconi Anemia Registry. The estimated incidence is 1 in 200,000 to 1 in 400,000 persons, but higher in Afrikaners (1 in 22,000) and Ashkenazi Jews (1 in 30,000).

CLINICAL FEATURES

Cutaneous Findings: Cutaneous abnormalities are present in almost 80% of patients (Figs. 130-10A to D).[112,113,116] Hyperpigmentation is present from birth or early childhood and is diffuse and accentuated over the neck, joints, and trunk. Café-au-lait spots and achromic lesions are also present.

Noncutaneous Findings: Hematopoietic manifestations usually have their onset before age 10 years and most commonly lead pediatricians to make the diagnosis of FA. These consist of a hypocellular bone marrow with progressive decrease in the number of circulating platelets, granulocytes, and erythrocytes. Skeletal malformations are common and often include aplasia or hypoplasia of the thumb, metacarpals, or radius.[112,113,115,116,117] Short stature, renal deformities, strabismus, microphthalmia, hypogonadism, and CNS abnormalities, including hyperreflexia and mild mental retardation, are also observed.

Figure 130-10 Skin and oral mucous membrane findings in Fanconi anemia (**A** to **D**) and dyskeratosis congenita (**E** to **H**). **A** to **D,** Fanconi anemia. **A,** Congenital absence of thumb. The second finger has been surgically altered to function as a thumb. Keratotic papules are present on the palm. **B,** Oral leukoplakia on right buccal mucosa (*arrow*). **C** and **D,** Dyspigmentation of Fanconi anemia. **C,** Hyperpigmentation of left axilla with discrete hyperpigmented and hypopigmented macules. **D,** Several irregular café-au-lait macules, smaller, fine, tanned, hyperpigmented macules, and dozens of guttate hypopigmented macules in the lower back. **E** to **H,** Dyskeratosis congenita. **E,** Oral leukoplakia involving the tongue. **F,** Severe atrophy of all fingernails and thickening of the palm. **G,** Longitudinal ridging and dystrophy of several fingernails with dyspigmentation and thickening of the palm. **H,** Poikiloderma showing reticular hypopigmentation and hyperpigmentation of the skin of the neck and chest. (Images **A-D,** Modified from Braun M, Giri N, Alter BP, et al. Thrombocytopenia, multiple mucosal squamous cell carcinomas, and dyspigmentation. *J Am Acad Dermatol* 2006;54:1056. Copyright © American Academy of Dermatology; Images **E-H,** Used with permission from Dr. Blanche Alter, NCI, Bethesda, MD.)

Complications: The frequency of acute myelogenous leukemia has been reported to be elevated 500-fold.[117,118,120,121] If patients survive aplastic anemia and/or leukemia (eg, as a result of bone marrow transplantation), they often develop solid tumors by the fifth decade of life, mostly squamous cell carcinomas of the head and neck and the anogenital area.

ETIOLOGY AND PATHOGENESIS

FA is genetically heterogeneous with 19 complementation groups (FANCA to FANCT). All 19 genes have been identified and all of the FA proteins have been shown to act in a common DNA damage recognition and repair pathway, which also involves *BRCA1* and *BRCA2* (These genes are mutated in hereditary breast cancer; *BRCA2* is identical to *FANCD1* and annotated as such) and multiple other proteins involved in cellular DNA damage responses.[122-135] Activation of this FA/BRCA pathway is thought to mediate DNA recombination to repair DNA strand breaks and DNA crosslinks, generated, for example, by ionizing radiation or DNA crosslinking agents, and to facilitate resolution of stalled replication forks.

DIAGNOSIS

Increased chromosome breakage after exposure to DNA crosslinking agents such as mitomycin C or diepoxybutane is a feature of FA. Central to the FA/BRCA pathway is the monoubiquitination of the FANCD2 protein. The inability of FA cells to ubiquitinate the

FANCD2 protein, as shown in Western blots after, for example, exposure to DNA crosslinking agents, is currently used as a screening tool to confirm the diagnosis of FA. Diagnostic testing, including DNA sequencing for FA is offered in a number of laboratories that are CLIA-certified for clinical testing (see https://www.cms.gov/Regulations-and-Guidance/Legislation/CLIA/Laboratory_Registry.htmlgenetests.org for the most recent listing).

DIFFERENTIAL DIAGNOSIS

Table 130-1 outlines the clinical features of hereditary disorders of genome instability and DNA repair needed for the differential diagnosis.

CLINICAL COURSE AND PROGNOSIS

Life span is limited mostly by the associated malignancies.

MANAGEMENT

There is no specific treatment for FA, and patients should be followed by a multispecialty team of pediatricians, oncologists, dentists, and medical geneticists. Allogeneic hematopoietic stem cell transplantation is the treatment of choice for aplastic anemia/myelodysplastic syndrome and leukemia. Specific protocols have been developed to take into account the cellular hypersensitivities to DNA damaging chemotherapeutic agents in FA. Patients, physicians, and researchers may obtain information from the Fanconi Anemia Research Fund, Inc. (http://www.fanconi.org) or from Fanconi Canada (http://www.fanconicanada.org).

DYSKERATOSIS CONGENITA

AT-A-GLANCE

- Dyskeratosis congenita is a rare telomere instability syndrome with an increased risk for pancytopenia, myelodysplasia, and acute myeloid leukemia.
- Dyskeratosis congenita is caused by a mutation in one of several telomere biology genes.
- Cells demonstrate shortened telomeres.
- Patients commonly present with a triad of reticulated hyperpigmentation, dystrophic nails, and mucosal leukoplakia.
- No specific treatment is available. Allogeneic hematopoietic stem cell transplantation is the treatment of choice for bone marrow failure and leukemia.

Dyskeratosis congenita, the Zinsser-Cole-Engman syndrome, is an X-linked multisystem disease with cutaneous, mucosal, ocular, GI, and hematologic abnormalities, and an increased incidence of cancer. There are also autosomal dominant and autosomal recessive forms. There is a broad phenotypic heterogeneity. Hoyeraal-Hreidarsson syndrome and Revesz syndrome are severe variants on the spectrum of telomere biology disorders. Less-severe variants with isolated manifestations, such as pulmonary fibrosis of myelodysplastic syndrome, also have been described.

EPIDEMIOLOGY

A registry at Hammersmith Hospital in London recruited 228 families having 354 affected patients from 40 countries.[136] More than 500 patients have been reported in the literature and the estimated incidence is 1 in 1 million persons.[137] Affected females may have either the autosomal dominant or autosomal recessive form.

CLINICAL FEATURES

Cutaneous Findings: The most common features are a triad of reticulated hyperpigmentation, dystrophic nails, and mucosal leukoplakia (see Fig. 130-10E to H).[138-141] During the first decade of life, patients develop reticulated poikiloderma in sun-exposed areas, with hyperpigmentation and, occasionally, bullae. Nail dystrophy is present in most patients beginning at approximately age 2 to 5 years. The nails initially split easily, then develop longitudinal ridging with irregular free edges. Eventually, the nails become smaller, resulting in only rudiments remaining. The fingernails are usually involved before the toenails. Other skin abnormalities include atrophic, wrinkled skin over the dorsum of hands and feet and hyperhidrosis and hyperkeratosis of palms and soles with disappearance of dermal ridges (absence of fingerprints).

Leukoplakia may be present in any mucosal site. The oral mucosa is the most frequent site, but leukoplakia is also found in the urethra, glans penis, vagina, and rectum. Lingual hyperkeratosis may be present.

Noncutaneous Findings: Approximately 50% of patients develop pancytopenia before the age of 10 years with a hematologic picture similar to FA. There is also a predisposition to both myelodysplasia and acute myeloid leukemia.[139,140]

Mucosal surfaces, such as the esophagus, urethra, and lacrimal duct, may become constricted and stenotic, resulting in dysphagia, dysuria, and epiphora. Multiple dental caries and early loss of teeth are common. Progressive pulmonary disease, including infections and fibrosis (and cirrhosis in some patients), was reported in 19% of affected males.[139] Approximately 20% of the patients had learning difficulties or mental retardation.[139] There are several reports of intracranial calcifications, especially of the basal ganglia,[142,143] similar to those seen in CS.

Complications: The majority (93%) of patients have been reported to develop bone marrow failure as the main cause (71%) of early death.[139,140] There is also an increased incidence of solid tumors, particularly squamous cell carcinoma of the mouth, rectum, cervix, vagina, esophagus, and skin. A large British kindred had Hodgkin disease and adenocarcinoma of the pancreas.[144]

ETIOLOGY AND PATHOGENESIS

Dyskeratosis congenita is caused by germline mutations in one of several telomere biology genes. *DKC1* is located on the q28 region of the X chromosome.[136,145-149] It encodes the protein dyskerin, which has a nucleolar function and a role in telomere maintenance and aging.[150-154] There is also evidence for an autosomal form with affected females[136,139,155,156] having mutations in the *TERC* gene, which is also involved in telomere function. Approximately 70% of the dyskeratosis congenita patients have a mutation in *DKC1*, *TERC*, or another gene involved in telomere biology (eg, *TERT*, *TINF2*, *NOLA2*, *NOLA3*, *NOP10*, *NHP2*, *WRAP53*, *CTC1*, *RTEL1*, *ACD*, and *PARN*). Many dyskeratosis congenita patients have very short telomeres and their telomere lengths decline with age. The shortest telomeres are associated with severe dyskeratosis congenita variants.[157]

DIAGNOSIS

Short telomere length is a typical finding in dyskeratosis congenita and used for diagnosis.[157] Testing for dyskeratosis congenita, including DNA sequencing, is offered in a number of laboratories that are CLIA-certified for clinical testing (see https://www.cms.gov/Regulations-and-Guidance/Legislation/CLIA/Laboratory_Registry.htmlgenetests.org for the most recent listing).

DIFFERENTIAL DIAGNOSIS

Table 130-1 outlines the clinical features of hereditary disorders of genome instability and DNA repair needed for the differential diagnosis.

CLINICAL COURSE AND PROGNOSIS

Life span is limited by bone marrow failure, myelodysplastic syndrome, and malignancies.

MANAGEMENT

There is no specific treatment of dyskeratosis congenita. Allogeneic hematopoietic stem cell transplantation is the treatment of choice for bone marrow failure and leukemia.[158] Lung transplantation may be considered for pulmonary fibrosis.

REFERENCES

1. Bielas JH, Loeb LA, Bielas JH, et al. Mutator phenotype in cancer: timing and perspectives. *Environ Mol Mutagen*. 2005;45:206-213.
2. Hoeijmakers JH. Genome maintenance mechanisms for preventing cancer. *Nature*. 2001;411:366-374.
3. Loeb LA. Cancer cells exhibit a mutator phenotype. *Adv Cancer Res*. 1998;72:25-56.
4. Mohrenweiser HW, Wilson DM 3rd, Jones IM,. Challenges and complexities in estimating both the functional impact and the disease risk associated with the extensive genetic variation in human DNA repair genes. *Mutat Res*. 2003;526:93-125.
5. Renwick A, Thompson D, Seal S, et al. ATM mutations that cause ataxia-telangiectasia are breast cancer susceptibility alleles. *Nat Genet*. 2006;38:873-875.
6. Su Y, Swift M. Mortality rates among carriers of ataxia-telangiectasia mutant alleles. *Ann Intern Med*. 2000;133:770-778.
7. Hickson ID. RecQ helicases: caretakers of the genome. *Nat Rev Cancer*. 2003;3:169-178.
8. Opresko PL, Cheng WH, Bohr VA. Junction of RecQ helicase biochemistry and human disease. *J Biol Chem*. 2004;279:18099-18102.
9. Harrigan JA, Bohr VA. Human diseases deficient in RecQ helicases. *Biochimie*. 2003;85:1185-1193.
10. Aubert G, Lansdorp PM. Telomeres and aging. *Physiol Rev*. 2008;88:557-579.
11. Savage SA, Alter BP. Dyskeratosis congenita. *Hematol Oncol Clin North Am*. 2009;23:215-231.
12. Wang Y, Cortez D, Yazdi P, et al. BASC, a super complex of BRCA1-associated proteins involved in the recognition and repair of aberrant DNA structures. *Genes Dev*. 2000;14:927-939.
13. DiGiovanna JJ, Kraemer KH. Shining a light on xeroderma pigmentosum. *J Invest Dermatol*. 2012;132:785-796.
14. Kraemer KH, Lee MM, Scotto J. Xeroderma pigmentosum. Cutaneous, ocular, and neurologic abnormalities in 830 published cases. *Arch Dermatol*. 1987;123:241-250.
15. Cleaver JE. Defective repair replication of DNA in xeroderma pigmentosum. *Nature*. 1968;218:652-656.
16. Kleijer WJ, Laugel V, Berneburg M, et al. Incidence of DNA repair deficiency disorders in Western Europe: Xeroderma pigmentosum, Cockayne syndrome and trichothiodystrophy. *DNA Repair (Amst)*. 2008;7:744-750.
17. Hirai Y, Kodama Y, Moriwaki S, et al. Heterozygous individuals bearing a founder mutation in the XPA DNA repair gene comprise nearly 1% of the Japanese population. *Mutat Res*. 2006;601:171-178.
18. Bradford PT, Goldstein AM, Tamura D, et al. Cancer and neurologic degeneration in xeroderma pigmentosum: long term follow-up characterises the role of DNA repair. *J Med Genet*. 2011;48:168-176.
19. Fassihi H, Sethi M, Fawcett H, et al. Deep phenotyping of 89 xeroderma pigmentosum patients reveals unexpected heterogeneity dependent on the precise molecular defect. *Proc Natl Acad Sci U S A*. 2016;113:E1236-E1245.
20. Brooks BP, Thompson AH, Bishop RJ, et al. Ocular manifestations of xeroderma pigmentosum: long-term follow-up highlights the role of DNA repair in protection from sun damage. *Ophthalmology*. 2013;120:1324-1336.

21. Totonchy MB, Tamura D, Pantell MS, et al. Auditory analysis of xeroderma pigmentosum 1971-2012: hearing function, sun sensitivity and DNA repair predict neurological degeneration. *Brain*. 2013; 136:194-208.
22. Kraemer KH, Patronas NJ, Schiffmann R, et al. Xeroderma pigmentosum, trichothiodystrophy and Cockayne syndrome: a complex genotype-phenotype relationship. *Neuroscience*. 2007;145:1388-1396.
23. Lai JP, Liu YC, Alimchandani M, et al. The influence of DNA repair on neurological degeneration, cachexia, skin cancer and internal neoplasms: autopsy report of four xeroderma pigmentosum patients (XP-A, XP-C and XP-D). *Acta Neuropathol Commun*. 2013;1:4.
24. Kraemer KH, Lee MM, Scotto J. DNA repair protects against cutaneous and internal neoplasia: evidence from xeroderma pigmentosum. *Carcinogenesis*. 1984;5:511-514.
25. Kraemer KH, Lee MM, Andrews AD, et al. The role of sunlight and DNA repair in melanoma and nonmelanoma skin cancer. The xeroderma pigmentosum paradigm. *Arch Dermatol*. 1994;130:1018-1021.
26. Oh KS, Khan SG, Jaspers NG, et al. Phenotypic heterogeneity in the XPB DNA helicase gene (ERCC3): xeroderma pigmentosum without and with Cockayne syndrome. *Hum Mutat*. 2006;27:1092-1103.
27. Khan SG, Metin A, Gozukara E, et al. Two essential splice lariat branchpoint sequences in one intron in a xeroderma pigmentosum DNA repair gene: mutations result in reduced XPC mRNA levels that correlate with cancer risk. *Hum Mol Genet*. 2004;13:343-352.
28. Khan SG, Oh KS, Emmert S, et al. XPC initiation codon mutation in xeroderma pigmentosum patients with and without neurological symptoms. *DNA Repair (Amst)*. 2009;8:114-125.
29. Boyle J, Ueda T, Oh KS, et al. Persistence of repair proteins at unrepaired DNA damage distinguishes diseases with ERCC2 (XPD) mutations: cancer-prone xeroderma pigmentosum vs. non-cancer-prone trichothiodystrophy. *Hum Mutat*. 2008;29: 1194-1208.
30. Oh KS, Emmert S, Tamura D, et al. Multiple skin cancers in adults with mutations in the XP-E (DDB2) DNA repair gene. *J Invest Dermatol*. 2011;131:785-788.
31. Emmert S, Slor H, Busch DB, et al. Relationship of neurologic degeneration to genotype in three xeroderma pigmentosum group G patients. *J Invest Dermatol*. 2002;118:972-982.
32. Inui H, Oh KS, Nadem C, et al. Xeroderma pigmentosum-variant patients from America, Europe, and Asia. *J Invest Dermatol*. 2008;128:2055-2068.
33. Reid-Bayliss KS, Arron ST, Loeb LA, et al. Why Cockayne syndrome patients do not get cancer despite their DNA repair deficiency. *Proc Natl Acad Sci U S A*. 2016;113:10151-10156.
34. Correa R, Salpea P, Stratakis CA. Carney complex: an update. *Eur J Endocrinol*. 2015;173:M85-M97.
35. Slor H, Batko S, Khan SG, et al. Clinical, cellular, and molecular features of an Israeli xeroderma pigmentosum family with a frameshift mutation in the XPC gene: sun protection prolongs life. *J Invest Dermatol*. 2000;115:974-980.
36. Tamura D, DiGiovanna JJ, Khan SG, et al. Living with xeroderma pigmentosum: comprehensive photoprotection for highly photosensitive patients. *Photodermatol Photoimmunol Photomed*. 2014;30:146-152.
37. Kraemer KH, DiGiovanna JJ, Moshell AN, et al. Prevention of skin cancer in xeroderma pigmentosum with the use of oral isotretinoin. *N Engl J Med*. 1988;318:1633-1637.
38. Yarosh D, Klein J, O'Conner A, et al. Effect of topically applied T4 endonuclease V in liposomes on skin cancer in xeroderma pigmentosum: a randomized study. *Lancet*. 2001;357:926-929.
39. Turner ML, Moshell AN, Corbett DW, et al. Clearing of melanoma in situ with intralesional interferon alfa in a patient with xeroderma pigmentosum. *Arch Dermatol*. 1994;130:1491-1494.
40. Sollitto RB, Kraemer KH, DiGiovanna JJ. Normal vitamin D levels can be maintained despite rigorous photoprotection: six years' experience with xeroderma pigmentosum. *J Am Acad Dermatol*. 1997;37: 942-947.
41. Ali JT, Mukasa Y, Coulson IH. Xeroderma pigmentosum: early diagnostic features and an adverse consequence of photoprotection. *Clin Exp Dermatol*. 2009;34:442-443.
42. Reichrath J. Sunlight, skin cancer and vitamin D: what are the conclusions of recent findings that protection against solar ultraviolet (UV) radiation causes 25-hydroxyvitamin D deficiency in solid organ-transplant recipients, xeroderma pigmentosum, and other risk groups? *J Steroid Biochem Mol Biol*. 2007;103:664-667.
43. Khan SG, Oh KS, Shahlavi T, et al. Reduced XPC DNA repair gene mRNA levels in clinically normal parents of xeroderma pigmentosum patients. *Carcinogenesis*. 2006;27:84-94.
44. Cockayne EA. Dwarfism with retinal atrophy and deafness. *Arch Dis Child*. 1936;11:1-8.
45. Rapin I. Disorders of nucleotide excision repair. *Handb Clin Neurol*. 2013;113:1637-1650.
46. Nance MA, Berry SA. Cockayne syndrome: review of 140 cases. *Am J Med Genet*. 1992;42:68-84.
47. Kubota M, Ohta S, Ando A, et al. Nationwide survey of Cockayne syndrome in Japan: incidence, clinical course and prognosis. *Pediatr Int*. 2015;57:339-347.
48. Wilson BT, Stark Z, Sutton RE, et al. The Cockayne Syndrome Natural History (CoSyNH) study: clinical findings in 102 individuals and recommendations for care. *Genet Med*. 2016;18:483-493.
49. Frouin E, Laugel V, Durand M, et al. Dermatologic findings in 16 patients with Cockayne syndrome and cerebro-oculo-facial-skeletal syndrome. *JAMA Dermatol*. 2013;149:1414-1418.
50. Trese MG, Nudleman ED, Besirli CG. Peripheral retinal vasculopathy in Cockayne syndrome. *Retin Cases Brief Rep*. 2017;11(3):232-235.
51. Laugel V. Cockayne syndrome: the expanding clinical and mutational spectrum. *Mech Ageing Dev*. 2013;134:161-170.
52. Gitiaux C, Blin-Rochemaure N, Hully M, et al. Progressive demyelinating neuropathy correlates with clinical severity in Cockayne syndrome. *Clin Neurophysiol*. 2015;126:1435-1439.
53. Koob M, Rousseau F, Laugel V, et al. Cockayne syndrome: a diffusion tensor imaging and volumetric study. *Br J Radiol*. 2016;89:20151033.
54. Laugel V. Cockayne syndrome. In: Adam MP, Ardinger HH, Pagon RA, et al, eds. GeneReviews [Internet]. Seattle, WA: University of Washington; 1993-2018 [December 28, 2000; updated June 14, 2012]. https://www.ncbi.nlm.nih.gov/books/NBK1342/#cockayne. Summary
55. Graham JM Jr, Hennekam R, Dobyns WB, et al. MICRO syndrome: an entity distinct from COFS syndrome. *Am J Med Genet A*. 2004;128A:235-245.

56. Wilson BT, Strong A, O'Kelly S, et al. Metronidazole toxicity in Cockayne syndrome: a case series. *Pediatrics*. 2015;136:e706-e708.
57. Lindenbaum Y, Dickson D, Rosenbaum P, et al. Xeroderma pigmentosum/Cockayne syndrome complex: first neuropathological study and review of eight other cases. *Eur J Paediatr Neurol*. 2001;5:225-242.
58. Rapin I, Lindenbaum Y, Dickson DW, et al. Cockayne syndrome and xeroderma pigmentosum. *Neurology*. 2000;55:1442-1449.
59. Tay CH. Ichthyosiform erythroderma, hair shaft abnormalities, and mental and growth retardation. A new recessive disorder. *Arch Dermatol*. 1971;104:4-13.
60. Price VH, Odom RB, Ward WH, et al. Trichothiodystrophy: sulfur-deficient brittle hair as a marker for a neuroectodermal symptom complex. *Arch Dermatol*. 1980;116:1375-1384.
61. Lehmann AR, Francis AJ, Giannelli F. Prenatal diagnosis of Cockayne's syndrome. *Lancet*. 1985;1:486-488.
62. Itin PH, Sarasin A, Pittelkow MR. Trichothiodystrophy: update on the sulfur-deficient brittle hair syndromes. *J Am Acad Dermatol*. 2001;44:891-920; quiz 921-924.
63. Liang C, Kraemer KH, Morris A, et al. Characterization of tiger-tail banding and hair shaft abnormalities in trichothiodystrophy. *J Am Acad Dermatol*. 2005;52:224-232.
64. Liang C, Morris A, Schlucker S, et al. Structural and molecular hair abnormalities in trichothiodystrophy. *J Invest Dermatol*. 2006;126:2210-2216.
65. Schlucker S, Liang C, Strehle KR, et al. Conformational differences in protein disulfide linkages between normal hair and hair from subjects with trichothiodystrophy: a quantitative analysis by Raman microspectroscopy. *Biopolymers*. 2006;82:615-622.
66. Faghri S, Tamura D, Kraemer KH, et al. Trichothiodystrophy: a systematic review of 112 published cases characterises a wide spectrum of clinical manifestations. *J Med Genet*. 2008;45:609-621.
67. Laugel V, Dalloz C, Durand M, et al. Mutation update for the CSB/ERCC6 and CSA/ERCC8 genes involved in Cockayne syndrome. *Hum Mutat*. 2010;31:113-126.
68. Brooks BP, Thompson AH, Clayton JA, et al. Ocular manifestations of trichothiodystrophy. *Ophthalmology*. 2011;118:2335-2342.
69. Corbett MA, Dudding-Byth T, Crock PA, et al. A novel X-linked trichothiodystrophy associated with a nonsense mutation in RNF113A. *J Med Genet*. 2015;52:269-274.
70. Pollitt RJ, Jenner FA, Davies M. Sibs with mental and physical retardation and trichorrhexis nodosa with abnormal amino acid composition of the hair. *Arch Dis Child*. 1968;43:211-216.
71. Baden HP, Jackson CE, Weiss L, et al. The physicochemical properties of hair in the BIDS syndrome. *Am J Hum Genet*. 1976;28:514-521.
72. Zhou X, Khan SG, Tamura D, et al. Brittle hair, developmental delay, neurologic abnormalities, and photosensitivity in a 4-year-old girl. *J Am Acad Dermatol*. 2010;63:323-328.
73. Ostergaard JR, Christensen T. The central nervous system in Tay syndrome. *Neuropediatrics*. 1996;27: 326-330.
74. Kuschal C, Botta E, Orioli D, et al. GTF2E2 mutations destabilize the general transcription factor complex TFIIE in individuals with DNA repair-proficient trichothiodystrophy. *Am J Hum Genet*. 2016;98:627-642.
75. Nakabayashi K, Amann D, Ren Y, et al. Identification of C7orf11 (TTDN1) gene mutations and genetic heterogeneity in nonphotosensitive trichothiodystrophy. *Am J Hum Genet*. 2005;76:510-516.
76. Dubaele S, Proietti De Santis L, Bienstock RJ, et al. Basal transcription defect discriminates between xeroderma pigmentosum and trichothiodystrophy in XPD patients. *Mol Cell*. 2003;11:1635-1646.
77. Moslehi R, Signore C, Tamura D, et al. Adverse effects of trichothiodystrophy DNA repair and transcription gene disorder on human fetal development. *Clin Genet*. 2010;77:365-373.
78. Tamura D, Merideth M, DiGiovanna JJ, et al. High-risk pregnancy and neonatal complications in the DNA repair and transcription disorder trichothiodystrophy: report of 27 affected pregnancies. *Prenat Diagn*. 2011;31:1046-1053.
79. Heller ER, Khan SG, Kuschal C, et al. Mutations in the TTDN1 gene are associated with a distinct trichothiodystrophy phenotype. *J Invest Dermatol*. 2015; 135:734-741.
80. Atkinson EC, Thiara D, Tamura D, et al. Growth and nutrition in children with trichothiodystrophy. *J Pediatr Gastroenterol Nutr*. 2014;59:458-464.
81. Tamura D, Khan SG, Merideth M, et al. Effect of mutations in XPD(ERCC2) on pregnancy and prenatal development in mothers of patients with trichothiodystrophy or xeroderma pigmentosum. *Eur J Hum Genet*. 2012;20:1308-1310.
82. German J. Bloom's syndrome. XX. The first 100 cancers. *Cancer Genet Cytogenet*. 1997;93:100-106.
83. Shahrabani-Gargir L, Shomrat R, Yaron Y, et al. High frequency of a common Bloom syndrome Ashkenazi mutation among Jews of Polish origin. *Genet Test*. 1998;2:293-296.
84. Singh DK, Ahn B, Bohr VA. Roles of RECQ helicases in recombination based DNA repair, genomic stability and aging. *Biogerontology*. 2009;10:235-252.
85. Thompson LH, Schild D. Recombinational DNA repair and human disease. *Mutat Res*. 2002;509:49-78.
86. Panneerselvam J, Wang H, Zhang J, et al. BLM promotes the activation of Fanconi anemia signaling pathway. *Oncotarget*. 2016;7:32351-32361.
87. Drosopoulos WC, Kosiyatrakul ST, Schildkraut CL. BLM helicase facilitates telomere replication during leading strand synthesis of telomeres. *J Cell Biol*. 2015;210:191-208.
88. Kong CM, Lee XW, Wang X. Telomere shortening in human diseases. *FEBS J*. 2013;280:3180-3193.
89. Zimmermann M, Kibe T, Kabir S, et al. TRF1 negotiates TTAGGG repeat-associated replication problems by recruiting the BLM helicase and the TPP1/POT1 repressor of ATR signaling. *Genes Dev*. 2014;28:2477-2491.
90. Chaganti RS, Schonberg S, German J. A manyfold increase in sister chromatid exchanges in Bloom's syndrome lymphocytes. *Proc Natl Acad Sci U S A*. 1974;7:4508-4512.
91. Peleg L, Pesso R, Goldman B, et al. Bloom syndrome and Fanconi's anemia: rate and ethnic origin of mutation carriers in Israel. *Isr Med Assoc J*. 2002;4:95-97.
92. Khan SG, Levy HL, Legerski R, et al. Xeroderma pigmentosum group C splice mutation associated with autism and hypoglcycinemia. *J Invest Dermatol*. 1998;115:791-796.
93. Oshima J, Sidorova JM, Monnat RJ Jr. Werner syndrome: clinical features, pathogenesis and potential therapeutic interventions. *Ageing Res Rev*. 2017;33: 105-114.
94. Ishikawa Y, Sugano H, Matsumoto T, et al. Unusual features of thyroid carcinomas in Japanese patients

with Werner syndrome and possible genotype-phenotype relations to cell type and race. *Cancer*. 1999;85:1345-1352.
95. Epstein CE, Martin GM, Schultz AL, et al. Werner syndrome. A review of its symptomatology, natural history, pathologic features, genetics and relationship to the natural aging process. *Medicine (Baltimore)*. 1966;45:177-221.
96. Ruprecht KW. Ophthalmological aspects in patients with Werner's syndrome. *Arch Gerontol Geriatr*. 1989;9:263-270.
97. Goto M, Miller RW, Ishikawa Y, et al. Excess of rare cancers in Werner syndrome (adult progeria). *Cancer Epidemiol Biomarkers Prev*. 1996;5:239-246.
98. Monnat RJ Jr. "...Rewritten in the skin": clues to skin biology and aging from inherited disease. *J Invest Dermatol*. 2015;135:1484-1490.
99. Chen L, Huang S, Lee L, et al. WRN, the protein deficient in Werner syndrome, plays a critical structural role in optimizing DNA repair. *Aging Cell*. 2003;2:191-199.
100. Opresko PL, Cheng WH, von KC, et al. Werner syndrome and the function of the Werner protein; what they can teach us about the molecular aging process. *Carcinogenesis*. 2003;24:791-802.
101. Morita K, Nishigori C, Sasaki MS, et al. Werner's syndrome—chromosome analyses of cultured fibroblasts and mitogen-stimulated lymphocytes. *Br J Dermatol*. 1997;136:620-623.
102. Li Y, Zhang W, Chang L, et al. Vitamin C alleviates aging defects in a stem cell model for Werner syndrome. *Protein Cell*. 2016;7:478-488.
103. Larizza L, Roversi G, Volpi L. Rothmund-Thomson syndrome. *Orphanet J Rare Dis*. 2010;5:2.
104. Lu L, Jin W, Wang LL. Aging in Rothmund-Thomson syndrome and related RECQL4 genetic disorders. *Ageing Res Rev*. 2017;33:30-35.
105. Wang LL, Levy ML, Lewis RA, et al. Clinical manifestations in a cohort of 41 Rothmund-Thomson syndrome patients. *Am J Med Genet*. 2001;102:11-17.
106. Kitao S, Shimamoto A, Goto M, et al. Mutations in RECQL4 cause a subset of cases of Rothmund-Thomson syndrome. *Nat Genet*. 1999;22:82-84.
107. Suter AA, Itin P, Heinimann K, et al. Rothmund-Thomson Syndrome: novel pathogenic mutations and frequencies of variants in the RECQL4 and USB1 (C16orf57) gene. *Mol Genet Genomic Med*. 2016;4:359-366.
108. Wang LL, Gannavarapu A, Kozinetz CA, et al. Association between osteosarcoma and deleterious mutations in the RECQL4 gene in Rothmund-Thomson syndrome. *J Natl Cancer Inst*. 2003;95:669-674.
109. Smith PJ, Paterson MC. Enhanced radiosensitivity and defective DNA repair in cultured fibroblasts derived from Rothmund Thomson syndrome patients. *Mutat Res*. 1982;94:213-228.
110. Yin J, Kwon YT, Varshavsky A, et al. RECQL4, mutated in the Rothmund-Thomson and RAPADILINO syndromes, interacts with ubiquitin ligases UBR1 and UBR2 of the N-end rule pathway. *Hum Mol Genet*. 2004;13:2421-2430.
111. Croteau DL, Popuri V, Opresko PL, et al. Human RecQ helicases in DNA repair, recombination, and replication. *Annu Rev Biochem*. 2014;83:519-552.
112. Kutler DI, Singh B, Satagopan J, et al. A 20-year perspective on the International Fanconi Anemia Registry (IFAR). *Blood*. 2003;101:1249-1256.
113. Auerbach AD. Fanconi anemia. *Dermatol Clin*. 1995;13:41-49.
114. Saftig P, Hunziker E, Wehmeyer O, et al. Impaired osteoclastic bone resorption leads to osteopetrosis in cathepsin-K-deficient mice. *Proc Natl Acad Sci U S A*. 1998;95:13453-13458.
115. Shimamura A, Alter BP. Pathophysiology and management of inherited bone marrow failure syndromes. *Blood Rev*. 2010;24:101-122.
116. De Kerviler E, Guermazi A, Zagdanski AM, et al. The clinical and radiological features of Fanconi's anaemia. *Clin Radiol*. 2000;55:340-345.
117. Gmyrek D, Syllm-Rapoport I. On Fanconi's anemia. Analysis of 129 cases [in German]. *Z Kinderheilkd*. 1964;91:297-337.
118. Alter BP. Cancer in Fanconi anemia, 1927-2001 [see comment]. *Cancer*. 2003;97:425-440.
119. Kerr B, Ashcroft GS, Scott D, et al. Rothmund-Thomson syndrome: two case reports show heterogeneous cutaneous abnormalities, an association with genetically programmed ageing changes, and increased chromosomal radiosensitivity. *J Med Genet*. 1996;33:928-934.
120. Auerbach AD, Allen RG. Leukemia and preleukemia in Fanconi anemia patients. A review of the literature and report of the International Fanconi Anemia Registry. *Cancer Genet Cytogenet*. 1991;51:1-12.
121. Rosenberg PS, Greene MH, Alter BP. Cancer incidence in persons with Fanconi anemia [see comment]. *Blood*. 2003;101:822-826.
122. Bogliolo M, Cabre O, Callen E, et al. The Fanconi anaemia genome stability and tumour suppressor network. *Mutagenesis*. 2002;17:529-538.
123. Ceccaldi R, Sarangi P, D'Andrea AD. The Fanconi anaemia pathway: new players and new functions. *Nat Rev Mol Cell Biol*. 2016;17:337-349.
124. D'Andrea AD, Grompe M. The Fanconi anemia/BRCA pathway. *Nat Rev Cancer*. 2003;3:23-34.
125. Dong H, Nebert DW, Bruford EA, et al. Update of the human and mouse Fanconi anemia genes. *Hum Genomics*. 2015;9:32.
126. Dunn J, Potter M, Rees A, et al. Activation of the Fanconi anemia/BRCA pathway and recombination repair in the cellular response to solar UV. *Cancer Res*. 2006;66(23):11140-11147.
127. Garcia-Higuera I, Taniguchi T, Ganesan S, et al. Interaction of the Fanconi anemia proteins and BRCA1 in a common pathway. *Mol Cell*. 2001;7:249-262.
128. Howlett NG, Taniguchi T, Durkin SG, et al. The Fanconi anemia pathway is required for the DNA replication stress response and for the regulation of common fragile site stability. *Hum Mol Genet*. 2005;14:693-701.
129. Joenje H, Patel KJ. The emerging genetic and molecular basis of Fanconi anemia. *Nat Rev Genet*. 2001;2:446-457.
130. Lomonosov M, Anand S, Sangrithi M, et al. Stabilization of stalled DNA replication forks by the BRCA2 breast cancer susceptibility protein. *Genes Dev*. 2003;17:3017-3022.
131. Osborn AJ, Elledge SJ, Zou L. Checking on the fork: the DNA-replication stress-response pathway. *Trends Cell Biol*. 2002;12:509-516.
132. Taniguchi T, D'Andrea AD. Molecular pathogenesis of Fanconi anemia: recent progress. *Blood*. 2006;107:4223-4233.
133. Taniguchi T, Garcia-Higuera I, Xu B, et al. Convergence of the Fanconi anemia and ataxia telangiectasia signaling pathways. *Cell*. 2002;109:459-472.

134. Thompson LH, Hinz JM, Yamada NA, et al. How Fanconi anemia proteins promote the four Rs: replication, recombination, repair, and recovery. *Environ Mol Mutagen*. 2005;45:128-142.
135. Wang W. Emergence of a DNA-damage response network consisting of Fanconi anaemia and BRCA proteins. *Nat Rev Genet*. 2007;8:735-748.
136. Vulliamy TJ, Marrone A, Knight SW, et al. Mutations in dyskeratosis congenita: their impact on telomere length and the diversity of clinical presentation. *Blood*. 2006;107:2680-2685.
137. Alter BP, Giri N, Savage SA, et al. Cancer in dyskeratosis congenita. *Blood*. 2009;113:6549-6557.
138. Dokal I. Dyskeratosis congenita in all its forms. *Br J Haematol*. 2000;110:768-779.
139. Knight S, Vulliamy T, Copplestone A, et al. Dyskeratosis congenita (DC) registry: identification of new features of DC. *Br J Haematol*. 1998;103:990-996.
140. Savage SA. Dyskeratosis congenita. In: Adam MP, Ardinger HH, Pagon RA, et al, eds. GeneReviews [Internet]. Seattle, WA: University of Washington; 1993-2018 [November 12, 2009; updated May 26, 2016]. https://www.ncbi.nlm.nih.gov/books/NBK22301/#dkc.Summary
141. Sirinavin C, Trowbridge AA. Dyskeratosis congenita: clinical features and genetic aspects. Report of a family and review of the literature. *J Med Genet*. 1975;12:339-354.
142. Kelly TE, Stelling CB. Dyskeratosis congenita: radiologic features. *Pediatr Radiol*. 1982;12:31-36.
143. Mills SE, Cooper PH, Beacham BE, et al. Intracranial calcifications and dyskeratosis congenita. *Arch Dermatol*. 1979;115:1437-1439.
144. Connor JM, Teague RH. Dyskeratosis congenita. Report of a large kindred. *Br J Dermatol*. 1981;105:321-325.
145. Hassock S, Vetrie D, Giannelli F. Mapping and characterization of the X-linked dyskeratosis congenita (DKC) gene. *Genomics*. 1999;55:21-27.
146. Dokal I, Bungey J, Williamson P, et al. Dyskeratosis congenita fibroblasts are abnormal and have unbalanced chromosomal rearrangements. *Blood*. 1992;80:3090-3096.
147. Heiss NS, Knight SW, Vulliamy TJ, et al. X-linked dyskeratosis congenita is caused by mutations in a highly conserved gene with putative nucleolar functions. *Nat Genet*. 1998;19:32-38.
148. Knight SW, Heiss NS, Vulliamy TJ, et al. X-linked dyskeratosis congenita is predominantly caused by missense mutations in the DKC1 gene. *Am J Hum Genet*. 1999;65:50-58.
149. Vulliamy TJ, Knight SW, Heiss NS, et al. Dyskeratosis congenita caused by a 3′ deletion: germline and somatic mosaicism in a female carrier. *Blood*. 1999;94:1254-1260.
150. Mitchell JR, Wood E, Collins K. A telomerase component is defective in the human disease dyskeratosis congenita. *Nature*. 1999;402:551-555.
151. Marciniak RA, Johnson FB, Guarente L. Dyskeratosis congenita, telomeres and human ageing. *Trends Genet*. 2000;16:193-195.
152. Vulliamy TJ, Knight SW, Mason PJ, et al. Very short telomeres in the peripheral blood of patients with X-linked and autosomal dyskeratosis congenita. *Blood Cells Mol Dis*. 2001;27:353-357.
153. Dokal I. Dyskeratosis congenita. A disease of premature ageing. *Lancet*. 2001;358(suppl):S27.
154. Collins K, Mitchell JR. Telomerase in the human organism. *Oncogene*. 2002;21:564-579.
155. Elliott AM, Graham GE, Bernstein M, et al. Dyskeratosis congenita: an autosomal recessive variant. *Am J Med Genet*. 1999;83:178-182.
156. Vulliamy T, Marrone A, Goldman F, et al. The RNA component of telomerase is mutated in autosomal dominant dyskeratosis congenita. *Nature*. 2001;413:432-435.
157. Alter BP, Rosenberg PS, Giri N, et al. Telomere length is associated with disease severity and declines with age in dyskeratosis congenita. *Haematologica*. 2012;97:353-359.
158. Ghavamzadeh A, Alimoghadam K, Nasseri P, et al. Correction of bone marrow failure in dyskeratosis congenita by bone marrow transplantation. *Bone Marrow Transplant*. 1999;23:299-301.

Chapter 131 :: Ectodermal Dysplasias

:: Elizabeth L. Nieman
& Dorothy Katherine Grange

AT-A-GLANCE

- A group of inherited disorders characterized by developmental abnormalities in 2 or more ectodermal structures.
- These include hair, teeth, nails, and sebaceous and sweat glands.
- There may be abnormalities in nonectodermal structures and functions.
- Distinction is based on clinical features, mode of inheritance, and molecular/genetic findings.
- Clinically distinct disorders may be due to different mutations in the same gene (allelic heterogeneity), and clinically similar conditions may be due to mutations in different genes (locus heterogeneity).

INTRODUCTION

The ectodermal dysplasias (EDs) are a complex and heterogenous group of inherited disorders that share developmental defects involving at least 2 of the major structures classically known to derive from the embryonic ectoderm: hair, teeth, nails, and sweat and other eccrine and sebaceous glands. Developmental disorders involving only one type of ectodermal structure, even if associated with other congenital malformations, are not classified as EDs. There are almost 200 conditions classified as EDs, and given the varied clinical presentations and clinical overlap, it can be difficult to diagnose them precisely.[1]

Various classification schemes have been proposed over the past several decades to help in ordering and thinking about these disorders. Freire-Maia and Pinheiro published an exhaustive review and classification system, with later updates, for these disorders using a numeric system.[2] Although this system developed a rational approach to a previously chaotic field, it has little use in clinical practice and does not account for the pathogenesis or genetics of specific conditions. Over the past few decades, many of the genes responsible for these disorders have been identified, leading to several attempts to reclassify the EDs based on molecular and developmental biopsy. In 2008, an international ED classification conference consisting of health care providers, researchers, patient advocate representatives, and administrators convened in an attempt to move toward a more useful and unified system. In 2009, a conference report was released outlining the goal of creating an integrated ED classification system based on the most recent clinical and molecular information available.[3] Given the rate of discovery of new molecular information, this has been challenging. Thus, in 2012, a second international conference was held resulting in the development of a multi-axis model approach to EDs.[4] This model will be based on a clinical/phenotype axis, a gene-based axis, and a functional/pathways axis and is still in the process of creation.

This chapter will only cover the EDs that are more common and most likely to present to a dermatologist for diagnosis and medical attention. As much as possible, it will be organized in concordance with the ED international classification conference, limited by the complexities discussed above. Given the evolving landscape of EDs, the reader is directed to the following resources for the most current information on EDs: https://omim.org (Online Catalog of Mendelian Inheritance in Man) and http://www.ncbi.nlm.nih.gov/gtr/ (an up-to-date listing of laboratories offering molecular testing).

Figure 131-1 is an algorithm showing the clinical approach to the diagnosis of EDs. The first step in the algorithm for making a specific diagnosis of an ED is to determine the presence of sweating (hidrotic) or absence of sweating (hypohidrotic/anhidrotic). The involvement of other ectodermal structures and of non–ectodermal derived tissues provides further branching points in a diagnostic hierarchy. Mode of inheritance may differ within a seemingly uniform diagnostic group, and care must be taken in evaluating family members before providing genetic counseling.

The National Foundation for Ectodermal Dysplasias (NFED; http://www.nfed.org) is a lay support group that has numerous informative pamphlets for families and physicians, as well as a strong advocacy program for dental care, insurance coverage, and research. With the knowledge gained from studies on the molecular pathways leading to EDs, there is hope that molecular-based therapies will be able to treat or replace defective or missing teeth, hair follicles, or eccrine sweat glands.[5-7]

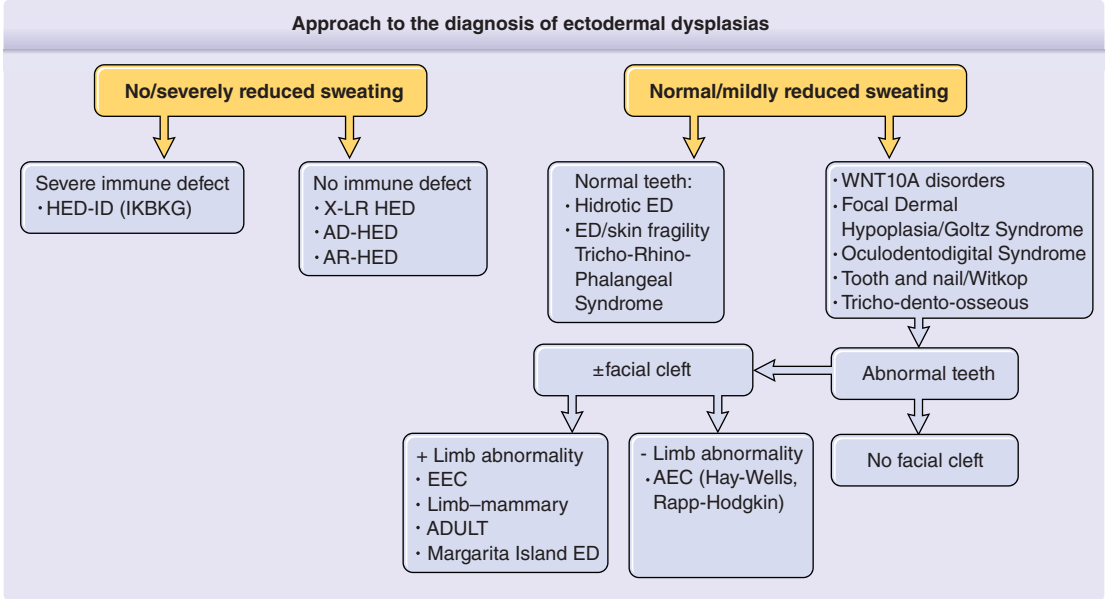

Figure 131-1 Approach to the diagnosis of ectodermal dysplasias. AD = autosomal dominant; ADULT = *a*cro-*d*ermato-*u*ngual-/*a*crimal-*t*ooth syndrome; AEC = *a*nkyloblepharon filiforme adnatum–*e*ctodermal dysplasia–*c*left palate syndrome; AR = autosomal recessive; ED = ectodermal dysplasia; EEC = ectrodactyly–ED–cleft lip/palate syndrome; HED = hypohidrotic ectodermal dysplasia; IM = immune defects; X-LR = X-linked recessive.

HYPOHIDROTIC ECTODERMAL DYSPLASIA: XLHED, ADHED, ARHED, HED-ID

AT-A-GLANCE

- Variants:
  - XLHED (OMIM 305100): XLR mutation of *EDA1* on Xq12-q13.1 encoding the triggering ligand molecule ectodysplasin-A
  - ADHED (OMIM 129490): AD mutation of *EDARADD/EDAR* on 1q42.2-q43/2q11-q13; the intracellular molecule adaptor of EDAR death domain/transmembrane receptor of EDA
  - ARHED (OMIM 224900): AR mutation of *EDARADD/EDAR* on 1q42.2-q43/2q11-q13; the intracellular molecule adaptor of EDAR death domain/transmembrane receptor of EDA
  - HED with immune deficiency (HED-ID; OMIM 300291): XLR mutation of *IKBKG* on Xq28 encoding NF-κB cytoplasmic inhibitor (also referred to as NF-κB essential modulator/NEMO)
- Ectodermal features: characterized by hypotrichosis, hypohidrosis, and hypodontia.
- Systemic features: characteristic facial features with frontal bossing and depressed midface. Often associated with atopic dermatitis, asthma, upper respiratory tract infections, pneumonias

INTRODUCTION

One of the earliest descriptions of hypohidrotic ectodermal dysplasia (HED) was in 1848, and involved male first cousins and their grandmother with sparse hair, missing teeth, and dry skin.[8] HED is the most common ED,[9] specifically the X-linked recessive (XLHED) form of HED, and accounts for 80% of the families registered with NFED. There are several forms of HED, including XLHED (also known as Christ–Siemens–Touraine syndrome), autosomal dominant HED (ADHED), autosomal recessive HED (ARHED), and HED with immunodeficiency (HED-ID). The autosomal dominant and autosomal recessive forms of HED are similar to XLHED, although the autosomal dominant form may be milder.[10] HED-ID should be considered in a male with HED and recurrent or significant infections.[11,12]

EPIDEMIOLOGY

XLHED occurs in all racial groups and is thought to have an incidence at birth of anywhere from 1 in 5,000 to 100,000 births.[10,13,14] Accurate prevalence and incidence data are not available for the other forms of HED.

CLINICAL FEATURES

Clinical features across the variants are similar. HED is characterized by hypotrichosis, hypohidrosis,

and hypodontia. Affected males with XLHED may present at birth with a collodion membrane or with marked scaling of the skin,[15] similar to congenital ichthyosis.

Scalp hair is usually sparse, fine, and blonde. It may thicken and darken at puberty, and secondary sexual hair is typically normal. Other body hair is usually sparse or absent.

The ability to sweat is significantly compromised, and most affected males with XLHED have marked heat intolerance.[16] The inability to sweat adequately in response to environmental heat results in an elevation of core temperature and bouts of unexplained high fevers, usually leading to an extensive workup for infectious disease, malignancy, or autoimmune disease before the correct diagnosis is recognized. In an older series of patients, intellectual disability was reported as a feature of XLHED. Currently, this is believed to have been due to damage from prolonged high fevers and seizures and not to be an intrinsic feature of the disorder.[17] Individuals with ADHED appear to have a milder defect in the ability to sweat.

The nails are usually normal, although there are reports of thin, fragile nails.[18] Fingerprint ridges are effaced. Periorbital wrinkling and hyperpigmentation are typical and often present at birth (Fig. 131-2). Eczema affects more than two-thirds of affected males and almost half of affected females.[19] Hyperplasia of sebaceous glands, particularly on the face, can develop over time and appear as small, pearly, skin-colored to white papules that may resemble milia.

Hypodontia, oligodontia, or anodontia are invariable features of XLHED in affected males. Hypoplastic alveolar ridges in an affected infant can be an early clue to the diagnosis of the disorder. Teeth that do erupt are usually peg-shaped and small (Fig. 131-2B).

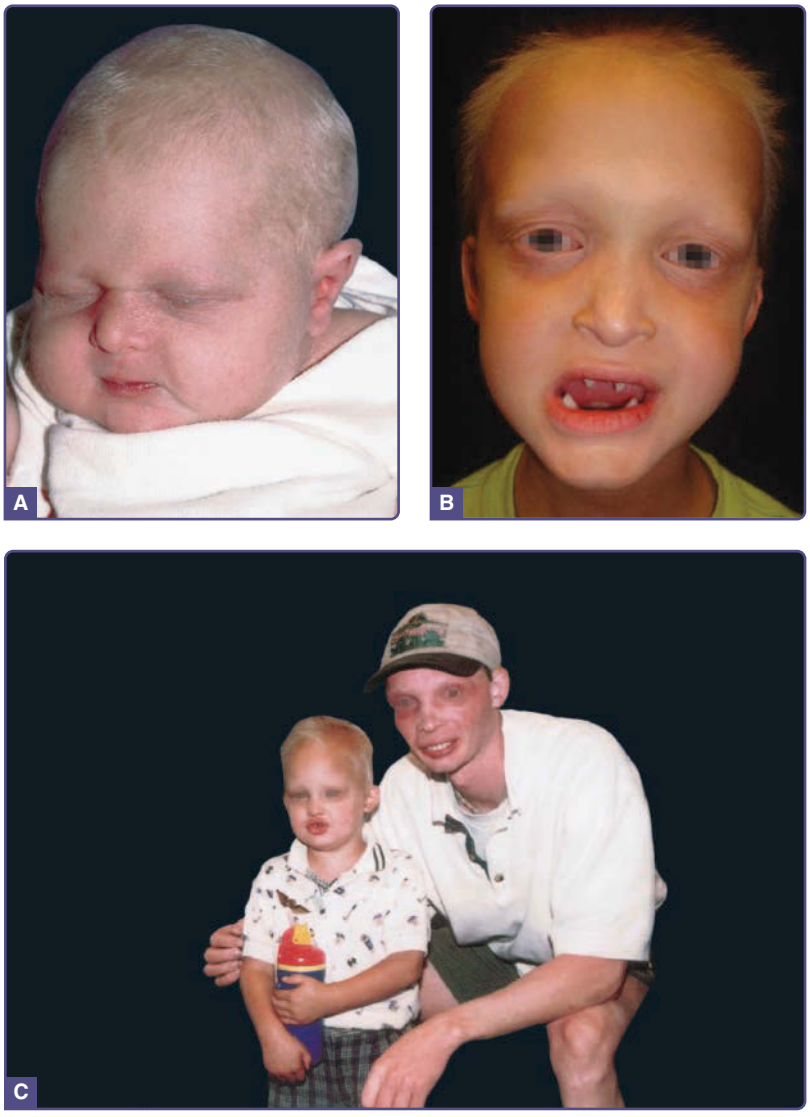

Figure 131-2 Hypohidrotic ectodermal dysplasia. **A,** Newborn with periorbital wrinkling, beaked nose. Diagnosis would not be suspected unless there was a positive family history. **B,** Peg-shaped teeth; fine periorbital wrinkling can be appreciated. **C,** Two unrelated males with X-linked hypohidrotic ectodermal dysplasia; adult is wearing dentures; periorbital wrinkling and hyperpigmentation are evident. (Used with permission from the National Foundation for Ectodermal Dysplasias.)

Figure 131-3 Hypohidrotic ectodermal dysplasia. **A,** Female carrier of X-linked hypohidrotic ectodermal dysplasia with her affected son. **B,** Two sisters with X-linked hypohidrotic ectodermal dysplasia manifesting to different degrees. Note periorbital hyperpigmentation, full everted lips, and sculpted noses. (Reproduced from Sybert V. Hypohidrotic ectodermal dysplasia: Argument against an autosomal recessive form clinically indistinguishable from X-linked hypohidrotic ectodermal dysplasia (Christ-Siemens-Touraine syndrome). *Pediatr Dermatol*. 1989;6:76-81; with permission. Copyright © 1989 John Wiley & Sons.)

The facial features of the disorder are characterized by frontal bossing and a depressed midface with a saddle nose and full, everted lips. Otolaryngologic and pulmonary manifestations include thick nasal secretions and impaction, ozena (atrophic rhinitis), sinusitis, recurrent upper respiratory tract infections and pneumonias, decreased saliva production, hoarse voice, and an increased frequency of asthma. The increased frequency of respiratory tract infections has been attributed to hypoplastic or absent mucus-secreting glands in the bronchial tree.[20] Gastroesophageal reflux and feeding difficulties may be a problem in infancy. The basis for this is unknown. Preliminary studies suggest that there may be failure to thrive in infancy and early childhood in as many as 20% to 40% of affected boys, with catch-up growth seen later.[21]

Female carriers for XLHED may be affected as severely as males or may show few, if any, signs of the disorder (Fig. 131-3). Between 60% and 80% of carrier females express some clinical signs of the disorder; the most frequent are patchy hypotrichosis and hypodontia or peg-shaped teeth. Heat intolerance, if present, is usually mild. Adult carrier women comment that they do not sweat much or that they do not like very warm weather, but it is unusual for a female to experience fever because of inability to sweat.[22]

ETIOLOGY AND PATHOGENESIS

HED is genetically heterogenous, with several forms related to different genes involved in the tumor necrosis factor α (TNF-α) signaling pathway.[9] Mutations in this pathway lead to interruption of the interaction between epithelial cells and underlying mesenchyme, leading to the clinically observed features that are similar between the different forms of HED. Figure 131-4 demonstrates the ectodysplasin signal transduction pathway and how it relates to each form of HED.

XLHED results from alterations in the gene *EDA1* encoding ectodysplasin-A located at Xq12-13.1.[10] Approximately 70% of affected males inherited the mutation from a carrier mother. *EDA1* codes for a

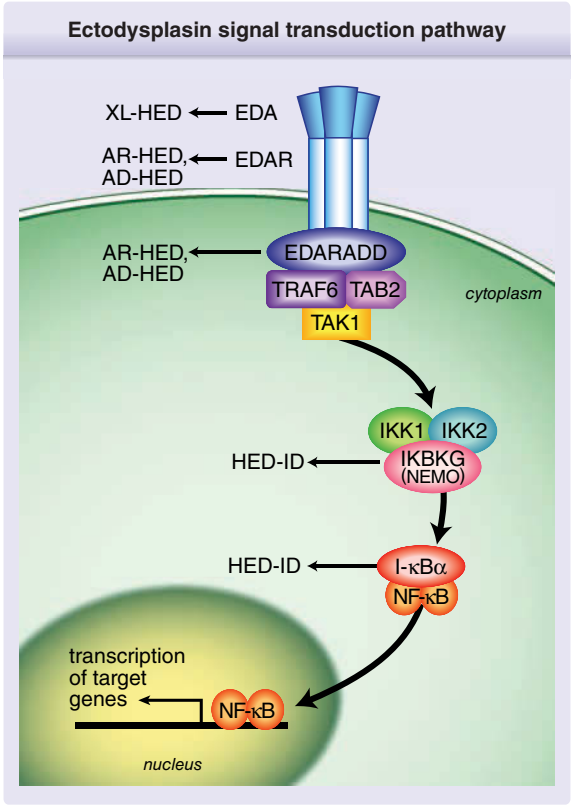

Figure 131-4 Ectodysplasin signal transduction pathway. (Image **B,** Reproduced from Rimoin D, Pyeritz R, Korf B, eds. *Emery and Rimoin's Principles and Practice of Medical Genetics*, 6th ed. Oxford, UK: Academic Press; 2013; Fig. 148-5; with permission. Copyright © Elsevier.)

transmembrane protein, ectodysplasin, which plays a role in regulation of the formation of ectodermal structures. It forms trimers and is expressed in keratinocytes, the outer root sheath of hair follicles, and sweat glands. It localizes to the lateral and apical surfaces of cells. A multitude of mutations in this gene causing XLHED have been identified. Interfamilial and intrafamilial variation occurs, but there are reports of genotype-phenotype correlation of skin and hair findings.[23]

Mutations in the autosomal genes, *EDAR*, located at 2q11-q13 and *EDARADD*, located at 1q42.2-q43, have been implicated in both an autosomal dominant form of hypohidrotic ectodermal dysplasia (ADHED; OMIM 129490) and in an autosomal recessive form (ARHED; OMIM 224900). As discussed above, these entities are clinically similar to XLHED, but are rarer. EDAR acts as a receptor for ectodysplasin and EDARADD acts as an intracellular adaptor protein that assists in transmitting the signal from the activated EDA receptor to the nucleus of the cell.[10]

Certain mutations in the X-linked *IKBKG* gene, which causes incontinentia pigmenti (IP) in females have been shown to result in HED-ID in males. There are 2 similar OMIM defined syndromes, HED-ID (OMIM#300291) and ectodermal dysplasia, anhidrotic with immunodeficiency, osteopetrosis, and lymphedema (OLEDAID; OMIM#300301) that describe males with ED and immune deficiency with mutations in *IKBKG*.[11,12] These patients demonstrate ED along with dysgammaglobulinemia and significant early morbidity and mortality. The complexity of the NFKB signaling pathway accounts for the diverse genotypes of HED-ID and immunologic phenotypes.

DIAGNOSIS

The diagnosis of HED is recognized readily when expected, such as when a child is born into a family with a known history of HED. However, without advance knowledge, the diagnosis can initially be clinically challenging. As the patient ages, the characteristic features of hypotrichosis, hypohidrosis, and hypodontia become more evident.[22] Hypoplastic alveolar ridges, indicating lack of teeth, can be an early diagnostic clue. A Panorex view of the jaw can assist in making the correct diagnosis. Although rarely necessary, evaluation of sweating by examination for sweat pores with iodine solution, quantification of pilocarpine-induced sweating,[23] or skin biopsy to assess for the absence of eccrine structures in the scalp and/or palmar region may help confirm a diagnosis.[24] In an isolated, fully expressing female, the autosomal dominant and recessive forms of HED need to be considered. Family history review is necessary, and mothers always should be examined fully to detect mild manifestations of the X-linked form. With the recent expansion and development of molecular genetic testing, definitive genetic diagnosis is becoming more readily available. Referral to a pediatric dermatologist or geneticist can assist in diagnosis.

On histopathology, the epidermis is thinned and flattened. There is a reduction in the number of sebaceous glands and hair follicles. Eccrine glands are absent or incompletely developed. Histologic evaluation of the skin is usually not necessary.

TABLE 131-1
Differential Diagnosis of Some Diagnostic Features of Ectodermal Dysplasias

- Collodion membrane
  - Self-healing collodion baby
  - Neutral lipid storage disease
  - Autosomal recessive congenital ichthyosis
    - Nonbullous congenital ichthyosiform erythroderma
    - Lamellar ichthyosis
  - Trichothiodystrophy
  - Storage diseases (eg, Gaucher)
  - Chondrodysplasia punctata
- Ankyloblepharon filiforme adnatum (AFA)
  - Lethal popliteal pterygium syndrome
  - Popliteal pterygium syndrome
  - Isolated AFA
  - AFA and cleft palate
- Hypodontia
  - Isolated hypodontia
  - Incontinentia pigmenti
- Skin fragility/erosions
  - Epidermolysis bullosa (all subtypes)
  - Incontinentia pigmenti
  - Acrodermatitis enteropathica
  - Congenital erythropoietic porphyria
- Atrophic streaks
  - Incontinentia pigmenti—stage 4
  - MIDAS (*mi*crophthalmia, *d*ermal *a*plasia, and *s*clerocornea)
  - Focal dermal hypoplasia

DIFFERENTIAL DIAGNOSIS

Table 131-1 reviews the differential diagnoses for many of the ectodermal dysplasias discussed in this chapter.

The scaling skin at birth may result in a misdiagnosis of congenital ichthyosis. Recurrent fever may be thought to have an infectious source or underlying autoinflammatory disorder.

CLINICAL COURSE, PROGNOSIS, AND MANAGEMENT

Maintenance of cool ambient temperatures is vital to prevent hyperpyrexia. Most children do well with simple measures, such as wet T-shirts and headbands, air conditioning in home and school, etc. Occasionally, cooling vests allow a broader range of

participation in sports and vigorous physical activity in warm climates.

Dental restoration is of primary importance, and early implementation of dentures and ultimate use of dental implants are mainstays of treatment.

Management of otolaryngologic complications, asthma, and recurrent infections needs to be individualized. The eczema may be quite refractory to care and difficult to manage.

Infants with HED are at increased risk of death due to hyperthermia and potentially other features of the disorder, such as infection.[25,26] In a survey of the Ectodermal Dysplasia International Registry (EDIR), 21% of XLHED reported a family history of infant or childhood death.[19]

Although infancy and childhood are complicated by many problems, most individuals with HED lead adult lives that allow them to function successfully in society. Heat intolerance seems to decrease because of the development of some ability to sweat in adolescence or to the development adaptation of lifestyle, or both.

Recombinant ectodysplasin protein injections of pregnant affected mice led to permanent rescue of the phenotypic features in the offspring.[27] Further, early postnatal injections were also shown to ameliorate the developmental defects. Similar results have been noted in affected canine models who were infused with recombinant ectodysplasin protein in the postnatal period, with resultant normalization of teeth, lacrimation, and sweating ability, as well as decreased eye and respiratory infections.[28,29] These developments in animal models have been encouraging. There are currently human trials under way.

HIDROTIC ECTODERMAL DYSPLASIA (CLOUSTON)

AT-A-GLANCE

- OMIM 129500, AD mutation of *GJB6* on 13q12 which encodes connexin 30, a connexin protein of the intercellular junction
- Sparse, wiry pale hair with progressive alopecia; variable onychodystrophy; progressive palmoplantar hyperkeratosis
- Normal sweating and teeth

EPIDEMIOLOGY

Hidrotic ED was first described in a French–Canadian kindred.[30] It has been reported in other ethnic groups, but the majority of affected individuals can trace their ancestry back to an original French–Canadian settler.

CLINICAL FEATURES

The scalp hair is wiry, brittle, and pale, and there is often patchy alopecia (Fig. 131-5). This progresses in adult life and may lead to total alopecia. Body and facial hair are affected. The nails may be milky white

Figure 131-5 Hidrotic ectodermal dysplasia (Clouston syndrome). **A,** Patchy alopecia in adult. Coarseness of hair can be appreciated. **B,** Palmar hyperkeratosis. **C,** Nail dystrophy.

in infancy and early childhood, gradually thickening and becoming dystrophic. The nail plates in adults are thick, short, and slow growing. They separate distally from the nail bed (Fig. 131-5C), and may cause pain. Anonychia has been reported. Not all the nails are necessarily affected to the same degree. Progressive palmar/plantar hyperkeratosis is common (Fig. 131-5B). In contrast to HED, sweating is normal, as are the teeth. Oral leukoplakia has been reported. Conjunctivitis and blepharitis, possibly due to poor function of sparse eyelashes, are common.[31]

ETIOLOGY AND PATHOGENESIS

Hidrotic ED is autosomal dominant with variable expression, and the degree of severity can vary within and between families. Males and females are affected in equal numbers and to equal degree.

The disorder is caused by mutations in a connexin gene, *GJB6*, which encodes the intercellular junction protein connexin 30.[32] Different mutations in the same gene are responsible for a form of nonsyndromic autosomal dominant deafness. Connexin mutations are involved in several other genodermatoses, such as keratitis-ichthyosis-deafness (KID) syndrome (Chaps. 47 and 48).

DIAGNOSIS

The diagnosis is straightforward with time. The involvement of nails and hair and palmar/plantar thickening, in the absence of other signs of ED, are reasonably specific. Again, genetic testing can be confirmatory.[31]

On histopathology, the thickened palms and soles show orthohyperkeratosis with a normal granular layer. On electron microscopy, an increase in the number of desmosomes in the cells of the stratum corneum is found. The hair shows nonspecific changes.

DIFFERENTIAL DIAGNOSIS

Other palmar/plantar hyperkeratoses do not have similar hair changes. Orofacial clefting differentiates other forms of autosomal dominant hidrotic EDs, such as ankyloblepharon–ED–cleft palate (AEC) syndrome. Although the nail changes are similar to those of pachyonychia congenita, the hair changes are distinctive.

CLINICAL COURSE, PROGNOSIS, AND MANAGEMENT

Occasionally, ablation of the nail matrix is necessary for relief of pain. Wigs may provide cosmetic benefit. Treatment of the palmoplantar keratoderma is not specific and minimally successful.

P63-RELATED ECTODERMAL DYSPLASIA SYNDROMES: AEC (HAY–WELLS/RAPP–HODGKIN); EEC; LIMB–MAMMARY SYNDROME; ACRO-DERMATO-UNGUAL–LACRIMAL–TOOTH (ADULT) SYNDROME; ISOLATED SPLIT HAND–SPLIT FOOT MALFORMATION

AT-A-GLANCE

- Variants: all of the conditions below are AD with a mutation of *TP63* on 3q27, which encodes the p63 transcription protein
  - Ankyloblepharon-ectodermal defects-clefting (AEC)/Hay–Wells/Rapp–Hodgkin syndrome (AEC/Hay–Wells OMIM 106260; Rapp–Hodgkin syndrome OMIM 129400)
  - Limb–mammary syndrome (OMIM 603543)
  - Acro-dermato-ungual-lacrimal-tooth (ADULT) syndrome (OMIM 103285)
  - Ectrodactyly-ED-cleft lip/palate syndrome 3 (EEC3; OMIM 604292)
- Ectodermal features: collodion membrane at birth, dry thin skin, erosive scalp dermatitis, patchy alopecia, coarse light hair, dyspigmentation, variable nail dystrophy.
- Systemic features: Ankyloblepharon filiforme adnatum, lacrimal duct atresia, cleft lip/palate, hypodontia, syndactyly, ectopic breast tissue and hypospadias.

INTRODUCTION

Mutations in *p63*, a tumor-suppressor gene mapped to 3q27, have been found in most, but not all, individuals with ankyloblepharon-ectodermal defects-clefting (AEC; Hay–Wells; Rapp–Hodgkin) syndrome.[33] The gene is expressed widely, including in the basal cells of proliferating epithelial tissues. Mutations in the same gene cause some cases of isolated split hand–split foot malformation, limb–mammary syndrome, and acro-dermato-ungual-lacrimal-tooth (ADULT) syndrome. There appear to be some genotype–phenotype correlations.[34]

AEC (HAY–WELLS/RAPP–HODGKIN) SYNDROME

EPIDEMIOLOGY

Hay–Wells syndrome was first described in 1976,[35] and has been found in ethnically and geographically disparate families. Rapp–Hodgkin syndrome was first described in 1968,[36] and although it had many clinical similarities to Hay–Wells syndrome, it was once thought to be a distinct clinical entity. More recently, it has become evident that Rapp–Hodgkin syndrome and Hay–Wells syndrome are allelic and should be considered variants of the same disorder, AEC syndrome.[37,38]

CLINICAL FEATURES

Eighty to 90% of affected infants present at birth with shiny red, cracking, peeling skin, and superficial erosions, similar to the appearance of a collodion membrane (Fig. 131-6A).[18] This sheds within a few weeks, and the skin underneath is dry and thin.

The scalp is almost invariably affected. Many individuals have chronic erosive dermatitis with abnormal granulation tissue on the scalp and recurrent bacterial infections (Fig. 131-6B).[39] There is alopecia of the scalp of variable extent along with hair that is often wiry, coarse, and light in color with an uncombable appearance. Sparseness to absence of body hair is typical.

Cutaneous dyspigmentation, both hypo- and hyperpigmentation, can be quite striking and is seen universally in affected patients.[40,41] The nails may be normal, hyperconvex and thickened, absent, or partially dystrophic, and all changes can be found in a single individual and can worsen with age. Effaced dermatoglyphics and palmoplantar erosive changes are also quite common. Sweating may be normal to slightly decreased. Although most affected individuals describe subjective heat intolerance, frank hyperpyrexia is uncommon.

Ankyloblepharon filiforme adnatum (AFA), the term for strands of skin between the eyelids, is seen in approximately 70% of affected infants (Fig. 131-6C).

Figure 131-6 Ankyloblepharon filiforme adnatum–ectodermal dysplasia–cleft palate (Hay–Wells) syndrome. **A,** Newborn with peeling collodion membrane. **B,** Scalp erosions. **C,** Fine strands of tissue (ankyloblepharon filiforme adnatum) between eyelids.

These may tear spontaneously prior to birth, and minimally involve the lateral eyelids or require surgical lysis. Lacrimal duct atresia or obstruction is common.

Supernumerary nipples and ectopic breast tissue are seen occasionally, as is mild cutaneous syndactyly of the second and third toes. More prominent limb defects, including ectrodactyly (abnormal development of the median rays of the hands and feet), have been observed.[42]

Historically, the main clinical differences between Hay–Wells and Rapp–Hodgkin syndrome included characteristic facial features with a short nasal columella and maxillary hypoplasia, thin upper lip, and full lower lip associated with Rapp–Hodgkin syndrome (Fig. 131-7A,B). Also, with Rapp–Hodgkin syndrome, the teeth may be conical and prone to caries (Fig. 131-7D), lacrimal puncta are aplastic in almost one-third of affected individuals, but AFA is rare, and scalp involvement with breakdown and granulation tissue formation is far less common.

Cleft palate, with or without cleft lip, occurs in 80% to 100% of reported cases, with some cases displaying submucosal cleft palate alone.[43] There is typically hypodontia with missing or misshapen teeth, and maxillary hypoplasia is also common.[44] Malformed auricles have been described in some. Recurrent otitis media and secondary conductive hearing loss are common and may be consequences of the cleft palate. Hypospadias has been described in affected males, and labial hypoplasia with absence of the opening of the vagina has been reported in a single female. These features are also reminiscent of the EEC syndrome.

DIAGNOSIS

See discussion of etiology and pathogenesis for information on genetic testing.

On histopathology, consistent changes include mild epidermal atrophy, focal orthokeratosis, prominent superficial vascular plexus, and pigment incontinence with melanophages.[45] Electron microscopy of hairs shows a defective cuticular structure, atrophy and loss of melanin, along with structural abnormalities including pili torti and pili trianguli et canaliculi. There is a decrease in the keratins of the basal and suprabasal layers of the epidermis and disorganized keratin filaments in the stratum corneum.

Figure 131-7 Rapp–Hodgkin syndrome. **A,** Affected infant at 5 months. **B,** Fine, blond, sparse hair; beginnings of nail changes on middle finger of right hand. **C,** Abnormal nails in same patient as (**A**), at age 4½ years with thickened and friable nail plates. **D,** Abnormal dentition, missing teeth, and peg teeth. (Images A and C, From Schroeder HW Jr, Sybert VP. Rapp-Hodgkin ectodermal dysplasia. *J Pediatr*. 1987;110(1):72-75; with permission. Copyright © Elsevier. Image **B,** Used with permission from the National Foundation for Ectodermal Dysplasias.)

DIFFERENTIAL DIAGNOSIS

Among the autosomal dominant EDs associated with clefting, EEC syndrome is characterized by bony hand and foot abnormalities not typically seen in AEC and also lacks the ankyloblepharon. The peeling, eroded skin of the newborn can lead to misdiagnosis of epidermolysis bullosa or congenital ichthyosis. AFA can occur in the absence of syndromic associations, and strands of tissue between the eyelids have been seen in several forms of arthrogryposis and in CHANDS (*c*urly *h*air, *a*nkyloblepharon, and *n*ail *d*ysplasia *s*yndrome), an autosomal recessive form of ED.

CLINICAL COURSE, PROGNOSIS, AND MANAGEMENT

Light emollients should be used until the collodion membrane sheds. Ankyloblepharon may require surgical lysis. Ongoing ocular hygiene is important. The skin erosions, especially of the scalp, are difficult to manage and prone to excessive granulation tissue and secondary infection. They should be managed with gentle wound care, dilute bleach or other antimicrobial soaks. Occlusive dressings should be avoided.[40] Grafting of skin to the scalp has not proven successful in most instances. Clefting requires a team approach for repair and followup for secondary issues, such as feeding difficulties, speech defects, orthodontia, and ear infections.

EEC SYNDROME (OMIM 129900,604292)

EEC syndrome is an ED classified as a multiple congenital anomaly syndrome because it has major involvement of structures other than those derived from the ectoderm. There are 3 variants of EEC syndrome, EEC1 (OMIM 129900), EEC2 (no OMIM number) and EEC3 (OMIM 604292). EEC1 and EEC2 have unknown gene product mutations, but EEC1 has been linked to a mutation on chromosome 7. EEC3 is caused by an autosomal dominant mutation in the tumor-suppressor gene *TP63*, designating the EECs as p63-related EDs. EEC syndrome has occurred in all racial groups worldwide, and all 3 forms share clinical manifestations.

CLINICAL FEATURES

The ectodermal dysplasia manifestations may be quite mild. The hair is usually blonde, coarse, and dry. It may be sparse and slow growing. Axillary and pubic hair also may be affected. The nails are dystrophic in approximately four-fifths of individuals with transverse ridging, pitting, and slow growth. Dry skin and thickening of the palms and soles can occur. Sweating is usually normal.[46]

The major distinguishing feature of EEC syndrome is ectrodactyly (Figs. 131-8A-C). The feet are involved more frequently than the hands, and there may be asymmetry of involvement.

Cleft palate, with or without cleft lip, occurs in 70% to 100% of affected individuals.[46,47] Hypodontia and premature loss of secondary teeth and the dental abnormalities associated with clefting are found in most affected individuals. Lacrimal gland abnormalities and secondary conductive hearing loss are common. Genitourinary abnormalities that include hydronephrosis and structural renal or genital malformations affect one-third or more of persons with EEC syndrome. Although intellectual disability has been reported, it is not believed to be an inherent feature of the disorder.

DIFFERENTIAL DIAGNOSIS

Disorders with limb defects that need to be considered in the differential diagnosis of EEC syndrome are odontotrichomelic syndrome (OMIM 273400), in which there are severe absence deformities of the limbs, and aplasia cutis congenita with limb defects (Adams–Oliver syndrome, OMIM 100300), which does not have clefting or ectodermal defects other than absence of skin. Cutis marmorata telangiectatica congenita (Chap. 103) has been described in some individuals with Adams–Oliver syndrome. Other EDs with clefting include AEC and limb–mammary syndrome, all of which are allelic to EEC syndrome. Ectrodactyly with cleft palate without ED (OMIM 129830) may be a distinct entity. There appear to be some families with EEC in whom linkage studies have suggested other causal genes located at different chromosomal loci. Prenatal diagnosis by ultrasound for detection of limb abnormalities is unreliable; genetic testing may prove useful in some families.

CLINICAL COURSE, PROGNOSIS, AND MANAGEMENT

As for other EDs with orofacial clefting and ophthalmologic involvement, management requires a team approach. Similarly, treatment for the limb defects must be individualized. Renal ultrasonography and a high index of suspicion for urinary tract problems are appropriate and warranted.

P63-RELATED ECTODERMAL DYSPLASIA SYNDROMES

ETIOLOGY AND PATHOGENESIS

AEC, EEC, split hand–split foot malformation, limb–mammary syndrome, and ADULT syndrome are

Figure 131-8 Ectrodactyly–ectodermal dysplasia–clefting syndrome. **A,** Hands of an affected adult. **B,** Hands and feet of affected infant. **C** and **D,** Feet and hands of parent of infant in (**B**) demonstrating variability of expression both among limbs and between family members. Note the nail dystrophy in the mildly affected mother, especially evident on the thumbs.

caused by mutations in the tumor-suppressor gene *TP63* mapped to 3q27. Different mutations within this gene have been implicated in the pathogenesis of these syndromes.[34,48] *TP63* is expressed widely, including in the basal cells of proliferating epithelial tissues.

AEC syndrome is an autosomal dominant disorder with complete penetrance and variable expression. The majority of alterations identified thus far in AEC syndrome have been missense mutations in the sterile α motif (SAM) domain of p63.

EEC syndrome is an autosomal dominant disorder with variable expression and reduced penetrance. Mutations in *TP63* have been found in most, but not all, individuals with EEC syndrome. The majority of mutations result in single–amino acid substitutions in the DNA-binding domain of p63.[33]

Similar to EEC, mutations in the DNA-binding domain of *TP63* are also found in split hand–split foot malformation.[49] Frameshift mutations in *TP63* cause limb–mammary syndrome, in which ectodermal structures other than the mammary gland often, but not always, appear normal. Among 3 unrelated families with ADULT syndrome, all shared the same point mutation in *p63*.[50]

WNT10A DISORDERS: ODONTO-ONYCHO-DERMAL DYSPLASIA (OODD), SCHOPF–SCHULZ–PASSARGE SYNDROME (SSPS)

AT-A-GLANCE

- Variants: all of the below are AR with a mutation of *WNT10A* (wingless-type MMTV integration site family, member 10A) on 2q35, which mediates β catenin–mediated specific intracellular signaling
  - Odonto-onycho-dermal dysplasia (OODD; OMIM 257980)
  - Schopf–Schulz–Passarge Syndrome (SSPS; OMIM 224750)

(Continued)

AT-A-GLANCE (*Continued*)

- Both OODD and SSPS demonstrate variable degrees of hypodontia, dystrophic nails, hypotrichosis, palmar plantar hyperkeratosis with hyperhidrosis, hypohidrosis on rest of body.
- SSPS is also characterized by eyelid hidrocystomas

INTRODUCTION

Odonto-onycho-dermal dysplasia (OODD) and Schopf–Schulz–Passarge Syndrome (SSPS) are both forms of ED caused by mutations in the *WNT10A* gene.

EPIDEMIOLOGY

Mutations in *WNT10A* have been reported in about 9% of EDs and in 25% of hypohidrotic ED (HED) patients who do not have mutations in *EDA*.[51,52] With recent advances in molecular genetic testing, *WNT10A* mutations have been found in about 16% of suspected cases of HED.[9]

CLINICAL FEATURES

OODD has a broad spectrum of clinical features. The most consistent finding is severe hypodontia to anodontia of the permanent teeth. Primary teeth are almost always normal in number but may be small and widely spaced (Fig. 131-9A).[53-55] The tongue may be smooth, with decreased fungiform and filiform papillae. The nails are dystrophic, and there can be congenital anonychia. Hair is absent at birth, progressing to dry, thin hair in older individuals. Eyebrows may be sparse. Skin changes include palmar erythema, palmar plantar hyperkeratosis (Fig. 131-9B),[56] and keratosis pilaris. The palms and soles commonly have hyperhidrosis, although there is hypohidrosis elsewhere on the body.

SSPS is characterized by eyelid hidrocystomas; in addition, the findings described above in OODD.[57]

ETIOLOGY AND PATHOGENESIS

OODD and SSPS are caused by mutations in *WNT10A* (wingless-type MMTV integrations site family, member 10A) gene.[57] Most cases are autosomal recessive, but up to 50% of heterozygotes may display clinical features.

Figure 131-9 WNT10A disorders. **A,** Note the widely spaced and scattered missing deciduous teeth with the characteristic thin upper lip. (Image reused from Bergendal B, Norderyd J, Zhou X, et al. Abnormal primary and permanent dentitions with ectodermal symptoms predict WNT10A deficiency. BMC Med Genet. 2016;17(1):88 with permission from BioMed Central.) **B,** Erythematous hyperkeratosis with erosions and fissures of the palmar hands and the plantar feet. (Images reused from Krøigård AB, Clemmensen O, Gjørup H, et al. Odonto-onycho-dermal dysplasia in a patient homozygous for a WNT10A nonsense mutation and mild manifestations of ectodermal dysplasia in carriers of the mutation. BMC Dermatol. 2016;16:3, with permission from BioMed Central.)

DIAGNOSIS

On histopathology, the skin shows orthokeratosis, hyperkeratosis, hypergranulosis, and mild acanthosis. When examined by EM, the hairs of OODD have longitudinal depressions. Again, genetic testing can be helpful.

CLINICAL COURSE, PROGNOSIS, AND MANAGEMENT

Restorative dentistry is important. Hyperkeratosis management is nonspecific and the nails usually require no treatment. There is potential increased risk of nonmelanoma skin cancer in SSP, and patients should be monitored appropriately.

FOCAL DERMAL HYPOPLASIA (GOLTZ SYNDROME; GOLTZ-GORLIN SYNDROME)

AT-A-GLANCE

- OMIM 305600
- XLD, *PORCN*, Xp11.23, involved in membrane targeting and secretion of Wnt proteins necessary for embryonic tissue development
- Cutaneous features: Blaschkoid dermal atrophy with fat herniations; progressive papillomas; patchy alopecia
- Extracutaneous features: microphthalmia and colobomas; oligodontia and enamel defects; numerous skeletal anomalies including syndactyly and osteopathia striata; developmental delays in 15%

INTRODUCTION

Focal dermal hypoplasia (FDH) is a rare ectodermal dysplasia with multisystem involvement, including skin, teeth, bones, and eyes with variable clinical manifestations.[58]

EPIDEMIOLOGY

FDH was first described in 1934.[59] Subsequently, there have been more than 200 case reports published.

CLINICAL FEATURES

The skin changes of FDH are the primary diagnostic features with considerable variability because of both postzygotic somatic mosaicism in both males and females and random X-chromosome inactivation in females. There is linear, punctate, streaky cribriform atrophy (Fig. 131-10), with telangiectasia distributed along the lines of Blaschko. The cribriform atrophy is marked by tiny ice pick–like depressions in the skin. Areas of thinned to absent dermis are irregularly distributed and the resultant herniations of fat appear as yellow–pink excrescences that are easily depressed on the skin surface (Fig. 131-10). Papillomas that may be raspberry-like or vascular develop throughout life and favor the perigenital, perioral, intertriginous, and mucosal surfaces. Other dermatologic features include pigmentary changes, patchy alopecia, brittle or sparse hair, and palmar and plantar hyperkeratoses. Some individuals have had hyperhidrosis and some have had aplasia cutis congenita.

The other organ systems most frequently involved in FDH are the skeleton, CNS, teeth, and eyes. Microphthalmia and colobomas are common, and the diagnosis of FDH should prompt a full ophthalmologic evaluation. Oligodontia, tooth dysplasia, and enamel defects are common. The skeletal abnormalities are too numerous to list; the most common are vertical banding of the bones (osteopathia striata), syndactyly (both cutaneous and bony), ectrodactyly, asymmetry, oligodactyly, and short stature. Intellectual disability has been reported in approximately 15% of cases. Defects in other organ systems have been described in a minority of cases, including cardiac defects, abdominal wall defects, and renal malformations.

ETIOLOGY AND PATHOGENESIS

Focal dermal hypoplasia is an X-linked dominant disorder, usually lethal in males. Case reports of males with the condition are believed to be due to mosaicism for postzygotic somatic mutations (as is true for incontinentia pigmenti); the presence of some normal cells allows survival in the male. The mutated gene is *PORCN*, the human homolog of the porcupine gene in *Drosophila*. *PORCN* is thought to be important for palmitoylation and secretion of Wnt protein, a key regulator of the development of skin and bone.[60,61]

It is important to inquire about the family history of lost pregnancies and a skewed male–female ratio in offspring, as these are clues to the mother being a carrier. Both mothers and fathers should be examined carefully; fathers may have subtle features and, presumably, represent individuals with postzygotic mutations for the *FDH* gene.

Figure 131-10 Focal dermal hypoplasia. **A,** Streaky and patchy involvement in the newborn. Note similarity to the distribution of lesions in incontinentia pigmenti. **B** and **C,** Same girl at age 2 showing atrophy and fat herniation. **D,** Now a young adult, erythema and atrophy, with dryness and scale, predominate. (Image **A,** From Sybert VP. *Genetic Skin Disorders*, 3rd ed. New York, NY: Oxford University Press; 2017; with permission.)

DIAGNOSIS

The diagnosis of FDH is challenging given the rarity of the syndrome. Biopsy can be helpful in demonstrating the dermal hypoplasia and increased capillaries in the papillary dermis.[58] Additionally, genetic testing is commercially available, but can be challenging in patients with postzygotic mutations.

DIFFERENTIAL DIAGNOSIS

Cribriform atrophy has been described in X-linked dominant Conradi–Hünermann syndrome (chondrodysplasia punctata), but ichthyosis is not a feature of FDH, and fat herniation is not part of Conradi–Hünermann. The Blaschkoid distribution of the atrophic lesions of IP is similar, but the blistering and hyperkeratosis of IP are not found in FDH. In microphthalmia and linear skin defects/microphthalmia, dermal aplasia, sclerocornea (MIDAS; OMIM 309801), the skin defects are limited to the head and neck; there is atrophy and scarring of the skin more similar to aplasia cutis congenita and not dermal atrophy alone. The disorders do share similar ocular abnormalities.

CLINICAL COURSE, PROGNOSIS, AND MANAGEMENT

There is no specific treatment for the dermatologic and systemic features of FDH. Areas of atrophy may

be prone to infection or become erosive. Papillomas can be excised if they interfere with function. Referral to otolaryngology may be necessary for management of papillomas of the larynx or trachea and preoperative evaluation for these lesions should be considered.[62] Use of vascular lasers to decrease the erythema of telangiectatic areas may have cosmetic benefit. As with most X-linked dominant disorders, clinical involvement varies considerably, and the range in severity is marked. This makes prognostic counseling difficult early in infancy, and usually it is wise to counsel patience and reassurance until the extent to which there is systemic involvement becomes clear.

INCONTINENTIA PIGMENTI

AT-A-GLANCE

- OMIM 308300
- XLD, *IKBKG* (also called NEMO), Xp28, encodes the I-kappa-B kinase gamma subunit protein involved in cell protection from apoptosis
- Cutaneous features: 4 characteristic stages involving (1) vesicobullous lesions; (2) verrucous lesions; (3) hyperpigmentation; and (4) hypopigmentation and atrophy. May also see hypotrichosis, cicatricial alopecia, and tooth defects.
- Extracutaneous features: ophthalmologic complications, CNS manifestations (seizures, developmental delay)

INTRODUCTION

Incontinentia pigmenti (IP), also known as male-lethal type Bloch–Sulzberger syndrome, was first described in 1906 by Garrod.[63] IP is an ectodermal dysplasia with highly variable involvement of skin, teeth, hair, nails, eyes, and the CNS.[64] The skin findings are the first clinical manifestation.[65]

EPIDEMIOLOGY

IP occurs in 1 in 50,000 to 150,000 newborns.[65] It is X-linked dominant and usually lethal in male fetuses; however, similar to FDH, there are reports of male cases in the setting of late postzygotic mutations, segmental involvement, or XXY genotype.

CLINICAL FEATURES

There are 4 characteristic stages of skin lesions, all of which occur along the lines of Blaschko. Not every stage may occur, and some stages may overlap.

- Stage I: Perinatal inflammatory stage with erythema, vesicles, and pustules with individual lesions lasting for several days to weeks (Fig. 131-11A). Present at birth in 50% and by 2 weeks of age in 90%. Typically resolves by 4 to 6 months, but may have recurrences with illnesses.[66]
- Stage II: Verrucous and hyperkeratotic papules persistent for several weeks to months, with reports of it lasting up to years (Fig. 131-11B).
- Stage III: Hyperpigmentation that usually presents around 6 months of age and persists for several years, with reports of persistence into adulthood. Highly variable extent, often unrelated to the distribution in the previous stages. Most frequently involves the groin and axillae.[64]
- Stage IV: Hypopigmentation and atrophy in previously affected areas. Starts with the resolution of the previous stages and lasting into adulthood.

Many of the cutaneous features resolve or become very subtle by the 20 years of age. Cicatricial and patchy alopecia are common and tend to be persistent. In adult females, areas of hypotrichosis on the legs and whorled alopecia of the scalp can be helpful clinically.[67]

Nail dystrophy is common during the second stage, but often mild.[64] There is a wide range of teeth findings, including hypodontia, microdontia, adontia, and conical teeth.

Ophthalmological involvement is present in 20% to 77%[64,65] of affected individuals and includes retinal neovascularization, strabismus, cataracts, optic atrophy, and retinal pigmentary abnormalities. It is important to screen for eye findings at the time of diagnosis because retinal neovascularization can result in retinal detachment, with the highest risk in the neonatal period and up to the first 6 years of life.[64] Given the risk of decreased visual acuity, repeat eye examinations are necessary.

CNS involvement is estimated at 10% to 30%, although it may be lower.[64,65] CNS abnormalities range from a single seizure to encephalopathy, ischemic stroke, and significant developmental delay. Symptoms most often present in the first year of life, which is consistent with the hypothesis that neurologic manifestations are a result of inflammation and vasculopathy/ischemia.[68] CNS manifestations highly impact morbidity and mortality, and predictive features, such as retinal neovascularization and male gender, are helpful for assessing risk.[68]

Unilateral breast aplasia is uncommon, but should be alert one to the possible diagnosis of IP.[69]

ETIOLOGY AND PATHOGENESIS

IP is an X-linked dominant disorder, typically lethal in males (see discussion regarding mosaicism for

Figure 131-11 Incontinentia pigmenti. **A,** Stage I. Edematous erythematous papules and vesicles following the lines of Blaschko on the lower leg. Note the early stage II verrucous papules on the toes. **B,** Stage II. Hyperkeratotic papules and papules and plaques with surrounding erythema. (Reproduced from Rimoin D, Pyeritz R, Korf B, eds. *Emery and Rimoin's Principles and Practice of Medical Genetics*, 6th ed. Oxford, UK: Academic Press; 2013; Figure 148-15; with permission. Copyright © Elsevier.)

postzygotic mutations above in FDH). About 80% of IP are due to mutations in the *IKBKG* gene, which encodes the I-kappa-B kinase gamma subunit protein (IKK-gamma). More than 50 distinct postzygotic somatic mutation variants in the *IKBKG* gene have been reported.

The IKK-gamma protein is widely expressed and binds to the IKK-alpha and IKK-beta proteins to activate the KF-kappa-B complex. This complex protects cells from TNF-induced apoptosis. The different stages of IP represent cell death of affected cells that are unable to activate this protective complex. It is proposed that after cells with the *IKBKG* mutation undergo apoptosis, they are replaced by unaffected cells. Late recurrences may be due to persistence of affected keratinocytes in the sites of previous lesions.[65]

DIAGNOSIS

In 2014, Minic et al updated the diagnostic criteria. Major criteria include any of the 4 stages of skin lesions. Minor criteria include dental, ocular, CNS, hair, nail, palate, breast, and nipple anomalies; family history; multiple male miscarriages; and histopathologic skin findings.[64,69]

Skin biopsy greatly aids in diagnosis, especially in suspected males, and histopathology is stage specific. Biopsy of vesiculobullous lesions reveals a spongiotic epidermis with eosinophilic infiltrates and microabscesses, and dyskeratosis. Verrucous lesions demonstrate hyperkeratosis, papillomatosis, and dyskeratosis.

Genetic testing is commercially available for *IKBKG* common deletion/duplication and gene sequencing, which identifies IP and HED-ID. About 75% of affected patients have the common 11.7kb deletion of exons 4 to 10.[65] Testing can confirm a clinical diagnosis, detect female carriers, and evaluate at-risk pregnancies in families carrying the IKBKG mutation. Without family history, prenatal diagnosis is difficult as there are no characteristic ultrasound features other than intrauterine growth retardation.[64]

DIFFERENTIAL DIAGNOSIS

The differential for IP depends on what point in the time course the patient is presenting. In the neonatal period, vesiculobullous disorders, including HSV, VZV, bullous impetigo, bullous mastocytosis, and epidermolysis bullosa, and other mosaic disorders, such as focal dermal hypoplasia and epidermal nevus syndrome, may be considered. Later on, linear epidermal nevus, ILVEN, and pigmentary mosaicism, can appear similar.

CLINICAL COURSE, PROGNOSIS, AND MANAGEMENT

Most affected individuals without significant complications in infancy do well with a normal life expectancy. Treatment is symptom directed. The skin changes do not require specific treatment other than wound care of blisters to prevent secondary infection.[64] There are reports of topical corticosteroids minimizing inflammation and accelerating healing in the first stage.[66] As with other EDs, dental evaluation and restoration is important.

A baseline eye examination at diagnosis and following the recommended guidelines for repeat examinations during the first 3 years of life is critical. Peripheral retinal photocoagulation can reduce the risk of retinal detachment. Referral to neurology at time of diagnosis for a comprehensive examination and anticipatory guidance should be considered and is imperative for the management of seizures, spasticity, or other deficits if needed.[64] If neurologic symptoms are present, MRI and EEG should be performed. MRI can be considered in affected individuals with retinal neovascularization.[64]

TOOTH AND NAIL SYNDROME (WITKOP SYNDROME)

AT-A-GLANCE

- OMIM 189500, AD mutation of *MSX1*on 4p16.1, which encodes the transcription factor Msx1
- Characterized by small, friable nails at birth that may improve over time; may have fine, sparse hair. Primary teeth are usually unaffected, but secondary teeth fail to erupt or have partial absence

EPIDEMIOLOGY

The earliest case was reported by Witkop in 1965, when he described a pedigree demonstrating autosomal dominant inheritance. Along with Hudson, he later went on to describe 23 cases in 6 families in 1975.[70] All demonstrated hypoplastic nails and hypodontia; the latter manifested as failure of permanent teeth to erupt.

CLINICAL FEATURES

In tooth and nail syndrome, the nails are thin, small, and friable and may show koilonychia at birth. Toenails are usually more severely involved than fingernails (Fig. 131-12). Nail changes improve with age and may be unappreciated in affected adults. A few individuals have reported thin, fine hair.[71]

Figure 131-12 Tooth–nail syndrome. **A,** Primary teeth still in place; failure of adult teeth to erupt. **B,** Dystrophic toenails with flattening of nail plates.

The primary teeth usually are unaffected, although they may be small. The secondary teeth may fail to erupt, and there can be partial or total absence (Fig. 131-12A). The mandibular incisors, second molars, and maxillary canines are missing most often.[70] No other ectodermal structures are affected.

ETIOLOGY AND PATHOGENESIS

A nonsense mutation in *MSX1*, a gene expressed in the developing teeth and nail beds, was first identified in 2001 in a 3-generation family.[72] In 2013, an unrelated patient was found to have an *MSX1* mutation as well.[73] Other mutations in *MSX1* have been associated with isolated tooth agenesis or tooth agenesis with cleft palate, and mouse models have demonstrated the role of *MSX1* in tooth and nail development.[72] Tooth and nail syndrome is autosomal dominant, with variable expression and intrafamilial variability.

DIAGNOSIS

This is an easy condition to miss. The nail changes may be subtle. The tooth abnormalities may be mild enough to escape detection by a physician. The lack of associated features, either dermatologic or systemic, readily distinguish Witkop syndrome from other EDs. Genetic testing is available.

DIFFERENTIAL DIAGNOSIS

There is a presumed autosomal recessive disorder termed taurodontia, absent teeth, and sparse hair (OMIM 272980) that appears similar.[74] Taurodontia refers to teeth with an elongated body and pulp chamber and short roots.

CLINICAL COURSE, PROGNOSIS, AND MANAGEMENT

The nails usually require no treatment. Restorative dentistry is important.

TRICHO-DENTO-OSSEOUS (TDO) SYNDROME

AT-A-GLANCE

- OMIM 190320, AD mutation of *DLX3* on 17q21.3-q22, which encodes the transcription factor homeobox protein DLX-3
- Ectodermal features: teeth, nail, and hair changes in the setting of normal sweating and skin
- Systemic features: increased bone density

INTRODUCTION

Tricho-dento-osseous (TDO) syndrome is a rare autosomal dominant ED that involves the teeth, hair, nails, and bone.[75] It has been described in several families, although exact epidemiologic information is lacking.

CLINICAL FEATURES

TDO involves the hair, teeth, and nails. Hair is kinky or extremely curly, especially during the neonatal period. Dental findings include enamel hypoplasia, hypocalcification, and taurodontism (enlargement of the body of the tooth and pulp chamber) in both primary and secondary teeth. Nails are often thickened with splitting in the superficial layers. Sweat gland function and skin are unaffected.

Skeletal findings included increased bone density of the long bones and skull. There can be craniosynostosis resulting in dolichocephaly.[76]

ETIOLOGY AND PATHOGENESIS

TDO is an autosomal dominant disorder caused by mutations in *DLX3*, which encodes the human distal-less homeobox. Depending on the mutation, there are different severities in phenotype, but penetrance is usually complete.[77] The DLX3 protein is a transcriptional activator in the development and differentiation of epithelial tissue and has been shown to regulate hair follicles.[78,79]

DIAGNOSIS

Clinical molecular genetic testing is available through several labs.

DIFFERENTIAL DIAGNOSIS

TDO has the same dental findings as amelogenesis imperfecta (hypomaturation-hypoplasia type) with taurodontism (AIHHT), but AIHHT lacks hair and nail findings.

CLINICAL COURSE, PROGNOSIS, AND MANAGEMENT

Management includes dental care for the enamel hypoplasia. Given its autosomal dominant nature, genetic counseling should be provided.

OCULO-DENTO-DIGITAL DYSPLASIA (ODDD)

AT A GLANCE

- OMIM 164200
- AD mutation of *GJA1* on 6p21-23.2, which encodes connexin 43, a connexin protein of the intercellular junction
- Characterized by sparse hair, enamel hypoplasia, camptodactyly, and small eyes

INTRODUCTION

Oculo-dento-digital dysplasia (ODDD) is an autosomal dominant ED with variable expression.

CLINICAL FEATURES

ODDD patients have sparse, dry, slow-growing scalp hair with absent or sparse eyelashes. Both the primary and secondary teeth have enamel hypoplasia, resulting in small, yellow, and friable teeth prone to decay. Sweat glands and skin are normal.

Although vision is normal, the eyes have short palpebral fissures with microcornea and/or microphthalmia. Digital changes include camptodactyly of the fourth and fifth fingers in more than 80% of cases, with possible syndactyly of the fourth and fifth digits. Other skeletal anomalies include hyperostosis of the skull, broad ribs and clavicles, and abnormal trabeculation of the long bones.[80]

ETIOLOGY AND PATHOGENESIS

ODDD is autosomal dominant and caused by mutations in the gene for connexin-43 (*GJA1*).[81] Clinical molecular genetic testing is available.

CLINICAL COURSE, PROGNOSIS, AND MANAGEMENT

Management includes dental care of the enamel hypoplasia. Although vision is normal, patients should be followed by ophthalmology as 10% to 15% develop glaucoma.[82]

TRICHO-RHINO-PHALANGEAL SYNDROME

AT-A-GLANCE

- Variants:
  - TRPS I (OMIM 190350): AD mutation of *TRPS1* on 8q23.2; mutation in the same gene causes TRPS III (OMIM 190351)
  - TRPS II (Langer–Giedion Syndrome; OMIM 150230): AD, contiguous gene syndrome involving TRPS1 and EXT1, 8q24.11-q24.13
- Characterized by sparse hair, prominent nose, receding chin, and cone-shaped epiphyses leading to deviation of the middle phalanges

INTRODUCTION

Tricho-rhino-phalangeal (TRP) syndrome is an AD malformation syndrome characterized by distinctive craniofacial and skeletal anomalies. Although it is not considered a typical ED given the involvement of hair alone without involvement of the teeth, nails, or sweat/sebaceous glands, this chapter best encompasses its other features.

CLINICAL FEATURES

TRPS I patients have sparse, brittle, slow-growing scalp hair. On light microscopy, pili torti can be appreciated. They have a prominent, pear-shaped nose with a broad high nasal bridge and bulbous tip. The philtrum is long and flat with a thin upper lip and receding chin (Fig. 131-13).[83]

Digital changes may not appear until several years of age and include cone-shaped epiphyses and deviation of the middle phalanges giving the appearance of crooked fingers. Other skeletal abnormalities include hip malformations and short stature.[84]

TRPS III has the features above in addition to the presence of severe brachydactyly and more pronounced short stature.[85] TRPSII combines the features of TRPS1 and multiple exostoses type 1. Additionally, these patients often have intellectual disabilities.[86]

Figure 131-13 Tricho-rhino-phalangeal syndrome. Note the sparse hair and eyebrows, bulbous nose and thin upper lip.

ETIOLOGY AND PATHOGENESIS

TRPS I and TRPS III are autosomal dominant and caused by a mutation in *TRPS1*, a transcription factor zinc finger protein.[83] TRPS II is caused by a deletion that includes both *TRPS1* and *EXT1*. Genetic testing is available to assist with diagnosis.

CLINICAL COURSE, PROGNOSIS, AND MANAGEMENT

For short stature, consideration should be given to growth hormone treatment on an individual basis.[87] The skeletal changes should be monitored and managed appropriately for pain if needed. Otoplasty and rhinoplasty can provide aesthetic correction.[88]

ACKNOWLEDGMENTS

The authors acknowledge the contributions of Alanna F. Bree, Nnenna Agim, and Virginia P. Sybert, authors of prior versions of this chapter.

REFERENCES

1. Visinoni AF, Lisboa-Costa T, Pagnan NA, et al. Ectodermal dysplasias: clinical and molecular review. *Am J Med Genet A.* 2009;149a(9):1980-2002.
2. Pinheiro M, Freire-Maia N. Ectodermal dysplasias: a clinical classification and a causal review. *Am J Med Genet.* 1994;53(2):153-162.
3. Salinas CF, Jorgenson RJ, Wright JT, et al. 2008 International Conference on Ectodermal Dysplasias Classification: conference report. *Am J Med Genet A.* 2009; 149a(9):1958-1969.
4. Salinas CF, Irvine AD, Itin PH, et al. Second International Conference on a classification of ectodermal dysplasias: development of a multiaxis model. *Am J Med Genet A.* 2014;164a(10):2482-2489.
5. Modino SA, Sharpe PT. Tissue engineering of teeth using adult stem cells. *Arch Oral Biol.* 2005;50(2): 255-258.
6. Del Rio M, Gache Y, Jorcano JL, et al. Current approaches and perspectives in human keratinocyte-based gene therapies. *Gene Ther.* 2004;11(suppl 1):S57-S63.
7. Ohyama M, Vogel JC. Gene delivery to the hair follicle. *J Investig Dermatol Symp Proc.* 2003;8(2):204-206.
8. Thurnam J. Two cases in which the skin, hair and teeth were very imperfectly developed. *Med Chir Trans.* 1848; 31:71-82.
9. Cluzeau C, Hadj-Rabia S, Jambou M, et al. Only four genes (*EDA1*, *EDAR*, *EDARADD*, and *WNT10A*) account for 90% of hypohidrotic/anhidrotic ectodermal dysplasia cases. *Hum Mutat.* 2011;32(1):70-72.
10. Trzeciak WH, Koczorowski R. Molecular basis of hypohidrotic ectodermal dysplasia: an update. *J Appl Genet.* 2016;57(1):51-61.
11. Zonana J, Elder ME, Schneider LC, et al. A novel X-linked disorder of immune deficiency and hypohidrotic ectodermal dysplasia is allelic to incontinentia pigmenti and due to mutations in IKK-gamma (NEMO). *Am J Hum Genet.* 2000;67(6):1555-1562.
12. Doffinger R, Smahi A, Bessia C, et al. X-linked anhidrotic ectodermal dysplasia with immunodeficiency is caused by impaired NF-kappaB signaling. *Nat Genet.* 2001;27(3):277-285.
13. Stevenson AC, Kerr CB. On the distribution of frequencies of mutation to genes determining harmful traits in man. *Mutat Res.* 1967;4(3):339-352.
14. Kishore M, Panat SR, Aggarwal A, et al. Hypohidrotic ectodermal dysplasia (ED): a case series. *J Clin Diagn Res.* 2014;8(1):273-275.
15. Scaling skin in the neonate: a clue to the early diagnosis of X-linked hypohidrotic ectodermal dysplasia (Christ-Siemens-Touraine syndrome). The Executive and Scientific Advisory Boards of the National Foundation for Ectodermal Dysplasias, Mascoutah, Illinois. *J Pediatr.* 1989;114(4, pt 1):600-602.
16. Basu S, Mitra M, Ghosh A. Evaluation of sweat production by pilocarpine iontophoresis: a noninvasive screening tool for hypohidrosis in ectodermal dysplasia. *Indian J Clin Biochem.* 2013;28(4):433-435.
17. Clarke A, Phillips DI, Brown R, et al. Clinical aspects of X-linked hypohidrotic ectodermal dysplasia. *Arch Dis Child.* 1987;62(10):989-996.
18. Sybert VP. *Genetic Skin Disorders.* New York: Oxford University Press; 1997.
19. Fete M, Hermann J, Behrens J, et al. X-linked hypohidrotic ectodermal dysplasia (XLHED): clinical and diagnostic insights from an international patient registry. *Am J Med Genet A.* 2014;164a(10):2437-2442.
20. Zankl A, Addor MC, Cousin P, et al. Fatal outcome in a female monozygotic twin with X-linked hypohidrotic ectodermal dysplasia (XLHED) due to a de novo t(X;9) translocation with probable disruption of the EDA gene. *Eur J Pediatr.* 2001;160(5):296-299.
21. Motil KJ, Fete TJ, Fraley JK, et al. Growth characteristics of children with ectodermal dysplasia syndromes. *Pediatrics.* 2005;116(2):e229-234.
22. Wright JT, Grange DK, Richter MK. Hypohidrotic ectodermal dysplasia. In: Pagon RA, Adam MP, Ardinger HH, et al, eds. *GeneReviews(R).* Seattle (WA): University of Washington, Seattle, 1993.
23. Burger K, Schneider AT, Wohlfart S, et al. Genotype-phenotype correlation in boys with X-linked hypohidrotic ectodermal dysplasia. *Am J Med Genet A.* 2014;164a(10):2424-2432.
24. Rouse C, Siegfried E, Breer W, et al. Hair and sweat glands in families with hypohidrotic ectodermal dysplasia: further characterization. *Arch Dermatol.* 2004;140(7): 850-855.
25. Bernstein R, Hatchuel I, Jenkins T. Hypohidrotic ectodermal dysplasia and sudden infant death syndrome. *Lancet.* 1980;2(8202):1024.
26. Ogden E, Schandl C, Tormos LM. Death due to complications of anhidrotic ectodermal dysplasia. *J Forensic Sci.* 2014;59(6):1672-1674.
27. Gaide O, Schneider P. Permanent correction of an inherited ectodermal dysplasia with recombinant EDA. *Nat Med.* 2003;9(5):614-618.
28. Casal ML, Lewis JR, Mauldin EA, et al. Significant correction of disease after postnatal administration

of recombinant ectodysplasin A in canine X-linked ectodermal dysplasia. *Am J Hum Genet.* 2007;81(5): 1050-1056.
29. Mauldin EA, Gaide O, Schneider P, et al. Neonatal treatment with recombinant ectodysplasin prevents respiratory disease in dogs with X-linked ectodermal dysplasia. *Am J Med Genet A.* 2009;149a(9): 2045-2049.
30. Clouston HR. The major forms of hereditary ectodermal dysplasia: (with an autopsy and biopsies on the anhydrotic type). *CMAJ.* 1939;40(1):1-7.
31. Der Kaloustian VM. Hidrotic ectodermal dysplasia 2. In: Pagon RA, Adam MP, Ardinger HH, et al, eds. *GeneReviews(R).* Seattle, WA: University of Washington, Seattle, 1993.
32. Lamartine J, Munhoz Essenfelder G, Kibar Z, et al. Mutations in GJB6 cause hidrotic ectodermal dysplasia. *Nat Genet.* 2000;26(2):142-144.
33. Celli J, Duijf P, Hamel BC, et al. Heterozygous germline mutations in the p53 homolog p63 are the cause of EEC syndrome. *Cell.* 1999;99(2):143-153.
34. van Bokhoven H, Hamel BC, Bamshad M, et al. p63 Gene mutations in EEC syndrome, limb-mammary syndrome, and isolated split hand-split foot malformation suggest a genotype-phenotype correlation. *Am J Hum Genet.* 2001;69(3):481-492.
35. Hay RJ, Wells RS. The syndrome of ankyloblepharon, ectodermal defects and cleft lip and palate: an autosomal dominant condition. *Br J Dermatol.* 1976;94(3): 277-289.
36. Rapp RS, Hodgkin WE. Anhidrotic ectodermal dysplasia: autosomal dominant inheritance with palate and lip anomalies. *J Med Genet.* 1968;5(4):269-272.
37. Kannu P, Savarirayan R, Ozoemena L, et al. Rapp-Hodgkin ectodermal dysplasia syndrome: the clinical and molecular overlap with Hay-Wells syndrome. *Am J Med Genet A.* 2006;140(8):887-891.
38. Clements SE, Techanukul T, Holden ST, et al. Rapp-Hodgkin and Hay-Wells ectodermal dysplasia syndromes represent a variable spectrum of the same genetic disorder. *Br J Dermatol.* 2010;163(3):624-629.
39. Vanderhooft SL, Stephan MJ, Sybert VP. Severe skin erosions and scalp infections in AEC syndrome. *Pediatr Dermatol.* 1993;10(4):334-340.
40. Julapalli MR, Scher RK, Sybert VP, et al. Dermatologic findings of ankyloblepharon-ectodermal defects-cleft lip/palate (AEC) syndrome. *Am J Med Genet A.* 2009;149a(9):1900-1906.
41. Berk DR, Crone K, Bayliss SJ. AEC syndrome caused by a novel p63 mutation and demonstrating erythroderma followed by extensive depigmentation. *Pediatr Dermatol.* 2009;26(5):617-618.
42. Sutton VR, Plunkett K, Dang DX, et al. Craniofacial and anthropometric phenotype in ankyloblepharon-ectodermal defects-cleft lip/palate syndrome (Hay-Wells syndrome) in a cohort of 17 patients. *Am J Med Genet A.* 2009;149a(9):1916-1921.
43. Cole P, Hatef DA, Kaufman Y, et al. Facial clefting and oro-auditory pathway manifestations in ankyloblepharon-ectodermal defects-cleft lip/palate (AEC) syndrome. *Am J Med Genet A.* 2009;149a(9):1910-1915.
44. Farrington F, Lausten L. Oral findings in ankyloblepharon-ectodermal dysplasia-cleft lip/palate (AEC) syndrome. *Am J Med Genet A.* 2009;149a(9):1907-1909.
45. Dishop MK, Bree AF, Hicks MJ. Pathologic changes of skin and hair in ankyloblepharon-ectodermal defects-cleft lip/palate (AEC) syndrome. *Am J Med Genet A.* 2009;149a(9):1935-1941.
46. Buss PW, Hughes HE, Clarke A. Twenty-four cases of the EEC syndrome: clinical presentation and management. *J Med Genet.* 1995;32(9):716-723.
47. Roelfsema NM, Cobben JM. The EEC syndrome: a literature study. *Clin Dysmorphol.* 1996;5(2):115-127.
48. McGrath JA, Duijf PH, Doetsch V, et al. Hay-Wells syndrome is caused by heterozygous missense mutations in the SAM domain of p63. *Hum Mol Genet.* 2001;10(3):221-229.
49. Ianakiev P, Kilpatrick MW, Toudjarska I, et al. Split-hand/split-foot malformation is caused by mutations in the p63 gene on 3q27. *Am J Hum Genet.* 2000;67(1):59-66.
50. Rinne T, Spadoni E, Kjaer KW, et al. Delineation of the ADULT syndrome phenotype due to arginine 298 mutations of the p63 gene. *Eur J Hum Genet.* 2006;14(8): 904-910.
51. Bohring A, Stamm T, Spaich C, et al. WNT10A mutations are a frequent cause of a broad spectrum of ectodermal dysplasias with sex-biased manifestation pattern in heterozygotes. *Am J Hum Genet.* 2009;85(1):97-105.
52. Nawaz S, Klar J, Wajid M, et al. WNT10A missense mutation associated with a complete odonto-onycho-dermal dysplasia syndrome. *Eur J Hum Genet.* 2009; 17(12):1600-1605.
53. Megarbane H, Haddad M, Delague V, et al. Further delineation of the odonto-onycho-dermal dysplasia syndrome. *Am J Med Genet A.* 2004;129a(2):193-197.
54. Arzoo PS, Klar J, Bergendal B, et al. WNT10A mutations account for (1/4) of population-based isolated oligodontia and show phenotypic correlations. *Am J Med Genet A.* 2014;164a(2):353-359.
55. Bergendal B, Norderyd J, Zhou X, et al. Abnormal primary and permanent dentitions with ectodermal symptoms predict WNT10A deficiency. *BMC Med Genet.* 2016;17(1):88.
56. Kroigard AB, Clemmensen O, Gjorup H, et al. Odonto-onycho-dermal dysplasia in a patient homozygous for a WNT10A nonsense mutation and mild manifestations of ectodermal dysplasia in carriers of the mutation. *BMC Dermatol.* 2016;16:3.
57. Castori M, Ruggieri S, Giannetti L, et al. Schopf-Schulz-Passarge syndrome: further delineation of the phenotype and genetic considerations. *Acta Derm Venereol.* 2008;88(6):607-612.
58. Ko CJ, Antaya RJ, Zubek A, et al. Revisiting histopathologic findings in Goltz syndrome. *J Cutan Pathol.* 2016;43(5):418-421.
59. Goltz RW. Focal dermal hypoplasia syndrome. An update. *Arch Dermatol.* 1992;128(8):1108-1111.
60. Grzeschik KH, Bornholdt D, Oeffner F, et al. Deficiency of PORCN, a regulator of Wnt signaling, is associated with focal dermal hypoplasia. *Nat Genet.* 2007;39(7):833-835.
61. Wang X, Reid Sutton V, Omar Peraza-Llanes J, et al. Mutations in X-linked PORCN, a putative regulator of Wnt signaling, cause focal dermal hypoplasia. *Nat Genet.* 2007;39(7):836-838.
62. Bostwick B, Van den Veyver IB, Sutton VR. Focal dermal hypoplasia. In: Pagon RA, Adam MP, Ardinger HH, et al, eds. *GeneReviews(R).* Seattle, WA: University of Washington, Seattle, 1993.
63. Arenas-Sordo Mde L, Vallejo-Vega B, Hernandez-Zamora E, et al. Incontinentia pigmenti (IP2): familiar case report with affected men. Literature review. *Med Oral Patol Oral Cir Bucal.* 2005;10(suppl 2): E122-E129.
64. Scheuerle AE, Ursini MV. Incontinentia Pigmenti. In: Adam MP, Ardinger HH, Pagon RA, et al, eds.

GeneReviews((R)). Seattle, WA: University of Washington, Seattle, 1993.
65. Fusco F, Paciolla M, Conte MI, et al. Incontinentia pigmenti: report on data from 2000 to 2013. *Orphanet J Rare Dis*. 2014;9:93.
66. Darne S, Carmichael AJ. Isolated recurrence of vesicobullous incontinentia pigmenti in a schoolgirl. *Br J Dermatol*. 2007;156(3):600-602.
67. Popli U, Yesudian PD. Whorled scarring alopecia—the only adult marker of incontinentia pigmenti. *Int J Trichology*. 2018;10(1):24-25.
68. Meuwissen ME, Mancini GM. Neurological findings in incontinentia pigmenti; a review. *Eur J Hum Genet*. 2012;55(5):323-331.
69. Minic S, Trpinac D, Obradovic M. Incontinentia pigmenti diagnostic criteria update. *Clin Genet*. 2014; 85(6):536-542.
70. Hudson CD, Witkop CJ. Autosomal dominant hypodontia with nail dysgenesis. Report of twenty-nine cases in six families. *Oral Surg Oral Med Oral Pathol*. 1975;39(3):409-423.
71. Garzon MC, Paller AS. What syndrome is this? Witkop tooth and nail syndrome. *Pediatr Dermatol*. 1996; 13(1):63-64.
72. Jumlongras D, Bei M, Stimson JM, et al. A nonsense mutation in MSX1 causes Witkop syndrome. *Am J Hum Genet*. 2001;69(1):67-74.
73. Ghaderi F, Hekmat S, Ghaderi R, et al. MSX1 mutation in witkop syndrome; a case report. *Iran J Med Sci*. 2013;38(2)(suppl):191-194.
74. Moller KT, Gorlin RJ, Wedge B. Oligodontia, taurodontia, and sparse hair growth—a syndrome. *J Speech Hear Disord*. 1973;38(2):268-271.
75. Islam M, Lurie AG, Reichenberger E. Clinical features of tricho-dento-osseous syndrome and presentation of three new cases: an addition to clinical heterogeneity. *Oral Surg Oral Med Oral Pathol Oral Radiol Endod*. 2005;100(6):736-742.
76. Haldeman RJ, Cooper LF, Hart TC, et al. Increased bone density associated with DLX3 mutation in the tricho-dento-osseous syndrome. *Bone*. 2004;35(4):988-997.
77. Wright JT, Hong SP, Simmons D, et al. DLX3 c.561_562delCT mutation causes attenuated phenotype of tricho-dento-osseous syndrome. *Am J Med Genet A*. 2008;146a(3):343-349.
78. Bryan JT, Morasso MI. The Dlx3 protein harbors basic residues required for nuclear localization, transcriptional activity and binding to Msx1. *J Cell Sci*. 2000;113(pt 22):4013-4023.
79. Hwang J, Mehrani T, Millar SE, et al. Dlx3 is a crucial regulator of hair follicle differentiation and cycling. *Development (Cambridge, England)*. 2008;135(18):3149-3159.
80. Judisch GF, Martin-Casals A, Hanson JW, et al. Oculodentodigital dysplasia. Four new reports and a literature review. *Arch Ophthalmol*. 1979;97(5):878-884.
81. Paznekas WA, Karczeski B, Vermeer S, et al. GJA1 mutations, variants, and connexin 43 dysfunction as it relates to the oculodentodigital dysplasia phenotype. Hum Mutat. 2009;30(5):724-733.
82. Mosaed S, Jacobsen BH, Lin KY. Case report: imaging and treatment of ophthalmic manifestations in oculodentodigital dysplasia. *BMC Ophthalmol*. 2016;16:5.
83. Momeni P, Glockner G, Schmidt O, et al. Mutations in a new gene, encoding a zinc-finger protein, cause tricho-rhino-phalangeal syndrome type I. *Nat Genet*. 2000;24(1):71-74.
84. Izumi K, Takagi M, Parikh AS, et al. Late manifestations of tricho-rhino-pharyngeal syndrome in a patient: Expanded skeletal phenotype in adulthood. *Am J Med Genet A*. 2010;152a(8):2115-2119.
85. Ludecke HJ, Schaper J, Meinecke P, et al. Genotypic and phenotypic spectrum in tricho-rhino-phalangeal syndrome types I and III. *Am J Hum Genet*. 2001;68(1): 81-91.
86. Ludecke HJ, Wagner MJ, Nardmann J, et al. Molecular dissection of a contiguous gene syndrome: localization of the genes involved in the Langer-Giedion syndrome. *Hum Mol Genet*. 1995;4(1):31-36.
87. Merjaneh L, Parks JS, Muir AB, et al. A novel TRPS1 gene mutation causing trichorhinophalangeal syndrome with growth hormone responsive short stature: a case report and review of the literature. *Int J Pediatr Endocrinol*. 2014;2014(1):16.
88. Morioka D, Hosaka Y. Aesthetic and plastic surgery for trichorhinophalangeal syndrome. *Aesthetic Plast Surg*. 2000;24(1):39-45.

Chapter 132 :: Genetic Immunodeficiency Diseases

:: Ramsay L. Fuleihan & Amy S. Paller

OVERVIEW OF GENETIC IMMUNODEFICIENCY DISEASES

Primary immunodeficiency diseases are inherited disorders of the immune system that result in an increased susceptibility to infection and an increased morbidity and mortality.[1] Many of these genetic immunodeficiency diseases are associated with a variety of cutaneous abnormalities, and recognition of these clinical features may allow an early diagnosis of primary immunodeficiency. Cutaneous abnormalities may include cutaneous infections, atopic-like or seborrheic-like dermatitis, macular erythemas, alopecia, poor wound healing, purpura, petechiae, telangiectasias, pigmentary dilution, cutaneous granulomas, extensive warts, angioedema, and lupus-like changes (Table 132-1). Other clinical features often include failure to thrive, visceral infection, autoimmune disorders, connective tissue/rheumatologic diseases, allergic reactions, and neoplasias.

CLINICAL FEATURES

Immunodeficiency should be suspected when patients have recurrent infections of increased duration or severity, particularly with unusual organisms. Incomplete clearing of infections, unexpected or severe complications of infection, or poor response to antibiotics may be associated.[2] Affected infants often grow poorly (failure to thrive). The most common noncutaneous abnormalities are infections, diarrhea, vomiting, hepatosplenomegaly, arthritis, adenopathy or paucity of lymph nodes/tonsils, and hematologic abnormalities.

The classification of genetic immunodeficiency disorders includes: (a) antibody deficiencies, (b) cellular deficiencies, (c) combined antibody and cellular deficiencies, (d) disorders of phagocytosis and cell killing, and (e) complement defects. The characteristic clinical signs of each group suggest that proper classification and laboratory tests may be used to confirm the diagnosis. The laboratory testing and clinical patterns of illness associated with each group of immunodeficiency disorders that allow their differential diagnosis are outlined in Table 132-2 and Fig. 132-1. The most important disorder in the differential diagnosis of all genetic immunodeficiency disorders is HIV infection. In addition to the lack of HIV antigen as detected by polymerase chain reaction in patients with genetic immunodeficiency, other features help to differentiate the disorders. Patients with HIV infection tend to show an inverted CD4-to-CD8 ratio and hypergammaglobulinemia, in contrast to the hypogammaglobulinemia of many patients with genetic immunodeficiency.

ANTIBODY DEFICIENCY DISORDERS

AGAMMAGLOBULINEMIA

AT-A-GLANCE

- Synonym: Bruton disease.
- Early-onset, recurrent bacterial infections.
- Absent or barely detectable tonsillar and cervical lymph node tissue.
- Profound hypogammaglobulinemia and decreased or absent peripheral B cells.

CLINICAL FEATURES

Agammaglobulinemia is characterized by recurrent pyogenic infections that often begin after 6 months of age, concurrent with the waning of maternal immunoglobulins. These patients have absent or barely detectable tonsils and cervical lymph nodes.[3] Skin infections, especially furunculosis and impetigo, are common and often surround body orifices. An atopic-like eczematous eruption that fails to improve with immunoglobulin (Ig) therapy has been described in many affected children. Pyoderma gangrenosum and noninfectious cutaneous granulomas have been reported. Childhood exanthematous disorders are handled appropriately, but the infections may recur, owing to a failure to develop specific antibodies.

Recurrent otitis media, sinusitis, bronchitis, and pneumonia are the earliest infectious manifestations and usually are caused by pneumococci, staphylococci, or *Haemophilus*. Untreated pulmonary infections may lead to progressive bronchiectasis and chronic pulmonary disease.[4] Patients can also suffer from chronic enteroviral infections and hearing loss from repeated otitis and sinusitis infections. Other common bacterial infections include conjunctivitis, osteomyelitis, septic arthritis, and meningitis. Protracted diarrhea may be caused by infection, particularly with *Giardia*, *Salmonella*, *Campylobacter*, or *Cryptosporidium* spp. Three virus groups cause problems: enterovirus, hepatitis B virus, and rotavirus. Patients have developed

TABLE 132-1
Manifestations of Genetic Immunodeficiencies

CUTANEOUS MANIFESTATIONS	ASSOCIATED IMMUNODEFICIENCY
Angioedema	Hereditary angioedema
Atopic-like dermatitis	IgA deficiency/IgM deficiency Chronic granulomatous disease Common variable immunodeficiency Elevated IgM with hypogammaglobulinemia Ectodermal dysplasia with immunodeficiency Hyperimmunoglobulinemia E syndrome Severe combined immunodeficiency Wiskott-Aldrich syndrome X-linked agammaglobulinemia
Cutaneous abscesses	Chronic granulomatous disease Hyperimmunoglobulinemia E syndrome Leukocyte adhesion deficiency
Cutaneous granulomas	Ataxia-telangiectasia Chronic granulomatous disease Chronic mucocutaneous candidiasis Common variable immunodeficiency Severe combined immunodeficiency, especially *TAP2* deficiency X-linked hypogammaglobulinemia
Cutaneous candidal infection	Chronic mucocutaneous candidiasis DiGeorge syndrome Hyperimmunoglobulinemia E syndrome Severe combined immunodeficiency especially TAP2 deficiency
Eosinophilic folliculitis, infantile	Hyperimmunoglobulinemia E syndrome
Graft-versus-host disease	DiGeorge syndrome Severe combined immunodeficiency
Lupus-like cutaneous change	IgA deficiency Chronic granulomatous disease, autosomal recessive Chronic granulomatous disease, X-linked carrier Common variable immunodeficiency Complement deficiency, early components Elevated IgM with hypogammaglobulinemia
Mucocutaneous telangiectasias	Ataxia-telangiectasia
Petechiae and/or purpura	Chédiak-Higashi syndrome
Pigmentary dilution/silvery hair	Griscelli syndrome
Pyoderma gangrenosum-like ulcerations	Wiskott-Aldrich syndrome Chédiak-Higashi syndrome Griscelli syndrome IgA deficiency Chédiak-Higashi syndrome Chronic granulomatous disease Hyperimmunoglobulinemia E syndrome Leukocyte adhesion deficiency
Seborrheic-like or exfoliative dermatitis	X-linked hypogammaglobulinemia Ataxia-telangiectasia "Leiner" phenotype: complement deficiency or dysfunction
Warts, extensive	Severe combined immunodeficiency X-linked agammaglobulinemia Common variable immunodeficiency Elevated IgM with hypogammaglobulinemia Epidermodysplasia verruciformis (see Chap. 166) IgM deficiency Severe combined immunodeficiency after transplantation (mutations in *IL2RG* or *JAK3*) WHIM syndrome

Ig, immunoglobulin; TAP, transporter associated with antigen processing or transporter, ATP-binding cassette; WHIM, warts, hypogammaglobulinemia, infections, myelokathexis.

TABLE 132-2
Patterns Associated with Primary Immune Deficiency

DISORDER	INFECTION	OTHER
Antibody	Sinopulmonary (pyogenic bacteria)	Autoimmune disease (autoantibodies, inflammatory bowel disease)
	GI (enterovirus, *Giardia*)	Minimal growth retardation
	Normal handling of fungal and viral infections (exception is enterovirus)	Paucity of lymphoid tissue
Cellular	Low-grade or opportunistic infections	Growth retardation
	Pneumonia (pyogenic bacteria, *Pneumocystis*, viruses)	Graft-versus-host disease
	GI (viruses)	Fatal infections from live vaccines
	Skin, mucous membranes (fungi)	Malignancy
Phagocytosis and cell killing	Skin, reticuloendothelial system (*Staphylococcus*, enteric bacteria, *Aspergillus*, *Mycobacteria*)	Ulcerative stomatitis
Complement	Alternative, late components	Early components
	Sepsis/blood-borne (streptococci, pneumococci, *Neisseria*)	Autoimmune disease (systemic lupus erythematosus, glomerulonephritis)
		C1 esterase inhibitor deficiency
		Angioedema

paralysis after administration of the live polio vaccine. A rheumatoid-like arthritis, characterized by chronic inflammation and swelling of the large joints, may develop in as many as one-third to one-half of boys with X-linked agammaglobulinemia (XLA) and is often caused by mycoplasmal infection (*Ureaplasma urealyticum*). Disseminated echovirus infection has caused meningoencephalitis and a dermatomyositis-like disorder with brawny edema, induration of the muscles with accompanying weakness, muscle contractures, and poikiloderma.

ETIOLOGY AND PATHOGENESIS

Agammaglobulinemia results from failure of development of B cells, most commonly from gene defects that prevent the assembly of a full B-cell antigen receptor. XLA is the most common cause of agammaglobulinemia and results from defects in a cytoplasmic tyrosine kinase, Bruton tyrosine kinase. XLA is inherited in an X-linked fashion, and approximately 50% of affected boys have a family history of the disorder.[5] Autosomal recessive agammaglobulinemia affects males and females equally and results from defects in the genes that encode for components of the pre–B-cell and B-cell receptors or in BLNK (B-cell linker), a scaffold protein that assembles signaling molecules associated with the pre–B-cell and B-cell receptor.

DIAGNOSIS

The diagnosis of agammaglobulinemia is made by serum concentrations of IgG, IgA, and IgM that are far below the 95% confidence limits for appropriate controls (usually less than 100 mg/dL total Ig) and by the virtual absence of B cells in the peripheral circulation (<1% of normal). The absence of the Bruton tyrosine kinase protein in patients with XLA can be detected by flow cytometry. Identification of a defect in one of the known genetic causes of agammaglobulinemia confirms the diagnosis and allows for genetic counseling and prenatal diagnosis.

CLINICAL COURSE, PROGNOSIS, AND MANAGEMENT

Early Ig replacement, intravenously or subcutaneously, and antibiotic use markedly reduces the risk of infections, although it may not be helpful in diminishing the risk and morbidity of chronic lung disease or chronic enterovirus infection.

COMMON VARIABLE IMMUNODEFICIENCY

AT-A-GLANCE

- Heterogeneous group of disorders in which both antibody deficiency and abnormalities of T cells may be found.
- Most common underlying gene defect is in the transmembrane activator and calcium-modulating cyclophilin ligand interactor (TACI) gene.
- May manifest during childhood, with peak onset in the second and third decades of life.

(Continued)

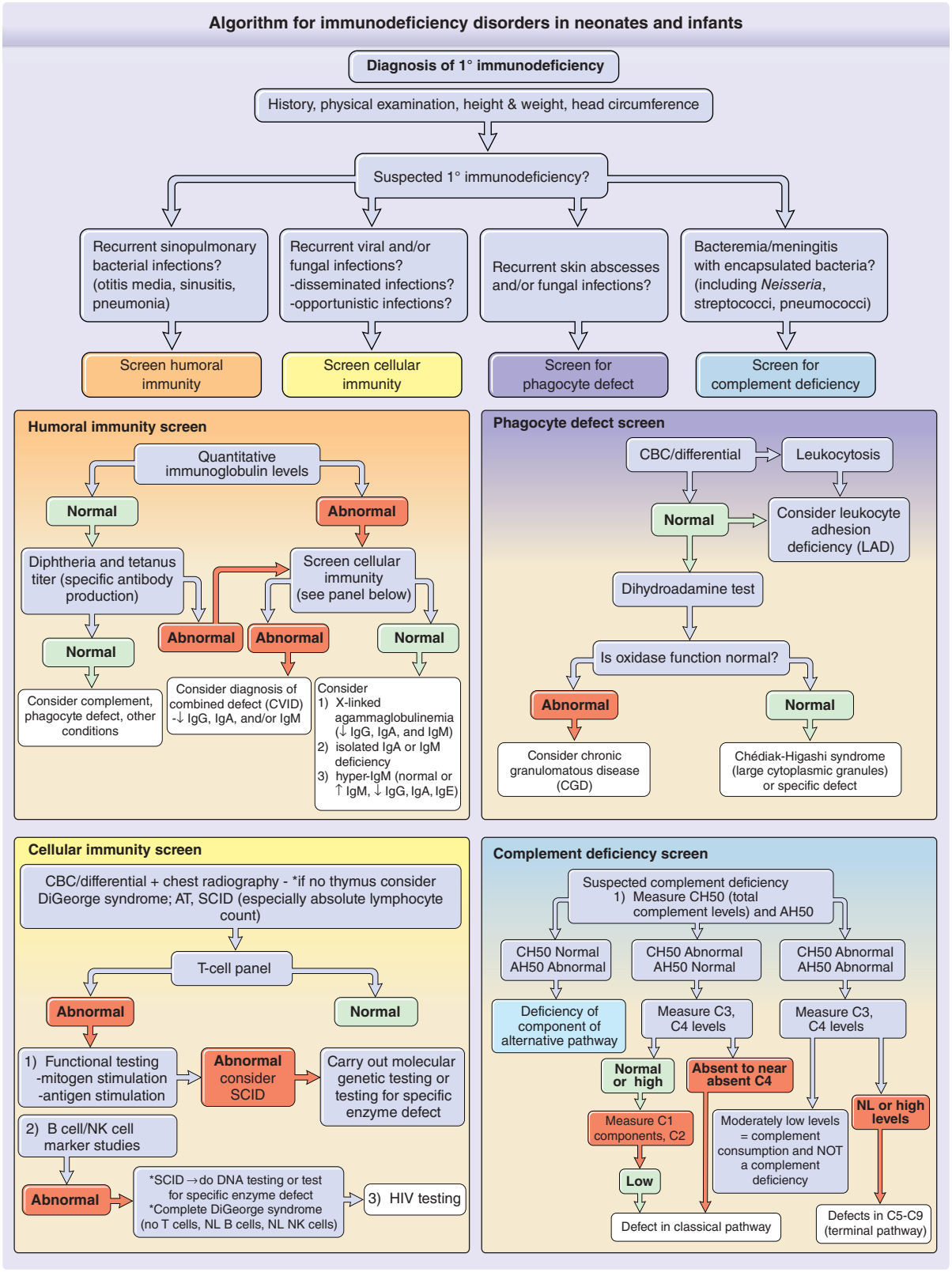

Figure 132-1 Algorithm for immunodeficiency disorders in neonates and infants. If the clinical presentation is concerning for severe combined immunodeficiency (SCID), this is a medical emergency and the patient needs immediate referral to an immunologist. AH50, alternative pathway 50% hemolytic activity; AT, ataxia-telangiectasia; CBC, complete blood cell count; CH50, 50% hemolytic complement; CVID, common variable immunodeficiency; Ig, immunoglobulin; NK cell, natural killer cell; NL, normal; ↓, decreased; ↑, increased.

AT-A-GLANCE (*Continued*)

- Diagnosis requires the presence of low levels of serum immunoglobulin (Ig) G with either low IgM and/or low IgA, defective antibody response to immunization, especially with pneumococcal antigens, with recurrent infections and/or typical autoimmune complications.
- Variable severity of autoimmune and infectious complications.

CLINICAL FEATURES

Common variable immunodeficiency (CVID) usually presents in young adults, but approximately 20% of cases are diagnosed before the age of 21 years.[6] Patients have infections similar to those in patients with XLA, particularly sinopulmonary infections, but are less susceptible to enteroviral infections and more susceptible to *Giardia* infections. Many patients with CVID have liver disease and GI disease, causing malabsorption syndromes. Noncaseating granulomas of skin (Fig. 132-2), lungs, liver, and spleen have been reported. Caseating granulomas of the skin and viscera, although rare, also have been described.[7,8] Extensive warts can be a major problem in individuals with CVID (Fig. 132-3). A comparison of skin manifestations in patients with CVID compared to IgA deficiency found that there was an increased incidence of atopic dermatitis without an elevated IgE level in patients with IgA deficiency, while there was an increased prevalence of psoriasis, skin infections, acne, alopecia, vitiligo, and aphthous ulcers in patients with CVID.[9] Lymphoid tissues often are enlarged, and splenomegaly with hypersplenism is also found, with 8.2% of CVID patients undergoing splenectomy.[6] Autoimmune disorders are especially frequent (28.6%), particularly autoimmune thrombocytopenia, autoimmune hemolytic anemia, rheumatoid arthritis, sicca syndrome, and pernicious anemia. Alopecia areata and lupus also have been described. In 10% to 20% of CVID patients, at least 1 family member is also immunodeficient, particularly with CVID or IgA deficiency.[10] The incidence of lymphoreticular malignancy and gastric carcinoma are markedly increased, particularly in the fifth and sixth decades of life.

Figure 132-2 Noncaseating granulomas on the legs of a child with common variable immunodeficiency. Cultures and special stains showed no organisms.

Figure 132-3 The dorsal aspect of the hands were covered with recalcitrant verrucae vulgaris in this girl with common variable immunodeficiency.

SELECTIVE IMMUNOGLOBULIN DISORDERS

AT-A-GLANCE

- Immunoglobulin A deficiency is usually asymptomatic; only 10% to 15% of affected individuals demonstrate clinical manifestations, including bacterial sinopulmonary infections and autoimmune disorders.

CELLULAR DEFICIENCIES

CHRONIC MUCOCUTANEOUS CANDIDIASIS

AT-A-GLANCE

- Heterogeneous group of disorders with altered immune responses selective to *Candida*.
- Recurrent, progressive candidal infections of the skin, nails, and mucous membranes.
- May be associated with the later development of endocrinopathy (APECED [*a*utoimmune *p*oly*e*ndocrinopathy, *c*andidiasis, and *e*ctodermal *d*ystrophy]).

Several clinical subtypes of chronic mucocutaneous candidiasis (CMC) have been defined (Table 132-3). They have varied clinical manifestations, variable immunodeficiency, and different forms of genetic inheritance. Patients with CMC may have childhood or mature onset, and familial or sporadic occurrence. In addition, CMC may be present with or without endocrinopathy. Patients with autoimmune polyendocrinopathy, candidiasis, and ectodermal dystrophy (APECED or autoimmune polyendocrine syndrome, Type 1) often have affected siblings. APECED and other familial forms of CMC are autosomal recessive. Autosomal dominant inheritance is seen in patients with associated keratitis.

CLINICAL FEATURES

Patients with CMC have recurrent, progressive infections of the skin, nails, and mucous membranes most commonly caused by *Candida albicans*. Depending on the subtype, the clinical presentation ranges from recurrent, recalcitrant thrush (Fig. 132-4) to mild erythematous scaling plaques (Fig. 132-5) with a few dystrophic nails to severe generalized, crusted granulomatous plaques (Fig. 132-6). The cutaneous plaques occur most commonly in intertriginous areas, periorificial sites, and the scalp, but they may be generalized. The nails are thickened, brittle, and discolored, and the paronychial areas are often erythematous, swollen, and tender. Scalp infections may lead to scarring and alopecia. Although the oral mucosa is the most frequent site of mucosal alteration, esophageal, genital, and laryngeal mucosae may be affected. Strictures may be formed by candidal infection at these mucosal sites. Scrapings and cultures from cutaneous or mucosal lesions demonstrate candidal organisms.

Patients with CMC rarely develop systemic candidiasis, but 50% may develop recurrent or severe infections caused by other organisms. In one study, 81% of patients with early-onset CMC also had infections with bacteria, fungi, and parasites, including bacterial septicemia.[11] Concomitant dermatophyte infections may occur.

In patients with APECED, the candidal infections tend to begin by 5 years of age, although the endocrinologic dysfunction may not be apparent until 12 to 13 years of age (see Fig. 132-6). The most commonly associated endocrinopathies are hypoparathyroidism (88%) and hypoadrenocorticism (60%). One-third of patients have candidiasis, hypoparathyroidism, and defective adrenal function. Other associated endocrinopathies or autoimmune disorders include gonadal insufficiency (45%), alopecia areata (20%), pernicious anemia (16%), thyroid abnormalities (12%), chronic active hepatitis or juvenile cirrhosis (9%), vitiligo, diabetes mellitus, and hypopituitarism. Chronic diarrhea and malabsorption have been reported in 25% of patients and usually are associated with hypoparathyroidism. Some affected patients also have pulmonary fibrosis, dental enamel hypoplasia, and keratoconjunctivitis. The "ectodermal dysplasia" features are likely to be secondary to the candidal infections or autoimmunity. Patients with APECED often have autoimmune antibodies, including antithyroglobulin, antimicrosomal, antiadrenal, and antimelanocyte antibodies, and rheumatoid factor. Autoantibodies also have been found in patients with CMC who do not have clinical endocrinologic disease.

ETIOLOGY AND PATHOGENESIS

T-helper 17 (Th17) cells play a critical role in immune defense against *Candida* and are impaired in their responsiveness in both APECED and non-APECED CMC patients.[12] Heterozygous mutations that activate the signal transducer and activator of transcription 1 gene (*STAT1*) are the most common cause,[13,14] and repress expression of interleukin (IL)-17 while promoting interferon signaling (see Table 132-3).[15-18] Mutations in isoforms of IL-17, IL-17 receptors, or *TRAF3IP2*, which regulates responses to IL-17, also have been described. APECED, an autosomal recessive form, results from loss-of-function mutations in the autoimmune regulator gene (*AIRE*). *AIRE* regulates the expression of self-antigens in thymic medullary epithelial cells, promoting immune tolerance through negative selection of autoreactive T cells and generation of antigen-specific regulatory T cells.[19] The retention of peripheral tissue-specific autoreactive T cells in APECED leads to the production of neutralizing autoantibodies, including against Th17-associated cytokines, leading to *Candida* infections and autoimmune disease.[20,21] Predisposition to *Candida* and dermatophyte infections is also a feature of mutations in the caspase recruitment domain family member-9 gene (*CARD9*)[22] and in the gene encoding dectin-1.[23]

DIAGNOSIS

Scrapings and cultures from lesions show candidal organisms. If a biopsy is done, the *C. albicans* are seen

TABLE 132-3
Subgroups of Chronic Mucocutaneous Candidiasis

CHRONIC MUCOCUTANEOUS CANDIDIASIS TYPE	INHERITANCE/GENE DEFECT	CLINICAL FEATURES	ASSOCIATED FEATURES
Familial chronic mucocutaneous candidiasis	Autosomal dominant gain-of-function mutations in *STAT1*	Candidiasis of the oral mucosa, nails and skin often begin in infancy; occasionally dermatophyte infections; squamous cell carcinoma, dental enamel defects, arterial aneurysms have been described	Most common are thyroid disease, vitiligo and alopecia areata, but other immune-mediated disorders occur with increased frequency May have bacterial (especially skin and lungs), and viral infections; invasive fungal and mycobacterial infections are uncommon
Autoimmune polyendocrinopathy, candidiasis, and ectodermal dystrophy (APECED) syndrome	Autosomal recessive Mutations in the *AIRE* (autoimmune regulator) gene More common in the Finnish population, Iranian Jews, and Sardinians	Oral and diaper area candidiasis > skin and nail begin before 5 years of age; up to 60% have urticarial eruptions	Often does not develop until adolescence or adulthood Hypoparathyroidism (90%) Hypoadrenalism (80%) Chronic diarrhea (up to 80%) Dental enamel hypoplasia (70%) Hypogonadism (up to 50%) Hepatitis (up to 40%) Pneumonitis (up to 40%) Sjögren syndrome (up to 40%) Alopecia areata (30%) Vitiligo (20%) Thyroid disease (20%) Diabetes (Type 1) (20%) Pernicious anemia (20%) Keratoconjunctivitis (20%) Hypopituitarism (15%) Hyposplenism (15%) Hypertension (15%) Nephritis (10%) Mucosal squamous cell carcinoma (10% of adults) Almost 100% have anti-Type I interferon antibodies Other autoantibodies common
Others	Autosomal recessive IL-17RA, IL-17RC (interleukin-17 receptors A and C) TRAF3IP2 (TRAF3-interacting protein 2) RORC (RAR-related orphan receptor C) CARD9 deficiency (caspase recruitment domain family member 9) Dectin-1 deficiency	All with mucosal candidiasis, dermatophytes	Mycobacterial infections (RORC) Invasive fungal infections (especially of brain) (CARD9)

Other genetic disorders with increased risk of chronic candida infections:

- Acrodermatitis enteropathica
- DiGeorge syndrome
- Ectodermal dysplasia-ectrodactyly-clefting
- Hypohidrotic ectodermal dysplasia with immunodeficiency (NFκB [nuclear factor kappa B] IA)
- Hyper-IgE syndrome
- Interleukin-12B/ IL-12RB1 deficiency
- Multiple carboxylase deficiency
- Severe combined immunodeficiency

Figure 132-4 Recurrent thrush and candidal cheilitis in a boy with mucocutaneous candidiasis.

only in the stratum corneum. Evidence of an immunologic defect, including skin test anergy and deficient in vitro lymphoproliferation or cytokine release in response to *Candida* antigens, is found in 75% of CMC patients. However, the variability reflects the underlying heterogeneity of CMC. Autoantibodies against Type I interferons are a sensitive and specific marker for APECED.[24]

DIFFERENTIAL DIAGNOSIS

Frequent *Candida* infections in infants, especially thrush, commonly accompany recurrent use of antibiotics, such as for otitis; without a reason for the recurrent *Candida* infections, HIV infection and CMC should be considered. Autoimmune disorders and endocrinopathies are a feature of IPEX (*i*mmune dysregulation, *p*olyendocrinopathy, *e*nteropathy, *X*-linked) syndrome,[25] but infections tend to be bacterial. However, fungal, bacterial, and viral infections may accompany autoimmune endocrinopathies in IL-2 receptor α chain (CD25) deficiency.[26]

Figure 132-5 Cutaneous candidal infections with hyperkeratotic candidal granulomas. The child responded to oral azole antifungal medications, but not to topical medications.

Figure 132-6 This 3-year-old child with hypothyroidism had oral thrush, intertriginous candidiasis, verrucous crusting on the scalp and face, and candidal onychomycosis. The warty growths shown in the photograph consisted of dried pus and serum, and grew only *Candida albicans.*

CLINICAL COURSE, PROGNOSIS, AND TREATMENT

Candidal lesions in patients with CMC generally respond to long-term systemically administered azole antifungal agents (itraconazole, fluconazole) or terbinafine.[27] Patients who are resistant usually respond to voriconazole (with its risk of phototoxicity), posaconazole, echinocandins, and/or amphotericin B with or without flucytosine. Cutaneous granulomas often are less responsive despite clearance of infection. Other therapies are granulocyte colony-stimulating factor (may increase IL-17 production),[28] nail avulsion, drainage of abscesses, and debridement of thick-crusted cutaneous plaques.

All patients with CMC should have an annual endocrine evaluation and patients with documented endocrinopathy or a family history of APECED should be monitored more closely. Patients who have a history of infections other than candidal should have further evaluation of their immune status.

CARTILAGE–HAIR HYPOPLASIA SYNDROME

AT-A-GLANCE

- Synonym: metaphyseal chondrodysplasia McKusick type.
- Autosomal recessive disorder, common in Amish and Finnish populations.
- Mutations in the RNA component of a ribonucleoprotein endoribonuclease, leading to defective cell-mediated and humoral immunity.
- Characterized by fine, sparse, hypopigmented hair, and short-limbed dwarfism.
- Supportive treatment with appropriate antibiotic use; bone marrow transplantation corrects immune deficiency but not dermis or cartilage.

COMBINED ANTIBODY AND T-CELL DEFICIENCY

HYPERIMMUNOGLOBULIN M SYNDROME

AT-A-GLANCE

- Most cases of hyperimmunoglobulin M syndrome have the X-linked recessive form with deficiency of CD40 ligand; common clinical features are recurrent sinopulmonary and GI tract infections, oral ulcerations, and verrucae.
- Autosomal recessive hyperimmunoglobulin M syndrome, except CD40 deficiency, does not have a susceptibility to opportunistic infections and lymphoid hyperplasia.

WISKOTT-ALDRICH SYNDROME

AT-A-GLANCE

- X-linked recessive.
- Mutations in WASP (Wiskott-Aldrich syndrome protein).
- Recalcitrant dermatitis.
- Recurrent pyogenic infections.
- Hemorrhage caused by thrombocytopenia and platelet dysfunction.
- Therapy: bone marrow stem cell transplantation.

CLINICAL FEATURES

Wiskott-Aldrich syndrome (WAS) is an X-linked recessive disorder with an incidence of approximately 4 per 1 million male births.[29,30] The classic triad of WAS is (a) hemorrhage caused by thrombocytopenia and platelet dysfunction, (b) recurrent pyogenic infections, and (c) recalcitrant dermatitis, but this triad appears in only 25% of patients. The bleeding diathesis, which is the most common manifestation of mutations in WAS, being present in 84% of patients, often manifests initially during the first weeks or months of life with bloody diarrhea. Epistaxis, hematemesis, hematuria, mucocutaneous petechiae, and intracranial hemorrhage also may occur. Recurrent bacterial infections begin in infancy as levels of placentally transmitted maternal antibodies diminish. These infections include furunculosis, conjunctivitis, otitis media and otitis externa, pansinusitis, pneumonia, meningitis, and septicemia. Infections with encapsulated bacteria such as *Pneumococcus*, *Haemophilus influenzae*, and *Neisseria meningitidis* predominate. Patients are also susceptible to infections caused by herpes and other viruses and to *Pneumocystis jiroveci*.

The atopic dermatitis associated with WAS, which occurs in approximately 80% of patients, usually develops during the first few months of life and may be quite severe. The face, scalp, and flexural areas are the most severely involved, although patients commonly have widespread involvement with progressive lichenification. The eruption may be more exfoliative than that of atopic dermatitis in individuals without WAS, and excoriated areas frequently have serosanguineous crusts (Fig. 132-7). Secondary bacterial infection of eczematous lesions is common, as are eczema herpeticum (Fig. 132-8) and molluscum contagiosum. IgE-mediated allergic problems, such as urticaria, food allergies, and asthma, are seen in addition to the atopic dermatitis.

Up to 40% of patients with WAS develop an autoimmune disorder.[31] The most common are vasculitis (particularly involving the skin, GI tract, brain, and heart) in 20% of patients, autoimmune hemolytic anemia in 14% of patients, and IgA nephropathy in up to 10% of patients.[32] Other immune-mediated cutaneous manifestations are angioedema, dermatomyositis, pyoderma gangrenosum, and erythema nodosum. Hepatosplenomegaly is common, and lymphadenopathy, transient arthritis, and joint effusions are present occasionally.

ETIOLOGY AND PATHOGENESIS

The defective gene is *WASP*, mapped to Xp11.22-11.23, which encodes WASP, a hematopoietic specific

Figure 132-7 Severe atopic dermatitis in a boy with Wiskott-Aldrich syndrome. Note the serosanguineous crusting.

Figure 132-8 Herpetic infection with pustules on the ear of a teenager with Wiskott-Aldrich syndrome. The patient was blind in this left eye owing to a previous ocular infection. After the pictured infection, the patient was administered prophylactic acyclovir and had no subsequent herpetic infections for a decade. Eventually, he became resistant to acyclovir and succumbed to his immunodeficiency.

cytoplasmic protein that functions in signaling and cytoskeletal organization. WASP couples the signals arising at the cell membrane with reorganization of the cellular cytoskeleton, resulting in cellular activation and promotion of cell motility.[33] Mutations in WASP affect organization of the immunologic synapse and T-cell activation, T-lymphocyte and B-lymphocyte migration, and initiation of the primary antibody response. There is a strong phenotype–genotype correlation; classic WAS occurs when WASP is absent or truncated, whereas X-linked thrombocytopenia occurs when mutated WASP is expressed. The atopic dermatitis is likely associated with the observed skewing of CD4+ T-cell differentiation toward Th2 cells with suppression of Th1 and regulatory T cells differentiation.[34] Alteration in homeostasis of peripheral B cells and reduced activation of regulatory T cells is thought to promote the development of the autoimmune manifestations of WAS.[35-37] Given the expression of WASP on epidermal Langerhans cells, abnormal interactions of Langerhans cells with T cells and the ability of Langerhans cells to move to the lymph node after antigen stimulation may be involved as well.

WAS patients have decreased function and number of both T and B lymphocytes, beginning in the first years of life. The lymphocytes of patients with WAS lack microvilli formed by actin bundles, resulting in defective chemotaxis and, in some patients, there is decreased expression of sialoglycoproteins (eg, CD43 and others) on lymphocytes and platelets. Defects in humoral immunity include abnormal serum Ig and decreased antibody response to polysaccharide antigens. WAS patients also have defects in natural killer (NK) cell cytotoxicity, dendritic cell migration, and activation, and impaired macrophage chemotaxis.

DIAGNOSIS

The diagnosis is suspected on the basis of the platelet abnormalities and associated atopic dermatitis, and confirmed by laboratory testing, particularly genotyping to identify the *WASP* mutation. The thrombocytopenia of WAS is persistent, and platelet counts may range from 1000 to 80,000 platelets/μL. A platelet count of <70,000/μL is required for formal diagnostic criteria. The platelets are small, and platelet aggregation is defective. Levels of IgM and, sometimes, IgG are low, and isohemagglutinins are absent. IgA, IgE, and IgD levels usually are elevated. Eosinophilia, leukopenia, and lymphopenia are also seen. Delayed hypersensitivity skin-test reactivity is diminished, and patients fail to respond to polysaccharide antigens. WASP can be detected by flow cytometry using intracellular staining with an antibody to WASP and sequencing of the *WASP* gene can confirm the diagnosis of WAS or X-linked thrombocytopenia, which results also from mutations in the *WASP* gene that do not affect immune function. Mutation analysis allows for prenatal diagnosis. Female carriers of WAS can be

detected by their selective inactivation of the abnormal X chromosome in lymphocytes and platelets.[38]

DIFFERENTIAL DIAGNOSIS

Other immunodeficiencies are characterized by eczematous dermatitis and increased susceptibility to infections, but WAS can usually be distinguished by the bleeding tendency and laboratory evidence of microthrombocytopenia.

CLINICAL COURSE, PROGNOSIS, AND TREATMENT

Therapeutic interventions allow some patients with WAS to survive into adulthood; however, a significant proportion die before the age of 10 years from infections secondary to hemorrhage, malignancies, or the complications of transplantation.[29,39]

Thirteen percent of patients with WAS develop lymphoreticular malignancies, especially non-Hodgkin lymphoma (especially diffuse large B-cell lymphomas), with a predominance of extranodal and brain involvement. Development of autoimmune hemolytic anemia is a poor prognostic factor and associated with the development of lymphoid malignancies; overall, 25% of patients with autoimmunity develop a malignancy.[32] 10% of patients die from these malignancies, usually as adolescents or young adults.

Appropriate antibiotics, immunizations, and transfusions of platelets and plasma decrease the risk of fatal infections and hemorrhage. Immunoglobulin replacement therapy is useful in some patients. Splenectomy has been advocated to ameliorate the bleeding abnormality in patients with recurrent severe hemorrhage, but this procedure increases the risk of infection from encapsulated bacterial organisms. Topical glucocorticoid preparations and Ig replacement may improve the dermatitis, and chronic administration of oral acyclovir is appropriate for patients with recurrent eczema herpeticum.

Bone marrow or stem cell transplantation is the treatment of choice for patients with recurrent problems, especially significant autoimmunity.[29,39] Full engraftment results in normal platelet number and function, normal immunologic status, and clearance of the dermatitis (T-lymphocyte engraftment). The 5-year survival rate for children younger than 5 years of age with human leukocyte antigen (HLA)-matched sibling donors is 87%; older patients and those with mismatched donors have survival rates of approximately 50%. Lentivirally transduced, WAS-reconstituted, autologous CD34+ cells have been administered in gene therapy trials, resulting in sustained clinical benefit in the majority of treated patients; dermatitis is improved or cleared and the risk of infection and autoimmune manifestations is reduced.[37,40,41] To avoid the risk of insertional oncogenesis from viral vectors, ongoing trials use self-inactivating lentiviral vectors and, more recently, zinc finger nucleases as a nonviral approach to the correction of WAS cells.[42]

SEVERE COMBINED IMMUNODEFICIENCY

AT-A-GLANCE

- Heterogeneous group of X-linked and autosomal recessive disorders with deficient cell-mediated and humoral immunity.
- Failure to thrive in early infancy; diarrhea; recurrent mucocutaneous candidiasis, bacterial, and viral infections; risk of graft-versus-host disease.
- Hematopoietic stem cell transplantation may provide a long-term cure.

Table 132-4 outlines the subtypes of severe combined immunodeficiency.

CLINICAL FEATURES

Infants with severe combined immunodeficiency (SCID) usually fail to gain weight by 3 to 6 months of age, following the onset of recurrent sinopulmonary and skin infections.[43,44] Persistent mucocutaneous candidiasis is often present at the time of diagnosis, and systemic candidal infections occur occasionally. Patients with SCID also may have chronic diarrhea and malabsorption caused by viral infections. *P. jiroveci* (*carinii*) pneumonia is often a presenting feature. Although bacterial infections usually respond to systemic antibiotics, viral infections tend to be fatal. Infants with SCID lack palpable lymphoid tissue despite recurrent infections.

In addition to cutaneous bacterial and candidal infections, the most common cutaneous eruptions are morbilliform or resemble seborrheic dermatitis. In some infants with SCID, biopsy sections show graft-versus-host disease (GVHD) (see Chap. 129). GVHD may result from in utero exposure to maternal lymphocytes, which is usually nonfatal, from transfusion with nonirradiated blood products, which is usually fatal, or may follow stem cell transplantation. Patients with GVHD most commonly present acutely with morbilliform erythema, papular dermatitis, or diffuse erythroderma. The face, neck, palms, and soles are usually affected initially, before the eruption becomes generalized. Severe cases are complicated by diffuse bullae or toxic epidermal necrolysis. The clinical presentation of GVHD from maternal engraftment (without transplantation) is

TABLE 132-4
Subtypes of Severe Combined Immunodeficiency

LYMPHOCYTE PROFILE	DISORDER	GENE	GENE PRODUCT FUNCTION
T−/B−/NK−	ADA deficiency[a,b]	*ADA*	Enzyme necessary for detoxification of metabolic products of the purine salvage pathway that cause lymphocytes to undergo apoptosis
	PNP deficiency	*PNP*	Enzyme necessary for detoxification of metabolic products of the purine salvage pathway that cause lymphocytes to undergo apoptosis: located downstream from ADA
T−/B−/NK+	RAG 1 or 2[c]	*RAG1/RAG2*	Required for somatic V, D, and J rearrangements during Band T-cell development
	Artemis deficiency[d,e]	*Artemis*	Required for DNA repair during somatic V, D, and J rearrangements during B-cell and T-cell development
	LIG4 syndrome[e,93]	*LIG4*	Ligase required for ATP-dependent repair of double-stranded DNA
T−/B+/NK−	X-linked severe combined immunodeficiency[a]	*IL2RG*	Common γ chain of IL-2, IL-4, IL-7, IL-9, IL-15, and IL-21
	Janus protein kinase deficiency	*JAK3*	Tyrosine kinase; primary signal transducer from common γ chain
T−/B+/NK+	IL-7 receptor (IL-7R) deficiency	*IL7R*	α Chain of IL-7 receptor
	T-cell receptor/CD3 complex deficiency	*CD3δ* and *CD3ε*	Facilitates expression of T-cell receptor/CD3 complex; block at pre–T-cell receptor stage of development
	CD45 deficiency[92]	*PTPRC*	Phosphatase that regulates immune cell signaling
	Winged helix nude deficiency	*WHN*	Defect in thymic development. Human homolog of nude mouse with total alopecia and onychodystrophy; critical transcription factor for thymic development
Other Defects in T-Cell Development			
CD4+ CD8− /B+/NK+	CD8 deficiency[94]	*CD8A*	Promotes survival and differentiation of activated T cells to memory CD8+ T cells
	ZAP-70 deficiency	*ZAP-70*	Signaling tyrosine kinase
	MHC class I deficiency/TAP deficiency (bare lymphocyte syndrome I)	*TAP1* *TAP2*	Transporter associated with antigen processing, transports peptides to assemble the class I molecule, dysregulated NK cells
CD4^{low} CD8+/B+/NK+	MHC class II deficiency (bare lymphocyte syndrome II)	*CIITA* *RFXB* *RFX5* *RFXAP*	Defects in the transactivating factors of MHC II molecules, nonfunctional CD4 T cells if present
T+/B+/NK+	T-cell receptor/CD3 complex deficiency	CD3γ	Chain facilitates expression of T-cell receptor/CD3 complex

[a]Most common severe combined immunodeficiency defects. X-linked severe combined immunodeficiency accounts for approximately 50% of patients. Adenosine deaminase deficiency accounts for approximately 20% of patients.

[b]Eighty-five percent to 90% of patients present in infancy with severe immunodeficiency; one-half have skeletal deformities, neurologic symptoms, behavior problems, and decreased IQ.

[c]Deletions/frameshift mutations of *RAG1 /RAG2* genes result in severe combined immunodeficiency phenotype. Less-severe mutations result in Omenn syndrome, which is clinically distinct from other forms of severe combined immunodeficiency. Mutations in other genes may lead to the Omenn phenotype and immunodeficiency.

[d]Common genetic defect seen in Athabascan-speaking Native Americans, the defect is called *SCIDA* in this population. Gene frequency may be as high as 2%. These patients have a higher incidence of oral/genital ulcers.

[e]Both *Artemis* and *LIG4* mutations lead to hypersensitivity to irradiation.

ADA, adenosine deaminase; ATP, adenosine triphosphate; IL, interleukin; MHC, major histocompatibility complex; NK, natural killer cell; PNP, purine nucleoside phosphorylase; RAG, recombination activating gene; TAP, transporter associated with antigen processing.

indistinguishable from the clinical presentation of GVHD from transplantation, but histopathologic features differ.[45] Biopsy sections from GVHD secondary to maternal engraftment show psoriasiform hyperplasia with parakeratosis and variable spongiosis in contrast to the vacuolar interface pattern observed in conventional GVHD. Overall, 83% of SCID patients with maternal engraftment develop skin manifestations. Oral and genital ulcerations are also seen in SCID, particularly in Athabascan-speaking Native American children with a defect in the *Artemis* gene.[46] Patients with Omenn syndrome show erythroderma, hepatosplenomegaly and lymphadenopathy with eosinophilia and increased IgE production.[47] B cells

tend to be undetectable, and T cells, although often increased in number, are nonfunctional. Omenn syndrome has been shown to be a phenotype with several underlying genetic bases. Most patients have RAG1/RAG2 mutations, but the phenotype of Omenn syndrome has been described in patients with mutations in *Artemis* and IL-7R. Two individuals with cartilage-hair hypoplasia and another with complete DiGeorge syndrome also showed features of Omenn syndrome.

The natural history of SCID is changing with the introduction of newborn screening for SCID and other T-cell lymphopenia.[48] Except for a few causes of SCID that may not present with T-cell lymphopenia at birth, patients are identified by newborn screening soon after birth and the diagnosis is established before serious infections develop. Early stem cell transplantation provides an excellent outcome irrespective of the source of the stem cells or the preparation regimen.[49]

ECTODERMAL DYSPLASIA WITH IMMUNODEFICIENCY

AT-A-GLANCE

- Mutations in nuclear factor κB (NF-κB) essential modulator, leading to abnormal NF-κB signaling.
- Characteristic facies of hypohidrotic ectodermal dysplasia.
- Often severe immunodeficiency; bacterial, atypical mycobacterial, and viral infections are common.
- Therapy: stem cell transplantation can correct the immunodeficiency but not the other features of the disease.

EPIDEMIOLOGY

X-linked recessive transmission is most common with an estimated incidence of 1:250,000 live male births.[50] An autosomal dominant form of ectodermal dysplasia with immunodeficiency also has been described.[51]

ETIOLOGY AND PATHOGENESIS

Several genetic disorders result from gene mutations in the nuclear factor κB (NF-κB) essential modulator (NEMO) and lead to abnormal NF-κB signaling (see Chaps. 75 and 131). One of these, hypohidrotic ectodermal dysplasia with immunodeficiency, results from hypomorphic mutations in the *NEMO* gene (also called *ectodermal dysplasia, anhidrotic, with immunodeficiency* or *Hyperimmunoglobulinemia M, immunodeficiency, X-linked with ectodermal dysplasia*). NF-κB is a DNA-binding transcription factor, and its ability to transcribe genes is regulated by a cytoplasmic inhibitor, IKB (inhibitor of nuclear factor κB). NF-κB signaling affects inflammation, apoptosis, development, and immunity. NF-κB activation requires phosphorylation of IKB by IKB kinase (IKK). IKK is composed of 2 catalytic components (IKKα and IKKβ) and a regulatory subunit, IKKγ or NEMO. NEMO has no catalytic function, but is the structural scaffold that supports the IKK complex. When NEMO is absent or defective, no functional IKK complex is formed and, as a result, NF-κB cannot translocate to the nucleus and activate gene transcription.

The hypomorphic mutations that cause anhidrotic ectodermal dysplasia with immunodeficiency allow early survival in males, in contrast to the large deletions in *NEMO* (usually of exons 4 to 10) that lead to incontinentia pigmenti in carrier females and fetal death in affected males (see Chap. 75). Female carriers of hypomorphic *NEMO* mutations often show mild features of incontinentia pigmenti, but may also express an incontinentia pigmenti phenotype with transient immunodeficiency.[52] In boys with hypomorphic mutations of *NEMO*, the ectodermal dysplasia phenotype results from impaired NF-κB signaling.[53] Immunodeficiency results from impaired NF-κB activation in response to signaling via antigen receptors, Toll-like receptors, IL-1 receptor, and the tumor necrosis factor (TNF) receptor family.[54] Gain-of-function mutations in IKBα, the component of the inhibitor of NF-κB that is phosphorylated by IKK, lead to an autosomal dominant form of ectodermal dysplasia with a distinct immunologic phenotype, characterized by a profound T-cell deficiency, but normal NK cytotoxicity and responses to *Mycobacteria*. Mutations in *NEMO* that cause immunodeficiency without the ectodermal dysplasia phenotype also have been reported.

CLINICAL FEATURES

Affected patients present with classic characteristics of hypohidrotic ectodermal dysplasia (Fig. 132-9). These include the characteristic facies, hypotrichosis or atrichia, hypohidrosis (leading to heat intolerance), hypodontia or anodontia with conical incisors, and associated dermatitis (see Chap. 131). A subset of patients has associated osteopetrosis and lymphedema in association with severe immunodeficiency. Boys with immunodeficiency from *NEMO* mutations without the features of hypohidrotic ectodermal dysplasia also have been described. In an analysis of 72 patients with *NEMO* mutations, only 77% had ectodermal dysplasia.[50] Bacterial infections early in infancy are common, particularly sepsis, pneumonia, otitis, sinusitis, and lymphadenitis. Recurrent pneumonias may lead to bronchiectasis. Common pathogens include *Streptococcus pneumoniae*, *H. influenzae*, *Klebsiella*, *Salmonella*, and *Pseudomonas*. Infections with atypical *Mycobacteria* and viruses, including cytomegalovirus (systemic and GI involvement), herpes simplex virus, molluscum contagiosum, human papillomavirus, and *Pneumocystis carinii*, are also reported.

The immunodeficiency is often severe, but its characteristics are variable with an apparent genotype–phenotype correlation that can be further

Figure 132-9 Ectodermal dysplasia with immunodeficiency gene mutation. This boy with a hypomorphic mutation in *NEMO* (nuclear factor κB essential modulator) showed failure to thrive, slightly exfoliative dermatitis, and the typical facial features of hypohidrotic ectodermal dysplasia. Note the small chin, the "pouty" lower lip, thin upper lip, and small, pinched nose with malar hypoplasia. His mother had a pigmented streak following a line of Blaschko, typical of that seen in incontinentia pigmenti. (Used with permission from Dr. Anthony Mancini.)

identified by in vitro reconstitution of the mutations. Immune dysfunction includes impaired B-cell Ig class switching with hypogammaglobulinemia (and often increased levels of IgM and/or IgA), impaired specific antibody production (particularly to polysaccharide antigens), deficient NK cell cytotoxicity, poor cytokine production in response to CD40 signaling, and autoinflammation, especially of the gut. Biopsy of skin may show evidence of keratinocyte apoptosis, reflecting the dysfunction in NF-κB signaling, and must be differentiated from GVHD.

TREATMENT AND PROGNOSIS

There is an increased mortality, with 36% of patients dying at a mean age of 6.4 years.[50] Therapy is guided by the patient's clinical and immunologic phenotype. Ectodermal dysplasia is treated supportively (see Chap. 131). Patients with impaired antibody production may benefit from Ig replacement. All infections (bacterial and viral) should be treated aggressively with the appropriate antibiotics/antivirals. Prophylaxis for both *P. jiroveci* and *Mycobacterium avium-intracellulare* should be considered. Stem cell transplantation may lead to immune reconstitution but may not correct the other manifestations of the disease.[55] The mothers and sisters of these patients should be offered genetic testing for the *NEMO* mutation and counseling.

ATAXIA-TELANGIECTASIA

AT-A-GLANCE

- Autosomal recessive disorder with mutations in *ataxia-telangiectasia mutated (ATM)*.
- Early onset of ataxia with progressive neurologic deterioration; conjunctival telangiectasia first appears in preschool years in most patients.
- Sinopulmonary infections, lymphoreticular neoplasia.
- Deficiency of IgA, IgE, IgG_2, IgG_4; variable manifestations of T-cell deficiency; high levels α-fetoprotein; chromosomal breaks; sensitive to irradiation.

EPIDEMIOLOGY

Ataxia-telangiectasia (AT; Online Mendelian Inheritance in Man [OMIM] #208900), also called *Louis-Bar syndrome*, is an autosomal recessive disorder with an estimated incidence of up to 1:40,000 and a carrier rate of up to 1%. Carriers have an increased risk of breast cancer, hematologic malignancies,[56,57] and ischemic heart disease, with a reduced life expectancy of approximately 8 years.[58] These heterozygotes show an increased risk of chromosomal breaks after exposure to irradiation in vitro, suggesting that mammograms in known carriers of AT are contraindicated.

CLINICAL FEATURES

Characteristic oculocutaneous telangiectasias begin near the ocular canthi and progress across the bulbar conjunctivae (Fig. 132-10). These telangiectasias usually appear when patients are 3 to 6 years of age; rarely have they been described at earlier ages. Cutaneous telangiectasias subsequently may develop on the malar prominences, ears, eyelids, anterior chest, and popliteal and antecubital fossae, and the dorsal aspects of the hands and feet (Fig. 132-11). The telangiectasias may be subtle and resemble fine petechiae, especially in the flexural areas. The development of telangiectasias may be related to sun exposure, because ocular,

Figure 132-10 Bulbar conjunctival telangiectasias in a patient with ataxia-telangiectasia.

Figure 132-11 Ataxia-telangiectasia. Telangiectasias inside and on the helix.

Figure 132-12 Noninfectious granulomatous dermatitis of a patient with ataxia-telangiectasia. These persistent lesions tend to ulcerate, but often respond to injections of triamcinolone acetonide.

but not cutaneous, telangiectasias develop in affected dark-skinned children. The development of telangiectasias may relate, at least in part, to the sensitivity of some AT strains to ultraviolet light.[59]

Progeric changes of the skin, including xerosis and gray hair, occur in 90% of patients.[60] During adolescence, the facial skin may become progressively more atrophic and sclerotic, causing a mask-like appearance. Occasionally, the ears, arms, and hands also become sclerodermatous. The hair may be diffusely gray by adolescence, and subcutaneous fat is generally lost in childhood. Recurrent severe impetigo often develops. Seborrheic dermatitis occurs in many patients, and the associated blepharitis may lead to a diagnosis of blepharoconjunctivitis rather than ocular telangiectasia. Mottled hyperpigmentation and hypopigmentation commonly occur and, together with the telangiectasias and atrophy, can resemble the poikiloderma of radiodermatitis, actinic damage, or scleroderma. Other pigmentary changes include café-au-lait spots that may be found in a dermatomal distribution, multiple ephelides, and vitiligo. Hypertrichosis of the arms and legs, alopecia areata, multiple warts, atopic dermatitis, keratosis pilaris, nummular eczema, and acanthosis nigricans also have been described in association with AT. Among the most common cutaneous manifestations are noninfectious cutaneous granulomas (Fig. 132-12).[61] These persistent, atrophic, and often ulcerative lesions are often mistaken for other granulomatous processes, including sarcoidosis, necrobiosis lipoidica diabeticorum, granuloma annulare, and granulomatous dermatitis.

Usually, the progressive cerebellar ataxia first becomes apparent during infancy (median age: 1.2 years) with swaying of the head and trunk and apraxia of eye movements, often years before skin or conjunctival abnormalities develop. In childhood, dysarthric speech, drooling, choreoathetosis, and myoclonic jerks become prominent. The diagnosis of AT is usually made at a median age of 7 years, after appearance of the mucocutaneous telangiectasia. Patients usually require a wheelchair by their teenage years.

Recurrent bacterial and viral sinopulmonary infections occur in up to 80% of patients; these are the most common cause of death, which is usually from bronchiectasis and respiratory failure. Approximately 75% of patients with AT may have growth retardation and endocrine disorders, especially ovarian agenesis or testicular hypoplasia and insulin-resistant diabetes.

Neoplasia occurs in 40% of surviving adolescents or young adults, although lymphoid malignancy has been described as the presenting sign during infancy. Most common are lymphomas (especially B-cell lymphoma; 200-fold increased risk) and leukemia (especially T-cell chronic lymphocytic leukemia; 70-fold increased risk). Basal cell carcinomas have been reported in young adults.

Patients with AT tend to have both humoral and cellular immunologic abnormalities. Serum IgA and IgE are absent or deficient in 70% and up to 80% of patients, respectively. Circulating anti-IgA antibodies are common in AT patients with IgA deficiency. Approximately 60% of patients have selective IgG_2 and IgG_4 deficiencies. Defective cell-mediated immunity is found in 70% of patients, particularly lymphopenia and deficient in vitro responses to antigens and

mitogens; T cells bearing γ/δ receptors are increased in number, while CD4+ T cells tend to be reduced.

Virtually all patients have elevated levels of α-fetoprotein (which is particularly significant after 2 years of age), and many have detectable carcinoembryonic antigen. Patients with AT often have elevated hepatic transaminases (40% to 50%), and glucose intolerance. DNA is exquisitely sensitive to X-irradiation, and patients also show an increased rate of telomere shortening. Spontaneous chromosomal abnormalities (fragments, breaks, gaps, and translocations) occur 2 to 18 times more frequently in patients with AT than in normal individuals and mainly involve chromosomes 2, 7, and 14. Rearrangements of chromosomes 7 and 14, and especially 14:14 translocations, seem to predict the development of lymphoreticular malignancy, including leukemia. The thymus is absent or hypoplastic, and the spleen may be reduced in size.

Among techniques to confirm diagnosis are an elevated serum α-fetoprotein level in children older than 8 months of age, analysis of radioresistant DNA synthesis (which demonstrates an abnormal S-phase checkpoint), radiosensitivity testing with the colony survival assay, immunoblotting for the ATM (ataxia-telangiectasia mutated) protein, assessment of ATM kinase activity, and molecular genetic testing.

PROGNOSIS, CLINICAL COURSE, AND TREATMENT

Therapy for AT is supportive and includes administration of antibiotics for infection, physiotherapy for pulmonary bronchiectasis, physical therapy to prevent contractures in patients with neurologic dysfunction, and sunscreens and sun avoidance to diminish actinic-like changes. Patients should be aggressively screened for malignancy, especially after the first decade of life. Intralesional injections of triamcinolone have helped promote healing of the painful, associated ulcerations, although the lesions do not clear completely with treatment. Autopsy findings indicate that approximately 50% of the patients die from pulmonary disease, the most common cause of death. Lymphoreticular malignancies, including lymphoid leukemia, are the second most common cause of death (15% of patients with AT). The remaining patients tend to die of both pulmonary disease and malignancy. Therapeutic radiation and radiomimetic chemotherapeutic agents, especially bleomycin, may lead to extensive tissue necrosis. The administration of small doses of other chemotherapeutic drugs and low-dose, fractionated radiation is the least-harmful means of managing these malignancies. In a small subset of patients with milder AT, treatment with aminoglycosides increased ATM gene function.[62] Death usually occurs by late childhood or early adolescence; the oldest surviving patient died at the age of 50 years. Prenatal diagnosis is currently best achieved by DNA analysis.

DISORDERS OF PHAGOCYTOSIS AND CELL KILLING

Patients with defects in phagocyte function or cell killing typically present during infancy or childhood with recurrent, unusual, and/or difficult-to-clear bacterial infections. Infections commonly seen include those of skin or mucosa, lung, lymph nodes, deep-tissue abscesses, or childhood periodontitis. The most distinctive disorders of phagocytosis and cell killing are chronic granulomatous disease (CGD), leukocyte adhesion deficiencies, Hyperimmunoglobulinemia E syndrome (HIES), and the silvery hair syndromes with immunodeficiency.[63] However, several disorders with neutropenia, neutrophil dysfunction, or cytokine dysfunction also lead to a decreased ability to engulf and/or kill organisms. These are reviewed in Table 132-5.

CHRONIC GRANULOMATOUS DISEASE

AT-A-GLANCE

- Group of disorders in which defective production of reactive oxygen intermediates impairs intracellular killing of microorganisms.
- X-linked or autosomal recessive.
- Mutations in genes that encode components of nicotinamide adenine dinucleotide phosphate oxidase system.
- Pneumonias, lymphadenopathy, hepatosplenomegaly, and skin infections.
- Granulomas, most commonly of lungs and liver.
- Lupus-like inflammation in carriers (X-linked) and patients.

CGD is a heterogeneous group of X-linked and autosomal recessive disorders.[64,65] Ninety percent of patients with the disorder are male, and the overall incidence is 1 in 200,000 to 250,000 persons. X-linked disease with deficiency of $gp91^{phox}$ occurs in 70% of affected individuals with signs and symptoms manifesting in the first year of life. Individuals with autosomal recessive disease are more likely to have some nicotinamide adenine dinucleotide phosphate (NADPH) oxidase activity, tend to present later in life (mean age of onset: 8 years), have milder signs and symptoms, and have longer survival.[66,67]

TABLE 132-5
Other Disorders of Phagocytosis or Cell Killing

DISORDER	GENETICS	GENE	FUNCTIONAL CONSEQUENCE	CLINICAL FINDINGS
Neutropenia				
Cyclic neutropenia	AD	*ELA2*	Defects in neutrophil elastase	Cycles of neutropenia and monocytopenia, approximately every 3 weeks; oral ulcers and fever when low
Severe congenital neutropenia	AD	*ELA1*	Defects in neutrophil elastase lead to abnormal neutrophil trafficking	Neutropenia, myelodysplastic syndrome, and acute myelogenous leukemia; neutropenia and lymphopenia; myeloid progenitors in circulation
	AD	*GF11*	Repressor of elastase transcription leads to accumulation of elastase	
Shwachman-Diamond syndrome (SBDS)	AR	*SBDS*	SBDS protein participates in metabolism of ribosomal RNA	Pancytopenia with myelodysplastic syndrome and acute myelogenous leukemia; pancreatic insufficiency; chondrodysplasia
WHIM[128]	AD	*CXCR4*	Receptor regulates development and migration of neutrophils; affects viral entry into cells	Chronic cutaneous and cervical warts, antibiotic-responsive bacterial sinopulmonary infections; often low Ig levels, peripheral neutropenia in the face of bone marrow hypercellularity (myelokathexis), and distinctive neutrophil morphology
Cytokine Defects				
	AR	*IL12B*	Absence of component of IL-12 and IL-23 that stimulates IFN-γ production	Severe mycobacterial infections. Disseminated bacille Calmette-Guérin after vaccination; severe *Salmonella* infections
	AR	*IL12RB1*	β_1-Chain of IL-12 and IL-23 receptors	
	AR, AD	*IFNGR1*	Affects ligand binding to IFN-γ receptor	
	AR	*IFNR2*	Affects IFN-γ receptor signaling	
	AR, AD	*STAT1*	Affects transcription in IFN receptor signaling	Also severe viral infections
	AR	*STAT5B*	As in Stat1, but also growth hormone receptor signaling	Also growth hormone insensitivity
Defects of Killing				
Myeloperoxidase deficiency	AR	*MPO*	Myeloperoxidase required for bacterial killing	Especially *Staphylococcus aureus* and candidal infections; may be asymptomatic
Specific granule deficiency	AR	*C/EBPE*	C/EBPε transcription factor required for granulocyte differentiation	Recurrent bacterial infections; neutrophils with 2 lobes

AD, autosomal dominant; AR, autosomal recessive; IFN, interferon; IL, interleukin; WHIM, warts, hypoimmunoglobulinemia, infections, and myelokathexis.

CLINICAL FEATURES

Pyodermas with associated regional lymphadenopathy/adenitis and dermatitis tend to affect body sites that are exposed to organisms, especially on the skin and lungs. Staphylococcal abscesses are found in 40% of patients, particularly of the perianal area, nares, and ears. Purulent inflammatory reactions may develop at sites of lymph node drainage or minor cutaneous trauma and heal slowly with scarring. Ecthyma gangrenosum may be the presentation in a neonate.[68] Staphylococcal infections are the most common, but other bacterial and fungal organisms that are killed by generation of reactive oxygen species may cause infection (*Aspergillus* spp., *Burkholderia cepacia*, *Candida* spp., *Klebsiella* spp., mycobacteria (including severe/disseminated bacille Calmette-Guérin infection),[69] *Nocardia* spp., and *Serratia marcescens* (especially abscesses with ulceration and osteomyelitis).[70]

Patients with CGD often develop chronic inflammatory granulomas, most commonly of the lungs and liver. Cutaneous granulomas are nodular and often necrotic. Granulomas can occlude vital structures, especially of the GI and genitourinary systems. Intraoral ulcerations resembling aphthous stomatitis, chronic gingivitis, perioral ulcers, scalp folliculitis, and seborrheic dermatitis also have been described in many patients. Female carriers for X-linked CGD do not have the increased risk of infections but may have cutaneous lesions of discoid or systemic lupus erythematosus, Jessner lymphocytic infiltration of the skin, aphthous stomatitis,

granulomatous cheilitis, photosensitivity, and/or Raynaud phenomenon.[71,72]

The lymph nodes, lungs, liver, spleen, and GI tract are the most frequent areas of noncutaneous involvement. Suppurative lymphadenitis with abscess and fistula formation usually affects cervical nodes. Pneumonia occurs in almost all affected children and may lead to abscess formation, cavitation, and empyema. Hepatosplenomegaly has been reported in 80% to 90% of patients; more than 30% of patients develop hepatic abscesses, and staphylococcal liver abscesses are almost pathognomonic to CGD. Other excessive inflammatory responses can include hemophagocytic lymphohistiocytosis[73] or features that resemble inflammatory bowel disease (anal fistulae, diarrhea), IgA nephropathy, sarcoidosis, and rheumatoid arthritis.[74,75]

Patients with bacterial and *Nocardia* spp. infections tend to be symptomatic and frequently have leukocytosis, anemia, and elevated sedimentation rate. In contrast, lack of fever, normal erythrocyte sedimentation rate, and few symptoms are more common in *Aspergillus* spp. infections. Thus, laboratory values within normal limits do not rule out infection in a CGD patient. Patients show an increased erythrocyte sedimentation rate, hypergammaglobulinemia, leukocytosis, and mild anemia; other immune function tests are otherwise usually normal.

ETIOLOGY AND PATHOGENESIS

CGD is caused by defects in the reduced NADPH oxidase, the enzyme complex responsible for the generation of superoxide. Normal bactericidal activity after phagocytosis requires the NADPH oxidase system, which consists of NADPH, an unusual phagocyte cytochrome b (b_{558}), and cytosolic proteins. In patients with CGD, this membrane-associated NADPH oxidase system fails to produce superoxide and other toxic oxygen metabolites. The oxidative molecules have direct microbicidal activity, but also act as intracellular signaling molecules, activating the release of primary granule proteins neutrophil elastase and cathepsin G inside the phagocytic vacuole that, in turn, are necessary to kill microbes. Mouse models of CGD show decreased regulatory T-cell activity, unrestrained γ/δ T-cell activity, and increased production of IL-1β, IL-8, and IL-17.[76] NADPH oxidase also modulates major histocompatibility complex Class II antigen presentation by B cells.[77]

In X-linked kindreds (approximately 70%), the *CYBB* gene encoding the gp91^{phox} (phagocyte oxidase) subunit of cytochrome b_{558} is mutated. Patients with autosomal recessive CGD are deficient in NADPH oxidase cytosolic factors (p47^{phox}—encoded by *NCF1*—in approximately 20% of patients; p67^{phox}—encoded by *NCF2*—in ≤5%; and p40^{phox}—encoded by *NCF4*—very rare); occasionally, the p22^{phox} (γ subunit of cytochrome b_{558}), which contains a docking site for p47^{phox}, is deficient (mutation in *CYBA*; ≤5% of patients). It is thought that cytochrome b_{558} is the membrane attachment site for these cytosolic factors that translocate from the cytosol to the plasma membrane, assembling oxidase components to allow activation of the NADPH oxidase.

The types of microbial organisms that cause infections in patients with CGD require intracellular killing and are usually catalase-positive. Only 5 organisms are responsible for the overwhelming majority of infections in CGD in North America and Europe: *Staphylococcus aureus*, *S. marcescens*, *B. cepacia*, *Nocardia* spp., and *Aspergillus* spp. The intense humoral and granulomatous responses of CGD are thought to be compensatory in the robust but ineffectual response to organisms.

DIAGNOSIS

The diagnosis of CGD is made on the basis of assays that rely on superoxide production. The dihydrorhodamine flow cytometry-based test (DHR 123 assay) is currently favored and can readily identify patients or carriers of X-linked disease[78]; the ferricytochrome c reduction assay is another quantitative measure of the respiratory burst. The screening test for CGD is the nitroblue tetrazolium (NBT) reduction assay, in which the yellow NBT becomes insoluble, oxidized form (blue formazan) when precipitated with normal oxidative metabolism. Quantitative NBT tests and chemiluminescence assays also may be performed. Immunoblot analysis confirms the absence of the glycoprotein 91^{phox} (gp91^{phox}) component; because deficiency of one component of cytochrome b_{558} leads to absence of the other, sequencing of the *gp91*^{phox} or *p22*^{phox} gene is necessary if absence is noted by immunoblot analysis. Immunoblots that show the absence of p47^{phox} or p67^{phox} can be diagnostic.

Biopsy of cutaneous granulomas shows histiocytic infiltrates associated with foreign-body giant cells and accumulation of neutrophils with necrosis. Although the histopathologic features of lupus erythematosus-like skin lesions in CGD patients and carriers may resemble those of lupus patients, immunofluorescence examination of lesional skin is usually negative.

DIFFERENTIAL DIAGNOSIS

Although the tests to measure respiratory burst are an easy screening test, other disorders of phagocytosis may be confused with CGD. Among these are the leukocyte adhesion defects (see section "Leukocyte Adhesion Deficiencies"), Shwachman-Diamond syndrome, myeloperoxidase deficiency, and defects in Toll receptor, interferon, or IL-12 signaling.

CLINICAL COURSE, PROGNOSIS, AND TREATMENT

Patients with X-linked CGD, p22^{phox} CGD, and p67^{phox} CGD tend to have a more-severe clinical course compared to patients with p47^{phox} CGD. The mean age of

TABLE 132-6
Treatment of Chronic Granulomatous Disease

TREATMENT	INDICATION	DOSE
Trimethoprim-sulfamethoxazole[a] (dicloxacillin if allergic)	Bacterial infections	5 mg/kg/day divided twice daily
Itraconazole[a]	Fungal infections	100 mg/day if patient weighs <50 kg; 200 mg/day if patient weighs >50 kg
Interferon-γ[a]	Infections	50 mcg/m^2 subcutaneously 3 × /week
Leukocyte transfusion	Life-threatening infections	
Bone marrow transplantation	Life-threatening infections	
Systemic glucocorticoids	Granulomas, particularly if obstructive	
Debridement/drainage/surgical intervention	Abscesses (particularly liver)	

[a]Regardless of genetic subgroup, the current recommendation is to use prophylaxis with trimethoprim-sulfamethoxazole, itraconazole, and interferon-γ.[136]

diagnosis of X-linked CGD is 3 years of age, and of autosomal recessive forms, 8 years of age. More than 90% of patients with non-p47^{phox} CGD have undetectable levels of superoxide production. Some patients develop severe infections as early as infancy whereas others unexpectedly develop a serious infection typical of CGD later during childhood.

Small foci of localized inflammation may not be associated with fever and may be difficult to detect without vigorous investigation of the lungs, liver, and bones by routine screening radiographs, scans, or ultrasonography. Cultures should be performed to identify the infectious agent, and invasive procedures may be necessary to obtain adequate tissue samples.

Patients with evidence of infection should be treated empirically with broad-spectrum parenteral antibiotics that cover *S. aureus* as well as Gram-negative organisms.[79] Intravenous therapy should be continued for at least 10 to 14 days, followed by a several-week course of oral antibiotics. Surgical interventions (drainage, debridement) may be required for deeper infections (Table 132-6). Trimethoprim-sulfamethoxazole therapy decreases the incidence of bacterial infection without increasing the incidence of fungal infection. Itraconazole is an effective agent for prophylaxis for fungal infections.[80] Prophylactic interferon (IFN)-γ decreases the number and severity of infections without increasing the incidence of chronic inflammatory complications in both X-linked and autosomal recessive CGD.[81] Use of IFN-γ is not accompanied by any measurable improvement in NADPH oxidase activity; its clinical benefit is related to enhanced phagocyte function and killing by nonoxidative mechanisms. Granulocyte transfusions have been used for rapidly progressive, life-threatening infections. The prophylactic administration of antibiotics and IFN-γ has reduced the mortality of CGD to approximately 2% per patient-year for autosomal CGD and 5% per year for X-linked CGD.[65] The most common causes of death are pneumonia and/or sepsis caused by *Aspergillus* or *B. cepacia*. Systemic glucocorticoids have been helpful for patients with obstructive visceral granulomas. Other therapies that may be of benefit for the inflammatory manifestations include anakinra, azathioprine, hydroxychloroquine, pioglitazone,[82] sirolimus, and thalidomide[83]; TNF inhibitors improve the colitis, but increase the risk of infection.

Stem cell transplantation may cure CGD and its use has increased.[84] Younger patients without infection at transplantation have the best outcome (survival >95%), but reduced-intensity conditioning regimens have been used for older individuals (including adults) and patients with recalcitrant infections or inflammation,[85] and should be considered if recurrent serious infections or corticosteroid-dependent inflammatory disease before irreversible organ damage occurs.[86]

Gene therapy has been performed for the p47^{phox}-deficient and X-linked forms of CGD. The use of retroviruses, however, may lead to insertional oncogenesis and myelodysplasia, necessitating safer approaches such as self-inactivating lentiviral vectors or nonviral techniques.[86-90]

LEUKOCYTE ADHESION DEFICIENCIES

AT-A-GLANCE

- Group of 4 disorders: 3 autosomal recessive (mutations in *ITGB2*, *SLC35C1*, or *FERMT3*) and 1 autosomal dominant (mutations in *Rac2*).
- Gingivitis and periodontitis.
- Poor wound healing; delayed separation of the umbilical stump and development of pyoderma gangrenosum-like necrotic ulcerations after wounding.
- Life-threatening bacterial and fungal infections.

HYPERIMMUNOGLOBULINEMIA E SYNDROME

AT-A-GLANCE

- Synonyms: Job syndrome, Buckley syndrome, hyperimmunoglobulin E recurrent infection syndrome.
- Most cases are autosomal dominant, but recessive forms with some different features have been described.
- Classic triad: (a) recurrent staphylococcal skin abscesses, (b) pneumonia with pneumatocele formation, and (c) high serum levels of IgE.
- Atopic dermatitis is a common manifestation.
- Scoliosis, fractures, and dental abnormalities are uniquely features of the more prevalent, autosomal dominant form.
- Autosomal recessive cases have severe viral infections and can develop severe neurologic complications.

HIES is rare (incidence 1 in 10^6).[91] It is found equally in males and females. Most cases are sporadic or consistent with an autosomal dominant inheritance. Autosomal recessive inheritance also has been described, but patients show different associated features.

CLINICAL FEATURES

The clinical presentation of individual patients with HIES may vary greatly.[91-93] Table 132-7 summarizes the most common clinical features and laboratory values of patients with sporadic or autosomal dominant HIES. The neonatal or infantile rash of HIES is often a papulopustular eruption with prominent crusting distributed on the scalp, face, neck, axillae, and diaper area.[94,95] The most consistent finding on skin biopsy is an eosinophilic spongiotic dermatitis, sometimes centered in the dermal follicles.[94] Early candidal infections of the skin, mucosae, and nails and/or infantile atopic dermatitis are other presentations; in patients with the eosinophilic papulopustules, the atopic dermatitis commonly follows later in infancy. Superinfection of the dermatitis with *S. aureus* is very common,[95] and patients show high levels of antistaphylococcal IgE antibodies. Staphylococcal skin infections include impetigo, furunculosis, paronychia, cellulitis, and characteristic "cold" abscesses (Fig. 132-13) that do not demonstrate the anticipated degree of erythema, warmth, and purulence. The abscesses occur most commonly on the head and neck and in intertriginous areas. Recurrent streptococcal pyoderma may also develop.

Pulmonary bacterial pneumonia, abscesses, and empyema are the most frequent systemic infections and may result in pneumatoceles that serve as the nidus for bacterial (often *Pseudomonas aeruginosa*) or fungal (especially *Aspergillus*) infection. The most common infecting organisms are *S. aureus* and *H. influenzae*. Other than pneumonias, deep-seated infections, bacteremia, and sepsis are rare.[96]

Facial and skeletal abnormalities are common. Patients develop progressive coarsening of facial features (see Fig. 132-13), probably reflecting the skeletal defects, but the recurrent facial pustulation and lichenification from dermatitis may contribute. Distinctive facial features, including prominent forehead, a broad nasal bridge, and wide nasal tip are universally present

TABLE 132-7
Characteristics of Hyperimmunoglobulinemia E Syndrome[131]

	INCIDENCE (%)
Immune System	
▪ Dermatitis	100
▪ Skin abscesses	87
▪ Recurrent pneumonia (3 or more, proved by radiography)	87
▪ Pneumatoceles	77
▪ Mucocutaneous candidiasis	83
Skeletal System	
▪ Characteristic fades	83
▪ Wide nose	65
▪ Failure of dental exfoliation (>3 teeth)	72
▪ Hyperextensibility	68
▪ Recurrent pathologic fractures	57
▪ Scoliosis (>10°)	63
Laboratory Values	
▪ Immunoglobulin E >2000 IU/mL or >10 times the age-specific norm	97
▪ Eosinophilia (>2 SD above the norm)	93

Figure 132-13 Coarse facial features, atopic dermatitis furuncles, and a cold abscess at the glabella in a boy with Hyperimmunoglobulinemia E syndrome.

by the age of 16 years. Dental anomalies include retention of primary teeth and lack of eruption of secondary teeth.[97] Osteopenia is common, and 57% of patients have had at least 3 pathologic fractures, especially of the long bones, ribs, and pelvis.[98,99] Scoliosis occurs in 63% of adult patients and hyperextensibility of joints in 68% of patients.[96] Milder phenotypes may reflect mosaicism.[100]

Autosomal recessive disease shares with autosomal recessive HIES the high serum IgE levels, peripheral eosinophilia, chronic eczematous dermatitis, and recurrent skin (including cold abscesses) and respiratory tract staphylococcal infections. However, patients with autosomal recessive HIES show no tendency to form pneumatoceles and have no skeletal or dental abnormalities.[101] Instead, autosomal recessive HIES is characterized by recurrent viral infections (eg, molluscum contagiosum, warts, herpes simplex and varicella-zoster), opportunistic infections, autoimmunity and devastating neurologic complications (especially vasculitis) that are often fatal in childhood (Fig. 132-14).[102-107] Of patients with autosomal recessive HIES, up to 24% may have the neonatal the neonatal papulopustular eruption and food allergies/asthma are more common than in autosomal dominant HIES. Patients with autosomal recessive HIES have an increased risk of mucocutaneous squamous cell carcinoma and lymphomas.

ETIOLOGY AND PATHOGENESIS

Three different gene defects have been identified in HIES. The most common is a dominant negative mutation in signal transducer and activator of transcription 3 (STAT3),[108,109] and is associated with a severe reduction of Th17 cells.[110] STAT3 signals downstream of IL-6, which, together with transforming growth factor–β, is important for the development of Th17 cells. The Th17 cell deficiency accounts for the increased susceptibility to *Candida* infection and, as Th17 activation is key, for innate immunity at epithelial surfaces through the development of antimicrobial peptides. The decreased cytokine signaling may account for the "cold" abscesses and destructive inflammation from increased expression of other proinflammatory cytokines. The osteopenia of HIES is thought to result from loss of STAT3-dependent downregulation of osteoclast differentiation.

Figure 132-14 This boy with autosomal recessive HIES caused by a *DOCK8* (dedicator of cytokinesis 8) mutation shows extensive molluscum contagiosum infection on the neck. (Used with permission from Dr. I. Barlan.)

Autosomal recessive HIES most often results from biallelic mutations in the dedicator of cytokinesis 8 (*DOCK8*), which encodes for a protein that is implicated in the regulation of the actin cytoskeleton that is critical for T-cell expansion and antibody responses.[102,103]

Mutations in *TYK2* have been found in a single patient with HIES,[111] although other patients with *TYK2* deficiency have increased viral and mycobacterial infections, but not HIES, suggesting that HIES may not be an important feature. Biallelic mutations in phosphoglucomutase 3, a glycosylation enzyme, also have been found to underlie an HIES-like autosomal recessive disorder with elevated IgE levels, atopy, autoimmunity, and neurocognitive abnormalities.[112-114]

DIAGNOSIS

By definition, serum IgE levels must be elevated, but normal levels of IgE increase markedly during childhood. Diagnostic criteria for autosomal dominant HIES have been established that include IgE levels greater than 1000 IU/mL and a weighted score of 5 clinical features (typical newborn rash, recurrent pneumonia, pathologic bone fractures, characteristic facies, and a high palate)[115]; these features and Th17 cell deficiency lead to a "probably" diagnosis, but are definitive with a heterozygous *STAT3* mutation. It should be recognized, however, that normal levels of IgE are age-dependent. Levels greater than 2000 IU/mL are seen in adolescents and adults; considerably lower levels are seen during infancy, given that the upper limit of normal in infants younger than age 1 year is 12.7 IU/mL and by 5 years of age is 47.1 IU/mL; an IgE level 10-fold above the 95th percentile for age is required for diagnosis. Eosinophilia of at least 2 SD above normal (usually above 700 cells/μL) is also a clinical manifestation. The total white blood cell count is typically normal and often fails to elevate in the setting of acute infection.

In the autosomal recessive forms, eosinophilia tends to be more severe (eg, 17,500/μL).[116] These patients have a global defect in T-cell activation (CD4>CD8 cells), which may explain their susceptibility to viral infections (including herpes and molluscum) in addition to bacterial and fungal infections. In contrast to autosomal dominant HIES, autosomal recessive HIES is associated with Th2 cell skewing. Deficiency of DOCK8 expression can be detected by flow cytometry.[117]

DIFFERENTIAL DIAGNOSIS

HIES is often considered in young pediatric patients with atopic dermatitis or WAS because of the high levels of IgE, eosinophilia, dermatitis, and recurrent staphylococcal infections. The coarse facial features, osteopenia,

recurrent pneumonia, and cold abscesses of autosomal dominant HIES help to distinguish it; the presence of platelet abnormalities also helps to distinguish WAS. In a study of 70 pediatric patients with a serum IgE level higher than 2000 IU/mL, 54 (77%) had atopic dermatitis and only 6 (8%) had HIES; the IgE level did not correlate with the diagnosis of HIES.[118] Other immunodeficiency syndromes can be confused with HIES (eg, Omenn, DiGeorge, IPEX, and IRAK-4 [IL-1R–associated kinase 4] deficiency), as well as Netherton syndrome and GVHD. Early candidal infections may lead to consideration of mucocutaneous candidiasis (and with mosaic STAT3 mutations, candida infections may be present without detectable Th17 cell deficiency.[100]

CLINICAL COURSE, PROGNOSIS, AND TREATMENT

Given the lack of correlation between serum levels of IgE, eosinophilia, and the susceptibility to severe infections, the clinical course is difficult to predict. Patients with autosomal recessive HIES have a more severe course related to the neurologic complications.

Antistaphylococcal antibiotics are effective for most cutaneous infections in patients with HIES, and oral triazole antifungals treat the mucocutaneous candidiasis. The prophylactic use of antistaphylococcal antibiotics markedly reduces the incidence of skin abscesses and pneumonia. The cutaneous and pulmonary abscesses often require incision and drainage and may require partial lung resections. Intravenous immunoglobulin therapy has been used successfully. Intravenous immunoglobulin may influence IgE levels as a consequence of an increased Ig catabolism or neutralization of the IgE. Ascorbic acid and cimetidine have decreased the number of infections and the chemotactic defect in some patients. Isotretinoin has been reported to eliminate the recurrent staphylococcal abscesses in an isolated patient without any change in immunologic status. Cyclosporine also has been used with good clinical and laboratory response. IFN-γ has shown inconsistent effects on IgE levels and infection susceptibility. Alendronate has been administered for the osteopenia.[99] There are anecdotal reports of improvement of the eczematous dermatitis of HIES with use of omalizumab, a monoclonal antibody directed against IgE.[119] INF-α has effectively treated the numerous warts[120] and severe herpetic infections[121,122] in DOCK8-deficient HIES. Stem cell transplantation is generally reserved for DOCK8-deficient HIES,[123-125] but has been successful in severe cases of STAT3-deficient HIES.[126]

WHIM SYNDROME

WHIM (*w*arts, *h*ypogammaglobulinemia, *i*nfections, and *m*yelokathexis) syndrome is an immunodeficiency that is characterized by neutropenia, hypogammaglobulinemia, and a susceptibility to infection by human papillomavirus. The disorder results from defects in the chemokine receptor gene *CXCR4*,[127,128] and thus mature neutrophils are not able to exit the bone marrow (myelokathexis). The susceptibility to human papillomavirus infections suggests an important role for CXCR4 in immunity to this virus. Plerixafor, a CXCR4 antagonist, increases circulating leukocytes, reduces infections and, in combination with imiquimod, markedly reduces associated warts that had previously been resistant to treatment.[129]

SILVERY HAIR SYNDROMES: CHÉDIAK-HIGASHI AND GRISCELLI SYNDROMES

The silvery hair syndromes comprise a group of autosomal recessive disorders in which a peculiar metallic sheen to hair, and often to skin, is noted (see also Chap. 75). Of these, Chédiak-Higashi and Griscelli (Type 2) syndromes have associated immunodeficiency (Table 132-8). Another syndrome with silvery hair, Elejalde syndrome, does not have associated immunodeficiency and may be allelic with the myosin 5a-deficient form of Griscelli syndrome (GS), with severe associated CNS dysfunction.

CHÉDIAK-HIGASHI SYNDROME

AT-A-GLANCE

- Autosomal recessive disorder of vesicle trafficking that results in giant organelles, including melanosomes, leukocyte granules, and platelet-dense granules.
- Mutations in *LYST*.
- Silvery hair; pigment speckling and often hyperpigmentation on nose and ears.
- Variable degree of photophobia and nystagmus.
- Diagnosis can be confirmed by pigment clumping in hair shaft and leukocyte granules in blood smears.
- Recurrent pyogenic infections and a mild bleeding diathesis.
- Life-threatening "accelerated phase" with pancytopenia and organomegaly as a result of lymphohistiocytic infiltration.
- Progressive neurologic deterioration.
- Therapy: transplantation.

TABLE 132-8
Characteristics of Griscelli and Chédiak-Higashi Syndromes

	GRISCELLI (GS1)	GRISCELLI (GS2)	GRISCELLI (GS3)	CHÉDIAK-HIGASHI
Gene defect/protein	*MYO5A*/myosin5a	*RAB27A*/Rab27a	a. Slac2-a/mlph b. *MYO5A* F-exon deletion	LYST/lysosomal transport protein
Functional consequence	Intracellular organelle transport and neurotransmitter secretion; interacts with Slac2-a/mlph	GTPase for organelle movement and transfer. Essential for T- and NK-lymphocyte cytotoxic granule release and target cell death; interacts with Slac2-a/mlph	Interacts with both myosin 5a and Rab27 to form a protein complex essential for melanosome movement to melanocytes	Protein required for final steps of membrane fusion and vesicle trafficking
Tissue expression	Brain; not in cytotoxic cells	Cytotoxic cells; not in brain	Slac2-a/mlph is not in cytotoxic cells	
Clinical features	Silvery metallic hair; mild skin pigment dilution; onset of neurologic disorder in infancy	Silvery metallic hair; mild skin pigment dilution; severe immune disorder with hemophagocytic syndrome; neurologic symptoms are associated with hemophagocytic syndrome and CNS infiltration	Silvery metallic hair	Silvery metallic hair and skin; recurrent infections; bleeding tendencies; progressive neurologic defects; immune disorder with hemophagocytic syndrome
Immune defects	None	T- and NK-cell function; hypogammaglobulinemia	None	T- and NK-cell function, diminished neutrophil chemotaxis and bactericidal activity
Hair mount	Large, uneven clusters of pigment	Same as GS1	Same as GS1	Granular, evenly distributed pigment
Skin in light microscopy	Pigmentary dilution in keratinocytes, accumulation of melanosomes in melanocytes	Same as GS1	Same as GS1	Pigmentary dilution in both keratinocytes and melanocytes
Skin in electron microscopy	Mature melanosomes filling epidermal melanocytes	Same as GS1	Same as GS1	Reduced numbers of giant melanosomes
Leukocyte granules	None	None	None	Large, cytoplasmic

GTPase, guanosine triphosphatase; mlph, melanophilin; NK, natural killer.

EPIDEMIOLOGY

Chédiak-Higashi syndrome (CHS) is a rare autosomal recessive disorder.[130,131] Parental consanguinity is often reported, and there are approximately 300 reported cases worldwide.

CLINICAL FINDINGS

Patients usually first show manifestations during infancy or early childhood. Pigment abnormalities occur in 75% of patients, particularly the silver sheen to the hair (Fig. 132-15A). Ocular hypopigmentation may cause photophobia, and strabismus and nystagmus are common. Visual acuity does not tend to be reduced. The skin is typically fair compared to other family members, but dark, slate-colored areas of pigmentation and diffuse, speckled hypopigmentation may be seen in the sun-exposed skin of dark-skinned individuals.[132-134]

Infections can be observed in the newborn period and continue throughout the lifetime of the patient. Infections most commonly involve the skin, lungs, and respiratory tract where microbes such as *S. aureus*, *Streptococcus pyogenes*, and *Pneumococcus* are prevalent. Deep ulcerations resembling pyoderma gangrenosum have been described.

Neurologic manifestations include muscle weakness, cranial and peripheral neuropathy, and progressive neurologic deterioration. CHS patients also exhibit a mild coagulation defect. Patients bruise easily, manifest petechiae, and have some mucosal bleeding, although platelet numbers remain normal.

ETIOLOGY AND PATHOGENESIS

CHS is caused by mutations in the *LYST* gene, located on chromosome lq42, which encodes a protein required for the final steps of vesicle trafficking and

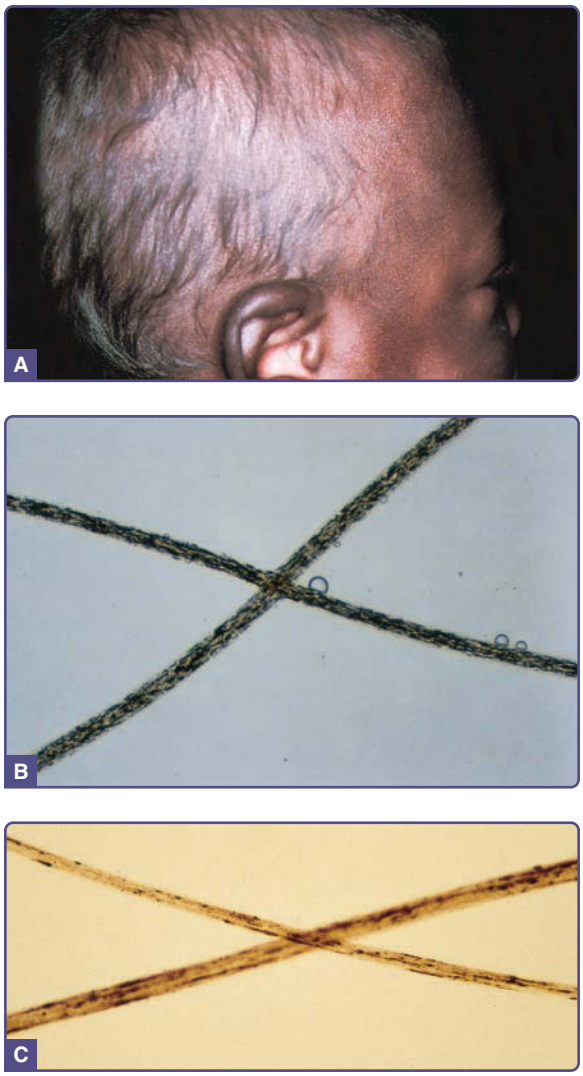

Figure 132-15 Silvery hair syndromes. **A,** Silvery sheen to the hair in a black infant; the patient had darkly pigmented eyes and skin. Note the accentuation of pigmentation on the ear helix. **B,** Small, evenly clumped pigment granules in the hairs of Chédiak-Higashi syndrome. **C,** Larger aggregates of irregularly spaced pigmentation in the hairs of a patient with Griscelli syndrome.

secretion.[135] The *LYST* gene is expressed in lysosomes and other secretory organelles (melanosomes, cytolytic granules, and platelet dense granules). Characteristic giant granules are thought to result from altered granule maturation and fusion. Enlarged melanosomes are unable to be transferred to keratinocytes. NK cells and cytotoxic T lymphocytes do not release proteolytic enzymes necessary for target cell killing. Cytotoxic T-lymphocyte–associated antigen is trapped in abnormally large vesicles rather than on the cell surface and thus may be unable to regulate T-cell activation, increasing the risk of lymphoproliferative disease. Platelet-dense granules are delayed in secretion of storage pools required for normal coagulation. Diminished chemotaxis of neutrophils and monocytes and delayed intracellular microorganism killing are often associated.

DIAGNOSIS

Diagnosis is usually suspected clinically because of the silvery sheen to the hair. The finding of large cytoplasmic granules in blood leukocytes is highly diagnostic. Hair shafts have evenly distributed small pigment granules (see Fig. 132-15B), in contrast to the irregular, large pigmentary clumping of GS (see Fig. 132-15C). Although not performed for diagnostic purposes, skin biopsy shows pigmentary dilution in both melanocytes and keratinocytes, and electron microscopy reveals giant melanosomes.

DIFFERENTIAL DIAGNOSIS

The silvery hair sheen is also seen in GS, but an unusual metallic hair sheen and skin hypopigmentation is a component as well of Hermansky-Pudlak syndrome (see Chap. 75). Silvery hair also has been described in a neonate with hypoproteinemia from congenital hydrops fetalis; the hair spontaneously repigmented[136] with clinical improvement. Pseudo-CHS granules are seen on smears in some cases of acute leukemia.[137]

The hemophagocytic syndrome associated with lymphohistiocytic proliferation of silvery hair syndromes needs to be distinguished from massive lymphoproliferation in other immunodeficiency disorders, particularly X-linked lymphoproliferative disorder (see "Antibody Deficiency Disorders" above), familial hemophagocytic lymphohistiocytosis, autoimmune lymphoproliferative syndrome, and immunodeficiency caused by mutations in the IL-2R. *Familial hemophagocytic lymphohistiocytosis* is a group of autosomal recessive disorders with hemophagocytosis and absence of NK-cell cytotoxicity that tends to be fatal without early stem cell transplantation.[138,139] The condition can result from mutations in either *PRF1*, which encodes perforin; *UNC13D*, which encodes Munc 13-4[140]; *STX11*, encoding syntaxin 11; or *STXBP2*, encoding Munc 18-2. All of these proteins are involved in the exocytosis and function of cytotoxic intracellular granules NK cells and cytotoxic T lymphocytes.

Mutations in several genes can lead to autosomal recessive or dominant autoimmune lymphoproliferative syndrome, also known as Canale-Smith syndrome.[141,142] These include the genes that encode Fas or CD95 (*TNFRSF6*), the cell-surface apoptosis receptor, and its ligand (*TNFSF6*), and the caspase proteins 8 and 10, proteases in the cascade leading to apoptosis. This group of disorders features autoimmune disorders (cytopenias, leukocytoclastic vasculitis, lupus erythematosus) and an increased risk of lymphoma, and is associated with increased numbers of circulating CD4−/CD8− α/β T cells. Immunodeficiency with extensive lymphocytic infiltration

of viscera is also a manifestation of autosomal recessive mutations in the α chain of the IL-2 receptor.[143] Patients demonstrate bacterial, viral, and fungal infections because of early apoptosis of the developing thymic T lymphocytes.

PROGNOSIS, CLINICAL COURSE, AND TREATMENT

The "accelerated phase" of hemophagocytic lymphohistiocytosis occurs in 85% of CHS patients and is usually triggered by Epstein-Barr virus infection. Viscera become infiltrated with lymphoid and histiocytic cells, which are sometimes atypical in appearance. Hepatosplenomegaly with jaundice, lymphadenopathy, pancytopenia, and a leukemia-like gingivitis with pseudomembranous sloughing of the buccal mucosa are associated. In this phase, petechiae, bruising and gingival bleeding are commonly seen, resulting from the thrombocytopenia and decreased hepatic synthesis of coagulation factors. Overwhelming infection or hemorrhage during the accelerated phase often lead to death. CHS may present with the accelerated phase.[144]

The mean age of death for untransplanted patients with CHS is 6 years, usually from overwhelming infection or hemorrhage during the lymphoma-like accelerated phase. Prenatal diagnosis has been achieved by examination of hair from fetal scalp biopsies and of leukocytes from fetal blood samples.

The treatment of choice for patients with CHS is early transplantation,[145-148] which corrects the immunologic status but does not affect the pigment abnormality nor inhibit the development of neurologic disorders that grow increasingly worse with age. Reduced intensity conditioning has been used with success, especially in patients transplanted before the accelerated phase occurs. Absence of cytotoxic T-cell function has been touted as predictive of the later occurrence of hemophagocytic lymphohistiocytosis, and as a biomarker for early transplantation. Management of CHS is otherwise largely supportive, with use of prophylactic antibiotics to avoid recurrent infections. Acyclovir, high-dose intravenous γ-globulin, vincristine, cyclosporine, and prednisone have been used to control the accelerated phase, but the accelerated phase is usually fatal.

GRISCELLI SYNDROME

AT-A-GLANCE

- Autosomal recessive group of disorders.
- Mutations in *MYO5A* (more neurologic), *RAB27A* (hemophagocytosis), or *Slac-2a*.
- Silvery hair is a hallmark.
- Diagnosis can be confirmed by pigment clumping in hair shaft, but smears show no leukocyte granules.
- Hemophagocytosis often precipitated by Epstein-Barr virus infection.
- Treatment: transplantation.

EPIDEMIOLOGY

The majority of affected patients with this autosomal recessive disorder are of Mediterranean or Middle Eastern origin and born into consanguineous families.

CLINICAL FINDINGS

The pigmentary dilution of GS is often limited to the hair, characterized by a silver-gray sheen with a few cases of skin involvement. The hair shaft shows large uneven clusters of pigment (see Fig. 132-15C) and the skin shows pigmentary dilution in keratinocytes but accumulation of melanosomes in melanocytes. Electron microscopy reveals numerous stage IV melanosomes in epidermal melanocytes. In contrast to CHS, smears of leukocytes do not show giant granules. The additional clinical features present in each subtype are dependent on the function and tissue expression of the defective protein. Patients with GS1 have a primary neurologic disorder that presents in infancy with hypotonia and developmental delay. Severe immune disorder characterized by hemophagocytic syndrome or an "accelerated phase of the disease" is seen in GS2. Hemophagocytic syndrome is characterized by infiltration of various organ systems by activated lymphocytes and macrophages. It develops at mean age of 36 months, and often is precipitated by a virus, particularly Epstein-Barr virus. Patients have fever, hepatosplenomegaly, neurologic impairment, coagulopathy, and pancytopenia. Patients with GS3 present solely with the pigmentary abnormalities.[149,150]

ETIOLOGY AND PATHOGENESIS

Mutations in 3 genes may underlie GS. GS1 is caused by a mutation in the *MYO5A* gene that encodes myosin-5a, a motor protein responsible for intracellular organelle transport. *MYO5A* is abundantly expressed in brain tissue and is important for neurotransmitter secretion. It is not expressed in cytotoxic cells. GS2 is caused by a mutation in the *RAB27A* gene, which encodes Rab27a, a guanosine triphosphatase protein involved in the function of the intracellular-regulated secretory pathway. It is essential for T-lymphocyte and NK-lymphocyte cytotoxic granule release and cell death. This defective cytotoxic activity most likely

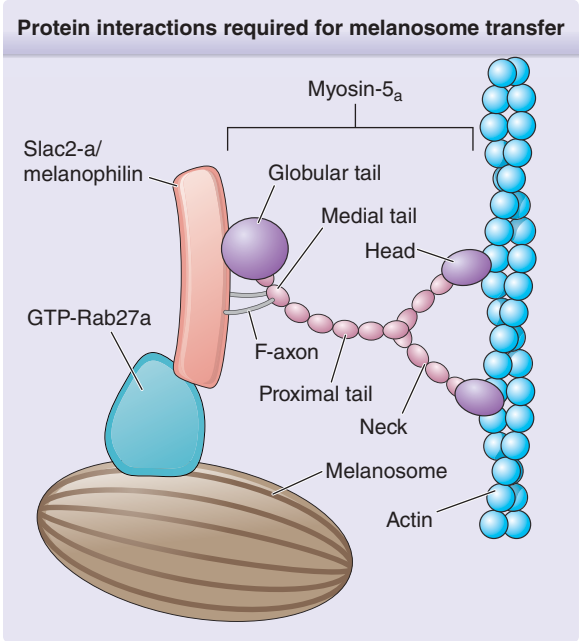

Figure 132-16 Protein interactions required for melanosome transfer. GTP, guanosine triphosphate. (Adapted with permission of ASCI: Ménasché G, Ho CH, Sanal O, et al. Griscelli syndrome restricted to hypopigmentation results from a melanophilin defect (GS3) or a MYO5A F-exon deletion (GS1). *J Clin Invest*. 2003;112:450-456. Permission conveyed through Copyright Clearance Center, Inc.)

leads to the uncontrolled activation of lymphocytes and macrophages in the hemophagocytic syndrome. Both *MYO5A* and *RAB27A* have been mapped to chromosome 15q21.1. The third type, GS3, is the result of a homozygous missense mutation in *Slac2-a/melanophilin* or a deletion of the *MYO5A* F-exon.[151] Melanophilin (also not expressed in cytotoxic cells) encodes a member of the Rab effector family and interacts with both myosin-5a (through the F-exon) and *RAB27A* to form a triprotein complex essential for the capture and local transport of melanosomes to the melanocytes (Fig. 132-16). All 3 genetic subtypes share the inability to construct this complex for melanosome transport, thus leading to the characteristic pigmentary abnormality of GS.

PROGNOSIS, CLINICAL COURSE, AND TREATMENT

GS has been uniformly fatal but now can be reversed by successful hematopoietic stem cell transplantation. Of patients with GS2, 85% have mutations in the *RAB27A* gene that lead to early protein truncation. They have the most-severe form of the disease, with early development of hemophagocytic syndrome and rapid progression. The median survival from the onset of the accelerated phase to death in these patients is 5 months. Most patients die by 5 years of age secondary to progressive CNS disease or recurrent infections. Missense mutations in the *RAB27A* gene show a milder phenotype with later age of hemophagocytic syndrome onset and a good response to chemotherapy treatment. Patients with GS1 do not develop hemophagocytic syndrome. Prenatal diagnosis has been achieved by examination of hair from fetal scalp biopsies and DNA analysis.

COMPLEMENT DEFICIENCY DISORDERS

AT-A-GLANCE

- Deficiency or dysfunction of early complement components is associated with autoimmune disorders, particularly systemic lupus erythematosus.
- Deficiency or dysfunction of early complement components leads to risk of infections caused by encapsulated bacteria.
- Deficiency of late complement components markedly increases susceptibility to neisserial infections.

Table 132-9 outlines the clinical manifestations of hereditary deficiency or dysfunction of complement components.

HEREDITARY ANGIOEDEMA

Hereditary angioedema (HAE) is almost always inherited in an autosomal dominant fashion with a spontaneous mutation rate of 25% (for clinical features and management, see Chap. 41).[152] It occurs in 1 in 150,000 persons and has no racial or ethnic predilection. Seventy-five percent of patients report a positive family history. There are 3 types of HAE. Type I is characterized by low antigenic levels of C1 inhibitor (C1 INH) and affects 85% of patients, whereas the remainder of patients have Type II, with low functional levels but normal/high antigenic levels of C1 INH. A third type of HAE does not show a deficiency of C1 INH. This type of HAE was previously thought to only affect women, although eventually, a family was described in which three male family members were affected.[153] One family in which the disease is transmitted as an autosomal recessive trait because of a mutation in the promoter region of the gene has been identified.[154]

HAE causes significant morbidity, especially if attacks are frequent and laryngeal edema is a

TABLE 132-9
Clinical Manifestations of Hereditary Deficiency or Dysfunction of Complement Components

MANIFESTATION	COMPONENT	PATHWAY	ASSOCIATIONS
Infection	C1q, C1r, C1s, C4, C2, C3	Classical	Autoimmune disorders, especially SLE
			Increased encapsulated bacterial infections
	Mannan-binding lectin	Lectin	Pyogenic infections in neonates and children (SLE)
	Factors H, I	Inhibitors, alternative	Recurrent pyogenic infections (C3 depletion)
	Properdin	Stabilizer, alternative	Fulminant neisserial infections
	CR3	Receptor for iC3b	LAD (see LAD Type 1)
	C5 to C9	Terminal (membrane attack complex)	Recurrent neisserial infections; milder with C9 deficiency
Autoimmune disorders	C1, C4, C2	Classical	Autoimmune disorders, especially SLE
			Increased encapsulated bacterial infections
			SLE
Exfoliative erythroderma	C3, C5	Shared, terminal	Failure to thrive, diarrhea, infections
Angioedema	C1 esterase inhibitor	Inhibitor, classical	Angioedema
Renal disease and/or hemolysis	Factor H	Inhibitor, alternative	Glomerulonephritis, atypical hemolytic uremic syndrome
	Decay accelerating factor (CD59)	Inhibitor, alternative	Hemolysis, thrombosis
	Membrane cofactor protein (CD46)	Inhibitor, alternative	Atypical hemolytic uremic syndrome
	C3	Shared	Membranoproliferative glomerulonephritis, severe bacterial infections

LAD, leukocyte adhesion deficiency; SLE, systemic lupus erythematosus.

significant risk for mortality. There are several treatment modalities available including the use of attenuated androgens, antifibrinolytic agents, plasma-derived C1 INH, a kallikrein inhibitor and a bradykinin receptor antagonist.[152] Plasma-derived C1 INH can be used acutely to treat angioedema attacks or preventatively if attacks are frequent or before known procedures.

REFERENCES

1. Picard C, Al-Herz W, Bousfiha A, et al. Primary immunodeficiency diseases: an update on the classification from the International Union of Immunological Societies Expert Committee for Primary Immunodeficiency 2015. *J Clin Immunol*. 2015;35(8):696-726.
2. Ochs HD, Hagin D. Primary immunodeficiency disorders: general classification, new molecular insights, and practical approach to diagnosis and treatment. *Ann Allergy Asthma Immunol*. 2014;112(6):489-495.
3. Smith CIE, Berglöf A. X-Linked Agammaglobulinemia. In: Adam MP, Ardinger HH, Pagon RA, et al., eds. *GeneReviews* [Internet]. Seattle, WA: University of Washington; 1993-2016. 2001 [updated August 4, 2016]. https://www.ncbi.nlm.nih.gov/books/NBK1453/.
4. Winkelstein JA, Marino MC, Lederman HM, et al. X-linked agammaglobulinemia: report on a United States registry of 201 patients. *Medicine (Baltimore)*. 2006;85(4):193-202.
5. Berglof A, Turunen JJ, Gissberg O, et al. Agammaglobulinemia: causative mutations and their implications for novel therapies. *Expert Rev Clin Immunol*. 2013;9(12):1205-1221.
6. Resnick ES, Moshier EL, Godbold JH, et al. Morbidity and mortality in common variable immune deficiency over 4 decades. *Blood*. 2012;119(7):1650-1657.
7. Pierson JC, Camisa C, Lawlor KB, et al. Cutaneous and visceral granulomas in common variable immunodeficiency. *Cutis*. 1993;52:221.
8. Torrelo A, Mediero IG, Zambrano A. Caseating cutaneous granulomas in a child with common variable immunodeficiency. *Pediatr Dermatol*. 1995;12:170.
9. Gualdi G, Lougaris V, Baronio M, et al. Burden of skin disease in selective IgA deficiency and common variable immunodeficiency. *J Investig Allergol Clin Immunol*. 2015;25(5):369-371.
10. Cunningham-Rundles C, Bodian C. Common variable immunodeficiency: clinical and immunological features of 248 patients. *Clin Immunol*. 1999;92:34.
11. Herrod HG. Chronic mucocutaneous candidiasis in childhood and complications of non-*Candida* infection: a report of the Pediatric Immunodeficiency Collaborative Study Group. *J Pediatr*. 1990;116:377-382.
12. Soltész B, Tóth B, Sarkadi AK, et al. The evolving view of IL-17-mediated immunity in defense against mucocutaneous candidiasis in humans. *Int Rev Immunol*. 2015;34:348-363.
13. van de Veerdonk FL, Plantinga TS, Hoischen A, et al. STAT1 mutations in autosomal dominant chronic mucocutaneous candidiasis. *N Engl J Med*. 2011;365:54-61.

14. Depner M, Fuchs S, Raabe J, et al. The extended clinical phenotype of 26 patients with chronic mucocutaneous candidiasis due to gain-of-function mutations in STAT1. *J Clin Immunol*. 2016;36:73-84.
15. Toubiana J, Okada S, Hiller J, et al. Heterozygous STAT1 gain-of-function mutations underlie an unexpectedly broad clinical phenotype. *Blood*. 2016;127: 3154-3164.
16. Puel A, Cypowyj S, Bustamante J, et al. Chronic mucocutaneous candidiasis in humans with inborn errors of interleukin-17 immunity. *Science*. 2011;332:65-68.
17. Boisson B, Wang C, Pedergnana V, et al. An ACT1 mutation selectively abolishes interleukin-17 responses in humans with chronic mucocutaneous candidiasis. *Immunity*. 2013;39:676-686.
18. Ling Y, Cypowyj S, Aytekin C, et al. Inherited IL-17RC deficiency in patients with chronic mucocutaneous candidiasis. *J Exp Med*. 2015;212:619-631.
19. Anderson MS, Su MA. AIRE expands: new roles in immune tolerance and beyond. *Nat Rev Immunol*. 2016;16:247-258.
20. Ferre EM, Rose SR, Rosenzweig SD, et al. Redefined clinical features and diagnostic criteria in autoimmune polyendocrinopathy-candidiasis-ectodermal dystrophy. *JCI Insight*. 2016;1:13.
21. Wolff AS, Sarkadi AK, Maródi L, et al. Anti-cytokine autoantibodies preceding onset of autoimmune polyendocrine syndrome type I features in early childhood. *J Clin Immunol*. 2013;33:1341-1348.
22. Glocker EO, Hennigs A, Nabavi M, et al. A homozygous CARD9 mutation in a family with susceptibility to fungal infections. *N Engl J Med*. 2009;361: 1727-1735.
23. Ferwerda B, Ferwerda G, Plantinga TS, et al. Human dectin-1 deficiency and mucocutaneous fungal infections. *N Engl J Med*. 2009;361:1760-1767.
24. Meloni A, Furcas M, Cetani F, et al. Autoantibodies against type I interferons as an additional diagnostic criterion for autoimmune polyendocrine syndrome type 1. *J Clin Endocrinol Metab*. 2008;93:4389-4397.
25. Halabi-Tawil M, Ruemmele FM, Fraitag S, et al. Cutaneous manifestations of immune dysregulation, polyendocrinopathy, enteropathy, X-linked (IPEX) syndrome. *Br J Dermatol*. 2009;160:645-651.
26. Caudy AA, Reddy ST, Chatila T, et al. CD25 deficiency causes an immune dysregulation, polyendocrinopathy, enteropathy, X-linked-like syndrome, and defective IL-10 expression from CD4 lymphocytes. *J Allergy Clin Immunol*. 2007;119:482-487.
27. van de Veerdonk FL, Netea MG. Treatment options for chronic mucocutaneous candidiasis. *J Infect*. 2016;72(suppl):S56-S60.
28. Wildbaum G, Shahar E, Katz R, et al. Continuous G-CSF therapy for isolated chronic mucocutaneous candidiasis: complete clinical remission with restoration of IL-17 secretion. *J Allergy Clin Immunol*. 2013;132:761-764.
29. Buchbinder D, Nugent DJ, Fillipovich AH, et al. Wiskott-Aldrich syndrome: diagnosis, current management, and emerging treatments. *Appl Clin Genet*. 2014;7:55-66.
30. Massaad MJ, Ramesh N, Geha RS, et al. Wiskott-Aldrich syndrome: a comprehensive review. *Ann N Y Acad Sci*. 2013;1285:26-43.
31. Dupuis-Girod S, Medioni J, Haddad E, et al. Autoimmunity in Wiskott-Aldrich syndrome: risk factors, clinical features, and outcome in a single-center cohort of 55 patients. *Pediatrics*. 2003;111:e622-e627.
32. Sullivan KE, Mullen CA, Blaese RM, et al. A multiinstitutional survey of the Wiskott-Aldrich syndrome. *J Pediatr*. 1994;125(6, pt 1):876-885.
33. Cotta-de-Almeida V, Dupré L, Guipouy D, et al. Signal integration during T lymphocyte activation and function: Lessons from the Wiskott-Aldrich syndrome. *Front Immunol*. 2015;6:47.
34. Bosticardo M, Marangoni F, Aiuti A, et al. Recent advances in understanding the pathophysiology of Wiskott-Aldrich syndrome. *Blood*. 2009;113(25):6288-6295.
35. Dosanjh A. Autoimmunity and immunodeficiency. *Pediatr Rev*. 2015;36:489-494.
36. Volpi S, Santori E, Abernethy K, et al. N-WASP is required for B-cell-mediated autoimmunity in Wiskott-Aldrich syndrome. *Blood*. 2016;127:216-220.
37. Pala F, Morbach H, Castiello MC, et al. Lentiviral-mediated gene therapy restores B cell tolerance in Wiskott-Aldrich syndrome patients. *J Clin Invest*. 2015;125:3941-3951.
38. Winkelstein JA, Fearon E. Carrier detection of the X-linked primary immunodeficiency diseases using X-chromosome inactivation analysis. *J Allergy Clin Immunol*. 1990;85:1090-1097.
39. Worth AJ, Thrasher AJ. Current and emerging treatment options for Wiskott-Aldrich syndrome. *Expert Rev Clin Immunol*. 2015;11:1015-1032.
40. Braun CJ, Boztug K, Paruzynski A, et al. Gene therapy for Wiskott-Aldrich syndrome—long-term efficacy and genotoxicity. *Sci Transl Med*. 2014;6(227):227ra33.
41. Aiuti A, Biasco L, Scaramuzza S, et al. Lentiviral hematopoietic stem cell gene therapy in patients with Wiskott-Aldrich syndrome. *Science*. 2013;341:1233151.
42. Laskowski TJ, Van Caeneghem Y, Pourebrahim R, et al. Gene correction of iPSCs from a Wiskott-Aldrich syndrome patient normalizes the lymphoid developmental and functional defects. *Stem Cell Reports*. 2016;7:139-148.
43. Chinn IK, Shearer WT. Severe combined immunodeficiency disorders. *Immunol Allergy Clin North Am*. 2015;35(4):671-694.
44. Rivers L, Gaspar HB. Severe combined immunodeficiency: recent developments and guidance on clinical management. *Arch Dis Child*. 2015;100(7):667-672.
45. Denianke KS, Frieden IJ, Cowan MJ, et al. Cutaneous manifestations of maternal engraftment in patients with severe combined immunodeficiency: a clinicopathologic study. *Bone Marrow Transplant*. 2001;28(3):227-233.
46. Kwong PC, O'Marcaigh AS, Howard R, et al. Oral and genital ulceration: a unique presentation of immunodeficiency in Athabascan-speaking American Indian children with severe combined immunodeficiency. *Arch Dermatol*. 1999;135(8):927-931.
47. Marrella V, Maina V, Villa A. Omenn syndrome does not live by V(D)J recombination alone. *Curr Opin Allergy Clin Immunol*. 2011;11(6):525-531.
48. Kwan A, Abraham RS, Currier R, et al. Newborn screening for severe combined immunodeficiency in 11 screening programs in the United States. *JAMA*. 2014; 312(7):729-738.
49. Pai SY, Logan BR, Griffith LM, et al. Transplantation outcomes for severe combined immunodeficiency, 2000-2009. *N Engl J Med*. 2014;371(5):434-446.
50. Hanson EP, Monaco-Shawver L, Solt LA, et al. Hypomorphic nuclear factor-kappaB essential modulator mutation database and reconstitution system identifies phenotypic and immunologic diversity. *J Allergy Clin Immunol*. 2008;122(6):1169-1177.e16.

51. Courtois G, Smahi A, Reichenbach J, et al. A hypermorphic IkappaBalpha mutation is associated with autosomal dominant anhidrotic ectodermal dysplasia and T cell immunodeficiency. *J Clin Invest*. 2003;112(7):1108-1115.
52. Martinez-Pomar N, Munoz-Saa I, Heine-Suner D, et al. A new mutation in exon 7 of NEMO gene: late skewed X-chromosome inactivation in an incontinentia pigmenti female patient with immunodeficiency. *Hum Genet*. 2005;118(3-4):458-465.
53. Orange JS, Geha RS. Finding NEMO: genetic disorders of NF-[kappa]B activation. *J Clin Invest*. 2003;112:983.
54. Uzel G. The range of defects associated with nuclear factor kappaB essential modulator. *Curr Opin Allergy Clin Immunol*. 2005;5:513.
55. Fish JD, Duerst RE, Gelfand EW, et al. Challenges in the use of allogeneic hematopoietic SCT for ectodermal dysplasia with immune deficiency. *Bone Marrow Transplant*. 2009;43(3):217-221.
56. Scott SP, Bendix R, Chen P, et al. Missense mutations but not allelic variants alter the function of ATM by dominant interference in patients with breast cancer. *Proc Natl Acad Sci U S A*. 2002;99(2):925-930.
57. Rothblum-Oviatt C, Wright J, Lefton-Greif MA, et al. Ataxia telangiectasia: a review. *Orphanet J Rare Dis*. 2016;11(1):159.
58. Swift M, Morrell D, Massey RB, et al. Incidence of cancer in 161 families affected by ataxia-telangiectasia. *N Engl J Med*. 1991;325(26):1831-1836.
59. Hannan MA, Hellani A, Al-Khodairy FM, et al. Deficiency in the repair of UV-induced DNA damage in human skin fibroblasts compromised for the ATM gene. *Carcinogenesis*. 2002;23(10):1617-1624.
60. Cohen LE, Tanner DJ, Schaefer HG, et al. Common and uncommon cutaneous findings in patients with ataxia-telangiectasia. *J Am Acad Dermatol*. 1984;10(3):431-438.
61. Paller AS, Massey RB, Curtis MA, et al. Cutaneous granulomatous lesions in patients with ataxia-telangiectasia. *J Pediatr*. 1991;119(6):917-922.
62. Lai CH, Chun HH, Nahas SA, et al. Correction of ATM gene function by aminoglycoside-induced read-through of premature termination codons. *Proc Natl Acad Sci U S A*. 2004;101(44):15676-15681.
63. Dinauer MC. Disorders of neutrophil function: an overview. *Methods Mol Biol*. 2007;412:489.
64. Chiriaco M, Salfa I, Di Matteo G, et al. Chronic granulomatous disease: clinical, molecular, and therapeutic aspects. *Pediatr Allergy Immunol*. 2016;27:242-253.
65. Winkelstein JA, Marino MC, Johnston RB Jr, et al. Chronic granulomatous disease. Report on a national registry of 368 patients. *Medicine (Baltimore)*. 2000;79(3):155-169.
66. Köker MY, Camcioğlu Y, van Leeuwen K, et al. Clinical, functional, and genetic characterization of chronic granulomatous disease in 89 Turkish patients. *J Allergy Clin Immunol*. 2013;132:1156-1163.
67. Kuhns DB, Alvord WG, Heller T, et al. Residual NADPH oxidase and survival in chronic granulomatous disease. *N Engl J Med*. 2010;363:2600-2610.
68. Prendiville B, Nopper AJ, Lawrence H, et al. Chronic granulomatous disease presenting with ecthyma gangrenosum in a neonate. *J Am Acad Dermatol*. 2014;71:e44-e45.
69. Marciano BE, Spalding C, Fitzgerald A, et al. Common severe infections in chronic granulomatous disease. *Clin Infect Dis*. 2015;60:1176-1183.
70. Friend JC, Hilligoss DM, Marquesen M, et al. Skin ulcers and disseminated abscesses are characteristic of *Serratia marcescens* infection in older patients with chronic granulomatous disease. *J Allergy Clin Immunol*. 2009;124:164-166.
71. Foti C, Cassano N, Martire B, et al. Lupus erythematosus-like lesions in a carrier of X-linked chronic granulomatous disease: a case report and personal considerations. *Int J Dermatol*. 2004;43(11):840-842.
72. Cale CM, Morton L, Goldblatt D. Cutaneous and other lupus-like symptoms in carriers of X-linked chronic granulomatous disease: incidence and autoimmune serology. *Clin Exp Immunol*. 2007;148:79-84.
73. Valentine G, Thomas TA, Nguyen T, et al. Chronic granulomatous disease presenting as hemophagocytic lymphohistiocytosis: a case report. *Pediatrics*. 2014;134:e1727-e1730.
74. De Ravin SS, Naumann N, Cowen EW, et al. Chronic granulomatous disease as a risk factor for autoimmune disease. *J Allergy Clin Immunol*. 2008;122:1097-1103.
75. Magnani A, Brosselin P, Beauté J, et al. Inflammatory manifestations in a single-center cohort of patients with chronic granulomatous disease. *J Allergy Clin Immunol*. 2014;134:655-662.
76. Lekstrom-Himes JA, Kuhns DB, Alvord WG, et al. Inhibition of human neutrophil IL-8 production by hydrogen peroxide and dysregulation in chronic granulomatous disease. *J Immunol*. 2005;174:411-417.
77. Crotzer VL, Matute JD, Arias AA, et al. Cutting edge: NADPH oxidase modulates MHC class II antigen presentation by B cells. *J Immunol*. 2012;189:3800-3804.
78. Jirapongsananuruk O, Malech HL, Kuhns DB, et al. Diagnostic paradigm for evaluation of male patients with chronic granulomatous disease, based on the dihydrorhodamine 123 assay. *J Allergy Clin Immunol*. 2003;111:374-379.
79. Kang EM, Malech HL. Advances in treatment for chronic granulomatous disease. *Immunol Res*. 2009;43:77-84.
80. Gallin JI, Alling DW, Malech HL, et al. Itraconazole to prevent fungal infections in chronic granulomatous disease. *N Engl J Med*. 2003;348(24):2416-2422.
81. A controlled trial of interferon gamma to prevent infection in chronic granulomatous disease. The International Chronic Granulomatous Disease Cooperative Study Group. *N Engl J Med*. 1991;324(8):509-516.
82. Migliavacca M, Assanelli A, Ferrua F, et al. Pioglitazone as a novel therapeutic approach in chronic granulomatous disease. *J Allergy Clin Immunol*. 2016;137:1913-1915.
83. Noel N, Mahlaoui N, Blanche S, et al. Efficacy and safety of thalidomide in patients with inflammatory manifestations of chronic granulomatous disease: a retrospective case series. *J Allergy Clin Immunol*. 2013;132:997-1000.
84. Martinez CA, Shah S, Shearer WT, et al. Excellent survival after sibling or unrelated donor stem cell transplantation for chronic granulomatous disease. *J Allergy Clin Immunol*. 2012;129:176-183.
85. Güngör T, Teira P, Slatter M, et al. Reduced-intensity conditioning and HLA-matched haemopoietic stem-cell transplantation in patients with chronic granulomatous disease: a prospective multicentre study. *Lancet*. 2014;383:436-448.
86. Cole T, Pearce MS, Cant AJ, et al. Clinical outcome in children with chronic granulomatous disease managed conservatively or with hematopoietic

stem cell transplantation. *J Allergy Clin Immunol*. 2013;132:1150-1155.
87. Malech HL, Mapels PB, Whiting-Theoblad N, et al. Prolonged production of NADPH oxidase-corrected granulocytes after gene therapy of chronic granulomatous disease. *Proc Natl Acad Sci U S A*. 1997;94: 12133-12138.
88. Stein S, Ott MG, Schultze-Strasser S, et al. Genomic instability and myelodysplasia with monosomy 7 consequent to EVI1 activation after gene therapy for chronic granulomatous disease. *Nat Med*. 2010;16:198-204.
89. Kaufmann KB, Chiriaco M, Siler U, et al. Gene therapy for chronic granulomatous disease: current status and future perspectives. *Curr Gene Ther*. 2014;14:447-460.
90. De Ravin SS, Reik A, Liu PQ, et al. Targeted gene addition in human CD34(+) hematopoietic cells for correction of X-linked chronic granulomatous disease. *Nat Biotechnol*. 2016;34:424-429.
91. Grimbacher B, Holland SM, Gallin JI, et al. Hyper-IgE syndrome with recurrent infections: an autosomal dominant multisystem disorder. *N Engl J Med*. 1999;340:692-702.
92. Farmand S, Sundin M. Hyper-IgE syndromes: recent advances in pathogenesis, diagnostics and clinical care. *Curr Opin Hematol*. 2015;22(1):12-22.
93. Chandesris MO, Melki I, Natividad A, et al. Autosomal dominant STAT3 deficiency and hyper-IgE syndrome: molecular, cellular, and clinical features from a French national survey. *Medicine (Baltimore)*. 2012;91:e1-e19.
94. Chamlin SL, McCalmont TH, Cunningham BB, et al. Cutaneous manifestations of hyper-IgE syndrome in infants and children. *J Pediatr*. 2002;141:572-575.
95. Eberting CL, Davis J, Puck JM, et al. Dermatitis and the newborn rash of hyper-IgE syndrome. *Arch Dermatol*. 2004;140:1119-1125.
96. Grimbacher B, Holland SM, Puck JM. Hyper-IgE syndromes. *Immunol Rev*. 2005;203:244.
97. Esposito L, Poletti L, Maspero C, et al. Hyper-IgE syndrome: dental implications. *Oral Surg Oral Med Oral Pathol Oral Radiol*. 2012;114(2):147-153.
98. Sowerwine KJ, Shaw PA, Gu W, et al. Bone density and fractures in autosomal dominant hyper IgE syndrome. *J Clin Immunol*. 2014;34(2):260-264.
99. Scheuerman O, Hoffer V, Cohen AH, et al. Reduced bone density in patients with autosomal dominant hyper-IgE syndrome. *J Clin Immunol*. 2013;33(5): 903-908.
100. Hsu AP, Sowerwine KJ, Lawrence MG, et al. Intermediate phenotypes in patients with autosomal dominant hyper-IgE syndrome caused by somatic mosaicism. *J Allergy Clin Immunol*. 2013;131(6):1586-1593.
101. Renner ED, Puck JM, Holland SM, et al. Autosomal recessive hyperimmunoglobulin E syndrome: A distinct disease entity. *J Pediatr*. 2004;144(1):93-99.
102. Zhang Q, Davis JC, Lamborn IT, et al. Combined immunodeficiency associated with DOCK8 mutations. *N Engl J Med*. 2009;361:2046-2055.
103. Engelhardt KR, Gertz ME, Keles S, et al. The extended clinical phenotype of 64 patients with dedicator of cytokinesis 8 deficiency. *J Allergy Clin Immunol*. 2015;136:402-412.
104. Aydin SE, Kilic SS, Aytekin C, et al. DOCK8 deficiency: clinical and immunological phenotype and treatment options—a review of 136 patients. *J Clin Immunol*. 2015;35(2):189-198.
105. Chu EY, Freeman AF, Jing H, et al. Cutaneous manifestations of DOCK8 deficiency syndrome. *Arch Dermatol*. 2012;148:79-84.
106. Boos AC, Hagl B, Schlesinger A, et al. Atopic dermatitis, STAT3- and DOCK8-hyper-IgE syndromes differ in IgE-based sensitization pattern. *Allergy*. 2014;69:943-953.
107. Alsum Z, Hawwari A, Alsmadi O, et al. Clinical, immunological and molecular characterization of DOCK8 and DOCK8-like deficient patients: single center experience of twenty-five patients. *J Clin Immunol*. 2013;33:55-67.
108. Minegishi Y, Saito M, Tsuchiya S, et al. Dominant-negative mutations in the DNA-binding domain of STAT3 cause hyper-IgE syndrome. *Nature*. 2007;448(7157):1058-1062.
109. Holland SM, DeLeo FR, Elloumi HZ, et al. STAT3 mutations in the hyper-IgE syndrome. *N Engl J Med*. 2007;357(16):1608-1619.
110. Renner ED, Rylaarsdam S, Anover-Sombke S, et al. Novel signal transducer and activator of transcription 3 (STAT3) mutations, reduced T(H)17 cell numbers, and variably defective STAT3 phosphorylation in hyper-IgE syndrome. *J Allergy Clin Immunol*. 2008;122(1):181-187.
111. Minegishi Y, Saito M, Morio T, et al. Human tyrosine kinase 2 deficiency reveals its requisite roles in multiple cytokine signals involved in innate and acquired immunity. *Immunity*. 2006;25:745-755.
112. Sassi A, Lazaroski S, Wu G, et al. Hypomorphic homozygous mutations in phosphoglucomutase 3 (PGM3) impair immunity and increase serum IgE levels. *J Allergy Clin Immunol*. 2014;133:1410-1419.
113. Zhang Y, Yu X, Ichikawa M, et al. Autosomal recessive phosphoglucomutase 3 (PGM3) mutations link glycosylation defects to atopy, immune deficiency, autoimmunity, and neurocognitive impairment. *J Allergy Clin Immunol*. 2014;133:1400-1409.
114. Yang L, Fliegauf M, Grimbacher B, et al. Hyper-IgE syndromes: reviewing PGM3 deficiency. *Curr Opin Pediatr*. 2014;26:697-703.
115. Woellner C, Gertz EM, Schäffer AA, et al. Mutations in STAT3 and diagnostic guidelines for hyper-IgE syndrome. *J Allergy Clin Immunol*. 2010;125:424-432.
116. Boos AC, Hagl B, Schlesinger A, et al. Atopic dermatitis, STAT3- and DOCK8-hyper-IgE syndromes differ in IgE-based sensitization pattern. *Allergy*. 2014;69:943-953.
117. Pai SY, de Boer H, Massaad MJ, et al. Flow cytometry diagnosis of dedicator of cytokinesis 8 (DOCK8) deficiency. *J Allergy Clin Immunol*. 2014;134(1):221-223.
118. Joshi AY, Iyer VN, Boyce TG, et al. Elevated serum immunoglobulin E (IgE): when to suspect hyper-IgE syndrome: a 10-year pediatric tertiary care center experience. *Allergy Asthma Proc*. 2009;30:23-27.
119. Bard S, Paravisini A, Avilés-Izquierdo JA, et al. Eczematous dermatitis in the setting of hyper-IgE syndrome successfully treated with omalizumab. *Arch Dermatol*. 2008;144:1662-1663.
120. Al-Zahrani D, Raddadi A, Massaad M, et al. Successful interferon-alpha 2b therapy for unremitting warts in a patient with DOCK8 deficiency. *Clin Immunol*. 2014;153:104-108.
121. Keles S, Jabara HH, Reisli I, et al. Plasmacytoid dendritic cell depletion in DOCK8 deficiency: rescue of severe herpetic infections with IFN-alpha 2b therapy. *J Allergy Clin Immunol*. 2014;133:1753-1755.e3.

122. Papan C, Hagl B, Heinz V, et al. Beneficial IFN-alpha treatment of tumorous herpes simplex blepharoconjunctivitis in dedicator of cytokinesis 8 deficiency. *J Allergy Clin Immunol*. 2014;133:1456-1458.
123. Cuellar-Rodriguez J, Freeman AF, Grossman J, et al. Matched related and unrelated donor hematopoietic stem cell transplantation for DOCK8 deficiency. *Biol Blood Marrow Transplant*. 2015;21:1037-1045.
124. Gatz SA, Benninghoff U, Schutz C, et al. Curative treatment of autosomal-recessive hyper-IgE syndrome by hematopoietic cell transplantation. *Bone Marrow Transplant*. 2011;46:552-556.
125. Boztug H, Karitnig-Weiss C, Ausserer B, et al. Clinical and immunological correction of DOCK8 deficiency by allogeneic hematopoietic stem cell transplantation following a reduced toxicity conditioning regimen. *Pediatr Hematol Oncol*. 2012;29:585-594.
126. Patel NC, Gallagher JL, Torgerson TR, et al. Successful haploidentical donor hematopoietic stem cell transplant and restoration of STAT3 function in an adolescent with autosomal dominant hyper-IgE syndrome. *J Clin Immunol*. 2015;35:479-485.
127. Wolach B, Eliakim A, Pomeranz A, et al. Cyclosporin treatment of hyperimmunoglobulin E syndrome. *Lancet*. 1996;347(8993):67.
128. Al Ustwani O, Kurzrock R, Wetzler M. Genetics on a WHIM. *Br J Haematol*. 2014;164(1):15-23.
129. McDermott DH, Liu Q, Velez D, et al. A phase 1 clinical trial of long-term, low-dose treatment of WHIM syndrome with the CXCR4 antagonist plerixafor. *Blood*. 2014;123(15):2308-2316.
130. Nagai K, Ochi F, Terui K, et al. Clinical characteristics and outcomes of Chédiak-Higashi syndrome: a nationwide survey of Japan. *Pediatr Blood Cancer*. 2013;60(10):1582-1586.
131. Introne WJ, Westbroek W, Golas GA, et al. Chediak-Higashi syndrome. In: Adam MP, Ardinger HH, Pagon RA, et al., eds. *GeneReviews* [Internet]. Seattle, WA: University of Washington; 1993-2018. 2009 [updated January 15, 2015]. https://www.ncbi.nlm.nih.gov/books/NBK5188/.
132. Anderson LL, Paller AS, Malpass D, et al. Chediak-Higashi syndrome in a black child. *Pediatr Dermatol*. 1992;9:31-36.
133. Al-Khenaizan S. Hyperpigmentation in Chediak-Higashi syndrome. *J Am Acad Dermatol*. 2003;49:S244-S246.
134. Raghuveer C, Murthy SC, Mithuna MN, et al. Silvery hair with speckled dyspigmentation: Chediak-Higashi syndrome in three Indian siblings. *Int J Trichology*. 2015;7:133-135.
135. Huizing M, Helip-Wooley A, Westbroek W, et al. Disorders of lysosome-related organelle biogenesis: Clinical and molecular genetics. *Annu Rev Genomics Hum Genet*. 2008;9:359-386.
136. Galve J, Martín-Santiago A, Clavero C, et al. Spontaneous repigmentation of silvery hair in an infant with congenital hydrops fetalis and hypoproteinemia. *Cutis*. 2016;97:E1-E5.
137. Vargas MT, Escamilla V, Morales-Camacho RM, et al. Multiple pseudo-Chediak-Higashi inclusions associated with MYC deletion in a patient with acute myeloid leukemia. *Acta Haematol*. 2015;133(4):321-323.
138. Cetica V, Sieni E, Pende D, et al. Genetic predisposition to hemophagocytic lymphohistiocytosis: report on 500 patients from the Italian registry. *J Allergy Clin Immunol*. 2016;137(1):188-196.
139. Degar B. Familial hemophagocytic lymphohistiocytosis. *Hematol Oncol Clin North Am*. 2015;29(5):903-913.
140. Giri PP, Biswas N, Chakravarty S. Familial hemophagocytic lymphohistiocytosis due to mutation of UNC13D gene. *Indian J Hematol Blood Transfus*. 2016;32(suppl 1):344-346.
141. Straus SE, Jaffe ES, Puck JM, et al. The development of lymphomas in families with autoimmune lymphoproliferative syndrome with germline Fas mutations and defective lymphocyte apoptosis. *Blood*. 2001;98(1):194-200.
142. George LA, Teachey DT. Optimal management of autoimmune lymphoproliferative syndrome in children. *Paediatr Drugs*. 2016;18(4):261-272.
143. Sharfe N, Dadi HK, Shahar M, et al. Human immune disorder arising from mutation of the alpha chain of the interleukin-2 receptor. *Proc Natl Acad Sci U S A*. 1997;94(7):3168-3171.
144. Maaloul I, Talmoudi J, Chabchoub I, et al. Chediak-Higashi syndrome presenting in accelerated phase: a case report and literature review. *Hematol Oncol Stem Cell Ther*. 2016;9(2):71-75.
145. Umeda K, Adachi S, Horikoshi Y, et al. Allogeneic hematopoietic stem cell transplantation for Chediak-Higashi syndrome. *Pediatr Transplant*. 2016;20:271-275.
146. Hamidieh AA, Pourpak Z, Yari K, et al. Hematopoietic stem cell transplantation with a reduced-intensity conditioning regimen in pediatric patients with Griscelli syndrome type 2. *Pediatr Transplant*. 2013;17:487-491.
147. Trottestam H, Beutel K, Meeths M, et al. Treatment of the X-linked lymphoproliferative, Griscelli and Chédiak-Higashi syndromes by HLH directed therapy. *Pediatr Blood Cancer*. 2009;52:268-272.
148. Lozano ML, Rivera J, Sánchez-Guiu I, et al. Towards the targeted management of Chediak-Higashi syndrome. *Orphanet J Rare Dis*. 2014;9:132.
149. Westbroek W, Klar A, Cullinane AR, et al. Cellular and clinical report of new Griscelli syndrome type III cases. *Pigment Cell Melanoma Res*. 2012;25:47-56.
150. Nouriel A, Zisquit J, Helfand AM, et al. Griscelli syndrome type 3: two new cases and review of the literature. *Pediatr Dermatol*. 2015;32:e245-e248.
151. Ménasché G, Ho CH, Sanal O, et al. Griscelli syndrome restricted to hypopigmentation results from a melanophilin defect (GS3) or a MYO5A F-exon deletion (GS1). *J Clin Invest*. 2003;112(3):450-456.
152. Cicardi M, Aberer W, Banerji A, et al. Classification, diagnosis, and approach to treatment for angioedema: consensus report from the Hereditary Angioedema International Working Group. *Allergy*. 2014;69(5):602-616.
153. Bork K, Gül D, Dewald G. Hereditary angio-oedema with normal C1 inhibitor in a family with affected women and men. *Br J Dermatol*. 2006;154(3):542-545.
154. Verpy E, Biasotto M, Brai M, et al. Exhaustive mutation scanning by fluorescence-assisted mismatch analysis discloses new genotype-phenotype correlations in angioedema. *Am J Hum Genet*. 1996;59(2):308-319.

Chapter 133 :: Skin Manifestations of Internal Organ Disorders

:: Amy K. Forrestel & Robert G. Micheletti

Frequently, cutaneous findings are relevant to the overall health of a patient. Even though some findings on the skin are the result of multisystem disease processes that affect the whole organism, primary skin diseases may also impact other organs and overall health, particularly when severe or longstanding.

A comprehensive chapter on cutaneous manifestations of systemic disease could encompass much of dermatology. This chapter's goal is to provide general information and principles, highlight key diseases that may not be discussed elsewhere, and group disorders into quick-reference charts organized by organ system. This chapter specifically focuses on cutaneous manifestations of cardiovascular, pulmonary, hepatic, GI, and renal disease.

CARDIOVASCULAR SYSTEM

Disturbances in the cardiovascular system causing decreased cardiac output can produce marked skin changes. Cyanosis is a purple-blue discoloration of the skin caused by an increase in the absolute amount of desaturated hemoglobin. It can be classified as "central," in which low arterial oxygen saturation is caused by lung disease or shunt physiology, or "peripheral," in which arterial oxygen saturation is normal but flow is reduced because of low-output cardiac failure or vasoconstriction. Central cyanosis is usually visible in warm areas of the skin, like the tongue, oral mucosa, and conjunctivae. Peripheral cyanosis is seen in cooler areas such as the nose, lips, earlobes, and fingertips.

In the acute setting (shock), the extremities can become cool and clammy with associated peripheral cyanosis, livedo, and mottling. If severe, this can progress into gangrene of the digits. Vasopressor medications used to support the blood pressure can exacerbate this problem by causing peripheral vasoconstriction. Chronic poor peripheral blood flow from heart failure or peripheral vascular disease can produce chronic edema, venous stasis, decreased hair, and ulceration of the lower legs.

Nail changes associated with cardiovascular disease include clubbing and the Quincke pulsation, which is flushing of the nail beds synchronous with the heartbeat, indicative of aortic regurgitation.

SELECT CONDITIONS

Table 133-1 outlines select conditions with cardiovascular and cutaneous manifestations.

ENDOCARDITIS

Cutaneous signs of endocarditis include Osler nodes, Janeway lesions, subungual splinter hemorrhages, purpura, and petechiae. Osler nodes and Janeway lesions may both present as erythematous or hemorrhagic macules, papules, or nodules. Whereas Osler nodes result from immune complex deposition and are painful, tender, and located distally on the digital tufts, Janeway lesions are nontender and located proximally on the palms and soles. Histologically, Osler nodes are a perivasculitis or necrotizing vasculitis *without* microabscess formation, whereas Janeway lesions exhibit vasculitis *with* microabscess formation. Both also may be found in patients with other conditions, namely systemic lupus erythematosus, gonococcemia, hemolytic anemia, and typhoid fever.

EARLOBE CREASE

The cutaneous finding of a diagonal earlobe crease (Frank sign) has been (controversially) associated with an increased risk of coronary artery disease. The finding is more common with older age and theorized to be a result of age-related loss of dermal and vascular elastic fibers.[1]

PSORIASIS

Psoriasis is recognized as a multisystem inflammatory disease associated with a number of important comorbidities. These include metabolic syndrome, obesity, nonalcoholic fatty liver disease, Type 2 diabetes mellitus, and cardiovascular disease (including increased myocardial infarction, stroke, and peripheral vascular disease).[2] Investigation into the impact of psoriasis treatment on these comorbid conditions is ongoing, but there have been reports of decreased rates of myocardial infarction after treatment with tumor necrosis factor inhibitors and methotrexate.[3]

INHERITED CONNECTIVE TISSUE DISEASE

Mutations causing defects in the structure and function of connective tissue (eg, collagen, elastic fibers) can lead to significant cutaneous and cardiovascular pathology. Diseases in this category include Ehlers-Danlos syndrome, Marfan syndrome, cutis laxa, progeria, and pseudoxanthoma elasticum. Loss of the supportive tissue results in skin that is hyperelastic,

TABLE 133-1
Conditions with Cardiovascular and Cutaneous Manifestations

DISEASE	CARDIAC FINDINGS	CUTANEOUS FINDINGS
Genetic		
Cardiofaciocutaneous syndrome	Structural heart defects, hypertrophic CMO	Ichthyosis, keratosis pilaris, sparse curly hair, coarse facies
Costello syndrome	Arrhythmias, structural heart defects, hypertrophic CMO	Loose skin, large mouth, acanthosis nigricans, periorificial papillomas
Carvajal syndrome	Dilated left ventricular CMO	Woolly hair, palmoplantar keratoderma
Cutis laxa	Aortic dilation and rupture, pulmonary artery stenosis, right-sided heart failure	Loose skin
Ehlers-Danlos syndrome	Aortic dilation and dissection, MV prolapse	Skin hyperelastic and fragile, delayed wound healing, atrophic scars
Fabry disease	Hypertrophic CMO, atherosclerosis, conduction abnormalities	Angiokeratoma corporis diffusum
Hemochromatosis	Dilated CMO, electrical disturbances	Diffuse skin hyperpigmentation
Homocystinuria	MV and TV prolapse, atherosclerosis	Livedo reticularis, malar rash, diffuse hypopigmentation, tissue-paper scars
LEOPARD syndrome	Conduction abnormalities, PV stenosis, hypertrophic CMO	Lentigines, café-au-lait macules
Marfan syndrome	Aortic dilation and dissection, MV and TV prolapse and regurgitation	Striae, arachnodactyly, elastosis perforans serpiginosa
Naxos disease	Dilated left ventricular CMO	Palmoplantar striate keratoderma, woolly scalp hair
NAME/LAMB/Carney complex	Atrial myxoma	Lentigines, coarse facies, blue nevi, cutaneous myxomas
Noonan syndrome	PV stenosis, hypertrophic CMO	Webbed neck, keratosis pilaris atrophicans, keloids, lymphedema
Progeria	Accelerated atherosclerosis	Graying and loss of hair; thin, hardened skin; mottled hyperpigmentation
Pseudoxanthoma elasticum	Accelerated atherosclerosis, MI, renovascular hypertension	Yellow papules and plaques, lax skin
Tuberous sclerosis	Cardiac rhabdomyomas, arrhythmias	Facial angiofibromas, periungual fibromas, ash-leaf macules, shagreen patch
Werner syndrome	Accelerated atherosclerosis	Graying and loss of hair; thin, hardened skin; ankle ulcerations
Neoplastic/Paraneoplastic		
Atrial myxoma	CHF, mitral regurgitation, constrictive pericarditis, arrhythmia	Embolic phenomena, peripheral cyanosis
Multicentric reticulohistiocytosis	Pericarditis, myocarditis, cardiomegaly, CHF	Erythematous nodules of the hands, extremities
Infectious		
Trichinosis	Eosinophilic infiltrate causing myocarditis, arrhythmias	Periorbital edema, splinter hemorrhages
Autoimmune/Rheumatologic		
Behçet syndrome	Pancarditis, coronary arteritis/aneurysm, arrhythmias, valvulopathy, thrombosis	Oral and genital ulcers, pustular eruptions, pyoderma gangrenosum-like lesions
Dermatomyositis	Myocarditis, conduction abnormalities, CHF. Increased risk of MI	Gottron papules, heliotrope rash, shawl sign, mechanic's hands
Polyarteritis nodosa	Coronary artery involvement, MI	Palpable purpura, livedo racemosa, subcutaneous nodules, ulcerations
Reactive arthritis	Valvulopathy, pericarditis	Keratoderma blenorrhagicum
Relapsing polychondritis	Valvulopathy, aneurysm, pericarditis, heart block, coronary arteritis	Red, edematous ears (sparing ear lobes), nasal tip
Rheumatoid arthritis	Pericarditis, myocarditis. Increased risk of CAD, CHF, atrial fibrillation	Rheumatoid nodules, ulcers, neutrophilic dermatosis
Rheumatic fever	Acute: pancarditis; Late: valvulopathy	Erythema marginatum, subcutaneous nodules

(*Continued*)

TABLE 133-1
Conditions with Cardiovascular and Cutaneous Manifestations (*Continued*)

DISEASE	CARDIAC FINDINGS	CUTANEOUS FINDINGS
Systemic lupus erythematosus	Pericarditis, myocarditis, conduction abnormalities, valvulopathy (Libman-Sacks), complete heart block (neonatal)	Malar rash, photosensitivity, oral ulcers, discoid, subacute, and other skin lesions
Systemic sclerosis	Pericarditis, myocarditis arrhythmias, pulmonary artery hypertension	Raynaud phenomenon, sclerosis, dyspigmentation, microstomia
Inflammatory		
DRESS	Eosinophilic myocarditis, pericarditis, conduction abnormalities	Diffuse morbilliform eruption with facial erythema and edema
Psoriasis	Increased cardiovascular disease, atherosclerosis	Well-demarcated erythematous plaques with micaceous scale
Kawasaki	Coronary artery aneurysm	Polymorphous exanthema, desquamation of palms and soles, lips
Erythroderma	Risk for high-output cardiac failure	Diffuse exfoliative erythema
Other		
Amyloidosis	CHF, conduction abnormalities, syncope, sudden death, restrictive CMO	Purpura, periorbital ecchymosis, waxy papules and plaques
Cholesterol emboli	Atherosclerotic vessels; embolization of cholesterol crystals	Livedo reticularis, ulcers, digital cyanosis
Erythromelalgia	Atherosclerosis, hypertension	Recurrent episodes of burning pain, erythema, and warmth in hands/feet
PHACES syndrome	Aortic coarctation, aortic arch abnormalities, structural abnormalities	Segmental infantile hemangioma
Sarcoidosis	Conduction abnormalities, arrhythmias, CMO, CHF, sudden cardiac death	Papules, nodules, plaques—predilection for scars and tattoos

CAD, coronary artery disease; CHF, congestive heart failure; CMO, cardiomyopathy; DRESS, drug rash with eosinophilia and systemic symptoms; LAMB, lentigines, atrial myxoma, mucocutaneous myxoma, and blue nevi; LEOPARD, lentigines, electrocardiographic abnormalities, ocular hypertelorism, pulmonary stenosis, abnormalities of genitalia, retardation of growth, and deafness; MI, myocardial infarction; MV, mitral valve; NAME, nevi, atrial myxoma, myxoid neurofibromas, and ephelides; PHACES, posterior fossa malformations, facial hemangiomas, arterial anomalies, cardiac anomalies and aortic coarctation, eye anomalies, and sternal clefting and/or supraumbilical raphe; PV, pulmonic valve; TV, tricuspid valve.

fragile, lax, and heals poorly. Vessel walls are similarly weakened. Patients can have aneurysms, dissections, and rupture of major arteries, as well as valvular prolapse and insufficiency. Progeria and progeroid conditions (such as Werner syndrome) have atrophic, tight skin with signs of premature aging like gray hair, accelerated atherosclerosis, and myocardial infarction.

AUTOIMMUNE CONNECTIVE TISSUE DISEASE

Systemic Lupus Erythematosus: Systemic lupus erythematosus (SLE) can affect all aspects of the heart and pericardium. Pericarditis is the most common manifestation, occurring in approximately 25% of patients during the course of their disease.[4] Pericarditis may be more common in patients with drug-induced lupus or photosensitive discoid lesions. Myocarditis is uncommon but can cause severe cardiomyopathy and arrhythmias. In Libman-Sacks endocarditis, deposits of immune complexes, fibrin, platelet thrombi, and mononuclear cells can build up on heart valves. This condition can cause significant mitral or aortic insufficiency as well as serve as a source of emboli resulting in purpuric macules at acral sites. It is often associated with the presence of antiphospholipid antibodies.[5] Patients with SLE also have an increased risk of coronary artery disease. Neonatal lupus occurs from transplacental transfer of maternal antibodies (most often anti-Ro/SSA).[6] It can cause an annular rash similar to subacute cutaneous lupus and, in some newborns, complete heart block.

Systemic Sclerosis: Pericarditis is common in systemic sclerosis (SSc) and may result in effusions and tamponade with significant associated morbidity. Small vessel disease of the myocardium causing patchy fibrosis is a hallmark of SSc and can cause systolic or diastolic heart failure as well as arrhythmias and sudden death.[7] Patients are also at increased risk of myocardial infarction.

ERYTHRODERMA

As a consequence of extensive peripheral vasodilation, erythrodermic patients, particularly those with preexisting cardiomyopathy, are at risk for high-output cardiac failure with secondary end-organ damage, such as liver and renal insufficiency.

PULMONARY SYSTEM

General cutaneous findings in pulmonary disease include cyanosis and clubbing. Digital clubbing is characterized by increased distal fingertip mass and longitudinal and transverse nail plate curvature. The Lovibond angle (ie, the angle between the nail plate and the proximal nailfold) is greater than 180 degrees in clubbed nails and typically less than 160 degrees in normal nails. Although digital clubbing can be hereditary, it is much more frequently seen in association with pulmonary or cardiovascular diseases, including lung cancer, interstitial pulmonary fibrosis, pulmonary tuberculosis, congestive heart failure, and cyanotic congenital heart disease. It occurs less frequently in extrathoracic disease such as inflammatory bowel disease and cirrhosis.

SELECT CONDITIONS

Table 133-2 outlines select conditions with pulmonary and cutaneous manifestations.

SARCOIDOSIS

Sarcoidosis is a multisystem granulomatous disease of unknown etiology most commonly affecting the respiratory tract (90%), skin (25%), and eyes. The skin manifestations are protean and consist of noncaseating granulomas that classically appear as smooth papules, plaques, or nodules, but can be psoriasiform, ulcerative, verrucous, or photodistributed. Lesions frequently appear around the mouth and nose and form within scars and tattoos. Many other nonspecific cutaneous findings can occur, including ichthyosis, erythema nodosum, and alopecia. Bilateral hilar adenopathy is the most common intrathoracic manifestation, but patients can develop severe parenchymal disease. Patients are often asymptomatic but may have dyspnea, chronic nonproductive cough, or severe respiratory failure.[8] Lupus pernio and angiolupoid sarcoidosis (extensive telangiectatic lesions) are often associated with chronic sarcoidosis and persistent pulmonary involvement. Additionally, patients with a high burden of lesions around the nose have higher rates of pulmonary fibrosis and sarcoidosis involving the upper respiratory tract.[9]

ANTINEUTROPHILIC CYTOPLASMIC ANTIBODY–ASSOCIATED VASCULITIS

The antineutrophilic cytoplasmic antibody–associated vasculitides are characterized by pauci-immune necrotizing vasculitis of small to medium-sized vessels, which can affect multiple organs, including the lungs and skin.

Granulomatosis with polyangiitis (formerly Wegener granulomatosis) classically presents with granulomatous inflammation of the upper and lower respiratory tract resulting in rhinorrhea, sinusitis, epistaxis, nasal septal perforation, dyspnea, cough, and hemoptysis. Chest imaging shows irregular infiltrates and nodules. Skin findings include palpable purpura, oral ulcers,

TABLE 133-2
Conditions with Pulmonary and Cutaneous Manifestations

DISEASE	PULMONARY FINDINGS	CUTANEOUS FINDINGS
Genetic		
Birt-Hogg-Dube syndrome	Lung cysts, spontaneous pneumothorax	Fibrofolliculomas, trichodiscomas, acrochordons
Hereditary hemorrhagic telangiectasia	Pulmonary vascular malformations, pulmonary hypertension	Mucosal, facial, and acral mat telangiectasias
Lipoid proteinosis	Weak cry or hoarseness from infiltration of laryngeal mucosa	Beaded papules on eyelid margin; verrucous keratotic plaques on the elbows, knees, hands
Marfan syndrome	Emphysematous changes, spontaneous pneumothorax	Striae, decreased subcutaneous fat, arachnodactyly, elastosis perforans serpiginosa
Yellow nail syndrome	Sinusitis, bronchiectasis, pleural effusions, respiratory tract infections	Nails thick, yellow/green color, increased curvature, onycholysis, absent lunulae
Neoplastic/Paraneoplastic		
Kaposi sarcoma	Asymptomatic or cough, hemoptysis; more common in AIDS-associated KS	Red/purple macules, papules, plaques, or nodules on skin and mucosa
Lymphomatoid granulomatosis	Pulmonary infiltrates, cavitary nodules, hemoptysis	Morbilliform exanthem, erythema, nodules, ulcers
Paraneoplastic pemphigus	Bronchiolitis obliterans	Mucocutaneous erosions and ulcerations
Multicentric reticulohistiocytosis	Pleural effusions, infiltrates	Erythematous nodules on hands, extremities

(*Continued*)

TABLE 133-2
Conditions with Pulmonary and Cutaneous Manifestations (*Continued*)

DISEASE	PULMONARY FINDINGS	CUTANEOUS FINDINGS
Infectious		
Invasive aspergillosis	Nodules, patchy infiltrates; cough, hemoptysis	Necrotic violaceous papules and plaques
Blastomycosis	Asymptomatic vs chronic > acute pneumonia. ARDS rare	Papulopustules and verrucous, crusted plaques
Cryptococcosis	Range from asymptomatic infection to severe pneumonia and ARDS	Protean; umbilicated or acneiform papules, nodules, plaques, ulceration
Larva migrans	Rare; persistent dry cough; eosinophilic, migratory infiltrates	Erythematous papule at site of larva penetration, serpiginous migratory tracks
Strongyloidiasis	Dry cough, dyspnea, wheezing, hemoptysis, ARDS	Ground itch at site of contact, urticarial eruption, periumbilical purpura
Tuberculosis	Hilar lymphadenopathy, nodules, cavitary lesions with cough, hemoptysis	Lupus vulgaris, scrofuloderma, orificial TB, miliary TB, tuberculids
Varicella	Pneumonia with patchy infiltrates, tachypnea, dry cough, hemoptysis	Papulovesicles, pustules, hemorrhagic crusts at different stages of development
Autoimmune/Rheumatologic		
Behçet syndrome	Pulmonary vascular lesions, infarction, hemoptysis, pleural effusions	Oral/genital ulcers, pustular eruptions, pyoderma gangrenosum-like lesions
Eosinophilic granulomatosis with polyangiitis (Churg-Strauss syndrome)	Allergic rhinitis, nasal polyps, asthma; later patchy infiltrates, nodules, pleural effusions	Palpable purpura, urticarial lesions, livedo reticularis, nonspecific dermatitis
Dermatomyositis	Interstitial lung disease	Gottron papules, heliotrope rash, shawl sign, mechanic's hands
Granulomatosis with polyangiitis (Wegener syndrome)	Sinusitis, epistaxis, nasal septal perforation, cough, hemoptysis	Palpable purpura, friable gingiva, ulcers, papulonecrotic lesions
Microscopic polyangiitis	Capillaritis, pulmonary infiltrates; no upper airway involvement	Palpable purpura, livedo reticularis, ulcers
Relapsing polychondritis	Hoarseness, structural insufficiency and airway collapse	Red, edematous ears (sparing ear lobes), nasal tip
Rheumatoid arthritis	ILD, rheumatoid nodules, bronchiolitis obliterans	Rheumatoid nodules, palpable purpura, ulcers, neutrophilic dermatoses
Systemic lupus erythematosus	Pleuritis, pneumonitis, diffuse alveolar hemorrhage, pulmonary hypertension	Malar rash, photosensitivity, oral ulcers, discoid, subacute, and other skin lesions
Systemic sclerosis	ILD, pulmonary hypertension	Raynaud phenomenon, sclerosis, dyspigmentation, microstomia
Urticarial vasculitis	Cough, dyspnea, hemoptysis, COPD, pleuritis, pleural effusions	Urticarial papules and plaques, often with purpuric component
Inflammatory		
Drug reaction with eosinophilia and systemic symptoms	Interstitial pneumonitis, pleural effusions	Diffuse morbilliform eruption with facial erythema and edema
Sweet syndrome	Neutrophilic alveolitis, pleural effusions, ARDS	Pink-purple edematous papules, nodules, plaques; pathergy
Other		
Amyloidosis	Pleural effusions, hoarseness, airway obstruction	Purpura, periorbital ecchymosis, waxy papules and plaques
Graft-versus-host disease	Bronchiolitis obliterans	*Acute:* morbilliform exanthem; *Chronic:* poikiloderma, lichen planus-like, scleroderma-like
Sarcoidosis	Hilar lymphadenopathy, parenchymal opacities. Cough, dyspnea, chest pain	Papules, nodules, plaques–predilection for scars and tattoos
Fat embolism syndrome	Hypoxemia, dyspnea	Petechial rash

ARDS, acute respiratory distress syndrome; COPD, chronic obstructive pulmonary disease; ILD, interstitial lung disease; KS, Kaposi sarcoma; TB, tuberculosis.

friable gingiva, pyoderma gangrenosum-like lesions, and papulonecrotic lesions on the extensor surfaces. In eosinophilic granulomatosis with polyangiitis (formerly Churg-Strauss syndrome), allergic rhinitis, nasal polyps, and asthma are followed by eosinophilic granulomatous infiltration with pulmonary infiltrates, pleural effusion, and nodules. Skin findings include palpable purpura, livedo reticularis, and urticarial lesions. Pulmonary involvement in microscopic polyangiitis, including dyspnea and pulmonary infiltrates without significant upper airway involvement, is the result of vasculitis without granulomatous inflammation. Skin findings include purpura, erythematous patches, livedo reticularis, urticarial papules, and ulcers.

AUTOIMMUNE CONNECTIVE TISSUE DISEASE

Rheumatoid Arthritis: Interstitial lung disease (ILD) is the most common pulmonary manifestation of rheumatoid arthritis and appears to correlate with high levels of rheumatoid factor.[10] Rheumatoid nodules in the lungs are often asymptomatic and occur more frequently in patients with concurrent subcutaneous nodules. Upper airway obstruction and bronchiolitis obliterans can also be seen.

Systemic Lupus Erythematosus: Pleuritis with or without pleural effusions occurs in half of patients with SLE. Primary lung involvement in SLE is varied and can include diffuse interstitial pneumonitis, acute pneumonitis, diffuse alveolar hemorrhage, diaphragm dysfunction with decreased lung volume, pulmonary hypertension with cor pulmonale, and fibrosing alveolitis.[11]

Systemic Sclerosis: Pulmonary involvement is seen in more than 70% of patients with SSc. The 2 main presentations are ILD and pulmonary arterial hypertension caused by pulmonary vascular disease, which can progress to cor pulmonale and right-sided heart failure. Symptoms usually consist of dyspnea on exertion and a nonproductive cough. There is also an increased risk of malignant lung neoplasms.

Dermatomyositis: ILD is seen in at least 10% of dermatomyositis cases, including both classic and amyopathic disease. Patients with antibodies to MDA-5 or to aminoacyl-transfer RNA synthetase enzymes such as Jo-1 have a much higher risk of ILD (up to 70%), and the disease in this context can be rapidly progressive and fatal.[12] Antisynthetase syndrome is a constellation of fever, myositis, inflammatory polyarthritis, ILD, Raynaud phenomenon, and mechanic's hands in a patient with anti–transfer RNA antibodies.

YELLOW NAIL SYNDROME

Yellow nail syndrome is an idiopathic phenomenon in which all 20 nails become thickened and yellow or yellow-green and overcurved. The cuticle disappears, and onycholysis and nail plate shedding are common. The nail abnormalities are associated with lymphedema and respiratory tract involvement, including pleural effusions, chronic bronchitis, bronchiectasis, and sinusitis.[13]

AQUAGENIC WRINKLING OF THE PALMS

Aquagenic wrinkling of the palms, also known as aquagenic palmoplantar keratoderma, is a rare condition with transient formation of edematous, translucent papules and plaques on the palms and digital pads within minutes of water exposure. Aquagenic wrinkling of the palms is associated with cystic fibrosis. The mechanism is unknown, but it is hypothesized that increased tonicity of sweat and increased aquaporins in eccrine sweat glands in patients with cystic fibrosis cause an osmotic shift of water across the epidermis.[14,15]

INFECTIOUS DISEASES

Various infectious diseases that primarily affect the respiratory tract may present with characteristic cutaneous findings that can aid in diagnosis. These include tuberculosis, endemic mycoses (eg, coccidiomycosis, blastomycosis), and angioinvasive fungi (eg, aspergillosis, mucormycosis).

HEPATOBILIARY SYSTEM

The stigmata of hepatobiliary disease and cirrhosis are well recognized but nonspecific.[16] Diseases such as hemochromatosis, Wilson disease, viral hepatitis, and primary biliary cirrhosis can have characteristic skin changes or be associated with certain dermatologic disorders, as discussed below.

VASCULAR LESIONS

Vascular lesions are common and include telangiectasias, spider angiomas, and palmar erythema. Spider angiomas are so named because of their structure with a central arteriole from which several small, twisted vessels radiate. Pressure over the central arteriole causes blanching of the whole lesion. Size ranges from that of a pinhead to 2 cm. Lesions are predominately located on the face, neck, and upper chest. In alcoholic cirrhosis, they are associated with the presence of esophageal varicosities and may be a predictive marker of future risk of esophageal bleeding.[17] Spider angiomas are also seen in healthy children. Other telangiectasias can be confluent in sun-exposed areas, giving the impression of almost exanthematous redness. This is known as "dollar paper markings," after the small threads visible in paper money held up to the light. It is thought that vascular lesions are

related to estrogen levels, as they can be associated with pregnancy, oral contraceptive pills, and men receiving estrogen therapy for prostate cancer. Portal hypertension causes development of porto-systemic collaterals, which appear as dilated abdominal wall veins (caput medusa).

NAIL CHANGES

In liver disease, nails can show a variety of changes such as clubbing, koilonychia (spoon shape), thickening, transverse white lines (Muehrcke nails), and brittleness. "Terry nails" are opaque and white except for a distal horizontal band that retains its normal pink color. Blue discoloration of the lunulae can be seen in Wilson disease. Koilonychia is associated with hemochromatosis as well as iron deficiency anemia.

JAUNDICE

Hyperbilirubinemia causes jaundice when bilirubin and its metabolites are bound by cells and connective tissue, producing a generalized yellow discoloration of the skin, mucous membranes, sclerae (ie, icterus), and other body tissues. This becomes evident when total serum bilirubin levels are above 3. Involvement of the sclerae differentiates jaundice from other causes of skin pigmentation, including carotenemia, quinacrine and busulfan dyspigmentation, and lycopenemia as a result of the ingestion of tomato juice. In addition to hepatobiliary disease, the hyperbilirubinemia may result from hemolysis, premature birth, and hereditary disorders such as Crigler-Najjar and Gilbert syndromes.

PIGMENTARY CHANGES

In addition to jaundice, liver disease is associated with other pigmentary changes. Patients with longstanding cirrhosis may develop guttate hypomelanosis or a diffuse muddy gray color.[18] In primary biliary cirrhosis (PBC), hyperpigmentation is common and can be generalized or in photodistributed areas, in linear palmar creases, or chloasma-like around the mouth and eyes. Accentuation of normal freckling and areolar pigmentation can also occur. In hemochromatosis, the skin can have a striking generalized metallic gray or bronze-brown color. There is accentuation in sun-exposed and traumatized skin, and occasionally there is buccal and conjunctival pigmentation.[19] The mechanism of hyperpigmentation varies. The pigmentation in PBC or longstanding cirrhosis is predominantly due to excess melanin with no stainable iron, whereas in hemochromatosis, both hemosiderin and excess melanin are present in the skin.

CHOLESTATIC PRURITUS

Pruritus can be severe and refractory in hepatobiliary disease. It is more common in primary biliary sclerosis, sclerosing cholangitis, and biliary obstruction compared to intrahepatic cholestasis. It is usually most severe on the extremities and only rarely involves the neck, face, and genitalia. Retained cutaneous bile acids are implicated, and bile salt-chelating resins typically provide some relief. However, there is poor correlation between plasma bilirubin and the severity of pruritus.

HORMONE-INDUCED SKIN CHANGES

Both sexes can experience striae distensae and loss of forearm, axillary, and pubic hair. Men may have a decreased rate of growth of facial hair, gynecomastia, and testicular atrophy.

OTHER SIGNS

Ascites may cause marked abdominal distension. Poor synthetic hepatic function causes hypoalbuminemia, which can result in edema and subsequent stasis dermatitis. Low fibrinogen and clotting factors, vitamin K deficiency, and decreased and dysfunctional platelets may result in purpura, epistaxis, and gingival bleeding.

SPECIFIC CONDITIONS

Table 133-3 outlines select conditions with hepatobiliary and cutaneous manifestations.

HEMOCHROMATOSIS

In hemochromatosis, a mutation in the *HFE* gene leads to increased intestinal iron absorption and subsequent iron overload. Iron deposition in the liver causes hepatomegaly, transaminitis, and eventual cirrhosis. There is an increased risk of hepatocellular carcinoma. Diffuse bronze hyperpigmentation is visible in approximately 70% of patients at presentation and is a result of both iron deposition and increased melanin.[20]

GRAFT-VERSUS-HOST DISEASE

Graft-versus-host disease (GVHD) is a common complication of allogeneic hematopoietic stem cell transplant when transplanted immune cells (the graft) recognize cells of the transplant recipient (the host)

TABLE 133-3
Conditions with Hepatobiliary and Cutaneous Manifestations

DISEASE	HEPATOBILIARY FINDINGS	CUTANEOUS FINDINGS
Genetic		
Hereditary hemorrhagic telangiectasia	Vascular malformations, high-output heart failure, biliary disease	Mucosal, facial, and acral mat telangiectasias
Erythropoietic porphyria	Protoporphyric hepatopathy	Sun sensitivity (burning, erythema, papulovesicles), lichenification dorsal hands
Hemochromatosis	Hepatomegaly, fibrosis, cirrhosis, increased risk for hepatocellular carcinoma	Bronze hyperpigmentation
Hereditary coproporphyria	Hepatocellular injury	Similar to porphyria cutanea tarda
Porphyria cutanea tarda	Hepatocellular injury	Photosensitivity with bullae, fragility, dyspigmentation
Variegate porphyria	Hepatocellular injury, increased risk hepatocellular carcinoma	Fragility, bullae, milia
Neoplastic/Paraneoplastic		
Langerhans cell histiocytosis	Cystic lesions, hepatocellular injury, sclerosing cholangitis	Erythematous to brown papules, plaques and nodules with scale, crusting
Mastocytosis	Hepatomegaly, hepatocellular injury, mast cell infiltration	Red-brown papules (urticaria pigmentosa), diffuse telangiectatic (TMEP [telangiectasia macularis eruptiva perstans]), skin thickening (diffuse cutaneous)
Infectious		
Schistosomiasis	Periportal fibrosis, portal hypertension, normal hepatocellular function	Cercarial dermatitis, Katayama fever, granulomatous genital and perianal lesions
Syphilis	Syphilitic hepatitis	Papulosquamous eruption involving palmoplantar surfaces, chancre, alopecia
Toxocariasis	Hepatic granulomas, hepatomegaly	Urticaria, cutaneous nodules
Tuberculosis	Hepatocellular or cholestatic injury, hepatic granulomas	Lupus vulgaris, scrofuloderma, orificial TB (tuberculosis), miliary TB, tuberculids
Varicella	Immunocompromised hosts–hepatitis	Vesiculopapules
Autoimmune/Rheumatologic		
Primary biliary cirrhosis	Biliary duct destruction, fibrosis	Pruritus, hyperpigmentation, lichen planus
Systemic lupus erythematosus	Hepatitis, thrombosis caused by antiphospholipid antibodies (Budd-Chiari, hepatic venoocclusive disease)	Malar rash, photosensitivity, oral ulcers, discoid, subacute, and other skin lesions
Inflammatory		
DRESS (drug rash with eosinophilia and systemic symptoms)	Most common organ involved; hepatitis	Diffuse morbilliform eruption with facial erythema and edema
Graft-versus-host disease	Cholestatic injury	*Acute:* morbilliform exanthem; *Chronic:* poikiloderma, lichen planus-like, scleroderma-like
Kawasaki	Transaminitis	Polymorphous exanthema, edema or desquamation of palms/soles, lips
Other		
Sarcoidosis	Most asymptomatic; granulomatous infiltration; cirrhosis rare	Papules, nodules, plaques—predilection for scars and tattoos
Amyloidosis	Hepatomegaly, cirrhosis	Purpura, periorbital ecchymosis, waxy papules and plaques

as foreign and initiate an immune response against host cells. The most commonly affected organs are the skin, liver, and GI tract. Liver disease usually occurs in patients with skin and gut involvement and is characterized by cholestatic injury. GVHD of the lower GI tract manifests with abdominal pain and diarrhea. Upper GI tract involvement can include xerostomia, mucositis, dysphagia, esophageal stricture, nausea, and vomiting. In the skin, acute GVHD most commonly presents with a nonspecific morbilliform eruption. In chronic GVHD, dermatologic findings are protean and include poikiloderma, lichen planus-like, and lichen sclerosis, morphea, or scleroderma-like lesions. The eyes and oral mucosa are commonly involved. GVHD severity staging includes serum bilirubin levels, quantity of diarrhea, and extent of skin involvement.

WILSON DISEASE

Wilson disease is a hereditary condition in which defective cellular copper transport leads to accumulation of copper in several organs—most commonly the liver, brain, and cornea. Corneal deposition is visible in the form of Kayser-Fleischer rings, which are brown or gray-green rings that can be seen with slit-lamp examination or occasionally are grossly visible.

PRIMARY BILIARY CIRRHOSIS

PBC is an autoimmune disease associated with antimitochondrial antibodies typically affecting women 40 to 60 years of age in which intrahepatic bile ducts are destroyed, resulting in hyperbilirubinemia and cirrhosis. It is notable because of the constellation of pruritus, jaundice, diffuse hyperpigmentation, and xanthomas seen in the disease. The xanthomas are typically eruptive, planar, or occasionally tuberous. Pruritus is common and often severe, and it precedes the development of jaundice. Hyperpigmentation occurs in 25% to 50% of patients and is caused by melanin deposition.[16] Lichen planus has a well-recognized association with PBC and may occur in either the presence or absence of penicillamine. The skin lesions can resolve following liver transplantation.[21] Occasionally, PBC occurs in conjunction with limited SSc (CREST [calcinosis cutis, Raynaud phenomenon, esophageal motility disorder, sclerodactyly, and telangiectasia] syndrome), a phenotype that is referred to as Reynolds syndrome. Patients with PBC also have a higher incidence of anticentromere antibodies (especially the antiprotein C isotype) and Sjögren syndrome.[22]

HEPATITIS

In any of the viral hepatitides, acute infection may result in a transient morbilliform, urticarial, or petechial rash. Hepatitis B (HBV) and hepatitis C virus (HCV) infection have some overlapping and unique cutaneous features (Table 133-4). Both HBV and HCV are associated with cryoglobulinemia, although it is more common in HCV infection. Mixed cryoglobulinemia in HCV infection is usually Type III, and it may indicate the presence of active viral replication.[23] Patients may develop recurrent palpable and retiform purpura, acrocyanosis, arthritis, mononeuritis, glomerulonephritis, and other complications.

Polyarteritis nodosa can be associated with HBV infection. In this setting, medium-vessel vasculitis is thought to result from the formation of immune complexes containing hepatitis B surface antigen and immunoglobulin.

Gianotti-Crosti syndrome (papular acrodermatitis) is an eruption of monomorphic, flat-topped, erythematous papules on the face and limbs. It is most often seen in children as a result of Epstein-Barr virus, but can be associated with HBV and, less often, HCV. This eruption is usually self-limited and asymptomatic and is occasionally accompanied by lymphadenopathy.

TABLE 133-4
Cutaneous Findings Associated with Hepatitis B and Hepatitis C

HEPATITIS B	HEPATITIS C
Small vessel vasculitis	Small vessel vasculitis
Urticaria, urticarial vasculitis	Urticaria, urticarial vasculitis
Serum sickness–like reaction	Serum sickness–like reaction
Pruritus	Pruritus
Erythema multiforme	Erythema multiforme
Cryoglobulinemia (C>B)	Cryoglobulinemia (C>B)
Porphyria cutanea tarda (C>B)	Porphyria cutanea tarda (C>B)
Sarcoidosis after interferon/ribavirin (C>B)	Sarcoidosis after interferon/ribavirin (C>B)
Erythema nodosum (B>C)	Erythema nodosum (B>C)
Gianotti-Crosti syndrome (B>C)	Gianotti-Crosti syndrome (B>C)
Polyarteritis nodosa	Lichen planus–erosive oral disease Necrolytic acral erythema

Other infectious agents and immunizations have been implicated in papular acrodermatitis.[24]

GASTROINTESTINAL SYSTEM

Diseases affecting both the skin and GI tract can cause GI bleeding, malabsorption/diarrhea, and abdominal pain.

GASTROINTESTINAL BLEEDING

Several diseases associated with GI bleeding also have cutaneous findings. These include diseases with vascular malformations such as hereditary hemorrhagic telangiectasia; defects in connective tissue such as pseudoxanthoma elasticum and Ehlers-Danlos, vascular type; neoplasms such as Kaposi sarcoma and mastocytosis; inflammatory bowel disease; and polyposis syndromes. Many vasculitides can affect the vessels of the gut and cause bleeding, including small vessel vasculitis, immunoglobulin A vasculitis (Henoch-Schönlein purpura), polyarteritis nodosa, and Behçet syndrome.

MALABSORPTION

Diseases causing dysmotility, GI infections, pancreatitis or pancreatic insufficiency, chronic inflammation, and short gut can all cause malabsorption and malnutrition.

Cutaneous manifestations of malnutrition are detailed elsewhere (see Chap. 123) but may include xerosis, eczematous dermatitis, cheilitis, alopecia or changes in hair texture, nail changes, and hyperpigmentation.

ABDOMINAL PAIN

This category is wide and encompasses many of the conditions listed above. In addition to these, neuropathic pain from herpes zoster can mimic an acute abdomen (particularly when pain precedes skin findings). Some porphyrias cause flares of abdominal pain, and acute allergic reactions and anaphylaxis often have prominent abdominal discomfort. Bruising of the skin around the umbilicus (Cullen sign) or the flanks (Grey Turner sign) are well-known features of acute pancreatitis but occur in less than 3% of cases.[24] Chronic pancreatitis may cause tender, subcutaneous nodular areas of fat necrosis (pancreatic panniculitis) that may ulcerate.

ESOPHAGEAL INVOLVEMENT

Extension of dermatologic disease into the pharynx and esophagus can cause significant dysphagia. Common etiologies include blistering dermatoses (epidermolysis bullosa, cicatricial pemphigoid), lichen planus, rheumatologic disorders (Behçet syndrome, SSc), toxic epidermal necrolysis, Darier disease, and infection (*Candida*, herpes simplex virus).

SPECIFIC CONDITIONS

Table 133-5 outlines select conditions with GI and cutaneous manifestations.

KAPOSI SARCOMA

Visceral involvement is more common in AIDS-related Kaposi sarcoma than in classic Kaposi sarcoma. The most common organs involved are the GI tract and lungs. Prior to antiretroviral therapy, the GI tract was involved in 40% of patients with Kaposi sarcoma at initial diagnosis and in up to 80% at autopsy. GI Kaposi sarcoma can occur in the absence of cutaneous lesions and can be asymptomatic, or it may cause abdominal pain, weight loss, or bleeding.

DERMATITIS HERPETIFORMIS

Dermatitis herpetiformis is a cutaneous finding that occurs in celiac disease when antitransglutaminase antibodies bind to keratinocytes. It is intensely pruritic and presents with grouped excoriated papules and vesicles over the buttocks and extensor surfaces.

TABLE 133-5
Conditions with Gastrointestinal and Cutaneous Manifestations

DISEASE	GI FINDINGS	CUTANEOUS FINDINGS
Genetic		
Blue rubber bleb nevus syndrome	GI bleeding from venous malformations in gut; chronic anemia > acute hemorrhage	Dark blue papules, nodules
Cowden disease	Esophageal acanthosis; stomach, small intestine, colon polyps; colorectal cancer	Facial trichilemmomas, oral papillomas with cobblestoning, acral keratoses
Cronkhite-Canada syndrome	Polyposis stomach and bowel; abdominal pain, severe protein-losing enteropathy	Patchy alopecia, nail changes, hyperpigmentation
Ehlers-Danlos syndrome, vascular	Diverticula, hernias, bowel perforation (sigmoid colon)	Thin translucent skin, characteristic facies, acrogeria
Fabry disease	Abdominal pain, diarrhea	Angiokeratoma corporis diffusum
Hereditary hemorrhagic telangiectasia	GI bleeding, most commonly stomach or duodenum	Mat telangiectasias (arteriovenous malformations)
Gardner syndrome	Adenomatous polyposis	Epidermoid cysts, fibromas, lipomas, pilomatricomas, facial osteomas
Muir-Torre syndrome	Colorectal cancer	Sebaceous neoplasms, keratoacanthomas
Neurofibromatosis I	GI stromal tumors	Café-au-lait macules, axillary freckling, neurofibromas, Lisch nodules
Peutz-Jeghers	Hamartomatous polyposis, mainly in small intestine, recurrent intussusception; increased risk adenocarcinoma	Pigmented macules around mouth, lips, buccal mucosa, digits
Porphyria–variegate	Abdominal pain	Fragility, blisters in sun-exposed skin
Pseudoxanthoma elasticum	GI bleeding	Yellow-orange papules and plaques, lax skin

(*Continued*)

TABLE 133-5
Conditions with Gastrointestinal and Cutaneous Manifestations (*Continued*)

DISEASE	GI FINDINGS	CUTANEOUS FINDINGS
Neoplastic/Paraneoplastic		
Carcinoid syndrome	Small bowel tumors cause 75%; abdominal cramps, diarrhea	Flushing, pellagra, facial edema and induration
Glucagonoma	Chronic diarrhea, abdominal pain, glucose intolerance, diabetes mellitus	Necrolytic migratory erythema
Mastocytosis	Of patients with abdominal symptoms, one-third experience pain, vomiting, diarrhea, bleeding	Red-brown papules (urticaria pigmentosa), diffuse telangiectatic (TMEP [telangiectasia macularis eruptiva perstans]), skin thickening (diffuse cutaneous)
Kaposi sarcoma	GI bleeding	Red/purple macules, papules, plaques, or nodules on skin and mucosa
Infectious		
Herpes zoster	Abdominal pain may mimic acute abdomen and precede cutaneous signs	Grouped vesicles in a dermatomal distribution
Strongyloidiasis	Abdominal pain, vomiting, diarrhea	Ground itch at site of contact, perianal urticarial eruption, periumbilical purpura
Tuberculosis	Enteritis, peritonitis	Lupus vulgaris, scrofuloderma, orificial tuberculosis (TB), miliary TB, tuberculids
Typhoid fever	Abdominal pain, diarrhea, constipation, intestinal perforation	Rose spots–salmon-colored macules on trunk
Autoimmune/Rheumatologic		
Behçet syndrome	Abdominal pain, diarrhea, bleeding, ulceration	Oral/genital ulcers, pustular eruptions, pyoderma gangrenosum-like lesions
Henoch-Schönlein purpura	Abdominal pain, vomiting, bloody diarrhea, intussusception	Palpable purpura of legs and buttocks
Malignant atrophic papulosis	GI bleeding, abdominal pain, diarrhea, bowel perforation	Crops of porcelain-white atrophic papules with telangiectatic border
Polyarteritis nodosa	Abdominal pain, nausea, melena, diarrhea; mesenteric arteritis, bowel ischemia	Subcutaneous nodules, livedo reticularis, ulcers
Systemic lupus erythematosus	Esophagitis, intestinal pseudoobstruction, protein-losing enteropathy, pancreatitis, mesenteric vasculitis, peritonitis	Malar rash, photosensitivity, oral ulcers, discoid, subacute, and other skin lesions
Systemic sclerosis	Dysphagia, reflux, gastroparesis, malabsorption, pseudoobstruction	Raynaud phenomenon, sclerosis, sclerodactyly, dyspigmentation, microstomia
Inflammatory		
Angioedema	Abdominal pain	Urticaria, edema
Crohn disease	Granulomatous inflammation of the bowel, often with skip lesions	Aphthae, granulomatous cheilitis, oral cobblestoning, erythema nodosum, vasculitis, pyoderma gangrenosum, perianal fistulae, ulcers
Pancreatitis	Abdominal pain, nausea, vomiting, diarrhea	Cullen sign, Grey Turner sign, panniculitis
Ulcerative colitis	Continuous inflammation of the rectum and large bowel; risk of toxic megacolon	Aphthae, pyoderma gangrenosum, vasculitis, erythema nodosum, fissures
Other		
Amyloidosis	GI bleeding, gastroparesis, constipation, intestinal pseudoobstruction	Purpura, periorbital ecchymosis, waxy papules and plaques
Scurvy	Gingivitis, gradual GI blood loss resulting in anemia	Perifollicular purpura, corkscrew hairs, conjunctival hemorrhage

INFLAMMATORY BOWEL DISEASE

Inflammatory bowel disease (IBD) manifests with recurrent episodes of abdominal pain, GI bleeding, and diarrhea. Ulcerative colitis involves the rectum and colon, whereas Crohn disease can involve any area of the intestinal tract and is often discontinuous. There are multiple cutaneous findings associated with IBD.

Oral lesions, including aphthae, are common and appear to be related to active bowel inflammation. Aphthae are nonspecific and can be seen in healthy patients. Crohn disease is associated with granulomatous cheilitis and granulomatous nodules in the oral mucosa, which can coalesce to give a "cobblestone" appearance.

Granulomas may also occur in the perineum, at colostomy and ileostomy sites, and in association with scars, sinuses, and fistulas. Rarely, granulomas occur at sites not contiguous with the bowel, such as the trunk and limbs, a finding termed *metastatic* Crohn disease.

Neutrophilic dermatoses are associated with both ulcerative colitis and Crohn disease. Pyoderma gangrenosum is classic, seen in 1% to 10% of patients.[25] IBD is the most common cause of pyoderma gangrenosum, responsible for 25% to 50% of cases. Pyoderma gangrenosum ulcers characteristically present with a violaceous or metallic gray undermined border and can preferentially involve the peristomal area, as well as sites of trauma. The activity of pyoderma gangrenosum does not necessarily parallel the activity of the IBD. Other IBD-associated neutrophilic dermatoses include Sweet syndrome, acneiform lesions, and panniculitis.

Other reactive dermatoses associated with IBD include small vessel vasculitis, polyarteritis nodosa, erythema multiforme, and epidermolysis bullosa acquisita. Additionally, IBD is associated with an increased frequency of alopecia areata, vitiligo, digital clubbing, and cutaneous signs of malnutrition.

POLYPOSIS SYNDROMES

There are 2 groups of hereditary polyposis: adenomatous syndromes (eg, familial adenomatous polyposis, Gardner syndrome) and hamartomatous syndromes (eg, Peutz-Jeghers and Cronkhite-Canada syndromes). Adenomas have proven malignant potential. Hamartomatous polyps represent proliferation and malformation of connective tissue of the intestinal mucosa and have less risk of malignancy. True adenomatous polyps are rare except in the colon and rectum, whereas hamartomatous lesions occur in all parts of the gut.

Familial adenomatous polyposis is an autosomal dominant condition consisting of many adenomatous polyps without extracolonic manifestations. It leads to colorectal cancer with nearly 100% certainty starting at age 20 to 30 years.

Gardner syndrome is a variant of familial adenomatous polyposis with the addition of epidermoid cysts, fibromas, lipomas, desmoid tumors, pilomatricomas, and osteomas of the facial bones and skull. The cutaneous lesions frequently predate GI manifestations.[26]

Peutz-Jeghers syndrome is characterized by small darkly pigmented macules on the lips, buccal mucosa, and digits. A histologically unique type of hamartomatous polyp occurs, mainly in the small intestine, which predisposes to recurrent intussusception. Bleeding is relatively rare, but up to 2% of patients develop adenocarcinoma of the stomach, duodenum, and colon. There is also an increased risk of malignancy in general.[27]

Cronkhite-Canada syndrome manifests on the skin with patchy alopecia and characteristic nail changes. Inflammatory polyps are present in the stomach and bowel, and abdominal pain with a severe protein-losing enteropathy is common.[28]

BOWEL-ASSOCIATED DERMATOSIS-ARTHRITIS SYNDROME

Following any surgery that results in formation of blind bowel loops (eg, jejunoileal bypass, biliopancreatic diversion, bowel resection), patients may present with a constellation of findings called bowel-associated dermatosis-arthritis syndrome.[29] Bowel-associated dermatosis-arthritis syndrome consists of a serum sickness-like syndrome with fever, malaise, arthritis, and myalgia followed by a skin eruption. The polyarthritis is nonerosive, asymmetric, episodic, and affects both small and large joints. Typical skin lesions include erythematous macules with central vesicle or pustule formation; however, erythema nodosum and panniculitis also have been described. The pathogenesis is uncertain, but the disease may be related to bacterial overgrowth and immune complex formation.

RENAL SYSTEM

Patients with end-stage renal disease (ESRD) develop a variety of cutaneous findings related to metabolic abnormalities, including anemia, calcium-phosphate dysregulation, and glucose intolerance. Skin manifestations include a sallow appearance, pruritus, xerosis, acquired perforating dermatosis, pseudoporphyria, calciphylaxis, and uremic frost.

The skin can be pale as a consequence of anemia and often exhibits a distinctive muddy hue, partly from accumulation of carotenoid and nitrogenous pigments (urochromes) in the dermis.[30] Uremic frost results from eccrine deposition of urea crystals on the skin surface of individuals with severe uremia.

RENAL PRURITUS

Renal pruritus is a major problem and may be seen in as many as 90% of those undergoing hemodialysis.[31-33] The etiology is thought to be multifactorial, including xerosis, peripheral neuropathy, mast cell hyperplasia, and increased serum histamine, vitamin A, parathyroid hormone, and inflammatory factors.[34-36] Clinically, the skin may appear normal or demonstrate secondary changes such as lichenification, excoriation, and hyperpigmentation.

NAIL CHANGES

Lindsay nails (half-and-half nails) are seen frequently in patients on dialysis and resolve with renal transplantation. They are characterized by a dull-white color proximally and a nonblanching red, pink, or brown color distally. Other abnormalities include Beau lines, onycholysis, and nailfold capillary abnormalities.

SPECIFIC CONDITIONS

Table 133-6 outlines select conditions with renal and cutaneous manifestations.

TABLE 133-6
Conditions with Renal and Cutaneous Manifestations

DISEASE	RENAL FINDINGS	CUTANEOUS FINDINGS
Genetic		
Birt-Hogg-Dube	Renal tumors	Fibrofolliculomas, trichodiscomas, acrochordons, connective tissue nevi
Fabry disease	Proteinuria, renal cysts, renal failure	Angiokeratoma corporis diffusum
Familial cutaneous leiomyomatosis	Renal cell carcinoma	Cutaneous leiomyomas
Nail-patella syndrome	Glomerulonephritis, proteinuria, renal tubular defects	Triangular lunulae, nail hypoplasia
Tuberous sclerosis	Renal angiomyolipomas, polycystic kidney disease, renal cell carcinoma	Facial angiofibromas, periungual fibromas, ash leaf macules, shagreen patch, connective tissue nevi
Von Hippel-Lindau disease	Renal cysts, clear-cell renal cell carcinomas	Nonspecific; hemangiomas and café-au-lait spots[a]
Infectious		
Loiasis	Hematuria, proteinuria	Transient edema (Calabar swelling) in areas of migrating worms, conjunctivitis
Autoimmune/Rheumatologic		
Behçet syndrome	Glomerulonephritis, interstitial nephritis	Oral and genital ulcers, acneiform pustules, pyoderma gangrenosum-like lesions
Henoch-Schönlein purpura	Glomerulonephritis (immunoglobulin A nephropathy)	Palpable purpura
Granulomatosis with polyangiitis (Wegener)	Glomerulonephritis	Palpable purpura, friable gingiva, ulcers, papulonecrotic lesions
Microscopic polyangiitis	Glomerulonephritis	Palpable purpura, erythematous patches, livedo reticularis, ulcers
Polyarteritis nodosa	Renal artery aneurysms, glomerulonephritis, hypertension	Subcutaneous nodules, livedo reticularis, ulcers
Rheumatoid arthritis	Glomerulonephritis, rheumatoid vasculitis	Rheumatoid nodules, ulcers, neutrophilic dermatoses
Systemic lupus erythematosus	Glomerulonephritis	Malar rash, photosensitivity, oral ulcers, discoid, subacute, and other skin lesions
Systemic sclerosis	Malignant hypertension, rapidly progressive renal failure	Sclerosis, sclerodactyly, poikiloderma, telangiectasia
Inflammatory		
DRESS (drug rash with eosinophilia and systemic symptoms)	Nephritis, hematuria, proteinuria	Diffuse morbilliform eruption with facial erythema and edema
Other		
Amyloidosis	Proteinuria, renal insufficiency	Purpura, periorbital ecchymoses, subcutaneous nodules or waxy plaques
Cholesterol emboli	Hematuria, eosinophiluria	Distal cyanosis, cutaneous necrosis, retiform purpura, splinter hemorrhages
Graft-versus-host disease	Nephritis or nephrotic syndrome	*Acute:* morbilliform exanthem; *Chronic:* poikiloderma, lichen planus-like, scleroderma-like
Nephrogenic fibrosing dermopathy	Renal insufficiency	Sclerosis of the extremities
Sarcoidosis	Hypercalciuria, nephrolithiasis, interstitial nephritis, granulomas	Papules, nodules, plaques–predilection for scars and tattoos

[a]Amin A, Burgess E. Skin manifestations associated with kidney cancer. *Semin Oncol.* 2016;43(3):408-412.

TABLE 133-7
Thyroid Disorders

DISEASE	THYROID FINDINGS	CUTANEOUS FINDINGS
Genetic		
Birt-Hogg-Dube syndrome	Medullary thyroid cancer	Fibrofolliculomas, trichodiscomas, fibrous papules, acrochordons, connective tissue nevi
Cowden syndrome	Follicular and papillary thyroid cancer; thyroid adenomas	Trichilemmomas
Werner syndrome	Thyroid cancer	Scleroderma-like changes with subcutaneous atrophy, leg ulcers, soft tissue calcifications, bird-like facies
Multiple endocrine neoplasia (MEN) 2A	Medullary thyroid cancer	Lichen amyloidosis
MEN 2B	Medullary thyroid cancer	Neuromas (which may involve all mucosal surfaces: oral mucosa, lips, tongue, conjunctivae); café-au-lait spots, facial lentigines, hyperpigmentation of the hands and feet
Drug reaction with eosinophilia and systemic symptoms (DRESS)	Thyroiditis	Exanthem, exfoliative dermatitis, pustular eruptions, Stevens-Johnson syndrome/toxic epidermal necrolysis
Autoimmune/Rheumatologic		
Grave disease	Autoimmune thyroid disease	Thyroid dermopathy (pretibial myxedema): painless nonpitting nodules and plaques with a waxy, indurated texture; thyroid acropachy (digital clubbing, soft-tissue swelling of the hands and feet); hyperpigmentation
Toxic multinodular goiter	Hyperthyroidism	Soft, warm, velvety skin texture; pruritus; diffuse nonscarring alopecia; soft, shiny brittle nails with increased rate of growth; Plummer nails; patient may also have vitiligo
Hashimoto thyroiditis	Hypothyroidism	Associated with alopecia areata, connective tissue disease (lupus and dermatomyositis), bullous pemphigoid, dermatitis herpetiformis, and chronic mucocutaneous candidiasis
Hypothyroidism	Hypothyroidism	Myxedema; atopic dermatitis, keratosis pilaris, fine wrinkling, impaired wound healing; absence of hair on lateral third of eyebrow (Hertoghe sign); slow-growing, brittle nails with hoarseness

CALCIPHYLAXIS

Metastatic calcification in ESRD results from dysfunction of calcium and phosphate homeostasis. Calcification of vessels is common in ESRD and is seldom symptomatic. Occasionally, however, deposition of calcium phosphate in the media of cutaneous vessels results in downstream ischemia and infarct known as calciphylaxis. Painful violaceous mottling and fixed livedo reticularis progress to firm plaques of retiform purpura, followed by black eschar, and ulceration. Mortality is high—roughly 50% at 1 year—most often from sepsis. Parathyroid hormone is usually elevated, while the calcium-phosphate product is often normal when checked. Treatment of calciphylaxis is multimodal and includes sodium thiosulfate, low calcium bath dialysis, non–calcium phosphate binders, bisphosphonates, calcimimetics, debridement of necrotic tissue, and aggressive wound care.

BULLOUS DISEASES OF HEMODIALYSIS

Porphyria cutanea tarda may occur in patients with ESRD on dialysis. Although the etiology of this phenomenon is unclear, inadequate clearance of plasma-bound porphyrins by the kidneys or hemodialysis may lead to porphyrin deposition in the skin, with resulting skin fragility and blister formation in sun-exposed areas.[37,38] Patients on hemodialysis may also produce or be exposed to compounds that alter normal heme synthesis.

Bullous dermatosis of dialysis or pseudoporphyria may occur in up to one-fifth of patients on hemodialysis. This condition is often clinically indistinguishable from porphyria cutanea tarda. Hypertrichosis is less common, and plasma porphyrin levels are typically normal.

When treating porphyria cutanea tarda or pseudoporphyria, phlebotomy can reduce iron levels in the liver, allowing new hepatic uroporphyrinogen decarboxylase to be formed.[39] However, patients with ESRD often have significant anemia and cannot tolerate phlebotomy. Erythropoietin may both lower total body iron stores and support phlebotomy as needed.[40,41] Low-dose hydroxychloroquine or chloroquine effectively clear porphyrins from the liver, but these may not be eliminated in the setting of poor renal function. Deferoxamine may lower serum porphyrin levels in some patients. Renal transplantation is an option in refractory disease.[42]

ACQUIRED PERFORATING DERMATOSES (KYRLE DISEASE)

Acquired perforating dermatoses are a spectrum of disorders associated with ESRD and diabetes that involve transepidermal elimination of collagen or elastic fibers. They occur in up to 10% of patients undergoing hemodialysis.[43] Clinically, patients develop hyperkeratotic papules or nodules with a central crust-filled plug on the trunk and extensor surfaces, often in a linear distribution.

Proposed mechanisms include diabetic microangiopathy, dysregulation of vitamin A or vitamin D metabolism, abnormality of collagen or elastic fibers, and inflammation and connective tissue degradation by dermal deposition of substances such as uric acid and calcium pyrophosphate.[44] Many authorities regard this entity as a response to trauma caused by scratching in chronic renal pruritus. Successful treatment depends on addressing the underlying etiology of pruritus. Topical and intralesional glucocorticoids, topical and systemic retinoids, cryotherapy, and ultraviolet light may be useful.

THYROID DISORDERS

Table 133-7 outlines the manifestations of thyroid disorders (see also Chap. 137, "Diabetes and Other Endocrine Diseases").

REFERENCES

1. Agouridis AP, Elisaf MS, Nair DR, et al. Ear lobe crease: a marker of coronary artery disease? *Arch Med Sci*. 2015;11(6):1145-1155.
2. Gelfand JM, Neimann AL, Shin DB, et al. Risk of myocardial infarction in patients with psoriasis. *JAMA*. 2006;296(14):1735.
3. Hugh J, Van Voorhees AS, Nijhawan RI, et al. From the Medical Board of the National Psoriasis Foundation: the risk of cardiovascular disease in individuals with psoriasis and the potential impact of current therapies. *J Am Acad Dermatol*. 2014;70(1):168.
4. Miner JJ, Kim AH. Cardiac manifestations of systemic lupus erythematosus. *Rheum Dis Clin North Am*. 2014;40(1):51-60.
5. Moder KG, Miller TD, Tazelaar HD. Cardiac involvement in systemic lupus erythematosus. *Mayo Clin Proc*. 1999;74(3):275-284.
6. Friedman DM, Rupel A, Buyon JP. Epidemiology, etiology, detection, and treatment of autoantibody-associated congenital heart block in neonatal lupus. *Curr Rheumatol Rep*. 2007;9(2):101-108.
7. Steen V. Targeted therapy for systemic sclerosis. *Autoimmun Rev*. 2006;5(2):122-124.
8. Baydur A, Alsalek M, Louie SG, et al. Respiratory muscle strength, lung function, and dyspnea in patients with sarcoidosis. *Chest*. 2001;120(1):102-108.
9. Rosenbach MA, English JC, Callen JP. Sarcoidosis. In: Callen J, Jorizzo J, eds. *Dermatological Signs of Systemic Disease*. St. Louis, MO: Elsevier; 2017:305-314.
10. Tanoue LT. Pulmonary manifestations of rheumatoid arthritis. *Clin Chest Med*. 1998;19(4):667.
11. Keane MP, Lynch JP III. Pleuropulmonary manifestations of systemic lupus erythematosus. *Thorax*. 2000;55(2):159-166.
12. Marie I, Hachulla E, Cherin P, et al. Interstitial lung disease in dermatomyositis and polymyositis. *Arthritis Rheum*. 2002;47(6):614.
13. Bull RH, Fenton DA, Mortimer PS. Lymphatic function in the yellow nail syndrome. *Br J Dermatol*. 1996;134(2):307-312.
14. Arkin LM, Flory JH, Shin DB, et al. High prevalence of aquagenic wrinkling of the palms in patients with cystic fibrosis and association with measurable increases in transepidermal water loss. *Pediatr Dermatol*. 2012;29(5):560-566.
15. Johns MK. Skin wrinkling in cystic fibrosis. *Med Biol Illus*. 1975;25(4):205-210.
16. Koulentaki M, Ioannidou D, Stefanidou M, et al. Dermatological manifestations in primary biliary cirrhosis patients: a case control study. *Am J Gastroenterol*. 2006;101(3):541.
17. Foutch PG, Sullivan JA, Gaines JA, et al. Cutaneous vascular spiders in cirrhotic patients: correlation with hemorrhage from esophageal varices. *Am J Gastroenterol*. 1988;83(7):723-726.
18. Viraben R, Couret B, Gorguet B. Disseminated reticulate hypomelanosis developing during primary biliary cirrhosis. *Dermatology*. 1997;195(4):382-383.
19. Smith KE, Fenske NA. Cutaneous manifestations of alcohol abuse. *J Am Acad Dermatol*. 2000;43:1-16; quiz 16-18.
20. Niederau C, Strohmeyer G, Stremmel W. Epidemiology, clinical spectrum and prognosis of hemochromatosis. *Adv Exp Med Biol*. 1994;356:293.
21. Oleaga JM, Gardeazabal J, Sanz de Galdeano C, et al. Generalized lichen planus associated with primary biliary cirrhosis which resolved after liver transplantation. *Acta Derm Venereol*. 1995;75(1):87.
22. Graham-Brown RA, Sarkany I, Sherlock S. Lichen planus and primary biliary cirrhosis. *Br J Dermatol*. 1982;106(6):699-703.
23. Nan DN, Fernandez-Ayala M, Garcia-Palomo D, et al. Atypical skin lesions associated with mixed cryoglobulinaemia and hepatitis C virus infection in a cocaine-consuming patient. *Br J Dermatol*. 2000;143(6):1330-1331.
24. Tay YK. Gianotti-Crosti syndrome following immunization. *Pediatr Dermatol*. 2110;18(3):262.
25. Bem J, Bradley EL III. Subcutaneous manifestations of severe acute pancreatitis. *Pancreas*. 1999;16(4):551-555.
26. Friedman S, Marion JF, Scheri E, et al. Intravenous cyclosporine in refractory pyoderma gangrenosum complicating inflammatory bowel disease. *Inflamm Bowel Dis*. 2001;7(1):1-7.
27. Tsao H. Update on familial cancer syndromes and the skin. *J Am Acad Dermatol*. 2000;42(6):939-969.
28. Doxey BW, Kuwada SK, Burt RW. Inherited polyposis syndromes: Molecular mechanisms, clinicopathology, and genetic testing. *Clin Gastroenterol Hepatol*. 2005;3(7):633-641.
29. Harned RK, Buck JL, Sobin LH. The hamartomatous polyposis syndromes: clinical and radiologic features. *AJR Am J Roentgenol*. 1995;164(3):565-571.
30. Kemp DR, Gin D. Bowel-associated dermatosis-arthritis syndrome. *Med J Aust*. 1990;152(1):43-45.
31. Murakami K, Nakanishi Y, Wakamatsu K, et al. Serum levels of 5-s-cysteinyldopa are correlated with skin

colors in hemodialysis patients but not in peritoneal dialysis patients. *Blood Purif*. 2009;28(3):209-215.
32. Gilchrest BA, Stern RS, Steinman TI, et al. Clinical features of pruritus among patients undergoing maintenance hemodialysis. *Arch Dermatol*. 1982;118(3): 154-156.
33. Stahle-Backdahl M. Uremic pruritus. *Semin Dermatol*. 1995;14(4):297-301.
34. Szepietowski JC, Sikora M, Kusztal M, et al. Uremic pruritus: a clinical study of maintenance hemodialysis patients. *J Dermatol*. 2002;29(10):621-627.
35. Mettang M, Weisshaar E. Pruritus: control of itch in patients undergoing dialysis. *Skin Therapy Lett*. 2010;15(2):1-5.
36. Vahlquist A, Stenstrom E, Torma H. Vitamin A and beta-carotene concentrations at different depths of the epidermis: a preliminary study in the cow snout. *Ups J Med Sci*. 1987;92(3):253-257.
37. Murtagh FE, Addington-Hall JM, Edmonds PM, et al. Symptoms in advanced renal disease: a cross-sectional survey of symptom prevalence in stage 5 chronic kidney disease managed without dialysis. *J Palliat Med*. 2007;10(6):1266-1276.
38. Poh-Fitzpatrick MB, Masullo AS, Grossman ME. Porphyria cutanea tarda associated with chronic renal disease and hemodialysis. *Arch Dermatol*. 1980;116(2): 191-195.
39. Poh-Fitzpatrick MB, Sosin AE, Bemis J. Porphyrin levels in plasma and erythrocytes of chronic hemodialysis patients. *J Am Acad Dermatol*. 1982;7(1):100-104.
40. Kelly MA, O'Rourke KD: Treatment of porphyria cutanea tarda with phlebotomy in a patient on peritoneal dialysis. *J Am Acad Dermatol*. 2001;44(2)(suppl):336-338.
41. Anderson KE, Goeger DE, Carson RW, et al. Erythropoietin for the treatment of porphyria cutanea tarda in a patient on long-term hemodialysis. *N Engl J Med*. 1990;322(5):315-317.
42. Sarkell B, Patterson JW. Treatment of porphyria cutanea tarda of end-stage renal disease with erythropoietin. *J Am Acad Dermatol*. 1993;29(3):499-500.
43. Stevens BR, Fleischer AB, Piering F, et al. Porphyria cutanea tarda in the setting of renal failure. Response to renal transplantation. *Arch Dermatol*. 1993;129(3): 337-339.
44. Farrell AM. Acquired perforating dermatosis in renal and diabetic patients. *Lancet*. 1997;349(9056):895-866.
45. Haftek M, Euvrard S, Kanitakis J, et al. Acquired perforating dermatosis of diabetes mellitus and renal failure: further ultrastructural clues to its pathogenesis. *J Cutan Pathol*. 1993;20(4):350-355.

Chapter 134 :: Cutaneous Paraneoplastic Syndromes

:: Manasmon Chairatchaneeboon & Ellen J. Kim

CUTANEOUS PARANEOPLASTIC SYNDROMES

Paraneoplastic syndromes refer to the remote effects of underlying neoplastic diseases. The clinical syndromes can occur in various organ systems, including endocrine, neuromuscular, cardiovascular, cutaneous, hematologic, GI, and renal. The symptoms are not the direct effect of metastases or tumor invasion, but may result from substances produced by the tumor (eg. hormones, peptides, or cytokines) or from immunologic or inflammatory reactions between malignant and normal tissues.

Cutaneous paraneoplastic syndromes (Table 134-1) are diverse dermatologic entities that suggest the presence of a remote malignancy. In some instances, they may appear before a cancer diagnosis and contribute to the discovery of an occult cancer, or they may also indicate recurrence in a patient with prior remission of cancer. Consequently, prompt recognition of the cutaneous paraneoplastic syndromes may lead to the detection of an underlying malignancy at an early and highly-treatable stage. However, the paraneoplastic manifestations may predate the diagnosis of the related neoplasm by many months or years. If an underlying cancer is not detectible, careful followup should continue for several years.

In addition to classic paraneoplastic dermatoses, this chapter also discusses direct tumor involvement of the skin and genodermatoses with malignant potential (Table 134-2). Although paraneoplastic dermatoses are not frequently seen in the clinical setting, recognition of these cancer-associated skin lesions is very important. The dermatologist may play a significant role in diagnosing an occult malignancy at earlier stages of disease.

HYPERKERATOTIC DERMATOSES

ACANTHOSIS NIGRICANS

Chap. 137, "Diabetes and Other Endocrine Diseases," provides additional information on benign acanthosis nigricans.

AT-A-GLANCE

- Acanthosis nigricans is a cutaneous marker, most commonly of insulin resistance and less frequently of genetic disorders and malignancy.
- Characterized by symmetric hyperpigmented, hyperkeratotic, verrucous plaques with a velvety texture on intertriginous skin and occasionally mucocutaneous areas.
- Darker skin pigmentation, insulin resistance, and obesity are more commonly associated with benign acanthosis nigricans.
- Malignant acanthosis nigricans often appears rapidly in older individuals and can involve atypical areas such as mucosal surfaces.

The term *acanthosis nigricans* was originally proposed by Unna, although the first cases were malignancy associated and described independently by Pollitzer and by Janovsky in 1890. Curth clinically classified acanthosis nigricans into malignant, benign, or syndromic acanthosis nigricans, or pseudoacanthosis nigricans (obesity related). Today acanthosis nigricans is classified into 2 broad categories: benign (familial, obesity related, hyperinsulinemic states, autoimmune disease associated) or malignant (malignancy associated). Malignant acanthosis nigricans typically occurs in older patients and frequently coexists with other paraneoplastic dermatoses such as tripe palms and the sign of Leser-Trélat.[1]

EPIDEMIOLOGY

The majority (80%) of acanthosis nigricans occurs idiopathically or in benign conditions such as endocrinopathies, heritable diseases, or drug use. Malignancy-associated acanthosis nigricans is rare, with approximately 1000 cases reported in the literature. It usually occurs in individuals older than 40 years of age, without gender, racial, or genetic predilection.[1]

CLINICAL FEATURES

The skin lesions first appear as a symmetric hyperpigmentation or a dirty appearance of the skin, followed by thickening and increased skin markings, resulting in hyperpigmented velvety plaques. The colors may vary

TABLE 134-1
Classic Paraneoplastic Dermatoses

PARANEOPLASTIC DERMATOSIS	MAJOR INTERNAL MALIGNANCY	PERCENT WITH CANCER	UNIQUE FEATURES
Hyperkeratotic Diseases			
Acanthosis nigricans	Adenocarcinomas: intraabdominal; gastric cancer (CA) (60%)	Unknown	Older age, rapid course, extensive, and oral involvement indicate malignancy associations; more common in benign condition with insulin resistance and metabolic syndromes
Acquired ichthyosis	Hodgkin lymphoma most common	Unknown	Spares flexures, palms, soles; can occur in several benign conditions
Pityriasis rotunda	GI and hematologic malignancies; hepatocellular CA most common	30% of Type I	Type I: African/Asian; <30 lesions, high rate of malignancy Type II: whites, familial; >30 lesions, cancer rare
Tripe palms	Lung CA most common; gastric CA second	>90%	Coexists with acanthosis nigricans in 70%
Leser-Trélat sign	Adenocarcinomas: GI (32%); lymphoproliferative disorders (20%)	Unknown	Seborrheic keratoses (SKs) with early onset, eruptive nature, pruritus; coexistence with acanthosis nigricans and/or tripe palms suggests paraneoplastic type
Bazex syndrome	Squamous cell carcinoma (SCC) of upper aerodigestive tract	Nearly 100%	Acral papulosquamous lesions (ears, nose), paronychia, onychodystrophy
Collagen–Vascular Diseases			
Dermatomyositis	Women: ovarian and breast CA Men: GI, respiratory tract CA Asians: nasopharyngeal CA	18%-25%	Older age, males predominate; refractory or flaring of previously well-controlled disease may signal malignancy
Progressive systemic sclerosis	Lung CA	3%-11%	Older age of onset, diffuse cutaneous disease, and RNA polymerase III autoantibodies
Reactive Erythemas			
Erythema gyratum repens	Lung CA	70%	Migratory "wood-grain" pattern; erythema
Necrolytic migratory erythema	Glucagonoma (pancreatic α cell tumor)	Nearly 100%	Can be first sign of glucagonoma syndrome; early recognition is important; most have metastatic tumors at the time of diagnosis
Neutrophilic Dermatoses			
Sweet syndrome	Acute myeloid leukemia (AML) most common	20%	Bullous and ulcerated skin lesions, subcutaneous nodules, oral mucosal involvement, anemia, and abnormal platelet count are more common with malignancy
Pyoderma gangrenosum	AML most common	4%-20%	Atypical presentation more common with malignancy; may be on a continuum with Sweet syndrome; immunoglobulin (Ig) A paraproteinemia is the most frequent associated gammopathy
Dermal Proliferative Diseases			
Multicentric reticulohistiocytosis	No specific cancer type or location	25%	Not parallel to malignancy
Necrobiotic xanthogranuloma	Monoclonal gammopathy of undetermined significance (MGUS) most common	80% (gammopathy)	Either IgG κ or λ light-chain monoclonal gammopathy; periorbital involvement, especially with necrosis; may develop multiple myeloma, recommend lifelong followup
Disorders of Dermal Deposition			
Scleromyxedema	MGUS most common; multiple myeloma rare	80% (gammopathy)	Most have IgG λ light-chain monoclonal gammopathy; only rarely convert to multiple myeloma, but poor prognosis if conversion occurs
Systemic amyloidosis	Multiple myeloma	20%	Macroglossia, pinch purpura, carpal tunnel clues to systemic amyloidosis; amyloid light chain (AL) amyloidosis is the most common form associated with malignancy; 1-year mean survival time

(*Continued*)

TABLE 134-1
Classic Paraneoplastic Dermatoses (*Continued*)

PARANEOPLASTIC DERMATOSIS	MAJOR INTERNAL MALIGNANCY	PERCENT WITH CANCER	UNIQUE FEATURES
Bullous Disorders			
Paraneoplastic pemphigus	Lymphoproliferative disorders; non-Hodgkin lymphoma most common; chronic lymphocytic leukemia (CLL) second most common	Nearly 100%	Can occur in Castleman disease and thymoma; parallels benign, but not malignant, tumors
Dermatitis herpetiformis	Non-Hodgkin lymphoma most common	4%	Occurs significantly more often in patients who do not follow a gluten-free diet
Other Changes			
Hypertrichosis lanuginosa acquisita	Men: lung, colorectal CA Women: colorectal, lung, or breast CA	Nearly 100%	Excessive downy hair initially concentrated on face, spreading caudally; usually appears in advanced or metastatic carcinomas
Trousseau syndrome	Pancreatic, brain, lung CA	20%-30%	Deep vein thrombosis (DVT) of unusual sites (eg. upper limbs), thrombosis of visceral organs and brain, and arterial thromboembolism suggest cancer association

and include yellow, brown, gray, and black. Although the skin lesions of acanthosis nigricans can occur almost anywhere on the body, they tend to affect the skinfold, flexural, and intertriginous areas. The most commonly involved locations are the axillae, neck, external genitalia, groin, face, inner thighs, antecubital and popliteal fossae, umbilicus, and perianal area. Acrochordons may develop, superimposed on the acanthosis nigricans or on other locations (Fig. 134-1). Hyperkeratosis of the nipple and areola also has been noted. Mucosal involvement tends to occur in the malignant form, but can also be seen in acanthosis nigricans without malignancy and is characterized by papillomatosis and thickening of mucosa with or without hyperpigmentation involving the oral cavity (lips, tongue, buccal mucosa, and palate) (Fig. 134-2), and, rarely, the esophagus, eyes, larynx, and anal and genital mucosae. Typically, patients with acanthosis nigricans are asymptomatic, but pruritus can be a problem in some patients. Oral and esophageal papillomatosis can cause sore mouth and dysphagia.[1]

The lesions of malignant and benign acanthosis nigricans are indistinguishable. However, malignancy-associated acanthosis nigricans usually appears abruptly and extensively. Mucosal involvement and generalized pruritus are more common. The co-occurrence with florid cutaneous papillomatosis and other paraneoplastic skin lesions, such as tripe palms (see "Tripe Palms" section) and Leser-Trélat sign (see "Leser-Trélat Sign" section), suggests the malignancy-associated form of acanthosis nigricans. Many types of malignancies have been reported in association with malignant acanthosis nigricans. A literature review shows that up to 90% of patients have an associated intraabdominal adenocarcinoma, of which approximately 60% are gastric cancer. Cancers of the uterus, liver, intestinal, ovary, kidney, breast, lung, pancreas, bladder, thyroid, and gallbladder have been reported, as have lymphoma and mycosis fungoides.[1]

ETIOLOGY AND PATHOGENESIS

The pathogenesis of acanthosis nigricans is poorly understood. In benign acanthosis nigricans, there is evidence that insulin plays a significant role through insulin-like growth factor-1 receptor signaling pathway (see Chap. 137). In acanthosis nigricans associated with inherited syndromes, insulin-like growth factor-1 receptor and fibroblast growth factor receptors may be implicated. In addition, genetic studies also demonstrate activation mutations of fibroblast growth factor receptors.[2]

In malignancy-associated acanthosis nigricans, it is proposed that the tumor produces transforming growth factor-α that is similar in structure to epidermal growth factor and binds to epidermal growth factor receptors and stimulates keratinocyte proliferation, which leads to development of acanthosis nigricans. This theory was based on observations in which the skin disorders improved or resolved following treatment of the underlying malignancy. For example, elevated urinary transforming growth factor-α and increased expression of epidermal growth factor receptor in lesional skin were noted in a patient with acanthosis nigricans, acrochordons, Leser-Trélat sign, and melanoma. The enhanced expression of this cytokine and its receptor normalized after removal of the melanoma, and the accompanying skin lesions improved postoperatively. In addition, some authors suggest that fibroblast growth factor and insulin-like growth factor-1 also may play a role in the pathogenesis of malignancy-associated acanthosis nigricans.[2,3]

DIAGNOSIS

Diagnosis of acanthosis nigricans is based on clinical features and distribution of the lesions. Histopathologic study is needed only to confirm diagnosis

TABLE 134-2

Genetic Syndromes Involving Skin and/or Mucous Membranes and Associated with Malignancy

SYNDROME	GENE/PROTEIN DEFECT	CUTANEOUS FINDINGS	OTHER CHARACTERISTIC FEATURES	MAJOR ASSOCIATED INTERNAL MALIGNANCY	MINOR ASSOCIATED INTERNAL MALIGNANCY
Autosomal Dominant					
Birt-Hogg-Dube syndrome[41]	*FLCN*	Fibrofolliculomas, trichodiscomas, acrochordons	Lung cysts, emphysema, recurrent spontaneous pneumothoraces	Renal carcinoma	Lipoma, parathyroid adenoma
Carney complex[42,43]	*PRKAR1A*	Mucocutaneous myxomas, nevi, lentigines, blue nevi	Adrenocortical disease	Myxomas (cardiac, skin), Sertoli cell testicular cancer	Other testicular cancers, breast cancer, thyroid neoplasms, pituitary adenoma, psammomatous melanotic schwannomas, ovarian tumors, osteochondromyxoma
Cowden disease[41,43,44]	*PTEN* (phosphatase and tensin homolog)	Trichilemmomas, acral papules and keratoses, oral papillomas, sclerotic fibromas	Macrocephaly, cerebellar dysfunction	Breast cancer, thyroid cancer, endometrial cancer, hamartomatous intestinal polyps	Colorectal cancer, kidney cancer, liposarcoma, malignant melanoma
Gardner disease[41,45]	*APC*	Epidermoid cysts, fibromas, pilomatricomas	Congenital hypertrophy of retinal pigment epithelium (CHRPE), supernumerary teeth, osteomas, desmoid tumors	Intestinal polyposis and colorectal adenocarcinoma (near 100%)	Thyroid cancer, bone and CNS tumors, pancreatic and hepatic carcinomas, hepatoblastomas, adrenal adenomas
Gorlin syndrome/nevoid basal cell carcinoma (BCC) syndrome[44,46]	*PTCH1, PTCH2, SUFU*	Multiple BCCs, epidermoid cysts, milia, palmoplantar pits	Calcified falx cerebri, bifid ribs, odontogenic cysts, macrocephaly, frontal bossing, hypertelorism	BCC, medulloblastoma	Meningiomas, ovarian fibromas and fibrosarcomas, ovarian desmoids, cardiac fibromas, rhabdomyosarcomas, ameloblastoma
Howel-Evans syndrome[43]	*TOC*	Palmoplantar keratoderma (non-transgrediens), oral leukoplakia	Esophageal papillomas	Esophageal carcinoma (up to 90%)	
Multiple endocrine neoplasia (MEN) I syndrome[42,44]	*MEN1*	Angiofibromas, collagenomas, lipomas	Various endocrine sequelae based on underlying tumor	Parathyroid adenomas, pancreatic islet cell tumors, gastrinomas, anterior pituitary tumors	Carcinoid tumors, adrenal cortical tumors, thyroid adenomas
MEN IIa syndrome[44]	*RET*	Scapular macular or lichen amyloidosis	Hirschsprung disease; no mucosal neuromas or marfanoid habitus	Medullary thyroid carcinoma (95%), pheochromocytomas, parathyroid tumors	
MEN IIb/III syndrome[43]	*RET*	Mucosal neuromas, thickened eyelids and lips, circumoral lentigines, diffuse pigmentation of the hands and feet, café-au-lait macules (CALMs)	Marfanoid habitus	Medullary thyroid carcinoma (95%), pheochromocytoma; no parathyroid tumors	Conjunctival neuromas, intestinal ganglioneuromas
Muir-Torre syndrome[41,46]	*MLH1, MSH2, MSH6*	Sebaceous tumors (epitheliomas, hyperplasias, adenomas, carcinomas), keratoacanthomas		Colorectal carcinomas, genitourinary cancers	Breast, lung, head and neck, small intestine carcinomas, hematologic malignancies

Neurofibromatosis (NF) I[44,45]	*NF1*	CALMs, NF, plexiform NF, axillary/inguinal freckling	Lisch nodules, glaucoma, sphenoid wing dysplasia, pseudoarthrosis of tibia, learning difficulties, seizures	Optic gliomas, neurofibrosarcoma, juvenile myelomonocytic leukemia	Astrocytomas, ependymoma, meningioma, peripheral nerve sheath tumor, pheochromocytoma, hematologic malignancies
Neurofibromatosis II[43,45]	*NF2*	Schwannomas, NF, CALMs, plexiform NF	Juvenile posterior subcapsular cataracts, deafness	Bilateral vestibular schwannomas (near 100%), spinal tumors, meningiomas	Gliomas, astrocytomas, intramedullary ependymomas
Peutz-Jeghers syndrome[43,44]	*STK11*	Perioral and mucosal lentigines	Intussusception, bowel obstruction	Multiple GI hamartomatous polyps (near 100%), GI carcinoma	Pancreatic, esophageal, breast cancer, ovarian cancer, lung cancer
Reed syndrome[41] (hereditary leiomyomatosis and renal cell carcinoma)	*FH*	Cutaneous leiomyomas (piloleiomyomas)	Uterine leiomyoma	Renal carcinoma	
Tuberous sclerosis[42,43]	*TSC1, TSC2*	Ash-leaf macules, shagreen patches, CALMs, facial angiofibromas, periungual fibromas, dental enamel pits	Tonic–clonic seizures, paraventricular calcification, subependymal nodules, retinal hamartomas, learning disabilities, autism	Intracranial cortical/subcortical tubers (near 100%), cardiac rhabdomyomas, renal angiomyolipomas, lung lymphangiomyomatosis	
Autosomal Recessive					
Ataxia-telangiectasia[43,44]	*ATM*	Telangiectasias (skin and conjunctiva), mask-like progeric facies, CALMs, poikiloderma	Ataxia, nystagmus, choreoathetosis, immunodeficiency, CNS degeneration, growth deficiency, radiosensitivity	Leukemia/lymphomas	Various solid tumors
Bloom syndrome[44,46]	*BLM/RECQL3*	Cheilitis, CALMs, malar poikiloderma	Immunodeficiency, short stature, hypogonadism, high-pitched voice	Leukemia/lymphoma; GI adenocarcinoma	Other solid tumors of various organs
Chédiak-Higashi syndrome[43]	*LYST*	Partial oculocutaneous albinism, silver hair, slate-gray skin, ecchymoses	Immunodeficiency, pyogenic infections (*Staphylococcus*), photophobia, neurodegeneration, mild coagulation defect	Lymphoma-like accelerated phase (85%)	
Fanconi anemia[43,44]	*FANC*	Short stature, CALMs microcephaly, thumb and/or radial anomalies thenar hypoplasia	Short stature, multiple birth anomalies, microcephaly, bone marrow failure, infection, radial anomalies	Acute myeloid leukemia/myelodysplastic syndrome, SCC	Gynecologic tumors, brain tumors, Wilms tumor, neuroblastoma
Griscelli syndrome[43]	*RAB27A, MYO5A*	Silver hair, partial albinism	Immunodeficiency, pancytopenia, neurodegeneration (*MYO5A*), hemophagocytic syndrome (*RAB27A*)	Lymphoma-like accelerated phase	
Rothmund-Thomson syndrome[46]	*RecQL4*	Poikiloderma, nail dystrophy, acral keratoses, photosensitivity, hypotrichosis	Short stature, radial anomalies, juvenile cataracts, hypogonadism	Osteogenic sarcomas	Nonmelanoma skin cancers, fibrosarcoma, non-Hodgkin lymphoma, thyroid adenoma, gastric carcinoma

(*Continued*)

TABLE 134-2

Genetic Syndromes Involving Skin and/or Mucous Membranes and Associated with Malignancy (*Continued*)

SYNDROME	GENE/PROTEIN DEFECT	CUTANEOUS FINDINGS	OTHER CHARACTERISTIC FEATURES	MAJOR ASSOCIATED INTERNAL MALIGNANCY	MINOR ASSOCIATED INTERNAL MALIGNANCY
Werner syndrome[43,46]	*RecQL2*	Premature aging, bird-like facies, sclerodermoid changes, ulcers	Short stature, cataracts, diabetes, osteoporosis, abnormal voice, hypogonadism, muscular atrophy	Thyroid carcinomas	Meningiomas, malignant melanoma, sarcomas, hematologic malignancies
Xeroderma pigmentosum (XP)[43,46]	XP (multiple proteins that form DNA repair complex), XPA to XPG, and XPV	Photosensitivity, actinic keratoses, lentigines, poikiloderma	Photophobia, multiple ocular complications, neurodegeneration (XPA, XPD)	Cutaneous cancers (BCC, SCC, and melanoma 100%), ocular cancers	Sarcomas, leukemia, lung cancer, breast cancer, gastric cancer, brain tumors
X-Linked Recessive					
Dyskeratosis congenita[43,44]	*DKC1* (XLR); *TERT/TERD* (AD); *NOP10* (AR)	Leukoplakia, nail dystrophy, reticulate pigmentation, poikilodermatous skin changes, alopecia, premature graying of the hair, palmoplantar hyperkeratosis, adermatoglyphia, hyperhidrosis	Pancytopenia, various ocular complications, mental retardation, pulmonary complications, esophageal stricture, microcephaly	Cutaneous and mucosal SCC, acute myeloid leukemia/myelodysplastic syndrome	Hodgkin lymphoma, GI carcinoma
Wiskott-Aldrich syndrome (WAS)[44]	WASP	Eczema, petechiae/purpura	Immunodeficiency (decreased IgM), recurrent infections, thrombocytopenia	Lymphomas/leukemia	Kaposi sarcoma, smooth muscle tumors, cerebellar astrocytoma
X-linked ichthyosis	*STS*	Adherent brown scales that spares face, palms, soles and flexural creases	Failure of maternal labor, comma-shaped corneal opacities, cryptorchidism	Testicular cancer	
Sporadic					
Beckwith-Wiedemann syndrome[43,44]	p57, H19, *LIT1*, *ICR1*, *CDKN1C*, *NSD1*	Capillary malformation, macroglossia, linear indentations on earlobes creases, helical pits	Omphalocele, mental retardation, hemihypertrophy, neonatal hypoglycemia	Wilms tumor, hepatoblastoma	Adrenocortical tumors, rhabdomyosarcoma, glioblastoma, neuroblastoma
Familial atypical multiple mole melanoma syndrome (dysplastic nevus syndrome)[43,44]	*CDKN2A*	Multiple dysplastic nevi, melanomas		Melanomas, pancreatic cancer	Lung, laryngeal, and breast carcinomas, SCC of the oropharynx
Maffucci syndrome	*IDH1*, *IDH2*	Venous malformations	Enchondromas, secondary fractures	Chondrosarcoma	Angiosarcoma and lymphangiosarcoma, fibrosarcoma, osteosarcoma

Figure 134-1 Acanthosis nigricans involving the axilla with numerous acrochordons.

in problematic cases. Histopathology of acanthosis nigricans classically shows hyperkeratosis and epidermal papillomatosis. There is only slight acanthosis and usually no hyperpigmentation. Horn pseudocyst formation and increased melanin pigmentation can be observed in some cases. The brown color of the lesion is caused by hyperkeratosis rather than melanin. The histopathologic findings cannot be distinguished from confluent and reticulated papillomatosis of Gougerot and Carteaud, seborrheic keratosis, or epidermal nevus.

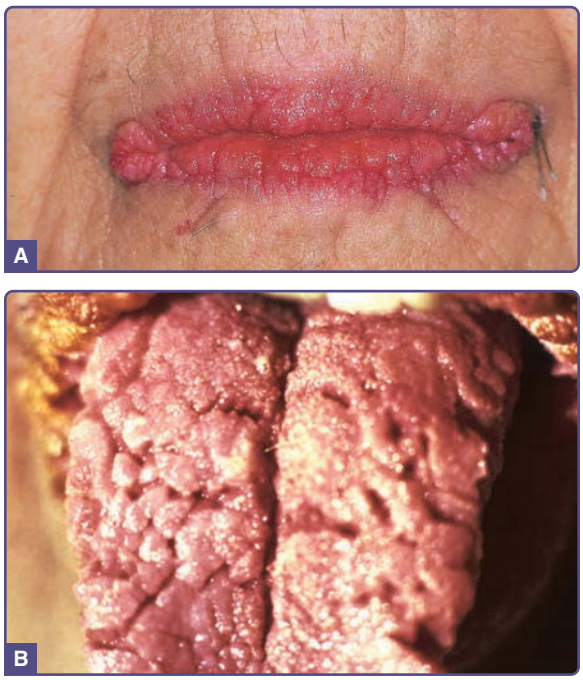

Figure 134-2 Acanthosis nigricans. **A,** Verrucous and papillomatous growths of the vermilion border of the lip. **B,** Velvety thickening of the tongue. (**A** and **B** are not the same patient.) (**A** and **B,** From Wolff K, Johnson RA. *Fitzpatrick's Color Atlas and Synopsis of Clinical Dermatology*, 6th ed. New York, NY: McGraw-Hill; 2009, with permission.)

DIFFERENTIAL DIAGNOSIS

The clinical differential diagnoses of malignant acanthosis nigricans include the conditions that present hyperpigmentation and patches or plaques in either flexural areas or a generalized distribution. Psoriasiform dermatitis, atopic dermatitis, pellagra, resolving pemphigus vegetans, parapsoriasis, cutaneous T-cell lymphoma, infections (eg. candidiasis, erythrasma, tinea corporis/cruris), pigmentary disorders (eg. hemochromatosis, Addison disease, Dowling-Degos disease), and others (eg, confluent and reticulated papillomatosis of Gougerot and Carteaud, Becker melanosis, epidermal nevus, and terra firma-forme dermatosis) are included in the differential diagnoses.

CLINICAL COURSE AND PROGNOSIS

Malignant acanthosis nigricans can occur before, during, or after the detection of cancer. It tends to parallel the course of the underlying malignancy. Skin lesions may regress after treatment of the underlying cancers, and recur following relapse or metastasis of the malignancies. Unfortunately, most associated malignancies present at an advanced stage, and thus the prognosis is usually poor.[2,4]

MANAGEMENT

Evaluation and studies are recommended in suspicious cases to identify the underlying endocrinopathy or malignancy. Older patients presenting with unintentional weight loss, rapid and extensive acanthosis nigricans with mucosal involvement, and have concomitant paraneoplastic skin lesions, should be investigated for underlying malignancy, especially of the GI tract.

Cosmetic appearance is often the patient's primary concern. Management of any co-occurring disease or malignancy often improves and may even resolve the acanthosis nigricans. Topical keratolytics, including the retinoids, and oral retinoids can reduce the appearance of acanthosis nigricans. Other oral medications reported to show improvement include dietary fish oil, metformin, and cyproheptadine, possibly by inhibition of tumor-secreted growth factors in the case of cyproheptadine. Other therapies found beneficial in case reports include calcipotriol, trichloroacetic acid peeling, and long-pulsed alexandrite laser.[3]

ACQUIRED ICHTHYOSIS

Chapter 47, "The Ichthyoses," provides additional information on acquired ichthyosis.

Acquired ichthyosis occurs in adulthood and may be associated with malignancies, endocrine and metabolic diseases, HIV and other infections, autoimmune diseases, nutritional deficiency, and drug reactions. Clinical manifestations include diffuse, symmetrical, plate-like scaling on trunk and extensor extremities, which usually spares flexures, palms, and soles. Malignancies associated with acquired ichthyosis include CD30+ lymphoproliferative disorders, mycosis fungoides, leiomyosarcoma, Kaposi sarcoma, multiple myeloma, and carcinomas of the ovary, breast, lung, and cervix. Hodgkin disease is the most common neoplasm; the ichthyosis usually occurs simultaneously with or after the diagnosis of lymphoma. As a sudden onset of ichthyosis in an adult may be a presenting sign of underlying malignancy, a careful malignancy screening, especially for lymphoma, is important. In lymphomas, acquired ichthyosis can be a cutaneous sign of the disease or a paraneoplastic phenomenon. However, this may be very difficult to identify in some cases, such as in mycosis fungoides, in which clinical and histopathologic findings can be indistinguishable between ichthyosiform mycosis fungoides and acquired ichthyosis related to mycosis fungoides.[5]

PITYRIASIS ROTUNDA

Pityriasis rotunda, a rare cutaneous disorder, is considered by some as a variant of acquired ichthyosis. It has been observed in association with chronic diseases, infections, and malignancies. GI (most commonly hepatocellular carcinoma) and hematologic malignancies are frequently reported among the various types of associated malignancies. However, pityriasis rotunda can occur in healthy people as well. Skin manifestations are characteristic, consisting of perfectly round or oval, asymptomatic, well-defined, hypopigmented or hyperpigmented ichthyosiform scaly patches that appear on the trunk and proximal extremities.[5] Type 1 pityriasis rotunda is associated with underlying malignant or systemic disease and presents with <30 skin lesions. It is more common in black and East Asian patients. Type 2 or familial pityriasis rotunda occurs in white patients and presents with more than 30 lesions (usually hypopigmented), and is not associated with any underlying disease.[5] Treatment of underlying disease may lead to resolution of skin lesions in Type 1 patients. In Type 2 patients, spontaneous improvement may be seen by adulthood. Topical treatments, such as retinoids, salicyclic acid, and lactic acid are useful treatments for the dryness and scaling associated with this condition.[5]

TRIPE PALMS

The term *tripe* refers to a rugose surface of the edible lining of a bovine foregut. It was first implicated in a clinical diagnosis of the keratoderma with ridging pattern of the palms and fingers in 1963, when a patient reported to his doctor that his hands looked similar to tripe. Tripe palms was first described in the literature by Clarke in 1977. He reported a patient with squamous cell carcinoma of the lung accompanied by malignant acanthosis nigricans and thickening of the palms in tripe pattern. Tripe palms has been recognized as a cutaneous sign of internal malignancy since then.[6]

EPIDEMIOLOGY

Tripe palms is a rare paraneoplastic dermatosis with approximately 100 cases reported in the literature. The association with malignancy is high, with a greater than 90% occurrence. It is found almost exclusively in adults, and is more common in men than in women.[6]

CLINICAL FEATURES

The palms are rough, thickened, and velvety with exaggerated dermatoglyphics. The texture of the ventral surface of hand and fingers may be moss-like, cobbled, or honeycombed (Fig. 134-3). Tripe palms usually coexists with malignant acanthosis nigricans, observed in approximately 70% of the patients. Several authors suggest that tripe palms may be a form of palmar acanthosis nigricans. The co-occurrence with other paraneoplastic skin lesions, such as florid cutaneous papillomatosis, pruritus, clubbing of the digits, and the sign of Leser-Trélat, can be also seen.[6]

Pulmonary and gastric carcinoma account for more than 50% of neoplasms associated with tripe palms. In patients with only tripe palms, pulmonary carcinoma

Figure 134-3 Tripe palm. The palmar ridges show maximal accentuation, thus mimicking the mucosa of the stomach of a ruminant.

is the most frequently associated malignancy, especially the squamous cell type. In patients with both tripe palms and acanthosis nigricans, gastric carcinoma is the most common carcinoma, followed by lung carcinoma. Other malignancies less often associated with tripe palms include those of the genitourinary tract, breast, head, and neck.[6,7]

ETIOLOGY AND PATHOGENESIS

Specific mechanisms of development have not been fully elucidated. Similar to acanthosis nigricans (see "Acanthosis Nigricans" section), there is limited evidence for the role of transforming growth factor-α released by tumor cells, inducing cellular proliferation in the pathogenesis of tripe palms. It is believed that tripe palms can be a variant of malignant acanthosis nigricans.[7]

DIAGNOSIS

Histopathology of tripe palms includes hyperkeratosis, acanthosis, and papillomatosis. These features closely resemble those pathologic findings observed in acanthosis nigricans and seborrheic keratoses. Additional findings can include dermal mucin and mast cells in approximately 20% of specimens.

DIFFERENTIAL DIAGNOSIS

The clinical differential diagnosis of tripe palms includes pachydermoperiostosis, hypertrophic pulmonary osteoarthropathy, acromegaly, thyroid acropachy, palmoplantar keratoderma, and acanthosis nigricans.

CLINICAL COURSE AND PROGNOSIS

Paraneoplastic tripe palms can occur before (48%), concurrently (21%), or after (31%) the diagnosis of malignancy. In one-third of patients, tripe palms parallels the course of the associated malignancy. The appearance of tripe palms in a known case of malignancy may be a sign of recurrence or metastasis of the tumor.[6]

MANAGEMENT

A complete malignancy workup, especially to rule out lung and stomach carcinoma, should be performed in all patients with tripe palms because of the high percentage of associated malignancy. A minimum workup should include a medical history, a complete physical examination, routine laboratory studies, a chest roentgenogram, and either a radiographic or an endoscopic evaluation of the upper GI tract. Additional investigations should be indicated by the findings of the initial workup.

Treatment of tripe palms is difficult and primarily aimed at the underlying malignancy. There is no specific therapy for tripe palms. Similar to acanthosis nigricans, there are anecdotal reports of improvement with oral retinoids alone and in combination with metformin. Approximately 30% of cases of tripe palms will resolve with treatment of the underlying tumor. However, there are many cases where remission of the cancer had no effect.

LESER-TRÉLAT SIGN

AT-A-GLANCE

- Rapid and eruptive increase in number and size of seborrheic keratoses.
- Pruritus is common.
- Often occurs with malignant acanthosis nigricans.
- Adenocarcinomas of the GI tract are the most common associated cancer, followed by lymphoproliferative malignancies.
- Rarely seen in benign conditions, such as pregnancy, HIV, heart transplantation, acromegaly, erythroderma, and drug reaction.

The sign of Leser-Trélat is characterized by the sudden increase in size and number of seborrheic keratoses (SKs) related to internal malignancy. This phenomenon is attributed to Edmund Leser and Ulysse Trélat, two European surgeons, who observed cherry hemangiomas (but not SKs) in patients with cancer in 1890. In 1900, Hollander was the first person who associated the appearance of numerous SKs with internal malignancy.[7,8]

EPIDEMIOLOGY

The sign of Leser-Trélat is a rare paraneoplastic dermatosis that occurs with equal frequency between men and women and among different races. Similar to the occurrence of malignancy, this sign is more common in older individuals.

This entity has remained controversial because the prevalence of both SKs and cancer is increased in the older population. Moreover, the identification of eruptive SKs is often based on the patient's self-reporting which is subjective. In a large population-based study of 1752 consecutive cases of SKs, there was no statistical evidence of an increased incidence of internal malignancy compared to the general population. Subanalysis of those presenting with eruptive SKs also failed to demonstrate an increased risk of internal malignancy. In other large studies of patients with SKs and a recent solid tumor, a comparison with age- and sex-matched controls has not demonstrated a difference in either the clinical features or numbers of SKs.[9] As such, large epidemiologic studies have not provided the evidence needed to conclusively define this sign as a true paraneoplastic dermatosis.

Although large studies have not shown a statistical difference, anecdotal evidence exists demonstrating that this sign may signify an internal malignancy. First, there are reports of eruptive SKs in patients in their 20s with internal malignancies. Clinically, Leser-Trélat sign often coexists with malignant acanthosis nigricans, a more established paraneoplastic phenomenon. Additionally, alterations in growth factor expression differ from control patients. Together, this suggests that the Leser-Trélat sign is a legitimate, but extremely uncommon, paraneoplastic dermatosis.[7,8]

CLINICAL FEATURES

Clinical features signifying a paraneoplastic phenomenon include numerous, widespread, eruptive SKs, predominantly on trunk and extremities. However, quantification of eruptive SKs in terms of length of the eruptive period and number and size of SKs required for the diagnosis is lacking. Individual SKs found in the sign of Leser-Trélat are similar to normal SKs, both clinically and histologically. Pruritus is a significant feature occurring in approximately half of patients. Cooccurrence with other hyperkeratotic paraneoplastic dermatoses is common, with approximately one-third having acanthosis nigricans. There are some case reports of Leser-Trélat sign coexisting with tripe palms as well.[8] The rapid occurrence of pruritic, eruptive SKs, especially in the setting of acanthosis nigricans should alert the clinician to a potential internal malignancy (Fig. 134-4).

Adenocarcinomas account for the majority of malignancies described with the sign of Leser-Trélat, in 32% of which the Leser-Trélat sign is associated with GI tract malignancies, particularly gastric cancer. Lymphoproliferative disorders, including Sézary syndrome, mycosis fungoides, other lymphomas, and leukemia, are the second most common associated malignancies, occurring in approximately 20% of patients. Other tumors, such as lung, bladder, kidney, and ovarian cancers, and melanoma, also have been reported.[7]

Figure 134-4 Leser-Trélat sign consisting of multiple pruritic eruptive seborrheic keratoses.

A Leser-Trélat–like eruption or eruptive SKs have been rarely reported in the setting of benign conditions, such as pregnancy, HIV, heart transplantation, acromegaly, and erythroderma, and in association with drugs, such as cytarabine and tumor necrosis factor-α inhibitors.[7,10] The term pseudosign of Leser-Trélat has been used to designate nonmalignancy-associated eruptive SKs. Unfortunately, these examples do not help to further define an already confusing and controversial clinical entity.

ETIOLOGY AND PATHOGENESIS

An exact pathogenesis has yet to be elucidated. However, similar to acanthosis nigricans and tripe palms, evidence also exists with the Leser-Trélat sign that an alteration in growth factor homeostasis is contributory. In several instances, a state of increased growth factor expression has been observed, with increased urinary levels of epidermal growth factors and transforming growth factor-α detected in patients with an underlying malignancy and eruptive SKs. Subsequently, growth factor levels decreased following primary tumor resection.[7]

In addition to increased levels of growth factor expression, lesional skin in paraneoplastic acanthosis nigricans and SKs has alterations in the extracellular matrix. It is unknown what the direct impact of growth factor signaling has on the skin. Proposed ideas include either inducing a hyperproliferative state primarily or by altering the surrounding environment such as via the extracellular matrix. These similar mechanisms further support the idea of a continuum between acanthosis nigricans and the Leser-Trélat sign.

DIAGNOSIS

A skin biopsy may be done to confirm the diagnosis. Histopathologic findings of SK in this syndrome are the same as the common SK and include epidermal hyperkeratosis, papillomatosis, and acanthosis with cystic inclusion of keratinous material (horn pseudocysts).

DIFFERENTIAL DIAGNOSIS

Differential diagnosis of the individual skin lesion in this syndrome is the same as for SKs, consisting of fibroepithelial polyp, epidermal nevus, melanocytic nevus, pigmented basal cell carcinoma, squamous cell carcinoma, malignant melanoma, warty dyskeratoma, verruca vulgaris, and condyloma acuminatum. In extensive and generalized SKs, which can appear in older healthy individuals, it is important to

distinguish the benign presentation from the signs of Leser-Trélat.

CLINICAL COURSE AND PROGNOSIS

Leser-Trélat sign can develop from approximately 5 months prior to 10 months after the diagnosis of malignancy. More than half of the patients have metastatic tumors at the time of diagnosis. The prognosis is poor, with an estimated survival time of 1 year after diagnosis. This eruption parallels the course of the underlying malignancy in some cases, but not as a general rule.

MANAGEMENT

Treatment should be directed toward the underlying tumor. If the lesions are symptomatic or cosmetically concerning to the patient, local treatment of SK, such as α-hydroxy acids, retinoids, trichloroacetic acid, cryosurgery with or without curettage, dermabrasion, laser, and shave removal, can be performed.

ACROKERATOSIS PARANEOPLASTICA OF BAZEX

AT-A-GLANCE

- Characteristic cutaneous lesions and distribution symmetrically involving the helices, nose, cheeks, digits, and nails.
- Lesions evolve from nonspecific dermatitis and paronychia to inflammatory plaques, acral keratoderma, and nail plate changes.
- Skin lesions often predate detection of internal malignancy.
- Upper aerodigestive tract malignancy is the most common.

Acrokeratosis paraneoplastica of Bazex was first presented in 1965 at the French Dermatological Society. Bazex and his colleagues described a patient with scaly erythematous lesions of the extremities who had a carcinoma of the pyriform fossa, whose skin lesions cleared after treatment of the carcinoma. The lesions were proposed as a cutaneous marker of internal malignancy.[11]

This condition is also known as Bazex syndrome, which is an eponym used to describe 2 different clinical entities. The first refers to *acrokeratosis paraneoplastica of Bazex*, which is discussed in this chapter, and the second is Bazex-Dupré-Christol syndrome, a very rare genodermatosis, characterized by congenital hypotrichosis, follicular atrophoderma, and basal cell carcinomas arising at an early age.

EPIDEMIOLOGY

More than 100 cases of Bazex syndrome have been reported in the medical literature. This condition is highly associated with underlying malignancy. It occurs almost exclusively in males older than age 40 years. Approximately 60% of the associated malignancies are squamous cell carcinomas of the upper aerodigestive tract. The second most common is lung cancer. Other less-common tumor locations are genitourinary and lower GI tract.[12]

CLINICAL FEATURES

The characteristic cutaneous findings are symmetrical erythematous to violaceous scaly patches or plaques over the acral extremities, ears, and bridge of the nose. Hyperpigmentation tends to appear in dark-skinned individuals. Vesicles and bullae are occasionally observed on the hands and feet. A bulbous enlargement of the distal phalanges has been described. The most common sites of involvement are the nails (77%), ears (76%), fingers (65%), nose (62%), palms (56%)/hands (51%), and soles (49%)/feet (44%). Several patients have an additional cutaneous paraneoplastic syndrome, which includes acquired ichthyosis, Leser-Trélat sign, and clubbing.[12] Bazex and Griffiths described 3 stages of skin lesions that parallel the growth and dissemination of the underlying tumor.

In the first stage, the neoplasm is frequently undetected. The helices, nose, fingers, and toes are usually affected in a symmetrical fashion. Early lesions are ill-defined scaly papules, simulating a nonspecific dermatitis. The eruption is classically asymptomatic, but pruritus may be a problem. Paronychia is the first sign of nail involvement (Fig. 134-5) and may be tender. Nail dystrophy, subungual hyperkeratosis, and onycholysis progressing to complete destruction of the nail plate have been reported.

During the second stage, the tumor exhibits symptoms, resulting from local extension or metastatic

Figure 134-5 Distal edema of toes, painful generalized paronychia, and distal subungual hyperkeratosis in early acrokeratosis paraneoplastica.

Figure 134-6 Keratoderma characteristically spares central aspects of plantar (and palmar) surfaces in acrokeratosis paraneoplastica.

spread, and the skin eruption becomes more extensive. The typical red-to-purple scaly plaques may involve the whole pinna, cheeks, or upper lip. The palms and soles develop a keratoderma that often spares the central volar surfaces, but may lead to painful fissures (Fig. 134-6). Nail plate changes include yellowing, thickening, onycholysis, and ridging, both horizontal and vertical.

The final stage is observed when the tumor goes untreated or fails to respond to treatment. All of the above signs and symptoms persist as the papulosquamous lesions begin to appear on other sites, such as trunk, elbows, knees, scalp, and dorsal hands and feet. Rarely, vesicles and bullae may be present, most commonly on the fingers, hands, and feet. Nail changes can be quite variable, ranging from the typical thickening to nail atrophy and loss of the nail plate.

ETIOLOGY AND PATHOGENESIS

The pathophysiology of acrokeratosis paraneoplastica remains unclear. Many authors propose an immunologic mechanism in which the antibodies against the tumor crossreact with keratinocyte and basement membrane antigen, or a T cell-mediated immune response to tumor-like antigens in the epidermis. The findings of immunoglobulins (IgG, IgA, IgM) and complement (C3) along the basement membrane zone in some patients have been observed. Some authors also suggest that epidermal growth factor secreted by the tumor may play a role in epidermal hyperplasia and hyperkeratosis, as mentioned in other hyperkeratotic dermatoses in this chapter. Other hypotheses include low serum levels of vitamin A and zinc.[12]

DIAGNOSIS

Histopathology is somewhat nonspecific. Psoriasiform dermatitis is the most common pattern. Hyperkeratosis, parakeratosis, and a superficial lymphohistiocytic infiltrate are the main histopathologic features. The interface changes, including vacuolar degeneration, dyskeratotic keratinocytes, lichenoid infiltrate, and melanin-containing macrophages in the dermis, are reported less frequently.[12]

In the context of histopathologic and characteristic cutaneous findings, acrokeratosis paraneoplastica of Bazex could be a possible diagnosis. If the patients have no history of malignancy, appropriate investigations should be promptly performed.

DIFFERENTIAL DIAGNOSIS

The differential diagnoses include psoriasis, pityriasis rubra pilaris, seborrheic or contact dermatitis, eczematous drug eruption, infections (eg. dermatophytosis, onychomycosis), lupus erythematosus, palmoplantar keratodermas, and mycosis fungoides. The distinguishing clinical feature, which is nearly always present in acrokeratosis paraneoplastica, is involvement of the helices of the ears (Fig. 134-7) and the tip of the nose. Typically, Bazex syndrome is resistant to conventional treatment.

CLINICAL COURSE AND PROGNOSIS

The skin eruption can occur before (67%), simultaneously (18%), or after (15%) the diagnosis of the neoplasm. The cutaneous lesions precede the diagnosis of

Figure 134-7 Characteristic helical inflammation with scale in acrokeratosis paraneoplastica.

the tumor by an average of 12 months. Acrokeratosis paraneoplastica is expected to resolve after successful treatment of the underlying malignancy and can reappear with tumor recurrence. However, nail dystrophy and pigmentary skin changes may persist despite significant improvement in the underlying malignancy and other skin lesions.[12]

MANAGEMENT

Treatment of the primary neoplasm is the most effective therapy. The skin lesions are typically resistant to standard therapies for hyperkeratotic conditions and few treatments specific for the cutaneous component of acrokeratosis paraneoplastica have been reported. Systemic retinoids have been used with variable success. Isolated reports suggest benefit from oral psoralen and ultraviolet A phototherapy, topical salicylic acid, and corticosteroids.

COLLAGEN–VASCULAR DISEASE

DERMATOMYOSITIS

Chapter 62, "Dermatomyositis," provides additional information on dermatomyositis.

Adult-onset dermatomyositis (DM) is significantly associated with malignancy. The risk of cancer is higher in DM than in polymyositis alone. Approximately 18% to 25% of patients with adult-onset DM may have malignancy, which is associated with decreased survival. The malignancy may occur before, simultaneously, or after the diagnosis of DM. The course of DM does not always follow the course of the malignancy. In contrast, juvenile-onset DM does not have a strongly increased risk of malignancy.

The clinical manifestations of DM with or without associated malignancy are similar. Previous studies reported predictive signs of accompanying malignancy, such as cutaneous necrosis, cutaneous vasculitis, lack of interstitial lung disease, dysphagia, male gender, elevated erythrocyte sedimentation rate, and an older age at onset. However, some of these findings are inconsistent and remain controversial. Recently, anti-p155 antibodies have been reported as a promising cancer marker in adult patients with DM.

Types of associated malignancies vary among studies and may reflect differences in malignancy risk across different populations. Lung, breast, ovarian, cervical, pancreatic, gastric, colorectal, and prostate malignancies are frequently reported; hematologic malignancies may also occur in association with DM. It has been noted that nasopharyngeal carcinoma is more common in the Asian population.[13]

In adult patients with DM, the risk of malignancy is highest in the first year after diagnosis, then steadily declines and remains slightly elevated even after 5 years. Therefore, all adult patients with DM should be evaluated for malignancy at the time of diagnosis, followed by long-term surveillance. There is no definitive guidelines for cancer screening in patients with DM. Most authors recommend an initial screening that includes a comprehensive history and physical examination (including a pelvic examination in women), standard laboratory tests (complete blood count, complete metabolic panel, urinalysis, stool occult blood testing), and chest radiography. Further investigation is directed by any abnormal findings. Some clinicians also recommend a colonoscopy and CT scans of the chest, abdomen, and pelvis. Additional age-, gender-, and ethnicity-appropriate malignancy screening, including a transvaginal pelvic sonography, Papanicolaou smear, and mammography for female patients, or an evaluation by an ear-nose-throat physician to exclude nasopharyngeal carcinoma for patients of Asian descent, should be considered.[13]

PROGRESSIVE SYSTEMIC SCLEROSIS

Chapter 63, "Systemic Sclerosis," provides additional information on progressive systemic sclerosis.

The majority of epidemiologic studies reveal an increased risk of cancer in patients with progressive systemic sclerosis (PSS) compared with general population, and demonstrated that men are at higher risk than women. The frequency of malignancy is approximately 3% to 11%.[14] The risk of cancer is higher within the first 12 months after a PSS diagnosis, and may be a paraneoplastic phenomenon. However, other studies included in a newer metaanalysis did not demonstrate an increase in the risk of cancer.[15]

Lung, bladder, breast, liver, esophageal, and oropharyngeal carcinoma, nonmelanoma skin cancer, and hematologic malignancies have been frequently reported in association with PSS. Lung cancer is the most frequent type of cancer in most studies, and may be associated with the presence of interstitial lung disease, as well as with history of smoking. Interestingly, there is a 25-fold increased incidence of tongue cancer in one U.S. study.[14,16]

This increased risk of cancer could be the result of damage from chronic inflammation and fibrosis, immunosuppressive therapies for PSS, an environmental exposure, and/or a genetic susceptibility to the development of both cancer and autoimmunity. Although the data are controversial, some studies suggest that the risk of cancer may be greater in patients with diffuse cutaneous disease. Several newer studies confirm an increased risk of cancer-associated PSS in patients with RNA polymerase III autoantibodies or an older age of PSS onset. These groups of patients may benefit from aggressive malignancy screening at diagnosis and long-term cancer surveillance.[16]

REACTIVE ERYTHEMAS

ERYTHEMA GYRATUM REPENS

Chapter 46, "Erythema Annulare Centrifugum and Other Figurate Erythemas," provides additional information on erythema gyratum repens.

This particular annular (*gyratum* is Latin for circle) erythema was thought to be one of the most specific dermatoses associated with underlying neoplasia. However, newer data demonstrate a higher proportion of associated benign conditions than previously reported. Erythema gyratum repens is a rare disease that presents with dramatic appearance and evolution. Nearly 100 cases are reported in the literature. It mostly affects adults in their 60s, men more than women (ratio: 2:1).

Numerous serpiginous bands are arranged in a parallel configuration of concentric red swirls over most of the body. This presentation is occasionally referred to as a "wood-grain" appearance (Fig. 134-8). Even more striking is the relatively rapid rate at which lesions migrate (*repens* is Latin for creeping), estimated at 1 cm per day. A fine scale may be found along the trailing edge of erythema (Fig. 134-9). The hands, feet, and face are commonly spared, except for occasional volar hyperkeratosis. Ichthyosis is present in many cases. Pruritus is universal and may be severe.[17]

An underlying malignancy is associated with erythema gyratum repens approximately 70% of the time. In more than 80% of cases, the cutaneous eruption appears before the diagnosis of malignancy with a mean period of 7 months (range: 1 to 72 months), but it can occur simultaneously or after the diagnosis of malignancy. Among patients with associated carcinoma, almost half of cases have lung cancer, whereas 8% have stomach cancer, 7% have esophageal cancer, and 5% have breast cancer. Individual case reports of many other types of associated tumors are published, as well as 5% of cases with an unknown primary. In those individuals with erythema gyratum repens who did not have a detectible underlying malignancy; some cases were idiopathic; some presented with concurrent conditions including concomitant skin disease (pityriasis rubra pilaris, psoriasis, ichthyosis), connective tissue disease (CREST [calcinosis cutis, Raynaud phenomenon, esophageal motility disorder, sclerodactyly, and telangiectasia] syndrome, rheumatoid arthritis), infection (tuberculosis), hypereosinophilic syndrome, or drug reaction (azathioprine).[18]

Figure 134-9 Erythema gyratum repens. Characteristic "wood-grain" pattern of erythema and slight scale in a woman with breast cancer. (Used with permission from Jill McKenzie, MD.)

Figure 134-8 Erythema gyratum repens. Serpiginous parallel bands on axilla and arm. (Used with permission from Michael Adler.)

The exact etiology of erythema gyratum repens is unknown, but it has been suggested that the tumor may induce a chemical alteration of the normal components of the surrounding tissue. Molecular mimicry ensues as the inflammatory response directed against the tumor crossreacts with benign cutaneous proteins. This theory is supported by documentation of IgG and C3 deposition at the basement membrane of affected skin and bronchial basement membrane in one case associated with lung cancer. Migration characterizes all of the figurate erythemas, but is notably rapid in erythema gyratum repens. The mechanism for this is not clear, although some studies have focused on fibroblast activity. Inflammatory cells and/or fibroblasts may mediate ground substance alterations, which may localize the inflammation that orchestrates the movement of the infiltrate in a patterned mode.[17]

Treatment of erythema gyratum repens involves locating and treating the primary malignancy. With adequate control of the cancer the rash usually abates, but this may not be possible in cases that are widely metastatic at the time of diagnosis. Otherwise, the eruption is often treatment resistant, although variable results occur with systemic steroids. Topical steroids,

vitamin A, and azathioprine have not been beneficial. The eruption has been known to resolve immediately before death, possibly because of generalized ante mortem immunosuppression.[17]

NECROLYTIC MIGRATORY ERYTHEMA

AT-A-GLANCE

- Painful, eroded, crusted intertriginous, and facial skin eruption.
- Highly suggestive of pancreatic malignancy (glucagonoma).
- Half of tumors are metastatic at the time of diagnosis.
- Pseudoglucagonoma syndrome occurs in absence of glucagonoma.
- Skin improves with treatment of underlying nutritional aberrations.

In 1942, Becker first described a patient with cutaneous eruptions in association with α-cell pancreatic tumor. In 1966, McGavran found another patient with similar clinical presentation and had hyperglucagonemia. Later, necrolytic migratory erythema (NME) was coined by Wilkinson in 1973 to describe the distinctive rash in patients with pancreatic cancer.[19]

EPIDEMIOLOGY

NME is a very rare paraneoplastic skin disorder that is considered a hallmark of glucagonoma and is present in more than two-thirds of patients at the time of tumor diagnosis.[19] Glucagonoma is an extremely rare, slow-growing neuroendocrine tumor of the α cells of the pancreas. The global incidence is approximately 1 in every 20 million people. It typically presents with glucagonoma syndrome.[2] There is no gender or race predilection, and it most commonly affects people in their sixth decade.

CLINICAL FEATURES

The skin lesions of NME are polymorphous, but erosions and crusts are usually apparent. Primary lesions are erythematous patches that evolve into plaques and develop central bullae. The blisters erode rapidly, form crusts, and eventually resolve. The erythematous and eroded annular patches and plaques coalesce into large geographic areas. They are typically painful and pruritic. The eruption disappears and reappears spontaneously over the course of weeks. The distribution of NME is characteristic and includes intertriginous areas (eg. groin, perineum, buttocks, and lower abdomen), the central face (especially perioral), and distal extremities (Fig. 134-10). Mucosal involvement manifests as angular cheilitis, atrophic glossitis, and stomatitis. Dystrophic nails may accompany the syndrome.[19,20]

Glucagonoma syndrome is characterized by NME, weight loss, sore mouth, diarrhea, diabetes mellitus, deep vein thrombosis, normochromic normocytic anemia, and neuropsychiatric disorders. Weight loss is the most common presenting sign. The glucagonoma tends to grow slowly. Metastasis to the liver, regional lymph nodes, and bone is common, but appears in late stage of the disease. Pseudoglucagonoma syndrome presents identically, but the α cell pancreatic tumor is not present, which may explain why the serum glucagon levels are not elevated. Underlying diseases identified in patients with the pseudosyndrome include liver disease, pancreatitis, celiac sprue, inflammatory bowel disease, acrodermatitis enteropathica, pellagra, and nonpancreatic malignancies.[19,20]

Figure 134-10 The glucagonoma syndrome, necrolytic migratory erythema. Flaccid and papulovesicular lesions (**A**) with erosions, crusting, and fissures around the orifices, and (**B**) appearing as geographic, circinate "necrolytic migratory erythema" in the groin. (**A** and **B** are not the same patient.)

Because NME can be the first manifestation of the syndromes, early recognition is important and may provide a better outcome.

ETIOLOGY AND PATHOGENESIS

The exact cause of NME remains unclear. The skin rash can be attributed to the metabolic effects of excess glucagon, as resolution of the rash can occur after surgical removal of the glucagonoma or normalizing the glucagon level with medication. Hyperglucagonemia stimulates hepatic gluconeogenesis leading to an increase in blood glucose level. The amino acid consumption in gluconeogenesis pathway contributes to a decrease in serum amino acid. Hypoaminoacidemia resulting in epidermal protein deficiency (histidine and tryptophan) may provoke epidermal necrosis. Glucagon also increases cutaneous levels of arachidonic acid, prostaglandins, and leukotrienes, which may induce a cutaneous inflammatory reaction. However, NME cannot be completely attributed to hyperglucagonemia, because it may appear without elevated levels of glucagon or a pancreatic tumor, as reported in pseudoglucagonoma syndrome. Deficiency of zinc, protein, essential fatty acid, and vitamin B may also play a role in NME development.[20]

DIAGNOSIS

The histopathology of NME is characteristic, but not pathognomonic. Acute lesions exhibit a striking degree of epidermal necrosis in the upper layers of the stratum spinosum and may detach from the viable epidermis underneath. Neutrophiic infiltrates in the necrotic layer resulting in subcorneal pustules can be observed. Chronic lesions show a psoriasiform dermatitis. Parakeratosis, loss of granular layers, basal vacuolization, and scattered necrotic keratinocytes may be demonstrated. These findings can be also seen in other nutritional deficiencies, graft-versus-host disease, connective tissue disorders, and phototoxic drug eruptions.[19,20]

Laboratory abnormalities include a dramatically elevated serum glucagon, usually greater than 1000 pg/mL (reference range: 50 to 150 pg/mL). Most patients have hyperglycemia and a normochromic normocytic anemia. Abnormal liver function is present and serum levels of amino acids, total protein, albumin, and cholesterol are low. Occasionally, zinc levels are also decreased. Imaging studies should be performed to detect the pancreatic tumor. Various methods, such as angiography, ultrasonography, CT, MRI, positron emission tomography, octreotide scintigraphy, and somatostatin receptor scintigraphy, have been used to identify the pancreatic tumor.[20]

DIFFERENTIAL DIAGNOSIS

Other disorders with cutaneous manifestations similar to NME include acrodermatitis enteropathica, nutritional deficiencies, psoriasis, eczema, seborrheic dermatitis, candidiasis, superficial pemphigus, and side effects of certain chemotherapies.

CLINICAL COURSE AND PROGNOSIS

In NME associated with glucagonoma syndrome, the course of the disease varies according to the stage at which the tumor is diagnosed. If the glucagonoma is not metastatic and can be completely resected, symptoms of the syndrome will resolve. Unfortunately, by the time of diagnosis, tumors are frequently large and metastatic in most cases. Fortunately, the tumors are slow growing and patients may experience symptom improvement by surgically reducing the tumor burden, although survival may not be affected by the procedure.

MANAGEMENT

The underlying cause for hyperglucagonemia must be addressed to eradicate the painful skin disease. For patients with glucagonoma, resection of the tumor is important for symptom relief. Complete surgical removal can be curative if the tumor is confined to the pancreas. This tumor is often resistant to chemotherapy. Somatostatin analog (octreotide, pasireotide, and lanreotide) improves the cutaneous symptoms and may delay tumor progression. Other therapeutic modalities, such as interferon, everolimus (mammalian target of rapamycin inhibitor), sunitinib (tyrosine kinase inhibitor), and peptide receptor radionuclide therapy, have been reported with favorable results. Supplementation to correct zinc, amino acid, or fatty acid deficiencies improves skin lesions in some cases.[19]

NEUTROPHILIC DERMATOSES

SWEET SYNDROME

Chapter 36, "Sweet Syndrome," provides additional information on Sweet syndrome.

Sweet syndrome, also known as acute febrile neutrophilic dermatosis, is characterized by fever, leukocytosis, and skin papules or plaques caused by dermal neutrophils. Malignancy is reported in approximately 21% of patients diagnosed with Sweet syndrome, either hematologic (15%) or solid (6%) malignancy. The most commonly-associated hematologic malignancy is acute myeloblastic leukemia. Other hematologic neoplasms include myeloproliferative neoplasms, diffuse large B-cell lymphoma, Hodgkin lymphoma, myelodysplastic syndrome, and myelofibrosis. The most common solid malignancies associated with Sweet syndrome are carcinomas of the genitourinary organs, breast, and GI tract, most frequently adenocarcinomas (57%).[21] Several authors proposed the features to distinguish malignancy-associated Sweet syndrome from the classical form of the disease. Malignancy-associated Sweet

syndrome is less-often preceded by upper respiratory tract infection, and the onset is temporally associated with the new discovery or relapse of cancer. In addition, there is no sex preponderance, whereas female sex is predominant in the classical form.[22]

Clinically, bullous and ulcerated skin lesions, subcutaneous nodules, and oral mucosal involvement may be more frequently observed in malignancy-associated than in classical Sweet syndrome. Laboratory abnormalities, including anemia (82% to 83%) and abnormal platelet count (68%), are reported in malignancy-associated Sweet syndrome. Although peripheral leukocytosis is one of the diagnostic criteria of Sweet syndrome, neutropenia can be observed in some patients with malignancy-associated Sweet syndrome. A small number of patients with hematologic malignancy demonstrate leukemia cutis concurrently with Sweet syndrome in lesional skin biopsy.[21,22]

The onset of Sweet syndrome can precede, follow, or appear concurrently with the diagnosis of a patient's neoplasm. The duration of Sweet syndrome is variable. Recurrence of lesions can occur not only in malignancy-affected patients, but also in individuals with either idiopathic or disease-associated Sweet syndrome. There are no specific guidelines for the treatment of malignancy-associated Sweet syndrome. Systemic corticosteroid and other standard treatments that are used in classical or idiopathic sweet syndrome are the mainstay of therapy. Successful treatment of underlying malignancy may result in complete resolution of malignancy-associated Sweet syndrome, and the reappearance of dermatologic findings may signify relapse of cancer.[21,22]

PYODERMA GANGRENOSUM

Chapter 37, "Pyoderma Gangrenosum," provides additional information on pyoderma gangrenosum.

Pyoderma gangrenosum (PG) is a rare, painful, ulcerating neutrophilic dermatosis associated with various internal diseases. The incidence of malignancy in patients with PG varies among studies, occurring in approximately 4% to 20% of PG patients.[23]

Hematologic malignancy is the most common associated neoplasm; other associated malignancies include acute and chronic myelogenous leukemia, chronic lymphocytic leukemia, multiple myeloma, myelodysplastic syndrome, polycythemia vera, Hodgkin lymphoma, and cutaneous T-cell lymphoma. Atypical features of PG, such as abrupt onset, superficial lesions, hemorrhagic bullae, and involvement of the upper extremities have been described in 27% of PG patients with underlying hematologic disease or malignancy.[24] Improvement of bullous PG with treatment of the underlying malignancy has been documented.

Monoclonal gammopathy of undetermined significance has been described by several authors as an associated condition with PG, with IgA as the most frequently associated paraproteinemia.[23] These gammopathies are clinically benign, but they occasionally progress to myeloma. Therefore, long-term monitoring is recommended.

Underlying solid tumors can also occur in patients with PG. Cancers of various organs, such as breast, prostate, lung, bladder, colon, liver, ovary, larynx, glioblastoma multiforme, and melanoma, have been occasionally reported.[23]

DERMAL PROLIFERATIVE DISORDERS

MULTICENTRIC RETICULOHISTIOCYTOSIS

Chapter 117, "Histiocytosis," provides additional information on multicentric reticulohistiocytosis.

Multicentric reticulohistiocytosis (MRH) is a rare, systemic disease presenting with destructive polyarthritis and typical cutaneous lesions. The isolated or grouped reddish brown to skin-colored papules and nodules are seen predominantly on the face and hands with a characteristic "coral bead" appearance of periungual papules. Up to 25% of patients have associated malignancies, and in some cases the diagnosis of multicentric reticulohistiocytosis precedes the diagnosis of cancer.[25]

There is no predominant type of associated cancer in this disease. Various neoplasms, including breast, lung, thyroid, GI, urogenital, sarcoma, lymphoma, leukemia, and melanoma, have been reported. The course of the disease may be self limtied without joint deformity; waxing and waning; or aggressive with mutilating arthritis. Spontaneous remission usually occurs after many years. It does not run a parallel course with the associated malignancy in the majority of patients. Treatment of the accompanying cancer will resolve joint and skin disease only in some reported cases. It is still debated among several authors whether to label multicentric reticulohistiocytosis as a paraneoplastic disorder. Regardless, a complete workup for underlying malignancy should be performed in every patient diagnosed with multicentric reticulohistiocytosis.[26]

NECROBIOTIC XANTHOGRANULOMA

Chapter 57, "Intercellular IgA Dermatosis (IgA Pemphigus)," provides additional information on necrobiotic xanthogranuloma.

Necrobiotic xanthogranuloma is a rare, non–Langerhans cell histiocytosis with a strong association with hematologic disorders. The skin is the most common site of involvement and more than 80% of patients have periorbital lesions. Extracutaneous involvement is rare. The lesions appear as yellowish to red-orange or violaceous papules, plaques, or nodules, with areas

of ulceration, telangiectasia, or atrophy. Most of the cases are asymptomatic with an indolent course.

Up to 80% of patients have monoclonal gammopathy of IgG type with either a κ or λ light chain.[27] The most common associated plasma cell dyscrasias are monoclonal gammopathies of undetermined significance, smoldering multiple myeloma, and multiple myeloma. Other hematologic abnormalities, including non-Hodgkin lymphoma, chronic lymphocytic leukemia, Hodgkin lymphoma, and lymphoplasmacytic lymphoma, may occur in association with necrobiotic xanthogranuloma.[27]

Patients with necrobiotic xanthogranuloma associated with monoclonal gammopathy are at risk of conversion to multiple myeloma. Consequently, careful monitoring should be continued for early detection of disease progression.[27]

DERMAL DEPOSITION

SCLEROMYXEDEMA

Chapter 67, "Scleredema and Scleromyxedema," provides additional information on scleromyxedema.

Scleromyxedema, the generalized form of papular mucinosis (lichen myxedematosus), is an uncommon disease associated with monoclonal gammopathy and systemic organ involvement. The typical cutaneous manifestations have a predilection for the face, arms, and hands. Cardiopulmonary, rheumatologic, GI, and neurologic involvement is common. The majority (80%) of patients with scleromyxedema has an IgGλ light chain monoclonal gammopathy of undetermined significance. Serum protein electrophoresis should be performed in conjunction with thyroid studies to rule out thyroid dysfunction and myxedema. Fortunately, the paraproteinemia only rarely converts to multiple myeloma, but when it occurs, it portends a poor prognosis. There are several case reports of other hematologic and nonhematologic malignancies among patients with scleromyxedema, including leukemia, Hodgkin or non-Hodgkin lymphoma, and some solid tumors. However, it is uncertain if some of the associated malignancies are incidental or associated with the treatment of scleromyxedema with agents, such as melphalan as a secondary malignancy.[28] The course of the disease is usually progressive and major systemic organ involvement may contribute to poor outcome.

SYSTEMIC AMYLOIDOSIS

Chapter 124, "The Porphyrias," provides additional information on systemic amyloidosis.

Primary systemic amyloidosis is referred to as AL amyloidosis, in which there is extracellular deposition of fibrils of monoclonal immunoglobulin light chain typically produced by a small plasma cell clone. Secondary (AA) amyloidosis occurs with autoimmune or inflammatory diseases, malignancies, and chronic infections. Skin manifestations of systemic amyloidosis include "pinch purpura" (periorbital bruising), macroglossia, and, less commonly, waxy skin thickening and subcutaneous nodules.

AL amyloidosis is the most common form associated with malignancy. The prognosis is generally poor, with median survival time if left untreated of 12 months. In AL amyloidosis, multiple organs and tissues (kidney, heart, liver, peripheral/autonomic nerve, soft tissue) are generally involved. It is important to distinguish the skin lesions in systemic AL amyloidosis from the less-common, localized, cutaneous variant, which does not progress to multisystem involvement.

Multiple myeloma is the most common associated malignancy, and is seen in approximately 20% of patients with AL amyloidosis.[29] Other neoplasms, such as non-Hodgkin lymphoma, mucosa-associated lymphoid tissue lymphoma, lymphoplasmacytic lymphoma, and other single case reports of solid-organ tumors, have been rarely reported. For all patients with suspected AL amyloidosis, serum and urine protein electrophoresis/immunofixation electrophoresis, serum free light chain assay, bone marrow biopsy, and skeletal imaging should be performed at baseline to rule out the presence of multiple myeloma.[30]

Some investigators have described an increased risk of non-Hodgkin lymphoma in transthyretin amyloidosis (ATTR).[31] In addition, certain neoplasms, such as hepatocellular carcinoma, renal cell carcinoma, Castleman disease, Hodgkin disease, and adult hairy cell leukemia, can cause reactive or secondary (AA) amyloidosis.[30]

BULLOUS DISORDERS

PARANEOPLASTIC PEMPHIGUS

Chapter 53, "Paraneoplastic Pemphigus," provides additional information on paraneoplastic pemphigus.

Paraneoplastic pemphigus is a life-threatening condition with a high mortality rate. Painful, hemorrhagic oral erosions are the earliest characteristic clinical finding. The polymorphous skin eruption, composed of pemphigus-like, bullous pemphigoid–like, erythema multiforme–like, graft-versus-host disease–like and lichen planus–like skin lesions, may involve any site. Multiorgan involvement, such as of the lung, thyroid, kidney, smooth muscle, and GI tract, is documented. The pathogenesis of paraneoplastic pemphigus involves both cellular and humoral immunity. Nearly all patients have an underlying neoplasm, most frequently a lymphoproliferative disease. The most commonly reported associated neoplasms are non-Hodgkin lymphoma, chronic lymphocytic leukemia, Castleman disease, and thymoma. The prognosis is poor in patients with malignancy-associated paraneoplastic pemphigus but may be better in patients with benign tumors.[32]

DERMATITIS HERPETIFORMIS

Chapter 59, "Dermatitis Herpetiformis," provides additional information on dermatitis herpetiformis.

Dermatitis herpetiformis is an autoimmune skin condition that presents as a severely pruritic skin eruption with polymorphous lesions and is associated with gluten sensitivity. The majority of studies have demonstrated a significantly increased risk of non-Hodgkin lymphoma in patients with dermatitis herpetiformis, even though the risk of malignancy overall is similar to general population.[33,34] It has been noticed that patients with longstanding dermatitis herpetiformis are at particular risk. The reported frequency of associated malignancy in patients with dermatitis herpetiformis is up to 4.3%, predominantly in males.[33] However, patients with dermatitis herpetiformis do not appear to have an increased mortality rate despite this association with non-Hodgkin lymphoma.[33,34]

The lymphomas associated with dermatitis herpetiformis can be either B-cell or T-cell lymphomas, and may occur both in and outside the GI tract as nodal or extranodal disease. In addition, the enteropathy-associated T-cell lymphoma, typically associated with celiac disease, has been reported in dermatitis herpetiformis patients.[34] A gluten-free diet may protect against the development of cancer, but more studies are needed to confirm this finding.[33,34]

BULLOUS PEMPHIGOID

Chapter 54, "Bullous Pemphigoid," provides additional information on bullous pemphigoid.

Bullous pemphigoid (BP) is an autoimmune blistering disorder that presents in elderly patients with intact skin blisters and pruritus. It remains debated whether there is an increased risk of malignancy in bullous pemphigoid, other than the risk related to the age of the patient. Several studies, including newer large epidemiologic studies, have not found an association between bullous pemphigoid and cancer. Other studies, however, especially from Japan, demonstrated a higher risk of malignancy in bullous pemphigoid patients, compared to the normal population. Many authors discourage a routine cancer screening in bullous pemphigoid patients, except in early-onset pemphigoid, history of malignancy, or standard treatment failure.[35]

MISCELLANEOUS

HYPERTRICHOSIS LANUGINOSA ACQUISITA

Acquired hypertrichosis lanuginosa ("malignant down") is a rare condition characterized by the relatively-sudden appearance of long, fine, nonpigmented lanugo (Latin for *down*) hairs. The lanugo hairs most frequently appear on the face and ears early in the course (Fig. 134-11). The hairs may grow to an impressive length; eyebrows and eyelashes may grow to inches long. The long fine hairs also may be seen on the trunk and limbs, including the axillae, but the palms, soles, suprapubic, and genital areas are usually spared. Acquired hypertrichosis lanuginosa often develops in a cephalocaudal direction and may be accompanied by glossitis, hypertrophy of tongue papillae, oral hyperpigmentation, disturbances of taste and smell, acanthosis nigricans, diarrhea, adenopathy, and weight loss.[36]

Figure 134-11 Hypertrichosis lanuginosa acquisita in a 19-year-old woman with pancreatic carcinoma.

This condition is frequently paraneoplastic and can be a marker of an underlying malignancy. It usually appears in advanced or metastasized carcinomas, and thus has a poor prognosis. The most commonly associated malignancies are lung and colorectal cancer in men, and colorectal cancer followed by lung and breast cancer in women. Ovary, uterus, and urinary bladder carcinoma, lymphoma, and leukemia also have been found in patients with acquired hypertrichosis lanuginosa, as have other malignancies.[37]

Acquired hypertrichosis lanuginosa must be distinguished from hirsutism and hypertrichosis associated with nonmalignant causes, including metabolic and endocrine diseases, such as anorexia nervosa, thyrotoxicosis, and porphyria cutanea tarda (see Chap. 124), or medications such as cyclosporine, phenytoin, penicillamine, spironolactone, psoralens, corticosteroids, interferon, diazoxide, or minoxidil.[36,37]

Patients presenting with acquired hypertrichosis lanuginosa without history of drug administration or underlying metabolic and endocrine or malignant diseases, should be suspected of an underlying

cancer. Appropriate diagnostic evaluations for the occult malignancy, especially of the lung, colon, rectum areas, and breast, should be considered.

TROUSSEAU SYNDROME

The definition of Trousseau syndrome has evolved over time. It originally described the occurrence of migratory thrombophlebitis associated with underlying gastric cancer. Later, it was expanded by several authors to include cancer-associated hypercoagulability with a wide range of clinical manifestations, including abnormal coagulation tests without clinical symptoms, superficial migratory thrombophlebitis, deep vein thrombosis, marantic endocarditis, pulmonary embolism, and massive thromboembolic phenomenon associated with disseminated intravascular coagulation. Venous thromboembolism (VTE) seems to be the most frequent clinical manifestation.[38]

Clinically, VTE in patients with malignancy can be more severe and more extensive than in patients without malignancy. Deep vein thrombosis of unusual sites, such as upper limbs, thrombosis of visceral organs and brain, and arterial thromboembolism have been reported to occur in cancer-associated cases. Trousseau syndrome composes approximately 20% to 30% of all VTE patients, and occurs in 1% to 8% of patients with underlying malignancy. The incidence has increased, possibly as a result of the more frequent use of newer thrombogenic chemotherapeutic and immunomodulatory agents (eg, thalidomide or lenalidomide) and the longer survival period in cancer patients. Unfortunately, VTE is the second most common cause of death in patients with cancer. Patients with active cancer have a 4 to 7 times higher risk of thrombosis than the normal population, and the risk is highest in certain cancers, such as pancreatic, brain, lung, stomach, and ovarian cancers.[38-40]

Although the pathogenesis of Trousseau syndrome in cancer patients is unclear, multiple factors are likely to be involved in the thrombogenic process. The combination of abnormal blood flow or stasis, vessel wall injury, and blood hypercoagulability, referred to as the *Virchow triad*, contributes to thrombus formation. Several studies have described the overexpression of tissue factor by tumor cells and the increase of plasma microparticles, which are involved in the coagulation pathway. Chemotherapy and tumor necrosis may induce inflammatory cytokines resulting in endothelial cell injury. Neutrophil extracellular traps (NETs), released as a result of neutrophil programmed cell death (NETosis), have effects on the intrinsic coagulation pathway. Moreover, several investigators have documented specific signaling pathways that contribute to the procoagulant phenotype of cancer cells, resulting from mutations in oncogenes (eg, K-*ras*, EGFR, PML/RAR-α, MET) and tumor suppressor genes (eg, *p53*, *PTEN*).[38,40]

As Trousseau syndrome can be a presenting manifestation of an occult cancer, several authors suggest an age-specific and sex-specific malignancy screening test in patients with idiopathic VTE. Treatment of the underlying malignancy along with anticoagulant therapy is recommended. Low-molecular-weight heparin is the first-line treatment.

GENETIC SYNDROMES INVOLVING SKIN AND/OR MUCOUS MEMBRANES AND ASSOCIATED WITH MALIGNANCY

It is important for clinicians to recognize cutaneous features of genetic conditions that predispose to internal malignancy. In several cases, cutaneous features predate the development of malignancy and increased surveillance may improve overall survival in these patients. For malignancies associated with a genodermatosis, there may be an increased risk for family members to develop cancer and appropriate genetic counseling and testing should be considered.

Table 134-2 outlines the characteristic cutaneous findings and the major associated internal malignancies for the genodermatoses with cancer susceptibility.[41-46]

DIRECT TUMOR INVOLVEMENT OF THE SKIN

CUTANEOUS METASTASES

Cutaneous metastases represent involvement of the skin by metastatic spread of a distant primary tumor. The overall incidence of cutaneous involvement is approximately 5%. The most common malignancies to metastasize to the skin in women are breast cancer, followed by colon cancer and melanoma. In men, the most common are lung cancer, followed by colon cancer and melanoma.[47]

Cutaneous metastases most commonly appear as a rapid onset of solitary or multiple, asymptomatic, skin-colored, mobile, firm, round or oval nodule(s). Metastatic breast cancer can present with various forms of skin lesions. For example, carcinoma erysipelatoides, presents with warm, tender erythematous patches or plaques resembling erysipelas or cellulitis (Fig. 134-12A), but without fever or leukocytosis. Another clinical variant is the leather-like skin changes of sclerosing metastatic breast cancer, known as carcinoma en cuirasse, which may later present as nodules and ulceration (Fig. 134-12B, C). Although carcinoma en cuirasse has been reported as the presenting sign of breast cancer, it more commonly occurs as a local recurrence after treatment of an underlying breast cancer. Both carcinoma erysipelatoides and carcinoma

Figure 134-12 **A,** Carcinoma erysipelatoides. Intralymphatic spread of mammary carcinoma that manifests as erysipelas-like erythema. **B,** Bilateral cutaneous metastases from underlying breast carcinoma. **C,** Carcinoma en cuirasse involving both breasts and thoracic wall.

en cuirasse are not restricted to breast cancer; they also can be seen in lung, kidney, GI tract, and other metastasizing malignancies.[48] Metastases from malignant melanoma are usually pigmented (Fig. 134-13). Often there is a bluish tint to the lesion, even if it is deep in the skin. However, even if the primary tumor was pigmented, the metastases may be amelanotic and vice versa.

The thorax is the most common site for cutaneous metastasis, as a result of the high frequency of metastatic breast and lung cancers. The scalp is another common site, for metastases from lung (Fig. 134-14), kidney, and breast tumors. On the scalp, the metastatic tumors typically present as single or multiple firm nodules, but scarring alopecia, known as *alopecia neoplastica*, can be occasionally seen, especially from metastatic breast cancer. The face and neck may be involved by metastases from oropharyngeal carcinomas. Metastases from renal and thyroid carcinoma may be pulsatile and may have a bruit.[48]

Several histopathologic features may help identify the source of the primary tumor. Microscopically, the collection of neoplastic cells, which usually resemble

Figure 134-13 Deeply pigmented cutaneous metastases from melanoma.

their malignancy of origin, is generally seen in the dermis and/or subcutaneous tissue. Additional features, such as tumor cells in an "Indian filing" pattern, lymphovascular invasion, necrosis, and a tumor-free "grenz zone," are also helpful for the diagnosis of metastatic skin lesions. In some types of cancers or poorly differentiated tumors, immunohistochemical staining is often required to achieve the correct diagnosis. For example, the immunohistochemical panel of CK7, CK20, and S-100 is a helpful tool in the diagnoses of breast, lung, and GI cancers and melanoma. Additional

Figure 134-14 Metastatic lung cancer presenting as forehead nodules.

recommended markers include TTF-1 (thyroid transcription factor-1; lung), HMB-45 (homatropine methylbromide; melanoma), PSA (prostate-specific antigen; prostate), estrogen/progesterone receptors (breast), and chromogranin (neuroendocrine tumors).[47,48]

Cutaneous metastases may indicate advanced disease and a poor prognosis. The estimated mean survival after the diagnosis of cutaneous metastases is 50% at 6 months. However, according to recent studies, patients with breast cancer may have a better prognosis than those with other cancers.[48]

LEUKEMIA AND LYMPHOMA CUTIS

Chapter 119, "Cutaneous Lymphoma," provides additional information on leukemia and lymphoma cutis.

Cutaneous metastases from leukemia and lymphoma are referred to as leukemia cutis and lymphoma cutis, respectively. Skin manifestations may have similar appearances in both diseases. The lesions generally appear as pink, red, and/or brown-to-purple macules, papules, plaques, and nodules, and are usually firm and painless.

Leukemia cutis is an extramedullary manifestation of leukemia, characterized by an invasion of leukemic cells into the epidermis, dermis, or subcutis. The skin eruptions can appear on the trunk, extremities, and head without sites of predilection. Occasionally, erythema, macules, blisters, ulcers, and erythroderma may be seen. Mucosal involvement, especially gum hypertrophy, is common. Nodular or plaque-like infiltration of the face can lead to the development of leonine facies. Rapid and generalized eruption of cutaneous lesions may suggest an acute form of leukemia. Leukemia cutis most frequently develops in patients with acute myeloid leukemia, particularly monocytic (M5) and myelomonocytic (M4) subtypes, but it can also occur in patients with other leukemia subtypes, such as chronic lymphocytic leukemia, chronic myeloid leukemia, chronic myelomonocytic leukemia, and acute lymphocytic leukemia. Most patients with leukemia cutis develop it after a known diagnosis of leukemia, but in rare cases, "aleukemic" leukemia cutis or leukemia cutis without systemic involvement can appear as a presenting manifestation months or years before developing systemic involvement. A skin biopsy is essential to confirm the diagnosis. Immunohistochemical and molecular genetic methods are essential for determining the subtype of leukemia. Treatment is targeted to the specific type of underlying leukemia. Some authors suggest that the appearance of leukemia cutis may indicate aggressive disease and a poor prognosis.[49]

Lymphoma cutis occurs when systemic lymphoma spreads secondarily to the skin. At times, it may be difficult to distinguish the primary cutaneous lymphoma from lymphoma cutis. Further staging evaluation is needed to document the origins of cutaneous lymphomas. Cutaneous dissemination can occur in both T-cell and B-cell lymphomas. Systemic anaplastic large-cell lymphoma is a T-cell lymphoma in which skin involvement occurs more commonly in the anaplastic lymphoma kinase–negative subtype. In adult T-cell leukemia-lymphoma, more than half of patients present with skin lesions at the time of diagnosis with chronic and smoldering subtypes resembling mycosis fungoides skin lesions. Cutaneous dissemination in Hodgkin lymphoma is much less frequent than in non-Hodgkin lymphoma.

Many types of systemic B-cell lymphomas can also have extranodal spread to the skin (systemic follicular lymphoma, marginal zone lymphoma, or diffuse large B-cell lymphoma), although primary cutaneous B-cell lymphomas may be more common than secondary skin involvement by systemic B-cell lymphomas. In lymphomatoid granulomatosis, skin is the most common extrapulmonary site, with lymphomatoid granulomatosis occurring in a progressive pattern in 50% of cases. Other rare types of B-cell lymphomas with cutaneous involvement include intravascular B-cell lymphoma and precursor B-cell lymphoblastic lymphoma.[50]

PAGET AND EXTRAMAMMARY PAGET DISEASES

Chapter 114, "Paget Disease," provides additional information on Paget and extramammary Paget diseases.

Paget disease of the nipple is a chronic erythematous scaling eruption of the nipple and areola indicating ductal carcinoma of the underlying breast. Extramammary Paget disease most commonly occurs in the anogenital skin, followed by the axillae and penis. It is classified into 3 types. The most common type appears as a primary intraepidermal adenocarcinoma. The second type (25%) is associated with visceral malignancy, most commonly of GI or genitourinary systems. The third type, the least common, is associated with an adjacent sweat gland carcinoma.

REFERENCES

1. Shah A, Jack A, Liu H, et al. Neoplastic/paraneoplastic dermatitis, fasciitis, and panniculitis. *Rheum Dis Clin North Am*. 2011;37(4):573-592.
2. Torley D, Bellus GA, Munro CS. Genes, growth factors and acanthosis nigricans. *Br J Dermatol*. 2002;147(6): 1096-1101.
3. Higgins SP, Freemark M, Prose NS. Acanthosis nigricans: a practical approach to evaluation and management. *Dermatol Online J*. 2008;14(9):2.
4. Zur RL, Shapero J, Shapero H. Pityriasis rotunda diagnosed in Canada: case presentation and review of the literature. *J Cutan Med Surg*. 2013;17(6):426-428.

5. Patel N, Spencer LA, English JC 3rd, et al. Acquired ichthyosis. *J Am Acad Dermatol*. 2006;55(4):647-656.
6. Cohen PR, Grossman ME, Silvers DN, et al. Tripe palms and cancer. *Clin Dermatol*. 1993;11(1):165-173.
7. Silva JA, Mesquita Kde C, Igreja AC, et al. Paraneoplastic cutaneous manifestations: concepts and updates. *An Bras Dermatol*. 2013;88(1):9-22.
8. Nanda A, Mamon HJ, Fuchs CS. Sign of Leser-Trélat in newly diagnosed advanced gastric adenocarcinoma. *J Clin Oncol*. 20 2008;26(30):4992-4993.
9. Fink AM, Filz D, Krajnik G, et al. Seborrhoeic keratoses in patients with internal malignancies: a case-control study with prospective accrual of patients. *J Eur Acad Dermatol Venereol*. 2009;23(11):1316-1319.
10. Eastman KL, Knezevich SR, Raugi GJ. Eruptive seborrheic keratoses associated with adalimumab use. *J Dermatol Case Rep*. 30 2013;7(2):60-63.
11. Bazex A, Dupre A, Christol B, et al. Paraneoplastic acrokeratosis [in French]. *Bull Soc Fr Dermatol Syphiligr*. 1969;76(4):537-538.
12. Bolognia JL. Bazex syndrome: acrokeratosis paraneoplastica. *Semin Dermatol*. 1995;14(2):84-89.
13. Femia AN, Vleugels RA, Callen JP. Cutaneous dermatomyositis: an updated review of treatment options and internal associations. *Am J Clin Dermatol*. 2013;14(4):291-313.
14. Szekanecz E, Szamosi S, Horvath A, et al. Malignancies associated with systemic sclerosis. *Autoimmun Rev*. 2012;11(12):852-855.
15. Onishi A, Sugiyama D, Kumagai S, et al. Cancer incidence in systemic sclerosis: meta-analysis of population-based cohort studies. *Arthritis Rheum*. 2013;65(7): 1913-1921.
16. Shah AA, Casciola-Rosen L. Cancer and scleroderma: a paraneoplastic disease with implications for malignancy screening. *Curr Opin Rheumatol*. 2015;27(6): 563-570.
17. Boyd AS, Neldner KH, Menter A. Erythema gyratum repens: a paraneoplastic eruption. *J Am Acad Dermatol*. 1992;26(5, pt 1):757-762.
18. Rongioletti F, Fausti V, Parodi A. Erythema gyratum repens induced by pegylated interferon alfa for chronic hepatitis C. *Arch Dermatol*. 2012;148(10): 1213-1214.
19. John AM, Schwartz RA. Glucagonoma syndrome: a review and update on treatment. *J Eur Acad Dermatol Venereol*. 2016;30(12):2016-2022.
20. Grewal P, Salopek TG. Is necrolytic migratory erythema due to glucagonoma a misnomer? A more apt name might be mucosal and intertriginous erosive dermatitis. *J Cutan Med Surg*. 2012;16(2):76-82.
21. Raza S, Kirkland RS, Patel AA, et al. Insight into Sweet's syndrome and associated-malignancy: a review of the current literature. *Int J Oncol*. 2013;42(5): 1516-1522.
22. Cohen PR. Sweet's syndrome—a comprehensive review of an acute febrile neutrophilic dermatosis. *Orphanet J Rare Dis*. 2007;2:34.
23. Al Ghazal P, Herberger K, Schaller J, et al. Associated factors and comorbidities in patients with pyoderma gangrenosum in Germany: a retrospective multicentric analysis in 259 patients. *Orphanet J Rare Dis*. 2013;8:136.
24. Bennett ML, Jackson JM, Jorizzo JL, et al. Pyoderma gangrenosum. A comparison of typical and atypical forms with an emphasis on time to remission. Case review of 86 patients from 2 institutions. *Medicine (Baltimore)*. 2000; 79(1):37-46.
25. El-Haddad B, Hammoud D, Shaver T, et al. Malignancy-associated multicentric reticulohistiocytosis. *Rheumatol Int*. 2011;31(9):1235-1238.
26. Islam AD, Naguwa SM, Cheema GS, et al. Multicentric reticulohistiocytosis: a rare yet challenging disease. *Clin Rev Allergy Immunol*. 2013;45(2):281-289.
27. Higgins LS, Go RS, Dingli D, et al. Clinical features and treatment outcomes of patients with necrobiotic xanthogranuloma associated with monoclonal gammopathies. *Clin Lymphoma Myeloma Leuk*. 2016;16(8):447-452.
28. Hummers LK. Scleromyxedema. *Curr Opin Rheumatol*. 2014;26(6):658-662.
29. Elsaman AM, Radwan AR, Akmatov MK, et al. Amyloid arthropathy associated with multiple myeloma: a systematic analysis of 101 reported cases. *Semin Arthritis Rheum*. 2013;43(3):405-412.
30. Merlini G, Seldin DC, Gertz MA. Amyloidosis: pathogenesis and new therapeutic options. *J Clin Oncol*. 2011;29(14):1924-1933.
31. Hemminki K, Li X, Forsti A, et al. Cancer risk in amyloidosis patients in Sweden with novel findings on non-Hodgkin lymphoma and skin cancer. *Ann Oncol*. 2014;25(2):511-518.
32. Frew JW, Murrell DF. Paraneoplastic pemphigus (paraneoplastic autoimmune multiorgan syndrome): clinical presentations and pathogenesis. *Dermatol Clin*. 2011;29(3):419-425, viii.
33. Collin P, Pukkala E, Reunala T. Malignancy and survival in dermatitis herpetiformis: a comparison with coeliac disease. *Gut*. 1996;38(4):528-530.
34. Viljamaa M, Kaukinen K, Pukkala E, et al. Malignancies and mortality in patients with coeliac disease and dermatitis herpetiformis: 30-year population-based study. *Dig Liver Dis*. 2006;38(6):374-380.
35. Balestri R, Magnano M, La Placa M, et al. Malignancies in bullous pemphigoid: a controversial association. *J Dermatol*. 2016;43(2):125-133.
36. Hovenden AL. Hypertrichosis lanuginosa acquisita associated with malignancy. *Clin Dermatol*. 1993;11(1): 99-106.
37. Slee PH, van der Waal RI, Schagen van Leeuwen JH, et al. Paraneoplastic hypertrichosis lanuginosa acquisita: uncommon or overlooked? *Br J Dermatol*. 2007;157(6):1087-1092.
38. Dicke C, Langer F. Pathophysiology of Trousseau's syndrome. *Hamostaseologie*. 2015;35(1):52-59.
39. Timp JF, Braekkan SK, Versteeg HH, et al. Epidemiology of cancer-associated venous thrombosis. *Blood*. 2013;122(10):1712-1723.
40. Key NS, Khorana AA, Mackman N, et al. Thrombosis in cancer: research priorities identified by a National Cancer Institute/National Heart, Lung, and Blood Institute Strategic Working Group. *Cancer Res*. 2016;76(13):3671-3675.
41. Ponti G, Pellacani G, Seidenari S, et al. Cancer-associated genodermatoses: skin neoplasms as clues to hereditary tumor syndromes. *Crit Rev Oncol Hematol*. 2013;85(3):239-256.
42. Shen Z, Hoffman JD, Hao F, et al. More than just skin deep: fasciocutaneous clues to genetic syndromes with malignancies. *Oncologist*. 2012;17(7):930-936.
43. Reyes MA, Eisen DB. Inherited syndromes. *Dermatol Ther*. 2010;23(6):606-642.
44. Kuhlen M, Borkhardt A. Cancer susceptibility syndromes in children in the area of broad clinical use of massive parallel sequencing. *Eur J Pediatr*. 2015;174(8): 987-997.

45. Somoano B, Tsao H. Genodermatoses with cutaneous tumors and internal malignancies. *Dermatol Clin*. 2008;26(1):69-87, viii.
46. Jaju PD, Ransohoff KJ, Tang JY, et al. Familial skin cancer syndromes: increased risk of nonmelanotic skin cancers and extracutaneous tumors. *J Am Acad Dermatol*. 2016;74(3):437-451; quiz 452-434.
47. El Khoury J, Khalifeh I, Kibbi AG, et al. Cutaneous metastasis: clinicopathological study of 72 patients from a tertiary care center in Lebanon. *Int J Dermatol*. 2014;53(2):147-158.
48. Fernandez-Anton Martinez MC, Parra-Blanco V, Aviles Izquierdo JA, et al. Cutaneous metastases of internal tumors. *Actas Dermosifiliogr*. 2013;104(10):841-853.
49. Wagner G, Fenchel K, Back W, et al. Leukemia cutis-epidemiology, clinical presentation, and differential diagnoses. *J Dtsch Dermatol Ges*. 2012;10(1):27-36.
50. Oluwole OO, Zic JA, Douds JJ, et al. Cutaneous manifestations and management of hematologic neoplasms. *Semin Oncol*. 2016;43(3):370-383.

Chapter 135 :: The Neurofibromatoses

:: Robert Listernick & Joel Charrow

AT-A-GLANCE

- Autosomal dominant condition with incidence of 1 in 3000 live births.
- Diagnosed clinically if 2 major features are present (see Table 135-1).
- Cutaneous neurofibromas:
  - Softer than the surrounding connective tissue and protrude just above the skin surface or lie just under the skin with an overlying violaceous hue.
- Subcutaneous neurofibromas:
  - Arise from peripheral nerves, both under the skin and deep in the viscera.
  - Generally much harder.
- Plexiform neurofibromas:
  - Generally present at birth or apparent during the first several years of life.
  - May lead to disfigurement, blindness (secondary to amblyopia, glaucoma, or proptosis), loss of limb function, or organ dysfunction by compression of vital structures.
- Mosaic neurofibromatosis Type 1 (segmental NF-1):
  - Manifestations of NF-1, usually limited to one area of the body.
  - Occurs as result of a postconceptional mutation in the *NF1* gene, leading to somatic mosaicism.

CLINICAL FEATURES

A consensus development conference was held by the National Institutes of Health in 1987 to establish diagnostic criteria to promote better clinical research and care of patients with neurofibromatosis Type 1 (NF-1).[1] The 7 diagnostic features recognized at this conference (Table 135-1), and the recommendation that 2 or more of these 7 features be present before a diagnosis of NF-1 is established, have proven extremely useful and continue to be used without modification more than 30 years later. Perhaps the one caveat is the identification of a separate autosomal dominant syndrome caused by an inactivating mutation of the gene encoding sprouty-related EVH1 domain-containing protein 1 (*SPRED1*), which leads to the development of café-au-lait spots, intertriginous freckling, and macrocephaly, but none of the other manifestations of NF-1 (Legius syndrome).[2]

CAFÉ-AU-LAIT SPOTS

Café-au-lait spots, which are flat, pigmented macules, are often the first manifestation of NF-1 to appear (Fig. 135-1). Frequently present at birth, they become more numerous as the infant grows; new ones may continue to appear throughout the first decade of life. Once noticed, they tend to grow in size in proportion to the overall growth of the child. Although infrequently found on the face, they may be noted anywhere on the body. The size, shape, and contour of café-au-lait spots are of no diagnostic significance, and the oft-quoted adage about smooth-edged café-au-lait spots being more typical of NF-1 rather than McCune-Albright syndrome is incorrect. When café-au-lait spots overlap each other, the area of overlap may be darker than either individual spot. When found within slate grey macules, they are typically surrounded by a more lightly pigmented halo. Individuals with large numbers of café-au-lait spots do not have "more-severe" NF-1, and the location of the macules in no way predicts the location of subsequent neurofibromas.

Café-au-lait spots represent collections of heavily pigmented melanocytes of neural crest origin in the epidermis. Although the cells may contain increased numbers of "giant" melanosomes, or melanin macroglobules, these are not unique to NF-1, and their presence or absence in biopsies is not helpful diagnostically.

INTERTRIGINOUS FRECKLING

Café-au-lait spots smaller than 5 mm are referred to as freckles, and are commonly present in the axillae, inguinal region, and under the breasts (Fig. 135-2). Unlike ordinary freckles in these locations, these lesions are not related to sun exposure, and are considered virtually pathognomonic of NF-1 (Crowe sign). Of all children ultimately diagnosed with NF-1, 81% will have intertriginous freckling by age 6 years.[3]

DISCRETE NEUROFIBROMAS

Neurofibromas, which consist of Schwann cells, mast cells, fibroblasts, and perineural cells, are benign nerve sheath tumors that appear as discrete masses

TABLE 135-1
Diagnostic Criteria for Neurofibromatosis Type 1[a]

- Six or more café-au-lait macules larger than 5 mm in greatest diameter in prepubertal individuals, and larger than 15 mm in greatest diameter in postpubertal individuals.
- Two or more neurofibromas of any type *or* 1 plexiform neurofibroma.
- Freckling in the axillary or inguinal regions.
- Optic glioma.
- Two or more iris Lisch nodules.
- A distinctive osseous lesion such as sphenoid dysplasia or thinning of long bone cortex with or without pseudarthrosis.
- A first-degree relative (parent, sibling, or offspring) with neurofibromatosis Type 1 by the above criteria.

[a]Patient must meet 2 or more of the listed criteria for diagnosis.

arising from peripheral nerves.[4] Cutaneous neurofibromas protrude just above the skin surface or lie just under the skin with an overlying violaceous hue (Fig. 135-3). They are softer than the surrounding connective tissue, often creating a "buttonholing" sensation when a finger is rubbed gently over the surface (Fig. 135-4). Subcutaneous neurofibromas that arise from peripheral nerves, both under the skin and deep in the viscera, are generally much harder (Fig. 135-5). If they arise from the dorsal root ganglia, they may grow through neural foramina, compressing the spinal cord, creating a "dumbbell" appearance. Subcutaneous neurofibromas in the neck may feel like a "beaded necklace," often being confused with lymph nodes. While fewer than 20% of children younger than 10 years of age have cutaneous neurofibromas, neurofibromas generally start appearing after puberty and increase in number as the patient grows older. Women who have NF-1 often comment on the appearance of cutaneous neurofibromas during pregnancy. The majority of adult patients with NF-1 probably have numerous

Figure 135-1 Café-au-lait spots.

Figure 135-2 Axillary freckling.

Figure 135-3 Cutaneous neurofibromas with overlying hyperpigmentation.

Figure 135-4 Multiple cutaneous neurofibromas.

Figure 135-6 Plexiform neurofibroma with overlying hyperpigmentation and hypertrichosis.

asymptomatic deep neurofibromas involving the dorsal roots and other larger nerves. On occasion, neurofibroma-associated pruritus may be severe enough to require treatment with antihistamines.

PLEXIFORM NEUROFIBROMAS

Plexiform neurofibromas, histologically similar to discrete neurofibromas, are benign peripheral nerve sheath tumors that involve single or multiple nerve fascicles, often arising from branches of major nerves.[5] They may elicit a "wormy" sensation on palpation, as a person feels multiple thickened nerve fascicles. Often there is overlying hyperpigmentation ("giant café-au-lait spot") or hypertrichosis (Fig. 135-6). Most plexiform neurofibromas are present at birth or become apparent during the first several years of life. Externally visible plexiform neurofibromas are easily identified and may lead to disfigurement, blindness (secondary to amblyopia, glaucoma, or proptosis), or loss of limb function (Figs. 135-7 to 135-9). In contrast, thoracic or abdominal plexiform neurofibromas may have no external manifestations but may have equally devastating consequences as a consequence of invasion or compression of vital structures (eg, ureters, bowel, spinal cord).

The growth rate of plexiform neurofibromas is highly variable. Periods of rapid growth alternating with long periods of quiescence are common. Malignant peripheral nerve sheath tumors, which generally arise from plexiform neurofibromas, may develop silently in deep plexiform neurofibromas and not give rise to symptoms until distant metastases have occurred. Even though loss of heterozygosity of *NF1* may lead to the formation of benign neurofibromas, the generation of malignant transformation of a benign plexiform neurofibroma may be caused by cell-cycle regulators beyond the *RAS* oncogene. For example, mice that have null mutations in both the *Nf1* and *p53* genes uniformly develop malignant tumors.[6] Physicians caring for individuals with NF-1 should be alert to development of a malignancy; plexiform neurofibromas should be biopsied if they exhibit rapid growth or cause significant pain or focal neurologic dysfunction. Positron emission tomography with 2-deoxy-2-[fluorine-18]fluoro-D-glucose integrated with computed tomography (^{18}F-FDG PET/CT) can be extremely useful in identifying the development of malignant peripheral nerve sheath tumor within a preexisting plexiform neurofibroma.[7,8]

Figure 135-5 Subcutaneous neurofibroma.

OPTIC PATHWAY TUMORS

Approximately 15% of children with NF-1 will develop optic pathway tumors (OPTs); however, less than half of these patients will ever develop symptoms, giving an

Figure 135-7 Progressive growth of facial plexiform neurofibroma.

overall incidence of *symptomatic* OPT of 7%.[9,10] Recent series of NF-1–associated OPTs have identified an approximately 2:1 female predominance of patients, as well as a lower incidence in African American children. These observations suggest the possibility that either hormonal factors or modifying genes may influence the development and prognosis of OPTs.[11,12]

The period of greatest risk for the development of symptomatic OPTs in NF-1 is during the first 6 years of life; the development of a symptomatic tumor after age 6 years is extremely unusual.[13,14] Thus, physicians caring for children with NF-1 should be sensitive to the signs and symptoms of OPTs in this young age group. Approximately 30% of children with symptomatic OPTs will present with the rapid onset of proptosis, with moderate to severe visual loss in the affected eye (Fig. 135-10). Another 30% of children who have symptomatic OPTs will have abnormal ophthalmologic examinations, without any visual symptoms, leading to discovery of the tumors. As young children rarely

Figure 135-8 Plexiform neurofibroma of left first toe leading to isolated macrodactyly.

Figure 135-9 Plexiform neurofibroma of left lower extremity leading to leg-length discrepancy.

Figure 135-10 Intraorbital optic nerve tumor causing proptosis.

complain of visual loss, even when severe, thorough annual eye examinations are imperative in all young children with NF-1. When present, ophthalmologic signs may include an afferent papillary defect, optic nerve atrophy, papilledema, strabismus, or defects in color vision. Finally, as many as 40% of children who have chiasmal tumors develop precocious puberty.[15] Accelerated linear growth will be the first sign of precocious puberty, underscoring the need for all children with NF-1 to have annual assessments of growth using standard growth charts. Children with chiasmal tumors often have no ophthalmologic symptoms or signs. Early detection of precocious puberty is important as both the accelerated linear growth and the development of secondary sexual characteristics can be can be aborted with the use of a long-acting luteinizing hormone-releasing hormone agonist.

LISCH NODULES

Lisch nodules are slightly raised, well-circumscribed melanocytic hamartomas of the iris thought to be virtually pathognomonic of NF-1 (Fig. 135-11). They are best seen using a slitlamp, which is necessary to distinguish them from the more commonly seen flat iris nevi, which are not associated with NF-1. They do not cause any functional impairment of vision. The frequency with which they are found increases with age; although Lisch nodules are found in more than 90% of adults with NF-1, only 30% of children with NF-1 who are younger than 6 years of age have them.[3]

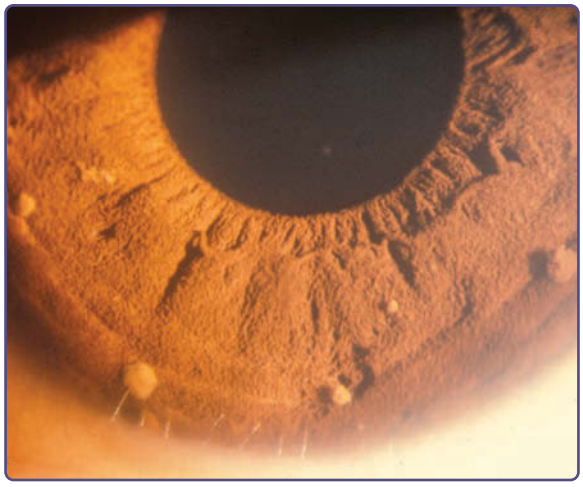

Figure 135-11 Lisch nodules.

DISTINCTIVE OSSEOUS LESIONS

There are 2 bony lesions distinctive enough to be included in the diagnostic criteria for NF-1. The first, dysplasia of the wing of the sphenoid bone, results in poor formation of the wall and/or floor of the orbit (Fig. 135-12). This congenital mesodermal dysplasia may be, but is not always, clinically apparent, leading to proptosis (from herniation of meninges or brain into the orbit) or enophthalmos.

Dysplasia of a long bone, characterized by congenital thinning and bowing, affects approximately 2% of children with NF-1 (Fig. 135-13). Although the tibia is most commonly affected, the femur, humerus and other long bones also may be involved. Even when the bone is intact, thinning and bowing produce a visible deformity, and the weakened mechanical properties of the bone predispose to fracture, particularly in the weight-bearing bones. Failure of primary union following a fracture results in a "false joint," or pseudarthrosis.[16]

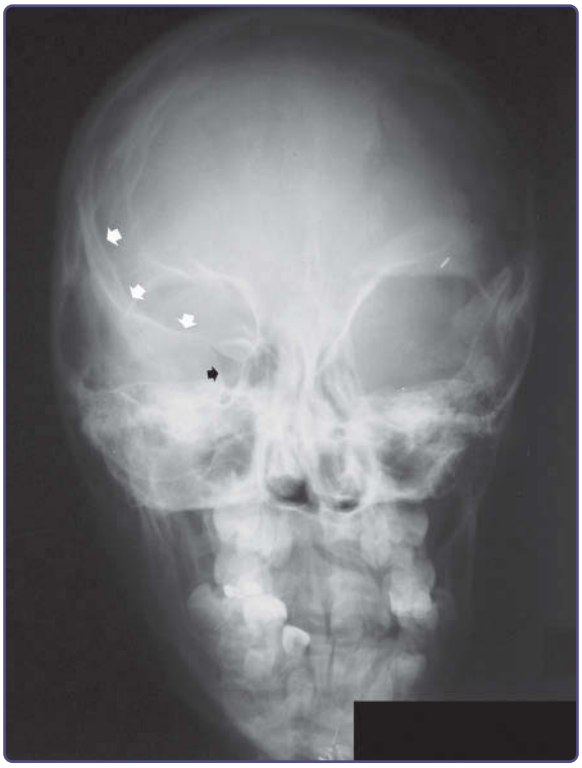

Figure 135-12 Sphenoid wing dysplasia. Arrows outline normal sphenoid wing in wall of right orbit. Contralateral sphenoid wing is dysplastic.

Figure 135-13 Tibial and fibular dysplasia.

ETIOLOGY AND PATHOGENESIS

EPIDEMIOLOGY

The "modern age" of neurofibromatosis began in 1981, with Riccardi's detailed clinical descriptions of the features and natural history of von Recklinghausen disease and the subsequent description of "central neurofibromatosis with bilateral acoustic neuroma."[17] With the availability of gene-based diagnosis, several distinct clinical syndromes have been identified: (a) NF-1, also known as von Recklinghausen disease; (b) NF-2, whose cardinal feature is the development of bilateral vestibular schwannomas; (c) segmental or mosaic NF-1; (d) Legius syndrome (*SPRED1* mutation) leading to autosomal dominant transmission of café-au-lait spots, intertriginous freckling, and macrocephaly; and (e) schwannomatosis. Both NF-1 and NF-2 occur equally in all ethnic groups. NF-1 occurs at an incidence of 1 in 3000 live births, whereas NF-2 is much less common with an estimated incidence of 1 in 40,000 live births.

GENETICS

NF-1 is inherited in an autosomal dominant fashion. Although the expressivity of NF-1 varies considerably, even among individuals in the same family who are genotypically identical, the disorder is considered to be 100% penetrant. Thus, apparent skipping of NF-1 between generations may be the result of misdiagnosis, nonpaternity, or the occurrence of a new mutation in the grandchild. Although a large number of *NF1* mutations have been described, only 2 genotype–phenotype correlations have been noted. Individuals who have deletions of the entire gene have an increased risk of facial dysmorphism, intellectual disability, early appearance of neurofibromas, and the presence of plexiform neurofibromas.[18] In addition, individuals who have a specific 3 base pair in-frame deletion in exon 17 of *NF1* may have café-au-lait spots, intertriginous freckling and Lisch nodules, but do not develop cutaneous, subcutaneous, or plexiform neurofibromas.[19] There is evidence that NF-1 is more severe when inherited from the mother rather than from the father.

NF1 is located on the long arm of chromosome 17, and encodes a protein called *neurofibromin*. Homozygosity for mutant *NF1* alleles has not been reported, probably because it is a lethal condition. *NF1* has an unusually high mutation rate, estimated at 2.4×10^{-5} to 10^{-4} gametes per generation, one of the highest of known inherited disorders. This may reflect the large size of the gene, which spans 350 kb of genomic DNA, and contains 59 exons that encode a peptide containing more than 2800 amino acids.[20] An alternative hypothesis is that there is some structural property of the gene that renders it particularly susceptible to mutation. New mutations account for approximately 50% of cases, and are usually on the paternally inherited allele. In contrast to many other dominant disorders, the frequency of new mutations does not appear to increase with advancing paternal age.[11]

MOLECULAR BIOLOGY

Most *NF1* mutations result in reduced intracellular levels of the *NF1* gene product, neurofibromin; this appears to be sufficient to cause many of the clinical manifestations of the disease. Tumorigenesis, including the development of benign dermal neurofibromas, appears to be dependent on inactivation of the normal *NF1* allele in somatic cells, a process referred to as loss of heterozygosity.[21] Loss of heterozygosity is a critical step in tumorigenesis in many inherited cancer predisposition syndromes (eg, retinoblastoma, Li-Fraumeni syndrome), and the genes involved are called *tumor-suppressor genes*. Tumorigenesis is initiated when both copies of the gene cease functioning normally—the first as a result of an inherited mutation, and the second as the result of a second somatic "hit" interfering with the function of the previously normal allele.

Neurofibromin is found in a variety of cell types, including neurons, oligodendrocytes, and nonmyelinating Schwann cells. Considerable evidence has been developed for the role of neurofibromin as a negative regulator of Ras.[20] The *RAS* gene family encodes membrane-associated, guanine nucleotide-binding proteins that are involved in the regulation of cellular

proliferation, differentiation, and learning. Ras exists in an active (Ras-GTP [guanosine triphosphate]) and inactive (Ras-GDP [guanosine diphosphate]) state. By favoring conversion of Ras from its active state to its inactive state, neurofibromin downregulates the downstream effects of Ras, which include promoting learning, memory, synaptic plasticity, and cell growth and proliferation. Mediators of the downstream effects of Ras include mitogen-activated protein kinase (MAPK), phosphatidylinositol 3′-kinase, protein kinase B, and mammalian target of rapamycin kinase.[22] *SPRED1* also inhibits activation of the MAPK pathway.[22]

In the brain, there are 3 major isoforms of Ras; K-*ras* is the primary target of neurofibromin activity.[23] Activation of Ras by neurofibromin stimulates G-protein activity, resulting in activation of adenylyl cyclase. Cyclic adenosine monophosphate and other downstream intermediates appear to play a role in cell growth, learning, and memory. Neurofibromin also associates with microtubules and plays a role in regulating γ-aminobutyric acid-ergic inhibitory neuronal activity in the hippocampus.[24]

Ras is a membrane-bound protein, and requires farnesylation (addition of a C15 isoprenoid to a cysteine residue near the *C*-terminus) for activity, a process that is catalyzed by farnesyltransferase. Agents that inhibit farnesyltransferase cause general inhibition of the Ras pathway, much as neurofibromin does. Farnesyltransferase inhibitors reverse the proliferative phenotype in *Nf1*-deficient mouse cells, and can reverse spatial learning impairments in a mouse model of NF-1, by decreasing Ras levels.[25] Inhibitors of downstream kinases of the MAPK pathway, such as MAPK kinase (MEK), have been shown to shrink plexiform neurofibromas in mouse models, leading the way for clinical trials that are ongoing.[26]

Loss of heterozygosity of *NF1* in Schwann cells has been shown to be a necessary event for the development of both discrete and plexiform neurofibromas.[27] Plexiform neurofibromas are comprised of Schwann cells, macrophages, mast cells, neurons and fibroblasts. Interestingly, neurofibromin-deficient Schwann cells secrete a substance that stimulates mast cell migration, which, in turn, stimulates production of extracellular matrix and angiogenesis.[5] Astrocytes lacking *NF1* expression cannot form optic nerve gliomas on their own; a brain environment heterozygous for *NF1* is necessary for the development of these tumors. Microglia, CNS immune surveillance cells, are involved in both optic nerve glioma formation and maintenance.[28]

DIAGNOSIS

Despite the identification of the *NF1* gene and its complete sequencing, the diagnosis of NF-1 remains primarily a clinical one. Although laboratory confirmation of the diagnosis is extremely useful in specific circumstances, in most cases it is unnecessary. As no common mutations have been identified, molecular diagnosis can only be based on strategies that screen the entire gene for mutations. This testing is available for both presymptomatic individuals and can be applied to prenatal diagnosis of NF-1 when a mutation has been identified in an affected parent.

Inexperienced clinicians often biopsy cutaneous masses in an effort to confirm the diagnosis of NF-1 in an individual with multiple café-au-lait spots or other stigmata of NF-1. Such procedures are invariably unnecessary as the clinical diagnosis of NF-1 is usually quite straightforward. Biopsy of a plexiform neurofibroma should be reserved for those situations in which the physician wishes to exclude the possibility of a malignancy.

TABLE 135-2
Differential Diagnosis of Syndromes Associated with Multiple Café-au-Lait Spots

Most Likely
- Neurofibromatosis Type 1
- Neurofibromatosis Type 2
- Familial café-au-lait spots (consider Legius syndrome)
- LEOPARD (lentigines, electrocardiographic abnormalities, ocular hypertelorism, pulmonary stenosis, abnormalities of genitalia, retardation of growth, and deafness) syndrome

Less Likely
- Tuberous sclerosis
- Fanconi anemia
- Multiple endocrine neoplasia Type 2B
- Bannayan-Riley-Ruvalcaba syndrome
- McCune-Albright syndrome (polyostotic fibrous dysplasia)
- Bloom syndrome
- Ataxia-telangiectasia

DIFFERENTIAL DIAGNOSIS

There are numerous syndromes in which café-au-lait spots may be seen (Table 135-2). However, there are several syndromes that have overlapping phenotypes with NF-1 that have caused confusion in the past.

NEUROFIBROMATOSIS TYPE 2

AT-A-GLANCE

- Autosomal dominant disorder with incidence of 1 in 40,000 live births.
- Hallmark is the presence of bilateral vestibular schwannomas.
- At risk for development of multiple meningiomas, schwannomas, gliomas, and neurofibromas throughout neural axis.

TABLE 135-3
Diagnostic Criteria for Neurofibromatosis Type 2

1. Bilateral vestibular schwannomas ***or***
2. A first-degree relative with neurofibromatosis Type 2 (NF-2) ***and***
   - Unilateral vestibular schwannoma ***or***
   - Any 2 of: meningioma, schwannoma, glioma, neurofibroma, posterior subcapsular lenticular opacities
3. Unilateral vestibular schwannoma ***and***
   - Any 2 of: meningioma, schwannoma, glioma, neurofibroma, posterior subcapsular lenticular opacities
4. Multiple meningiomas ***and***
   - Unilateral vestibular schwannoma ***or***
   - Any two of: schwannoma, glioma, neurofibroma, cataract

NF-2 is an autosomal dominant condition characterized by bilateral vestibular schwannomas, meningiomas (intracranial, intraspinal, and optic nerve sheath), schwannomas (dorsal roots of the spinal cord, peripheral nerves, and cranial nerves), ependymomas and gliomas of the CNS, and juvenile posterior subcapsular cataracts.[29] The estimated birth incidence is 1 in 40,000 live births. Even though it is much less common than NF-1, its morbidity is much greater, with patients frequently becoming paralyzed and deaf. The most recent clinical diagnostic criteria have led to increased sensitivity in establishing the diagnosis, particularly in those cases without a positive family history (Table 135-3). Approximately 60% of patients present in adulthood with hearing loss, tinnitus, or loss of balance. The younger the age at presentation, the greater the ultimate severity of the disease. Children are more apt to present with a non–eighth nerve tumor, such as an optic nerve sheath meningioma. Ophthalmologic findings include juvenile posterior subcapsular cataracts (60% to 80% of patients), retinal hamartomas, combined hamartomas of the retina and retinal pigment epithelium, and optic nerve sheath meningiomas.[30,31]

Individuals with NF-2 may have several café-au-lait spots, but rarely have more than 6; intertriginous freckling is not seen. The characteristic cutaneous lesion of NF-2 is the cutaneous schwannoma (Fig. 135-14). It is a plaque-like, slightly raised lesion with a faint violaceous hue, occasionally with hair. Less commonly, cutaneous neurofibromas, indistinguishable from those seen in NF-1, may be found.

Figure 135-14 Cutaneous schwannoma.

NF-2 is caused by mutations in a gene on chromosome 22 which encodes the membrane-related protein merlin. As in NF-1, the *NF2* gene is a tumor-suppressor gene that downregulates cellular growth. The exact cellular pathways by which this control is exerted have yet to be delineated.

MOSAIC NEUROFIBROMATOSIS TYPE 1

The term *segmental neurofibromatosis* or *mosaic NF-1* refers to individuals who have manifestations of NF-1, usually café-au-lait macules and neurofibromas, limited to one area of the body.[32] Ruggieri and Huson have proposed use of the term *mosaic localized NF-1* for these individuals, as an acknowledgment that the pathogenesis of this condition is a postconceptional mutation in *NF1* leading to somatic mosaicism.[33] Somatic mosaicism was confirmed in a patient in whom the mutant *NF1* allele was present in a mosaic pattern in cultured fibroblasts from a café-au-lait macule and absent in fibroblasts from normal skin.[34]

The vast majority of patients with segmental NF-1 have café-au-lait macules or intertriginous freckling limited to one area of the body (Fig. 135-15). These individuals are at risk for developing complications of NF-1 in the affected area, most commonly neurofibromas. Localized manifestations of NF-1 other than café-au-lait macules, freckling, or cutaneous neurofibromas may also represent examples of somatic mosaicism. There have been numerous reports of isolated plexiform neurofibromas, including 1 case in which loss of heterozygosity of *NF1* in Schwann cells from the tumor was demonstrated. As only 50% of cases of tibial pseudarthrosis occur in the context of NF-1, the others may actually represent cases of mosaic NF-1. Other examples of mosaic NF-1 include a child who had a unilateral optic pathway glioma that acted that acted biologically like an NF-1–associated tumor and individuals with isolated sphenoid bone dysplasia.

Genetic counseling of patients with segmental NF-1 is problematic. Many of these patients are misdiagnosed as having NF-1, leading to unnecessary anxiety and inappropriate genetic counseling. In addition, gonadal mosaicism for NF-1 has been demonstrated; patients with segmental NF-1 have had offspring with complete NF-1.

NEUROFIBROMATOSIS TYPE 1–NOONAN SYNDROME

It has been recognized that there are individuals who meet the diagnostic criteria for NF-1, yet have many

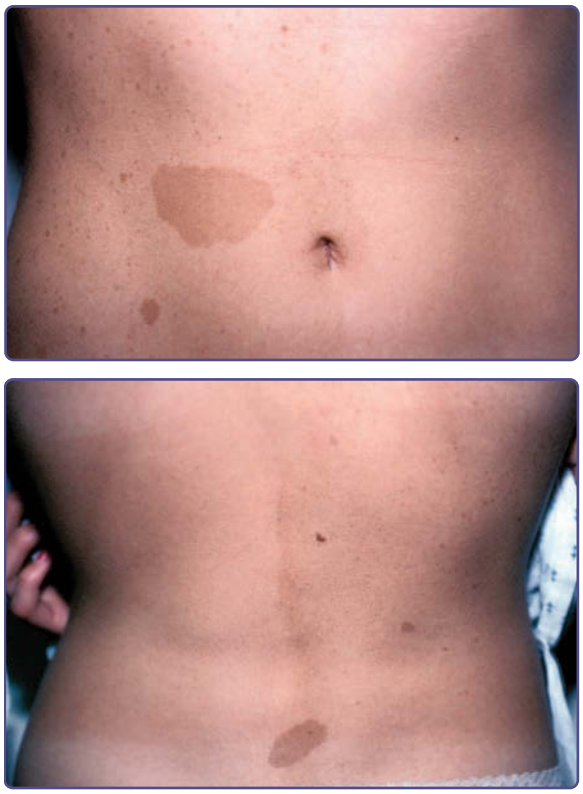

Figure 135-15 Mosaic neurofibromatosis Type 1. Note that the café-au-lait spots and freckling are limited to one side of body.

features of Noonan syndrome, which is characterized by hypertelorism, ptosis, downslanting palpebral fissures, low-set, posteriorly rotated ears, webbed neck, pectus deformities, and short stature. More than 50% of children with Noonan syndrome have cardiovascular disease, most commonly pulmonary valve stenosis. Noonan syndrome is caused by mutations in the gene *PTPN11* in 50% of cases. Mutations in multiple other genes (*KRAS*, *SOS1*, *BRAF*, *MEK1*, *MEK2*, *RIT1*, *HRAS*, and *RAF1*) also are associated with this phenotype. Genetic testing shows that most individuals with LEOPARD (lentigines, electrocardiographic abnormalities, ocular hypertelorism, pulmonary stenosis, abnormalities of genitalia, retardation of growth, and deafness) syndrome also have mutations in *PTPN11*.[35] Studies have documented mutations in the *NF1* gene in 16 of 17 unrelated subjects who clinically had the NF-1–Noonan phenotype; no mutations in *PTPN11* were found.[36] Thus, it appears that the vast majority of cases of NF-1–Noonan syndrome are caused by mutations in *NF1*.

LEGIUS SYNDROME

Families have been identified who have autosomal dominant transmission of café-au-lait spots, intertriginous freckling, and macrocephaly without any other manifestations of NF-1, including neurofibromas, in whom no *NF1* mutation was detected. Further genetic studies of these individuals revealed mutations in *SPRED1*, a gene that negatively regulates the MAPK pathway.[2] None of these individuals has discrete neurofibromas, plexiform neurofibromas, Lisch nodules, OPTs, or NF-1–specific bony abnormalities. A study of 15 families with Legius syndrome documented a normal full scale IQ in affected individuals but a significantly lower performance IQ when compared to unaffected family members.[37] Genetic testing for *SPRED1* mutations is available in individuals suspected of having Legius syndrome in whom sequencing of *NF1* has failed to detect a mutation.

SCHWANNOMATOSIS

It had been noted for some time that there are patients who develop multiple schwannomas but who fail to develop other manifestations of NF-2, particularly vestibular schwannomas. Patients with this condition, now called *schwannomatosis*, develop multiple, painful schwannomas within peripheral nerves and paraspinal nerve roots.[38] The tumors most often start appearing during the second and third decades of life. Surgery of individual lesions is often necessary to treat intractable pain. In contrast to NF-2, individuals with schwannomatosis have a normal life span. Before making a diagnosis of schwannomatosis, it is extremely important to exclude the possibility of NF-2 by both genetic testing and performing an MRI scan to look for vestibular schwannomas. Current diagnostic criteria for a *definite* diagnosis of schwannomatosis in individuals 30 years of age or older include: (a) 2 or more nonintradermal schwannomas, at least 1 with histologic confirmation, and (b) diagnostic criteria for NF-2 not fulfilled, and (c) no evidence of vestibular schwannoma on MRI, and (d) no first-degree relative with NF-2, and (e) no germline *NF2* mutation.[39] Germline mutations in the tumor-suppressor genes *SMARCB1/INI1*, previously implicated in the development of rhabdoid tumors in infants and young children, as well as mutations in *LTZR1* have been identified as the cause of a large number of the familial cases of schwannomatosis. However, most cases are sporadic and caused by mutations in as-yet unidentified genes.[40]

CLINICAL COURSE, PROGNOSIS, AND MANAGEMENT

RADIOGRAPHIC EVALUATION

There is debate as to whether patients with NF-1 should be "screened" for the presence of hidden, internal plexiform neurofibromas; newer studies using whole-body MRI have demonstrated an incidence as high as 55%.[41,42] If current chemotherapeutic trials

prove successful in the treatment of rapidly growing tumors, their identification at an early age may become more important using this technique.

SKELETAL COMPLICATIONS

All children with NF-1 should be regularly screened for scoliosis, beginning in early childhood. Scoliosis is the most common skeletal manifestation of NF-1, affecting 10% to 30% of patients. Scoliosis is divided into dystrophic and nondystrophic types. Dystrophic scoliosis is the result of primary bone dysplasia, and may present very early in childhood, typically resulting in a sharply angulated curve spanning relatively few vertebral bodies (Fig. 135-16). It is often accompanied by extreme rotation, scalloping of the posterior margins of the vertebral bodies, vertebral wedging, defective pedicles, and enlargement of the neural foramina and spinal canal. The curvature may progress rapidly, necessitating surgery that may be particularly complicated because of the complex, multiplanar curves, poor quality of bone, potential for nerve root and spinal cord injury, and the presence of intraspinal and extraspinal neurofibromas. The nondystrophic type of scoliosis is more common, and is similar to idiopathic scoliosis in adolescents. Many children can be managed expectantly or with bracing.[43]

Localized regions of bony overgrowth may also occur in children with NF-1 and are often in areas free of neurofibromas. The overgrowth may affect only a single digit or a larger region such as a hand or an extremity, but true hemihypertrophy is unusual. Bony overgrowth may also occur in a region affected by a plexiform neurofibroma.

Figure 135-16 Dystrophic scoliosis.

CANCER

There is little doubt that NF-1 predisposes an individual to an increased risk for certain cancers. In a population-based Finnish study, an estimated lifetime cancer risk was 59.6%. Individuals with NF-1 were found to be at increased risk for cancers not traditionally thought to be part of the NF-1 spectrum of disease, most notably breast cancer which had a standardized incidence ratio of 11.1 for NF-1 women younger than 40 years of age when compared to women in the general population.[44]

MALIGNANT PERIPHERAL NERVE SHEATH TUMORS

Malignant peripheral nerve sheath tumors almost exclusively arise from preexisting plexiform neurofibromas. Estimates of the lifetime risk for the development of this tumor vary but may be as high as 13%.[45] As the outcome of therapy is poor, physicians should be diligently aware of the early symptoms referable to these tumors, including a rapidly growing mass or unexplained pain or dysfunction. Although conventional imaging cannot identify malignant tissue within a benign plexiform neurofibroma, newer modalities, such as ^{18}F-FDG PET coupled with either CT or MRI, have been shown to have excellent sensitivity and specificity.[7,8]

PHEOCHROMOCYTOMA

Pheochromocytoma clearly is associated with NF-1, with an incidence potentially as high as 1.4%. In a comprehensive review, the mean age at presentation was 42 years; 84% had solitary adrenal tumors, 10% had bilateral adrenal tumors, and 6% had ectopic tumors in the abdominal sympathetic chain, organ of Zuckerkandl, and the bladder.[46] Catecholamine-associated symptoms and hypertension each were present in 61% of the patients; 22% of the patients had neither of these findings. Malignant pheochromocytomas were found in 11.5% of patients, often with distant metastases at presentation. Loss of heterozygosity of the *NF1* has been demonstrated both in NF-1–associated and sporadic pheochromocytomas.[47]

LEUKEMIA

There is an increased risk of juvenile chronic myelomonocytic leukemia and acute lymphoblastic leukemia in children with NF-1. Homozygous inactivation of *NF1* in the bone marrow cells children with NF-1 and malignant myeloid disorders has been identified, suggesting that neurofibromin plays a role in down-regulating the growth of immature myeloid cells.[48] In addition, a population-based study in the United Kingdom identified that NF-1 individuals had a relative risk of developing acute lymphoblastic leukemia of 5.4 times the general population.[49]

OTHER TUMORS

Children with NF-1 may develop juvenile xanthogranulomas, which are yellowish papules less than 1 cm in diameter that are usually found on the head or trunk and may be multiple (Fig. 135-17). An unusual association between juvenile xanthogranulomas, NF-1, and the development of myeloid leukemias has been reported.[50] Although the pathogenesis is obscure, this association also has been observed independent of NF-1. Some authors have recommended "screening" blood counts for individuals who have juvenile xanthogranulomas and NF-1. Given that the precise magnitude of the risk is unknown, but certainly extremely small, this recommendation only serves to increase parental anxiety without providing any useful information and is not endorsed by the authors.

Rhabdomyosarcoma also occurs more frequently in individuals with NF-1.[51] Other tumors that appear to occur more frequently in adults with NF-1 are somatostatinomas of the duodenum and the ampulla of Vater, and GI stromal tumors. Compared to those tumors seen in non–NF-1 individuals, GI stromal tumors in NF-1 rarely arise in the pancreas, are smaller, and generally are not associated with hormonal symptoms (ie, diabetes, steatorrhea, and gallbladder disease).[52]

VASCULOPATHY

Patients with NF-1 may have a vasculopathy affecting essentially any arterial vessel. Clinical manifestations may include renal artery stenosis with hypertension, cerebral infarcts, bleeding aneurysms, and intermittent claudication of an extremity. This vasculopathy is a developmental problem not related to compression of an arteriole by a neurofibroma, and appears to be acquired after birth, as the appearance of new lesions and the progression of preexisting ones have been described. Characteristic pathologic changes have been described in all layers of the vascular wall which ultimately leads to narrowing of the arterial lumen.

Figure 135-17 Multiple juvenile xanthogranulomas on the forehead.

The most commonly identified vascular lesion in patients with NF-1 is in the renal artery, leading to renovascular hypertension.[53] Renal artery vasculopathy should be considered in any adult NF-1 patient with hypertension that is not easily controlled with a single antihypertensive medication; all NF-1 children should be evaluated for this complication. Aortography with selective angiography of the renal arteries should be used to confirm the diagnosis. If the blood pressure is uncontrollable using oral antihypertensives, percutaneous transluminal angioplasty can be performed and repeated if initially unsuccessful. Cerebral artery vasculopathy may lead to poststenotic proliferation of small capillaries, termed, *moyamoya*, which can recurrently bleed leading to strokes.

UNIDENTIFIED BRIGHT OBJECTS

Brain MRI of children with NF-1 frequently demonstrates regions of increased signal intensity on T2-weighted images, referred to as "unidentified bright objects" or UBOs (Fig. 135-18). UBOs may be found in the internal capsule, basal ganglia, cortex, cerebellar hemispheres, optic tract, or brainstem. They do not enhance and are not associated with compression of surrounding tissue, which distinguish them from neoplasms. UBOs are present in approximately 60% of children with NF-1, but disappear with age and are uncommon in adults. They are not associated with focal neurologic signs and are of uncertain significance. Past histopathologic studies have shown that the UBOs corresponded to areas of myelin vacuolization with increased water content. In addition, a recent study using diffusion tensor imaging provided further evidence that UBOs were caused by changes in the intramyelin water pool without demyelination or axonal damage.[54]

INTELLIGENCE AND LEARNING DISABILITIES

Contrary to gross misstatements in the older literature, the mean IQ of patients with NF-1 is only 5 to 10 points lower than the general population and unaffected siblings. However, learning disabilities, defined as discrepancies between ability (intellect) and performance, are quite common with an estimated prevalence of 30% to 60%.[55] Although earlier reports suggested there might be a specific "cognitive phenotype" in NF-1

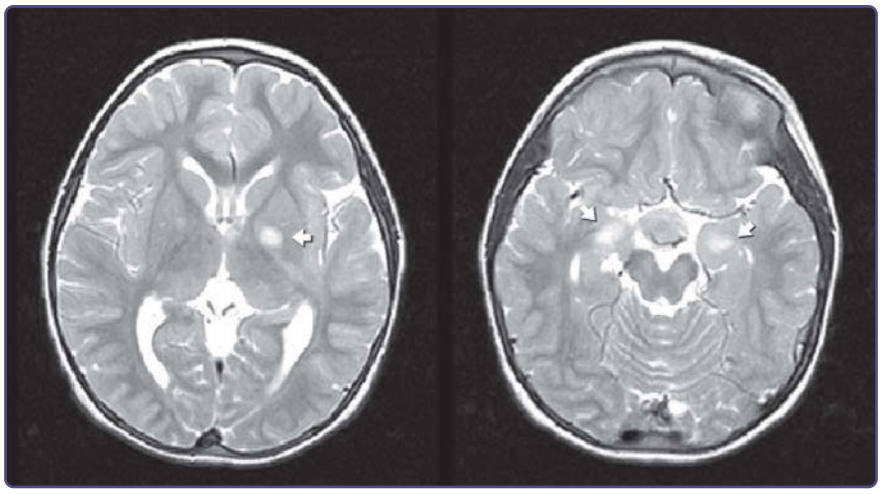

Figure 135-18 T2- weighted MRI hyperintensity, termed "unidentified bright object."

characterized by an excess of visual/perceptual disabilities, newer studies demonstrate that verbal deficits (eg, reading) are at least as common as nonverbal disabilities in individuals with NF-1. These learning disabilities are lifelong and can affect adult functioning. Many children with NF-1 also have poor attention and impulse control, and may be diagnosed with attention deficit hyperactivity disorder, significantly interfering with school performance and learning. Stimulant medications may have a profound beneficial effect on the ability of these individuals to succeed academically and professionally.[56,57]

MANAGEMENT OF NEUROFIBROMATOSIS TYPE 1

Individuals with NF-1 are best cared for within a multidisciplinary clinic that has access to a wide range of subspecialists. The exact physician composition of the clinic is less important than the ability to obtain expeditious subspecialty consultation. All first-degree relatives should be examined for the cutaneous manifestations of NF-1 and should undergo slitlamp examination at the first visit to ascertain the presence of Lisch nodules. Yearly visits allow the physician to identify NF-1 complications early, while providing counseling and dissemination of information regarding NF-1. Individuals and families can obtain further information from the websites of the 2 national support groups: the Children's Tumor Foundation (www.ctf.org) and the Neurofibromatosis Network (www.nfnetwork.org).

All children with NF-1 who are 10 years old or younger should have yearly complete ophthalmologic examinations looking for signs of an OPT. These should include assessment of visual acuity, color vision, visual fields, funduscopy, and slitlamp examination. As almost all OPTs arise in children in this age group, the frequency of ophthalmologic examinations can be reduced in children older than 10 years of age. Yearly measurements of weight and height should be plotted on standardized growth charts, as the earliest indication of precocious puberty may be accelerated linear growth. Blood pressure measurements should be obtained at each visit to look for signs of renovascular hypertension. In addition, the spine should be examined each year for early signs of scoliosis.

CAFÉ-AU-LAIT SPOTS

Café-au-lait spots on the face are unusual in individuals with NF-1. On occasion, they do occur and affected individuals may seek to improve cosmesis. Attempts at removing café-au-lait spots with laser therapy have provided very mixed results. Copper vapor laser therapy provided good to excellent results in 15 of 16 treated patients.[58] Use of the Q-switched 755-nm alexandrite laser produced good to excellent results in 56% of treated patients and poor results in 17%.[59] Use of low-fluence 1064-nm Q-switched neodymium:yttrium-aluminum-garnet (Nd:YAG) laser therapy induced greater than 50% clearance in 75% of the café-au-lait spots treated.[60]

DISCRETE CUTANEOUS NEUROFIBROMAS

Discrete cutaneous neurofibromas may be removed surgically to improve cosmesis or to prevent local irritation, for example, in the hairline while brushing or on the foot rubbing against the shoe. Deeper neurofibromas may require surgical removal when pushing on vital structures, such as a dorsal root neurofibroma that infiltrates the neural foramen and compresses the spinal cord. Complications of surgery include regrowth of the original tumor and nerve damage. In individuals who have severe pruritus from a large burden of cutaneous neurofibromas, antihistamines

may provide symptomatic relief. Uncontrolled anecdotal case reports suggest that ketotifen, an antihistamine and mast cell stabilizer, has provided relief from pruritus and pain and prevented the rapid growth of new neurofibromas.[61] Use of the carbon dioxide laser under general anesthesia to remove hundreds of cutaneous neurofibromas has resulted in markedly increased quality of life and decreased pain and pruritus for patients.[62] The residua of a flat smooth depigmented scar was not thought to be an impediment to such surgery by most patients. In another study, when compared to electrosurgery and carbon dioxide laser ablation, erbium:yttrium aluminium garnet (Er:YAG) laser ablation was superior.[63]

PLEXIFORM NEUROFIBROMAS

Until recently, the treatment of plexiform neurofibromas was limited to surgical debulking either to improve cosmesis or to prevent loss of function (eg, upper airway obstruction, blindness). Such surgery was highly limited in its efficacy; complete resection was impossible given the highly infiltrative nature of these tumors and tumor regrowth was common. Thus, there has been considerable interest in the development of nontraditional chemotherapy for use against these tumors. Unsurprisingly, the design of studies to test the efficacy of such agents was initially fraught with complications. Plexiform neurofibromas are quite different biologically from more conventional solid neoplasms. Lack of growth following treatment may be part of the natural history of the tumor rather than a true therapeutic response. In addition, tumor burden may be difficult to quantify radiographically; plexiform neurofibromas may "spread" along nerve roots sending out multiple finger-like projections, quite different than a single, solid tumor mass.

These difficulties largely have been overcome by data collected at the National Cancer Institute. Volumetric MRI has enabled researchers to accurately measure changes in growth of complex tumors in 3 dimensions and to show that tumor volume was a meaningful end point to use in clinical trials.[64] They demonstrated that younger patients had the most rapid growth of plexiform tumors that that new plexiform tumors were extremely unlikely to appear after the first few years of life.[65] Finally, the hormonal changes in puberty did not seem to accelerate the growth of these tumors.[66]

Armed with this information, several studies were performed to assess the impact of biologics on the growth of plexiform neurofibromas. Studies using pirfenidone, an antifibrotic agent that decreases proliferation of fibroblasts and collagen matrix synthesis, and a farnesyltransferase inhibitor that downregulates *Ras*, did not yield promising results.[67,68] Sirolimus, an inhibitor of the mammalian target of rapamycin, prolonged the time to progression by only 4 months in patients with progressive plexiform neurofibromas.[69] Based on in vitro studies of the important role of mast cell c-Kit receptor signaling, administration of imatinib to a 3-year-old with an unresectable airway plexiform neurofibroma led to 70% diminution in size during 3 months of therapy.[70] In addition, in a subsequent study, 17% of patients receiving imatinib had a 20% or more decrease in tumor volume.[71] If future studies demonstrate potential efficacy, the role of screening imaging to detect "hidden" plexiform neurofibromas will need to be readdressed.

OPTIC PATHWAY TUMORS

There has been considerable debate regarding the role of screening neuroimaging in the care of asymptomatic children with NF-1. Routine "screening" would be important if it led to early detection of OPTs and early initiation of therapy that prevented visual deterioration. A longitudinal study of children with NF-1 failed to identify any tumors in which early detection altered the patient's clinical course.[9] Moreover, targeted screening of very young children with NF-1, the high-risk group for the development of OPTs, failed, as 3 children developed symptomatic tumors shortly after having had normal MRI scans.[72] Brainstem tumors in both children and adults with NF-1 are generally more indolent than their counterparts in non–NF-1 individuals, suggesting that routine screening would not be beneficial.[73] Thus, the National Neurofibromatosis Foundation Optic Pathway Task Force has recommended against routine screening neuroimaging of all children with NF-1.[14] Although there are no comparable longitudinal data for adults regarding the performance of "routine" MRI scans of the head and spinal cord, it seems reasonable to perform such testing only in individuals who have symptoms or signs suggestive of CNS pathology.

Once identified, OPT should be followed by serial MRI and ophthalmologic examinations. Traditionally, treatment had been initiated only after demonstration of clear radiographic progression or deterioration of vision. However, a recent multicenter retrospective study from 10 institutions of 115 children treated for OPTs demonstrated that radiographic outcomes did not predict visual acuity outcomes.[74] Because the goal of treatment should be preservation of vision with minimization of side effects of therapy, tumor growth without visual decline might not be a priori an acceptable reason to institute therapy. When necessary, treatment with carboplatin and vincristine has proven effective in the management of these tumors.[75] Radiation therapy, while a mainstay of treatment of progressive CNS neoplasms not associated with NF-1, is not appropriate for NF-1–associated OPTs because of the risk of vasculopathy, second malignancies, and detrimental neurocognitive and endocrinologic side effects in very young children.

REFERENCES

1. Neurofibromatosis. Conference statement. National Institutes of Health Consensus Development Conference. *Arch Neurol*. 1988;45(5):575-578.
2. Denayer E, Chmara M, Brems H, et al. Legius syndrome in fourteen families. *Hum Mutat*. 2011;32(1):E1985-E1998.

3. Obringer AC, Meadows AT, Zackai EH. The diagnosis of neurofibromatosis-1 in the child under the age of 6 years. *Am J Dis Child*. 1989;143(6):717-719.
4. Carroll SL, Ratner N. How does the Schwann cell lineage form tumors in NF1? *Glia*. 2008;56(14):1590-1605.
5. Staser K, Yang FC, Clapp DW. Pathogenesis of plexiform neurofibroma: tumor-stromal/hematopoietic interactions in tumor progression. *Annu Rev Pathol*. 2012;7:469-495.
6. Brossier NM, Carroll SL. Genetically engineered mouse models shed new light on the pathogenesis of neurofibromatosis type I-related neoplasms of the peripheral nervous system. *Brain Res Bull*. 2012;88(1):58-71.
7. Ferner RE, Golding JF, Smith M, et al. [18F]2-fluoro-2-deoxy-D-glucose positron emission tomography (FDG PET) as a diagnostic tool for neurofibromatosis 1 (NF1) associated malignant peripheral nerve sheath tumours (MPNSTs): a long-term clinical study. *Ann Oncol*. 2008;19(2):390-394.
8. Combemale P, Valeyrie-Allanore L, Giammarile F, et al. Utility of 18F-FDG PET with a semi-quantitative index in the detection of sarcomatous transformation in patients with neurofibromatosis type 1. *PLoS One*. 2014;9(2):e85954.
9. Listernick R, Charrow J, Greenwald M, et al. Natural history of optic pathway tumors in children with neurofibromatosis type 1: a longitudinal study. *J Pediatr*. 1994;125(1):63-66.
10. Listernick R, Charrow J, Greenwald MJ, et al. Optic gliomas in children with neurofibromatosis type 1. *J Pediatr*. 1989;114(5):788-792.
11. Johnson KJ, Fisher MJ, Listernick RL, et al. Parent-of-origin in individuals with familial neurofibromatosis type 1 and optic pathway gliomas. *Fam Cancer*. 2012;11(4):653-656.
12. Diggs-Andrews KA, Brown JA, Gianino SM, et al. Sex Is a major determinant of neuronal dysfunction in neurofibromatosis type 1. *Ann Neurol*. 2014;75(2):309-316.
13. Listernick R, Ferner RE, Liu GT, et al. Optic pathway gliomas in neurofibromatosis-1: controversies and recommendations. *Ann Neurol*. 2007;61(3):189-198.
14. Listernick R, Louis DN, Packer RJ, et al. Optic pathway gliomas in children with neurofibromatosis 1: consensus statement from the NF1 Optic Pathway Glioma Task Force. *Ann Neurol*. 1997;41(2):143-149.
15. Habiby R, Silverman B, Listernick R, et al. Precocious puberty in children with neurofibromatosis type 1. *J Pediatr*. 1995;126(3):364-367.
16. Stevenson DA, Little D, Armstrong L, et al. Approaches to treating NF1 tibial pseudarthrosis: consensus from the Children's Tumor Foundation NF1 Bone Abnormalities Consortium. *J Pediatr Orthop*. 2013;33(3):269-275.
17. Riccardi VM. Von Recklinghausen neurofibromatosis. *N Engl J Med*. 1981;305(27):1617-1627.
18. Kluwe L, Nguyen R, Vogt J, et al. Internal tumor burden in neurofibromatosis type I patients with large NF1 deletions. *Genes Chromosomes Cancer*. 2012;51(5):447-451.
19. Upadhyaya M, Huson SM, Davies M, et al. An absence of cutaneous neurofibromas associated with a 3-bp inframe deletion in exon 17 of the NF1 gene (c.2970-2972 delAAT): evidence of a clinically significant NF1 genotype-phenotype correlation. *Am J Hum Genet*. 2007;80(1):140-151.
20. Ratner N, Miller SJ. A RASopathy gene commonly mutated in cancer: the neurofibromatosis type 1 tumour suppressor. *Nat Rev Cancer*. 2015;15(5):290-301.
21. Spurlock G, Knight SJ, Thomas N, et al. Molecular evolution of a neurofibroma to malignant peripheral nerve sheath tumor (MPNST) in an NF1 patient: correlation between histopathological, clinical and molecular findings. *J Cancer Res Clin Oncol*. 2010;136(12):1869-1880.
22. Hirata Y, Brems H, Suzuki M, et al. Interaction between a domain of the negative regulator of the Ras-ERK pathway, SPRED1 protein, and the GTPase-activating protein-related domain of neurofibromin is implicated in Legius syndrome and neurofibromatosis type 1. *J Biol Chem*. 2016;291(7):3124-3134.
23. Dasgupta B, Li W, Perry A, et al. Glioma formation in neurofibromatosis 1 reflects preferential activation of K-RAS in astrocytes. *Cancer Res*. 2005;65(1):236-245.
24. Li C, Cheng Y, Gutmann DA, et al. Differential localization of the neurofibromatosis 1 (NF1) gene product, neurofibromin, with the F-actin or microtubule cytoskeleton during differentiation of telencephalic neurons. *Brain Res Dev Brain Res*. 2001;130(2):231-248.
25. Costa RM, Federov NB, Kogan JH, et al. Mechanism for the learning deficits in a mouse model of neurofibromatosis type 1. *Nature*. 2002;415(6871):526-530.
26. Jessen WJ, Miller SJ, Jousma E, et al. MEK inhibition exhibits efficacy in human and mouse neurofibromatosis tumors. *J Clin Invest*. 2013;123(1):340-347.
27. Steinmann K, Kluwe L, Friedrich RE, et al. Mechanisms of loss of heterozygosity in neurofibromatosis type 1-associated plexiform neurofibromas. *J Invest Dermatol*. 2009;129(3):615-621.
28. Gutmann DH. Microglia in the tumor microenvironment: taking their TOLL on glioma biology. *Neuro Oncol*. 2015;17(2):171-173.
29. Slattery WH. Neurofibromatosis type 2. *Otolaryngol Clin North Am*. 2015;48(3):443-460.
30. Firestone BK, Arias JD, Shields CL, et al. Bilateral combined hamartomas of the retina and retinal pigment epithelium as the presenting feature of neurofibromatosis type 2 (Wishart type). *J Pediatr Ophthalmol Strabismus*. 2014;51:e33-e36.
31. McLaughlin ME, Pepin SM, Maccollin M, et al. Ocular pathologic findings of neurofibromatosis type 2. *Arch Ophthalmol*. 2007;125(3):389-394.
32. Tanito K, Ota A, Kamide R, et al. Clinical features of 58 Japanese patients with mosaic neurofibromatosis 1. *J Dermatol*. 2014;41(8):724-728.
33. Ruggieri M, Huson SM. The clinical and diagnostic implications of mosaicism in the neurofibromatoses. *Neurology*. 2001;56(11):1433-1443.
34. Tinschert S, Naumann I, Stegmann E, et al. Segmental neurofibromatosis is caused by somatic mutation of the neurofibromatosis type 1 (NF1) gene. *Eur J Hum Genet*. 2000;8(6):455-459.
35. Tartaglia M, Gelb BD, Zenker M. Noonan syndrome and clinically related disorders. *Baillieres Best Pract Res Clin Endocrinol Metab*. 2011;25(1):161-179.
36. De Luca A, Bottillo I, Sarkozy A, et al. NF1 gene mutations represent the major molecular event underlying neurofibromatosis-Noonan syndrome. *Am J Hum Genet*. 2005;77(6):1092-1101.
37. Denayer E, Descheemaeker MJ, Stewart DR, et al. Observations on intelligence and behavior in 15 patients with Legius syndrome. *Am J Med Genet C Semin Med Genet*. 2011;157C(2):123-128.
38. Lu-Emerson C, Plotkin SR. The neurofibromatoses. Part 2: NF2 and schwannomatosis. *Rev Neurol Dis*. 2009;6(3):E81-E86.
39. Baser ME, Friedman JM, Evans DG. Increasing the specificity of diagnostic criteria for schwannomatosis. *Neurology*. 2006;66(5):730-732.

40. Smith MJ, Isidor B, Beetz C, et al. Mutations in LZTR1 add to the complex heterogeneity of schwannomatosis. *Neurology*. 2015;84(2):141-147.
41. Jett K, Nguyen R, Arman D, et al. Quantitative associations of scalp and body subcutaneous neurofibromas with internal plexiform tumors in neurofibromatosis 1. *Am J Med Genet A*. 2015;167(7):1518-1524.
42. Plotkin SR, Bredella MA, Cai W, et al. Quantitative assessment of whole-body tumor burden in adult patients with neurofibromatosis. *PLoS One*. 2012;7(4):e35711.
43. Crawford AH, Herrera-Soto J. Scoliosis associated with neurofibromatosis. *Orthop Clin North Am*. 2007;38(4):553-562.
44. Uusitalo E, Leppavirta J, Koffert A, et al. Incidence and mortality of neurofibromatosis: a total population study in Finland. *J Invest Dermatol*. 2015;135(3):904-906.
45. Evans DG, Baser ME, McGaughran J, et al. Malignant peripheral nerve sheath tumours in neurofibromatosis 1. *J Med Genet*. 2002;39(5):311-314.
46. Walther MM, Herring J, Enquist E, et al. von Recklinghausen's disease and pheochromocytomas. *J Urol*. 1999;162(5):1582-1586.
47. Bausch B, Borozdin W, Mautner VF, et al. Germline NF1 mutational spectra and loss-of-heterozygosity analyses in patients with pheochromocytoma and neurofibromatosis type 1. *J Clin Endocrinol Metab*. 2007;92(7):2784-2792.
48. Staser K, Park SJ, Rhodes SD, et al. Normal hematopoiesis and neurofibromin-deficient myeloproliferative disease require Erk. *J Clin Invest*. 2013;123(1):329-334.
49. Stiller CA, Chessells JM, Fitchett M. Neurofibromatosis and childhood leukaemia/lymphoma: a population-based UKCCSG study. *Br J Cancer*. 1994;70(5):969-972.
50. Jans SR, Schomerus E, Bygum A. Neurofibromatosis type 1 diagnosed in a child based on multiple juvenile xanthogranulomas and juvenile myelomonocytic leukemia. *Pediatr Dermatol*. 2015;32(1):e29-e32.
51. Crucis A, Richer W, Brugieres L, et al. Rhabdomyosarcomas in children with neurofibromatosis type I: a national historical cohort. *Pediatr Blood Cancer*. 2015;62(10):1733-1738.
52. Takazawa Y, Sakurai S, Sakuma Y, et al. Gastrointestinal stromal tumors of neurofibromatosis type I (von Recklinghausen's disease). *Am J Surg Pathol*. 2005;29(6):755-763.
53. Srinivasan A, Krishnamurthy G, Fontalvo-Herazo L, et al. Spectrum of renal findings in pediatric fibromuscular dysplasia and neurofibromatosis type 1. *Pediatr Radiol*. 2011;41(3):308-316.
54. Billiet T, Madler B, D'Arco F, et al. Characterizing the microstructural basis of "unidentified bright objects" in neurofibromatosis type 1: a combined in vivo multicomponent T2 relaxation and multi-shell diffusion MRI analysis. *Neuroimage Clin*. 2014;4:649-658.
55. Sangster J, Shores EA, Watt S, et al. The cognitive profile of preschool-aged children with neurofibromatosis type 1. *Child Neuropsychol*. 2011;17(1):1-16.
56. Lidzba K, Granstroem S, Leark RA, et al. Pharmacotherapy of attention deficit in neurofibromatosis type 1: effects on cognition. *Neuropediatrics*. 2014;45(4):240-246.
57. Lion-Francois L, Gueyffier F, Mercier C, et al. The effect of methylphenidate on neurofibromatosis type 1: a randomised, double-blind, placebo-controlled, crossover trial. *Orphanet J Rare Dis*. 2014;9:142.
58. Somyos K, Boonchu K, Somsak K, et al. Copper vapour laser treatment of cafe-au-lait macules. *Br J Dermatol*. 1996;135(6):964-968.
59. Wang Y, Qian H, Lu Z. Treatment of cafe au lait macules in Chinese patients with a Q-switched 755-nm alexandrite laser. *J Dermatolog Treat*. 2012;23(6):431-436.
60. Kim HR, Ha JM, Park MS, et al. A low-fluence 1064-nm Q-switched neodymium-doped yttrium aluminium garnet laser for the treatment of cafe-au-lait macules. *J Am Acad Dermatol*. 2015;73(3):477-483.
61. Riccardi VM. Ketotifen suppression of NF1 neurofibroma growth over 30 years. *Am J Med Genet A*. 2015;167(7):1570-1577.
62. Meni C, Sbidian E, Moreno JC, et al. Treatment of neurofibromas with a carbon dioxide laser: a retrospective cross-sectional study of 106 patients. *Dermatology*. 2015;230(3):263-268.
63. Kriechbaumer LK, Susani M, Kircher SG, et al. Comparative study of CO2- and Er:YAG laser ablation of multiple cutaneous neurofibromas in von Recklinghausen's disease. *Lasers Med Sci*. 2014;29(3):1083-1091.
64. Dombi E, Solomon J, Gillespie AJ, et al. NF1 plexiform neurofibroma growth rate by volumetric MRI: relationship to age and body weight. *Neurology*. 2007;68(9):643-647.
65. Nguyen R, Dombi E, Widemann BC, et al. Growth dynamics of plexiform neurofibromas: a retrospective cohort study of 201 patients with neurofibromatosis 1. *Orphanet J Rare Dis*. 2012;7:75.
66. Dagalakis U, Lodish M, Dombi E, et al. Puberty and plexiform neurofibroma tumor growth in patients with neurofibromatosis type I. *J Pediatr*. 2014;164(3):620-624.
67. Widemann BC, Babovic-Vuksanovic D, Dombi E, et al. Phase II trial of pirfenidone in children and young adults with neurofibromatosis type 1 and progressive plexiform neurofibromas. *Pediatr Blood Cancer*. 2014;61(9):1598-1602.
68. Widemann BC, Dombi E, Gillespie A, et al. Phase 2 randomized, flexible crossover, double-blinded, placebo-controlled trial of the farnesyltransferase inhibitor tipifarnib in children and young adults with neurofibromatosis type 1 and progressive plexiform neurofibromas. *Neuro Oncol*. 2014;16(5):707-718.
69. Weiss B, Widemann BC, Wolters P, et al. Sirolimus for non-progressive NF1-associated plexiform neurofibromas: an NF clinical trials consortium phase II study. *Pediatr Blood Cancer*. 2014;61(6):982-986.
70. Yang FC, Ingram DA, Chen S, et al. Nf1-dependent tumors require a microenvironment containing Nf1+/– and c-kit-dependent bone marrow. *Cell*. 2008;135(3):437-448.
71. Robertson KA, Nalepa G, Yang FC, et al. Imatinib mesylate for plexiform neurofibromas in patients with neurofibromatosis type 1: a phase 2 trial. *Lancet Oncol*. 2012;13(12):1218-1224.
72. Listernick R, Charrow J, Greenwald M. Emergence of optic pathway gliomas in children with neurofibromatosis type 1 after normal neuroimaging results. *J Pediatr*. 1992;121(4):584-587.
73. Ullrich NJ, Raja AI, Irons MB, et al. Brainstem lesions in neurofibromatosis type 1. *Neurosurgery*. 2007;61(4):762-766; discussion 766-767.
74. Fisher MJ, Loguidice M, Gutmann DH, et al. Visual outcomes in children with neurofibromatosis type 1-associated optic pathway glioma following chemotherapy: a multicenter retrospective analysis. *Neuro Oncol*. 2012;14(6):790-797.
75. Brossier NM, Gutmann DH. Improving outcomes for neurofibromatosis 1-associated brain tumors. *Expert Rev Anticancer Ther*. 2015;15(4):415-423.

Chapter 136 :: Tuberous Sclerosis Complex

:: Thomas N. Darling

AT-A-GLANCE

- Autosomal dominant syndrome with variable expressivity.
- Manifested by hamartomatous tumors in multiple organs, including brain (causing seizures), eyes, heart, kidneys, lungs, and skin.
- Skin lesions occur in nearly all individuals and are important for diagnosis.
- Skin lesions include hypomelanotic macules, "confetti" lesions, facial angiofibromas, fibrous cephalic plaques, shagreen patches, and ungual fibromas.
- Hypomelanotic macules appear at birth or shortly thereafter and are most useful in early diagnosis.
- Although the skin lesions are benign, they may require treatment because of symptoms or disfigurement.
- Skin lesions can be treated with surgery or topical sirolimus.

Tuberous sclerosis complex (TSC) is a genetic disease caused by mutations in a tumor-suppressor gene, either *TSC1* or *TSC2*, which affects multiple organs, typically the brain, heart, kidneys, lungs, and skin.[1] TSC commonly presents with seizures during infancy but some individuals remain undiagnosed until adulthood.[2] Most individuals will experience difficulties related to a wide range of cognitive, behavioral, and psychiatric disorders encompassed by the umbrella term TSC-associated neuropsychiatric disorders (TAND).[3] Skin lesions adversely affect quality of life[4] and dermatologists are frequently called upon to diagnose or treat the skin manifestations of TSC.

EPIDEMIOLOGY

The incidence of TSC is as high as 1 in 6000 live births with a prevalence of approximately 1 in 25,000.[5,6] It occurs with equal frequency in males and females and in different races and ethnicities. Hereditary transmission is evident in approximately one-third of patients. Sporadic disease occurs in about two-thirds of patients, caused by de novo mutations.[7]

CLINICAL FEATURES

CUTANEOUS FINDINGS

Individuals with TSC may develop multiple different types of skin findings, including hypomelanotic macules, facial angiofibromas, fibrous cephalic plaques, shagreen patches, and ungual fibromas.[8] Some skin findings, such as hypomelanotic macules, may appear at birth, whereas others, such as ungual fibromas, may not appear until adulthood. Most individuals eventually manifest at least 1 skin finding, but there is variability in severity between individuals.[9] The ability to recognize TSC-related skin findings is important for diagnosis as skin lesions constitute several of the major and minor features for clinical diagnosis (see section "Diagnosis").[10,11]

HYPOMELANOTIC MACULES

Hypomelanotic macules (Fig. 136-1) are observed in more than 90% of children with TSC.[12,13] The macules are often present at birth or appear within the first few years of life and may fade or disappear in adulthood.[9] The ultraviolet light of a Wood lamp may improve detection, especially in lightly pigmented individuals (Fig. 136-2).[8]

Hypomelanotic macules typically measure 0.5 to 3.0 cm in diameter. They are off-white and incompletely depigmented as in vitiligo. Some are oval at one end and taper to a point at the other. Such lesions are called *ash-leaf spots* because of their resemblance to the leaf of the European mountain ash.[14] They number from 1 to more than 20. They can be located anywhere on the body, but tend to occur most often on the trunk and buttocks. When located on the scalp, they cause poliosis.[12]

Three or more hypopigmented macules measuring 5 mm or greater in longest dimension constitutes a major feature for the diagnosis of tuberous sclerosis.[10] One or 2, and in rare individuals up to 3, hypomelanotic macules occur in 4.7% of the general population.[15] A less-common type of hypopigmentation is the "confetti" skin lesion (Fig. 136-3), which is considered a minor feature for diagnosis.[10] It typically occurs on the legs below the knees or on the forearms, and consists of multiple hypopigmented macules 2 to 3 mm in diameter.[12,14]

FACIAL ANGIOFIBROMAS

Angiofibromas generally appear between 2 and 5 years of age and eventually affect 75% to 90% of patients.[9,12,13] These 1 to 3 mm in diameter, pink to red papules have

Figure 136-1 Hypomelanotic ash-leaf macules on the lower leg of a child with tuberous sclerosis complex.

Figure 136-3 Confetti-like hypopigmented macules on the lower leg of an adult with tuberous sclerosis complex.

a smooth surface (Fig. 136-4). They may be hyperpigmented, especially in individuals with darker pigmentation. They occur on the central face and are often concentrated in the alar grooves (Fig. 136-5), extending symmetrically onto the cheeks and to the nose, nasal opening, and chin, with relative sparing of the upper lip and lateral face. They may number from 1 to more

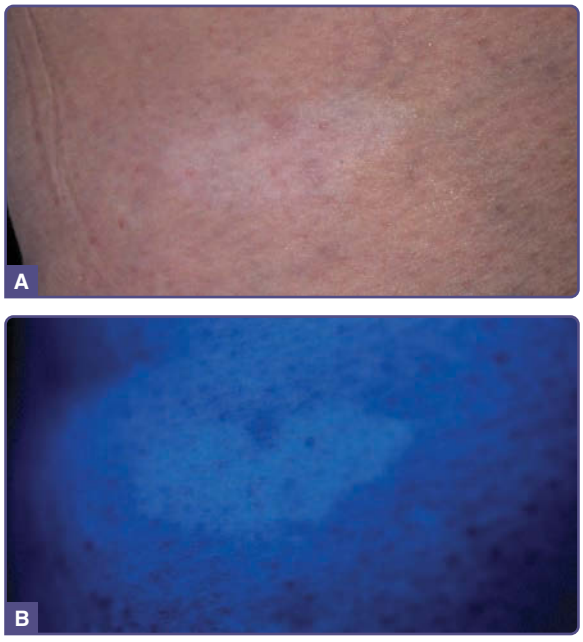

Figure 136-2 **A,** Hypomelanotic macules on the lateral chest of an adult with tuberous sclerosis complex. The macules may be easily overlooked. **B,** Wood lamp accentuates the macules.

Figure 136-4 Multiple facial angiofibromas on the nose, cheeks, and chin, with relative sparing of the upper lip is commonly observed in tuberous sclerosis complex.

Figure 136-5 Angiofibromas are often larger in the alar grooves and may become less erythematous over time, as in this adult with tuberous sclerosis complex.

than 100. Lesions may coalesce to form large nodules, especially in the alar grooves.[12,13] Sometimes lesions occur on the forehead, scalp, or eyelids. Adults may develop angiofibromas on the nipples.[16] Angiofibromas may be unilateral in rare cases. Unilateral angiofibromas may indicate a segmental or mosaic defects.[17]

The development of papules may be preceded by mild erythema that is intensified by emotion or heat. During puberty, angiofibromas may grow in size and number. During adulthood they tend to be stable in size, but redness may gradually diminish.[8]

Three or more angiofibromas comprise a major feature.[10] A solitary angiofibroma is clinically and histologically indistinguishable from the fibrous papule that occurs sporadically as a single lesion in the general population. The development of multiple angiofibromas with onset later in adolescence or early adulthood is not specific for TSC and may, instead, indicate multiple endocrine neoplasia Type 1 or Birt-Hogg-Dubé syndrome.[11]

FIBROUS CEPHALIC PLAQUE

The fibrous cephalic plaque, previously called forehead plaque, may be congenital or show gradual development over years.[12] It is present in approximately 40% of patients.[9,12,13] It is an irregular, soft to firm, connective tissue nevus with the color of the normal surrounding skin, red, or hyperpigmented in darkly pigmented individuals (Fig. 136-6). The plaque classically develops on the forehead, but can occur on the scalp, cheeks, and elsewhere on the face. The fibrous cephalic plaque and/or multiple angiofibromas is a major feature for diagnosis.[10]

SHAGREEN PATCH

The shagreen patch is observed in approximately 50% of patients.[9,12,13] It may be present in infancy, but usually becomes apparent later. It is a firm or rubbery irregular plaque ranging in size from 1 to 10 cm (Fig. 136-7).

Figure 136-6 The forehead fibrous plaque in tuberous sclerosis complex is often pink-red and has a bumpy surface and irregular outline.

The surface may appear bumpy with coalescing papules and nodules, or the patch may have the surface appearance of an orange peel. The color may be that of the surrounding skin, or it may be slightly pink or brown. There may be scattered smaller oval papules with or without a larger plaque (Fig. 136-8). The most common location is on the lower back to sacral region; less commonly, the patch is on the mid or upper back, buttocks, or thighs.[8]

UNGUAL FIBROMAS

Ungual fibromas, also known as *Koenen tumors*, usually appear after the first decade and eventually affect

Figure 136-7 The shagreen patch in tuberous sclerosis complex is a firm, bumpy plaque that is usually located on the lower back.

Figure 136-8 The shagreen patch may consist of grouped, dermal papules that are minimally elevated above the skin.

Figure 136-10 Periungual fibromas emanating from the proximal nailfold in tuberous sclerosis complex causes a longitudinal groove in the nail.

more than 85% of adults with TSC.[9,13] They are more common on the toes than on the fingers.[18]

Ungual fibromas measure 1 mm to 1 cm in diameter. They arise from under the proximal nailfold (periungual fibromas) and under the nail plate (subungual fibromas). Periungual fibromas are red papules and nodules that are firm, pointed, and hyperkeratotic, or soft and rounded (Fig. 136-9). They press on the nail matrix and cause a longitudinal groove, and sometimes a groove forms without an evident papule (Fig. 136-10).[18] Subungual fibromas are visible through the nail plate as red or white oval lesions or as red papules emerging from the distal nail plate, causing distal subungual onycholysis (Fig. 136-11). In addition to ungual fibromas, individuals with TSC may develop "red comets" (subungual red streaks), splinter hemorrhages, and longitudinal leukonychia.[18]

The presence of 2 or more ungual fibromas is a major feature for diagnosis of TSC.[10] Solitary lesions (also termed *acral* or *acquired digital fibrokeratomas*) are also observed in the general population, especially after nail trauma.[19]

OTHER SKIN LESIONS

Folliculocystic and collagen hamartomas are large plaques with follicular comedo-like openings and cysts observed in association with TSC.[20] Molluscum fibrosum pendulum (skin tags) is the name given to multiple fibroepithelial polyps in TSC (Fig. 136-12).[12] Skin tags are common in the general population, so these are not useful for diagnosis. Miliary fibromas are patches of multiple minute papules, usually on the neck or trunk that appear like "gooseflesh."[8] Pachydermodactyly is a benign thickening of the proximal fingers that has been observed in a few patients with TSC.[18]

DENTAL PITTING

Multiple pits of the dental enamel are observed in up to 100% of TSC patients.[21] These pits can be tiny pinpoint lesions or larger crater-like lesions (Fig. 136-13). They occur on both deciduous and permanent teeth. The identification of these lesions is enhanced by using a dental plaque stain. Dental pits can also be seen in the general population, albeit with lower prevalence and at lower numbers than in TSC.[21] The presence of more than 3 dental pits is a minor feature for diagnosis.[10]

INTRAORAL FIBROMAS

Approximately 50% of TSC patients have intraoral fibromas (Fig. 136-14).[13] These sometimes occur in the

Figure 136-9 Multiple periungual and subungual fibromas on the toes in a patient with tuberous sclerosis complex.

Figure 136-11 Subungual fibromas may disrupt the normal nail anatomy in tuberous sclerosis complex, causing distal onycholysis.

Figure 136-12 Molluscum fibrosum pendulum, another name for multiple skin tags in tuberous sclerosis complex, is observed on the neck in this patient.

Figure 136-14 Multiple gingival fibromas in an adult with tuberous sclerosis complex.

first decade but are more common in adulthood. They are most common on the gingivae, but also occur on the buccal and labial mucosa, hard palate, and tongue. Some patients have diffuse gingival overgrowth. Gingival overgrowth is a common side effect of anticonvulsants, especially phenytoin and cyclosporine, but gingival overgrowth can be observed in TSC even in patients not treated with anticonvulsants or immunosuppressive agents.[21] Two or more intraoral fibromas are a minor feature for diagnosis.[10] Oral fibromas in the general population are typically single and form at sites of trauma, usually on the tongue or buccal mucosa.[21]

NONCUTANEOUS FINDINGS

BRAIN

Cerebral lesions include cortical dysplasia (tubers and white matter migration lines), subependymal nodules, and subependymal giant cell astrocytomas. Seizures occur in approximately 80% of patients, with onset in most patients in the first 3 years of life. Epilepsy is most likely infantile spasms or focal seizures, but may be tonic, atonic, or tonic–clonic seizures.[22] The first-line treatment of infantile spasms is vigabatrin.[23] Seizures are treated with anticonvulsant drugs as used in other forms of epilepsy. Epilepsy surgery may be required for seizures intractable to anticonvulsant therapy.[23] Other approaches used to reduce seizures include ketogenic diet, vagus nerve stimulation, and possibly mammalian target of rapamycin (mTOR) inhibitors.[22]

TAND encompasses a range of behavioral, intellectual, and psychosocial difficulties.[3] Approximately half of individuals with TSC will have intellectual disability, ranging from mild to profound. Even those with normal intellectual abilities may have deficits in recall memory, attention, or executive function. Nearly half of individuals with TSC have autism spectrum disorder or attention deficit hyperactivity disorder. Aggressive behavior, impulsivity, and sleep disorders are also common, and adolescents and adults may have anxiety and depressive disorders. TSC affects self-esteem and family and peer relationships.[22]

Subependymal nodules occur in approximately 80% of individuals with TSC, and subependymal giant cell astrocytomas develop in approximately 5% to 15% of individuals with TSC. Subependymal giant cell astrocytomas may be treated using an mTOR inhibitor or acute obstructive hydrocephalus may require surgical resection and possibly shunting.[22,23]

Figure 136-13 Multiple dental enamel pits are seen in nearly all patients with tuberous sclerosis complex.

HEART

Cardiac rhabdomyomas occur in approximately 80% of infants with TSC and nearly 100% of fetuses with multiple cardiac rhabdomyomas have TSC.[24] These neoplasms are often asymptomatic and spontaneously regress, but they may cause fetal hydrops and stillbirth or heart failure shortly after birth. Treatment of cardiac rhabdomyomas with mTOR inhibitors may speed regression. Cardiac arrhythmias are common in TSC, including slow, fast, and irregular rhythms.[24]

KIDNEYS

Angiomyolipomas are observed in up to 80% of TSC patients and are usually renal but may be hepatic.[10,25]

Additional renal lesions include renal cysts in approximately 30% and renal cell carcinoma in 2% to 3% of TSC patients. Polycystic kidney disease from contiguous *TSC2-PKD1* deletion is present in approximately 1 in 20 patients.[25] Renal lesions can cause renal insufficiency, hypertension, and potentially fatal retroperitoneal hemorrhage. Patients may require selective embolization followed by corticosteroids as first-line therapy for angiomyolipomas with acute hemorrhage. Treatment with an mTOR inhibitor is first-line therapy for asymptomatic growing angiomyolipomas.[23,25]

LUNGS

Lung involvement in TSC includes lymphangioleiomyomatosis (LAM), multifocal micronodular pneumocyte hyperplasia, and clear cell tumors of the lung.[10] LAM develops in females with TSC during the third or fourth decade of life and the risk of disease increases with age. Radiographic evidence of LAM was observed in up to 80% of adult females with TSC older than age 40 years.[26] It may cause spontaneous pneumothorax, chylothorax, dyspnea, cough, and hemoptysis.[27] mTOR inhibitors may be used to treat LAM patients with moderate to severe lung disease or rapid progression.[23]

EYES

Retinal hamartomas are observed in 30% to 50% of TSC patients.[10] The most common type is flat and translucent. Also common are elevated, opaque, and sometimes calcified multinodular "mulberry" lesions.[28] Retinal hamartomas are usually stable in size but enucleation has been required for enlarging retinal astrocytomas. Retinal hamartomas can be similar to retinal lesions in neurofibromatosis Type 1 and may appear similar to retinoblastomas.[28] TSC patients may also have retinal achromic patches that appear as hypopigmented patches in the retina.[10]

OTHER ORGANS

Hamartomatous polyps have been observed in the colon and rectum of TSC patients.[29] Benign tumors sometimes occur in the spleen, thymus, and thyroid. TSC also may be associated with pituitary, parathyroid, and islet cell tumors.[30] Arterial stenotic-occlusive disease and arterial aneurysms including aortic and intracranial aneurysms have been observed.[31] Bone lesions in TSC are usually asymptomatic and may be sclerotic (calvaria, pelvis, vertebrae, ribs, and long bones) or cystic (phalanges).[32,33]

COMPLICATIONS

None of the skin lesions in TSC is prone to malignant degeneration, but the lesions can be a major cosmetic concern for the patient, causing social isolation and difficulties with self-esteem.[34] Angiofibromas, facial plaques, and ungual fibromas can be painful or bleed spontaneously or in response to minor trauma. Ungual fibromas can cause nail dystrophy and eventual loss of the nail. Large facial lesions may obstruct vision or occlude the nasal passages.[35]

ETIOLOGY AND PATHOGENESIS

TSC is caused by mutations in a tumor-suppressor gene, either *TSC1* or *TSC2*. The *TSC1* gene maps to chromosome band 9q34 and consists of 23 exons that encodes a 130-kDa protein called *hamartin* or TSC1. The *TSC2* gene maps to chromosome band 16p13.3 and includes 42 exons that encodes a 200-kDa protein called *tuberin* or TSC2.[7] The mutations observed in patients with TSC are inactivating mutations located anywhere along the sequence of *TSC1* or *TSC2*.[7] Consistent with Knudson's 2-hit hypothesis, most TSC tumors, including skin tumors, show a second somatic mutation that inactivates the wild-type allele.[36] TSC1 and TSC2 form a complex that inhibits signaling through the mechanistic target of rapamycin complex 1 (mTORC1) pathway (Fig. 136-15). Loss of TSC1/TSC2 function leads to increased mTORC1 signaling and increased cell growth.[37] Sirolimus (rapamycin) inhibits mTORC1 activity and treats TSC tumors. A xenograft mouse model of TSC demonstrated that TSC2-null fibroblast-like cells are the inciting cells in angiofibromas, inducing angiogenesis and hair follicle neogenesis. Treatment with rapamycin normalized the pathologic changes but failed to eradicate the TSC2-null cells.[38]

RISK FACTORS

Patients with mutations in *TSC2* tend to exhibit a more-severe phenotype than those with mutations in *TSC1*. Immediately adjacent to *TSC2* on chromosome 16 is *PKD1*, the gene mutated in polycystic kidney disease. Some patients with TSC have severe, early-onset renal cystic disease, and most of these patients have a contiguous deletion of *TSC2* and *PKD1*.[7] Tuber count and early onset epilepsy is associated with impairment of intellectual abilities.[39] Skin manifestations have been reported in association with epilepsy, including higher likelihood of epilepsy in those with angiofibromas or shagreen patch,[40] and fibrous forehead plaque with ipsilateral cerebral abnormalities and contralateral seizures.[41] Analysis of somatic second-hit mutations in angiofibromas has shown the presence of ultraviolet-signature mutations, suggesting that sun exposure may worsen TSC skin findings.[36]

DIAGNOSIS

The diagnosis of TSC is based on either genetic or clinical criteria (Table 136-1).[10] The genetic criterion requires the identification of a mutation in *TSC1* or *TSC2* that

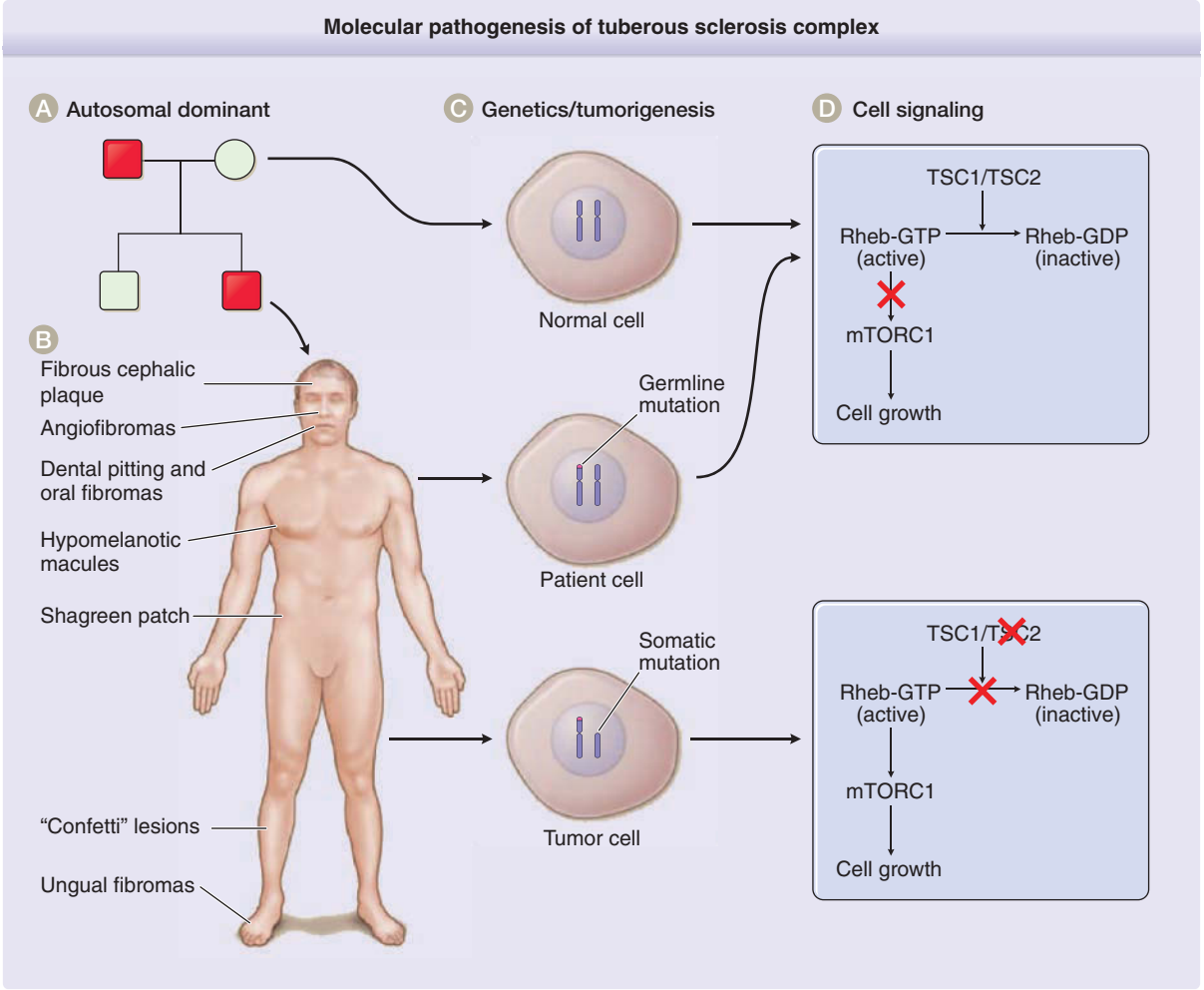

Figure 136-15 Molecular pathogenesis of tuberous sclerosis complex (TSC). **A,** An example is shown in which a mutation in *TSC2* is passed from the father (*red square*) to the son (*red square*), whereas the mother (*white circle*) and another son (*white square*) are unaffected. **B,** Skin lesions are observed in the son at the indicated locations. **C,** A cell from the mother shows 2 normal alleles for *TSC2* on chromosome band 16p13.3. A cell from the son shows the *TSC2* mutation inherited from his father. A tumor from the son has this germline mutation and a "second-hit" mutation, detectable as loss of heterozygosity at this locus, that inactivates the other allele. **D,** TSC2, in a complex with TSC1, is a guanosine triphosphatase–activating protein, converting active Ras-homolog enriched in brain (Rheb) guanosine triphosphate (GTP) to inactive Rheb guanosine diphosphate (GDP). Rheb-GTP activates mammalian target of rapamycin complex 1 (mTORC1), a kinase that increases protein translation and cell growth, so TSC2 normally acts to inhibit cell growth. Loss of TSC2 function in tumors results in increased levels of Rheb-GTP, activation of mTORC1, and increased cell growth.

clearly inactivates the function of the TSC1 or TSC2 proteins in DNA from normal tissue. The demonstration of a pathogenic mutation is sufficient to make a definite diagnosis of TSC. Using standard approaches for DNA analysis, approximately 10% to 25% of individuals with TSC will have no mutation identified. Therefore, a normal result does not exclude the possibility of TSC and clinical criteria are still important. The clinical criteria are categorized as major or minor features, with cutaneous and oral lesions comprising 4 of 11 major features and 3 of 6 minor features. Using clinical criteria, a definite diagnosis of TSC requires the presence of 2 or more major features or 1 major feature with 2 or more minor features. A possible diagnosis of TSC is made based on the presence of either 1 major feature or 2 or more minor features.[10]

SUPPORTIVE STUDIES

PATHOLOGY

A skin biopsy may be useful when internal manifestations of TSC are lacking or if the diagnosis of TSC hinges on skin lesions for satisfying clinical criteria.[11] Hypomelanotic macules have normal numbers of melanocytes, in contrast to the lesions of vitiligo, in which melanocytes are absent. The melanocytes in hypomelanotic macules have poorly developed dendritic processes, and melanosomes are decreased in numbers, size, and melanization.[42] Angiofibromas contain plump, spindle-shaped, or stellate fibroblastic cells in the dermis among increased numbers of dilated

TABLE 136-1

Diagnostic Criteria for Tuberous Sclerosis Complex (Updated at 2012 Conference)

Genetic Criterion

Pathogenic mutation in *TSC1* or *TSC2* in DNA from normal tissue

Major Features

1. Hypomelanotic macules (≥3, at least 5 mm diameter)
2. Angiofibromas (≥3) or fibrous cephalic plaque
3. Ungual fibromas (≥2)
4. Shagreen patch
5. Multiple retinal hamartomas
6. Cortical dysplasias[a]
7. Subependymal nodules
8. Subependymal giant cell astrocytoma
9. Cardiac rhabdomyoma
10. Lymphangioleiomyomatosis[b]
11. Angiomyolipomas (≥2)[b]

Minor Features

1. "Confetti" skin lesions
2. Dental enamel pits (≥3)
3. Intraoral fibromas (≥2)
4. Retinal achromic patch
5. Multiple renal cysts
6. Nonrenal hamartomas

[a]Includes tubers and cerebral white matter radial migration lines.

[b]A combination of the 2 major clinical features (lymphangioleiomyomatosis and angiomyolipomas) without other features does not meet criteria for a definite diagnosis.

Definite diagnosis: Pathogenic mutation *or* 2 major features *or* 1 major feature with ≥2 minor features.

Possible diagnosis: One major feature *or* ≥2 minor features.

vessels (Fig. 136-16). Collagen fibers are oriented in an onionskin pattern around follicles and vessels. The epidermis shows melanocytic hyperplasia and flattening of rete ridges. Periungual fibromas are similar, but with more extensive hyperkeratosis and a variable increase in vascularity (Fig. 136-17). The shagreen patch has sclerotic bundles of collagen in the reticular dermis, often with reduced elastic fibers (Fig. 136-18).[8]

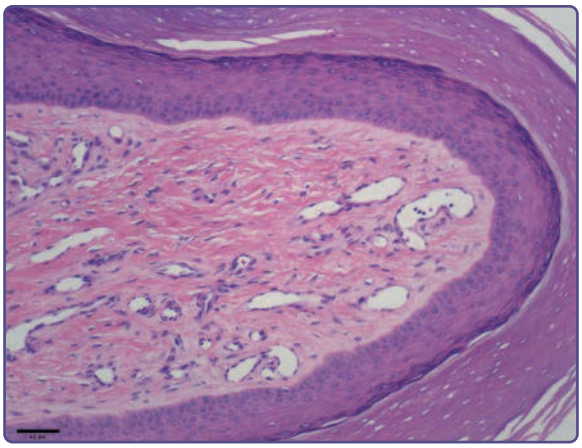

Figure 136-17 Periungual fibromas may exhibit dense collagen bundles and ectatic vessels, sparse to increased fibroblastic cells, and acanthosis and hyperkeratosis.

IMAGING AND LABORATORY TESTING

Besides dermatologic and ophthalmologic examination, the initial evaluation of a patient suspected to have TSC includes MRI of the brain and abdomen.[23] MRI of the brain, with and without gadolinium, evaluates for tubers, subependymal nodules, migrational defects, and subependymal giant cell astrocytoma. MRI of the abdomen assesses for renal angiomyolipomas and cysts, as well as extrarenal hamartomas and aortic aneurysms. These imaging studies and additional studies described next are used to confirm the diagnosis of TSC and to determine the extent of disease in those known to have TSC. Additional studies include (a) a baseline routine electroencephalogram even without reported seizures; (b) evaluation for TAND; (c) blood pressure and renal glomerular filtration rate; (d) high-resolution chest computed tomography (HRCT) and pulmonary function testing if

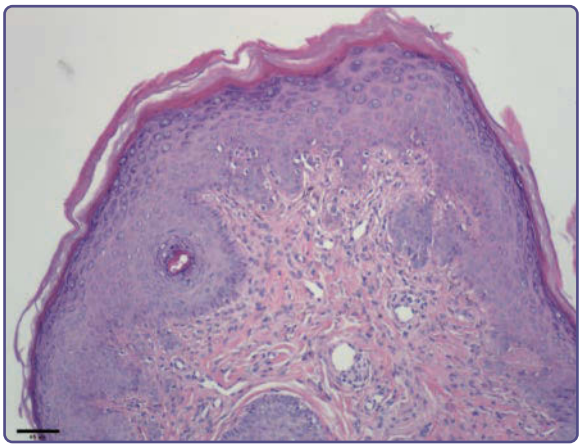

Figure 136-16 Angiofibromas are composed of ectatic vessels and fibroblastic cells that can be large, stellate, and sometimes multinucleated. There is fibrosis that may form concentric rings around vessels and adnexal structures.

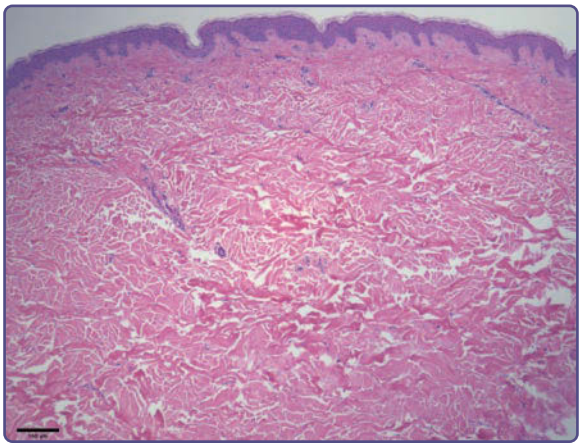

Figure 136-18 The shagreen patch shows thickened collagen bundles that appear disordered. Elastic fibers are decreased in amount compared to normal skin.

symptomatic or as baseline in asymptomatic females 18 years of age or older; (e) an echocardiogram and electrocardiogram to evaluate for rhabdomyomas and arrhythmia in pediatric patients, especially if younger than 3 years of age; and (f) a baseline electrocardiogram at any age.[23]

MOLECULAR DIAGNOSIS

The identification of a pathogenic mutation in *TSC1* or *TSC2* is now sufficient for the diagnosis of TSC even without diagnostic clinical findings.[10] Genetic testing may yield false-negative or inconclusive results in approximately 10% to 25% of TSC patients.[1] Most of these cases are caused by intronic mutations or somatic mosaicism.[43] Molecular genetic testing can provide additional information for genetic counseling, and it can be used in prenatal diagnosis. When a pathogenic mutation has been identified, it may be used to screen at-risk family members.[1]

DIAGNOSTIC ALGORITHM

Individuals with skin findings suggestive of 1 cutaneous major feature of TSC should be queried for TSC-associated symptoms and family history. A thorough skin and oral examination should be performed. Those manifesting at least 1 additional major feature or 2 minor features should undergo TSC diagnostic evaluation to determine baseline disease extent.[23] In absence of additional skin or oral lesions, skin biopsy may be performed to confirm the clinical diagnosis (Fig. 136-19). Individuals with skin lesions characteristic of TSC should proceed to complete diagnostic evaluation. Those with skin lesions nonspecific or atypical of TSC should be first considered for other conditions to avoid unnecessary TSC workup.[44] Some patients will not meet criteria for a definitive diagnosis. These patients should receive a diagnosis of possible TSC and consideration given to performing a future reevaluation.

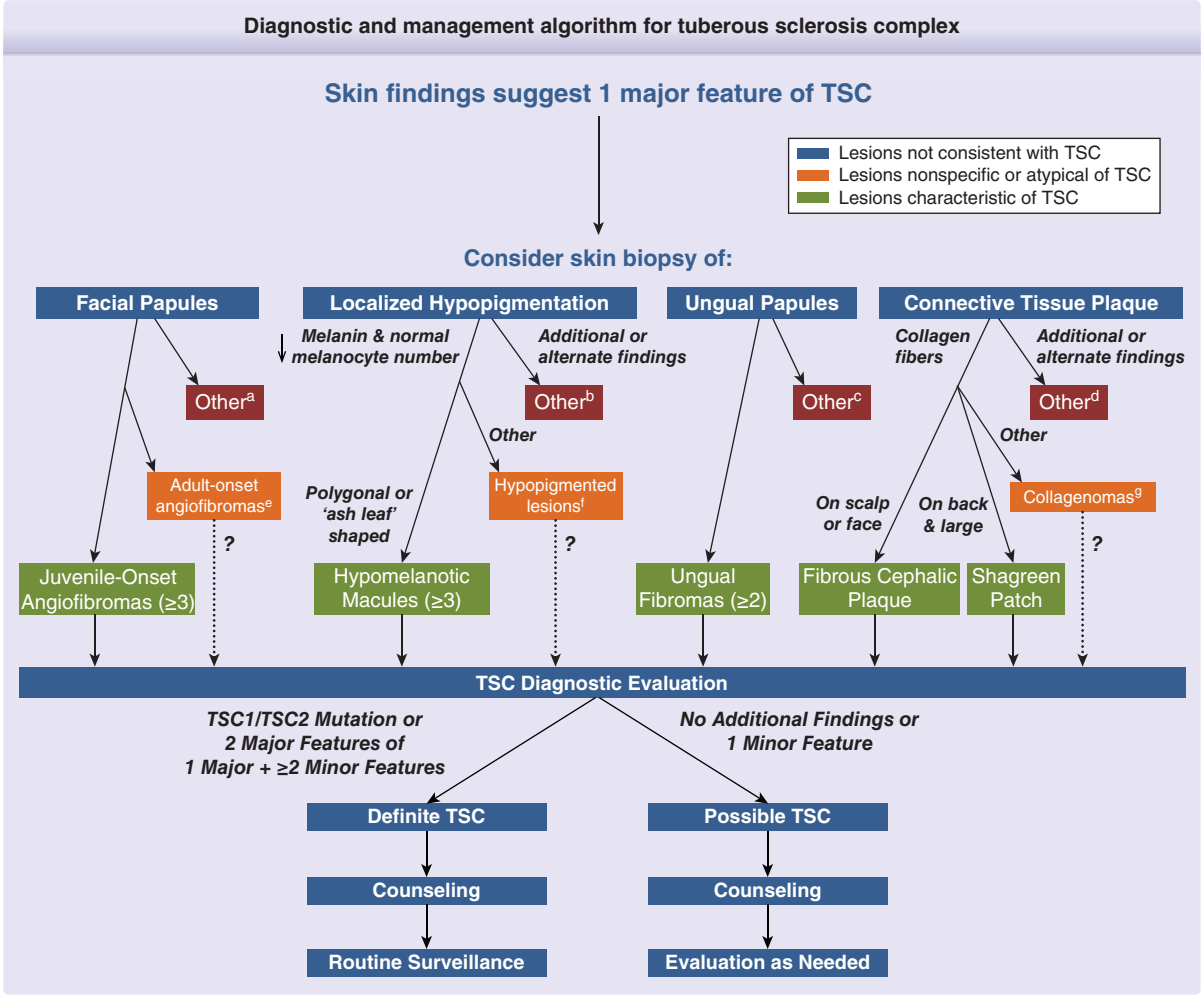

Figure 136-19 Diagnostic and management algorithm for tuberous sclerosis complex (TSC). Skin lesions may be categorized as not consistent (*red*), nonspecific or atypical (*orange*), or characteristic (*green*) of TSC. **A** and **E,** see Table 136-3; **B** and **F,** see Table 136-2; **C,** see Table 136-4; **D** and **G,** see Table 136-5. (Adapted from Nathan N, Burke K, Moss J, et al. A diagnostic and management algorithm for individuals with an isolated skin finding suggestive of tuberous sclerosis complex. *Br J Dermatol*. 2017;176(1):220-223.)

TABLE 136-2
Differential Diagnosis of Hypomelanotic Macules

B* in *Fig. 136-19
- Piebaldism
- Vitiligo
- Waardenburg syndrome
- Postinflammatory hypopigmentation
- Sarcoidosis
- Hypopigmented mycosis fungoides
- Pityriasis alba
- Idiopathic guttate hypomelanosis
- Leprosy
- Nevus anemicus

F* in *Fig. 136-19
- Nevus depigmentosus (congenital isolated or segmental lesion with serrated border)
- Hypomelanosis of Ito (congenital macules arranged in whorls or streaks following Blaschko lines)
- Progressive macular hypomelanosis (adolescent or adult onset of nummular, confluent macules concentrated on the trunk)
- Tuberous sclerosis complex (may also present with hypopigmented macules of Blaschkoid or segmental morphology)

DIFFERENTIAL DIAGNOSIS

Tables 136-2, 136-3, 136-4, and 136-5 summarize differential diagnoses for several major features of TSC.

CLINICAL COURSE AND PROGNOSIS

Individuals with tuberous sclerosis exhibit decreased overall survival compared with the general population. The causes of premature death include renal failure, intractable seizures, obstructive hydrocephalus, cardiac outflow obstruction, arrhythmia, respiratory failure, pneumothorax, and hemorrhage from an aneurysm or a tumor, especially angiomyolipomas.[45,46]

TABLE 136-3
Differential Diagnosis of Angiofibromas

A* in *Fig. 136-19
- Acne vulgaris
- Rosacea
- Verruca
- Dermal melanocytic nevi
- Syringomas
- Trichoepitheliomas (multiple familial trichoepithelioma)
- Fibrofolliculomas/trichodiscomas (Birt-Hogg-Dubé syndrome)
- Tricholemmomas (Cowden syndrome)
- Sebaceous tumors (Muir-Torre syndrome)

E* in *Fig. 136-19
- Fibrous papules (single or few)
- Multiple endocrine neoplasia Type 1
- Birt-Hogg-Dubé syndrome
- Tuberous sclerosis complex adult-onset angiofibromas

TABLE 136-4
Differential Diagnosis of Ungual Fibroma

C* in *Fig. 136-19
- Digital mucous cyst
- Subungual exostosis
- Subungual corn (heloma)
- Wart
- Pyogenic granuloma
- Squamous cell carcinoma
- Onychomycosis
- Psoriasis

Fatal events may occur at any age. Brain and heart tumors may cause death in infancy, whereas lung and kidney tumors are more likely to cause premature death in adulthood. The prognosis for the individual patient depends on disease expressivity. Some individuals have a normal life span with few medical complications.

MANAGEMENT

MEDICATIONS

The management of TSC skin tumors has changed with the use of mTOR inhibitors. The U.S. Food and Drug Administration has approved oral mTOR inhibitors for treating several TSC-associated tumors, such as everolimus for subependymal giant cell astrocytomas and renal angiomyolipomas, and sirolimus for LAM.[47] Most patients treated with an oral mTOR inhibitor for internal tumors will show improvement in their skin lesions.[48,49] Therefore, appropriate management may involve monitoring for skin improvement in those on systemic therapy. Oral mTOR inhibitors may delay wound healing, but surgical intervention may be indicated for lesions failing to respond to oral therapy or for urgent clinical situations such as bleeding or functional impairment.[11]

TABLE 136-5
Differential Diagnosis of Shagreen Patch

D* in *Fig. 136-19
- Nonfamilial elastoma or familial elastoma
- Dermatofibrosis lenticularis disseminata (in Buschke-Ollendorf syndrome)
- Dermal nevi
- Xanthomas
- Granulomatous disease

G* in *Fig. 136-19
- Familial cutaneous collagenomas or eruptive collagenoma
- Multiple endocrine neoplasia Type 1 collagenomas
- Sclerotic fibroma (Cowden syndrome)
- Isolated connective tissue nevus
- Tuberous sclerosis complex collagenomas

Systemic treatment with mTOR inhibitors is associated with a variety of adverse effects, such as stomatitis, mouth ulceration, acne-like skin lesions, infections, hypertriglyceridemia, hypercholesterolemia, bone marrow suppression, proteinuria, joint pain, and noninfectious pneumonitis. The potential for these adverse effects limits the use of systemic mTOR inhibitors in the treatment of skin lesions alone.[11] To reduce the potential for adverse effects, several investigators have used mTOR inhibitors applied topically. Angiofibromas in most patients became flatter and decreased in redness.[50] Hypomelanotic macules increased in pigmentation.[51] Adverse effects were minimal and systemic levels were mostly undetectable.[50] A double-blind, placebo-controlled, phase 2 randomized clinical trial showed that topical sirolimus 0.2% gel was safe and effective for treating TSC angiofibromas.[52] It is expected that long-term treatment will be required and skin lesions may worsen after discontinuing therapy.

PROCEDURES

Indications for treatment of TSC-related skin lesions may include pain, bleeding, functional interference, or disruption of social interactions.[11] Angiofibromas have been treated by excision, curettage, chemical peel, cryosurgery, dermabrasion, electrosurgery, and different types of laser procedures.[8,11,35,53] Multiple sessions using several approaches may be required for optimal results. Potential complications of surgical treatments include infection, hypertrophic scarring, postinflammatory hyperpigmentation, and hypopigmentation. Treated angiofibromas tend to recur over a couple of years, and new lesions may form.[35] Ungual fibromas are usually treated by excision, but these lesions also have a high recurrence rate. Hypomelanotic macules may be temporarily concealed using self-tanning lotions or makeup matched to the person's skin color. The shagreen patch is usually left untreated, but it can be excised.[8,35]

COUNSELING

Upon diagnosing an infant with TSC, a major aspect of care is answering questions and addressing the concerns of the family. Unfortunately, many parents report negative experiences because of physician insensitivity and the provision of inaccurate information and inadequate support.[54] Parents should be educated about possible evolution or development of skin lesions and available treatments. Parents should be advised to maintain good sun protection for their children as this may lessen the future severity of angiofibromas.[11] Other important educational aspects include informing parents to recognize infantile spasms, discussing the potential need for an individual educational program, and counseling adolescent and adult females about the risks of smoking or estrogen use in oral contraceptives because of their potential to worsen LAM.[23] Patients should be promptly referred to other specialists, social services, and genetic counseling as indicated. Inform individuals and families about organizations dedicated to TSC, such as the Tuberous Sclerosis Alliance (http://www.tsalliance.org).

SURVEILLANCE

After diagnosis, the patient should have periodic surveillance for the development of new lesions or changes in existing lesions.[23] MRI of the brain is recommended every 1 to 3 years in asymptomatic TSC patients younger than age 25 years to monitor for development of subependymal giant cell astrocytoma and, more frequently, for positive findings. MRI of the abdomen should be performed every 1 to 3 years to evaluate for progression of angiomyolipomas and renal cystic disease. Additional recommendations include: (a) annual screening for TAND throughout childhood and as needed; (b) annual tests of blood pressure and renal glomerular filtration rate; (c) clinical screening for LAM symptoms and HRCT every 5 to 10 years for asymptomatic at-risk individuals, or, for those with LAM, annual pulmonary function testing and HRCT every 2 to 3 years; (d) electrocardiogram every 3 to 5 years in asymptomatic patients of all ages and, for pediatric patients with asymptomatic cardiac rhabdomyomas, echocardiogram every 1 to 3 years until resolved; (e) annual skin examination; (f) dental examination every 6 months with panoramic radiographs by age 7 years; and (g) annual ophthalmologic evaluation in patients with previously identified ophthalmologic lesions or vision symptoms.[23]

SCREENING

A child with TSC may be born to parents who do not carry the diagnosis of TSC. This may represent a de novo mutation, parental mosaicism, or it may indicate that 1 parent has a very mild form of TSC that has escaped detection. Both parents should be carefully screened for clinical manifestations or for the pathogenic mutation, if known. Screening begins with examination of the skin, oral mucosa, teeth, and retina. Most affected family members will show TSC lesions with this approach, but additional imaging studies are recommended in their absence.[1] If 1 parent has TSC, there is a 50% chance that subsequent children will inherit the mutation. To identify additional family members at risk of TSC, obtain a 3-generation family history.[23]

If neither parent has TSC, it is possible that there is alternate paternity or undisclosed adoption. Another possibility is that 1 parent is mosaic for a mutation in *TSC1* or *TSC2*.[43] This has profound implications for genetic counseling. Whereas it would be extremely unlikely for parents of a child with a de novo mutation to have another affected child, germline mosaicism in

1 parent increases the risk of having another child with TSC. An estimate of the overall risk that apparently unaffected parents will have a second child with TSC is approximately 1% to 2%.[1]

REFERENCES

1. Northrup H, Koenig MK, Pearson DA, et al. Tuberous sclerosis complex. In: Adam MP, Ardinger HH, Pagon RA, et al, eds. *GeneReviews*. Seattle, WA: University of Washington; 1993-2018 [updated September 3, 2015].
2. Seibert D, Hong CH, Takeuchi F, et al. Recognition of tuberous sclerosis in adult women: delayed presentation with life-threatening consequences. *Ann Intern Med*. 2011;154(12):806-813, W-294.
3. de Vries PJ, Whittemore VH, Leclezio L, et al. Tuberous sclerosis associated neuropsychiatric disorders (TAND) and the TAND Checklist. *Pediatr Neurol*. 2015;52(1): 25-35.
4. Crall C, Valle M, Kapur K, et al. Effect of angiofibromas on quality of life and access to care in tuberous sclerosis patients and their caregivers. *Pediatr Dermatol*. 2016;33(5):518-525.
5. Devlin LA, Shepherd CH, Crawford H, et al. Tuberous sclerosis complex: clinical features, diagnosis, and prevalence within Northern Ireland. *Dev Med Child Neurol*. 2006;48(6):495-499.
6. Osborne JP, Fryer A, Webb D. Epidemiology of tuberous sclerosis. *Ann N Y Acad Sci*. 1991;615:125-127.
7. Curatolo P, Moavero R, Roberto D, et al. Genotype/phenotype correlations in tuberous sclerosis complex. *Semin Pediatr Neurol*. 2015;22(4):259-273.
8. Darling TN, Moss J, Mausner M. Dermatologic manifestations of tuberous sclerosis complex. In: Kwiatkowski DJ, Whittemore VH, Thiele EA, eds. *Tuberous Sclerosis Complex: Genes, Clinical Features, and Therapeutics*. Weinheim, Germany: Wiley-VCH Verlag; 2010:285-309.
9. Wataya-Kaneda M, Tanaka M, Hamasaki T, et al. Trends in the prevalence of tuberous sclerosis complex manifestations: an epidemiological study of 166 Japanese patients. *PLoS One*. 2013;8(5):e63910.
10. Northrup H, Krueger DA. Tuberous sclerosis complex diagnostic criteria update: recommendations of the 2012 International Tuberous Sclerosis Complex Consensus Conference. *Pediatr Neurol*. 2013;49(4):243-254.
11. Teng JM, Cowen EW, Wataya-Kaneda M, et al. Dermatologic and dental aspects of the 2012 International Tuberous Sclerosis Complex Consensus Statements. *JAMA Dermatol*. 2014;150(10):1095-1101.
12. Jozwiak S, Schwartz RA, Janniger CK, et al. Skin lesions in children with tuberous sclerosis complex: their prevalence, natural course, and diagnostic significance. *Int J Dermatol*. 1998;37(12):911-917.
13. Webb DW, Clarke A, Fryer A, et al. The cutaneous features of tuberous sclerosis: a population study. *Br J Dermatol*. 1996;135(1):1-5.
14. Fitzpatrick TB. History and significance of white macules, earliest visible sign of tuberous sclerosis. *Ann N Y Acad Sci*. 1991;615:26-35.
15. Vanderhooft SL, Francis JS, Pagon RA, et al. Prevalence of hypopigmented macules in a healthy population. *J Pediatr*. 1996;129(3):355-361.
16. Nathan N, Tyburczy ME, Hamieh L, et al. Nipple Angiofibromas with loss of TSC2 are associated with tuberous sclerosis complex. *J Invest Dermatol*. 2016;136(2):535-538.
17. Hall MR, Kovach BT, Miller JL. Unilateral facial angiofibromas without other evidence of tuberous sclerosis: case report and review of the literature. *Cutis*. 2007;80(4):284-288.
18. Aldrich CS, Hong CH, Groves L, et al. Acral lesions in tuberous sclerosis complex: insights into pathogenesis. *J Am Acad Dermatol*. 2010;63(2):244-251.
19. Zeller J, Friedmann D, Clerici T, et al. The significance of a single periungual fibroma: report of seven cases. *Arch Dermatol*. 1995;131(12):1465-1466.
20. Torrelo A, Hadj-Rabia S, Colmenero I, et al. Folliculocystic and collagen hamartoma of tuberous sclerosis complex. *J Am Acad Dermatol*. 2012;66(4): 617-621.
21. Sparling JD, Hong CH, Brahim JS, et al. Oral findings in 58 adults with tuberous sclerosis complex. *J Am Acad Dermatol*. 2007;56(5):786-790.
22. Curatolo P, Moavero R, de Vries PJ. Neurological and neuropsychiatric aspects of tuberous sclerosis complex. *Lancet Neurol*. 2015;14(7):733-745.
23. Krueger DA, Northrup H. Tuberous sclerosis complex surveillance and management: recommendations of the 2012 International Tuberous Sclerosis Complex Consensus Conference. *Pediatr Neurol*. 2013;49(4): 255-265.
24. Hinton RB, Prakash A, Romp RL, et al. Cardiovascular manifestations of tuberous sclerosis complex and summary of the revised diagnostic criteria and surveillance and management recommendations from the International Tuberous Sclerosis Consensus Group. *J Am Heart Assoc*. 2014;3(6):e001493.
25. Kingswood JC, Bissler JJ, Budde K, et al. Review of the tuberous sclerosis renal guidelines from the 2012 Consensus Conference: Current Data and Future Study. *Nephron*. 2016;134(2):51-58.
26. Cudzilo CJ, Szczesniak RD, Brody AS, et al. Lymphangioleiomyomatosis screening in women with tuberous sclerosis. *Chest*. 2013;144(2):578-585.
27. Johnson SR, Taveira-DaSilva AM, Moss J. Lymphangioleiomyomatosis. *Clin Chest Med*. 2016;37(3):389-403.
28. Hodgson N, Kinori M, Goldbaum MH, et al. Ophthalmic manifestations of tuberous sclerosis: a review. *Clin Exp Ophthalmol*. 2017;45(1):81-86.
29. Santos L, Brcic I, Unterweger G, et al. Hamartomatous polyposis in tuberous sclerosis complex: case report and review of the literature. *Pathol Res Pract*. 2015;211(12):1025-1029.
30. Dworakowska D, Grossman AB. Are neuroendocrine tumours a feature of tuberous sclerosis? A systematic review. *Endocr Relat Cancer*. 2009;16(1):45-58.
31. Salerno AE, Marsenic O, Meyers KE, et al. Vascular involvement in tuberous sclerosis. *Pediatr Nephrol*. 2010;25(8):1555-1561.
32. Avila NA, Dwyer AJ, Rabel A, et al. CT of sclerotic bone lesions: imaging features differentiating tuberous sclerosis complex with lymphangioleiomyomatosis from sporadic lymphangioleiomyomatosis. *Radiology*. 2010;254(3):851-857.
33. Manoukian SB, Kowal DJ. Comprehensive imaging manifestations of tuberous sclerosis. *AJR Am J Roentgenol*. 2015;204(5):933-943.
34. Kane Y. The "bumps" on my face. *J Am Acad Dermatol*. 2004;51(1)(suppl):S11-S12.
35. Sweeney SM. Pediatric dermatologic surgery: a surgical approach to the cutaneous features of tuberous sclerosis complex. *Adv Dermatol*. 2004;20:117-135.
36. Tyburczy ME, Wang JA, Li S, et al. Sun exposure causes somatic second-hit mutations and angiofibroma

development in tuberous sclerosis complex. *Hum Mol Genet*. 2014;23(8):2023-2029.
37. Laplante M, Sabatini DM. mTOR signaling in growth control and disease. *Cell*. 2012;149(2):274-293.
38. Li S, Thangapazham RL, Wang JA, et al. Human TSC2-null fibroblast-like cells induce hair follicle neogenesis and hamartoma morphogenesis. *Nat Commun*. 2011;2:235.
39. Bolton PF, Clifford M, Tye C, et al. Intellectual abilities in tuberous sclerosis complex: risk factors and correlates from the Tuberous Sclerosis 2000 Study. *Psychol Med*. 2015;45(11):2321-2331.
40. Jeong A, Wong M. Systemic disease manifestations associated with epilepsy in tuberous sclerosis complex. *Epilepsia*. 2016;57(9):1443-1449.
41. Galahitiyawa J, Wanigasinghe J, Seneviratne J, et al. Cutaneous markers of systemic manifestations of tuberous sclerosis complex. *Int J Dermatol*. 2015;54(1): e52-e55.
42. Jimbow K. Tuberous sclerosis and guttate leukodermas. *Semin Cutan Med Surg*. 1997;16(1):30-35.
43. Tyburczy ME, Dies KA, Glass J, et al. Mosaic and intronic mutations in TSC1/TSC2 explain the majority of TSC patients with no mutation identified by conventional testing. *PLoS Genet*. 2015;11(11):e1005637.
44. Nathan N, Burke K, Moss J, et al. A diagnostic and management algorithm for individuals with an isolated skin finding suggestive of tuberous sclerosis complex. *Br J Dermatol*. 2017;176(1):220-223.
45. Shepherd CW, Gomez MR, Lie JT, et al. Causes of death in patients with tuberous sclerosis. *Mayo Clin Proc*. 1991;66(8):792-796.
46. Byard RW, Blumbergs PC, James RA. Mechanisms of unexpected death in tuberous sclerosis. *J Forensic Sci*. 2003;48(1):172-176.
47. Capal JK, Franz DN. Profile of everolimus in the treatment of tuberous sclerosis complex: an evidence-based review of its place in therapy. *Neuropsychiatr Dis Treat*. 2016;12:2165-2172.
48. Nathan N, Wang JA, Li S, et al. Improvement of tuberous sclerosis complex (TSC) skin tumors during long-term treatment with oral sirolimus. *J Am Acad Dermatol*. 2015;73(5):802-808.
49. Sasongko TH, Ismail NF, Zabidi-Hussin Z. Rapamycin and rapalogs for tuberous sclerosis complex. *Cochrane Database Syst Rev*. 2016;7:CD011272.
50. Jozwiak S, Sadowski K, Kotulska K, et al. Topical use of mammalian target of rapamycin (mTOR) Inhibitors in tuberous sclerosis complex—a comprehensive review of the literature. *Pediatr Neurol*. 2016;61:21-27.
51. Wataya-Kaneda M, Tanaka M, Yang L, et al. Clinical and histologic analysis of the efficacy of topical rapamycin therapy against hypomelanotic macules in tuberous sclerosis complex. *JAMA Dermatol*. 2015;151(7): 722-730.
52. Wataya-Kaneda M, Nakamura A, Tanaka M, et al. Efficacy and Safety of Topical Sirolimus Therapy for Facial Angiofibromas in the Tuberous Sclerosis Complex: A Randomized Clinical Trial. *JAMA Dermatol*. 2017;153(1):39-48.
53. Ali FR, Mallipeddi R, Craythorne EE, et al. Our experience of carbon dioxide laser ablation of angiofibromas: case series and literature review. *J Cosmet Laser Ther*. 2016;18(7):372-375.
54. Whitehead LC, Gosling V. Parent's perceptions of interactions with health professionals in the pathway to gaining a diagnosis of tuberous sclerosis (TS) and beyond. *Res Dev Disabil*. 2003;24(2):109-119.

Chapter 137 :: Diabetes and Other Endocrine Diseases

:: April Schachtel & Andrea Kalus

DIABETES MELLITUS

AT-A-GLANCE

- The incidence of diabetes in America is increasing steadily with the epidemic of obesity.
- Fourteen percent of health care expenditures in America are diabetes related.
- Metabolic abnormalities in glucose and insulin relate directly to diabetic thick skin, limited joint mobility, eruptive xanthomas, and acanthosis nigricans.
- Neuropathy, vasculopathy, and immune dysfunction associated with diabetes contribute directly to lower-extremity ulcers and certain cutaneous infections.
- Diabetes-associated skin conditions without a known pathogenesis include: necrobiosis lipoidica, granuloma annulare, diabetic dermopathy, acquired perforating dermatosis, and bullosis diabeticorum.

EPIDEMIOLOGY

Diabetes mellitus (DM) is a major cause of morbidity and mortality in the United States; 2017 estimates suggest 23.4 million Americans have known diabetes.[1] Approximately 14% of all health care expenditures in the United States are directly attributable to the medical care of diabetes. Men and women diagnosed with diabetes at age 40 years are expected to lose 12 and 14 life-years, respectively.[2] Major studies show that tight glycemic control decreases microvascular disease (ie, retinopathy, neuropathy, nephropathy), but that coronary vascular disease, the major contributor to morbidity and mortality in patients with diabetes, receives no benefit from intensive glycemic control in patients with longstanding diabetes. In one large, randomized, controlled trial with approximately a third of patients having known coronary artery disease, intensive glycemic control was, in fact, associated with an increase in mortality. Newly diagnosed Type 2 diabetes appears to have long-term benefit from similar degrees of tight control.[3] New guidelines for glycemic control (glycosylated hemoglobin [HbA_{1c}] <7%) attempt to balance this body of evidence.[4] Tight glycemic control may have a beneficial effect on a subset of skin-related, diabetes-associated disorders, but evidence is generally lacking.

Diabetes is characterized by a state of relative or complete insulin deficiency, leading to defects in glucose, fat, and protein metabolism. In Type 1 diabetes (formerly insulin-dependent DM), an insufficiency of insulin occurs through a gradual, immune-mediated destruction of β islet cells in the pancreas, marked by autoantibodies. In Type 2 diabetes (formerly noninsulin-dependent DM), chronic hyperglycemia occurs mainly through end-organ insulin resistance followed by a progressive decrease in pancreatic insulin release associated with aging. Diabetes can be diagnosed by a fasting blood glucose level of 126 mg/dL or higher, a random value of 200 mg/dL or higher, or an HbA_{1c} level of 6.5% or above. A genetic predisposition and a strong association with obesity exist in Type 2 diabetes. In both types of diabetes, abnormalities of insulin and elevated blood glucose levels lead to metabolic, vascular, neuropathic, and immunologic abnormalities. Affected organs include the cardiovascular, renal, and nervous systems, the eyes, and the skin.

CLINICAL FEATURES

Nearly all patients with diabetes have cutaneous findings related to their condition, including those listed in Table 137-1. Some diabetes-associated skin conditions are a direct result of the related metabolic changes such as hyperglycemia and hyperlipidemia. Progressive damage to the vascular, neurologic, or immune systems also contributes significantly to skin manifestations. The mechanisms for other diabetes-associated skin conditions remain unknown. The cutaneous disorders associated with DM are characterized in the following section by disorders with evidence for metabolic, vascular, neurologic, or immunologic pathogenesis induced by glucose and insulin abnormalities and by disorders associated with diabetes, but without a clear pathogenesis.

ETIOLOGY AND PATHOGENESIS

Hyperglycemia leads to nonenzymatic glycosylation of structural and regulatory proteins, including collagen. Although nonenzymatic glycosylation occurs normally with aging, the process is greatly accelerated

TABLE 137-1
Approach to the Patient with Diabetes

Cutaneous Findings in Diabetes
- Acanthosis nigricans
- Limited joint mobility and scleroderma-like syndrome
- Scleredema diabeticorum
- Eruptive xanthomas
- Bacterial infections (streptococcal, malignant external otitis, necrotizing fasciitis)
- Fungal infections (candidal, onychomycosis, mucormycosis)
- Foot ulcers
- Necrobiosis lipoidica
- Granuloma annulare
- Diabetic dermopathy
- Acquired perforating disorders
- Bullosis diabeticorum

Related Features in Diabetes
- Retinopathy
- Nephropathy
- Neuropathy
- Cardiovascular disease
- Peripheral vascular disease
- Hyperlipidemia
- Hypertension

Diagnosis
- Diabetes can be diagnosed by a fasting blood glucose level of 126 mg/dL or higher, a random value of 200 mg/dL or higher, or an HbA_{1c} level of 6.5% or above.

Management
- Diet and exercise
- Referral to primary care provider or endocrinologist for medical management with either oral hypoglycemic agents or insulin
- Always perform a foot examination
- Address modifiable risk factors

in diabetes.[5,6] Nonenzymatic glycosylation leads to the formation of advanced glycation end products (AGEs) that are responsible for decreases in both acid solubility and enzymatic digestion of cutaneous collagen. Disorders such as diabetic thick skin and limited joint mobility (LJM) are thought to result directly from accumulation of AGEs.[7] Studies show that the degree of cutaneous AGEs correlates strongly with retinopathy, nephropathy, and other microvascular complications of diabetes.[8] There is increased interest in noninvasive measurement of AGEs in the skin and correlation with diabetes micro and macro vascular risks.[9]

Derangements of immunoregulatory mechanisms also occur in diabetes. Hyperglycemia and ketoacidosis diminish chemotaxis, phagocytosis, and bactericidal ability of white blood cells.[10] Historically, infections were a major cause of death in the diabetic patient. This has changed dramatically with improved glucose control and antibiotic use. Despite these improvements, certain infections, such as malignant external otitis, necrotizing soft-tissue infections, and the devastating disease of mucormycosis, occur more frequently in patients with diabetes.[11]

Metabolic abnormalities, including hyperinsulinemia, as is seen in early insulin-resistant Type 2 diabetes, contribute to cutaneous manifestations. The action of insulin on the insulin-like growth factor-1 (IGF1) receptor appears to mediate the abnormal epidermal proliferation and resulting phenotype of acanthosis nigricans.[12] Dysregulated lipid metabolism occurs with diabetes-associated insulin deficiency. Defective lipid processing can lead to massive hypertriglyceridemia, manifesting in the skin as eruptive xanthomas. Naturally, disorders of lipid processing also play an integral role in the vasculopathies of diabetes.

Macroangiopathy and microangiopathy contribute significantly to the cutaneous complications of diabetes. In patients with diabetes, there is increased "leakiness" or vessel wall permeability, decreased vascular responsiveness to sympathetic innervation, and less ability to respond to thermal and hypoxemic stress.[10] Combined with arteriosclerosis of large vessels, these microvascular abnormalities contribute to the formation of diabetic ulcers. In addition, a loss of cutaneous sensory innervation occurs with diabetes, predisposing patients to infection and injury. The loss of neuroinflammatory cell signaling plays a causal role in nonhealing, lower-extremity ulcers.[13] Patients with diabetes who lack lower-extremity vibratory perception have a 15.5-fold increased probability of leg amputation.[14]

CUTANEOUS DISORDERS OF DIABETES MELLITUS ASSOCIATED WITH METABOLIC, VASCULAR, NEUROLOGIC OR IMMUNOLOGIC ABNORMALITIES

ACANTHOSIS NIGRICANS

Epidemiology: Acanthosis nigricans is probably the most readily recognized skin manifestation of diabetes. Acanthosis nigricans is common in the general population, and most cases are linked to obesity and insulin resistance. In some cases, increased androgen production is also identified.[15,16] Drug-related and idiopathic acanthosis nigricans or familial acanthosis nigricans are additional causes.[17] In general, though, acanthosis nigricans should be considered a prognostic indicator for developing Type 2 diabetes.[18] The prevalence of acanthosis nigricans varies among different ethnic groups. In one study, despite similar obesity rates, the prevalence was lower in whites (0.5%) and Hispanics (5%) than in African American children (13%).[16] This finding suggests a possible genetic predisposition or increased sensitivity of the skin to hyperinsulinemia among certain populations.[18] Although historical data emphasizes the relationship between acanthosis nigricans and malignancy, a true

association is rare.[19] Only when the onset is particularly rapid, the clinical findings are florid, or in the nonobese or nondiabetic adult with acanthosis nigricans is an evaluation for malignancy beyond routine age-appropriate screening warranted.

Clinical Features: Acanthosis nigricans presents as brown to gray-black papillomatous cutaneous thickening in the flexural areas, including the posterolateral neck, axillae, groin, and abdominal folds. The distribution is usually symmetric. The affected skin has a dirty, velvety texture. In some cases, oral, esophageal, pharyngeal, laryngeal, conjunctival, and anogenital mucosal surfaces may be involved. In general, however, the back of the neck is the most consistently and severely affected area (Fig. 137-1).[18] The development of superimposed acrochordons in involved areas is well described (Fig. 137-2). In particularly florid cases, involvement on the back of the hands over the knuckles and even on the palms can be seen. When the palms are involved, the rugated appearance of the palmar surface has been called *tripe palms* and is usually associated with acanthosis nigricans seen in the setting of malignancy. In the majority of cases, the most important factor in diagnosing acanthosis nigricans is recognizing the usually associated hyperinsulinemia, which is a known risk factor for Type 2 diabetes and the metabolic syndrome.

The histopathology of clinical lesions demonstrates papillomatosis and hyperkeratosis but minimal acanthosis. Hyperpigmentation of the basal layer has been variably demonstrated, and the brown color of the lesions is attributed to the hyperkeratosis by most.[20,21]

Etiology and Pathogenesis: Insulin clearly plays a central role in the presentation of acanthosis nigricans. In a subset of women with hyperandrogenism and insulin resistance with acanthosis nigricans, loss-of-function mutations in the insulin receptor or anti–insulin-receptor antibodies can be found (Type A and Type B syndrome).[22] It is postulated that excess growth factor stimulation in the skin causes the aberrant proliferation of keratinocytes and fibroblasts that results in the phenotype of acanthosis nigricans.[15] In states of insulin resistance and hyperinsulinemia, acanthosis nigricans may result from excess insulin binding to IGF1 receptors on keratinocytes and fibroblasts.[12] IGF1 receptors are expressed on basal keratinocytes and are upregulated in proliferative conditions.[23] Studies show that high concentrations of insulin stimulate fibroblast proliferation through IGF1 receptors in vitro.[24] Other members of the tyrosine kinase receptor family, including the epidermal growth factor receptor and the fibroblast growth factor receptor, have been implicated in acanthosis nigricans. Several genetic syndromes (Crouzon and SADDAN [severe achondroplasia with developmental delay and acanthosis nigricans]) with mutations in fibroblast growth factor receptor 3 result in acanthosis nigricans in the absence of hyperinsulinemia or obesity, implicating this growth factor receptor in the pathogenesis of acanthosis nigricans.[23] In several reports of acanthosis nigricans associated with malignancy, evidence suggests that transforming growth factor-β released from the tumor cells may stimulate keratinocyte proliferation via the epidermal growth factor receptors.[25,26] Support for the role of different growth factors in the pathogenesis of acanthosis nigricans continues to accrue.

In addition to the direct effects of hyperinsulinemia on keratinocytes, insulin also appears to augment androgen levels in women. High insulin levels stimulate the production of ovarian androgens and ovarian hypertrophy with cystic changes.[22] Although associated with elevated androgen levels, the acanthosis nigricans in women with polycystic ovarian syndrome (PCOS) does not respond reliably to antiandrogen therapy, implicating the relative importance of hyperinsulinemia over hyperandrogenism in acanthosis nigricans. Several drugs also have been reported to

Figure 137-2 Acanthosis nigricans involving the axilla with numerous acrochordons.

Figure 137-1 Acanthosis nigricans involving the neck.

cause acanthosis nigricans, including systemic glucocorticoids, nicotinic acid, and estrogens such as diethylstilbestrol.[15]

Management: Treatment of acanthosis nigricans is generally ineffective. Topical treatment with calcipotriol,[27] salicylic acid, glycolic acid peels, urea, systemic, and topical retinoids have all been used with anecdotal success.[28] Long-pulsed alexandrite laser was effective in 1 patient.[29] When identifiable, treatment of the underlying cause may be beneficial. Improvement or resolution does occur with weight loss in some obese patients.[12,15] Medications that improve insulin sensitivity, such as metformin, have a theoretic benefit. Removal of an offending medication generally results in clearance of the skin.[30] In patients with acanthosis nigricans in association with malignancy, there is usually improvement following treatment of the underlying malignancy. The skin finding may present before or after the diagnosis of malignancy is made. When it is associated with malignancy, a tumor of intraabdominal origin, usually gastric, is seen in the majority of cases.[31] It has been repeatedly described that patients' skin improves with chemotherapy and remits with recurrences.

DIABETIC THICK SKIN

Several specific syndromes are associated with localized thickening of the skin in diabetes. The common underlying pathogenesis involves biochemical alterations in dermal collagen and mucopolysaccharides. The clinical syndromes are a result of increased deposition and improper degradation of these constituents, likely related to the formation of AGEs.

LIMITED JOINT MOBILITY AND SCLERODERMA-LIKE SYNDROME

Diabetic LJM, or cheiroarthropathy, presents as tightness and thickening of the skin and periarticular connective tissue of the fingers, resulting in a painless loss of joint mobility. Initial involvement of the distal interphalangeal joints of the fifth digit usually progresses proximally to involve all fingers. Larger joints of the elbow, knee, and foot may be affected. The actual joint space, however, remains uninvolved, as LJM is not a true arthropathy. This disorder is characterized by the "prayer sign," which is an inability to approximate the palmar surfaces and interphalangeal joint spaces with the hands pressed together and fingers separated (Fig. 137-3). In addition to joint contractures, the skin may appear thickened, waxy, and smooth with apparent loss of adnexa, resembling skin changes in scleroderma.

Of adult patients with Type 1 diabetes, 30% to 50% have LJM, and it is common in Type 2 diabetes as well. LJM is associated with increased duration of diabetes and poor glucose control.[32,33] One longitudinal prospective study showed a 2.5-fold increase in the risk of LJM for every unit increase in the HbA_{1c}.[33] In addition, it appears that LJM may be correlated with the presence of microvascular disease.[34]

Most important, the evidence indicates that intensive insulin therapy is central in prevention and, possibly, treatment of LJM and scleroderma-like syndrome. Long-term tight glycemic control leads to decreased skin AGEs,[8] and tight glycemic control is associated with delayed onset and severity of LJM.[33] On the basis of improvements in diabetes management, a fourfold

Figure 137-3 Limited joint mobility in a 31-year-old male patient with Type 1 diabetes mellitus. The patient is unable to approximate the palmar surface of the proximal and distal interphalangeal joints with palms pressed together (known as the "prayer sign"). **A,** Ulnar view; only fingertips are approximated. **B,** Radial view; straining to press palms together.

reduction in the frequency of LJM has been reported.[35] Treatment of LJM is difficult and should focus on tight control of blood glucose as well as physical therapy to preserve active range of motion.

Although the scleroderma-like skin changes can occur independently, they often occur together with LJM in patients with diabetes. The scleroderma-like syndrome is not associated with systemic sclerosis but does correlate with the duration of diabetes, the severity of joint contractures, and retinopathy.[36] It appears that the historical description of "diabetic hand syndrome" represents a combination of LJM and the scleroderma-like syndrome.

SCLEREDEMA DIABETICORUM (SEE CHAP. 67)

Scleredema of diabetes (scleredema diabeticorum) presents with the insidious onset of painless, symmetric induration and thickening of the skin on the upper back and neck. Spreading to the face, shoulders, and anterior torso also may occur. The skin retains a nonpitting, woody, *peau d'orange* quality. Identical changes occur with postinfectious scleredema, usually associated with streptococcal pharyngitis. In scleredema associated with infection, however, the onset is often sudden, and the symptoms usually remit over time. Scleredema diabeticorum affects 2.5% to 14% of patients with diabetes.[37,38] Scleredema diabeticorum is a disease of longstanding diabetes associated with obesity. Most patients have Type 2 diabetes. This disorder has not been reported in children.

The pathogenesis of scleredema diabeticorum is postulated to be unregulated production of extracellular matrix molecules by fibroblasts, leading to thickened collagen bundles and increased deposition of glycosaminoglycans (mainly hyaluronic acid). Studies using in vitro fibroblast analysis from involved skin have variably demonstrated increased synthesis of glycosaminoglycans and Type 1 collagen.[39] However, most of these reports involved nondiabetic patients with paraproteinemia and are based on small numbers of cases.

Patients with scleredema diabeticorum may experience decreased sensation to pain and light touch over the affected areas and difficulties with upper-extremity and neck range of motion. Extreme cases may result in full loss of range of motion. Unlike in LJM and scleroderma-like syndrome, the presence of scleredema does not correlate with retinopathy, nephropathy, neuropathy, or principal vascular disease.[37] However, no large-scale prospective study has been done. Most patients with scleredema diabeticorum become insulin dependent, are difficult to treat, and have multiple complications of diabetes.[39] Treatment of scleredema diabeticorum is usually unsuccessful. Case reports describe treatment with radiotherapy, low-dose methotrexate, bath psoralen and ultraviolet A light (PUVA), extracorporeal photopheresis, factor XIII, and prostaglandin E_1.[40-42] Weight reduction and physical therapy to preserve range of motion may be useful.

Figure 137-4 Eruptive xanthomas appear as yellow-orange papules and plaques on a male patient with Type 2 diabetes mellitus. (Used with permission from Greg Raugi, MD.)

ERUPTIVE XANTHOMAS (SEE CHAP. 126)

Eruptive xanthomas present clinically as 1-mm to 4-mm, reddish-yellow papules on the buttocks and extensor surfaces of the extremities (Fig. 137-4). The lesions occur in crops and may coalesce into plaques over time. Although eruptive xanthomas are generally asymptomatic, there is often underlying severe hypertriglyceridemia (>1000 mg/dL) and potentially undiagnosed diabetes. Uncontrolled diabetes is a common cause of massive hypertriglyceridemia. Histologic and biochemical studies show that lipoproteins (mainly chylomicrons) in the blood permeate cutaneous vessel walls and accumulate in macrophages in the dermis.[43] Initially, triglycerides predominate in the skin lesions but, because triglycerides are mobilized more easily than cholesterol, the lesions contain progressively more cholesterol as they resolve.[43]

In addition to eruptive xanthomas, triglyceride levels above 4000 mg/dL may cause lipemia retinalis. On funduscopic examination, lipemia retinalis appears as pale pink to white retinal arterioles and venules. The fundus may have a milky hue. Untreated, severe hypertriglyceridemia may also present clinically with abdominal pain, hepatosplenomegaly, pancreatitis, or dyspnea from decreased pulmonary diffusing capacity and abnormal hemoglobin oxygen affinity.[44] Treatment of hypertriglyceridemia involves lifestyle modification and control of the underlying diabetes. The eruptive xanthomas respond rapidly and usually resolve completely in 6 to 8 weeks.[45]

CUTANEOUS INFECTIONS

In diabetic patients, there is not strong evidence for an increased susceptibility to infections in general, but several skin infections do occur more commonly, with greater severity, or with a greater risk for complications in patients with DM. Joshi and colleagues have reviewed this subject.[11]

TABLE 137-2
Infections More Common or More Severe in Diabetic Patients

BACTERIA	FUNGAL AND YEAST
▪ Invasive group B *Streptococcus*	▪ *Candida*
▪ Invasive group A *Streptococcus*	▪ Dermatophyte
▪ Malignant external otitis	▪ Rhinocerebral mucormycosis
▪ Necrotizing fasciitis	

There is extensive research on the pathogenesis of immune dysfunction in diabetes. Although some studies could not detect defects at the cellular level,[46] other studies show that leukocyte chemotaxis, adherence, and phagocytosis are impaired in patients with diabetes, especially during hyperglycemia and diabetic acidosis.[47] Further studies show that cutaneous T-cell function and response to antigen challenge are also decreased in diabetes.[11] Table 137-2 outlines some of the skin infections that occur more commonly or more severely in diabetic patients.

Figure 137-5 "Diabetic foot." Two larger ulcers overlying the first right and second left metacarpophalangeal joints in a 56-year-old man with diabetes of 20 years' duration. There is significant sensory neuropathy and peripheral vascular disease.

DIABETIC ULCERS

Epidemiology: Foot ulcers are a significant problem for patients with diabetes, occurring in 15% to 25% of diabetic patients.[48] Patients with diabetes have an estimated increased risk of lower-extremity amputation that is 10 to 30 times greater than that of the general population. Lower-extremity ulcers account for 25% of all hospital stays for patients with diabetes and are the proximal cause of amputation in 84% of patients.[49] Of diabetic patients with foot ulcers, 14% to 24% will eventually undergo amputation.[50]

Clinical Features: Callus formation precedes necrosis and breakdown of tissue over bony prominences of feet, usually on great toe and sole, over first and/or second metacarpophalangeal joints. Ulcers are surrounded by a ring of callus and may extend to underlying joint and bone (Fig. 137-5). Complications are soft-tissue infection and osteomyelitis.

Etiology and Pathogenesis: Many of the factors previously described in this chapter contribute to the pathogenesis of diabetic ulcers. Peripheral neuropathy, pressure, and trauma are thought to play prominent roles in the development of diabetic ulcers. Neuropathy (associated with uncontrolled hyperglycemia) is one of the major predictors of diabetic ulcers.[14] Patients with diabetes also suffer the loss of cutaneous sensory nerves.[51] The subsequent diminished neuroinflammatory signaling via neuropeptides to keratinocytes, fibroblasts, endothelial cells, and inflammatory cells may adversely affect wound healing.[52] Excessive plantar pressure develops from foot deformities (Charcot arthropathy). In a study of 314 diabetic patients with ulcers, ill-fitting shoes and socks were the most common reasons for foot ulcers.[53] Callus formation is a sign of excess friction and often precedes foot ulcers. Wearing running shoes demonstrates a measurable reduction of calluses.[54] Once an ulcer develops, peripheral vascular disease and intrinsic wound healing disturbances contribute to adverse outcomes. Known factors associated with foot ulceration in the setting of diabetes include previous foot ulceration, prior lower-extremity amputation, long duration of diabetes (>10 years), impaired visual acuity, onychomycosis, and poor glycemic control.[55]

Management: Treatment of diabetic ulcers requires modification of factors that contribute to ulcer formation, including, stasis dermatitis, leg edema, and skin infection. Standard therapy for neuropathic diabetic ulcers includes debridement, off-loading (often non–weight-bearing), moist wound care, and protective dressings (Fig. 137-6).

There has been substantial interest in developing adjunctive therapies for diabetic ulcers, including growth factors and skin-replacement products, but data have not supported their use as a replacement for standard wound care. Recombinant platelet-derived growth factor for the topical treatment of diabetic foot ulcers demonstrates a modest benefit if used with adequate off-loading, debridement, and control of infection.[56] A large multicenter, clinical trial of a bilayered living skin equivalent[57] showed 56% healing at 12 weeks as compared with 38% healing at 12 weeks for standard care. The most favorable published results for a monolayered living skin equivalent and platelet-derived growth factor show roughly comparable improvement in healing to that reported for bilayered living skin equivalents when each is compared

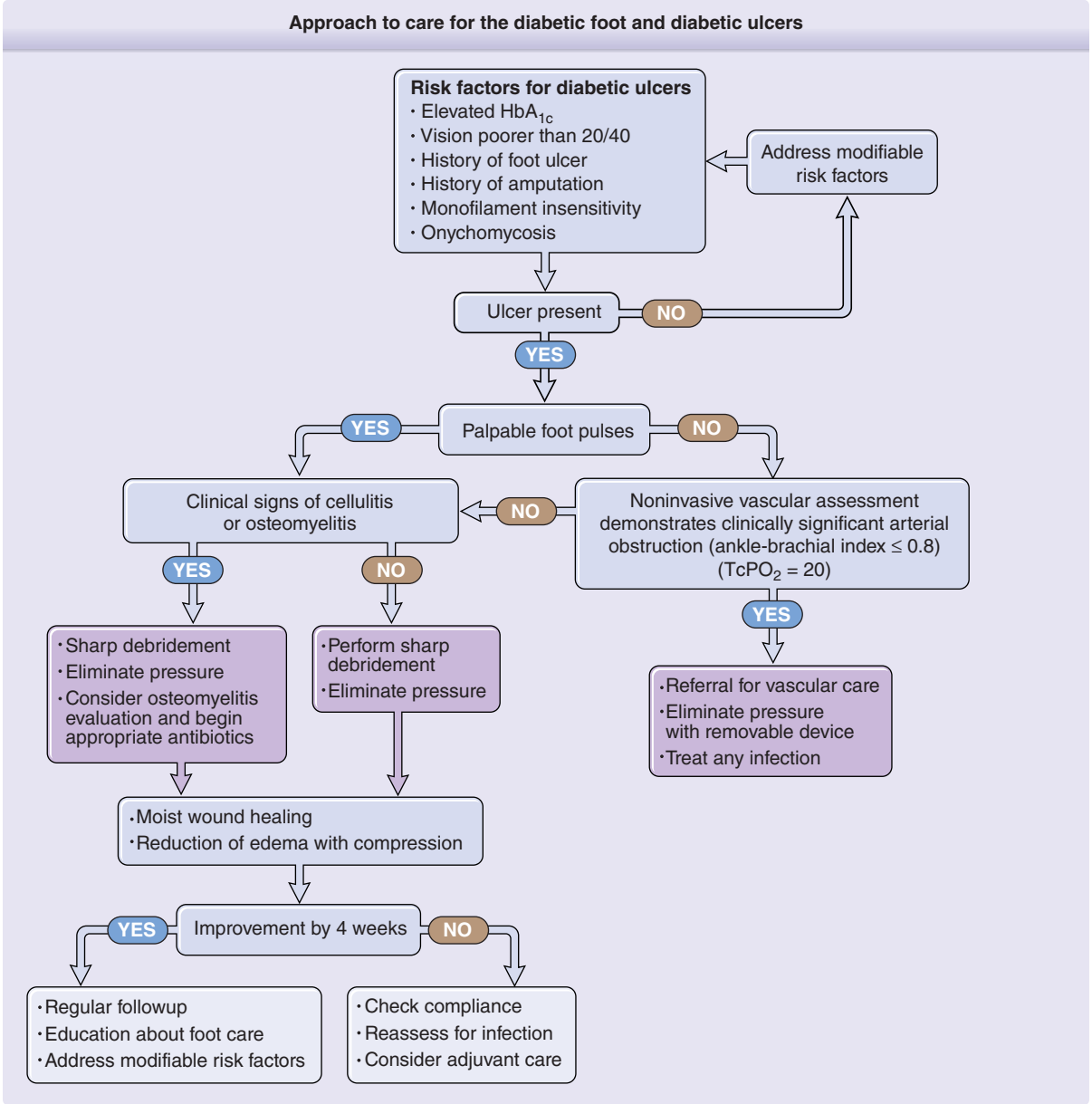

Figure 137-6 Approach to the care of the diabetic foot and diabetic ulcers. HbA_{1c}, hemoglobin A_{1c}; $TcPO_2$, transcutaneous oxygen tension.

with standard care or placebo.[57] These technologies await definitive analysis of cost-effectiveness compared with standard older approaches. Even though the studies available do not support the routine use of these biologic approaches, these approaches may have a role in the treatment of large ulcers (>2 cm) or of ulcers that are poorly responsive to standard therapy. A recent metaanalysis makes the point that, typically, a higher percentage of ulcers heal during a 12-week study period with biologic products than with standard therapy, but analysis of cost-effectiveness is made difficult by differences in study designs, short duration of studies, different cost structures, the absence of quality-of-life measures, and pharmaceutical funding of the primary studies and analysis.[58]

Prevention: Ulcer prevention is the most important intervention physicians and other health care professionals can provide for diabetic patients. An excellent review of ulcer prevention was published by Singh and colleagues.[48] Optimizing glycemic control is well supported to prevent the neuropathy that is so intimately associated with foot ulceration. The risk of a foot ulcer increases in nearly direct proportion to every 1% increase in HbA_{1c}.[55] Foot examination should be part of every patient visit if diabetes is on the problem list. Failure to perceive touch of a Semmes-Weinstein 10-g monofilament means a patient lacks protective sensation in the foot tested. If tinea pedis is present, it should be treated to prevent the associated skin barrier

TABLE 137-3

General Foot Care Guidelines for Patients with Diabetes

- Examine feet every day, including areas between the toes.
- Regular washing of feet with careful drying, especially between the toes.
- Water temperature should always be less than 37°C (98.6°F) and checked first with the hand rather than the foot.
- Barefoot walking indoors or outdoors and wearing of shoes without socks is discouraged.
- Daily inspection and palpation of the inside of the shoes for irregular surfaces or foreign objects.
- If vision is impaired, patients should not try to treat their feet (eg, nails) by themselves.
- Emollients should be used for dry skin, but not between the toes.
- Change stockings daily.
- Stockings should be worn with seams inside out or, preferably, without any seams at all.
- Nails should be cut straight across.
- Corns and calluses should not be cut by patients but by a health care provider.
- The patient must ensure that the feet are examined regularly by a health care provider.
- The patient should seek early health care attention for any blister, cut, scratch, sore, ingrown toenail, or dermatitis.

disruption. Smoking cessation should be encouraged. Patients should be counseled about the importance of daily foot care (Table 137-3).

Specialized ulcer care teams have published impressive results on the prevention and healing of ulcers.[59] This multidisciplinary team approach is becoming more important in the treatment of diabetic ulcers in large population centers. Patients with a history of ulceration are at high risk for reulceration (34% at 1 year, 61% at 3 years, and 70% at 5 years).[60] Intensifying education (formal foot care classes) and prevention efforts in this group, along with lifelong surveillance, is required.

DISORDERS ASSOCIATED WITH DIABETES MELLITUS BUT OF UNKNOWN PATHOGENESIS

NECROBIOSIS LIPOIDICA

Coined by Urbach in 1932 as *necrobiosis lipoidica diabeticorum*, this disorder was named after characteristic histologic findings and was first described in patients with diabetes. Because not all patients have concurrent diabetes, the shortened term, *necrobiosis lipoidica* (NL) is preferred.

Clinical Features: Classically, NL presents with 1 to several sharply demarcated yellow-brown plaques on the anterior pretibial region (Fig. 137-7). The lesions have a violaceous, irregular border that may be raised and indurated. Early on, NL often presents as red-brown papules and nodules that may mimic sarcoid or granuloma annulare (GA). Over time, the lesions flatten, and a central yellow or orange area becomes atrophic, and, commonly, telangiectasias are visible, taking on the characteristic "glazed-porcelain" sheen. Aside from the shins, other sites of predilection include ankles, calves, thighs, and feet. Fifteen percent of patients develop lesions on the upper extremities

Figure 137-7 Necrobiosis lipoidica. **A,** A single orange plaque with atrophy of the overlying epidermis and arborizing telangiectasias is seen on the lower leg of a patient with diabetes mellitus; the crust marks an area of early ulceration. **B,** Older lesions with striking central atrophy involving both the dermis and epidermis.

and trunk that tend to be more papulonodular. Although pain and pruritus have been reported, most lesions are asymptomatic. Anesthesia of the plaques does occur.[61]

The clinical course is often indolent, with spontaneous remission in less than 20% of cases.[10] The plaques tend to stabilize over time, and formation of new lesions tapers off. However, the possibility of ulceration, a poor spontaneous remission rate, and cosmetic concerns lead patients to seek treatment. Ulceration, the most serious complication, occurs in approximately 13% to 35% of cases on the legs.[62,63] A few cases of squamous cell carcinoma arising in chronic ulcerative lesions of NL have been reported.[64] Multiple reports document the association of NL with GA and sarcoidosis.[65]

Epidemiology and Pathogenesis: Epidemiologic data show that the mean age of onset is around 30 years, with women representing 3 times more cases than men.[62] The most often quoted statistics concerning the association of NL with diabetes are from a 1966 retrospective study at the Mayo Clinic. Of 171 patients with NL, 67% had diabetes at diagnosis, and another 5% to 10% had glucose tolerance abnormalities.[62] However, in a 1999-study of 65 patients with NL, only 11% had diabetes after 15 years of followup.[66] Conversely, the prevalence of NL has been found to be only 0.3% to 3% in patients with diabetes.[62] Although lacking full concordance, NL definitely has a strong association with diabetes and remains a valid marker of the disease. The pathogenesis of this skin disease is unclear.[63] The degree of hyperglycemia and diabetic control does not appear to correlate with the presence of NL.[67]

Management: Treatment of NL is disappointing. Case reports and small, uncontrolled trials provide the basis for treatment decisions. Early application of potent topical glucocorticoids might slow progression.[63] Although improvement can be seen with intralesional injection of glucocorticoids to the active border, the risk of ulceration with this treatment modality should be considered. A few case reports and 1 series of 6 patients[68] showed benefit with short-term systemic glucocorticoids. Aspirin and dipyridamole have produced variable results.[63] Anecdotal reports exist that support the use of tumor necrosis factor-α inhibitors, topical retinoids, and topical PUVA. Treatment with fumaric acid esters in 18 patients was reported to improve lesions clinically and histologically.[69]

Given the generally benign nature of the lesions, physicians should consider the adage "do no harm." Focus should be on prevention of ulcers. When ulceration occurs in patients with NL, the same wound care principles apply as for all diabetic ulcers. Healing of ulcerated lesions with cyclosporine has been demonstrated in several patients.[70] Surgical excision down to fascia and split-thickness skin grafting remain as the last resort for recalcitrant ulcers in NL.[71]

GRANULOMA ANNULARE (SEE CHAP. 34)

The association of GA with diabetes is weaker than that of NL. Although most patients with GA are in good health, without underlying systemic illness, an association with diabetes is supported in the literature. Dabski and Winklemann[72] found diabetes in 9.7% of patients with localized GA and 21% of patients with generalized GA. An additional small retrospective case-control study showed an increased prevalence of diabetes among patients with GA (18%) as compared with the prevalence in age-matched controls (8%).[73] Furthermore, there is an impression that diabetes is found more frequently in patients with adult-onset GA and in those with generalized or perforating GA, and that these patients tend to experience a more chronic, relapsing course of GA. The pathogenesis is unclear. Clinical findings and treatment of GA are discussed in Chap. 34.

DIABETIC DERMOPATHY

Clinical Features: Atrophic skin lesions of the lower extremity, or shin spots, were first characterized and proposed as a cutaneous marker for diabetes in 1964.[74] Shortly after, Binkley coined the term *diabetic dermopathy* to correlate the pathologic changes with those of retinopathy, nephropathy, and neuropathy.[75] Diabetic dermopathy presents as small (<1 cm), atrophic, pink to brown, scar-like macules on the pretibial areas (Fig. 137-8). The lesions are asymptomatic and clear within 1 to 2 years with slight residual atrophy or hypopigmentation.[75] The appearance of new lesions gives the sense that the pigmentation and atrophy are persistent.

An association seems to exist between diabetic dermopathy and the more serious complications of diabetes. In a study of 173 patients with diabetes, the incidence of shin spots correlated with the duration of diabetes and the presence of retinopathy, nephropathy, and neuropathy.[76] Diabetic dermopathy does not, however, correlate with obesity or hypertension in

Figure 137-8 Diabetic dermopathy with hyperpigmented macules on the anterior lower legs.

patients with diabetes.[77] No treatment is necessary for the individual atrophic tibial lesions. They are asymptomatic and are not directly associated with an increase in morbidity.

Etiology and Pathogenesis: Controversy has existed about the disorder's etiology, specificity for diabetes, and association with other microangiopathic complications of diabetes.

The prevalence of shin spots in ambulatory patients with diabetes varies. In a population-based study from Sweden, diabetic dermopathy was found in 33% of patients with Type 1 diabetes and in 39% of patients with Type 2 diabetes, compared with 2% of controls.[78] In other studies, the prevalence rate for individuals without diabetes ranges from 1.5% for healthy medical students to 20% for a group of nondiabetic endocrine patients.[77] Diabetic dermopathy occurs more often in patients with an increased duration of diabetes and is more frequent in men.[77]

It is likely that the lesions are related to antecedent trauma. Lithner[79] induced diabetic dermopathy on the legs of diabetic patients with heat and cold injury, whereas nondiabetic control subjects healed without residual change. When questioned, most patients attribute the changes to injury, but are often unable to recall preceding trauma.

ACQUIRED PERFORATING DISORDERS (SEE CHAP. 71)

The acquired perforating disorders comprise an overlapping group of disorders characterized by transepidermal elimination or "spitting" of altered dermal constituents. Included in this group are Kyrle disease, reactive perforating collagenosis, perforating folliculitis, and elastosis perforans serpiginosa.[80] These disorders and their treatment[81] are fully described in Chap. 71.

Clinically, these lesions appear as pruritic, keratotic papules mainly on the extensor surfaces of the extremities. Papules and nodules with a perforating component may also occur on the trunk and face. Many are follicular and contain a prominent central keratotic plug. The papules may be grouped, or coalesce to form verrucous plaques. Treatment of the perforating disorders is usually unsuccessful. Retinoic acid, topical glucocorticoids, and PUVA are partially successful.[81]

BULLOSIS DIABETICORUM

Clinical Features: The abrupt, spontaneous development of blisters on the lower extremities without other demonstrable cause is a rare characteristic skin manifestation of diabetes. Bullosis diabeticorum is characterized by bullae on the lower extremities, usually the toes, feet, and shins, arising in normal skin. Occasionally, the distal upper extremities are involved. The blisters are usually painless and not pruritic. Healing occurs within 2 to 5 weeks and rarely leaves scarring. The condition may recur as successive crops of bullae over many years. Studies of affected individuals excluded other blistering skin disorders, and revealed no abnormalities of porphyrin metabolism.[82] Histopathologic examination of the bullae shows an inconsistent level of separation varying from intraepidermal to subepidermal.[83] No immunopathologic features are consistently observed (Table 137-4).

TABLE 137-4
Differential Diagnosis and Evaluation of Bullosis Diabeticorum

Differential Diagnosis
- Bullous impetigo
- Bullous pemphigoid
- Epidermolysis bullosa acquisita
- Porphyria cutanea tarda
- Bullous erythema multiforme
- Insect bite reaction

Laboratory Tests
- Skin biopsy for histology and immunofluorescence
- Bacterial cultures
- Screening for porphyrins

Bullosis diabeticorum runs a benign course without involvement of large body surface areas. The only serious complication is that of secondary infection, which should be managed with culture and appropriate antibiotics if suspected. Otherwise, therapy is supportive. The real importance of this disorder is that of correct diagnosis because several of the blistering skin diseases have a high rate of morbidity and require potentially toxic systemic treatments. Exclusion of these entities is important. The patient should be educated, reassured, and wound care implemented.

Etiology and Pathogenesis: The pathogenesis of diabetic bullae is unknown. Patients with bullosis diabeticorum do not have a history of antecedent trauma or infection. One study found a decreased threshold to suction-induced blister formation in patients with diabetes.[82] Reduced suction blister time is also observed with increasing age in nondiabetic subjects.[83] Although a history of antecedent trauma is not elicited, this finding suggests a role of increased skin fragility in diabetic bullae. Perhaps the formation of AGEs leads to increased fragility.

OBESITY AND THE METABOLIC SYNDROME

EPIDEMIOLOGY

Obesity is characterized by excess fat mass and defined according to the body mass index (BMI [kg/m^2]), a calculation based on weight and height (BMI = body weight [in kg] ÷ square of stature [height in meters]). BMI is correlated with body fat and the World Health Organization defines overweight as a BMI greater

than 25 and obesity as greater than 30 kg/m^2. For Americans, the risk of becoming overweight or obese in adulthood is high. As part of the National Health and Nutrition Examination Survey (NHANES) in 2012, 35% of adults were obese.[84]

CLINICAL FEATURES

Physiologic changes in the skin related to obesity include alterations in epidermal barrier function,[85,86] increased sweating along with larger skin folds, increased skin surface pH in intertriginous areas,[87] poor lymphatic drainage, impaired wound healing in animal models,[88] and impaired responsiveness of the microvasculature.[89] Several reviews regarding obesity and dermatology have been published.[90,91] Table 137-5 lists the cutaneous disorders seen in obesity. Detailed discussion of findings and treatments for these disorders are found in the appropriate sections of the text.

It is now well recognized that the presence of abdominal—central rather than subcutaneous—obesity (more than just increased BMI) is associated with insulin resistance, hyperlipidemia, hypertension, and vascular inflammation (Table 137-6). The coexistence of these disorders increases the risk for diabetes and cardiovascular disease and has been called the metabolic syndrome. It is not clear that the metabolic syndrome confers risk beyond that of the individual components, but because the traits cooccur, those with 1 trait are likely to have others. The most important therapy is weight reduction and exercise along with adequate control of cardiac risk factors.

TABLE 137-5
Cutaneous Disorders Associated with Obesity

Metabolic
- Acanthosis nigricans
- Acrochordons
- Keratosis pilaris
- Hyperandrogenism
- Hirsutism
- Tophaceous gout

Infectious
- Candidiasis
- Dermatophytosis
- Intertrigo
- Cellulitis
- Erysipelas
- Necrotizing fasciitis

Mechanical
- Plantar hyperkeratosis
- Striae distensae
- Lymphedema
- Elephantiasis nostras verrucosa
- Venous stasis
- Cellulite

Miscellaneous
- Hidradenitis suppurativa
- Adiposis dolorosa
- Psoriasis

TABLE 137-6
Definition of the Metabolic Syndrome (Any 3 of 5 Traits)

1. Abdominal Obesity
2. Serum triglycerides ≥150 mg/dL (or drug treatment of elevated triglycerides)
3. Serum high-density lipoprotein cholesterol (HDL-C) <40 mg/dL in men and <50 mg/dL in women (or drug treatment of low HDL-C)
4. Blood pressure ≥130/85 mm Hg (or drug treatment of elevated blood pressure)
5. Fasting plasma glucose ≥100 mg/dL (or drug treatment of elevated blood glucose)

ETIOLOGY AND PATHOGENESIS

Contributing factors to obesity are nutritional choices, activity and exercise, medications, and, rarely, one of several endocrine disorders. In the setting of nutrient excess and weight gain, numerous comorbid factors occur that may contribute to further weight gain by increasing energy intake or decreasing energy expenditure. These include inflammation and insulin resistance, depression and emotional eating, degenerative joint disease, obstructive sleep apnea, gonadal dysfunction, vitamin D deficiency. Familial studies suggest a strong genetic basis for human obesity. The genetics of obesity are complex, although most human obesity is likely polygenic, multiple single genes have been identified as key regulators of body adiposity. Three of these genes (leptin, proopiomelanocortin [*POMC*], and agouti-related protein [*AgRP*]) with dermatologic relevance are discussed in detail below.

The hormone leptin is secreted by adipose tissue in proportion to total body fat. Leptin regulates energy homeostasis, neuroendocrine function, and metabolism.[92] Rare cases in humans have shown that leptin deficiency causes extreme obesity, hyperphagia, diabetes, neuroendocrine abnormalities, and infertility, all of which can be reversed by administration of exogenous leptin. However, most obese humans are leptin resistant, have high circulating levels of leptin, and pharmacologic leptin administration has not proven to be a successful weight-loss strategy. Leptin resistance appears to be at the hypothalamic leptin receptor or downstream.[92] Congenital and acquired forms of lipoatrophy (HIV or highly active antiretroviral therapy associated) are characterized by low leptin levels and metabolic abnormalities, including insulin resistance, hyperlipidemia, and fatty liver. Leptin treatment in these patients can improve insulin resistance, lipid abnormalities, and fat distribution.[93,94]

Leptin stimulates the hypothalamic melanocortin pathway including hypothalamic neurons expressing POMC. Cleavage of POMC results in peptide agonists for all 5 homologous melanocortin receptors. The melanocortin 1 receptor (MC1R) is expressed on melanocytes and mutations in MC1R are known to cause red hair and fair skin.[95] Inactivating mutations in MC4R and to a lesser degree MC3R are associated with obesity. Studies estimate that inactivating

mutations in MC4R account for up to 6% of all severe cases of early-onset obesity. Further emphasizing the importance of the POMC pathway is the finding that homozygous loss of function of POMC (complete POMC deficiency) produces obesity, pale skin, and red hair.[96]

AgRP is an endogenous hypothalamic melanocortin receptor antagonist, which causes obesity when overexpressed. Although studies have found high serum AgRP levels in obese men,[97] the role of AgRP in common obesity is unclear. The gene is closely related to *agouti*, a skin pigmentation gene, which causes yellow coat color and obesity when overexpressed in mice.

The hormonal regulation of obesity is similarly complex and several gut hormones are likely involved in the regulation of food intake. The gastric-derived, appetite-stimulating hormone ghrelin impacts obesity and diabetes by modulating body weight, insulin secretion, and gastric motility.[98] Serum ghrelin levels rise before meals and are thought to promote food intake. Sharp rises are seen in states of starvation and after weight loss in obesity. This likely contributes to weight regain. Interestingly, postgastric bypass surgery patients have altered ghrelin secretion and this may be one of the reasons for the long-term success of this surgical treatment of obesity.[99] Ghrelin receptors are located in the pituitary and hypothalamus and stimulate growth hormone (GH1) release and regulate energy expenditure (see Fig. 137-15).[93] Ghrelin antagonists have been considered as a treatment of obesity, metabolic syndrome, and diabetes.

MANAGEMENT

The cornerstones of treatment of overweight and obesity are dietary changes, increased physical activity, and behavioral modification. In high-risk patients with comorbid conditions, pharmacologic therapy (orlistat or lorcaserin, among others) can be considered as an additional intervention. In clinically severe obesity, surgical therapies may be appropriate. All successful patients will require long-term nutritional adjustments that reduce caloric intake. The role of liposuction in weight loss has been studied and despite the removal of a large volume of subcutaneous adipose tissue there was no improvement seen in the metabolic risk factors associated with obesity.[100,101]

THYROID DISEASE

AT-A-GLANCE

- The most common cause of hyperthyroidism is Graves disease, characterized by the triad of autoimmune thyroid disease, eye disease, and thyroid dermopathy (pretibial myxedema).
- Toxic multinodular goiter is another cause of hyperthyroidism that should be considered, particularly in elderly individuals.
- Serious signs of thyrotoxicosis include atrial fibrillation and fever.
- Hashimoto thyroiditis and thyroid ablation for treatment of hyperthyroidism are the 2 most common causes of hypothyroidism.
- The best screening test for thyroid disease is thyrotropin (thyroid-stimulating hormone), which is elevated in hypothyroidism and depressed or absent in hyperthyroidism.

EPIDEMIOLOGY

Thyroid disease is very common worldwide. Enlargement of the thyroid gland, known as goiter, is estimated to affect around 700 million people worldwide.[102] The majority of these worldwide cases are secondary to iodine deficiency. However, hypothyroidism and hyperthyroidism are very prevalent even in industrialized countries. The overall incidence of hyperthyroidism in the U.S. population is estimated at 1%, but may be 4 to 5 times higher in older women.[103] As salt is routinely iodized in these countries, the major causes of goiter are Hashimoto thyroiditis, multinodular goiter, and Graves disease. Graves disease accounts for 60% to 80% of all cases of hyperthyroidism and was first described as an association between goiter, palpitations, and exophthalmos.[104] Although the incidence of Graves disease is similar between whites and Asians, it appears to be lower in blacks.[104] After Graves disease, the next most common cause of hyperthyroidism is *toxic multinodular goiter*.[105] *Toxic adenoma* and *toxic multinodular goiter* refer to the hyperplastic growth of thyroid tissue that functions independently of thyroid-stimulating hormone (TSH) regulation, resulting in inappropriately elevated levels of thyroid hormone. Toxic multinodular goiter is more common in areas of low iodine intake, particularly in patients older than age 50 years.[106]

Population-based screening with laboratory testing found hypothyroidism in 4.6% of the U.S. population, and more than 90% of individuals identified with hypothyroidism were asymptomatic.[103]

The majority of thyroid disease is acquired, but thyroid disease also can be congenital. Congenital hypothyroidism is the most common treatable cause of intellectual disability, and occurs in up to 1 in 3000 neonates worldwide. Causes are an absent or anatomically defective gland, inborn errors of thyroid metabolism, or iodine deficiency.[107] Congenital hyperthyroidism is much less common, and although 0.2% of pregnant women have Graves disease, only approximately 1% of the resultant neonates will have hyperthyroidism, with most cases resulting

from the transfer of maternal thyroid-activating autoantibodies.[108]

CLINICAL FEATURES

CUTANEOUS MANIFESTATIONS OF HYPERTHYROIDISM

Table 137-7 describes an approach to the patient with hyperthyroidism.

The cutaneous changes of hyperthyroidism have been likened to infant's skin and described as soft, warm, and velvety in texture. Pruritus can be a manifestation of thyroid disease, and laboratory screening for thyroid disease is often included when working up patients experiencing diffuse pruritus without obvious rash. Scalp hair in patients with hyperthyroidism is often soft and fine, and in certain cases may be accompanied by a diffuse nonscarring alopecia analogous to telogen effluvium. Patients with hyperthyroidism frequently have soft, shiny, and brittle nails with an increased rate of growth. A small percentage of patients with hyperthyroidism will have Plummer nails, which exhibit a concave shape with distal onycholysis (see Chap. 91). Plummer nails also can be found in a variety of other conditions and are not pathognomonic for hyperthyroidism. Vitiligo appears to be overrepresented in patients with Graves disease, but not in patients with other forms of hyperthyroidism. Vitiligo often predates the diagnosis of thyroid disease and does not improve with the treatment of the hyperthyroidism (see Chap. 76).

Thyroid dermopathy (in the past referred to as *pretibial myxedema*) is a classic manifestation of Graves disease (see Fig. 137-11). The term *thyroid dermopathy* is used in this chapter because the lesions can occur at any site on the body, are not limited to the pretibial region, and the name does not suggest myxedema as a cause.[109] It is most commonly seen with Graves disease, but has been reported in patients with Hashimoto thyroiditis as well. Although there are reports of patients who have presented with thyroid dermopathy as their initial finding, thyroid dermopathy is usually a late manifestation of thyroid disease. Almost all patients with thyroid dermopathy also have thyroid ophthalmopathy, another manifestation of Graves disease.[110] The presence of thyroid dermopathy and acropachy are markers of the severity of the autoimmune disease process and signal a risk for severe ophthalmopathy.[111] The clinical appearance of thyroid dermopathy can be quite varied. Classically, thyroid dermopathy occurs bilaterally as painless nonpitting nodules and plaques with variable coloring and a waxy, indurated texture (Fig. 137-9). The distribution can range from localized to diffuse, but by far the most common location

TABLE 137-7
Approach to the Patient with Hyperthyroidism

Cutaneous Findings in Hyperthyroidism
- Soft, velvety, infant-like skin
- Thyroid dermopathy (in Graves disease)
- Soft, fine hair with diffuse nonscarring alopecia
- Facial flushing
- Palmar erythema
- Hyperpigmentation
- Plummer nails
- Thyroid acropachy (in Graves disease)
- Hyperpigmentation

Related Features
- Hyperhidrosis
- Atrial fibrillation
- Ophthalmopathy (in Graves disease)
- Goiter
- High-output heart failure
- "Thyroid storm"

Diagnosis
- Best initial test is serum thyroid-stimulating hormone (low in hyperthyroidism)
- Other tests include serum free thyroxine (T_4), total triiodothyronine (T_3), and thyrotropin receptor antibodies
- Radioactive iodine uptake and imaging

Management
- Appropriate surgical and endocrine consultation
- Propranolol for symptomatic treatment of tremor, tachycardia, and sweating, if no contraindications are present
- Propylthiouracil to inhibit thyroid hormone metabolism and conversion of T_4 to T_3
- Methimazole to inhibit thyroid hormone synthesis
- Radioiodine ablation of the thyroid gland

Figure 137-9 Hyperthyroidism with thyroid dermopathy in a classic location on the anterior shins. Note that infiltrated plaques extend to the calf and are partially hyperkeratotic. An isolated nodule is also present on the dorsum of the foot.

is on the extensor surfaces of the legs.[110] In some cases the skin has a peau d'orange appearance. An extreme form of diffuse thyroid dermopathy has been termed the *elephantiasic* variant, which occurs in less than 1% of patients with Graves disease and is characterized by progressive thickening and gray-black hyperpigmentation of the pretibial skin accompanied by a woody, firm edema with nodule formation.[109] Biopsies of thyroid dermopathy reveal a thickened dermis with splayed collagen fibrils and abundant mucin, usually hyaluronic acid, in the interstitial space.

The exact pathophysiology underlying thyroid dermopathy is still unclear. Autoantibodies that bind the TSH receptor (TSHR) on fibroblasts are seen and may trigger synthesis of glycosaminoglycans. However, antibodies that bind TSHR on fibroblasts are present in patients without thyroid dermopathy, indicating there are likely other factors involved. The presence of dependent edema in the lower extremities may contribute to either fibroblast stimulation or hyaluronic acid accumulation, and thus account for the tendency of thyroid dermopathy to occur in this anatomic site.[109]

Thyroid acropachy refers to digital clubbing, soft-tissue swelling of the hands and feet, and the presence of characteristic periosteal reactions.[109] This very rare clinical finding is almost always associated with thyroid dermopathy and exophthalmos, and typically presents after the diagnosis and treatment of hyperthyroidism. Like thyroid dermopathy, thyroid acropachy also has been reported in patients with hypothyroidism or euthyroidism. Clubbing occurs most frequently on the first, second, and fifth metacarpals, the proximal phalanges of the hand, and the first metatarsal and proximal phalanges of the feet.[109] The radiographic findings are characterized by a lamellar periosteal reaction of the hands or wrists, with long bones only rarely involved. Because increased osteoblastic activity has been observed in the diaphyseal parts of small bones, the use of bone scan has been suggested as a sensitive way to aid in diagnosis.[112] The mechanisms underlying thyroid acropachy remain unknown, although interestingly, a large case series identified a disproportionately high percentage of smokers (80%) in patients with thyroid acropachy.[113]

Systemic signs and symptoms of hyperthyroidism and hypothyroidism are variably present and are summarized in Table 137-8. The effects of excess thyroid hormone on other organ systems can also result in cutaneous findings. Hyperpigmentation similar to that seen in Addison disease has been seen with patients with hyperthyroidism, with increased pigment in the palmar creases, gingiva, and buccal mucosa that is usually more prominent in individuals with darker skin. It has been postulated that the hyperpigmentation may be the result of increased corticotropin (ACTH) resulting from accelerated cortisol metabolism.[109] The cardiovascular effects of thyroid hormone excess include atrial fibrillation, increased cardiac output, and decreased peripheral vascular resistance, resulting in increased blood flow to the skin which manifests as facial flushing and palmar erythema. The increase in metabolism, along with increased peripheral blood flow and temperature dysregulation, can also result in a generalized hyperhidrosis as well as high-output cardiac failure.

There is extensive literature regarding the association between thyroid disease and urticaria (see Chap. 41).[114] Several studies have found a much higher incidence of thyroid disease in patients with chronic urticaria compared with control populations, although the mechanism behind this association remains unclear. Treatment with levothyroxine has been reported to improve the urticaria in some patients with thyroid disease, particularly Hashimoto thyroiditis, but strong evidence is lacking.[115,116] Other dermatologic conditions that have been reported in association with Graves disease include dermatitis herpetiformis, Sweet syndrome, pemphigoid gestationis, vitiligo, pemphigus vulgaris, anetoderma, and middermal elastolysis.[109]

TABLE 137-8
Symptoms, Clinical Findings, and Complications of Thyroid Disease

HYPERTHYROIDISM	HYPOTHYROIDISM
Symptoms	**Symptoms**
▪ Unintentional weight loss	▪ Unexplained weight gain
▪ Heat intolerance/sweating	▪ Fatigue
▪ Palpitations	▪ Cold intolerance
▪ Agitation/emotional lability	▪ Constipation
▪ Multiple daily loose stools	▪ Dry skin
▪ Pruritus	▪ Muscle weakness
▪ Weakness	▪ Carpal tunnel syndrome
▪ Oligomenorrhea in women	▪ Hoarseness
	▪ Decreased body temperature
	▪ Facial swelling
	▪ Menorrhagia in women
Clinical Findings and Complications	**Clinical Findings and Complications**
▪ Goiter	▪ Goiter
▪ Tachycardia	▪ Cold, doughy skin
▪ Atrial fibrillation	▪ Bradycardia
▪ High-output cardiac failure	▪ Facial and finger swelling
▪ Fine tremor	▪ Slowed relaxation of deep tendon reflexes
▪ Hot sweaty extremities	▪ Hair loss/lateral eyebrow loss
▪ Ophthalmopathy	▪ Pericardial effusion
▪ Agitation/confusion	▪ Myocardial infarction or congestive heart failure with aggressive thyroid hormone replacement
▪ Muscle weakness/wasting	▪ Coma and death without treatment
▪ "Thyroid storm" with fever, confusion, dehydration, and eventual death, if untreated	

CUTANEOUS MANIFESTATIONS OF HYPOTHYROIDISM

Table 137-9 outlines an approach to the patient with hypothyroidism.

In hypothyroidism, decreased core temperature and increased peripheral vasoconstriction cause the skin to be cool and pale. The skin is also xerotic, and the stratum corneum is poorly hydrated. The xerosis can mimic acquired ichthyosis. Histologically, the epidermis is thin, and there is hyperkeratosis with follicular plugging. The generalized distribution of these findings can help distinguish these changes from those of atopic dermatitis and keratosis pilaris, which tend to be more prominent on the extremities. A fine wrinkling of the skin also can be seen. Yellow-orange discoloration of the skin can be seen secondary to the accumulation of beta-carotene in the stratum corneum, which is thought to be the result of increased circulating carotene from diminished hepatic conversion of beta-carotene to vitamin A. This "pseudojaundice" can be distinguished from true jaundice because it spares the sclerae.[117] Hypothyroidism is also a rare cause of acquired palmoplantar keratoderma, which responds well to treatment with thyroxine.[118]

Myxedema is the most classic finding associated with hypothyroidism and is distinct from the thyroid dermopathy seen with Graves disease. Myxedema occurs as a result of dermal accumulation of mucopolysaccharides, namely, hyaluronic acid and chondroitin sulfate, and tends to resolve with treatment of the hypothyroidism. The myxedema tends to be generalized but can appear more striking in the extremities. Characteristic facial changes can be seen, including a broadened nose, thickened lips, puffy eyelids, and macroglossia with a smooth and clumsy tongue. The skin can be doughy, swollen, and waxy, but without pitting. Wound healing is impaired.

The hair in patients with hypothyroidism is coarse, dry, and brittle with slowed growth. The alopecia seen in hypothyroidism can be either diffuse or patchy. Hypothyroidism can result in increased numbers of hair follicles in telogen, as well as telogen effluvium when the onset of hypothyroidism is abrupt. There can be a characteristic pattern of eyebrow loss involving the outer third of the eyebrows. Although body hair can be diminished, hypothyroidism can also result in increased lanugo hair on the back, shoulders, and extremities. The nails in hypothyroidism grow slowly and can be thickened and brittle with longitudinal and transverse striations.

Hypothyroidism caused by iodine deficiency or Hashimoto thyroiditis can be associated with goiter. In patients with a goiter, compression of the recurrent laryngeal nerve can result in hoarseness. Large goiters can cause tracheal or esophageal displacement. In extreme cases, large retrosternal goiters can cause the Pemberton sign, which consists of facial plethora when patients raise their arms above their head owing to compression of the jugular veins.[119] Hashimoto thyroiditis also is associated with several other dermatologic disorders, including alopecia areata, vitiligo, connective tissue disease (including lupus and dermatomyositis), bullous pemphigoid, dermatitis herpetiformis, and chronic mucocutaneous candidiasis (CMC).[120-124]

TABLE 137-9
Approach to the Patient with Hypothyroidism

Cutaneous Findings
- Myxedema
- Cool temperature
- Doughy, dry skin with fine wrinkling
- Yellow-orange carotenemia
- Dry, brittle hair
- Slow growth of hair and nails

Related Features
- Macroglossia
- Broadened nose, thickened lips, puffy eyelids
- Impaired wound healing
- Cretinism in patients with congenital hypothyroidism
- "Myxedema coma"

Diagnosis
- Best initial test is serum thyroid-stimulating hormone (elevated in hypothyroidism)
- Other useful tests include serum free thyroxine (T_4), total triiodothyronine (T_3), antithyroperoxidase (anti-TPO) antibodies, and lipid panel

Management
- Appropriate endocrine consultation
- Oral thyroxine replacement (usually in the range of 75 to 150 µg/day)
- Careful followup for heart, lung, and adrenal disease

ETIOLOGY AND PATHOGENESIS

Thyroid hormone is synthesized in the thyroid gland and plays an important role in regulating the body's metabolism. Hyperthyroidism is the result of excess levels of thyroid hormone, whereas hypothyroidism is characterized by hypometabolism secondary to inappropriately low levels of thyroid hormone. Thyroid hormone synthesis is heavily dependent on iodine and consequently changes in iodine intake can result in both hyperthyroidism and hypothyroidism.

Synthesis of thyroid hormone is regulated by the pituitary gland via the release of TSH in response to hypothalamic production of thyrotropin-releasing hormone. TSH acts on the thyroid gland by binding to the TSHR, a G-protein–coupled receptor, triggering thyroid hormone synthesis and release. Levels of TSH and thyrotropin-releasing hormone are both tightly controlled by circulating levels of thyroxine (T_4) and triiodothyronine (T_3), which provide feedback regulation. Inappropriate activation of TSHR is thought to cause the hyperthyroidism seen in Graves disease, in which almost all patients have long-acting thyroid-stimulating autoantibodies that bind and activate TSHR.[125]

Most thyroid hormone in the blood is bound by plasma proteins. These include thyroid-binding globulin, which is the major determinant of protein binding.

TABLE 137-10
Medical Conditions That Can Affect Thyroid Hormone Levels

Increased Thyroid-Binding Globulin
- Pregnancy
- Infectious/chronic active hepatitis
- Cirrhosis
- Acute intermittent porphyria

Decreased Thyroid-Binding Globulin
- Hereditary thyroid-binding globulin deficiency
- Severe systemic illness
- Active acromegaly
- Cushing syndrome
- Nephrotic syndrome

Decreased Peripheral Conversion of Thyroxine (T_4) to Triiodothyronine (T_3)
- Fasting/malnutrition
- Systemic illness
- Physical trauma
- Postoperative state

A variety of medical conditions (Table 137-10) and medications (Table 137-11) can alter levels of thyroid hormone-binding proteins and/or peripheral conversion of T_4 to T_3 (which is responsible for most of thyroid hormone's effects).[126]

TABLE 137-11
Medications Affecting Thyroid Hormone Levels

Drugs That Affect Thyroid Hormone Secretion
- Lithium (decreases secretion)
- Iodide (can increase or decrease secretion)
- Amiodarone (contains iodine, can increase or decrease secretion)

Drugs That Increase Serum Thyroid-Binding Globulin Concentrations
- Estrogens/tamoxifen
- Heroin/methadone
- 5-Fluorouracil

Drugs That Decrease Serum Thyroid-Binding Globulin Concentrations
- Androgens
- Anabolic steroids
- Slow-release nicotinic acid
- Glucocorticoids

Drugs That Increase Metabolism of Thyroid Hormone
- Phenobarbital
- Rifampin
- Phenytoin
- Carbamazepine
- Tyrosine kinase inhibitors (imatinib, sorafenib, etc.)[131]

Drugs That Decrease Deiodination of Thyroxine to Triiodothyronine
- Propylthiouracil (used to treat hyperthyroidism)
- Amiodarone
- β-Blockers
- Glucocorticoids
- Certain radiographic contrast dyes

Drugs That Decrease Thyroid-Stimulating Hormone
- Bexarotene

Adapted from Surks MI, Sievert R. Drugs and thyroid function. *N Engl J Med*. 1995;333:1688.

Hyperthyroidism can be broadly classified into 2 categories: (a) high radioiodine (radioactive iodine) uptake and (b) low radioiodine uptake. The presence of high radioiodine uptake indicates increased synthesis of thyroid hormone, whereas diminished or absent radioiodine uptake suggests either an exogenous source of thyroid hormone or the thyroid inflammation with release of preformed thyroid hormone into the circulation. Evidence suggests that genetic predisposition as well as environmental factors, including infection, may play a role in the pathogenesis of autoimmune thyroid disease.[127] In the case of toxic adenoma, molecular studies have identified a high prevalence of TSHR mutations, resulting in a receptor that triggers thyroid hormone synthesis in the absence of bound TSH.[128]

Although some of the cutaneous findings seen in hyperthyroidism are indirect consequences of thyroid hormone's actions on other tissues, most of the skin manifestations of thyroid disease result from the direct effects of thyroid hormones on the keratinized epithelium of the epidermis, hair, and nails as well as effects on stromal cells in the dermis. Thyroid hormone is essential for optimal epidermal proliferation both in vitro and in vivo.[129] Thyroid hormone regulates genes involved in keratinocyte proliferation, stimulates the expression of certain keratins, and plays an important role in hair growth and hair cycling by acting on the stem cells in the hair follicle bulge.[129,130]

Ironically, the most common cause of hypothyroidism without a goiter is the surgical or radioiodine-induced ablation of the thyroid gland for the treatment of Graves disease. The most common cause of hypothyroidism with a goiter in North America is Hashimoto thyroiditis. Less common causes of hypothyroidism include inherited defects in hormone synthesis or drugs that affect hormone synthesis or metabolism (see Table 137-11). Bexarotene, a selective retinoid-X–receptor agonist (see Chap. 119) used to treat cutaneous T-cell lymphoma, causes a central hypothyroidism by suppressing the production and release of TSH, which leads to decreased levels of T_3 and T_4.[131,132] Hypopituitarism is another rare cause of hypothyroidism.

DIAGNOSIS AND LABORATORY TESTS

The diagnosis of thyroid-related cutaneous disease is often suspected clinically, although in certain instances a skin biopsy may prove helpful in confirming the diagnosis. The clinical diagnosis of thyroid disease is confirmed by abnormal thyroid function tests. Serum TSH is recommended as an initial screen, and any abnormalities in TSH should be followed up with measurements of serum free T_4 to confirm whether the abnormal TSH truly reflects a thyroid disorder. Other tests that can be useful include measurement of serum total T_3 and antithyroid antibodies. This combination of tests will diagnose the vast majority of patients with suspected thyroid disease.

MANAGEMENT

The mainstay of treatment of the cutaneous findings of thyroid disease is normalization of thyroid function, either through replacement of thyroid hormone for hypothyroidism or through the use of medications, radioiodine ablation, or surgery for hyperthyroidism. Complete or partial remission of cutaneous findings can be seen even in the absence of any localized topical treatment.[113] However, thyroid dermopathy and thyroid acropachy can persist even in patients who are effectively treated for their thyroid disease, and the current treatment options for thyroid dermopathy can be classified as either experimental or palliative at best. Topical glucocorticoids with adjuvant compression have been used with some success for many years.[117] Other reported treatments for thyroid dermopathy include systemic corticosteroids, intralesional corticosteroids, octreotide, intravenous immunoglobulin, plasmapheresis, pentoxifylline, complete decongestive physiotherapy, and even surgical excision (not recommended given the high rate of recurrence after surgery).[113,133,134] The success of these therapies is still controversial and based on small, uncontrolled case series and anecdotal reports. No specific treatment for thyroid acropachy is available. It is typically less symptomatic than thyroid dermopathy, although pain management is sometimes required. Tobacco use is thought to be a risk factor for severe manifestations of Graves disease and patients who use tobacco should be strongly urged to quit.[113]

PARATHYROID DISEASE

AT-A-GLANCE

- The most common cause of hypercalcemia in outpatients is hyperparathyroidism, whereas the most common cause of hypercalcemia in hospitalized patients is malignancy.
- The most common causes of hypocalcemia are vitamin D deficiency and surgically induced hypoparathyroidism.
- Calciphylaxis is most commonly seen in the setting of secondary hyperparathyroidism related to renal failure.

EPIDEMIOLOGY

The annual incidence of primary hyperparathyroidism has decreased since 1992 to about 20 cases per 100,000 person-years, potentially reflecting a decrease in the use of ionizing radiation to the neck, which is a known risk factor for developing primary hyperparathyroidism.[135] The majority of cases occur in individuals older than 45 years of age, with an approximate 2:1 female-to-male predominance.

CLINICAL FEATURES

Parathyroid disease most often presents with abnormal serum calcium levels. Table 137-12 outlines the physical findings and symptoms associated with hypercalcemia and hypocalcemia. Skin manifestations are rare in patients with hyperparathyroidism and hypercalcemia but can be impressive. Table 137-13 outlines the suggested approach to a patient with suspected hyperparathyroidism. Cutaneous calcinosis (sometimes referred to as *calcinosis cutis* or *metastatic calcinosis*) is thought to be partly caused by the combination of elevated calcium and phosphate (see Chap. 128).[136] Subcutaneous calcifications are typically found in a symmetric distribution, often overlying large joints or in linearly arrayed papules and plaques that are skin-colored and firm to palpation (Fig. 137-10). These lesions can be pruritic and can exert pressure on surrounding tissues. Chronic urticaria also is associated with hyperparathyroidism.[137] Signs or symptoms of hyperparathyroidism in combination with certain cutaneous tumors, such as angiofibromas, collagenomas, café-au-lait macules, and lipomas, should prompt a workup for multiple endocrine neoplasia Type 1 (MEN1). MEN1 is caused by mutations in the *MEN1* gene and characterized by tumors of the anterior pituitary, pancreas, and parathyroid glands. Table 137-14 shows the differential diagnosis of hypercalcemia.

Calciphylaxis (also called calcific uremic arteriolopathy) is a rare, but life-threatening, cutaneous condition associated with hyperparathyroidism. Calciphylaxis occurs most often in the setting of chronic renal failure and secondary hyperparathyroidism, although there are reports of calciphylaxis associated with primary hyperparathyroidism and normal renal function. Other risk factors include obesity, diabetes, protein C

TABLE 137-12
Physical Findings Associated with Hypercalcemia and Hypocalcemia

Hypercalcemia
- Anorexia
- Nausea and vomiting
- Constipation
- Muscle weakness and bone pain
- Lethargy and coma
- Anxiety and depression
- Polyuria and polydipsia
- Nephrolithiasis

Hypocalcemia
- Increased neuromuscular irritability and tetany
- Chvostek sign: induced tetany of the facial muscles induced by tapping the facial nerve just anterior to the ear
- Trousseau sign of hypocalcemia: carpal spasm with inflation of blood pressure cuff
- Peripheral and perioral paresthesias
- Seizures
- Bronchospasm/laryngospasm
- Lengthening of QT interval on electrocardiogram

TABLE 137-13
Approach to the Patient with Suspected Hyperparathyroidism

Cutaneous Findings
- Cutaneous (metastatic) calcinosis
- Calciphylaxis

Related Disorders
- Renal disease
- Multiple endocrine neoplasia Type 1 (MEN1) with angiofibromas, collagenomas, café-au-lait macules, and lipomas
- History of head/neck irradiation

Diagnosis
- Best initial tests are serum calcium and serum parathyroid hormone levels
- If malignancy is suspected, serum parathyroid hormone-related peptide

Management
- Identify underlying cause of hyperparathyroidism
- Appropriate endocrine, surgery, and nephrology consultation
- Hospitalization for acute cases with severe hypercalcemia
- Aggressive fluid resuscitation to treat severe hypercalcemia
- Phosphate replacement as warranted
- Dialysis as needed for acute renal failure
- Calciphylaxis warrants aggressive wound care and management of infections
- Surgical parathyroidectomy

or protein S deficiency, and warfarin administration. Calciphylaxis is caused by calcium deposition in the walls of small- to medium-sized vessels, resulting in vascular occlusion and overlying skin necrosis. Clinically, patients present initially with tender violaceous patches that may exhibit a mottled or reticular pattern. Subsequently, involved areas become indurated and exquisitely painful, with eventual ulceration and eschar formation that can lead to tissue gangrene (Fig. 137-11). Both the trunk and extremities can be involved, and the most common locations are the thighs, buttocks, and breasts. Most patients with calciphylaxis have a normal calcium-phosphate product (serum calcium × serum phosphate), although a calcium-phosphate product of greater than 70 mg/dL has often been cited as a predisposing risk factor. The histologic finding of calcium deposits in vessel walls coupled with compatible clinical findings is diagnostic. Calciphylaxis has a very poor prognosis, with reported mortality rates up to 80%, usually from infection. Excellent wound care and management of infections is critical. An accumulating number of case reports using the calcium-sequestering compound sodium thiosulfate in an intravenous infusion have demonstrated considerable efficacy, particularly in patients with renal disease.[138] Even though large clinical trials are lacking, the lack of any serious short-term side effects reported with sodium thiosulfate suggests serious consideration of this therapy for patients with calciphylaxis. Parathyroidectomy has been effective in the treatment of some, but not all, patients with calciphylaxis and hyperparathyroidism, and firm evidence that supports this practice is lacking. The calcimimetic agent cinacalcet has shown promise in some case reports in the treatment of calciphylaxis in patients with hyperparathyroidism.[139] There are also small case series reporting successful treatment of calciphylaxis using hyperbaric oxygen.[140]

Figure 137-10 Papules of cutaneous calcinosis are arranged in a linear array in the skin overlying the mandible.

Hypoparathyroidism is associated with scaly, hyperkeratotic, and edematous puffy skin (Table 137-15).[141] Patients may complain of paresthesias secondary to

TABLE 137-14
Differential Diagnosis of Hypercalcemia

Increased Parathyroid Hormone
- Solitary adenoma
- Multiple adenomas (ie, multiple endocrine neoplasia Type 1 [MEN1])
- Tertiary hyperparathyroidism with renal failure

Increased Parathyroid Hormone-Related Peptide
- Squamous cell carcinoma
- Renal carcinoma
- Bladder carcinoma
- Human T-cell leukemia virus Type 1
- Breast cancer
- Lymphoma

Increased Serum 1,25-OH Vitamin D
- Sarcoidosis
- Excess ingestion

Increased Bone Resorption of Calcium
- Myeloma
- Lymphoma
- Breast cancer

Renal Failure
- Secondary hyperparathyroidism
- Tertiary hyperparathyroidism
- Vitamin D intoxication

Milk-Alkali Syndrome (Hypercalcemia Associated with Ingestion of Calcium-Based Antacids and Milk)

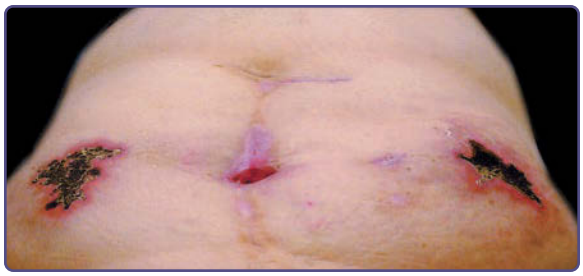

Figure 137-11 Calciphylaxis in a patient with chronic renal failure. Note the stellate-shaped necrotic plaques on the abdomen and the scars from peritoneal dialysis. The thighs and buttocks are often involved. A deep biopsy that includes subcutaneous fat can help make the diagnosis if it demonstrates the characteristic findings of calcification in the media of small- and medium-sized vessels. Histologically, subcutaneous calcium deposits and fat necrosis also can be seen.

hypocalcemia. Patchy alopecia and generalized thinning of the hair have been reported. Nails can be brittle with transverse ridging. Hypoparathyroidism with hypocalcemia is associated with flares of psoriasis, which is interesting in light of the response of psoriasis to the Vitamin D analog calcipotriene.[142] These skin abnormalities often resolve with normalization of serum calcium levels, suggesting that they are the result of changes in calcium homeostasis rather than parathyroid hormone (PTH) deficiency.

Hypoparathyroidism in the setting of familial autoimmune polyglandular syndrome Type 1 is associated with CMC and adrenal failure.[143] The CMC can precede the diagnosis of hypoparathyroidism, although the CMC does not improve significantly with treatment of the hypoparathyroidism with calcium and vitamin D. Other findings in these patients include dental enamel hypoplasia, vitiligo, and the cutaneous manifestations of adrenal failure (see section "Addison Disease").

Pseudohypoparathyroidism is the term for end-organ lack of responsiveness to PTH. The hypocalcemia and hyperphosphatemia of hypoparathyroidism is present, but serum PTH is elevated. Although several variants of pseudohypoparathyroidism have been described, perhaps the best characterized is Albright hereditary osteodystrophy.[144] These patients present with a constellation of findings that include short stature, developmental delay, obesity, rounded facies, dental hypoplasia, and shortened bones of the hands and feet. Characteristic shortening of the fourth metacarpal leads to a dimpling of the fourth knuckle, known as the *Albright sign*. These patients can also have subcutaneous ossifications and calcifications.

TABLE 137-15

Approach to the Patient with Suspected Hypoparathyroidism

Cutaneous Findings
- Scaly, hyperkeratotic, puffy skin
- Patchy alopecia with thinning hair
- Brittle nails with transverse ridging

Related Findings
- Paresthesias
- Neuromuscular irritability
- Bronchospasm or laryngospasm
- Electrocardiogram changes

Diagnosis
- Serum calcium, phosphorous, and intact parathyroid hormone levels
- Serum magnesium levels to rule out hypomagnesemia
- Electrocardiogram to rule out QT elongation

Management
- Vitamin D or vitamin D metabolites (eg, calcitriol at 0.2 to 1 µg/day)
- Calcium supplementation at 2 to 3 g of elemental calcium per day
- Magnesium supplementation when appropriate
- Endocrinology and nephrology consultation

ETIOLOGY AND PATHOGENESIS

PTH is synthesized and secreted by the parathyroid glands in response to low levels of serum calcium and acts as one of the main regulators of calcium in the body. Elevations in serum PTH (hyperparathyroidism) increase serum calcium, whereas decreased levels of PTH (hypoparathyroidism) can lead to hypocalcemia. PTH acts through varying mechanisms that include the stimulation of vitamin D production, stimulation of calcium absorption in the GI tract, regulation of renal reabsorption of calcium and phosphate, and direct regulation of calcium mobilization from bone. Circulating free calcium acts on the parathyroid glands to control the release of PTH. Serum PTH then acts on target tissues by binding the PTH/PTH-related peptide (PTHrP) receptor, which is mainly expressed in the kidneys and bones, resulting in changes in calcium metabolism and an increase in serum calcium. Because abnormal levels of PTH primarily alter levels of serum calcium, it is not surprising that the skin manifestations of parathyroid disease are primarily the result of calcium dysregulation. The skin is likely a site of PTH action, although the exact effects of PTH on skin are not well understood. Keratinocytes produce a PTH-related peptide (PTHrP) that has been implicated in regulating keratinocyte growth and differentiation and uses the same receptors as PTH.[145-148] PTHrP-receptor interactions are thought to play in important role in the regulation of the hair cycle.[149] Elevated PTHrP also can be seen in the setting of squamous cell carcinomas and other malignancies and can result in malignancy-related hypercalcemia in these patients.[150]

Primary hyperparathyroidism results from abnormal function of the parathyroid gland, resulting in inappropriately elevated levels of PTH. In 80% of diagnosed cases, the cause of hyperparathyroidism is parathyroid hyperplasia, parathyroid carcinoma, or a parathyroid adenoma.

Secondary hyperparathyroidism occurs most often in the setting of renal disease. Altered metabolism of calcium, vitamin D, and phosphorous leads to elevated

PTH. Hypersecretion of PTH results in hyperphosphatemia, and because of end-organ resistance to PTH there is persistent hypocalcemia despite the elevated PTH. In patients with renal failure and longstanding secondary hyperparathyroidism, hyperplastic parathyroid tissue can become autoactivated, resulting in tertiary hyperparathyroidism. This condition is characterized by persistent hypersecretion of PTH despite hypercalcemia.

Primary hypoparathyroidism is most often iatrogenic as a result of the removal of the parathyroid glands during a thyroidectomy. There are also several genetic and nongenetic congenital causes of primary hypoparathyroidism, although these are much less common. Secondary hypoparathyroidism refers to decreased PTH secretion secondary to a primary process that causes hypercalcemia.

DIAGNOSIS AND LABORATORY TESTS

The diagnosis of parathyroid disease can be made with measurements of serum calcium, phosphorous, and intact PTH. Total calcium levels may need to be corrected for low albumin. In the case of hypercalcemia related to malignancy, measurement of PTHrP also may be useful in the workup.

MANAGEMENT

The main treatment for hyperparathyroidism is partial or total parathyroidectomy (see Table 137-13). For hypoparathyroidism, treatment focuses on correction of serum calcium and phosphate (see Table 137-13). In the setting of acute hypercalcemia, aggressive fluid and electrolyte management are essential.

DISORDERS OF THE ADRENAL GLANDS

AT-A-GLANCE

- Excessive production of cortisol manifests as Cushing syndrome and results from pituitary oversecretion of corticotropin or excess production of cortisol by the adrenal glands.
- Destruction of the adrenal gland with resulting loss of glucocorticoids, mineralocorticoids, and adrenal androgens is known as Addison disease.
- Although many etiologies of Addison disease are described, the most common cause is autoimmune destruction with detectable circulating autoantibodies.

CUSHING SYNDROME

Cushing syndrome describes chronic exposure to excess corticosteroids. The most common cause is exogenous corticosteroid administration, but there are endogenous causes as well. In the normal physiology of the hypothalamic–pituitary–adrenal axis, corticotropin-releasing hormone is secreted from the hypothalamus and stimulates the production of corticotropin, also known as ACTH, by the anterior pituitary. ACTH is synthesized as part of a larger precursor molecule, POMC. The relationship of POMC to ACTH is important in diseases of the adrenal gland and the resulting skin manifestations. POMC is processed into several peptides, including melanocyte-stimulating hormone and ACTH, which stimulate the production of cortisol from the adrenal cortex. In a classic negative feedback manner, cortisol inhibits corticotropin-releasing hormone and ACTH production.

CLINICAL FEATURES

The clinical presentation of Cushing syndrome may be subtle (Table 137-16). Skin findings may be present, and if careful attention is paid to the relationship of skin findings and systemic complaints, the diagnosis can be made early in the clinical course. Common skin complaints are easy bruisability and skin thinning. Mild hypertrichosis often of the lanugo type and acne may occur. Frank hirsutism and severe acne raise the possibility of a tumor that also secretes androgens. The development of multiple violaceous striae wider than 1 cm on the abdomen or proximal extremities is highly suggestive of Cushing

TABLE 137-16
Approach to the Patient with Cushing Syndrome

Cutaneous Findings in Cushing Syndrome
- Increased central adiposity (moon facies and buffalo hump) with thinning of the extremities
- Skin thinning and easy bruisability
- Violaceous striae
- Acanthosis nigricans
- Increased dermatophyte and candidal skin and nail infections
- Hyperpigmentation (rare)

Related Features
- Diabetes
- Hypertension
- Osteoporosis
- Irregular menses

Diagnosis
- Measurement of 24-hour urinary free cortisol and late-night salivary cortisol
- Failure to suppress cortisol production with a low-dose dexamethasone suppression test

Management
- Appropriate endocrine and surgical consultation
- Surgical removal of pituitary or adrenal tumor
- Adrenal enzyme inhibitors
- Radiation therapy

syndrome. The width and color of these striae differentiate them from the striae commonly seen in pregnancy and weight gain. Relatively dramatic changes in fat distribution often occur along with a generalized gain in weight. Central obesity develops, along with concurrent thinning of the arms and legs with loss of muscle mass. Increased facial fat results in a rounded appearance of the face, often with increased redness and telangiectasias. This appearance has been referred to as a *moon facies*. In addition to truncal obesity, there is an increase in the size of the dorsocervical fat pad, known as a *buffalo hump* and there is increased fat in the supraclavicular fossae. Men may experience gynecomastia.

Although unusual, hyperpigmentation can occur in cases of Cushing syndrome caused by a massive increase in ACTH production either from the pituitary or, more commonly, an ectopic source.[151] ACTH itself, in addition to melanocyte-stimulating hormone derived from POMC, can stimulate increased melanin synthesis. This is similar to the hyperpigmentation more commonly associated with Addison disease. Acanthosis nigricans also may be seen because Cushing syndrome contributes to insulin resistance, and patients often develop diabetes. The immunosuppressive effects of glucocorticoids result in increased dermatophyte and candidal nail and skin infections. Women may experience irregular menses or amenorrhea. Additional extracutaneous signs and symptoms of Cushing syndrome include hypertension, osteoporosis, and decreased muscle mass and strength.[151]

EPIDEMIOLOGY, ETIOLOGY, AND PATHOGENESIS

The overall incidence of endogenous Cushing syndrome is about 10 persons per 1 million persons per year, with a female predominance.[152] It can be divided into 2 categories. The first category is caused by inappropriately high secretion of ACTH, usually from a pituitary microadenoma. It is given the unique name of *Cushing disease*. The excess ACTH drives glucocorticoid production in the adrenals. Rarely, ectopic (nonpituitary) production of ACTH results in Cushing syndrome. This clinical presentation is most often associated with a pulmonary carcinoid tumor or small cell lung carcinoma, although numerous other tumor types have been reported.[153] The second category of endogenous Cushing syndrome results from excess cortisol produced by the adrenal cortex independent of regulation by ACTH. This is usually caused by an adrenal adenoma, which may be benign or malignant, or is the result of generalized hyperplasia of the adrenal gland. Cushing syndrome can be seen in the McCune-Albright syndrome and in association with primary pigmented nodular adrenocortical disease in the Carney complex.[154,155]

DIAGNOSIS AND LABORATORY TESTS

Diagnostic confirmation of Cushing syndrome requires demonstration of excess cortisol production. The Endocrine Society recommends testing with a 24-hour urine free cortisol (repeated at least twice), late night salivary cortisol (repeated twice), or a low-dose dexamethasone suppression test.[156] Additional testing, including a high-dose dexamethasone suppression test, can be useful to determine if the source of the excess cortisol production is from the pituitary or elsewhere. Hypercortisolism may be present in patients without true Cushing syndrome. This is known as *pseudo-Cushing syndrome* and can be caused by obesity, major depressive disorders, and chronic alcohol abuse. It resolves with treatment of the underlying condition.

MANAGEMENT

The primary treatment of Cushing syndrome is surgical removal of the ectopic focus of ACTH production. Cure is achieved in the majority of patients, but resistant disease requires radiation in the case of pituitary disease or medical therapy with adrenal enzyme inhibitors such as ketoconazole or the adrenolytic agent mitotane.[151] Historically, Cushing syndrome was treated with bilateral adrenalectomy. This frequently resulted in Nelson syndrome, which is characterized by unchecked ACTH production from an enlarging pituitary adenoma with resulting hyperpigmentation. Neurosurgical resection of the tumor is considered first-line therapy.[157]

ADDISON DISEASE

CLINICAL FEATURES

Table 137-17 outlines an approach to the patient with Addison disease.

Destruction of the adrenal glands and the resulting life-threatening deficiency of glucocorticoids and

TABLE 137-17
Approach to the Patient with Addison Disease

Cutaneous Findings in Addison Disease
▪ Hyperpigmentation of skin and mucous membranes
▪ Longitudinal pigmented bands in the nails
▪ Vitiligo
▪ Decreased axillary and pubic hair in women
▪ Calcification of auricular cartilage in men
Related Features
▪ Abdominal pain
▪ Electrolyte abnormalities (hyponatremia and hyperkalemia)
▪ Postural hypotension
▪ Anorexia and weight loss
▪ Fatigue
▪ Shock, coma, and death, if untreated
Diagnosis
▪ Failure to respond adequately to corticotropin stimulation test
Management
▪ Lifelong replacement therapy of glucocorticoids and mineralocorticoids

mineralocorticoids is known as *Addison disease*. The estimated prevalence is 120 per million persons in Western countries.[158,159] It is suspected that many more cases remain undiagnosed. The most recognized cutaneous manifestation of Addison disease is hyperpigmentation of skin and mucous membranes. This occurs after longstanding adrenal insufficiency and would not be present in a patient with acute adrenal crisis unless the patient also had a history of chronic adrenal insufficiency. The hyperpigmentation is accentuated in sun-exposed areas, flexural folds, and skin creases, including the creases on the palms (Fig. 137-12). Pigment may develop in scars and longitudinal pigmented bands may appear in the nails. These pigment changes develop because persistently low cortisol levels do not provide negative regulatory feedback to the hypothalamus and pituitary. This results in unchecked production of POMC, ACTH, and melanocyte-stimulating hormone, which increase melanogenesis. Interestingly, vitiligo can be also seen in 10% to 20% of these patients.[160] Axillary and pubic hair may be sparse in women because of the loss of adrenal androgens. This does not occur in men because the testes maintain adequate androgen levels. Adrenal insufficiency can also cause calcification of auricular cartilage, known as "petrified ears."[161] Extracutaneous symptoms include weakness, anorexia, weight loss, abdominal pain, postural hypotension, and electrolyte abnormalities.

Figure 137-12 **A,** This patient with Addison disease demonstrates the characteristic hyperpigmentation of the skin with accentuation in sun-exposed areas. **B,** Palmar creases are also hyperpigmented compared to a normal hand.

ETIOLOGY AND PATHOGENESIS

Historically, the most common cause of Addison disease was tuberculosis infection, but now autoimmune disease as part of the autoimmune polyglandular syndromes 1 and 2 is the most common etiology. In autoimmune cases, circulating autoantibodies can be detected to enzymes of the adrenal cortex, including 21-hydroxylase and 17-hydroxylase. There is lymphocytic infiltration of the adrenal glands with damage and scarring as a result.

Infectious causes of adrenal insufficiency remain the next most common etiology; tuberculosis is still a major problem in many areas of the world. Addison disease is increasingly recognized in patients with AIDS and, in these patients, infection with cytomegalovirus and *Mycobacterium avium-intracellulare* are common causes.[162,163] Fungal infections, including histoplasmosis, blastomycosis, paracoccidioidomycosis, coccidioidomycosis, and cryptococcosis, also are reported to cause Addison disease.[163] Bilateral adrenal hemorrhage in the setting of an acute severe bacterial infection is known as the *Waterhouse-Friderichsen syndrome*. Classically, this is a result of meningococcal infection, although other infectious causes have been reported.[163] Other rare causes of Addison disease include medications, congenital adrenal hypoplasia, and infiltrative disorders such as amyloidosis, sarcoidosis, and metastatic carcinomas. The surgical treatment of Cushing syndrome can be an additional cause of adrenal insufficiency.

DIAGNOSIS AND LABORATORY TESTS

Acute adrenal crisis can develop in the setting of chronic adrenal insufficiency and may be life-threatening. In an acute crisis, a blood sample should be obtained for measurement of cortisol, but therapy with intravenous hydrocortisone should be instituted immediately. In chronic adrenal insufficiency, the diagnosis is confirmed using the cosyntropin stimulation test. This involves the IV administration of synthetic ACTH and the measurement of serum cortisol 30 and 60 minutes later. Inability to produce adequate cortisol is diagnostic. Chronic replacement therapy is necessary and may require dose adjustments for illness or

severe stress. The cutaneous findings improve gradually with treatment, with the exception of auricular calcification.

ESTROGEN AND PROGESTERONE

AT-A-GLANCE

- Exogenous estrogen, either through oral contraceptives or hormone replacement, is the most common cause of estrogen excess.
- Wrinkling, xerosis, and atrophy are signs of estrogen deficiency.
- Triple-ingredient preparations are first-line therapy for treating melasma if patients are not content with covering cosmetics.

EPIDEMIOLOGY

The most commonly encountered cause of estrogen excess is the pharmacologic use of estrogens for birth control, treatment of dysfunctional uterine bleeding, or postmenopausal hormone replacement. Approximately 25% of women of child-bearing age in the United States use oral contraceptives.[164] Ovarian, testicular, or hypothalamic tumors can also cause estrogen excess. Estrogen deficiency occurs most commonly as a result of menopause, which occurs around 50 years of age on average. Other, less common causes of estrogen deficiency include pituitary or gonadal failure and exercise-induced amenorrhea.

CLINICAL FEATURES: CUTANEOUS MANIFESTATIONS OF ESTROGEN EXCESS AND DEFICIENCY

Estrogen can have both desired and undesired effects on the skin. Estrogen replacement therapy in postmenopausal women can reverse epidermal atrophy and restore cutaneous collagen. The inhibitory actions of estrogen on sebum production can lead to improvement of acne with oral contraceptive therapy, particularly with the use of estrogen-dominant preparations. Despite high circulating estriol during pregnancy, the relative androgen excess due to elevated progesterone can exacerbate acne in some patients. Telogen effluvium characterized by diffuse loss of scalp or body hair can occur after delivery or discontinuation of oral contraceptives. Both pregnant women and patients taking synthetic estrogens can be more prone to certain side effects of estrogen, including telangiectasias, palmar erythema, spider angiomas, and pigmentary changes.

Figure 137-13 Melasma is demonstrated in a symmetric pattern on the face of a young woman. The upper lip is also a common site of involvement.

Melanocytic lesions, including preexisting nevi and malignant melanoma, can darken during pregnancy. Hyperpigmentation of the nipples, linea nigra, and genitalia also can be seen. Melasma, sometimes referred to as the *mask of pregnancy*, presents as irregularly shaped, hyperpigmented patches on the forehead, cheeks, nose, upper lip, chin, and neck (Fig. 137-13). It is associated with pregnancy and oral contraceptive use, among other factors. Although melasma may improve after delivery, it can persist or reoccur with subsequent pregnancies. Melasma may persist even after discontinuation of the oral contraceptives. In the very rare cases of men with melasma, the etiology is thought to be sun exposure or familial susceptibility rather than estrogen excess, but the clinicopathologic features are similar to those seen in female patients.[165]

In clinical states characterized by elevated estrogen levels, including pregnancy and the use of oral contraceptives, increased hair growth over the face, breasts, and extremities can be seen. This phenomenon may be a result of the complex interplay of estrogens and androgenic hormones rather than a direct effect of increased estrogen levels on the hair follicles themselves. Autoimmune progesterone dermatitis and estrogen dermatitis have been described in the literature and are characterized by a polymorphous eruption marked by cyclical premenstrual flares that may include pruritus, eczematous dermatitis, and urticaria. The diagnosis may be made by separate subcutaneous injection of both estrogen and progesterone in the skin of the forearm. Persistence of a papule for more than 24 hours is considered a positive test, as is the presence

of an immediate urticarial wheal that fades over hours in the case of urticaria.[166] Oral contraceptives have been implicated as a cause of erythema nodosum. Pregnancy and high estrogen levels also are associated with hyperkeratosis of the nipples.[167]

Estrogen deficiency from either menopause or pituitary failure can result in hot flashes, epithelial atrophy of the genitalia, and decreased breast size. Certain medications, such as danazol, leuprolide, and clomiphene citrate, can induce a pharmacologic menopause that presents with flushing. Flushing episodes accompanied by uncomfortable heat lasting several minutes can occur in younger women immediately before or during their period when estrogen levels are at their lowest.

ETIOLOGY AND PATHOGENESIS

Estrogen receptors are found throughout the skin, including on keratinocytes, sebaceous glands, eccrine and apocrine glands, in hair follicles, on dermal fibroblasts, and on melanocytes. In women of reproductive age, reported variations in dermatologic responses seen throughout the menstrual cycle suggest that estrogens and progesterone have important effects on the clinical presentation of numerous disease states of the skin.[168] Estrogen receptors are found in greater numbers in women compared with men. The main observations regarding the effects of estrogen on skin come from studies of postmenopausal women, in whom estrogen deprivation leads to skin wrinkling, xerosis, and atrophy. Increased epidermal and dermal thickness, increased water-holding capacity, changes in lipid composition of the stratum corneum, and improvement in skin laxity all occur with estrogen replacement, highlighting the important effects of this hormone throughout the skin.[169] Estrogen deficiency also has been reported to hinder wound healing, which subsequently improves with estrogen replacement. Estrogens also are reported to suppress sebaceous gland function and tend to inhibit hair growth.

The most potent naturally occurring estrogen is estradiol, which is the principal estrogen secreted by the ovaries. Estrone, another estrogen secreted by the ovaries, is synthesized primarily in peripheral tissues. During pregnancy, the main estrogen is estriol, which is synthesized by the placenta. Progesterone is the main hormone secreted by the corpus luteum, and peak levels are seen after ovulation. Gonadal hormones are not entirely specific, and progesterone is able to crossreact by binding to androgen receptors to exert androgenic or antiandrogenic effects.

MANAGEMENT

The Pigmentary Disorders Academy generated a consensus statement on the treatment of melasma and recommended the use of fixed "triple-ingredient" combinations as first-line therapy.[170] Topical retinoids, corticosteroids, azelaic acid, and hydroquinone-based bleaching creams have been used in various combinations to treat melasma for many years. Kligman's formula, first developed in 1975, is the classic triple-ingredient melasma preparation, consisting of 5% hydroquinone, 0.1% tretinoin, and 0.1% dexamethasone in a hydrophilic ointment. Dual-ingredient combinations or single agents are reasonable alternatives. For refractory cases, chemical peels (ie, glycolic acid or trichloroacetic acid) in combination with topical therapy can be tried, but postinflammatory hyperpigmentation is a concern. Lasers also can be considered but have shown variable results. Given the exacerbation of hyperpigmentation with sun exposure, sun avoidance and the consistent use of broad-spectrum sunscreens is very important in the treatment of all patients with melasma.

ANDROGENIC HORMONES

AT-A-GLANCE

- The peripheral conversion of testosterone to 5α-dihydrotestosterone is important in the pathophysiology of androgenetic alopecia.
- Hirsutism secondary to androgen excess has a characteristic distribution that includes the beard area, chest, back, and suprapubic region.

EPIDEMIOLOGY

In males, cutaneous manifestations of androgen excess occur most commonly with either the onset of sexual maturation or with androgen replacement therapy. Androgen-secreting tumors are a much less common cause of androgen excess. In women, androgen excess can occur from congenital adrenal hyperplasia (CAH). CAH is the result of a deficiency of enzymes in adrenal enzymes such as 21-hydroxylase (encoded by the gene *CYP21A2*), which accounts for more than 90% of cases of CAH.[171] Deficiency of CYP21 is inherited as an autosomal recessive trait and results in accumulation of 17-hydroxyprogesterone. Although the progestins in oral contraceptives are listed as potential causes of hirsutism because of their chemical similarity to testosterone, they likely do not cause androgenic effects at clinically used doses based on data from animal studies. PCOS occurs in approximately 5% of premenopausal women in the United States, and is characterized by insulin resistance, polycystic ovaries, and the presence of androgenic cutaneous findings such as acne, hirsutism, and androgenetic alopecia. PCOS is also associated with the metabolic syndrome, which is characterized by obesity, hypertension, lipid abnormalities, diabetes,

and heart disease. Androgenetic alopecia affects approximately 50% of men older than age 40 years, and potentially as many women as well, with most patients showing signs of alopecia by age 30 years (see Chap. 85).

CLINICAL FEATURES: CUTANEOUS MANIFESTATIONS OF ANDROGEN EXCESS

Androgen-related skin conditions are commonly seen in dermatology practice. Although our knowledge regarding acne pathogenesis is still incomplete, at least part of acne's pathophysiology involves the response of sebaceous glands to androgens. In most males and females, acne tends to subside after adolescence (see Chap. 78). Cases of severe persistent acne should elicit a differential diagnosis that includes causes of persistent androgen excess, including CAH, PCOS in women, or an androgen-secreting tumor (Fig. 137-14), in addition to rosacea and chemically-induced acne. In the appropriate clinical setting, laboratory studies may be helpful in determining the source of androgen excess (Table 137-18). Performance-enhancing anabolic steroids are derivatives of testosterone, and the resulting androgen excess can manifest as acne.

There is some genetic variation underlying the response of hair follicles to androgens as evidenced by the varying degrees of hirsutism seen among women with different ethnic backgrounds but similar serum androgen levels. Hirsutism secondary to androgen excess occurs in a characteristic distribution involving the beard region of the face, the chest, the upper back, and the suprapubic area.

Figure 137-14 Hyperandrogenism manifests clinically in this woman with an androgen-secreting adrenal tumor. Note the characteristic facial hair, the receding hairline, and the acneiform eruption on the chest.

TABLE 137-18
Approach to the Female Patient with Suspected Hyperandrogenism

History and Physical Findings Concerning for Hyperandrogenism
- Sudden onset of acne
- Severe acne refractory to conventional treatments
- Irregular menstrual periods
- Hirsutism

Laboratory Evaluation[a]
- Dehydroepiandrosterone sulfate (DHEA-S): screens for adrenal androgen source
  - Elevated in adrenal tumors and congenital adrenal hyperplasia
- Testosterone: screens for ovarian source
  - Elevated in polycystic ovarian syndrome
  - Some adrenal tumors can also secrete testosterone
- Luteinizing hormone–follicle stimulating hormone ratio
  - Ratio >2 to 3 can be consistent with polycystic ovarian syndrome

[a]Laboratory evaluation is most accurate when patient is off oral contraceptives for 4 to 6 weeks and if tests are drawn before menses.
Adapted from Thiboutot D. Acne: hormonal concepts and therapy. *Clin Dermatol*. 2004;22:419.

Paradoxically, although androgens can cause excess hair, they are also responsible for male-pattern (androgenetic) alopecia. Scalp hairs are converted first to indeterminate hairs and then to vellus hairs. In men, the pattern is characteristic and consists of symmetric recession of the hairline on the frontal and frontoparietal scalp along with hair loss on the vertex. In women, the frontal hairline is usually preserved, and the pattern is mostly diffuse thinning of the crown of the scalp without areas of frank alopecia. Although androgenetic alopecia can be acquired in patients with androgen excess, it is most commonly an incompletely characterized genetic disorder that appears to be inherited in an autosomal dominant manner (see Chap. 85).

ETIOLOGY AND PATHOGENESIS

Like estrogen receptors, androgen receptors are also present throughout the skin. In men, androgens are synthesized in the testes and adrenal glands, whereas in women androgens are secreted by the ovaries and adrenal glands. In addition to testosterone, progesterone, dehydroepiandrosterone (DHEA), and DHEA sulfate (DHEA-S) are all natural androgens that can

lead to cutaneous findings when they are present in excess.[172] Testosterone is subsequently converted in peripheral target tissues to the active metabolite 5α-dihydrotestosterone (5α-DHT) by the enzyme 5α-reductase. 5α-DHT binds the androgen receptor with greater affinity than testosterone.

Androgens are significant regulators of hair growth and sebaceous gland function. Androgens also play a role in the control of wound healing, epidermal differentiation, and the regulation of dermal fibroblasts. Androgen receptors have a trophic distribution throughout the body that is most evident with the appearance of "male pattern" hair growth on the face, chest, and back, as well as areas of hair loss on the scalp. Both estrogens and androgens bind to sex hormone–binding globulin. Sex hormone–binding globulin levels are decreased by the synthetic progestins found in oral contraceptives (eg, norgestrel, norethindrone, norgestimate, and desogestrel), as well as in obesity, acromegaly, hypothyroidism, and insulin resistance. The decreased sex hormone–binding globulin results in higher levels of circulating androgens and accounts, in part, for why androgenic findings can be associated with these conditions.

MANAGEMENT

In women whose acne appears to be hormonally driven, the use of antiandrogens, including the diuretic spironolactone, or oral contraceptive pills containing progestins with low androgenic or antiandrogenic activity, may prove more effective than conventional topical and oral acne medications. These drugs act as competitive inhibitors of dihydrotestosterone binding to androgen receptors. Specific 5α-reductase inhibitors, such as finasteride, can be used to treat androgenetic alopecia, although this medication is contraindicated in women of child-bearing age because of possible effects on development of genitalia and gonads in the male fetus. The use of finasteride has been linked to an increased risk of high-grade prostate cancer but without an increase in the absolute risk of prostate cancer in men, although similar data on men using finasteride for hair loss has not been reported.[173] Other side effects of finasteride therapy in men include depression, decreased libido, and erectile dysfunction.[174] These sexual adverse effects are persistent despite stopping finasteride in some patients. Finasteride treatment in postmenopausal women has not demonstrated significant benefit in a large placebo-controlled trial.[175]

Cyproterone acetate is an antiandrogen and progestin that is not available in the United States, although it has shown promise in the treatment of acne when used in other countries in oral contraceptive preparations. Flutamide is an androgen receptor antagonist that is rarely used due to the risk of fatal hepatitis as well as concerns about effects on fetal development in women of child-bearing age.[176]

DISORDERS OF GROWTH HORMONE

AT-A-GLANCE

- Growth hormone plays a central role in longitudinal growth.
- In children, growth hormone deficiency manifests as short stature, while gigantism occurs from oversecretion of growth hormone before puberty, when the growth plates in long bones are still open.
- The disease acromegaly occurs in adults after the growth plates have closed.
- Acromegaly results from oversecretion of growth hormone, usually from a pituitary adenoma.

ACROMEGALY

Growth hormone (GH) is secreted by the pituitary in a pulsatile fashion and reaches its maximum rate of secretion during puberty and then declines over time. Secretion of GH is primarily regulated by GH-releasing hormone (GHRH), somatostatin, and the natural GH secretagogue ghrelin.[177] GHRH and ghrelin stimulate the release of GH, whereas somatostatin has an inhibitory effect. The peripheral effects of GH are largely indirectly mediated through production of IGF1 in the liver. GH contributes significantly to linear growth in children, increases protein synthesis, mobilizes stored triglycerides, and antagonizes the action of insulin (Fig. 137-15).

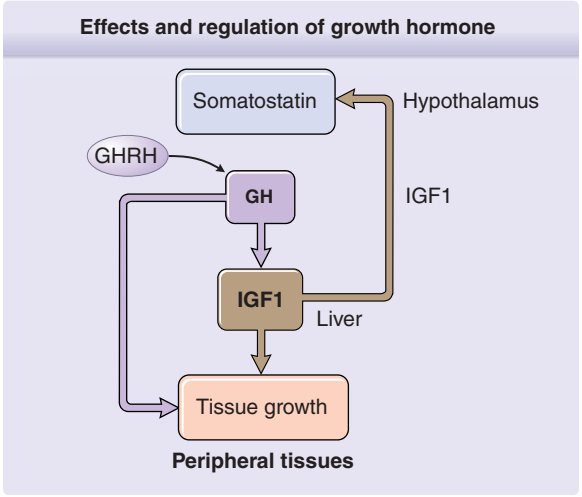

Figure 137-15 Effects and regulation of growth hormone (GH). GHRH, growth hormone–releasing hormone; IGF1, insulin-like growth factor-1.

CLINICAL FEATURES

Table 137-19 outlines an approach to the patient with acromegaly.

The clinical manifestations of acromegaly include the overgrowth of bone and connective tissue, metabolic effects, and localized tumor mass effects. The onset is insidious, and the average age at the time of diagnosis is 40 to 45 years, although the condition has often been present for many years before the diagnosis.[178] The metabolic effects include diabetes, hypertension, and hyperlipidemia. There is a gradual coarsening of facial features with frontal bone bossing and increasing shoe, ring, glove, and hat size (Fig. 137-16B).[179] Macroglossia and prognathism of the jaw may be seen. The skin becomes thickened, almost doughy, with deep prominent grooves on the forehead and around the nasolabial folds (Fig. 137-16A). Cutis verticis gyrata may develop on the scalp. Heel pads and the pads of the digits become thickened. Nails are thickened and brittle, and some patients develop hirsutism. Hyperhidrosis and malodor are common. Many patients develop acanthosis nigricans and multiple acrochordons with or without frank diabetes. Retinal angioid streaks can be seen in acromegaly (as well as in osteogenesis imperfecta and pseudoxanthoma elasticum). Histologically, there is dense deposition of glycosaminoglycans in the papillary and superficial reticular dermis. Often, coarse collagen bundles with normal elastin and increased numbers of fibroblasts are seen in the dermis.

TABLE 137-19
Approach to the Patient with Acromegaly

Cutaneous Findings in Acromegaly
- Enlargement of hands and feet with a doughy texture
- Increased ring, glove, shoe, and hat size
- Jaw enlargement with separation of teeth (prognathism)
- Frontal bossing
- Macroglossia
- Cutis verticis gyrata
- Acanthosis nigricans
- Hirsutism
- Hyperhidrosis
- Thick brittle nails

Related Features
- Diabetes
- Hypertension
- Hyperlipidemia

Diagnosis
- Elevated serum insulin-like growth factor-1 levels
- Failure to suppress growth hormone levels by oral glucose-tolerance test

Management
- Appropriate endocrine and surgical consultation
- Surgical removal of adenoma by transsphenoidal resection
- Somatostatin analogs or growth hormone receptor antagonists for residual disease
- Radiation therapy is an option for resistant cases

ETIOLOGY AND PATHOGENESIS

Excessive production of GH is almost always caused by a pituitary adenoma. In children, this results in pituitary gigantism, whereas in adults, excessive GH manifests as the clinical syndrome acromegaly. This syndrome is diagnosed in approximately 11 people per 1 million every year in the United States.[180] Very rarely, acromegaly is caused by a GH-producing tumor in the hypothalamus or by an ectopic tumor such as small cell lung cancer or carcinoid tumor.[179] The incidence of acromegaly caused by pituitary tumors is approximately 10% to 12% in patients with Carney complex, a genetic syndrome characterized by pigmented lesions, myxomas, and multiple endocrine tumors.[181] It is also present in approximately 20% of patients with McCune-Albright syndrome.[182]

DIAGNOSIS AND LABORATORY TESTS

Measurement of serum GH is highly variable and diagnostically unreliable because of the pulsatile pattern of secretion. Plasma IGF1 levels are dependent on GH and are fairly stable throughout a 24-hour period. Therefore, serum IGF1 levels can be used as a surrogate measurement of GH, and are elevated in acromegaly. Further workup with assistance from a consulting endocrinologist may include an oral glucose tolerance test. In the proper clinical setting, failure to suppress the GH level to less than 1 ng/mL 1 to 2 hours after 75 g of oral glucose is diagnostic for acromegaly.[179]

MANAGEMENT

Because most cases of GH excess are caused by a pituitary adenoma, the primary therapy is surgical removal. This is most commonly accomplished through a selective transsphenoidal resection.[179] Residual disease after surgery is more common in larger adenomas. Somatostatin analogs such as octreotide inhibit GH secretion and are used for the medical treatment of residual disease after surgery. They are increasingly being considered as potential primary therapy in select cases. In resistant cases, radiation therapy can be considered.

GROWTH HORMONE DEFICIENCY AND PANHYPOPITUITARISM

GH deficiency occurs in both children and adults and can be inherited or acquired. The primary clinical manifestation of this deficiency in children is

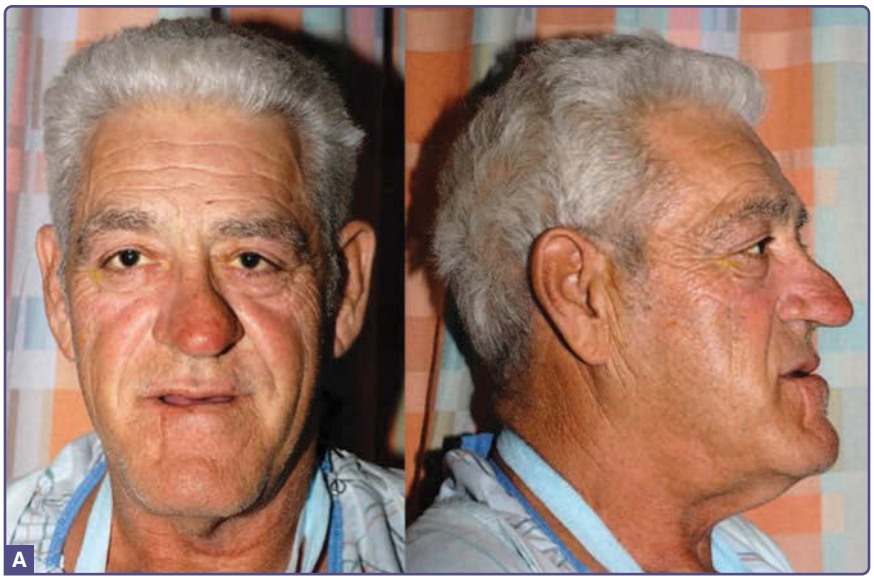

Figure 137-16 **A,** The facial changes in acromegaly include temporal wasting, broadening of the nose, deep grooves on the forehead and around the nasolabial folds, as well as jaw enlargement. **B,** Acral enlargement is a prominent feature of acromegaly and is easily demonstrated in comparison with a normal hand. (Used with permission from Brad Anawalt, MD.)

abnormally short stature. This can be corrected by the administration of GH. The clinical presentation of GH deficiency in adults includes decreased lean body mass, decreased strength and exercise capacity (partly the result of decreased sweating) and a loss of general vitality. GH replacement therapy in adults is a complex discussion that is beyond the scope of this chapter. Practice guidelines have been established by the Endocrine Society for the assessment and treatment of GH deficiency in adults.[183] In patients with panhypopituitarism, there is total loss of all pituitary function, including GH secretion (Table 137-20). These patients typically present with symptoms from either a space-occupying lesion in the pituitary or hormone dysregulation. These

TABLE 137-20
Causes of Hypopituitarism

- Mass lesions: nonfunctioning pituitary adenoma, cyst, craniopharyngioma, metastasis
- Infectious causes: tuberculosis, histoplasmosis
- Pituitary infarction: known as Sheehan syndrome when occurs in the setting of childbirth
- Pituitary apoplexy: sudden hemorrhage into the pituitary
- Lymphocytic hypophysitis
- Infiltrative disorders: hemochromatosis, sarcoidosis, Langerhans cell histiocytosis
- Head trauma
- Surgery or radiation

Figure 137-17 In this patient with panhypopituitarism, fine wrinkling and pale skin can be seen as well as other features suggestive of hypothyroidism. Her decreased pigmentation is contrasted by that of her nurse on the right. Patients with panhypopituitarism often present with findings of multiple endocrine disorders.

symptoms may be a manifestation of imbalance in any number of endocrine systems that are regulated at the level of the pituitary including features of hypothyroidism. Skin findings that have been described in these patients include fine wrinkling of the skin, decreased pigmentation, and decreased to absent pubic and axillary hair (Fig. 137-17).

ACKNOWLEDGMENTS

We acknowledge and sincerely appreciate the contributions to this chapter from the authors of previous editions, Dr. John Olerud and Dr. Andy Chien.

REFERENCES

1. Economic Costs of Diabetes in the U.S. in 2017. *Diabetes Care*. 2018;41(5):917-928.
2. Narayan KM, Boyle JP, Thompson TJ, et al. Lifetime risk for diabetes mellitus in the United States. *JAMA*. 2003;290(14):1884-1890.
3. Holman RR, Paul SK, Bethel MA, et al. 10-year follow-up of intensive glucose control in type 2 diabetes. *N Engl J Med*. 2008;359(15):1577-1589.
4. Skyler JS, Bergenstal R, Bonow RO, et al. Intensive glycemic control and the prevention of cardiovascular events: implications of the ACCORD, ADVANCE, and VA diabetes trials: a position statement of the American Diabetes Association and a scientific statement of the American College of Cardiology Foundation and the American Heart Association. *Diabetes Care*. 2009;32(1):187-192.
5. Beisswenger PJ, Moore LL, Curphey TJ. Relationship between glycemic control and collagen-linked advanced glycosylation end products in type I diabetes. *Diabetes Care*. 1993;16(5):689-694.
6. Dyer DG, Dunn JA, Thorpe SR, et al. Accumulation of Maillard reaction products in skin collagen in diabetes and aging. *J Clin Invest*. 1993;91(6):2463-2469.
7. Buckingham BA, Uitto J, Sandborg C, et al. Scleroderma-like changes in insulin-dependent diabetes mellitus: clinical and biochemical studies. *Diabetes Care*. 1984;7(2):163-169.
8. Monnier VM, Bautista O, Kenny D, et al. Skin collagen glycation, glycoxidation, and crosslinking are lower in subjects with long-term intensive versus conventional therapy of type 1 diabetes: relevance of glycated collagen products versus HbA1c as markers of diabetic complications. DCCT Skin Collagen Ancillary Study Group. Diabetes Control and Complications Trial. *Diabetes*. 1999;48(4):870-880.
9. Noordzij MJ, Mulder DJ, Oomen PH, et al. Skin autofluorescence and risk of micro- and macrovascular complications in patients with Type 2 diabetes mellitus—a multi-centre study. *Diabet Med*. 2012;29(12):1556-1561.
10. Olerud JE. *Ellenburg & Rifkin's Diabetes Mellitus*. 6th ed. New York, NY: McGraw-Hill; 2003.
11. Joshi N, Caputo GM, Weitekamp MR, et al. Infections in patients with diabetes mellitus. *N Engl J Med*. 1999;341(25):1906-1912.
12. Cruz PD Jr, Hud JA Jr. Excess insulin binding to insulin-like growth factor receptors: proposed mechanism for acanthosis nigricans. *J Invest Dermatol*. 1992;98(6)(suppl):82S-85S.
13. Ansel JC, Armstrong CA, Song I, et al. Interactions of the skin and nervous system. *J Investig Dermatol Symp Proc*. 1997;2(1):23-26.
14. Reiber GE, Pecoraro RE, Koepsell TD. Risk factors for amputation in patients with diabetes mellitus. A case-control study. *Ann Intern Med*. 1992;117(2):97-105.
15. Schwartz RA. Acanthosis nigricans. *J Am Acad Dermatol*. 1994;31(1):1-19; quiz 20-22.
16. Stuart CA, Pate CJ, Peters EJ. Prevalence of acanthosis nigricans in an unselected population. *Am J Med*. 1989;87(3):269-272.

17. Tasjian D, Jarratt M. Familial acanthosis nigricans. *Arch Dermatol*. 1984;120(10):1351-1354.
18. Stuart CA, Gilkison CR, Smith MM, et al. Acanthosis nigricans as a risk factor for non-insulin dependent diabetes mellitus. *Clin Pediatr (Phila)*. 1998;37(2):73-79.
19. Andreev V. Malignant acanthosis nigricans. *Semin Dermatol*. 1984;3(4):265.
20. Brown J, Winkelmann RK. Acanthosis nigricans: a study of 90 cases. *Medicine (Baltimore)*. 1968;47(1):33-51.
21. Elder D, Elenitsas R, Jaworsky C, et al, eds. *Lever's Histopathology of the Skin*. 8th ed. Philadelphia, PA: Lippincott Williams and Wilkins; 1997.
22. Dunaif A. Insulin resistance and the polycystic ovary syndrome: mechanism and implications for pathogenesis. *Endocr Rev*. 1997;18(6):774-800.
23. Torley D, Bellus GA, Munro CS. Genes, growth factors and acanthosis nigricans. *Br J Dermatol*. 2002;147(6): 1096-1101.
24. Flier JS, Usher P, Moses AC. Monoclonal antibody to the type I insulin-like growth factor (IGF-I) receptor blocks IGF-I receptor-mediated DNA synthesis: clarification of the mitogenic mechanisms of IGF-I and insulin in human skin fibroblasts. *Proc Natl Acad Sci U S A*. 1986;83(3):664-668.
25. Ellis DL, Kafka SP, Chow JC, et al. Melanoma, growth factors, acanthosis nigricans, the sign of Leser-Trelat, and multiple acrochordons. A possible role for alpha-transforming growth factor in cutaneous paraneoplastic syndromes. *N Engl J Med*. 1987;317(25):1582-1587.
26. Koyama S, Ikeda K, Sato M, et al. Transforming growth factor-alpha (TGF alpha)-producing gastric carcinoma with acanthosis nigricans: an endocrine effect of TGF alpha in the pathogenesis of cutaneous paraneoplastic syndrome and epithelial hyperplasia of the esophagus. *J Gastroenterol*. 1997;32(1):71-77.
27. Bohm M, Luger TA, Metze D. Treatment of mixed-type acanthosis nigricans with topical calcipotriol. *Br J Dermatol*. 1998;139(5):932-934.
28. Blobstein SH. Topical therapy with tretinoin and ammonium lactate for acanthosis nigricans associated with obesity. *Cutis*. 2003;71(1):33-34.
29. Rosenbach A, Ram R. Treatment of acanthosis nigricans of the axillae using a long-pulsed (5-msec) alexandrite laser. *Dermatol Surg*. 2004;30(8):1158-1160.
30. Coates P, Shuttleworth D, Rees A. Resolution of nicotinic acid-induced acanthosis nigricans by substitution of an analogue (acipimox) in a patient with type V hyperlipidaemia. *Br J Dermatol*. 1992;126(4):412-414.
31. Kebria MM, Belinson J, Kim R, et al. Malignant acanthosis nigricans, tripe palms and the sign of Leser-Tre'lat, a hint to the diagnosis of early stage ovarian cancer: a case report and review of the literature. *Gynecol Oncol*. 2006;101(2):353-355.
32. Frost D, Beischer W. Limited joint mobility in type 1 diabetic patients: associations with microangiopathy and subclinical macroangiopathy are different in men and women. *Diabetes Care*. 2001;24(1):95-99.
33. Silverstein JH, Gordon G, Pollock BH, et al. Long-term glycemic control influences the onset of limited joint mobility in type 1 diabetes. *J Pediatr*. 1998;132(6):944-947.
34. Rosenbloom AL, Silverstein JH, Lezotte DC, et al. Limited joint mobility in childhood diabetes mellitus indicates increased risk for microvascular disease. *N Engl J Med*. 1981;305(4):191-194.
35. Infante JR, Rosenbloom AL, Silverstein JH, et al. Changes in frequency and severity of limited joint mobility in children with type 1 diabetes mellitus between 1976-78 and 1998. *J Pediatr*. 2001;138(1):33-37.
36. Buckingham B, Perejda AJ, Sandborg C, et al. Skin, joint, and pulmonary changes in type I diabetes mellitus. *Am J Dis Child*. 1986;140(5):420-423.
37. Cole GW, Headley J, Skowsky R. Scleredema diabeticorum: a common and distinct cutaneous manifestation of diabetes mellitus. *Diabetes Care*. 1983;6(2):189-192.
38. Sattar MA, Diab S, Sugathan TN, et al. Scleroedema diabeticorum: a minor but often unrecognized complication of diabetes mellitus. *Diabet Med*. 1988;5(5):465-468.
39. Varga J, Gotta S, Li L, et al. Scleredema adultorum: case report and demonstration of abnormal expression of extracellular matrix genes in skin fibroblasts in vivo and in vitro. *Br J Dermatol*. 1995;132(6):992-999.
40. Cohn BA, Wheeler CE Jr, Briggaman RA. Scleredema adultorum of Buschke and diabetes mellitus. *Arch Dermatol*. 1970;101(1):27-35.
41. Seyger MM, van den Hoogen FH, de Mare S, et al. A patient with a severe scleroedema diabeticorum, partially responding to low-dose methotrexate. *Dermatology*. 1999;198(2):177-179.
42. Lee MW, Choi JH, Sung KJ, et al. Electron beam therapy in patients with scleredema. *Acta Derm Venereol*. 2000;80(4):307-308.
43. Parker F, Bagdade JD, Odland GF, et al. Evidence for the chylomicron origin of lipids accumulating in diabetic eruptive xanthomas: a correlative lipid biochemical, histochemical, and electron microscopic study. *J Clin Invest*. 1970;49(12):2172-2187.
44. Chait A, Robertson HT, Brunzell JD. Chylomicronemia syndrome in diabetes mellitus. *Diabetes Care*. 1981;4(3):343-348.
45. Parker F. Xanthomas and hyperlipidemias. *J Am Acad Dermatol*. 1985;13(1):1-30.
46. Valerius NH, Eff C, Hansen NE, et al. Neutrophil and lymphocyte function in patients with diabetes mellitus. *Acta Med Scand*. 1982;211(6):463-467.
47. Gallacher SJ, Thomson G, Fraser WD, et al. Neutrophil bactericidal function in diabetes mellitus: evidence for association with blood glucose control. *Diabet Med*. 1995;12(10):916-920.
48. Singh N, Armstrong DG, Lipsky BA. Preventing foot ulcers in patients with diabetes. *JAMA*. 2005;293(2): 217-228.
49. Pecoraro RE, Reiber GE, Burgess EM. Pathways to diabetic limb amputation. Basis for prevention. *Diabetes Care*. 1990;13(5):513-521.
50. American Diabetes Association. Consensus Development Conference on Diabetic Foot Wound Care: 7-8 April 1999, Boston, Massachusetts. American Diabetes Association. *Diabetes Care*. 1999;22(8):1354-1360.
51. Levy DM, Karanth SS, Springall DR, et al. Depletion of cutaneous nerves and neuropeptides in diabetes mellitus: an immunocytochemical study. *Diabetologia*. 1989;32(7):427-433.
52. Antezana M, Sullivan S, Usui M, et al. Neutral endopeptidase activity is increased in the skin of subjects with diabetic ulcers. *J Invest Dermatol*. 2002;119(6):1400-1404.
53. Apelqvist J, Larsson J, Agardh CD. The influence of external precipitating factors and peripheral neuropathy on

the development and outcome of diabetic foot ulcers. *J Diabet Complications*. 1990;4(1):21-25.
54. Soulier SM. The use of running shoes in the prevention of plantar diabetic ulcers. *J Am Podiatr Med Assoc*. 1986;76(7):395-400.
55. Boyko EJ, Ahroni JH, Cohen V, et al. Prediction of diabetic foot ulcer occurrence using commonly available clinical information: the Seattle Diabetic Foot Study. *Diabetes Care*. 2006;29(6):1202-1207.
56. Wieman TJ, Smiell JM, Su Y. Efficacy and safety of a topical gel formulation of recombinant human platelet-derived growth factor-BB (becaplermin) in patients with chronic neuropathic diabetic ulcers. A phase III randomized placebo-controlled double-blind study. *Diabetes Care*. 1998;21(5):822-827.
57. Edmonds M, Bates M, Doxford M, et al. New treatments in ulcer healing and wound infection. *Diabetes Metab Res Rev*. 2000;16(suppl 1):S51-S54.
58. Langer A, Rogowski W. Systematic review of economic evaluations of human cell-derived wound care products for the treatment of venous leg and diabetic foot ulcers. *BMC Health Serv Res*. 2009;9:115.
59. Van Gils CC, Wheeler LA, Mellstrom M, et al. Amputation prevention by vascular surgery and podiatry collaboration in high-risk diabetic and nondiabetic patients. The Operation Desert Foot experience. *Diabetes Care*. 1999;22(5):678-683.
60. Apelqvist J, Larsson J, Agardh CD. Long-term prognosis for diabetic patients with foot ulcers. *J Intern Med*. 1993;233(6):485-491.
61. Mann RJ, Harman RR. Cutaneous anaesthesia in necrobiosis lipoidica. *Br J Dermatol*. 1984;110(3):323-325.
62. Muller SA, Winkelmann RK. Necrobiosis lipoidica diabeticorum. A clinical and pathological investigation of 171 cases. *Arch Dermatol*. 1966;93(3):272-281.
63. Lowitt MH, Dover JS. Necrobiosis lipoidica. *J Am Acad Dermatol*. 1991;25(5, pt 1):735-748.
64. Imtiaz KE, Khaleeli AA. Squamous cell carcinoma developing in necrobiosis lipoidica. *Diabet Med*. 2001; 18(4):325-328.
65. Crosby DL, Woodley DT, Leonard DD. Concomitant granuloma annulare and necrobiosis lipoidica. Report of a case and review of the literature. *Dermatologica*. 1991;183(3):225-229.
66. O'Toole EA, Kennedy U, Nolan JJ, et al. Necrobiosis lipoidica: only a minority of patients have diabetes mellitus. *Br J Dermatol*. 1999;140(2):283-286.
67. Dandona P, Freedman D, Barter S, et al. Glycosylated haemoglobin in patients with necrobiosis lipoidica and granuloma annulare. *Clin Exp Dermatol*. 1981;6(3):299-302.
68. Petzelbauer P, Wolff K, Tappeiner G. Necrobiosis lipoidica: treatment with systemic corticosteroids. *Br J Dermatol*. 1992;126(6):542-545.
69. Kreuter A, Knierim C, Stucker M, et al. Fumaric acid esters in necrobiosis lipoidica: results of a prospective noncontrolled study. *Br J Dermatol*. 2005; 153(4):802-807.
70. Darvay A, Acland KM, Russell-Jones R. Persistent ulcerated necrobiosis lipoidica responding to treatment with cyclosporin. *Br J Dermatol*. 1999;141(4): 725-727.
71. Dubin BJ, Kaplan EN. The surgical treatment of necrobiosis lipoidica diabeticorum. *Plast Reconstr Surg*. 1977;60(3):421-428.
72. Dabski K, Winkelmann RK. Generalized granuloma annulare: clinical and laboratory findings in 100 patients. *J Am Acad Dermatol*. 1989;20(1):39-47.
73. Veraldi S, Bencini PL, Drudi E, et al. Laboratory abnormalities in granuloma annulare: a case-control study. *Br J Dermatol*. 1997;136(4):652-653.
74. Melin H. An atrophic circumscribed skin lesion in the lower extremities of diabetics. *Acta Med Scand*. 1964;176(suppl 423):1-75.
75. Binkley GW. Dermopathy in diabetes mellitus. *Arch Dermatol*. 1965;92(1):106-107.
76. Shemer A, Bergman R, Linn S, et al. Diabetic dermopathy and internal complications in diabetes mellitus. *Int J Dermatol*. 1998;37(2):113-115.
77. Danowski TS, Sabeh G, Sarver ME, et al. Shin spots and diabetes mellitus. *Am J Med Sci*. 1966;251(5):570-575.
78. Borssen B, Bergenheim T, Lithner F. The epidemiology of foot lesions in diabetic patients aged 15-50 years. *Diabet Med*. 1990;7(5):438-444.
79. Lithner F. Cutaneous reactions of the extremities of diabetics to local thermal trauma. *Acta Med Scand*. 1975;198(4):319-325.
80. Rapini RP, Herbert AA, Drucker CR. Acquired perforating dermatosis. Evidence for combined transepidermal elimination of both collagen and elastic fibers. *Arch Dermatol*. 1989;125(8):1074-1078.
81. Faver IR, Daoud MS, Su WP. Acquired reactive perforating collagenosis. Report of six cases and review of the literature. *J Am Acad Dermatol*. 1994;30(4):575-580.
82. Bernstein JE, Levine LE, Medenica MM, et al. Reduced threshold to suction-induced blister formation in insulin-dependent diabetics. *J Am Acad Dermatol*. 1983;8(6):790-791.
83. Toonstra J. Bullosis diabeticorum. Report of a case with a review of the literature. *J Am Acad Dermatol*. 1985;13(5, pt 1):799-805.
84. Ogden CL, Carroll MD, Kit BK, et al. Prevalence of childhood and adult obesity in the United States, 2011-2012. *JAMA*. 2014;311(8):806-814.
85. Loffler H, Aramaki JU, Effendy I. The influence of body mass index on skin susceptibility to sodium lauryl sulphate. *Skin Res Technol*. 2002;8(1):19-22.
86. Guida B, Nino M, Perrino NR, et al. The impact of obesity on skin disease and epidermal permeability barrier status. *J Eur Acad Dermatol Venereol*. 2010;24(2):191-195.
87. Yosipovitch G, Tur E, Cohen O, et al. Skin surface pH in intertriginous areas in NIDDM patients. Possible correlation to candidal intertrigo. *Diabetes Care*. 1993;16(4):560-563.
88. Enser M, Avery NC. Mechanical and chemical properties of the skin and its collagen from lean and obese-hyperglycaemic (ob/ob) mice. *Diabetologia*. 1984;27(1):44-49.
89. de Jongh RT, Serné EH, IJzerman RG, et al. Impaired local microvascular vasodilatory effects of insulin and reduced skin microvascular vasomotion in obese women. *Microvasc Res*. 2008;75(2):256-262.
90. Yosipovitch G, DeVore A, Dawn A. Obesity and the skin: skin physiology and skin manifestations of obesity. *J Am Acad Dermatol*. 2007;56(6):901-916; quiz 917-920.
91. Scheinfeld NS. Obesity and dermatology. *Clin Dermatol*. 2004;22(4):303-309.
92. Kelesidis T, Kelesidis I, Chou S, et al. Narrative review: the role of leptin in human physiology: emerging clinical applications. *Ann Intern Med*. 2010;152(2): 93-100.
93. Oral EA, Simha V, Ruiz E, et al. Leptin-replacement therapy for lipodystrophy. *N Engl J Med*. 2002;346(8):570-578.

94. Lee JH, Chan JL, Sourlas E, et al. Recombinant methionyl human leptin therapy in replacement doses improves insulin resistance and metabolic profile in patients with lipoatrophy and metabolic syndrome induced by the highly active antiretroviral therapy. *J Clin Endocrinol Metab*. 2006;91(7):2605-2611.
95. Schaffer JV, Bolognia JL. The melanocortin-1 receptor: red hair and beyond. *Arch Dermatol*. 2001;137(11): 1477-1485.
96. Krude H, Biebermann H, Luck W, et al. Severe early-onset obesity, adrenal insufficiency and red hair pigmentation caused by POMC mutations in humans. *Nat Genet*. 1998;19(2):155-157.
97. Katsuki A, Sumida Y, Gabazza EC, et al. Plasma levels of agouti-related protein are increased in obese men. *J Clin Endocrinol Metab*. 2001;86(5):1921-1924.
98. Sonnett TE, Levien TL, Gates BJ, et al. Diabetes mellitus, inflammation, obesity: proposed treatment pathways for current and future therapies. *Ann Pharmacother*. 2010;44(4):701-711.
99. Inui A, Asakawa A, Bowers CY, et al. Ghrelin, appetite, and gastric motility: the emerging role of the stomach as an endocrine organ. *FASEB J*. 2004;18(3):439-456.
100. Klein S, Fontana L, Young VL, et al. Absence of an effect of liposuction on insulin action and risk factors for coronary heart disease. *N Engl J Med*. 2004;350(25): 2549-2557.
101. Mohammed BS, Cohen S, Reeds D, et al. Long-term effects of large-volume liposuction on metabolic risk factors for coronary heart disease. *Obesity (Silver Spring)*. 2008;16(12):2648-2651.
102. Andersson M, Takkouche B, Egli I, et al. Current global iodine status and progress over the last decade towards the elimination of iodine deficiency. *Bull World Health Organ*. 2005;83(7):518-525.
103. Hollowell JG, Staehling NW, Flanders WD, et al. Serum TSH, T(4), and thyroid antibodies in the United States population (1988 to 1994): National Health and Nutrition Examination Survey (NHANES III). *J Clin Endocrinol Metab*. 2002;87(2):489-499.
104. Weetman AP. Graves' disease. *N Engl J Med*. 2000;343(17):1236-1248.
105. De Leo S, Lee SY, Braverman LE. Hyperthyroidism. *Lancet*. 2016;388(10047):906-918.
106. Laurberg P, Cerqueira C, Ovesen L, et al. Iodine intake as a determinant of thyroid disorders in populations. *Best Pract Res Clin Endocrinol Metab*. 2010;24(1):13-27.
107. Buyukgebiz A. Congenital hypothyroidism clinical aspects and late consequences. *Pediatr Endocrinol Rev*. 2003;1(suppl 2):185-190; discussion 190.
108. Polak M. Hyperthyroidism in early infancy: pathogenesis, clinical features and diagnosis with a focus on neonatal hyperthyroidism. *Thyroid*. 1998;8(12): 1171-1177.
109. Ai J, Leonhardt JM, Heymann WR. Autoimmune thyroid diseases: etiology, pathogenesis, and dermatologic manifestations. *J Am Acad Dermatol*. 2003;48(5):641-659; quiz 660-662.
110. Fatourechi V, Pajouhi M, Fransway AF. Dermopathy of Graves disease (pretibial myxedema). Review of 150 cases. *Medicine (Baltimore)*. 1994;73(1):1-7.
111. Fatourechi V, Bartley GB, Eghbali-Fatourechi GZ, et al. Graves' dermopathy and acropachy are markers of severe Graves' ophthalmopathy. *Thyroid*. 2003;13(12): 1141-1144.
112. Parker LN, Wu SY, Lai MK, et al. The early diagnosis of atypical thyroid acropachy. *Arch Intern Med*. 1982;142(9):1749-1751.
113. Fatourechi V, Ahmed DD, Schwartz KM. Thyroid acropachy: report of 40 patients treated at a single institution in a 26-year period. *J Clin Endocrinol Metab*. 2002;87(12):5435-5441.
114. Dreskin SC, Andrews KY. The thyroid and urticaria. *Curr Opin Allergy Clin Immunol*. 2005;5(5):408-412.
115. Kim DH, Sung NH, Lee AY. Effect of levothyroxine treatment on clinical symptoms in hypothyroid patients with chronic urticaria and thyroid autoimmunity. *Ann Dermatol*. 2016;28(2):199-204.
116. Bagnasco M, Minciullo PL, Saraceno GS, et al. Urticaria and thyroid autoimmunity. *Thyroid*. 2011;21(4): 401-410.
117. Doshi DN, Blyumin ML, Kimball AB. Cutaneous manifestations of thyroid disease. *Clin Dermatol*. 2008;26(3):283-287.
118. Miller JJ, Roling D, Spiers E, et al. Palmoplantar keratoderma associated with hypothyroidism. *Br J Dermatol*. 1998;139(4):741-742.
119. Basaria S, Salvatori R. Images in clinical medicine. Pemberton's sign. *N Engl J Med*. 2004;350(13):1338.
120. Biro E, Szekanecz Z, Czirjak L, et al. Association of systemic and thyroid autoimmune diseases. *Clin Rheumatol*. 2006;25(2):240-245.
121. Callen JP, McCall MW. Bullous pemphigoid and Hashimoto's thyroiditis. *J Am Acad Dermatol*. 1981;5(5): 558-560.
122. Coleman R, Hay RJ. Chronic mucocutaneous candidosis associated with hypothyroidism: a distinct syndrome? *Br J Dermatol*. 1997;136(1):24-29.
123. Puavilai S, Puavilai G, Charuwichitratana S, et al. Prevalence of thyroid diseases in patients with alopecia areata. *Int J Dermatol*. 1994;33(9):632-633.
124. Zettinig G, Weissel M, Flores J, et al. Dermatitis herpetiformis is associated with atrophic but not with goitrous variant of Hashimoto's thyroiditis. *Eur J Clin Invest*. 2000;30(1):53-57.
125. Rees Smith B, McLachlan SM, Furmaniak J. Autoantibodies to the thyrotropin receptor. *Endocr Rev*. 1988;9(1):106-121.
126. Surks MI, Sievert R. Drugs and thyroid function. *N Engl J Med*. 1995;333(25):1688-1694.
127. Prabhakar BS, Bahn RS, Smith TJ. Current perspective on the pathogenesis of Graves' disease and ophthalmopathy. *Endocr Rev*. 2003;24(6):802-835.
128. Derwahl M, Manole D, Sobke A, et al. Pathogenesis of toxic thyroid adenomas and nodules: relevance of activating mutations in the TSH-receptor and Gs-alpha gene, the possible role of iodine deficiency and secondary and TSH-independent molecular mechanisms. *Exp Clin Endocrinol Diabetes*. 1998;106(suppl 4): S6-S9.
129. Safer JD, Crawford TM, Holick MF. Topical thyroid hormone accelerates wound healing in mice. *Endocrinology*. 2005;146(10):4425-4430.
130. Contreras-Jurado C, Lorz C, Garcia-Serrano L, et al. Thyroid hormone signaling controls hair follicle stem cell function. *Mol Biol Cell*. 2015;26(7):1263-1272.
131. Hamnvik OP, Larsen PR, Marqusee E. Thyroid dysfunction from antineoplastic agents. *J Natl Cancer Inst*. 2011;103(21):1572-1587.
132. Sherman SI, Gopal J, Haugen BR, et al. Central hypothyroidism associated with retinoid X receptor-selective ligands. *N Engl J Med*. 1999;340(14):1075-1079.

133. Pingsmann A, Ockenfels HM, Patsalis T. Surgical excision of pseudotumorous pretibial myxedema. *Foot Ankle Int*. 1996;17(2):107-110.
134. Susser WS, Heermans AG, Chapman MS, et al. Elephantiasic pretibial myxedema: a novel treatment for an uncommon disorder. *J Am Acad Dermatol*. 2002;46(5):723-726.
135. Wermers RA, Khosla S, Atkinson EJ, et al. Incidence of primary hyperparathyroidism in Rochester, Minnesota, 1993-2001: an update on the changing epidemiology of the disease. *J Bone Miner Res*. 2006;21(1):171-177.
136. Walsh JS, Fairley JA. Calcifying disorders of the skin. *J Am Acad Dermatol*. 1995;33(5, pt 1):693-706; quiz 707-710.
137. Dagher HN, Aboujaoude ZC, Jabbour SA. Chronic urticaria: an unusual initial manifestation of primary hyperparathyroidism. *Endocr Pract*. 2002;8(1): 47-49.
138. Schlieper G, Brandenburg V, Ketteler M, et al. Sodium thiosulfate in the treatment of calcific uremic arteriolopathy. *Nat Rev Nephrol*. 2009;5(9):539-543.
139. Vedvyas C, Winterfield LS, Vleugels RA. Calciphylaxis: a systematic review of existing and emerging therapies. *J Am Acad Dermatol*. 2012;67(6):e253-e260.
140. An J, Devaney B, Ooi KY, et al. Hyperbaric oxygen in the treatment of calciphylaxis: a case series and literature review. *Nephrology (Carlton)*. 2015;20(7):444-450.
141. Jabbour SA. Cutaneous manifestations of endocrine disorders: a guide for dermatologists. *Am J Clin Dermatol*. 2003;4(5):315-331.
142. Lee Y, Nam YH, Lee JH, et al. Hypocalcaemia-induced pustular psoriasis-like skin eruption. *Br J Dermatol*. 2005;152(3):591-593.
143. Makitie O, Sochett EB, Bondestam S, et al. Bone health in autoimmune polyendocrinopathy-candidiasis-ectodermal dystrophy (APECED): findings in 25 adults. *Clin Endocrinol (Oxf)*. 2006;64(5):489-494.
144. Wilson LC, Hall CM. Albright's hereditary osteodystrophy and pseudohypoparathyroidism. *Semin Musculoskelet Radiol*. 2002;6(4):273-283.
145. Foley J, Longely BJ, Wysolmerski JJ, et al. PTHrP regulates epidermal differentiation in adult mice. *J Invest Dermatol*. 1998;111(6):1122-1128.
146. Sharpe GR, Dillon JP, Durham B, et al. Human keratinocytes express transcripts for three isoforms of parathyroid hormone-related protein (PTHrP), but not for the parathyroid hormone/PTHrP receptor: effects of 1,25(OH)2 vitamin D3. *Br J Dermatol*. 1998;138(6):944-951.
147. Lowik CW, Hoekman K, Offringa R, et al. Regulation of parathyroid hormonelike protein production in cultured normal and malignant keratinocytes. *J Invest Dermatol*. 1992;98(2):198-203.
148. Atillasoy EJ, Burtis WJ, Milstone LM. Immunohistochemical localization of parathyroid hormone-related protein (PTHRP) in normal human skin. *J Invest Dermatol*. 1991;96(2):277-280.
149. Diamond AG, Gonterman RM, Anderson AL, et al. Parathyroid hormone hormone-related protein and the PTH receptor regulate angiogenesis of the skin. *J Invest Dermatol*. 2006;126(9):2127-2134.
150. Donovan PJ, Achong N, Griffin K, et al. PTHrP-mediated hypercalcemia: causes and survival in 138 patients. *J Clin Endocrinol Metab*. 2015;100(5):2024-2029.
151. Orth DN. Cushing's syndrome. *N Engl J Med*. 1995;332(12):791-803.
152. Beauregard C, Dickstein G, Lacroix A. Classic and recent etiologies of Cushing's syndrome: diagnosis and therapy. *Treat Endocrinol*. 2002;1(2):79-94.
153. Ilias I, Torpy DJ, Pacak K, et al. Cushing's syndrome due to ectopic corticotropin secretion: twenty years' experience at the National Institutes of Health. *J Clin Endocrinol Metab*. 2005;90(8):4955-4962.
154. Jabbour SA. Skin manifestations of hormone-secreting tumors. *Dermatol Ther*. 2010;23(6):643-650.
155. Stratakis CA. Cushing syndrome caused by adrenocortical tumors and hyperplasias (corticotropin-independent Cushing syndrome). *Endocr Dev*. 2008;13:117-132.
156. Nieman LK, Biller BM, Findling JW, et al. The diagnosis of Cushing's syndrome: an Endocrine Society clinical practice guideline. *J Clin Endocrinol Metab*. 2008;93(5):1526-1540.
157. Palermo NE, Ananthakrishnan S. Re-examining Nelson's syndrome. *Curr Opin Endocrinol Diabetes Obes*. 2015;22(4):313-318.
158. Ten S, New M, Maclaren N. Clinical review 130: Addison's disease 2001. *J Clin Endocrinol Metab*. 2001;86(7):2909-2922.
159. Laureti S, Vecchi L, Santeusanio F, et al. Is the prevalence of Addison's disease underestimated? *J Clin Endocrinol Metab*. 1999;84(5):1762.
160. Zelissen PM, Bast EJ, Croughs RJ. Associated autoimmunity in Addison's disease. *J Autoimmun*. 1995;8(1):121-130.
161. Barkan A, Glantz I. Calcification of auricular cartilages in patients with hypopituitarism. *J Clin Endocrinol Metab*. 1982;55(2):354-357.
162. Jameson JL, De Groot LJ. *Endocrinology: Adult and Pediatric*. Philadelphia, PA: Elsevier Health Sciences; 2010.
163. Alevritis EM, Sarubbi FA, Jordan RM, et al. Infectious causes of adrenal insufficiency. *South Med J*. 2003;96(9):888-890.
164. Daniels K, Daugherty J, Jones J, et al. Current contraceptive use and variation by selected characteristics among women aged 15-44: United States, 2011-2013. *Natl Health Stat Report*. 2015(86):1-14.
165. Sarkar R, Puri P, Jain RK, et al. Melasma in men: a clinical, aetiological and histological study. *J Eur Acad Dermatol Venereol*. 2010;24(7):768-772.
166. Shelley WB, Shelley ED, Talanin NY, et al. Estrogen dermatitis. *J Am Acad Dermatol*. 1995;32(1):25-31.
167. Higgins HW, Jenkins J, Horn TD, et al. Pregnancy-associated hyperkeratosis of the nipple: a report of 25 cases. *JAMA Dermatol*. 2013;149(6):722-726.
168. Farage MA, Berardesca E, Maibach H. The possible relevance of sex hormones on irritant and allergic responses: their importance for skin testing. *Contact Dermatitis*. 2010;62(2):67-74.
169. Hall G, Phillips TJ. Estrogen and skin: the effects of estrogen, menopause, and hormone replacement therapy on the skin. *J Am Acad Dermatol*. 2005;53(4):555-568; quiz 569-572.
170. Rendon M, Berneburg M, Arellano I, et al. Treatment of melasma. *J Am Acad Dermatol*. 2006;54(5)(suppl 2):S272-S281.
171. Forest MG. Recent advances in the diagnosis and management of congenital adrenal hyperplasia due to 21-hydroxylase deficiency. *Hum Reprod Update*. 2004;10(6):469-485.
172. Chen W, Thiboutot D, Zouboulis CC. Cutaneous androgen metabolism: basic research and clinical perspectives. *J Invest Dermatol*. 2002;119(5):992-1007.
173. Wilt TJ, MacDonald R, Hagerty K, et al. Five-alpha-reductase Inhibitors for prostate cancer prevention. *Cochrane Database Syst Rev*. 2008(2):Cd007091.

174. Traish AM, Melcangi RC, Bortolato M, et al. Adverse effects of 5α-reductase inhibitors: what do we know, don't know, and need to know? *Rev Endocr Metab Disord*. 2015;16(3):177-198.
175. van Zuuren EJ, Fedorowicz Z, Schoones J. Interventions for female pattern hair loss. *Cochrane Database Syst Rev*. 2016;(5):Cd007628.
176. Thiboutot D. Acne: hormonal concepts and therapy. *Clin Dermatol*. 2004;22(5):419-428.
177. Khatib N, Gaidhane S, Gaidhane AM, et al. Ghrelin: ghrelin as a regulatory peptide in growth hormone secretion. *J Clin Diagn Res*. 2014;8(8):MC13-MC17.
178. Rajasoorya C, Holdaway IM, Wrightson P, et al. Determinants of clinical outcome and survival in acromegaly. *Clin Endocrinol (Oxf)*. 1994;41(1):95-102.
179. Melmed S. Acromegaly. *N Engl J Med*. 2006;355(24):2558-2573.
180. Burton T, Le Nestour E, Neary M, et al. Incidence and prevalence of acromegaly in a large US health plan database. *Pituitary*. 2016;19:262-267.
181. Correa R, Salpea P, Stratakis C. Carney complex: an update. *Eur J Endocrinol*. 2015;173(4):M85-M97.
182. Salenave S, Boyce AM, Collins MT, et al. Acromegaly and McCune-Albright syndrome. *J Clin Endocrinol Metab*. 2014;99(6):1955-1969.
183. Molitch ME, Clemmons DR, Malozowski S, et al. Evaluation and treatment of adult growth hormone deficiency: an Endocrine Society clinical practice guideline. *J Clin Endocrinol Metab*. 2011;96(6):1587-1609.

Vascular Diseases PART 22

Chapter 138 :: Cutaneous Necrotizing Venulitis

:: Nicholas A. Soter

AT-A-GLANCE

- The signature lesions of cutaneous necrotizing venulitis (CNV) are palpable purpura, erythematous to violaceous papules that do not blanch when the skin is pressed.
- Palpable purpura persist for 1 to 4 weeks and resolve at times with transient hyperpigmentation and/or atrophic scars.
- CNV may be associated with episodes of recurrent and chronic urticaria and angioedema.
- Lesions may occur anywhere on the skin but are most common on the lower extremities or over dependent areas such as the back and gluteal regions.
- CNV may be associated with connective tissue diseases, malignant conditions, cryoglobulinemia, antineutrophil cytoplasmic or antiphospholipid antibody syndromes.
- CNV has many precipitating causes, but infections and drugs are most common.
- The most widely recognized subgroup of idiopathic cutaneous necrotizing vasculitis in children is immunoglobulin A vasculitis.
- Histopathologic criteria include necrosis of the blood vessels with the deposition of fibrinoid material and dermal cellular infiltrates that consist of neutrophils with nuclear debris, mononuclear cells, and extravasated erythrocytes.
- Therapeutic approaches are divisible into removal of antigen, treatment of any underlying disorder, and treatment of CNV.

Necrotizing angiitis or vasculitis comprises a diverse group of disorders that combine inflammation with necrosis of the blood vessels. The vascular damage may result from immunologic and/or inflammatory mechanisms. Clinical syndromes are based on criteria that include the gross appearance and the histopathologic alterations of the vascular lesions, the caliber of the affected blood vessels, the frequency of involvement of specific organs, and laboratory abnormalities. Necrotizing vasculitis may be a primary disease, may develop as a feature of a systemic disorder, or may be idiopathic. Although there is no standard classification of the vasculitides, the American College of Rheumatology classification and the International Chapel Hill Consensus criteria are widely used.[1,2]

Necrotizing vasculitis in the skin predominantly involves venules and is known as cutaneous necrotizing venulitis/vasculitis (CNV), cutaneous small-vessel vasculitis, and leukocytoclastic vasculitis. The occurrence of CNV in association with systemic involvement of the small blood vessels has been termed *hypersensitivity angiitis/vasculitis*, *systemic polyangiitis*, and *microscopic polyangiitis* (see Chap. 139). CNV may be restricted to the skin, may occur in association with an underlying chronic disease, may be precipitated by infections or drugs, or may develop for unknown reasons (Table 138-1). Systemic forms of necrotizing vasculitis that affect larger blood vessels are considered in Chap. 139, "Systemic Necrotizing Arteritis."

HISTORICAL PERSPECTIVE

Various syndromes of necrotizing vasculitis were described in the 19th century, including necrotizing vasculitis of small blood vessels, described by Schönlein in 1837 and by Henoch in 1847. In 1952, Zeek differentiated systemic hypersensitivity angiitis that involved small blood vessels from polyarteritis nodosa. In various countries, different diagnostic terms were used to describe necrotizing vasculitis of the small blood vessels in the skin, which were perceived to be arterioles in the 1960s but were shown to be venules in the 1970s by multiple investigators.

TABLE 138-1

Cutaneous Necrotizing Venulitis: Associated Disorders and Events

Associated Chronic Disorders
- Rheumatoid arthritis
- Sjögren syndrome
- Systemic lupus erythematosus
- Hypergammaglobulinemic purpura
- Paraneoplastic vasculitis
- Cryoglobulinemia
- Ulcerative colitis
- Cystic fibrosis
- Antineutrophil cytoplasmic or antiphospholipid antibody syndromes

Precipitating Events
- Bacterial, viral, mycobacterial, and rickettsial infections
- Therapeutic and diagnostic agents

Idiopathic Disorders
- Immunoglobulin A vasculitis (Henoch-Schönlein purpura)
- Acute hemorrhagic edema of infancy
- Urticarial venulitis
- Erythema elevatum diutinum
- Nodular vasculitis
- Livedoid vasculopathy
- Genetic complement deficiencies
- Eosinophilic vasculitis
- Idiopathic

EPIDEMIOLOGY

In a population-based study in Minnesota, the overall incidence of CNV was 4.5 per 100,000 person-years. The most common subtypes were cutaneous small-vessel vasculitis in 45% and immunoglobulin (Ig) A vasculitis in 30% of persons with CNV. The most common etiology was idiopathic. CNV was accompanied by systemic involvement in 4%.[3] In a study in France, the 5-year survival rate was 75.6%. Age older than 65 years at the outset of vasculitis was the only factor that was significantly associated with a shorter survival.[4] In this study, 18% of patients experienced relapses, especially when vascular thrombosis was identified in the skin biopsy specimen, when an antineutrophil cytoplasmic antibody (ANCA) was present, when hepatic liver enzymes were elevated, and when peripheral neuropathy was present. When the skin was the single organ involved, there were no relapses. IgA vasculitis is the most common form of CNV in children. Geographic variations in vasculitis may reflect an environmental influence, and seasonal variations in the incidence of vasculitis may suggest an infectious etiology.

CLINICAL FEATURES

The skin lesions of CNV are polymorphous. Erythematous to violaceous papules that do not blanch when the skin is pressed, known as *palpable purpura*, are the signature lesions (Fig. 138-1A). Macules, papules, urticaria/angioedema, pustules, vesicles, hemorrhagic blisters (Fig. 138-1B), necrosis and ulcers (Fig. 138-1C), and livedo reticularis may be present. Occasionally, there is subcutaneous edema below the area of the dermal lesions.

The eruption most often appears on the lower extremities or over dependent areas, such as the back and gluteal regions. The lesions may occur anywhere on the skin but are uncommon on the face, palms, soles, and mucous membranes. The clinical lesions are episodic and may recur over weeks to years. Palpable purpura persist for 1 to 4 weeks and resolve at times with transient hyperpigmentation and/or atrophic scars. Lesional symptoms include pruritus or burning and, less commonly, pain.

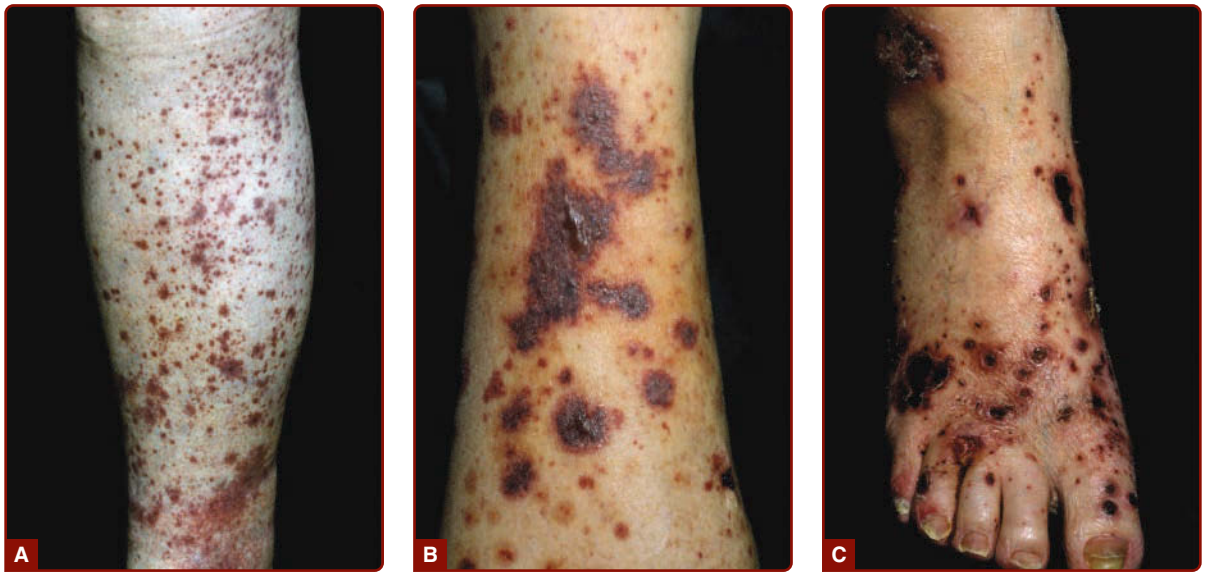

Figure 138-1 **A,** Palpable purpura on the lower leg in a patient with Henoch-Schönlein purpura. **B,** Palpable purpura with more-severe tissue damage with hemorrhagic vesicles and bullae. **C,** With even more tissue damage, multiple necrosis, and ulcers.

Fever, malaise, arthralgias, or myalgias may accompany an episode of cutaneous vascular lesions, irrespective of a defined underlying cause or associated disease. Systemic involvement of the small blood vessels most commonly occurs in the synovia, GI tract, voluntary muscles, peripheral nerves, and kidneys.

ASSOCIATED CHRONIC DISORDERS

CNV is associated with connective tissue diseases, notably rheumatoid arthritis, Sjögren syndrome, systemic lupus erythematosus (SLE), and hypergammaglobulinemic purpura. It rarely occurs in mixed connective tissue disease, relapsing polychondritis, polymyositis/dermatomyositis, ankylosing spondylitis,[5] and scleroderma. In patients with rheumatoid arthritis and CNV, the development of vascular lesions is related to the severity of the disease, which is generally, but not always, seropositive. Patients with rheumatoid arthritis often have involvement of larger vessels with associated peripheral neuropathy, nailfold infarcts, and digital gangrene.

In patients with SLE, CNV is associated with exacerbations of the underlying disease. Patients with anti-Ro antibody have a greater risk for the development of CNV. Vasculitis, however, is rare in patients with subacute cutaneous lupus erythematosus. Some women with necrotizing vasculitis without connective tissue disease have anti-Ro antibodies, and their infants may be born with neonatal lupus erythematosus.

In patients with Sjögren syndrome, the vascular lesions are located predominantly on the lower extremities and appear after exercise. Both hyperpigmentation and cutaneous ulcers are common features. Patients with Sjögren syndrome and CNV have a higher prevalence of articular involvement, peripheral neuropathy, Raynaud phenomenon, and renal involvement, as well as the presence of anti-Ro antibody. Hypergammaglobulinemic purpura occurs in older women and may be associated with Sjögren syndrome, SLE, or a lymphoproliferative disorder. Dermatomyositis in children, but not in adults, may be associated with vasculitis of the GI tract.

Paraneoplastic vasculitis[6] describes CNV with associated malignant conditions. Hematologic disorders constitute the most common group of malignant disorders, especially chronic myelomonocytic leukemia, non-Hodgkin lymphoma, Hodgkin disease, chronic lymphocytic leukemia, myelodysplastic syndrome, and acute myelogenous leukemia. Less commonly, CNV is related to solid tumors, especially renal, lung, colon, breast, and prostate. However, the association between CNV and neoplasia is rare. It is not necessary to evaluate all patients with CNV for associated malignant conditions.

Cryoglobulins (see Chap. 144), especially mixed Types II and III, may be found in patients with idiopathic CNV and in patients with CNV that is associated with connective tissue diseases, lymphoproliferative disorders, propylthiouracil administration, and hepatitides A, B, and C virus infections. Hepatitis C virus is the most common infection, especially when it is associated with cryoglobulinemia. CNV occurs in patients with cystic fibrosis, inflammatory bowel diseases of the colon, and Behçet disease.

ANCAs are associated with various forms of necrotizing vasculitis. ANCAs are present in patients with microscopic polyangiitis and cutaneous vasculitis with hepatitis C virus infection (see Chap. 139). The most common cutaneous feature in patients with ANCAs is palpable purpura. Microscopic polyangiitis is associated with small-vessel systemic vasculitis that involves the cutaneous venules and arterioles, the kidneys with necrotizing and crescentic glomerulonephritis, the lungs with pulmonary hemorrhage or interstitial pneumonia, and perinuclear ANCAs (pANCAs). Erythematous macules, purpura, and livedo reticularis are cutaneous manifestations in microscopic polyangiitis. IgA ANCAs are present in acute IgA vasculitis in children.

Various subtypes of antiphospholipid antibodies occur in patients with necrotizing vasculitis. IgA anticardiolipin antibodies were detected in some patients with idiopathic CNV. IgA anticardiolipin, IgA and IgM anti–phosphatidyl serine–prothrombin complex, and IgA antibody-β_2 glycoprotein antibodies were detected in adults with IgA vasculitis. IgM anti–phosphatidyl serine–prothrombin complex antibodies were detected in adults with CNV. IgG and IgM anticardiolipin antibodies were detected in some individuals with livedoid vasculitis.

PRECIPITATING INFECTIONS AND DRUGS

Infections[7] and drugs[8-10] may precipitate episodes of CNV. The most commonly recognized infectious agents are β-hemolytic *Streptococcus*, *Staphylococcus aureus, Mycobacterium leprae,* and hepatitides B and C viruses. Transient episodes of urticaria may occur early in the course of hepatitis B virus infection and represent immune complex–induced vasculitis. Cutaneous vasculitis has been recognized in a limited number of individuals with HIV infection; the skin lesions consisted of palpable purpura, which at times had a follicular localization, and cutaneous ulcers.

Erythema nodosum leprosum, which appears as cutaneous nodules in lepromatous leprosy, is a form of necrotizing vasculitis that involves capillaries, venules, arterioles, small-to-medium-size arteries, and veins. The vascular lesions occur spontaneously or are precipitated by the administration of chemotherapeutic agents. They may be accompanied by fever, malaise, arthralgias, lymphadenopathy, and polyneuritis.

Necrotizing vasculitis that is caused by the direct invasion of the blood vessel wall occurs in septicemia caused by *Neisseria meningitidis, Neisseria gonorrhoeae,*

Pseudomonas, *Haemophilus influenzae*, *Rickettsia*, *Candida*, and infectious endocarditis; in Rocky Mountain spotted fever; and in infections localized at the site of a catheter.

Palpable purpura is one of the less-common forms of drug reactions. The most commonly incriminated therapeutic agents were antibiotics, especially β-lactam agents, penicillin, and cephalosporins; nonsteroidal antiinflammatory agents; acetaminophen (paracetamol); allopurinol; anticonvulsants; propylthiouracil; hydralazine; granulocyte colony-stimulating factor/granulocyte-macrophage colony-stimulating factor; penicillamine; phenytoin; isotretinoin; methotrexate; and levamisole in cocaine.[11] Propylthiouracil[12] and hydralazine may cause vasculitis in association with ANCAs. Cutaneous vasculitis also has occurred after the administration of streptokinase, radiocontrast media, and staphylococcal protein A column immunoadsorption therapy. CNV is one of the most frequent autoimmune disorders triggered by anti–tumor necrosis factor biologic agents.[13]

IDIOPATHIC DISORDERS

Table 138-2 summarizes idiopathic small vessel vasculitides.

IMMUNOGLOBULIN A VASCULITIS

The most widely recognized subgroup of idiopathic CNV is IgA vasculitis,[14-18] which formerly was known as anaphylactoid purpura and Henoch-Schönlein purpura. It comprises 75% of CNV in children and 25% of CNV in adults. Most cases occur in the autumn and winter, and often are preceded by a history of a recent upper respiratory tract infection, especially in children. Sites of involvement include the skin, synovia, GI tract, and kidneys. Symptoms may include abdominal pain, melena, arthralgia, and hematuria. Long-term morbidity from progressive renal disease depends on the degree of initial renal damage. The distribution of skin lesions on the upper and lower extremities is a predictive factor for long-term renal

TABLE 138-2
A Summary of Idiopathic Small Vessel Vasculitides

	EPIDEMIOLOGY	MANIFESTATIONS
IgA vasculitis (formerly Henoch-Schönlein purpura)	75% of CNV in children 25% of CNV in adults	History of recent upper respiratory tract infection; involvement of skin, synovia, GI tract, kidneys; associated with abdominal pain, melena, arthralgia and hematuria; risk for progressive renal disease
Acute hemorrhagic edema of infancy	Infants and children <2 years of age	Painful, edematous petechiae and ecchymoses on head and distal extremities; may have associated facial edema; lesions may appear targetoid with bullae and necrosis; resolves within 1 to 3 weeks without sequelae
Urticarial venulitis (*urticarial vasculitis*)	Women most often affected; may be associated with serum sickness, connective tissue disorders, hematologic and malignant conditions, infections, or may be idiopathic	Erythematous, indurated wheals with a foci of purpura; may be associated with macular erythema, angioedema, livedo reticularis, nodules and bullae; persists for as long as 5 days; episodes may be chronic and recurrent
Erythema elevatum diutinum	Rare; most common in 4th to 6th decades	Symmetric, persistent, red-purple or red-brown plaques over joints or extensors and over gluteal area
Nodular vasculitis (*erythema induratum*)	More common in women between 30 and 40 years of age; may be associated with *Mycobacterium tuberculosis* infection (Erythema induratum) and hepatitis C virus infection	Tender, red, subcutaneous nodules over calves without systemic manifestations; may be recurrent
Livedoid vasculopathy (livedoid vasculitis, livedo vasculitis, segmental hyalinizing vasculitis, atrophie blanche)	More common in women; may occur in association with connective tissue disorders, malignancies, hypercoagulable states, thrombophilia	Chronic recurrent episodic exacerbations; arteriosclerosis or stasis of the lower extremities
Sneddon syndrome	May be associated with SLE	Livedo racemosa and livedoid vasculopathy are associated with ischemic cerebrovascular lesions, hypotension, and extracerebral arterial and venous thromboses
Eosinophilic vasculitis	Idiopathic	Recurrent, pruritic, purpuric papular skin lesions, urticarial plaques, and angioedema

CNV, cutaneous necrotizing venulitis; IgA, immunoglobulin A; SLE, systemic lupus erythematosus.

involvement. Adults with onset after 60 years of age have a worse prognosis, owing to an increased risk of renal disease. Approximately 23% of IgA vasculitis patients experience a relapse. Longer duration of the initial episode, abdominal pain, joint manifestations, and the lack of an infectious cause were associated with relapses. Complete recovery occurred in 82.7% of those with relapses.

ACUTE HEMORRHAGIC EDEMA OF INFANCY

This uncommon disorder affects infants and children younger than 2 years of age, with a slight predominance in boys.[19] It has been classified by some as a variant of IgA vasculitis, while others consider it is a distinct clinical entity. The lesions appear as painful, edematous petechiae and ecchymoses that affect the head and distal portions of the extremities. Facial edema may be the initial sign. The skin lesions may be associated with a target-like appearance and may develop bullae and necrosis. Infections, drugs, or immunizations may be triggering factors. Acute hemorrhagic edema of infancy is distinguished from IgA vasculitis by its age distribution, lack of systemic features, and resolution within 1 to 3 weeks without sequelae.

URTICARIAL VENULITIS

Episodes of recurrent and chronic urticaria and angioedema may be a clinical manifestation of CNV.[20] Known as *urticarial vasculitis/venulitis*, this edematous form of necrotizing venulitis occurs in patients with serum sickness, connective tissue disorders, hematologic and other malignant conditions, an IgM_K M component, infections, and, rarely, physical urticarias; after the administration of a variety of therapeutic agents; and as an idiopathic disorder.[21] The term *hypocomplementemic urticarial vasculitis syndrome* (HUVS) has been used to describe patients with more severe systemic manifestations, hypocomplementemia with low Clq levels, and an autoantibody to the collagen-like region of Clq.[22]

The skin lesions appear as erythematous, occasionally indurated, wheals that may contain foci of purpura (Fig. 138-2). Other skin manifestations include angioedema, macular erythema, livedo reticularis, nodules, and bullae. Although the individual urticarial lesions may last for fewer than 24 hours, they often persist for up to 3 to 5 days. The lesions are pruritic or possess a burning or painful quality; they usually resolve without residua although some individuals may develop contusions or hyperpigmentation. The episodes of urticaria are chronic, range in duration from months to years, and vary in frequency. Approximately 70% of affected individuals are women. The prevalence of this disorder remains unknown. General features include fever, malaise, and myalgia; the lymph nodes, liver, and spleen may be enlarged. Extracutaneous features involve the synovium, kidneys, GI tract, lungs, eyes, heart, CNS, peripheral nerves, and blood vessels. These extracutaneous features are more extensive in patients with HUVS.

Figure 138-2 Urticarial venulitis. Some of the wheals have been marked 24 hours previously to demonstrate persistent character of the urticaria.

The natural history of urticarial vasculitis is unknown, although individuals have been described with historic episodes of cutaneous lesions for up to 25 years. In one series of patients followed for 1 year, 40% experienced complete resolution of skin lesions; in another series of individuals followed for as long as 14 years, resolution occurred in only 1 patient. Sjögren syndrome and SLE have developed. Deaths have been reported from pulmonary disease, sepsis, and myocardial infarction.

The prevalence of urticarial vasculitis in individuals with chronic idiopathic urticaria is unknown, although series have reported rates that range from 1% to 50%. Most of these data have been reported from histopathologic studies in tertiary referral centers. The prevalence of urticarial vasculitis in a prospective clinical study in a university hospital in India was 11.4%.

Schnitzler syndrome[23,24] consists of episodes of urticarial vasculitis that is characterized by an infiltrate of neutrophils in the dermis and, less commonly, CNV that occur in association with a monoclonal IgM_K M component. Associated features include fever, lymphadenopathy, hepatosplenomegaly, bone pain, a sensorimotor neuropathy, and renal failure. It is a recurrent disorder with periods of spontaneous remission. Evolution into hematologic malignant conditions has been reported in 15% of Schnitzler syndrome patients.

ERYTHEMA ELEVATUM DIUTINUM

Erythema elevatum diutinum occurs as symmetric, persistent, red-purple or red-brown plaques that are predominantly distributed over the joints of extensor surfaces and over the gluteal area (see Chap. 140).

Figure 138-3 Nodular vasculitis with ulcers on lower legs.

NODULAR VASCULITIS

Nodular vasculitis appears as tender, red, subcutaneous nodules over the lower extremities, especially the calves, without systemic manifestations (Fig. 138-3). At times, lesions develop on the thighs, buttocks, trunk, and arms, and ulcerated nodules may be present. Recurrent episodes are common. It is more common in women and has a peak incidence in individuals between 30 and 40 years of age. Erythema induratum is a form of nodular vasculitis, which has been associated with *Mycobacterium tuberculosis* infection, as demonstrated by polymerase chain reaction amplification for *M. tuberculosis* DNA in skin biopsy specimens. Various sizes of blood vessels, including venules, are affected. Erythema induratum also is associated with hepatitis C virus infection.

LIVEDOID VASCULOPATHY AND SNEDDON SYNDROME

Livedoid vasculopathy (Fig. 138-4), also known as livedoid vasculitis, livedo vasculitis, segmental hyalinizing vasculitis, and atrophie blanche, occurs as recurrent, painful ulcers of the lower extremities in association with persistent livedo reticularis (livedo racemosa) that often is deep purple in color. Healing results in sclerotic pale areas that are surrounded by telangiectasias termed *atrophie blanche* (Fig. 138-5). The clinical course is chronic with recurrent episodic exacerbations. Systemic involvement is not a feature of idiopathic livedoid vasculopathy. Many patients have arteriosclerosis or stasis of the lower extremities. Livedoid vasculopathy is more common in women and may occur in patients with connective tissue disorders, in malignant conditions, hypercoagulable states, in thrombophilia, and as an idiopathic

Figure 138-4 Livedoid vasculitis with recurrent, painful ulcers and livedo reticularis.

disorder.[25] Protein C and protein S deficiencies, factor V Leiden gene mutation, activated protein C resistance, prothrombin gene mutation, hyperhomocysteinemia, and antithrombin deficiency have been reported. Atrophie blanche, however, probably represents the end stage of a variety of forms of vascular damage in the skin. Elevated levels of fibrinopeptide A, homocysteine, and plasminogen activator inhibitor may occur. Pathogenesis has focused on a hypercoagulable state with fibrin thrombi in the lumina of the superficial blood vessels. Some consider this condition to be a thrombogenic vasculopathy rather than a small-vessel vasculitis. Antiphospholipid antibodies have been detected in a few individuals.

Figure 138-5 Atrophie blanche over the medial malleolus with porcelain-white atrophy, telangiectases, and ulcers.

Sneddon syndrome is a condition in which livedo racemosa and livedoid vasculopathy are associated with ischemic cerebrovascular lesions, hypotension, and extracerebral arterial and venous thromboses.[26,27] This condition may be associated with SLE. Antiendothelial cell antibodies, antiphospholipid antibodies, anti–β_2-glycoprotein antibodies, and antiprothrombin antibodies were detected in some patients.

GENETIC COMPLEMENT DEFICIENCIES

Genetic C2 deficiency has been recognized in association with CNV in 3 children and in 2 siblings with human leukocyte antigen (HLA)-A25, HLA-B18, and HLA-DR2 (w15) haplotype. C4 deficiency was present in 1 child with CNV and in 1 adult with CNV, and augmented C4 messenger RNA expression.[28] Deficiencies of C4A and C4B isotypes were found in some children and adults with IgA vasculitis. A partial C4B deficiency with C4A1, C4A3, and C4B1, and a null allele B*QO was reported in a 51-year-old woman with CNV.[29] A complete deficiency of complement factor 1 with a homozygous missense mutation in exon 2 of the *CF1* gene was reported in a 25-year-old woman with CNV.[29]

EOSINOPHILIC VASCULITIS

Eosinophilic vasculitis has been described as an idiopathic syndrome in individuals with recurrent, pruritic, and purpuric papular skin lesions, urticarial plaques, and angioedema. Skin biopsy specimens showed an infiltrate that is composed of eosinophils that express CD40 and vascular cell adhesion molecule (VCAM)-1 on endothelial cells of involved vessels. Eosinophilic vasculitis also has been described in some individuals with the hypereosinophilic syndrome (see Chap. 40) and in others with connective tissue disorders. There may be depressed complement levels, peripheral eosinophilia, elevated major basic protein levels, and a prolonged eosinophil survival time.

IDIOPATHIC

CNV that does not meet the criteria for a recognized syndrome is classified as idiopathic. Most cases are idiopathic.

ETIOLOGY AND PATHOGENESIS

Experimental studies in animal models and observations in humans implicate immune complexes as a major pathobiologic mechanism in the production of CNV. Data obtained in animal models suggest that the localization of immune complexes in venules is related to vasoactive amines and subsequent vasopermeability alterations. Additional factors that are operative in the localization of immune complexes include endothelial cell surface receptors and the defective clearance of immune complexes by the reticuloendothelial system.

The most frequently postulated mechanisms in the production of CNV are the local deposition of circulating immune complexes that are formed during antigen excess or the formation of immune complexes in situ in the skin. Immune complexes may activate the complement system and lead to the generation of C5a anaphylatoxin that degranulates mast cells and attracts neutrophils, which release lysosomal enzymes that damage tissue. The neutrophil superoxide-generating system may produce reactive oxygen products, which also cause tissue injury. The generation of the chemoattractant leukotriene B_4 from infiltrating neutrophils enhances the influx of neutrophils. The initial neutrophilic infiltrate contains few CD3, CD4, CD1a, and CD36 cells as these cells are prominent in the later phase, with the adhesion receptors intercellular adhesion molecule-1 (ICAM-1) and lymphocyte function-associated antigen-1. In IgA vasculitis, the fragmentation of neutrophils was attributed to apoptosis on the basis of the detection of inducible nitric oxide synthase and nitrotyrosine in the infiltrates and the detection of interleukin (IL)-8 on vascular endothelial cells. Long penetration PTX3, which inhibits phagocytosis of apoptotic neutrophils by macrophages, was detected in skin biopsy specimens of idiopathic CNV and of IgA vasculitis about blood vessels and at sites of infiltrates with leukocytoclasia.

In CNV, circulating immune complexes have been demonstrated in serum as mixed-type cryoglobulins and indirectly by assays that detect C1q precipitins, materials that bind to complement receptors on human lymphocytoid (Raji) cells, materials that bind to monoclonal rheumatoid factor, and substances that function in the antibody-dependent cellular cytotoxicity inhibition assay. The presence of immune complexes is inferred from the occurrence of serum hypocomplementemia with activation of the classic activating pathway and by the detection of increased plasma levels of C4a and C3a anaphylatoxins.

In CNV, immune complexes have been detected in lesional tissues by their ultrastructural observation as electron-dense subendothelial deposits; the membrane-attack complex, C5b-9, of the complement system has been detected on the surface of endothelial cells and infiltrating neutrophils. Decay-accelerating factor, which is a regulatory complement protein that prevents the assembly of the membrane-attack complex, was not present on the surface of endothelial cells of the superficial dermal microvasculature. Tissue immune complexes also have been detected by direct immunofluorescence techniques as deposited immunoglobulins and complement proteins. In time–course studies of the evolution of cutaneous vascular lesions, immune reactants have been identified in lesions that are less than 24 hours old. Antigens have been identified only in a few instances as bacterial, viral, mycobacterial, or rickettsial proteins by direct immunofluorescence techniques or by the polymerase chain reaction.

A role for lymphocytes in the production of CNV is suggested by a perivenular infiltrate in skin lesions that is rich in lymphocytes with large and hyperchromatic nuclei. The lymphocytes express CD3, CD4, CD1a, CD36, ICAM-1, and lymphocyte function-associated antigen-1. Lymphocytes may be activated by immune complexes, by cellular immune mechanisms, and by primary activation in autoimmune disease to produce lymphokines. In CNV, there were increased numbers of factor XIIIa+–derived dendrocytes, which are involved in antigen presentation to T cells. Endothelial cells also can present antigens to and activate T lymphocytes. Activated macrophages secrete chemokines and lysosomal enzymes. γ/δ T cells have been detected in CNV with a neutrophil-rich pattern and with an infectious etiology. In these specimens, a 72-kDa heat shock protein was expressed by endothelial cells and antigen-presenting cells.

The participation of mast cells in CNV is suggested by hypogranulated mast cells with shed extracellular granules and by the development of vascular lesions after the intracutaneous injection of histamine in patients with active episodes of CNV. Mast cells can be activated directly by immune complexes through FcγRIII or by C5a. Through the production of histamine, prostaglandin D_2, and cysteinyl leukotrienes, the mast cell could alter venular permeability; interendothelial cell gaps have been noted in venules in patients with CNV. Eosinophils and neutrophils may be recruited by mast cell–derived chemotactic factors. The neutral proteases and acid hydrolases of mast cells may facilitate tissue damage, and the release of tumor necrosis factor-α (TNF-α) may increase expression of E-selectin on endothelial cells and facilitate neutrophil recruitment.

Evidence for the role of the mast cell also is provided by time–course analyses of the sequential histopathologic changes in individuals with physical urticaria. In a patient with circulating immune complexes and hypocomplementemia, in whom cold and trauma elicited CNV, initial mast cell degranulation was followed by the infiltration of neutrophils, the deposition of fibrin, and venular endothelial cell necrosis. A postulated sequence of events would be the activation of the mast cell by physical stimuli, the release of vasoactive mediators, the deposition of circulating immune complexes with activation of the complement system, the influx of neutrophils, and the development of CNV. Another example of the time–course analysis of CNV in human skin was provided by an individual with exercise-induced vasculitis. At 3 hours, the number of mast cells decreased, and the eosinophil was the first cell to appear around the venules with the deposition of eosinophil peroxidase. TNF-α levels were elevated, E-selectin was expressed on endothelial cells, and an influx of neutrophils appeared with the deposition of neutrophil elastase and the development of CNV.

In a study of 10 adult patients with CNV,[30] skin biopsy specimens were obtained from early petechial lesions and the later lesions of palpable purpura. The number of mast cells that contained tryptase and chymase were decreased in the early lesions, which suggested degranulation. The levels of chymase as well as α_1-antichymotrypsin continued to decrease with the progression of vasculitis, which suggested inhibition by antichymotrypsin. IgG, IgM, IgA, and fibrin increased in palpable purpura.

Early in the course of necrotizing venulitis, endothelial cells show increased expression of ICAM-1 and E-selectin without the expression of VCAM-1in response to TNF-α. Because E-selectin is an adhesion molecule for neutrophils and for skin-homing, memory T lymphocytes, the increase in E-selectin is associated with an infiltrate of neutrophils that express CD11b within the first 24 hours.

In the acute phase of IgA vasculitis, endothelin-1, serum insulin-like growth factor-1,[31] insulin-like growth factor–binding protein-3, plasma matrix metalloproteinase-9, ICAM-1, VCAM-1, TNF-α, tumor necrosis factor-like inducer of apoptosis weak,[32] IL-1β, IL-2 receptor, IL-6, IL-8, IL-33,[33] transforming growth factor-β, vascular endothelial cell growth factor, high-mobility group box-1,[34] visfatin,[35] CCL5, CXCLlb, CX_3CL,[36] and urine leukotriene E_4 levels were elevated. However, the pathogenic roles of these mediators remain undefined. IgA antiendothelial cell antibodies bind to endothelial cells and enhance endothelial cell production of IL-8 via the mitogen-activated protein kinase/extracellular signal-regulated kinase pathways.

In skin biopsy specimens from patients with idiopathic CNV, hypersensitivity vasculitis, urticarial vasculitis, and IgA vasculitis, E-selectin was detected on endothelial cells of lesions that were less than 48 hours old and was associated with an infiltrate of neutrophils that expressed CD11b. The endothelial cells expressed HLA-DR and very-late-activating antigen-1 but not P-selectin, and the perivascular cells expressed VCAM-1 and HLA-DR. Diminished cutaneous fibrinolytic activity with reduced release of plasminogen activator from venular endothelial cells occurs in patients with CNV; the subsequent reduction in fibrinolytic activity leads to fibrin deposition. Increased levels of plasma thrombomodulin, tissue-type plasminogen activator, and plasminogen activator inhibitor-1 were detected in patients with IgA vasculitis.

Cutaneous nerve fibers can release neuropeptides that cause vasodilation, such as substance P, neurokinin A, and calcitonin gene-related peptide. Substance P activates mast cells and macrophages and increases fibrinolytic activity that is mediated by plasminogen activator. Calcitonin gene-related peptide induces expression of E-selectin on endothelial cells and is chemotactic for T lymphocytes.

Eosinophils are minor infiltrating cells in CNV except in eosinophilic vasculitis and drug-induced CNV. Eosinophils produce leukotriene C_4 and platelet-activating factor, which increase vascular permeability. Eosinophil granule proteins are toxic to endothelial cells and cause the release of mediators from mast cells.

Associations have been recognized between small-vessel necrotizing vasculitis and ANCAs, which have specificity for proteins of the cytoplasmic granules of neutrophils and the lysosomes of monocytes.

Two forms are recognized: cytoplasmic (cANCAs) that are directed against proteinase 3 and perinuclear (pANCAs) that are directed against myeloperoxidase. TNF-α facilitates neutrophil activation and cell-surface expression of proteinase 3 and myeloperoxidase, which bind to ANCAs and increase the adherence of neutrophils to endothelial cells resulting in endothelial cell injury. Antiendothelial cell antibodies have been detected in the sera of patients with systemic vasculitis, rheumatoid arthritis with vasculitis, microscopic polyangiitis, and Sneddon syndrome.

An increased prevalence of the HLA haplotype HLA-A11, Bw35 in patients with CNV and associated connective tissue disorders suggests that genetic factors may be operative. HLA-DRB1 genotype associations were detected in patients with CNV and IgA vasculitis in Spain.

DIAGNOSIS

LABORATORY TESTING

The laboratory evaluation of patients with CNV depends on information obtained from the history and physical examination (Table 138-3). An elevated erythrocyte sedimentation rate is the most consistent abnormal laboratory finding. The platelet count usually is normal. Other abnormalities reflect either a coexistent chronic disorder or the involvement of additional organ systems. Occasionally, leukocytosis, anemia, thrombocytosis, abnormal urine sediment, circulating immune complexes, rheumatoid factor, and antinuclear antibodies have been reported in idiopathic disease.

Serum complement levels are usually normal. Hypocomplementemia may develop in patients with concomitant connective tissue diseases or cryoglobulinemia and reflects the associated disease or the composition of the cryoglobulin. Hypocomplementemia also occurs in some individuals with idiopathic CNV and in 40% of individuals with urticarial venulitis.

In patients with the HUVS, a low-molecular-weight 7s C1q precipitin, which has been identified as an IgG autoantibody against the collagen-like region of C1q, was detected. Autoantibodies to vascular endothelial cells were detected in patients with HUVS, in patients with SLE and urticarial vasculitis, and in patients with urticarial vasculitis alone. In IgA purpura, serum IgA_1 levels are elevated, IgA ANCAs may be present, and urinary endothelin-1 levels may be elevated. In patients with CNV, various types of circulating immune complexes and IgA ANCAs have been described. IgG autoantibodies to IgE and to FcεRIα also have been identified in some patients with urticarial venulitis.

TABLE 138-3
Laboratory Evaluation of Cutaneous Necrotizing Venulitis

- Erythrocyte sedimentation rate
- Complete blood count with differential analysis
- Platelet count
- Urinalysis
- 24-Hour urine protein and creatinine clearance
- Blood chemistry profile
- Serum protein electrophoresis
- Immunoelectrophoresis
- Hepatitis B antigen and hepatitis A and C antibodies
- Cryoglobulins
- CH_{50} (50% hemolytic complement)
- Antinuclear antibody
- Rheumatoid factor
- Antineutrophil cytoplasmic antibodies
- Antiphospholipid antibodies
- Circulating immune complexes
- Stool guaiac test
- Skin biopsy

HISTOPATHOLOGY

In skin biopsy specimens of palpable purpura and urticarial vasculitis stained with hematoxylin and eosin, the histopathologic criteria requisite for the diagnosis of CNV include necrosis of the blood vessels with deposition of fibrinoid material and dermal cellular infiltrates that consist of neutrophils with nuclear debris, mononuclear cells, and extravasated erythrocytes (Fig. 138-6A). The dermal inflammatory infiltrates vary in intensity and are usually perivenular in location, but may be dispersed widely. In patients with CNV associated with bacterial infections, the biopsy specimens showed a greater number of neutrophils.[37] Some patients with connective tissue disorders and cutaneous vasculitis have an infiltrate of inflammatory cells composed of eosinophils with deposited major basic protein and decreased numbers of mast cells. Eosinophils may be present in increased numbers in drug-induced CNV. The fibrinoid material consists of fibrin, necrotic endothelial cells, immunoreactants, and antigens.

Studies with 1-μm–thick sections[38] show 2 distinct cellular patterns in CNV: one rich in neutrophils and the other in lymphocytes. The infiltrate of neutrophils regresses with the persistence of an infiltrate of mononuclear cells; repeat biopsy specimens in some patients consistently demonstrated an infiltrate of mononuclear cells. In a time–course study over 6 days of the evolution of experimentally induced CNV in a patient with physical urticaria, the number of infiltrating neutrophils decreased without a concomitant increase in lymphocytes although the number of monocytes/macrophages was increased at 48 hours and 72 hours. Other features in both cell patterns of CNV include hypogranulated mast cells, macrophages containing debris, and the perivenular and interstitial deposition of fibrin. Venular alterations in both cell patterns consist of endothelial-cell swelling, activation of nuclei, wrinkling of nuclear membranes, necrosis

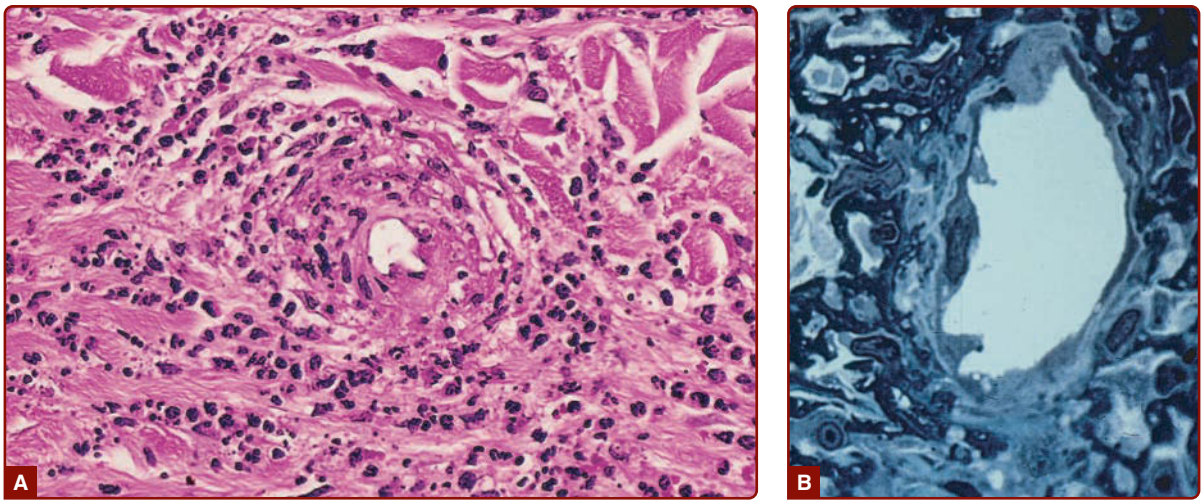

Figure 138-6 **A,** Perivenular infiltrate of neutrophils with fibrin deposition (hematoxylin and eosin stain, ×50 in the original magnification). **B,** Endothelial cell necrosis of a venule with perivenular fibrin and neutrophils (1-μm section, Giemsa stain, ×1000 in the original magnification).

(see Fig. 138-6B), and basement membrane reduplication and thickening. The arterioles are not affected.

By direct immunofluorescence techniques, fibrin deposition in venules is routinely identified in biopsy specimens, whereas the deposition of immunoglobulins and complement proteins varies widely.[39,40] IgG, IgM, and IgA have been detected. In one study,[41] IgA deposits were related to absence of autoimmune and inflammatory disorders, IgM deposits to the presence of autoimmune and inflammatory disorders, and IgG deposits to a positive ANCA. IgA is deposited about blood vessels in the skin, intestines, and kidneys in IgA vasculitis and has become an immunopathologic marker of this condition (Fig. 138-7). In the skin in IgA vasculitis, IgA_1 is the dominant subclass that is deposited. C3 is the most frequently detected immunoreactant, but it is the only complement protein that has been sought with frequency in CNV.

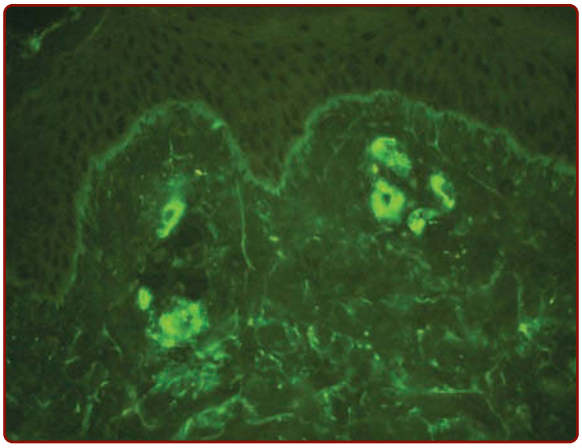

Figure 138-7 Immunofluorescence study of the skin showing deposition of IgA in the venules of the superficial dermis. (Image courtesy of Dr. James E. Fitzpatrick and used with permission.)

DIFFERENTIAL DIAGNOSIS

Table 138-4 outlines the differential diagnosis of CNV.

MANAGEMENT

Therapeutic approaches may be divided into removal of the antigen, treatment of an underlying disorder, and treatment of CNV. Therapeutic approaches in the

TABLE 138-4
Differential Diagnosis of Cutaneous Necrotizing Venulitis

DISORDER	CLINICAL CONSIDERATIONS
Petechiae or purpura caused by thrombocytopenia	The lesions are flat
Trauma to skin of elderly individuals with vascular fragility, dermatoheliosis, chronic aspirin ingestion, and endogenous or iatrogenic hypercorticism	The lesions are flat
Scurvy	Hemorrhagic follicular papules with corkscrew hairs over the lower extremities
Disseminated intravascular coagulation (purpura fulminans)	Extensive areas of purpura with a slate-gray color
Septic emboli	Finite numbers of hemorrhagic papules, pustules, and vesicles that are distributed over the acral areas
Atheromatous embolism	Purpura, livedo reticularis, nodules, and ulcers distributed over acral areas with blue or discolored toes
Calcinosis cutis	Indurated purpura, livedo reticularis, nodules and ulcers

treatment of necrotizing vasculitis consist of prevention of the deposition of immune complexes, suppression of the inflammatory response, modulation of underlying immunopathologic mechanisms, and local therapy. When the eruption is associated with a precipitating event, withdrawal of the medication or treatment of the infection results in resolution of the cutaneous lesions. If a coexistent chronic disease is present, treatment of the underlying disease may be associated with improvement in the cutaneous vascular lesions. In many cases, CNV is a self-limited condition, and double-blind, placebo-controlled, prospective trials of therapeutic agents are usually lacking.

The treatment of CNV (Table 138-5) depends on an analysis of the cutaneous disability as well as on the toxicity and side effects of the therapeutic agents. H_1 antihistamines are used in patients with palpable purpura to alleviate lesional symptoms and perhaps to reduce tissue deposition of circulating immune complexes. Nonsteroidal antiinflammatory agents are combined with the H_1 antihistamine. Depending on the therapeutic response, colchicine can be added to or substituted for these agents. However, colchicine was shown to have no significant therapeutic effect in a prospective, randomized, controlled trial. If there is no benefit, dapsone or hydroxychloroquine sulfate can be used. If there still is no therapeutic response, a major decision must be made because systemic glucocorticoids, azathioprine, methotrexate, cyclosporine, mycophenolate mofetil, cyclophosphamide, plasmapheresis, intravenous immunoglobulin, infliximab, adalimumab, etanercept, and rituximab are associated with serious side effects. Although all of these agents are reported to benefit some patients, controlled clinical trials are not available. The administration of interferon-α is associated with clearing of cutaneous vasculitis in patients with hepatitis C virus infection.

The treatment of patients with urticarial vasculitis is similar to those with palpable purpura. Additional case reports exist on the treatment of patients with intramuscular gold therapy, cyclophosphamide-dexamethasone pulse therapy, mycophenolate mofetil, thalidomide, anakinra, cinnarizine, and psoralen plus ultraviolet A photochemotherapy. In an open-label pilot study in 10 patients with urticarial venulitis, improvement was noted after a single, subcutaneous dose of canakinumab.[42] In patients with Schnitzler syndrome, IL-1 inhibition is the only completely efficient treatment with the use of anakinra, canakinumab, or rilonacept.

In the treatment of livedoid vasculitis, support stockings are useful. Empiric trials of aspirin and dipyridamole, colchicine, dapsone, danazol, low-dose heparin, systemic glucocorticoids, nicotinic acid, low-molecular-weight dextran, phenformin, ethylestrenol, nifedipine, pentoxifylline, and rivaroxaban[43] have been used. Infusions of prostacyclin, prostaglandin E_1, intravenous immunoglobulin, rituximab, tissue plasminogen activator, hyperbaric oxygen therapy, and psoralen plus ultraviolet A photochemotherapy have been used successfully in a few patients.

TABLE 138-5

Agents Used in the Treatment of Cutaneous Necrotizing Venulitis

- H_1 antihistamines
- Nonsteroidal antiinflammatory agents
- Colchicine
- Hydroxychloroquine sulfate
- Systemic glucocorticoids
- Methotrexate
- Cyclosporine
- Mycophenolate mofetil
- Intravenous gammaglobulin
- Plasmapheresis
- Infliximab
- Etanercept
- Adalimumab
- Rituximab

REFERENCES

1. Calabrese LH, Michel BA, Bloch DA, et al. The American College of Rheumatology 1990 criteria for the classification of hypersensitivity vasculitis. *Arthritis Rheum*. 1990;33(8):1108-1113.
2. Jennette JC, Falk RJ, Bacon PA, et al. 2012 Revised International Chapel Hill Consensus Conference nomenclature of vasculitides. *Arthritis Rheum*. 2013;65(1):1-11.
3. Arora D, Wetter DA, Gonzalez-Santiago TM, et al. Incidence of leukocytoclastic vasculitis, 1996-2010: a population-based study in Olmsted County, Minnesota. *Mayo Clin Proc*. 2014;89(11):1515-1524.
4. Bouiller K, Audia S, Devilliers H, et al. Etiologies and prognostic factors of leukocytoclastic vasculitis with skin involvement: a retrospective study in 112 patients. *Medicine (Baltimore)*. 2016;95(28):e4238.
5. Kobak S, Yilmaz H, Karaarsian A, et al. Leukocytoclastic vasculitis in a patient with ankylosing spondylitis. *Case Rep Rheumatol*. 2014;2014:653837.
6. Loricera J, Calvo-Rio V, Ortiz-Sanjuán F, et al. The spectrum of paraneoplastic cutaneous vasculitis in a defined population: incidence and clinical features. *Medicine (Baltimore)*. 2013;92(6):331-343.
7. Loricera J, Blanco R, Hernandez JL, et al. Cutaneous vasculitis associated with severe bacterial infections: a study of 27 patients from a series of 766 cutaneous vasculitis. *Clin Exp Rheumatol*. 2015;33(2)(suppl 89):536-543.
8. Ortiz-Sanjuán F, Blanco R, Hernandez JL, et al. Drug-associated cutaneous vasculitis: study of 239 patients from a single referral center. *J Rheumatol*. 2014;41(11):2201-2207.
9. Loricera J, Blanco R, Oritz-Sanjuán F, et al. Single-organ cutaneous small-vessel vasculitis according to the 2012 revised International Chapel Hill Consensus Conference nomenclature of vasculitides: a study of 60 patients from a series of 766 cutaneous vasculitis cases. *Rheumatology (Oxford)*. 2015;54(1):77-82.
10. Khetan P, Sethuraman G, Khaitan BK, et al. An aetiological & clinicopathological study on cutaneous vasculitis. *Indian J Med Res*. 2012;135(1):107-113.
11. Patnaik S, Balderia P, Vanchhawng L, et al. Is levamisole-induced vasculitis a relegated diagnostic possibility?

A case report and review of literature. *Am J Case Rep*. 2015;16:658-662.
12. Zivanovic D, Dobrosavljevic D, Nikolic M, et al. Cryoglobulins and multispecific antineutrophil cytoplasmic antibodies in propylthiouracil-induced necrotizing cutaneous vasculitis-a new association. *Eur J Dermatol*. 2012;22(5):707-709.
13. Ramos-Casals M, Roberto-Perez-Alvarez, Diaz-Lagares C, et al; BIOGEAS Study Group. Autoimmune diseases induced by biological agents: a double-edged sword? *Autoimmun Rev*. 2010;9(3):188-193.
14. Park SJ, Suh J-S, Lee JH, et al. Advances in our understanding of the pathogenesis of Henoch-Schönlein purpura and the implications for improving its diagnosis. *Expert Rev Clin Immunol*. 2013;9(12):1223-1238.
15. Calvo-Rio V, Hernández JL, Ortiz-Sanjuán F, et al. Relapses in patients with Henoch-Schönlein purpura: analysis of 417 patients from a single center. *Medicine (Baltimore)*. 2016;95(28):e4217.
16. Linskey KR, Kroshinsky D, Mihm MC Jr, et al. Immunoglobulin-A-associated small-vessel vasculitis: a 10-year experience at the Massachusetts General Hospital. *J Am Acad Dermatol*. 2012;66(5):813-822.
17. Hong S, Ahn S, Lim D, et al. Late-onset IgA vasculitis in adult patients exhibits distinct clinical characteristics and outcomes. *Clin Exp Rheumatol*. 2016;34(3) (suppl 97):S77-S83.
18. Calvo-Rio V, Loricera J, Mata C, et al. Henoch-Schönlein purpura in Northern Spain: clinical spectrum of the disease in 417 patients from a single center. *Medicine (Baltimore)*. 2014;93(2):106-113.
19. Ting TV. Diagnosis and management of cutaneous vasculitis in children. *Pediatr Clin North Am*. 2014;61(2): 321-346.
20. Moreno-Suárez F, Pulpillo-Ruiz A, Zulucta Dorado T, et al. Urticaria vasculitis: estudio retrospectivo de 15 casos. *Actas Dermosifiliogr*. 2013;104(7):579-585.
21. Loricera J, Calvio-Rio V, Mata, et al. Urticarial vasculitis in Northern Spain: clinical study of 21 cases. *Medicine (Baltimore)*. 2014;93(1):53-60.
22. Jachiet M, Flaguel B, Deroux A, et al. The clinical spectrum and therapeutic management of hypocomplementemic urticarial vasculitis: data from a French nationwide study of fifty-seven patients. *Arthritis Rheum*. 2015; 67(2):527-534.
23. Simon A, Asli B, Braun-Falco M, et al. Schnitzler's syndrome: diagnosis, treatment, and follow-up. *Allergy*. 2013;68(5):562-568.
24. Gameiro A. Gouveia M, Pereira M, et al. Clinical characterization and long-term follow-up of Schnitzler syndrome. *Clin Exp Immunol*. 2016;41(5):461-467.
25. Vasudevan B, Neema S, Verma R. Livedoid vasculopathy: a review of pathogenesis and principles of management. *Indian J Dermatol Venereol Leprol*. 2016; 82(5):478-488.
26. Wu S, Xu Z, Liang H. Sneddon's syndrome: a comprehensive review of the literature. *Orphanet J Rare Dis*. 2014;9:215.
27. Bersano A, Morbin M, Ciceri E, et al. The diagnostic challenge of Divry van Bogaert and Sneddon syndrome: report of three cases and literature review. *J Neurol Sci*. 2016;364:77-83.
28. Kosada S, Osada S, Kaneko T, et al. Cutaneous vasculitis and glomerulonephritis associated with C4 deficiency. *Clin Exp Dermatol*. 2013;38(5):492-495.
29. Bay JT, Katzenstein TL, Kofoed K, et al. Novel CF1 mutation in a patient with leukocytoclastic vasculitis may redefine the clinical spectrum of Complement factor 1 deficiency. *Clin Immunol*. 2015;160(2):315-318.
30. Lipitsa T, Naukkarinen A, Harvima IT. Mast cell tryptase and chymase in the progress of cutaneous vasculitis. *Arch Dermatol Res*. 2015;307(10):917-924.
31. Chen T, Guo ZP, Zhang Y-H, et al. Elevated serum heme oxygenase-1 and insulin-like growth factor-1 levels in patients with Henoch-Schönlein purpura. *Rheumatol Int*. 2011;31(3):321-326.
32. Chen T, Guo Z-p, Li L, et al. TWEAK enhances E-selection and ICAM-1 expression, and may contribute to the development of cutaneous vasculitis. *PLoS One*. 2013;8(2):e56830.
33. Chen T, Jia R-z, Guo Z-p, et al. Elevated serum interleukin-33 levels in patients with Henoch-Schönlein purpura. *Arch Dermatol Res*. 2013;305(2):173-177.
34. Chen T, Guo Z-p, Wang W-j, et al. Increased serum HMGB1 levels in patients with Henoch-Schönlein purpura. *Exp Dermatol*. 2014;23(6):419-423.
35. Cao N, Chen T, Guo Z-P, et al. Elevated levels of visfatin in patients with Henoch-Schönlein purpura. *Ann Dermatol*. 2014;26(3):303-307.
36. Chen T, Guo Z-p, Jiao X-y, et al. CCL5, CXCL16, and CX3CL1 are associated with Henoch-Schönlein purpura. *Arch Dermatol Res*. 2011;303(10):715-725.
37. Loricera J, González-Vela C, Blanco R, et al. Histopathologic differences between cutaneous vasculitis associated with severe bacterial infection and cutaneous vasculitis secondary to other causes: study of 52 patients. *Clin Exp Rheumatol*. 2016;34(3)(suppl 97): 93-97.
38. Soter NA, Mihm MC Jr, Gigli I, et al. Two distinct cellular patterns in cutaneous necrotizing angiitis. *J Invest Dermatol*. 1976;66(6):344-350.
39. Nandeesh B. Tirumalae R. Direct immunofluorescence in cutaneous vasculitis: experience from a referral hospital in India. *Indian J Dermatol*. 2013;58(1):22-25.
40. Alalwani M, Billings SD, Gota CE. Clinical significance of immunoglobulin deposition in leukocytoclastic vasculitis: a 5-year retrospective study of 88 patients at Cleveland Clinic. *Am J Dermatopathol*. 2014;36(9): 723-729.
41. Takatu CM, Heringer APR, Aoki V, et al. Clinicopathologic correlation of 282 leukocytoclastic vasculitis cases in a tertiary hospital: a focus on immunofluorescence findings at the blood vessel wall. *Immunol Res*. 2017;65(1):395-401.
42. Krause K, Mahamed A, Weller K, et al. Efficacy and safety of canakinumab in urticarial vasculitis: an open-label study. *J Allergy Clin Immunol*. 2013;132(3):751-754.
43. Lee JM, Kim IH. Case series of recalcitrant livedoid vasculopathy treated with rivaroxaban. *Clin Exp Dermatol*. 2016;41(5):559-561.

Chapter 139 :: Systemic Necrotizing Arteritis

:: Peter A. Merkel & Paul A. Monach

AT-A-GLANCE

- Cutaneous vasculitis can be a presenting feature of a systemic disease affecting other organ systems. Thus, all patients with cutaneous vasculitis need to be evaluated for possible systemic vasculitis including all forms of small- and medium-vessel vasculitis.
- Additional testing for vasculitis is guided by findings from medical history and physical examination, but should usually include routine laboratory testing of renal function, evaluating for hepatitis B and C viral infections, serologic testing for ANA and ANCA, selected radiographic imaging, and other tests as indicated by presentation.
- Skin biopsy is nearly always essential to establish a diagnosis of vasculitis and biopsies can help determine the type of vasculitis.
- Mimics of idiopathic vasculitis need to be considered, especially including infection, malignancy, thrombosis, or embolic disease.
- Drug-induced vasculitis frequently presents with skin lesions. However, all patients with suspected drug-induced disease should still be evaluated for other possible causes or types of vasculitis.
- Treatment of vasculitis that involves the skin is guided by the disease and the organ systems involved. For the systemic necrotizing vasculitides, glucocorticoids are always used, initially at high doses for severe disease. Additional immunosuppressive medications depend on the type of vasculitis, extent of disease, and comorbidities of the patient.
- Treatment of suspected drug-induced vasculitis may include discontinuing the suspected etiologic agent and careful observation but could also involve treatment with glucocorticoids or other drugs.
- Use of immunosuppressive medications should be overseen by physicians experienced with the use of this class of drugs.
- Comprehensive clinical followup of all patients with vasculitis is an essential aspect of management.

INTRODUCTION

The term *vasculitis* can be defined broadly to mean inflammation of blood vessels. Although vasculitis sometimes affects a single organ, particularly the skin, to most clinicians *vasculitis* connotes a group of diseases in which inflammation of the blood vessels is the major, but not the only, pathologic process. The systemic vasculitides are a wide-ranging set of diseases that are mostly idiopathic, rare, and multisystemic. These diseases involve such variety of clinical presentations and pathologies that all clinicians in every medical and surgical specialty will encounter such patients.

Vasculitis of the skin is fairly common, and skin disease is a frequent manifestation in many forms of vasculitis, especially small- and medium-vessel arteritis where skin lesions may be the presenting symptom of a systemic illness.

This chapter focuses on skin disease in the systemic vasculitides. Isolated forms of skin vasculitis and some of the systemic vasculitides are covered in Chap. 138. In addition to outlining the skin manifestations of vasculitis in general and for specific types of vasculitis, this chapter will provide an approach to patients with skin disease in which vasculitis is a diagnostic consideration.

Multiple systems for classifying vasculitis exist, a situation that reflects a lack of clear understanding of the underlying pathophysiology and the overlap of clinical features among many types of vasculitis.[1-6] The most commonly accepted approach is to sort them by the size(s) of the predominant vessel involved (small, medium, or large) and then subdivide or group diseases, as appropriate (Fig. 139-1).

Classification criteria and definitions have been developed for many, but not all, specific types of vasculitis. These systems were designed for use in clinical research to create fairly homogenous study cohorts and were not meant to be used as "diagnostic" criteria.[2] Nonetheless, clinicians will find these criteria helpful in their approach to the field. The most widely used criteria for vasculitis are from the classification criteria of the American College of Rheumatology[4,5] and the disease definitions of the Chapel Hill Consensus Conference.[6] Furthermore, some classes are no longer advised for use (eg, *hypersensitivity vasculitis* is a term that has lost specific meaning). It should be emphasized that the term *leukocytoclastic vasculitis* does not refer to a specific disease but is a pathologic description that often, but not always, applies to vasculitis in the skin or other organs. There are also some separate sets of criteria for pediatric patients.[7]

An important extension of the Chapel Hill Consensus Conference process is the recently completed Addendum that provides a comprehensive set of definitions for vasculitis of the skin.[8]

A new international initiative is under way to reconsider the classification of the vasculitides and take into consideration data regarding the clinical and pathophysiologic aspects of vasculitis not available when the

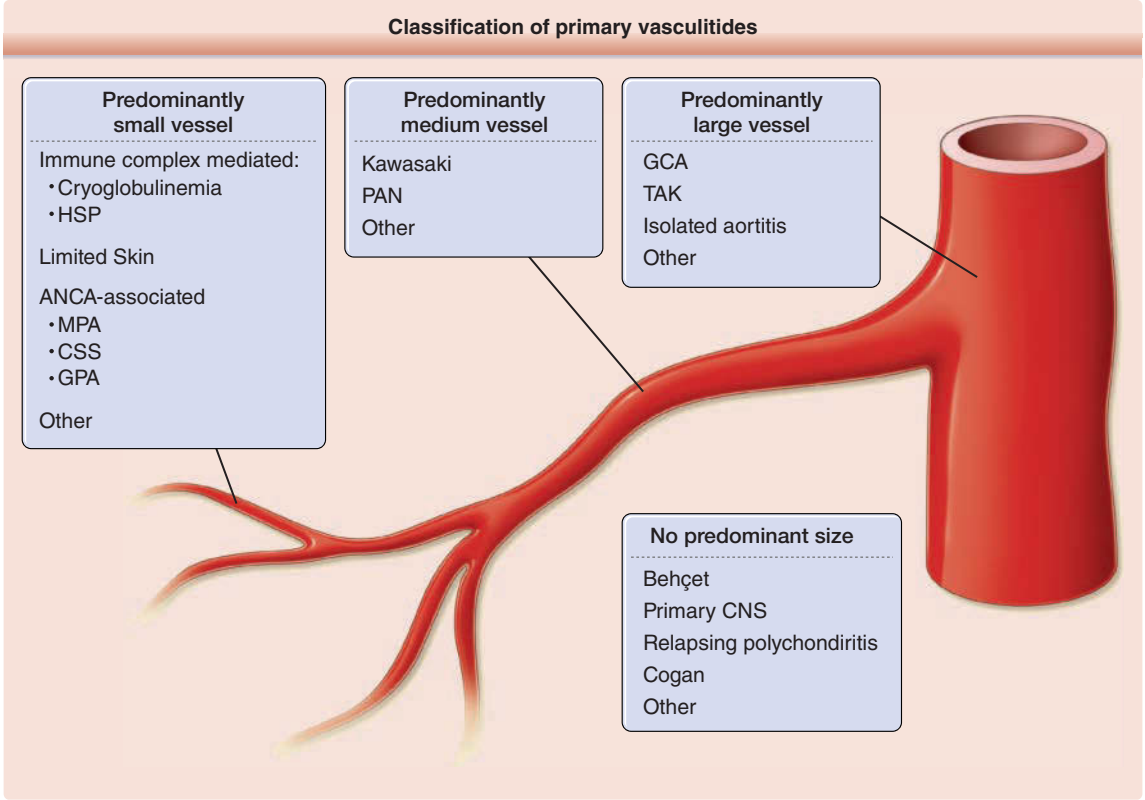

Figure 139-1 Classification of the primary vasculitides. ANCA, antineutrophil cytoplasmic antibodies; CSS, Churg–Strauss syndrome; GCA, giant cell arteritis; GPA, granulomatosis with polyangiitis (Wegener); HSP, Henoch–Schönlein purpura; MPA, microscopic polyangiitis; PAN, polyarteritis nodosa; TAK, Takayasu arteritis. (Redrawn from Watts RA et al: Systemic vasculitis—Is it time to reclassify? Rheumatology (Oxford). 2011;50(4):643-645.)

prior systems were created; such new elements include testing for antineutrophil cytoplasmic autoantibodies (ANCA) and greater availability of advanced imaging techniques for large arterial disease.[2]

EPIDEMIOLOGY

With the probable exception of drug/toxin-induced vasculitis, all forms of idiopathic vasculitis are considered rare, "orphan" diseases in the United States (prevalences of less than 200,000 people); similar designations exist in Europe and elsewhere.

Vasculitis occurs in people of both sexes, all ages, and all major racial/ethnic groups. However, some forms are more common in certain groups. For example, Takayasu arteritis is substantially more common in women than men, Kawasaki disease is almost exclusively a disease of young children, and giant cell arteritis is limited to older adults. Granulomatosis with polyangiitis (Wegener) mostly occurs in whites and Behçet disease is markedly more common in countries in the Eastern Mediterranean as well as Japan and Korea. The demographic differences among the vasculitides are of scientific interest as clues to etiology and can be helpful in developing a differential diagnosis.[9] Not surprisingly, vasculitides in which there is strong regional variation have genetic risk factors in the HLA region.[10-13] However, the epidemiologic tendencies, including genetics, are not so strong as to fully exclude the diagnosis of a specific form of vasculitis in any one person, and exceptions to the typical epidemiology occur regularly.

CLINICAL FEATURES

CUTANEOUS FINDINGS

The appearance of cutaneous vasculitis reflects the size and depth of the involved vessels, the severity of inflammation and red blood cell extravasation, and the density of damaged vessels and resulting tissue destruction. For example, vasculitis caused by immune complexes in the dermal microvasculature often first appears as a tiny, bright red circle due to red blood cell extravasation, which becomes palpable once it reaches about 2 mm in diameter. A high density of such lesions, however, may produce areas of confluent purpura and/or central necrosis or ulceration. Vasculitis of small arteries (also referred to confusingly as "medium-vessel"), which lie deeper in the skin and subcutaneous tissues, produces nodules that are often erythematous but not as bright red as purpura, or livedo racemosa if the involved vessels are predominantly parallel to the surface. Ulceration and digit ischemia are more readily produced in medium-vessel than in small-vessel vasculitis.

The classic presentation of small-vessel vasculitis in the skin is palpable purpura, but other presentations are common. These include nonpalpable purpura that can be either round or have angular borders (retiform purpura), papules, urticarial lesions, nodules of different sizes and at different depths, bullous lesions, and ulcers (Figs. 139-3, 139-4, 139-6 to 139-12). Edema in and near visibly affected areas is common.

Symptoms attributable to cutaneous vasculitis vary widely. Purpura or livedo may be asymptomatic or produce pain that is often described as stinging or burning but sometimes as itching. Nodules and ulcers are usually painful. Severe pain in a region not affected by nodules, ulcers, or confluent purpura should raise suspicion for neuropathy or inflammatory arthritis.

NONCUTANEOUS FINDINGS

It is the presence or absence of particular features in the history and physical examination that give the first clue whether a patient has a disease involving multiple organ systems. A list of important signs and symptoms in different forms of vasculitis is shown in Table 139-1.

ETIOLOGY AND PATHOGENESIS

With the exception of infection-related vasculitis (eg, hepatitis B virus in many cases of polyarteritis nodosa and hepatitis C virus in most cases of cryoglobulinemic vasculitis) and drug-induced vasculitis, the etiology of most types of vasculitis is unknown. Similarly, the pathogenesis of the vasculitides remains an area of active investigation. This section summarizes the current thinking on causes and mechanisms of vasculitis with the caveat that although much of the evidence outlined in this section is strong, the pathogenesis of these diseases is almost certainly even more complex.

Broadly speaking, the small-vessel vasculitides follow one of 2 pathways: (1) immune complex deposition or (2) non–immune complex mediated pathology that likely involves ANCA. Immune complexes consist of immunoglobulins, the antigens they are bound to, and complement components, and can form in a wide range of immune responses to microbes, autoantigens, or drugs. In a small percentage of antibody responses, the concentrations and properties of antibody and antigen favor deposition in the microvasculature, which may lead to activation of neutrophils and necrotizing vasculitis with destruction of endothelial cells. ANCA are directed against the neutrophil proteins myeloperoxidase (MPO) or proteinase-3 (PR3), which are primarily contained in intracellular granules but are also translocated to the cell surface or released via degranulation or excretion of neutrophil extracellular traps (NETs), allowing access to ANCA, activation of neutrophils, involvement of complement components, and necrotizing vasculitis. Genetics appear to contribute modestly to ANCA-associated vasculitis, with the genes identified so far being associated with the specificity of the antibody to PR3 or MPO.[10,11] Although the humoral immune system plays key roles in the pathogenesis of small-vessel vasculitis, there is evidence for the additional importance of cellular immune responses in these diseases.

Large-vessel vasculitides, in contrast, are thought to be mediated by T cells activating macrophages in the walls of large arteries. In giant cell arteritis (GCA), both IL-17-secreting (Th17) and interferon-γ–secreting (Th1) cells are prominent. T cells enter the artery wall by the vasa vasorum, so the endothelium remains intact. Multiple studies implicating different infectious agents in GCA have not been reproducible, so it continues to be regarded as an autoimmune disease, as is Takayasu arteritis. Although these diseases have similar microscopic pathology, they have quite different epidemiology, moderately different vessel distributions, and different genetics. Genetics contributes modestly to both diseases via the HLA locus, but that is in the class II region in GCA and class I in Takayasu arteritis, with little overlap otherwise.[12,13]

The etiology and pathogenesis of polyarteritis nodosa (PAN) that is not associated with hepatitis B virus infection are unclear, including uncertainty about whether it is mediated by antibodies and whether it is a syndrome with many rare causes or has 1 or a few major causes. No genetic studies have been published; an HLA association would support the existence of a predominant target antigen but would not identify the target as an autoantigen or a microbe. Individual lesions may clearly show neutrophils with necrosis and destruction of the endothelium or may show a more mixed infiltrate with an intact endothelium, but it is uncertain whether the latter finding represents a different disease process or healing from a recent necrotizing lesion. This uncertainty is reflected in application of new nomenclature such as "macular arteritis" for the latter situation when it is limited to the skin, leading to the counterproposal that it be considered a subtype of "cutaneous PAN."

DIAGNOSIS

DIAGNOSTIC ALGORITHM

When a patient presents with skin lesions that are concerning for possible vasculitis, answers to 3 questions should be sought quickly:

1. *Is the lesion due to vasculitis?*
2. *Are other organ systems involved in the illness?*
3. *Are there additional findings on medical interview, physical examination, laboratory testing, or radiographic imaging that can help establish a specific diagnosis?*

If a diagnosis of vasculitis is obtained, then it is imperative to ask 2 more questions:

4. *Is it possible to make a diagnosis of a specific type of vasculitis for the patient?*
5. *Does the patient need immediate treatment and/or hospitalization?*

TABLE 139-1

Major Signs, Symptoms, and Disease Processes of the Primary Vasculitides[a]

ORGAN SYSTEM	SIGNS AND SYMPTOMS	DISEASE PROCESS	TYPE OF VASCULITIS
General			
	Fever	Systemic inflammation	Many of the systemic vasculitides
	Fatigue/malaise	Systemic inflammation	Most of the systemic vasculitides
	Weight loss	Systemic inflammation	Most of the systemic vasculitides
Eye			
	Red eye	Episcleritis, scleritis, uveitis, conjunctivitis	GPA, MPA, RPC, BD, others
	Acute visual loss or amaurosis fugax	Arterial insufficiency	GCA, TAK
	Proptosis	Orbital granuloma ("pseudotumor")	GPA
	Tearing	Dacryocystitis with lacrimal duct occlusion	GPA, EGPA
Ear			
	Hearing loss	Sensorineural hearing loss Conductive hearing loss	GPA, MPA, EGPA, GCA GPA, EGPA, RPC
	Ear pain and fullness	Mastoiditis and/or other inflammation of upper airway, auditory tube, middle ear	GPA, EGPA
	External ear redness, tenderness, swelling	Chondritis	RPC, GPA, EGPA
Nose and Sinuses			
	Epistaxis, nasal crusting and discharge	Nasal mucosal inflammation	GPA, EGPA
	Nasal bridge collapse (saddle nose deformity)	Nasal cartilage inflammation	GPA, RPC
	Nasal polyps	Eosinophilic nasal inflammation	EGPA
	Facial pain/tooth pain	Sinusitis	GPA, EGPA
	Anosmia	Olfactory epithelium/cells damage	GPA, EGPA
Oral Cavity			
	Painful oral ulcers	Aphthous ulcers	BD, GPA
	Gingival pain and swelling	Gingival inflammation	GPA
	Jaw claudication	Arterial insufficiency to muscles of mastication	GCA
Pulmonary			
	Hemoptysis	Alveolar hemorrhage Pulmonary artery rupture Pulmonary embolus Pulmonary nodules	GPA, MPA BD GPA, MPA, EGPA, BD GPA, EGPA
	Dyspnea/cough	(See causes of hemoptysis above) Pulmonary infiltrates Bronchitis/large airway collapse Pleuritis	GPA, MPA, EGPA GPA, RPC GPA, EGPA
	Stridor/dyspnea	Subglottic stenosis	GPA, RPC
	Wheezing	Asthma Large airway collapse	EGPA GPA, RPC
Cardiovascular			
	Angina	Coronary arteritis Aortic root/valvular disease	TAK TAK, GCA, BD, RPC
	Congestive heart failure	Myocarditis Aortic valve insufficiency	EGPA, GPA TAK, GCA
	Limb claudication	Large artery stenosis	TAK, GCA
GI			
	Abdominal ischemic pain	Arterial insufficiency	PAN, IGAV, GCA, TAK
	Lower GI bleeding	Mucosal ulcers or infarction	IGAV, EGPA, GPA, MPA, PAN

(*Continued*)

TABLE 139-1
Major Signs, Symptoms, and Disease Processes of the Primary Vasculitides[a] (*Continued*)

ORGAN SYSTEM	SIGNS AND SYMPTOMS	DISEASE PROCESS	TYPE OF VASCULITIS
Renal			
	Gross hematuria	Renal infarction	PAN
		Glomerulonephritis (rare cause of gross hematuria)	GPA, MPA, EGPA, IGAV, Cryo
CNS			
	Headache, scalp tenderness	Cranial arteritis	GCA, TAK
	Lightheadedness/syncope	Arterial insufficiency to brain	GCA, TAK
	Cranial neuropathy	Inflammation of nerves; rarely mass lesion	GCA, GPA, MPA
Peripheral Nervous System			
	Sensory/motor dysfunction	Inflammation of nerves; rarely mass lesion	EGPA, GPA, MPA, PAN, Cryo
Musculoskeletal			
	Polyarthralgia	Polyarthritis	GPA, GCA, TAK, Cryo, IGAV, BD
	Shoulder and hip girdle pain	Polymyalgia rheumatica	GCA
	Muscle weakness	Myositis	EGPA
Skin			
	Purpura	Small-vessel vasculitis	GPA, MPA, EGPA, PAN, IGAV, Cryo
	Painful nodules, deep ulcers	Medium-vessel vasculitis	PAN, GPA, MPA, Cryo
	Digital ischemia/gangrene	Medium-large artery stenosis	GCA, TAK, PAN, GPA, MPA, Cryo
	Superficial nodules	Granulomas	GPA, EGPA
	Papules, acnelike lesions	Papulopustular lesions	BD
	Painful, red nodules	Erythema nodosum	BD, TAK
	Peripheral edema	Deep vein thrombosis	GPA, MPA, EGPA, BD

[a]This list is not inclusive of all manifestations for all diseases.

BD, Behçet disease; Cryo, cryoglobulinemic vasculitis; EGPA, eosinophilic granulomatosis with polyangiitis; GCA, giant cell arteritis; GPA, granulomatosis with polyangiitis; IgAV, IgA vasculitis (Henoch–Schönlein); MPA, microscopic polyangiitis; PAN, polyarteritis nodosa; RPC, relapsing polychondritis; TAK, Takayasu arteritis. RPC, an autoimmune disease defined by destruction of cartilage, is included in this table because several of its features overlap with those of GPA. As with BD, about 30% of patients with RPC also have vasculitis, with a wide range of vessel sizes involved.

A suggested approach to a patients with skin lesions suspected of being due to vasculitis is shown in Fig. 139-2. The answer to the first question is often obtained by skin biopsy, a procedure indicated in many cases of palpable purpura or other lesions when a diagnosis of vasculitis is not otherwise easily established. The second question is addressed by a thorough review of systems and physical examination and routine laboratory testing that can usually be completed rapidly. The third question is addressed by more specialized laboratory tests for which results typically take several days to return. It is important to quickly identify organ system involvement and how "sick" the patient is (or might soon be), because some causes of cutaneous vasculitis require no treatment but others require immediate hospitalization for initiation of immune-suppressive and supportive therapy.

Given the broad range of entities that fall under the category "vasculitis," and the even larger number of diseases that are also reasonably considered when evaluating a patient suspected of having vasculitis, a vast number and range of diagnostic tests are often considered in such cases. However, obtaining a thorough medical history and conducting a detailed physical examination should enable the clinician to limit the types of vasculitis under consideration and prioritize the ordering of diagnostic tests. Not all tests need to be ordered for all patients suspected of having vasculitis. This approach must of course be balanced by a desire to be open-minded to atypical presentations of vasculitis as well as a range of infections, malignancies, and other diseases in the differential diagnosis of such patients. Evaluation for possible vasculitis usually occurs in parallel to evaluation for other processes.

REVIEW OF SYSTEMS

A full review of systems with assessment of the overall severity of illness is the single most important component of the early evaluation of a patient suspected of having vasculitis. Together, the diseases that cause cutaneous vasculitis can affect all organ systems, and in most cases that involvement will cause symptoms, renal disease being a prominent exception. Although some symptoms are clearly more concerning than others (hemoptysis vs dry cough, painful red eye vs mild arthralgias), even relatively mild symptoms can be a clue that disease is not limited to the skin. A list of important signs and symptoms in different forms of vasculitis is shown in Table 139-1.

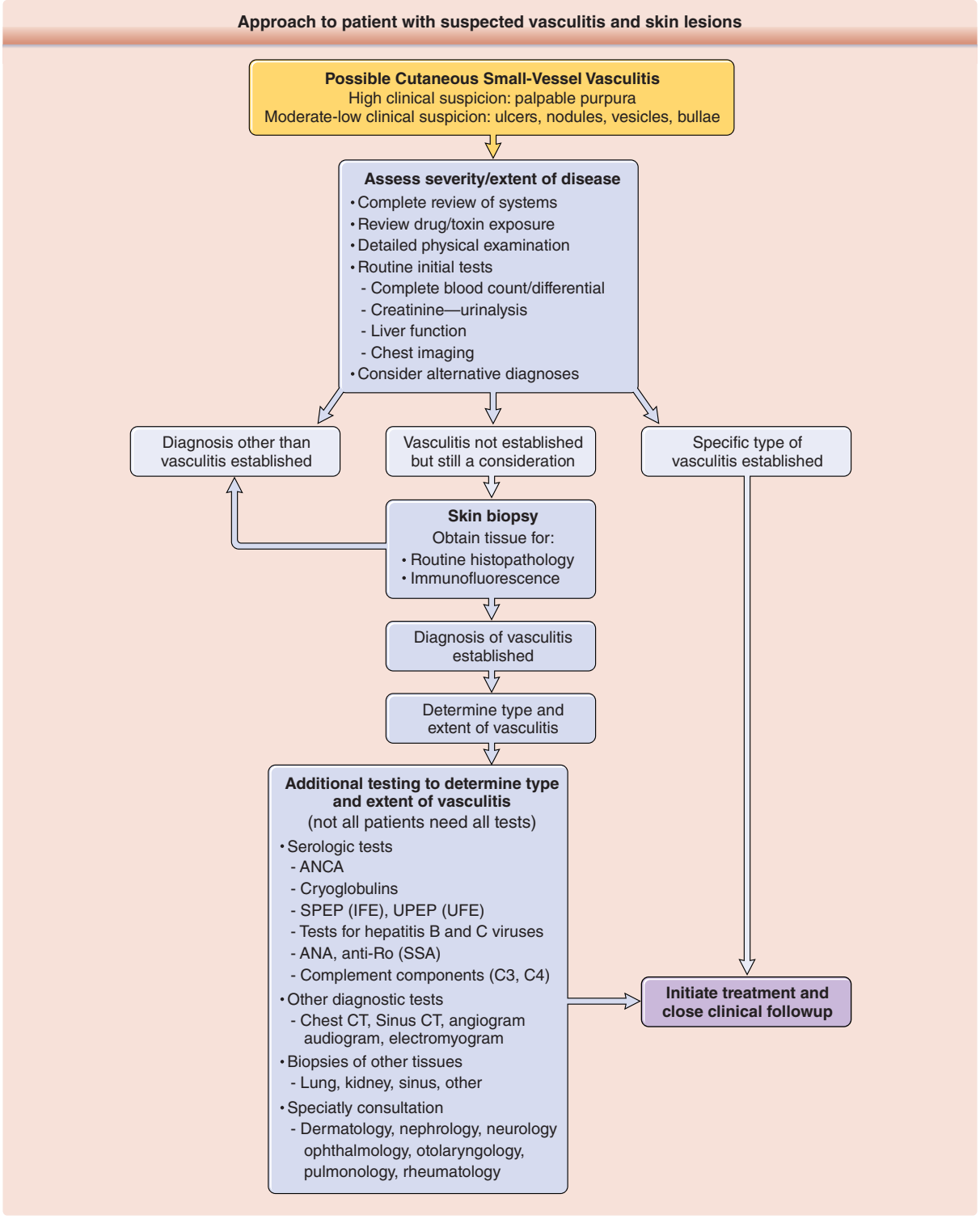

Figure 139-2 Approach to the patient with suspected vasculitis and skin lesions. ANCA, antineutrophil cytoplasmic antibodies; ANA, antinuclear antibodies; CT, computed tomography; IFE, immunofixation electrophoresis; SPEP, serum protein electrophoresis; UPEP, urine protein electrophoresis.

MEDICAL HISTORY, MEDICATION USE, AND EXPOSURES TO TOXINS OR INFECTIOUS DISEASES

It is critical to know the full medical history of any patient suspected of having vasculitis. Other diseases may either have vasculitis as a component of the illness (eg, lupus) or may cause skin lesions that mimic vasculitis. Drug-induced vasculitis is common, and skin lesions, usually but not always purpura, are the most common manifestation of drug-induced vasculitis.[14] The list of drugs reported to cause vasculitis is enormous, with almost every class of medication implicated in possible cases of drug-induced vasculitis. It is useful to ask about prescription, nonprescription, and "alternative" or herbal mediation use in the prior 6 to 12 months since the effect of some mediations may persist after usage ends. Patients should also be asked about use of illegal or recreational drugs because several such agents, including methamphetamines, cocaine, and others have been implicated in cases of vasculitis. Occupational or other exposure to nondrug toxins should be asked about.

The patient should be asked about not only usual signs and symptoms of infection but also recent travel, sick contacts, and risks for sexually transmitted diseases.

PHYSICAL EXAMINATION

Beyond a careful and full assessment of the skin, a multisystem examination is useful to determine whether symptoms are associated with objective abnormalities, or whether there are findings that a patient has not noticed. Vital signs are essential, but a patient with normal blood pressure can still have severe glomerulonephritis. The eyes should be inspected for redness and proptosis. The anterior nasal cavity can be easily visualized with an otoscope. Evidence of lymphadenopathy should be sought. Cardiac, lung, and abdominal examinations can give clues to underlying disease, but normal examinations do not rule out pathology. Similarly, absent pulses, asymmetric blood pressure readings, and bruits are helpful but imperfect measures to screen for large-vessel vasculitis. A complete joint examination is important and any findings suggestive of synovitis (joint swelling, warmth, redness) must be further investigated; however, many patients with vasculitis will have arthralgias without joint effusions. A full neurologic examination is one of the most valuable components of the evaluation and triage of a patient suspected of having vasculitis; subtle sensory and even motor abnormalities are often missed on initial evaluation.

The more detailed and expert examinations that can be performed by ophthalmologists and otolaryngologists are often extremely helpful in evaluating patients suspected of having vasculitis. Urgent referral is often indicated in patients with concerning symptoms such as new visual impairment, painful or red eyes, hoarseness or stridor, or hearing loss.

SUPPORTIVE STUDIES

SKIN BIOPSY

The method for diagnosing vasculitis depends on the type of vasculitis suspected, which is often based on size of vessel involved. Vasculitides affecting the skin usually involve small and medium-sized vessels, and these vessels are amenable to biopsy (Fig. 139-3). Given the ease and low risk of skin biopsies, they play an important role in diagnosing vasculitis, and an equally important role in establishing a diagnosis other than vasculitis. A standard punch biopsy is sufficient to diagnose small-vessel vasculitis, but a deeper and wider excision may be necessary to capture information on medium-sized vessels.[15,16] Lesions that should be approached with a deeper biopsy include subcutaneous nodules, livedo racemosa, or deep ulcers (Fig. 139-4). Many types of small-vessel vasculitis may also involve medium-sized skin vessels. It is important to realize that the difference between "small" and "medium" vessels is somewhat subjective, and skin pathologists often make such distinctions more than other pathologists who see larger biopsy specimens.

Sometimes the presence of a typical clinical syndrome makes biopsy unnecessary. For example, IgA vasculitis (Henoch-Schönlein) in children is often diagnosed on clinical grounds alone and some cases of ANCA-associated or cryoglobulinemic vasculitis can be diagnosed confidently by combining clinical features with specific serologic tests. Behçet disease and Kawasaki disease are diagnosed based on the clinical syndromes; biopsy is usually not performed on the skin lesions that are common in these diseases, and such biopsies are often nondiagnostic.

It is generally recommended to biopsy a skin lesion that has been clinically apparent for less than 48 hours, if possible, to maximize the chance of finding the typical features of acute neutrophilic vasculitis, including fibrinoid necrosis, extravasation of erythrocytes, extravasation of neutrophils with release of nuclear debris (leukocytoclasia), and the presence of immune deposits.[15,16] Processing of tissue is different for conventional histopathology or immunofluorescence testing; if immunofluorescence is desired, then either 2 biopsies need to be performed or a single biopsy needs to be divided before processing. The latter approach may damage the tissue.[15]

As discussed throughout this chapter, the histologic finding of leukocytoclastic vasculitis is helpful in confirming the diagnosis of vasculitis but does nothing to establish an etiology from among the broad number of possibilities. Microscopy sometimes reveals features that are suggestive but not diagnostic of vasculitis,

Figure 139-3 Different skin manifestations of systemic vasculitis. **A,** Purpura. **B,** Bullae. **C,** Ulcer.

such as leukocytoclasia without fibrinoid necrosis. The finding of a perivascular infiltrate, particularly if it consists predominantly of mononuclear cells but even if it is neutrophilic, is also nonspecific. Certain features, when seen in addition to leukocytoclastic vasculitis, are strongly suggestive of particular diseases, such as extravascular granulomas with geographic necrosis (granulomatosis with polyangiitis), or eosinophil-rich extravascular granulomas (eosinophilic granulomatosis with polyangiitis),[17] but these features are seen in a minority of biopsies in these diseases.

A predominance of IgA over IgG/IgM by immunofluorescence is suggestive but not diagnostic of IgA vasculitis (Henoch–Schönlein). The presence of

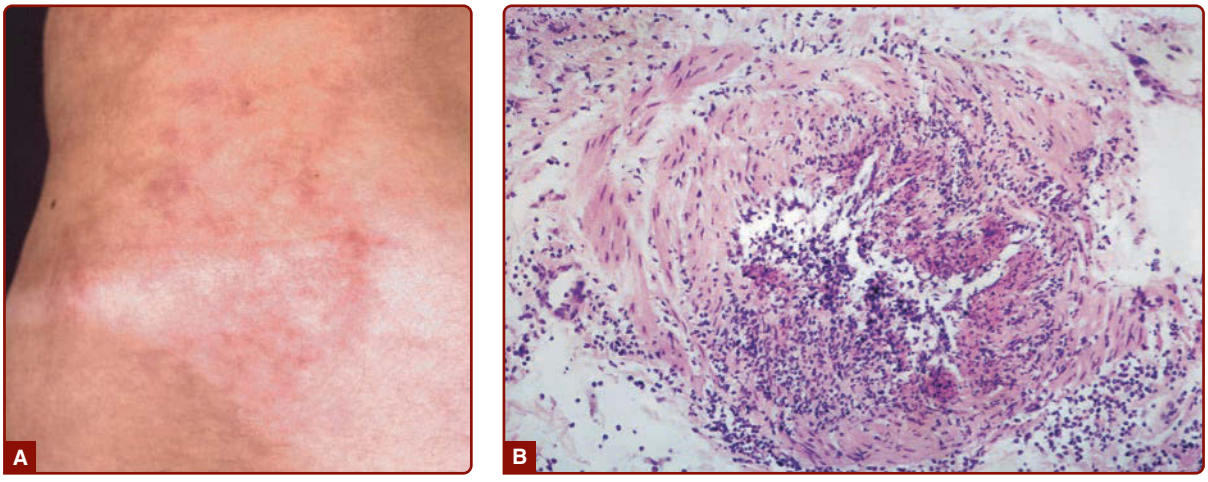

Figure 139-4 **A,** A patient with polyarteritis nodosa with "starburst" livedo made up of a cluster of nodular lesions. **B,** Histopathology of skin lesions in polyarteritis nodosa showing segmental necrotizing arteritis.

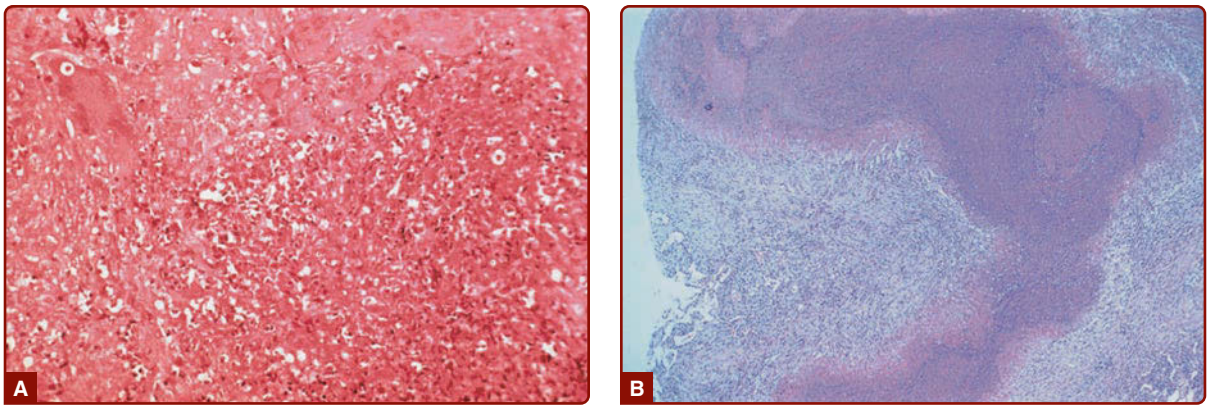

Figure 139-5 **A,** Lung histopathology from a patient with granulomatosis with polyangiitis (Wegener) demonstrating necrosis, giant cells, and mixed cellular inflammation. **B,** "Geographic necrosis" in a low-power view of an open lung biopsy specimen from a patient with granulomatosis with polyangiitis (Wegener).

deposits of IgG, IgM, and/or complement is suggestive of one of several immune complex–mediated etiologies, including drug hypersensitivity, postinfectious vasculitis, cryoglobulinemia, and vasculitis secondary to systemic lupus erythematosus, Sjögren syndrome, or rheumatoid arthritis.[17]

OTHER BIOPSIES

Vasculitis is often diagnosed by biopsy of other organs, such as kidney, lung, muscle, or peripheral nerve or even from surgical specimens (Fig. 139-5). Kidney or lung biopsies are more likely than skin biopsies to show pathology diagnostic of a particular disease. Nonetheless, a skin biopsy establishing the diagnosis of vasculitis may preclude the need for more invasive biopsies.

LABORATORY TESTING

Although individual laboratory tests on their own are almost never diagnostic for vasculitis, such tests are essential in the evaluation of a patient in whom cutaneous vasculitis is being considered. Laboratory testing may identify organ systems involved in the disease process, especially renal disease. Furthermore, in the proper setting, selected serologic tests may establish an etiology for vasculitis. However, serologic tests usually complement rather than substitute for biopsy, particularly in a patient with skin lesions that can be readily biopsied.

TESTS OF RENAL FUNCTION

Tests for renal disease are the most important to order in evaluating a patient suspected of having vasculitis because renal disease is common in many vasculitides and is rarely accompanied by signs or symptoms until end-stage renal failure occurs. Urinalysis, including both dipstick and microscopic examinations, should be performed on all patients in whom vasculitis is suspected and repeated in patients in whom vasculitis of small or medium-sized vessels is established in another organ system. The presence of any blood on the routine dipstick tests needs to be followed by an examination for red blood cell casts by someone specifically trained to look for casts (many nephrologists, some rheumatologists, but few laboratory technicians in North America). Measurement of serum creatinine is critical to estimate the glomerular filtration rate (GFR). Small changes in creatinine, even within the normal range, may be early evidence of decline in GFR. Although small-vessel vasculitis affecting the glomeruli is expected to produce hematuria, usually accompanied by red blood cell casts and proteinuria, vasculitis affecting only medium-sized vessels (eg, polyarteritis nodosa) typically produces either isolated hematuria or a normal urinalysis. Urinalysis and serum creatinine are equally important tests and are complementary; neither alone is sufficient to exclude renal disease in vasculitis.

TESTS OF LIVER FUNCTION

Vasculitis, particularly polyarteritis nodosa, can involve the liver, but significant hepatic dysfunction is rare. Liver function tests are thus of limited value in diagnosing vasculitis, but they do provide a baseline against which future values can be compared if, as is often the case, potentially hepatotoxic drugs are to be used for treatment. Liver function tests can also provide an early hint at infection with hepatitis B or C viruses, both of which are associated with vasculitis, but do not substitute for serologic testing for these infections. Normal liver function tests do not rule out infectious hepatitis.

COMPLETE BLOOD COUNT

A complete blood count should be ordered on all patients suspected of having vasculitis. Many patients with active vasculitis have anemia and/or

thrombocytosis, but the same is true of a wide range of inflammatory diseases. Severe anemia can be a clue to serious GI involvement from various forms of vasculitis. The white blood cell count and differential also can be clues to the presence of infection or hematologic malignancy. However, leukocytosis is usually nonspecific and is also commonly caused by use of glucocorticoids. An elevated absolute eosinophil is found in most untreated patients with eosinophilic granulomatosis with polyangiitis (Churg–Strauss), and a count greater than 1000 cells/μL helps differentiate this disease from asthma and atopy.

ACUTE PHASE REACTANTS

The erythrocyte sedimentation rate (ESR) and levels of C reactive protein (CRP) are elevated in many patients with vasculitis, but the diagnostic sensitivity and specificity of these tests are not particularly high. Thus, these tests are not particularly helpful in either establishing or excluding a diagnosis of vasculitis. Furthermore, the levels of ESR and CRP do not correlate well with stage or severity of disease. ESR and CRP are often elevated in conditions that mimic vasculitis in the skin, as well as in many serious systemic diseases, including infections and malignancies. Patients with active vasculitis can have normal ESR and CRP values, and patients may remain in clinical remission despite persistent elevation of these markers after treatment.

AUTOIMMUNE SEROLOGIES

Testing for autoantibodies is often a critical component of establishing the type of vasculitis present, but it is important to recognize that serologic testing on its own is never diagnostic and should never substitute for clinical judgment.

Testing for ANCA and anti–glomerular basement membrane (GBM) antibodies, as well as antinuclear antibodies (ANA) to address the alternative possibility of systemic lupus erythematosus, is advised for any patient presenting with pulmonary hemorrhage and/or acute renal insufficiency with an active urinary sediment. ANCA-associated vasculitis (AAV) and lupus can present with vasculitis of the skin, but anti-GBM disease does not, so the latter topic will not be discussed further.

ANTINEUTROPHIL CYTOPLASMIC ANTIBODIES (ANCA)

Approximately 90% of patients with microscopic polyangiitis, 75% of patients with granulomatosis with polyangiitis, and 40% of patients with eosinophilic granulomatosis with polyangiitis will test positive for ANCA.[18-21] Modern ANCA testing includes both immunofluorescence staining of neutrophils for the cytoplasmic (c-ANCA) or perinuclear (p-ANCA) patterns and enzyme-linked immunosorbent assays (ELISAs) for specific autoantigens (PR3 and MPO).[21-23] Specificity of positive testing for anti-PR3 and anti-MPO antibodies for AAV is quite high,[22-24] but specificity of p-ANCA staining in the absence of anti-MPO antibodies is low. Thus, positive tests for ANCA by ELISA are essential to consider ANCA testing positive for purposes of diagnosing vasculitis.

The predictive value of positive ANCA testing depends on the setting. In cases of biopsy-proven vasculitis or clinical "surrogates" of a biopsy of vasculitis, such as diffuse alveolar hemorrhage or acute renal failure with an "active" urinary sediment, positive testing for anti-PR3/MPO ANCA is highly specific. In the setting of nonspecific constitutional and musculoskeletal symptoms, the positive predictive value of ANCA testing is lower.

ANTINUCLEAR ANTIBODIES (ANA)

Testing for ANA and related autoantibodies is useful when there is suspicion of systemic lupus or Sjögren syndrome. ANA testing is extremely sensitive (>95%) but not specific for the diagnosis of lupus. With the exception of anti-Ro (SSA) antibodies, additional tests for specific nuclear antigens, including double-stranded DNA, Smith, RNP, and La (SSB), should only be ordered if the ANA is positive and lupus is still under consideration. Only 80% of patients with Sjögren syndrome test positive for either rheumatoid factor, anti-Ro (SSA), or anti-La (SSB) antibodies, so negative tests do not rule out this diagnosis.

RHEUMATOID FACTOR (RF)

Testing for rheumatoid factor is rarely useful in establishing either the diagnosis or specific type of vasculitis. The sensitivity and specificity of rheumatoid factor for Sjögren syndrome or cryoglobulinemic vasculitis are low. Although at least 70% of patients with rheumatoid arthritis test positive for rheumatoid factor, the test is positive in more than 95% of patients with rheumatoid vasculitis.[25] However, because rheumatoid vasculitis typically occurs in patients with longstanding, severe rheumatoid arthritis, such testing has little additive value.

PARAPROTEINS (ABNORMAL IMMUNOGLOBULINS, INCLUDING CRYOGLOBULINS)

Cryoglobulins are immune complexes (immunoglobulins and their target antigens) that precipitate in the cold and are associated with clinical syndromes in which vasculitis is a prominent component (see Chap. 144). Cryoglobulinemia most commonly results from chronic infection with hepatitis C virus, but rheumatoid arthritis, systemic lupus erythematosus, Sjögren syndrome, and hematologic malignancies are also all associated with cryoglobulinemia. Testing for cryoglobulins requires careful attention to specimen handling and processing since

incorrect practice at any one of several steps results in a high false-negative rate. Similarly, standard serum protein electrophoresis testing may not pick up some immunoglobulin clones, and immunofixation electrophoresis is a more comprehensive screen for clonal immunoglobulins.

Vasculitis also has been associated with monoclonal gammopathies (myeloma, plasmacytoma, or lymphoma) in the absence of cryoglobulinemia.[26]

COMPLEMENT

Total hemolytic complement is measured using the CH50, but since this assay is cumbersome and suffers from variability between laboratories, measurement in serum of the complement proteins C3 and C4 is usually sufficient, and is useful for assessing patients with cutaneous vasculitis in several settings. In patients with cryoglobulinemic vasculitis, C4 levels are usually severely depleted whereas C3 levels are less depleted or even normal.[27,28] One or both of these components are low in 70% of patients with rheumatoid vasculitis,[25] which is useful because rheumatoid arthritis is generally not associated with low circulating complement. In contrast, because systemic lupus erythematosus is commonly associated with low complement in a variety of settings, low complement helps to raise the suspicion for lupus but is not specific for vasculitis in SLE. A subset of patients whose cutaneous vasculitis presents as urticaria (hence the term *urticarial vasculitis*), but who cannot be diagnosed with lupus or another underlying disease, have depletion of complement (Chap. 138).

SELECTED TESTING FOR INFECTIOUS DISEASES

Many infections can cause skin lesions that either include vasculitis or mimic vasculitis. Chronic infection with hepatitis C virus is strongly associated with cryoglobulinemic vasculitis, and it also can be associated with polyarteritis nodosa in the absence of cryoglobulins.[29] Chronic hepatitis B virus infection was the cause of many cases of polyarteritis nodosa before the widespread adoption of vaccination programs.[30] Thus, patients with known or suspected vasculitis affecting small or medium-sized arteries should be screened for hepatitis B and C infections.

Endocarditis can cause both true vasculitis, presumably through deposition of immune complexes, and lesions that mimic vasculitis, through septic emboli. Blood cultures are appropriate for some patients suspected of small-vessel vasculitis. Interestingly, bacteremia can be a cause of a positive test for ANCA that is not associated with vasculitis.[31]

Numerous and diverse infections have been implicated in causing secondary vasculitis, usually of small vessels and limited to the skin. Testing for specific organisms should therefore be based on a history of exposure or a suspicious clinical syndrome (eg, sore throat or acute diarrhea).

Several uncommon infections directly infect and damage vascular endothelial cells and thus produce lesions that can either be regarded as vasculitis or as mimics of vasculitis; numerous organisms have been implicated, mostly in the form of case reports.

SCREENING FOR DRUGS OF ABUSE

Toxicology screens for commonly used drugs of abuse may be appropriate for some clinical situations where vasculitis is suspected. In particular, both cocaine and methamphetamines have been associated with cutaneous vasculitis and/or arterial vasospasm, and nasal inhalation of cocaine can produce destructive nasal disease as severe as that seen in ANCA-associated vasculitis, although certain clinical features may help distinguish the 2 causes.[32,33] There is a now well-recognized form of destructive vasculopathy/vasculitis associated with exposure to levamisole, an antihelminthic and immunomodulatory agent that is an adulterant of illegal cocaine, especially in North America. Levamisole can lead to characteristic gangrenous lesions as well as positive tests for both anti-MPO and anti-PR3 ANCA.[34] Levamisole use can be confirmed by testing in urine.

IMAGING

CHEST IMAGING

A chest radiograph is an appropriate screening test for any patient suspected of having vasculitis. For a patient with pulmonary symptoms, computed tomography (CT) is usually indicated, because plain radiographs will frequently not detect small nodules or subtle but significant infiltrates. In patients diagnosed with granulomatosis with polyangiitis, microscopic polyangiitis, or eosinophilic granulomatosis with polyangiitis (Churg–Strauss), a screening CT is indicated for staging purposes and to establish a baseline, even in asymptomatic patients.

If subglottic stenosis is suspected, CT of the neck/trachea can be a helpful adjunct to direct laryngoscopy.

SINUS IMAGING

Sinus involvement is extremely common in granulomatosis with polyangiitis and eosinophilic granulomatosis with polyangiitis, and the ability to evaluate the sinuses on physical examination is limited even for an otolaryngologist. CT of the sinuses can help assess the possibility of granulomatosis with polyangiitis or eosinophilic granulomatosis with polyangiitis and is useful in staging and restaging disease once one of those diagnoses is made and treatment is initiated. However, the CT appearance of sinus inflammation

in these diseases does not allow discrimination from other causes of sinusitis, and patients with prior damage from vasculitis often have persistent abnormalities. Nasal inflammation is better assessed by physical examination than by CT.

ANGIOGRAPHY

Angiography has a central role in the diagnosis and management of large- and medium-vessel vasculitis. Conventional catheter-based dye angiography has the highest resolution but is an invasive procedure and still does not allow visualization of most small vessels. Angiography based on CT and magnetic resonance (MR) are increasingly replacing the use of catheter-based angiography.[35]

The role of angiography in the diagnosis of vasculitis of the skin is limited to either establishing the underlying type of vasculitis (eg, abdominal angiography demonstrating multiple aneurysms and stenoses in polyarteritis nodosa) or evaluating the arterial supply in patients with gangrene.

OTHER DIAGNOSTIC STUDIES

NERVE CONDUCTION STUDIES AND ELECTROMYOGRAPHY

Nerve conduction studies should never replace a full neurologic examination, and most patients with neurologic manifestations of vasculitis do not need such testing. Thus, nerve conduction testing is not recommended for screening asymptomatic patients, but can be useful for providing objective evidence of neuropathy and for distinguishing between compressive (ie, mechanical) and non-compressive neuropathy, with the latter type including neuropathy due to vasculitis and many other medical causes. Electromyography (EMG) can establish the presence of myopathy, but not the cause. Nerve conduction studies are painful and require expertise not always readily available.

AUDIOLOGY TESTING

An audiogram is critical in diagnosing and distinguishing between conductive and/or sensorineural hearing loss. Hearing loss is a commonly missed manifestation of small-vessel vasculitis, including among elderly patients.[36] Sensorineural hearing loss is a cranial neuropathy and may rapidly lead to irreversible hearing loss. Although an audiogram is not generally indicated for screening an asymptomatic patient, a baseline audiogram is advised for all patients with an established diagnosis of ANCA-associated vasculitis (granulomatosis with polyangiitis, microscopic polyangiitis, or eosinophilic granulomatosis with polyangiitis).

SUMMARIES OF THE VASCULITIDES

MICROSCOPIC POLYANGIITIS

Microscopic polyangiitis (MPA) is a multisystem vasculitis of small and also sometimes medium-sized vessels.[37,38] Pauci-immune glomerulonephritis develops in the majority of patients, and pulmonary hemorrhage, peripheral and cranial neuropathy, musculoskeletal, and constitutional symptoms are also common; cardiac and GI involvement are less common. Most patients with microscopic polyangiitis are positive for ANCA, usually with specificity for antibodies to myeloperoxidase (MPO).[39] Although rapidly progressive glomerulonephritis and/or diffuse alveolar hemorrhage commonly lead to diagnosis, microscopic polyangiitis often features a prolonged prodrome limited to musculoskeletal and constitutional symptoms.[40]

The skin is frequently involved in microscopic polyangiitis.[20] The most common cutaneous lesion is palpable purpura and the pathology is indistinguishable from other types of leukocytoclastic vasculitis[17,41] (Fig. 139-6). Vasculitis of medium-sized vessels, leading to digital ischemia, subcutaneous nodules, livedo reticularis, and deep ulcers, can rarely occur in microscopic polyangiitis.

GRANULOMATOSIS WITH POLYANGIITIS

Granulomatosis with polyangiitis encompasses all the features of microscopic polyangiitis but also many additional manifestations caused by necrotizing granulomatous inflammation, and the 2 syndromes are currently considered distinct entities. Chronic inflammation of the upper airway (nasal cavity, sinuses, auditory tube, and middle ear) is present in about

Figure 139-6 Purpura in a patient with microscopic polyangiitis.

Figure 139-7 Skin ulcer in a patient with granulomatosis with polyangiitis (Wegener).

90% of patients, often but not always as the initial manifestation.[18,42,43] Cavitary pulmonary nodules, orbital pseudotumor, and subglottic stenosis are also common and important features. Vasculitis of the eye (scleritis and episcleritis) is also much more common in granulomatosis with polyangiitis than in microscopic polyangiitis.[18,37,42-44] Most patients with granulomatosis with polyangiitis who have involvement of multiple organ systems will test positive for ANCA.[44,45] The majority ANCA type in this disease is C-ANCA/anti-PR3; however, P-ANCA/anti-MPO is also not uncommon. Patients with disease seemingly restricted to the upper airway are only ANCA-positive in about 70% of cases, which can make diagnosis more challenging.[21,44]

In addition to palpable purpura and other presentations typical of small-vessel vasculitis, additional skin lesions occur in granulomatosis with polyangiitis and reflect a combination of vasculitis and necrotizing granulomatous disease, including neutrophilic and granulomatous dermatitis with papules (particularly on the extensor surfaces of the elbows), subcutaneous nodules, and ulcers[17,46-49] (Figs. 139-7 and 139-8). Vasculitis and extravascular granulomatous disease are sometimes seen in the same biopsy, facilitating diagnosis. As with MPA, manifestations attributable to involvement of medium-sized vessels also can be seen (Fig. 139-9).

EOSINOPHILIC GRANULOMATOSIS WITH POLYANGIITIS

Eosinophilic granulomatosis with polyangiitis is often included among the ANCA-associated vasculitides since approximately 40% of patients test positive for ANCA,[50] and there is considerable overlap in features of eosinophilic granulomatosis with polyangiitis with both granulomatosis with polyangiitis and microscopic polyangiitis. However, eosinophilic granulomatosis with polyangiitis has unique features, the most prominent being a history of asthma (often severe or poorly controlled), and blood eosinophilia. Nasal polyps, constitutional symptoms, and rashes, all typical of atopy, are also common. The presence of pulmonary infiltrates on chest imaging (eosinophilic pneumonia) provides an important distinction from asthma. The most common presentation of severe vasculitis in eosinophilic granulomatosis with polyangiitis is acute peripheral neuropathy with involvement of the heart, GI tract, brain, and eyes less commonly. Glomerulonephritis and pulmonary hemorrhage occur in about 10% and less than 5%, respectively, of patients with eosinophilic granulomatosis with polyangiitis.[19,51,52]

Cutaneous disease is more common in eosinophilic granulomatosis with polyangiitis than in systemic granulomatous vasculitis or microscopic polyangiitis.[19,51,52] Palpable and nonpalpable purpura, reflecting vasculitis histologically, comprise about 50% of cutaneous lesions.[17] Eosinophilic dermatitis and granulomatous dermatitis rich in both neutrophils and eosinophils are also common and produce erythematous macules, papules, and nodules. As with granulomatosis with polyangiitis, small-vessel vasculitis and extravascular eosinophilic and/or granulomatous

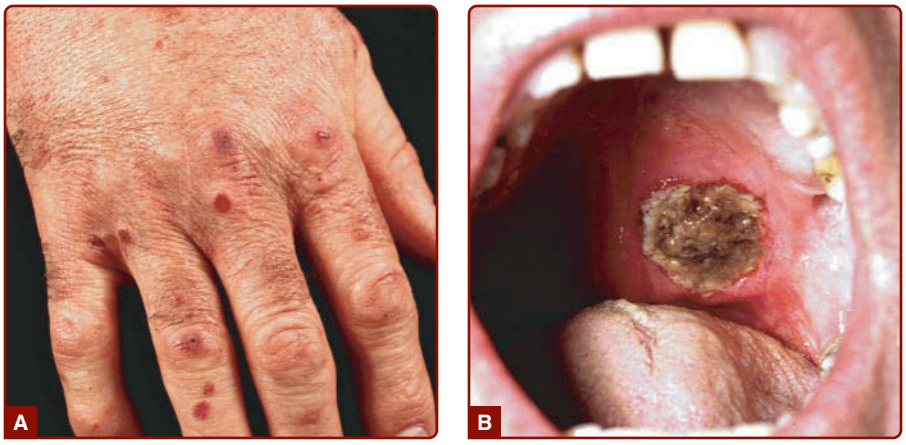

Figure 139-8 Granulomatosis with polyangiitis (Wegener). **A,** Palpable purpura **B,** Deep ulcer on the soft palate.

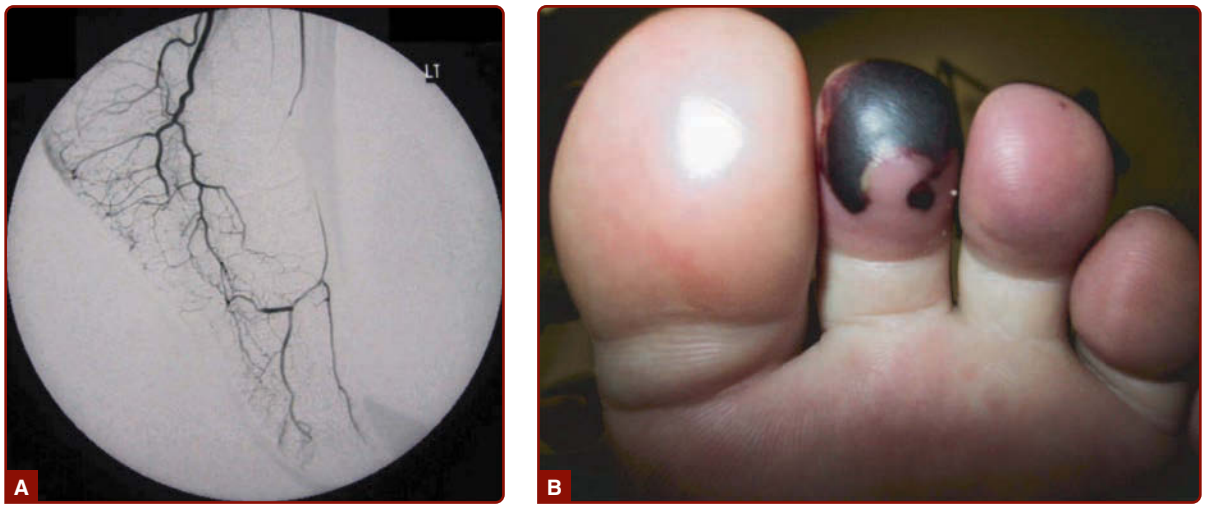

Figure 139-9 Granulomatosis with polyangiitis (Wegener). **A,** Vasculitis and occlusion of the dorsal pedal artery. **B,** Gangrenous toe secondary to the occlusion in panel A.

disease are sometimes seen in the same biopsy. While the skin lesions of eosinophilic granulomatosis with polyangiitis often contain eosinophils, with or without vasculitis, eosinophil-rich skin biopsies are not unique to this disease and can be seen in other types of vasculitis.

CRYOGLOBULINEMIC VASCULITIS

See Chap. 144 "Cryoglobulinemia and Cryofibrinogenemia."

IGA VASCULITIS (HENOCH–SCHÖNLEIN)

See Chap. 138 "Cutaneous Necrotizing Venulitis."

VASCULITIS ASSOCIATED WITH OTHER AUTOIMMUNE DISEASES

Vasculitis is seen relatively commonly in patients with systemic lupus (10% to 36%)[53,54] and Sjögren syndrome (10%)[55] but is now extremely uncommon in rheumatoid arthritis.[56,57] Vasculitis in these diseases affects mostly small vessels, with some medium-vessel disease. The vasculitis may cause peripheral neuropathy, GI ischemia, and CNS disease, with other visceral involvement being rare. Inflammatory bowel disease and relapsing polychondritis[58] also have been associated with vasculitis involving small, medium, or large vessels.

MALIGNANCY-ASSOCIATED VASCULITIS

Vasculitis temporally associated with a solid malignancy has been described in many case reports and a few larger series.[59] Diverse malignancies have been implicated. Small-vessel vasculitis of the skin appears to be most common, and reports of remission of vasculitis after surgical resection of the tumor (and no other therapy) are suggestive of a causal relationship. Hematologic malignancies with or without associated paraproteinemias can result in vasculitis.[26] On the other hand, the comprehensive medical testing and imaging associated with evaluating a patient with possible vasculitis can lead to discovery of a malignancy in a patient with vasculitis, and the 2 diagnoses may be unrelated.

CUTANEOUS LEUKOCYTOCLASTIC ANGIITIS

All of the diseases and syndromes described to this point are defined by a combination of clinical and laboratory parameters. Cutaneous leukocytoclastic angiitis, in contrast, is a histologic term defined by the absence of evidence of systemic disease. The term undoubtedly encompasses many etiologies, and appears in this list only to serve as a reminder that cutaneous vasculitis is not always a marker of systemic disease. If, and only if, a patient has biopsy-proven vasculitis, has no evidence of involvement of other organ systems by vasculitis, and has no clinical of laboratory evidence to support a specific form of vasculitis or a coexisting autoimmune inflammatory disease, should the diagnosis of cutaneous

leukocytoclastic angiitis be tentatively made. This term appears in the nomenclature of the Chapel Hill Consensus Conference of 1994 to acknowledge that vasculitis limited to the skin is relatively common.[7] It has been estimated that about 20% of such cases follow a wide range of infections, and another 20% are associated with drug exposure.[17] However, it is quite problematic to label skin-only vasculitis as a separate disease entity, and all such patients should be followed carefully for the possible evolution to a more systemic form of vasculitis.

DRUG-INDUCED VASCULITIS

Reactions to drugs have been implicated in about 20% of cases of cutaneous small-vessel vasculitis,[15] but the exact frequency of drug-induced disease is hard to establish due to incomplete reporting of cases and difficulty in firmly establishing causality of any one agent. Most categories of drugs have been implicated as causing vasculitis, but the number of reports for a given drug may represent reporting bias rather than relative risk.[14,60] Cutaneous small-vessel disease is the norm, but medium-vessel vasculitis and visceral involvement have been reported. The literature is undoubtedly biased toward severe cases, but there are numerous reports of serious or fatal internal organ involvement (particularly renal, pulmonary, and hepatic). There is also a now well-accepted subset of drug-induced ANCA-associated vasculitis (antibodies usually directed against myeloperoxidase), especially involving propylthiouracil and related agents, hydralazine, but also other drugs.[61,62]

The cutaneous presentation of drug-induced vasculitis is indistinguishable from other causes of small-vessel vasculitis (ie, usually purpura but sometimes with other lesions) (Fig. 139-10).

It is essential that a comprehensive review of all prescription, nonprescription, illegal, and "alternative" drugs and supplements be undertaken for all patients suspected of having vasculitis.

Figure 139-10 Leukocytoclastic vasculitis after administration of granulocyte macrophage colony-stimulating factor for aplastic anemia.

Establishing a diagnosis of drug-induced vasculitis may lead to avoidance of treatment with glucocorticoids and immunosuppressive drugs in favor of clinical followup after drug discontinuation. However, 2 important caveats must be kept in mind in such cases: (1) drug discontinuation alone may not resolve the disease and severe disease may be present necessitating treatment, and (2) the diagnosis of drug-induced vasculitis may be wrong and the patient really has another form of vasculitis; thus, careful and prolonged followup of all patients is required.

BEHÇET DISEASE

See Chap. 141 "Adamantiades-Behçet Disease."

POLYARTERITIS NODOSA

Idiopathic vasculitis of medium-sized vessels (ie, small or medium-sized muscular arteries) can present in one or multiple organ systems. "Classic" polyarteritis nodosa involves multiple organ systems and presents with some combination of skin disease, myalgia, hypertension (from renal artery involvement), abdominal pain, neuropathy, and/or testicular pain. However, many patients do not present with the full set of manifestations, and disease limited to muscle and nerve, single internal organs, or to the skin are well-described variants. When the disease is limited to the skin, it is sometimes referred to as cutaneous polyarteritis nodosa; however, some of these patients will later manifest disease in other organs.

Interpreting the literature on polyarteritis nodosa is problematic since the term was formerly used to describe several forms of vasculitis now considered to be distinct diseases (particularly microscopic polyangiitis).[63,64] Historically, many cases of polyarteritis nodosa were associated with chronic infection with hepatitis B, but that association has declined markedly in countries in which vaccination against hepatitis B has become routine.[64] Whether the remaining, rare entity still known as polyarteritis nodosa represents one, a few, or many etiologies, or even whether there is a unified fundamental pathophysiology (eg, immune complex disease), is unclear.

The most common cutaneous features of polyarteritis nodosa are livedo reticularis/racemosa (a lacy pattern of cutaneous blood vessels on the legs, and not always easy to distinguish from a benign consequence of vasoconstriction of more superficial vessels) (Fig. 139-11), painful cutaneous nodules or ulcers (Fig. 139-12), and digital ischemia.[65,66] These manifestations reflect vasculitis of "medium-sized" arteries in the subcutis, which are frequently too deep to be sampled in a routine punch biopsy.[15]

Figure 139-11 Livedo reticularis.

KAWASAKI DISEASE

See Chap. 142 "Kawasaki Disease."

PRIMARY VASCULITIS OF THE CNS

This rare disease is limited to the CNS (hence, no cutaneous findings) and presents with symptoms of encephalopathy, multiple small strokes, and often headache.[67,68]

Figure 139-12 Leg ulcer in a patient with polyarteritis nodosa.

GIANT CELL ARTERITIS

Giant cell arteritis (temporal arteritis) is currently considered strictly a disease of adults older than 50 years that is markedly more common with advancing age. It is mostly a disease of people of Northern European ancestry. Cranial arteritis is a common feature with this term indicating stenosis or occlusion of 1 or more branches of the carotid artery to produce headache (70% to 80%), jaw claudication (50%), and monocular (and rarely binocular) blindness (15%). Polymyalgia rheumatica, which includes pain and stiffness of the shoulder and hip girdles, is seen in at least 30% to 40% of patients and may occur without cranial disease. Constitutional symptoms are common, including fever, malaise, and weight loss. Involvement of the aorta and its major branches produces symptoms similar to Takayasu arteritis and is present in 15% to 20% of patients. Diagnosis of GCA is usually confirmed by temporal artery biopsy (Fig. 139-13).

Palpable nodularity of the temporal artery is present in 30% to 40% of cases and is the only cutaneous manifestation of GCA apparent on examination. Scalp necrosis and digital ischemia are rare complications.[69,70]

TAKAYASU ARTERITIS

Takayasu is a rare form of vasculitis (prevalence <1:100,000) involving the aorta and its major branches.[71-76] Many patients are diagnosed as young adults, and 90% are female. The typical presentation of Takayasu is limb claudication. Dizziness, constitutional symptoms, and severe hypertension (from renal artery stenosis) are also common. Cerebral infarction can occur. Coronary occlusions with angina or infarction and bowel ischemia are less common but life-threatening complications. Absent pulse(s), abnormal blood pressure readings, and arterial bruits are common but not universal findings. Diagnosis is made by angiography.

Lesions resembling erythema nodosum or pyoderma gangrenosum[77] have been described repeatedly in Takayasu, with pathology of nodular lesions often, but not always, showing vasculitis and thereby differing from typical erythema nodosum.[78,79] Although complete occlusion of subclavian arteries is common, digital ischemia is rare.

CLINICAL COURSE AND PROGNOSIS

The severity of vasculitis varies widely, but all of the named diseases have the potential to cause permanent damage to vital organs. All forms of vasculitis

Figure 139-13 **A,** Histopathology of the temporal artery from a patient with giant cell arteritis shows necrosis of the media, inflammatory infiltrates consisting of lymphocytes, and giant cells. There is also subintimal proliferation of fibroblasts and fibrosis. **B,** Elastic tissue stain reveals destruction of the lamina interna and externa.

are treatable, and the goal is to make the diagnosis and start treatment before damage has occurred. After successful treatment with immune-suppressive drugs, some forms of vasculitis are more likely to recur than others. Granulomatosis with polyangiitis with anti-PR3 antibodies recurs in well over 50% of cases in the absence of long-term treatment, whereas microscopic polyangiitis with anti-MPO antibodies recurs in fewer than 50%. Polyarteritis nodosa and eosinophilic granulomatosis with polyangiitis also recur in fewer than 50% of patients, although in eosinophilic granulomatosis with polyangiitis, chronic asthma and/or sinonasal disease recur in most patients and require long-term treatment. IgA vasculitis is usually monophasic or resolves after a few episodes in children but is more likely to be chronic in adults. Cryoglobulinemic vasculitis secondary to hepatitis C virus is usually, but not always, cured by eradication of the virus, whereas it usually recurs in the absence of eradication. Vasculitis associated with connective tissue diseases can be monophasic, episodic, or chronic and varies widely in severity.

Treatment is also a source of morbidity. Glucocorticoids are used in almost all forms of severe vasculitis and carry numerous risks at high doses or with long-term use even at moderate or low doses. Almost all other medications used to treat vasculitis increase risk of infection but are considered preferable to glucocorticoids on those grounds and others.

Mortality in the first 3 to 6 months of severe vasculitis affecting vital organs is around 10%, because of either complications of vasculitis (eg, pulmonary hemorrhage, bowel perforation, or cardiomyopathy) or to infection. After that, as treatment is reduced and vasculitis usually remains in control, mortality is reduced dramatically but appears to remain somewhat higher than expected.[80] Other than advanced age, the predictors of higher risk of mortality reflect prior organ damage: kidney damage in the case of granulomatosis with polyangiitis and microscopic polyangiitis,[81] and cardiac damage in the case of eosinophilic granulomatosis with polyangiitis.[82]

MANAGEMENT

GENERAL APPROACH TO TREATMENT OF SYSTEMIC VASCULITIS

When establishing a treatment regimen for a patient with vasculitis, consideration must be given to both the severity of the current presentation and the likelihood of disease progression and recurrence. An overview is presented in Fig. 139-14. For an increasing number of vasculitides, treatment is guided by results of relatively large randomized controlled trials. However, for many situations, clinicians still rely upon either extrapolation from trials in other diseases or empiric treatment based on small case series or personal experience.

For vasculitides expected to have extended courses and/or to include severe manifestations, the general approach is to plan for 2 phases of treatment: remission induction and remission maintenance.[83,84] Remission induction usually involves use of high-dose glucocorticoids with steady dose taper combined with a short course (3-6 months) of a fairly rapid-acting and potent immunosuppressive agent. For example,

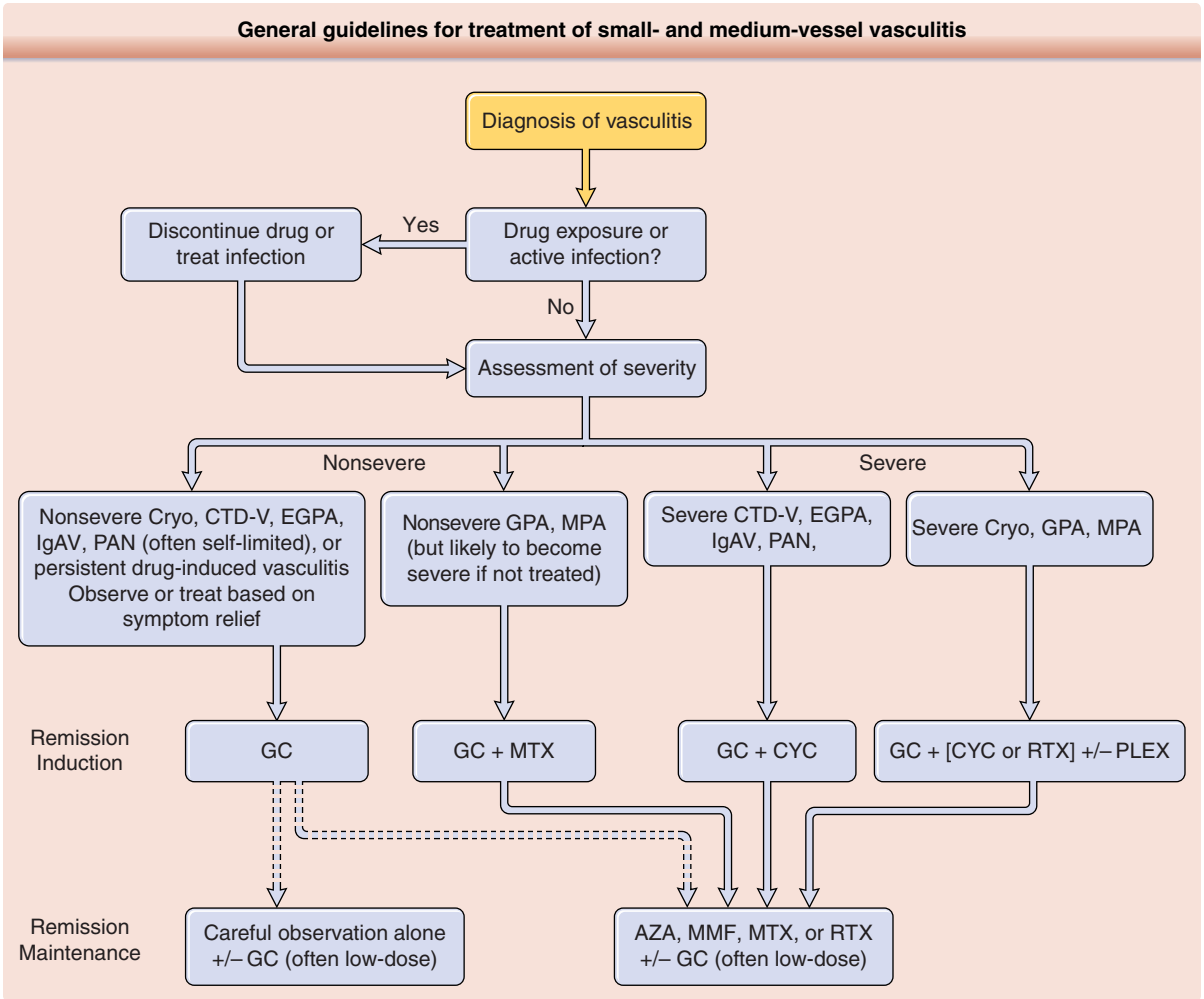

Figure 139-14 General guidelines for treatment of small- and medium-vessel vasculitis. It is important to recognize that approaches will vary substantially based on severity and comorbidity, and high-quality data are not available to guide treatment of many forms of vasculitis. Once the diagnosis is established and treatable causes are identified or excluded, severity is assessed by the organ systems involved and the severity of disease in that organ system. For example: CNS and cardiac involvement are always considered severe; GI, renal, and peripheral nerve disease usually severe; skin manifestations usually not severe; musculoskeletal not severe. Dashed lines indicate where multiple options exist. CTD-V, vasculitis associated with a systemic connective tissue disease (eg, systemic lupus erythematosus, Sjögren syndrome, rheumatoid arthritis); Cryo, cryoglobulinemic vasculitis; EGPA, eosinophilic granulomatosis with polyangiitis (Churg–Strauss); GPA, granulomatosis with polyangiitis (Wegener); IgAV, IgA vasculitis (Henoch–Schönlein); MPA, microscopic polyangiitis; PAN, polyarteritis nodosa; GC, glucocorticoids; AZA, azathioprine; CYC, cyclophosphamide; MMF, mycophenolate; MTX, methotrexate; PLEX, plasma exchange; RTX, rituximab. Treatment of giant cell arteritis and Takayasu arteritis includes GC, but the options for glucocorticoid-sparing drugs differ from the algorithm shown here. The approach to treatment for Behçet disease is complex and does not fit readily into algorithms with other vasculitides.

cyclophosphamide, rituximab, and methotrexate all have roles in remission induction for ANCA-associated vasculitis. Remission maintenance usually involves prolonged use of a non–cyclophosphamide-based regimen to allow for glucocorticoids to be either fully discontinued or maintained at a low dose (eg, ≤10 mg prednisone daily). However, although the above approach is usual for the ANCA-associated vasculitides, polyarteritis nodosa, and some other forms of severe systemic disease for which there are data from clinical trials to guide treatment, it is less commonly used for other vasculitides in which glucocorticoids alone may suffice as therapy.

Clinicians must always remain alert to the possibilities of (1) a different diagnosis (either a different form of vasculitis or an entirely different disease); (2) development of additional manifestations of vasculitis; and (3) treatment-related side effects, some of which can mimic vasculitis (infections, skin reactions, etc).

An important aspect of caring for patients with vasculitis is determining who and when *not* to treat. "Watchful waiting" may be a reasonable management approach when (1) a diagnosis is not clear and no major organ system appears threatened; (2) there is an obvious cause or etiology for the vasculitis that is either reversible (toxin/drug) or self-limited

(some infections); (3) uncertainly exists as to whether the patient's symptoms are due to a flare of disease or the result of either chronic damage or another process.

A critical component to the care of patients with vasculitis is close, regular clinical followup. Vasculitis often progresses rapidly, and most forms of vasculitis have high rates of relapse. Depending on the form of vasculitis, regular office visits should be accompanied by laboratory and radiographic monitoring. Close followup should occur not only at the start of the disease process, but also for years following diagnosis.

TREATMENTS FOR SYSTEMIC VASCULITIS

A comprehensive list of drugs used in the treatment of the various systemic vasculitides and details of treatment regimens is beyond the scope of this chapter (additional information about specific agents is available in Chaps. 184, "Glucocorticoids," 190, "Cytotoxic and Antimetabolic Agents," 192, "Immunosuppressive and Immunomodulatory Drugs," and 193, "Immunobiologicals: Targeted Therapy Against Cytokines, Cytokine Receptors, and Growth Factors in Dermatology").

GLUCOCORTICOIDS

Glucocorticoids remain the mainstay of therapy for vasculitis given the rapidity of action, reliability of response, and physicians' familiarity with dosing and side effects. Glucocorticoids are usually the initial drug used to treat vasculitis and may be the only agent used for some forms of the disease. However, additional agents are often prescribed because either the dose of glucocorticoids needed to maintain disease control is unacceptably high or disease control is not attained by glucocorticoids alone. The acute and chronic toxicities are often underappreciated and the potential cumulative damage from chronic or recurrent use of glucocorticoids may be substantial.

OTHER IMMUNOSUPPRESSIVE AGENTS

A wide variety of additional immunosuppressive agents are used for treatment of the vasculitides. The proven effectiveness of the alkylating agent cyclophosphamide for the ANCA-associated vasculitides and, to a lesser extent, other forms of vasculitis, have helped establish this drug as the standard of care for initial treatment of severe forms of vasculitis.[42,85-87] Other alkylating agents are now rarely prescribed for vasculitis. Although effective in many, but certainly not all, cases, cyclophosphamide is also associated with serious toxicities, many of which are related to total cumulative dose (eg, female and male infertility, bladder cancer). Therefore, the past 3 decades have seen the emergence of "cyclophosphamide-sparing" regimens that usually have patients transition from an initial course of treatment with cyclophosphamide to a more prolonged course of a less toxic immunosuppressive agent, especially either methotrexate[88,89] or azathioprine.[86,90] Mycophenolate, cyclosporine A, and other agents also have been used for maintenance therapy.

Apremilast has now been demonstrated to have efficacy in the treatment of mucocutaneous manifestations of Behçet disease.[91,92]

BIOLOGIC AGENTS

More recently, "biologic" agents, drugs created using recombinant DNA techniques to target specific components of the immune system, have been studied for use in treating vasculitis, often with a goal of being either cyclophosphamide-sparing or glucocorticoid-sparing. The recent demonstration that rituximab, a B cell–depleting therapy, is as effective as cyclophosphamide for induction of remission in AAV is considered a major advance for the field.[93-95] Mepolizumab, a monoclonal antibody to anti-interleukin 5, has been demonstrated to have efficacy in the treatment of eosinophilic granulomatosis with polyangiitis.[96] Two trials have demonstrated the efficacy of tocilizumab, a monoclonal antibody to interleukin 6, for the treatment of giant cell arteritis.[97,98] Promising data on the use of abatacept, a CTLA-4 immunoglobin, to treat giant cell arteritis also has been published.[99] However, studies examining the efficacy of anti-TNF agents for either granulomatosis with polyangiitis or giant cell arteritis have been highly disappointing.[100,101] There are many new biologic agents under consideration for use in the treatment of vasculitis, and clinical trials are needed to properly evaluate these new treatments.

OTHER TREATMENTS

Although a variety of other drug classes, including colchicine, antibiotics (dapsone and others), and "alternative" therapies have been promoted for treatment of various forms of vasculitis, good evidence is generally lacking for the efficacy of these agents.

The role of plasma exchange in the treatment of vasculitis remains controversial. There is some evidence for efficacy of plasma exchange in patients with AAV and severe renal disease[102] and possibly forms of cryoglobulinemic vasculitis. A large international multicenter, but randomized, trial of plasma exchange for AAV is nearing completion.

COMMON ERRORS IN THE DIAGNOSIS AND TREATMENT OF SYSTEMIC VASCULITIS

Given the huge spectrum of disease manifestations in vasculitis, the potential toxicities of treatments for vasculitis, and the serious ramifications of missing alternative diagnoses, especially infections, diagnostic misclassification is a major concern. Establishing a firm diagnosis of vasculitis based on physical examination and laboratory findings alone is a common problem. This is especially true for skin disease since not all purpura is due to vasculitis and not all skin disease in vasculitis is purpuric. Clinicians are cautioned against making a diagnosis of vasculitis in the skin without a biopsy; the exception to this guideline is if the patient has a clearly established diagnosis of vasculitis based on other evidence, but even then, it may be necessary to know what is causing a skin lesion. Many types of skin lesions improve with treatment with glucocorticoids so response to empiric use of this treatment is not diagnostically useful.

Undertreatment or delayed initiation of immunosuppressive therapy is a common problem for patients with systemic vasculitis. Undertreatment may take the form of failure to recognize multiorgan system disease, delay or reluctance to initiate immunosuppressive medications other than glucocorticoids for those forms of vasculitis for which such therapy has been shown to be useful, or underdosing of immunosuppressive agents.

Another common mistake is extending the course of treatment with medium-high doses of glucocorticoids beyond what is necessary to control an acute flare of vasculitis or the more serious manifestations.

MEDICAL EMERGENCIES RELATED TO THE PRIMARY VASCULITIDES

The systemic vasculitides vary greatly in their rate of progression and level of medical severity. However, it is imperative that all clinicians caring for patients with vasculitis understand that these diseases are often organ- and life-threatening and that progression to emergency situations may be rapid. Furthermore, vasculitis can accelerate rapidly even after a long period of slowly changing or even indolent disease. Table 139-2 outlines several of the most common situations in which patients require emergency care but this list is incomplete and clinicians must be vigilant about considering these and other potentially rapidly progressive problems.

TABLE 139-2
Medical Emergencies Related to the Primary Vasculitides

EMERGENCY MANIFESTATIONS OF VASCULITIS	TYPE OF VASCULITIS
Ophthalmologic	
Threatened vision; monocular blindness	GCA, TAK
▪ Scleritis	GPA, MPA, RPC
▪ Uveitis	BD
Pulmonary	
Subglottic stenosis	GPA, RPC
▪ Alveolar hemorrhage	GPA, MPA, EGPA
▪ Diffuse inflammatory infiltrates	GPA, MPA, EGPA
▪ Pulmonary embolus	GPA, MPA, EGPA, BD
Cardiovascular	
Malignant hypertension—Renal arterial stenoses	TAK, GCA, PAN
▪ Rapid-onset cardiomyopathy/ heart failure	EGPA
▪ Angina/myocardial infarction	TAK, GCA
▪ Gangrene—digital ischemia	GCA, TAK, PAN, GPA, MPA
▪ Aneurysm dissection (aorta or branches)	PAN, BD, GCA, TAK
GI	
Mesenteric ischemia	PAN, IgAV, GCA, TAK
Renal	
Glomerulonephritis/rising creatinine/renal failure	GPA, MPA, EGPA, IgAV, PAN, Cryo
Neurologic	
Headache	GCA
▪ Syncope	GCA, TAK
▪ Stroke	GPA, MPA, EGPA, BD, GCA, TAK
▪ Sensorineural hearing loss or other cranial neuropathies	GPA, MPA
▪ Mononeuritis multiplex	EGPA, PAN, GPA, MPA
Other Organ-Threatening Disease	Any systemic vasculitis

BD, Behçet disease; Cryo, cryoglobulinemic vasculitis; EGPA, eosinophilic granulomatosis with polyangiitis; GCA, giant cell arteritis; GPA, granulomatosis with polyangiitis; IgAV, IgA vasculitis (Henoch–Schönlein); MPA, microscopic polyangiitis; PAN, polyarteritis nodosa; RPC, relapsing polychondritis; TAK, Takayasu arteritis.

REFERENCES

1. Basu N, Watts R, Bajema I, et al. EULAR points to consider in the development of classification and diagnostic criteria in systemic vasculitis. *Ann Rheum Dis.* 2010;69(10):1744-1750.
2. Watts RA, Suppiah R, Merkel PA, et al. Systemic vasculitis—is it time to reclassify? *Rheumatology (Oxford).* 2011;50(4):643-645.
3. Lie JT. Nomenclature and classification of vasculitis: plus ca change, plus c'est la meme chose. *Arthritis Rheum.* 1994;37(2):181-186.
4. Hunder GG, Arend WP, Bloch DA, et al. The American College of Rheumatology 1990 criteria for the

classification of vasculitis. Introduction. *Arthritis Rheum.* 1990;33(8):1065-1067.
5. Fries JF, Hunder GG, Bloch DA, et al. The American College of Rheumatology 1990 criteria for the classification of vasculitis. Summary. *Arthritis Rheum.* 1990;33(8):1135-1136.
6. Jennette JC, Falk RJ, Bacon PA, et al. 2012 revised International Chapel Hill Consensus Conference Nomenclature of Vasculitides. *Arthritis Rheum.* 2013;65(1):1-11.
7. Ozen S, Ruperto N, Dillon MJ, et al. EULAR/PReS endorsed consensus criteria for the classification of childhood vasculitides. *Ann Rheum Dis.* 2006; 65(7):936-941.
8. Sunderkötter CH, Zelger B, Chen KR, et al. Nomenclature of Cutaneous Vasculitis: Dermatologic Addendum to the 2012 Revised International Chapel Hill Consensus Conference Nomenclature of Vasculitides. *Arthritis Rheumatol.* 2018;70(2):171-184.
9. Mahr AD, Neogi T, Merkel PA. Epidemiology of Wegener's granulomatosis: Lessons from descriptive studies and analyses of genetic and environmental risk determinants. *Clin Exp Rheumatol.* 2006;24(2) (suppl 41):S82-S91.
10. Lyons PA, Rayner TF, Trivedi S, et al. Genetically distinct subsets within ANCA-associated vasculitis. *N Engl J Med.* 2012;367(3):214-223.
11. Merkel PA, Xie G, Monach PA, et al. Identification of functional and expression polymorphisms associated with risk for antineutrophil cytoplasmic autoantibody-associated vasculitis. *Arthritis Rheumatol.* 2017;69(5): 1054-1066.
12. Carmona FD, Vaglio A, Mackie SL, et al. A Genome-wide Association Study Identifies Risk Alleles in Plasminogen and P4HA2 Associated with Giant Cell Arteritis. *Am J Hum Genet.* 2017;100(1):64-74.
13. Carmona FD, Coit P, Saruhan-Direskeneli G, et al. Analysis of the common genetic component of large-vessel vasculitides through a meta-Immunochip strategy. *Sci Rep.* 2017;7:43953.
14. Merkel PA. Drug-induced vasculitis. *Rheum Dis Clin North Am.* 2001;27(4):849-862.
15. Carlson JA, Ng BT, Chen KR. Cutaneous vasculitis update: diagnostic criteria, classification, epidemiology, etiology, pathogenesis, evaluation and prognosis. *Am J Dermatopathol.* 2005;27(6):504-528.
16. Carlson JA. The histological assessment of cutaneous vasculitis. *Histopathology.* 2010;56(1):3-23.
17. Carlson JA, Chen KR. Cutaneous vasculitis update: small vessel neutrophilic vasculitis syndromes. *Am J Dermatopathol.* 2006;28(6):486-506.
18. WGET Research Group. Limited versus severe Wegener's granulomatosis: baseline data on patients in the Wegener's granulomatosis etanercept trial. *Arthritis Rheum.* 2003;48(8):2299-2309.
19. Guillevin L, Cohen P, Gayraud M, et al. Churg-Strauss syndrome. Clinical study and long-term follow-up of 96 patients. *Medicine (Baltimore).* 1999;78(1):26-37.
20. Guillevin L, Durand-Gasselin B, Cevallos R, et al. Microscopic polyangiitis: clinical and laboratory findings in eighty-five patients. *Arthritis Rheum.* 1999; 42(3):421-430.
21. Hoffman GS, Specks U. Antineutrophil cytoplasmic antibodies. *Arthritis Rheum.* 1998;41(9):1521-1537.
22. Merkel PA, Polisson RP, Chang Y, et al. Prevalence of antineutrophil cytoplasmic antibodies in a large inception cohort of patients with connective tissue disease. *Ann Intern Med.* 1997;126(11):866-873.
23. Savige J, Gillis D, Benson E, et al. International consensus statement on testing and reporting of Antineutrophil Cytoplasmic Antibodies (ANCA). *Am J Clin Pathol.* 1999;111(4):507-513.
24. Choi HK, Liu S, Merkel PA, et al. Diagnostic performance of antineutrophil cytoplasmic antibody tests for idiopathic vasculitides: metaanalysis with a focus on antimyeloperoxidase antibodies. *J Rheumatol.* 2001;28(7):1584-1590.
25. Voskuyl AE, Hazes JM, Zwinderman AH, et al. Diagnostic strategy for the assessment of rheumatoid vasculitis. *Ann Rheum Dis.* 2003;62(5):407-413.
26. Wooten MD, Jasin HE. Vasculitis and lymphoproliferative diseases. *Semin Arthritis Rheum.* 1996;26(2): 564-574.
27. Sene D, Ghillani-Dalbin P, Thibault V, et al. Long-term course of mixed cryoglobulinemia in patients infected with hepatitis C virus. *J Rheumatol.* 2004; 31(11):2199-2206.
28. Rieu V, Cohen P, Andre MH, et al. Characteristics and outcome of 49 patients with symptomatic cryoglobulinaemia. *Rheumatology (Oxford).* 2002;41(3):290-300.
29. Ramos-Casals M, Munoz S, Medina F, et al. Systemic autoimmune diseases in patients with hepatitis C virus infection: characterization of 1020 cases (The HISPAMEC Registry). *J Rheumatol.* 2009;36(7):1442-1448.
30. Guillevin L, Lhote F, Gayraud M, et al. Prognostic factors in polyarteritis nodosa and Churg-Strauss syndrome. A prospective study in 342 patients. *Medicine (Baltimore).* 1996;75(1):17-28.
31. Mahr A, Batteux F, Tubiana S, et al. Brief report: prevalence of antineutrophil cytoplasmic antibodies in infective endocarditis. *Arthritis Rheumatol.* 2014;66(6):1672-1677.
32. Trimarchi M, Gregorini G, Facchetti F, et al. Cocaine-induced midline destructive lesions: clinical, radiographic, histopathologic, and serologic features and their differentiation from Wegener granulomatosis. *Medicine (Baltimore).* 2001;80(6):391-404.
33. Trimarchi M, Nicolai P, Lombardi D, et al. Sinonasal osteocartilaginous necrosis in cocaine abusers: experience in 25 patients. *Am J Rhinol.* 2003;17(1):33-43.
34. Pearson T, Bremmer M, Cohen J, et al. Vasculopathy related to cocaine adulterated with levamisole: a review of the literature. *Dermatol Online J.* 2012;18(7):1.
35. Kissin EY, Merkel PA. Diagnostic imaging in Takayasu arteritis. *Curr Opin Rheumatol.* 2004;16(1):31-37.
36. Bakthavachalam S, Driver MS, Cox C, et al. Hearing loss in Wegener's granulomatosis. *Otol Neurotol.* 2004;25(5):833-837.
37. Villiger PM, Guillevin L. Microscopic polyangiitis: clinical presentation. *Autoimmun Rev.* 2010;9(12):812-819.
38. Savage CO, Winearls CG, Evans DJ, et al. Microscopic polyarteritis: presentation, pathology and prognosis. *Q J Med.* 1985;56(220):467-483.
39. Niles JL, Bottinger EP, Saurina GR, et al. The syndrome of lung hemorrhage and nephritis is usually an ANCA-associated condition. *Arch Intern Med.* 1996 26;156(4):440-445.
40. Agard C, Mouthon L, Mahr A, et al. Microscopic polyangiitis and polyarteritis nodosa: how and when do they start? *Arthritis Rheum.* 2003;49(5):709-715.
41. Niiyama S, Amoh Y, Tomita M, et al. Dermatological manifestations associated with microscopic polyangiitis. *Rheumatol Int.* 2008;28(6):593-595.
42. Hoffman GS, Kerr GS, Leavitt RY, et al. Wegener granulomatosis: an analysis of 158 patients. *Ann Intern Med.* 1992;116(6):488-498.

43. Reinhold-Keller E, Beuge N, Latza U, et al. An interdisciplinary approach to the care of patients with Wegener's granulomatosis: long-term outcome in 155 patients. *Arthritis Rheum.* 2000;43(5):1021-1032.
44. Stone JH. Limited versus severe Wegener's granulomatosis: baseline data on patients in the Wegener's granulomatosis etanercept trial. *Arthritis Rheum.* 2003;48(8):2299-2309.
45. Finkielman JD, Lee AS, Hummel AM, et al. ANCA are detectable in nearly all patients with active severe Wegener's granulomatosis. *Am J Med.* 2007;120(7):643.e9-643.e14.
46. Frances C, Du LT, Piette JC, et al. Wegener's granulomatosis. Dermatological manifestations in 75 cases with clinicopathologic correlation. *Arch Dermatol.* 1994;130(7):861-867.
47. Daoud MS, Gibson LE, DeRemee RA, et al. Cutaneous Wegener's granulomatosis: clinical, histopathologic, and immunopathologic features of thirty patients. *J Am Acad Dermatol.* 1994;31(4):605-612.
48. Barksdale SK, Hallahan CW, Kerr GS, et al. Cutaneous pathology in Wegener's granulomatosis. A clinicopathologic study of 75 biopsies in 46 patients. *Am J Surg Pathol.* 1995;19(2):161-172.
49. Hu CH, O'Loughlin S, Winkelmann RK. Cutaneous manifestations of Wegener granulomatosis. *Arch Dermatol.* 1977;113(2):175-182.
50. Sable-Fourtassou R, Cohen P, Mahr A, et al. Antineutrophil cytoplasmic antibodies and the Churg-Strauss syndrome. *Ann Intern Med.* 2005;143(9):632-638.
51. Solans R, Bosch JA, Perez-Bocanegra C, et al. Churg-Strauss syndrome: outcome and long-term follow-up of 32 patients. *Rheumatology (Oxford).* 2001;40(7):763-771.
52. Lanham JG, Elkon KB, Pusey CD, et al. Systemic vasculitis with asthma and eosinophilia: a clinical approach to the Churg-Strauss syndrome. *Medicine (Baltimore).* 1984;63(2):65-81.
53. Calamia KT, Balabanova M. Vasculitis in systemic lupus erythematosis. *Clin Dermatol.* 2004;22(2):148-156.
54. Drenkard C, Villa AR, Reyes E, et al. Vasculitis in systemic lupus erythematosus. *Lupus.* 1997;6(3):235-242.
55. Ramos-Casals M, Anaya JM, Garcia-Carrasco M, et al. Cutaneous vasculitis in primary Sjogren syndrome: classification and clinical significance of 52 patients. *Medicine (Baltimore).* 2004;83(2):96-106.
56. Watts RA, Mooney J, Lane SE, et al. Rheumatoid vasculitis: becoming extinct? *Rheumatology (Oxford).* 2004;43(7):920-923.
57. Bartels C, Bell C, Rosenthal A, et al. Decline in rheumatoid vasculitis prevalence among US veterans: a retrospective cross-sectional study. *Arthritis Rheum.* 2009;60(9):2553-2557.
58. Frances C, el Rassi R, Laporte JL, et al. Dermatologic manifestations of relapsing polychondritis. A study of 200 cases at a single center. *Medicine (Baltimore).* 2001;80(3):173-179.
59. Solans-Laque R, Bosch-Gil JA, Perez-Bocanegra C, et al. Paraneoplastic vasculitis in patients with solid tumors: report of 15 cases. *J Rheumatol.* 2008; 35(2):294-304.
60. ten Holder SM, Joy MS, Falk RJ. Cutaneous and systemic manifestations of drug-induced vasculitis. *Ann Pharmacother.* 2002;36(1):130-147.
61. Choi HK, Merkel PA, Walker AM, et al. Drug-associated antineutrophil cytoplasmic antibody-positive vasculitis: prevalence among patients with high titers of antimyeloperoxidase antibodies. *Arthritis Rheum.* 2000;43(2):405-413.
62. Choi HK, Merkel PA, Niles JL. ANCA-positive vasculitis associated with allopurinol therapy. *Clin Exp Rheumatol.* 1998;16(6):743-744.
63. Adu D, Howie AJ, Scott DG, et al. Polyarteritis and the kidney. *Q J Med.* 1987;62(239):221-237.
64. Guillevin L, Mahr A, Callard P, et al. Hepatitis B virus-associated polyarteritis nodosa: clinical characteristics, outcome, and impact of treatment in 115 patients. *Medicine (Baltimore).* 2005;84(5):313-322.
65. Daoud MS, Hutton KP, Gibson LE. Cutaneous periarteritis nodosa: a clinicopathological study of 79 cases. *Br J Dermatol.* 1997;136(5):706-713.
66. Chen KR. Cutaneous polyarteritis nodosa: a clinical and histopathological study of 20 cases. *J Dermatol.* 1989;16(6):429-442.
67. Moore PM, Cupps TR. Neurological complications of vasculitis. *Ann Neurol.* 1983;14(2):155-167.
68. Calabrese LH, Duna GF, Lie JT. Vasculitis in the central nervous system. *Arthritis Rheum.* 1997;40(7): 1189-1201.
69. Tsianakas A, Ehrchen JM, Presser D, et al. Scalp necrosis in giant cell arteritis: case report and review of the relevance of this cutaneous sign of large-vessel vasculitis. *J Am Acad Dermatol.* 2009;61(4):701-706.
70. Baum EW, Sams WM Jr, Payne RR. Giant cell arteritis: a systemic disease with rare cutaneous manifestations. *J Am Acad Dermatol.* 1982;6(6):1081-1088.
71. Kerr GS, Hallahan CW, Giordano J, et al. Takayasu arteritis. *Ann Intern Med.* 1994;120(11):919-929.
72. Vanoli M, Daina E, Salvarani C, et al. Takayasu's arteritis: A study of 104 Italian patients. *Arthritis Rheum.* 2005;53(1):100-107.
73. Jain S, Kumari S, Ganguly NK, et al. Current status of Takayasu arteritis in India. *Int J Cardiol.* 1996;54(suppl):S111-S116.
74. Ishikawa K, Maetani S. Long-term outcome for 120 Japanese patients with Takayasu's disease. Clinical and statistical analyses of related prognostic factors. *Circulation.* 1994;90(4):1855-1860.
75. Lupi-Herrera E, Sanchez-Torres G, Marcushamer J, et al. Takayasu's arteritis. Clinical study of 107 cases. *Am Heart J.* 1977;93(1):94-103.
76. Maksimowicz-McKinnon K, Clark TM, Hoffman GS. Limitations of therapy and a guarded prognosis in an American cohort of Takayasu arteritis patients. *Arthritis Rheum.* 2007;56(3):1000-1009.
77. Ujiie H, Sawamura D, Yokota K, et al. Pyoderma gangrenosum associated with Takayasu's arteritis. *Clin Exp Dermatol.* 2004;29(4):357-359.
78. Perniciaro CV, Winkelmann RK, Hunder GG. Cutaneous manifestations of Takayasu's arteritis. A clinicopathologic correlation. *J Am Acad Dermatol.* 1987;17(6):998-1005.
79. Pascual-Lopez M, Hernandez-Nunez A, Argues-Montanes M, et al. Takayasu's disease with cutaneous involvement. *Dermatology.* 2004;208(1):10-15.
80. Flossman O, Berden A, de Groot K, et al. Long-term patient survival in ANCA-associated vasculitis. *Ann Rheum Dis.* 2011;70(3):488-494.
81. Westman K, Flossmann O, Gregorini G. The long-term outcomes of systemic vasculitis. *Nephrol Dial Transplant.* 2015;30(suppl 1):i60-i66.
82. Comarmond C, Pagnoux C, Khellaf M, et al. Eosinophilic granulomatosis with polyangiitis (Churg-Strauss): clinical characteristics and long-term followup

of the 383 patients enrolled in the French Vasculitis Study Group cohort. *Arthritis Rheum.* 2013;65:270-281.
83. Yates M, Watts RA, Bajema IM, et al. EULAR/ERA-EDTA recommendations for the management of ANCA-associated vasculitis. *Ann Rheum Dis.* 2016;75(9):1583-1594.
84. Mukhtyar C, Guillevin L, Cid MC, et al. EULAR recommendations for the management of large vessel vasculitis. *Ann Rheum Dis.* 2009;68(3):318-323.
85. Fauci AS, Katz P, Haynes BF, et al. Cyclophosphamide therapy of severe systemic necrotizing vasculitis. *N Engl J Med.* 1979;301(5):235-238.
86. Jayne D, Rasmussen N, Andrassy K, et al. A randomized trial of maintenance therapy for vasculitis associated with antineutrophil cytoplasmic autoantibodies. *N Engl J Med.* 2003;349(1):36-44.
87. Gayraud M, Guillevin L, Cohen P, et al. Treatment of good-prognosis polyarteritis nodosa and Churg-Strauss syndrome: comparison of steroids and oral or pulse cyclophosphamide in 25 patients. French Cooperative Study Group for Vasculitides. *Br J Rheumatol.* 1997;36(12):1290-1297.
88. De Groot K, Rasmussen N, Bacon PA, et al. Randomized trial of cyclophosphamide versus methotrexate for induction of remission in early systemic antineutrophil cytoplasmic antibody-associated vasculitis. *Arthritis Rheum.* 2005;52(8):2461-2469.
89. Sneller MC, Hoffman GS, Talar-Williams C, et al. An analysis of forty-two Wegener's granulomatosis patients treated with methotrexate and prednisone. *Arthritis Rheum.* 1995;38(5):608-613.
90. Pagnoux C, Mahr A, Hamidou MA, et al. Azathioprine or methotrexate maintenance for ANCA-associated vasculitis. *N Engl J Med.* 2008;359(26):2790-2803.
91. Hatemi G, Melikoglu M, Tunc R, et al. Apremilast for Behçet's syndrome—a phase 2, placebo-controlled study. *N Engl J Med.* 2015;372(16):1510-1518.
92. A phase 3 randomized, double-blind study to evaluate the efficacy and safety of Apremilast (CC-10004) in subjects with active Behcet's disease. ClinicalTrials.gov Identifier: NCT02307513.
93. Jones RB, Tervaert JW, Hauser T, et al. Rituximab versus cyclophosphamide in ANCA-associated renal vasculitis. *N Engl J Med.* 2010;363(3):211-220.
94. Stone JH, Merkel PA, Spiera R, et al. Rituximab versus cyclophosphamide for ANCA-associated vasculitis. *N Engl J Med.* 2010;363(3):221-232.
95. Guillevin L, Pagnoux C, Karras A, et al. Rituximab versus azathioprine for maintenance in ANCA-associated vasculitis. *N Engl J Med.* 2014;371(19):1771-1780.
96. Wechsler ME, Akuthota P, Jayne D, et al. Mepolizumab or placebo for eosinophilic granulomatosis with polyangiitis. *N Engl J Med.* 2017;376(20):1921-1932.
97. Villiger PM, Adler S, Kuchen S, et al. Tocilizumab for induction and maintenance of remission in giant cell arteritis: a phase 2, randomised, double-blind, placebo-controlled trial. *Lancet.* 2016;387(10031):1921-1927.
98. Stone JH, Tuckwell K, Dimonaco S, et al. Trial of tocilizumab in giant-cell arteritis. *N Engl J Med.* 2017;377(4):317-328.
99. Langford CA, Cuthbertson D, Ytterberg SR, et al. A randomized, double-blind trial of abatacept (CTLA-4Ig) for the treatment of giant cell arteritis. *Arthritis Rheumatol.* 2017;69(4):837-845.
100. WGET Research Group. Etanercept plus standard therapy for Wegener's granulomatosis. *N Engl J Med.* 2005;352(4):351-361.
101. Hoffman GS, Cid MC, Rendt-Zagar KE, et al. Infliximab for maintenance of glucocorticosteroid-induced remission of giant cell arteritis: a randomized trial. *Ann Intern Med.* 2007;146(9):621-630.
102. Jayne DR, Gaskin G, Rasmussen N, et al. Randomized trial of plasma exchange or high-dosage methylprednisolone as adjunctive therapy for severe renal vasculitis. *J Am Soc Nephrol.* 2007;18(7):2180-2188.

Chapter 140 :: Erythema Elevatum Diutinum

:: Theodore J. Alkousakis & Whitney A. High

AT-A-GLANCE

- Rare disorder, with around 250 case reports in literature.
- A chronic leukocytoclastic vasculitis typified by a distinctive clinical pattern of symmetric, erythematous, violaceous, or yellow–brown papules, nodules, or plaques.
- Sites of involvement often include the skin overlying the joints of the hands and fingers, or extensor surfaces like the elbows, knees, legs, and Achilles tendon. The trunk is usually spared.
- Coexisting diseases include monoclonal paraproteinemia, lymphoproliferative disorders, chronic infections, autoimmune conditions, and connective tissue disease.
- Histopathology reveals a leukocytoclastic vasculitis in early-stage disease, and mixed inflammation and fibrosis in late-stage disease.

Erythema elevatum diutinum (EED) is a rare, chronic leukocytoclastic vasculitis (LCV) that presents as largely symmetric papules and plaques, chiefly over joints and upon extensor surfaces, with a pink, erythematous, brown, violaceous, or yellow hue. Cases now recognized as EED were first reported by Hutchinson[1,2] in 1878, and Bury[3] in 1889. The current nosology, EED, was proposed by Radcliffe-Crocker and Williams in 1894,[4] with the last part of the name, *diutinum*, meaning "long-lasting."

Radcliffe-Crocker and Williams proposed a division of cases into "Bury-type" (more often seen in young women with a personal and/or family history rheumatism), and "Hutchinson-type" (more often seen in older men with gout). In 1932, so-called extracellular cholesterosis of Urbach[5] was proposed as a third form. In 1929, Weidman and Besancon classified EED as a vasculitis,[6] and this conclusion is now widely held. EED is no longer subdivided, and all forms are considered a spectrum of the disorder.

EPIDEMIOLOGY

The incidence of EED is unknown, with only about 250 cases reported in the literature.[7] A case series, culled from a tertiary care center, and spanning 60 years, contained only 13 cases.[8] EED may present at any age but is most common in the fourth through sixth decades of life. One of the original cases reported occurred in a 6-year-old.[2] Men were thought to be affected more often, but with so few cases reported, it is difficult to ascertain any definitive sexual or ethnic predilection.

CLINICAL FEATURES

EED typically first presents as edematous, erythematous to violaceous papules, nodules, and plaques, distributed relatively symmetrically upon the skin overlying the joints of the fingers, toes, and hands (Fig. 140-1), or upon the extensor surfaces, such as the elbows (Fig. 140-2), wrists, knees (Fig. 140-3), ankles, legs, and Achilles tendon. Purpura, petechiae, vegetative lesions,[9] ulcerations, and bullous appearance may occur in association with EED.[10]

Individual lesions of EED are round to oval, usually smooth and without scale (Fig. 140-4). The lesions are not fixed to the underlying structures. EED is uncommon on the face, ears, buttocks, and genitals. The torso and mucosal membranes are also typically spared. Involvement of the retroauricular area or the palmoplantar skin is uncommon.[11-13]

Lesions of EED may be asymptomatic, or the condition may be associated with pruritus, pain, burning, stinging, paresthesia, or neuropathy.[14] Systemic symptoms, such as arthralgia and fever, may be experienced with the eruption. Over time, EED can coalesce into irregular patterns. Although early lesions of EED are often soft and possibly tender, older lesions may be firm or doughy. Lesions of EED may become more firm, raised, and erythematous in the evening hours.[8,15,16]

Over time, lesions of EED can become darker brown or violaceous in color. Fibrosis may ensue. Yellow hues may be observed, with the latter resembling xanthomata. The varied appearance of chronic EED may be even more pronounced in HIV-infected persons, and the condition can resemble Kaposi sarcoma or bacillary angiomatosis.

The natural course of EED varies. Spontaneous resolution can transpire, usually after 5 to 10 years of disease activity, while in other cases, fixed lesions last decades.[17,18] The condition may wax and wane slowly, or flares or crops of disease can erupt rapidly, over weeks or months. Streptococcal infections can precipitate outbreaks. Cold weather can exacerbate symptoms or cause new lesions.

PATHOGENESIS

The pathogenesis of EED is not fully understood. A hypothesis is the formation of antigen-antibody complexes leads to deposition of immune complexes in blood vessel walls.[19] This leads to complement activation, with chemotaxis of neutrophils, the latter perhaps due to overexpression of IL-8.[20] A leukocytoclastic vasculitis ensues, and repeated episodes of this vasculitis lead to fibrosis and other sequelae of late disease.

Figure 140-1 Erythema elevatum diutinum. Nodular lesions on dorsal hand present for several years.

Evidence in support of this proposed mechanism includes (1) the inducing of lesions with injection of streptokinase, leading to streptokinase-streptodornase complexes[21]; (2) deposition of IgG, IgM, IgA, and fibrin in vascular and perivascular locations on direct immunofluorescence examination[19]; and (3) increased C1q-binding activity and enhanced IL-8 responses in the sera of affected patients.[20,22]

ASSOCIATED CONDITIONS

EED has been associated with a variety of medical conditions: infections (streptococcal, hepatitis B, syphilis, tuberculosis, HIV), monoclonal and polyclonal gammopathies, inflammatory bowel disease and celiac disease, connective tissue disease (rheumatoid arthritis, ankylosing spondylitis, lupus erythematosus, dermatomyositis, relapsing polychondritis, granulomatous polyangiitis), and lymphoproliferative and myelodysplastic conditions (myelodysplasias, lymphoma, leukemia, myeloma) (see Table 140-1). In some series, the most frequent association with EED was an

Figure 140-3 Crusted brown and violaceous papules over knee and anterior thigh.

Figure 140-2 Multiple erythematous scaly papules coalescing into plaques on extensor elbow.

Figure 140-4 Smooth, flesh-colored to slightly erythematous papules on extensor fingers over proximal interphalangeal joints.

TABLE 140-1
Entities Associated with Erythema Elevatum Diutinum

DISEASE CATEGORY	SPECIFIC CONDITIONS
Autoimmune/ Connective Tissue Disorders	Rheumatoid arthritis Ankylosing spondylitis Relapsing polychondritis Cutaneous or systemic lupus erythematosus Granulomatosis with polyangiitis Myasthenia gravis Celiac disease Dermatitis herpetiformis Sjogren syndrome Autoimmune keratolysis of the eye
Infectious diseases	Chronic bacterial infections HIV-1, HIV-2 Streptococcal infection/rheumatic fever Measles virus Human herpesvirus 6 Syphilis Tuberculosis Hepatitis B
Inflammatory disorders	Crohn disease Ulcerative colitis Mixed cryoglobulinemia Pyoderma gangrenosum
Malignancy	IgA/IgG paraproteinemia (monoclonal gammopathy/monoclonal gammopathy of undetermined significance/myeloma) Myelodysplasia Polycythemia vera Hairy-cell leukemia Chronic lymphocytic leukemia B-cell lymphoma/non-Hodgkin lymphoma Lymphadenopathy-associated virus/human T-cell lymphotrophic virus Type 3 Lung cancer Prostate cancer
Medications	Rifampin Pyrazinamide Isoniazid Streptomycin
Miscellaneous	Pulmonary infiltrates/pleural effusions Hypothyroidism Mosquito bites Insulin-dependent diabetes mellitus Hyper-IgD D syndrome Hypereosinophilic syndrome Acro-osteolysis Hemophilia Peripheral ulcerative keratitis

IgA paraproteinemia,[8] although the severity of EED did not appear dependent on total paraprotein levels.

DIAGNOSIS

The diagnosis of EED is suspected when appropriate clinical findings are present, but it is established via skin biopsy. A biopsy to establish EED should contain the full thickness of the dermis and extend into the upper subcutis. Most often, a deep punch technique is utilized.

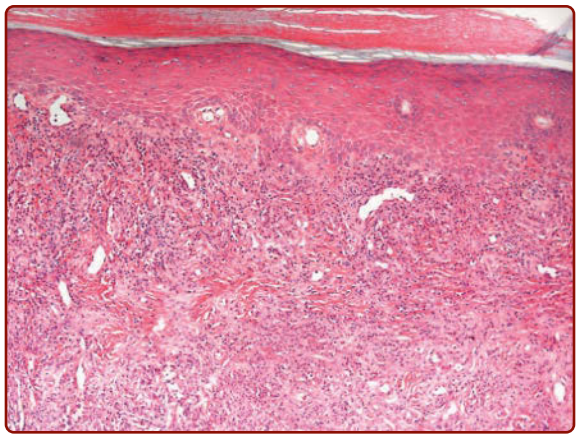

Figure 140-5 Early-stage lesion of erythema elevatum diutinum: Focal leukocytoclastic vasculitis with a fairly dense perivascular and interstitial infiltrate composed of neutrophils, lymphocytes, histiocytes, and leukocytoclastic debris. Mild capillary proliferation is also evident.

The histologic findings by light microscopy depend on the temporal course. Leukocytoclastic vasculitis is a central feature of disease process. Early EED often demonstrates neutrophilic infiltrates and neutrophilic pyknotic debris, as well as fibrin, surrounding the upper and middermal vascular plexii (Fig. 140-5). Lymphocytes, histiocytes, and even a few eosinophils, may accompany this neutrophilic infiltrate. Late EED becomes progressively more fibrotic, and perhaps even sclerotic, on occasion.[23] In some late-stage cases, it can be difficult to appreciate a vasculitis. In addition, intracellular lipid deposition and rare cholesterol clefts may be seen, especially in admixed histiocytes, may be seen in late-stage disease.[24]

Direct immunofluorescence studies of EED often reveal the non-specific deposition of IgG, IgM, IgA, C3, and fibrin in perivascular locations.[25]

There are no laboratory studies to confirm a diagnosis of EED. Because of the range of conditions associated with EED, it is common to consider the following lab tests: complete blood count, comprehensive metabolic panel, HIV screening, immunofixation electrophoresis, streptozyme test, hepatitis B and C screening, antinuclear antibody (ANA), antineutrophil cytoplasmic antibodies, antiphospholipid antibodies, and urinalysis (Table 140-2). Immunofixation electrophoresis has been advocated, over serum protein electrophoresis.[8] A chest radiograph should also be considered.

DIFFERENTIAL DIAGNOSIS

The clinical differential diagnosis of EED depends on the chronicity and symptomatology of the lesions. The main conditions to consider and their differentiating clinical and histologic features are reviewed in Table 140-3.

In the setting of HIV-positive persons, the clinical appearance EED can mimic various stages of Kaposi

TABLE 140-2
Laboratory Tests to Consider for a Patient with Erythema Elevatum Diutinum

- Complete blood count
- Comprehensive metabolic panel
- HIV screening
- Immunofixation electrophoresis
- Streptozyme test
- Hepatitis B and C panel
- Antinuclear antibodies (ANA)
- Antineutrophil cytoplasmic antibodies
- Antiphospholipid antibodies
- Urinalysis
- Chest radiograph

sarcoma (patch, plaque, or nodular disease) and bacillary angiomatosis.

Of special mention in the histologic differential diagnosis of EED is granuloma faciale (GF). GF is a rare disorder, characterized by red-brown to violaceous papules and plaques, often with a *peau d'orange* appearance. The face is the most common location for GF. Histologic similarities between GF and EED include a leukocytoclastic vasculitis with concentric perivascular fibrosis in later lesions. GF is more likely to demonstrate admixed plasma cells and eosinophils, whereas EED is more likely to demonstrate histiocytes and granulomatous areas. Indeed, some dermatopathologists have advocated for the term "localized chronic fibrosing vasculitis" to represent a late-stage common endpoint of GF and EED.[26,27]

MANAGEMENT

Treatment of early EED can facilitate a dramatic response, and continued therapy is advocated to prevent recrudescence. The goals of therapy include symptomatic relief, clearing of lesions, and appropriate management of associated conditions.

Sulfone-based therapies, including dapsone and sulfapyridine, represent first-line agents.[10,15,19,21] Rapid improvement may transpire in the first 48 hours, with complete resolution of all lesions over weeks or months. However, lesions often recur rapidly with discontinuation. Although not completely elucidated, it is thought the mechanism of action involves the inhibition of chemotaxis and function of neutrophils.

Additional anecdotal therapies, culled from case reports and with varied success and reproducibility, include niacinamide and tetracyclines,[28] colchicine,[29] addition of nonsteroidal antiinflammatory drugs (diclofenac),[30] chloroquine,[31] phenformin,[32] clofazimine,[15] and cyclophosphamide[33] as a single agent or combined with plasma exchange.[34]

TABLE 140-3
The Differential Diagnosis of Erythema Elevatum Diutinum

DISEASE STAGE	DIAGNOSIS	DIFFERENTIATING CLINICAL FEATURES	DIFFERENTIATING HISTOLOGIC FEATURES
Early	Granuloma Annulare	Expanding, annular lesions overlying joints. Disseminated GA more often associated with diabetes.	Palisaded and/or interstitial granulomatous infiltrate without vasculitis.
	Acute febrile neutrophilic dermatosis (Sweet syndrome)	Reactive condition characterized by tender, erythematous, edematous papules and plaques on the head/neck, upper trunk, and extremities.	Papillary dermal edema with sheets of neutrophils, but without a frank vasculitis.
	Rheumatoid neutrophilic dermatitis	Associated with rheumatoid arthritis. Presents with asymptomatic papules, plaques, or nodules, on the hands, forearms, neck and trunk.	Dense dermal neutrophilic infiltrate without vasculitis.
	Palisaded and granulomatous neutrophilic dermatosis	Rare. Associated with rheumatoid arthritis, connective tissue disease, and lymphoproliferative disorders. Presents as erythematous papules on the extensor surfaces of the upper extremities.	Sparse mixed perivascular infiltrate, to interstitial and/or palisaded granulomas with fibrosis, but without vasculitis.
	Neutrophilic dermatosis of the hands	A localized variant of acute febrile neutrophilic dermatosis and/or pyoderma gangrenosum. Papules, pustules, and ulcerations, typically of the dorsal hands.	Sheets of neutrophils. Although vessels may be affected, not considered a primary vasculitis.
Chronic	Dermatofibroma	Limited lesions, typically on lower extremities. Sudden eruptive dermatofibromata may be associated with lupus erythematosus.	Fibrohistiocytic cells intercalated between and among collagen bundles with overlying epidermal induction.
	Xanthoma (particularly tuberous xanthomas)	Occur on extensor surfaces and overlying tendons (like the Achilles tendon).	Foamy, lipid laden histiocytes with minimal fibrosis.
	Rheumatoid nodules	Associated with rheumatoid arthritis. Found in the deeper soft tissue over the elbow	Deeply situated palisaded granulomas with fibrinoid degeneration, but without frank vasculitis.
	Multicentric reticulohistiocytoma	Associated with destructive arthropathy and telescoping digits.	Histiocytic cells with characteristic "muddy rose" or "ground glass" cytoplasm.

Systemic corticosteroids are of variable efficacy. The addition of prednisone may be helpful in recalcitrant cases or when faced with dapsone-associated anemia.[35] However, in the setting of certain underlying associated illnesses, systemic steroids might be best avoided. Intralesional corticosteroids or high-potency topical corticosteroids can be effective in limited disease.

When EED is associated with an underlying condition or infection, appropriate management of that illness can hasten resolution. For example, in HIV-positive patients, antiretroviral therapy should be added to sulfone-based therapy. The treatment of underlying paraproteinemias also improves the symptoms of EED.[15]

Lastly, even with appropriate treatment, EED may remain nonresponsive or it may recur at various points across a lifetime. Moreover, chronic, fibrotic lesions are unlikely to respond to any therapy.[8]

REFERENCES

1. Hutchinson J. *Illustrations of Clinical Surgery.* Vol. 1. London: J and A Churchill Ltd; 1878:42.
2. Hutchinson J. On two remarkable cases of symmetrical purple congestion of the skin in patches, with induration. *Br J Dermatol.* 1888;1:10.
3. Bury JS. A case of erythema with remarkable nodular thickening and induration of the skin associated with intermittent albuminuria. *Illus Med News.* 1889;3:145.
4. Radcliffe-Crocker H, Williams C. Erythema elevatum diutinum. *Br J Dermatol.* 1894;6:1-9, 33-38.
5. Urbach E, Epstein E, Lorenz K. Extazelluläre cholesterinose. *Arch Dermat Syph (Berlin).* 1932;166:243-272.
6. Weidman FD, Besancon JH. Erythema elevatum *diutinum*. *Arch Derm Syphilol.* 1929;20:593-620.
7. Patnala GP, Sunandini AP, Yandapalli PS. Erythema elevatum diutinum in association with IgA monoclonal gammopathy: a rare case report. *Indian Dermatol Online J.* 2016;7:300-303.
8. Yiannias JA, El-Azhary RA, Gibson LE. Erythema elevatum diutinum: a clinical and histopathologic study of 13 patients. *J Am Acad Dermatol.* 1992;26:38-44.
9. Stevanovich DV. Erythema elevatum diutinum (a vegetating and ulcerative variant). *Dermatol Monatchr.* 1971;157:345-355.
10. Vollum DI. Erythema elevatum diutinum—vesicular lesions and sulphone response. *Br J Dermatol.* 1968;80:178-183.
11. Gibson LE, El-Azhary R. Erythema elevatum diutinum. *Clin Dermatol.* 2000;18:295.
12. Dowd PM, Munro DD. Erythema elevatum diutinum. *J R Soc Med.* 1983;76:310.
13. Chowdhury MM, Inaloz HS, Motley RJ, et al. Erythema elevatum diutinum and IgA paraproteinaemia: "a preclinical iceberg." *Int J Dermatol.* 2002;41:368.
14. Nguyen GH, Guo EL, Norris D. A rare case of erythema elevatum diutinum presenting as diffuse neuropathy. *JAAD Case Rep.* 2016;3(1):1-3.
15. Farella V, Lotti T, Difonzo EM, et al. Erythema elevatum diutinum. *Int J Dermatol.* 1994;33(9):638-640.
16. Katz SI, Gallin JI, Hertz KC, et al. Erythema elevatum diutinum: skin and systemic manifestations, immunologic studies, and successful treatment with dapsone. *Medicine (Baltimore).* 1977;56(5):443-455.
17. High WA, Hoang MP, Stevens K, et al. Late-stage nodular erythema elevatum diutinum. *J Am Acad Dermatol.* 2003;49:764-767.
18. Wilkinson SM, English JC, Smith NP, et al. Erythema elevatum diutinum: a clinicopathological study. *Clin Exp Dermatol.* 1992;17:87-93.
19. Gibson LE, Su WP. Cutaneous vasculitis. *Rheum Dis Clin North Am.* 1990;16(2):309-324.
20. Grabbe J, Haas N, Moller A, et al. Erythema elevatum diutinum—evidence for disease-dependent leucocyte alterations and response to dapsone. *Br J Dermatol.* 2000;143(2):415-420.
21. Wolff H, Shever R, Maciejewski W, et al. Erythema elevatum diutinum: immunoelectromicroscopical study of leukocytoclastic vasculitis within the intracutaneous test reaction induced by streptococcal antigen [in German]. *Arch Dermatol Res.* 1978;261(11):17-26.
22. Katz SI, Gallin JI, Hertz KC, et al. Erythema elevatum diutinum: skin and systemic manifestations, immunologic studies, and successful treatment with dapsone. *Medicine.* 1977;56:443-455.
23. High WA, Stewart D, Essary LR, et al. Sclerotic fibroma-like change in various neoplastic and inflammatory skin lesions: is sclerotic fibroma a distinct entity? *J Cutan Pathol.* 2004;31:373-378.
24. Kanitakis J, Cozzani E, Lyonnet S, et al. Ultrastructural study of chronic lesions of erythema elevatum diutinum: "extracellular cholesterosis" is a misnomer. *J Am Acad Dermatol.* 1993;29:363-367.
25. Shimizu S, Nakamura Y, Togawa Y, et al. Erythema elevatum diutinum with primary Sjögren syndrome associated with IgA antineutrophil cytoplasmic antibody. *Br J Dermatol.* 2008;159:733-735.
26. Carlson JA, LeBoit PE. Localized chronic fibrosing vasculitis of the skin: an inflammatory reaction that occurs in settings other than erythema elevatum diutinum and granuloma faciale. *Am J Surg Pathol.* 1997;21:698-705.
27. Navarro R, de Argila D, Fraga J, et al. Erythema elevatum diutinum or extrafacial granuloma faciale? *Actas Dermosifiliogr.* 2010;101:814-815.
28. Kohler IK, Lorincz AL. Erythema elevatum diutinum treated with niacinamide and tetracycline. *Arch Dermatol.* 1980;116(6):693-695.
29. Henriksson R, Hofer PA, Hornqvist R. Erythema elevatum diutinum—a case successfully treated with colchicine. *Clin Exp Dermatol.* 1989;14(6):451-453.
30. Yıldız F, Karakaş T. Erythema elevatum diutinum coexisting with ankylosing spondylitis. *Eur J Rheumatol.* 2015;2(2):73-75.
31. Kint A, de Cuyper C. Erythema elevatum diutinum. *Hautarzt.* 1980;31(8):447-449.
32. Schumacher H, Carroll E, Taylor F, et al. Erythema elevatum diutinum: Cutaneous vasculitis, impaired clot lysis and response to phenformin. *J Rheumatol.* 1977;4(1):103-112.
33. Krrok G, Waldenström JG. Relapsing annular erythema and myeloma successfully treated with cyclophosphamide. *Acta Med Scand.* 1978;203(4):289-292.
34. Chow RK, Benny WB. Erythema elevatum diutinum associated with IgA paraproteinemia successfully controlled with intermittent plasma exchange. *Arch Dermatol.* 1996;132(11):1360-1364.
35. Delgado J, Gómez-Cerezo J, Sigüenza M, et al. Relapsing polychondritis and erythema elevatum diutinum: an unusual association refractory to dapsone. *J Rheumatol.* 2001;28(3):634-635.

Chapter 141 :: Adamantiades–Behçet Disease

:: Christos C. Zouboulis

AT-A-GLANCE

- Rare disease with worldwide distribution but strongly varying prevalence; certain ethnic groups are mainly affected.
- A genetically determined disorder with a probable environmental triggering factor.
- Multisystem occurrence, with oral aphthous ulcers, genital ulcers, papulopustules, erythema nodosum–like lesions, uveitis, and arthropathy as the most common signs.
- Inflammatory disease representing a neutrophilic vascular reaction or vasculitis.
- Chronic, relapsing, and progressive course with a potentially poor prognosis (especially in males with systemic presenting signs; mortality, 0%-6%).

Adamantiades–Behçet disease is a multisystem inflammatory disease of unknown etiology. It is classified as a systemic vasculitis involving all types and sizes of blood vessels and characterized clinically by recurrent oral aphthous and genital ulcers, skin lesions, iridocyclitis/posterior uveitis, and arthritis. These findings are occasionally accompanied by vascular, GI, neurologic, or other manifestations.[1,2]

HISTORICAL ASPECTS

Hippocrates of Kos (460-377 BC) used the designation "στοματα αφθωδεα, ελκωδεα" (oral aphthous ulcers) in a probable first description of a patient with the disease (*Epidemion Book III*, Case 7). The disease is named after Benediktos Adamantiades, a Greek ophthalmologist and Hulûsi Behçet, a Turkish dermatologist, who, in 1931 and 1937, respectively, described patients with the characteristic clinical complex.[3] The first international multidisciplinary conference was organized by 2 dermatologists, Drs M. Monacelli and P. Nazarro, in 1964 in Rome, Italy.

EPIDEMIOLOGY

Adamantiades–Behçet disease occurs worldwide with varying prevalence, being endemic in the Eastern and Central Asian and the Eastern Mediterranean countries (along the so-called Silk Road) and rare in Northern European countries, Central and Southern Africa, the Americas, and Australia.[4] A prevalence of 80 to 420 patients per 100,000 inhabitants has been reported in Turkey,[5] 7 to 30 patients per 100,000 inhabitants in the rest of the Asian continent (Japan, 14-31:100,000; Korea, 35:100,000; Northern China, 14:100,000; Saudi Arabia, 20:100,000; Iran, 17:100,000), and 1.5 to 7.5 per 100,000 in Southern Europe.[4] In Northern Europe (0.27-1.18:100,000) and the United States (0.75:100,000), the disease is rare.[6,7] The increasing prevalence of the disease is due to its chronic nature. Its annual incidence is low; 0.75 to 1.0 new cases per 100,000 inhabitants were assessed in Japan (1990) and Germany (2005).[6] Adamantiades–Behçet disease most often affects patients in their 20s and 30s; however, early and late onsets (first year of life to 72 years) have been reported. Juvenile disease rates are 2% to 21% in different ethnic groups. Its prevalence was estimated to be 0.17:100,000 in France.[8,9] In contrast to old Japanese and Turkish reports of male predominance, the male-to-female ratio drastically decreased in the last 20 years.[10] Currently, both genders are equally affected overall; however, male predominance is still observed in Arab populations, and female predominance is evident in Korea, China, some Northern European countries, and the United States.

ETIOLOGY AND PATHOGENESIS

The etiology of the disease remains unknown, although genetic factors, infectious agents, environmental pollution, immunologic mechanisms, and endothelial and clotting factors have been implicated and studied intensively.[1,2,11] The endemic occurrence along the historical Silk Road, the major involvement of certain ethnic groups (mostly of Turkmenic and Mongol descent), and associated immunogenetic data support the hypothesis that the disease followed the migration of these old nomadic tribes.[2,11] On the other hand, the wide variation of the disease prevalence in the same ethnic group in association with different geographic areas of residence indicates an additional environmental triggering factor. Therefore, transfer of genetic material and/or of an unknown exogenous agent may have been responsible for the expansion of the disease.[2,11]

GENETICS AND IMMUNOGENETICS

There is no specific mode of Mendelian transmission in Adamantiades–Behçet disease.[2,11-15] Familial occurrence with regional differences has been reported, being more frequent in Korea (15%) than in Japan

or China (2%-3%), and in Arab countries, Israel, and Turkey (2%-18%) than in Europe (0%-5%).[4,13,14] An earlier disease onset in children compared with their parents, and a higher frequency of familial cases in juveniles than in adults, has been observed.[8,13,14]

A significant association exists between the disease and human leukocyte antigen-B_{51} (HLA-B_{51}) in Japan, the Middle East, and the Mediterranean countries; however, this relationship is not as strong in Western countries.[12,15,16] The allele also seems to be associated with a more severe prognosis and ocular involvement.[4,13,17] Its exact role in the disease mechanism is still unknown; however, it may be involved in the disease development through specific antigen presentation, molecular mimicry with microbial antigens, or participation in linkage disequilibrium with a presently unknown susceptibility gene.[14]

In an effort to explain the disease process, it has been suggested that Adamantiades–Behçet disease constitutes one of a newly termed group of diseases, the "MHC-I-opathies."[18] Recent work analyzing the peptidome of HLA-B_{51} suggests that altered peptide presentation by HLA-B_{51} is vital to the disease process. It is likely that (1) natural killer or other cell interactions, perhaps mediated by leucocyte immunoglobulin-like receptor or killer immunoglobulin-like receptor, are culpable in pathogenesis, or (2) HLA misfolding may lead directly to inflammation.

Among the 24 currently described alleles, HLA-B_{5101} and -B_{5108} have most frequently been associated with Adamantiades–Behçet disease.[19] Shared amino acid residues (defining the Bw4 epitope) are crucial for antigen binding and natural killer cell interactions,[20] and Bw_4 was also reported to contribute to the severity of the disease.[21] Genes possibly associated with the disease have been localized on chromosome 6 in the region between the *tumor necrosis factor* gene and *HLA-B* or *HLA-C* genes, including the *major histocompatibility complex class I chain A* gene (A6 allele) and genes for heat shock proteins.[14-17,19,22] In addition, a susceptibility locus mapped to 6p22-23 was detected.[19] Lately, associations on chromosomes 1p31.3 [interleukin (IL) 23R-IL12RB2] and 1q32.1 (IL10) were found by genomewide association studies.[20,23] A haplotype association of *IL-8* gene with Adamantiades–Behçet disease was also detected.[24] Polymorphisms in genes encoding for host effector molecules may contribute to the disease susceptibility and/or severity of the disease, such as in IL-23R reported in a Chinese Han population.[25] New gene associations with *ERAP-1*, *CCR1-CCR3*, *KLRC4*, and *STAT4* genes have been reported.[26]

INFECTIOUS PRECIPITANTS

Adamantiades–Behçet disease is not considered contagious as no horizontal transmission has ever been reported. However, viral and bacterial infections have been implicated in initiating immunopathologic pathways, leading to the onset of the disease.[2,11,27]

VIRAL AGENTS

Early theories of the pathogenesis of Adamantiades–Behçet disease proposed a viral or other infectious etiology.[11] Partial transcription of herpes simplex virus Type 1 (HSV-1) DNA in patients' peripheral blood lymphocytes was reported. HSV-1 DNA was detected in patients' saliva and oral and genital ulcers, and HSV-1 antibodies were found in patients' serum.

BACTERIAL AGENTS

The disease activity has been known to correlate with bacterial infection, particularly *Streptococci*.[11,27] *Streptococcus sanguinis* dominates the flora of the oral mucosa in patients with the disease and appears to be the most relevant *Streptococcus* strain as a provoking factor for initiation of the disease.[27] *Streptococcus* antigens and antistreptococcal antibodies are frequently found in the oral mucosa and serum of patients. The involvement of immunoglobulin A protease-producing *S. sanguinis* is proposed as an explanation for chronic infection leading to initiation of Adamantiades–Behçet disease. High titers of the immunogenic *S. sanguinis* antigen KTH-1 have been detected in patients. In addition, exposure of the patients to *Streptococcus* antigens may be a major provoking factor for disease activity. The lipoprotein of *Mycoplasma fermentans* MALP-404 was found in the serum of patients with Adamantiades–Behçet disease but not in healthy controls.[28] Interestingly, MALP-404 contains a peptide motif, which can be presented by HLA-B_{51}. A possible role for bacterial stimulation of monocytes via Toll-like receptor-2 producing neutrophil-stimulating proinflammatory factors in Adamantiades–Behçet disease was detected.[29]

IMMUNOLOGIC MECHANISMS

Immunologic mechanisms are considered to play a major role in the pathogenesis of Adamantiades–Behçet disease.[2,11,27] The disease has currently been classified among the autoinflammatory disorders,[30] which are caused by primary dysfunction of the innate immune system.

AUTOIMMUNE MECHANISMS

The major microscopic finding at most sites of active disease is an immune-mediated occlusive vasculitis. The pathergy reaction (see section "Clinical Findings") is induced by the rapid accumulation of neutrophils (hyperchemotaxis) and later by T lymphocytes and monocytes/macrophages at needle prick sites. The disease has been considered to be a typical Th1-mediated inflammatory disease, characterized by elevated levels of Th1 cytokines such as IFN-γ, IL-2, and TNF-α. Recently, some studies reported that

Th17-associated cytokines were increased; thus, Th17 cells and the IL17/IL23 pathway may play important roles in the pathogenesis of Adamantiades–Behçet disease.[31] T cells in the peripheral blood and in the involved tissues are increased, and a predominant T helper 1 immune response induced by IL-12 has been demonstrated.[32] Patients' lymphocytes also express CD29 molecules and bind to endothelial cells in active disease. In addition to defective T-cell immunity, B-cell activation is impaired. Circulating immune complexes, together with enhanced neutrophil migration, may be involved; diversity of T cells indicates that specific T-cell responses to several antigens may lead to the variety of symptoms.[33] Tropomyosins and the 160-kDa polypeptide kinectin have been detected as autoantigens in Adamantiades–Behçet disease.[34,35]

HEAT SHOCK PROTEINS

Increased levels of heat shock protein (HSP)–specific antibodies in serum have been found in Adamantiades–Behçet disease.[36,37] T cells respond to 60-kDa HSP, and 4 different peptide determinants within 60-kDa HSP identified by T-cell epitope mapping have been suggested to be involved in the pathogenesis of the disease.

CYTOKINE MEDIATORS

Various proinflammatory cytokines, such as IL-1, -8, -12, -17, -23, and tumor necrosis factor-α, are elevated in the sera of patients with Adamantiades–Behçet disease.[38-42] In particular, IL-8 seems to play an important role, can also be released by endothelial cells, has a potent effect on the inflammatory response, and is a sensitive marker of disease activity.[38-40] Cytokine release may be dependent on the involved organ.[38,39,41]

ENDOTHELIAL CELLS

The endothelium seems to be the primary target; however, it may just be subject to the bizarre behavior of the immune system.[43] An immunoglobulin M-type, 47-kDa cell surface HSP against endothelial α-enolase was identified in the serum of patients with Adamantiades–Behçet disease.[44] Plasma endothelin-1 concentrations were found significantly increased, perhaps indicating vasoconstriction and being the direct result of elevated synthesis by injured vascular endothelial cells. Thrombomodulin, a cell surface glycoprotein of vascular endothelium, which is also increased in the plasma of patients with active disease, potentially damages the endothelial cells.

EPIGENETICS

Epigenetic studies on Adamantiades–Behçet disease have shown the role of alterations in the methylation level of interspersed repetitive sequence elements, histone modifications such as H3K4me27 and H3K4me3, upregulation of miR-182 and miR-3591-3p as well as downregulation of miR-155, miR-638, and miR-4488 in the pathogenesis of the disease.[45]

CLINICAL FINDINGS

Adamantiades–Behçet disease is a chronic, recurrent, multisystem, and, occasionally, life-threatening disorder.[1,2,4] Recurrent oral aphthous ulcers, recurrent genital ulcers, skin manifestations, ocular lesions, and arthritis/arthropathy are the most frequent clinical manifestations.[1,6] Vascular, GI, neurologic, psychiatric, pulmonary, renal, and cardiac manifestations; epididymitis; and other findings can also occur (Fig. 141-1). The clinical picture usually develops within a few months after the presenting sign; both an acute multisystem presentation and long-term development of the disease over the years are possible. The fulfillment of the International Diagnostic Criteria[46] supports the diagnosis.

MUCOCUTANEOUS LESIONS

Recurrent oral aphthous and genital ulcers are the most frequently observed mucosal manifestations. Oral aphthous ulcers are the presenting sign in more than 80% of the cases.[1,4,6] Although recurrent aphthous stomatitis is a common disorder, only a few patients progress to Adamantiades–Behçet disease, and it is not possible to determine in whom or when the transition may occur. Typically, lesions are multiple, painful, 1 to 3 cm in diameter, and sharply margined with a fibrin-coated base and surrounding erythema (Fig. 141-2). Oral aphthous ulcers usually heal without scarring (92%). Genital ulcers may not recur as often and usually heal with a characteristic scar (64%-88%; Fig. 141-3). Spontaneous healing of aphthae occurs within 4 days to 1 month; genital ulcers may persist longer. Large oral ulcerations can also be associated with problems such as pharyngeal involvement, dysphagia, and dyspnea or fistulae involving the pharynx, larynx, trachea, or esophagus. Genital ulcers can occur on the penis, scrotum, vagina, labia, and urethra, and also in the anal, perineal, and inguinal regions.

Skin lesions that should be accepted as diagnostically relevant in Adamantiades–Behçet disease should be confined to pustular vasculitic lesions (including pathergy lesions, see Fig. 141-4A), erythema nodosum–like lesions (Fig. 141-4B), Sweet-like lesions, pyoderma gangrenosum–like lesions, and palpable purpuric lesions of necrotizing venulitis (Fig. 141-5).[47-49] All of these lesions are characterized in their early stages by a neutrophilic vascular reaction.[48] Single acneiform lesions or follicle-based pustules should not be considered relevant.[50]

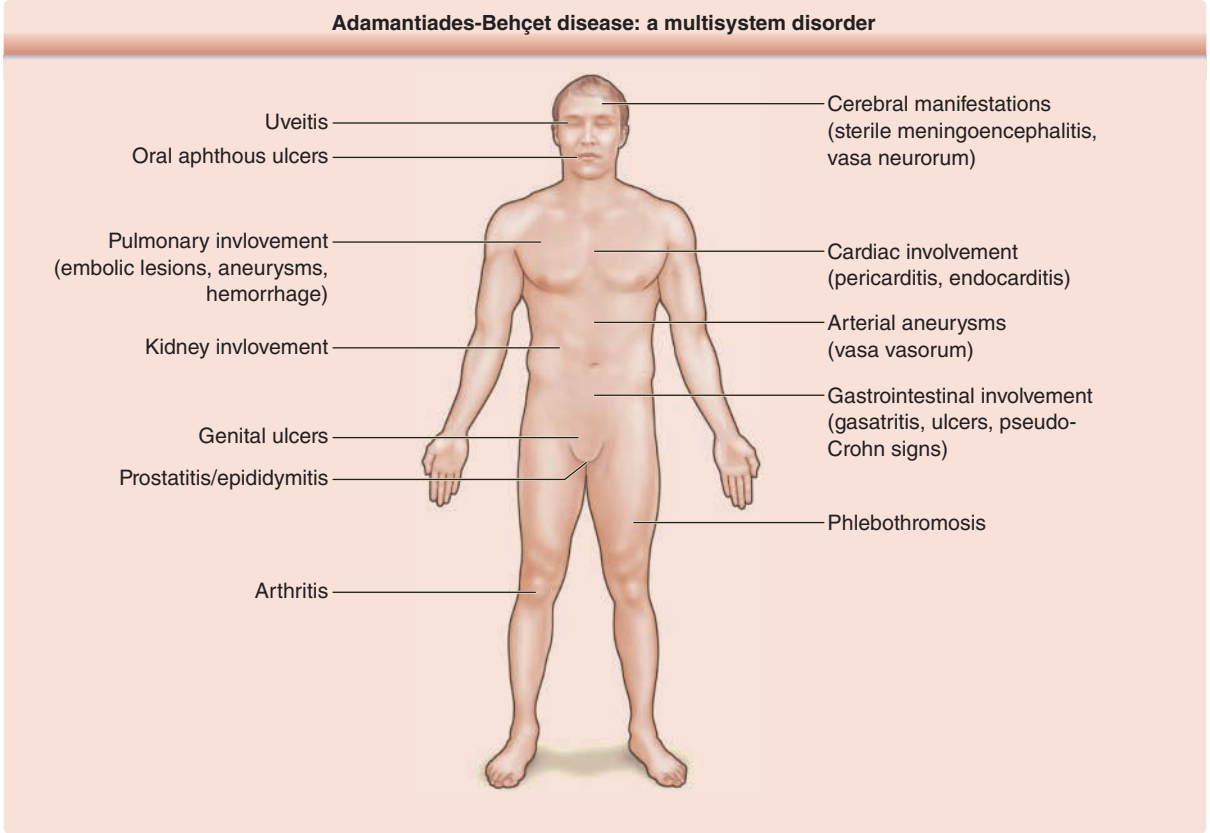

Figure 141-1 Adamantiades–Behçet disease: a multisystem disorder.

To standardize the evaluation of mucocutaneous severity, a Mucocutaneous Activity Index has currently been established.[51] This is a specific score that can help with therapeutic decisions and reduce morbidity; however, it still lacks validation.

SYSTEMIC LESIONS

Ocular involvement is the major cause of morbidity in patients with Adamantiades–Behçet disease. The most diagnostically relevant lesion is posterior uveitis (also

Figure 141-2 (**A**) Single and (**B**) multiple oral aphthous ulcers. (**A** from Altenburg A et al. Epidemiology and clinical manifestations of Adamantiades-Behçet disease in Germany—current pathogenetic concepts and therapeutic possibilities. *J Dtsch Dermatol Ges*. 2006;4:49, with permission. Copyright © 2006 John Wiley & Sons.)

Figure 141-3 (**A**) Genital ulcer healing with (**B**) a demarcated flat scar.

Figure 141-4 (**A**) Positive pathergy test and (**B**) erythema nodosum–like lesion in Adamantiades–Behçet disease.

called *retinal vasculitis*), which can lead to blindness (Fig. 141-6A). Other ocular lesions include anterior uveitis, hypopyon (pus in the anterior chamber of the eye, which is now—due to early treatment—uncommon; see Fig. 141-6B), and secondary complications such as cataract, glaucoma, and neovascular lesions.[52] Retinal inflammation can lead to vascular occlusion and, ultimately, tractional retinal detachment. Severe vitreous involvement, chronic cystoid macular edema, and possible—presumably also vasculitic—involvement of the optic nerve can result in vision loss.[53] Recurrent vasculitic changes can ultimately lead to ischemic optic nerve atrophy.

The characteristic arthritis is a nonerosive, asymmetric, sterile, seronegative oligoarthritis; however, symmetric polyarticular involvement is common. Joint manifestations frequently occur first in one knee or ankle and then the other as migratory monoarthritis, then in both joints simultaneously, and finally affecting nearly all joints.[1] An HLA-B27-positive, erosive sacroiliitis has to be excluded.

Systemic vascular involvement can be significant and includes venous occlusions and varices, arterial occlusions, and aneurysms, often being migratory. Cases of large-vein thrombosis (inferior vena cava, cranial venous sinuses) or large-artery aneurysms are potentially fatal.[1,2,4,6] Arterial involvement is rather

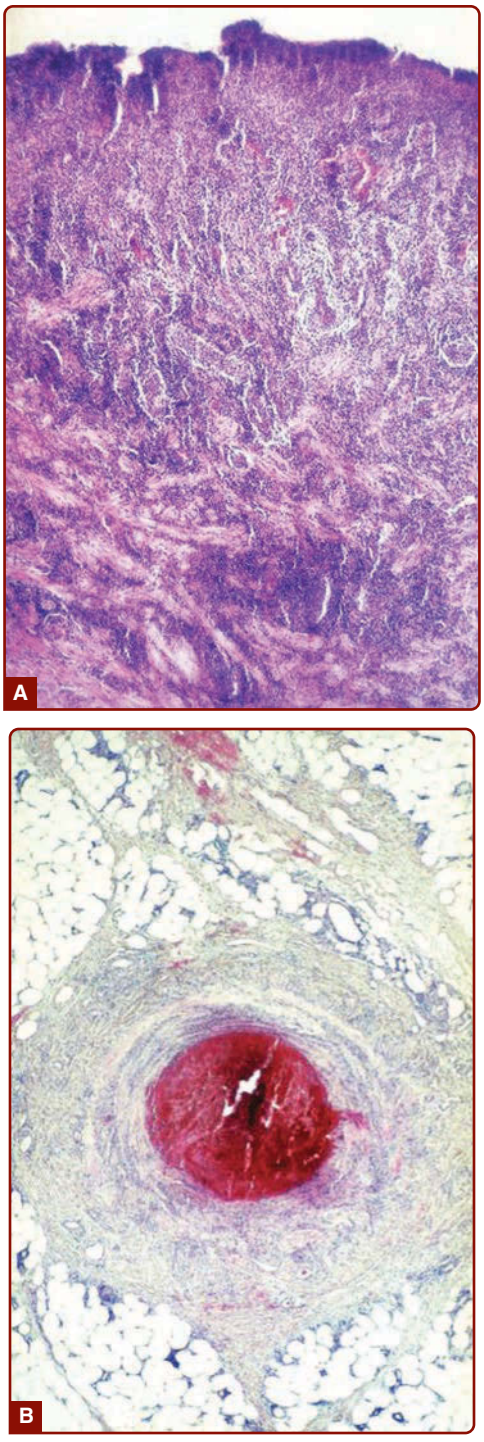

Figure 141-5 **A,** Abundant mixed inflammatory infiltrate dominated by neutrophils in an oral ulcer of Adamantiades–Behçet disease. **B,** Vessel thrombosis in an erythema nodosum–like lesion.

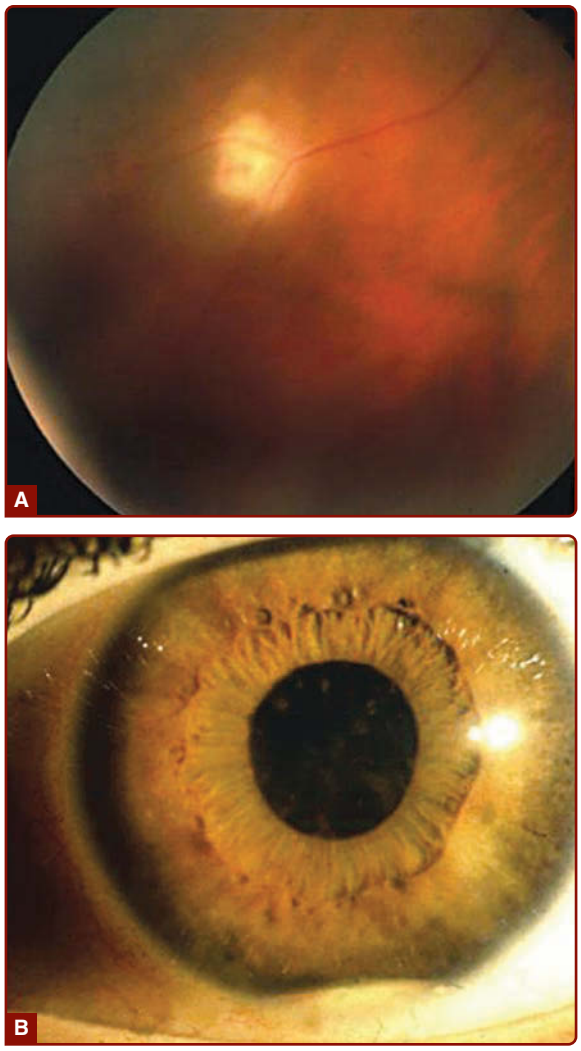

Figure 141-6 **A,** Posterior uveitis. **B,** Hypopyon iritis. (From Altenburg A et al. Epidemiology and clinical manifestations of Adamantiades-Behçet disease in Germany—current pathogenetic concepts and therapeutic possibilities. *J Dtsch Dermatol Ges*. 2006;4:49, with permission. Copyright © 2006 John Wiley & Sons.)

rare and usually presents in the form of thromboses and, less often, of aneurysms, resulting from multicentric arteritis. Aneurysms may develop in large arteries as a result of vasculitis of the vasa vasorum with penetration of the lamina elastica. Pulmonary artery aneurysms are the principal feature of pulmonary involvement in Adamantiades–Behçet disease, occasionally resulting in coughing and hemoptysis. Cardiac involvement can include myocarditis, coronary arteritis, endocarditis, and valvular disease. A wide spectrum of renal manifestations can occur, varying from minimal-change disease to proliferative glomerulonephritis and rapidly progressive crescentic glomerulonephritis. Immune complex deposition is thought to be responsible for the underlying pathogenesis of glomerulonephritis in some cases. Carotid plaques, pulse-wave velocity, and flow-mediated dilation represent clinical biomarkers of prognosis.[54]

GI complaints can be a symptom for aphthae throughout the GI tract and can rarely result in perforation and peritonitis (0.5%). On the other hand, GI involvement has an acute exacerbating course with ulcers, most commonly in the ileocolonic area.[55] These ulcers can be large and deep, causing perforation and

massive bleeding. Inflammatory bowel disease has to be excluded.

Sterile prostatitis and epididymitis can be present in male patients without genital ulcers.[56] Significant neurologic manifestations occur in approximately 10% of patients and may be delayed in onset.[2,4,6] Meningoencephalitis, cerebral venous sinus thrombosis, benign intracranial hypertension, cranial nerve palsies, brainstem lesions, and pyramidal or extrapyramidal lesions have been described. Poor prognosis is associated with a progressive course, relapses after treatment, repeated attacks, and cerebellar symptoms or parenchymal disease. Neurologic manifestations usually present with severe headache. Further symptoms include gait disturbance, dysarthria, vertigo, and diplopia as well as hyperreflexia, epileptic seizures, hemiplegia, ataxia, or a positive Babinski reflex. Psychiatric symptoms, such as depression, insomnia, or memory impairment, are also signs of neurologic involvement.

DIAGNOSIS

The diagnosis of Adamantiades–Behçet disease is based on clinical signs, as pathognomonic laboratory tests or histologic characteristics are absent. There are several sets of diagnostic criteria with the current International Criteria[46] being the most accurate among them (Table 141-1).

HISTOPATHOLOGY

Characteristic histopathologic features of Adamantiades–Behçet disease are vasculitis and thrombosis (Fig. 141-5). Biopsies from early mucocutaneous lesions show a neutrophilic vascular reaction with endothelial swelling, extravasation of erythrocytes, and leukocytoclasia or a fully developed leukocytoclastic vasculitis with fibrinoid necrosis of blood vessel walls.[1,6] Although there are reports of lesions that consist primarily of a lymphocytic perivasculitis, most of these lesions are likely older. The neutrophilic vascular reaction should be considered the predominant histopathologic finding.[7,49,57]

TABLE 141-1
International Criteria for Behçet Disease[46]

SYMPTOM	POINTS
Ocular lesions (recurrent)	2
Oral aphthosis (recurrent)	2
Genital aphthosis (recurrent)	2
Skin lesions (recurrent)	1
CNS	1
Vascular manifestations	1
Positive pathergy test[b]	1

[a]BCD scoring: score ≥4 indicates Adamantiades–Behçet disease.
[b]Though the main scoring system does not require the pathergy test, if it *is* conducted, a positive result may be included for 1 extra point.

SPECIAL TESTS

PATHERGY TEST

A positive pathergy test (hyperreactivity reaction) manifests within 48 hours as an erythematous papule (>2 mm) or pustule at the site of a skin needle prick or after intracutaneous injection of 0.1-mL isotonic saline using a 20-gauge needle without prior disinfection of the injection site (Fig. 141-4A). The skin prick is generally placed at an angle of 45°, 3 to 5 mm intracutaneously on the volar forearm. Erythema without infiltration is considered a negative finding. Provoked oral aphthae and genital ulcers after injection or injury (such as chorioretinitis in the corneal region of the eye after photocoagulation of the ocular fundus region) can also be considered as positive pathergy phenomenon. Broader pathergy phenomena also include the occurrence of aneurysms around vascular anastomoses as well as local recurrence of ulcers after resection of affected bowel segments. Although a positive pathergy reaction is a sign of Adamantiades–Behçet disease, it is not pathognomic, as it can also occur in patients with pyoderma gangrenosum, rheumatoid arthritis, Crohn disease, and genital herpes infection.

RADIOLOGIC FINDINGS

Scintigraphic evidence of arthritis is found in 50% of the patients.[6] Cranial MRI allows documentation of hypodense or atrophic changes in the brain. Electroencephalographic detection of diffuse α-waves is considered a positive finding. Vascular lesions can be detected by angiography. Because of the rarity of disease, documentation of characteristic imaging can be supportive for the diagnosis.[58]

DIFFERENTIAL DIAGNOSIS

Refer to Table 141-2.[6,59]

CLINICAL COURSE AND PROGNOSIS

The clinical course of Adamantiades–Behçet disease is variable. There can be a delay of up to several years before the diagnosis is made, and this may influence the prognosis. Mucocutaneous and joint manifestations usually occur first. Recurrent erythema nodosum and $HLAB_{51}$ positivity are risk factors for the

TABLE 141-2
Differential Diagnosis of Adamantiades–Behçet Disease[6,50]

- Oculocutaneous/mucocutaneous syndromes
  - Erythema multiforme exudativum and variants, including Stevens–Johnson syndrome
  - Vogt–Koyanagi–Harada syndrome
  - Reiter disease
  - Bullous autoimmune diseases: Pemphigus vulgaris, cicatricial mucous membrane pemphigoid, epidermolysis bullosa acquisita
  - Viral infections (herpes, coxsackie, echo)
  - Syphilis
- Articulomucocutaneous syndromes
  - Systemic lupus erythematosus
  - MAGIC syndrome (*m*outh *a*nd *g*enital ulcers with *i*nflamed cartilage)
  - Yersiniosis
  - Arthropathic psoriasis
- GI/mucocutaneous syndromes
  - Ulcerative colitis, Crohn disease
  - Tuberculosis
  - Bowel-associated dermatitis-arthritis syndrome
- Aphthae
  - Recurrent aphthous stomatitis (RAS)
  - Cyclic neutropenia
  - Herpes simplex infection
- Genital ulcers
  - Ulcus vulvae acutum (Lipschütz ulcer)
  - Herpes simplex infection
  - Sexually transmitted infections
- Uveitis
  - Other forms of uveitis
- Arthritis
  - Ankylosing spondylitis
  - Juvenile rheumatoid arthritis
- CNS manifestation
  - Multiple sclerosis
  - Neuro-Sweet disease
- Lung manifestation
  - Sarcoidosis

development of superficial thrombophlebitis and vision loss,[4,13,53] and superficial thrombophlebitis, ocular lesions, and male gender are risk factors for the development of systemic vessel involvement.[4,13,56,60] A severe course, including blindness, meningoencephalitis, hemoptysis, intestinal perforation, and severe arthritis, occurs in approximately 10% of patients. Blindness often can be prevented with early aggressive therapy of posterior uveitis. Lethal outcome has been seen in 0 to 6% of affected patients in different ethnic groups. CNS and pulmonary and large vessel involvement, as well as bowel perforation, are the major life-threatening complications; death may also result as a complication of immunosuppressive therapy. Markers of severe prognosis include HLA-B_{51} positivity, male gender, and early development of systemic signs.[4] Indeed, there is an association of male gender with ocular involvement, vascular involvement, superficial and deep venous thrombosis, cardiac involvement, folliculitis, and papulopustular lesions, whereas females present more often genital ulcers, erythema nodosum, and joint involvement.[56] Onset in childhood does not necessarily predict a poor prognosis.[8] Spontaneous remissions of certain or all manifestations of the disease have been observed. Ophthalmic and neurologic sequelae are leading causes of morbidity, followed by severe vascular and GI manifestations, and their effects on morbidity may be cumulative.

TREATMENT

The choice of treatment for patients with Adamantiades–Behçet disease depends on the site and severity of the clinical manifestations of the disease. Recurrent aphthae are most often treated with palliative agents, such as mild diet, avoidance of irritating agents, and potent topical glucocorticoids and local anesthetics[61-63]; recently, topical hyaluronic acid 0.2% gel 2 times a day over 30 days was found effective[64] (Table 141-3). For the topical treatment of genital ulcers and skin lesions, corticosteroid and antiseptic creams can be applied for up to 7 days. Painful genital ulcerations can be managed by topical anesthetics in cream. Corticosteroid injections (triamcinolone acetonide, 0.1-0.5 mL/lesion) can be helpful in recalcitrant

TABLE 141-3
Topical Treatment of Oral Aphthous Ulcers[63]

- Mild diet
- Avoidance of hard, spicy, or salty nutrients and irritating chemicals, such as toasted bread, nuts, oranges, lemons, tomatoes, spices (pepper, paprika, curry), alcohol- or CO_2-containing drinks, mouthwashes, toothpastes containing sodium lauryl sulfate[a]
- Topical treatment of the aphthous oral ulcers includes:
  - Caustic solutions (silver nitrate, 1%-2%; tinctura myrrha, 5%-10% weight/volume; H_2O_2, 0.5%; methyl violet, 0.5%) 1-2 times a day
  - Antiseptic and anti-inflammatory preparations (amlexanox, 5% in oral paste[a]; triclosan, 0.1% mouthwash solution and in toothpastes[a]; amyloglucosidase- and glucoseoxidase-containing toothpastes[a]; hexetidine, 1%, chlorhexidine, 1%-2% mouthwash solutions; benzydamine; camomile extracts); 3% diclofenac in 2.5% hyaluronic acid[a]; hyaluronic acid 0.2% gel; tetracycline mouthwash (as glycerine solution 250 mg/5 mL glycerine) 2 min 4-6 times a day[a] (caveat: pregnancy); doxycycline in isobutylcyanoacrylate[a]
  - Corticosteroids (triamcinolone mucosal ointment, dexamethasone mucosal paste, betamethasone pastilles) 4 times a day or during the night (ointment/paste) or intrafocal infiltrations with triamcinolone suspension 0.1-0.5 mL per lesion
  - Anesthetics (lidocaine, 2%-5%; mepivacaine, 1.5%; tetracaine, 0.5%-1% gels or mucosal ointments) 2-3 times a day (caveat: allergy)
  - 5-Aminosalicylic acid (5% cream) 3 times a day (reduces the duration of lesions and the pain intensity)
  - Cyclosporine A, 500 mg solution for mouthwash 3 times a day (effective as topical immunosuppressive drug)
  - Sucralfate suspension, 5 mL × 4 times a day[a] (for oral aphthous and genital ulcers)
  - A close association of smoking with a decrease of recurrences of oral aphthous ulcers has been described.

[a]Small, randomized, double-blind, placebo-controlled trial against placebo.

ulcerations. They can also be beneficial on panuveitis and cystoid macular edema as a single intravitreal injection (triamcinolone acetonide 4 mg).[65,66]

Patients with mucocutaneous lesions resistant to topical treatment, those with systemic involvement, and patients with markers of poor prognosis are candidates for systemic treatment.[61-63,67-69] Several compounds have been found effective in randomized, double-blind, placebo-controlled trials[70-90] (Table 141-4). Additional treatments have been successful in studies with a lower grade of evidence (Table 141-5).[2,16,48,71-83] Oral and intravenous prednisolone can be combined with other immunosuppressants, colchicine, dapsone, sulfasalazine, or interferon-α. A synergistic effect with cyclosporine A has been described in patients with ocular involvement. Prednisolone is one of the few medications that can be used during pregnancy. Colchicine can be combined with immunosuppressants and interferon-α. A rapid relapse often occurs after discontinuing cyclosporine A, interferon-α, dapsone, or infliximab.[73,76,78]

PREVENTION

- Patients with severe or progressive recurrent aphthous stomatitis should be followed up for years as potential candidates for Adamantiades–Behçet disease, particularly those patients with familial occurrence of the disease.
- Patients with suspected Adamantiades–Behçet disease should be referred early for specialist advice.
- Male patients with systemic involvement as a presenting sign and/or an early age of onset should be treated systemically because of the poor prognosis.

TABLE 141-4
Studied Systemic Treatments of Adamantiades–Behçet Disease[a]

DRUG	DOSE	INDICATION	REF.
Methylprednisolone	40 mg every 3 wk IM	Erythema nodosum (but not orogenital ulcers)	70
Rebamipide	300 mg/d orally (caveat: pregnancy, lactation)	Oral ulcers	71
Colchicine	1-2 mg/d orally (caveat: pregnancy, lactation—induces oligozoospermia)	Oral aphthous ulcers, genital ulcers, folliculitis, erythema nodosum	72
	1.5 mg/d	Erythema nodosum, arthritis, genital ulcers, (oral ulcers in females)	73
		Ineffective	74
Dapsone	100 mg/d orally (caveat: pregnancy, lactation—methemoglobin increase: ascorbic acid, 500 mg/d)	Oral ulcers, genital ulcers, skin lesions, pathergy test	75
Azathioprine	2.5 mg/kg/d (caveat: pregnancy, lactation, severe liver disease, bone marrow depression, severe infection, children)	Recent-onset ocular disease	76
Interferon-α 2a	6×10^6 IU 3 times a week SC (caveat: pregnancy, lactation—induces psychotic signs, psoriasis, myopathy)	Oral ulcers, genital ulcers, papulopustular lesions	77
Interferon-α	1000 and 2000 IU/d orally	Ineffective	78
Thalidomide	100 or 300 mg/d (caveat: pregnancy, lactation—induces polyneuropathy: minimized at 25 mg/d)	Oral ulcers, genital ulcers, papulopustular lesions	79
Cyclosporine A	10 mg/kg/d orally (against colchicine, 1 mg/d orally) (caveat: lactation, renal insufficiency—induces pathologic CNS findings)	Ocular manifestations, oral ulcers, skin lesions, genital ulcers	80
	5 mg/kg/d orally (against cyclophosphamide pulses)	Visual acuity	81
	5 mg/d orally (against conventional treatment)	Ocular attacks	82
Adalimumab	80 mg SC (initial dose), 40 mg SC every other week starting 1 wk after the initial dose	Intermediate uveitis, posterior uveitis and panuveitis	83,84
Daclizumab	1 mg/kg BW IV every 2 wk	Ineffective	85
Etanercept	25 mg 2 times a week orally (caveat: pregnancy, lactation)	Oral ulcers, nodular lesions, papulopustular lesions (not pathergy test)	86
Secukinumab	300 mg SC every 2 wk	Ineffective	87
Apremilast	30 mg 2 times a day orally over 12 wk	Oral ulcers	88
Aciclovir	5 × 800 mg for 1 wk + 2 × 400 mg/d for 11 wk	Ineffective	89
Azapropazone	900 mg/d over 3 wk orally	Arthritis, ineffective	90

[a]Evidence grade A—randomized, double-blind, placebo-controlled trials except otherwise mentioned.

TABLE 141-5
Other Systemic Treatments of Adamantiades-Behçet Disease[a]

DRUG	DOSE	INDICATION
Corticosteroids	5-60 mg/d prednisolone equivalent orally 100-1000 mg/d IV over 1-3 d (alone or in combination) (caveat: diabetes —induce psychosis)	Active disease Acute exacerbation (particularly uveitis, neurologic manifestations)
Indomethacin	100 mg/d PO	mucocutaneous lesions, arthritis
Pentoxifylline Oxpentifylline	300 mg × 1-3/d PO 400 mg × 3/d PO	oral ulcers (particularly in children)
Irsoglandine	2-4 mg/d PO	Recurrent oral ulcers
Cyclosporin A	3-6 mg/kg/d PO (serum levels: 100-150 ng/mL) (caveat: lactation, renal insufficiency—induces pathologic CNS findings)	Uveitis, mucocutaneous signs, thrombophlebitis, acute hearing loss
Tacrolimus	0.05-0.2 mg/kg/d PO (serum levels: 15-25 ng/mL)	Refractory uveitis
Interferon-α	9×10^6 IU 3 times a week / 3-9 × 10^6 IU 5 times a week SC (3×10^6 IU 3 times a week maintenance dose) (caveat: pregnancy, lactation—induces psychotic signs, psoriasis, myopathy) 1.5-3 × 10^6 IU 3 times a week according to body weight	Ocular lesions, long-term visual prognosis, arthritis, vascular lesions Corticodependent uveitis in children
Cyclophosphamide	1 g/mo IV bolus (caveat: hemorrhagic cystitis: mesna 200 mg)	Uveitis, neurologic manifestations
Chlorambucil	0.1 mg/d orally (2 mg/d maintenance dose) (caveat: cumulative toxicity)	Neurologic manifestations, uveitis, thrombosis, mucocutaneous lesions
Methotrexate	7.5-20 mg once a week orally (caveat: pregnancy, lactation, severe bone marrow depression, liver dysfunction, acute infections, GI ulcers, kidney insufficiency)	Severe mucocutaneous lesions, arthritis, progressive psychosis or dementia
Infliximab	5 mg/kg IV days 1, 7, 14, 28 or days 1, 14 / 1, 30 / 1, 45 (caveat: pregnancy, lactation)	Acute uveitis, refractory posterior uveitis, neurologic manifestations, intestinal involvement, vascular involvement
Adalimumab		Refractory ocular lesions, GI lesions
Anakinra	100 mg/d SC; escalation to 200 mg/d after 1 mo and 300 mg/d after 6 mo in partial responders (caveat: mild infections)	Oral ulcers, ocular lesions
Canakinumab		Ocular lesions
Gevokizumab	30 or 60 mg once in 4 wk IV or SC (on top of a stable immunosuppressive regimen).	Ocular lesions
Ustekinumab	90 mg SC at weeks 0, 4, and every 12 wk (caveat: headache)	oral ulcers
Alemtuzumab	12 mg/d IV (caveat: infusion reactions, onset of symptomatic thyroid disease)	Ocular lesions
Allicin	20 mg 3 times a day orally over 12 wk (caveat: unpleasant smell, nausea, vomiting, abdominal pain, allergic reaction)	Oral ulcers, skin lesions
Sulfasalazine	1.5-3 g/d orally	GI ulcers
Thalidomide	2 mg/kg/d orally; increased to 3 mg/kg/d if necessary or decreased to 1-0.5 mg/kg/d according to the response (caveat: neurotoxicity)	Intestinal involvement (in children)

[a]Evidence grade B—well-conducted open clinical trial.

REFERENCES

1. Davatchi F, Chams-Davatchi C, Shams H, et al. Behçet's disease: epidemiology, clinical manifestations, and diagnosis. *Expert Rev Clin Immunol.* 2017;13(1):57-65.
2. Alpsoy E. Behçet's disease: a comprehensive review with a focus on epidemiology, etiology and clinical features, and management of mucocutaneous lesions. *J Dermatol.* 2016;43(6):620-632.
3. Zouboulis CC, Keitel W. A Historical review of early descriptions of Adamantiades-Behçet's disease. *J Invest Dermatol.* 2002;119(1):201-205.
4. Zouboulis CC. Epidemiology of Adamantiades-Behçet's disease. In: Zierhut M, Ohno S, eds. *Immunology of Behçet's Disease.* Lisse, PA: Swets & Zeitlinger; 2003:1.
5. Azizlerli G, Koese AK, Sarica R, et al. Prevalence of Behçet's disease in Istanbul, Turkey. *Int J Dermatol.* 2003;42(10):803-806.
6. Altenburg A, Mahr A, Maldini C, et al. Epidemiology and clinical aspects of Adamantiades-Behçet disease in Germany [in German]. Current data. *Ophthalmologe.* 2012;109(6):531-541.
7. Wessman LL, Andersen LK, Davis MDP. Incidence of diseases primarily affecting the skin by age group:

population-based epidemiologic study in Olmsted County, Minnesota, and comparison with age-specific incidence rates worldwide [published online ahead of print January 29, 2018]. *Int J Dermatol.* doi:10.1111/ijd.13904.
8. Vaiopoulos AG, Kanakis MA, Kapsimali V, et al. Juvenile Adamantiades-Behçet disease. *Dermatology.* 2016;232(2):129-136.
9. Koné-Paut I. Behçet's disease in children, an overview. *Pediatr Rheumatol Online J.* 2016;14(1):10.
10. Kim DY, Choi MJ, Cho S, et al. Changing clinical expression of Behçet disease in Korea during three decades (1983–2012): chronological analysis of 3674 hospital-based patients. *Br J Dermatol.* 2014;170(2):458-461.
11. Zouboulis CC, May T. Pathogenesis of Adamantiades-Behçet's disease. *Adv Exp Med Biol.* 2003;528:161-171.
12. Durrani K, Papaliodis GN. The genetics of Adamantiades-Behcet's disease. *Semin Ophthalmol.* 2008;23(1):73-79.
13. Zouboulis CC, Turnbull JR, Martus P. Univariate and multivariate analyses comparing demographic, genetic, clinical, and serological risk factors for severe Adamantiades-Behçet's disease. *Adv Exp Med Biol.* 2003;528:123-126.
14. Morton LT, Situnayake D, Wallace GR. Genetics of Behçet's disease. *Curr Opin Rheumatol.* 2016;28(1):39-44.
15. Fietta P. Behçet's disease: familial clustering and immunogenetics. *Clin Exp Rheumatol.* 2005;23(suppl 38):S96.
16. de Menthon M, Lavalley MP, Maldini C, et al. HLA-B51/B5 and the risk of Behçet's disease: a systematic review and meta-analysis of case-control genetic association studies. *Arthritis Rheum.* 2009;61(10):1287-1296.
17. Horie Y, Meguro A, Ohta T, et al. HLA-B51 carriers are susceptible to ocular symptoms of Behçet disease and the association between the two becomes stronger towards the east along the Silk Road: a literature survey. *Ocul Immunol Inflamm.* 2017;25(1):37-40.
18. Giza M, Koftori D, Chen L, et al. Is Behçet's disease a "class 1-opathy"? The role of HLA-B*51 in the pathogenesis of Behçet's disease. *Clin Exp Immunol.* 2018;191(1):11-18.
19. Zierhut M, Mizuki N, Ohno S, et al. Immunology and functional genomics of Behçet's disease. *Cell Mol Life Sci.* 2003;60(9):1903-1922.
20. Remmers EF, Cosan F, Kirino Y, et al. Genome-wide association study identifies variants in the MHC class I, IL10, and IL23R-IL12RB2 regions associated with Behçet's disease. *Nat Genet.* 2010;42(8):698-702.
21. Papoutsis N, Bonitsis N, Altenburg A, et al. HLA-antigens and their importance as prognostic-marker in Adamantiades-Behçet's disease (ABD)—Is HLA-Bw4 a new prognostic marker? Abstracts of the 14th International Conference on Behçet's disease, London, UK, 2010:163.
22. Escudier M, Bagan J, Scully C. Behçet's disease (Adamantiades syndrome). *Oral Dis.* 2006;12(2):78-84.
23. Mizuki N, Meguro A, Ota M, et al. Genome-wide association studies identify IL23R-IL12RB2 and IL10 as Behçet's disease susceptibility loci. *Nat Genet.* 2010;42(8):703-706.
24. Lee EB, Kim JY, Zhao J, et al. Haplotype association of IL-8 gene with Behcet's disease. *Tissue Antigens.* 2007;69(2):128-132.
25. Jiang Z, Yang P, Hou S, et al. IL-23R gene confers susceptibility to Behcet's disease in a Chinese Han population. *Ann Rheum Dis.* 2010;69(7):1325-1328.
26. Hatemi G, Seyahi E, Fresko I, et al. Behçet's syndrome: a critical digest of the 2012–2013 literature. *Clin Exp Rheumatol.* 2013;31(3)(suppl 77):108-117.
27. Kaneko F, Tojo M, Sato M, et al. The role of infectious agents in the pathogenesis of Behçet's disease. *Adv Exp Med Biol.* 2003;528:181-183.
28. Zouboulis CC, Turnbull JR, Mühlradt PF. High seroprevalence of anti-Mycoplasma fermentans antibodies in patients with malignant aphthosis. *J Invest Dermatol.* 2003;121(1):211-212.
29. Neves FS, Carrasco S, Goldenstein-Schainberg C, et al. Neutrophil hyperchemotaxis in Behçet's disease: a possible role for monocytes orchestrating bacterial-induced innate immune responses. *Clin Rheumatol.* 2009;28(12):1403-1410.
30. Gül A. Behçet's disease as an autoinflammatory disorder. *Curr Drug Targets Inflamm Allergy.* 2005;4(1):81-83.
31. Nanke Y, Yago T, Kotake S. The role of Th17 cells in the pathogenesis of Behcet's disease. *J Clin Med.* 2017;6(7):E74.
32. Yanagihori H, Oyama N, Nakamura K, et al. Role of IL-12B promoter polymorphism in Adamantiades-Behçet's disease susceptibility: an involvement of Th1 immunoreactivity against *Streptococcus sanguinis antigen*. *J Invest Dermatol.* 2006;126(7):1534-1540.
33. Freysdottir J, Hussain L, Farmer I, et al. Diversity of γδ T cells in patients with Behçet's disease is indicative of polyclonal activation. *Oral Dis.* 2006;12(3):271-277.
34. Mahesh SP, Li Z, Buggage R, et al. Alpha tropomyosin as a self-antigen in patients with Behçet's disease. *Clin Exp Immunol.* 2005;140(2):368-375.
35. Lu Y, Ye P, Chen SL, et al. Identification of kinectin as a novel Behçet's disease autoantigen. *Arthritis Res Ther.* 2005;7(5):R1133-R1139.
36. Direskeneli H, Saruhan-Direskeneli G. The role of heat shock proteins in Behçet's disease. *Clin Exp Rheumatol.* 2003;21(4)(suppl 30):S44-S48.
37. Birtas-Atesoglu E, Inanc N, Yavuz S, et al. Serum levels of free heat shock protein 70 and anti-HSP70 are elevated in Behçet's disease. *Clin Exp Rheumatol.* 2008;26(suppl 50):S96-S98.
38. Katsantonis J, Adler Y, Orfanos CE, et al. Adamantiades-Behçet's disease: serum IL-8 is a more reliable marker for disease activity than C-reactive protein and erythrocyte sedimentation rate. *Dermatology.* 2000;201(1):37-39.
39. Durmazlar SP, Ulkar GB, Eskioglu F, et al. Significance of serum interleukin-8 levels in patients with Behcet's disease: high levels may indicate vascular involvement. *Int J Dermatol.* 2009;48(3):259-264.
40. Polat M, Vahaboglu G, Onde U, et al. Classifying patients with Behçet's disease for disease severity, using a discriminating analysis method. *Clin Exp Dermatol.* 2009;34(2):151-155.
41. Chi W, Zhu X, Yang P, et al. Upregulated IL-23 and IL-17 in Behçet patients with active uveitis. *Invest Ophthalmol Vis Sci.* 2008;49(7):3058-3064.
42. Habibagahi Z, Habibagahi M, Heidari M. Raised concentration of soluble form of vascular endothelial cadherin and IL-23 in sera of patients with Behçet's disease. *Mod Rheumatol.* 2010;20(2):154-159.
43. Kalayciyan A, Zouboulis CC. An update on Behçet's disease. *J Eur Acad Dermatol Venereol.* 2007;21(1):1-10.
44. Lee KH, Chung HS, Kim HS, et al. Human alpha-enolase from endothelial cells as a target antigen of anti-endothelial cell antibody in Behçet's disease. *Arthritis Rheum.* 2003;48(7):2025-2035.

45. Alipour S, Nouri M, Sakhinia E, et al. Epigenetic alterations in chronic disease focusing on Behçet's disease: review. *Biomed Pharmacother.* 2017;91:526-533.
46. International Team for the Revision of the International Criteria for Behçet's Disease (ITR-ICBD). The International Criteria for Behçet's Disease (ICBD): a collaborative study of 27 countries on the sensitivity and specificity of the new criteria. *J Eur Acad Dermatol Venereol.* 2014;28(3):338-347.
47. Kienbaum S, Zouboulis CC, Waibel M, et al. Papulopustular skin lesions in Adamantiades-Behçet's disease show a similar histopathological pattern as the classical mucocutaneous manifestations. In: Wechsler B, Godeau P, eds. *Behçet's disease, International Congress Series 1037.* Amsterdam: Excerpta Medica; 1993:331.
48. Oh SH, Han EC, Lee JH, et al. Comparison of the clinical features of recurrent aphthous stomatitis and Behçet's disease. *Clin Exp Dermatol.* 2009;34(6): e208-e212.
49. Jorizzo JL, Abernethy JL, White WL, et al. Mucocutaneous criteria for the diagnosis of Behçet's disease: an analysis of clinicopathologic data from multiple international centers. *J Am Acad Dermatol.* 1995;32(6):968-976.
50. Rogers RS 3rd. Pseudo-Behçet's disease. *Dermatol Clin.* 2003;21(1):49-69.
51. Scherrer MAR, Rocha VB, Garcia LC. Behçet's disease: review with emphasis on dermatological aspects. *An Bras Dermatol.* 2017;92(4):452-464.
52. Krause L, Köhler AK, Altenburg A, et al. Ocular involvement in Adamantiades-Behçet's disease in Berlin, Germany. *Graefes Arch Clin Exp Ophthalmol.* 2009;247(5):661-666.
53. Sakamoto M, Akazawa K, Nishioka Y, et al. Prognostic factors of vision in patients with Behçet disease. *Ophthalmology.* 1995;102(2):317-321.
54. Protogerou AD, Nasothimiou EG, Sfikakis PP, et al. Non-invasive vascular biomarkers in patients with Behçet's disease: review of the data and future perspectives. *Clin Exp Rheumatol.* 2017;35(suppl 108):100-107.
55. Hatemi I, Hatemi G, Çelik AF. Gastrointestinal involvement in Behçet disease. *Rheum Dis Clin North Am.* 2018;44(1):45-64.
56. Bonitsis NG, Luong Nguyen LB, LaValley MP, et al. Gender-specific differences in Adamantiades-Behçet's disease manifestations: an analysis of the German registry and meta-analysis of data from the literature. *Rheumatology (Oxford).* 2015;54(1):121-133.
57. Kienbaum S. Chemotactic neutrophilic vasculitis: a new histopathological pattern of vasculitis found in mucocutaneous lesions of patients with Adamantiades-Behçet's disease. In: Wechsler B, Godeau P, eds. *Behçet's disease, International Congress Series 1037.* Amsterdam: Excerpta Medica; 1993:337.
58. Mehdipoor G, Davatchi F, Ghoreishian H, et al. Imaging manifestations of Behcet's disease: key considerations and major features. *Eur J Radiol.* 2018;98:214-225.
59. Kaneko F, Togashi A, Nomura E, Nakamura K. Behçet's disease and diseases for its differential diagnosis in dermatology. An annual report of the Behçet's Disease Research Committee of Japan, 1999;128.
60. Coskun B, Öztürk P, Saral Y. Are erythema nodosum-like lesions and superficial thrombophlebitis prodromal in terms of visceral involvement in Behçet's disease? *Int J Clin Pract.* 2005;59(1):69-71.
61. Zouboulis CC. Adamantiades-Behçet's disease. In: Katsambas AD, Lotti TM, Dessinioti C, et al, eds. *European Handbook of Dermatological Treatments.* 3rd ed. New York: Springer; 2015:33.
62. Bonitsis NG, Altenburg A, Krause L, et al. Current concepts in the treatment of Adamantiades-Behçet's disease. *Drugs Future.* 2009;34:749.
63. Altenburg A, El-Haj N, Micheli C, et al. The treatment of chronically recurring aphthous mouth ulcers. *Dtsch Arztebl Int.* 2014;111:665-673.
64. Lee JH, Jung JY, Bang D. The efficacy of topical 0.2% hyaluronic acid gel on recurrent oral ulcers: comparison between recurrent aphthous ulcers and the oral ulcers of Behçet's disease. *J Eur Acad Dermatol Venereol.* 2008;22(5):590-595.
65. Atmaca LS, Yalçindağ FN, Ozdemir O. Intravitreal triamcinolone acetonide in the management of cystoid macular edema in Behçet's disease. *Graefes Arch Clin Exp Ophthalmol.* 2007;245(3):451-456.
66. Tuncer S, Yilmaz S, Urgancioglu M, et al. Results of intravitreal triamcinolone acetonide (IVTA) injection for the treatment of panuveitis attacks in patients with Behçet disease. *J Ocul Pharmacol Ther.* 2007;23(4):395-401.
67. Pipitone N, Olivieri I, Cantini F, et al. New approaches in the treatment of Adamantiades-Behçet's disease. *Curr Opin Rheumatol.* 2006;18(1):3-9.
68. Hatemi G, Silman A, Bang D, et al. Management of Behçet disease: a systematic literature review for the European League Against Rheumatism evidence-based recommendations for the management of Behçet disease. *Ann Rheum Dis.* 2009;68(10): 1528-1534.
69. Sota J, Rigante D, Lopalco G, et al. Biological therapies for the treatment of Behçet's disease-related uveitis beyond TNF-alpha blockade: a narrative review. *Rheumatol Int.* 2018;38(1):25-35.
70. Mat C, Yurdakul S, Uysal S, et al. A double-blind trial of depot corticosteroids in Behçet's syndrome. *Rheumatology (Oxford).* 2006;45(3):348-352.
71. Matsuda T, Ohno S, Hirohata S, et al. Efficacy of rebamipide as adjunctive therapy in the treatment of recurrent oral aphthous ulcers in patients with Behçet's disease: a randomised, double-blind, placebo-controlled study. *Drugs R D.* 2003;4(1):19-28.
72. Davatchi F, Sadeghi Abdollahi B, Tehrani Banihashemi A, et al. Colchicine versus placebo in Behçet's disease: randomized, double-blind, controlled crossover trial. *Mod Rheumatol.* 2009;19(5):542-549.
73. Yurdakul S, Mat C, Tüzün Y, et al. A double-blind trial of colchicine in Behçet's syndrome. *Arthritis Rheum.* 2001;44(11):2686-2892.
74. Aktulga E, Altaç M, Müftüoglu A, et al. A double blind study of colchicine in Behcet's disease. *Haematologica.* 1980;65(3):399-402.
75. Sharquie KE, Najim RA, Abu-Raghif AR. Dapsone in Behçet's disease: a double-blind, placebo-controlled, cross-over study. *J Dermatol.* 2002;29(5):267-279.
76. Yazici H, Pazarli H, Barnes CG, et al. A controlled trial of azathioprine in Behçet's disease. *N Engl J Med.* 1990;322(5):281-285.
77. Alpsoy E, Durusoy C, Yilmaz E, et al. Interferon alfa-2a in the treatment of Behçet's disease: a randomized placebo-controlled and double-blind study. *Arch Dermatol.* 2002;138(4):467-471.
78. Kiliç H, Zeytin HE, Korkmaz C, et al. Low-dose natural human interferon-alpha lozenges in the treatment

of Behçet's syndrome. *Rheumatology (Oxford).* 2009;48(11):1388-1391.
79. Hamuryudan V, Mat C, Saip S, et al. Thalidomide in the treatment of the mucocutaneous lesions of the Behçet syndrome. A randomized, double-blind, placebo-controlled trial. *Ann Intern Med.* 1998;128(6): 443-450.
80. Masuda K, Nakajima A, Urayama A, et al. Double-masked trial of cyclosporin versus colchicine and long-term open study of cyclosporin in Behçet's disease. *Lancet.* 1989;1(8647):1093-1096.
81. Ozyazgan Y, Yurdakul S, Yazici H, et al. Low dose cyclosporin A versus pulsed cyclophosphamide in Behcet's syndrome: a single masked trial. *Br J Ophthalmol.* 1992;76:241-243.
82. BenEzra D, Cohen E, Chajek T, et al. Evaluation of conventional therapy versus cyclosporine A in Behcet's syndrome. *Transplant Proc.* 1988;20(suppl 4):136-143.
83. Jaffe GJ, Dick AD, Brézin AP, et al. Adalimumab in patients with active noninfectious uveitis. *N Engl J Med.* 2016;375(10):932-943.
84. Nguyen QD, Merrill PT, Jaffe GJ, et al. Adalimumab for prevention of uveitic flare in patients with inactive non-infectious uveitis controlled by corticosteroids (VISUAL II): a multicentre, double-masked, randomised, placebo-controlled phase 3 trial. *Lancet.* 2016;388(10050):1183-1192.
85. Buggage RR, Levy-Clarke G, Sen HN, et al. A double-masked, randomized study to investigate the safety and efficacy of daclizumab to treat the ocular complications related to Behçet's disease. *Ocul Immunol Inflamm.* 2007;15(2):63-70.
86. Melikoglu M, Fresko I, Mat C, et al. Short-term trial of etanercept in Behçet's disease: a double blind, placebo controlled study. *J Rheumatol.* 2005; 32(1):98-105.
87. Dick AD, Tugal-Tutkun I, Foster S, et al. Secukinumab in the treatment of noninfectious uveitis: results of three randomized, controlled clinical trials. *Ophthalmology.* 2013;120(4):777-787.
88. Hatemi G, Melikoglu M, Tunc R, et al. Apremilast for Behçet's syndrome—a phase 2, placebo-controlled study. *N Engl J Med.* 2015;372(16):1510-1518.
89. Davies UM, Palmer RG, Denman AM. Treatment with acyclovir does not affect orogenital ulcers in Behcet's syndrome: a randomized double-blind trial. *Br J Rheumatol.* 1988;27(4):300-302.
90. Moral F, Hamuryudan V, Yurdakul S, Yazici H. Ineffi-cacy of azapropazone in the acute arthritis of Behcet's syndrome: a randomized, double blind, placebo controlled study. *Clin Exp Rheumatol.* 1995;13:493-495.

Chapter 142 :: Kawasaki Disease

:: Anne H. Rowley

AT-A-GLANCE

- Kawasaki disease (KD) is a multisystem inflammatory process of unknown but suspected infectious etiology.
- Highest incidence is in Asian children; 1 in 80 Japanese children develops KD by age 5 years.
- KD is the most common cause of acquired heart disease in children in developed nations.
- KD affects all blood vessels in the body, but primarily damages medium-sized muscular arteries such as the coronary arteries.
- Major symptoms are prolonged high fever, conjunctival injection, oral mucosal changes such as red lips and pharynx and strawberry tongue, redness and swelling of the hands and feet, erythematous polymorphic rash, and cervical lymphadenopathy.
- Inflammation in the coronary arteries can lead to aneurysms with subsequent myocardial infarction, aneurysm rupture, and sudden death.
- Treatment with intravenous immunoglobulin (IVIG) and aspirin, when given in the first 10 days of fever, reduces the prevalence of coronary artery abnormalities from 25% in those treated with aspirin alone, to 5% in those who receive IVIG with aspirin.
- Long-term complications are confined to the heart and vascular tree, primarily thrombosis and stenosis of the major coronary arteries with myocardial ischemia.

Kawasaki disease (KD), the leading cause of acquired heart disease in children in developed nations, is a multisystem inflammatory illness that particularly affects blood vessels, especially the coronary arteries. Approximately 25% of untreated children develop coronary artery abnormalities, including dilation and aneurysms that can lead to myocardial infarction and sudden death.[1,2] The etiology is unknown, but clinical and epidemiologic data support an infectious cause. In KD, an intense inflammatory cell response develops in a wide array of organs and tissues[3]; in medium-sized arteries such as the coronary arteries, this response can damage collagen and elastin fibers in the vessel walls and lead to loss of their normal structural integrity with resultant ballooning or aneurysm formation. Despite a limited understanding of KD pathogenesis, a very effective therapy exists in the form of intravenous immunoglobulin (IVIG) with aspirin; when given in the first 10 days of fever, this therapy reduces the prevalence of coronary artery abnormalities from 25% in untreated patients to 5% in those who receive the therapy.[4] Because the etiology is unknown, no diagnostic test exists, and the diagnosis is made clinically. Classic KD is diagnosed in a patient with prolonged fever and 4 of 5 other clinical features. However, incomplete forms of illness, in which a child manifests prolonged fever with fewer than 4 other clinical features of the illness and subsequently develops coronary artery abnormalities, are well-recognized. The existence of these incomplete forms of illness results in a major diagnostic dilemma for physicians in establishing the diagnosis accurately in children with prolonged fever of uncertain cause.

HISTORICAL PERSPECTIVE

KD is named for Dr. Tomisaku Kawasaki, a Japanese pediatrician who first recognized the clinical features of the illness. He described 50 cases of a new illness in 1967 in the Japanese-language literature that he termed *mucocutaneous lymph node syndrome*.[5] It was not until later that some of the children with this newly described illness experienced sudden death; autopsy revealed myocardial infarction from thrombosis of coronary artery aneurysms. Prior to Dr. Kawasaki's description of the clinical features, KD was recognized only by pathologists at autopsy, who called the disease *infantile periarteritis nodosa*.[6] Dr. Kawasaki described the illness in the English-language literature in 1974; this report was closely followed by a description of the same illness, observed independently in the early 1970s in Hawaii by Dr. Marian Melish and colleagues.[7,8] Since that time, it has become clear that although the attack rate of KD is highest in Asian, particularly Japanese, Korean, and Chinese children, all racial and ethnic groups around the world are affected by the illness.

EPIDEMIOLOGY

KD is predominantly an illness of young children, with 80% of cases occurring in children ages 6 months to 5 years.[9,10] However, infants younger than 6 months of age can be affected, often manifest incomplete forms of the illness, and can have particularly severe KD.[11,12] Similarly, KD can occur in older children and teenagers, in whom the diagnosis is often delayed, and who may also have more-severe KD with a higher prevalence of coronary artery abnormalities.[11-13] Therefore, the diagnosis must be considered in all pediatric age groups.

Boys are more commonly affected than girls at a ratio of 3:2. The incidence of KD is approximately 10-fold higher in Japanese than in white children.[9,10]

Approximately 1 in 80 Japanese children develop KD by the age of 5 years; the peak age of illness is 9 to 11 months of age in both Japan and the United States.[9,10] The higher attack rate in Japanese children persists in those who adopt a Western diet and lifestyle, and is likely related to a genetic predisposition to KD among Asian children.[14] The risk of KD in siblings is 10-fold higher than in the general population, and the incidence of KD in children born to parents who had KD is twice as high as in the general population.[15,16] Recurrence is rare, occurring in approximately 3% of cases in Japan.[10]

Many epidemiologic features of KD suggest an infectious agent is the cause. Among these are the well-described epidemics of illness[14,17-19] and the geographic wave-like spread of illness during an epidemic, compatible with spread of an infectious agent.[19] Cases in the United States are more common in the winter and spring.[9]

CLINICAL FEATURES

CUTANEOUS FINDINGS

A generalized exanthem is commonly observed in KD, is most pronounced on the trunk and extremities, and generally takes 1 of 3 forms: morbilliform (Fig. 142-1A), targetoid (Fig. 142-1B), or scarlatiniform (diffuse erythema, Fig. 142-1C). Bullae, vesicles, and ulcerative lesions are not observed, but a fine micropustular rash, especially on the extensor surfaces, occasionally occurs. The rash may be pruritic. In the acute febrile phase of illness, groin erythema and desquamation are commonly observed (Fig. 142-2), and can be mistaken for candidal diaper dermatitis or even a staphylococcal scalded skin syndrome. The skin changes in the groin can be seen both in children in diapers and toilet-trained children. Classic periungual desquamation of the fingers and toes does not begin until the second to third week after fever begins, and can progress to involve the entire hand and foot (Fig. 142-3); treatment should be administered well before its appearance. In the third to sixth week after illness, transverse lines across the fingernails (Beau lines) are often apparent. These grow out with the nail.

In countries where bacille Calmette-Guérin vaccine is routinely administered, such as in Japan, a common finding in children with KD is erythema and swelling at the site of bacille Calmette-Guérin vaccine administration; the mechanism is unknown but the process resolves with treatment of KD. Although KD results in a vasculitis affecting all arteries and veins in the body, blood vessels in the skin are not prominently affected, and skin biopsy is not useful for diagnosis because pathologic findings are nonspecific.

NONCUTANEOUS FINDINGS

KD should be considered in the differential diagnosis of any child with prolonged fever without other

Figure 142-1 The exanthems observed acute in Kawasaki disease. **A,** Erythematous morbilliform exanthem; **B,** targetoid or urticarial changes; **C,** diffuse erythema.

Figure 142-2 Erythematous desquamating groin rash of acute Kawasaki disease.

explanation. In KD, all clinical features may not be present simultaneously. Therefore, it is important to query parents and physicians who saw the patient during the course of a prolonged febrile illness as to the presence of the other 5 clinical features of the illness: conjunctival injection, oral mucosal changes, changes of the hands and feet, rash, and cervical adenopathy. Children with KD often have significant enough swelling and discomfort of the hands and feet that they will refuse to pick up objects or to walk (Fig. 142-4). This is not commonly observed in children with most other illnesses in the differential diagnosis of KD, and can provide an important clue to the diagnosis. Similarly, extreme irritability is common in KD, and not as common in most other illnesses in the differential diagnosis. Without specific therapy, fever in KD is daily, high spiking, intermittent, and lasts for 1 to 2 weeks. The

Figure 142-3 Desquamation of the feet in the subacute phase of Kawasaki disease; this process began periungually and progressed to involve the entire soles.

Figure 142-4 Erythema and edema of the hands in Kawasaki disease.

illness is often divided into 3 stages: the acute febrile phase, the subacute phase (that begins when fever resolves and continues until all clinical features have normalized), and the convalescent phase (that follows the subacute phase and continues until the erythrocyte sedimentation rate [ESR] normalizes, usually at 6 to 8 weeks after the onset of fever).

Conjunctival injection in KD is bilateral and nonexudative. There may be limbal sparing (Fig. 142-5). Photophobia is a common accompanying feature. Oral findings include red, swollen, dry, cracked lips that may bleed (Fig. 142-6), a "strawberry" tongue, and erythema of the mouth and throat. Oral ulcers are not a feature of KD. Palmar and plantar erythema is a common feature, and there can be an abrupt transition from marked erythema to normal skin at the wrists and ankles. The hands and feet can be edematous and painful. Cervical adenopathy is the least commonly observed clinical feature, occurring in approximately 75% of children with classic KD, but can be the most prominent feature in a subset of patients who are often treated with multiple different courses of antibiotic therapy without improvement before the correct diagnosis is made.[20] Cervical adenopathy is usually

Figure 142-5 Conjunctival injection with limbal sparing in acute Kawasaki disease.

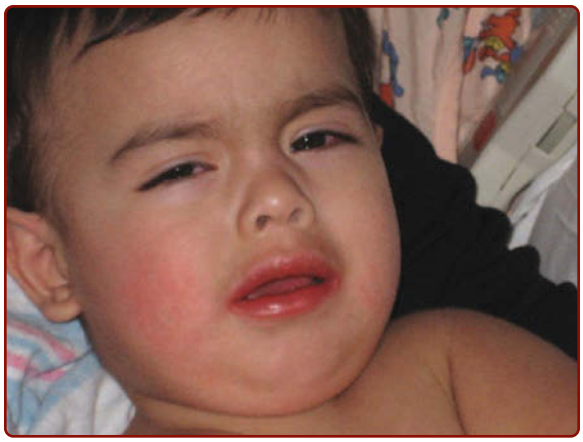

Figure 142-6 Typical facial features of acute Kawasaki disease showing conjunctival injection and red dry lips.

unilateral, may or may not be associated with superficial erythema and/or tenderness to palpation, and is nonfluctuant. Because KD is a multisystem inflammatory process, many organs and tissues are involved in the inflammatory process, leading to a variety of associated clinical features (Table 142-1). In particular, arthritis can occur during the acute febrile phase, involving the small interphalangeal joints and larger joints, or may occur during the subacute phase of illness, usually involving the larger joints such as the knees and ankles. Aseptic meningitis is a common finding in patients who undergo lumbar puncture.

TABLE 142-1
Associated Clinical Features of Kawasaki Disease

Cardiovascular
- Coronary artery aneurysms
- Myocarditis
- Pericardial effusion
- Aneurysms of other medium-sized arteries (uncommon)
- Valvular disease (rare)
- Peripheral gangrene (rare)

Respiratory
- Pneumonitis: interstitial or peribronchial infiltrates on chest X-ray, usually without respiratory distress
- Pulmonary nodules (rare)

Gastrointestinal
- Hepatitis
- Obstructive jaundice
- Gallbladder hydrops
- Diarrhea

Musculoskeletal
- Arthritis

Genitourinary
- Urethritis
- Hydrocele

Neurologic
- Marked irritability
- Aseptic meningitis
- Facial palsy (uncommon)
- Sensorineural hearing loss (uncommon)

Other
- Anterior uveitis
- Erythema and induration at the site of a bacille Calmette-Guérin (BCG) vaccine

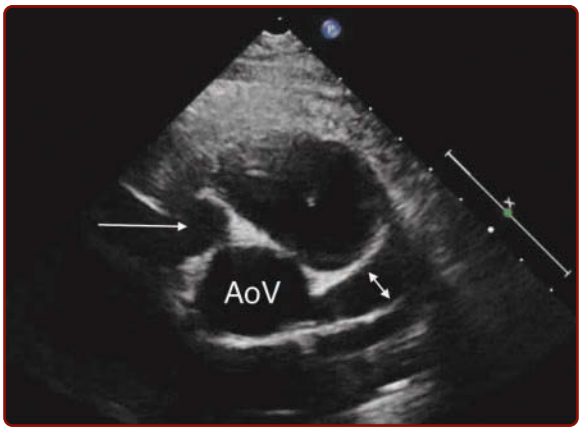

Figure 142-7 Coronary artery aneurysms in Kawasaki disease demonstrated by echocardiography. *AoV*, aortic valve; *double arrow*, aneurysm of proximal left anterior descending coronary artery; *single arrow*, large aneurysm of proximal right coronary artery.

COMPLICATIONS

As noted above, approximately 25% of untreated children develop coronary artery abnormalities, including dilation and aneurysms (Fig. 142-7), which can result in myocardial infarction, aneurysm rupture, and sudden death. Myocardial infarction can occur from thrombosis of an aneurysm, which is most common in the first few months after the onset, or from coronary artery stenosis, which occurs months to years following the illness. Aneurysm rupture is less common and usually occurs within the first month after the onset. More than 50% of KD patients have myocarditis during the acute febrile phase, manifested clinically as tachycardia disproportionate to fever, which generally improves rapidly with IVIG therapy. In the acute phase of illness, a pericardial effusion can be present; this resolves spontaneously. In patients with the most-severe coronary artery aneurysms, aneurysms of other medium-sized arteries can also be observed, most commonly in the iliac, femoral, and axillary arteries. Valvulitis significant enough to require valve replacement is rarely reported. Although KD is a systemic inflammatory disease affecting multiple organs and tissues, there are no known long-term consequences of the disease outside of the heart and blood vessels.

ETIOLOGY AND PATHOGENESIS

The etiology of KD remains unknown. The hypothesis that best fits the available clinical, immunologic, and epidemiologic data is that KD results from infection

with a ubiquitous etiologic agent that usually results in asymptomatic infection, but causes KD in a small subset of genetically predisposed individuals. Genetic predisposition is a common theme in susceptibility and host response to infectious diseases. It is likely that KD is polygenic. Intensive investigation of genetic factors influencing susceptibility to KD is ongoing by several international collaborative groups. A functional polymorphism in the *ITPKC* gene, which is a negative regulator of T-cell activation, is associated with KD susceptibility and risk of developing coronary artery abnormalities[21]; other immune genes, such as *CASP3*, *BLK*, *CD40*, *FCGR2A*, and *ORAI1*, also appear to be associated with KD susceptibility.[22-24]

Three linked pathologic processes are characteristic of KD vasculopathy, which most significantly affects the coronary arteries: neutrophilic necrotizing arteritis, which occurs in the first 2 weeks after fever onset; subacute/chronic vasculitis, which begins in the first 2 weeks but can persist for months to years and is comprised of lymphocytes (predominately CD8 T lymphocytes[25]), plasma cells (particularly immunoglobulin [Ig] A plasma cells[26,27]), eosinophils, and macrophages; and luminal myofibroblastic proliferation, which is closely associated with subacute/chronic vasculitis and can result in progressive arterial stenosis.[28] These 3 processes explain the potential adverse outcomes of KD. Necrotizing arteritis can result in necrosis and sloughing of the intima and media; in its most severe form only a thin layer of adventitia may remain, resulting in giant aneurysms that occasionally rupture, but more commonly accumulate layers of thrombi, which can become occlusive and cause myocardial infarction. Subacute/chronic arteritis is associated with luminal myofibroblastic proliferation and progressive arterial stenosis, which with or without overlying thrombi can lead to myocardial infarction.[28] Adaptive immune responses in KD have been demonstrated to be antigen-driven.[29-31] The presence of IgA plasma cells and CD8 T cells as primary components of the inflammatory infiltrate in acute KD suggests an immune response to an intracellular pathogen with a respiratory portal of entry. Synthetic versions of these oligoclonal IgA antibodies identify antigen in acute KD tissues, which appears to reside in intracytoplasmic inclusion bodies containing protein and RNA, and are highly suggestive of a viral etiology, although the specific agent has so far eluded identification, perhaps because of a lack of homology to known viral families.[32-35] The immune transcriptional profile of KD arteritis has features of an antiviral immune response, such as activated cytotoxic T-lymphocyte and Type I interferon-induced gene upregulation;[36] this information should help guide the development of new immunomodulatory therapies for KD arteritis.

RISK FACTORS

Asian children, particularly Japanese, Chinese, and Korean children, have the highest attack rates of KD.[10,14] Infants and older children have the highest prevalence of coronary artery abnormalities following KD.[11-13] Risk-scoring systems have been developed in Japan that are useful in determining those KD children who are at highest risk of developing coronary artery disease and allowing for selective intensification of primary KD therapy.[37] However, these scoring systems do not accurately predict risk of coronary artery disease in non-Japanese, multiethnic populations.[38]

DIAGNOSIS

In the absence of knowledge of the etiology of KD, a diagnostic test is not available. Laboratory findings in acute KD are nonspecific but quite characteristic. A complete blood count reveals either a normal or elevated white blood cell count with a neutrophil predominance. A low white blood cell count with lymphocyte predominance would be distinctly unusual in KD. A normochromic, normocytic anemia can be present, and resolves spontaneously with resolution of KD. The platelet count is normal in the first week of illness, although thrombocytopenia has been reported to be associated with a more severe outcome. Thrombocytosis, with platelet counts sometimes exceeding 1,000,000/mm^3, is characteristic of the subacute phase of KD, peaking in the second to third week after the onset of fever. This feature, like periungual desquamation, is not useful in making a diagnosis of KD in the first week of fever. Patients with anemia and low albumin levels may be at higher risk of developing coronary artery disease. A mild elevation of the liver transaminases is commonly observed in acute KD. Occasionally, obstructive jaundice occurs. Gallbladder hydrops, with accompanying right upper quadrant abdominal pain, resolves spontaneously and does not require surgical intervention. Sterile pyuria is also commonly observed. Acute-phase reactants such as the C-reactive protein (CRP) and the ESR are characteristically elevated in patients with acute KD, and the CRP is sometimes used to follow clinical response in patients refractory to IVIG therapy. Once IVIG is given, the ESR cannot be used to follow clinical response, because IVIG itself transiently increases the ESR. A complete blood count and CRP or ESR should be performed at baseline, and the CRP repeated at 2 to 3 weeks and 6 to 8 weeks after onset to monitor for resolution of inflammation.

PATHOLOGY

Skin and lymph node biopsies reveal nonspecific findings in KD and are not useful in establishing the diagnosis.

IMAGING

Echocardiography should be performed in all children with suspected KD, and should be performed at

diagnosis, at 2 to 3 weeks after fever onset, and at 6 to 8 weeks after fever onset.[39] The peak time to detect coronary artery dilation is 2 to 3 weeks after onset of fever, during the subacute phase of illness. Patients who do not manifest coronary artery abnormalities on any of these 3 echocardiograms may not require additional studies, although some centers perform 1 additional echocardiogram at 1 year after the onset. In patients who develop coronary artery dilation, more frequent echocardiograms will be needed during the acute phase and in followup; these should be scheduled in consultation with a pediatric cardiologist. In particular, frequent echocardiograms are advisable in the first few weeks in patients in whom coronary artery luminal diameters are continuing to expand; these patients are at particularly high risk of developing coronary artery thrombosis. Electrocardiogram in the acute febrile phase of illness most often shows a prolonged PR interval and/or nonspecific ST- and T-wave changes. CT angiography or magnetic resonance angiography can be useful in evaluating the coronary arteries of teenagers in whom adequate images of the coronary arteries may be difficult to obtain by echocardiography, and of children with particularly severe coronary artery disease.[40,41]

DIAGNOSTIC ALGORITHM

A diagnosis of classic KD is made in the presence of prolonged fever lasting 5 or more days, with 4 of the following 5 clinical features in the absence of another explanation for the illness: (a) nonpurulent bulbar conjunctival injection; (b) red, swollen, dry lips, which may crack and bleed; (c) redness and swelling of the hands and feet; (d) rash; and (e) cervical lymphadenopathy, 1.5 cm or larger in diameter (Table 142-2). Experienced physicians can make a diagnosis of KD before the fifth day of fever in children with classic features. A patient with prolonged fever and fewer than 4 of the other features of the illness can be diagnosed with KD if coronary artery abnormalities develop.

Incomplete (or atypical) KD refers to children with prolonged fever and fewer than 4 of the other features of illness who have a laboratory profile compatible with KD. Such patients should undergo echocardiography and be considered for treatment with IVIG because KD patients, particularly infants, do not always manifest classic diagnostic criteria during the acute febrile phase of illness, yet can develop coronary artery abnormalities. The American Heart Association Committee on Rheumatic Fever, Endocarditis, and Kawasaki Disease has published an algorithm to assist the clinician in diagnosing incomplete KD.[39] This algorithm emphasizes the importance of combining clinical features, laboratory findings, and echocardiographic findings in making a diagnosis (Table 142-3). In difficult cases, consultation with a KD expert should

TABLE 142-2
Diagnostic Criteria for Classic Kawasaki Disease

Fever ≥5 days,[a] high spiking and intermittent, with at least 4 of the 5 clinical features[b]:

1. Bilateral, nonexudative conjunctival injection.
2. Oral mucosal changes, including red, dry, cracked lips, pharyngeal erythema, and/or strawberry tongue.
3. Changes of the hands and feet: erythema of palms and soles and/or swelling of the hands and feet during the acute phase, and/or periungual desquamation of the fingers and toes during the subacute phase.
4. Rash: erythematous morbilliform, scarlatiniform, or targetoid.
5. Cervical lymphadenopathy ≥1.5 cm in diameter.

[a]The diagnosis can be made before the fifth day of fever by experienced physicians if the patient has the other clinical features of the illness.
[b]In the absence of another explanation for the illness.

TABLE 142-3
Criteria for Diagnosis of Incomplete Kawasaki Disease

Fever for ≥5 days with 2 or 3 compatible clinical features of KD and

- ESR ≥40 mm/h and/or CRP ≥3.0 mg/dL
  - If patient has at least 3 compatible laboratory features,[a] perform echocardiogram and begin treatment.
  - If patient has fewer than 3 compatible laboratory features,[a] but has dilated coronary arteries by echocardiogram (Z score of LAD or RCA ≥2.5), begin treatment.
  - If patient has fewer than 3 compatible laboratory features[a] and LAD and RCA Z scores <2.5, but has at least 3 supportive echocardiographic features,[a] begin treatment.
  - If patient has fewer than 3 compatible laboratory features,[a] LAD and RCA Z scores <2.5, and fewer than 3 supportive echocardiographic features,[b] then follow patient and consider other diagnoses. If fevers persist and no other diagnosis is established, consider repeating laboratory tests and echocardiogram and consider consulting a KD expert. If fever resolves, KD is unlikely.
- ESR <40 mm/h and/or CRP <3.0 mg/dL
  - Follow patient. If fever continues, reevaluate clinically and consider repeating ESR and CRP. If fever resolves but patient develops typical periungual desquamation, perform echocardiogram.

[a]Compatible laboratory features:

1. Albumin ≤3.0 g/dL
2. Anemia for age
3. Elevated alanine aminotransferase
4. Platelet count ≥450,000/mm^3 after the 7th day of illness
5. White blood cell (WBC) ≥15,000/mm^3
6. Urinalysis with ≥10 WBC/high-power field

[b]Supportive echocardiographic features:

1. Lack of tapering
2. Decreased left ventricular function
3. Mitral regurgitation
4. Pericardial effusion
5. Z scores of LAD or RCA of 2.0 to 2.5

CRP, C-reactive protein; *ESR*, erythrocyte sedimentation rate; *LAD*, left anterior descending coronary artery; *RCA*, right coronary artery.
Data from Newburger JW, Takahashi M, Gerber MA, et al. Diagnosis, treatment, and long-term management of Kawasaki disease: a statement for health professionals from the Committee on Rheumatic Fever, Endocarditis and Kawasaki Disease, Council on Cardiovascular Disease in the Young, American Heart Association. *Circulation*. 2004;110(17):2747-2771.

be considered. If the patient is not treated for KD but develops typical periungual desquamation after fever has resolved, and an alternative diagnosis that could explain this clinical finding has not been established (such as scarlet fever), an echocardiogram should be repeated. Infants 6 months of age or younger can have mild or subtle clinical findings with KD, but have a high risk of developing coronary artery abnormalities. Therefore, infants with fever for 1 week or longer without other explanation should have laboratory testing performed. If evidence of an inflammatory process is present, an echocardiogram should be ordered and KD considered, even in the absence of other clinical features of the illness.

DIFFERENTIAL DIAGNOSIS

The KD child with prolonged high fever, marked conjunctival injection, red, swollen hands and feet, erythematous rash, and red, cracked, bleeding lips who has a markedly elevated ESR and/or CRP and an elevated peripheral white blood cell count with a neutrophil predominance has a very distinctive illness and usually does not pose any difficulties in diagnosis. In other patients who have only some of the clinical features of KD, or in whom clinical findings are not as dramatic, other diagnoses must be carefully considered (Table 142-4).

In areas where measles is still prevalent, differentiating the 2 disorders can be difficult. Classically, patients with measles have rash that begins on the face behind the ears and Koplik spots in the mouth; neither of these features is observed in KD. Later in the course of measles infection, the rash becomes diffuse and Koplik spots are no longer visible. Conjunctival injection and edema of the hands and feet can be observed in both disorders. In uncomplicated measles, the peripheral white blood cell count and the ESR are generally low. The measles IgM antibody is virtually always positive by the appearance of the measles rash, and is the best single test to differentiate the two conditions.

Group A streptococcal infection should be considered in the differential diagnosis of a KD patient with a scarlatiniform rash, and can be excluded by a negative throat culture. Diagnostic uncertainty could arise in a KD patient who is a group A streptococcal carrier. Administration of antibiotic therapy followed by reevaluation in 24 to 48 hours generally clarifies the diagnosis; children with group A streptococcal pharyngitis have a rapid response to therapy, while antibiotics are ineffective in KD. Adenovirus infection can mimic KD. The presence of exudative conjunctivitis and exudative pharyngitis suggests adenovirus as the most likely diagnosis. Other viruses can occasionally cause prolonged fever, such as enterovirus; in differentiating KD patients from those with uncomplicated viral infection, laboratory tests such as the ESR, CRP, and urinalysis can be helpful, as pyuria and markedly elevated acute-phase reactants are more typical of KD.

Drug hypersensitivity reactions can mimic KD. Oral and mucosal ulcers observed in Stevens–Johnson syndrome are absent in KD. Edema of the face, particularly around the eyes, is much more suggestive of drug reaction than KD. In general, the ESR and CRP are either normal or only mildly elevated in drug hypersensitivity reactions.

Staphylococcal scalded skin syndrome is easily distinguished by the classic finding of painful skin in staphylococcal scalded skin syndrome, which is not observed in KD, and by flaccid blisters, desquamation, and a positive Nikolsky sign, which is present in staphylococcal scalded skin syndrome and absent in KD.

Although hypotension is unusual in KD, a KD shock syndrome occurs rarely,[42,43] and toxic shock syndrome is in the differential diagnosis of such patients. Renal involvement and elevated creatinine phosphokinase are more likely to be observed in toxic shock syndrome than in KD. IVIG administered for a possible diagnosis of KD may serve as adjunctive therapy for toxic shock syndrome.

Juvenile rheumatoid arthritis is a diagnosis of exclusion, and an occasional patient with this disorder might initially be diagnosed with and treated for incomplete KD. The correct diagnosis may become apparent when fever recurs following reduction of high-dose aspirin therapy, implying an original clinical response to aspirin rather than to IVIG.

TABLE 142-4
Differential Diagnosis of Kawasaki Disease

- Measles
- Adenovirus infection
- Enterovirus infection
- Scarlet fever
- Staphylococcal scalded skin syndrome
- Toxic shock syndrome
- Drug hypersensitivity reaction
- Juvenile rheumatoid arthritis

If patient has epidemiologic risk factor:

- Rocky Mountain spotted fever
- Leptospirosis

CLINICAL COURSE AND PROGNOSIS

Approximately 85% of KD children treated with IVIG and aspirin within the first 10 days of illness respond with rapid resolution of fever and other clinical signs. The vast majority of KD patients who are promptly diagnosed and treated do well, without developing cardiac complications. However, approximately 15% of KD children treated within the first 10 days of illness continue to have fever following a single infusion of IVIG with aspirin and require additional therapy; these patients have a higher risk of developing coronary

artery abnormalities.[44] A study assessing KD patients treated within the first 10 days of illness indicated that 18% had a coronary artery Z score higher than 2 at week 5 after the onset.[45] The larger the aneurysm, the less likely that the luminal diameter will return to normal over time. Very large or "giant" coronary artery aneurysms are associated with the most-severe outcomes.[46] A decrease in luminal diameter of an aneurysm can result from thrombosis or luminal myofibroblastic proliferation, which can lead to coronary artery stenosis and myocardial infarction.[28] In young infants and children, myocardial infarction usually presents as shock, emesis, and/or abdominal pain.[47] Patients with significant coronary artery disease may require catheter intervention procedures,[48] coronary artery bypass surgery,[49] or, rarely, heart transplantation.[50] Cardiovascular risk assessment should be performed at intervals dependent upon the severity of coronary artery abnormalities.[39]

MANAGEMENT

INTERVENTIONS

MEDICATIONS

A single infusion of IVIG 2 g/kg with aspirin (80-100 mg/kg/day given every 6 hours orally) should be administered to children with acute KD as soon as possible after diagnosis (Table 142-5) as demonstrated in a study by Newburger and colleagues.[51] This regimen, when administered to children with KD within the first 10 days of fever, was shown to reduce the prevalence of coronary artery abnormalities from 25% in untreated patients to 5% in those who receive the therapy. However, this study was performed prior to use of coronary artery Z scores to identify coronary artery dilation, and more recent studies suggest a higher prevalence of coronary artery dilation in KD patients overall than was previously appreciated.[45,52] Most children experience rapid resolution of fever and other clinical signs following treatment, as well as improvement in acute-phase reactants. The mechanism of action of IVIG in KD is unknown.

Aspirin is given in high doses during acute KD for antiinflammatory effect. It is generally continued at 80 to 100 mg/kg/day until the 14th illness day, or until the patient has been afebrile for at least 2 days. Aspirin is then reduced to 3 to 5 mg/kg/day given in a single daily dose, for its antithrombotic effect. Aspirin is discontinued at 6 to 8 weeks after onset if all echocardiograms have been normal and acute-phase reactants have normalized. If coronary artery abnormalities develop, low-dose aspirin is continued. Depending upon the severity of coronary artery disease, other therapies, such as clopidogrel and warfarin, may be indicated[39]; such decisions should be made in consultation with a pediatric cardiologist.

IVIG and aspirin is also given to KD patients who present after the 10th day of illness if fever and/or clinical and laboratory signs of ongoing inflammation are present, although the efficacy of the therapy in this clinical situation is uncertain. In Japan, risk-scoring systems have been developed that can predict which Japanese children are at highest risk of developing coronary artery abnormalities with good accuracy, and the "RAISE" study showed that primary therapy with IVIG and a tapering course of prednisolone over 2 to 3 weeks improved outcomes in high-risk patients.[37] Unfortunately, risk-scoring systems have thus far performed poorly in multiethnic populations such as in North America, making the selection of patients in non-Japanese populations for intensified primary therapy more problematic.[38]

Approximately 15% of acute KD patients do not respond to initial therapy; optimal therapy for these patients with "refractory" KD is unknown. Most of these patients will respond to a second 2 g/kg IVIG infusion.[44] In patients who do not respond to initial therapy and are already in a high-risk category because of the presence of coronary artery dilation, a second dose of IVIG given with prednisolone in a tapering regimen over 2 to 3 weeks should be considered.[53] Other options for IVIG nonresponders include high-dose intravenous methylprednisolone once daily for 3 days or infliximab.[54,55] More specific therapy awaits the identification of the cause of KD.

COUNSELING

Patients who do not develop coronary artery abnormalities are not known to develop any long-term sequelae. Patients who have coronary artery abnormalities with normalization of the luminal diameter over time should be followed by a pediatric cardiologist; these patients may be at risk of developing arterial stenoses in the future. Patients with significant persisting coronary artery abnormalities should be followed by a pediatric cardiologist who can make recommendations about long-term therapy and activity restrictions based upon guidelines established by the American Heart Association.[39]

TABLE 142-5
Treatment of Acute Kawasaki Disease

- Intravenous gammaglobulin (IVIG) 2 g/kg infused over 10 to 12 hours; monitor vital signs carefully during infusion, with aspirin 80 to 100 mg/kg/day divided every 6 hours orally until the 14th illness day or until patient is afebrile for at least 2 days, then reduce dose to 3 to 5 mg/kg/day as a single daily dose.
- Aspirin is discontinued if echocardiograms at 2 to 3 weeks and 6 to 8 weeks are normal and when acute-phase reactants have normalized.

TREATMENT ALGORITHM

Table 142-5 outlines the approach to treatment of KD.

REFERENCES

1. Amano S, Hazama F, Hamashima Y. Pathology of Kawasaki disease: II. Distribution and incidence of the vascular lesions. *Jpn Circ J*. 1979;43(8):741-748.
2. Amano S, Hazama F, Hamashima Y. Pathology of Kawasaki disease: I. Pathology and morphogenesis of the vascular changes. *Jpn Circ J*. 1979;43(7):633-643.
3. Amano S, Hazama F, Kubagawa H, et al. General pathology of Kawasaki disease. On the morphological alterations corresponding to the clinical manifestations. *Acta Pathol Jpn*. 1980;30(5):681-694.
4. Newburger JW, Takahashi M, Burns JC, et al. The treatment of Kawasaki syndrome with intravenous gamma globulin. *N Engl J Med*. 1986;315(6):341-347.
5. Kawasaki T. Acute febrile mucocutaneous syndrome with lymphoid involvement with specific desquamation of the fingers and toes in children [in Japanese]. *Arerugi*. 1967;16(3):178-222.
6. Landing BH, Larson EJ. Are infantile periarteritis nodosa with coronary artery involvement and fatal mucocutaneous lymph node syndrome the same? Comparison of 20 patients from North America with patients from Hawaii and Japan. *Pediatrics*. 1977;59(5):651-662.
7. Kawasaki T, Kosaki F, Okawa S, et al. A new infantile acute febrile mucocutaneous lymph node syndrome (MLNS) prevailing in Japan. *Pediatrics*. 1974;54(3): 271-276.
8. Melish ME, Hicks RM, Larson EJ. Mucocutaneous lymph node syndrome in the United States. *Am J Dis Child*. 1976;130(6):599-607.
9. Holman RC, Belay ED, Christensen KY, et al. Hospitalizations for Kawasaki syndrome among children in the United States, 1997-2007. *Pediatr Infect Dis J*. 2010;29(6):483-488.
10. Makino N, Nakamura Y, Yashiro M, et al. Descriptive epidemiology of Kawasaki disease in Japan, 2011-2012: from the results of the 22nd nationwide survey. *J Epidemiol*. 2015;25(3):239-245.
11. Burns JC, Wiggins JW Jr, Toews WH, et al. Clinical spectrum of Kawasaki disease in infants younger than 6 months of age. *J Pediatr*. 1986;109(5):759-763.
12. Momenah T, Sanatani S, Potts J, et al. Kawasaki disease in the older child. *Pediatrics*. 1998;102(1):e7.
13. Rosenfeld EA, Corydon KE, Shulman ST. Kawasaki disease in infants less than one year of age. *J Pediatr*. 1995;126(4):524-529.
14. Dean AG, Melish ME, Hicks R, et al. An epidemic of Kawasaki syndrome in Hawaii. *J Pediatr*. 1982;100(4): 552-557.
15. Fujita Y, Nakamura Y, Sakata K, et al. Kawasaki disease in families. *Pediatrics*. 1989;84(4):666-669.
16. Uehara R, Yashiro M, Nakamura Y, et al. Kawasaki disease in parents and children. *Acta Paediatr*. 2003;92(6):694-697.
17. Bell DM, Brink EW, Nitzkin JL, et al. Kawasaki syndrome: description of two outbreaks in the United States. *N Engl J Med*. 1981;304(26):1568-1575.
18. Salo E, Pelkonen P, Pettay O. Outbreak of Kawasaki syndrome in Finland. *Acta Paediatr Scand*. 1986;75(1): 75-80.
19. Yanagawa H, Nakamura Y, Kawasaki T, et al. Nationwide epidemic of Kawasaki disease in Japan during winter of 1985-86. *Lancet*. 1986;2(8516):1138-1139.
20. Stamos JK, Corydon K, Donaldson J, et al. Lymphadenitis as the dominant manifestation of Kawasaki disease. *Pediatrics*. 1994;93(3):525-528.
21. Onouchi Y, Gunji T, Burns JC, et al. ITPKC functional polymorphism associated with Kawasaki disease susceptibility and formation of coronary artery aneurysms. *Nat Genet*. 2008;40(1):35-42.
22. Onouchi Y, Ozaki K, Buns JC, et al. Common variants in CASP3 confer susceptibility to Kawasaki disease. *Hum Mol Genet*. 2010;19(14):2898-2906.
23. Onouchi Y, Ozaki K, Burns JC, et al. A genome-wide association study identifies three new risk loci for Kawasaki disease. *Nat Genet*. 2012;44(5):517-521.
24. Onouchi Y, Fukazawa R, Yamamura K, et al. Variations in ORAI1 gene associated with Kawasaki disease. *PLoS One*. 2016;11(1):e0145486.
25. Brown TJ, Crawford SE, Cornwall ML, et al. CD8 T lymphocytes and macrophages infiltrate coronary artery aneurysms in acute Kawasaki disease. *J Infect Dis*. 2001;184(7):940-943.
26. Rowley AH, Eckerley CA, Jack HM, et al. IgA plasma cells in vascular tissue of patients with Kawasaki syndrome. *J Immunol*. 1997;159(12):5946-5955.
27. Rowley AH, Shulman ST, Mask CA, et al. IgA plasma cell infiltration of proximal respiratory tract, pancreas, kidney, and coronary artery in acute Kawasaki disease. *J Infect Dis*. 2000;182(4):1183-1191.
28. Orenstein JM, Shulman ST, Fox LM, et al. Three linked vasculopathic processes characterize Kawasaki disease: a light and transmission electron microscopic study. *PLoS One*. 2012;7(6):e38998.
29. Choi IH, Chwae YJ, Shim WS, et al. Clonal expansion of CD8+ T cells in Kawasaki disease. *J Immunol*. 1997;159(1):481-486.
30. Lee HH, Shin JS, Kim DS. Immunoglobulin V(H) chain gene analysis of peripheral blood IgM-producing B cells in patients with Kawasaki disease. *Yonsei Med J*. 2009;50(4):493-504.
31. Rowley AH, Shulman ST, Spike BT, et al. Oligoclonal IgA response in the vascular wall in acute Kawasaki disease. *J Immunol*. 2001;166(2):1334-1343.
32. Rowley AH, Baker SC, Shulman ST, et al. Cytoplasmic inclusion bodies are detected by synthetic antibody in ciliated bronchial epithelium during acute Kawasaki disease. *J Infect Dis*. 2005;192(10):1757-1766.
33. Rowley AH, Baker SC, Shulman ST, et al. RNA-containing cytoplasmic inclusion bodies in ciliated bronchial epithelium months to years after acute Kawasaki disease. *PLoS One*. 2008;3(2):e1582.
34. Rowley AH, Baker SC, Shulman ST, et al. Detection of antigen in bronchial epithelium and macrophages in acute Kawasaki disease by use of synthetic antibody. *J Infect Dis*. 2004;190(4):856-865.
35. Rowley AH, Baker SC, Shulman ST, et al. Ultrastructural, immunofluorescence, and RNA evidence support the hypothesis of a "new" virus associated with Kawasaki disease. *J Infect Dis*. 2011;203(7):1021-1030.
36. Rowley AH, Wylie KM, Kim KY, et al. The transcriptional profile of coronary arteritis in Kawasaki disease. *BMC Genomics*. 2015;16(1):1076.
37. Kobayashi T, Saji T, Otani T, et al. Efficacy of immunoglobulin plus prednisolone for prevention of coronary artery abnormalities in severe Kawasaki disease (RAISE study): a randomised, open-label, blinded-endpoints trial. *Lancet*. 2012;379(9826):1613-1620.
38. Son MB, Newburger JW. Management of Kawasaki disease: corticosteroids revisited. *Lancet*. 2012;379(9826): 1571-1572.
39. McCrindle BW, Rowley AH, Newburger JW, et al. Diagnosis, Treatment, and Long-Term Management of Kawasaki Disease: A Scientific Statement for Health

Professionals From the American Heart Association. *Circulation*. 2017;135(17):e:927-e999.
40. Tacke CE, Romeih S, Kuipers IM, et al. Evaluation of cardiac function by magnetic resonance imaging during the follow-up of patients with Kawasaki disease. *Circ Cardiovasc Imaging*. 2013;6(1):67-73.
41. Kanamaru H, Sato Y, Takayama T, et al. Assessment of coronary artery abnormalities by multislice spiral computed tomography in adolescents and young adults with Kawasaki disease. *Am J Cardiol*. 2005;95(4):522-525.
42. Dominguez SR, Friedman K, Seewald R, et al. Kawasaki disease in a pediatric intensive care unit: a case-control study. *Pediatrics*. 2008;122(4):e786-e790.
43. Kanegaye JT, Wilder MS, Molkara D, et al. Recognition of a Kawasaki disease shock syndrome. *Pediatrics*. 2009;123(5):e783-e789.
44. Wallace CA, French JW, Kahn SJ, et al. Initial intravenous gammaglobulin treatment failure in Kawasaki disease. *Pediatrics*. 2000;105(6):E78.
45. Printz BF, Sleeper LA, Newburger JW, et al. Noncoronary cardiac abnormalities are associated with coronary artery dilation and with laboratory inflammatory markers in acute Kawasaki disease. *J Am Coll Cardiol*. 2011;57(1):86-92.
46. Suda K, Iemura M, Nishiono H, et al. Long-term prognosis of patients with Kawasaki disease complicated by giant coronary aneurysms: a single-institution experience. *Circulation*. 2011;123(17):1836-1842.
47. Nakano H, Saito A, Ueda K, et al. Clinical characteristics of myocardial infarction following Kawasaki disease: report of 11 cases. *J Pediatr*. 1986;108(2):198-203.
48. Ishii M, Ueno T, Akagi T, et al. Guidelines for catheter intervention in coronary artery lesion in Kawasaki disease. *Pediatr Int*. 2001;43(5):558-562.
49. Kitamura S, Tsuda E, Kobayashi J, et al. Twenty-five-year outcome of pediatric coronary artery bypass surgery for Kawasaki disease. *Circulation*. 2009;120(1):60-68.
50. Checchia PA, Pahl E, Shaddy RE, et al. Cardiac transplantation for Kawasaki disease. *Pediatrics*. 1997;100(4):695-699.
51. Newburger JW, Takahashi M, Beiser AS, et al. A single intravenous infusion of gamma globulin as compared with four infusions in the treatment of acute Kawasaki syndrome. *N Engl J Med*. 1991;324(23):1633-1639.
52. Dominguez SR, Anderson MS, El-Adawy M, et al. Preventing coronary artery abnormalities: a need for earlier diagnosis and treatment of Kawasaki disease. *Pediatr Infect Dis J*. 2012;31(12):1217-1220.
53. Kobayashi T, Morikawa A, Ikeda K, et al. Efficacy of intravenous immunoglobulin combined with prednisolone following resistance to initial intravenous immunoglobulin treatment of acute Kawasaki disease. *J Pediatr*. 2013;163(2):521-526.
54. Burns JC, Best BM, Mejias A, et al. Infliximab treatment of intravenous immunoglobulin-resistant Kawasaki disease. *J Pediatr*. 2008;153(6):833-838.
55. Wright DA, Newburger JW, Baker A, et al. Treatment of immune globulin-resistant Kawasaki disease with pulsed doses of corticosteroids. *J Pediatr*. 1996;128(1):146-149.

Chapter 143 :: Pigmented Purpuric Dermatoses

:: Alexandra Haden & David H. Peng

AT-A-GLANCE

- A group of dermatoses characterized by petechiae, pigmentation, and occasionally, telangiectasia.
- Found most commonly on the lower extremities; however, lesions may involve the upper body but rarely become generalized.
- Benign, generally asymptomatic eruptions that tend to be chronic with flares and remissions.
- Common histopathologic features include a superficial lymphocytic infiltrate, erythrocyte extravasation, and hemosiderin deposition.
- Clinical variation between eruptions led to their subclassification into eponymic groups; however, frequent overlap may make differentiation difficult.

Pigmented purpuric eruptions (also called *pigmented purpuric dermatoses* [PPDs]) are a group of dermatoses that are characterized by petechiae, pigmentation, and, occasionally, telangiectasia. They are most commonly located on the lower extremities; however, lesions may involve the trunk and upper extremities, or, rarely, become generalized. They are subdivided into clinical subcategories, which include progressive pigmentary dermatosis (Schamberg disease), purpura annularis telangiectodes (Majocchi purpura), pigmented purpuric lichenoid dermatosis of Gougerot and Blum, eczematid-like purpura of Doucas and Kapetanakis, and lichen aureus (Table 143-1). These dermatoses are benign and generally asymptomatic, but tend to run a chronic course with flares and remissions. Despite differing clinical presentations, the subtypes of PPDs share common histopathologic features, including a superficial lymphocytic infiltrate, erythrocyte extravasation and hemosiderin deposition.

EPIDEMIOLOGY

PPDs are relatively uncommon. They may present at any age, including in children, and are most common in middle age (see Table 143-1). There is no ethnic predisposition, although the granulomatous variant has been reported more commonly in patients of Asian descent.[1] In general, PPDs occur more frequently in males, except for the Majocchi subtype, which is seen more frequently in females.[2]

CLINICAL FEATURES

PROGRESSIVE PIGMENTARY DERMATOSIS (SCHAMBERG DISEASE)

Schamberg first described an eruption of irregularly shaped reddish-brown patches with "pin head sized reddish puncta, closely resembling grains of cayenne pepper" over the legs of a 15-year-old boy in 1901.[3] Schamberg disease is the most common of the PPDs to occur in children. It is, however, more common overall in adults with a peak incidence in the fifth decade.[4] The lesions are insidious in their development and are usually asymptomatic. The lower extremities are the most common site of involvement. Lesions can involve the trunk or the upper extremities (Figs. 143-1 and 143-2). Schamberg disease is chronic and persistent with flares and remissions occurring indefinitely.

PURPURA ANNULARIS TELANGIECTODES (MAJOCCHI PURPURA)

Majocchi described the first case of purpura annularis telangiectodes in 1896 in a 21-year-old male who presented with annular patches of follicular and punctate reddish-brown macules with telangiectasias and purpura on the lower extremities.[5] This subtype of PPD is characterized by its distinctive annular pattern (Fig. 143-3). Individual lesions begin as punctate telangiectatic macules that extend peripherally with central hypopigmentation or slight atrophy.[1] Lesions may be solitary or multiple in number. The lower extremities are the most common site of involvement and lesions can extend to involve the upper extremities and trunk. Majocchi purpura are generally asymptomatic and last several months with flares and remissions. As opposed to other subtypes of PPDs, Majocchi purpura presents most commonly in young adult females.[2,6]

TABLE 143-1
Subtypes of Pigmented Purpuric Dermatoses

	SCHAMBERG	MAJOCCHI	GOUGEROT AND BLUM	DOUCAS AND KAPETANAKIS	ITCHING PURPURA	LICHEN AUREUS
Average age of presentation	40s	30s	40s	40s	50s	20s-30s
Sex	M > F	F > M	M > F	M > F	M > F	M > F
Onset	Insidious	Abrupt	Insidious	Abrupt	Abrupt	Abrupt
Primary lesion	Red-brown macule with pinpoint petechiae ("cayenne pepper")	Annular plaques with border of telangiectasia and purpura	Lichenoid papule	Red-brown macule + scale	Red-brown macule	Orange-brown papule or plaque

F, female; M, male.

PIGMENTED PURPURIC LICHENOID DERMATOSIS OF GOUGEROT AND BLUM

In 1925, Gougerot and Blum reported a pigmented eruption on the lower extremity of a 41-year-old man.[7] This subtype is clinically distinguished by the presence of reddish-brown round or polygonal lichenoid papules and plaques, with a background of purpura or telangiectasias (Fig. 143-4). The term *lichenoid* describes this clinical appearance of lichenoid papules and plaques rather than the underlying histology. Its clinical appearance can be mistaken for Kaposi sarcoma. Similar to other subtypes of PPDs, pigmented purpuric lichenoid dermatosis of Gougerot and Blum is most commonly found on the lower extremities, occasionally involves the trunk and upper extremities, and runs a chronic course.

Figure 143-1 Pigmented purpuric dermatosis: Schamberg disease. Multiple, discrete, and confluent nonpalpable, nonblanching purpuric lesions of many months' duration on the legs. Acute microhemorrhages resolve with deposition of hemosiderin, creating a disfiguring dark-brown peppered stain.

ECZEMATID-LIKE PURPURA OF DOUCAS AND KAPETANAKIS

Eczematid-like purpura was first described by Doucas and Kapetanakis in 1953 in a group of patients with an asymptomatic seasonal eruption occurring in the spring and summer.[8] It is distinguished

Figure 143-2 "Cayenne pepper" appearance of Schamberg disease. (From Wolff K, Johnson R, Saavedra AP, et al. *Fitzpatrick's Color Atlas and Synopsis of Clinical Dermatology*, 8th ed. New York, NY: McGraw-Hill; 2017, with permission.)

Figure 143-3 Pigmented purpuric dermatosis: Majocchi disease. Multiple nonpalpable, nonblanching purpuric lesions arranged in annular configurations and associated with tiny telangiectasias. Note brownish discoloration of older lesions.

clinically by mild scaling overlying pinpoint erythematous macules and patches with associated pruritus. Lichenification can occur from repeated scratching. Histopathologically, spongiosis is present, in addition to the classic histopathologic features of PPD. This subtype spreads rapidly over a period of 15 to 30 days and will subsequently fade without treatment over several months to years, although recurrence is possible.

LICHEN AUREUS

In 1958, Martin first reported this subtype of PPD under the term *lichen purpuricus*, which was later named *lichen aureus* in 1960 by Calnan to emphasize its vivid yellow-orange color.[9,10] As opposed to pigmented purpuric lichenoid dermatosis of Gougerot and Blum, where lichenoid refers to the clinical morphology of the lesions, in lichen aureus, *lichen* refers to both its clinical and histopathologic features. This

Figure 143-4 Lichenoid dermatosis of Gougerot and Blum. (Used with permission from Dr. April Armstrong.)

Figure 143-5 Lichen aureus. (Used with permission from Dr. Ashley Crew.)

subtype presents with more localized and persistent lesions with circumscribed macules or papules that are a distinctive gold, rust, or orange color (Fig. 143-5). Histologically a dense, band-like lichenoid infiltrate of inflammatory cells is seen. The lesions are generally asymptomatic but at times are intensely pruritic. They are most commonly localized to one lower extremity, but other body sites can be involved, and a segmental distribution has been reported.[11,12] This disorder has a predilection for young adult males, with a peak incidence in the second and third decades. It runs a chronic course, with stable or slowly progressing lesions.

ITCHING PURPURA (DISSEMINATED PRURIGINOUS ANGIODERMATITIS)

Itching purpura, also known as disseminated pruriginous angiodermatitis, presents acutely with widely disseminated orange-brown to purpuric lesions associated with severe pruritus.[13,14] The lesions first appear on the dorsal feet or lower extremities and then spread upward, sometimes with involvement of the trunk. Purpuric lesions are more apparent along the waistline, axilla, antecubital and popliteal fossae. Although this subtype of PPD has a chronic course, spontaneous remissions are possible.

UNILATERAL LINEAR CAPILLARITIS (SEGMENTAL PIGMENTED PURPURA)

In 1990, a transient PPD in a segmental distribution on the lower trunk of a middle-aged woman was reported. Later, Riordan and colleagues reported PPDs in 4 young men with linear and pseudodermatomal patterns, which they termed *unilateral linear capillaritis*.[15] Both "segmental pigmented purpura" and "quadrantic capillaropathy" are considered subtypes of unilateral linear capillaritis.[16,17] This PPD is clinically distinguished by its linear or segmental distribution. It tends to have a favorable prognosis, with spontaneous resolution occurring more commonly than in the other subtypes of PPDs.

GRANULOMATOUS PIGMENTED PURPURA

The first report of the granulomatous variant of PPDs was in 1996 by Saito and Matsuoka and since then more than 17 cases have been reported.[18-20] It is most common in middle age and has been reported more commonly in patients of Asian descent.[1,20] Clinically, the lesions appear similar to other PPDs with purpuric and brown macules developing most commonly on the lower extremities and dorsal feet. This subtype is distinguished by its histopathologic findings. In addition to the classic histopathologic features of a PPD, a granulomatous infiltrate is present. The granulomatous infiltrate is most commonly located in the papillary dermis, but may be in the mid to deep dermis separate from a more superficially located lichenoid infiltrate. Systemic granulomatous disorders and infectious processes (mycobacterial and deep fungal) must be ruled out in these patients. Hyperlipidemia is a relatively common association with granulomatous pigmented purpura with 9 of 17 reported cases showing elevated cholesterol levels in a review from 2014.[19]

PIGMENTED PURPURIC DERMATOSIS/MYCOSIS FUNGOIDES OVERLAP

In 1988, Barnhill and Braverman reported the first cases of pigmented purpura-like eruptions progressing to mycosis fungoides.[21] Furthermore, the first patient diagnosed with lichen aureus in the United States was later diagnosed with mycosis fungoides (MF; see Chap. 119). Some evidence supports the idea that lichenoid variants of PPD may be precursors of MF, with similar histologic findings and clonal populations of lymphocytes.[22-29] Although there is no clear connection between these 2 diseases, and the occurrence of MF in the setting of a PPD is rare, 3 different relationships have been reported: MF mimicking pigmented purpura clinically, pigmented purpura evolving into MF, and pigmented purpura that simulates MF histologically.

In a study of T-cell clonality and markers, T-cell monoclonality of PPD was most likely to predict progression to MF, whereas the absence of certain T-cell markers was a less reliable predictor.[30] It is important to note that both MF and PPD can display clonality. Histologic clues of MF are subtle and include greater lymphoid atypia in the intraepidermal lymphocytes compared to dermal lymphocytes, large intraepidermal groups of lymphocytes anywhere in the epidermis, or many lymphocytes in the spinous layer.[30,31] Santucci and colleagues suggested that to distinguish early MF from its inflammatory mimickers the most important feature is lymphocytes with extremely convoluted, medium to large nuclei, that are single or clustered in the epidermis and in small sheets in the dermis.[32] Ackerman compared the histologic features of lichenoid purpuric eruptions with plaque stage MF and noted many similarities, concluding that it may be impossible to differentiate these two on a histologic basis alone.[33]

The differentiation between PPD and MF can be difficult and requires the integration of clinical, histologic and immunophenotypic information.[30,33] PPDs with large areas of confluence, reticular arrangements, a superimposed violaceous hue, or pruritus that has been present or relapsing for several years are suspicious for MF. There is a predominance in adult males.[21,34] For selected patients, long-term followup is needed to monitor for evolution into MF, even though the overall incidence of MF occurring in association with PPD is rare.

ETIOLOGY AND PATHOGENESIS

There are 3 different views on the pathogenesis of PPDs. The first is that there is a disturbance or weakness of cutaneous blood vessels, leading to capillary fragility and erythrocyte extravasation. This proposed mechanism, however, does not account for the inflammatory infiltrate that is also seen in these eruptions. The second theory is that PPDs develop from a humoral immune response. This theory is supported by direct immunofluorescence studies showing vascular deposition of C3, C1q, immunoglobulin M, or immunoglobulin A.[35,36] The final theory is that PPDs develop as a result of a cellular immune response.[37,38] This theory suggests that the inflammatory infiltrate, consisting of lymphocytes, macrophages, and Langerhans cells, leads to vascular fragility and subsequent extravasation of erythrocytes. Aiba and Tagami used immunohistologic studies in 8 cases of Schamberg disease to demonstrate that the dermal infiltrate was predominantly composed of helper-inducer T-cells and

OKT6-reactive cells, whereas the epidermis showed intercellular staining with human leukocyte antigen-DR antibody and OKT6 antibody.[39] Based on this study, they concluded that a cellular immune reaction, specifically with Langerhans cell, likely plays an important role in the pathogenesis. Additionally, Ghersetich and colleagues showed that cell-mediated mechanisms may be important in the development of Schamberg disease as CD4+ T cells and CD1a dendritic cells predominate in early lesions and this infiltrate clears with potent topical steroid therapy.[38]

PPD may be induced by multiple drugs (Table 143-2).[1,40-53] These drug-induced eruptions are more likely to be generalized, but still present with lower-extremity involvement. They are often transient, with a mean duration of 3 to 4 months, with many cases resolving within a few weeks.[53] A temporal relationship may be difficult to establish as patients can be taking the culprit medication for months to years prior to the onset of the eruption. Rechallenge has been used to confirm diagnosis.

In addition to medications, other causes also have been implicated (Table 143-3).[54-61] A handful of cases show familial involvement, with one report of an autosomal dominant inheritance pattern.[62] Gravity and increased venous pressure may account for the lesions localizing to the lower extremities. Overall, the majority of cases of PPDs are idiopathic.

TABLE 143-2
Drugs Implicated in Pigmented Purpuric Dermatoses

- Acetaminophen
- Aminoglutethimide
- Ampicillin
- Aspirin
- Bezafibrate
- Bufexamac
- Carbamazepine
- Carbromal
- Carbutamide
- Chlordiazepoxide
- Diltiazem
- Dipyridamole
- Topical fluorouracil
- Furosemide
- Glipizide
- Glybuzole
- Hydralazine
- Infliximab
- Interferon-α
- Isotretinoin
- Medroxyprogesterone acetate
- Meprobamate
- Minocycline
- Nitroglycerin
- Nonsteroidal antiinflammatory drugs
- Phenobarbital
- Pseudoephedrine
- Raloxifene
- Reserpine
- Sildenafil
- Tartrazine (food additive)
- Thiamine
- Trichlormethiazide
- Zomepirac sodium

TABLE 143-3
Other Implicated Causes of Pigmented Purpuric Dermatoses

- Contact dermatitis
  - Disperse dyes
  - Paraphenylenediamine
  - Black rubber
  - Cobalt
  - Benzoyl peroxide
  - Epoxy resin
  - Methylmethacrylate
  - Eutectic mixture of local anesthetics
- Venous stasis/acroangiodermatitis
- Step aerobics
- Strenuous exercise
- Rheumatoid arthritis
- Systemic lupus erythematosus
- Diabetes mellitus
- Thyroid dysfunction
- Hyperlipidemia
- Benign hyperglobulinemic purpura (of Waldenstrom)/ dysproteinemic purpura)
- Hodgkin disease
- Hepatitides B and C
- Odontogenic infection
- Polycythemia
- Hereditary spherocytosis
- Porphyrias
- Purpuric mycosis fungoides

DIAGNOSIS

Diagnosis is generally made clinically and may be supported by histopathologic examination. The clinical measurement of capillary fragility by application of a sphygmomanometer (Hess test) does not appear to be reliable, as increased capillary fragility is not consistently seen in PPD. The patient's medical history, medications, and potential contact allergens should be reviewed. MF should be considered if the lesions are chronic and unremitting.

SUPPORTIVE STUDIES

LABORATORY TESTING

Laboratory testing is not required for diagnosis. In selected cases, laboratory testing may include a complete blood cell count with peripheral smear (to rule out thrombocytopenia or other hematologic disorders), coagulation studies (to rule out other causes of purpura), as well as an antinuclear antibody, rheumatoid factor, and hepatitis serologies.[1]

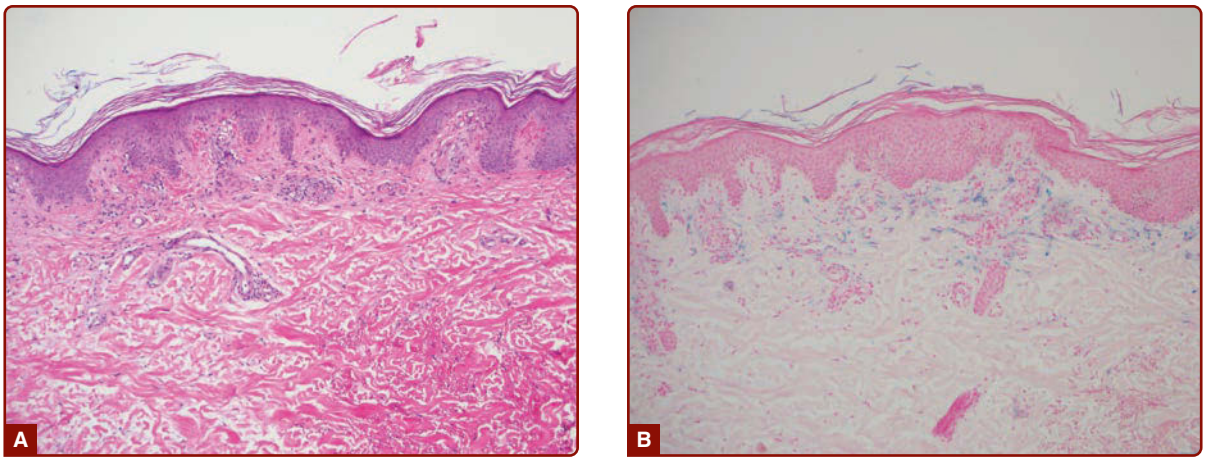

Figure 143-6 **A,** Pigmented purpuric dermatosis showing superficial perivascular lymphocytes and extravasated erythrocytes. **B,** Hemosiderin deposition highlighted by Prussian Blue staining. (Used with permission from Gene H. Kim, MD.)

PATHOLOGY

All PPDs share similar histopathology. A lymphocytic perivascular infiltrate is present in the papillary dermis with endothelial swelling and extravasated erythrocytes and hemosiderin deposition within macrophages (Fig. 143-6). In older lesions, there is less inflammation, and extravasated red cells may no longer be present. Although there is no consensus on whether a capillaritis is present, Ackerman asserts that there is no true capillaritis because of the lack of fibrin in the luminal walls and absence of thrombi.[1] The epidermis may show spongiosis and parakeratosis, particularly in pigmented purpuric lichenoid dermatitis of Gougerot and Blum and eczematid-like purpura of Doucas and Kapetanakis. In lichen aureus, there is a band-like mononuclear infiltrate in the upper dermis separated from the epidermis by a thin rim of uninvolved collagen. In granulomatous pigmented purpura, a granulomatous infiltrate is present either in the papillary dermis, or in the mid to deep dermis, which separated from a more superficially located lichenoid infiltrate.

DIFFERENTIAL DIAGNOSIS

Table 143-4 outlines the differential diagnosis of PPD.

CLINICAL COURSE AND PROGNOSIS

PPDs are benign and commonly asymptomatic. In general, PPDs are chronic with flares and remissions. Exceptions to this chronic course include unilateral linear capillaritis and drug-induced PPDs, which tend to have shorter clinical courses and more favorable overall prognoses.

MANAGEMENT

Management of PPD is challenging, as treatments are often ineffective. The patient's medical history, medications, and potential contact allergens should be reviewed. If the eruption is induced by a drug or contact allergen, discontinuation of the causative agent can lead to complete resolution. However, residual pigmentation may persist for years.

INTERVENTIONS

MEDICATIONS

Common initial therapies include topical steroids and antihistamines, which are particularly helpful in treating associated pruritus, as well as the use of compression stockings to treat associated venous insufficiency. In addition to topical steroids, topical pimecrolimus has been used. Treatment with topical pimecrolimus twice daily for 10 weeks cleared lichen aureus lesions in a 10-year-old boy. The patient had a minor flare after discontinuation that responded to 2 weeks of repeat treatment.[63] Intralesional corticosteroids have

TABLE 143-4
Differential Diagnosis of Pigmented Purpuric Dermatoses

- Contact dermatitis
- Leukocytoclastic vasculitis
- Stasis dermatitis and purpura
- Angioma serpiginosum
- Kaposi sarcoma (Gougerot-Blum)
- Mycosis fungoides
- Sarcoidosis
- Scurvy
- Hypergammaglobinemic purpura

also led to improvement, although tissue atrophy may develop and the development of new lesions is not prevented.[6]

Oral bioflavonoid (rutoside, 50 mg twice daily) and ascorbic acid (500 mg twice daily) given to 3 patients with chronic PPD in an open trial led to clearance in all 3 patients within 4 weeks with maintenance of remission 3 months after treatment.[64] In a pilot study, calcium dobesilate, 500 mg twice daily, was given to 9 patients for 3 months.[65] Seven patients had mild-to-moderate improvement that was sustained at 1 year after cessation of therapy. Griseofulvin, 500 mg to 750 mg daily, improved existing lesions within a week and stopped new lesions within a mean of 33 days in an open trial of 6 patients.[66] Colchicine, 0.5 mg twice daily, cleared a 28-year-old woman with recalcitrant Schamberg disease.[67] Minocycline also has been reported to be beneficial.

Pentoxifylline, which inhibits T-cell adherence to endothelial cells and keratinocytes, may be helpful. A randomized, investigator-blinded trial compared pentoxifylline, 400 mg 3 times daily, with topical betamethasone dipropionate cream, 0.05% twice daily, for 2 months. Patients treated with pentoxifylline had significantly greater improvement than those treated with the topical steroid. However, the response was not sustained after discontinuation of the medication.[68]

Immunosuppressants, such as systemic corticosteroids, cyclosporine, and methotrexate are often effective but are rarely indicated because of the benign nature of the disorder as well as recurrence upon discontinuation of these medications.[6,69] Methotrexate was reported to clear a patient with Majocchi purpura with just 15 mg weekly dosing for 4 weeks, although she had reoccurrence when the medication was discontinued. Again, aggressive therapy is not often warranted for this benign condition unless a generalized eruption or severe symptoms occur.

PHOTOTHERAPY AND LASER THERAPY

Psoralen and ultraviolet A light (PUVA) and narrowband ultraviolet B (nbUVB) have both been reported to clear lesions.[70-79] The phototherapy-induced immunosuppression of the cell-mediated response is the proposed mechanism.[6]

Gudi and White were the first to report the effectiveness of nbUVB in treating a patient with Schamberg disease.[70] In a report by Lasocki and Kelly, nbUVB was used to maintain disease suppression while tapering oral prednisolone. The patient remained clear on a once-every-2-week dosing, but had recurrence when UVB was completely stopped.[71] Additional cases have reported effectiveness of nbUVB in the treatment of PPD.[72-75]

PUVA inhibits T-cell interleukin-2 production and leads to resolution of the perivascular lymphocytic infiltrate.[76] Krisa and colleagues treated 7 patients with PUVA with clearance after 7 to 20 treatments.[77] Five of these patients remained in remission and 2 patients relapsed, but responded to a second course of PUVA. In another report, a cohort of 11 patients with PPDs responded to PUVA.[78]

Photodynamic therapy has been reported as beneficial as it affects both immunomodulation and vascular destruction.[80] In addition, successful clearance of Schamberg disease with the use of a 595-nm pulsed-dye laser after 5 monthly treatments has been reported.[81]

COUNSELING

Patients should be counseled about the benign but chronic and relapsing nature of these eruptions. Ongoing follow up may be warranted to monitor disease progression. Setting the expectation of treating symptoms, rather than aiming to cure the condition, may lead to improved patient satisfaction, as treatments to clear the eruption are often ineffective.

ACKNOWLEDGMENTS

The authors acknowledge the contributions of Theresa Schroeder Devere and Anisha B. Patel, the former authors of this chapter.

REFERENCES

1. Sardana K, Sarkar R, Sehgal VN. Pigmented purpuric dermatoses: an overview. *Int J Dermatol*. 2004;43(7):482-488.
2. Kim DH, Seo SH, Ahn HH, et al. Characteristics and clinical manifestations of pigmented purpuric dermatosis. *Ann Dermatol*. 2015;27(4):404-410.
3. Schamberg JF. A peculiar progressive pigmentary disease of the skin. *Br J Dermatol*. 1901;13:1.
4. Torrela A, Requena C, Mediero IG, et al. Schamberg's purpura in children: a review of 13 cases. *J Am Acad Dermatol*. 2003;48(1):31-33.
5. Majocchi D. Sopra una dermatosi telangiectode non ancora descritta: purpura annularis. *G Ital Mal Veni*. 1896;31:263.
6. Hoesly FJ, Hueter CJ, Shehan JM. Purpura annularis telangiectodes of Majocchi: case report and review of the literature. *Int J Dermatol*. 2009;48(10):1129-1133.
7. Gougerot H, Blum P. Purpura angioscleux prurigeneux avec elements lichenoides. *Bull Soc Fr Dermatol Syphiligr*. 1925;32:161.
8. Doucas C, Kapetenakis J. Eczematid-like purpura. *Dermatologica*. 1953;106(2):86-95.
9. Marten RH. Case for diagnosis. *Trans St Johns Hosp Dermatol Soc*. 1958;30:98.
10. Calnan CD. Lichen aureus. *Br J Dermatol*. 1960;72:373-374.
11. Mishra D, Maheshwari V. Segmental lichen aureus in child. *Int J Dermatol*. 1991;30(9):654-655.
12. Ruiz-Esmenjaud J, Dahl MV. Segmental lichen aureus: onset associated with trauma and puberty. *Arch Dermatol*. 1988;124(10):1572-1574.
13. Mosto SJ, Casala AM. Disseminated pruriginous angiodermatitis (itching purpura). *Arch Dermatol*. 1965;91(4):351-356.

14. Pravda DJ, Moynihan GD. Itching purpura. *Cutis*. 1980; 25:147.
15. Riordan CA, Darley C, Markey AC, et al. Unilateral linear capillaritis. *Clin Exp Dermatol*. 1992;17(3):182-185.
16. Higgins EM, Cox NH. A case of quadrantic capillaropathy. *Dermatologica*. 1990;180(2):93-95.
17. Pock L, Capkova S. Segmental pigmented purpura. *Pediatr Dermatol*. 2002;19(6):517-519.
18. Saito R, Matsuoka Y. Granulomatous pigmented purpuric dermatosis. *J Dermatol*. 1996;23(8):551-555.
19. Battle LR, Shalin SC, Gao L. Granulomatous pigmented purpuric dermatosis. *Clin Exp Dermatol*. 2015; 40(4):387-390.
20. MacKenzie Al, Biswas A. Granulomatous pigmented purpuric dermatosis: report of a case with atypical clinical presentation including dermoscopic findings. *Am J Dermatopathol*. 2015;37(4):311-314.
21. Barnhill RL, Braverman IM. Progression of pigmented purpura-like eruptions to mycosis fungoides: report of three cases. *J Am Acad Dermatol*. 1998;19(1, pt 1): 25-31.
22. Martinez W, del Pozo J, Vázquez J, et al. Cutaneous T-cell lymphoma presenting as disseminated, pigmented, purpura-like eruption. *Int J Dermatol*. 2001;40(2):140-144.
23. Ugajin T, Satoh T, Yokozeki H, et al. Mycosis fungoides presenting as pigmented purpuric eruption. *Eur J Dermatol*. 2005;15(6):489-491.
24. Kazakov DV, Burg G, Kempf W. Clinicopathological spectrum of mycosis fungoides. *J Eur Acad Dermatol Venereol*. 2004;18(4):397-415.
25. Georgala S, Katoulis AC, Symeonidou S, et al. Persistent pigmented purpuric eruption associated with mycosis fungoides: a case report and review of the literature. *J Eur Acad Dermatol Venereol*. 2001;15(1): 62-64.
26. Puddu P, Ferranti G, Frezzolini A, et al. Pigmented purpura-like eruption as cutaneous sign of mycosis fungoides with autoimmune purpura. *J Am Acad Dermatol*. 1999;40(2, pt 2):298-299.
27. Cather JC, Farmer A, Jackow C, et al. Unusual presentation of mycosis fungoides as pigmented purpura with malignant thymoma. *J Am Acad Dermatol*. 1998;39 (5, pt 2):858-863.
28. Toro JR, Sander CA, LeBoit PE. Persistent pigmented purpuric dermatitis and mycosis fungoides: stimulant, precursor, or both: a study by light microscopy and molecular methods. *Am J Dermatopathol*. 1997; 19(2):108-118.
29. Lor P, Krueger U, Kempf W, et al. Monoclonal rearrangement of the T cell receptor gamma-chain in lichenoid pigmented purpuric dermatitis of Gougerot-Blum responding to topical corticosteroid therapy. *Dermatology*. 2002;205(2):191-193.
30. Magro CM, Schaefer JT, Crowson AN, et al. Pigmented purpuric dermatosis: classification by phenotypic and molecular profiles. *Am J Clin Pathol*. 2007;128(2): 218-229.
31. Hanna S, Walsh N, D'Intino Y, et al. Mycosis fungoides presenting as pigmented purpuric dermatitis. *Pediatr Dermatol*. 2006;23(4):350-354.
32. Santucci M, Biggeri A, Feller AC, et al. Efficacy of histologic criteria for diagnosing early mycosis fungoides: an EORTC Cutaneous Lymphoma Study Group investigation. *Am J Clin Pathol*. 2000;24(1):40-50.
33. Ameen M, Darvay A, Black MM, et al. CD8-positive mycosis fungoides presenting as capillaritis. *Br J Dermatol*. 2000;142(3):564-567.
34. Lipsker D, Cribier B, Heid E, et al. Cutaneous lymphoma manifesting as pigmented, purpuric capillaries [in French]. *Ann Dermatol Venereol*. 1999;126(4):321-326.
35. Ratnam KV, Su WP, Peters MS. Purpura simplex (inflammatory purpura without vasculitis): a clinicopathologic study of 174 cases. *J Am Acad Dermatol*. 1991;25(4): 642-647.
36. Iwatsuki K, Aoshima T, Tagami H, et al. Immunofluorescence study in purpura pigmentosa chronica. *Acta Derm Venereol*. 1980;60(4):341-345.
37. von den Driesch P, Simon M Jr. Cellular adhesion antigen modulation in purpura pigmentosa chronica. *J Am Acad Dermatol*. 1994;30(2, pt 1):193-200.
38. Ghersetich I, Lotti T, Bacci S, et al. Cell infiltrate in progressive pigmented purpura (Schamberg's disease): immunophenotype adhesion receptors, and intercellular relationships. *Int J Dermatol*. 1995;34(12):846-850.
39. Aiba S, Tagami H. Immunohistologic studies in Schamberg's disease: evidence for cellular immune reaction in lesional skin. *Arch Dermatol*. 1988;124(7):1058-1062.
40. Nishioka K, Katayama I, Masuzawa M, et al. Drug-induced chronic pigmented purpura. *J Dermatol*. 1989;16(3): 220-222.
41. Kwon SJ, Lee CW. Figurate purpuric eruptions on the trunk: acetaminophen-induced rashes. *J Dermatol*. 1998;25(11):756-758.
42. Stratakis CA, Chrousos GP. Capillaritis (purpura simplex) associated with use of aminoglutethimide in Cushing's syndrome. *Am J Hosp Pharm*. 1994;51(20):2589-2591.
43. Voelter WW. Pigmented purpuric dermatosis-like reaction to topical fluorouracil. *Arch Dermatol*. 1983; 119(11):875-876.
44. Gupta G, Holmes SC, Spence E, et al. Capillaritis associated with interferon-alfa treatment of chronic hepatitis C infection. *J Am Acad Dermatol*. 2000;43(5, pt 2): 937-938.
45. Yung A, Gouldern V. Pigmented purpuric dermatosis (capillaritis) induced by bezafibrate. *J Am Acad Dermatol*. 2005;53(1):168-169.
46. Adams BB, Gadenne AS. Glipizide-induced pigmented purpuric dermatosis. *J Am Acad Dermatol*. 1999;41 (5, pt 2):827-829.
47. Tsao H, Lerner LH. Pigmented purpuric eruption associated with injection medroxyprogesterone acetate. *J Am Acad Dermatol*. 2000;43(2, pt 1):308-310.
48. Erbagci Z, Tuncel A, Erkilic S, et al. Progressive pigmentary purpura related to raloxifene. *Saudi Med J*. 2005;26(2):314-316.
49. Kalinke DU, Wuthrich B. Purpura pigmentosa progressive in type III cryoglobulinemia and tartrazine intolerance. A follow-up over 20 years [in German]. *Hautarzt*. 1999;50(1):47-51.
50. Inui S, Itami S, Yoshikawa K. A case of lichenoid purpura possibly caused by diltiazem hydrochloride. *J Dermatol*. 2001;28(2):100-102.
51. Waltermann K, Marsch WCh, Kreft B. Bufexamac-induced pigmented purpuric eruption [in German]. *Hautarzt*. 2009;60(5):424-427.
52. Díaz-Jara M, Tornero P, Barrio MD, et al. Pigmented purpuric dermatosis due to pseudoephedrine. *Contact Dermatitis*. 2002;46(5):300-301.
53. Kaplan R, Meehan SA, Leger M. A case of isotretinoin-induced purpura annularis telangiectodes of Majocchi and review of substance-induced pigmented purpuric dermatosis. *JAMA Dermatol*. 2014;150(2):182-184.
54. Komericki P, Aberer W, Arbab E, et al. Pigmented purpuric contact dermatitis from Disperse Blue 106 and 124 dyes. *J Am Acad Dermatol*. 2001;45(3):456-458.

55. Foti C, Elia G, Filotico R, et al. Purpuric clothing dermatitis due to Disperse Yellow 27. *Contact Dermatitis*. 1998;39(5):273.
56. Koch P, Baum HP, John S. Purpuric patch test reaction and venulitis due to methyl methacrylate in a dental prosthesis. *Contact Dermatitis*. 1996;34(3):213-215.
57. De Waard-van der Spek FB, Oranje AP. Purpura caused by EMLA is of toxic origin. *Contact Dermatitis*. 1997;36(1):11-13.
58. van Joost T, van Ulsen J, Vuzevski VD, et al. Purpuric contact dermatitis to benzoyl peroxide. *Contact Dermatitis*. 1990;22(2, pt 2):359-361.
59. Wahba-Yahav AV. Schamberg's purpura: association with persistent hepatitis B surface antigenemia and treatment with pentoxifylline. *Cutis*. 1994;54(3): 205-206.
60. Dessoukey MW, Abdel-Dayem H, Omar MF, et al. Pigmented purpuric dermatosis and hepatitis profile: a report on 10 patients. *Int J Dematol*. 2005;44(6):486-488.
61. Satoh T, Yokozeki H, Nishioka K. Chronic pigmented purpura associated with odontogenic infection. *J Am Acad Dermatol*. 2002;46(6):942-944.
62. Sethuraman G, Sugandhan S, Bansal A, et al. Familial pigmented purpuric dermatoses. *J Dermatol*. 2006;33(9): 639-641.
63. Böhm M, Bonsmann G, Luger TA. Resolution of lichen aureus in a 10-year-old child after topical pimecrolimus. *Br J Dermatol*. 2004;151(2):519-520.
64. Reinhold U, Seiter S, Ugurel S, et al. Treatment of progressive pigmented purpura with oral bioflavonoids and ascorbic acid: an open pilot study in 3 patients. *J Am Acad Dermatol*. 1999;41(2, pt 1):207-208.
65. Agrawal SK, Gandhi V, Bhattacharya SN. Calcium dobesilate (Cd) in pigmented purpuric dermatosis (PPD): a pilot evaluation. *J Dermatol*. 2004;31(2):98-103.
66. Tamaki K, Yasaka N, Osada A, et al. Successful treatment of pigmented purpuric dermatosis with griseofulvin. *Br J Dermatol*. 1995;132(1):159-160.
67. Geller M. Benefit of colchicine in the treatment of Schamberg's disease. *Ann Allergy Asthma Immunol*. 2000; 85(3):246.
68. Panda S, Malakar S, Lahiri K. Oral pentoxifylline vs topical betamethasone in Schamberg disease: a comparative randomized investigator-blinded parallel-group trial. *Arch Dermatol*. 2004;140(4):491-493.
69. Okada K, Ishikawa O, Miyachi Y. Purpura pigmentosa chronica successfully treated with oral cyclosporin A. *Br J Dermatol*. 1996;134(1):180-181.
70. Fathy H, Abdelgaber S. Treatment of pigmented purpuric dermatoses with narrow-band UVB: a report of six cases. *J Eur Acad Dermatol Venereol*. 2011;25(5): 603-606.
71. Lasocki AL, Kelly RI. Narrowband UVB therapy as an effective treatment for Schamberg's disease. *Australas J Dermatol*. 2008;49(1):16-18.
72. Kocaturk E, Kavala M, Zindanci I, et al. Narrowband UVB treatment of pigmented purpuric lichenoid dermatitis (Gougerot-Blum). *Photodermatol Photoimmunol Photomed*. 2009;25(1):55-56.
73. Karadag AS, Bilgili SG, Onder S, et al. Two cases of eczematid-like purpura of Doucas and Kapetanakis responsive to narrow band ultraviolet B treatment. *Photodermatol Photoimmunol Photomed*. 2013;29(2): 97-99.
74. Gudi VS, White MI. Progressive pigmented purpura (Schamberg's disease) responding to TL01 ultraviolet B therapy. *Clin Exp Dermatol*. 2004;29(6):683-684.
75. Dhali TK, Chahar M, Haroon MA. Phototherapy as an effective treatment for Majocchi's disease—case report. *An Bras Dermatol*. 2015;90(1):96-99.
76. Ling TC, Gouldern V, Goodfield MJ. PUVA therapy in lichen aureus. *J Am Acad Dermatol*. 2001;45(1):145-146.
77. Krisa J, Hunyadi J, Dobozy A. PUVA treatment of pigmented purpuric lichenoid dermatitis (Gougerot-Blum). *J Am Acad Dermatol*. 1992;27(5, pt 1):778-780.
78. Seckin D, Yazici Z, Senol A, et al. A case of Schamberg's disease responding dramatically to PUVA treatment. *Photodermatol Photoimmunol Photomed*. 2008; 24(2):95-96.
79. Wong WK, Ratnam KV. A report of two cases of pigmented purpuric dermatosis treated with PUVA therapy. *Acta Derm Venereol*. 1991;71(1):68-70.
80. Kim SK, Kim EH, Kim YC. Treatment of pigmented purpuric dermatosis with topical photodynamic therapy. *Dermatology*. 2009;219(2):184-186.
81. D'Ambrosia RA, Rajpara VS, Glogau RG. The successful treatment of Schamberg's disease with the 595nm vascular laser. *Dermatol Surg*. 2011;37(1):100-101.

Chapter 144 :: Cryoglobulinemia and Cryofibrinogenemia

:: Julio C. Sartori-Valinotti & Mark D. P. Davis

Cryoglobulins are circulating immunoglobulins found in both serum and plasma that reversibly precipitate or gel upon cold exposure. Cryofibrinogens result from precipitation of fibrinogens on cold exposure and are detectable only in plasma samples, not serum. This chapter focuses on conditions that lead to either microvascular occlusion (Type I cryoglobulinemia and cryofibrinogenemia) or small- and medium-sized vessel vasculitis (Type II and III cryoglobulinemia) with emphasis on lesion morphology and cutaneous manifestations.

CRYOGLOBULINEMIA

AT-A-GLANCE

- Cryoglobulins are circulating immunoglobulin complexes found in plasma or serum that reversibly precipitate in cold temperatures.
- Cryoglobulinemia may be asymptomatic or cause a clinical syndrome involving the skin: purpura at distal sites is the hallmark. Livedo reticularis, acrocyanosis, ulceration, or gangrene also may be seen.
- Cryoglobulins are classified based on molecular properties into Types I, II, III (Brouet classification).
- Type I cryoglobulins consist of a single monoclonal immunoglobulin (typically IgG) or light chain. They occur with hematologic malignancies such as multiple myeloma. If symptomatic, they present with a noninflammatory occlusive vasculopathy.
- Type II cryoglobulins consist of a monoclonal immunoglobulin (typically IgM) complexed with a polyclonal immunoglobulin (typically IgG).
- Type III cryoglobulins consist of purely polyclonal immunoglobulin complexes; Type II-III refers to an intermediate state with oligoclonal immunoglobulin.
- Types II and III are also referred to as mixed cryoglobulinemias. They are caused by chronic hepatitis C virus (HCV) infection in >90% of cases, whereas in a minority of cases no etiology can be identified, designating them as "essential mixed" cryoglobulinemias. They present as the cryoglobulinemic vasculitis syndrome, an immune complex vasculitis involving the skin, neural, and renal tissues.
- Therapy primarily consists of controlling the underlying disease. In addition, immunosuppressants, plasma exchange, or targeting of cryoglobulin-producing B-cell clones may alleviate the cryoglobulin burden.

INTRODUCTION

DEFINITIONS AND HISTORICAL PERSPECTIVES

In 1933, Wintrobe and Buell first noted the in vitro phenomenon of cryoprecipitation, the cold-induced precipitation of plasma or serum proteins that is reversible upon rewarming at 37°C (98.6°F).[1] In 1947, Lerner and Watson described immunoglobulins and mixtures of immunoglobulins with other proteins that precipitate in the cold and called them cryoglobulins.[2] In 1974, Brouet introduced the classification of cryoglobulins based on molecular properties that is widely used.[2] Cryoglobulinemia describes the presence of cryoglobulins in a patient's serum (Fig. 144-1). It can be asymptomatic, meaning that its presence usually goes clinically undetected, or it can cause occlusive vasculopathy or the so-called cryoglobulinemic syndrome, which is characterized by immune-complex deposition causing vasculitis that involves the skin and other tissues.

The classification scheme of Brouet, estimated frequency, and composition of cryoglobulins is depicted in Table 144-1. Type I cryoglobulins consist of a single monoclonal immunoglobulin (Ig), typically IgM, less commonly IgG, IgA, or free Ig light chains (Bence Jones proteins). Complement components are not routinely found in Type I cryoprecipitates. Type I cryoglobulins are often present in substantial amounts, ranging from 1 to 30 mg/mL. The large molecular size of monoclonal IgM and other molecular characteristics, such as absence of sialic acid moieties, deficient carbohydrate side chains, and weak noncovalent factors may predispose these immunoglobulins to precipitation.[3]

Type II and Type III cryoglobulins are immune complexes composed of polyclonal IgGs and mono- or polyclonal IgMs classically referred to as "mixed cryoglobulinemias." Type II and Type III cryoglobulins are typically present in relatively small amounts

Figure 144-1 Whitish cryoprecipitates after keeping tube at 4°C (39.2°F) for 48 hours and centrifugation.

and generally result from chronic inflammatory states. Type II and Type III cryoglobulins may fix complement.

Type II cryoglobulins represent a mixture of 2 Ig components: polyclonal immunoglobulins are associated with a monoclonal Ig that exhibits rheumatoid factor (RF) activity. Typically, a monoclonal IgM RF is complexed with a polyclonal IgG. HCV infection is the classical underlying disease.

A mixture of polyclonal immunoglobulins or polyclonal Ig-nonimmunoglobulin cryoprecipitates results in detection of Type III cryoglobulins. Polyclonal IgM–IgG cryoglobulins with complement as an integral component are the most frequent scenario in Type III cryoglobulinemia that is commonly associated with HCV infection or connective tissue diseases.

A new type of cryoglobulins, not included in the original Brouet classification, called Type II-III cryoglobulin, containing polyclonal IgG associated with a mixture of polyclonal and monoclonal (oligoclonal) IgM, has been described.[4] This type of cryoprecipitate describes an intermediate, developing state between Types III and II, suggesting a continuous transition from a purely polyclonal to a partially monoclonal composition by a process of successive clonal selection.

EPIDEMIOLOGY

Because of the heterogeneity of clinical presentations, including nonclinically apparent disease, the overall prevalence of this syndrome is probably underreported but has been estimated at 1 to 7 in 100,000.[5] Geographic differences in the distribution of hepatitis C infection are responsible for the predominance of mixed cryoglobulinemia in Southern Europe as compared to Northern Europe or the United States.[6] "Essential mixed cryoglobulinemia," or mixed cryoglobulinemia without an identifiable cause, is more common in females than males with a 3:1 ratio. The average age at onset is 54 years. Many cases formerly known as "essential" have been found to be associated with HCV and other infectious etiologies.[7]

An association with infectious diseases has been reported in 75% of patients, autoimmune disease in 24%, and hematologic diseases in 7%.[8] The vast majority (>90%) of mixed cryoglobulinemias occurs in association with chronic HCV infection. On average, 30% of chronically HCV-infected subjects develop cryoglobulinemia, and this proportion can go up to 90% when patients with very longstanding disease are examined.[9-11] On average, symptomatic cryoglobulinemic vasculitis syndrome is present in only 2% to 5% of chronically HCV-infected patients,[12] though figures as high as 15% have been proposed.[13,14] More recently, non–HCV-related infectious cryoglobulinemic vasculitis has been reported in association with hepatitis B virus (HBV), cytomegalovirus, Epstein–Barr virus, parvovirus B19, HIV, and bacterial, fungal, and mycobacterial infections.[15]

CLINICAL FEATURES

CUTANEOUS FINDINGS

Cutaneous lesions are the most frequent manifestation, occurring in up to 90% of patients.

Type I cryoglobulinemia per se is often asymptomatic and cutaneous signs are related to hyperviscosity and/or thrombosis that induce ischemic vasculopathy presenting as Raynaud phenomenon, digital ischemia (Fig. 144-2) that may progress to gangrene (Fig. 144-3), livedo reticularis, acrocyanosis (Fig. 144-4) or retiform purpura. These vascular occlusive lesions are typically cold induced. Infarction, hemorrhagic crusts, ulcers, and lesions on the head and oral or nasal mucosa are relatively more common in Type I than in mixed cryoglobulinemia.[16]

Type II and III cryoglobulinemic vasculitis is mediated by deposition of antigen–antibody complexes in small and medium-sized arteries, leading to inflammation of, preferentially, small blood vessel walls (capillaries, venules, or arterioles). Intermittent orthostatic palpable purpura, frequently observed late in the afternoon when highest cryoglobulin concentrations are present, is the most common presentation and particularly affects the lower extremities (Fig. 144-5). The face and the trunk, with the exception of the lower abdomen, are usually spared.[2] The clinical signs can vary from sporadic isolated petechiae or erythematous macules to severe vasculitic lesions with ulcerations. Leukocytoclastic vasculitis is the

TABLE 144-1
Types of Cryoglobulins, Composition of Cryoprecipitates, and Disease Associations

TYPE OF CRYOGLOBULINEMIA (ESTIMATED FREQUENCY)	COMPOSITION OF CRYOPRECIPITATES	DISEASE ASSOCIATIONS
Type I (25%)	Monoclonal IgM (sometimes IgG, IgA), immunoglobulin light chain, complexed to other proteins	Hematologic disorders ▪ Multiple myeloma ▪ Waldenström macroglobulinemia ▪ Plasma cell dyscrasias, monoclonal gammopathy of undetermined significance (MGUS) ▪ Other lymphoproliferative diseases with M components
Type II (25%)	Combination of monoclonal (usually IgM with rheumatoid factor activity) and polyclonal (usually IgG) immunoglobulins	Chronic infection ▪ Viral (HCV) Autoimmune diseases ▪ Sjögren syndrome ▪ Cold agglutinin disease Hematologic disorders ▪ Waldenström macroglobulinemia ▪ Chronic lymphocytic leukemia ▪ B-cell non-Hodgkin lymphoma
Type III (50%)	Polyclonal immunoglobulins	Chronic infection ▪ Viral (HCV, HIV, HBV) ▪ Bacterial (subacute bacterial endocarditis, leprosy, spirochetal) ▪ Fungal, parasitic Autoimmune diseases ▪ Systemic lupus erythematosus ▪ Rheumatoid arthritis ▪ Dermatomyositis/polymyositis ▪ Inflammatory bowel diseases ▪ Biliary cirrhosis
Type II and III (frequency unknown)	Oligoclonal IgM, intermediate state between the entirely polyclonal Type III and the monoclonal, polyclonal Type II	Chronic infection (HCV) Autoimmune diseases Lymphoproliferative diseases Chronic liver disease Proliferative glomerulonephritis

Data from Crowson AN et al. Cutaneous vasculitis: A review. *J Cutan Pathol*. 2003;30:161-173; and Kallemuchikkal U, Gorevic PD. Evaluation of cryoglobulins. *Arch Pathol Lab Med*. 1999;123:119-25.

histopathologic hallmark of mixed cryoglobulinemia and is easily detectable by skin biopsy. Approximately 15% of individuals with circulating cryoglobulins have symptomatology consistent with cryoglobulinemic vasculitis. Erythematous papules, ecchymosis, and dermal nodules also can be seen.[14] Postinflammatory hyperpigmentation is also common (40% of patients).[7] Nail-fold capillary abnormalities are common and include dilation, altered orientation, capillary shortening, and neoangiogenesis.[17]

Figure 144-2 Blue discoloration of the distal aspect of the left first toe as the earliest finding of impending digital ischemia in a patient with cryoglobulinemia.

Figure 144-3 Digital gangrene of the distal right second and third fingers in a patient with cryoglobulinemia Type I. Note the well-demarcated color changes and absence of inflammation (erythema).

Figure 144-4 Acrocyanosis and livedo reticularis in a patient with cryoglobulinemia in the setting of multiple myeloma.

NONCUTANEOUS FINDINGS

The most common extracutaneous manifestations in patients with mixed cryoglobulinemic vasculitis are weakness and arthralgias or arthritis[14] but serious internal organ involvement also occur. The association of purpura, arthralgias, and weakness, known as the "Meltzer triad," is seen in about 25% to 30% of patients.[18,19]

Figure 144-5 Leukocytoclastic vasculitis in a patient with mixed cryoglobulinemia manifested as palpable purpura.

Renal involvement is a serious complication, typically manifests early in the course of the disease and can present as a broad range of clinical findings, including hematuria with or without renal insufficiency (41%), isolated proteinuria, nephrotic syndrome (21%) or acute nephritic syndrome.[20] Chronic renal insufficiency without significant renal abnormalities and acute renal failure are less common. The incidence of renal disease in cryoglobulinemia varies from 5% to 60% and is typically immune complex mediated (Type II and III), but may also occur secondary to thrombosis (Type I). Membranoproliferative glomerulonephritis (MPGN) is more common in mixed cryoglobulinemia.

Neurologic manifestations, typically affecting the sensory peripheral nervous system secondary to epineural vasculitis, frequently complicate the clinical course of patients with mixed cryoglobulinemia. Patients typically describe paresthesias with burning symptoms in the lower limbs, often with nocturnal exacerbation, leading to severely compromised quality of life. Electromyographic and nerve conduction studies demonstrated peripheral neuropathy in up to 80% of patients with mixed cryoglobulinemia,[21,22] but many symptom-based demographic studies report prevalence of only 5% to 45%. Isolated polyneuropathy is more common with Type II than Type III cryoglobulinemia, but multifocal neuropathy and polyneuropathy are the most common form in Type III cryoglobulinemia.[23] Restless leg syndrome may be the major manifestation of peripheral neuropathy in middle-aged women with mixed cryoglobulinemia.[24] Peripheral neurologic disease manifests as a progressive, chronic distal mild sensory neuritis and only rarely as acute mononeuritis. Clinically apparent CNS dysfunction is rare. Hyperviscosity due to high levels of monoclonal cryoglobulins in Type I cryoglobulinemia, typically seen in Waldenström macroglobulinemia and less frequently in multiple myeloma, can induce microcirculation impairment and neurologic symptoms: blurring or loss of vision, headache, vertigo, nystagmus, dizziness, sudden deafness, diplopia, ataxia, confusion, dementia, disturbances of consciousness, stroke, seizures, somnolence, or coma. A characteristic retinal venous engorgement ("sausaging") on funduscopic inspection can serve as a diagnostic clue.

Musculoskeletal complaints, typically arthralgias and myalgias, are described in more than 70% of persons with cryoglobulinemia, predominantly in Type II and III disease. Arthralgias classically affect the proximal interphalangeal and metacarpophalangeal joints of the hands, the knees, and ankles. Clear clinical signs of myositis or arthritis are rare.[25]

Pulmonary involvement. Approximately 40% of patients are symptomatic with dyspnea, cough, or pleuritic pain. Pulmonary function tests often reveal evidence of small airways disease and chest radiographs sometimes show interstitial infiltrates or signs of subclinical alveolitis.[26,27] Severe pulmonary disease, for example, bronchiolitis obliterans organizing pneumonia (BOOP), or pulmonary vasculitis are very

uncommon.[28] Pulmonary-renal syndrome also has been described.[29]

Other. Thyroid disorders and diabetes mellitus seem to be associated with cryoglobulinemia.[30] Nonspecific abdominal pain can affect 2% to 22%. Intestinal vasculitis of the small mesenteric vessels leading to acute abdomen has been reported.

ETIOLOGY AND PATHOGENESIS

Type I cryoglobulinemia is associated with hematologic disorders, such as Waldenström macroglobulinemia, multiple myeloma, or lymphoproliferative diseases. Non-Hodgkin B-cell lymphoma is the most frequently encountered hematologic malignancy.

Circulating mixed (Types II and III) cryoglobulins are commonly detected in a great number of infectious or systemic disorders (see Table 144-1). The term *essential* is reserved for instances of mixed cryoglobulinemia in the absence of a well-defined underlying disease and accounts for only a minority of cryoglobulinemic patients.

Prevalence of serum anti-HCV antibodies and/or HCV RNA in cryoglobulinemic patients ranges from 70% to 100%. Type II cryoglobulinemia is more strongly associated with HCV than Type III (90% vs 70%, respectively). Presence of cryoglobulins increases with duration of HCV infection: cryoglobulins are found in 55% to 90% of patients with longstanding infection. However, overt cryoglobulinemic syndrome develops in only 2% to 5% of these cases.[12] The precise role of viral or host factors contributing to this discrepancy remains largely unknown. Specific HCV genotypes or distinct HLA subtypes, like HLA-DR11 or HLA-DR6 may predispose to extrahepatic systemic manifestations of cryoglobulinemia.[31,32] Pathogenesis of mixed cryoglobulinemia is probably a multifactorial and multistep process. Viral HCV antigens exert a chronic stimulus on the host immune system, resulting in specific immune dysregulatory mechanisms with B-cell proliferation and autoantibody production. HCV-related B-cell lymphoproliferative disorders comprise a spectrum of disease, ranging from asymptomatic clonal B-cell expansions to pathogenic cryoglobulinemia and lymphoma. From that perspective, HCV-associated mixed cryoglobulinemia is a benign lymphoproliferative B-cell disease with a potential for subsequent development of B-cell lymphoma.[19,33] Development of HCV-associated cryoglobulinemic vasculitis syndrome is associated with longstanding infection, old age, Type II cryoglobulins, higher cryoglobulin levels, and clonal B-cell expansion.[34] The mechanism for B-cell activation and proliferation may be explained in part due to the presence of a t(14;18) translocation involving a rearrangement of *bcl-2* and inhibition of apoptosis.[6]

In cases of HCV-associated mixed cryoglobulinemia, there is complex interaction between several inflammatory cytokines that amplifies and perpetuates the autoimmune process. Elevated serum levels of interleukin (IL)-1beta, IL-6, and tumor necrosis factor (TNF)-alpha have been found in these patients[35] in addition to T-helper 1 chemokines, CXCL11 and CXCL10.[36] High levels of CXCL10 are found in patients with clinically active vasculitis and autoimmune thyroiditis.[37]

Using environmental scanning electron microscopy and energy dispersive X-ray spectroscopy microanalysis, higher concentration of microparticles and nanoparticles were found in HCV-associated mixed cryoglobulinemia than in controls, further supporting a role for environmental factors in the pathogenesis of this condition.[38]

The group of non-HCV-induced mixed cryoglobulinemias is small. An association of cryoglobulinemia with other infectious viral agents, for example, hepatitis B virus,[39] and HIV, with or without HCV coinfection, has been demonstrated.[40] HIV infection does seem to play a role in the generation of circulating cryoglobulins.[41] Parvovirus B19 has been implicated in a mild form of cryoglobulinemic syndrome.[42] Another important and well-known association is the one with Sjögren syndrome. According to one study, 16% of patients with primary Sjögren syndrome had cryoglobulins, and of those, 56% had cryoglobulinemic syndrome.[43,44] Importantly, Sjögren syndrome patients who meet diagnostic criteria for cryoglobulinemic vasculitis at the time of diagnosis have increased mortality.[45] A study by the same group found cryoglobulinemia in 25% of patients with systemic lupus erythematosus.[46] A rare association between antiphospholipid syndrome and cryoglobulinemia has recently been reported.[47]

DIAGNOSIS

In almost all cases, the possibility of a diagnosis of cryoglobulinemia or cryoglobulinemic syndrome is primarily suggested by the presence of purpura of the distal extremities or by acral cyanosis and necrosis, depending on the potential presence of Type I or Types II and III cryoglobulinemia. Alternatively, the potential diagnosis may be suggested by the presence of a candidate underlying disease. A targeted review of systems and subsequent clinical examination will guide the physician toward the entire picture of organ involvement or differential diagnoses. The laboratory panel must include parameters relevant to both cryoglobulinemia and important differential diagnoses. Table 144-2 presents an algorithm for the diagnostic approach to the patient, including laboratory testing.

LABORATORY TESTING

In clinical practice, cryoglobulin testing is underutilized, most probably due to the expenditure of time and stringent temperature requirements. They can be

TABLE 144-2
Algorithm for Patients with Suspected Cryoglobulinemia

History and Examination (Including Optional Technical Methods)

Ask for

- Cold sensitivity
- Weakness, musculoskeletal complaints, arthralgia
- Alcohol consumption, hereditary liver disease, history of hepatitis
- Known infections (HCV, HBV, HIV)
- Urine abnormalities (hematuria, foamy urine, edema)
- Paresthesias
- Difficulties in concentrating (suggesting CNS involvement)

Look for

- Acrocyanosis, Raynaud phenomenon (suggesting Type I cryoglobulinemia)
- Purpura of distal extremities (suggesting Type II and III cryoglobulinemia)
- Peripheral neuropathy (consider electromyographic testing)
- Joint swelling (suggestive for rheumatoid arthritis, SLE)
- Lymph node enlargement (suggesting lymphoma)

Technical examination (optional)

- Ultrasonography: Liver abnormalities, splenomegaly (suggesting lymphoma)
- Electrocardiography, echocardiography (suggesting SLE)
- Ophthalmology: Eye involvement, chorioretinitis (suggesting Behçet disease or sarcoidosis)

Mandatory Laboratory Testing in Cryoglobulinemia

- Cryoglobulins (establishing the diagnosis when positive; stringent laboratory workup at 37°C is needed)
- Complete blood count, including differential
- Creatinine, BUN
- Complement levels
- IgA level (suggestive for liver disease or Henoch–Schönlein Purpura)
- ANA, SS-B, SS-A (positive in SLE- and Sjögren syndrome–associated cryoglobulinemia)
- ANCA (possibly positive, or suggesting granulomatosis with polyangiitis [Wegener] or microscopic polyangiitis)
- Rheumatoid factor RF (positive in Type II cryoglobulinemia with a very high titer)
- Urinalysis. If positive, add microscopic examination of urinary sediment
- Hepatitis A, B, C serology
- Look for other viruses, such as parvovirus B19, HIV, if appropriate
- Further workup for hepatic failure if appropriate

Histology

- Consider skin biopsy
  - To confirm leukocytoclastic vasculitis (stain for complement and immune complexes)
  - To rule out other forms of vasculitis
- Consider renal biopsy (discern between MPGN I and other forms)
- Consider hepatic biopsy

falsely negative and should be obtained during active flares and repeated several weeks apart. By current standard laboratory techniques, most healthy individuals will have undetectable circulating cryoglobulins.

Serum must be obtained in warm tubes at 37°C in the absence of anticoagulants. Temperature should be kept at 37°C up until laboratory processing. After clotting and centrifugation at 37°C, the separated serum is stored at 4°C and inspected daily for a precipitate. Type I cryoglobulins tend to precipitate within the first 24 hours (at concentrations >5 mg/mL), whereas Type III cryoglobulins may require 7 days (Fig. 144-1). For calculation of cryocrit (volume of packed cryoglobulins as percentage of original serum volume), the cryoprecipitate has to be spun in a graded (Wintrobe) tube. A cryocrit ≥2% is considered to be positive. Cryocrit levels usually do not correlate with severity and prognosis of disease.

Some authors recommend proof of reversibility of the cryoprecipitate by rewarming an aliquot at 37°C for 24 hours.[7] For phenotyping and identification of cryoglobulin components, specific immunologic assays are performed at 37°C.

Clinical diagnosis of hyperviscosity can be established by measuring serum viscosity with an Oswald-type viscometer. Reference serum viscosity, measured as flow time through the viscometer of the patient's serum divided by that of water or saline, is between 1.4 and 1.8, whereas most symptomatic patients have values between 5 and 8. Again, clinical manifestations are often not proportional to serum viscosity.

As hypocomplementemia (with the typical pattern of low or undetectable C4 and normal or relatively normal C3 levels) occurs in up to 90% of patients with mixed cryoglobulinemia, C3 and C4 levels, usually measured in nephelometric immunoassays, should be routinely determined. A sudden increase in complement C4, raised to abnormally high levels, can be observed in some patients developing a B-cell lymphoma.[48]

RF is often positive in Type II and III cryoglobulinemia. Testing for antinuclear antibodies (ANAs, SS-A, SS-B) and other autoantibodies is indicated when there is a clinical suspicion of underlying systemic connective tissue disease, such as SLE or Sjögren syndrome. Although the immunofluorescence ANA assay is the current diagnostic gold standard, titer and specificity of ANAs may vary considerably.

Serological studies for hepatitis C and HIV should be conducted. Confirmation of other viral (hepatitis B, Epstein–Barr virus, and cytomegalovirus) or bacterial agents should be considered and may be warranted in the appropriate clinical scenario.

DIFFERENTIAL DIAGNOSIS

See Table 144-3 for an overview on differential diagnosis of cryoglobulinemia (and cryofibrinogenemia).

CLINICAL COURSE AND PROGNOSIS

Prognosis is defined by the severity of the cryoglobulinemic syndrome and by the treatability of the underlying disease causing cryoglobulinemia.

In Type I cryoglobulinemia, this will depend on the nature and stage of the hematologic disease.

TABLE 144-3
Differential Diagnosis of Cryoglobulinemia and Cryofibrinogenemia

CONDITION	DIFFERENTIAL DIAGNOSIS	COMMENTS
Type I cryoglobulinemia Cryofibrinogenemia	Thromboembolic conditions: ▪ Inheritable or acquired hypercoagulable states (protein C or S deficiency, antiphospholipid syndrome, lupus anticoagulant) ▪ Thrombocytopenic disorders (thrombotic thrombocytopenic purpura, idiopathic thrombocytopenic purpura) ▪ Paroxysmal nocturnal hemoglobinuria ▪ Disseminated intravascular coagulation ▪ Atherosclerotic peripheral vascular disease ▪ Thromboangiitis obliterans ▪ Livedoid vasculopathy ▪ Drug-induced (ie, heparin, warfarin) ▪ Atheroemboli, cholesterol emboli, septic emboli, atrial myxoma Hyperviscosity due to: ▪ Thrombocytosis (essential or secondary) ▪ Polyclonal or monoclonal gammopathies that are not cryoglobulins (ie, multiple myeloma, Waldenstrom macroglobulinemia) Primary cutaneous disorders: ▪ Urticaria ▪ Livedo or livedoid vasculitis ▪ Neutrophilic dermatoses ▪ Lipodermatosclerosis ▪ Panniculitis ▪ Idiopathic perniosis (chilblains) Oxalosis Calciphylaxis Hemoglobinopathies Infections (malaria, babesiosis)	Conditions that present with Raynaud phenomenon, noninflammatory retiform purpura, digital ischemia, gangrene and/or acrocyanosis due to vascular occlusion
Types II and III cryoglobulinemia	Small- and medium-vessel vasculitis: ▪ IgA vasculitis ▪ ANCA-associated (granulomatosis with polyangiitis, eosinophilic granulomatosis with polyangiitis, microscopic polyangiitis, polyarteritis nodosa) ▪ Rheumatic vasculitides (lupus erythematosus, rheumatoid arthritis, dermatomyositis, Sjögren syndrome) ▪ Drug-induced ▪ Infection-related (bacterial endocarditis, Rickettsia rickettsia, Neisseria meningitidis)	Conditions that primarily present with palpable purpura due to small- and medium-vessel vasculitis

A favorable prognosis in a patient with Type I cryoglobulinemia can only be expected when control of the underlying disease can be achieved. In contrast, patients with cryoglobulinemic vasculitis (Type II or III), have increased associated morbidity and mortality. Consequently, 10-year-survival rates are significantly lower than in the normal population because of renal involvement, intestinal vasculitis and widespread vasculitis, liver and cardiac disease, cardiovascular complications, and myeloproliferative disorders.[49-51] These data integrate a heterogeneous population that included hepatitis C–associated cases that were treated by differing approaches ranging from symptomatic steroid therapy to antiviral treatment.

Recent studies better elucidate the differences in prognosis and long-term complications in patients with mixed cryoglobulinemia based on HCV status. It seems that patients with non-HCV mixed cryoglobulinemia have lower gammaglobulin levels, increased frequency of renal involvement, 4-fold increased risk of developing B-cell lymphoma, and overall higher mortality rate than their HCV-positive counterparts.[33] These observations may be explained in part by the fact that HCV-associated cryoglobulinemic vasculitis can be treated with antivirals. Indeed, in this group of patients, response to antiviral therapy significantly reduces the mortality rate and changes the spectrum of complications. Infection is the most common cause of death in HCV patients with mixed cryoglobulinemia, followed by complications related to liver and cardiac involvement.[52]

COMPLICATIONS

Acute severe complications directly caused by cryoglobulins are rare with any type of cryoglobulinemia. The organs most vulnerable to complications are the nervous system and the kidneys. In Type I cryoglobulinemia, they are mostly related to an acute vaso-occlusive crisis caused by increased serum viscosity leading to acute acral ischemia or to cerebral and renal ischemia, causing stroke or acute renal failure, respectively. In addition, the underlying hematologic disease of Type I cryoglobulinemia can directly cause renal

failure (myeloma kidney). At advanced stages, complications are defined by the underlying hematologic disease itself: immunosuppression leading to infection and sepsis, coagulation disorders with severe bleeding, and side effects of hematologic disease–specific treatments.

Renal involvement remains a poor prognostic sign in patients with cryoglobulinemic vasculitis, with 15% progressing to end-stage renal disease (ESRD).[49] MPGN I from any cause including noncryoglobulinemic ones has a poor prognosis: 50% progress to ESRD within 10 years. Small studies report successful treatment of MPGN I by antiviral strategies.[53,54] The prognosis of cryoglobulinemia with no identified underlying disease (essential mixed cryoglobulinemia) is not predictable, and, again, renal involvement is associated with poor prognosis (renal failure in 10% of patients).[55] In cases of noninfectious mixed cryoglobulinemic glomerulonephritis, severe infectious and new-onset lymphoma severely impacted long-term outcome.[56]

Mixed cryoglobulinemic vasculitis may involve the peripheral nerves, leading to life-threatening situations or cause acute-on-chronic renal failure. Advanced stages of the underlying disease (mostly hepatitis C or other types of liver disease) can result in acute liver failure or problems associated with hepatic insufficiency, such as coagulation disorders, malnutrition, ascites, and the hepatorenal syndrome. Skin necrosis and vasculitic lesions can be entry sites for infection. Catastrophic individual patient courses have been described.[57]

MANAGEMENT

Three levels of treatment can be considered when treating cryoglobulinemia: (1) etiologic treatment, which is aimed at the cure or safe containment of the underlying disease; (2) pathophysiologic treatment, which is aimed at reducing the production of cryoglobulins although the underlying etiology remains untreated; and (3) symptomatic treatment that is aimed at reducing the cryoglobulin burden by removal from plasma or at mitigating the tissue's vasculitic reaction. Sometimes a combination of these approaches is used. The decision for initiation of a therapy should be informed by the severity of the symptoms, with benefits outweighing risks. Cryoglobulinemia without symptoms does not justify treatment, unless there is an underlying condition that merits therapy.

TYPE I CRYOGLOBULINEMIA

Etiologic treatment is the treatment of choice. The underlying hematologic disease, typically multiple myeloma, Waldenström macroglobulinemia, or lymphoma must be treated with chemotherapy directed by a hematologist according to current standards of care. In addition to this, severely symptomatic hyperviscosity syndrome of Type I cryoglobulinemia can be reduced by repeated plasma exchange or by cryofiltration. This may be necessary as a bridging therapy until therapy of the underlying disease shows an effect. In plasma exchange, the patient's plasma is removed by an apheresis membrane and substituted using approximately 3.5 L of donor plasma per session. Cryofiltration operates by passing the patient's cooled plasma through a specialized membrane unit designed to remove cryoprecipitates without necessitating plasma substitution.[58] However, this latter approach may be hampered by rapid clogging of the membrane in the setting of high cryoglobulin concentrations. In severe cases of Type I cryoglobulinemia, it may be necessary that these removal procedures be performed daily over a period of 2 weeks or more.

HCV-ASSOCIATED TYPE II AND III CRYOGLOBULINEMIA IN PATIENTS WITH MILD TO MODERATE DISEASE

The primary therapeutic approach depends on disease severity. Patients with mild to moderate cryoglobulinemic vasculitis without major organ failure are best treated using antiviral agents. Although the effects of the treatment exhibit some delay, the approach has the advantage of offering a potentially complete and sustained remission of the vasculitic syndrome. This has been shown by a series of pioneering studies employing regimens of interferon alone or in combination with ribavirin in patients with HCV and cryoglobulinemia.[59-62] Among those therapeutic regimens, the highest response rates were found using the current gold standard of therapy, PEGylated interferon α-2b and ribavirin.[59,63] Recovery rates for symptoms are as follows: purpura 87.5%, arthralgia 82%, peripheral neuropathy 74%, and nephropathy 50%. The rate of sustained viral response was similar to large study populations without cryoglobulinemia: 62.5%. The regimen is detailed in the current statements on the management of hepatitis C of the American Gastroenterological Association.[64] There are several limitations of antiviral combination therapy. Applicability in renal insufficiency is reduced because of drug accumulation. Recommendations for dosage adjustment have been published in the current Kidney Disease: Improving Global Outcomes (KDIGO) guidelines.[65] Although ribavirin is contraindicated at an estimated GFR <50 mL/min, it is a desirable drug rendering interferon therapy markedly more powerful.[63,66] Therefore, a dosage regimen guided by plasma levels has been proposed that could allow for off-label administration in settings of a GFR <50 mL/min.[67] Of note, ribavirin can cause hemolytic anemia requiring pausing or dosage adjustments. Interdisciplinary collaboration with expert hepatologists and nephrologists is recommended.

HCV-ASSOCIATED TYPE II AND III CRYOGLOBULINEMIA IN PATIENTS WITH SEVERE DISEASE

In the case of organ failure, such as overt renal failure, possibly accompanied by the nephrotic syndrome

or neuropathy, initial pathophysiologic and symptomatic therapy are required to achieve a reasonably rapid response. Traditionally, an immunosuppressive combination therapy using steroids possibly followed by cyclophosphamide, azathioprine, or chlorambucil has been used.[68] The use of the chimeric anti-CD20 antibody, rituximab, has recently emerged as a powerful alternative to classic immunosuppression.[69] The antibody targets B-lymphocytes, leading to a depletion of 95% of the B-lymphocytic population. Thereby, the cryoglobulin-producing B lymphocytic clone is markedly reduced, leading to marked cryoglobulin level reduction and consecutive remission. Taken together, this represents a pathophysiologic approach to treatment. One recent clinical trial compared the efficacy and safety profile of a combination of pegylated interferon-α (Peg-IFN-α) and ribavirin, with or without rituximab. More patients in the rituximab group had complete response and greater than 80% had sustained clearance of HCV RNA for up to 3 years compared to only 40% of patients in the Peg-IFN-α and ribavirin only group.[70] Another similar study found that patients in the Peg-IFN-α/ribavirin/rituximab arm had a shorter time to clinical remission, better renal response rates, and higher rates of cryoglobulin clearance.[71] In light of these findings, some authors recommend rituximab combined with Peg-IFN-α/ribavirin as the preferred therapeutic regimen in patients with severe or refractory/relapsing disease, renal involvement, and in those in whom rapid clinical response is needed.[72,73] Though reported to be generally well tolerated in patients with cryoglobulinemic syndrome, rituximab has several limitations. It should not be used in patients with overt skin ulceration because of interference with wound healing. A recent report has pointed to a severe complication with worsening of cryoglobulinemic vasculitis syndrome in patients with high baseline levels of mixed cryoglobulins receiving rituximab.[74]

TYPE II AND III CRYOGLOBULINEMIC VASCULITIS NOT ASSOCIATED WITH HCV

In Type II and III cryoglobulinemic vasculitis not associated with HCV, therapeutic regimens have not been extensively studied. In mild to moderate disease, conservative measures including the avoidance of cold temperatures, resting, and the use of nonsteroidal antiinflammatory drugs such as colchicine may be sufficient. For more severe cases, a combination of rituximab and oral prednisone showed greater efficacy at achieving complete clinical, renal, and immunologic responses compared to the combination of alkylating agents and prednisone at the expense of more severe infections in the rituximab group. Mortality rates, however, were similar in both groups.[75] Therefore, rituximab-based regimens are more effective but should be used judiciously because of the high prevalence of infections.

CRYOFIBRINOGENEMIA

AT-A-GLANCE

- Cryofibrinogenemia results from cryoprecipitation of patients' native fibrinogen or fibrin by-products in plasma but not serum.
- Cryofibrinogenemia is classified as essential or secondary (associated with malignancies, collagen vascular diseases, and thrombotic disorders).
- Cryofibrinogenemia is rare, but probably underestimated in clinical practice.
- Typical clinical features result from thrombosis (thrombotic phenomena of skin and viscera) and are often life-threatening.

EPIDEMIOLOGY

Cryofibrinogenemia is often clinically asymptomatic. Of note, 2% to 9% of healthy persons may have demonstrable amounts of cryofibrinogen, usually in concentrations less than 50 mg/L. In the past, cryofibrinogenemia was considered rare, but recent single-center studies indicate that this disorder is possibly underrecognized because of the infrequency with which it causes symptoms, and inconsistencies in laboratory investigations producing falsely negative results. Patients are usually diagnosed between the fifth and seventh decades of life. Initial studies noted the prevalence of cryofibrinogenemia among hospitalized patients between 3.4% and 13%, with a female predilection (female–male ratio 4:1) without age or racial differences. In a study by Saadoun and coworkers, 2312 hospitalized patients were tested for cryofibrinogenemia between 1996 and 2006.[76] A total of 515 (22.2%) patients had positive test results, of whom 88% had secondary and 12% had essential cryofibrinogenemia. Another retrospective, single-hospital, 10-year report identified 61 patients having cryofibrinogenemia, which was essential in 18 (29.5%) and secondary in 43 (70.5%) patients.[77]

CLINICAL FEATURES

Some people with cryofibrinogenemia are asymptomatic, whereas others have clinical features resulting from thrombosis that can be life-threatening when untreated.

CUTANEOUS FINDINGS

Patients with cryofibrinogenemia typically report a temporal association between cold exposure and onset of symptoms. Clinical signs in cryofibrinogenemia are mostly cutaneous and are typically located on cold-exposed areas (hands, feet, buttocks, ear, nose). These cold-sensitive lesions often reflect cold-induced

thromboses, increased viscosity, and/or vascular reactivity. Palpable purpura with underlying leucocytoclastic vasculitis is the most frequent clinical presentation. Other cutaneous features can include painful ulcerations, livedo racemosa, Raynaud phenomenon, segmental swelling, lower extremity nodules, painful or pruritic erythema (perniosis) of the extremities, and cold urticaria. Cryofibrinogenemia may clinically simulate calciphylaxis, which is usually seen in patients with ESRD.

NONCUTANEOUS FINDINGS

Nonspecific constitutional complaints of fever and malaise are common. Cryofibrinogenemia has a broad spectrum of clinical manifestations including vessel, kidney, musculoskeletal, and/or neuronal involvement. Various thrombotic events, nephritic or nephrotic syndrome, arthralgia, myalgia, multineuritis, and fever have been reported.[78] In a recent study, the main clinical manifestations included purpura (46.6%), skin necrosis (36.6%), and arthralgia (31.6%), with cold sensitivity in 40% and overall thrombotic events occurring in up to 40% of cases. A high cryofibrinogen plasma concentration was a significant predisposing factor for thrombotic events.[76] Thrombotic events include cerebrovascular accidents (stroke, ocular thrombi, including retinal arterial and/or venous occlusions), myocardial infarction, limb and bowel ischemia or infarction, and pulmonary emboli, although a causal relationship has not been proven for all described cases.

ETIOLOGY AND PATHOGENESIS

Precipitation of patients' native fibrinogen or fibrin byproducts in plasma, but not serum, was first described by Korst and Kratochvil in 1955.[79] Cryofibrinogenemia can be classified as primary (also named essential or idiopathic) or secondary. Diagnosis of primary cryofibrinogenemia requires the presence of cryofibrinogens in plasma, absence of cryoglobulins, and one or more compatible clinical features, such as cold-induced thromboses, increases in blood viscosity and/or vascular reactivity, in an otherwise healthy individual. Some authors hypothesize that essential cryofibrinogenemia might be a prerequisite for a secondary disease.

Secondary cryofibrinogenemia is diagnosed when an associated disease or drug is present. The most frequently associated disorders include malignancy, infections, and connective tissue and autoimmune diseases (see Table 144-4).

Cryofibrinogen is characteristically composed of fibrinogen, fibrin, fibronectin, and/or fibrin degradation products. Other components include albumin, cold-insoluble globulin, factor VIII, and plasma proteins, as well as the plasmin activity inhibitors α1-antitrypsin and α2-macroglobulin. Pathology in cryofibrinogenemia is attributed to "in situ" thrombosis, leading to thrombotic occlusion of small and medium-sized dermal vessels and resultant ischemia. Defects in the fibrinolysis process might lead to further clotting in small and medium arteries. Additional immunologic mechanisms may play a significant role in the pathophysiology of cryofibrinogenemia.

Secondary forms of cryofibrinogenemia are significantly more frequent in patients with combined cryofibrinogenemia and cryoglobulinemia than in those with isolated cryofibrinogenemia (79 vs 47%).[80] Among HCV-infected patients, cryofibrinogenemia is common, and closely correlated with cryoglobulinemia. In a study of 143 patients with HCV infection, 53 (37%) had cryofibrinogen levels >50 mg/L. Forty-seven of these cryofibrinogen-positive patients (89%) had positive tests for cryoglobulins.[81]

TABLE 144-4
Conditions Associated with Cryofibrinogenemia

Endocrine Disorders
Diabetes mellitus
Hypothyroidism (Hashimoto disease)
Graves disease
Infections
Viral (VZV, EBV, HC)
Bacterial (*Klebsiella pneumoniae*, *Mycoplasma pneumoniae*)
Severe sepsis
Malignancy
Adenocarcinoma (gastric, lung)
Hepatocarcinoma
Ovarian cancer
Prostate cancer
Hematologic Disorders
Multiple myeloma
Waldenstrom macroglobulinemia
Lymphoma (follicular, B cell, T cell)
Chronic myelomonocytic leukemia
Autoimmune Diseases
Mixed connective tissue disease
Sjögren syndrome
Dermatomyositis
Polymyositis
Rheumatoid arthritis
Systemic lupus erythematosus
Systemic sclerosis
Vasculitis
ANCA-associated vasculitis
Giant cell arteritis
Behçet disease
Polyarteritis nodosa
Henoch–Schönlein purpura
Cutaneous Disorders
Psoriasis
Pyoderma gangrenosum
Drugs
Oral contraceptive agents
Miscellaneous
Sarcoidosis
Spondyloarthropathy
Inflammatory bowel disease.

EBV, Epstein–Barr virus; HCV, hepatitis C virus; VZV, varicella-zoster virus.

DIAGNOSIS

LABORATORY TESTING

Laboratory workup is critical for the accuracy of cryofibrinogen detection and ideally includes separation in a temperature-controlled centrifuge.

The warm blood specimen should be anticoagulated with citrate, EDTA, or oxalate, but not heparin, which nonspecifically precipitates fibrinogen and may result in a false positive result. The formation of a cryoprecipitate may also lead to a false negative result if the sample was not collected at 37°C. The sample should be processed within an hour. After centrifugation at 37°C, the plasma is placed in a Wintrobe tube, refrigerated at 4°C, and observed for the formation of a precipitate for 72 hours. The cryocrit is quantitated by centrifuging the specimen while it remains cooled to 4°C. Each millimeter of visible precipitate in the Wintrobe tube represents 1% of cryocrit.

In parallel, a cryoglobulin test is simultaneously performed in a sample without anticoagulants, to ensure that the plasma precipitate is cryofibrinogen and not cryoglobulin.

Affinity-chromatography, immunodiffusion, and/or electrophoresis are used for quantitation and/or identification of the individual cryofibrinogen components using antifibrinogen, anti–heavy-chain and anti–light-chain antibodies.[80,82]

HISTOLOGIC FEATURES

Irrespective of the anatomic site, cryofibrinogenemia shows an occlusive thrombotic diathesis comprising eosinophilic refractile deposits within vessel lumina with extension into the vessel intima, with or without an accompanying characteristic granulomatous vasculitis.[77,83] Cryofibrinogen precipitates have a cylindrical configuration in ultrastructural analysis, which is often displayed within the vessel lumina. Examination of renal deposits showed fibrillary material within glomerular capillary lumina and tubules with unique morphologic features not previously described.[78]

DIFFERENTIAL DIAGNOSIS

Table 144-3 provides a comprehensive list of differential diagnosis of cryoglobulinemia and cryofibrinogenemia.

CLINICAL COURSE AND PROGNOSIS

Clinical data regarding prognosis in cryofibrinogenemia are limited. In one study, 3 of 60 patients with essential cryofibrinogenemia died after a mean followup of 85 months.

COMPLICATIONS

Typical complications due to thrombotic events include gangrene (5%), septicemia (5%), and leg amputation (3.3%).[76] In some cases, essential cryofibrinogenemia might suggest a secondary disease, particularly lymphomas.[84] In a 2008 report, 27% of patients with primary cryofibrinogenemia developed lymphoma after a 5-year followup period.[77]

MANAGEMENT

Smoking cessation, avoidance of cold exposure, and eliminating the use of vasoconstricting drugs are nonpharmacologic interventions that are recommended but are only partially effective. In secondary cryofibrinogenemia, specific treatment of the underlying disease can lead to improvement in related symptoms.

For essential cryofibrinogenemia, various pharmacologic agents including fibrinolytic approaches and immunosuppressive agents have been proposed. Oral stanozolol (2-4 mg twice daily), a synthetic derivative of testosterone with substantial fibrinolytic properties, has been effective after several days of treatment.[85] Streptokinase (sometimes in combination with streptodornase), given intravenously (25,000-200,000 U/d) has a more rapid onset of action than stanozolol. The use of colchicine (0.6 mg twice daily) in combination with high-dose pentoxifylline (800 mg 3 times daily) has been described.[86]

Combinations of glucocorticoids (prednisone 10-60 mg/d) with low-dose aspirin, for nonsevere cases, or other immunosuppressive agents, for severe disease (azathioprine 150 mg/d or chlorambucil 10 mg/d) also have been used in small studies with some benefit, including successful treatment of acute attacks.[87,88]

Plasmapheresis might be considered when high levels of cryofibrinogens are present and are associated with monoclonal proteins (as seen in myeloma, Waldenström macroglobulinemia), hyperviscosity, or clinically significant thrombosis. Long-term repeated plasmaphereses and antiimmunoglobulin adsorption improved the symptoms in one patient with secondary cryofibrinogenemia.[89]

Regular followups are mandatory because of the high risk of symptom recurrence and development of lymphoma years after the initial diagnosis.[77,90]

ACKNOWLEDGMENTS

The authors acknowledge the significant contributions of Holger Schmid and Gerald S. Braun, the former authors of this chapter.

REFERENCES

1. Wintrobe MM, Buell MV. Hyperproteinemia associated with multiple myeloma. With report of a case in which an extraordinary hyperproteinemia was associated with thrombosis of the retinal veins and symptoms suggesting Raynaud's disease. *Bull Johns Hopkins Hosp.* 1933;52:156-165.
2. Brouet JC, Clauvel JP, Danon F, et al. Biologic and clinical significance of cryoglobulins. A report of 86 cases. *Am J Med.* 1974;57(5):775-788.
3. Zinneman HH. Cryoglobulins and pyroglobulins. *Pathobiol Annu.* 1980;10:83-104.
4. Tissot JD, Schifferli JA, Hochstrasser DF, et al. Two-dimensional polyacrylamide gel electrophoresis analysis of cryoglobulins and identification of an IgM-associated peptide. *J Immunol Methods.* 1994;173(1):63-75.
5. Roccatello D, Fornasieri A, Giachino O, et al. Multicenter study on hepatitis C virus-related cryoglobulinemic glomerulonephritis. *Am J Kidney Dis.* 2007;49(1):69-82.
6. Ferri C, Mascia MT. Cryoglobulinemic vasculitis. *Curr Opin Rheumatol.* 2006;18(1):54-63.
7. Ferri C. Mixed cryoglobulinemia. *Orphanet J Rare Dis.* 2008;3:25.
8. Trejo O, Ramos-Casals M, García-Carrasco M, et al. Cryoglobulinemia: study of etiologic factors and clinical and immunologic features in 443 patients from a single center. *Medicine (Baltimore).* 2001;80(4):252-262.
9. Lunel F, Musset L, Cacoub P, et al. Cryoglobulinemia in chronic liver diseases: role of hepatitis C virus and liver damage. *Gastroenterology.* 1994;106(5):1291-1300.
10. Pawlotsky JM, Ben Yahia M, Andre C, et al. Immunological disorders in C virus chronic active hepatitis: a prospective case-control study. *Hepatology.* 1994;19(4):841-848.
11. Santagostino E, et al. High prevalence of serum cryoglobulins in multitransfused hemophilic patients with chronic hepatitis C. *Blood.* 1998;92(2):516-519.
12. Cacoub P, Poynard T, Ghillani P, et al. Extrahepatic manifestations of chronic hepatitis C. MULTIVIRC Group. Multidepartment Virus C. *Arthritis Rheum.* 1999;42(10):2204-2212.
13. Cacoub P, Costedoat-Chalumeau N, Lidove O, et al. Cryoglobulinemia vasculitis. *Curr Opin Rheumatol.* 2002;14(1):29-35.
14. Fiorentino DF. Cutaneous vasculitis. *J Am Acad Dermatol.* 2003;48(3):311-340.
15. Terrier B, Marie I, Lacraz A, et al. Non HCV-related infectious cryoglobulinemia vasculitis: results from the French nationwide CryoVas survey and systematic review of the literature. *J Autoimmun.* 2015;65:74-81.
16. Cohen SJ, Pittelkow MR, Su WP. Cutaneous manifestations of cryoglobulinemia: clinical and histopathologic study of seventy-two patients. *J Am Acad Dermatol.* 1991;25(1, pt 1):21-27.
17. Rossi D, Mansouri M, Baldovino S, et al. Nail fold videocapillaroscopy in mixed cryoglobulinaemia. *Nephrol Dial Transplant.* 2004;19(9):2245-2249.
18. Meltzer M, Franklin EC. Cryoglobulinemia—a study of twenty-nine patients. I. IgG and IgM cryoglobulins and factors affecting cryoprecipitability. *Am J Med.* 1966;40(6):828-836.
19. Monti G, Galli M, Invernizzi F, et al. Cryoglobulinaemias: a multi-centre study of the early clinical and laboratory manifestations of primary and secondary disease. GISC. Italian Group for the Study of Cryoglobulinaemias. *Q J Med.* 1995;88(2):115-126.
20. Perico N, Cattaneo D, Bikbov B, et al. Hepatitis C infection and chronic renal diseases. *Clin J Am Soc Nephrol.* 2009;4(1):207-220.
21. Ferri C, La Civita L, Cirafisi C, et al. Peripheral neuropathy in mixed cryoglobulinemia: clinical and electrophysiologic investigations. *J Rheumatol.* 1992;19(6):889-895.
22. Manganelli P, Pavesi G, Fiocchi A, et al. Peripheral neuropathy with mixed cryoglobulinemia [in Italian]. *Recenti Prog Med.* 1990;81(11):681-685.
23. Gemignani F, Pavesi G, Fiocchi A, et al. Peripheral neuropathy in essential mixed cryoglobulinaemia. *J Neurol Neurosurg Psychiatry.* 1992;55(2):116-120.
24. Gemignani F, Marbini A, Di Giovanni G, et al. Cryoglobulinaemic neuropathy manifesting with restless legs syndrome. *J Neurol Sci.* 1997;152(2):218-223.
25. Weinberger A, Berliner S, Pinkhas J. Articular manifestations of essential cryoglobulinemia. *Semin Arthritis Rheum.* 1981;10(3):224-229.
26. Viegi G, Fornai E, Ferri C, et al. Lung function in essential mixed cryoglobulinemia: a short-term follow-up. *Clin Rheumatol.* 1989;8(3):331-338.
27. Bertorelli G, et al. Subclinical pulmonary involvement in essential mixed cryoglobulinemia assessed by bronchoalveolar lavage. *Chest.* 1991;100(5):1478-1479.
28. Zackrison LH, Katz P. Bronchiolitis obliterans organizing pneumonia associated with essential mixed cryoglobulinemia. *Arthritis Rheum.* 1993;36(11):1627-1630.
29. Abdulkarim T, Saklayen M, Yap J. Cryoglobulinemia due to hepatitis C with pulmonary renal syndrome. *Case Rep Nephrol.* 2013;2013:278975.
30. Antonelli A, Ferri C, Fallahi P, et al. Type 2 diabetes in hepatitis C-related mixed cryoglobulinaemia patients. *Rheumatology (Oxford).* 2004;43(2):238-240.
31. Cacoub P, Renou C, Kerr G, et al. Influence of HLA-DR phenotype on the risk of hepatitis C virus-associated mixed cryoglobulinemia. *Arthritis Rheum.* 2001;44(9):2118-2124.
32. Sebastiani GD, Bellisai F, Caudai C, et al. Association of extrahepatic manifestations with HLA class II alleles and with virus genotype in HCV infected patients. *J Biol Regul Homeost Agents.* 2005;19(1-2):17-22.
33. Saadoun D, Sellam J, Ghillani-Dalbin P, et al. Increased risks of lymphoma and death among patients with non-hepatitis C virus-related mixed cryoglobulinemia. *Arch Intern Med.* 2006;166(19):2101-2108.
34. Sene D, Ghillani-Dalbin P, Thibault V, et al. Long-term course of mixed cryoglobulinemia in patients infected with hepatitis C virus. *J Rheumatol.* 2004;31(11):2199-2206.
35. Antonelli A, Ferri C, Ferrari SM, et al. Serum levels of proinflammatory cytokines interleukin-1beta, interleukin-6, and tumor necrosis factor alpha in mixed cryoglobulinemia. *Arthritis Rheum.* 2009;60(12):3841-3847.
36. Antonelli A, Fallahi P, Ferrari SM, et al. Parallel increase of circulating CXCL11 and CXCL10 in mixed cryoglobulinemia, while the proinflammatory cytokine IL-6 is associated with high serum Th2 chemokine CCL2. *Clin Rheumatol.* 2013;32(8):1147-1154.
37. Mazzi V, Ferrari SM, Giuggioli D, et al. Role of CXCL10 in cryoglobulinemia. *Clin Exp Rheumatol.* 2015;33(3):433-436.
38. Artoni E, Sighinolfi GL, Gatti AM, et al. Micro and nanoparticles as possible pathogenetic co-factors in mixed cryoglobulinemia. *Occup Med (Lond).* 2017;67(1):64-67.
39. Levo Y, Gorevic PD, Kassab HJ, et al. Association between hepatitis B virus and essential mixed cryoglobulinemia. *N Engl J Med.* 1977;296(26):1501-1504.

40. Dimitrakopoulos AN, Kordossis T, Hatzakis A, et al. Mixed cryoglobulinemia in HIV-1 infection: the role of HIV-1. *Ann Intern Med.* 1999;130(3):226-230.
41. Fabris P, Tositti G, Giordani MT, et al. Prevalence and clinical significance of circulating cryoglobulins in HIV-positive patients with and without co-infection with hepatitis C virus. *J Med Virol.* 2003;69(3):339-343.
42. Chiche L, Grados A, Harlé JR, et al. Mixed cryoglobulinemia: a role for parvovirus b19 infection. *Clin Infect Dis.* 2010;50(7):1074-1075.
43. Ramos-Casals M, Anaya JM, García-Carrasco M, et al. Cutaneous vasculitis in primary Sjogren syndrome: classification and clinical significance of 52 patients. *Medicine (Baltimore).* 2004;83(2):96-106.
44. Ramos-Casals M, Cervera R, Yagüe J, et al. Cryoglobulinemia in primary Sjogren's syndrome: prevalence and clinical characteristics in a series of 115 patients. *Semin Arthritis Rheum.* 1998;28(3):200-205.
45. Retamozo S, Gheitasi H, Quartuccio L, et al. Cryoglobulinaemic vasculitis at diagnosis predicts mortality in primary Sjogren syndrome: analysis of 515 patients. *Rheumatology (Oxford).* 2016;55(8):1443-1451.
46. Garcia-Carrasco M, Ramos-Casals M, Cervera R, et al. Cryoglobulinemia in systemic lupus erythematosus: prevalence and clinical characteristics in a series of 122 patients. *Semin Arthritis Rheum.* 2001;30(5):366-373.
47. Shachaf S, Yair M. The correlation between antiphospholipid syndrome and cryoglobulinemia: case series of 4 patients and review of the literature. *Rev Bras Reumatol Engl Ed.* 2016;56(1):2-7.
48. Vitali C, Ferri C, Nasti P, et al. Hypercomplementaemia as a marker of the evolution from benign to malignant B cell proliferation in patients with type II mixed cryoglobulinaemia. *Br J Rheumatol.* 1994;33(8):791-792.
49. Ferri C, Sebastiani M, Giuggioli D, et al. Mixed cryoglobulinemia: demographic, clinical, and serologic features and survival in 231 patients. *Semin Arthritis Rheum.* 2004;33(6):355-374.
50. Della Rossa A, Marchi F, Catarsi E, et al. Mixed cryoglobulinemia and mortality: a review of the literature. *Clin Exp Rheumatol.* 2008;26(5)(suppl 51):S105-S108.
51. Saccardo E, Novati P, Sironi D, et al. Causes of death in symptomatic cryoglobulinemia: 30 years of observation in a Department of Internal Medicine. *Dig Liver Dis.* 2007;39(suppl 1):S52-S54.
52. Landau DA, Scerra S, Sene D, et al. Causes and predictive factors of mortality in a cohort of patients with hepatitis C virus-related cryoglobulinemic vasculitis treated with antiviral therapy. *J Rheumatol.* 2010;37(3):615-621.
53. Bruchfeld A, Lindahl K, Ståhle L, et al. Interferon and ribavirin treatment in patients with hepatitis C-associated renal disease and renal insufficiency. *Nephrol Dial Transplant.* 2003;18(8):1573-1580.
54. Sabry AA, Sobh MA, Sheaashaa HA, et al. Effect of combination therapy (ribavirin and interferon) in HCV-related glomerulopathy. *Nephrol Dial Transplant.* 2002;17(11):1924-1930.
55. Gorevic PD, Kassab HJ, Levo Y, et al. Mixed cryoglobulinemia: clinical aspects and long-term follow-up of 40 patients. *Am J Med.* 1980;69(2):287-308.
56. Zaidan M, Terrier B, Pozdzik A, et al; CryoVas study group. Spectrum and prognosis of noninfectious renal mixed cryoglobulinemic GN. *J Am Soc Nephrol.* 2016;27(4):1213-1224.
57. Monti G, Saccardo F. Emergency in cryoglobulinemic syndrome: what to do? *Dig Liver Dis.* 2007;39(suppl 1):S112-S115.
58. Siami GA, Siami FS, Ferguson P, et al. Cryofiltration apheresis for treatment of cryoglobulinemia associated with hepatitis C. *ASAIO J.* 1995;41(3):M315-M318.
59. Cacoub P, Saadoun D, Limal N, et al. PEGylated interferon alfa-2b and ribavirin treatment in patients with hepatitis C virus-related systemic vasculitis. *Arthritis Rheum.* 2005;52(3):911-915.
60. Casato M, Agnello V, Pucillo LP, et al. Predictors of long-term response to high-dose interferon therapy in type II cryoglobulinemia associated with hepatitis C virus infection. *Blood.* 1997;90(10):3865-3873.
61. Mazzaro C, Zorat F, Caizzi M, et al. Treatment with peg-interferon alfa-2b and ribavirin of hepatitis C virus-associated mixed cryoglobulinemia: a pilot study. *J Hepatol.* 2005;42(5):632-638.
62. Naarendorp M, Kallemuchikkal U, Nuovo GJ, et al. Longterm efficacy of interferon-alpha for extrahepatic disease associated with hepatitis C virus infection. *J Rheumatol.* 2001;28(11):2466-2473.
63. Saadoun D, Resche-Rigon M, Thibault V, et al. Antiviral therapy for hepatitis C virus--associated mixed cryoglobulinemia vasculitis: a long-term followup study. *Arthritis Rheum.* 2006;54(11):3696-3706.
64. Ghany MG, Strader DB, Thomas DL, et al. Diagnosis, management, and treatment of hepatitis C: an update. *Hepatology.* 2009;49(4):1335-1374.
65. Kidney Disease: Improving Global Outcomes (KDIGO). KDIGO clinical practice guidelines for the prevention, diagnosis, evaluation, and treatment of hepatitis C in chronic kidney disease. *Kidney Int Suppl.* 2008;(109):S1-S99.
66. Dienstag JL, McHutchison JG. American Gastroenterological Association technical review on the management of hepatitis C. *Gastroenterology.* 2006;130(1):231-264; quiz 214-217.
67. Bruchfeld A, Lindahl K, Schvarcz R, et al. Dosage of ribavirin in patients with hepatitis C should be based on renal function: a population pharmacokinetic analysis. *Ther Drug Monit.* 2002;24(6):701-708.
68. Saadoun D, Delluc A, Piette JC, et al. Treatment of hepatitis C-associated mixed cryoglobulinemia vasculitis. *Curr Opin Rheumatol.* 2008;20(1):23-28.
69. Cacoub P, Delluc A, Saadoun D, et al. Anti-CD20 monoclonal antibody (rituximab) treatment for cryoglobulinemic vasculitis: where do we stand? *Ann Rheum Dis.* 2008;67(3):283-287.
70. Dammacco F, Tucci FA, Lauletta G, et al. Pegylated interferon-alpha, ribavirin, and rituximab combined therapy of hepatitis C virus-related mixed cryoglobulinemia: a long-term study. *Blood.* 2010;116(3):343-353.
71. Saadoun D, Resche Rigon M, Sene D, et al. Rituximab plus Peg-interferon-alpha/ribavirin compared with Peg-interferon-alpha/ribavirin in hepatitis C-related mixed cryoglobulinemia. *Blood.* 2010;116(3):326-334; quiz 504-505.
72. Terrier B, Cacoub P. Cryoglobulinemia vasculitis: an update. *Curr Opin Rheumatol.* 2013;25(1):10-18.
73. Saadoun D, Resche-Rigon M, Sene D, et al. Rituximab combined with Peg-interferon-ribavirin in refractory hepatitis C virus-associated cryoglobulinaemia vasculitis. *Ann Rheum Dis.* 2008;67(10):1431-1436.
74. Sene D, Ghillani-Dalbin P, Amoura Z, et al. Rituximab may form a complex with IgMkappa mixed cryoglobulin and induce severe systemic reactions in patients with hepatitis C virus-induced vasculitis. *Arthritis Rheum.* 2009;60(12):3848-3855.
75. Terrier B, Krastinova E, Marie I, et al. Management of noninfectious mixed cryoglobulinemia vasculitis: data

from 242 cases included in the CryoVas survey. *Blood.* 2012;119(25):5996-6004.
76. Saadoun D, Elalamy I, Ghillani-Dalbin P, et al. Cryofibrinogenemia: new insights into clinical and pathogenic features. *Am J Med.* 2009;122(12):1128-1135.
77. Belizna CC, Tron F, Joly P, et al. Outcome of essential cryofibrinogenaemia in a series of 61 patients. *Rheumatology (Oxford).* 2008;47(2):205-207.
78. Singh A, Gaber LW. Nephrotic syndrome and chronic renal insufficiency associated with essential cryofibrinogenemia. *Nephrol Dial Transplant.* 2007;22(6): 1772-1775.
79. Korst DR, Kratochvil CH. Cryofibrinogen in a case of lung neoplasm associated with thrombophlebitis migrans. *Blood.* 1955;10(9):945-953.
80. Blain H, Cacoub P, Musset L, et al. Cryofibrinogenaemia: a study of 49 patients. *Clin Exp Immunol.* 2000;120(2):253-260.
81. Delluc A, Saadoun D, Ghillani-Dalbin P, et al. Cryofibrinogen in patients with hepatitis C virus infection. *Am J Med.* 2008;121(7):624-631.
82. Musset L, Diemert MC, Taibi F, et al. Characterization of cryoglobulins by immunoblotting. *Clin Chem.* 1992;38(6):798-802.
83. Nash JW, Ross P Jr, Neil Crowson A, et al. The histopathologic spectrum of cryofibrinogenemia in four anatomic sites. Skin, lung, muscle, and kidney. *Am J Clin Pathol.* 2003;119(1):114-122.
84. Lee J, Apisarnthanarax N, Jordon RE, et al. Cryofibrinogenemia in a patient with B-cell lymphoma. *Clin Lymphoma.* 2000;1(3):234-237; discussion 238-239.
85. Kirsner RS, Eaglstein WH, Katz MH, et al. Stanozolol causes rapid pain relief and healing of cutaneous ulcers caused by cryofibrinogenemia. *J Am Acad Dermatol.* 1993;28(1):71-74.
86. Chartier M, Falanga V. Healing of ulcers due to cryofibrinogenemia with colchicine and high-dose pentoxifylline. *Am J Clin Dermatol.* 2009;10(1):39-42.
87. Amdo TD, Welker JA. An approach to the diagnosis and treatment of cryofibrinogenemia. *Am J Med.* 2004; 116(5):332-337.
88. Michaud M, Pourrat J. Cryofibrinogenemia. *J Clin Rheumatol.* 2013;19(3):142-148.
89. Euler HH, Zeuner RA, Béress R, et al. Monoclonal cryo-antifibrinogenemia. *Arthritis Rheum.* 1996;39(6): 1066-1069.
90. Belizna C, Loufrani L, Subra JF, et al. A 5-year prospective follow-up study in essential cryofibrinogenemia patients. *Autoimmun Rev.* 2011;10(9):559-562.

Chapter 145 :: Raynaud Phenomenon

:: Drew Kurtzman & Ruth Ann Vleugels

AT-A-GLANCE

- Raynaud phenomenon is a vascular disorder characterized by recurrent episodic attacks of digital ischemia provoked by exposure to cold or emotional stress.
- Affects up to 10% of the population, 4:1 female-to-male ratio.
- Classified as primary (idiopathic) and secondary (underlying disease or cause present) forms; severity ranges from mild/benign to severe with loss of tissue and risk of amputation.
- Connective tissue diseases, particularly systemic sclerosis, are among the most common underlying causes of secondary Raynaud phenomenon.
- Behavioral modification, pharmacologic therapies, and surgical interventions are effective at reducing the frequency and severity of attacks.

Raynaud phenomenon (RP) is a common disorder characterized by recurrent attacks of arterial vasoconstriction resulting in hypoperfusion of the digits and acral tissues. Episodes of RP are triggered by exposure to cold or, less commonly, emotional stress. Classically, RP exhibits a triphasic sequence of color changes of the digits of the hands and/or feet: well-demarcated pallor (corresponding to vasoconstriction and ischemia), followed by cyanosis (venous stasis), and, finally, erythema (compensatory reperfusion) upon rewarming.[1] However, not all patients demonstrate this classic triad of color changes.

Depending on the presence or absence of an underlying disorder, 2 forms of RP are recognized and usually display divergent disease courses. Primary (idiopathic) RP represents an exaggerated physiologic response to cold or emotional stimuli caused by functional changes in blood vessels and their innervation.[2] By definition, primary RP does not result in tissue injury. Secondary RP, which occurs as a result of a systemic disorder or drug exposure, is distinguished by a more aggressive course that can lead to profound tissue ischemia and eventuate in cutaneous ulceration, scarring, or digital gangrene. Management of RP centers on behavioral changes to avoid attacks and on pharmacologic and nonpharmacologic therapies to allay symptoms and reduce morbidity. When present, treatment of the underlying cause remains a critical component of managing secondary disease.

EPIDEMIOLOGY

Precise epidemiologic data on RP are lacking. True estimates are biased by underreporting because many patients with RP never seek medical attention and by the greater attention that has been given to secondary forms of the disease. RP likely affects up to 10% of the general population and 90% of patients with systemic sclerosis (SSc).[3-5] Despite study biases, cases of primary RP far outnumber those of secondary disease and comprise up to 90% of all cases.[6,7] Symptoms of RP often develop during the second decade of life, and there is a strong female predominance, with an estimated 4:1 female-to-male prevalence ratio. Increases in the frequency and severity of attacks during menstrual cycles suggest that female hormones play a role in the pathogenesis of RP.[8] Differences in seasonal skin temperatures, alcohol use, age, smoking status, and marital status between women and men also explain the sex differences observed.[9,10] Familial aggregation has been noted in some series, substantiating a role for genetic predisposition.[11] Other associations reported in epidemiologic studies include living in a cold climate, certain occupations, cardiovascular disease, low body mass index, and use of vibratory tools.

CLINICAL FEATURES

HISTORY

A clear description of vasospastic attacks is fundamental to the diagnosis of RP. Patients with RP report episodic attacks of white or blue digits induced by cold exposure and, less commonly, by emotional stimuli. Often, only a portion of the digit is affected, and the thumbs are typically spared. Patients rarely volunteer the classic tri-sequence color change, and most only recognize the pallor phase. During attacks, affected digits are numb and, upon rewarming, become bright red and may be accompanied by throbbing pain. If pain is prominent during the ischemic (pallor) phase, a secondary cause is more likely. Other features suggestive of secondary disease are cutaneous ulceration or thumb involvement, as these are rarely seen in primary RP.[2] Episodes of RP usually last for 30 minutes, but can persist for hours. Although the fingers and toes are classically affected, attacks may involve the nose, earlobes, or nipples.

A careful review of systems is needed to screen for symptoms that point to an underlying disorder as a cause for secondary RP. Arthralgias, dysphagia,

muscle weakness, photosensitivity, gastroesophageal reflux, shortness of breath, or sicca symptoms suggest a connective tissue disorder. Claudication indicates atherosclerotic arterial disease. A careful review of medications allows for identification of a potential drug cause. Use of vibratory tools or perpetual hand trauma helps to establish an occupational exposure or hobby as the cause for RP.

CUTANEOUS FINDINGS

Well-demarcated pallor or cyanosis extending from the tip to the more proximal segments of the digits of the fingers or toes typifies the skin changes seen in RP (Fig. 145-1). The skin distal to the line of ischemia is cold and pale, while the proximal skin is often pink and warm. As digits rewarm, blanched skin becomes cyanotic, secondary to low blood flow and deoxygenation, and then transitions to bright red, due to reactive hyperemia. Persistent ischemic discoloration in spite of rewarming suggests secondary disease.

Trophic changes of the digits are signs of prolonged attacks of RP and also point to secondary disease. Other skin changes may include atrophy, dystrophic nail changes, and alopecia on the dorsal surfaces of the digits. If present, true sclerodactyly warrants a high degree of suspicion for SSc. In the setting of longstanding RP with repeated bouts of ischemia, digital tapering may occur, which can be challenging to distinguish from sclerodactyly for many clinicians. Ulcerations, which can be extremely painful and punctuated at night, favor the pulp of the finger and the nail unit. Ulcers heal slowly, leaving characteristic small, pitted scars (Fig. 145-2). Ulcers may become infected and can even result in digital osteomyelitis. Although rare, gangrene and autoamputation of distal portions of the digits can occur.

Careful inspection of the proximal nailfold, giving attention to the capillaries with the aid of microscopy (or handheld dermoscopy), is a critical part of evaluating the patient with RP. In a large, single institution study prospectively following 586 patients with RP, the presence of an abnormal nailfold capillary pattern (capillary enlargement and/or capillary loss) at baseline predicted the development of SSc in 151 (25.8%) of patients during a 15-year followup period.[12] When accompanied by an SSc-specific autoantibody, abnormal capillaries portended a 60-fold increased risk for progression to SSc among subjects in their cohort. The authors concluded that microvascular damage, which can be assessed by evaluating the proximal nailfold capillaries, is an independent predictor for progression to SSc, highlighting the importance of this examination finding.

Figure 145-1 Triphasic color changes on the fingers of a patient with primary Raynaud phenomenon.

Figure 145-2 Pitted scarring involving fourth and fifth fingertips in a patient with Raynaud phenomenon in the setting of systemic sclerosis.

The presence of hand edema (puffy hands), sclerodactyly, mat telangiectasias, or calcinosis in a patient with RP points to a potential diagnosis of SSc. Other cutaneous findings may imply a specific secondary disorder, for example, purpura, indicating a blood dyscrasia, or jaundice, suggesting viral hepatitis.

OTHER FINDINGS

In addition to a careful skin examination, peripheral pulses should be evaluated and blood pressure obtained in both arms. An Allen test also should be performed to assess arterial and capillary function of the hands. In this test, the examiner simultaneously compresses the radial and ulnar arteries, while the patient opens and closes the fist to induce blanching of the palm. Selective arterial filling is judged by the rate of color return as pressure is sequentially released from the radial and ulnar arteries. Abnormal filling implies structural disease of the microcirculation, raising the suspicion for a secondary form of RP or the presence of a thrombus. A positive Allen test should be confirmed with a more definitive diagnostic evaluation such as a Doppler study or angiogram. Vascular obstruction from the thoracic outlet syndrome can be assessed by the Adson maneuver, which tests for diminution of the radial pulse with exaggerated movement of the neck and shoulder. A careful neurologic

examination looking for signs of sympathetic nervous system hyperactivity, abnormal reflexes, or muscular weakness or atrophy can help identify an underlying neurologic disorder.

ASSOCIATIONS

By definition, primary RP develops without an identifiable systemic or drug cause. Several studies have examined the long-term outcome of patients with primary RP.[6,12-14] Progression to a secondary form, most commonly a connective tissue disease such as SSc or systemic lupus erythematosus, is as high as 15% during the first decade of onset. Features predictive of progression include nailfold capillary abnormalities, hand edema (puffy hands), positive Allen's test, and antinuclear antibodies.[12,14]

Secondary RP develops in the context of various disorders and/or drug and toxin exposures (Tables 145-1 and 145-2).

TABLE 145-1
Causes of Secondary Raynaud Phenomenon

Connective Tissue Disease
- Systemic sclerosis (SSc)
- Systemic lupus erythematosus
- Dermatomyositis and polymyositis
- Mixed connective tissue disease
- Systemic vasculitis
- Sjögren syndrome

Obstructive Arterial Disease
- Atherosclerosis
- Thromboangiitis obliterans (Buerger disease)
- Thromboembolism
- Thoracic outlet syndrome

Neurologic Disorders
- Carpal tunnel syndrome
- Reflex sympathetic dystrophy
- Hemiplegia
- Poliomyelitis
- Multiple sclerosis
- Syringomyelia

Occupation/Environmental Exposure
- Vibration injury (lumberjacks, pneumatic hammer operators)
- Posttraumatic injury (hypothenar hammer syndrome, crutch pressure)
- Vinyl chloride exposure
- Cold injury

Hyperviscosity Disorders
- Cryoproteins (cryoglobulins, cryofibrinogens)
- Cold agglutinins
- Macroglobulins
- Polycythemia
- Thrombocytosis

Miscellaneous
- Hypothyroidism
- Infections (bacterial endocarditis, Lyme disease, viral hepatitis)
- Malignancy
- Primary pulmonary hypertension
- Arteriovenous fistula

TABLE 145-2
Drugs Associated with Raynaud Phenomenon

- β-Adrenergic blockers
- Ergotamines
- Oral contraceptives
- Methysergide
- Bleomycin
- Vinblastine
- Clonidine
- Bromocriptine
- Cyclosporine
- Amphetamines
- Interferon-α and interferon-β
- Imatinib

CONNECTIVE TISSUE DISEASES

The connective tissue diseases are the most common cause of secondary RP. Among patients with SSc, 80% to 90% manifest symptoms of RP. It is the presenting sign in approximately one-third of patients with SSc and may be the only manifestation of the disease for years. Among patients with systemic lupus erythematosus, autoimmune myositis, and systemic vasculitis, RP develops in up to a third. Interestingly, although patients with rheumatoid arthritis often complain of mottled skin changes accompanying cold hands, the incidence of RP appears to be equal to that of the general population.[15] Arteriograms of patients with connective tissue diseases often show digital and sometimes ulnar or radial artery obstructions.

NEUROLOGIC DISORDERS

Any neurologic condition that results in impaired use of a limb may be associated with sympathetic nervous system disturbances and RP. Although distinct from RP, thermoregulatory changes may be a prominent feature of reflex sympathetic dystrophy and can simulate RP.[16] Nerve root compression may also cause RP. RP infrequently complicates carpal tunnel syndrome, but if it does develop, the pattern of involvement conforms to the innervation of the median nerve, affecting the first, index, and middle fingers.[17,18] RP may also develop from neurovascular compression at the thoracic outlet by cervical ribs, scalene muscles, bony defects of the cervical vertebrae or clavicle, or shoulder compression syndromes.[19,20]

OCCUPATIONAL FACTORS

RP is common among individuals with certain occupations. Specifically, individuals who work with

vibratory tools, such as air hammers, chainsaws, and rivet guns, and those who experience prolonged exposure to cold temperatures, such as butchers, ice cream workers, and fish packers, are at risk for RP. The prevalence of RP appears to correlate with the vibration level of the tool used, duration of use, and the duration of exposure to cold temperatures.[21] Vinyl chloride manufacturing in the polymer industry also confers a risk for developing RP.[22]

MEDICATIONS AND TOXINS

A variety of medications can cause or exacerbate RP (see Table 145-2). Mechanistically, drugs may cause peripheral vasoconstriction, endothelial injury, neurotoxicity, or local enhancement of blood viscosity.[23] β-Adrenergic blockers, a widely prescribed class of antihypertensives, are the most common cause of iatrogenic RP.[24,25] Unopposed peripheral vasoconstriction likely accounts for the development of RP, and specific drugs within the class, for example, propranolol, exhibit a higher propensity to cause disease than do other drugs.[25] Other drugs capable of causing RP by vasoconstrictive mechanisms include clonidine, ergot alkaloids (for migraine headaches), dopaminergic agonists, centrally acting stimulants such as methylphenidate and dextroamphetamine, cyclosporine, sympathomimetics (pseudoephedrine, phenylephrine), and cocaine.[26-35]

Chemotherapies, in particular bleomycin, cisplatin, and vinblastine, are also well-known causes of RP, likely precipitating symptoms by toxin-mediated endothelial dysfunction.[36-39] Although the risk of developing RP appears to be commensurate with the cumulative dose of chemotherapy, there are reports of RP after a single injection of bleomycin for the treatment of common warts, supporting the concept that idiosyncratic reactions may also account for some cases.[40]

RP is a known side effect of treatment with interferon.[23,41] Administration of both isotypes of interferon (α and β) can cause severe RP, and some interferon-induced cases have even required surgical amputation because of the ischemic injury sustained.[42] The pathophysiology of interferon-induced RP is potentially related to several mechanisms, including a direct vasospastic effect, an increase in blood viscosity, a deposition of immune complexes, and arterial occlusion by thrombi.[43-45]

Sulfasalazine, propofol, amphotericin B, and, more recently, the tyrosine kinase inhibitors, also have been reported to cause RP.[23]

In cases of drug-induced RP, discontinuation of the offending medication usually reverses symptoms, but in some instances, the vascular changes are permanent and may require disease-specific interventions. Notably, in patients with preexisting RP, many of these medications can exacerbate disease symptoms. Careful attention to a patient's medication regimen allows for appropriate substitutions to be made to mitigate disease activity.

MISCELLANEOUS DISORDERS

Patients with hyperviscosity from cryoglobulins, cryofibrinogens, macroglobulins, cold agglutinins, and polycythemia can develop RP. Endocrine disorders, infections, and a variety of malignancies, may also manifest with symptoms of RP.

ETIOLOGY AND PATHOGENESIS

Although the pathogenesis of RP is incompletely understood, it appears that complex interactions between the vasculature, nervous system, and circulating cytokines are responsible for its development.[2,46]

VASCULAR ABNORMALITIES

Several studies have demonstrated that endothelial-dependent vasodilation is reduced in both primary and SSc-related RP.[47-50] Inadequate production of vasodilatory mediators, including nitric oxide and prostacyclin, appears to be critical for this impaired vasodilation.[51] In addition, excessive vasoconstriction, partly caused by high circulating levels of endothelin-1 and angiotensin II, contributes to acral hypoperfusion.[52,53] Inhibition of the endothelin-1 receptor with bosentan attenuates symptoms of SSc-associated RP, substantiating the pathogenic role of this vasoconstrictor in RP.[54,55] These functional blood vessel abnormalities (impaired vasodilation and enhanced vasoconstriction) are present in both forms of RP. Structural derangements of the microvasculature and digital arteries also occur in secondary RP and augment impaired digital perfusion.[2,56] Microangiopathy and intimal wall hyperplasia characterize these structural changes and promote ongoing vascular injury, likely accounting for the progressive nature of some cases of secondary RP.

NEURAL ABNORMALITIES

Aberrant signals from the autonomic nervous system, afferent sensory nerves, and the CNS are implicated in the pathogenesis of RP.[2] Blood vessels receive innervation from 3 primary sources including sympathetic, parasympathetic, and sensory neurons.[46] An imbalance favoring the activation of neurally mediated vasoconstrictive pathways has been demonstrated in RP. Calcitonin gene-related peptide–immunoreactive sensory neurons are reduced in the skin of fingers in patients with SSc-associated RP and primary RP compared to healthy controls, and by altering the neurovascular axis, this deficiency contributes to defective vasodilation.[57] Moreover, hyperresponsive α_2-adrenoceptors that govern

vasoconstriction in response to cold stimuli have been detected in the digital arteries of individuals with RP.[58,59] Central mechanisms may also contribute to RP, as attacks can be elicited by emotional stress. The inability to habituate to episode-provoking stimuli has been cited as a cause for CNS-mediated RP.[60,61]

INTRAVASCULAR ABNORMALITIES

Platelet activation, increased thrombin generation, defective fibrinolysis, reduced red cell deformability, aberrant white blood cell activation, and increased viscosity collectively constitute the intravascular alterations seen in RP.[2] Secondary forms of the disease display a higher likelihood of several of these abnormalities being present simultaneously.[62] Oxidative stress imposed on endothelial cells through peroxidation of cell membranes and hypoxia-reperfusion injury, as a result of recurrent ischemic and hyperemic insults, also contribute to SSc-associated RP and, to a lesser extent, to primary RP.[2]

OTHER MECHANISMS

A variety of other factors likely play a role in the genesis of RP, but are poorly defined. Among those described, hormonal influences from estrogen and genetic predisposition have the strongest data supporting an etiologic association.[62] Polymorphisms in genes encoding portions of the neuromuscular acetylcholine receptor and serotonin 1B and serotonin 1E receptors may confer genetic susceptibility to developing primary RP.[63]

DIAGNOSIS

Primary RP is common, and although a large subset of patients never seek medical attention, many with primary RP do so out of concern for the possibility of an underlying connective tissue disorder.[2] Criteria for the diagnosis of primary RP have been developed and validated (Table 145-3).[64-66] An expert consensus definition of primary RP has been proposed based on a 3-step algorithm.[67] To satisfy a diagnosis of primary RP, patients must have evidence of their fingers having unusual cold sensitivity, experience at least biphasic color changes during vasospastic episodes (white and blue), and have a minimum of 3 of the following features present: attacks triggered by stimuli other than cold (eg, emotional stress); involvement of both hands, even if asymmetric; attacks accompanied by numbness or paresthesias; color changes characterized by a well-demarcated border between affected and unaffected skin; photographs that strongly support a diagnosis of RP; episodes occurring at other body sites (eg, nose, ears, feet, and nipples); and triphasic color changes (white, blue, red).

TABLE 145-3
Criteria for Primary Raynaud Phenomenon

- Vasospastic attacks precipitated by exposure to cold or emotional stimuli
- Bilateral involvement of extremities
- Normal vascular examination with symmetric peripheral pulses and normal nailfold capillary microscopy
- Absence of gangrene or, if present, limited to the skin of the fingertips
- No evidence of an underlying disease, drug, or occupational exposure that could be responsible for vasospastic attacks
- Negative antinuclear antibody test
- Normal erythrocyte sedimentation rate
- History of symptoms for at least 2 years

Combined criteria of Allen and Brown[64] and Le Roy and Medsger.[65]

In addition to classic symptoms, the diagnosis of secondary RP requires the simultaneous identification of a systemic disorder, medication, or toxin exposure known to cause the disease. Secondary RP is more likely in the following settings: an age at onset of 30 years or older; episodes that are intense, painful, asymmetric, or associated with ischemic skin lesions; clinical signs suggestive of a connective tissue disease, such as arthritis or abnormal lung function; specific autoantibodies; and evidence of microvascular disease seen on nailfold microscopy, particularly capillary dropout and giant capillary loops.[68-70]

LABORATORY STUDIES

In all patients with RP, a complete blood count, erythrocyte sedimentation rate, urinalysis, and antinuclear antibody testing should be obtained.[68] In patients with abnormal antinuclear antibody titers, testing for antibodies to specific nuclear antigens, for example, centromere or topoisomerase, are helpful to identify specific connective tissue diseases such as SSc. Notably, a positive antinuclear antibody without antigen specificity carries a lower risk of a concomitant connective tissue disorder, as compared to antigen-specific autoantibodies.[13,71,72]

Additional laboratory studies may be warranted based on findings from the history and physical examination and include a comprehensive chemistry panel; thyroid function tests; measurement of C3 and C4 complement levels; serum protein electrophoresis and immunofixation electrophoresis; testing for rheumatoid factor; and evaluation for cryoglobulins. A chest radiograph may detect a cervical rib in patients with symptoms of thoracic outlet obstruction. If proximal large vessel disease is suspected, for example in the case of unilateral RP or when peripheral pulses are difficult to palpate, arterial Doppler investigations are necessary.[2] Abnormal Doppler studies require further evaluation with appropriate imaging and/or referral to a vascular specialist.

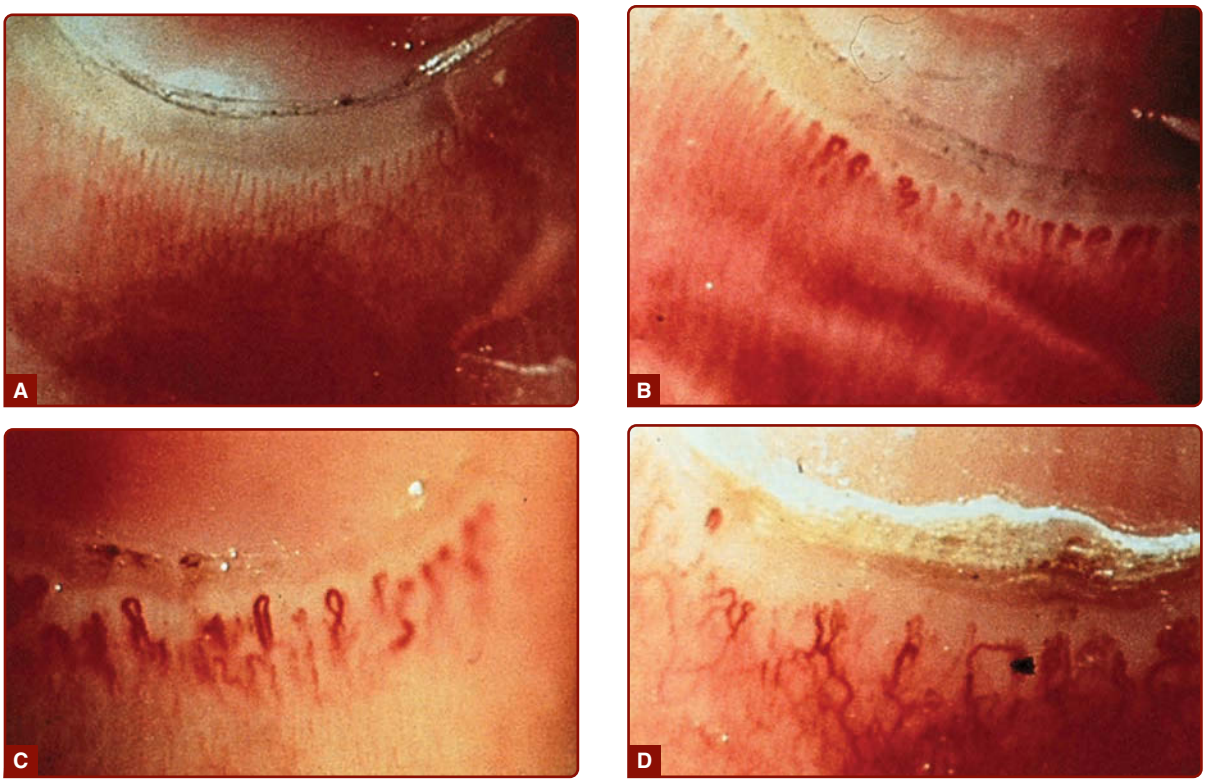

Figure 145-3 Nailfold capillary microscopy in a normal patient (**A**) compared to 3 patients with systemic sclerosis showing dilated capillaries (**B**), capillary tortuosity with dropout (**C**), and a telangiectatic pattern (**D**).

SPECIAL TESTING

Nailfold capillaroscopy is a helpful adjunctive tool to predict progression to SSc. Whereas normal nailfolds consisting of uniformly sized capillaries with regular spacing are reassuring and are present in the majority of cases of primary RP, capillary dilation (giant capillaries) with focal hemorrhage and areas of avascularity (capillary dropout) are highly specific for and can predict transition to SSc (Fig. 145-3).[2,70,73] In SSc-associated RP, serial nailfold capillary microscopy examinations show progressive decreases in the total number of nailfold capillary loops, and end-stage changes, which include haphazardly arranged vessels (telangiectasia) and near total loss of capillaries, correlate with advanced sclerodactyly.[74] These dynamic nailfold changes are not observed in primary RP.

Thermal imaging (thermography) is a newer diagnostic technique that measures digital and acral surface temperatures and may be able to distinguish between patients with primary RP and those with SSc.[75] By determining the temperature differences between distal fingertips and the dorsal hand ("distal–dorsal difference"), parameters derived from thermography appear to reliably predict whether a structural vascular defect (eg, related to SSc) is present. Thermography awaits further validation, and its usefulness is limited by its cost and availability.

Other techniques that have been used to diagnose RP include laser Doppler imaging, plethysmography, and finger systolic pressure measurements.[76-78] As of this writing, such tests are not routinely used in clinical practice, but may ultimately provide practical, noninvasive methods to assist in the diagnosis of RP.

DIFFERENTIAL DIAGNOSIS

The major forms of vascular disease that must be distinguished from RP are physiologic cold fingers, acrocyanosis, pernio, erythromelalgia, livedo reticularis, and reflex sympathetic dystrophy (Table 145-4).

Many patients experience cold, sometimes painful digits without a color change in response to cold temperature exposure. This condition is physiologic and, although pronounced in some individuals, represents normal sympathetic nervous system activity. This type of response to cold exposure is not synonymous with RP.

TABLE 145-4
Differential Diagnosis of Raynaud Phenomenon

- Physiologic response to cold temperature
- Acrocyanosis
- Pernio
- Erythromelalgia
- Livedo reticularis
- Reflex sympathetic dystrophy

Acrocyanosis is a functional vascular condition characterized by blue-violet discoloration of acral skin as a result of diminished oxyhemoglobin.[79,80] Defects in central oxygenation, as seen in cardiac and pulmonary diseases, or local hypoxia are responsible for the manifestations of the disorder. Acrocyanosis is much less common than RP, and by definition, the color changes seen in acrocyanosis are persistent, irrespective of exposure to cold temperature or other stimuli. Triphasic color changes are not seen in acrocyanosis.

Pernio is an acral, inflammatory dermatosis that develops in response to exposure to cold, wet conditions. Lesions of pernio appear as erythematous to violaceous macules, papules, or plaques that symmetrically involve the toes and/or fingers. Rarely, the heels, thighs, nose, and ears may be affected. Hemorrhagic lesions, bullae, loss of the nails, and ulcerations may complicate severe cases. If ulcerations develop, secondary infections may supervene. Pain, pruritus, and a burning sensation may accompany lesions of pernio. The disorder is typically benign and self-limiting, and lesions last approximately 1 to 3 weeks. Uncomplicated cases of pernio do not require treatment, but when present in patients with concomitant connective tissue disease, it may be more challenging to manage and necessitate disease-specific therapy.

Erythromelalgia is a rare, functional vascular disease characterized by pain, burning, edema, and erythema, most often of the extremities. Unlike RP, affected limbs are characteristically warm. Exercise, standing, walking, limb dependency, and warm exposure trigger episodes of erythromelalgia. Attacks of erythromelalgia tend to occur in the evening and at night, and can disrupt sleep. The feet are affected in 90% of patients, whereas the hands are involved in only 25%.[81] Rarely, the face and the ears may be involved. Because of the extreme warmth and burning pain experienced, patients seek various ways to cool the affected area, and often find relief with limb elevation or immersion in ice water. Immersion in ice water causes reactive vasoconstriction that may lead to skin breakdown and cold water tissue injury, eventuating in infection and, rarely, autoamputation. Erythromelalgia may be primary, or may occur as a result of a systemic disorder. Although the etiology and pathogenesis of erythromelalgia are poorly understood, it is thought to relate to abnormalities of platelet function, changes in vascular dynamics, and dysfunction of voltage-gated sodium channels.[82,83] Cases of coexisting erythromelalgia and RP have been described, and some investigators view the 2 disorders as existing on a spectrum, with RP representing the excessive vasoconstrictive form and erythromelalgia representing the exaggerated vasodilatory form.[82]

Livedo reticularis is a very common skin change resulting from a localized physiologic response to cold exposure and appears as a mottled, well-formed reticulated (net-like) vascular pattern that blanches with pressure. Although any body site may be affected, lesions preferentially occur on the limbs, particularly the lower extremities. Livedo reticularis develops from alterations in blood flow through the cutaneous microvasculature.[84] It may be a primary physiologic response or, less commonly, associated with an underlying condition, especially disorders that alter blood viscosity or cause intraluminal vascular obstruction.

Reflex sympathetic dystrophy is a rare, painful disorder accompanied by vasomotor instability that results from autonomic nervous system dysfunction.[85] Most cases arise after injury to a limb. Consequently, changes seen in reflex sympathetic dystrophy favor the upper and lower extremities, as well as the hands. Complex alterations in nociceptive nerve terminals amplify pain signals from the CNS and are thought to cause the disorder. Reflex sympathetic dystrophy characteristically progresses through various stages that ultimately result in soft-tissue destruction.[85] The second stage of disease, which is characterized by pain and vasomotor instability, develops months after nerve injury has occurred and may resemble RP. Distinguishing features include disproportionate levels of pain, hypotrichosis or hypertrichosis, nail changes, hyperhidrosis or anhidrosis, and, in advanced stages, soft-tissue atrophy.

CLINICAL COURSE AND PROGNOSIS

The clinical course of RP is largely dictated by whether the disorder is primary or secondary. The vast majority of cases of primary RP exhibit an indolent course. Simple behavioral modifications alone usually suffice to control the disease. Complications such as digital ulceration, soft-tissue atrophy, and bone loss rarely occur in primary RP.

In contrast, secondary RP has a more guarded prognosis. In secondary disease, repeated bouts of prolonged digital ischemia result in skin breakdown, soft-tissue injury, ulceration, and, occasionally, autoamputation. These complications are more frequent in inadequately treated patients. Digital pulp cellulitis (felon) and osteomyelitis may also complicate secondary RP, especially after the development of cutaneous ulceration.

Raynaud crisis is a rapidly progressive form of RP that is characterized by acute, potentially catastrophic tissue ischemia and is considered a medical emergency. Without intervention, Raynaud crisis results in digital infarction and may lead to digit loss. Patients with secondary RP should be alerted to the possibility of developing this rare complication, which is heralded by extreme pain and persistent white-blue color changes in a digit that will not rewarm. Susceptibility to Raynaud crisis is highest among patients with SSc with coexisting macrovascular disease and positive anti-centromere antibodies.[86]

RP can have a profound impact on a patient's quality of life. When controlling for severe pulmonary and GI disease in a study examining RP activity in SSc patients, patient-reported health assessment questionnaire pain and disability scores, as well as visual analog scale severity scores were greater for RP and

digital ulcers compared to breathing and intestinal complaints, indicating a more substantial impact on quality of life.[87] High levels of depressed mood and feelings of anxiety related to attacks of RP were also found in the study's cohort.

The development of digital ulcers is a poor prognostic sign. Apart from morbidity directly related to digital ulcers, higher incidences of disability, pain, and limited hand function accompany this complication.[87]

A validated, reliable measure of RP activity, the Raynaud Condition Score (RCS), has been developed.[87] The score represents a global composite of objective metrics (number of attacks per day, length of each attack) and a subjective, patient-reported severity score. The severity score component is administered on either a visual analog scale (0 to 100) or an 11-point Likert scale, averaged over a 1- or 2-week period. While primarily used to assess response to therapy in clinical trials, implementation of the RCS as a practice tool has gained popularity, allowing clinicians to assign a severity score to patients in order to gauge suitability for an intervention and to objectively follow their outcome. The RCS and other RP measures, including the health assessment questionnaire's pain and disability scale and mood scales, are highly sensitive to changes in RP activity and can discriminate between subjects with and without digital ulcers.[87] Recently, the minimally important difference, representing the smallest improvement in a score that patients perceive as beneficial, and the Patient Acceptable Symptom State, defined as the absolute value beyond which patients consider themselves well, have been established for the RCS.[88] These estimates, a 14- to 15-point improvement (0 to 100, visual analog scale) and a score of 34 points or less for the minimally important difference and Patient Acceptable Symptom State, respectively, will assist with objectively evaluating the success of treatments for RP using meaningful end points in future clinical trials.

MANAGEMENT

The management of RP centers on attenuating the frequency, severity, and duration of attacks as well as treating ischemia-related complications. These goals can be achieved through the implementation of behavioral modification, pharmacologic therapies, and procedural interventions. In some cases, a combination approach is necessary. When causes of secondary RP are identified, treatment of the underlying disorder may result in improvement of RP. When a drug or occupational exposure is suspected, cessation of the culprit medication or removing the patient from the causal environment is necessary.

BEHAVIORAL MODIFICATION

Table 145-5 outlines effective behavior modifications. Mild RP is generally amenable to lifestyle changes that minimize exposure to the cold. Dressing warmly with layered clothing and maintaining a higher-than-normal thermostat setting while indoors are easy habits for patients to implement. Limiting time spent outdoors during the winter, wearing insulated mittens or gloves and thick socks, and using hand or foot warmers, are also helpful. Patients should be taught to recognize and terminate attacks of RP promptly by returning to a warmer environment and applying heat to affected digits if symptoms persist after acclimating. In addition, counseling to maintain a warm core temperature (including wearing hats and additional layers centrally) should be reinforced at each patient encounter. This measure prevents the reflexive, peripheral vasoconstriction that accompanies a drop in core temperature, as blood shunts centrally to rewarm the body. Smoking cessation in smokers with RP and counseling to avoid secondhand smoke in nonsmokers should be emphasized because nicotine induces cutaneous vasoconstriction and can provoke attacks of RP. Caffeine has mixed vasoactive properties, but one of its major downstream effects is to enhance vasoconstriction by blocking adenosine receptors. Consequently, limiting caffeine consumption should also be considered in caffeine-sensitive patients. Stress modification is important to minimize vasoconstriction in those with hyperactivity of the sympathetic nervous system. Counseling, training in relaxation, biofeedback techniques, and, in anxiety-provoked cases, anxiolytics may be beneficial.

TABLE 145-5
Behavioral Modification

1. Dress warmly and layer clothing
2. Maintain higher-than-normal thermostat settings indoors
3. Limit time spent outdoors during winter
4. Use hand or foot warmers
5. Recognize and terminate attacks early
6. Smoking cessation and/or avoidance of secondhand smoke
7. Limit caffeine consumption

PHARMACOLOGIC INTERVENTIONS

Table 145-6 outlines pharmacologic therapies for Raynaud phenomenon.

VASODILATORS

Calcium channel blockers (CCBs) are the preferred first-line therapy for both primary and SSc-associated RP in patients who do not respond to behavioral modification alone.[89-91] The dihydropyridine class of CCBs (nifedipine, amlodipine, nicardipine, and felodipine) are the least cardioselective and appear to be the most efficacious in terms of reducing the frequency and severity of attacks of RP.[46] Their beneficial effect

TABLE 145-6
Pharmacologic Therapies for Raynaud Phenomenon

CLASS	DRUGS	DOSE & ADMINISTRATION
Vasodilators	Nifedipine	30 to 89 mg by mouth each evening
	Amlodipine	5 to 20 mg by mouth every day
	Diltiazem	30 to 120 mg by mouth thrice daily
	Tadalafil	20 mg by mouth every day
	Sildenafil	20 mg by mouth thrice daily
	L-Arginine	2 to 8 g by mouth every day
Inhibitors of vasoconstriction	Losartan	25 to 100 mg by mouth every day
	Enalapril	5 to 20 mg by mouth twice daily
	Quinapril	20 to 80 mg by mouth every day
	Fluoxetine	20 to 40 mg by mouth every day
	Bosentan	62.5 mg by mouth twice daily × 2 weeks, then increase to 125 mg by mouth twice daily
	Prazosin	1 to 5 mg by mouth twice daily
Other medications	Aspirin	150 to 325 mg by mouth every day
	Pentoxifylline	400 to 800 mg by mouth thrice daily
Infusions[a]	Sodium nitroprusside	0.3 to 10 mcg/kg/min
	Iloprost	0.5 to 2 ng/kg/min
	Alprostadil	6 to 10 ng/kg/min

[a]Typically reserved for Raynaud crisis.

has been confirmed in several randomized, blinded, placebo-controlled trials. Diltiazem, a nondihydropyridine CCB, also reduces vasospastic episodes in both primary and secondary RP.[92] A metaanalysis of 18 trials evaluating CCBs as a primary intervention for RP demonstrated an average decrease of 2.8 to 5 attacks and a 33% reduction of symptom severity during a 1-week period.[89] Adverse side effects from CCBs occur in up to 15% of users and include headache, flushing, hypotension, and lower-extremity edema.[93] Side effects can be dose-dependent or idiosyncratic. In SSc patients with esophageal dysmotility, CCBs can also exacerbate gastroesophageal reflux symptoms.[46,94] Commencing treatment with a low dose followed by a gradual escalation until the desired response is achieved is the most effective approach. Furthermore, selection of a once-daily, sustained-release preparation is preferable to shorter-acting formulations and encourages patient compliance. In addition, when the sustained-release dose is given nightly, CCBs are better tolerated, even in patients with low baseline blood pressures.

Studies implicating the pathogenic deficiency of nitric oxide in RP have led to an interest in strategies that increase tissue levels of nitric oxide as a therapeutic approach. Nitric oxide stimulates smooth muscle relaxation by increasing intracellular concentrations of cyclic guanosine monophosphate, and results in vasodilation and increased digital perfusion. Initial studies exploiting this pathway showed promise, as topical nitrates attenuated symptom severity and improved digital ulcer healing times in patients with connective tissue disease–associated RP in a randomized, placebo-controlled trial.[95] Subsequent studies have validated the efficacy of other nitric oxide substitutes such as L-arginine and sodium nitroprusside.[96] Although promising, difficulty associated with their administration (eg, sodium nitroprusside requires intravenous infusion) and the limited availability of some these agents has hindered their routine use in clinical practice.

More recently, the phosphodiesterase (PDE) inhibitors have emerged as a promising class of medications for managing patients with CCB-refractory RP. These vasodilators exert their biologic effects by enhancing nitric oxide signaling via inhibition of cyclic guanosine monophosphate degradation, resulting in improved tissue perfusion. In a double-blind, randomized, placebo-controlled trial examining the effect of the PDE inhibitor tadalafil in individuals with CCB-refractory RP, those receiving tadalafil had significant improvements in multiple outcome measures including frequency and duration of RP attacks, RCS, digital ulcer healing time, prevention of digital ulcers, physician and patient global assessments, health assessment questionnaire disability and pain scales, and several quality-of-life domains at the end of a 6-week period.[97] Similar results have been published for sildenafil, a shorter-acting PDE inhibitor, with a comparable safety and tolerability profile.[98] PDE inhibitors are usually well tolerated, but occasional side effects include headache, dyspepsia, dizziness, and, rarely, visual disturbances. Interestingly, not every placebo-controlled trial evaluating the utility of PDE inhibitors for secondary RP has demonstrated benefit.[99,100] The issue of reproducibility among these null trials has been ascribed to insufficient powering, as many trials used small sample sizes and each showed trends favoring PDE inhibitor over placebo. A recent metaanalysis examining the data across all studies has substantiated the efficacy of PDE inhibitors for treating secondary RP.[101] In the authors' experience, the addition of sildenafil to a CCB-based therapeutic regimen has typically resulted in disease improvement, including the amelioration of digital ulcers.

Prostaglandins and their analogs possess potent vasodilatory properties and have been used successfully to treat both primary and SSc-associated RP. As of this writing, iloprost, a chemically stable synthetic prostacyclin analog that dilates the peripheral vasculature and inhibits platelet adhesion and aggregation, has been the most rigorously studied. Intravenous administration of

iloprost attenuates the severity and number of attacks of RP and leads to more rapid digital ulcer healing time in patients with SSc-associated RP.[102,103] In some trials, the effects of iloprost were sustained and led to a decreased requirement for ongoing therapies. In fact, in a 12-month prospective, parallel-group trial assessing the outcomes of subjects with SSc-associated RP assigned to receive either iloprost infusions at 6-week intervals or conventional vasodilator therapy, individuals in the iloprost intervention arm had significant reductions in RP severity scores and required fewer ancillary therapies.[104] Additional end points of significance favoring the iloprost treatment group, while controlling for immunomodulatory therapy, included improvement in modified Rodnan skin scores and diffusion capacity for carbon monoxide, reflecting reduced cutaneous sclerosis and enhanced pulmonary function, respectively. As a result of their findings, the authors concluded that iloprost might act as a disease-modifying agent in SSc-associated RP. Owing to the expense and occasional hypersensitivity associated with intravenous administration, an oral formulation of iloprost has been developed. A single randomized, placebo-controlled trial confirmed the efficacy of oral iloprost for RP,[105] but this finding was not replicated in a larger, multicenter study.[106] Consequently, intravenous, but not oral, iloprost is recommended for the management of refractory RP in the setting of SSc.[107]

INHIBITORS OF VASOCONSTRICTION

Angiotensin-converting enzyme inhibitors and angiotensin II receptor antagonists have been investigated for treating RP. Both act on the renin–angiotensin system and impede vasoconstriction by reducing the downstream activity of angiotensin. Despite mixed results with enalapril[108,109] and quinapril,[110] a greater treatment response using once-daily losartan was observed when compared to nifedipine in a parallel-group trial over a 12-week period in participants with both primary and secondary RP.[111] This data supports the use of direct angiotensin receptor inhibitors over indirect inhibitors (angiotensin-converting enzyme inhibitors) for managing RP, although both are effective. In select circumstances, for example, scleroderma renal crisis, angiotensin-converting enzyme inhibitors may be the preferred option.

Several studies have implicated serotonin as an important mediator in the development of RP.[112,113] An in vivo human experiment infusing serotonin into the brachial artery reproduced the characteristic color changes seen in RP, confirming that serotonin is a potent vasoconstrictor in the peripheral circulation under physiologic circumstances.[114] In the periphery, selective serotonin reuptake inhibitors (SSRIs) block serotonin uptake by platelets, which decreases arterial vasoconstriction. Centrally, serotonin acts as a vasodilator, and by increasing the availability of serotonin in the CNS, SSRIs facilitate centrally mediated peripheral vasodilation. The results of 1 randomized, controlled trial demonstrated that the SSRI fluoxetine was more efficacious than nifedipine in terminating attacks and decreasing the severity of RP over a 6-week period.[115] SSRIs may, therefore, represent a rational choice in patients who have not adequately responded to CCBs. Given their anxiolytic properties, SSRIs may be especially desirable in patients with anxiety and RP triggered by emotional stimuli.

As previously mentioned, endothelin-1 contributes to the pathogenesis of RP by inducing vasoconstriction. Bosentan, an oral endothelin receptor antagonist, has demonstrated efficacy for treating SSc-associated RP.[55] Apart from improving symptoms of RP, bosentan decreased ulcer healing time and prevented the formation of new ulcers in 2 similar cohorts of patients with SSc-associated digital ulcers.[116,117] Dose-dependent elevation of hepatic transaminases is seen during treatment with bosentan in up to 10% of individuals, and rare occurrences of cirrhosis and fulminant liver failure have been reported with its use. Although prescribers should exercise caution prior to choosing this agent, in carefully selected circumstances, bosentan may prove to be an indispensable option, particularly in the setting of refractory digital ulcers.

α-Adrenergic blockers, in particular the α_1-adrenoceptor inhibitor prazosin, can also effectively treat RP. In a Cochrane database review, investigators found high-quality evidence from 2 randomized, controlled trials that demonstrated a beneficial effect of prazosin over placebo in patients with SSc-associated RP.[118] Side effects, including postural hypotension, drowsiness, and fatigue, were common among treatment participants, but were mild overall and could be avoided by nighttime administration.[119] A recent Phase II, randomized, placebo-controlled trial investigating the effect of a novel, high-potency α_2-adrenoceptor antagonist in subjects with SSc-associated RP showed no benefit over placebo in terms of recovery from a cold challenge test.[120] For unclear reasons, it appears that selective blockade of α_1-adrenergic but not α_2-adrenergic receptors is an effective treatment strategy for RP.

Recent advancements in our understanding of cold-induced vasoconstriction have identified the Rho family of kinases as putative targets for RP. Cold exposure initiates a cascade of events involving the activation of the sympathetic nervous system and release of norepinephrine, ultimately resulting in cutaneous vasoconstriction. Norepinephrine stimulates vascular smooth muscle cells to contract, and this latter process is controlled in part by activation of the Rho kinase pathway.[121] Rho kinases play a central role in regulating actin-dependent and myosin-dependent vasoconstriction,[122] which created interest in exploiting this pathway as a mechanism-based approach to treating RP. Unfortunately, results from a randomized, placebo-controlled trial using the Rho kinase inhibitor fasudil failed to show benefit in terms of skin temperature recovery time and digital blood flow following a cold challenge in individuals with SSc-associated RP.[123] The trial's investigators attributed the study design and selection of participants with advanced disease as possible explanations for its failure. Future studies will seek to address whether Rho kinase inhibition is relevant for treating RP.

OTHER MEDICATIONS

Aspirin and other antiplatelet therapies are routinely used in RP, despite a paucity of data to support their use. These agents likely exert benefit by reducing local thrombosis and platelet-mediated vasoconstriction, the latter of which results from the release of vasoactive mediators by platelets. Occasionally, aspirin therapy can worsen RP. This phenomenon may be explained by its effect on reducing the production of vasodilatory prostaglandins.[46]

Agents that alter blood viscosity and the hemorrheologic dynamics of red cells, such as pentoxifylline, also have been used to treat RP.[124,125] These are preferable in select settings, such as in cases of cryoprecipitable disorders or Waldenström macroglobulinemia in which vascular sludging contributes to the development of RP, or in individuals with a baseline low blood pressure who are intolerant of CCBs. Pentoxifylline also can be added to an existing drug regimen to enhance therapeutic efficacy.

Anticoagulants and thrombolytic agents are most useful when treating RP secondary to an embolus or vasoocclusive event. In Raynaud crisis, heparin may be indicated during the acute phase of ischemia to prevent irreversible tissue injury. A pilot study showed benefit from adding low-molecular-weight heparin to a conventional RP treatment protocol in a cohort of patients with primary and secondary RP, the effect of which was maximal by 20 weeks of daily use.[126] When considering heparin for RP, the risk of serious bleeding must be balanced against any potential benefit it may confer. Anticoagulation with warfarin is not routinely recommended to treat RP. Notable exceptions include cases in which a thrombotic diathesis exists, or in cases of SSc in which warfarin is specifically selected to treat associated calcinosis cutis.[127]

As oxidative stress likely contributes to RP, there is ongoing interest in using antioxidants to placate the symptoms and sequelae of the disorder. Intravenous *N*-acetylcysteine significantly reduced the frequency and severity of RP attacks as well as the number of digital ulcers in a cohort of 20 patients with SSc.[128] The therapy was well tolerated, and no substantial side effects were observed. Other studies have also supported the role of antioxidant therapy for RP.[129] The benefits of antioxidants are potentially greatest when used early in the course of disease.[46]

Several complementary and alternative medicines have been used for RP with no demonstrable benefit as of this writing.[130]

PROCEDURAL INTERVENTIONS

BOTULINUM NEUROTOXIN

Interest in botulinum neurotoxin (BoNT) as a treatment of RP emerged after a series of ex vivo experiments demonstrated a blunting effect on arterial contraction following incubation with modest concentrations of BoNT.[131] A seminal clinical report followed, in which 2 patients with severe, multidrug-resistant RP were given local injections of BoNT and subsequently experienced substantial improvements in both patient-reported disease activity and digital perfusion, as measured by laser Doppler interferometry.[132] A larger, prospective study comprised of 11 patients with pharmacologically refractory RP secondary to connective tissue disease supported these findings.[133] According to the study results, after digital injections with BoNT, each subject achieved clinically meaningful improvement in RP-associated pain, 9 of the 11 reported decreased severity and frequency of vasospastic episodes, and previously nonhealing ulcers spontaneously healed following therapy in 9 subjects. Benefit was observed as early as 24 hours after injection, and all subjects experienced pain relief within 48 hours. Numerous subsequent studies, including 1 placebo-controlled trial, have further validated BoNT as an effective option for RP, particularly in the setting of multiple medication failures.[134,135] Complications related to BoNT injections include dysesthesia and transient hand weakness, but the rate is acceptably low. The effect of BoNT usually lasts for months, but some reports have indicated ongoing benefit for up to a year.

Mechanistically, BoNT decreases muscle tone by preventing the presynaptic release of acetylcholine at the neuromuscular endplate. This results in paralysis of both striated and smooth muscle, including the musculature encasing blood vessels.[136] Chemodenervation with BoNT therefore enhances digital perfusion via toxin-mediated vasodilation. In addition to its direct effect on muscle, BoNT blocks the recruitment of α_2-adrenoceptors and decreases C-fiber nociceptor density, which raises the threshold of smooth muscle reactivity to cold stimuli and attenuates pain, respectively.[131,137]

A standardized technique for injecting BoNT has been reported and is easy to perform because it uses reliable anatomic landmarks.[138] At the metacarpophalangeal flexion crease, 5 to 10 units of onabotulinumtoxinA (BoNT type A) are injected while aiming proximally toward the neurovascular plexus. Approximately 40 to 100 units of onabotulinumtoxinA are used per hand, and in most instances, injection of the thumb is unnecessary. In some highly responsive individuals, pain relief is felt almost instantaneously. Use of a topical anesthetic under occlusion prior to injections makes the procedure more tolerable.

In the authors' experience, use of BoNT as an adjunctive therapy for RP has resulted in notable improvements in patient and physician global assessments, particularly among those who have failed multiple medical interventions.

SYMPATHECTOMY

In rare instances, aggressive medical therapies are insufficient to adequately control RP. In such scenarios,

surgical intervention may be warranted. The most commonly performed surgery is a sympathectomy, which serves to permanently sever vasoconstrictive signals from the sympathetic nervous system innervating the hands. As of this writing, 2 techniques, either a thoracocervical or a digital approach, are used and appear to be comparable in terms of benefit.

Thoracocervical sympathectomy is the traditional approach for RP and can be performed in either an open fashion or using an endoscopic technique. The goal of the procedure is to transect postganglionic fibers that exit via the thoracic sympathetic chain and fuse with the cervical stellate ganglion to innervate the hand. Outcomes data are mixed. Although early reports documented poor long-term outcomes with high rates of symptom recurrence and postoperative complications,[139] advances in surgical techniques have yielded better results. A review collating the most recent outcomes data indicated that short-term improvement after thoracic sympathectomy was achieved in 92% and 89% of patients with primary and secondary RP, respectively.[140] Healing of refractory digital ulcers following the procedure was also high, with 98% of patients deriving benefit, the majority of which had complete resolution. Data from the same review showed that long-term improvement (on the order of years) was higher among patients with secondary RP (89%) compared to those with primary RP (58%). While promising, complications related to thoracic sympathectomy are not uncommon and can include the development of hyperhidrosis, Horner syndrome, and persistent neuropathic pain.[139] If the procedure proves unsuccessful, the recurrence of symptoms generally occurs after 6 months.

Localized digital sympathectomy is an alternative procedure that appears to have comparable efficacy to the thoracocervical approach. The operation involves careful stripping of the adventitia containing the autonomic nerve plexus from the palmar arterial arch, common digital arteries, and/or proper digital arteries.[141,142] As a result of the meticulous nature of the procedure, its availability is limited to specialized centers. Serious complications are very infrequent. Postoperative pain and scar formation constitute the major cause for procedure-related morbidity. A novel 2-step incision technique for performing digital artery sympathectomy for RP has been published, with similar results in terms of symptom improvement and lower rates of scar formation, faster postoperative recovery time, and better aesthetic outcomes.[143]

SURGICAL DEBRIDEMENT AND AMPUTATION

Surgical debridement may be needed for chronic, nonhealing ulcers and if devitalized necrotic tissue develops. If gangrene supervenes, amputation may be required. Osteomyelitis developing in the context of a digital ulcer may also mandate partial digit amputation.

VASCULAR RECONSTRUCTION

Surgical reconstruction of the digital arteries is rarely indicated for RP. It may provide relief of symptoms and improve digital perfusion if proximal artery occlusion develops, which is most often seen in the setting of severe SSc, advanced atherosclerosis, or chronic thromboembolic disease.[144]

SPECIAL CONSIDERATIONS

ULCER CARE

Digital ulcers from RP can be extremely painful and often take weeks or months to heal. Pain control is important because pain may lead to vasospasm and provoke additional bouts of ischemia. In some instances, opioids are needed to control symptoms.

Digits with ulcers should be soaked in a tepid antiseptic solution twice daily to soften or loosen crusts or eschars. After drying, plain petrolatum is applied to the ulcer, and the digit is covered with an occlusive dressing. Maximum tolerated pharmacologic therapies should be employed throughout treatment of an ulcer to promote wound healing by improving blood flow to the area. Importantly, local wound care alone without pharmacologic intervention to improve digital blood flow is unlikely to result in ulcer resolution.

Infection is a common complication of digital ulcers and typically manifests with increasing pain, erythema, swelling, or purulent drainage. Cultures usually demonstrate *Staphylococcus* species, and treatment with cephalosporins, or in the case of methicillin-resistant *Staphylococcus aureus*, trimethoprim-sulfamethoxazole, clindamycin, or a tetracycline, are usually effective. Antimicrobial therapy should be directed by the local antibiogram when available.

CRITICAL ISCHEMIA

Raynaud crisis is typified by critical ischemia and always requires urgent intervention. The guiding principle for managing Raynaud crisis is early diagnosis and intervention to preempt irreversible tissue injury. Patients with critical ischemia require hospitalization and intravenous prostaglandin therapy.[2,145] Iloprost dosed 0.5 to 2 ng/kg by continuous infusion should be given over several hours on 3 consecutive days. Intraarterial phentolamine also has been successfully used in cases of Raynaud crisis, but its administration requires monitoring in an acute care setting given the risk for hemodynamic instability. Analgesics and antibiotics are often coadministered when digital ulcers are present. Skilled nursing and podiatry care (for toe involvement) is an important element of ulcer care, and wound assessments should be performed at routine intervals. It is essential to exclude competing diagnoses when evaluating the patient with critical ischemia. Medium-vessel vasculitis, thromboembolism, and severe atherosclerotic

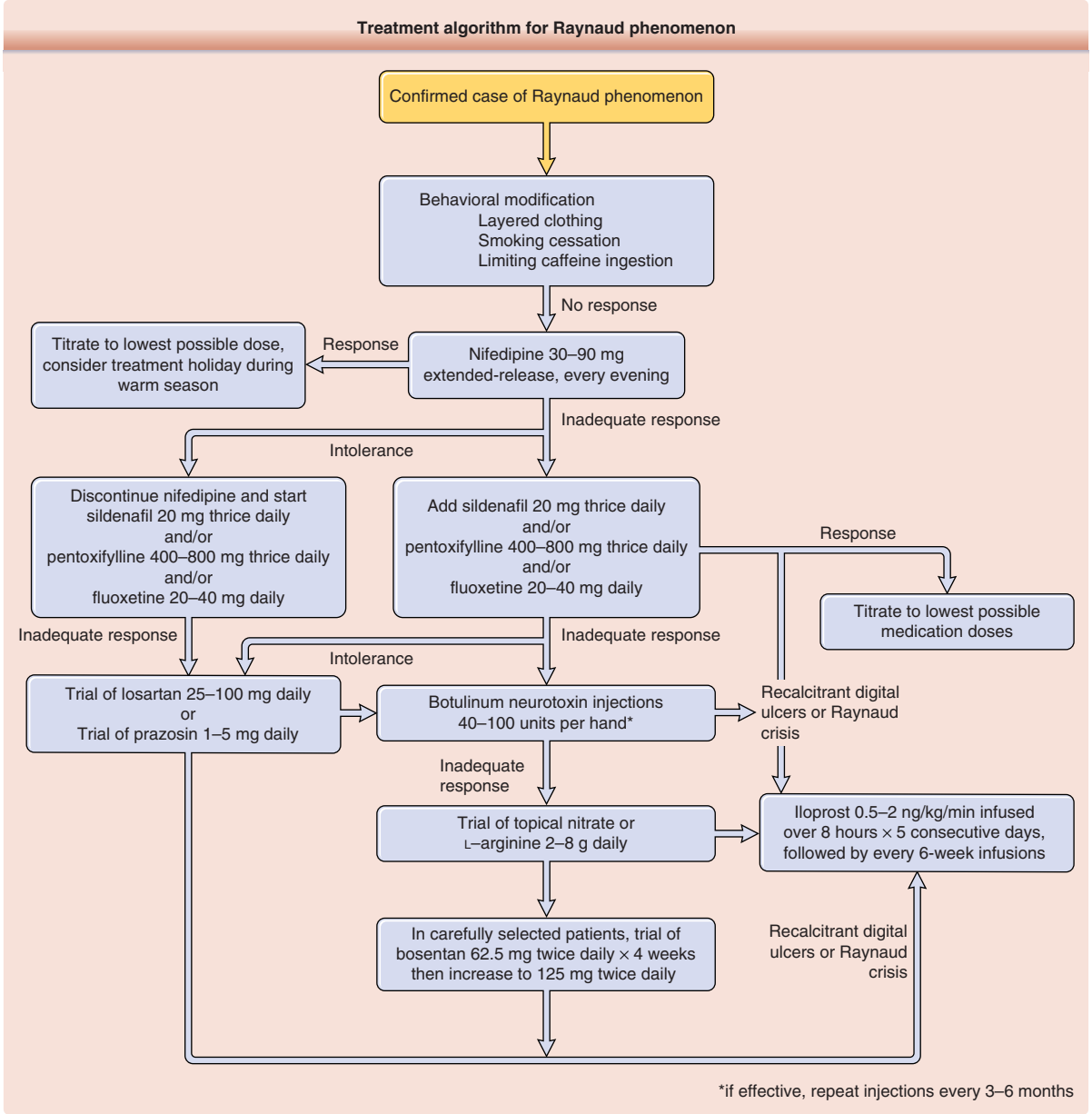

Figure 145-4 Treatment algorithm for Raynaud phenomenon.

disease may mimic Raynaud crisis, but their management differs substantially. Anticoagulation therapy with heparin may be considered if signs of tissue ischemia continue despite aggressive medical therapy. A digital block with lidocaine or bupivacaine can provide pain relief and serves as a chemical sympathectomy to reverse vasoconstriction. Surgical interventions may be considered as a salvage effort in unresponsive patients.

TREATMENT ALGORITHM

Figure 145-4 outlines a treatment algorithm for managing the patient with RP.

REFERENCES

1. Block JA, Sequeira W. Raynaud's phenomenon. *Lancet*. 2001;357(9273):2042-2048.
2. Herrick AL. The pathogenesis, diagnosis and treatment of Raynaud phenomenon. *Nat Rev Rheumatol*. 2012;8(8):469-479.
3. Brand FN, Larson MG, Kannel WB, et al. The occurrence of Raynaud's phenomenon in a general population: the Framingham Study. *Vasc Med*. 1997;2(4):296-301.
4. Gelber AC, Wigley FM, Stallings RY, et al. Symptoms of Raynaud's phenomenon in an inner-city African-American community: prevalence and self-reported cardiovascular comorbidity. *J Clin Epidemiol*. 1999;52(5):441-446.

5. Medsger TA Jr. Natural history of systemic sclerosis and the assessment of disease activity, severity, functional status, and psychologic well-being. *Rheum Dis Clin North Am.* 2003;29(2):255-273, vi.
6. Hirschl M, Kundi M. Initial prevalence and incidence of secondary Raynaud's phenomenon in patients with Raynaud's symptomatology. *J Rheumatol.* 1996;23(2): 302-309.
7. Riera G, Vilardell M, Vaque J, et al. Prevalence of Raynaud's phenomenon in a healthy Spanish population. *J Rheumatol.* 1993;20(1):66-69.
8. Greenstein D, Jeffcote N, Ilsley D, et al. The menstrual cycle and Raynaud's phenomenon. *Angiology*. 1996;47(5):427-436.
9. Gardner-Medwin JM, Macdonald IA, Taylor JY, et al. Seasonal differences in finger skin temperature and microvascular blood flow in healthy men and women are exaggerated in women with primary Raynaud's phenomenon. *Br J Clin Pharmacol.* 2001;52(1):17-23.
10. Fraenkel L, Zhang Y, Chaisson CE, et al. Different factors influencing the expression of Raynaud's phenomenon in men and women. *Arthritis Rheum.* 1999;42(2):306-310.
11. Freedman RR, Mayes MD. Familial aggregation of primary Raynaud's disease. *Arthritis Rheum.* 1996; 39(7):1189-1191.
12. Koenig M, Joyal F, Fritzler MJ, et al. Autoantibodies and microvascular damage are independent predictive factors for the progression of Raynaud's phenomenon to systemic sclerosis: a twenty-year prospective study of 586 patients, with validation of proposed criteria for early systemic sclerosis. *Arthritis Rheum.* 2008;58(12):3902-3912.
13. Spencer-Green G. Outcomes in primary Raynaud phenomenon: a meta-analysis of the frequency, rates, and predictors of transition to secondary diseases. *Arch Intern Med.* 1998;158(6):595-600.
14. Hirschl M, Hirschl K, Lenz M, et al. Transition from primary Raynaud's phenomenon to secondary Raynaud's phenomenon identified by diagnosis of an associated disease: results of ten years of prospective surveillance. *Arthritis Rheum.* 2006;54(6):1974-1981.
15. Hartmann P, Mohokum M, Schlattmann P. The association of Raynaud's syndrome with rheumatoid arthritis—a meta-analysis. *Clin Rheumatol.* 2011; 30(8):1013-1019.
16. Herrick A, el-Hadidy K, Marsh D, et al. Abnormal thermoregulatory responses in patients with reflex sympathetic dystrophy syndrome. *J Rheumatol.* 1994; 21(7):1319-1324.
17. Chung MS, Gong HS, Baek GH. Prevalence of Raynaud's phenomenon in patients with idiopathic carpal tunnel syndrome. *J Bone Joint Surg Br.* 1999;81(6): 1017-1019.
18. Hartmann P, Mohokum M, Schlattmann P. The association of Raynaud's syndrome with carpal tunnel syndrome: a meta-analysis. *Rheumatol Int.* 2012;32(3):569-574.
19. Grassi W, De Angelis R, Lapadula G, et al. Clinical diagnosis found in patients with Raynaud's phenomenon: a multicentre study. *Rheumatol Int.* 1998;18(1):17-20.
20. Pistorius MA, Planchon B. Incidence of thoracic outlet syndrome on the epidemiology and clinical presentation of apparently primary Raynaud's phenomenon. A prospective study in 570 patients. *Int Angiol.* 1995;14(1):60-64.
21. Palmer KT, Griffin MJ, Syddall H, et al. Prevalence of Raynaud's phenomenon in Great Britain and its relation to hand transmitted vibration: a national postal survey. *Occup Environ Med.* 2000;57(7):448-452.
22. Laplanche A, Clavel F, Contassot JC, et al. Exposure to vinyl chloride monomer: report on a cohort study. *Br J Ind Med.* 1987;44(10):711-715.
23. Khouri C, Blaise S, Carpentier P, et al. Drug-induced Raynaud's phenomenon: beyond beta-blockers. *Br J Clin Pharmacol.* 2016;82(1):6-16.
24. Mohokum M, Hartmann P, Schlattmann P. The association of Raynaud syndrome with beta-blockers: a meta-analysis. *Angiology.* 2012;63(7):535-540.
25. Khouri C, Jouve T, Blaise S, et al. Peripheral vasoconstriction induced by beta-blockers: a systematic review and a network meta-analysis. *Br J Clin Pharmacol.* 2016;82(2):549-560.
26. Flavahan NA. A vascular mechanistic approach to understanding Raynaud phenomenon. *Nat Rev Rheumatol.* 2015;11(3):146-158.
27. Robb LG. Severe vasospasm following ergot administration. *West J Med.* 1975;123(3):231-235.
28. Duvoisin RC. Digital vasospasm with bromocriptine. *Lancet.* 1976;2(7978):204.
29. Rudnick A, Modai I, Zelikovski A. Fluoxetine-induced Raynaud's phenomenon. *Biol Psychiatry.* 1997;41(12): 1218-1221.
30. Bell C, Coupland N, Creamer P. Digital infarction in a patient with Raynaud's phenomenon associated with treatment with a specific serotonin reuptake inhibitor. A case report. *Angiology.* 1996;47(9):901-903.
31. Peiro AM, Margarit C, Torra M. Citalopram-induced Raynaud's phenomenon. *Rheumatol Int.* 2007;27(6): 599-601.
32. Goldman W, Seltzer R, Reuman P. Association between treatment with central nervous system stimulants and Raynaud's syndrome in children: a retrospective case-control study of rheumatology patients. *Arthritis Rheum.* 2008;58(2):563-566.
33. Deray G, Le Hoang P, Achour L, et al. Cyclosporin and Raynaud phenomenon. *Lancet.* 1986;2(8515): 1092-1093.
34. Arinsoy T, Derici U, Yuksel A, et al. Cyclosporine—a treatment and a rare complication: Raynaud's phenomenon. *Int J Clin Pract.* 2005;59(7):863-864.
35. Balbir-Gurman A, Braun-Moscovici Y, Nahir AM. Cocaine-Induced Raynaud's phenomenon and ischaemic finger necrosis. *Clin Rheumatol.* 2001;20(5): 376-378.
36. Berger CC, Bokemeyer C, Schneider M, et al. Secondary Raynaud's phenomenon and other late vascular complications following chemotherapy for testicular cancer. *Eur J Cancer.* 1995;31A(13-14): 2229-2238.
37. Glendenning JL, Barbachano Y, Norman AR, et al. Long-term neurologic and peripheral vascular toxicity after chemotherapy treatment of testicular cancer. *Cancer.* 2010;116(10):2322-2331.
38. Fossa SD, Lehne G, Heimdal K, et al. Clinical and biochemical long-term toxicity after postoperative cisplatin-based chemotherapy in patients with low-stage testicular cancer. *Oncology.* 1995;52(4):300-305.
39. Brydoy M, Oldenburg J, Klepp O, et al. Observational study of prevalence of long-term Raynaud-like phenomena and neurological side effects in testicular cancer survivors. *J Natl Cancer Inst.* 2009;101(24): 1682-1695.
40. Epstein E. Intralesional bleomycin and Raynaud's phenomenon. *J Am Acad Dermatol.* 1991;24(5, pt 1): 785-786.

41. Mohokum M, Hartmann P, Schlattmann P. Association of Raynaud's syndrome with interferons. A meta-analysis. *Int Angiol.* 2012;31(5):408-413.
42. Schapira D, Nahir AM, Hadad N. Interferon-induced Raynaud's syndrome. *Semin Arthritis Rheum.* 2002; 32(3):157-162.
43. Zeidman A, Dicker D, Mittelman M. Interferon-induced vasospasm in chronic myeloid leukaemia. *Acta Haematol.* 1998;100(2):94-96.
44. Roy V, Newland AC. Raynaud's phenomenon and cryoglobulinaemia associated with the use of recombinant human alpha-interferon. *Lancet.* 1988; 1(8591):944-945.
45. Rot U, Ledinek AH. Interferons beta have vasoconstrictive and procoagulant effects: a woman who developed livedo reticularis and Raynaud phenomenon in association with interferon beta treatment for multiple sclerosis. *Clin Neurol Neurosurg.* 2013;115(suppl 1):S79-S81.
46. Bakst R, Merola JF, Franks AG Jr, et al. Raynaud's phenomenon: pathogenesis and management. *J Am Acad Dermatol.* 2008;59(4):633-653.
47. Bedarida G, Kim D, Blaschke TF, et al. Venodilation in Raynaud's disease. *Lancet.* 1993;342(8885):1451-1454.
48. Herrick AL. Pathogenesis of Raynaud's phenomenon. *Rheumatology (Oxford).* 2005;44(5):587-596.
49. Anderson ME, Moore TL, Hollis S, et al. Endothelial-dependent vasodilation is impaired in patients with systemic sclerosis, as assessed by low dose iontophoresis. *Clin Exp Rheumatol.* 2003;21(3):403.
50. Gunawardena H, Harris ND, Carmichael C, et al. Maximum blood flow and microvascular regulatory responses in systemic sclerosis. *Rheumatology (Oxford).* 2007;46(7):1079-1082.
51. Rajagopalan S, Pfenninger D, Kehrer C, et al. Increased asymmetric dimethylarginine and endothelin 1 levels in secondary Raynaud's phenomenon: implications for vascular dysfunction and progression of disease. *Arthritis Rheum.* 2003;48(7):1992-2000.
52. Zamora MR, O'Brien RF, Rutherford RB, et al. Serum endothelin-1 concentrations and cold provocation in primary Raynaud's phenomenon. *Lancet.* 1990;336(8724):1144-1147.
53. Duprez DA. Role of the renin-angiotensin-aldosterone system in vascular remodeling and inflammation: a clinical review. *J Hypertens.* 2006;24(6): 983-991.
54. Vancheeswaran R, Azam A, Black C, et al. Localization of endothelin-1 and its binding sites in scleroderma skin. *J Rheumatol.* 1994;21(7):1268-1276.
55. Ramos-Casals M, Brito-Zeron P, Nardi N, et al. Successful treatment of severe Raynaud's phenomenon with bosentan in four patients with systemic sclerosis. *Rheumatology (Oxford).* 2004;43(11):1454-1456.
56. Bukhari M, Herrick AL, Moore T, et al. Increased nailfold capillary dimensions in primary Raynaud's phenomenon and systemic sclerosis. *Br J Rheumatol.* 1996;35(11):1127-1131.
57. Bunker CB, Terenghi G, Springall DR, et al. Deficiency of calcitonin gene-related peptide in Raynaud's phenomenon. *Lancet.* 1990;336(8730):1530-1533.
58. Coffman JD, Cohen RA. Role of alpha-adrenoceptor subtypes mediating sympathetic vasoconstriction in human digits. *Eur J Clin Invest.* 1988;18(3):309-313.
59. Flavahan NA, Cooke JP, Shepherd JT, et al. Human postjunctional alpha-1 and alpha-2 adrenoceptors: differential distribution in arteries of the limbs. *J Pharmacol Exp Ther.* 1987;241(2):361-365.
60. Edwards CM, Marshall JM, Pugh M. Lack of habituation of the pattern of cardiovascular response evoked by sound in subjects with primary Raynaud's disease. *Clin Sci (Lond).* 1998;95(3):249-260.
61. Edwards CM, Marshall JM, Pugh M. The cutaneous vasoconstrictor response to venous stasis is normal in subjects with primary Raynaud's disease. *Clin Auton Res.* 1999;9(5):255-262.
62. Pamuk GE, Turgut B, Pamuk ON, et al. Increased circulating platelet-leucocyte complexes in patients with primary Raynaud's phenomenon and Raynaud's phenomenon secondary to systemic sclerosis: a comparative study. *Blood Coagul Fibrinolysis.* 2007; 18(4):297-302.
63. Susol E, MacGregor AJ, Barrett JH, et al. A two-stage, genome-wide screen for susceptibility loci in primary Raynaud's phenomenon. *Arthritis Rheum.* 2000;43(7):1641-1646.
64. Allen EV, Brown GE. Raynaud's disease: a clinical study of one hundred and forty-seven cases. *JAMA.* 1932;99(18):1472-1478.
65. LeRoy EC, Medsger TA Jr. Raynaud's phenomenon: a proposal for classification. *Clin Exp Rheumatol.* 1992;10(5):485-488.
66. Brennan P, Silman A, Black C, et al. Validity and reliability of three methods used in the diagnosis of Raynaud's phenomenon. The UK Scleroderma Study Group. *Br J Rheumatol.* 1993;32(5):357-361.
67. Maverakis E, Patel F, Kronenberg DG, et al. International consensus criteria for the diagnosis of Raynaud's phenomenon. *J Autoimmun.* 2014;48-49:60-65.
68. Wigley FM. Clinical practice. Raynaud's phenomenon. *N Engl J Med.* 2002;347(13):1001-1008.
69. Pavlov-Dolijanovic S, Damjanov NS, Vujasinovic Stupar NZ, et al. Late appearance and exacerbation of primary Raynaud's phenomenon attacks can predict future development of connective tissue disease: a retrospective chart review of 3,035 patients. *Rheumatol Int.* 2013;33(4):921-926.
70. Ingegnoli F, Boracchi P, Gualtierotti R, et al. Improving outcome prediction of systemic sclerosis from isolated Raynaud's phenomenon: role of autoantibodies and nail-fold capillaroscopy. *Rheumatology (Oxford).* 2010;49(4):797-805.
71. Kallenberg CG, Wouda AA, Hoet MH, et al. Development of connective tissue disease in patients presenting with Raynaud's phenomenon: a six year follow up with emphasis on the predictive value of antinuclear antibodies as detected by immunoblotting. *Ann Rheum Dis.* 1988;47(8):634-641.
72. Wollersheim H, Thien T, Hoet MH, et al. The diagnostic value of several immunological tests for antinuclear antibody in predicting the development of connective tissue disease in patients presenting with Raynaud's phenomenon. *Eur J Clin Invest.* 1989;19(6):535-541.
73. Maricq HR, LeRoy EC. Patterns of finger capillary abnormalities in connective tissue disease by "wide-field" microscopy. *Arthritis Rheum.* 1973;16(5):619-628.
74. ter Borg EJ, Piersma-Wichers G, Smit AJ, et al. Serial nailfold capillary microscopy in primary Raynaud's phenomenon and scleroderma. *Semin Arthritis Rheum.* 1994;24(1):40-47.
75. Anderson ME, Moore TL, Lunt M, et al. The "distal-dorsal difference": a thermographic parameter by which to differentiate between primary and secondary Raynaud's phenomenon. *Rheumatology (Oxford).* 2007;46(3):533-538.

76. Murray AK, Moore TL, Manning JB, et al. Noninvasive imaging techniques in the assessment of scleroderma spectrum disorders. *Arthritis Rheum.* 2009;61(8):1103-1111.
77. Rosato E, Borghese F, Pisarri S, et al. Laser Doppler perfusion imaging is useful in the study of Raynaud's phenomenon and improves the capillaroscopic diagnosis. *J Rheumatol.* 2009;36(10):2257-2263.
78. Herrick AL, Clark S. Quantifying digital vascular disease in patients with primary Raynaud's phenomenon and systemic sclerosis. *Ann Rheum Dis.* 1998;57(2):70-78.
79. Das S, Maiti A. Acrocyanosis: an overview. *Indian J Dermatol.* 2013;58(6):417-420.
80. Heidrich H. Functional vascular diseases: Raynaud's syndrome, acrocyanosis and erythromelalgia. *Vasa.* 2010;39(1):33-41.
81. Kelly R, Baker C. Other vascular disorders. In: Bolognia JL, Jorizzo JL, Schaffer JV, editors. *Dermatology.* 3rd ed. Philadelphia, PA: Elsevier Saunders; 2012:1747-1756.
82. Berlin AL, Pehr K. Coexistence of erythromelalgia and Raynaud's phenomenon. *J Am Acad Dermatol.* 2004;50(3):456-460.
83. Yang Y, Wang Y, Li S, et al. Mutations in SCN9A, encoding a sodium channel alpha subunit, in patients with primary erythermalgia. *J Med Genet.* 2004;41(3):171-174.
84. Gibbs MB, English JC 3rd, Zirwas MJ. Livedo reticularis: an update. *J Am Acad Dermatol.* 2005;52(6):1009-1019.
85. Phelps GR, Wilentz S. Reflex sympathetic dystrophy. *Int J Dermatol.* 2000;39(7):481-486.
86. Youssef P, Englert H, Bertouch J. Large vessel occlusive disease associated with CREST syndrome and scleroderma. *Ann Rheum Dis.* 1993;52(6):464-466.
87. Merkel PA, Herlyn K, Martin RW, et al. Measuring disease activity and functional status in patients with scleroderma and Raynaud's phenomenon. *Arthritis Rheum.* 2002;46(9):2410-2420.
88. Khanna PP, Maranian P, Gregory J, et al. The minimally important difference and patient acceptable symptom state for the Raynaud's condition score in patients with Raynaud's phenomenon in a large randomised controlled clinical trial. *Ann Rheum Dis.* 2010;69(3):588-591.
89. Thompson AE, Pope JE. Calcium channel blockers for primary Raynaud's phenomenon: a meta-analysis. *Rheumatology (Oxford).* 2005;44(2):145-150.
90. Thompson AE, Shea B, Welch V, et al. Calcium-channel blockers for Raynaud's phenomenon in systemic sclerosis. *Arthritis Rheum.* 2001;44(8):1841-1847.
91. Ennis H, Hughes M, Anderson ME, et al. Calcium channel blockers for primary Raynaud's phenomenon. *Cochrane Database Syst Rev.* 2016;2:CD002069.
92. Rhedda A, McCans J, Willan AR, et al. A double blind placebo controlled crossover randomized trial of diltiazem in Raynaud's phenomenon. *J Rheumatol.* 1985;12(4):724-727.
93. Comparison of sustained-release nifedipine and temperature biofeedback for treatment of primary Raynaud phenomenon. Results from a randomized clinical trial with 1-year follow-up. *Arch Intern Med.* 2000;160(8):1101-1108.
94. Kahan A, Bour B, Couturier D, et al. Nifedipine and esophageal dysfunction in progressive systemic sclerosis. A controlled manometric study. *Arthritis Rheum.* 1985;28(5):490-495.
95. Franks AG Jr. Topical glyceryl trinitrate as adjunctive treatment in Raynaud's disease. *Lancet.* 1982;1(8263):76-77.
96. Freedman RR, Girgis R, Mayes MD. Acute effect of nitric oxide on Raynaud's phenomenon in scleroderma. *Lancet.* 1999;354(9180):739.
97. Shenoy PD, Kumar S, Jha LK, et al. Efficacy of tadalafil in secondary Raynaud's phenomenon resistant to vasodilator therapy: a double-blind randomized cross-over trial. *Rheumatology (Oxford).* 2010;49(12):2420-2428.
98. Fries R, Shariat K, von Wilmowsky H, et al. Sildenafil in the treatment of Raynaud's phenomenon resistant to vasodilatory therapy. *Circulation.* 2005;112(19):2980-2985.
99. Herrick AL, van den Hoogen F, Gabrielli A, et al. Modified-release sildenafil reduces Raynaud's phenomenon attack frequency in limited cutaneous systemic sclerosis. *Arthritis Rheum.* 2011;63(3):775-782.
100. Schiopu E, Hsu VM, Impens AJ, et al. Randomized placebo-controlled crossover trial of tadalafil in Raynaud's phenomenon secondary to systemic sclerosis. *J Rheumatol.* 2009;36(10):2264-2268.
101. Roustit M, Blaise S, Allanore Y, et al. Phosphodiesterase-5 inhibitors for the treatment of secondary Raynaud's phenomenon: systematic review and meta-analysis of randomised trials. *Ann Rheum Dis.* 2013;72(10):1696-1699.
102. Wigley FM, Seibold JR, Wise RA, et al. Intravenous iloprost treatment of Raynaud's phenomenon and ischemic ulcers secondary to systemic sclerosis. *J Rheumatol.* 1992;19(9):1407-1414.
103. Wigley FM, Wise RA, Seibold JR, et al. Intravenous iloprost infusion in patients with Raynaud phenomenon secondary to systemic sclerosis. A multicenter, placebo-controlled, double-blind study. *Ann Intern Med.* 1994;120(3):199-206.
104. Scorza R, Caronni M, Mascagni B, et al. Effects of long-term cyclic iloprost therapy in systemic sclerosis with Raynaud's phenomenon. A randomized, controlled study. *Clin Exp Rheumatol.* 2001;19(5):503-508.
105. Black CM, Halkier-Sorensen L, Belch JJ, et al. Oral iloprost in Raynaud's phenomenon secondary to systemic sclerosis: a multicentre, placebo-controlled, dose-comparison study. *Br J Rheumatol.* 1998;37(9):952-960.
106. Wigley FM, Korn JH, Csuka ME, et al. Oral iloprost treatment in patients with Raynaud's phenomenon secondary to systemic sclerosis: a multicenter, placebo-controlled, double-blind study. *Arthritis Rheum.* 1998;41(4):670-677.
107. Pope J, Fenlon D, Thompson A, et al. Iloprost and cisaprost for Raynaud's phenomenon in progressive systemic sclerosis. *Cochrane Database Syst Rev.* 2000(2):CD000953.
108. Challenor VF, Waller DG, Hayward RA, et al. Subjective and objective assessment of enalapril in primary Raynaud's phenomenon. *Br J Clin Pharmacol.* 1991;31(4):477-480.
109. Janini SD, Scott DG, Coppock JS, et al. Enalapril in Raynaud's phenomenon. *J Clin Pharm Ther.* 1988;13(2):145-150.
110. Gliddon AE, Dore CJ, Black CM, et al. Prevention of vascular damage in scleroderma and autoimmune Raynaud's phenomenon: a multicenter, randomized, double-blind, placebo-controlled trial of the angiotensin-converting enzyme inhibitor quinapril. *Arthritis Rheum.* 2007;56(11):3837-3846.
111. Dziadzio M, Denton CP, Smith R, et al. Losartan therapy for Raynaud's phenomenon and scleroderma: clinical and biochemical findings in a fifteen-week,

randomized, parallel-group, controlled trial. *Arthritis Rheum.* 1999;42(12):2646-2655.
112. Seibold JR. Serotonin and Raynaud's phenomenon. *J Cardiovasc Pharmacol.* 1985;7(suppl 7):S95-S98.
113. Dees C, Akhmetshina A, Zerr P, et al. Platelet-derived serotonin links vascular disease and tissue fibrosis. *J Exp Med.* 2011;208(5):961-972.
114. Halpern A, Kuhn PH, Shaftel HE, et al. Raynaud's disease, Raynaud's phenomenon, and serotonin. *Angiology.* 1960;11:151-167.
115. Coleiro B, Marshall SE, Denton CP, et al. Treatment of Raynaud's phenomenon with the selective serotonin reuptake inhibitor fluoxetine. *Rheumatology (Oxford).* 2001;40(9):1038-1043.
116. Humbert M, Cabane J. Successful treatment of systemic sclerosis digital ulcers and pulmonary arterial hypertension with endothelin receptor antagonist bosentan. *Rheumatology (Oxford).* 2003;42(1): 191-193.
117. Korn JH, Mayes M, Matucci Cerinic M, et al. Digital ulcers in systemic sclerosis: prevention by treatment with bosentan, an oral endothelin receptor antagonist. *Arthritis Rheum.* 2004;50(12):3985-3993.
118. Pope J, Fenlon D, Thompson A, et al. Prazosin for Raynaud's phenomenon in progressive systemic sclerosis. *Cochrane Database Syst Rev.* 2000(2):CD000956.
119. Surwit RS, Gilgor RS, Allen LM, et al. A double-blind study of prazosin in the treatment of Raynaud's phenomenon in scleroderma. *Arch Dermatol.* 1984; 120(3):329-331.
120. Herrick AL, Murray AK, Ruck A, et al. A double-blind, randomized, placebo-controlled crossover trial of the alpha2C-adrenoceptor antagonist ORM-12741 for prevention of cold-induced vasospasm in patients with systemic sclerosis. *Rheumatology (Oxford).* 2014;53(5):948-952.
121. Bailey SR, Eid AH, Mitra S, et al. Rho kinase mediates cold-induced constriction of cutaneous arteries: role of alpha2C-adrenoceptor translocation. *Circ Res.* 2004;94(10):1367-1374.
122. Flavahan NA. Regulation of vascular reactivity in scleroderma: new insights into Raynaud's phenomenon. *Rheum Dis Clin North Am.* 2008;34(1):81-87; vii.
123. Fava A, Wung PK, Wigley FM, et al. Efficacy of Rho kinase inhibitor fasudil in secondary Raynaud's phenomenon. *Arthritis Care Res (Hoboken).* 2012;64(6): 925-929.
124. Neirotti M, Longo F, Molaschi M, et al. Functional vascular disorders: treatment with pentoxifylline. *Angiology.* 1987;38(8):575-580.
125. Goldberg J, Dlesk A. Successful treatment of Raynaud's phenomenon with pentoxifylline. *Arthritis Rheum.* 1986;29(8):1055-1056.
126. Denton CP, Howell K, Stratton RJ, et al. Long-term low molecular weight heparin therapy for severe Raynaud's phenomenon: a pilot study. *Clin Exp Rheumatol.* 2000;18(4):499-502.
127. Cukierman T, Elinav E, Korem M, et al. Low dose warfarin treatment for calcinosis in patients with systemic sclerosis. *Ann Rheum Dis.* 2004;63(10):1341-1343.
128. Sambo P, Amico D, Giacomelli R, et al. Intravenous *N*-acetylcysteine for treatment of Raynaud's phenomenon secondary to systemic sclerosis: a pilot study. *J Rheumatol.* 2001;28(10):2257-2262.
129. Denton CP, Bunce TD, Dorado MB, et al. Probucol improves symptoms and reduces lipoprotein oxidation susceptibility in patients with Raynaud's phenomenon. *Rheumatology (Oxford).* 1999;38(4):309-315.
130. Malenfant D, Catton M, Pope JE. The efficacy of complementary and alternative medicine in the treatment of Raynaud's phenomenon: a literature review and meta-analysis. *Rheumatology (Oxford).* 2009;48(7):791-795.
131. Morris JL, Jobling P, Gibbins IL. Differential inhibition by botulinum neurotoxin A of cotransmitters released from autonomic vasodilator neurons. *Am J Physiol Heart Circ Physiol.* 2001;281(5):H2124-H2132.
132. Sycha T, Graninger M, Auff E, et al. Botulinum toxin in the treatment of Raynaud's phenomenon: a pilot study. *Eur J Clin Invest.* 2004;34(4):312-313.
133. Van Beek AL, Lim PK, Gear AJ, et al. Management of vasospastic disorders with botulinum toxin A. *Plast Reconstr Surg.* 2007;119(1):217-226.
134. Iorio ML, Masden DL, Higgins JP. Botulinum toxin A treatment of Raynaud's phenomenon: a review. *Semin Arthritis Rheum.* 2012;41(4):599-603.
135. Jenkins SN, Neyman KM, Veledar E, et al. A pilot study evaluating the efficacy of botulinum toxin A in the treatment of Raynaud phenomenon. *J Am Acad Dermatol.* 2013;69(5):834-835.
136. Clemens MW, Higgins JP, Wilgis EF. Prevention of anastomotic thrombosis by botulinum toxin a in an animal model. *Plast Reconstr Surg.* 2009;123(1):64-70.
137. Matic DB, Lee TY, Wells RG, et al. The effects of botulinum toxin type A on muscle blood perfusion and metabolism. *Plast Reconstr Surg.* 2007;120(7): 1823-1833.
138. Neumeister MW. Botulinum toxin type A in the treatment of Raynaud's phenomenon. *J Hand Surg Am.* 2010;35(12):2085-2092.
139. Gordon A, Zechmeister K, Collin J. The role of sympathectomy in current surgical practice. *Eur J Vasc Surg.* 1994;8(2):129-137.
140. Coveliers HM, Hoexum F, Nederhoed JH, et al. Thoracic sympathectomy for digital ischemia: a summary of evidence. *J Vasc Surg.* 2011;54(1):273-277.
141. el-Gammal TA, Blair WF. Digital periarterial sympathectomy for ischaemic digital pain and ulcers. *J Hand Surg Am.* 1991;16(4):382-385.
142. Balogh B, Mayer W, Vesely M, et al. Adventitial stripping of the radial and ulnar arteries in Raynaud's disease. *J Hand Surg Am.* 2002;27(6):1073-1080.
143. Jeon SB, Ahn HC, Ahn YS, et al. Two-step incision for periarterial sympathectomy of the hand. *Arch Plast Surg.* 2015;42(6):761-768.
144. Taylor MH, McFadden JA, Bolster MB, et al. Ulnar artery involvement in systemic sclerosis (scleroderma). *J Rheumatol.* 2002;29(1):102-106.
145. Hummers LK, Wigley FM. Management of Raynaud's phenomenon and digital ischemic lesions in scleroderma. *Rheum Dis Clin North Am.* 2003;29(2):293-313.

Chapter 146 :: Malignant Atrophic Papulosis (Degos Disease)

:: Dan Lipsker

AT-A-GLANCE

- Malignant atrophic papulosis (Degos disease) is a rare, primary vasoocclusive disorder, affecting mainly the skin, the GI tract, and the CNS.
- Diagnosis relies on clinical and pathologic evaluation and correlation.
- Characterized by numerous, typical, porcelain-white, atrophic papules, with a rim of rosy erythema and/or telangiectasia.
- Pathology shows a wedge-shaped area of dermal necrosis with edema and mucin deposition.
- Benign forms without extracutaneous involvement are possible.

Köhlmeier first described malignant atrophic papulosis in the early 1940s, and Degos, Delort, and Tricot recognized it as a specific entity a year later.[1-3] We now know that the clinically distinctive lesion of so-called Degos disease is a marker of cutaneous thrombooblitterative vasculopathy rather than of a specific disease per se. Such lesions can be found in at least 2 distinctive clinical settings: (a) as an apparent idiopathic disease, either classic Degos disease or its benign variant, or (b) as a surrogate clinical finding in some connective tissue diseases such as the antiphospholipid syndrome, lupus erythematosus, dermatomyositis, and systemic sclerosis.

EPIDEMIOLOGY

Classic Degos disease is rare, with approximately 250 reported cases in the literature. It almost always occurs in whites, but cases have been observed in African American patients and in Japan. The disease most commonly presents between the third and fourth decades but can occur at any age. Men are more often affected than women (ratio: 3:1). The majority of cases are sporadic, but familial cases have been described, and most of these cases are consistent with an autosomal dominant pattern of inheritance.[4]

ETIOLOGY AND PATHOGENESIS

The etiology of Degos disease is poorly understood. The histopathologic findings suggest a primary vasoocclusive process, and vascular coagulopathy and/or endothelial cell damage should be considered as the major pathogenic mechanism. Several disease processes may converge to produce the clinical and histologic findings. A combination of prothrombotic factors possibly plays a role in triggering the full-blown disease. Extensive studies of prothrombotic factors have been performed in patients with Degos disease, and no single abnormality has been repeatedly identified. Assier and colleagues did not find antiphospholipid or antiendothelial cell antibodies in their series of 15 patients.[5] Inhibition of fibrinolysis and platelet abnormalities, including increased platelet adhesiveness and spontaneous aggregation, have been reported in some patients.[5-8] Strong stromal cell–derived factor-1/CXCL12 expression of the inflammatory cells was reported in 2 Japanese patients. This could contribute to platelet aggregation via the CXCR4 receptor.[9] Magro and colleagues suggested that Degos disease could be an interferon-α–mediated endotheliopathy syndrome,[10] and that the membranolytic complement attack complex C5b-9 could contribute to the thrombogenic microangiopathy.[10,11] However, complement-mediated injury is probably a late event, explaining why targeted treatment with an anti-C5 antibody, eculizumab, can effectively rescue the acutely ill, but has no effect on occlusive fibrointimal arteriopathy.[11]

CLINICAL FINDINGS

Figure 146-1 outlines an approach to the patient with suspected Degos disease.

HISTORY

Patients present with small cutaneous lesions that are usually neither pruritic nor painful. In some, history and/or review of systems will reveal signs indicative

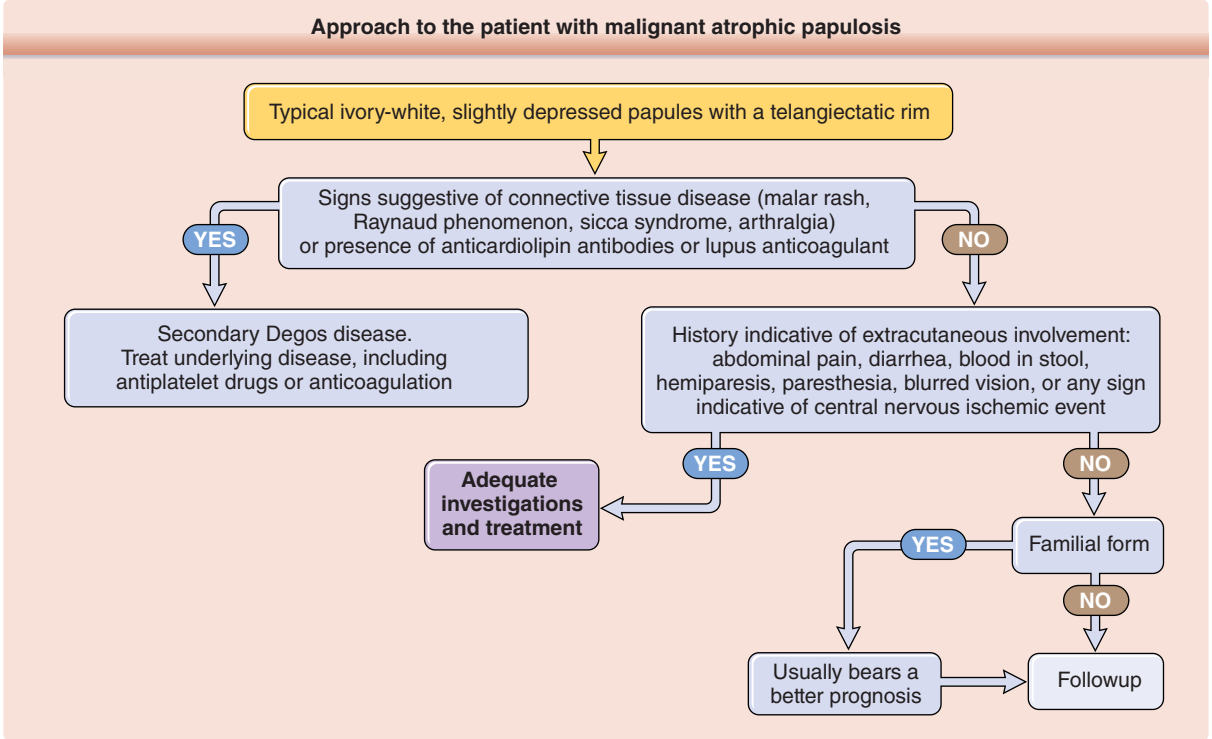

Figure 146-1 Approach to the patient with malignant atrophic papulosis (Degos disease).

of extracutaneous involvement: abdominal pain, diarrhea, melena, nausea, blurred vision, hemiparesis, paresthesia, or any other sign indicative of an ischemic event. History can also give a clue to previous thromboembolic or obstetrical events suggestive of the antiphospholipid antibody syndrome. A preceding infection is sometimes reported.[12]

CUTANEOUS AND OCULAR LESIONS

Cutaneous lesions start as crops of 2 to 10 mm, largely asymptomatic or mildly pruritic, rose-colored macules that progress quickly to round, smooth, often dome-shaped, firm papules (Fig. 146-2). Some lesions display central umbilication and/or necrosis (Fig. 146-3). These lesions evolve over days or weeks to porcelain-white, atrophic papules with a rim of rosy erythema and/or telangiectasias (Fig. 146-4). A fully developed lesion closely resembles the changes of atrophie blanche. In time, the reddish border disappears, and only a varicelliform white scar remains. The lesions of Degos disease are typically discreet, but they may coalesce, leading to polycyclic atrophic areas or ulcerations.

The lesions are most often located on the trunk and limbs. Palms, soles, face, scalp, and genitalia are usually spared, although exceptions occur. Exclusive acral localization is suggestive of connective tissue disease rather than Degos disease. A linear distribution has been reported.[13] Eye involvement is possible. The most common manifestation is an avascular patch on the conjunctivae, but sclerae, episclera, retina, choroids, and optic nerves may be affected.

Figure 146-2 Numerous typical papules of malignant atrophic papulosis (Degos disease) in a young man.

Figure 146-3 Papule with central ulceration in a patient with malignant atrophic papulosis (Degos disease).

CLASSIC DEGOS DISEASE

In classic Degos disease, the number of cutaneous lesions varies from a few to more than 100. Cutaneous findings usually precede the systemic manifestations. GI findings include bowel perforation and peritonitis, and the CNS findings include hemorrhagic or ischemic stroke. Cutaneous lesions rarely occur simultaneously or after GI or CNS involvement. Postmortem studies have revealed small-vessel thrombotic involvement of many organs, including kidney, bladder, prostate, liver, pleura, pericardium, lung, and eyes.[14] Some patients with classic Degos disease have antiphospholipid antibodies, which raises the possibility of a relationship with a primary antiphospholipid syndrome.

BENIGN DEGOS DISEASE

A benign form of Degos disease is now widely recognized. In this form, only skin involvement is found, and most of the familial cases are benign.[4] Development during pregnancy has been reported in a patient with antiphospholipid antibodies,[15] as well as a case occurring in a patient with AIDS.[16] Skin changes consistent with Degos disease have been described at the sites of injection of interferon, a drug known to induce atrophie blanche–like lesions.[17-19] There is no clearcut distinction between the classic and the benign form of Degos disease, and there is no way to predict which patients will develop extracutaneous involvement.

Figure 146-4 Typical pathognomonic papules of malignant atrophic papulosis (Degos disease) with a porcelain-white center and an erythematous raised border.

DEGOS DISEASE–LIKE LESIONS OR SECONDARY DEGOS DISEASE

Degos disease–like lesions can occur in patients with lupus erythematosus, especially those with antiphospholipid antibodies, dermatomyositis, systemic sclerosis, granulomatosis with polyangiitis (Wegener granulomatosis), Crohn disease, opioid-induced thrombotic microangiopathy, and during parvovirus B19 viremia, a virus with a known affinity for endothelial cells.[20-25]

LABORATORY TESTS

HISTOPATHOLOGY

Fully developed lesions of Degos disease demonstrate a cell-poor, wedge-shaped area of mild-to-severe dermal necrosis with dermal edema and copious mucin deposition, extending from the papillary dermis to the deep reticular dermis (Fig. 146-5). At the base of the lesion, occluded vessels with occasional thrombosis, thickened vessel walls with intimal fibrosis, proliferating endothelial cells, and a sparse perivascular lymphocytic infiltrate can be found (Fig. 146-6). A full-blown leukocytoclastic, neutrophilic vasculitis is never found in patients with malignant atrophic papulosis, signifying this entity should not be classified as vasculitis. Numerous secondary, epidermal changes can be found: hyperkeratosis, interface dermatitis,

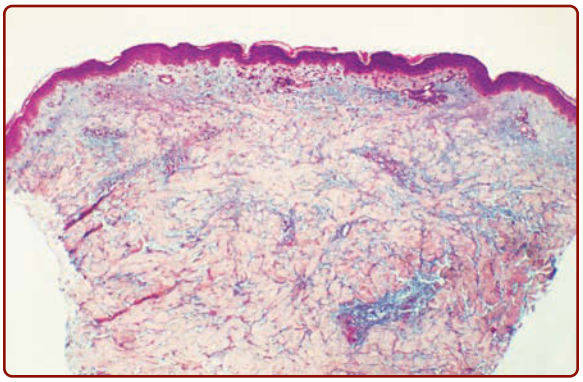

Figure 146-5 A wedge-shaped, cell-poor area of dermal necrosis, with copious mucin deposition, extending from the papillar dermis to the deep part of the reticular dermis (hematoxylin-eosin-saffron-Astra blue stain, ×40 magnification).

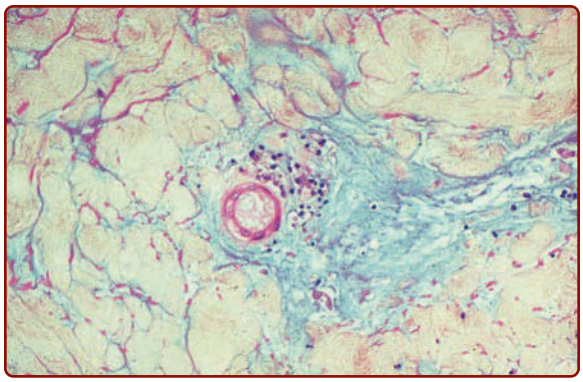

Figure 146-6 In the deeper reticular dermis, prominent mucin deposition and a sparse lymphocytic infiltrate is seen around a blood vessel (hematoxylin-eosin-saffron-Astra blue, ×200 magnification).

scattered necrotic keratinocytes, and atrophy. An associated sclerosing panniculitis was reported in one patient.[26] Results of direct immunofluorescence studies have been inconsistent. Electron microscopy occasionally reveals tubuloreticular aggregates within endothelial cells of uncertain significance.

Because some of the histopathologic findings, such as mucinous infiltration of the dermis, interface dermatitis, and a perivascular lymphocytic dermal infiltrate, are shared by lupus erythematosus and dermatomyositis, Degos disease is considered by some as a possible variant of lupus erythematosus.[22]

OTHER LABORATORY TESTS AND SPECIAL TESTS

There is no diagnostic or prognostic marker of the disease. A search for antinuclear antibodies, lupus anticoagulant, and anticardiolipin antibodies should be performed in each patient. All patients should be screened for the presence of antiphospholipid antibodies/lupus anticoagulant and cryoglobulins. An extensive exploration of hemostasis will sometimes reveal abnormalities. When the disease starts with sudden onset, parvovirus B19 infection should be suspected and circulating viral DNA should be searched for by polymerase chain reaction.[23]

Clinical evaluation can confirm secondary Degos disease if signs suggestive of connective tissue disease or antiphospholipid syndrome are present. If the clinical evaluation reveals signs of intestinal or cerebral involvement (pain, diarrhea, hemiparesis, blurred vision, paresthesia), imaging studies, including cerebral MRI and/or endoscopic evaluation/laparoscopy, are mandatory.

DIAGNOSIS

The diagnosis is usually established clinically, because of the distinctive skin lesions. A confirmatory biopsy should always be performed.

TABLE 146-1
Differential Diagnosis of Malignant Atrophic Papulosis (Degos Disease)

Conditions with White and/or Necrotic Papules

Common
- Atrophie blanche

Less Common
- Cutaneous lichen sclerosus
- Pityriasis lichenoides
- Lymphomatoid papulosis
- Syphilids, tuberculids
- Cutaneous Kikuchi disease (histiocytic necrotizing lymphadenitis)
- Clear-cell papulosis
- Calcinosis cutis
- Fibroelastolytic papulosis of the neck
- White lentiginosis
- Scar, artifactual disease

Always Rule Out
- Connective tissue disease with Degos disease–like lesions
- Crohn disease
- Granulomatosis with polyangiitis (Wegener granulomatosis)
- Opioid-induced thrombotic microangiopathy
- Parvovirus B19 infection

DIFFERENTIAL DIAGNOSIS

Table 146-1 outlines the differential diagnosis of malignant atrophic papulosis (Degos disease).

COMPLICATIONS

GI hemorrhage, perforation, and peritonitis are the most frequent complications of the disease and are the major ominous events, occurring in up to 73% of the 30% of patients with the systemic form of the disease.[27] Neurologic complications, including hemiparesis, aphasia, multiple cranial nerve involvement, monoplegia, sensory disturbances, and seizures, are less common. Rarely, progressive neurologic involvement can lead to death, especially in children. Exceptionally, death can result from respiratory failure or myocardial infarction. Thus, death related to an ischemic cerebral or GI event is the major complication of Degos disease, conferring a 5-year survival rate in patients with systemic disease of approximately 54%.[27]

PROGNOSIS AND CLINICAL COURSE

Extracutaneous manifestations will occur in approximately 30% of patients within 2 or 3 years after diagnosis.[27] Although absence of visceral involvement 2 years after diagnosis portends a better prognosis, systemic involvement can occur many years after the initial presentation of cutaneous lesions, making it impossible to predict the outcome. Nevertheless,

if no extracutaneous manifestations have occurred 7 years after diagnosis, the probability of a benign monosymptomatic cutaneous course is greater than 90%.[27] Lethality is greater than 50% if patients present with extracutaneous involvement, and most of these patients die within 2 to 3 years, mainly because of severe intestinal involvement. Familial Degos disease bears a better prognosis.[4]

TREATMENT

As a consequence of the rarity of Degos disease, there are no controlled clinical trials of therapy, but only anecdotal reports. As some aspects of Degos disease resemble livedoid vasculopathy, some treatments reported to be effective in patients with livedoid vasculopathy are worth trying (see table below). The treatment of secondary Degos disease occurring in patients with known connective tissue disease should involve the introduction of antiplatelet agents in addition to the standard treatments otherwise required by those patients.

Patients with classic Degos disease should be screened for all known preventable cardiovascular risk factors. Patients should cease smoking, and their lipid levels should be screened and lowered, if necessary, using statins.

First-line treatment of patients with Degos disease should include platelet aggregation inhibitors (aspirin, clopidogrel, dipyridamole; Table 146-2). A substantial number of patients responded to aspirin and dipyridamole.[6,7,16] A number of anecdotal treatments, including antibiotics, chloroquine, immunosuppressive agents, phenylbutazone, and fibrinolytics, have been reported and have had variable success. Systemic steroids have been reported to exacerbate the disease and should not be prescribed.[28] The tumor necrosis factor inhibitor infliximab was not effective in one report.[29] Heparin and other anticoagulation strategies, such as vitamin K inhibitors (warfarin, fluindione) have variable success rates. Yet, borrowing from livedoid vasculopathy, low-molecular-weight heparin and the newer anticoagulants might warrant a trial in the acutely ill patient who is not responding to antiplatelet agents.[30] Intravenous immunoglobulins should be considered in patients who are not responding to other treatments or are the acutely ill.[23,31] As the membranolytic complement attack complex C5b-9 seems involved in the pathogenesis of Degos disease, there is a rationale for using the monoclonal antibody eculizumab.[10-12] Eculizumab targets C5 and inhibits its cleavage to C5a and C5b by the C5 convertase, preventing the generation of the terminal complement complex C5b-9. A few patients treated with eculizumab had a substantial response, especially in the acute thrombotic phase,[11] but others did not respond or progress under treatment.[32-34] Treprostinil, a prostacyclin analog, was found to be effective in 1 patient with systemic sclerosis/lupus erythematosus overlap and Degos disease–like skin lesions and in a 17-year-old patient with severe Degos disease progressing on eculizumab.[34]

TABLE 146-2

Treatment of Malignant Atrophic Papulosis (Degos Disease)

First-line treatment	Aspirin (100-325 mg) and dipyridamole (3 × 400 mg)
Second-line treatment	Heparin and other anticoagulation strategies
Unresponsive or acutely ill patients	Intravenous immunoglobulins (1 g/kg/day for 2 days or 0.4 g/kg/day for 5 days) Eculizumab, treprostinil
Adjunctive measures	Control of cardiovascular risk factors

REFERENCES

1. Köhlmeier W. Multiple Hautnekrosen bei thrombangiitis obliterans. *Arch Dermatol Syph*. 1941;181:783.
2. Degos R, Delort J, Tricot R. Dermatite papulosquameuse atrophiante. *Bull Soc Fr Dermatol Syphiligr*. 1942;49:148.
3. Degos R, Delort J, Tricot R. Papulose atrophiante maligne (syndrome cutaneo-intestinal mortel). *Bull Mem Soc Med Hop Paris*. 1948;64:803.
4. Pinault AL, Barbaud A, Weber-Muller F, et al. Forme familiale bénigne de maladie de Degos. *Ann Dermatol Venereol*. 2004;131:989.
5. Assier H, Chosidow O, Piette JC, et al. Absence of antiphospholipid antibodies and anti-endothelial cell antibodies in malignant atrophic papulosis: a study of 15 cases. *J Am Acad Dermatol*. 1995;33:831.
6. Caux F, Aractingi S, Scrobohaci ML, et al. Anomalies de la fibrinolyse dans la maladie de Degos. *Ann Dermatol Venereol*. 1994;121:537.
7. Drucker CR. Malignant atrophic papulosis: response to antiplatelet therapy. *Dermatologica*. 1990;180:90.
8. Torrelo A, Sevilla J, Mediero IG, et al. Malignant atrophic papulosis in an infant. *Br J Dermatol*. 2002;146:916.
9. Meephansan J, Komine M, Hosoda S, et al. Possible involvement of SDF-1/CXCL12 in the pathogenesis of Degos disease. *J Am Acad Dermatol*. 2013;68(1):138-143.
10. Magro CM, Poe JC, Kim C, et al. Degos disease: a C5b-9/interferon-α-mediated endotheliopathy syndrome. *Am J Clin Pathol*. 2011;135(4):599.
11. Magro CM, Wang X, Garrett-Bakelman F, et al. The effects of eculizumab on the pathology of malignant atrophic papulosis. *Orphanet J Rare Dis*. 2013;8:185.
12. Pati S, Muley SA, Grill MF, et al. Post-streptococcal vasculopathy with evolution to Degos' disease. *J Neurol Sci*. 2011;300(1-2):157.
13. Kirkup ME, Hunt SJ, Pawade J, et al. Inflammatory linear vasculopathy mimicking Degos' disease. *Br J Dermatol*. 2004;150:1212.
14. Howsden SM, Hodge SJ, Herndon JH, et al. Malignant atrophic papulosis of Degos. *Arch Dermatol*. 1976;112:1582.
15. Bogenrieder T, Kuske M, Landthaler M, et al. Benign Degos' disease developing during pregnancy and followed for 10 years. *Acta Derm Venereol*. 2002;82:284.
16. Requena L, Farina C, Barat A. Degos disease in a patient with acquired immunodeficiency syndrome. *J Am Acad Dermatol*. 1998;38:852.

17. Bugatti L, Filosa G, Nicolini M, et al. Atrophie blanche associated with interferon-alfa adjuvant therapy for melanoma: a cutaneous side effect related to the procoagulant activity of interferon? *Dermatology*. 2002;204:154.
18. Zuber J, Martinez F, Droz D, et al. Alpha-interferon-associated thrombotic microangiopathy: a clinico-pathologic study of 8 patients and review of the literature. *Medicine (Baltimore)*. 2002;81:321.
19. Zaharia D, Truchot F, Ronger-Savle S, et al. Benign form of atrophic papulosis developed at injection sites of pegylated-alpha-interferon: is there a pathophysiological link? *Br J Dermatol*. 2014;170(4):992.
20. Stephansson EA, Niemi KM, Jouhikainen T, et al. Lupus anticoagulant and the skin. A longterm follow-up study of SLE patients with special reference to histopathological findings. *Acta Derm Venereol*. 1991;71:416.
21. High WA, Aranda J, Patel SB, et al. Is Degos' disease a clinical and histological end point rather than a specific disease? *J Am Acad Dermatol*. 2004;50:895.
22. Ball E, Newburger A, Ackerman AB. Degos' disease: a distinctive pattern of disease, chiefly of lupus erythematosus, and not a specific disease per se. *Am J Dermatopathol*. 2003;25(4):308-320.
23. Dyrsen ME, Iwenofu OH, Nuovo G, et al. Parvovirus B19-associated catastrophic endothelialitis with a Degos-like presentation. *J Cutan Pathol*. 2008;35: 20-25.
24. Guhl G, Diaz-Ley B, Delgado Y, et al. Wegener's granulomatosis: a new entity in the growing differential diagnosis of Degos' disease. *Clin Exp Dermatol*. 2009;34:e(1).
25. Magro CM, Toledo-Garcia A, Pala O, et al. Opioid associated intravenous and cutaneous microvascular drug abuse (skin-popping) masquerading as Degos disease (malignant atrophic papulosis) with multiorgan involvement. *Dermatol Online J*. 2015;21(9).
26. Grilli R, Soriano ML, Izquierdo MJ, et al. Panniculitis mimicking lupus erythematosus profundus: a new histopathologic finding in malignant atrophic papulosis (Degos disease). *Am J Dermatopathol*. 1999;21:365.
27. Theodoridis A, Konstantinidou A, Makrantonaki E, et al. Malignant and benign forms of atrophic papulosis (Köhlmeier-Degos disease): systemic involvement determines the prognosis. *Br J Dermatol*. 2014;170:110-115.
28. Burg G, Vieluf D, Stolz W, et al. Malignant atrophic papulosis (Köhlmeier-Degos disease [in German]. *Hautarzt*. 1989;40:480-485.
29. De Breucker S, Vandergheynst F, Decaux G. Inefficacy of intravenous immunoglobulins and infliximab in Degos' disease. *Acta Clin Belg*. 2008;63(2):99.
30. Hairston BR, Davis MD, Gibson LE, et al. Treatment of livedoid vasculopathy with low-molecular-weight heparin: report of 2 cases. *Arch Dermatol*. 2003;139:987.
31. Zhu KJ, Zhou Q, Lin AH, et al. The use of intravenous immunoglobulin in cutaneous and recurrent perforating intestinal Degos disease (malignant atrophic papulosis). *Br J Dermatol*. 2007;157(1):206.
32. Scheinfeld N. Commentary on "Degos disease: a C5b-9/interferon-α-mediated endotheliopathy syndrome" by Magro et al: a reconsideration of Degos disease as hematologic or endothelial genetic disease. *Dermatol Online J*. 2011;17(8):6.
33. Theodoridis A, Makrantonaki E, Zouboulis CC. Malignant atrophic papulosis (Köhlmeier-Degos disease)—a review. *Orphanet J Rare Dis*. 2013;8:10.
34. Shapiro LS, Toledo-Garcia AE, Farrell JF. Effective treatment of malignant atrophic papulosis (Köhlmeier-Degos disease) with treprostinil-early experience. *Orphanet J Rare Dis*. 2013;8:52.

Chapter 147 :: Vascular Malformations

:: Laurence M. Boon, Fanny Ballieux, & Miikka Vikkula

VASCULAR MALFORMATIONS

AT-A-GLANCE

- The worldwide prevalence is roughly 0.3%, mostly accounted for by capillary malformations.
- Congenital, localized (although sometimes extensive or multifocal), and well-demarcated lesions of malformed vessels of various types: capillary, venous, lymphatic, arteriovenous, and combined
- Histologically consist of enlarged, tortuous vessels of various types.
- Caused by inherited or somatic mutations in various gene
- Can be isolated, combined, or part of a syndrome
- Management: multidisciplinary approach

INTRODUCTION

DEFINITION

Vascular malformations are believed to arise because of errors in the development of vessels that occur during the 4th to 10th weeks of intrauterine life. Most vascular malformations are sporadic, although several families with inherited forms have been identified. They are very heterogeneous.[1]

CLASSIFICATION

For many years, vascular anomalies were grouped under the term *angioma*, hampering precise classification and leading to incorrect diagnosis and improper management. For example, the term *hemangioma* has been used both for vascular malformations, often venous (cavernous hemangioma), as well as for vascular tumors (strawberry hemangioma). This nomenclature changed in 1982 with the development of a biologic classification by Mulliken and Glowacki.[2,3] This classification system organized vascular anomalies based on clinical, hemodynamic, radiologic, and histologic features. It divided vascular anomalies into two major categories: (1) vascular tumors (with cellular proliferation, hemangioma being the most common; see Chap. 118), and (2) vascular malformations (structural anomalies of blood vessels) that are subsequently subdivided, depending on the affected vessel type, into arterial, capillary, lymphatic, or venous malformations (VMs). In 1996, this classification was adopted and further developed by the International Society for the Study of Vascular Anomalies (ISSVA; Table 147-1).[4]

Vascular malformations mostly affect a single vessel type (Fig. 147-1), yet combined malformations also exist. They are named according to the affected vessel types, capillary-venous or venolymphatic malformation, for instance. In addition to isolated forms, vascular malformations occur in syndromes such as Klippel-Trenaunay syndrome (KTS, capillary-lymphatic-VM with limb hypertrophy), Maffucci syndrome (multiple enchondromas associated with multiple venous anomalies and high incidence of malignancy), CLOVES (congenital lipomatous overgrowth with vascular malformations, epidermal nevi, and spinal or skeletal anomalies or scoliosis) syndrome, or Parkes Weber syndrome (high-flow vascular malformation of the extremity with soft tissue hypertrophy).[4]

EPIDEMIOLOGY

Vascular malformations affect about 0.3% of the population with most of these being capillary malformations (CMs). Vascular malformations are mostly congenital, even though they may be diagnosed later in life.[5]

CLINICAL FEATURES

Vascular malformations grow proportionately with the patient. Usually they do not regress. Most frequently, they are well-demarcated and localized. They can affect any part of the body, including the viscera. In rare instances, they can be the stigmata of deep lesions or the first sign of a syndrome. Vascular malformations are rheologically divided into *slow flow* (capillary, lymphatic, venous, and combined) and *fast flow* (arterial, arteriovenous, and combined) (Table 147-2).[4] They can lead to esthetic or functional impairment or even threaten life in rare instances.[6]

TABLE 147-1
Classification of Vascular Anomalies

VASCULAR TUMORS	VASCULAR MALFORMATIONS
Hemangiomas	**Capillary**
Infantile hemangioma	Capillary malformation (CM, also called port-wine stain)
Congenital hemangioma	Telangiectasia (hereditary benign telangiectasia, essential telangiectasia)
Rapidly-involuting congenital hemangioma (RICH)	Hereditary hemorrhagic telangiectasia (HHT)
Noninvoluting congenital hemangioma (NICH)	Capillary malformation–arteriovenous malformation (CM-AVM)
	Sturge-Weber syndrome
Hemangioendotheliomas	**Venous**
Kaposiform hemangioendothelioma	Venous malformation (VM)
Tufted angioma	Familial form: cutaneo-mucosal venous malformation (VMCM)
	Glomuvenous malformation (GVM)
	Blue rubber bleb nevus or Bean syndrome (BRBN)
Angiosarcoma	**Lymphatic**
	Lymphatic malformation (LM)
	Primary Lymphedemas
	Arterial
	Arteriovenous malformation (AVM)
	Capillary malformation–arteriovenous malformation (CM-AVM)
	Arteriovenous fistula (AVF)
	Syndromic Malformations
	Slow flow
	Klippel-Trenaunay syndrome (capillary–lymphatic–venous malformation with limb hypertrophy)
	Maffucci syndrome
	CLOVES (congenital lipomatous overgrowth with vascular malformations, epidermal nevi, and spinal or skeletal anomalies or scoliosis) syndrome
	Fast flow
	Parkes Weber syndrome

ETIOLOGY AND PATHOGENESIS

Several genes have been identified to be mutated in the inherited forms of vascular malformations (Table 147-3). Somatic genetic mutations have also been unraveled as the cause of many common sporadic lesions.[7-15]

DIAGNOSIS

The diagnosis is usually based on clinical features in 90% of superficial malformations.

SUPPORTIVE STUDIES

Pathology: Histologically, vascular malformations consist of enlarged, tortuous vessels with quiescent endothelium. In contrast to hemangioma, there is neither a parenchymal mass nor overt cellular proliferation.

Imaging: Radiologic investigation is needed to delineate the extent of a malformation but rarely for diagnosis unless the malformation is deeply located. Doppler ultrasonography is a very useful noninvasive radiologic examination that provides clues for differentiating the various types. Magnetic resonance imaging (MRI) details the extension and precise location of the lesion.[16]

Genetic Testing: Because a germline or somatic genetic cause is known for a large number of vascular anomalies, genetic testing can be used to confirm or help make the precise diagnosis. For somatic mutations, a biopsy of the affected tissue is needed. For inherited mutations, a blood test is sufficient to make the diagnosis.

MANAGEMENT

Treatment of vascular malformations depends on the affected vessel type, the location of the lesion, the age of the patient, and the symptoms. Because many lesions are extensive, patients should be aware that a complete cure is often not possible and that recurrence occurs. Treatment can be difficult and with severe complications. Extensive or complex lesions should always be managed by a multidisciplinary team.

CAPILLARY MALFORMATIONS

AT-A-GLANCE

- Worldwide occurrence. Prevalence is roughly 0.3%.
- Congenital, slow-flow malformations of the capillary bed
- Pinkish-red to purple in color; tend to darken and thicken with time
- Can be part of a sporadic syndrome, such as Sturge-Weber syndrome or KTS
- Can be part of the inherited capillary malformation-arteriovenous malformation phenotype
- Pathology: capillaries that are increased in size and number with abnormal innervation.

Figure 147-1 Vascular malformations of various vessel types. **A,** Capillary malformation of left lower extremity and genitalia. **B,** Subcutaneous lymphatic malformation invading the cubital nerve. **C,** Extensive venous malformation of right lower extremity, causing pain, swelling, and coagulopathy. **D,** Arteriovenous malformation of the sole. **E,** Nidus of the lesion on arteriography.

Capillary malformations mainly occur sporadically, although there are well-documented pedigrees showing autosomal dominant inheritance.[17] When inherited, they are usually multiple and part of the capillary malformation–arteriovenous malformation (CM-AVM) phenotype, which associates atypical CMs with arteriovenous malformation (AVM, see Arteriovenous Malformations later).[18-23]

EPIDEMIOLOGY

CMs, commonly called *port-wine stain*, is a slow-flow vascular malformation with a prevalence of 0.3%.[5] There is no sex preponderance.

Although most often an isolated finding, in rare instances, CM can be the cutaneous hallmark of occult spinal dysraphism, especially if located in the lumbosacral area.[24] Other blanchable, pink patches, known as *stork bite, angel's kiss, salmon patch, nevus simplex,* or *nevus flammeus neonatorum*, are often confused with CM. They are located on the nape of the neck (81%), the eyelids (45%), or the glabella (33%).[25] When located on the occiput, the moniker *Unna nevus* may be used (Fig. 147-2). These patches have a much higher incidence (42%) in white infants than in black infants (31%).[26] They are also present in various syndromes, such as Beckwith-Wiedemann and Rubinstein-Taybi syndromes. These lesions (with the exception of the Unna nevus) disappear spontaneously around the age of 1 to 4 years. In contrast, true CMs persist lifelong.

TABLE 147-2
Clinical Characteristics of Vascular Malformations

	CAPILLARY	VENOUS	LYMPHATIC	ARTERIOVENOUS
Skin color	Red	Normal-bluish-purple	Normal to yellowish-purple	Normal to red
Aspect	Flat	Flat to raised	Raised to vesicular	Flat to raised
Temperature	Normal	Normal	Normal	Warm
Palpation	Normal	Compressible	Firm, noncompressible	Thrill, bruit
Associations	—	Phleboliths, deformation	—	Ulceration, deformation
Radiology	No flow	Slow flow	Slow flow, cyst	Fast flow
Histology	Dilated capillaries D2-40 negative	Thin-walled venous channels D2-40 negative	Cystic lymphatic channels D2-40 positive	Arterialized veins D2-40 negative
Etiology	See Table 147-3			
Treatment	Pulsed-dye laser	Sclerotherapy, surgery, sirolimus medication	Surgery, sclerotherapy, sirolimus medication	Embolization followed by surgical resection of nidus

SYNDROMIC DISORDERS

CMs can be part of a syndrome, such as phakomatosis pigmentovascularis (PPV), Sturge-Weber syndrome (SWS), KTS, Parkes Weber syndrome, CLOVES syndrome, PTEN (phosphatase and tensin homolog) Hamartoma tumor syndrome, diffuse capillary malformation with overgrowth (DCMO), and macrocephaly–capillary malformation (M-CM, also called megalencephaly–capillary malformation–polymicrogyria syndrome). None of these syndromes is inherited.

PHAKOMATOSIS PIGMENTOVASCULARIS

PPV is thought to be an embryogenic anomaly affecting the vasomotor nerves and the melanocytes, both derived from neural crest. It manifests as a large, metameric CMs, usually located on the trunk or the extremities, in association with pigmented cutaneous lesions, such as a pigmented nevus, a nevus spilus, a café-au-lait patch, or an atypical Mongolian spot (see Chap. 77) that is not located on the sacrum (Fig. 147-3).[27] Nevus anemicus can also be seen in the vicinity as a twin spot.[28]

STURGE-WEBER SYNDROME

When located in the frontopalpebral area, CM can be part of SWS (Fig. 147-4A). This neuro-oculo-cutaneous syndrome associates a cutaneous CM of the ophthalmic branch of the trigeminal nerve (V1) with a homolateral leptomeningeal capillary-venous malformation (CVM) and a choroid CVM. Glaucoma is often present (Fig. 147-4B). SWS is associated with a high risk of epilepsy and mental retardation because of anomalies of the venous drainage of the encephalon, as well as with glaucoma, buphthalmos, and sometimes retinal detachment.[29]

DIFFUSE CAPILLARY MALFORMATION WITH OVERGROWTH

Patients with DCMO have hemihypertrophy, which can be total, regional, or contralateral. CM can be diffuse over the entire body. This entity is characterized by a reticulated, ill-defined CM.[30] The lesions do not follow the lines of Blaschko (Fig. 147-5A).

MACROCEPHALY–CAPILLARY MALFORMATION

A well-delineated, dark CM of the vermillion border, the tip of the nose, or both associated with macrocephaly is often pathognomonic of M-CM. These patients have megalencephaly and are at risk of mental retardation.[31] There are two reports of M-CM associated with Wilms tumor in the literature.[32]

CLINICAL FEATURES

CUTANEOUS FINDINGS

CM is a red, homogenous, congenital lesion that is often unilateral, sometimes bilateral, but usually not median. CMs involve skin and subcutis and sometimes mucosa (see Fig. 147-5). Their color varies from pinkish-red to deep purple with a geographic contour or a dermatomal distribution. Lesions are flat and painless, do not bleed spontaneously, and are never warm on palpation in contrast to AVM (see later). Acquired CM can be seen after trauma.[33]

Fifty percent of CMs are located on the face, where they follow the distribution of the trigeminal nerve: ophthalmic branch V1 (front and upper eyelid), maxillary branch V2 (lower eyelid, cheek, and upper lip) (see Figs. 147-4A and 147-5B), or mandibular V3

TABLE 147-3
The Genetic Causes of Vascular Anomalies

SPORADIC MALFORMATIONS		INHERITED MALFORMATIONS	
DIAGNOSIS	**MUTATED GENE**	**DIAGNOSIS**	**MUTATED GENE**
Capillary Malformations (CMs)			
CM	*GNAQ*	CM-AVM1	*RASA1*
Sturge-Weber syndrome		CM-AVM2	*EPHB4*
Phakomatosis pigmentovascularis (PPV)	*GNAQ* or *GNA11*		
Macrocephaly–capillary malformation (M-CM)	*AKT3*, *PIK3CA*, *PIK3R2*		
Venous Malformations (VMs)			
VM	*TIE2* (60%) *PIK3CA* (20%)	Mucocutaneous venous malformations (VMCM)	*TIE2*
Blue rubber bleb nevus (BRBN)	*TIE2*	Glomuvenous malformation (GVM)	*GLOMULIN*
Multifocal venous malformation (MVM)			
Verrucous venous malformation (VVM)	*MAP3K3*		
Maffucci syndrome	*IDH1*, *IDH2*		
Lymphatic Malformations (LMs)			
LM	*PIK3CA*	Nonne-Milroy lymphedema	*VEGFR3*
CLOVES (congenital lipomatous overgrowth with vascular malformations, epidermal nevi, and spinal or skeletal anomalies or scoliosis)		Nonne-Milroy–like lymphedema	*VEGF-C*
Klippel-Trenaunay syndrome (KTS)		Lymphedema distichiasis	*FOXC2*
		Microcephaly, chorioretinopathy, lymphedema, mental retardation	*KIF11*
		Hypotrichosis–lymphedema–telangiectasia	*SOX18*
		Hennekam lymphedema–lymphangiectasia 1	*CCBE1*
		Hennekam lymphedema–lymphangiectasia 2	*FAT4*
		Hennekam lymphedema–lymphangiectasia 3	*ADAMTS3*
		Emberger syndrome	*GATA2*
		Fetal chylothorax	*ITGA9*
		Lymphedema–choanal atresia	*PTPN14*
		Four-limb lymphedema	*GJC2 (CX47)*
Arteriovenous Malformations (AVMs)			
Extracranial AVM	*MAP2K1*	Hereditary hemorrhagic telangiectasia (HHT)1	*ENG*
Brain AVM	*KRAS*	HHT2	*ACVRL1 (ALK1)*
		HHT3	*SMAD4, GDF2*
		Phosphatase and tensin (PTEN) homolog (protein encoded by PTEN gene)	*PTEN*

(lower lip, chin, and mandible). CM can be diffuse over the entire body, often with associated hemihypertrophy (see Fig. 147-5A). This entity is called *diffuse capillary malformation with overgrowth* (see earlier discussion).

When inherited, CMs are usually small and multifocal, such as in CM-AVM1 and 2. These small CMs vary in size from a couple mm to several centimeters in size. They are often round-to-oval, pink, red, or brown in color and are often surrounded with a pale halo (Fig. 147-6).[18,34] The lesions are well-circumscribed and blanch on pressure with a diascopy. Some of them are present at birth, but others appear later. They grow with the child and are asymptomatic. Bier spots, white cutaneous spots surrounded by a pale halo of redness, are seen in both entities. In contract to CM-AVM1, CMs in CM-AVM2 can be more telangiectatic in appearance, especially periorally and on the upper thorax.[23] CM-AVM1 is characterized by the presence of CMs in 97%, AVMs or arteriovenous fistulas (AVFs) in 24% (10% intra–central nervous system [CNS], 13% extra-CNS), and Parkes Weber phenotype in 8% of patients.[21,35] In CM-AVM2, the risk of a fast-flow lesion seems to be less frequent because the respective penetrances are 93% (CM), 19% (AVM), and 7% (Parkes Weber).

Figure 147-2 Nevus flammeus neonatorum (also called nevus simplex) on the glabella, upper eyelids, and upper lip (**A**) of a 6-week-old neonate who also has an Unna nevus on the occiput (**B**).

NONCUTANEOUS FINDINGS

In rare instances, CM can be the stigmata of an underlying anomaly such as lumbar dysraphism underneath a sacral CM. Cutaneous lesions of PPV can be associated with systemic, visceral (hypoplasia of the larynx, intestinal polyposis), muscular (scoliosis), or neurologic (mental retardation, epilepsy, intracranial) signs and symptoms in 60% of cases.[36]

Figure 147-3 Clinical characteristics of phakomatosis pigmentovascularis. A large metameric capillary malformation with atypical extensive dermal melanocytosis located on the back.

SWS is associated with a high risk of epilepsy and mental retardation because of anomalies of the venous drainage of the encephalon, as well as with glaucoma, buphthalmos, and sometimes retinal detachment.[29] Patients with DCMO have hemihypertrophy, which can be total, regional, or contralateral. They have also associated toe anomalies (in 30%) and prominent veins.[30] In CM-AVM1 or 2, there is a 20% to 30% risk of an associated AVM located on the skin, the brain, or the spine.[21,35] A well-delineated dark CM of the vermillion border or the tip of the nose associated with macrocephaly is often pathognomonic of M-CM, and these patients have megalencephaly and are at risk of mental retardation.[31]

COMPLICATIONS

The major concern for a patient with a CM is cosmetic because of the visible discoloration. *Hypertrophy* of soft (often lips and gums) and underlying hard tissues can occur with time, especially when the CM affects the V2 and V3 dermatomes or the extremities (Fig. 147-7D and 147-7). *Overgrowth* of the maxilla or mandible leads to skeletal asymmetry, occlusal tilt, and open-bite deformity. When the child has atopic dermatitis, psoriasis, or acne, lesions are worse in the area of CM, a finding known as the Meyerson phenomenon.[37] Evenly thickened skin, purple nodules, and pyogenic granulomas can develop by adolescence (Fig. 147-7B and 147-7C).[38,39]

ETIOLOGY AND PATHOGENESIS

Facial CM is thought to be caused by clonal expansion of abnormal cells originating from the neural crest.[40]

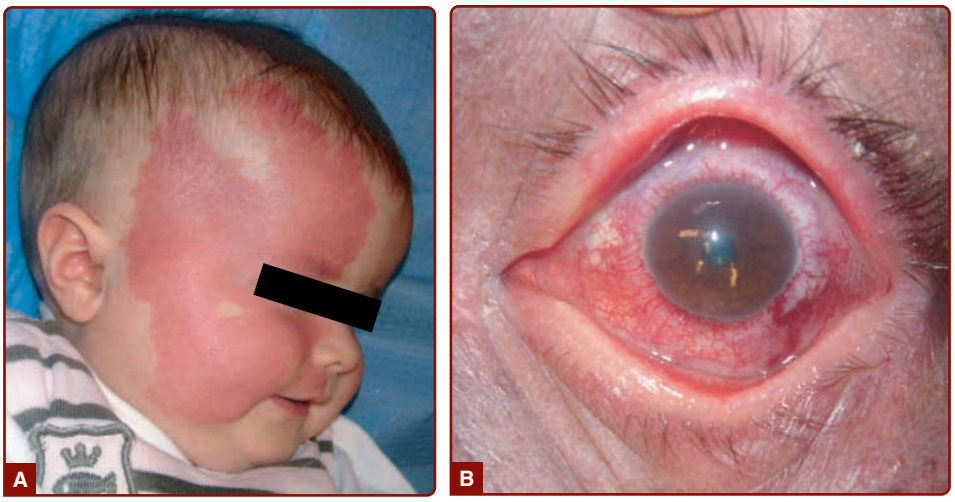

Figure 147-4 Extensive right facial capillary malformation. **A,** Involving the ophthalmic and maxillary branches of the trigeminal nerve in a 6-month-old girl with Sturge-Weber syndrome. **B,** Choroid capillary–venous malformation causing vision loss in a 50-year-old man with Sturge-Weber syndrome.

Somatic activating mutations in *GNAQ* have been identified as the cause of facial CM with hypertrophy as well as of SWS.[13] GNAG is a q class of G-protein α subunits that mediates signals between G protein–coupled receptors and their downstream effectors. Mutations in *GNAQ* and *GNA11* have also been identified in pigmented lesions such as blue nevi, nevus of Ota, uveal melanoma, and PPV.[41,42]

The inherited CM-AVM1 is caused by inactivating mutations in *RASA1*.[21] This gene encodes a GTPase-activating protein, which negatively regulates Ras activity. CM-AVM2 is caused by inactivating mutations in *EPHB4*.[23] EPHB4 is usually expressed in venous endothelial cells and its ligand EPHINB2 on arterial endothelial cells. They regulate arteriovenous identity. EPHB4 interacts with RASA1 to regulate RAS-MAPK signaling, and loss of EPHB4 or RASA1 in CM-AVM likely activates this signaling pathway. M-CM is caused by activating mutations in *AKT3*, *PIK3CA*, and *PIK3R2*.[43]

DIAGNOSIS

SUPPORTIVE STUDIES

Pathology: Histologically, CM is characterized by dilated capillaries of the papillary and upper reticular dermis combined with areas of increased number of normal-looking capillaries (Fig. 147-8).[44] Endothelial cells are flat. Factor VIII, fibronectin, and basement membrane protein are normal, but S100 staining shows abnormal innervation.[45,46]

Imaging: No imaging studies are mandatory for a CM except in rare situations. If a so-called "CM" is painful, warm, or spontaneously bleeds, Doppler ultrasound is indicated to exclude the diagnosis of a fast-flow malformation, such as an AVM, Parkes Weber syndrome, or a proliferating hemangioma.

Figure 147-5 Several aspects of capillary malformations. **A,** Light red lesions involving half of the body. **B,** Dark red lesions on the face with mucosal involvement and soft tissue hypertrophy. **C,** More localized on the shoulder and arm.

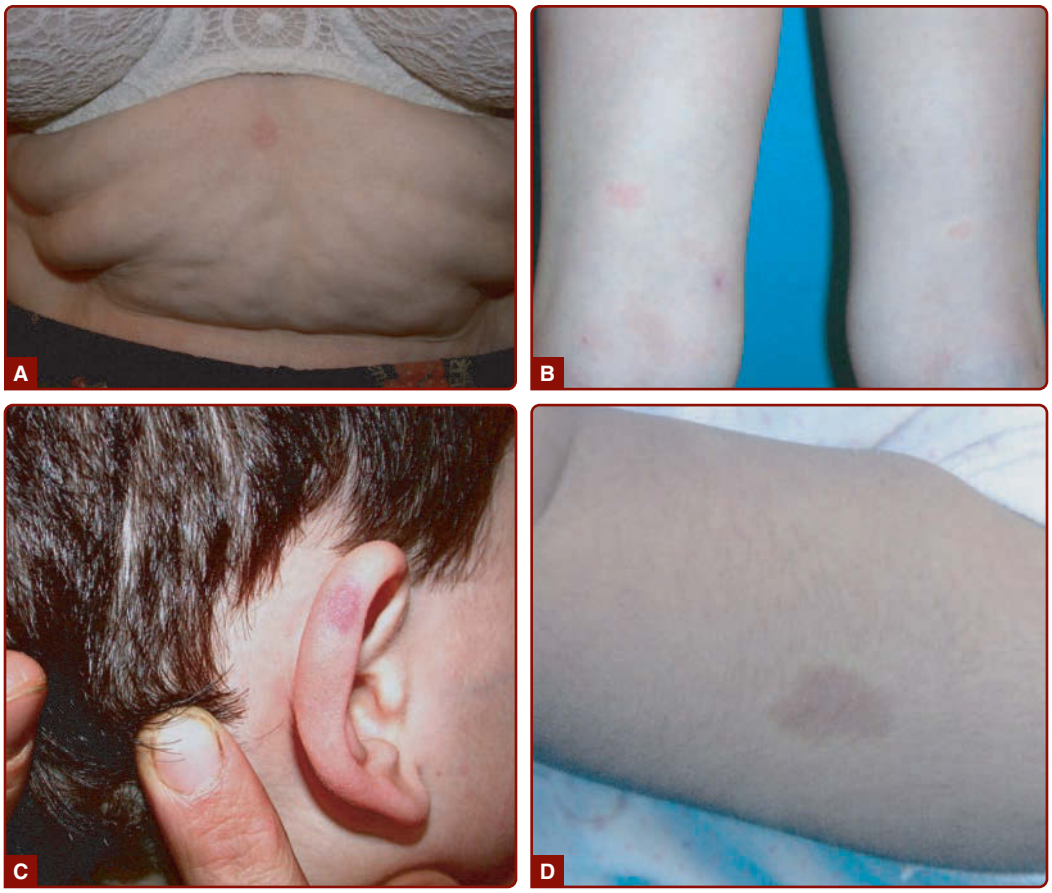

Figure 147-6 **A–D,** Examples of small atypical capillary malformations which belong to CM-AVM (capillary malformation-arteriovenous malformation). **D,** Note the pale halo surrounding the lesion.

CM located in the frontopalpebral area, especially if the inner part of the upper eyelid is involved, can be part of SWS. Therefore, for these CMs, an ophthalmologic and neurologic examination is mandatory. They need to be done during the first months of life and repeated once a year until puberty, even if normal at younger age.[47] A brain MRI should also be done to evaluate the occurrence of associated leptomeningeal CVM. In patients with PPV, ophthalmologic, neurologic, and orthopedic follow-up is mandatory because of the common association of CM with systemic lesions. In patients with extensive CMs of the lower extremity, such as in DCMO, a scaniometry study (leg length films) is needed to evaluate possible progressive growth discrepancy around the age of 4 to 6 years and needs to be repeated until the end of growth to allow the orthopedist to correct the discrepancy at the adequate time. Serial renal ultrasound examinations are also indicated to rule out the appearance of a Wilms tumor. MRI of the spinal cord is indicated in the presence of a lumbosacral CM. Brain and spinal MRI should be considered in patients with CM-AVM.

Genetic Testing: Genetic testing is indicated, especially in patients with multifocal lesions (CM-AVM1 and 2) because of increased risk for intracerebral fast-flow lesions. These patients should be screened for *RASA1* and *EPHB4*. Pale, uncharacteristic, and inconspicuous CMs can be sign of PHTS, especially if these vascular lesions are associated with macrocephaly (see AVM later). Because of increased cancer risk, such patients should be screened for *PTEN* mutations. Identification of a germline mutation would enable precise counseling and surveillance.

DIFFERENTIAL DIAGNOSIS

See Table 147-4.

CLINICAL COURSE AND PROGNOSIS

CM is present at birth and never regresses spontaneously. During the first weeks of life, they can slightly fade, as the hemoglobin level of the newborn decreases. Subsequently, the red hue stabilizes, and the lesion grows in proportion to the rest of the body. Around puberty, as well as later in life, CM slowly thickens and darkens with time. It often becomes raised and nodular (see Fig. 147-7).[38] Pyogenic

Figure 147-7 Clinical evolution of capillary malformation: darkening and thickening with time. **A,** At age 6 months. **B,** At age 33 years. **C,** Development of pyogenic granuloma. **D,** Soft tissue hypertrophy. **E,** Mucosal hypertrophy.

granuloma can occur with time, as well as soft tissue or bony hypertrophy.[39]

MANAGEMENT

The goal of management is to monitor for associated complications and minimize the impact of the CM on self-esteem and quality of life. Camouflage using a foundation such as Covermark is still an effectively approach (Fig. 147-9)

INTERVENTIONS

Orthopedic Considerations: In the presence of leg-length discrepancy, an early-adapted shoe lift is needed if leg-length discrepancy is over 1.5 cm to prevent compensatory tilting of the pelvis. Epiphysiodesis is sometimes necessary when the child is approximately 11 to 13 years old.

Procedures: Laser treatment is the gold standard therapy for most CM. Pulsed-dye laser with its specific wavelength (585 or 595 nm) and a short pulse duration (400–1500 ms) currently gives the best results in infants and children by lightening the red color of the CM. There are few complications. Multiple sessions (6–12) are needed, and general anesthesia may be necessary as the procedure is painful. Laser treatment is more efficient on the cervicofacial and trunk area than on the extremities. Early treatment during childhood does not reduce the number of laser sessions.[48] The use of a dynamic cooling system to avoid heating the epidermis allows higher laser fluencies, resulting in optimal lightening of the lesion. Recurrence can occur after cessation of therapy.[49] Laser has no impact on associated hypertrophy.[6,50]

Contour resection is considered to treat complications such as pyogenic granuloma or lip hypertrophy.[6]

Counseling: Genetic and psychological counseling for the patients and their families are part of multidisciplinary management. Patient organizations dedicated to vascular anomalies also have an important role in supporting patients and their families.

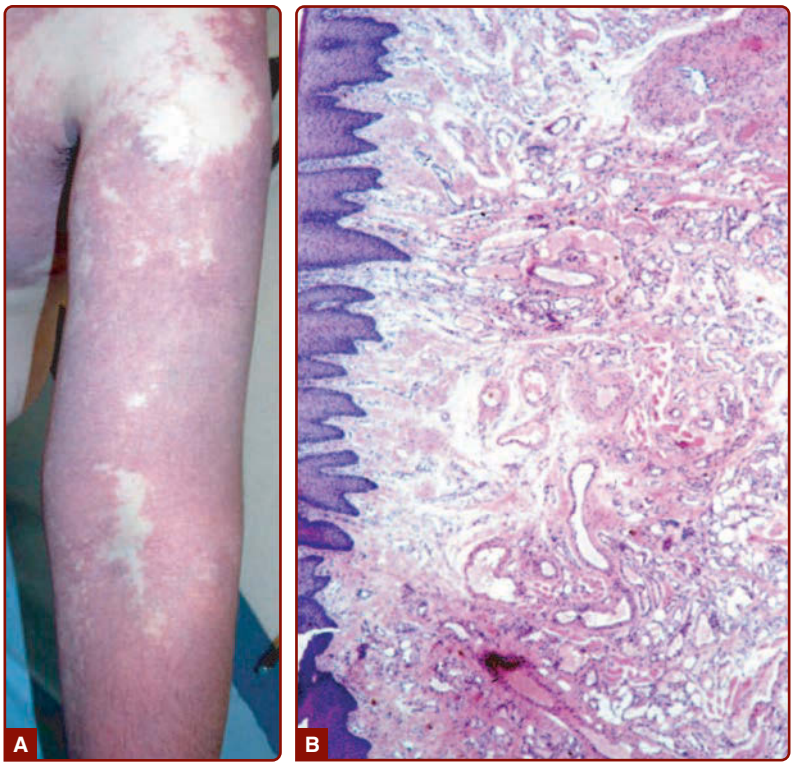

Figure 147-8 **A,** Extensive capillary malformation of upper extremity. **B,** Histologically, capillary malformation is characterized by dilated capillaries of normal number in the papillary and upper reticular dermis in combination with areas of increased number of normal-looking capillaries (hematoxylin and eosin staining).

PREVENTION

In patients with SWS, ophthalmologic follow-up, started immediately after birth is essential because reducing visual impairment will depend on the promptness of treatment. Prophylactic antiepileptic medication to prevent neural cell death has also been advocated, although randomized prospective studies to support efficacy are lacking at this time.[51,52]

Figure 147-9 Efficient noninvasive management of facial capillary malformation using cosmetic makeup.

TABLE 147-4
Differential Diagnosis of Capillary Malformation

Based on Morphology

Most Likely

Faint pink median patch
- Unna nevus
- Nevus flammeus neonatorum (nevus simplex)

Multiple, inherited
- CM of CM-AVM

Telangiectatic patch
- CMTC
- HHT
- CM-AVM2
- Essential telangiectasia
- Unilateral nevoid telangiectasia

Warm on palpation
- Proliferating hemangioma
- AVM
- AVF

Ulcerated or painful
- AVM
- AVF

Rule Out

Small, multiple
- Mastocytosis
- CM of CM-AVM

Based on Location

Most Likely

Occiput
- Unna nevus

Glabella, upper eyelid, nape of neck
- Stork bite, angel's kiss, salmon patch

Consider

Extremity
- CMTC
- Klippel-Trenaunay syndrome
- Parkes Weber syndrome

Faint on trunk
- M-CM

Rule Out

Scalp
- Adams-Oliver syndrome
- Multiple telangiectasia near canthus
- Ataxia telangiectasia

AVF, arteriovenous fistula; AVM, arteriovenous malformation; CM, capillary malformation; CM-AVM, capillary malformation-arteriovenous malformation; CMTC, cutis marmorata telangiectatica congenita; HHT, hereditary hemorrhagic telangiectasia; M-CM, macrocephaly capillary malformation.

VENOUS ANOMALIES

AT-A-GLANCE

- Most common referral to specialized centers for vascular anomalies; incidence unknown but is substantially lower than for CM and estimated at 1 in 10,000
- Congenital slow-flow malformation of the venous bed
- Bluish in color, localized or extensive, solitary or multifocal
- Compressible on palpation; presence of phleboliths
- Associated with consumptive coagulation abnormalities in about 40% of cases
- Histologically consists of ectatic venous-like channels with anomalies in mural cells
- Mainly sporadic but can be inherited as an autosomal dominant trait
- Inherited venous anomalies: cutaneomucosal venous malformation (1%), glomuvenous malformation (>5%)
- Syndromic venous malformation: KTS, blue rubber bleb nevus, Maffucci syndrome.

INTRODUCTION

A VM is a congenital lesion made up of venous-type vessels of the skin or mucosa but can involve any structure (subcutis, muscles, bones, and nerves) and any organ (CNS, gastrointestinal [GI] tract). Fifty percent of VMs are located in the cervicofacial area, and 37% are on the extremities. VMs are mainly isolated but can be part of complex vascular disorders, such as the KTS, Maffucci, and blue rubber bleb nevus (BRBN) syndromes.[53,54]

EPIDEMIOLOGY

Venous anomalies are the most common VMs referred to specialized center with an overall incidence of 1 in 10,000 in the population.[54] They mainly occur sporadically, although 1% are inherited mucocutaneous venous malformations (VMCMs) and 5% are inherited glomuvenous malformations (GVMs). No sex preponderance is reported.[55] Both VMCM and GVM have an age-dependant variation in penetrance, which reaches its maximum by 20 years of age (87% for VMCM and 92.7% for GVM).[56] Large VMCMs and GVMs are present at birth. However, 17% of affected individuals develop new small lesions over time.[55] BRBN syndrome is rare and occurs sporadically with about 200 cases reported in the literature.

SYNDROMIC DISORDERS

Syndromes with a venous anomaly include BRBN syndrome, KTS (see Lymphatic Malformations later), and Maffucci syndrome.

Figure 147-10 Blue rubber bleb nevus syndrome. Pathognomonic multiple small, dark blue, nipple-like lesions on the toe.

BLUE RUBBER BLEB NEVUS SYNDROME

BRBN is characterized by numerous malformations of the venous system that involve the skin and visceral organs. It is commonly characterized by one large "dominant" VM lesion associated with multiple small, dark blue, nipple-like lesions, the latter being typically located on the palm and soles (Fig. 147-10).[15] These cutaneous lesions are associated with multiple small GI VMs, often responsible for chronic anemia.[15,57]

MAFFUCCI SYNDROME

Maffucci syndrome is a rare disorder characterized by multiple enchondromas associated with subcutaneous VMs of the distal extremities (Fig. 147-11). The disease starts during childhood with the development of enchondromas of the bones of hands and feet, as well as of the long bones. Deformities and shortening of extremities often occur. Subcutaneous vascular nodules appear later, around puberty, on the fingers and the toes. Phleboliths may become present.[58]

CLINICAL FEATURES

The features of venous anomalies are summarized in Table 147-5.

CUTANEOUS FINDINGS

VMs are usually solitary but can be multifocal, the latter suggesting an inheritable disorder in most instances.[54] They may be relatively localized or extensive within an anatomic region. The most common location is the head and neck area (Fig. 147-12A and 147-12D–F). VMs can affect any tissue or organ (Figs. 147-12 to 147-14).

VMs are congenital, light to dark bluish lesions. Deep VM has a normal overlying skin color and is often diagnosed only at puberty or later in life with the onset of pain. Size varies from small spongy blebs to large lesions of several centimeters in diameter. Skin temperature is normal. There is no thrill or bruit. VMs are larger when in a dependent position and can easily be emptied by compression or facilitating venous drainage. Palpation is not painful unless thrombosis occurs.[54,59]

VM lesions in VMCM are small and multifocal. They are more reminiscent of small sporadically occurring VMs than BRBNs. They can enlarge with time and are often asymptomatic. The VMs are generally small (<5 cm), and more than 80% of patients have more than two lesions. Some are present at birth; most lesions appear by puberty. Mucosal lesions involve the lips, tongue, and buccal mucosa.[60,61]

In rare instances, VM can be sporadic yet multiple. These multifocal venous malformations (MVMs) are very similar to the VMCM lesions, yet there is no family history of the same findings.[15]

GVM is a bluish to purple, raised venous anomaly characterized by multifocality, hyperkeratosis, and nodularity with a cobblestone surface (see Fig. 147-13C). In rare cases (especially in newborns), the lesions may be flat and purple in color, mimicking CM[62]; this plaque-like GVM usually darkens with time. GVMs are usually present at birth and slowly expand during childhood.

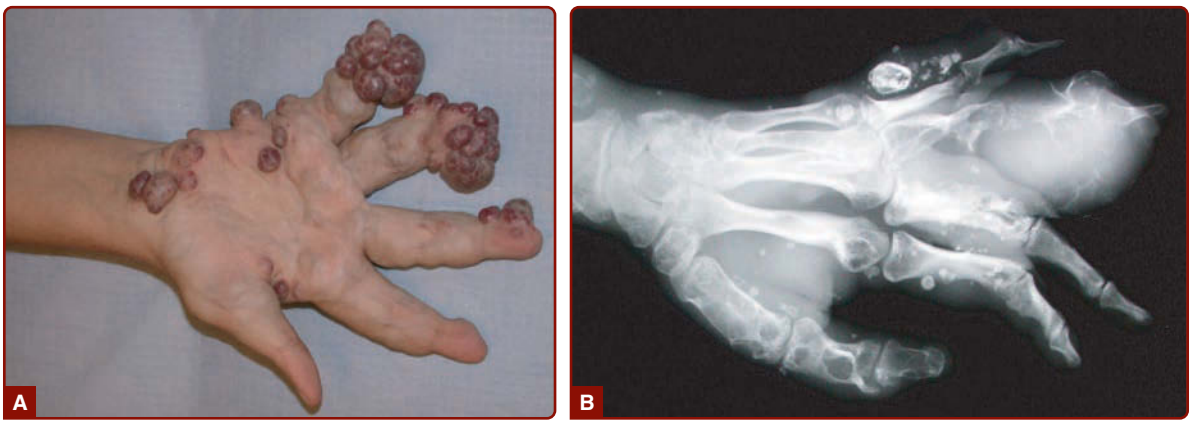

Figure 147-11 Clinical (**A**) and radiologic (**B**) aspects of Maffucci syndrome. Multiple venous malformations and enchondromas deforming the hand and fingers.

TABLE 147-5
Characteristics of Venous Anomalies

	VENOUS MALFORMATION	VENOUS MALFORMATION CUTANEOMUCOSAL	GLOMUVENOUS MALFORMATION	BLUE RUBBER BLEB NEVUS SYNDROME
Location	50% head and neck	Extremities, mucosa	70% extremities	Especially palms and soles
Skin color	Normal to bluish-purple	Bluish	Bluish-red-purple	Bluish-dark-blue
Aspect	Flat to raised	Raised, dome shaped	Raised, cobblestone Plaquelike, hyperkeratotic	Dome shaped, nipple-like
	Single, large	Multiple, small	Multiple	Multiple, small, often + 1 large lesion
Palpation	Phleboliths	Compressible	Noncompressible, painful	Firm, rubbery, spongy
Associated	Coagulopathy	—	—	Visceral venous malformation, coagulopathy
Radiologic	Phleboliths	Venous channels	No phlebolith	Venous channels
Tissue involved	Often deep location	Cutis, subcutis	Cutis, subcutis	Often deep component
Histology	Thin-walled venous channels	Thin-walled venous channels	Glomus cells	Thin-walled venous channels
Inheritance	Sporadic	Autosomal dominant	Autosomal dominant	Sporadic

New small lesions appear with time. In contrast to VM, GVM is often painful on palpation and cannot be completely emptied by compression. GVMs are usually multifocal and located on the extremities, involving the skin and subcutis. They are rarely encountered in mucosae, and intestinal hemorrhage is not present. Patients with GVMs have normal mental and physical development. Diagnosis of GVM is based on clinical and histologic evaluation of the cutaneous lesions. Genetic testing can differentiate small multifocal GVMs from VMCMs.[55]

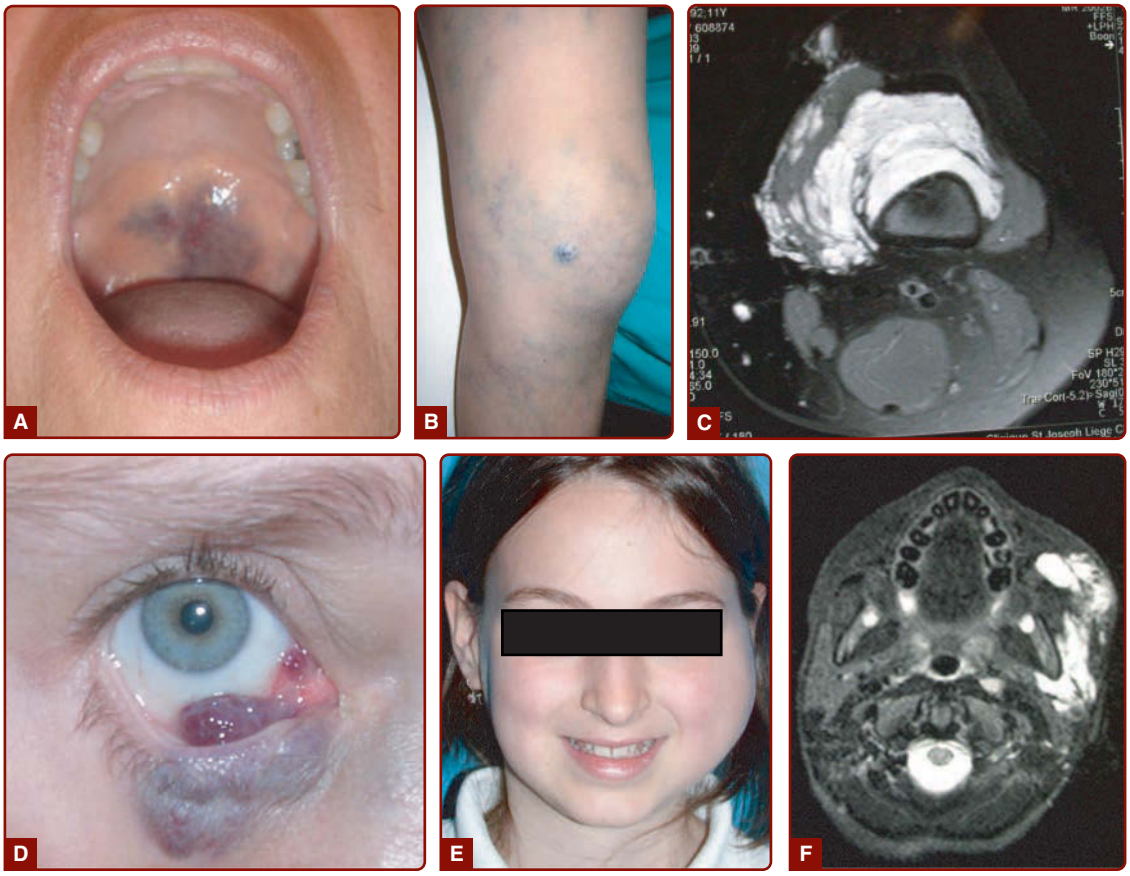

Figure 147-12 Various venous malformations. **A.** Of the soft palate, causing sleeping apnea. **B** and **C,** Of the knee, causing hemarthroses; confirmed by T2-weighted images. **D.** Of the mucosal eyelid. **E** and **F,** Of the cheek, causing facial asymmetry and pain.

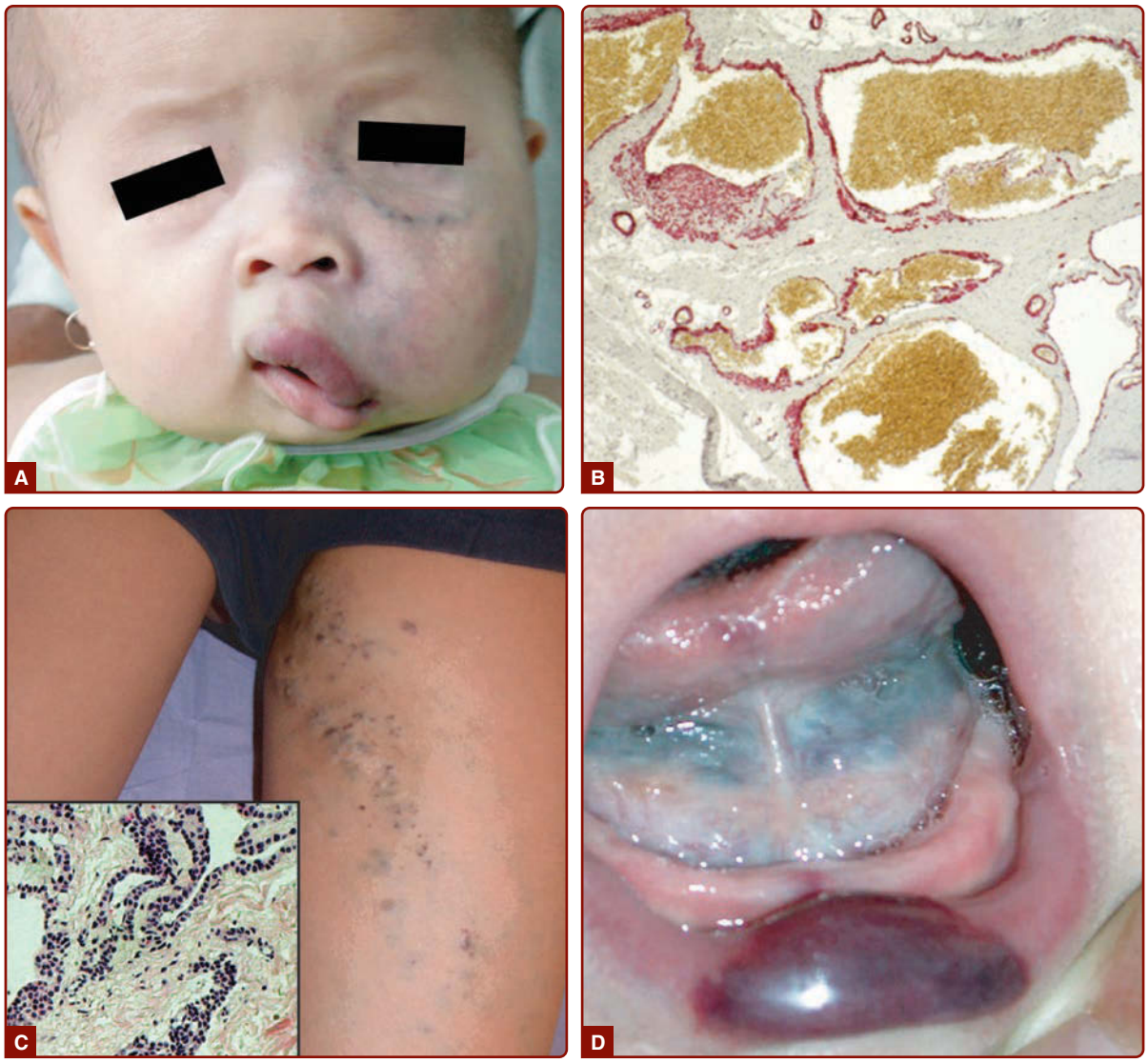

Figure 147-13 Venous malformations (VMs). **A,** Extensive hemifacial VM causing soft tissue hypertrophy and lip deformation in a 6-month-old boy. **B,** Histologically, VM consists of ectatic venous-like channels with anomalies in mural cells (hematoxylin and eosin). **C,** Superficial glomuvenous malformation of the inner thigh. Note the presence of mural glomus cells on histology (hematoxylin and eosin). **D,** Mucosal VM involving the lower lip and floor of the mouth.

Verrucous Venous Malformation: Verrucous venous malformation (VVM), previously known as verrucous hemangioma, is a rare congenital vascular anomaly. Although VVM expresses an immunohistochemical profile similar to vascular neoplasms (Wilms tumor 1 and GLUT-1 positive), it is distinct from infantile hemangioma because it is usually noted at birth and never spontaneously involutes. Mainly located on the legs, VVM can also be found on the head and the trunk. It initially appears as a bluish macule that later becomes erythematous-violaceous in color and after trauma and secondary infections often evolves into a verrucous nodule (see Fig. 147-14). It never involves muscles or deep tissues.[63]

Figure 147-14 Verrucous venous malformation (previously known as verrucous hemangioma) on the lower extremity, causing oozing. It is purple-red in color and slightly raised, with hyperkeratosis.

NONCUTANEOUS FINDINGS

Patients with VMCM, like those with sporadically occurring MVM, seldom have VMs located in internal

organs, such as the lungs, kidneys, brain, or GI tract.[15] Extracutaneous manifestations of BRBN include GI tract involvement. The small bowel is the predominant region; however, VMs can occur in any site from the oral cavity to the anal mucosa. In rare instances, VMs can also be seen in brain, lungs, and kidneys, as well as other organs.[57]

COMPLICATIONS

VM is usually unilateral, causing asymmetry and progressive, slowly worsening distortion (see Figs. 147-12 and 147-13). Depending on their size and location, VMs can cause pain, particularly in the morning on awakening, and anatomic distortion and can even threaten life because of bleeding, expansion, or obstruction of vital structures. Migraine is a common feature when VM is located in the temporal muscle. Whereas oropharyngeal VM can impair speech and cause difficulties in swallowing, pharyngeal or laryngeal lesions can compromise the airway and cause snoring and sleeping apnea.[54]

On the extremities, VMs often involve muscles and joints. They cause *muscle weakness, hypotrophy*, and sometimes hypertrophy, resulting in leg-length discrepancy, which is less severe than in KTS. Intraarticular bleeding, if the malformation is located in the knee joint, leads to early-onset arthrosis.[64] Genital VM often occurs with limb VM and can cause dyspareunia. GI VM may lead to chronic anemia.

Local thrombosis is usually responsible for acute pain that lasts for several days and resolves as phleboliths, which can be identified by palpation or by radiography. VM rarely causes pulmonary embolism, although this complication can occur when large draining veins exist.[65,66]

Chronic localized intravascular coagulopathy (LIC) is associated with solitary or syndromic spongy VMs. It is characterized by elevated D-dimer level (>500 ng/mL) in 40% of patients. Severe LIC with low fibrinogen levels is common in large VMs of the extremities and rare in the cervicofacial area. A number of events, such as surgery, sclerotherapy, and hormonal influences, can trigger the conversion of LIC to disseminated intravascular coagulopathy (DIC).[67]

In contrast to skin lesions, GI lesions, as seen in patients with BRBN, have a tendency to bleed. They may spontaneously rupture, causing acute hemorrhage and even death. However, most of the bleeding tends to progress slowly, resulting in chronic and occult blood loss that can lead to iron-deficiency anemia. Other complications include intussusception, volvulus, and bowel infarction, which are to be considered in patients with BRBN and abdominal pain. Morbidity depends on the extent of GI involvement.[57] VVM often ulcerates.[63]

ETIOLOGY AND PATHOGENESIS

VMCM is inherited as an autosomal dominant disorder caused by germline mutations in the *TEK* gene, which encodes the angiopoietin receptor, TIE2.[68,69] The inherited mutations cause hyperphosphorylation of the receptor even in the absence of a ligand. Somatic second hits have been found in VMCM tissues of two patients: one caused loss of membranous expression of the second, wild-type, allele; two others occurred on the allele with the inherited mutation, causing an increase in hyperphosphorylation.[15,70] These mutations activate the PI3K/AKT signaling pathway in endothelial cells.[71,72]

GVM is caused by dominant, loss-of-function mutations in the *glomulin* gene.[73] In addition, a somatic second hit is required for lesions to form, leading to complete loss of function of glomulin. The most common second hit is acquired uniparental isodisomy, which leads to homozygosity of the inherited mutation.[73,74] This explains the variable expressivity regarding penetrance, the extent of the lesions, and the number of lesions within family members.[75] So far, a mutation in *glomulin* has been found in almost all GVM families tested, demonstrating locus homogeneity.[75-77] Glomulin seems to be expressed in vascular smooth muscle cells, but its exact function remains unknown.

Sporadic VMs are also caused by genetic mutations. Sixty percent are caused by activating somatic mutations in *TIE2*.[70] The mutations differ from the inherited ones seen in VMCM. The most common mutation in VMs (L914F) has not been identified in VMCM, and the most common inherited mutation in VMCM (R849W) has not been identified in single somatic VM. This suggests that whereas the recurrent somatic mutations have effects too detrimental to be supported in the germline and probably cause lethality, the inherited ones have weaker effects that require additional changes (somatic second hits).[70-72]

Another 20% of sporadically occurring VMs are caused by somatic mutations in the *PIK3CA* gene.[10] The same mutations are seen in cancers. They activate the PI3K/AKT signaling pathway, as do the mutations in *TIE2*, underscoring perturbations in this signaling activity to underlie pathogenesis of VMs.[10,11]

MVM is also caused by *TIE2* mutations. Similar to VMCM, these patients often have two *TIE2* mutations. Most frequently, a R915C mutation is present as a mosaic change, and a somatic Y897C mutation occurs on top of the R915C change on the same allele. This explains the lack of family history (the first mutation has appeared de novo in a mosaic fashion in the patient), multifocality (the mosaic mutation is a predisposing change, like the inherited mutations are in VMCM), and the clinical similarity with VMCM lesions (both have similar, albeit not the same, double cis mutations).[15] VVM is caused by somatic *MAP3K3* mutations.[78] BRBN syndrome, like VMCM, MVM, and 60% of VMs, is also caused by mutations in *TIE2*. BRBN mutations are not detectable in the blood; they are somatic.[15] Yet in distinct, distally located lesions of the same patient with BRBN, the same double mutations can be identified with equal allele frequencies. The most common is a T1105N–T1106P double mutation. This suggests that the separate and even newly appearing lesions are formed by endothelial cells

that originate form a single common site, such as the dominant lesion or bone marrow. The BRBN-causing *TIE2* mutations cause strong hyperphosphorylation of the receptor, and the endothelial cells acquire increased colony-forming capacity, survival, and faster migration.[15]

Maffucci syndrome is caused by somatic mutations in *IDH1 and 2*.[79-81]

DIAGNOSIS

SUPPORTIVE STUDIES

Laboratory Testing: A coagulation profile with platelet count, fibrinogen, and D-dimer level should be done in any patients with a pure VM or complex malformation with a venous component because the D-dimer level is elevated in about 40% of VMs. This blood test, done at the first consultation, should be repeated around puberty and whenever the malformation becomes painful. This is never the case in a patient with GVM or other simple vascular anomalies. Associated low fibrinogen is pathognomonic of severe LIC. Severe LIC can easily decompensate to DIC with severe bleeding during interventional or surgical procedures.[67,82-84]

Pathology: VMs are histologically composed of ectatic vascular channels of venous type with flat endothelium. The vascular walls are thin and lined by a discontinuous layer of mural smooth muscle cells positive for smooth muscle-α-actin.[85] Basement membranes are also thin. In contrast, GVM is histologically characterized by distended venous channels surrounded by mural "glomus cells," which are aberrantly differentiated smooth muscle cells. Glomus cells are round or polygonal, instead of being elongated, like the normal vascular smooth muscle cells.[86] By immunohistochemistry, glomus cells stain positively for smooth muscle-α-actin and vimentin, but they are negative for desmin, von Willebrand factor, and S100.[87] By in situ hybridization, they are also negative for glomulin.[76]

VVM is characterized by hyperkeratotic epidermis on top of small blood vessels with a multilaminated membrane located in the dermis and the subcutis. Focal positive staining for GLUT-1 is seen.[63] Histopathologic examination of patients with Maffucci syndrome shows features of spindle cell hemangioendothelioma.

Imaging: Plain radiography can identify the calcification of phleboliths, which are pathognomonic of LIC in a VM. It can also show the presence of multiple enchondromas in patients with Maffucci syndrome (see Fig. 147-11). Doppler ultrasonography is noninvasive and can confirm the slow-flow nature of the lesion. In contrast to lymphatic malformations (LMs), the venous channels are compressible with the probe.[88] MRI imaging with spin-echo T1- and T2-weighted and fat-saturation sequences depicts the exact anatomic location of the lesion (see Fig. 147-12).[89] This will highlight the more cellular component, as well as the more superficial location of GVM compared with VM. Atypical MRI findings require a biopsy to rule out a sarcoma or neurofibroma.

In the presence of palmar-plantar multifocal lesions typical of BRBN (see Fig. 147-10), an endoscopy, colonoscopy, or wireless capsule endoscopy should be performed to detect GI lesions.

These radiologic examinations are mandatory for pretherapeutic evaluation of any venous anomaly.

Genetic Testing: Consider genetic testing for *TIE2* and *glomulin* mutations in patients with multifocal lesions. This differentiates the conditions and enables genetic counseling.

DIFFERENTIAL DIAGNOSIS

See Table 147-6.

TABLE 147-6
Differential Diagnosis of Venous Malformation

Based on Morphology

Most Likely

Bluish subcutaneous mass, noncompressible
- Infantile hemangioma (deep)
- Lymphatic malformation

With multiple enchondromas
- Maffucci syndrome

Consider

Hyperkeratotic
- GVM, if on extremity
- Cutaneous lesions of CCM
- VVM

Rule Out

Superficial, collateral normal veins
- Deep venous insufficiency, iatrogenic stenosis, or congenital agenesis

Bluish nonvascular lesion

Based on Location

Consider

Base of the nose
- Normal prominent veins

Scalp or forehead
- Sinus pericranii
- Underlying Galen malformation

Subungual
- Solitary glomus tumor

Cheek
- Blue nevus

Brain
- Developmental venous anomaly
- CCM

Rule Out

Neck; deep mass
- Thyroglossal duct
- Bronchogenic cyst

CCM, cerebral cavernous malformation; GVM, glomuvenous malformation; VVM, verrucous venous malformation

An unusual pathway of cerebral drainage, a cerebral developmental venous anomaly that consists of dilated intramedullary veins converging into a larger draining vein, can be seen in 0.5% of the population. In contrast, it is present in 20% of patients with extensive head and neck VMs. Although usually asymptomatic, this anomaly can cause headache.

CLINICAL COURSE AND PROGNOSIS

VMs grow proportionately with the patient. They never regress spontaneously. Initially, asymptomatic lesions often become painful in response to trauma or in altered hormonal states (puberty or pregnancy). They may also expand following thrombosis. No oncogenic transformation of this condition has been described. The major complications are life-threatening GI hemorrhage and airway compression. Patients with inherited venous anomalies, as well as BRBN and MVM, tend to develop additional small lesions with time.[15] Patients with Maffucci syndrome have a high incidence of malignancies (40%), mainly chondrosarcoma but also glioma, fibrosarcoma, and angiosarcoma.[58]

MANAGEMENT

Treatment of venous anomalies is warranted when lesions are symptomatic or for cosmetic purposes. The most common indications for treatment are pain and functional impairment.[54] Their management is often multidisciplinary, involving hematologists, surgeons, and interventional radiologists.

INTERVENTIONS

Medical Management: Compression garments can be helpful to decrease swelling and pain in VMs of the extremity by decreasing venous pressure. In contrast, compression increases pain in GVM patients and is not indicated in this situation.

Low-molecular-weight heparin (LMWH; LMWH, 100 IU anti-Xa/kg/day) is usually given to patients with signs of LIC 24 hours before and for another 5 days after surgical procedures to minimize hemorrhagic risk. The same treatment is given to patients with painful episodes of local thrombosis. In this circumstance, the duration of treatment is usually 2 weeks.[54,67,84]

Bleeding from GI BRBN lesions can be managed conservatively with iron supplementation and blood transfusions.

With the understanding of the underlying pathophysiologic mechanisms (activation of the PI3K-AKT signaling), targeted molecular therapies are becoming possible. *Rapamycin* (sirolimus) was promising in a preclinical VM-mouse model trial.[90] A phase II clinical trial for difficult-to-treat extensive VMs or complex slow-flow vascular anomalies not amenable to conventional management also gave encouraging results.[90,91] Patients experienced almost complete relief of pain and symptoms, reduced coagulopathy when present, improved function, and increased self-perceived quality of life. Bleeding in sporadic VM as well as in BRBN stopped within 24 hours. Side effects were minor and included mucositis, mild headache, fatigue, and diarrhea. Moreover, a statistically significant reduction in volume was observed with MRIs in most patients that reached 1-year follow-up. A multicentric European Study (VASE; NCT 02638389) is ongoing to determine which subtypes of VMs are best suited for rapamycin treatment and for how long the treatment should be continued. Rapamycin should not be considered as treatment for small, localized, and asymptomatic slow-flow vascular malformations that respond to standard of care.[92]

Procedures: Percutaneous intralesional sclerotherapy is the primary treatment for VM, in contrast to GVM. Absolute ethanol is the most efficient sclerosing agent.[93] Local compression or intralesional coils are used to prevent dissemination of ethanol into the systemic circulation. Local complications include inflammation, edema, blistering, necrosis, chronic drainage, and temporary or permanent nerve deficit. Systemic complications, such as renal or pulmonary toxicity, myocardial depression, and cardiac arrest, have been reported. Multiple sclerotherapy sessions are often needed because VMs have a propensity to recanalize and recur. Alternatives to ethanol sclerotherapy are sodium tetradecyl-sulphate foam or lauromacrogol that are effective for small VMs and cause fewer local adverse effects. Positive response was seen in 49.5% (for pain) and 52.7% (for mass reduction), within the 86 patients (91 VMs) involved in one study.[94] Detergent sclerosants have been used as microfoams, using air bubbles or carbon dioxide to increase volume and surface contact with endothelium. However, neurologic complications have been described in 2% of cases. A modified radiopaque ethanol sclerosing agent was therefore developed. It traps ethanol within a mesh of ethylcellulose to increase viscosity.[95,96]

Surgical resection is often performed after sclerotherapy.[53] In patients with BRBN, endoscopic coagulation with Nd:YAG (neodymium-doped yttrium aluminum garnet)laser, bipolar or argon plasma coagulation, and band-ligation are useful. An open surgery allowing surgical resection of all GI lesions can eradicate the need for blood transfusion as well as the common intermittent abdominal pain caused by intussuception.[97,98] In patients with GVM, skin graft is often needed if excision is undertaken. VVM is also best treated with surgical resection. Closure often necessitates a skin graft.

Counseling: In patients with VMCM or GVM, genetic counseling should be provided for affected families, informing patients of a 50% risk of inheriting

the disease-causing mutation and of the variability in clinical expression. Psychosocial counseling and patient organizations dedicated to vascular anomalies are also an important asset for patients and their families.

LYMPHATIC ANOMALIES

AT-A-GLANCE

- Worldwide occurrence of LM is unknown, but it is less frequent than that of VM.
- Congenital, sporadic, slow-flow malformations of lymphatic vessels
- LMs consist of micro- or macrocysts filled with lymphatic fluid.
- Histologically consist of dilated lymphatic channels with flat endothelium that expresses D2-40.
- Primary lymphedema can be inherited as an autosomal trait.
- Infection is the most common complication that can lead to septicemia.

INTRODUCTION

LMs are localized morphogenic errors of the lymphatic vessels. They consist of small vesicles or large cysts filled with lymphatic fluid. Macrocystic LM can be diagnosed in utero as early as the first trimester of pregnancy.[99] However, most LMs are diagnosed during infancy, before the age of 2 years. Some can manifest only at puberty or during adulthood. They can be isolated, combined with other vascular anomalies, or be part of a syndrome.

Primary lymphedema is not a localized lesion but a more generalized condition, in which the lymph fluid accumulates in the interstitial tissue. Lower extremities are most commonly affected. It can be uni- or bilateral. Primary lymphedema can be an isolated condition or part of a syndrome, and it can occur sporadically or as an inherited disorder.

EPIDEMIOLOGY

LM is a congenital disorder of unknown incidence. It occurs sporadically in contrast to primary lymphedema, which can be inherited, usually as an autosomal dominant trait, in up to 20% of cases. Primary lymphedema is divided into congenital (Milroy disease, Online Mendelian Inheritance in Man [OMIM] #153100) and late onset (presenting at puberty, Meige disease, OMIM #153200). It can be isolated or part of a syndrome, such as in Turner and Noonan syndromes.[100]

SYNDROMIC DISORDERS

KLIPPEL-TRENAUNAY SYNDROME

Klippel-Trenaunay syndrome is a combined capillary–lymphatic–venous malformation associated with hypertrophy of the affected limb. Lower limbs are affected in 70% of cases. It is characterized by a geographic, widespread CM associated with lymphatic vesicles. The persistence of a persistent embryonic vein located on the lateral side of the thigh is pathognomonic.[101,102]

CLOVES SYNDROME

CLOVES syndrome is an eponym for congenital lipomatous overgrowth with vascular malformations, epidermal nevi, and skeletal anomalies.[103] This nonhereditary disorder is characterized by progressive asymmetric hypertrophy, multiple truncal lipomatous masses with paraspinal fast-flow or slow-flow vascular anomalies (or both), epidermal nevus or nevi, acral lesions, and skeletal or spinal anomalies (Fig. 147-15).

Figure 147-15 Capillary–lymphatic–venous malformation of right lower extremity with soft tissue hypertrophy (CLOVES syndrome).

The most important differential diagnoses are other overgrowth syndromes, such as the Proteus syndrome and Proteus-like syndrome.[104]

GENERALIZED LYMPHATIC ANOMALY

Generalized lymphatic anomaly (GLA) is a rare condition in which LMs can invade several organs such as the mediastinum, lungs, pleura, GI tract, bones, and soft tissue.[105]

GORHAM-STOUT SYNDROME

Gorham-Stout syndrome, or "vanishing bone disease," is an aggressive rare lymphatic disorder characterized by progressive demineralization and destruction of bones, which are replaced by lymphatic vessels and capillaries.[106]

CLINICAL FEATURES

CUTANEOUS FINDINGS

LMs are composed of microcysts (Figs. 147-16 and 147-17), previously termed *lymphangioma circumscriptum*) or macrocysts (>1 cm in diameter, previously known as *cystic hygroma*) that grow proportionally with the child (see Figs. 147-1B, 147-16, and 147-17). They are filled with clear or serosanguineous fluid (see Fig. 147-17B). Whereas macrocystic LM manifests as a soft, multilobulated, well-defined mass, microcystic LMs are ill-defined and often invade adjacent structures. Dermal LMs can manifest as small, millimeter-sized vesicles, clear (see Figs. 147-16D and 147-17A) or dark red in color (when there is intracystic bleeding), that can bleed and become purple and nodular.

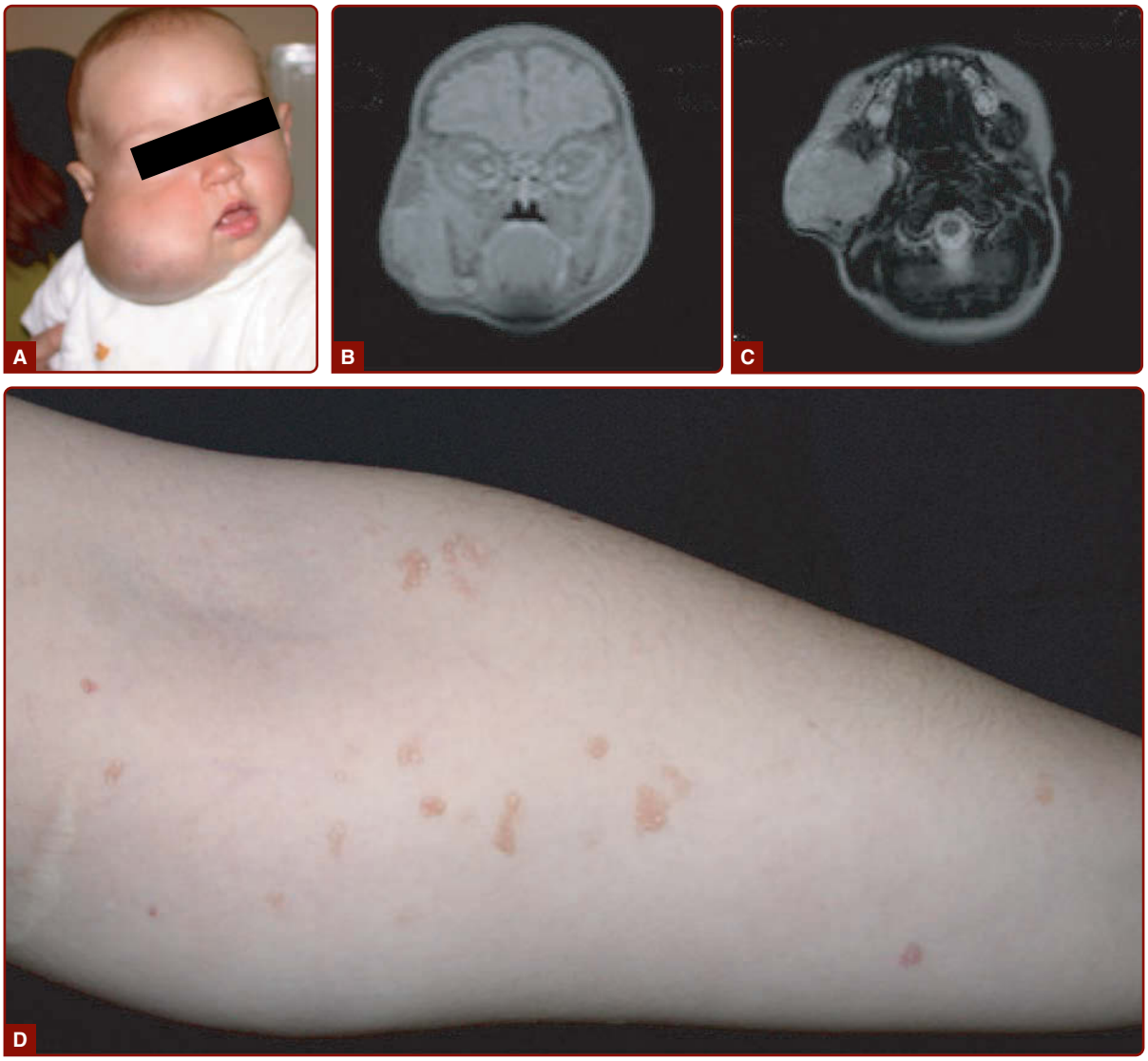

Figure 147-16 Various aspects of lymphatic malformation (LM). Bluish discoloration (**A**) of extensive LM of cheek, as seen on computed tomography scan (**B** and **C**). Small clear vesicles of dermal LM (**D**).

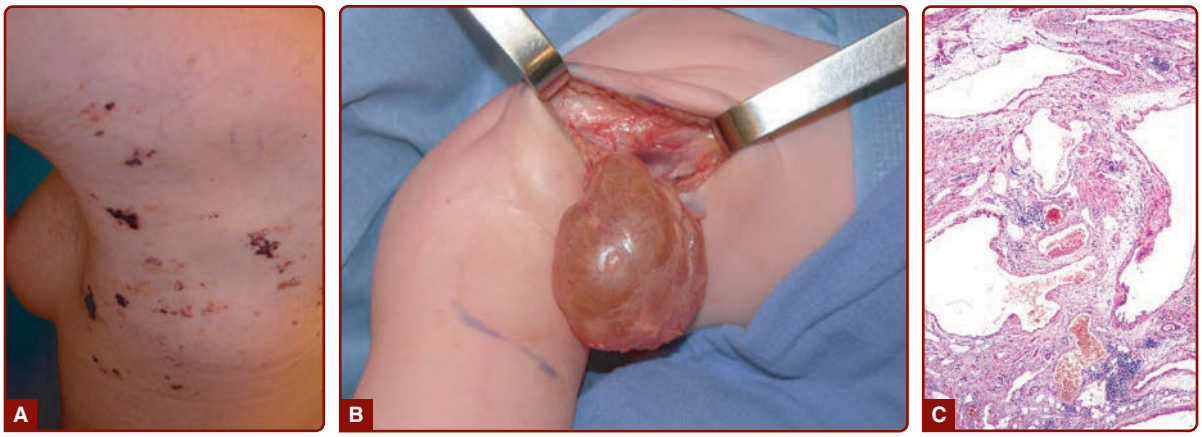

Figure 147-17 **A,** Microcystic, dermal lymphatic malformation (LM) consisting of clear and dark-red vesicles. **B,** Intraoperative view of a macrocystic LM of axilla showing a well-delineated cyst filled with clear lymph fluid. **C,** Histologically, LM consists of dilated lymphatic channels with flat endothelium (hematoxylin and eosin).

Angiokeratoma Circumscriptum: Angiokeratoma circumscriptum, or capillary-lymphatic malformation (CLM), is a combined, well-demarcated lesion often located on an extremity. The lesion is pink to bluish-red in color, slightly raised, and usually hyperkeratotic. Clinically, angiokeratoma circumscriptum, angiokeratoma of Mibelli (circumscribed, dark-red, hyperkeratotic plaques on distal extremities), and angiokeratoma of Fordyce (very common hyperkeratotic, blue-black papules on the scrotum of elderly men) are recognized. They are to be differentiated from angiokeratomas of Fabry disease (see Chap. 127) and from VVM (previously known as verrucous hemangioma; see earlier VM section).

Lymphedema: Lymphedema is characterized by swelling of the affected body part, usually a lower extremity, and caused by accumulation of lymphatic fluid into the extracellular space caused by intrinsic lymphatic dysfunction (Fig. 147-18). Various phenotypes exist depending on the age of onset, location, and associated anomalies.[107,108]

Congenital Lymphedema: Milroy disease is suspected in the presence of swelling of the dorsum of the feet with a family history of lymphedema. Lymphedema is present at birth, often bilateral, and affects the lower limbs below the knees.[109] Other features can be associated with congenital lymphedema, such as hydrocele (37% of males), prominent veins (23%), upslanting toenails (14%), papillomatosis (10%), or urethral abnormalities in males (4%).

NONCUTANEOUS FINDINGS

Pulmonary embolism can occur in patients with KTS or CLOVES syndrome.[110] Depending on the affected organ, symptoms such as pleural effusion, ascites, and malabsorption can occur in patients with GLA.[105] Painful pathological fractures are common in patients with Gorham-Stout syndrome.[106]

COMPLICATIONS

LM can suddenly enlarge in response to cough, inflammation, fever, viral or bacterial infection, or intralesional bleeding (Fig. 147-19). Recurrent cellulitis is the major complication, especially in patients with KTS, and it can evolve into septicemia if not promptly treated. Local redness and warmth appear, and the lesion becomes painful.

Facial asymmetry, especially of the mandible, is commonly associated with microcystic LM (see Fig. 147-16). Intraorbital LM is responsible for ocular dystopia and exophthalmia, as well as orbital enlargement. LM on the tongue impairs speech and produces oozing and halitosis. Airway obstruction is common when the base of the tongue or the cervicofacial area is affected.[111] Extensive limb LM can cause elephantiasis. Extension into the pleura can occur and cause chylothorax. Visceral LM can cause protein-losing enteropathy and hypoalbuminemia. Patients with KTS as well as patients with CLOVES are at high risk of pulmonary embolism because of the persistent embryonic vein and the presence of ectatic thoracic veins, respectively.[110]

Lymphedema is complicated by cellulitis in 20% of cases. More rarely, pleural effusion, even in utero; hydrops fetalis; and chylous ascites can be observed.[108,112,113]

ETIOLOGY AND PATHOGENESIS

LMs, as well as KTS and CLOVES syndrome, are caused by mosaic or somatic mutations in *PIK3CA* that activate the PI3K/AKT/mTor signaling pathway.[11,12,114,115]

More than 20 genes have been identified to be mutated in various forms primary lymphedema.[108] Milroy disease is caused by inherited loss-of-function mutations in vascular endothelial growth factor receptor 3 (*VEGFR3*).[116-118] Mutations in the same gene

Figure 147-18 Various types of congenital primary lymphedema characterized by lymphedema of lower limb, below the knees (**A**); with papillomatosis (**B**); with upslanting toenails (**C**); that can evolve into elephantiasis (**D**).

are also responsible for sporadic hydrops fetalis and generalized subcutaneous edema.[119] Lymphedema-distichiasis is caused by loss-of-function mutations in the FOXC2 transcription factor.[120] Lymphedema associated with microcephaly, with or without chorioretinopathy or developmental delay, is caused

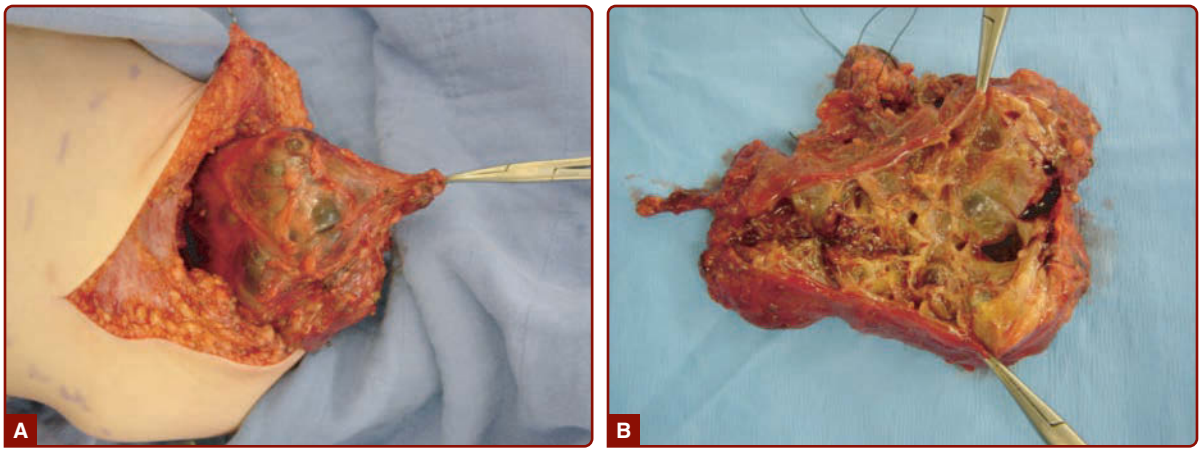

Figure 147-19 Intraoperative view of an axillary lymphatic malformation that had suddenly increased in size because of intracystic bleeding.

by dominantly inherited mutations in *KIF11*.[121,122] Hypotrichosis–lymphedema–telangiectasia, which has an autosomal-dominant or -recessive pattern of inheritance, is caused by mutations in *SOX18*.[118] Hennekam syndrome (OMIM #235510) is an autosomal recessive generalized lymphatic dysplasia characterized by intestinal lymphangiectasia with severe and progressive lymphedema of the limbs, genitalia, and face, as well as severe mental retardation.[123] Mutations have been identified in *CCBE1* (collagen and calcium-binding EGF domains 1).[107,124] Lymphedema is associated with hematologic malignancies in Emberger syndrome caused by *GATA2* mutations.[125] In about 35% to 40% of patients with familial primary lymphedema, a germline mutation can be identified.[108,126]

DIAGNOSIS

SUPPORTIVE STUDIES

Pathology: LMs are characterized by dilated, flat-endothelium-lined channels of variable wall thickness (see Fig. 147-8C). No blood cells are seen in these spaces, except after intracystic bleeding or in the presence of a combined lymphatic-venous malformation. Macrocystic LM consists of a single or multiple lymphatic cysts surrounded by a thick fibrous membrane. The cysts do not communicate with each other. Endothelial cells express specific lymphatic markers, such as podoplanin, D2-40, and VEGFR-3.[44,127] Lymphedema is characterized by abnormalities in the primary peripheral lymphatic capillaries, collecting lymphatic vessels, or lymphatic valves and lymphovenous valves. This is pronounced in the affected limb but is sometimes also seen on the contralateral side. Extensive dermal fibrosis is often present.[44]

Imaging: Doppler ultrasound shows microcysts, macrocysts, or both separated by thin septa. In contrast to VMs, they are not compressible by the probe. MRI also demonstrates the cystic nature of the lesion, with often discernable fluid-fluid levels.[128,129] Computed tomography (CT) is the best study to show bony involvement.

Doppler ultrasonography of the deep venous system of the affected lower limb and the pelvic area is needed in patients with KTS and CLOVES. Moreover, because CLOVES syndrome is characterized by progressive overgrowth during infancy, careful follow-up every 6 months is recommended until the end of puberty. Follow-up consists of clinical examination, scaniometry (leg length films), and abdominal ultrasonography because of the increased risk of cryptorchidism, hydrocele, renal atrophy, and Wilms tumor.[130] Additional investigations should be done according to symptoms.

Genetic Testing: Genetic panel–based testing is available in accredited diagnostic laboratories. Such screens help identify germline mutations and can aid management. For example, identification of a germline *GATA2* mutation indicates specific cancer surveillance programs, and a *KIF11* mutation implies a need for detailed ophthalmologic and developmental examination.

TABLE 147-7
Differential Diagnosis of Lymphatic Malformation

Most Likely
- Infantile hemangioma

Consider
- Venous malformation
- Teratoma
- Fibrosarcoma or rhabdomyosarcoma

Rule Out
Vulvar
- Acquired lymphangiectasia caused by radiotherapy
- Acquired lymphangiectasia caused by Crohn disease

DIFFERENTIAL DIAGNOSIS

See Table 147-7.

CLINICAL COURSE AND PROGNOSIS

LM usually grows with the child. It can cause asymmetry with bony overgrowth. Increases in size can be seen during infection or intralesional bleeding. Episodic reports of spontaneous involution exist. Because regression is commonly seen after local infection, it may be caused by postinflammatory autosclerosis. Patients with Gorham-Stout syndrome have a poor prognosis; it is lethal in 16% of cases.

MANAGEMENT

INTERVENTIONS

Medical Management: Systemic antibiotics should be used to treat intralesional bacterial infection as well as early cellulitis in both isolated and syndromic LM. Antiinflammatory drugs may be required to alleviate pain. Patients with CLOVES or KTS syndrome need to receive LMWH at prophylactic dosages of 100 anti-Xa/kg/day before any surgical procedure; this should be continued for another 10 to 20 days postoperatively to avoid perioperative decompensation of their coagulation abnormalities, and more importantly, to reduce the risk of life-threatening postoperative pulmonary embolism.[110] Rapamycin has been effectively

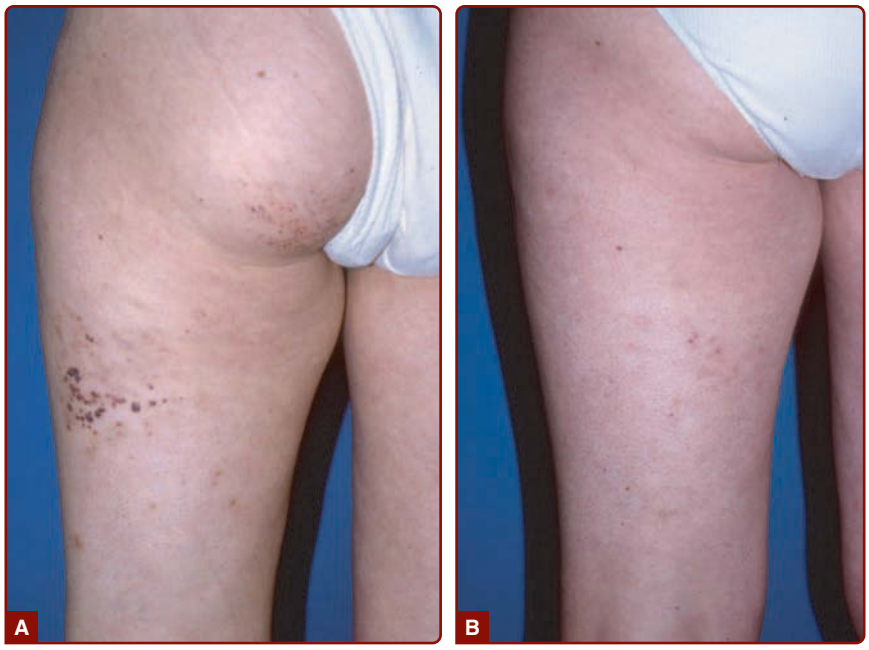

Figure 147-20 Dermal lymphatic malformation (**A**) efficiently treated with carbon dioxide laser (**B**).

used for extensive LMs resistant to standard treatment, as well as for patients with KTS and GLA. Although none had complete resolution, several patients experienced cessation of lymphatic leakage and infection and reduction of volume of the malformation. Side effects were minor.[131,132]

Lymphedema is best treated with elastic stockings, massage, and pneumatic compression devices. Sildenafil was suggested as effective in the treatment of LM,[133] but further studies have not confirmed its efficacy and highlighted potential side effects, such as infections and bleeding.[134,135]

Procedures: Nd:YAG laser or carbon dioxide laser photocoagulation has been used to treat dermal LM vesicles that cause oozing (Fig. 147-20). Macrocystic LM is treated with fluid aspiration followed by percutaneous, intralesional injection of sclerosing agents performed by an interventional radiologist. Sclerosing agents include sodium tetradecyl sulfate, pure ethanol, OK432 (extract from a killed strain of group A *Streptococcus pyogenes*: picibanil), doxycycline, and bleomycin. Side effects vary from fever and erythema to edema.[136,137]

Surgical resection is another alternative for LM, CLOVES, and KTS syndrome.[138,139] Results depend on the anatomical site and extension of the lesion. Recurrence is frequent because it is difficult to differentiate microcystic LM from adjacent normal tissue. This leads to either incomplete resection or unnecessary sacrifice of normal structures.

Counseling: Family and patient education regarding the cause and treatment is necessary for primary lymphedema because it can be inherited and associated with other important medical problems, necessitating inclusion in special surveillance programs. Psychosocial counseling and patient organizations dedicated to vascular anomalies are also an important help for patients and their families.

ARTERIOVENOUS MALFORMATIONS

AT-A-GLANCE

- Worldwide occurrence; rare but exact frequency unknown
- Congenital, fast-flow malformations that can be occult until puberty
- Histologically consist of direct communications between arteries and veins
- Usually sporadic but can have a genetic predisposition as in CM-AVM, hereditary hemorrhagic telangiectasia, or PHTS
- Most difficult vascular malformation to treat; need a multidisciplinary approach

INTRODUCTION

Fast-flow vascular malformations, namely AVM and AVF, are the most severe and devastating malformations. AVF is usually the result of trauma. AVM is characterized by the presence of a "nidus," the epicenter of the lesion that is composed of direct communications between multiple feeding arteries and draining veins

without an intervening normal capillary bed. AVMs are present at birth, although they are not always visible. They can be localized or extensive and evolve with age.

EPIDEMIOLOGY

The incidence of AVM is unknown. No sex preponderance has been identified. It is a rare, usually sporadic, fast-flow vascular malformation. Hereditary hemorrhagic telangiectasia (HHT) is an autosomal inherited disorder with a prevalence of 1 in 5000 individuals.[140] CM-AVM is another familial form with autosomal dominant inheritance and a similar prevalence estimate.[19-23]

SYNDROMIC DISORDERS

BONNET-DECHAUME-BLANC OR WYBURN-MASON SYNDROME

Bonnet-Dechaume-Blanc or Wyburn-Mason syndrome is a sporadic, syndromic AVM located in the centrofacial or hemifacial area (or both), with oculo-orbital and cerebral involvement.[141] It rarely follows a trigeminal distribution like SWS. Intracerebral AVMs are common in Bonnet-Dechaume syndrome and can cause epistaxis, exophthalmos, and hemianopia. Mental retardation can also occur.

COBB SYNDROME

Cobb syndrome is another sporadic, syndromic AVM that associates cutaneous and spinal cord AVMs of the same metamere.[142] The cutaneous lesion masquerades as a CM, although it is warm on palpation. Cobb syndrome manifests in childhood with a sudden onset of back or lower extremity pain associated with sensory disturbance. Other neurologic complications (pain, sensory and motor disturbances, and neurogenic bladder) can occur depending on the location and extension of the AVM.

HEREDITARY HEMORRHAGIC TELANGIECTASIA

Individuals with HHT demonstrate combinations of the following triad: multiple cutaneous and mucosal telangiectasias, often located on the mucosal lip; epistaxis; and a positive family history.[143] The diagnosis is clinical, in accordance with the Curaçao criteria. The estimated frequencies of manifestations in HHT patients are spontaneous, recurrent epistaxis, 90%; skin telangiectasia, 75%; hepatic or pulmonary AVMs, 30%; and GI bleeding, 15%.[144] In 30% of patients with HHT, a hepatic, pulmonary, or cerebral AVM (or a combination of any of these AVMs) can be seen.[144] In contrast, in 23% of patients with CM-AVM1 and 13% of patients with CM-AVM2, an intracerebral or intraspinal AVM is present.[18,19,22,23,35]], but there is no risk for visceral AVM as in HHT. Vein of Galen aneurysmal malformation is also part of the phenotype. Recurrent epistaxis is typically the initial manifestation of HHT. The nosebleeds can be severe enough to require blood transfusions. Pulmonary AVMs affect approximately 30% of patients with HHT and are particularly common in HHT1. These patients are at higher risk of stroke and brain abscess than in the healthy population because the normal filtering function of the lung is lost. Migraine headaches occur in 13% to 50% of cases. Recurrent painless GI bleeding occurs in 10% to 40% of patients. Symptoms may include abdominal pain, jaundice, symptoms of high-output cardiac failure, and bleeding from esophageal varices.[145]

PARKES WEBER SYNDROME

Parkes Weber syndrome is characterized by a large, congenital, cutaneous, red vascular stain on an extremity in association with soft tissue and skeletal hypertrophy of the affected limb and underlying multiple arteriolar-venular microfistulas.[146] The affected extremity, often the lower one, is longer and larger than the contralateral one. Although often sporadic, it can be part of CM-AVM. In these cases, there are small, multifocal CMs located on other parts of the body. The signs and symptoms worsen with age. Affected patients can develop congestive heart failure.

PHOSPHATASE AND TENSIN HOMOLOG HAMARTOMA TUMOR SYNDROME

PHTS is an autosomal-dominant disorder that includes patients with Bannayan-Riley-Ruvalcaba syndrome and Cowden syndrome because 60% and 81% of them, respectively, have a mutation in *PTEN*.[147] These patients typically have macrocephaly, penile freckling, multiple developmental venous anomalies in the brain, fast-flow VMs (54%), and an increased risk of malignancy. The VMs are often multifocal (57%) and musculoskeletal and associated with ectopic fat deposition and disruption of the normal tissue architecture.[147,148]

CLINICAL FEATURES

CUTANEOUS FINDINGS

AVMs usually manifest as cutaneous, faint, red to purple, ill-defined masses with a thrill, a bruit, or a pulsation of increased amplitude (Figs. 147-21 to 147-23; see also Figs. 147-1D and 147-1E). About one third of AVMs are present at birth, another -third appear during childhood or at puberty, and the rest

Figure 147-21 Stage 2 arteriovenous malformation of the left thigh mimicking an infantile hemangioma that did not disappear at 8 years of age (**A**). Arteriography showing the nidus confirmed the diagnosis (**B**).

manifest in adulthood because hormonal changes and trauma usually trigger the growth of an AVM. AVMs can affect any tissue and organ. Seventy percent of AVMs are located on the head and neck. They never regress spontaneously and get worse with time.[149] In 1985, Schobinger staged AVMs according to their severity. Schobinger stage I is a red stain with bruit and pulses of increased amplitude. With age, puberty, or trauma, AVM can worsen, and veins become prominent and tortuous (Schobinger stage II; Fig. 147-22) and subsequently darker and painful, and they ulcerate and bleed (Schobinger stage III; see Fig. 147-23). The final stage of a large AVM is cardiac failure (Schobinger stage IV; see Fig. 147-23).[150] The patient often reports hearing his or her cardiac pulse.

CM-AVM (see earlier discussion of CM-AVM) manifests as multiple atypical CMs that are randomly distributed (see Fig. 147-6) and associated with fast-flow lesions—AVM, AVF, or Parkes Weber syndrome—in 30% (CM-AVM1) or 20% (CM-AVM2) of patients. The expressivity is highly variable within families, from small, asymptomatic CMs to life-threatening AVMs. The fast-flow lesions (AVM or AVF) are either cutaneous or subcutaneous, with or without intramuscular and intraosseous involvement. About 10% to 15% of patients with CM-AVM have a Parkes Weber phenotype affecting the lower (two thirds of such cases) or the upper extremity. The AVMs can be asymptomatic, but complications occur depending on the location and size.[19-21]

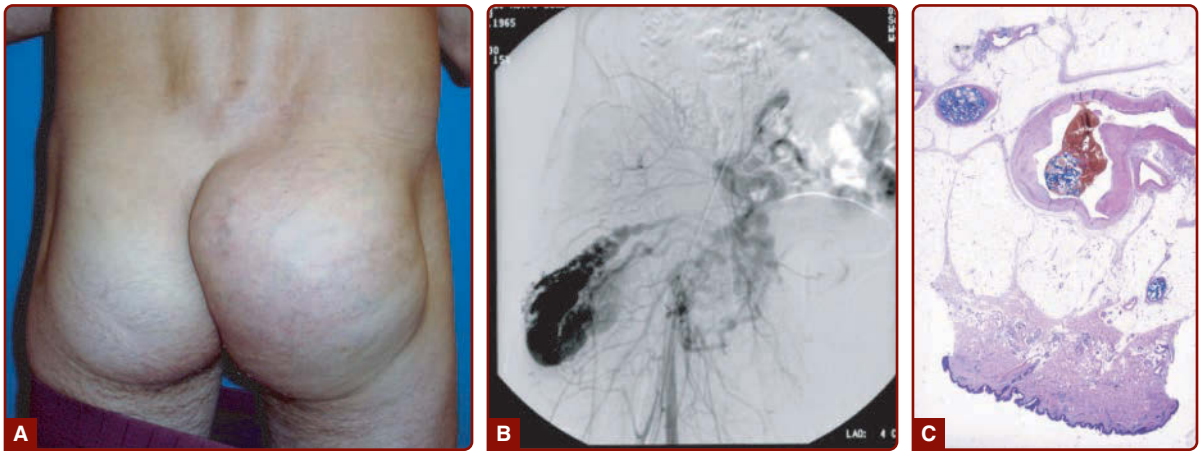

Figure 147-22 **A,** Extensive arteriovenous malformation deforming the right buttock. **B,** Arteriography showing nidus of the malformation. **C,** Histology shows direct connection between artery and vein, with thrombotic material secondary to embolization procedure.

Figure 147-23 Stage 2 arteriovenous malformation (AVM; **A**) evolving into stage 4 AVM (**B**).

NONCUTANEOUS FINDINGS

In 30% of patients with HHT, a hepatic, pulmonary, or cerebral AVM (or a combination of any of these AVMs).[144] In 23% of patients CM-AVM1 and 13% of patients with CM-AVM2, an intracerebral or intraspinal AVM (or both) is present.[18,19,22,23,35]

COMPLICATIONS

AVMs involving the face can as well destroy the bone structure underneath and can cause gingival bleeding or epistaxis as well as hypertrophic asymmetry. Bony hypertrophy is a common feature of facial AVM, which causes asymmetry. AVM of an extremity often causes peripheral ischemia due to blood flow steel phenomenon. Cardiac failure is rare (Schobinger stage IV), especially during childhood. Puberty and trauma as well as hormonal influence can trigger appearance of AVMs. Intracerebral AVM such as in Bonnet-Dechaume syndrome, can cause epistaxis, exophthalmos, and hemianopia. Mental retardation can also occur.

Cobb syndrome manifests in childhood with a sudden onset of back or lower extremity pain associated with sensory disturbance. Other neurologic complications (pain, sensory and motor disturbances, and neurogenic bladder) can occur depending on the location and extension of the AVM.

Recurrent epistaxis is typically the initial manifestation of HHT. The nosebleeds can be severe enough to require blood transfusions. The prevalence of brain AVM is 1000-fold higher in patients with HHT1 than in the general population (1 in 10,000) and 100-fold higher in patients with HHT2. A similar increased risk is seen in CM-AVM1 and 2. Patients with HHT with pulmonary AVMs and telangiectasia of the GI tract are at risk for life-threatening hemorrhage. Other sites of bleeding may include sites in the kidney, spleen, bladder, liver, meninges, and brain. Strokes may be either hemorrhagic or ischemic.

These patients are at higher risk of stroke and brain abscess than in the healthy population because the normal filtering function of the lung is lost. Migraine headaches occur in 13% to 50% of the cases. Recurrent painless GI bleeding occurs in 10% to 40% of patients. Symptoms may include abdominal pain, jaundice, symptoms of high-output cardiac failure, and bleeding from esophageal varices.[145]

Patients with CM-AVM can exhibit intrauterine life-threatening intracerebral bleeding caused by vein of Galen aneurysmal malformation.[22,151] The brain and medullary AVMs can also bleed postnatally.[22,35,151]

ETIOLOGY AND PATHOGENESIS

Underlying genetic defects have been identified for the fast-flow vascular malformations of CM-AVM (OMIM #608354), HHT (OMIM #187300), and PHTS (OMIM #153480 and 158350). These disorders are inherited as an autosomal-dominant pattern with a penetrance of about 95% for the cutaneous CMs or telangiectasias.[18,19,22,151]

HHT is caused by alterations in the transforming growth factor-β signaling pathway. The genes implicated

in HHT are *ENG*, encoding endoglin (HHT type 1), and *ACVRL1* (formerly called *ALK1*, HHT type 2); *SMAD4*, and *GDF2* are less frequently involved.[152-155]

Endoglin and ACVL1 are type III and type I transforming growth factor-β receptors, and both are well-expressed on vascular endothelial cells. Loss-of-function of this signaling concomitantly increases PI3K-AKT signaling.[156]

CM-AVM1 is caused by loss-of-function mutations in *RASA1*.[18,20] RASA1 encodes P120RASGAP, a GTPase regulating RAS activity. It converts the active GTP-bound RAS into its inactive GDP-bound form.[61,62,157] The high intrafamilial phenotypic variability is explained by the necessity of a somatic second-hit mutation to occur.[21,158] In 30% of patients with CM-AVM1, the mutation is de novo. CM-AVM2 is caused by loss-of-function mutation in *EPHB4*, which encodes an endothelial cell receptor in venous vessels. The ligand EPHRINB2, in contrast to EPHB4, is expressed in arterial endothelial cells. This bidirectional ligand–receptor system is important for arteriovenous identity and separation. EPHB4 signals using p120RASGAP, and the loss of function of either gene causes increased RAS-MAPK signaling.[18,159-162]

AVM can also be caused by loss-of-function mutation in *PTEN*, a tumor suppressor gene, as seen in patients with PHTS.[163] PTEN regulates PI3K-AKT activity, and this seems to be regulated at least in part by the HHT receptor complex (see earlier). Loss of function of one of the partners of this complex or of PTEN itself leads to activation of PI3K.

Sporadic extracranial AVMs are caused by somatic activating *MAP2K1 (MEK)* mutations.[14] Brain AVM are caused by another activating mutation in *KRAS*, which is also involved in the RAS-MAPK signaling pathway.[164]

DIAGNOSIS

SUPPORTIVE STUDIES

Pathology: Histologically, AVMs are poorly demarcated and consist of distorted arteries and veins with thickened muscle walls caused by arteriovenous shunting and fibrosis (see Fig. 147-22C).

Imaging: Ultrasonography and color Doppler show no mass but an aggregation of high-velocity arterial and pulsatile venous flow with low resistance. Vessels are tortuous. On the extremities, noninvasive follow-up is performed by comparing the arterial outflow of the affected limb with the unaffected one. MRI is preferred over CT to delineate the extent of an AVM and differentiate AVM from hemangiomas and other VMs. Flow voids, corresponding to fast-flow vessels, are pathognomonic of AVM. Arteriography is needed before any treatment to determine feeding arteries and the nidus (see Figs. 147-1E and 147-22B).

Genetic Testing: Genetic testing is indicated in patients with an AVM that is associated with multifocal cutaneous CMs (CM-AVM) or telangiectasias (HHT). Molecular diagnosis helps genetic counseling and guide further imaging for eventual undetected malformations. Patients with AVM with associated macrocephaly should be screened for *PTEN* mutations. Identification of a germline mutation would enable precise counseling and inclusion in cancer surveillance programs.

DIFFERENTIAL DIAGNOSIS

See Table 147-8.

During childhood, AVM is often mistaken for a CM or hemangioma because of its presentation as a faint, ill-defined, macular red stain. However, disproportionate warmth on palpation is a clue to its fast-flow component. A pulse, thrill, and bruit are other signs supporting AVM. Doppler ultrasonography can help differentiate a slow-flow CM from a fast-flow AVM or hemangioma. Hemangiomas have equatorial feeding arteries, peripheral veins, variable echogenicity, and fast flow but no true arteriovenous shunting.

Other dermatologic lesions can mimic AVM. Epithelioid hemangioendothelioma occurs in the extremity as a purple and locally aggressive lesion. Tumid lupus erythematosus, sarcoidosis of the face, and Melkersson-Rosenthal syndrome of the lip can mimic AVM. Dabska tumor can simulate an AVM on a child when it is located in the ear.

CLINICAL COURSE AND PROGNOSIS

AVMs tend to worsen with time, causing local destruction or life-threatening bleeding. Puberty and trauma trigger growth of the lesion. Improper management, often because of misdiagnosis, such as ligation of feeding arteries, or partial resection of the nidus, can have

TABLE 147-8
Differential Diagnosis of Arteriovenous Malformation

Most Likely

At birth
- Congenital hemangioma
- Infantile fibrosarcoma
- Other sarcoma

Rapid growth after birth
- Infantile hemangioma

Rule Out

Ear, nose
- Lupus erythematosus tumidus
- Sarcoidosis
- Dabska tumor

Lip
- Melkersson-Rosenthal syndrome

dramatic consequences and expansion of the AVM (see Fig. 147-23). The CMs in CM-AVM are harmless and usually of only cosmetic importance, although flow characteristics are commonly abnormal.

MANAGEMENT

This fast-flow VM is the most complex and difficult vascular anomaly to treat. Its management is multidisciplinary. AVMs should be followed by periodic evaluation. The goal of cure of an AVM is based on obliteration (by embolization) and complete removal of the nidus. Partial resection and proximal ligation of the feeding arteries lead to severe complications, recurrence, and reexpansion over time. Furthermore, ligature of the proximal arteries prevents access to the nidus for embolization, stimulates recruitment of new feeding arteries, and therefore expands the malformation. Mismanagement of AVM can lead to amputation.[19]

INTERVENTIONS

Medications: In a limb AVM or multiple AVFs, elastic stockings can stabilize the lesion and protect the skin, especially in the early stage. Because AVM is difficult to eradicate, the focus of management is often to control the evolution of the malformation rather than to cure the patient.[40,45] A pharmacologic approach with Marimastat, a synthetic matrix metalloproteinase inhibitor, has been used to treat extensive AVMs with good results. It reduced extension of the malformation and decreased pain and bruit.[46] Unfortunately, the drug is no longer available. Thalidomide was successfully used to reduce the frequency and duration of nosebleeds in patients with HHT.[165] It has also been used in unresectable stage 3 AVMs for which standard treatment had not been successful. For some patients, it was used in combination with embolization to improve efficacy.

Procedures: *Superselective embolization*: In contrast to AVF, superselective arterial embolization alone is only palliative and is done only in unresectable, complicated AVM. The embolized particles need to reach the epicenter of the lesion to avoid refilling of the nidus through new collaterals.[166] Direct puncture of the nidus is another possibility in patients with previous arterial ligation or embolization.[167] The most common materials are liquids (ethanol, isobutylcyanoacrylate), particles (Ivalon), foam, and implantable devices (coils, microspheres). Embolization is rarely curative unless performed for an arteriovenous fistula. Embolization can be used alone (palliative approach) or followed by complete surgical excision (curative approach). The site of injection must be as close as possible to the nidus to permit a superselective approach. Proximal occlusion is responsible of secondary refilling of the nidus through collateral arteries.[24]

Radical excision: Surgical resection is usually done only after embolization to minimize perioperative bleeding.[168] Excision should be complete and radical with carcinologic margins when possible. It is preceded with superselective embolization to occlude the nidus and reduce intraoperative bleeding.[19,26] The overlying skin can be saved if normal; otherwise, it is widely excised. Coverage options include tissue expansion or a local or free flap.[29] Cutaneous expansion can be done before embolization or surgery but may act as a trigger to stimulate growth of the malformation. Early intervention for "quiescent AVM" (Schobinger stage I) is debatable and should be considered only if complete resection is possible.[169] Follow-up for at least 5 years with annual Doppler ultrasonography or MRI (or both) is mandatory after any treatment.

For patients with Parkes Weber syndrome, treatment should be as conservative as possible. Epiphysiodesis may be necessary to control leg-length discrepancy. This procedure can sometimes aggravate the AVM.[146] For patients with HHT, multiple treatments have been tried to reduce bleeding, including topical application of antiinflammatory drugs, laser, or surgery. Because of the extensiveness of the lesions, they all give limited symptom-free intervals.

Counseling: Genetic counseling is mandatory in CM-AVM, HHT, and PHTS.

REFERENCES

1. Boon LM, Ballieux F, Vikkula M. Pathogenesis of vascular anomalies. *Clin Plast Surg*. 2011;38(1):7-19.
2. Mulliken JB, Glowacki J. Hemangiomas and vascular malformations in infants and children: a classification based on endothelial characteristics. *Plast Reconstr Surg*. 1982;69(3):412-422.
3. Mulliken JB. *Mulliken and Young's Vascular Anomalies: Hemangiomas and Malformations*. 2nd ed. New York: Oxford University Press; 2013.
4. Wassef M, Blei F, Adams D, et al. Vascular anomalies classification: recommendations from the International Society for the Study of Vascular Anomalies. *Pediatrics*. 2015;136(1):e203-e214.
5. Jacobs AH, Walton RG. The incidence of birthmarks in the neonate. *Pediatrics*. 1976;58(2):218-222.
6. Elajmi A, Clapuyt P, Hammer F, et al. Management of vascular anomalies in children. *Ann Chir Plast Esthet*. 2016;61(5):480-497.
7. Brouillard P, Vikkula M. Genetic causes of vascular malformations. *Hum Mol Genet*. 2007;16(Spec No. 2): R140-R149.
8. Limaye N, Boon LM, Vikkula M. From germline towards somatic mutations in the pathophysiology of vascular anomalies. *Hum Mol Genet*. 2009;18(R1):R65-R74.
9. Nguyen HL, Boon LM, Vikkula M. Genetics of vascular malformations. *Semin Pediatr Surg*. 2014;23(4): 221-226.
10. Limaye N, Kangas J, Mendola A, et al. Somatic activating PIK3CA mutations cause venous malformation. *Am J Hum Genet*. 2015;97(6):914-921.
11. Boscolo E, Coma S, Luks VL, et al. AKT hyperphosphorylation associated with PI3K mutations in lymphatic endothelial cells from a patient with lymphatic malformation. *Angiogenesis*. 2015;18(2):151-162.

12. Luks VL, Kamitaki N, Vivero MP, et al. Lymphatic and other vascular malformative/overgrowth disorders are caused by somatic mutations in PIK3CA. *J Pediatr*. 2015;166(4):1048-54 e1-e5.
13. Shirley MD, Tang H, Gallione CJ, et al. Sturge-Weber syndrome and port-wine stains caused by somatic mutation in GNAQ. *N Engl J Med*. 2013;368(21):1971-1979.
14. Couto JA, Huang AY, Konczyk DJ, et al. Somatic MAP2K1 mutations are associated with extracranial arteriovenous malformation. *Am J Hum Genet*. 2017;100(3):546-554.
15. Soblet J, Kangas J, Natynki M, et al. Blue rubber bleb nevus (BRBN) syndrome is caused by somatic TEK (TIE2) mutations. *J Invest Dermatol*. 2017;137(1):207-216.
16. Burrows PE, Laor T, Paltiel H, et al. Diagnostic imaging in the evaluation of vascular birthmarks. *Dermatol Clin*. 1998;16(3):455-488.
17. Eerola I, Boon LM, Watanabe S, et al. Locus for susceptibility for familial capillary malformation ("port-wine stain") maps to 5q. *Eur J Hum Genet*. 2002;10(6):375-380.
18. Eerola I, Boon LM, Mulliken JB, et al. Capillary malformation-arteriovenous malformation, a new clinical and genetic disorder caused by RASA1 mutations. *Am J Hum Genet*. 2003;73(6):1240-1249.
19. Boon LM, Mulliken JB, Vikkula M. RASA1: variable phenotype with capillary and arteriovenous malformations. *Curr Opin Genet Dev*. 2005;15(3):265-269.
20. Revencu N, Boon LM, Mulliken JB, et al. Parkes Weber syndrome, vein of Galen aneurysmal malformation, and other fast-flow vascular anomalies are caused by RASA1 mutations. *Hum Mutat*. 2008;29(7):959-965.
21. Revencu N, Boon LM, Mendola A, et al. RASA1 mutations and associated phenotypes in 68 families with capillary malformation-arteriovenous malformation. *Hum Mutat*. 2013;34(12):1632-1641.
22. Revencu N, Boon LM, Mulliken JB, et al. RASA1 and capillary malformation-arteriovenous malformation. In: Erickson RP, Wynshaw-Boris A, eds. *Inborn Errors of Development: The Molecular Basis of Clinical Disorders of Morphogenesis*. New York: Oxford University Press; 2016:1423-1428.
23. Amyere M, Revencu N, Helaers R, et al. Germline loss-of-function mutations in EPHB4 cause a second form of capillary malformation–arteriovenous malformation (CM-AVM2) deregulating RAS-MAPK signaling. *Circulation*. 2017;136(11):1037-1048.
24. Enjolras O, Boukobza M, Jdid R. Cervical occult spinal dysraphism: MRI findings and the value of a vascular birthmark. *Pediatr Dermatol*. 1995;12(3):256-259.
25. Leung AK, Telmesani AM. Salmon patches in Caucasian children. *Pediatr Dermatol*. 1989;6(3):185-187.
26. Pratt AG. Birthmarks in infants. *AMA Arch Derm Syphilol*. 1953;67(3):302-305.
27. Ruiz-Maldonado R, Tamayo L, Laterza AM, et al. Phacomatosis pigmentovascularis: a new syndrome? Report of four cases. *Pediatr Dermatol*. 1987;4(3):189-196.
28. Happle R. Phacomatosis pigmentovascularis revisited and reclassified. *Arch Dermatol*. 2005;141(3):385-388.
29. Boukobza M, Enjolras O, Cambra M, et al. Sturge-Weber syndrome. The current neuroradiologic data. *J Radiol*. 2000;81(7):765-771.
30. Lee MS, Liang MG, Mulliken JB. Diffuse capillary malformation with overgrowth: a clinical subtype of vascular anomalies with hypertrophy. *J Am Acad Dermatol*. 2013;69(4):589-594.
31. Toriello HV, Mulliken JB. Accurately renaming macrocephaly-cutis marmorata telangiectatica congenita (M-CMTC) as macrocephaly-capillary malformation (M-CM). *Am J Med Genet A*. 2007;143A(24):3009.
32. Peterman CM, Vadeboncoeur S, Mulliken JB, et al. Wilms tumor screening in diffuse capillary malformation with overgrowth and macrocephaly-capillary malformation: a retrospective study. *J Am Acad Dermatol*. 2017;77(5):874-878.
33. Adams BB, Lucky AW. Acquired port-wine stains and antecedent trauma: case report and review of the literature. *Arch Dermatol*. 2000;136(7):897-899.
34. Larralde M, Abad ME, Luna PC, et al. Capillary malformation-arteriovenous malformation: a clinical review of 45 patients. *Int J Dermatol*. 2014;53(4):458-461.
35. Thiex R, Mulliken JB, Revencu N, et al. A novel association between RASA1 mutations and spinal arteriovenous anomalies. *Am J Neuroradiol*. 2010;31(4):775-779.
36. Segatto MM, Schmitt EU, Hagemann LN, et al. Phacomatosis pigmentovascularis type IIa—case report. *Ann Bras Dermatol*. 2013;88(6 suppl 1):85-88.
37. Hofer T. Meyerson phenomenon within a nevus flammeus. The different eczematous reactions within port-wine stains. *Dermatology*. 2002;205(2):180-183.
38. Klapman MH, Yao JF. Thickening and nodules in port-wine stains. *J Am Acad Dermatol*. 2001;44(2):300-302.
39. Valeyrie L, Lebrun-Vignes B, Descamps V, et al. Pyogenic granuloma within port-wine stains: an alarming clinical presentation. *Eur J Dermatol*. 2002;12(4):373-375.
40. Etchevers HC, Vincent C, Le Douarin NM, et al. The cephalic neural crest provides pericytes and smooth muscle cells to all blood vessels of the face and forebrain. *Development*. 2001;128(7):1059-1068.
41. Van Raamsdonk CD, Bezrookove V, Green G, et al. Frequent somatic mutations of GNAQ in uveal melanoma and blue naevi. *Nature*. 2009;457(7229):599-602.
42. Thomas AC, Zeng Z, Riviere JB, et al. Mosaic activating mutations in GNA11 and GNAQ are associated with phakomatosis pigmentovascularis and extensive dermal melanocytosis. *J Invest Dermatol*. 2016;136(4):770-778.
43. Riviere JB, Mirzaa GM, O'Roak BJ, et al. De novo germline and postzygotic mutations in AKT3, PIK3R2 and PIK3CA cause a spectrum of related megalencephaly syndromes. *Nat Genet*. 2012;44(8):934-940.
44. Wassef M, Vanwijck R, Clapuyt P, et al. Vascular tumours and malformations, classification, pathology and imaging. *Ann Chir Plast Esthet*. 2006;51(4-5):263-281.
45. Finley JL, Clark RA, Colvin RB, et al. Immunofluorescent staining with antibodies to factor VIII, fibronectin, and collagenous basement membrane protein in normal human skin and port wine stains. *Arch Dermatol*. 1982;118(12):971-975.
46. Breugem CC, Hennekam RC, van Gemert MJ, et al. Are capillary malformations neurovenular or purely neural? *Plast Reconstr Surg*. 2005;115(2):578-587.
47. Enjolras O, Riche MC, Merland JJ. Facial port-wine stains and Sturge-Weber syndrome. *Pediatrics*. 1985;76(1):48-51.
48. van der Horst CM, Koster PH, de Borgie CA, et al. Effect of the timing of treatment of port-wine stains with the flash-lamp-pumped pulsed-dye laser. *N Engl J Med*. 1998;338(15):1028-1033.

49. Michel S, Landthaler M, Hohenleutner U. Recurrence of port-wine stains after treatment with the flashlamp-pumped pulsed dye laser. *Br J Dermatol*. 2000;143(6):1230-1234.
50. Passeron T, Salhi A, Mazer JM, et al. Prognosis and response to laser treatment of early-onset hypertrophic port-wine stains (PWS). *J Am Acad Dermatol*. 2016;75(1):64-68.
51. Ville D, Enjolras O, Chiron C, et al. Prophylactic antiepileptic treatment in Sturge-Weber disease. *Seizure*. 2002;11(3):145-150.
52. Arzimanoglou AA, Andermann F, Aicardi J, et al. Sturge-Weber syndrome: indications and results of surgery in 20 patients. *Neurology*. 2000;55(10):1472-1479.
53. Boon LM, Vanwijck R. Medical and surgical treatment of venous malformations. *Ann Chir Plast Esthet*. 2006;51(4-5):403-411.
54. Dompmartin A, Vikkula M, Boon LM. Venous malformation: update on aetiopathogenesis, diagnosis and management. *Phlebology*. 2010;25:224-235.
55. Boon LM, Mulliken JB, Enjolras O, et al . Glomuvenous malformation (glomangioma) and venous malformation: distinct clinicopathologic and genetic entities. *Arch Dermatol*. 2004;140(8):971-976.
56. Brouillard P, Boon LM, Mulliken JB, et al. Mutations in a novel factor, glomulin, are responsible for glomuvenous malformations ("glomangiomas"). *Am J Hum Genet*. 2002;70(4):866-874.
57. Ballieux F, Boon LM, Vikkula M. Blue bleb rubber nevus syndrome. *Handb Clin Neurol*. 2015;132:223-230.
58. Kaplan RP, Wang JT, Amron DM, et al. Maffucci's syndrome: two case reports with a literature review. *J Am Acad Dermatol*. 1993;29(5 Pt 2):894-899.
59. Boon L, Mulliken J, Enjolras O, et al. Glomuvenous malformation ("glomangioma") is a distinct clinicopathologic and genetic entity. *Eur J Hum Genet*. 2002;10:123.
60. Boon LM, Vikkula M. Multiple cutaneous and mucosal venous malformations. In: Pagon RA, Bird TD, Dolan CR, Stephens K, eds. *GeneReviews*. Seattle; 1993.
61. Vikkula M, Boon LM, Carraway KL 3rd, et al. Vascular dysmorphogenesis caused by an activating mutation in the receptor tyrosine kinase TIE2. *Cell*. 1996;87(7):1181-1190.
62. Mallory SB, Enjolras O, Boon LM, et al. Congenital plaque-type glomuvenous malformations presenting in childhood. *Arch Dermatol*. 2006;142(7):892-896.
63. Tennant LB, Mulliken JB, Perez-Atayde AR, et al. Verrucous hemangioma revisited. *Pediatr Dermatol*. 2006;23(3):208-215.
64. Hein KD, Mulliken JB, Kozakewich HP, et al. Venous malformations of skeletal muscle. *Plast Reconstr Surg*. 2002;110(7):1625-1635.
65. Berenguer B, Burrows PE, Zurakowski D, et al. Sclerotherapy of craniofacial venous malformations: complications and results. *Plast Reconstr Surg*. 1999;104(1):1-11; discussion 12-15.
66. Rodriguez-Manero M, Aguado L, Redondo P. Pulmonary arterial hypertension in patients with slow-flow vascular malformations. *Arch Dermatol*. 2010;146(12):1347-1352.
67. Dompmartin A, Acher A, Thibon P, et al. Association of localized intravascular coagulopathy with venous malformations. *Arch Dermatol*. 2008;144(7):873-877.
68. Wouters V, Limaye N, Uebelhoer M, et al. Hereditary cutaneomucosal venous malformations are caused by TIE2 mutations with widely variable hyper-phosphorylating effects. *Eur J Hum Genet*. 2010;18(4):414-420.
69. Wouters V, Boon LM, Mulliken JB, et al. TIE2 and cutaneomucosal venous malformation. In: Epstein C, Erickson RP, Wynshaw-Boris A, eds. *Inborn Errors of Development: The Molecular Basis of Clinical Disorders of Morphogenesis*. 2nd ed. New York: Oxford University Press; 2008:491-494.
70. Limaye N, Wouters V, Uebelhoer M, et al. Somatic mutations in angiopoietin receptor gene TEK cause solitary and multiple sporadic venous malformations. *Nat Genet*. 2009;41(1):118-124.
71. Uebelhoer M, Natynki M, Kangas J, et al. Venous malformation-causative TIE2 mutations mediate an AKT-dependent decrease in PDGFB. *Hum Mol Genet*. 2013;22(17):3438-3448.
72. Nätynki M, Kangas J, Miinalainen I, et al. Common and specific effects of TIE2 mutations causing venous malformations. *Hum Mol Genet*. 2015;24(22):6374-6389.
73. Brouillard P, Ghassibé M, Boon L, et al. Identification of novel glomulin gene mutations responsible for inherited glomuvenous malformations (glomangiomas). *Am J Hum Genet*. 2002;71(4):521.
74. Amyere M, Aerts V, Brouillard P, et al. Somatic uniparental isodisomy explains multifocality of glomuvenous malformations. *Am J Hum Genet*. 2013;92(2):188-196.
75. Brouillard P, Ghassibe M, Penington A, et al. Four common glomulin mutations cause two thirds of glomuvenous malformations ("familial glomangiomas"): evidence for a founder effect. *J Med Genet*. 2005;42(2):e13.
76. Brouillard P, Enjolras O, Boon LM, et al. Glomulin and glomuvenous malformation. In: Epstein CJ, Erickson RP, Wynshaw-Boris A, eds. *Inborn Errors of Development: The Molecular Basis of Clinical Disorders of Morphogenesis*. 2nd ed. New York: Oxford University Press; 2008:1561-1565.
77. Brouillard P, Boon LM, Revencu N, et al. Genotypes and phenotypes of 162 families with a glomulin mutation. *Mol Syndromol*. 2013;4(4):157-164.
78. Couto JA, Vivero MP, Kozakewich HP, et al. A somatic MAP3K3 mutation is associated with verrucous venous malformation. *Am J Hum Genet*. 2015;96(3):480-486.
79. Couvineau A, Wouters V, Bertrand G, et al. PTHR1 mutations associated with Ollier disease result in receptor loss of function. *Hum Mol Genet*. 2008;17(18):2766-2775.
80. Pansuriya TC, van Eijk R, d'Adamo P, et al. Somatic mosaic IDH1 and IDH2 mutations are associated with enchondroma and spindle cell hemangioma in Ollier disease and Maffucci syndrome. *Nat Genet*. 2011;43(12):1256-1261.
81. Amyere M, Dompmartin A, Wouters V, et al. Common somatic alterations identified in Maffucci syndrome by molecular karyotyping. *Mol Syndromol*. 2014;5(6):259-267.
82. Mazoyer E, Enjolras O, Laurian C, et al. Coagulation abnormalities associated with extensive venous malformations of the limbs: differentiation from Kasabach-Merritt syndrome. *Clin Lab Haematol*. 2002;24(4):243-51.
83. Hermans C, Dessomme B, Lambert C, et al. Venous malformations and coagulopathy. *Ann Chir Plast Esthet*. 2006;51(4-5):388-393.
84. Dompmartin A, Ballieux F, Thibon P, et al. Elevated D-dimer level in the differential diagnosis of venous malformations. *Arch Dermatol*. 2009;145(11):1239-1244.

85. Wassef M, Enjolras O. Superficial vascular malformations: classification and histopathology. *Ann Pathol*. 1999;19(3):253-264.
86. Kato N, Kumakiri M, Ohkawara A. Localized form of multiple glomus tumors: report of the first case showing partial involution. *J Dermatol*. 1990;17(7):423-428.
87. Goodman TF, Abele DC. Multiple glomus tumors. A clinical and electron microscopic study. *Arch Dermatol*. 1971;103(1):11-23.
88. Paltiel HJ, Burrows PE, Kozakewich HP, et al. Soft-tissue vascular anomalies: utility of US for diagnosis. *Radiology*. 2000;214(3):747-754.
89. Konez O, Burrows PE. Magnetic resonance of vascular anomalies. *Magn Reson Imaging Clin North Am*. 2002;10(2):363-388, vii.
90. Boscolo E, Limaye N, Huang L, et al. Rapamycin improves TIE2-mutated venous malformation in murine model and human subjects. *J Clin Invest*. 2015;125(9):3491-3504.
91. Boon LM, Hammer J, Seront E, et al. Rapamycin as novel treatment for refractory-to-standard-care slow-flow vascular malformations. *Plast Reconstr Surg*. 2015;136(4 suppl):38.
92. Yuksekkaya H, Ozbek O, Keser M, et al. Blue rubber bleb nevus syndrome: successful treatment with sirolimus. *Pediatrics*. 2012;129(4):e1080-e1084.
93. Hammer FD, Boon LM, Mathurin P, et al. Ethanol sclerotherapy of venous malformations: evaluation of systemic ethanol contamination. *J Vasc Interv Radiol*. 2001;12(5):595-600.
94. Park HS, Do YS, Park KB, et al. Clinical outcome and predictors of treatment response in foam sodium tetradecyl sulfate sclerotherapy of venous malformations. *Eur Radiol*. 2016;26(5):1301-1310.
95. Sannier K, Dompmartin A, Théron J, et al. A new sclerosing agent in the treatment of venous malformations. *Study on 23 cases Intervent Radiol*. 2004;10:113-127.
96. Dompmartin A, Blaizot X, Théron J, et al. Radiopaque ethylcellulose-ethanol is a safe and efficient sclerosing agent for venous malformations. *Eur Radiol*. 2011;21(12):2647-2656.
97. Fishman SJ, Fox VL. Visceral vascular anomalies. *Gastrointest Endosc Clin North Am*. 2001;11(4):813-834, viii.
98. Fishman SJ, Smithers CJ, Folkman J, et al. Blue rubber bleb nevus syndrome: surgical eradication of gastrointestinal bleeding. *Ann Surg*. 2005;241(3):523-528.
99. Marler JJ, Fishman SJ, Upton J, et al. Prenatal diagnosis of vascular anomalies. *J Pediatr Surg*. 2002;37(3):318-326.
100. Sybert VP, McCauley E. Turner's syndrome. *N Engl J Med*. 2004;351(12):1227-1238.
101. Cohen MM Jr. Klippel-Trenaunay syndrome. *Am J Med Genet*. 2000;93(3):171-175.
102. Oduber CE, van der Horst CM, Hennekam RC. Klippel-Trenaunay syndrome: diagnostic criteria and hypothesis on etiology. *Ann Plast Surg*. 2008;60(2):217-223.
103. Alomari AI, Thiex R, Mulliken JB. Hermann Friedberg's case report: an early description of CLOVES syndrome. *Clin Genet*. 2010;78(4):342-347.
104. Biesecker LG, Happle R, Mulliken JB, et al. Proteus syndrome: diagnostic criteria, differential diagnosis, and patient evaluation. *Am J Med Genet*. 1999;84(5):389-395.
105. Lala S, Mulliken JB, Alomari AI, et al. Gorham-Stout disease and generalized lymphatic anomaly—clinical, radiologic, and histologic differentiation. *Skeletal Radiol*. 2013;42(7):917-924.
106. Moller G, Priemel M, Amling M, et al. The Gorham-Stout syndrome (Gorham's massive osteolysis). A report of six cases with histopathological findings. *J Bone Joint Surg Br*. 1999;81(3):501-506.
107. Connell F, Kalidas K, Ostergaard P, et al. Linkage and sequence analysis indicate that CCBE1 is mutated in recessively inherited generalised lymphatic dysplasia. *Hum Genet*. 2010;127(2):231-241.
108. Brouillard P, Boon L, Vikkula M. Genetics of lymphatic anomalies. *J Clin Invest*. 2014;124(3):898-904.
109. Brice G, Child AH, Evans A, et al. Milroy disease and the VEGFR-3 mutation phenotype. *J Med Genet*. 2005;42(2):98-102.
110. Alomari AI, Burrows PE, Lee EY, et al. CLOVES syndrome with thoracic and central phlebectasia: increased risk of pulmonary embolism. *J Thorac Cardiovasc Surg*. 2010;140(2):459-463.
111. Edwards PD, Rahbar R, Ferraro NF, et al. Lymphatic malformation of the lingual base and oral floor. *Plast Reconstr Surg*. 2005;115(7):1906-1915.
112. Ghalamkarpour A, Morlot S, Raas-Rothschild A, et al. Hereditary lymphedema type I associated with VEGFR3 mutation: the first de novo case and atypical presentations. *Clin Genet*. 2006;70(4):330-335.
113. Daniel-Spiegel E, Ghalamkarpour A, Spiegel R, et al. Hydrops fetalis: an unusual prenatal presentation of hereditary congenital lymphedema. *Prenat Diagn*. 2005;25(11):1015-1018.
114. Osborn AJ, Dickie P, Neilson DE, et al. Activating PIK3CA alleles and lymphangiogenic phenotype of lymphatic endothelial cells isolated from lymphatic malformations. *Hum Mol Genet*. 2015;24(4):926-938.
115. Kurek KC, Luks VL, Ayturk UM, et al. Somatic mosaic activating mutations in PIK3CA cause CLOVES syndrome. *Am J Hum Genet*. 2012;90(6):1108-1115.
116. Irrthum A, Karkkainen MJ, Devriendt K, et al. Congenital hereditary lymphedema caused by a mutation that inactivates VEGFR3 tyrosine kinase. *Am J Hum Genet*. 2000;67(2):295-301.
117. Evans AL, Bell R, Brice G, et al. Identification of eight novel VEGFR-3 mutations in families with primary congenital lymphoedema. *J Med Genet*. 2003;40(9):697-703.
118. Irrthum A, Devriendt K, Chitayat D, et al. Mutations in the transcription factor gene SOX18 underlie recessive and dominant forms of hypotrichosis-lymphedema-telangiectasia. *Am J Hum Genet*. 2003;72(6):1470-1478.
119. Ghalamkarpour A, Holnthoner W, Saharinen P, et al. Recessive primary congenital lymphoedema caused by a VEGFR3 mutation. *J Med Genet*. 2009;46(6):399-404.
120. Mansour S, Brice GW, Jeffery S, et al. Lymphedema-distichiasis syndrome. In: Pagon RA, Adam MP, Ardinger HH, et al, eds. *GeneReviews*. Seattle; 1993.
121. Ostergaard P, Simpson MA, Mendola A, et al. Mutations in KIF11 cause autosomal-dominant microcephaly variably associated with congenital lymphedema and chorioretinopathy. *Am J Hum Genet*. 2012;90(2):356-362.
122. Schlogel MJ, Mendola A, Fastre E, et al. No evidence of locus heterogeneity in familial microcephaly with or without chorioretinopathy, lymphedema, or mental retardation syndrome. *Orphanet J Rare Dis*. 2015;10:52.
123. Hennekam RC, Geerdink RA, Hamel BC, et al. Autosomal recessive intestinal lymphangiectasia and lymphedema, with facial anomalies and mental retardation. *J Med GenetAm J Med Genet*. 1989;34(4):593-600.

124. Alders M, Hogan BM, Gjini E, et al. Mutations in CCBE1 cause generalized lymph vessel dysplasia in humans. *Nat Genet*. 2009;41(12):1272-1274.
125. Ostergaard P, Simpson MA, Connell FC, et al. Mutations in GATA2 cause primary lymphedema associated with a predisposition to acute myeloid leukemia (Emberger syndrome). *Nat Genet*. 2011;43(10):929-931.
126. Mendola A, Schlogel MJ, Ghalamkarpour A, et al. Mutations in the VEGFR3 signaling pathway explain 36% of familial lymphedema. *Mol Syndromol*. 2013;4(6):257-266.
127. Galambos C, Nodit L. Identification of lymphatic endothelium in pediatric vascular tumors and malformations. *Pediatr Dev Pathol*. 2005;8(2):181-189.
128. Dubois J, Garel L, Abela A, et al. Lymphangiomas in children: percutaneous sclerotherapy with an alcoholic solution of zein. *Radiology*. 1997;204(3):651-654.
129. Dubois J, Garel L, Grignon A, et al. Imaging of hemangiomas and vascular malformations in children. *Acad Radiol*. 1998;5(5):390-400.
130. Peterman CM, Fevurly RD, Alomari AI, et al. Sonographic screening for Wilms tumor in children with CLOVES syndrome. *Pediatr Blood Cancer*. 2017;64(12).
131. Hammill AM, Wentzel M, Gupta A, et al. Sirolimus for the treatment of complicated vascular anomalies in children. *Pediatr Blood Cancer*. 2011;57(6):1018-1024.
132. Adams DM, Trenor CC 3rd, Hammill AM, et al. Efficacy and safety of sirolimus in the treatment of complicated vascular anomalies. *Pediatrics*. 2016;137(2):1-10.
133. Swetman GL, Berk DR, Vasanawala SS, et al. Sildenafil for severe lymphatic malformations. *N Engl J Med*. 2012;366(4):384-386.
134. Rankin H, Zwicker K, Trenor CC 3rd. Caution is recommended prior to sildenafil use in vascular anomalies. *Pediatr Blood Cancer*. 2015;62(11):2015-2017.
135. Koshy JC, Eisemann BS, Agrawal N, et al. Sildenafil for microcystic lymphatic malformations of the head and neck: a prospective study. *Int J Pediatr Otorhinolaryngol*. 2015;79(7):980-982.
136. Mathur NN, Rana I, Bothra R, et al. Bleomycin sclerotherapy in congenital lymphatic and vascular malformations of head and neck. *Int J Pediatr Otorhinolaryngol*. 2005;69(1):75-80.
137. Claesson G, Kuylenstierna R. OK-432 therapy for lymphatic malformation in 32 patients (28 children). *Int J Pediatr Otorhinolaryngol*. 2002;65(1):1-6.
138. Harsha WJ, Perkins JA, Lewis CW, et al. Pediatric admissions and procedures for lymphatic malformations in the United States: 1997 and 2000. *Lymphat Res Biol*. 2005;3(2):58-65.
139. Ballieux F, Modarressi A, Hammer F, et al. Reconstructive surgery in the management of a patient with CLOVES syndrome. *J Plast Reconstr Aesthet Surg*. 2013;66(12):1813-1815.
140. Hosman AE, Devlin HL, Silva BM, et al. Specific cancer rates may differ in patients with hereditary haemorrhagic telangiectasia compared to controls. *Orphanet J Rare Dis*. 2013;8:195.
141. Lester J, Ruano-Calderon LA, Gonzalez-Olhovich I. Wyburn-Mason syndrome. *J Neuroimaging*. 2005; 15(3):284-285.
142. Rodesch G, Hurth M, Alvarez H, et al. Classification of spinal cord arteriovenous shunts: proposal for a reappraisal—the Bicetre experience with 155 consecutive patients treated between 1981 and 1999. *Neurosurgery*. 2002;51(2):374-379; discussion 379-380.
143. Letteboer TG, Mager HJ, Snijder RJ, et al. Genotype-phenotype relationship for localization and age distribution of telangiectases in hereditary hemorrhagic telangiectasia. *J Med GenetAm J Med Genet A*. 2008;146A(21):2733-2739.
144. Morgan T, McDonald J, Anderson C, et al. Intracranial hemorrhage in infants and children with hereditary hemorrhagic telangiectasia (Osler-Weber-Rendu syndrome). *Pediatrics*. 2002;109(1):E12.
145. Govani FS, Shovlin CL. Hereditary haemorrhagic telangiectasia: a clinical and scientific review. *Eur J Hum Genet*. 2009;17(7):860-871.
146. Enjolras O, Chapot R, Merland JJ. Vascular anomalies and the growth of limbs: a review. *J Pediatr Orthop B*. 2004;13(6):349-357.
147. Tan WH, Baris HN, Burrows PE, et al. The spectrum of vascular anomalies in patients with PTEN mutations: implications for diagnosis and management. *J Med Genet*. 2007;44(9):594-602.
148. Cohen MM Jr. Vasculogenesis, angiogenesis, hemangiomas, and vascular malformations. *J Med GenetAm J Med Genet*. 2002;108(4):265-274.
149. Enjolras O, Logeart I, Gelbert F, et al. Arteriovenous malformations: a study of 200 cases. *Ann Dermatol Venereol*. 2000;127(1):17-22.
150. Kohout MP, Hansen M, Pribaz JJ, et al. Arteriovenous malformations of the head and neck: natural history and management. *Plast Reconstr Surg*. 1998;102(3):643-654.
151. Revencu N, Boon LM, Mulliken JB, et al. RASA1 and capillary malformation-arteriovenous malformation. In: Epstein C, Erickson R, Wynshaw-Boris A, eds. *Inborn Errors of Development: The Molecular Basis of Clinical Disorders of Morphogenesis*. 2nd ed. Oxford, UK: Oxford University Press; 2008:647-650.
152. Johnson DW, Berg JN, Baldwin MA, et al. Mutations in the activin receptor-like kinase 1 gene in hereditary haemorrhagic telangiectasia type 2. *Nat Genet*. 1996;13(2):189-195.
153. McAllister KA, Grogg KM, Johnson DW, et al. Endoglin, a TGF-beta binding protein of endothelial cells, is the gene for hereditary haemorrhagic telangiectasia type 1. *Nat Genet*. 1994;8(4):345-351.
154. Gallione CJ, Repetto GM, Legius E, et al. A combined syndrome of juvenile polyposis and hereditary haemorrhagic telangiectasia associated with mutations in MADH4 (SMAD4). *Lancet*. 2004;363(9412): 852-859.
155. Wooderchak-Donahue WL, McDonald J, O'Fallon B, et al. BMP9 mutations cause a vascular-anomaly syndrome with phenotypic overlap with hereditary hemorrhagic telangiectasia. *Am J Hum Genet*. 2013;93(3):530-537.
156. Ola R, Dubrac A, Han J, et al. PI3 kinase inhibition improves vascular malformations in mouse models of hereditary haemorrhagic telangiectasia. *Nat Commun*. 2016;7:13650.
157. Blume-Peytavi U, Adler YD, Geilen CC, et al. Multiple familial cutaneous glomangioma: a pedigree of 4 generations and critical analysis of histologic and genetic differences of glomus tumors. *J Am Acad Dermatol*. 2000;42(4):633-639.
158. Macmurdo CF, Wooderchak-Donahue W, Bayrak-Toydemir P, et al. RASA1 somatic mutation and variable expressivity in capillary malformation/arteriovenous malformation (CM/AVM) syndrome. *J Med GenetAm J Med Genet A*. 2016;170(6):1450-1454.

159. van der Geer P, Henkemeyer M, Jacks T, et al. Aberrant Ras regulation and reduced p190 tyrosine phosphorylation in cells lacking p120-Gap. *Mol Cell Biol*. 1997;17(4):1840-1847.
160. Henkemeyer M, Rossi DJ, Holmyard DP, et al. Vascular system defects and neuronal apoptosis in mice lacking ras GTPase-activating protein. *Nature*. 1995;377(6551):695-701.
161. Kawasaki J, Aegerter S, Fevurly RD, et al. RASA1 functions in EPHB4 signaling pathway to suppress endothelial mTORC1 activity. *J Clin Invest*. 2014;124(6):2774-2784.
162. Xiao Z, Carrasco R, Kinneer K, et al. EphB4 promotes or suppresses Ras/MEK/ERK pathway in a context-dependent manner: implications for EphB4 as a cancer target. *Cancer Biol Ther*. 2012;13(8):630-637.
163. Zhou XP, Marsh DJ, Hampel H, et al. Germline and germline mosaic PTEN mutations associated with a Proteus-like syndrome of hemihypertrophy, lower limb asymmetry, arteriovenous malformations and lipomatosis. *Hum Mol Genet*. 2000;9(5):765-768.
164. Nikolaev SI, Vetiska S, Bonilla X, et al. Somatic activating KRAS mutations in arteriovenous malformations of the brain. *N Engl J Med*. 2018;378(3):250-261.
165. Lebrin F, Srun S, Raymond K, et al. Thalidomide stimulates vessel maturation and reduces epistaxis in individuals with hereditary hemorrhagic telangiectasia. *Nat Med*. 2010;16(4):420-428.
166. Burrows PE, Fellows KE. Techniques for management of pediatric vascular anomalies. In: Cope C, ed. *Current Techniques in Interventional Radiology*. Philadelphia: Current Medicine; 1995:12-27.
167. Yakes WF, Rossi P, Odink H. How I do it. Arteriovenous malformation management. *Cardiovasc Intervent Radiol*. 1996;19(2):65-71.
168. Wu JK, Bisdorff A, Gelbert F, et al. arteriovenous malformation: evaluation, management, and outcome. *Plast Reconstr Surg*. 2005;115(4):985-995.
169. Liu AS, Mulliken JB, Zurakowski D, et al. Extracranial arteriovenous malformations: natural progression and recurrence after treatment. *Plast Reconstr Surg*. 2010;125(4):1185-1194.

Chapter 148 :: Cutaneous Changes in Arterial, Venous, and Lymphatic Dysfunction

:: Sabrina A. Newman

OBSTRUCTIVE PERIPHERAL ARTERIAL DISEASE

AT-A-GLANCE

- Most commonly caused by atherosclerosis of the vessels supplying the lower extremity.
- Affects 15% of the U.S. adult population older than age 65 years.
- Stenosis or obstruction of the large arteries to the lower extremities leading to supply–demand mismatch, initially with exertion, but may progress to occur at rest.
- Intermittent claudication with exertional muscle pain or fatigue, critical limb ischemia with rest pain or tissue compromise, and acute limb ischemia.
- Cutaneous findings from hypoperfusion range from dry skin, hair loss, and malformed toenails to ulceration and gangrene.

Peripheral arterial disease (PAD) occurs when atherosclerosis causes stenosis or occlusion in the distal aorta and large arteries of the lower abdomen, pelvis, and legs. Patients may be asymptomatic, experience exertional ischemic leg symptoms (intermittent claudication), or develop critical limb ischemia. The most classic symptom of PAD is intermittent claudication, which is usually described as pain, fatigue, or tiredness in a defined muscle group distal to the diseased vascular segment upon walking that is relieved by rest. The location of the pain differs depending on the anatomical location of the arterial lesions. Because the disease is most common in the distal superficial femoral artery, patients most commonly present with claudication in the calf muscle area (the muscle group just distal to the arterial disease). When the disease affects the more proximal aortoiliac vessels, thigh and buttock muscle claudication predominates. The discomfort tends to be highly reproducible within the same muscle groups and is precipitated by the same level of exertion. It is crucial to determine the amount of walking distance, a standard measure that quantifies severity and response to treatment, before the onset of symptoms. Resolution within several minutes of rest is an expected finding. Patients with inadequate collateral circulation may complain of cold extremities, hyperesthesia, rest pain, discolored toes, or skin breakdown. Ischemic rest pain typically affects the foot and may interfere with sleep or necessitate sleeping with the leg in a dependent position. Peripheral edema may then occur.

EPIDEMIOLOGY

Although atherosclerotic obstructive PAD has a prevalence of only 3% in patients 40 to 59 years of age, this rises to up to 20% in the older than age 65 years group. This translates into approximately 8.5 million cases in the United States, and this number is expected to increase along with aging demographics.[1-3] PAD is often unrecognized clinically, and more than one-half of all patients are asymptomatic. Gender predisposition shows preponderance in males, although the incidence in females rises rapidly after menopause. Anatomically, superficial femoral artery disease predominates, with development of symptoms typically in the seventh decade. Interestingly, symptoms from aortoiliac disease usually present a decade earlier.

CLINICAL FEATURES

Acute limb ischemia secondary to vessel thrombosis or embolism presents more dramatically with (a) severe pain, usually persistent at rest, (b) pallor, (c) pulselessness, (d) paresthesias, and (e) paralysis (the "5 Ps"). Poikilothermia (a cold extremity) may be added to this pentad of clinical findings (Table 148-1). The presence of neurologic symptoms indicates severe ischemia and need for emergent evaluation.

Because atherosclerosis is a systemic disease process, patients who present with claudication attributable to PAD can be expected to have atherosclerosis elsewhere. Hence, it is common for patients to present with symptoms related to disease affecting the other vascular territories.

CUTANEOUS FINDINGS

The cutaneous findings in PAD will vary depending on the severity of arterial obstruction and tissue ischemia (Table 148-2). Limbs in patients with intermittent claudication may appear normal, although associated clinical findings may include hair loss, coldness, cyanosis, and/or thickened and malformed toenails. In patients with severe ischemia, the skin is apt to be atrophic, dry, and shiny. In patients with rest pain, the foot

TABLE 148-1
Acute Limb Ischemia: 6 Ps

1. Pain
2. Pallor
3. Pulselessness
4. Paresthesia
5. Paralysis
6. Poikilothermia

is usually bright red and cold in dependency. Ulcerations most often start at the tips of the toes or on the heel of the foot and are extremely painful, except when diabetic neuropathy is also present (Fig. 148-1). Ulcers also occasionally start on the lower calves or lateral aspect of the heel. They frequently demonstrate irregular borders and a pale base. The heels may show cracks in the skin with numerous fissures. When gangrene occurs, usually 1 or more toes become black, dry, and mummified (Fig. 148-2). Superimposed infection is a major concern. Important associated signs of infection include purulent discharge or decay (wet gangrene), and (often) surrounding tissue erythema and swelling.

NONCUTANEOUS FINDINGS

Decreased or absent pulses distal to the stenotic arterial segment are the hallmark noncutaneous finding in PAD. Bruits on auscultation over the diseased segment of vessel as a result of turbulent flow also may be present. It is also possible to find normal palpable pulses in a patient who presents with symptoms suggestive of intermittent claudication. In such a case, the clinician can have the patient walk around the office (or perform toe raises) until the symptoms are reproduced and then palpate for pulses. Exercise may "unmask" the stenosis, causing the atherosclerotic lesion to become significant, and should diminish the strength of the pulses distal to the lesion. The collateral circulation to limbs affected by PAD can be evaluated by simple bedside examination. With the patient supine, elevation of the limb at a 45-degree angle for 2 minutes should not produce pallor. Collateral circulation is deemed inadequate if the toes and feet become pale. The patient then assumes a sitting position with the legs dependent, and the time for filling of the foot veins and flushing of the feet is measured. The veins should fill within 20 seconds and the feet flush immediately in a warm environment. When these times exceed 30 seconds, the collateral circulation is deemed inadequate, and the patient must be observed frequently for the development of rest pain, ulcers, or gangrene. Venous filling times are of limited value when varicose veins coexist.

TABLE 148-2
Cutaneous Findings in Peripheral Arterial Disease

- Pallor
- Coolness of the extremities
- Dependent rubor
- Subcutaneous atrophy
- Hair loss
- Brittle toenails
- Absence of sweating
- Ulceration
- Gangrene
- Tenderness
- Regional edema

Figure 148-1 Obstructive peripheral arterial disease. An ulcer is seen on the medial aspect of the foot at the base of the great toe. **A,** Foot pallor with elevation of limb suggests severe ischemia. **B,** Foot erythema with the leg in a dependent position, termed *dependent rubor*, also suggests severe ischemia.

Figure 148-2 Necrotic toe in a patient with peripheral arterial obstructive disease. There is marked dependent rubor of the toes and distal aspect of the foot.

COMPLICATIONS

The major direct complications of PAD relate to limb loss from progressive severe ischemia or superimposed infection. In patients with rest pain or tissue loss, the risk of infection is high and wound healing slow or absent. Under these circumstances, the need for revascularization is more urgent to avoid the need for amputation. Superimposed infection needs to be aggressively treated with antibiotics, wound debridement, and local foot care; if the infection is rapidly progressive, it presents a medical emergency.

ETIOLOGY AND PATHOGENESIS

Atherosclerotic risk factors are similar to those identified for coronary artery disease and include diabetes mellitus, hypertension, hyperlipidemia, smoking, family history of vascular disease, and obesity. Among these, diabetes mellitus and smoking are the most significant and are associated with a doubling of relative risk. Patients with diabetes mellitus develop the disease at an earlier age than nondiabetic patients, and have more-severe and progressive disease. The anatomic distribution of obstruction differs from nondiabetic patients with less aortoiliac involvement and more extensive disease of the runoff vessels below the knees. However, superficial femoral artery disease is similar in both populations. Approximately 50% of patients have hyperlipidemia. PAD is also more commonly encountered in patients with hypertension.

The pathologic findings in atherosclerosis occur in large- and medium-sized arteries, and are morphologically diverse, with focal accumulation of lipids and lipoproteins, mucopolysaccharides and collagen, smooth muscle cells and macrophages, and calcium deposits in variable quantities. Localized areas of intimal thickening secondary to smooth muscle cell proliferation and lipid-laden macrophages are seen in early stages with disruption of the internal elastic lamina. The media is often atrophic with thin strands of smooth muscle, lipid pools, collagen tissue, and calcium deposits. Enlarging plaques encroach on the lumen despite dilation of the artery, and the plaques may ulcerate. Hemorrhages occur in the arterial wall. Thrombi may also form and occlude the narrowed arterial lumen.

The etiology of atherosclerosis is complex and multifactorial, but progressive buildup of plaque narrows the vessel lumen, and complete occlusion may develop acutely secondary to thrombosis. Because disease progression is usually over an extended time period, collateral blood vessels have time to develop and are usually robust. Tissue perfusion to the affected limb is often adequate at rest, but the blood pressure distal to the occlusions is decreased secondary to high resistance and limited flow through collateral vessels. Under resting conditions, normal blood flow to extremity muscle groups averages 300 to 400 mL/min. Once exercise begins, blood flow increases up to 10-fold owing to the increase in cardiac output and compensatory vasodilation at the tissue level. When exercise ceases, the blood flow returns to normal within minutes. In patients with PAD, resting blood flow may be similar to that of a healthy person. However, during exercise, blood flow cannot maximally increase in muscle tissue because of fixed proximal arterial stenoses. When the metabolic demands of the muscle exceed blood flow, claudication symptoms ensue. At the same time, a longer recovery period is required for blood flow to return to baseline once exercise is terminated. Dermatologic changes imply severe compromise of tissue perfusion, often secondary to tandem high-grade stenoses or occlusions present at multiple levels in the arterial tree.

DIAGNOSIS

Figure 148-3 outlines an approach to diagnosing PAD. An ankle-brachial index (ABI) is the recommended diagnostic test to assess for PAD. It is the ratio of the blood pressure at the ankle to the blood pressure in the upper arm (brachium). The ankle systolic pressure in the supine, resting position should be equal to, or greater, than the brachial artery systolic pressure. Thus, a normal ABI range is 1.00 to 1.40. A value less than or equal to 0.90 is considered abnormal, and values of 0.91 to 0.99 are defined as "borderline." Of note, patients with heavily calcified or "noncompressible" vessels, most commonly persons with diabetes or of advanced age, may have falsely elevated ABIs (greater than 1.4) despite the presence of significant PAD. Under these circumstances, a toe-brachial index should be used to establish the diagnosis of PAD, as smaller vessels are rarely affected. When the ABI is borderline or normal despite symptoms suggestive of claudication, an exercise ABI is recommended.[4,5]

ABI values are of prognostic use for determination of wound healing or the need for revascularization. Other vascular diagnostic methods include segmental pressures, Doppler waveform analysis, pulse volume recordings, or ABI with duplex ultrasonography to document the presence and location of PAD in the lower extremity.

Magnetic resonance angiography and computed tomographic angiography are competitive technologies used to demonstrate precise anatomic location and extent of disease in the arteries, but supply limited hemodynamic information. Magnetic resonance angiography is often preferred because of lack of ionizing radiation or need for iodine-based contrast dye, but may not be tolerated by claustrophobic individuals. Conventional catheter-based arteriography is usually reserved for definitive evaluation in patients about to undergo vascular surgery, or as a necessary component of percutaneous angioplasty or stenting procedures (Fig. 148-4).

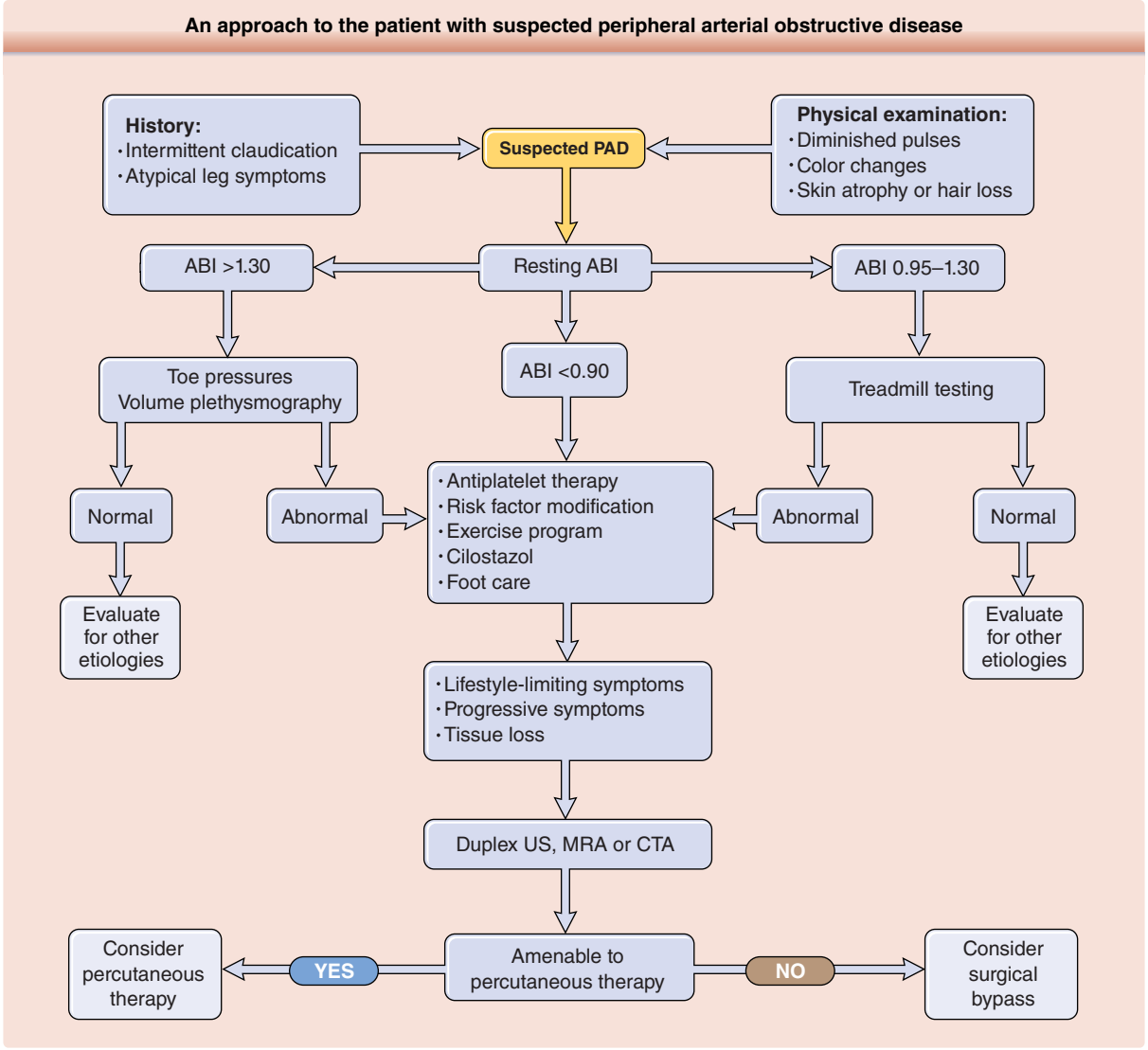

Figure 148-3 An approach to the patient with suspected peripheral arterial obstructive disease. ABI, ankle-brachial index; CTA, computed tomographic angiography; duplex US, duplex ultrasonography; MRA, magnetic resonance angiography; PAD, peripheral arterial disease.

DIFFERENTIAL DIAGNOSIS

The diagnosis of PAD can usually be made by the typical history of intermittent claudication and palpation for diminished or absent pulses in the limbs. The ABI is usually diminished, although occasional patients may have normal values at rest. When the diagnosis remains in doubt, a helpful provocative maneuver to increase blood flow is to exercise the patient. Postexercise blood flow may be limited by the arterial obstructive disease, and repeat ABI will then be diminished.

The differential diagnosis of PAD includes both local factors and systemic disorders (Table 148-3). Arterial obstructive disease is just one of several potential etiologies for the development of a foot ulcer (Table 148-4). However, ulcer location and associated symptoms can be helpful in differentiating some of the causes (Table 148-5). In particular, diabetic neuropathic foot ulcers, or other diseases resulting in neuropathy, may develop on the heel, toes, or shin in the presence of normal pulses. These painless (neurotrophic) ulcers are caused by repetitive trauma not noticed by the patient because of the peripheral neuropathy. With regard to the foot, ulcers often occur over pressure points with a surrounding callus. Arterial limb ulcers differ; they are exquisitely tender, do not have a preference for pressure points on the foot, and lack a surrounding callus.

Thromboangiitis obliterans also causes intermittent claudication, ulcers, and gangrene. It occurs in young smokers (onset of symptoms before the age of 45 years) and is often associated with superficial thrombophlebitis and vasospasm. In contrast to PAD, it affects medium-sized and smaller arteries, most commonly in the upper extremities.

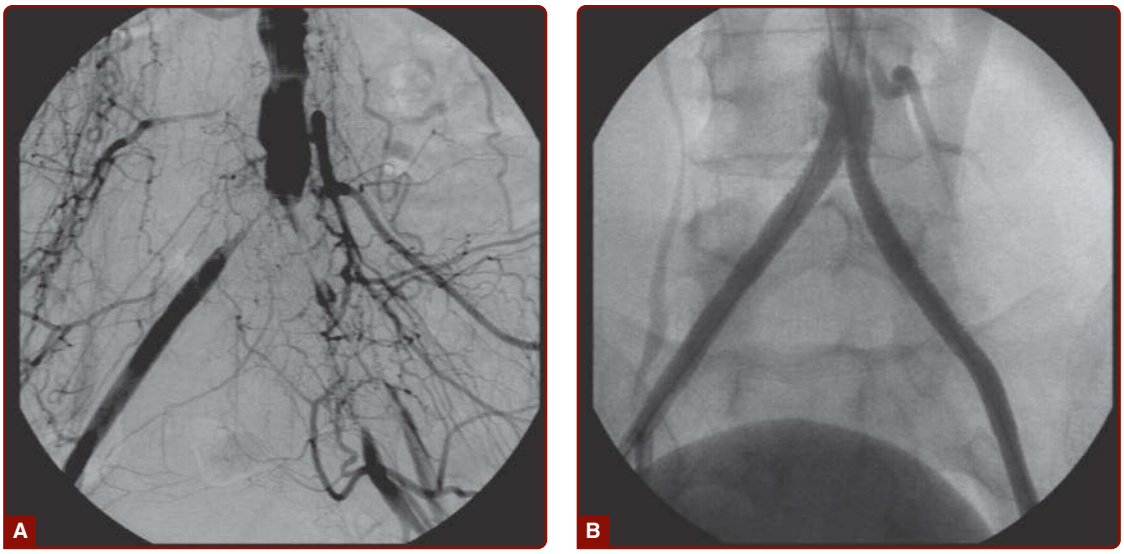

Figure 148-4 **A,** Contrast angiography demonstrating extensive peripheral artery occlusive disease involving the bilateral iliac arteries with stenoses and occlusions. **B,** Recanalization of the iliac arteries after placement of bilateral iliac artery stents.

Occlusive vascular disease confined to focal anatomic locations in young patients with minimal traditional risk factors for atherosclerosis should raise suspicion for alternative etiologies. For example, popliteal artery occlusion may occur secondary to entrapment by calf muscles or cystic adventitial disease. In popliteal artery occlusion, an abnormal anatomical insertion of the medial gastrocnemius muscle head causes compression of the popliteal artery, with the tibial pulses disappearing on plantar (or dorsi) flexion of the foot and full extension of the knee. Pain is aggravated with walking but less so with running because knee extension is not as severe with running as it is with walking. In cystic adventitial disease, adventitial cysts of unclear etiology compress the vessel lumen, most commonly in the popliteal artery (85%) or, rarely, in the external iliac or femoral arteries, presenting as intermittent claudication. Surgical excision of the cysts usually alleviates symptoms although, in the event of complete vessel occlusion, an interposition graft may be necessary.

Neurogenic claudication (pseudoclaudication) is often a difficult diagnosis to distinguish and is caused by compression or intermittent ischemia of the lower spinal cord or cauda equina with exercise. Etiologic factors are prolapsed intervertebral discs, congenital stenosis, or hypertrophic bony ridging of the spinal canal. In contrast to PAD, leg pain may occur in the erect position without exercise and be affected by changes in posture, neurologic signs may be present before or after exercise, and peripheral pulses are normal. The pain is frequently relieved by leaning forward against a solid surface or by sitting. Dilemmas in diagnosis and management can occur when both conditions coexist. MRI or CT scan of the spine is used to confirm the diagnosis.

TABLE 148-3
Differential Diagnosis of Obstructive Peripheral Arterial Disease

Local Factors
- Trauma (including iatrogenic)
- Arterial dissection
- Cystic adventitial disease
- Thrombosed popliteal artery aneurysm
- Arterial entrapment syndromes
- Extrinsic compression

Systemic Disease
- Primary thrombotic disorder (thrombophilia)
- Embolic
- Thromboangiitis obliterans
- Vasculitic disorders (particularly giant cell arteritis or Takayasu arteritis)

CLINICAL COURSE AND PROGNOSIS

The most feared consequence of PAD is severe limb-threatening ischemia leading to amputation. Fortunately, the peripheral vascular outcomes in patients

TABLE 148-4
Differential Diagnosis of Foot Ulcers

- Obstructive peripheral arterial disease
- Microvascular disease
- Chronic venous insufficiency
- Neuropathic (particularly diabetic neuropathy)
- Infection (diabetes or fungal)
- Trauma

TABLE 148-5
Comparison of Different Leg Ulcer Types

	ARTERIAL	VENOUS	NEUROPATHIC
Common sites	Tips of toes, lateral heel, lower calves	Below the knee; commonly the medial malleolar area	Heels, toes, shins, pressure points
Characteristic appearance	Very tender ulcer, with irregular borders and a pale base; gangrene and a superimposed infection may be present	Tender, shallow ulcer with an irregular red base	Painless ulcer with a surrounding callus
Appearance of nearby skin	Atrophic, dry, and shiny	Hyperpigmented; may have accompanying stasis dermatitis or edema, visible varicosities	Smooth; may have accompanying anhidrosis and sensory deficiency

with intermittent claudication as a consequence of PAD tend to be relatively benign, with studies showing that 60% to 90% of such patients remained stable over a period of 5 to 9 years.[6] In a large prospective study of 1440 patients with intermittent claudication, only 176 patients (12.2%) were reported to require amputation during a followup period of 10 years. Occasional patients show spontaneous improvement in symptoms, most likely secondary to enhanced collateral blood flow, although plaque regression is possible. However, patients with diabetes mellitus tend to have progressive disease, and their amputation rate is fourfold greater than for patients without diabetes. In patients with diabetic neuropathy, trauma to the limbs must be avoided, and special shoes may be required. Ongoing smokers also have greater amputation and vascular graft occlusion rates than nonsmokers.

In contrast with the limb-related outcomes, the risk of associated cardiovascular morbidity and mortality is high in patients with PAD because they often have advanced atherosclerosis present in multiple vascular beds.[1,5] The 5-year mortality in patients with intermittent claudication is 30%, with death largely attributed to cardiovascular causes. In addition, another 20% of patients will incur a nonfatal myocardial infarction or stroke. The association between PAD and cardiovascular morbidity and mortality is independent of prior history of cardiovascular disease and independent of known cardiovascular risk factors. Studies also show that more-severe PAD, as indicated by a lower ABI value, is associated with greater risk of cardiovascular mortality than mild PAD, as evidenced by a higher ABI value. It should be emphasized that PAD of any severity (as documented by an abnormal ABI) may be used to identify the individuals with an increased risk of cardiovascular events and mortality.[7]

MANAGEMENT

The goal of medical management should include measures to halt the progression of the disease as well as to alleviate the symptoms. The measures to halt the progression of disease include cessation of smoking and optimization of risk factors, such as diabetes mellitus, hypertension, and hyperlipidemia. For patients with symptoms of intermittent claudication, an exercise program is often the treatment of choice (Table 148-6). Patients are instructed to exercise to the threshold of tolerable pain, briefly rest, and then exercise again for a total duration of 30 to 60 minutes a day in excess of their normal activity, 3 or more times a week.[1,8] The exercise period must be performed in 1 session, with walking being the preferred modality. Drawing on data from several studies, approximately 80% of patients may be expected to show significant improvements in exercise tolerance through these techniques. Even though the exact mechanism for improvement in walking distance with exercise remains unknown, regular exercise is thought to condition the muscles to work more efficiently (more extraction of blood) and increase collateral vessel formation. The magnitude of benefit associated with exercise programs for claudication appears to be greater than that reported for clinical trials of pharmacologic therapy. Patients should be

TABLE 148-6
Treatment of Obstructive Peripheral Arterial Disease

	SYMPTOM RELIEF	RISK REDUCTION
First-line therapy	Exercise program Cilostazol (Pletal) Pentoxifylline (Trental)	Smoking cessation Statin therapy (target low-density lipoprotein <100 mg/dL) Aspirin Glycemic control Antihypertensive therapy Other lipid therapy
Second-line therapy	Percutaneous revascularization (angioplasty, stent, atherectomy, cryotherapy) Surgical revascularization (endarterectomy or bypass)	Clopidogrel (Plavix)

further instructed to keep their feet warm, clean, and dry; and extremes of temperature should be avoided because ischemic tissue is more susceptible to burning and to frostbite than normal tissue. Cuts or severe bruises of the limbs or feet should be treated immediately. Conventional vasodilators appear to have no value in treatment.

Two agents have been approved for the indication of intermittent claudication in the United States. Cilostazol, a phosphodiesterase inhibitor with antiplatelet and vasodilatory properties, is an effective treatment to improve symptoms and increase walking distance.[1] Cilostazol improves maximal walking distance by 40% to 60% after 12 to 24 weeks of therapy.[1,9] Side effects include GI symptoms and headaches. It is contraindicated in patients with congestive heart failure. Pentoxifylline affects red cell deformability and blood viscosity and can be considered as second-line alternative therapy to cilostazol. Although it improves pain-free and maximal walking distance, the degree of improvement varies among studies.[10] Other agents, such as propionyl-L-carnitine, L-arginine, and ginkgo biloba are not well established.

Endovascular intervention with angioplasty or stenting is highly effective for aortoiliac disease and is often indicated for moderate, or lifestyle-limiting claudication. Angioplasty, or stenting, of the superficial femoral artery is technically feasible but limited in applicability by high restenosis rates, particularly in the setting of long occlusions, a common scenario in this location. Despite this limitation, it is a valid therapeutic option for patients with focal disease, severe claudication, or tissue loss. Endovascular management of infrapopliteal (below the knee) disease is associated with extremely high restenosis rates, and is usually a temporizing measure to allow increased blood flow for wound healing. Surgical bypass techniques are effective but are generally high-risk procedures in a population with frequent comorbidities, and are usually reserved for patients with severe intermittent claudication or rest pain, or to allow healing of ulcers and gangrene. Sympathectomy is not of value for intermittent claudication, but has been used in the past to allow small ulcers or areas of gangrene to heal. In patients with rest pain, ulcers, or gangrene who are technically unrevascularizable or a very high risk for surgery, treatment options are limited. A period of rest with legs dependent may improve some patients, but amputation is a frequent outcome. Parenterally administered prostacyclin or prostaglandin E_1, despite some favorable reports of success, has not yet been thoroughly evaluated and is an expensive mode of therapy.

Dry gangrene of the digits or lower limbs should be allowed to spontaneously demarcate. Soaking or ointments are unnecessary. The edges of the gangrenous areas should be kept open if possible and observed frequently for infection. Pain medication is usually necessary for 2 to 3 months with digital gangrene. A conservative approach and patience will save many digits and extremities. Infected (wet) gangrenous areas must be actively debrided and appropriate antibiotics administered. Amputations may be necessary.

PREVENTION

The grim statistics regarding cardiovascular outcomes in these patients emphasize the need for aggressive secondary prevention by modifying appropriate cardiovascular risk factors when possible. Tobacco smoking is absolutely contraindicated. Continued smoking has been identified as the most consistent adverse risk factor associated with the progression of the disease. Smoking even 1 or 2 cigarettes a day can interfere with PAD treatments. Smokers also have significantly higher rates of amputation compared with nonsmokers. The rate of in-hospital amputation was 23% in smokers and 10% in nonsmokers. On the other hand, quitting smoking slows the progress of PAD and also reduces the rates of amputation required. Hypertension and diabetes mellitus should be controlled, and hyperlipidemias should be treated with a target low-density lipoprotein of less than 100 mg/dL (or <70 mg/dL with uncontrolled or multiple risk factors) as per recent guidelines for secondary prevention. All patients with PAD should be on a statin with the goal of preventing progression of PAD, in addition to prevention of myocardial infarction and stroke. Antiplatelet therapy is also indicated to reduce the risk of myocardial infarction, stroke, or vascular death in individuals with atherosclerotic lower extremity PAD.[11]

The use of thienopyridines, such as clopidogrel, may be of additional benefit, but may be associated with higher bleeding rates (particularly with combined therapy) and expense. Use of antiplatelet therapy is a must for those with PAD but should be individualized.

ATHEROMATOUS EMBOLISM

AT-A-GLANCE

- Atheromatous embolism is the embolization of small pieces of atheromatous debris from the more proximal arteries to the smaller distal arteries.
- Synonyms include *cholesterol embolism*, *atheroembolism*, *blue toe syndrome*, and *pseudovasculitis syndrome*.
- More common with advanced age and after invasive procedures.
- Manifestations include blue or discolored toes, livedo racemosa, gangrene, necrosis, ulceration, and fissure.
- Renal failure and stroke from systemic involvement.
- Diagnosis confirmed by cholesterol clefts in skin, kidney, or skeletal muscle biopsies.
- Treatment focuses on prevention during invasive procedures and elimination of the embolic source. Medical therapy may include antiplatelet therapy and statin agents; the use of anticoagulation is controversial and often avoided.

EPIDEMIOLOGY

The epidemiology of atheromatous embolism is poorly defined as a consequence of underreporting and difficulties establishing a clinical diagnosis.[12] Routine autopsy series of the adult population suggest an incidence of atheromatous embolism of between 0.15% and approximately 4%.[13] The incidence increases dramatically in the presence of severe atherosclerotic disease. Atheromatous embolism has been found in more than 20% of deaths following cardiac surgery or angiography. However, it should be emphasized that the rate of clinically detected atheromatous embolism appears to be reasonably low (less than 1%). The atheromatous embolism appears to be more common in males than in females, with a reported male-to-female ratio of approximately 3.4:1.[12,13] It is strongly associated with older age, with the mean age reported to range from 66 to 72 years.[13]

ETIOLOGY AND PATHOGENESIS

The pathogenesis of atheromatous embolism involves the occlusion of small arteries and arterioles (50 to 900 μm in diameter) by atheromatous debris (so-called cholesterol crystals) that is dislodged from a proximal atherosclerotic plaque, followed by a foreign-body inflammatory cascade. This inflammatory process leads to further occlusion with thrombus formation, endothelial cell proliferation, and intimal fibrosis, which may result in ischemia, infarction, and necrosis. The clinical picture is characterized by impaired perfusion of the skin and muscle as a result of small vessel occlusion, although nearly any organ of the body may be involved.

The major risk factor for the development of atheromatous embolism is atherosclerotic disease of the thoracic or abdominal aorta. The risk is higher with more extensive atheroma burden (defined by thickness above 4 mm) or unfavorable plaque features, such as protruding mobile plaque.[14] Coexistent vascular disease, including coronary artery disease, PAD, and even an abdominal aortic aneurysm are risk factors. The more traditional atherosclerotic risk factors also increase the risk of atheromatous embolism, with older age (older than 60 years) being prominent.

Atheromatous embolism often occurs after an invasive procedure.[13,15] Angiography, endovascular procedures, and both cardiac and vascular surgical procedures may create mechanical trauma to the vessel and destabilize an atherosclerotic plaque. Anticoagulation, primarily with warfarin, and thrombolytic therapy are potential risk factors. It has been postulated that anticoagulation may delay the healing of irregular or ulcerated plaques. Embolic events may occur spontaneously, although minor stressors, such as coughing or straining, may be provocative factors.

CLINICAL FINDINGS

HISTORY

The clinical presentation of atheromatous embolism, although it can occur spontaneously, usually follows an invasive procedure such as an invasive angiographic or vascular surgical procedure. The clinical manifestations may be immediate, or delayed by several days to weeks after the inciting event. The precise clinical syndrome depends on the location of the source of embolism and the pattern and distribution of flow downstream. This may range from subtle clinical findings to catastrophic systemic embolic complications. Nearly any organ of the body may be involved. Involvement of the ascending aorta may result in systemic complications, including transient ischemic attacks, strokes, or retinal manifestations, and involvement of the descending or abdominal aorta may lead to lower-extremity ischemia, renal failure, mesenteric ischemia, or hemorrhagic pancreatitis. As the more common sites for severe atheromatous disease are in the abdominal aorta and iliac arteries, the signs and symptoms more often result from embolism to the lower half of the body. Lower-extremity involvement typically presents with manifestations of discolored or ulcerated painful toes and tender calf muscles.

In addition, constitutional symptoms, including fever and weight loss, may be seen as a result of hypermetabolism associated with the inflammatory process.

CUTANEOUS LESIONS

The dermatologic manifestations are often the presenting complaint (Table 148-7). The most common of these findings are related to tissue or digital ischemia and include cyanosis, necrosis, gangrene, ulcerations, and fissures. The finding of tender, cool, blue, or purple toes with normal pulses, found in the "blue toe syndrome," is common (Fig. 148-5A). Approximately 50% of patients will have livedo racemosa, which typically involves the foot and leg, but may extend onto the trunk or buttocks. Erythematous lesions are often seen on the lateral aspect of the foot and calcaneal region.

TABLE 148-7
Cutaneous Findings in Atheromatous Embolism

- Blue or purple toes
- Livedo racemosa
- Gangrenous digits
- Ulcers
- Fissures
- Nodules
- Petechiae
- Purpura
- Splinter hemorrhages

Figure 148-5 **A,** Typical appearance of blue toes caused by multiple atheromatous emboli to the lower limbs in a patient with extensive atheromatous disease of the aorta. **B,** Development of ulceration of the tip of the toes caused by atheromatous embolism with a faint reticular pattern on the forefoot typical of livedo racemosa.

Although advanced ischemic manifestations, such as ulcers or gangrene, may be present (Fig. 148-5B), the surrounding areas are normally perfused tissue. There may be other cutaneous manifestations, often hemorrhagic in nature, including petechiae, ecchymosis, purpura, and splinter hemorrhages. Raised, painful, inflammatory nodules may occur.

RELATED PHYSICAL FINDINGS

Examination of the vascular system often reveals normal pedal and proximal pulses, because the small arteries are occluded with cholesterol emboli, rather than the larger superficial arteries. However, systolic bruits may be heard on auscultation over the aorta or common femoral arteries. Tenderness of skeletal muscles, particularly in the calf, may be detected. Funduscopic examination, revealing cholesterol embolus within branching points of the retinal arteries (Hollenhorst plaques), is a specific but insensitive finding because most atheromatous emboli arise from a source distal to the aortic arch. Fever may be present.

COMPLICATIONS

There are numerous ischemic complications depending upon the organ involved. These include the kidneys, mesenteric circulation, and CNS. Renal atheroembolic disease is a consequence of showering of emboli to the renal parenchymal branch vessels. An intense inflammatory process may ensue, producing glomerular sclerosis, tubular atrophy, and interstitial fibrosis. Although there is variable timing of onset and progression of disease, there typically is a several-week delay after the inciting event before the development of renal dysfunction. New onset of hypertension or overt renal failure may ensue. It is rare to develop gross hematuria or frank renal infarction. The development of renal failure is one of the more ominous complications with a high mortality in affected individuals.

The CNS is another feared site of involvement with atheromatous embolism. There is concern for ischemic manifestations such as transient ischemic attacks, stroke, and paralysis. However, other less-readily appreciated manifestations may ensue, such as encephalopathy or a progressive neurologic decline.

The GI tract is perhaps the third most common organ system involved with atheromatous embolism. The manifestations may be nonspecific abdominal complaints such as abdominal pain, nausea, vomiting, or diarrhea. More-severe ischemic manifestations may be seen with GI bleeding or bowel infarction. The colon is the most common site in the GI tract to be affected. Establishing a diagnosis may be difficult as endoscopy findings are often nonspecific, and biopsy may miss the classic findings. Splenic infarction, cholecystitis, gangrene of the gall bladder, pancreatitis, and pancreatic necrosis also have been reported.

DIAGNOSIS

LABORATORY TESTS

The laboratory tests are typically nonspecific and depend upon the organ involved and the severity of disease. An elevated erythrocyte sedimentation rate,

thrombocytopenia, hypocomplementemia, leukocytosis, and anemia may all be seen as a consequence of the systemic inflammatory response. Azotemia, proteinuria, microscopic hematuria, eosinophilia, and even eosinophiluria may be seen with renal involvement. Transient eosinophilia has been reported in up to 80% of those with renal involvement. Involvement of the GI tract may lead to anemia and blood in the stool. Injury to the liver, gallbladder, or pancreas may lead to abnormal liver function tests and elevated pancreatic enzymes.

SPECIAL TESTS

Contrast angiography may reveal diffuse atherosclerotic involvement of the vessels proximal to the lesions, but is typically avoided due to the risk of precipitating further embolic events. Noninvasive imaging techniques such as computed tomographic angiography or magnetic resonance angiography are useful to evaluate for atherosclerotic disease within the aorta or other large vessels. Although stenotic atherosclerotic disease is the most common finding, aneurysmal disease also may be present. Transthoracic echocardiography is often helpful to evaluate for a cardiac source, but the more definitive transesophageal echocardiography can also assess the thoracic aorta for plaque.

Definitive diagnosis of cholesterol embolization requires demonstration of cholesterol crystals, which are birefringent under polarized light. However, as a result of the solubility of cholesterol with typical solvents used in processing of tissue for histopathology, cholesterol crystals appear as empty clefts. Skin, muscle, or renal biopsies may reveal these characteristic elongated, needle-shaped clefts in small arterial vessels. There also may be inflammatory infiltrates, intimal thickening, and perivascular fibrosis, as well as giant cells. The sensitivity of the biopsy depends upon the site. Muscle biopsy seems to be the most sensitive test, reportedly being positive in more than 95% of cases, but is technically difficult, painful, and risky to obtain. The sensitivity of skin biopsy has varied from 40% to 90%. Skin biopsies offer maximum yield when obtained directly from areas of suspected emboli, such as those with livedo racemosa, but should be cautiously obtained or avoided in areas of more overt ischemic injury.

DIFFERENTIAL DIAGNOSIS

Because of its clinical similarity to other systemic diseases, atheromatous embolism is often misdiagnosed. Blue or ulcerated painful digits, livedo racemosa, petechiae, and tender calf muscles in the presence of normal pulses suggest the diagnosis of atheromatous emboli. However, it is difficult to establish the diagnosis, when the clinical features are subtle and nonspecific. Thus, a high index of suspicion is needed, especially in the setting of a history of preexisting atherosclerotic disease and a specific precipitating event. Definitive diagnosis can be made by skin, muscle, or even renal biopsies. Several other entities must be considered in the differential diagnosis of atheromatous embolism (Table 148-8).

TABLE 148-8
Differential Diagnosis of Atheromatous Embolism

- Antiphospholipid antibodies
- Atrial myxoma
- Calciphylaxis
- Chilblains (or pernio)
- Cryoglobulinemia
- Heparin-induced thrombocytopenia
- Malignancies
- Multiple myeloma
- Nonbacterial thrombotic endocarditis
- Polyarteritis nodosa
- Subacute bacterial endocarditis
- Thrombocytopenia, polycythemia
- Thrombotic embolism
- Vasculitis
- Warfarin-induced skin necrosis

Moreover, among patients who develop acute renal failure, it is important to distinguish from contrast nephropathy, which is typically reversible. Renal failure caused by atheromatous emboli usually develops over 1 to 4 weeks after an angiographic procedure and shows partial recovery, whereas contrast-induced renal failure typically appears soon after testing and begins to recover within 3 to 5 days.

CLINICAL COURSE AND PROGNOSIS

The prognosis of cholesterol embolism is generally poor, in part because of the severe underlying atherosclerosis. The outcome also depends upon the organ system affected with the emboli. Estimates of mortality range from 20% to 30% for 1-year mortality. The poorest outcomes have been reported in those with emboli arising from a suprarenal location.

The syndrome usually subsides, and lesions heal following successful surgical or medical treatment, although spontaneous resolution may occur. Recurrent embolism may result in limb loss in the absence of surgical or interventional management options. In the "malignant multisystem" disease, most patients die within 1 year if treatment is unsuccessful. The prognosis is extremely poor in the presence of systemic complications, particularly renal failure or stroke. The development of end-stage renal disease

due to atheromatous embolism is a strong predictor of death.

MANAGEMENT

Early recognition is essential to minimize end-organ damage and improve the clinical outcomes.[13] Preventing further ischemic insult, supportive care, and removal of the atheromatous source are the mainstays of therapy.[14] Elimination of the source of the emboli can often be accomplished by surgical bypasses or endarterectomy although many of these patients have contraindications to major surgery. Endovascular procedures with covered stents also may be considered; however, this approach may carry significant risk with the potential to exacerbate further embolization.

Medical therapies have not been well studied, and recommendations are based on the results from small series or anecdotal reports. Antiplatelet agents, such as aspirin, dipyridamole, or clopidogrel, are most often tried, and if successful, should be continued long-term. Antithrombotic therapy such as subcutaneous heparin or low-molecular-weight heparin may be beneficial with some patients, suggesting that these agents may reduce the secondary small-vessel thrombosis. Warfarin is usually avoided because of potential for exacerbating the process, but this concern has a limited basis. There is even a proposed beneficial effect of long-term anticoagulation to prevent embolic events in those with extensive mobile aortic atheroma. The use of statins may aid in plaque stabilization and has clear established benefits in prevention of cardiovascular ischemic events in those with vascular disease. Other agents, such as iloprost and cilostazol, have limited evidence to suggest benefit, but have been tried in those with renal dysfunction (iloprost) and cutaneous lesions (cilostazol). Systemic corticosteroids are not recommended. As most of these patients have severe underlying atherosclerosis, they should be aggressively treated for secondary prevention of cardiovascular disease with optimization of the risk factors.

PREVENTION

Because of the rarity of the disease and the difficulties in establishing the diagnosis, increased awareness of the problem is important. Primary prevention in high-risk patients, targeted to avoid the development of atherosclerotic plaque, should be performed. Once atherosclerosis develops, avoiding unnecessary invasive procedures is advised. When angiography is necessary, more cautious techniques with the use of soft-tipped guidewires and more flexible catheters help to reduce the risk. In addition, protective devices, such as filters, baskets, and balloon occlusion, have been used. In patients with atheromatous disease of the abdominal aorta and iliac arteries, use of a brachial artery approach is often considered. Surgical techniques also have been refined with less aortic manipulation and circulation arrest, which may help to minimize the chance of developing this disorder.

THROMBOANGIITIS OBLITERANS (BUERGER DISEASE)

AT-A-GLANCE

- Rare inflammatory occlusive disease affecting medium and small arteries and veins, most commonly in the extremities.
- Predominantly affects males, at age 20 to 40 years.
- Extremely strong association with smoking; often abates with smoking cessation.
- Clinical manifestations include ischemia, cold sensitivity, or claudication of the foot, leg, or hand, which progress to ischemic ulcers, peripheral cyanosis, gangrene, or superficial thrombophlebitis.

Thromboangiitis obliterans (TAO), also known as Buerger disease, is a rare, progressive, inflammatory and thrombotic disease that predominately affects small- and medium-sized arteries of the extremities. It is strongly associated with the use of tobacco products, and seen mostly in men between the ages of 20 and 40 years.

EPIDEMIOLOGY

The prevalence of this disease is greatest in Mediterranean countries, the Middle East, and Asia, and it is relatively less common in people of northern European descent.[16] Males are afflicted with a higher prevalence than females (with a male-to-female ratio of 3:1), although an increased incidence in females has occurred in recent years, likely reflecting the pattern of tobacco use.[17] Patients are usually between the ages of 20 and 40 years. Since 1990 there has been a marked decline in the reported prevalence of TAO in the United States, possibly reflecting the impact of adoption of strict diagnostic criteria for this disease entity, although declining smoking prevalence may also play a role. In 1947, the prevalence of the disease in the United States was estimated at 104 cases per 100,000 population; however, the prevalence has been estimated at 12 to 20 cases per 100,000 population more recently.[16]

CLINICAL FEATURES

CUTANEOUS FINDINGS

The most common initial complaints are claudication of the foot or lower calf, digital cyanosis or gangrene, or rest pain. Involvement of multiple limbs is typical. Patients may present with ulcers of the toes or fingers. Although the lower extremities are affected most often, more than one-third of patients have upper-extremity involvement. Ulcerations or gangrenous areas are characteristically extremely painful. Superficial thrombophlebitis, often migratory, may occur in up to 40% of patients.[16] Cold sensitivity or even classical Raynaud phenomenon may be observed.

The cutaneous findings of TAO are similar to that of PAD. Common findings include ulceration or gangrene of digits (feet worse than hands; Fig. 148-6), peripheral cyanosis or Raynaud phenomenon, and superficial thrombophlebitis, often migratory, with indurated red nodules.

The hands and feet of patients with the disease are usually cold and mildly edematous. They may develop cyanotic, ulcerated, or gangrenous and very painful digits. Typically, the distal pulses (dorsalis pedis, posterior tibial, and ulnar pulses) are absent, while the more proximal pulses are preserved. During episodes of thrombophlebitis, small-indurated red, tender nodules will be found, which follow the course of superficial veins and are common on the thigh or calf. Typical changes of Raynaud phenomenon, with well-demarcated pallor or cyanosis of the digits, may be seen on exposure to cold; one or more extremities may be involved. Sensory abnormalities reflecting ischemic neuropathy have been observed in advanced cases. Nailfold examination with capillaroscopy may reveal multiple dilated capillary loops.

Figure 148-6 Necrotic toe in a patient with thromboangiitis obliterans; this appearance may be seen with other arterial occlusive processes.

ETIOLOGY AND PATHOGENESIS

The etiology of TAO remains unknown. The disease occurs almost exclusively in smokers and often abates with the cessation of tobacco smoking. Increased cellular sensitivity to types I and III collagen has been reported in comparison to a group of normal individuals and patients with atherosclerotic disease. An increased prevalence of human leukocyte antigen (HLA)-A9, HLA-A54, and HLA-B5 has been observed in these patients, suggesting a genetic component to the disease.[18] Tissue ischemia is produced by an inflammatory reaction involving medium- and small-sized arteries of the extremities and superimposed obstruction by thrombi. Despite the inflammatory process, TAO is considered serologically silent, and even during active disease, inflammatory markers, such as erythrocyte sedimentation rate and C-reactive protein levels, are usually normal. In one report, serum anti-endothelial cell antibody titers were found to be high, and impaired endothelial-dependent vasodilation to acetylcholine has been demonstrated to occur even in nonobstructed limbs. Veins also may be involved. Occasionally, cardiac, intestinal, and cerebral vessels are involved.

DIAGNOSIS

Even though a variety of diagnostic criterions have been published, a uniform criterion does not exist. Figure 148-7 presents an approach to TAO. Diagnosis of TAO typically relies on the clinical presentation and arteriography findings. Arteriography findings, in particular findings of corkscrew-shaped collaterals, are typical, but not pathognomonic for the condition. Because TAO is not limited to a single limb, abnormal arteriography findings are often bilateral. Exclusion of arteriosclerosis, or risk factors of other occlusive vasculopathies is crucial to establishing the diagnosis of TAO.

Histopathologic findings of arteries and veins on biopsy demonstrate inflammatory thrombus infiltrated with polymorphonuclear leukocytes and multinucleated giant cells.[19] A biopsy is not required to make the diagnosis, but can be used in atypical presentations.

DIFFERENTIAL DIAGNOSIS

Table 148-9 outlines the differential diagnosis for TAO.

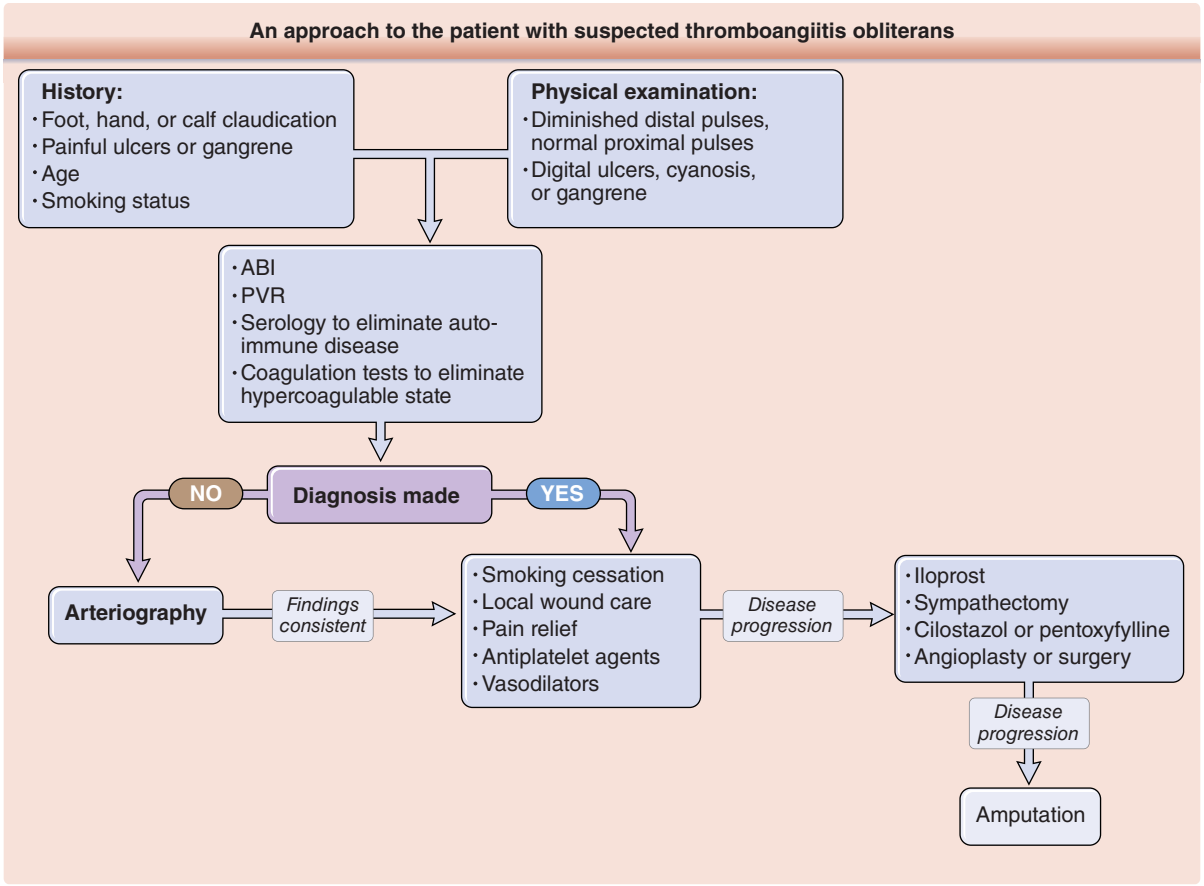

Figure 148-7 An approach to the patient with suspected thromboangiitis obliterans. ABI, ankle-brachial index; PVR, pulse-volume recording.

MANAGEMENT

Table 148-10 presents management options for TAO. Smoking cessation results in dramatic improvement. Avoidance of smokeless (chewing) tobacco and nicotine-containing patches is also necessary for disease abatement. A *Cochrane Database Review* revealed that, compared to aspirin, the IV prostacyclin analog, iloprost, improves ulcer healing and eliminates rest pain.[15] In addition to pharmacologic agents, local wound care and adequate analgesic therapy is imperative. Cilostazol, clopidogrel, pentoxifylline, or oral prostanoid is often initiated in the treatment of TAO, despite the absence of data from large randomized trials. Bypass surgery and angioplasty have been reported, but are suboptimal therapeutic options because of the small size and distal location of the vessels affected. Sympathectomy may help patients with a prominent vasospastic component. Vascular endothelial growth

TABLE 148-9
Differential Diagnosis of Thromboangiitis Obliterans

- Warfarin necrosis
- Livedoid vasculopathy
- Disseminated intravascular coagulation
- Purpura fulminans
- Cryoglobulinemia type 1
- Cryofibrinogenemia
- Cholesterol emboli
- Antiphospholipid syndrome
- Thrombotic thrombocytopenic purpura
- Levamisole-adulterated cocaine thrombotic vasculopathy

TABLE 148-10
Treatment of Thromboangiitis Obliterans

	IMPROVE BLOOD FLOW	SYMPTOM RELIEF
First-line therapy	Smoking cessation IV iloprost	Local wound care Analgesics
Second-line therapy	Antiplatelet agents Oral vasodilators Cilostazol (Pletal) Pentoxifylline (Trental)	
Third-line therapy	Angioplasty Surgical endarterectomy or bypass	Sympathectomy Amputation

factor gene therapy may prove of value, but has not yet been well studied. In those with refractory disease with nonhealing ulcers, gangrene, or intractable pain, surgical amputation of the affected distal limbs is often unavoidable.

PREVENTION

Absolute discontinuation of tobacco use is the only strategy proven to prevent the progression of TAO. Smoking as few as 1 or 2 cigarettes daily, using chewing tobacco, or even using nicotine replacements may keep the disease active.[20] The following strategies are important in prevention of complications from the disease: use of well-fitting protective footwear to prevent foot trauma and thermal or chemical injury, avoidance of cold environments, and avoidance of drugs that lead to vasoconstriction.

LIVEDO RETICULARIS AND LIVEDO RACEMOSA

AT-A-GLANCE

- Livedo is an ischemic dermopathy characterized by a violaceous reticular or "net-like" mottling of the skin.
- Livedo reticularis is a primary disorder affecting young to middle-aged females that is benign. The livid conical discoloration is symmetric, reversible, and uniform.
- Livedo racemosa is a secondary disorder that is pathologic and permanent. The livid conical discoloration is asymmetric, irreversible, and "broken."
- Differentiating benign livedo reticularis from pathologic livedo racemosa is imperative.
- Antiphospholipid antibody testing should be obtained on all patients presenting with livedo racemosa.

EPIDEMIOLOGY

Livedo reticularis is typically a primary disorder that affects young to middle-aged females (20 to 50 years of age) who are otherwise healthy.[21] Amantadine-induced livedo reticularis is also more common in females. The epidemiologic factors of livedo racemosa are dependent on the underlying condition. It is the most frequent dermatologic manifestation in patients with antiphospholipid syndrome, present in 25% of patients with primary antiphospholipid syndrome, and in up to 70% of patients with systemic lupus erythematosus–associated antiphospholipid syndrome.[22] The distinction between livedo racemosa and livedo reticularis is an evolving concept that is neither universally quoted nor referred to in most of the older literature.

CLINICAL FEATURES

With the exception of a subjective feeling of coldness, the majority of patients with livedo reticularis are asymptomatic (Table 148-11). Patients often present with concerns regarding their skin discoloration. A minority describe mild pain and numbness. The symptoms are worse during winter months. Livedo racemosa-associated symptoms are related to the causative secondary disorder.

CUTANEOUS LESIONS

In livedo reticularis, a symmetric, fishnet-like red or purple mottling surrounds a pallorous conical core (Fig. 148-8). This discoloration is aggravated by cold exposure and may completely dissipate with warming. The livid rings are most pronounced on the lower extremities yet the abdomen and upper extremities can be affected.

In contradistinction to the symmetric and uniform reticular pattern of livedo reticularis, the discoloration of livedo racemosa is asymmetric, irregular, and "broken" (Fig. 148-9; see Table 148-11). Although it may improve with warming, it does not resolve completely. Attendant skin manifestations of livedo racemosa may include purpura, nodules, macules, ulcerations,

TABLE 148-11
Comparison of Livedo Reticularis and Livedo Racemosa

	LIVEDO RETICULARIS	LIVEDO RACEMOSA
Condition	Benign	Pathologic
Associated conditions	Occasionally drug-related (amantadine)	See Table 148-12
Symptoms	Asymptomatic; mild pain or numbness	Symptoms related to associated causative disorder
Characteristic appearance	Symmetric, fishnet-like red or purple mottling with a pale conical core over lower extremities, abdomen or upper extremities (see Fig. 148-8)	Asymmetric, irregular, and "broken" (see Fig. 148-9)
Surrounding skin	Unaffected	Purpura, nodules, macules, ulcerations, atrophie blanche–type scarring
Aggravating/relieving factors	Aggravated by cold, relieved by warming	May improve with warming but no complete resolution

Figure 148-8 Symmetric and relatively uniform, conical rings of primary, reversible livedo reticularis (cutis marmorata).

and/or atrophie blanche-type scarring. When associated with livedoid vasculitis, painful ulcerations of the ankles and forefeet may occur.

In both livedo reticularis and racemosa, the skin is palpably cool.

NONCUTANEOUS FINDINGS

Livedo reticularis and livedo racemosa are often associated with vasospastic digits or acrocyanosis. With exception of the characteristic skin changes, the examination in livedo reticularis is otherwise unremarkable. Patients with livedo racemosa may have concurrent abnormal physical findings related to their underlying disease (eg, aphasia and lateralizing neurologic signs associated with Sneddon syndrome).

Figure 148-9 Permanent and "broken" rings of secondary livedo racemosa on the buttocks and thighs in a woman who had cerebrovascular thrombosis. This is an example of Sneddon syndrome.

ETIOLOGY AND PATHOGENESIS

In both disorders, the characteristic ring-like mottling results from (patho)physiologic changes within the cutaneous microvascular system. Anatomically, the dermis is perfused via perpendicularly oriented ascending arterioles. Individual arterioles arborize into a capillary bed at the skin surface. Ultimately, the capillary beds empty into a conical-appearing, peripherally located subpapillary venous plexus.

Pathophysiologically, livedo arises from either deoxygenation or venodilation within the venous plexus.[23] Decreased arteriolar perfusion is the predominant cause of deoxygenation within the venous plexus. Diminished arteriolar flow can result from vasospasm, hyperviscosity, and/or thrombosis. Physiologic arteriolar vasospasm produces the reversible cutaneous discoloration of livedo reticularis. The livedo reticularis can occur as a physiologic reaction to cold exposure, when it is known as cutis marmorata, or the skin color changes may be unrelated to ambient temperature. Protracted arteriolar vasospasm, thrombosis, and/or hyperviscosity underlie the pathologic skin changes of livedo racemosa. Venodilation of the venous plexus may be provoked by hypoxia or autonomic dysfunction.

A possible role for endothelial cells also has been suggested in the subset of patients with antiphospholipid syndrome with livedo racemosa. The interaction of antiphospholipid antibodies with endothelial cells could induce livedo racemosa and also lead to increased production of procoagulant substances such as tissue factor, plasminogen activator inhibitor-1, and endothelin. Increased tissue factor expression on endothelial cells induced by antiphospholipid antibodies could be responsible, in part, for hypercoagulability and might explain the thrombosis in both arterial and venous circulation that characterizes these patients.[22]

Amantadine-induced livedo reticularis has traditionally been ascribed to catecholamine provoked arteriolar vasospasm; however, an interaction between amantadine and *N*-methyl-D-aspartic acid receptors in the skin may be responsible in some unexplained fashion.[24]

Livedoid vasculopathy is a rare ulcerative subtype of livedo racemosa caused by fibrinolytic abnormalities and microcirculatory thrombosis.

DIAGNOSIS

LABORATORY TESTING

In livedo reticularis, laboratory testing is typically negative and consequently is unwarranted. An antiphospholipid antibody panel should be obtained on all

patients presenting with livedo racemosa. A complete thrombophilia panel is warranted in the rare patient with livedoid vasculopathy (see Chap. 138). The need for additional laboratory analysis in a patient with livedo racemosa should be directed by the clinical assessment.

A skin biopsy is not required in livedo reticularis as the findings are nonspecific. A large punch or wedge biopsy of the deep reticular dermis and subcutaneous fat is sometimes helpful in identifying the secondary cause of livedo racemosa. Selection of the correct biopsy site (seemingly uninvolved skin in the center of the lesion) is essential for detection of relevant vascular pathology. The biopsy findings are highly variable and reflect the associated livedo racemosa etiology. For instance, cholesterol clefts suggest atheroembolic disease, calcification of the vessels and interstitium indicate calciphylaxis, noninflammatory arteriolar obstruction occurs with Sneddon syndrome, livedoid vasculopathy is associated with extensive fibrin deposition and microthrombi (see Chap. 138), whereas fibrinoid necrosis is present in polyarteritis nodosa (see Chap. 139).

DIFFERENTIAL DIAGNOSIS

Identifying the characteristic mottled skin discoloration easily makes the diagnosis of livedo. It is paramount that the clinicians distinguish between livedo reticularis and livedo racemosa. Once a diagnosis of livedo racemosa is established, the secondary cause (Table 148-12) should be sought by appropriate clinical laboratory tests. Diagnostic difficulties may occur when no other pathologic signs except livedo racemosa are found. This clinical condition, known as *idiopathic livedo racemosa*, may represent a very early stage of Sneddon syndrome.

TABLE 148-12
Conditions Associated with Livedo Racemosa

- Antiphospholipid antibody syndrome
- Atheroembolic disease
- Atrial myxoma
- Calciphylaxis
- Chronic pancreatitis
- Collagen vascular disease
- Cryoglobulinemia/cryofibrinogenemia/cold agglutinin disease
- Erythema ab igne
- Hyperoxaluria
- Infections
- Livedoid vasculopathy
- Myeloproliferative syndromes (polycythemia vera, essential thrombocytosis)
- Paraproteinemias
- Sneddon syndrome
- Vasculitis (especially polyarteritis nodosa)

CLINICAL COURSE AND PROGNOSIS

The prognosis for livedo reticularis is excellent as this is primarily a cosmetic condition. Livedo racemosa–associated prognosis is less favorable and parallels the associated disease. Of interest, livedo racemosa has been identified as a marker for predicting multisystem thrombosis in the antiphospholipid antibody syndrome. Additionally, up to 40% of patients manifest livedo racemosa as the initial sign of the antiphospholipid antibody syndrome.[25] In addition, an increased rate of pregnancy loss has been recognized in patients with widespread livedo racemosa who were seronegative for antiphospholipid antibodies, suggesting that livedo racemosa may be an independent risk factor for pregnancy loss in the absence of antiphospholipid syndrome. Livedoid vasculopathy tends to be a relapsing condition marked by recurrent painful ulcerations and subsequent atrophie blanche-type scars.

MANAGEMENT

Other than cold avoidance, medical treatment for primary livedo reticularis is typically unwarranted. As a last resort, vasodilator therapy may be tried in the patient who is socially inhibited by the cosmetic appearance of the disorder. The symptoms may improve spontaneously with age.

Therapy of livedo racemosa should be directed toward the underlying disorder. Patients with livedo racemosa and the antiphospholipid antibody syndrome with thrombosis require anticoagulation. Treatment of livedoid vasculopathy is often unsatisfactory, but potentially beneficial medications include anticoagulants, antiplatelet agents, immunosuppressants, pentoxifylline, danazol, and tissue plasminogen activator. Alternatively, hyperbaric oxygen and psoralen plus ultraviolet A light therapy also have been successfully used to treat livedoid vasculopathy.

ERYTHROMELALGIA (ERYTHERMALGIA)

AT-A-GLANCE

- Intense, burning pain with marked erythema, typically of the lower extremity.
- Typically intermittent. May be precipitated by exercise.
- Primary disorder or secondary to a myeloproliferative disorder.

(Continued)

AT-A-GLANCE (*Continued*)

- Cutaneous manifestations are often a result of attempts to alleviate the symptoms with immersion and thermal injury.
- Aspirin may be effective for secondary erythromelalgia.

Red, hot, painful extremities with characteristic intense, burning pain characterize erythromelalgia. It most commonly affects the lower extremities but may affect the upper extremities as well as other body parts, such as the face and ears. Involvement is usually symmetric, although it can be unilateral in secondary cases. The symptoms are typically intermittent in nature, but may become constant. Onset can be gradual or abrupt, and usually is precipitated by activities that increase the body temperature, such as exercise, ambient temperature, or the use of heavy blankets at night. The episodes also can be triggered by dependency of the limb, wearing socks, or tight shoes, and sometimes with the ingestion of alcohol or spicy foods. There are also reports of episodes triggered by ingestion of some drugs, such as pergolide, bromocriptine, and calcium channel blockers (nifedipine, felodipine, and nicardipine). In contrast, cold exposure (eg, standing on a cold floor) or immersion in ice water often relieves the flares.

Patients with both erythromelalgia and Raynaud phenomenon also have been described. During the hyperemic phase of Raynaud phenomenon, patients often complain of erythromelalgic-like symptoms. It is postulated that both syndromes have a common basis in a dysfunction of the regulation of vasomotor tone.[24]

EPIDEMIOLOGY

This is a rare disorder with limited epidemiologic data available. In Norway, the incidence is estimated to be 0.25 per 100,000 population with a prevalence of 2 per 100,000 population.[26] In the United States, extrapolation from a series of erythromelalgia patients at the Mayo Clinic suggests an incidence of 1.3 case per 100,000 patients.[27] Primary erythromelalgia may occur at any age with an uncertain gender predilection, although recent studies seem to suggest a female predominance.[27] In contrast, secondary erythromelalgia has an equal sex distribution and occurs mostly after the third decade.[28]

CLINICAL FEATURES

CUTANEOUS LESIONS

Examination during attacks reveals warm, red, extremely sensitive extremities with normal pulses (Fig. 148-10). Between flares, the extremities may appear normal. The constant use of ice water leads to maceration of the skin, secondary infection, ulcers, and necrosis.

Figure 148-10 Intense erythema of the feet with associated burning pain typical of erythromelalgia.

NONCUTANEOUS FINDINGS

Physical examination is usually unremarkable in primary erythromelalgia; however, it may reveal signs of an underlying disorder in the secondary erythromelalgia. The peripheral pulses are usually normal or bounding.

ETIOLOGY AND PATHOGENESIS

The etiology and pathogenesis of the erythromelalgia are unknown. Several mechanisms have been postulated for primary erythromelalgia, including arteriovenous shunting and a small fiber neuropathy. It has been speculated that precapillary sphincters may be constricted while arteriovenous shunts are open, leading to an increased total perfusion but a deficient nutritive blood flow.[29] Substances produced by local hypoxia lead to increased local blood flow, warmth, redness, and pain. In contrast, the genetics of erythromelalgia appears to be supporting a neuropathic basis. A mutation in *SCN9A*, the gene encoding voltage-gated sodium channels of sensory nerves, has been reported in inherited erythromelalgia.[30]

Secondary erythromelalgia occurs in polycythemia, thrombocythemia, and autoimmune disorders, and is hypothesized to be caused by platelet breakdown products based on the response to aspirin therapy.

DIAGNOSIS

Erythromelalgia is diagnosed based on evaluation of the characteristic symptoms and signs of the disease.

TABLE 148-13
Differential Diagnosis of Erythromelalgia

- Complex regional pain syndrome
- Peripheral neuropathy
- Raynaud phenomenon (hyperemic phase)
- Systemic lupus erythematosus

There is often a delay in diagnosis given the intermittent nature of the condition. Photos taken by the patient during a flare can be beneficial. Alternatively, provoking a flare with use of exercise or immersion of the affected area in hot water for at least 10 minutes may be required to assist with definitive diagnosis. Family history is necessary to assess for inherited primary erythromelalgia.

Secondary erythromelalgia, caused by polycythemia vera or essential thrombocythemia, should be ruled out by first obtaining a laboratory test for a complete blood count. If abnormalities are present, additional specialized testing may be required.

DIFFERENTIAL DIAGNOSIS

Table 148-13 outlines the differential diagnosis for erythromelalgia.

CLINICAL COURSE AND PROGNOSIS

The natural history of erythromelalgia is extremely variable.[31] Symptoms may be mild for several years or totally disabling within weeks. It has been reported that with long-term followup, symptoms were worse in 32%, unchanged in 27%, improved in 31%, and resolved in 10% of patients. Many patients become disabled, being unable to work or carry on daily activities. As a result of the profound impact upon their life with intractable symptoms, patients have even been known to commit suicide. There is a decrease in survival compared with age- and gender-matched controls.

MANAGEMENT

Limited data is available to guide therapy, primarily based upon case reports or small series. Treatment is focused on prevention of flares and symptom control. Behavioral modifications should include efforts to keep the limbs cool and avoid the use of ice water or prolonged soaking. Cool air, such as from air conditioners or fans, can provide symptom relief, although prolonged exposure is not recommended. Topical therapies, such as a lidocaine patch, can be of tremendous help. Topical formulations that contain a combination of amitriptyline, ketamine, and gabapentin may also provide relief.

Pharmacologic therapy has varied, but often has focused on vasoactive drugs and drugs that affect the nervous system. Most vasoactive drugs, including calcium-channel blockers and β blockers, have been minimally effective in treating this disorder. Drugs used to treat neuropathy, such as serotonin reuptake inhibitors, tricyclic antidepressants, and gabapentin, have been used and may provide some relief. Combinations of these medications are often required, and starting with a low dose is advised to avoid side effects. Numerous other agents, including misoprostol, antihistamines, IV iloprost, lorazepam, cyproheptadine, piroxicam, and pizotifen, have been tried in selected cases. The prostaglandin E_1 analog misoprostol was evaluated in a double-blind crossover trial and found to be superior to placebo.

Surgical or medical sympathectomies also have been tried but have had mixed results. As a result of the chronic pain that can be associated with erythromelalgia, pain rehabilitation with the use of biofeedback, and even hypnosis, may be beneficial.

In secondary erythromelalgia, aspirin is often of great benefit.

PREVENTION

There are no established measures to prevent the development of erythromelalgia. The focus has been to prevent flares once the disorder occurs. The key to prevention is to avoid exacerbating factors and to prophylactically cool the involved extremity. The other preventive measures are to prevent the development of secondary complications often as a result of prolonged cold exposure, either from ice water or excessive cold blowing air.

CHRONIC VENOUS DISEASE

AT-A-GLANCE

- One percent to 3% of U.S. health care expenses are for peripheral venous diseases and their complications.
- Venous ulcers are the most common.
- Risk factors include genetics, obesity, female gender, pregnancy, and occupations requiring prolonged standing, surgery, trauma, and malignancies.
- Peripheral venous disease should be considered part of a spectrum including the following:
  - Early signs: tenderness, edema, hyperpigmentation, and varicose veins.
  - Late signs: atrophie blanche, lipodermatosclerosis, and venous ulcers.

(Continued)

AT-A-GLANCE (*Continued*)

- Venous ulcers are located exclusively below the knee after venous pump failure, most often secondary to prior thrombosis.
- Treatment for all stages includes leg elevation, compression, treatment of infection and dermatitis.
- Deep venous disease is associated with thromboembolism.

Chronic venous disease of the peripheral veins includes a spectrum of findings ranging from telangiectasias to reticular veins and varicose veins. Chronic venous insufficiency is a result of persistent ambulatory venous hypertension of the lower-extremity venous system, which results in a spectrum of clinical findings from edema and tenderness to venous ulceration (Table 148-14).

EPIDEMIOLOGY

Chronic venous disease is extremely common and has a prevalence in the adult population of up to 30%.[32] Although estimated cost and time lost from work have not been objectively assessed in more than 2 decades, estimates state that 25 million adults in the United States have varicose veins and 6 million have evidence of advanced disease.[33] Venous ulcers, as a result of chronic venous insufficiency, cause significant disability and are estimated to be 1% of the adult population. The care of venous ulcers is estimated to cost $3 billion annually.[34]

Risk factors for chronic venous disease include heredity, age, female sex, obesity, pregnancy, prolonged standing, phlebitis, previous leg injury, and greater height.[34]

TABLE 148-14

Common Signs and Symptoms of Peripheral Venous Disease

Symptoms
- Leg fullness
- Aching discomfort
- Heaviness
- Nocturnal leg cramps
- Bursting pain on standing

Signs

Very Early
- Tenderness to palpation

Early
- Edema
- Hyperpigmentation
- Stasis dermatitis
- Varicose veins

Late
- Venous ulcers
- Atrophie blanche
- Lipodermatosclerosis
- Acroangiodermatitis of Mali
- Postphlebitic syndrome

CLINICAL FINDINGS

CUTANEOUS LESIONS

There is a spectrum of clinical manifestations of chronic venous disease starting with telangiectasias and reticular veins on one end of the spectrum, and advanced chronic venous insufficiency, including skin ulcerations and fibrosis, at the other end. Once there is chronic venous insufficiency, findings include dilated veins (varicose veins), edema, leg pain, and cutaneous changes. The earliest finding is perimalleolar edema that ascends up the leg, followed by soft tissue tenderness, even of normal appearing skin. Tenderness if often elicited when palpating for the presence of edema.

Varicose veins, especially noticeable when the patient is standing, and smaller varicosities appear about the dorsum of the foot and ankle (see Chap. 212). Although they are usually asymptomatic, patients may complain of aching, cramping, itching, fatigue, and swelling that are worse with prolonged standing. Superficial thrombophlebitis can develop along the course of the varicose vein and present with an area of induration, erythema, warmth, and tenderness.

Stasis dermatitis, characterized by erythema, scaling, pruritus, erosions, crusting, and occasional vesicles and serous drainage may occur during any stage of chronic venous insufficiency (Fig. 148-11). It typically occurs in the medial supramalleolar region where microangiopathy is most intense. Over time, lesions may lichenify. It is important to evaluate for coexisting allergic contact dermatitis, as up to 80% of patients

Figure 148-11 Bilateral venous disease with dermatitis and extensive hemosiderosis.

with venous leg ulcers develop contact sensitization to topical therapies.

In lipodermatosclerosis (sclerosing panniculitis, hypodermatitis sclerodermiformis), pliable subcutaneous fat is gradually replaced by fibrosis, and the skin begins to feel firm and indurated. This is a fibrosing panniculitis characterized by a bound down plaque that begins at the medial ankle and extends circumferentially around the entire distal lower leg.[35] As the fibrosis increases, it may constrict and strangle the lower leg further, impeding venous and lymphatic flow and leading to brawny edema above and below the fibrosis. These late changes resemble an inverted champagne bottle (see Fig. 148-11).

Occasionally, lipodermatosclerosis can present acutely with bright red erythema and tenderness and mimics cellulitis, except systemic signs and symptoms are lacking. Lack of response to oral antibiotics and a relapsing nature eventually lead to the diagnosis. This is a result of acute inflammation of the subcutaneous fat, and a septal panniculitis can be seen histopathologically in this setting (see Chap. 73).

Atrophie blanche refers to skin overlying areas of fibrosis that often appears porcelain white and atrophic. Fully established lesions of atrophie blanche consist of irregular, smooth, atrophic stellate plaques with surrounding hyperpigmentation and telangiectasias (Fig. 148-12). Although mostly related to venous stasis, atrophie blanche also may be associated with an underlying disorder of hypercoagulation (eg, antiphospholipid syndrome, inherited coagulopathies), livedoid vasculitis (see Chap. 138), or autoimmune disease (eg, scleroderma, lupus erythematosus).[36] Acroangiodermatitis (pseudo-Kaposi sarcoma, congenital dysplastic angiopathy, arteriovenous malformation with angiodermatitis) has purple macules, nodules, or verrucous plaques on the dorsal feet and toes of patients with longstanding venous insufficiency and mimics Kaposi sarcoma clinically and histologically. Identical lesions have been described in arteriovenous malformations of the legs, arteriovenous shunts for hemodialysis, paralyzed limbs, and amputation stumps.

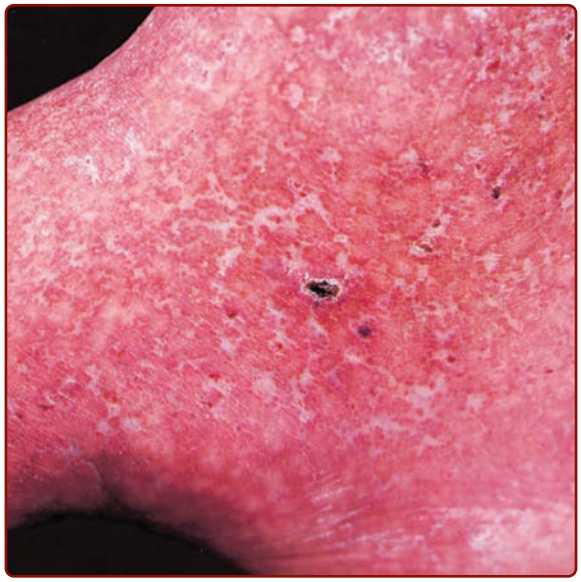

Figure 148-12 Atrophie blanche with irregular porcelain-white atrophic scars, small ulcerations, and crusting.

Figure 148-13 Venous ulceration in an area of lipodermatosclerosis, hemosiderosis, inflammation, and varicosities on the foot. Note lipodermatosclerosis constricts lower leg below the calf ("inverted champagne bottle").

The soft-tissue injury that precedes ulceration begins in the subcutis, and visible changes may not appear for some time. Frequently one notes the appearance of petechial lesions, which have the appearance of cayenne pepper sprinkled about the gaiter area. As the hemoglobin in the petechial lesions breaks down, the iron remains in the skin as hemosiderin, which may lead to impressive discoloration (see Fig. 148-11).

Although ulceration is classically located in the gaiter area (Fig. 148-13), *venous ulcers* have been described as ulcers occurring anywhere below the knee. Venous ulcers are typically tender, shallow, irregular, and have a red-base (Figs. 148-13 and 148-14). They are usually located on the medial ankle or along the line of the long or short saphenous veins. Clinical distinction should be made with other common ulcers of the lower extremity (see Table 148-5) as shown in Table 148-15.

COMPLICATIONS

Recurrent ulceration is frequent. Any open wound provides a portal of entry for bacteria, and cellulitis, although infrequent, may develop at any time. Stasis dermatitis is itchy and the skin is easily excoriated and may become infected. In addition, these patients are easily sensitized to the topical agents they apply, and contact dermatitis is common, especially that caused by topical antibiotics. The dermatitis of venous disease may become generalized as an id reaction and may rarely produce an exfoliative erythroderma. Many of these individuals are predisposed to thrombi,

Figure 148-14 Venous ulceration with stasis dermatitis, edema, and varicosities.

and recurrent episodes of venous thrombosis are not uncommon.

All patients with advanced venous disease have some degree of lymphatic impairment, though lymphatic impairment may also result from inherited defects in lymphatic development or destruction of lymphatics after cellulitis, lymphangitis, surgical interruption, or radiation. Loss of lymphatic drainage from the lower leg may lead to verrucous changes and cutaneous hypertrophy, called elephantiasis nostras (see section "Secondary Lymphedema").

ETIOLOGY AND PATHOGENESIS

A venous ulcer occurs after failure of the calf muscle pump. The heart pumps blood down to the foot; the calf muscle pump (when upright) returns venous blood to the heart. Venous blood from the skin and subcutis collects in the superficial venous system, including the greater and lesser saphenous veins and its tributaries, moves through the fascia in a series of "perforating" or "communicating" veins, and fills the muscle-enveloped deep venous system. With muscle contraction, the deep veins are compressed; one-way valves in the deep system allow the now high-pressure flow to move against gravity, and one-way valves in the perforators close to prevent–pressure injury in the skin (Fig. 148-15). In all patients with venous disease there is failure of these one-way valves, and this can result in varicose veins (Fig. 148-16). The severity of venous disease is influenced by the number and

TABLE 148-15
Differential Diagnosis of Leg Ulcers

Vascular Diseases
- Arterial (hypertensive atherosclerotic, vasospastic)
- Venous (venous stasis ulcer)

Metabolic Disorders
- Diabetes mellitus
- Gout
- Necrobiosis lipoidica diabeticorum
- Pancreatic (pancreatitis, carcinoma)
- Porphyria cutanea tarda

Infections
- Bacterial (especially *Staphylococcus aureus*, *Streptococcus*)
- Fungal (deep fungal, mycetoma)
- Opportunistic in immunocompromised
- Spirochetal (syphilis)
- Viral

Vasculitis
- Granulomatosis with polyangiitis (Wegener granulomatosis)
- Hypersensitivity vasculitis
- Lymphomatoid granulomatosis
- Polyarteritis
- Rheumatoid vasculitis
- Systemic lupus erythematosus

Lymphedema
- Congenital
- Postinfectious
- Postirradiation
- Postsurgical

Drugs
- Anticoagulant necrosis (Coumadin, heparin)
- Drug-induced vasculitis
- Ergotism
- Halogens (bromide, iodide)
- Hydroxyurea

Hematologic Abnormalities
- Dysproteinemia (cryoglobulinemia, macroglobulinemia)
- Hypercoagulable states (protein C, protein S, antithrombin III deficiency, activated protein C resistance, prothrombin gene polymorphism)
- Leukemia
- Lupus anticoagulant syndrome
- Paroxysmal nocturnal hemoglobinuria
- Polycythemia vera
- Sickle cell anemia
- Thalassemia

Tumors
- Cutaneous (basal cell cancer, squamous cell cancer, sarcoma, malignant melanoma, Merkel cell)
- Kaposi sarcoma
- Secondary (metastatic carcinoma, lymphoma)

Miscellaneous
- Bullous diseases (epidermolysis bullosa)
- Burns
- Idiopathic
- Insect bites (brown recluse spider)
- Pressure ulcers, neuropathic ulcers
- Pyoderma gangrenosum
- Sweet syndrome
- Trauma (including factitial)
- Ulcerative lichen planus

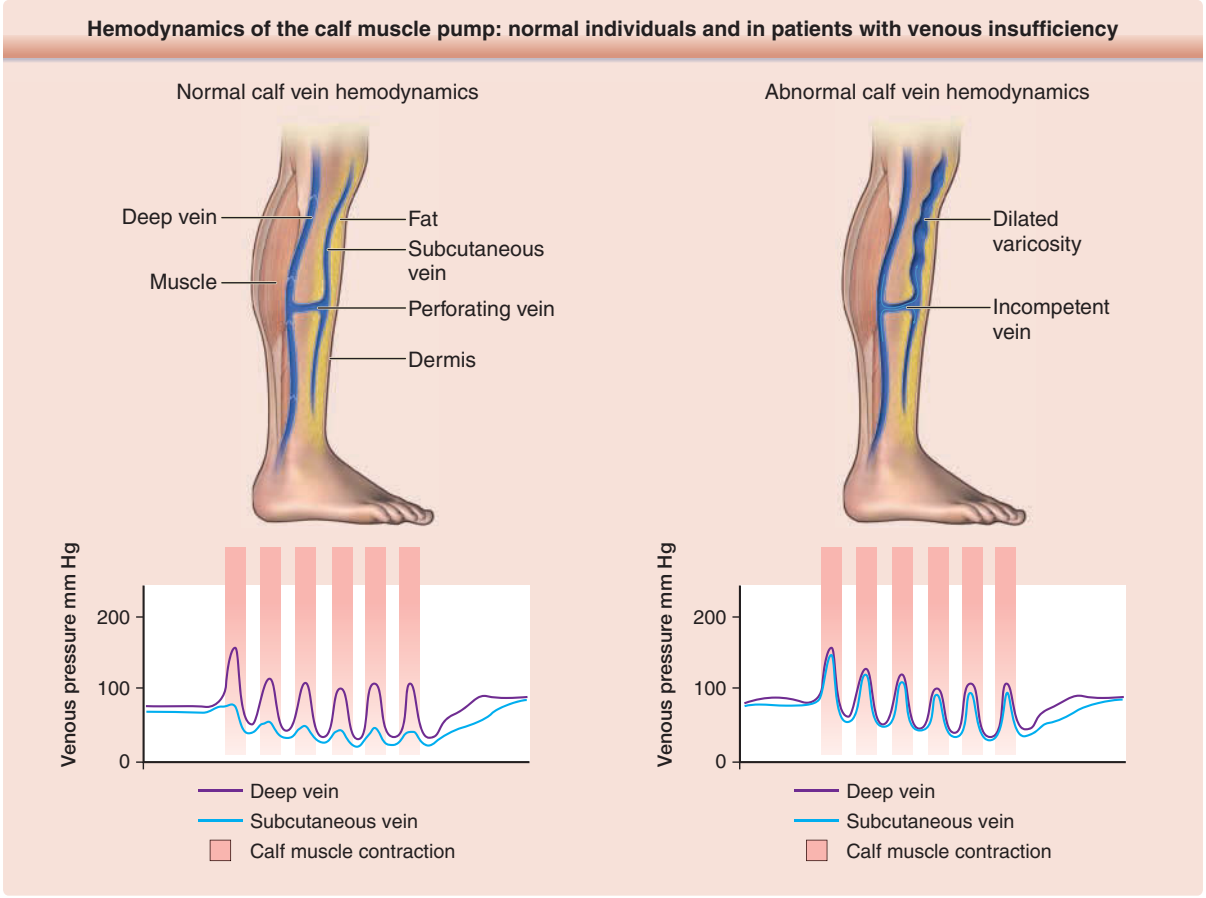

Figure 148-15 Anatomy and hemodynamics of the calf muscle pump in normal individuals and in patients with venous insufficiency. Venous insufficiency is characterized by high-pressure reflux from deep veins into the superficial veins and small vessels of the skin.

Figure 148-16 Extensive varicose veins on the calf and thigh.

distribution of incompetent valves and is worsened by any impairment of leg muscle function or ankle joint range of motion—all critical components of the calf muscle pump. Any obstruction to venous return (eg, thrombosis, radiation fibrosis) or elevation of right atrial pressure (eg, pulmonary hypertension, heart failure) further compromises venous return. Chap. 212 provides a more detailed description of the anatomy and hemodynamics of the venous system of the lower extremities.

The most common cause of venous valvular failure is thrombosis. The nidus for venous thrombosis is typically the valve cusp, and when the thrombus is lysed by plasmin, valve function is often lost as well. Calf muscle pump failure after deep venous thrombosis is often referred to as the *postphlebitic syndrome*.[33]

Once valves fail, especially those in the perforators, high-pressure blood in the deep system refluxes into the unsupported veins of the skin. There is then vascular leakage of fibrinogen producing "fibrin cuffs" that may interfere with tissue nourishment. In addition, white blood cell trapping leads to soft-tissue injury, inflammation, and, eventually, fibrosis, as the subcutaneous fat is replaced by scar, resulting in lipodermatosclerosis.

DIAGNOSIS

LABORATORY TESTS AND IMAGING STUDIES

It is crucial to exclude arterial disease as a cause of ulceration. A useful bedside screening test for PAD is to calculate the ratio of the systolic blood pressure in the ankle (as measured by Doppler) to the systolic pressure in the brachial artery (also measured by Doppler). This ankle-brachial index is greater than or equal to 1 in normal individuals. Anything less than 1 is an indication of PAD. The lower the ratio, the more severe the arterial obstruction. An ankle-brachial index is reliable except in the presence of calcified vessels, which are noncompressible and therefore a true systolic pressure cannot be measured.

Having excluded arterial disease as a cause of ulceration, a clinical diagnosis of venous disease is sufficient for the initiation of empiric therapy in most cases (Fig. 148-17). When the diagnosis is in doubt, skin biopsy may be useful. Tissue should be sent for both histology and tissue culture. Functional testing of calf muscle pump function and venous valvular function using plethysmography is occasionally useful. Duplex Doppler ultrasonography can be useful to document valvular incompetence and to evaluate patients for possible sclerotherapy or surgery (see Chap. 212).

Histologic signs of venous hypertension include hemosiderin deposition, lobular superficial and/or deep dermal neovascularization, and fibrosis of the dermis and subcutaneous tissue in later stages. These histologic findings are found in all clinical manifestations of chronic venous disease.

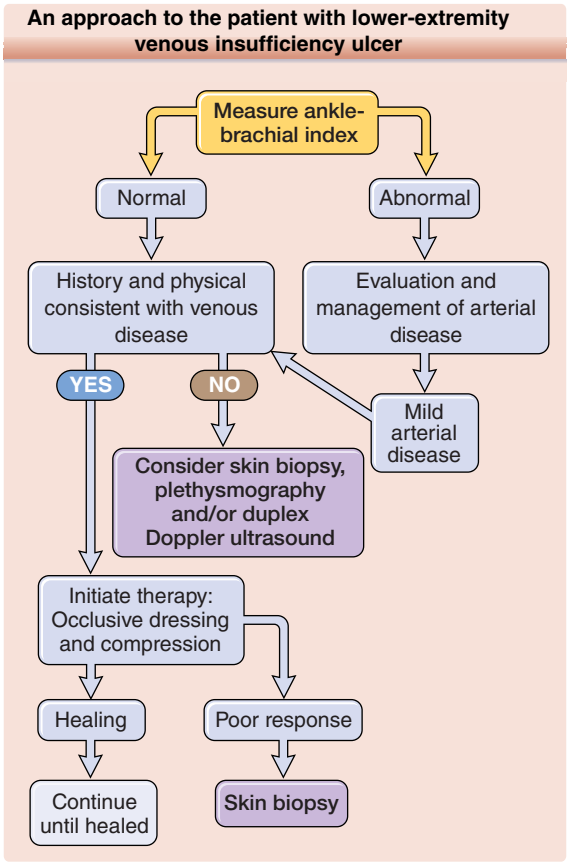

Figure 148-17 An approach to the patient with lower-extremity venous insufficiency ulcer.

DIFFERENTIAL DIAGNOSIS

Together Tables 148-5 ("Comparison of Different Leg Ulcer Types") and 148-15 ("Differential Diagnosis of Leg Ulcers") outline the differential diagnosis of chronic venous disease.

CLINICAL COURSE AND PROGNOSIS

The prognosis for healing areas of ulceration and inflammation is excellent in the absence of comorbid illness that interferes with healing. The vast majority of patients with uncomplicated chronic venous disease respond well to ambulatory outpatient therapy as outlined in "Management" below. Permanent changes include hemosiderosis and fibrosis that develop before the initiation of therapy. Loss of valvular function is irreversible. In the absence of continual lifelong cutaneous support in the form of inelastic wraps or elastic stockings, skin and soft-tissue injury continues.

MANAGEMENT

Table 148-16 outlines the treatment of chronic venous insufficiency. Treatment for all clinical manifestations of chronic venous insufficiency includes therapies that lower venous pressure and improve venous and lymphatic flow by mechanical means, dressings, drugs, and surgery.

Given the limitations of bed rest as an effective therapy, the focus is now on an ambulatory outpatient approach to the management of venous ulceration. Most experts agree on the essential role of compression in treating chronic venous insufficiency.[37] Hence, unless there are contraindications (arterial occlusive disease or abnormal ankle, brachial indexes), compression therapy should remain part of any treatment regimen for chronic venous disease.

Toward the end of the 19th century, Paul Gerson Unna recognized that by providing a compression bandage to the distal extremity he could heal venous ulcers in an ambulatory patient population using a zinc-impregnated gauze wrap, the "Unna boot." Although the literature over the years continued to document the success of this approach, it proved difficult to achieve

TABLE 148-16
Treatment of Chronic Venous Insufficiency

Mechanical
- Compression bandages
- Compression stockings
- Intermittent pneumatic compression pumps
- Leg elevation

Drug Therapy
- Aspirin
- Horse chestnut seed extract
- Pentoxifylline
- Topical steroids (for stasis dermatitis)

Dressings
- Occlusive hydrocolloid or gel dressings
- Wet and dry nonadherent dressings
- Zinc paste-impregnated bandages (Unna boot)

Surgery
- Calf varicosity avulsions
- Endovenous laser therapy
- Long saphenous vein stripping
- Radiofrequency ablation
- Saphenofemoral/saphenopopliteal junction disconnection
- Sclerotherapy
- Subfascial endoscopic perforator vein ligation

graduated compression with this wrap, and compliance was poor. Eventually, the addition of a self-adherent second layer (Coban, for example) over a zinc wrap was introduced as the "Duke boot" (Fig. 148-18). This has proven to be easy to apply with reproducible, graduated, inelastic compression to counter the outflow from perforator incompetence, and is the cornerstone of venous ulcer management.[38]

In 1962, George Winter reported the use of an occlusive layer enhanced healing in a pig model of acute wounds. His data suggested a roughly 100% improvement in the rate of wound healing simply by providing a moist environment. The impact on wound care has been dramatic. There are now thousands of such dressings on the market and although they differ in composition, absorption, gas exchange, and cost, all provide a moist environment. Underneath such dressings, fibrinopurulent and necrotic debris, aided by host and bacterial enzymes, dissolves painlessly. One can take advantage of these dressings to provide the best local environment for the wound, followed by a compression wrap to address the underlying hemodynamic disturbance (see Chap. 149).

Figure 148-18 Compression bandage using a zinc paste primary layer (Unna boot) followed by Coban at full stretch.

Mechanical therapy is the mainstay of treatment for all clinical manifestations of chronic venous insufficiency. Daily use of elastic compression stockings reduces swelling in some patients with postthrombotic syndrome, and may prevent worsening of established postthrombotic syndrome and reduce recurrence of healed venous ulcers.[38] Each pharmaceutical therapy targets a specific clinical aspect of chronic venous insufficiency. Diuretics may be used in the short-term for treating severe edema. Aspirin (300 to 325 mg/day)[39,40] and pentoxifylline[41,42] may improve healing of chronic venous ulcers, although data is insufficient to recommend in all cases. Finally, topical steroids and emollients aid resolution of stasis dermatitis.

Although all wounds harbor potential pathogens, there is no evidence that routine use of antibiotics is helpful in patients with venous ulcer. If cellulitis is suspected, empiric therapy with coverage for *Staphylococcus aureus* and streptococci is warranted. Topical antibiotics, especially mupirocin, are useful for folliculitis due to *S. aureus* and streptococci. With the increasing incidence of community acquired methicillin-resistant *S. aureus* in this population, culture and sensitivity are suggested for suspected skin and soft tissue infections. Horse chestnut seed extract (*Aesculus hippocastanum* L.), often standardized to 50 mg escin twice daily, is an herbal remedy that appears to be safe and effective as a short-term treatment for leg pain and swelling.[43]

Venous disease is progressive and irreversible. Patients must be educated about the need for continual hemodynamic support after the wound has healed. Graduated stockings that provide a minimum of 30 to 40 mm Hg at the ankle should be carefully fitted to all patients and worn for their lifetime. It is a mistake to place elastic stockings on edematous limbs, especially those limbs that are tender. Compression bandaging should be used until all edema, inflammation, and tenderness have resolved before fitting the patient with stockings.

In carefully selected cases, sclerotherapy or surgical techniques, especially endovenous ablation, may close incompetent perforators and correct the hemodynamic abnormalities that lead to venous ulcer (see Chap. 212).[44,45]

PREVENTION

Prevention of venous thrombosis prevents venous insufficiency. Because many thrombotic traits are genetic, it is likely those patients at extra risk for thrombosis may be identified and treated for this risk before an event, and efforts to prevent thrombosis during elective surgery and hospitalization should reduce the

numbers of postphlebitic limbs. Once a patient develops venous thrombosis, elastic compression stockings are the only proven method to reduce the risk of postthrombotic syndrome.[38]

Valvular failure may develop during pregnancy. Therefore, the use of supportive stockings throughout maternity, although not proven, can be recommended. If one's occupation or lifestyle involves long periods of immobility (long-distance flights appear to be especially risky), stockings are advisable.

LYMPHEDEMA

AT-A-GLANCE

- Lymphatics are essential for the clearing of extravascular fluids and debris and as conduits for transport of immunocompetent cells during the initiation of an immune response.
- Genetic defects causing lymphedema in childhood or early adult life are often caused by defects in the genes *VEGFR3* (encoding vascular growth factor receptor) and *FOXC2*, a transcription factor.
- Lymphedema acquired in adult life is often related to chronic venous disease, after mastectomy with radiation and node removal, and, in certain geographic locations, filariasis.
- Cellulitis may complicate all forms of lymphedema and should be aggressively treated.

The lymphatic vasculature plays a crucial role in the return of interstitial fluid to the bloodstream, absorption of dietary lipids, and trafficking of immune cells. Valves in collecting lymphatic vessels allow lymph to be efficiently returned to the bloodstream, and their formation is a key event during maturation of the lymphatic vasculature. Defects in lymphatic valve formation contribute to aberrant lymphatic function in lymphedema syndromes.[46]

Edema is an excess of fluid in the body tissues. Although most of this fluid is in the interstitial spaces, there is usually excess fluid both in the vascular bed and within cells. When this becomes chronic, inflammatory cells and their cytokines lead to an irreversible state. This chronic accumulation of protein-rich fluid may occur as a consequence of conditions that predispose to chronic edema, such as venous stasis; or it may occur because of lymphatic failure secondary to trauma, malignancy, disease, or genetic mutations that give rise to nonfunctional lymphatics.

Lymphedema refers specifically to swelling of a part of the body due to impaired lymph transport capacity as a consequence of a malformation or malfunction of the lymphatics.

Primary lymphedema is a congenitally determined intrinsic or constitutional fault in lymphatic drainage. This is most commonly due to mutations in specific genes that are critical to lymphatic development or function, but may arise as a result of a developmental abnormality due to unknown causes *in utero*. Depending on the cause, primary lymphedema may present at any age (Fig. 148-19).

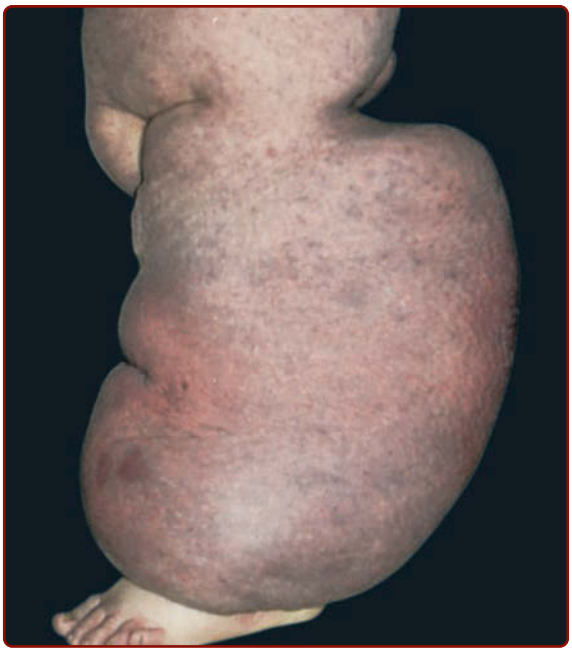

Figure 148-19 Lymphedema of the left leg in a 47-year-old firefighter. The extreme swelling began at birth and was painless. Note the lack of stasis pigmentation or ulceration. The patient functioned normally at work and wanted no treatment.

Secondary lymphedema occurs when previously normal lymphatics suffer an external insult such as disease, infection (eg, repeated episodes of erysipelas), trauma, or surgery, and subsequently lose their functional capability, giving rise to lymphedema. The most common cause worldwide is parasitic infection. In industrialized countries, secondary lymphedema occurs following trauma, infection, surgery, malignancy, or radiation therapy.[47]

In all the clinical disorders discussed, lymphedema may be transient and pitting with pressure, but with time becomes fixed, and is accompanied by adipose tissue hypertrophy, fibrosis, and epidermal hyperplasia (Fig. 148-20) that eventually makes pitting less evident.[48]

Patients with lymphedema are susceptible to recurrent erysipelas, physical impairment, and psychosocial stigmatization, and may be at increased risk of malignancy such as lymphangiosarcoma.

PRIMARY LYMPHEDEMA

EPIDEMIOLOGY

Primary lymphedema is thought to occur in approximately 1 to 3 of every 10,000 live births.[49] It also can be

Figure 148-20 Verrucous skin changes in chronic lymphedema.

a feature of certain inherited chromosomal conditions, such as Aagenaes syndrome (cholestasis and lymphedema), Noonan syndrome, Klinefelter syndrome, Turner syndrome, and Prader-Willi syndrome.[50]

EMBERGER SYNDROME

Emberger syndrome (OMIM [Online Mendelian Inheritance in Man]: 614038) is the cooccurrence of primary lymphedema and myelodysplasia/acute myeloid leukemia.

Clinical Features: In addition to unilateral or bilateral lymphedema of the lower extremities, patients with Emberger syndrome also have a low CD4:CD8 ratio, immune dysfunction (widespread cutaneous warts), sensorineural deafness, and genital lymphedema.[51] These patients require monitoring because of their predisposition to acute myeloid leukemia. Lymphedema precedes the hematologic abnormalities.

Etiology and Pathogenesis: Emberger syndrome is an autosomal dominant primary lymphedema syndrome caused by mutations in *GATA2*, which regulates the transcription of genes that are important for both development and maintenance of lymphovenous and lymphatic vessel valves.[52] Transcription factor GATA2 is also crucial for hematopoietic stem cell development during both embryogenesis and adulthood. It is known now that deficiency in this transcription factor encompasses a broad phenotype that includes immunodeficiency, bone marrow failure, pulmonary disease, and vascular/lymphatic dysfunction.[53]

MILROY SYNDROME

Milroy syndrome (OMIM: 153100) is a congenital primary lymphedema that leads to disability and disfiguring swelling of the lower extremities. It is also known as hereditary lymphedema IA and Nonne-Milroy lymphedema. Onset is usually at birth or in early childhood, and the severity can vary but often progresses with time.[54,55] It is a relatively rare condition with an estimated frequency of approximately 1 in 6000 live births, and there is a 2.3:1 female predominance in pedigrees.[55] This sex ratio may be the result of more-severe disease in males that leads to hydrops fetalis and fetal death.[56]

Clinical Features: Bilateral lower-limb asymmetric swelling is most common with deep creases noted over the toes. Large superficial veins can be visible during infancy. Nail and skin changes all occur, such as toenail upslanting ("ski jump") dysplasia or skin papillomatosis (greatest over second toe). Skin infections and hydroceles are also common. Hypoproteinemia from intestinal loss of albumin via intestinal lymphangiectasias, chylous ascites, and scrotal edema are known complications.[54] Thickening of the skin overlying the digits leads to a positive Kaposi-Stemmer sign (inability to pinch up a fold of skin between the second and third toe on the dorsum of the foot).

Etiology and Pathogenesis: Milroy syndrome is an autosomal dominant disease caused by a mutation in *VEGFR3* (also called the *FLT4* gene).[55] This causes impaired tyrosine kinase activity of the VEGFR3 receptor, which disrupts lymphangiogenesis. Prenatal ultrasonography can show edematous legs in the fetus. Skin biopsy from swollen feet of patients who possess the *VEGFR3* mutation reveals abundant skin lymphatics that are confirmed to be nonfunctional by fluorescence microlymphangiography.[57] Interestingly, lymphangiography also demonstrates dysplastic lymphatics in both clinically affected and clinically normal extremities, emphasizing the complexity of the pathophysiology that ultimately leads to disease.

The mechanism by which Milroy lymphedema develops appear to be the result of functional failure of the lymphatics as opposed to absence of initial lymphatics.[57] Penetrance is relatively high (80%), but not complete, suggesting a role of additional genetic or environmental factors resulting in variation of clinical expression.

LYMPHEDEMA-DISTICHIASIS

Clinical Features: Lymphedema typically develops during puberty, but may be delayed until early adulthood, especially in females. The lymphedema will commonly worsen in severity over time, and may be complicated by recurrent infection and eventual papillomatosis. A double row of eyelashes (*distichiasis*) are aberrant eyelashes arising along the posterior border of the eyelid margin, which frequently leads to eyelash

irritation of the cornea and photophobia. Other associated findings of this syndrome include cardiac defects, varicose veins, cleft palate, spinal extradural cysts, and other ophthalmologic complications. Given the complexity of this disorder and the possibility of systemic involvement, treatment of this disorder frequently requires a multidisciplinary approach, including dermatologists, pediatricians, and geneticists.[58]

Etiology and Pathogenesis: Autosomal dominant nonsense and frameshift mutations in the forkhead transcription factor FoxC2 cause abnormalities in morphogenesis of the lymphatic valves in this disease.[59] Radiographic studies of patients with lymphedema-distichiasis show lymph and venous reflux of the lower limbs, illustrating the primary valve failure. Distichiasis, a double row of eyelashes, develops as a result of failure of proper differentiation of eyelid follicles into meibomian glands.[58] Although the *FOXC2* mutation is specific for lymphedema-distichiasis,[59] further investigation has illustrated that lymphedema with ptosis may actually be one of the variable manifestations of *FOXC2* mutations, rather than a distinct disorder.[60]

SECONDARY LYMPHEDEMA

EPIDEMIOLOGY

The prevalence of chronic edema in a community sample in London was 1.33 per 1000 people and 5.4 per 1000 persons older than the age of 65 years.[61] Twenty-five percent of chronic edema was related to malignancy; 29% of patients had at least 1 episode of cellulitis during the year before the survey; and 70% to 80% of patients were female.[61]

Worldwide, lymphedema caused by filariasis is estimated to affect 100 million individuals and is considered to be the second leading cause of permanent disability in the world.[62,63] For the epidemiology, clinical manifestations, and treatment of filariasis, see Chap. 177.

Other infectious diseases with lymphedema are much less common and include lymphogranuloma venereum, granuloma inguinale (see Chaps. 173 and 174), and tuberculosis (see Chap. 157).

In regions of tropical Africa, Central America, and the Indian subcontinent where filariasis is uncommon, there is a condition of chronic lymphedema called *podoconiosis* or *nonfilarial elephantiasis*. This condition causes edematous feet and legs, and is usually bilateral. Podoconiosis is not infectious in origin. It is caused by chronic inoculation of microparticles of silica through the soles of barefoot walkers.[64]

CLINICAL FEATURES

Typically, patients will present with a persistently edematous extremity without concurrent pain or inflammation (Table 148-17). The foot is often involved first, and initially lesions pit with pressure. Patients presenting later in the disease course may present with nonpitting edema. Feet may illustrate swollen toes with upturned nails. Thickening of the skin over the digits may be present, as may the Kaposi-Stemmer sign. If the condition has been longstanding, the skin overlying the affected extremity may show generalized thickening, papillomatosis, or verrucous tissue overgrowth (see Fig. 148-20). Fungal and bacterial infections, or viral warts also may be present.

TABLE 148-17
Signs and Symptoms of Lymphedema

Symptoms
▪ Edematous extremity
▪ Heaviness
▪ Indentations from socks on standing
▪ Indentations improve overnight
▪ Painless
Signs
Early
▪ Erysipelas
▪ Pitting edema
Late
▪ Nonpitting edema
▪ Papillomatosis
▪ Secondary infections (bacterial, fungal, viral warts)
▪ "Ski-jump" upturned toe nails
▪ Thickened, woody skin
▪ Verrucous tissue overgrowth

Unilateral lymphedema suggests localized obstructing factors, but bilateral lymphedema does not rule out anatomic obstruction, as the obstruction may be in the pelvis or abdomen.

Inflammation as manifested by redness, pain, and swelling is not lymphedema, but can be pyogenic infection, most commonly with *S. aureus* or *Streptococcus pyogenes*. Systemic antibiotics should be started before waiting for red lymphangitic streaking. A common complication is contact dermatitis from the use of topical antibiotics or multiple emollients and antiinflammatory creams. However, itch is often the dominant symptom in this case.

Prolonged lymphedema leads to fibrosis and epidermal hyperplasia with verrucous hyperkeratosis. Ulceration rarely occurs, although the edema and hyperkeratotic changes may be profound. Lymphangiosarcoma, called Stewart-Treves syndrome when associated with postmastectomy lymphedema, is a potential complication in chronically lymphedematous locations (see Chap. 118).

DIAGNOSIS

If there is doubt regarding the clinical diagnosis of lymphedema, especially when trying to differentiate from edema, there are various studies that may be employed for diagnostic confirmation. Isotopic lymphoscintigraphy is recommended, but radiocontrast

lymphangiography also can be used.[65,66] CT and MRI are other radiographic options, although not ideal. MRI is preferred over CT because of its ability to detect water. These modalities should reveal the characteristic "honeycomb" pattern of the subcutaneous tissue present in chronic lymphedema.[65] This pattern is not present in other types of edema. Venous duplex ultrasonography may be required to rule out concomitant deep venous thrombosis and to assess for chronic venous insufficiency as a cause for swelling.

Special Tests: Diagnosis of filariasis (see Chap. 177) includes assays to detect filarial antigens, and ultrasonography to visualize living adult worms, even in the absence of microfilaremia.[67]

DIFFERENTIAL DIAGNOSIS

Chronic venous insufficiency can present with very similar features of early lymphedema. In this clinical context, both conditions will have pitting edema, and the characteristic skin changes of late-stage lymphedema have not yet developed. However, chronic venous insufficiency is typically bilateral, rather than unilateral as in lymphedema. It is imperative to exclude medical causes of lower-extremity swelling (Table 148-18). An uncommon clinical mimic to lymphedema is lipedema of the leg. This syndrome is caused by bilateral adipose deposition, usually in the buttocks and lower extremities. This leads to enlargement that stops abruptly at the level of the malleoli, characteristically sparing the feet. This distinctive clinical presentation is referred to as "armchair legs."[47] This condition predominates among overweight women who spend the majority of their time with their legs in a dependent position. Chronic immobility leads to decreased lymphatic drainage and subsequent lymphedema.

CLINICAL COURSE AND PROGNOSIS

Lymphedema is chronic and can be disabling. Pain, heaviness, and discomfort in the affected limb are common symptoms as lymphedema progresses. Extremities affected by lymphedema are at increased risk of skin breakdown, lymph fluid leakage, and infections. Cellulitis, erysipelas, tinea pedis, and lymphangitis are common complications of longstanding lymphedema and can subsequently worsen lymphedema.

MANAGEMENT

There is no cure for lymphedema; thus the goal is to improve mobility of the limb and minimize secondary complications. A combination of elevation, exercise, compression garments/devices, skin care aimed at preventing infection, and manual lymphatic drainage, usually via massage, are the mainstays of management (Table 148-19).[47,68] In patients with primary and secondary lymphedema, in the absence of venous or arterial disease, manual lymphatic drainage and sequential pneumatic pumps, in addition to compression wraps and garments, may be useful.

Exercise under compression is beneficial for lymphedema by enhancing lymph flow and potentially improving protein resorption. Lymph moves faster during limb activity and exercise. A combination of flexibility training, aerobic training, and strengthening exercises—while wearing compression garments or devices—significantly improve lymphedema.[68]

Drug therapy for lymphedema, in general, has been inadequate. Diuretics are frequently prescribed, and not only do they not alleviate the symptoms, they may actually worsen the condition and should not be used as a primary treatment for lymphedema. There is some evidence to suggest the efficacy of coumarin therapy. Coumarin apparently reduces capillary filtration as well as reduces fibrotic tissue deposition.[47]

Recurrent cellulitis, erysipelas, and lymphangitis are a significant problem in lymphedematous sites, and there is both a rationale and results that encourage long-term antibiotic use (eg, 2.4 million units of benzathine-penicillin G IM every 2 weeks, or cephalexin).[69] Interdigital maceration and tinea pedis create a portal of entry for bacteria. Thus prompt antifungal management and avoidance of web space moisture is necessary.

Lymphatic microsurgery to bypass obstructed nodes can be considered if nonsurgical treatments are unsuccessful. This procedure is not commonly performed in the United States, but the literature from studies of this procedure performed in Europe is considerable. The surgery consists of the formation of multiple end-to-end lymphatic–venous anastomoses.[68,70] Congenital

TABLE 148-18
Differential Diagnosis of Secondary Lymphedema

- Chronic venous insufficiency
- Filariasis
- Medical disease
  - Congestive Heart Failure
  - Drug-induced edema
  - Hypoalbuminemia
  - Lipedema "armchair sign"
  - Obesity
  - Pregnancy
  - Protein-losing nephropathy
  - Renal Failure
- Podoconiosis
- Postphlebitic syndrome
- Recurrent infection

TABLE 148-19
Therapeutic Options

- Compression by multilayered wrappings or compression garments
- Elevation
- Exercise (under compression)
- Manual lymphatic drainage
- Skin care
- Surgery

lymphatic disorders have been treated with this intervention in the early childhood years with dramatic results.[68,70]

Low-level laser therapy, either in combination with pneumatic compression or as a solo intervention, has been studied in patients with postoperative lymphedema, primarily in postmastectomy lymphedema. Results are encouraging, and patients have had improvements in the total volume of affected limbs at followup analysis of up to 1 year.[71]

Excisional or suction-assisted lipectomy (liposuction) may be an option in selected patients who are not eligible for other treatment options, or in whom other therapeutic modalities have failed.

Prevention: Any patient with lymphedema, whatever the cause, should keep their feet dry, nails trimmed, and prevent and aggressively treat pyogenic infection. Use of topical antifungal therapy is encouraged.

LOCALIZED AREAS OF LYMPHEDEMA

Lymphedema is common in some locations, especially on the face, vulva, and penis, and can lead to superficial lesions termed *lymphangiectasia*. These focal areas of lymphedema occur from obstruction of previously normal lymphatics, progressing to lymphatic valve incompetence, lymph reflux, and retrograde lymph flow to the skin. This leads to blister-like lesions full of lymphatic fluid called *lymphangiectasias*. These most commonly occur after trauma, treatment for malignancy, or infection. These lesions are highly symptomatic and distressing. They are frequently painful, pruritic, and exudative. Carbon dioxide laser ablation is a currently favored treatment modality for superficial lesions.[72] Because the underlying obstructed lymph vessels are not corrected by laser ablation, recurrences are common.[73] Other options for treatment include surgical excision, superficial radiotherapy, and sclerotherapy.[73-75]

ACKNOWLEDGMENTS

The author acknowledges the contributions of Veerendra Chadachan, Steven M. Dean, Robert T. Eberhardt, Craig N. Burkhart, Chris Adigun, and Claude S. Burton, the former authors of this chapter.

REFERENCES

1. Rooke TW, Hirsch AT, Misra S, et al. 2011 ACCF/AHA focused update of the guideline for the management of patients with peripheral artery disease (updating the 2005 guidelines): a report of the American College of Cardiology Foundation/American Heart Association Task Force on Practice Guidelines. *J Am Coll Cardiol.* 2011;58(19):2020-2045.
2. Hirsch AT, Haskal ZJ, Hertzer NR, et al. ACC/AHA 2005 guidelines for the management of patients with peripheral arterial disease (lower extremity, renal, mesenteric, and abdominal aortic): executive summary a collaborative report from the American Association for Vascular Surgery/Society for Vascular Surgery, Society for Cardiovascular Angiography and Interventions, Society for Vascular Medicine and Biology, Society of Interventional Radiology, and the ACC/AHA Task Force on Practice Guidelines (Writing Committee to Develop Guidelines for the Management of Patients With Peripheral Arterial Disease) endorsed by the American Association of Cardiovascular and Pulmonary Rehabilitation; National Heart, Lung, and Blood Institute; Society for Vascular Nursing; TransAtlantic Inter-Society Consensus; and Vascular Disease Foundation. *J Am Coll Cardiol.* 2006;47(6):1239-1312.
3. Fowkes FG, Rudan D, Rudan I, et al. Comparison of global estimates of prevalence and risk factors for peripheral artery disease in 2000 and 2010. *Lancet.* 2013;382(9901);1329-1340.
4. Skelly CL, Cifu AS. Screening, evaluation and treatment of peripheral arterial disease. *JAMA.* 2016;316(14): 1486-1487.
5. Conte MS, Pomposelli FB, Clair DG, et al. Society for Vascular Surgery practice guidelines for atherosclerotic occlusive disease of the lower extremity. *J Vasc Surg.* 2015;61(suppl 3);2S-41S.
6. Imparato AM, Kim GE, Davidson T, et al. Intermittent claudication: its natural course. *Surgery.* 1975;78(6): 795.
7. O'Hare AM, Katz R, Shlipak MG, et al. Mortality and cardiovascular risk across the ankle-arm index spectrum: results from the Cardiovascular Health Study. *Circulation.* 2006;113(3):388-393.
8. Malgor RD, Alahdab F, Elraiyah TA, et al. A systemic review for the screening for peripheral arterial disease in asymptomatic patients. *J Vasc Surg.* 2015;61(suppl 3): 42S-53S.
9. Dawson DL, Cutler BS, Meissner MH, et al. Cilostazol has beneficial effects in treatment of intermittent claudication: results from a multicenter, randomized, prospective, double-blind trial. *Circulation.* 1998; 98(7):678-686.
10. Salhiyyah K, Senanayake E, Abdel-Hadi M, et al. Pentoxifylline for intermittent claudication. *Cochrane Database Syst Rev.* 2012;1:CD005262.
11. Mozaffarian D, Benjamin EJ, Go AS, et al. Executive summary: heart disease and stroke statistics—2016 update: a report from the American Heart Association. *Circulation.* 2016;133(4):447-454.
12. Liew YP, Bartholomew JR. Atheromatous embolization. *Vasc Med.* 2005;10(4):309-326.
13. Fukumoto Y, Tsutsui H, Tsuchihashi M, et al. The incidence and risk factors of cholesterol embolization syndrome, a complication of cardiac catheterization: a prospective study. *J Am Coll Cardiol.* 2003;42(2):211-216.
14. Ismail I, Agarwal A, Aggarwal S, et al. Aortic atherosclerosis: a common source of cerebral emboli, often overlooked! *Am J Ther.* 2016;23(1):e268-e272.
15. Saric M, Kronzon I. Cholesterol embolization syndrome. *Curr Opin Cardiol.* 2011;26(6):472-479.
16. Rivera-Chavarría IJ, Brenes-Gutierrez JD. Thromboangiitis obliterans (Buerger's disease). *Ann Med Surg (Lond).* 2016;29(7):79-82.
17. Gallagher K, Tracci M, Scovell S. Vascular arteritides in women. *J Vasc Surg.* 2013;57(4)(suppl):27S-36S.

18. McLoughlin GA, Helsby CR, Evans CC, et al. Association of HLA-A9 and HLA-B5 with Buerger's disease. *Br Med J.* 1976;13(2):1165-1166.
19. Del Conde I, Peña C. Buerger disease (thromboangiitis obliterans). *Tech Vasc Interv Radiol.* 2014;17(4): 234-240.
20. Olin JW, Shih A. Thromboangiitis obliterans (Buerger's disease). *Curr Opin Rheumatol.* 2006;18(1):18-24.
21. Gibbs MB, English JC, Zirwas, MJ. Livedo reticularis: an update. *J Am Acad Dermatol.* 2005;52(6):1009-1019.
22. Uthman IW, Khamastha MA. Livedo racemosa: a striking dermatological sign for the antiphospholipid syndrome. *J Rheumatol.* 2006;33(12):2379-2382.
23. Vollum DI, Parkes JD, Doyle D. Livedo reticularis during amantadine treatment. *Br Med J.* 1971;12(2):627-628.
24. Berlin AL, Pehr K. Coexistence of erythromelalgia and Raynaud's phenomenon. *J Am Acad Dermatol.* 2004; 50(3):456.
25. Toubi E, Krause I, Fraser A, et al. Livedo reticularis is a marker for predicting multi-system thrombosis in antiphospholipid syndrome. *Clin Exp Rheumatol.* 2005;23(4):499-504.
26. Cohen JS. Erythromelalgia: new theories and new therapies. *J Am Acad Dermatol.* 2000;43(5, pt 1):841-847.
27. Andersen LK, Davis MD. Sex differences in the incidence of skin and skin-related diseases in Olmsted County, Minnesota, United States, and a comparison with other rates published worldwide. *Int J Dermatol.* 2016;55(9):939-955.
28. Reed KB, Davis MD. Incidence of erythromelalgia: a population-based study in Olmsted County, Minnesota. *J Eur Acad Dermatol Venereol.* 2009;23(1):13-15.
29. Cook-Norris RH, Tollefson MM, Cruz-Inigo BA, et al. Pediatric erythromelalgia: a retrospective review of 32 cases evaluated at Mayo Clinic over a 37-year period. *J Am Acad Dermatol.* 2012;66(3):416-423.
30. McDonnell A, Schulman B, Ali Z, et al. Inherited erythromelalgia due to mutations in SCN9A: natural history, clinical phenotype and somatosensory profile. *Brain.* 2016;139(pt 4):1052-1065.
31. Tang Z, Chen Z, Tang B, et al. Primary erythromelalgia: a review. *Orphanet J Rare Dis.* 2015;30(10):127.
32. Beebe-Dimmer JL, Pfeifer JR, Engle JS, et al. The epidemiology of chronic venous insufficiency and varicose veins. *Ann Epidemiol.* 2005;15(3):175-184.
33. Bergan JJ, Schmid-Schönbein GW, Smith PD, et al. Chronic venous disease. *N Engl J Med.* 2006; 355(5): 488-498.
34. Fowkes FG, Evans CJ, Lee AJ. Prevalence and risk factors for chronic venous insufficiency. *Angiology.* 2001; 52(suppl 1):S5-S15.
35. Barron GS, Jacob SE, Kirsner RS. Dermatologic complications of chronic venous disease: medical management and beyond. *Ann Vasc Surg.* 2007;21(5): 652-662.
36. Gibson GE, Su WP, Pittelkow MR. Antiphospholipid syndrome and the skin. *J Am Acad Dermatol.* 1997; 36(6, pt 1):970-982.
37. Gloviczki P, Comerota AJ, Dalsing MC, et al. The care of patients with varicose veins and associated chronic venous diseases: clinical practice guidelines of the Society for Vascular Surgery and the American Venous Forum. *J Vasc Surg.* 2011;53(5 suppl):2S-48S.
38. Subbiah R, Aggarwal V, Zhao H, et al. Effect of compression stockings on post thrombotic syndrome in patients with deep vein thrombosis: a meta-analysis of randomised controlled trials. *Lancet Haematol.* 2016;3(6):e293-e300.
39. de Oliveira Carvalho PE, Magolbo NG, De Aquino RF, et al. Oral aspirin for treating venous leg ulcers. *Cochrane Database Syst Rev.* 2016;2:CD009432.
40. Ibbotson SH, Layton AM, Davies JA, et al. The effect of aspirin on haemostatic activity in the treatment of chronic venous leg ulceration. *Br J Dermatol.* 1995;132(3):422-426.
41. Jull A, Waters J, Arroll B. Pentoxifylline for treatment of venous leg ulcers: a systematic review. *Lancet.* 2002;359(9317):1550.
42. Jull AB, Arroll B, Parag V, et al. Pentoxifylline for treating venous leg ulcers. *Cochrane Database Syst Rev.* 2012;12:CD001733.
43. Pittler MH, Ernst E. Horse chestnut seed extract for chronic venous insufficiency. *Cochrane Database Syst Rev*. 2012;11:CD003230.
44. Tenbrook JA Jr, Iafrati MD, O'donnell TF Jr, et al. Systematic review of outcomes after surgical management of venous disease incorporating subfascial endoscopic perforator surgery. *J Vasc Surg.* 2004; 39(3):583-589.
45. Chaby G, Viseux V, Ramelet AA, et al. Refractory venous leg ulcers: a study of risk factors. *Dermatol Surg.* 2006; 32(4):512-519.
46. Petrova TV, Karpanen T, Norrmén C, et al. Defective valves and abnormal mural cell recruitment underlie lymphatic vascular failure in lymphedema distichiasis. *Nat Med.* 2004;10(9):974-981.
47. Kerchner K, Fleischer A, Yosipovitch G. Lower extremity lymphedema update: pathophysiology, diagnosis, and treatment guidelines. *J Am Acad Dermatol.* 2008;59(2):324-331.
48. Murdaca G, Cagnati P, Gulli R, et al. Current views on diagnostic approach and treatment of lymphedema. *Am J Med.* 2012;125(2):134-140.
49. Kurland LT, Molgaard CA. The patient record in epidemiology. *Sci Am.* 1981;245(4):54-63.
50. Saito Y, Nakagami H, Kaneda Y, et al. Lymphedema and therapeutic lymphangiogenesis. *Biomed Res Int.* 2013;2013:804675.
51. Ostergaard P, Simpson MA, Connell FC, et al. Mutations in GATA2 cause primary lymphedema associated with a predisposition to acute myeloid leukemia (Emberger syndrome). *Nat Genet.* 2011;43(10):929-931.
52. Kazenwadel J, Betterman KL, Chong C, et al. GATA2 is required for lymphatic vessel valve development and maintenance. *J Clin Invest.* 2015;125(8):2979-2994.
53. Spinner MA, Sanchez LA, Hsu AP, et al. GATA2 deficiency: a protean disorder of hematopoiesis, lymphatics and immunity. *Blood.* 2014;123(6):809-821.
54. Gordon K, Schulte D, Brice G, et al. Mutation in vascular endothelial growth factor-C, a ligand for vascular endothelial growth factor receptor-3, is associated with autosomal dominant Milroy-like primary lymphedema. *Circ Res.* 2013;112(6):956-960.
55. Balboa-Beltran E, Fernandez-Seara MJ, Perez-Munuzuri A, et al. A novel stop mutation in the vascular endothelial growth factor-C gene (VEGFC) results in Milroy-like disease. *J Med Genet.* 2014;51(7):475-478.
56. Ghalamkampour A, Morlot S, Raas-Rothschild A, et al. Hereditary lymphedema type I associated with VEGFR 3 mutation: the first de novo case and atypical presentations. *Clin Genet.* 2006;70(4):330-335.
57. Connell F, Brice G, Mortimer P. Phenotypic characterization of primary lymphedema. *Ann N Y Acad Sci.* 2008;1131:140-146.
58. Brice G, Mansour S, Bell R, et al. Analysis of the phenotypic abnormalities in lymphoedema-distichiasis

syndrome in 74 patients with FOXC2 mutations or linkage to 16q24. *J Med Genet*. 2002;39(7):478-483.
59. Mellor RH, Brice G, Stanton AW, et al. Mutations in FOXC2 are strongly associated with primary valve failure in veins of the lower limb. *Circulation*. 2007;115(14): 1912-1920.
60. Rezaie T, Ghoroghchian R, Bell R, et al. Primary non-syndromic lymphedema (Meige disease) is not caused by mutations in FOXC2. *Eur J Hum Genet*. 2008;16(3):300-304.
61. Moffatt CJ, Franks PJ, Doherty DC, et al. Lymphoedema: an underestimated health problem. *Q J Med*. 2003;96(10):731-738.
62. Shenoy RK, Bockarie MJ. Lymphatic filariasis in children: clinical features, infection burdens and future prospects for elimination. *Parasitology*. 2011;138(12): 1559-1568.
63. Rizzo JA, Belo C, Lins R, et al. Children and adolescents infected with *Wuchereria bancrofti* in Greater Recife, Brazil: a randomized, year-long clinical trial of single treatments with diethylcarbamazine or diethylcarbamazine-albendazole. *Ann Trop Med Parasitol*. 2007;101(5):423-433.
64. Bekele K, Deribe K, Amberbir T, et al. Burden assessment of podoconiosis in Wayu Tuka Woreda, East Wollega zone, western Ethiopia: a community-based cross-sectional study. *BMJ Open*. 2016;6:e012308.
65. Dimakakos E, Koureas A, Koutoulidis V, et al. Interstitial magnetic resonance lymphography: the clinical effectiveness of a new method. *Lymphology*. 2008; 41(3):116-125.
66. Liu N, Zhang Y. Magnetic resonance lymphangiography for the study of lymphatic system in lymphedema. *J Reconstr Microsurg*. 2016;32(1):66-71.
67. Thomsen EK, Sanuku N, Baea M, et al. Efficacy, safety, and pharmacokinetics of coadministered diethylcarbamazine, albendazole, and ivermectin for treatment of bancroftian filariasis. *Clin Infect Dis*. 2016;62(3): 334-341.
68. Ogawa Y. Recent advances in medical treatment for lymphedema. *Ann Vasc Dis*. 2012;5(2):139-144.
69. Vignes S, Dupuy A. Recurrence of lymphedema associated cellulitis (erysipelas) under prophylactic antibiotherapy: a retrospective cohort study. *J Eur Acad Dermatol Venereol*. 2006;20(7):818-822.
70. Baumeister RG, Mayo W, Notohamiprodjo M, et al. Microsurgical lymphatic vessel transplantation. *J Reconstr Microsurg*. 2016;32(1):34-41.
71. Smoot B, Chiavola-Larson L, Lee J, et al. Effect of low-level laser therapy on pain and swelling in women with breast cancer-related lymphedema: a systematic review and meta-analysis. *J Cancer Surviv*. 2015; 9(2):287-304.
72. Savas JA, Ledon J, Franca K, et al. Carbon dioxide laser for the treatment of microcystic lymphatic malformations (lymphangioma circumscriptum): a systematic review. *Dermatol Surg*. 2013;39:1147-1157.
73. Niti K, Manish P. Microcystic lymphatic malformation (lymphangioma circumscriptum) treated using a minimally invasive technique of radiofrequency ablation and sclerotherapy. *Dermatol Surg*. 2010;36:1711-1717.
74. Yoon G, Kim HS, Lee YY, et al. Clinical outcomes of primary surgical treatment for acquired vulvar lymphangioma circumscriptum. *Arch Gynecol Obstet*. 2016;293:157-162.
75. Wiegand S, Eivazi B, Zimmermann AP, et al. Sclerotherapy of lymphangiomas of the head and neck. *Head Neck*. 2011;33:1649-1655.

Chapter 149 :: Wound Healing

:: Afsaneh Alavi & Robert S. Kirsner

AT-A-GLANCE

- While acute and chronic wounds are different, all chronic wounds start as an acute wound.
- In acute wounds, there is an orderly progression from injury to coagulation, inflammation, cell and matrix proliferation, cell migration, and tissue remodeling.
- In the initial phases, a wide range of growth factors, including platelet-derived growth factor and transforming growth factor-β_1, play an important role. In the proliferation/migration and modeling phases, tissue matrix metalloproteinases (MMPs), integrins, basic fibroblast growth factor, and epidermal growth factor are critical. MMP-1, MMP-9, and MMP-10 are essential for remodeling.
- For acute wounds, moist wounds heal faster, and a variety of wound dressings are available, including hydrogels, polyurethane films, hydrocolloids, foams, alginates, superabsorbent dressings, and collagen-based products.
- In chronic wounds, the linear progression between the sequential phases of acute wound healing is lost. Chronic wounds are often the result of ischemia, pressure, and infection; healing, in part, is dependent on addressing these factors.
- Healing after skin grafting is also different, as it depends on revascularization, either neovascularization or inosculation.

Wound healing involves a complex but overlapping sequential series of events aimed at barrier restoration, from hemostasis to inflammation, proliferation, and remodeling. Many mediators, such as platelets, neutrophils, macrophages, cytokines, growth factors, matrix metalloproteinases, and their inhibitors regulate these events.[1] Some wounds fail to move through these stages in an orderly and timely fashion and become chronic wounds. All these components play a role in healing, and alteration in one or more of these components may impair healing and/or lead to abnormal scar formation, such as a hypertrophic scar or keloid.[2] Wounds can be categorized by the depth of the wound, which helps predict the amount of scarring that will occur. Greater scarring occurs in full-thickness versus partial or spilt-thickness wounds. Figure 149-1 outlines these differences.

DIFFERENT TYPES OF WOUND HEALING

Primary healing, also called healing by primary or first intention, is the closure of the wound soon after wound creation, as seen in surgical wounds and clean lacerations. Wound closure is aided by approximation of the wound edges using sutures, glues, tapes, or mechanical devices, and in side-to-side closure and with grafts and flaps.

Delayed primary healing is the slightly delayed closure of a wound, typically by a few days. As an example, a contaminated wound may first be treated with antimicrobials to assure eradication of bacteria that might delay healing.

In healing by *secondary intention*, the open wound heals through a process that includes granulation tissue formation and epithelialization. Commonly employed after an excessive loss of soft tissue, such as major trauma or severe burns, the large defect requires ingrowth of granulation tissue and extracellular matrix (ECM) formation. Myofibroblasts plays a major role in this type of healing,[1] appearing 3 days after the injury and reaching a maximum level 10 to 21 days postinjury. Secondary intention healing may result in wound contracture and can cause functional restriction.

Tertiary intention occurs when a wound originally closed by primary intention dehisces and then heals by secondary intention.

The time to complete healing depends on many factors such as the depth of the wound, location of the wound (eg, facial wounds heal faster than acral wounds), vascular supply, presence of infection, and wound shape (smaller diameter wounds heal faster than larger diameter wounds of the same size/area.)[3]

MECHANISMS OF WOUND HEALING

PHASES OF WOUND HEALING

Tissue injury triggers a cascade of sequential, overlapping events that have been categorized into several phases, including: (a) coagulation, (b) the inflammatory phase, (c) the proliferative (and migratory) phase, and (d) the remodeling phase. Figure 149-2 illustrates these phases in diagrammatic form, and Fig. 149-3 shows specific events that take place during the various phases. The cell types primarily involved in wound

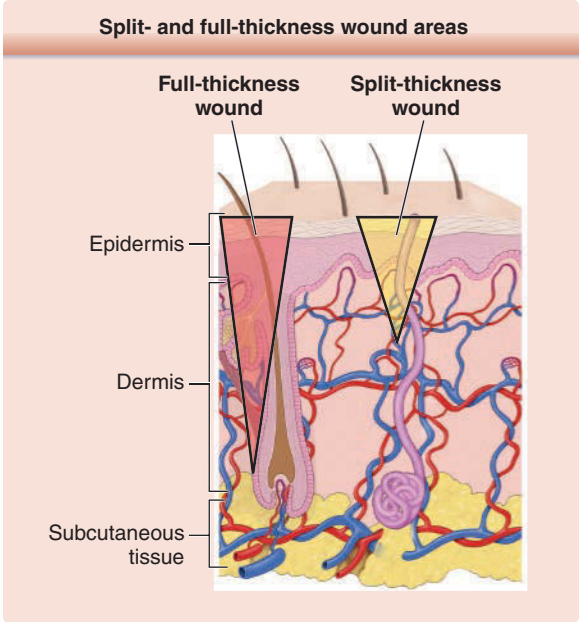

Figure 149-1 Diagrammatic representation of the skin, with 2 inverted triangles representing either a split-thickness or full-thickness wound. Extending the injury below the reservoir of keratinocytes present in skin appendages (full-thickness wound) removes the capability of the keratinocytes to populate the defect from within the wound bed, which means healing has to occur from the wound edges and more scarring takes place.

healing are platelets, neutrophils, and macrophages, fibroblasts, endothelial cells, and epithelial cells. More recently, increasing importance is accumulating for the role, either directly or indirectly, of lymphocytes.[4,5]

COAGULATION

Immediately after injury, disruption of blood vessels leads to local release of blood cells and bloodborne elements, resulting in clot formation and activation of the intrinsic and extrinsic coagulation cascade.[3] While the blood clot within the vessel lumen provides hemostasis, the clot within the injury site acts as a provisional matrix for cell migration, leads to further formation of ECM,[6] and provides a reservoir for cytokines and growth factors.[7,8] Platelets degranulate and release α granules which secret growth factors including platelet-derived growth factors, insulin-like growth factors, epidermal growth factors, transforming growth factor-β, and platelet factor 4. Platelets also release a number of chemotactic factors that attract other platelets, leukocytes, and fibroblasts to the site of injury.[8,9] The clot also contains fibrin, fibronectin, vitronectin, von Willebrand factor, and thrombospondin, which provide a matrix for cell migration. Vasoactive amines released from platelets, such as serotonin, facilitate cell migration by increased microvascular permeability. Hageman factor XII is a specific enzyme released following platelet aggregation to initiate the intrinsic coagulation cascade. Prothrombin transforms into thrombin, converting soluble fibrinogen to insoluble fibrin. Additionally, injured

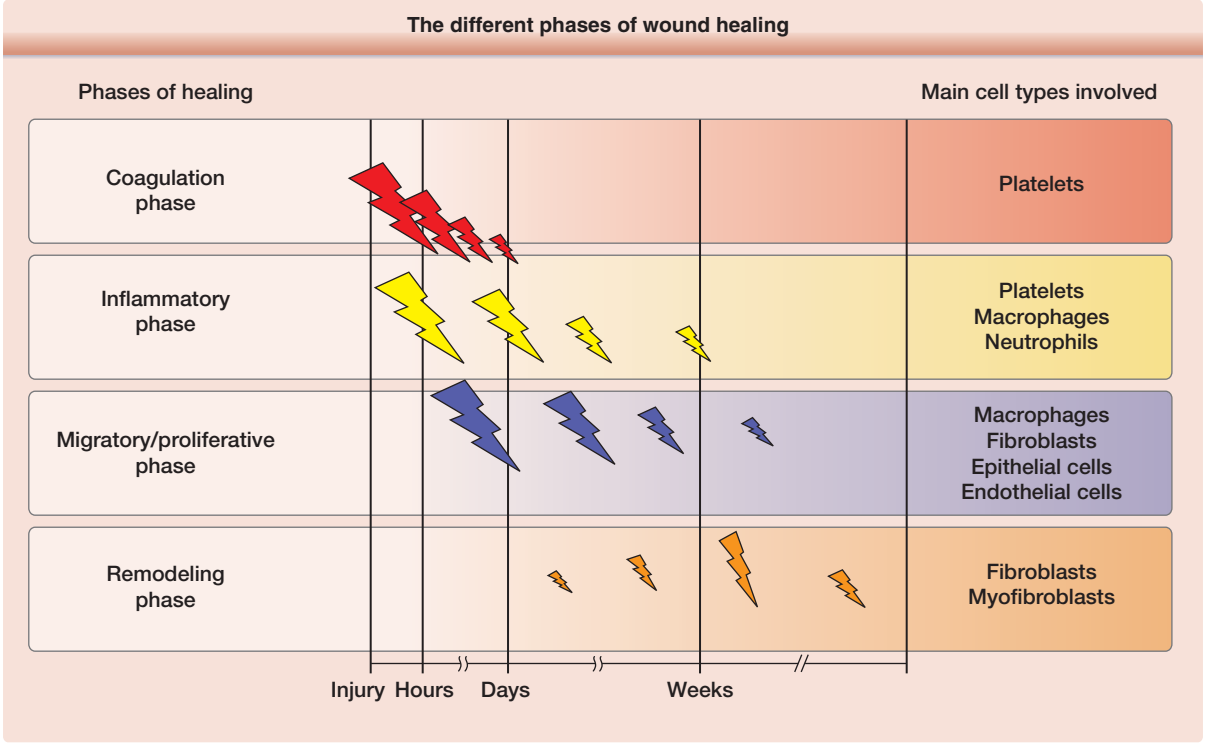

Figure 149-2 Schematic, different of the different phases of wound healing.

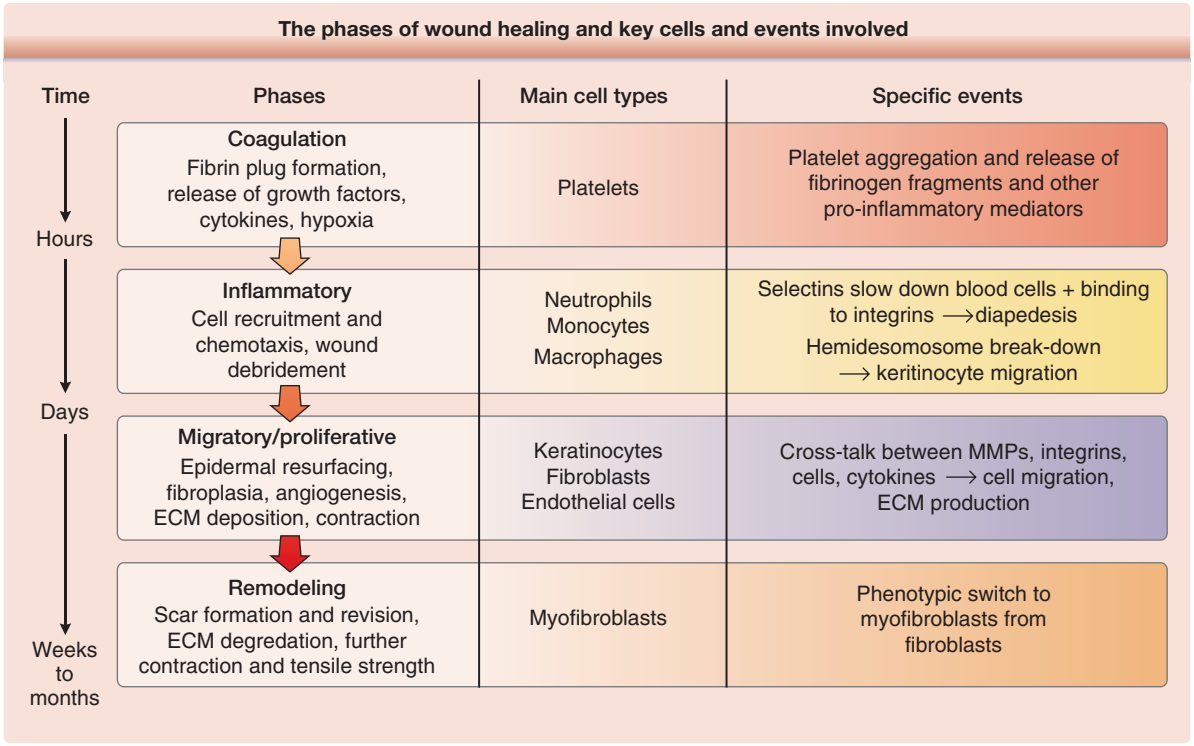

Figure 149-3 The phases of wound healing, and key cells and events involved. (Reprinted from Falanga V. Wound healing and its impairment in the diabetic foot. *The Lancet*. 2005;366:1736-1743; with permission. Copyright © Elsevier.)

tissue releases a tissue factor that activates the extrinsic coagulation pathway.[9]

INFLAMMATION

Inflammation begins with activation of classic and alternative complement cascades and subsequent neutrophil infiltration to the wound site within 24 to 48 hours of injury. White cells have multiple functions, including phagocytosis of necrotic material and bacteria, as well as the production of certain critical cytokines.[10,11] Leukocytes adhere to the adjacent blood vessels (margination) and actively move through the vessel wall via diapedesis. Leukocytes release enzymes and oxygen-derived free radicals. After the first few days, the constituency of white cells changes as neutrophils are replaced by macrophages.[12]

Macrophages, often considered the most important regulatory cells in the wound healing inflammatory process, typically appear in the wound site 72 hours after the injury. Macrophages, key regulator cells for repair, are the main phagocytic cells and release proteolytic enzymes such as a variety of collagenases. Macrophages also produce growth factors responsible for the smooth muscle proliferation and endothelial cell and fibroblast proliferation, all of which contribute to ECM production. This hypoxic environment is associated with high levels of proteases and low pH, both of which contribute to activation of growth factors.[11]

Monocytes are attracted to the injury site by kallikrein, fibrinopeptides, and fibrin-degradation products; some of these same chemoattractants are also responsible for recruitment of neutrophils.[13,14] Other more specific chemoattractants further recruit monocytes, including collagen fragments, fibronectin, elastin, and transforming growth factor (TGF)-β_1. Monocytes undergo a phenotypic change to tissue macrophages critical for the progression of healing.[15,16] Macrophages release chemotactic factors to attract fibroblasts to the wound area. Importantly, they display impressive plasticity, and at least 2 subsets of macrophages exist and have distinct phenotypes in various stages of healing (see below). They also produce a variety of growth factors, such as platelet-derived growth factor (PDGF), fibroblast growth factors (FGFs), and vascular endothelial growth factors (VEGFs), as well as TGF-β and TGF-α. Alterations in tissue macrophages or circulating monocytes lead to poor intrinsic debridement, delay proliferation of fibroblasts, and allow for inadequate angiogenesis and overall poor healing.[17]

Macrophages are divided into M1 (or classically activated) and M2 (or alternatively activated) macrophages. M1 phenotype macrophages are activated by interferon-γ and tumor necrosis factor (TNF)-α following wound formation. They release interleukin (IL)-12 and promote a proinflammatory T-helper (Th)-1 immune response early on. Subsequently, M2 macrophages, activated by IL-4 and IL-13, work to downregulate inflammation by releasing antiinflammatory cytokines such as IL-10. These M2 macrophages present later in healing during granulation tissue formation.[17-19]

ABNORMAL INFLAMMATORY PHASE

Immediately after injury, local vasodilation, extravasation of blood and fluid, and lymphatic drainage blockage (in some cases) can lead to cardinal symptoms of inflammation such as heat, redness, pain, and swelling. The acute inflammatory response may last 2 weeks; however, prolongation of inflammation (chronic inflammation) may delay healing.[20]

With chronic inflammation, the wound often contains necrotic tissue and pathogenic organisms. In this case, granulocytes disappear and mononuclear cells, particularly monocytes, lymphocytes, and macrophages, become the predominant cells at the site of inflammation.

From the clinical standpoint, certain wounds, such as pyoderma gangrenosum, have excessive inflammation and treatment, with corticosteroids for example, leads to downregulation of inflammation and healing. Fine-tuning the inflammatory response may represent a therapeutic target for other wounds as well.[21]

PROLIFERATION

The proliferative phase, characterized by fibroblast migration, deposition of ECM, and formation of granulation tissue, normally starts at about day 3 after wounding and lasts for 2 to 4 weeks. Figure 149-4 illustrates events that occur in the proliferative/migratory and remodeling phases. An important event in this phase is reepithelialization. This critical event also involves migration of keratinocytes and the interdependence between keratinocyte movement over the provisional fibrin matrix, recruitment of fibroblasts and endothelial cells, and ECM formation.[22]

Growth factors, such as PDGF and TGF-β, attract fibroblasts to the wound. Fibroblasts subsequently proliferate and produce a matrix consisting of fibronectin and hyaluronan initially, and collagen and proteoglycans later. These components are essential for new ECM formation and tissue repair. ECM serves both as turgor of soft tissue and as a scaffold and regulator of cell adhesion and growth. It is made of an interstitial matrix of adhesive proteins embedded in proteoglycan and glycosaminoglycan gel as well as the fibrinous structural proteins collagen and elastin.[23]

Fibroblasts make collagen, the most abundant protein in the body, and noncollagenous proteins. During the proliferative phase, collagen synthesis is induced by PDGF, basic FGF (bFGF), TGF-β, IL-1, and TNF. There are 18 different types of collagen. Fibrillar collagens, such as I, III, and V, form the connective tissue in the healing wound, and nonfibrillar forms, such as collagen IV, form the basement membrane.

Collagen gene expression is regulated by multiple factors such as TGF-β and FGF. TGF-β stimulates production of collagen I and collagen III. The overexpression of matrix metalloproteinases (MMPs) and/or impaired counteraction of tissue inhibitor of metalloproteinases (TIMPs) contributes to delayed healing and fibrosis. Interaction between these cytokines is extremely important. The fibroblasts in patients with longstanding diabetic foot ulcers show a decreased response to TGF-β_1 and decreased expression of TGF-β receptors. Although overexpression may be problematic, tissue matrix MMPs and other enzymes, such as plasminogen activator inhibitor, are critical to the movement of cells through provisional structural matrix components.

Adhesive proteins, including fibronectin (FN), laminin, thrombospondin, and integrins, help guide cellular migration.[24] FN is a large heterodimer linked to cell surfaces, basal membranes, and the ECM. FN can attach to ECM components such as collagen, fibrin,

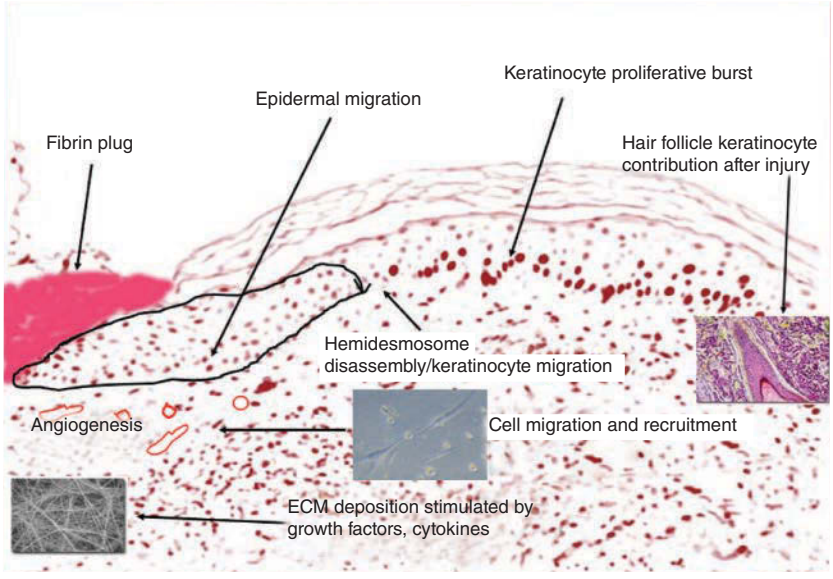

Figure 149-4 Schematic, using a modified photomicrograph section, of the events taking place shortly after injury, including formation of a fibrin plug, epidermal migration, and extracellular matrix deposition.

and proteoglycan, or to integrins and directly mediate the cell migration. FN also activates intracellular signaling pathways to increase the sensitivity of certain cells, such as endothelial cells, to growth factors.[25]

Integrins are important in cell–cell and cell–matrix adhesion, serving to regulate interaction between ECM and the cytoskeleton. The integrins, consisting of at least 24 αβ heterodimers (18 α and 8 β subunits), are transmembrane cell surface receptors that bind the ECM to cytoskeletal structures.[25] The integrin profile is very dynamic during the repair process. For example, dermal fibroblasts undergo a switch from α_2 to α_3 and α_5 integrin subunits. As another example, endothelial cells cannot respond to angiogenic stimuli without the expression of $\alpha v\beta_5$ integrin. Certain polypeptide growth factors are essential to angiogenesis, including bFGF and VEGF.[25,26] Table 149-1 highlights the main cytokines and growth factors shown to play a role in the repair process.

Another constituent of ECM are noncollagenous proteins such as proteoglycans, which are glycosaminoglycans (dermatan sulfate, heparin sulfate) linked to a protein backbone that modulate cell growth and differentiation. Additionally, glycosaminoglycans without a protein core (hyaluronan) are also important components of the ECM.

Histopathology of a granulating wound bed shows proliferation of fibroblasts and capillaries in a loose ECM. Neovascularization, or formation of new blood vessels, is characteristic of this stage. Several factors induce angiogenesis as a part of granulation tissue development; new capillaries sprout, invading the fibrin and FN-rich clot. The density of blood vessels is reduced over time with scar formation and as the wound moves toward the remodeling phase.[26] Fibroblast replication and longevity are enhanced in hypoxia, and low oxygen tension stimulates clonal expansion of dermal fibroblasts seeded as single cells.[27] Moreover, the synthesis of a number of growth factors is enhanced in hypoxic cells.

After a provisional matrix has formed, keratinocytes migrate to epithelize the wound. MMP function is critical for allowing keratinocytes at the edge of the wound to detach from their hemidesmosomal and

TABLE 149-1

The Major Growth Factors Involved in Wound Healing and Their Functions[39]

GROWTH FACTOR	MAJOR SOURCES	FUNCTION
Epidermal growth factor (EGF)	Platelets, macrophages, fibroblasts	Epithelialization Fibroblast proliferation Keratinocyte proliferation Angiogenesis
Transforming growth factor (TGF)-α	Keratinocytes, macrophages, fibroblasts, lymphocytes	Keratinocyte migration
TGF-β	Macrophages, fibroblasts, keratinocytes, platelets	Inflammation, angiogenesis, reepithelialization, connective tissue regeneration, remodeling $TGF-\beta_1$, $TGF-\beta_2$: promote fibrosis and scar formation $TGF-\beta_3$: antiscar properties
Activins	Fibroblasts, keratinocytes	Epithelialization
Fibroblast growth factor (FGF)	Keratinocytes, fibroblasts, smooth muscle cells, chondrocytes, endothelial cells, mast cells	FGF-2: granulation tissue formation, reepithelialization, tissue remodeling, fibroblast migration, collagen formation FGF-7, FGF-10: increase transcription factors, detoxification of reactive oxygen species FGF-7: neovascularization
Platelet-derived growth factor	Platelets, macrophages, vascular endothelium, fibroblasts	Fibroblast proliferation Angiogenesis Matrix formation
Vascular endothelial growth factor (A-E)	Keratinocytes, endothelial cells, fibroblasts, smooth muscle cells, platelets, neutrophils, macrophages	Angiogenesis
Granulocyte-macrophage colony-stimulating factor	Macrophages Fibroblasts Endothelial cells Natural killer cells Mast cells	Keratinocyte proliferation Epithelialization Cell migration Chemotaxis Angiogenesis
Interleukin (IL)-1	Monocytes Macrophages Keratinocytes	Keratinocyte proliferation Fibroblast proliferation Angiogenesis Neutrophil chemotaxis
IL-6	Neutrophils Monocytes	Keratinocytes proliferation Neutrophil chemotaxis

desmosomal attachments and migrate across the provisional matrix. Other proteins play important roles, including plasminogen activator inhibitor, a serine protein inhibitor that functions as the main inhibitor of tissue plasminogen activator, and urokinase plasminogen activator.[28]

Upregulation of tissue plasminogen activator and urokinase plasminogen activator are important for keratinocyte migration, which may depend on crosstalk and interactions between $\alpha_3\beta_1$, keratinocytes, and collagen. These events lead to the induction of MMP-1 (collagenase-1 or interstitial collagenase), which is important for keratinocyte migration and epithelialization.[6] MMP-9 plays a fundamental role in "cutting" Type IV and Type VII collagen, which are essential components of the basement membrane and anchoring fibrils, and promotes inflammation and neutrophil migration. For keratinocyte migration to occur, a necessity exists to break down these complex structures anchoring the basal keratinocytes to the basement membrane and neighboring keratinocytes. This process is as complex as the structure itself, and involves interactions between MMPs, integrins, growth factors, and structural proteins. In the normal resting state, laminin-332 is bound to $\alpha_6\beta_4$-integrin, the latter linking the intracellular keratin filaments of keratinocytes to the basement membrane. As a result of the interaction of integrins (including their phosphorylation status) with the ECM and their receptor clustering on the surface of keratinocytes, important morphologic changes, such as lamellipodia formation, occur for keratinocyte locomotion.[29-31] Migration of keratinocytes is essential for resurfacing of the wound.[26,32]

Keratinocytes begin to migrate from the wound edge and from skin appendages within the first 24 hours. The hair bulge, the germinative portion of the hair, is an important reservoir for keratinocytes in partial thickness wounds. A series of events in migration involves elongation of keratinocytes, development of pseudopod-like projection of lamellipodia, loss of cell-to-cell adhesion, retraction of intracellular tonofilaments, and formation of actin filaments at the edge of the cytoplasm, all of which occur while the proliferative ability of keratinocytes is inhibited.

To facilitate migration, there is a marked increase in mitotic activity within the basal epithelial cells of the wound edge from 12 hours, extending lamellipodia along the wound edges. Subsequently keratinocytes lose their attachment to the underlying dermis to migrate in a leapfrog fashion. Eventually a new basement membrane forms and further growth and differentiation of epithelial cells establishes the stratified epithelium. The process of epithelialization is facilitated in a moist environment, serving as the biologic basis for modern occlusive dressings.

REMODELING

The final phase, remodeling, is typically the longest phase, involving the continuous synthesis and breakdown of collagen as the ECM evolves. Starting early in the healing process, wound remodeling may continue for months. The interaction of ECM and fibroblasts causes wound contraction and is influenced by multiple cytokines, including TGF-β, PDGF and bFGF.

The remodeling of the ECM, as well as the movement of cells, is highly dependent on MMPs and serine proteases.[33] An important component of this dependence on MMPs is MMP-driven degradation of ECM and the resulting exposure of selective bioactive ECM segments that influence cell behavior, including migration and proliferation.[6,33]

Metalloproteinases produced by fibroblasts, neutrophils, keratinocytes, and macrophages, include interstitial collagenase (degrades collagen Types I, II, and III), gelatinases (degrades denatured collagen and FN) and stromelysins (degrades proteoglycans, laminin, FN, and amorphous collagen). MMP-10 (stromelysin) breaks down other noncollagenous ECM components and facilitates migration.[6,11,34] Other mediators, such as thymosin-β, upregulate MMPs during wound repair.[35] The activity of MMPs are tightly regulated because they may degrade essential collagens and impair healing. They are activated by certain proteins (plasmin) and inhibited by specific tissue inhibitors of metalloproteinases. Table 149-2 summarizes certain MMPs and their prominent effect in wound healing.

During the remodeling process, a phenotypic switch occurs in certain cell subpopulations from fibroblasts to myofibroblasts.[36] Although the early process of healing relies largely on matrix accumulation, which, in turn, facilitates cell migration, later healing requires a dampening of ECM formation to a level that at least approximates the preinjury state. However, the remodeling phase is more than a breakdown of excess macromolecules formed during the proliferative phase of wound healing. During this phase, cells within the wound are returned to a stable phenotype, ECM material is altered (ie, collagen Type III to collagen Type I), and granulation tissue disappears.[11,26] Granulation tissue evolves to a scar composed of less-active fibroblasts, dense collagen, and fragments of elastic tissue along with the rest of ECM. Scar matures and the tensile strength increases to a maximum of 80% strength of noninjured skin. In full-thickness wounds, contraction is responsible for 40% of the decrease in wound size.

FETAL HEALING

During early embryogenesis, wounded fetal tissue heals without fibrosis. Regeneration, as opposed to repair, occurs. Later in embryogenesis (last trimester) and after childbirth, repair (as opposed to regeneration) occurs, with resulting fibrosis. Among factors that affect scarring, fibromodulin is a small glycoprotein that mediates scarless healing in fetal skin.[37]

TABLE 149-2

Matrix Metalloproteinases Proteinases with Well-Established, Functional Effects on Wound Healing

EFFECT	COMMON NAMES	CORRESPONDING MMP DESIGNATION	SOME SPECIFIC EFFECTS
Keratinocyte proliferation and migration	Collagenase 1 Gelatinase A Stromelysin 2 Matrilysin-1 Epilysin	MMP-1 MMP-2 MMP-10 MMP-7 MMP-28	Increased migration
Endothelial cell (EC) migration	Collagenase 3 Gelatinase A MT1-MMP	MMP-13 MMP-2 MMP-14	Increases EC migration Needed for angiogenesis Needed for angiogenesis
Cell migration	Stromelysin 1 Stromelysin 2 Matrilysin-2	MMP-3 MMP-10 MMP-26	Required for excisional wounds
Inflammation	Collagenase 2 Gelatinase A Gelatinase B Matrilysin-1	MMP-8 MMP-2 MMP-9 MMP-7	Antiinflammatory Antiinflammatory Promotes inflammation
Neutrophil migration	Gelatinase B MT6-MMP	MMP-9 MMP-25	Increases neutrophil migration
Apoptosis	Collagenase 2 MT1-MMP MT2-MMP MT6-MMP	MMP-8 MMP-14 MMP-15 MMP-25	Prevents apoptosis Antiapoptotic

MMP, matrix metalloprotease; MT, membrane type.

GROWTH FACTORS AND CYTOKINES

Wound healing is regulated by multiple growth factors and cytokines released at the wound site. Growth factors are biologically active polypeptides that can alter the growth, differentiation and metabolism of a target cell. They are important elements in the healing of wounds. Table 149-1 lists the major growth factors and cytokines involved in healing and their respective roles.[38-40] Although potentially important in healing from a therapeutic standpoint, only PDGF-BB, bFGF, and granulocyte-macrophage colony-stimulating factor (GM-CSF) are used clinically in the management of wounds, and only PDGF is approved for wound healing by the U.S. Food and Drug Administration (FDA).

EPIDERMAL GROWTH FACTOR FAMILY

Epidermal growth factor (EGF) family members bind to a tyrosine kinase transmembrane protein or EGF receptor.[41] EGFR normally localizes throughout the epidermis with its membranous presence being more prominent in the basal layer. EGFR plays an important role in reepithelialization by increasing keratinocyte proliferation and cell migration.[42,43]

EGF is secreted in a paracrine fashion by platelets, macrophages and fibroblasts and acts on keratinocytes. Faulty location of the EGF receptor may be problematic in some nonhealing wounds. An in vitro study demonstrated the presence of EGFR in the cytoplasm, rather than the extracellular membrane, of cells in non,healing wounds, suggesting receptor downregulation within chronic wounds.[42-44] TGF-α is another member of the EGF family that is secreted by keratinocytes, macrophages, fibroblasts, and lymphocytes, and works in an autocrine fashion.[45,46] TGF-α induces expression of keratin 6 and keratin 16 (present in proliferating keratinocytes) and increases keratinocyte migration.[47]

TRANSFORMING GROWTH FACTOR-β FAMILY

TGF-β family members include TGF-β_1 to TGF-β_3, bone morphogenic proteins, and activins. TGF-β_1, TGF-β_2, and TGF-β_3 promote the migration of fibroblasts and endothelial cells and deposition of extracellular matrices by fibroblasts during granulation tissue formation. TGF-β_1 predominates in wound healing.[48] Interestingly, TGF-β_1 and TGF-β_2 promote fibrosis and scar formation, whereas TGF-β_3 has antifibrotic properties.[49] TGF-β, produced by macrophages, fibroblasts, keratinocytes, and platelets, is important

in the wound healing processes of inflammation, angiogenesis, reepithelialization, and connective tissue regeneration.[48,50] TGF-β_1 facilitates recruitment of inflammatory cells, and promotes macrophage mediated debridement and granulation tissue formation. During reepithelialization, TGF-β_1 shifts keratinocyte integrin expression toward a more migratory subtype.[51] In the remodeling phase, TGF-β_1 plays a major role in collagen production and inhibits collagen breakdown by inhibiting MMP-1, MMP-3, and MMP-9, and promoting TIMP-1.[52,53]

TGF-β_1 plays an important role in the formation of hypertrophic scars and keloids by overexpression of connective tissue growth factor.[54] In fetal wounds, deceases in TGF-β_1 transcription help explain the scarless healing that is seen.[55]

Activins are members of the TGF-β family produced by fibroblasts and keratinocytes and play role in reepithelization. Activin inhibits keratinocyte proliferation and induces terminal differentiation of keratinocytes. bone morphogenic proteins are another member of the family involved in keratinocyte differentiation. Overexpression of bone morphogenic protein-6 is associated with delayed healing.[39,56]

FIBROBLAST GROWTH FACTOR FAMILY

The 3 main members of the FGF family involved in wound healing are FGF-2, FGF-7, and FGF-10. FGFs are produced by keratinocytes, fibroblasts, smooth muscle cells, chondrocytes, endothelial cells, and mast cells.[57] FGF receptors 1 to 4 are tyrosine kinase transmembrane proteins that work like EGFR.[45]

bFGF or FGF-2 plays a role in granulation tissue formation, reepithelialization, and tissue remodeling.[58] FGF-2 regulates the synthesis of ECM components, and facilitates keratinocyte and fibroblast migration and collagenase formation. bFGF is decreased in chronic wounds.[59]

FGF-7 or keratinocyte growth factor-1 and FGF 10 or keratinocyte growth factor-2. FGF-7 and FGF-10 are secreted in a paracrine fashion, found only on keratinocytes, and have a role in reepithelialization. FGF-7 and FGF-10 increase transcription factors involved in detoxification of reactive oxygen species. FGF-7 is a strong mitogen of vascular endothelial cells and is important during neovascularization.[60]

PLATELET-DERIVED GROWTH FACTOR FAMILY

PDGFs, produced by platelets, macrophages, vascular endothelium, fibroblasts, and keratinocytes, bind to 2 different transmembrane tyrosine kinase receptors (α and β).[61] Upon injury PDGF is released from degranulating platelets. PDGF, chemotactic for monocytes, macrophages, and neutrophils, is a mitogen for fibroblasts and smooth muscle cells in vitro. PDGF also stimulates macrophages to produce growth factors such as TGF-β.[62] PDGF plays an important role in blood vessel maturation and works synergistically with hypoxia to stimulate VEGF formation in vitro. However, PDGF angiogenic activity is less than FGF and VEGF.[63] While not directly affecting keratinocyte migration, PDGF plays role in reepithelialization by in vitro production of insulin-like growth factor-1 and thrombospondin-1. PDGF also enhances the proliferation of fibroblasts and, in turn, the production of ECM. Recombinant human PDGF-BB (becaplermin) is the only FDA-approved drug for nonhealing neuropathic diabetic foot ulcers.[64,65]

VASCULAR ENDOTHELIAL GROWTH FACTOR FAMILY

Members of the VEGF family include VEGF-A to VEGF-E and placental growth factor.[66] VEGF-A, which is secreted by keratinocytes, endothelial cells, fibroblast smooth muscle cells, platelets, neutrophils, and macrophages, binds to a tyrosine kinase surface receptor that is located on the endothelial surface of blood vessels, early in wound healing angiogenesis.[67] Platelets release VEGF-A upon injury. Macrophages release VEGF-A directly but also release TNF-α, which induces VEGF-A expression on keratinocytes and fibroblasts. Hypoxia is a major stimulus for release of VEGF-A, and the VEGF-A gradient parallels the hypoxia gradient. VEGF-A is also involved mainly in the inflammatory stage of wound healing. Placental growth factor is expressed by keratinocytes and endothelial cells as a proangiogenic molecule. Placental growth factor stimulates cultured fibroblast migration and stimulates granulation tissue formation.[68]

GRANULOCYTE-MONOCYTE COLONY-STIMULATING FACTOR

GM-CSF has particular importance in the inflammatory stage of wound healing by increasing keratinocyte proliferation and enhancing reepithelialization. GM-CSF promotes proliferation and differentiation of neutrophils and hence increases host defenses.[69] GM-CSF indirectly upregulates IL-6. In 2 studies on diabetic foot ulcers, in total 67 patients with infected diabetic foot ulcers were treated either with placebo or topical GM-CSF. Although GM-CSF improved neutrophil function and increased absolute neutrophil numbers, the addition of topical GM-CSF to standard care had no additional beneficial clinical effect.[69]

PROINFLAMMATORY CYTOKINES

Proinflammatory cytokines, including IL-1, IL-6, and TNF-α, are upregulated in the inflammatory phase of wound healing. IL-1 is produced by monocytes, macrophages, monocytes, and keratinocytes, with both paracrine and autocrine functions. IL-1 induces expression of keratin 6 and keratin 16 in migrating keratinocytes,

and activates fibroblasts to secrete FGF-7.[70] IL-6 is produced by neutrophils and monocytes with mitogenic and proliferative effect on keratinocytes and chemoattractive effects on neutrophils. TNF-α and IL-1β are increased in chronic wounds. The effect of exogenous TNF is dependent on the concentration and duration of exposure.[70,71] TNF-α at low levels promotes healing by stimulating inflammation and increasing macrophage-produced growth factors, whereas at higher levels TNF-α impairs wound healing by suppressing production of ECM and TIMP and increasing MMPs. Chronic inflammation stimulates production of TNF-α and IL-1β that synergistically increases production of MMPs and suppress production of TIMPs.[72]

CHEMOKINES

Chemokines are a family of small cytokines or signaling proteins that attract neutrophils to the site. Macrophage chemoattractant protein-1 (or CCL2) is induced by keratinocytes and is chemoattractant for monocyte/macrophages, T cells, and mast cells.[73]

Interferon-inducible protein 10 (or CXCL10) is another cytokine that negatively impacts wound healing. Interferon-inducible protein 10 inhibits migration of fibroblasts. IL-8 increases keratinocyte migration and proliferation, and is a chemoattractant of neutrophils.[74]

CLINICAL ISSUES IN WOUND HEALING

WOUND BED PREPARATION

Although the majority of wounds heal in a timely manner, a proportion of wounds stall and do not follow the stages of healing. A nonhealing wound needs wound bed preparation to promote healing. The concept of wound bed preparation has been summarized using the pneumonic *TIME*: *T*issue debridement, *I*nfection/inflammation, *M*oisture balance, *E*pithelia edge tissue.[21,32,75]

Tissue debridement plays a key role in tissue preparation by removing nonviable tissue and pathogenic bacteria. Multiple techniques to debride exist, including surgical, enzymatic, biologic, mechanical, and autolytic techniques. Newer tools, such as low-frequency ultrasound and hydrosurgery devices, have been developed.[76] Table 149-3 lists techniques used for tissue debridement.

Treating infection and inflammation implies assessment of the need for topical antiseptic and/or systemic antibiotic use to control infection and subsequent inflammation. Although inflammation is a physiologic process in wound healing, inappropriate inflammation can cause delayed healing. Infection may be classically seen as a host response, as in cellulitis. Bacteria may also delay healing through formation of biofilm, seen in 60% of chronic wounds. Biofilms are colonies of microorganisms that protect themselves through community living, in part by a surrounding glycocalyx (Fig. 149-5). Disruption of biofilms with debridement, with or without antimicrobial agents, helps alleviate persistent inflammation.[77]

TABLE 149-3
Debridement Techniques

DEBRIDEMENT TECHNIQUES	ADVANTAGES	DISADVANTAGES
Surgical, sharp (with scissors and/or scalpel)	High speed Selectivity	Painful procedure, expensive Needs skilled professionals Contraindicated in ischemic tissue and bleeding disorders
Enzymatic (collagenase)	Low pain	Medium cost and low selectivity Some patients are allergic to the enzyme preparation
Biologic (larval therapy)	High speed and high selectivity Medium pain	High cost Contraindicated in bleeding diathesis and deep, tunneling wounds
Mechanical (wet to dry dressings, hydrotherapy, ultrasonography)	Medium speed	Painful Nonselective
Autolytic (endogenous enzymes with moisture-retentive dressings)	Low pain	Low speed Low selectivity Relatively high cost Contraindicated in infected wounds Risk of exposed bone/tendon and friable skin

The term *antimicrobial* includes disinfectants, antiseptics, and antibiotics. Antiseptics are broad spectrum with less risk of bacterial resistance. The difference between antibiotics and antiseptics is that antiseptics are nonspecific, while antibiotics work specifically on bacteria functions or processes such as disputing cell wall function but also can allow bacteria opportunity to mutate and develop resistance. As a result, topical antibiotics are not recommended for chronic wounds because of the risk of antibiotic resistance. A variety of modern antiseptic-impregnated dressings have been used to reduce microorganism numbers in the dressings and, in theory, on the wound surface. Their effect on biofilm organisms is less-well defined. Table 149-4 lists these antiseptics.

Moisture imbalance involves the assessment and management of wound exudate. While acute wound fluid promotes cell growth and is rich in cytokines and growth factors, chronic wound fluid inhibits cell growth and contains high levels of proteases and proinflammatory cytokines. Thus, acute wounds

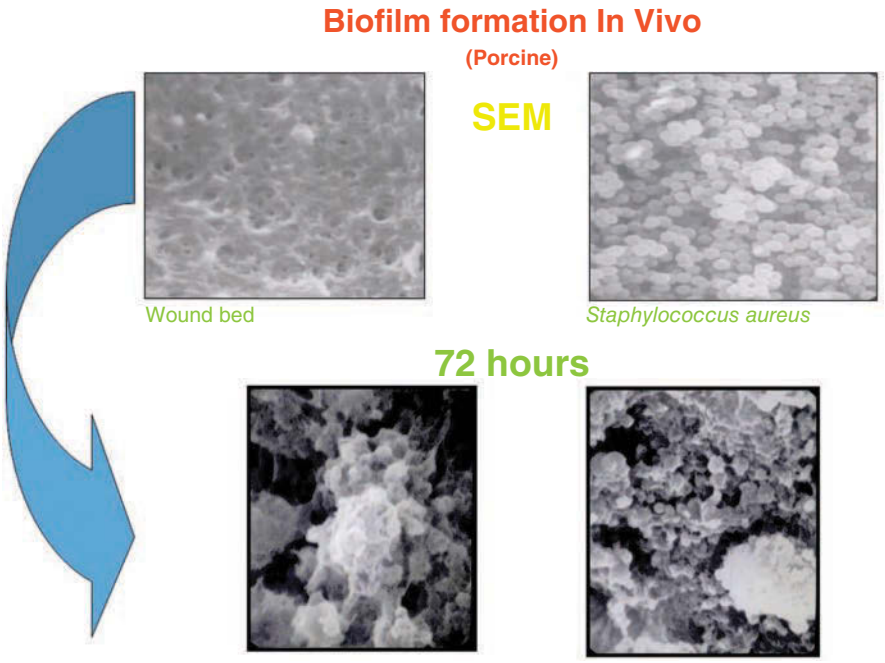

Figure 149-5 Biofilm formation. Colonies of microorganisms with a surrounding glycocalyx. SEM, scanning electron micrograph.

benefit from contact with wound fluid, whereas chronic wounds do not. Moisture can hinder wound healing in other ways as well: extra moisture can damage periwound skin, and lack of moisture can hinder keratinocyte migration.

The major dressing types (Table 149-5) include hydrogels, transparent polyurethane films, hydrocolloids, gelling fibers, alginates, foams, superabsorbents, and collagen products. In determining the most appropriate dressing for a particular wound, one must consider the need for absorption of exudate (foams and alginates), the need for additional moisture (hydrogels), and whether the wound and its epithelial edges can tolerate the often subtle (but important) trauma that comes from removal of adhesive dressings such as films. Thin contact layers, consisting of different polymeric materials, some with perforations, allow wound fluid to escape and are useful in preventing tissue injury upon dressing changes.

Edge assessment involves the assessment of nonadvancing wound edges and proper use of therapies to advance the wound edge.[21] Keratinocytes from the edge of chronic wounds often abnormally express *c-myc* and treatments, such as debridement, which remove or reverse this cellular biomarker, can promote keratinocyte migration.[78-80]

TABLE 149-4
Common Antiseptics Used in Wound Healing[109,110,125,126]

ANTISEPTICS	MAIN ADVANTAGES	MAIN DISADVANTAGES
Iodine Based:		
Povidine-iodine 10% ▪ Cadexomer iodine ▪ Inadine	▪ Broad spectrum ▪ Good penetration to biofilm ▪ Proinflammatory	▪ Toxic to granulation tissue in high concentration ▪ Risk of thyroid dysfunction ▪ Risk of contact dermatitis
Chlorhexidine Based:		
▪ PHMB (polyhexamethylene biguanide)—foam, gauze	▪ Broad spectrum ▪ 0.02% concentration use for wound irrigation	▪ May damage cartilage/ear toxicity
Silver-Based:		
▪ Microcrystalline silver ▪ Silver sulfadiazine cream ▪ Silver nitrate sticks	Antiinflammatory, antibacterial, antifungal, antiviral	Silver toxicity, argyria with silver sulfasalazine; silver sulfadiazine + silver nitrate sticks may produce pseudoeschar/delay healing
Honey-Based:		
▪ Honey alginate ▪ Honey gel	Antiinflammatory, best for hard adherent eschar	Risk of botulism; may promote bacterial growth

TABLE 149-5
Main Categories of Dressings[109,110,125,126]

DRESSING CATEGORY	INGREDIENTS	FUNCTION	COMMENTS
Hydrogels	▪ Polymers with high water content	▪ Provide moisture ▪ Nonpainful	▪ Needs secondary dressings ▪ Contraindicated in infected wounds ▪ Needs frequent dressing change
Films	▪ Semipermeable adhesive sheets of elastic polyurethane ▪ Impermeable to water and bacteria	▪ Transparent	▪ Adherent (trauma when removed) ▪ Nonabsorbent
Hydrocolloids	▪ Hydrophilic colloid particles bound to polyurethane film ▪ Some composed of gelatin, pectin, and carboxy methylcellulose	▪ Long wear time ▪ Autolytic debridement	▪ Nonabsorptive ▪ Trauma with removal ▪ Allergy to adhesives ▪ Smell
Calcium alginates	▪ Sheets (wick laterally) ▪ Ropes (wick upward) ▪ From seaweed-kelp	▪ Hemostatic ▪ Absorptive ▪ Autolytic debridement	▪ Need secondary dressing
Gelling fibers	▪ Sheets or ribbons	▪ Absorptive ▪ Autolytic debridement	▪ Needs secondary dressing
Foams	▪ Polyurethane foam fluid exchange with partial fluid retention if variable pore size	▪ Absorbent	▪ Bulky and may macerate surrounding skin
Superabsorbent dressings	▪ Fiber technology/conducts moisture	▪ Absorbent ▪ Diaper technology	▪ Bulky
Collagen-based dressings	▪ Bovine-derived collagen dressings	▪ Promote healing ▪ Reduce matrix metalloproteinases	▪ Cost

SKIN GRAFTS

Skin grafts are categorized by the amount of tissue being grafting. For example, split-thickness grafts include a portion of dermis and full-thickness grafts contain the entire dermis. The likelihood of the survival and whether wound contracture is reduced depends on the amount of dermis in the graft. Split-thickness skin grafts can survive in areas with less vascularity but also are less likely to prevent wound contracture, whereas full-thickness skin grafts require better vascularity for survival and but can better prevent contracture.

While skin grafting is centuries old, modern grafting is thought to have begun with the first skin autotransplant done in 1869 by Reverdin and then in 1929 by Brown and colleagues who introduced the technique of the split-thickness skin graft.[81] The healing of a skin graft, however, is different from the description provided earlier of the events after acute injury. One distinguishing feature of skin graft "take" or healing is the dependence of the graft on the recipient wound bed for revascularization, which requires several unique physiologic events.

Much of the remainder of skin graft healing involves events in common with the normal wound healing process. Infiltration by fibroblasts in the graft occurs 3 to 5 days after grafting, followed by a progressive increase in both graft and recipient fibroblasts within the graft.[82,83] Although graft "take" allows for donor tissue to replace missing tissue in the recipient wound, skin grafts may also stimulate wound healing of the recipient site, and this ability can be augmented. For example "prewounding" of the donor site skin prior to grafting enhances the graft's ability to stimulate healing.[83,84] Ki67 antibody and β_1-integrin expression after grafting has been noted, as has production of stimulatory growth factors and cytokines, implying that healing stimuli were provided by the grafts.[85]

SKIN SUBSTITUTES

Skin substitutes are divided into 2 main groups of cellular and acellular matrix products (Table 149-6).[86]

CELLULAR PRODUCTS

The cellular skin substitute products with best available evidence are the bilayered living cellular construct (BLCC), Apligraf (Organogenesis, Canton, MA) and cellular dermal matrix, Dermagraft (Organogenesis, Canton, MA). BLCC is a tissue-engineered cellular matrix composed of bovine Type I collage with neonatal foreskin fibroblasts for dermal component and human neonatal keratinocytes for epidermis.[87] BLCC has FDA approval for venous leg ulcers (VLUs) greater than 4 weeks' duration and for full-thickness diabetic foot ulcers present for longer than 3 weeks. The evidence supports the safety and efficacy of up to 5 applications of BLCC. An example of its efficacy is 47% of chronic, hard-to-heal VLUs present longer than 1 year treated with BLCC healed after 24 weeks compared to 19% in the group with compression alone.[88]

TABLE 149-6
Cellular and Acellular Matrices[86]

NAMES	ADVANTAGE	FDA APPROVAL
Cellular Matrices:		
Bilayered living cellular construct (Apligraf, Organogenesis, Canton, MA)	Dermal part: Bovine Type I collagen with human neonatal foreskin fibroblasts Epidermal part: keratinocytes	Noninfected partial- and full-thickness venous leg ulcers, >1 month duration Full-thickness diabetic foot ulcers, >3 weeks' duration
Cellular dermal matrix (Dermagraft, Organogenesis, Canton, MA)	Human neonatal foreskin fibroblasts cultured onto a bioresorbable glycolic acid scaffold (polyglactin 910)	Full-thickness diabetic foot ulcers >6 weeks' duration that do not involve tendon, muscle, joint capsule, or bones
Dehydrated human amnion/chorion membrane (DHACM) (Epifix, MiMedx Group Inc., Marietta, GA)	DHACM is composed of a single layer of epithelial cells, a basement membrane, and an avascular connective tissue matrix	DHACM is composed of a single layer of epithelial cells, a basement membrane, and an avascular connective tissue matrix
Cryopreserved placental membrane (Grafix, Osiris Therapeutics, Inc., Columbia, MD)	Human viable wound matrix provides the wound with mesenchymal stem cells, neonatal fibroblasts, epithelial cells, growth factors, and angiogenic factors	Human viable wound matrix provides the wound with mesenchymal stem cells, neonatal fibroblasts, epithelial cells, growth factors, and angiogenic factors
Acellular Matrices:		
Dermal regeneration matrix (Integra Dermal Regeneration Template, Integra, Life Sciences, Plainsboro, NJ)	Composed of a crosslinked bovine tendon collagen and glycosaminoglycan dermal equivalent, and a semipermeable polysiloxane (silicone) epidermal equivalent	FDA-approved device (510[k] for diabetic foot ulcers)
Porcine small intestinal submucosa (Cook Biotech, West Lafayette, Indiana)	Derived from small intestinal submucosa of porcine; 3-dimensional extracellular matrix that acts as a scaffold to allow for cellular migration, formation of granulation tissue, and vascularization of the wound	FDA-approved 510(k)-cleared medical device
Cadaveric allograft (AlloDerm Regenerative Tissue Matrix [RTM], LifeCell, , Branchburg, NJ)	Cadaveric human skin that has been processed to remove the epidermis and cells that lead to tissue rejection and graft failure	Regulated by the FDA as human tissue for transplantation
Poly-*N*-acetyl glucosamine–derived membrane (Talymed, Marine Polymer Technologies Inc., Danvers, MA)	Composed of poly-*N*-acetyl glucosamine shortened fibers that are derived from microalgae	FDA approved—510(k)

Cellular dermal matrix is composed of human neonatal foreskin fibroblasts cultured onto a bioabsorbable glycolic acid scaffold. The fibroblasts secrete collagen, matrix proteins, growth factors, and cytokines. It has FDA approval for diabetic foot ulcers of longer than 6 weeks' duration.

Human placental products also are used to speed healing of chronic wounds. The 2 supported by evidence (albeit less robust) include dehydrated human amnion/chorion membrane (Epifix, MiMedx, Marietta, GA) and cryopreserved placental membrane (Grafix, Osiris Therapeutics Inc.). Epifix is composed of a single layer of epithelial cells, a basement membrane, and a connective tissue matrix. Grafix is composed of placental membrane, a source of mesenchymal stem cells, neonatal fibroblasts, epithelial cells, growth factors, and angiogenic cells.[89-92]

ACELLULAR PRODUCTS

Acellular products function as a scaffold for cellular migration, proliferation, and matrix formation. Examples of acellular products include dermal regeneration matrix, porcine small intestinal submucosa, cadaveric allograft, and poly-*N*-acetyl glucosamine.[86]

INTEGRA Dermal Regeneration Template (Integra LifeSciences Corp.) is a bilayered acellular matrix composed of crosslinked bovine tendon collagen, a glycosaminoglycan dermal equivalent, and a semipermeable polysiloxane epidermal equivalent. It is approved for burns and diabetic foot ulcers. In a recent study on diabetic foot ulcer patients, 51% of patients on Dermal Regeneration Template achieved complete healing, compared to 32% of controls.[93,94] Porcine small intestine submucosa (Oasis, Smith, & Nephew) is a scaffold for cellular migration, granulation tissue formation and neovascularization. The evidence supports the successful use of small intestine submucosa in patients with diabetic foot ulcers and VLUs.[95] Cadaveric allograft is made of cadaveric human skin. It is indicated for tissue repair in abdominal wall and breast reconstruction.[96] Poly-*N*-acetyl glucosamine (Talymed) is derived from microalgae and has FDA approval for a variety of wounds. Poly-*N*-acetyl glucosamine has also antibacterial properties.[97]

STEM CELL THERAPY

The use of stem cells in the management of wounds aims to replace the wound resident cells with new cells with the potential to respond to wound healing process signals. Numerous animal studies and a small number of pilot studies in human have shown that bone marrow mesenchymal cells can promote wound healing.[98,99] In 2003, freshly applied autologous bone marrow aspirate and cultured bone marrow cells helped 3 wounds heal.[100,101] In animal models, the use of stem cells is associated with healing and increase in tensile strength. In addition to bone marrow–derived cells, other sources of stem cells, such as fat and hair follicles, may be beneficial.[98]

However, most studies of adult stem cell therapy for human wounds have used cultured bone marrow–derived mesenchymal stem cells.[102] The improvement of wounds with adult stem cells may be a result of either integration of the stem cells or their paracrine effects.[103] Topically applied autologous mesenchymal stem cells accelerate the healing of human and murine wounds.[104] The first randomized, controlled trial reported the use of bone marrow mesenchymal stem cell application via IM and subcutaneous injection to chronic nonhealing wounds with success compared to standard care.[105]

CHRONIC WOUNDS AND IMPAIRED HEALING

Acute wounds, such as those created by surgery or by trauma, have a predictable time-frame for healing and generally heal quite readily when not interrupted. Impaired healing in chronic wounds may be a consequence of many factors.

Some chronic wounds are the result of ischemia, pressure, and infection or a combination, thereof.[26] There is still considerable controversy whether hyperglycemia itself plays a pathophysiologic role in the development of ulcers in patients with diabetes mellitus, although neutrophil function is impaired in this setting, and the propensity to infection is enhanced in the diabetic state.[26] Importantly, the notion of "small vessel disease" in diabetes mellitus has not been shown to be an obstructive phenomenon. Revascularization of the diabetic foot is now viewed as standard care in the presence of large vessel disease and good run-off circulation.

Perhaps the best example of truly impaired healing, not related to undue pressure and poor arterial supply, is venous ulceration. The underlying abnormality in the development of venous ulcers is the presence of sustained ambulatory venous pressure, also known as *venous hypertension*, which refers to the inability of venous pressure in the leg and feet to decrease in response to exercise.[106] It should also be recognized that the tissue surrounding chronic wounds is not normal and has been altered by the primary pathogenic mechanisms or inability to heal readily. Clinically, the best example of this is the intense fibrosis surrounding venous ulcers, as seen in lipodermatosclerosis.[107,108] Lipodermatosclerosis is a risk factor for ulceration, and venous ulcers surrounded by lipodermatosclerosis are more difficult to heal.[109,110]

Evidence suggests an alteration of the cellular makeup of wounds that do not heal. Fibroblasts derived from venous ulcers are unresponsive to certain selected cytokines and growth factors.[111] For example, venous ulcer fibroblasts are unresponsive to the action of TGF-β_1 and PDGF.[111,112] The lack of response to stimuli such as TGF-β_1 may be because of decreased expression of Type II TGF-β receptors. This receptor abnormality also leads to decreased phosphorylation of key TGF-β signaling proteins, including Smad2, Smad3, and mitogen-activated protein kinases.[113] Cells in diabetic ulcers are altered, such that chronic wounds are said to be "stuck" in a certain phases of the repair process.[114] An association has been reported between some of these cellular alterations and the inability to heal.[115,116]

AGE-RELATED CHANGES IN WOUND HEALING

The population is aging, and older adults are more prone to develop all type of wounds, including VLUs, arterial ulcers, and pressure ulcers. For both acute and chronic wounds, aging is associated with delayed healing. The healing response by ECM changes throughout life.[117] Overexpression of MMPs has been shown in elderly skin.[117] The vasoregulation in aged skin includes fewer progenitor cells, impaired perfusion and changes in temperature regulation. Age-associated aberrations in macrophage function delay vascularization, collagen formation, and remodeling. Mitochondrial dysfunction and lower levels of antioxidants also are associated with aging. Comorbidities and polypharmacy may also factor into delayed healing in the elderly population.[118-120]

BASIC STANDARDS OF WOUND CARE

Reversing or treating the underlying cause of impaired healing is the focus of wound care treatment. Treatment relies in part on wound etiology. A thorough history and examination, along with adjunctive diagnostic tests, such as wound biopsy, vascular studies, imaging, tissue culture, and laboratory analysis may help with diagnosis.[121,122] The most common lower extremity ulcers are venous, diabetic, and arterial ulcers. Chronic wounds are common. VLUs have a 2% prevalence in developed countries, and diabetic foot ulcers occur in 1 in 4 patients with diabetes mellitus over their lifetime.[17,123,124]

Using VLUs as an example, the fundamental of treatment is compression therapy with adjunctive medical and surgical therapies.[109,110,125,126] With regard to medical therapy, pentoxifylline has been tested in several large randomized trials for its ability to accelerate the healing of venous ulcers. The results have varied, and it may be that a high dose of pentoxifylline, 800 mg 3 times a day, is more effective than 400 mg 3 times a day.[127] Whether the use of pentoxifylline should be considered standard therapy for venous ulcers is unclear at the moment. The anabolic steroid stanozolol has been effective in diminishing the induration of lipodermatosclerosis, and in the acute and painful phase of lipodermatosclerosis, when compression bandages and stockings are too painful to use.[128] Danazol may be a useful substitute for stanozolol if it is not available. Recent studies show an effect of statins in the healing of VLUs (and possibly diabetic foot ulcers).[129,130] The only known medical approach for decreasing recurrence of venous ulcers seems to be graded elastic stockings, with a pressure at the ankle in the range of 40 mm Hg along. Surgical therapy is an adjunct, if indicated. Stockings should be considered a lifelong therapy to help prevent ulcer recurrence and the other manifestations of venous disease.

PREDICTING WOUND CLOSURE

Several recent studies now allow the prediction of whether a wound will heal in a timely fashion from simple observation in the first 3 to 4 weeks of therapy. The methods used to predict wound closure range from simple measurements of wound size (width and length) and change in wound area, to computerized planimetric analysis and assessment of migration of the wound edge.[131] In a study of 56,488 wounds, it was shown that a percent change of approximately 30% at 4 weeks could predict wound closure with a sensitivity of 0.67, a specificity of 0.69, and had a positive and negative predictive value of 0.80 and 0.52, respectively.[132] In practical terms, the appearance of the wound edge is important. Steep edges imply no progress of the wound, while the edges of healing wounds become less steep and begin to migrate toward the center. The implications of the ability to predict closure are very important. By 4 weeks, the clinician should be able to determine whether the current therapy should be continued or whether a change is required, including a complete reassessment of the clinical situation. The prognostic value of the healing rate by 4 weeks of therapy has been confirmed.[132,133]

CONCLUSIONS

Wound healing is a complex process of overlapping phases of inflammation, proliferation and remodeling. The burden of wounds on millions of people is globally underappreciated. There are still challenges, in terms of improving the fundamentals of care in limited-resource countries, as well as research gaps in smart biologic dressings, bioengineered skin, and stem cell therapy. We need continued and increased understanding of the science involved. It is also possible that lessons learned from failure to heal, as in chronic wounds, will provide valuable lessons for the general principles of surgical and acute wound healing.

REFERENCES

1. Enoch S, Leaper DJ. Basic science of wound healing. *Surgery (Oxford).* 2008;26:31-37.
2. Li J, Chen J, Kirsner R. Pathophysiology of acute wound healing. *Clin Dermatol.* 2007;25:9-18.
3. Kirsner RS, Eaglstein WH. The wound healing process. *Dermatol Clin.* 1993;11:629-640.
4. Nosbaum A, Prevel N, Truong HA, et al. Cutting edge: regulatory T cells facilitate cutaneous wound healing. *J Immunol.* 2016;196(5):2010-2014.
5. Vatankhah N, Jahangiri Y, Landry GJ, et al. Predictive value of neutrophil-to-lymphocyte ratio in diabetic wound healing. *J Vasc Surg.* 2017;65(2):478-483.
6. Xue M, Le NT, Jackson CJ. Targeting matrix metalloproteases to improve cutaneous wound healing. *Expert Opin Ther Targets.* 2006;10:143-155.
7. Werner S, Grose R. Regulation of wound healing by growth factors and cytokines. *Physiol Rev.* 2003;83:835-870.
8. Patel S, Maheshwari A, Chandra A. Biomarkers for wound healing and their evaluation. *J Wound Care.* 2016;25:46-55.
9. Golebiewska EM, Poole AW. Platelet secretion: From haemostasis to wound healing and beyond. *Blood Rev.* 2015;29:153-162.
10. Leaper D. Perfusion, oxygenation and warming. *Int Wound J.* 2007;4(suppl 3):4-8.
11. Ramasastry SS. Acute wounds. *Clin Plast Surg.* 2005;32:195-208.
12. Rothwell SW, Sawyer E, Dorsey J, et al. Wound healing and the immune response in swine treated with a hemostatic bandage composed of salmon thrombin and fibrinogen. *J Mater Sci Mater Med.* 2009;20:2155-2166.
13. Frechette JP, Martineau I, Gagnon G. Platelet-rich plasmas: growth factor content and roles in wound healing. *J Dent Res.* 2005;84:434-439.
14. Martin P, Leibovich SJ. Inflammatory cells during wound repair: the good, the bad and the ugly. *Trends Cell Biol.* 2005;15:599-607.
15. Baum CL, Arpey CJ. Normal cutaneous wound healing: clinical correlation with cellular and molecular events. *Dermatol Surg.* 2005;31:674-686; discussion 686.
16. Pull SL, Doherty JM, Mills JC, et al. Activated macrophages are an adaptive element of the colonic epithelial progenitor niche necessary for regenerative responses to injury. *Proc Natl Acad Sci U S A.* 2005;102:99-104.
17. Snyder RJ, Lantis J, Kirsner RS, et al. Macrophages: a review of their role in wound healing and their therapeutic use. *Wound Repair Regen.* 2016;24:613-629.
18. Pradhan L, Cai X, Wu S, et al. Gene expression of pro-inflammatory cytokines and neuropeptides in diabetic wound healing. *J Surg Res.* 2011;167:336-342.

19. Pradhan L, Nabzdyk C, Andersen ND, et al. Inflammation and neuropeptides: the connection in diabetic wound healing. *Expert Rev Mol Med.* 2009;11:e2.
20. Katz MH, Alvarez AF, Kirsner RS, et al. Human wound fluid from acute wounds stimulates fibroblast and endothelial cell growth. *J Am Acad Dermatol.* 1991;25:1054-1058.
21. Panuncialman J, Falanga V. The science of wound bed preparation. *Surg Clin North Am.* 2009;89:611-626.
22. Laplante AF, Germain L, Auger FA, Moulin V. Mechanisms of wound reepithelialization: hints from a tissue-engineered reconstructed skin to long-standing questions. *FASEB J.* 2001;15:2377-2389.
23. Chandler LA, Gu DL, Ma C, et al. Matrix-enabled gene transfer for cutaneous wound repair. *Wound Repair Regen.* 2000;8:473-479.
24. Becchetti A, Arcangeli A. Integrins and ion channels in cell migration: implications for neuronal development, wound healing and metastatic spread. *Adv Exp Med Biol.* 2010;674:107-123.
25. Zhou HM, Wang J, Elliott C, et al. Spatiotemporal expression of periostin during skin development and incisional wound healing: lessons for human fibrotic scar formation. *J Cell Commun Signal.* 2010;4:99-107.
26. Falanga V. Wound healing and its impairment in the diabetic foot. *Lancet.* 2005;366:1736-1743.
27. Lokmic Z, Musyoka J, Hewitson TD, et al. Hypoxia and hypoxia signaling in tissue repair and fibrosis. *Int Rev Cell Mol Biol.* 2012;296:139-185.
28. Ghosh AK, Vaughan DE. PAI-1 in tissue fibrosis. *J Cell Physiol.* 2012;227:493-507.
29. Choma DP, Milano V, Pumiglia KM, et al. Integrin alpha3beta1-dependent activation of FAK/Src regulates Rac1-mediated keratinocyte polarization on laminin-5. *J Invest Dermatol.* 2007;127:31-40.
30. Choma DP, Pumiglia K, DiPersio CM. Integrin alpha3beta1 directs the stabilization of a polarized lamellipodium in epithelial cells through activation of Rac1. *J Cell Sci.* 2004;117:3947-3959.
31. Yan C, Grimm WA, Garner WL, et al. Epithelial to mesenchymal transition in human skin wound healing is induced by tumor necrosis factor-alpha through bone morphogenic protein-2. *Am J Pathol.* 2010;176:2247-2258.
32. Falanga V. Wound bed preparation: future approaches. *Ostomy Wound Manage.* 2003;49:30-33.
33. Schultz GS, Wysocki A. Interactions between extracellular matrix and growth factors in wound healing. *Wound Repair Regen.* 2009;17:153-162.
34. Toy LW. Matrix metalloproteinases: their function in tissue repair. *J Wound Care.* 2005;14:20-22.
35. Philp D, Scheremeta B, Sibliss K, et al. Thymosin beta4 promotes matrix metalloproteinase expression during wound repair. *J Cell Physiol.* 2006;208:195-200.
36. Shephard P, Martin G, Smola-Hess S, et al. Myofibroblast differentiation is induced in keratinocyte-fibroblast co-cultures and is antagonistically regulated by endogenous transforming growth factor-beta and interleukin-1. *Am J Pathol.* 2004;164:2055-2066.
37. Leavitt T, Hu MS, Marshall CD, et al. Scarless wound healing: finding the right cells and signals. *Cell Tissue Res.* 2016;365:483-493.
38. Bao P, Kodra A, Tomic-Canic M, et al. The role of vascular endothelial growth factor in wound healing. *J Surg Res.* 2009;153:347-358.
39. Barrientos S, Stojadinovic O, Golinko MS, et al. Growth factors and cytokines in wound healing. *Wound Repair Regen.* 2008;16:585-601.
40. Tomic-Canic M, Ayello EA, Stojadinovic O, et al. Using gene transcription patterns (bar coding scans) to guide wound debridement and healing. *Adv Skin Wound Care.* 2008;21:487-492; quiz 493-494.
41. Oda K, Matsuoka Y, Funahashi A, et al. A comprehensive pathway map of epidermal growth factor receptor signaling. *Mol Syst Biol.* 2005;1:2005.0010.
42. Yahata Y, Shirakata Y, Tokumaru S, et al. A novel function of angiotensin II in skin wound healing. Induction of fibroblast and keratinocyte migration by angiotensin II via heparin-binding epidermal growth factor (EGF)-like growth factor-mediated EGF receptor transactivation. *J Biol Chem.* 2006;281:13209-13216.
43. Tokumaru S, Sayama K, Shirakata Y, et al. Induction of keratinocyte migration via transactivation of the epidermal growth factor receptor by the antimicrobial peptide LL-37. *J Immunol.* 2005;175:4662-4668.
44. Pullar CE, Baier BS, Kariya Y, et al. Beta4 integrin and epidermal growth factor coordinately regulate electric field-mediated directional migration via Rac1. *Mol Biol Cell.* 2006;17:4925-4935.
45. Bennett SP, Griffiths GD, Schor AM, et al. Growth factors in the treatment of diabetic foot ulcers. *Br J Surg.* 2003;90:133-146.
46. Hashimoto K. Regulation of keratinocyte function by growth factors. *J Dermatol Sci.* 2000;24(suppl 1): S46-S50.
47. White LA, Mitchell TI, Brinckerhoff CE. Transforming growth factor beta inhibitory element in the rabbit matrix metalloproteinase-1 (collagenase-1) gene functions as a repressor of constitutive transcription. *Biochim Biophys Acta.* 2000;1490:259-268.
48. Rolfe KJ, Irvine LM, Grobbelaar AO, et al. Differential gene expression in response to transforming growth factor-beta1 by fetal and postnatal dermal fibroblasts. *Wound Repair Regen.* 2007;15:897-906.
49. Tyrone JW, Marcus JR, Bonomo SR, et al. Transforming growth factor beta3 promotes fascial wound healing in a new animal model. *Arch Surg.* 2000; 135:1154-1159.
50. Eppley BL, Woodell JE, Higgins J. Platelet quantification and growth factor analysis from platelet-rich plasma: implications for wound healing. *Plast Reconstr Surg.* 2004;114:1502-1508.
51. Mitra R, Khar A. Suppression of macrophage function in AK-5 tumor transplanted animals: role of TGF-beta1. *Immunol Lett.* 2004;91:189-195.
52. Papakonstantinou E, Aletras AJ, Roth M, et al. Hypoxia modulates the effects of transforming growth factor-beta isoforms on matrix-formation by primary human lung fibroblasts. *Cytokine.* 2003;24:25-35.
53. Zeng G, McCue HM, Mastrangelo L, et al. Endogenous TGF-beta activity is modified during cellular aging: effects on metalloproteinase and TIMP-1 expression. *Exp Cell Res.* 1996;228:271-276.
54. Colwell AS, Phan TT, Kong W, et al. Hypertrophic scar fibroblasts have increased connective tissue growth factor expression after transforming growth factor-beta stimulation. *Plast Reconstr Surg.* 2005;116:1387-1390; discussion 1391-1392.
55. Lin RY, Sullivan KM, Argenta PA, et al. Exogenous transforming growth factor-beta amplifies its own expression and induces scar formation in a model of human fetal skin repair. *Ann Surg.* 1995;222:146-154.
56. Shimizu A, Kato M, Nakao A, et al. Identification of receptors and Smad proteins involved in activin signalling in a human epidermal keratinocyte cell line. *Genes Cells.* 1998;3:125-134.

57. Ceccarelli S, Cardinali G, Aspite N, et al. Cortactin involvement in the keratinocyte growth factor and fibroblast growth factor 10 promotion of migration and cortical actin assembly in human keratinocytes. *Exp Cell Res*. 2007;313:1758-1777.
58. Sogabe Y, Abe M, Yokoyama Y, et al. Basic fibroblast growth factor stimulates human keratinocyte motility by Rac activation. *Wound Repair Regen*. 2006;14: 457-462.
59. Powers CJ, McLeskey SW, Wellstein A. Fibroblast growth factors, their receptors and signaling. *Endocr Relat Cancer*. 2000;7:165-197.
60. Ornitz DM, Xu J, Colvin JS, et al. Receptor specificity of the fibroblast growth factor family. *J Biol Chem*. 1996;271:15292-15297.
61. Niessen FB, Andriessen MP, Schalkwijk J, et al. Keratinocyte-derived growth factors play a role in the formation of hypertrophic scars. *J Pathol*. 2001;194:207-216.
62. Uutela M, Wirzenius M, Paavonen K, et al. PDGF-D induces macrophage recruitment, increased interstitial pressure, and blood vessel maturation during angiogenesis. *Blood*. 2004;104:3198-3204.
63. Edelberg JM, Aird WC, Wu W, et al. PDGF mediates cardiac microvascular communication. *J Clin Invest*. 1998;102:837-843.
64. Margolis DJ, Cromblehome T, Herlyn M, et al. Clinical protocol. Phase I trial to evaluate the safety of H5.020CMV.PDGF-b and limb compression bandage for the treatment of venous leg ulcer: trial A. *Hum Gene Ther*. 2004;15:1003-1019.
65. Margolis DJ, Crombleholme T, Herlyn M. Clinical protocol: phase I trial to evaluate the safety of H5.020CMV. PDGF-B for the treatment of a diabetic insensate foot ulcer. *Wound Repair Regen*. 2000;8:480-493.
66. Saaristo A, Tammela T, Farkkilā A, et al. Vascular endothelial growth factor-C accelerates diabetic wound healing. *Am J Pathol*. 2006;169:1080-1087.
67. Jazwa A, Loboda A, Golda S, et al. Effect of heme and heme oxygenase-1 on vascular endothelial growth factor synthesis and angiogenic potency of human keratinocytes. *Free Radic Biol Med*. 2006;40:1250-1263.
68. Cianfarani F, Zambruno G, Brogelli L, et al. Placenta growth factor in diabetic wound healing: altered expression and therapeutic potential. *Am J Pathol*. 2006;169:1167-1182.
69. Kastenbauer T, Hornlein B, Sokol G, et al. Evaluation of granulocyte-colony stimulating factor (filgrastim) in infected diabetic foot ulcers. *Diabetologia*. 2003;46: 27-30.
70. Komine M, Rao LS, Kaneko T, et al. Inflammatory versus proliferative processes in epidermis. Tumor necrosis factor alpha induces K6b keratin synthesis through a transcriptional complex containing NFkappa B and C/EBPbeta. *J Biol Chem*. 2000;275:32077-32088.
71. Finnerty CC, Herndon DN, Przkora R, et al. Cytokine expression profile over time in severely burned pediatric patients. *Shock*. 2006;26:13-19.
72. Wallace HJ, Stacey MC. Levels of tumor necrosis factor-alpha (TNF-alpha) and soluble TNF receptors in chronic venous leg ulcers—correlations to healing status. *J Invest Dermatol*. 1998;110:292-296.
73. Wetzler C, Kampfer H, Stallmeyer B, et al. Large and sustained induction of chemokines during impaired wound healing in the genetically diabetic mouse: prolonged persistence of neutrophils and macrophages during the late phase of repair. *J Invest Dermatol*. 2000;115:245-253.
74. Dipietro LA, Reintjes MG, Low QE, et al. Modulation of macrophage recruitment into wounds by monocyte chemoattractant protein-1. *Wound Repair Regen*. 2001;9:28-33.
75. Schultz GS, Sibbald RG, Falanga V, et al. Wound bed preparation: a systematic approach to wound management. *Wound Repair Regen*. 2003;11(suppl 1): S1-S28.
76. Gethin G, Cowman S, Kolbach DN. Debridement for venous leg ulcers. *Cochrane Database Syst Rev*. 2015;CD008599.
77. Wolcott RD, Rumbaugh KP, James G, et al. Biofilm maturity studies indicate sharp debridement opens a time- dependent therapeutic window. *J Wound Care*. 2010;19:320-328.
78. Woo K, Ayello EA, Sibbald RG. The edge effect: current therapeutic options to advance the wound edge. *Adv Skin Wound Care*. 2007;20:99-117; quiz 118-119.
79. Kirsner RS, Warriner R, Michela M, et al. Advanced biological therapies for diabetic foot ulcers. *Arch Dermatol*. 2010;146:857-862.
80. Veves A, Falanga V, Armstrong DG, et al. Graftskin, a human skin equivalent, is effective in the management of noninfected neuropathic diabetic foot ulcers: a prospective randomized multicenter clinical trial. *Diabetes Care*. 2001;24(2):290-295.
81. Alrubaiy L, Al-Rubaiy KK. Skin substitutes: a brief review of types and clinical applications. *Oman Med J*. 2009;24:4-6.
82. Shimizu R, Kishi K. Skin graft. *Plast Surg Int*. 2012; 2012:563493.
83. Kirsner RS, Falanga V, Eaglstein WH. The biology of skin grafts. Skin grafts as pharmacologic agents. *Arch Dermatol*. 1993;129:481-483.
84. Zell D, Hu S, Kirsner RS. A paradigm shift in the mechanisms of graft rejection. *J Invest Dermatol*. 2008;128:1874.
85. Kirsner RS, Falanga V, Kerdel FA, et al. Skin grafts as pharmacological agents: pre-wounding of the donor site. *Br J Dermatol*. 1996;135:292-296.
86. Hughes OB, Rakosi A, Macquhae F, et al. A review of cellular and acellular matrix products: indications, techniques, and outcomes. *Plast Reconstr Surg*. 2016;138:138S-147S.
87. Hu S, Kirsner RS, Falanga V, et al. Evaluation of Apligraf persistence and basement membrane restoration in donor site wounds: a pilot study. *Wound Repair Regen*. 2006;14:427-433.
88. Falanga V, Sabolinski M. A bilayered living skin construct (APLIGRAF) accelerates complete closure of hard-to-heal venous ulcers. *Wound Repair Regen*. 1999;7:201-207.
89. Serena TE, Carter MJ, Le LT, et al. A multicenter, randomized, controlled clinical trial evaluating the use of dehydrated human amnion/chorion membrane allografts and multilayer compression therapy vs. multilayer compression therapy alone in the treatment of venous leg ulcers. *Wound Repair Regen*. 2014;22:688-693.
90. Zelen CM, Gould L, Serena TE, et al. A prospective, randomised, controlled, multi-centre comparative effectiveness study of healing using dehydrated human amnion/chorion membrane allograft, bioengineered skin substitute or standard of care for treatment of chronic lower extremity diabetic ulcers. *Int Wound J*. 2015;12:724-732.
91. Zelen CM, Serena TE, Snyder RJ. A prospective, randomised comparative study of weekly versus

biweekly application of dehydrated human amnion/chorion membrane allograft in the management of diabetic foot ulcers. *Int Wound J.* 2014;11:122-128.
92. Lavery LA, Fulmer J, Shebetka KA, et al. The efficacy and safety of Grafix(®) for the treatment of chronic diabetic foot ulcers: results of a multi-centre, controlled, randomised, blinded, clinical trial. *Int Wound J.* 2014;11:554-560.
93. Yao M, Attalla K, Ren Y, et al. Ease of use, safety, and efficacy of integra bilayer wound matrix in the treatment of diabetic foot ulcers in an outpatient clinical setting: a prospective pilot study. *J Am Podiatr Med Assoc.* 2013;103:274-280.
94. Driver VR, Lavery LA, Reyzelman AM, et al. A clinical trial of Integra Template for diabetic foot ulcer treatment. *Wound Repair Regen.* 2015;23:891-900.
95. Mostow EN, Haraway GD, Dalsing M, et al. Effectiveness of an extracellular matrix graft (OASIS Wound Matrix) in the treatment of chronic leg ulcers: a randomized clinical trial. *J Vasc Surg.* 2005;41:837-843.
96. Brigido SA. The use of an acellular dermal regenerative tissue matrix in the treatment of lower extremity wounds: a prospective 16-week pilot study. *Int Wound J.* 2006;3:181-187.
97. Kelechi TJ, Mueller M, Hankin CS, et al. A randomized, investigator-blinded, controlled pilot study to evaluate the safety and efficacy of a poly-*N*-acetyl glucosamine-derived membrane material in patients with venous leg ulcers. *J Am Acad Dermatol.* 2012;66:e209-e215.
98. Dabiri G, Heiner D, Falanga V. The emerging use of bone marrow-derived mesenchymal stem cells in the treatment of human chronic wounds. *Expert Opin Emerg Drugs.* 2013;18:405-419.
99. Derakhshani A, Raoof M, Dabiri S, et al. Isolation and evaluation of dental pulp stem cells from teeth with advanced periodontal disease. *Arch Iran Med.* 2015;18:211-217.
100. Quesenberry P, Colvin G, Lambert JF, et al. Marrow stem cell potential within a continuum. *Ann N Y Acad Sci.* 2003;996:209-221.
101. Quesenberry PJ, Colvin GA, Abedi M, et al. The marrow stem cell: the continuum. *Bone Marrow Transplant.* 2003;32(suppl 1):S19-S22.
102. Fu X, Sun X. Can hematopoietic stem cells be an alternative source for skin regeneration? *Ageing Res Rev.* 2009;8:244-249.
103. Templin C, Grote K, Schledzewski K, et al. Ex vivo expanded haematopoietic progenitor cells improve dermal wound healing by paracrine mechanisms. *Exp Dermatol.* 2009;18:445-453.
104. Falanga V, Iwamoto S, Chartier M, et al. Autologous bone marrow-derived cultured mesenchymal stem cells delivered in a fibrin spray accelerate healing in murine and human cutaneous wounds. *Tissue Eng.* 2007;13:1299-1312.
105. Dash A, Maiti R, Akantappa Bandakkanavar TK, et al. Intramuscular drotaverine and diclofenac in acute renal colic: a comparative study of analgesic efficacy and safety. *Pain Med.* 2012;13:466-471.
106. Falanga V, Eaglstein WH. The "trap" hypothesis of venous ulceration. *Lancet.* 1993;341:1006-1008.
107. Kirsner RS, Pardes JB, Eaglstein WH, et al. The clinical spectrum of lipodermatosclerosis. *J Am Acad Dermatol.* 1993;28:623-627.
108. Miteva M, Romanelli P, Kirsner RS. Lipodermatosclerosis. *Dermatol Ther.* 2010;23:375-388.
109. Alavi A, Sibbald RG, Phillips TJ, et al. What's new: management of venous leg ulcers: treating venous leg ulcers. *J Am Acad Dermatol.* 2016;74:643-664; quiz 665-666.
110. Alavi A, Sibbald RG, Phillips TJ, et al. What's new: management of venous leg ulcers: approach to venous leg ulcers. *J Am Acad Dermatol.* 2016;74:627-640; quiz 641-642.
111. Kim BC, Kim HT, Park SH, et al. Fibroblasts from chronic wounds show altered TGF-beta-signaling and decreased TGF-beta Type II receptor expression. *J Cell Physiol.* 2003;195:331-336.
112. Agren MS. Matrix metalloproteinases (MMPs) are required for re-epithelialization of cutaneous wounds. *Arch Dermatol Res.* 1999;291:583-590.
113. Pastar I, Stojadinovic O, Krzyzanowska A, et al. Attenuation of the transforming growth factor beta-signaling pathway in chronic venous ulcers. *Mol Med.* 2010;16:92-101.
114. Loots MA, Lamme EN, Zeegelaar J, et al. Differences in cellular infiltrate and extracellular matrix of chronic diabetic and venous ulcers versus acute wounds. *J Invest Dermatol.* 1998;111:850-857.
115. Mendez MV, Stanley A, Park HY, et al. Fibroblasts cultured from venous ulcers display cellular characteristics of senescence. *J Vasc Surg.* 1998;28:876-883.
116. Mendez MV, Stanley A, Phillips T, et al. Fibroblasts cultured from distal lower extremities in patients with venous reflux display cellular characteristics of senescence. *J Vasc Surg.* 1998;28:1040-1050.
117. Gould L, Abadir P, Brem H, et al. Chronic wound repair and healing in older adults: current status and future research. *J Am Geriatr Soc.* 2015;63:427-438.
118. Gurtner GC, Werner S, Barrandon Y, et al. Wound repair and regeneration. *Nature.* 2008;453:314-321.
119. Ashcroft GS, Horan MA, Herrick SE, et al. Age-related differences in the temporal and spatial regulation of matrix metalloproteinases (MMPs) in normal skin and acute cutaneous wounds of healthy humans. *Cell Tissue Res.* 1997;290:581-591.
120. Ashcroft GS, Kielty CM, Horan MA, et al. Age-related changes in the temporal and spatial distributions of fibrillin and elastin mRNAs and proteins in acute cutaneous wounds of healthy humans. *J Pathol.* 1997;183:80-89.
121. Morton LM, Phillips TJ. Wound healing and treating wounds: differential diagnosis and evaluation of chronic wounds. *J Am Acad Dermatol.* 2016;74:589-605; quiz 605-606.
122. Powers JG, Higham C, Broussard K, et al. Wound healing and treating wounds: Chronic wound care and management. *J Am Acad Dermatol.* 2016:74:607-625; quiz 625-626.
123. Grey JE, Harding KG, Enoch S. Venous and arterial leg ulcers. *BMJ.* 2006;332:347-350.
124. VanGilder C, Amlung S, Harrison P, et al. Results of the 2008-2009 International Pressure Ulcer Prevalence Survey and a 3-year, acute care, unit-specific analysis. *Ostomy Wound Manage.* 2009;55:39-45.
125. Alavi A, Sibbald RG, Mayer D, et al. Diabetic foot ulcers: part II. Management. *J Am Acad Dermatol.* 2014;70:21.e21-21.e24; quiz 45-46.
126. Alavi A, Sibbald RG, Mayer D, et al. Diabetic foot ulcers: part I. Pathophysiology and prevention. *J Am Acad Dermatol.* 2014;70:1.e1-1.e18; quiz 19-20.
127. Falanga V, Fujitani RM, Diaz C, et al. Systemic treatment of venous leg ulcers with high doses of pentoxifylline: efficacy in a randomized,

placebo-controlled trial. *Wound Repair Regen*. 1999;7:208-213.
128. Helfman T, Falanga V. Stanozolol as a novel therapeutic agent in dermatology. *J Am Acad Dermatol*. 1995;33:254-258.
129. Fox JD, Baquerizo-Nole KL, Macquhae F, et al. Comment on Yang et al. Association of statin use and reduced risk of lower-extremity amputation among patients with diabetes: a nationwide population-based cohort observation. *Diabetes Care* 2016;39: e54-e55. Diabetes Care. 2016;39:e159-e160.
130. Yang TL, Lin LY, Huang CC, et al. Association of statin use and reduced risk of lower-extremity amputation among patients with diabetes: a nationwide population-based cohort observation. *Diabetes Care*. 2016;39:e54-55.
131. Tallman P, Muscare E, Carson P, et al. Initial rate of healing predicts complete healing of venous ulcers. *Arch Dermatol*. 1997;133:1231-1234.
132. Gelfand JM, Hoffstad O, Margolis DJ. Surrogate endpoints for the treatment of venous leg ulcers. *J Invest Dermatol*. 2002;119:1420-1425.
133. Cardinal M, Eisenbud DE, Phillips T, et al. Early healing rates and wound area measurements are reliable predictors of later complete wound closure. *Wound Repair Regen*. 2008;16:19-22.

This page intentionally left blank

Bacterial Diseases PART 23

Chapter 150 :: Superficial Cutaneous Infections and Pyodermas

:: Lloyd S. Miller

Normal human skin is colonized soon after birth by a large number of bacteria that live as commensals on the epidermis and in epidermal appendages (ie, the skin microbiome). For example, coagulase-negative *Staphylococci* (*Staphylococcus epidermidis*) are inoculated during vaginal passage and coryneform bacteria take up residence on neonatal skin shortly after birth. Within weeks after birth, neonatal skin is colonized with many different species of bacteria, fungi and viruses that comprise the human skin microbiome (see Chap. 16).

This chapter discusses superficial cutaneous infections and pyodermas. Pyodermas are infections of the skin that are pyogenic (ie, filled with pus). The majority of the cutaneous pyodermas are caused by *Staphylococcus aureus* or group A *Streptococcus* (GAS) (also known as *Streptococcus pyogenes*). These Gram-positive bacteria cause a broad clinical spectrum of infections ranging from superficial pyodermas to more invasive skin and soft-tissue infections (SSTIs; see Chaps. 151 to 153) depending on the organism, the anatomic location of infections, and on host factors. In addition, this chapter also discusses other common superficial bacterial skin infections, including pitted keratolysis, which is thought to be caused by *Kytococcus sedentarius*, *Dermatophilus congolensis* or other *Corynebacterium* spp., erythrasma, which is caused by *Corynebacterium minutissimum*, and trichobacteriosis, which is caused by *Corynebacterium* spp.

STAPHYLOCOCCAL SKIN INFECTIONS

AT-A-GLANCE

- *Staphylococcus aureus* is the most common cause of superficial purulent skin infections (pyodermas).
- Thirty percent of individuals are continuously colonized with *S. aureus*, and occasional carriage is found in up to 60% of healthy people. This represents a common source and risk factor for infection.
- Contributing factors include immunosuppressive disorders, diabetes mellitus, atopic dermatitis, and preexisting tissue injury.
- Local manifestations include impetigo, ecthyma, folliculitis, and furunculosis.
- Systemic reactions include staphylococcal scalded-skin syndrome, staphylococcal scarlet fever, and staphylococcal toxic shock syndrome.
- Pathology: dense neutrophilic infiltration.
- Treatment: topical, oral, or parenteral antibiotics; change predisposing conditions, if possible. When planning therapy, consider antimicrobial resistance patterns.

Staphylococci are classified into 2 major groups: (a) coagulase-negative *Staphylococci* (*S. epidermidis*) and (b) coagulase-positive *Staphylococci* (*S. aureus*). Whereas *S. epidermidis* is primarily a harmless commensal bacterium found on the surface of human skin, *S. aureus* can be found as both a harmless commensal bacterium as well as an aggressive and deadly pathogen. In 1928, Alexander Fleming found that golden-colored *S. aureus* colonies were seen growing throughout a petri dish, except in one area contaminated by the mold *Penicillium chrysogenum* (also known as *Penicillium notatum*). This led to Fleming's important discovery of penicillin and started the golden age of antibiotics. However, as antibiotic use became widespread so did the development of antibiotic resistance, which has complicated treatment of bacterial infections. These antibiotic-resistant bacteria include the widespread emergence of hospital-acquired and community-acquired methicillin-resistant *S. aureus* (MRSA) strains, as well as antibiotic resistance developing in commensal bacteria such as *S. epidermidis*. As a result, this chapter provides current recommended treatments to cover for antibiotic resistance.

EPIDEMIOLOGY

S. epidermidis is a major commensal bacterium found on the surface of human skin. Individuals carry many transient and resident colonizing strains of *S. epidermidis*, the most common coagulase-negative strain. *S. epidermidis* is a common colonizer of the skin but is capable of causing superficial and invasive infections, particularly on implanted foreign materials such as surgical implants and catheters or in cases of immunosuppression.

Using traditional microbiologic techniques, *S. aureus* is found permanently colonized in the anterior nares in approximately 30% of the population.[1] Carriage is transient in other individuals. Approximately 60% of healthy individuals are intermittent carriers of *S. aureus* at some site in the skin or mucosa.[1] Common sites of colonization typically include moist areas of the skin, such as the inguinal region, axillae, and perirectal skin, as well as the nasal, pharynx, or rectal mucosa.[2] Conditions predisposing to *S. aureus* colonization include atopic dermatitis, diabetes mellitus, renal insufficiency patients on dialysis, intravenous drug use, liver dysfunction, and certain genetic or acquired immunosuppressive disorders, including HIV infection.[3] Colonization by *S. aureus* is found at some body site in up to 37% of patients presenting with purulent community-acquired methicillin-resistant *S. aureus* (CA-MRSA) infections.[2]

S. aureus is the most common cause of primary pyodermas and SSTIs, as well as of secondary infections (superinfections) on disease-altered skin (Table 150-1). In the United States, SSTIs cause approximately 14.2 million outpatient and emergency department visits and nearly 870,000 hospital admissions per year.[4,5] In addition, CA-MRSA is the most frequent cause of SSTIs that present to emergency departments

TABLE 150-1

Infections and Toxin Syndromes Involving the Skin and Soft Tissues Caused By *Staphylococcus aureus*

Sites of Colonization (Carrier State)
- Anterior nares
- Throat
- Axillae, perineum
- Hands
- Involved skin in individuals with atopic dermatitis

Sites of Colonization in Neonates (and Sites of Infection)
- Skin
- Umbilicus
- Circumcision site
- Conjunctivae

Superficial Pyodermas
- Primary pyodermas
  - Skin
    - Impetigo
    - Bullous impetigo
    - Ecthyma
    - Botryomycosis
  - Hair follicles
    - Superficial folliculitis (follicular or Bockhart impetigo)
    - Folliculitis (sycosis barbae)
    - Furuncle (boil)
    - Carbuncle
  - Intertriginous sites
    - Intertrigo
    - Perianal dermatitis
  - Digital infections
    - Paronychia
    - Whitlow or felon
    - Blistering distal dactylitis
  - After skin disruption
    - Trauma (physical, thermal)
    - Foreign body (intravascular catheter, prosthetic device)
  - Secondary pyodermas
    - Impetiginization of dermatoses such as atopic dermatitis, herpes simplex (superinfection)
    - Certain primary immunodeficiency disorders (eg, Job's syndrome, chronic granulomatous disease)

Invasive Infections
- Acute lymphangitis, lymphadenitis
- Erysipelas
- Cellulitis
- Abscesses (dermal and subcutaneous)
- Necrotizing fasciitis
- Pyomyositis
- Bacteremia, septicemia

Metastatic Skin Infections Associated With Bacteremia (Often *S. aureus* Acute Infectious Endocarditis)
- Abscesses (superficial and deep)
- Septic vasculitis (pustular purpura)

Purpura Fulminans
- Disseminated intravascular coagulation associated with staphylococcal bacteremia
- Meningococcemia-like syndrome

Staphylococcal Toxin-Associated Syndromes
- Staphylococcal scalded-skin syndrome
- Staphylococcal scarlet fever
- Staphylococcal toxic shock syndrome

in the United States.[6,7] *S. aureus* pyodermas and SSTIs can invade the bloodstream, producing bacteremia and metastatic infection such as osteomyelitis, acute infective endocarditis, and abscesses in many organs and tissues. Antibiotic resistance has become an emerging problem, especially with MRSA, which causes between 80,000 and 111,000 invasive infections per year in the United States.[8,9] Some strains of *S. aureus* also produce exotoxins, which can cause constellations of cutaneous and systemic symptoms, such as staphylococcal scalded-skin syndrome, staphylococcal scarlet fever, and staphylococcal toxic shock syndrome (see Chap. 152).

Transfer of *S. aureus* bacteria to patients occurs predominantly via contact with skin of other persons or fomites rather than through the air.[10] Any individuals with open staphylococcal infections are high-risk potential carriers and transmitters of infection. Nasal carriage of *S. aureus* appears to be a major risk factor for postoperative surgical wound infections.[11] Nasal colonization among neonates is associated with *S. aureus* infections in newborns in nurseries and neonatal and pediatric intensive care units.[12] The rate of *S. aureus* bacteremia is also higher in nasal carriers of *S. aureus*.[12] There are particular concerns with increasing rates with antibiotic-resistant *S. aureus* strains such as hospital-acquired MRSA, which has been endemic in hospitals worldwide beginning in the 1960s. Careful handling of patients, strict hand-washing procedures, and isolation of patients with open draining staphylococcal infections are important in the reduction of transmission of *Staphylococci*. In addition, since the late 1990s there has been an epidemic of CA-MRSA strains, such as US300 in the United States, which are causing SSTIs in healthy individuals outside hospital settings and without known risk factors for infection.[13-15]

CLINICAL FEATURES

CUTANEOUS FINDINGS

Impetigo: Two clinical patterns of impetigo are recognized: nonbullous and bullous. Nonbullous accounts for 70% of impetigo cases and can be caused by *S. aureus* (most commonly), or GAS, or both in combination. It is more often seen in children, but can be seen in adults of all ages. Typically, nonbullous impetigo arises on the face (especially around the nares) or extremities after trauma. It starts as erythematous papules that become vesicles and pustules that rupture and lead to honey-colored crusted papules on an erythematous base (Fig. 150-1). In nares carriers of *S. aureus*, nonbullous impetigo often presents with a transient papule or pustule in or around the nares with associated pruritus or soreness (Fig. 150-2), which evolves into the typical honey-colored crusted papules and plaques.

Bullous impetigo is caused by *S. aureus* strains that express certain exfoliative toxins (see section "Etiology and Pathogenesis") that cleave desmoglein 1 in the epidermis, resulting in clusters of thin-roofed bullae, vesicles, and/or pustules. Bullae usually arise on areas of grossly normal skin and can easily rupture, creating crusted and erythematous erosions that may have a residual collarette of scale that represent remnants of the bullae and vesicles. Bullous impetigo occurs most commonly in newborns and older infants, and is characterized by the rapid progression of vesicles to flaccid bullae (Fig. 150-3). Decades ago, extensive bullous impetigo (archaic terms: pemphigus neonatorum or Ritter disease) occurred in epidemics within neonatal nurseries. Bullae usually arise on areas of grossly normal skin. The Nikolsky sign (sheet-like removal of

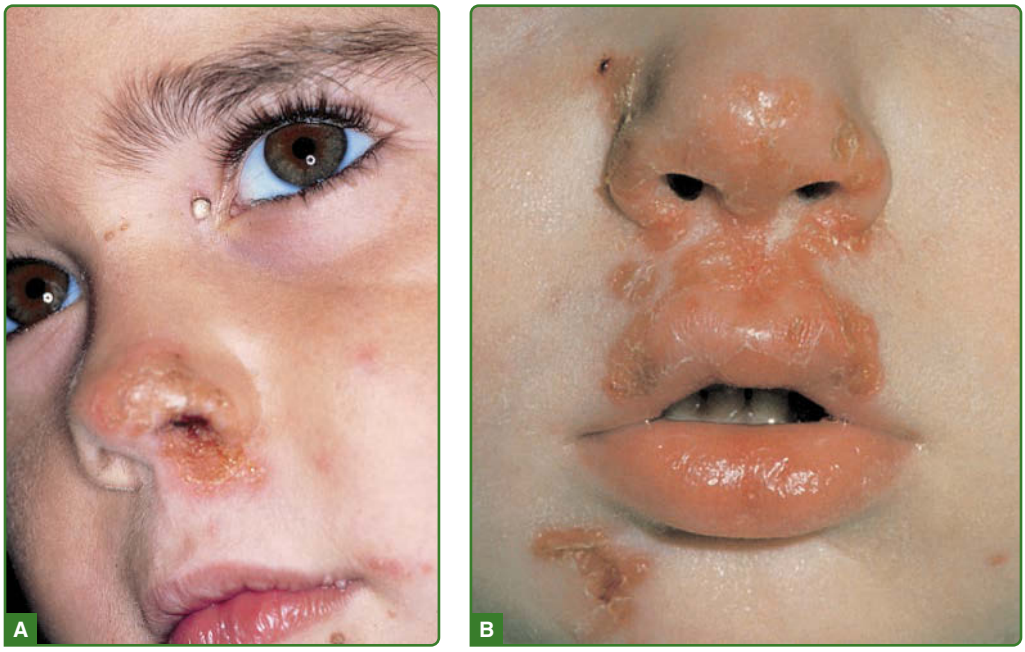

Figure 150-1 *Staphylococcus aureus:* impetigo. Erythema and honey-colored crusting on the nose and upper lip area (**A**), which can spread to involve the entire centrofacial region (**B**).

Figure 150-2 *Staphylococcus aureus*: nasal carriage with impetigo. Erythema with a small pustule on the tip of the nose and nares in an individual whose nares are colonized by *S. aureus*.

epidermis by shearing pressure) is not present. Bullae initially contain clear yellow fluid that subsequently becomes dark yellow and turbid (Fig. 150-3A), and their margins are sharply demarcated without an erythematous halo. The bullae are superficial and within a day or two they rupture and collapse, forming thin, light-brown to golden-yellow crusts (Fig. 150-3B). So-called *bullous varicella* represents superinfection of varicella lesions by *S. aureus* strains that express exfoliative toxins (bullous impetiginization).

Intact skin is usually resistant to "impetiginization." However, conditions with disrupted epidermal barrier or integrity are predisposed to *S. aureus* impetiginization such as atopic dermatitis, insect bites, epidermal dermatophytoses, herpes simplex, varicella, abrasions, lacerations, and thermal burns. Constitutional symptoms are absent. Regional lymphadenopathy may be present in up to 90% of patients with prolonged, untreated infections. If untreated, the lesions may slowly enlarge and involve new sites over several weeks. In some individuals, lesions resolve spontaneously; in others, the lesions extend into the dermis, forming an ulcer (see "Ecthyma" below).

Ecthyma: Ecthyma can be caused by *S. aureus* and/or GAS and classically evolves from untreated impetigo occluded by footwear and clothing and extends more deeply, penetrating the epidermis and producing "punched-out" ulcers in which dirty grayish-yellow crust and purulent material can be debrided (Fig. 150-4). The margin of the ulcers are indurated, raised, and violaceous, and the granulating base extends deeply into the dermis. There is typically surrounding edema. Untreated ecthymatous lesions enlarge over weeks to months to a diameter of 2 to 3 cm or more, and unlike impetigo, often heal with scarring. Ecthyma occurs most commonly on the lower extremities of children, neglected elderly patients, and individuals with diabetes. Poor hygiene and neglect are key elements in pathogenesis. Ecthymatous lesions can also evolve from a primary pyoderma or within a preexisting dermatosis or site of trauma. Ecthyma should be distinguished from ecthyma gangrenosum, which is a cutaneous ulcer caused by *Pseudomonas aeruginosa* and resembles staphylococcal or streptococcal ecthyma (see Chap. 154).

Folliculitis: Folliculitis is a pyoderma that begins within the hair follicle, and is classified according to the depth of invasion (superficial and deep), and microbial etiology (Table 150-2). Superficial folliculitis also has been termed *follicular* or *Bockhart impetigo*. A small,

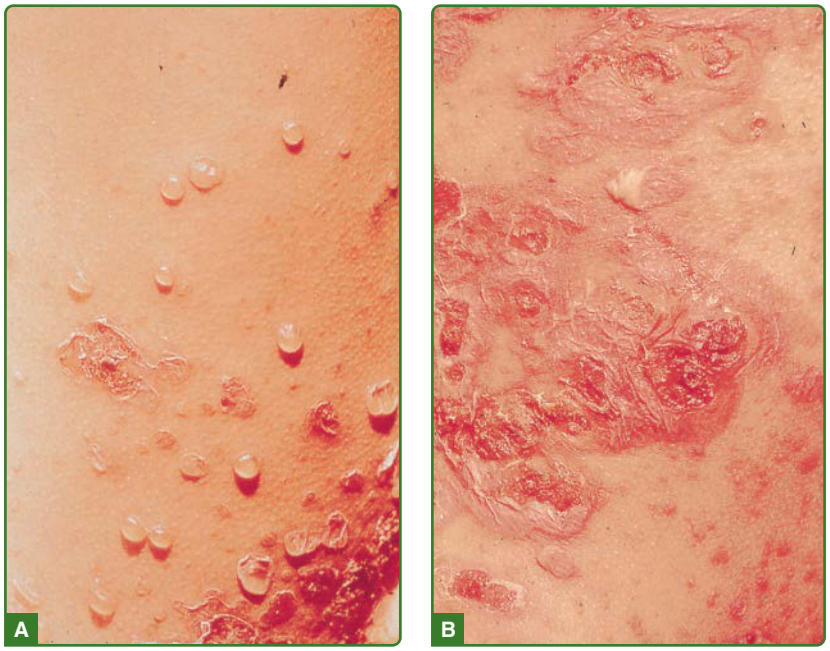

Figure 150-3 *Staphylococcus aureus*: bullous impetigo. Multiple vesicles with clear and turbid contents (**A**) that rapidly coalesce to form flaccid bullae (**B**).

Figure 150-4 *Staphylococcus aureus*: ecthyma. Multiple thickly crusted ulcers on the leg of a patient with diabetes and renal failure. Ecthymatous lesions were also present on the other leg, the arms, and the hands.

fragile, dome-shaped pustule occurs at the infundibulum (ostium or opening) of a hair follicle, often on the scalps of children and in the beard area (Fig. 150-5), axillae, extremities, and buttocks of adults. Isolated staphylococcal folliculitis is particularly common on the buttocks of adults. *Periporitis staphylogenes* refers to

TABLE 150-2
Classification of Infectious Folliculitis

Bacterial Folliculitis
- *Staphylococcus aureus* folliculitis
  - Periporitis staphylogenes
  - Superficial (follicular or Bockhart impetigo)
  - Deep (eg, sycosis barbae) (may progress to furuncle [boil], carbuncle, or abscess)
- *Pseudomonas aeruginosa* folliculitis ("hot tub" folliculitis)
- Gram-negative folliculitis (often occurring in acne vulgaris patients on the face or back while on antibioitc therapy)
- Syphilitic folliculitis (secondary; acneiform)

Fungal Folliculitis
- Dermatophytic folliculitis
  - Tinea capitis
  - Tinea barbae
  - Majocchi granuloma
- *Malassezia* folliculitis (formerly *Pityrosporum* folliculitis)
- *Candida* folliculitis

Viral Folliculitis
- Herpes simplex virus folliculitis
- Follicular molluscum contagiosum

Infestation
- Follicular molluscum contagiosum
- Demodicidosis

Figure 150-5 *Staphylococcus aureus*: superficial folliculitis. Multiple pustules confined to the beard area.

secondary infection of miliaria of neonates by *S. aureus*. Staphylococcal blepharitis is a *S. aureus* infection of the eyelids, presenting with scaling or crusting of the eyelid margins, often with associated conjunctivitis; the differential diagnosis includes seborrheic dermatitis and rosacea of the eyelid. Sycosis barbae is a deep folliculitis with perifollicular inflammation occurring in the bearded areas of the face and upper lip (Fig. 150-6). If untreated, the lesions may become more deeply seated and chronic. Lupoid sycosis is a deep, chronic form of sycosis barbae associated with scarring, usually occurring as a circinate lesion. A central cicatrix surrounded by pustules and papules gives the appearance of lupus vulgaris (see Chap. 157).

S. aureus folliculitis must be differentiated from other folliculocentric infections. These include 3 noninfectious and inflammatory follicular disorders that are more common in black men: (a) pseudofolliculitis barbae, which occurs on the lower beard area (Fig. 150-7); (b) folliculitis keloidalis or acne keloidalis nuchae, on the nape of the neck; and (c) perifolliculitis capitis, on the scalp. *S. aureus* can cause secondary infection in these inflammatory disorders. Exposure to

Figure 150-6 Sycosis barbae. Deep staphylococcal folliculitis of the mustache region.

Figure 150-7 Pseudofolliculitis barbae. Multiple papules in the lower beard area caused by ingrowing of the curved hair shaft in a black man who shaves. If pustules are present, secondary *Staphylococcus aureus* infection must be ruled out.

Figure 150-8 **A,** Furuncle of the upper lip. The lesion is nodular, and the central necrotic plug is covered by purulent crust. Several small pustules are seen lateral to the center of the lesion. **B,** Multiple furuncles. Multiple abscesses on the buttocks of long standing in a young man with inflammatory bowel disease. The lesions healed with scarring after a prolonged course of systemic antibiotics.

mineral oils, tar products, and cutting oils can cause an irritant folliculitis. Acne vulgaris, drug-induced acneiform eruptions, rosacea, hidradenitis suppurativa, acne necrotica of the scalp, and eosinophilic folliculitis of HIV disease must be distinguished from infectious folliculitis as well. Also, "hot tub" folliculitis may be caused by *P. aeruginosa* (see Chap. 154). Dermatophytic folliculitis must be differentiated from *S. aureus* folliculitis. In fungal infections, hairs are usually broken or loosened, and there are suppurative or granulomatous nodules rather than pustules. Also, in dermatophytic folliculitis, plucking of hairs is usually painless (see Chap. 160).

Furuncles: A furuncle or boil is a deep-seated inflammatory nodule that develops around a hair follicle, usually from a preceding, more superficial folliculitis and often evolves into an abscess. A furuncle starts as a hard, tender, red folliculocentric nodule in hair-bearing skin that enlarges and becomes painful and fluctuant after several days (ie, undergoes abscess formation; Fig. 150-8A). Rupture occurs with discharge of pus, and often a core of necrotic material. The pain surrounding the lesion then subsides, and the redness and edema diminish over several days to several weeks. Furuncles may occur as solitary lesions or as multiple lesions in sites such as the buttocks (Fig. 150-8B). Furuncles typically arise in hair-bearing sites, particularly in regions subject to friction, occlusion, and perspiration, such as the neck, face, axillae, and buttocks. They may complicate preexisting lesions such as atopic dermatitis, excoriations, abrasions, scabies, or pediculosis, but occur more often in the absence of any local predisposing causes. In addition, a variety of systemic host factors are associated with furunculosis, including obesity, blood dyscrasias, defects in neutrophil function, and immunosuppression caused by systemic glucocorticoids, chemotherapy, or immunoglobulin deficiency states. The process is often more extensive in patients with diabetes. However, the majority of patients with problems of furunculosis appear to be otherwise healthy.

Carbuncles: A carbuncle is a more extensive, deeper, communicating, infiltrated, and serious inflammatory lesion that develops when suppuration occurs in thick inelastic skin when multiple, closely set furuncles coalesce. A carbuncle characteristically presents as an extremely painful lesion at the nape of the neck, the back, or thighs (Fig. 150-9). Fever and malaise are often present, and the patient may appear quite ill. The involved area is red and indurated, and multiple pustules soon appear on the surface, draining externally around multiple hair follicles. The lesion soon develops a yellow-gray irregular crater at the center, which may then heal slowly by granulating, although the area may remain deeply violaceous for a prolonged period. The resulting permanent scar is often dense and readily evident.

Abscesses: *S. aureus* dermal and subcutaneous abscesses commonly occur in folliculocentric

Figure 150-9 Carbuncle. This lesion represents multiple confluent furuncles draining pus from multiple openings.

infections—that is, folliculitis, furuncles, and carbuncles as described earlier. Abscesses can also occur at sites of trauma, foreign bodies, burns, or sites of insertion of intravenous catheters. The initial lesion is an erythematous nodule. If untreated, the lesion often enlarges, with the formation of a pus-filled cavity (Fig. 150-10). CA-MRSA should be suspected in all patients with a skin abscess as this is a common presentation for these virulent *S. aureus* strains.[15,16]

Botryomycosis: Botryomycosis is a rare pyogenic disease that presents as a purulent, chronic, subcutaneous infection. Predisposing factors include trauma, immunosuppression (HIV disease, hyperimmunoglobulin E syndrome), chronic alcoholism, and diabetes mellitus. Lesions (usually solitary) can occur in skin, bone, and liver. Cutaneous botryomycosis usually presents as a solitary lesion or a few lesions, often occurring in the genital area. The lesion has the gross appearance of a ruptured epidermal inclusion cyst (an erythematous circumscribed tender nodule), or prurigo nodularis (Fig. 150-11). In the majority of reported cases, a foreign body has played a role in initiating or perpetuating the lesion.

Figure 150-10 *Staphylococcus aureus* abscess. A large painful abscess on the heel of a patient with diabetes improved clinically; however, the severe pain persisted. Radiographs of the heel revealed a broken-off sewing needle. The patient had sensory neuropathy and was unaware of stepping on this foreign body.

Figure 150-11 *Staphylococcus aureus* botryomycosis. A plaque on the chest had been present for several months in this HIV-infected individual. The diagnosis was confirmed on lesional biopsy findings and culture.

Staphylococcal Paronychia: Individuals exposed to hand trauma or chronic moisture are predisposed to staphylococcal paronychia, as well as to other causes of paronychia (eg, *Candida, Pseudomonas, Streptococcus,* dermatophytes). *S. aureus* is the major infectious cause of acute paronychia, usually around the fingernails, often originating from a break in the skin, such as a hangnail. Clinically, skin and soft tissue of the proximal and lateral nailfold are red, hot, and tender, and can progress to abscess formation if not treated (Fig. 150-12). In contrast, chronic or recurrent paronychia caused by *Candida albicans* is an infection of the space created by separation of the proximal dorsal nail plate and the undersurface of the proximal nailfold. Candidal paronychia is most common in individuals who have their hands in water for a great deal of time (see Chap. 161).

Staphylococcal Whitlow: A whitlow (or felon) is a purulent infection or abscess involving the bulbous distal end of a finger. The most common causes are *S. aureus* and herpes simplex virus. The portal of entry of *S. aureus* is a traumatic injury or possible extension of an acute paronychia. This infection is usually very painful. An obvious portal of entry is often apparent. The finger bulb is red, hot, tender, and edematous, with possible abscess formation (Fig. 150-13). In contrast, individuals with herpetic whitlows usually have a history of lesions occurring in the same site and present with grouped hemorrhagic vesicles, which may become confluent and form a single bulla (see Chap. 164).

Figure 150-12 *Staphylococcus aureus* paronychia. An abscess is seen in the dorsum of the finger, beginning in a small break in the cuticle. In contrast, *Candida* paronychia is a space infection, occurring in the space created by the separation of the proximal dorsal nail plate and the overlying proximal nailfold.

NONCUTANEOUS FINDINGS

In response to more-severe *S. aureus* SSTIs, which typically occur with deep furunculosis and abscesses, there might be signs of a systemic infection (eg, fever, chills, rigors, myalgias, mental status changes, hemodynamic instability) or systemic inflammatory response syndrome, which includes temperature higher than 38°C (100.4°F) or lower than 36°C (96.8°F), tachypnea exceeding 24 breaths per minute, tachycardia exceeding 90 beats per minute, or white blood cell count higher than 12,000 or less than 400 cells/μL.[6,17] These cases require immediate systemic antibiotic therapy (see section "Management").

Figure 150-13 *Staphylococcus aureus* whitlow (felon). A pyogenic granuloma arose 1 week after trauma to the bulb of the thumb. A week later, the bulb became swollen, erythematous, and very tender. Abscess formation is seen with loculation of pus. Radiographs showed early osteomyelitis complicating the whitlow.

COMPLICATIONS

If untreated, invasive infection can complicate all of these *S. aureus* skin infections and result in cellulitis, lymphangitis, and bacteremia, which can lead to life-threating *S. aureus* infections in many organs and tissues, including osteomyelitis, septic arthritis, abscesses of various organs (brain, liver, etc), endocarditis, pneumonia, and sepsis. Lesions about the lips and nose raise the specter of spread via the facial and angular emissary veins to the cavernous sinus. Fortunately, these complications are uncommon. However, the risk for invasive infection is higher with deeper infections, such as furuncles, carbuncles, and abscesses, in an unpredictable fashion, and manipulation of such lesions is particularly dangerous and may facilitate spread of the infection via the bloodstream. *S. aureus* exotoxins can result in staphylococcal scalded-skin syndrome, staphylococcal scarlatiniform eruption, toxic shock syndrome, recalcitrant erythematous, desquamating disorders, and recurrent toxin-mediated perineal erythema (see Chap. 152). Staphylococcal scalded-skin syndrome is more likely to occur in infants and in adults who are immunocompromised or have impaired renal function.

ETIOLOGY AND PATHOGENESIS

Risk factors for *S. aureus* SSTIs, include colonization by *S. aureus* in mucosal sites (especially the nares) and on the skin, which may be transient or represent a prolonged carrier state. In addition, patients with preexisting tissue injury or inflammation (surgical wounds, burns, trauma, atopic dermatitis, retained foreign body) all are at higher risk of *S. aureus* SSTIs.[18] Patients with immunodeficiency disorders, such as HIV and AIDS, or who are on systemic corticosteroids are also predisposed to *S. aureus* SSTI. Any condition that results in defective neutrophil number or function, including genetic (eg, chronic granulomatous disease) or acquired (eg, persons with diabetes, cancer patients on chemotherapy) disorders are highly susceptible to *S. aureus* SSTIs as well as to *S. aureus* invasive and systemic infections.[18] Finally, rare patients with genetic or acquired deficiency of interleukin (IL)-17 responses (eg, Job's syndrome) are also susceptible to *S. aureus* SSTIs.[19]

The pathogenesis of *S. aureus* SSTIs involves many different virulence factors that promote colonization

and infection and evade host immune detection and function.[1,20-22] For example, *S. aureus* secretes pore-forming toxins that lyse host cells such as neutrophils and macrophages, thereby preventing the host defense function of these cells.[20] There are 2 main families of *S. aureus* pore-forming toxins: (a) single-component α-hemolysin (also known as α-toxin) and (b) biocomponent leukotoxins, includingPanton–Valentine leukocidin (PVL or LukSF–PV), γ-hemolysin AB and γ-hemolysin CB (HlgAB and HlgCB), leukocidin ED (LukED) and leukocidin AB (LukAB; also known as LukGH).[20] These toxins have specific host cell targets. For example, α-toxin targets ADAM10, PVL targets C5a receptors, LukAB targets CD11b and LukED targets CCR5, CXCR1, and CXCR2.[20] In particular, α-toxin and PVL are associated with the virulence of *S. aureus*, including CA-MRSA.[1] High serum antibody titers against α-toxin correlate with protection against recurrent *S. aureus* SSTIs.[23] In addition, *S. aureus* secretes phenol-soluble modulins (PSMs), including $PSM\alpha_1$-$PSM\alpha_4$, $PSM\beta_1$, $PSM\beta_2$, and PSMδ (δ-toxin), which lyse human leukocytes and erythrocytes.[24] PSMα is associated with the enhanced virulence of CA-MRSA.[24]

Certain *S. aureus* strains produce and secrete exfoliative toxins. Bullous impetigo is caused certain types of exfoliative toxins (including types ETA, ETB, and ETD [ETC has no activity in humans]). These exfoliative toxins are serine proteases that target desmoglein 1,[25] the desmosomal cadherin that is also the target of autoantibodies in pemphigus foliaceus (see Chap. 52).[26] ETA and ETB are the most common and are located in *S. aureus* bacteriophages (ie, phage group II) whereas ETD is located in the bacterial chromosome.[25] These exfoliative toxins result in intraepithelial bullae formation in bullous impetigo when the toxin is secreted locally in the skin, and in staphylococcal scalded-skin syndrome when the toxin is present systemically (see Chap. 152).[25]

There are at least 24 different superantigens produced by *S. aureus* that are enterotoxins (also called pyrogenic toxin superantigens), including toxic shock syndrome toxin-1 (TSST-1), enterotoxins (serotypes A, B_n, C_n, D, E, and G [*n* refers to multiple variants]), SE-like (SE-1) superantigens (serotypes H, I, J, and K).[21] Superantigens have the ability to nonspecifically activate T cells by interacting with the human leukocyte antigen–DR molecules (major histocompatibility complex II) on antigen-presenting cells and the variable region of the β subunit of the T-cell receptor without antigen present, resulting in nonspecific activation of CD4+ T cells. TSST-1 is the toxin largely responsible for *S. aureus* toxic shock syndrome, which is characterized by high fever, hypotension, scarlet fever–like rash, desquamation of skin, and multiorgan dysfunction. With relevance to *S. aureus* SSTIs, *S. aureus* superantigens (especially SEB) can increase the severity of atopic dermatitis by driving cutaneous inflammation, promoting T-helper type 2 (Th2) responses, and inducing production of immunoglobulin (Ig) E antibodies (some of the IgE is directed against the superantigens themselves).[21]

S. aureus has many different mechanisms to inhibit neutrophil function, therapy increasing virulence and pathogenicity, and these are described in detail elsewhere.[22] However, some examples include *S. aureus* inhibition of neutrophil chemotaxis through production of chemotaxis inhibitory protein of *S. aureus* (CHIPS) or staphopain A (ScpA), which block complement and formyl peptide receptors or CXCR2 neutrophil-attracting chemokines, respectively. *S. aureus* also inhibits neutrophil extravasation from blood vessels via its production of staphylococcal superantigen-like 5 and 11 (SSL5, SSL11) and extracellular adherence protein (Eap), which block P-selectin and intercellular adhesion molecule (ICAM)-1, respectively, to inhibit neutrophil rolling and adhesion to endothelium.[22] *S. aureus* also produces several virulence factors that inhibit neutrophil function, including catalase, alkyl hydroperoxide reductase and staphyloxanthin (the yellow carotenoid pigment responsible for the golden color of *S. aureus* colonies), which all inhibit reactive oxygen-mediated killing. *S. aureus* also produces adenosine synthase A (AdsA) and staphylococcal nuclease (Nuc), which degrade neutrophil extracellular traps (NETs) to prevent NETosis-mediated killing of *S. aureus*.[22] Finally, *S. aureus* expresses protein A on its surface, which binds antibody in the incorrect orientation, which effectively blocks antibody-mediated phagocytosis by neutrophils and macrophages.[22]

IMMUNITY

The skin has innate immune mechanisms that protect against *S. aureus* colonization and infection. These include the constitutive and inducible production of antimicrobial peptides (by keratinocytes and other resident stromal and immune cells in the skin), which have bacteriostatic or bactericidal activity against *S. aureus* (eg, human β-defensins 2 and 3, cathelicidin, and RNase7).[18] In addition, resident and recruited skin and immune cells express pattern recognition receptors that recognize components of *S. aureus* during an infection to initiate inflammatory immune responses, especially neutrophil recruitment and abscess formation, which are required for control of the infection and bacterial clearance.[27] These include Toll-like receptor 2 (TLR2), which recognizes *S. aureus* lipoproteins, lipoteichoic acid and peptidoglycan, and nucleotide-binding oligomerization domain-containing protein 2 (NOD2), which recognizes muramyl dipeptide (a breakdown product of *S. aureus* peptidoglycan). In addition, *S. aureus* activates the inflammasome via its pore-forming toxins and phagosomal rupture, resulting in caspase-1 activation and proteolytic processing of IL-1β into its active and secreted form.[18] IL-1β is a critical cytokine for inducing neutrophil recruitment and abscess formation to a site of *S. aureus* infection in the skin.[18] In addition, IL-17 likely produced by Th17 cells (which is in part induced by IL-1β) also plays a key role in promoting neutrophil recruitment during a *S. aureus* skin infection.[18] Recurrent *S. aureus* skin infections are common, suggesting that the adaptive immune responses, such as antibody responses and

T-cell responses, are not entirely capable of preventing all *S. aureus* skin reinfections. This is highlighted by the failure of antibody-based vaccination strategies in clinical trials that target *S. aureus* surface components to facilitate antibody-mediated phagocytosis.[18] However, it is thought that generation of Th17 cells and Th1 cells likely provide some degree of protection against recurrent *S. aureus* skin infections.[18]

DIAGNOSIS

LABORATORY TESTING

For impetigo and ecthyma, the diagnosis is typically made on clinical appearance. However, Gram stain and culture of pus or exudates are generally recommended to diagnose the cause of the infection as *S. aureus* (including MRSA) and/or GAS.[17] For typical and uncomplicated cases of impetigo or ecthyma, empiric therapy can be started without performing these tests. For large furuncles, carbuncles, and abscesses, the diagnosis is also made clinically. However, and culture of pus following incision and drainage or from open draining lesions is strongly recommended.[17] Gram stain will typically reveal Gram-positive cocci in clusters (*S. aureus*) or chains (GAS) or a combination of cocci in clusters and chains when both organisms are involved. Bacterial culture and sensitivity testing will provide important information to direct appropriate antibiotic coverage and to help monitor for potential complications of *S. aureus* (see section "Complications") or GAS infections (see section "Streptococcal Skin Infections - Complications"). In patients with extensive furuncles, carbuncles, or abscesses, body temperature, respiratory rate, and blood counts should be obtained to evaluate for systemic infection or systemic inflammatory response syndrome (see "Noncutaneous Findings" section) as these patients require more aggressive parenteral antibiotic therapy.[17] These extensive infections are most commonly caused by CA-MRSA strains, which often are multidrug resistant strains and the antibiotic susceptibility testing is exceedingly important to determine adequate antibiotic coverage. Blood cultures can also be obtained if there is a suspicion for bacteremia or invasive infection.

PATHOLOGY

In general, skin biopsies are not typically performed in uncomplicated cases of impetigo, ecthyma, folliculitis/furunculosis, carbuncles, or abscesses. However, biopsy or aspiration of extensive furuncles, carbuncles, or abscesses are recommended in immunocompromised patients and in patients with fever and neutropenia for histologic evaluation (including microorganism staining), and microbiology cultures and antibiotic sensitivities to help with the diagnosis and to determine antibiotic susceptibility.[17] Histologic examination of a furuncle shows a dense polymorphonuclear inflammatory process in the dermis and subcutaneous fat. In carbuncles, multiple abscesses that separated by connective-tissue trabeculae are present in the dermis (especially along the edges of the hair follicles) and reach the surface of the skin through openings in the undermined epidermis.

IMAGING

Imaging is not typically indicated except in cases of febrile neutropenic patients with extensive furuncles, carbuncles, or abscesses. Ultrasonography can be used to direct needle aspiration of a furuncle, carbuncle, or abscess for culture and antibiotic susceptibility testing. In addition, radiographic imaging (X-ray, CT, or MRI) can be performed to determine the depth and extent of an infection. This is particularly important if there is a concern for underlying osteomyelitis (eg, in cases of *S. aureus*-infected foot ulcers in diabetic patients) or if there is a suspected indolent pulmonary site of *S. aureus* infection, which can spread to the overlying skin and soft tissues.[17]

DIAGNOSTIC ALGORITHM

Figure 150-14 shows a diagnostic and management algorithm for *S. aureus* and GAS SSTIs.

DIFFERENTIAL DIAGNOSIS

Table 150-3 outlines the differential diagnoses of impetigo, ecthyma, and furunculosis.

CLINICAL COURSE AND PROGNOSIS

Most *S. aureus* superficial skin infections and pyodermas can successfully be treated with appropriate management (see "Management" below). However, there is a high rate of recurrent *S. aureus* skin infections that can continue for many years. This is especially the case with furunculosis and skin abscesses caused by CA-MRSA, which are reported to recur in 30% to 50% of patients.[28-31] If untreated, there is a potential for invasive spread of the infection, resulting in cellulitis, lymphangitis, and bacteremia. From the bloodstream, *S. aureus* can disseminate and cause infections of many organs and tissues such as osteomyelitis, septic arthritis, abscesses of various organs, endocarditis, pneumonia and sepsis.

MANAGEMENT

A major problem in treating staphylococcal infections has been the emergence of antibiotic-resistant strains.[13-15] Hospital-acquired MRSA and CA-MRSA strains are resistance to methicillin, which

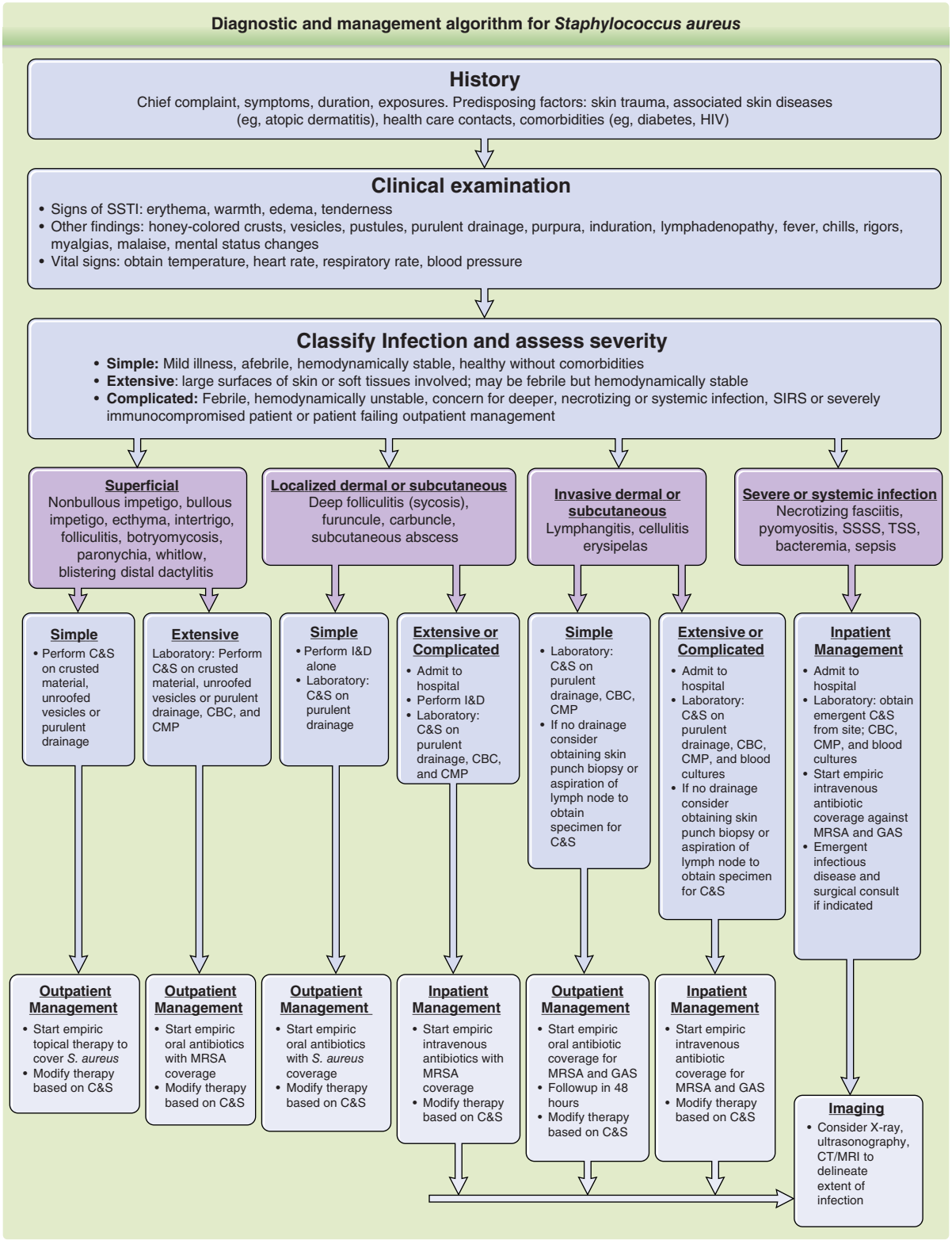

Figure 150-14 Diagnostic and management algorithm for *Staphylococcus aureus* and group A *Streptococcus* (GAS) skin and soft tissue infections (SSTIs). *Abbreviations:* C&S, culture and sensitivity; CBC, complete blood count; CMP, comprehensive metabolic panel; I&D, incision and drainage; MRSA, methicillin-resistant *S. aureus*; SIRS, severe inflammatory response syndrome; SSSS, staphylococcal scalded-skin syndrome; TSS, toxic shock syndrome.

TABLE 150-3
Differential Diagnosis of *Staphylococcus aureus* Pyodermas

Nonbullous Impetigo (*Staphylococcus aureus* or Group A *Streptococcus*)[a]
- Herpes simplex (*always rule out*)
- Herpes zoster/Varicella (*always rule out*)
- Scabies (*always rule out*)
- Seborrheic dermatitis
- Atopic dermatitis
- Allergic contact dermatitis
- Epidermal dermatophyte infections
- Tinea capitis
- Insect bite reaction
- Burns
- Erythema multiforme
- Pemphigus foliaceous
- Cellulitis
- Pediculosis capitis

Bullous Impetigo (*Staphylococcus aureus*)[a]
- Herpes simplex (*always rule out*)
- Herpes zoster/Varicella (*always rule out*)
- Bullous tinea (*always rule out*)
- Bullous fixed-drug eruption (*always rule out*)
- Bullous drug eruption
- Contact dermatitis
- Bullous insect bites
- Staphylococcal scalded skin syndrome
- Thermal burns
- Pemphigus vulgaris
- Bullous pemphigoid
- Erythema multiforme
- Dermatitis herpetiformis

Ecthyma (*Staphylococcus aureus* or Group A *Streptococcus*)
- Ecthyma gangrenosum
- Sporotrichosis
- Nontuberculosis mycobacterial skin infection (eg, *Mycobacterium marinum*)
- Papulonecrotic tuberculids
- Insect bites
- Pyoderma gangrenosum
- Leishmaniasis
- Anthrax
- Orf
- Other causes of ulcers (eg, vasculitis)

Furunculosis (*Staphylococcus aureus*)
- Cystic acne
- Kerion
- Hidradenitis suppurativa
- Ruptured epidermal inclusion cysts
- Furuncular myiasis
- Apical dental abscess
- Osteomyelitis

[a]Any of these disorders may occur primarily and become secondarily impetiginized with *S. aureus* or group A *Streptococcus*.

indicates that these strains are resistant to all β-lactam antibiotics (ie, penicillins and cephalosporins). Many of these strains are also multidrug resistant and have variable resistance to macrolides, fluoroquinolones, tetracyclines, clindamycin, and trimethoprim-sulfamethoxazole (TMP-SMX).[13-15] There is an increasing number of reports of vancomycin intermediate-resistant *S. aureus* strains, which have impacted the effectiveness of vancomycin therapy. However, true vancomycin-resistant *S. aureus* strains are exceeding rare with only several cases reported.

INTERVENTIONS, MEDICATIONS, AND PROCEDURES

Impetigo, Ecthma, and Folliculitis: Impetigo (nonbullous and bullous) can be treated with oral or topical antimicrobials (Table 150-4). Local topical treatments include mupirocin 2% topical ointment or retapamulin 1% ointment twice daily for 5 to 7 days, along with gentle physical removal of the superficial crusts by cleansing with soap and water.[17] Fusidic acid is an equally effective topical agent for localized impetigo and has few adverse side effects, but it is currently unavailable in the United States. Oral therapy can be used for impetigo and is recommended for ecthyma and uncomplicated folliculitis.[17] Because *S. aureus* isolates from impetigo, ecthyma and folliculitis are more frequently caused by methicillin-sensitive *S. aureus*, dicloxacillin (or similar penicillinase-resistant semisynthetic penicillin) (adults: 250 to 500 mg orally 4 times a day; not typically used in children) or cephalexin (adults: 500 mg orally 4 times a day; children 50 to 100 mg/kg/day divided 3 to 4 times per day) is recommended.[17] In general, oral antibiotic treatment should be continued 7 days (10 days if streptococci are isolated; see below). For patients allergic to penicillin or β-lactams, erythromycin could serve as a substitute (adults: 250 to 500 mg orally 4 times a day; children: 40 mg/kg/day divided 3 to 4 times per day).[17] However, erythromycin-resistant *S. aureus* is common among isolates that cause impetigo in children.[17] Other oral treatment options for *S. aureus* impetigo in children include amoxicillin plus clavulanic acid (25 mg/kg/day given 3 times a day) or clindamycin (15 mg/kg/day 3 or 4 times a day). If CA-MRSA is suspected as the causative organism, doxycycline (adults: 100 mg twice daily; children: not recommended for children younger than age 8 years), clindamycin (adults: 300 to 450 mg 3 to 4 times a day; children: 20 to 40 mg/kg/day in divided doses) or TMP-SMX (1 double-strength tablet twice daily; children: 8 to 12 mg/kg/day [trimethoprim component] divided 2 times per day) are recommended for initial empiric therapy, but the choice of antibiotic might need to be changed based on the clinical response and antibiotic sensitivity results.[17] Of note, tetracyclines (including doxycycline) should not be used in children younger than 8 years old, and a recent study found that clindamycin and TMP-SMX were equally and highly effective for uncomplicated SSTIs in pediatric patients.[30]

Furuncles, Carbuncles, and Abscesses: For simple furuncles, carbuncles, and abscesses, incision and drainage (I&D) alone is often performed and is likely to be adequate but additional antibiotic coverage has a better cure rate (see Table 150-4).[17] Local

TABLE 150-4
Management of *Staphylococcus aureus* Skin Infections

INFECTION	TREATMENT	ADULT DOSING	PEDIATRIC DOSING	DURATION
Impetigo (localized and simple)	Mupirocin 2% ointment	Twice daily	Twice daily	5- to 7-day course
	Retapamulin 1% ointment	Twice daily	Twice daily	
	Fusidic acid 1% cream (not available in U.S.)	2-4 times daily	2-4 times daily	
Impetigo, ecthyma, folliculitis (methicillin-sensitive *S. aureus* [MSSA])	Dicloxacillin	250-500 mg po 4 times daily	Not typically used in children	7-day course recommended, depending on clinical response
	Cephalexin	500 mg po 4 times daily	50-100 mg/kg/day (3-4 divided doses)	
	Erythromycin	200-500 mg po 4 times daily	30-50 mg/kg/day (3-4 divided doses)	
	Amoxicillin/clavulanic acid	875/125 mg po twice daily	25 mg/kg/day (3 divided doses)	
	Clindamycin	300-450 mg po 3-4 times daily	20-30 mg/kg/day (3-4 divided doses)	
Impetigo, ecthyma, folliculitis (methicillin-resistant *S. aureus* [MRSA])	Clindamycin	300-450 mg po 3-4 times daily	20-40 mg/kg/day (3-4 divided doses)	7-day course recommended, depending on clinical response
	Trimethoprim-sulfamethoxazole (TMP-SMX)	1 double-strength (DS) tab twice daily	8-12 mg/kg/day (TMP dose) (divided twice daily)	
	Doxycycline	100 mg po twice daily	Not for children <8 years old	
	Minocycline	200 × 1 + 100 mg po twice daily	Not for children <8 years old	
Furuncles, carbuncles, abscesses (simple)	Incision and drainage (consider oral antibiotics in below row)	Not applicable	Not applicable	
Furuncles, carbuncles, abscesses that are not drainable and are associated with cellulitis	Incision and drainage	Not applicable	Not applicable	7- to 14-day course recommended, depending on clinical response
	Clindamycin	300-450 mg po 3-4 times daily	20-40 mg/kg/day (3-4 divided doses)	
	TMP-SMX	1 double-strength (DS) tab po twice daily	8-12 mg/kg/day (TMP dose) (divided twice daily)	
	Doxycycline	100 mg po twice daily	Not for children <8 years old	
	Minocycline	200 × 1 + 100 mg po twice daily	Not for children <8 years old	
	Linezolid	600 mg po twice daily	10 mg/kg/dose po thrice daily (maximum: 600 mg/dose)	
Complicated MRSA skin and soft-tissue infection (SSTI)	Vancomycin	15-20 mg/kg IV q8-12h	40 mg/kg/day IV (4 divided doses q6h)	7- to 14-day course recommended, depending on clinical response
	Linezolid	600 mg po or IV twice daily	10 mg/kg/dose po or IV thrice daily (maximum: 600 mg/dose)	
	Daptomycin	4 mg/kg IV daily	Not determined	
	Ceftaroline	600 mg IV q12h	8-12 mg/kg/dose IV q8h	
	Clindamycin	600 mg po or IV thrice daily	10-13 mg/kg/dose po or IV q6-8h (maximum: 40 mg/kg/day)	
	Telavancin	10 mg/kg IV daily	Not determined	
	Quinupristin-dalfopristin	7.5 mg/kg IV q8-12h	Not determined	
Nares and skin decolonization	Mupirocin 2% ointment	Twice daily × 5 to 10 days		Can be repeated monthly × 3 months
	Chlorhexidine soap	Daily × 5 to 14 days		
	Bleach baths	Twice weekly × 3 months		
	Rifampin (included *only in combination* with an oral antibiotic regimen above)	300 mg twice daily + other oral antibiotic × 7-14 days		

Information derived from the clinical practice guidelines for the treatment of skin and soft-tissue infections (available at http://www.idsociety.org/uploadedFiles/IDSA/Guidelines-Patient_Care/PDF_Library/Skin%20and%20Soft%20Tissue.pdf) and MRSA infections (available at http://www.idsociety.org/uploadedFiles/IDSA/Guidelines-Patient_Care/PDF_Library/MRSA.pdf) from the Infectious Diseases Society of America (IDSA).[18,19]
O, orally; IV, intravenous; q, every; h, hours.

application of moist heat, which helps promote drainage, can also be helpful. Although I&D can be effective alone without antibiotic therapy, adjunctive antibiotic therapy should be added as described above for impetigo/ecthyma/folliculitis if the patients failed prior treatment with I&D alone, if there is severe or extensive disease with multiple sites of infection, surrounding cellulitis or signs of systemic infection or inflammation (see section "Noncutaneozus Findings") and in patients predisposed to SSTIs such as immunosuppressed patients (eg, HIV/AIDS, diabetic patients, cancer chemotherapy patients, and patients on systemic immunosuppressive agents, and if the patients are very young or very old), and in areas in which I&D is difficult (eg, face, hands, and genitalia).[6,17] The addition of systemic antibiotics does appear to have an added benefit as patients with skin abscesses treated with I&D plus TMP-SMX had a better cure rate than I&D plus placebo.[32] For severe infections or infections in a dangerous area, maximal antibiotic dosage should be employed by the parenteral route. CA-MRSA should be suspected in all serious purulent infections.[6] Vancomycin or other systemic parenteral agents (eg, daptomycin, linezolid, or ceftaroline), which all have anti–CA-MRSA activity, are indicated for these patients.[6] Linezolid is also available as an oral agent and has excellent (100%) bioavailability when given orally or intravenously.[6] Other parenteral agents with activity against MRSA, such as telavancin and quinupristin-dalfopristin, are reserved only for salvage therapy for treatment failures and complicated cases.[6] Of note, with vancomycin intermediate-resistant *S. aureus* strains in which the vancomycin minimal inhibitory concentration is equal to or greater than 2 µg/mL, an alternative to vancomycin should be used such as linezolid or daptomycin.[6] Antibiotic treatment should be continued for at least 7 to 14 days and, in general, antimicrobial therapy should be continued until all evidence of inflammation has regressed. The choice of antibiotic might have to be changed when culture sensitivity results become available. Draining lesions should be covered with dry bandages to prevent autoinoculation and diligent hand-washing performed.

For recurrent furuncles, carbuncles, and abscesses at the same site of prior infection, a source for other etiologies should be considered, such as hidradenitis suppurativa, a pilonidal cyst, or a foreign body.[17] Children or adults with recurrent abscesses that began in childhood should be evaluated for neutrophil disorders or other primary immunodeficiency syndromes.[17] Treatment of recurrences should be based on antibiotic susceptibility results, typically with a 5- to 10-day course of an oral antibiotic against the causative pathogen, although the duration of the course should be individualized and based on the clinical response.[6,17] Decolonization regimens should be considered in patients who suffer recurrent infections (see "Prevention/Screening" below).

Botryomycosis, Paronychia, and Whitlow: For botryomycosis, local treatment with warm saline compresses to promote drainage and local antibiotics (eg, mupirocin or clindamycin) may be sufficient to control infection. More extensive cases require systemic antibiotic therapy as described above (see Table 150-4). Management of paronychia caused by *S. aureus* includes oral and topical antibiotics, and I&D of abscesses. Management of a staphylococcal whitlow requires I&D of loculated abscess(es) within the tissue and intravenous antibiotic therapy. X-ray (or MRI) imaging of the involved finger is indicated to determine the presence of osteomyelitis. CA-MRSA should be suspected in all cases.

TREATMENT ALGORITHM

Table 150-4 outlines the management of *S. aureus* skin infections.

PREVENTION/SCREENING

All patients with *S. aureus* SSTIs should be educated about preventive measures to prevent autoinoculation and spread of *S. aureus* infections to other close contacts and individuals.[6,17] Draining wounds should be kept clean and covered with clean and dry bandages. Frequent cleansing of hands with soap and water and/or alcohol-based hand gels is especially important after contacting infected skin. Patients should avoid using or sharing personal hygiene items that have come in contact with infected skin, such as disposable razors, linens, and towels. Because fomites in the environment can serve as a reinfection source, surfaces that are frequently touched by bare skin, including door knobs, countertops, bath tubs, and toilet seats, should be routinely and repeatedly cleaned with antimicrobial commercial cleansers and detergents.[6]

In cases of recurrent *S. aureus* SSTIs despite appropriate treatment and the aforementioned personal and environmental hygienic measures, decolonization of the patients can be attempted.[6] Nasal decolonization of *S. aureus* can be achieved with mupirocin ointment administered to the nares twice daily for 5 to 10 days along with body decolonization with either daily chlorhexidine cleansing solution for 5 to 14 days or bleach baths. The nares and body decolonization procedures can be repeated on a monthly basis for 3 months. A typical regimen for bleach baths is 1 teaspoon of bleach per 1 gallon of water or one-quarter cup of bleach per one-quarter bathtub of water (approximately 13 gallons of water) and can be performed for 15 minutes twice weekly for 3 months. If these decolonization measures are ineffective, oral antibiotic treatment according to the treatment regimens above could be used in conjunction with rifampin (typically 300 mg twice daily). Importantly, rifampin can only be used in combination with other systemic antibiotics because rapid antibiotic resistance develops if rifampin is used as a single agent.

In cases in which there is evidence for household or interpersonal transmission, in addition to the personal and environmental hygiene measures described above, symptomatic contacts should be treated and

decolonization of asymptomatic household contacts can also be performed according to the above procedures for nasal and body decolonization. Surveillance cultures of nares or body sites following decolonization regimens are typically not necessary in the absence of recurrent infections.

STREPTOCOCCAL SKIN INFECTIONS

AT-A-GLANCE

- Group A *Streptococcus* (ie, *Streptococcus pyogenes*) is a common cause of superficial purulent skin infections (pyodermas). Skin infections are less commonly caused by non-Group A *Streptococcal* spp.
- Group A *Streptococcus* is the leading cause of bacterial pharyngitis and approximately 20% to 30% of individuals recovering from an infection are asymptomatic carriers and can serve as sources of transmission and recurrent infection.
- Local manifestations include impetigo, ecthyma, intertrigo, and blistering distal dactylitis.
- Invasive skin infections, such as erysipelas, cellulitis, and necrotizing fasciitis, can occur.
- Pathology: abundant neutrophilic infiltration.
- Treatment: topical, oral, or parenteral antibiotics; change predisposing conditions. Cover empirically for *S. aureus* (as antibiotic resistance is more common) until etiology is known.

TABLE 150-5

Infections and Toxin Syndromes Involving the Skin and Soft Tissues Caused By Group A *Streptococcus*

Sites of Colonization (Carrier State)
- Nasopharyngeal mucosa
- Upper airways
- Skin

Superficial Pyodermas
- Nonintertriginous skin
  - Impetigo (nonbullous)
  - Ecthyma
  - Blistering distal dactylitis
- Intertriginous skin
  - Perianal streptococcal cellulitis
  - Streptococcal vulvovaginitis
  - Streptococcal intertrigo

Invasive Infections
- Acute lymphangitis, lymphadenitis
- Erysipelas
- Cellulitis
- Necrotizing fasciitis
- Bacteremia, septicemia

Streptococcal Toxin-Associated Syndromes
- Scarlet fever
- Streptococcal toxic shock syndrome
- Streptococcal gangrene

Nonsuppurative Complications
- Poststreptococcal glomerulonephritis
- Rheumatic fever
- Rheumatic heart disease
- Guttate psoriasis

Other Associated Cutaneous Reactions
- Erythema nodosum
- Erythema multiforme
- Vasculitis

GAS is a Gram-positive extracellular bacterial pathogen that is a common cause of pyogenic skin infections, consistent with its scientific name *Streptococcus pyogenes* from the Latin for "pus-generating." Superficial skin infections caused by GAS include impetigo, ecthyma, intertrigo, and blistering distal dactylitis, and is the most common cause of bacterial pharyngitis (ie, "strep throat") (Table 150-5).[33] Scarlet fever is most commonly associated with GAS pharyngitis and includes a morbilliform rash, strawberry tongue, and desquamation of skin that is caused by streptococcal pyrogenic exotoxins (see Chap. 152).[33] GAS also causes more-invasive SSTIs, such as erysipelas, which is an infection of the superficial layers of the skin and lymphatics, and cellulitis, which is an infection that spreads through deep dermal and subcutaneous tissues (see Chap. 151).[33] GAS can also cause necrotizing fasciitis, which is a deep soft-tissue infection resulting in necrosis of subcutaneous fat and fascia, often leading to sepsis, shock, multiorgan failure, and death (see Chap. 153). Other severe infections caused by GAS include lymphangitis, bacteremia, septic arthritis, osteomyelitis, pneumonia, meningitis, and streptococcal toxic shock syndrome.[33] After a GAS infection, immunologic-mediated diseases such as guttate psoriasis, acute rheumatic fever, rheumatic heart disease, and glomerulonephritis may ensue.[33]

Lancefield grouping uses antigenic differences in cell wall carbohydrates and has identified 20 different species of coagulase-negative, β-hemolytic streptococcal species. GAS is classified as group A whereas *Streptococcus agalactiae* and *Enterococcus faecalis* are classified as group B and group D, respectively. GAS isolates can be further classified using serotyping against the M protein, a key virulence factor of GAS infection.[34] With advances in molecular biology, GAS strains are currently classified using sequences of the 5′ variable region of the *emm* gene that codes for the M protein and more than 200 *emm* types have been identified. Although there is substantial temporal and geographic variability of *emm* types, certain *emm* types are associated with various different disease manifestations. For example, impetigo is associated with *emm* types 33, 41, 42, 52, 53, and 70, and necrotizing fasciitis is associated with *emm* types 1, 3, and 28.[34]

EPIDEMIOLOGY

Globally, the World Health Organization estimates that each year there are more than 100 million superficial skin infections caused by GAS and more than 600 million cases of pharyngitis.[33] The major source of GAS transmission is from respiratory droplets from patients with infections or colonization in the upper respiratory tract.[35,36] It is estimated that 15% of school-age children and 4% to 10% of adults in industrialized countries suffer from GAS pharyngitis, which could be more than 5 times higher in developing countries.[35,36] After recovery from GAS pharyngitis, GAS may persist in approximately 20% to 30% of individuals and these asymptomatic carriers can serve as sources for GAS transmission.[35,36] Another source of GAS infection is from patients with GAS skin infections such as impetigo and infected wounds. The major factor in the spread from a carrier or an infected person is the proximity to the individual disseminating the bacteria. Thus, family members or close contacts are at a greater risk of infection than the general population during outbreaks. GAS impetigo predominantly in preschool-age children and is more common in warmer, more humid climates than in temperate zones. Its peak seasonal incidence is in the late summer and early fall. Non–group A streptococci (eg, groups B, C, and G) are less-common causes of impetigo, such as group B streptococci, which can cause impetigo in newborns.

CLINICAL FEATURES

CUTANEOUS FINDINGS

Impetigo: GAS is a common cause of nonbullous impetigo that presents as a crusted superficial infection of the skin with the same clinical appearance as *S. aureus* impetigo (see "Impetigo" above) (see Fig. 150-1). The inflammatory process of impetigo is superficial and begins with a unilocular vesicopustule located between the stratum corneum above and the stratum granulosum below and is usually situated near the opening of a hair follicle. Organisms, as well as leukocytes and cell debris, then fill the vesicopustules, which rapidly evolve into honey-colored crusted papules. Pruritus and burning may occur, but the lesions are usually painless. Preexisting lesions, such as scabies, varicella, or eczema, predispose to superinfection with GAS impetigo. Crowding, poor hygiene, and neglected minor skin trauma contribute to the spread of streptococcal impetigo in families. Minor outbreaks have also occurred among athletes involved in contact sports. Although the majority of cases occur in children of preschool age, older children and adults of all ages can be affected.

Streptococcal Ecthyma: GAS is also a cause of ecthyma that is indistinguishable from *S. aureus* ecthyma (see "Ecthyma" above).

Figure 150-15 Group A streptococcal intertrigo. A sharply marginated erythematous and oozing plaque in the axilla, which was also present in the other axilla, inframammary area, and inguinal folds, was painful in this HIV-infected woman.

Intertriginous Streptococcal Infections: GAS pyodermas can occur in occluded sites, such as the perineum/perianal region, vulva/vagina, axillae (Fig. 150-15), inframammary region, groin, preputial sac, and web spaces of the feet. Perianal (group A) streptococcal "cellulitis" occurs principally in children, presenting with intense perianal erythema (Fig. 150-16), pain on defecation, blood-streaked stools associated with anal fissures, and chronicity if untreated.[37] It is often confused with psoriasis, candidiasis, seborrheic dermatitis, inflammatory bowel disease, pinworm infection, or a behavioral problem. The infection can also involve the penis and vulva.

Blistering Distal Dactylitis: GAS and *S. aureus* are responsible for the majority of cases of blistering distal dactylitis, also called *bulla repens*, usually occurring in children and adolescents. However, group B *Streptococcus* has reported to rarely cause this infection. A large, tense blister develops, filled with seropurulent fluid, over the volar skin pad of distal fingers or toes (Fig. 150-17). The blisters are often surrounded by an erythematous base. The lesion may be more proximally located on the finger or extend to involve the nailfolds.

Acute Lymphangitis: Acute lymphangitis is an inflammatory process involving the subcutaneous lymphatic channels. It is usually caused by GAS, but occasionally may be caused by *S. aureus* or other organisms, such as *Pasteurella multocida* (eg, from an animal bite) or herpes simplex virus. The portal of entry of the infectious organism is commonly a wound on an extremity, an infected blister, or paronychia. Clinically,

Figure 150-16 Group A streptococcal intertrigo: perianal streptococcal cellulitis. Well-demarcated erosive erythema in the perianal region and perineum in an 8-year-old boy who complained of soreness.

Figure 150-18 Acute lymphangitis of forearm due to *Staphylococcus aureus*. There is a tender linear streak extending proximally from a small area of cellulitis on the volar wrist.

acute lymphangitis presents as the rapid onset of red linear streaks, which may be a few millimeters to several centimeters in width, extending from the local portal of entry toward the regional lymph nodes, which are usually enlarged and tender (Fig. 150-18). Systemic manifestations of infection may occur either before any evidence of infection that is present at the site of inoculation or after the initial lesion has subsided. The patient may notice pain over an area of redness proximal to the original break in the skin. Systemic symptoms are often more prominent than expected from the degree of local pain and erythema. In the upper extremities, acute lymphangitis usually can be differentiated from subacute or chronic sporotrichoid syndrome caused by organisms such as *Sporothrix schenckii*. In the lower extremities, superficial thrombophlebitis may produce somewhat similar linear areas of tender erythema. The absence of a portal of entry and of tender regional adenopathy is helpful in distinguishing superficial thrombophlebitis from acute lymphangitis.

Figure 150-17 Group A streptococcal blistering dactylitis. A blister is seen on a toe adjacent to the nailfold; the patient also had group A streptococcal intertrigo of an abdominal skin fold.

An unusual spread of GAS or *S. aureus* lymphangitis infection of the thumb (paronychia) or of the interdigital webs between the thumb and index finger may occur occasionally. Lymphatic drainage from this area can bypass the lymph nodes at the elbow and drain into the axillary nodes, which, in turn, communicate with the subpectoral nodes and the pleural lymphatics. As a consequence, subpectoral abscesses and pleural effusion can develop. The subpectoral infection may dissect downward and appear over the lower chest and upper abdomen as an area of cellulitis. This is a very serious illness. The clinical clues to the development of this sequence of events are provided by the location of the original infection on the thumb or medial surface of the index finger and the early occurrence of axillary pain.

NONCUTANEOUS FINDINGS

In response to more severe GAS pyodermas, there might be signs and symptoms of systemic infection or inflammation and these are the same as the

noncutaneous findings of *S. aureus* pyodermas (see "Clinical Features" above).

COMPLICATIONS

GAS superficial skin infections can become more invasive and result in GAS erysipelas and cellulitis (see Chap. 151) or severe infections such as streptococcal gangrene and necrotizing fasciitis (see Chap. 153). Other associated cutaneous sequelae, include erythema nodosum (see Chap. 73), erythema multiforme–like lesions (which may occur during GAS or *S. aureus* bacteremia in infants and young children) (see Chap. 43), and erythema marginatum (ie, cutaneous lesions of acute rheumatic fever) (see Chap. 152). Scarlet fever and toxic streptococcal syndromes caused by GAS toxins can also occur during and following GAS pharyngitis or skin infections (see Chap. 152). Rarely, during or following GAS pharyngitis or skin infections, patients (especially children and adolescents) can develop acute guttate psoriasis (see Chap. 28).

After GAS pharyngitis or skin infection, endemic and epidemic acute poststreptococcal glomerulonephritis can occur as well as acute rheumatic fever and rheumatic heart disease.[38] Poststreptococcal glomerulonephritis typically occurs 1 to 3 weeks following GAS pharyngitis and 3 to 6 weeks following GAS impetigo.[38] The disease is rare in developed countries (occurring in 0.3 per 100,000 individuals) and is more common in developing countries (occurring in 9.5 to 28.5 per 100,000 individuals). However, the frequency of occurrence of acute poststreptococcal glomerulonephritis from a known GAS nephritogenic strains is 10% to 15% overall and is higher following a GAS skin infection (25%) than following GAS pharyngitis (approximately 5%). Poststreptococcal glomerulonephritis is the most common cause of acute nephritis in children (typically 3 to 12 years old), but can also occur in adults. Clinically, it typically presents with edema, hematuria, and hypertension. Even though this entity usually resolves without specific treatment, renal failure can occur in some cases.[38]

Acute rheumatic fever occurs in less than 1% of patients with a GAS infection, and typically occurs 2 weeks following a GAS pharyngitis infection. In rare instances or certain geographic locations, rheumatic fever has been reported to occur after a GAS skin infection. Diagnosis is made according to Jones criteria, consisting of major manifestations in organs and tissues (joints [arthritis], heart [endocarditis], brain [chorea], skin [erythema marginatum], and subcutaneous tissue [nodules]) as well as minor criteria.[38] Although carditis can occur in up to 60% of cases of acute rheumatic fever (with mitral and aortic valves typically involved), the progression to rheumatic heart disease is poorly understood, but does seem to correlate with the severity of the course of the acute rheumatic fever and the frequency of recurrences.[38] Rheumatic heart disease has a variable clinical course from asymptomatic valvular disease to heart failure, and has long-term complications of acute infectious endocarditis, thromboembolic disease, atrial fibrillation, and progressive valvular stenosis or incompetence, requiring lifelong medical and surgical management. Sydenham chorea (involuntary, rapid, and purposeless movements of the face or limbs associated with emotional lability) can appear with acute rheumatic fever and up to 6 months after the preceding GAS infection. Finally, it should be mentioned that pediatric autoimmune neuropsychiatric disorders with streptococcal infection (PANDAS) with symptoms of choreoathetosis, obsessive-compulsive disorder, or tic disorder (eg, Tourette syndrome) has been hypothesized to be associated with an antecedent GAS infection.[38]

ETIOLOGY AND PATHOGENESIS

The primary invasive streptococcal pyodermas are almost exclusively a result of GAS, which is usually considerably more invasive than of other streptococci. Nonsuppurative postinfectious complications are limited mostly to those produced by GAS. Risk factors for GAS skin infections include colonization by GAS in the nasopharynx and skin, as well as crowding, poor hygiene, and poverty.[33] Like *S. aureus*, individuals with preexisting tissue injury or inflammation (surgical wounds, burns, trauma, atopic dermatitis, scabies, dermatophyte infection, retained foreign body) all are at higher risk for GAS skin infections.[33] Blunt trauma into muscle is a risk factor for GAS necrotizing fasciitis.[33]

Lancefield classification uses cell wall carbohydrates to distinguish 20 different species of coagulase-negative, β-hemolytic streptococcal species (A to H and K to V).[34] The presence of streptococci of groups other than A in skin lesions may represent either surface colonization or actual secondary infection in preexisting dermatoses. Group C streptococci and group G streptococci occasionally have been implicated in impetiginous lesions, secondarily infected dermatitis, and wound infections with lymphangitis, and even in erysipelas and cellulitis (see Chap. 151). Streptococci of groups B (eg, *S. agalactiae*) and D (eg, *E. faecalis*) have been isolated from infections of skin lesions secondary to ischemia or venous stasis, and have particularly involved the perineal area and operative wound sites. As with most secondary infections, those caused by group B and group D streptococci are frequently mixed infections with enteric bacteria or *S. aureus*. Group B streptococci may cause cellulitis and otitis in neonates and, sometimes, in adults. Group L streptococci (*Streptococcus dysgalactiae*) (often carried by pigs, cattle, and poultry) have been responsible for impetigo, secondarily infected wounds, and paronychias in meat handlers.

As mentioned above, there are more than 200 subtypes of GAS that can be classified by sequencing the 5′ region of the *emm* gene, which codes for the M protein, a fibrillate structure extending from the bacterial cell surface.[34] In addition, chromosomal arrangements

of the *emm* gene can also be classified into patterns A to E.[34] Patterns A, B, and C are associated with pharyngitis; pattern D is associated with skin infections; and pattern E is associated with both pharyngitis and skin infections.[34] The M protein is an important virulence factor of GAS and it is a multifunctional protein that can inhibit different host immune defenses.[34] For example, the M protein can bind to regulators of the complement system (including factor H and factor H–like protein 1 and C4-binding protein), which results in decreased activation of the classic and alternative complement pathways, as well as in inhibition of complement (C3b)-mediated phagocytosis.[34] The M protein also interacts with Fc region of IgG, which results in inhibition of antibody-mediated phagocytosis.[34] The M protein can induce inflammation by interacting with TLR2 on human monocytes leading to production of proinflammatory cytokines (eg, IL-6, IL-1β, and tumor necrosis factor–α).[34] Finally, the M protein can facilitate invasion of host cells by binding to components of the extracellular matrix, such as fibronectin, and these complexes can be recognized by integrins expressed on host cells, resulting in host-cell invasion and pathogenicity.[34] Another mechanism by which M protein can facilitate invasion into host cells is through its binding of CD46 on human keratinocytes, which results in invasion of these cells.[34]

Similar to *S. aureus*, GAS also produces pore-forming toxins. Two of the key pore-forming toxins are streptolysin O and streptolysin S.[34] Streptolysin O and streptolysin S contribute to GAS-mediated β-hemolysis on blood agar medium.[34] Streptolysin O produces large pores in host-cell membranes, leading to apoptosis of neutrophils, macrophages, and epithelial cells.[34] Streptolysin S has cytolytic activity against many different host-cell types, including neutrophils, lymphocytes, erythrocytes, and platelets, which leads to defective immune function and increased inflammation that contribute to vascular injury and tissue necrosis.[34]

GAS produces up to 11 known superantigens (also called streptococcal pyrogenic exotoxins). These include streptococcal pyrogenic exotoxin serotypes A, C, and G to M, as well as the streptococcal mitogenic exotoxin $SMEZ_n$.[21] These GAS superantigens nonspecifically activate T cells and contribute to the pathogenesis these infections. In addition, GAS superantigens are also responsible for both streptococcal toxic shock syndrome and manifestations of scarlet fever, and they are thought to contribute to the pathogenesis of erysipelas and more-invasive GAS infections.[21]

Neutrophils are an important cell type in host defense against GAS and *S. aureus* infections. Like *S. aureus*, GAS has several mechanisms to evade neutrophil immune function. For example, GAS produces glutathione peroxidase, superoxide dismutase, alkylhydroperoxidase and alkylhydroperoxidase reductase, which all inhibit reactive oxygen-mediated killing. Furthermore, both the cell wall–anchored nuclease A (SpnA) and the bacteriophage-encoded DNase Sda1 degrade NETs to prevent NETosis-mediated killing of GAS.[33]

IMMUNITY

The innate immune response against GAS, involves antimicrobial peptides and is similar to *S. aureus* (see "Immunity" in section "Etiology and Pathogenesis" of Staphylococcal skin infections). Of note, GAS is susceptible to killing by human β-defensins 1 to 3 and cathelicidin.[33,39] However, in addition to recognition of GAS components by TLR2, NOD2, and the inflammasome, TLR9 appears to play a key role in host defense against GAS skin infections.[33,39] TLR9 is found in endosomal membranes of host cells and recognizes hypomethylated DNA from bacteria, as well as GAS DNA, to elicit a Type I interferon (IFNα/β)-mediated immune response. In addition, TLR9 promotes oxidative burst and clearance of GAS infections.[33,39] Neutrophil recruitment to the site of infection is an important immune response to control GAS (and *S. aureus*) SSTIs, which is in part mediated by the pattern recognition receptors TLR2, NOD2, and TLR9.[33,39] Regarding adaptive immunity against GAS, both antibody and T-cell responses likely contribute to host defense.[33] In particular, antibodies and T-cell responses directed against the M protein of GAS protect against colonization and protection.[40,41] This antibody response is effective against a particular strain expressing the same M protein. However, because there are more than 200 different *emm* types identified among clinical isolates, immunity against a single M protein type does not necessarily confer protection to M proteins comprised of a different amino acid sequence.[40,41] Similarly, an effective human vaccine against M protein and other components or toxins of GAS has been challenging because of the substantial genetic diversity among clinical isolates.[40,41]

DIAGNOSIS

LABORATORY TESTING

As with *S. aureus*, for impetigo and ecthyma caused by GAS, the diagnosis is typically made on clinical appearance. However, Gram stain and bacterial culture and sensitivity of pus or exudates are generally recommended to diagnose the cause of the infection.[17] This is important because GAS requires a longer treatment course and is associated with immunologic-mediated sequelae that need to be monitored. Gram stain will typically reveal Gram-positive cocci in chains (GAS), or clusters (*S. aureus*), or a combination of both in infections involving both pathogens.[17] In patients with extensive infection, concerns for systemic infection, or in cases of acute lymphangitis, body temperature, respiratory rate, and peripheral blood counts should be obtained to evaluate for systemic infection or inflammation (systemic inflammatory response syndrome), as these patients would require more aggressive systemic antibiotic therapy.[17] In cases of acute lymphangitis, cultures from the skin are often negative (because the infection is restricted to lymphatic channels), but a

culture from aspirated fluid or from a biopsy of the portal of entry or a suppurative lymph node might reveal the etiologic agent. Blood cultures can also be obtained in all cases of lymphangitis or if there is a suspicion for bacteremia or invasive infection. In patients developing poststreptococcal glomerulonephritis, rheumatic fever, rheumatic heart disease or guttate psoriasis, antistreptolysin O and anti-deoxyribonuclease B antibody titers are helpful to determine whether or not there was an antecedent GAS infection.[42] Of note, high antistreptolysin O titers are more common after GAS pharyngitis, whereas high antideoxyribonuclease B titers are more common following GAS skin infections and at least 1 of the antibodies is typically positive in 95% of cases.[42]

PATHOLOGY

In general, skin biopsies are not typically performed in uncomplicated cases of impetigo, ecthyma, intertriginous infections, blistering distal dactylitis or acute lymphangitis. However, biopsies are recommended in immunocompromised patients or in patients with fever and neutropenia for histologic evaluation (including microorganism staining) and microbiology cultures and antibiotic sensitivities to diagnose the pathogenic organism and to help direct appropriate antibiotic therapy.[17]

IMAGING

Imaging is not typically indicated except in cases of acute lymphangitis in which there is evidence of spread into the axillary nodes, which would raise suspicion of a subpectoral abscesses and pleural effusion, especially if cellulitis is observed over the lower chest and upper abdomen. In these cases, radiographic imaging (ie, chest X-ray or CT imaging) is indicated to determine the extent of chest infection.

DIAGNOSTIC ALGORITHM

Figure 150-14 shows a diagnostic and management algorithm for *S. aureus* and GAS SSTIs.

DIFFERENTIAL DIAGNOSIS

Table 150-3 outlines the differential diagnoses for impetigo and ecthyma. Table 150-6 outlines the differential diagnoses of intertrigo, blistering distal dactylitis, and acute lymphangitis.

TABLE 150-6
Differential Diagnosis of Group A *Streptococcus* Pyodermas

Intertrigo (Group A *Streptococcus* or *Staphylococcus aureus*)
- *Candida* intertrigo
- Contact dermatitis
- Seborrheic dermatitis
- Atopic dermatitis
- Erythrasma
- Inverse psoriasis
- Scabies
- Tinea cruris or tinea corporis
- Familial benign pemphigus (Hailey-Hailey disease)
- Keratosis follicularis (Darier disease)
- Pemphigus vegetans
- Extramammary Paget disease
- Mycosis fungoides
- Acrodermatitis enteropathica
- Langerhans cell histiocytosis

Blistering Distal Dactylitis (Group A *Streptococcus* or *Staphylococcus aureus*)
- Bullous impetigo
- Herpes simplex
- Traumatic/friction blister
- Burn
- Bullous drug eruption
- Bullous cellulitis
- Bullous pemphigoid (localized)
- Insect bite reaction
- Epidermolysis bullosa
- Porphyria cutanea tarda
- Pseudoporphyria

Acute Lymphangitis (Group A *Streptococcus* or *Staphylococcus aureus*)
- Contact dermatitis
- Cellulitis
- Superficial thrombophlebitis
- Sporotrichosis
- *Mycobacterium marinum* infection
- Filariasis
- Leishmaniasis
- *Nocardia* infection
- Myositis

CLINICAL COURSE AND PROGNOSIS

If untreated, GAS impetigo may persist and new lesions may develop over the course of several weeks. Thereafter, the infection tends to resolve spontaneously unless there is some underlying cutaneous disorder such as atopic dermatitis. If untreated, some lesions become chronic and deeper, such as ecthyma. Complicating erysipelas, cellulitis, or bacteremia are unusual. GAS ecthyma, intertrigo, and blistering distal dactylitis usually can be successfully treated with appropriate management (see "Management"). However, GAS may persist in approximately 20% to 30% of individuals and these asymptomatic carriers can serve as common sources for GAS transmission and potential recurrent infection.[35,36] If infections are untreated or neglected, there is a potential for invasive spread of the infection, resulting in erysipelas, cellulitis, lymphangitis, bacteremia, and necrotizing fasciitis. Acute lymphangitis is a serious invasive infection that requires prompt treatment because it can frequently lead to bacteremia with metastatic infection of various organs. Other potential complications of GAS skin infections are discussed above (see "Clinical Features").

MANAGEMENT

INTERVENTIONS, MEDICATIONS, AND PROCEDURES

Topical therapy for GAS impetigo is the same as for *S. aureus* (mupirocin 2% topical ointment or retapamulin 1% ointment twice daily for 5 days with removal of the superficial crusts by cleansing with soap and water).[17] By clinical findings alone, the cause of nonbullous impetigo cannot be accurately distinguished between GAS and *S. aureus*. As most cases of nonbullous impetigo are caused by *S. aureus*, and if the etiology is unknown and systemic therapy is desired, it is reasonable to empirically cover for *S. aureus* using dicloxacillin or cephalexin (described above).[17] However, in contrast to *S. aureus*, the systemic antibiotic treatment of superficial pyodermas (eg, impetigo, ecthyma, and intertrigo) known to be caused by GAS is penicillin and treatment should be continued for 10 days to ensure eradication of the infection (Table 150-7). A 10-day course of oral penicillin V potassium (penicillin VK) can be given to adults (250 to 500 mg 4 times a day) or children (250 to 500 mg 2 to 3 times daily [25 to 45 mg/kg/day divided 2 to 3 times/day]).[17] In young children, a 10-day course amoxicillin-clavulanic acid (250 to 500 mg twice daily [25 to 45 mg/kg/day of the amoxicillin component twice daily]) can be used in place of oral penicillin V. As an alternative, a single dose of long-acting benzathine penicillin G can be given intramuscularly (1,200,000 units for adults or 600,000 units for children). In patients with penicillin or β-lactam hypersensitivity/allergy, a 10-day course of erythromycin can be administered for adults (250 to 500 mg orally 4 times/day) or children (30 to 50 mg/kg/day by mouth in divided doses 4 times/day), which is acceptable given that erythromycin resistance among GAS isolates in most areas of the United States is less than 7%.[33] However, it should be noted that 20% or more of GAS strains are resistant to erythromycin in certain geographic areas (eg, Poland [42%], Hong Kong [28%], Italy [25%], Portugal [24%], and Spain [21%][33]) and other alternatives should be used, such as clindamycin orally for 10 days in adults (300 to 450 mg 3 times a day) or children (20 to 30 mg/kg/day divided 3 to 4 times a day). Blistering distal dactylitis

TABLE 150-7

Management of Skin Infections Caused by Group A *Streptococcus*

INFECTION	TREATMENT	ADULT DOSING	PEDIATRIC DOSING	DURATION
Impetigo (localized and simple)	Mupirocin 2% ointment	Twice daily	Twice daily	5- to 7-day course
	Retapamulin 1% ointment	Twice daily	Twice daily	
	Fusidic acid 1% cream (not available in U.S.)	2-4 times daily	2-4 times daily	
Impetigo, ecthyma (group A *Streptococcus* [GAS])	Penicillin VK	250-500 mg po 4 times daily	25-45 mg/kg/day (2-3 divided doses)	10-day course recommended, depending on clinical response
	Amoxicillin-clavulanic acid	875/125 mg po twice daily	25-45 mg/kg/day (amoxicillin dose) twice daily	
	Benzathine penicillin G	1.2 million units IM × 1 dose	600,000 units IM × 1 dose	
	Cephalexin	500 mg po 4 times daily	50-100 mg/kg/day (3-4 divided doses)	
	Erythromycin	200-500 mg po 4 times daily	30-50 mg/kg/day (3-4 divided doses)	
	Clindamycin	300-450 mg po thrice daily	20-30 mg/kg/day (3-4 divided doses)	
Lymphangitis (GAS)	Penicillin	2-4 million units IV q4-6h	60,000-100,000 units/kg/dose IV q6h	10- to 14-day course recommended, depending on clinical response
	Clindamycin	600-900 mg IV q8h	10-13 mg/kg/dose IV q8h	
	Nafcillin	1-2 g IV q4-6h	50 mg/kg/dose IV q6h	
	Cefazolin	1 g IV q8h	33 mg/kg/dose IV q8h	
	Vancomycin	15-20 mg/kg IV q8-12h	40 mg/kg/day IV (4 divided doses q6h)	
	Linezolid	600 mg po or IV twice daily	10 mg/kg/dose po or IV thrice daily (maximum: 600 mg/dose)	
	Daptomycin	4 mg/kg IV daily	Not determined	
	Telavancin	10 mg/kg IV daily	Not determined	
Recurrent GAS infections	Clindamycin	350-450 mg po thrice daily	20-30 mg/kg/day (3-4 divided doses)	10-day course recommended depending on clinical response
	Amoxicillin-clavulanic acid	875/125 mg po twice daily	25-45 mg/kg/day (amoxicillin dose) twice daily	

Information derived from the "Clinical Practice Guidelines for the Treatment of Skin and Soft-Tissue Infections"[17] (available at http://www.idsociety.org/uploadedFiles/IDSA/Guidelines-Patient_Care/PDF_Library/Skin%20and%20Soft%20Tissue.pdf) and Clinical Practice Guideline for the Diagnosis and Management of Group A Streptococcal Pharyngitis: 2012 Update (available at https://www.idsociety.org/uploadedFiles/IDSA/Guidelines-Patient_Care/PDF_Library/2012%20Strep%20Guideline.pdf) from the Infectious Diseases Society of America (IDSA).[43]

O, orally; IV, intravenous; q, every; h, hours.

can be treated the same way as GAS pyodermas but I&D is often required to release subungual pus.

For acute GAS lymphangitis, children older than age 3 years or adults without comorbidities that appear nontoxemic can be treated with the above antibiotics in an outpatient setting. However, if patients have signs of systemic infection (eg, fever, chills, rigors, myalgias, mental status changes, hemodynamic instability) or inflammation (systemic inflammatory response syndrome), they should admitted to the hospital and treated aggressively with intravenous antibiotics as required for complicated erysipelas or cellulitis (see Chap. 151).

TREATMENT ALGORITHM

Table 150-7 outlines the management of skin infections caused by GAS.

PREVENTION/SCREENING

In general, patients hospitalized with GAS infections should be isolated until the organisms have been eradicated by antibiotic treatment. Although the initial treatment antibiotic courses can clear the lesions of GAS pyodermas and prevent recurrence for a short time, GAS can persist on or newly colonize unaffected skin in spite of this therapy. Individuals with a single reoccurrence can be treated with same oral antibiotic therapy as an initial GAS pyoderma (see Table 150-7). However, patients with recurrent episodes of GAS infections can also be treated with a 10-day course of clindamycin (adults: 300 to 450 mg twice daily; children: 20 to 30 mg/kg/day in 3 equally divided doses) or amoxicillin-clavulanic acid (adults: 875/125 mg twice daily; children: 40 mg/kg/day in 3 equally divided doses). Clindamycin or amoxicillin-clavulanic acid also have been used effectively as secondary prophylaxis against recurrent GAS pharyngitis.[43] In addition, prophylactic penicillin (or other appropriate GAS antibiotics) is indicated for close family contacts (particularly children) of patients with recurrent GAS skin or pharyngitis.

There is no evidence to suggest that treatment of GAS pyoderma can prevent subsequent poststreptococcal glomerulonephritis in any individual. However, systemic antibiotics should be used for all GAS infections during outbreaks of poststreptococcal glomerulonephritis to help eliminate nephritogenic strains of GAS from the community.[17]

PITTED KERATOLYSIS

AT-A-GLANCE

- Pitted keratolysis involves the formation of small crateriform pits that coalesce to form a large, discrete defect with serpiginous borders on the plantar surface of the foot.
- More commonly found in young men and is associated with warm moist skin and occlusive shoes.
- The etiologic agent is not entirely clear but many include *Kytococcus sedentarius* (formerly *Micrococcus sedentarius*), *Dermatophilus congolensis*, and *Corynebacterium* spp.
- Treatment typically includes measures and agents to keep the feet dry and decrease hyperhidrosis in combination with topical antibiotics (eg, clindamycin or erythromycin) and keratolytics.

Pitted keratolysis involves the stratum corneum of the web spaces and plantar surface of the feet. Originally named *keratoma plantare sulcatum* by Castellani in 1910, this disease has become more commonly called by its current name after Taplin and Zaias coined it in 1967. The disease was first seen in those who went barefooted during the rainy season.

EPIDEMIOLOGY

Pitted keratolysis occurs in adults and children of both sexes, but adult males with sweaty feet are most susceptible (approximately 90% of cases) with a male-to-female ratio of approximately 8:1.[44] Pitted keratolysis is much more common in tropical climates than in temperate ones.

CLINICAL FEATURES

Pitted keratolysis presents as a superficial erosion of the stratum corneum, composed of numerous small crateriform pits coalescing to form a large discrete defect with serpiginous borders on the plantar surface of the foot. The pits are usually larger than 0.7 mm in diameter, but at times are smaller than 0.5 mm in diameter. The pits have elongated configurations along the plantar furrows and are located predominantly on the pressure-bearing hyperkeratotic areas of the feet, such as the ventral aspect of the toe, ball of the foot, and the heel, but they also are seen on non–pressure-bearing areas.[44] The web spaces between the toes also are commonly involved sites, and may be the only manifestation (Fig. 150-19). The diagnosis is made clinically. Sliminess of the skin, often manifests by the foot sticking to the socks, is also a common complaint (70% of cases). The feet are typically very malodorous (two-thirds of patients) and one-third of patients complain of pain, burning, or irritation.

Figure 150-19 Pitted keratolysis. The web spaces between the toes are sharply eroded. Interdigital tinea pedis and erythrasma may occur concurrently.

ETIOLOGY AND PATHOGENESIS

The specific bacterial species that causes pitted keratolysis is not entirely clear. However, *K. sedentarius* (formerly *Micrococcus sedentarius*), *D. congolensis* and *Corynebacterium* spp. have been implicated as the etiologic agents of this disease. It is thought that warm, moist skin as a consequence of protective or occlusive shoes in warmer climates leads to softening of the stratum corneum and a more neutral pH of the surface of this skin, which enhances proteolytic activity of these bacteria to allow them to invade the stratum corneum and produce the characteristic clinical lesions. By electron microscopy, the bacterial organisms can be found inside keratinocytes in the stratum corneum and stratum granulosum.

DIAGNOSIS

The diagnosis is made clinically. However, Gram staining of scrapings may detect the microorganism more readily than potassium hydroxide examination. Bacterial cultures are often not helpful as multiple species of bacteria grow out. A biopsy is usually unnecessary but if one is performed, Gram, periodic acid–Schiff, and methenamine silver stains reveal the bacterial organisms in the walls and bases of the crateriform defects in the upper layer of the stratum corneum. The organisms appear as coccoid forms located more superficially and filamentous forms with branches and septa are seen in deeper locations.[44]

DIFFERENTIAL DIAGNOSIS

Interdigital tinea pedis can present with erosive lesions in the web spaces as is often misdiagnosed in cases of pitted keratolysis. Erythrasma in the web spaces is usually hyperkeratotic but can be erosive.

MANAGEMENT

Prophylactic measures are aimed at keeping the feet as dry as possible and wearing well-fitted and nonocclusive shoes as much as possible.[44] Inert antiseptic foot powders often help. Socks and shoes should also be changed often and socks should be washed at least at 60°C (140°F) to help kill the bacteria.[44] Aluminum chloride 20% solution to decrease hyperhidrosis is often helpful. Similarly, botulinum toxin has been used to decrease hyperhidrosis to help treat pitted keratolysis. A benzoyl peroxide cleanser or 5% gel/cream are effective therapies in most cases as well. Other commonly used topical adjunctive agents include clindamycin and erythromycin solutions, as well as imidazole derivatives (eg, miconazole) and fusidic acid.[44] These topical agents can be combined with keratolytics to decrease the hyperkeratosis and enhance the topical drug penetration into the skin.[44] Systemic use of clindamycin and erythromycin can be attempted in severe cases.[44]

ERYTHRASMA

AT-A-GLANCE

- Erythrasma is a superficial bacterial infection of the skin characterized by well-defined but irregular reddish-brown patches, occurring in the intertriginous areas, or by fissuring and white maceration in the toe clefts.
- It is more common in tropical climates and in patients with obesity, diabetes, or immunosuppression (eg, HIV disease).
- The etiologic agent is *Corynebacterium minutissimum*, which produces coproporphyrin III and a coral red fluorescence that can be seen on Wood's lamp evaluation.
- Treatment typically includes topical clindamycin or erythromycin, and oral antibiotics, such as a 2-week course of oral erythromycin or a single dose of clarithromycin, can be used for widespread involvement or cases not responding to topical therapy.

Erythrasma is a common superficial bacterial infection of the skin characterized by well-defined but irregular reddish-brown patches, occurring in the intertriginous areas, or by fissuring and white maceration in the toe clefts. In the groin, it is commonly misdiagnosed as tinea cruris for many months before proper diagnosis is made.

EPIDEMIOLOGY

C. minutissimum, the etiologic agent of erythrasma, is a short, Gram-positive rod with subterminal granules. The infection is more common in tropical than in temperate climates and in obese and diabetic patients. Generalized erythrasma is much more common in the tropics. Erythrasma is more common in males and may occur in an asymptomatic form in the genitocrural area. In cases involving immunocompromised patients, such as patients with HIV disease, *C. minutissimum* may progress to bacteremia, cellulitis, costochondral abscess, and pyelonephritis.[44]

CLINICAL FEATURES

The most common site of involvement are the web spaces of the feet, where erythrasma presents as a hyperkeratotic white macerated plaque (Fig. 150-20), especially between the fourth and fifth toes. In the genitocrural, axillary, and inframammary regions, the lesions present as well-demarcated, reddish-brown, superficial, finely scaled, and finely wrinkled patches appearing as thin as cigarette paper (Fig. 150-21). In these sites, the patches have a relatively uniform appearance as compared with tinea corporis or cruris, which often have central clearing. Concomitant infection can occur with *Candida* or dermatophytes. Wood's lamp examination of erythrasma reveals a coral-red fluorescence caused by coproporphyrin III production by the bacteria. The fluorescence may persist after eradication of the *Corynebacterium* as the pigment remains within a thick stratum corneum. Symptoms vary from a completely asymptomatic form, through a generalized form with scaly lamellated plaques on the trunk, inguinal area, and web spaces of the feet. When pruritic, irritation of lesions may cause secondary changes of excoriations and lichenification.

Figure 150-20 Erythrasma. Hyperkeratosis with a yellowish hue in the web space of the foot. The 3 lateral web spaces of both feet were involved. The potassium hydroxide preparation was negative; Wood's lamp examination showed a bright coral red fluorescence.

Figure 150-21 Erythrasma. Well-demarcated reddish-brown patches in the axilla (**A**) and groin (**B**). The potassium hydroxide preparations were negative; Wood's lamp examination showed a bright coral red fluorescence.

ETIOLOGY AND PATHOGENESIS

Warm and moist skin in areas of skin folds create an environment in which erythrasma can develop.

DIAGNOSIS

Culture of the specific *Corynebacterium* in abundance from the lesion corroborates the diagnosis. Gram-stained imprints of the stratum corneum show rod-like, Gram-positive organisms in large numbers. The bacteria in the stratum corneum can also be seen on skin biopsies stained with periodic acid–Schiff, methenamine silver, or Gram stain. The diagnosis is strongly suggested by the location and superficial character of the process, but can be confirmed by demonstration of the characteristic coral-red fluorescence with Wood's lamp illumination.

DIFFERENTIAL DIAGNOSIS

Tinea versicolor is distinguished from erythrasma by the lesions on the trunk being most numerous at non-intertriginous sites. Tinea cruris tends to have an active scaling border with central clearing. Inverse psoriasis usually presents as sharply demarcated plaques with a shiny red color in the intergluteal cleft, inguinal folds, and axillae.

CLINICAL COURSE AND PROGNOSIS

The disease may remain asymptomatic for years or may undergo periodic exacerbations. Relapses occasionally occur even after successful antibiotic treatment.

MANAGEMENT

For localized erythrasma, especially of the web spaces of the feet, benzoyl peroxide cleanser and 5% gel are effective in most cases.[44,45] Clindamycin or erythromycin (2% solution) or azole creams are several of the many effective topical agents. Fusidic acid has been used outside the United States. For widespread involvement, oral erythromycin 250 mg 4 times a day for 14 days is effective. Alternatives, including clarithromycin 1 g given as a single oral dose, as well as oral tetracycline or chloramphenicol, have been used successfully.[44,45] For secondary prophylaxis, an antibacterial benzoyl peroxide cleanser when showering is effective.

TRICHOBACTERIOSIS

AT-A-GLANCE

- Trichobacteriosis is a bacterial infection of the hair shaft.
- Clinically, it typically affects the axillary or pubic hair and consists of tan, reddish, yellow, or black concretions on the surface of the hair shaft, which represent biofilms of *Corynebacterium* spp.
- Trichobacteriosis is asymptomatic other than its appearance.
- Treatment involves removing the hair by shaving, decreasing hyperhidrosis, and topical benzoyl peroxide, antibiotics, and antiperspirants.

CLINICAL FEATURES

Trichobacteriosis (formerly called *trichomycosis*) is a bacterial infection of the hair shaft (not fungal as its previous name had implied) characterized by what appears to be nodular thickenings on the hair shaft that are composed of colonies of aerobic *Corynebacterium* spp. Trichobacteriosis more commonly occurs in the axillae, but can also occur in the pubic area. The bacteria produce various pigments, giving the nodules a range of colors. The concretions on the hair shaft are usually a tan color but may be reddish, yellow, or black (Fig. 150-22). Lesions are most dense and may be present only in the central portion of the axillary hair. Trichobacteriosis is asymptomatic except for the patient's concern regarding their appearance and because they are malodorous.

ETIOLOGY AND PATHOGENESIS

Although the exact etiology is unclear, disturbances in sweat production and bacterial proliferation are likely needed for trichobacteriosis development. In addition, a warm moist environment and poor hygiene are predisposing factors. The nodules themselves are caused by encapsulated biofilms of corynebacteria adherent to the hair shaft without penetration.

Figure 150-22 Trichobacteriosis. Tan-yellow concretions on the hair shafts of the axilla.

DIAGNOSIS

The diagnosis is usually made on the basis of the clinical findings. The concretions can be visualized using a potassium hydroxide preparation. Wood's lamp can often reveal a pale yellowish fluorescence. Ultraviolet light enhanced visualization represents a newer diagnostic modality and highlights in white the presence of the corynebacteria biofilms on the hair shaft. Pediculosis pubis infestation with multiple eggs on the hair shaft should be considered in the differential diagnosis and ruled out.

MANAGEMENT

The involved hair can be removed by shaving. Benzoyl peroxide cleansers and gels/creams are effective as treatment and prevention against recurrence of trichobacteriosis. Topical clindamycin or erythromycin solutions (and imidazole derivatives) can be used as well. Improved hygiene and cleansing practices and regular use of antiperspirants such as aluminum chloride might reduce recurrences.

REFERENCES

1. Tong SY, Chen LF, Fowler VG Jr. Colonization, pathogenicity, host susceptibility, and therapeutics for *Staphylococcus aureus*: what is the clinical relevance? *Semin Immunopathol*. 2012;34(2):185-200.
2. Yang ES, Tan J, Eells S, et al. Body site colonization in patients with community-associated methicillin-resistant *Staphylococcus aureus* and other types of *S. aureus* skin infections. *Clin Microbiol Infect*. 2010;16(5):425-431.
3. Montgomery CP, David MZ, Daum RS. Host factors that contribute to recurrent staphylococcal skin infection. *Curr Opin Infect Dis*. 2015;28(3):253-258.
4. Edelsberg J, Taneja C, Zervos M, et al. Trends in US hospital admissions for skin and soft tissue infections. *Emerg Infect Dis*. 2009;15(9):1516-1518.
5. Hersh AL, Chambers HF, Maselli JH, et al. National trends in ambulatory visits and antibiotic prescribing for skin and soft-tissue infections. *Arch Intern Med*. 2008;168(14):1585-1591.
6. Liu C, Bayer A, Cosgrove SE, et al. Clinical practice guidelines by the infectious diseases society of america for the treatment of methicillin-resistant *Staphylococcus aureus* infections in adults and children. *Clin Infect Dis*. 2011;52(3):e18-e55.
7. Moran GJ, Krishnadasan A, Gorwitz RJ, et al. Methicillin-resistant *S. aureus* infections among patients in the emergency department. *N Engl J Med*. 2006;355(7):666-674.
8. Dantes R, Mu Y, Belflower R, et al. National burden of invasive methicillin-resistant Staphylococcus aureus infections, United States, 2011. *JAMA Intern Med*. 2013;173(21):1970-1978.
9. Klevens RM, Morrison MA, Nadle J, et al. Invasive methicillin-resistant *Staphylococcus aureus* infections in the United States. *JAMA*. 2007;298(15):1763-1771.
10. Miller LG, Diep BA. Clinical practice: colonization, fomites, and virulence: rethinking the pathogenesis of community-associated methicillin-resistant *Staphylococcus aureus* infection. *Clin Infect Dis*. 2008;46(5):752-760.
11. Bode LG, Kluytmans JA, Wertheim HF, et al. Preventing surgical-site infections in nasal carriers of *Staphylococcus aureus*. *N Engl J Med*. 2010;362(1):9-17.
12. Zacharioudakis IM, Zervou FN, Ziakas PD, et al. Meta-analysis of methicillin-resistant *Staphylococcus aureus* colonization and risk of infection in dialysis patients. *J Am Soc Nephrol*. 2014;25(9):2131-2141.
13. David MZ, Daum RS. Community-associated methicillin-resistant *Staphylococcus aureus*: epidemiology and clinical consequences of an emerging epidemic. *Clin Microbiol Rev*. 2010;23(3):616-687.
14. DeLeo FR, Otto M, Kreiswirth BN, et al. Community-associated meticillin-resistant *Staphylococcus aureus*. *Lancet*. 2010;375(9725):1557-1568.
15. Elston DM. Community-acquired methicillin-resistant *Staphylococcus aureus*. *J Am Acad Dermatol*. 2007;56(1):1-16; quiz 17-20.
16. Daum RS. Clinical practice. Skin and soft-tissue infections caused by methicillin-resistant *Staphylococcus aureus*. *N Engl J Med*. 2007;357(4):380-390.
17. Stevens DL, Bisno AL, Chambers HF, et al. Practice guidelines for the diagnosis and management of skin and soft tissue infections: 2014 update by the Infectious Diseases Society of America. *Clin Infect Dis*. 2014;59(2):e10-e52.
18. Miller LS, Cho JS. Immunity against *Staphylococcus aureus* cutaneous infections. *Nat Rev Immunol*. 2011;11(8):505-518.
19. Patel DD, Kuchroo VK. Th17 cell pathway in human immunity: lessons from genetics and therapeutic interventions. *Immunity*. 2015;43(6):1040-1051.
20. Alonzo F 3rd, Torres VJ. The bicomponent pore-forming leucocidins of *Staphylococcus aureus*. *Microbiol Mol Biol Rev*. 2014;78(2):199-230.
21. Spaulding AR, Salgado-Pabon W, Kohler PL, et al. Staphylococcal and streptococcal superantigen exotoxins. *Clin Microbiol Rev*. 2013;26(3):422-447.
22. Thammavongsa V, Kim HK, Missiakas D, et al. Staphylococcal manipulation of host immune responses. *Nat Rev Microbiol*. 2015;13(9):529-543.
23. Fritz SA, Tiemann KM, Hogan PG, et al. A serologic correlate of protective immunity against community-onset *Staphylococcus aureus* infection. *Clin Infect Dis*. 2013;56(11):1554-1561.
24. Peschel A, Otto M. Phenol-soluble modulins and staphylococcal infection. *Nat Rev Microbiol*. 2013;11(10):667-673.
25. Bukowski M, Wladyka B, Dubin G. Exfoliative toxins of *Staphylococcus aureus*. *Toxins (Basel)*. 2010;2(5):1148-1165.
26. Amagai M, Matsuyoshi N, Wang ZH, et al. Toxin in bullous impetigo and staphylococcal scalded-skin syndrome targets desmoglein 1. *Nat Med*. 2000;6(11):1275-1277.
27. van Kessel KP, Bestebroer J, van Strijp JA. Neutrophil-mediated phagocytosis of *Staphylococcus aureus*. *Front Immunol*. 2014;5:467.
28. Fritz SA, Camins BC, Eisenstein KA, et al. Effectiveness of measures to eradicate *Staphylococcus* aureus carriage in patients with community-associated skin and soft-tissue infections: a randomized trial. *Infect Control Hosp Epidemiol*. 2011;32(9):872-880.
29. Fritz SA, Hogan PG, Hayek G, et al. Household versus individual approaches to eradication of

community-associated *Staphylococcus aureus* in children: a randomized trial. *Clin Infect Dis*. 2012;54(6):743-751.
30. Miller LG, Daum RS, Creech CB, et al. Clindamycin versus trimethoprim-sulfamethoxazole for uncomplicated skin infections. *N Engl J Med*. 2015;372(12):1093-1103.
31. Miller LG, Quan C, Shay A, et al. A prospective investigation of outcomes after hospital discharge for endemic, community-acquired methicillin-resistant and -susceptible *Staphylococcus aureus* skin infection. *Clin Infect Dis*. 2007;44(4):483-492.
32. Talan DA, Mower WR, Krishnadasan A, et al. Trimethoprim-sulfamethoxazole versus placebo for uncomplicated skin abscess. *N Engl J Med*. 2016;374(9):823-832.
33. Walker MJ, Barnett TC, McArthur JD, et al. Disease manifestations and pathogenic mechanisms of group A streptococcus. *Clin Microbiol Rev*. 2014;27(2):264-301.
34. Metzgar D, Zampolli A. The M protein of group A streptococcus is a key virulence factor and a clinically relevant strain identification marker. *Virulence*. 2011;2(5):402-412.
35. Carapetis JR, Steer AC, Mulholland EK, et al. The global burden of group A streptococcal diseases. *Lancet Infect Dis*. 2005;5(11):685-694.
36. Ralph AP, Carapetis JR. Group A streptococcal diseases and their global burden. *Curr Top Microbiol Immunol*. 2013;368:1-27.
37. Clegg HW, Giftos PM, Anderson WE, et al. Clinical perineal streptococcal infection in children: epidemiologic features, low symptomatic recurrence rate after treatment, and risk factors for recurrence. *J Pediatr*. 2015;167(3):687-693.e1-e2.
38. Martin WJ, Steer AC, Smeesters PR, et al. Post-infectious group A streptococcal autoimmune syndromes and the heart. *Autoimmun Rev*. 2015;14(8):710-725.
39. Fieber C, Kovarik P. Responses of innate immune cells to group A Streptococcus. *Front Cell Infect Microbiol*. 2014;4:140.
40. Dale JB, Fischetti VA, Carapetis JR, et al. Group A streptococcal vaccines: paving a path for accelerated development. *Vaccine*. 2013;31(suppl 2):B216-B222.
41. Henningham A, Gillen CM, Walker MJ. Group A streptococcal vaccine candidates: potential for the development of a human vaccine. *Curr Top Microbiol Immunol*. 2013;368:207-242.
42. Sen ES, Ramanan AV. How to use antistreptolysin O titre. *Arch Dis Child Educ Pract Ed*. 2014;99(6):231-238.
43. Bisno AL, Gerber MA, Gwaltney JM Jr, et al. Practice guidelines for the diagnosis and management of group A streptococcal pharyngitis. Infectious Diseases Society of America. *Clin Infect Dis*. 2002;35(2):113-125.
44. Blaise G, Nikkels AF, Hermanns-Lê T, et al. Corynebacterium-associated skin infections. *Int J Dermatol*. 2008;47(9):884-890.
45. Holdiness MR. Management of cutaneous erythrasma. *Drugs*. 2002;62(8):1131-1141.

Chapter 151 :: Cellulitis and Erysipelas

:: David R. Pearson & David J. Margolis

AT-A-GLANCE

- Common infection of the deep dermis and subcutaneous tissue most often caused by streptococcal and staphylococcal species, resulting in erythema, swelling, warmth, and pain of the affected site.
- Unilateral lower-extremity involvement is typical and systemic symptoms are usually absent.
- Important local risk factors include compromise of the skin barrier or underlying lymphovascular system.
- Diagnosis is most often made clinically because of frequently equivocal or negative workups.
- Treatment consists of antibiotics, but multiple recurrences may be observed.
- Common variants:
  - *Erysipelas:* sharply demarcated, bright red, edematous plaques resulting from superficial lymphatic infiltration.
  - *Purulent cellulitis:* localized pustules or abscesses associated with cellulitis.

Cellulitis is a common infection of the deep dermis and subcutaneous tissue, most often caused by bacteria, that presents with the classic signs of inflammation as described by the Roman scholar Celsus in the first century CE: redness (*rubor*), swelling (*tumor*), heat (*calor*), and pain (*dolor*). *Erysipelas* is a variant of cellulitis that predominantly affects the superficial lymphatic vessels and surrounding tissue. Unlike the ill-defined plaques characterizing classic cellulitis, erysipelas demonstrates sharply marginated edematous plaques and is strikingly red in color. Diagnosis may be challenging and relies predominantly on clinical findings as laboratory, serologic, microbiologic, histopathologic, and imaging studies are often equivocal or negative. For these reasons, despite the high prevalence of these infections, misdiagnosis is common and may lead to both treatment-related morbidity and significant health care costs.

DEFINITIONS

Most modern studies group classic cellulitis and erysipelas together under the simple term *cellulitis* when evaluating pathogenesis, risk factors, diagnosis, and treatment; this chapter follows that convention. Other cutaneous bacterial infections, including pyodermas (Chap. 150), toxin-mediated infections (Chap. 152), and necrotizing soft-tissue infections (Chap. 153) are considered separately.

HISTORICAL PERSPECTIVE

Skin and soft-tissue infections have been described for thousands of years.[1] In the preantibiotic era, cellulitis had a mortality rate of approximately 11% and only two-thirds of patients treated were cured with treatment.[2] Early therapies in the antibiotic era, including ultraviolet light, penicillin, and sulfonamide, significantly reduced mortality, although study designs were comparatively simpler than modern clinical trials.[2] In recent years, the emergence of community-acquired methicillin-resistant *Staphylococcus aureus* (MRSA), an increasingly common cause of cellulitis, has affected the epidemiology and treatment of this infection.

EPIDEMIOLOGY

Cellulitis is common and has increased in prevalence: in 1997 there were 4.6 million ambulatory visits for cellulitis or abscess in the United States, and this increased to 9.6 million in 2005.[3] The incidence rate increased from 17.3 to 32.5 per 1000 population during this time period, which parallels the rise of community-acquired MRSA.[3,4] In the United States, rates appear to have stabilized, although they continue to rise in other economically developed nations.[5,6] More than 10% of hospitalizations for infectious diseases in the Unites States are because of cellulitis, and hospitalizations for cellulitis in the United States have increased from approximately 300,000 in 1999 to more than 530,000 in 2013, with an estimated cost of $3.7 billion.[7,8]

Recurrent cellulitis represents 22% to 49% of patients, but its specific epidemiology is not well characterized.[9,10] Each reoccurrence increases the risk of subsequent episodes, because of local and systemic risk factors (see section "Risk Factors").[11,12] Most patients with recurrent cellulitis can be managed in the ambulatory setting and only a minority require hospitalization.[10]

CLINICAL FEATURES

CUTANEOUS FINDINGS

Classic cellulitis presents acutely with spreading, ill-defined erythema and edema, and is often warm and painful. The lower extremity is the most common site in adults, but the upper extremities, trunk, and head and neck may be involved (Fig. 151-1). Children are more likely than adults to have facial involvement. It is unilateral in the vast majority of cases, and bilateral involvement should prompt consideration of an alternative diagnosis, except in rare circumstances.[13] Linear

Figure 151-1 Cellulitis with ill-defined erythema on the lower leg. Note the subtle, streaky lymphangiitis extending proximally.

streaking, lymphangiitis, and tender regional lymphadenopathy may be observed, as well as small areas of spared intervening skin, so-called "skip areas." When there is significant involvement of the lymphatics or superficial edema, the skin may acquire a peau d'orange appearance. Bulla formation and superficial necrosis can result in epidermal sloughing or erosions (Fig. 151-2). Hemorrhage may be observed as the result of disruption of superficial vessels by inflammation and edema. The presence of crepitus, anesthesia, or pain disproportionate to clinical findings should raise concern for a necrotizing soft-tissue infection (see Chap. 153).

Figure 151-2 Cellulitis with swelling, erythema, and tenderness. **A,** Note blister formation on the lower extremity. **B,** Cellulitis emanating from an upper-extremity abscess.

NONCUTANEOUS FINDINGS

Fever is an inconsistent complication of cellulitis and may be present in 12% to 71% of hospitalized patients; it may be even less common in patients who require only outpatient management.[13,14] Tachycardia may be observed.[13] Hemodynamic instability should prompt assessment for complicating sepsis, toxin-mediated systemic illness, or other serious infection.

COMPLICATIONS

Lymphatic damage leading to lymphedema is a frequent complication of cellulitis that increases the risk of recurrence (Fig. 151-3).[9,11,12] Superficial thrombophlebitis may be seen in the acute setting, but the risk of deep venous thrombosis is low.[15] More serious complications in treated patients are uncommon, but may include bacteremia, which occurs in approximately 5% of patients, and its sequelae, including sepsis, bacterial endocarditis, postinfectious glomerulonephritis, and toxin-mediated systemic syndromes (see Chaps. 152 and 155).[16,17] Spread of infection to deeper tissues is rare in the absence of other risk factors or chronic systemic disease.

CLINICAL VARIANTS

Erysipelas shares many clinical features with classic cellulitis, but the area of involvement is sharply demarcated and bright red in color. The most common site

Figure 151-3 Recurrent cellulitis. Note the patchy, ill-defined erythema with "skip areas" on the medial thigh and lower leg. This pattern may be observed more frequently in recurrent cellulitis as a result of underlying lymphatic damage.

Figure 151-4 Erysipelas. There is painful, warm erythema of the lower extremity with well-defined borders.

of involvement is the leg in 76% to 90% of cases, followed by the face and upper extremity (Figs. 151-4 and 151-5).[18,19] Fever is more common than in classic cellulitis.[18] Recurrence may be observed but systemic complications are uncommon.

Purulent cellulitis is defined by the presence of pustules or abscess development, which may precede or follow cellulitis (Fig. 151-6A). There should be a higher suspicion for *Staphylococcus aureus* as the causative organism.[20] If purulent collections are identified by physical examination or ultrasonography, there should be strong consideration for incision and drainage in addition to culture-directed and sensitivity-directed antibiotics (see also Chap. 150).

Surgical site infections localize to the site of surgery and are often accompanied by purulence (see Fig. 151-6B). *S. aureus* is commonly cultured, but other organisms may predominate depending upon the anatomic location and type of surgery.

Bite wounds may give rise to cellulitis at the site of inoculation in 20% to 30% of cases (see Chap. 182).[21] Dog bites are usually associated with crush injuries, whereas cat bites, because of the sharper teeth of cats, inject organisms into deeper tissue spaces, including joint spaces, tendon sheaths, and bone. Human bites are often polymicrobial and can result from direct biting or indirectly from contact of a fist to another person's teeth ("fight bite").

Periorbital or *preseptal cellulitis* is an infection anterior to the orbital septum, and demonstrates erythema, swelling, warmth, and pain in a periorbital distribution. Like classic cellulitis, there may be a clear portal of entry for infection. Patients may or may not have systemic symptoms, and neurologic sequelae are absent.[22]

Orbital cellulitis, in contrast, is infection posterior to the septum with involvement of the orbit proper. It usually results from direct extension of sinusitis, and may manifest with similar cutaneous findings to periorbital cellulitis.[22] Proptosis, bulbar conjunctival edema, ophthalmoplegia, and decreased visual acuity are important clues to diagnosis, and necessitate rapid evaluation and treatment.[22] Orbital cellulitis may be complicated by permanent vision loss or posterior spread of infection into the brain.

Bilateral cellulitis, where infection occurs simultaneously on both extremities, is rare in the absence of predisposing factors such as penetrating trauma. Most of these patients are misdiagnosed (see section "Differential Diagnosis"); however, patients with deficient cellular immunity, such as solid organ transplantation recipients or individuals with HIV, may be at greater risk of true bilateral infection. In this patient population atypical causes of cellulitis should be considered, including disseminated cryptococcosis.[23,24]

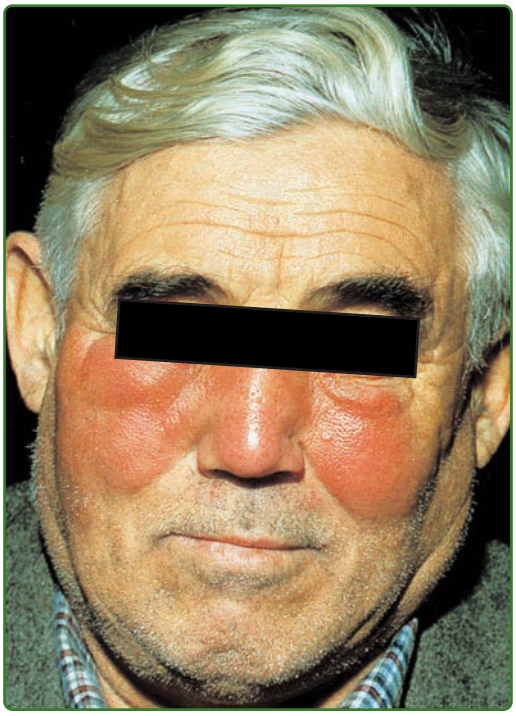

Figure 151-5 Erysipelas. Painful, edematous erythema with sharp margination on both cheeks and the nose. There is tenderness, and the patient has fever and chills.

ETIOLOGY AND PATHOGENESIS

Microbial pathogens gain access to the deep dermal and subcutaneous tissues through breaks in the skin, where they can spread into lymphatics, blood vessels, and interstitial spaces. A portal of entry can be identified in up to 62% of patients, with toe web infections as the most common etiology.[19] Disseminated infection with secondary seeding of the skin is a rare cause of cellulitis that may occur in immunocompromised patients.

Figure 151-6 **A,** Cellulitis after puncture trauma. The forearm is swollen, erythematous, and tender; there is abscess formation. **B,** Cellulitis, caused by *Staphylococcus aureus* infection, arising at the site of a surgical excision. Note discharge of pus.

Given the difficulty in culturing or identifying causative pathogens, cellulitis may be relatively paucimicrobial, with a significant portion of the clinical symptoms and signs due to host inflammatory responses to killed bacteria and bacterial exotoxins.

MICROBIOLOGY

Group A β-hemolytic streptococci (*Streptococcus pyogenes*) and staphylococci (particularly *S. aureus*) are the most commonly identified pathogens, but the specific incidence is difficult to characterize as identification of the causative organism occurs in less than one-third of cases.[16,19,25,26] Historically, erysipelas was attributed solely to streptococci, but recent studies have found a microbial profile that is similar to the microbial profile of classic cellulitis.[16] Other streptococcal species (groups B, C, and G) and coagulase-negative staphylococci are less-often encountered, but may be of increasing importance in hospitalized patients. Prior to widespread vaccination, which began in the late 1980s, *Haemophilus influenzae* Type B was observed in up to 6% of children with any systemic infection.[27] Surgical site infections, pressure or diabetic ulcers, and those with cellular immunodeficiency may be at greater risk for polymicrobial or atypical infections, including enterococci, *Pseudomonas* spp., Gram-negative anaerobes, mycobacteria, and disseminated fungal infections such as cryptococcosis. Cellulitis resulting from bite wounds may be polymicrobial and include Gram-negative anaerobes such as *Pasteurella* spp., *Eikenella* spp., and *Capnocytophaga canimorsus* (see Chap. 182). Aquatic trauma may lead to cellulitis from atypical organisms including *Aeromonas* spp., *Erysipelothrix rhusiopathiae*, *Mycobacterium marinum* or other atypical mycobacteria, and *Vibrio vulnificus*.[28]

Table 151-1 lists common and uncommon causes of cellulitis and variants.

TABLE 151-1
Microbiology of Cellulitis

TYPE OF INFECTION	MOST COMMON CAUSE (S)	SELECT UNCOMMON CAUSES
Cellulitis and erysipelas (including periorbital/orbital cellulitis)	Group A streptococci (*Streptococcus pyogenes*); *Staphylococcus aureus*	Groups B, C, or G streptococci; coagulase-negative staphylococci; *Streptococcus iniae*; *Streptococcus pneumoniae*; *Haemophilus influenzae* (children); *Escherichia coli*, *Proteus* spp., other Enterobacteriaceae, and other Gram-negative anaerobes; *Neisseria* spp.; *Moraxella* spp.; *Campylobacter jejuni*; *Cryptococcus* spp. and other disseminated fungal organisms (immunocompromised); *Legionella pneumophila*, *Legionella micdadei*; *Pseudomonas aeruginosa* (secondary to bacteremia)
Cellulitis from animal and human bites (see Chap. 182)	*Pasteurella* spp.; streptococci, staphylococci	*Bacteroides* spp.; *Bartonella henselae* (cat); *Capnocytophaga canimorsus* (dog); *Eikenella* spp. (human); *Fusobacterium* spp.; *Moraxella* spp.
Cellulitis from aquatic trauma (exposure-specific)	*Aeromonas* spp.; *Erysipelothrix rhusiopathiae*; *Mycobacterium marinum* and other atypical mycobacteria; *Vibrio vulnificus*	

TABLE 151-2
Systemic and Local Risk Factors for Primary and Recurrent Cellulitis

Systemic/Environmental	Local
▪ Age ▪ Obesity ▪ Systemic disease: renal, hepatic, or autoimmune connective tissue diseases, malignancy; immunosuppression[a] (including diabetes, HIV, and iatrogenic) ▪ Summer season	▪ Disrupted skin barrier (toe web infections such as tinea pedis, inflammatory dermatoses, penetrating trauma, including iatrogenic causes) ▪ Compromised lymphovascular system (edema/lymphedema, venous insufficiency, peripheral arterial disease)

[a]Controversial as a risk factor for routine cellulitis. Immunosuppression should prompt consideration of unusual presentations or atypical pathogens and may require more aggressive treatment.

RISK FACTORS

Cellulitis is more common in men than women, and its incidence rises during summer months and markedly with increasing patient age.[6,8] Other systemic or epidemiologic risk factors include obesity, renal or hepatic disease, connective tissue disease, and malignancy, but immunodeficiency (including iatrogenic or from systemic conditions such as HIV or diabetes) as a predisposing factor for routine cellulitis is controversial.[6,29-31] Compromise of the skin barrier or underlying lymphovascular system are important local risk factors, and may result from lymphedema, toe web infection, inflammatory dermatoses, peripheral vascular disease, or iatrogenic causes, including IV line placement, surgical site intervention (which may disrupt both the skin barrier and underlying lymphovascular system), and postradiation changes.[6,29,31] Of these, lymphedema confers the highest risk at more than 70-fold, followed by disruption of the skin barrier at nearly 24-fold.[31]

Recurrent cellulitis has similar risk factors to primary infection. Lymphedema, age, obesity, and prior surgical site intervention are among the most important.[32] Like primary cellulitis, recurrent infection is frequently misdiagnosed (see section "Diagnosis" and "Differential Diagnosis").

Table 151-2 summarizes both systemic and local risk factors for primary and recurrent cellulitis.

DIAGNOSIS

The diagnosis of cellulitis is most often made by clinical history and physical examination as there are no reliably accurate diagnostic studies. The cardinal symptoms and signs of erythema, swelling, warmth, and pain, even when accompanied by fever, leukocytosis, or elevated inflammatory markers, may be observed in clinical mimics of cellulitis known collectively as *pseudocellulitis* (see section "Differential Diagnosis").[29] Misdiagnosis rates of greater than 30% have been observed in acute care settings (emergency department or hospital) and lead to hundreds of millions of dollars in avoidable health care spending.[33-36] Consultation of a dermatologist improves diagnostic accuracy, shortens duration of unnecessary antibiotic use, and improves short-term clinical outcomes.[35,37] Despite its high prevalence, there is clear need for improved diagnostic testing for cellulitis.

SUPPORTIVE STUDIES

LABORATORY TESTING

Leukocytosis (≥10,000 cells/μL) is present in 34% to 50% of patients, and inflammatory markers such as the erythrocyte sedimentation rate and C-reactive protein are elevated in more than 75% of patients, but these laboratory findings are nonspecific and also may be seen in pseudocellulitis.[13,19,38] Procalcitonin has been reliably used in serious systemic bacterial infections, but its usefulness as a surrogate biomarker in localized cellulitis has not been consistent, and additional prospective studies are necessary.[39-41]

Serologic tests for cellulitis are controversial, as they may not reliably distinguish acute infection from prior exposure. Antistreptolysin O responses are more limited in cutaneous than upper respiratory tract infections, typically appear after 1 week, peak at 3 to 6 weeks, and decline at less-well-defined rates, thereby complicating the diagnosis of both primary and recurrent cellulitis.[42] The anti-DNase B test peaks at 6 to 8 weeks, later than is useful for clinical decision making in the acute setting.[42]

MICROBIAL CULTURE

Skin swabs and surface wound cultures are often unhelpful, as they are commonly polymicrobial and determination of colonization versus true pathogenicity is challenging.[14,29] Positive polymerase chain reaction swabs for MRSA carriage have correlated with an increased overall risk of cellulitis, but their usefulness in acute infection is debated.[43] Needle aspiration followed by aspirate culture has shown widely disparate diagnostic usefulness, ranging from less than 5% to 40%, but may be more useful in patients with underlying systemic risk factors.[14,44] Blood cultures are not routinely performed in uncomplicated cellulitis as they are positive in only approximately 5% of cases.[16,17] However, in certain high-risk populations, such as the elderly, the immunocompromised, the systemically ill, and those with penetrating trauma, or if there is concern for atypical or severe systemic infection, blood cultures should be drawn. The 2014 update to the Infectious Diseases Society of America (IDSA) guidelines on the diagnosis and management of skin and soft-tissue infections does not recommend routinely culturing blood or cutaneous aspirates or swabs.[26] In contrast, pustules, abscesses, or

other fluid collections associated with purulent cellulitis should be drained and cultured early during diagnostic workup.[26,29]

PATHOLOGY

Because the histopathologic findings of cellulitis are nonspecific, biopsy is not routinely performed. A sparse to moderately dense superficial and deep perivascular lymphocytic infiltrate with variable amounts of neutrophils may be seen, sometimes with background dermal edema, but Gram stains are frequently negative. Skin biopsy can be useful in evaluating for pseudocellulitis, depending upon the underlying etiology. Submission of skin biopsies for tissue culture is not routinely recommended, as the biopsies are positive in only 20% to 30% of cases.[26] If there is concern for an atypical causative organism, including mycobacteria, fungi, or viruses, or in immunocompromised or other high-risk patient populations, a biopsy for histopathologic evaluation and tissue culture should be performed.

Molecular techniques for microbe detection, including polymerase chain reaction of skin biopsies, do not reliably differentiate clinically involved from uninvolved skin and are often negative.[26,39] Routine use has not been widely adopted.

IMAGING

For uncomplicated cellulitis, imaging studies are not diagnostic. Ultrasonography or MRI can be helpful in identifying localized fluid collections in purulent cellulitis for guidance of incision and drainage. MRI also may be used to identify involvement of deeper tissues, such as pyomyositis or osteomyelitis, rare complications of severe or longstanding cellulitis. CT or MRI can be useful in differentiating cellulitis from necrotizing soft-tissue infections.

EMERGING DIAGNOSTIC MODALITIES

Given the high rate of misdiagnosis and lack of accurate and reliable studies, there is interest in finding better diagnostic methods for cellulitis. The ALT-70 (Table 151-3), a risk prediction model generated to predict the likelihood of lower-extremity cellulitis among admitted patients, is based on asymmetry (unilaterality) of infection, leukocytosis equal to or greater than 10,000 cells/μL, tachycardia equal to or greater than 90 beats/min, and patient age equal to or greater than 70 years.[13] A score of 0 to 2 points indicates a negative predictive value greater than 83.3%, and 5 points or higher indicates a positive predictive value greater than 82.2% for cellulitis.[13] A skin surface temperature gradient greater than 0.47°C (0.85°F) between a patient's involved and uninvolved skin, as determined by thermal imaging, has also shown promise, with a sensitivity of 96.6% for the diagnosis of cellulitis, but additional confirmatory studies are needed.[45] Genetic testing may prove useful; a recent pilot study found that HLA-DQA1 expression was 34-fold higher among cases with cellulitis than controls.[39]

TABLE 151-3
ALT-70 Risk Prediction for Cellulitis

Asymmetry (unilateral)	3 points[a]
Leukocytosis ≥10,000 cells/μL	1 point
Tachycardia ≥90 beats/min	1 point
70 years of age or older	2 points

[a]A score of 0 to 2 = ≥83.3% likelihood of pseudocellulitis; a score of ≥5 points = ≥82.2% likelihood of true cellulitis.

DIFFERENTIAL DIAGNOSIS

The differential diagnosis for cellulitis is broad, and includes causes of pseudocellulitis as well as causes of other infectious etiologies (Table 151-4). In difficult cases, skin biopsy or other laboratory markers may be useful for diagnosis when placed into the clinical context of the patient.

The most common cause of pseudocellulitis is stasis dermatitis.[29,30,46,47] Stasis dermatitis is commonly bilateral, which may aid in differentiating it from cellulitis; however, it is often asymmetric and may be unilateral (Fig. 151-7A). The chronicity, association of scaling and pruritus, absence of fever or leukocytosis, and response to compression, elevation, and topical corticosteroids can assist in diagnosis. Other lymphovascular diseases

TABLE 151-4
Differential Diagnosis of Cellulitis[a]

Inflammatory
- **Stasis dermatitis**
- **Irritant/allergic contact dermatitis and other eczematous dermatitides**
- Drug eruption
- Vasculitides
- Panniculitides (eg, lipodermatosclerosis, erythema nodosum)
- Neutrophilic dermatoses (eg, pyoderma gangrenosum, Sweet syndrome)
- Follicular occlusion (eg, hidradenitis suppurativa)
- Sarcoidosis
- Autoimmune connective tissue diseases
- Radiation dermatitis

Vascular
- **Edema/lymphedema**
- Deep venous thrombosis
- Superficial thrombophlebitis
- Hematoma

Infectious
- **Dermatophytoses**
- Cutaneous candidiasis
- Erythema migrans
- Necrotizing soft-tissue infections
- Acute/chronic paronychia
- Cutaneous mycobacterial infections

Neoplastic/Paraneoplastic
- Cutaneous lymphoma
- Paget disease
- Carcinoma erysipeloides
- Erythromelalgia

Miscellaneous
- **Arthropod bite**
- Gout/pseudogout
- Calciphylaxis
- Wells syndrome (eosinophilic cellulitis)
- Hereditary periodic fever syndromes (eg, familial Mediterranean fever)

[a]Commonly misdiagnosed pseudocellulitides are highlighted in bold.

Figure 151-7 **A,** Stasis dermatitis with linear excoriations. The eruption is eczematous with evidence of scratching (because of pruritus), which would be atypical in cellulitis. Note the "marker sign," commonly observed in hospitalized patients seen by dermatology consultants, which is testament to the difficulty of diagnosis. **B,** Cutaneous small-vessel vasculitis attributed to naproxen use. The purpuric eruption is bilateral and located in areas of dependency, consisting of coalescing papules and plaques with secondary blister formation. This patient has low-grade elevated temperatures.

and sequelae, including deep venous thrombosis, hematoma, lipodermatosclerosis, and chronic edema or lymphedema, are commonly encountered and may mimic cellulitis. Eczematous dermatitides, such as allergic or irritant contact and asteatotic dermatitis, are usually discriminated by the presence of scaling and pruritus and absence of fever or leukocytosis. Bilateral involvement or geometric borders may be observed and aid diagnosis. Gout or pseudogout may mimic localized, early cellulitis, and can be accompanied by fever and leukocytosis, but typically overlies a joint. Erythema nodosum and small-vessel vasculitides tend to present as multifocal eruptions, but fever and leukocytosis are variably present (Fig. 151-7B).

Erythema migrans is an important infectious mimic of cellulitis in endemic areas, may not present in the classic annular configuration, and can be accompanied by fever or systemic symptoms. The patient may not recall a history of tick bite. Other arthropod bites are usually multifocal without systemic symptoms. It is important to exclude necrotizing soft-tissue infections when evaluating cellulitis, as they require emergent surgical evaluation and debridement.

CLINICAL COURSE AND PROGNOSIS

The natural history of acute cellulitis is rarely observed in the modern era, however prior to use of antibiotics, therapeutic cure was achieved in approximately two-thirds of patients with an 11% mortality rate.[2] Cure rates are difficult to estimate in clinical trials because of the lack of definitive biomarkers for infection, but average approximately 80% to 85%, and are interestingly higher in complicated cellulitis than uncomplicated cases.[48] These relatively low cure rates may be related to inadvertent inclusion of pseudocellulitis into antimicrobial trials, or prolonged time to complete recovery beyond the usual clinical assessment period.[48,49] Without treatment, infection can spread into the bloodstream and become life-threatening.

Prognosis for treated cellulitis is good and modern mortality rates are negligible in uncomplicated cases treated with antibiotics. The recovery period is usually several weeks, although by 30 days as many as 20% of patients have not yet returned to normal activities.[49] Recurrence occurs in more than 10% of patients.[11] This risk increases with number of previous reoccurrences, which is suggestive of predisposing systemic or local risk factors for infection.

The common practice of outlining the involved area of cellulitis may be useful to monitor response to treatment, although indistinct margins, presence of "skip areas," and occasional transient progression of erythema despite other evidence of clinical improvement may make interpretation difficult in some patients.[50] Serial high-quality photographs can provide an alternative, reliable method to monitor treatment response, particularly in the inpatient setting where the primary provider may change during a patient's hospitalization.[50]

MANAGEMENT

Empiric antibiotic therapy directed against streptococcal and staphylococcal species is recommended for the treatment of cellulitis, but the evidence of superiority for one regimen over another has not been definitively established.[51] Treatment recommendations vary based upon the presence of purulence, systemic symptoms, and overall clinical assessment, the patient's underlying risk factors, and community rates of drug-resistant pathogens. Outpatient therapy with oral antibiotics is appropriate in hemodynamically stable patients without evidence of systemic infection, but hospitalization may be required in the seriously ill, immunocompromised patients, or with failure of outpatient therapy.

Table 151-5 outlines the treatments for bacterial cellulitis.

TABLE 151-5
Treatments for Bacterial Cellulitis

DISEASE	SEVERITY	FIRST-LINE ANTIBIOTICS	ALTERNATIVE ANTIBIOTICS
Nonpurulent cellulitis	Mild (no evidence of systemic disease); outpatient setting with oral therapy	▪ Cephalexin ▪ Dicloxacillin ▪ Penicillin V	▪ Clindamycin ▪ Macrolides (azithromycin, erythromycin)
	Moderate (≥2 SIRS criteria or failure of outpatient therapy); acute care setting with IV therapy	▪ Cefazolin ▪ Ceftriaxone ▪ Penicillin G	▪ Clindamycin ▪ Consider vancomycin if associated IVDU or known MRSA colonization/infection
	Severe (≥2 SIRS criteria with rapid progression, hypotension, or evidence of end-organ damage) or immunocompromised; hospitalization with IV therapy ▪ Consider surgical evaluation for necrotizing soft-tissue infection ▪ Cultures and sensitivities	▪ Broad-spectrum with vancomycin and piperacillin-tazobactam ▪ Narrow as appropriate per cultures and sensitivities	
Purulent cellulitis	Mild (no evidence of systemic disease); outpatient setting with oral therapy ▪ Incise and drain; consider cultures and sensitivities	MSSA suspected: ▪ Cephalexin ▪ Dicloxacillin MRSA suspected: ▪ Clindamycin ▪ Tetracyclines (doxycycline, minocycline, tetracycline) ▪ Trimethoprim-sulfamethoxazole	▪ Clindamycin
	Moderate (≥2 SIRS criteria or failure of outpatient therapy); acute care setting with IV therapy ▪ Incise and drain; cultures and sensitivities	MSSA suspected: ▪ Oxacillin ▪ Nafcillin ▪ Cefazolin MRSA suspected: ▪ Vancomycin ▪ Clindamycin	▪ Clindamycin ▪ Linezolid (MRSA)
	Severe (≥2 SIRS criteria with rapid progression, hypotension, or evidence of end-organ damage) or immunocompromised; hospitalization with IV therapy ▪ Consider surgical evaluation for necrotizing soft-tissue infection ▪ Incise and drain; cultures and sensitivities	▪ Broad-spectrum with vancomycin and piperacillin-tazobactam ▪ Narrow as appropriate per cultures and sensitivities	▪ Clindamycin ▪ Daptomycin ▪ Ceftaroline ▪ Telavancin ▪ Tigecycline

IVDU, IV drug use; MRSA, methicillin-resistant *Staphylococcus aureus*; MSSA, methicillin-sensitive *Staphylococcus aureus*; SIRS, systemic inflammatory response syndrome (temperature >38°C [100.4°F] or <36°C [96.8°F]; pulse >90 beats/min; respiratory rate >20 breaths/min; or leukocyte count >12,000 cells/μL or <4000 cells/μL).

ANTIBIOTICS

NONPURULENT CELLULITIS

Nonpurulent cellulitis without systemic evidence of infection should be treated with oral antistreptococcal antibiotics such as cephalexin, dicloxacillin, or penicillin V. In cases of true Type I hypersensitivity reactions to penicillins or cephalosporins, clindamycin or macrolides should be considered.[26,29] No difference in failure rate between β-lactams and non–β-lactams has been demonstrated, although some studies have shown higher rates of treatment-related adverse events (predominantly GI symptoms) among patients treated with non–β-lactams.[52,53] Addition of clindamycin or trimethoprim-sulfamethoxazole, both agents with activity against MRSA, to β-lactam antibiotics have not demonstrated significant benefits over β-lactam coverage alone for uncomplicated nonpurulent cellulitis.[49,54]

Patients with evidence of systemic infection, including 2 or more systemic inflammatory response syndrome criteria (temperature >38°C [100.4°F] or <36°C [96.8°F]; pulse >90 beats/min; respiratory rate >20 breaths/min; or leukocyte count >12,000 cells/μL or <4000 cells/μL), or those who fail outpatient treatment should receive parenteral antibiotics such as cefazolin, ceftriaxone, or penicillin G.[26] Clindamycin

should be used in patients with true Type I hypersensitivity reactions to penicillins or cephalosporins. If there is associated penetrating trauma, including injection drug use, or known MRSA colonization or infection elsewhere, empiric coverage with vancomycin may be indicated. Severe infections with rapid progression, hypotension, end-organ dysfunction, or in immunocompromised patients or in those suspected of having atypical or resistant organisms should be treated with broad-spectrum parenteral antibiotics and narrowed according to culture and sensitivity results.[26,29]

PURULENT CELLULITIS

Patients with purulent cellulitis should be cultured and fluid collections incised and drained. In mild disease, empiric therapy with oral anti-staphylococcal antibiotics should be initiated while awaiting culture and sensitivity results. The decision to treat for methicillin-sensitive *S. aureus* (MSSA) versus MRSA should depend upon clinical suspicion based on host or environmental factors, including history of known MRSA colonization, patient risk factors, and local rates of MRSA infections. Cephalexin and dicloxacillin are first-line agents of choice in MSSA, whereas clindamycin, tetracyclines, and trimethoprim-sulfamethoxazole are used in MRSA. In these cases, concomitant coverage for streptococcal species may be required.[26,29] If penicillin or cephalosporin allergy exists, clindamycin is an alternative. Note some geographic regions demonstrate high rates of inducible clindamycin resistance in *S. aureus* isolates.

Patients with systemic infection or failure of outpatient treatment require parenteral antibiotics (Table 151-6). Oxacillin, nafcillin, and cefazolin, or clindamycin in penicillin-allergic or cephalosporin-allergic patients, are appropriate for MSSA.[26,29] Vancomycin, clindamycin, or linezolid are preferred in MRSA.[26,29] Severe infections or infections in special patient populations require broad-spectrum parenteral antibiotic coverage, including against MRSA, while awaiting culture and sensitivity results.

DURATION

The optimal duration of antibiotic therapy has not been identified in clinical trials. The IDSA guidelines recommend 5 days for uncomplicated patients, with extension of therapy if signs of infection persist.[26] In general, 5 to 10 days are recommended for uncomplicated patients with slightly longer courses (7 to 14 days) for immunocompromised patients.[29] Reassessment at 24 to 72 hours is important to assess response to therapy.

TABLE 151-6
Indications for Parenteral Administration of Antibiotics

At least 2 or more of the following
Temperature >38°C (100.4°F) or <36°C (96.8°F)
Pulse >90 beats/min
Respiratory rate >20 breaths/min
Leukocyte count >12,000 cells/μL or <4000 cells/μL
or
Failed outpatient treatment

RECURRENT CELLULITIS AND PROPHYLAXIS

Recurrent episodes of cellulitis may require longer treatment courses or hospitalization, although the majority can be managed in the ambulatory setting. Risk factors for recurrence should be addressed (see section "Prevention"). Although controversial, prophylactic antibiotics, such as low-dose penicillin or erythromycin, should be considered if there are 3 to 4 recurrences per year despite these efforts.[26] Prophylaxis may reduce both the incidence of first reoccurrence after primary cellulitis and subsequent recurrences, but these effects diminish after discontinuation of therapy.[55-58] Optimal type, dosing, and duration of antibiotics require further investigation. Prophylaxis has demonstrated cost-effectiveness, but long-term tolerability data is lacking and its effects on antibacterial resistance patterns are unknown.[59]

ADJUNCTIVE TREATMENTS

Combination therapy with antibiotics and adjunctive antiinflammatories, including nonsteroidal antiinflammatory drugs (NSAIDs) and systemic corticosteroids, may be beneficial in some patients. NSAIDs may reduce time to regression of inflammation.[60,61] However, there are concerns over their effects on neutrophil chemotaxis as NSAID use has been correlated with an increased risk of skin infection in children with varicella.[62,63]

Despite concerns over immunosuppressive effects, the addition of prednisolone to antibiotics has demonstrated shortened time to healing in uncomplicated erysipelas with a trend toward decreased relapse, and oral corticosteroids in combination with parenteral antibiotics reduced resolution time and ocular complications in orbital cellulitis.[64-66] The IDSA guidelines recommend consideration of systemic corticosteroids in nondiabetic adult patients with cellulitis.[26]

PREVENTION

Treatment of predisposing factors, including lymphedema, toe web infections, and local skin barrier defects, and underlying medical conditions is recommended to prevent primary and recurrent episodes of cellulitis. Decolonization strategies for MRSA carriage are controversial and their effectiveness in reducing the risk of cellulitis requires further study.[67]

ACKNOWLEDGMENTS

The author acknowledges the contributions of Adam D. Lipworth, Arturo P. Saavedra, Arnold N. Weinberg, and Richard Allen Johnson, the former authors of this chapter.

REFERENCES

1. Stevens D. Antimicrobial agents for complicated skin and skin-structure infections: noninferiority margins, placebo-controlled trials, and the complexity of clinical trials. *Clin Infect Dis.* 2009;49:392-394.
2. Spellberg B, Talbot GH, Boucher HW, et al. Antimicrobial agents for complicated skin and skin-structure infections: justification of noninferiority margins in the absence of placebo-controlled trials. *Clin Infect Dis.* 2009;49:383-391.
3. Hersh AL, Chambers HF, Maselli JH, et al. National trends in ambulatory visits and antibiotic prescribing for skin and soft-tissue infections. *Arch Intern Med.* 2008;168:1585-1591.
4. Como-Sabetti K, Harriman KH, Buck JM, et al. Community-associated methicillin-resistant *Staphylococcus aureus*: trends in case and isolate characteristics from six years of prospective surveillance. *Public Health Rep.* 2009;124(3):427-435.
5. Marcelin JR, Challener DW, Tan EM, et al. Incidence and effects of seasonality on nonpurulent lower extremity cellulitis after the emergence of community-acquired methicillin-resistant *Staphylococcus aureus*. *Mayo Clin Proc.* 2017;92(8):1227-1233.
6. Cannon J, Rajakaruna G, Dyer J, et al. Severe lower limb cellulitis: defining the epidemiology and risk factors for primary episodes in a population-based case-control study. *Clin Microbiol Infect.* 2018. [Epub ahead of print]
7. Yorita KL, Holman RC, Sejvar JJ, et al. Infectious disease hospitalizations among infants in the United States. *Pediatrics.* 2008;121(2):244-252.
8. Peterson R, Polgreen L, Cavanaugh J, et al. Increasing incidence, cost, and seasonality in patients hospitalized for cellulitis. *Open Forum Infect Dis.* 2017; 4(1):ofx008.
9. Jorup-Ronstrom C, Britton S. Recurrent erysipelas: predisposing factors and costs of prophylaxis. *Infection.* 1987;15(2):105-106.
10. St John J, Strazzula L, Vedak P, et al. Estimating the health care costs associated with recurrent cellulitis managed in the outpatient setting. *J Am Acad Dermatol.* 2018;78(4):749-753.
11. Cannon J, Dyer J, Carapetis J, et al. The epidemiology and risk factors for recurrent severe lower limb cellulitis: a longitudinal cohort study. *Clin Microbiol Infect.* 2018. [Epub ahead of print]
12. Cox NH. Oedema as a risk factor for multiple episodes of cellulitis/erysipelas of the lower leg: a series with community. *Br J Dermatol.* 2006;155(5):947-950.
13. Raff AB, Weng QY, Cohen JM, et al. A predictive model for diagnosis of lower extremity cellulitis: a cross-sectional study. *J Am Acad Dermatol.* 2017;76(4): 618-625.e2.
14. Hirschmann JV, Raugi GJ. Lower limb cellulitis and its mimics: part I. Lower limb cellulitis. *J Am Acad Dermatol.* 2012;67(2):163.e1-e12.
15. Gunderson CG, Chang JJ. Risk of deep vein thrombosis in patients with cellulitis and erysipelas: a systematic review and meta-analysis. *Thromb Res.* 2013;132(3):336-340.
16. Gunderson CG, Martinello RA. A systematic review of bacteremias in cellulitis and erysipelas. *J Infect.* 2012;64(2):148-155.
17. Perl B, Gottehrer NP, Raveh D, et al. Cost-effectiveness of blood cultures for adult patients with cellulitis. *Clin Infect Dis.* 1999;29(6):1483-1488.
18. Bonnetblanc JM, Bédane C. Erysipelas: recognition and management. *Am J Clin Dermatol.* 2003;4(3):157-163.
19. Krasagakis K, Valachis A, Maniatakis P, et al. Analysis of epidemiology, clinical features and management of erysipelas. *Int J Dermatol.* 2010;49(9):1012-1017.
20. Moran GJ, Krishnadasan A, Gorwitz RJ, et al. Methicillin-resistant S. aureus infections among patients in the emergency department. *N Engl J Med.* 2006;355(7):666-674.
21. Rothe K, Tsokos M, Handrick W. Animal and human bite wounds. *Dtsch Arztebl Int.* 2015;112(25):433-443.
22. Givner LB. Periorbital versus orbital cellulitis. *Pediatr Infect Dis J.* 2002;21(12):1157-1158.
23. Chakradeo K, Paul Chia Y, Liu C, et al. Disseminated cryptococcosis presenting initially as lower limb cellulitis in a renal transplant recipient-a case report. *BMC Nephrol.* 2018;19:18.
24. Nishioka H, Takegawa H, Kamei H. Disseminated cryptococcosis in a patient taking tocilizumab for Castleman's disease. *J Infect Chemother.* 2018;24:138-141.
25. Chira S, Miller LG. Staphylococcus aureus is the most common identified cause of cellulitis: a systematic review. *Epidemiol Infect.* 2010;138(3):313-317.
26. Stevens DL, Bisno AL, Chambers HF, et al. Practice guidelines for the diagnosis and management of skin and soft tissue infections: 2014 update by the Infectious Diseases Society of America. *Clin Infect Dis.* 2014;59(2):e10-e52.
27. Inamadar AC, Palit A. Blue cellulitis: a rare entity in the era of Hib conjugate vaccine. *Pediatr Dermatol.* 2004;21(1):90-91.
28. Diaz JH, Lopez FA. Skin, soft tissue and systemic bacterial infections following aquatic injuries and exposures. *Am J Med Sci.* 2015;349(3):269-275.
29. Raff AB, Kroshinsky D. Cellulitis: a review. *JAMA.* 2016; 316(3):325-337.
30. Bailey E, Kroshinsky D. Cellulitis: diagnosis and management. *Dermatol Ther.* 2011;24(2):229-239.
31. Dupuy A, Benchikhi H, Roujeau JC, et al. Risk factors for erysipelas of the leg (cellulitis): case-control study. *BMJ.* 1999;318(7198):1591-1594.
32. Karppelin M, Siljander T, Vuopio-Varkila J, et al. Factors predisposing to acute and recurrent bacterial non-necrotizing cellulitis in hospitalized patients: a prospective case-control study. *Clin Microbiol Infect.* 2010;16(6):729-734.
33. Weng QY, Raff AB, Cohen JM, et al. Costs and consequences associated with misdiagnosed lower extremity cellulitis. *JAMA Dermatol.* 2017;153(2):141-146.
34. Levell NJ, Wingfield CG, Garioch JJ. Severe lower limb cellulitis is best diagnosed by dermatologists and managed with shared care between primary and secondary care. *Br J Dermatol.* 2011; 164(6):1326-1328.
35. Ko L, Garza-Mayers A, St John J, et al. Effect of dermatology consultation on outcomes for patients with presumed cellulitis: a randomized clinical trial. *JAMA Dermatol.* 2018;154(5):529-536.

36. Li D, Xia F, Khosravi H, et al. Outcomes of early dermatology consultation for inpatients diagnosed with cellulitis. *JAMA Dermatol.* 2018;154(5):537-543.
37. Arakaki RY, Strazzula L, Woo E, et al. The impact of dermatology consultation on diagnostic accuracy and antibiotic use among patients with suspected cellulitis seen at outpatient internal medicine offices: a randomized clinical trial. *JAMA Dermatol.* 2014;150(10):1056-1061.
38. Lazzarini L, Conti E, Tositti G, et al. Erysipelas and cellulitis: clinical and microbiological spectrum in an Italian tertiary care hospital. *J Infect.* 2005; 51(5):383-389.
39. Pallin DJ, Bry L, Dwyer RC, et al. Toward an objective diagnostic test for bacterial cellulitis. *PLoS One.* 2016;11(9):e0162947.
40. Rast AC, Knobel D, Faessler L, et al. Use of procalcitonin, C-reactive protein and white blood cell count to distinguish between lower limb erysipelas and deep vein thrombosis in the emergency department: a prospective observational study. *J Dermatol.* 2015;42(8):778-785.
41. Noh SH, Park SD, Kim EJ. Serum procalcitonin level reflects the severity of cellulitis. *Ann Dermatol.* 2016;28(6):704-710.
42. Shet A, Kaplan EL. Clinical use and interpretation of group A streptococcal antibody tests: a practical approach for the pediatrician or primary care physician. *Pediatr Infect Dis J.* 2002;21(5):420-426.
43. Chen CJ, Wang SC, Chang HY, et al. Longitudinal analysis of methicillin-resistant and methicillin-susceptible Staphylococcus aureus carriage in healthy adolescents. *J Clin Microbiol.* 2013;51(8):2508-2514.
44. Sachs MK. The optimum use of needle aspiration in the bacteriologic diagnosis of cellulitis in adults. *Arch Intern Med.* 1990;150(9):1907-1912.
45. Ko LN, Raff AB, Garza-Mayers AC, et al. Skin surface temperatures measured by thermal imaging aid in the diagnosis of cellulitis. *J Invest Dermatol.* 2018;138(3):520-526.
46. Hirschmann JV, Raugi GJ. Lower limb cellulitis and its mimics: part II. Conditions that simulate lower limb cellulitis. *J Am Acad Dermatol.* 2012;67(2): 177.e1-177.e9.
47. Strazzula L, Cotliar J, Fox LP, et al. Inpatient dermatology consultation aids diagnosis of cellulitis among hospitalized patients: a multi-institutional analysis. *J Am Acad Dermatol.* 2015;73(1):70-75.
48. Obaitan I, Dwyer R, Lipworth AD, et al. Failure of antibiotics in cellulitis trials: a systematic review and meta-analysis. *Am J Emerg Med.* 2016;34(8):1645-1652.
49. Brindle R, Williams OM, Davies P, et al. Adjunctive clindamycin for cellulitis: a clinical trial comparing flucloxacillin with or without clindamycin for the treatment of limb cellulitis. *BMJ Open.* 2017;7(3):e013260.
50. Kak V, Miller L, Lessing JN, et al. Therapy for cellulitis. *JAMA.* 2016;316(19):2045-2046.
51. Kilburn SA, Featherstone P, Higgins B, et al. Interventions for cellulitis and erysipelas. *Cochrane Database Syst Rev.* 2010;(6):CD004299.
52. Madaras-Kelly KJ, Remington RE, Oliphant CM, et al. Efficacy of oral β-Lactam versus non-β-lactam treatment of uncomplicated cellulitis. *Am J Med.* 2008;121(5):419-425.
53. Ferreira A, Bolland M, Thomas M. Meta analysis of randomised trials comparing a penicillin or cephalosporin with a macrolide or lincosamide in the treatment of cellulitis or erysipelas. *Infection.* 2016;44:607-615.
54. Moran GJ, Krishnadasan A, Mower WR, et al. Effect of cephalexin plus trimethoprim-sulfamethoxazole vs cephalexin alone on clinical cure of uncomplicated cellulitis: a randomized clinical trial. *JAMA.* 2017; 317(20):2088-2096.
55. Thomas KS, Crook AM, Nunn AJ, et al. Penicillin to prevent recurrent leg cellulitis. *N Engl J Med.* 2013;368(18):1695-1703.
56. UK Dermatology Clinical Trials Network's PATCH Trial Team, Thomas K, Crook A, et al. Prophylactic antibiotics for the prevention of cellulitis (erysipelas) of the leg: results of the UK Dermatology Clinical Trials Network's PATCH II trial. *Br J Dermatol.* 2012;166:169-178.
57. Dalal A, Eskin-Schwartz M, Mimouni D, et al. Interventions for the prevention of recurrent erysipelas and cellulitis. *Cochrane Database Syst Rev.* 2017;6:CD009758.
58. Oh CC, Ko HC, Lee HY, et al. Antibiotic prophylaxis for preventing recurrent cellulitis: a systematic review and meta-analysis. *J Infect.* 2014;69(1):26-34.
59. Mason JM, Thomas KS, Crook AM, et al. Prophylactic antibiotics to prevent cellulitis of the leg: economic analysis of the PATCH I & II trials. *PLoS One.* 2014;9(2):e82694.
60. Dall L, Peterson S, Simmons T, et al. Rapid resolution of cellulitis in patients managed with combination antibiotic and anti-inflammatory therapy. *Cutis.* 2005;75(3):177-180.
61. Davis JS, Mackrow C, Binks P, et al. A double-blind randomised controlled trial of ibuprofen compared with placebo for uncomplicated cellulitis of the upper or lower limb. *Clin Microbiol Infect.* 2017;23(4):242-246.
62. Chosidow O, Saiag P, Pinquier L, et al. Nonsteroidal anti-inflammatory drugs in cellulitis: a cautionary note. *Arch Dermatol.* 1991;127:1845-1846.
63. Mikaeloff Y, Kezouh A, Suissa S. Nonsteroidal anti-inflammatory drug use and the risk of severe skin and soft tissue complications in patients with varicella or zoster disease. *Br J Clin Pharmacol.* 2008;65(2):203-209.
64. Bergkvist PI, Sjöbeck K. Antibiotic and prednisolone therapy of erysipelas: a randomized, double blind, placebo-controlled study. *Scand J Infect Dis.* 1997;29(4):377-382.
65. Bergkvist PI, Sjöbeck K. Relapse of erysipelas following treatment with prednisolone or placebo in addition to antibiotics: a 1-year follow-up. *Scand J Infect Dis.* 1998;30(2):206-207.
66. Pushker N, Tejwani LK, Bajaj MS, et al. Role of oral corticosteroids in orbital cellulitis. *Am J Ophthalmol.* 2013;156(1):178-183.e1.
67. Loeb M, Main C, Walker-Dilks C, et al. Antimicrobial drugs for treating methicillin-resistant Staphylococcus aureus colonization. *Cochrane Database Syst Rev.* 2003;(4):CD003340.

Chapter 152 :: Gram-Positive Infections Associated with Toxin Production

:: Jeffrey B. Travers

AT-A-GLANCE

- Gram-positive infections are caused by *Staphylococcus aureus* and/or Group A *Streptococcus* toxin-producing bacteria.
- Characteristic syndromes (all with skin manifestations): can be divided into 3 categories depending the predominant clinical presentation:
  - Predominantly cutaneous
    - Local: bullous impetigo
    - Generalized: *Staphylococcus* scalded-skin syndrome
  - Cutaneous and systemic
    - Local: recurrent toxin mediated erythema (recurrent perineal erythema)
    - Generalized: recalcitrant erythematous desquamating disorder
    - Other abortive hybrids of predominantly systemic manifestations
  - Predominately systemic
    - Generalized: toxic shock syndrome *Staphylococcus* (predominantly) or *Streptococcus*
    - Scarlet fever: *Streptococcus* (predominantly) or *Staphylococcus*

Skin infections with the Gram-positive bacteria *Staphylococcus aureus* and group A *Streptococcus* (*Streptococcus pyogenes*) are an important source of morbidity and mortality. These bacteria exert many of their effects via their ability to express toxins which can induce characteristic syndromes including staphylococcal scalded-skin syndrome and toxic shock syndrome. Moreover, the production of these toxins is thought to be behind the ability of infection with these bacteria to initiate and/or propagate inflammatory and neoplastic skin diseases. As is outlined in this chapter, the clinician needs to be aware that there are not only classical syndromes, but, also partial ones in which Gram-positive toxins are likely inducing effects.

EPIDEMIOLOGY

FACTORS IN TOXIN-MEDIATED DISEASE

Staphylococcal and streptococcal pathogenicity are caused by production of a repertoire of immunomodulatory proteins, including toxins, exoenzymes, and adhesins (reviewed in Dinges and colleagues[1]). Among the best characterized of these are the toxins, which are outlined in Table 152-1.

Many risk factors play a role in the ability of a toxin-forming *Staphylococcus* or *Streptococcus* to produce disease. The development of disease is related to the resistance of the host to infection and to the virulence of the organism. The host's resistance depends, among other factors, on intact skin and mucous membranes serving as barriers to invasion and the host's ability to mount an immune response (eg, neutralizing antibodies) against such toxins. Colonization by virulent *Staphylococcus* or *Streptococcus* toxin-producing organisms exposed to optimal, focal conditions for growth and toxin production (eg, menstruation plus tampon use or abscess) allows these bacteria to initiate and/or propagate infection.

Thus, minor defects in these barriers, such as those produced by superficial excoriations, toe web fungal infections, or, alternatively, major defects produced by surgery, trauma, burns, or foreign substances (packing, sutures, intravascular catheters, shunts), increase the risk of infection. In addition to these factors, the host response is important. For example, if a patient has an underlying immunodeficiency and cannot produce adequate neutralizing antibodies or as in chronic granulomatous disease where neutrophils lack the oxidative burst to destroy catalase-positive bacteria (eg, *S. aureus*), the patient would be at increased risk for colonization/infection by toxin-producing bacteria. Finally, the types of immune cells activated play an important role in the subsequent host response, especially as it relates to toxins that act as superantigens. As is detailed in this chapter, the ability of a superantigen to activate numerous T cells is based upon the variable region of the T-cell receptor. This could result in various types of responses, depending on the specificity of the individual T-cell that is activated.

DISEASES CAUSED BY EXFOLIATIVE TOXINS

S. aureus–mediated production of exfoliative toxin results in a spectrum of blistering skin disorders ranging from localized bullous impetigo to a severe generalized form, staphylococcal scalded-skin syndrome (SSSS). SSSS is a generalized exanthematous disease consisting of cutaneous tenderness and widespread superficial blistering and denudation.

TABLE 152-1
Toxins and Diseases Caused by *Staphylococcus aureus* and Group A *Streptococcus*

BACTERIA	TOXIN	TOXIN TYPE	CLINICAL DISEASE
Staphylococcus aureus	Exfoliatin type A (ETA)	Epidermolytic	Bullous impetigo Staphylococcal scalded skin syndrome (SSSS)
	Exfoliatin type B (ETB)	Epidermolytic	SSSS Bullous impetigo
	Toxic shock syndrome toxin 1 (TSST-1)	Superantigen	Toxic shock syndrome (TSS) (menstrual >> nonmenstrual), food poisoning
	Staphylococcal enterotoxins A to C (SEA, SEB, SEC)	Superantigen	TSS (nonmenstrual > menstrual), food poisoning
Streptococcus pyogenes	Streptococcal pyrogenic exotoxins A and C (SPEA, SPEC)	Superantigen	TSS (nonmenstrual), scarlet fever

ETIOLOGY AND PATHOGENESIS

Exfoliative toxins (ETs) are made by certain strains of *S. aureus* (usually phage group 2). Exfoliatin A and B (ETA and ETB) are 2 serologically distinct proteins produced by *S. aureus*.[2] ETs are serine proteases that bind to the cell-adhesion molecule desmoglein-1 and cleave it resulting in a loss of cell–cell adhesion.[3] Consistent with the pattern of desmoglein-1 protein expression, which is found in the upper part of the epidermis, the epidermolysis takes place usually between the stratum spinosum and granulosum. This results in a very-thin-walled, flaccid blister that is easily disrupted, exhibiting a positive Nikolsky sign. The pathophysiology of ET resembles that of the autoimmune blistering disease pemphigus foliaceus, with both diseases targeting desmoglein-1. Presumably, staphylococcal bacteria have evolved this toxin to allow the bacteria to proliferate and spread beneath the stratum corneum barrier of the skin. There are 2 forms of ET-mediated disease: localized bullous impetigo and systemic SSSS. Studies suggest that the majority of localized bullous impetigo are caused by ETA and systemic forms, such as SSSS, are caused by ETB, possibly because of a lower titer of anti–ETB-neutralizing antibodies in the general population.[4] Although some reports suggest that ETs can also act as superantigens (see below) in addition to their epidermolytic activities,[5] this has been questioned.[6]

CLINICAL FEATURES

LOCALIZED FORM (BULLOUS IMPETIGO)

Figures 152-1 and 152-2 show the blisters of bullous impetigo in a child.

Infection of the upper part of the skin (epidermis) by *S. aureus* or *S. pyogenes* results in impetigo contagiosum. Impetigo, which may account for up to 10% of all pediatric skin problems, consists of honey-colored crusts on an erythematous base. Approximately 25% of cases of impetigo are bullous as a result of local ET-expressing *Staphylococcus* without hematogenous dissemination. As is the case with SSSS, bullous impetigo tends to be a disease of children, although adult cases can also occur. The early lesions of bullous impetigo are cloudy vesicles or bullae surrounded by an erythematous rim. These blisters often rupture leaving superficial erosions. Lesions at various stages can often be seen. The lesions tend to be found around exposed parts of body and around orifices. Diagnosis is usually based upon clinical appearance. In contrast to SSSS, confirmation of diagnosis can be easily obtained by aspiration of blister fluid for Gram stain and cultures will reveal *S. aureus*.

Figure 152-1 Bullous impetigo in a child. Blisters are initially filled with cloudy fluid and later rupture, resulting in erosions and crusting.

Figure 152-2 Bullous impetigo in a child. Note blisters filled with cloudy fluid and lesions that have ruptured, leading to erosions and crusting.

GENERALIZED FORM (STAPHYLOCOCCAL SCALDED-SKIN SYNDROME)

Figures 152-3 and 152-4 depict clinical findings of SSSS in children.

The clinical features of SSSS were first described in 1878 by the German physician Baron Gotfried Ritter von Rittershain, who reported almost 300 cases of "dermatitis exfoliativa neonatorum" among young children.[7] The term *Ritter disease* is still used to denote generalized SSSS in neonates. Outbreaks of SSSS tend to occur in clusters as a consequence of cross-infection. Typically, neonatal or maternity hospital staff colonized or infected with ET-producing staphylococci is the source of these outbreaks. Although more commonly seen in infants and children, SSSS also can be seen in adults. The risk factors for adults include a compromised immune response allowing for growth of the *S. aureus* and possibly impaired amounts of toxin-neutralizing antibodies or renal insufficiency decreasing the clearance of the toxin. Affected individuals initially exhibit a faint, orange-red macular exanthem sparing mucosal surfaces in association with a purulent conjunctivitis, otitis media, nasopharyngeal infection or occasionally pyogenic skin infection such as from an umbilical stump or boil (carbuncle). Perioricial and flexural accentuation of the exanthema is often noted. Although the early rash is not distinctive in appearance, the concomitant cutaneous tenderness is usually present at this early stage. Tenderness can be often so severe that an infant will refuse to lie down or allow anyone to hold them. Within 1 to 2 days the rash progresses from an exanthematous scarlatiniform to a blistering eruption. Characteristic, very superficial, tissue-paper-like wrinkling of the epidermis progresses to large flaccid bullae in flexural and perioricial surfaces. A positive Nikolsky sign can be elicited by stroking the skin, resulting in a superficial

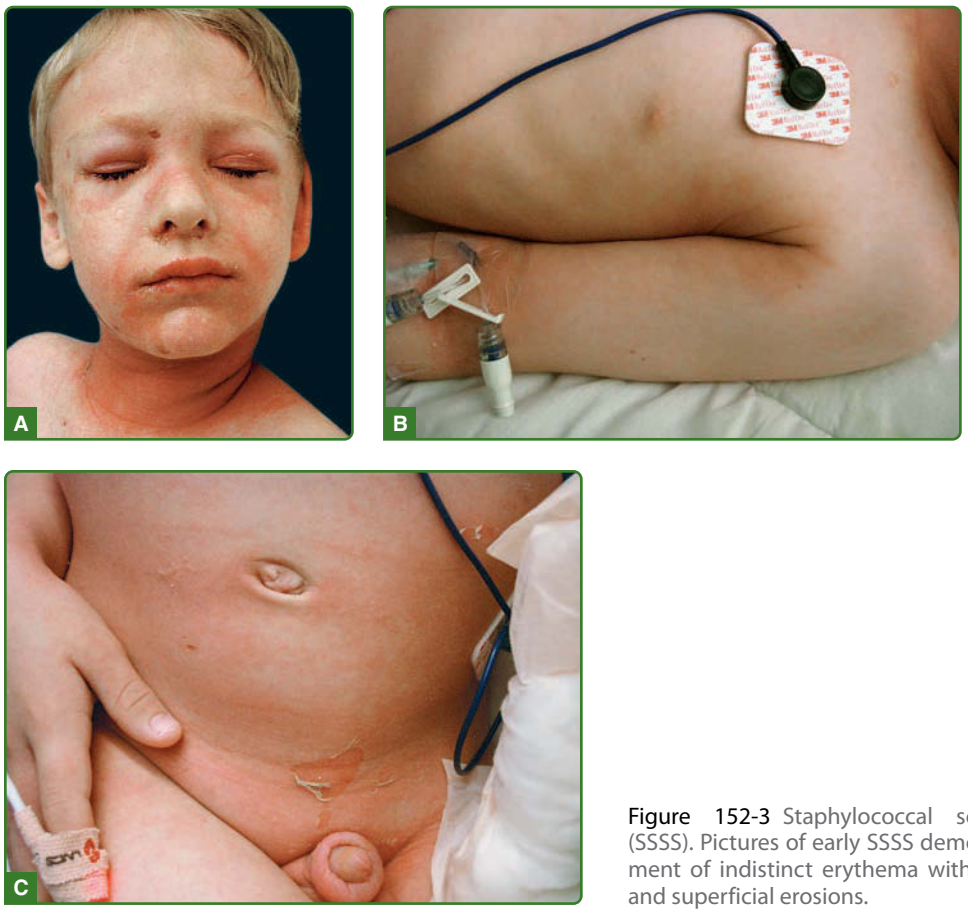

Figure 152-3 Staphylococcal scalded-skin syndrome (SSSS). Pictures of early SSSS demonstrating the development of indistinct erythema with positive Nikolsky sign and superficial erosions.

Figure 152-4 Staphylococcal scalded-skin syndrome (SSSS). Pictures of later SSSS. **A,** The same patient as in Figure 156-3A, 24 hours later, with erythema and more superficial blisters with desquamation of large sheets. **B,** Superficial erosions with underlying denuded skin. **C,** Characteristic crusting with superficial erosions noted on face of this 10-month-old with SSSS.

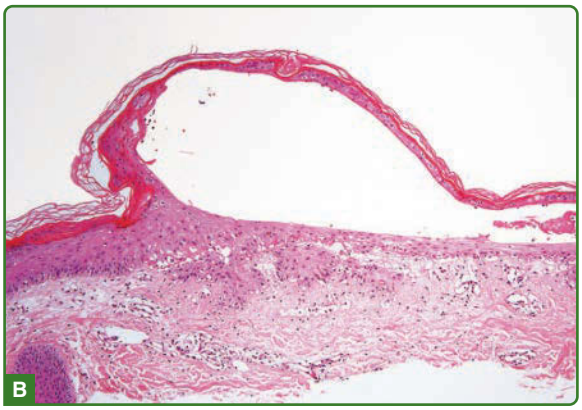

Figure 152-5 Histology of (**A**) bullous impetigo (×200 magnification) versus (**B**) staphylococcal scalded-skin syndrome (SSSS) (×100 magnification). In both conditions, the intraepidermal cleavage induced by the epidermolytic toxin occurs within or just below the stratum granulosum. Note paucity of cells in generalized disease (SSSS) in comparison to the large numbers of leucocytes found in the localized form (bullous impetigo).

blister. Large sheets of epidermal surface are typically shed, revealing a moist underlying erythematous base. At this stage, the disease looks very worrisome, as if a generalized scalding burn had occurred. Although fevers are often present, the infants and children do not usually appear toxic. The cutaneous process usually resolves by use of antibiotics, with superficial desquamation and healing complete within 5 to 7 days. Cultures obtained from an intact blister are usually sterile, consistent with the pathogenesis of a hematogenously disseminated toxin originating from a distant focus of infection inducing the disease.

INTERMEDIATE (ABORTIVE) FORMS

In addition to localized bullous impetigo and generalized SSSS, intermediate forms of staphylococcal-mediated eruptions in which blistering can be apparent can be encountered. One scenario is that localized bullous impetigo evolves to produce regionally limited bullae and denuded areas that may or may not actually harbor *S. aureus*. A possibly abortive form of SSSS known as the scarlatiniform variant with features of

the early erythrodermic and final desquamative stages yet very little blister formation also has been described (see section "Staphylococcal Scarlet Fever").[8] Again, because *S. aureus* bacteria strains can produce both exfoliative and other superantigenic toxins, and ETs could potentially have superantigenic activity,[5] it is not surprising that rarely overlapping syndromes with features of toxic shock and scalded skin can be observed (see sections "Toxic Shock Syndrome" and "Staphylococcal Scarlet Fever").

DIAGNOSIS AND DIFFERENTIAL DIAGNOSIS

All forms of SSSS are characterized by intraepidermal cleavage with splitting beneath and within the stratum granulosum (see histology in Fig. 152-5). The cleavage space may contain either partially or totally unattached acantholytic cells. However, the remainder of the epidermis is usually unremarkable and the dermis contains few inflammatory cells. In localized bullous impetigo, more inflammatory cells including neutrophils can be often visualized.

The principal diagnostic problem is distinguishing generalized SSSS from toxic epidermal necrolysis (TEN) (see Chap. 44). It should be noted that the cases that represented Lyell's first description of TEN actually included some that were probably SSSS.[9] The age distributions of SSSS (neonates, children) and TEN tend to be different, yet much overlap occurs. Use of frozen sections that can rapidly differentiate the superficial subgranular epidermolysis in SSSS versus the characteristic full-thickness epidermal necrosis and dermal–epidermal separation seen in TEN can be very helpful.

TREATMENT AND PROGNOSIS

Therapy for bullous impetigo may constitute topical mupirocin ointment therapy alone and/or oral antibiotics. Prognosis for recovery is excellent. Therapy for SSSS should be directed toward eradication of *S. aureus*, which generally requires hospitalization and intravenous antistaphylococcal antibiotics. For uncomplicated cases, oral antibiotics can usually be substituted after several days. The use of suitable antibiotics combined with supportive skin care and management of potential fluid and electrolyte abnormalities resulting from the widespread disruption of barrier function will usually be sufficient to ensure rapid recovery. Neonates benefit from incubators to maintain body temperature and humidity. Nonadherent dressings, including petrolatum-impregnated gauze, placed over the widespread areas of superficial blistering are helpful. Antibiotic mupirocin ointment applied several times each day to clearly impetiginized areas, including the original source, is often a helpful adjunct to the systemic antibiotics.

Major complications of SSSS are serious fluid and electrolyte disturbances. The mortality in uncomplicated pediatric SSSS is very low (2%) and is not usually associated with sepsis. Adult mortality is higher (approximately 10%) as a result of the concomitant morbidity factors and increased likelihood of sepsis.

DISEASES CAUSED BY SUPERANTIGENIC TOXINS

ETIOLOGY AND PATHOGENESIS

Superantigens are a group of microbial and viral proteins that differ in several important respects from conventional peptide antigens (Fig. 152-6) (reviewed in McCormick and colleagues[10] and Brosnahan and Schlievert[11]). First, unlike conventional protein antigens, which are taken up and processed by antigen-presenting cells, superantigens exert their effects as globular extracellular intact proteins. Similar to peptide antigens, class II major histocompatibility complex (MHC) molecules are involved; however, they do not interact with the MHC peptide β-antigen-binding groove, but instead bind to conserved amino

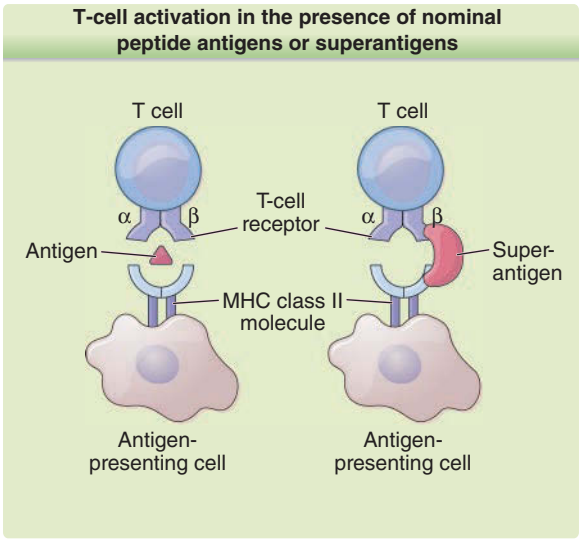

Figure 152-6 T-cell activation in the presence of nominal peptide antigens (*left*) or superantigens (*right*). The peptide antigen binds in the groove of the major histocompatibility complex (MHC) class II molecule and activates only antigen-specific T cells through the T-cell receptor. In contrast, a superantigen is a large globular protein that binds to the MHC class II molecule outside the antigen-binding groove and directly crosslinks the MHC class II molecule and the Vβ chain of the T-cell receptor, leading to polyclonal T-cell activation.

acid residues that are on the outer walls of the peptide antigen-binding groove. Thus, whereas recognition of conventional peptide antigens by the T-cell receptor is restricted by MHC alleles, recognition of superantigens is generally not MHC restricted. Second, superantigens primarily recognize and bind to the variable region of the T-cell receptor β chain (Vβ). This is in contrast to nominal peptide antigens, which require recognition by all 5 variable elements (ie, Vβ, Dβ, Jβ, Vα, and Jα) of the T-cell receptor. Therefore, the responding frequency of a superantigen for resting T cells is several orders of magnitude greater (up to 30%) than a conventional peptide antigen (0.01% to 0.1%) The unique ability of a superantigen to bind directly to (and signal through) MHC class II molecules, and crosslink (and thus activate) a large percentage of T cells expressing relevant T-cell receptor Vβ chains, provides an explanation for the potent immune stimulation seen with these molecules. Of note, in comparison to nominal antigens, activation of superantigen-mediated T cells tends to generate increased numbers of T cells expressing the skin homing receptor cutaneous lymphocyte antigen (CLA).[12] Given that CLA-positive T cells are the T-cell type that traffics readily to the skin, the increased numbers of CLA-positive T cells generated by these agents is thought to be responsible for the high propensity of cutaneous manifestations in these conditions. Superantigens lead to a massive release of cytokines, including tumor necrosis factor α, interleukin-1, and interleukin-6. This cytokine "storm" is in great part responsible for a capillary leak syndrome and accounts for the majority of the clinical manifestations seen in superantigen-mediated diseases. The prototypical disease caused by superantigens is toxic shock syndrome (TSS) caused by staphylococcal or streptococcal toxins (see next). Although specific syndromes, such as TSS and scarlet fever, have characteristic findings, overlap syndromes have been described. Given that the individual clinical findings are the summation of amount(s) and type(s) of toxins and the types of cells responding to activation, it should not be surprising that heterogeneity in clinical presentations could occur.

Unlike syndromes associated with ETs, which usually do not exhibit significant systemic symptoms, those resulting from superantigens are characterized by systemic manifestations. Superantigen-mediated toxin syndromes can be divided into *intermediate cutaneous and systemic* or *predominantly systemic* based on the relative amounts of systemic toxicity. Disorders that have predominantly systemic manifestations are scarlet fever and the most ominous toxin-mediated disease, TSS The *intermediate cutaneous and systemic* category would include syndromes such as recalcitrant erythematous desquamating disorder (REDD) and toxin-mediated erythema, which are less systemic versions of TSS and scarlet fever, respectively. All of these superantigen-mediated disorders are diagnosed based on clinical findings, and can be caused by toxins produced by either *S. aureus* or group A *Streptococcus*.

TOXIC SHOCK SYNDROME

Figure 152-7 illustrates TSS caused by *S. aureus.*

TSS is an inflammatory response characterized by fever, rash, hypotension, and multiorgan involvement representing the severe end of the spectrum of superantigen-mediated diseases. Although first described in 1978 in a series of children with *S. aureus* infection,[13] TSS became recognized with reports of epidemics associated with use of highly absorbent tampons in menstruating women in the early 1980s.[14] Presumably the tampon served as a nidus for infection, the blood adding protein and neutralizing the normally bactericidal acidic vaginal pH. Since the first descriptions, TSS has been shown to be associated with many types of staphylococcal and streptococcal infections.

CLINICAL FINDINGS

Staphylococcal Toxic Shock Syndrome: The most common staphylococcal toxin associated with TSS is TSS toxin-1 (TSST-1), and is the predominant toxin associated with menstrual-associated cases. TSST-1 appears unique among superantigens in its ability to cross mucosal surfaces. With the removal of highly absorbent tampons from the market and patient education, the numbers of menstruation-associated TSS have decreased steadily, and at present the incidence of nonmenstrual TSS exceeds that of menstrual-associated cases. Nonmenstrual TSS is associated with postsurgical wounds, sinusitis, osteomyelitis, influenza, intravenous drug use, burn wounds, and gynecologic infection (especially in the postpartum period). Other staphylococcal toxins, including staphylococcal enterotoxin B (SEB) and enterotoxin C (SEC), also can be found. SEB and SEC superantigenic toxins comprise approximately 50% of nonmenstrual TSS. The host response is an important factor in the development of

Figure 152-7 Toxic shock syndrome (TSS). Patient in intensive care unit with TSS caused by *Staphylococcus aureus*. Note patient's eruption is nonspecific erythema around intertriginous areas and face. The eruption associated with staphylococcal TSS varies and could be morbilliform, scarlatiniform, or even pustular.

TSS as studies have shown an increased susceptibility in patients who do not have neutralizing antibodies against TSST-1.[15]

The symptoms of TSS begin with acute onset of fever, sore throat, and myalgia. Diarrhea is common, and vomiting may also occur. The rash is most often a macular erythema but a scarlatiniform type can sometimes be seen. The eruption usually begins on the trunk and spreads to the extremities, and can involve palms and soles. Especially if the patient is hypotensive, the eruption tends to be more prominent on the trunk than extremities. Symptoms of hypotension include orthostatic dizziness, fainting, and overt shock. Nonpurulent conjunctival hyperemia, pharyngeal inflammation and strawberry tongue (see section "Scarlet Fever") are invariably present. Signs of decreased mentation can also occur. The rash will desquamate within 1 to 2 weeks after beginning. Table 152-2 lists the Centers for Disease Control and Prevention (CDC) criteria for TSS. Cases of lesser severity that do not meet the full definition probably do occur frequently, especially with earlier recognition and treatment. In nonmenstruation cases, especially those associated with postoperative infections, the classic signs of a localized infection, such as erythema, pain, and purulence, can be absent (often in contrast to streptococcal TSS).

Streptococcal Toxic Shock Syndrome: Streptococcal TSS was described in the late 1980s as a disease similar to staphylococcal TSS, but caused by invasive group A *Streptococcus*. Streptococcal TSS is more commonly encountered than the staphylococcal form (2 to 4 cases vs 0.3 to 0.5 cases per 100,000 population, respectively).[16] The majority of cases of streptococcal TSS are caused by streptococcal pyrogenic exotoxin A (SPEA), yet other superantigenic toxins including streptococcal pyrogenic exotoxin B (SPEB), streptococcal pyrogenic exotoxin C (SPEC), and involvement of other non–group A *Streptococcus* also have been reported. Although not associated with tampon use, streptococcal TSS can result from nearly any type of group A streptococcal infection. The most common types of infections appear to be wounds, and streptococcal TSS has been well-described as a complication of varicella and influenza A. However, in many cases the route of infection cannot be determined. The initial presentation is skin pain often localized to an extremity. The localized pain often progresses over several days to localized erythema and edema to cellulitis associated with necrotizing fasciitis and myositis with concomitant streptococcal invasion of the bloodstream. It should be noted that blood cultures are positive in more than half of patients with streptococcal TSS, in contrast to only 10% of patients with staphylococcal TSS. Thus, a patient with signs of TSS and a localized cellulitis should suggest streptococcal TSS, as soft-tissue infections are not usually seen with staphylococcal TSS. Although very young, elderly, diabetic or immunocompromised patients would be more susceptible to streptococcal TSS, the majority of cases have occurred in otherwise healthy adults.

DIFFERENTIAL DIAGNOSIS

Table 152-3 outlines the differential diagnoses of TSS. The differential diagnosis of staphylococcal TSS includes exclusion of septic shock, staphylococcal exfoliative syndromes, Rocky Mountain spotted fever, viral hemorrhagic shock, measles, leptospirosis, and Stevens-Johnson syndrome. Although Kawasaki syndrome has many similar clinical findings, including

TABLE 152-2

Centers for Disease Control and Prevention 2011 Case Definition of Staphylococcal Toxic Shock Syndrome

MAJOR CRITERIA (ALL 4 MUST BE MET)	MULTISYSTEM INVOLVEMENT (3 OR MORE MUST BE MET)	NORMAL TEST RESULTS (IF PERFORMED)
Fever: temperature >38.9°C (102°F)	**GI:** vomiting or diarrhea at onset of illness	Blood, throat, or cerebrospinal fluid cultures (blood cultures may be positive for *Staphylococcus aureus*)
Rash: diffuse macular erythroderma	**Muscular:** severe myalgia or creatine kinase level twice upper limit of normal	Rise in titer in antibody tests for Rocky Mountain spotted fever, leptospirosis, or measles
Desquamation: 1 to 2 weeks after onset of illness, particularly on palms/soles	**Mucous membrane:** oropharyngeal, conjunctival or vaginal hyperemia	
Hypotension: systolic blood pressure <95 mm Hg for adults, or less than 5th percentile by age for children <16 years of age, or orthostatic syncope	**Renal:** blood urea nitrogen or creatinine level twice upper limit of normal, or >5 white blood cells per high-power field in urine in absence of urinary tract infection	
	Hepatic: total bilirubin, aspartate aminotransferase, or alanine aminotransferase level at least twice upper limit of normal	
	Hematologic: platelets <100,000/mm^3	
	CNS: disorientation or alterations in consciousness without focal neurologic signs when fever and hypotension are absent	

Probable TSS: A case that meets the laboratory criteria and in which 4 of the 5 clinical criteria described above are present.

Confirmed TSS: A case that meets the laboratory criteria and in which all 5 clinical criteria described above are present, including desquamation (unless the patient dies before desquamation takes place).

TABLE 152-3
Differential Diagnoses of Toxic Shock Syndrome

Septic shock
Staphylococcal exfoliative syndromes
Rocky Mountain spotted fever
Viral hemorrhagic shock
Measles
Leptospirosis
Stevens-Johnson syndrome
Kawasaki syndrome

swelling of extremities and desquamation of palms and soles during convalescence, Kawasaki syndrome differs in that the course of fever is prolonged and diarrhea and hypotension are absent. Streptococcal-mediated syndromes, including scarlet fever and, especially, streptococcal TSS, can mimic staphylococcal TSS.

In a patient with fever, rash, and hypotension, a thorough search for possible sites of staphylococcal and streptococcal infection is critical. Surgical wounds should be carefully examined even if no clinical signs of infection are apparent. Vaginal examination and removal of tampon or other foreign body should be done, and vaginal irrigation with saline or povidone-iodine has been recommended.

TREATMENT AND PROGNOSIS

The treatment of TSS is supportive (and usually in the intensive care setting) as well as to eradicate the offending *S. aureus*. Large doses of a beta-lactamase–resistant, antistaphylococcal antibiotic (eg, nafcillin) have been historically used. Because these agents have been known to increase TSST-1 in vitro (probably as a result of cell lysis), concomitant clindamycin or linezolid (both of which will inhibit bacterial protein toxin production) treatment is often used. Given the increasing amounts of methicillin-resistant staphylococci in the community, vancomycin is often recommended. Beta-lactamase–resistant penicillins are of lesser value, not only because of emerging resistance, but also because they have less effect on high levels of bacteria (in contrast to clindamycin or vancomycin). Todd has recommended a combination of vancomycin and clindamycin for suspected serious staphylococcal infections pending culture and sensitivity.[17] Intravenous immunoglobulin (IVIG; which presumably acts in part by neutralizing antibodies against toxins) has been used and appears to have significant promise.[18] As of this writing, IVIG is used in severe or recalcitrant cases. Contraindications to IVIG include previous hypersensitivity to it or immunoglobulin A deficiency. Systemic corticosteroids are controversial, and probably are of lesser impact, possibly because of the report that superantigen-mediated immune cell activation is associated with corticosteroid resistance.[19]

Although clearly a life-threatening disease, the mortality rate of staphylococcal TSS is only approximately 5%, probably because the majority of cases are in otherwise healthy young individuals, as well as because increased recognition of this entity has resulted in earlier intervention. Unfortunately, recurrences can be seen in up to 20% TSS patients. Women who have had TSS should avoid using tampons during menstruation as it will increase the likelihood of reinfection. Diaphragms and contraceptive sponges should also be avoided in this population.

The treatment of streptococcal TSS is similar to staphylococcal TSS. For cases associated with necrotizing fasciitis/myositis, rapid recognition and conservative surgical debridement of devitalized tissue are imperative. IVIG is becoming more recognized as an important part of treatment of streptococcal TSS, especially as the mortality rate in this disease can be greater than 30%.[18] One study has confirmed that IVIG treatment in streptococcal TSS results in statistically significant decreased mortality.[18]

RECALCITRANT ERYTHEMATOUS DESQUAMATING DISORDER

A new presentation of a toxin-mediated disorder, termed *recalcitrant erythematous, desquamating disorder* (REDD), was first described in 1992.[20] The clinical findings include fever and hypotension. The rash of REDD consists of diffuse macular erythema with delayed desquamation. Other findings in common with TSS include ocular and oral mucosal injection and strawberry tongue. Staphylococci producing TSST-1, SEA or SEB have been isolated from various places, including nasal sinuses, soft tissues, and blood. Although the majority of cases described as of this writing had AIDS, some REDD patients without AIDS have been reported. In contrast to TSS, this is a prolonged disease (measured in weeks to several months) in which only several of the TSS criteria are met. Again, the diagnosis is often established by careful examination for occult colonization/infection in a susceptible individual.

SCARLET FEVER

Figure 152-8 illustrates the enanthem and exanthem of Streptococcal scarlet fever.

Scarlet fever is a syndrome characterized by exudative pharyngitis, fever, and scarlatiniform rash. It is most commonly caused by pyrogenic exotoxin-producing group A *Streptococcus*, although staphylococcal infections can produce a similar-appearing disease. The exact mechanism by which toxins produce the symptomology is unclear. Compelling studies by Schlievert that the scarlatiniform eruption could only be induced in mice that were previously sensitized against toxins, suggests that a combination of a conventional delayed type and superantigen-mediated processes are occurring.[21] It should be noted that streptococcal toxins, especially

Figure 152-8 Scarlet fever: exanthem and enanthem. **A** and **B,** Significant erythema with a sandpaper texture is noted on trunk. **C,** Beefy "strawberry" red tongue. **D,** Poststreptococcal desquamation.

SPEA has areas of significant homology with collagen, which could provide a mechanism for rare autoimmune sequelae of streptococcal scarlet fever, including renal failure and rheumatic fever.[22,23] It should be noted that scarlet fever is no longer the major public health threat it was in the past; not only because of antibiotic treatment but that most streptococcal isolates causing scarlet fever express the less virulent SPEB and SPEC rather than SPEA.

STREPTOCOCCAL SCARLET FEVER

Streptococcal scarlet fever is a childhood disease, and is most common in winter and early spring. It is estimated that up to 10% of childhood group A streptococcal pharyngitis patients develop scarlet fever. Approximately 12 hours to 5 days after exposure, an abrupt prodrome consisting of pharyngitis, headache, vomiting, abdominal pain, and fever develops. The rash appears 1 to 2 days after onset of the illness, first on the neck and then extending to the trunk and extremities, although sparing the palms and soles. The exanthem texture is usually coarse like fine-grade sandpaper, and the erythema blanches with pressure. The skin can be mildly pruritic, but usually is not painful. A few days following generalization of the exanthem, it becomes more intense around skinfolds and lines of confluent petechiae resulting from increased capillary fragility (the Pastia sign) can be seen. The generalized exanthem begins to fade 3 to 4 days after onset and a desquamative phase begins, usually starting with the face. Peeling from the palms and fingers and sometimes soles occurs approximately a week later and can last for as long as 1 month.

Oral findings of streptococcal scarlet fever include edematous, erythematous tonsils sometimes covered with a yellow, gray, or white exudate and tender anterior cervical lymphadenopathy is common. Petechiae and punctuate red macules are seen on the soft palate and uvula (Forchheimer spots). A flushed face with circumoral pallor is also commonly noted. The tongue in scarlet fever has characteristic changes. During the first 2 days of the disease, the tongue has a white coat through which the red and edematous papillae project (white strawberry tongue). After 2 days, the tongue desquamates resulting in a red tongue with prominent papillae (red strawberry tongue).

The diagnosis of scarlet fever is made by the characteristic clinical signs and confirmed by rapid streptococcal test or throat culture. Scarlet fever usually follows a benign course and any undue morbidity/mortality is likely to be from suppurative complications, including peritonsillar abscess, sinusitis, pneumonia, and meningitis, or from nonsuppurative complications associated with immune-related rheumatic fever or glomerulonephritis. The risk of acute rheumatic fever following an untreated group A streptococcal infection is estimated to be approximately 3% in epidemics, and 0.3% in endemic scenarios. The risk of glomerulonephritis can be up to 15% after infection with nephritogenic group A streptococcal strain. In addition to pharyngitis, group A *Streptococcus* can cause scarlet fever–like eruptions from skin (often surgical wounds) or uterine infections.

Treatment of scarlet fever is by antibiotics (penicillin or erythromycin for a 10-day course) and supportive care. Fever usually abates within 12 to 24 hours after initiation of antibiotic therapy. Recurrences are common.

STAPHYLOCOCCAL SCARLET FEVER

Staphylococcal scarlet fever, also known as scarlatiniform erythroderma/rash, was first described in 1927 and until recently was considered to be a milder or abortive form of SSSS.[21] Patients usually develop a generalized erythroderma with a roughened, sandpaper-like texture. The exanthem of staphylococcal scarlet fever tends to be more tender than corresponding streptococcal scarlet fever. Systemic signs, including malaise and fever, are invariably present. Within a few days of initiation of rash, thick flakes develop and the entire skin desquamates over the next week. Unlike generalized SSSS, the scarlatiniform eruption is not associated with the formation of bullae or superficial exfoliation and can be very difficult to differentiate from other infectious erythrodermal causes, such as TSS and streptococcal scarlet fever. Scarlet fever induced by staphylococci differs from streptococcal-mediated disease by the lack of pharyngitis. A study by Wang and colleagues examined the clinical characteristics and toxin(s) detected from 20 children with staphylococcal scarlet fever.[23] They found that all of the patient's staphylococcal infections arose from the skin; 16 of 20 cases from furuncles/carbuncles; 2 each from abscesses or wound infections. All of the *S. aureus* strains expressed SEB. Of note, SEB shows significant protein sequence homology with SPEA, a known exotoxin associated with streptococcal scarlet fever. Yet other studies have implicated other staphylococcal enterotoxins.[24] One explanation for this heterogeneity of toxins associated with this disorder is that the diagnosis is made upon clinical grounds. It is possible that staphylococcal scarlet fever represents an incomplete form of TSS, in which toxins spread from the skin and thus activating the skin-associated lymphoid tissue rather than mucosal-associated lymphoid tissue. Because most cases of streptococcal scarlet fever arise from a pharyngitis, the lack of pharyngitis in a patient with characteristic rash and other clinical signs of scarlet fever should alert the clinician to look for a localized nidus of infection (eg, furuncle) that could be cultured to establish the diagnosis.

DIFFERENTIAL DIAGNOSIS

The diagnosis of scarlet fever is made upon clinical grounds with supporting positive bacterial cultures. The differential diagnosis of scarlet fever would include other toxin-mediated disorders, including SSSS. Although Kawasaki syndrome has many similar clinical findings, including mucosal involvement (eg, strawberry tongue), and swelling of extremities and desquamation of palms and soles during convalescence, Kawasaki syndrome differs in that the course of fever is prolonged and cultures would be expected to be negative. Atypical drug hypersensitivity reactions can have some cutaneous but less likely mucosal features and there is usually a history of an offending drug and peripheral eosinophilia. Scarlet fever from group A *Streptococcus* can usually be differentiated from that induced by *S. aureus* as the usual nidus of infection in streptococcal scarlet fever is from a pharyngitis whereas the staphylococcal variant usually has its infectious nidus in the skin.

TREATMENT AND PROGNOSIS

The treatment of scarlet fever includes antibiotics to eradicate the offending bacteria. If the localized nidus of infection is an abscess or furuncle/carbuncle, then this should be drained. Acute rheumatic fever or glomerulonephritis are not associated with staphylococcal scarlet fever. For situations in which more systemic signs resembling TSS are becoming apparent, then the treatment could resemble TSS (see above).

TOXIN-MEDIATED ERYTHEMA (RECURRENT TOXIN-MEDIATED PERINEAL ERYTHEMA)

In 1996, Manders and colleagues recognized a previously unreported toxin-mediated disorder, which they termed *recurrent toxin-mediated perineal erythema*.[25] Recurrent toxin-mediated perineal erythema is characterized by a striking diffuse macular perineal erythema that occurs within 24 to 48 hours after a pharyngitis with a toxin-producing group A *Streptococcus* or *S. aureus*. Clinical findings seen in scarlet fever, including a strawberry tongue, as well as erythema, edema, and, later, palmoplantar desquamation, are commonly found in recurrent perineal erythema. Fever, hypotension, and other systemic signs of scarlet fever or TSS are characteristically absent, although diarrhea is a common feature. Recurrences are more frequently

found in this localized form. It has been proposed by Manders that that the term *toxin-mediated erythema* be used to describe the following clinical settings in which a toxin-producing *Staphylococcus* or *Streptococcus* can be found: recurrent erythroderma associated with a preceding bacterial pharyngitis; isolated episodes of toxin-mediated erythema without recurrences; and patients with episodic mild hypotension, fever, and typical mucocutaneous findings in the absence of full criteria for TSS.[26]

OTHER DISEASES INITIATED AND/OR EXACERBATED BY SUPERANTIGENS

In addition to the ability of superantigens to induce characteristic diseases including TSS, scarlet fevers, and gastroenteritis, recent evidence is accumulating indicating that these potent immunomodulatory agents can initiate and/or exacerbate other skin disorders.

PSORIASIS

Psoriasis (see Chap. 28) is an autoimmune T-cell–driven keratinocyte hyperproliferative disease involving skin and, rarely, joints. Superantigens have been implicated in psoriasis in at least 2 settings, the guttate (acute eruptive) form and where psoriasis flares in response to becoming secondarily infected.[27,28]

The acute guttate form of psoriasis is characterized by the rapid onset of small erythematous psoriasiform papules which can be generalized. This form can develop during or most commonly right after a group A streptococcal infection (usually pharyngitis). More commonly found in children and young adults, guttate psoriasis has been estimated to be the initiation of psoriasis in up to 20% of patients. Studies examining a series of guttate psoriasis patients have demonstrated the association of an SPEC-expressing group A *Streptococcus* along with expansion of the appropriate T-cell receptor β Vβ pattern in the skin lesions and in perilesional skin.[27] These and other supporting studies do suggest that the superantigen-mediated systemic activation of T cells and MHC II–expressing accessory cells, resulting in the uncovering of the specific oligoclonal activation seen in chronic lesions, is a plausible explanation for how infection could initiate this form of psoriasis.

In addition to the ability of systemic activation by a superantigen to initiate psoriasis, accumulating evidence has emerged that a localized infection with a superantigen-secreting microbe could be the trigger for worsening of psoriasis. For example, patients with psoriasis have an increased cutaneous reactivity to the topical application of small (nanogram) amounts of superantigens, which is caused by the increased levels of keratinocyte MHC II expression seen in patients with activated psoriasis.[28] Thus, guttate psoriasis and flaring of existing psoriasis should prompt a careful examination and treatment of microbial infections. In women, a history of possible menstrual-associated flares of psoriasis (especially with tampon use) should prompt appropriate investigations and treatment.

AUTOECZEMATIZATION (ID) RESPONSE

The autoeczematization (id) response is an acute, generalized skin reaction to a variety of stimuli. This stimulus may be a preexisting or new dermatitis (most often on the lower leg), or skin infection with fungi, bacteria, viruses, or parasites. The erythematous and papular pruritic rash often develops at distant sites and tends to be symmetric. No concomitant systemic toxicities are usually seen. One common clinical scenario is a patient with known stasis dermatitis who develops an allergic skin reaction to topical agent (neomycin-containing antibiotic) used on the leg. Given the ability of superantigens to stimulate significantly high numbers of T cells expressing CLA and thus use these homing receptors to traffic to skin, localized bacterial infection with a superantigen-producing *S. aureus* or group A *Streptococcus* could result in an autoeczematization response. Thus, careful examination of a patient with autoeczematization response for a microbial trigger is warranted.

ATOPIC DERMATITIS

Secondary infection with *S. aureus* or group A *Streptococcus* is a well-known trigger for atopic dermatitis (see Chap. 22). It is estimated that *S. aureus* can be cultured from essentially all subjects with atopic dermatitis (reviewed in Ong and Leung[29]). Studies demonstrate that skin from subjects with active atopic dermatitis have decreased levels of antimicrobial proteins.[30] This lack of antimicrobial proteins may provide one explanation for the almost universal bacterial infection associated with flaring atopic dermatitis. The mechanism(s) by which bacterial infection can worsen atopic dermatitis is an active area of study and, not surprisingly, superantigens have been implicated. In addition to the "usual" mechanism of crosslinking T-cell receptor and MHC-II molecules, it has been shown that many atopic dermatitis patients have immunoglobulin E antibodies that recognize these globular proteins.[31] Thus, in addition to being a superantigen, these toxins can act as allergens in this population. Other gram-positive bacterial products have been associated with the worsening of atopic dermatitis. This includes the lytic toxin staphylococcal delta-toxin, which has been shown to trigger mast cell degranulation.[32] High levels (mcg/cm^2) of the bacterial cell wall constituent lipoteichoic acid are found on clinically impetiginized atopic skin,[33] which could have clinical significance as lipoteichoic acid acts on both toll-like receptor 2 as well as the platelet-activating factor receptor.[34]

CUTANEOUS T-CELL LYMPHOMA

Although potential infectious causes for cutaneous T-cell lymphoma (CTCL; see Chap. 119) have been extensively investigated, the etiology for this rare T-cell dyscrasia remains as yet unknown (reviewed in Mirvish and colleagues[35]). However, several observations suggest that staphylococcal toxins could be playing a role in the clinical progression of CTCL. First, CTCL patients exhibit high levels of *S. aureus* colonization, and this bacteria is a major source of both local and systemic infections in this population. Second, *S. aureus* infection is reported to correlate with CTCL disease severity. Consistent with this notion, antibiotic treatment of *S. aureus* is reported to improve CTCL disease activity in this population of infected patients.

Multiple studies have taken advantage of the fact that superantigens activate specific β patterns to examine CTCL T-cell β patterns as supporting evidence for a role for toxin involvement. In particular, the Duvic group reported that in erythrodermic CTCL patients, those culture-positive for a TSST-1–expressing *S. aureus* exhibited overrepresentation of the β pattern associated with TSST-1 (T-cell receptor β 2.1).[36] The most likely interpretation of these studies is that superantigens are not causing CTCL, but, can worsen disease activity. Thus, patients with CTCL need to be closely monitored and treated appropriately for secondary infection.

REFERENCES

1. Dinges MM, Orwin PM, Schlievert PM. Exotoxins of *Staphylococcus aureus*. *Clin Microbiol Rev.* 2000;13:16.
2. Ladhani S, Joannou CL, Lochrie DP, et al. Clinical, microbial, and biochemical aspects of the exfoliative toxins causing staphylococcal scalded-skin syndrome. *Clin Microbiol Rev.* 1999;12:224.
3. Amagai M, Matsuyoshi N, Wang ZH, et al. Toxin in bullous impetigo and staphylococcal scalded-skin syndrome targets desmoglein I. *Nat Med.* 2000;6:1275.
4. Yamasaki O, Yamaguchi T, Sugai M, et al. Clinical manifestations of staphylococcal scalded skin syndrome depend on serotypes of exfoliative toxins. *J Clin Microbiol.* 2005;43:1890.
5. Rago JV, Vath GM, Bohach GA, et al. Mutational analysis of the superantigen staphylococcal exfoliative toxin A (ETA) *J Immunol.* 2000;164:2207.
6. Plano LR, Gutman DM, Woischnik M, et al. Recombinant *Staphylococcus aureus* exfoliative toxins are not bacterial superantigens. *Infect Immun.* 2000;68:3048.
7. Ritter von Rittershain G. Die exfolative Dermatitis jüngerer Sauglinge. *Zentralzeitung fur Kinderheilkunde*. 1878;2:3.
8. Melish ME, Glasgow A. The staphylococcal scalded skin syndrome: development of an experimental mouse model. *N Engl J Med.* 1970;282:1114.
9. Lyell A. Toxic epidermal necrolysis: An eruption resembling scalding of the skin. *Br J Dermatol.* 1956;68:355.
10. McCormick JK, Yarwood JM, Schlievert PM. Toxic shock syndrome and bacterial superantigens: an update. *Annu Rev Microbiol.* 2001;55:77.
11. Brosnahan AJ, Schlievert PM. Gram-positive bacterial superantigen outside-in signaling causes toxic shock syndrome. *FEBS J* 2011;278:4649.
12. Leung DY, Gately M, Trumble A, et al. Bacterial superantigens induce T cell expression of the skin-selective homing receptor, the cutaneous lymphocyte-associated antigen, via stimulation of interleukin 12 production. *J Exp Med.* 1995;181(2):747.
13. Todd JK, Kapral FA, Fishaut M, et al. Toxic shock syndrome associated with phage group I staphylococci. *Lancet.* 1978;2:1116.
14. Shands KN, Schmid GP, Dan BB, et al. Toxic shock syndrome in menstruating women: association with tampon use and *Staphylococcus aureus* and clinical features in 52 cases. *N Engl J Med.* 1980;303:1436.
15. Rosten PM, Bartlett KH, Chow AW. Serologic responses to toxic shock syndrome (TSS) toxin-1 in menstrual and nonmenstrual TSS. *Clin Invest Med.* 1988; 11(3):187.
16. Lappin E, Ferguson AJ. Gram-positive toxic shock syndromes. *Lancet Infect Dis.* 2009;9(5):281.
17. Todd JK. Staphylococcal infections. *Pediatr Rev.* 2005;26:444.
18. Linner A, Darenberg J, Sjolin J, et al. Clinical efficacy of polyspecific intravenous immunoglobulin therapy in patients with streptococcal toxic shock syndrome: a comparative observational study. *Clin Infect Dis.* 2014;59:851.
19. Li LB, Goleva E, Hall CF, et al. Superantigen-induced corticosteroid resistance of human T cells occurs through activation of the mitogen-activated protein kinase kinase/extracellular signal-regulated kinase (MEK-ERK) pathway. *J Allergy Clin Immunol.* 2004;114:1059.
20. Cone LA, Woodard DR, Byrd RG, et al. A recalcitrant, erythematous, desquamating disorder associated with toxin-producing staphylococci in patients with AIDS. *J Infect Dis.* 1992;165(4):638.
21. Schlievert PM. Staphylococcal scarlet fever: role of pyrogenic exotoxins. *Infect Immun.* 1981;31(2):732.
22. Reid SD, Hoe NP, Smoot LM, et al. Group A streptococcus: allelic variation, population genetics, and host-pathogen interactions. *J Clin Invest.* 2001;107: 393.
23. Wang CC, Lo WT, Hsu CF, et al. Enterotoxin B is the predominant toxin involved in staphylococcal scarlet fever in Taiwan. *Clin Infect Dis.* 2004;38(10):1498.
24. Jarraud S, Cozon G, Vandenesch F, et al. Involvement of enterotoxins G and I in staphylococcal toxic shock syndrome and staphylococcal scarlet fever. *J Clin Microbiol.* 1999;37:2446.
25. Manders SM, Heymann WR, Atillasoy E, et al. Recurrent toxin-mediated perineal erythema. *Arch Dermatol.* 1996;132(1):57.
26. Manders SM. Toxin-mediated streptococcal and staphylococcal disease. *J Am Acad Dermatol.* 1998;39:383.
27. Leung DY, Travers JB, Giorno R, et al. Evidence for a streptococcal superantigen-driven process in acute guttate psoriasis. *J Clin Invest.* 1995;96:2106.
28. Travers JB, Hamid QA, Norris DA, et al. Epidermal HLA-DR and the enhancement of cutaneous reactivity to superantigenic toxins in psoriasis. *J Clin Invest.* 1999;104(9):1181.
29. Ong PY, Leung DY. Bacterial and viral infections in atopic dermatitis: a comprehensive review. *Clin Rev Allergy Immunol.* 2016;51(3):329-337.
30. Ong PY, Ohtake T, Brandt C, et al. Endogenous antimicrobial peptides and skin infections in atopic dermatitis. *N Engl J Med.* 2002;347(15):1151.
31. Leung DY, Harbeck R, Bina P, et al. Presence of IgE antibodies to staphylococcal exotoxins on the skin

of patients with atopic dermatitis. Evidence for a new group of allergens. *J Clin Invest.* 1993;92(3):1374.
32. Nakamura Y, Oscherwitz J, Cease KB, et al. Staphylococcus δ-toxin promotes allergic skin disease by inducing mast cell degranulation. *Nature.* 2013;503(7476):397.
33. Travers JB, Kozman A, Mousdicas N, et al. Infected atopic dermatitis lesions contain pharmacologic amounts of lipoteichoic acid. *J Allergy Clin Immunol.* 2010; 125:146.
34. Zhang Q, Mousdicas N, Yi Q, et al. Staphylococcal lipoteichoic acid inhibits delayed-type hypersensitivity reactions via the platelet-activating factor receptor. *J Clin Invest.* 2005;115:2855.
35. Mirvish JJ, Pomerantz RG, Falo LD Jr, et al. Role of infectious agents in cutaneous T-cell lymphoma: facts and controversies. *Clin Dermatol.* 2013;31:423.
36. Jackow CM, Cather JC, Hearne V, et al. Association of erythrodermic cutaneous T-cell lymphoma, superantigen-positive Staphylococcus aureus, and oligoclonal T-cell receptor V beta gene expansion. *Blood.* 1997;89:32.

Chapter 153 :: Necrotizing Fasciitis, Necrotizing Cellulitis, and Myonecrosis

:: Avery LaChance & Daniela Kroshinksy

AT-A-GLANCE

This chapter discusses necrotizing, gangrenous, and purulent bacterial infections of the skin, soft tissue, fascia, and muscle. Broadly speaking, the different entities can be characterized by anatomic depth of infection with necrosis extending to the skin (gangrenous cellulitis), fascia (necrotizing fasciitis), and muscle (pyomyositis). However, it should be noted that there is significant overlap between these entities in terms of presentation, clinical course, and treatment. Given this, some current literature groups these infections (as well as necrotizing fungal infections) into 1 larger, overarching subgroup of *necrotizing soft-tissue infections*.[1] Trends in how the medical community chooses to approach and classify these disease entities may change with time and this broader, all-encompassing nomenclature may become the favored terminology in the future. Given the clinical and management nuances for each of these categories, as well as the fact that the term *necrotizing soft-tissue infections* has not been broadly accepted, this chapter describes the clinical features intrinsic to each separately here. The reader is encouraged to follow how classification for this group of infections may evolve in the literature in the years to come.

NECROTIZING FASCIITIS

HISTORICAL PERSPECTIVES

Necrotizing fasciitis is a rare, rapidly progressive infection of the skin and subcutaneous soft tissue that tracks down to and spreads rapidly along the fascial plane. The disease is characterized by progressive necrosis and high mortality rates in the absence of prompt diagnosis and management.

Initial signs and symptoms of necrotizing fasciitis were described by Hippocrates in the fifth century BC.[2] In 1871, this group of infections was named "hospital gangrene" by Joseph Jones, a surgeon who served in the Confederate Army and subsequently went on to become the Secretary of the Southern Historical Society where he spent time chronicling disease states he encountered in the war.[1,3] In 1918, Pfanner diagnosed a patient with a necrotizing beta-hemolytic streptococcal infection and coined the term *necrotizing erysipelas*.[4] In 1924, a case series of necrotizing infection of the skin and subcutaneous tissue described as "streptococcal gangrene" was reported by Melany.[4] The term *necrotizing fasciitis* was finally introduced by Wilson in 1951 to 1952 to encompass both gas-forming and non–gas-forming necrotizing soft-tissue infections encompassing and spreading along the fascial plane.[2,3] Only recently was necrotizing fasciitis thought to represent part of a larger group of necrotizing and gangrenous soft-tissue infections. More recent literature includes necrotizing fasciitis as one of several necrotizing soft-tissue infections, that are grouped together given similarities in behavior, diagnosis, management, and poor prognosis without prompt intervention.[1,3]

EPIDEMIOLOGY

Data surrounding current necrotizing fasciitis epidemiology is limited. A 2013 study by Psoinos and colleagues utilized the Nationwide Inpatient Sample Database to examine necrotizing soft-tissue infection epidemiology as a group within the United States.[5] This study found 56,527 admissions for necrotizing soft-tissue infections during the period 1998 to 2010, which is an average of 3800 to 5800 admissions for necrotizing soft-tissue infections annually in the United States.[5] Over this time, the incidence peaked in 2004 and demonstrated a downtrend from 2004 to 2010.[5] Conversely, a 2015 study by Oud and Watkins that evaluated data for all inpatient admissions for necrotizing fasciitis in Texas demonstrated, a rise in hospitalization for necrotizing fasciitis over time from 59 cases of necrotizing fasciitis per 1 million patient-years in 2001 to 2002 to 76 cases of necrotizing fasciitis per 1 million patient-years in 2009 to 2010.[6] Studies of the pediatric population are limited. One small study showed the worldwide prevalence of pediatric necrotizing fasciitis between 2010 and 2015 to be 0.8 per 1 million patient-years.[7]

From 2003 to 2013, a total of 9871 deaths from necrotizing fasciitis were reported in the United States, or approximately 4.8 deaths per 1 million patient-years.[8] Arif and colleagues, in a study of these deaths, determined that deaths were higher in black, Hispanic, and Native American individuals than in whites.[8] Death was also found to be lower among Asian American individuals.[8]

ETIOLOGY, MICROBIOLOGY, PATHOGENESIS

The majority of necrotizing fasciitis and other necrotizing soft-tissue infections are community acquired via bacterial introduction through a break in the skin.[9] Although prior surgical sites can be portals of entry,

pathogens are often introduced into the skin and subcutaneous tissue through cuts, scrapes, or sites of minor prior trauma, such as bug bites, animal bites, or injection sites in intravenous drug users.[9] In more tropical climates, numerous cases of necrotizing fasciitis have been described following snake bites with a particularly high incidence from the *Naja atra* snake.[10] In a minority of patients, the site of bacterial introduction is never identified, and, in some cases, infection is attributed to prior nonpenetrating trauma (ie, bruise).[9]

Once the bacterial pathogen enters the skin, infection quickly tracks down to and spreads along the fascia. This tracking process is assisted by bacterial release of enzymes that cause tissue breakdown and assist with rapid progression of disease. Although necrotizing fasciitis can involve underlying muscle, often infection tracks along the superficial fascia overlying the muscle without significant muscle involvement.

Although some cases of necrotizing fasciitis occur in otherwise healthy patients, a majority of cases are found in patients with predisposing comorbidities which are thought to place patients at increased risk for developing necrotizing fasciitis.[11] Comorbidities found at increased rates in patients with necrotizing fasciitis include diabetes, cardiovascular disease, IV drug abuse, peripheral vascular disease, venous stasis, vascular insufficiency, obesity, smoking, alcohol abuse, cirrhosis, malignancy, corticosteroid use, and chronic kidney disease.[2,3,9,11] In particular, cardiovascular disease and diabetes are thought to portend the highest risk of necrotizing fasciitis.[2,3] Additionally, patients who are either postpartum or postabortion can develop necrotizing fasciitis along the uterus or at sites of prior episiotomies.[9]

Necrotizing fasciitis in the adult population is often polymicrobial with up to 5 pathogens identified in many cases.[11] Polymicrobial infections are particularly high in 4 specific clinical scenarios: (a) bowel-associated infections (perianal abscesses, penetrating abdominal traumas, or bowel surgery associated); (b) decubitus ulcers; (c) IV drug users; and (d) spread from genital sites.[9] Alternatively, pediatric populations have a higher incidence of monomicrobial infections when compared with infections in adults.[7]

Table 153-1 lists the numerous pathogens identified as causative of or contributors to necrotizing soft-tissue infections/necrotizing fasciitis. Among these, the most common isolate found in community-acquired necrotizing soft-tissue infections is *Streptococcus pyogenes*, and in hospital-acquired infections, the most common isolates are *Staphylococcus aureus*, followed by *Escherichia coli* and *Pseudomonas* spp.[11,12] For patients with diabetes, necrotizing infection caused by *Klebsiella pneumoniae* is described with increased frequency.[13]

TABLE 153-1

Bacterial Subspecies Isolated in Patients Presenting with Necrotizing Fasciitis

Gram Positive

- *Bacillus* spp.[2]
- Coagulase-negative *Staphylococcus*[41]
- *Enterococcus* spp.[2]
- Group B *Streptococcus*[41]
- Group D *Streptococcus*[41]
- Non-A, non-B, non-D *Streptococcus*[41]
- *Staphylococcus aureus*[11]
- *Streptococcus milleri* group
- *Streptococcus pneumoniae*[2]
- *Streptococcus pyogenes*[11]
- *Viridans streptococci*[41]

Gram Negative

- *Acinetobacter* spp.[2]
- *Aeromonas* spp.[9]
- *Eikenella corrodens*
- *Enterobacter cloacae*[2]
- *Escherichia coli*[2,11]
- *Haemophilus influenzae*
- *Klebsiella* spp.[2]
- *Morganella* spp.[25]
- *Proteus* spp.[2]
- *Pseudomonas* spp.[11]
- *Salmonella* group B factors 4 and 5[41]
- *Serratia Marcescens*[2]
- *Stenotrophomonas maltophilia*[2]
- *Vibrio* spp.[41]

Anaerobic Bacteria

- Anaerobic gram-negative rods[2]
- *Bacteroides* spp.[25]
- *Citrobacter freundii*[2]
- *Clostridium* spp.[2]
- *Fusobacterium necrophorum*[16]
- *Lactobacillus* spp.[16]
- *Peptostreptococcus* spp.[41]
- *Prevotella* spp.[16]
- *Propionibacterium acnes*[16]

CLINICAL FEATURES

CUTANEOUS FEATURES

Early cutaneous changes of necrotizing fasciitis can be quite subtle, and, in the early stages, defining features of erythema, pain, and surrounding edema often mimic classic cellulitis.[2,9] As disease progresses, cutaneous findings can become much more pronounced with more dramatic changes in color (deep erythema or violaceous changes), bullae, and eventually gangrenous or necrotic changes of the skin and subcutaneous tissues.[2,9] Additionally, as lesions worsen, edema can become much more pronounced, occasionally with subcutaneous emphysema and/or firm, woody induration of the surrounding skin and subcutaneous tissue.[2,9] Severe focal pain can precede any identifiable cutaneous changes with pain often spreading outward as disease progresses. During more advanced stages of infection, early sites of involvement can lose this initial sensation of pain and develop progressive anesthesia over involved areas.[2,9] Approximately 66% of cases are reported to begin in the lower extremities with proximal spread following inoculation.[9]

NONCUTANEOUS FEATURES

Although symptoms often start locally at the site of infection, as the disease progresses severe systemic

symptoms commonly arise. Often, patients develop systemic illness shortly after the development of cutaneous findings with early complaints of malaise, fever, nausea, and vomiting.[2] Eventually, tachycardia, disorientation, and lethargy often develop as patients progress to take on a septic physiology.[2,9] Given this, many patients progress to require intensive care unit level of care.

SUBTYPES OF NECROTIZING FASCIITIS

MICROBIOLOGIC SUBTYPING OF NECROTIZING FASCIITIS INFECTIONS

Subtyping of necrotizing fasciitis, particularly that based on microbiology, is a source of debate in the literature with no general consensus surrounding classification guidelines. Furthermore, much of the literature does not use any standardized classification system for these infections with a majority of current publications dividing necrotizing fasciitis into simply "monomicrobial" or "polymicrobial" without labeling infections with a standard specific subclassification title. We favor this broader "monomicrobial" versus "polymicrobial" subgrouping; however, given that several subtypes based on microbiology are described in the literature, these subtypes are outlined here to familiarize the reader with these proposed classification systems.

Some authors propose subtyping necrotizing fasciitis infections into 4 major groups based on the microbial pathogens identified within the infection (Table 153-2).[2] Of note, when this classification system is used, the frequency of these subtypes varies regionally. For example, Type III infections, caused by *Vibrio* spp., have increased in frequency in Asian and Australian populations where there is increased exposure to tropical waters.[2] However, using this classification system for populations with less marine-based activity results in a majority of cases being caused by Type I or Type II necrotizing fasciitis. In these non–aquatic-based populations, Type I necrotizing fasciitis predominates with approximately 60% of necrotizing fasciitis being caused by pathogens in this grouping, and the remaining approximately 40% being caused by subspecies in Type II necrotizing fasciitis.[2]

More frequently, groups simplify the classification scheme into grouping all polymicrobial infections into *Type I necrotizing fasciitis* and all monomicrobial infections into *Type II necrotizing fasciitis*.[2,3] From this subgroup, some of the older literature describes an entity called *synergistic necrotizing cellulitis*, which is defined by a *Type I necrotizing fasciitis* with necrosis extending down to and involving the muscle.[14] However, this term has not been used in newer literature; instead, the term *necrotizing soft-tissue infections* has been adopted.

TABLE 153-2
Proposed Cutaneous Variants of Necrotizing Fasciitis

CUTANEOUS VARIANT	DEFINING FEATURES
Type I necrotizing fasciitis	▪ 1 or more anaerobic species ▪ 1 or more facultative anaerobic streptococci (streptococci other than *Streptococcus pyogenes*) ▪ Members of the aerobic Gram-negative rod grouping *Enterobacteriaceae*[2]

Type II necrotizing fasciitis	▪ Often monomicrobial
	▪ Hemolytic *Streptococcus*
	  ▪ Group A *Streptococcus* (*S. pyogenes*)
	  ▪ Rarely hemolytic *Streptococcus* group C or group G
	▪ ± Coinfection (or monoculture) with *Staphylococcus aureus*[2]

Type III necrotizing fasciitis	▪ *Vibrio* subspecies ▪ Result of puncture wound caused by fish or marine insect[2]
Type IV necrotizing fasciitis	▪ Fungal cases caused by candidal necrotizing fasciitis ▪ Very rare[2]

Meleney gangrene was used to describe polymicrobial cases of necrotizing fasciitis resulting from the synergistic relationship of multiple bacterial species and is also no longer used.[15]

ANATOMIC SUBTYPING OF NECROTIZING FASCIITIS INFECTIONS

Cervical and Craniofacial Necrotizing Fasciitis: *Cervical and craniofacial necrotizing fasciitis* describes a very rare subtype of disease that has an anatomic predilection for the head and neck region.[4] Although trauma is the most common source of infection in these patients, odontogenic, pharyngeal, or tonsillar infections as well as nasal malignancy have been described as additional sources.[4] A few studies have proposed a clinical staging system specifically for cervical necrotizing fasciitis with Stage 1 characterized by tenderness, erythema, swelling, and heat; Stage 2 characterized by blistering and bullae; and Stage 3 characterized by crepitus, anesthesia, and skin necrosis.[16] This staging system has not been adopted more broadly for necrotizing fasciitis at other anatomic locations.

Fournier Gangrene: *Fournier gangrene* refers to necrotizing fasciitis localized to the genitalia, perineum, anus, and, occasionally, skin of the lower abdomen.[3,17] Age at presentation is generally 50 to 60 years, and a majority of these adult patients with Fournier gangrene have significant underlying comorbidities, particularly diabetes mellitus or underlying immunocompromised status.[9,17] Rarely, Fournier

gangrene also is noted in the pediatric population, particularly before the age of 3 years, which is thought possibly to be secondary to introduction of infection through underlying diaper dermatitis.[7] Generally, infection stems from underlying retroperitoneal or perianal infection, untreated perirectal abscess, severe urinary tract infection, or trauma to the genital area; given the mechanism of bacterial spread, cases are nearly always polymicrobial (with mixed aerobic and anaerobic pathogens) in nature.[9,17] Additionally, it is important to note that, although the focus of this chapter is on necrotizing bacterial infection of the skin, cases of fungal-mediated Fournier gangrene have been reported in the literature.[18]

Depending on the clinical scenario, infection can begin slowly or progress rapidly and the constellation of symptoms at onset includes erythema, edema, and pain involving the genitalia and surrounding skin.[9] As with cases of necrotizing fasciitis at other sites, clinical findings at onset can be subtle and characterized solely by focal swelling in the genital area with little to no cutaneous changes.[17] Systemic symptoms can include septic shock (like in other forms of necrotizing fasciitis) as well as urinary retention. A CT scan can be obtained fairly rapidly to help delineate anatomic areas of involvement prior to surgical treatment in this sensitive area.[17] Akin to other forms of necrotizing fasciitis, surgical intervention is the first line of therapy and, importantly for patients with extensive rectal involvement, diverting colostomy can be considered to help minimize fecal contamination of surgical wounds and to assist with wound healing following surgical debridement.[17]

DIAGNOSIS

Given the surgical urgency for treating necrotizing fasciitis, surgical consultation and exploration of the concerning site remain the gold standard for diagnosis.[9,19] Firm diagnosis hinges on the unveiling of fascial involvement during surgical exploration and a defining feature of necrotizing fasciitis is notable easy dissection along the superficial fascial planes in attempts made to probe along the edge of an open wound.[2,9] Deep debridement will demonstrate a gray, dusky, edematous fascial plane.[9] Additionally, dissection should reveal underlying necrosis often with a thin, stringy-brown exudate from sites of dissection.[9] Scoring systems and other alternative diagnostic tests as of this writing have been more useful in ruling out necrotizing soft-tissue infection than aiding with confirming diagnosis.[9]

A thorough cutaneous examination can play a key role in helping to determine which patients warrant prompt surgical evaluation for diagnosis and/or debridement. If diagnosis is unclear during clinical examination, a small exploratory incision can be made into the center of the site in question to look for underlying diagnostic features as listed in "Clinical Features" section.[9] If not already performed while awaiting surgical consultation, tissue culture should be obtained during the first surgical debridement to help guide antimicrobial therapy.[3] Deep tissue cultures are preferred to superficial swabs given the increased sensitivity of deep tissue cultures in identifying the culprit organism(s).[9]

In situations in which surgical evaluation is delayed, biopsy can be performed to determine the architecture of involved tissue and for tissue culture. Given the emergent nature of this process, any biopsies taken for standard processing should be sent for frozen sectioning and rush histopathologic reading.[9] In general, it is thought that if the index of suspicion is high enough to warrant biopsy for necrotizing fasciitis, the patient is better served by proceeding straight to gross surgical examination by dissection, if this option is available in the practice setting.[9]

In 2004 a laboratory scoring system, the Laboratory Risk Indicator for Necrotizing Fasciitis (LRINEC), was proposed to help detect early cases of necrotizing fasciitis and allow for expedient surgical intervention.[20] This score combines values for C-reactive protein, white blood cell count, hemoglobin, sodium, creatinine, and glucose as predictive markers for early-onset necrotizing fasciitis, as outlined in Table 153-3.[20] Early clinical suspicion for necrotizing fasciitis with a score of 6 points or more with this LRINEC system had a positive predictive value of 92% and negative predictive value of 96% in initial studies evaluating the diagnostic accuracy of this scoring system.[20] Despite this, the scoring system has not been adequately studied in larger patient populations, limiting its generalizability and widespread acceptance as a first-line diagnostic tool. These initial rates for sensitivity and specificity were shown to be lower in a followup study investigating these parameters, but the study was limited by the retrospective nature of the study design.[2]

It is prudent to draw blood cultures in patients with necrotizing fasciitis as part of the initial workup

TABLE 153-3
Laboratory Risk Indicator for Necrotizing Fasciitis (LRINEC) Score

LABORATORY TEST	VALUE	SCORE
C-reactive protein (mg/L)	<150	0
	≥150	4
Leukocyte count (10^9/L)	<15	0
	15-25	1
	>25	2
Hemoglobin (mmol/L)	>8.4	0
	6.8-8.4	1
Sodium (mmol/L)	≥135	0
	<135	2
Creatinine (μmol/L)	≤141	0
	>141	2
Glucose (mmol/L)	≤10	0
	>10	1
Total		13

Score of 6 points or greater thought to be consistent with necrotizing fasciitis.[20]

TABLE 153-4
Differential Diagnoses for Necrotizing Fasciitis

Infectious Differential Diagnosis
- Abscess[2]
- Cellulitis[2]
- Erysipelas[16]
- Invasive/deep fungal infection[21]

Noninfectious Differential Diagnosis
- Necrotizing Sweet syndrome[23,24]
- Pyoderma gangrenosum[22]

even though bacteremia is present only in a minority of these patients.[11] As discussed above, superficial wound cultures have a low sensitivity and specificity for determining culprit pathogens causing infection, but needle aspirate of fluid from involved sites of skin and subcutaneous tissue can be used in cases where surgical intervention is delayed to help identify the causative pathogen.[9]

Certain key features, such as thickening and inflammation of fascial planes, can be seen on MRI and CT and help support a diagnosis of necrotizing fasciitis.[9] However, the sensitivity and specificity of these tests have not been determined. Additionally, if clinical suspicion is high, these studies are thought to just delay time to surgical diagnosis.[9] Radiology may be a useful investigative tool as part of a full workup in cases where clinical suspicion for necrotizing fasciitis is low to help avoid unnecessary surgical intervention for patients without necrotizing fasciitis.

DIFFERENTIAL DIAGNOSIS

Table 153-4 outlines the differential diagnosis of necrotizing fasciitis.

CLINICAL COURSE AND PROGNOSIS

Although some progress has been made in recent years in management of necrotizing fasciitis, mostly in increased awareness of the need for prompt surgical intervention, adult mortality rates remain high at 20% to 30%.[2,3,5,11,19,25] Pediatric mortality is generally reported to be lower with recent literature demonstrating mortality rates of approximately 10% to 15%.[7] Most deaths in necrotizing fasciitis are secondary to underlying bacteremia, septic shock, and/or multiorgan failure.[13,25] Given the high risks of morbidity and mortality, patients with confirmed or suspected necrotizing fasciitis should be managed as an inpatient and management attempts should not be made to care for these patients in the outpatient setting.[9]

Table 153-5 identifies the patient factors, clinical parameters, and disease characteristics that are associated with an increased risk of mortality for patients with necrotizing fasciitis. On a systems level, delayed surgical intervention and interhospital transfer are associated with an increased risk of mortality; given this, efforts should be made to have patients undergo

TABLE 153-5
Factors Found in Literature to Be Associated with a High Mortality Risk in Patients with Necrotizing Fasciitis

PATIENT CHARACTERISTICS	CLINICAL PRESENTATION	DISEASE CHARACTERISTICS
Older age[11,19,41-43]	Acute renal failure[42,44]	Hospital-acquired necrotizing fasciitis[11]
Female gender[43]	Severe sepsis or septic shock[11,42]	Sacral involvement[25]
Low body mass index[3]	Less pain at presentation[25]	Multifocal infection[11,25,45]
Race[8]	Lower frequency of fever at presentation[25]	Air in the involved soft tissue or surrounding infection[41]
Increased comorbidities or immunosuppression at baseline[3,8,11,19,41,43,46,47]: - Coronary artery disease - Malignancy - Peripheral vascular disease - Hemodialysis-dependent chronic kidney disease - Cirrhosis - Congestive heart failure - History of gout - Obesity - Diabetes mellitus	Laboratory abnormalities at presentation[25,41,45,46]: - Lower hemoglobin - Lower platelet count - Higher creatinine - Greater LRINEC score - Greater SOFA score - Increased band polymorphonuclear neutrophils - Activated partial thromboplastin time >60 s - Serum albumin <2.5 mg/dL - Serum protein <6 g/dL	Specific microbiology characteristics: - Monobacterial Gram-negative infections[25] - Polybacterial infections - Pseudomonal infections[25] - *Proteus* infections[25] - *Aeromonas* infection[41]
	Bacteremia	Traumatic injuries leading to infection[25,45]
	Hypotension on admission[43,46]	Skin necrosis on presentation[43,44,48]
	Pulse >130 beats/min[43]	Hemorrhagic bullae at presentation[48]

LRINEC, Laboratory Risk Indicator for Necrotizing Fasciitis; SOFA, Sequential Organ Failure Assessment.

at least initial surgical debridement at their presenting hospital.[19,26] In general, anatomic location of disease has not been found to be a risk factor for mortality.

Of note, for patients who survive, morbidity remains high given aggressive surgical interventions and prolonged hospital course. Amputation is common for patients with limb disease and patients with underlying diabetes mellitus have an increased risk of requiring surgical amputation as treatment of limb necrotizing fasciitis.[13] Additionally, following discharge, the recovery process for patients who survive necrotizing fasciitis is often long and laborious.

MANAGEMENT

Even though prompt initiation of appropriate antibiotics is crucial, rapid surgical intervention remains the mainstay of therapy for patients with necrotizing fasciitis.[11] Surgical intervention less than 24 hours following onset is associated with improved clinical outcomes.[20] Despite this, in reality, delays in surgical management are persistent, with a significant subset of patients receiving delayed (longer than 24 hours) surgical intervention demonstrating need for continued education on diagnosis, workup, and treatment of this surgical emergency.[2]

Surgical interventions include radical debridement of necrotic tissue at baseline with possible amputation for severe limb disease.[2] Ultimately, full surgical debridement of all necrotic areas involved in the underlying infection is essential to achieving therapeutic success.[9] Generally, this is not achieved in one debridement, but rather by staged, daily debridings until no further areas of involvement are found on surgical exploration.[9] Following surgical debridement, wound closure is often achieved through vacuum-assisted closure devices and skin grafting.[2] There is insufficient data to support hyperbaric oxygen therapy in these patients at this point in time; however, research toward this end is ongoing.[9,16]

Although not the first-line treatment of necrotizing fasciitis, antibiotics are a crucial adjunctive therapy. In 2014, the Infectious Diseases Society of America (IDSA) published updated guidelines surrounding antimicrobial selection for patients with necrotizing infections of the skin, fascia, and muscle (Table 153-6).[9] These guidelines are applicable to all infections covered in this chapter. As with most aggressive infections, broad-spectrum antibiotics are recommended initially, with narrowing based on data from tissue culture obtained from biopsy or during surgical debridement. The IDSA recommends initial broad-spectrum antimicrobial therapy with either vancomycin, linezolid, or daptomycin used in conjunction with either piperacilling-tazobactam, carbapenem, ceftriaxone plus metronidazole, or fluoroquinolone plus metronidazole while awaiting culture data.[9] Antibiotics should be continued until final surgical debridement has been completed, patient is afebrile for 48 to 72 hours, and patient has clinically stabilized.[9]

Lesions of necrotizing fasciitis release a significant amount of drainage. As such, fluid resuscitation and close monitoring of vitals and underlying electrolyte balance is crucial.[9] Early studies suggest some benefit to the use of IV immunoglobulin in patients with necrotizing fasciitis; however, data is limited and there is no strong evidence to support its routine use in patients with necrotizing fasciitis.[9]

GANGRENOUS OR NECROTIZING CELLULITIS

Necrotizing or gangrenous cellulitis accounts for necrotizing infections with or without gas formation localized to the skin and subcutaneous tissue but not extending deep enough to involve the underlying fascia or muscles. In recent literature, these more superficial infections are also grouped into the larger umbrella term *necrotizing soft-tissue infections*, and broadly speaking, the same bacterial subspecies responsible for necrotizing fasciitis and pyomyositis can cause a similar necrotizing, rapidly progressive infection of the skin and subcutaneous tissue. Given this, there is relatively sparse current literature focusing on "gangrenous or necrotizing cellulitis" exclusively rather than grouping these diseases into larger groups of necrotizing soft-tissue infections.

Some prior literature grouped gangrenous or necrotizing cellulitis infections into either clostridial or nonclostridial crepitant or gangrenous cellulitis.[27] The *Clostridium* spp. are known more widely for causing severe crepitant myonecrosis or "gas gangrene" as discussed in "Clostridial Gas Gangrene" section.[27] The term *clostridial crepitant cellulitis* arose to describe cases of limited, superficial, and focal infections of the skin, often without severe systemic symptoms and caused by this same bacterial subgroup.[27] These clostridial crepitant cellulitis infections, as opposed to traditional cellulitis, were characterized by extensive subcutaneous emphysema with often minimal overlying skin changes.[27] Tissue necrosis in these cases was limited to superficial skin and subcutaneous tissue.[27]

Nonclostridial necrotizing cellulitis can be either gas forming or non gas forming. Aside from the *Clostridium* spp., gas can also be produced by other anaerobic of facultative bacterial species. These include *Peptostreptococcus* spp., *Bacteroides* spp., *Enterobacteriaceae*, and *Klebsiella* spp.[27] The defining feature for infections caused by each of these gas-forming bacteria is subcutaneous emphysema and each of these bacterial species can cause infection confined to the skin or extending more deeply into the muscle or fascia.

Gram-negative bacilli are common pathogens identified in patients with non–gas-forming necrotizing cellulitis, many of which are acquired by exposure to marine animals or aquatic environments.[28] Marine-associated necrotizing skin infections are most commonly caused by *Vibrio* spp. or *Aeromonas* spp.,[28] but a number of other less-common aquatic pathogens can cause similar presentations (Table 153-7). *Vibrio vulnificus* is the most virulent of this group of curved Gram-negative bacilli found in coastal waters.[28]

TABLE 153-6
Infectious Diseases Society of America 2014 Guidelines for Antimicrobial Management for Patients with Necrotizing Soft-Tissue Infections[9]

TYPE OF INFECTION	FIRST-LINE ANTIMICROBIAL AGENT	ADULT DOSAGE	PEDIATRIC DOSAGE BEYOND NEONATAL PERIOD	AGENTS FOR PATIENTS WITH SEVERE PENICILLIN ALLERGY
Mixed infections	Piperacillin-tazobactam plus vancomycin	3.37 g q6-8h IV; 30 mg/kg/day in 2 divided doses	60 to 75 mg/kg/dose of the piperacillin component q6h IV; 10 to 13 mg/kg/dose q8h IV	Clindamycin or metronidazole with an aminoglycoside or fluoroquinolone
	Imipenem-cilastatin	1 g q6-8h IV	Not available (n/a)	n/a
	Meropenem	1 g q8h IV	20 mg/kg/dose q8h IV	n/a
	Ertapenem	1 g daily IV	15 mg/kg/dose q12h IV for children 3 months to 12 years of age	n/a
	Cefotaxime plus metronidazole or clindamycin	2 g q6h IV; 500 mg q6h IV; 600 to 900 mg q8h IV	50 mg/kg/dose q6h IV; 7.5 mg/kg/dose q6h IV; 10 to 13 mg/kg/dose q8h IV	n/a
Streptococcus	Penicillin plus clindamycin	2 to 4 million units q4-6h IV (adult); 600 to 900 mg q8h IV	60,000 to 100,000 units/kg/dose q6h IV; 10 to 13 mg/kg/dose q8h IV	Vancomycin, linezolid, quinupristin/dalfopristin, daptomycin
Staphylococcus aureus	Nafcillin	1 to 2 g q4h IV	50 mg/kg/dose q6h IV	Vancomycin, linezolid, quinupristin/dalfopristin, daptomycin
	Oxacillin	1 to 2 g q4h IV	50 mg/kg/dose q6h IV	
	Cefazolin	1 g q8h IV	33 mg/kg/dose q8h IV	
	Vancomycin (for resistant strains)	30 mg/kg/day in 2 divided doses IV	15 mg/kg/dose q6h IV	
	Clindamycin	600 to 900 mg q8h IV	10 to 13 mg/kg/dose q8h IV	Bacteriostatic; potential cross-resistance and emergence of resistance in erythromycin-resistant strains; inducible resistance in methicillin-resistant *S. aureus*
Clostridium spp.	Clindamycin plus penicillin	600 to 900 mg q8h IV; 2 to 4 million units q4-6h IV (adult)	10 to 13 mg/kg/dose q8h IV; 60,000 to 100,000 units/kg/dose q6h IV	n/a
Aeromonas hydrophila	Doxycycline plus ciprofloxacin or ceftriaxone	100 mg q12h IV; 500 mg q12h IV; 1 to 2 g q24h IV	Not recommended for children but may need to use in life-threatening situations	n/a
Vibrio vulnificus	Doxycycline plus ceftriaxone or cefotaxime	100 mg q12h IV; 1 g 4 times daily IV; 2 g thrice daily IV	Not recommended for children but may need to use in life-threatening situations	n/a

Adapted from Stevens DL, Bisno AL, Chambers HF, et al. Practice guidelines for the diagnosis and management of skin and soft tissue infections: 2014 update by the Infectious Diseases Society of America. *Clin Infect Dis*. 2014;59(2):e10-e52. By permission of Oxford University Press on behalf of the Infectious Diseases Society of America.

TABLE 153-7
Causes of Marine-Based Necrotizing Cellulitis[28]

- *Aeromonas* spp.
- *Edwardsiella tarda*
- *Erysipelothrix rhusiopathiae*
- *Plesiomonas shigelloides*
- *Streptococcus iniae*
- *Vibrio* spp.

Data from Vinh DC, Embil JM. Severe skin and soft tissue infections and associated critical illness. *Curr Infect Dis Rep*. 2007;9(5):415-21.

Again, infection is often the result of inoculation through prior wound or site of trauma.[28] Clinically, bullae are a common defining feature found in patients with infection secondary to *Vibrio* spp. Not uncommonly, patients with *Vibrio* spp. infection can develop fulminant sepsis/shock. Patients with underlying renal disease, liver dysfunction, or immunosuppression at baseline are at increased risk for more-severe infection and fulminant sepsis associated with *Vibrio* spp. infection, also termed *vibriosis*.[28]

For each of these entities, the same management guidelines as those used in necrotizing fasciitis as

outlined above can be followed. Surgical debridement, albeit more limited than for necrotizing fasciitis, in conjunction with antimicrobial therapy as outlined by the IDSA guidelines, remains the cornerstone of therapy.[27] Overall, it is clear that there is significant overlap in clinical presentation, microbiology, management, and treatment between necrotizing fasciitis and gangrenous or necrotizing cellulitis, suggesting that these forms of necrotizing or gangrenous cellulitis are thought to represent one point on a spectrum of severity within the larger group of necrotizing soft-tissue infections.

MYONECROSIS

The 2 major infections included within the group of myonecrosis are pyomyositis and clostridial gas gangrene. Both entities are characterized by necrotic infections stemming from within and around the subcutaneous muscle. Although these infections can involve the more superficial structures—fascia, skin, and subcutaneous soft tissue—the focus of the infection and associated necrosis is located within the confines of the muscle itself. Each is described separately below.

PYOMYOSITIS

HISTORICAL PERSPECTIVES

Pyomyositis is an infection characterized by bacterial infection leading to collections of purulent material within the body of 1 or more muscles in affected patients.[9] Early reports of symptoms and surgical findings reflecting the disease we now refer to as pyomyositis were found in reports of Julius Scriba, a German surgeon, dating back to 1885 while working abroad in Japan.[29] However, pyomyositis was first classified as a disease entity in the 19th century by Virchow, who called the disease "spontaneous acute myositis."[29] Literature for this disease was then increased by a Japanese surgeon Miyake Hayari who published a case series of 33 patients with this disease.[29] In the early 20th century, additional cases were recognized in populations from warmer, more tropical climates, giving the disease the label tropical pyomyositis, which is still used commonly today.[29]

EPIDEMIOLOGY

Pyomyositis is described more frequently in tropical climates with the majority of cases reported in Asia, Africa, the Caribbean, and Oceania; additionally, even in these warmer climates, the infection has been described to occur with increased frequency during warmer, more humid months.[29] More recently, infections have been described with increased frequency in more temperate climates, which is thought to be possibly linked to increased frequency of community-acquired cases of methicillin-resistant *Staphylococcus aureus* in these climates.[29,30] One recent study estimated that the prevalence of pyomyositis in the developed world ranges from 1 per 1145 to 1 per 4000 emergency department hospital admissions.[30] A Brazilian study found that pyomyositis accounted for approximately 1% of all hospital admissions.[31]

As opposed to most other entities discussed in this chapter, pyomyositis in tropical climates occurs more frequently in children than adults.[30,31] In temperate climates, however, pyomyositis is more common in adult populations with multiple medical comorbidities.[31]

ETIOLOGY, MICROBIOLOGY, PATHOGENESIS

In addition to patients who live in warmer/tropical climates, pyomyositis occurs with increased frequency in patients who are immunosuppressed (eg, HIV) or have diabetes mellitus.[9] Additionally, bacteremia or other local skin and soft-tissue infections preceding cases of pyomyositis are thought to increase risk for subsequent development of this type of infection.[30] Pyomyositis infections demonstrate a predilection for the lower extremities and pelvic girdle, and occur more commonly following localized trauma or muscle overuse.[9]

A majority of pyomyositis infections (90%) are caused by *S. aureus*.[9] It has been postulated that Panton-Valentine leukocidin, which is a cytotoxin secreted by some staphylococcal strains, plays a role in pyomyositis development and the ability for *Staphylococcus* organisms to create intramuscular abscesses in this disease.[29] Nonstaphylococcal infections can be caused by *S. pneumoniae* or Gram-negative enteric bacteria.[9] Table 153-8 lists the bacterial causes of pyomyositis. Less commonly, pyomyositis can be caused by viral, parasitic, or fungal pathogens.[29]

CLINICAL FEATURES

Cutaneous Features: Given the depth of infection, there may be very few cutaneous changes seen in early pyomyositis.[32] Because of this, diagnosis is often delayed.[32] As lesions progress, patients often develop more focal pain that can be reproduced by palpation to this area.[32] Eventually, patients may develop a firm, woody induration over areas of involvement, demonstrate fluctuance, or develop areas of overlying cutaneous erythema and inflammation.[9,32]

TABLE 153-8
Microbiology of Pyomyositis

- *Escherichia coli*[29]
- *Klebsiella pneumoniae*[51]
- *Mycobacterium tuberculosis*[50]
- *Salmonella*[49]
- *Staphylococcus aureus*
- *Streptococcus pneumoniae*

Noncutaneous Features: Presenting symptoms for patients with infectious myositis are often vague or nonspecific and can include focal limb pain, muscle tenderness, and fever.[9] Focal pain can manifest itself as limp or restricted limb movement, particularly for those infections found in the pelvic girdle region.[30] As the disease progresses, however, patients with a delay in diagnosis can become progressively sicker, eventually developing sepsis and disseminated systemic infection.[32]

A clinical staging system for this disease has been suggested to describe the progression of symptoms found in patients with pyomyositis. Stage I involves inflammation and pain surrounding the infected muscle with associated leukocytosis. At this point there may be mild induration of the subcutaneous tissue structures; however, cutaneous changes are typically absent.[29] Stage II is characterized by suppuration with abscess formation within the muscle belly; this stage is associated with severe focal pain, fever, and swelling overlying the affected muscle.[29] This stage generally lasts 1 to 3 weeks. Stage III is characterized by progression to systemic disease with septic physiology, shock, and multifocal abscess formation.[29]

DIAGNOSIS

As opposed to some of the more superficial necrotizing processes, given the depth of this infection, MRI remains the gold standard for pyomyositis diagnosis.[9] Patients with pyomyositis will demonstrate muscle inflammation and intramuscular abscess formation on MRI. CT scan and ultrasonography are other helpful imaging modalities that can be used for this entity when MRI is not available or not practical to use to establish a diagnosis.[9,32] However, CT scan is limited by lack of definition of soft-tissue structures and ultrasonography is helpful only to characterize superficial abscesses.[9] Plain X-ray can give clues to suggest soft-tissue swelling, but lacks the capability to define underlying soft-tissue structures.[9] Interventional radiology-guided drainage of purulent material can help confirm the diagnosis and identify causative pathogens with culture, after which appropriate narrowing of antimicrobial therapy can occur. For persistently febrile patients despite ongoing antimicrobial therapy, repeat, serial imaging studies can be used to assess for remaining collections of purulence.[9]

Blood cultures in pyomyositis are crucial, but positivity rates are low, ranging from 5% to 30% of cases.[9] Leukocytosis, elevated erythrocyte sedimentation rate, and elevated C-reactive protein can also be seen in patients with pyomyositis; these tests can help to suggest a diagnosis for patients presenting with vague early symptoms.[32]

DIFFERENTIAL DIAGNOSIS

Table 153-9 outlines the differential diagnosis of pyomyositis.

TABLE 153-9
Differential Diagnosis of Pyomyositis

Infectious Differential Diagnosis	Noninfectious Differential Diagnosis
Bacterial meningitis[35]	Deep vein thrombosis[36]
Cellulitis	Hematoma
Osteomyelitis[33]	Malignancy[33]
Septic arthritis[34]	Transient synovitis[33]

CLINICAL COURSE AND PROGNOSIS

Mortality rates are reportedly lower (0.89% to 10%) in pyomyositis than some of the other disease entities covered in this chapter.[31,37,38] Factors shown to increase risk of mortality for patients with pyomyositis include septic physiology, hypotension, tachycardia, lower Glasgow coma score, higher Sequential Organ Failure Assessment (SOFA) score, elevated laboratory markers, including blood urea nitrogen, creatinine, bilirubin, and serum glutamic pyruvate transaminase.[37]

MANAGEMENT

Management options for pyomyositis involve both antimicrobials as well as surgical interventions. However, as opposed to many of the other entities in this chapter which are considered surgical emergencies, surgical intervention is not always required for pyomyositis; some patients are able to be managed conservatively with antibiotics alone or antibiotics with percutaneous abscess drainage.[30] The need for surgical intervention depends on extent and severity of disease.[30] When surgical intervention is required, orthopedic surgical specialists are often called upon for operative wash out and abscess decompression at sites of infection.[32]

Antimicrobial treatment of pyomyositis should also start broadly with vancomycin. Piperacillin-tazobactam, ampicillin-tazobactam, or carbapenem should be added to vancomycin empirically for patients who have multiple comorbidities, are immunocompromised, or developed infection as the result of a penetrating wound.[9] Again, once causative pathogens are identified, narrowing of antimicrobials to oral agents can be achieved with a goal of a 2- to 3-week course of treatment.[9] Based on the severity of infection and the clinical response to antibiotics, antibiotic regimens often can be changed from IV to oral.[30] Patients with pyomyositis whose cultures are positive for methicillin-sensitive *S. aureus* should be narrowed to either cefazolin or an antistaphylococcal penicillin (eg, nafcillin or oxacillin).[9]

CLOSTRIDIAL GAS GANGRENE

HISTORICAL PERSPECTIVES

Clostridium subspecies are a group of anaerobic or aerotolerant, Gram-positive, toxin-producing bacterial rods commonly found in soil and human and animal feces.[28] As opposed to the more superficial infection of "clostridial crepitant cellulitis," clostridial gas gangrene is a much deeper infection characterized by severe necrosis of skeletal muscle caused by the *Clostridium* subspecies.[28] The disease is rapidly progressive, often accompanied by severe systemic symptoms with risk for progression to multiorgan system shock. The disease became infamous in World War II when soldiers were found to develop soft-tissue infections at sites of contaminated prior battle wounds that were characterized by crepitus or gas release upon surgical intervention.[28]

ETIOLOGY, MICROBIOLOGY, PATHOGENESIS

Similar to what was discovered in World War II, today clostridial myonecrosis is most often found at sites of localized trauma or prior surgical intervention.[28] Infections can also occur in the postpartum period or following medical or spontaneous abortion.[28] Spontaneous (nontraumatic) cases of clostridial gas gangrene occur most frequently in patients with underlying gastric malignancy or underlying neutropenic gastritis.[9,28] GI cancers, such as colon cancer, can allow for bowel perforation and hematogenous spread of *Clostridium* organisms to previously healthy, nontraumatized sites of seeding.[9]

The most common causative organisms of clostridial myonecrosis are *Clostridium perfringens*, *Clostridium novyi*, *Clostridium histolyticum*, and *Clostridium septicum*.[9] *Clostridium sordellii* myonecrosis can be found in myonecrotic infections of the uterus and perineum in the postpartum and postabortive periods.[28] Cases related to trauma are most commonly caused by *C. perfringens* and spontaneous non–trauma-related cases are most commonly caused by *C. septicum*.[9,28] Clostridial myonecrosis in IV drug users is most commonly caused by *C. sordellii* and *C. novyi* subspecies.[28]

CLINICAL FEATURES

Patients with spontaneous, nontraumatic forms of clostridial myonecrosis can develop acute abdominal pain followed by pain localized to a limb where the infection has seeded.[28] Once infection has seeded, lesions of clostridial myonecrosis progress rapidly over the course of 24 hours to develop pronounced color changes to overlying skin. The lesions begin with pallor and progress on to other color changes, including a deep bronze followed by purple-red mottling.[9,28] The rapid doubling time of *Clostridium* species (as little as 10 minutes) is thought to contribute to the rapid progression of these diseases, with time from inoculation to fulminant disease ranging from a few hours to 3 days.[28] Disease progression and muscle necrosis can move at a rate of a few inches per hours.[28] Overlying skin can become edematous, tense, and firm with overlying bullae filled with a red-blue fluid.[9] Pain is often severe and is a prominent feature of clostridial myonecrosis.[28] Gas collection in tissue manifests as overlying crepitus and is the cardinal feature of clostridial myonecrosis as it is in clostridial crepitant cellulitis.[9] A brownish discharge with a foul smell, described as "dishwater exudate," can be noted.[28] Given depth of infection and structures involved, postpartum and post abortive patients often do not have associated skin findings.[28]

Overall, given the speed of progression of infection, patients with clostridial myonecrosis or gas gangrene become sick rapidly. They can develop an influenza-like prodrome and then develop tachycardia, fever, diaphoresis, tachypnea, hypotension, and a feeling of impending doom shortly after the start of these infection.[9,28] Also, as swelling spreads up the extremity, patients can develop intense edema localized to the extremity involved and risk for compartment syndrome is high.[28] Progressive myonecrosis can lead to myoglobinuria and subsequent renal failure.[28] Ultimately, systemic symptoms often progress to shock and multiorgan system failure.[9]

DIAGNOSIS

The triad of soft-tissue crepitus, severe pain, and tachycardia disproportionate to the fever is thought to be diagnostic of clostridial myonecrosis.[28] In reality, however, the diagnosis is often suggested clinically when gas collections are noted overlying the cutaneous findings described above and then confirmed with surgical exploration.[9,28] Surgical exploration reveals myonecrosis on gross surgical examination.[28] Tissue or exudate retrieved during surgical exploration and sent for microbiologic studies will reveal large Gram-positive or Gram-variable "blunt-end" rods from sites of infection.[9,28]

Laboratory studies are not required for the diagnosis of this infection. However, cases of clostridial myonecrosis are often associated with leukocytosis (leukemoid reaction), hemoconcentration, and laboratory evidence of end-organ damage.[28] With shock, patients can develop associated disseminated intravascular coagulopathy.[28] Similar to necrotizing fasciitis, imaging studies for clostridial myonecrosis are discouraged out of concern that the studies may only serve to delay treatment. However, if imaging studies are pursued, MRI or CT scan may demonstrate gas pockets or collections in the soft tissue surrounding infection.[9]

CLINICAL COURSE AND PROGNOSIS

Given rapid progression and associated systemic toxicity, cases of clostridial myonecrosis are associated

with a high rate of morbidity and mortality. As with necrotizing fasciitis, morbidity is aggravated by delay in surgical intervention.[39] When occurring in limbs, the amputation rate is high; early amputation has been shown to decrease morbidity overall.[39] For patients who avoid amputation, limb function for affected limbs is rarely preserved.[39] Mortality rates for clostridial myonecrosis are reported to be as high as 100% and are highest among patients who initially present in shock.[39]

MANAGEMENT

Similar to necrotizing fasciitis, surgical debridement is the mainstay of therapy for patients with clostridial myonecrosis.[9] Additionally, these patients also often require multiple surgical debridements, and amputations of involved limbs may be necessary.[28] Given the clinically tenuous nature of these patients, intensive care unit–level care is often needed to closely monitor and replete fluids and electrolytes as necessary.[9] Broad-spectrum antibiotics should be started based on the IDSA guidelines, as outlined in Table 153-6, pending confirmation of clostridial pathogens.[9] Once diagnosis is confirmed to be secondary to a *Clostridium* subspecies, antibiotics of choice are clindamycin plus high-dose penicillin.[9,28] Combined therapy has been recommended given that approximately 5% of *Clostridium* subspecies will demonstrate resistance to clindamycin monotherapy.[9] Patients with penicillin allergy can be treated with clindamycin monotherapy or with metronidazole.[9] However, penicillin and metronidazole are thought to have opposing factors and their concomitant use is not recommended.[28]

As with necrotizing fasciitis, there is insufficient evidence to support hyperbaric oxygen therapy for patients with clostridial myonecrosis and it is thought that these procedures, which often require transporting patients to another facility or building, only delay or interrupt surgery and antibiotics, which are the cornerstones of therapy for these patients. Given this, the IDSA discouraged use of hyperbaric oxygen therapy in these patients in their 2014 guidelines for managements of skin and soft-tissue infections.[9] This notion received further support in the 2015 Cochrane review of treatment options for clostridial gas gangrene, which, again, demonstrated no overall benefit for patients receiving adjunctive hyperbaric oxygen therapy as a part of their overall care.[40]

REFERENCES

1. Hussein QA, Anaya DA. Necrotizing soft tissue infections. *Crit Care Clin*. 2013;29(4):795-806.
2. van Stigt SF, de Vries J, Bijker JB, et al. Review of 58 patients with necrotizing fasciitis in the Netherlands. *World J Emerg Surg*. 2016;11:21.
3. Park SJ, Kim DH, Choi CI, et al. Necrotizing soft tissue infection: analysis of the factors related to mortality in 30 cases of a single institution for 5 years. *Ann Surg Treat Res*. 2016;91(1):45-50.
4. Adekanye AG, Umana AN, Offiong ME, et al. Cervical necrotizing fasciitis: management challenges in poor resource environment. *Eur Arch Otorhinolaryngol*. 2016;273(9):2779-2784.
5. Psoinos CM, Flahive JM, Shaw JJ, et al. Contemporary trends in necrotizing soft-tissue infections in the United States. *Surgery*. 2013;153(6):819-827.
6. Oud L, Watkins P. Contemporary trends of the epidemiology, clinical characteristics, and resource utilization of necrotizing fasciitis in Texas: a population-based cohort study. *Crit Care Res Pract*. 2015;2015:618067.
7. Zundel S, Lemarechal A, Kaiser P, et al. Diagnosis and treatment of pediatric necrotizing fasciitis: a systematic review of the literature. *Eur J Pediatr Surg*. 2017;27(2):127-137.
8. Arif N, Yousfi S, Vinnard C. Deaths from necrotizing fasciitis in the United States, 2003-2013. *Epidemiol Infect*. 2016;144(6):1338-1344.
9. Stevens DL, Bisno AL, Chambers HF, et al. Practice guidelines for the diagnosis and management of skin and soft tissue infections: 2014 update by the Infectious Diseases Society of America. *Clin Infect Dis*. 2014;59(2):e10-e52.
10. Mao YC, Liu PY, Hung DZ, et al. Bacteriology of *Naja atra* snakebite wound and its implications for antibiotic therapy. *Am J Trop Med Hyg*. 2016;94(5):1129-1135.
11. Hua C, Sbidian E, Hemery F, et al. Prognostic factors in necrotizing soft-tissue infections (NSTI): A cohort study. *J Am Acad Dermatol*. 2015;73(6):1006-1012.e8.
12. Zarb P, Coignard B, Griskeviciene J, et al. The European Centre for Disease Prevention and Control (ECDC) pilot point prevalence survey of healthcare-associated infections and antimicrobial use. *Euro Surveill*. 2012;17(46).
13. Cheng NC, Tai HC, Chang SC, et al. Necrotizing fasciitis in patients with diabetes mellitus: clinical characteristics and risk factors for mortality. *BMC Infect Dis*. 2015;15:417.
14. Sada A, Misago N, Okawa T, et al. Necrotizing fasciitis and myonecrosis "synergistic necrotizing cellulitis" caused by *Bacillus cereus*. *J Dermatol*. 2009;36(7):423-426.
15. Meleney FL. Bacterial synergism in disease processes: with a confirmation of the synergistic bacterial etiology of a certain type of progressive gangrene of the abdominal wall. *Ann Surg*. 1931;94(6):961-81.
16. Elander J, Nekludov M, Larsson A, et al. Cervical necrotizing fasciitis: descriptive, retrospective analysis of 59 cases treated at a single center. *Eur Arch Otorhinolaryngol*. 2016;273(12):4461-4467.
17. Lohsiriwat V. Anorectal emergencies. *World J Gastroenterol*. 2016;22(26):5867-5878.
18. Crowell W, Roberts R, Tarry S. Fungal Fournier's gangrene in an immunocompromised patient. *Urol Case Rep*. 2016;4:1-3.
19. Holena DN, Mills AM, Carr BG, et al. Transfer status: a risk factor for mortality in patients with necrotizing fasciitis. *Surgery*. 2011;150(3):363-370.
20. Wong CH, Khin LW, Heng KS, et al. The LRINEC (Laboratory Risk Indicator for Necrotizing Fasciitis) score: a tool for distinguishing necrotizing fasciitis from other soft tissue infections. *Crit Care Med*. 2004;32(7):1535-1541.
21. Aytekin S, Guder H, Goktay F, et al. Pyoderma gangrenosum and necrotizing fasciitis-like opportunistic invasive cutaneous fungal infection. *Int J Dermatol*. 2016;55(10):e563-e565.

22. de Souza EF, da Silva GA, Dos Santos GR, et al. Pyoderma gangrenosum simulating necrotizing fasciitis. *Case Rep Med*. 2015;2015:504970.
23. Kroshinsky D, Alloo A, Rothschild B, et al. Necrotizing Sweet syndrome: a new variant of neutrophilic dermatosis mimicking necrotizing fasciitis. *J Am Acad Dermatol*. 2012;67(5):945-954.
24. de Moya MA, Wong JT, Kroshinsky D, et al. Case records of the Massachusetts General Hospital. Case 28-2012. A 30-year-old woman with shock and abdominal-wall necrosis after cesarean section. *N Engl J Med*. 2012;367(11):1046-1057.
25. Jabbour G, El-Menyar A, Peralta R, et al. Pattern and predictors of mortality in necrotizing fasciitis patients in a single tertiary hospital. *World J Emerg Surg*. 2016;11:40.
26. Hadeed GJ, Smith J, O'Keeffe T, et al. Early surgical intervention and its impact on patients presenting with necrotizing soft tissue infections: a single academic center experience. *J Emerg Trauma Shock*. 2016;9(1):22-27.
27. Bryant P, Carapetis J, Matussek J, et al. Recurrent crepitant cellulitis caused by *Clostridium perfringens*. *Pediatr Infect Dis J*. 2002;21(12):1173-1174.
28. Vinh DC, Embil JM. Severe skin and soft tissue infections and associated critical illness. *Curr Infect Dis Rep*. 2007;9(5):415-421.
29. Verma S. Pyomyositis in children. *Curr Infect Dis Rep*. 2016;18(4):12.
30. Moriarty P, Leung C, Walsh M, et al. Increasing pyomyositis presentations among children in Queensland, Australia. *Pediatr Infect Dis J*. 2015;34(1):1-4.
31. Borges AH, Faragher B, Lalloo DG. Pyomyositis in the upper Negro river basin, Brazilian Amazonia. *Trans R Soc Trop Med Hyg*. 2012;106(9):532-537.
32. Kumar MP, Seif D, Perera P, et al. Point-of-care ultrasound in diagnosing pyomyositis: a report of three cases. *J Emerg Med*. 2014;47(4):420-426.
33. Chong X, Ashik M, Arjandas M. Obturator internus pyomyositis in a child: a case report. *Malays Orthop J*. 2014;8(1):69-70.
34. Ghazala CG, Fatone E, Bentley R, et al. Primary bacterial gluteal pyomyositis: a rare disease in temperate climates presenting as suspected septic arthritis of the hip. *J Emerg Med*. 2016;51(3):319-321.
35. Itaya S, Kobayashi Z, Tomimitsu H, et al. Pneumococcal pyomyositis of the neck muscles. *Intern Med*. 2016;55(15):2069-2071.
36. Narayanan M, Mookherjee S, Spector TB, et al. MSSA brain abscess and pyomyositis presenting as brain tumour and DVT. *BMJ Case Rep*. 2013;2013.
37. Sharma A, Kumar S, Wanchu A, et al. Clinical characteristics and predictors of mortality in 67 patients with primary pyomyositis: a study from North India. *Clin Rheumatol*. 2010;29(1):45-51.
38. Drosos G. Pyomyositis. A literature review. *Acta Orthop Belg*. 2005;71(1):9-16.
39. Aggelidakis J, Lasithiotakis K, Topalidou A, et al. Limb salvage after gas gangrene: a case report and review of the literature. *World J Emerg Surg*. 2011;6:28.
40. Yang Z, Hu J, Qu Y, et al. Interventions for treating gas gangrene. *Cochrane Database Syst Rev*. 2015(12): CD010577.
41. Huang KF, Hung MH, Lin YS, et al. Independent predictors of mortality for necrotizing fasciitis: a retrospective analysis in a single institution. *J Trauma*. 2011;71(2):467-473.
42. Kao LS, Lew DF, Arab SN, et al. Local variations in the epidemiology, microbiology, and outcome of necrotizing soft-tissue infections: a multicenter study. *Am J Surg*. 2011;202(2):139-145.
43. Khamnuan P, Chongruksut W, Jearwattanakanok K, et al. Necrotizing fasciitis: risk factors of mortality. *Risk Manag Healthc Policy*. 2015;8:1-7.
44. Krieg A, Dizdar L, Verde PE, et al. Predictors of mortality for necrotizing soft-tissue infections: a retrospective analysis of 64 cases. *Langenbecks Arch Surg*. 2014;399(3):333-341.
45. Lee YC, Hor LI, Chiu HY, et al. Prognostic factor of mortality and its clinical implications in patients with necrotizing fasciitis caused by *Vibrio vulnificus*. *Eur J Clin Microbiol Infect Dis*. 2014;33(6):1011-1018.
46. Yeung YK, Ho ST, Yen CH, et al. Factors affecting mortality in Hong Kong patients with upper limb necrotising fasciitis. *Hong Kong Med J*. 2011;17(2):96-104.
47. Nisbet M, Ansell G, Lang S, et al. Necrotizing fasciitis: review of 82 cases in South Auckland. *Intern Med J*. 2011;41(7):543-548.
48. Khamnuan P, Chongruksut W, Jearwattanakanok K, et al. Clinical predictors for severe sepsis in patients with necrotizing fasciitis: an observational cohort study in northern Thailand. *Infect Drug Resist*. 2015;8:207-216.
49. Gandhi A, Phadke P. *Salmonella* pyomyositis with concurrent osteomyelitis presenting as piriformis syndrome. *J Assoc Physicians India*. 2016;64(1):55.
50. Osorio J, Barreto J, Benavides J, et al. Tuberculous pyomyositis in an immunosuppressed patient. *Biomedica*. 2016;36(0):23-28.
51. Liao WH, Lai CC, Huang SH, et al. Rectus femoris pyomyositis caused by *Klebsiella pneumoniae*. *Surg Infect (Larchmt)*. 2014;15(4):464-465.

Chapter 154 :: Gram-Negative Coccal and Bacillary Infections

:: Breanne Mordorski & Adam J. Friedman

The Gram stain, developed in the late 1800s by Hans Christian Gram, is used to distinguish 2 major categories of bacteria. Gram-positive bacteria retain the purple hue of the initial crystal violet stain, whereas Gram-negative bacteria are decolorized and subsequently stain red by safranin or carbol fuchsin. While Gram-positive bacteria have thick walls of peptidoglycan and secondary polymers that are relatively impermeable and resist decolorization, Gram-negative bacteria have a thin peptidoglycan layer with an outer lipid membrane bilayer that is readily disrupted by this process.[1]

Gram-negative bacteria may be further categorized by their morphology and metabolic capabilities. Gram-negative cocci found in clinical isolates typically represent *Neisseria* spp., which may be identified as *Neisseria meningitidis* or *Neisseria gonorrhoeae* depending on maltose fermenting activity. On the other hand, Gram-negative bacilli may be subdivided based on morphology, including coccobacilli, comma-shaped bacilli, fusiform bacilli, and rods. Gram-negative rods, for example, can be further subdivided by lactose fermenting activity, oxidase positivity, and so on.[2] This chapter focuses on cutaneous manifestations of Gram-negative infections not already covered in other chapters. Many manifestations occur from direct invasion of the skin or subcutaneous tissues, and may be accompanied by signs such as fever or hypotension attributable to the patient's immune response.

INFECTIONS CAUSED BY *NEISSERIA MENINGITIDIS*

AT-A-GLANCE

- Worldwide, *Neisseria meningitidis* is responsible for 1.2 million cases of infection and 135,000 deaths annually.
- Disseminated meningococcal infection may present as (a) meningitis alone, (b) acute meningococcemia with or without meningitis, or (c) chronic meningococcemia.
- In acute meningococcemia, a classic petechial rash is present in approximately 60% of patients, most commonly on the extremities. In severe cases, necrosis of the skin and underlying tissue may necessitate amputation.
- The rash of chronic meningococcemia more commonly consists of rose-colored macules and papules, although petechiae, nodules, vesicles, and pustules may be present. The rash may wax and wane with periodic fevers.
- Mortality rates for meningococcal infection in the United States are 10% to 15% with 11% to 19% of survivors suffering from long-term sequelae.
- The gold standard for diagnosis is culture isolation of *N. meningitidis* from blood, cerebrospinal fluid, other bodily fluids, or skin biopsy tissues. Polymerase chain reaction is useful when cultures are negative.
- The single most important factor in the treatment of acute meningococcal infection is early initiation of antibiotics.
- In the United States, vaccination with a capsular polysaccharide conjugate vaccine against serogroups A, C, W135, and Y is recommended for all patients at 11 or 12 years of age with a booster at age 16 years.

INTRODUCTION AND BACTERIOLOGY

N. meningitidis is a maltose-fermenting aerobic Gram-negative diplococcus. It is a fastidious organism, meaning it has complex nutritional requirements and will die within hours on nonliving surfaces. It grows on blood agar, trypticase soy agar, chocolate agar, and modified Thayer-Martin agar, which consists of a chocolate agar base with growth factors and antibiotics that select for pathogenic *Neisseria* spp. On blood agar, colonies are light gray, nonhemolytic, round, and glistening, and have a clearly defined edge.[3,4]

While some strains do not have a capsule, pathogenic *N. meningitidis* is almost always encapsulated, allowing differentiation into serogroups based on capsular polysaccharides. At least 13 serogroups have been identified; however, only 6 (A, B, C, W-135, X, and Y) cause life-threatening disease. The capsule is vital for *N. meningitidis* survival in the blood as it inhibits antibody-mediated and complement-mediated killing, as well as phagocytosis. Capsules decrease the visibility of *N. meningitidis* to the host immune system via molecular mimicry, a phenomenon perhaps best illustrated by serogroup B, whose capsular polysaccharides

closely resemble those found on human neuronal cells. Vaccination against *N. meningitidis* serogroup B has proven especially challenging, as the capsular antigen is poorly immunogenic, necessitating the use of alternate antigens in the creation of vaccines.[5]

As with other Gram-negative bacteria, *N. meningitidis* has a subcapsular envelope comprised of an outer membrane bilayer, a peptidoglycan layer and a cytoplasmic membrane bilayer. The outer membrane bilayer contains pili, opacity proteins (Opa, Opc), factor H binding protein, and lipooligosaccharide (LOS). Pili and opacity proteins enable *N. meningitidis* adherence to host cells and tissues, and both undergo phase and antigenic variation. Pili may also undergo posttranscriptional glycosylation, promoting secretion of soluble pilin units that compete with antipilin antibodies. Type IV pili drive initial *N. meningitidis* adherence to nasopharyngeal epithelium and aggregation into microcolonies. Later in the bloodstream, Type IV pili enable adherence to endothelial cells, mediate vascular damage, and facilitate the breach of the blood–brain barrier.[4,6,7] Factor H binding protein binds factor H, a downregulator of the alternative complement pathway, to the surface of *N. meningitidis*, where it serves to degrade complement component C3.[8] In the setting of infection, LOS binds a variety of receptors on dendritic and monocytic cells, including lipopolysaccharide binding protein, CD14, and myeloid differentiation protein 2, part of the toll-like receptor (TLR)-4 complex. Together, LOS and other outer membrane components trigger downstream production of proinflammatory cytokines and chemokines, activation of complement, and simultaneous activation and inhibition of coagulation pathways.[9] Studies show a direct correlation between serum levels of LOS and severity of meningococcal infection, and high serum LOS is correlated with poor prognosis.

EPIDEMIOLOGY

There are approximately 1.2 million cases of *N. meningitidis* infection each year, leading to 135,000 deaths worldwide. Infections continue to occur in both developed and developing countries. Of note, the "meningitis belt" in sub-Saharan Africa encompasses 18 countries from Ethiopia to Senegal and is characterized by large epidemics of primarily meningococcal meningitis, which have occurred approximately every 8 to 10 years since 1905. The cause of these epidemics is poorly understood, although it is thought that humidity and dust play a role. Interestingly, peak *N. meningitidis* infection in developed countries typically corresponds with viral respiratory illnesses during winter months, whereas *N. meningitidis* infection in Africa occurs during the dry season.[4,10]

Humans are the exclusive natural host for *N. meningitidis*, and approximately 6% of the population develops nasopharyngeal carriage each year. Nasopharyngeal carriage persists for weeks to months and distribution varies with age: 0.5 to 1% carriage in infants and young children, 5% in adolescents, and 20% to 40% in young adults. The containment of infection to the nasopharynx is mediated by undetermined host and environmental factors, as well as host immunity. Sporadic *N. meningitidis* infection occurs most frequently in young children as a consequence of waning levels of protective maternal antibodies. However, in epidemics, older children, especially those living in crowded living quarters such as college dormitories, have higher infection rates. Overall, males have a higher risk of infection, whereas females have higher mortality.[4,10,11]

N. meningitidis infection is primarily caused by serogroups A, B, C, W-135, X, and Y. Serogroup A has been responsible for the largest and most devastating outbreaks in sub-Saharan Africa, whereas serogroups B and C most frequently cause disease in developed countries. Serogroup B accounts for 30% to 40% of cases in the United States and up to 80% in Europe, whereas serogroup C is responsible for approximately 30% of cases in both the United States and Europe. W-135 has caused infections with high mortality in sub-Saharan Africa, and since the 1990s it has been known to affect travelers to Saudi Arabia during the Hajj pilgrimage. Serogroup Y has emerged in the United States, accounting for approximately 25% of disease, particularly meningococcal pneumonia in older adults, as well as meningitis and meningococcemia in infants younger than 6 months old. Serogroup X is the most recent serogroup to emerge as a cause of disease in sub-Saharan Africa.[4,11]

CLINICAL FEATURES

N. meningitidis carriage is often asymptomatic, although upper respiratory tract infection–like symptoms may occur.[12] If *N. meningitidis* breaches the nasopharyngeal epithelium, patients may develop acute meningococcemia with or without meningitis, or meningitis alone. Acute meningococcemia is characterized by fever and a petechial rash, which may progress to fulminant septicemia within a matter of hours. More rarely, patients may develop chronic meningococcemia, which presents over weeks to months with recurrent fevers, migratory arthralgias, and a rash of varied morphology.[13,14]

CUTANEOUS FINDINGS

Acute meningococcemia is known to produce a petechial rash; however, this hallmark is not always present. In a study of 752 patients in the Netherlands, 601 had cutaneous exam data, of which 363 (60%) had petechiae on presentation. Petechiae were more common in children ages 1 to 18 (74%) than infants (48%) or adults (45%).[15] When present, petechiae are small and irregular with a "smudged" appearance, and may occur all over the body, including palms, soles, mucous membranes, and conjunctiva, although the extremities

Figure 154-1 Acute meningococcemia may be accompanied by petechial lesions of the skin (**A**), mucous membranes and conjunctiva (**B**). (Reproduced with permission from Baselga E, Drolet BA, Esterly NB. Purpura in infants and children. *J Am Acad Dermatol*. 1997;37[5]:673-705. Copyright © American Academy of Dermatology.)

Figure 154-2 Acute meningococcemia with disseminated intravascular coagulation may produce purpura fulminans, characterized by retiform purpura and necrosis of the skin (**A**), which may progress to gangrene of the digits and distal extremities (**B**). (Reproduced with permission from Mishkin DR, Rosh AJ. Female infant with fever and rash. *Ann Emerg Med*. 2009;54[2]:155-180. Copyright © Elsevier; and David R. Mishkin, MD.)

are the most common location (Fig. 154-1).[11] Extensive petechiae with central necrosis or bullae may also develop. Although the presence of petechiae do not predict the risk of mortality, a rapid increase in their number and size correlates with fulminant disease progression.[15] Purpura fulminans may occur with severe disseminated intravascular coagulation (DIC) caused by sepsis, characterized by retiform purpura and necrosis of the skin, which may extend to subcutaneous tissues and, occasionally, muscle and bone (Fig. 154-2). Patients affected by DIC and purpura fulminans tend to have low levels of protein C.[13,16] In some cases of acute meningococcemia, patients may display transient macular or papular eruptions, similar to those seen in viral exanthems.[17]

Cutaneous manifestations of chronic meningococcemia are polymorphous, and may fade and recur with intermittent fevers. Skin findings often occur around painful joints or pressure points, and, from most common to least common, include (a) rose-colored macules and papules, (b) slightly indurated and tender erythema nodosum-like nodules, (c) petechiae, (d) petechiae with vesicular or pustular centers, (e) minute hemorrhages with an areola of paler erythema, and (f) grossly hemorrhagic areas with pale blue-gray centers.[18]

NONCUTANEOUS FINDINGS

Patients with acute meningococcemia may present with lethargy, anorexia, headache, nausea/vomiting,

myalgias, arthralgias, cold or discolored extremities, hypotension, altered mental status, renal failure, acute respiratory distress syndrome, and DIC.[9,13] With severe DIC, the patient is at risk for Waterhouse-Friderichsen syndrome, a life-threatening condition characterized by adrenal hemorrhage and ensuing adrenal crisis, often accompanied by purpura fulminans.[13,16] With breach of the blood–brain barrier, patients may develop meningococcal meningitis, which is marked by meningism (nuchal rigidity, headache, photophobia), fever, nausea/vomiting, and altered mental status. Kernig and Brudzinski signs may become positive.[9] Rarely, meningococcemia may lead to septic foci in other locations, including septic arthritis, purulent pericarditis, and bacterial endocarditis. More commonly, a delayed immune complex-mediated syndrome can occur while patients are in recovery, which may include a range of symptoms due to sterile arthritis, vasculitis, pleuritis, pericarditis, or episcleritis.[19,20]

COMPLICATIONS

Severe cases of meningococcemia may require amputation of digits or extremities, as well as extensive skin grafting.[9] Purpura fulminans, in particular, frequently leads amputation and scarring, and may even cause abnormal bone growth in children.[13] Survivors of severe meningococcemia may require weeks of mechanical ventilation or dialysis.[9] With meningitis, the most common sequela is sensorineural hearing loss or deafness, although seizures, motor problems, hydrocephalus, mental retardation, and cognitive and behavioral problems may also occur.[9,13]

In some cases, chronic meningococcemia can evolve into acute meningococcemia, meningitis or carditis.[14,21] In one case report, a patient thought to have Sweet syndrome was treated with corticosteroids and subsequently developed meningococcal meningitis. Retrospective, nonroutine polymerase chain reaction (PCR) and silver staining of skin biopsy specimens revealed chronic meningococcemia.[14]

ETIOLOGY AND PATHOGENESIS

N. meningitidis is known to reside in the nasopharynx of healthy individuals, and can be transferred from person to person via respiratory droplets or by direct contact, such as kissing. When invasive disease occurs, it typically arises within 2 weeks of acquisition.[11]

Meningococci adherent to the nasopharyngeal epithelium undergo phase variation of Type IV pili and opacity proteins. In the development of invasive disease, *N. meningitidis* traverses epithelial cells via parasite directed endocytosis, entering capillaries and small veins in the underlying submucosal tissue.[4] Once in the bloodstream, *N. meningitidis* preferentially adheres to microvessel endothelium where it proliferates rapidly, forming microcolonies. Type IV pili facilitate both adherence and crosstalk with endothelial cells, ultimately leading to reshaping of endothelial cell membranes with formation of filopodia-like protrusions.[7] *N. meningitidis* adherence and presence of LOS triggers the production of proinflammatory cytokines of the innate immune system, including interleukin (IL)-6, IL-8, and tumor necrosis factor-α, which also contribute to endothelial damage.[22] Vascular damage alters endothelial antithrombotic properties, leading to widespread thrombosis. This is associated with blood flow alterations, red blood cell congestion, vessel engorgement, and leakage. Edema, infarction of overlying skin, and red blood cell extravasation are responsible for the cutaneous findings associated with acute meningococcemia. Of note, even though *N. meningitidis* is tightly adherent to endothelial cells, it may not always be present in the bloodstream to a great extent. Thus, some patients may show negative blood cultures despite large quantities of bacteria adherent to the microvessels.[22]

In some patients, *N. meningitidis* develops a remarkably tight interaction with endothelial cells of the brain microvasculature, characterized by the assembly of "cortical plaques," comprised of actin and other proteins, beneath the adherent bacteria. This interaction, also mediated by Type IV pili, facilitates compromise of the blood–brain barrier, enabling infection of the subarachnoid spac.[6,9] *N. meningitidis* continues to proliferate in the cerebrospinal fluid (CSF) to levels 10^3 to 10^5 times those seen in the blood, leading to production of proinflammatory cytokines and meningism.[9] While other causes of bacterial meningitis, such as *Streptococcus pneumoniae*, may seed the brain, leading to focal neurologic signs, this typically does not happen with *N. meningitidis.*

In chronic meningococcemia, bacteria adhere to microvasculature endothelium, and although nonpurpuric lesions do not reveal disruption of microvasculature under light microscopy, both purpuric and nonpurpuric lesions reveal *N. meningitidis* in the extravascular space. Studies indicate a role for *N. meningitidis*–driven remodeling of interendothelial junctions, leading to meningococcal perivascular invasion via the paracellular route in chronic meningococcemia.[23]

RISK FACTORS

The single greatest risk factor for disseminated meningococcal disease is a lack of bactericidal antibodies.[9] Patients with anatomic or functional asplenia, HIV infection, or defects in the terminal (C5 to C9) or alternative complement pathways are at increased risk, as well. Specifically, a deficiency in properdin, a positive regulator of the alternative complement pathway confers increased susceptibility.[6] Other at-risk groups include adolescents and young adults living in crowded conditions, such as military barracks

or college dormitories, infants and young children in daycare centers, and those exposed to tobacco smoke.[4,11]

DIAGNOSIS

Initial diagnosis of *N. meningitidis* infection is typically clinical, as systemic infection constitutes a medical emergency, and treatment should not be delayed waiting for test results. Blood cultures should be swiftly collected and empiric antimicrobial therapy administered immediately. Lumbar puncture is also warranted, in addition to fluid collection from other bodily sites of suspected dissemination; however, such tests should never delay therapy.[13]

LABORATORY TESTING

The gold standard for diagnosis is culture isolation of *N. meningitidis* from blood, CSF, synovial fluid, pleural fluid, pericardial fluid, or skin biopsy tissues. This enables etiologic confirmation as well as determination of antibiotic susceptibility.[11] In acute meningococcemia, blood cultures may be positive in 40% to 80% of patients, and sensitivity declines quickly following initiation of antibiotics.[24] Cultures from CSF and other organ sites may also have a low sensitivity, especially once antibiotics are started. In one study of 9 children with positive CSF cultures, 1 child had sterile CSF within 15 minutes of antibiotic administration, 3 had sterile CSF within 1 hour, and all were sterile within 2 hours. By comparison, CSF sterilization in pneumococcal or group B streptococcal infection typically takes several hours.[25] In the setting of meningococcal meningitis, CSF leukocytes typically exceed 100×10^6/L with elevated protein and decreased glucose; however, 1 or more of these classic findings may be absent.[9]

The skin may provide another site for bacterial isolation, either via needle aspiration of cutaneous lesions or punch biopsy. One study isolated *N. meningitidis* from 86% of meningococcemia patients via needle aspiration,[26] and another study found 72% sensitivity among patients evaluated with either needle aspiration or biopsy.[21] In contrast to blood and CSF, meningococci have been cultured from skin lesions up to 13 hours following antibiotic administration.[9] In a prospective study of 31 patients and 12 controls, the sensitivities of blood, CSF, and skin biopsy cultures were 56%, 50%, and 36%, respectively. When culture and Gram staining were combined, the sensitivities were 56% (blood), 64% (CSF), and 56% (skin biopsy). In 3 patients, the diagnosis was made on positive skin biopsy results alone.[27]

Given suboptimal sensitivities of cultures and Gram staining, patients with a high suspicion for infection despite negative workup may benefit from PCR. Although PCR cannot determine antibiotic sensitivities, it can quickly type *N. meningitidis* strains. PCR is highly sensitive (96%) and specific (100%), and because live bacteria are not required, sensitivity is not diminished by initiation of antibiotics. Additionally, PCR takes less than 4 hours, and in-house test results are typically available the same day as collection.[28] Despite these advantages, cultures have not been replaced by PCR given that it cannot determine sensitivities and does not have widespread availability. For these reasons, PCR for blood and CSF is indicated when cultures are uninformative and is not typically employed in initial diagnostic workup.[21]

PCR is also being investigated in skin biopsy specimens, which may offer even higher sensitivity compared to PCR of blood or CSF samples.[11] This testing modality may be especially useful in chronic meningococcemia as skin lesions are nonspecific, and positive cultures may be more difficult to come by because of waxing and waning bacterial levels. At least 4 cases of chronic meningococcemia have been reported with negative blood cultures, and diagnosis was established based on PCR of skin biopsies alone.[14,21,23] Silver staining and immunohistochemical staining of skin lesions also may be useful in both acute and chronic cases of meningococcal disease.[14,29]

Additional tests used in meningococcal meningitis include a latex agglutination assay and rapid dipstick test. Agglutination kits use latex beads with antibodies to capsular antigens, capable of detecting serogroups A, C, W135, and Y, with significantly lower sensitivity for serogroup B. This is problematic given the high proportion of serogroup B infections in the United States and Europe, and for this reason, latex agglutination tests are not routinely performed.[30] The rapid dipstick test, developed to detect serogroups A, C, W135, and Y in CSF, was found to detect 90% of meningitis cases caused by A and W135 in Niger when compared to PCR. Given the favorable sensitivity and ability to be administered by nonspecialized staff members, this test is especially valuable in developing countries.[31]

PATHOLOGY

Routine pathology of skin biopsy specimens may reveal findings consistent with necrotizing vasculitis,[32] including perivascular infiltrates comprised of neutrophils and monocytes with microvascular thrombosis and perivascular hemorrhage.[13,22] Gram stain may reveal Gram-negative cocci.[32] In the setting of chronic meningococcemia, perivascular infiltrates are comprised of lymphocytes and neutrophils, and leukocytoclastic vasculitis may be appreciated in petechial lesions.[12]

DIFFERENTIAL DIAGNOSIS

Table 154-1 outlines the differential diagnosis for acute and chronic meningococcemia.

TABLE 154-1
Differential Diagnosis for Acute and Chronic Meningococcemia

CONDITIONS	CONSIDERATIONS
Acute Meningococcemia	
Enteroviral infection	Patients may present with fever, aseptic meningitis, and petechial rash.
Sepsis caused by another bacterial organism	Although classically associated with *Neisseria meningitidis*, purpura fulminans may occur with *Streptococcus pneumoniae*, *Haemophilus influenzae*, *Staphylococcus aureus*, and groups A and B β-hemolytic streptococci.
Acute bacterial endocarditis	Mucous membrane and conjunctival lesions, as well as subungual splinter hemorrhages, may be present. Petechial eruptions may be seen in acute *S. aureus* endocarditis.
Toxic shock syndrome	Presents with fever, rash (macular erythema), and hypotension.
Rocky Mountain spotted fever	Patients present with fever, myalgias, and headache. A rash may follow 3 to 5 days later; petechiae are seen in 50% of cases.
Leptospirosis	Patients have fevers and myalgias, may develop meningitis and/or petechial rash.
Chronic Meningococcemia	
Disseminated gonococcemia	Triad of "dermatitis", migratory polyarthritis, and tenosynovitis may be present.
Sweet syndrome	Fever, neutrophilia, arthralgias, and painful erythematous plaques, which may be recurrent.
Subacute bacterial endocarditis	May include a polymorphous petechial rash and/or joint symptoms in the setting of prolonged fever.
Cutaneous small vessel vasculitis	Occurs in Henoch-Schönlein purpura, or may be secondary to connective tissue disease (rheumatoid arthritis, Sjögren syndrome, systemic lupus erythematosus), infections, or drugs. Characterized by palpable purpura, although eruption may be polymorphous and episodic, occurring with fever and arthralgias. Henoch-Schönlein purpura may include abdominal pain, melena, and hematuria.
Rat-bite fever	Paroxysmal fever, migratory polyarthritis in 50% of cases, and rash 2 to 4 days following fever onset; classically, red-purple macules and papules.
Rheumatic fever	Fever, migratory polyarthritis, and cutaneous findings (erythema marginatum may occur in recurrent crops).

CLINICAL COURSE AND PROGNOSIS

If untreated, acute meningococcal infection usually ends fatally and is capable of killing previously heathy children and adults in as few as 12 hours.[4] *N. meningitidis* proliferates rapidly, leading to shock and multiple organ failure, which is the direct cause of death in 9 of 10 patients who die from acute meningococcal infection in developed countries. Far fewer patients die from meningitis leading to brain edema and herniation.[9] With chronic meningococcemia, some patients may spontaneously recover, although without treatment the infection is more likely to worsen, potentially progressing to affect vital functions and lead to death. For treated chronic meningococcemia, prognosis is excellent.[21]

As of 2012, mortality rates for meningococcal infection were 10 to 15% in the United States, and among survivors, 11% to 19% suffered from long-term sequelae such as limb loss, hearing loss, cognitive dysfunction, visual impairment, educational difficulties, motor nerve deficits, seizure disorders, and behavioral problems.[4,33] In a study of 752 patients in the Netherlands presenting with meningococcal disease over a 28-month period, case fatality rate was 6.7% overall, but reached 16% in adults older than age 50 years. Approximately half of all fatalities died within 12 hours of arriving at the hospital, with two-thirds passing away within 24 hours.[15]

MANAGEMENT

The single most important factor in the treatment of acute meningococcal infection is early initiation of antibiotics. Ideally, no more than 30 minutes should pass between a presumptive diagnosis and administration of intravenous therapy. Diagnostic testing should never be a reason for delayed treatment.[34] Although less emergent, chronic meningococcemia is treated with similar antibiotic regimens and all patients should be offered a comprehensive immunologic workup including complement pathway deficiencies after the infection has been effectively treated.[14]

MEDICATIONS

Prior to obtaining antibiotic sensitivity results, patients should be treated with a third-generation cephalosporin such as ceftriaxone or cefotaxime. If testing reveals a penicillin minimum inhibitory concentration less than 0.1 µg/mL, penicillin G or ampicillin may be used.[30] For patients who are allergic to penicillin and cephalosporin, chloramphenicol is an alternative.[34] During outbreaks in sub-Saharan Africa a single dose

of intramuscular long-acting chloramphenicol or ceftriaxone may be used.[35] As a result of significant antibiotic resistance, ciprofloxacin and sulfonamides are no longer recommended.[4] Standard antibiotic duration is 7 days.[11,30]

For cases complicated by septic shock, patients may require large volumes of fluids, as well as vasoactive drugs.[9] Although not widely available, patients with purpura fulminans may benefit from protein C concentrate, which has improved survival and limited amputations in small studies.[36] Although useful in pneumococcal meningitis, dexamethasone has not shown any benefit in meningococcal meningitis and should not be given in these patients.[37]

PROCEDURES

Patients with extensive necrosis and limb ischemia may require surgical debridement, skin grafting, muscular flap coverage for limb salvage, and/or amputation of digits or limbs.[13]

PREVENTION

Meningococcal disease can be prevented through population-wide vaccination and antibiotic chemoprophylaxis in close contacts of infected patients. Droplet precautions should be maintained from presumptive diagnosis until at least 24 hours after initiation of an effective antibiotic regimen.[11,30]

Chemoprophylaxis: Close contacts are defined as those who have had prolonged contact (>8 hours) within close proximity (<3 feet) of an infected patient, or those who have had direct exposure to the patient's oral secretions from 7 days before the onset of symptoms until 24 hours following initiation of effective antibiotics.[11] This may include family, friends, romantic partners, roommates, colleagues, contacts at school or daycare centers, contacts in college dormitories or military training centers, or travelers seated directly next to the patient on a long flight. As chemoprophylaxis is not warranted in those with brief contact, most health care workers do not require treatment, unless they have had direct exposure to respiratory secretions via suctioning or intubation.[33]

In ideal situations, chemoprophylaxis in those meeting criteria should be initiated within 24 hours of identification of an index patient. Otherwise, treatment should be initiated as soon as possible. Chemoprophylaxis administered more than 14 days after exposure is not recommended.[33] Antibiotics recommended for chemoprophylaxis include rifampin (children and adults; 4 doses given over 2 days), ciprofloxacin (adults; single dose), and ceftriaxone (children, adults, and pregnant women; single intramuscular dose). Rifampin and ciprofloxacin are not recommended in pregnancy.[11,33,34]

Vaccination: In the United States, there are several meningococcal vaccines available (Table 154-2). The Advisory Committee on Immunization Practices recommends immunization with a conjugate quadrivalent vaccine, Menactra or Menveo, for all patients 11 to 18 years old. Ideally, patients should be vaccinated at 11 or 12 years old with a booster at age 16 years. If the first dose is given at age 16 years or older, a booster is not needed.[33,38] In adolescents receiving Menactra, the effectiveness of inducing immunity is estimated to be approximately 80% to 85%.[39] Serogroup B meningococcal vaccines, Bexsero and Trumenba (licensed by the FDA in 2015 and 2014, respectively), are also recommended in the United States for certain high-risk patients age 10 years and older. For patients who are not high-risk, routine vaccination has not been recommended. However, clinical discretion may be used for elective administration in patients 16 to 23 years old, with preferred ages for vaccination between 16 years and 18 years.[38,40] The Advisory Committee on Immunization Practices outlines special vaccination guidelines for high-risk individuals, including those with asplenia, complement deficiencies (C3, C5 to C9, properdin, factor D, factor H), HIV, microbiologists routinely working with *N. meningitidis*, military recruits, college freshmen living in dormitories, and those traveling or residing in areas where meningococcal disease is epidemic or hyperendemic (eg, countries in the meningitis belt of sub-Saharan Africa during dry season or Mecca, Saudi Arabia, during the annual Hajj).[33,38]

TABLE 154-2
Meningococcal Vaccines Available in the United States

VACCINE	SEROGROUPS	TYPE OF VACCINE
Menactra (MenACWY-DT)	A, C, W-135, Y	Polysaccharide conjugate with diphtheria toxoid
Menveo (MenACWY-CRM)	A, C, W-135, Y	Polysaccharide conjugate with mutant diphtheria toxin (CRM197)
Menomune (MPSV4)	A, C, W-135, Y	Polysaccharide, unconjugated
MenHibrix (HibMenCY)	**C, Y,** ***Haemophilus influenzae*** **type b**	Polysaccharide conjugate with tetanus toxoid
Bexsero (MenB-4C)	B	Includes 3 recombinant proteins—neisserial adhesion A (NadA), factor H binding protein (FHbp), and neisserial heparin binding antigen (NHBA)—as well as outer membrane vesicles (OMV) from a New Zealand epidemic strain (NZ98/254)
Trumenba (MenB-FHbp)	B	Includes 2 recombinant FHbp antigens

INFECTIONS CAUSED BY *PSEUDOMONAS AERUGINOSA*

AT-A-GLANCE

- *Pseudomonas aeruginosa* is a ubiquitous Gram-negative rod, with a predilection for aqueous environments. It may be recognized by its sweet, grape-like odor and blue-green color conferred by pyocyanin pigment.
- *P. aeruginosa* is an important cause of nosocomial and ventilator-acquired pneumonia, cystic fibrosis lung infections, urinary tract infections in catheterized patients, and secondary cutaneous infection of burns, diabetic foot ulcers, surgical incision sites, and puncture wounds.
- Primary cutaneous infections, such as green nail syndrome, toe web infection, folliculitis, hot-foot syndrome, external otitis, and perichondritis typically necessitate a breach in skin integrity.
- Pseudomonal folliculitis and hot-foot syndrome are self-limited. The majority of other localized *P. aeruginosa* infections improve rapidly with topical or oral therapy, except for malignant otitis externa, which is invasive with a mortality rate of approximately 20%.
- Bacteremia and ecthyma gangrenosum typically affect hospitalized immunocompromised hosts, especially those with neutropenia.
- *P. aeruginosa* bacteremia is associated with higher mortality than bacteremia caused by other Gram-negative organisms. Mortality for patients with ecthyma gangrenosum ranges from 30% to 70%.
- Patients with serious *P. aeruginosa* infection require prompt initiation of systemic antibiotics with antipseudomonal activity. Drug resistance, including multidrug-resistant *P. aeruginosa* is a major challenge for therapy.

INTRODUCTION AND BACTERIOLOGY

Pseudomonas aeruginosa is an oxidase-positive, non-lactose fermenting, obligately aerobic Gram-negative rod with motility conferred by a single flagellum. It has a characteristic blue-green color and grape-like odor and can grow at temperatures up to 42°C (107.6°F). *P. aeruginosa* produces pyoverdin, a green-yellow pigment that fluoresces under a Wood lamp and is common to all fluorescent *Pseudomonas* species. It also produces pyocyanin, a blue-green nonfluorescent pigment specific to *P. aeruginosa.* It grows on blood, tryptic soy, and cetrimide agar, as well as MacConkey agar, where colonies appear white because of an absence of lactose fermentation.[41,42]

P. aeruginosa cutaneous infections typically necessitate a breach in skin integrity, as caused by maceration, dermatophyte infection, indwelling catheters, trauma or burns. Invasion of the skin and subcutaneous tissues is attributed to alkaline protease, protease IV, and elastases, which degrade cutaneous structures, and components of the host immune system. When *P. aeruginosa* makes contact with host cells, a Type III secretion may be activated by which exoenzymes (ExoS, ExoT, ExoU, and ExoY) are directly translocated into the host cell. ExoS interacts with TLRs to induce tumor necrosis factor-α production, ExoT binds adenosine diphosphate–ribosyltransferase, ExoU damages cell membranes, and ExoY binds adenylate cyclase.[43,44] *P. aeruginosa* also secretes exotoxin A, which inhibits eukaryotic elongation factor 2 via adenosine diphosphate–ribosylation, similar to diphtheria toxin, thereby inhibiting elongation of polypeptides during protein synthesis, leading to cell death.[43] Patients with higher serum levels of anti–exotoxin A antibodies experience milder *P. aeruginosa* septicemia.[44] Additional *P. aeruginosa* virulence factors include lipopolysaccharide, a TLR4 agonist and septic shock mediator common to other Gram-negative bacteria[45]; pyocyanin, which exerts proinflammatory and oxidative effects[46]; pyoverdin and pyochelin iron scavengers; and quorum sensing, which involves intercellular signaling to coordinate gene transcription and mediation of other virulence factors, such as biofilm formation.[44]

During prolonged colonization, *P. aeruginosa* may convert to a mucoid phenotype via overproduction of alginate, which scavenges macrophage free radicals, impairs phagocytosis, inhibits neutrophil chemotaxis and complement activation, and enables biofilm formation. Biofilms are particularly important in the setting of wound infections and osteomyelitis, vascular and urinary catheter-associated infections, lung infections in cystic fibrosis, and endocarditis in intravenous drug users where they confer resistance to antibiotics, as well as host immunity. Other mechanisms of antibiotic resistance include multidrug efflux pumps, beta-lactamases and downregulation of porins in the outer membrane bilayer.[43]

EPIDEMIOLOGY

P. aeruginosa is a ubiquitous bacterium, with a predilection for aqueous environments. It can be recovered from virtually any environmental water source, and its hardiness enables survival even under the nutritionally stringent conditions of distilled water where it uses dissolved gases and residual ions for growth. *P. aeruginosa* has been identified in the conjunctival microflora and feces of healthy patients, and has been isolated from practically every source within hospitals, from water reservoir systems to the hands of health care workers.[42,43]

While *P. aeruginosa* can cause minor infections in otherwise healthy patients with a compromised skin barrier, *P. aeruginosa* is an important cause of major, life-threating infections in immunocompromised patients, such as those with uncontrolled diabetes, neutropenia, hematologic disorders, cancer, or transplanted organs, or those receiving prolonged treatment with steroids or antibiotics.[44] *P. aeruginosa* accounts for 4% to 6% of all hospital-acquired bloodstream infections, although rates may be as high as 20% in intensive care units.[43] It is the number one pathogen responsible for lung injury among ventilator-dependent patients and those with cystic fibrosis, the second most common cause of nosocomial pneumonia, and the third most common cause of urinary tract infection, especially in catheterized patients. *P. aeruginosa* is frequently isolated from burn wounds, diabetic foot ulcers, surgical incision sites, and puncture wounds.[43,44,47] The growing presence of *P. aeruginosa*, especially in hospital settings, has been attributed to antibiotic use. Among 200 hospitals in the United States, *P. aeruginosa* multidrug resistance was 22% in the setting of pneumonia and 15% among bloodstream infections.[48]

CLINICAL FEATURES

P. aeruginosa cutaneous infection may occur from direct inoculation, typically in the setting of skin-barrier compromise, or secondary to *P. aeruginosa* bacteremia. Local conditions associated with direct inoculation include green nail syndrome, toe web infection, folliculitis, hot-foot syndrome, external otitis, and perichondritis, whereas ecthyma gangrenosum and nonspecific cutaneous findings, most commonly subcutaneous nodules, are associated with bacteremia (Table 154-3).

CUTANEOUS FINDINGS

Green Nail Syndrome and Toe Web Infection: Green nail syndrome, or chloronychia, is characterized by nail dyspigmentation that may be greenish-yellow, greenish-blue, greenish-brown, or greenish-black. Dyspigmentation results from the accumulation of debris and pyocyanin, which adheres to the underside of the nail plate. It may affect the entire or partial nail and is typically limited to one or two digits. Many patients present with a triad of dyspigmentation, onycholysis, and paronychia (Fig. 154-3).[41,42,49]

P. aeruginosa toe web infection presents with thickened, macerated skin with a characteristic moth-eaten appearance and yellow-green purulence.[12,41] Vesicles, pustules, and erosions may be present with a hyperkeratotic rim. The infection can affect toe web spaces, as well as the sole of the foot, and patients sometimes complain of burning and pain.[42]

Folliculitis and Hot-Foot Syndrome: *P. aeruginosa* folliculitis, commonly "hot tub folliculitis," presents with discrete, follicular papules and pustules that heal with fine desquamation and hyperpigmented macules. Urticarial lesions may occur in some patients. Onset is sudden, approximately 24 hours following exposure to contaminated hot tubs or whirlpools and may be associated with pruritus or pain. Commonly affected areas include the upper trunk, axillary folds, hips, and buttocks, typically including areas covered by the patient's bathing suit (Fig. 154-4A). The Montgomery (areolar) glands may be affected in both sexes.[41,42] Of note, acne patients treated with long courses of tetracycline antibiotics occasionally may develop folliculitis caused by Gram-negative bacteria, including *P. aeruginosa.*

A related entity, hot-foot syndrome, has been described following emersion in contaminated wading pools and hot tubs, usually in children. It presents with acute painful, erythematous, warm plantar nodules. One report described an outbreak of hot-foot syndrome among 40 children within approximately 40 hours of spending time in a wading pool with a rough, abrasive floor.[50] Another report described similar findings on both the soles and palms of 33 children following use of a contaminated hot tub (see Fig. 154-4B, C).[51]

External Otitis and Perichondritis: Otitis externa, or "swimmer's ear," is characterized by acute onset of edema and erythema or discoloration of the external auditory canal, sometimes with maceration, discharge and/or regional lymphadenopathy. There is often tenderness with tragal pressure or movement of the pinna, and patients may complain of pruritus.[41,52] Although the condition is most common among children 5 to 14 years of age, it can occur in all age groups following submersion of the head in water.[53]

In elderly patients, especially those with diabetes, external otitis may progress to life-threatening malignant otitis externa, an invasive condition leading to skull-base osteomyelitis. Malignant otitis externa is characterized by an insidious onset with edema, erythema, and persistent discharge from the ear canal with severe pain that appears disproportionate to examination findings. Early cases usually lack fever or constitutional symptoms. The presence of granulation tissue in the floor of the external auditory canal at the bony–cartilaginous junction is a classic finding, and frank necrosis of the canal also may be present. Tympanic membrane visualization is often blocked by discharge and granulation tissue.[41,42]

Perichondritis of the ear helix or tragus may be caused by *P. aeruginosa* following commercial piercings as a result of contaminated cleansing agents, as well as following trauma or acupuncture.[42] The ear is typically swollen, erythematous, and tender, and prompt treatment is essential because of rapid progression to cartilage necrosis.

Bacteremia and Ecthyma Gangrenosum: *P. aeruginosa* bacteremia is associated with cutaneous manifestations in approximately one-third of cases, the most recognized of which include subcutaneous nodules, ecthyma gangrenosum, and gangrenous cellulitis, although pustules, abscesses, vesicles, bullae, petechiae, and maculopapular eruptions also have been reported.

TABLE 154-3

Summary Table for *Pseudomonas aeruginosa* Infection

	CLINICAL FEATURES	RISK FACTORS	LABORATORY TESTS	COURSE AND PROGNOSIS	MANAGEMENT
Green nail syndrome	Greenish-yellow, greenish-blue, greenish-brown, or greenish-black dyspigmentation of the nail (chloronychia)	Prolonged submersion in fresh water	Nail specimens for culture Wood lamp: white and green fluorescence	Responsive to treatment	Detachment of nail plate and topical antimicrobial for 1 to 4 months; acetic acid soaks Preventive measures
***Pseudomonas* toe web infection**	Thickened, macerated skin with moth eaten appearance and yellow-green purulence; web space and sole of foot may be affected	Persistently wet feet in heat and humidity			Usually, both antifungal and antibacterial therapy are required; topical antibacterials (gentamicin) or oral antibacterials; Castellani paint, gentian violet, acetic acid soaks
***Pseudomonas* folliculitis**	Discrete, follicular papules and pustules of sudden onset (24 hours following exposure); upper trunk, axillary folds, hips and buttocks typically affected	Recreational use of hot tubs, whirlpools, swimming pools	Unroofing pustule and bacterial culture Punch biopsy of nodules (for hot-foot syndrome) Water sample of suspected sources	Self-limited	Avoidance of predisposing factors; symptomatic care Oral antibiotics (ciprofloxacin) for protracted cases or significant discomfort
Hot-foot syndrome	Acute painful, erythematous, warm plantar nodules				
External otitis and perichondritis	Acute-onset edema, erythema, and discoloration of the external auditory canal; tenderness with tragal pressure; severe pain disproportionate to examination findings may indicate malignant otitis externa	Swimmers with prolonged excess moisture in the ear canal, use of ear-occluding devices; dermatologic conditions affecting skin integrity of the auditory canal	Otoscopy (to rule out otitis media) Cultures of ear discharge Blood cultures (if constitutional symptoms present)	Malignant otitis externa is invasive with 20% mortality	Antimicrobial ear drops, wick placement for severe disease; oral antibacterials (ciprofloxacin) for severe cases or immunocompromised patients; perichondritis: drainage and extended antibacterial therapy (6 to 8 weeks); malignant otitis externa warrants referral to a surgical otolaryngology service
Bacteremia and ecthyma gangrenosum	Subcutaneous nodules, cellulitis, pustules, absent	Neutropenia, hematologic malignancy, CD4+ lymphocyte count <50 cells/mm^3	Biopsies reveal necrotizing or hemorrhagic vasculitis, epidermal and dermal necrosis	Bacteremia: 30-day mortality rate of 39%; ecthyma gangrenosum: 30% to 70% mortality rate	Prompt intravenous empiric therapy with an antipseudomonal β-lactam

Figure 154-3 *Pseudomonas* green nail syndrome often occurs in those with preexisting onycholysis, especially when frequently submerged in fresh water. (Reproduced with permission from Shemer A, Daniel CR. Common nail disorders. *Clin Dermatol.* 2013;31(5):578-586. Copyright © Elsevier.)

Subcutaneous nodules are typically warm, erythematous, indurated, usually nonfluctuant, and they may be painful or painless. They have been reported on the face, neck, chest, abdomen, back, and extremities.[41,42]

Ecthyma gangrenosum is responsible for necrotic cutaneous lesions associated with *P. aeruginosa* bacteremia, especially in neutropenic patients, although, rarely, bacteremia may be absent. It begins with a painless, infarcted gunmetal gray macule or papule with surrounding erythema. As the ecthyma develops, the lesion becomes more indurated and pustules or hemorrhagic bullae may develop. Over a rapid course of 12 to 18 hours the patient is left with a necrotic, ulcerative eschar with a halo of tender erythema (Fig. 154-5). Ecthyma gangrenosum may be solitary or numerous, with lesions most commonly affecting the anogenital region (57%), extremities (30%), trunk (6%), and face (6%).[42,54,55]

NONCUTANEOUS FINDINGS

Even in the absence of bacteremia, mild *P. aeruginosa* infections, such as folliculitis or otitis externa, may present with fever and malaise. As bacteremic patients progress to sepsis, they may present with fever, tachycardia, tachypnea, altered mental status, and hypotension. Most patients with ecthyma gangrenosum present with fever and other constitutional signs, although sometimes these may be absent.

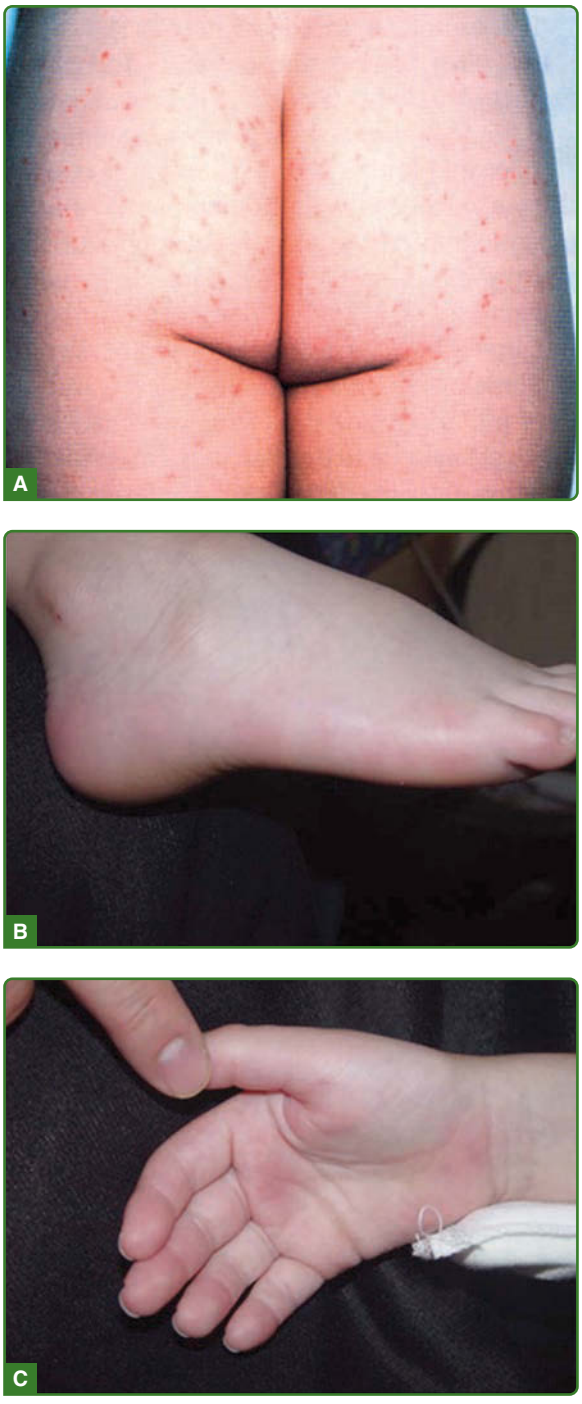

Figure 154-4 Exposure to contaminated hot tubs, whirlpools, or wading pools may lead to pseudomonal folliculitis, typically affecting areas covered by the patient's bathing suit (**A**). Children may present with hot-foot syndrome, characterized by painful, erythematous plantar nodules (**B**), which may also affect the palms (**C**). (Image **A,** Used with permission from Kenneth E. Greer, MD. Previously published in Wortman PD. Bacterial infections of the skin. *Curr Probl Dermatol*. 1993;5[6]:197-224; and Images **B** and **C,** from Yu Y, Cheng AS, Wang L, et al. Hot tub folliculitis or hot hand–foot syndrome caused by *Pseudomonas aeruginosa*. *J Am Acad Dermatol*. 2007;57[4]:596-600.)

Figure 154-5 This patient with ecthyma gangrenosum has multifocal gunmetal gray, necrotic ulcers scattered across the suprapubic area with halos of erythema. (Reproduced with permission from Cresce N, Marchetti MA, Russell M. A sea sickness? Ecthyma gangrenosum. *Am J Med*. 2014; 127[7]:592-594. Copyright © Elsevier.)

Both otitis externa and malignant otitis externa may lead to severe swelling of the external auditory canal, producing conductive hearing loss. As necrosis and osteomyelitis associated with malignant otitis externa progresses, patients may experience cranial nerve palsies, most commonly affecting the facial nerve, as well as trismus, or lockjaw, when the temporomandibular joint is affected.[42]

ETIOLOGY AND PATHOGENESIS

GREEN NAIL SYNDROME AND TOE WEB INFECTION

Green nail syndrome typically occurs in patients whose digits are subjected to prolonged submersion in fresh water, especially with soap or detergents. Patients whose nailbeds are more easily accessible to pathogens due to onycholysis, chronic paronychia or other nail disorders, such as psoriasis, are particularly at risk.[49]

Pseudomonas toe web infection is found in patients with persistently wet feet as a consequence of closed-toe, tight-fitting shoes, occupational or recreational exertion, and/or warm, humid weather. Infection may also occur secondarily in the setting of tinea pedis.[41]

FOLLICULITIS AND HOT-FOOT SYNDROME

Pseudomonal folliculitis and hot-foot syndrome occur following recreational use of hot tubs, whirlpools, and, less commonly, swimming pools that lack adequate halogenation. Folliculitis outbreaks most commonly occur following submersion in water heated above 38 °C, as *P. aeruginosa* is heat tolerant, and infection risk increases with duration of bathing. The most frequent *P. aeruginosa* serotype isolated from pseudomonal folliculitis is O-11, although serotypes O-4, O-6, and O-9 also have been implicated.[41,42]

EXTERNAL OTITIS

Pathogenesis of external otitis is best understood through examination of basic anatomy and physiology of the external auditory canal. The outer cartilaginous portion is lined with skin containing cerumen glands, sebaceous glands, and hair follicles. The inner bony portion contains thin skin devoid of adnexal structures and a dermis that is in direct contact with underlying periosteum. Cerumen provides a sticky, hydrophobic protective layer that repels water and traps fine debris, as well as an antimicrobial lysozyme and pH of 6.9, which discourage microbial growth. The canal is self-cleaning by lateral epithelial migration, a process that slows with age.

Those at risk for external otitis include swimmers with prolonged excess moisture in their ear canal, those who scratch or aggressively clean their ears, use ear-occluding devices such as earphones or hearing aids, or suffer from dermatologic conditions such as psoriasis, atopic dermatitis or seborrheic dermatitis. Any of these factors may contribute to breakdown of the skin-cerumen barrier in the external auditory canal. This breakdown then triggers inflammation, pruritus (with further scratching), edema and obstruction, ultimately leading to changes in the quantity and quality of cerumen production, impaired epithelial migration and increased pH of the canal, creating an environment hospitable to microorganisms. *P. aeruginosa* is involved in approximately 50% of external otitis cases, and is by far the most common etiologic agent. The next most common cause is *Staphylococcus aureus,* followed by a variety of other aerobic bacteria, anaerobes, and fungi.[56,57]

In malignant otitis externa, *P. aeruginosa* invades the soft tissues at the bony–cartilaginous junction of the external canal, which may lead to infection and necrosis of the cartilage, mastoid process, temporal bone, and, eventually, the base of the skull. The predominance of malignant otitis externa in elderly diabetic patients may be the result of microangiopathy of the ear canal, as well as an increased pH of diabetic cerumen. Although elderly diabetics are the most commonly affected group, malignant otitis externa has also been reported in younger, nondiabetic patients with HIV, as well as in nondiabetic elderly people following aural surgery or water irrigation. Overall, more than 95% of cases are caused by *P. aeruginosa,* although malignant otitis externa in HIV patients also may be caused by *Aspergillus* spp.[58]

BACTEREMIA AND ECTHYMA GANGRENOSUM

P. aeruginosa bacteremia is usually seen in hospitalized patients, especially those with neutropenia, hematologic malignancy, CD4+ lymphocyte count less than

50 cells/mm^3, or other immunocompromised states. Those with recent courses of antimicrobial therapy, chemotherapy, invasive devices, or surgical procedures are also at higher risk.[43,59] Bacteremia may occur as a result of direct bloodstream inoculation, such as through an intravenous catheter, or secondary to invasive infection. Primary infection sites commonly leading to bacteremia include the lungs, urinary and GI tracts, and skin and soft tissues, especially wound infections.[60] Pseudomonal skin infections that typically remain localized in immunocompetent patients may become a source of bacteremia in immunocompromised patients. For example, pseudomonal toe web infection may progress to cellulitis, osteomyelitis and sepsis, especially in overweight persons with diabetes.[61]

Approximately 1.3% to 3% of patients with *P. aeruginosa* bacteremia develop ecthyma gangrenosum from perivascular bacterial invasion of the media and adventitia of small veins and arteries. Rarely, ecthyma gangrenosum caused by *P. aeruginosa* has been reported in the absence of bacteremia.[55,62] Although *P. aeruginosa* is the most well-known cause of ecthyma gangrenosum, cases also have been reported as being caused by a variety of Gram-negative (*Aeromonas hydrophila*, *Escherichia coli, Burkholderia cepacia*) and Gram-positive (group A streptococci, *S. aureus*) bacteria, as well as fungi (*Candida, Aspergillus, Mucor, Fusarium* spp.).[12,55]

DIAGNOSIS

LABORATORY TESTING

Green Nail Syndrome and Toe Web Infection: In patients with green nail syndrome, nail specimens collected for cultures frequently reveal *P. aeruginosa*, as well as fungi associated with onycholysis. *P. aeruginosa* also can be cultured from toe web infections, and illumination under a Wood lamp may reveal that the infection fluoresces white and green. Toe web infections that are scraped and subjected to a potassium hydroxide preparation may reveal dermatophytes associated with tinea pedis.[41]

Folliculitis and Hot-Foot Syndrome: Pseudomonal folliculitis may be diagnosed via unroofing and culture of pustules, and bacterial subtyping frequently reveals serotype O-11.[42] When the diagnosis of hot-foot syndrome is uncertain, a punch biopsy of a nodule may be performed for pathology and culture.[50] Water samples from suspected sources, such as hot-tubs and wading pools, also may be tested for *P. aeruginosa* contamination.

External Otitis and Perichondritis: The diagnosis of uncomplicated external otitis is typically clinical and should include otoscopy to distinguish from otitis media. Cultures should be collected when external otitis is severe, chronic, recurrent, nonresponsive to treatment, or occurring after aural surgery or in immunocompromised patients.[63] Perichondritis should be cultured following incision and drainage.[64]

Suspicion for malignant otitis externa warrants prompt referral to a surgical otolaryngology service. Ear discharge should be sent for cultures, and blood cultures should be collected, especially when constitutional symptoms or fevers are present. Routine laboratory test results are often normal, except for erythrocyte sedimentation rate and C-reactive protein, which are usually elevated and may be used to monitor disease activity.[41,65]

Bacteremia and Ecthyma Gangrenosum: Blood cultures should be collected from any patient with suspected *P. aeruginosa* bacteremia and/or ecthyma gangrenosum. Cutaneous findings associated with bacteremia should be cultured whenever possible, and subcutaneous nodules in bacteremic patients are frequently biopsied. Suspected ecthyma gangrenosum warrants a culture of any lesion exudates, as well as a biopsy for pathology and culture.[41,42]

PATHOLOGY

Hot-Foot Syndrome: If biopsied, hot-foot syndrome may reveal perivascular, interstitial, and periadnexal infiltration of neutrophils that extend to the lobules of subcutaneous fat, and may include deep dermal or subcutaneous abscesses. Specimens may also show focal areas of vasculitis with thrombi.[50]

Bacteremia and Ecthyma Gangrenosum: Subcutaneous nodules associated with *P. aeruginosa* bacteremia reveal an acute vasculitis and suppurative panniculitis with visible Gram-negative rods.[42] Ecthyma gangrenosum is characterized by a necrotizing hemorrhagic vasculitis, a necrosed epidermis and upper dermis, and variable inflammatory infiltrates depending on the hematologic status of the patient. Gram-negative bacteria may be visualized between the collagen bundles, as well as in the media and adventitia of small vessels, classically with intimal sparing.[32,41,42]

IMAGING

Malignant Otitis Externa: CT or MRI may be used in malignant otitis externa patients to visualize disease extension into the bony structures. If the infectious nature of the disease is uncertain following examination and laboratory testing, patients may require a biopsy, as imaging cannot differentiate squamous cell carcinoma of the external auditory canal from malignant otitis externa.[65]

DIFFERENTIAL DIAGNOSIS

Table 154-4 outlines the differential diagnosis for *Pseudomonas aeruginosa* infections.

TABLE 154-4
Differential Diagnosis for *Pseudomonas aeruginosa* Infections

P. AERUGINOSA INFECTION	DIFFERENTIAL DIAGNOSIS
Green nail syndrome	Subungual hematoma Melanocytic nevus Melanoma Onychomycosis caused by *Aspergillus*, *Candida*, or dermatophytes Infection with other Gram-negative or Gram-positive bacteria
Pseudomonal toe web infection	Toe web infection caused by dermatophytes, *Aspergillus*, *Candida*, or other Gram-negative or Gram-positive bacteria Erythrasma Pitted keratolysis Atopic dermatitis Psoriasis
Pseudomonal folliculitis	Other bacterial folliculitis Eosinophilic folliculitis Papular urticaria Acne vulgaris Steroid acne Insect bites Miliaria rubra
Hot-foot syndrome	Plantar urticaria Palmoplantar eccrine hidradenitis Chilblains Erythema multiforme Erythema nodosum
External otitis	Chronic suppurative otitis media External otitis caused by other aerobic bacteria, anaerobic bacteria, or fungi Contact, atopic, or seborrheic dermatitis Psoriasis Squamous cell carcinoma
Malignant external otitis	Malignant otitis externa caused by *Aspergillus* spp. (especially in HIV patients) Squamous cell carcinoma with temporal bone involvement
Ecthyma gangrenosum	Ecthyma gangrenosum caused by other Gram-negative or Gram-positive bacteria or fungi Pyoderma gangrenosum Calciphylaxis Septic emboli Cutaneous anthrax Cutaneous aspergillosis Acute meningococcemia

CLINICAL COURSE AND PROGNOSIS

Pseudomonal folliculitis and hot-foot syndrome are benign and self-limited, and the majority of other localized *P. aeruginosa* infections improve rapidly with topical or oral therapy. Malignant otitis externa is invasive and carries a mortality rate of approximately 20%.[66]

P. aeruginosa bacteremia is associated with higher mortality than bacteremia caused by other Gram-negative organisms. In one study, the 30-day mortality rate was 39%.[67] In another study, a comparison between *P. aeruginosa* bacteremia patients who received timely, appropriate therapy and those who experienced a 1- to 2-day delay in treatment had cure rates of 74% and 46%, respectively.[68] For patients with ecthyma gangrenosum, the mortality rate ranges from 30% to 70%, with multiple lesions, prolonged neutropenia, and delayed therapy correlating with a poor prognosis.[41]

MANAGEMENT

When required, systemic treatment of *P. aeruginosa* infection is limited to select antibiotics with antipseudomonal activity, including certain penicillins (ticarcillin-clavulanic acid, piperacillin-tazobactam), cephalosporins (cefepime, ceftazidime, cefoperazone), monobactams (aztreonam), carbapenems (meropenem, doripenem, imipenem/cilastatin), fluoroquinolones (ciprofloxacin, levofloxacin), aminoglycosides (gentamicin, tobramycin, amikacin), and polymyxins (colistin). However, *P. aeruginosa* may develop resistance to any of these agents, typically as a consequence of previous exposure. Resistance development is especially rapid against imipenem/cilastatin because of downregulation of a carbapenem-specific porin in the outer membrane bilayer, as well as ciprofloxacin as a consequence of drug efflux and mutation of drug targets (DNA gyrase, topoisomerase IV).[43]

GREEN NAIL SYNDROME AND TOE WEB INFECTION

Green nail syndrome should be treated via removal of detached nail plate, followed by application of a topical antimicrobial for 1 to 4 months. Topical antimicrobials may include 2% sodium hypochlorite, aminoglycosides (eg, tobramycin, gentamicin), fluoroquinolones (eg, ciprofloxacin, nadifloxacin), polymyxin B, or bacitracin. Acetic acid soaks also have been used. When patients do not respond to topical treatment or topical therapy is not preferred, oral ciprofloxacin may be used for 2 to 3 weeks. Any topical or oral intervention should be accompanied by avoidance of chronic moisture or submersion in water.[12,41,42,49]

Pseudomonal toe web infections typically require both antibacterial and antifungal therapy, in addition to debridement of any necrotic tissue. Topical antibacterial treatment, such as with gentamicin cream, may be sufficient in mild cases, whereas more fulminant cases require oral antibacterials (eg, ciprofloxacin) and severe cases, especially in persons with diabetes, warrant intravenous therapy. Application of Castellani (carbol-fuchsin) paint, gentian violet, or acetic acid soaks also may be employed.[42,69]

FOLLICULITIS AND HOT-FOOT SYNDROME

Given the self-limited nature of pseudomonal folliculitis and hot-foot syndrome, most patients are treated with exposure removal and symptomatic care. Oral ciprofloxacin can be used in protracted cases or those associated with significant discomfort. Use of topical gentamicin or tobramycin cream with diluted acetic acid baths also have been reported.[42]

EXTERNAL OTITIS AND PERICHONDRITIS

External otitis treatment should include gentle removal of canal debris, followed by administration of antimicrobial ear drops, which may be selected from a variety of antibiotic, antiseptic, or combination antibiotic/glucocorticoid solutions. Meta-analyses have not revealed significant differences between topical interventions, except that acetic acid antiseptic was less effective than combination antibiotic–glucocorticoid solution among patients with unresolved symptoms after 1 week.[52,70] Wick placement should be pursued for patients with severe disease or a completely occluded canal. Oral ciprofloxacin should be given for 7 to 10 days for coverage of *P. aeruginosa* and *S. aureus* in immunocompromised patients or those with extended infection beyond the external canal (eg, periaural cellulitis).[63]

Patients with perichondritis require prompt culture and drainage with through-and-through incisions, initiation of oral ciprofloxacin, and follow up of sensitivity data to ensure adequate treatment. Extended therapy may be required as cartilaginous ear structures have poor blood supply. Timely, appropriate therapy is essential because of the risk of cartilage necrosis and permanent ear deformity.[71]

Malignant otitis externa warrants prompt referral to a surgical otolaryngology service. Treatment includes debridement of necrotic tissue and a prolonged course of systemic antibiotics, as required for osteomyelitis. Ciprofloxacin may be used for 6 to 8 weeks against sensitive strains. Fluoroquinolone-resistant strains require 6 to 10 weeks of an antipseudomonal β-lactam, such as piperacillin-tazobactam, ceftazidime, or cefepime. Mastoidectomy or other surgical intervention may be required in extensive cases.[41,42,72]

BACTEREMIA AND ECTHYMA GANGRENOSUM

In patients with suspected *P. aeruginosa* bacteremia, the primary site of infection should always be addressed, if known, and any infected catheters should be removed. Patients require prompt intravenous empiric therapy, typically with an antipseudomonal β-lactam. When empiric combination therapy is desired, especially in those with neutropenia, burn wounds, ecthyma gangrenosum or signs of sepsis, an aminoglycoside is commonly added. In patients with renal insufficiency, a fluoroquinolone may be added instead. Once susceptibility results are available, patients may be switched to an appropriate monotherapy, as combination regimens have not been shown to improve mortality or prevent emergence of antibiotic resistant *P. aeruginosa*. Aminoglycosides should never be used as monotherapy when other options are available. Alternative antibiotics for multidrug-resistant infections include ceftazidime-avibactam, ceftolozane-tazobactam, and colistin. Because colistin is the only option against some multidrug-resistant strains, it is increasingly used despite very high rates of nephrotoxicity.[41-43,73-75]

PREVENTION

Green nail syndrome can be prevented by wearing gloves while dishwashing and discarding or sterilizing contaminated sponges. Toe web infection may be avoided by keeping feet dry and treating underlying fungal infections. To prevent recurrence of pseudomonal folliculitis, hot tubs should be drained and superchlorinated or scrubbed with quaternary ammonium compounds.[42,49] Patients prone to external otitis should be advised not to clean the ear with fingers, cotton swabs, or other foreign objects. Following submersion of the head in water, ears can be dried noninvasively by tilting the head or using a blow dryer (1 foot away from the ear, on low setting). Homemade ear drops comprised of 1:1 5% acetic acid (white vinegar) and isopropyl alcohol (rubbing alcohol) have been employed after water exposure as a preventive measure.[41]

Given the prevalence of *P. aeruginosa* in inpatient settings, hospital-acquired infections may be minimized via handwashing, sterile technique, cleaning shared equipment, and strict contact isolation of patients with multidrug resistant infection. Burn patients should receive wound care that reduces colonizing bacteria, including wound cleaning, debridement, dressings, and application of silver sulfadiazine.[43]

INFECTIONS CAUSED BY *BARTONELLA* SPECIES

AT-A-GLANCE

- *Bartonella* are facultative intracellular Gram-negative bacilli, that parasitize erythrocytes.
- *Bartonella henselae* is responsible for cat scratch disease, bacillary angiomatosis, and endocarditis. The vector is the cat flea (*Ctenocephalides felis*), cats are reservoir hosts, and infection in humans is incidental.

(Continued)

AT-A-GLANCE (*Continued*)

- *Bartonella quintana* causes trench fever, bacillary angiomatosis, and endocarditis. Humans serve as reservoir hosts, and the human body louse (*Pediculus humanus*) is the vector.
- *Bartonella bacilliformis* is the etiologic agent of Carrion disease, a biphasic infection with an acute phase known as *Oroya fever*, followed by a chronic phase, verruga peruana. Humans are the only known reservoir hosts, and the vector is the sand fly (*Lutzomyia verrucarum*).
- *Bartonella* species cause prolonged intraerythrocytic bacteremia in natural reservoir hosts, but not incidental hosts, thereby positioning themselves to be spread from reservoir to reservoir via blood-sucking arthropods.
- *Bartonella* may generate angiomatous lesions in bacillary angiomatosis and verruga peruana by stimulating angiogenesis and inhibiting endothelial cell apoptosis in the setting of an immunocompromised host.
- Cat scratch disease typically occurs in immunocompetent hosts. Rather than generating angiomatous lesions, *B. henselae* may instigate granuloma formation by inhibiting phagocytic uptake and delaying bacterial death within macrophages.
- Culture isolation of *Bartonella* is difficult in clinical practice, and specimens may require weeks of incubation. An indirect fluorescent antibody assay is frequently used.

INTRODUCTION AND BACTERIOLOGY

Bartonella is a genus of fastidious, facultative intracellular Gram-negative bacilli, which frequently parasitize erythrocytes because of their inability to synthesize heme or protoporphyrin X. They are best cultured on 5% rabbit or sheep blood agar at 35°C to 37°C (95°F to 98.6°F) with 5% to 10% carbon dioxide and 40% humidity. Even under ideal conditions, primary isolates require several days or weeks for visible growth, which in practice makes diagnosis challenging.[76,77]

Bartonella belong to the α_2 subgroup of the class *Proteobacteria*, which includes other intracellular parasites, such as *Brucella, Rickettsia,* and *Ehrlichia*. The *Bartonella* genus includes more than 30 species, many of which reside in animals, and only some cause human disease. *Bartonella* infection is often arthropod borne (flea, louse, sand fly), but it also can be transmitted via animal scratches or bites.[76]

The 3 most clinically relevant *Bartonella* species are *Bartonella henselae, Bartonella quintana*, and *Bartonella bacilliformis* (Table 154-5). *B. henselae* is responsible for cat scratch disease (CSD), as well as some cases of bacillary angiomatosis (BA) and endocarditis. The vector is the cat flea (*Ctenocephalides felis*), and cats are reservoir hosts, and infection in humans is incidental. *B. quintana* causes trench fever, BA, and endocarditis. Humans serve as reservoir hosts, and the human body louse (*Pediculus humanus*) is the vector. *B. bacilliformis* is the etiologic agent of Carrion disease, a biphasic infection with an acute phase known as Oroya fever, followed by a chronic phase, verruga peruana. Humans are the only known reservoir hosts of *B. bacilliformis*, and the vector is the sand fly (*Lutzomyia verrucarum*).[76,77]

EPIDEMIOLOGY

CAT SCRATCH DISEASE

CSD is the most common *Bartonella* infection. Although the disease has a worldwide distribution, there is an increased prevalence in warm, humid climates where cat fleas (*C. felis*) are most abundant, and peak occurrence is in fall and winter. CSD typically affects immunocompetent patients, especially children and young adults, with a median age of 15 years. There is typically a history of cat contact, scratches, or bites, although this is not always found. Although cats are the main reservoir for the causative agent, *B. henselae*, rare cases have been associated with dogs.

In the United States, more than 40,000 cases of CSD and more than 2000 associated hospitalizations are reported each year. The findings of 2 California studies indicate a substantial rate of cat infection. One study isolated *B. henselae* from the blood in 25 (41%) of 61 healthy impounded or pet cats, while the other study found *B. henselae* antibodies in 166 (81%) of 205 cats.[76,78,79]

TABLE 154-5
***Bartonella* Species Infections**

SPECIES	DISEASE	VECTOR	RESERVOIR
Bartonella bacilliformis	Carrion disease (Oroya fever and verruga peruana)	*Lutzomyia verrucarum* (sand fly)	Human
Bartonella henselae	Cat scratch disease, bacillary angiomatosis, endocarditis	*Ctenocephalides felis* (cat flea)	Cat
Bartonella quintana	Trench fever, bacillary angiomatosis, endocarditis	*Pediculus humanus* (human body louse)	Human

TRENCH FEVER

Trench fever was perhaps the most widespread *Bartonella* infection of the past. It is best known for affecting soldiers throughout World War I, during which an estimated 1 million people were infected. Infections rose again, but to a lesser extent, during World War II, after which the incidence of trench fever became rare. Currently, trench fever is considered a reemerging disease among homeless people in urban areas, sometimes termed *urban trench fever*. The classic patient is a homeless, alcoholic man with poor hygiene, and patients are often immunocompetent.

The etiologic agent, *B. quintana*, is passed from person to person via the human body louse (*P. humanus*) vector. As with *B. henselae* in cats, *B. quintana* may cause a chronic, asymptomatic bacteremia in human reservoirs. In a 1997 study in Marseilles, France, *B. quintana* bacteremia was identified in 10 (14%) of 71 homeless people evaluated in an emergency department, who lacked any clinical signs or symptoms of infection.[76,78,80]

BACILLARY ANGIOMATOSIS

BA was first described as a new condition in HIV-infected patients in 1983, especially those with CD4+ lymphocyte counts less than 100 cells/mm^3. It is occasionally reported in other immunocompromised patients, including patients after cardiac or renal transplantation and those receiving chemotherapy for hematologic malignancies. It is rarely reported in immunocompetent patients. Currently, BA is uncommon given the widespread use of antiretroviral therapy. In a study in Germany, the incidence was estimated to be 1.2 cases per 1000 HIV-infected patients.[81]

BA may be caused by either *B. henselae* or *B. quintana*, and each accounts for roughly half of all cases in the United States. By contrast, *B. quintana* has been the main etiologic agent in Europe; *B. henselae* has only recently been documented as an etiologic agent of BA in Europe.[78]

BA lesions have been identified in the skin, as well as in visceral organs, bone, and lymph nodes. Epidemiologic studies indicate that the skin is the most common site of disease, ranging from 55% to 90% of total cases. *B. henselae* and *B. quintana* have an approximately equal tendency to cause cutaneous lesions, while *B. henselae* is the primary cause of liver, splenic, and lymph node lesions, and *B. quintana* is the primary cause of lesions in the subcutis and bone.[76,77]

CARRION DISEASE

Carrion disease, which includes Oroya fever and verruga peruana, is typically found in the Andean valleys of Peru, Colombia, and Ecuador. This corresponds with the ecologic distribution of the sand fly vector (*L. verrucarum*) for *B. bacilliformis*. Recently, however, the disease was identified outside of these river valleys, presenting public health problems across various areas of Peru, Columbia, and Ecuador, which have been attributed to climate change. Cases also have been reported in Bolivia, Chile, and Guatemala.[76,78,82]

Humans are the only known reservoirs of *B. bacilliformis*, and those native to endemic regions may serve as carriers, with prolonged asymptomatic bacteremia. Compared to travelers who often develop severe infection, natives with Carrion disease are more likely to experience a mild course, and may frequently present with only the chronic phase of disease, verruga peruana, without a history of Oroya fever. One study in a Peruvian valley community found a 0.5% baseline prevalence of asymptomatic *B. bacilliformis* bacteremia, and Carrion disease occurred in the community at a rate of 12.7 per 100 person-years over a 2-year period. Children younger than age 5 years had the highest incidence of disease, which declined linearly with age and was attributed to acquired immunity. In the community, the disease followed a cluster pattern with 70% of cases arising in 18% of households. This pattern is seen in other endemic diseases, such as malaria and leishmaniasis, and is consistent with the "20/80 rule," which states that approximately 80% of the disease burden will be found in 20% of households.[78,83]

CLINICAL FEATURES

Table 154-6 summarizes the diseases caused by *Bartonella* species.

CUTANEOUS FINDINGS

Cat Scratch Disease: Three to 10 days following inoculation via cat exposure, CSD begins with an erythematous papule at the inoculation site. The papule typically persists for 1 to 3 weeks, during which time it may become vesicular, followed by a crusted papule of 2 to 6 mm in diameter. Less commonly, the lesion may be pustular or nodular. Three to 50 days following inoculation, patients develop regional lymphadenomegaly, most commonly affecting the axillary, cervical, inguinal, epitrochlear or preauricular nodes. At first, lymph nodes are soft but become firm and tender, often with erythema of the overlying skin. Suppuration occurs in 10% to 15% of patients. Lymphadenitis is typically the presenting sign, although the inoculation site lesion may still be appreciable at presentation (Fig. 154-6). Examination should include thorough inspection of interdigital spaces, skin creases, and scalp. In 5% to 10% of cases the inoculation site may include the eye (nonsuppurative conjunctivitis, ocular granuloma) or mucous membranes (oral ulceration). Specifically, the Parinaud oculoglandular syndrome can arise when the inoculation site occurs near the eye, characterized by unilateral granulomatous conjunctivitis with ipsilateral preauricular and submandibular lymphadenopathy. Other, less common, cutaneous findings associated with CSD include morbilliform eruptions, urticaria, erythema nodosum, erythema multiforme, and erythema marginatum.[76,78,84]

TABLE 154-6

Summary Table of Diseases Caused by *Bartonella* Species

DISEASE	CUTANEOUS FINDINGS & DISEASE COURSE	NONCUTANEOUS FINDINGS	LABORATORY TESTS	COURSE & PROGNOSIS	TREATMENT
Cat scratch disease (CSD)	Erythematous papule at inoculation site (3 to 10 days after inoculation) Papule becomes vesicular and crusts (1 to 3 weeks) Regional lymphadenopathy (3 to 50 days postinoculation), with suppuration in 10% to 15% Parinaud oculoglandular syndrome (inoculation near eye)	Fever, chills, malaise, headache, weight loss, nausea, vomiting or splenomegaly Liver and spleen may develop granulomatous inflammation CSD neuroretinitis may develop	Serology: indirect fluorescent antibody assay Lymph node biopsy: Warthin-Starry staining and polymerase chain reaction (PCR) may identify organisms Skin cultures usually negative	Lymphadenopathy resolves in a median of 7 weeks; CSD lymphadenitis is benign and self-limited, disseminated manifestations may be life threatening	Mild to moderate cases: no treatment recommended Large, bulky lymphadenopathy: azithromycin, doxycycline, erythromycin; needle aspiration of suppurative lymph nodes Liver or spleen involvement: rifampicin alone or in combination with gentamicin or trimethoprim-sulfamethoxazole Ocular CSD: doxycycline, or doxycycline + rifampicin
Trench fever	Fever (of approximately 5 days duration) occurs 5 to 20 days after exposure and recurs cyclically Cutaneous features include erythematous macules or papules over abdomen, chest, and back	Accompanying chills, malaise, anorexia, or diaphoresis, as well as retroorbital pain, headache, muscle aches, joint or shin pain; conjunctival injection and splenomegaly may occur	Blood culture is confirmatory, but often difficult Indirect fluorescent antibody assay; PCR blood tests	Course is often mild	Oral doxycycline × 28 days + IV gentamicin × 14 days *or* oral doxycycline *or* erythromycin *or* azithromycin × 4 to 6 weeks
Bacillary angiomatosis	Nodular or pedunculated papule that may ulcerate or bleed; lesions may be solitary or multiple; mucosa also affected	Liver (peliosis hepatis), spleen (splenic peliosis), bone (most commonly radius and tibia) and lymph nodes may be affected Respiratory tract, GI tract, and brain may be involved	Skin biopsy often diagnostic; additional staining for Warthin-Starry; PCR Indirect fluorescent antibody assay	Responsive to antibiotic therapy within 1 week, with clearance within 1 month Relapses may occur when antibiotics are given for <3 months	Uncomplicated BA, peliosis and osteomyelitis: oral doxycycline *or* erythromycin × 3 to 4 months Severe cases: oral doxycycline *or* erythromycin, + rifamycin HL? *Bartonella* endocarditis: doxycycline + gentamicin × 2 weeks
Carrions disease	After ~60 days of incubation, symptoms of Oroya fever develop: acute bacteremic syndrome, hemolytic anemia; verruga peruana develops 2 months later, with eruptive angiomatous lesions resembling bacillary angiomatosis	Nonspecific prodrome (fever, chills, malaise, headache, anorexia, myalgias, arthralgias) Severe hemolytic anemia with jaundice, dyspnea and confusion may occur, with hepatosplenomegaly and generalized lymphadenopathy	Blood smear with Giemsa staining for presence of blue-colored intraerythrocytic or extraerythrocytic bacilli	Oroya fever lasts 1 to 4 weeks	Uncomplicated Oroya fever: ciprofloxacin alone *or* chloramphenicol + β-lactam × 14 days Severe disease: ciprofloxacin + ceftriaxone HL? Transfusions (red blood cells) should be considered Verruga peruana: rifampicin × 14 to 21 days *or* streptomycin IM

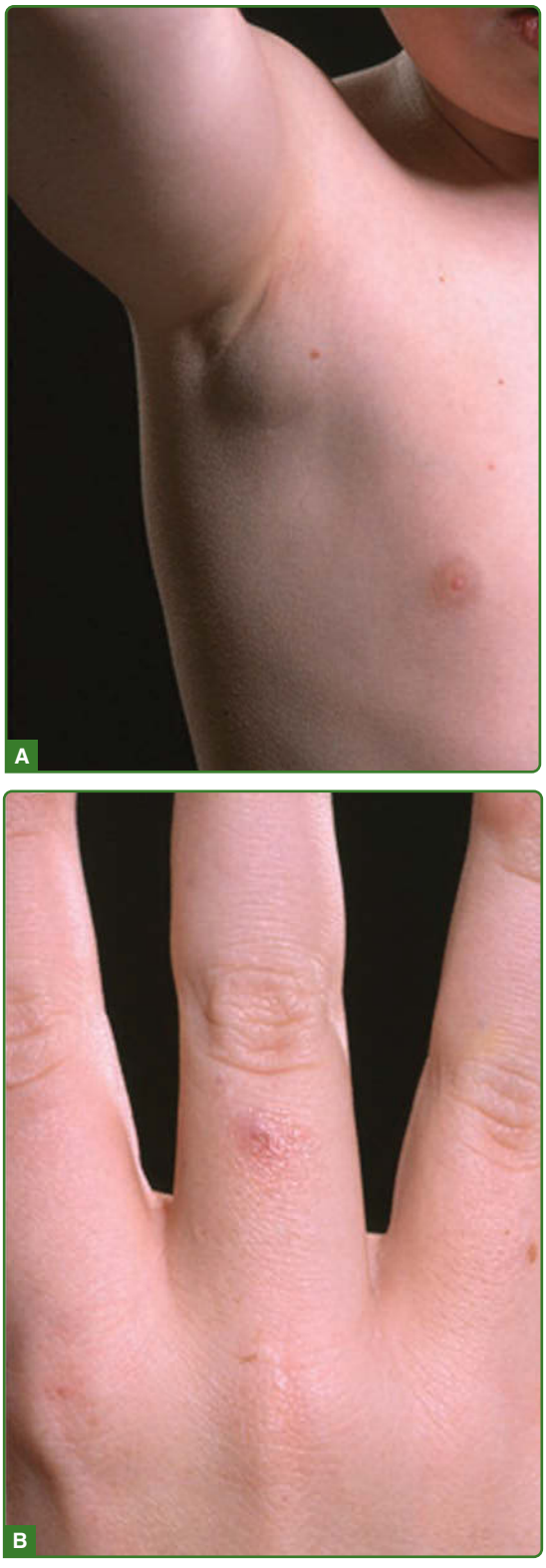

Figure 154-6 Regional lymphadenitis is frequently the presenting sign of cat scratch disease (**A**). An inoculation site papule (**B**) persists for 1 to 3 weeks and may be present at the time of initial presentation. (Reproduced with permission from Stutchfield CJ, Tyrrell J. Evaluation of lymphadenopathy in children. *Paediatr Child Health*. 2012;22[3]:98-102. Copyright © Elsevier.)

Trench Fever: Five to 20 days following exposure to human body louse (*P. humanus*), patients may develop trench fever, also known as 5-day fever, quintan fever, shinbone fever, shank fever, and His-Werner disease. It is characterized by cyclic fevers of approximately 5 days' duration, and as many as 90% of patients may develop crops of erythematous macules or papules, which may be found across the abdomen, chest, and back.[76,78,85]

Bacillary Angiomatosis: The characteristic BA lesion is a reddish-purple, angiomatous papule approximately 1 cm in diameter. The lesion also may be nodular or pedunculated. The surface is smooth or verrucous and may ulcerate and occasionally bleed (Fig. 154-7). Less-common BA variants include subcutaneous nodules and hyperkeratotic plaques. When present, subcutaneous nodules are deep-seated and tender with overlying erythematous or normal-colored skin, sometimes with ulceration. Lesions may be solitary or multiple, occurring in a localized area or, rarely, disseminated across the body. BA may also affect the mucosa, and oral lesions have been reported with and without the presence of cutaneous findings, specifically affecting the gingiva, buccal mucosa, oral labial mucosa, hard palate, and posterior pharynx.[78,86,87]

Carrion Disease: Following sand fly (*L. verrucarum*) exposure in an endemic area of South America, there is an incubation period of approximately 60 days (range: 1 to 30 weeks) before patients may exhibit symptoms of Oroya fever, an acute bacteremic syndrome and hemolytic anemia, with an associated increase in development of opportunistic infections. Approximately 2 months (range: 2 weeks to several years) following Oroya fever, patients may develop verruga peruana, an eruptive angiomatous cutaneous condition that resembles BA.

Verruga peruana, or Peruvian wart, is characterized by eruptive crops of angiomatous nodular and/or verrucous lesions, primarily on the head and distal extremities. Mucous membranes of the mouth, conjunctiva and nose may be affected, as well. Lesions range from red to purple and vary in size from papules of only a few millimeters in diameter to pedunculated or sessile plaques, several centimeters in size. In many patients, the lesions bleed, ulcerate, or become complicated with secondary infection (Fig. 154-8).[76,78,88,89]

NONCUTANEOUS FINDINGS

Cat Scratch Disease: Some patients with CSD may have fever, chills, malaise, headache, weight loss, nausea, vomiting, or splenomegaly. A variety of uncommon, extranodal manifestations of CSD may also occur, which often lack characteristic lymphadenitis and an inoculation site papule, making diagnosis especially challenging. Atypical manifestations include granulomatous hepatitis or splenitis, neuroretinitis, encephalitis, myelitis, peripheral neuropathy, facial nerve palsy, arthritis, osteomyelitis, mediastinal masses, and atypical pneumonia.

Figure 154-7 Bacillary angiomatosis may be solitary or multifocal, and feature angiomatous papules and nodules with smooth (**A**) or verrucous (**B**) surfaces that may ulcerate and occasionally bleed. (Image **A,** Reproduced from Claasens S, Schwartz IS, Jordaan HF, et al. Bacillary angiomatosis presenting with polymorphic skin lesions. *IDCases*. 2016;6:77-78; Image **B,** Rodriguez O, Campbell LR, Bacha JM, et al. Successful treatment of bacillary angiomatosis with oral doxycycline in an HIV-infected child with skin lesions mimicking Kaposi sarcoma. *JAAD Case Rep*. 2016;2[1]:77-79. Copyright © Elsevier.)

CSD may affect the liver, spleen or both with granulomatous inflammation. Symptoms may include fever, abdominal pain, and weight loss. On examination, the liver and/or spleen may be enlarged and tender, and liver function tests may be mildly abnormal. The erythrocyte sedimentation rate and C-reactive protein levels are frequently elevated. Hepatosplenic CSD should not be confused with BA-associated peliosis hepatis or splenic peliosis, which usually affects HIV-infected or other immunocompromised patients. CSD neuroretinitis is characterized by acute unilateral blurred vision resulting from optic nerve edema, often with an afferent pupillary defect. Funduscopic examination may reveal hemorrhages, cotton wool spots, and a stellate macular exudate or "macular star."[76,90-92]

Figure 154-8 Verruga peruana features eruptive crops of angiomatous nodular and/or verrucous lesions, which may be pedunculated or sessile, ranging from red to purple and varying from a few millimeters to several centimeters in size. (Reproduced with permission from Maguiña C, Guerra H, Ventosilla P. Bartonellosis. *Clin Dermatol*. 2009;27[3]:271-280. Copyright © Elsevier.)

Trench Fever: Trench fever is characterized by sudden-onset febrile episodes of approximately 5 days' duration, associated with chills, malaise, anorexia, or diaphoresis, as well as retroorbital pain, headache, muscle aches, joint pain, or shin pain. In addition to a truncal rash, patients may exhibit conjunctival injection and splenomegaly. Fevers may occur over a course of 4 to 6 weeks during which patients may experience up to 8 episodes of fever, lasting approximately 5 days each. Although the names "5-day fever" and "quintan fever" denote this cyclic pattern, which is most commonly seen, patients also may have only a single febrile episode lasting 4 to 5 days or a persistent fever lasting 2 to 6 weeks.[76,78,85]

Bacillary Angiomatosis: BA may cause extracutaneous angiomatous proliferation, with or without

concurrent angiomatous skin lesions. Typical sites include the liver (peliosis hepatis), spleen (splenic peliosis), bone and lymph nodes. Rarely affected sites include the respiratory tract, GI tract, and brain. Regardless of the site of disease, BA patients may have fever, chills, malaise, headache, or anorexia.

Peliosis hepatis is characterized by abdominal pain, hepatomegaly, and splenomegaly. Patients often have elevated alkaline phosphatase and normal or slightly elevated bilirubin and aminotransferases. With splenic peliosis, thrombocytopenia and pancytopenia have been reported.[76,93,94] Bony involvement is characterized by painful, isolated, lytic lesions. The radius or tibia are most commonly affected, and may be accompanied by overlying cellulitis.[76,86,95]

Carrion Disease: Patients with Oroya fever present with a nonspecific prodrome of fever, chills, malaise, headache, anorexia, myalgias, and arthralgias. This is followed by a rapid deterioration with pallor, jaundice, dyspnea, and/or confusion, associated with a severe hemolytic anemia caused by a parasitic erythrocyte infection. Patients may also exhibit hepatosplenomegaly and generalized lymphadenopathy. Severe cases may include heart failure, convulsions, coma, anasarca, and multiorgan failure. With verruga peruana, the eruption of cutaneous lesions may be accompanied by nonspecific constitutional symptoms.[76,78]

COMPLICATIONS

Infection with *B. henselae* or *B. quintana* may be complicated by endocarditis, often termed *culture-negative endocarditis*, as repeat cultures are frequently negative. *Bartonella* endocarditis usually occurs in those with underlying heart valve abnormalities. Patients have a chronic clinical course characterized by fever, and vegetations are visible in 90% of patients undergoing echocardiography.[93]

During the hemolytic phase of Oroya fever, patients are predisposed to infection by a number of opportunistic pathogens. Infections may include *Salmonella* spp. (typhoidal and nontyphoidal strains), *Shigella dysenteriae, S. aureus, Enterobacter* spp., toxoplasmosis reactivation, disseminated histoplasmosis, *Pneumocystis jiroveci* pneumonia, and malaria, to name a few.[89] One study of 68 patients with Oroya fever in Peru found that 36 (53%) had cardiovascular complications. Among the patients with complications, rates of heart failure, pericardial effusion, pulmonary edema, cardiogenic shock, cardiac tamponade and myocarditis were 91%, 44%, 36%, 17%, 11%, and 11%, respectively.[96]

ETIOLOGY AND PATHOGENESIS

A common theme among *Bartonella* species is their propensity to cause prolonged intraerythrocytic bacteremia in natural reservoir hosts, but not incidental hosts, thereby positioning themselves to be spread from reservoir to reservoir via bloodsucking arthropods. Rather than spreading through the bites of arthropods, *Bartonella* is transmitted via arthropod feces, coupled with superficial scratching of the skin. As an example, cat fleas harboring *B. henselae* feed on cats, during which time they excrete feces containing *Bartonella*. As the cat scratches its skin in an area infested with fleas, a cat may inoculate itself intradermally with *B. henselae* and, simultaneously contaminate its claws with feces. Cats may also contaminate their saliva by eating fleas. Subsequently, humans become incidental hosts of *B. henselae* after being scratched, bitten, or licked by a cat whose claws and/or saliva have been contaminated with flea feces. Humans serve as reservoir hosts for both *B. quintana* and *B. bacilliformis*. Similarly, bacteria are transmitted from person to person via human body lice and sandflies, respectively, specifically when bacteria in the arthropod feces is inoculated through the skin via scratching.[76,77]

Once reservoir hosts have been inoculated with *Bartonella*, a prolonged, subclinical intraerythrocytic bacteremia may occur. This has been documented in cats with *B. henselae*,[79] homeless people with *B. quintana*,[80] and members of a Peruvian valley community with *B. bacilliformis*.[83] One 2-year study that followed a naturally infected cat showed that the animal had persistent *B. henselae* bacteremia for the first 5 months postinoculation. Following a 2-month abacteremic period, the bacteremia reoccurred. For the remainder of the study, the cat became cyclically bacteremic for 2-month intervals with interspersed abacteremic periods of approximately 2 months each.[97]

The tendency to produce prolonged, subclinical bacteremic infections indicate that *Bartonella* have adapted to circumvent the immune systems of their reservoir hosts. The mechanisms by which they achieve this feat have been investigated in detail.[77] Briefly, *Bartonella* express lipopolysaccharide that is only weakly recognized by TLR4, a receptor known to activate the innate immune system and mediate septic shock following recognition of lipopolysaccharide borne by Gram-negative bacteria. In fact, *B. quintana* lipopolysaccharide does not stimulate the production of proinflammatory cytokines in human monocytes and may actually act as a TLR4 antagonist.[98] Furthermore, some *Bartonella* species, including *B. bacilliformis*, express flagella that have undergone amino acid changes, while preserving motility. Thus, their flagella are not recognized by TLR5, a receptor of the innate immune system responsible for recognizing an evolutionarily conserved portion of bacterial flagellin.[99]

In addition to evading hosts' innate immune systems, *Bartonella* may subvert adaptive immunity via antigenic variation. This has been demonstrated by several *Bartonella* antigens, including cell-adhesion molecules, Vomps and BadA, as well as Trw-T4SS, a Type 4 secretion system involved in erythrocyte adhesion. Vomp-specific antibodies are the most frequently detected human immunoglobulins against *B. quintana*, and the Vomp locus has been shown to undergo extensive genetic rearrangements in vivo.[100] Additionally, cat models have demonstrated the development of

genetically distinct *B. henselae* clones at different peaks of relapsing bacteremia.[101] Sometimes, the cats demonstrated bacteremia even in the presence of high specific titers, and at one point in the experiment no increase in specific immunoglobulin G was observed during a subsequent bacteremic episode. Finally, *Bartonella* elude both humoral and cellular immunity by naturally parasitizing host erythrocytes. As a consequence of a lack of major histocompatibility complexes, erythrocytes cannot present antigens on their surfaces, thereby offering a protective environment, at least for the life span of the erythrocyte.[77]

Besides interacting closely with erythrocytes, *Bartonella* are known to have an affinity for endothelial cells. This affinity plays an important role, not only in promoting vascular proliferation in the setting of disease, but also in maintaining the carrier state in natural reservoir hosts. Multiple observations point to the existence of a primary niche within reservoir hosts where *Bartonella* persist and can be periodically seeded into the circulation. Although a few theories exist as to the primary niche of *Bartonella*, the endothelial cell hypothesis is the most widely accepted.[77,102] *B. henselae, B. quintana*, and *B. bacilliformis* have all been shown to adhere to and invade endothelial cells.[77]

To demonstrate the role of *Bartonella* in the generation of angiomatous lesions, one study showed that *B. henselae* increased cell migration and secretion of vascular endothelial growth factor in human, but not feline, endothelial cells.[103] Further investigations have indicated that *Bartonella*-mediated vascular endothelial growth factor upregulation occurs via activation of hypoxia-inducible factor-1, a transcription factor and mediator of vascular endothelial growth factor expression, via cellular hypoxia induced by intracellular bacterial replication.[77] *Bartonella* also have been hypothesized to secrete their own angiogenic factor; stimulate endothelial growth factors, IL-1b, IL-8, and angiopoietin 2 from macrophages and endothelial cells; and downregulate endothelial apoptosis via decreased IL-12 and interferon-γ. Inoculation of endothelial cells with *B. henselae* or *B. quintana* is known to increase their life span, and inhibit in vitro actinomycin D–induced apoptosis.[76,77,93]

In addition to these mechanisms by which *Bartonella* promotes vascular proliferation, the formation of angiomatous lesions such as BA and verruga peruana appears to necessitate a host immunocompromised state. For example, *B. henselae* and *B. quintana* infection lead to BA in those with diminished CD4+ lymphocyte counts and phagocytic dysfunction.[78] This could be compared with the immunologic dysfunction caused by Oroya fever, which is known to put hosts at risk for opportunistic infection.[78] During *B. bacilliformis* infection, erythrocytes have demonstrated a significant increase in IL-10 production, which downregulates cytokines, CD4+ cells, macrophages, and dendritic cells.[104] This is accompanied by decreased CD4+ lymphocytes and increased CD8+ lymphocytes in the peripheral blood with an inversion of the CD4+-to-CD8+ ratio and impaired cellular immunity.[78]

Given these observations, it is thought that host immune responses to *Bartonella*, as well as differing virulence across bacterial strains, influence the pathologic processes and clinical manifestations that occur in different patients infected with the same *Bartonella* species.[78] For example, *B. henselae* in patients with a low CD4+ lymphocyte count leads to BA, whereas *B. henselae* in immunocompetent patients leads to CSD, characterized by granulomatous lymphadenitis, as well as granulomatous inflammation in visceral organs. Studies of *B. henselae*–macrophage interaction indicate that BadA adhesion molecules inhibit phagocytic uptake. When successfully phagocytized, *B. henselae* enter macrophages via a specialized vacuolar compartment, termed a *Bartonella*-containing vacuole, which lacks early endocytic marker proteins. In later stages of infection, *Bartonella*-containing vacuoles fuse with lysosomes, eventually leading to bacterial destruction.[77]

DIAGNOSIS

LABORATORY TESTING

Table 154-6 summarizes the laboratory tests for diseases caused by *Bartonella* species.

Cat Scratch Disease: CSD is typically diagnosed via serology, specifically an indirect fluorescent antibody (IFA) assay. Although not routinely required in patients with a classic presentation, a lymph node biopsy may be sent for histology, Warthin-Starry staining, and PCR. PCR also may be performed on lymph node aspirates. Although tissue samples may be sent for culture, they are frequently negative. Skin testing for CSD is no longer performed. Biopsies of liver and spleen have also fallen out of favor when involvement is suspected, as imaging findings in the setting of a positive IFA are often adequate.[76,105]

Trench Fever: Trench fever may be confirmed by isolating *B. quintana* from the blood. However, given the difficulty associated with *Bartonella* culture isolation, IFA assay is often used. In some settings, PCR blood tests are also available. Biopsy does not play a role in the diagnosis of trench fever.[76,80]

Bacillary Angiomatosis: BA is often diagnosed via skin biopsy, which should be sent for histology, Warthin-Starry staining, and PCR. IFA may be used. BA lesions associated with peliosis hepatis and splenic peliosis may be biopsied, as well.[76,78]

Carrion Disease: In the diagnosis of Carrion disease, *B. bacilliformis* identification is often attempted by inspecting a Giemsa-stained blood smear for blue-colored intraerythrocytic or extraerythrocytic bacilli. Blood cultures are often collected during the acute phase (Oroya fever), when as many as 71% of patients may yield positive results within 2 to 4 weeks. The successful isolation of *B. bacilliformis* drops dramatically

during the chronic phase (verruga peruana).[89] Skin biopsy of verruga peruana lesions may be sent for histology, and Warthin-Starry or Giemsa stains to enhance *B. bacilliformis* visualization. IFA assay and PCR are available, although these may not be feasible in resource-poor settings.[76]

PATHOLOGY

Cat Scratch Disease: The inoculation-site papule of CSD features areas of stellate necrosis surrounded by rims of histiocytes, neutrophils, and occasional giant cells. Epidermal changes may include acanthosis or ulceration.[32] Warthin-Starry silver stain may show bacilli within the area of necrosis, although the bacteria are diminished as the lesion resolves. Similar findings are also seen on lymph node biopsy, with lymphoid hyperplasia and arteriolar proliferation (Fig. 154-9).[76,106]

Bacillary Angiomatosis: BA is characterized by a lobular accumulation of rounded blood vessels featuring plump endothelial cells with cell necrosis, atypia, and mitoses. There is a mixed inflammatory infiltrate with a neutrophil predominance and intermittent leukocytoclasia. Bacilli maybe seen in intracellular or extracellular clumps with Warthin-Starry silver stain (Fig. 154-10).[76,78]

Liver biopsy in peliosis hepatis may reveal cystic, blood-filled spaces within the hepatic parenchyma. There may be an excess of misshapen endothelial cells forming capillary-like sprouts and a mixed inflammatory infiltrate of histiocytes and neutrophils. Warthin-Starry silver stain may identify bacilli.[77,94]

Carrion Disease: Verruga peruana features an intense angioblastic proliferation with sheets of endothelial cells and neutrophils comprising most of the cellular infiltrate. Interspersed macrophages, lymphocytes and plasma cells may be seen. Warthin-Starry or Giemsa stain are used to visualize *Bartonella* organisms, which may be found as intracellular inclusions, as well as free organisms in the extracellular matrix.[76]

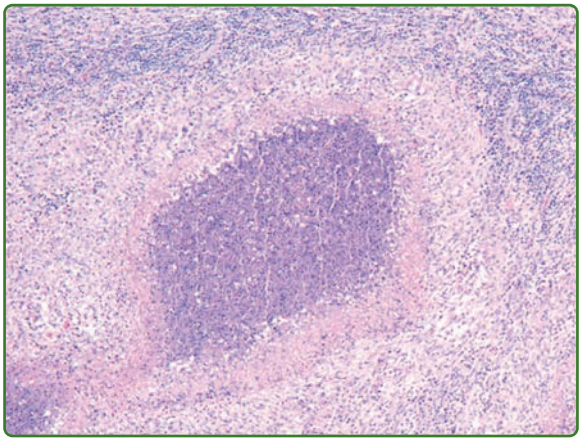

Figure 154-9 Lymph nodes affected by cat scratch disease reveal inflammatory, granulomatous changes featuring central microabscesses surrounded by rings of histiocytes and occasional giant cells, as seen here at ×100 magnification. (Reproduced with permission from Angelakis E, Raoult D. Pathogenicity and treatment of *Bartonella* infections. *Int J Antimicrob Agents*. 2014;44[1]:16-25. Copyright © Elsevier.)

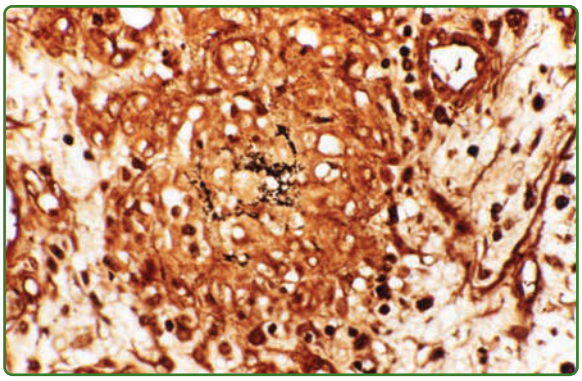

Figure 154-10 Bacillary angiomatosis is characterized by lobular proliferations of endothelial cells with mixed, neutrophil-predominant infiltrates and bacilli seen in intracellular or extracellular clumps on Warthin-Starry silver stain, as shown here at ×1000 magnification. (Reproduced with permission from Angelakis E, Raoult D. Pathogenicity and treatment of *Bartonella* infections. *Int J Antimicrob Agents*. 2014;44[1]:16-25. Copyright © Elsevier.)

IMAGING

Cat Scratch Disease: An abdominal CT of patients with hepatic or splenic CSD will show scattered, multiple hypodense areas, which are hypoechoic on ultrasonography.[107]

Bacillary Angiomatosis: An abdominal CT of patients with peliosis hepatis and/or splenic peliosis shows organomegaly and scattered hypodense lesions.[94] In patients with bony involvement, radiographs reveal lytic lesions with cortical destruction and periosteal reaction. Technetium scans demonstrate increased uptake.[86,95]

DIFFERENTIAL DIAGNOSIS

Table 154-7 outlines the differential diagnosis for *Bartonella* infections.

CLINICAL COURSE AND PROGNOSIS

Table 154-6 summarizes the clinical courses and prognoses for diseases caused by *Bartonella* species.

CAT SCRATCH DISEASE

Inoculation-site lesions persist for 1 to 3 weeks and lymphadenopathy resolves in a median of 7 weeks,

TABLE 154-7
Differential Diagnosis for *Bartonella* Infections

BARTONELLA INFECTION	DIFFERENTIAL DIAGNOSIS
Cat scratch disease	Sporotrichosis, paracoccidioidomycosis, histoplasmosis Tuberculosis, atypical mycobacteria Sarcoidosis Nocardiosis Foreign-body granuloma HIV infection Syphilis Lymphogranuloma venereum Epstein-Barr virus Lymphoma Kikuchi-Fujimoto disease
Trench fever	Enteric fever Brucellosis Leptospirosis Dengue Relapsing fever Typhus Malaria Viral exanthem
Bacillary angiomatosis	Kaposi sarcoma Epithelioid hemangioma Pyogenic granuloma Angiokeratoma Cherry angioma Dermatofibroma Tuberculosis, atypical mycobacteria, or dimorphic fungi Verruga peruana
Carrion disease	Oroya fever Malaria Brucellosis Viral hepatitis Leptospirosis Hematologic malignancy Aplastic or hemolytic anemia Verruga peruana Pyogenic granuloma Hemangioma Warts Bacillary angiomatosis Kaposi sarcoma Yaws Lymphomatoid papulosis Malignant lymphoma Angiolymphoid hyperplasia with eosinophilia

although 6 to 24 months of prolonged lymphadenopathy occur in 20% of cases. Cutaneous manifestations heal without scarring. CSD lymphadenitis is benign and self-limited, while disseminated manifestations may be life threatening.[76]

TRENCH FEVER

Trench fever typically follows a mild course, although some cases may be fairly debilitating. Death is rare.[76]

BACILLARY ANGIOMATOSIS

BA responds well to antibiotic therapy, with lesions improving within 1 week and full clearance often occurring within 1 month. However, BA may become life-threatening in the absence of treatment. Relapses are not uncommon, especially when antibiotic treatment is given for less than 3 months.[76]

CARRION DISEASE

Oroya fever lasts 1 to 4 weeks. Clinical severity ranges from mild to severe with 44% to 88% mortality among untreated patients. When treated with antibiotics, mortality is less than 10%, although if symptoms fail to resolve within 72 hours, complications should be suspected.[93] Severe cases are more likely to occur in travelers versus patients native to endemic regions. When deaths occur, they are usually associated with opportunistic infection[76,89]

In addition to a milder disease course, patients native to endemic regions frequently present with verruga peruana in the absence of any history of Oroya fever. Lesions of verruga peruana usually erupt over a course of 3 to 6 months, although they may continue to appear for years if left untreated. In the absence of complications, lesions heal without scarring.[76]

MANAGEMENT

Table 154-6 summarizes the management of diseases caused by *Bartonella* species.

CAT SCRATCH DISEASE

Classic CSD is benign, self-limited, and responds poorly to antimicrobial therapy. Consequently, no treatment is recommended for mild to moderate disease. In patients with large, bulky lymphadenopathy, azithromycin, doxycycline, and erythromycin have been used. When lymph nodes suppurate, needle aspiration is likely to be beneficial, and surgical removal may be considered in those with large, painful nodes unresponsive to an extended course of treatment. For those with liver and/or spleen involvement, rifampicin alone or in combination with gentamicin or trimethoprim-sulfamethoxazole should be used. Ocular CSD is typically treated with doxycycline because of superior ocular penetration; a combination of doxycycline and rifampicin also has been employed.[76,93,108,109]

TRENCH FEVER

A randomized trial supports the use of 28 days of oral doxycycline plus 14 days of IV gentamicin for the treatment of trench fever. Treatment of uncomplicated disease also may be attempted with a 4- to 6-week course of oral doxycycline, erythromycin, or azithromycin. Because of unreliable activity,

trimethoprim-sulfamethoxazole, fluoroquinolones, penicillins, and first-generation cephalosporins should not be used.[76,110,111]

BACILLARY ANGIOMATOSIS

Erythromycin or doxycycline for 3 or more months may be used to treat uncomplicated BA, peliosis, and osteomyelitis. Azithromycin and clarithromycin are alternative therapies. In severe cases, combination therapy should be employed with erythromycin or doxycycline plus a rifamycin, and intravenous therapy may initially be required. *Bartonella* endocarditis should be treated with doxycycline with the addition of gentamicin for 2 weeks; a rifamycin can be substituted for gentamicin in the setting of renal insufficiency.[112] Rifampicin, a potent cytochrome P450 inducer, requires dose adjustments in patients who are also receiving antiretroviral therapy. Because of unreliable activity, trimethoprim-sulfamethoxazole, fluoroquinolones, penicillins, and first-generation cephalosporins should not be used.[76]

CARRION DISEASE

First-line treatment of uncomplicated Oroya fever includes ciprofloxacin or combination therapy with chloramphenicol and a β-lactam. Fourteen days is a common duration of treatment. Success also has been reported with trimethoprim-sulfamethoxazole, macrolides, and norfloxacin. For severe disease, ciprofloxacin plus ceftriaxone may be used, and red blood cells should be transfused if the hematocrit falls below 20%. Patients with complications, such as coma, convulsions, and edema, are often given short courses of dexamethasone.[76,89,93,113]

Verruga peruana may be treated with rifampicin for 14 to 21 days. Intramuscular streptomycin is an alternative.[93,108] Other antibiotics that have demonstrated successful treatment include azithromycin, ciprofloxacin, and erythromycin. Chloramphenicol and penicillins are not effective against verruga peruana.[76]

ENTERIC FEVER CAUSED BY *SALMONELLA*

AT-A-GLANCE

- Worldwide, approximately 13.5 million cases of enteric fever occur each year.
- Disease is spread by chronic carriers and contracted following ingestion of contaminated water or food.
- Regions with the greatest density of enteric fever include south-central and southeastern Asia and areas of southern Africa.
- Rose spots are the classic cutaneous manifestation, occurring in 30% of cases. They are most commonly seen when antibiotic treatment has been delayed.
- Symptoms include fever, abdominal pain, and constipation or diarrhea.
- The most common complications are intestinal bleeding, ileal perforation, and encephalopathy.
- With antibiotics, death from enteric fever occurs in less than 1% of cases.

INTRODUCTION AND BACTERIOLOGY

Salmonella is a genus of Gram-negative, oxidase-negative, flagellate rods that do not ferment lactose and grow best on MacConkey or *Salmonella-Shigella* agar. Currently, there are only 2 identified species of *Salmonella*, *Salmonella enterica* and *Salmonella bongori.* Although previous classification systems have included more *Salmonella* species, genetic analysis has since indicated that they are more appropriately classified as subspecies and serovars. Thus, *S. enterica* has been divided into 6 subspecies, one of which is *S. enterica* subsp. *enterica.* Within subspecies *enterica* there are more than 1000 serovars, differentiated by O (somatic) and H (flagellar) antigens.[114]

Salmonella is responsible for 2 major clinical syndromes: enteric fever and gastroenteritis; enteric fever is the focus of this chapter. The classic cause of enteric fever is *S. enterica* subsp. *enterica* serovar Typhi (*Salmonella typhi*), although *Salmonella paratyphi* A, *S. paratyphi* B, *S. paratyphi* C, and *Salmonella choleraesuis* also have been implicated. Thus, the term *enteric fever* encompasses both typhoid and paratyphoid fever.

EPIDEMIOLOGY

Worldwide, approximately 13.5 million cases of enteric fever occur each year,[115] with the greatest prevalence among children and young adults. Approximately 350 cases occur annually in the United States, most of which are associated with travel to endemic regions; only approximately 18% are domestically acquired. Infections attained in endemic areas are more likely to be drug-resistant. Enteric fever is endemic in many developing countries, especially resource-poor areas with overcrowding and inadequate sanitation. Regions with the greatest density of disease include south-central and southeastern Asia and areas of southern Africa.

Humans are the only hosts of *S. typhi,* while other serovars are widespread in nature and can be carried by mammals, poultry, and reptiles. Although worldwide studies indicate that *S. typhi* is the most frequent

cause of enteric fever, *S. paratyphi* A appears to be responsible for a growing portion of disease in multiple Asian countries. In some studies, *S. paratyphi* A has accounted for 50% of *Salmonella* bloodstream isolates among enteric fever patients. This finding is concerning, as current available vaccines have either limited or no protection against paratyphoid fever.[115-118]

CLINICAL FEATURES

Traditionally, it has been thought that typhoid fever has a more robust presentation that is associated with greater severity and rates of complications compared to paratyphoid fever. However, this hypothesis has not held true in recent investigations, which show that it is not possible to predict the etiologic organism of enteric fever based on clinical presentation.[119-122]

CUTANEOUS FINDINGS

Rose spots are the classic cutaneous manifestation of enteric fever, presenting several days following the onset of symptoms. They are estimated to occur in approximately 30% of cases, and are more likely to be observed in patients where antibiotic treatment has been delayed. Rose spots are described as asymptomatic, blanching, erythematous to pale-pink papules, usually on the abdomen, chest, or back. They occur in crops that fade over 3 to 5 days and can easily be missed on darkly pigmented skin. Other cutaneous manifestations of enteric fever may include erythema multiforme, Sweet syndrome, hemorrhagic bullae, pustular dermatitis, or erythema typhosum, a generalized erythematous eruption.[12,123,124] In rare cases, ulcerative lesions of the vulva or scrotum have been the presenting symptom of enteric fever.[125,126]

Of note, rose spots may be seen to a lesser extent in psittacosis, leptospirosis, brucellosis, rat-bite fever, and shigellosis, although in these contexts they are not well-described.[124]

NONCUTANEOUS FINDINGS

Following an incubation period of 1 to 2 weeks, patients present with fever and nonspecific flu-like symptoms (malaise, anorexia, nausea, myalgias, headache). Fever is initially low and rises in a stepwise fashion, often reaching 39°C to 40°C (102.2°F to 104°F), and may be accompanied by relative bradycardia. Over time, patients develop abdominal pain, and diarrhea or constipation. Diarrhea is common in children and HIV patients, while constipation is more likely to occur in adults. On examination, patients may have abdominal tenderness or hepatosplenomegaly. Patients can also experience intermittent confusion or apathy, and convulsions have been described in young children.

White cell counts, hemoglobin, and platelets may all be reduced, although children are prone to leukocytosis. Liver enzymes are frequently 2 to 3 times the upper limit of normal. In one study of 60 patients with enteric fever, rose spots, relative bradycardia, splenomegaly, thrombocytopenia, and elevated aspartate aminotransferase were found to have the strongest predictive value for enteric fever.[116,127]

COMPLICATIONS

Complications arise in 10% to 15% of patients and may include GI bleeding, intestinal perforation, and encephalopathy. GI bleeding occurs most frequently, and although most patients do not require a blood transfusion, this complication may be fatal in some cases. The most serious complication is intestinal perforation, which occurs in 1% to 3% of hospitalized patients and usually affects the ileum. It may present overtly as an acute abdomen, or in a more surreptitious fashion with simple worsening of abdominal pain, a rising heart rate, and falling blood pressure.

In 1% to 4% of cases, infection persists as a chronic carrier state, defined by excretion of *Salmonella* in the stool for more than 12 months after infection. Less commonly, patients may exhibit chronic urinary carriage, especially in those with urinary tract abnormalities or concurrent *Schistosoma haematobium* bladder infection. Chronic carriage most frequently occurs in women, elderly patients, and patients with cholelithiasis. In some patients, infection may proceed directly to a chronic carrier state, as up to 25% of long-term carriers have no history of enteric fever. Carriers pose a major infection risk to others, especially when they are involved in food preparation, and carriage confers an increased risk of gallbladder carcinoma, as well as other cancers. Eradication should be attempted in these patients with antimicrobial therapy to decrease the infection risk to others; however, it is unclear how eradication may impact the risk of carcinogenesis.[116,128]

ETIOLOGY AND PATHOGENESIS

Typhoidal *Salmonella* is acquired by ingesting contaminated water or food, usually while traveling or residing in developing countries. Following ingestion, bacteria survive passage through gastric acid and arrive in the small bowel, where they are able to breach the epithelium via 1 of 2 pathways. Bacteria may enter the mucosa via M cells, an antigen-presenting cell associated with lymphoid tissue throughout the gut, or via uptake by epithelial cells, as mediated by the cystic fibrosis transmembrane conductance regulator (CFTR) protein that is mutated in cystic fibrosis. Thus, variation in the *CFTR* gene is correlated with a degree of protection against enteric fever.

Following penetration of the epithelium, bacteria replicate in the submucosa and cause hypertrophy of Peyer patches. Hypertrophy and necrosis of the small intestine may cause abdominal pain and microscopic or macroscopic compromise of the mucosal barrier,

potentially leading to secondary bacteremia, intestinal bleeding, or ileal perforation.[129] From the small intestine, *Salmonella* disseminate via the blood and lymphatic system, leading to systemic infection.[130,131] Ultimately, bacteria infiltrate tissue macrophages of the liver, spleen, and bone marrow, which may serve as sources for infection relapse or facilitate rare manifestations such as pericarditis, visceral abscesses, or osteomyelitis. The bone marrow is a potential source for diagnostic cultures, even after the initiation of antimicrobial therapy.[132]

DIAGNOSIS

LABORATORY TESTING

Blood cultures are the standard mode of diagnosis, and are positive in 40% to 80% of cases, depending on prior antimicrobial therapy. Cultures of bone marrow are more sensitive, yielding positive results in 80% to 95% of cases even after several days of antibiotics; however, this is invasive and should be reserved for complicated cases where the diagnosis remains uncertain. Other potential culture sources include rose spots, stool, urine, and intestinal secretions (via duodenal string capsule). One study of enteric fever patients demonstrated positive culture rates from rose spots, stool, and urine of 63%, 37%, and 7%, respectively.[116,133] Serologic tests are of limited utility, except in the diagnosis of chronic carriers, who may be identified by measuring serum antibodies against the Vi polysaccharide antigen.[128]

PATHOLOGY

Biopsy of rose spots may reveal dilated capillaries with edema and perivascular infiltrates of histiocytes and few neutrophils.[124,134]

DIFFERENTIAL DIAGNOSIS

The differential diagnosis for enteric fever comprises a variety of infectious and some noninfectious diseases. Such conditions include malaria, amebiasis, dengue fever, visceral leishmaniasis, brucellosis, typhus, miliary tuberculosis, influenza, slow-onset appendicitis, and lymphoproliferative disease.

CLINICAL COURSE AND PROGNOSIS

With antibiotics, fever resolves in 3 to 5 days with full recovery occurring over weeks to months. Enteric fever may relapse in 5% to 10% of patients, even with adequate therapy, usually 2 to 3 weeks following the resolution of fever. Death occurs in less than 1% of cases, although mortality may be significantly higher in resource-poor regions. The mortality rate associated with ileal perforation ranges from 10% to 32%.[116]

MANAGEMENT

MEDICATIONS

Enteric fever should be treated with systemic antimicrobial therapy. Commonly used treatments include ciprofloxacin, ofloxacin, azithromycin, and ceftriaxone. However, ciprofloxacin is no longer recommended as a first-line empiric treatment for patients returning from South Asia because of rising resistance in this region. In cases of suspected ciprofloxacin resistance, ofloxacin or azithromycin may be used. Ceftriaxone is especially useful in the treatment of severe or complicated enteric fever. Typhoidal organisms demonstrate significant resistance to ampicillin, trimethoprim-sulfamethoxazole, and chloramphenicol, and thus these agents are no longer routinely employed.[135]

PREVENTION

Two vaccines available for enteric fever include Ty21a, a live attenuated oral vaccine, as well as a parenteral Vi polysaccharide vaccine. Because *S. paratyphi* serovars do not display the Vi antigen, it is assumed that the Vi polysaccharide vaccine does not offer protection against paratyphoid fever. There is some evidence that the Ty21a vaccine offers limited protection against *S. paratyphi* A and *S. paratyphi* B.[118]

RHINOSCLEROMA CAUSED BY *KLEBSIELLA RHINOSCLEROMATIS*

Klebsiella rhinoscleromatis is a subspecies of *Klebsiella pneumoniae* (*K. pneumoniae* subsp. *rhinoscleromatis*), a lactose-fermenting Gram-negative rod. It is known to cause rhinoscleroma, a rare chronic granulomatous disease affecting the nose and upper respiratory tract. Endemic areas include Africa, the Middle East, Central and South America, Central and Eastern Europe, China, India, and Indonesia. *K. rhinoscleromatis* are contracted by inhaling contaminated respiratory droplets, and infection begins in the nasal mucosa, although it may spread to affect the nasopharynx, pharynx, oral cavity, paranasal sinuses, orbit, larynx, trachea, and even bronchi. Iron deficiency and defective cellular immunity are predisposing factors, with defective cellular immunity explaining the presence of Mikulicz cells that have phagocytosed and retained *K. rhinoscleromatis* bacilli.[136-138]

Rhinoscleroma progresses through 3 phases of disease. First, the atrophic phase, which lasts several

months, is characterized by symptoms of the common cold. Patients may experience nasal blockage accompanied by a purulent, foul-smelling discharge. Next, the proliferative phase lasts months to years and is marked by the development of granulomatous nodules, nasal deformity, hyposmia, dysphagia, dysphonia, stridor, and difficulty breathing. In the final cicatricial stage, areas of involvement undergo extensive sclerosis (Fig. 154-11).[138]

Rhinoscleroma may be diagnosed via culture isolation of *K. rhinoscleromatis* from nasal swabs, blood, or biopsy specimens. Biopsied tissue reveals plasma cells, lymphocytes, Russell bodies, and pathognomonic Mikulicz cells, which are large vacuolated histiocytes containing *K. rhinoscleromatis*. Mikulicz cells can be visualized with CD68 immunostaining, and Warthin-Starry silver stain may show *K. rhinoscleromatis* residing in Mikulicz cells. Periodic acid–Schiff staining can be used to enhance Russell bodies. A CT scan may show nonenhancing homogeneous soft-tissue crypt-like irregular masses with nodular deformity and distinct edge definition. Lesions of the larynx and trachea appear as concentric irregular airway narrowing. Rhinoscleroma must be differentiated from tuberculosis, leprosy, sarcoidosis, mucocutaneous leishmaniasis, dimorphic fungal infection, granulomatosis with polyangiitis, lymphoma, and basal or squamous cell carcinoma. The condition is treated with antimicrobial therapy and surgical correction of airway obstructions. In the absence of established guidelines, commonly used antibiotics include tetracycline, rifampicin, ciprofloxacin, and trimethoprim-sulfamethoxazole. Antibiotic therapy should continue for 3 to 6 months until repeat histology and cultures are negative. Despite prolonged therapy, rhinoscleroma has a high incidence of relapse.[138-140]

CELLULITIS CAUSED BY *HAEMOPHILUS INFLUENZAE*

Haemophilus influenzae is a fastidious, Gram-negative coccobacillus that grows on chocolate agar and requires hemin (factor X) and nicotinamide adenine dinucleotide (factor V) for growth. The bacteria may be rough or encapsulated, and encapsulated strains are divided into 6 types based on capsular polysaccharide antigens (a through f). Rough strains are primarily responsible for acute otitis media, pneumonia and chronic bronchitis exacerbations. Prior to the widespread use of *H. influenzae* type b (Hib) vaccines, this organism was a well-known cause of meningitis, epiglottitis, and cellulitis, especially facial cellulitis in children.[141] Although Hib-associated infections have fallen dramatically since the implementation of vaccines, they may still be seen in developing countries or other areas with low rates of vaccination.

Figure 154-11 Rhinoscleroma in an Egyptian woman (**A**) with pronounced deformity of the nose and cheeks, as well as in a Guatemalan man (**B**) presenting 17 years following initial onset. (Reproduced with permission from Friedmann I. Ulcerative/necrotizing diseases of the nose and paranasal sinuses. *Curr Diagn Pathol*. 1995;2[4]:236-255; and Sedano HO, Koutlas IG. Respiratory scleroma: a clinicopathologic and ultrastructural study. *Oral Surg Oral Med Oral Pathol Oral Radiol Endod*. 1996;81[6]:665-671. Copyright © Elsevier.)

Typical Hib facial cellulitis presents in children between 3 and 24 months of age, usually following a mild upper respiratory tract infection. Patients rapidly develop high fever, irritability and unilateral facial swelling, especially in the buccal or periorbital region. The affected area is usually warm, edematous and erythematous, classically with a violaceous hue. In contrast to other causes of cellulitis, Hib cellulitis was frequently associated with bacteremia, with positive blood cultures in approximately 75% of patients. This was especially significant because of the propensity of this organism to cause secondary infection, particularly meningitis. For this reason, lumbar puncture was once a routine measure in the evaluation of facial cellulitis in children; however, this measure has since been discontinued.[142] Recent reports have indicated a decline in *H. influenzae*–associated facial cellulitis. When identified, nontypeable strains have been implicated, which have not been associated with bacteremia.[143,144] *H. influenzae*–associated facial cellulitis is diagnosed by culture of the affected area to rule out other common organisms, including streptococci and staphylococci. Third-generation cephalosporins, such as ceftriaxone or cefotaxime, are the drugs of choice.

REFERENCES

1. Beveridge TJ. Use of the Gram stain in microbiology. *Biotech Histochem.* 2001;76(3):111-118.
2. Jorgensen JH, Pfaller MA, Carroll KC. *Manual of Clinical Microbiology*. Washington, DC: ASM Press; 2015.
3. Mahon CR, Lehman DC, Manuselis G. *Textbook of Diagnostic Microbiology*. 5th ed. Philadelphia, PA: Elsevier Saunders; 2014.
4. Rouphael NG, Stephens DS. *Neisseria meningitidis*: biology, microbiology, and epidemiology. *Methods Mol Biol*. 2012;799:1-20.
5. Green LR, Eiden J, Hao L, et al. Approach to the discovery, development, and evaluation of a novel *Neisseria meningitidis* serogroup B vaccine. *Methods Mol Biol*. 2016;1403:445-469.
6. Kolappan S, Coureuil M, Yu X, et al. Structure of the *Neisseria meningitidis* type IV pilus. *Nat Commun.* 2016;7:13015.
7. Imhaus AF, Duménil G. The number of *Neisseria meningitidis* type IV pili determines host cell interaction. *EMBO J.* 2014;33(16):1767-1783.
8. Madico G, Welsch JA, Lewis LA, et al. The meningococcal vaccine candidate GNA1870 binds the complement regulatory protein factor H and enhances serum resistance. *J Immunol.* 2006;177(1):501-510.
9. Brandtzaeg P, van Deuren M. Classification and pathogenesis of meningococcal infections. *Methods Mol Biol*. 2012;799:21-35.
10. Scheld MW, Marra CM, Whitley RJ. *Infections of the Central Nervous System*. 4th ed. Philadelphia, PA: Lippincott Williams & Wilkins; 2014.
11. Takada S, Fujiwara S, Inoue T, et al. Meningococcemia in adults: a review of the literature. *Intern Med.* 2016;55(6):567-572.
12. Bolognia JL, Jorizzo JI, Schaffer JV, eds. *Dermatology*. 3rd ed. Philadelphia, PA: Elsevier Saunders; 2012.
13. Sabatini C, Bosis S, Semino M, et al. Clinical presentation of meningococcal disease in childhood. *J Prev Med Hyg.* 2012;53(2):116-119.
14. Wenzel M, Jakob L, Wieser A, et al. Corticosteroid-induced meningococcal meningitis in a patient with chronic meningococcemia. *JAMA Dermatol.* 2014;150(7):752-755.
15. De Greeff S, de Melker H, Schouls L, et al. Pre-admission clinical course of meningococcal disease and opportunities for the earlier start of appropriate intervention: a prospective epidemiological study on 752 patients in the Netherlands, 2003-2005. *Eur J Clin Microbiol Infect Dis.* 2008;27(10):985-992.
16. Hale AJ, LaSalvia M, Kirby JE, et al. Fatal purpura fulminans and Waterhouse-Friderichsen syndrome from fulminant *Streptococcus pneumoniae* sepsis in an asplenic young adult. *IDCases.* 2016;6:1-4.
17. Feldman H. Meningococcal infections. *Adv Intern Med.* 1972;18:117.
18. Cohen MS, Rutala W, Weber D. Gram-negative coccal and bacillary infections. In: Goldsmith LA, Katz SI, Gilchrest BA, et al, eds. *Fitzpatrick's Dermatology in General Medicine*. 8th ed. New York, NY: McGraw-Hill; 2012:2183-2186.
19. Van Deuren M, Brandtzaeg P, van der Meer JW. Update on meningococcal disease with emphasis on pathogenesis and clinical management. *Clin Microbiol Rev.* 2000;13(1):144-166.
20. Goedvolk C, Von Rosenstiel I, Bos A. Immune complex associated complications in the subacute phase of meningococcal disease: incidence and literature review. *Arch Dis Child*. 2003;88(10):927-930.
21. Parmentier L, Garzoni C, Antille C, et al. Value of a novel *Neisseria meningitidis*–specific polymerase chain reaction assay in skin biopsy specimens as a diagnostic tool in chronic meningococcemia. *Arch Dermatol.* 2008;144(6):770-773.
22. Melican K, Veloso PM, Martin T, et al. Adhesion of *Neisseria meningitidis* to dermal vessels leads to local vascular damage and purpura in a humanized mouse model. *PLoS Pathog.* 2013;9(1):e1003139.
23. Dupin N, Lecuyer H, Carlotti A, et al. Chronic meningococcemia cutaneous lesions involve meningococcal perivascular invasion through the remodeling of endothelial barriers. *Clin Infect Dis.* 2012;54(8):1162-1165.
24. Strelow VL, Vidal JE. Invasive meningococcal disease. *Arq Neuropsiquiatr.* 2013;71(9B):653-658.
25. Kanegaye JT, Soliemanzadeh P, Bradley JS. Lumbar puncture in pediatric bacterial meningitis: defining the time interval for recovery of cerebrospinal fluid pathogens after parenteral antibiotic pretreatment. *Pediatrics.* 2001;108(5):1169-1174.
26. Van Deuren M, Van Dijke BJ, Koopman R, et al. Rapid diagnosis of acute meningococcal infections by needle aspiration or biopsy of skin lesions. *BMJ.* 1993;306(6887):1229-1232.
27. Arend S, Lavrijsen A, Kuijken I, et al. Prospective controlled study of the diagnostic value of skin biopsy in patients with presumed meningococcal disease. *Eur J Clin Microbiol Infect Dis.* 2006;25(10):643-649.
28. Bryant PA, Li HY, Zaia A, et al. Prospective study of a real-time PCR that is highly sensitive, specific, and clinically useful for diagnosis of meningococcal disease in children. *J Clin Microbiol.* 2004;42(7):2919-2925.
29. Guarner J, Greer PW, Whitney A, et al. Pathogenesis and diagnosis of human meningococcal disease

using immunohistochemical and PCR assays. *Am J Clin Pathol*. 2004;122(5):754-764.
30. Tunkel AR, Hartman BJ, Kaplan SL, et al. Practice guidelines for the management of bacterial meningitis. *Clin Infect Dis*. 2004;39(9):1267-1284.
31. Collard J-M, Wang X, Mahamane AE, et al. A five-year field assessment of rapid diagnostic tests for meningococcal meningitis in Niger by using the combination of conventional and real-time PCR assays as a gold standard. *Trans R Soc Trop Med Hyg*. 2014;108(1):6-12.
32. Busam K. *Dermatopathology*. 2nd ed. Philadelphia, PA: Elsevier Saunders; 2015.
33. Cohn AC, MacNeil JR, Clark TA, et al. Prevention and control of meningococcal disease: recommendations of the Advisory Committee on Immunization Practices (ACIP). *MMWR Recomm Rep*. 2013;62(RR-2):1-28.
34. Mandell GL, Bennett JE, Dolin R. *Mandell, Douglas, and Bennett's Principles and Practice of Infectious Diseases*. 7th ed. Philadelphia, PA: Churchill Livingstone; 2010.
35. Nathan N, Borel T, Djibo A, et al. Ceftriaxone as effective as long-acting chloramphenicol in short-course treatment of meningococcal meningitis during epidemics: a randomised non-inferiority study. *Lancet*. 2005;366(9482):308-313.
36. White B, Livingstone W, Murphy C, et al. An open-label study of the role of adjuvant hemostatic support with protein C replacement therapy in purpura fulminans–associated meningococcemia. *Blood*. 2000;96(12):3719-3724.
37. Brouwer MC, McIntyre P, Prasad K, et al. Corticosteroids for acute bacterial meningitis. *Cochrane Database Syst Rev*. 2015;(9):CD004405.
38. Robinson CL. Advisory Committee on Immunization Practices recommended immunization schedules for persons aged 0 through 18 years—United States, 2016. *Am J Transplant*. 2016;16(6):1928-1929.
39. MacNeil JR, Cohn AC, Zell ER, et al. Early estimate of the effectiveness of quadrivalent meningococcal conjugate vaccine. *Pediatr Infect Dis J*. 2011;30(6):451-455.
40. Folaranmi T, Rubin L, Martin SW, et al. Use of serogroup B meningococcal vaccines in persons aged≥ 10 years at increased risk for serogroup B meningococcal disease: Recommendations of the Advisory Committee on Immunization Practices, 2015. *MMWR Morb Mortal Wkly Rep*. 2015;64(22):608-612.
41. Agger WA, Mardan A. *Pseudomonas aeruginosa* infections of intact skin. *Clin Infect Dis*. 1995;20(2): 302-308.
42. Wu DC, Chan WW, Metelitsa AI, et al. *Pseudomonas* skin infection. *Am J Clin Dermatol*. 2011;12(3):157-169.
43. Driscoll JA, Brody SL, Kollef MH. The epidemiology, pathogenesis and treatment of Pseudomonas aeruginosa infections. *Drugs*. 2007;67(3):351-368.
44. Andonova M, Urumova V. Immune surveillance mechanisms of the skin against the stealth infection strategy of *Pseudomonas aeruginosa*—review. *Comp Immunol Microbiol Infect Dis*. 2013;36(5):433-448.
45. Lavoie EG, Wangdi T, Kazmierczak BI. Innate immune responses to *Pseudomonas aeruginosa* infection. Microbes Infect. 2011;13(14):1133-1145.
46. Hall S, McDermott C, Anoopkumar-Dukie S, et al. Cellular effects of pyocyanin, a secreted virulence factor of *Pseudomonas aeruginosa*. *Toxins (Basel)*. 2016;8(8):236.
47. Solomon S, Horan T, Andrus M, et al. National Nosocomial Infections Surveillance (NNIS) system report, data summary from January 1992 through June 2003, issued August 2003. *Am J Infect Control*. 2003;31(8):481-498.
48. Zilberberg MD, Shorr AF. Prevalence of multidrug-resistant *Pseudomonas aeruginosa* and carbapenem-resistant *Enterobacteriaceae* among specimens from hospitalized patients with pneumonia and bloodstream infections in the United States from 2000 to 2009. *J Hosp Med*. 2013;8(10):559-563.
49. Chiriac A, Brzezinski P, Foia L, et al. Chloronychia: green nail syndrome caused by *Pseudomonas aeruginosa* in elderly persons. *Clin Interv Aging*. 2015;10:265.
50. Fiorillo L, Zucker M, Sawyer D, et al. The *Pseudomonas* hot-foot syndrome. *N Engl J Med*. 2001;345(5):335-338.
51. Yu Y, Cheng AS, Wang L, et al. Hot tub folliculitis or hot hand–foot syndrome caused by *Pseudomonas aeruginosa*. *J Am Acad Dermatol*. 2007;57(4):596-600.
52. Rosenfeld RM, Schwartz SR, Cannon CR, et al. Clinical practice guideline acute otitis externa. *Otolaryngol Head Neck Surg*. 2014;150(1)(suppl):S1-S24.
53. Centers for Disease Control and Prevention. Estimated burden of acute otitis externa--United States, 2003-2007. *MMWR Morb Mortal Wkly Rep*. 2011;60(19):605.
54. Ishikawa T, Sakurai Y, Tanaka M, et al. Ecthyma gangrenosum-like lesions in a healthy child after infection treated with antibiotics. *Pediatr Dermatol*. 2005;22(5):453-456.
55. Sarkar S, Patra AK, Mondal M. Ecthyma gangrenosum in the periorbital region in a previously healthy immunocompetent woman without bacteremia. *Indian Dermatol Online J*. 2016;7(1):36.
56. Osguthorpe JD, Nielsen DR. Otitis externa: review and clinical update. *Am Fam Physician*. 2006;74(9):1510-1516.
57. Lee H, Kim J, Nguyen V. Ear infections: otitis externa and otitis media. *Prim Care*. 2013;40(3):671-686.
58. Driscoll P, Ramachandrula A, Drezner D, et al. Characteristics of cerumen in diabetic patients: a key to understanding malignant external otitis? *Otolaryngol Head Neck Surg*. 1993;109(4):676.
59. Schechner V, Nobre V, Kaye KS, et al. Gram-negative bacteremia upon hospital admission: when should *Pseudomonas aeruginosa* be suspected? *Clin Infect Dis*. 2009;48(5):580-586.
60. Sifuentes-Osornio J, González R, Ponce-de-Leon A, et al. Epidemiology and prognosis of *Pseudomonas aeruginosa* bacteremia in a tertiary care center. *Rev Invest Clin*. 1997;50(5):383-388.
61. Atzori L, Zucca M, Lai M, et al. Gram-negative bacterial toe web intertrigo. *Eur Med J Dermatol*. 2014;2:106-111.
62. El Baze P, Thyss A, Caldani C, et al. *Pseudomonas aeruginosa* O-11 folliculitis: development into ecthyma gangrenosum in immunosuppressed patients. *Arch Dermatol*. 1985;121(7):873-876.
63. Llor C, McNulty CA, Butler CC. Ordering and interpreting ear swabs in otitis externa. *BMJ*. 2014;349: g5259.
64. Rowshan HH, Keith K, Baur D, et al. *Pseudomonas aeruginosa* infection of the auricular cartilage caused by "high ear piercing": a case report and review of the literature. *J Oral Maxillofac Surg*. 2008;66(3): 543-546.
65. Rubin J, Victor LY. Malignant external otitis: insights into pathogenesis, clinical manifestations, diagnosis, and therapy. *Am J Med*. 1988;85(3):391-398.
66. Loh S, Loh WS. Malignant otitis externa an Asian perspective on treatment outcomes and

prognostic factors. *Otolaryngol Head Neck Surg.* 2013;148(6):991-996.
67. Kang C-I, Kim S-H, Kim H-B, et al. *Pseudomonas aeruginosa* bacteremia: risk factors for mortality and influence of delayed receipt of effective antimicrobial therapy on clinical outcome. *Clin Infect Dis*. 2003;37(6):745-751.
68. Bodey GP, Jadeja L, Elting L. *Pseudomonas* bacteremia: retrospective analysis of 410 episodes. *Arch Intern Med.* 1985;145(9):1621-1629.
69. Aste N, Atzori L, Zucca M, et al. Gram-negative bacterial toe web infection: a survey of 123 cases from the district of Cagliari, Italy. *J Am Acad Dermatol.* 2001;45(4):537-541.
70. Kaushik V, Malik T, Saeed SR. Interventions for acute otitis externa. *Cochrane Database Syst Rev.* 2010;(1):CD004740.
71. Noel SB, Scallan P, Meadors MC, et al. Treatment of *Pseudomonas aeruginosa* auricular perichondritis with oral ciprofloxacin. *J Dermatol Surg Oncol.* 1989;15(6):633-637.
72. Mion M, Bovo R, Marchese-Ragona R, et al. Outcome predictors of treatment effectiveness for fungal malignant external otitis: a systematic review. *Acta Otorhinolaryngol Ital.* 2015;35(5):307.
73. Vardakas KZ, Tansarli GS, Bliziotis IA, et al. β-Lactam plus aminoglycoside or fluoroquinolone combination versus β-lactam monotherapy for *Pseudomonas aeruginosa* infections: a meta-analysis. *Int J Antimicrob Agents.* 2013;41(4):301-310.
74. van Duin D, Bonomo RA. Ceftazidime/avibactam and ceftolozane/tazobactam: second-generation β-lactam/β-lactamase combinations. *Clin Infect Dis.* 2016;63(2):234-241.
75. Sabuda DM, Laupland K, Pitout J, et al. Utilization of colistin for treatment of multidrug-resistant *Pseudomonas aeruginosa*. *Can J Infect Dis Med Microbiol*. 2008;19(6):413-418.
76. Maguiña C, Guerra H, Ventosilla P. Bartonellosis. *Clin Dermatol.* 2009;27(3):271-280.
77. Pulliainen AT, Dehio C. Persistence of *Bartonella* spp. stealth pathogens: from subclinical infections to vasoproliferative tumor formation. *FEMS Microbiol Rev.* 2012;36(3):563-599.
78. Chian CA, Arrese JE, Piérard GE. Skin manifestations of *Bartonella* infections. *Int J Dermatol.* 2002;41(8):461-466.
79. Chomel BB, Kasten RW, Floyd-Hawkins K, et al. Experimental transmission of Bartonella henselae by the cat flea. *J Clin Microbiol*. 1996;34(8):1952-1956.
80. Brouqui P, Lascola B, Roux V, et al. Chronic *Bartonella quintana* bacteremia in homeless patients. *N Engl J Med.* 1999;340(3):184-189.
81. Plettenberg A, Lorenzen T, Burtsche B, et al. Bacillary angiomatosis in HIV-infected patients—an epidemiological and clinical study. *Dermatology.* 2000;201(4):326-331.
82. Clemente NS, Ugarte-Gil CA, Solórzano N, et al. *Bartonella bacilliformis*: a systematic review of the literature to guide the research agenda for elimination. *PLoS Negl Trop Dis*. 2012;6(10):e1819.
83. Chamberlin J, Laughlin LW, Romero S, et al. Epidemiology of endemic *Bartonella bacilliformis*: a prospective cohort study in a Peruvian mountain valley community. *J Infect Dis*. 2002;186(7):983-990.
84. Lappin MR, Davis WL, Hawley JR, et al. A flea and tick collar containing 10% imidacloprid and 4.5% flumethrin prevents flea transmission of *Bartonella henselae* in cats. *Parasit Vectors.* 2013;6(1):26.
85. Varela G, Vinson J, Molina-Pasquel C. Trench fever. III. Induction of clinical disease in volunteers inoculated with Rickettsia quintana propagated on blood agar. *Am J Trop Med Hyg*. 1969;18(5):713-722.
86. Koehler JE, Tappero JW. Bacillary angiomatosis and bacillary peliosis in patients infected with human immunodeficiency virus. *Clin Infect Dis*. 1993;17(4):612-624.
87. Monteil R, Michiels J-F, Hofman P, et al. Histological and ultrastructural study of one case of oral bacillary angiomatosis in HIV disease and review of the literature. *Eur J Cancer B Oral Oncol.* 1994;30(1):65-71.
88. Maguiña C, Ugarte-Gil C, Breña P, et al. Actualización de la Enfermedad de Carrión. Update of Carrion's disease. *Rev Medica Hered.* 2008;19(1):036-041.
89. Maguiña C, García PJ, Gotuzzo E, et al. Bartonellosis (Carrion's disease) in the modern era. *Clin Infect Dis*. 2001;33(6):772-779.
90. Fretzayas A, Papadopoulos NG, Moustaki M, et al. Unsuspected extralymphocutaneous dissemination in febrile cat scratch disease. *Scand J Infect Dis.* 2001;33(8):599-603.
91. Reed JB, Scales DK, Wong MT, et al. *Bartonella henselae* neuroretinitis in cat scratch disease: diagnosis, management, and sequelae. *Ophthalmology.* 1998;105(3):459-466.
92. Arisoy ES, Correa AG, Wagner ML, et al. Hepatosplenic cat-scratch disease in children: selected clinical features and treatment. *Clin Infect Dis.* 1999;28(4):778-784.
93. Angelakis E, Raoult D. Pathogenicity and treatment of *Bartonella* infections. *Int J Antimicrob Agents.* 2014;44(1):16-25.
94. Perkocha LA, Geaghan SM, Yen TB, et al. Clinical and pathological features of bacillary peliosis hepatis in association with human immunodeficiency virus infection. *N Engl J Med.* 1990;323(23):1581-1586.
95. Baron A, Steinbach L, LeBoit P, et al. Osteolytic lesions and bacillary angiomatosis in HIV infection: radiologic differentiation from AIDS-related Kaposi sarcoma. *Radiology.* 1990;177(1):77-81.
96. Maguiña Vargas C, Ordaya Espinoza E, Ugarte-Gil C, et al. Compromiso cardiovascular en la fase aguda de la enfermedad de Carrión o bartonelosis humana: 20 años de experiencia en Hospital Nacional Cayetano Heredia. *Acta Médica Peruana*. 2008;25(1):30-38.
97. Abbott RC, Chomel BB, Kasten RW, et al. Experimental and natural infection with Bartonella henselae in domestic cats. *Comp Immunol Microbiol Infect Dis.* 1997;20(1):41-51.
98. Popa C, Abdollahi-Roodsaz S, Joosten LA, et al. *Bartonella quintana* lipopolysaccharide is a natural antagonist of Toll-like receptor 4. *Infect Immun.* 2007;75(10):4831-4837.
99. Andersen-Nissen E, Smith KD, Strobe KL, et al. Evasion of toll-like receptor 5 by flagellated bacteria. *Proc Natl Acad Sci U S A.* 2005;102(26):9247-9252.
100. Boonjakuakul JK, Gerns HL, Chen Y-T, et al. Proteomic and immunoblot analyses of *Bartonella quintana* total membrane proteins identify antigens recognized by sera from infected patients. *Infect Immun.* 2007;75(5):2548-2561.
101. Kabeya H, Maruyama S, Irei M, et al. Genomic variations among *Bartonella henselae* isolates derived from naturally infected cats. *Vet Microbiol.* 2002;89(2):211-221.

102. Dehio C. *Bartonella*–host-cell interactions and vascular tumour formation. *Nat Rev Microbiol*. 2005;3(8):621-631.
103. Berrich M, Kieda C, Grillon C, et al. Differential effects of *Bartonella henselae* on human and feline macro- and micro-vascular endothelial cells. *PLoS One*. 2011;6(5):e20204.
104. Harms A, Dehio C. Intruders below the radar: molecular pathogenesis of *Bartonella* spp. *Clin Microbiol Rev*. 2012;25(1):42-78.
105. Vermeulen MJ, Diederen BM, Verbakel H, et al. Low sensitivity of *Bartonella henselae* PCR in serum samples of patients with cat-scratch disease lymphadenitis. *J Med Microbiol*. 2008;57(8):1049-1050.
106. Piérard-Franchimont C, Quatresooz P, Piérard GE. Skin diseases associated with Bartonella infection: facts and controversies. *Clin Dermatol*. 2010;28(5): 483-488.
107. van Ierland-van Leeuwen M, Peringa J, Blaauwgeers H, et al. Cat scratch disease, a rare cause of hypodense liver lesions, lymphadenopathy and a protruding duodenal lesion, caused by *Bartonella henselae*. *BMJ Case Rep*. 2014;2014.
108. Prutsky G, Domecq JP, Mori L, et al. Treatment outcomes of human bartonellosis: a systematic review and meta-analysis. *Int J Infect Dis*. 2013;17(10): e811-e819.
109. King KY, Hicks MJ, Mazziotti MV, et al. Persistent cat scratch disease requiring surgical excision in a patient with MPGN. *Pediatrics*. 2015;135(6):e1514-e1517.
110. Foucault C, Raoult D, Brouqui P. Randomized open trial of gentamicin and doxycycline for eradication of *Bartonella quintana* from blood in patients with chronic bacteremia. *Antimicrob Agents Chemother*. 2003;47(7):2204-2207.
111. Ohl ME, Spach DH. *Bartonella quintana* and urban trench fever. *Clin Infect Dis*. 2000;31(1):131-135.
112. Panel on Antiretroviral Guidelines for Adults and Adolescents. Guidelines for the use of antiretroviral agents in HIV-1-infected adults and adolescents. Department of Health and Human Services. May 30, 2018. Available at http://aidsinfo.nih.gov/contentfiles/lvguidelines/AdultandAdolescentGL.pdf
113. Rolain J, Brouqui P, Koehler J, et al. Recommendations for treatment of human infections caused by *Bartonella* species. *Antimicrob Agents Chemother*. 2004;48(6):1921-1933.
114. Grimont PA, Weill F-X. *Antigenic Formulae of the Salmonella Serovars*. 9th ed. Paris, France: WHO Collaborating Centre for Reference and Research on Salmonella; 2007. Available at http://docplayer.net/1605957-Antigenic-formulae-of-the-salmonella-serovars.html
115. Imanishi M, Newton A, Vieira A, et al. Typhoid fever acquired in the United States, 1999-2010: epidemiology, microbiology, and use of a space–time scan statistic for outbreak detection. *Epidemiol Infect*. 2015; 143(11):2343-2354.
116. Parry CM, Hien TT, Dougan G, et al. Typhoid fever. *N Engl J Med*. 2002;347:1770-1782.
117. Crump JA, Luby SP, Mintz ED. The global burden of typhoid fever. *Bull World Health Organ*. 2004;82(5): 346-353.
118. Crump JA, Mintz ED. Global trends in typhoid and paratyphoid fever. *Clin Infect Dis*. 2010;50(2): 241-246.
119. Maskey AP, Day JN, Tuan PQ, et al. *Salmonella enterica* serovar *Paratyphi* A and *S. enterica* serovar *Typhi* cause indistinguishable clinical syndromes in Kathmandu, Nepal. *Clin Infect Dis*. 2006;42(9): 1247-1253.
120. Vollaard AM, Ali S, Widjaja S, et al. Identification of typhoid fever and paratyphoid fever cases at presentation in outpatient clinics in Jakarta, Indonesia. *Trans R Soc Trop Med Hyg*. 2005;99(6):440-450.
121. Meltzer E, Schwartz E. Enteric fever: a travel medicine oriented view. *Curr Opin Infect Dis*. 2010;23(5): 432-437.
122. Patel TA, Armstrong M, Morris-Jones SD, et al. Imported enteric fever: case series from the hospital for tropical diseases, London, United Kingdom. *Am J Trop Med Hyg*. 2010;82(6):1121-1126.
123. Burns T, Breathnach S. *Rook's Textbook of Dermatology*, Vol. 4. London, UK: Blackwell Scientific; 1992.
124. Litwack KD, Hoke AW, Borchardt KA. Rose spots in typhoid fever. *Arch Dermatol*. 1972;105(2):252-255.
125. Cohen JI, Bartlett JA, Corey GR. Extra-intestinal manifestations of salmonella infections. *Medicine (Baltimore)*. 1987;66(5):349-388.
126. Raveendran KM, Viswanathan S. Typhoid fever, below the belt. *J Clin Diagn Res*. 2016;10(1):OD12-OD13.
127. Kuvandik C, Karaoglan I, Namiduru M, et al. Predictive value of clinical and laboratory findings in the diagnosis of enteric fever. *New Microbiol*. 2009;32(1):25.
128. Shukla VK, Singh H, Pandey M, et al. Carcinoma of the gallbladder—is it a sequel of typhoid? *Dig Dis Sci*. 2000;45(5):900-903.
129. Toapanta FR, Bernal PJ, Fresnay S, et al. Oral wild-type *Salmonella typhi* challenge induces activation of circulating monocytes and dendritic cells in individuals who develop typhoid disease. *PLoS Negl Trop Dis*. 2015;9(6):e0003837.
130. Kohbata S, Yokoyama H, Yabuuchi E. Cytopathogenic effect of *Salmonella typhi* GIFU 10007 on M cells of murine ileal Peyer's patches in ligated ileal loops: an ultrastructural study. *Microbiol Immunol*. 1986;30(12):1225-1237.
131. van de Vosse E, de Visser AW, Al-Attar S, et al. Distribution of CFTR variations in an Indonesian enteric fever cohort. *Clin Infect Dis*. 2010;50(9):1231-1237.
132. Gasem M, Dolmans W, Isbandrio B, et al. Culture of *Salmonella typhi* and *Salmonella paratyphi* from blood and bone marrow in suspected typhoid fever. *Trop Geogr Med*. 1994;47(4):164-167.
133. Gilman R, Terminel M, Levine M, et al. Relative efficacy of blood, urine, rectal swab, bone-marrow, and rose-spot cultures for recovery of *Salmonella typhi* in typhoid fever. *Lancet*. 1975;305(7918): 1211-1213.
134. Hornick RB, Greisman S, Woodward T, et al. Typhoid fever: pathogenesis and immunologic control. *N Engl J Med*. 1970;283(14):739-746.
135. Dave J, Sefton A. Enteric fever and its impact on returning travellers. *Int Health*. 2015;7(3):163-168.
136. Fernández Vozmediano J, Armario Hita J, Cabrerizo AG. Rhinoscleroma in three siblings. *Pediatr Dermatol*. 2004;21(2):134-138.
137. Hart C, Rao S. Rhinoscleroma. *J Med Microbiol*. 2000;49(5):395-396.
138. Mukara B, Munyarugamba P, Dazert S, et al. Rhinoscleroma: a case series report and review of the literature. *Eur Arch Otorhinolaryngol*. 2014;271(7): 1851-1856.
139. Bailhache A, Dehesdin D, François A, et al. Rhinoscleroma of the sinuses. *Rhinology*. 2008;46(4):338-341.
140. Talwar A, Patel N, Chen L, et al. Rhinoscleroma of the tracheobronchial tree: bronchoscopic, PET, and

CT correlation. *Indian J Chest Dis Allied Sci*. 2008; 50(2):225.
141. Leibovitz E, Jacobs MR, Dagan R. *Haemophilus influenzae*: a significant pathogen in acute otitis media. *Pediatr Infect Dis J*. 2004;23(12):1142-1152.
142. Fisher RG, Benjamin DK Jr. Facial cellulitis in childhood: a changing spectrum. *South Med J*. 2002; 95(7):672-675.
143. Rimon A, Hoffer V, Prais D, et al. Periorbital cellulitis in the era of *Haemophilus influenzae* type B vaccine: predisposing factors and etiologic agents in hospitalized children. *J AAPOS*. 2008;45(5):300-304.
144. Sharma A, Liu ES, Le TD, et al. Pediatric orbital cellulitis in the *Haemophilus influenzae* vaccine era. *J AAPOS*. 2015;19(3):206-210.

Chapter 155 :: The Skin in Infective Endocarditis, Sepsis, Septic Shock, and Disseminated Intravascular Coagulation

:: Joseph C. English III & Misha Rosenbach

AT-A-GLANCE

- *Infective endocarditis:* staphylococcal, streptococcal, and enterococcal bacteria cause 80% of cases; intravenous drug use is the most common cause of right-sided infective endocarditis.
- *Sepsis:* Gram-positive and Gram-negative bacteria, fungi, and viruses may cause sepsis; 10th leading cause of death in the United States for all races and sexes at age 45 years and older.
- *Disseminated intravascular coagulation:* most commonly a consequence of sepsis; results from systemic activation of the coagulation cascade.
- *Cutaneous manifestations of these entities include:* splinter hemorrhages, Janeway lesions, Osler nodules, erythroderma, cellulitis, purpura, hemorrhage, purpura fulminans, and skin necrosis.

INFECTIVE ENDOCARDITIS

DEFINITION AND HISTORICAL PERSPECTIVE

Infective endocarditis (IE) is defined as inflammation of the endocardial lining of the heart (naïve or prosthetic heart valves, mural endocardium) and implanted material caused by infection from bacteria or fungus.[1,2] The historical definitions of IE as acute, subacute, and chronic IE have been discarded for a more appropriate description based on infectious agent and the infected endocardial structure.[3,4]

EPIDEMIOLOGY

The incidence of IE is 3 to 10 cases per 100,000 people.[4,5] The male-to-female ratio is 2:1 and the incidence peaks at 194 cases per million in men 75 to 79 years of age.[5] Pediatric cases are rare. Rheumatic heart disease in the setting oral cavity procedures is the most-common cause in low-income countries; however, IE is now more commonly seen in health care–associated cases in the setting of valvular heart disease, prosthetic valves, implantable pacemakers and defibrillators, hemodialysis, IV lines, and invasive procedures in higher-income countries.[5] In addition, risk factors include a history of IE, diabetes, cancer, congenital heart disease, dental procedures, HIV disease, IV drug abuse.[1,4-6]

CLINICAL FEATURES

The most common clinical presentations of IE include fever and a new cardiac murmur; consequently, IE should be considered in the differential diagnosis of all fevers, embolic events of unknown origin, and patients with persistently positive blood cultures.[5] The modified Duke criteria (Table 155-1),[7] help make the diagnosis of IE. Newer reviews of the Duke criteria for diagnosing IE note its continual importance in identifying IE.[2]

CUTANEOUS

Cutaneous signs of IE (splinter hemorrhages, petechiae/purpura, Janeway lesions, Osler nodes) are nonspecific but may help the dermatologist in assisting the primary medical team in diagnosing IE during the inpatient consultation.[8-10] Cutaneous findings are caused either by embolic events, thrombosis, or focal vasculitis, and are more commonly found in left-sided IE.[6] IE patients with skin manifestations had higher rates of cerebral emboli without increased mortality, whereas Janeway lesions were more frequently associated with extracerebral emboli, and if purpura was present, larger valvular vegetations occurred.[10]

Splinter hemorrhages (Fig. 155-1) are 1- to 2-mm red-brown or black longitudinal streaks under the nail plate. They are seen in approximately 15% of patients with IE and are considered to be of greater diagnostic value if proximally located. Splinter hemorrhages associated with IE are the result of small capillary vasculitis, or from microemboli. In the absence of other signs or symptoms of IE, the mere presence of splinter hemorrhage is not specific enough evidence to warrant a workup. Crops of petechiae are commonly seen in the buccal membrane, conjunctival mucosa, soft palate and extremities.

Janeway lesions are painless, irregular, nonblanchable, erythematous maculopapules that appear on the palms and soles and last days to weeks (Fig. 155-2).

TABLE 155-1
Modified Duke Criteria for Infective Endocarditis

A clinically definite case is defined as fulfilling 2 major, 1 major plus 3 minor, or 5 minor criteria.

- A clinically suspicious case is defined as fulfilling 1 major and 1 minor, or 3 minor criteria

Major Criteria

1. **Microbiologic**
   a. Two separate blood cultures positive for typical microorganism
   or
   b. Persistently positive blood culture for typical microorganism
   or
   c. Single positive blood culture for *Coxiella burnetii* or a Phase I immunoglobulin G antibody titer to *C. burnetii* ratio greater than 1:800
2. **Evidence of endocardial involvement**
   a. New valvular regurgitation
   or
   b. Positive echocardiogram showing oscillating echogenic intracardiac mass at the site of endocardial injury, a periannular abscess, or new dehiscence of a prosthetic valve

Minor Criteria

1. Predisposition to infective endocarditis
2. Fever
3. Vascular phenomena such as Osler nodes or Roth spots
4. Immunologic factors such as a positive rheumatoid factor or glomerulonephritis
5. Serologic evidence of active infection not meeting microbiologic major criteria

Histologically, thrombi are found in small vessels in the absence of vasculitis. Neutrophilic microabscesses can be seen in the dermis with occasional Gram-positive organisms. Osler nodes present as painful red papulonodules with a pale center on the fingertips lasting days to weeks. Osler nodes are painful, perhaps because of involvement of the glomus bodies located in the fingertips. Histologically, neutrophilic microabscesses are present in the dermis, and arteriolar microemboli may contain Gram-positive cocci.

Figure 155-1 Globular proximal splinter hemorrhage and several distal linear splinter hemorrhages in a patient with infective endocarditis. (Image used with permission from William James, MD, and James Fitzpatrick, MD.)

Figure 155-2 Janeway lesions of infectious endocarditis.

Septic emboli of valvular vegetation fragments can cause ischemia of distal extremities. Toes are most commonly involved, followed by fingers, and this condition presents as reticulated purpura or purple digit similar to that seen in cholesterol emboli syndrome (see Chap. 148). Although this condition generally resolves without sequelae, tissue necrosis or gangrene can result. In addition patients may have nonspecific acrocyanosis from hypoxemia and livedo reticularis from sepsis and embolization.[11,12]

NONCUTANEOUS FINDINGS

In addition to fever and new cardiac murmur, patients may have anorexia, weight loss, and malaise. More commonly, signs of stroke, meningitis, congestive heart failure, myocardial infarction, renal failure, pneumonitis, acute abdomen, peripheral emboli, and metastatic infections are present.[5,6] Splenomegaly and ocular findings (conjunctival hemorrhage or Roth spots) are less often present.

COMPLICATIONS

Most concerning and severe complications of IE are neurologic in nature.[4] Up to 50% of nervous system complications are ischemic lesions.[13] In addition hemorrhagic strokes, transient ischemic attack, brain abscess, and meningitis may occur.

ETIOLOGY AND PATHOGENESIS

IE is classified based on valve (native valve vs prosthetic valve), and source of infection (community or health care acquired). The causative organisms in 80% of IE cases are staphylococci, streptococci (coagulase negative and viridans group) or enterococci.[5] The most common cause of IE in high-income countries is *Staphylococcus aureus* for both naïve and

prosthetic valves.[5] Rare causes may be from HACEK (*Haemophilus, Aggregatibacter, Cardiobacterium, Eikenella, Kingella*) organisms, as well as *Bartonella*, *Brucella*, and *Coxiella* species, and fungi (ie, *Candida*). Culture-negative IE (5% to 10%) occurs in the setting of patients receiving antibiotics before cultures obtained or infection with fastidious bacterium.[4]

Endothelial damage can occur in setting of electrodes or catheter trauma, from particles in IV drugs or chronic inflammation.[4] After injury, the release of inflammatory mediators and tissue factor leads to a platelet-fibrin thrombus that easily allows bacterial adherence.[5] Bacterial adhesion proteins help induce the formation of bacterial biofilms on the valves that potentiate antibiotic resistance, resulting in the development of valvular vegetations that can cause local tissue destruction and embolic events.[5]

Native valve endocarditis occurs most commonly in the setting of valvular disease or in people who use IV drugs.[6] IV drug users are particularly susceptible to IE even though most have no preexisting structural heart disease.[6] More than half of the cases of IE in injection drug users are right-sided, involving the tricuspid valve. Prosthetic valve endocarditis can be classified as early (in the first 2 months following valve replacement) or late (2 months or later). Early prosthetic valve endocarditis is most commonly caused by coagulase-negative streptococci or by *S. aureus* and late prosthetic valve endocarditis can be caused by any of the infectious organism that can cause IE.[6]

DIAGNOSIS

SUPPORTIVE STUDIES

Laboratory Testing: Bacterial cultures (3 sets prior to antibiotics) detect bacteremia and guide appropriate antibiotic therapy. If unable to culture and surgery is performed, removed valves also can be cultured and, along with broad-ranged polymerase chain reaction sequencing and immunostaining techniques, can help identify the organism.[4] Erythrocyte sedimentation rate, C-reactive protein, antineutrophilic cytoplasmic antibody (ANCA), and rheumatoid factor elevation, as well as anemia and red cell casts/pyuria on urinalysis, are laboratory findings.[5]

Pathology: Histologic findings of the cutaneous manifestations of IE are nonspecific.

Clinical pathologic correlation of systemic symptoms and skin lesions with findings of extravasated red blood cells, fibrinoid degeneration of vasculature, karyorrhexis, and Gram-positive/negative organisms in microemboli on pathology are suggestive of IE.

Imaging: An EKG baseline is necessary to monitor for changes in conduction that may indicate worsening disease.[5] Echocardiography allows the visualization of the valves and can provide information as to the level of myocardial involvement. Transthoracic echocardiography is less invasive and less expensive than transesophageal echocardiography. When these imaging modalities are used in combination valvular vegetations can be detected in the majority of cases.[4] Other potential imaging studies include high-resolution cardiac CT and ^{18}F-fluorodeoxyglucose positron emission tomography CT.[1,5] Vegetations larger than 10 mm are associated with a greater embolic risk.[5] Emboli to the CNS leads to stroke; brain abscess and meningitis and can be identified with MRI.[1]

DIFFERENTIAL DIAGNOSIS

The differential diagnosis of IE includes noninfectious endocarditis from neoplastic or immunologic sources.[1] Examples include atrial myxomas, other cardiac tumors and nonbacterial thrombotic endocarditis, such as Libman-Sacks endocarditis from systemic lupus erythematosus, and hypercoagulable states (eg, cancer, antiphospholipid antibody syndrome).[6] Table 155-2 outlines the differential diagnosis of splinter hemorrhages. Janeway lesions and Osler nodes can be similar in appearance to septic emboli and neutrophilic eccrine hidradenitis. Cases of culture-negative, ANCA-positive bacterial endocarditis, particularly in the presence of cutaneous manifestations such as purpura, may mimic ANCA-associated vasculitis.[14]

CLINICAL COURSE AND PROGNOSIS

The prognosis and clinical course of IE varies per patient based on the variable infecting organisms and associated clinical comorbidities (presence of emboli and the extent of cardiac damage).[4] Poor prognostic indicators are left-sided IE, vegetation size (>10 mm), prosthetic valves, older age, diabetes, immunosuppression, heart failure, renal failure, septic shock, brain hemorrhage, and infections from methicillin-resistant *S. aureus*,

TABLE 155-2
Differential Diagnosis of Splinter Hemorrhages

- Atopic dermatitis
- Cryoglobulinemia
- Drug-induced
  - Vascular endothelial growth factor receptor inhibitors
  - Tetracyclines
- Endocarditis
- Idiopathic
- Internal malignancy
- Psoriasis
- Scurvy
- Thyrotoxicosis
- Trauma
- Trichinosis
- Vasculitis

fungi, or polymicrobial infections.[4,6] The 5-year mortality rate of IE is approximately 40%.[4,6] Right-sided IE (tricuspid valve) has a better prognosis.[5,6] Right-sided IV drug user IE has a 5% to 9% mortality rate and recurring IE is seen most often in IV drug users. A person with a prosthetic (mechanical and biologic heart valve has a 3% to 4% chance of developing IE, and if the person develops IE, the person has up to a 50% 1-year mortality.[5] Multidisciplinary management, early diagnosis, and treatment improve outcomes.[15] Neurologic failure is a major determinant of short-term prognosis.[13] Cerebral embolic disease and congestive heart failure are the most common causes of death.[16]

MANAGEMENT

INTERVENTIONS

The goal of IE treatment should focus on eliminating infection with the appropriate antibiotic, early surgical intervention, and the treatment of complications.

Medications: Appropriate antibiotic therapy should be initiated in suspected cases of IE after blood cultures have been drawn and sensitivities have been identified. Long-term (4 to 6 weeks) parenteral antibiotics, usually with a penicillin derivative (eg, penicillin G, ceftriaxone, gentamycin, vancomycin) are used to treat both streptococcal and staphylococcal IE. Enterococcal IE requires ampicillin or penicillin with gentamycin or streptomycin and others based on antibiotic resistance.[3,17] Duration, frequency, and antibiotics also vary based on Native or prosthetic valve IE. Antibiotic treatment reduces the risk of subsequent embolism and decreases sepsis, organ damage, and death. Treatment of IE caused by other organisms is reviewed elsewhere.[3]

Procedures: Recent data suggest surgical intervention within 48 hours of diagnosing IE and when vegetations are larger than 10 mm decreases the risk of death in IE.[16,18] Failure of parenteral antibiotic therapy, perivulvar abscess, valvular destruction/dysfunction with heart failure, persistent fever, and ischemic neurologic complications are settings that require surgery.[1,4,5] Surgery should be avoided for 3 weeks if IE is complicated by hemorrhagic strokes or if cerebral damage is severe.[13]

PREVENTION/SCREENING

Good oral, dental, and skin hygiene are important for patients at risk for IE.[4] Currently, prophylactic antibiotics for skin surgery are not indicated for procedures performed on noninfected surgically scrubbed skin regardless of cardiac history. Guidelines issued by the American Heart Association in May 2007 shifted from recommending antibiotic prophylaxis for patients at increased risk for IE, to recommending IE prophylaxis for patients who have a high risk of an adverse outcome associated with IE and who are to have a procedure that involves a contaminated or infected wound, or surgery on oral or nasal mucosa.[19] For dermatologists, this would include patients with a prosthetic heart valve, a personal history of IE, valvulopathy in a cardiac transplant patient, or an unrepaired cyanotic heart defect.

SEPSIS AND SEPTIC SHOCK

DEFINITION AND HISTORICAL PERSPECTIVE

The Third International Consensus Definitions for Sepsis and Septic Shock, which was published in *JAMA* in 2016 after a literature review and expert deliberation, has redefined sepsis and eliminated the historical terms *sepsis syndrome*, *septicemia*, and *severe sepsis*. Sepsis is defined as life-threatening organ dysfunction that results from a dysregulated host response to infection.[20] Septic shock is a subset of sepsis in which vasopressor therapy is required to maintain a mean arterial pressure of 65 mm Hg or greater, and having a serum lactate level greater than 2 mmol/L persisting after fluid resuscitation.[21]

EPIDEMIOLOGY

Sepsis is a leading cause of critical illness, morbidity, and mortality.[22] A review of U.S. hospitalizations from 2004 to 2009 revealed the annual incidence of sepsis varied from 300 to 1031 per 100,000 population with an annual average increase of 13%.[23] In 2011, the 1.1 million cases of sepsis was the most expensive condition treated in the United States by all payers, accounting for roughly $20 billion of hospital costs.[24] In 2020, sepsis cases are estimated to reach 2 million.[25] The increased incidence is associated with the aging populations, an increase in syndrome recognition, and specific use of billing codes that can easily be tabulated. Over the next several years, with the newer consensus definition, a more uniform and consistent methodology may be instituted to enable an assessment of the true incidence of this syndrome of physiologic, pathologic, and biochemical reactions to infection.[22,23,26]

CLINICAL FEATURES

CUTANEOUS

The causative organism in sepsis is not always identifiable by routine culture. The use of real-time polymerase chain reaction, fluorescence in situ hybridization, and matrix-assisted laser desorption ionization time of flight mass spectrometry will enhance quicker

identification; however, differentiating the cause of organ dysfunction is often clinically difficult.[25,26] In some cases, the cutaneous examination and histologic evaluation of diseased skin can provide clues to the identity of the responsible pathogen, providing a valuable clinical tool in the management of the septic patient and the critical role for skin evaluation by the dermatologist in the intensive care unit.

Erythroderma in the septic patient suggests staphylococcal or streptococcal toxic shock syndrome (TSS).[27] Patients with TSS are usually young and otherwise healthy. Patients with staphylococcal TSS are much more likely to be erythrodermic but much less likely to have positive blood culture than are patients with streptococcal TSS. Streptococcal TSS is commonly associated with a necrotizing soft-tissue infection.

The finding of pustules on the skin of a septic patient, particularly in the neonate or immunocompromised individual, may be suggestive of fungal infection, particularly with *Candida* species. Congenital candidiasis, most often seen in infants born to mothers with vaginal candidiasis, is generally a skin-limited disease. However, in the septic infant with pustules, candidemia should be considered.

The vasculitis[28] and coagulopathy[29] that can occur in the septic patient may cause purpura, sometimes prominent in the nailfold small capillaries (Fig. 155-3). Purpura is particularly prominent in those patients with thrombocytopenia. Such infections are seen most commonly in oncology patients undergoing bone marrow transplantation. In the immunocompromised host, opportunistic fungal infection, such as with *Aspergillus* spp., *Fusarium* spp., and *Candida* spp., often presents as erythematous papules, petechiae or pustules that progress to purpuric lesions (Fig. 155-4).[30]

Pustules resulting from disseminated gonococcemia are acrally located, typically tender and a characteristic gun-metal gray color, hemorrhagic or black, and are most commonly seen in the otherwise healthy adolescent or young adult. Gram staining of the pustule will reveal intracellular Gram-negative diplococci. In its most extreme form, meningococcemia can cause stellate purpura (Fig. 155-5) and retiform to purpura fulminans (Fig. 155-6). Pustules also may be secondary to a local inoculation site, as in the case of staphylococcal sepsis.

Figure 155-4 Petechiae from *Fusarium* sepsis in an immunosuppressed patient.

Cellulitis is characterized by intense local inflammation in the presence of relatively few infectious organisms, and blood cultures are rarely positive (see Chap. 153).[31] Most commonly occurring on the legs, the affected extremity is typically erythematous, hyperemic, and edematous. The most common causes of cellulitis are *S. aureus* and group A *Streptococcus*. Rarely,

Figure 155-3 Proximal nailfold purpura from leukocytoclastic vasculitis caused by *Clostridium difficile* sepsis.

Figure 155-5 Stellate purpura from meningococcemia.

Figure 155-6 Retiform or purpura fulminans from meningococcemia.

anaerobic organisms, including clostridial species and other anaerobic bacteria species such as *Bacteroides*, *Peptostreptococcus*, and *Peptococcus*, are the causative organism. In immunosuppressed patients, *Cryptococcus neoformans* can also cause cellulitis, particularly in the setting of AIDS, although rates are increasing in the organ transplant population. Patients with liver compromise can develop hemorrhagic bullous cellulitis from *Vibrio vulnificus*, a Gram-negative bacterium that lives in warm marine environments and becomes concentrated in filter-feeding shellfish. Infection occurs either via consumption of contaminated organisms, such as raw oysters, or through contact with infected water. Mortality rates exceed 40% in those with *V. vulnificus* sepsis.[32]

A more aggressive local soft-tissue infection, necrotizing fasciitis or necrotizing soft-tissue infection, can be associated with positive blood cultures later in the course of the disease because of hematogenous seeding by the organisms.[33] Clinically, necrotizing fasciitis is rapidly progressive, initially painful, and accompanied by fever and leukocytosis (see Chap. 153). Necrotic soft-tissue infections have a higher mortality rate when associated with hospital-acquired infections, patients older than age 75 years, severe peripheral vascular disease, and coexistent sepsis/septic shock.[34]

Ecthyma gangrenosum (see Chap. 154) begins as an erythematous papule that expands and eventually becomes a necrotic bulla. Lesions are most commonly seen between the umbilicus and the knees. Classic ecthyma gangrenosum represents cutaneous seeding of bacteria, usually *Pseudomonas aeruginosa*, from a hematogenous source and is seen almost exclusively in neutropenic patients, often in association with an underlying malignancy. Nonclassical cases have been reported with *Aeromonas hydrophila*, *Escherichia coli*, *Citrobacter freundii*, and *Corynebacterium diphtheriae*, fungal infection including *Candida*, *Aspergillus*, *Fusarium*, and mucormycosis-causing species, and even herpes simplex virus.[35]

NONCUTANEOUS

The septic patient presents with fever, prostration, oliguria, tachycardia, and tachypnea. Signs of pneumonia, meningitis, or peritonitis may occur.[36] The qSOFA (quick Sequential [sepsis-related] Organ Failure Assessment) score criteria (consisting of a respiratory rate greater than 22 breaths/min, altered mental status, and systolic blood pressure less than 100 mm Hg) is a new bedside index to identify patients outside of critical care units to help determine if the patient is transitioning from infection to sepsis.[22,26] The differentiation of sepsis from infection is the presence of organ dysfunction. New-onset organ dysfunction should raise the possibility of underlying infection. The organ systems commonly affected in sepsis include the renal, hepatic, central nervous, pulmonary, GI, and cardiovascular systems. The presentation of sepsis can be highly variable (the depth of which cannot be reviewed adequately in this format) and is shaped by type of pathogen, sex, age, race, genomics, preexisting acute illness overlapping with long-term comorbidities, immunosuppression, drug use, environment, medications, and interventions.[22]

COMPLICATIONS

Complications of sepsis and septic shock include death, loss of limbs from hypoperfusion, and permanent organ dysfunction. Septic patients may also develop acute respiratory distress syndrome and often fall into coma.[25] Sepsis and septic shock can lead to complications of disseminated intravascular coagulation (DIC), which is a devastating coagulopathy that adds to the already significant mortality of sepsis and septic shock.[25]

ETIOLOGY AND PATHOGENESIS

Sepsis and septic shock are initiated by a complex interaction through the infectious agent (Gram-negative and Gram-positive bacteria, fungi, viruses), cytokines (interleukin [IL]-1 IL-18) and Toll-like receptors on immune and nonimmune cells. Activation of stress-responsive transcription factors (eg, nuclear factor κB, activator protein-1) causes nuclear activation of inflammatory genes (sepsis response signatures), which causes a "genomic storm" from increased production of multiple mediators (eg, tumor necrosis factor-α, IL-6, IL-8, cyclooxygenase-2, nitric oxide, interferon-B). Subsequent microvascular dysfunction, injury, and apoptosis leads to organ dysfunction.[25,26,37] Hypotension in septic shock is most likely produced by overproduction of cyclooxygenase-2 and nitric oxide.[25]

DIAGNOSIS

SUPPORTIVE STUDIES

Recently, the Third International Consensus Definitions for Sepsis and Septic Shock, on assessment of clinical criteria for sepsis, recommended the use of the

SOFA score in the critical care setting for its greater predictive value.[20] This criteria includes scores from 0 to 4 for the patient's partial pressure arterial oxygen/fraction of inspired oxygen, mean arterial pressure, platelet count, bilirubin, Glasgow coma scale score, urine output, and creatinine. SOFA scores greater than 2 are suggestive of a 10% mortality risk in the general hospitalized patient with suspected infections.[20,22] A patient with septic shock requires vasopressors to maintain a mean arterial pressure of 65 mm Hg and have a serum lactate level of greater than 2 mmol/L.[21]

Laboratory Testing: Blood cultures can be helpful in guiding treatment of septic patients; however, only 30% to 50% of septic patients will have positive blood cultures. Decreasing thrombocytopenia (below 150×10^9/L) is a strong and independent predictor of adverse outcomes in this clinical setting.[38] Hyperbilirubinemia (>1.2 mg/dL), renal insufficiency (creatinine >1.2 mg/dL) and urine output (<500 mL) are concerning for a worse prognosis.[22] Serum lactate is not part of the SOFA criteria but can be a clinical outcome predictor of mortality in septic shock.[39] The septic patient will generally have a white blood cell count greater than 12×10^9/L or less than 4×10^9/L, or a bandemia of greater than 10%, and elevated C-reactive protein and procalcitonin levels.

Pathology: Histologic analysis of the cutaneous findings in the setting of sepsis and septic shock is very important. It can help determine the infectious agent, signs of vasculopathy or vasculitis that can be pertinent in patient care.

Imaging: The use of chest radiography, ultrasonography, CT, and MRI, is used by critical care physicians to help locate potential infection sources, as well as to monitor organ dysfunction. Brain MRI in septic shock may identify leukoencephalopathy and ischemic stroke[40] and contrast-enhanced CT scan has been used in to evaluate renal volume and attenuation can increase or decrease as the severity of the sepsis increases or decreases.[41] Noninvasive optical monitoring and transcutaneous oximetry are used in sepsis patients to monitor for microcirculatory collapse and subsequent sepsis shock.[42]

DIFFERENTIAL DIAGNOSIS

Table 155-3 outlines the differential diagnosis of skin findings in the septic patient.

CLINICAL COURSE AND PROGNOSIS

Sepsis precedes septic shock in up to 50% of affected patients.[43] Sepsis enters the top 10 leading causes of death for all races and sexes at age 45 years and older in 2013 data.[44] In-hospital mortality has ranged from 15% to 30% in different studies.[23] Septic shock is associated with a higher risk of mortality (up to 50%) then sepsis alone.[21]

TABLE 155-3
Differential Diagnosis of Skin Findings in the Septic Patient

- Erythroderma
  - Staphylococcal or streptococcal toxic shock syndrome
  - Severe cutaneous adverse reactions (drug reactions)
  - Cutaneous T-cell lymphoma
  - Psoriasis
- Papules and pustules
  - Candidemia
  - Disseminated gonococcemia
  - Folliculitis
  - Miliaria
  - Acute generalized exanthematous pustulosis
- Purpura
  - Invasive fungal infection, especially in thrombocytopenic patient
  - Disseminated intravascular coagulation
  - Vasculitis (infectious, neoplastic, drug-induced, or autoimmune)
  - Trauma induced
  - Heparin or Coumadin necrosis
  - Thrombotic thrombocytopenic purpura
  - Cryoglobulinemia
  - Calciphylaxis
- Cellulitis
  - Infectious cellulitis
  - Necrotizing fasciitis
  - Stasis dermatitis
- Ecthyma gangrenosum
  - Pseudomonal ecthyma gangrenosum
  - Nonpseudomonal bacterial or fungal ecthyma gangrenosum
  - Herpes simplex infection in immunosuppressed patient
  - Necrotizing vasculitis
  - Cryoglobulinemia

MANAGEMENT

INTERVENTIONS

A recent metaanalysis showed that early goal-directed therapy (the *Surviving Sepsis Campaign*) reduces the risk of mortality among patients with sepsis and septic shock.[45,46] Early goal-directed therapy focuses on improving blood volume, cellular hypoxia, and tissue and organ perfusion within the first 6 hours. This includes early recognition of the diagnosis, timely hemodynamic support focusing on fluid resuscitation, vasopressors and inotropic medication, blood transfusion, and adequate antibiotic administration.[45,46] Although initial therapy may occur in the emergency department or hospital wards, patients need to go to an intensive care unit for extensive hemodynamic monitoring (ie, central line) and individualized care. Even though the use of anticoagulant therapy has not shown benefits in sepsis or sepsis-induced coagulopathy, decreased mortality was found in the sepsis-induced DIC population.[47] Recombinant

human soluble thrombomodulin improves organ dysfunction in the setting of sepsis-induced DIC.[48,49] The development of biomarkers that can identify a specific inflammatory source of sepsis may in the future direct therapy in sepsis and septic shock as it has in the field of oncology.[26]

PREVENTION

The prevention of sepsis in a hospital setting is achieved by the implementation of basic infection-control measures, including routine hand washing and the minimization and regular replacement of indwelling catheters. In patients who are immunocompromised, particularly in the setting of organ transplantation or AIDS, the use of prophylactic antibiotics can help to reduce the incidence of sepsis. The use of vaccinations (eg, *Streptococcus pneumoniae*, *Haemophilus influenzae*, *Neisseria meningitidis*) also has been shown to decrease hospitalizations and sepsis.[25]

DISSEMINATED INTRAVASCULAR COAGULATION

DEFINITION AND HISTORICAL PERSPECTIVE

Since the late 1990s DIC has been defined as an acquired reactive syndrome of consumptive hypercoagulation, insufficient anticoagulation, hemorrhage, systemic vascular inflammation, and endothelial dysfunction.[50,51] The physiologic abnormalities of simultaneous bleeding and thrombosis may lead to organ dysfunction and eventual death. DIC is caused most commonly caused by infection and sepsis but has multiple other etiologies, several of which can overlap within a given patient's disease course (Table 155-4).[52] The onset of DIC in the neonatal period is suggestive of protein C or protein S deficiency.

TABLE 155-4

Settings in Which Disseminated Intravascular Coagulation Can Occur

- Hepatic failure
- Immunologic reaction to drugs or toxins
- Malignancy
- Obstetrical complication (amniotic fluid embolism, placental abruption)
- Protein C or protein S deficiency
- Sepsis
- Transfusion reactions
- Transplant reaction
- Trauma
- Vascular abnormalities (aortic aneurysm, cardiac arrest)

EPIDEMIOLOGY

The true incidence is DIC is unknown. However, a recent population-based retrospective study from 2004 to 2010 performed in the United States, noted that the incidence of DIC had decreased during this time frame.[53] The incidence increased with age in men and women, with men having a greater incidence then women. The overall incidence rate, however, declined from 26.2 to 18.6 per 100,000 population, which was significant for men but not for women.[53] The mortality rate remained the same. Approximately 30% to 50% of septic patients, 7% of cancer patients with solid malignancy, and 15% to 20% of patients who present with acute lymphoblastic leukemia develop DIC.[52,54]

CLINICAL FEATURES

CUTANEOUS

The most characteristic cutaneous finding in DIC is diffuse noninflammatory retiform purpura from extensive microvascular occlusion, which is referred to as purpura fulminans.[29] Skin lesions may develop bullae, active hemorrhage, and necrosis (Fig. 155-7). Patients with purpura fulminans may present with ischemic digits or extremities (Fig. 155-8) that if left untreated can progress to gangrene.

Figure 155-7 Purpura fulminans with bullae from *Escherichia coli* sepsis-induced disseminated intravascular coagulation.

Figure 155-8 Acral ischemic changes from sepsis-associated disseminated intravascular coagulation. (Image used with permission from Kaitlin V. Peters, MD.)

NONCUTANEOUS FINDINGS

DIC can affect all organ systems. It commonly can cause chest pains, shortness of breath, headache, speech changes, paralysis, pain, and swelling of extremities as a consequence of clotting. The bleeding diathesis of DIC will cause hematuria and hematochezia.

COMPLICATIONS

Complications of DIC include tissue necrosis and infection, often requiring amputation of limbs or digits, multiorgan failure, and death. In its most extreme form, patients with DIC can develop the Waterhouse-Friderichsen syndrome, most commonly seen in meningococcal sepsis (see Chap. 154). This is a syndrome of multiorgan failure characterized by a petechiae or purpura, coagulopathy, cardiovascular collapse, and bilateral adrenal hemorrhage.[55] DIC also can be associated with obstetric complications, including preeclampsia, abruption, and amniotic fluid embolism. In these cases, the placenta appears to play a central role in the hemostatic pathway.[56]

ETIOLOGY AND PATHOGENESIS

DIC represents systemic activation of the coagulation cascade. This leads to fibrin deposition in the vasculature which can cause organ ischemia and death. In addition, the consumption of platelets and coagulation factors can lead to bleeding. In DIC, coagulation activation is a tissue factor dependent. Inflammatory cytokines such as tumor necrosis factor-α promote damage to endothelial cells and activation of mononuclear cells. These cells then produce tissue factor, which binds to factor VIIa and activates downstream coagulation cascades. Thrombin generation is amplified by defective anticoagulant mechanisms and results in increased fibrin deposition. The fibrin that is generated fails to be degraded by the fibrinolytic system. In the healthy state, antithrombin regulates thrombin activity. In DIC, antithrombin levels are low as a result of continuous consumption, degradation by neutrophil elastase, and impaired synthesis caused by liver failure in some settings. Fibrinolysis is inhibited by plasminogen activator inhibitor Type I (PAI-1). Studies show that individuals with high plasma levels of PAI-1 are at higher risk of mortality in DIC.[52] This correlates with a mutation in PAI-1 that is associated with higher PAI-1 plasma concentrations. Thus, some individuals may be genetically predisposed (4G4G genotype of PAI-1 promoter polymorphism) to fatal outcomes from DIC because of a point mutation in PAI-1.[57]

DIAGNOSIS

SUPPORTIVE STUDIES

Several diagnostic scoring algorithms exist that assign numerical values to particular laboratory findings. These allow the calculation of a single numerical score that is helpful in predicting the presence of and mortality from DIC, but uniformity in clinical practice varies and is reviewed elsewhere.[58]

Laboratory Testing: Routine laboratory testing in DIC is characterized by decreased platelet count ($<100 \times 10^9$/L), prolonged prothrombin and activated partial thromboplastin time, elevated fibrin degradation products (eg, D-dimer), and decreased protease inhibitors (protein C, protein S, antithrombin) and fibrinogen.[52] Other laboratory testing used may include decreased ADAMTS13 (a disintegrin and metalloprotease with a thrombospondin Type 1 motif member 13) activity, and elevated PAI-1, van Willebrand factor, thrombomodulin, thrombin–antithrombin complex, and plasmin–plasmin inhibitor complex.[59,60] Unfortunately, no one laboratory test can diagnosis DIC.

Pathology: Histologic evaluation of purpura fulminans reveals occlusive microthrombi, extravasated red blood cells, and varying degrees of epidermal death and necrosis.

Imaging: As with laboratory testing, no one study can diagnosis DIC. However, the use of ultrasonography, CT, and MRI can be used as needed by intensivists in determining underlying etiologies that can initiate DIC.

DIFFERENTIAL DIAGNOSIS

The differential diagnosis of DIC includes massive blood loss, thrombocytopenic thrombotic purpura, the

hemolytic uremic syndrome, the HELLP (hemolysis, elevated liver enzymes, low platelets) syndrome seen in obstetric patients, heparin-induced thrombocytopenia, vitamin K deficiency, and liver insufficiency.[52] The differential of purpura fulminans includes catastrophic antiphospholipid antibody syndrome, calciphylaxis, and monoclonal cryoglobulinemia.[29]

CLINICAL COURSE AND PROGNOSIS

The abnormalities in hemostasis in DIC vary by the underlying cause and several clinical expressions may occur, such as bleeding or hyperfibrinolysis type (leukemia, obstetric disease, aortic aneurysms); organ failure or hypercoagulation type (sepsis); massive bleeding or consumptive with hypercoagulation and hyperfibrinolysis type (bleeding after major surgery, trauma, or obstetric disease); and nonsymptomatic type.[59] Shifts may occur between types of DIC within a given patient's illness.

DIC is an independent predictor for organ failure and mortality. Patients with thrombocytopenia ($<50 \times 10^9$/L) and DIC have a greater risk of bleeding.[52] The mortality risk is doubled in patients with DIC who are septic or have experienced trauma.

MANAGEMENT

INTERVENTIONS

Medications: A review of published management of DIC demonstrates a limited and heterogeneous approach for both diagnosis and management among clinicians.[58,61] Although there is no treatment consensus, the basic tenets of treatment include treatment of the underlying disease and treatment of hemostatic abnormalities. Platelets, plasma transfusion, anticoagulation (low-molecular-weight heparin, recombinant human soluble thrombomodulin), or fibrinolytics based on the type of DIC can be initiated by intensivists.[52,62]

There is very little published experience regarding the treatment of the cutaneous necrosis seen in DIC. Skin necrosis secondary to DIC is similar to that seen in full-thickness cutaneous burns. Possible excision of necrotic tissue and coverage with autografts, and/or amputation of extremities are treatment options.

PREVENTION

Most interventions in DIC are aimed at minimizing organ damage and bleeding. Prevention of DIC itself can be achieved by the prompt diagnosis and treatment of its causes, particularly sepsis.

REFERENCES

1. Thuny F, Grisoli D, Cautela J, et al. Infective endocarditis: prevention, diagnosis and management. *Can J Cardiol*. 2014:30:1046-1057.
2. Topan A, Carstina D, Slavcovich A, et al. Assessment of the Duke criteria for the diagnosis of infective endocarditis after 20 years. *Clujul Med*. 2015;88:321-326.
3. Chopra T, Kaatz GW. Treatment strategies for infective endocarditis. *Expert Opin Pharmacother*. 2010;11: 345-360.
4. Hoen B, Duval X. Infective endocarditis. *N Engl J Med*. 2013;368:1425-1433.
5. Cahill TJ, Prendergast BD. Infective endocarditis. *Lancet*. 2016;387(10021):882-893.
6. Colville T, Sharma V, Albouaini K. Infective endocarditis in intravenous drug users: a review article. *Postgrad Med J*. 2016;92:105-111.
7. Li JS, Sexton DJ, Mick N, et al. Proposed modifications to Duke criteria for the diagnosis of infective endocarditis. *Clin Infect Dis*. 2000;30:633-638.
8. Hirai T, Koster M. Osler's nodes, Janeway lesions and splinter hemorrhages. *BMJ Case Rep*. 2013;2013.
9. Seth K, Buckley J, deWolff J. Splinter hemorrhages, Osler's nodes, Janeway lesions and Roth spots: the peripheral stigmata of endocarditis. *Br J Hosp Med (Lond)*. 2013;74:C139-C142.
10. Servy A, Valeyrie-Allanore L, Alla F, et al. Prognostic value of skin manifestations of infective endocarditis. *JAMA Dermatol*. 2014;150:494-500.
11. Brown PJ, Zirwas MJ, English JC 3rd. The purple digit: an algorithmic approach to diagnosis. *Am J Clin Dermatol*. 2010;11:103-116.
12. Gibbs MB, English JC 3rd, Zirwas MJ. Livedo reticularis: an update. *J Am Acad Dermatol*. 2005;52: 1009-1019.
13. Novy E, Sonneville R, Mazighi M, et al. Neurologic complications of infective endocarditis: new breakthrough in diagnosis and management. *Med Mal Infect*. 2013; 43:443-450.
14. Ying CM, Yao DT, Ding HH, et al. Infective endocarditis with antineutrophil cytoplasmic antibody: report of 13 cases and literature review. *PLoS One*. 2014;9: e89777.
15. Chirillo F, Scotton P, Rocco R, et al. Impact of a multidisciplinary management strategy on the outcome of patients with native valve infective endocarditis. *Am J Cardiol*. 2013;112:1171-1176.
16. Kang DH, Kim YJ, Kim SH, et al. Early surgery versus conventional treatment for infective endocarditis. *N Engl J Med*. 2012;366:2466-2473.
17. Sabe MA, Shrestha NK, Menon V. Contemporary drug treatment of infective endocarditis. *Am J Cardiovasc Drugs*. 2013;13:251-258.
18. Okonta KE, Adamu YB. What size of vegetation is an indication for surgery in endocarditis. *Interact Cardiovasc Thorac Surg*. 2012;15:1052.
19. Wilson W, Taubert KA, Gewitz M, et al. Prevention of infective endocarditis: guidelines from the American Heart Association: a guideline from the American Heart Association Rheumatic Fever, Endocarditis, and Kawasaki Disease Committee, Council on Cardiovascular Disease in the Young, and the council on Clinical Cardiology, Council on Cardiovascular Surgery and Anesthesia, and the Quality of Care and Outcomes Research Interdisciplinary Working Group. *Circulation*. 2007;116:1736-1754.

20. Seymour CW, Liu VX, Iwashyna TJ, et al. Assessment of clinical criteria for sepsis for the third international consensus definitions for sepsis and septic shock. *JAMA*. 2016;315:762-774.
21. Shankar-Hari M, Phillips GS, Levy ML, et al. Developing a new definition and assessing new clinical criteria for septic shock for the third international consensus definitions for sepsis and septic shock. *JAMA*. 2016;315:775-787.
22. Singer M, Deutschman CS, Seymour CW, et al. The third international consensus definitions for sepsis and septic shock. *JAMA*. 2016;315:801-810.
23. Gaieski DF, Edwards JM, Kallan MJ, et al. Benchmarking the incidence and mortality of severe sepsis in the United States. *Crit Care Med*. 2013;41:1167-1174.
24. Torio CM, Andrews RM. *National Inpatient Hospitals Costs: the Most Expensive Conditions by Payer, 2011*. Healthcare Cost and Utilization Project, Statistical Brief #160. Rockville, MD: Agency for Health Care Policy and Research; 2013. Available at: http://www.ncbi.nlm.nih.gov/books/NBK169005.
25. Hawiger J, Veach A, Zienkiewicz J. New paradigms in sepsis: from prevention to protection of failing microcirculation. *J Thromb Haemost*. 2015;13:1743-1756.
26. Abraham E. New definitions for sepsis and septic shock continuing evolution but with much still to be done. *JAMA*. 2016;315:757-759.
27. Lappin E, Ferguson AJ. Gram-positive toxic shock syndromes. *Lancet*. 2009;9:281-290.
28. Forentino DF. Cutaneous vasculitis. *J Am Acad Dermatol*. 2003;48:311-340.
29. Thornsberry LA, Losicco KI, English JC 3rd. The skin and hypercoagulable states. *J Am Acad Dermatol*. 2013;69:450-462.
30. Gaona-Flores VA, Campos-Navarro LA, Cervantes-Tovar RM, et al. The epidemiology of fungemia in an infectious disease hospital in Mexico City. *Med Mycol*. 2016;54(6):600-604.
31. Hirschman JV, Raugi GJ. Lower limb cellulitis and its mimics. Part I. Lower limb cellulitis. *J Am Acad Dermatol*. 2012;67:e1-e12.
32. Horseman MA, Surani S. A comprehensive review of vibrio vulnificus: an important cause of sever sepsis and skin and soft-tissue infections. *Int J Infect Dis*. 2011;15:e157-e166.
33. Hakkarainen TW, Kopari NM, Pham TN, et al. Necrotizing soft tissue infections: review and current concepts in treatment, systems of care and outcomes. *Curr Probl Surg*. 2014;51:344-362.
34. Hua C, Sbidian E, Hemery F, et al. Prognostic factors in necrotizing soft-tissue infections (NTSI): a cohort study. *J Am Acad Dermatol*. 2015;73:1006-1012.
35. Reich HL, Fadeyi DW, Naik NS, et al., Nonpseudomonal ecthyma gangrenosum. *J Am Acad Dermatol*. 2004;50:S114-S117.
36. Vincent JL, Mira JP, Antonelli M. Sepsis: older and newer concepts. *Lancet*. 2016;4:237-240.
37. Davenport EE, Burnham KL, Radhakrishnan J, et al. Genomic landscape of the individual host response and outcomes in sepsis: a prospective cohort study. *Lancet*. 2016;4(4):259-271.
38. Levi M. Platelets in critical illness. *Semin Thromb Hemost*. 2016;42(3):252-257.
39. Chertoff J, Chisum M, Garcia B, et al. Lactate kinetics in sepsis and septic shock: a review of the literature and rationale for further research. *J Intensive Care*. 2015;3:39.
40. Polito A, Eischwald F, Maho AL, et al. Pattern of brain injury in the acute setting of human septic shock. *Crit Care*. 2013;17:R204.
41. Sasaguri K, Yamaguchi K, Nakazono T, et al. Sepsis patients' renal manifestations on contrast-enhanced CT. *Clin Radiol*. 2016:71:617.e1-e7.
42. Lima A. Current status of tissue monitoring in the management of shock. *Curr Opin Crit Care*. 2016;22:274-278.
43. Rocha LL, Pessoa CMS, Correa TD, et al. Current concepts on hemodynamic support and the therapy in septic shock. *Rev Bras Anestesiol*. 2015;65:395-402.
44. Heron M. Deaths: leading cause for 2013. *Natl Vital Stat Rep*. 2016;65:1-95.
45. Lu J, Wang X, Chen Q, et al. The effect of early goal-directed therapy on mortality in patients with severe sepsis and septic shock: a meta-analysis. *J Surg Res*. 2016;202(2):389-397.
46. Dellinger RP, Levy MM, Rhodes A, et al. Surviving sepsis campaign: international guidelines for management of severe sepsis and septic shock: 2012. *Crit Care Med*. 2013;41:580-637.
47. Umemura Y, Yamakawa K, Ogura H, et al. Efficacy and safety of anticoagulant therapy in three specific populations with sepsis: a meta-analysis of randomized controlled trials. *J Thromb Haemost*. 2016;14(3):518-530.
48. Yamakawa K, Fujimi S, Mohri T, et al. Treatment effects of recombinant human soluble thrombomodulin in patients with severe sepsis: a historical control study. *Crit Care*. 2011;25:R123.
49. Ogawa Y, Yamakawa K, Ogura H, et al. Recombinant human soluble thrombomodulin improves mortality and respiratory dysfunction in patients with severe sepsis. *J Trauma Acute Care Surg*. 2012;72:1150-1157.
50. Gando S, Meziani F, Levi M. What's new in the diagnostic criteria of disseminated intravascular coagulation? *Intensive Care Med*. 2016;42:1062-1064.
51. Levi M, Ten Chate H. Disseminated intravascular coagulation. *N Engl J Med*. 1999;341:586-592.
52. Levi M, van der Poll T. Disseminated intravascular coagulation: a review for the internist. *Intern Emerg Med*. 2013;8:23-32.
53. Singh B, Hanson AC, Alhurani R, et al. Trends in the incidence and outcomes of disseminated intravascular coagulation in critically ill patients (2004-2010): a population based study. *Chest*. 2013;143:1235-1242.
54. Marcel L. Management of cancer-associated disseminated intravascular coagulation. *Thromb Res*. 2016;140(suppl 1):566-570.
55. Sonavane A, Baradkar V, Salunkhe P, et al. Waterhouse-Friderichsen syndrome in an adult patient with meningococcal meningitis. *Indian J Dermatol*. 2011;56:326-328.
56. Cunningham FG, Nelson DB. Disseminated intravascular coagulation syndromes in obstetrics. *Obstet Gynecol*. 2015;126:999-1011.
57. Binder A, Endler G, Muller M, et al. 4G4G genotype of the plasminogen activator inhibitor-1 promoter polymorphism associated with disseminated intravascular coagulation in children with systemic meningococcemia. *J Thromb Haemost*. 2007;10:2049-2054.
58. Di Nisio M, Thachil J, Squizzato A. Management of disseminated intravascular coagulation: A survey of the international society on thrombosis and haemostasis. *Thromb Res*. 2015:136:239-242.

59. Wada H, Matsumoto T, Yamashita Y. Diagnosis and treatment of disseminated intravascular coagulation (DIC) according to four DIC guidelines. *J Intensive Care*. 2014;2:15-22.
60. Iba T, Ito T, Maruyama I, et al. Potential diagnostic markers for disseminated intravascular coagulation of sepsis. *Blood Rev*. 2016;30(2):149-155.
61. Squizzato A, Hunt BJ, Kinasewitz GT, et al. Supportive management strategies for disseminated intravascular coagulation. An international consensus. *Thromb Haemost*. 2016;115(5):896-904.
62. Itoh S, Shirabe K, Kohnoe S, et al. Impact of recombinant human soluble thrombomodulin for disseminated intravascular coagulation. *Anticancer Res*. 2016:36:2493-2496.

Chapter 156 :: Miscellaneous Bacterial Infections with Cutaneous Manifestations

:: Scott A. Norton & Michael A. Cardis

ANTHRAX

AT-A-GLANCE

- A large Gram-positive rod, *Bacillus anthracis*, changes into dormant spores under environmentally harsh conditions. Spores are infectious particles that revert to active bacillary form in host tissues.
- Natural pathogen of livestock, especially sheep, goats, and cattle. Most human diseases are occupationally related to exposure to live animals or animal products.
- Cutaneous anthrax is the most common form and is associated with the lowest morbidity. Inhalational and GI anthrax are more virulent and frequently lethal.
- Cutaneous lesions arise from percutaneous spore inoculation, usually unnoticed. They present as painless edematous papules or plaques that develop jet-black central eschars.
- The organism is a Centers for Disease Control and Prevention Category A bioweapon in aerosolizable micropowder form. There is no potential for human-to-human transmission of inhalational anthrax.

ETIOLOGY AND EPIDEMIOLOGY

Anthrax (Fig. 156-1) is a zoonotic infectious disease caused by *Bacillus anthracis*, a large aerobic, spore-forming Gram-positive rod.[1] Anthrax occurs naturally in ruminant mammals, such as sheep, cattle, and goats. Human disease is seen most often in agrarian, livestock-dependent regions. Consequently, human anthrax usually follows agricultural or industrial exposure, either through direct handling of infected animals or contaminated soil or through the processing of hides, wool, hair, or meat.[2] Anthrax has potential as a class A bioweapon (Table 156-1) because it is easily aerosolized and often lethal.

The clinical presentation of human anthrax depends on the route of inoculation. Each of anthrax's forms has distinctive clinical, epidemiologic, and prognostic features.[3]

In 95% of human cases, the disease is acquired through percutaneous inoculation of anthrax spores. Human anthrax also can be acquired as inhalational and GI disease. Recent cases in the United States of both forms were associated with recreational use of drums made of unprocessed animal hides imported from West Africa.[4,5]

In 2009, a novel mode of anthrax transmission known as "*injectional anthrax*," which resulted from exposure to contaminated heroin, emerged in Europe. Injectional anthrax has a distinct clinical course that is more insidious than cutaneous anthrax because it presents without an eschar. It is more virulent, too, with a much higher mortality rate than cutaneous disease.[6-8]

Outbreaks still occur in endemic areas.[9-14] During the late 20th century, thousands of people in the African nations of Zambia and Zimbabwe developed anthrax.[15] More than 90% of cases were cutaneous and the remainder represented an equal mix of inhalational and GI disease. Dying animals typically release vegetative bacilli into the environment, which then convert into the dormant, yet infectious, spores. There are ongoing outbreaks of animal anthrax among free-ranging wood bison (Athabaskan buffalo) in Northern Canada,[16] several species of antelope in Zambia,[17] hippopotami in Uganda, and domesticated grazing animals in North Dakota.[18]

The major virulence factors of the bacterium are its poly-γ-D-glutamic acid capsule, and the tripartite anthrax toxin that contains 3 proteins: protective antigen, lethal factor, and edema factor.[19] The protective antigen is the best target for vaccines or immunotherapy.

CLINICAL FINDINGS

HISTORY

After an incubation period of 1 to 7 days, patients may experience low-grade fever and malaise, and develop a painless papule at the exposed site. As the lesion enlarges, the surrounding skin becomes increasingly edematous. Pain, if present, is usually the result of edema-associated pressure or secondary infection.

CUTANEOUS LESIONS

Cutaneous anthrax develops when spores enter minor breaks in the skin, especially on exposed parts of the hands, legs, and face (see Fig. 156-1). In the hospitable environment of human skin, spores revert to their rod forms and produce their toxins. A dermal papule, often resembling an arthropod bite reaction, develops over

Figure 156-1 Anthrax. The classic cutaneous lesion of a primary infection in anthrax is a painless papule that evolves into a hemorrhagic bulla with surrounding brawny nonpitting edema. Note the typical localization on the hand. The name *anthrax* comes from the Greek word *ανθραξ (anthrax)*, meaning coal, which refers to the coal-black hue of the lesions of cutaneous anthrax.

several days, and then progresses through vesicular, pustular, and escharotic phases. Lesions are surrounded by varying degrees of edema. Depending on the manner of inoculation, 1 to several lesions may appear, and there may be regional lymphadenitis, malaise, and fever. Individual lesions may appear pustular, leading to the name "malignant pustule," but they do not suppurate. In anthrax, true pustules are rare; a primary pustular lesion is unlikely to be cutaneous anthrax.

The lesion enlarges into a glistening pseudobulla that becomes hemorrhagic with central necrosis and may be umbilicated (see Fig. 156-1). The necrotic ulcer is usually painless, which is an important feature for differentiating it from a brown recluse spider bite. There may be small satellite papules and vesicles that may extend along lymphatics in a sporotrichoid manner. An area of brawny, nonpitting edema ("malignant edema") often surrounds the main lesion. Lesional progression is caused by toxins and is unaffected by antibiotic therapy. Fatigue, fever, chills, and tender regional adenopathy may cause an ulceroglandular syndrome. The eschar dries and separates in 1 to 2 weeks.[20-24]

RELATED PHYSICAL FINDINGS

Cutaneous anthrax may cause fever, tachycardia, and hypotension.

HISTOPATHOLOGY

The prominent features are hemorrhagic edema, dilated lymphatics, and epidermal necrosis. Bacilli may be found in the eschar. Anthrax is toxin-mediated and induces scant inflammatory infiltrate. Immunohistochemical stains are quite useful.[25]

TREATMENT

Naturally occurring anthrax is treated with penicillin or doxycycline. Weaponized anthrax, on the other hand, may be resistant to these antibiotics; consequently, a fluoroquinolone is recommended for the initial treatment of confirmed or suspected bioterrorism-associated anthrax, even in pregnant women and children. Once drug sensitivities have been established, the patient may be switched to another antibiotic as clinically indicated. Antibiotics will kill activated *B. anthracis* bacilli but will not alter tissue damage already caused by toxins.[26,27] To neutralize the anthrax toxins, the Centers for Disease Control and Prevention (CDC) now possesses human antianthrax immunoglobulin and monoclonal antibodies directed against the toxins are in development. The U.S. Food and Drug Administration (FDA) has licensed a humanized monoclonal antibody, raxibacumab, that has specificity for the bacterial protective antigen, to be used in cases of inhalational anthrax.

Although cutaneous anthrax is usually an uncomplicated and readily treatable infection, public health concerns warrant hospitalization. Standard universal precautions are appropriate but specific measures against secondary respiratory transmission are unnecessary because anthrax is not transmitted from person-to-person.

Parenteral crystalline penicillin G (2 million units every 6 hours) was the treatment of choice prior to the 2001 bioterrorism outbreak. In one study, smears and cultures from vesicles or from the necrotic tissue beneath the eschar became negative within 6 hours of initiation of penicillin therapy. Treatment of primary cutaneous anthrax is continued with parenteral therapy until the local edema disappears or the lesion dries up over 1 to 2 weeks. When the edema resolves, the patient may complete the 60-day treatment with oral therapy.

Other than to obtain material for culture or histopathology, incision and debridement of the cutaneous lesion is unnecessary. First, the lesions contain no purulent material needing evacuation and, second, without effective antibiotics, these procedures increase the risk of bacteremic spread of the disease.

PROGNOSIS AND CLINICAL COURSE

Untreated cutaneous anthrax, particularly if nonedematous, is a largely self-resolving disease. In contrast, some lesions, especially ones with massive edema, pose the risk of bacteremia with subsequent septicemia. Thus, the mortality rate of untreated cutaneous anthrax is roughly 5% to 20%. With prompt and appropriate antibiotics, there is rapid defervescence and clinical improvement. Massive facial edema associated

TABLE 156-1
Overview of Bacterial Infections

INFECTION	EXPECTED DEMOGRAPHIC DISTRIBUTION	TYPICAL PRESENTATION (SKIN)[a]	TYPICAL EXPOSURE	BIOWEAPON POTENTIAL[b]	TREATMENT
Anthrax	Worldwide, especially developing agrarian areas	Painless edematous plaque with central black ulcer or eschar	Goats, sheep, cattle, or products made from them	A	Penicillin, doxycycline, ciprofloxacin
Tularemia	North America, Europe	Ulceroglandular: painful papule that ulcerates and forms eschar	Tick bites, rabbits, rodents	A	Aminoglycoside, fluoroquinolone, doxycycline
Plague	Worldwide, especially southwestern United States and India	Buboes (tender regional lymphadenopathy) followed by purpura and gangrene	Flea bites, spread from infected rodents	A	Aminoglycoside, doxycycline, cotrimoxazole
Brucellosis	Worldwide, especially developing agrarian areas	Variable; skin manifestations present in <5% of patients	Cattle, sheep, goats, or untreated milk	B	Doxycycline plus aminoglycoside or rifampin
Glanders	Rare and focal in Asia, Middle East	Nodule with cellulitis that ulcerates; later, deep abscesses and sinuses	Donkeys, mules, horses	B	Sulfadiazine, gentamycin, doxycycline
Pasteurella infection	Worldwide	Rapid onset of cellulitis at bite site followed by necrosis	Dog or cat bite	NR	Amoxicillin plus clavulanic acid
Rat-bite fever (streptobacillary)	Worldwide, especially Asia	Morbilliform eruption with fever followed by arthritis	Rats or their excreta	NR	Amoxicillin plus clavulanic acid
Seal finger	Cool coastal regions worldwide	Extremely painful nodule on finger	Seals or sea lions	NR	Tetracycline, ceftriaxone
Listeriosis	Worldwide	In neonates, generalized petechiae, papules, and pustules	In neonates, infected mother with transfer in utero or shortly after birth	NR	Ampicillin or penicillin IV
Vibrio vulnificus infection	Worldwide	Necrotizing fasciitis, hemorrhagic bullae often beginning as a wound infection	Warm saltwater or brackish water or undercooked seafood	NR	Doxycycline and ceftazidime IV, debridement of lesions
Aeromonas hydrophila infection	Worldwide	Cellulitis evolving to abscess formation; often beginning as a wound infection	Fresh or brackish water, contaminated fish	NR	Third-generation cephalosporins, fluoroquinolones; debridement
Melioidosis	Wet tropical areas, especially Southeast Asia and northern Australia	Indolent abscesses; suppurative parotitis (in children)	Wet soil (classically rice paddies), flooded regions	B	Ceftazidime plus a carbapenem IV, then prolonged oral amoxicillin clavulanic acid or TMP-SMX
Erysipeloid	Worldwide	Tender violaceous plaque on hand at site of injury	Contaminated fish, shellfish, poultry, meat, and animal products	NR	Penicillin, ampicillin, ceftriaxone, fluoroquinolone
Streptococcus iniae infection	Worldwide, especially freshwater fish farms	Rapid onset of hand cellulitis following a puncture wound	Contaminated farm-raised fish	NR	Penicillin, cephalosporin
Leptospirosis	Worldwide, especially the tropics	Papules, petechiae, jaundice	Contaminated freshwater, moist soil, or animal urine	NR	Doxycycline, penicillin
Diphtheria	Worldwide where immunization is not practiced	Pustule or superinfected abrasion, evolving to an ulcer with gray membrane at base	Asymptomatic human carriers	NR	Penicillin IV or erythromycin plus antitoxin

[a]For many entities, multiple presentations are possible depending on the route of inoculation (percutaneous entry, oral ingestion, or inhalation). See text.
[b]If aerosolized, per criteria of the Centers for Disease Control and Prevention.
A, highest (systemic disease, often fatal); B, substantial (severe systemic disease, sometimes fatal); NR, not rated; TMP-SMX, trimethoprim-sulfamethoxazole.

with cutaneous lesions of the head or neck may lead to respiratory compromise, requiring intubation or tracheostomy and systemic corticosteroids. Palpebral lesions may scar the eyelids and edema-associated seventh-nerve palsy may occur.[28] Because of high mortality rates, patients with injectional, inhalational, or GI anthrax should be placed in intensive care units.

PREVENTION

In nonendemic areas, any case of anthrax requires immediate reporting to public health authorities and a prompt public health response because of the threat of intentional criminal or terroristic release. Although anthrax is a dangerous disease, it is not transmitted from person-to-person. Instead, the spore is the infectious propagule. Therefore patients with anthrax—of whatever clinical presentation—do not require isolation.

An anthrax vaccine has been in use since 1954 for people with occupational exposure to natural anthrax (eg, veterinarians, wildlife biologists). The CDC recently released new guidelines on its use in the post-9/11 era for routine occupational use and for preoutbreak and postoutbreak exposure use.[29]

Although cutaneous anthrax is usually an uncomplicated and readily treatable infection, public health concerns warrant hospitalization. Standard universal precautions are appropriate but specific measures against secondary respiratory transmission are unnecessary because anthrax is not transmitted from person-to-person.

TULAREMIA (*FRANCISELLA TULARENSIS* INFECTIONS)

AT-A-GLANCE

- Caused by *Francisella tularensis*, a Gram-negative coccobacillus found in rabbits, rodents, other mammals, and their immediate environments in temperate and cold regions of North America.
- Has diverse clinical presentations related to route of transmission. Ulceroglandular disease after tick bites is most common.
- Bacteria are easily aerosolized and highly infectious in small inocula; consequently, tularemia poses risks of laboratory accidents or use as a bioweapon.

ETIOLOGY AND EPIDEMIOLOGY

Tularemia is a zoonotic infectious disease caused by *Francisella tularensis*, a pleomorphic Gram-negative coccobacillus found in nearly 200 species of mammals and their immediate environments. The most important groups known to carry the bacterium are lagomorphs (rabbits and hares) and rodents. The bacteria are highly virulent and require a low inoculum for infection. They can be transmitted in multiple ways, and cause 6 major clinical presentations, which are defined by their route of transmission and are known as glandular, ulceroglandular, oculoglandular, oropharyngeal, typhoidal, and pneumonic forms of tularemia.[30]

Tularemia, also known as deerfly fever, rabbit plague, and rabbit fever, was first described in the United States in the early 20th century. It occurs solely in temperate and cold regions of the Northern Hemisphere. The most common form in the United States is ulceroglandular disease in which organisms are inoculated directly into the skin by minor trauma or by bites of infected arthropods that maintain the enzootic cycle. Before 1950, most U.S. infections occurred in hunters who handled infected rabbits and hares. Two incidence peaks each year corresponded with summer and winter hunting seasons. Currently, 100 to 150 U.S. cases occur each year, mostly in Arkansas, Missouri, and Oklahoma, with transmission of the organism largely via tick bites. The most common tick vectors are *Dermacentor variabilis*, *Amblyomma americanum*, and, in Europe, *Ixodes* sp.[31-35]

Of several subspecies, the most virulent (*F. tularensis* subspecies *tularensis*) lives only in the North America. A more benign one (*F. tularensis* subspecies *holarctica*) is the only subspecies in Eurasia. Although these bacteria do not produce spores, they can survive environmentally—and maintain infectivity—for months.[33,34]

Tularemia is transmitted in other ways, too. Other arthropod vectors include the deerfly (*Chrysops discalis*) in the Western United States, and mosquitoes in Scandinavia and the Baltic region.[36] An outbreak of pulmonary tularemia on Martha's Vineyard, Massachusetts, was associated with springtime mowing of tall grass.[37] The precise environmental source was not clear, perhaps aerosolization of animal excreta in the grass. Domestic cats may spread the organism via direct contact, bite, or aerosol. In parts of Europe, aquatic rodents (muskrats and beavers), household rodents, and drinking water contaminated by these animals are the major sources of infection. *F. tularensis holarctica* can maintain a long-term aquatic lifecycle, leading to waterborne disease, and in some European countries, mosquitos may serve as mechanical vectors of the disease.[38]

Rarely, direct inoculation into conjunctivae or ingestion of poorly cooked, contaminated meat causes infection. There is no human-to-human transmission. A second species, *Francisella philomiragia*, can infect patients with inherited defects in phagocytosis such as chronic granulomatous disease.

CLINICAL FINDINGS

HISTORY

Duration of incubation varies with size of inoculum, ranging from 2 to 10 days. All forms of tularemia

Figure 156-2 Tularemia. A chancre-like ulcer with raised margins on the dorsum of the fourth digit with accompanying axillary lymphadenopathy. The rash on the chest is unrelated and is pityriasis versicolor.

present as a sudden flu-like illness characterized by fever, headache, malaise, and myalgia.

CUTANEOUS LESIONS

In ulceroglandular tularemia, a painful red papule appears at the inoculation site (Fig. 156-2). It enlarges rapidly and evolves into a necrotic chancriform ulcer often covered by a black eschar. Regional lymph nodes are large and tender.[37] Bacteremia may cause sepsis and virulent pneumonia. In 2 recent Scandinavian outbreaks with the less-virulent *F. tularensis holarctica* type of tularemia, primarily caused by mosquitoborne ulceroglandular disease, approximately one-third of nearly 300 patients developed nonspecific secondary cutaneous manifestations, such as erythema nodosum, erythema multiforme, or an asymptomatic id-like papular eruption on the extremities.[36,39]

Tularemia is a chancre-like ulcer with raised margins on the dorsum of the fourth digit with accompanying axillary lymphadenopathy. The rash on the chest is unrelated and is pityriasis versicolor.

RELATED PHYSICAL FINDINGS

In oculoglandular tularemia, organisms are introduced directly into the conjunctivae, for example, after handling an infected tick or rabbit. This causes purulent conjunctivitis with pain, edema, and local adenopathy. In a recent outbreak in Bulgaria, more than 90% of cases were oropharyngeal, reflecting transmission via contaminated well water. Swallowing the organism may cause ulcerative pharyngotonsillitis with cervical adenopathy or may cause "typhoidal" tularemia.[40] Pulmonary tularemia may be primary (ie, caused by inhalation of organisms) but is more often because of bacteremic spread from another focus.

LABORATORY FINDINGS

Laboratories should be notified of suspected tularemia so that cultures can be set under biohazard conditions to avoid aerosolization. *F. tularensis* grows best on cysteine-supplemented blood agar, producing nonmotile, nonsporulating, pleomorphic, Gram-negative coccobacilli. Some reference laboratories also use animal inoculation techniques.

HISTOPATHOLOGY

The pathogen survives intracellularly in phagocytes, and small granulomas develop in lymph nodes, liver, and spleen. Some lesions may caseate and progress to frank abscess formation. Hepatic granulomas may resemble tuberculosis or brucellosis.

DIFFERENTIAL DIAGNOSIS

The primary lesion of tick-transmitted tularemia resembles a pyogenic infection (such as a furuncle, paronychia, or common ecthyma), the initial lesion of anthrax, *Pasteurella multocida* infection, or sporotrichosis. Prominent regional adenopathy may suggest cat-scratch disease, plague, or melioidosis. Fever after a tick bite might suggest Rocky Mountain spotted fever, but that usually has an exanthem rather than a chancriform lesion. Other tickborne febrile diseases include other rickettsioses, ehrlichiosis, babesiosis, and viral tick fevers. Because *F. tularensis* is difficult to grow, the diagnosis is usually made by serologic tests showing a rise in titers. Although the subspecies of *F. tularensis* are clinically and epidemiologically distinct, they are serologically indistinguishable.[33]

TREATMENT

A presumptive diagnosis of tularemia on clinical and epidemiologic grounds is sufficient to initiate treatment while awaiting serologic confirmation (see Table 156-1). Treatment consists of an aminoglycoside antibiotic, such as gentamicin (or streptomycin, if available), or a fluoroquinolone; these should be given for at least 10 days. A tetracycline antibiotic, such as doxycycline, given for at least 15 days is an acceptable alternative. Patients improve within 24 to 48 hours, but treatment should continue for at least 7 to 10 afebrile days to reduce the risk of relapse.

COURSE, PROGNOSIS, AND COMPLICATIONS

Untreated pulmonary and typhoidal tularemia have mortality rates of approximately 30%. Without

antibiotics, ulceroglandular disease lasts many weeks and has a mortality rate of 5%. Brief courses of antibiotics may permit relapse but, with proper treatment, uncomplicated recovery is expected.

PREVENTION

Hunters and animal handlers should wear impervious gloves when handling game, especially rabbits. Game meat should be cooked thoroughly, even if stored frozen for long periods. A live-attenuated (but rarely used) vaccine was developed in Russia; the U.S. government is currently funding vaccine research. The disease is reportable in the United States and any cluster of pulmonary tularemia cases should raise concerns of bioterrorism.[34,41] Antibiotic prophylaxis with ciprofloxacin is useful in patients with proven exposure.[38]

PLAGUE

AT-A-GLANCE

- Focal enzootic sites worldwide, including the southwestern United States. Human disease is caused by bites from infected fleas or direct contact with rodent reservoirs.
- The bubonic form is the most common, producing large tender lymph nodes (buboes) proximal to the site of fleabite. All forms can lead to sepsis, distal gangrene (origin of the term *black death*), and death.
- Pneumonic plague because of respiratory spread of aerosolized *Yersinia pestis* has a high mortality and is a possible weapon of bioterrorism.

ETIOLOGY AND EPIDEMIOLOGY

Plague is a severe, acute, febrile zoonosis caused by the aerobic Gram-negative bacillus *Yersinia pestis*. Plague is found on every continent except Antarctica, and exists in an enzootic cycle, infecting humans through contact with rodent reservoirs or flea vectors. Human plague has 3 clinical forms: (a) bubonic; (b) bubonic-septicemic, a more virulent form resulting from secondary bacteremia and sepsis; and (c) pneumonic (fulminant disease resulting from respiratory spread). Distal purpura and gangrene associated with septicemic plague likely gave rise to the term *black death*. The plague bacillus likely evolved from the fecal–oral pathogen, *Yersinia pseudotuberculosis,* by acquiring several virulence plasmids.[42]

Endemic or sylvatic plague occurs in wild rodents in the western United States, parts of South America, much of sub-Saharan Africa, and across Southern Asia. In most places, plague is sporadic but Madagascar currently has epidemic plague.[43,44] There are several thousand cases of plague worldwide each year and the disease prevalence is increasing across Africa; Madagascar alone accounts for nearly half the number of human cases each year.[42,45]

In the United States, human disease is almost always transmitted by fleas. Direct handling of infected rodents, rabbits, or their carcasses can also transmit plague. Some cases are transmitted by direct contact with pet dogs or cats that become ill after contact with infected wild animals. Between 1990 and 2005, 107 plague cases, more than 80% bubonic, were reported in the United States, averaging 7 per year, mostly in summertime. In western states, winter cases are often linked with handling of animal carcasses while hunting. In recent years, epizootics have occurred among prairie dogs, and sporadic human cases were seen on several Indian reservations, associated with ground squirrels.[46] Rarely, bacteremic bubonic disease may evolve into pneumonic plague and further initiate respiratory spread to others.[47,48]

The flea associated with epidemic plague in the Old World is *Xenopsylla cheopis*, but fleas in other genera (eg, *Anomiopsyllus*, *Aetheca*, *Pulex*) are also vectors in the United States.

Plague is an historically important disease, causing more than 100 million deaths during several pandemics over the past 15 centuries. Because *Y. pestis* can be aerosolized, it is devastatingly lethal, and can spread from person-to-person; it is considered a Category A biologic weapon (see Table 156-1). *Y. pestis* produces an intracellular toxin and virulence factors.

CLINICAL FINDINGS

HISTORY

Bubonic plague incubates for roughly 2 to 6 days, followed by the sudden onset of high fever, prostration, malaise, myalgia, backache, and tachycardia. Primary pneumonic plague has a shorter incubation time.

CUTANEOUS LESIONS

In bubonic plague, the initial skin lesion is related to the fleabite and may appear as papular urticaria. However, the hallmark of bubonic plague is prominent, exquisitely tender regional lymphadenopathy with extensive subcutaneous edema. Inguinal buboes are most common in adults; cervical and axillary buboes are more common in children.[42]

Any form of plague can lead to overwhelming endotoxic septicemia accompanied by disseminated intravascular coagulopathy (see Chap. 155). Subsequent purpura and gangrene are most severe on distal extremities.[49]

RELATED PHYSICAL FINDINGS

Primary septicemic plague lacks buboes and presents with typical Gram-negative sepsis. Many patients also have severe abdominal pain, nausea, vomiting, and bloody diarrhea. Pneumonic plague has an abrupt onset with high fever, tachycardia, tachypnea, chest pain, and dyspnea. Within 24 hours of onset, the patient is critically ill and producing bloody sputum laden with *Y. pestis*. Meningitis may complicate all forms of plague.

LABORATORY FINDINGS

In bubonic plague, organisms can be cultured from lymph node aspirates and blood; in pneumonic plague, sputum or tracheal washes. Lymph node aspirates are obtained by using a sterile syringe to inject 1 mL of saline into the center of a bubo and withdrawing purulent material until the pus is tinged with blood. Special transport medium (eg, Cary-Blair medium) is helpful but the culture may be performed in standard brain–heart nutrient broth. The organisms appear as Gram-negative coccobacilli with a Gram stain but their bipolar bacillary appearance is more distinctive with Wright-Giemsa or Wayson stain.[42,50] Bacilli can sometimes be seen on stained buffy coat smears. Leukocytosis occurs in all forms of the disease. Renal failure and disseminated intravascular coagulopathy may occur in severe cases. Bacteria can be cultured on standard blood agar media. Direct fluorescent antibody assays, enzyme-linked immunosorbent assay, and polymerase chain reaction testing are useful when available, but serologic tests are less reliable.[49,51] Histopathologically, acute inflammatory changes are seen in the involved nodes. Immunohistochemical stains of tissue biopsy specimens may show organisms.[52]

DIFFERENTIAL DIAGNOSIS

Most patients with bubonic plague present with the rapid onset of a toxic febrile illness, painful buboes, and evidence of an arthropod bite without surrounding cellulitis. Bubonic plague should be distinguished from tularemia, lymphogranuloma venereum, cat-scratch disease, chancroid, Kikuchi disease, and suppurative lymphadenitis caused by staphylococcal or streptococcal infection. Pneumonic plague must be differentiated from other acute bacterial pneumonias. Epidemiologic considerations and the tempo of the illness are major points in the differential diagnosis. The diagnosis is made by examining Gram-stained (or specific fluorescent antibody–stained) smears of infected material or by culturing organism from blood, sputum, or aspirated buboes. Serologic methods help retrospectively by demonstrating a fourfold or greater rise in titers. A convalescent passive hemagglutination titer of greater than 1:16 suggests the diagnosis.

TREATMENT

Because the original drug of choice, streptomycin, is not widely available, another aminoglycoside antibiotic, gentamicin, is the preferred treatment (although the FDA has not approved it for this indication; see Table 156-1). Doxycycline is also effective and may be the treatment of choice when oral therapy is required or to use as postexposure prophylaxis. Cotrimoxazole is useful when combination therapy is desired.[50] Patients with pneumonic plague must be placed in respiratory isolation to prevent further transmission. The course of treatment, irrespective of medication, is 10 days. Ordinarily, buboes should not be drained until they are well-localized and antibiotic therapy has been started.[53]

PROGNOSIS AND CLINICAL COURSE

Pneumonic and septicemic plague, if untreated, are nearly always fatal. Untreated bubonic plague has a mortality rate of approximately 50% but early antibiotic therapy has reduced this to 5% to 10%. Because primary septicemic plague lacks telltale buboes, the clinical suspicion of plague is often delayed, hence antibiotics are started late and mortality is high.

PREVENTION

Most cases in the United States are acquired peridomestically so it is important in endemic areas to control rodents around homes. Children should be taught to avoid rodent nests, burrows, and dead animals. Pets should be given regular flea treatments, examined properly when ill, and trained not to hunt small mammals or eat sick or dead mammals. Rabbit hunters should wear gloves when handling carcasses. With pneumonic cases, respiratory isolation is mandatory and close contacts should receive antibiotic prophylaxis with doxycycline or cotrimoxazole. Plague vaccine is no longer available. Because the disease is a zoonosis, it is considered ineradicable, so prevention through rodent control is the most important way to prevent plague.[42,45]

BRUCELLOSIS

AT-A-GLANCE

- Zoonosis transmitted by contact with infected animals or consumption of contaminated dairy products.
- May be transmitted via aerosolized bacteria, hence the concern regarding the use of *Brucella* in bioterrorism.

(Continued)

AT-A-GLANCE (*Continued*)

- Usually presents with undulant fever and can involve all organ systems, especially the joints, reproductive organs, liver, and CNS. Endocarditis can be fatal.
- Cutaneous lesions are seen in fewer than 5% of patients, usually children. Variable morphologies include vasculitis, erythema nodosum, panniculitis, abscesses, and polymorphous papules, pustules, and papulosquamous lesions. Children with acute brucellosis may have a violaceous papulonodular eruption primarily on the trunk and lower extremities.

ETIOLOGY AND EPIDEMIOLOGY

Brucellosis is caused by any of 4 species of *Brucella*, which ordinarily infect livestock, especially cattle, sheep, and goats. It is transmitted to humans by contact with infected animals or animal products, ingestion of unpasteurized or contaminated dairy products, and, rarely, by inhalation of aerosolized bacteria. There are approximately 500,000 human cases per year worldwide, making it one of the most common zoonoses worldwide. The highest incidence is in underdeveloped agrarian areas where there are poor health controls for herds, where people consume raw dairy products, and the populations are nomadic with less access to medical care. These regions include East Africa, grazing areas of upland South and Central America, and the belt of nations extending from Spain and Portugal across the Mediterranean basin, through Asia from Turkey and the Middle East, and across the former Soviet republics to Mongolia. Domesticated animals are reservoirs for *Brucella*, and the 2 species that most commonly infect humans are *Brucella melitensis* ("from Malta," where the disease was first described) and *Brucella abortus*. *Brucella suis*, and *Brucella canis* are less common pathogens.[54-58]

In the United States, brucellosis has largely been eliminated by proper animal husbandry practices. Still, there are 100 to 200 cases annually, mostly in travelers who ate raw dairy products in endemic areas or in people who consume illegally imported unpasteurized Mexican dairy products. Those at high risk include herders, farmers, veterinarians, and abattoir workers. Hunters who handle carcasses of large game, such as deer, elk, and wild pigs, are also at risk.

People can become infected by ingestion or inhalation of the pathogens or via contact through conjunctiva or open skin. The bacteria then invade reticuloendothelial tissues and typically evade host defenses as intracellular pathogens.[58]

Contaminated unpasteurized milk or cheese is the most common source for human infection. Also, direct contact with infected animals, their placentae, or excreta may allow organisms to enter through abraded skin. Droplet inhalation can occur in abattoir workers. *Brucella* multiply intracellularly in many tissues and may persist for prolonged periods, leading to acute and chronic disease. Although *Brucella* is an intracellular pathogen, AIDS patients do not have more frequent or severe disease.

In the past, most U.S. infections were caused by *B. abortus* after contact with infected cattle and dairy products. This species may cause bovine abortions and stillbirths, so handling infected fetuses or placentae is risky. Dog owners are at increased risk of infections with *B. canis*.[56]

CLINICAL FINDINGS

HISTORY

The incubation period varies and is usually 1 to 3 weeks, but may be 2 months or longer. The disease presents either as an acute febrile, flu-like bacteremic syndrome or as a chronic disease with nonspecific signs and symptoms such as weakness, anorexia, headache, and low-grade fever. Relapses occur in approximately 15% of patients, often after an ineffective antibiotic regimen.

CUTANEOUS LESIONS

Skin manifestations occur in fewer than 5% of patients and are more common in children than in adults. Furthermore, skin lesions, when present, vary widely, appearing as vasculitis, erythema nodosum, panniculitis, abscesses, and polymorphous papules, pustules, and papulosquamous lesions. This is because cutaneous brucellosis can be related to direct inoculation, hematogenous spread, deposition of antigen–antibody complexes, or hypersensitivity reactions. Children with acute cutaneous brucellosis typically have a violaceous papulonodular eruption primarily on the trunk and lower extremities. Rarely, *Brucella*-related osteomyelitis or suppurative lymph nodes may create cutaneous abscesses or sinuses.[59-64]

A rare but distinctive dermatosis is seen in veterinarians or farmers who handle infected animals or tissues[65] and develop a severe contact hypersensitivity reaction to *Brucella* antigens. This presents with discrete, elevated, red papules on the hands or arms that may ulcerate. Needle-stick injuries while handling the live-attenuated *Brucella* vaccine also causes local reactions.[51]

RELATED PHYSICAL FINDINGS

Brucellosis can involve every organ system, although there are no pathognomic clinical findings. The disease can be debilitating but it is rarely fatal. Joints, reproductive organs, liver, and the CNS are, in order,

the most frequently involved. Nearly all patients have a characteristic undulant fever (alternating pattern of several febrile days followed by several afebrile days). Arthritis can be axial (eg, sacroiliitis) or peripheral. The disease shows a predilection for reproductive organs, which leads to miscarriages, stillbirths, mastitis, prostatitis, orchitis, and epididymitis. Spinal osteomyelitis is well described, and endocarditis can be fatal. Persistent neuropsychiatric findings occur in 5% of patients.[58]

LABORATORY FINDINGS

Patients often have leukopenia, anemia, and elevated liver enzymes. Blood cultures may be positive during the acute illness. Because organisms are easily aerosolized and highly infectious, culture must be under Biosafety Level III conditions. *Brucella* are nonmotile, coccobacillary, Gram-negative rods that grow best in enriched media and hypercapnic conditions with 8% to 10% CO_2. Serodiagnosis is challenging.[58]

HISTOPATHOLOGY

The papulonodular eruption shows focal perivascular and periadnexal lymphohistiocytic granulomatous inflammation. Macular lesions have a nonspecific, mild, lymph perivascular infiltrate. The panniculitis usually shows septolobular inflammation with abundant plasma cells. Hepatic and splenic lesions contain small, noncaseating granulomas. Caseation necrosis and calcification may occur in *B. suis* infections.[55,56]

DIFFERENTIAL DIAGNOSIS

The clinical diagnosis of brucellosis is challenging and the epidemiologic suspicion is often delayed. Confirmation by culture or by serological techniques is necessary but the laboratory techniques are difficult.[58] The diagnosis is usually made on the basis of epidemiologic information, coupled with isolation of the organism, finding high or rising agglutination titers, or detecting organisms from a clinical specimen by direct fluorescent antibody technique. For cultures, bone marrow specimens have the highest yield. An agglutination titer of greater than 1:160 is sufficient to begin treatment. Confirmatory titers should be obtained 7 to 14 days later. In chronic disease, immunoglobulin G antibodies indicate continuing or recrudescent infection. Cross-reactions with *F. tularensis*, the cause of tularemia, are known, and recent cholera vaccination may stimulate a false-positive *Brucella* agglutination.

The differential diagnosis includes other acute bacterial infections, such as salmonellosis, listeriosis, tuberculosis, and endocarditis. Hodgkin disease may mimic many findings of brucellosis. Vertebral osteomyelitis is sometimes the sole manifestation of brucellosis.

TREATMENT

Brucellosis requires prolonged multidrug therapy with antimicrobials that penetrate into cells. Optimal therapy consists of doxycycline combined with either streptomycin, which is difficult to obtain, or gentamicin. The World Health Organization recommends an oral–oral regimen of doxycycline and rifampin (see Table 156-1). Treatment should last at least 6 weeks; shorter courses carry a risk for relapse.[58]

PROGNOSIS AND CLINICAL COURSE

Perhaps 5% of brucellosis patients die, mostly because of *B. melitensis* endocarditis. Early treatment results in rapid improvement but relapses occur in approximately 10% to 15% of patients with suboptimal treatment. Chronic brucellosis can cause disabling fevers, arthritis, fatigue, and nonspecific neuropsychiatric changes.[57]

PREVENTION

In Western nations, brucellosis is largely preventable through occupational precautions such as wearing gloves when handling game or products of conception from livestock. People should avoid unpasteurized dairy products and be especially vigilant when traveling in endemic countries. Vaccines exist for animals but not humans. Brucellosis is a reportable disease and any occurrence should initiate a search for—and possible destruction of—the animal or food source. The CDC categorizes *Brucella* as a Category B bioweapon, so a criminal source also must be considered.[56,58]

GLANDERS

AT-A-GLANCE

- Rare zoonosis caused by the Gram-negative bacillus *Burkholderia mallei* (formerly *Pseudomonas mallei*), found focally in Asia and the Middle East.
- Animal glanders occurs in horses, mules, and donkeys. Humans are infected through direct occupational exposure to animal reservoirs.
- Most human cases are acquired by direct inoculation into skin or contact of open skin with an infected animal or its secretions. Inhalational transmission is rare.
- A cutaneous ulcer develops after a 1- to 5-day incubation period, followed by several presentations: ulceroglandular syndrome, localized abscesses (acute or chronic), or bacteremic dissemination (often fatal).

ETIOLOGY AND EPIDEMIOLOGY

Glanders is a rare zoonosis caused by the Gram-negative bacillus *Burkholderia mallei* (formerly *Pseudomonas mallei*). Glanders occurs mostly in horses, mules, donkeys, and related species, and exists focally in Asia and the Middle East.[66] The disease is usually fatal in donkeys and mules, but may cause a chronic suppurative condition, called *farcy*, in horses. Human cases are usually the result of direct exposures to animal reservoirs. In endemic areas, animal handlers, veterinarians, and abattoir workers have the greatest risks of exposure.[67-69]

CLINICAL FINDINGS

HISTORY

Human glanders may present in several ways, depending whether the disease is transmitted via cutaneous inoculation or respiratory inhalation: acute localized infection, chronic cutaneous infection, acute pulmonary disease, and septicemia.[70,71] Most cases are acquired transcutaneously, and a local ulcer develops within 1 to 5 days. Regional lymph nodes may then enlarge, producing a ulceroglandular syndrome.

CUTANEOUS LESIONS

The 2 types of cutaneous glanders are (a) an acute, febrile, disseminated, infectious process that may resolve in a few weeks and (b) an indolent, relapsing, chronic infection, with multiple cutaneous or subcutaneous abscesses and draining sinuses. Abscesses may develop in muscle, liver, or spleen.

In acute glanders, a nodule surrounded by cellulitis appears at the site of inoculation (see Table 156-1). Local swelling and suppuration occur, the lesion ulcerates, and regional lymphadenopathy develops. The ulcer is painful and has irregular edges with a gray-yellow base. Nodules rapidly develop along lymphatics that drain the initial lesion. These become necrotic and ulcerated, forming sinuses. Widespread dissemination quickly follows, with multiple nodular necrotic abscesses in subcutaneous tissues and muscle. Lesions frequently coalesce into gangrenous areas.

During bacteremic spread, patients have fevers, rigors, and night sweats. The characteristic eruption is composed of crops of papules, bullae, and pustules. These may be generalized or localized to the face and neck, in which case involvement of the nasal mucosa, either initially or by secondary spread, is prominent. Mucopurulent, bloody nasal discharge is common. Infection may spread to the paranasal sinuses, pharynx, and lungs.

In chronic glanders, cutaneous and subcutaneous nodules appear on the extremities and occasionally on the face. The lesions ulcerate, and draining sinuses develop. Ulceration of the hard palate and perforation of the nasal septum can occur. If the organisms are inhaled, pulmonary disease may produce pneumonia, pulmonary abscesses, or pleural effusions. Septicemic glanders is usually fatal.

LABORATORY FINDINGS

Histopathologic examination of the skin and other involved organs shows a suppurative, necrotic process containing numerous intracellular and extracellular bacteria. Chronic glanders causes granulomatous changes.

DIFFERENTIAL DIAGNOSIS

The diagnosis is made on an epidemiologic basis, examination of Gram-stained smears of pus, and isolation of the organism from abscesses. Furthermore, in the pulmonary and septicemic forms, organisms may be recovered from blood, sputum, or urine. Acute glanders may resemble miliary tuberculosis. The multiple subcutaneous abscesses suggest staphylococcal or deep fungal infections or melioidosis. Lymphonodular disease resembles sporotrichosis, nocardiosis, tularemia, New World leishmaniasis, and *Mycobacterium marinum* infection.

TREATMENT

The CDC recommends treatment with sulfadiazine, although in vitro data indicate that *B. mallei* is susceptible to ceftazidime, gentamicin, doxycycline, imipenem, and ciprofloxacin. Patients with subcutaneous or visceral abscesses may require treatment for up to 1 year.[70-72] Because the disease has largely disappeared, few evidence-based recommendations are available.

PROGNOSIS, CLINICAL COURSE, AND COMPLICATIONS

Untreated septicemic glanders causes widespread abscesses in lungs, liver, spleen, muscles, and is nearly always fatal.

PREVENTION

The usual way to control zoonotic or epizootic glanders has been to destroy infected animals. Such measures have nearly eradicated this once common equine infection and eliminated transmission to humans in

industrialized countries. In the United States, glanders is a reportable disease. There are no vaccines against *B. mallei* infection for humans or animals. However, vaccines might be developed because of the bioweapon potential of this pathogen.[69]

PASTEURELLA MULTOCIDA INFECTIONS

AT-A-GLANCE

- Normal flora in oropharynx of many domestic animals. Most human infections are from dog or cat bites.
- Local pain and swelling appear rapidly, usually less than 2 days after exposure.
- Gram-negative organism; nevertheless, infection is treated with penicillin or presumptively with amoxicillin/clavulanic acid.

ETIOLOGY AND EPIDEMIOLOGY

Pasteurella multocida is a small, ovoid, Gram-negative rod that can cause local skin infection with regional adenitis after a superficial animal bite, scratch, or lick,[73] or septic arthritis and osteomyelitis after a deeper animal bite. Respiratory tract infections unassociated with trauma occur in rare cases, and bacteremia may accompany meningitis or osteomyelitis.

P. multocida commonly colonizes the oropharynx and nasopharynx of healthy cats, dogs, rats, mice, pigs, and other livestock, and poultry. Nearly all patients with *P. multocida* infection have had animal exposure, most commonly a dog or cat bite. Cat teeth are often longer and sharper than those of dogs and therefore may penetrate more deeply to cause septic arthritis or osteomyelitis. Compromising conditions such as cirrhosis, malignancy, and chronic obstructive pulmonary disease coexist in most severe cases.[74-79]

Neonatal pasteurellosis can be acquired by exposure to animals, usually pet dogs and cats in the household, even without known or recognized traumatic contact, possibly via respiratory droplets from the animal, or via vertical transmission from an asymptomatic mother.[80]

CLINICAL FINDINGS

HISTORY

Local pain and swelling occur within a few days of an animal bite or contact exposure. Fever is uncommon.

CUTANEOUS LESIONS

Redness, swelling, ulceration, and seropurulent drainage develop at the bite site. Cellulitis may progress rapidly and extensively, producing lymphangitis or local necrosis. Purpura fulminans and necrotizing fasciitis with septic shock have been reported.[74,81]

RELATED PHYSICAL FINDINGS

Regional adenopathy may be present. Deep bites may introduce organisms into a joint or beneath periosteum and cause septic arthritis or osteomyelitis.

LABORATORY FINDINGS

Mild leukocytosis is present. After several weeks, a radiograph of underlying bone may show osteomyelitis. The organism is Gram-negative, and Wright-Giemsa stain reveals a bipolar appearance. Histopathologically, an acute pyogenic response is seen.[75]

DIFFERENTIAL DIAGNOSIS

The diagnosis is suspected when a painful infection develops rapidly (<2 days) at the site of an animal bite. Approximately 75% of infected cat bites are caused by *P. multocida*. Local ulceration and proximal lymphadenitis mimic ulceroglandular tularemia, but *P. multocida* characteristically produces a necrotizing cellulitis and not chancriform syndrome. The diagnosis is confirmed by isolation of the organism, although treatment is often initiated according to an animal bite protocol or based on the history of a rapidly appearing painful cellulitis after a dog or cat bite.[81,82]

TREATMENT

Because most animal bite wounds show polymicrobial contamination, an amoxicillin-clavulanic acid preparation should be started after a dog or cat bite. Although *P. multocida* is a Gram-negative organism, most strains are susceptible to penicillin, which is the drug of choice if only *Pasteurella* is cultured. If one suspects that the bite reached periosteum, oral penicillin should be given until the local lesion is well healed. *P. multocida* is also susceptible to doxycycline, later-generation cephalosporins, and trimethoprim-sulfamethoxazole (see Table 156-1).

PROGNOSIS AND CLINICAL COURSE

Infection usually responds promptly to antibiotic therapy. Osteomyelitis, abscesses, and remnant foreign bodies should be treated surgically as well as

medically. *P. multocida* infections may be more severe or lead to sepsis in immunocompromised or AIDS patients.

PREVENTION

A great many animal bites are unprovoked by family pets onto a child's hand, therefore judicious selection of pets and instruction to children are useful, but not guaranteed, ways to reduce domestic animal bites.[83]

RAT-BITE FEVER

AT-A-GLANCE

- Rat-bite fever refers to 2 clinically similar zoonoses caused by *Streptobacillus moniliformis* and *Spirillum minus*.
- Infection is usually acquired through rat bite or ingestion of rat-contaminated food or drink.
- The disease is characterized by the classic triad of fever, polyarthralgias, and rash.

ETIOLOGY AND EPIDEMIOLOGY

The term *rat-bite fever* applies to 2 clinically similar zoonoses that are both attributable to contact with rats or their excreta. The more common form is caused by *Streptobacillus moniliformis*, a pleomorphic Gram-negative rod found in the nasopharyngeal flora of most wild and laboratory rats, which are asymptomatic carriers, and is excreted in their urine.[84] Carnivores that prey on wild rodents may also transmit infection. Infections with *S. moniliformis* arise in 1 of2 ways: (a) direct contact with infected animals, usually through a bite, or (b) ingestion of food or drink contaminated by rat urine, feces, or other secretions.[85] In both forms, patients have an acute flu-like infection characterized by a clinical triad of fever, polyarthralgias or arthritis, and rash. In 1926, an outbreak in Haverhill, Massachusetts, caused by consumption of milk tainted by rat excreta led to the designation *Haverhill fever* or *erythema arthriticum epidemicum*.

The other pathogen implicated in rat-bite fever is *Spirillum minus*, a Gram-negative spirochete. Spirillary rat-bite fever differs in its geographic distribution, incubation period, and milder arthritis. It occurs almost exclusively in East Asia. Its Japanese name is *sodoku*.[83]

Both diseases are most common where people live in crowded, unsanitary conditions ideal for rats. Although streptobacillary fever occurs worldwide, it is most common in Asia. Most U.S. cases occur in children with a new pet rat. Person-to-person transmission is unknown. Rat-bite fever is nonreportable so its exact incidence is not known.[86]

CLINICAL FINDINGS

HISTORY

Streptobacillary disease has an asymptomatic incubation period of 1 to 7 days, and, in rare cases, as long as 3 weeks. Often, the rat bite has healed by the time a flu-like illness begins with fever, chills, headache, stiff neck, nausea and vomiting, and myalgia. A rash begins to appear several days later. Spirillary rat-bite fever has an incubation period of longer than 14 days.

CUTANEOUS LESIONS

Approximately 75% of patients with streptobacillary fever develop a morbilliform eruption, usually 2 to 3 days after the fever. Individual lesions can be macular, morbilliform, or petechial. Lesions are most prominent on the palms, soles, and around joints but may become generalized, resembling measles.[86-88] There can be hemorrhagic acral vesicles, resembling lesions of leukocytoclastic vasculitis or gonococcemia.[89] Notably, when the rash appears, the rat bite has usually healed and only rarely shows evidence of infection, inflammation, or regional adenopathy. A week or so after resolution of the disease, the palms and soles have a characteristic desquamation that may resemble Kawasaki disease.

In contrast, the bite producing spirillary fever is usually tender, red, indurated, or ulcerated when the rash appears.[90] Cutaneous lesions are larger and are prominent on the abdomen, thus resembling the rose spots of typhoid. There can be tender regional lymphadenopathy and lymphangitis.[91]

RELATED PHYSICAL FINDINGS

Within a week of the febrile symptoms, arthritis usually develops, predominantly involving large joints. The arthritis may be an asymmetric polyarthritis resembling rheumatoid arthritis but is rarely suppurative. Regional lymphadenopathy may be present. Infection may involve the liver, kidneys, meninges, and heart valves.[84] Arthritis is uncommon in *S. minus* infection.[89]

LABORATORY FINDINGS

Gram stains of *S. moniliformis* shows Gram-negative filamentous branching chains, interspersed with bead-like swellings, hence the name *moniliformis,* meaning "necklace-shaped." The organisms, however, are pleomorphic in shape and staining qualities, possibly resembling Gram-positive rods.[84] If cultured properly, the organism can be recovered from blood, joint fluid, or palmar pustules. It is fastidious in culture; growth is inhibited by the sodium polyanethol sulfonate found

in most aerobic blood-culture bottles. It grows best on trypticase-soy broth or supplemented thioglycolate broth in which characteristic "puffball" colonies are seen. Anaerobic culture media, which lack the sulfonates, permits slow growth and should be held for several additional days. Histopathologic examination of purpuric lesions shows a lymphocytic vasculitis with focal intravascular thrombi.[88] In fulminant cases, filamentous organisms have been seen in silver-stained tissues.[86] Approximately one-third of patients have false-positive Venereal Disease Research Laboratory tests, but no specific serologic tests are currently available.

S. minus cannot be cultured in vitro. Darkfield microscopy may reveal characteristic spirochetes.

DIFFERENTIAL DIAGNOSIS

The diagnosis should be suspected in any person with unexplained fevers and recent rat exposure.[86] The triad of fever, arthritis, and acral rash, accompanied by a history of a recent rat bite, should raise suspicion. The differential diagnosis should also include other causes of fever, rash, and arthralgia, such as meningococcemia, disseminated gonococcemia, acute rheumatic fever, rheumatoid arthritis, endocarditis, Lyme disease, viral exanthems (eg, from coxsackievirus), ehrlichiosis and rickettsioses, leptospirosis, secondary syphilis, typhoid, and *P. multocida* infection.

Blood cultures are the best way to confirm the diagnosis of streptobacillary rat-bite fever. Several features help differentiate the 2 types of rat-bite fever. In *S. moniliformis* infection the incubation period is shorter (usually <10 days vs >14 days),[91] the bite site usually heals before systemic symptoms begin, the rash is more peripheral, and arthritis is more common (60% vs 20%).

TREATMENT

The treatment of choice for someone who becomes ill after a rat bite is amoxicillin-clavulanic acid. In patients allergic to penicillins, doxycycline is acceptable. Once *S. moniliformis* is identified, penicillin is the drug of choice. In general, rat bites should be cleansed promptly and thoroughly. Tetanus immunization status should be checked. Although there are no established guidelines, one might consider a prompt prophylactic course of penicillin or doxycycline after any rat bite.[85]

PROGNOSIS, CLINICAL COURSE, AND COMPLICATIONS

Untreated disease may last for a few days to several weeks and 10% to 20% are fatal, usually from endocarditis. If diagnosed early, appropriate antibiotics produce a prompt clinical response although migratory arthritis may persist after bacteriologic cure.

PREVENTION

To prevent rat-bite fever, dwellings should be rat proofed and open water supplies should be protected from contamination by rat excreta. Persons who handle rats should wear gloves, wash their hands frequently, and avoid hand-to-mouth contact when around rats. Children with pet rats should be taught these simple precautions.[87]

SEAL FINGER

AT-A-GLANCE

- Occupational zoonosis after contact with seals or sea lions. Occurs worldwide in marine environments.
- Usually presents as an exquisitely painful nodule on the distal phalanx of the finger that may progress to tenosynovitis or joint destruction.
- The pathogen is likely to be a marine *Mycoplasma* found in the seal's normal oropharyngeal flora. The infection responds quickly to tetracyclines.

ETIOLOGY AND EPIDEMIOLOGY

Seal finger is an occupational zoonosis that occurs only after direct contact with seals, sea lions, and similar marine mammals (order Pinnipedia), transmitted via bites or through open skin after handling seals or their carcasses. Seal finger is characterized by intensely painful red nodules, usually on the distal phalanx. Untreated, it can evolve into tenosynovitis, osteitis, and joint destruction.[92,93] Although this has not been fully confirmed, seal finger appears to be caused by a group of *Mycoplasma* that is part of the normal oropharyngeal flora of pinnipeds.[94]

CLINICAL FINDINGS

People at risk include hunters, zookeepers, and marine biologists. Seal finger is common in cold water coastal areas around Scandinavia, Greenland, Newfoundland, and similar environments in the Southern Hemisphere. Most cases occur during the spring sealing season. Incubation is usually approximately 4 days, rarely as long as 3 weeks. A furuncle-like lesion appears at the inoculation site, followed by severe pain, marked swelling, and stiffness.[92,93]

DIFFERENTIAL DIAGNOSIS

The differential diagnosis includes other pathogens transmitted in a cold marine environment. Erysipeloid is less painful, has a more violaceous hue, and usually extends beyond the original entry site. *M. marinum* infection is usually painless and indolent. Seal pox is an orthopoxvirus infection transmitted through contact with mouths of seals and other pinnipeds. Staphylococcal or streptococcal pyodermas may have a similar picture. Herpetic whitlow can also cause a painful distal phalanx. Culture should be attempted on special *Mycoplasma* media.

TREATMENT

Seal finger does not respond to the β-lactam antibiotics frequently prescribed presumptively for cellulitis caused by *Staphylococcus*, *Streptococcus*, or *Erysipelothrix*. The lack of response to β-lactams further suggests seal finger. Tetracyclines are the treatment of choice and must be continued for 4 to 6 weeks (see Table 156-1). Older accounts describe occasional sealers who amputated their own fingers to rid themselves of the excruciatingly painful digit.[95]

LISTERIOSIS (*LISTERIA MONOCYTOGENES* INFECTIONS)

AT-A-GLANCE

- Caused by anaerobic Gram-positive bacillus transmitted in fecal–oral manner through consumption of contaminated dairy products.
- Human listeriosis is most common in pregnant women, neonates, and patients with AIDS, and in foodborne outbreaks. May cause miscarriages, stillbirths, and virulent neonatal infections.
- Generalized petechiae, papules, or pustules may be seen in neonatal listeriosis, especially in meconium-stained newborns.

ETIOLOGY AND EPIDEMIOLOGY

Listeria monocytogenes is an anaerobic Gram-positive bacillus found widely in soil, water, vegetation, and the gut flora of humans and other animals. Exposure to this organism occurs through fecal–oral contamination, but the disease has an opportunistic nature, appearing in very young, very old, pregnant, and immunocompromised individuals. *L. monocytogenes* is found in the feces of many domestic and wild animals and birds, and is widespread in the environment.[96] Typically, livestock become infected by eating manure-contaminated silage; this can cause abortions, septicemia, and a peculiar form of encephalitis called *circling disease*.[97]

Human listeriosis is uncommon but occurs in 3 typical settings: (a) sporadic disease in pregnant women and neonates; (b) sporadic disease in AIDS patients; and (c) foodborne outbreaks.[98] Humans usually become infected by eating contaminated, unpasteurized, or improperly pasteurized dairy products. In adults, the disease can present as septicemia, meningitis, vaginal infection, pneumonitis, or oculoglandular syndrome, and can cause miscarriages and stillbirths.[70] Infantile listeriosis presents acutely with septicemia, meningitis and meningoencephalitis, and septic granulomatosis (granulomatosis infantiseptica).

Primary cutaneous listeriosis is rare and usually follows occupational exposure where there has been direct cutaneous inoculation from animal products of conception.[99] Typically, skin infections manifest as nonpainful, nonpruritic, self-limited, localized, papulopustular, or vesiculopustular eruptions in healthy persons. Less commonly, skin lesions may arise from hematogenous dissemination in compromised hosts with invasive disease.[100]

Approximately 5% of humans are fecal carriers of *Listeria*. Higher rates of carriage have been observed in family contacts of patients with listeriosis. Several outbreaks have implicated unpasteurized soft cheeses imported from Mexico or vegetables from farms that fertilize crops with manure.[101]

The highest incidence of human listeriosis is seen among infants in the perinatal period, which suggests that the transmission occurs in utero or at birth. One-fourth of adult cases occur in pregnant women. Many other adult cases occur in patients with altered cellular immunity, such as those with Hodgkin disease, leukemia, or AIDS, and in those who have undergone organ transplantation. Hepatic disorders, such as cirrhosis and iron overload, also predispose to infection. Recent reports suggest that biologic therapies that interfere with tumor necrosis factor activity, such as treating psoriatic arthritis with infliximab, may increase the risk for listeriosis.[102]

CLINICAL FINDINGS

HISTORY

Early-onset neonatal listeriosis develops in infants infected in utero by untreated bacteremic mothers shortly before labor begins. Findings are evident at birth or become apparent within the first few days. These neonates are acutely ill and have generalized pustular, papular, or petechial skin lesions. Late-onset neonatal listeriosis occurs several weeks after a healthy

birth, is presumably acquired postpartum, and usually presents as meningitis.[101,103,104]

Listeriosis from foodborne organisms usually causes outbreaks of acute gastroenteritis in families or communities. Patients have fever, vomiting, and nonbloody diarrhea, but this form lacks skin lesions.

CUTANEOUS LESIONS

In septic infants, cutaneous lesions appear as generalized petechiae, papules, or pustules. Veterinarians or farmers who handle infected bovine fetuses may develop an acute febrile illness with headache, malaise, and regional adenopathy. Tender red papules develop on exposed surfaces and may evolve into pustules over 2 to 3 days. These contain the characteristic Gram-positive rods.

RELATED PHYSICAL FINDINGS

Neonates with early-onset listeriosis are often meconium-stained at birth, lethargic, and have an enlarged liver and spleen. CNS listeriosis has a spectrum of neurologic manifestations, ranging from typical acute bacterial meningitis, abscesses, encephalitis, and infarcts.[104]

LABORATORY FINDINGS

L. monocytogenes is a small pleomorphic bacillus that often appears coccoid in infected tissues and body fluids. Pustules, meconium, cerebrospinal fluid, or blood cultures reveal the characteristic Gram-positive rods. The organism is β-hemolytic when cultured on sheep blood agar and exhibits a characteristic tumbling motility when grown in broth. In adults with meningitis, the cerebrospinal fluid contains neutrophils, but about one-third of meningitic infants have a mononuclear response.

HISTOPATHOLOGY

Skin lesions show focal necrosis, neutrophilic infiltrates, and monocytes around blood vessels. In septic patients, viscera may show abscesses and granulomas.

DIFFERENTIAL DIAGNOSIS

Neonatal listeriosis should be suspected in a meconium-stained newborn with intrauterine growth retardation who develops a papular skin eruption or subsequently failure to thrive. The differential diagnosis includes other in utero neonatal infections such as toxoplasmosis, cytomegalovirus infection, rubella, disseminated herpes simplex infection, and disseminated bacterial infections, such as those caused by group B streptococci, *Escherichia coli, Salmonella,* and *Pseudomonas*.

TREATMENT

Neonates with listeriosis should be treated with IV ampicillin (or penicillin) (see Table 156-1). Penicillin-allergic patients may be treated with cotrimoxazole or erythromycin. Cephalosporins are generally ineffective.[96] Primary cutaneous listeriosis appears to be self-limited in most cases, and the role for antibiotics is unclear, but nevertheless prudent to administer.[100]

PROGNOSIS, CLINICAL COURSE, AND COMPLICATIONS

In neonatal septicemia or meningitis, mortality is approximately 50%, even with treatment. In adults, prompt treatment is usually effective, unless there is a severe underlying debility. Pregnant women, even if treated, are at risk for miscarriage.

PREVENTION

Prepartum strategies to reduce neonatal group B streptococcal infections may also reduce risk of neonatal listeriosis.[104]

Farmers should not feed contaminated silage to livestock nor use untreated manure to fertilize crops. Still, it is almost impossible to guarantee *Listeria*-free foods. Therefore, people at greatest risk should avoid foods typically linked to listeriosis, such as raw (unpasteurized) dairy products, unwashed vegetables, and poorly cooked meats. Veterinarians and farmers should use gloves and protective garments when handling aborted fetuses or placentae.[103]

VIBRIO VULNIFICUS INFECTIONS

AT-A-GLANCE

- Noncholera *Vibrio* organisms are found in warm saltwater worldwide. Exposures occur via percutaneous injury, often minor (eg, while ocean fishing), or via ingestion of filter-feeding shellfish, which concentrate organisms.
- Severe illness presents with necrotizing fasciitis, hemorrhagic bullae, and hypotensive shock. Cirrhosis and other liver diseases predispose to a virulent, often fatal, course.

ETIOLOGY AND EPIDEMIOLOGY

Vibrio are facultatively anaerobic, pleomorphic, Gram-negative rods found in marine waters, estuaries, brackish lakes, and their sediments wherever the water temperature is above 20°C (68°F). The most well-known vibriosis is cholera, caused by antigenic strains of *Vibrio cholerae*. Although cholera organisms do not infect the skin, many other *Vibrio* do. The most important of these, *Vibrio vulnificus* can cause fulminant cellulitis, myositis, necrotizing fasciitis, and death.[105]

People become infected with *V. vulnificus* through oral or percutaneous exposure, which leads to 3 distinct clinical syndromes: gastroenteritis, primary sepsis (with or without secondary skin and soft-tissue infection), and primary wound infection.[106,107] After eating contaminated raw or undercooked seafood, people who have chronic liver disease (especially hemochromatosis), renal failure, diabetes mellitus, or who are otherwise immunocompromised, are at risk for primary septicemia. Percutaneous infections are acquired by handling raw seafood, by entering saltwater with an open wound, or by experiencing skin trauma while in or around saltwater. Immunocompromised individuals are again at increased risk for secondary septicemia.[108,109]

V. vulnificus lives in warm seawater, where it colonizes the skin of fish and is concentrated in filter-feeding shellfish, such as oysters. Infections are particularly common along the Gulf of Mexico and, because of global warming, are now found in increasingly higher latitudes, such as on the Baltic Sea.[110-112]

Most cases of wound infection are sporadic and depend more on host susceptibilities than environmental conditions. However, after Hurricane Katrina struck the Gulf Coast in 2005, thousands of people were exposed to brackish floodwaters. There were 18 known cases of *Vibrio* wound infections—14 caused by *V. vulnificus*, 3 caused by *Vibrio parahaemolyticus*, and 1 unspeciated case.[113] Each year in the United States, approximately 100 persons are infected with *V. vulnificus* with approximately 50% mortality.[107]

CLINICAL FINDINGS

HISTORY

There is nearly always a history of contact with saltwater, injury while ocean fishing, or consumption or handling of shellfish. After oral exposure, primary septicemia often begins with watery diarrhea, fever, chills, nausea, vomiting, and abdominal pain. People with wound infections usually recall an open skin lesion present before the saltwater exposure or a percutaneous injury during the exposure. *Vibrio* cellulitis is painful and has a rapid onset within 12 to 24 hours of exposure. Secondary bacteremia with sepsis may occur several days later.[114]

Figure 156-3 *Vibrio vulnificus* cellulitis with hemorrhagic plaque and bullae on the legs of an older diabetic patient with cirrhosis.

CUTANEOUS LESIONS

Infected wounds may present as pustules, lymphangitis, or cellulitis. These infections may be mild or may develop into rapidly progressive, painful cellulitis with extensive skin necrosis, myositis, and necrotizing fasciitis (Fig. 156-3). Secondary bacteremia may cause metastatic cutaneous lesions.[108,115] In septic patients, large hemorrhagic bullae commonly arise on the extremities or trunk and usually progress to necrotic ulcers and necrotizing fasciitis (see Table 156-1).

RELATED PHYSICAL FINDINGS

V. vulnificus septicemia causes high fever, tachycardia, and hypotension. One-third of patients develop Gram-negative septic shock.

LABORATORY FINDINGS

In primary septicemia, leukopenia is more common than leukocytosis. Thrombocytopenia is typical and may be part of disseminated intravascular coagulation. Usually, there is laboratory evidence for the person's predisposing condition (eg, diabetes). All *Vibrio* species can be grown in regular blood culture media and cause hemolysis on sheep blood agar, but only *V. vulnificus* ferments lactose on MacConkey agar. Histopathology shows noninflammatory bulla, epidermal necrosis, hemorrhage, and bacteria in dermal vessels. Radiographic studies show accumulations of nonspecific soft-tissue edema.

DIFFERENTIAL DIAGNOSIS

A cirrhotic or diabetic patient with fever, shock, and hemorrhagic bulla within several days of saltwater exposure or of eating raw oysters should alert the

physician to possible *Vibrio* septicemia, especially if the exposure occurred along the American Gulf Coast.

Similar presentations include disseminated intravascular coagulation, clostridial myonecrosis, meningococcemia, purpura fulminans, any form of necrotizing fasciitis, and other aggressive soft-tissue infections. Wound infections sustained in fresh water suggest infection with *Aeromonas* rather than *Vibrio*. Clostridial myonecrosis may present with necrotizing fasciitis and shock, but is further suggested by local wound crepitus and the finding of Gram-positive rods.

TREATMENT

Primary or secondary septicemia caused by *V. vulnificus* (or other *Vibrio* sp.) requires prompt management of hypotensive shock, parenteral administration of antibiotics, and vigorous debridement of necrotic lesions. Amputation of the affected limb may be necessary. The antibiotics of choice are a combination of doxycycline and ceftazidime (see Table 156-1). Alternatives to doxycycline include chloramphenicol, ciprofloxacin, and minocycline. Alternatives to ceftazidime include cefotaxime. Application of compresses with modified Dakin solution (0.025% sodium hypochlorite) may help arrest the progression of the cutaneous lesions.[116]

PROGNOSIS, CLINICAL COURSE, AND COMPLICATIONS

The mortality rate for *V. vulnificus* primary septicemia is approximately 50%, about 3 times higher than the mortality for wound infections caused by the same organism.

PREVENTION

People with cirrhosis, diabetes, AIDS, and other immunocompromising illnesses should not eat raw shellfish and, if they have open skin wounds, should not enter seawater, estuaries, or brackish lakes. If an at-risk individual exposes open skin to saltwater, the site should be cleansed promptly with soap and clean water. Similarly, these individuals should not handle raw fish and shellfish. Vigilant attention to onset of illness is then required. Some authorities consider of a course of prophylactic oral doxycycline for an immunocompromised person with a high-risk exposure. In 2003, California began to require special processing of raw Gulf oysters harvested from April 1 to October 31, to eliminate *V. vulnificus*, which has reduced the number oyster-associated *Vibrio* infections.[117]

OTHER CUTANEOUS *VIBRIO* INFECTIONS

The most common other *Vibrio* to cause wound infections are *V. parahaemolyticus* and nontoxigenic *V. cholerae* (ie, antigenic strains other than 01 and 139). Usually, these *Vibrio* cause an infection after oral exposure, producing an acute but self-limited noninflammatory gastroenteritis. Wound infections may occur after open skin is exposed to saltwater. The disease course is usually less severe than that of *V. vulnificus* although in an immunocompromised host, it may cause hemorrhagic bulla, shock, and necrotizing fasciitis.

AEROMONAS HYDROPHILA INFECTIONS

AT-A-GLANCE

- Caused by a facultatively anaerobic Gram-negative bacillus found in fresh and brackish water worldwide.
- Usually presents as cellulitis after exposure to fresh or brackish water but may cause necrotizing fasciitis or myonecrosis.
- Sepsis risk in cirrhotic and immunocompromised patients.

ETIOLOGY AND EPIDEMIOLOGY

Aeromonas hydrophila is a facultatively anaerobic, Gram-negative bacillus that causes opportunistic human infections. Except for the freshwater habitat of *Aeromonas*, its taxonomic, ecologic, and epidemiologic profiles resemble those of *Vibrio* sp. Aeromonads are found in fresh and brackish water worldwide and are natural pathogens of many aquatic animals, including fish, amphibians, and reptiles. Human *Aeromonas* infections are usually associated with exposure to contaminated fresh or brackish water. The organism is typically linked with gastroenteritis,[118] but in an increasing number of cases, it has been implicated in skin, soft tissue, and muscle infections, as well as in septicemic disease.[119,120] An increasing number of soft-tissue infections are associated with the medical use of leeches (*Hirudo medicinalis*).[121-123] Medical leeches harbor the bacterium as an obligatory endosymbiont that is essential for digestion of host erythrocytes.[124] Recent reports describe a generalized folliculitis acquired after exposure to presumably contaminated waters of hot tubs or children's inflatable swimming pools.[125,126]

Fish tanks, swimming pools, and tap water have been contaminated with these organisms, leading to

occasional small common-source outbreaks.[127] After the 2004 tsunami off the coast of Sumatra, approximately one-quarter of the isolates from hundreds of patients hospitalized after prolonged water exposure were from *Aeromonas* spp.[128] Other traumatic events, during occupational or recreational exposure to contaminated aquatic environments, are frequently associated with *Aeromonas* skin and soft-tissue infections.[119]

CLINICAL FINDINGS

HISTORY

The key historical feature is the contact of open skin with fresh or brackish water. In healthy individuals, *Aeromonas* infections may remain localized, but compromised hosts are at risk for severe soft-tissue and septicemic disease.[81,129]

CUTANEOUS LESIONS

The most common presentation is cellulitis associated with a laceration, often followed by abscess formation or spread to deeper subcutaneous tissues. Myonecrosis or necrotizing fasciitis may mimic clostridial gas gangrene in its rapid onset (1 to 2 days after exposure) and swift progression with severe pain, marked swelling, serosanguineous bullae, crepitation, and systemic toxicity. The exudate often has a foul or fishy odor. Occasionally, bacteremia produces ecthyma gangrenosum-like lesions.[81,130,131] The folliculitis associated with hot tubs clinically resembles *Pseudomonas*-induced hot tub folliculitis.[125]

RELATED PHYSICAL FINDINGS

Jaundice and other evidence of underlying disease may be present.

LABORATORY FINDINGS

Gram-stained aspirates from abscesses or bullae may contain Gram-negative bacilli. Wound cultures yield multiple microbes in more than 50% of cases, and specimens should be plated on both sheep blood agar and MacConkey agar. Blood cultures are rarely positive for the organism. A radiograph may detect gas in deeper soft tissues.

DIFFERENTIAL DIAGNOSIS

A history of open skin exposed to fresh or brackish water, followed by local cellulitis (often with gas formation), increasing pain, and foul discharge suggests *Aeromonas* infection. The differential diagnosis includes staphylococcal or streptococcal cellulitis (including *Streptococcus pyogenes* or *Streptococcus iniae*), clostridial myonecrosis, necrotizing fasciitis, and *V. vulnificus* infection.

PROGNOSIS AND CLINICAL COURSE

With extensive surgical intervention and appropriate antimicrobial therapy, patients improve rapidly. Prognosis is excellent except in immunocompromised individuals with bacteremia.

TREATMENT

Prompt surgical exploration and debridement are essential, guided radiographically, if possible. *A. hydrophila* produces β-lactamase and is resistant to first-generation penicillins and cephalosporins. Most isolates are susceptible to third-generation cephalosporins, fluoroquinolones, and aminoglycosides (but not streptomycin). *Aeromonas*, particularly in the developing world, are developing resistance to several antibiotics so it is essential to conduct antibiotic sensitivity tests.[120] Consideration must be given to the polymicrobial nature of these infections, so results of Gram-staining and culture should guide antimicrobial selection. Two other less-pathogenic species of *Aeromonas*, *Aeromonas caviae* and *Aeromonas sobria*, have similar antibiotic sensitivity profiles.[81,130]

There are no current recommendations for the treatment of pool water associated *Aeromonas* folliculitis. The case reports describe the condition in immunocompetent individuals who were treated with either topical gentamicin or oral fluoroquinolones.[125,126]

PREVENTION

Individuals who are immunocompromised or who have chronic liver disease should promptly clean any wounds or open skin that are exposed to fresh or brackish water. In addition, they should not undergo leech therapy.

Patients who do undergo leech therapy should consider antibiotic prophylaxis beforehand. *A. hydrophila* infection accounts for nearly all associated infectious complications. *Aeromonas* infections associated with medical leech therapy are often resistant to quinolone antibiotics.[124]

MELIOIDOSIS

AT-A-GLANCE

- Caused by *Burkholderia pseudomallei* (formerly *Pseudomonas pseudomallei*), a Gram-negative aerobic bacillus that lives as a saprophyte in freshwater and damp soil.
- Occurs in humans and animals, primarily in wet tropical areas such as Southeast Asia and

(Continued)

AT-A-GLANCE (*Continued*)

coastal northern Australia. People who develop melioidosis elsewhere usually had prior exposure in endemic areas.

- Rice farmers, particularly if compromised by diabetes mellitus or chronic renal disease, are most susceptible.
- The disease is acquired after exposure to contaminated soil or water, either directly via the skin or through inhalation of particulate soil or dust.
- Clinical presentation ranges from focal indolent cutaneous and subcutaneous abscesses to fulminant pneumonia with septicemia.
- On the CDC's Category B list of possible bioweapon agents.

ETIOLOGY AND EPIDEMIOLOGY

Melioidosis is caused by *Burkholderia pseudomallei* (formerly *Pseudomonas pseudomallei*), a motile, pleomorphic, Gram-negative aerobic bacillus. The organism is a natural saprophyte found in freshwater and damp soil in the humid tropics. Melioidosis infects humans, a variety of birds, and domestic and wild mammals in endemic areas, but animals are not regarded as reservoirs for human infection. Although sporadic cases occur pantropically, melioidosis has its greatest incidence in Southeast Asia, especially Singapore and northeastern Thailand, and in coastal areas of Australia's Northern Territory. Apart from rare laboratory-acquired infections, cases of melioidosis in the United States and Europe have occurred only in people previously exposed in endemic areas.[132,133]

Most cases of melioidosis are transmitted by exposure of open skin to contaminated soil or water. Cutaneous melioidosis can be a primary disease, in which infection was acquired via percutaneous inoculation and the principal manifestations of this disease appear in the skin.

In Thailand, melioidosis is most common in rice farmers and has a male-to-female ratio of 4:1, consistent with occupational exposure patterns. Serologic surveys in endemic areas of rural Thailand show that 5% to 20% of inhabitants have antibodies, suggesting prior, presumably asymptomatic, infections. The frequency of pulmonary disease suggests that melioidosis also may be acquired by inhalation of contaminated droplets, soil, or dust.[134,135] Individuals with diabetes mellitus, chronic renal disease, or alcoholic liver disease are at greater risk for infection and severe disease.

There is a marked seasonality in cases of melioidosis with peak incidence during rainy monsoon seasons. After the December 2004 tsunami, hundreds of thousands of people were exposed to flood waters and cases of severe postimmersion pneumonic melioidosis were reported throughout the region.[136-142]

During the Vietnam War, extensive immersion in rice paddies and similar conditions led to cases of melioidosis among American servicemen. Several cases were reported in Vietnam veterans whose disease appeared decades later, and the only plausible exposure was to rice paddies long before.[138]

Direct human-to-human transmission is rare. *B. pseudomallei* is infectious when aerosolized and is regarded as a Category B bioweapon for its potential use on livestock or humans. If an individual without characteristic travel or exposure history develops melioidosis, or if there is a cluster of cases, deliberate exposure may have occurred.[139]

B. pseudomallei is phylogenetically close to *B. mallei*, the cause of glanders, and the clinical presentations of both diseases are often similar. However, the organisms have different environmental niches and the diseases occur after different exposures.

CLINICAL FINDINGS

HISTORY

Melioidosis has 2 principal clinical presentations: (a) acute melioidosis with suppurative skin lesions, pneumonia, or septicemia; and (b) chronic melioidosis, the more common form of the disease, with involvement of the lungs, skin (subcutaneous abscesses and draining sinuses), bones, joints, liver, and spleen. Approximately 50% of cases involve the lungs, caused either by inhalation of pathogens or by bacteremia from a cutaneous exposure, although most patients have no obvious breaks in the skin. HIV infection does not appear to increase either the risk of acquiring the disease or its severity.[132,140]

The incubation period can be as brief as 2 or 3 days. Acute pneumonic melioidosis usually starts abruptly with fever, chills, cough, dyspnea, and chest pain. Acute septicemic melioidosis may also arise from a cutaneous focus. In 50% of patients, no source for the bacteremia can be identified, but many individuals have minor abrasions on their feet.[127]

Chronic melioidosis may follow acute disease, but more commonly starts as an indolent pulmonary infection or as a low-grade febrile illness with multiple subcutaneous abscesses. Recrudescence of latent infection years after exposure may be associated with a subsequent debility, presenting as persistent, unexplained fever.[143]

CUTANEOUS LESIONS

Approximately 15% to 20% of human melioidosis cases have cutaneous manifestations, which are largely nonspecific. The inoculation site of primary cutaneous melioidosis, seen primarily in children, is frequently an ulcer, occasionally with a purulent exudate.[144] Acute septicemia may follow minor cutaneous disease. Disseminated disease can produce multiple superficial pustules or, more rarely, ecthyma gangrenosum or necrotizing fasciitis. In chronic melioidosis, draining sinuses and subcutaneous abscesses, particularly of

the scalp, are common. In children, a common presentation is acute suppurative parotitis, usually unilateral, associated with parotid pain and fever.[132,133,141,142,144-146]

RELATED PHYSICAL FINDINGS

Acute pulmonary presentations range from bronchitis to acute pneumonia, lung abscess, or empyema. Septicemia can lead to jaundice, hepatosplenomegaly, miliary pulmonary disease, myocarditis, and severe gastroenteritis. Chronic pulmonary melioidosis resembles fibrocavitary tuberculosis or lung abscesses both clinically and radiologically. The disseminated form of chronic disease may extend over many months, causing septic arthritis, osteomyelitis, suppurative lymphadenopathy, and visceral abscesses.

LABORATORY FINDINGS

B. pseudomallei grows on ordinary agar but the addition of gentamicin prevents overgrowth by other bacteria. The laboratory should be alerted of possible melioidosis so that special media can be used.[147,148] Polymerase chain reaction tests are more rapid than culture.[149,150] On histopathologic examination, sharply circumscribed abscesses are found in many organs and in the subcutaneous tissues, often with a surrounding granulomatous response.

DIFFERENTIAL DIAGNOSIS

The disease is a great imitator and diagnosis requires confirmed identification of the organism. Acute melioidosis may mimic typhoid fever, staphylococcal pneumonia, disseminated fungal infections (particularly from *Penicillium marneffei* in Thailand), glanders, or septicemia.[151] Chronic melioidosis resembles pulmonary tuberculosis, nocardiosis, deep fungal infection, and bacterial lung abscess. Chronic skin infections and draining sinuses in individuals from endemic areas should raise the possibility of melioidosis, as should an acute suppurative parotitis in a child from an endemic area.[152]

The diagnosis is supported by a recent or remote history of travel to Southeast Asia or northern Australia in a patient with unexplained sepsis. The finding of bipolar-stained Gram-negative bacilli strengthens the diagnosis. Culture of the organism establishes the etiology. Rising antibody titers also confirm the diagnosis. The indirect hemagglutination assay is the most commonly used test in Southeast Asia because it is simple to perform and cheap.[149,150,153]

TREATMENT

Antibiotic susceptibility must be determined for each isolate. In Australia's Northern Territory, where melioidosis is relatively common, treatment consists of at least 2 weeks of IV antibiotics (usually ceftazidime and carbapenem). This should be followed by several months of high-dose oral therapy with an antibiotic such as trimethoprim-sulfamethoxazole[144] or amoxicillin-clavulanic acid (or longer in the case of osteomyelitis or multiple suppurative foci) to reduce the risk of relapse.[133,154] Abscesses should be drained surgically, but only after the patient is taking appropriate antibiotics to help prevent bacteremia.

PROGNOSIS, CLINICAL COURSE, AND COMPLICATIONS

In septicemic melioidosis accompanied by shock and dissemination to skin and viscera, mortality is approximately 50%. In localized cutaneous melioidosis without bacteremia, mortality is less than 9%.

PREVENTION

There are no vaccines against melioidosis. People with diabetes or chronic renal disease should avoid exposure to fresh water when in endemic areas, particularly if they have open skin wounds. After such exposures, the skin should be cleansed thoroughly but there are no data on antibiotic prophylaxis.

ERYSIPELOID

AT-A-GLANCE

- An occupational zoonosis is caused by *Erysipelothrix rhusiopathiae* and associated with percutaneous trauma while handling raw fish or poultry.
- Classic dermatologic presentation is localized nonsuppurative purple-red plaques on the dorsal hands. Rare chronic and bacteremic forms exist.

ETIOLOGY AND EPIDEMIOLOGY

Erysipeloid, an acute infection of traumatized skin caused by *Erysipelothrix rhusiopathiae* (formerly *Erysipelothrix insidiosa*), occurs most frequently in fishermen, butchers, kitchen workers, and others who handle raw fish, poultry (especially turkey), and meat products.[149,150,155-157] The disease is especially common in pigs, where it is known as swine erysipelas. In humans, erysipeloid occurs primarily during the

summer months and can be considered an occupational dermatosis.

E. rhusiopathiae is a thin, Gram-positive, microaerophilic, nonmotile bacillus that is hardy enough to survive putrefaction of tissue and exposure to saltwater or freshwater. The organism is found in rats, birds, the slime on saltwater fish, and crabs and other shellfish, and is associated with poultry, meats, hides, and bones.

In humans, organisms usually enter broken skin on the hands and takes 1 of the 4 clinical forms: (a) a local nonsuppurative cutaneous infection (erysipeloid of Rosenbach); (b) a diffuse chronic cutaneous form consisting of multiple plaques with sharply defined angular borders; (c) subacute bacterial endocarditis, particularly of the aortic valve; or (d) a bacteremic form without endocarditis, usually found only in immunocompromised patients. The disease does not seem to confer lasting immunity.[158]

CLINICAL FINDINGS

HISTORY

The patient is usually employed in the fishing or animal product industry. After inoculation, there is an incubation period of 2 to 7 days. Initially, burning pain occurs at the injured site, then a violaceous dermal plaque develops. Lymphangitis and regional adenopathy occasionally occur, as well as low-grade fever and malaise. Bacteremia and endocarditis are rare but serious sequelae. Untreated, erysipeloid usually heals on its own within 3 weeks.

CUTANEOUS LESIONS

The distinctive erysipeloid lesion is usually on a finger or the back of the hand; is violaceous, warm, and tender; and has well-defined, raised margins with an angular or polygonal border (Fig. 156-4). It often involves the web spaces but spares the terminal phalanges and does not progress beyond the wrist. The borders usually expand, whereas the central region clears without desquamation or ulceration. Rarely, multiple lesions distant from the original site of injury arise, presumably through bacteremic spread. Postinflammatory hyperpigmentation may persist after the lesion resolves.

RELATED PHYSICAL FINDINGS

Arthritis may be associated with the local lesion, and, in rare cases, distant joints are involved. Sepsis produces typical peripheral stigmata, including signs of endocarditis.[156]

LABORATORY FINDINGS

Gram stains rarely show *E. rhusiopathiae*, although culturing tissue from the advancing edge may reveal the organism. Growth occurs best on serum-fortified media between 30°C and 37°C (86°F and 98.6°F) under hypercapnic conditions. Agar-gel diffusion precipitation or fluorescent antibody techniques are helpful in establishing the diagnosis.[149,150]

Figure 156-4 Erysipeloid. Characteristically, the violaceous, sharply marginated lesion is composed of macules and plaques and is located on the hand.

HISTOPATHOLOGY

The findings are nonspecific but may include marked superficial dermal edema, vascular dilation, and mixed lymphocytic and neutrophilic perivascular infiltrates.

DIFFERENTIAL DIAGNOSIS

The character of the local lesion in a person handling fresh meat or fish products suggests the diagnosis. As its name suggests, erysipeloid resembles other forms of bacterial cellulitis or erysipelas. It may resemble a severe, acute irritant contact dermatitis. In erysipelas, the central area is most affected region compared with central clearing in erysipeloid. "Seal finger" may be mistaken for erysipeloid.

TREATMENT

The treatment of choice for erysipeloid is high-dose penicillin or ampicillin for 7 to 10 days. Patients who cannot take penicillins may be treated with a third-generation cephalosporin (such as ceftriaxone), imipenem, or ciprofloxacin (see Table 156-1). This

recommendation is based primarily on in vitro studies, not clinical experience. If arthritis, septicemia, or endocarditis is present, the penicillin dosage should be increased and the drug should be administered IV for several weeks.[156]

PROGNOSIS, CLINICAL COURSE, AND COMPLICATIONS

Untreated lesions usually last for 2 to 3 weeks but may have waxing-and-waning cycles over several months. Improvement is often dramatic and recurrence is rare if penicillin is administered. The prognosis in systemic infections depends on early and appropriate treatment. The bacteremic form occasionally leads to endocarditis with its attendant morbidity and mortality.

PREVENTION

Erysipeloid can be prevented by wearing gloves when handling live animals or animal products and by washing skin wounds promptly with soap and water.

STREPTOCOCCUS INIAE INFECTIONS

AT-A-GLANCE

- Caused by a recently recognized streptococcal species that colonizes or infects freshwater fish, such as tilapia, grown in intense aquaculture.
- Most human clinical cases present as cellulitis of the hand after an accidental puncture wound during preparation of live fish for cooking.
- Bacteremia commonly occurs.

ETIOLOGY AND EPIDEMIOLOGY

S. iniae is a recently recognized Gram-positive coccus that colonizes the skin of freshwater fish, particularly those raised in intense aquaculture.

It has been found in tilapia, hybrid bass, rainbow trout, coho salmon, and other species, and can cause fatal epizootics of piscine meningoencephalitis.[159] The species name derives from the Amazonian freshwater dolphin, *Inia geoffrensis*, from which it was first isolated. In dolphins, *S. iniae* causes slow-growing nodular abscesses of the skin and subcutaneous tissues, giving it the vernacular name "golf ball disease." The condition has been noted only in captive dolphins that presumably are exposed to *S. iniae* in the fish in their diets.[160]

In humans, *S. iniae* infection usually causes hand cellulitis after the handling of live freshwater fish, particularly farm-raised tilapia (*Tilapia* sp. and *Oreochromis* sp.). Most cases have been reported in cities in China and in Asian communities in North America, particularly Toronto, where the practice of buying live fish for home preparation, rather than buying fresh fish that have already been killed and cleaned, is common.[161] Because of these cultural practices, most people who develop *S. iniae* infection are elderly (average age: >65 years) individuals of East Asian descent. Furthermore, most have underlying medical conditions, such as diabetes mellitus or cirrhosis, that predispose them to infection.[162]

CLINICAL FINDINGS

HISTORY AND CUTANEOUS LESIONS

The key element in the history is the rapid onset of hand cellulitis within 1 to 3 days after the handling of live farm-raised fish. Ascending lymphangitis and fever are early features, but neither skin necrosis nor bullae occur.[163]

RELATED PHYSICAL FINDINGS

Bacteremia frequent complicates *S. iniae* cellulitis and may lead to septic arthritis, meningitis, osteomyelitis, and endocarditis.[163]

LABORATORY FINDINGS

Cellulitis with *S. iniae* is probably underdiagnosed because many practitioners treat hand cellulitis empirically as if it were caused by *Staphylococcus aureus* or *S. pyogenes.* Furthermore, confirmation by culture of *S. iniae* is difficult because the organism exhibits variable hemolysis and cannot be placed into a Lancefield group. In culture, it resembles *Streptococcus viridans*, *Streptococcus uberis*, and *Streptococcus dysgalactiae*.

DIFFERENTIAL DIAGNOSIS

As of this writing, all reported cases have followed the culinary handling of live freshwater fish, usually tilapia. The diagnosis should be considered in individuals who develop hand cellulitis after such exposure, with or without recognized percutaneous injury. Other common causes of cellulitis (*S. pyogenes, S. aureus*) as well as other freshwater and fishborne pathogens (*A. hydrophila* and *V. vulnificus*) should be considered.

PROGNOSIS AND TREATMENT

The infection will respond within 2 to 4 days to penicillin, the treatment of choice. The pathogen is also susceptible to cephalosporins, macrolides, quinolones, and vancomycin, but is resistant to tetracyclines. Treatment should be maintained for 10 days or longer if there are extracutaneous complications.[163]

PREVENTION

Aquaculture farms are becoming increasingly aware of *S. iniae* infections in their produce and have an economic incentive to maintain healthy fish. Nevertheless, cooks who prepare live-bought, aquaculture-raised fish will continue to be exposed to this pathogen.

CHROMOBACTERIUM VIOLACEUM INFECTIONS

Chromobacterium violaceum is a facultatively anaerobic, Gram-negative, motile, flagellated bacillus found as a saprophyte in tropical and subtropical freshwater and soil. It is rarely pathogenic except to people with disorders of neutrophil function, especially inherited chronic granulomatous disease, who have difficulty generating an adequate host response to catalase-producing organisms, such as *C. violaceum*. Infection occurs after open skin is exposed to a contaminated source, such as stagnant or muddy water. Nearly all U.S. cases have occurred in southeastern states during summer months. After exposure, cellulitis and fevers soon develop. Pustules and nodules may appear, followed by regional adenopathy. The organisms may disseminate hematogenously, causing ecthyma gangrenosum, visceral abscesses, abdominal pain, septic shock, and death. *C. violaceum* should be cultured on a tryptophan-supplemented medium, where it will produce water-insoluble, metallic-appearing, dark-purple colonies. It is often misidentified as a *Vibrio* or *Aeromonas* or regarded as a contaminant, which delays proper treatment, possibly leading to fatal consequences in immunodeficient patients who are vulnerable to this organism. Biopsy shows a necrotizing vasculitis, bacilli in the vessels, and minimal neutrophilic infiltrate.

Treatment consists of surgical drainage of cutaneous and visceral abscesses, along with several weeks of parenteral antibiotics. Limited data show that parenteral carbapenems, chloramphenicol with gentamicin, and fluoroquinolones are effective. A prolonged course of oral doxycycline or cotrimoxazole is necessary to reduce risk of relapse. Subsequent fevers or abdominal pain may indicate need for abdominal CT or ultrasonographs to screen for abscesses. Melioidosis has a similar epidemiology, occurring in people exposed to stagnant water in tropical and subtropical environments, skin and soft-tissue lesions, sepsis and visceral abscesses, with shock and death. Anyone with *C. violaceum* infection requires evaluation for immunodeficiency, particularly chronic granulomatous disease.[164]

LEPTOSPIROSIS

AT-A-GLANCE

- Waterborne zoonosis with worldwide distribution caused by serovars of *Leptospira interrogans*, which are excreted in urine of reservoir animals, especially rodents. Outbreaks during rainy seasons or after flooding in areas with poor sanitation.
- Most human cases are mild or subclinical. In severe cases there may be fever, hepatic and renal failure, jaundice, hemorrhage, and death.
- Cutaneous findings include jaundice, conjunctival suffusion, petechiae, and nonspecific papules.

ETIOLOGY AND EPIDEMIOLOGY

Leptospirosis is a waterborne zoonosis caused by *Leptospira interrogans*. The disease is found worldwide, except in the polar regions, wherever animal urine can contaminate bodies of freshwater. Rodents are the most important reservoirs, although more than 160 species of mammals are known to harbor *Leptospira*, including wild, farm, pet, and laboratory animals. Infected humans can also serve as transient reservoirs, particularly in urban slums in the wet tropics. Reservoir animals excrete leptospires in their urine, which contaminate the environment and can survive in water sources for months to years.[165] Humans generally acquire the disease through broken skin after direct contact with an infected animal or exposure to contaminated water or soil. People are infected less commonly through mucous membranes, ingestion of contaminated water, or inhalation of fomites.[166,167]

L. interrogans thrives in warm freshwater, so leptospirosis has its highest incidence in tropical areas, particularly those with inadequate sanitation and where people go barefoot. Leptospirosis is an important cause of undifferentiated fever in the developing world, along with dengue, malaria, and typhoid. Serologic surveys in some endemic regions suggest that more than 80% of people had prior infection.[168] The disease is most prevalent among children who play or swim in contaminated water and among adults with occupational exposures (eg, sugarcane workers or rice farmers) to infected animals or to contaminated soil and water. Travelers to hyperendemic areas, particularly ecotourists or adventure travelers who are exposed to contaminated water, are at increased risk.

Many outbreaks of leptospirosis have been reported after heavy rains and floods as they cause sewers to overflow.[169] Hawaii has the highest incidence in the United States.[167,169]

CLINICAL FINDINGS

HISTORY

Patients usually have had recent occupational or recreational contact with contaminated water or mud. Most human infections are asymptomatic, self-limited, and detectable only on serologic surveys. Ill patients have 1 of 2 clinical forms of the disease: (a) a mild anicteric form that resolves without complications, or (b) a severe, icteric form (Weil disease). Both forms typically have 2 phases: the acute bacteremic phase, followed by the delayed immune or convalescent phase. Incubation usually takes 5 to 14 days and then the leptospiremic phase begins suddenly with headache, fever, chills, nausea, vomiting, abdominal pain, and myalgia (particularly of the calves and thighs). This initial nonspecific phase continues for about a week, then defervescence occurs.[170]

After several relatively asymptomatic days, the second phase of illness begins with low-grade fever. In severe cases, rash, meningitis, uveitis, and hepatic and renal failure may develop.

CUTANEOUS LESIONS

In the first week of illness, the conjunctivae become suffused (red but not exudative). Skin lesions occur in fewer than 50% of cases. These consist of nonspecific macules, papules, urticaria, and petechiae, mostly on the trunk. Petechiae are a consequence of profound thrombocytopenia. Desquamation and infarcts have been observed on the hands or feet of some infected children. Weil disease has prominent hepatic (jaundice) and renal (hematuria, azotemia) components. Hemorrhages occur in a variety of organs, including the skin, and petechiae are common on the palate. A variant called *pretibial fever* or *Fort Bragg fever*, caused by *L. interrogans* serovariant *autumnalis*, has a distinctive rash that appears on the fourth or fifth day of illness, consisting of slightly raised, 1- to 5-cm, tender, erythematous papules on the shins. The rash subsides within 4 to 7 days.[171]

RELATED PHYSICAL FINDINGS

Most patients present with a fever of unknown origin without localizing signs. Other physical findings depend on the severity of the presentation, ranging nuchal rigidity in aseptic meningitis; or jaundice, hepatomegaly, and interstitial nephritis in Weil disease. Some patients have generalized hemorrhages with epistaxis, hematuria, and GI bleeding, and pretibial fever with splenomegaly.

LABORATORY FINDINGS

Laboratory tests help establish the diagnosis and the disease's severity. Direct isolation of leptospires is possible from the blood or cerebrospinal fluid during the acute phase or from urine during the convalescent phase. A recently developed serum dipstick assay rapidly detects antileptospire immunoglobulin M or immunoglobulin M antibodies. Thrombocytopenia is common but the white blood cell count is widely variable, reaching levels up to 40,000 cells/μL in Weil disease. A cerebrospinal fluid pleocytosis, with up to several hundred mononuclear cells, may be present. Liver function abnormalities and jaundice are common. Azotemia and hematuria occur in patients with renal involvement.[166]

TREATMENT

Public health authorities in endemic areas recommend starting antibiotic therapy early, perhaps presumptively, to reduce the risk of severe disease while laboratory confirmation is awaited. Doxycycline is effective and can be taken prophylactically for short-term exposure in a hyperendemic area. Penicillin also has been recommended, although controlled studies are lacking, and it may precipitate a Jarisch-Herxheimer reaction (see Table 156-1).

PROGNOSIS, CLINICAL COURSE, AND COMPLICATIONS

Perhaps 90% of patients have either asymptomatic or mild anicteric disease. Both forms resolve spontaneously without complications. In Weil disease, close attention must be given to fluid and renal status. Untreated Weil disease has a mortality rate of 5% to 40%, usually from renal failure, less often from cardiopulmonary failure or pulmonary hemorrhage. Late sequelae among survivors of untreated illness include neuropsychiatric diseases.[172]

PREVENTION

Water sanitation and rodent control measures will reduce the incidence of leptospirosis in a community. There is no vaccine against leptospirosis. Individuals who expect frequent contact with contaminated water or soils (eg, military personnel or adventure travelers) should consider protective clothing and other ways to limit exposures or they may decrease the risk of disease by taking prophylactic doxycycline 200 mg, once weekly during these periods.[166,170]

DIPHTHERIA

AT-A-GLANCE

- Classic diphtheria produces adherent gray membranous pharyngeal lesions, which may cause lethal airway obstruction. Exotoxin may cause latent peripheral neuritis or lethal cardiomyopathy.
- Cutaneous diphtheria usually affects the legs and begins as tender pustules that break down to punched-out ulcers covered by gray membranes. It is primarily found in the tropics or in travelers returning from these areas.
- Diphtheria can be prevented with toxoid immunization. It is treatable with antibiotics and antitoxin.

ETIOLOGY AND EPIDEMIOLOGY

Diphtheria is an acute febrile illness caused by *Corynebacterium diphtheriae* that in 90% of cases affects the pharynx and mucous membranes of the upper respiratory tract. The clinical manifestations of diphtheria are caused by (a) acute membranous obstruction of the airway, and (b) the tardive effects of a potent exotoxin on the myocardium and on cranial and peripheral nerves. The classic oropharyngeal lesion is a gray, leathery membrane along the tonsils and soft palate. Cutaneous diphtheria, which is far less common, can present either as a primary skin lesion or as a secondary infection of an existing break in the skin. Cutaneous diphtheria occurs most commonly in people living in or returning from tropical areas.[173,174]

Indeed, diphtheria is an underrecognized skin pathogen in travelers returning from endemic areas, and prior immunization may not prevent subsequent cutaneous infection.[174,175] Cutaneous lesions may appear after insect bites, and coinfection with other skin commensals is common, which can lead to an impetiginized appearance. Diphtheria should be in the differential in a returning traveler with a nonhealing ulcer.[176]

Although diphtheroids are widespread in nature, humans are the only natural host for *C. diphtheriae*, which colonizes the pharynx of asymptomatic individuals. Disease occurs when a nonimmune person, usually someone very young or very old, is infected by a toxigenic strain of *C. diphtheriae*. Epidemics occur when such strains become widespread among nonimmune individuals. Diphtheria has been largely controlled in Western nations by routine childhood immunization, which is directed against diphtheria's exotoxin, not against the bacteria itself.

With the decline of the public health system in the former Soviet states, epidemic diphtheria began there in the early 1990s, infecting more than 150,000 people and causing more than 5000 deaths. In the United States, diphtheria occurs mainly in marginalized populations (such as homeless people or migrant workers) who live in crowded, unhygienic conditions and lack periodic reimmunizations. Three outbreaks among in indigent alcoholics in Seattle between 1972 and 1982 involved more than 1000 cases, of which 86% were cutaneous.[177]

Because of the widespread use of toxoid immunization, the disease is rare in this country. It should be stressed, however, that this protection does not prevent the development of the carrier state and subsequent spread of organisms to susceptible nonimmunes.

CLINICAL FINDINGS

HISTORY

Classic diphtheria presents with pharyngitis and low-grade fever 2–5 days after exposure to a carrier or, much more rarely, to fomites. A thick or leathery grayish white membrane adheres to pharyngeal walls and tonsillar pillars, and usually spreads asymmetrically onto the soft palate and uvula. As the disease progresses, the patient's neck becomes painful and swollen. There is often a unilateral bloody nasal discharge. Patients appear to have a toxic process, and ensuing tracheal edema may obstruct the airway, causing lethal suffocation.

Cutaneous diphtheria typically affects the lower extremity, involves 1 or more sites, and may occur with or without concomitant pharyngeal disease. In roughly one-third of patients with cutaneous diphtheria, the same strain of *C. diphtheriae* can be recovered from the respiratory tract, which suggests inadvertent autoinoculation as the cause of the skin lesions.

CUTANEOUS LESIONS

There are 2 types of skin involvement. The first is primary cutaneous diphtheria, which starts acutely as a tender pustule and then breaks down to form an enlarging oval punched-out ulcer with a gray membrane at the base (see Table 156-1). Later, the membrane becomes dark brown, and the ulcer's border acquires edematous, rolled, bluish margins.[175,176]

Wound diphtheria is a secondary infection by *C. diphtheriae* of an existing break in the skin. This type accounts for almost all cases of cutaneous diphtheria reported in the United States. Preexisting skin lesions affected include those caused by abrasions, chronic dermatoses (eg, eczema or scabies), and common pyodermas already infected with *Staphylococcus* or *Streptococcus*. A painful ulcer is partly covered by a brownish-gray membrane, drains pus, and is surrounded by edema and erythema. In the outbreak in Seattle among indigent alcoholics, coinfection with *S. pyogenes* occurred in 73% of diphtheritic skin lesions.[177] *C. diphtheriae* has been recovered from

lesions resembling impetigo, ecthyma, and infected insect bites. Whether these are truly infected or merely colonized is not clear. Mucosa of the nose, conjunctivae, or vagina can exhibit membranous diphtheria, although these cases are quite rare.

RELATED PHYSICAL FINDINGS

The most important other manifestations of diphtheria are the toxin's effects on the heart and nerves. Myocarditis and conductive heart block may develop 1 to 2 weeks after onset, whereas cranial or peripheral neuropathies may develop 2 weeks to several months after the primary lesion. Neurologic manifestations include blurred vision, diplopia, numbness of the tongue, palatal paralysis, and peripheral motor and sensory neuropathies. A Guillain-Barré–like syndrome has been reported in 3% to 5% of patients with cutaneous diphtheria.

LABORATORY FINDINGS

C. diphtheriae can be isolated from either the skin ulcer or pharyngeal membrane. It is a Gram-positive, club-shaped rod that exhibits metachromatic bipolar granules on staining with methylene blue. The organism grows well on standard culture media, but other bacteria may obscure it. Therefore, selective media such as Löffler or tellurite agar should be used. The histopathologic features of cutaneous diphtheria are nondiagnostic, and the membrane is composed of coagulation necrosis and inflammatory cells. Not all strains of *C. diphtheriae* produce diphtheria toxin, so it is recommended that the pathogen be sent to a reference laboratory to determine the toxigenicity of the particular strain.

DIFFERENTIAL DIAGNOSIS

Cutaneous diphtheria may resemble deep streptococcal or staphylococcal ecthyma, tropical ulcer, Buruli ulcer, cutaneous anthrax, cutaneous tularemia, pyoderma gangrenosum, and other entities listed on Table 156-1. Tropical ulcer, also painful, usually extends into or below the fascia. Buruli ulcer is painless. Most bacterially infected ulcers do not develop membranous coverings. Cutaneous deep fungal infections (eg, coccidioidomycosis) usually have irregular hyperkeratotic borders and lack surrounding erythema.

Diphtheria should be suspected in a patient with membranous tonsillar pharyngitis with asymmetric extension onto the soft palate and uvula. In methylene blue–stained smears from the edge of the membrane, the characteristic beaded metachromatic rods can be seen, but confirmation requires culture and demonstration of toxin production. However, the presence of a classic pharyngeal membrane is sufficient evidence to begin immediate treatment for diphtheria. Pharyngitis caused by *Streptococci*, gonococci, infectious mononucleosis, primary syphilis, Vincent's angina, or candidiasis can resemble faucial diphtheria (or can complicate the diagnosis of diphtheria).[173,178]

TREATMENT

Pharyngotonsillar diphtheria requires treatment with antibiotics (to kill the bacteria) and antitoxin (to neutralize the exotoxin). Treatment should be started on clinical suspicion without awaiting culture confirmation, because toxin produced in the interim might damage the myocardium irreversibly.

Cutaneous diphtheria must be treated with antibiotics and antitoxin (see Table 156-1). The antibiotic of choice is high-dose IV penicillin or, for those unable to take penicillin, erythromycin. Diphtheria antitoxin, available from the CDC, is administered IV after careful testing for horse serum hypersensitivity. Injection of antitoxin subcutaneously around and under the ulcer, along with superficial application to the lesion, may be beneficial, but data are incomplete. After antitoxin and antibiotics are administered, the membrane should be debrided and the ulcer kept clean. Patients with either form of the disease should be isolated for roughly 14 days.

PROGNOSIS, CLINICAL COURSE, AND COMPLICATIONS

If treatment is started early, the prognosis is excellent. Pharyngeal cultures should be repeated 2 weeks after completing treatment. In untreated, unimmunized persons with cutaneous diphtheria, ulcers may persist for as long as 6 months. Myocarditis and heart block may lead to congestive heart failure. Neurologic signs may appear 5 weeks to 5 months after the onset of illness and almost always resolve. Diphtheria deaths are usually the result of acute airway obstruction.

PREVENTION

The disease is largely preventable through routine immunizations. Many adults are unaware that they should receive a dose of tetanus and diphtheria toxoid (called Td) every 10 years. If a case of cutaneous or pharyngeal diphtheria does occur, close contacts, even if asymptomatic, should undergo cultures of their oropharynx and nasopharynx and of any skin lesions. All contacts should receive antibiotic prophylaxis with oral erythromycin or penicillin (or a single IM injection of benzathine penicillin). In addition, contacts whose diphtheria immunization status is unclear or incomplete should be immunized with diphtheria toxoid. For children, 7 years of age and older, and adults, the adult

formulation of the combined Td preparation should be used rather than the pediatric diphtheria, pertussis, and tetanus (DPT) vaccine. Modern epidemics are controlled through mass immunizations.

OTHER CUTANEOUS DIPHTHEROID INFECTIONS

Corynebacterium ulcerans is a common commensal organism in cattle. Humans are rarely infected but can become ill after direct contact with cattle or by drinking raw milk. Pharyngeal disease is most common but cutaneous lesions, resembling those caused by *C. diphtheriae,* have been reported. Some strains of *C. ulcerans* produce the same diphtheria exotoxin, albeit in smaller quantities.[179] *Corynebacterium pseudotuberculosis,* which causes caseous lymphadenitis in ruminants, occasionally causes a similar necrotizing lymphadenitis in humans.

An organism closely related to corynebacteria, *Rhodococcus equi* (formerly *Corynebacterium equi*), causes pulmonary disease in AIDS patients. Rarely, this organism, which resembles *C. diphtheriae* on Gram-staining, can cause skin and soft-tissue infections in healthy individuals, especially those exposed to horse manure or after an injury contaminated with soil.

REFERENCES

1. Hart CA, Beeching NJ. A spotlight on anthrax. *Clin Dermatol.* 2002;20:365.
2. Anthrax. In: Heymann DL, ed. *Control of Communicable Diseases Manual.* 20th ed. Washington, DC: American Public Health Association; 2006:21.
3. Swartz MN. Recognition and management of anthrax—an update. *N Engl J Med.* 2001;345:1621.
4. Centers for Disease Control and Prevention (CDC). Gastrointestinal anthrax after an animal-hide drumming event—New Hampshire and Massachusetts, 2009. *MMWR Morb Mortal Wkly Rep.* 2010;59(28):872-877.
5. Centers for Disease Control and Prevention (CDC). Tularemia—Missouri, 2000-2007. *MMWR Morb Mortal Wkly Rep.* 2009;58(27):744-748.
6. Berger T, Kassirer M, Aran AA. Injectional anthrax—new presentation of an old disease. *Euro Surveill.* 2014;19(32).
7. Hicks CW, Sweeney DA, Cui X, et al. An overview of anthrax infection including the recently identified form of disease in injection drug users. *Intensive Care Med.* 2012;38(7):1092-1104.
8. Adalja AA, Toner E, Inglesby TV. Clinical management of potential bioterrorism-related conditions. *N Engl J Med.* 2015;372(10):954-962.
9. Woods CW, Ospanov K, Myrzabekov A, et al. Risk factors for human anthrax among contacts of anthrax-infected livestock in Kazakhstan. *Am J Trop Med Hyg.* 2004;71(1):48-52.
10. Shiferaw G. Anthrax in Wabessa village in the Dessie Zuria district of Ethiopia. *Rev Sci Tech.* 2004;23(3):951-956.
11. Ichhpujani RL, Rajagopal V, Bhattacharya D, et al. An outbreak of human anthrax in Mysore (India). *J Commun Dis.* 2004;36(3):199-204.
12. Thappa DM, Karthikeyan K. Anthrax: an overview within the Indian subcontinent. *Int J Dermatol.* 2001;40(3):216-222.
13. Karahocagil MK, Akdeniz N, Akdeniz H, et al. Cutaneous anthrax in Eastern Turkey: a review of 85 cases. *Clin Exp Dermatol.* 2008;33(4):406-411.
14. Ray TK, Hutin YJ, Murhekar MV. Cutaneous anthrax, West Bengal, India, 2007. *Emerg Infect Dis.* 2009;15(3):497-499.
15. Siamudaala VM, Bwalya JM, Munang'andu HM, et al. Ecology and epidemiology of anthrax in cattle and humans in Zambia. *Jpn J Vet Res.* 2006;54(1):15-23.
16. Nishi JS, Ellsworth TR, Lee N, et al. An outbreak of anthrax (*Bacillus anthracis*) in free-roaming bison in the Northwest Territories, June-July 2006. *Can Vet J.* 2007;48(1):37-38.
17. Clegg SB, Turnbull PC, Foggin CM, et al. Massive outbreak of anthrax in wildlife in the Malilangwe Wildlife Reserve, Zimbabwe. *Vet Rec.* 2007;160(4):113-118.
18. Mongoh MN, Dyer NW, Stoltenow CL, et al. Risk factors associated with anthrax outbreak in animals in North Dakota, 2005: a retrospective case-control study. *Public Health Rep.* 2008;123(3):352-359.
19. Friebe S, van der Goot FG, Bürgi J. The ins and outs of anthrax toxin. *Toxins (Basel).* 2016;8(3).
20. Caksen H, Arabaci F, Abuhandan M, et al. Cutaneous anthrax in eastern Turkey. *Cutis.* 2001;67(6):488-492.
21. Smego RA Jr, Gebrian B, Desmangels G. Cutaneous manifestations of anthrax in rural Haiti. *Clin Infect Dis.* 1998;26(1):97-102.
22. Maguiña C, Flores Del Pozo J, Terashima A, et al. Cutaneous anthrax in Lima, Peru: retrospective analysis of 71 cases, including four with a meningoencephalic complication. *Rev Inst Med Trop Sao Paulo.* 2005;47(1):25-30.
23. Demirdag K, Ozden M, Saral Y, et al. Cutaneous anthrax in adults: a review of 25 cases in the eastern Anatolian region of Turkey. *Infection.* 2003;31(5):327-330.
24. Irmak H, Buzgan T, Karahocagil MK, et al. Cutaneous manifestations of anthrax in Eastern Anatolia: a review of 39 cases. *Acta Med Okayama.* 2003;57(5):235-240.
25. Shieh WJ, Guarner J, Paddock C, et al. The critical role of pathology in the investigation of bioterrorism-related cutaneous anthrax. *Am J Pathol.* 2003;163(5):1901-1910.
26. Carucci JA, McGovern TW, Norton SA, et al. Cutaneous anthrax management algorithm. *J Am Acad Dermatol.* 2002;47(5):766-769.
27. Bartlett JG, Inglesby TV Jr, Borio L. Management of anthrax. *Clin Infect Dis.* 2002;35(7):851-858.
28. Faghihi G, Siadat AH. Cutaneous anthrax associated with facial palsy: case report and literature review. *J Dermatolog Treat.* 2003;14(1):51-53.
29. Wright JG, Quinn CP, Shadomy S, et al. Use of anthrax vaccine in the United States: recommendations of the Advisory Committee on Immunization Practices (ACIP), 2009. *MMWR Recomm Rep.* 2010;59(RR-6):1-30.
30. Şenel E, Satılmış Ö, Acar B. Dermatologic manifestations of tularemia: a study of 151 cases in the mid-Anatolian region of Turkey. *Int J Dermatol.* 2015;54(1):e33-e37.
31. Jacobs RF. Tularemia. *Adv Pediatr Infect Dis.* 1996;12:55-69.

32. Tularemia. In: Heymann DL, ed. *Control of Communicable Diseases Manual.* 18th ed. Washington DC: American Public Health Association; 2006:573.
33. Farlow J, Wagner DM, Dukerich M, et al. *Francisella tularensis* in the United States. *Emerg Infect Dis.* 2005;11(12):1835-1841.
34. Hayes EB. Tularemia. In: Goodman JL, Dennis DT, Sonenshine DE, eds. *Tick-Borne Diseases of Humans.* Washington, DC: ASM Press; 2005:207.
35. Eisen RJ, Mead PS, Meyer AM, et al. Ecoepidemiology of tularemia in the southcentral United States. *Am J Trop Med Hyg.* 2008;78(4):586-594.
36. Jounio U, Renko M, Uhari M. An outbreak of holarctica-type tularemia in pediatric patients. *Pediatr Infect Dis J.* 2010;29(2):160-162.
37. Cerný Z. Skin manifestations of tularemia. *Int J Dermatol.* 1994;33(7):468-470.
38. Maurin M, Gyuranecz M. Tularaemia: clinical aspects in Europe. *Lancet Infect Dis.* 2016;16(1):113-124.
39. Eliasson H, Bäck E. Tularaemia in an emergent area in Sweden: an analysis of 234 cases in five years. *Scand J Infect Dis.* 2007;39(10):880-889.
40. Kantardjiev T, Ivanov I, Velinov T, et al. Tularemia outbreak, Bulgaria, 1997-2005. *Emerg Infect Dis.* 2006; 12(4):678-680.
41. Feldman K, Enscore RE, Lathrop SL, et al. An outbreak of primary pneumonic tularemia on Martha's Vineyard. *N Engl J Med.* 2001;345(22):1601-1606.
42. Prentice MB, Rahalison L. Plague. *Lancet*. 2007; 369(9568):1196-1207.
43. Boisier P, Rahalison L, Rasolomaharo M, et al. Epidemiologic features of four successive annual outbreaks of bubonic plague in Mahajanga, Madagascar. *Emerg Infect Dis.* 2002;8(3):311-316.
44. Migliani R, Chanteau S, Rahalison L, et al. Epidemiological trends for human plague in Madagascar during the second half of the 20th century: a survey of 20,900 notified cases. *Trop Med Int Health.* 2006;11(8):1228-1237.
45. Stenseth NC, Atshabar BB, Begon M, et al. Plague: past, present, and future. *PLoS Med.* 2008;5(1):e3.
46. Foster CL, Mould K, Reynolds P, et al. Clinical problem-solving. Sick as a dog. *N Engl J Med.* 2015; 372(19):1845-1850.
47. Plague. In: Heymann DL, ed. *Control of Communicable Diseases Manual.* 18th ed. Washington, DC: American Public Health Association; 2006:406.
48. Centers for Disease Control and Prevention (CDC). Human plague–four states, 2006. *MMWR Morb Mortal Wkly Rep.* 2006;55(34):940-943. Accessed February 2, 2018.
49. Infectious Disease Epidemiology Section of the Louisiana Office of Public Health. Plague. Revised September 25, 2004. http://ldh.la.gov/assets/oph/Center-PHCH/Center-CH/infectious-epi/EpiManual/PlagueManual.pdf.
50. Butler T. Plague into the 21st century. *Clin Infect Dis.* 2009;49(5):736-742.
51. Chanteau S, Rahalison L, Ralafiarisoa L, et al. Development and testing of a rapid diagnostic test for bubonic and pneumonic plague. *Lancet.* 2003;361(9353):211-216.
52. Guarner J, Shieh WJ, Greer PW, et al. Immunohistochemical detection of *Yersinia pestis* in formalin-fixed, paraffin-embedded tissue. *Am J Clin Pathol.* 2002;117(2):205-209.
53. Koirala J. Plague: disease, management, and recognition of act of terrorism. *Infect Dis Clin North Am.* 2006;20(2):273-287.
54. Brucellosis. In: Heymann DL, ed. *Control of Communicable Diseases Manual.* 18th ed. Washington, DC: American Public Health Association; 2006:82.
55. Pappas G, Akritidis N, Bosilkovski M, et al. Brucellosis. *N Engl J Med.* 2005;352(22):2325-2336.
56. Pappas G, Papadimitriou P, Akritidis N, et al. The new global map of human brucellosis. *Lancet Infect Dis.* 2006;6(2):91-99.
57. Al-Nassir W. Brucellosis. Medscape website. https://emedicine.medscape.com/article/213430-overview. Updated June 16, 2017. Accessed February 2, 2018.
58. Franco MP, Mulder M, Gilman RH, et al. Human brucellosis. *Lancet Infect Dis.* 2007;7(12):775-786.
59. Metin A, Akdeniz H, Buzgan T, Delice I. Cutaneous findings encountered in brucellosis and review of the literature. *Int J Dermatol.* 2001;40(7):434-438.
60. Milionis H, Christou L, Elisaf M. Cutaneous manifestations in brucellosis: case report and review of the literature. *Infection.* 2000;28(2):124-126.
61. Nagore E, Sánchez-Motilla JM, Navarro V, et al. Leukocytoclastic vasculitis as a cutaneous manifestation of systemic infection caused by *Brucella melitensis*. *Cutis.* 1999;63(1):25-27.
62. Perez C, Hernandez R, Murie M, et al. Relapsing leucocytoclastic vasculitis as the initial manifestation of acute brucellosis. *Br J Dermatol.* 1999;140(6):1177-1178.
63. Mazokopakis E, Christias E, Kofteridis D. Acute brucellosis presenting with erythema nodosum. *Eur J Epidemiol.* 2003;18(9):913-915.
64. Akcali C, Savas L, Baba M, et al. Cutaneous manifestations in brucellosis: a prospective study. *Adv Ther.* 2007;24(4):706-711.
65. Ashford DA, di Pietra J, Lingappa J, et al. Adverse events in humans associated with accidental exposure to the livestock brucellosis vaccine RB51. *Vaccine.* 2004;22(25-26):3435-3439.
66. Larsen JC, Johnson NH. Pathogenesis of *Burkholderia pseudomallei* and *Burkholderia mallei*. *Mil Med.* 2009; 174(6):647-651.
67. Rega PP. CBRNE–Glanders and melioidosis. Medscape website. https://emedicine.medscape.com/article/830235-overview. Updated August 16, 2015. Accessed February 2, 2018.
68. Centers for Disease Control and Prevention (CDC). Glanders. https://www.cdc.gov/glanders/index.htm. Updated October 31, 2017. Accessed February 2, 2018.
69. Dvorak GD, Spickler AR. Glanders. *J Am Vet Med Assoc.* 2008;233(4):570-577.
70. Srinivasan A, Kraus CN, DeShazer D, et al. Glanders in a military research microbiologist. *N Engl J Med.* 2001;345(4):256-258.
71. Centers for Disease Control and Prevention (CDC). Laboratory-acquired human glanders–Maryland, May 2000. *MMWR Morb Mortal Wkly Rep.* 2000;49(24): 532-535.
72. Bossi P, Tegnell A, Baka A, et al. Bichat guidelines for the clinical management of glanders and melioidosis and bioterrorism-related glanders and melioidosis. *Euro Surveill.* 2004;9(12):E17-E18.
73. Godey B, Morandi X, Bourdinière J, et al. Beware of dogs licking ears. *Lancet.* 1999;354(9186):1267-1268.
74. Arons MS, Fernando L, Polayes IM. *Pasteurella multocida*–the major cause of hand infections following domestic animal bites. *J Hand Surg Am.* 1982; 7(1):47-52.
75. Hara H, Ochiai T, Morishima T, et al. *Pasteurella canis* osteomyelitis and cutaneous abscess after a domestic dog bite. *J Am Acad Dermatol.* 2002;46(5)(suppl):S151-S152.

76. Matsui T, Kayashima K, Kito M, et al. Three cases of Pasteurella multocida skin infection from pet cats. *J Dermatol.* 1996;23(7):502-504.
77. Talan DA, Citron DM, Abrahamian FM, et al. Bacteriologic analysis of infected dog and cat bites. *N Engl J Med.* 1999;340(2):85-92.
78. Talan DA, Abrahamian FM, Moran GJ, et al. Clinical presentation and bacteriologic analysis of infected human bites in patients presenting to emergency departments. *Clin Infect Dis.* 2003;37(11):1481-1489.
79. Migliore E, Serraino C, Brignone C, et al. Pasteurella multocida infection in a cirrhotic patient: case report, microbiological aspects and a review of literature. *Adv Med Sci.* 2009;54(1):109-112.
80. Nakwan N, Nakwan N, Atta T, et al. Neonatal pasteurellosis: a review of reported cases. *Arch Dis Child Fetal Neonatal Ed.* 2009;94(5):F373-F376.
81. Vinh DC, Embil JM. Severe skin and soft tissue infections and associated critical illness. *Curr Infect Dis Rep.* 2006;8(5):375-383.
82. Presutti RJ. Prevention and treatment of dog bites. *Am Fam Physician.* 2001;63(8):1567-1572.
83. Rat-bite fever. In: Heymann DL, ed. *Control of Communicable Diseases Manual.* 18th ed. Washington, DC: American Public Health Association; 2006:448.
84. Tandon R, Lee M, Curran E, et al. A 26-year-old woman with a rash on her extremities. *Clin Infect Dis.* 2006;43(12):1585-1586, 1616-1617.
85. Centers for Disease Control and Prevention (CDC). Fatal rat-bite fever–Florida and Washington, 2003. *MMWR Morb Mortal Wkly Rep.* 2005;53(51):1198-1202.
86. Ojukwu IC, Christy C. Rat-bite fever in children: case report and review. *Scand J Infect Dis.* 2002;34(6):474-477.
87. Freels LK, Elliott SP. Rat bite fever: Three case reports and a literature review. *Clin Pediatr (Phila).* 2004;43(3):291-295.
88. Andre JM, Freydiere AM, Benito Y, et al. Rat bite fever caused by *Streptobacillus moniliformis* in a child: human infection and rat carriage diagnosed by PCR. *J Clin Pathol.* 2005;58(11):1215-1216.
89. Elliott SP. Rat bite fever and *Streptobacillus moniliformis*. *Clin Microbiol Rev.* 2007;20(1):13-22.
90. Schachter ME, Wilcox L, Rau N, et al. Rat-bite fever, Canada. *Emerg Infect Dis.* 2006;12(8):1301-1302.
91. Gaastra W, Boot R, Ho HT, et al. Rat bite fever. *Vet Microbiol.* 2009;133(3):211-228.
92. White CP, Jewer DD. Seal finger: a case report and review of the literature. *Can J Plast Surg.* 2009;17(4): 133-135.
93. Kouliev T, Cui V. Treatment and prevention of infection following bites of the Antarctic fur seal (*Arctocephalus gazella*). *Open Access Emerg Med.* 2015;7:17-20.
94. Westley BP, Horazdovsky RD, Michaels DL, et al. Identification of a novel Mycoplasma species in a patient with septic arthritis of the hip and seal finger. *Clin Infect Dis.* 2016 15;62(4):491-493.
95. Hartley JW, Pitcher D. Seal finger—tetracycline is first line. *J Infect.* 2002;45(2):71-75.
96. Allerberger F, Wagner M. Listeriosis: a resurgent foodborne infection. *Clin Microbiol Infect.* 2010;16(1): 16-23.
97. Listeriosis. In: Heymann DL, ed. *Control of Communicable Diseases Manual.* 18th ed. Washington, DC: American Public Health Association; 2006:338.
98. Aureli P, Fiorucci GC, Caroli D, et al. An outbreak of febrile gastroenteritis associated with corn contaminated by *Listeria monocytogenes*. *N Engl J Med.* 2000;342(17):1236-1241.
99. Zelenik K, Avberšek J, Pate M, et al. Cutaneous listeriosis in a veterinarian with the evidence of zoonotic transmission—a case report. *Zoonoses Public Health.* 2014;61(4):238-241.
100. Godshall CE, Suh G, Lorber B. Cutaneous listeriosis. *J Clin Microbiol.* 2013;51(11):3591-3596.
101. Weinstein KB. *Listeria monocytogenes* Infection (Listeriosis). Medscape website. https://emedicine.medscape.com/article/220684-overview. Updated December 1, 2017. Accessed February 2, 2018.
102. Kelesidis T, Salhotra A, Fleisher J, et al. *Listeria endocarditis* in a patient with psoriatic arthritis on infliximab: are biologic agents as treatment for inflammatory arthritis increasing the incidence of *Listeria* infections? *J Infect.* 2010;60(5):386-396.
103. Lambotte O, Fihman V, Poyart C, et al. *Listeria monocytogenes* skin infection with cerebritis and haemophagocytosis syndrome in a bone marrow transplant recipient. *J Infect.* 2005;50(4):356-358.
104. Posfay-Barbe KM, Wald ER. Listeriosis. *Semin Fetal Neonatal Med.* 2009;14(4):228-233.
105. Cholera and other vibrioses. In: Heymann DL, ed. *Control of Communicable Diseases Manual.* 18th ed. Washington, DC: American Public Health Association; 2006:125.
106. Horseman MA, Surani S. A comprehensive review of *Vibrio vulnificus*: an important cause of severe sepsis and skin and soft-tissue infection. *Int J Infect Dis.* 2011;15(3):e157-e166.
107. Daniels NA. *Vibrio vulnificus* oysters: pearls and perils. *Clin Infect Dis.* 2011;52(6):788-792.
108. Ulusarac O, Carter E. Varied clinical presentations of *Vibrio vulnificus* infections: a report of four unusual cases and review of the literature. *South Med J.* 2004;97(2):163-168.
109. Patel VJ, Gardner E, Burton CS. *Vibrio vulnificus* septicemia and leg ulcer. *J Am Acad Dermatol.* 2002;46(5) (suppl):S144-S145.
110. Kuhnt-Lenz K, Krengel S, Fetscher S, et al. Sepsis with bullous necrotizing skin lesions due to *Vibrio vulnificus* acquired through recreational activities in the Baltic Sea. *Eur J Clin Microbiol Infect Dis.* 2004;23(1):49-52.
111. Frank C, Littman M, Alpers K, et al. *Vibrio vulnificus* wound infections after contact with the Baltic Sea, Germany. *Euro Surveill.* 2006;11(8):E060817.1.
112. Andersson Y, Ekdahl K. Wound infections due to *Vibrio cholerae* in Sweden after swimming in the Baltic Sea, summer 2006. *Euro Surveill.* 2006;11(8):E060803.2.
113. Centers for Disease Control and Prevention (CDC). *Vibrio* illnesses after Hurricane Katrina—multiple states, August-September 2005. *MMWR Morb Mortal Wkly Rep.* 2005;54(37):928-931.
114. Said R, Volpin G, Grimberg B, et al. Hand infections due to non-cholera *Vibrio* after injuries from St Peter's fish (*Tilapia zillii*). *J Hand Surg Br.* 1998;23(6):808-810.
115. Calif E, Shalom S. Hand infections caused by delayed inoculation of *Vibrio vulnificus*: does human skin serve as a potential reservoir of vibrios? *Hand Surg.* 2004;9(1):39-44.
116. Wilhelmi BJ, Calianos TA 2nd, Appelt EA, et al. Modified Dakin's solution for cutaneous vibrio infections. *Ann Plast Surg.* 1999;43(4):386-389.
117. Vugia DJ, Tabnak F, Newton AE, et al. Impact of 2003 state regulation on raw oyster-associated *Vibrio vulnificus* illnesses and deaths, California, USA. *Emerg Infect Dis.* 2013;19(8):1276-1280.

118. Ashdown LR, Koehler JM. The spectrum of *Aeromonas*-associated diarrhea in tropical Queensland, Australia. *Southeast Asian J Trop Med Public Health.* 1993;24(2): 347-353.
119. Janda JM, Abbott SL. The genus *Aeromonas*: taxonomy, pathogenicity, and infection. *Clin Microbiol Rev.* 2010;23(1):35-73.
120. Ghenghesh KS, Ahmed SF, El-Khalek RA, et al. *Aeromonas*-associated infections in developing countries. *J Infect Dev Ctries.* 2008;2(2):81-98.
121. Papadakis V, Poniros N, Katsibardi K, et al. Fulminant *Aeromonas hydrophila* infection during acute lymphoblastic leukemia treatment. *J Microbiol Immunol Infect.* 2012;45(2):154-157.
122. Haycox CL, Odland PB, Coltrera MD, et al. Indications and complications of medicinal leech therapy. *J Am Acad Dermatol.* 1995;33(6):1053-1055.
123. Ouderkirk JP, Bekhor D, Turett GS, et al. *Aeromonas* meningitis complicating medicinal leech therapy. *Clin Infect Dis.* 2004;38(4):e36-e37.
124. Giltner CL, Bobenchik AM, Uslan DZ, et al. Ciprofloxacin-resistant *Aeromonas hydrophila* cellulitis following leech therapy. *J Clin Microbiol.* 2013;51(4):1324-1326.
125. Julià Manresa M, Vicente Villa A, Gené Giralt A, et al. *Aeromonas hydrophila* folliculitis associated with an inflatable swimming pool: mimicking *Pseudomonas aeruginosa* infection. *Pediatr Dermatol.* 2009;26(5): 601-603.
126. Mulholland A, Yong-Gee S. A possible new cause of spa bath folliculitis: *Aeromonas hydrophila*. *Australas J Dermatol.* 2008;49(1):39-41.
127. Peacock SJ. Melioidosis. *Curr Opin Infect Dis.* 2006; 19(5):421-428.
128. Kespechara K, Koysombat T, Pakamol S, et al. Infecting organisms in victims from the tsunami disaster: experiences from Bangkok Phuket Hospital, Thailand, *International Journal of Disaster Medicine*, 2005;3:1-4, 66-70. doi: 10.1080/1503143060069424.
129. Gold WL, Salit IE. *Aeromonas hydrophila* infections of skin and soft tissue: report of 11 cases and review. *Clin Infect Dis.* 1993;16(1):69-74.
130. Skoll PJ, Hudson DA, Simpson JA. *Aeromonas hydrophila* in burn patients. *Burns.* 1998;24(4):350-353.
131. Kelly KA, Koehler JM, Ashdown LR. Spectrum of extraintestinal disease due to *Aeromonas* species in tropical Queensland, Australia. *Clin Infect Dis.* 1993;16(4):574-579.
132. Cheng AC, Currie BJ. Melioidosis: epidemiology, pathophysiology, and management. *Clin Microbiol Rev.* 2005;18(2):383-416.
133. White NJ. Melioidosis. *Lancet.* 2003;361(9370): 1715-1722.
134. Maharjan B, Chantratita N, Vesaratchavest M, et al. Recurrent melioidosis in patients in northeast Thailand is frequently due to reinfection rather than relapse. *J Clin Microbiol.* 2005;43(12):6032-6034.
135. Currie BJ, Fisher DA, Anstey NM, et al. Melioidosis: acute and chronic disease, relapse and re-activation. *Trans R Soc Trop Med Hyg.* 2000;94(3):301-304.
136. Cheng AC, Jacups SP, Gal D, et al. Extreme weather events and environmental contamination are associated with case-clusters of melioidosis in the Northern Territory of Australia. *Int J Epidemiol.* 2006;35(2):323-329.
137. Currie BJ, Jacups SP. Intensity of rainfall and severity of melioidosis, Australia. *Emerg Infect Dis.* 2003; 9(12):1538-1542.
138. Ngauy V, Lemeshev Y, Sadkowski L, et al. Cutaneous melioidosis in a man who was taken as a prisoner of war by the Japanese during World War II. *J Clin Microbiol.* 2005;43(2):970-972.
139. Melioidosis. In: Heymann DL, ed. *Control of Communicable Diseases Manual.* 18th ed. Washington, DC: American Public Health Association; 2006:386.
140. Limmathurotsakul D, Chaowagul W, Chierakul W, et al. Risk factors for recurrent melioidosis in northeast Thailand. *Clin Infect Dis.* 2006;43(8):979-986.
141. Thng TG, Seow CS, Tan HH, et al. A case of nonfatal cutaneous melioidosis. *Cutis.* 2003(4);72:310-312.
142. Torrens JK, McWhinney PH, Tompkins DS. A deadly thorn: a case of imported melioidosis. *Lancet.* 1999; 353(9157):1016.
143. Currie BJ, Jacups SP, Cheng AC, et al. Melioidosis epidemiology and risk factors from a prospective whole-population study in northern Australia. *Trop Med Int Health.* 2004;9(11):1167-1174.
144. Gibney KB, Cheng AC, Currie BJ. Cutaneous melioidosis in the tropical top end of Australia: a prospective study and review of the literature. *Clin Infect Dis.* 2008;47(5):603-609.
145. Tran D, Tan HH. Cutaneous melioidosis. *Clin Exp Dermatol.* 2002;27(4):280-282.
146. Wang YS, Wong CH, Kurup A. Cutaneous melioidosis and necrotizing fasciitis caused by *Burkholderia*. *Emerg Infect Dis.* 2003;9(11):1484-1485.
147. Peacock SJ, Chieng G, Cheng AC, et al. Comparison of Ashdown's medium, *Burkholderia cepacia* medium, and *Burkholderia pseudomallei* selective agar for clinical isolation of *Burkholderia pseudomallei*. *J Clin Microbiol.* 2005;43(10):5359-5361.
148. Ulrich RL, Ulrich MP, Schell MA, et al. Development of a polymerase chain reaction assay for the specific identification of *Burkholderia mallei* and differentiation from *Burkholderia pseudomallei* and other closely related Burkholderiaceae. *Diagn Microbiol Infect Dis.* 2006;55(1):37-45.
149. Dunbar SA, Clarridge JE III. Potential errors in recognition of *Erysipelothrix rhusiopathiae*. *J Clin Microbiol.* 2000;38(3):1302-1304.
150. Brooke CJ, Riley TV. *Erysipelothrix rhusiopathiae*: bacteriology, epidemiology and clinical manifestations of an occupational pathogen. *J Med Microbiol.* 1999;48(9):789-799.
151. Kingsley PV, Arunkumar G, Tipre M, et al. Pitfalls and optimal approaches to diagnose melioidosis. *Asian Pac J Trop Med.* 2016;9(6):515-524.
152. Currie BJ, Fisher DA, Howard DM, et al. Endemic melioidosis in tropical northern Australia: A 10-year prospective study and review of the literature. *Clin Infect Dis.* 2000;31(4):981-986.
153. Athan E, Allworth AM, Engler C, et al. Melioidosis in tsunami survivors. *Emerg Infect Dis.* 2005;11(10): 1638-1639.
154. Cheng AC, Fisher DA, Anstey NM, et al. Outcomes of patients with melioidosis treated with meropenem. *Antimicrob Agents Chemother.* 2004;48(5): 1763-1765.
155. Barnett JH, Estes SA, Wirman JA, et al. Erysipeloid. *J Am Acad Dermatol.* 1983;9(1):116-123.
156. Gorby GL, Peacock JE Jr. *Erysipelothrix rhusiopathiae* endocarditis: microbiologic, epidemiologic, and clinical features of an occupational disease. *Rev Infect Dis.* 1988;10(2):317-325.
157. Facklam R, Elliott J, Shewmaker L, et al. Identification and characterization of sporadic isolates of *Streptococcus iniae* isolated from humans. *J Clin Microbiol.* 2005;43(2):933-937.

158. Bonar CJ, Wagner RA. A third report of golf ball disease in an Amazon River dolphin (*Inia geoffrensis*) associated with *Streptococcus iniae*. *J Zoo Wildl Med.* 2003;34(3):296-301.
159. de Siqueira IC, Dias J, Ruf H, et al. *Chromobacterium violaceum* in siblings, Brazil. *Emerg Infect Dis.* 2005;11(9):1443-1445.
160. Sirinavin S, Techasaensiri C, Benjaponpitak S, et al. Invasive *Chromobacterium violaceum* infection in children: case report and review. *Pediatr Infect Dis J.* 2005;24(6):559-561.
161. Lau SK, Woo PC, Tse H, et al. Invasive *Streptococcus iniae* infections outside North America. *J Clin Microbiol.* 2003;41(3):1004-1009.
162. Baiano JC, Barnes AC. Towards control of *Streptococcus iniae*. *Emerg Infect Dis.* 2009;15(12):1891-1896.
163. Weinstein MR, Litt M, Kertesz DA, et al. Invasive infectious due to a fish pathogen, *Streptococcus iniae*. *N Engl J Med.* 1997;337(9):589-594.
164. Brown KL, Stein A, Morrell DS. Ecthyma gangrenosum and septic shock syndrome secondary to *Chromobacterium violaceum*. *J Am Acad Dermatol.* 2006;54(5)(suppl):S224-S228.
165. Puca E, Pilaca A, Kalo T, et al. Ocular and cutaneous manifestation of leptospirosis acquired in Albania: a retrospective analysis with implications for travel medicine. *Travel Med Infect Dis.* 2016;14(2):143-147.
166. Leptospirosis. In: Heymann DL, ed. *Control of Communicable Diseases Manual.* 18th ed. Washington, DC: American Public Health Association; 2006:384.
167. Katz AR, Ansdell VE, Effler PV, et al. Leptospirosis in Hawaii, 1974-1998: epidemiologic analysis of 353 laboratory-confirmed cases. *Am J Trop Med Hyg.* 2002;66(1):61-70.
168. Haake DA. Molecular epidemiology of leptospirosis in the Amazon. *PLoS Med.* 2006;3(8):e302.
169. Centers for Disease Control and Prevention (CDC). Brief report: leptospirosis after flooding of a university campus—Hawaii, 2004. *MMWR Morb Mortal Wkly Rep.* 2006;55(5):125-127.
170. Phraisuwan P, Whitney EA, Tharmaphornpilas P, et al. Leptospirosis: skin wounds and control strategies, Thailand, 1999. *Emerg Infect Dis.* 2002;8(12):1455-1459.
171. Gompf SG. Leptospirosis. Medscape website. https://emedicine.medscape.com/article/220563-overview. Updated June 13, 2018. Accessed February 2, 2018.
172. Wilson MR, Naccache SN, Samayoa E, et al. Actionable diagnosis of neuroleptospirosis by next-generation sequencing. *N Engl J Med.* 2014;370(25):2408-2417.
173. Diphtheria. In: Heymann DL, ed. *Control of Communicable Diseases Manual.* 18th ed. Washington, DC: American Public Health Association; 2006:188.
174. May ML, McDougall RJ, Robson JM. *Corynebacterium diphtheriae* and the returned tropical traveler. *J Travel Med.* 2014;21(1):39-44.
175. Sánchez ME, Alvarez JB, León SH. Chronic nonhealing ulcerated nodules in a Spanish boy after traveling. *JAMA Dermatol.* 2015;151(11):1247-1248.
176. Nelson TG, Mitchell CD, Sega-Hall GM, et al. Cutaneous ulcers in a returning traveller: a rare case of imported diphtheria in the UK. *Clin Exp Dermatol.* 2016;41(1):57-59.
177. Harnisch JP, Tronca E, Nolan CM, et al. Diphtheria among alcoholic urban adults: a decade of experience in Seattle. *Ann Intern Med.* 1989;111(1):71-82.
178. Hart PE, Lee PY, Macallan DC, et al. Cutaneous and pharyngeal diphtheria imported from the Indian subcontinent. *Postgrad Med J.* 1996;72(852):619-620.
179. Wagner J, Ignatius R, Voss S, et al. Infection of the skin caused by *Corynebacterium ulcerans* and mimicking classical cutaneous diphtheria. *Clin Infect Dis.* 2001;33(9):1598-1600.

Chapter 157 :: Tuberculosis and Infections with Atypical Mycobacteria

:: Aisha Sethi

AT-A-GLANCE

- Infection with *Mycobacterium tuberculosis* or other very closely related strains, as well as the inflammatory reaction of the host define, the disease (tuberculosis [TB]).
- One-third of the world's population is infected with TB.
- TB is the main cause of death of patients infected with HIV.
- TB usually affects the lung, but virtually all other organ systems may be involved.
- TB of the skin is a relatively rare manifestation with a wide spectrum of clinical findings depending on the source of infection and the immune status of the host.
- Diagnosis is based on clinical manifestations, histopathologic analysis, demonstration of the relevant mycobacteria in tissue or in culture and host reaction to *M. tuberculosis* antigen.
- Treatment is with standard multidrug regimens; cases of multidrug-resistant TB or extensively multidrug-resistant TB require special attention.
- Course and prognosis depend on the immune status of the host. Treatment is curative except for patients with a severely compromised immune system.

Tuberculosis (TB) is still an important worldwide disease. TB is currently the ninth leading cause of death worldwide and the leading cause from an infectious agent, ranking higher than HIV/AIDS. In 2016, 6.3 million new cases of TB were reported, which was up from 6.1 million in 2015. There were 476,774 reported cases of HIV-positive TB, of whom 85% were on antiretroviral therapy.[1] In 2016, there were an estimated 1.3 million TB deaths among HIV-negative people. An additional 374,000 deaths were reported among HIV-positive people. An estimated 10.4 million people fell ill with TB in 2016: The highest burden of disease was in 5 countries: India, Indonesia, China, the Philippines, and Pakistan.

In 2008, a total of 12,898 incident TB cases were reported in the United States; the TB rate declined 3.8% from 2007 to 4.2 cases per 100,000 population, the lowest rate recorded since national reporting began in 1953. In 2008, the TB rate in foreign-born persons in the United States was 10 times higher than in U.S.-born persons. TB rates among Hispanics and blacks were nearly 8 times higher than among non-Hispanic whites, and rates among Asians were nearly 23 times higher than among non-Hispanic whites. To ensure that TB rates decline further in the United States, especially among foreign-born persons and minority populations, TB prevention and control capacity should be increased. Additional capacity should be used to (a) improve case management and contact investigations; (b) intensify outreach, testing, and treatment of high-risk and hard-to-reach populations; (c) enhance treatment and diagnostic tools; (d) increase scientific research to better understand TB transmission; and (e) continue collaboration with other nations to reduce TB globally.[2]

HIV-positive people are approximately 20 times more likely than HIV-negative people to develop TB in countries with a generalized HIV epidemic, and between 26 and 37 times more likely to develop TB in countries where HIV prevalence is lower.

The so-called atypical mycobacteria (mycobacteria other than *Mycobacterium tuberculosis* [MOTT]) cause skin disease more frequently than does *M. tuberculosis*. They exist in various reservoirs in the environment. Among these organisms are obligate and facultative pathogens as well as nonpathogens. In contrast to the obligate pathogens, facultative pathogens do not cause disease by person-to-person spread.

EPIDEMIOLOGY

Tuberculosis of the skin has a worldwide distribution. Once more prevalent in regions with a cold and humid climate, it now occurs mostly in the tropics. Cutaneous TB incidence parallels that of pulmonary TB and developing countries still account for the majority of cases in the world. The emergence of resistant strains and the AIDS epidemic have led to an increase in all forms of TB (Table 157-1).

The 2 most frequent forms of skin tuberculosis are lupus vulgaris (LV) and scrofuloderma (Fig. 157-1). In the tropics, LV is rare, whereas scrofuloderma and verrucous lesions predominate. LV is more than twice as common in women than in men, whereas tuberculosis verrucosa cutis is more often found in men. Generalized miliary tuberculosis is seen in infants (and adults with severe immunosuppression or AIDS), as is primary inoculation tuberculosis. Scrofuloderma usually occurs in adolescents and the elderly, whereas LV may affect all age groups.

The pandemic of AIDS, with its profound and progressive suppression of cellular immune functions, has led to a resurgence of tuberculosis and the appearance

TABLE 157-1
Classification of Cutaneous Tuberculosis

	HOST IMMUNE STATUS	CLINICAL DISEASE
Exogenous infection	Naïve Immune	Primary inoculation tuberculosis Tuberculosis verrucosa cutis
Endogenous spread	High Low	Lupus vulgaris Scrofuloderma Acute miliary tuberculosis Orificial tuberculosis Metastatic tuberculous abscess (tuberculous gumma)
Tuberculosis caused by bacille Calmette-Guérin	Naïve	Normal primary complex-like reaction Perforating regional adenitis Postvaccination lupus vulgaris
Tuberculids	Not clear	Tuberculids: ▪ Lichen scrofulosorum ▪ Papulonecrotic tuberculid Facultative tuberculids: ▪ Nodular vasculitis ▪ Erythema nodosum

or recognition of new mycobacterial pathogens. The *Mycobacterium avium*-intracellulare complex is the most common cause of disseminated bacterial infections in patients with AIDS in the United States, but is much less frequently so in Europe. In AIDS patients, *Mycobacterium kansasii* is more common than *M. tuberculosis*. The incidence of tuberculosis in patients with AIDS is almost 500 times than that in the general population. Cutaneous disease in AIDS patients is frequently caused by MOTT.

Figure 157-1 Scrofuloderma in an Ethiopian patient. (Used with permission from Dr. Kassahun Bilcha.)

ETIOLOGY AND PATHOGENESIS

THE *MYCOBACTERIUM*

Mycobacteria multiply intracellularly, and are initially found in large numbers in the tissue.

M. tuberculosis, *Mycobacterium bovis*, and, under certain conditions, the attenuated bacille Calmette-Guérin (BCG) organism cause all forms of skin tuberculosis.

In LV, the bacteria often have virulence as low as that of the BCG. A large number of bacteria can be found in the lesions of a primary chancre or of acute miliary tuberculosis; in the other forms, their number in the lesions is so small that it may be difficult to find them.

M. tuberculosis may become dormant in the host tissue.

New diagnostic tools are emerging,[3,4] as described below.

THE HOST

The human species is quite susceptible to infection by *M. tuberculosis*, with big differences among populations and individuals. Populations that have been in longstanding contact with tuberculosis are, in general, less susceptible than those who have come into contact with mycobacteria more recently, presumably reflecting widespread immunity from subclinical infection. Age, state of health, environmental factors, and particularly the immune system are of importance. In Africans, tuberculosis frequently takes an unfavorable course, and tuberculin sensitivity may be more pronounced than in whites.

ROUTE OF INFECTION

Cutaneous inoculation leads to a tuberculous chancre or to tuberculosis verrucosa cutis (Fig. 157-2), depending on the immunologic state of the host.

Spread of mycobacteria may occur by continuous extension of a tuberculous process in the skin (scrofuloderma) by way of the lymphatics (LV), or by hematogenous dissemination (acute miliary tuberculosis of the skin or LV).

DIAGNOSIS

TUBERCULIN REACTION (KOCH PHENOMENON)

An extract of *M. tuberculosis* (tuberculin) was shown to produce a different skin reaction in sensitized individuals than in naïve individuals, and this difference

Figure 157-2 Tuberculosis verrucosa cutis on the foot of an Ethiopian patient. (Used with permission from Dr. Kassahun Bilcha.)

became the basis of a widely used diagnostic test. This reaction is a delayed-type hypersensitivity reaction, induced by mycobacteria during primary infection. This "old tuberculin" has now been replaced by purified protein derivative (PPD). More recently, purified species-specific antigens have been developed.[5]

Local intradermal injection (the method most widely used) leads to the local tuberculin reaction, which usually reaches its maximum intensity after 48 hours. It consists of a sharply circumscribed area of erythema and induration, and in highly hypersensitive recipients or after large doses, a pallid central necrosis may appear.

In an attempt to quantify the tuberculin reaction, an assay known as the QuantiFERON-TB Gold test was developed to measure specific antigen-driven interferon-γ synthesis by whole blood cells and was approved by the U.S. Food and Drug Administration (FDA) in 2005.

Tuberculin sensitivity usually develops 2 to 10 weeks after infection and persists throughout life. The state of sensitivity of an individual infected with *M. tuberculosis* is of considerable significance in the pathogenesis of tuberculosis skin lesions.

In patients with clinical tuberculosis, an increase in skin sensitivity usually indicates a favorable prognosis, and in tuberculous skin disease accompanied by high levels of skin sensitivity, the number of bacteria within the lesions is small. Tuberculin sensitivity (skin reactivity) is not necessary for immunity, however, and sensitivity and immunity do not always parallel each other.

QUANTIFERON-TB GOLD TEST

In 2005, the FDA approved QuantiFERON-TB Gold (QFT-G) as an in vitro diagnostic aid. In this test, blood samples are mixed with antigens and controls. For QFT-G, the antigens include mixtures of synthetic peptides representing 2 *M. tuberculosis* proteins: ESAT-6 and CFP-10. After incubation of the blood with antigens for 16 to 24 hours, the amount of interferon (IFN)-γ is measured.

If the patient is infected with *M. tuberculosis*, their white blood cells will release IFN-γ in response to contact with the TB antigens. The QFT-G results are based on the amount of IFN-γ that is released in response to the antigens.

Although more sensitive than the tuberculin skin test, the QFT-G may be negative in patients with early active tuberculosis and indeterminate results are more common in immunocompromised individuals and young children. Another similar assay, the T-SPOT.*TB* test, measures the number of IFN-γ–producing T cells and is currently available in Europe. QFT-G testing is indicated for diagnosing infection with *M. tuberculosis*, including both TB disease and latent TB infection. Whenever *M. tuberculosis* infection or disease is being diagnosed by any method, the optimal approach includes coordination with the local or regional public health TB control programs.

HISTOPATHOLOGY

The hallmark of tuberculosis and infections with some of the slow-growing atypical mycobacteria is the tubercle: an accumulation of epithelioid histocytes with Langhans-type giant cells among them and a varying amount of caseation necrosis in the center, surrounded by a rim of lymphocytes and monocytes. Although this tuberculoid granuloma is highly characteristic of several forms of tuberculosis, it may be mimicked by deep fungal infections, syphilis, and leprosy, as well as other diseases. As in leprosy, the histopathologic features of skin tuberculosis may be reflective of the host's immune status.

POLYMERASE CHAIN REACTION PROCEDURE

The polymerase chain reaction (PCR) procedure has been used increasingly to ascertain the presence of mycobacterial DNA in skin specimens.[6] Although the detection of specific DNA in tissues has yielded valuable information and will conceivably gain importance in the future, interpretation of the results of these tests in individual patients is still problematic.[7] In one study, samples from 16 of 20 patients with sarcoidosis contained mycobacterial DNA, both tuberculous and nontuberculous.[8] In another study of patients with confirmed or highly probable cutaneous tuberculosis or with erythema induratum, believed to indicate a host response to the infection, PCR testing showed 100% sensitivity and specificity in multibacillary disease. In paucibacillary disease, PCR testing showed 55% sensitivity and specificity, and only 80% of PCR-positive patients responded to antituberculosis therapy.[6]

TREATMENT OF CUTANEOUS TUBERCULOSIS

In general, the management of cutaneous tuberculosis is similar to that of tuberculosis of other organs.[9-12] Chemotherapy is usually the treatment of choice (Tables 157-2 and 157-3), but ancillary measures may be required. Vaccines against *M. tuberculosis* have been attempted,[9] but are still not available.

Although they are not yet established as a therapeutic option, cytokines such as interleukin-2, interferon-γ, interleukin-12, and granulocyte-macrophage colony-stimulating factor may help to control intracellular pathogens and thereby shorten the duration of therapy and overcome drug resistance.[13] The immunomodulatory drug thalidomide may prove to be useful in controlling problems related to the inflammatory response that may follow treatment of multibacillary infection and could become a useful adjunctive drug, as it is in the treatment of leprosy.

SPECIAL CONSIDERATIONS IN TREATING TUBERCULOSIS OF THE SKIN

In contrast to systemic infection, for which triple-drug therapy is recommended, tuberculosis verrucosa cutis and localized forms of LV without evidence of associated internal tuberculosis may be treated with isoniazid alone for up to 12 months. Because viable mycobacteria have been found in clinically healed lesions, treatment should be continued for at least 2 months after complete involution of the lesions. Surgical intervention is quite helpful in scrofuloderma, because it reduces morbidity and shortens the required length of chemotherapy. Small lesions of LV or tuberculosis verrucosa cutis are also best excised, but tuberculostatics should be given concomitantly. Plastic surgery is important as a corrective measure in cases of longstanding LV with mutilation.

Extensively multidrug-resistant TB is defined as resistance to at least rifampicin and isoniazid from among the first-line anti-TB drugs (which is the definition of multidrug resistant TB) in addition to resistance to any fluoroquinolone, and to at least 1 of the 3 injectable second-line anti-TB drugs used in TB treatment (capreomycin, kanamycin, and amikacin). The Centers for Disease Control and Prevention and World Health Organization have outlined that extensively drug resistant TB poses a grave global public health threat and has a higher risk of death as it renders patients virtually untreatable with currently available drugs.[14]

SKIN DISEASES CAUSED BY *MYCOBACTERIUM TUBERCULOSIS AND MYCOBACTERIUM BOVIS* INFECTION

Infection with *M. tuberculosis* used to be thought to result in characteristic clinical features.[15] However, with increasing number of cases in immunocompromised individuals and improved diagnostic tools, many uncharacteristic manifestations have been discovered.

PRIMARY INOCULATION TUBERCULOSIS (TUBERCULOUS CHANCRE, TUBERCULOUS PRIMARY COMPLEX)

EPIDEMIOLOGY

Tuberculous chancre and affected regional lymph nodes constitute the tuberculous primary complex in the skin. The condition is believed rare, but its incidence may be underestimated. In some regions with a high prevalence of tuberculosis and poor living conditions, primary inoculation tuberculosis of the skin is not unusual. Children are most often affected.

ETIOLOGY AND PATHOGENESIS

Tubercle bacilli are introduced into the tissue at the site of minor wounds. Oral lesions may be caused by bovine bacilli in unpasteurized milk and occur after mucosal trauma or tooth extraction. Primary inoculation tuberculosis is initially multibacillary, but becomes paucibacillary as immunity develops.

CLINICAL FINDINGS

The chancre initially appears 2 to 4 weeks after inoculation and presents as a small papule, crust, or erosion with little tendency to heal. Sites of predilection are the face, including the conjunctivae and oral cavity, as well as the hands and lower extremities. A painless ulcer develops, which may be quite insignificant or may enlarge to a diameter of more than 5 cm (Fig. 157-3). It is shallow with a granular or hemorrhagic base studded with miliary abscesses or covered by necrotic tissue. The ragged edges are undermined and of a reddish-blue hue. As the lesions grow older, they become more indurated, with thick adherent crusts.

Wounds inoculated with tubercle bacilli may heal temporarily but break down later, giving rise to

TABLE 157-2
Therapy Guidelines for *Mycobacterium Tuberculosis* Infections

INITIAL PHASE			CONTINUATION PHASE			RANGE OF TOTAL DOSES (MINIMAL DURATION)	RATING (EVIDENCE)[a,b]	
REGIMEN	DRUGS	INTERVAL AND DOSES[c] (MINIMAL DURATION)	REGIMEN	DRUGS	INTERVAL AND DOSES[c,d] (MINIMAL DURATION)		HIV$^-$	HIV$^+$
1	INH	7 days per week for 56 doses (8 weeks) or 5 days per week for 40 doses (8 weeks)[e]	1a	INH/RIF	7 days per week for 126 doses (18 weeks) or 5 days per week for 90 doses (18 weeks)[e]	184 to 130 (26 weeks)	A (I)	A (II)
	RIF		1b	INH/RIF			A (I)	A (II)[c]
	PZA		1c[f]	INH/RPT	Twice weekly for 36 doses (18 weeks) Once weekly for 18 doses (18 weeks)	92 to 76 (26 weeks) 74 to 58 (26 weeks)	B (I)	E (I)
	EMB							
2	INH	7 days per week for 14 doses (2 weeks), then twice weekly for 12 doses (6 weeks), or 5 days per week for 10 doses (2 weeks)[e], then twice weekly for 12 doses (6 weeks)	2a 2b[f]	INH/RIF	Twice weekly for 36 doses (18 weeks) Once weekly for 18 doses (18 weeks)	62 to 58 (26 weeks) 44 to 40 (26 weeks)	A (II)	B (II)[c]
	RIF			INH/RPT			B (I)	E (I)
	PZA							
	EMB							
3	INH	Three times weekly for 24 doses (8 weeks)	3a	INH/RIF	Three times weekly for 54 doses (18 weeks)	78 (26 weeks)	B (I)	B (II)
	RIF							
	PZA							
	EMB							
4	INH	7 days per week for 56 doses (8 weeks) or 5 days per week for 40 doses (8 weeks)[e]	4a	INH/RIF	7 days per week for 217 doses (31 weeks) or 5 days per week for 155 doses (31 weeks)[e] Twice weekly for 62 doses (31 weeks)	273 to 195 (39 weeks)	C (I)	C (II)
	RIF		4b	INH/RIF				
						118 to 102 (39 weeks)	C (I)	C (II)
	EMB							

[a]Definitions of evidence ratings: A, preferred; B, acceptable alternative; C, offer when A and B cannot be given; E, should never be given.

[b]Definitions of evidence ratings: I, randomized clinical trial; II, data from clinical trials that were not randomized or were conducted in other populations; III, expert opinion.

[c]Directly Observed Therapy (DOT). Among patients with extrapulmonary tuberculosis, regimen 1 is recommended as initial therapy unless the organisms are known or strongly suspected of being resistant to the first-line drugs. If PZA cannot be used in the initial phase (ie, regimen 4), the continuation phase must be increased to 7 months. Doses of medications (maximum dose) when given daily: EMB (ethambutol) 18 mg/kg (1600 mg); INH (isoniazid), 5 mg/kg (300 mg); PZA (pyrazinamide), 25 mg/kg (2000 mg); RIF (rifampin), 10 mg/kg (600 mg); RPT (rifapentine), which is given once weekly at 10 mg/kg.
When DOT is used, drugs may be given 5 days/week and the necessary number of doses adjusted accordingly. Although there are no studies that compare 5 with 7 daily doses, extensive experience indicates this would be an effective practice.

[d]Patients with cavitation on initial chest radiograph and positive cultures at completion of 2 months of therapy should receive an 8-month (31-week; either 217 doses [daily] or 62 doses [twice weekly]) continuation phase.

[e]Five-day-a-week administration is always given by DOT. Rating for 5 day/week regimens is AIII. Not recommended for HIV-infected patients with CD4+ cell counts <100 cells/mL.

[f]Options 1c and 2b should be used only in HIV-negative patients who have negative sputum smears at the time of completion of 2 months of therapy and who do not have cavitation on initial chest radiograph. For patients started on this regimen and found to have a positive culture from the 2-month specimen, treatment should be extended an extra 3 months.

From American Thoracic Society, CDC, and Infectious Disease Society of America. Treatment of tuberculosis. *MMWR Recomm Rep.* 2003;52(RR-11):1-77.

TABLE 157-3
Antituberculosis Drugs Currently in Use in the United States

FIRST-LINE DRUGS	SECOND-LINE DRUGS
Isoniazid	Cycloserine
Rifampin	Ethionamide
Rifapentine	Levofloxacin[a]
Rifabutin[a]	Moxifloxacin[a]
Ethambutol	Gatifloxacin[a]
Pyrazinamide	*p*-Aminosalicylic acid
	Streptomycin
	Amikacin/kanamycin[a]
	Capreomycin

[a]Not approved by the U.S. Food and Drug Administration for use in the treatment of tuberculosis.

From American Thoracic Society, CDC, and Infectious Disease Society of America. Treatment of tuberculosis. *MMWR Recomm Rep*. 2003;52(RR-11):1-77.

granulating ulcers. Mucosal infections result in painless ulcers or fungating granulomas. Inoculation tuberculosis of the finger may present as a painless paronychia. Inoculation of puncture wounds may result in subcutaneous abscesses.

Slowly progressive, regional lymphadenopathy develops 3 to 8 weeks after the infection (see Fig. 157-3) and may rarely be the only clinical finding. After weeks or months, cold abscesses may develop that perforate to the surface of the skin and form sinuses. The lymph nodes draining the primary glands also may be involved. Body temperature may be slightly elevated. The disease may take a more acute course, and in half of the patients, fever, pain, and swelling simulate a pyogenic infection. Early, there is an acute nonspecific inflammatory reaction in both skin and lymph nodes, and mycobacteria are easily detected by Fite stain. After 3 to 6 weeks, the infiltrate and the regional lymph nodes acquire a tuberculoid appearance and caseation may occur.

Figure 157-3 Primary inoculation tuberculosis. Note tuberculous chancre on the thigh and regional lymphadenopathy. A positive tuberculin reaction is noted on the arm.

TABLE 157-4
Differential Diagnosis of Primary Inoculation Tuberculosis

Most Likely
- Sporotrichosis
- Syphilis

Consider
- Bartonellosis
- Tularemia

Always Rule Out
- Other mycobacterioses

DIAGNOSIS

Any ulcer with little or no tendency to heal and unilateral regional lymphadenopathy in a child should arouse suspicion. Acid-fast organisms are found in the primary ulcer and draining nodes in the initial stages of the disease. The diagnosis is confirmed by bacterial culture. The PPD reaction is negative initially and later converts to positive (see Fig. 157-3).

DIFFERENTIAL DIAGNOSIS

The differential diagnosis encompasses all disease with a primary complex (Table 157-4).

COURSE

If untreated, the condition may last up to 12 months. Rarely, LV develops at the site of a healed tuberculous chancre. The regional lymph nodes usually calcify.

The primary tuberculous complex usually produces immunity, but reactivation of the disease may occur. Hematogenous spread may give rise to tuberculosis of other organs, particularly of the bones and joints. It may also lead to acute miliary disease with a fatal outcome. Erythema nodosum occurs in approximately 10% of cases.

TUBERCULOSIS VERRUCOSA CUTIS (WARTY TUBERCULOSIS, PROSECTOR'S WART, LUPUS VERRUCOSUS)

ETIOLOGY AND PATHOGENESIS

Tuberculosis verrucosa cutis is a paucibacillary disorder caused by exogenous reinfection (inoculation) in previously sensitized individuals with high immunity.

Inoculation occurs at sites of minor wounds or, rarely, from the patient's own sputum. Members of professional groups handling infectious material are at risk. Children may become infected playing on contaminated ground.

CLINICAL FINDINGS

Lesions usually occur on the hands or, in children, on the lower extremities as a small asymptomatic papule or papulopustule with a purple inflammatory halo. They become hyperkeratotic and are often mistaken for a common wart. Slow growth and peripheral expansion lead to the development of a verrucous plaque with an irregular border (Fig. 157-4). Fissures discharging pus extend into the underlying brownish-red to purplish infiltrated base. The lesion usually is solitary, but multiple lesions may occur. Regional lymph nodes are rarely affected.

Lesions progress slowly and, if untreated, persist for many years. Spontaneous involution eventually occurs, leaving an atrophic scar.

HISTOPATHOLOGY

The most prominent histopathologic features are pseudoepitheliomatous hyperplasia with marked hyperkeratosis, a dense inflammatory infiltrate, and abscesses in the superficial dermis or within the pseudoepitheliomatous rete pegs. Epithelioid cells and giant cells are found in the upper and middle dermis. Typical tubercles are uncommon, and the infiltrate may be nonspecific.

DIFFERENTIAL DIAGNOSIS

Table 157-5 outlines the differential diagnosis of tuberculosis verrucosa cutis.

Figure 157-4 Tuberculosis verrucosa cutis on the back of the hand.

TABLE 157-5
Differential Diagnosis of Tuberculosis Verrucosa Cutis

Most Likely
Blastomycosis
Hyperkeratotic lupus vulgaris
Hypertrophic lichen planus
Warts or keratoses

Consider
Bromoderma
Chromomycosis
Tertiary syphilis

Always Rule Out
Lesions caused by other mycobacteria

LUPUS VULGARIS (TUBERCULOSIS LUPOSA)

EPIDEMIOLOGY

LV is an extremely chronic, progressive form of cutaneous tuberculosis occurring in individuals with moderate immunity and a high degree of tuberculin sensitivity. Once common, LV has declined steadily in incidence. It has always been less common in the United States than in Europe. Females appear to be affected 2 to 3 times as often as males; all age groups are affected equally.

ETIOLOGY AND PATHOGENESIS

LV is a postprimary, paucibacillary form of tuberculosis caused by hematogenous, lymphatic, or contiguous spread from elsewhere in the body. Spontaneous involution may occur, and new lesions may arise within old scars. Complete healing rarely occurs without therapy.

CLINICAL FINDINGS

Lesions are usually solitary, but two or more sites may be involved simultaneously. In patients with active pulmonary tuberculosis, multiple foci may develop. In approximately 90% of patients, the head and neck are involved. LV usually starts on the nose, cheek, earlobe, or scalp and slowly extends onto adjacent regions. Other areas are rarely involved.

The initial lesion is a brownish-red, soft or friable macule or papule with a smooth or hyperkeratotic surface. On diascopy, the infiltrate exhibits a typical apple jelly color. Progression is characterized by elevation, a deeper brownish color (Fig. 157-5), and formation of a plaque (Fig. 157-5). Involution in one area with expansion in another often results in a gyrate outline border. Ulceration may occur. Hypertrophic forms appear as a soft nodule or plaque with a hyperkeratotic surface. The mucosae may be primarily involved or become affected by the extension of skin lesions. Infection is

Figure 157-5 **A,** Slightly raised, brownish plaque of lupus vulgaris. **B,** Large plaque of lupus vulgaris of 10 years' duration involving the cheek, jaw, and ear.

manifest as small, soft, gray or pink papules, ulcers, or friable granulating masses.

After a transient impairment of immunity, particularly after measles (thus the term *lupus postexanthematicus*), multiple disseminated lesions may arise simultaneously in different regions of the body as a consequence of hematogenous spread from a latent tuberculous focus. During and after the eruption, a previously positive tuberculin reaction may become negative, but will usually revert to positive as the general condition of the patient improves.

HISTOPATHOLOGY

The most prominent histopathologic feature is the formation of typical tubercles. Secondary changes may be superimposed: epidermal thinning and atrophy or acanthosis with excessive hyperkeratosis or pseudoepitheliomatous hyperplasia. Acid-fast bacilli are usually not found. Nonspecific inflammatory reactions may partially conceal the tuberculous structures. Old lesions are composed chiefly of epithelioid cells and may be impossible to distinguish from sarcoidal infiltrates.

DIAGNOSIS

Typical LV plaques may be recognized by the softness of the lesions, brownish-red color, and slow evolution. The apple jelly nodules revealed by diascopy are highly characteristic; finding them may be decisive, especially in ulcerated, crusted, or hyperkeratotic lesions. The result of the tuberculin test is strongly positive except during the early phases of postexanthematic lupus. Bacterial culture results may be negative, in which case the clinical diagnosis can usually be supported by positive PCR results for *M. tuberculosis.*

DIFFERENTIAL DIAGNOSIS

Table 157-6 outlines the differential diagnosis of LV.

COMPLICATIONS

Involvement of the nasal or auricular cartilage may result in extensive destruction and disfigurement (Fig. 157-6). Atrophic scarring, with or without prior ulceration, is characteristic, as is recurrence within a scar. Fibrosis may be pronounced and mutilating.

Dry rhinitis is often the only symptom of early nasal LV, but lesions may also destroy the cartilage of the nasal septum. Scarring of the soft palate and laryngeal stenosis also occur.

COURSE

LV is a very long-term disorder and without therapy progresses over many years to functional impairment and disfiguration (see Fig. 157-6). Longstanding LV may lead to the development of carcinoma

TABLE 157-6
Differential Diagnosis of Lupus Vulgaris

Most Likely
- Discoid lupus erythematosus
- Sarcoidosis

Consider
- Leprosy
- Lupoid leishmaniasis
- Lymphocytoma
- Tertiary syphilis

Always Rule Out
- Blastomycosis or other deep mycotic infections

Figure 157-6 Lupus vulgaris of long duration that has led to the destruction of the nose. Ulcerating squamous cell carcinoma has developed on the upper lip.

Figure 157-7 Scrofuloderma in the clavicular region. Note abscess formation, ulceration, and extrusion of purulent and caseous material.

(see Fig. 157-6). Squamous cell carcinomas outnumber basal cell carcinomas by far, and the risk of metastases is high. In 40% of patients, there is associated tuberculous lymphadenitis, and 10% to 20% have active pulmonary tuberculosis or tuberculosis of the bones and joints.[16] Pulmonary tuberculosis is 4 to 10 times more frequent in patients with LV than in the general population.

SCROFULODERMA (TUBERCULOSIS COLLIQUATIVA CUTIS)

EPIDEMIOLOGY

Prevalence is higher among children, adolescents, and the aged.

ETIOLOGY AND PATHOGENESIS

Scrofuloderma is subcutaneous tuberculosis leading to cold abscess formation and a secondary breakdown of the overlying skin. It may be either multibacillary or paucibacillary.

Scrofuloderma represents contiguous involvement of the skin overlying another site of infection (eg, tuberculous lymphadenitis, tuberculosis of bones and joints, or tuberculous epididymitis).

CLINICAL FINDINGS

Scrofuloderma most often occurs in the parotideal, submandibular, and supraclavicular regions and may be bilateral. It first presents as a firm, subcutaneous nodule, usually well defined, freely movable, and asymptomatic. As the lesion enlarges, it softens. After months, liquefaction with perforation occurs, causing ulcers and sinuses (Fig. 157-7). The ulcers are linear or serpiginous with undermined, inverted, bluish edges and soft, granulating floors. Sinusoidal tracts undermine the skin. Clefts alternate with soft nodules. Scar tracts develop and bridge ulcerative areas or even stretches of normal skin. Tuberculin sensitivity is usually pronounced.

HISTOPATHOLOGY

Massive necrosis and abscess formation in the center of the lesion are nonspecific. However, the periphery of the abscesses or the margins of the sinuses contain tuberculoid granulomas.

DIAGNOSIS

If there is an underlying tuberculous lymphadenitis or bone and joint disease, the diagnosis usually presents no difficulty. Positive results on culture confirm the diagnosis.

DIFFERENTIAL DIAGNOSIS

Table 157-7 outlines the differential diagnosis of scrofuloderma.

COURSE

Spontaneous healing does occur, but the course is very protracted, and it may be years before lesions have

TABLE 157-7
Differential Diagnosis of Scrofuloderma

Most Likely
- Hidradenitis suppurativa
- Sporotrichosis

Consider
- Actinomycosis
- *Mycobacterium scrofulaceum* infection
- Severe forms of acne conglobata
- Syphilitic gummas

Always Rule Out
- *Mycobacterium avium*-intracellulare lymphadenitis

been completely replaced by scar tissue. Presence of the typical cribriform scars permits a correct diagnosis, even after the process has become quiescent. LV may develop at or near the site of scrofuloderma.

ORIFICIAL TUBERCULOSIS (TUBERCULOSIS ULCEROSA CUTIS ET MUCOSAE, ACUTE TUBERCULOUS ULCER)

ETIOLOGY AND PATHOGENESIS

Orificial tuberculosis is a rare form of tuberculosis of the mucous membranes and orifices that is caused by autoinoculation of mycobacteria from progressive tuberculosis of internal organs.

The underlying disease is far advanced pulmonary, intestinal, or, rarely, genitourinary tuberculosis. Mycobacteria shed from these foci in large numbers are inoculated into the mucous membranes.

CLINICAL FINDINGS

A small yellowish or reddish nodule appears on the mucosa and breaks down to form a soft ulcer with a typical punched-out appearance, undermined edges, and circular or irregular border (Fig. 157-8). The ulcer floor often exhibits multiple yellowish tubercles and bleeds easily. The surrounding mucosa is edematous and inflamed. Lesions may be single or multiple and are extremely painful, resulting in dysphagia.

The tongue is most frequently affected, particularly the tip and the lateral margins, but the soft and hard palates are also common sites. In advanced cases, the lips are involved, and the oral condition often represents an extension of ulcerative tuberculosis of the pharynx and larynx. In patients with intestinal tuberculosis, lesions develop around the anus, and in females with active genitourinary disease, the vulva is involved.

Figure 157-8 Orificial tuberculosis in advanced cavitary pulmonary tuberculosis.

HISTOPATHOLOGY

There is a massive nonspecific inflammatory infiltrate and necrosis, but tubercles with caseation may be found deep in the dermis. Mycobacteria are easily demonstrated.

DIFFERENTIAL DIAGNOSIS

Table 157-8 outlines the differential diagnosis of orificial tuberculosis.

COURSE

Orificial tuberculosis is a symptom of advanced internal disease and usually portends a fatal outcome.

SEQUELAE OF BACILLE CALMETTE–GUÉRIN INOCULATION

Vaccination with attenuated bovine BCG appears to protect infants and young children from the more serious

TABLE 157-8
Differential Diagnosis of Orificial Tuberculosis

Most Likely
- Aphthous ulcers

Consider
- Syphilitic lesions (not painful)

Always Rule Out
- Squamous cell carcinoma

forms of tuberculosis, but its ability to prevent disease in adults remains uncertain. In the United States, guidelines for BCG immunization have been developed.[17,18]

In the normal course of BCG vaccination, an infiltrated papule develops after approximately 2 weeks, attains a size of approximately 10 mm after 6 to 12 weeks, ulcerates, and then slowly heals, leaving a scar. Vaccination may provoke an accelerated reaction in a previously infected person. The regional lymph nodes may enlarge, but usually heal without breaking down. Tuberculin sensitivity appears 5 to 6 weeks after vaccination.

The true incidence of complications caused by the BCG organism is difficult to ascertain, but it is extremely low in comparison to the great number of vaccinations performed in Europe in the past 50 years.[19] Problems include the following:

- LV at or near the vaccination site (latency of months to years).
- Koch phenomenon in individuals sensitive to tuberculin (see section "Tuberculin Reaction [Koch Phenomenon]").
- Regional adenitis, sometimes severe and with systemic symptoms, more often in children.
- After deep injection, local abscesses, excessive ulceration.
- Scrofuloderma with suppuration for 6 to 12 months.
- Generalized tuberculid-like reactions (rare).
- Generalized adenitis, osteitis, organ tuberculosis (eg, in the joints) occasionally.

THE TUBERCULIDS

Lichen scrofulosorum, erythema induratum, papulonecrotic tuberculids, lupus miliaris disseminatus faciei, and other eruptions with rather exotic designations were originally included in the tuberculids (Table 157-9).

With the sharp decline in incidence and the effective treatment of tuberculosis in developed countries, the tuberculids also became rare. However, this does not apply to areas in which tuberculosis is still common, and with the recent resurgence of tuberculosis associated with AIDS in some Western countries, some tuberculids are also being observed again.

The pathogenic relationship of the tuberculids to tuberculosis is still poorly understood. Although there is no doubt that such a relationship exists for some tuberculids, in other cases it appears highly unlikely.

PCR testing revealed *M. tuberculosis* DNA in skin lesions of erythema induratum/nodular vasculitis and papulonecrotic tuberculid in one series of patients, but in another, results were uniformly negative.[20,21] Thus, *M. tuberculosis* infection may be responsible directly or indirectly for some cases of these diseases but not all, and the usefulness of lesional PCR testing may vary among clinical settings. Consistent with this statement, antituberculosis drugs are beneficial in some cases but not all; spontaneous involution may occur, and some patients appear to respond well to other therapies. It should be noted that, although not considered a tuberculid, sarcoidosis has been postulated to result from an immunologic reaction to mycobacterial antigens.[22]

The following discussion includes only those conditions for which a preponderance of the evidence supports a tuberculous etiology (see Table 157-9).

TABLE 157-9
Tuberculids

TERMINOLOGY: RELATIONSHIP TO TUBERCULOSIS	ENTITIES
Tuberculids: conditions in which *Mycobacterium tuberculosis*/*Mycobacterium bovis* appears to play a significant role	Lichen scrofulosorum Papulonecrotic tuberculid
Facultative tuberculids: conditions in which *M. tuberculosis*/*M. bovis* may be one of several pathogenic factors	Nodular vasculitis/erythema induratum of Bazin Erythema nodosum
Nontuberculids: conditions formerly designated as tuberculids; there is no relationship to tuberculosis	Lupus miliaris disseminatus faciei Rosacea-like tuberculid Lichenoid tuberculid

LICHEN SCROFULOSORUM

EPIDEMIOLOGY AND PATHOGENESIS

Lichen scrofulosorum is an uncommon lichenoid eruption ascribed to hematogenous spread of mycobacteria in an individual strongly sensitive to *M. tuberculosis*. Usually associated with chronic tuberculosis of the lymph nodes, bones, or pleura, it also has been observed after BCG vaccination and in association with *M. avium*-intracellulare infections.[23]

CLINICAL FINDINGS

Lesions are usually confined to the trunk and occur most often in children and adolescents with active tuberculosis. The lesions are asymptomatic, firm, follicular or perifollicular flat-topped yellowish or pink papules, sometimes with fine scale. Lichenoid grouping is pronounced, and lesions may coalesce to form rough, discoid plaques. Lesions persist for months, but spontaneous involution eventually occurs. Antituberculosis therapy results in complete resolution within weeks.

HISTOPATHOLOGY

Superficial tuberculoid granulomas develop around hair follicles or independent of the adnexa. Mycobacteria are not seen in the sections and cannot be cultured from biopsy material.

TABLE 157-10
Differential Diagnosis of Lichen Scrofuloderma

Most Likely
- Lichen nitidus
- Lichen planus

Consider
- Lichenoid secondary syphilis
- Micropapular forms of sarcoidosis

DIFFERENTIAL DIAGNOSIS

Table 157-10 outlines the differential diagnosis of lichen scrofuloderma.

PAPULONECROTIC TUBERCULID

EPIDEMIOLOGY

Papulonecrotic tuberculid is a symmetric eruption of necrotizing papules, appearing in crops and healing with scar formation that occurs preferentially in children or young adults. It is rarely reported but may not be uncommon in populations with a high prevalence of tuberculosis.

ETIOLOGY AND PATHOGENESIS

As a rule, bacteria cannot be demonstrated in lesions. In most cases, the tuberculin test shows a positive reaction, and associated pulmonary or extrapulmonary tuberculosis is common. LV has been reported to evolve with papulonecrotic tuberculid. Lesions are reported to respond promptly to antituberculosis therapy whether or not a tuberculous focus is identified.

In studies of skin lesions in patients with papulonecrotic tuberculid, *M. tuberculosis* DNA was detected in approximately 50% of the skin biopsies (11 of 22 samples).[24-26] *M. kansasii* infection was documented in 1 patient.[27]

Some cases of papulonecrotic tuberculid have been associated with discoid lupus erythematosus, arthritis, or erythema nodosum. Although papulonecrotic tuberculid is classified as an id reaction and therefore, by definition, is not a result of direct involvement of the skin by the organism, some of the lesions have been positive on culture. It seems most likely that papulonecrotic tuberculid is a reaction to particulate tuberculous antigen and, in some cases, to living organisms as well.[28]

CLINICAL FINDINGS

Sites of predilection are the extensor aspects of the extremities, buttocks, and lower trunk (Fig. 157-9), but the eruption may become widespread. Distribution is symmetric, and consists of disseminated crops of livid or dusky red papules with a central depression and an adherent crust over a crater-like ulcer. There is spontaneous involution, which leaves pitted scars.

Figure 157-9 Papulonecrotic tuberculid on the forearm.

HISTOPATHOLOGY

Characteristically, a wedge-shaped necrotic area in the upper dermis extends into the epidermis. The inflammatory infiltrate surrounding this necrotic area may be nonspecific, but is usually tuberculoid. Involvement of the blood vessels is a cardinal feature and consists of an obliterative and sometimes granulomatous vasculitis leading to thrombosis and complete occlusion of the vascular channels.

DIFFERENTIAL DIAGNOSIS

Table 157-11 outlines the differential diagnosis of papulonecrotic tuberculid.

NODULAR VASCULITIS/ ERYTHEMA INDURATUM OF BAZIN

Chapter 73 discusses nodular vasculitis in detail.

TABLE 157-11
Differential Diagnosis of Papulonecrotic Tuberculid

Most Likely
- Pityriasis lichenoides et varioliformis acuta
- Prurigo

Consider
- Lichen urticatus
- Secondary syphilis

Always Rule Out
- Leukocytoclastic necrotizing vasculitis

ERYTHEMA NODOSUM

Chapter 73 discusses erythema nodosum in detail.

DISEASES CAUSED BY MYCOBACTERIA OTHER THAN *MYCOBACTERIUM TUBERCULOSIS*

AT-A-GLANCE

- A heterogeneous group of diseases caused by a variety of obligate or facultatively pathogenic mycobacteria other than those of the *Mycobacterium tuberculosis* complex.
- Involvement depends on the type of *Mycobacterium*, the route of infection, and the immune status of the host.
- Various organs may be involved.
- Mycobacteria other than *M. tuberculosis* (MOTT) are more often the cause of skin disease than *M. tuberculosis*.
- Diagnosis relies on histopathologic analysis and the results of culture.
- Incidence is unknown, but endemic areas exist for certain types of MOTT.
- Treatment is unlike that of tuberculosis, and no strict international guidelines have been developed. Effective antibiotics are known for each mycobacterial species but should be checked by sensitivity testing.

MOTT were identified as human pathogens in 1938 (*Mycobacterium fortuitum*), in 1948 (*Mycobacterium ulcerans*), and in 1954 (*Mycobacterium marinum*). However, overshadowed by the infectious disease burden caused by *Mycobacterium leprae* and *M. tuberculosis*, the pathogenic potential of slow-growing MOTT species was recognized only in recent decades. Because MOTT infections usually closely mimic infections with *M. tuberculosis*, and the bacteria have strict and often unusual requirements for culture, they are still probably underdiagnosed.

ETIOLOGY AND PATHOGENESIS

MOTT are widely distributed in nature and are usually commensals or saprophytes, rather than pathogens. Atypical mycobacteria are usually acquired from environmental sources such as water or soil, and their role in disease reflects their natural distribution and, possibly, local lifestyles. These organisms are thought to cause mycobacterial skin disease more often than does *M. tuberculosis*. Cases tend to be sporadic, but certain types of exposures may lead to small community outbreaks.[29,30] Any organ or organ system may be affected (Table 157-12), but MOTT seem much less likely to disseminate than *M. tuberculosis*, and infections usually run a more benign and limited course. As a rule, MOTT are much less responsive to antituberculosis drugs but may be sensitive to other chemotherapeutic agents.

Only 2 organisms, *M. ulcerans* and *M. marinum*, produce a characteristic clinical picture. An immunosuppressed state of the host or damage to a particular organ (eg, in *M. kansasii* infection of the lung) facilitates these infections.

New mycobacterial pathogens are described from time to time, which suggests that their full pathogenic potential is not yet appreciated. Recently, an outbreak of skin disease caused by a nontuberculous mycobacteria in Pacific Islanders from Satowan was reported in the literature.[31] These patients presented with long-standing verrucous and keloidal plaques (locally known as "spam" disease; Fig. 157-10). Histopathologic and PCR data demonstrated a nontuberculous mycobacterial infection as the cause.

TABLE 157-12
Organ Involvement in Infections with Atypical Mycobacteria

MYCOBACTERIAL SPECIES	ORGAN INVOLVEMENT	
	SKIN, SUBCUTIS	LYMPH NODES, OTHER ORGANS
Mycobacterium tuberculosis/ *Mycobacterium bovis* complex (including *Mycobacterium africanum* and bacille Calmette-Guérin)	+	+
Mycobacterium marinum	+	–
Mycobacterium ulcerans	+	–
Mycobacterium gordonae	+	–
Mycobacterium haemophilum	+	–
Mycobacterium kansasii	+	+
Mycobacterium avium-intracellulare complex (including *Mycobacterium scrofulaceum*)	+	+
Fast growers: *Mycobacterium fortuitum*, *Mycobacterium chelonae*, *Mycobacterium abscessus*	+	–

IDENTIFICATION OF MYCOBACTERIA OTHER THAN *MYCOBACTERIUM TUBERCULOSIS*

As with other infectious diseases, the diagnosis of mycobacterial infection depends on the identification

Figure 157-10 Verrucous plaque of "spam" disease on the knee of a Pacific Islander patient. (Used with permission from Dr. Joseph Lillis.)

of the microorganism isolated from the host. Specimens for culture should be sent to a special laboratory familiar with the special growth requirements of these organisms.

Antigens for intradermal skin testing (PPDs) for many of the clinically relevant mycobacterial species have been prepared in analogy to PPD from *M. tuberculosis*, but their accessibility is very limited and they are therefore little used.

Histopathologic analysis is supportive but cannot distinguish among mycobacterial species, because all share similar histopathologic features.[32]

Table 157-13 summarizes treatment for MOTT. Importantly, some MOTT organisms are resistant to standard tuberculosis therapy. PCR testing for mycobacterial DNA is not yet reliable enough to play a role in the diagnosis of disease but can sometimes be useful in distinguishing among species.

SKIN INFECTIONS WITH MYCOBACTERIA OTHER THAN *MYCOBACTERIUM TUBERCULOSIS*

MYCOBACTERIUM ULCERANS (BURULI ULCER DISEASE)

The natural habitat of *M. ulcerans* is still not known, and it has never been found outside the human body, but *M. ulcerans* infection occurs in wet, marshy, or swampy areas and seems to have to do with contaminated water. *M. ulcerans* is the third most frequent mycobacterial pathogen, after *M. tuberculosis* and *M. leprae*.

Clinical Findings: The disease is found most often in children and young adults, and affects females more often than males. A subcutaneous nodule gradually enlarges and eventually ulcerates. A blister may develop before ulceration. The ulcer is deeply undermined, and necrotic fat is exposed (Fig. 157-11). The preceding nodule, as well as the ulcer, is painless, and the patient continues to feel well. The painless nature of the ulcer has been attributed to nerve damage and tissue destruction caused by the toxin mycolactone. The lesions may occur anywhere on the body but tend to be limited to the extremities in adults. They may be large, involving a whole limb. The ulceration may persist for months and years, and healing and progression of the ulceration may occur in the same patient. This process may lead to appreciable and sometimes disabling scarring and lymphedema. Neither lymphadenopathy nor any constitutional signs appear at any time unless the disease process is complicated by bacterial superinfection.

Differential Diagnosis: Table 157-14 outlines the differential diagnosis of *M. ulcerans* lesions.

MYCOBACTERIUM MARINUM (*MYCOBACTERIUM BALNEI*, FISH TANK/SWIMMING POOL GRANULOMA)

M. marinum occurs in freshwater and saltwater, including swimming pools and fish tanks.

Clinical Findings: Risk factors for *M. marinum* infection are a history of trauma and water- or fish/seafood-related hobbies and occupations. The disease begins as a violaceous papule at the site of a trauma 2 to 3 weeks after inoculation. Patients may have a nodule or a psoriasiform or verrucous plaque at the site of inoculation, usually the hands, feet, elbows, or knees (Fig. 157-12). The lesions may ulcerate. Usually, the lesions are solitary, but occasionally lymphocutaneous spread occurs. They may heal spontaneously within 1 to 2 years, with residual scarring. Occasionally, the lesions are suppurative, rather than granulomatous, and may be multiple in both normal and immunosuppressed hosts.

Differential Diagnosis: Table 157-15 outlines the differential diagnosis of *M. marinum* lesions.

MYCOBACTERIUM KANSASII

M. kansasii is the atypical *Mycobacterium* most closely related to *M. tuberculosis*. It is usually acquired from the environment. Endemic areas include Texas, Louisiana, the Chicago area, California, and Japan. Skin disease

TABLE 157-13
Treatment of Infections with Mycobacteria Other Than *Mycobacterium Tuberculosis*

	MYCOBACTERIUM SPECIES							
TREATMENT	***ULCERANS***	***MARINUM***	***KANSASII***	***INTRACELLULARE-AVIUM***	***SCROFULACEUM***	***HAEMOPHILUM***	***CHELONAE***	***FORTUITUM***
Amikacin			+				+	+
Ansamycin				+				
Azithromycin				+				
Cefoxitin								+
Ciprofloxacin								+
Clarithromycin				+	+		+	
Clofazimine	+			+				
Cotrimoxazole	+							
Cycloserine			+					
Dapsone	+							
Doxycycline		+					+	
Erythromycin							+	
Ethambutol[a]	+	+	+	+				
Ethionamide			+	+				
Imipenem								+
Isoniazid			+	+	+			
Kanamycin			+					
Minocycline	+	+	+	+		+[b]		
Rifampicin	+	+	+	+	+			
Rifamycin			+	+		+		
Streptomycin[a]	+		+	+				
Tobramycin								+
Surgery	+				+		+	+

[a]Usual antituberculosis drugs.
[b]Alone or in combination with ciprofloxacin or rifampicin.

Figure 157-11 *Mycobacterium ulcerans* infection in a child in Uganda. The knee bears an ulcer with an infiltrated undermined margin and a base of necrotic adipose and connective tissue. (Used with permission from M. Dietrich, MD.)

TABLE 157-14
Differential Diagnosis of *Mycobacterium Ulcerans* Lesions

EARLY LESIONS	LATE LESIONS
Most Likely	
Foreign-body granuloma	Blastomycosis or other deep fungus infection
Sebaceous cyst	Pyoderma gangrenosum
Consider	
Phycomycosis	Suppurative panniculitis
Nodular fasciitis	
Appendageal tumor	
Always Rule Out	
Panniculitis	Necrotizing cellulitis
Nodular vasculitis	

Figure 157-12 **A,** *Mycobacterium marinum* infection on the back of the hand. Granulomatous nodular lesion with central ulceration at the site of inoculation. (Used with permission from A. Kuhlwein, MD.) **B,** Verrucous, violaceous plaque with central spontaneous clearing occurring at the site of an abrasion sustained in a fish tank. The lesion was caused by *M. marinum*.

caused by *M. kansasii* usually occurs in adults, and is more common in individuals with underlying immunosuppression caused by Hodgkin disease, treatment for organ transplantation, or AIDS. Inoculation is usually attributable to minor trauma such as a puncture wound.

Clinical Findings: *M. kansasii* infection may present in several forms. Most frequently, there are papules in a sporotrichoid distribution. Sometimes, subcutaneous nodules extend to deeper structures and may result in a carpal tunnel syndrome or joint disease. An ulcerated plaque may also develop as a metastatic lesion. Disseminated disease caused by *M. kansasii* infection occurs in immunosuppressed patients, and such patients have cellulitis and abscesses rather than granulomatous lesions. The most commonly affected organ is the lung, usually in patients with other pulmonary conditions (silicosis, emphysema). Infection may also cause cervical lymphadenopathy. As with *M. tuberculosis*, *M. kansasii* present in nasopharyngeal secretions can lead to periorificial cutaneous infection. These infections usually progress slowly, although a chronic stable lesion or even spontaneous regression may occur. Drug therapy should be initiated as soon as the diagnosis is made.

Differential Diagnosis: Table 157-16 outlines the differential diagnosis of *M. kansasii* lesions.

MYCOBACTERIUM SCROFULACEUM

Mycobacterium scrofulaceum is widely distributed in the environment.

Clinical Findings: The usual manifestation of *M. scrofulaceum* infection is cervical lymphadenitis, frequently unilateral, in children, mainly between the ages of 1 and 3 years. Submandibular and submaxillary nodes are typically involved, rather than the tonsillar and anterior cervical nodes, as is characteristic for *M. tuberculosis* infection. There are no constitutional symptoms. Involved lymph nodes enlarge slowly over several weeks, and eventually ulcerate and develop fistulas. There is rarely an evidence of lung or other organ involvement. In most cases, the disease is benign and self-limited.

TABLE 157-15
Differential Diagnosis of *Mycobacterium Marinum* Lesions

Most Likely
- Blastomycosis
- Coccidioidomycosis
- Sporotrichosis

Consider
- Histoplasmosis
- Nocardiosis
- Tertiary syphilis
- Yaws

Always Rule Out
- Other mycobacterial infections

TABLE 157-16
Differential Diagnosis of *Mycobacterium Kansasii* Lesions

Most Likely
- Sporotrichosis

Consider
- Tuberculosis

Always Rule Out
- Other granulomatous infections of the skin

Differential Diagnosis: The differential diagnosis includes other forms of bacterial lymphadenitis; viral infections, including mumps and mononucleosis; and malignancy, including solid tumors, lymphoma, and leukemia.

MYCOBACTERIUM AVIUM-INTRACELLULARE

M. avium-intracellulare encompasses organisms with a wide variety of microbiologic and pathogenic properties. More than 20 subtypes can be separated by immunologic techniques, although this is not necessary for clinical purposes.

These organisms are usually grouped together with *M. scrofulaceum* in the so-called *M. avium*-intracellulare–scrofulaceum complex, but are separated here for clinical reasons. Whereas *M. scrofulaceum* produces only a benign, self-limited lymphadenopathy with no organ involvement, *M. avium*-intracellulare infection usually causes lung disease or, less frequently, osteomyelitis. It may also produce a cervical lymphadenitis with sinus formation that is clinically indistinguishable from tuberculous scrofuloderma.

Clinical Findings: Primary skin disease caused by *M. avium*-intracellulare has been reported in rare instances, presenting as single or multiple painless, scaly yellowish plaques, sometimes resembling LV, or as subcutaneous nodules with a tendency to ulceration and a slowly progressive, chronic course. Sometimes, skin involvement occurs secondary to disseminated infection with *M. avium*-intracellulare. Skin lesions have included generalized cutaneous ulcerations, granulomas, infiltrated erythematous lesions on the extremities, pustules, and soft-tissue swelling. *M. avium*-intracellulare infections are an important cause of morbidity in patients with AIDS (see Chap. 168).

MYCOBACTERIUM SZULGAI, MYCOBACTERIUM HAEMOPHILUM, MYCOBACTERIUM GENAVENSE

Mycobacterium szulgai, *Mycobacterium haemophilum*, and *Mycobacterium genavense* are rarely found to cause human disease in cases of otherwise unexplained cervical lymphadenitis, cellulitis, draining nodules and plaques, bursitis, pneumonia, and subcutaneous granulomatous eruptions.

MYCOBACTERIUM FORTUITUM, MYCOBACTERIUM CHELONAE, MYCOBACTERIUM ABSCESSUS

M. fortuitum, Mycobacterium chelonae, and *Mycobacterium abscessus*—3 species of fast-growing, facultative pathogenic mycobacteria—were previously grouped in the *M. fortuitum* complex but are now recognized as distinct species. These organisms seem to be widely distributed and can commonly be found in soil and water. Contamination of various materials, including surgical supplies, occurs but does not always result in clinical disease.

Clinical Findings: *M. fortuitum, M. chelonae,* and *M. abscessus* cause similar clinical diseases. Infection usually follows a puncture wound or a surgical procedure. The disease manifests itself as a painful red infiltrate at the site of inoculation; there are no signs of dissemination and no constitutional symptoms. Cold postinjection abscesses, especially in the tropics, also may be caused by fast-growing mycobacteria. Recent cases in the United States have followed after pedicures and water immersion in salons.

The lesion is a dark red nodule, often with abscess formation and clear fluid drainage. Healthy children and adults may become infected, but disseminated disease usually occurs in hemodialysis patients or other immunologically compromised individuals. The disease course consists of multiple recurrent episodes of abscesses on the extremities or a generalized macular and papular eruption. Internal organs may be involved.

Histopathology: There is simultaneous occurrence of polymorphonuclear leukocyte microabscesses and granuloma formation with foreign-body–type giant cells, the so-called dimorphic inflammatory response. There is usually necrosis but no caseation. Acid-fast bacilli may occasionally be found within microabscesses.

Diagnosis: Organisms of the *M. fortuitum* complex may be identified by special laboratories to permit a rational treatment.

ACKNOWLEDGMENTS

The author thanks Bernard Naafs, MD, for his work on this chapter in the previous editions of this book.

REFERENCES

1. WHO report 2009–Global Tuberculosis Control. http://apps.who.int/iris/bitstream/handle/10665/44241/9789241598866_eng.pdf;sequence=1. Last accessed March 13, 2010.
2. Centers for Disease Control and Prevention (CDC). Trends in tuberculosis—United States, 2008. *MMWR Morb Mortal Wkly Rep.* 2009;58:249.
3. Pai M, Kalantri S, Dheda K. New tools and emerging technologies for the diagnosis of tuberculosis: part II. Active tuberculosis and drug resistance. *Expert Rev Mol Diagn.* 2006;6:423.
4. Pai M, Kalantri S, Dheda K. New tools and emerging technologies for the diagnosis of tuberculosis: part I. Latent tuberculosis. *Expert Rev Mol Diagn.* 2006;6:413.
5. Tsiouris SJ, Austin J, Toro P, et al. Results of a tuberculosis-specific IFN-gamma assay in children at high risk for tuberculosis infection. *Int J Tuberc Lung Dis.* 2006;10:939.

6. Tan SH, Tan HH, Sun YJ, et al. Clinical utility of polymerase chain reaction in the detection of Mycobacterium tuberculosis in different types of cutaneous tuberculosis and tuberculids. *Ann Acad Med Singapore.* 2001;30:3.
7. Barbagallo J, Tager P, Ingleton R, et al. Cutaneous tuberculosis: diagnosis and treatment. *Am J Clin Dermatol.* 2002;3:319.
8. Li N, Bajoghli A, Kubba A, Bhawan J. Identification of mycobacterial DNA in cutaneous lesions of sarcoidosis. *J Cutan Pathol.* 1999;29:271.
9. Young DB, Stewart GR. Tuberculosis vaccines. *Br Med Bull.* 2002;62:73.
10. Myers JP. New recommendations for the treatment of tuberculosis. *Curr Opin Infect Dis.* 2005;18:133.
11. Murali MS, Sajjan BS. DOTS strategy for control of tuberculosis epidemic. *Indian J Med Sci.* 2002;56:16.
12. Iseman MD. Tuberculosis therapy: past, present and future. *Eur Respir J Suppl.* 2002;36:87s.
13. Holland SM. Cytokine therapy of mycobacterial infections. *Adv Intern Med.* 2000;45:431.
14. Centers for Disease Control and Prevention (CDC). Extensively Drug Resistant (XDR) TB Update. https://www.cdc.gov/tb/default.htm. Accessed March 14, 2010.
15. Zouhair K, Akhdari N, Nejjam F, et al. Cutaneous tuberculosis in Morocco. *Int J Infect Dis.* 2007;11:209.
16. Kivanc-Altunay I, Baysal Z, Ekmekçi TR, et al. Incidence of cutaneous tuberculosis in patients with organ tuberculosis. *Int J Dermatol.* 2003;42:197.
17. Jensen PA, Lambert LA, Iademarco MF, et al. Guidelines for preventing the transmission of Mycobacterium tuberculosis in health-care settings, 2005. *MMWR Recomm Rep.* 2005;54(RR-17):1.
18. The role of BCG vaccine in the prevention and control of tuberculosis in the United States. A joint statement by the Advisory Council for the Elimination of Tuberculosis and the Advisory Committee on Immunization Practices. *MMWR Recomm Rep.* 1996;45(RR-4):1.
19. Bellet JS, Prose NS. Skin complications of bacillus Calmette-Guérin immunization. *Curr Opin Infect Dis.* 2005;18:97.
20. Degitz K. Detection of mycobacterial DNA in the skin. Etiologic insights and diagnostic perspectives. *Arch Dermatol.* 1996;132:71.
21. Tan SH, Tan BH, Goh CL, et al. Detection of Mycobacterium tuberculosis DNA using polymerase chain reaction in cutaneous tuberculosis and tuberculids. *Int J Dermatol.* 1999;38:122.
22. Drake WP, Newman LS. Mycobacterial antigens may be important in sarcoidosis pathogenesis. *Curr Opin Pulm Med.* 2006;12:359.
23. Komatsu H, Terunuma A, Tabata N, et al. Mycobacterium avium infection of the skin associated with lichen scrofulosorum: report of three cases. *Br J Dermatol.* 1999;141:554.
24. Victor T, Jordaan HF, Van Niekerk DJ, et al. Papulonecrotic tuberculid. Identification of Mycobacterium tuberculosis DNA by polymerase chain reaction. *Am J Dermatopathol.* 1992;14:491.
25. Jordan HF, Schneider JW, Abdulla EA. Nodular tuberculid: a report of four patients. *Pediatr Dermatol.* 2000;17:183.
26. Senol M, Ozcan A, Aydin A, et al. Disseminated lupus vulgaris and papulonecrotic tuberculid: case report. *Pediatr Dermatol.* 2000;17:133.
27. Callahan EF, Licata AL, Madison JF. Cutaneous Mycobacterium kansasii infection associated with a papulonecrotic tuberculid reaction. *J Am Acad Dermatol.* 1997;36:497.
28. Hay RJ. Cutaneous infection with *Mycobacterium tuberculosis*: how has this altered with the changing epidemiology of tuberculosis? *Curr Opin Infect Dis.* 2005;18:93.
29. Rastogi N, Legrand E, Sola C. The mycobacteria: an introduction to nomenclature and pathogenesis. *Rev Sci Tech.* 2001;20:21.
30. Saiman L. The mycobacteriology of non-tuberculous mycobacteria. *Paediatr Respir Rev.* 2004;5(suppl A): S221.
31. Lillis JV, Ansdell VE, Ruben K, et al. Sequelae of World War II: an outbreak of chronic cutaneous nontuberculous mycobacterial infection among Satowanese islanders. *Clin Infect Dis.* 2009;48:1541.
32. Bartralot R, Pujol RM, García-Patos V, et al. Cutaneous infections due to nontuberculous mycobacteria: histopathological review of 28 cases. Comparative study between lesions observed in immunosuppressed patients and normal hosts. *J Cutan Pathol.* 2000;27:124.

Chapter 158 :: Actinomycosis, Nocardiosis, and Actinomycetoma

:: Francisco G. Bravo, Roberto Arenas, & Daniel Asz Sigall

Actinomyces and *Nocardia* are a group of filamentous bacteria belonging to the same class, Actinobacteria, and same order, Actinomycetales. They cause human disease with prominent skin involvement. Microorganisms under this category were wrongly classified as fungi for a long time, because of their tendency to produce branching filaments, mimicking radiating hyphae (from the Greek *actino*, meaning *sun*). Their taxonomy is still evolving, resulting in continuous reclassification of different species in old and new families. Anaerobic endogenous *Actinomyces*, which are part of our normal respiratory, intestinal, and genitourinary flora, will cause localized suppurative disease with fistula formation that is analogous to the lumpy jaw of cattle. Aerobic environmental *Nocardia* sp. can cause primary cutaneous disease, ranging from cellulitis to paronychia to abscesses, with the most striking presentation being a lymphocutaneous, sporotrichoid syndrome; cutaneous nocardiosis as a consequence of hematogenous dissemination from a pulmonary source is also seen, but it is characteristically of a state of immunosuppression. In addition, other aerobic environmental species of *Nocardia* and *Actinomyces* will cause 1 of the 2 known forms of mycetoma, the actinomycetoma.

The sulfur granule or grain, a clumping of filamentous bacteria seen in infected living tissue, is considered characteristic of the infection by these microorganisms, but is not always present and is also not specific (Table 158-1). Practicing dermatologists should be aware of the various morphologic variants of these diseases and the measures that should be taken to ensure the appropriate culturing techniques required for isolation.

ACTINOMYCOSIS

AT-A-GLANCE

- Worldwide distribution, relatively uncommon.
- *Actinomyces* are part of normal upper respiratory, intestinal, and genitourinary flora.
- *Actinomyces israelii* is the most common causative agent, usually as part of a polymicrobial infection, mixed with anaerobes and Gram-positive cocci.
- Classical presentation is a chronic, localized, infiltrative, bulging process with abscess fistula formation and draining sinuses.
- Most common location is cervicofacial (related to dental pathology), followed by chest wall, abdominal, and pelvic involvement.
- Pathologic findings include a chronic inflammatory infiltrate with granulation tissue or granuloma formation.
- Grains (sulfur granules) are characteristic but neither invariably present nor pathognomonic.

DEFINITION

Actinomycosis can be defined as a chronic, progressive, indolent infection by endogenous *Actinomyces* species, which are common inhabitants of the human mucosal surfaces, including the oral cavity, pharynx, distal esophagus, and genitourinary tract. This endogenous source is the main concept used to distinguish actinomycosis from actinomycetoma; in the case of mycetomas, the infection agent is an environmental actinomyces, making the bacteria responsible for the infection of exogenous origin.

HISTORICAL PERSPECTIVE

Actinomycosis was described by Israel in 1878; its causative agent, originally named *Streptothrix israeli* (currently *Actinomyces israelii*), was described by Kruse in 1896. It remained the only described etiologic agent of the disease until 1951, where *Actinomyces naeslundii* was implicated in other human cases, while *Actinomyces odontolyticus* and *Actinomyces viscosus* were described in 1958 and 1969, respectively. Currently, 25 validly published *Actinomyces* species recovered from human material are recognized.[1]

EPIDEMIOLOGY

Actinomycosis has a worldwide distribution and is relatively rare, with a tendency to decline, especially in

TABLE 158-1
Diagnostic Approach to Diseases That Produce Grains

DISEASE	ACTINOMYCOSIS	NOCARDIOSIS	ACTINOMYCETOMA	EUMYCETOMA	BOTRYOMYCOSIS
Clinical pattern	Lump with draining sinuses	Sporotrichoid, cellulitis, abscesses	Lump with draining sinuses	Lump with draining sinuses	Lump with draining sinuses
Site	Cervicofacial, thorax, abdomen, pelvic	Extremities (upper > lower)	Feet, back, extremities	Feet, mainly	Hand, head, feet
Source	Endogenous flora	Environment	Environment	Environment	Endogenous and environment
Most common agent	*Actinomyces israelii*	*Nocardia brasiliensis* *Nocardia asteroides*	*Nocardia brasiliensis* *Actinomadura madurae* *Actinomadura pelletieri* *Streptomyces somaliensis*	*Madurella mycetomatis* *Madurella grisea* *Pseudallescheria boydii*	*Staphylococcus aureus* *Escherichia coli* *Pseudomonas aeruginosa*
Grains, clinically or histologically	Common	Rare (only in disseminated cases)	Always	Always	Always
Grain contents	Filamentous bacteria	Filamentous bacteria	Filamentous bacteria	Hyphae	Cocci (most common)
Staining	Gram positive	Gram positive Weak acid-fast bacillus	Gram positive Weak acid-fast bacillus (only if *Nocardia*)	Periodic acid-Schiff, Grocott	Gram positive

developed countries, because of a higher standard of oral care and the disease's susceptibility to many antibiotics. It is more commonly seen in males, ages 20 to 60 years, although females predominate in cases of genitourinary actinomycosis, because of its relationship to the use of intrauterine devices (IUDs). Nowadays, there is a tendency to see more subtle cases, restricted to the oral cavity and before the formation of fistula toward the cutaneous surface. Diagnosis in such circumstances requires a high index of suspicion.

CLINICAL FEATURES

Actinomycosis should be suspected when dealing with 1 of 3 features: a mass-like inflammatory infiltrate of the skin and subcutaneous tissue, sinus formation with drainage, and a relapsing or refractory clinical course after short-term therapy with antibiotics. Actinomycotic granules may be seen macroscopically and is always very suggestive of the diagnosis.

CUTANEOUS FINDINGS

Cervicofacial actinomycosis is the most frequent form of disease[2,3] accounting for approximately 55% of cases. Commonly, there is a history of poor dental hygiene, dental or periodontal disease, dental procedure, surgery, or penetrating trauma through the oral mucosa. Most of the infections start as a periapical abscess. The most common location is on the jaw angle and high cervical area (60%), followed by the cheek (16%), the chin (13%), and, less commonly, the temporomandibular joint and the retromandibular area. The lesion starts as a solid mass in any of those locations, and initially may be confused with a neoplastic process (Fig. 158-1). It may progress to form recurring abscesses and later will spread to adjacent structures, not respecting anatomic planes. Propagation to lymph nodes is

Figure 158-1 Cervicofacial actinomycosis. A solid mass on the mandibular angle that can be confused with a neoplastic process.

Figure 158-2 Typical cervicofacial actinomycosis: a lump with sinus formation. (Used with permission from Wilson Delgado, DDS, and Lepoldo Meneses, DDS, Universidad Peruana Cayetano Heredia, Lima, Peru.)

Figure 158-3 Thoracic actinomycosis from a patient who died from disseminated disease.

uncommon but eventually may involve the orbit, cranium, spine, and even vascular structures. The lesion is sometimes reported as painless, but pain may be present, as well as fever and leukocytosis. With extension to the skin surface, sinus tracts appear (Fig. 158-2). The overlying skin may have a purplish red hue. Trismus may develop. Bone involvement, mostly of the jaw, is present in 10% of cases. More limited disease may produce a mass or an ulcer, affecting any structure in the mouth or the nasopharyngeal region. Extension to the ear may present as chronic otitis media or mastoiditis. In addition to orbital involvement, there are reported cases of lacrimal canaliculitis and endophthalmitis. Regional lymphadenopathy is uncommon.

Thoracic actinomycosis comprises 15% to 20% of cases. The common source of infection is the aspiration of a microorganism from the oropharynx, although other routes are possible, such as propagation of cervicofacial disease to the mediastinum. The disease may involve the lung, pleura, mediastinum, and chest wall. The course is indolent, with chest pain, fever, weight loss, cough, and, less frequently, hemoptysis, mimicking tuberculosis. Radiologically, the disease will present as a mass or pneumonia, with pleural involvement by continuity. Relevant to dermatologists, up to 26% of cases will have chest wall involvement, the so-called empyema necessitans, with the development of a cutaneous abscess and sinus formation (Fig. 158-3). Parenchymal, pleural, and chest wall disease occurring together will make actinomycosis a most likely diagnosis. Mediastinal actinomycosis may show either as anterior chest wall disease (rarely sternal involvement), or paraspinal abscess. Involvement of breast tissue and breast implants also has been described.

Abdominal actinomycosis represents approximately 20% of all cases. It is usually the consequence of spreading from the GI tract or from the female genital tract. Appendicitis and diverticulitis are common precipitating events and appendicitis or diverticulitis may be present in up to 65% of cases; the clinical presentation will be of a right iliac fossa mass. Any organ in the peritoneal cavity may be affected; by local extension, the disease may spread to the abdominal wall or perineum. An inflammatory mass may eventually appear in the skin surface of the abdominal region or the perineum, with later development of fistula. In the perianal area, multiple abscesses and fistula formation may occur. The disease may spread from the anal area to the buttocks, thighs, scrotum and groin.

Primary pelvic disease most often originates from ascending infection from the female genital tract, and less often from abdominal disease. The role of the IUD as a risk factor has been clearly established and infection is usually associated with its use for longer than 2 years. Studies show that IUD usage averages 8 years.

Punch or fist actinomycosis represents a particularly uncommon but interesting clinical presentation. It usually follows blunt trauma of a closed fist against a person's mouth; similar findings may originate from a human bite. Punch actinomycosis usually involves the proximal phalanges and metacarpal bones. The actinomycosis appears as a soft-tissue infection that eventually spreads to the bony structures. Grains are commonly seen in this particular form.[4]

NONCUTANEOUS FINDINGS

Actinomycosis of the CNS may present as brain abscess, meningitis, meningoencephalitis, subdural empyema, actinomycoma, or spinal abscess. It is usually secondary to hematogenous spread or direct extension of orocervical infection. Other sites affected include bones, muscle tissue, and prosthetic joints.

ETIOLOGY AND PATHOGENESIS

The term *actinomycosis* implies disease produced by endogenous, anaerobic, or microaerophile, Gram-positive, non–spore-forming bacteria, belonging to the families Actinomycetaceae, genus *Actinomyces*.[1] Their normal habitat is human mucosal surfaces, with considerable host specificity, from the mouth to the upper respiratory, GI, and female genital tracts. Species known to cause disease in humans include *A. israelii*, *Actinomyces gerencseriae*, *A. naeslundii*, *A. viscosus*, *A. odontolyticus*, and *Actinomyces meyeri*. In orocervical disease, the predominant species include *A. israelii*, *A. naeslundii*, *A. viscosus*, and *A. odontolyticus*, whereas in thoracic disease, *Actinomyces graevenitzii*, seems to predominate. The disease in most cases is mixed with other microorganisms sharing the same habitat, so it should be considered a synergistic infection, with the *Actinomyces* playing the role of guiding organism, defining the course, the symptoms, and the ultimate prognosis. Accompanying organisms may vary in number, from 1 to 9 different species, and may include *Fusarium* and *Bacteroides* species, microaerophile and anaerobic streptococci, *Aggregatibacter* species, and aerobic coagulase negative staphylococci.[1] This concomitant flora may be partly responsible for the disease course. In recent years, with better culturing techniques and molecular microbiology, more than 1 *Actinomyces* has been isolated from a single lesion in several patients, stressing the possibility that single bacterial isolation, common in the past, was a technical artifact.

The infection has its portal of entry at a break on a mucous membrane. Most cervical and facial cases originate from periapical abscesses or after dental procedures. *Actinomyces* bacteremia seems to occur quite often after dental procedures.

Thoracic cases represent involvement of the chest wall by local spreading either from pleural or lung disease acquired by obstruction or aspiration. The same mechanism of spreading applies to disease of the abdominal wall, secondary to gut or genital pathology, following appendicitis, diverticulitis, surgery, or trauma. Perineal disease occurs as a consequence of involvement of the internal organs of the pelvis, often secondary to use of an intravaginal device or IUD. The only exception to the endogenous origin of the infection is hand involvement that follows fist or bite trauma.[4]

In tissue, the bacteria cluster in filamentous aggregates, the so-called *sulfur granules* (grains; see Table 158-1). They are commonly surrounded by acute and chronic inflammation, usually neutrophils, granulation tissue, and fibrosis. Foamy histiocytes may be part of the infiltrate but true granuloma formation is rare. The fistula formation may give way to drainage of granules, but their presence by themselves should not be considered specific for this disease, as they also can be seen in mycetomas and botryomycosis.

RISK FACTORS

Although most patients are immunocompetent, conditions linked to immunosuppression, such as prolonged administration of steroids, bisphosphonates, leukemia with chemotherapy, HIV, lung and renal transplant receipt, alcoholism, and local tissue damage by trauma, recent surgery, or radiation, all are associated with the disease.[3]

DIAGNOSIS

LABORATORY TESTING

Most diagnoses are based on the clinical isolation of *Actinomyces* species. Laboratory tests considered useful include direct examination of draining material, culture, and biopsy. Direct examination will show the presence of filamentous *Actinomyces* on Gram stain. The isolation of *Actinomyces* in culture should be considered diagnostic, if coming from a sterile site. However, positive culture rates are as low as 35% in some series. The processing should be done in anaerobic conditions, and the laboratory should be notified of the clinical suspicion of actinomycosis. Negative culture can be the result of previous antibiotic treatment, overgrowth of concomitant microorganisms or inadequate methodology.

Best material is purulent drainage, tissue, or microscopic granules, and avoidance of any antibiotic treatment is recommended before culturing; swabs are not considered an appropriate sampling method. Appropriate culture media include thioglycolate with 0.5 sterile rabbit serum at 35°C (95°F) for 14 days. Colonies may appear within 5 to 7 days, but up to 2 weeks may be required. *A. israelii* classically will produce a "molar tooth" colony on agar and will look clumpy on broth. *A. odontolyticus* colonies are red or rusty in color. *Actinomyces* are indole-negative. The microbiologic identification of different species occurs only in a minority of cases. Tests for urease, catalase, gelatin hydrolysis, and fermentation of cellobiose, trehalose, and arabinose can be performed. New techniques that can be used include polymerase chain reaction, sequencing or restriction analysis of amplified 16S ribosomal DNA, fluorescence in situ hybridization, and mass spectrometry.[3]

PATHOLOGY

The presence of granules, either microscopically or macroscopically, is very relevant, especially if obtained from tissues not connected to mucosal surfaces. Grains are usually yellow (hence the name *sulfur granules*), but can be white, pinkish gray, gray, or brown. In tissue samples, special stains, such as Brown-Brenn, Gram, Giemsa, or Gomori, are required to demonstrate filamentous structures. The number of grains may be scanty: 25% of specimens in a study of 181 cases had a

single granule in the whole sample.[3] The microscopic examination of the granules may reveal the Splendore-Hoeppli phenomena, a rim of eosinophilic material surrounding the granules in tissue cuts. The lack of staining with Fite-modified acid-fast stain separates *Actinomyces* from *Nocardia* species, which is usually acid-fast positive. Eumycetoma granules stain positive with periodic acid–Schiff and Gomori, as any other fungus, whereas granules from botryomycosis should show clumps of nonfilamentous bacteria. Direct immunofluorescent staining is available for some species, including *A. israelii*.

IMAGING

In early stages, imaging features are nonspecific and nondiagnostic. Computed tomography and magnetic resonance in advanced stages may show nonspecific findings, such as an abscess or phlegmon, but may give good anatomical references that facilitate the aspiration of pus material suitable for direct examination and cultures.

DIFFERENTIAL DIAGNOSIS

Depending on the site affected, the differential diagnosis includes infections such as tuberculosis, noninfectious inflammatory processes such as hidradenitis and inflammatory bowel disease, and neoplasia (Table 158-2).

MANAGEMENT

MEDICATIONS

Historically, the treatment of actinomycosis requires high-dose antibiotics given for a long period. The treatment of choice is penicillin G, 18 to 24 million units IV for 2 to 6 weeks, followed by oral penicillin or amoxicillin, to be given for 6 to 12 months. The risk of developing penicillin resistance is low. However, this prolonged therapy may not be needed in all patients. Cervicofacial disease or any limited disease can receive a shorter course of therapy. A good rule to follow is to give therapy until full resolution of clinically evident disease. Some authors recommend the initial use of a β-lactam and a β-lactam inhibitor such as clavulanate or tazobactam, which provide additional cover against potential β-lactam producers such as *Staphylococcus aureus* and Gram-negative anaerobes. Alternative treatment for those allergic to penicillin includes tetracycline, doxycycline, erythromycin, and clindamycin. Imipenem has been used successfully as short-term therapy. Chloramphenicol is the alternative to penicillin in cases of CNS involvement. Some studies show that many species of actinomyces are susceptible to new drugs, such as linezolid and tigecycline. Risk factors for relapse or death include duration of disease longer than 2 months, lack of antibiotic therapy or surgical therapy, and needle aspiration rather than open drainage or excision.

With early diagnosis and more limited disease, compared to the bulky disease of the past, treatment can be shorter: 30 days for cervicofacial disease and 3 months for pelvic or thoracic disease.[3,5] In such cases, clinical response should be closely monitored. Periapical actinomycosis can be successfully treated with curettage and 10 days of antibiotic therapy.

PROCEDURES

Surgery is indicated for bulky disease involving the chest, abdomen, pelvis, and CNS. Its aim should be resection of necrotic tissue, excision of sinus tracts, draining of empyemas and abscesses, and curettage of bone, always accompanied by antibiotic therapy.

PREVENTION

Good oral hygiene and prevention of periodontal disease may decrease colonization by *Actinomyces*. Physicians dealing with patients using an IUD should be aware of the risk of developing the disease.

TABLE 158-2

Differential Diagnosis of Actinomycosis (Site-Specific)

Most Likely

- *Face:* tuberculosis, odontogenic abscesses, parotid tumors
- *Chest:* tuberculosis, neoplasm, pyogenic infections
- *Abdomen and pelvis:* tuberculosis, inflammatory bowel disease, hidradenitis suppurativa, neoplasm

Consider

- *Face:* lupus panniculitis, granuloma inguinale
- *Pelvis:* granuloma inguinale

NOCARDIOSIS

AT-A-GLANCE

- Aerobic Gram-positive filamentous bacteria.
- Worldwide distribution, environmentally acquired infection, results from primary traumatic inoculation.
- Pulmonary infections mostly in immunocompromised patients and skin infections mostly in immunocompetent patients.
- Primary skin disease mostly caused by *Nocardia brasiliensis*. If it is a consequence of hematogenous dissemination, the most likely microorganism is *Nocardia asteroides*.

(Continued)

AT-A-GLANCE (*Continued*)

- Cutaneous nocardiosis can take the form of either cellulitis or more characteristic lymphocutaneous nodules in a sporotrichoid pattern; skin lesions in the form of hemorrhagic pustules or abscesses occur in disseminated disease.
- Diagnosis is based on Gram stain of clinical specimen showing thin, Gram-positive branching bacteria, weakly positive with acid-fast staining; microbiologic isolation of *Nocardia* sp. is diagnostic, but requires keeping cultures under observation 5 to 7 days.
- Treatment: sulfonamides.

DEFINITIONS

Cutaneous nocardiosis is the infection of skin by environmental *Nocardia sp*, either as a result of direct inoculation through trauma, thus is, primary cutaneous nocardiosis, or as a consequence of hematogenous seeding, usually from a pulmonary source. Primary cutaneous nocardiosis is a disease of immunocompetent patients, whereas secondary hematogenous spreading is seen in the context of immunosuppression.

HISTORICAL PERSPECTIVE

Edward Nocard described the filamentous bacteria *Norcadia* sp. In 1888, after its clinical isolation from cattle affected by farcy. The first human case was described by Eppinger in 1890, in a patient with pulmonary and pleural involvement, under the name "pseudotuberculosis." Since then, multiple reports have emphasized the relevance of pulmonary and cutaneous nocardiosis as the most common clinical presentations, with the potential for systemic dissemination.

EPIDEMIOLOGY

By 2017, approximately 1000 cases of nocardiosis were reported annually in the United States.[6] However, considering the increasing number of transplantation patients, patients immunosuppressed by chemotherapy, patients on chronic corticosteroid therapy, HIV patients not receiving appropriated antiviral therapy, and patients with primary pulmonary diseases such as chronic obstructive pulmonary disease, the number of cases occurring annually is probably underestimated. At least 50% of patients will have some sort of immunosuppression. Nocardiosis occurs most commonly in males. The most common presentation of nocardiosis is pulmonary disease. Agricultural occupation is common in pulmonary nocardiosis, but a history of environmental exposure on a farm or in the wilderness is also common in the primary cutaneous form. Primary cutaneous involvement represents from 5% to 24% of nocardiosis cases. The higher incidence of primary cutaneous nocardiosis in Europe may be explained on the basis of more frequent isolation of *Nocardia brasiliensis* in the environment.[6]

CLINICAL FEATURES

CUTANEOUS FINDINGS

Cutaneous involvement by *Nocardia* can manifest either as an abscess, cellulitis, or more characteristically, as lymphocutaneous nodules in a sporotrichoid pattern. Disseminated disease also can be present in the skin as a consequence of hematogenous spread, from hemorrhagic pustules to ecthyma and abscesses.[7] In most series, skin disease is second in frequency after pulmonary involvement. Mycetoma caused by *Nocardia* is discussed above under "Actinomycetoma."

Predisposing factors for primary cutaneous nocardiosis include soil or sand exposure while gardening or farming; or superficial injury from domestic shrubbery, outdoor falls, or accidents. The frequent history of thorn injury or gardening may suggest, incorrectly, a diagnosis of sporotrichosis. Insect bites, cat scratches, or just barely contact with them have been reported as the portal of entry, especially in children.[8]

Most patients with primary cutaneous nocardiosis are immunocompetent, but *Nocardia* cutaneous infection may also occur in the context of immunosuppression. A series of nocardial infections in AIDS patients showed skin lesions in 11% of cases, most commonly cutaneous abscesses and suppurative adenitis.[9] Relevant to dermatologist, nocardiosis has been described in patients receiving anti–tumor necrosis factor biologic therapy for Crohn disease, and also as a complication of immunosuppressive therapy in the context of pemphigus.[10,11]

The disease has been also described in ulcerative bullous, linear/keloid, and nodulopustular forms (Fig. 158-4A) that may evolve into the more specific sporotrichoid pattern (Fig. 158-4B). This sporotrichoid or lymphocutaneous forms may account for 24% of all *Nocardia* cutaneous infections (Fig. 158-4B).[12] The first case proven to be caused by *N. brasiliensis* was described by Alarcon; the patient developed acute nodular suppurative lymphadenitis after injuring the finger with a rose thorn. Although the upper extremity is the most common location, disease of the lower extremity and cervicofacial region also have been reported. A common history is appearance of a solitary papule or nodule on the upper limbs, 2 to 4 weeks after cutaneous inoculation. Then, proximal nodules develop along lymphatic drainage. The primary lesion is initially warm and tender, then becomes fluctuant, and later ulcerates. Systemic symptoms are mild. Regional lymphadenitis is common but lymphangitis is unusual.

Patients may also present acutely with eccrine hidradenitis, or chronically with hyperkeratotic plaques. Cutaneous nocardiosis may begin suddenly, reactivate after months to years, or follow a chronic course for up to 10 years. A case of

Figure 158-4 **A,** Early lesions of lymphocutaneous nocardiosis. **B,** Lymphocutaneous nocardiosis: typical sporotrichoid pattern. (Used with permission from Daniel Asz and Roberto Arenas, Hospital Manuel Gea González, Mexico City, Mexico.)

simultaneous infection in a husband and wife also has been described. Very rarely, pure cutaneous disease may lead to systemic illness. The cellulitis form most commonly affects the lower extremities, as compared to sporotrichoid form, in which the upper extremities are most often involved. The face has been reported as a rare site, with multiple draining sinuses, but no grains, which distinguishes the cutaneous form from the mycetoma form.[13] Children frequently present with cellulitis, abscesses, and lymphadenitis affecting the lower extremities and trunk; 20% of cases have lesions at multiple sites.[8]

Sternal wound infections usually develop 1 month after thoracic surgery. The symptoms include erythema, clear-to-purulent drainage, wound dehiscence, and/or fever. Diabetes mellitus seems to be the only identifiable risk factor. At least in one outbreak, the hands of an anesthesiologist were culture positive for *Nocardia farcinica*. In another case of sternal osteomyelitis and mediastinal abscess, the patient's occupation (carrying wooden crates loaded with vegetables) may have been the only risk factor for infection, in the absence of chest surgery or trauma.

NONCUTANEOUS FINDINGS

Pulmonary disease is the most common form of clinical infection, but, compared to primary cutaneous diseases, is often caused by different species (*Nocardia asteroides* predominates). The disease may take the form of an acute pneumonia or a chronic process with bronchopneumonia, abscesses, and development of cavities. In 10% of pulmonary actinomycosis there is spreading to the adjacent skin.

Bacteremia resulting from *Nocardia* is seen in patients with concomitant malignancy, and *N. asteroides* is the agent most commonly isolated. Cutaneous or subcutaneous nodules and abscesses occur in many patients, and the skin may be the portal of entry in some cases. Catheter-associated nocardemia is well documented.

ETIOLOGY AND PATHOGENESIS

The *Nocardia* genus includes more than 80 species; approximately 30 of those species have been described as cause of human disease. The *Nocardia* species of medical importance include *N. asteroides*, most commonly associated with lung and systemic disease, and *N. brasiliensis*, most commonly associated with skin infection. The most common cause of primary cutaneous nocardiosis is *N. brasiliensis*, but *N. asteroides*, *Nocardia otitidiscaviarum*, *Nocardia nova*, *N. farcinica*, and most recently, *Nocardia takedensis* also have been implicated.[14] It is only recently that many of those species have been completely separated, especially those of the *N. asteroides* group. It is interesting to note that *Nocardia* species belong to a subgroup of bacteria called the *aerobic nocardioform actinomycetes* that also include *Mycobacterium*, *Corynebacterium*, *Rhodococcus*, and *Gordona*. All these microorganisms have mycolic acid as constituent of their cell wall, which explains the varying acid fastness on appropriate staining.

The usual inflammatory response in infected tissue is neutrophilic, with branching, beading filamentous bacteria within abscesses. Sulfur granules are uncommon in primary cutaneous nocardiosis; they have been described in disseminated disease. They are more commonly seen and consider characteristic when the clinical picture is that of mycetoma (see section "Actinomycetoma").

Certain virulent strains of *Nocardia* are resistant to neutrophil-mediated killing.[15] They can inhibit phagosome-lysosome fusion in vitro, giving rise to L-forms able to survive inside macrophages. The existence of cell wall–deficient L-forms may explain the occasional late relapse. The presence of superoxide dismutase in growth media is characteristic of the more virulent strains. Complex cell wall glycolipids also contribute to virulence.[15]

The initial neutrophilic reaction is followed by a more cell-related immune response that is responsible

for clearing the infection from the lung tissue and prevents dissemination. If this fails, a chronic neutrophilic response results in a more indolent course. Lack of cellular immunity predisposes transplantation and AIDS patients to infection, with transplantation patients accounting for up to 13% of cases in the United States.[6] Some species are considered more difficult to treat: *N. farcinica* has a high degree of resistance to various antibiotics, especially third-generation cephalosporins and aminoglycosides. Another recently described species, *Nocardia pseudobrasiliensis*, has a higher rate of dissemination.

RISK FACTORS

In cases of primary cutaneous nocardiosis, the classical presentation is in a immunocompetent patient. However, many cases of pulmonary nocardiosis with subsequent dissemination take place in the context of immunosuppression. Cases as such are associated with malignancy (either solid organ or hematologic) on chemotherapy or corticosteroid, transplantation (renal and heart transplantations are the most common), AIDS, IV drug abuse, systemic lupus, and nephrotic syndrome.[6,7,16] Corticosteroids, either alone or in conjunction with other drugs that cause immunosuppression, are an important risk factor for developing nocardiosis.

DIAGNOSIS

The definitive diagnosis of nocardiosis can only be made when the isolation of *Nocardia* species is accomplished in culture.

LABORATORY TESTING

Laboratory tests considered useful include direct examination of clinical specimens, culture, and biopsy. The importance of direct microscopic examination for the presence of granules, especially in disseminated cases and lesions that are suppurative, cannot be overemphasized. Organisms are detected as Gram-positive, branched, filamentous "hyphae" (in reality, they are bacteria). They characteristically branch at right angles. Acid-fast stains, including Fite-Faraco and the modified Kinyoun technique, stain the filamentous bacteria. For isolation, cultures should be kept under observation for up to 2 to 3 weeks. The microorganisms grow satisfactorily on most of the nonselective media used for isolation of bacteria, mycobacterium, and fungi. Because the slow growth of *Nocardia* colonies over 2 days to 2 weeks on routine culture media allows bacterial overgrowth, isolation of this organism from soil and nonsterile sites may be difficult. *Nocardia* do not survive the digestive procedures used routinely in mycobacterial culture. Thayer-Martin and buffered charcoal-yeast extract agar may be used, and pretreatment of specimens with a low pH potassium chloride–hydrochloric acid solution for 4 minutes is required.

After initial isolation, subcultures should be incubated at 25°C (77°F), 35°C (95°F), and 45°C (113°F). *N. asteroides* grows best at 35°C (95°F). Aerial "hyphae," giving a chalky appearance, are seen macroscopically in cultures; however, in the early stages of growth, they are only seen with the microscope. *N. asteroides* complex colonies vary from salmon pink to orange, whereas *N. brasiliensis* are usually orange, and *N. otitidiscaviarum* are usually pale. Identification of genus can be achieved by microscopic and colonial morphology, growth requirements, metabolism of glucose, arylsulfatase production, growth in lysozyme, and phenotypic molecular characteristics. Genotyping methods, including polymerase chain reaction, DNA hybridization, and sequencing of 16 ribosomal RNA, are useful, if available. The RNA sequencing on 16S ribosomal RNA is the best tool and has become the gold standard for the identification of *Nocardia* species. The identification of the species allows a more precise selection of adequate antimicrobial agents. However, it is expensive, requires sophisticated equipment, and is time consuming.[17]

PATHOLOGY

Patterns described on histology include monocytic infiltrates, fibrinopurulent exudates, granuloma formation, chronic granuloma formation, chronic nodular dermatitis, microabscess formation, and coccobacillary organisms; the presence of granules has been described in disseminated cases.[6]

IMAGING

X-ray patterns that can be seen in pulmonary nocardiosis include irregular nodular, reticulonodular or diffuse pneumonitic patterns. CT scans will also help to identify cavitary lesions.

DIAGNOSTIC ALGORITHM

In the case of sporotrichoid lesions, bacterial, mycologic, and mycobacterial cultures are indicated, as the differential diagnosis will include, in addition to nocardiosis, sporotrichosis, tuberculosis, and atypical bacteria, such as *Mycobacterium marinum*. In cases occurring in geographic areas where leishmaniasis is prevalent, direct examination, NNN (Novy-MacNeal-Nicolle) culture, and leishmanin intradermal test also should be included in the diagnostic workup. The biopsy will enable determination of whether granulomas are present in the infiltrate.

DIFFERENTIAL DIAGNOSIS

The differential diagnosis for primary cutaneous nocardiosis depends on the clinical form: abscesses have to be differentiated from suppurative processes caused by *S. aureus*, whereas in the cases of lymphocutaneous, sporotrichoid forms, the differential diagnosis includes "most likely" and "less likely" infections and other noninfectious processes (Table 158-3).

TABLE 158-3
Differential Diagnosis of Lymphocutaneous Nocardiosis

Most Likely
- Sporotrichosis
- *Mycobacterium marinum* infection
- Leishmaniasis
- Pyoderma caused by *Staphylococcus aureus*

Consider
- Cryptococcosis
- Tuberculosis
- *Mycobacterium kansasii*, *Mycobacterium chelonae*, and *Mycobacterium fortuitum*
- Cysticercosis

Rule Out
- Epithelioid sarcoma
- Metastatic disease

CLINICAL COURSE, MANAGEMENT, AND PROGNOSIS

In cases of primary cutaneous nocardiosis, the disease has a good prognosis when appropriate antibiotic therapy is given. Disseminated nocardiosis, especially nocardiosis associated with immunosuppression, extensive pulmonary involvement, or bacteremia, has a less-favorable prognosis. Spontaneous resolution or good clinical response despite inappropriate therapy has been described in children with *Nocardia* cellulitis or lymphadenitis.[8]

The treatment of *Nocardia* infection is appropriate antimicrobial therapy and surgical drainage and debridement. Factors to consider include site and severity of infection, the immune status of the host, potential for interactions, and the species of *Nocardia* involved.

MEDICATIONS

Sulfonamides, alone or in combination with trimethoprim, as trimethoprim-sulfamethoxazole (TMP-SMX), are the cornerstone of therapy for *Nocardia* infections, but are ineffective against *N. otitidiscaviarum*.[18] For primary cutaneous nocardiosis of mild to moderate intensity, sulfonamide (either sulfadiazine or sulfisoxazole) alone has been considered adequate therapy but other authors consider TMP-SMX the treatment of choice, despite lack of controlled trials. This recommendation is based on synergistic activity of both drugs in vitro against *Nocardia*. The commercially available preparation has a fixed ratio of 1:5, and the dose currently recommended is 5 to 10 mg/kg TMP and 25 to 50 mg/kg SMX in 2 to 4 divided doses. For primary cutaneous nocardiosis, 5 mg/kg of TMP should be sufficient. Clinical improvement should be seen within 3 to 10 days, and 1 to 4 months of treatment should be curative for sporotrichoid nodules and cutaneous ulcers. Prolonged therapy is required for immunosuppressed patients. Minocycline 100 to 200 mg twice a day is considered the alternative treatment in cases of sulfonamide hypersensitivity or poor tolerance.

In more-severe cases or disease involving other organs, a combination of sulfonamide with a second agent is recommended. The second-line drugs most recommended are amikacin, imipenem, and ceftriaxone. Alternative second-line drugs include amoxicillin-clavulanate and linezolid. Immunosuppression is a good indication for a 2-drug regimen, including amikacin; an 88% cure rate has been reported when this drug is used.[6] Sternal infections caused by *N. asteroides* have responded to oral ofloxacin therapy. *N. farcinica* has a high degree of resistance to various antibiotics, especially third-generation cephalosporin and imipenem, and combined therapy is highly recommended. For extracutaneous nocardiosis, extended treatment with parenteral therapy followed by an oral regimen is necessary.

PROCEDURES

Surgery is indicated in cases of abscesses (drainage) or extensive necrosis (debridement).[19]

PREVENTION

The low incidence of *Nocardia* infections in immunodeficient states does not justify prophylactic use of antibiotics. AIDS patients receiving TMP-SMX for *Pneumocystis* organisms are already protected against *Nocardia*.

ACTINOMYCETOMA

AT-A-GLANCE

- Actinomycetoma is caused by bacteria, as opposed to eumycetoma, which is caused by fungi.
- More commonly seen in the tropics ("mycetoma belt").
- Several microorganisms cause the disease. Some species are specific for some geographic areas. In the Americas, *Nocardia brasiliensis* predominates.
- More common in men and in lower extremities.
- Visceral involvement has bad prognosis.
- Characteristic painless subcutaneous mass, with sinus formation and seropurulent discharge that contains grains (mycetoma triad).
- Macroscopic or microscopic grains are usually white. Gram staining shows filamentous bacteria.

DEFINITIONS

Mycetomas are chronic infections of the skin, underlying tissues, sometimes bones, and, rarely, viscera, caused by either bacteria (actinomycetomas) or fungi (eumycetomas).[20] Only actinomycetoma is discussed further in this chapter. Actinomycetomas present clinically as tumor-like swelling and sinus tracts, with discharge of grains that can be seen either microscopically or with the naked eye.

HISTORICAL PERSPECTIVE

Although the first modern description of Madura foot is attributed to Gill in 1842, in the holy city of Madurai, India, the disease was already described in ancient writings from India itself, under the name "padavalmika," meaning "foot anthill," around the fourth and fifth centuries AD.[21] The first medical case of mycetoma in Mexico was described by Cicero in 1911, but analysis of bone remains related to the Tlatilco culture, during the period from 1400 BC to 200 AD, has allowed speculation about the existence of the disease in pre-Hispanic Mexico.[22]

EPIDEMIOLOGY

Mycetoma has been included in the "top 17" list of neglected tropical diseases[13,20] and was submitted to the executive board of the World Health Organization in the World Health Assembly.[16,20,23-25]

The disease has a worldwide distribution but the endemic zone or "mycetoma belt" is placed around de Tropic of Cancer and includes African, Asian, and Latin American countries, especially India, Sudan, Somalia, Mexico, and Venezuela. In Mexico (97%), South America, and Australia, *N. brasiliensis* is the leading cause of actinomycetomas; in Africa, Saudi Arabia, and India, *Streptomyces somaliensis*, *Actinomadura pelletieri*, and *Actinomadura madurae* predominate. *A. madurae* is also identified as the etiologic agent in 10% to 15% of cases in Mexico and Venezuela.[26-28] Occasional cases are seen in the United States, particularly in the southern states. Actinomycetoma affects mainly men, with a male-to-female ratio of 3:1, and age ranges from 21 to 40 years old; frequency in patients younger than age 18 years is 4%, with similar incidence in both sexes.[29,30] The infection most commonly affects agricultural rural workers in developing countries in tropical and subtropical zones or those involved in outdoor activities.[28]

CLINICAL FEATURES

CUTANEOUS FINDINGS

Actinomycetoma is a chronic, localized, slowly progressive, painless disease of the skin and subcutaneous tissue. The pathologic process begins with a minor traumatic injury. Walking barefooted or wearing sandals may be considered a risk factor for these infections in rural communities. The lower limbs are involved in 71% of cases (Fig. 158-5), the foot being the most common site (Figs. 158-6 and 158-7). The lower leg, knee, and thigh, as well as the hand, forearm (Figs. 158-8 and 158-9), face, neck, and abdominal wall, also may be affected. In Mexico, the upper back (Figs. 158-10 and 158-11) is involved in 17% to 25% of cases in relation to occupational activity, such as firewood collection. The trunk is considered a high-risk area, because of the possibility of dissemination to the spinal cord and lungs.[28] Actinomycetoma caused by *Nocardia* species is a very inflammatory process characterized by tumefaction, a tumor-like or nodular-appearing soft-tissue swelling, deformity, and discharging sinus tracts with communicating channels that exudate pus (97%) (Fig. 158-6). Some authors consider pathognomonic a triad of a painless subcutaneous mass, sinus formation, and purulent or seropurulent discharge that contains grains. Ulceration, crusting, and scarring are also observed.[20] Mycetoma caused by *A. madurae*,

Figure 158-5 Actinomycetoma of the lower leg. Multiple, indolent, coalescing nodules.

Figure 158-6 Advanced case of mycetoma of the foot produced by *Nocardia* species; typical location, with multiple draining sites.

Figure 158-7 Typical mycetoma caused by *Actinomadura madurae*.

Figure 158-8 Mycetoma of the hand and wrist caused by *Nocardia brasiliensis*. Note gross deformity. (Used with permission from Roberto Arenas, MD, Hospital Manuel Gea González, Mexico City, Mexico.)

Figure 158-9 Radiograph shows associated marked destruction of bones and underlying soft tissues. (Used with permission from Roberto Arenas, MD, Hospital Manuel Gea González, Mexico City, Mexico.)

Figure 158-10 Dorsal actinomycetoma caused by *Nocardia brasiliensis*.

A. pelletieri, and *S. somaliensis* are less inflammatory with smaller sinus tracts; *A. madurae* is mainly seen in women with plantar involvement (Fig. 158-7).[27] With many of these agents, the granules may be seen with the naked eye (see Table 158-1). Usually, they are creamy in color; the exception will be *A. pelletieri*, in which the granules are red.

NONCUTANEOUS FINDINGS AND COMPLICATIONS

The course is chronic and progressive, with potential involvement of bones, lung, and abdominal viscera. In women, mycetomas increase in size during pregnancy and spontaneously improve after delivery. Advanced cases may cause functional disability. Atypical clinical forms include the cryptic mycetoma (without sinus tracts), the so-called *minimycetoma* (single or multiple small lesions observed mainly in children and adolescents), and the occasional inguinal "metastatic" lesions from a primary mycetoma of the foot.[20]

ETIOLOGY AND PATHOGENESIS

Microorganisms reported to cause actinomycetomas include 3 genera: *Nocardia*, *Actinomadura*, and

Figure 158-11 **A,** Huge scapulothoracic mycetoma caused by *Nocardia brasiliensis*. Note multiple fistulae. **B,** Closeup. Note doughnut-shaped masses and purulent drainage. (**B,** Used with permission from Maria Cecilia Albornoz, MD, Instituto de Biomedicina, Caracas, Venezuela.)

Streptomyces. The most frequent causes are *N. brasiliensis*, *A. madurae*, *A. pelletieri,* and *S. somaliensis*. Less frequent causes are *N. asteroides*, *N. otitidiscaviarum (N. caviae)*, *Nocardiopsis dassonvillei*, and *Nocardia transvalensis. N. pseudobrasiliensis, Nocardia veterana, Nocardia mexicana, N. farcinica, Nocardia aobensis, N. takedensis, Nocardia harenae, Streptomyces sudanensis* sp. nov, and *Actinomadura latina* have been reported as new agents in human actinomycetoma.[31-35]

Recent taxonomic studies (using DNA hybridization and ribosomal RNA gene sequencing) have confirmed marked heterogeneity among the genera of aerobic actinomycetes. Genomes of *N. brasiliensis, S. somaliensis,* and *A. madurae* have been described.[36-38]

Innate, as well as T-helper (Th)1-type and Th2-type immunity are involved in the host response against *N. brasiliensis*. CD8+ lymphocytes and macrophages are the main cells implicated. It has been shown that not only macrophages but also dendritic cells become foamy cells in either in vitro infection or an in vivo experimental actinomycetoma model by *N. brasiliensis*.[39]

N. brasiliensis as an intracellular bacterium modulates macrophage cytokine production, which helps survival of the pathogen.[40] In patients with actinomycetoma, the levels of immunoglobulin (Ig) G_1, IgG_2, IgG_3, IgG_4, and IgM are higher than in a control group. Those findings suggest that the increase or deficiency of a determined immunoglobulin class, as well as the relationship between different subclasses, play a role in the pathogenesis of actinomycetoma. In an experimental model of *N. brasiliensis* infection, hyperimmune sera with high levels of *N. brasiliensis* antigens did not protect against the infection, but IgM antibodies did.

RISK FACTORS

Walking barefoot in areas of high prevalence is consider a risk factor for the disease.

DIAGNOSIS

LABORATORY TESTING

Microbiologic diagnosis by identification of causal agent is limited to expert hands. No reliable serologic tests are available, but molecular techniques to identify relevant antigens or microorganisms have shown a real usefulness.[24]

Clinical specimens must be sent for direct examination, Gram stain, and culture. On direct examination, *Nocardia* granules are microscopic with a yellowish color (Fig. 158-12). Granules produced by other agents are macroscopic: those of *A. madurae* are white, yellow, or cream (Fig. 158-13), whereas grains from *A. pelletieri* are red and those of *S. somaliensis* are cream to brown color. Fine-needle aspiration cytology has been reported as a good diagnostic tool. The cell block technique of mycetoma aspirates can be used for cytodiagnosis, showing findings similar to histopathologic sections.[41]

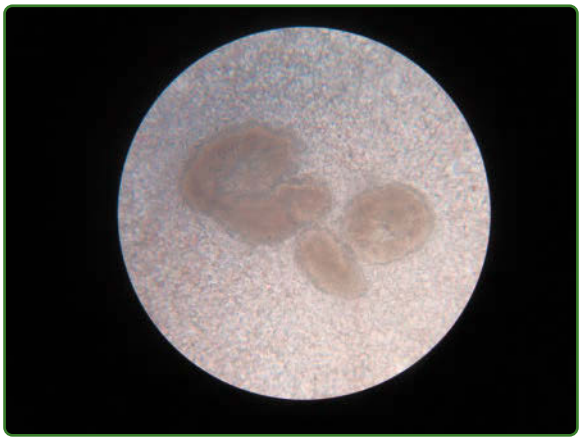

Figure 158-12 *Nocardia* species granules in direct examination (Lugol iodine stain, ×40 magnification).

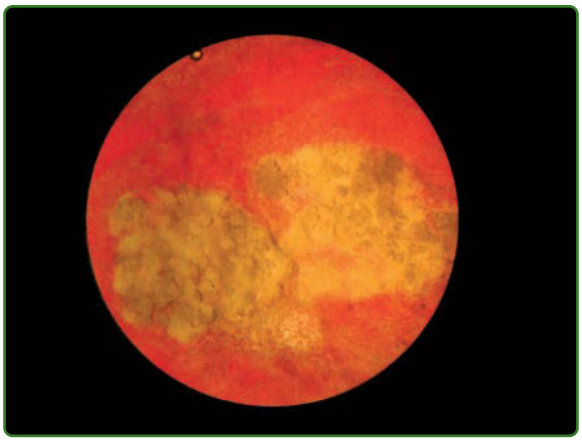

Figure 158-13 *Actinomadura madurae* granules in direct examination (Lugol iodine stain, ×10 magnification).

The microorganisms can be cultured on Sabouraud dextrose agar or Lowenstein-Jensen at room temperature; *Nocardia* strains are white-yellow hard colonies. Microscopically, the very thin filaments are Gram-positive and acid fast with the Kinyoun stain. *A. madurae* produce slowly growing beige or pink colonies; *A. pelletieri* colonies are red. *S. somaliensis* produce beige or tanned colonies. *Actinomadura, A. israelii,* and *Streptomyces* species are acid-fast–negative.[20]

Biochemistry can be used for identification. *N. brasiliensis* hydrolyzes casein and tyrosine, but not xanthine; *N. otitidiscaviarum* is negative to casein and tyrosine and positive to xanthine testing; *N. asteroides* is negative to all these tests.

The most precise diagnosis method for etiologic agents is molecular biology; the most applicable are the DNA-based identification tools such as loop-mediated isothermal amplification.

An enzyme-linked immunosorbent assay has been described for the diagnosis of mycetoma caused by *N. brasiliensis*; it has been proposed as a method to assess the response to therapy. This test detects antibodies against 2 immune-dominant antigens (24 and 26 kDa). An additional advantage of this particular assay might be its demonstrated cross-reactivity with *N. asteroides*.[42] Other diagnostic tools are latex bead agglutination assays and dipsticks, but a discriminatory antigen needs to be selected.[43]

PATHOLOGY

Skin biopsy plays an important role in the diagnosis of actinomycetoma. Typically, in tissue sections stained with hematoxylin and eosin, there is a suppurative reaction characterized by the presence of polymorphonuclear cells, fibrosis, neovascularization, and, rarely, a granulomatous reaction with a tuberculoid granuloma.[20] *Nocardia* infection is characterized by granules 30 to 200 µm in diameter, partially basophilic to amphophilic, with an amorphous eosinophilic

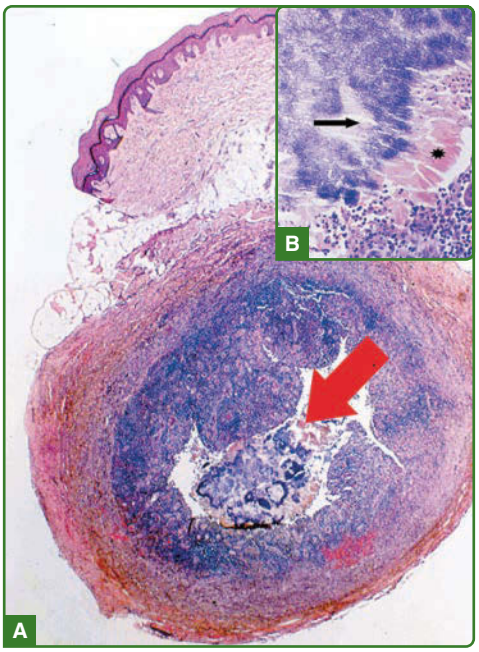

Figure 158-14 **A,** Skin biopsy of an *Actinomadura* mycetoma shows the granule (*red arrow*) inside the inflammatory reaction (hematoxylin-and-eosin stain, ×20 magnification). **B,** The contrast between the blue fibrillary material (*black arrow*), representing bacteria, and the eosinophilic proteinaceous material of the Splendore-Hoeppli phenomenon (*star*) (hematoxylin-and-eosin stain, ×100 magnification).

radially arranged material on the periphery (the so-called Splendore-Hoeppli phenomenon). Granules of *A. madurae* are soft and bigger (1 to 3 mm diameter), purple with a cartographic shape and an eosinophilic fringe (Fig. 158-14). *A. pelletieri* granules are firm and red with a diameter of 200 to 500 µm. Granules of *S. somaliensis* are rounded, hard, pale, and 1.5 to 10 mm in diameter.[20] These organisms stain in tissue with Gomori methenamine silver, periodic acid–Schiff, and the Brown-Brenn modification of the Gram stain.

IMAGING

Regarding the different imaging techniques, conventional radiographs are used to identify the limits of lesions and to determine if bone is affected.[44] The most common radiographic abnormalities are soft-tissue swelling, extrinsic pressure, bony periosteal reaction, erosion, sclerosis, joint involvement, and bone cavities ("geoda").[45] Ultrasonography is also a useful tool, showing hyperreflective echoes that help to differentiate between mycetoma (actinomycetoma and eumycetoma) and nonmycetoma. These hyperreflective echoes are observed only in mycetoma; however, when sinus tracts are present, the images may not be as clear. In eumycetoma, the grain cement produces numerous sharp bright hyperreflective echoes; in actinomycetoma, the findings are less distinct, probably because of the smaller size and the consistency of grains.[44]

Currently, MRI and CT are the most accurate diagnostic tools to determine the disease extent, especially in trunk mycetomas; they also provide evidence about the degree of visceral, muscular, and vascular invasion, and an estimate of the size of the involvement; however, those techniques do not allow to discriminate between actinomycetoma and eumycetoma.[46,47] The "dot-in-circle" sign on MRI is considered very characteristic of mycetoma, and is observed as multiple, small, round-shaped hyperintense lesions surrounded by a low-signal intensity rim (the circle), and a central, low-signal focus (the dot).[48]

DIFFERENTIAL DIAGNOSIS

The differential diagnosis includes other infections causing fistulae, such as eumycotic mycetoma, actinomycosis, botryomycosis, scrofuloderma, and atypical mycobacterial infections (Table 158-4). Botryomycosis is a condition that can mimic actinomycetoma and eumycetoma, both clinically and histologically. The disease can be caused by several organisms, most commonly *S. aureus*, *Escherichia coli*, *Pseudomonas aeruginosa*, *Proteus vulgaris*, *Actinobacillus* species, *Streptococcus* species, Gram-negative coccobacilli, *Propionibacterium acnes*, and other anaerobic bacteria. The cutaneous form accounts for 75% of the cases; visceral involvement, mainly the lung, is rare. The disease is characterized by localized areas of infiltration, with mass effect and draining sinuses. Extension to the underlying structures, including bone, is not rare. Most commonly affected areas are exposed surfaces, such as hands, head, and feet. Patients usually have a predisposing factor such as local trauma, a foreign body, diabetes or HIV. Botryomycosis is also characterized by the presence of granules, which can be seen macroscopically and microscopically. As in mycetoma, the center of the granule will show agglomeration of the causal agent, most commonly, Gram-positive cocci. The Splendore-Hoeppli phenomenon also may be seen around the granules. Rarely, tuberculosis may present as pseudomycetoma.[49]

MANAGEMENT

Therapy for patients with actinomycetoma should be individualized. Economic considerations may influence the choice of therapy, particularly in developing countries.

TABLE 158-4
Differential Diagnosis of Actinomycetoma

- Eumycotic mycetoma
- Actinomycosis
- Botryomycosis
- Atypical mycobacterial infection
- Scrofuloderma and tuberculous pseudomycetoma

Molecular identification of the causal agents and development of genetic markers for disease can improve management. Cure can be defined by a lack of clinical activity, the absence of grains and negative cultures. The cure rates vary between 60% and 90%. Treatment periods should be prolonged, especially in those cases with bone and visceral involvement, where the prognosis is poor.[50]

MEDICATIONS

Actinomycetoma is currently treated with antibiotics, which can be used alone or, preferentially, in combination, depending on the localization, dissemination, and severity of the disease.[51] The combined therapy prevents the development of drug resistance and allows eradicating any residual infection. The treatment of choice in actinomycetoma caused by *N. brasiliensis* is diaminodiphenylsulfone (Dapsone) 100 to 200 mg/day (3 to 5 mg/kg) plus TMP-SMX 160/800 mg twice a day for several months in initial cases; the treatment should continue for up to 2 years.[20] Dapsone also can be combined with streptomycin, 1 g/day; clofazimine, 100 mg/day; rifampin, 300 mg twice/day; tetracycline, 1 g/day; or isoniazid, 300 to 600 mg/day. Some resistant cases have been treated with amoxicillin, 500 mg, plus clavulanic acid, 125 mg/day for 5 months, especially in pregnancy. The use of clindamycin, ciprofloxacin, and moxifloxacin has been suggested in *Nocardia* infections.[52]

One of the best inhibitory effects in vitro is achieved with the use of aminoglycosides. Amikacin alone or combined with imipenem are powerful antibiotics used as alternative treatments for severe or multiresistant mycetomas, especially those with bone and visceral involvement. In adults, amikacin is administered 15 mg/kg/day (500 mg IM twice a day) for 3 weeks; ototoxicity and nephrotoxicity may develop.[53] Alternative, less-effective drugs include kanamycin, fosfomycin, or streptomycin. Carbapenems, such as imipenem and meropenem, have a broad microbicidal activity refractory to hydrolysis by β-lactamases. They have demonstrated good in vitro and in vivo activity against *N. asteroides* complex, good in vitro sensitivity against *A. madurae*, and apparent low in vitro activity against *N. brasiliensis*. Imipenem has been proposed as a suitable option for severe *N. brasiliensis* infection refractory to other drug therapies.[54] Patients under therapy with IV imipenem must be hospitalized; the drug can be given as monotherapy at 500 mg 3 times daily, or in combination with intravenous amikacin in a dose of 500 mg twice daily (15 mg/kg) in cycles of 21 days, especially in patients with pulmonary or peritoneal involvement.[50]

Ramam and colleagues[55] used a 2-step regimen consisting of an intensive phase of therapy with intravenous penicillin (1,000,000 IU every 6 hours) plus intravenous gentamicin (80 mg twice a day), followed by oral TMP-SMX (80 to 400 mg twice a day) for 5 to 7 weeks.

Linezolid, an oxazolidinone, has shown in vitro antimicrobial activity against *N. brasiliensis*; it also has demonstrated efficacy in patients with nocardiosis. Its

main disadvantage of this alternative is the cost. It is available as intravenous and oral preparations. The benzothiazinones are a new class of drugs that inhibit decaprenylphosphoryl-β-D-ribose oxidase (DprE1), an essential enzyme involved in the cell wall biosynthesis of Corynebacterineae. These are new antimycetoma potential drugs and could be combined with oxazolidinone molecules.[56]

Patient followup is always important, and improvement should be monitored by clinical assessment as well as by laboratory tests: hemoglobin level, white cell count, C-reactive protein, erythrocyte sedimentation rate, enzyme-linked immunosorbent assay (when available), biopsy, and culture. The use of dapsone can be associated with methemoglobinemia, hemolytic anemia, and hypersensitivity syndrome; determination of 6-glucose phosphate dehydrogenase enzyme is obligatory whenever dapsone is used. All cases receiving amikacin treatment requires close clinical observation with audiometry and renal function tests every 3 to 5 weeks to detect auditory and nephrotoxicity and adjustment dose. Carbapenems should not be prescribed in patients who are allergic to penicillin and other β-lactam antibiotics. Linezolid can cause diarrhea, headache, and nausea, but the most important adverse effect is myelosuppression. TMP-SMX is associated with many severe dermatologic reactions.[51]

PROCEDURES

Amputation is not indicated in actinomycetoma because the high risk of lymphangitic or hematogenous dissemination. Functional impairment is common with osseous, pulmonary, or abdominal visceral involvement. The disease may be fatal.

REFERENCES

1. Könönen E, Wade WG. Actinomyces and related organisms in human infections. *Clin Microbiol Rev.* 2015;28(2):419.
2. Smego RA Jr, Foglia G. Actinomycosis. *Clin Infect Dis.* 1998;26(6):1255.
3. Wong VK, Turmezei TD, Weston VC. Actinomycosis. *BMJ.* 2011;343:d6099.
4. Mert A, Bilir M, Bahar H, et al. Primary actinomycosis of the hand: a case report and literature review. *Int J Infect Dis.* 2001;5:112.
5. Sudhakar SS, Ross JJ. Short-term treatment of actinomycosis: two cases and a review. *Clin Infect Dis.* 2004;38:444.
6. Lederman ER, Crum NF. A case series and focused review of nocardiosis: clinical and microbiologic aspects. *Medicine (Baltimore).* 2004;83:300.
7. Mosel D, Harris L, Fisher E, et al. Disseminated *Nocardia* infection presenting as hemorrhagic pustules and ecthyma in a woman with systemic lupus erythematosus and antiphospholipid antibody syndrome. *J Dermatol Case Rep.* 2013;7(2):52.
8. Fergie JE, Purcell K. Nocardiosis in South Texas children. *Pediatr Infect Dis J.* 2001;20:711.
9. Biscione F, Cecchini D, Ambrosioni J, et al. Nocardiosis in patients with human immunodeficiency virus infection [in Spanish]. *Enferm Infecc Microbiol Clin.* 2005;23:419.
10. Singh SM, Rau NV, Cohen LB, et al. Cutaneous nocardiosis complicating management of Crohn's disease with infliximab and prednisone. *CMAJ.* 2004;171(9):1063.
11. Leshem YA, Gdalevich M, Ziv M, et al. Opportunistic infections in patients with pemphigus. *J Am Acad Dermatol.* 2014;71(2):284.
12. Smego RA Jr, Castiglia M, Asperilla MO. Lymphocutaneous syndrome. A review of non-sporothrix causes. *Medicine (Baltimore).* 1999;78:38.
13. Saoji VA, Saoji SV, Gadegone RW, et al. Primary cutaneous nocardiosis. *Indian J Dermatol.* 2012;57(5):404.
14. Chung E, Pulitzer MP, Papadopoulos EB, et al. Lymphangitic papules caused by *Nocardia takedensis*. *JAAD Case Rep.* 2015;1(3):126.
15. Lerner PI. Nocardiosis. *Clin Infect Dis.* 1996;22:891.
16. Chen B, Tang J, Lu Z, et al. Primary cutaneous nocardiosis in a patient with nephrotic syndrome: a case report and review of the literature. *Medicine (Baltimore).* 2016;95(3):e2490.
17. Hirayama T, Takazono T, Horai Y, et al. Pulmonary nocardiosis caused by *Nocardia concava* with a literature review. *Intern Med.* 2016;55(9):1213.
18. Corti ME, Villafañe-Fioti MF. Nocardiosis: a review. *Int J Infect Dis.* 2003;7(4):243.
19. Ricci JA, Weil AA, Eberlin KR. Necrotizing cutaneous nocardiosis of the hand: a case report and review of the literature. *J Hand Microsurg.* 2015;7(1):224.
20. Arenas R, Lavalle P. Mycetoma (Madura foot). In: Arenas R, Estrada R, eds. *Tropical Dermatology*. Georgetown, Texas, US: Landes, 2001;51.
21. Schwartz E, Shpiro A. Madura foot or Philoctetes foot? *Isr Med Assoc J.* 2015;17(7):442.
22. Mansilla-Lory J, Contreras-Lopez E. Mycetoma in pre-Hispanic Mexico: study of the bone collection of the Tlatilco culture. *Rev Med Inst Mex Seguro Soc.* 2009;47(3):237.
23. World Health Organization (WHO). *The 17 Neglected Tropical Diseases*. Geneva, Switzerland: World Health Organization; 2013.
24. Zijlstra EE, van de Sande WW, Welsh O, et al. Mycetoma: a unique neglected tropical disease. *Lancet Infect Dis.* 2016;16(1):100.
25. Nenoff P, van de Sande WW, Fahal AH, et al. Eumycetoma and actinomycetoma—an update on causative agents, epidemiology, pathogenesis, diagnostics and therapy. *J Eur Acad Dermatol Venereol.* 2015;29 (10):1873.
26. Dieng MT. Actinomycetomas in Senegal: study of 90 cases. *Bull Soc Pathol Exot.* 2005;98:18.
27. Davila MR, Arenas R, Asz-Sigall D et al. Epidemiologia de los micetomas en el Estado de Guanajuato, Mexico. *Monografias en Dermatologia*. 2006;19:24.
28. Bonifaz A, Tirado-Sánchez A, Calderón L, et al. Mycetoma: experience of 482 cases in a single center in Mexico. *PLoS Negl Trop Dis.* 2014;8(8):3102.
29. Bonifaz A, Ibarra G, Saul A et al. Mycetoma in children. Experience with 15 cases. *Pediatr Infect Dis J.* 2007;26: 50-52.
30. Lopez-Martinez R, Mendez-Tovar LJ, Bonifaz A, et al. Actualización der la epidemiologia del micetoma en México. Revisión de 3,933 casos. *Gac Med Mex.* 2013;149:586.
31. Quintana ET, Wierzbicka K, Mackiewicz P, et al. *Streptomyces sudanensis* sp. *nov.*, a new pathogen

isolated from patients with actinomycetoma. *Antonie Van Leeuwenhoek*. 2008;93(3):305.
32. Ichinomiya A, Nishimura K, Takenaka M, et al. Mycetoma caused by *Nocardia transvalensis* with repeated local recurrences for 25 years without dissemination to viscera. *J Dermatol.* 2014;41(6):556-557.
33. Kresch-Tronik NS, Carrillo-Casas EM, Arenas R, et al. *Nocardia harenae*, an uncommon causative organism of mycetoma: report on two patients. *J Med Microbiol.* 2012;61:1153.
34. Kresh-Tronik NS, Carrillo-Casas EM, Arenas R, et al. First case of mycetoma associated with *Nocardia takedensis*. *J Dermatol.* 2013;40(2):135-136.
35. Vongphoumy I, Dance DA, Dittrich S, et al. Case report: actinomycetoma caused by *Nocardia aobensis* from Lao PDR with favorable outcome after short-term antibiotic treatment. *PLoS Negl Trop Dis.* 2015;9(4).
36. Vera-Cabrera L, Ortiz R, Elizondo R, et al. Complete genome sequence of *Nocardia brasiliensis* HUJEG-1. *J Bacteriol.* 2012;194(10):2761.
37. Kirby R, Sangal V, Tucker NP, et al. Draft genome sequence of the human pathogen *Streptomyces somaliensis*, a significant cause of actinomycetoma. *J Bacteriol.* 2012;194(13):3544.
38. Vera-Cabrera L, Ortiz-Lopez R, Elizondo-Gonzalez R, et al. Draft genome sequence of *Actinomadura madurae* LIID-AJ290, isolated from a human mycetoma case. *Genome Announc.* 2014;2(2):e00201.
39. Meester I, Rosas-Taraco AG, Salinas-Carmona MC. *Nocardia brasiliensis* induces formation of foamy macrophages and dendritic cells in vitro and in vivo. *PLoS One.* 2014;9(6):e100064.
40. Salinas-Carmona MC, Zúñiga JM, Pérez-Rivera LI, et al. *Nocardia brasiliensis* modulates IFN-gamma, IL-10, and IL-12 cytokine production by macrophages from BALB/c mice. *J Interferon Cytokine Res.* 2009;29(5):263.
41. Yousif BM, Fahal AH, Shakir MY. A new technique for the diagnosis of mycetoma using fixed blocks of aspirated material. *Trans R Soc Trop Med Hyg.* 2010;104(1):6.
42. Salinas-Carmona MC, Welsh O, Casillas SM. Enzyme-linked immunosorbent assay for serological diagnosis of *Nocardia brasiliensis* and clinical correlation with mycetoma infections. *J Clin Microbiol.* 1993;31:2901.
43. Van de Sande WW, Mahgoub el S, Fahal AH, et al. The mycetoma knowledge gap: identification of research priorities. *PLoS Negl Trop Dis.* 2014;8(3):e2667.
44. Van de Sande WW, Fahal AH, Goodfellow M, et al. Merits and pitfalls of currently used diagnostic tools in mycetoma. *PLoS Negl Trop Dis.* 2014;8(7):e2918.
45. Abd El-Bagi ME, Fahal AH. Mycetoma revisited. Incidence of various radiographic signs. *Saudi Med J.* 2009;30(4):529.
46. Bonifaz A, González-Silva A, Albrandt-Salmerón A, et al. Utility of helical computed tomography to evaluate the invasion of actinomycetoma; a report of 21 cases. *Br J Dermatol.* 2008;158(4):698.
47. Fahal A, Mahgoub el S, El Hassan AM, et al. Head and neck mycetoma: the Mycetoma Research Centre experience. *PLoS Negl Trop Dis.* 2015;9(3):e0003587.
48. Laohawiriyakamol T, Tanutit P, Kanjanapradit K, et al. The "dot-in-circle" sign in musculoskeletal mycetoma on magnetic resonance imaging and ultrasonography. *Springerplus.* 2014;3:671.
49. Pizzariello G, Fernadez Pardal P, D'Atri G. Pseudomycetoma tuberculoso. Presentacion de 8 casos. *Med Cutan Ibero Lat Am.* 2013;41(6):254.
50. Ameen M, Arenas R. Developments in the management of mycetomas. *Clin Exp Dermatol.* 2008;34:1.
51. Welsh O, Al-Abdely HM, Salinas-Carmona MC, et al. Mycetoma medical therapy. *PLoS Negl Trop Dis.* 2014;8(10):e3218.
52. Chacon-Moreno BE, Welsh O, Cavazos-Rocha N, et al. Efficacy of ciprofloxacin and moxifloxacin against Nocardia brasiliensis in vitro and in an experimental model of actinomycetoma in BALB/c mice. *Antimicrob Agents Chemother.* 2009;53(1):295.
53. Welsh O, Sauceda E, Gonzalez J, et al. Amikacin alone and in combination with trimethoprim-sulfamethoxazole in the treatment of actinomycotic mycetoma. *J Am Acad Dermatol.* 1987;17(3):443.
54. Ameen M, Arenas R, Vasquez del Mercado E, et al. Efficacy of imipenem therapy for Nocardia actinomycetomas refractory to sulfonamides. *J Am Acad Dermatol.* 2010;62(2):239.
55. Ramam M, Garg T, D'Souza P, et al. A two-step schedule for the treatment of actinomycotic mycetomas. *Acta Derm Venereol.* 2000;80(5):378.
56. González-Martínez NA, Lozano-Garza HG, Castro-Garza J, et al. In vivo activity of the benzothiazinones PBTZ169 and BTZ043 against *Nocardia brasiliensis*. *PLoS Negl Trop Dis.* 2015;9(10):e0004022.

Chapter 159 :: Leprosy

:: Claudio Guedes Salgado, Arival Cardoso de Brito, Ubirajara Imbiriba Salgado, & John Stewart Spencer

AT A GLANCE

- Definition: A chronic granulomatous disease affecting mainly the skin and nerves caused by the obligate intracellular pathogen *Mycobacterium leprae*.
- Involvement: Primarily the skin and nerves, but causing sequelae to a wide range of tissues and systems including eyes, upper respiratory tract, lymphoid tissue, testicles, muscles, and bones.
- Diagnosis: Based on clinical signs and symptoms, hallmarks include loss of sensation within skin lesions, nerve swelling or pain, or demonstration of acid-fast bacilli in skin smears or biopsies.
- Incidence: 214,783 new cases detected worldwide in 2016, essentially unchanged for the last 4 years. More than 80% of all new cases are detected in only 3 countries—India, Brazil, and Indonesia.
- Long-term morbidity: Despite the global use of multidrug therapy in use since the mid-1980s, up to 30% to 50% of all leprosy patients will experience some type of reactional episode that may result in a permanent neurologic deficit or disability.
- A clinical challenge: The long incubation time prior to the slow development of diverse symptoms (3-7 years postinfection), the very low rate of disease progression in infected individuals, and issues with misdiagnosis all create challenges to the development of ways to interrupt transmission.
- An immunologic spectrum of disease: Understanding what genetic factors and the interplay of innate and adaptive immune responses of the host that leads to resistance or susceptibility to disease are critical in developing novel treatment approaches.

INTRODUCTION

DEFINITION

Leprosy is a chronic granulomatous infection caused by *Mycobacterium leprae*, that infects mucous cutaneous tissues and peripheral nerves, leading to loss of sensation on the skin—with or without dermatologic lesions—and the development of incapacities during the progression of the disease. WHO states that any individual in endemic countries presenting skin lesions with definite sensory loss or positive skin smears may be diagnosed with leprosy.[1]

HISTORICAL PERSPECTIVE

Leprosy is one of the oldest diseases known to afflict mankind. Gerhard Armauer Hansen, a Norwegian physician, was the first to describe the *M. leprae* bacillus in 1873, identifying the first bacterial pathogen associated with human disease. The name Hansen disease is used in some countries, like Brazil, to lessen the stigma associated with the common name. The characteristic destructive changes that lead to disfigurement, deformity, and disability were among the hallmarks of the disease that allowed it to become stigmatized in ancient times.[2] Speculations about the existence of leprosy in ancient India, Egypt, and China have been proposed, with the earliest paleopathological evidence found in 4000-year-old bones from the Balathal burial site in Rajasthan, western India.[3] The first use of molecular techniques using polymerase chain reaction (PCR) to detect *M. leprae* DNA specific sequences in ancient bones dated to AD 600 was described in 1994.[4] PCR was used to identify *M. leprae* DNA in 1st century CE bones from the Tomb of the Shroud burial site in Israel, the earliest known date of existence of leprosy in this region.[5] Using paleopathological and molecular methods to analyze ancient bones from archeological sites, burial grounds, and cemeteries, evidence of the spread of leprosy has emerged, indicating the spread of the disease from Western and Central Asia from the 4th century AD into Eastern and Central Europe occurred mainly due to human migrations associated with military campaigns, expansion of territories, or migrations to effect colonization.[6] Houses were established to quarantine those with leprosy and other communicable diseases, called lazarets, in 7th-century France, but it was not until the return of the Crusaders from AD 1100 coming back from countries of the Ottoman Empire where leprosy was endemic that the disease became an increasing problem.

Leprosy in Europe and the United Kingdom peaked in the 13th and 14th centuries and then began a slow decline. Comparison of the *M. leprae* whole genome

obtained from ancient European, UK, and Scandinavian gravesites show only a few dozen single nucleotide polymorphism (SNP) changes over the last 1000 years, with no mutations in any genes related to increased virulence or pathogenesis.[7] The essentially clonal nature of *M. leprae* from the ancient to modern times suggests that the precipitous decrease in leprosy prevalence was independent of features of the pathogen and were more likely related to changes in host resistance or environment. Since people with lepromatous leprosy likely had a weakened immune status, they were more likely to succumb to other infections. Events thought to have contributed to a higher death rate in those with leprosy included a serious famine in 1325, followed by the outbreak of plague, or Black Death, in 1349 that killed between one-third and two-thirds of the population in Europe and the United Kingdom. Such massive death would have severely curtailed the support networks of hospices and leprosaria whose religious clergy, patrons and physicians had cared for patients, but were likely decimated. There is also suggestive evidence that increases in population density, overcrowded living conditions, and the rise of tuberculosis after the 15th century contributed to death by coinfections with multiple diseases.[8] As those susceptible individuals succumbed to disease, the innate resistance of the surviving population to mycobacterial infection and other diseases common during that period likely improved, and coupled with improved socioeconomic conditions, sanitation, and hygiene, the lines of transmission of infection were broken. Currently, endemic cases of leprosy in Europe and the United Kingdom are extremely rare.

Comparative genomic studies of *M. leprae* isolates all over the world revealed a remarkable conservation of the genome (99.995% identity among all strain types), showing the existence of 215 polymorphic sites consisting mainly of SNPs. Four of these SNPs represented 4 main strain types that showed very strong geographical associations that were used to trace the evolution and distribution of *M. leprae* based on human migration patterns throughout history.[9] SNP Type 1 was found primarily in Southeast Asia; SNP Type 2 was found mainly in East Africa; SNP Type 3 was associated with the European/North African region, whereas SNP Type 4 was found mainly in West Africa. Leprosy did not exist in North or South America until its introduction via colonialism from Europe (SNP Type 3) and from the importation of slaves from Africa (SNP Type 4). These four main types were subdivided into 16 subtypes based on further characterization of SNPs and insertion/deletion events from modern and ancient *M. leprae* genomes from a total of 400 samples from 28 different regions of the world, namely SNP Type 1 (A-D), Type 2 (E-H), Type 3 (I-M), and Type 4 (N-P).[10] Besides humans, *M. leprae* is also found as a zoonotic infection in armadillos in the Southern United States,[11] and recently in red squirrels in the British Isles.[12] Interestingly, both armadillo and squirrel *M. leprae* have the same SNP subtype, 3I, indicating a common European ancestry.

EPIDEMIOLOGY

Leprosy is still a serious neglected disease. WHO refers the number of new cases is gradually decreasing in the last 10 years, from 265,661 in 2006 to 210,758 in 2015,[13] but different groups of researchers have demonstrated that the hidden endemics may be high,[14,15] the number of cases in children is increasing[16] or stable,[17] whereas the proportion of multibacillary patients is increasing[18] and cases with grade 2 disability seem to be stable,[19] but high,[20] indicating late diagnosis. Altogether, these factors demonstrate that instead of a true decline of new cases, delay[21] and absence of diagnosis seem to be the main problems.[15,22,23] In fact, mathematical modeling shows that in 2020 we may have 4 million cases of undiagnosed leprosy worldwide, that is, almost 20 times more than the present number of cases diagnosed annually.[24]

The definition of leprosy has changed with time. There is currently no laboratory test to diagnose leprosy. Once a patient completes multidrug therapy, the individual is usually removed from the registry and is no longer considered a case, even if disability and reactional episodes continue long after treatment. For decades, treatment of leprosy was done continuously with dapsone alone (monotherapy), and all cases that received dapsone monotherapy were registered in the system. Because of this practice, the prevalence of leprosy remained high, with more than 10 million patients on the registry during the 1980s. With the implementation of multidrug therapy in 1982, treatment was shortened to, at most, 2 years. The active registry then changed to only those being treated, while those who completed their therapy were subsequently "cleared." Thus, over the course of a decade, millions of patients who completed multidrug therapy and did not have symptoms were purged from registries.[25] The net effect was that within 20 years after the introduction of multidrug therapy, leprosy prevalence was markedly reduced by more than 85%[13] although the new case detection rate has remained relatively stable at more than 200,000 worldwide for almost 10 years (Fig. 159-1).

Currently, the most important epidemiologic indicators of leprosy burden are the new case detection rate by country, and the proportion of cases in children, those with multibacillary disease and those with grade 2 disability, indicating a late diagnosis.[13] Although India has the highest number of leprosy cases in the world, Brazil has the highest new case detection rate among all countries (Fig. 159-2). However, when we look at the other 2 most significant parameters, the percentage of cases in children (Fig. 159-3) and those with grade 2 disability (Fig. 159-4), there is a clear shift, with most of the reporting countries considered as high or very high, whereas Brazil, India, and Indonesia have medium or low percentages. Although these 3 countries collectively account for >80% of the global leprosy burden, the large number of cases reported dilutes the percentage of both children with leprosy and those with grade 2 disability, while countries who report

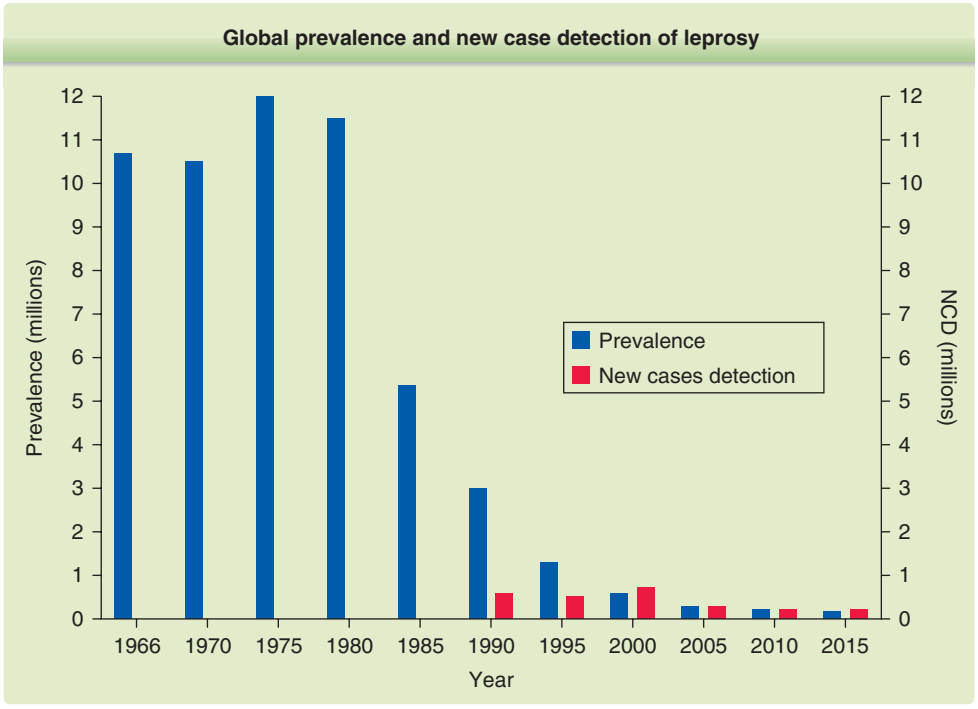

Figure 159-1 Historic evolution of global prevalence and new case detection of leprosy. The first formal attempt to estimate the global leprosy burden was made by WHO in 1966, when the case load was estimated to be 10,786,000, of whom 60% were not registered for treatment. Global detection was first reported in 1991, with 584,000 new cases detected worldwide in 1990. Currently, the new case detection is one of the most important epidemiologic indicators of leprosy burden, together with the proportion of children and proportions of grade 2 disability. (Used with permission from Prof. Josafá Barreto, Pará Federal University, Brazil.)

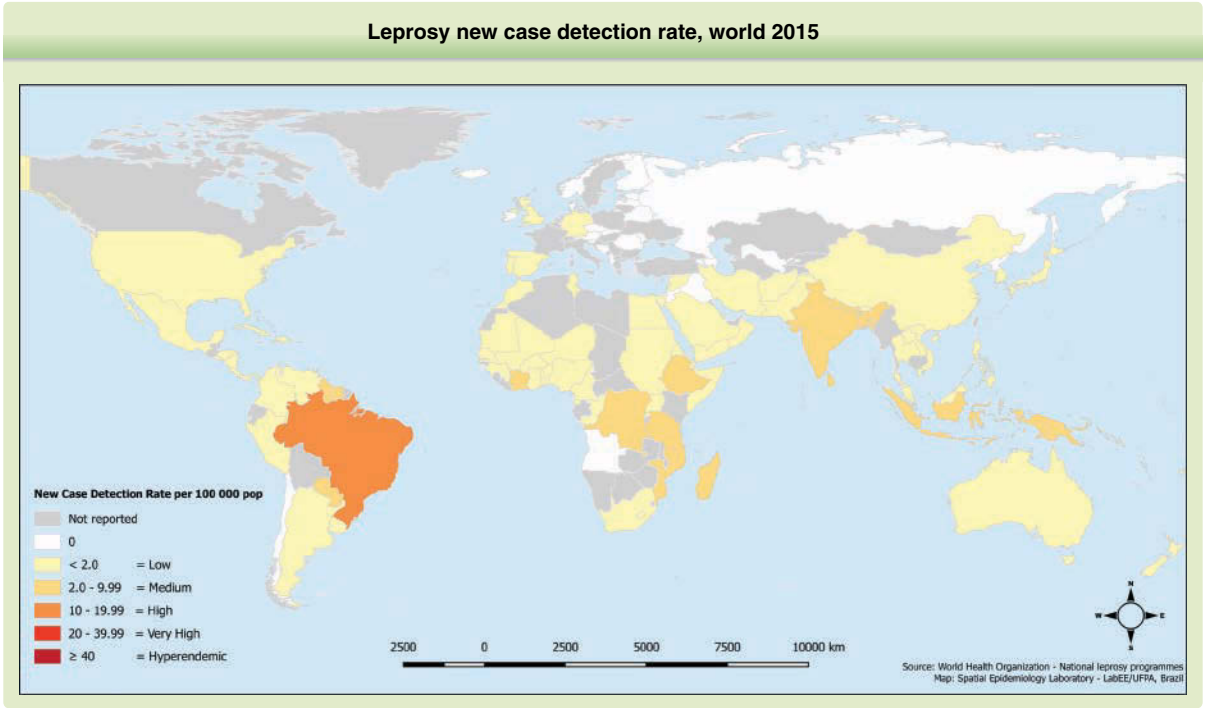

Figure 159-2 Leprosy new case detection rate per 100,000 population in the world, 2015. More than 210,000 new cases were reported in 136 countries or territories in 2015. India, Brazil, and Indonesia accounted for 81% of the global burden of leprosy. The global new case detection rate was 3.2. (Used with permission from Prof. Josafá Barreto, Pará Federal University, Brazil.)

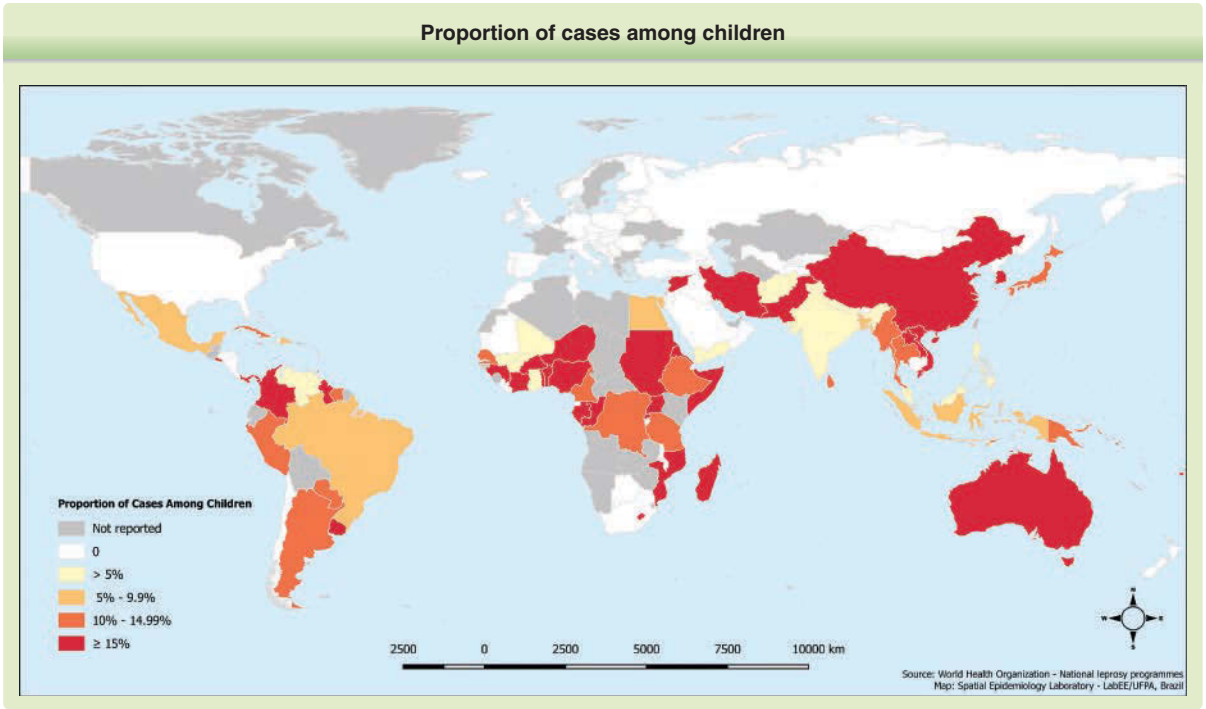

Figure 159-3 Proportion of leprosy cases among children below 15 years old, 2015. Although there is no specific classification from "low" to "high" for this indicator, it is a robust indicative of active source of infection in the community where they live. (Used with permission from Prof. Josafá Barreto, Pará Federal University, Brazil.)

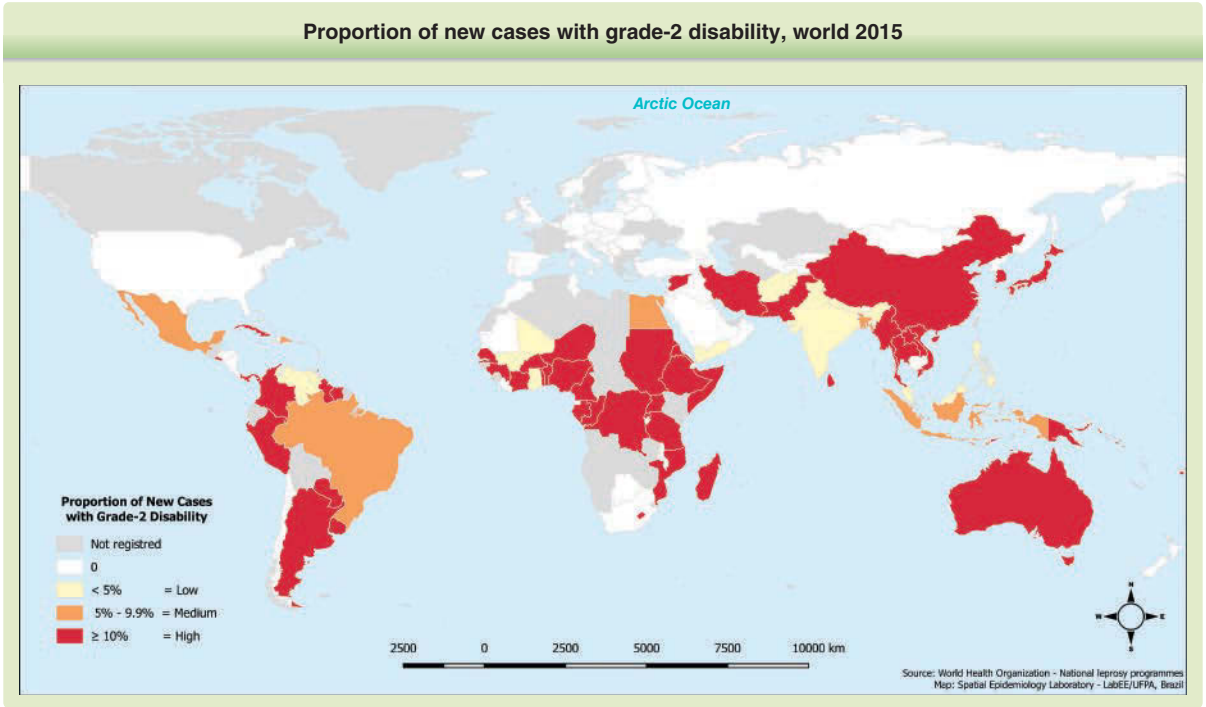

Figure 159-4 Proportion of new leprosy cases with grade 2 disability at diagnosis, 2015. It reflects long delays in the diagnosis of leprosy, highlighting a failure of the health services system and gaps in the approach to control the disease. (Used with permission from Prof. Josafá Barreto, Pará Federal University, Brazil.)

less than 1000 new cases per year generally have much higher rates in both categories. A high or very high percentage of these 2 parameters likely means that children and adults are diagnosed only when presenting classical pathognomonic lesions of leprosy and/or disabilities, indicating late diagnosis.[15,21]

CLINICAL FEATURES

CUTANEOUS FINDINGS

During the IV International Leprosy Congress in Madrid, 1953, leprosy was classified in 2 stable forms, tuberculoid leprosy and lepromatous leprosy, and a borderline group between these 2 polar forms. In 1966, Ridley and Jopling proposed a 5-group classification system based on clinical, histopathologic, and immunologic criteria[26] that is still in use for classifying leprosy. The colonization of skin and invasion of peripheral nerves by the bacilli, followed by innate and adaptive immune responses by the host, results in the clinical spectrum of leprosy (Fig. 159-5). There is an overall genetic resistance toward developing leprosy, with more than 90% of people having a natural immunity, with cell-mediated immunity being most important in preventing disease progression.

All patients, except those with primary neural leprosy,[27] first present 1 or a few hypopigmented macules on the skin. Indeterminate leprosy (Fig. 159-6) may last for months or years before moving to spontaneous cure or toward one of the poles or borderline forms of the clinical spectrum, depending mainly on the cell-mediated immunity of the host against the bacilli.

At one end of the spectrum with a better cell-mediated immunity, there is polar tuberculoid leprosy, where well-defined plaques, usually a few in just one segment of the body, hypochromic and/or erythematous, sometimes atrophic, present with papules or tubercles that are mainly circinate on the periphery of the lesions (Fig. 159-7). A special self-healing type of tuberculoid leprosy, infantile nodular leprosy, can be found as a single nodular lesion, but also as papules or plaques, usually on the face of the child (Fig. 159-8).[28]

At the other end of the spectrum lies polar lepromatous leprosy, which is established by a complete lack of cell-mediated immunity, usually presenting with plentiful nodular lesions disseminated throughout the body, associated with diffuse infiltration (Fig. 159-9),

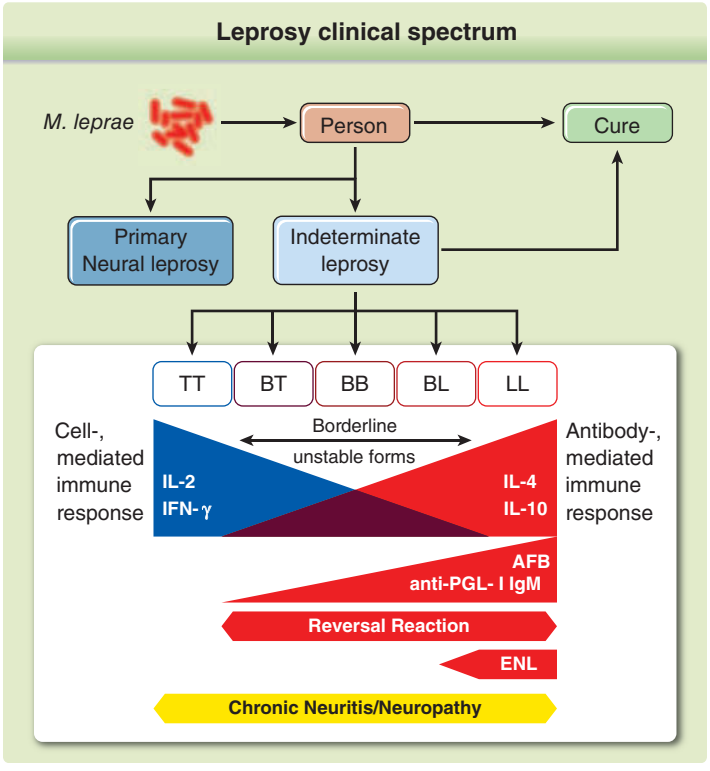

Figure 159-5 Leprosy clinical spectrum. Up to 80% of people exposed to *M. leprae* may solve the problem and get rid of the bacilli before appearance of symptoms or after subclinical leprosy. Some patients will develop primary neural leprosy, with no skin lesions. All those with skin lesions pass through an indeterminate form, and then evolve to a polar tuberculoid leprosy (TT) or lepromatous leprosy (LL) disease or to an unstable borderline form of leprosy. The paucibacillary (PB) pole toward TT has a good cellular immune response (CIR), with the presence of Th1 cytokines, while multibacillary pole toward LL present an impaired CIR and a high antibody response, with Th2 cytokines. Acid-fast bacilli and anti-PGL-I IgM are, both, low or negative on PB and increase through multibacillary pole. Reversal reaction may happen especially in borderline leprosy, whereas erythema nodosum leprosum occurs in borderline-lepromatous leprosy (BL) and LL patients. Chronic neuritis or neuropathy may happen in primary neural leprosy and in all but the indeterminate leprosy clinical form.

Figure 159-6 Indeterminate leprosy. Macular hypochromic lesion on the lower back.

including the ears (Fig. 159-10) and face, that may have facial features so marked that it gives the appearance of a lion's face, known as leonine facies (Fig. 159-11).[29] A special type of lepromatous leprosy is histoid leprosy, that has an even higher bacillary load than the usual lepromatous leprosy, with rafts of bacilli called globi, presenting diffuse shiny nodules and papules, and a variable degree of skin infiltration (Fig. 159-12).[30] Some cases of lepromatous leprosy are a challenge for less experienced health professionals to diagnose when the main skin manifestation is infiltration (Fig. 159-13). This special type is called Lucio leprosy, first described by Lucio and Alvarado in Mexico in 1852.[31] Isolation and characterization of this new species from Lucio patients, called *Mycobacterium lepromatosis*,[32] and whole genome sequencing[33] have now firmly established that this closely related mycobacterium causes this form of leprosy found mainly in Mexico and the Caribbean.

The 3 borderline forms (borderline-tuberculoid, borderline-borderline, and borderline-lepromatous)

Figure 159-8 Infantile nodular leprosy. Presence of 2 tuberous lesions on the face of a child from a family where 2 adults were diagnosed with multibacillary leprosy.

in between are all immunologically unstable. All borderline patients have skin infiltration, varying from a few to many lesions, in one or many areas of the body. Although tuberculoid leprosy patients have just papules or tubercles with no infiltration, borderline-tuberculoid leprosy presents a clear infiltrative band around the periphery of the lesions, changing from a very sharp border in tuberculoid leprosy to a more diffuse infiltrated outer layer in borderline-tuberculoid leprosy (Fig. 159-14). As the forms progress toward the

Figure 159-7 Tuberculoid leprosy. A well-circumscribed lesion, with a central macular hypochromic and atrophic appearance, and a peripheric group of papules distributed in annular pattern.

Figure 159-9 Lepromatous leprosy. Multiples nodules (hansenomes or lepromes) disseminated throughout the skin, associated to diffuse infiltration.

Figure 159-10 Lepromatous leprosy. Papules, nodules, and infiltration on the ear of a child. He had also many lesions on other parts of the skin.

lepromatous end in borderline-borderline (Fig. 159-15) with its classical foveolar lesions, and borderline-lepromatous leprosy (Fig. 159-16), effective cell-mediated immunity decreases, allowing a progressive spread and increase in the number of bacilli, an increase in infiltration of the lesions, with the evolution to form more nodular lesions, often involving the face and ears.

The diagnosis of leprosy is based on the detection of hypo- or total anesthesia in the lesions that may be associated with hypohidrosis and alopecia. Tuberculoid leprosy patients can present both dryness of the skin and alopecia restricted to the territory of the lesions. In contrast, lepromatous leprosy patients may show extensive areas of dryness, especially on the legs, and in advanced cases may result in madarosis and hair loss in different parts of the skin. Borderline patients follow the same pattern, with more restricted features in borderline-tuberculoid leprosy and more diffuse in borderline-lepromatous leprosy.

Paresthesia is a frequent symptom associated with leprosy cases. Burning, numbness, tickling, and other

Figure 159-11 Leonine facies. Lepromatous patient with diffuse nodules and infiltration on the face, resulting in a lion's face appearance.

Figure 159-12 Lepromatous leprosy histoid or Wade leprosy. Presence of nodules, which may be disseminated or scattered, some resembling molluscum contagiosum lesions, as in the picture, but note the presence of a nodule on the right nipple, and also some infiltration with a claw formation on the left hand.

Figure 159-13 Lepromatous leprosy. Diffuse infiltration of the skin.

Figure 159-14 Borderline-tuberculoid leprosy. Presence of various hypochromic annular lesions, with papules and infiltration on the periphery, located on the buttocks and thighs of a child.

Figure 159-15 Borderline-borderline leprosy. Two foveolar lesions on the upper dorsal thorax.

sensations may be present within the lesions or following the territory innervated by the nerve trunks in the affected area. Patients may feel these sensations in acute crisis, especially at night in cold weather, that may recur frequently, becoming increasingly common with the progression of the disease. All types of leprosy lesions must be submitted to a thorough sensitivity evaluation, including vasomotor reflex, sweating function, thermal, pain, and tactile sensitivity.

Dilation of blood capillaries as a secondary axon reflex erythema, which is dependent on nerve integrity, may be tested using a 1:1000 histamine solution, injected intradermally in normal and lesional skin. Within 5 to 10 seconds, erythema will result from the direct action of histamine on the capillaries, causing vasodilation in both areas, normal and lesional. Two minutes after this a secondary erythema caused by capillary dilation will occur only on normal skin. The last phase of triple Lewis response is exudation of liquid to the dermis, resulting in wheal formation in both areas. Therefore, the triple Lewis response is incomplete only on lesional skin, with the absence of secondary erythema.

Figure 159-16 Borderline-lepromatous leprosy. Foveolar and nodular infiltrated lesions.

Iodine-starch or alizarin red[34] may be used to assess sweating function of leprosy lesions. After iodine painting followed by starch, or after alizarin red, exercise may be required to induce sweating. When autonomic nerve function is affected sweating is impaired or completely absent and the skin remains dry. On normal skin, a bluish or dark brown (iodine-starch) or violet (alizarin red) color will appear, while there will be no reaction (anhidrosis) or irregular sweating (hypohidrosis) on leprosy lesions.

Thermal, pain and tactile, and Semmes-Weinstein Monofilaments tests are all directly dependent on correct verbal responses from the patient. Therefore, it is crucial to explain what each test is for, how to give proper feedback for the sensation elicited, and to perform the test on normal non-lesional skin sites to familiarize the individual with the sensation before testing lesion areas to measure any changes.

The thermal test is based on the capacity to discriminate between hot and cold sensitivity on touching the skin with 2 tubes containing hot (±45°C [113°F]) or cold water. The tube surface is touched on lesional and normal skin randomly, followed by recording the patients' answers. The professional must be careful to avoid touching lesional and normal skin at the same time, especially for smaller lesions.

Pain sensitivity is based on the ability to distinguish between the tip or the base of a needle, since one produces pain whereas the other does not. Also, randomly, lesional and nonlesional skin must be touched with the tip or the base of the needle, followed by recording the answers. A clear limitation of this method is the use of a perforating instrument, that may cause fear to some patients, especially children.

Tactile sensitivity is tested using a cotton wad, and the patient should answer if he/she senses the light touch of the cotton touching the skin, both normal or lesional. Semmes-Weinstein Monofilaments or esthesiometer kits are monofilament lines graded in thickness with different colors that are attached to plastic posts to apply different amounts of target pressure to the skin. The color and range of target force varies from green (range 0.008-0.07 g, normal skin sensation), the thinnest of which is like the sensation of a mosquito landing on skin, to the thickest, red (up to 300 g).[35] These devices are simple and cheap and can easily measure diminished or loss of protective sensation cause by diabetic neuropathy or neuropathy cause by leprosy nerve damage. Loss of sensation using the blue Semmes-Weinstein monofilaments indicates diminished sensation of light touch (0.16-0.4 g), purple indicates diminished protective sensation (0.6-2 g), and red indicates more profound loss of protective sensation (4-300 g). More recently, the simplicity and ease of use of Semmes-Weinstein monofilaments have supplanted all of the other tactile, thermal, and pain tests.[36] After showing the patient how the monofilament works and getting a "yes" response if he or she feels the touch, various thicknesses of Semmes-Weinstein monofilaments can test areas of skin randomly inside and outside the suspect lesion, as depicted in Video 159-1 at mhprofessional.com/fitzderm9evideos. Even children

as young as 6 to 7 years old can respond very well to this kind of test, and those children who are not able to communicate well can still point to the place on the skin if they feel the device touching it (see Video 159-1 at mhprofessional.com/fitzderm9evideos).

In conclusion, the "classic" cases as defined by Ridley-Jopling classification have well-defined lesions, associated with a range of signs and symptoms, which facilitate the diagnosis of leprosy. After 35 years of multidrug therapy, the challenge now is to diagnose cases early, with the goal to eliminate disabilities.

NONCUTANEOUS FINDINGS

Although leprosy diagnosis is based primarily on the presence of skin lesions, usually when dermatologic signs are detected, at this point the peripheral nerves have been already invaded and damaged by *M. leprae* itself and/or by the response of our immune system. In fact, nerves may be the first target of *M. leprae*, and the infection itself together with immune cell infiltration and inflammation that can be clinically detected by palpation.

Palpation of the peripheral nerve trunks can establish nerve thickness and tenderness. However, even for highly trained health professionals, it is not a simple task to detect differences in thickness from one side to the other, or to decide if the nerve is soft, and therefore normal, or fibrotic. Furthermore, those differences should be considered only when it is associated to some functional harm, as (1) loss of sensation defined by hypo- or total anesthesia on the territory of the nerve; (2) motor dysfunction, as in the case of interosseous muscle hypotrophy; or (3) autonomic alteration, as with skin sweating deficit.

Although tuberculoid leprosy patients may have conspicuous alterations in just one specific peripheral nerve trunk, usually in the same segment of the skin lesion, lepromatous leprosy patients often present thickness and tenderness variations in many nerves, accompanied or not with functional alterations in different segments of the body. Borderline-tuberculoid, borderline-borderline, and borderline-lepromatous leprosy patients usually present nerve changes, varying from a few nerve trunks affected in borderline-tuberculoid leprosy to many in borderline-lepromatous leprosy. In many cases, there is some degree of pain, spontaneously reported by the patient, or mentioned during palpation.

Besides upper and lower limbs, the face also may be affected when facial or trigeminal nerves are damaged, which can result in hypo- or anesthesia, including on the cornea, and muscle hypotrophy, especially when palpebral muscles are involved, resulting in lagophthalmos (Fig. 159-17).

The presence of any of these changes in peripheral nerve trunks detected by palpation or functional loss eliminates the diagnosis of indeterminate leprosy. On the other hand, between 5% and 17% of all leprosy patients only have signs of nerve inflammation or

Figure 159-17 Lagophthalmos on the right eye.

functional deficit without any skin lesions, in which case the diagnosis may be pure neuritic, or the more common term *primary neural leprosy*,[37] because up to 35% of such cases may develop skin lesions after the diagnosis of primary neural leprosy.[38]

Primary neural leprosy accounts for about 4% to 8% of all leprosy cases, although in India it may be as high as 17%.[37] A positive acid-fast bacilli result on slit-skin smear eliminates primary neural leprosy, but a nerve biopsy can demonstrate the presence of acid-fast bacilli in 16% of these cases, whereas PCR is positive in almost half of them.[39] Definitive diagnosis of primary neural leprosy is not a simple task and may require clinical signs, nerve histopathology, electrophysiology, and ultrasonography,[37] although most of those techniques are not available in highly endemic countries.

Endocrine dysfunctions, after nerve and skin lesions, are most prominent in patients, but are not readily detected, reaching up to 25% of cases[40] leading to, among other problems, hypothyroidism, euthyroid sick syndrome, hypogonadism, sterility and osteoporosis.[41] Levels of testosterone were inversely correlated with the number of skin lesions,[40] and the level of adrenal androgen dehydroepiandrosterone sulphate had an inverse correlation with interleukin (IL)-6 and tumor necrosis factor (TNF)-α, whereas gonadotropins—luteinizing hormone and follicle-stimulating hormone—were positively correlated with proinflammatory cytokines,[42] suggesting a possible neuro-immune-endocrine correlation in leprosy.

COMPLICATIONS

The natural history of leprosy is the evolution to impairment, especially with the eyes, hands, and feet, in both soft tissues and bones, leading to disfigurement and deformity, the origin of all leprosy-related stigma. Even with bacteriological cure after multidrug therapy implementation, and assistance from social networks involved in education, training, and reintegration of those with disabilities into society, estimates

of the numbers of people living with varying levels of disability, including Grade 1 (partially disabled) to Grade 2 (can be completely disabled and unable to work) caused by *M. leprae* are likely between 1 and 4 million worldwide.[43]

With the eyes, loss of corneal sensation can result in wounds, followed by infection and blindness, whereas hypotrophy of palpebral muscles may result in lagophthalmos, which can also contribute to corneal infection. Advanced cases, especially in multibacillary leprosy, mostly toward the lepromatous leprosy pole, may present characteristic facial bone malformations, resorption, and pitting, particularly involving destruction of the anterior nasal spine, resorption of the alveolar process of the maxilla, sometimes with loss of teeth, collectively characterized as rhinomaxillary syndrome.[44]

For hands and feet, complications start with a loss of sensation that may lead to wound formation (Fig. 159-18) after burns, trauma, or repetitive moderate pressure–induced skin disruption not detected by the patient, with possible evolution to fissures and ulcers, soft tissue inflammatory autolysis, muscle atrophy, bone decalcification, osteitis and resorption (Fig. 159-19), fusion and joint dislocation, osteoarthritis, and destruction.[45] At the same time, interosseous hypotrophy or amyotrophy may result in paresis or paralysis, leading to formation of claw and/or drop hand or foot (see Video 159-2 at mhprofessional.com/fitzderm9evideos), that may be mobile at first, and constitute severe impairments to leprosy patients,[46] like walking (see Video 159-3 at mhprofessional.com/fitzderm9evideos).

Figure 159-18 Ulcers in a hypotrophic and anhidrotic hand of a LL patient.

Figure 159-19 Fixed claws and bone resorption associated with anhidrosis and atrophy as sequels on the hands of a borderline-lepromatous leprosy patient.

ETIOLOGY AND PATHOGENESIS

RISK FACTORS

Mycobacterium leprae, a noncultivable obligate intracellular pathogen that mainly damages skin and peripheral nerves, is the causative agent of leprosy, resulting in a broad range of skin lesions with anesthesia, peripheral neuropathy through nerve damage, and muscle weakness and atrophy leading to bone loss by resorption, with related deformity, disfigurement, and disability along with the social stigmatization associated with this disease afflicting mankind for thousands of years. Although *M. leprae* shares roughly 1,439 gene orthologs and homologs with *M. tuberculosis*, a reductive evolutionary event that occurred between 10 and 20 million years ago resulted in massive gene deletion and decay, resulting in the transformation of nearly half of all coding genes into nonfunctional truncated gene remnants or pseudogenes.[47] This process of reductive evolution has occurred in several obligate intracellular pathogens, including Rickettsia and Chlamydia, and is thought to be a survival response to dramatic changes in ecological niche or lifestyle. The streamlining and elimination of many genes and pathways once required for survival as a free-living species would be superfluous in an intracellular habitat, resulting in deletion or inactivation of large parts of the genome. Thus, *M. tuberculosis* has 4.41 Mb, where >90% of the genome encodes 3,998 protein coding sequences, whereas *M. leprae* has 3.27 Mb, where just under 50% of the genome codes for 1614 functional genes, with the remainder coding for 1306 pseudogenes and gene remnants whose complete counterparts can be found in *M. tuberculosis*. The combined effect of gene reduction has created a minimal gene set, reducing the number of genes involved in all functional metabolic pathways, including critical pathways involved in gene regulation, detoxification, DNA repair, transport

or efflux of metabolites and small molecules, while generally decreasing the frequency of genes in degradative pathways versus synthetic ones and a paucity of respiratory enzymes. Because of these deficiencies, *M. leprae* has one of the longest doubling times of any bacteria, around 13 days, possibly explaining the exceptionally long incubation time between infection and development of clinical disease, usually between 3 and 7 years, although in some cases up to 20 years. The failure to grow *M. leprae* in axenic medium despite decades of attempts is probably the result of the combined effects of gene reduction and mutations in key metabolic pathways.

One of the hallmarks of the leprosy bacillus is the ability to attach and invade Schwann cells associated with the peripheral nervous system, which leads to colonization and inflammation within nerves, causing nerve damage, demyelination, and neuropathy. Binding to the laminin-2 molecule in the basal lamina of Schwann cells is mediated by 2 bacterial cell wall components, the laminin-binding protein (encoded by ML1683c) and the terminal trisaccharide of the *M. leprae*–specific phenolic glycolipid I (PGL-I).[48] Transmission is thought to occur through the aerosol route, with the bacillus gaining entry and colonizing resident macrophages within the nasal mucosa and turbinate,[49] then disseminating to tissues and nerves through the bloodstream. Early events involved in host–pathogen interaction at the cellular level is likely mediated by host genes involved in pattern recognition receptors and mycobacterial uptake (Toll-like receptors [TLR], nucleotide-binding oligomerization domain containing 2 [NOD2], and mannose receptor C-Type 1 lectin [MRC1]), which modulate autophagy. For example, bacterial cell wall lipoproteins that recognize and bind TLR 1/2 heterodimer ligands on the host cell surface trigger an innate immune response, the outcome of which will determine whether the bacillus is contained or killed within a granuloma or grows uncontrollably. There is an overall genetic resistance toward developing leprosy, with more than 90% of people worldwide having a natural immunity.[50] Early innate immune responses to mycobacteria binding to these pattern recognition receptors and entry into the cell regulates cellular metabolism to activate NF-κB and vitamin D receptor pathways to upregulate cytokine production and genes that are critical to form and maintain granulomas required to contain the bacilli, including TNF, interferon gamma (IFN-γ) and lymphotoxin alpha. What occurs next is likely determined by the complex interplay of the adaptive immune response involving cell-mediated and humoral immune responses, with T helper 1 (Th1) cytokines and a pro-inflammatory response leading to heightened cell-mediated responses controlling bacterial growth and preventing dissemination, and a shift to T helper 2 (Th2) cytokine production downregulating the inflammatory response and leading to uncontrolled growth, high levels of ineffective antibody responses to bacterial antigens, and progressively worsening disease symptoms.

Epidemiologic studies, including twin studies, complex segregation analyses, and genomewide analyses in various genetically diverse populations from different leprosy endemic countries have indicated the probable importance of host genetics in the susceptibility or resistance to this disease. Twin studies conducted in India in the 1960s and 1970s showed that there was an overwhelming concordance (60%-80%) for monozygotic twin pairs to develop leprosy.[51,52] Genomewide analysis studies examining linkage and association of multiple gene candidates suggest that there is genetic control involved in the susceptibility of developing leprosy and a predilection to develop a particular form of disease. Evidence for the latter is seen in Mexico and the Philippines, where 90% of cases develop the lepromatous form of the disease, whereas about equal numbers of patients develop tuberculoid or lepromatous disease in many African countries and in Brazil. Extensive studies have implicated associations with human leukocyte antigen (*HLA*) complex genes (class I and class II) because of their primary role in the adaptive host immune response, and a number of alleles are overrepresented for leprosy susceptibility or the development of either the tuberculoid or lepromatous subtype when particular ethnic populations in different countries were examined. There is also a shared genetic background between leprosy and a number of inflammatory diseases, including Crohn disease (nucleotide-binding oligomerization domain containing 2 [*NOD2*]), myocardial infarction (lymphotoxin α [*LTA*]), Type 1 diabetes and psoriasis (vitamin D receptor [*VDR*]), and Parkinson disease (E3 ubiquitin-protein ligase [*PARK2*]).[50] More recently, genomewide association studies examining SNP differences between leprosy cases and controls in China have increased the list of genes that may be involved in regulating innate and adaptive immune response pathways associated with susceptibility or resistance to leprosy.[53] Fifteen SNPs detected among 6 genes were associated with leprosy (*HLA-DR-DQ*, *RIPK2*, *TNFSF15*, *CCDC122*, *C13orf31*, and *NOD2*), whereas pathway analysis identified a total of 35 genes involved in a single network involved in leprosy susceptibility or resistance.

Besides genetic risk factors, many studies have shown that there are a number of other factors, operational or socioeconomic, that increase the risk or predispose individuals toward developing disease. Household contacts living within a dwelling with an untreated multibacillary leprosy index case have the highest risk of eventually coming down with disease, particularly if the household contact is a blood relative to the index case.[54] Individuals who have a positive anti-PGL-I titer have up to an 8-fold higher risk of developing leprosy. Other risk factors include living in an endemic or hyperendemic area for leprosy, poverty, living in high-density households with >2 persons sleeping together in a room, poor nutritional status, poor sanitation or lack of clean water, and lack of health care availability.[55] Improving these underlying problems would greatly decrease the likelihood of those at risk of leprosy from ever developing this disease.

DIAGNOSIS

SUPPORTIVE STUDIES

PATHOLOGY

Physiopathology of Leprosy: The routes used by *M. leprae* to gain access to the target cells, mainly Schwann cells, have always been a matter of discussion. Basically, 4 different pathways have been proposed: (1) naked nerve filaments in the epidermis; (2) entrance of *M. leprae* in the epidermis, and from there to other Schwann cells; (3) phagocytosis of *M. leprae* by dermal macrophages, which then invade the perineurium, liberating bacilli to enter Schwann cells; and (4) through the blood, that is, *M. leprae* could gain access to the nerve by intraneural capillaries. Enlarged endothelial cells could facilitate bacilli entrance to the nerve system, and finally to Schwann cells.[56]

M. leprae interaction with and engulfment by endothelial cells was identified long ago.[57] Armadillo studies showed epineural thickening following *M. leprae* infection of macrophages of lymphatic and vascular endothelial cells.[58] Although this model of infection is well known, it is still not clear how *M. leprae* is then transferred from those cells to Schwann cells.

Once *M. leprae* reaches the extracellular matrix, PGL-I[48] or a histonelike 21-kDa laminin-binding protein[59] binds to the laminin α2 chain to invade Schwann cells. The presence of the G domain of α-dystroglycan (α-DG) might be necessary for the adherence of *M. leprae* to Schwann cells.[60] The matrix cytoskeleton link (α-DG, α2-laminin, β-DG) may be the route used by *M. leprae* to enter the host cell (Fig. 159-20).

M. leprae bypass neuregulin receptor (an epidermal growth factor family component) and does a direct bacterial ligation to ErbB2, signaling with no ErbB3 heterodimerization and amplifying Erk1/2 signaling that may induce myelin sheath degradation.[61] In addition, using a nonclassical pathway and MEK-independent signaling, *M. leprae* can activate Erk1/2 directly by lymphoid cell kinase (p56LcK), inducing cell proliferation and maintaining its niche of proliferation.[62] On infection, there is an increased expression of 9-*O*-acetyl GD3 ganglioside, a molecule involved in anti-apoptotic signaling and nerve regeneration (Fig. 159-20). Immunoblocking of 9-*O*-acetyl GD3 ganglioside on Schwann cells reduces Erk1/2 and cell proliferation.[63]

M. leprae can dedifferentiate and reprogram adult Schwann cells to stem cell–like cells, possibly using this to promote dissemination of infection.[64] Bacilli survival may be maintained by different mechanisms. After invasion (Fig. 159-20), *M. leprae* interferes with (1) endocytic maturation inhibiting vesicle acidification of phagosomes[65]; (2) host-cell lipid homeostasis, inducing and accumulating lipid droplets through cytoskeleton reorganization and PI3K signaling, independently of TLR-2[66]; and (3) oxidative pathways, by an intensification of glucose uptake and augmentation of glucose-6-phosphate dehydrogenase, that once inhibited can decrease *M. leprae* viability by up to 70%.[67]

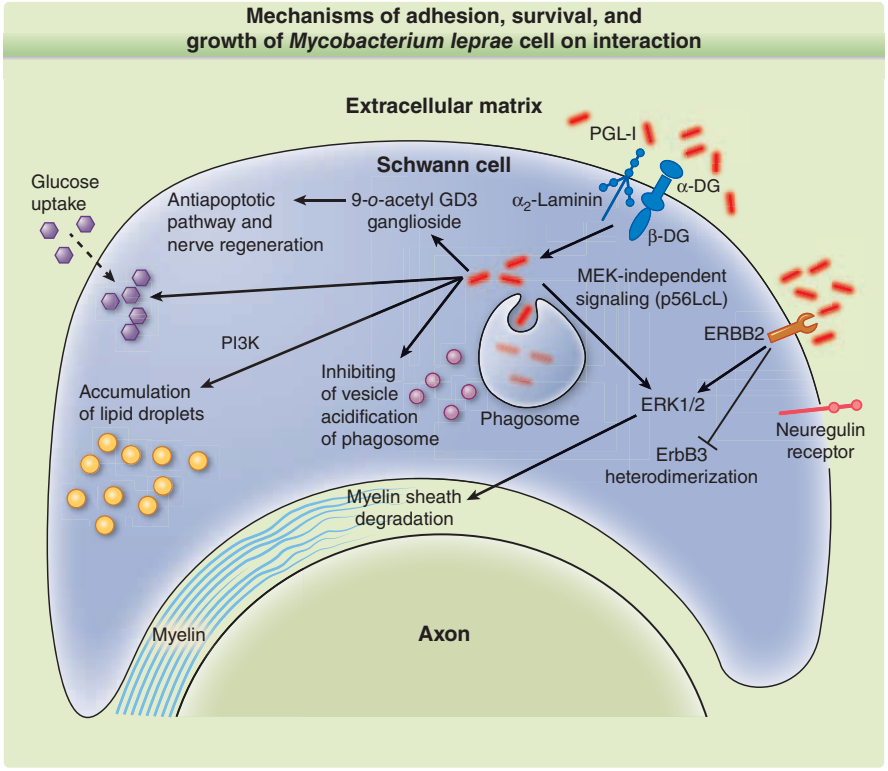

Figure 159-20 Host cell interaction of *M. leprae*. The figure shows the main mechanisms of entrance and maintenance of the bacteria inside a Schwann cell.

The immune response may initiate at any phase of the host–bacteria interaction. Epidemiologic surveys in hyperendemic areas in Brazil show a high percentage (up to 50% or more) of anti-PGL-I IgM antibodies circulating among schoolchildren, indicating infection with *M. leprae* followed by an early antibody response against the bacilli.[68] Although nerve demyelination may occur in T and B lymphocyte–depleted mice,[69] diverse immune reactions occur during infection.

There is a well-characterized dichotomy in the human immune response in leprosy, with those at the tuberculoid end of the spectrum having a strong Th1 cell–mediated response whereas those at the lepromatous end have a skewed Th2 response with T-cell anergy present. Tuberculoid leprosy cases have a strong Th1 response, with IL-2, TNF-α, IFN-γ, and IL-12 cytokine production, whereas lepromatous leprosy patients have a Th2 response, with IL-4, IL-5, IL-10 and high levels of antibody production. Those characteristics are found also in the skin, where generally the 2 situations may appear as demonstrated by the progressive disorganization of the immune cells that infiltrate the skin[70] in histochemical stained tissue sections of lesions. Tuberculoid leprosy patients present a well-organized granuloma containing epithelioid cells, $CD4^+$ T cells, a good cell–mediated immunity, almost no antibody production, and no bacilli found by slit-skin smear bacilloscopy. On the other hand, lepromatous leprosy patients demonstrate a massive infiltration of foamy macrophages filled with large numbers of bacilli, with few lymphocytes, mostly $CD8^+$ T cells, and a defective cell-mediated immunity with high titers of antibodies to *M. leprae* antigens, including to PGL-I.[71]

Toll-like receptors, such as TLR-1, TLR-2, and TLR-4, along with DC-SIGN (CD209) and CD163 may be involved in macrophage/dendritic cell interactions with *M. leprae*. TLR-1 and TLR-2 have a higher expression in tuberculoid leprosy in comparison with lepromatous leprosy lesions, and TLR-1/TLR-2 heterodimers mediate monocyte and dendritic cell activation, stimulating TNF-α and IL-12 production[72] (Fig. 159-19). *M. leprae* can also stimulate TNF-α, IL-6, and CXCL10 (IP-10) production through TLR-4 signaling in macrophages.[73] On the other hand, TLR-2 signaling in Schwann cells is related to apoptosis.[74]

M. leprae increases IL-10 expression in dendritic cells through DC-SIGN signaling, activating Raf-1, resulting in acetylation of the NFκB p65 subunit after TLR-induced activation of NFκB.[75] IL-10 induces phagocytosis by macrophages through DC-SIGN and differentiates monocytes into foamy macrophages by upregulation of oxidized low-density lipoprotein uptake, whereas IL-15 induces the vitamin D antimicrobial pathway, exhibiting less phagocytosis.[76] Together with upregulation of DC-SIGN and indoleamine 2,3-dioxygenase, CD163 is also increased and contributes to iron uptake and to the creation of an advantageous environment for *M. leprae* entry and survival in lepromatous leprosy macrophages[77] (Fig. 159-20). *M. leprae* can modulate NFκB activation in Schwann cells, a function that can be inhibited by thalidomide.[78] Moreover, metalloproteinases 2 and 9 and TNF-α are upregulated in Schwann cells, macrophages and endothelial cells in primary neural leprosy nerves,[79] that result in a prominent endoneurial infiltrate, with perineurial fibrosis and enlargement in comparison to non-leprosy peripheral neuropathy.[80]

Besides the Th1/Th2 cytokine profile, other factors, such as IL-17, cathelicidin LL-37, and insulinlike growth factor I also seem to be important in leprosy physiopathology. VCAM-1 is augmented in the serum of leprosy patients,[81] whereas vascular endothelial growth factor and thromboplastin expression is increased by endothelial cells of leprosy patients.[82] IL-17 is low in all leprosy patients in comparison to nonleprosy controls, but even lower in lepromatous leprosy.[83] Although IL-17-producing $CD4^+CD45RO^+$ Th17 cells were increased in peripheral blood mononuclear cells of tuberculoid leprosy patients, IL-10-producing $Foxp3^+$ Treg cells were 5 times more prevalent in lepromatous leprosy than in tuberculoid leprosy patients, indicating a role for Tregs in multibacillary leprosy development.[84] Cathelicidin LL-37, a unique cathelicidin family member of host defense peptides found in humans that is known to modulate the immune response against *M. tuberculosis*, is low in all leprosy patients[85] (Fig. 159-21). Insulinlike growth factor I, known to decrease macrophage antimicrobial capacity, inhibiting *M. leprae* killing,[86] was also found to be low in lepromatous leprosy patients, mostly among those who did not develop Type 2 reaction or erythema nodosum leprosum (ENL).[87]

ENL, an immunologic Type III hypersensitivity response, occurs with immune complex deposition[88] with anti-PGL-I and anti-monocyte chemoattractant protein-I antibodies,[89] upregulation of Th17, IL-6, IL-1β, sIL2R, and sIL6R; a decrease of the Treg response; and an influx of neutrophils in the lesions[90] (Fig. 159-21). In addition, ENL can be initiated on IFN-γ intradermal injection in lepromatous leprosy patients,[91] there is an increase in the $CD4^+/CD8^+$ ratio, high serum levels of TNF-α are found,[92] and the use of TLR-9 agonists augments TNF-α, IL-6, and IL-1β.[93] E-selectin is expressed in a vascular pattern, higher in ENL than in nonreactional lepromatous leprosy patients,[94] and FcγRI increases in circulating neutrophils of ENL patients[95] (Fig. 159-21).

Gene expression analysis showed an increased expression of a "cell movement" biologic group, including P-selectin, E-selectin, and neutrophil adhesion to endothelial cells, with migration and inflammation. In vitro stimulation of TLR-2 induced IL-1β and FcR expression, that together with IFN-γ and granulocyte macrophage colony–stimulating factor, augmented E-selectin expression, and increased neutrophil adhesion to endothelial cells.[94] Thalidomide inhibited this neutrophil recruitment pathway, decreases neutrophil influx, FcγRI expression, and TNF-α production. C1qA, B, and C components of the classical complement pathway, and the receptors C3AR1 and C5AR1, were also increased in lepromatous leprosy patients.[59]

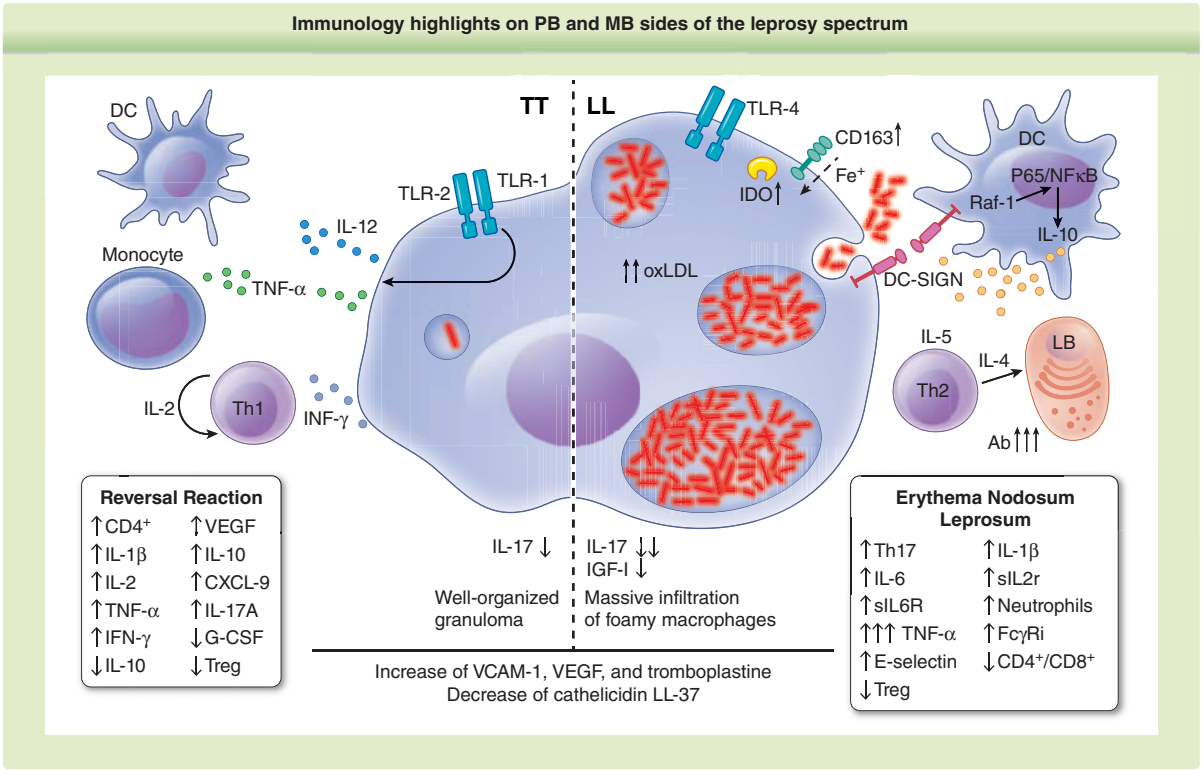

Figure 159-21 Immunology of leprosy. The main differences of tuberculoid leprosy and lepromatous leprosy poles are demonstrated, together with the key variations between reversal reaction and erythema nodosum leprosum.

Type 1 reaction or reversal reaction, a Type IV hypersensitivity immune response, is caused by a specific increase in cell-mediated immunity against *M. leprae*, and may rapidly evolve to nerve damage. Together with an increase of $CD4^+$ T cell infiltration associated with IL-1β, IL-2, TNF-α, and IFN-γ upregulation[96] (Fig. 159-21), an augmentation of CC chemokines monocyte chemoattractant protein-I and RANTES[97] is observed.

Also, vascular endothelial growth factor, IL-10, CXCL-9, and IL-17A were demonstrated to be upregulated on the reversal reaction onset, together with downregulation of IL-10 and granulocyte colony-stimulating factor. This profile was related to a decrease of $CD39^+CCL4^+CD25^{++}$ regulatory T-cell subsets and an increase of *GNLY*, *GZMA/B*, and *PRF1* genes associated with cytotoxic T cell.[98]

LABORATORY TESTING

Further reduction in leprosy would require the diagnosis of those in the early stages of disease to allow treatment to prevent nerve damage and impairment, but it is estimated that most patients experience up to 2 years delay in diagnosis.[99] Reasons for this are complicated, but include a reduction in the numbers of trained leprosy clinicians and laboratory technicians worldwide and the incorporation of leprosy diagnosis into the general family health delivery system, resulting in increased levels of misdiagnosis or delays in beginning treatment. When there are doubts about the clinical diagnosis, laboratory tests can be used to assist or confirm a presumptive case of leprosy.

The clinical spectrum of leprosy shows a range of pathologic manifestations in skin lesions and nerve damage that is aligned with the competence of the host's immune response, and is dependent on the strength and interaction of both cell-mediated and antibody responses.[100] The standard for laboratory diagnosis in a skin biopsy is the detection of acid-fast bacilli by the Fite-Faraco modification of the carbol fuchsin technique and characteristic cellular histologic patterns that make up the immunopathologic types of leprosy as detected by hematoxylin–eosin staining. The widely used Ridley-Jopling classification system[26] divides the disease into 5 forms based on the number of acid-fast bacilli and the degree of lymphocytic infiltration and organization, as described in pathology (above). Bacilloscopy of multiple skin biopsies or slit-skin smear can establish the bacillary index on a logarithmic scale, which can range from 0 (no acid-fast bacilli detected in tuberculoid leprosy lesions) to 6+ (>1000 acid-fast bacilli per field in lepromatous leprosy) (Fig. 159-22). For treatment purposes, detection of acid-fast bacilli in skin lesions or slit-skin smear automatically places the patient in the multibacillary category to receive 12 months of multidrug therapy.

There is currently no laboratory test capable of diagnosing leprosy or identifying asymptomatic individuals who are progressing toward developing

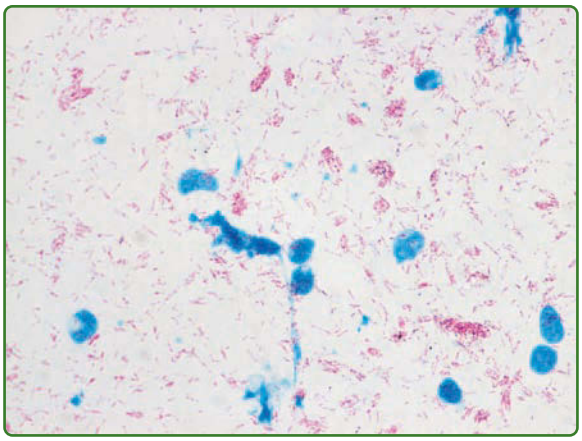

Figure 159-22 Acid-fast bacilli of a slit-skin smear of a lepromatous leprosy patient. The cells are in blue and the bacteria are in red, forming globi.

early symptoms, so the development of a simple and cheap test that could assist health professionals to correctly diagnose the disease based on immunologic or metabolomic biomarkers of infection is desirable. A number of research groups have developed a variety of tests that partially achieve this goal, measuring antibody titers to mycobacterial antigens by rapid lateral flow devices; cell-mediated cytokine release assays (such as the detection of IFN-γ, similar to commercial whole blood assays used to detect infection by *M. tuberculosis*); amplification of mycobacterial DNA by PCR; or the use of metabolomics to detect molecular features specific to *M. leprae* infection in the blood or urine. Laboratory assays adapted to assess leprosy patient antibody titers to the *M. leprae*–specific antigen, PGL-I, have been in use for more than 30 years[101,102] and include enzyme-linked immunosorbent assays and lateral flow devices that use the soluble synthetic disaccharide of PGL-I coupled to either bovine or human albumin, called ND-O-BSA or ND-O-HSA, respectively. Another is the protein antigen LID-1, composed of the fusion of 2 well-recognized *M. leprae* proteins, ML0405 and ML2331, that is recognized by >95% of lepromatous patients.[103] Coupling the synthetic disaccharide of PGL-I to LID-1 and incorporating this NDO-LID glycoprotein in a lateral flow test resulted in enhanced sensitivity to detect leprosy patients, even those at the paucibacillary end of the spectrum.[104] Another group has combined lateral flow assays with up-converting phosphor reporter technology to assess both anti-PGL-I titers along with T cell–mediated cytokine responses (IFN-γ, IL-10, and others) in a single sample. The ability to quantitate the ratio of inflammatory Th1 cytokines versus down-regulating Th2 responses provides more information about the complex interplay of cellular and humoral immunity within individuals that can be used to better predict those with asymptomatic infection or who are progressing to disease.[105,106] Another method that has been used to diagnose difficult cases is the molecular detection of the *M. leprae*–specific repetitive RLEP sequence by PCR. Because there are 37 copies of the RLEP sequence in the genome, this enables the detection of as few as 3 bacterial genomes in a sample. Recent evidence indicates that individuals who are RLEP PCR positive in biopsies of skin lesion sites, earlobe slit-skin smear, or the nasal turbinate as well as having a positive anti-PGL-I titer likely have asymptomatic infection and are at the highest risk of developing disease.[49] Our own household contact studies in hyperendemic areas in Pará, Brazil, support these findings. Initial results of multiple families living in "hot zones" indicated that in many instances >80% of household contacts had a positive anti-PGL-I titer, >70% were positive for RLEP by PCR in slit-skin smear, with up to 65% being positive for both biomarkers, demonstrating extreme rates of infection, with 1 or more individuals in each household diagnosed with leprosy based on clinical signs (Salgado et al, unpublished observations). Finally, metabolomics has been used to identify molecular features found in the serum of leprosy patients, indicating that there was an increase of circulating polyunsaturated fatty acids and phospholipids in individuals with lepromatous disease.[107] A recent report has even shown that molecular features of infection can be identified by mass spectrometry simply by pressing silica plates against patient skin lesions.[108] Moreover, the leprosy miRNome sequencing has been recently published, and revealed new markers involved on leprosy physiopathology[109]

Although advances have been made in identifying biomarkers of infection by many research groups, translating this to a rapid, cheap, point-of-care test that will aid in diagnosing all patients throughout the leprosy clinical spectrum, including asymptomatic individuals, has a long way to go. Currently, leprosy diagnosis must remain in the competent hands of well-trained leprosy clinicians and health care workers. We have shown the importance of targeting schoolchildren in school-based surveillance and followup of household contacts of those diagnosed children to detect cases early in the disease process. The use of a Geographic Information System, spatial analysis tools, and laboratory tests (anti-PGL-I enzyme-linked immunosorbent assay and RLEP PCR) has enhanced the ability to identify "hot zones" within hyperendemic cities,[110,111] which can then allow focused targeting of foci of infection by community health care agents working in local areas. Nevertheless, given the complexities of examining, diagnosing, and ensuring treatment to individuals living in hyperendemic areas,[15] developing a simple laboratory test to diagnose leprosy early is highly desirable and would facilitate breaking the lines of transmission to eventually reach the goal of leprosy elimination.

HISTOPATHOLOGY

Skin biopsies should include the dermis and, if possible, subcutis of a lesion. Hematoxylin–eosin staining is complemented using the Fite-Faraco staining method or another method to detect acid-fast bacilli.

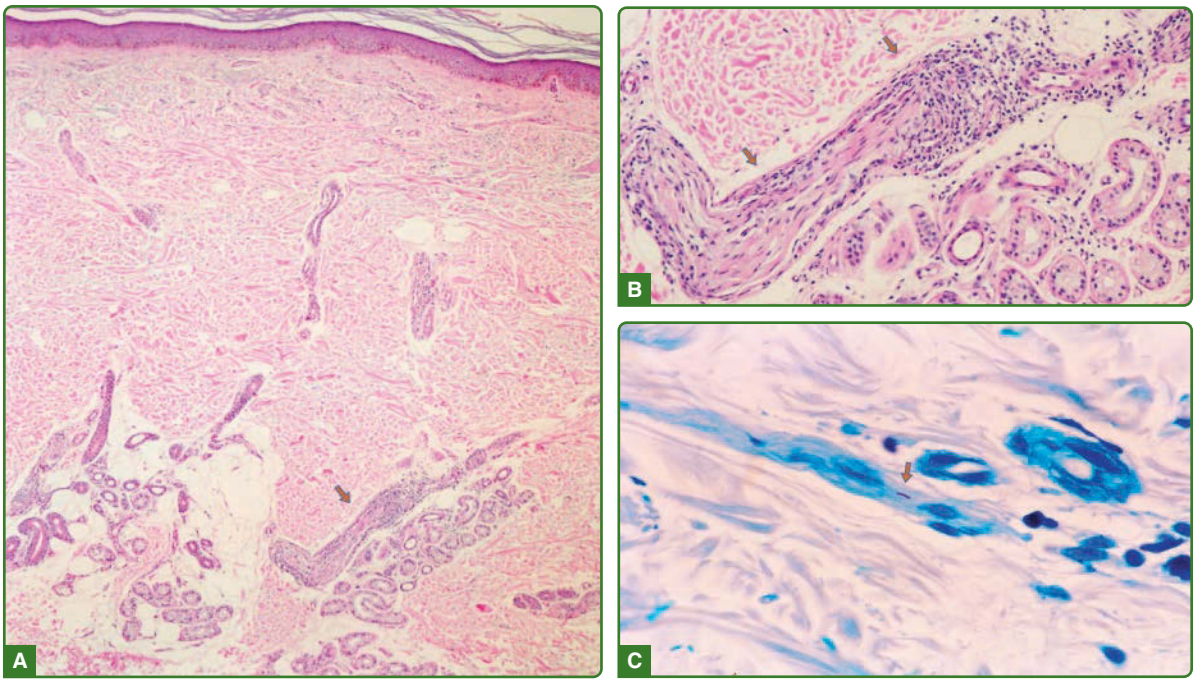

Figure 159-23 Indeterminate leprosy histopathology. Up to 70% of the indeterminate cases may have an unspecific histopathology. In 30% it is possible to observe a perineural infiltrate with nerve delamination (**A** and **B,** arrows), as demonstrated here, and if extensively searched, sometimes it is possible to find an acid-fast bacilli (**C,** arrow). (Used with permission from Dr. Jaison Barreto, Lauro de Souza Lima Institute, Brazil.)

Histopathologic findings are graded according to the Ridley and Jopling scale.[26] The tissue response in *Indeterminate* leprosy is nonspecific. The normal epidermis or basal layer of the skin show melanin reduction. Perivascular or perineural, superficial and deep dermal infiltration by few macrophages and lymphocytes are common findings. Sometimes the infiltrate surrounds skin appendages and rarely there are bacilli in nerves (Fig. 159-23).

Tuberculoid leprosy shows an epidermis that is usually normal and the subepidermal clear zone is absent. There is a noncaseating dermal granulomatous process composed chiefly of activated macrophages (epithelioid cells) with $CD4^+$ T cells in the center of the epithelioid cells, $CD8^+$ T cells in the mantle surrounding the granuloma, and giant cells of the Langhans type. Granulomas may contact the epidermis and are often arranged around nerves and vessels. Peripheral nerve involvement, cellular infiltration of sweat glands, and invasion of the arrectores pilorum muscle by a granulomatous infiltrate is common. There are no acid-fast bacilli or when they are present are found more frequently within peripheral nerves, arrectores pilorum muscle, or even granulomas[112,113] (Fig. 159-24).

The histopathology of the *borderline-tuberculoid* form can be distinguished from tuberculoid leprosy by the presence of a subepidermal grenz zone. In general, there is no well-defined granuloma with organized collections of epithelioid cells, and there is a reduction in the frequency of lymphocytes and scarce Langhans cells with rare acid-fast bacilli (Fig. 159-25).

In *borderline-borderline*, there are aggregates of epithelioid cells, scarce dispersed lymphocytes, no Langhans multinucleated giant cells, and increasing numbers of acid-fast bacilli (Fig. 159-26).

Borderline-lepromatous leprosy shows a subepidermal grenz zone, aggregates of macrophages, occasional epithelioid cells with abundant cytoplasm, and some foamy cells, with few lymphocytes. A great number of bacilli and some globi can be found (Fig. 159-27).[114]

In *lepromatous leprosy* there is a normal to flattened epidermis, subepidermal grenz zone, aggregates and sheets of foamy macrophages admixed with predominantly CD8+ lymphocytes and plasma cells throughout the dermis and into the subcutaneous fat. Huge numbers of acid-fast bacilli and globi are found within foamy macrophages (Virchow cells), nerves, arrectores pilorum muscle, follicular epithelium, and sweat glands (Fig. 159-28).

Histoid leprosy is characterized by epidermal atrophy, a subepidermal grenz zone, and a dermis showing sheets of predominantly spindle-shaped cells with nuclear pyknosis and foamy cytoplasm, vacuolated, and arranged in a storiform pattern. Some polygonal-shaped cells, macrophages, and inflammatory cells are present. Some cases may show a pseudocapsule. The lesion resembles a fibrohistiocytic tumor (Fig. 159-29). The Fite-Faraco stain reveals a large number of acid-fast bacilli, mostly as rafts or globi (Fig. 159-30). Bacilli can be located in nerves, Schwann cells, eccrine glands, and in the vascular endothelium. CD68-positive macrophages and spindle cells are present in histoid leprosy.[115]

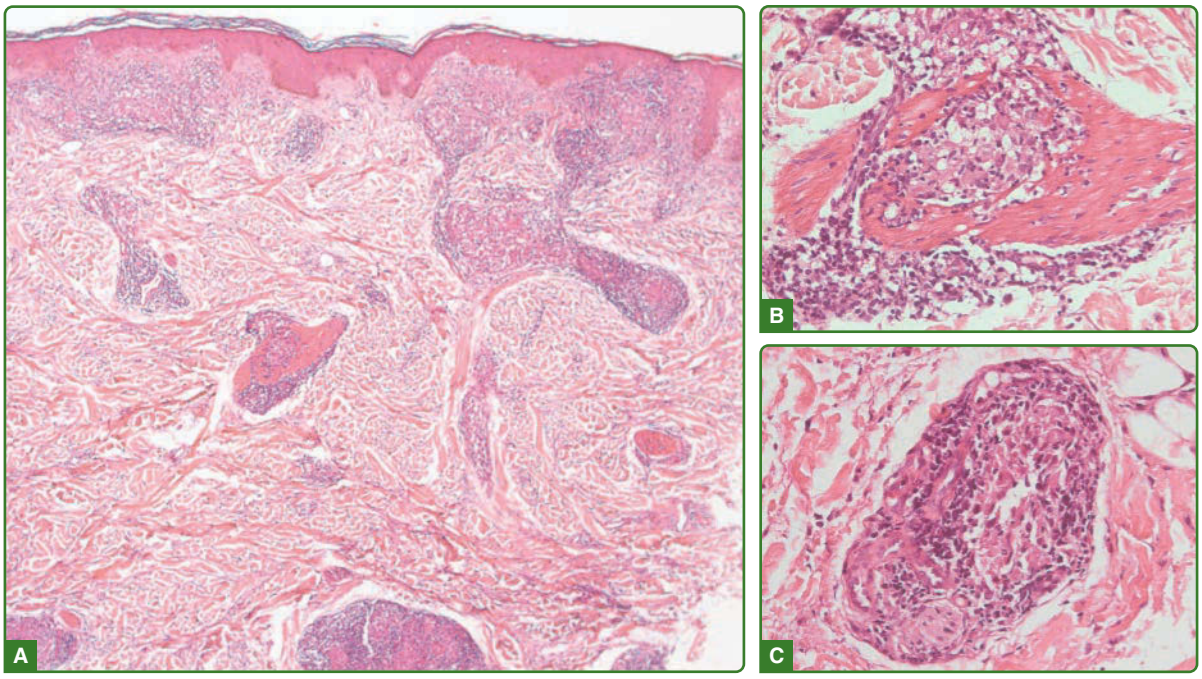

Figure 159-24 Tuberculoid leprosy histopathology. Presence of deep and superficial well-developed granuloma, that touch the epidermis (**A**), associated with lymphocyte infiltration surrounding or invading and destroying skin appendages, like nerves, erector pili muscle (**B**), or sweat gland (**C**).

In leprosy reversal reaction, the histopathologic features are edema both extracellular as in epithelioid cell granulomas, increased number of lymphocytes and Langhans giant cells in the infiltrate, small collections of epithelioid cells, as well as a poorly organized granuloma. Fibrinoid necrosis is present in severe cases of reversal reaction. Bacilli are found in macrophages and nerves (Fig. 159-31). The downgrading reaction reveals aggregates of foamy macrophages, a remarkable reduction or complete absence in the

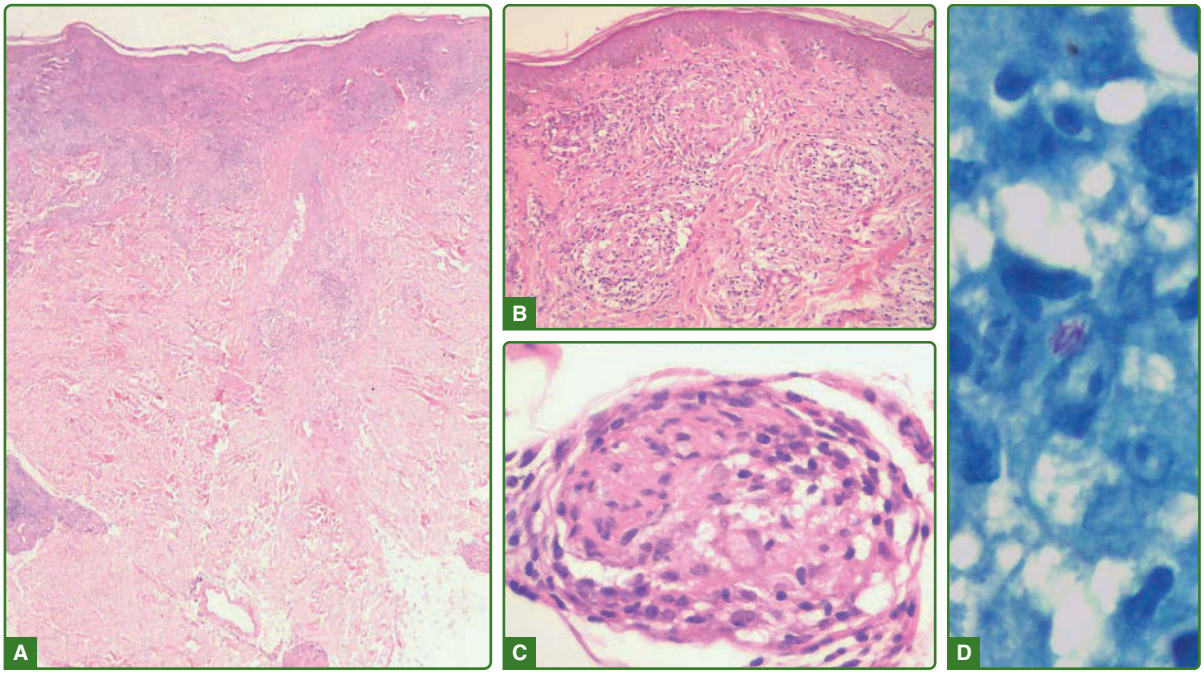

Figure 159-25 Borderline-tuberculoid leprosy histopathology. Deep and superficial tuberculoid granuloma (**A**) that does not touch the epidermis (**B**). The tuberculoid granuloma may be seen invading the nerves (**C**), and acid-fast bacilli can be found (**D**, 100×). (Used with permission from Dr. Jaison Barreto, Lauro de Souza Lima Institute, Brazil.)

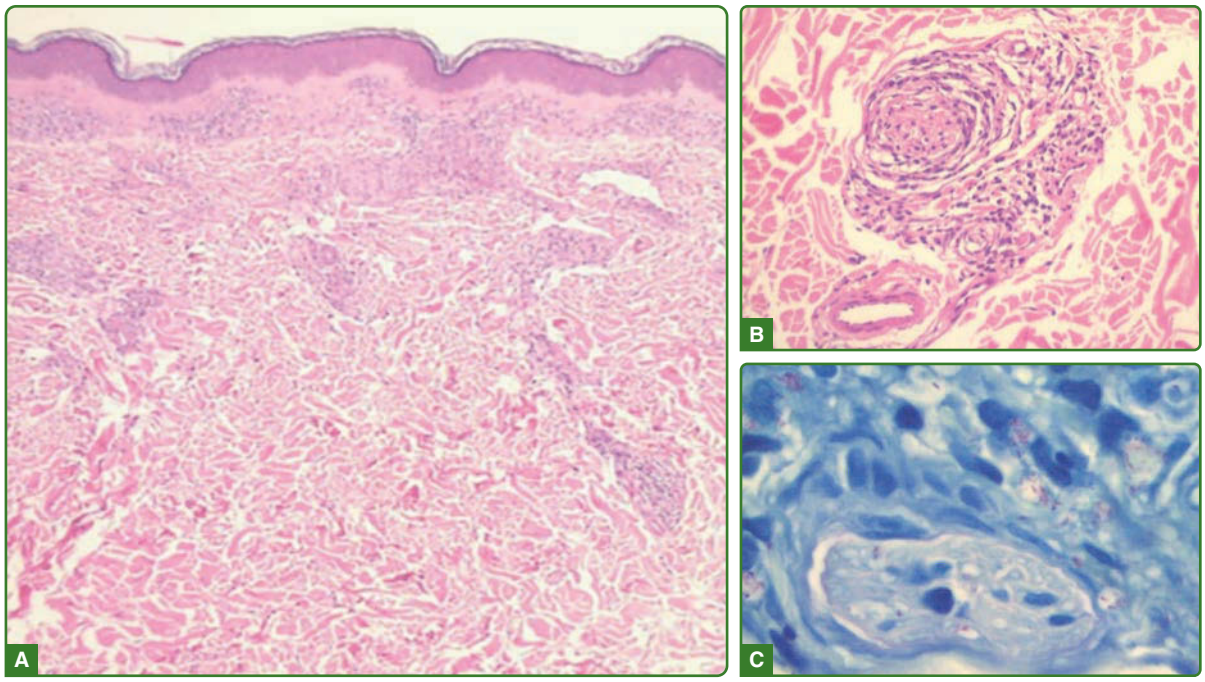

Figure 159-26 Borderline-borderline leprosy histopathology. Deep and superficial tuberculoid granuloma that does not touch the epidermis, starting to form a grenz zone (**A**). Inflammatory cells are invading cutaneous annexes and nerves, that are degenerated (**B**), and acid-fast bacilli can be found more easily, some forming globi (**C**). (Used with permission from Dr. Cleverson Soares, Lauro de Souza Lima Institute, Brazil.)

number of lymphocytes, and acid-fast bacilli in greater numbers.[116,117]

ENL or Type 2 reaction. The characteristic histologic features are edema and a mixed inflammatory infiltrate in the dermis and in the subcutis, predominantly neutrophils with eosinophils, lymphocytes, aggregates of foamy macrophages, plasma cells, and mast cells. Vasculitis and a mixed lobular and septal panniculitis

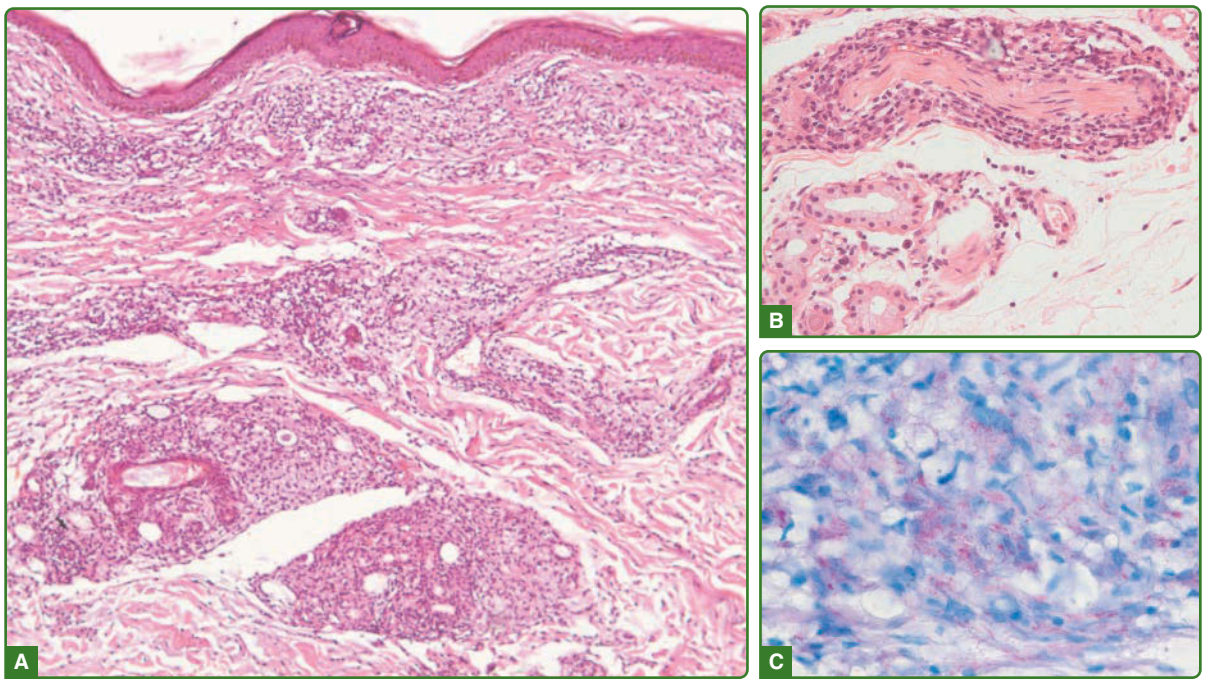

Figure 159-27 Borderline-lepromatous leprosy histopathology. There is a mixed macrophage lymphocytic inflammatory infiltrate (macrophage granuloma) on superficial and deep dermis (**A**). The mixed infiltrate does not touch the epidermis and may be seen surrounding or invading nerve bundles (**B**). A large number of acid-fast bacilli is seen (**C**).

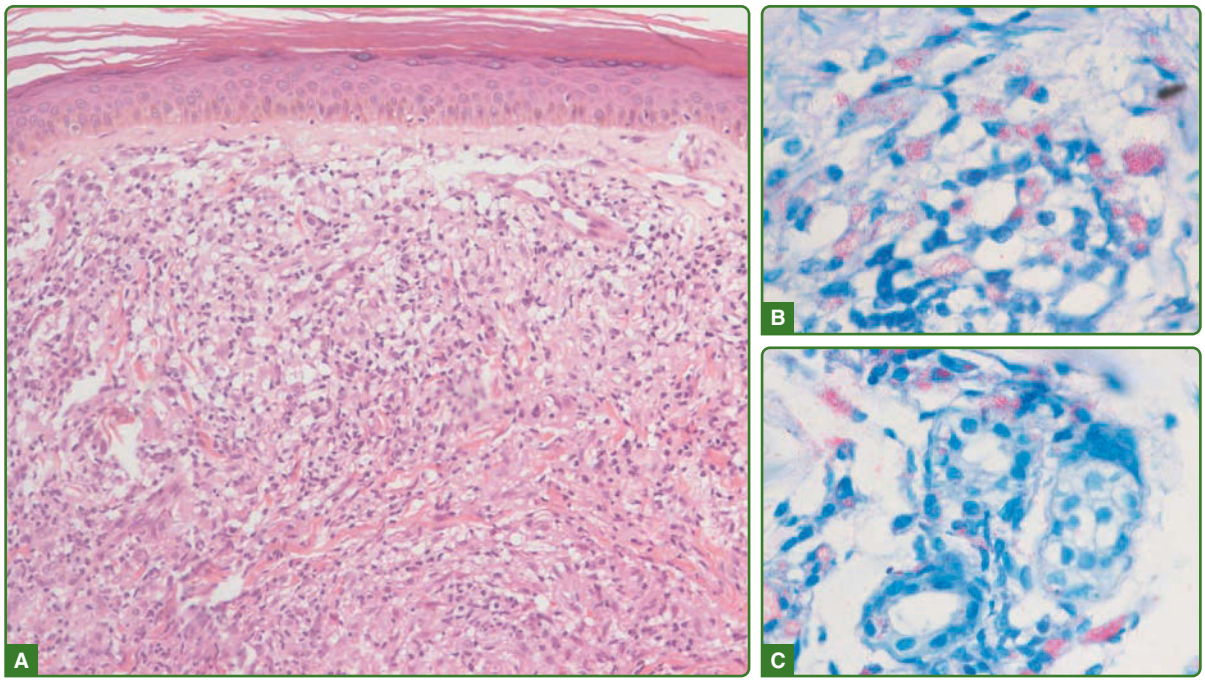

Figure 159-28 Lepromatous leprosy histopathology. An inflammatory infiltrate composed mostly by foamy macrophages is observed on the dermis. The epidermis is flattened, and there is a clear grenz zone on the dermal–epidermal interface (**A**). Fite-Faraco demonstrate acid-fast bacilli globi inside macrophages (**B**) and on sweat glands cells (**C**).

are present in most cases (Fig. 159-32). Bacilli in large numbers, usually granular in appearance, are easily found. The predominant lymphocyte present in ENL is the T-helper cell, whereas T-suppressor cells predominate in the lepromatous leprosy.[117,118]

Lucio phenomenon or erythema necrotisans. The main microscopic features are that of a cutaneous or subcutis necrotizing vasculitis. There is fibrinoid necrosis of small and medium-sized vessels. The other histologic picture reported in *Lucio phenomenon* are necrosis of

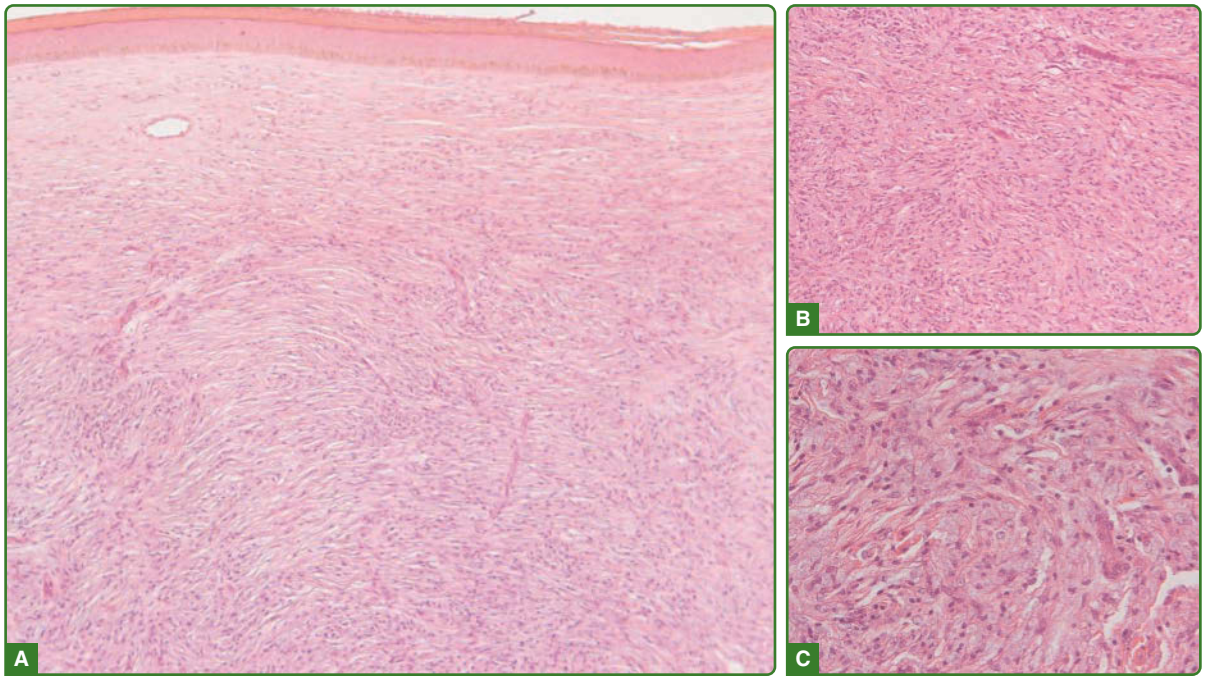

Figure 159-29 Lepromatous leprosy histoid Wade leprosy histopathology. A flattened epidermis is observed over a dense inflammatory infiltrate (**A**) of spindle and epithelioid cells arranged in a storiform or fasciculated pattern (**B**), which may have a foamy aspect on closer view (**C**).

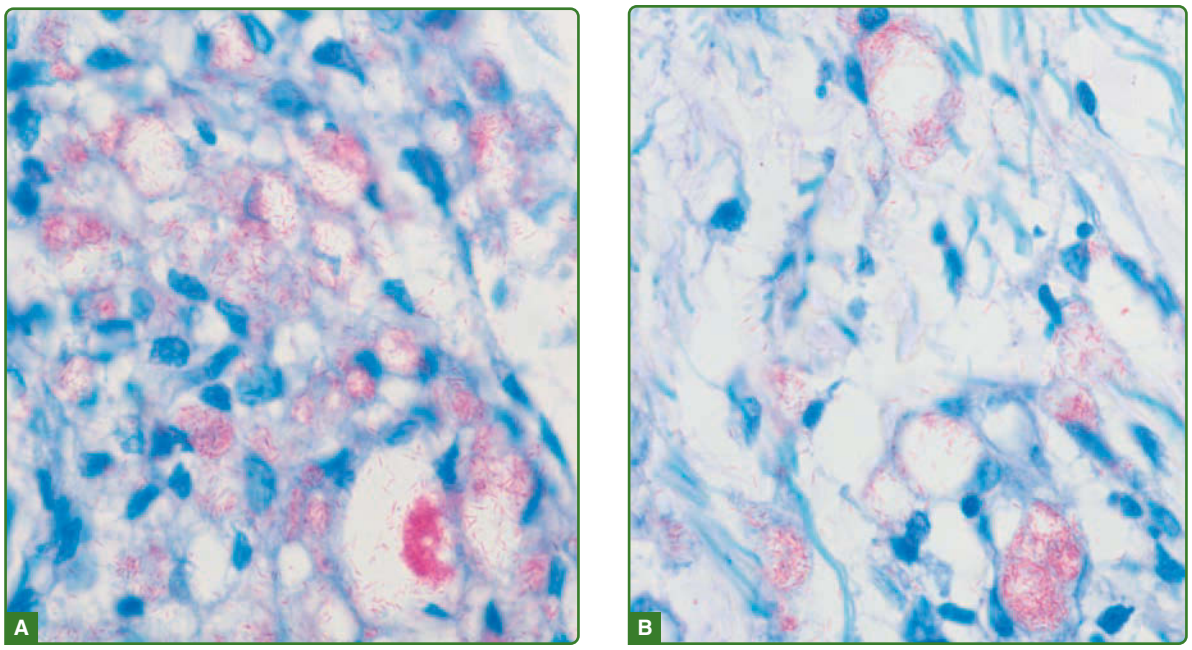

Figure 159-30 Globi. Aggregates of bacilli (globi) inside the host cells, as seen here inside macrophages (**A** and **B**), is a characteristic of *M. leprae*.

epidermis and superficial dermis, micro-abscess formation, angiogenesis, endothelial swelling, vascular occlusion caused by luminal thrombi, and deposits of fibrin in small blood vessel walls of the dermis and the subcutis. There is a mixed dermal and/or subcutis infiltrate of neutrophils, eosinophils, lymphocytes, and nuclear dust. Bacilli are found in endothelial cells, in blood vessels, nerves, arrectores pilorum muscle, follicular epithelium, sebaceous glands, and sweat glands.[119-122]

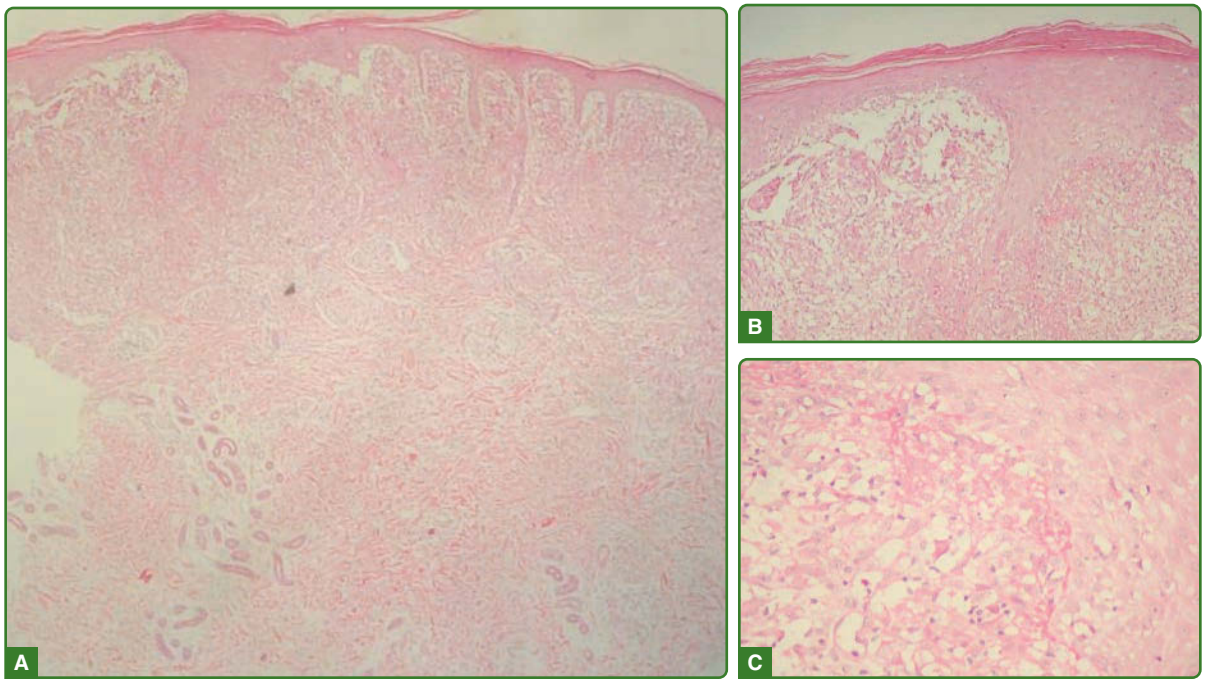

Figure 159-31 Histopathology reversal reaction. Presence of an inflammatory infiltrate, associated to epithelial hyperplasia (**A**) and foci of epidermal aggression with dermal edema (**B**) and fibrin deposit (**C**). (Used with permission from Dr. Jaison Barreto, Lauro de Souza Lima Institute, Brazil.)

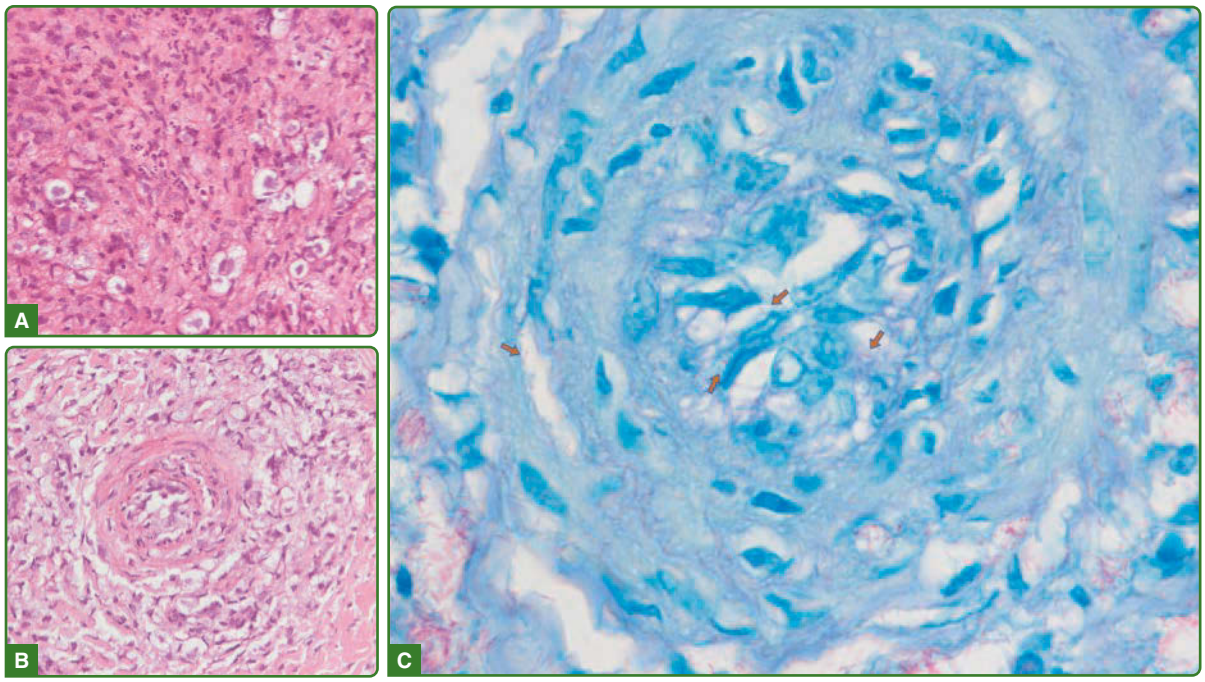

Figure 159-32 Histopathology erythema nodosum leprosum. A mixed inflammatory infiltrate, composed of foamy macrophages with large vacuoles and neutrophils (**A**) is shown. Foamy macrophages are also seen surrounding a vessel undergoing fibrinoid necrosis and presenting aggregates of inflammatory cells in its lumen and wall (**B**), where Fite-Faraco reveals the presence of large amounts of globi, and single bacilli inside a vessel and in its wall (**C**, arrows).

NERVE CONDUCTION STUDY—ELECTRONEUROMYOGRAPHY

Leprosy neuropathy manifests as asymmetric focal or multifocal lesions, mononeuropathy or mononeuritis multiplex, caused by the direct damage of nerves by *M. leprae* and by an inflammatory immune response of the host. There is chronic neuropathy, with acute exacerbations resulting from reversal reaction or ENL. Besides focal lesions, entrapment of the enlarged nerves is also a concern, that may require surgical intervention to decompress the nerve. Evaluation includes nerve palpation, pain evaluation, sensory assessment, muscle power measurement and autonomic examination.

Electroneuromyography is a refined tool for nerve function assessment at diagnosis, and for patient followup to detect and characterize new lesions, especially during reversal reaction or ENL, or to evaluate entrapment syndromes and neuropathic pain. Leprosy neuropathy starts with Schwann cell demyelination that may evolve to axon loss. Commonly affected sites include the elbow for the ulnar nerve, the carpal tunnel for the median nerve, the fibula head for the fibular nerve, and the tarsal tunnel for the posterior tibial nerve, all which are key areas for evaluating neuropathy.[123]

IMAGING

High-resolution ultrasound use for peripheral nerve evaluation is an established procedure. However, only recently has it seen more use in the evaluation of nerve function impairment in leprosy neuropathy. Clinical examination of nerve enlargement may be difficult to measure, even for experienced leprologists, and there are no robust parameters to be recorded to followup the leprosy patient during and after multidrug therapy.

High-resolution ultrasound can be used for evaluation of echogenicity, vascularity, and nerve thickening, using objective parameters and values for several neuropathies, including leprosy.[124] In addition, nerve abscesses and entrapment also can be detected early and evaluated.[123] Its utilization for leprosy neuropathy evaluation is still evolving, but very promising. Echogenicity abnormalities, intraneural Doppler and post-multidrug therapy cross-sectional areas above normal limits, with less than 30% reduction, have been linked to poor outcomes. Worsening of nerve abnormalities after multidrug therapy were found independent of leprosy classification or presence of reactions.[125]

DIAGNOSTIC ALGORITHM

See Fig. 159-33.

DIFFERENTIAL DIAGNOSIS

See Table 159-1.

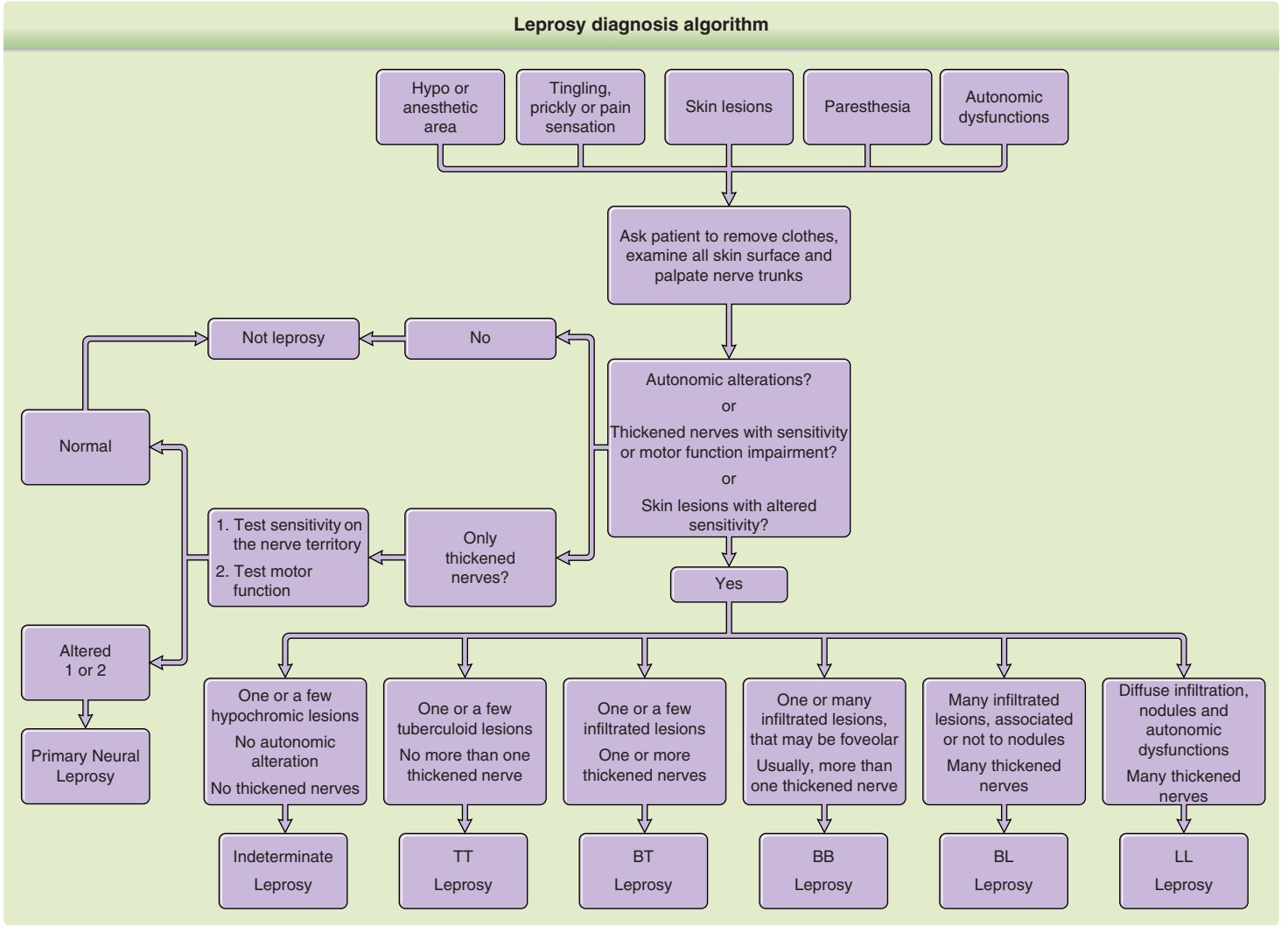

Figure 159-33 Leprosy diagnosis. At any time, it is possible to ask for laboratory examinations: slit-skin smear for acid-fast bacilli or for PCR, biopsy for histopathology, and anti-PGL-I serology.

TABLE 159-1
Differential Diagnosis

Primary Lesions

- **Macules and patches.** The hypopigmentation of pityriasis alba and indeterminate leprosy mimic each other. If the patient was born in, or had resided in, an endemic area, then the distinction between the two may be made by neurologic or histologic examination. Hypopigmented BL plaques can be so faintly indurated as to mimic patches. Telangiectasias may be eruptive or present as mats on the face and upper trunk.
- **Papular to nodular lesions.** In the dermis, leprosy may mimic, or be mimicked, by dermatofibromas, histiocytomas, lymphomas, sarcoidosis, neurofibromatosis, syphilis, anergic leishmaniasis, paracoccidioidomycosis, chromoblastomycosis, sporotrichosis, lobomycosis, tuberculosis, and other granulomas. Eruptive and recurrent inflammatory subcutaneous nodules may be ENL, erythema nodosum, erythema induratum, and vasculitis. Palpable, but not visible, subcutaneous nodules in Lucio leprosy may mimic lipomas.
- **Plaques.** Erythematous plaques may mimic mycosis fungoides. Plaques without pigmentary change may be wheal like in appearance, causing confusion with urticaria. Hypopigmented plaques may mimic papulosquamous eruptions. Islands of normal skin within a plaque may suggest psoriasis.
- **Polymorphous vesiculobullous eruption/Dermoepidermal separation.** They may occur in ENL. IgM is deposited not uncommonly at the epidermal basement membrane in LL. These antibodies are not necessarily pathogenic but may confuse diagnosis.
- **Annular lesions.** Leprosy may mimic, or be mimicked by, annular erythemas, sarcoidosis, syphilis, or tinea.

Secondary Lesions

- **Infarcts.** Lucio phenomenon lesions and necrotic ENL mimic septic infarcts.
- **Ulcers.** Ulcers occur in Lucio phenomenon and ENL secondary to vascular occlusion. In patients with nerve destruction, neurotrophic ulcers occur on the plantar surface, patients with Leg ulcers secondary to venous insufficiency are seen in Lucio leprosy.

Clinical Constellations

- **Systemic lupus erythematosus–like changes.** Fusiform fingers, swan neck deformity, false positive syphilis tests, antiphospholipid antibodies, lupus anticoagulant, hyperglobulinemia, and anemia.
- **Vasculitis.** A true vasculitis may occur in ENL, Lucio phenomenon, and Lucio leprosy. Clinically, leprosy lesions of a nodular character may be misdiagnosed as "vasculitis."

CLINICAL COURSE AND PROGNOSIS

One of the most important problems during the leprosy clinical course is the appearance of acute or subacute episodes of inflammation, defined as reactions. Leprosy reactions, caused by immune response against *M. leprae* antigens, are divided into Type 1 or reversal reaction, involving mainly peripheral nerves and skin, and Type 2 or ENL, that may have localized or systemic symptoms. Acute neuritis also may be considered as a type of reaction.

Reactions never occur in Indeterminate patients. Up to 50% of all patients on multidrug therapy may present reactions during treatment, but these reactions can also occur before and after therapy. Neuropathy present at the time of diagnosis, multibacillary leprosy, extent of the disease, and the presence of lesions overlying peripheral nerve trunks are factors that increase the risk of reactions and nerve function impairment.[126] Reversal reaction and ENL may happen together in some patients (Table 159-2).

Reversal reaction can occur in up to 30% of patients, whereas tuberculoid leprosy cases are seldom affected,[127] the majority of the reactional episodes occur in borderline forms, mainly borderline-lepromatous and borderline-borderline, followed by lepromatous leprosy.[128] It starts as a sudden worsening of skin lesions and nerve function impairment, with no apparent systemic involvement. Besides prereactional lesions presenting more infiltration and desquamation, previous and newly developing lesions may be bright red, hot, and sensitive to the touch (Fig. 159-34), sometimes ulcerated, frequently associated with peripheral nerve enlargement, and usually accompanied by pain. Reversal reaction requires immediate intervention, because it can result in nerve impairment and permanent disabilities.

ENL is an aggressive vasculitis with immune complex deposition affecting different organs, resulting in, among other sequelae, neuritis, panniculitis, glomerulonephritis, arthralgia, epididymitis, orchitis, eye inflammation, osteitis and lymphadenitis with systemic symptoms such as fever, edema and malaise.[129]

TABLE 159-2
Lepra Reactions and Management

	REVERSAL REACTION (TYPE I)	ERYTHEMA NODOSUM LEPROSUM (TYPE II)
Predominant leprosy subtype	Borderline-tuberculoid Borderline-borderline Borderline lepromatous Lepromatous leprosy	Lepromatous leprosy
Signs and symptoms	Acute worsening of skin lesions Acute worsening of nerve function impairment No apparent systemic symptoms	Erythema nodosum Erythema polymorphous Severe cutaneous necrotizing vasculitis Fever, edema, malaise
Extracutaneous involvement	Neuritis	Neuritis Panniculitis Glomerulonephritis Arthralgia Epididymitis Orchitis Eye inflammation Osteitis Lymphadenitis
Treatment	Prednisone (1-2 mg/kg/d with slow taper ~3 mo)	Thalidomide 100-400 mg/d AND prednisone (1-2 mg/kg/d) OR Pentoxifylline 400 mg thrice a day

Figure 159-34 Reversal reaction. Reappearance or worsening of pre-multidrug therapy lesions, during or after treatment (**A**), usually presenting severe infiltrated lesions, that may coalesce in small, foveolar (**B**) or large scaly (**C**) plaques.

A high bacillary index and diffuse skin infiltration are important risk factors[130] and 65% of the cases have more than one episode of ENL.[131] The main skin manifestation is erythema nodosum, more palpable than visible (Fig. 159-35), and may be accompanied by erythema polymorphous or severe cutaneous necrotizing vasculitis (Lucio phenomenon) (Fig. 159-36).

Immunologic disorders, like HIV and HTLV infections, immunosuppressive drugs, or immunobiological medications can interfere with the resolution of leprosy. The first case of leprosy occurring as a result of immune reconstitution inflammatory syndrome (IRIS) in an HIV-infected individual was described in 2003.[132] The upgrading of the cell-mediated immune response due to antiviral therapy in AIDS patients is now well recognized in IRIS,[133] and the percentage of HIV and other viral infections in leprosy patients is high, indicating that all leprosy patients should be tested for HIV, HBV, HCV and HTLV-1.[134] Viral coinfection decreases the

Figure 159-35 Erythema nodosum leprosum. Presence of fever and malaise with painful subcutaneous nodules that are easy to palpate, but much less apparent then reversal reactions lesions.

Figure 159-36 Lucio phenomenon. Small and large ulcers with infiltration in lepromatous leprosy patients. Slit-skin smear of those patients is loaded heavily with acid-fast bacilli.

survival of leprosy patients,[135] whereas increasing rates of neuritis, nerve function impairment, and leprosy relapses.[134] Anti-TNF therapy can result in the development of clinical leprosy in infected individuals following cessation of the immunobiological medication[136-138] regardless of whether reactional episodes are involved.

It is important to distinguish reactions from relapses. Reactions may occur before, during, and a few years after multidrug therapy. Usually, they are acute, with a rapid appearance of new lesions and infiltration of the old ones, deterioration of neural function, and/or systemic involvement, responding well to treatment with antiinflammatory drugs. On the other hand, relapses in general are slowly progressing, almost always with resurgence of primary lesions followed by the gradual appearance of new lesions, together with nerve involvement, and, in contrast, there is no response to antiinflammatory drugs. A true relapse must be defined after confirmation of completion of the first treatment by the patient. If the full course of treatment is confirmed, it becomes necessary to test for drug resistance, although reinfection cannot be ruled out. If the patient was wrongly classified, then an insufficient length of therapy may be the case. Histopathology can be useful to distinguish a reaction from a case of relapse.[139]

Although leprosy is well known for loss of skin sensation, neuropathic pain may arise during or after multidrug therapy, due to tissue inflammation or dysfunction of the nervous system.[140] Nerve trunk pain onset may be spontaneous or appear after palpation, either abrupt or insidious, but many patients experience recurrent episodes. More than half of the patients have some pain episode during or after multidrug therapy, with a higher prevalence in lepromatous leprosy, decreasing toward the borderline and tuberculoid forms. The most affected nerves are ulnar and tibial.[140] If the pain persists during treatment, or becomes long-lasting after completing multidrug therapy, it may be defined as chronic neuritis or neuropathy.[141]

MANAGEMENT

INTERVENTIONS

MEDICATIONS

There are, basically, 3 groups of medications used for treating leprosy: antibiotics, antiinflammatory or immunosuppressants and analgesic drugs. The first group, antibiotics, has a well-defined standard for treatment, the WHO Multidrug Therapy drug regimen, that contains rifampicin and dapsone, with or without clofazimine, in monthly blister packs. Antiinflammatory drugs, usually prednisone and thalidomide, are prescribed to control leprosy reactions by reducing inflammation, whereas analgesics are used to control neuropathic pain.

Before the discovery of sulfones' power to improve leprosy signs by Guy Faget in 1941,[142] chaulmoogra oil, drug used in India for decades, was the only commonly used treatment for leprosy, although its efficacy was questionable, as it generally induced only a localized inflammatory response in the skin.

Dapsone is a simple, low-cost, highly effective drug for leprosy, used in a daily dose of 100 mg or 1 to 2 mg/kg. The drug is absorbed by the GI tract and eliminated through the kidneys. It is usually well tolerated, although it is dependent on the presence of the enzyme glucose 6-phosphate dehydrogenase (G6PD), an X-chromosomally transmitted enzyme, that is lacking in 400 million people worldwide, mostly in tropical areas where malaria is present[143] and also where leprosy is prevalent. G6PD deficiency leads to serious hemolytic events by oxidative stress, including the formation of methemoglobin that is clinically detected as a violet color on sclera, lips, and the extremities of fingers together with malaise, headache, and dyspnea. In addition to a high level of hemolysis, G6PD-deficient patients using dapsone are at a greater risk of developing severe life-threatening hemolytic anemia, and must change their medication.[144] Dapsone hypersensitivity syndrome, a rare but potentially fatal event, presents with fever and cutaneous rash, eventually involving internal organs, especially the lungs, with eosinophilic infiltrates and pneumonitis. It may occur at any time during treatment, and it may be related to drug rash with eosinophilia and systemic symptoms (DRESS syndrome).[145]

Clofazimine is a pigment that, in addition to its unknown antibiotic mechanism, also has antiinflammatory properties. The main objection as far as patients are concerned is its affinity to fat tissue and macrophage deposits leading to skin hyperpigmentation, especially in the lesions. An additional side effect is skin dryness that together with pigmentation, gives the skin a highly xerodermic appearance (Fig. 159-37). It is used in a dose of 300 mg once a month, and 50 mg per day, only in multibacillary patients. Clofazimine is well-tolerated by leprosy patients.[146]

Rifampicin is highly bactericidal, and unlike the daily administration of dapsone and clofazimine, it is

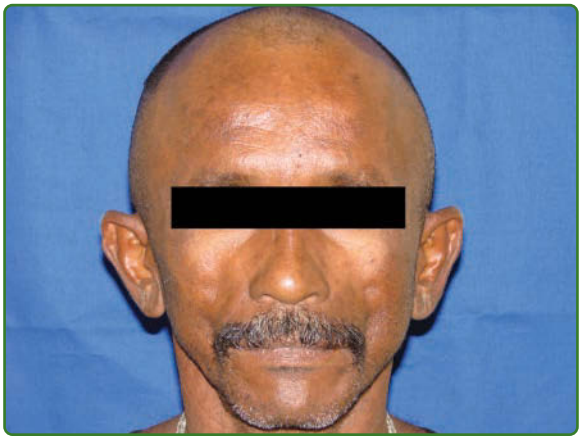

Figure 159-37. Clofazimine pigmentation. Brownish color and dry skin in a patient on multibacillary multidrug therapy.

only administered once per month with supervision, 450 mg to children and 600 mg to adults. Adverse effects include face and neck redness, pruritus and cutaneous rash, loss of appetite, nausea, vomiting, and diarrhea, malaise (which may require cessation of the drug), purpura, and epistaxis. Flulike syndrome, a not well-understood immunologic side effect occurring with the use of intermittent doses of rifampicin, is characterized by fever, asthenia, myalgia, and headache, sometimes accompanied by bone pain. Eosinophilia, nephritis, thrombocytopenia, and shock may eventually develop. Although considered rare, it was the major side effect reported in a Brazilian study with 20,667 leprosy patients on multidrug therapy.[147]

Multidrug therapy schemes used today are the same as 1982 when they were first implemented (Table 159-3), with dapsone, clofazimine, and rifampicin prescribed for multibacillary cases for up to 24 months, or dapsone and rifampicin for 6 months for paucibacillary patients. Pregnancy and breastfeeding do not contraindicate the use of multidrug therapy.[144] In the 1960s, together with the confirmation of clofazimine and rifampicin[148] efficacy against *M. leprae*, the first cases of dapsone-resistant leprosy appeared.[149] In the 1970s, WHO decided to replace dapsone monotherapy in favor of a 3-drug strategy with dapsone, rifampicin, and clofazimine combined in a new drug regimen to treat leprosy called multidrug therapy. Although drug resistance in leprosy appears to remain low,[150] reports of MDR-leprosy are increasing in the literature,[151-153] and it may be a concern for leprosy treatment in the near future.[154] The substitute drugs available, either to resistant strains or to patients with side effects on multidrug therapy, ofloxacin, minocycline, or clarithromycin (Table 159-3), appear to be safe and effective for leprosy treatment,[146] but new alternative drugs are necessary.

Although there are a few well-structured clinical trials for treating nerve damage in leprosy, with moderate-quality evidence, including one with intravenous methylprednisolone pulse therapy,[155] WHO recommends leprosy reactions must be immediately treated with antiinflammatory or immunosuppressant drugs.[144] The most widely used are corticosteroids and thalidomide. Reversal reaction can be treated with prednisone at doses of 1 to 2 mg/kg/d in a regressive scheme, diminishing 10% to 15% of the dose every 15 days, with a complete cycle of treatment lasting up to 3 months. If there is a worsening of the clinical situation, it may be necessary to go back to the previous higher dose, extending this level of corticosteroid treatment for 30 to 45 days, followed by tapering off again.

Glucose levels and blood pressure must be controlled during the use of corticosteroids. Glaucoma, cataracts, moon face, striae, adrenal gland atrophy, and osteoporosis may occur with long term usage, and as with other immunosuppressive agents, other infectious diseases, such as systemic fungal infections and tuberculosis may arise. In addition, *Strongiloydes stercoralis* hyperinfection is a concern. Ivermectin 200 µg/kg/d for 2 days, repeated after 2 weeks, can be used in prevention.[156] After an equivalence conversion calculation, prednisone may be replaced by other steroids, including its metabolite prednisolone, dexamethasone, or deflazacort. Calcium intake of 1200 to 1500 mg/d and vitamin D supplements are recommended for any patient using glucocorticoids, independent of dose and duration of therapy.[157]

ENL may be treated with 100 to 400 mg/d of thalidomide. As thalidomide is a teratogenic drug, it is mandatory to test for pregnancy and prescribe 2 contraceptive methods before starting therapy in women of childbearing age. Usually, ENL appears with nerve damage, and concomitant treatment with steroids is required. Higher doses of prednisone, up to 2 mg/kg/d, are linked to improved nerve function outcome, but if therapy is initiated immediately after the first signs of reaction, lower doses of 1 mg/kg/d may have the same effect.[158] If ENL is associated with any other tissue inflammation, like orchitis or iritis, or

TABLE 159-3
Antibacterial Treatment of Leprosy Recommendations

RECOMMENDING ORGANIZATION	DISEASE TYPE	RIFAMPICIN	DAPSONE	CLOFAZIMINE	DURATION	FOLLOWUP
World Health Organization	PB	600 mg/mo	100 mg/d	—	6 mo	No mandated followup. To return as needed
	MB	600 mg/mo	100 mg/d	50 mg/d	1 y	No mandated followup
				300 mg/mo		
						To return as needed
US Public Health Service	PB	600 mg/d	100 mg/d	—	1 y	At 6-mo intervals for 5 y
	MB	600 mg/d	100 mg/d	50 mg/d	2 y	At 6-mo intervals for 10 y
Other Microbicidal Agents	**Dose**					
Clarithromycin	500 mg/d					
Minocycline (substitute for dapsone or clofazimine)	100 mg/d					
Ofloxacin	400 mg/d					

PB, paucibacillary; MB, multibacillary.

with reactions of the hands and feet, as with osteoarthritis and soft tissue inflammation, steroids are also necessary. In cases where the use of thalidomide must be avoided, pentoxifylline 400 mg, 3 times a day, is an alternative drug, quite useful for controlling limb edema and systemic symptoms.[159]

Steroids and thalidomide may help patients with neuropathic pain by reducing edema and immunologic reactions targeting the nerve, especially in acute episodes. However, its treatment continues to be a challenge, especially for those with chronic neuritis/neuropathy. Central nerve system drugs, such as the tricyclic antidepressants amitriptyline and imipramine or the anticonvulsants carbamazepine and gabapentin have been used in an attempt to control chronic neuritis/neuropathy in those patients, but these drugs do not interfere with the nerve damage process, and therefore do not protect leprosy patients from nerve deterioration. Although some anecdotal reports show that immunosuppressive agents, like cyclosporine and azathioprine, may be useful for treating chronic neuritis/neuropathy patients, a recent trial with azathioprine did not show improvement in patients with reversal reaction.[160] More research is necessary in physiopathology and with new drugs for treating neuropathic pain.

PROCEDURES

Simple preventive techniques may be used by patients to prevent the progression of damage. Massage and hydration of the skin of hands and feet are necessary to avoid fissures, ulcers, and fixed claw formation. In addition to the use of special boot soles or customized shoes for feet with loss of sensation and with disabilities, self-examination is mandatory for early detection and immediate treatment of trauma. For hands, adduction, abduction, and opposition movements are necessary to keep trophic muscles and healthy joints. Adaptation of working instruments and household items help to prevent trauma and burns. For eyes, the use of lubricating eye drops may prevent keratitis in cases of lagophthalmos. In more complex cases, the patients may be referred to specialized centers for more complex treatments with a multiprofessional team for physical, psychological, and social rehabilitation.

In different stages of leprosy, surgery may be necessary. Nerve abscess is infrequent, appearing more in primary neural leprosy and tuberculoid leprosy and less toward the lepromatous leprosy pole, but it may be the first clinical manifestation[161] of disease. In such cases, abscess drainage is mandatory, and the content must be sent to the laboratory for investigation. Nerve decompression may be used to improve leprosy neuropathy and muscular function, albeit there are no reliable clinical trials to definitely prove its usefulness.[162] Finally, reconstructive surgery may recover some functional aspects in the hands and feet, such as the ability to hold a glass or the capacity to raise the feet; correct eye problems, like lagophthalmos, preventing keratitis, infection, and blindness; and improve aesthetics as in the surgical correction of nose collapse, which is nowadays rare,[163] or the interosseous and first web space atrophy of the hands.[164]

COUNSELING

Counseling is a key process involved in leprosy patient management. Nerve damage and its management include counseling and harm reduction.[165] Although there was improvement in the last decades by the presence of active social movements fighting against discrimination, helping to reintegrate people into society, and banning discriminatory laws, stigma is still present in modern society. Although curable, leprosy is still a disease resulting in serious disabilities, and even patients diagnosed at the first stages of disease fear evolution through incapacities. Therefore, counseling should be available for every person diagnosed with leprosy, and their families.[166] Self-care groups are necessary, but they should not be exclusive. Leprosy-related disability care and management must be included with care for disabilities caused by other diseases in the general health services.[167]

TREATMENT ALGORITHM

See Fig. 159-38.

PREVENTION/SCREENING

There is one fundament requirement for leprosy prevention, that being contact examination. It should be a mandatory part of any leprosy program in endemic countries to examine all household contacts, and some programs expand this concept to social contacts, those who work or have closer proximity with the index case. A household contact has a 5- to 8-fold higher risk of contracting leprosy than a person without contact with a case (Fig. 159-39). However, even if there is constant vigilance, only up to 30% of the cases in a community will be detected among the household contacts; therefore, other genetic or environmental factors may be involved in the maintenance of the infection.[168]

Early detection of cases is another tool for the efficient prevention of leprosy. Besides contact examination, leprosy campaigns in the general population or in special communities, such as schoolchildren,[110] may be used to raise awareness, to diminish stigma, and to increase detection of early cases of leprosy. Although chemoprophylaxis with rifampicin has shown some degree of protection (57%) in the first 2 years, after 4 years no difference was observed in comparison between rifampicin and placebo groups[169]; therefore there is no current official recommendation to use chemoprophylaxis in leprosy contacts. For immunoprophylaxis, Brazil has been using Bacillus Calmette-Guerin (BCG) revaccination in contacts for a long time. An 18-year followup study found 56% protection for

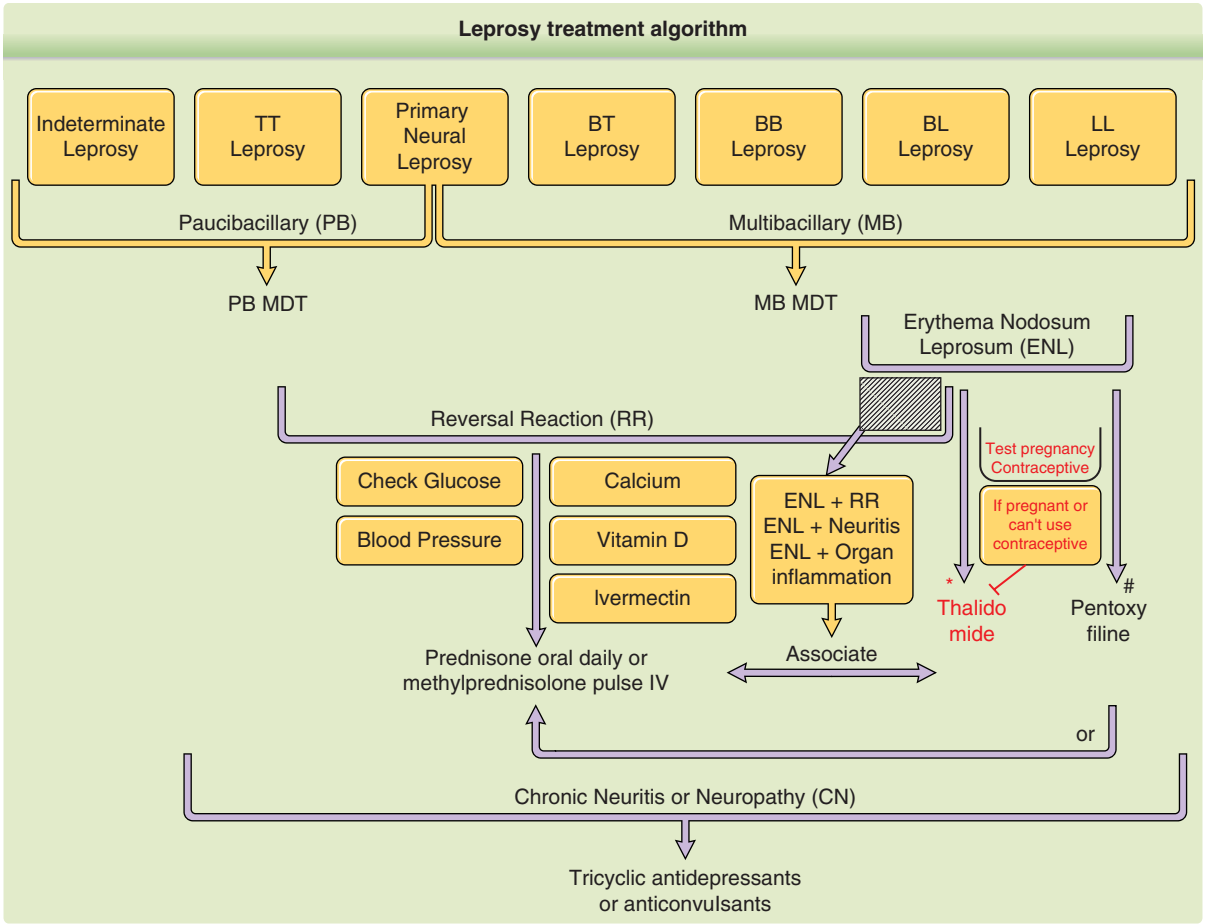

Figure 159-38 Leprosy treatment. Multidrug therapy is the choice for leprosy treatment. However, when there is intolerance to any of the drugs, available alternatives may be used, as ofloxacin, minocycline, or clarithromycin. Also, if there is no answer to multidrug therapy, drug resistance may be tested, and the same alternative drugs used in place of 1 or more multidrug therapy drugs. For reactions, thalidomide is not available in all countries, and may even be prohibited. *It is not permitted to prescribe thalidomide to pregnant women or to women of childbearing age. If it is necessary to use it, some countries have strict rules or laws that may require a pregnancy test and the use of contraceptives to prescribe thalidomide. #Pentoxyfiline is a "category C" drug for pregnancy and, therefore, it should be used only if the potential benefits justify the potential risk to the fetus.

Figure 159-39 Contact examination is mandatory on leprosy programs. Note the macular hypochromic anesthetic lesion on a child that the father was diagnosed with lepromatous leprosy.

BCG-vaccinated contacts,[170] compared those who were not vaccinated; hence, Brazil guidelines for leprosy continue to include BCG vaccination for all household contacts.

REFERENCES

1. WHO | Diagnosis of leprosy. In: WHO [Internet]. World Health Organization; 2016. http://www.who.int/lep/diagnosis/en/. Accessed January 7, 2017.
2. Belcastro MG, Mariotti V, Facchini F, et al. Leprosy in a skeleton from the 7th century necropolis of Vicenne-Campochiaro (Molise, Italy). *Int J Osteoarchaeol.* 2005;15(6):431-448.
3. Robbins G, Mushrif Tripathy V, et al. Ancient skeletal evidence for leprosy in India (2000 B.C.). *PLoS One.* 2009;4(5):e5669.
4. Rafi A, Spigelman M, Stanford J, et al. DNA of *Mycobacterium leprae* detected by PCR in ancient bone. *Int J Osteoarchaeol.* 1994;4:287-290.

5. Matheson CD, Vernon KK, Lahti A, et al. Molecular exploration of the first-century tomb of the shroud in Akeldama, Jerusalem. *PLoS One.* 2009;4.
6. Donoghue HD, Michael Taylor G, Marcsik A, et al. A migration-driven model for the historical spread of leprosy in medieval Eastern and Central Europe. *Infect Genet Evol.* 2015;31:250-256.
7. Schuenemann VJ, Singh P, Mendum TA, et al. Genome-wide comparison of medieval and modern *Mycobacterium leprae*. *Science.* 2013;341(6142):179-183.
8. Donoghue HD, Marcsik A, Matheson C, et al. Co-infection of *Mycobacterium tuberculosis* and *Mycobacterium leprae* in human archaeological samples: a possible explanation for the historical decline of leprosy. *Proc Biol Sci.* 2005;272(1561):389-394.
9. Monot M, Honoré N, Garnier T, et al. On the origin of leprosy. *Science.* 2005;308(5724):1040-1042.
10. Monot M, Honore N, Garnier T, et al. Comparative genomic and phylogeographic analysis of *Mycobacterium leprae*. *Nat Genet.* 2009;41(12): 1282-1289.
11. Truman RW, Singh P, Sharma R, et al. Probable zoonotic leprosy in the Southern United States. *N Engl J Med.* 2011;364(17):1626-1633.
12. Avanzi C, Del-Pozo J, Benjak A, et al. Red squirrels in the British Isles are infected with leprosy bacilli. *Science.* 2016;354:744-747.
13. Global leprosy update, 2015: time for action, accountability and inclusion. Relev épidémiologique Hebd / Sect d'hygiène du Secrétariat la Société des Nations = Wkly Epidemiol Rec / Heal Sect Secr Leag Nations. 2015;91:405-420.
14. Kumar A, Husain S, Kumar A, et al. The burden of new leprosy cases in india: a population-based survey in two states. *ISRN Trop Med.* 2013;2013:1-8.
15. Salgado CG, Barreto JG, da Silva MB, et al. What do we actually know about leprosy worldwide? *Lancet Infect Dis.* 2016;16(7):778.
16. Muthuvel T, Isaakidis P, Shewade HD, et al. Leprosy trends at a tertiary care hospital in Mumbai, India, from 2008 to 2015. *Glob Health Action.* 2016;9:32962.
17. Dogra S, Narang T, Khullar G, et al. Childhood leprosy through the post-leprosy-elimination era: a retrospective analysis of epidemiological and clinical characteristics of disease over eleven years from a tertiary care hospital in North India. *Lepr Rev.* 2014;85(4):296-310.
18. Kuruwa S, Joshua V, Shetty V, et al. Trends and spatial clustering of leprosy cases over a decade in a hyperendemic area of western Maharashtra, India. *Lepr Rev.* 2016;87:294-304.
19. Monteiro LD, Martins-Melo FR, Brito AL, et al. Physical disabilities at diagnosis of leprosy in a hyperendemic area of Brazil: trends and associated factors. *Lepr Rev.* 2015;86(3):240-250.
20. Shumet T, Demissie M, Bekele Y. Prevalence of disability and associated factors among registered leprosy patients in All Africa TB and Leprosy Rehabilitation and Training Centre (ALERT), Addis Ababa, Ethiopia. *Ethiop J Health Sci.* 2015;25(4):313-320.
21. Henry M, GalAn N, Teasdale K, et al. Factors contributing to the delay in diagnosis and continued transmission of leprosy in Brazil—an explorative, quantitative, questionnaire based study. *PLoS Negl Trop Dis.* 2016;10(3):e0004542.
22. Kumar A, Girdhar BK. Is increasing MB ratio a positive indicator of declining leprosy? *J Commun Dis.* 2006;38(1):24-31.
23. Salgado CG, Barreto JG, da Silva MB, et al. Are leprosy case numbers reliable? *Lancet Infect Dis.* 2018;18(2):135-137.
24. Smith WC, van Brakel W, Gillis T, et al. The missing millions: a threat to the elimination of leprosy. *PLoS Negl Trop Dis.* 2015;9(4):e0003658.
25. Bennett BH, Parker DL, Robson M. Leprosy: steps along the journey of eradication. *Public Health Rep.* 2008;123(2):198-205.
26. Ridley DS, Jopling WH. Classification of leprosy according to immunity. *Int J Lepr.* 1966;31:21.
27. Garbino JA, Marques W, Barreto JA, et al. Primary neural leprosy: systematic review. *Arq Neuropsiquiatr.* 2013;71(6):397-404.
28. Fakhouri R, Sotto MN, Manini MI, et al. Nodular leprosy of childhood and tuberculoid leprosy: a comparative, morphologic, immunopathologic and quantitative study of skin tissue reaction. *Int J Lepr Other Mycobact Dis.* 2003;71(3):218-226.
29. Salgado CG, Barreto JG. Images in clinical medicine. Leonine facies: lepromatous leprosy. *N Engl J Med.* 2012;366(15):1433.
30. Kaur I, Dogra S, De D, et al. Histoid leprosy: a retrospective study of 40 cases from India. *Br J Dermatol.* 2009;160(2):305-310.
31. Lucio R, Escuela de M de M, Alvarado I. Opúsculo sobre El Mal de San Làzaro, ó Elefanciasis de Los Griegos. Mexico; 1852.
32. Han XY, Seo YH, Sizer KC, et al. A new *Mycobacterium* species causing diffuse lepromatous leprosy. *Am J Clin Pathol.* 2008;130(6):856-864.
33. Singh P, Benjak A, Schuenemann VJ, et al. Insight into the evolution and origin of leprosy bacilli from the genome sequence of Mycobacterium lepromatosis. *Proc Natl Acad Sci U S A.* 2015;112(14):4459-4464.
34. Illigens BMW, Gibbons CH. Sweat testing to evaluate autonomic function. *Clin Auton Res.* 2009;19(2): 79-87.
35. Lehman LF, Orsini MB, Nicholl AR. The development and adaptation of the Semmes-Weinstein monofilaments in Brazil. *J Hand Ther.* 1993;6(4):290-297.
36. Villarroel MF, Orsini MBP, Lima RC, et al. Comparative study of the cutaneous sensation of leprosy-suspected lesions using Semmes-Weinstein monofilaments and quantitative thermal testing. *Lepr Rev.* 2007;78(2):102-109.
37. Kumar B. Pure or Primary neuritic Leprosy (PNL). *Lepr Rev.* 2016;87:450-455.
38. Suneetha S, Sigamoni A, Kurian N, et al. The development of cutaneous lesions during follow-up of patients with primary neuritic leprosy. *Int J Dermatol.* 2005;44(3):224-229.
39. Jardim MR, Antunes SL, Santos AR, et al. Criteria for diagnosis of pure neural leprosy. *J Neurol.* 2003;250:806-809.
40. Kumar KVS, Singh R, Bhasin R, et al. Endocrine dysfunction in patients of leprosy. *Indian J Endocrinol Metab.* 2015;19:369.
41. Leal ÂM, Foss NT. Endocrine dysfunction in leprosy. *Eur J Clin Microbiol Infect Dis.* 2009;28(1):1-7.
42. Leal ÂMO, Magalhães PKR, Souza CS, et al. Pituitary-gonadal hormones and interleukin patterns in leprosy. *Trop Med Int Health.* 2006;11(9):1416-1421.
43. Richardus J, Dik J, Habbema F, et al. The impact of leprosy control on the transmission of *M. leprae*: is elimination being attained? *Lepr Rev.* 2007;78(4):330-337.
44. Andersen JG, Manchester K. The rhinomaxillary syndrome in leprosy: a clinical, radiological and

palaeopathological study. *Int J Osteoarchaeol.* 1992; 2(2):121-129.
45. Boulton AJM. Diabetic foot—what can we learn from leprosy? Legacy of Dr Paul W. Brand. In *Diabetes/Metabolism Research and Reviews*. Chichester: Wiley; 2012:3-7.
46. Van Brakel WH, Anderson AM. Impairment and disability in leprosy: in search of the missing link. *Indian J Lepr.* 1997;69(4):361-376.
47. Singh P, Cole ST. *Mycobacterium leprae*: genes, pseudogenes and genetic diversity. *Future Microbiol.* 2011;6:57-71.
48. Ng V, Zanazzi G, Timpl R, et al. Role of the cell wall phenolic glycolipid-1 in the peripheral nerve predilection of *Mycobacterium leprae*. *Cell.* 2000;103(3):511-524.
49. Araujo S, Freitas LO, Goulart LR, et al. Molecular evidence for the aerial route of infection of *Mycobacterium leprae* and the role of asymptomatic carriers in the persistence of leprosy. *Clin Infect Dis.* 2016;63(11):1412-1420.
50. Alter A, Grant A, Abel L, et al. Leprosy as a genetic disease. *Mamm Genome.* 2011;22(1-2):19-31.
51. Mohamed Ali P, Ramanujam K. Leprosy in twins. *Int J Lepr.* 1966;34(4):405-407.
52. Chakravartti MR, Vogel F. A twin study on leprosy [Internet]. Thieme; 1973. https://books.google.com.br/books/about/A_twin_study_on_leprosy.html?id=aXhrAAAAMAAJ&redir_esc=y.
53. Zhang FR, Huang W, Chen SM, et al. Genomewide association study of leprosy. *N Engl J Med.* 2009;361(27):2609-2618.
54. Moet FJ, Pahan D, Schuring RP, et al. Physical distance, genetic relationship, age, and leprosy classification are independent risk factors for leprosy in contacts of patients with leprosy. *J Infect Dis.* 2006;193(3):346-353.
55. Barreto JG, Bisanzio D, Frade MAC, et al. Spatial epidemiology and serologic cohorts increase the early detection of leprosy. *BMC Infect Dis.* 2015;15:527.
56. Job CK. Nerve damage in leprosy. *Int J Lepr.* 1988;57:532-539.
57. Scollard DM. Association of *Mycobacterium leprae* with human endothelial cells in vitro. *Lab Invest.* 2000;80:663-669.
58. Scollard DM, McCormick G, Allen JL. Localization of *Mycobacterium leprae* to endothelial cells of epineurial and perineurial blood vessels and lymphatics. *Am J Pathol.* 1999;154(5):1611-1620.
59. Shimoji Y, Ng V, Matsumura K, et al. A 21-kDa surface protein of *Mycobacterium leprae* binds peripheral nerve laminin-2 and mediates Schwann cell invasion. *Proc Natl Acad Sci U S A.* 1999;96(17):9857-9862.
60. Rambukkana A, Yamada H, Zanazzi G, et al. Role of alpha-dystroglycan as a Schwann cell receptor for *Mycobacterium leprae*. *Science.* 1998;282(5396): 2076-2079.
61. Tapinos N, Ohnishi M, Rambukkana A. ErbB2 receptor tyrosine kinase signaling mediates early demyelination induced by leprosy bacilli. *Nat Med.* 2006;12(8):961-966.
62. Tapinos N, Rambukkana A. Insights into regulation of human Schwann cell proliferation by Erk1/2 via a MEK-independent and p56Lck-dependent pathway from leprosy bacilli. *Proc Natl Acad Sci U S A.* 2005;102(26):9188-9193.
63. Ribeiro-Resende VT, Ribeiro-Guimarães ML, Rodrigues Lemes RM, et al. Involvement of 9-*O*-acetyl GD3 ganglioside in *Mycobacterium leprae* infection of Schwann cells. *J Biol Chem.* 2010;285(44): 34086-34096.
64. Masaki T, Qu J, Cholewa-Waclaw J, et al. Reprogramming adult Schwann cells to stem cell-like cells by leprosy bacilli promotes dissemination of infection. *Cell.* 2013;152(1-2):51-67.
65. Alves L, De Mendonça Lima L, Da Silva Maeda E, et al. *Mycobacterium leprae* infection of human Schwann cells depends on selective host kinases and pathogen-modulated endocytic pathways. *FEMS Microbiol Lett.* 2004;238(2):429-437.
66. Mattos KA, Lara FA, Oliveira VG, et al. Modulation of lipid droplets by *Mycobacterium leprae* in Schwann cells: a putative mechanism for host lipid acquisition and bacterial survival in phagosomes. *Cell Microbiol.* 2011;13(2):259-273.
67. Medeiros RC, De Vasconcelos Girardi KD, Cardoso FK, et al. Subversion of Schwann cell glucose metabolism by *Mycobacterium leprae*. *J Biol Chem.* 2016;291(41):21375-21387.
68. Barreto JG, Guimarães L de S, Frade MAC, et al. High rates of undiagnosed leprosy and subclinical infection amongst school children in the Amazon Region. Memórias do Inst Oswaldo Cruz. 2012;107(suppl):60-67.
69. Rambukkana A, Zanazzi G, Tapinos N, et al. Contact-dependent demyelination by *Mycobacterium leprae* in the absence of immune cells. *Science.* 2002;296(5569):927-931.
70. Sieling PA, Modlin RL. Cytokine patterns at the site of mycobacterial infection. *Immunobiology.* 1994;191(4-5):378-387.
71. VanVoorhis W, Kaplan G, Sarno E, et al. The cutaneous infiltrates of leprosy: cellular characteristics and the predominant T-cell phenotypes. *N Engl J Med.* 1982;307(26):1593-1597.
72. Krutzik SR, Ochoa MT, Sieling PA, et al. Activation and regulation of Toll-like receptors 2 and 1 in human leprosy. *Nat Med.* 2003;9(5):525-532.
73. Polycarpou A, Holland MJ, Karageorgiou I, et al. *Mycobacterium leprae* activates Toll-like receptor-4 signaling and expression on macrophages depending on previous Bacillus Calmette-Guerin vaccination. *Front Cell Infect Microbiol.* 2016;6:72.
74. Oliveira RB, Ochoa MT, Sieling PA, et al. Expression of Toll-like receptor 2 on human Schwann cells: a mechanism of nerve damage in leprosy. *Infect Immun.* 2003;71(3):1427-1433.
75. Gringhuis SI, den Dunnen J, Litjens M, et al. C-type lectin DC-SIGN modulates Toll-like receptor signaling via Raf-1 kinase-dependent acetylation of transcription factor NF-??B. *Immunity.* 2007;26(5): 605-616.
76. Montoya D, Cruz D, Teles RMB, et al. Divergence of macrophage phagocytic and antimicrobial programs in leprosy. *Cell Host Microbe.* 2009;6(4):343-353.
77. Moura DF, de Mattos KA, Amadeu TP, et al. CD163 favors *Mycobacterium leprae* survival and persistence by promoting anti-inflammatory pathways in lepromatous macrophages. *Eur J Immunol.* 2012;42(11):2925-2936.
78. Pereira RMS, Calegari-Silva TC, Hernandez MO, et al. *Mycobacterium leprae* induces NF-κB-dependent transcription repression in human Schwann cells. *Biochem Biophys Res Commun.* 2005;335(1):20-26.
79. Teles RMB, Antunes SLG, Jardim MR, et al. Expression of metalloproteinases (MMP-2, MMP-9, and TACE) and TNF-α in the nerves of leprosy patients. *J Peripher Nerv Syst.* 2007;12(3):195-204.
80. Antunes SLG, Chimelli L, Jardim MR, et al. Histopathological examination of nerve samples from pure

neural leprosy patients: obtaining maximum information to improve diagnostic efficiency. *Mem Inst Oswaldo Cruz.* 2012;107(2):246-253.
81. Martinuzzo ME, de Larranaga GF, Forastiero RR, et al. Markers of platelet, endothelial cell and blood coagulation activation in leprosy patients with antiphospholipid antibodies. *Clin Exp Rheumatol.* 2002;20(4):477-483.
82. Nogueira MR, Latini AC, Nogueira ME. The involvement of endothelial mediators in leprosy. *Mem Inst Oswaldo Cruz.* 2016;111(10):635-641.
83. Da Motta-Passos I, Malheiro A, Gomes Naveca F, et al. Decreased RNA expression of interleukin 17A in skin of leprosy. *Eur J Dermatol.* 2012;22(4):488-494.
84. Sadhu S, Khaitan BK, Joshi B, et al. Reciprocity between regulatory T cells and Th17 cells: relevance to polarized immunity in leprosy. *PLoS Negl Trop Dis.* 2016;10(1):e0004338.
85. Matzner M, Al Samie AR, Winkler HM, et al. Low serum levels of cathelicidin LL-37 in leprosy. *Acta Trop.* 2011;117(1):56-59.
86. Batista-Silva LR, Rodrigues LS, Vivarini Ade C, et al. *Mycobacterium leprae*-induced insulin-like growth factor I attenuates antimicrobial mechanisms, promoting bacterial survival in macrophages. *Sci Rep.* 2016;6:27632.
87. Rodrigues LS, Hacker MA, Illarramendi X, et al. Circulating levels of insulin-like growth factor-I (IGF-I) correlate with disease status in leprosy. *BMC Infect Dis.* 2011;11:339.
88. Wemambu SN, Turk JL, Waters MF, et al. Erythema nodosum leprosum: a clinical manifestation of the arthus phenomenon. *Lancet.* 1969;2(7627):933-935.
89. Rojas RE, Demichelis SO, Sarno EN, et al. IgM antiphenolic glycolipid I and IgG anti-10-kDa heat shock protein antibodies in sera and immune complexes isolated from leprosy patients with or without erythema nodosum leprosum and contacts. *FEMS Immunol Med Microbiol.* 1997;19(1):65-74.
90. Polycarpou A, Walker SL, Lockwood DNJ. A systematic review of immunological studies of erythema nodosum leprosum. *Front Immunol.* 2017;8:233.
91. Sampaio EP, Moreira AL, Sarno EN, et al. Prolonged treatment with recombinant interferon gamma induces erythema nodosum leprosum in lepromatous leprosy patients. *J Exp Med.* 1992;175(6):1729-1737.
92. Sarno EN, Grau GE, Vieira LM, et al. Serum levels of tumour necrosis factor-alpha and interleukin-1 beta during leprosy reactional states. *Clin Exp Immunol.* 1991;84(1):103-108.
93. Dias AA, Silva CO, Santos JP, et al. DNA sensing via TLR-9 constitutes a major innate immunity pathway activated during erythema nodosum leprosum. *J Immunol.* 2016;197(5):1905-1913.
94. Lee DJ, Li H, Ochoa MT, et al. Integrated pathways for neutrophil recruitment and inflammation in leprosy. *J Infect Dis.* 2010;201(4):558-569.
95. Schmitz V, Prata RB, Barbosa MG, et al. Expression of CD64 on circulating neutrophils favoring systemic inflammatory status in erythema nodosum leprosum. *PLoS Negl Trop Dis.* 2016;10(8):e0004955.
96. Yamamura M, Wang XH, Ohmen JD, et al. Cytokine patterns of immunologically mediated tissue damage. *J Immunol.* 1992;149(4):1470-1475.
97. Kirkaldy AA, Musonda AC, Khanolkhar-Young S, et al. Expression of CC and CXC chemokines and chemokine receptors in human leprosy skin lesions. *Clin Exp Immunol.* 2003;134(3):447-453.
98. Geluk A, Van Meijgaarden KE, Wilson L, et al. Longitudinal immune responses and gene expression profiles in type 1 leprosy reactions. *J Clin Immunol.* 2014;34(2):245-255.
99. Henry M, GalAn N, Teasdale K, et al. Factors contributing to the delay in diagnosis and continued transmission of leprosy in Brazil—an explorative, quantitative, questionnaire based study. *PLoS Negl Trop Dis.* 2016;10(3):1-12.
100. Scollard DM, Adams LB, Gillis TP, et al. The continuing challenges of leprosy. *Clin Microbiol Rev.* 2006;19(2):338-381.
101. Cho SN, Fujiwara T, Hunter SW, et al. Use of an artificial antigen containing the 3,6-di-*O*-methyl-beta-D-glucopyranosyl epitope for the serodiagnosis of leprosy. *J Infect Dis.* 1984;150(3):311-322.
102. Spencer JS, Brennan PJ. The role of *Mycobacterium leprae* phenolic glycolipid I (PGL-I) in serodiagnosis and in the pathogenesis of leprosy. *Lepr Rev.* 2011;82(4):344-357.
103. Duthie MS, Hay MN, Morales CZ, et al. Rational design and evaluation of a multiepitope chimeric fusion protein with the potential for leprosy diagnosis. *Clin vaccine Immunol.* 2010;17(2):298-303.
104. Duthie MS, Raychaudhuri R, Tutterrow YL, et al. A rapid ELISA for the diagnosis of MB leprosy based on complementary detection of antibodies against a novel protein-glycolipid conjugate. *Diagn Microbiol Infect Dis.* 2014;79:233-239.
105. Corstjens PL, de Dood CJ, van der Ploeg-van Schip JJ, et al. Lateral flow assay for simultaneous detection of cellular- and humoral immune responses. *Clin Biochem.* 2011;44(14-15):1241-1246.
106. Bobosha K, Tjon Kon Fat EM, van den Eeden SJF, et al. Field-evaluation of a new lateral flow assay for detection of cellular and humoral immunity against *Mycobacterium leprae*. *PLoS Negl Trop Dis.* 2014 8;8(5):e2845.
107. Al-Mubarak R, Vander Heiden J, Broeckling CD, et al. Serum metabolomics reveals higher levels of polyunsaturated fatty acids in lepromatous leprosy: potential markers for susceptibility and pathogenesis. *PLoS Negl Trop Dis.* 2011;5(9):e1303.
108. Lima EDO, De Macedo CS, Esteves CZ, et al. Skin imprinting in silica plates: a potential diagnostic methodology for leprosy using high-resolution mass spectrometry. *Anal Chem.* 2015;87(7):3585-3592.
109. Salgado CG, Pinto P, Bouth RC, et al. miRNome expression analysis reveals new players on leprosy immune physiopathology. *Front Immunol.* 2018;9:463.
110. Barreto JG, Bisanzio D, Guimarães Lde S, et al. Spatial analysis spotlighting early childhood leprosy transmission in a hyperendemic municipality of the Brazilian Amazon region. *PLoS Negl Trop Dis.* 2014;8(2):e2665.
111. Barreto JG, Bisanzio D, Frade MAC, et al. Spatial epidemiology and serologic cohorts increase the early detection of leprosy. *BMC Infect Dis.* 2015;15:527.
112. Reddy RR, Singh G, Sacchidanand S, et al. A comparative evaluation of skin and nerve histopathology in single skin lesion leprosy. *Indian J Dermatol Venereol Leprol.* 2005;71(6):401-405.
113. Weng XM, Chen SY, Ran SP, et al. Immuno-histopathology in the diagnosis of early leprosy. *Int J Lepr Other Mycobact Dis.* 2000;68(4):426-433.
114. Massone C, Belachew WA, Schettini A. Histopathology of the lepromatous skin biopsy. *Clin Dermatol.* 2015;33(1):38-45.

115. Wade HW. The histoid variety of lepromatous leprosy. *Int J Lepr.* 1963;31:129-142.
116. Lockwood DNJ, Lucas SB, Desikan KV, et al. The histological diagnosis of leprosy type 1 reactions: identification of key variables and an analysis of the process of histological diagnosis. *J Clin Pathol.* 2008;61(5):595-600.
117. Kahawita IP, Walker SL, Lockwood DNJ. Leprosy type 1 reactions and erythema nodosum leprosum. *An Bras Dermatol.* 2008;83(1):75-82.
118. Walker SL, Saunderson P, Kahawita IP, et al. International workshop on erythema nodosum leprosum (ENL)—consensus report; the formation of ENLIST, the ENL international study group. *Lepr Rev.* 2012;83(4):396-407.
119. Rea TH, Jerskey RS. Clinical and histologic variations among thirty patients with Lucio's phenomenon and pure and primitive diffuse lepromatosis (Latapi's lepromatosis). *Int J Lepr Other Mycobact Dis.* 2005;73(3):169-188.
120. Sehgal VN. Lucio's phenomenon/erythema necroticans. *Int J Dermatol.* 2005;44(7):602-605.
121. Vargas-Ocampo F. Diffuse leprosy of Lucio and Latapí: a histologic study. *Lepr Rev.* 2007;78(3):248-260.
122. Monteiro R, Abreu MAMM de, Tiezzi MG, et al. Lucio's phenomenon: another case reported in Brazil. *An Bras Dermatol.* 2012;87(2):296-300.
123. Garbino JA, Heise CO, Marques W. Assessing nerves in leprosy. *Clin Dermatol.* 2016;34(1):51-58.
124. Goedee HS, Brekelmans GJF, van Asseldonk JTH, et al. High resolution sonography in the evaluation of the peripheral nervous system in polyneuropathy—a review of the literature. *Eur J Neurol.* 2013;20(10):1342-1351.
125. Lugão HB, Frade MAC, Marques W Jr, et al. Ultrasonography of leprosy neuropathy: a longitudinal prospective study. *PLoS Negl Trop Dis.* 2016;10(11): e0005111.
126. van Brakel WH, Nicholls PG, Das L, et al. The INFIR Cohort Study: investigating prediction, detection and pathogenesis of neuropathy and reactions in leprosy. Methods and baseline results of a cohort of multibacillary leprosy patients in north India. *Lepr Rev.* 2005;76(1):14-34.
127. Kumar B, Dogra S, Kaur I. Epidemiological characteristics of leprosy reactions: 15 years experience from North India. *Int J Lepr Other Mycobact Dis.* 2004;72(2):125-133.
128. Nery JAC, Vieira LMM, De Matos HJ, et al. Reactional states in multibacillary Hansen disease patients during multidrug therapy. *Rev Inst Med Trop Sao Paulo.* 1998;40(6):363-370.
129. Walker SL, Balagon M, Darlong J, et al. ENLIST 1: an international multi-centre cross-sectional study of the clinical features of erythema nodosum leprosum. *PLoS Negl Trop Dis.* 2015;9(9):e0004065.
130. Pocaterra L, Jain S, Reddy R, et al. Clinical course of erythema nodosum leprosum: an 11-year cohort study in Hyderabad, India. *Am J Trop Med Hyg.* 2006;74:868-879.
131. Saunderson P, Gebre S, Byass P. ENL reactions in the multibacillary cases of the AMFES cohort in central Ethiopia: incidence and risk factors. *Lepr Rev.* 2000;71(3):318-324.
132. Lawn SD, Wood C, Lockwood DN. Borderline tuberculoid leprosy: an immune reconstitution phenomenon in a human immunodeficiency virus-infected person. *Clin Infect Dis.* 2003;36(1):e5-e6.
133. Talhari C, Mira MT, Massone C, et al. Leprosy and HIV coinfection: a clinical, pathological, immunological, and therapeutic study of a cohort from a Brazilian referral center for infectious diseases. *J Infect Dis.* 2010;202(3):345-354.
134. Machado PR, Machado LM, Shibuya M, et al. Viral coinfection and leprosy outcomes: a cohort study. *PLoS Negl Trop Dis.* 2015;9(8):e0003865.
135. Lechat MF, Shrager DI, Declercq E, et al. Decreased survival of HTLV-I carriers in leprosy patients from the Democratic Republic of the Congo: a historical prospective study. *J Acquir Immune Defic Syndr Hum Retrovirol.* 1997;15(5):387-390.
136. Scollard DM, Joyce MP, Gillis TP. Development of leprosy and type 1 leprosy reactions after treatment with infliximab: a report of 2 cases. *Clin Infect Dis.* 2006;43:e19-e22.
137. Freitas DS, Machado N, Andrigueti FV, et al. Lepromatous leprosy associated with the use of anti-TNFα therapy: case report. *Rev Bras Reumatol.* 2010;50(3):336-339.
138. Antônio JR, Soubhia RMC, Paschoal VDA, et al. Biological agents: investigation into leprosy and other infectious diseases before indication. *An Bras Dermatol.* 2013;88:23-25.
139. Pannikar V, Jesudasan K, Vijayakumaran P, et al. Relapse or late reversal reaction? *Int J Lepr Other Mycobact Dis.* 1989;57(2):526-528.
140. Stump PR, Baccarelli R, Marciano LH, et al. Neuropathic pain in leprosy patients. *Int J Lepr Other Mycobact Dis.* 2004;72(2):134-138.
141. Sena CBC De, Salgado CG, Tavares CMP, et al. Cyclosporine A treatment of leprosy patients with chronic neuritis is associated with pain control and reduction in antibodies against nerve growth factor. *Lepr Rev.* 2006;77(2):121-129.
142. Faget GH, Pogge RC, Johansen FA, et al. The promin treatment of leprosy. A progress report. *Public Health Rep.* 1943;58(48):1729.
143. Peters AL, Van Noorden CJF. Glucose-6-phosphate dehydrogenase deficiency and malaria: cytochemical detection of heterozygous G6PD deficiency in women. *J Histochem Cytochem.* 2009;57(11): 1003-1011.
144. WHO. *WHO Model Prescribing Information: Drugs Used in Leprosy [Internet]*. Geneva: WHO; 1998. http://apps.who.int/medicinedocs/en/d/Jh2988e/.
145. Kosseifi SG, Guha B, Nassour DN, et al. The dapsone hypersensitivity syndrome revisited: a potentially fatal multisystem disorder with prominent hepatopulmonary manifestations. *J Occup Med Toxicol.* 2006;1:9.
146. Abinader MVM, Da Gracnulla Souza Cunha M, Cunha C. Adverse effects of alternative therapy (minocycline, ofloxacin and clofazimine) in leprosy multibacillary patients, in health care center, Manaus, Amazonas, Brazil. *J Am Acad Dermatol.* 2015;72(5):AB124.
147. Brasil MT, Opromolla DV, Marzliak ML, et al. Results of a surveillance system for adverse effects in leprosy's WHO/MDT. *Int J Lepr Other Mycobact Dis.* 1996;64(2):97-104.
148. Limalde S, Opromolla DV. First results on the treatment of leprosy with rifamycin SV. *Chemotherapia (Basel).* 1963;10:668-678.
149. Pettit JH, Rees RJ. Sulphone resistance in leprosy. An experimental and clinical study. *Lancet.* 1964;2(7361):673-674.

150. Williams DL, Gillis TP. Drug-resistant leprosy: monitoring and current status. *Lepr Rev.* 2012;83(3):269-281.
151. da Silva Rocha A, Cunha MDG, Diniz LM, et al. Drug and multidrug resistance among *Mycobacterium leprae* isolates from Brazilian relapsed leprosy patients. *J Clin Microbiol.* 2012;50(6):1912-1917.
152. Williams DL, Hagino T, Sharma R, et al. Primary multidrug-resistant leprosy, United States. *Emerg Infect Dis.* 2013;19(1):179-181.
153. Beltrán-Alzate C, López Díaz F, Romero-Montoya M, et al. Leprosy drug resistance surveillance in colombia: the experience of a sentinel country. *PLoS Negl Trop Dis.* 2016;10(10):e0005041.
154. Benjak A, Avanzi C, Singh P, et al. Phylogenomics and antimicrobial resistance of the leprosy bacillus *Mycobacterium leprae*. *Nat Commun.* 2018;9(1):352.
155. Van Veen NH, Nicholls PG, Smith WC, et al. Corticosteroids for treating nerve damage in leprosy. *Cochrane Database Syst Rev.* 2016;(5):CD005491.
156. Keiser PB, Nutman TB. *Strongyloides stercoralis* in the immunocompromised population. *Clin Microbiol Rev.* 2004;17(1):208-217.
157. Buckley L, Guyatt G, Fink HA, et al. 2017 American College of Rheumatology guideline for the prevention and treatment of glucocorticoid-induced osteoporosis. *Arthritis Care Res (Hoboken).* 2017;69(8): 1095-1110.
158. Garbino JA, Virmond MDCL, Ura S, et al. A randomized clinical trial of oral steroids for ulnar neuropathy in type 1 and type 2 leprosy reactions. *Arq Neuropsiquiatr.* 2008;66(4):861-867.
159. Sales AM, de Matos HJ, Nery JAC, et al. Double-blind trial of the efficacy of pentoxifylline vs thalidomide for the treatment of type II reaction in leprosy. *Brazilian J Med Biol Res.* 2007;40(2):243-248.
160. Lockwood DNJ, Darlong J, Govindharaj P, et al. AZALEP: a randomized controlled trial of azathioprine to treat leprosy nerve damage and Type 1 reactions in India: main findings. *PLoS Negl Trop Dis.* 2017;11(3):e0005348.
161. Omar AE, Hussein MR. Clinically unsuspected neuritic leprosy with caseation necrosis. *Ultrastruct Pathol.* 2012;36(6):377-380.
162. Wan EL, Rivadeneira AF, Jouvin RM, et al. Treatment of peripheral neuropathy in leprosy: the case for nerve decompression. *Plast Reconstr Surg Glob Open.* 2016;4(3):e637.
163. Schwarz RJ, Macdonald M. A rational approach to nasal reconstruction in leprosy. *Plast Reconstr Surg.* 2004;114(4):876-882; discussion 883-884.
164. Duerksen F, Virmond M. Carvable silicone rubber prosthetic implant for atrophy of the first web in the hand. *Lepr Rev.* 1990;61(3):267-272.
165. White C, Franco-Paredes C. Leprosy in the 21st century. *Clin Microbiol Rev.* 2015;28(1):80-94.
166. Thakor HG, Murthy PS. Counselling of leprosy affected persons and the community. *J Indian Med Assoc.* 2004;102(12):684-687.
167. Madhavan K, Vijayakumaran P, Ramachandran L, et al. Sustainable leprosy related disability care within integrated general health services: findings from Salem District, India. *Lepr Rev.* 2007;78(4):353-361.
168. Fine PE, Sterne JS, Pönnighaus JM, et al. Household and dwelling contact as risk factors for leprosy in northern Malawi. *Am J Epidemiol.* 1997;146(1): 91-102.
169. Moet FJ, Pahan D, Oskam L, et al. Effectiveness of single dose rifampicin in preventing leprosy in close contacts of patients with newly diagnosed leprosy: cluster randomised controlled trial. *BMJ.* 2008;336(7647):761-764.
170. Düppre NC, Camacho LAB, da Cunha SS, et al. Effectiveness of BCG vaccination among leprosy contacts: a cohort study. *Trans R Soc Trop Med Hyg.* 2008;102(7):631-638.

Fungal Diseases PART 24

Chapter 160 :: Superficial Fungal Infection

:: Lauren N. Craddock & Stefan M. Schieke

AT-A-GLANCE

- Mycoses are divided among 3 forms: *superficial*, *subcutaneous*, and *deep/systemic.*
- Superficial fungal infection is defined as a dermatophyte infection of keratinized tissues including skin, hair, and nails.
- Dermatophyte species are contained in 3 genera (*Epidermophyton*, *Microsporum*, and *Trichophyton*), which are further divided according to 3 natural habitats (humans, animals, and soil).
- *Trichophyton* is the most common genera isolated in the United States.
- *Trichophyton rubrum* is the most common cause of dermatophytosis of the skin.
- *Trichophyton tonsurans* is the most common cause of tinea capitis in the United States.
- Piedra, which consists of white and black forms, is an asymptomatic superficial fungal infection of the hair shaft.
- Onychomycosis is the name given to dermatophytosis of the nails.
- Microscopic examination, culture, Wood light evaluation, and histopathology may all be useful in confirming diagnosis.
- Several topical and oral antifungals are available for effective treatment of dermatophytosis.
- Infections involving hair bearing skin and nails typically require oral treatment.

MYCOSES

Mycoses are divided among 3 forms: (a) *superficial*, involving stratum corneum, hair, and nails; (b) *subcutaneous*, involving dermis and/or subcutaneous tissue; and (c) *deep/systemic*, representing hematogenous spread of organisms including opportunistic pathogens in immunocompromised hosts. This chapter focuses on the superficial mycoses and their patterns of integumentary infections (Table 160-1). Table 160-2 is a glossary of terms used in this chapter.

DERMATOPHYTES

The kingdom of fungi comprises more than 1.5 million species worldwide. Dermatophytes (the term is derived from the Greek words for "skin plant") are represented by approximately 40 species divided among the 3 genera *Trichophyton*, *Microsporum*, and *Epidermophyton*, all falling within the Arthrodermataceae family. In the United States, *Trichophyton* species, namely *Trichophyton rubrum* and *Trichophyton interdigitale*, represent the most common isolated species. Dermatophytes are classified further according to their natural habitats—humans, other animals, and soil. Their ability to attach to, invade, and use keratin as a source of nutrition underlies the pathogenesis of superficial fungal infection of skin, hair, and nails, and is termed *dermatophytosis*.[1]

TAXONOMY

Recent modifications to the taxonomical system of dermatophytes affecting clinical practice require mention. While classic taxonomy is governed by what is phenotypically observable, recent inclusion of data from genotypical analysis has necessitated regrouping of some taxa, as many of these genotypical differences are not reflected phenotypically, and vice versa.[2] Contradictions between what is phenotypically observable and found via genomic analysis make devising such a taxonomical system for dermatophytes difficult. According to the classic, yet still current, rules

TABLE 160-1
Patterns of Integumentary Infections by Superficial Mycoses

GENERA	SKIN	HAIR	NAILS
Trichophyton	×	×	×
Microsporum	×	×	
Epidermophyton	×		×
Tinea nigra	×		
Black piedra		×	
White piedra		×	

of taxonomy governing nomenclature, a species must be identifiable in nature, with physical specimens able to be cultured and proven to be sexually isolated from others, before they may be formally named. Conversely, newer molecular ecologic studies using sequencing of variable genomic regions, such as the internal transcribed spacer regions, of pooled fungal ribosomal DNA have discovered (a) more internal transcribed spacer regions than there are in known/observable species, (b) multiple species may have identical internal transcribed spacer regions, and (c) there may be multiple forms of internal transcribed spacer in one species' genome.[3] Current fungal taxonomy includes a synthesis of the new genomic data and classic phenotypical characterizations.

In the case of dermatophytes, many species overall have very little genetic diversity and may live in the same environmental niche. Phenotypically, this is reflected by similar clinical manifestations being caused by multiple taxonomically different dermatophyte species. The additional classification of superficial fungi according to natural habitat is clinically relevant, as anthropophilic, zoophilic, and geophilic dermatophytoses provide important information about the source of infection and may demonstrate varied clinical features.

TABLE 160-2
Glossary of Terms

- *Anthropophilic*—preferring humans over other animals as the natural habitat.
- *Arthroconidia*—asexual spore produced by segmentation of hyphae.
- *Dematiaceous*—melanin in the cell walls of its conidia, hyphae, or both results in a darkly colored fungus.
- *Ectothrix*—dermatophyte growth pattern with spores forming a sheath on the outside of the hair shaft.
- *Endothrix*—dermatophyte growth pattern with spore formation within the hair shaft.
- *Favus*—dermatophyte growth pattern with hyphae and air spaces within the hair shaft.
- *Geophilic*—preferring the soil over humans and animals as natural habitat.
- *Hyphae*—long, filamentous fungus cells forming a branching network called mycelium.
- *Macroconidia*—asexual large multinucleate spores produced by vegetative reproduction.
- *Microconidia*—asexual small spores produced by vegetative reproduction.
- *Zoophilic*—preferring animals over humans as the natural habitat.

ANTHROPHILIC

Anthrophilic species are typically restricted to human hosts and are transmitted via direct contact. Infected skin or hair retained in clothing, combs, caps, socks, and towels, for example, also serve as source reservoirs. Unlike the sporadic geophilic and zoophilic infections, anthropophilic infections are often epidemic in nature. These dermatophytes have adapted to humans as hosts and elicit a mild to noninflammatory host response.

ZOOPHILIC

Zoophilic species are transmitted to humans from animals. Cats, dogs, rabbits, guinea pigs, birds, horses, cattle, and other animals are common sources of infection. Transmission may occur through direct contact with the animal itself, or indirectly via infected animal hair. Exposed areas, such as the scalp, beard, face, and arms, are favored sites of infection. *Microsporum canis* is often transmitted to humans from cats and dogs, whereas guinea pigs and rabbits are a frequent source of human infection with zoophilic strains of *T. interdigitale.* Although host adaptation by zoophilic dermatophytes may lead to relatively silent infections, these dermatophytes tend to produce acute and intense inflammatory responses in humans.[1]

GEOPHILIC

Geophilic fungi cause sporadic human infection upon direct contact with the soil. *Microsporum gypseum* is the most common geophilic dermatophyte cultured from humans. There is a potential for epidemic spread as a consequence of the higher virulence of geophilic strains, as well as an ability to form long-lived spores that may reside in blankets or grooming tools. As with zoophilic infections, geophilic dermatophytes typically result in intense inflammatory responses.[4]

Table 160-3 lists the most commonly encountered dermatophyte pathogens according to their natural habitats and reservoirs. As there are still texts that use the classical names, to avoid confusion and to remain broadly reflective of the literature, this chapter uses both old and current nomenclatures.

EPIDEMIOLOGY

Superficial fungal infection is a worldwide problem that affects more than 25% of the population.[5] Some species demonstrate ubiquitous distribution, whereas others are geographically limited. Accordingly,

TABLE 160-3
Habitats and Hosts of Common Dermatophytes

HABITAT	DERMATOPHYTE	HOST
Anthropophilic	*Trichophyton rubrum* (**syn:** *Trichophyton megninii, Trichophyton gourvilii*)	Humans
	Trichophyton tonsurans	
	Trichophyton interdigitale (**syn:** *Trichophyton mentagrophytes* **var.** *interdigitale*)	
	Trichophyton schoenleinii	
	Trichophyton soudanense	
	Trichophyton violaceum (**syn:** *Trichophyton yaoundei*)	
	Trichophyton concentricum	
	Microsporum audouinii	
	Microsporum ferrugineum	
	Epidermophyton floccosum	
Zoophilic	*Trichophyton mentagrophytes* (**syn:** *Trichophyton mentagrophytes* **var.** *quinckeanum*)	Rodents
	Trichophyton interdigitale (**syn:** *Trichophyton mentagrophytes* **var.** *mentagrophytes, Trichophyton mentagrophytes* **var.** *granulosum*)	Rodents
	Trichophyton erinacei	Hedgehogs
	Trichophyton simii	Primates
	Trichophyton verrucosum	Cattle
	Microsporum canis (**syn:** *Microsporum distortum, Microsporum equinum*)	Cats, dogs, horses
	Microsporum amazonicum	Rodents
	Microsporum gallinae	Poultry
	Microsporum nanum	Pigs
	Microsporum persicolor	Rodents
Geophilic	*Microsporum gypseum*	Soil
	Microsporum cookei	
	Microsporum persicolor	
	Trichophyton vanbreuseghemii	
	Trichophyton eboreum	
	Trichophyton terrestre	

predominant species reflect considerable geographic differences, as in the case of tinea capitis. In the United States, *Trichophyton tonsurans* replaced *Microsporum audouinii* as the most common cause of tinea capitis in the second half of the 20th century, and *M. canis* has now become the second most common cause.[6] In Europe, *M. canis* remains the most common cause of tinea capitis despite a significantly increased incidence of *T. tonsurans*.[7] The etiologic profile is quite different in Africa where *M. audouinii*, *Trichophyton soudanense*, and *Trichophyton violaceum* are the most prevalent pathogens.[8] However, human travel and migration results in dynamic patterns of infection. As an example, *T. soudanense* and *T. violaceum*, typically restricted to Africa, were isolated in U.S. cases of tinea capitis in 2007.[9]

Clinical presentations of dermatophytoses depend not only on the source, but also on host factors. Immunocompromised individuals are more susceptible to refractory dermatophyte infections or to deep mycoses.[10,11] Interestingly, only the severity of dermatophytosis appears to be increased with HIV infection, and not the prevalence.[12] Other host factors, such as age, sex, and race, appear to be additional epidemiologic factors for infection, although their relationship to dermatophyte susceptibility remains unclear. As an example, dermatophyte infections are 5 times more prevalent in males than females. Finally, local customs may also influence rates and patterns of dermatophytoses. The use of macerating occlusive footwear, for example, in industrialized nations has made tinea pedis and onychomycosis much more common in these regions.[13]

CLINICAL FEATURES

Clinical features of the dermatophytoses vary depending upon the causative dermatophyte (as discussed before) and the site of infection (ie, skin, hair, or nails). Skin dermatophytoses are generally named according to the following paradigm: the word *tinea* (Latin for "worm") followed by a Latin term denoting location or other descriptive factor. Diagnoses within this category include tinea barbae, tinea capitis, tinea corporis, tinea cruris, tinea favosa (derivative of Latin *favus*, meaning "honeycomb"), tinea manuum, tinea nigra, and tinea pedis. Dermatophytosis of the hair is known as *piedra*, and of the nails as *onychomycosis*. A dermatophytid or id reaction (autoeczematization) is an acute inflammatory dermatitis at sites distant from the primary inflammatory fungal infection. (See individual diagnoses listed alphabetically under the section "Dermatophytoses" for more detail.)

PATHOGENESIS

Dermatophytes exhibit a broad armamentarium of enzymes (eg, keratinolytic proteases, lipases) and other virulence factors to allow adherence, use of keratin as a source of nutrients, invasion, and growth of mycelial elements for survival in keratinized tissues. As a consequence of keratin degradation with subsequent release of proinflammatory mediators, the host develops an inflammatory response of varying degree. The degree of inflammation is dependent upon pathogen and host factors. The classic "ringworm," or annular, morphology of tinea corporis results from an inflammatory host response against a spreading dermatophyte, followed by a reduction or clearance of fungal elements from within the plaque, and (in many cases) spontaneous resolution of the infection.

ADHERENCE

Dermatophytes overcome several lines of host defense before hyphae begin to thrive in keratinized tissues. The first step is successful adherence of arthroconidia, asexual spores formed by fragmentation of hyphae, to keratin via adhesin to result in alteration of gene expression.[14,15] Dermatophytes make selective use of their proteolytic armamentarium during adherence and invasion.[16,17] Following several hours of successful adherence, the spores begin to germinate in preparation for the next step in the infective chain of events, invasion.

INVASION

Trauma and maceration facilitate penetration of dermatophytes through the skin. Invasion of germinating fungal elements is further accomplished through secretion of specific proteases, lipases, and ceramidases, the digestive products of which also serve as fungal nutrients.[18] Interestingly, components of the fungal cell wall, including β-glucan, galactomannans, and chitin, show inhibitory effects on keratinocyte proliferation (to allow invasion before desquamation) and cell-mediated immunity (discussed in the following section "Host Response").[19,20] Once dermatophytes penetrate through the epidermis to the dermis, binding of adhesin to elastin again changes gene expression.[14]

HOST RESPONSE

Dermatophytes encounter a range of host responses from the nonspecific, innate to the well-tuned, adaptive immune systems. In the line of defense mechanisms, the epithelial surface, antimicrobial peptides (defensins, cathelicidins, S100 proteins, fungistatic fatty acids in sebum), and competing bacterial flora represent the first barrier against invading fungal elements.[13,21,22] Besides acting as a passive physical barrier, epidermal keratinocytes play a more active role by expressing multiple pattern recognition receptors including C-type lectin receptors and multiple Toll-like receptors (TLRs) located either on the cell surface (TLR1, TLR2, TLR4, TLR5, and TLR6) or in the endosomes (TLR3 and TLR9).[23] The innate immune system is able to monitor for microbes via these pattern recognition receptors, which function to bridge innate and adaptive immunity upon recognition of pathogen-associated molecular patterns to result in targeted cytokine production, recruitment, and polarization of relevant T, B, and natural killer lymphocyte subsets.[21] The specific immune response generated depends upon the cell type involved.[24] Monocytes, macrophages, neutrophils, epithelial, and endothelial cells phagocytize and directly kill fungi.[24] Upon TLR binding of a fungal pathogen-associated molecular pattern, mannan, keratinocytes (a) increase proliferation to promote shedding, (b) increase secretion of antimicrobial peptides (such as human β defensins, ribonuclease 7, and Psoriasin) to inhibit growth of dermatophytes, and (c) increase secretion of proinflammatory cytokines (interferon-α, tumor necrosis factor-α, interleukin [IL]-1β, IL-8, IL-16, and IL-17) to further activate the immune system.[23,25,26] A C-type lectin receptor called Dectin-1 binds β-1,3-glucan on fungi to activate the SYK–CARD-9 signaling pathway in neutrophils, macrophages, and dendritic cells to promote IL-23 production and subsequent T-helper (Th)-17 cell induction.[21] Dendritic cells mature and promote differentiation of naïve T cells into effector Th cell subtypes after uptake of fungi.[25] Once dermatophytes are able to penetrate into deeper layers of the epidermis, new nonspecific defenses emerge, such as competition for iron by unsaturated transferrin and activation of complement to inhibit fungal growth.[20]

The next level of defense is cell-mediated immunity resulting in a specific delayed-type hypersensitivity response against invading fungi. The degree of inflammatory reaction depends on the host's immune status as well as the dermatophyte species involved. The inflammatory response associated with this hypersensitivity correlates with clinical resolution, while defective Th1 cell-mediated immunity, important for the activation of phagocytes at the site of infection, may result in chronic or recurrent dermatophytosis.[24] In patients with chronic infection, it has been reported that *T. rubrum* conidia cause macrophages to increase production of tumor necrosis factor-α and IL-10 without increased IL-12 or nitric oxide, decrease costimulatory molecules, and inhibit phagocytosis; thus, when conidia are ingested, the macrophage is unable to digest the conidia, which continue growing inside until they rupture the macrophage.[23] The Th2 response does not appear to be protective, as patients with elevated fungal antigen antibody titers are observed to have widespread dermatophyte infections.[27] A possible role for the Th17 response to dermatophyte infections is suggested by the discovery of hyphal elements binding to Dectin-2, a C-type lectin pattern recognition receptor on dendritic cells, critical for inducing Th17 responses.[28,29] Recall that many innate immune cells release proinflammatory cytokines. Some of these, such as IL-1β, transforming growth factor-β, and IL-6, promote the development of Th17 cells from naïve T cells via signal transducer and activator of transcription (STAT)-3 to induce transcription of the Th17 lineage retinoic acid-related orphan receptor gt.[21] Furthermore, cell expansion and maintenance of Th17 cells is promoted by IL-23. In return, Th17 secretion of IL-17A, IL-17F, and IL-22 activates epithelial cells, granulopoiesis, neutrophil recruitment, and production of chemokines and antimicrobial factors crucial for epithelial immunity against fungi.[21] Thus, a successful host response to dermatophyte infection is dependent upon well-orchestrated interaction and participation of both the innate, nonspecific, and adaptive, cellular immune systems.

Some fungi have evolved to evade immune surveillance. For example, anthropophilic dermatophytes

induce secretion of a limited cytokine profile from keratinocytes in vitro compared to zoophilic species.[30,31] One study found the mannans from *T. rubrum* are more capable of inhibiting mitogen-induced lymphoproliferation than those of *M. canis*.[20] This difference may reflect the augmented inflammatory response generally clinically observed with zoophilic species.

In the case of the most common dermatophytic pathogen, *T. rubrum* is first recognized by keratinocytes when fungal pathogen-associated molecular patterns are sensed by pattern recognition receptors (as discussed above) to result in increased expression and transportation of TLRs (such as TLR2) to the surface of keratinocytes, with subsequent increased recognition, and secretion of proinflammatory cytokines, including interferon-inducible protein-10 and monocyte chemotactic protein-1.[32] In one study, after 24 hours of contact with *T. rubrum* conidia, surface expression of TLR2 was downregulated, resulting in decreased keratinocyte release of proinflammatory cytokines.[32] In another study, viable intact conidia inhibited TLR2 and TLR6 expression and decreased human beta defensin-1 and human beta defensin-2 production.[23] Thus, after an initial, short-lived inflammatory response resulting in clearance of active infection, *T. rubrum* is able to manipulate and evade surveillance by the epithelial innate immune system as inert conidia so as to survive until conditions are favorable for germination and recurrent infection.

GENETICS

Despite epidemiologic observation suggesting a genetic predisposition to dermatophyte infection, molecular insight confirming this hypothesis has been relatively lacking. Genetic mutations in the TLRs and their adaptors may result in increased susceptibility to bacterial and viral infection, but not to fungal infection.[21] Polymorphisms of TLR1 and TLR4 are associated with increased risk of invasive fungal disease, and polymorphisms of TLR3 are associated with cutaneous candidiasis.[21] Polymorphisms of the C-type lectin receptor Dectin-1 and mutations of CARD-9 with decreased IL-17 production are associated with chronic mucocutaneous candidiasis along with chronic dermatophyte infections.[21,33] Multiple mutations are associated with increased susceptibility to other fungi, such as IL-17 receptor and cytokine genes, *STAT1* and *STAT3*, *DOCK8*, *Tyk2*, *AIRE*, *IL-12RB1*, and *MST1/STK4*, which increase mucocutaneous fungal infections; and *CYBB*, *NCF1*, *NCF2*, *NCF4*, *CYBA*, *MAGT1*, and *RAG1*, which increase invasive fungal infections.[21]

DIAGNOSIS

Table 160-4 outlines common laboratory dermatophyte identification methods.

TABLE 160-4
Common Laboratory Dermatophyte Identification Methods

LABORATORY TEST	METHOD	FUNCTION	FINDINGS
Potassium hydroxide preparation (KOH)	Scales from advancing border, subungual debris, or affected hair removed and placed on a glass slide. KOH 10% dropped on specimen and covered with a cover slip. The undersurface of the glass slide may be gently heated with a low-lit flame.	KOH solution and gentle heating softens keratin and highlights the dermatophyte.	Long, narrow, septated and branching hyphae.
Culture	Sabouraud medium (4% peptone, 1% glucose, agar, water).	Facilitates growth of dermatophytes.	Microscopic morphology of microconidia and macroconidia, along with culture features including surface topography and pigmentation. The reader is referred to http://www.mycology.adelaide.edu.au/ for a comprehensive characterization of fungal colonies. Common colonies are characterized in Table 160-5.
	Modified Sabouraud medium (addition of chloramphenicol, cycloheximide, and gentamicin).	Facilitates growth of dermatophytes and inhibits growth of non–*Candida albicans*, *Cryptococcus*, *Prototheca* species, *Phaeoannellomyces werneckii*, *Scytalidium* species, and *Ochroconis gallopava*.	
Dermatophyte test medium	Scales from the advancing border, subungual debris, or affected hair embedded in the medium.	Medium contains the pH indicator phenol red. Dermatophytes use proteins, which result in excess ammonium ion and an alkaline environment.	Incubation at room temperature for 5 to 14 days results in change in medium color from yellow to bright red in the presence of a dermatophyte.
Histopathology special stains: periodic acid–Schiff (PAS) and Grocott methenamine silver (GMS)	Tissue may be obtained by skin or nail biopsy techniques.	Stains fungal cell wall to detect fungal elements in tissue sections.	Pink (PAS) or black (GMS) fungal elements noted in the stratum corneum

The clinical diagnosis of a dermatophyte infection can be confirmed by microscopic detection of fungal elements, by identification of the species through culture, or by histologic evidence of the presence of hyphae in the stratum corneum. In addition, fluorescence patterns under Wood light examination may support a clinical suspicion.

MICROSCOPIC EXAMINATION

Although microscopic evaluation of potassium hydroxide (KOH)-treated samples of scale does not allow for speciation or characterization of the susceptibility profile, it can be used as a quick and inexpensive bedside tool to provide evidence of dermatophytosis. In dermatophytosis involving the skin, hair, or nails, septate and branching hyphae without constriction (Fig. 160-1) may be visualized under microscopic examination with 10% to 20% KOH preparation. All superficial dermatophytes appear identical when visualized in this manner. Because KOH examination may yield false-negative results in up to 15% of cases, patients suspected of having dermatophytosis on clinical impression should be treated.[34] Culture confirmation should be considered whenever systemic treatment is warranted, such as in the case of onychomycosis.

To perform KOH examination of the skin, collect scale by scraping the involved area with a dull edge (eg, a no. 15 blade or edge of slide) outward from the advancing margins. This same technique may be used to scrape under affected nails (but diagnosis of onychomycosis is best confirmed with histopathology or culture as discussed further). Scrapings are then placed on a glass slide, covered with a coverslip, and prepared with 10% to 20% KOH. Place several drops of KOH on the slide adjacent to the coverslip edge, allowing capillary action to wick the fluid under the coverslip. A paper towel may then be used to blot excess KOH solution from around the coverslip. Penetration of KOH into keratin may be aided by either slightly warming the slide with a low-intensity flame or by addition of dimethylsulfoxide (DMSO) in KOH solution. Some may also find the adding a drop of blue or black stain such as chlorazol black (in similar fashion as KOH solution above) helpful for better identifying fungal elements (as seen in Fig. 160-1). Hairs should be plucked (not cut), placed on a glass slide, prepared with 10% to 20% KOH, and covered with a coverslip. Slightly warming the slide with a low-intensity flame allows better penetration of the KOH solution into keratin. Low-power microscopy will reveal 3 possible patterns of infection (Fig. 160-2): (a) ectothrix—small or large arthroconidia forming a sheath around the hair shaft; (b) endothrix—arthroconidia within the hair shaft; or (c) favus—hyphae and air spaces within the hair shaft.

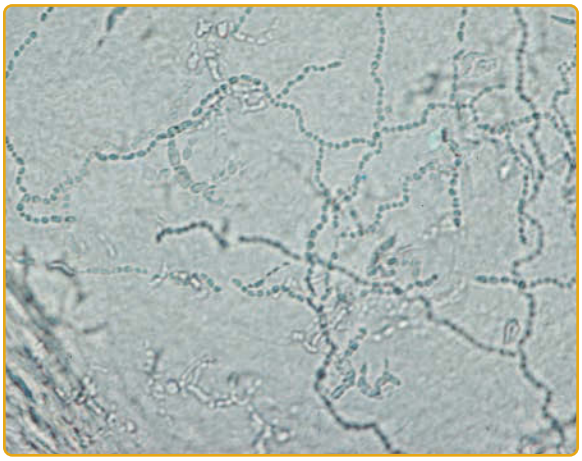

Figure 160-1 Microscopic examination of skin scrapings (scales) revealing septate, branching hyphae.

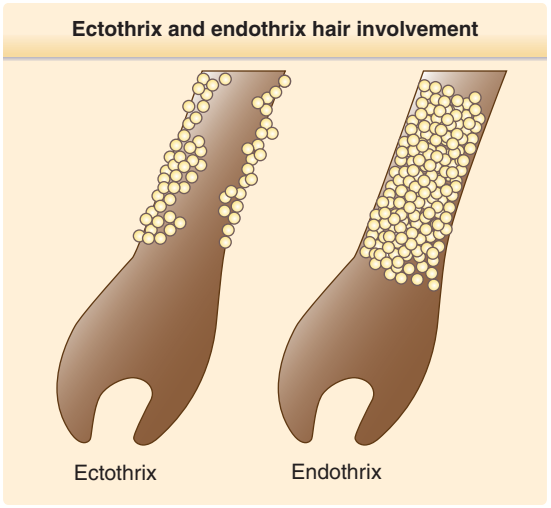

Figure 160-2 Graphic demonstration of ectothrix and endothrix hair involvement.

CULTURE

Speciation of superficial fungi is based on macroscopic, microscopic, and metabolic characteristics of the organism. Although some dermatophytes are readily identified on the basis of their primary isolation cultures, most require further differentiation through subcultures on specific media (identification culture) or through specific biochemical tests.

Sabouraud dextrose agar (SDA) is the most commonly used isolation medium for dermatophytes and it serves as the medium on which most morphologic descriptions are based. Elimination of contaminant molds, yeast, and bacteria is achieved by the addition of cycloheximide and chloramphenicol (± gentamicin) to the medium making it highly selective for the isolation of dermatophytes. The development of colonies can take 5 to 7 days in the case of *Epidermophyton floccosum* and up to 4 weeks for *Trichophyton verrucosum*. Cultures

are incubated at room temperature (20°C to 25°C [68°F to 77°F]) for at least 4 weeks before being finalized as no growth. Dermatophyte test medium is an alternative isolation medium that contains the pH indicator phenol red. The medium turns red when dermatophyte proteolytic activity increases the pH to 8 or above, and it remains amber with the growth of most saprophytes. Nondermatophyte acidic byproducts turn the medium yellow. Although dermatophyte test medium serves as a good alternative for isolation of dermatophytes, it may not allow for their direct identification because of altered growth, and thus morphology, of dermatophytes in dermatophyte test medium. Table 160-5 describes general microscopic features of microconidia and macroconidia of the 3 genera of dermatophytes, and Table 160-6 describes colony and microscopic features of the most common dermatophyte species.

Identification of isolated fungi is facilitated by subculture on specific media such as potato dextrose agar or Borelli lactritmel agar that stimulate sporulation, production of pigment and development of typical morphology. Finally, dermatophytes may be differentiated further by their ability to grow on autoclaved polished rice, perforate short strands of hair in vitro, hydrolyze urea (urease test), or require nutritional supplementation for growth (Table 160-7).

TABLE 160-5
Microscopic Features of Dermatophyte Microconidia and Macroconidia

GENERA	MICROCONIDIA	MACROCONIDIA
Trichophyton	Smooth walled; used for identification	Absent or nondiagnostic
Microsporum	Absent or nondiagnostic	Rough walled; used for identification
Epidermophyton	Absent	Smooth walled; used for identification

TABLE 160-6
Colony and Microscopic Morphology Features of the Most Common Dermatophytes

ORGANISM	COLONY MORPHOLOGY		MICROSCOPIC APPEARANCE
Epidermophyton floccosum	Flat feathery colonies with a central fold and yellow to dull gray-green pigment. Yellow to brown reverse pigment.	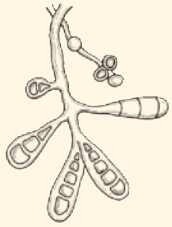	Numerous thin and thick-walled, club-shaped macroconidia.
Microsporum audouinii	Flat and white to gray with widely spaced radial grooves. Tan to salmon reverse pigment. Salmon-pink pigment on PDA. No growth on polished rice.	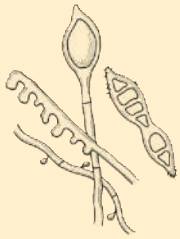	Terminal chlamydoconidia and pectinate (comb-like) hyphae.
Microsporum canis	Flat, white to light yellow, coarsely hairy, with closely spaced radial grooves. Yellow to orange reverse pigment. Yellow on PDA. Growth on polished rice.		Numerous thick walled and echinulate spindle shaped macroconidia with terminal knobs and more than 6 cells.
Microsporum gypseum	Flat and granular with tan to buff pigment, no reverse pigment.	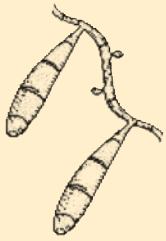	Numerous thin-walled pickle-shaped macroconidia without knobs and less than 6 cells.

(*Continued*)

TABLE 160-6
Colony and Microscopic Morphology Features of the Most Common Dermatophytes (*Continued*)

ORGANISM	COLONY MORPHOLOGY		MICROSCOPIC APPEARANCE
Trichophyton interdigitale	White to creamy with a cottony, mounded surface. None to light brown reverse pigment. No pigment on PDA. Urease positive, which helps to distinguish it from *Trichophyton rubrum*.		Grape-like clusters of round microconidia, rare cigar-shaped macroconidia, occasional spiral hyphae. Hair perforation positive, which helps to distinguish it from *T. rubrum*.
Trichophyton rubrum	Mounded white center with maroon periphery. Maroon reverse pigment. Cherry red on PDA. Urease negative.	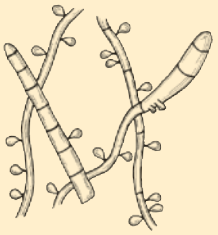	Few tear-shaped microconidia, rare pencil-shaped macroconidia. Hair perforation negative.
Trichophyton schoenleinii	Heaped or folded and whitish. Colorless to yellow-tan reverse pigment.	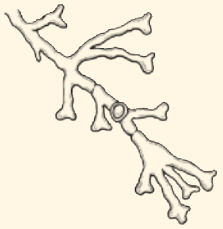	Knobby antler-like hyphae (favic chandeliers), numerous chlamydoconidia.
Trichophyton tonsurans	Suede-like center with feathery periphery, white to yellow or maroon color. Reverse pigment usually dark maroon, sometimes none to yellow. Partial thiamine requirement.	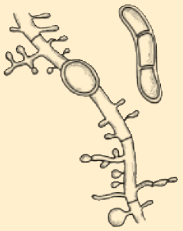	Numerous multiform microconidia and rare cigar-shaped macroconidia.
Trichophyton verrucosum	Small and heaped, although sometimes flat, white to yellow-gray. Reverse pigment none to yellow. Requires thiamine and usually inositol for growth.	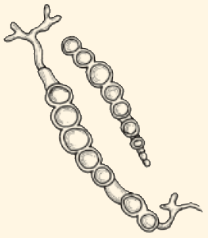	Chains of chlamydoconidia on SDA. Long and thin "rat-tail" macroconidia with thiamine.
Trichophyton violaceum	Waxy and heaped, deep purplish-red. Purple reverse pigment. Partial thiamine requirement.	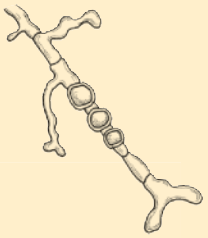	Irregular hyphae with intercalary chlamydoconidia. No micro- or macroconidia on SDA, rare micro- and macroconidia with thiamine.

PDA, potato dextrose agar; SDA, Sabouraud's dextrose agar.
Used with permission from David Ellis, PhD.

TABLE 160-7
***Trichophyton* Nutritional Growth Requirements**

Urease test	Differentiates *Trichophyton interdigitale* (positive) from *Trichophyton rubrum* (negative)	
Hair perforation test	Differentiates *T. interdigitale* (positive) from *T. rubrum* (negative)	
Nutritional requirement	Differentiates *Trichophyton* species	
	Thiamine	*Trichophyton tonsurans*
		Trichophyton concentricum
		Trichophyton violaceum
	Thiamine + inositol	*Trichophyton verrucosum*
	Nicotinic acid	*Trichophyton equinum*
	Histidine	*Trichophyton megninii*
Growth on polished rice	Differentiates *Microsporum* species	
	Good growth	*Microsporum canis*
	Poor growth	*Microsporum audouinii*
		Microsporum distortum

TABLE 160-8
Pattern of Hair Infection and Fluorescence

PATTERN	DERMATOPHYTE	FLUORESCENCE
Endothrix	*Trichophyton soudanense* *Trichophyton violaceum* *Trichophyton tonsurans* *Trichophyton gourvilii* *Trichophyton yaoundei*	None
Ectothrix	*Microsporum canis* *Microsporum audouinii* *Microsporum distortum* *Microsporum ferrugineum*	Yellow-green
	Microsporum fulvum *Microsporum gypseum*	None
	Trichophyton megninii *Trichophyton interdigitale* *Trichophyton rubrum* *Trichophyton verrucosum*	None
Favus	*Trichophyton schoenleinii*	Blue-gray, occasional

HISTOPATHOLOGY

Skin biopsy is not often employed in the workup of typical dermatophytoses. Localized cutaneous eruptions suspected to represent dermatophytosis with equivocal KOH examination are often treated despite the lack of confirmation. Biopsy may confirm the diagnosis when a systemic agent is being considered for treatment of a recalcitrant or more widespread eruption. Biopsy may be used to aid in the diagnosis of Majocchi granuloma in which KOH examination of scale on the surface more often may be negative. Biopsy is also sometimes useful in confirming the presence of hyphae involving hair shafts on the scalp in tinea capitis, although culture is necessary to allow speciation of the pathogen. When present, hyphae may be appreciated in the stratum corneum on hematoxylin-and-eosin (H&E) staining. However special stains, most commonly periodic acid–Schiff (PAS) and methenamine silver stains, highlight hyphae that may otherwise be subtle in appearance on routine staining. Whereas culture is the most specific test for onychomycosis, PAS examination of nail clippings is the most sensitive and obviates the need to wait weeks for a result.[35] Full-thickness nail clippings for H&E or culture should involve the dystrophic portion, as proximal from the distal edge as possible without causing injury.

WOOD LIGHT FLUORESCENCE

Examination of involved hair bearing areas, such as the scalp or beard, with a Wood lamp (365 nm) may reveal pteridine fluorescence of hair infected with particular fungal pathogens. Hairs that fluoresce should be selected for further examination, including culture. Although ectothrix organisms *M. canis* and *M. audouinii* will fluoresce on Wood light examination, the endothrix organism *T. tonsurans* will not fluoresce. *T. tonsurans*, which is now the most common cause of tinea capitis in the United States, thus limits the use of Wood light examination. Table 160-8 lists common patterns of dermatophyte hair involvement and fluorescence.

MANAGEMENT

Table 160-9 outlines the treatment of dermatophytes, Table 160-10 lists oral antifungal agents, and Table 160-11 lists topical antifungal agents.

Multiple systemic and topical antifungal agents are available to treat dermatophytoses of skin, hair and nails.[36-38] Of note, dermatoses involving hair-bearing skin and nails typically require oral treatment. See individual diagnoses in the section "Dermatophytoses" for more information.

CLINICAL COURSE AND PROGNOSIS

The clinical course of dermatophytosis varies according to pathogen and host factors. As discussed before, some dermatophytes are able to evade or suppress host immune function, and some hosts are unable to mount an effective immune response to clear infection. As such, the severity of each infection is variable according to the combination of these factors.

TABLE 160-9
Treatment of Dermatophytes

DISEASE	TOPICAL TREATMENT	SYSTEMIC TREATMENT

Tinea capitis (requires systemic treatment)	Only as adjuvant
	Selenium sulfide 1% or 2.5%
	Zinc pyrithione 1% or 2%
	Povidone-iodine 2.5%
	Ketoconazole 2%
		Adults
		▪ Griseofulvin, 20 to 25 mg/kg/day × 6 to 8 weeks
		▪ Terbinafine, 250 mg/day × 2 to 8 weeks
		▪ Itraconazole, 5 mg/kg/day × 2 to 4 weeks
		▪ Fluconazole, 6 mg/kg/day × 3 to 6 weeks
		Children
		▪ Griseofulvin, daily × 6 to 8 weeks
		  ▪ Age 1 month to 2 years: 10 mg/kg/day
		  ▪ Age ≥2 years: 20 to 25 mg/kg/day (micro)
		  ▪ Age ≥2 years: 10 to 15 mg/kg/day (ultramicro)
		▪ Terbinafine daily × 2 to 4 weeks
		  ▪ Weight <20 kg: 62.5 mg/day
		  ▪ Weight 20 to 40 kg: 125 mg/day
		  ▪ Weight >40 kg: 250 mg/day
		▪ Itraconazole
		  ▪ 3 to 5 mg/kg/day × 2 to 4 weeks
		  ▪ 5 mg/kg/day × 1 week/month × 2 to 3 months
		▪ Fluconazole (not standard therapy)
		  ▪ 6 mg/kg/day × 3 to 6 weeks
		  ▪ 6 mg/kg once weekly × 8 to 12 weeks

Tinea barbae (requires systemic treatment)	Only as adjuvant Zinc pyrithione 1% or 2% Povidone-iodine 2.5%	▪ Griseofulvin 1 g/day × 6 weeks ▪ Terbinafine 250 mg/day × 2 to 4 weeks ▪ Itraconazole 200 mg/day × 2 to 4 weeks ▪ Fluconazole 200 mg/day × 4 to 6 weeks
Tinea corporis/cruris	Allylamines Imidazoles Tolnaftate Butenafine Ciclopirox Gentian violet	Adults ▪ Terbinafine 250 mg/day × 2 to 4 weeks ▪ Itraconazole 100 mg/day × 1 week ▪ Fluconazole 150 to 300 mg/day × 4 to 6 weeks ▪ Griseofulvin 500 mg/day × 2 to 4 weeks Children ▪ Terbinafine 3 to 6 mg/kg/day × 2 weeks ▪ Itraconazole 5 mg/kg/day × 1 week ▪ Griseofulvin 10 to 20 mg/kg/day × 2 to 4 weeks
Tinea pedis/manuum	Allylamine Imidazoles Ciclopirox Benzylamine Tolnaftate Undecenoic acid	Adults ▪ Terbinafine 250 mg/day × 2 weeks ▪ Itraconazole 200 mg twice daily × 1 week ▪ Fluconazole 150 mg/week × 3 to 4 weeks Children ▪ Terbinafine 3 to 6 mg/kg/day × 2 weeks ▪ Itraconazole 5 mg/kg/day × 2 weeks

Onychomycosis	Ciclopirox
	Amorolfine
	Tioconazole
	Efinaconazole
		Adults
		▪ Terbinafine 250 mg/day × 6 to 12 weeks
		▪ Itraconazole 200 mg/day × 2 to 3 months, *or*
		▪ Pulse 400 mg daily × 1 week/month × 2 to 3 months
		▪ Fluconazole 150 to 300 mg/week × 3 to 12 months
		Children
		▪ Terbinafine daily × 6 to 12 weeks
		  ▪ Weight 10 to 20 kg: 62.5 mg/day
		  ▪ Weight 20 to 40 kg: 125 mg/day
		  ▪ Weight >40 kg: 250 mg/day
		▪ Itraconazole 1 week/month × 2 to 3 months
		  ▪ Weight <20 kg: 5 mg/kg/day
		  ▪ Weight 20 to 40 kg: 100 mg/day
		  ▪ Weight 40 to 50 kg: 200 mg/day
		  ▪ Weight >50 kg: 200 mg twice daily
		▪ Fluconazole 3 to 6 mg/kg/week × 3 to 6 months

TABLE 160-10
Oral Antifungal Agents

MEDICATION	DRUG CLASS	INDICATIONS	WARNINGS/MONITORING
Fluconazole	Triazole	Onychomycosis Tinea barbae Tinea capitis Tinea corporis/cruris Tinea pedis/manuum	*Adverse effects:* headache, GI upset *Caution:* liver and/or renal impairment *Contraindications:* pregnancy, concurrent QT-prolonging medications Monitor liver function tests, basic metabolic panel, complete blood cell count; pregnancy test prior to start in females Pregnancy category D
Griseofulvin	Inhibits fungal mitosis	Tinea barbae Tinea capitis (first-line *Microsporum*) Tinea corporis/cruris Tinea pedis/manuum	*Adverse effects:* headache, GI upset *Caution:* liver impairment *Contraindications:* porphyria, pregnancy, hepatic failure Check pregnancy test prior to start in females Pregnancy category X
Itraconazole	Triazole	Onychomycosis Tinea barbae Tinea capitis Tinea corporis/cruris Tinea pedis/manuum	*Adverse effects:* headache, GI upset *Caution/contraindication:* cardiac failure, hepatotoxicity Monitor liver function tests, basic metabolic panel, complete blood cell count baseline and at 1 month Check pregnancy test prior to start in females Pregnancy category C
Terbinafine	Allylamine	Onychomycosis (first-line) Tinea barbae Tinea capitis Tinea corporis/cruris Tinea pedis/manuum	*Adverse effects:* GI upset, taste disturbance, elevation of liver enzymes Risk of hepatotoxicity Monitor liver function tests baseline and at 1 month Pregnancy category B

TABLE 160-11
Topical Antifungal Agents

MEDICATION	CLASS/MECHANISM	FORMULATION	USE	ADMINISTRATION	WARNING/PRECAUTIONS
Amorolfine	Morpholine	Liquid, 250 mg/5 mL	Onychomycosis (dermatophyte or *Candida*) treatment and/or relapse prophylaxis	Apply 1 to 2 times/week after gentle nail filing × 6 to 12 months	Not available in the United States
Butenafine	Synthetic allylamine	Cream, 1%	Tinea corporis, cruris, pedis, versicolor	Apply 1 to 2 times daily for 1 to 4 weeks	Pregnancy category C Children ≥12 years of age
Ciclopirox	Inhibits DNA, RNA, and protein synthesis	Cream, 0.77% Suspension, 0.77% Gel, 0.77%	Tinea corporis, cruris, pedis, versicolor; cutaneous *Candida*; seborrheic dermatitis	Apply twice daily	Pregnancy category B Cream and suspension, children >10 years of age Gel and shampoo, children >16 years of age Solution, children ≥12 years of age
		Shampoo, 0.1%	Seborrheic dermatitis	Apply, wait 5 to 10 minutes prior to rinsing; use 2 to 3 times/week to treat, 1 to 2 times/week to maintain	
		Solution, 8%	Onychomycosis	Apply to nail and surrounding skin at bedtime × 7 days, then remove with rubbing alcohol and repeat	
Clotrimazole	Imidazole	Cream, 1% Ointment, 1% Solution, 1%	Tinea corporis, cruris, pedis, versicolor	Apply twice daily × 1 to 4 weeks	Pregnancy category B
Econazole	Imidazole	Cream, 1% Foam, 1%	Tinea corporis, cruris, pedis, versicolor	Apply 1 to 2 times daily × 2 to 4 weeks	Pregnancy category C Children ≥12 years of age

(*Continued*)

TABLE 160-11
Topical Antifungal Agents (*Continued*)

MEDICATION	CLASS/MECHANISM	FORMULATION	USE	ADMINISTRATION	WARNING/PRECAUTIONS
Efinaconazole	Triazole	Solution, 10%	Onychomycosis	Apply daily × 48 weeks	Pregnancy category C
Gentian violet	Antifungal Antibiotic	Solution, 1% and 2%	Superficial cutaneous infections, effective against some Gram+ bacteria (*Staphylococcus* sp.), fungi, some yeasts	Apply 1 to 2 times daily	Pregnancy category not classified Stains skin and clothing May tattoo open wounds
Ketoconazole	Imidazole	Cream, 2% Foam, 2% Gel, 2% Shampoo, 1% and 2%	Tinea corporis, cruris, pedis, versicolor; cutaneous *Candida*; seborrheic dermatitis Tinea capitis adjuvant, tinea versicolor, seborrheic dermatitis	Apply 1 to 2 times daily Apply, wait 5 to 10 mins prior to rinsing; use 2 to 3 times/week to treat, 1 to 2 times/week as prophylaxis	Pregnancy category C Children ≥12 years of age
Miconazole	Imidazole	Aerosol, 2% Cream, 2% Lotion, 2% Ointment, 2% Powder, 2% Solution, 2%	Tinea corporis, cruris, pedis	Apply twice daily × 4 weeks	Pregnancy category not classified Children ≥2 years of age May increase serum concentration of vitamin K agonist
Povidine-iodine	Broad-spectrum germicidal agent	Wash, 7.5% Shampoo, 7.5%	Tinea capitis and barbae adjuvant, seborrheic dermatitis	Use twice weekly until controlled, then once weekly	Pregnancy category C Use with caution in children Hypersensitivity to iodine contraindication
Selenium sulfide	Cytostatic effects on keratinocytes	Foam, 2.25% Lotion, 2.25% Shampoo, 1% and 2.3%	Tinea capitis adjuvant, tinea versicolor, seborrheic dermatitis	Foam: twice daily Lotion: Apply, rinse after 10 minutes once daily × 1 week, then once monthly × 3 months Shampoo: Apply, wait 5 to 10 mins prior to rinsing; use 2 to 3 times/week to treat, 1 to 2 times/week as prophylaxis	Pregnancy category C Children ≥2 years of age
Terbinafine	Allylamine	Cream, 1% Gel, 1% Solution, 1%	Tinea corporis, cruris, pedis, versicolor; cutaneous candidiasis	Apply 1 to 2 times daily × 1 to 2 weeks	Pregnancy category not classified Children ≥12 years of age
Tioconazole	Imidazole	Solution, 28%	Onychomycosis	Apply twice daily × 6 to 12 months	Not available in the United States Possible allergic contact dermatitis
Tolnaftate	Distorts hyphae and mycelial growth	Aerosol, 1% Cream, 1% Lotion, 1% Powder, 1% Solution, 1%	Tinea corporis, cruris, pedis	Apply twice daily × 2 to 4 weeks	Pregnancy category not classified Children ≥2 years of age
Zinc pyrithione	Keratolytic	Bar, 2% Liquid/wash, 0.5% Shampoo, 2%	Tinea capitis and barbae adjuvant; seborrheic dermatitis	Use at least 2 times/week	Pregnancy category C

DERMATOPHYTOSES

DERMATOPHYTID (ID) REACTION

A dermatophytid (or id) reaction is an inflammatory dermatitis occurring at sites distant from the primary dermatophytosis (such as tinea pedis or kerion) in 4% to 5% of patients.[39] Although the precise mechanism is unknown, the id reaction is associated with a delayed-type hypersensitivity response to the *Trichophyton* test, and so may involve a local delayed-type hypersensitivity response to systemically absorbed fungal antigen.[40] Id reactions appear polymorphic, ranging in morphology from follicular or nonfollicular papules and vesicles of the hands and feet to reactive erythemas including erythema nodosum, erythema annulare centrifugum, or urticaria.[41-44] Unlike the primary eruption, the id eruption is both KOH examination negative and culture negative. The 3 criteria for establishing the presence of an id eruption are (a) dermatophytosis on another part of body, (b) absence of fungal elements from the id eruption, and (c) resolution of the id eruption with clearing of the primary dermatophyte infection.

ONYCHOMYCOSIS

Onychomycosis describes fungal infection of the nail caused by dermatophytes, nondermatophyte molds, or yeasts. *Tinea unguium* refers strictly to dermatophyte infection of the nail. Clinically, 3 types of onychomycosis are distinguished: (a) distolateral subungual onychomycosis (DLSO), (b) proximal subungual onychomycosis (PSO), and (c) white superficial onychomycosis (WSO).

EPIDEMIOLOGY

Onychomycosis is the most prevalent nail disease and accounts for approximately 50% of all causes of onychodystrophy. It affects up to 14% of the population, with both an increasing prevalence[45] and an overall increasing incidence among older individuals.[46] Onychomycosis is also increasing in incidence among children and adolescents, and accounts for up to 20% of dermatophyte infections diagnosed in children.[47] Risk factors for nail infection include age, male sex, nail trauma, immunosuppression (including HIV infection and diabetes mellitus), and peripheral vascular insufficiency.[48] Patients with HIV and with a CD4 T-lymphocyte count of less than 400 cells/μL (reference range: 1200 to 1400 cells/μL) and who are on immunosuppressants or have defective polymorphonuclear chemotaxis have an increased risk of onychomycosis, which tends to be more widespread and involve all 20 nails.[36]

The increasing prevalence of onychomycosis may be secondary to wearing of tight shoes, increasing numbers of individuals on immunosuppressive drugs and with diabetes mellitus, and an increased use of communal locker rooms. The dermatophytosis commonly begins as tinea pedis before extending to the nail bed, where eradication is more difficult. This site serves as a reservoir for local recurrence or for infections spreading to other areas. Up to 40% of patients with toenail onychomycosis show concomitant skin infections, most commonly tinea pedis (30%).[49]

CLINICAL FEATURES

Table 160-12 summarizes the subtypes and most common causes of onychomycosis.

Distolateral Subungual Type: DLSO is the most common form of onychomycosis. It begins with invasion of the stratum corneum of the hyponychium and distal nail bed, forming a whitish to brownish–yellow opacification at the distal edge of the nail (Fig. 160-3A). The infection then spreads proximally up the nail bed to the ventral nail plate. Hyperproliferation (or altered differentiation) of the nail bed in response to the infection results in subungual hyperkeratosis, while progressive invasion of the nail plate results in an increasingly dystrophic nail.

Proximal Subungual Type: PSO (see Fig. 160-3B) results from infection of the proximal nailfold primarily with *T. rubrum* and *Trichophyton megninii* and is apparent as a white-to-beige opacity on the proximal nail plate. This opacity gradually enlarges to affect the entire nail and eventuates in subungual hyperkeratosis, leukonychia, proximal onycholysis, and/or destruction of the entire nail. Patients with PSO should be screened for HIV, as it has been identified as an a marker for this disease.[6,50]

White Superficial Type: WSO (see Fig. 160-3C) results from direct invasion of the dorsal nail plate resulting in white to dull yellow, sharply bordered patches anywhere on the surface of the toenail. It is usually caused by *T. interdigitale*, although nondermatophyte molds such as *Aspergillus*, *Scopulariopsis*, and *Fusarium* are also known pathogens. *Candida* species may invade the hyponychial epithelium to eventually affect the entire thickness of the nail plate.[51]

Other Clinical Presentations: Total dystrophy of the nail may result from almost complete destruction of the nail plate secondary to any of the foregoing varieties of onychomycosis; this is known as total dystrophic onychomycosis.[36] Primary total dystrophic onychomycosis is rare, usually caused by *Candida*, and typically affects immunocompromised patients.[36] Multiple patterns of onychomycosis may present in the same individual, most commonly with the combination of PSO with WSO or DLSO with WSO.[36] Secondary bacterial infection of the nail is possible. Infection with *Pseudomonas aeruginosa* presents as a green or black discoloration under the nail. It is also possible to have mixed infections with both a dermatophyte and yeast form, such as *Candida*.

TABLE 160-12
Subtypes of Superficial Fungal Infections and Their Most Common Causes

Onychomycosis	
Distolateral subungual type	*Trichophyton rubrum*,[a] *Trichophyton interdigitale*
Proximal subungual type	*Trichophyton rubrum*, *Trichophyton megninii*
White superficial type	*Trichophyton interdigitale* (also the following nondermatophytes: *Aspergillus*, *Scopulariopsis*, *Fusarium*, *Candida* **sp.**)
Total dystrophic onychomycosis	*Candida* **sp.**
Tinea Barbae	
Superficial type	*Trichophyton violaceum*
Inflammatory type	*Trichophyton interdigitale*
Tinea Capitis	
Inflammatory	*Microsporum audouinii*, *Microsporum canis*, *Microsporum gypseum*, *Microsporum nanum*, *Trichophyton interdigitale*, *Trichophyton schoenleinii*, *Trichophyton tonsurans*, *Trichophyton verrucosum*
Noninflammatory	*Microsporum audouinii*, *Microsporum canis*, *Microsporum ferrugineum*, *Trichophyton tonsurans*
Black dot	*Trichophyton tonsurans*, *Trichophyton violaceum*
Favus	*Trichophyton schoenleinii*, *Trichophyton violaceum*, *Trichophyton mentagrophytes*
Tinea Corporis	
Tinea Corporis	Adults: *Trichophyton rubrum* Children: *Microsporum canis*
Tinea incognito	*Trichophyton rubrum*
Majocchi's granuloma	*Trichophyton rubrum*, *Trichophyton interdigitale*, *Microsporum canis*
Tinea imbricata	*Trichophyton concentricum*
Tinea cruris	*Trichophyton rubrum*, *Epidermophyton floccosum*, *Trichophyton interdigitale*, *Trichophyton verrucosum*
Tinea nigra	*Hortaea werneckii*
Tinea Pedis	
Interdigital type	*Trichophyton rubrum*, *Trichophyton interdigitale*, *Epidermophyton floccosum*
Chronic hyperkeratotic (moccasin) type	*Trichophyton rubrum*, *Epidermophyton floccosum*
Vesicobullous type	*Trichophyton interdigitale* (usually zoophilic strains)
Adult ulcerative type	*Trichophyton interdigitale* (zoophilic strains) with combined Gram-negative bacterial superinfection
Tinea Manuum	
Tinea manuum	*Trichophyton rubrum*, *Trichophyton interdigitale*, *Epidermophyton floccosum*

[a]A single dermatophyte may have more than one presentation.

Figure 160-3 Tinea unguium. **A,** Distal subungual type. Discoloration, thickening and subungual debris of the distal aspect of the toenails. **B,** Proximal subungual type. Discoloration and thickening of the proximal nail in a patient with AIDS; Kaposi sarcoma is also seen on the fourth toe. **C,** White superficial type. Irregular opaque white patches on various parts of the nail plates.

ETIOLOGY AND PATHOGENESIS

In the majority of cases, onychomycosis is caused by dermatophytes, with *T. rubrum* and *T. interdigitale* responsible for approximately 90% of all cases. *T. tonsurans* and *E. floccosum* are also well-documented causative agents.[52] Yeast and nondermatophyte molds such as *Acremonium*, *Aspergillus*, *Fusarium*, *Scopulariopsis brevicaulis*, and *Scytalidium* are the source of approximately 10% of toenail onychomycosis. Interestingly, *Candida* species are responsible for up to 30% of fingernail cases, whereas nondermatophyte molds were not

detected in diseased fingernails.[53] *Candida* (and irritant dermatitis) may also cause chronic paronychia.

Risk factors for onychomycosis include increasing age, male sex, peripheral vascular disease, trauma, hyperhidrosis, and immunosuppressed states, including HIV, diabetes mellitus, and medication-induced immunosuppression.[36] In children, onychomycosis may be responsible for up to 15% of onychodystrophies.[36] As in adults, prevalence increases with age and may be associated with occlusive footwear.

DIAGNOSIS

Table 160-4 outlines common laboratory dermatophyte identification methods and Table 160-6 outlines the colony and microscopic morphology features of the most common dermatophytes.

Although onychomycosis is responsible for 50% of dystrophic nails, laboratory diagnostic confirmation prior to treatment with potentially toxic oral antifungal treatments is judicious. KOH examination of subungual debris, culture of the nail plate and accompanying debris on SDA (with and without antimicrobials), and PAS staining of nail clippings are most useful. However, KOH examination is often negative even when clinical suspicion is high, and nails with hyphae reported on KOH examination often yield negative cultures. The simplest measure to minimize false-negatives caused by sampling error is to maximize sample size and repeat collections. The following guidelines are suggested to discern pathogens from contaminants: (a) if a dermatophyte is isolated on culture, it is considered a pathogen; (b) a nondermatophyte mold or yeast cultured is significant only if hyphae, spores, or yeast cells are seen on microscopic examination, and (c) there is repeated heavy growth of a nondermatophyte mold without concurrent isolation of a dermatophyte.[54] Whereas culture is the most specific test for onychomycosis, PAS examination of nail clippings is the most sensitive,[35] and it obviates the need to wait weeks for a result. As such, we recommend collection of nail clippings, with inclusion of full thickness of the most proximal affected areas obtainable without causing trauma, for PAS and H&E examination.

On histopathology (see Table 160-4), hyphae are seen between the nail laminae parallel to the surface and have a predilection for the ventral nail and stratum corneum of the nail bed.[55] The epidermis may show spongiosis and focal parakeratosis, and there is a minimal dermal inflammatory response. In WSO, the organisms are present superficially on the dorsal nail and display unique "perforating organs" and "eroding fronds." In candidal onychomycosis there is invasion of pseudohyphae throughout the entire nail plate, adjacent cuticle, granular layer, and stratum spinosum of the nail bed, as well as the hyponychial stratum corneum.[51]

DIFFERENTIAL DIAGNOSIS

Table 160-13 outlines the differential diagnosis of onychomycosis.

TABLE 160-13
Differential Diagnosis of Onychomycosis

Most Likely
- Psoriasis, lichen planus, chronic trauma, onychogryphosis

Consider
- Pachyonychia congenita, acquired and congenital leukonychias, Darier-White disease, yellow nail syndrome

Rule Out
- Melanoma

MANAGEMENT

Table 160-9 outlines the treatment of dermatophytes.

The management of onychomycosis depends on several factors, including the severity of nail involvement, presence or absence of tinea pedis, treatment efficacy, and potential adverse effects. Even though it is reasonable to not treat nail involvement, concurrent tinea pedis should always be treated to decrease risk of cellulitis, particularly in the settings of diabetes mellitus, chronic venous stasis, and other causes of chronic lower-extremity edema (see the discussion of the treatment of tinea pedis).

Systemic Therapy: An oral antifungal (see Table 160-10) is required for onychomycosis involving the matrix area, or when a shorter treatment regimen or higher chance for clearance/cure is desired. Selection of the antifungal agent should be based on the causative organism, potential adverse effects, risk of drug interactions, and comorbidities in each patient. Of note, griseofulvin is no longer considered standard treatment for onychomycosis because of its prolonged treatment course, potential for adverse effects and drug interactions, and its relatively low cure rates.

Topical Therapy: In patients with distal nail involvement, WSO, and/or contraindication for systemic treatment, topical therapy (see Table 160-11) should be considered.

Combination therapy regimens may have a higher clearance rate than either oral or topical treatments alone. Studies have been performed using combination therapy regimens with topical tioconazole, ciclopirox, and amorolfine with mixed results.[36,56,57] In vitro fungicidal activity demonstrated by thymol, camphor, menthol, and oil of *Eucalyptus citriodora* offers the potential for additional therapeutic strategies to treat onychomycosis.[58,59] Thymol 4% prepared in ethanol may be used as drops applied to the nail plate and hyponychium. The application to nails of commercially available topical preparations with thymol, such as Vicks VapoRub, has anecdotally led to success. Topical therapy may be useful as a means to prevent recurrence.

Mechanical Intervention: Trimming, debridement, nail bed curettage, and nail abrasion may speed delivery of medications to the site of action. Other options for refractory cases include laser, surgical avulsion, or chemical removal of the nail with 40%

urea compounds in combination with topical or oral antifungals.

PIEDRA

Piedra is an asymptomatic superficial fungal infection of the hair shaft also known as trichomycosis nodularis. Black piedra is caused by *Piedraia hortae*, whereas white piedra is caused by pathogenic species of the *Trichosporon* genus, namely *Trichosporon asahii*, *Trichosporon ovoides*, *Trichosporon inkin*, *Trichosporon mucoides*, *Trichosporon asteroides*, and *Trichosporon cutaneum*.[60]

EPIDEMIOLOGY

Black piedra is seen commonly in humans and primates of tropical areas of South America, the Pacific Islands, and the Far East, and less commonly in Africa and Asia. *P. hortae* is present in the soil, stagnant water, and crops. Scalp hair is most often affected. In fact, infection is encouraged for religious and esthetic reasons by some indigenous cultures.[61]

White piedra is most common in temperate and semitropical climates of South America and Asia, the Middle East, India, Africa, and Japan. It occurs infrequently in the United States and Europe. White piedra affects facial, axillary, and genital hair more commonly than scalp hair. *T. ovoides* is found more commonly on scalp hair, *T. inkin* on pubic hair, and *T. asahii* on other body surfaces. Person-to-person transmission is rare, and infection is not associated with travel to endemic areas.[62]

CLINICAL FINDINGS

Black piedra is characterized by firmly attached, hard or gritty, brown-black–colored concretions on the hair shaft that vary in size from the microscopic range to a few millimeters in size. Concretions are most commonly noted on frontal portions of the scalp. Black piedra weakens the hair shaft and results in hair breakage.

White piedra consists of softer and less-adherent whitish to beige–colored concretions that are discrete or may coalesce into sleeve-like structures along the hair shaft. These concretions affect the outer layers of the hair shaft and may be easily detached. Broken hairs, although sometimes present, are less common than in black piedra.[60]

DIAGNOSIS

Nodules of black piedra examined by KOH preparation display a periphery of aligned hyphae and a well-organized center of thick-walled cells packed closely together, sometimes termed *pseudoparenchyma*. These nodules are mostly outside of the hair shaft. *P. hortae* grows well, albeit slowly, on most laboratory media and is uninhibited by cycloheximide. The nodules of white piedra have a less organized and more intrapilar appearance than do nodules of black piedra. Hyphae are arranged perpendicularly to the hair shaft. *T. asahii* thrives on SDA and it is inhibited by cycloheximide. Microscopy readily differentiates piedra from nits, hair casts, developmental hair shaft defects, and trichomycosis axillaris. In addition, the nodules of trichomycosis axillaris are usually smaller and may fluoresce under a Wood lamp.

TABLE 160-14
Differential Diagnosis of Piedra

Most Likely
▪ Pediculosis, trichomycosis axillaris, tinea capitis
Consider
▪ Monilethrix

DIFFERENTIAL DIAGNOSIS

Table 160-14 summarizes the differential diagnosis of piedra.

MANAGEMENT

Shaving the infected hair is curative and represents the best treatment of both black and white piedra, although this approach should be supplemented with a topical azole preparation (see Table 160-11). Because of high relapse rates, as well as evidence for intrafollicular organisms in white piedra, some advocate the use of a systemic antifungal agent such as itraconazole.[62]

TINEA BARBAE

EPIDEMIOLOGY

Tinea barbae, as its name would imply, occurs predominantly in the beard area of males. The incidence of tinea barbae has decreased as improved sanitation has reduced transmission by contaminated barbers' razors. Direct exposure to cattle, horses, or dogs is now the more common mode of acquisition, and thus accounts for a shift in prevalence toward farmers or ranchers in rural settings.

CLINICAL FINDINGS

Table 160-12 summarizes the subtypes and most common causes of tinea barbae.

Tinea barbae affects the face unilaterally and involves the beard area more often than the moustache or upper lip. Two forms exist, superficial and inflammatory types.

Superficial Type: Caused by anthropophilics such as *T. violaceum*, this form of tinea barbae is less

Figure 160-4 Tinea barbae. **A,** Superficial type. Scattered follicular papules, pustules, and small nodules, which may be easily mistaken for *Staphylococcus aureus* folliculitis. **B,** Kerion type. Sharply demarcated red edematous nodule studded with multiple yellowish weeping pustules. Note hairs have been lost from this nodule.

inflammatory and resembles tinea corporis or bacterial folliculitis. The active border shows perifollicular papules and pustules accompanied by mild erythema (Fig. 160-4A). Alopecia, if present, is reversible.

Inflammatory Type: Usually caused by *T. interdigitale* (zoophilic strains) or *T. verrucosum*, inflammatory tinea barbae is the most common clinical presentation. It presents analogously to kerion formation in tinea capitis with boggy-crusted plaques and a seropurulent discharge (see Fig. 160-4B). Hairs are lusterless, brittle, and easily epilated to demonstrate a purulent mass around the root. Perifollicular pustules may coalesce and eventuate in abscess-like collections of pus, sinus tracts, and scarring alopecia.

ETIOLOGY AND PATHOGENESIS

Tinea barbae is most commonly caused by the zoophilic strains of *T. interdigitale* (formerly named *Trichophyton mentagrophytes* var. *mentagrophytes*), *T. verrucosum*, and, less commonly, *M. canis*. Among the anthropophilic organisms, *Trichophyton schoenleinii*, *T. violaceum*, and certain strains of *T. rubrum* (formerly named *T. megninii*) cause tinea barbae in endemic areas.[63]

DIAGNOSIS

Table 160-4 outlines common laboratory dermatophyte identification methods and Table 160-6 outlines the colony and microscopic morphology features of the most common dermatophytes.

DIFFERENTIAL DIAGNOSIS

Table 160-15 summarizes the differential diagnosis of tinea barbae.

MANAGEMENT

Table 160-9 outlines the treatment of dermatophytes, Table 160-10 lists oral antifungal agents, and Table 160-11 lists topical antifungal agents.

Like tinea capitis (see below), an oral antifungal is usually necessary in the treatment of tinea barbae. Systemic glucocorticoids used for the first week of therapy are helpful in cases with severe inflammation.

TINEA CAPITIS

Tinea capitis describes a dermatophyte infection of hair and scalp typically caused by *Trichophyton* and *Microsporum* species, with the exception of *Trichophyton concentricum*.

EPIDEMIOLOGY

Tinea capitis is most commonly observed in children between the ages of 3 and 14 years.[37] The fungistatic effect of fatty acids in sebum may help to explain the sharp decrease in incidence after puberty.[64] Overall prevalence of the carrier state is approximately 4% in the United States, with a peak prevalence of approximately 13% in girls of sub-Saharan African American descent.[65]

TABLE 160-15
Differential Diagnosis of Tinea Barbae

Most Likely
- Bacterial folliculitis (sycosis vulgaris), pseudofolliculitis barbae, acne vulgaris, rosacea, contact dermatitis, perioral dermatitis, candidal folliculitis

Rule Out
- Herpes simplex, halogenoderma

For unknown reasons, tinea capitis is generally more common among children of African descent. Transmission is increased with decreased personal hygiene, overcrowding, and low socioeconomic status. The anthropophilic dermatophyte *T. tonsurans* is the most prevalent species found in the United States and United Kingdom, while *M. canis* remains the most common cause of tinea capitis in Europe.[37,66] Organisms responsible for tinea capitis have been cultured from fomites such as combs, caps, pillowcases, toys, and theater seats. Even after shedding, hairs may harbor infectious organisms for more than 1 year.[67] The high prevalence of asymptomatic carriers thwarts eradication of the disease.

CLINICAL FINDINGS

Table 160-12 summarizes the subtypes and most common causes of tinea capitis.

The clinical appearance of tinea capitis depends on the causative species and other factors, such as the host immune response. In general, dermatophyte infection of the scalp results in hair loss and scaling with varying degrees of an inflammatory response.

Noninflammatory Type: Also called the seborrheic form of tinea capitis (because scale is the predominant feature),[68] noninflammatory tinea capitis is seen most commonly with anthropophilic organisms such as *M. audouinii* or *Microsporum ferrugineum.* Arthroconidia may form a sheath around affected hairs, turning them gray and causing them to break off just above the level of the scalp. Alopecia may be imperceptible or, in more inflammatory cases, may have circumscribed erythematous scaly patches of nonscarring alopecia with breakage of hairs ("gray patch" type; Fig. 160-5). Patches often occur on the occiput.[67] When involving an ectothrix pattern, infected hairs may exhibit green fluorescence under Wood light (see Table 160-8).

"Black Dot" Tinea Capitis: The "black dot" form of tinea capitis (Fig. 160-6) is typically caused by the anthropophilic endothrix organisms *T. tonsurans* and *T. violaceum*. Hairs broken off at the level of the scalp leave behind grouped black dots within patches of polygonal-shaped alopecia with finger-like margins. Normal hairs also remain within patches of broken hairs. Diffuse scaling is also often present. Even though "black dot" tinea capitis tends to be minimally inflammatory, some patients may develop follicular pustules, furuncle-like nodules, or, in rare cases, kerion—a boggy, inflammatory mass studded with broken hairs and follicular orifices oozing with pus.[69]

Inflammatory Type: Zoophilic or geophilic pathogens, such as *M. canis*, *M. gypseum,* and *T. verrucosum*, are more likely to cause an inflammatory type of tinea capitis via a hypersensitivity reaction. Resultant inflammation ranges from follicular pustules to furunculosis (Fig. 160-7) or kerion (Fig. 160-8). Intense inflammation may also result in scarring alopecia. The scalp is usually pruritic or tender. Posterior cervical lymphadenopathy is often present, and may serve as a clinical pearl in differentiating tinea capitis from other inflammatory disorders involving the scalp.

Figure 160-5 Tinea capitis "gray patch" type. A large, round, hyperkeratotic plaque of alopecia, a result of breaking off of hair shafts close to the surface, gives the appearance of a mowed wheat field on the scalp of a child. Remaining hair shafts and scales exhibit a green fluorescence when examined with a Wood lamp. *Microsporum canis* was isolated on culture.

DIAGNOSIS

Table 160-4 outlines common laboratory dermatophyte identification methods and Table 160-6 outlines the colony and microscopic morphology features of the most common dermatophytes.

Infection of hair by dermatophytes follows 3 main patterns—ectothrix, endothrix, and favus. Dermatophytes establish infection in the perifollicular stratum corneum and spread around and into the hair shaft of

Figure 160-6 "Black dot" tinea capitis caused by *Trichophyton tonsurans*.

Figure 160-7 Inflammatory tinea capitis caused by *Microsporum canis*. Along with alopecia, there are inflammatory papules, pustules, and nodules. This patient also had posterior cervical lymphadenopathy.

mid- to late-anagen hairs before descending into the follicle to penetrate the cortex. With hair growth, the infected part of the hair rises above the surface of the scalp where it may break because of its increased fragility.

In *ectothrix* infections (see Fig. 160-2), although hyphae are also present within the hair shaft, only the arthroconidia on the surface of the hair shaft may be visualized and the cuticle is destroyed. On Wood lamp examination, a yellow-green fluorescence may be detected, depending on the causative organism. In *endothrix* infections (see Fig. 160-2), arthroconidia and hyphae remain within the hair shaft and leave the cortex and cuticle intact. This pattern of tinea capitis is associated with the appearance of "black dots," which represent broken hairs at the surface of the scalp. *Endothrix* organisms do not show fluorescence on Wood lamp examination. *Favus* is characterized by longitudinally arranged hyphae and air spaces within the hair shaft. Arthroconidia are not usually noted in infected hairs of favus.

On histopathology of tinea capitis, PAS and methenamine silver stains readily reveal hyphae around and within hair shafts. The dermis demonstrates a perifollicular mixed cell infiltrate with lymphocytes, histiocytes, plasma cells, and eosinophils. Follicular disruption leads to an adjacent foreign-body giant cell reaction. Markedly inflammatory lesions, such as a kerion, demonstrate an acute infiltrate of polymorphonuclear leukocytes within the dermis and follicle.[70] Organisms may not be visualized in kerion because the intense host response destroys many of the fungal organisms. However, fungal antigens may be detectable with immunofluorescent techniques.[71]

Figure 160-8 Kerion of the scalp.

DIFFERENTIAL DIAGNOSIS

Table 160-16 summarizes the differential diagnosis of tinea capitis.

MANAGEMENT

Table 160-9 outlines the treatment of tinea capitis, Table 160-10 lists oral antifungal agents, and Table 160-11 lists topical antifungal agents.

Infections involving hair-bearing skin usually necessitate oral antifungal treatment, as dermatophytes penetrating the follicle are typically "out of reach" for topically applied agents. As such, topical therapy alone is not recommended for the management of tinea capitis.[37] It is reasonable to begin empiric oral treatment reflecting local epidemiology and the most likely culprit organism while awaiting confirmatory mycology.[37]

Adjuvant Therapy: Selenium sulfide (1% and 2.5%), zinc pyrithione (1% and 2%), povidone-iodine (2.5%), and ketoconazole (2%) are shampoo preparations that help eradicate dermatophytes from the scalp. Adjunctive use of these shampoos is recommended 2 to 4 times weekly for 2 to 4 weeks.[72] The thrice weekly use

TABLE 160-16
Differential Diagnosis of Tinea Capitis

Most Likely
- Seborrheic dermatitis, contact dermatitis, pustular or plaque psoriasis, atopic dermatitis, bacterial pyodermas, folliculitis decalvans, lichen planopilaris, and dissecting cellulitis of the scalp

Consider
- Alopecia areata, trichotillomania, pseudopelade, psoriasiform reaction to tumor necrosis factor-α inhibitor

Rule Out
- Discoid lupus erythematosus, syphilis

of ketoconazole 2% shampoo or selenium sulfide 2.5% by all household members also reduces transmission by decreasing the shedding of spores.[73] Oral glucocorticoids may reduce the incidence of scarring associated with markedly inflammatory varieties of tinea capitis. Although there is no consistent evidence for improved cure rates with use of oral glucocorticoids, they appear to relieve pain and swelling associated with infections. The usual regimen is prednisone 1 to 2 mg/kg each morning during the first week of therapy.

TINEA CORPORIS

Tinea corporis refers to any dermatophytosis of glabrous skin except palms, soles, and the groin.

EPIDEMIOLOGY

Tinea corporis may be transmitted directly from infected humans or animals, via fomites, or it may occur via autoinoculation from reservoirs of dermatophyte colonization on the feet.[74] Children are more likely to contract zoophilic pathogens, especially *M. canis*, from dogs or cats. Occlusive clothing and a humid climate are associated with more frequent and severe eruptions.[75] Wearing of occlusive clothing, frequent skin-to-skin contact, and minor traumas, such as the mat burns in competitive wrestling, create an environment in which dermatophytes flourish. "Tinea corporis gladiatorum" is caused most commonly by *T. tonsurans*, and it occurs most frequently on the head, neck, and arms.[76]

CLINICAL FINDINGS

Table 160-12 summarizes the subtypes and most common causes of tinea corporis.

The classic presentation is that of an annular ("ringworm"-like; Fig. 160-9A) or serpiginous plaque with scale across the entire active erythematous border. The border, which may be vesicular, advances centrifugally. The center of the plaque is usually scaly but may exhibit complete clearance. Whereas concentric vesicular rings suggest tinea incognito (often caused by *T. rubrum*), the erythematous concentric rings of tinea imbricata demonstrate little to no vesiculation. *T. rubrum* infections may also present as large, confluent, polycyclic (Fig. 160-9B) or psoriasiform (Fig. 160-9C) plaques, especially in immunosuppressed individuals.

Majocchi granuloma is a superficial and subcutaneous dermatophytic infection involving deeper portions of the hair follicles, presenting as scaly, follicular papules and nodules that coalesce in an annular arrangement (Fig. 160-10). It is most commonly caused by *T. rubrum*, *T. interdigitale*, and *M. canis*. Majocchi granuloma is observed on the legs of women who become inoculated after shaving or who apply topical corticosteroids to the involved area, thereby facilitating infection. It also has been increasingly observed among immunocompromised patients.[77]

Figure 160-9 Tinea corporis. **A,** Annular. Tinea corporis demonstrating the classic annular or "ringworm"-like configuration and advancing raised erythematous and scaly border. Note that because the dorsum of the foot is predominantly involved, this eruption is considered tinea corporis and not tinea pedis. **B,** Polycyclic. Tinea corporis demonstrating multiple polycyclic red erythematous plaques with a raised scaly border. **C,** Psoriasiform. Tinea corporis resembling psoriasis.

ETIOLOGY AND PATHOGENESIS

Although any dermatophyte can cause tinea corporis, it is caused most commonly caused by *T. rubrum*, which is also the most likely candidate in cases with

Figure 160-10 Majocchi granuloma. Follicular papules and nodules with scale coalescing to form an annular-shaped plaque on the leg of a woman applying topical corticosteroids to the area.

concomitant follicular involvement.[69] *E. floccosum*, *T. interdigitale* (anthropophilic and zoophilic strains), *M. canis*, and *T. tonsurans* are also common pathogens.[1] Tinea imbricata, caused by *T. concentricum*, is limited geographically to areas of the Far East, South Pacific, and South and Central America.

DIAGNOSIS

Table 160-4 outlines common laboratory dermatophyte identification methods and Table 160-6 outlines the colony and microscopic morphology features of the most common dermatophytes.

DIFFERENTIAL DIAGNOSIS

Table 160-17 summarizes the differential diagnosis of tinea corporis.

MANAGEMENT

Table 160-9 outlines the treatment of tinea corporis, Table 160-10 lists oral antifungal agents, and Table 160-11 lists topical antifungal agents.

For isolated plaques on the glabrous skin, topical allylamines (eg, terbinafine), imidazoles (eg, clotrimazole), tolnaftate, butenafine, and ciclopirox are effective. Most are applied twice daily for 2 to 4 weeks. Oral antifungal agents are reserved for widespread or more inflammatory eruptions.

TABLE 160-17
Differential Diagnosis of Tinea Corporis

Most Likely
- Erythema annulare centrifugum, nummular eczema, psoriasis, tinea versicolor, subacute cutaneous lupus erythematosus, cutaneous candidiasis

Consider
- Contact dermatitis, atopic dermatitis, pityriasis rosea, seborrheic dermatitis

Rule Out
- Mycosis fungoides, parapsoriasis, secondary syphilis

TINEA CRURIS

Tinea cruris is a dermatophytosis of the groin, genitalia, pubic area, and perineal and perianal skin. The designation is a misnomer, because in Latin, "cruris" means "of the leg." It is the second-most common type of dermatophytosis worldwide.

EPIDEMIOLOGY

Much like tinea corporis, tinea cruris spreads via direct contact or fomites, and is exacerbated by occlusion and humidity. Autoinfection from distant reservoirs of *T. rubrum* or *T. interdigitale* on the feet, for example, is common.[74] Tinea cruris is 3 times more common in men, and adults are affected more often than children.

CLINICAL FINDINGS

Tinea cruris presents classically as a well-marginated annular plaque with a scaly raised border that extends from the inguinal fold to the inner thigh, often bilaterally. Presentation with erythematous, scaly patches with papules and vesicles involving the inner thighs is also common but perhaps less obvious. Pruritus is common, as is pain when plaques are macerated or secondarily infected. Plaques in tinea cruris caused by *E. floccosum* are more likely to demonstrate central clearing with involvement of the genitocrural crease and medial upper thigh. In contrast, plaques in tinea cruris caused by *T. rubrum* coalesce with extension to the pubic, perianal, buttock, and lower abdominal areas (Fig. 160-11). Genitalia (including the scrotum)

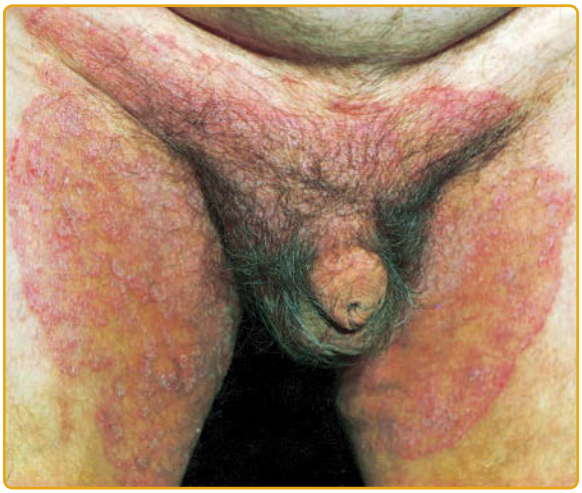

Figure 160-11 Tinea cruris. Annular erythematous plaques with a raised scaling border expanding from the inguinal on the inner thighs and pubic region.

TABLE 160-18
Differential Diagnosis of Tinea Cruris

Most Likely
- Erythrasma, cutaneous candidiasis, intertrigo, contact dermatitis, inverse psoriasis, seborrheic dermatitis, lichen simplex chronicus, folliculitis

Consider
- Familial benign pemphigus, Darier-White disease, histiocytosis

are infrequently affected and may be useful to distinguish from other conditions such as inverse psoriasis.[63]

ETIOLOGY AND PATHOGENESIS

Most tinea cruris is caused by *T. rubrum* and *E. floccosum*, the latter being most often responsible for epidemics.[63] *T. interdigitale* and *T. verrucosum* are implicated less often.

DIAGNOSIS

Table 160-4 outlines common laboratory dermatophyte identification methods and Table 160-6 outlines the colony and microscopic morphology features of the most common dermatophytes.

DIFFERENTIAL DIAGNOSIS

Table 160-18 summarizes the differential diagnosis of tine cruris.

MANAGEMENT

Medical treatment of tinea cruris is the same as that for tinea corporis, which is discussed earlier.

In addition to medical treatment, it also may be helpful to correct any underlying moisture issues in the affected area (with use of loose-fitted clothing and regular application of barrier-protective zinc-containing cream) or other areas of infection (eg, tinea pedis). If tinea pedis is present, in addition to medical treatment targeting the feet, one might also recommend the patient apply socks before underwear so as to prevent autoinoculation of the area.

TINEA FAVOSA

Tinea favosa or favus (Latin for "honeycomb") is a chronic dermatophyte infection of the scalp that rarely involves glabrous skin and/or nails, and is characterized by thick yellow crusts (scutula) within the hair follicles that lead to scarring alopecia.

EPIDEMIOLOGY

Favus is usually acquired before adolescence, but may extend into adulthood.[78] It is associated with malnutrition and poor hygiene. Over the last century, favus has become geographically limited and is now seen almost exclusively in Africa, the Middle East, and parts of South America. Even these regions have had a dramatic decrease in incidence with studies from South Africa, Libya, and Arabia suggesting disappearance of favus over the last few decades.[79-81]

CLINICAL FINDINGS

During the first 3 weeks of infection, early favus is characterized by patchy perifollicular erythema with slight scaling and matting of the hair. Progressive hyphal invasion distends the follicle, first producing a yellow-red follicular papule, then a yellow concave crust (scutulum) around a single dry hair (Fig. 160-12) that is less brittle than hair of endothrix infections. The scutulum may reach 1 cm in diameter, engulfing surrounding hairs, and coalescing with other scutula to form large, adherent mats with an unpleasant cheese-like or musky odor. Over several years, the plaques advance peripherally leaving behind central, atrophic areas of alopecia.[63]

ETIOLOGY AND PATHOGENESIS

T. schoenleinii is the most common cause of human favus, with *T. violaceum* and *M. gypseum* also as rare isolates.[63] Although favus occurs in animals including domesticated birds (*Microsporum gallinae*) and mice (*T. mentagrophytes* formerly named *T. mentagrophytes* var. *quinckeanum*), there exist only a few reports of human infection by the same pathogens responsible for animal favus.[82]

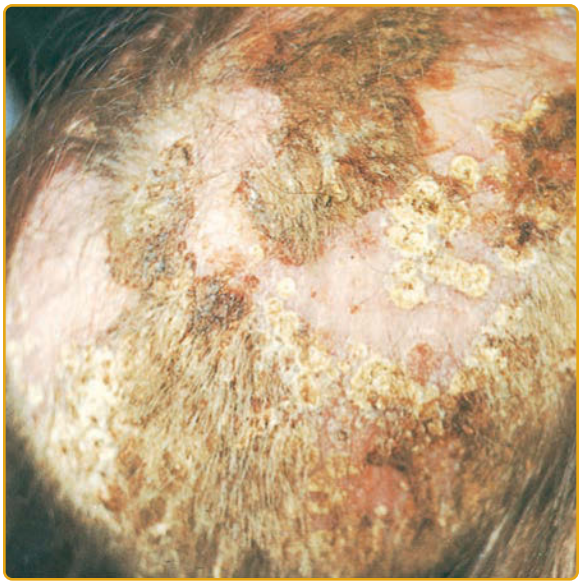

Figure 160-12 Favus caused by *Trichophyton schoenleinii*. Note the numerous yellow scutula.

DIAGNOSIS

Table 160-4 outlines common laboratory dermatophyte identification methods and Table 160-6 outlines the colony and microscopic morphology features of the most common dermatophytes.

T. schoenleinii exhibits subtle, blue-gray fluorescence along the entire hair with Wood lamp examination. Microscopy with KOH preparation reveals hyphae arranged lengthwise around and within the hair shaft, rare arthroconidia, and vacant air spaces.[63]

DIFFERENTIAL DIAGNOSIS

Table 160-13 outlines the differential diagnosis of onychomycosis.

MANAGEMENT

Treatment is the same as for tinea capitis.

TINEA MANUUM

Tinea manuum is discussed with tinea pedis under the section "Tinea Pedis and Tinea Manuum."

TINEA NIGRA

Tinea nigra is a superficial dermatomycosis caused by dematiaceous, darkly pigmented, *Hortaea werneckii* (formerly named *Phaeoannellomyces werneckii* and *Exophiala werneckii*).[83]

EPIDEMIOLOGY

Tinea nigra occurs in tropical or subtropical areas, including Central and South America, Africa, and Asia. Its incidence is low in the United States and Europe. Although the majority of the approximately 150 North American cases reported since 1950 were associated with tropical travel,[63] endemic foci exist in the coastal southeastern United States and in Texas. Person-to-person transmission is rare.[84] Tinea nigra has a female-to-male predilection of 3:1.

CLINICAL FINDINGS

Tinea nigra is found on otherwise healthy people and presents typically as an asymptomatic, mottled brown to greenish-black macule or patch with minimal to no scale on the palms or soles (Fig. 160-13). The macule is often darkest at the advancing border. Because of its coloration and location on palms and soles, tinea nigra is frequently misdiagnosed as acral lentiginous melanoma.

Figure 160-13 Tinea nigra palmaris. An irregular, brownish-black patch on the palm caused by *Hortaea werneckii*.

ETIOLOGY AND PATHOGENESIS

Tinea nigra is almost always caused by *H. werneckii*, although other dematiaceous fungi such as *Stenella araguata* may produce the same clinical picture. Dematiaceous fungi are commonly found in soil, sewage, and decaying vegetation.[84] Tinea nigra arises after trauma to the skin with subsequent inoculation, and a typical incubation period of 2 to 7 weeks.

DIAGNOSIS

KOH examination of scrapings from the macule reveals brown to olive-colored, thick branching hyphae, along with oval to spindle-shaped yeast cells that occur singly or in pairs with a central transverse septum. Cultures performed on SDA with cycloheximide and chloramphenicol grow within 1 week. The colony is initially yeast-like with a brown to shiny black color and appears as typical 2-celled yeast forms under microscopic examination. With time, mycelial growth predominates creating a fuzzy grayish-black colony.

DIFFERENTIAL DIAGNOSIS

Table 160-19 outlines the differential diagnosis of tinea nigra.

MANAGEMENT

Table 160-9 outlines the treatment of dermatophytes and Table 160-11 lists topical antifungal agents.

Tinea nigra responds readily to topical therapy with a keratolytic (Whitfield ointment, 2% salicylic acid), tincture of iodine, or topical antifungal.[85,86] Treatment should be continued for 2 to 4 weeks after clinical

TABLE 160-19
Differential Diagnosis of Tinea Nigra

Most Likely
- Junctional nevus, dysplastic nevus, melanoma

Consider
- Chemical exposure

Rule Out
- Addison disease, syphilis, yaws

resolution to prevent relapse. Although oral ketoconazole, itraconazole, and terbinafine are also effective, systemic therapies are rarely indicated.[83]

TINEA PEDIS AND TINEA MANUUM

Tinea pedis denotes dermatophytosis of the feet, whereas tinea manuum involves the palmar and interdigital areas of the hands. Infection of the dorsal aspects of feet and hands is considered to be tinea corporis.

EPIDEMIOLOGY

Occurring worldwide, tinea pedis and tinea manuum are the most common dermatophytoses. Estimated to be approximately 10%, the high prevalence is attributed primarily to modern occlusive footwear, although increased worldwide travel also has been implicated.[63] Incidence of tinea pedis is higher among those using communal baths, showers, or pools. With the ubiquitous presence of dermatophytes in the environment, however, it may be that host factors, such as an individual's immune response to dermatophytes, play a determining role in the development of tinea pedis.

Tinea manuum is acquired through direct contact with an infected person or animal, the soil, or via autoinoculation. Most commonly only 1 hand (*singular*: tinea manus) is involved, concomitant with infection of feet and toenails for which the term *two feet–one hand* syndrome has been coined. This classic presentation of tinea manus represents a secondary infection of the hand acquired from excoriating and picking infected feet and toenails.[87] Tinea manuum should be suspected in individuals who have fine dry scaling of the palm or palms, often accentuated in the creases.

CLINICAL FINDINGS

Table 160-12 summarizes the subtypes and most common causes of tinea pedis and tinea manuum.

Tinea pedis may present as any of the following forms, or combinations thereof.

Interdigital Type: The interdigital type, the most common presentation of tinea pedis, begins as scaling, erythema, and maceration of the interdigital and subdigital skin of the feet, particularly between the lateral third and fourth and fourth and fifth toes (Fig. 160-14A). Under appropriate conditions, the infection will spread to the adjacent sole or instep, but it rarely involves the dorsum. Occlusion and bacterial coinfection (*Pseudomonas*, *Proteus*, and *Staphylococcus aureus*) soon produce the interdigital erosions with pruritus and malodor that are characteristic of the dermatophytosis complex, or "athlete's foot."

Chronic Hyperkeratotic (Moccasin) Type: Chronic hyperkeratotic (moccasin) type tinea pedis, is characterized by patchy or diffuse scaling on the soles and the lateral and medial aspects of the feet, in a distribution similar to a moccasin on a foot (see Fig. 160-14B). The degree of erythema is variable, and there may also exist a few minute vesicles that heal with collarets of scale less than 2 mm in diameter. The most common pathogen is *T. rubrum* followed by *E. floccosum* and anthropophilic strains of *T. interdigitale*.

Vesiculobullous Type: Vesiculobullous type of tinea pedis, typically caused by zoophilic strains of *T. interdigitale* (formerly named *T. mentagrophytes* var. *mentagrophytes*), features tense vesicles larger than 3 mm in diameter, vesiculopustules, or bullae on the soles and periplantar areas (see Fig. 160-14C). This type

Figure 160-14 Tinea pedis. **A,** Interdigital type. The interdigital space is macerated with opaque white scales and has erosions. **B,** Moccasin type. Patchy erythema and scaling in a moccasin distribution on the foot. The arciform pattern of scales is characteristic. **C,** Bullous type. Ruptured bullae, erosions and erythema on the plantar aspect of the great toe. Hyphae were detected on KOH 10% preparation obtained from epithelial cell on the roof of the inner aspect of the bulla.

Figure 160-15 Tinea pedis and manus. "Two feet–one hand" presentation of *Trichophyton rubrum*. Scaling in the involved (*right*) hand is accentuated in the creases.

of tinea pedis is uncommon in childhood but has been caused by *T. rubrum*.[88]

Acute Ulcerative Type: Acute ulcerative type tinea pedis caused by zoophilic *T. interdigitale* in combination with Gram-negative bacterial superinfection produces vesicles, pustules, and purulent ulcers on the plantar surface. Cellulitis, lymphangitis, lymphadenopathy, and fever are frequently associated.

Vesicular Id Reaction: Vesiculobullous and acute ulcerative types commonly produce a vesicular id reaction, either on the lateral foot or toes, or on the lateral aspects of the fingers.

Tinea Manuum: Dermatophyte infection of the hand usually has a noninflammatory presentation with diffuse dry scaling and accentuation in the creases (Fig. 160-15). However, vesicles, pustules, and exfoliation may be present, especially when zoophilic dermatophytes are involved. Tinea manuum commonly occurs in association with moccasin-type tinea pedis and onychomycosis, all of which should be treated to minimize relapse.[89]

ETIOLOGY AND PATHOGENESIS

Tinea pedis and tinea manuum are caused predominantly by *T. rubrum* (most common), *T. interdigitale*, and *E. floccosum*.

DIAGNOSIS

Table 160-4 outlines common laboratory dermatophyte identification methods and Table 160-6 outlines the colony and microscopic morphology features of the most common dermatophytes.

KOH examination of blister roofs (vesicules or bullae) yields the highest rate of positive findings. Histopathologic evaluation of tinea pedis reveals fungal organisms highlighted in the stratum corneum by PAS or methenamine silver stains, sometimes accompanied by foci of neutrophils. There also may be a sparse, chronic, superficial perivascular infiltrate in the dermis. Subcorneal or spongiotic intraepithelial vesiculation may be seen in the vesiculobullous type of tinea pedis.

TABLE 160-20
Differential Diagnosis of Tinea Pedis

Most Likely
- *Interdigital:* erosio interdigitalis blastomycetica, erythrasma, bacterial coinfection
- *Hyperkeratotic:* dyshidrosis, psoriasis, contact dermatitis, atopic dermatitis, hereditary or acquired keratodermas
- *Vesiculobullous:* dyshidrosis, contact dermatitis, pustular psoriasis, bacterid or other autoeczematization, palmoplantar pustulosis, bacterial pyodermas, scabies

Consider
- Pityriasis rubra pilaris

Rule Out
- Reactive arthritis

DIFFERENTIAL DIAGNOSIS

Table 160-20 outlines the differential diagnosis of tinea pedis.

MANAGEMENT

Table 160-9 outlines the treatment of dermatophytes, Table 160-10 lists oral antifungal agents, and Table 160-11 lists topical antifungal agents.

Mild interdigital tinea pedis without bacterial involvement is treated topically with allylamine, imidazole, ciclopirox, benzylamine, tolnaftate, or undecenoic acid–based creams. Terbinafine cream applied twice daily for 1 week is effective in 66% of cases.[90] Topical or systemic corticosteroids may be helpful for symptomatic relief during the initial period of antifungal treatment of vesiculobullous tinea pedis. Associated onychomycosis is common, and if present, requires a more durable oral treatment of the onychomycosis to prevent recurrence of tinea pedis. Maceration, denudation, pruritus, and malodor obligate a search for bacterial coinfection by Gram stain and culture, the results of which most often demonstrate the presence of Gram-negative organisms including *Pseudomonas* and *Proteus*. Patients suspected of having Gram-negative coinfections should be treated with a topical or systemic antibacterial agent based on the culture and sensitivity report. Another useful treatment of both cutaneous fungal and bacterial (including pseudomonas) infection is the use of dilute acetoacetic acid soaks; this may be of particular benefit to reduce the risk of cellulitis in patients with diabetes mellitus, chronic venous stasis or other causes of lower-extremity edema.

ACKNOWLEDGMENTS

Many thanks, to Dr. Amit Garg who served as senior author of previous editions and provided the great majority of clinical images in this chapter.

REFERENCES

1. Aly R. Ecology and epidemiology of dermatophyte infections. *J Am Acad Dermatol.* 1994;31:S21.
2. Graser Y, Scott J, Summerbell R. The new species concept in dermatophytes—a polyphasic approach. *Mycopathologia.* 2008;166:239.
3. Hibbett D. The invisible dimension of fungal diversity. *Science.* 2016;351:1150-1151.
4. Greer DL. An overview of common dermatophytes. *J Am Acad Dermatol.* 1994;31:S112.
5. Havlickova B, Czaika VA, Friedrich M. Epidemiological trends in skin mycoses worldwide. *Mycoses.* 2008;51(suppl 4):2.
6. Foster KW, Ghannoum MA, Elewski BE. Epidemiologic surveillance of cutaneous fungal infection in the United States from 1999 to 2002. *J Am Acad Dermatol.* 2004;50:748.
7. Ginter-Hanselmayer G, Weger W, Ilkit M, et al. Epidemiology of tinea capitis in Europe: current state and changing patterns. *Mycoses.* 2007;50(suppl 2):6.
8. Seebacher C, Bouchara JP, Mignon B. Updates on the epidemiology of dermatophyte infections. *Mycopathologia.* 2008;166:335.
9. Magill SS, Manfredi L, Swiderski A, et al. Isolation of *Trichophyton violaceum* and *Trichophyton soudanense* in Baltimore, Maryland. *J Clin Microbiol.* 2007; 45:461.
10. Chastain MA, Reed RJ, Pankey GA. Deep dermatophytosis: report of 2 cases and review of the literature. *Cutis.* 2001;67:457.
11. Tsang P, Hopkins T, Jimenez-Lucho V. Deep dermatophytosis caused by *Trichophyton rubrum* in a patient with AIDS. *J Am Acad Dermatol.* 1996;34:1090.
12. Johnson RA. Dermatophyte infections in human immune deficiency virus (HIV) disease. *J Am Acad Dermatol.* 2000;43:S135.
13. Garg AP, Muller J. Fungitoxicity of fatty acids against dermatophytes. *Mycoses.* 1993;36:51.
14. Bitencourt TA, Macedo C, Franco ME, et al. Transcription profile of *Trichophyton rubrum conidia* grown on keratin reveals the induction of an adhesin-like protein gene with a tandem repeat pattern. *BMC Genomics.* 2016;17:249.
15. Baeza LC, Bailao AM, Borges CL, et al. cDNA representational difference analysis used in the identification of genes expressed by *Trichophyton rubrum* during contact with keratin. *Microbes Infect.* 2007;9:1415.
16. Staib P, Zaugg C, Mignon B, et al. Differential gene expression in the pathogenic dermatophyte *Arthroderma benhamiae* in vitro versus infection. *Microbiology.* 2010;156(pt 3):884-895.
17. Baldo A, Mathy A, Tabart J, et al. Secreted subtilisin Sub3 from *Microsporum canis* is required for adherence to but not for invasion of the epidermis. *Br J Dermatol.* 2010;162(5):990-997.
18. Monod M, Capoccia S, Lechenne B, et al. Secreted proteases from pathogenic fungi. *Int J Med Microbiol.* 2002;292:405.
19. Blake JS, Dahl MV, Herron MJ, et al. An immunoinhibitory cell wall glycoprotein (mannan) from *Trichophyton rubrum*. *J Invest Dermatol.* 1991;96:657.
20. Dahl MV. Dermatophytosis and the immune response. *J Am Acad Dermatol.* 1994;31:S34.
21. Lilic D. Unravelling fungal immunity through primary immune deficiencies. *Curr Opin Microbiol.* 2012; 15:420-426.
22. Treat J, James WD, Nachamkin I, et al. Growth inhibition of *Trichophyton* species by *Pseudomonas aeruginosa*. *Arch Dermatol.* 2007;143:61.
23. García-Madrid LA, Huizar-López M del R, Flores-Romo L, et al. *Trichophyton rubrum* manipulates the innate immune functions of human keratinocytes. *Cent Eur J Biol.* 2011;6:902-910.
24. Romani L. Immunity to fungal infections. *Nat Rev Immunol.* 2011;11:275-288.
25. Firat YH, Simanski M, Rademacher F, et al. Infection of keratinocytes with *Trichophytum rubrum* induces epidermal growth factor-dependent RNase 7 and human beta-defensin-3 expression. *PLoS One.* 2014;9:e93941.
26. Jensen JM, Pfeiffer S, Akaki T, et al. Barrier function, epidermal differentiation, and human beta-defensin 2 expression in tinea corporis. *J Invest Dermatol.* 2007;127:1720.
27. Leibovici V, Evron R, Axelrod O, et al. Imbalance of immune responses in patients with chronic and widespread fungal skin infection. *Clin Exp Dermatol.* 1995;20:390.
28. Sato K, Yang XL, Yudate T, et al. Dectin-2 is a pattern recognition receptor for fungi that couples with the Fc receptor gamma chain to induce innate immune responses. *J Biol Chem.* 2006;281:38854.
29. Robinson MJ, Osorio F, Rosas M, et al. Dectin-2 is a Syk-coupled pattern recognition receptor crucial for Th17 responses to fungal infection. *J Exp Med.* 2009;206:2037.
30. Shiraki Y, Ishibashi Y, Hiruma M, et al. Cytokine secretion profiles of human keratinocytes during *Trichophyton tonsurans* and *Arthroderma benhamiae* infections. *J Med Microbiol.* 2006;55:1175.
31. Tani K, Adachi M, Nakamura Y, et al. The effect of dermatophytes on cytokine production by human keratinocytes. *Arch Dermatol Res.* 2007;299:381.
32. Huang X, Yi J, Yin S, et al. Trichophyton rubrum conidia modulate the expression and transport of Toll-like receptor 2 in HaCaT cell. *Microb Pathog.* 2015;83-84:1-5.
33. Glocker EO, Hennigs A, Nabavi M, et al. A homozygous CARD9 mutation in a family with susceptibility to fungal infections. *N Engl J Med.* 2009;361:1727.
34. Panasiti V, Borroni RG, Devirgiliis V, et al. Comparison of diagnostic methods in the diagnosis of dermatomycoses and onychomycoses. *Mycoses.* 2006;49:26.
35. Weinberg JM, Koestenblatt EK, Tutrone WD, et al. Comparison of diagnostic methods in the evaluation of onychomycosis. *J Am Acad Dermatol.* 2003;49:193.
36. Ameen M, Lear JT, Madan V, et al. British Association of Dermatologists' guidelines for the management of onychomycosis 2014. *Br J Dermatol.* 2014;171: 937-958.
37. Fuller LC, Barton RC, Mohd Mustapa MF, et al. British Association of Dermatologists' guidelines for the management of tinea capitis 2014. *Br J Dermatol.* 2014; 171(3):454-463.
38. Hawkins DM, Smidt AC. Superficial fungal infections in children. *Pediatr Clin North Am.* 2014;61(2):443-455.
39. Grappel SF, Bishop CT, Blank F. Immunology of dermatophytes and dermatophytosis. *Bacteriol Rev.* 1974; 38:222.
40. Kaaman T, Torssander J. Dermatophytid—a misdiagnosed entity? *Acta Derm Venereol.* 1983;63:404.
41. Veien NK, Hattel T, Laurberg G. Plantar *Trichophyton rubrum* infections may cause dermatophytids on the hands. *Acta Derm Venereol.* 1994;74:403.
42. Gianni C, Betti R, Crosti C. Psoriasiform id reaction in tinea corporis. *Mycoses.* 1996;39:307.

43. Calista D, Schianchi S, Morri M. Erythema nodosum induced by kerion celsi of the scalp. *Pediatr Dermatol.* 2001;18:114.
44. Weary PE, Guerrant JL. Chronic urticaria in association with dermatophytosis. Response to the administration of griseofulvin. *Arch Dermatol.* 1967;95:400.
45. Gupta AK, Jain HC, Lynde CW, et al. Prevalence and epidemiology of unsuspected onychomycosis in patients visiting dermatologists' offices in Ontario, Canada—a multicenter survey of 2001 patients. *Int J Dermatol.* 1997;36:783.
46. Ghannoum MA, Hajjeh RA, Scher R, et al. A large-scale North American study of fungal isolates from nails: the frequency of onychomycosis, fungal distribution, and antifungal susceptibility patterns. *J Am Acad Dermatol.* 2000;43:641.
47. Lange M, Roszkiewicz J, Szczerkowska-Dobosz A, et al. Onychomycosis is no longer a rare finding in children. *Mycoses.* 2006;49:55.
48. Svejgaard EL, Nilsson J. Onychomycosis in Denmark: prevalence of fungal nail infection in general practice. *Mycoses.* 2004;47:131.
49. Szepietowski JC, Reich A, Garlowska E, et al. Factors influencing coexistence of toenail onychomycosis with tinea pedis and other dermatomycoses: a survey of 2761 patients. *Arch Dermatol.* 2006;142:1279.
50. Prose NS, Abson KG, Scher RK. Disorders of the nails and hair associated with human immunodeficiency virus infection. *Int J Dermatol.* 1992;31:453.
51. Zaias N. Onychomycosis. *Arch Dermatol.* 1972;105:263.
52. Effendy I, Lecha M, Feuilhade de Chauvin M, et al. Epidemiology and clinical classification of onychomycosis. *J Eur Acad Dermatol Venereol.* 2005;19(suppl 1):8.
53. Gupta AK, Jain HC, Lynde CW, et al. Prevalence and epidemiology of onychomycosis in patients visiting physicians' offices: a multicenter Canadian survey of 15,000 patients. *J Am Acad Dermatol.* 2000;43:244.
54. Summerbell RC, Cooper E, Bunn U, et al. Onychomycosis: a critical study of techniques and criteria for confirming the etiologic significance of nondermatophytes. *Med Mycol.* 2005;43:39.
55. Scher RK, Daniel CR. *Nails: Therapy, Diagnosis, Surgery*. Philadelphia, PA: Saunders; 1997.
56. Baran R. Topical amorolfine for 15 months combined with 12 weeks of oral terbinafine, a cost-effective treatment for onychomycosis. *Br J Dermatol.* 2001; 145(suppl 60):15.
57. Gupta AK. Ciclopirox topical solution, 8% combined with oral terbinafine to treat onychomycosis: a randomized, evaluator-blinded study. *J Drugs Dermatol.* 2005;4:481.
58. Ramsewak RS, Nair MG, Stommel M, et al. In vitro antagonistic activity of monoterpenes and their mixtures against "toe nail fungus" pathogens. *Phytother Res.* 2003;17:376.
59. Pinto E, Pina-Vaz C, Salgueiro L, et al. Antifungal activity of the essential oil of *Thymus pulegioides* on *Candida*, *Aspergillus* and dermatophyte species. *J Med Microbiol.* 2006;55:1367.
60. Schwartz RA. Superficial fungal infections. *Lancet.* 2004;364:1173.
61. Coimbra Junior CE, Santos RV. Black piedra among the Zoró Indians from Amazonia (Brazil). *Mycopathologia.* 1989;107:57.
62. Kalter DC, Tschen JA, Cernoch PL, et al. Genital white piedra: epidemiology, microbiology, and therapy. *J Am Acad Dermatol.* 1986;14:982.
63. Rippon JW. Dermatophytosis and dermatomycosis. In: Rippon JW, ed. *Medical Mycology: Pathogenic Fungi and the Pathogenic Actinomycetes* . Philadelphia, PA: Saunders; 1988:169.
64. Shy R. Tinea corporis and tinea capitis. *Pediatr Rev.* 2007;28:164.
65. Sharma V, Hall JC, Knapp JF, et al. Scalp colonization by *Trichophyton tonsurans* in an urban pediatric clinic-asymptomatic carrier state. *Arch Dermatol.* 1988;124:1511.
66. Patel GA, Schwartz RA. Tinea capitis: still an unsolved problem? *Mycoses.* 2011;54(3):183-188.
67. Howard R, Frieden IJ. Tinea capitis: new perspectives on an old disease. *Semin Dermatol.* 1995;14:2.
68. Arenas R, Toussaint S, Isa-Isa R. Kerion and dermatophytic granuloma. Mycological and histopathological findings in 19 children with inflammatory tinea capitis of the scalp. *Int J Dermatol.* 2006;45:215.
69. Smith ML. Tinea capitis. *Pediatr Ann.* 1996;25:101.
70. Langley JB. Fungal diseases. In: Elder D, ed. *Lever's Histopathology of the Skin*. Philadelphia, PA: Lippincott; 1997:517.
71. Imamura S, Tanaka M, Watanabe S. Use of immunofluorescence staining in kerion. *Arch Dermatol.* 1975;111:906.
72. Pomeranz AJ, Sabnis SS. Tinea capitis: epidemiology, diagnosis and management strategies. *Paediatr Drugs.* 2002;4:779.
73. Elewski BE. Treatment of tinea capitis: beyond griseofulvin. *J Am Acad Dermatol.* 1999;40:S27.
74. Rebell G, Zaias N. Introducing the syndromes of human dermatophytosis. *Cutis.* 2001;67:6.
75. Taplin D. Dermatophytosis in Vietnam. *Cutis.* 2001;67:19.
76. Adams BB. Tinea corporis gladiatorum. *J Am Acad Dermatol.* 2002;47:286.
77. Elgart ML. Tinea incognito: an update on Majocchi granuloma. *Dermatol Clin.* 1996;14:51.
78. Khan KA, Anwar AA. Study of 73 cases of tinea capitis and tinea favosa in adults and adolescents. *J Invest Dermatol.* 1968;51:474.
79. Morar N, Dlova NC, Gupta AK, et al. Tinea capitis in Kwa-Zulu Natal, South Africa. *Pediatr Dermatol.* 2004;21:444.
80. Gargoom AM, Elyazachi MB, Al-Ani SM, et al. Tinea capitis in Benghazi, Libya. *Int J Dermatol.* 2000;39:263.
81. Venugopal PV, Venugopal TV. Tinea capitis in Saudi Arabia. *Int J Dermatol.* 1993;32:39.
82. Besbes M, Cheikhrouhou F, Sellami H, et al. Favus due to *Trichophyton mentagrophytes* var. *quinckeanum*. *Mycoses.* 2003;46:358.
83. Schwartz RA. Superficial fungal infections. *Lancet.* 2004;364:1173.
84. Vanvelsor H, Singletary H. Tinea nigra palmaris. A report of 15 cases from coastal North Carolina. *Arch Dermatol.* 1964;90:59.
85. Burke WA. Tinea nigra: treatment with topical ketoconazole. *Cutis.* 1993;52:209.
86. Shannon PL, Ramos-Caro FA, Cosgrove BF, et al. Treatment of tinea nigra with terbinafine. *Cutis.* 1999;64:199.
87. Daniel CR 3rd, Gupta AK, Daniel MP, et al. Two feet-one hand syndrome: a retrospective multicenter survey. *Int J Dermatol.* 1997;36:658.
88. Neri I, Piraccini BM, Guareschi E, et al. Bullous tinea pedis in two children. *Mycoses.* 2004;47:475.
89. Seeburger J, Scher RK. Long-term remission of two feet-one hand syndrome. *Cutis.* 1998;61:149.
90. Lebwohl M, Elewski B, Eisen D, et al. Efficacy and safety of terbinafine 1% solution in the treatment of interdigital tinea pedis and tinea corporis or tinea cruris. *Cutis.* 2001;67:261.

Chapter 161 :: Yeast Infections

:: Iris Ahronowitz & Kieron Leslie

This chapter reviews the spectrum of cutaneous yeast infections caused by *Candida* and *Malassezia* yeasts, both of which are frequent commensal organisms on human hosts. *Candida* behaves as an opportunistic pathogen, producing fairly characteristic patterns of inflammatory skin, mucosal, and nail infection, with the potential to produce invasive and sometimes life-threatening disseminated disease. *Malassezia*, by contrast, produces several superficial cutaneous patterns is rarely a culprit in systemic disease.

CANDIDIASIS

AT-A-GLANCE

- *Candida* species produce a variety of inflammatory mucosal and cutaneous manifestations.
- Favored areas of involvement include the oral mucosa and lips, fingers and nails, intertriginous zones, and genitalia.
- A variety of conditions can predispose patients to chronic mucocutaneous candidiasis with diffuse skin, mucosal, and nail involvement.
- *Candida* can cause invasive disease, including bloodstream infection, and is the most common culprit in fatal fungal sepsis.
- Risk factors for infection include extremes of age, malnutrition, obesity, diabetes, and immune deficiency.
- In mucocutaneous disease, morphology can be very helpful in making a clinical diagnosis, although confirmatory testing with potassium hydroxide preparations, culture, and histopathology (and in invasive disease, serology and polymerase chain reaction) also may be helpful.
- Treatment includes topical imidazoles and nystatin, and in more-severe disease, systemic agents, including oral azoles and echinocandins.

EPIDEMIOLOGY

Candida yeasts are found throughout the environment and are also common commensals of the human skin, oropharyngeal, respiratory, GI, and genital mucosa. Candidal colonization has been reported in the oral mucosa of more than 40% of healthy adults, with higher rates of carriage in women and smokers.[1] At least 15 of the more than 200 *Candida* species have been implicated in human disease. Although *Candida albicans* is the most commonly implicated *Candida* species in localized mucocutaneous candidiasis, an increasing number of other species have been implicated in mucocutaneous disease, including *Candida glabrata, Candida tropicalis, Candida krusei, Candida parapsilosis,* and *Candida dubliniensis.* Additionally, while *albicans* is still the single most common species, non-*albicans* species collectively now account for the majority of invasive candidiasis and candidemia.[2] Other specific risk factors for infection are described below (see section "Risk Factors").

CLINICAL FEATURES

CUTANEOUS FINDINGS

Localized *Candida* infection in the skin classically presents as beefy-red patches and plaques with satellite papules and pustules at the periphery (Fig. 161-1). Intertriginous areas, particularly the axillae, inframammary folds, groin folds, and infrapannus area, are frequently affected, and maceration may be an additional feature in these sites (Fig. 161-2A, B). *Candida* also may be implicated in miliaria arising on occluded skin surfaces, manifesting as small monomorphous vesicles (Fig. 161-3). On oropharyngeal mucosal surfaces, background erythema with adherent whitish material may be seen, as in the pseudomembranous form of oropharyngeal candidiasis (thrush) (Fig. 161-4A, D), however an erythematous form, characterized by a shiny depapillated lingual surface, as in median rhomboid glossitis, also occurs, and may be seen in those who wear dentures (Fig. 161-4B). Additionally, fissuring and crusting at the oral commissures may be seen in angular cheilitis (also known as perleche; Fig. 161-4C). In breastfeeding women, nipple candidiasis may present with shiny erythema of the areola and nipple, which may be associated with flaking of the skin, and thrush may concurrently be apparent in the infant's mouth.[3] On genital skin and mucosa, including the vulva, glans penis, and prepuce, *Candida* may present with patchy erythema or erythematous plaques with associated itching and burning sensation. In patients with vulvovaginitis, a thick, white, curd-like discharge is typical. Pustules are seen more frequently in balanitis and balanoposthitis than in vulvitis (Fig. 161-5). In the diaper area, the classic presentation is beefy-red erythematous plaques with satellite papules and pustules (Fig. 161-2C). In the interdigital spaces, particularly the third webspace of the hands, a macerated whitish plaque on erythematous background (erosio interdigitalis blastomycetica) may be seen, especially in patients with chronic exposure to moisture from wet work (Fig. 161-2D).

Figure 161-1 Typical morphology of cutaneous candidiasis demonstrating erythematous papules coalescing into plaques, with satellite papules and vesiculopustules.

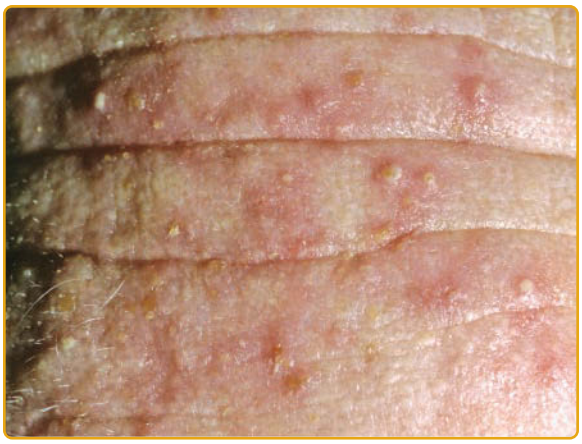

Figure 161-3 Miliaria caused by *Candida* seen on the forehead of a diabetic patient who had applied a partially occlusive dressing for headache symptoms.

Figure 161-2 Examples of *Candida* intertrigo. **A,** Erythematous papules becoming confluent over the inguinal area with prominent satellite papules (with scrotal involvement, in contrast to tinea cruris). **B,** Erythematous plaques with erosion and satellite papules. **C,** Diaper candidiasis demonstrated erythematous, partially eroded plaques, and satellite papules. **D,** Erosio interdigitalis blastomycetica demonstrating an erythematous plaque with prominent maceration in the interdigital webspace.

Figure 161-4 **A,** Oral candidiasis (pseudomembranous form, thrush). Typical white palatal patches and plaques. **B,** Atrophic candidiasis demonstrating a shiny erythematous depapillated areas under areas in contact with dentures. **C,** Angular cheilitis (perleche) demonstrating fissured erythematous plaques at the bilateral oral commissures. **D,** Hyperplastic candidiasis on the dorsal lingual surface.

Figure 161-5 Balanoposthitis caused by *Candida* demonstrating pustules on the glans penis and foreskin.

Candida also has been implicated in chronic paronychia, which presents with erythema of the proximal nailfold area with loss of the cuticle and skin breakdown (sometimes with associated onycholysis and nail dystrophy; Fig. 161-6A). More recently, however, the *Candida* has been hypothesized to play a secondary role as a colonizer with either chronic wet work leading to skin barrier breakdown or chronic contact dermatitis being the primary insult.[4] *Candida*, usually starting as paronychia, can also directly invade the nail plate and produce onychomycosis (5% to 10% of onychomycosis overall is caused by *Candida*; Fig. 161-6B), and is implicated in several presentations, including a distal subungual presentation and total dystrophic onychomycosis.[5,6] *Candida* onychomycosis is more often seen in the fingernails than in the toenails, and is often associated with pain on pressure or movement of the nail plate (both of these features are in contrast to dermatophytes), and more often affects the dominant hand.[6] Exposure to moisture and occupational wet work are important risk factors.

Patients with chronic mucocutaneous candidiasis may present with erythematous plaques with overlying scale reminiscent of plaque psoriasis (Fig. 161-7).

Figure 161-6 **A,** Chronic paronychia caused by *Candida albicans* demonstrating erythematous, edematous proximal nail-fold with onycholysis and mild dystrophy. **B,** Severely inflammatory candidal paronychia that has spread to the nail plate to produce onychomycosis.

In patients with candidemia, the presence of skin lesions, most typically discrete sparse lesions ranging from erythematous papules with central pallor or necrosis to erythematous nodules to (less commonly) plaques, may be an important clue to the diagnosis (Fig. 161-8).[7] The distribution favors the trunk and proximal extremities although the head and face may be involved. These classic skin lesions are reported to appear approximately 10% to 30% of the time in candidemia, and are most commonly seen in *C. tropicalis* infection.[8]

NONCUTANEOUS FINDINGS

In patients with candidemia, the classic clinical triad of fever, rash, and myalgia has been described as a sufficient basis for initiation of empiric treatment for presumptive invasive candidiasis in a hospitalized patient.[9] The myalgia is the result of hematogenous dissemination of *Candida* to muscle (usually in the lower extremities) causing muscle abscesses, clinically presenting with a warm, sore muscle and seen in up to 25% of patients with candidemia.[10] Additionally, chorioretinitis, vitreitis, and endophthalmitis may

Figure 161-7 Patient with chronic mucocutaneous candidiasis. Sharply marginated erythematous plaques with prominent scaling, reminiscent of plaque psoriasis.

Figure 161-8 Disseminated candidiasis with candidemia. Neutropenic febrile patient with acute myeloid leukemia demonstrating erythematous papules and nodules on the hand, some with central pustulation. Biopsy demonstrated *Candida* organisms and blood cultures were positive for *Candida tropicalis*.

result from hematogenous spread in roughly 4% to 7% of patients with candidemia.[11,12] Although a majority of patients do complain of symptoms that include visual changes (if able to articulate symptoms), ocular *Candida* is also detected in asymptomatic patients.[11]

COMPLICATIONS

Candida may cause multiorgan failure as a manifestation of septic shock, or may hematogenously disseminate to any organ in the setting of candidemia, with the liver, spleen, kidneys, heart (and heart valves), and meninges among the more common. Retinal involvement may be painless and result in permanent visual loss.

ETIOLOGY AND PATHOGENESIS

Although typically a commensal organism, *Candida* does act as an opportunistic pathogen under favorable circumstances, including alteration in normal flora or immune function, a breach of skin, or a breach of mucosal integrity. A variety of virulence factors assist it in establishing infection, including, importantly, the ability to adhere to human epithelial cells.[13] *Candida* infection elicits both innate and adaptive host immune responses largely through the interleukin-17 (IL-17) pathway, and defects in this pathway, including in genes such as *STAT1, STAT3, IL17F, IL17RA,* among many others, are associated with susceptibility to chronic mucocutaneous candidiasis.[14,15] Recent research also has identified that mutations in caspase recruitment domain-containing protein 9 (*CARD9*), a molecule necessary for the induction of T-helper-17 cells, result in a specific defect in the ability of neutrophils to kill *Candida,* resulting in vulnerability to invasive *Candida* infections.[16] Interestingly, the importance of the IL-17 pathway to *Candida* susceptibility is borne out in patients taking the increasingly prevalent IL-17–blocking medications, with early evidence suggesting an increase in *Candida* infections in psoriasis and psoriatic arthritis patients taking the new anti–IL-17 medications brodalumab, secukinumab, and ixekizumab.[17]

RISK FACTORS

Risk factors for localized/superficial *Candida* infections include extremes of age; diabetes; obesity; pregnancy; HIV/AIDS (although prevalence has decreased significantly in the era of highly active antiretroviral therapy)[18]; and use of broad-spectrum antibiotics, corticosteroids, or immunosuppressive medications, specifically anti–IL-17-blocking medications as discussed above. Risk factors for oral candidiasis include xerostomia; wearing of dentures or other oral hardware; inhaled and systemic corticosteroids; vitamin deficiencies; radiation therapy to the head/neck; and hypothyroidism.[1] Risk factors for invasive candidiasis/candidemia include neutropenia and neutrophil dysfunction (including *CARD9* mutations); hematologic malignancy; stem cell transplantation; indwelling intravascular catheters (including patients on hemodialysis); intensive care unit placement; and immunosuppressive medications.[19]

DIAGNOSIS

Figure 161-9 is an algorithm summarizing current recommendations for diagnosing cutaneous candidiasis.

SUPPORTIVE STUDIES

The morphology may be distinctive and sufficient to make a clinical diagnosis in many cases of superficial *Candida* skin infection. Rapid confirmation may be achieved with bedside potassium hydroxide (KOH) preparation (either from a scraping from an intact pustule, or a touch preparation from a punch biopsy specimen) demonstrating pseudohyphae and budding yeast (Fig. 161-10).

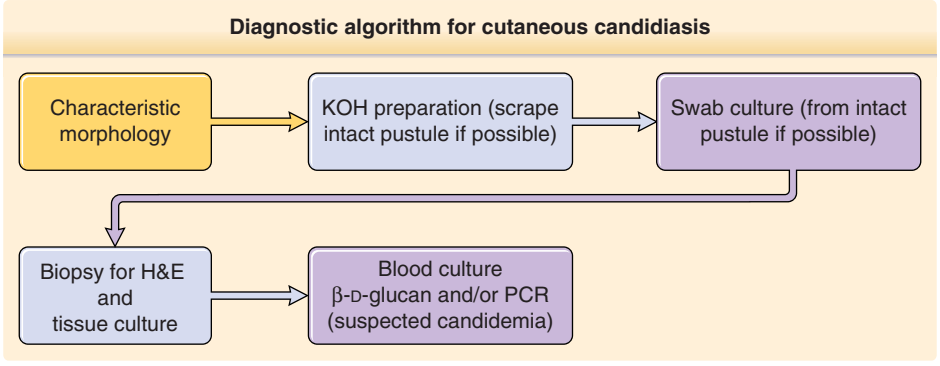

Figure 161-9 Diagnostic algorithm for cutaneous candidiasis. H&E, hematoxylin and eosin; KOH, potassium hydroxide; PCR, polymerase chain reaction.

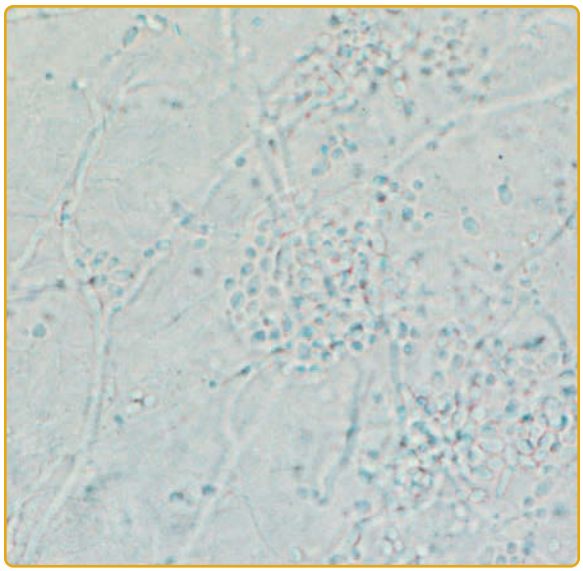

Figure 161-10 Potassium hydroxide (KOH) preparation demonstrating *Candida* forms including pseudohyphae and budding yeasts.

LABORATORY TESTING

Definitive diagnosis and speciation can be achieved via either swab culture (taken from an intact pustule if possible) or tissue culture from biopsy specimens taken from affected areas. In patients suspected of having candidemia, positive blood cultures are still considered the "gold standard" however with poor sensitivity (approximately 50%), adjunctive techniques such as β-D-glucan assay and polymerase chain reaction may be helpful.[20]

PATHOLOGY

Skin biopsies are of variable yield in making the diagnosis. While in localized mucocutaneous candidiasis, organisms may sometimes be readily seen in the epithelium with Grocott methenamine silver or periodic acid–Schiff staining, in patients with disseminated candidiasis, organisms (sometimes forming microabscesses) are more likely to be found in and around the dermal blood vessels, although sometimes only a mononuclear inflammatory infiltrate is seen.[21]

DIFFERENTIAL DIAGNOSIS

Table 161-1 summarizes the differential diagnosis for cutaneous candidiasis.

CLINICAL COURSE AND PROGNOSIS

While most localized mucocutaneous *Candida* infections cause minor symptoms and respond readily to treatment, in patients with underlying risk factors (see "Risk Factors" before) infection may be recurrent and chronic, contributing to varying degrees of morbidity although not life-threatening. By contrast, mortality in patients with candidemia is significant, at 35% over 12 weeks in one larger study[2]; in some case series, the mortality exceeds 80%.[8]

TABLE 161-1
Differential Diagnosis for Cutaneous Candidiasis

For Cutaneous Candidiasis
- Seborrheic dermatitis
- Tinea corporis/dermatophytosis
- Impetigo
- Erythrasma
- Intertrigo
- Irritant contact dermatitis
- Allergic contact dermatitis
- Atopic dermatitis
- Bacterial folliculitis
- Herpes simplex or herpes zoster (localized or folliculitis)

For Oral Mucosal Candidiasis/Thrush
- Herpes simplex virus infection
- Oral hairy leukoplakia
- Morsicatio buccarum (chronic cheek chewing)
- Lichen planus white sponge nevus

For Paronychia and Onychomycosis
- Tinea unguium (dermatophyte nail infection)
- Nondermatophyte mold infections (eg, *Acremonium*, *Alternaria*)
- Acute bacterial paronychia
- Herpetic whitlow
- Squamous cell carcinoma

For Disseminated Candidiasis
- Disseminated fungal infections: *Fusarium*, *Aspergillus*, zygomycosis
- Bacterial sepsis including meningococcemia, gonococcemia, and ecthyma gangrenosum
- Disseminated herpes simplex, primary varicella, or disseminated herpes zoster

MANAGEMENT

Table 161-2 summarizes the management of cutaneous candidiasis. The Infectious Diseases Society of America guidelines were most recently updated in 2016 (as of this writing) and provide clinicians with comprehensive guidance in the treatment of localized and disseminated *Candida* infections,[22] as summarized below, and may be consulted for further detailed recommendations. Areas not covered by these guidelines include the treatment of localized cutaneous candidiasis, chronic mucocutaneous candidiasis, paronychia, and onychomycosis, for which other relevant sources are provided.

CUTANEOUS CANDIDIASIS

First-line treatment of localized disease includes topical formulations of imidazoles (ketoconazole, clotrimazole, miconazole, econazole) in various formulations, which may include creams or powders. Nystatin

TABLE 161-2
Candidiasis Treatment Algorithm

	FIRST LINE	SECOND LINE
Cutaneous	Topical imidazoles Topical nystatin	Oral fluconazole
Paronychia	Avoid wet work/use of gloves Topical corticosteroids Topical tacrolimus	Topical imidazole solutions Thymol 40% in ethanol Dilute acetic acid soaks
Onychomycosis	Oral itraconazole Oral fluconazole	Oral terbinafine
Oral (thrush)	Mild: ▪ Clotrimazole troches ▪ Miconazole buccal tablets ▪ Disinfect dentures Severe or immunosuppressed: ▪ Oral fluconazole	Nystatin suspension Itraconazole, posaconazole, voriconazole, or amphotericin B solutions/suspensions
Vulvovaginitis	Topical miconazole, clotrimazole, terconazole	Oral fluconazole
Balanoposthitis	Topical antifungal creams	Low- to mid-potency topical corticosteroids (adjunctive)
Chronic mucocutaneous	Oral imidazoles Oral triazoles (voriconazole and posaconazole) Long courses often required	Resistant disease: ▪ Echinocandins ▪ Liposomal amphotericin ▪ Flucytosine
Disseminated (candidemia) ***Infectious disease consultation is required***	Hemodynamically stable immunocompetent patients: ▪ Echinocandin (caspofungin, micafungin, or anidulafungin) ▪ Fluconazole Neutropenic patients: ▪ Empiric echinocandin ▪ Switch to fluconazole once stable	Liposomal amphotericin

topical is also effective. More severe cases typically require short courses of oral antifungals such as fluconazole 150 mg for several doses.

ORAL CANDIDIASIS

Clotrimazole 10-mg troches 5 times daily or miconazole 50-mg buccal tablets for 1 to 2 weeks is first-line treatment, with nystatin suspension 100,000 units/mL, 4 to 6 mL 4 times daily for 1 to 2 weeks as an alternative. Moderate and severe cases may require fluconazole 100 to 200 mg oral daily for 1 to 2 weeks. Itraconazole, posaconazole, voriconazole, and amphotericin B solutions and suspensions are alternatives for refractory or resistant disease. For denture wearers, disinfection of dentures is an important adjunctive step to prevent reinfection; the most effective methods for removal of *Candida* include soaking with commercially available effervescent denture tablets or a dilute bleach concentration of 1:32 or higher.[23,24] For HIV-positive patients, initiation of highly active antiretroviral therapy is recommended to decrease chances of recurrence. For patients with recurrent disease, chronic suppressive dosing of fluconazole 150 mg orally 3 times weekly can be helpful.

PARONYCHIA AND ONYCHOMYCOSIS

First-line treatment of *Candida* onychomycosis is itraconazole given orally as pulsed dosing at 400 mg daily for 1 week monthly or 200 mg daily continuous dosing, for a total minimum duration of 4 weeks for fingernail and 12 weeks for toenail disease. Fluconazole is considered equally effective and can be given at 50 mg daily or 300 mg weekly dosing for similar durations. Although terbinafine has lower efficacy, cure rates are improved by longer courses of 250 mg daily for 4 months or longer, which makes compliance a potential concern.[6]

For chronic paronychia, avoidance of wet work or wearing of gloves to keep the skin dry is recommended. Given recent evidence that *Candida* colonization may play a secondary role, with the primary insult being skin barrier breakdown resulting from wet work and possible contact dermatitis,[4] a role for topical corticosteroids has been demonstrated. In a randomized trial, topical corticosteroids were shown to yield a higher cure rate than systemic antifungals.[25] Topical tacrolimus also is effective.[26] Topical imidazole solutions, as well as thymol 40% compounded in ethanol or dilute acetic acid soaks, also have been used adjunctively in the treatment of chronic paronychia.

VULVOVAGINITIS AND BALANITIS

Topical antifungals such miconazole and clotrimazole are first-line treatment for *Candida* vulvovaginitis. Oral fluconazole (usually 150 mg in a single dose) is an alternative. Two to 3 doses 72 hours apart are recommended for more-severe cases, and even longer

courses for recurrent cases. For balanitis and balanoposthitis, topical antifungal creams, in some cases in conjunction with low- to mid-potency topical corticosteroids, are employed.

CHRONIC MUCOCUTANEOUS CANDIDIASIS

Given the high likelihood of recurrence, prolonged courses of oral imidazoles or newer triazoles (including voriconazole and posaconazole) are first-line treatment. Because of the development of resistance, echinocandins, liposomal amphotericin, or flucytosine is sometimes required.[27]

DISSEMINATED CANDIDIASIS

Treatment of patients with invasive candidiasis should be undertaken with the assistance of an infectious disease specialist. Either an echinocandin (caspofungin, micafungin, or anidulafungin) or fluconazole is a first-line treatment recommended in hemodynamically stable immunocompetent patients.

Neutropenic patients should be started on empiric echinocandin and switched to fluconazole once stable.[22] Resistance to azoles and echinocandins is a potential concern, particularly in non–*Candida albicans* species disease and in patients with prior exposure to these medications. Lipid formulation amphotericin B is an alternative in situations of resistance to first-line agents. Followup blood cultures and ophthalmologic examination are recommended for all patients with candidemia.

MALASSEZIA

AT-A-GLANCE

- *Malassezia* species are normal flora of human skin.
- *Malassezia* species can produce a variety of clinical presentations including pityriasis (tinea) versicolor, *Malassezia* folliculitis, seborrheic dermatitis, and neonatal cephalic pustulosis. Rarely, *Malassezia* species have been implicated in systemic infections, including catheter-related fungemia.
- The diagnosis can be made via potassium hydroxide (KOH) preparation or skin biopsy. The organism is not typically cultured for this purpose as it requires special growing conditions (additional lipid).
- *Malassezia* skin infections generally respond readily to topical treatments, including azole antifungals and selenium sulfide–based preparations. More extensive cases or those with folliculitis may require systemic antifungals.
- *Malassezia* infections tend to have high recurrence rates and may require prophylactic treatment to prevent further episodes.

EPIDEMIOLOGY

Malassezia (formerly known as *Pityrosporum*) are lipophilic dimorphic fungi that have been implicated in several skin conditions: pityriasis (tinea) versicolor, and *Malassezia* folliculitis. These organisms also have been identified at increased rates in inflammatory conditions including seborrheic dermatitis and atopic dermatitis, although their role in these conditions is less clear and thought to be more an exacerbating factor rather than a true infection.[28] There are currently 14 species in the genus *Malassezia*, of which 11 have been detected as commensals on human skin.[29] Colonization tends to occur by the age of 3 to 6 months, with earlier colonization in the neonatal phase associated with length of neonatal intensive care unit stays.[30] Higher rates of *Malassezia* skin infections are seen in tropical climates and at the ages of peak sebum production (adolescence to young adulthood).[31] In pityriasis versicolor and *Malassezia* folliculitis, *Malassezia globosa* is the most commonly isolated species,[32,33] with *Malassezia restricta* and *Malassezia sympodialis* also frequently isolated from *Malassezia* folliculitis.[34]

These fungi also have been found to play a role in internal infections, with *Malassezia* (most frequently *M. restricta* and *M. globosa*) isolated from the sinuses of both healthy controls and patients with chronic rhinosinusitis.[35] *Malassezia* species also are implicated in urinary tract infections, meningitis, pneumonia, and nosocomial bloodstream infections.[36,37] Cather-related fungemia has been reported in neonates (most commonly by *Malassezia pachydermatis*, particularly preterm infants receiving parenteral lipid infusions and those with prolonged vascular catheterization.[38] *Malassezia* fungemias also have been described in a series of immunocompromised older children and adults (with leukemias, solid tumors, diabetes, and severe combined immunodeficiency) with indwelling catheters, none of whom were receiving lipid infusions.[39]

CLINICAL FEATURES

CUTANEOUS FINDINGS

Pityriasis versicolor is a superficial *Malassezia* infection most commonly seen in adolescents and young adults. This condition is also known as tinea versicolor, but this nomenclature may be misleading as other tinea presentations are caused by dermatophytes rather than yeast. This condition manifests with asymptomatic to mildly pruritic patches and thin plaques with overlying fine scale favoring the neck, chest and back, upper arms, and, less commonly, the scalp, abdomen, and groin areas (Fig. 161-11). The name "versicolor" alludes to the spectrum of skin color changes that may be seen including hypopigmentation and hyperpigmentation, as well as erythematous to salmon-colored skin lesions (Fig. 161-12).

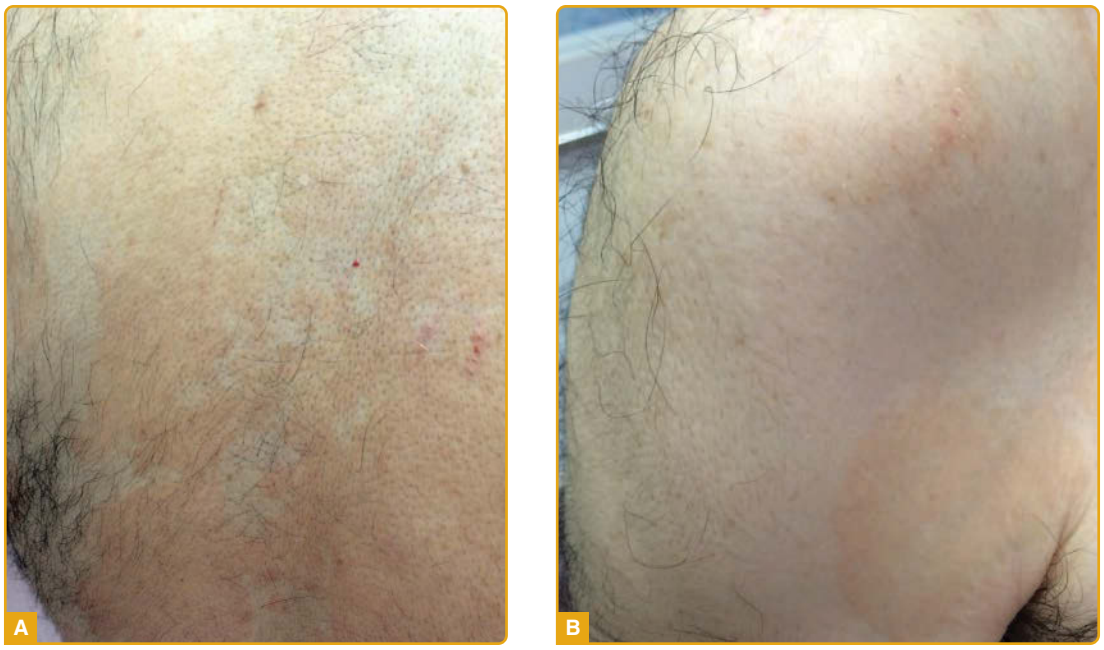

Figure 161-11 Pityriasis (tinea) versicolor. **A,** Multiple round to oval salmon-colored patches over the trunk. **B,** Salmon-colored patches and thin plaques on the shoulder and upper arm with fine overlying scale.

Malassezia folliculitis presents as follicularly based erythematous monomorphic papules and pustules on the face, trunk, and upper arms (Fig. 161-13A). In contrast to acne vulgaris, comedones are a not a feature, and *Malassezia* folliculitis tends to spare the centrofacial areas.[33] The lesions are often, but not always, pruritic. The condition is frequently diagnosed as misdiagnosed as acne vulgaris, and may even appear concurrently with acne.

ETIOLOGY AND PATHOGENESIS

Malassezia are normal flora of human skin, and rely upon hydrolysis of their human host sebum triglycerides as they lack a fatty acid synthase to allow endogenous production of C14-C16 saturated fatty acids.[28,40] The free fatty acids thereby produced are believed to provoke inflammation in the skin of the host, as evidenced by the presence of a perivascular inflammatory infiltrate on histopathology.[31] In pityriasis versicolor, the organism is able to transition to its pathogenic mycelial form and invade the stratum corneum. The pigmentary alterations produced in the skin are believed to be achieved via several mechanisms. The hypopigmentation seen especially in darker-skinned patients is thought to be a result of the production of azelaic acid, a dicarboxylic acid that inhibits of tyrosinase (an enzyme that catalyzes a key step in melanin synthesis) and also may be directly cytotoxic to melanocytes,[41] while hyperpigmented lesions have been attributed to increased melanosomes and thickening of the stratum corneum.[42]

RISK FACTORS

Tropical climates and heavy sweating are associated with increased rates of both pityriasis versicolor and *Malassezia* folliculitis. In addition, immunosuppression, oral antibiotics, and corticosteroids also are reported risk factors for *Malassezia* folliculitis.[43] There has not been a consistent gender predilection reported.

DIAGNOSIS

Figure 161-14 summarizes the diagnostic recommendations for cutaneous *Malassezia* infections.

SUPPORTIVE STUDIES

Pityriasis versicolor is often diagnosed visually based on its fairly distinctive morphology. Dermoscopy has been recommended as an ancillary tool in making the diagnosis of pityriasis versicolor as it highlights the fine scaling that may not always be readily visible to the naked eye.[44] In both pityriasis versicolor and *Malassezia* folliculitis, illumination with a Wood lamp may reveal yellow-green fluorescence.

KOH preparation can be a particularly useful in-clinic diagnostic test for pityriasis versicolor or *Malassezia* folliculitis and it will reveal short hyphae and yeast forms (the "ziti and meatballs" sign; Fig. 161-15). Although a superficial scraping of skin scales is adequate in pityriasis versicolor, the use of a comedone extractor or a needle to puncture an intact pustule is recommended to obtain a specimen in cases of *Malassezia* folliculitis where the yeast is situated

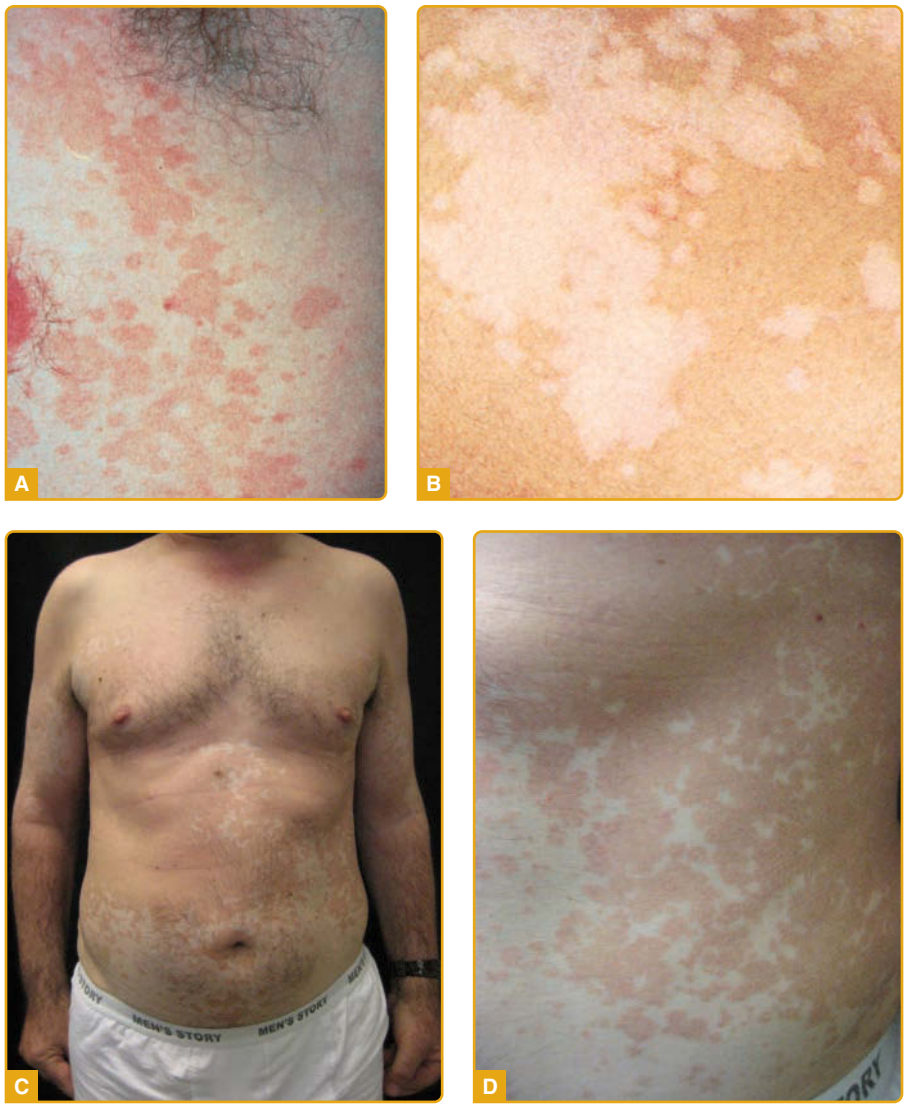

Figure 161-12 Pityriasis (tinea) versicolor. **A,** Erythematous macules and patches. **B,** Hypopigmented macules and patches that can be mistaken for vitiligo. **C,** Salmon-pink macules coalescing into patches. **D,**Characteristic fine overlying scale seen close up.

Figure 161-13 **A,** *Malassezia* folliculitis on the chest. **B,** Histopathology demonstrating yeast forms in the follicular infundibulum on hematoxylin-and-eosin (H&E) staining.

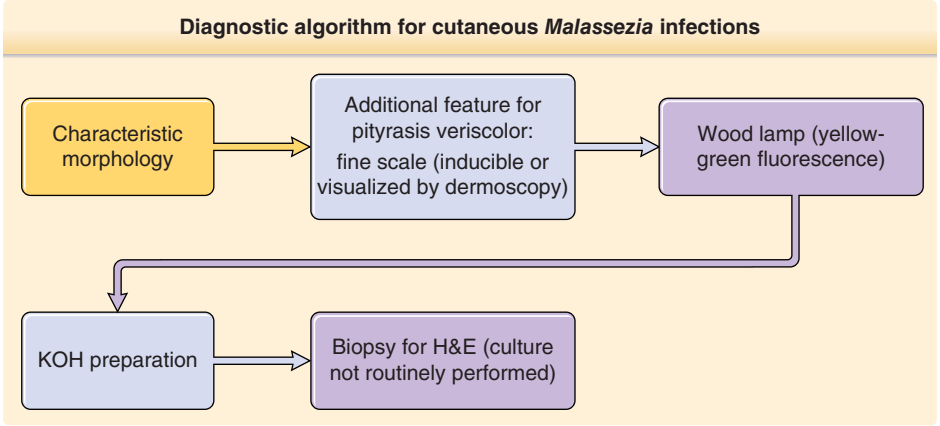

Figure 161-14 Diagnostic algorithm for cutaneous *Malassezia* infections. H&E, hematoxylin and eosin; KOH, potassium hydroxide.

deeper within the follicle.[34,45] Staining with calcofluor white or May-Grunwald-Giemsa stain may improve visualization.[43]

LABORATORY TESTING

Culture is not generally used to confirm *Malassezia* infection because of the organism's lipid requirement, which makes culture more logistically challenging—a layer of olive oil must be added or special growth media such as modified Dixon are required—and this is complicated further by slightly different growth requirements among different species.[31]

PATHOLOGY

Histopathology demonstrates *Malassezia* yeast forms; in pityriasis versicolor, they may be seen within the stratum corneum, while in *Malassezia* folliculitis they are found within dilated infundibula of plugged follicles in association with keratin debris (see Fig. 161-13B).[46] A perivascular inflammatory infiltrate of lymphocytes, histiocytes, and neutrophils may be seen, which is typically mild unless the follicle has ruptured. A periodic acid–Schiff stain will highlight the organism.

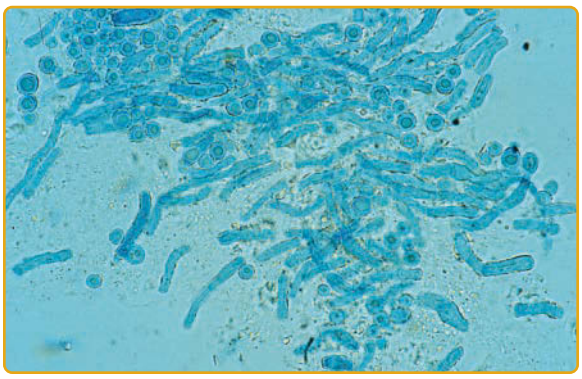

Figure 161-15 Potassium hydroxide (KOH) preparation of *Malassezia* demonstrating "ziti and meatballs" appearance of hyphae and yeast forms.

DIFFERENTIAL DIAGNOSIS

Table 161-3 summarizes the differential diagnosis for cutaneous *Malassezia* infections.

CLINICAL COURSE AND PROGNOSIS

Superficial *Malassezia* infections are generally innocuous, and although most will respond readily to appropriate antifungal therapy, recurrence is common, particularly in those individuals with strong risk factors. Preterm neonates, immunosuppressed patients, and patients on

TABLE 161-3
Differential Diagnosis for Cutaneous *Malassezia* Infections

For Pityriasis Versicolor:
- Seborrheic dermatitis
- Pityriasis rosea
- Pityriasis alba
- Confluent and reticulated papillomatosis of Gougerot and Carteaud
- Tinea corporis/dermatophytosis
- Impetigo
- Secondary syphilis
- Mycosis fungoides
- Erythrasma
- Irritant contact dermatitis
- Allergic contact dermatitis
- Atopic dermatitis
- Epidermodysplasia verruciformis

For *Malassezia* Folliculitis:
- Acne vulgaris
- Bacterial folliculitis
- Steroid folliculitis
- Eosinophilic folliculitis
- Rosacea
- *Demodex* folliculitis

TABLE 161-4
Treatment Algorithm for Cutaneous *Malassezia* Infections

	FIRST LINE	SECOND LINE
Pityriasis versicolor	Shampoos (pyrithione zinc or selenium sulfide) Propylene glycol in aqueous solution Topical imidazoles (ketoconazole)	Oral fluconazole Oral itraconazole
Malassezia **folliculitis**	Topical antifungal ± keratolytic (propylene glycol)	Oral itraconazole

parenteral lipid infusions are at higher risk of disseminated infection, as discussed above.

MANAGEMENT

Table 161-4 summarizes the management of cutaneous *Malassezia* infections. For pityriasis versicolor, first-line treatments are topical and include shampoos (pyrithione zinc or selenium sulfide), propylene glycol in aqueous solution, and azole antifungal creams (ketoconazole is the most studied).[45] For particularly extensive involvement or disease refractory to topicals, oral antifungal medications, including fluconazole (300 mg for 2 doses 7 days apart) or itraconazole (200 mg daily for 7 days), are effective; however, fluconazole may be preferable because of its more variable bioavailability.[45,47] Ketoconazole, once a mainstay of treatment, is no longer recommended as on May 19, 2016, the U.S. Food and Drug Administration issued a statement warning against the use of oral ketoconazole for skin and nail fungal infections because of risk of liver damage and adrenal dysfunction.[48] Despite a complete mycologic cure, pigmentary changes (particularly hypopigmented patches) may take many months to resolve and patients should be counseled about appropriate expectations.

Given the high propensity for recurrence, prophylactic long-term treatment may be warranted in some patients; options include either periodic use of topical selenium sulfide shampoo or ketoconazole 2% shampoo, or itraconazole 200 mg twice daily 1 day per month for 6 months.[49]

For *Malassezia* folliculitis, given the presence of the fungus deep within the hair follicle, monotherapy with topical antifungals is of less reliable efficacy. The addition of a keratolytic such as propylene glycol may improve the efficacy of topical antifungal treatment.[45] Ultimately, many patients may require systemic treatment, with itraconazole being the best-studied treatment (200 mg daily for 1 to 3 weeks).[45]

REFERENCES

1. Arendorf TM, Walker DM. The prevalence and intra-oral distribution of *Candida albicans* in man. *Arch Oral Biol.* 1980;25:1-10.
2. Horn DL, Neofytos D, Anaissie EJ, et al. Epidemiology and outcomes of candidemia in 2019 patients: data from the prospective antifungal therapy alliance registry. *Clin Infect Dis.* 2009;48:1695-1703.
3. Barrett ME, Heller MM, Fullerton Stone H, et al. Dermatoses of the breast in lactation. *Dermatol Ther.* 2013;26:331-336.
4. Bahunuthula RK, Thappa DM, Kumari R, et al. Evaluation of role of Candida in patients with chronic paronychia. *Indian J Dermatol Venereol Leprol.* 2015;81:485-490.
5. Elewski BE. Onychomycosis: pathogenesis, diagnosis, and management. *Clin Microbiol Rev.* 1998;11:415-429.
6. Ameen M, Lear JT, Madan V, et al. British Association of Dermatologists' guidelines for the management of onychomycosis 2014. *Br J Dermatol.* 2014;171:937-958.
7. Grossman ME, Fox LP, Kovarik C, et al. *Cutaneous Manifestations of Infection in the Immunocompromised Host*. Berlin, Germany: Springer Science & Business Media; 2012.
8. Bae GY, Lee HW, Chang SE, et al. Clinicopathologic review of 19 patients with systemic candidiasis with skin lesions. *Int J Dermatol.* 2005;44:550-555.
9. Jarowski CI, Fialk MA, Murray HW, et al. Fever, rash, and muscle tenderness. A distinctive clinical presentation of disseminated candidiasis. *Arch Intern Med.* 1978;138:544-546.
10. Crum-Cianflone NF. Nonbacterial myositis. *Curr Infect Dis Rep.* 2010;12:374-382.
11. Adam MK, Vahedi S, Nichols MM, et al. Inpatient ophthalmology consultation for fungemia: prevalence of ocular involvement and necessity of funduscopic screening. *Am J Ophthalmol.* 2015;160:1078-1083.e2.
12. Shah CP, McKey J, Spirn MJ, et al. Ocular candidiasis: a review. *Br J Ophthalmol.* 2008;92:466-468.
13. Munro CA, Bates S, Buurman ET, et al. Mnt1p and Mnt2p of *Candida albicans* are partially redundant alpha-1,2-mannosyltransferases that participate in O-linked mannosylation and are required for adhesion and virulence. *J Biol Chem.* 2005;280:1051-1060.
14. Kashem SW, Kaplan DH. Skin immunity to *Candida albicans*. *Trends Immunol.* 2016;37:440-450.
15. Pichard DC, Freeman AF, Cowen EW. Primary immunodeficiency update: part II. Syndromes associated with mucocutaneous candidiasis and noninfectious cutaneous manifestations. *J Am Acad Dermatol.* 2015;73:367-381; quiz 381-382.
16. Drewniak A, Gazendam RP, Tool AT, et al. Invasive fungal infection and impaired neutrophil killing in human CARD9 deficiency. *Blood.* 2013;121:2385-2392.
17. Saunte DM, Mrowietz U, Puig L, et al. *Candida* infections in psoriasis and psoriatic arthritis patients treated with IL-17 inhibitors and their practical management. *Br J Dermatol.* 2017;177(1):47-62.
18. Patuwo C, Young K, Lin M, et al. The changing role of HIV-associated oral candidiasis in the era of HAART. *J Calif Dent Assoc.* 2015;43:87-92.
19. Alangaden GJ. Nosocomial fungal infections: epidemiology, infection control, and prevention. *Infect Dis Clin North Am.* 2011;25:201-225.
20. Clancy CJ, Nguyen MH. Finding the "missing 50%" of invasive candidiasis: how nonculture diagnostics will improve understanding of disease spectrum and transform patient care. *Clin Infect Dis.* 2013;56(9):1284-1292.
21. Jacobs MI, Magid MS, Jarowski CI. Disseminated candidiasis. Newer approaches to early recognition and treatment. *Arch Dermatol.* 1980;116:1277-1279.

22. Pappas PG, Kauffman CA, Andes DR, et al. Clinical practice guideline for the management of candidiasis: 2016 update by the Infectious Diseases Society of America. *Clin Infect Dis.* 2016;62:e1-e50.
23. Buergers R, Rosentritt M, Schneider-Brachert W, et al. Efficacy of denture disinfection methods in controlling *Candida albicans* colonization in vitro. *Acta Odontol Scand.* 2008;66:174-180.
24. Dahlan AA, Haveman CW, Ramage G, et al. Sodium hypochlorite, chlorhexidine gluconate, and commercial denture cleansers as disinfecting agents against *Candida albicans*: an in vitro comparison study. *Gen Dent.* 2011;59:e224-e229.
25. Tosti A, Piraccini BM, Ghetti E, et al. Topical steroids versus systemic antifungals in the treatment of chronic paronychia: an open, randomized double-blind and double dummy study. *J Am Acad Dermatol.* 2002;47:73-76.
26. Rigopoulos D, Gregoriou S, Belyayeva E, et al. Efficacy and safety of tacrolimus ointment 0.1% vs. betamethasone 17-valerate 0.1% in the treatment of chronic paronychia: an unblinded randomized study. *Br J Dermatol.* 2009;160:858-860.
27. Firinu D, Massidda O, Lorrai MM, et al. Successful treatment of chronic mucocutaneous candidiasis caused by azole-resistant *Candida albicans* with posaconazole. *Clin Dev Immunol.* 2011;2011:283239.
28. Harada K, Saito M, Sugita T, et al. *Malassezia* species and their associated skin diseases. J. *Dermatology.* 2015;42:250-257.
29. Findley K, Oh J, Yang J, et al. Topographic diversity of fungal and bacterial communities in human skin. *Nature.* 2013;498:367-370.
30. Ashbee HR, Leck AK, Puntis JW, et al. Skin colonization by *Malassezia* in neonates and infants. *Infect Control Hosp Epidemiol.* 2002;23:212-216.
31. Gupta AK, Bluhm R, Summerbell R. Pityriasis versicolor. *J Eur Acad Dermatol Venereol.* 2002;16:19-33.
32. Morishita N, Sei Y, Sugita T. Molecular analysis of *Malassezia* microflora from patients with pityriasis versicolor. *Mycopathologia.* 2006;161:61-65.
33. Durdu M, Güran M, Ilkit M. Epidemiological characteristics of *Malassezia* folliculitis and use of the May-Grünwald-Giemsa stain to diagnose the infection. *Diagn Microbiol Infect Dis.* 2013;76:450-457.
34. Akaza N, Akamatsu H, Sasaki Y, et al. *Malassezia* folliculitis is caused by cutaneous resident *Malassezia* species. *Med Mycol.* 2009;47:618-624.
35. Gelber JT, Cope EK, Goldberg AN, et al. Evaluation of *Malassezia* and common fungal pathogens in subtypes of chronic rhinosinusitis. *Int Forum Allergy Rhinol.* 2016;6:950-955.
36. Chang HJ, Miller HL, Watkins N, et al. An epidemic of *Malassezia pachydermatis* in an intensive care nursery associated with colonization of health care workers' pet dogs. *N Engl J Med.* 1998;338:706-711.
37. Baker RM, Stegink RJ, Manaloor JJ, et al. *Malassezia* pneumonia: a rare complication of parenteral nutrition therapy. *JPEN J Parenter Enteral Nutr.* 2016;40(8):1194-1196.
38. Chryssanthou E, Broberger U, Petrini B. *Malassezia pachydermatis* fungaemia in a neonatal intensive care unit. *Acta Paediatr.* 2001;90:323-327.
39. Barber GR, Brown AE, Kiehn TE, et al. Catheter-related *Malassezia furfur* fungemia in immunocompromised patients. *Am J Med.* 1993;95:365-370.
40. Saunders CW, Scheynius A, Heitman J. *Malassezia* fungi are specialized to live on skin and associated with dandruff, eczema, and other skin diseases. *PLoS Pathog.* 2012;8:e1002701.
41. Nazzaro-Porro M, Passi S. Identification of tyrosinase inhibitors in cultures of *Pityrosporum*. *J Invest Dermatol.* 1978;71:205-208.
42. Galadari I, el Komy M, Mousa A, et al. Tinea versicolor: histologic and ultrastructural investigation of pigmentary changes. *Int J Dermatol.* 1992;31:253-256.
43. Rubenstein RM, Malerich SA. *Malassezia (Pityrosporum)* folliculitis. *J Clin Aesthet Dermatol.* 2014;7:37-41.
44. Zhou H, Tang XH, De Han J, et al. Dermoscopy as an ancillary tool for the diagnosis of pityriasis versicolor. *J Am Acad Dermatol.* 2015;73, e205–206.
45. Hald M, Arendrup MC, Svejgaard EL, et al. Evidence-based Danish guidelines for the treatment of *Malassezia*-related skin diseases. *Acta Derm Venereol.* 2015; 95:12-19.
46. Mittal RR, Prasad D, Singh P. Comparative histopathology of pityriasis versicolor and *Pityrosporum* folliculitis. *Indian J Dermatol Venereol Leprol.* 1992;58:262.
47. Hu SW, Bigby M. Pityriasis versicolor: a systematic review of interventions. *Arch Dermatol.* 2010;146:1132-1140.
48. U.S. Food and Drug Administration (FDA). FDA drug safety communication: FDA warns that prescribing of Nizoral (ketoconazole) oral tablets for unapproved uses including skin and nail infections continues; linked to patient death. http://www.fda.gov/Drugs/DrugSafety/ucm500597.htm. Updated July 26, 2013. Accessed September 11, 2016.
49. Faergemann J, Gupta AK, Al Mofadi A, et al. Efficacy of itraconazole in the prophylactic treatment of pityriasis (tinea) versicolor. *Arch Dermatol.* 2002;138:69-73.

Chapter 162 :: Deep Fungal Infections

:: Roderick J. Hay

Deep fungal infections comprise 2 distinct groups of conditions: subcutaneous mycoses and systemic mycoses. Neither are common, and the subcutaneous mycoses, with some exceptions, are largely confined to the tropics and subtropics. In recent years, the systemic mycoses have become important opportunistic infectious complications in immunocompromised patients, including those with AIDS and patients receiving treatment for malignancies. They also include a group of primary respiratory tract infections, such as histoplasmosis and coccidioidomycosis, which may affect otherwise healthy individuals and those with underlying illness. The fungi that cause these respiratory tract infections are usually dimorphic or exist in a different morphologic phase (eg, yeast or mold) at different stages of their life cycle.

Patients with subcutaneous fungal infections often present to a physician with signs of skin involvement. By contrast, patients with systemic mycoses only occasionally have skin lesions, either following direct involvement of the skin as a portal of entry or after dissemination from a deep focus of infection. There are a number of excellent texts about fungi and the diseases they cause.[1-4]

Treatment of these conditions remains difficult in many cases, although there is now a wide range of antifungal drugs with different modes of action.

SUBCUTANEOUS MYCOSES

AT-A-GLANCE

Subcutaneous mycoses:

- Are usually sporadic.
- Are contracted in the tropics and subtropics.
- May cause chronic disability.
- Are best diagnosed by histopathology, except for sporotrichosis.
- Often require months of successful antifungal treatment.

The subcutaneous mycoses (Table 162-1), or mycoses of implantation, are infections caused by fungi that have been introduced directly into the dermis or subcutaneous tissue through a penetrating injury, such as a thorn prick. Although many are tropical infections, others, such as sporotrichosis, are also prevalent in temperate climates; any of these infections may present as an imported disease in a patient who has originated from an endemic area, sometimes after a lapse of many years. The most common subcutaneous mycoses are sporotrichosis, mycetoma, and chromoblastomycosis. Rarer infections include lobomycosis and subcutaneous mucormycosis.

SPOROTRICHOSIS

DEFINITIONS

Sporotrichosis is a subcutaneous or systemic fungal infection caused by the dimorphic fungus *Sporothrix*. Based on molecular techniques, there are now known to be at least 5 different species that vary in geographic distribution: *Sporothrix schenckii*, *Sporothrix brasiliensis*, *Sporothrix globosa*, *Sporothrix luriei*, and *Sporothrix mexicana*.[5,6]

HISTORICAL PERSPECTIVE

The fungus occurs in the natural environment, presumably in mold (cells growing in a chain) form, but develops as a yeast (cells growing as single cells) in infections. The most frequent site of this infection is the dermis or subcutis. There is also a systemic form of sporotrichosis whose clinical features range from pulmonary infection to arthritis or meningitis. One important characteristic of the diagnosis of cutaneous lesions is the scarcity of organisms in tissue, making confirmation of the diagnosis by microscopy potentially difficult.[6] Sometimes in tissue, fungal cells are surrounded by an eosinophilic refractile fringe, the asteroid body, that is a characteristic of the organism, although a similar phenomenon may occur with other infectious organisms (eg, *Schistosome* eggs).

EPIDEMIOLOGY

Infections occur in both temperate and tropical countries. They are seen in North, South, and Central America, including the southern United States and Mexico, as well as in Africa, Egypt, Japan, and Australia.[6] The countries where the highest rates of infection occur are Mexico, Brazil, and South Africa. However, sometimes hyperendemic areas are found where large numbers of cases occur.[7] In the United States, infections are most common in the midwestern river valleys. Infections are now rare in much of Europe. In nature, the fungus grows on decaying vegetable matter such as plant debris, leaves, and wood. Although it is usually a cause of sporadic infection, *Sporothrix* also may affect groups of workers exposed to the organism, such as those using straw as a packing material, gardeners,

TABLE 162-1
Summary of Subcutaneous Mycoses

SUBCUTANEOUS MYCOSES	CAUSATIVE AGENTS	EPIDEMIOLOGY	CLINICAL FEATURES	HISTOPATHOLOGY	TREATMENT
Sporotrichosis	*Sporothrix schenckii* *S. brasiliensisSporothrix brasiliensis* *Sporothrix globosa* *Sporothrix luriei* *Sporothrix mexicana*	North, South, Central Americas, including southern United States and Mexico, Africa, Egypt, Japan, Australia	Lymphangitic: dermal nodule that breaks down into a small ulcer Fixed: localized to one site, with granuloma formation and ulceration	Mixed granulomatous reaction with neutrophilic microabscesses Fungus is 3 to 5 μm, cigar-shaped or oval Distinctive asteroid body	Itraconazole 200 mg once daily Terbinafine 200 mg once daily treatment continued until 1 week after clinical resolution
					Saturated solution of potassium iodide (SSKI), 4 to 6 mL thrice daily × 3 to 4 weeks
Mycetoma (maduromycosis, Madura foot)	Fungal (eumycetoma) Filamentous bacteria (actinomycetoma): *Nocardia* sp. *Madurella mycetomatis* *Streptomyces somaliensis* *Scedosporium apiospermum*	Usually in dry tropical areas, such as Central America, Mexico, Sudan, and the Middle East	The foot, lower leg, or hand is commonly involved; may affect head or back Characterized by a firm, painless nodule that spreads slowly with development of papules and draining sinus tracts; later signs include local swelling, chronic sinus formation, and bone involvement	Chronic inflammatory reaction with neutrophil abscesses and scattered giant cells and fibrosis Grains found at center	*Eumycetoma:* Ketoconazole 200 mg Itraconazole 200 mg Voriconazole 200 to 400 mg daily × several months
					Actinomycetoma: Dapsone + streptomycin Sulfamethoxazole-trimethoprim + rifampin or streptomycin
					Surgery, either local dissection or (in severe cases) amputation
Chromoblastomycosis (chromomycosis)	*Philaophora verrucosa* *Fosecaea pedrosoi* *Fonsecaea compactum* *Wangiella dermatitidis* *Cladophialophora carrionii*	Central and South America, Caribbean, Africa, South Asia, Australasia, Japan	The feet, legs, arms, or upper trunk are commonly involved Begins as a slowly expanding warty papule; may be a plaque-like lesion with an atrophic center. May develop satellite lesions from autoinoculation	Mixed granulomatous response, with small neutrophilic abscesses and exuberant epidermal hyperplasia The organism may appear singly or in small groups of brown-pigmented cells	Itraconazole 200 mg once daily *or* Terbinafine 250 mg once daily *or* IV amphotericin B (up to 1 mg/kg/day) Treatment continued for several months, until clinical resolution
					Surgery only as an adjunct to medical treatment; lesions can be spread by surgery

Phaeohyphomycosis (phaeomycotic cyst, cystic chromomycosis)	*Exophiala jeanselmei* *Wangiella dermatitidis*	More common in the tropics	Lesions present as cysts.	Cyst wall consists of palisades of macrophages and other inflammatory cells surrounded by a fibrous capsule; fungal hyphae may be found in the macrophage zone	Surgical excision advised, but relapse may occur
Lobomycosis (keloidal blastomycosis, Lobo disease)	*Lacazia loboi*	Central and tropical South America	Usually exposed areas such as legs, arms, and face; may spread by autoinoculation Characterized by keloid-like lesions	Large, pop-bead organisms within histiocytes and multinucleated giant cells	Antifungal therapy is not effective Surgical removal is the main treatment
Subcutaneous mucormycosis	*Basidiobolus ranarum* (*Basidiobolus haptosporus*)	South America, Africa, Indonesia	Develop around limb-girdle sites A firm, slowly spreading woody cellulitis	Chronic granulomatous response with many eosinophils; fungi are present as large, strap-like hyphae without cross walls or septa Splendore-Hoeppli phenomenon	Ketoconazole 400 mg daily Itraconazole 100 to 200 mg daily Treatment with SSKI (similar to sporotrichosis treatment)
	Conidiobolus coronatus		Facial involvement, beginning in the inferior nasal turbinates and spreading to the central part of the face; swelling is hard and painless		
Rhinosporidiosis	*Rhinosporidium seeberi*	Southern India, Sri Lanka, South America, the Caribbean, and South Africa	The nasal mucosa is the main affected site; conjunctival mucosa also may be susceptible Characterized by polyps studded with white flecks	Large sporangia or spore sacs in different phases of development	Surgical excision is the only treatment

forestry workers, and those whose recreational activities bring them into contact with plant debris. A recent outbreak of sporotrichosis in Brazil (mainly caused by *S. brasiliensis*) has accentuated the role of exposure to other sources of infection, in this domestic or feral cats. The organism is thought to be introduced into the skin through a local injury.

CLINICAL FEATURES

Cutaneous Findings: The 2 clinical varieties of sporotrichosis are the subcutaneous and systemic forms of disease.[5,8,9] Subcutaneous sporotrichosis is by far the more common and includes 2 main forms: (a) lymphangitic and (b) fixed infections. The lymphangitic form is the more common and usually develops on exposed skin sites such as hands or feet. The first sign of infection is the appearance of a dermal nodule that breaks down into a small ulcer. Draining lymphatics become inflamed and swollen, and a chain of soft secondary nodules develops along the course of the lymphatic (Fig. 162-1); these also may break down and ulcerate. In the fixed variety, which accounts for approximately 15% of cases, the infection remains localized to 1 site, such as the face, and a granuloma develops that subsequently may ulcerate. Satellite nodules or ulcers may form around the rim of the primary lesion. Other clinical variants of subcutaneous sporotrichosis may mimic mycetoma, lupus vulgaris, and chronic venous ulceration. In some cases, deep extension of the infection may affect joints or tendon sheaths. Patients with AIDS who develop sporotrichosis often have multiple cutaneous lesions[9] without prominent lymphatic involvement, but deep infections, such as arthritis, are also reported.

Noncutaneous Findings: In the much rarer systemic form of sporotrichosis, lesions can develop almost anywhere, although chronic lung nodules, with cavitation, arthritis, and meningitis have been described most frequently. These may coexist with cutaneous lesions of sporotrichosis.

Figure 162-1 Sporotrichosis. An ulcerated nodule is seen on the thumb, with proximal lymphangitic spread represented by subcutaneous nodules. (Used with permission from Takeji Nishikawa, MD.)

DIAGNOSIS

Laboratory Testing: The best sources of diagnostic material are smears, exudates, and biopsies. *Sporothrix* is seen very rarely in direct microscopic examination because yeasts are usually present only in small numbers; the organism can be isolated readily on Sabouraud agar. In primary culture, the fungus grows as a mold, with compact, white colonies that darken with age. Microscopically, the hyphae produce small oval or triangular conidia either on specialized hyphae or elsewhere on the mycelium. Ideally, the organism should be converted to yeast phase on enriched media such as brain-heart infusion agar at 37°C (98.6°F) to complete the identification.

Pathology: Pathologically, sporotrichosis causes a mixed granulomatous reaction with neutrophil microabscesses. The fungus, if present, is usually in the form of small (3 to 5 μm) cigar-shaped or oval yeasts that may, on occasion, be surrounded by a thick, radiating eosinophilic fringe forming the distinctive asteroid body. Organisms are usually sparsely distributed in lesions, and it may be necessary to scan several sections to identify a single yeast. An intradermal sporotrichin skin test is available in some countries and may have a role to play in allowing the physician to identify the most appropriate laboratory investigations to instigate.

DIFFERENTIAL DIAGNOSIS

Conditions commonly confused with sporotrichosis are mycobacterial (see Chap. 157) and primary cutaneous *Nocardia* infections (see Chap. 158) and leishmaniasis (see Chap. 178). The nontuberculous mycobacterial infection caused by *Mycobacterium marinum* (fish-tank granuloma), in particular, closely resembles lymphangitic sporotrichosis.

CLINICAL COURSE AND PROGNOSIS

With the correct treatment, cases of sporotrichosis resolve readily, but untreated they can persist for more than 3 years.

MANAGEMENT

Interventions: Although spontaneous remissions may occur, most patients are treated with antifungal chemotherapy.[10] Treatments include itraconazole (200 mg daily) and terbinafine (250 mg daily), which are better tolerated, and intravenous amphotericin B for deep infection; as of this writing there has been little experience with voriconazole or posaconazole. In all cases, treatment is continued for at least 1 week after clinical resolution. A cheaper alternative is potassium iodide (saturated solution), 4 to 6 mL thrice daily, which is effective in the cutaneous types of sporotrichosis and should be continued for 3 to 4 weeks after clinical cure. The daily dose is built up slowly from

1 mL thrice daily over 2 to 3 weeks to avoid side effects such as hypersalivation and nausea. This is an inexpensive form of therapy, but it is unpalatable.

Prevention: There is no preventive management.

MYCETOMA (MADUROMYCOSIS, MADURA FOOT)

DEFINITIONS

Mycetoma is a chronic localized infection caused by different species of fungi or actinomycetes. It is characterized by the formation of aggregates of the causative organisms, known as *grains* that are found within abscesses. These either drain via sinuses onto the skin surface or involve adjacent bone, causing a form of osteomyelitis. Grains are discharged onto the skin surface via these sinuses. The disease advances by direct spread, and distant metastatic sites of infection are very rare. Mycetomas caused by species of fungi are known as *eumycetomas*, and those caused by aerobic actinomycetes or filamentous bacteria are known as *actinomycetomas* (see Chap. 158). The organisms are usually soil or plant saprophytes[11] that are only incidental human pathogens.

HISTORICAL PERSPECTIVE

Mycetoma has been designated a neglected tropical disease by the World Health Organization.[12]

EPIDEMIOLOGY

Mycetomas are mainly, but not exclusively, found in the dry tropics where there is low annual rainfall.[11,12] They are sporadic infections that are seldom common, even in endemic areas.[13] Occasionally, nonimported cases are reported from temperate climates, although in these cases, the most common organism is *Scedosporium apiospermum*. Actinomycetomas caused by *Nocardia* sp. are most common in Central America and Mexico. In other parts of the world, the most common organism is a fungus, *Madurella mycetomatis*. The actinomycete *Streptomyces somaliensis* is isolated most often from patients originating from Sudan and the Middle East. The causative organisms of mycetoma have been isolated or detected by molecular methods from either soil or plant material, including Acacia thorns, in endemic areas.

The organisms are implanted subcutaneously, usually after a penetrating injury. It is unusual to find any underlying predisposition in patients with mycetoma, and the persistence of the organism after the initial inoculation appears to be related to its ability to evade host defenses through a variety of adaptations, such as cell-wall thickening and melanin deposition.[14]

Figure 162-2 Mycetoma. Brawny edema and crusted papules on the plantar surface.

CLINICAL FEATURES

Cutaneous Features: The clinical features of both fungal and actinomycete mycetomas are very similar.[12] They are most common on the foot, lower leg, or hand, although head or back involvement also may occur. Infection of the chest wall is most characteristic of *Nocardia* infections (see Chap. 158). The earliest stage of infection is a firm, painless nodule that spreads slowly with the development of papules and draining sinus tracts over the surface (Fig. 162-2).

Complications: Local tissue swelling, chronic sinus formation, and later bone involvement distort and deform the original site of infection (Figs. 162-3 and 162-4). Lesions are seldom painful except in the late stages and where sinus tracts are about to emerge onto the skin surface.

Noncutaneous Findings: Dissemination from the initial site is exceptionally rare, although local lymphadenopathy may occur.

Figure 162-3 Eumycetoma caused by *Scedosporium* leading to significant distortion of the forefoot.

Figure 162-4 Mycetoma. Chronic fibrotic involvement of the foot with lymphatic spread to the popliteal fossa.

DIAGNOSIS

Laboratory Testing: Finding the mycetoma grains is the key to establishing the diagnosis, and these are generally discharged from the openings of sinus tracts. However, they also may be obtained by removing the surface crust from a pustule or sinus tract with a sterile needle and gently squeezing the edges. Grains are 250- to 1000-µm white, black, or red particles that can be seen with the naked eye (Table 162-2). Direct microscopy of grains is important because it will show whether the grain is composed of the small actinomycete or broader fungal filaments. In general, it is not possible to distinguish the fine actinomycete filaments in potassium hydroxide (KOH) mounts or, for that matter, in hematoxylin-and-eosin–stained material. In addition, black grains are always caused by fungi; red grains, by actinomycetes (Table 162-2).

Final identification requires isolation of the causal agent in culture. In view of the number of possible species, a series of different culture media and conditions of incubation should be used. Morphologic and physiologic characteristics are used to distinguish between the genera and species. There are now a few examples where the organism has been identified using specific primers through use of the polymerase chain reaction (PCR). Serology is diagnostically helpful only in some cases (eg, in *S. somaliensis)*, and even then, more as a guide to therapeutic response. In a few centers, molecular tools are used to identify organisms and this has resulted in changes in their nomenclature (see Table 162-2).

Pathology: Histologically, there is a chronic inflammatory reaction with neutrophil abscesses and scattered giant cells and fibrosis.[11] Grains are found in the center of the inflammation. Their size and shape may help in the identification, although with nonpigmented (pale or white grain) eumycetomas, this is seldom sufficient (Fig. 162-5).

Imaging: X-ray changes include periosteal erosion and proliferation, as well as the development of lytic lesions in the bone. Bone scans or MRI may identify bone lesions and soft-tissue changes at an earlier stage.

TABLE 162-2

Macroscopic and Histopathologic Features of Mycetoma Grains[a]

ORGANISMS	HEMATOXYLIN AND EOSIN SECTION APPEARANCES
Eumycetoma	
Dark grains	
Madurella mycetomatis, Madurella fahalii, M. sudanensis	Cement present, vesicles sometimes prominent
Trematosphaeria grisea	Cement absent, compact outer layer
Falciformispora senegalensis	Cement in outer zone, dark periphery with vesicular center
Exophiala jeanselmei	Cement absent, often hollow
Medicopsis romeroi	Cement lacking, compact outer layer
Pale grains	
Fusarium sp., Acremonium, Scedosporium apiospermum, Aspergillus nidulans, Neotestudina rosati	Compact, pigment lacking, interwoven fungal filaments (*Scedosporium apiospermum* may have prominent vesicles)
Actinomycetoma	
Pale (white to yellow) grains	
Actinomadura madurae	Basophilic-stained fringe in layers
Nocardia brasiliensis	Small, pale blue, eosinophilic fringe
Yellow to brown grains	
Streptomyces somaliensis	Grains fractured, basophilic, or pink
Red to pink grains	
Actinomadura pelletieri	Small, basophilic layers

[a]Helpful rules of thumb:

- Black or dark grains are always produced by fungi;
- Red grains are always produced actinomycetes;
- But pale (white) grains may be produced by either fungi or actinomycetes.

DIFFERENTIAL DIAGNOSIS

Chronic bacterial or tuberculous osteomyelitis may resemble mycetoma. Actinomycosis (see Chap. 158) is also similar but usually develops close to certain sites, such as the mouth or the cecum, where the causative organisms are sometimes commensal.

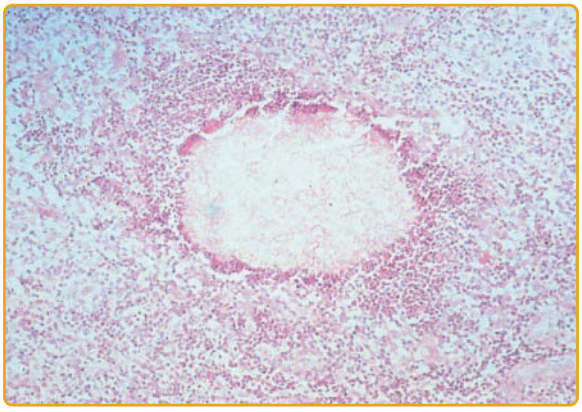

Figure 162-5 Pale eumycetoma grain (hematoxylin-and-eosin stain).

CLINICAL COURSE AND PROGNOSIS

There is no spontaneous remission.

MANAGEMENT

Medications: Of the fungal causes of mycetoma, some cases of *M. mycetomatis* infection respond to ketoconazole 200 mg, itraconazole 200 mg, or voriconazole 200 to 400 mg daily over several months. For the others, a trial of therapy with griseofulvin or terbinafine is worth attempting. However, responses to chemotherapy are unpredictable, although antifungals may slow the course of infection.

Actinomycetomas (see Chap. 158) generally respond to antibiotics such as a combination of dapsone with streptomycin or sulfamethoxazole-trimethoprim plus rifampin or streptomycin. Amikacin, moxifloxacin, or imipenem also may be used in recalcitrant *Nocardia* infections. The responses in all but a few cases are good.[15]

Procedures: Surgery, usually amputation, is the definitive procedure and may have to be used in advanced cases. However, in defined lesions surgical dissection following antifungal therapy can produce excellent results.[15]

Prevention: Diagnosis of early lesions will form part of a new targeted strategy for mycetoma.

CHROMOBLASTOMYCOSIS (CHROMOMYCOSIS)

DEFINITIONS

Chromoblastomycosis is a chronic fungal infection of the skin and subcutaneous tissues caused by pigmented (dematiaceous) fungi that are implanted into the dermis from the environment. In the ensuing inflammation, they form thick-walled single cells or cell clusters (sclerotic or muriform bodies), and these may elicit a marked form of pseudoepitheliomatous hyperplasia, which is often accompanied by transepidermal elimination of organisms.

HISTORICAL PERSPECTIVE

The infection can be caused by a number of different pigmented fungi, the most common being *Phialophora verrucosa*, *Fonsecaea pedrosoi*, *Fonsecaea compactum*, *Wangiella dermatitidis*, and *Cladophialophora carrionii*.[16]

EPIDEMIOLOGY

The fungi that cause chromoblastomycosis can be isolated in the environment from wood, plant debris, or soil.[17] The majority of infections are caused by *F. pedrosoi* and *C. carrionii*. As with other subcutaneous mycoses, infection follows implantation through a tissue injury. The infection is found as a sporadic condition in Central and South America, and rarely in North America. It occurs in the Caribbean region, Africa (particularly Madagascar), South Asia, Australasia, and Japan. It also may occur as an imported infection outside the usual endemic areas. The disease is most frequent in male rural workers.

CLINICAL FEATURES

Cutaneous Findings: The initial site of the infection is usually on the feet, legs, arms, or upper trunk. The clinical features vary.[17] The initial lesion is often a warty papule that expands slowly over months or years (Figs. 162-6 and 162-7). Alternatively, lesions may be plaque-like with an atrophic center. The more common verrucous form spreads slowly and locally. Individual lesions may be very thick and often develop secondary bacterial infection. Satellite lesions around the initial site of infection are local extensions of the infection and usually are produced by scratching.

Complications: Complications of chromoblastomycosis include local lymphedema, leading to elephantiasis and squamous cell carcinomas in some chronic lesions.

DIAGNOSIS

Laboratory Testing: The typical sclerotic or muriform fungal cells can be seen in skin scrapings taken from the surface of lesions, particularly areas

Figure 162-6 Chromoblastomycosis. A solitary, large, verrucous plaque surrounded by a halo of erythema is seen on the calf. (Used with permission from Ted Rosen, MD, and Howard Rubin, MD.)

Figure 162-7 Closeup view of chromoblastomycosis. Note hyperkeratosis with pigmentation.

where there is a small, dark spot on the skin surface, using KOH mounts.

In culture, these fungi are very similar in gross macroscopic appearance, producing black colonies with a downy surface. Their cultural identification depends on demonstrating the presence of different but specific types of sporulation, and either single or multiple sporulation mechanisms may be seen in each organism. Accurate differentiation between the different fungi may be difficult. At this stage, the choice of treatment does not depend critically on correct identification of the organisms, although there may be differences in the speed of response to azole drugs (see section "Management (mycetoma)").

Pathology: The lesions also should be biopsied because the pathologic changes and presence of muriform cells are typical. The histology shows a mixed granulomatous response, with small neutrophil abscesses and often exuberant epidermal hyperplasia.[18] The organisms, which are often seen either in giant cells or in neutrophil abscesses, appear singly or in small groups of brown pigmented cells, often with a single or double septum and thick cell wall.

DIFFERENTIAL DIAGNOSIS

The disease must be differentiated from podoconiosis or chronic tropical lymphedema with hyperplasia (mossy foot), which is a result of a reaction to soil microparticles. Other chronic verrucous lesions, such as tuberculosis, sporotrichosis, and blastomycosis, should also be considered. The identification of organisms in the lesions of chromoblastomycosis is essential.

CLINICAL COURSE AND PROGNOSIS

There is no spontaneous remission.

MANAGEMENT

Medications: The main treatments for chromoblastomycosis are itraconazole, 200 mg daily[19]; terbinafine, 250 mg daily[20]; and, in extensive cases, IV amphotericin B (up to 1 mg/kg daily). The responses of these fungi to different antifungal agents do not appear to differ significantly, although there is some evidence that *C. carrionii* responds more rapidly to terbinafine and itraconazole. In any event, treatment is continued until there is clinical resolution of lesions, which usually takes several months. Extensive lesions often respond poorly to conventional treatment and combinations of antifungal drugs, for example, amphotericin B and flucytosine or itraconazole and terbinafine, have been used.

Procedures: Lesions can be spread by surgery, which should be used only as an adjunctive therapy after drug treatment. The local application of heat might be helpful in some instances.

PHAEOHYPHOMYCOSIS (PHAEOMYCOTIC CYST, CYSTIC CHROMOMYCOSIS)

Phaeohyphomycosis is a rare infection characterized by the formation of subcutaneous inflammatory cysts or plaques. It is caused by dematiaceous fungi, the most common of which are *Exophiala jeanselmei* and *W. dermatitidis*, but some 103 species have been described as causal agents.[21] However, unlike in chromoblastomycosis, these organisms form short, irregular, pigmented hyphae in tissue. The infection may occur in any climatic area, although it is more common in the tropics. It also may appear in immunosuppressed patients, particularly those receiving long-term glucocorticoid therapy. The lesions present as cysts and may be mistaken for other similar structures, such as synovial or Baker cysts. The diagnosis is usually made after surgical excision. Histologically, the cyst wall consists of palisades of macrophages and other inflammatory cells surrounded by a fibrous capsule, and the fungal hyphae are found in the macrophage zone. Although the fungi in tissue lesions are usually pigmented, this is not always the case; cystic lesions caused by nonpigmented fungi are called *hyalohyphomycotic cysts*. The treatment is surgical excision, although relapse can occur, particularly in immunocompromised patients.

LOBOMYCOSIS (KELOIDAL BLASTOMYCOSIS, LOBO DISEASE)

Lobomycosis is an uncommon infection seen in Central and tropical South America, often in remote rural areas. The source of the organism is unknown,

although similar lesions have been found on freshwater dolphins. Lobomycosis is characterized by the appearance of keloid-like skin lesions on exposed sites.[22] Although it cannot be cultured in vitro, it is caused by a fungus, *Lacazia loboi*, that forms chains of rounded cells in tissue, each joined by a small tubule. Lesions may occur anywhere on the body but usually are found on exposed parts such as the legs, arms, and face. They can spread from site to site by autoinoculation. Antifungal drugs are not effective, and surgical removal is the main treatment.

SUBCUTANEOUS MUCORMYCOSIS (BASIDIOBOLOMYCOSIS, SUBCUTANEOUS PHYCOMYCOSIS, AND CONIDIOBOLOMYCOSIS, [RHINO]-ENTOMOPHTHOROMYCOSIS]

Subcutaneous mucormycosis is a rare tropical subcutaneous mycosis characterized by the development and spread of a chronic, firm, swelling involving subcutaneous tissue. There are 2 main varieties caused by different organisms.[23] The first, most often caused by *Basidiobolus ranarum* (*Basidiobolus haptosporus*), is more common in children. It occurs in a wide variety of countries and environments from South America to Africa and Indonesia. The organism can be found in plant debris and in the intestinal tracts of reptiles and amphibians. Lesions usually develop around limb girdle sites and present with a firm, slowly spreading, woody cellulitis. The second form, caused by *Conidiobolus coronatus*, is seen in adults. The organism can be isolated from soil, plant debris, and some insects. The early infection starts in the region of the inferior turbinates of the nose. Spread involves the central part of the face, and once again, the swelling is hard and painless. It may cause very severe deformity of the nose, lips, and cheeks. These infections are distinct to those caused by related fungi.

Histopathologically, a chronic granulomatous response with large numbers of eosinophils can be seen. The fungi are present as large, strap-like hyphae without cross walls or septa. They are also often surrounded by refractile eosinophilic material (Splendore-Hoeppli phenomenon). The organisms can be cultured readily on Sabouraud agar. Ketoconazole (400 mg daily) and itraconazole (100 to 200 mg daily) also may be useful in this condition, although experience as of this writing is limited to a few cases. Lesions also respond to oral treatment with potassium iodide, given in similar doses to those used in sporotrichosis (see "Management" under "Sporotrichosis").

RHINOSPORIDIOSIS

Rhinosporidiosis is a chronic infection caused by the organism *Rhinosporidium seeberi*, which causes the development of polyps affecting the mucous membranes. The organism has never been cultured, and it is now thought to be an aquatic protist and a member of the Mesomycetozoea. Rhinosporidiosis is seen most often in Southern India and Sri Lanka. Cases also have been described in South America, the Caribbean, and South Africa. Exposure to water (lakes, pools) is associated with the infection. The main site affected is the nasal mucosa, but the conjunctival mucosa also may be affected.[24] The infection causes the development of polyps that are studded with white flecks; these are small cysts or sporangia containing small spores. These are best seen in histopathologic sections, where the large sporangia or spore sacs in different phases of development are readily seen. The only treatment is surgical excision.

SYSTEMIC MYCOSES

AT-A-GLANCE

- Where the patient has lived or visited is important for diagnosis of systemic mycoses.
- History of underlying disease states and their treatment is critical.
- Erythema nodosum may be caused by some endemic mycoses (eg, coccidioidomycosis).
- Skin biopsy is important in making the diagnosis.
- Positive fungal culture must be interpreted with caution, as the organism identified may simply be colonizing the site.
- Warn the laboratory if you are sending material from a suspected endemic mycosis case for culture, as these are dangerous pathogens and require containment facilities.
- Treatment may require prolonged therapy with IV drugs such as amphotericin B, voriconazole, and caspofungin.

The systemic mycoses are fungal infections whose initial portal of entry into the body is usually a deep site such as the lung, GI tract, or paranasal sinuses. They have the capacity to spread via the bloodstream to produce a generalized infection. In practice, there are 2 main varieties of systemic mycosis: (a) the opportunistic mycoses and (b) the endemic respiratory mycoses.

The chief opportunistic systemic mycoses seen in humans are systemic or deep candidiasis, aspergillosis, and systemic zygomycosis. These affect patients with severe underlying disease states, such as AIDS, or with neutropenia associated with malignancy, as well

TABLE 162-3
Underlying Predisposition and Opportunistic Systemic Mycoses

PREDISPOSITION	INFECTION
Neutropenia (whatever cause) functional neutrophil defects	Aspergillosis, oropharyngeal, and/or systemic candidiasis, mucormycosis, infections caused by rare organisms
CD4 lymphopenia (eg, AIDS)	Oropharyngeal candidiasis, cryptococcosis, and endemic respiratory mycoses such as histoplasmosis, nocardiosis
Biologic therapy (eg, anti–tumor necrosis factor or anti–interferon-γ)	Endemic mycoses (eg, histoplasmosis, coccidioidomycosis, *Talaromyces* infection)
Diabetes mellitus	Mucormycosis
Heart valve surgery	Various but mainly *Candida albicans* and non-*albicans Candida* sp.
Abdominal surgery	Candidiasis

as recipients of solid-organ transplantations, immunomodulating biologic therapies, or extensive surgery. With the use of combination antiretroviral therapy, the incidence of systemic mycoses in patients infected with HIV has dropped considerably. In the neutropenic patient in particular, other fungi also may cause infection occasionally. Different underlying conditions predispose to different mycoses; Table 162-3 outlines a scheme for this. Generally, skin involvement is not common with most of these opportunistic infections, which can occur in any climate and environment. The clinical manifestations of the opportunistic mycoses are also variable because they depend on the site of entry of organism and the underlying disease.

The endemic respiratory mycoses are histoplasmosis (classic and African types), blastomycosis, coccidioidomycosis, paracoccidioidomycosis, and infections due to *Talaromyces marneffei*. The clinical manifestations of these infections are affected by the underlying state of the patient, and many develop in the presence of particular immunodeficiency states, notably AIDS. However, they follow similar clinical patterns in all infections. These infections also may affect otherwise healthy individuals. They have well-defined endemic areas determined by factors that favor the survival of the causative organisms in the environment, such as climate. The usual route of infection is via the lung (Fig. 162-8).

In practice, because of the tendency for both groups of infections to develop in predisposed patients, the distinction between opportunistic and endemic

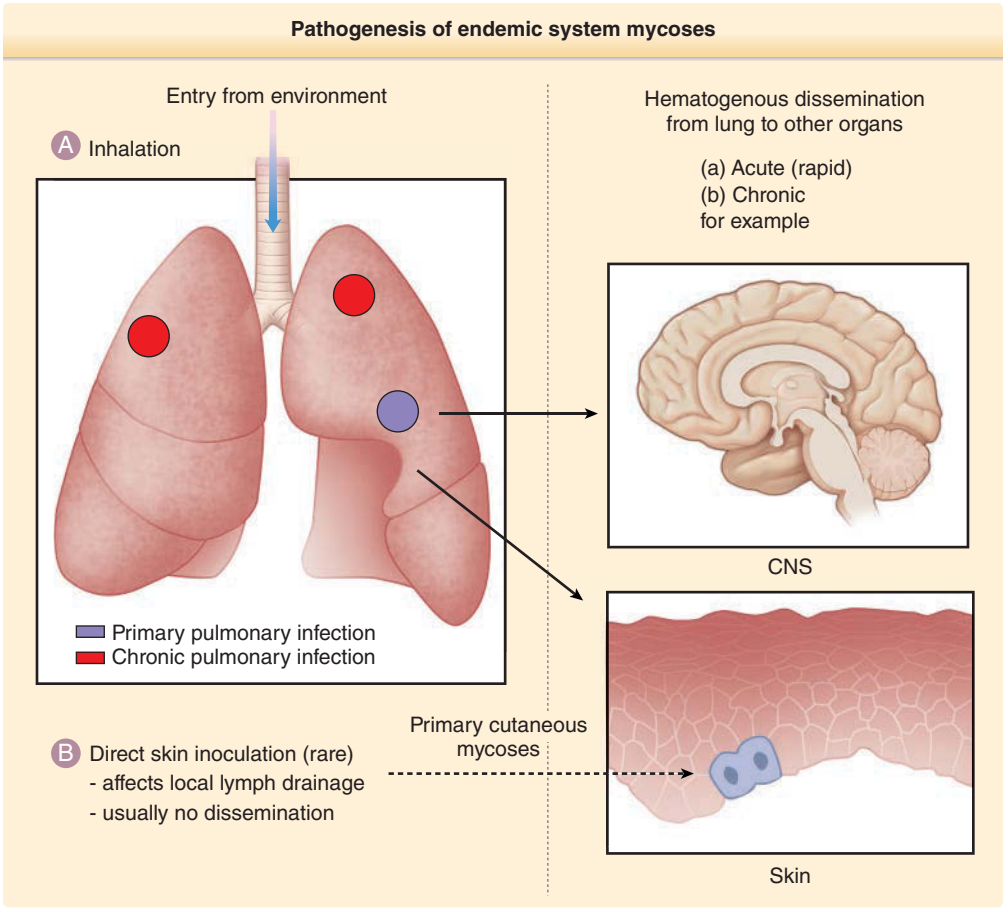

Figure 162-8 The route of infection and dissemination to the skin of the endemic (respiratory) mycoses.

mycoses is blurred. This is particularly the case with cryptococcosis, which shares clinical and pathologic features of the 2 main types of respiratory systemic mycoses but is mainly seen now in untreated AIDS patients.

HISTOPLASMOSIS

DEFINITION

Fungi of the dimorphic genus *Histoplasma* cause a number of different infections in animals and humans. These range from equine farcy, or equine histoplasmosis, a disseminated infection of horses caused by *Histoplasma farciminosum* to 2 human infections known as (a) classic or small-form histoplasmosis and (b) African histoplasmosis. These are caused, respectively, by 2 variants of *Histoplasma capsulatum*: (1) *H. capsulatum* var. *capsulatum* and (2) *H. capsulatum* var. *duboisii*. They can be distinguished because their respective yeast phases differ in size, the *capsulatum* variety producing cells from 2 to 5 µm in diameter and the *duboisii* form producing cells of 10 to 15 µm in diameter. The other important differences are in their epidemiology and clinical manifestations. They also show minor antigenic differences that are apparent in serodiagnosis but their mycelial phases are identical.

HISTORICAL PERSPECTIVE

The 2 types of human infections are referred to here as histoplasmosis and African histoplasmosis because this nomenclature is used most widely.

SMALL-FORM OR CLASSIC HISTOPLASMOSIS OR HISTOPLASMOSIS CAPSULATI

DEFINITIONS

Histoplasmosis results from infection with the dimorphic fungus *H. capsulatum* var. *capsulatum*. A sexual state of this fungus, *Ajellomyces capsulatus*, also has been described. The infection starts as a pulmonary infection that, in most individuals, is asymptomatic and heals spontaneously, the only evidence of exposure being the development of a positive intradermal skin test reaction to a fungal antigenic extract, histoplasmin.[25] However, there is, in addition, a symptomatic disease that includes respiratory tract infections and acute or chronic pulmonary histoplasmosis, as well as a disseminated infection that may spread to affect the skin or mucous membranes. Direct inoculation into the skin may occur as a result of a laboratory accident.

EPIDEMIOLOGY

Histoplasmosis occurs in many countries from the Americas to Africa, India, and the Far East. In the United States, it is endemic in the Mississippi and Ohio River valleys, where often more than 80% of the population may have acquired the infection asymptomatically. Exposure rates are usually lower in all other endemic areas, although high rates are also found in northern South America and some Caribbean islands. Histoplasmosis is not found in Europe. *H. capsulatum* is an environmental organism that can be isolated from soil, particularly when it is contaminated with bird or bat excreta. The disease is acquired by inhalation of spores, and epidemics of respiratory tract infection may occur in persons exposed to a spore-laden environment when exploring caves or cleaning sites heavily contaminated with bird droppings, such as bird roosts or barns. Although any person can acquire histoplasmosis through inhalation, it causes a distinctive disseminated infection in patients with disease affecting cellular immune capacity, such as AIDS or lymphoma.[26,27]

CLINICAL FEATURES

The spectrum of histoplasmosis includes both asymptomatic and benign symptomatic infections, and a progressive disseminated variety with bloodstream spread to multiple organs.[25] Skin lesions may develop as a result of immune-complex formation in the primary infection (erythema multiforme) or from direct spread after dissemination from the lungs; rarely, infections may develop at a point of inoculation into the skin.

Asymptomatic forms of histoplasmosis are, by definition, without signs or symptoms, but those exposed usually have a positive histoplasmin skin test. The percentage of skin test reactors in the community indicates the chances of exposure, and, in endemic areas, this may range from 5% to 90%. Occasionally, asymptomatic pulmonary nodules removed at surgical exploration or autopsy are found to contain *Histoplasma*.

Acute Pulmonary Histoplasmosis: In acute pulmonary histoplasmosis, patients are often exposed to large quantities of spores such as may be encountered in a cave or after cleaning a bird-infested area. Patients present with cough, chest pain, and fever, often with accompanying joint pains and rash—toxic erythema, erythema multiforme, or erythema nodosum. These skin rashes are not common, occurring in fewer than 15% of patients, but they may be precipitated by treatment of the acute infection. On chest radiography, there is often diffuse mottling, which may calcify with time.

Chronic Pulmonary Histoplasmosis: Chronic pulmonary histoplasmosis usually occurs in adults and presents with pulmonary consolidation and cavitation, closely resembling tuberculosis. Skin involvement is not seen.

Acute Progressive Disseminated Histoplasmosis: In patients with acute disseminated histoplasmosis, there is widespread dissemination to other organs, such as the liver and spleen, lymphoreticular system, and bone marrow. Patients present with progressive weight loss and fever. This form is the type that is most likely to occur in untreated AIDS patients, who often develop skin lesions as a manifestation of disseminated infection (Fig. 162-9).[28] There are papules, small nodules, or small molluscum-like lesions that subsequently may develop into shallow ulcers. These skin lesions are more common in HIV-positive patients than in others with disseminated histoplasmosis. Diffuse micronodular pulmonary infiltrates also may develop. Patients have progressive and severe weight loss, fever, anemia, and hepatosplenomegaly.

The distinction between acute and chronic dissemination in histoplasmosis is somewhat artificial because these merely represent extremes of behavior, with progression occurring over a few months, on the one hand, and over several years, on the other. Intermediate forms occur, and other organs such as the meninges and heart may be affected.

Chronic Progressive Disseminated Histoplasmosis: Chronic disseminated histoplasmosis may appear months or years after a patient has left an endemic area. The most common clinical presenting features are oral or pharyngeal ulceration, hepatosplenomegaly, or adrenal insufficiency (Addison disease) resulting from adrenal infiltration. The mouth ulcers are often large, irregular, and persistent, and may affect the tongue as well as the buccal mucosa. The patients otherwise may appear well, but it is important to investigate for evidence of infection elsewhere (eg, by abdominal CT scan). Adrenal infection in particular should be excluded.

Figure 162-9 Histoplasmosis, disseminated. Multiple erythematous keratotic papules and small plaques resembling guttate pattern psoriasis are seen on the chest and arm of a man with advanced HIV disease. (Used with permission from J. D. Fallon, MD.)

Primary Cutaneous Histoplasmosis: Primary cutaneous histoplasmosis is rare and follows inoculation of the organism into the skin, for instance, after accidental laboratory-acquired or postmortem room-acquired infection. The primary lesion is a nodule or indurated ulcer, and there is often local lymphadenopathy.

DIAGNOSIS

Laboratory Testing: The diagnosis of histoplasmosis is established by identifying the small intracellular yeast-like cells of *Histoplasma* in sputum, peripheral blood, bone marrow, or biopsy specimens. *Histoplasma* must be separated from *T. marneffei* because the 2 organisms are of a similar size, although the latter shows characteristic septa formation. The identity of the organism should be confirmed by culture; it grows as a mold at room temperature. The white, cottony colonies develop at room temperature on Sabouraud glucose agar to produce 2 types of spores, the larger (8 to 15 µm in diameter), rounded, tuberculate macroconidia being typical; the smaller microconidia are infectious. Confirmation of the identity should be obtained by demonstrating ribosomal RNA using a DNA probe. Mycelial-phase cultures of *H. capsulatum* are very infectious, and laboratories receiving specimens should be warned about the suspected diagnosis.

The intradermal histoplasmin skin test is an epidemiologic tool that is of no help in diagnosis. In patients with disseminated histoplasmosis, it is often negative. By contrast, serology is often useful in diagnosis. A rising complement-fixation titer indicates dissemination. Precipitins detected by immunodiffusion are also valuable because the presence of antibodies to specific H and M antigens correlates well with active or recent infection.[28] A new development, particularly helpful in AIDS patients, has been serologic or urine tests for the detection of circulating *Histoplasma* antigens.[29] PCR-based molecular diagnostic methods are available in some centers.

Pathology: In histopathologic sections, *H. capsulatum* is an intracellular parasite often seen in macrophages. The cells are small (2 to 4 µm in diameter) and oval in shape with small buds (Fig. 162-10). Mycelial forms are seen rarely in tissue.

DIFFERENTIAL DIAGNOSIS

The organism is the same size as a number of others causing deep mycoses such as *T. marneffei* and small forms of *Blastomyces* and *Cryptococcus* (see "Laboratory Testing" above). It is also similar in size to *Leishmania* sp., and in the tropics, kala azar is an important part of the differential diagnosis. These observations emphasize the importance of carrying out appropriate laboratory tests to confirm the diagnosis.

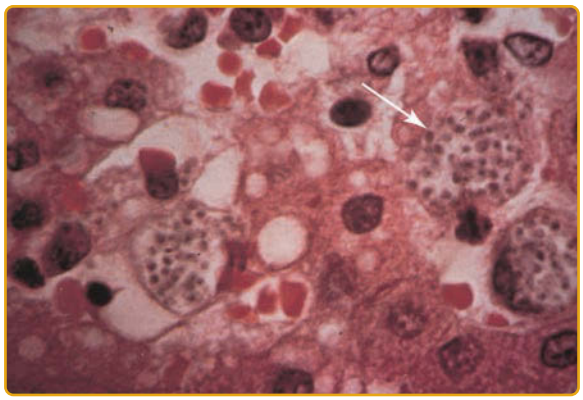

Figure 162-10 Histoplasmosis, disseminated. Lesional biopsy specimen shows dermal macrophages packed with dozens of tiny yeast forms of *Histoplasma capsulatum* (*arrow*).

AFRICAN HISTOPLASMOSIS (LARGE-FORM HISTOPLASMOSIS OR HISTOPLASMOSIS DUBOISII)

African histoplasmosis is sporadic and uncommon even in AIDS patients.[30] It is seen in patients from areas south of the Sahara and north of the Zambezi River in Africa. Infections seen outside Africa are all imported. The most common clinically involved sites are the skin and bone, although lymph nodes and other organs, including the lungs, may be affected. Skin lesions range from small papules resembling molluscum contagiosum to cold abscesses, draining sinuses, or ulcers. It is not clear if there is an asymptomatic form of African histoplasmosis as in classic histoplasmosis. The diagnosis is confirmed by culture and microscopy (direct microscopy or histopathology). The organisms of *H. capsulatum* var. *duboisii* are different from the smaller *capsulatum* forms. They are usually 10 to 15 µm in diameter, slightly pear-shaped, and clustered in giant cells. *Histoplasma* serology, using conventional tests, is often negative in African histoplasmosis.

CLINICAL COURSE AND PROGNOSIS

Prognosis depends on the site and type of infection. But the choice of therapy for histoplasmosis generally depends on the severity of the illness.

MANAGEMENT

Medications: For patients with some disseminated or localized forms of the disease, oral itraconazole (200 to 400 mg daily) is highly effective. It also has been used for long-term suppressive treatment of the disease in AIDS patients after primary therapy either with itraconazole or amphotericin B.[31] However, there is now evidence that provided CD4 counts do not fall in patients on highly active antiretroviral therapy (HAART) therapy (see Chap. 173), suppressive treatment can be discontinued. In AIDS, some patients receiving treatment of histoplasmosis, an immune reconstitution syndrome has been reported after commencing HAART therapy with intestinal obstruction, uveitis, and arthralgia. Intravenous amphotericin B (up to 1 mg/kg daily) is given to patients with widespread and severe infections and is the main alternative used. Posaconazole and voriconazole are effective in some cases. In African histoplasmosis, itraconazole is also the treatment of choice, but once again, in severe cases amphotericin B may be used.[30]

BLASTOMYCOSIS (NORTH AMERICAN BLASTOMYCOSIS)

Blastomycosis is a chronic mycosis caused by the dimorphic pathogen *Blastomyces dermatitidis*.[32] Its chief sites of involvement are the lungs, but disseminated forms of the infection may affect skin, bones, CNS, and other sites.

EPIDEMIOLOGY

Blastomycosis is found in North America and Canada.[33] Most cases, though, come from the Great Lakes region and southern states of the United States. It also occurs sporadically in Africa, with the largest numbers of cases coming from Zimbabwe,[34] and cases also have been reported from the Middle East and India.

It is thought that the natural habitat of *Blastomyces* is in some way related to wood debris and is close to rivers or lakes or in areas subjected to periodic flooding. However, it is difficult to isolate *Blastomyces* from the natural environment.[35] Blastomycosis also may affect domestic animals such as dogs.

CLINICAL FEATURES

As with histoplasmosis, there is a subclinical form of the infection; its prevalence has not been defined in detail because of lack of a commercial *Blastomyces* skin-test antigen and the extent of antigenic crossreactivity with fungi such as *Histoplasma*. Primary cutaneous blastomycosis is also very rare and follows trauma to the skin and the subsequent introduction of fungus, for instance, in laboratory workers or pathologists.[36] After inoculation, an erythematous, indurated area with a chancre appears in 1 to 2 weeks with associated lymphangitis and lymphadenopathy.

Pulmonary blastomycosis is very similar in clinical presentation to pulmonary tuberculosis.[33,36,37] There may be no symptoms, or there may be low-grade fever, chest pain, cough, and hemoptysis, and unlike

Figure 162-11 Blastomycosis. Inflammatory plaque with ulceration resembling pyoderma gangrenosum on the calf. (Used with permission from Elizabeth M. Spiers, MD.)

histoplasmosis, it often coexists with disseminated disease. Skin lesions are a common presenting feature of disseminated blastomycosis.[36,38] They are often symmetric and usually affect the face and extremities. The early lesion is a papule or nodule, which may ulcerate and discharge pus. With time, this enlarges to form a hyperkeratotic lesion, often with central ulceration and/or scarring (Figs. 162-11 and 162-12). Oral lesions are less common. Multiple skin lesions are often found in disseminated infection. Other patients may present with nodules and abscesses, and in many patients lesions of different morphologies are present. African patients with blastomycosis have a higher frequency

Figure 162-12 Blastomycosis. Chronic verrucous plaque on the cheek.

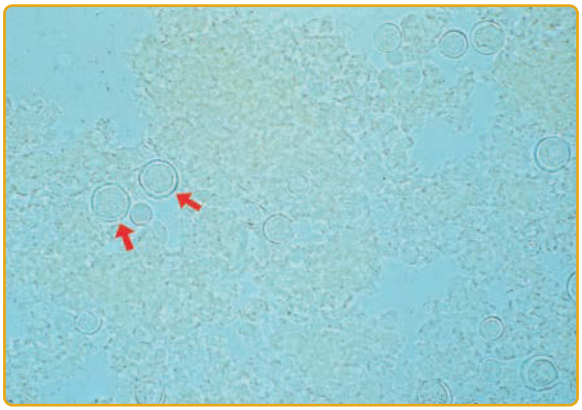

Figure 162-13 Direct preparation (potassium hydroxide) of *Blastomyces* (*arrows*).

of skin and bone involvement.[34] Although blastomycosis can affect almost any organ, other common sites for dissemination include the bone, the epididymis, and the adrenal gland. Less commonly, there is widespread rapid dissemination with multiple organ involvement, and *B. dermatitidis* can produce a form of adult respiratory distress syndrome. Skin lesions in widespread disseminated disease are usually papules, abscesses, or small ulcers. Widespread blastomycosis has been described in AIDS patients, but it is not common.[39]

DIAGNOSIS

Laboratory Testing: The fungus can be found in KOH mounts of pus, skin scrapings, or sputum as thick-walled, rounded, refractile, spherical cells with broad-based buds (Fig. 162-13). In culture, the fungus grows as a mycelial fungus at room temperature. It produces small, rounded, or pear-shaped conidia. At higher temperature (37°C [98.6°F]) and on enriched media, it produces yeast forms with the characteristic buds. Molecular probes will confirm the identity. These are often found in giant cells or surrounded by neutrophils (Fig. 162-14). Precipitating antibodies to

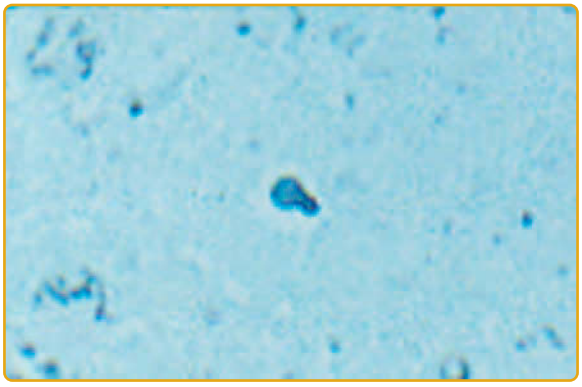

Figure 162-14 Blastomycosis. Lesional biopsy specimen shows a budding yeast form (Gomori methenamine silver stain).

B. dermatitidis are often present in the sera of infected patients, and a characteristic precipitin line, the E band, has been described in a high proportion of proven cases; there is also an enzyme-linked immunosorbent assay for blastomycosis. There is also an antigen detection system that is most accurate in urine samples.

Pathology: In tissue sections, the typical organisms with broad buds may be found, although it may be necessary to search several fields to find the characteristic cells.

DIFFERENTIAL DIAGNOSIS

The chronic skin granulomas must be differentiated from those caused by tuberculosis, other deep mycoses, nonmelanoma skin cancers, pyoderma gangrenosum, and drug reactions caused by bromides and iodides.

CLINICAL COURSE AND PROGNOSIS

As with histoplasmosis, the course depends on the site of infection and the presence of any underlying disease.

MANAGEMENT

Medications: Treatment is similar to that used for histoplasmosis; itraconazole (200 to 400 mg daily) is used in the less-severe forms of the infection or when there is only localized spread. Voriconazole is also active against this infection. Treatment is usually given for at least 6 months. Followup surveillance is necessary because relapse can occur, particularly where there are deep sites of infection or the patient is immunosuppressed. Amphotericin B (up to 1 mg/kg daily) is generally used for the treatment of widespread disseminated forms of blastomycosis.

COCCIDIOIDOMYCOSIS (COCCIDIOIDAL GRANULOMA, VALLEY FEVER, SAN JOAQUIN VALLEY FEVER, DESERT RHEUMATISM)

DEFINITIONS

Coccidioidomycosis is the infection caused by the fungal species *Coccidioides immitis* and *Coccidioides posadasii*; *C. posadasii* is phenotypically identical to *C. immitis* and produces identical disease, but is mainly found outside California. Both show an unusual form of dimorphism, with a mold form at room temperature and the development of spherules, large spore-containing structures, in infected tissue. As with other endemic mycoses, there are asymptomatic, acute and chronic pulmonary, and disseminated forms. The disease can affect otherwise healthy individuals or predisposed patients, including those with AIDS.

EPIDEMIOLOGY

C. immitis is endemic in some semidesert areas of South and Southwest of the United States, and *C. posadasii* elsewhere (Arizona, New Mexico, and Texas) and in parts of Mexico and Central and South America. The climate of the endemic areas is marked by very high summer temperatures and low annual rainfall, demonstrated by a characteristic vegetation with cacti and mesquite bushes. Skin tests with coccidioidin show that the incidence of exposure in endemic areas may be as high as 95%. The fungus is found in soil and can affect other animals as well as humans. Exposure may result from a brief visit to an endemic area, and local weather can determine exposure rates.[40] For instance, dust storms may cause infection in large numbers of individuals. The usual route of infection is respiratory, although direct implantation into the skin can occur rarely.

CLINICAL FEATURES

As with other systemic mycoses, there is an asymptomatic or subclinical form of coccidioidomycosis that is common in endemic areas, judging by the percentages of skin test reactors to coccidioidin in the healthy population. The primary pulmonary form, which is the most common clinical type, presents as a chest infection with fever, cough, and chest pain. Complications such as pleural effusion may occur. Erythema multiforme or erythema nodosum,[40] often accompanied by arthralgia or anterior uveitis, occurs from the third to the seventh week in approximately 10% to 15% of patients, and is more common in females. Sometimes an early, generalized, macular and erythematous rash is seen in some patients.

The chronic pulmonary form of the disease presents with chronic cough and resembles tuberculosis. Skin lesions normally do not occur in this phase.

In the rare primary skin infection,[41] after inoculation, there is an indurated nodule that develops 1 to 3 weeks after local trauma. This is followed by regional lymphadenopathy.

Disseminated coccidioidomycosis develops in fewer than 0.5% of infected individuals. It is mainly seen in patients from certain ethnic backgrounds (African Americans, Filipinos, and Mexicans),[40] apparently independent of occupational exposure or socioeconomic class, in pregnant women, and in immunosuppressed patients, including those with AIDS.[42,43] In disseminated disease, lesions may develop in the skin, subcutaneous tissues, bones, joints, and all organs. The skin lesions (Fig. 162-15) are papules, nodules, abscesses, granulomas, ulcers, or discharging sinuses in which there is underlying bone or joint disease. Some lesions appear as flat plaques with central atrophy. Meningitis is an important complication of dissemination and is usually

Figure 162-15 Coccidioidomycosis, disseminated. Two intact and ulcerated papules/nodules are seen on the cheek and nose of this comatose patient with coccidioidomycotic meningitis. (Used with permission from Francis Renna, MD.)

not associated with signs of infection in other sites. In AIDS patients, persistent pneumonia, skin lesions, and widespread dissemination can all occur.

DIAGNOSIS

Laboratory Testing: A characteristic of the laboratory findings is the ability of *Coccidioides* to form spore-containing spherules. These are large (up to 250 µm in diameter) and can be seen in KOH mounts of sputum, cerebrospinal fluid, or pus. In culture, colonies of *Coccidioides* are mycelial, fast growing, white, and cottony. On microscopy, there are chains of arthrospores at intervals on the older mycelium. *Coccidioides* in the mold phase is highly infectious, and cultures should be handled carefully. There is, as yet, no commercial molecular test for coccidioidomycosis.

A variety of serologic tests are of value in the diagnosis and prognosis of coccidioidomycosis.[44] Precipitins develop in approximately 90% of infected individuals within 2 to 6 weeks but are short-lived; complement-fixing antibodies are characteristic of more-severe infections and, in active infection, increase to a maximum after 6 months. Skin tests with coccidioidin are of little value in diagnosing infections. Spherulin is an antigen obtained from spherules of *C. immitis* and may be better than coccidioidin for detecting sensitization. However, in severe infections, cutaneous anergy to both is common.

Pathology: Spherules containing large endospores can be seen in tissue sections, although there are a variety of less-distinct intermediate stages in spherule formation that also can be seen. Before endospores form, the cytoplasm of the immature spherule is basophilic and subsequently breaks up into spores. Mycelium is seen rarely in histopathologic sections.

DIFFERENTIAL DIAGNOSIS

Physicians in endemic areas should be aware of the connection between erythema nodosum and coccidioidomycosis. It also may occur in visitors to endemic areas after only a short stay.

CLINICAL COURSE AND PROGNOSIS

As with histoplasmosis, the course depends on the site of infection and the presence of any underlying disease.

MANAGEMENT

Medications: No specific therapy apart from rest is necessary in the primary pulmonary infection, and there is little evidence that the symptoms are either improved or shortened by giving an oral azole drug, even though it is widespread practice. For disseminated disease, the results of treatment are still variably, but amphotericin B (1 mg/kg daily), itraconazole (200 to 400 mg daily), or fluconazole (200 to 600 mg daily) can all be given.[45] Experience with the newer antifungal agents, such as voriconazole and posaconazole, is limited at present. It is important to follow patients carefully, given the frequency of relapse. Meningitis and progressive disseminated infection involving multiple sites are all particularly refractory to therapy. Generally, soft-tissue coccidioidomycosis (skin and joint) has a better prognosis, and the mortality in patients who present with such lesions is low.

Prevention: A vaccine, Spherulin, for coccidioidomycosis has been studied, but the results were inconclusive and at present there is no immunization against this infection.[45]

PARACOCCIDIOIDOMYCOSIS (SOUTH AMERICAN BLASTOMYCOSIS, PARACOCCIDIOIDAL GRANULOMA)

DEFINITIONS

Paracoccidioides brasiliensis is a dimorphic fungus that causes a respiratory tract infection with a tendency to disseminate to the mucous membranes and lymph nodes. It is confined to Central and South America.[46]

EPIDEMIOLOGY

Paracoccidioidomycosis has been reported from most Latin American countries, but the infection is found most commonly in parts of Brazil, Colombia, and Argentina. The infection does not occur in the United States, although it has been reported in

Mexico. Exposure rates can be estimated by skin test reactivity and appear to be equal in both males and females, although the prevalence of positive reactors in endemic areas seldom exceeds 25%; work with a skin test derived from purified glycoprotein 43 antigen generally demonstrates that exposure rates are higher than previously believed. The active infection is seen predominantly in males. The mechanism is thought to be connected to the presence of a cytoplasmic estrogen receptor on the fungus, and, in vitro, estradiol suppresses the conversion of mycelium to yeast.[47] The ecologic niche of the organisms is unknown, but the condition is much more frequent in rural areas; exposure is associated with proximity to water or areas of high atmospheric humidity.[48]

CLINICAL FEATURES

There are a number of different clinical patterns of paracoccidioidomycosis infection that depend on the predominant site of clinical involvement. These include the lung (pulmonary form), the mucous membranes (mucocutaneous form), and the lymph nodes (lymphatic form). Many patients have a mixed type of infection with involvement of different organ groups.[46]

Patients rarely present with an acute form of pulmonary infection, although this has been observed rarely and reported to subside while dissemination occurs. More usually, pulmonary infection tends to be chronic and slowly progressive with weight loss and chronic cough. The lesions may be bilateral and nodular on chest radiography, and there is often extensive fibrosis. Other sites of involvement include mucocutaneous areas. Oral or circumoral lesions are common in the mucocutaneous forms of paracoccidioidomycosis; lesions also occur in the nose, conjunctivae, or around the anus. These lesions may be small granulomas or ulcers. They heal with scarring, which may cause considerable deformity.

The cervical lymph nodes are sometimes enlarged, tender, and tethered to the overlying skin; they rarely suppurate. Other systemic sites of involvement include the spleen, intestines, lungs, and liver. Paracoccidioidomycosis is uncommon in AIDS patients, although there is a widespread variety that is a more rapidly progressive form of disseminated infection occurring in young adults or older children without recognizable predisposition.[49]

DIAGNOSIS

Laboratory Testing: Sputum, exudates, and scrapings can be screened using KOH. They show numbers of round yeasts with a characteristic form of multiple budding in which a parent cell is surrounded by large numbers of smaller buds. The organism is dimorphic and produces a cottony mycelial-phase growth on primary isolation at room temperature. Once again, the characteristic yeast phase can be induced on enriched media such as brain–heart infusion agar at 37°C (98.6°F). Serology is very helpful in confirming the diagnosis, the main tests being the immunodiffusion assay and a complement-fixation test. Antibodies to pb27 and 87-kDa antigens have been found to be highly specific for this infection in immunoblotting. There are also antigen-detection tests useful for monitoring patients with disseminated disease.

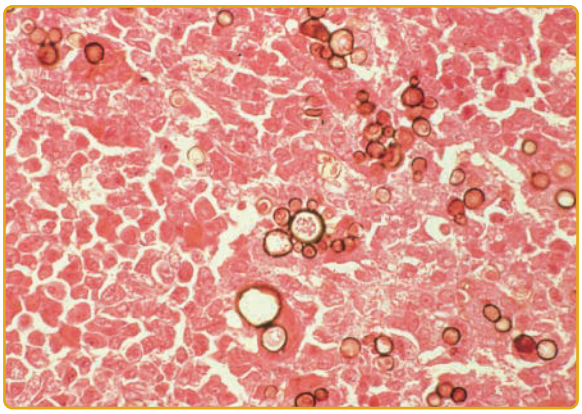

Figure 162-16 Biopsy of oral mucosal lesion showing multiple budding *Paracoccidioides brasiliensis*.

Pathology: Histopathologically, there is a mixed granulomatous response with fibrosis. The organisms can be seen with special fungal stains such as methenamine silver (Grocott modification). In tissue, the characteristic budding pattern can be seen, although it may be necessary to search several fields to find the most typical structures (Fig. 162-16). In widespread infections, masses of small yeast forms may be mistaken for *Histoplasma*.

DIFFERENTIAL DIAGNOSIS

Differential diagnosis includes tuberculosis, leishmaniasis, and other deep mycoses.

CLINICAL COURSE AND PROGNOSIS

As with histoplasmosis, the course depends on the site of infection and the presence of any underlying disease.

MANAGEMENT

Medications: The treatment of choice in most cases is itraconazole, which can produce remissions in 3 to 6 months.[50] Voriconazole produces similar responses. Relapses can occur, and, where possible, patients should be reviewed periodically after primary therapy. In very extensive infections and in severely ill patients, such as those with the progressive disseminated type of infection, intravenous amphotericin B may be necessary. Severe pulmonary or intraoral fibrosis may remain after treatment.

INFECTIONS CAUSED BY *TALAROMYCES MARNEFFEI* (PENICILLIOSIS, PENICILLIOSIS MARNEFFEI)

DEFINITIONS

T. marneffei infection is a more recently recognized disease found in Southeast Asia. *T. marneffei* was originally thought to be a member of the common genus *Penicillium*.[51] It shows an unusual pattern of dimorphism in that it develops yeast-like cells that reproduce with septal formation, dividing the cells into two. It is inhaled via the lungs, and it is not known whether there is a primary cutaneous form of the infection.

EPIDEMIOLOGY

The natural source of *T. marneffei* is unknown. Infections are confined to Southeast Asia, particularly Thailand, South China, and Vietnam. However, there are reports in other Asian countries, including Northeast India, and imported cases are seen in Europe and the United States. Natural infections are known to occur in bamboo rats of the genus *Cannomys*, which are large burrowing rodents. The infection affects otherwise healthy individuals as well as those with immune defects and is most common after the rainy season.[52] Patients with AIDS, as well as those receiving rituximab biologic therapy, appear to be particularly susceptible to this infection.

CLINICAL FEATURES

There has been no work to demonstrate that there is a subclinical form of *Talaromyces* infection, even though this is likely. Patients usually present with localized pulmonary or disseminated disease. The chest signs are those of chronic pulmonary disease.[53,54] More than 50% of AIDS patients with this infection have multiple skin lesions, which are umbilicated papules that may enlarge and ulcerate. They are usually widely scattered on the face and trunk. Other organs, including the liver, GI tract, spleen, and bone marrow, may be affected.

DIAGNOSIS

Laboratory Testing: *T. marneffei* forms characteristic yeast-like cells that are divided by a septum in tissue and are best seen in histopathologic sections stained with methenamine silver. These cells are small (2 to 4 µm in diameter) and difficult to see in blood films or skin or bone marrow smears, but they may be highlighted with stains such as leishmanin. In culture, *T. marneffei* is a green or grayish mold that produces typical conidiophores and a diffusible red pigment. There is no commercial serologic test as yet, although both antigen detection systems and PCR have been used in diagnosis, the PCR for identification of cultures.

DIFFERENTIAL DIAGNOSIS

The main differential diagnosis is with other disseminated mycoses, such as histoplasmosis and cryptococcosis, which also can be found in the endemic area in AIDS patients. Biopsy and, when necessary, culture will distinguish between the different causes.

CLINICAL COURSE AND PROGNOSIS

As with histoplasmosis, the course depends on the site of infection and the presence of any underlying disease.

MANAGEMENT

Medications: In severe cases, amphotericin B is necessary. In many cases, however, there is a good response to itraconazole (200 to 400 mg daily). In AIDS patients, this is continued after initial therapy to prevent relapse.[54]

CRYPTOCOCCOSIS

DEFINITIONS

Cryptococcosis is the infection caused by the encapsulated yeasts *Cryptococcus neoformans* and *Cryptococcus gattii*. Although the main portal of entry is through inhalation into the lungs, the disease usually presents with signs of extrapulmonary dissemination such as meningitis. Cutaneous lesions can develop as a result of dissemination or, rarely, through inoculation. It is associated with HIV infection.[55]

EPIDEMIOLOGY

Cryptococcosis has a worldwide distribution although exposure rates probably differ markedly in different countries. *C. neoformans* has 2 variants: (a) *C. neoformans* var. *neoformans* and (b) *C. neoformans* var. *grubii*.

These correspond to 3 clusters of serotypes: (a) D, (b) A, and (c) B or C.[56] The *neoformans* and *grubii* varieties can be isolated from pigeon excreta and are more common in AIDS patients; the *gattii* form is found in the debris of certain eucalyptus trees in Australia, and California as well as some tropical areas, but it is less often isolated from AIDS patients. Two sexual varieties called *Filobasidiella neoformans* and *Filobasidiella bacillispora* correspond to the *neoformans/grubii* and *gattii* species, respectively. Clinically the main differences to be seen are those between the *neoformans* and *gattii* species, for example, a higher prevalence of

symptomatic pulmonary disease with the *gattii* species. Patients with certain immunodeficiency states caused by AIDS, malignant lymphomas, sarcoidosis, collagen disease, carcinoma, and those receiving systemic glucocorticoid therapy are particularly susceptible. The incidence of cryptococcosis in patients with established untreated AIDS varied in different countries, from 3% to 6% in the United States, to 3% in the United Kingdom, to more than 12% in parts of Africa (eg, Democratic Republic of the Congo). However, with the widespread use of HAART therapy the incidence has declined. Strains of serotype D are more likely to be found in skin lesions, which occur in 10% to 15% of cases of disseminated cryptococcosis.

CLINICAL FEATURES

The advent of the AIDS epidemic affected the epidemiology of cryptococcosis considerably, and in areas such as northern Thailand, it is one of the main secondary complications of HIV infection.[55] There is probably a subclinical form of cryptococcosis because unaffected individuals may have positive skin tests. However, the most common clinical manifestation of disease is meningoencephalitis. This presents with classic signs of meningitis, changes in consciousness, mental changes, and nerve palsies. In AIDS patients, these signs may be only weakly expressed. Pulmonary infection can be found in approximately 10% of those with meningitis. Chest signs include the appearance of nodular shadows, cavitation, and pleural effusion. Patients with AIDS often present with fever and mild headache, and few other features of infection.[55] Cutaneous lesions may develop in approximately 10% of cases, but are seldom pathognomonic.[57-60] Acneiform papules or pustules progressing to warty or vegetating, crusted plaques, ulcers, and hard infiltrated plaques or nodules are characteristic of widespread systemic infection (Fig. 162-17). Cold abscesses, cellulitis, and nodular lesions also occur. In otherwise healthy patients and in those with sarcoidosis, lesions may be solitary, and in such patients, they may be the only clinical manifestation of infection.

In primary cutaneous cryptococcosis with direct inoculation of organisms into the skin, the skin lesions are usually solitary nodules that break down and ulcerate. Local lymphadenopathy also develops. The term *primary cutaneous cryptococcosis* is also used loosely to describe solitary lesions of cryptococcosis, but in many such cases there is also evidence of dissemination to other internal organs. It is important to investigate all patients who present with cutaneous lesions for evidence of dissemination to other sites.[58]

DIAGNOSIS

Laboratory Testing: Cryptococci are large (5 to 15 μm in diameter), budding cells with capsules that are best observed by direct microscopy of India ink or Nigrosin mounts (Fig. 162-18). The organism is not difficult to grow in culture. Various biochemical features, such as the production of urease and the ability to pigment on *Guizotia* seed medium, are characteristic; molecular probes can be used to confirm the identity. Serologic tests are rapid and specific. The main test is an antigen-detection assay using latex agglutination or enzyme-linked immunosorbent assay, and this is simple and very rapid to perform on blood or cerebrospinal fluid. Very high titers are found in serum and cerebrospinal fluid from AIDS patients. Non-AIDS patients with single, localized skin lesions are often antigen negative.

Figure 162-17 Cryptococcosis, disseminated. Multiple, discrete, skin-colored papules, and nodules resembling molluscum contagiosum are seen on the face of a male with advanced HIV disease. (Used with permission from Loïc Vaillant, MD.)

Pathology: In tissue sections, the large pleomorphic yeasts stimulate either a granulomatous reaction

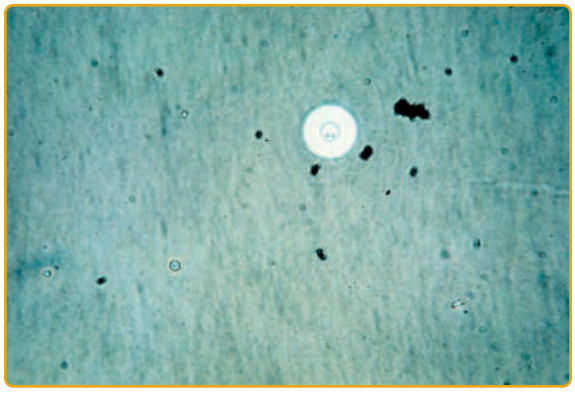

Figure 162-18 Cryptococcosis. India ink preparation of cerebrospinal fluid.

or very little inflammation. The capsules of the cells can be stained using the mucicarmine or Alcian blue stains.

DIFFERENTIAL DIAGNOSIS

Cryptococcal skin lesions may mimic a range of other conditions, particularly other systemic mycoses in AIDS patients. It is important to biopsy and culture suspicious lesions in immunocompromised patients.

MANAGEMENT

Medications: The most frequently used drug regimen in the non-AIDS patient is IV amphotericin B combined with flucytosine. In patients with single skin lesions and no other signs of infection, alternatives such as fluconazole or itraconazole can be used. Because there is a very high relapse rate in AIDS patients, the usual policy is to give a 10- to 14-day course of amphotericin B with or without flucytosine, followed by long-term fluconazole.[61] However, it is possible to stop long-term suppressive therapy in patients receiving HAART. High-dose fluconazole given on its own is an alternative approach.

CUTANEOUS ASPECTS OF SYSTEMIC OPPORTUNISTIC MYCOSES

Skin lesions are not common with the opportunistic fungal infections, but they can occur in some patients, particularly in certain predisposed groups. When they occur, their presence may be very helpful because it is possible to biopsy easily accessible lesions to establish the diagnosis.

SYSTEMIC CANDIDIASIS

Systemic candidiasis follows dissemination of *Candida* sp. from the GI tract or via the bloodstream. Skin lesions can occur, especially in 2 situations: (a) in neutropenic patients, there is often a severe disseminated disease with widespread skin nodules and associated muscle pains,[62] and (b) in IV drug abusers, candidiasis may present with a follicular, pustular rash in the beard area and scalp. Other lesions include retinal and vitreal deposits and abscesses around the costochondral junctions.

Systemic candidiasis is usually treated with IV amphotericin B (conventional or lipid-associated), caspofungin, or fluconazole. Resistance to some azole drugs, such as fluconazole and ketoconazole, is more common with certain non-*albicans Candida* sp., and these antifungal agents should be avoided in infections caused by these species. Newly recognized species, such as *Candida auris*, have been found to cause systemic infection resistant to common therapeutic drugs such as fluconazole and amphotericin B.[63]

MUCORMYCOSIS (PHYCOMYCOSIS, ZYGOMYCOSIS)

Mucormycosis is a rare disease caused by Mucoromycetes fungi such as *Mucor, Lichtheimia*, and *Rhizopus*. *Cunninghamella bertholletiae* and *Saksenaea vasiformis* are less-common causes. These fungi cause disease in patients with poorly controlled diabetes, neutropenia, or renal disease. Direct invasion through abrasions has been reported following trauma from a natural disaster (eg, during a mudslide or tsunami).[64] They can invade necrotic burned areas or involve the facial skin secondary to invasive infection of the paranasal sinuses (Fig. 162-19). Mucormycosis also has been caused by close apposition of the skin with contaminated dressing materials in the case of *Rhizopus rhizopodiformis*[65] or with wooden tongue depressors in the case of *Rhizopus microsporus*.[66] These fungi have a tendency to invade blood vessels, causing widespread infarction. Infections may respond to IV amphotericin, and recent results with lipid-associated amphotericin B formulations have been encouraging.

OTHER OPPORTUNISTIC MYCOSES

Other fungi causing systemic infections also may produce skin lesions in the process of bloodstream dissemination. The best known of these organisms are *Aspergillus*, *Scedosporium*, *Trichosporon*, and *Fusarium*. Skin infection is seen mainly in severely immunocompromised patients such as those with neutropenia.

Aspergillus may produce large necrotic lesions such as ecthyma gangrenosum, but smaller papules and cold abscesses also can occur.[67] *Fusarium* infections may produce widely distributed target-like lesions that may undergo central necrosis and, in some cases, digital cellulitis and superficial white onychomycosis precede dissemination.[68] Treatment for all these infections is usually amphotericin B, although voriconazole is increasingly used with aspergillosis.

DIAGNOSIS

Laboratory Testing: Laboratory confirmation of the diagnosis is fraught with difficulties chiefly because many of the organisms are also commensals in human sites; because they occur in severely ill patients, the capacity to produce diagnostic antibody titers is compromised. The interpretation of laboratory data is consequently difficult and has to be related to the

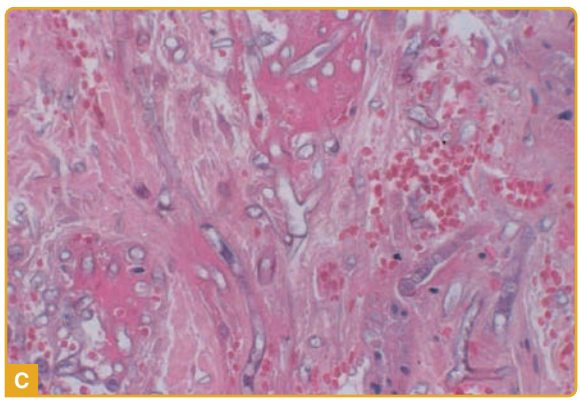

Figure 162-19 Mucormycosis. **A,** The face of this young woman with diabetes mellitus shows proptosis, unilateral facial edema, and a right-sided facial palsy associated with infection beginning in the right maxillary sinus. **B,** Ulcer. **C,** Hyphae in tissue.

clinical state of the patient. Newer tests for aspergillosis and candidiasis, such as detection of galactomannan (aspergillosis) or PCR-based molecular assays, are proving helpful in some cases.

Pathology: Ideally, a histologic diagnosis should be made, although biopsy may be impossible because of the risk of bleeding.

MANAGEMENT

In many cases, the diagnosis of a systemic mycosis is presumptive, and treatment is given empirically.

ACTINOMYCOSIS AND NOCARDIOSIS

Actinomycosis is an infection caused by filamentous bacteria that form large granules (sulfur granules) in abscess cavities. Draining sinuses communicate from the center of the abscess to the skin or mucosal surface. Nocardiosis is an acute and chronic infection also caused by filamentous bacteria. These lead to localized skin, subcutaneous, and systemic infections. Actinomycosis and nocardiosis are discussed in detail in Chap. 158.

REFERENCES

1. Chandler FW, Ajello L, Kaplan W. *A Colour Atlas and Textbook of the Histopathology of Mycotic Diseases*. London, UK: Wolfe Medical; 1980:92, 98.
2. Merz WG, Hay RJ. *Topley and Wilson's Microbiology and Microbial Infections: Medical Mycology*. London, UK: Hodder Arnold; 2005.
3. Kibbler CC, Mackenzie DWR, Odds FC, et al. *Principles and Practice of Clinical Mycology*. Chichester, UK: Wiley; 1996.
4. Dismukes WE, Pappas PG, Sobel JD. *Clinical Mycology*. New York, NY: Oxford University Press; 2003.
5. Rodrigues AM, de Hoog G, Zhang Y, et al. Emerging sporotrichosis is driven by clonal and recombinant *Sporothrix* species. *Emerg Microbes Infect.* 2014;3(5):e32.
6. Ramos-e-Silva M, Vasconcelos C, Carneiro S, et al. Sporotrichosis. *Clin Dermatol.* 2007;25:181.
7. Pappas PG, Tellez I, Deep AE, et al. Sporotrichosis in Peru: description of an area of hyperendemicity. *Clin Infect Dis.* 2000;30:65.
8. da Rosa AC, Scroferneker ML, Vettorato R, et al. Epidemiology of sporotrichosis: a study of 304 cases in Brazil. *J Am Acad Dermatol.* 2005;52:451.
9. Bibler MR, Luber HJ, Glueck HI, et al. Disseminated sporotrichosis in a patient with HIV infection after treatment for acquired factor VIII inhibitor. *JAMA.* 1986;256:3125.
10. Kauffman CA, Hajjeh R, Chapman SW. Practice guidelines for the management of patients with sporotrichosis. For the Mycoses Study Group. Infectious Diseases Society of America. *Clin Infect Dis.* 2000; 30:684.
11. Fahal AH. Mycetoma: a thorn in the flesh. *Trans R Soc Trop Med Hyg.* 2004;98:3.

12. Zijlstra EE, van de Sande WWJ, Welsh O, et al. Mycetoma: a unique neglected tropical disease. *Lancet Infect Dis.* 2016;16:100.
13. Ahmed AO, van Leeuwen W, Fahal A, et al. Mycetoma caused by *Madurella mycetomatis*: a neglected infectious burden. *Lancet Infect Dis.* 2004;4:566.
14. Wethered DB, Markey MA, Hay RJ, et al. Ultrastructural and immunogenic changes in the formation of mycetoma grains. *J Med Vet Mycol.* 1986;25:39.
15. Welsh O, Al-Abdely HM, Salinas-Carmona MC, et al. Mycetoma medical therapy. *PLoS Negl Trop Dis*. 2014;8:e3218.
16. Esterre P. Chromoblastomycosis. In: Merz WG, Hay RJ, eds. *Topley and Wilson's Microbiology and Microbial Infections: Medical Mycology*. London, UK: Hodder Arnold; 2004:356.
17. López Martínez R, Méndez Tovar LJ. Chromoblastomycosis. *Clin Dermatol.* 2007;25:188.
18. Goette DK, Robertson D. Transepithelial elimination in chromomycosis. *Arch Dermatol.* 1984;120:400.
19. Restrepo A. Treatment of tropical mycoses. *J Am Acad Dermatol.* 1994;31:S91.
20. Bonifaz A, Saúl A, Paredes-Solis V, et al. Treatment of chromoblastomycosis with terbinafine: experience with four cases. *J Dermatolog Treat.* 2004;16:47.
21. Matsumoto T, Ajello L, Matsuda T, et al. Developments in hyalohyphomycosis and phaeohyphomycosis. *J Med Vet Mycol.* 1994;32:329.
22. Brun AM. Lobomycosis in three Venezuelan patients. *Int J Dermatol.* 1999;38:302.
23. Yang X, Li Y, Zhou X, et al. Rhinofacial conidiobolomycosis caused by *Conidiobolus coronatus* in a Chinese rice farmer. *Mycoses.* 2010;53:369-373.
24. Arseculeratne SN. Rhinosporidiosis: what is the cause? *Curr Opin Infect Dis.* 2005;18:113.
25. Ali T. Clinical use of anti-TNF therapy and increased risk of infections. *Drug Healthc Patient Saf*. 2013;5:79.
26. Cano MV, Hajjeh RA. The epidemiology of histoplasmosis: a review. *Semin Respir Infect.* 2001;16:109.
27. Kauffman CA. Histoplasmosis: a clinical and laboratory update. *Clin Microbiol Rev.* 2010;20:115.
28. Gutierrez ME, Canton A, Sosa N, et al. Disseminated histoplasmosis in patients with AIDS in Panama: a review of 104 cases. *Clin Infect Dis.* 2005;40:1199.
29. Wheat LJ, Kohler RB, Tewari RP. Diagnosis of disseminated histoplasmosis by detection of *Histoplasma capsulatum* antigen in serum and urine specimen. *N Engl J Med.* 1986;314:83.
30. Khalil MA, Hassan AW, Gugnani HC. African histoplasmosis: report of four cases from north-eastern Nigeria. *Mycoses.* 1998;41:293.
31. Wheat J. Endemic mycoses in AIDS: a clinical review. *Clin Microbiol Rev.* 1995;8:149.
32. Lemos LB, Guo M, Baliga M. Blastomycosis: organ involvement and etiologic diagnosis. A review of 123 patients from Mississippi. *Ann Diagn Pathol.* 2000; 4:391.
33. Bradsher RW, Chapman SW, Pappas PG. Blastomycosis. *Infect Dis Clin North Am.* 2003;17:21.
34. Emerson PA, Higgins E, Branfoot A. North American blastomycosis in Africans. *Br J Dis Chest.* 1984;78:286.
35. Baumgardner DJ, Steber D, Glazier R, et al. Geographic information system analysis of blastomycosis in northern Wisconsin, USA: waterways and soil. *Med Mycol.* 2005;43:117.
36. Bradsher RW. A clinician's view of blastomycosis. *Curr Top Med Mycol.* 1994;5:181.
37. McAdams HP, Rosado-de-Christenson ML, Lesar M, et al. Thoracic mycoses from endemic fungi: radiologic-pathologic correlation. *Radiographics.* 1995;15:255.
38. Weil M, Mercurio MG, Brodell RT, et al. Cutaneous lesions provide a clue to mysterious pulmonary process: pulmonary and cutaneous North American blastomycosis infection. *Arch Dermatol.* 1996;132:822.
39. Herd AM, Greenfield SB, Thompson GW, et al. Miliary blastomycosis and HIV infection. *CMAJ.* 1990;143:1329.
40. Rosenstein NE, Emery KW, Werner SB, et al. Risk factors for severe pulmonary and disseminated coccidioidomycosis: Kern County, California, 1995-1996. *Clin Infect Dis.* 2001;32:708.
41. Chang A, Tung RC, McGillis TS, et al. Primary cutaneous coccidioidomycosis. *J Am Acad Dermatol.* 2003;49:944.
42. Crum NF, Lederman ER, Stafford CM, et al. Coccidioidomycosis: a descriptive survey of a reemerging disease. Clinical characteristics and current controversies. *Medicine (Baltimore)*. 2004;83:149.
43. Ampel NM. Coccidioidomycosis in persons infected with HIV-1. *Ann N Y Acad Sci.* 2007;1111:336.
44. Martins TB, Jaskowski TD, Mouritsen CL, et al. Comparison of commercially available enzyme immunoassay with traditional serological tests for detection of antibodies to *Coccidioides immitis*. *J Clin Microbiol.* 1995;33:940.
45. Galgiani JN. Coccidioidomycosis. *Clin Infect Dis.* 2005;41:1217.
46. Ramos-E-Silva M, Saraiva Ldo E. Paracoccidioidomycosis. *Dermatol Clin.* 2008;26:257.
47. Restrepo A, Salazar ME, Cano LE, et al. Estrogens inhibit mycelium to yeast transformation in the fungus *Paracoccidioides brasiliensis*: implications for resistance of females to paracoccidioidomycosis. *Infect Immun.* 1984;46:346.
48. Simões LB, Marques SA, Bagagli E. Distribution of paracoccidioidomycosis: determination of ecologic correlates through spatial analyses. *Med Mycol.* 2004;42:517.
49. Caseiro MM, Etzel A, Soares MC, et al. Septicemia caused by Paracoccidioides brasiliensis (Lutz, 1908) as the cause of death of an AIDS patient from Santos, São Paulo State, Brazil—a nonendemic area. *Rev Inst Med Trop Sao Paulo.* 2005;47:209.
50. Negroni R, Palmieri O, Koren F, et al. Oral treatment of paracoccidioidomycosis and histoplasmosis with itraconazole in humans. *Rev Infect Dis.* 1987;9:S47.
51. Segretain G. Description d'une nouvelle espece de penicillium: *Penicillium marneffei* n. sp. *Bull Soc Mycol Fr.* 1959;75:412.
52. Chariyalertsak S, Sirisanthana T, Supparatpinyo K, et al. Seasonal variation of disseminated *Penicillium marneffei* infections in northern Thailand: a clue to the reservoir? *J Infect Dis.* 1996;173:1490.
53. Lu PX, Zhu WK, Liu Y, et al. Acquired immunodeficiency syndrome associated disseminated Penicillium marneffei infection: report of 8 cases. *Chin Med J.* 2005;118:1395.
54. Supparatpinyo K, Khamwan C, Baosoung V, et al. Disseminated *Penicillium marneffei* infection in southeast Asia. *Lancet.* 1994;344:110.
55. Mitchell TG, Perfect JR. Cryptococcosis in the era of AIDS: 100 years after the discovery of *Cryptococcus neoformans*. *Clin Microbiol Rev.* 1995;8:515.
56. Bennett JE, Kwon-Chung KJ, Howard DH. Epidemiologic differences among serotypes of *Cryptococcus neoformans*. *Am J Epidemiol.* 1984;120:582.
57. Manrique P, Mayo J, Alvarez JA, et al. Polymorphous cutaneous cryptococcosis: nodular, herpes-like, and molluscum-like lesions in a patient with the acquired immunodeficiency syndrome. *J Am Acad Dermatol.* 1992;26:122.
58. Murakawa GJ, Kerschmann R, Berger T. Cutaneous cryptococcus infection and AIDS: report of 12 cases

and review of the literature. *Arch Dermatol.* 1996; 132:545.
59. Manfredi R, Mazzoni A, Nanetti A, et al. Morphologic features and clinical significance of skin involvement in patients with AIDS-related cryptococcosis. *Acta Derm Venereol.* 1996;76:72.
60. Pomar V, Carrera G, Paredes R, et al. Disseminated cryptococcosis resembling milliary tuberculosis in an HIV-1-infected patient. *Lancet Infect Dis.* 2005;5:189.
61. Pappas PG, Perfect JR, Cloud GA, et al. Cryptococcosis in human immunodeficiency virus–negative patients in the era of effective azole therapy. *Clin Infect Dis.* 2001;33:690.
62. Bae GY, Lee HW, Chang SE, et al. Clinicopathologic review of 19 patients with systemic candidiasis with skin lesions. *Int J Dermatol.* 2005;44:550.
63. Lee WG, Shin JH, Uh Y, et al. First three reported cases of nosocomial fungemia caused by *Candida auris*. *J Clin Microbiol.* 2011;49:3139.
64. Hay RJ. Mucormycosis: an infectious complication of traumatic injury. *Lancet.* 2005;365:830.
65. Gartenberg G, Bottone EJ, Keusch GT, et al. Hospital-acquired mucormycosis (*Rhizopus rhizopodiformis*) of skin and subcutaneous tissue: epidemiology, mycology and treatment. *N Engl J Med.* 1978;299:1115.
66. Mitchell SJ, Gray J, Morgan ME, et al. Nosocomial infection with *Rhizopus microsporus* in preterm infants associated with wooden tongue depressors. *Lancet.* 1996; 348:441.
67. Wong J, McCracken G, Ronan S, et al. Coexistent cutaneous *Aspergillus* and cytomegalovirus infection in a liver transplant recipient. *J Am Acad Dermatol.* 2001;44:370.
68. Marcoux D, Jafarian F, Joncas V, et al. Deep cutaneous fungal infections in immunocompromised children. *J Am Acad Dermatol.* 2009;61:857.

This page intentionally left blank

Viral Diseases PART 25

Chapter 163 :: Exanthematous Viral Diseases

:: Vikash S. Oza & Erin F. D. Mathes

MEASLES

AT-A-GLANCE

- Prodrome of fever, cough, coryza, and conjunctivitis
- Koplik spots on the buccal mucosa are pathognomonic
- Morbilliform eruption lasts 3 to 5 days
- Severe complications include pneumonia and post-measles encephalomyelitis
- Vitamin A treatment may reduce morbidity and mortality

Measles, or rubeola, is a highly contagious, viral disease that remains an important cause of morbidity and mortality worldwide. The incidence and mortality rates are highest in developing countries, particularly in Africa and Asia where large populations are unvaccinated.

EPIDEMIOLOGY

A measles vaccine was first licensed in the United States in 1968. Prior to the introduction of the vaccine, approximately 90% of Americans were infected with measles prior to 15 years old.[1] By 2000, endemic transmission of measles within the United States ceased and measles was declared eliminated.[2] However, measles outbreaks continue to occur in the United States partly because of travel to countries with higher rates of measles and the spread of the virus in U.S. communities with pockets of unvaccinated people.[3] For instance, a multistate outbreak in late 2014 as a consequence of transmission at Disneyland in Anaheim, California, was responsible for 111 of the total 189 cases of measles in the United States in 2015.[4]

Worldwide, measles rates have also precipitously declined as the result of the implementation of measles vaccine programs. As of 2014, 85% of children across the globe had received at least 1 dose of the measles vaccine.[5] Despite this improvement, measles is still a leading cause of childhood mortality with 114,900 deaths in 2014.[5] The epidemiology of measles in the developing world is highly dependent on funding resources, public health infrastructure and political stability.

ETIOLOGY AND PATHOGENESIS

Measles virus is a highly contagious, single-stranded, enveloped RNA virus that is a member of the Paramyxoviridae family. Humans are the only natural hosts. Transmission occurs via person-to-person contact or airborne respiratory secretions. Infectious droplets have been reported to remain airborne for up to 2 hours, allowing for easy transmission in public spaces.[6]

The measles virus enters the host via the respiratory mucosa or conjunctiva where it can replicate, spread locally to lymphatic nodes and later disseminate into the bloodstream. The humoral immune system controls viral replication and confers antibody protection, whereas the cell-mediated response eliminates infected cells. A transient immunosuppression occurs during measles virus infection, causing depressed delayed-type hypersensitivity and T-cell counts, as well as an increased risk of bacterial infections.[7]

Figure 163-1 Measles. The pathognomonic Koplik spots of measles appear as tiny white lesions—"grains of sand"—surrounded by an erythematous halo. They precede the generalized rash by 1 to 2 days. (Image used with permission from the Fitzsimmons Army Medical Center Dermatology Archive.)

Figure 163-2 The morbilliform eruption of measles in a toddler.

CLINICAL FEATURES

Measles infection is characterized by an incubation period, prodrome and exanthem. The incubation period from acquiring the virus to developing fever ranges between 7 and 21 days.

The prodrome consists of fever (as high as 40.5°C [104.9°F]), malaise, conjunctivitis (palpebral, extending to lid margin), coryza, and cough (brassy or barking) and can last up to 4 days. Koplik spots are the pathognomonic enanthem of measles and develop during the prodrome. The spots begin as small, bright red macules that have a 1- to 2-mm blue-white speck within them and are typically found on the buccal mucosa near the second molars (Fig. 163-1). Koplik spots typically occur 48 hours prior to the onset of the rash and only last 12 to 72 hours. Koplik' spots may be absent if a patient presents several days into the patient's rash.[8]

The measles exanthem consists of nonpruritic, erythematous macules and papules progressing in a cranial-to-caudal direction. The exanthem begins on the forehead and behind the ears (Fig. 163-2) and spreads to involve the neck, trunk, and extremities (Fig. 163-3). The hands and feet are involved. Lesions may coalesce, especially on the face and neck. The rash usually peaks within 3 days and begins to disappear in 4 to 5 days in the order that it appeared. Desquamation and brownish dyspigmentation in fair patients can occur as the rash resolves.[8]

DIAGNOSIS

The laboratory diagnosis of measles is based on virus detection or positive serologic findings. The measles virus can be isolated using real-time reverse transcription polymerase chain reaction (PCR) from nasopharyngeal aspirates, throat swabs, blood or urine. Viral detection is most successful when collection occurs within 3 days of the rash's onset.

Serologic studies are also very useful in confirming the diagnosis of measles. Enzyme-linked immunoassays are commonly used. A positive serum immunoglobulin (Ig) M antibody for measles confirms the diagnosis. IgM testing is typically positive on the first day of the rash and remains positive for at least 30 days afterward. Within the first 72 hours of the rash, the IgM assay may be falsely negative, so repeat testing should be considered if there is a high clinical suspicion.[9] IgG confirmation of a measles diagnosis requires

Figure 163-3 Measles. Classic morbilliform exanthem with red papules spreading from forehead and postauricular area to neck, trunk and then extremities. (Used with permission from Wolff K, Johnson R, Saavedra AP, et al. *Fitzpatrick's Color Atlas and Synopsis of Clinical Dermatology*, 8th ed. New York, NY: McGraw-Hill; 2017.)

documentation of a fourfold increase in titers, therefore serum samples should be drawn during the rash and weeks later during the convalescent stage. In the United States, measles should be reported to the local or state health department which can also help with selecting and processing laboratory tests.

DIFFERENTIAL DIAGNOSIS

Table 163-1 outlines the differential diagnosis of measles.

CLINICAL COURSE AND PROGNOSIS

Uncomplicated measles is self-limited, lasting 10 to 12 days. An infected patient is considered to be contagious 5 days prior to the onset of the rash until 4 days after the onset of the rash.

Complications from measles infection occur in approximately 40% of cases.[8] Complications include severe diarrhea; pneumonia (either viral or superimposed bacterial infection); otitis media; transient immunosuppression with lymphopenia and decreased cell-mediated immunity; encephalitis, and a rare form of a progressive neurodegenerative disease termed *subacute sclerosing panencephalitis*. Most deaths are attributed to either respiratory illness or encephalitis. In developing nations, measles remains a major cause of infant mortality. Patient groups at risk for complications include infants, the elderly, pregnant women, the immunocompromised, and the malnourished.

MANAGEMENT

The management of measles is supportive as there are no specific antiviral therapies approved Table 163-2). Treatment focuses on antipyretics, fluids, and managing complications related to bacterial superinfection, respiratory compromise, and neurologic sequela. In the hospitalized setting, patients should be on standard and airborne transmission precautions for 4 days after the rash onset (entire duration of illness in immunocompromised patients).[10] The World Health Organization recommends that vitamin A should be administered to all children with measles regardless of their country of residence.[8] Vitamin A deficiency is associated with increased disease severity and risk for complications, likely through depressing cell-mediated immunity. A 2005 Cochrane review of vitamin A supplementation to treat measles in children found an association between using vitamin A (200,000 international units per day or 100,000 international units per day for infants) on 2 consecutive days and a reduced risk of measles mortality in children younger than 2 years old.[11]

Ribavirin is a medication that has been used in children with severe disease or an immunocompromised state. A randomized trial of 100 children found decreased duration of symptoms, hospital stay, and risk of complications in children receiving ribavirin compared to supportive therapy.[12] However, larger studies are needed prior to recommending this therapy as part of routine practice.

Postexposure prophylaxis plays an important role in curtailing outbreaks and decreasing morbidity of the virus. Individuals at risk for severe illness and complications (infants younger than 1 year of age, pregnant women, unimmunized, and immunocompromised) should be given measles immunoglobulin if presenting within 6 days of exposure. Measles immunoglobulin can be given either via an IM (0.5 mL/kg; maximum dose: 15 mL) or IV route (400 mg/kg). In healthy individuals, the measles-mumps-rubella (MMR) vaccine should be given to boost immunity if it can be administered within 72 hours of measles exposure.[10]

TABLE 163-1
Differential Diagnosis of Measles

Most Likely
- Drug hypersensitivity reaction
- Rubella

Consider
- Henoch-Schönlein purpura (atypical cases)
- Other viral infection (parvovirus, enterovirus, adenovirus, human herpesvirus-6, Epstein-Barr virus)
- Rocky Mountain spotted fever (atypical cases)

Always Rule Out
- Graft-versus-host disease (recent bone marrow transplantation)
- Kawasaki disease

TABLE 163-2
Treatments for Measles

- First-line
  - Immunoglobulin, IM[a]
  - Measles vaccine
  - Supportive care
  - Treat secondary infections
  - Vitamin A[a]
- Second-line
  - Ribavirin[a]

[a]In select cases; please see text.

PREVENTION (IMMUNIZATIONS)

The incidence of measles has decreased worldwide as a direct result of immunization. Two doses of the

live-attenuated measles vaccine (with the first dose at or after 12 months of age) produces detectable levels of antibody in 99% of individuals, conferring lifelong immunity.[10] The measles vaccine is typically administered in the form of combination vaccines: MMR vaccine or MMR and varicella vaccine. The second dose of the vaccine should be administered no sooner than 28 days later. The American Academy of Pediatrics, recommends MMR at age 12 to 15 months and then again prior to school entry, between 4 and 6 years old.

Measles vaccine administration is contraindicated in individuals who have a moderate to severe illness, as well as in those who have had an immediate anaphylactic reaction to a previous measles vaccine. It is also contraindicated in pregnant women and those with impaired immune systems (HIV infection, immunosuppressive therapy). Hypersensitivity reactions can occur to components of the vaccine, such as gelatin, neomycin, or egg white cross-reacting proteins.[10]

RUBELLA

AT-A-GLANCE

- Also called German measles and 3-day measles.
- Epidemic disease; worldwide distribution.
- Short prodrome; rash duration of 2 to 3 days.
- Enlargement of cervical, suboccipital, and postauricular glands.
- High risk of fetal malformations with congenital infection (microcephaly, congenital heart disease, and deafness), particularly in the first trimester.

EPIDEMIOLOGY

Rubella virus has a worldwide distribution with outbreaks occurring most frequently in late winter and early spring months. Humans are the only hosts for infection.[13] School-age children, adolescents, and young adults most often develop the disease. Epidemics occasionally occur in developing countries, especially where vaccines are unavailable.

Since introduction of the rubella vaccine in the United States in 1969, the incidences of rubella and congenital rubella syndrome have drastically declined with no widespread epidemics occurring in the United States. Since 2003, fewer than 20 cases are reported annually in the United States.[14] Occasional outbreaks have largely been attributed to failure to vaccinate susceptible individuals. Yet, recent serologic surveys indicate that approximately 10% of the United States–born population older than age 5 years is susceptible to rubella.[13,14] Epidemiologic studies have identified that individuals born outside the country or in a vaccine-poor area have an increased risk of rubella.[13]

ETIOLOGY AND PATHOGENESIS

Rubella is an enveloped positive-stranded RNA virus in the Togaviridae family that is spread through direct or droplet contact from nasopharyngeal secretions.[13] Infected individuals shed virus for 5 to 7 days before and up to 14 days after onset of rash,[15] with viremia unlikely after the rash occurs. In most individuals, infection leads to lifelong immunity.

Congenital rubella occurs when a nonimmunized, susceptible, pregnant woman is exposed to the virus. Transplacental infection of the fetus occurs during the viremic stage. The risk is greatest to a fetus exposed to the virus in the first trimester. Congenitally infected infants may shed the virus through urine, blood, and nasopharyngeal secretions for up to 12 months after birth, thus being a potential source of viral exposure to other susceptible individuals.[13,15]

CLINICAL FINDINGS

HISTORY

Primary rubella infection is typically a mild, subclinical disease, particularly in adults.[13,15] The prodrome is characterized by low-grade fever, myalgia, headache, conjunctivitis, rhinitis, cough, sore throat, and lymphadenopathy; symptoms that may last up to 4 days and often resolve with appearance of rash. Up to 50% of children with primary rubella infection may have a subclinical infection or present only with lymphadenopathy or rash (no prodrome).[15] Conversely, older adults may have more-severe and persistent prodromal symptoms that may make distinction from rubeola difficult in some situations. The presence of Koplik spots in the mouth favors rubeola. As the prodrome resolves and the rash begins to appear, some patients develop an enanthem consisting of tiny red macules on the soft palate and uvula (Forchheimer spots).[16] This enanthem is not diagnostic for rubella.

CUTANEOUS LESIONS

The exanthem, occurring 14 to 17 days after exposure, is characterized by pruritic pink to red macules and papules that begin on the face, quickly progressing to involve neck, trunk, and extremities (Fig. 163-4).[15] Lesions on the trunk may coalesce, whereas those on the extremities often remain more discrete. The rash usually begins to disappear in 2 to 3 days, unlike rubeola, which can be more persistent and clears the head and neck first. Desquamation may follow resolution of the rash.

RELATED PHYSICAL FINDINGS

Lymphadenopathy is usually most severe in the posterior cervical, suboccipital, and postauricular lymph

Figure 163-4 Rubella. Erythematous macules and papules appearing initially on the face and spreading to trunk, arms, legs within 24 hours.

nodes, and is noted up to 7 days before the rash appears.[13] Enlargement of the nodes may persist for several weeks.

Adults, particularly women (up to 70%), may develop arthritis of small and large joints with rubella infection.[13] Joint symptoms often first appear as the rash fades and can last several weeks. In some individuals, the symptoms may become persistent or recurrent, and joint swelling may progress to joint effusion.

DIAGNOSIS

Diagnosis is typically made using serology to detect rubella-specific IgM antibody (up to 8 weeks after infection) or to document a fourfold rise in antibody titer in acute and convalescent-phase serum.[16] As with measles, rubella cases should be reported to local or state health departments.

Viral culture (nose, throat, blood, urine, cerebrospinal fluid [CSF], and synovial fluid) is sensitive but often difficult because of the influence of timing, collection procedure, and transport on the specimen.[17] Reverse transcription PCR may be used to detect rubella virus from throat swab or oral fluid with subsequent genotyping of strains to identify a source during outbreaks.[17] Complete blood cell count usually shows leukopenia with relative neutropenia. Increased numbers of atypical lymphocytes or abundant plasma cells may be noted as well. Patients with meningeal involvement have lymphocytes in the CSF.

CONGENITAL RUBELLA SYNDROME

Women who are infected with rubella during pregnancy may only exhibit minor clinical symptoms, however the effects of rubella infection on the fetus can be profound.[15] The greatest risk of fetal malformation is in the early stages of pregnancy. Up to 85% of fetuses exposed to rubella within the first 12 weeks of gestation develop serious sequelae such as microcephaly with mental retardation; congenital heart disease (ventricular septal defect, patent ductus arteriosus, pulmonary artery stenosis); sensorineural deafness; cataracts; glaucoma; low birthweight; and fetal death.[14-16] Neonatal manifestations of congenital infection include growth retardation, interstitial pneumonitis, radiolucent bone disease, hepatosplenomegaly, thrombocytopenia, and dermal erythropoiesis ("blueberry muffin lesions").[13]

Diagnosis of congenital rubella infection is obtained by isolating rubella virus in the throat, cataracts, urine, or CSF of the affected neonate. Serologic testing is not as sensitive, but is easily available for confirmatory testing. IgM antibody can be detected from birth to 1 month of age; IgG antibody titers may be stable or increase over several months. Laboratory confirmation of congenital infection in children older than age 1 year is difficult as viral isolation is rare.[13,15]

DIFFERENTIAL DIAGNOSIS

Table 163-3 outlines the differential diagnosis of rubella.

CLINICAL COURSE AND PROGNOSIS

Rubella is typically a self-limited disease. Infants who have congenital rubella are infectious until viral shedding from the nasopharynx and urinary tract ends.

TABLE 163-3
Differential Diagnosis of Rubella

Most Likely
- Drug hypersensitivity reaction
- Rubeola (measles)

Consider
- Other viral infection (enterovirus, adenovirus, parvovirus, human herpesvirus-6)

Always Rule Out
- Streptococcal scarlet fever

For the differential diagnosis of congenital rubella syndrome with blueberry muffin lesions, see Table 163-10.

The majority of infants (85%) infected in utero excrete virus in the first month of life; 1% to 3% of infants infected in utero continue to excrete virus in the second year of life.[13,16] Pregnant women caring for these infants are at risk for developing rubella. Clinical course depends on how severely affected the fetus is from intrauterine infection.

Rarely, rubella infection may lead to encephalitis (1 in 6000 cases), with mortality rates varying from 0% to 50%.[16] Other rare complications include peripheral neuritis, optic neuritis, encephalitis, myocarditis, pericarditis, hepatitis, orchitis, hemolytic anemia, thrombocytopenia, and hemophagocytic syndrome.[15]

MANAGEMENT

Treatment of primary, uncomplicated rubella is supportive. Standard and droplet precautions are recommended for patients with rubella for 7 days after rash onset.[13] In nonpregnant individuals, rubella vaccine administration within 3 days of exposure theoretically may prevent illness, although this is yet to be proven.[13] Limited data indicate that IM immunoglobulin (0.55 mL/kg) as postexposure prophylaxis for rubella-susceptible patients may decrease infection, viral shedding, and rate of viremia.[13,18]

Neonates with congenital rubella syndrome require supportive care as well as appropriate attention to significant health issues. These infants are contagious and should be isolated to prevent transmission to susceptible individuals.[13,15] Contact isolation is recommended for these infants until they are at least 12 months old or repeated cultures are negative after 3 months of age.[13]

PREVENTION (IMMUNIZATIONS)

Rubella vaccine is typically administered as part of a threefold vaccine (MMR) or fourfold vaccine (MMR and varicella) at 12 to 15 months of age and again at 4 to 6 years of age. Seroconversion after a single dose of MMR vaccine occurs in 95% of individuals.[13,14] It is imperative that individuals at risk for rubella infection are immunized, such as health care workers, military recruits, college students, and recent immigrants.[13]

Potential adverse reactions to rubella vaccine occur in susceptible individuals and include fever (6 to 12 days after vaccine), morbilliform rash, lymphadenopathy, and arthralgia. Febrile seizures occur more frequently in children 1 to 2 years old when receiving the first MMR vaccine.[13]

Pregnant women should not receive the rubella vaccine because of the theoretical risk to the fetus.[19] Any woman receiving the rubella vaccine should not become pregnant for 28 days. Infants of vaccinated breastfeeding mothers may become infected with rubella via breastmilk. Typically, they develop a mild erythematous exanthem of macules and papules with no serious effects.[16]

Certain immunosuppressed and immunodeficient patients should not be vaccinated with live-attenuated virus vaccines, including rubella. Vaccine strain rubella virus has been found in cutaneous granulomas in immunodeficient hosts.[20]

ERYTHEMA INFECTIOSUM AND PARVOVIRUS B19 INFECTION

AT-A-GLANCE

- Erythema infectiosum (fifth disease): childhood illness with "slapped cheeks" followed by an erythematous, lacy eruption on the trunk and extremities.
- Symmetric polyarthritis, particularly of the small joints in adults.
- Papular purpuric gloves-and-socks syndrome: pruritic erythema, edema, and petechiae of the hands and feet, fever, and oral erosions in adolescents.
- Aplastic crisis in patients with increased red blood cell turnover, chronic anemia in immunocompromised persons, and fetal hydrops.

EPIDEMIOLOGY

Erythema infectiosum (fifth disease) is worldwide in distribution, can occur throughout the year, and can affect all ages. It tends to occur in epidemics, especially associated with school outbreaks in the late winter and early spring. Serologic studies show increasing prevalence of antibodies with age—from 15% to 60% of children 5 to 19 years of age to more than 90% in the elderly.[21] Previous infection with B19 seems to confer lifelong immunity.

The incubation period for erythema infectiosum is from 4 to 14 days. Low-grade fever and nonspecific complaints occur at the time of viremia, 6 to 14 days after inoculation, followed by rash at day 17 or 18.[22] Parvovirus B19 is thought to be transmitted primarily by the respiratory route via aerosolized droplets during the viremic phase.[22] After the rash of erythema infectiosum appears, B19 is usually not found in respiratory secretions or serum, suggesting that persons with erythema infectiosum are infectious only before the onset of the rash.

The virus seems to be effectively spread after close contact. The secondary attack rate among susceptible household contacts is approximately 50%. Transmission may occur via blood transfusion, from blood products, and vertically from mother to fetus.[23]

ETIOLOGY AND PATHOGENESIS

The B19 virus belongs to the family Parvoviridae and the genus *Erythrovirus*. B19 lacks an envelope and contains single-stranded DNA. It is the smallest single-stranded DNA-containing virus known to infect humans, measuring 18 to 26 µm in diameter. Parvoviruses are widespread in veterinary medicine, but animal parvoviruses are not thought to be transmissible to humans.[24]

The more serious manifestations of parvovirus infection relate to the fact that the virus infects and lyses erythroid progenitor cells. The blood group P antigen (globoside) is a receptor of parvovirus. Because some individuals lack P antigen, they are not susceptible to infection with B19.[25] In patients with increased red blood cell destruction or loss who depend on compensatory increases in red cell production to maintain stable red cell indices, B19 infection may lead to transient aplastic crisis. Such patients include those with anemia associated with acute or chronic blood loss. When parvovirus infects the erythroblasts in a developing fetus with decreased red cell survival, the result may be hemolysis and anemia. Anemia may trigger congestive heart failure, edema (fetal hydrops), and possibly fetal death. Additionally, parvovirus B19 DNA can be detected in nonerythroid tissues and is associated with increased inflammatory gene expression in these tissues.[26] Immune complex deposition also has been implicated in some of the manifestations of B19 infection, including erythema infectiosum.

CLINICAL FEATURES

PARVOVIRUS B19 IN CHILDREN

Most infections caused by B19 are asymptomatic and unrecognized. Fifth disease, the most common clinical picture associated with the virus, usually begins with nonspecific symptoms such as headache, coryza, and low-grade fever approximately 2 days before the onset of the rash.[27] Patients may have headache, pharyngitis, fever, malaise, myalgia, coryza, diarrhea, nausea, cough, and conjunctivitis coinciding with the rash. Approximately 10% of children with erythema infectiosum develop arthralgia or arthritis. Large joints are affected more often than small joints.[28] Occasionally, children may present with chronic joint complaints suggestive of juvenile idiopathic arthritis.

The characteristic rash begins with confluent, erythematous, edematous plaques on the malar eminences, the "slapped cheeks" (Fig. 163-5). As the facial rash fades over 1 to 4 days, pink to erythematous macules or papules appear on the trunk, neck, and extensor surfaces of the extremities. These lesions have some central fading, giving them a lacy or reticulated appearance (Fig. 163-6).[27] The rash can be morbilliform, confluent, circinate, or annular, and there are reports of palmar and plantar involvement.[28] The eruption

Figure 163-5 Erythema infectiosum. Child with the characteristic "slapped cheeks."

typically lasts 5 to 9 days, but can recur for weeks or months with triggers such as sunlight, exercise, temperature change, bathing, and emotional stress. In some outbreaks, pruritus is a major feature of the rash in children.[28]

There have been occasional reports of parvovirus B19 associated with generalized petechiae, and vascular purpura, including Henoch–Schönlein purpura.[29,30] A microvesicular eruption also has been reported.[31] An enanthem consisting of erythema of the tongue and pharynx and red macules on the buccal mucosa and palate can occur.

Figure 163-6 Reticulate and annular erythema of the torso and upper limbs in acute parvovirus B19 infection. (Image from Mage V, Lipsker D, Barbarot S, et al. Different patterns of skin manifestations associated with parvovirus B19 primary infection in adults. *J Am Acad Dermatol.* 2014;71(1):62-69, with permission. Copyright © American Academy of Dermatology.)

PARVOVIRUS B19 IN ADULTS

Acute arthropathy is the primary manifestation of B19 viral infection in adults.[32] It occurs mainly in women and affects the knees and the small joints of the hands. Other joints, such as the spine and costochondral joints, are occasionally involved. This symmetric polyarthritis is usually of sudden onset and is self-limited but can be persistent or recurrent for months. It may mimic Lyme arthritis or rheumatoid arthritis.

The constitutional symptoms are usually more severe in adults than in children. Fever, adenopathy, and a mild arthritis without a rash is the usual course. Women are more likely than men to have joint complaints and rash, whereas men often present with only a flu-like illness.[32] Some adults may have fatigue, malaise, and depression for weeks after the infection. Asymptomatic infection can certainly occur in adults as well as in children. Numbness and tingling of the fingers and pruritus have been reported with or without a rash.[33] It has been suggested that if pruritus is a complaint in a patient with acute-onset arthritis, parvovirus should be considered as a possible cause.

The rash in adults, if present at all, is usually macular and blotchy or lacy, often on the extremities, and rarely demonstrates the characteristic slapped-cheek appearance.[32] Other cutaneous manifestations associated with B19 infection in adults include purpura, vesicles and pustules, palmoplantar desquamation, a morbilliform exanthema, occasional oral petechiae and small erosions, and livedo reticularis.

PAPULAR PURPURIC GLOVES-AND-SOCKS SYNDROME

In 1990, a unique syndrome of pruritic erythema and edema of the hands and feet with petechiae, fever, and oral erosions was described.[34] This rare exanthem, now known as *papular purpuric gloves-and-socks syndrome*, seems to affect teenagers and adults. However, it also can affect children.[35] Patients usually have mild prodromal symptoms of fatigue and low-grade fever, myalgia, and arthralgia. Subsequently, itchy, painful, symmetric edema and erythema of the distal hands and feet occurs. Purpuric papules appear on the hands and feet with abrupt demarcation at the wrists and ankles. The enanthem, if present, arises on the lips, soft palate, and buccal mucosa. The syndrome resolves spontaneously within 2 weeks. Importantly, papular purpuric gloves-and-socks syndrome is contagious when the eruption is present, in contrast to erythema infectiosum.

DIAGNOSIS

LABORATORY TESTING

In patients with erythema infectiosum, laboratory results are usually normal. Patients with aplastic crisis have reticulocytopenia and anemia, the severity of which depends on the degree of underlying anemia. Reticulocytopenia, anemia, lymphopenia, neutropenia, and thrombocytopenia can occur in healthy individuals with B19 infection, although these are usually not significant enough to cause clinical symptoms. The erythrocyte sedimentation rate is rarely elevated, and in some cases of parvovirus-associated arthritis, rheumatoid factor has been positive.

Detection of recent infection is usually performed with assays for IgM antibody. IgM can be detected within a few days after onset of illness and is present for up to 6 months in many cases, although there is a decline in titer in the second month after onset. The sensitivity of IgM ranges from 62% to 70%. IgG can be identified by the seventh day of illness and lasts for years and is therefore best for documenting past infection. Parvovirus antibody is often not detectable in immunodeficient persons.

PCR is used to detect B19 DNA. This technique is considered one of the most sensitive approaches for detection of the virus within a number of different specimens including serum or plasma, amniotic fluid, placental or fetal tissue, or bone marrow. It is considered the test of choice in an immunocompromised patient, and to confirm fetal infection. One caveat is that parvovirus DNA fragments may be present for more than a year after infection, however this does not always indicate that the viable virus is present.[36] PCR should be used along with IgM and IgG in pregnant patients.[37]

PATHOLOGY

The histopathologic changes in the skin of patients with erythema infectiosum include a sparse superficial perivascular lymphocytic infiltrate that is not considered diagnostic. Immunohistochemical techniques can be used to detect B19 parvovirus antigen in a number of different tissues.

DIFFERENTIAL DIAGNOSIS

Table 163-4 outlines the differential diagnosis of parvovirus B19 infection.

PROGNOSIS AND CLINICAL COURSE

Parvovirus B19 infection in healthy individuals is self-limited. The eruption of erythema infectiosum and the parvovirus arthropathy usually resolve in 1 to 2 weeks, but can recur or persist for months. If untreated, transient aplastic crisis can be fatal, but most patients recover in 1 week. Chronic anemia from B19 usually resolves if treated with γ-globulin. Fetal hydrops can lead to fetal death if not treated.

TABLE 163-4
Differential Diagnosis of Parvovirus B19 Infection

Most Likely
- Drug reaction
- Enteroviral infection
- Erysipelas on the cheek
- Erythema infectiosum
- Hand-foot-mouth disease
- Papular purpuric gloves-and-socks syndrome

Consider
- Atypical measles
- Collagen vascular disease (systemic lupus erythematosus, dermatomyositis)
- Erythema infectiosum
- Measles
- Papular purpuric gloves-and-socks syndrome
- Roseola
- Rubella

Always Rule Out
- Kawasaki disease
- Rocky Mountain spotted fever
- Scarlet fever

COMPLICATIONS

An increasing number of complications from parvovirus B19 are now recognized. Subclinical infection is quite common. However, this virus can be responsible for a variety of hematologic, rheumatologic, and neurologic abnormalities.

TRANSIENT APLASTIC CRISIS

Parvovirus B19 is the most common cause of transient aplastic crisis in patients with chronic hemolytic anemias,[38] as well as in other conditions of decreased red cell production or increased red cell destruction. The aplastic crisis may be the initial manifestation of the underlying hematologic disease. Patients typically have fever and constitutional complaints, followed 1 week later by fatigue, pallor, and worsening anemia.[38] Cutaneous manifestations are rarely seen with the aplastic crisis. The hemoglobin may fall below 4 µg/dL and is not associated with reticulocyte production. Bone marrow examination shows hypoplasia or aplasia of the erythroid series. Red blood cell transfusion may be necessary, and most patients recover in 1 week, although the problem can be fatal if untreated. Transient red cell aplasia can occur in healthy persons without underlying hematologic abnormalities.[38] It is likely that the aplasia is missed in individuals without disorders of shortened erythrocyte survival because the hemoglobin does not drop low enough to cause symptoms.

CHRONIC B19 INFECTION

In immunocompromised patients, B19 infection can cause a serious, prolonged anemia from persistent lysis of red blood cell precursors.[39] Parvovirus-related chronic anemia has been reported in HIV-infected patients, as well as in transplantation recipients and those with congenital immunodeficiencies, acute leukemias, lupus erythematosus, and during the first year of life without immunodeficiency. These patients respond dramatically to IV γ-globulin, suggesting that antibody is the main defense to human parvovirus infection.[39]

FETAL B19 INFECTION

Fetal infection with B19 may result in either an unaffected fetus or spontaneous abortion (especially in the first half of pregnancy), hydrops fetalis in the second half of pregnancy, congenital anemia, and even late fetal death.[37] Nonimmune fetal hydrops is the most common complication of intrauterine infection with B19. Because B19 virus can infect erythroid precursors, extensive hemolysis can occur in the fetus, leading to severe anemia, tissue anoxia, high-output heart failure, and generalized edema. The fetus may show ultrasonographic evidence of subcutaneous edema, ascites, pleural effusion, pericardial effusion, placental edema, and polyhydramnios. The overall risk of fetal death is not clearly known, but recent studies suggest that this risk is approximately 6.5% with maternal infection.[37] The risk of fetal death for a woman with unknown serologic status is estimated to be less than 2.5% after a household exposure and less than 1.5% after a significant work exposure. It seems that in B19-infected pregnant women, 33% to 50% of fetuses are infected, with an adverse outcome in 10% of infected fetuses.[37,40] Furthermore, approximately 50% of women of childbearing age are immune to parvovirus infection because of prior infection.

Because parvoviruses are known teratogens in animals, there has been much concern about whether they cause birth defects in humans, but it appears that parvovirus B19 is not a common cause of birth defects.

OTHER COMPLICATIONS

There are reports of B19 infection causing encephalitis, meningitis, brachial neuritis, a myasthenia-like syndrome, and motor weakness. Parvovirus infection has been blamed for a granulomatosis with polyangiitis (Wegener) illness, polyarteritis nodosa, Kawasaki disease, and a systemic lupus erythematosus-like picture.[41-43] In addition, there are reports of other hematologic complications, including idiopathic thrombocytopenic purpura, transient neutropenia, myocarditis, a hemophagocytic syndrome, and the Blackfan-Diamond syndrome.

TREATMENT

There is no specific treatment available for parvovirus B19 infection. Erythema infectiosum is a benign

TABLE 163-5
Treatments for Parvovirus B19 Infections

▪ Erythema infectiosum	Supportive treatment of fatigue, malaise, pruritus, arthralgia
▪ Chronic anemia	IV immunoglobulin
▪ Transient aplastic crisis	Oxygen and/or blood transfusion may be necessary
▪ Hydrops fetalis	Possible intrauterine exchange transfusion

condition, and usually no treatment is necessary. Supportive therapy for relief of fatigue, malaise, pruritus, and arthralgia may be needed. The chronic anemia of persistent B19 infection may be treated successfully with commercially available IV immunoglobulin,, which contains neutralizing anti-B19 antibodies. Transient aplastic crisis, which can be life-threatening, may require oxygen therapy and blood transfusion.

Serologic testing for B19 IgG and IgM should be offered to pregnant women who are exposed to parvovirus B19. Infected pregnant women are followed by frequent ultrasonograms. Evidence of hydrops fetalis warrants umbilical cordocentesis to check for anemia, viral DNA, IgG, and IgM. The management of infected fetuses is controversial. Some physicians advocate observation because spontaneous resolution is common. Fetuses with severe anemia and compromise are usually managed with intrauterine exchange transfusion, but this procedure does carry risk Table 163-5).

PREVENTION

There is currently no vaccine to prevent parvovirus B19 infection. Vaccine development has been problematic; however, Phase II clinical trials have been completed.[44] It is not known whether immunoglobulin given around the time of exposure prevents infection or alters the course of the disease.

Because patients with erythema infectiosum are no longer infectious by the time they develop the illness, control measures directed toward these individuals are not likely to be effective. If these persons are hospitalized, no special precautions need to be taken. Because the virus is transmitted before the rash appears, the disease is easily spread in situations of close prolonged contact such as schools, day care centers, workplaces, and homes.

Patients with aplastic crisis or immunosuppression with chronic B19 anemia may have high-titer viremia and are particularly infectious. These individuals should be placed in respiratory and contact isolation if hospitalized, and pregnant health care providers should not care for them directly. Hospital workers are at risk of contracting nosocomial infections from these patients and could spread the virus to patients if adequate precautions are not taken.

EPSTEIN-BARR VIRUS

AT-A-GLANCE

- Epstein-Barr virus is also known as human herpesvirus 4.
- In developed countries, primary infection most often occurs during adolescence/early adulthood.
- Infectious mononucleosis is characterized by the triad of fever, lymphadenopathy, and pharyngitis.
- Morbilliform exanthem with primary infection; most common after administration of ampicillin or amoxicillin.
- Oral hairy leukoplakia, nasopharyngeal carcinoma, Burkitt lymphoma, Hodgkin disease, Kikuchi histiocytic necrotizing lymphadenitis, and certain types of cutaneous T-cell lymphoma are associated with Epstein-Barr virus infection.

Ebstein-Barr virus (EBV), also known as human herpesvirus 4, is a ubiquitous viral infection. Primary infection occurs early in life followed by lifelong, latent infection. EBV has been implicated in a diverse set of inflammatory dermatologic disorders and neoplasms. The manifestations of EBV infection are strongly influenced by the patient's age and immunologic status.

EPIDEMIOLOGY

EBV is a worldwide pathogen with more than 90% of adults latently infected.[45] The age of onset of primary EBV infection is in part dependent on geographic location and socioeconomic status. Patients from developing countries or of lower socioeconomic status are more likely to acquire EBV during early childhood. Early childhood EBV infection is frequently asymptomatic or nonspecific in presentation and does not present with infectious mononucleosis, a manifestation characteristic of EBV infection during adolescence and young adulthood. Within in the United States, 50% of 6- to 8-year-old children are seropositive for EBV.[46] The rest of the population acquires EBV infection later in life with 89% of the population becoming seropositive by 18 to 19 years old.[46] Risk factors for early seropositivity include lower household income, parental education level, uninsured status, and being Mexican American or Black (non-Hispanic).[46]

ETIOLOGY AND PATHOGENESIS

EBV is an enveloped, double-stranded DNA virus with a genome that encodes approximately 100 proteins.

EBV exists as 2 distinct types, EBV-1 and EBV-2, but no specific differences in symptoms or disease associations have been identified between the two. EBV-1 is found worldwide and EBV-2 infection occurs most often in Africa.[47]

EBV is typically transmitted via saliva from patients with recent primary infection or from low-grade viral shedding in patients with latent EBV infection. After infectious mononucleosis, viral shedding continues for a median duration of 6 months.[48] The virus also has been isolated from breastmilk, cervical epithelial cells, and semen.[49]

EBV often first infects oropharyngeal epithelial cells with subsequent infection of B-lymphocytes in the oropharynx.[50] EBV infects B lymphocytes through the binding of the EBV glycoprotein gp350 with CD21 on the surface of B cells. The infected B cells are then activated, and their population is expanded.[51] These B lymphocytes allow dissemination of the virus throughout the lymphoreticular system. A clonal expansion of cytotoxic T lymphocytes allows recovery from primary and reactivation infection and is the source of the atypical lymphocytes associated with EBV infection.[52] Symptoms occur after a 4- to 8-week incubation period and likely result from this immunologic response.

EBV establishes an indefinite latent infection within B cells. EBV can periodically reactivate and be shed in oral secretions. An impaired cellular immune system can result in poorly controlled primary EBV infection, EBV reactivation, and promote EBV-induced malignancy. Both X-linked lymphoproliferative disease and GATA2 deficiency are inherited immunodeficiencies particularly associated with impaired immune responses to EBV infection.[53]

CLINICAL FEATURES

INFECTIOUS MONONUCLEOSIS

EBV is transmitted through bodily fluids, especially saliva, and then infects the oropharyngeal epithelium. An incubation period of 30 to 50 days occurs prior to symptoms.[54] The most common manifestation of EBV infection in adolescents and adults is infectious mononucleosis, also referred to as the "kissing disease." Infectious mononucleosis presents with the classic triad of fever, lymphadenopathy, and pharyngitis in approximately 50% of cases.[55] Fevers can last 1 to 3 weeks and lymphadenopathy can be tender and frequently found in the posterior cervical chain. Accompanying pharyngitis can vary in intensity from mild erythema to grossly enlarged tonsils with white exudate that can impact breathing. Other systemic features include fatigue, headache, mild transaminitis, cytopenias, and atypical lymphocytosis.

EBV can infect nearly every organ. Complications of infectious mononucleosis occur in approximately 20% of patients and include airway obstruction, autoimmune hemolytic anemia or thrombocytopenia, neutropenia, myocarditis, and hepatitis. Splenomegaly occurs in 50% of patients and typically resolves by the fourth to sixth week of illness.[56] Splenic rupture is a rare, potentially life-threatening complication more common in young men. The risk of splenic rupture is estimated at 0.1% and is spontaneous in greater than 50% of cases.[57] EBV also is associated with various neurologic complications that typically occur within 1 month of illness including aseptic meningitis, transverse myelitis, peripheral neuritis, Guillain-Barré syndrome, and cranial nerve palsies.[55] EBV infection during pregnancy is not thought to be teratogenic.[58]

Cutaneous eruptions with infectious mononucleosis occur in up to 25% of cases and can adopt a morbilliform, scarlatiniform, urticarial, erythema multiforme-like, or petechial morphology.[59] Eruptions also frequently occur when patients with infectious mononucleosis are treated with antibiotics, classically ampicillin. This association was first described in the 1960s and coined the *ampicillin rash*.[60] Beginning 7 to 10 days after the initiation of ampicillin, patients develop a generalized, pruritic, morbilliform rash with an erythematous or copper color that resolves in a week (Fig. 163-7). This eruption also has been reported with other antibiotics, such as amoxicillin, cephalexin, erythromycin, and levofloxacin. *Ampicillin rash* was originally cited as occurring in up to 100% of antibiotic-exposed patients, but the current literature indicates a much lower rate of only 30%.[59] The rash is thought to be a result of EBV-induced antibodies that are produced in response to

Figure 163-7 Morbilliform rash in Epstein-Barr virus infection. (From Rabach I, Berti I, Bibalo C, Longo G. A curious rash. *J Pediatr.* 2013;162(5):1071-1072, with permission.)

the administered drug and form complement-fixing immune complexes.[61] The exanthem does not usually indicate a permanent allergy to the medication.[62]

NON–SEXUALLY RELATED ACUTE GENITAL ULCERS

EBV infection also has been implicated in the development of non–sexually related acute genital ulcers or Lipschütz ulcers.[63] Lipschütz ulcers frequently occur in prepubertal or adolescent females and present as painful, multiple ulcers with red-purple ragged edges on the medial or outer surface of the labia minora. The ulcers are often deep with a necrotic or fibrinous base and can adopt a "kissing" pattern if symmetric.[49] Inguinal lymphadenopathy can also be frequently found on exam. Less common locations for Lipschutz ulcers include the labia majora and inner thighs. Ulcers can also occur in males with involvement of the scrotum (Fig. 163-8). EBV-associated genital ulcers are not recurrent and self-resolve in 2 to 6 weeks. Patients may be misdiagnosed as having herpes simplex infections, Behçet disease, or as victims of sexual abuse. The role of EBV in these ulcers has been confirmed by the detection of EBV DNA via PCR from ulcers and serology confirming acute infection.[64] Other infectious implicated in causing Lipschütz ulcers include cytomegalovirus (CMV), group A *Streptococcus*, mumps, *Salmonella*, toxoplasmosis, influenza A virus, and *Mycoplasma pneumoniae*.[49]

OTHER NONNEOPLASTIC ASSOCIATIONS WITH EPSTEIN-BARR VIRUS

EBV infection also is associated with multiple inflammatory dermatologic conditions, including Gianotti-Crosti syndrome when the infection occurs in young children, erythema multiforme, leukocytoclastic vasculitis, erythema nodosum, erythema annulare centrifugum, pityriasis lichenoides, granuloma annulare, and cold urticaria.[49]

Figure 163-8 Two scrotal ulcers in a patient with documented Epstein-Barr virus infection.

NEOPLASTIC CONDITIONS

The latent infection established by EBV is linked to the development of several malignancies, including nasopharyngeal carcinoma, Burkitt lymphoma, and Hodgkin lymphoma Table 163-6).[65] EBV-associated malignancies occur mainly in patients who are immunocompromised because of HIV infection or congenital immunodeficiency, and those who receive immunosuppressant therapy, such as organ transplant recipients. Latent EBV infection of lymphocytes may allow for their transformation, immortalization, and eventual malignant transformation.[66] Different EBV genes are expressed in each type of malignancy and the biology is quite complex.

Nasal-type extranodal natural killer/T cell lymphoma (ENK/T) is strongly associated with EBV.[67] Hallmarks of this aggressive, non-Hodgkin lymphoma include a natural killer–cell phenotype (expression of CD2, CD56, and cytoplasmic CD3 but a lack of surface CD3), angioinvasion and necrosis.[68] ENK/T is rare in the United States, Europe, and Africa, but is endemic in Asia, especially Southern China, and among native populations of Central and South America. Males are more commonly affected than females in a 2:1 ratio, and the tumor typically presents around 50 years of age.[69] The nasal type presents with an ulcerated midfacial tumor, previously termed *lethal midline granuloma*, that can lead to nasal obstruction, facial swelling, sinusitis, and destruction of the underlying sinuses and palate. Extranasal ENK/T can also occur and involve the skin, soft tissue, GI tract, and testes. Radiation therapy is typically used for localized disease and combined with chemotherapy for advanced stages.

TABLE 163-6

Epstein-Barr Virus–Associated Lymphoproliferative Diseases and Malignancy

B-cell neoplasms
- EBV+ diffuse large B-cell lymphoma of the elderly
- Endemic Burkitt lymphoma
- Hodgkin lymphoma

T-cell and natural killer cell neoplasms
- Angioimmunoblastic T-cell lymphoma
- Extranodal natural killer/T-cell lymphoma
- Hydroa vacciniforme–like lymphoproliferative disease
- Subcutaneous panniculitis-like T-cell lymphoma[a]

Hemophagocytic syndrome

Leiomyosarcoma[b]

Posttransplantation lymphoproliferative disorder

[a]Most cases of subcutaneous panniculitis T-cell lymphoma are sporadic but Epstein-Barr virus (EBV) positivity has been reported in Asian patients.
[b]EBV-associated smooth muscle tumors have been reported in immunocompromised children.

Another rare EBV-driven T-cell disorder is hydroa vacciniforme–like lymphoproliferative (HVLL) disease. HVLL disease affects children from Asia and Central and South America. Patients present similarly to photoinduced, self-resolving hydroa vacciniforme with the development of vesicles, crusting, and varicelliform scarring.[70] However, HVLL is distinguished by systemic symptoms (fever, weight loss, hepatosplenomegaly, and lymphadenopathy), extensive facial edema, ulcerations and scarring, and lesions located in photoprotected sites.[70] Histopathology reveals a monoclonal proliferation of T cells with a CD8 phenotype and less often a natural killer–cell phenotype.[71] The clinical course is variable and patients can have prolonged periods of relapsing fevers and skin eruptions. Severe cases can progress to develop hematophagocytic syndrome and natural killer/T-cell lymphoma.[70] GATA2 deficiency has been implicated in some cases of HVLL.[53]

Lymphomatoid granulomatosis is a rare, angioinvasive proliferation of EBV-infected B cells and a reactive, polyclonal T-cell population.[72] Pulmonary involvement is seen in almost all patients presenting with cough, fever, and cavitary lung nodules that at times can mimic Wegner granulomatosis.[66] Cutaneous involvement may be a presenting feature and is documented in up to 40% of cases.[73] As a result of the angiocentric and destructive proliferation, patients may present with stellate ulceration and subcutaneous nodules for which the differential may include medium-vessel vasculitis/vasculopathy and angioinvasive opportunistic infections.[74] A diagnosis of lymphomatoid granulomatosis should prompt a workup of an underlying immunodeficiency, as it has been described in the setting of immunosuppressive medications, congenital immunodeficiency, and autoimmune disease.[75] Lymphomatoid granulomatosis most often presents in the fourth to sixth decade of life and requires the initiation of chemotherapy.

EBV is also strongly associated with other B-cell neoplasms, including Burkitt lymphoma, Hodgkin lymphoma, and EBV+ diffuse large B-cell lymphoma of the elderly.

DIAGNOSIS

The diagnosis of infectious mononucleosis should be considered in adolescents and young adults who present with fever, fatigue, pharyngitis, and lymphadenopathy. Suggestive features of primary EBV infection include splenomegaly, posterior, as opposed to anterior, cervical lymphadenopathy and lymphocytosis with a predominance of atypical lymphocytes (defined as more than 10% of total lymphocytes). Other nonspecific laboratory abnormalities include mild neutropenia, thrombocytopenia, and transaminitis.

Heterophile antibody and EBV-specific antibodies can be used to confirm an EBV infection. The monospot test is a heterophile antibody test frequently used to confirm infectious mononucleosis in adolescents and adults with classic symptoms because of its rapid turnaround time and high specificity in the appropriate clinical setting. A heterophile antibody is an antibody that recognizes antigens on erythrocytes from a different specifies; in the case of the monospot test, it is antibodies against horse red blood cells produced in a person with an EBV infection. The sensitivity of rapid diagnosis heterophile antibody tests is approximately 85%.[76] The monospot test may be negative in the first week of infection and is not a sensitive test for children younger than 4 years old.[77]

EBV-specific antibodies are often employed to confirm EBV infection in young children and when a suspicion for EBV infection remains high despite a negative heterophile antibody test. Host IgM and IgG antibodies form against viral capsid antigen (VCA) and are positive during acute infection. IgM VCA wanes 3 months after clinical illness and IgG VCA remains positive for life. EBV nuclear antigen (EBNA) is expressed when the virus establishes latency; consequently, IgG to EBNA becomes positive usually 6 to 12 weeks after symptoms develop. A positive IgM VCA and negative IgG EBNA confirms acute infection, whereas a positive IgG EBNA argues against an acute EBV infection. Lastly, antibodies to early antigen also can be tested and are present at the onset of the illness. IgG to early antigen exists as 2 subsets, anti-D and anti-R. Anti-D antibodies occur during recent infection and resolve with recovery. The clinical significance of anti-R antibodies is not clear.[78]

PCR-based assays to detect EBV viral load can be useful in detecting infection in immunocompromised states where a host's antibody production may be compromised. EBV serum PCR studies are also frequently used to monitor for posttransplantation lymphoproliferative disease as trending high viral loads serve as a marker for impending posttransplantation lymphoproliferative disease.[79] PCR testing on tissue also may be used to identify EBV-induced neoplasms.

The histopathology of the morbilliform exanthem associated with EBV is nonspecific with a mild perivascular infiltrate of inflammatory cells. Specific cutaneous manifestations of EBV may show their own characteristic histopathologic features.

DIFFERENTIAL DIAGNOSIS

Table 163-7 outlines the differential diagnosis of infectious mononucleosis.

CLINICAL COURSE AND PROGNOSIS

Recovery from infectious mononucleosis is typically over 2 to 3 weeks without specific treatment.[65] Disease may be more protracted in older adults. Chronic active EBV infection occurs rarely. It begins as a primary

TABLE 163-7
Differential Diagnosis of Infectious Mononucleosis

Most Likely
- Cytomegalovirus mononucleosis
- Group A streptococcal infection
- Toxoplasmosis

Consider
- Adenovirus
- Enterovirus
- Measles
- Rubella
- Viral hepatitis

Always Rule Out
- Drug rash with eosinophilia and systemic symptoms syndrome
- Primary exanthem of HIV

EBV infection and persists for more than 6 months with severe illness and histologic evidence for organ disease. EBV DNA or antigens can be demonstrated from tissue, and usually EBV antibody titers are significantly elevated.

MANAGEMENT

Treatment for uncomplicated infectious mononucleosis is symptomatic Table 163-8). Acetaminophen or nonsteroidal antiinflammatory agents may be useful in treating the fever or throat discomfort. Because splenomegaly is often an associated finding, contact sports should be avoided until the spleen has returned to its normal size to avoid splenic rupture.

Systemic corticosteroids have been used to reduce the duration of fever or pharyngeal symptoms in infectious mononucleosis. However, a large metaanalysis failed to show any clinical benefit and therefore systemic steroids should not be used to treat typical cases of infectious mononucleosis.[80] Acyclovir has some activity against EBV through the inhibition of the EBV DNA polymerase. A reduction of viral shedding has been documented with acyclovir treatment, but clinical benefit has not; as a result, acyclovir is not routinely used in the management of EBV infection.[81]

A commercial vaccine against EBV is not currently available, but investigations are underway with the goal of reducing EBV infection burden, particularly in high-risk patients.[82]

TABLE 163-8
Treatment for Epstein-Barr Virus Infectious Mononucleosis

First-line therapy	Fever, throat discomfort, myalgia, headache	Acetaminophen/ nonsteroidal antiinflammatory drugs
	Splenomegaly	Avoid contact sports until spleen size normalizes to prevent splenic rupture
Second-line therapy	Impending airway obstruction, thrombocytopenia, hemolytic anemia	Systemic corticosteroids

GIANOTTI-CROSTI SYNDROME

AT-A-GLANCE

- Papular acrodermatitis of childhood.
- Common, self-limited dermatosis.
- Monomorphic dome-shaped or flat-topped papules symmetrically distributed on face and extensor extremities.
- Associated with multiple viral triggers and immunizations.
- Historically associated with hepatitis B infection, but now more often triggered by Epstein-Barr virus.

Gianotti-Crosti syndrome (GCS), also known as *infantile papular acrodermatitis* and *papular acrodermatitis of childhood*, is a common, self-limited exanthem. GCS typically affects children between the ages of 3 months and 15 years, with the peak age of onset being 1 to 6 years.[83] Adult cases are uncommon and almost exclusively occur in women. GCS was first described in 1953 by one of Italy's first pediatric dermatologists, Fernandino Gianotti, and his chairman, Professor Agostino Crosti, in Milan.[84] Since this time, GCS is widely known to dermatologists and pediatricians alike as a distinct childhood exanthem with varying infectious triggers.

ETIOLOGY AND PATHOGENESIS

GCS is believed to be an immune reaction to a preceding virus, bacterium, or vaccine, and not related to direct infection of the skin. In cases of EBV-associated GCS, EBV antigen was unable to be isolated from involved skin.[85] The likelihood of developing GCS is likely dependent upon how a host immunologically responds to a preceding infection. Both young age and a history of atopic dermatitis are host risk factors associated with GCS.[86]

Viral infections are the most common trigger of GCS. An association between GCS and hepatitis B was first published in the 1970s, and, for some time thereafter, hepatitis B was thought to be the exclusive

Figure 163-9 **A** and **B,** Erythematous edematous monomorphous dome-shaped papules on the extensor extremities in a toddler with Gianotti-Crosti syndrome.

cause of GCS. More recent studies implicate numerous other infections agents. In most developed countries, EBV is frequently cited as the most common cause of GCS.[87] Other important viral causes include molluscum pox virus, CMV, echovirus, poxvirus, poliovirus, coxsackievirus (A6, A16, B4, and B5), parvovirus B19, HIV, hepatitis A, hepatitis C, mumps virus, human herpesvirus-6, vaccinia virus, rubella virus and parainfluenza virus.[83] Often overlooked, GCS complicates approximately 5% of cases of molluscum contagiosum, and therefore a recent history or concurrent molluscum should be explored in children with GCS.[88] Bacterial pathogens include *M. pneumoniae*, *Borrelia burgdorferi*, *Bartonella henselae*, and group A β-hemolytic *Streptococcus*.[83] Lastly, a number of vaccines have been documented as preceding the onset of GCS, including influenza, diphtheria-pertussis-tetanus (DPT), bacillus Calmette-Guérin, *Haemophilus influenzae* type b, MMR, hepatitis B, Japanese encephalitis, and oral polio vaccine. Despite these varied infectious triggers, the clinical morphology of GCS remains consistent.

CLINICAL FEATURES

GCS presents with an abrupt onset of symmetrically distributed, monomorphous papules or papulovesicles on the face, extensor surface of extremities, and buttocks (Fig 163-9). Papules range between 1 and 5 mm in size, are pink to red-brown in color, often are dome shaped or flat-topped, and can coalesce to form large plaques. Infrequently, lesions may be hemorrhagic or have scale. Involvement of the trunk, palms, soles, or mucosal surfaces makes a diagnosis of GCS unlikely. Pruritus is the most common accompanying symptom.

Patients with GCS are typically well appearing. GCS can be preceded by malaise, pharyngitis, low-grade fever, and lymphadenopathy (typically cervical, axillary, or inguinal). Noncutaneous findings may also reflect the underlying infectious process triggering GCS, such as hepatomegaly and lymphadenopathy in the setting of hepatitis B infection or splenomegaly in the setting of EBV.

DIAGNOSIS

GCS is a clinical diagnosis. Usually, no further workup is needed. A skin biopsy is rarely needed owing to the characteristic features of GCS. In the setting of hepatomegaly, splenomegaly, or hepatitis, a laboratory workup for viral hepatitis (hepatitides A, B, and C, EBV, and CMV) should be performed.

DIFFERENTIAL DIAGNOSIS

Table 163-9 outlines the differential diagnosis of GCS.

TABLE 163-9
Differential Diagnosis of Gianotti-Crosti Syndrome

Most Likely
- Id reaction
- Papular urticaria

Consider
- Erythema infectiosum
- Erythema multiforme
- Follicular eczema
- Hand-foot-mouth disease
- Lichen planus
- Lichenoid drug eruption
- Molluscum contagiosum
- Pityriasis lichenoides et varioliformis acuta
- Pityriasis rosea

Always Rule Out
- Henoch-Schönlein purpura
- Infectious mononucleosis
- Scabies

CLINICAL COURSE AND PROGNOSIS

GCS is self-limited; however, families should be counseled that it might last longer than most rashes associated with viruses. GCS gradually fades over 10 to 60 days. GCS resolves without scarring but can resolve with temporary, postinflammatory hyperpigmentation or hypopigmentation. Reactive lymphadenopathy associated with GCS may take months to fully resolve.

MANAGEMENT

No treatment is necessary in the majority of cases. In some patients, medium-potency topical steroids may decrease the duration of lesions when applied once daily for 1 to 2 weeks. However, patients should be monitored closely because worsening of findings with topical steroid use has been documented.[89] Oral antihistamines or topical antiitch lotions may diminish severe pruritus.

HUMAN CYTOMEGALOVIRUS

AT-A-GLANCE

- Cytomegalovirus is also known as human herpesvirus 5.
- High prevalence in the population.
- Establishes latent infection and is capable of reactivation in immunosuppressed states.
- Primary infection is mainly asymptomatic; it is the cause of severe morbidity and mortality in utero and in immunocompromised patients.
- Petechiae and blueberry muffin syndrome occur with congenital infection.
- Congenital infection is major cause of hearing loss.
- Infected cells are cytomegalic with intranuclear inclusions.

EPIDEMIOLOGY

Human cytomegalovirus (HCMV) is ubiquitous around the world. The seroprevalence in the population increases with age, with 10% to 20% of children infected before they reach puberty. By adulthood, the prevalence of HCMV is 40% to 100%. For unclear reasons, there is a higher prevalence in developing countries and areas of low socioeconomic status. HCMV is the most common congenital viral infection in humans, with an incidence of 0.5% to 2% of live births in the United States.[90] Ten percent to 15% of congenital infections exhibit sequelae.[90] Nearly all HIV-infected patients are infected with HCMV.[91] It is a significant cause of morbidity in bone marrow transplant and solid-organ transplant patients.

CLINICAL FEATURES

CONGENITAL HUMAN CYTOMEGALOVIRUS INFECTION

History: Congenital HCMV (cytomegalic inclusion disease of the newborn) occurs mostly in children of primiparous women with primary infection during pregnancy. Fifty-five percent of maternal primary HCMV infections result in intrauterine HCMV infection of the fetus, and approximately one-third of those are symptomatic. Reactivation or secondary HCMV infection of a HCMV-immune woman during pregnancy rarely results in symptomatic HCMV infection for the baby.[90]

Cutaneous Lesions: Cutaneous findings in the newborn include a petechial rash secondary to thrombocytopenia, jaundice caused by hepatitis and blueberry muffin lesions from dermal erythropoiesis. In one study, approximately 70% of children with symptomatic congenital HCMV infections had petechiae and jaundice.[92] Dermal erythropoiesis, also known as *thrombocytopenic purpura* or *blueberry muffin syndrome*, also can be seen with congenital rubella, toxoplasmosis, and blood dyscrasias. These purpuric lesions are present at birth and evolve during the first 24 to 48 hours of life. They are papular and range from 2 to 10 mm in diameter. Lesions are initially dark-blue to violaceous and fade to red or copper-brown. They regress during the first 6 weeks of life despite continued presence of the virus. Histology shows plaque-like aggregates of nucleated cells and nonnucleated erythrocytes in the reticular dermis.[93]

Related Physical Findings: Related findings include hepatosplenomegaly in virtually all newborns, microcephaly, periventricular calcifications, ventriculomegaly, encephalitis, chorioretinitis, hearing loss or neurodevelopmental sequelae, intrauterine growth retardation, and postnatal failure to thrive. After congenital HCMV infection, approximately 50% of symptomatic and 10% of asymptomatic children have hearing loss.[90,94]

PERINATAL HUMAN CYTOMEGALOVIRUS INFECTIONS

History: Perinatal infection with HCMV is very different from congenital HCMV infection, and is without diffuse visceral or CNS involvement. Transmission of the virus occurs via cervical secretions, breastmilk, or

blood transfusions between 4 and 16 weeks of age. It is usually asymptomatic, although it may be manifested by self-limited lymphadenopathy, hepatosplenomegaly, or afebrile pneumonitis.[90]

Cutaneous Lesions: There are usually no cutaneous findings with perinatal HCMV infection. Uncommon presentations for HCMV infection in infants and children include GCS, gray pallor, hepatosplenomegaly with self-limited respiratory deterioration in preterm infants, and cutaneous vasculitis.[95,96] Perineal ulcers have been reported in an immunocompetent preterm infant.[97]

HUMAN CYTOMEGALOVIRUS INFECTION IN IMMUNOCOMPETENT ADULTS AND CHILDREN

History: Although primary HCMV infection in the immunocompetent patient is usually asymptomatic, some can present with an infectious mononucleosis–like picture. Approximately 10% of infectious mononucleosis cases are caused by HCMV. Symptoms and signs are indistinguishable from EBV-induced mononucleosis, including fever, malaise, splenomegaly, hepatitis, and peripheral and atypical lymphocytosis. Unlike EBV mononucleosis, HCMV-induced mononucleosis patients do not typically have pharyngitis and lymphadenopathy.[98] Given the lack of heterophile antibodies, HCMV mononucleosis is also known as heterophile-negative mononucleosis. HCMV mononucleosis can occur between 3 and 6 weeks after exposure to CMV-positive blood products.[98]

Reactivation of various herpesviruses, including HCMV, EBV, human herpesvirus (HHV)-6, and HHV-7, has been reported in the setting of drug-induced hypersensitivity syndrome (see Chap. 45) and other severe cutaneous adverse drug reactions, which, in some cases, might lead to multiorgan failure after the causative drug is discontinued.[99]

Cutaneous Lesions: A few patients with HCMV mononucleosis develop a rubelliform or morbilliform eruption; if given ampicillin, 80% to 100% of patients develop a morbilliform rash within 1 week.[100] There are reports of erythema nodosum and urticaria associated with acute HCMV mononucleosis.[101] Cutaneous ulcers caused by CMV have been reported in patients with severe cases of drug-induced hypersensitivity syndrome.[102]

HUMAN CYTOMEGALOVIRUS AND THE IMMUNOCOMPROMISED

History: Immunocompromised patients are at risk for both HCMV primary infection and reactivation, resulting in persistent viremia and disseminated systemic disease. Immunosuppressive agents, such as azathioprine and cyclophosphamide alone, can reactivate HCMV disease, as can systemic corticosteroids in conjunction with other immunosuppressive agents. CMV infection in this setting is defined as evidence of CMV replication with or without disease symptoms. CMV disease is defined as CMV infection with these symptoms: viral syndrome with fever, malaise, leukopenia, and thrombocytopenia; or tissue invasive disease with variable pneumonitis, enteritis, hepatitis, retinitis, and CNS disease.[103]

Solid-Organ Transplantation Recipients: Solid-organ transplantation recipients who are not infected with HCMV but who receive an organ from an HCMV-positive individual are at highest risk of developing HCMV disease posttransplantation. Additional risk factors include higher levels of immunosuppression and allograft rejection.

Bone Marrow Transplantation Patients: The risk of HCMV disease in bone marrow transplantation patients is lower with the use of seronegative donors and of leukocyte-depleted blood products.[104] Risk factors for both first and subsequent CMV infection in seropositive patients include myeloablative conditioning, graft-versus-host disease, lymphoma/myeloma, and low CD3 graft content.[105]

HIV-Infected Patients: HCMV retinitis was seen in up to 25% of HIV-infected patients before the use of highly active antiretroviral therapy.[106] Other clinical manifestations of HCMV infection include immune recovery vitreitis, encephalopathy, peripheral polyradiculopathy, pneumonitis, and colitis.[107] Asymptomatic CMV coinfection in HIV-infected patients on highly active antiretroviral therapy may impair CD4:CD8 ratio normalization.[108]

Cutaneous Lesions: Cutaneous manifestations of HCMV disease in immunocompromised patients are rare compared with involvement of other organs. Perianal and rectal ulceration are most common.[109] Also seen are indurated hyperpigmented nodules or plaques, papular and purpuric eruptions, vesiculobullous lesions, purpura, petechiae, indurated plaques, and, occasionally, verrucous and necrotic nodules.[110-112] Some of these cutaneous manifestations may be caused by infection of the endothelium of cutaneous blood vessels.[109]

DIAGNOSIS

The gold standard for diagnosis of HCMV infection is viral culture from blood using human fibroblasts. Because it takes days to several weeks to see the cytopathic effect in culture, culture has been supplanted by PCR for the diagnosis of active HCMV infection.[103,113] The diagnosis of congenital HCMV infection can be made by detection of virus in urine or saliva via PCR.[113] HCMV PCR also can be used to identify primary infection in children younger than 12 months of age as they shed the virus for long periods of time.

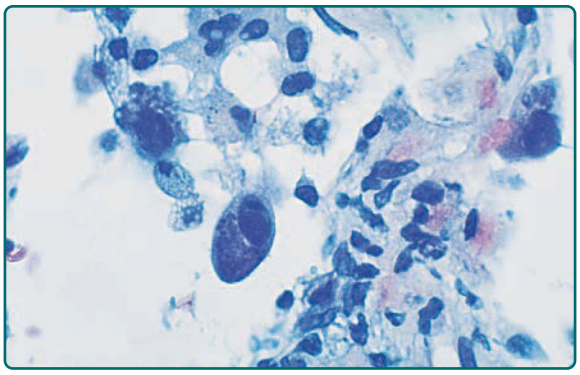

Figure 163-10 Intracellular inclusions in a cell infected by human cytomegalovirus. (From Konstadt JW, Gatusso P, Eng A, et al. Disseminated cytomegalovirus infection with cutaneous involvement in a heart transplant patient. *Clin Cases Dermatol.* 1990;2:3.)

HCMV serology (IgG) is the most reliable method to determine past infection and is used as part of pretransplantation screening. In immunocompetent individuals, IgM is usually positive during primary infection, although the reported sensitivity of IgM varies. Rheumatoid factor and EBV IgM may yield false-positive results.[114] IgG may be negative during active infection, but a subsequent fourfold rise in IgG titer is indicative of infection. In immunocompromised patients, quantitative nucleic acid amplification testing for CMV is the most widely used test for diagnosis, and monitoring response to treatment.[103]

The characteristic histologic feature of CMV infection is cytomegalic cells with nuclear inclusions. In the skin, enlarged endothelial cells with large intranuclear inclusions and a clear halo (owl's eye cells) are seen in small dermal vessels.[115] Cytopathic changes seen in the vascular lumen vary according to the stage of infection of each cell, including intranuclear and intracytoplasmic inclusions (Fig. 163-10). Histologic diagnosis is specific but sensitivity is low.

The diagnosis of invasive CMV disease can be challenging because the presence of the virus does not mean causality given that the virus establishes latency after primary infection.

DIFFERENTIAL DIAGNOSIS

Tables 163-10 and 163-11 outline the differential diagnosis of HCMV blueberry muffin syndrome and mononucleosis infection, respectively.

PROGNOSIS AND CLINICAL COURSE

HCMV disease in immunocompetent individuals is usually self-limited. Immunocompromised patients with systemic HCMV disease have a poor prognosis and suffer direct effects of CMV disease in addition to indirect effects such as allograft rejection, higher risk of other infections, graft-versus-host disease, and secondary malignancies.[103]

TABLE 163-10
Differential Diagnosis of Congenital Human Cytomegalovirus (Blueberry Muffin Syndrome)

Most Likely
- Causes of dermal (extramedullary) hematopoiesis
  - Congenital infection
    - Enterovirus
    - Herpes simplex virus infection
    - Rubella
    - Toxoplasmosis
  - Hereditary spherocytosis
  - Rhesus and ABO incompatibility
  - Twin–twin transfusion syndrome

Consider
- Langerhans cell histiocytosis
- Neonatal lupus erythematosus

Always Rule Out
- Congenital leukemia
- Neuroblastoma with skin metastases

COMPLICATIONS

Possible complications of postnatal HCMV infection include interstitial pneumonia, hemolytic anemia, splenic infarction, thrombocytopenia and hemolytic anemia, hepatitis, Guillain-Barré syndrome, meningoencephalitis, myocarditis, arthritis, and GI/genitourinary syndromes (colitis, esophagitis, cervicitis, and urethral syndromes).

MANAGEMENT

HCMV infection in immunocompetent hosts is usually asymptomatic or self-limited, not requiring treatment with antiviral drugs. Ganciclovir, valacyclovir, foscarnet, and cidofovir have been approved for systemic

TABLE 163-11
Differential Diagnosis of Human Cytomegalovirus Mononucleosis

Most Likely
- Epstein-Barr virus mononucleosis

Consider
- Toxoplasmosis
- Viral hepatitis

Always Rule Out
- Lymphoma

treatment of HCMV disease. Ganciclovir and valacyclovir are also used for HCMV prophylaxis.[103] Oral valganciclovir for 6 months improves hearing and neurodevelopmental outcomes in patients with symptomatic congenital HCMV infection.[116]

PREVENTION

Prevention of HCMV infection in HCMV-negative transplanted patients can be achieved with use of blood and tissues from HCMV-negative donors. Preemptive (at time of high risk for disease but before symptoms) or prophylactic treatment with ganciclovir, valganciclovir, or valacyclovir can be used for immunocompromised individuals who are at risk of infection from blood transfusions or organ transplantation with ganciclovir. Risk stratification for preemptive versus prophylactic treatment depends on various risk factors, including type of transplant, immunosuppression, and other host factors.[103] There are currently no candidate vaccines that are near licensure.[116]

HUMAN HERPESVIRUS 6

AT-A-GLANCE

- Causes exanthem subitum (roseola infantum, sixth disease).
- Febrile seizures often without rash in children.
- High seroprevalence in general population by 1 year of age.
- Reactivation in immunocompromised individuals is a cause of morbidity.

Consistent with other herpesviruses, HHV-6 infection is chronic, existing in a latent stage with the ability to reactivate. HHV-6 primary infection often presents either as an acute febrile illness or as the distinct illness exanthem subitum (ES), also known as *roseola infantum* and *sixth disease*.

EPIDEMIOLOGY

HHV-6 is a common viral infection with up to 80% of the population acquiring the infection by 2 year of age.[117] Primary infection typically occurs between the ages of 6 months and 2 years when maternal passive immunity wanes.[117] Primary infection exhibits seasonal variation with the highest incidence in spring; summer and fall epidemics also have been reported.

ETIOLOGY AND PATHOGENESIS

HHV-6 is a member of the β-Herpesviridae subfamily and exists as 2 distinct species: HHV-6a and HHV-6b. HHV-6b causes ES and reactivates in immunocompromised hosts. It is unclear what diseases, if any, are caused by HHV-6a.[118]

HHV-6 infects a wide range of human cells, including monocytes/macrophages, natural killer cells, and neuronal cells, such as astrocytes, and preferentially infects activated CD4+ T lymphocytes. The immune regulatory protein CD46 is the cellular receptor for HHV-6 infection.[119] HHV-6 viral DNA may also integrate into host cell chromosomes in up to 1% of the general population, thereby serving as an alternative means of HHV-6 persistence.[120]

As the salivary glands are an important site of viral replication, HHV-6 transmission occurs via shared saliva and can readily be detected in the saliva of adults and children.[117] In transplantation recipients, most cases of HHV-6 infection constitute reactivation of latent infection; however, transmission of HHV-6 from the donor organ has been infrequently described.[121]

The incubation period for HHV-6 infection is 5 to 15 days, with an average of 10 days. Viremia in immunocompetent children lasts 3 to 4 days in ES, whereas viremia from HHV-6 reactivation in allogeneic bone marrow transplantation patients lasts weeks.[120]

CLINICAL FEATURES

HHV-6 primary infection in early childhood may be subclinical or can present with nonspecific symptoms, including high fever, irritability, rhinorrhea, and diarrhea. The fever lasts approximately 3 to 7 days and is followed by the characteristic rash of roseola in only 23% of cases.[122,123]

HHV-6 infection can also occur when the virus reactivates in the setting of immunosuppression. HHV-6 reactivation is particularly common in stem cell transplantation patients where reactivation occurs in 50% of patients and peaks 2 to 4 weeks posttransplantation.[124] HHV-6 reactivation is thought to occur less frequently in solid-organ transplantation patients. Reactivation may be asymptomatic or result in fever, diarrhea, morbilliform rash, and transient myelosuppression.

EXANTHEM SUBITUM

HHV-6 is the cause of ES, also known as *roseola*, which was first described in 1910.[125] The hallmark of ES is the development of "rose"-colored macules and papules measuring 2 to 5 mm and surrounded by a white halo (Fig. 163-11). The exanthem lasts 3 to 5 days and is widespread spread on the neck and trunk, and occasionally occurs on the face and proximal extremities. A unique feature of ES is that

Figure 163-11 **A** and **B,** Exanthem subitum in an infant showing truncal pink macules and some papules that appeared 1 day after defervescence.

it presents 1 day before to 1 to 2 days after the fever resolves, as opposed to most viral exanthems where eruptions occur at the onset of the illness. Children with ES may also have palpebral edema resulting in a "sleepy" appearance and erythematous papules on the soft palate (Nagayama spots) that may precede the viral exanthem.

PITYRIASIS ROSEA

See Chap. 31 and "Human Herpesvirus 7" below.

ROSAI-DORFMAN DISEASE

The HHV-6 genome has been detected in tissue from patients with sinus histiocytosis with massive lymphadenopathy or Rosai-Dorfman disease (see Chap. 117), and immunohistochemical studies suggest a possible pathogenic involvement.[126,127]

DRUG-INDUCED HYPERSENSITIVITY SYNDROME

Although HHV-6 reactivation is well-described in drug hypersensitivity reactions (see Chap. 45), its role in driving systemic inflammation in this setting is unclear.

DIAGNOSIS

HHV-6 primary infection in childhood and in the setting of ES is typically a clinical diagnosis and laboratory testing is rarely needed. A challenge in the laboratory testing of HHV-6 is distinguishing between latent versus active replicating infection. Most patients older than 2 years of age are seropositive for HHV-6 and approximately 5% of healthy adults are IgM-positive at any given time.[128] A fourfold increase of HHV-6 IgG during the convalescent stage is suggestive of HHV-6 infection.

Quantitative real-time PCR is increasingly being used to detect HHV-6 infection with intermediate and high levels of HHV-6 DNA suggestive of active, as opposed to latent, infection. Real-time PCR testing also can be performed on any tissue. Qualitative real-time PCR does not distinguish latent from active infection. Because of the low sensitivity and longer turnaround time, viral culture is rarely employed.

CLINICAL COURSE AND PROGNOSIS

HHV-6 primary infection and ES in childhood is generally benign and self-limited. Fever typically resolves in 1 week and the rash over 3 to 5 days. The most common complication of a primary infection is the development of a febrile seizure. Febrile seizures occur in 8% of children with primary infection.[102] Rare complications of primary infection also include hepatitis, mononucleosis-like syndrome, meningoencephalitis, hemophagocytic syndrome, pneumonitis, and thrombocytopenia.[122] Treatment is not typically needed for the immunocompetent patient.

Although HHV-6 in transplantation recipients is linked to various complications, establishing

pathogenicity is challenging given that these hosts are frequently coinfected by other viral infections and the limitations of PCR technology to distinguish between latent and active infection. In bone marrow transplantation recipients, complications include subacute encephalitis, bone marrow suppression, pneumonitis, and thrombotic microangiopathy. The role of HHV-6 in triggering or increasing the severity of acute graft-versus-host disease is controversial.[129]

MANAGEMENT

There are no controlled clinical trials, and no compounds have been formally approved for treatment of HHV-6 infection. The same drugs used for HCMV treatment and prophylaxis have been used for HHV-6. The activities of various antiviral compounds against HHV-6 have been tested in vitro.[130] Several case reports support the clinical effectiveness of ganciclovir in HHV-6 treatment and prophylaxis.[131] Foscarnet and cidofovir might also prove to be useful.[131]

PREVENTION

Prophylaxis with ganciclovir may prevent HHV-6 reactivation in bone marrow transplantation and stem cell transplantation recipients, but low-dose prophylaxis may facilitate the development of resistance.[132] Preemptive therapy (treatment after systemic detection of virus but before clinical symptoms of disease) has been proposed instead.

HUMAN HERPESVIRUS 7

AT-A-GLANCE

- Human herpesvirus 7 causes a small subset of cases of exanthem subitum.
- Primary infection typically occurs later in life than human herpesvirus 6 infection.

EPIDEMIOLOGY

In seroconversion studies, 10% of ES cases are caused by HHV-7.[133] Primary infection occurs during childhood, but later than, and at a slower rate than, infection with HHV-6. Both viruses are ubiquitous in adulthood and have a worldwide distribution. HHV-7 can be isolated from saliva samples of healthy seropositive adults.[134]

ETIOLOGY AND PATHOGENESIS

HHV-7 is a member of the β-Herpesviridae family. Even though it has significant homology to HHV-6, it is serologically and biologically distinct. HHV-7 establishes persistent infection in salivary glands, and transmission is likely through saliva.[134] Latent virus can be activated in vitro from peripheral blood mononuclear cells, and its DNA can be found in CD4+ T cells. Similar to many other herpesviruses, HHV-7 can downregulate expression of CD4 and major histocompatibility complex class I, which may play a role in establishment of latency or pathogenesis.[134,135] Reactivation of HHV-7 occurs more often than reactivation of HHV-6.[136]

CLINICAL FEATURES

EXANTHEM SUBITUM

HHV-7 causes a small subset of ES cases. When HHV-7 is associated, ES tends to occur later in life than when HHV-6 is associated.[134] The rash associated with HHV-7 is lighter in color and occurs later in the course of the disease than HHV-6–associated ES.[134]

PITYRIASIS ROSEA

HHV-7 DNA has been isolated from skin biopsy specimens, peripheral blood mononuclear cells, and plasma of patients with pityriasis rosea (see Chap. 31) and not controls.[137] However, these findings have not been confirmed by other studies. It is possible that the inflammatory milieu in pityriasis rosea activates HHV-7 and HHV-6 within the lesions, but there is no evidence for causality.

LICHEN PLANUS

HHV-7 DNA and virion-like structures have been found in lesional lichen planus skin samples compared to nonlesional skin and psoriatic skin samples.[89] Although suggestive, further studies are needed to establish a causal relationship.

DIAGNOSIS

There is limited cross-reactivity between HHV-7 and HHV-6 in serologic studies. Because of high prevalence, a single positive IgG is not sufficient to establish a diagnosis. PCR is widely available and is useful for timely diagnosis. Diagnosis of active infection by PCR can only be made from acellular material such as CSF, serum, or plasma, because the virus is latent in peripheral blood mononuclear cells and tissue.

TABLE 163-12
Differential Diagnosis for Human Herpesvirus 6– and Human Herpesvirus 7–Associated Exanthem Subitum

Most Likely
- Drug hypersensitivity reaction
- Enterovirus (including coxsackie, echovirus)
- Human herpesvirus–associated exanthem subitum

Consider
- Adenovirus
- Epstein–-Barr virus
- Fifth disease (erythema infectiosum, parvovirus)
- Measles/rubeola
- Rubella (German measles)

Always Rule Out
- Kawasaki disease
- Scarlet fever

Immunohistochemical studies for viral antigens in biopsy specimens can be performed.

DIFFERENTIAL DIAGNOSIS

Table 163-12 outlines the differential diagnosis of HHV-6– and HHV-7–associated ES.

CLINICAL COURSE AND PROGNOSIS

ES is a self-limiting disease that does not require specific antiviral treatment. Disease in immunocompromised patients can be more serious and require treatment.

Complications of HHV-7–associated ES include acute hemiplegia and febrile seizures with CSF findings consistent with encephalitis and hepatitis.[138]

MANAGEMENT

Treatment for HHV-7 has not been evaluated in clinical trials but can be guided by treatment recommendations for HHV-6.

ENTEROVIRUSES

Human enteroviruses cause a variety of exanthems and clinical syndromes. They are small, single-stranded RNA picornaviruses and include echovirus, coxsackieviruses A and B, and poliovirus.[139] Most enterovirus infections are benign. However, nonpolio enteroviruses are also the most common cause of aseptic (viral) meningitis and, rarely, can cause life-threatening infections involving encephalitis, myocarditis, or sepsis.[139] Severe infections are more common in neonates and immunocompromised individuals.

Enteroviruses are one of the most common causes of nonspecific exanthems. Infected patients present with scattered, pink, small macules and papules that fade within 1 week. Exanthems may also include petechiae and purpuric macules and therefore may be confused with more life-threatening infections such as Rocky Mountain spotted fever or meningococcemia. Well-described exanthems caused by enteroviruses include hand-foot-mouth disease; coxsackievirus A6–associated atypical hand-foot-mouth disease; herpangina; eruptive pseudoangiomatosis; and the Boston exanthem.

HAND-FOOT-MOUTH DISEASE

AT-A-GLANCE

- Hand-foot-mouth disease is a viral exanthem seen mostly commonly in children in summer and fall.
- Erosions in the mouth and papulovesicles on the palms and soles.
- Caused by enteroviruses including coxsackievirus A16 and enterovirus 71.
- Self-resolving without serious sequelae in the majority of cases, but may have serious complications when caused by enterovirus 71.

Hand-foot-mouth disease (HFMD) is the best-recognized enteroviral exanthem with a worldwide distribution.

EPIDEMIOLOGY

Children younger than 10 years of age are most frequently affected, and infected adults rarely show signs of infection. In temperate climates, HFMD is most common in the summer and fall.

ETIOLOGY AND PATHOGENESIS

Traditionally, HFMD has been caused by coxsackievirus A16 and enterovirus 71. Other causes of often HFMD include coxsackieviruses A5, A6, A7, A9, A10, A16, B1, B2, B3, and B5, echoviruses, and other enteroviruses.[140]

Viral transmission is via the fecal–oral route and, less commonly, respiratory inhalation. Once inhaled or ingested, virus replication ensues in the oropharynx and/or GI tract with subsequent viremia. The incubation period of HFMD is believed to be short,

lasting 3 to 6 days, with viral shedding lasting up to 5 weeks.[141]

CLINICAL FEATURES

HFMD usually begins with a nonspecific prodrome involving low-grade fever (38°C to 39°C [100.4°F to 102.2°F]) that lasts 1 to 2 days, malaise, and, occasionally, abdominal pain or upper respiratory tract symptoms. Sore throat or a sore mouth is common and can lead to poor oral intake and dehydration.

The hallmark of HFMD is the development of a vesicular eruption on the palms and soles. The lesions start as bright pink macules and papules that progress to small 4- to 8-mm vesicles with surrounding erythema. Vesicles quickly erode and form yellow to gray, oval or "football-shaped" erosions surrounded by an erythematous halo. Cutaneous vesicles are found on the palms, soles (Figs. 163-12B and 163-12C), sides of hands and feet, buttocks and, occasionally, external genitalia. In classic HFMD, nearly all patients also develop an enanthem consisting of similarly appearing oral erosions involving the tongue (Fig. 163-12A) buccal mucosa, hard palate, and, less frequently, the oropharynx.

DIAGNOSIS

HFMD is a clinical diagnosis and laboratory tests are typically not needed. If laboratory confirmation is required, viral culture or PCR based assays can be performed. The virus can be recovered from skin vesicles as well as throat and stool swabs. PCR is frequently performed on the CSF and serum when working up systemic viral infection.[142]

Skin biopsies are not typically performed. Nonspecific findings, such as intraepidermal blister formation from vacuolar and degeneration of keratinocytes, are seen as in other viral blisters.[143]

CLINICAL COURSE AND PROGNOSIS

The cutaneous vesicles in HFMD typically crust over and fade in in 7 to 10 days. Onychomadesis has occasionally been reported as a consequence of coxsackievirus A16 and enterovirus 71 infections.

Patients with HFMD rarely experience complications. The most common serious complication associated with HFMD is aseptic meningitis. Aseptic meningitis is rarely life threatening, and patients typically do not develop permanent sequela. However, enterovirus 71, an important cause of HFMD outbreaks in Asia, is associated with severe illness. Epidemics of enterovirus 71 are associated with severe neurologic disease, including encephalitis, encephalomyelitis, and polio-like syndromes. Enterovirus 71 infection may also lead to myocarditis, pulmonary edema, pulmonary hemorrhage, and death.[144]

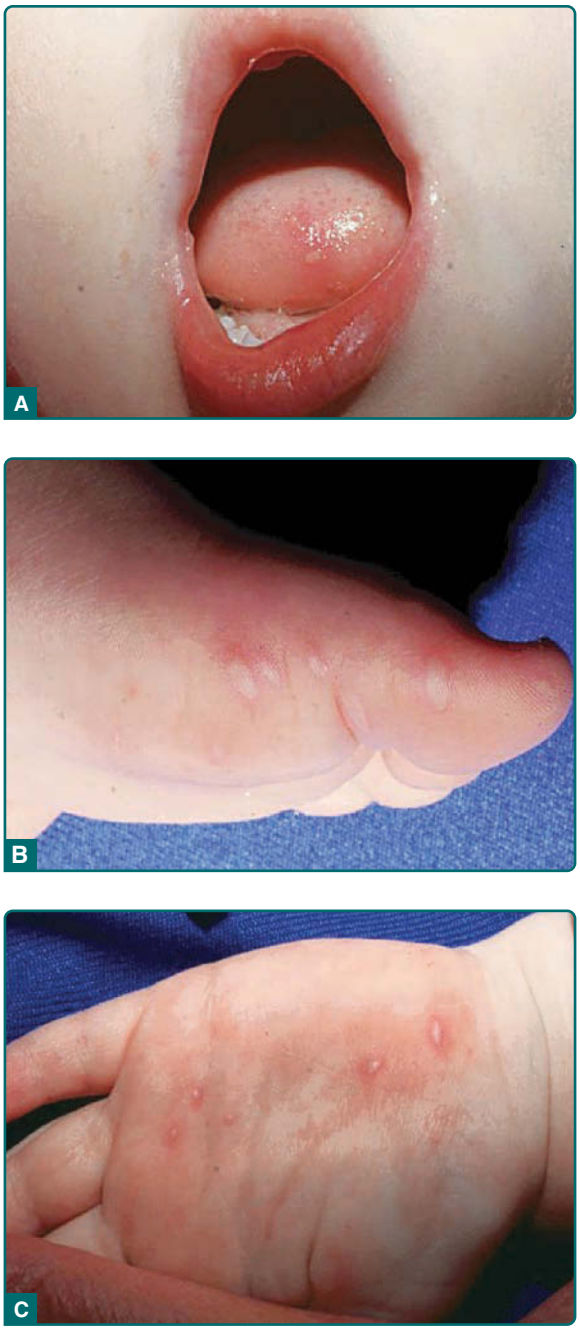

Figure 163-12 Classic hand-foot-mouth disease in a toddler. **A,** Vesicles and surrounding erythema on the tongue. **B** and **C,** Elliptical, "football-shaped" vesicles with halo of erythema on the palms and soles.

MANAGEMENT

Treatment is typically supportive with attempts to reduce discomfort and dehydration. Novel antiviral agents and vaccine development targeting enterovirus 71 is an active area of investigation because of the strain's virulence, geographic spread, rising prevalence, and risk for devastating brainstem encephalitis.[145]

COXSACKIEVIRUS A6–ASSOCIATED ATYPICAL HAND-FOOT-MOUTH DISEASE

AT-A-GLANCE

- Papulovesicles, vesicles and erosions on the palms, soles, extremities and perioral area.
- Oral erosions occur less frequently than in classic hand-foot-mouth disease.
- Large bullae and purpuric macules may occur.
- Self-resolving without serious sequela in the majority of cases.

An emerging cause of HFMD disease in many countries around the world is coxsackievirus A6 (CVA6).[146] Within the United States, CVA6 was first isolated as the cause of clinically atypical HFMD disease in 2011, and is now commonly identified in HFMD outbreaks.[147] Compared to classic HFMD, CVA6 infection frequently results in a cutaneous presentation that is more varied and extensive in distribution. Presumably because of a lack of previous immunity, adults may also present with CVA6-associated HFMD.[148]

ETIOLOGY AND PATHOGENESIS

Similar to other enteroviruses, CVA6 is transmitted via a fecal–oral route and less often via respiratory secretions.

CLINICAL FEATURES

In keeping with classic HFMD, CVA6-associated HFMD frequently presents with erythematous macules and vesicles on the palmoplantar surfaces and buttocks. However, the exanthem is not limited to those sites. Papulovesicles, rounded vesicles, and erosions commonly involve the upper and lower extremities and the perioral area, occasionally leading to a misdiagnosis of bullous impetigo (Fig. 163-13). Diffuse involvement with the exanthem extending onto the trunk may also occur.[149] In a review of 81 patients with CVA6 disease, the exanthem involved greater than 10% body surface area in 61% of patients.[147] CVA6 infection can result in the development of large bullae measuring greater than 2 cm, typically in children younger than 1 year of age (Fig. 163-14) and acrally distributed petechiae and purpura, often in children older than 5 years of age, which may be confused for leukocytoclastic vasculitis.[147] Localization of vesicles and erosions of atopic dermatitis is also well described and has been termed *eczema coxsackium*, highlighting that this presentation may mimic eczema herpeticum (Fig. 163-15). Clinical features more suggestive of eczema coxsackium include concurrent oral aphthae, palmoplantar macules and vesicles, perioral involvement, the lack of herpetiform grouping of vesicles, and the onset occurring the context of family or community outbreak. The CVA6 exanthem generally resolves in 1 to 2 weeks.

Figure 163-13 Coxsackievirus A6–associated hand-foot-mouth disease with perioral distribution.

Oral ulcerations, a defining feature in classic HFMD, found in nearly 100% of patients, are seen less frequently in CVA6 infection and are documented in CVA6-associated HFMD in only 50% of cases.[147] Viral prodrome symptoms associated with CVA6 infection include fever, sore throat, headache, cough, and diarrhea.

DIAGNOSIS

In complicated cases, CVA6 infection can be confirmed by performing enterovirus reverse-transcriptase PCR on samples collected by swabs from stool, throat, the base of skin vesicles, or serum samples.[150] PCR is more sensitive in the detection of CVA6 than enterovirus culture.

Skin biopsies of this exanthem have revealed intraepidermal vesiculation with a predilection for the stratum granulosum and upper stratum spinulosum and a neutrophil rich infiltrate.[151]

Figure 163-14 Coxsackievirus A6–associated hand-foot-mouth disease with large bullae on the sole of an infant. (Image used with permission from Dr. Ilona Frieden.)

Figure 163-15 Eczema coxsackium. Localization of vesicles and erosions to affected areas of atopic dermatitis in a coxsackievirus A6–infected patient.

DIFFERENTIAL DIAGNOSIS

Table 163-13 outlines the differential diagnosis of HFMD.

CLINICAL COURSE AND PROGNOSIS

Despite the occasionally extensive cutaneous presentation, CVA6 is not generally associated with severe systemic illness. Therefore, CVA6 infections appear to be more in keeping with CVA16 than enterovirus 71. The 2 most common complications of CVA6 are desquamation of the hands and feet, which often occurs weeks after the exanthem resolves, and onychomadesis, which occurs 1 to 2 months later. Onychomadesis may occur in the absence of any history of the HFMD exanthema, and all patients with CVA6-associated HFMD should be made aware of this complication.[152] Patients with onychomadesis can be expected to have normal nail growth after the shedding is complete.

TABLE 163-13
Differential Diagnosis of Hand-Foot-Mouth Disease

Most Likely
- Eczema herpeticum

Consider
- Autoimmune blistering disorder (eg, liner immunoglobulin A bullous dermatosis)
- Disseminated herpes zoster
- Drug eruption
  - Stevens-Johnson syndrome
- Erythema multiforme
- Leukocytoclastic vasculitis
- Varicella

Always Rule Out
- Herpes simplex virus infection

MANAGEMENT

The management of CVA6 HFMD is supportive and focuses on managing pain, and local wound care for larger vesicles and bullae.

ERUPTIVE PSEUDOANGIOMATOSIS

Cherry and colleagues first described a syndrome in 1969 in which 4 children with acute echovirus infection (2 with echovirus 25 and 2 with echovirus 32) developed small, 2- to 4-mm, red papules that resembled angiomas on the face and extremities.[153] The papules blanched on pressure and were surrounded by a small, 1- to 2-mm, halo. The eruption was short lived and typically resolved within 10 days.[154] Patients often had associated fever, malaise, headache, diarrhea, and respiratory complaints.

While echovirus was first linked to eruptive pseudoangiomatosis, the etiology in most cases cannot be identified. Adenovirus, CMV, arthropod bites, and immunocompromised states also have been identified in eruptive pseudoangiomatosis cases.

Other children and adults have been described with similar outbreaks. Although a virus is likely to cause eruptive pseudoangiomatosis, echoviruses have not been consistently confirmed as the causative agent.[155-158]

UNILATERAL LATEROTHORACIC EXANTHEM

AT-A-GLANCE

- Unilateral laterothoracic exanthem is also called *asymmetric periflexural exanthem of childhood*.
- Typically affects children 1 to 5 years of age.
- Pink papules that start in a large flexural region, become bilateral, but remain asymmetric.
- Probably viral etiology.

Figure 163-16 Rough pink papules in the right axilla, characteristic of unilateral laterothoracic exanthem. (Used with permission from Antonio Torrelo, MD.)

Unilateral laterothoracic exanthem (ULE), also known as *asymmetric periflexural exanthem of childhood*, has a seasonal variation and occurs most frequently in late winter and early spring. It typically occurs in children between 1 and 5 years of age, but may be seen from 8 months to 10 years of age.[159] Rare cases in adults have been reported.[160] There is a slight female predominance, and it is more common in whites.

ETIOLOGY AND PATHOGENESIS

The etiology of ULE is unknown, but because of its seasonality, associated viral symptoms and lack of response to antibiotics, a viral trigger is suspected. The pathogenesis is also unknown.

CLINICAL FEATURES

ULE typically presents with 1- to 2-mm, pinpoint, pruritic, pink papules with a surrounding pale halo localized to a large flexural region like the axillae or groin. The papules then spread centrifugally (Fig. 163-16). ULE can become bilateral and more widespread within 5 to 15 days, but a unilateral and asymmetric distribution remains. A variety of morphologies also have been described, including macules, papules, morbilliform, annular, scarlatiniform, and annular.[159] Pruritus may be severe.

In cases of ULE, a preceding viral syndrome consisting of mild upper respiratory tract, low-grade fever, or GI tract symptoms can often be elicited. In the area of the eruption, enlargement of regional lymph nodes are frequently identified.

DIAGNOSIS

ULE is a clinical diagnosis and no laboratory tests are indicated.

DIFFERENTIAL DIAGNOSIS

Table 163-14 outlines the differential diagnosis of ULE.

CLINICAL COURSE AND PROGNOSIS

The rash typically lasts from 2 to 6 weeks but may last as long as 2 months. Resolution is spontaneous and without scarring. During the healing stage, desquamation and postinflammatory pigment change also may be present as the exanthem resolves.

TABLE 163-14
Differential Diagnosis of Unilateral Laterothoracic Exanthem

Most Likely
▪ Allergic or irritant contact dermatitis
▪ Scarlet fever
Consider
▪ Other viral exanthems
Always Rule Out
▪ Atopic dermatitis
▪ Herpes zoster

TABLE 163-15
Viral Infections with Characteristic Exanthems

	ETIOLOGIC AGENT	CHARACTERISTIC EXANTHEM OR ASSOCIATED RASH	EXTRACUTANEOUS MANIFESTATIONS, ENANTHEMS
Measles (*Rubeola*)	*Paramyxoviridae*	Nonpruritic, erythematous macules and papules with craniocaudal spread	Fever, malaise, conjunctivitis, coryza, cough, Koplik spots
Rubella (*3-day measles; German measles*)	*Togaviridae*	Pruritic pink to red macules and papules on the face, progressing to neck, trunk, and extremities	Low-grade fever, myalgia, headache, conjunctivitis, rhinitis, cough, sore throat, lymphadenopathy; Forchheimer spots
Erythema Infectiosum (*fifth disease*)	*Parvovirus (B19)*	Confluent, erythematous, edematous plaques on malar eminence (slapped cheek); lesions may recur for weeks or months	Erythema of the tongue, pharynx and red macules on the buccal mucosa and palate; acute arthropathy in adults
Papular purpuric gloves-and-socks syndrome		Itchy, painful, symmetric edema and erythema of the distal hands and feet with abrupt demarcation at the wrists and ankles	Fatigue, low-grade fever, myalgia and arthralgia; enanthem on the lips, soft palate and buccal mucosa
Epstein-Barr virus	*Epstein-Barr viruses 1 and 2 (human herpesvirus 4)*	"Ampicillin rash" in individuals treated with antibiotics; Gianotti-Crosti syndrome; erythema multiforme, leukocytoclastic vasculitis, erythema nodosum, erythema annulare centrifugum, pityriasis lichenoides, granuloma annulare, cold urticaria	Fever, lymphadenopathy and pharyngitis (Infectious mononucleosis); acute genital ulcers (Lipschütz ulcers) with associated inguinal lymphadenopathy; neoplastic conditions (see Table 163-6)
Gianotti-Crosti syndrome (*popular acrodermatitis of childhood; infantile popular acrodermatitis*)	Various viral and bacterial pathogens	Symmetrical monomorphic papules or papulovesicles on the face, extensors, and buttocks	Malaise, pharyngitis, low-grade fever, and lymphadenopathy
Human cytomegalovirus[a]	*Cytomegalovirus (human herpesvirus-5)*	Erythema nodosum, morbilliform eruption similar to ampicillin rash of Epstein-Barr virus infection; urticaria	Infectious mononucleosis–like symptoms
Exanthem subitum (*roseola infantum, sixth disease*)	*Human herpesvirus-6*	Rose-colored macules and papules surrounded by a white halo over the neck and trunk	High fever, irritability, rhinorrhea, and diarrhea; palpebral edema; Nagayama spots
Hand-foot-mouth disease	*Coxsackievirus A16 and Enterovirus 71*	Vesicular eruption of the palms and soles, with "football-shaped" erosions surrounded by an erythematous halo	Low-grade fever, malaise, abdominal pain or upper respiratory tract symptoms, sore throat or sore mouth; oral erosions of the tongue, buccal mucosa, hard palate, and oropharynx
Atypical hand-foot-mouth disease	*Coxsackievirus A6*	Papulovesicles, vesicles, and erosions of the palms, soles, extremities, and perioral; oral mucosa less frequently involved	Fever, sore throat, headache, cough, and diarrhea
Eruptive pseudoangiomatosis	*Echovirus 25, echovirus 32*	Small papules resembling angiomas on the face and extremities	Fever, malaise, headache, diarrhea, and respiratory complaints
Unilateral thoracic exanthema (*symmetric periflexural exanthema of childhood*)	Unknown, likely viral trigger	Pinpoint pink papules with pale halo localized to large flexural region; unilateral and asymmetric distribution; pruritus	Mild upper respiratory tract, low-grade fever or GI symptoms

[a]Congenital infections, infections in neonates, and immunocompromised individuals are discussed in the text.

MANAGEMENT

Treatment for ULE is typically focused on controlling pruritus. This can be done with topical corticosteroids, antiitch lotions, and oral antihistamines.

SUMMARY

Table 163-15 summarizes viral infections with characteristic exanthems.

REFERENCES

1. Langmuir AD, Henderson DA, Serfling RE, et al. The importance of measles as a health problem. *Am J Public Health Nations Health*. 1962; 52(2)Suppl:1-4. PMID: 14462171.
2. Papania MJ, Wallace GS, Rota PA, et al. Elimination of endemic measles, rubella, and congenital rubella syndrome from the Western hemisphere: the US experience. *JAMA Pediatr*. 2014;168(2):148-155.
3. Fiebelkorn AP, Redd SB, Gallagher K, et al. Measles in the United States during the postelimination era. *J Infect Dis*. 2010;202(10):1520-1528.

4. Zipprich J, Winter K, Hacker J, et al. Measles outbreak—California, December 2014-February 2015. *MMWR Morb Mortal Wkly Rep.* 2015;60(6):153-154.
5. World Health Organization (WHO). Measles. http://www.who.int/en/news-room/fact-sheets/detail/measles. Updated February 19, 2018. Accessed October 4, 2016.
6. Chen RT, Goldbaum GM, Wassilak SG, et al. An explosive point-source measles outbreak in a highly vaccinated population. Modes of transmission and risk factors for disease. *Am J Epidemiol.* 1989;129(1):173-182.
7. Hirsch RL, Griffin DE, Johnson RT, et al. Cellular immune responses during complicated and uncomplicated measles virus infections of man. *Clin Immunol Immunopathol.* 1984;31(1):1-12.
8. Moss WJ, Griffin DE. Measles. *Lancet.* 2012;379(9811):153-164.
9. Helfand RF, Kebede S, Mercader S, et al. The effect of timing of sample collection on the detection of measles-specific IgM in serum and oral fluid samples after primary measles vaccination. *Epidemiol Infect.* 1999;123(3):451-455.
10. Committee on Infectious Diseases, American Academy of Pediatrics. Measles. In: Kimberlin DW, Brady MT, Jackson MA, Long SS, eds. *Red Book: 2015 Report of the Committee on Infectious Diseases*. 30th ed. Elk Grove Village, IL: American Academy of Pediatrics; 2015: 535-547. (Available at: https://redbook.solutions.aap.org/DocumentLibrary/9781581109276.pdf.)
11. Yang HM, Mao M, Wan CM. Vitamin A for treating measles in children. *Cochrane Database Syst Rev.* 2005;(4):CD001479.
12. Pal G. Effects of ribavirin on measles. *J Indian Med Assoc.* 2011;109(9):666-667.
13. Committee on Infectious Diseases, American Academy of Pediatrics. Rubella. In: Kimberlin DW, Brady MT, Jackson MA, Long SS, eds. *Red Book: 2015 Report of the Committee on Infectious Diseases*. 30th ed. Elk Grove Village, IL: American Academy of Pediatrics; 2015: 730-737. (Available at: https://redbook.solutions.aap.org/DocumentLibrary/9781581109276.pdf.)
14. Louie JK, Shaikh-Laskos R, Preas C, et al. Re-emergence of another vaccine-preventable disease?-Two cases of rubella in older adults. *J Clin Virol.* 2009;46(1):98-100.
15. Vander Straten MR, Tyring SK. Rubella. *Dermatol Clin.* 2002;20(2):225-231.
16. Control and prevention of rubella: evaluation and management of suspected outbreaks, rubella in pregnant women, and surveillance for congenital rubella syndrome. *MMWR Morb Mortal Wkly Rep.* 2001;50(RR-12):1-23.
17. Nakayama T. Laboratory diagnosis of measles and rubella infection. *Vaccine.* 2009;27(24):3228-3229.
18. Young MK, Cripps AW, Nimmo GR, et al. Post-exposure passive immunisation for preventing rubella and congenital rubella syndrome. *Cochrane Database Syst Rev.* 2015;(9):CD010586.
19. Badilla X, Morice A, Avila-Aguero ML, et al. Fetal risk associated with rubella vaccination during pregnancy. *Pediatr Infect Dis J.* 2007;26(9):830-835.
20. Perelygina L, Plotkin S, Russo P, et al. Rubella persistence in epidermal keratinocytes and granuloma M2 macrophages in patients with primary immunodeficiencies. *J Allergy Clin Immunol.* 2016;138(5):1436-1439.e11.
21. Cohen BJ, Buckley MM. The prevalence of antibody to human parvovirus B19 in England and Wales. *J Med Microbiol.* 1988;25(2):151-153.
22. Anderson MJ, Higgins PG, Davis LR, et al. Experimental parvoviral infection in humans. *J Infect Dis.* 1985;152(2):257-265.
23. McCarter-Spaulding D. Parvovirus B19 in pregnancy. *J Obstet Gynecol Neonatal Nurs.* 31(1):107-112.
24. Cohen B. Parvovirus B19: an expanding spectrum of disease. *BMJ.* 1995;311(7019):1549-1552.
25. Brown KE, Hibbs JR, Gallinella G, et al. Resistance to parvovirus B19 infection due to lack of virus receptor (erythrocyte P antigen). *N Engl J Med.* 1994;330(17):1192-1196.
26. Adamson-Small LA, Ignatovich IV, Laemmerhirt MG, et al. Persistent parvovirus B19 infection in non-erythroid tissues: possible role in the inflammatory and disease process. *Virus Res.* 2014;190:8-16.
27. Feder HM, Anderson I. Fifth disease. A brief review of infections in childhood, in adulthood, and pregnancy. *Arch Intern Med.* 1989;149(10):2176-2178.
28. Plummer FA, Hammond GW, Forward K, et al. An erythema infectiosum—like illness caused by human parvovirus infection. *N Engl J Med.* 1985;313(2):74-79.
29. Edmonson MB, Riedesel EL, Williams GP, et al. Generalized petechial rashes in children during a parvovirus B19 outbreak. *Pediatrics.* 2010;125(4):e787-e792.
30. Lefrère JJ, Couroucé AM, Soulier JP, et al. Henoch-Schönlein purpura and human parvovirus infection. *Pediatrics.* 1986;78(1):183-184.
31. Martín JM, Beteta G, Allende A, et al. Parvovirus B19-associated microvesicular eruption. *Pediatr Dermatol.* 2015;32(6):e303-e304.
32. Woolf AD, Campion G V, Chishick A, et al. Clinical manifestations of human parvovirus B19 in adults. *Arch Intern Med.* 1989;149(5):1153-1156.
33. Faden H, Gary GW, Korman M. Numbness and tingling of fingers associated with parvovirus B19 infection. *J Infect Dis.* 1990;161(2):354-355.
34. Harms M, Feldmann R, Saurat JH. Papular-purpuric "gloves and socks" syndrome. *J Am Acad Dermatol.* 1990;23(5, pt 1):850-854.
35. Petter G, Rytter M, Haustein UF. Juvenile papular-purpuric gloves and socks syndrome. *J Eur Acad Dermatol Venereol.* 2001;15(4):340-342.
36. Molenaar-de Backer MW, de Waal M, Sjerps MC, et al. Validation of new real-time polymerase chain reaction assays for detection of hepatitis A virus RNA and parvovirus B19 DNA. *Transfusion.* 2016;56(2):440-448.
37. Dijkmans AC, de Jong EP, Dijkmans BA, et al. Parvovirus B19 in pregnancy: prenatal diagnosis and management of fetal complications. *Curr Opin Obstet Gynecol.* 2012;24(2):95-101.
38. Kerr JR. A review of blood diseases and cytopenias associated with human parvovirus B19 infection. *Rev Med Virol.* 2015;25(4):224-240.
39. Kurtzman G, Frickhofen N, Kimball J, et al. Pure red-cell aplasia of 10 years' duration due to persistent parvovirus B19 infection and its cure with immunoglobulin therapy. *N Engl J Med.* 1989;321(8):519-523.
40. Prospective study of human parvovirus (B19) infection in pregnancy. Public Health Laboratory Service Working Party on Fifth Disease. *BMJ.* 1990;300(6733):1166-1170.
41. Kerr JR. The role of parvovirus B19 in the pathogenesis of autoimmunity and autoimmune disease. *J Clin Pathol.* 2016;69(4):279-291.
42. Nigro G, Pisano P, Krzysztofiak A. Recurrent Kawasaki disease associated with co-infection with parvovirus B19 and HIV-1. *AIDS.* 1993;7(2):288-290.

43. Corman LC, Dolson DJ. Polyarteritis nodosa and parvovirus B19 infection. *Lancet.* 1992;339(8791):491.
44. Rogo LD, Mokhtari-Azad T, Kabir MH, et al. Human parvovirus B19: a review. *Acta Virol.* 2014;58(3):199-213.
45. Levin LI, Munger KL, Rubertone MV, et al. Temporal relationship between elevation of Epstein-Barr virus antibody titers and initial onset of neurological symptoms in multiple sclerosis. *JAMA.* 2005;293(20):2496.
46. Dowd JB, Palermo T, Brite J, et al. Seroprevalence of Epstein-Barr virus infection in U.S. children ages 6-19, 2003-2010. *PLoS One.* 2013;8(5):e64921.
47. Farrell PJ. Epstein-Barr virus strain variation. *Curr Top Microbiol Immunol.* 2015;390(pt 1):45-69.
48. Fafi-Kremer S, Morand P, Brion J-P, et al. Long-term shedding of infectious Epstein-Barr virus after infectious mononucleosis. *J Infect Dis.* 2005;191(6):985-989.
49. Hall LD, Eminger LA, Hesterman KS, et al. Epstein-Barr virus: dermatologic associations and implications: part I. Mucocutaneous manifestations of Epstein-Barr virus and nonmalignant disorders. *J Am Acad Dermatol.* 2015;72(1):1-19.
50. Sixbey JW, Nedrud JG, Raab-Traub N, et al. Epstein-Barr virus replication in oropharyngeal epithelial cells. *N Engl J Med.* 1984;310(19):1225-1230.
51. Fingeroth JD, Weis JJ, Tedder TF, et al. Epstein-Barr virus receptor of human B lymphocytes is the C3d receptor CR2. *Proc Natl Acad Sci U S A.* 1984;81(14):4510-4514.
52. Callan MF, Steven N, Krausa P, et al. Large clonal expansions of CD8+ T cells in acute infectious mononucleosis. *Nat Med.* 1996;2(8):906-911.
53. Cohen JI, Dropulic L, Hsu AP, et al. Association of GATA2 deficiency with severe primary Epstein-Barr virus (EBV) infection and EBV-associated cancers. *Clin Infect Dis.* 2016;63(1):41-47.
54. Dunmire SK, Grimm JM, Schmeling DO, et al. The incubation period of primary Epstein-Barr virus infection: viral dynamics and immunologic events. *PLoS Pathog.* 2015;11(12):e1005286.
55. Cohen JI. Epstein-Barr virus infection. *N Engl J Med.* 2000;343(7):481-492.
56. Hosey RG, Kriss V, Uhl TL, et al. Ultrasonographic evaluation of splenic enlargement in athletes with acute infectious mononucleosis. *Br J Sports Med.* 2008;42(12):974-977.
57. Farley DR, Zietlow SP, Bannon MP, et al. Spontaneous rupture of the spleen due to infectious mononucleosis. *Mayo Clin Proc.* 1992;67(9):846-853.
58. Avgil M, Diav-Citrin O, Shechtman S, et al. Epstein-Barr virus infection in pregnancy—a prospective controlled study. *Reprod Toxicol.* 2008;25(4):468-471.
59. Chovel-Sella A, Ben Tov A, Lahav E, et al. Incidence of rash after amoxicillin treatment in children with infectious mononucleosis. *Pediatrics.* 2013;131(5):e1424-e1427.
60. Patel BM. Skin rash with infectious mononucleosis and ampicillin. *Pediatrics.* 1967;40(5):910-911.
61. Ikediobi NI, Tyring SK. Cutaneous manifestations of Epstein-Barr virus infection. *Dermatol Clin.* 2002;20(2):283-289.
62. Weary PE, Cole JW, Hickam LH. Eruptions from ampicillin in patients with infectious mononucleosis. *Arch Dermatol.* 1970;101(1):86-91.
63. Farhi D, Wendling J, Molinari E, et al. Non-sexually related acute genital ulcers in 13 pubertal girls: a clinical and microbiological study. *Arch Dermatol.* 2009;145(1):38-45.
64. Sárdy M, Wollenberg A, Niedermeier A, et al. Genital ulcers associated with Epstein-Barr virus infection (ulcus vulvae acutum). *Acta Derm Venereol.* 2011;91(1):55-59.
65. Cohen JI. Epstein-Barr virus infection. *N Engl J Med.* 2000;343(7):481-492.
66. Ok CY, Li L, Young KH. EBV-driven B-cell lymphoproliferative disorders: from biology, classification and differential diagnosis to clinical management. *Exp Mol Med.* 2015;47:e132.
67. Harabuchi CY, Yamanaka N, Kataura A, et al. Epstein-Barr virus in nasal T-cell lymphomas in patients with lethal midline granuloma. *Lancet.* 1990;20(335):128-130.
68. Choi Y-L, Park J-H, Namkung J-H, et al. Extranodal NK/T-cell lymphoma with cutaneous involvement: "nasal" vs. "nasal-type" subgroups—a retrospective study of 18 patients. *Br J Dermatol.* 2009;160(2):333-337.
69. Au W, Weisenburger DD, Intragumtornchai T, et al. Clinical differences between nasal and extranasal natural killer/T-cell lymphoma: a study of 136 cases from the International Peripheral T-Cell Lymphoma Project. *Blood.* 2009;113(17):3931-3937.
70. Quintanilla-Martinez L, Ridaura C, Nagl F, et al. Hydroa vacciniforme-like lymphoma: a chronic EBV+ lymphoproliferative disorder with risk to develop a systemic lymphoma. *Blood.* 2013;122(18):3101-3110.
71. Xu Z, Lian S. Epstein-Barr virus-associated hydroa vacciniforme-like cutaneous lymphoma in seven Chinese children. *Pediatr Dermatol.* 2010;27(5):463-469.
72. Myers JL, Kurtin PJ, Katzenstein AL, et al. Lymphomatoid granulomatosis. Evidence of immunophenotypic diversity and relationship to Epstein-Barr virus infection. *Am J Surg Pathol.* 1995;19(11):1300-1312.
73. Eminger LA, Hall LD, Hesterman KS, et al. Epstein-Barr virus: dermatologic associations and implications: part II. Associated lymphoproliferative disorders and solid tumors. *J Am Acad Dermatol.* 2015;72(1):21-34.
74. McNiff JM, Cooper D, Howe G, et al. Lymphomatoid granulomatosis of the skin and lung. An angiocentric T-cell-rich B-cell lymphoproliferative disorder. *Arch Dermatol.* 1996;132(12):1464-1470.
75. Roschewski M, Wilson WH. Lymphomatoid granulomatosis. *Cancer J.* 2012;18(5):469-474.
76. Linderholm M, Boman J, Juto P, et al. Comparative evaluation of nine kits for rapid diagnosis of infectious mononucleosis and Epstein-Barr virus-specific serology. *J Clin Microbiol.* 1994;32(1):259-261.
77. Pitetti RD, Laus S, Wadowsky RM. Clinical evaluation of a quantitative real time polymerase chain reaction assay for diagnosis of primary Epstein-Barr virus infection in children. *Pediatr Infect Dis J.* 2003;22(8):736-739.
78. Hess RD. Routine Epstein-Barr virus diagnostics from the laboratory perspective: still challenging after 35 years. *J Clin Microbiol.* 2004;42(8):3381-3387.
79. Holman CJ, Karger AB, Mullan BD, et al. Quantitative Epstein-Barr virus shedding and its correlation with the risk of post-transplant lymphoproliferative disorder. *Clin Transplant.* 2012;26(5):741-747.
80. Rezk E, Nofal YH, Hamzeh A, et al. Steroids for symptom control in infectious mononucleosis. *Cochrane Database Syst Rev.* 2015;(11):CD004402.
81. van der Horst C, Joncas J, Ahronheim G, et al. Lack of effect of peroral acyclovir for the treatment of acute infectious mononucleosis. *J Infect Dis.* 1991;164(4):788-792.
82. Smith C, Khanna R. The development of prophylactic and therapeutic EBV vaccines. *Curr Top Microbiol Immunol.* 2015;391:455-473.

83. Brandt O, Abeck D, Gianotti R, et al. Gianotti-Crosti syndrome. *J Am Acad Dermatol.* 2006;54(1):136-145.
84. Crosti A, Gianotti F. Eruptive dermatosis of probable viral origin situated on the acra [in French]. *Dermatologica.* 1957;115(5):671-677.
85. Smith KJ, Skelton H. Histopathologic features seen in Gianotti-Crosti syndrome secondary to Epstein-Barr virus. *J Am Acad Dermatol.* 2000;43(6):1076-1079.
86. Chuh A, Zawar V, Lee A, et al. Is Gianotti-Crosti syndrome associated with atopy? A case-control study and a postulation on the intrinsic host factors in Gianotti-Crosti syndrome. *Pediatr Dermatol.* 2016; 33(5):488-492.
87. Hofmann B, Schuppe HC, Adams O, et al. Gianotti-Crosti syndrome associated with Epstein-Barr virus infection. *Pediatr Dermatol.* 14(4):273-277.
88. Berger EM, Orlow SJ, Patel RR, et al. Experience with molluscum contagiosum and associated inflammatory reactions in a pediatric dermatology practice: the bump that rashes. *Arch Dermatol.* 2012;148(11): 1257-1264.
89. De Vries HJ, van Marle J, Teunissen MB, et al. Lichen planus is associated with human herpesvirus type 7 replication and infiltration of plasmacytoid dendritic cells. *Br J Dermatol.* 2006;154(2):361-364.
90. Bialas KM, Swamy GK, Permar SR. Perinatal cytomegalovirus and varicella zoster virus infections: epidemiology, prevention, and treatment. *Clin Perinatol.* 2015;42(1):61-75, viii.
91. Gallant JE, Moore RD, Richman DD, et al. Incidence and natural history of cytomegalovirus disease in patients with advanced human immunodeficiency virus disease treated with zidovudine. The Zidovudine Epidemiology Study Group. *J Infect Dis.* 1992;166(6):1223-1227.
92. Boppana SB, Pass RF, Britt WJ, et al. Symptomatic congenital cytomegalovirus infection: neonatal morbidity and mortality. *Pediatr Infect Dis J.* 1992; 11(2):93-99.
93. Brough AJ, Jones D, Page RH, et al. Dermal erythropoiesis in neonatal infants. A manifestation of intrauterine viral disease. *Pediatrics.* 1967;40(4):627-635.
94. Fowler KB, Boppana SB. Congenital cytomegalovirus (CMV) infection and hearing deficit. *J Clin Virol.* 2006;35(2):226-231.
95. Heilbron B, Saxe N. Scleredema in an infant. *Arch Dermatol.* 1986;122(12):1417-1419.
96. Ballard RA, Drew WL, Hufnagle KG, et al. Acquired cytomegalovirus infection in preterm infants. *Am J Dis Child.* 1979;133(5):482-485.
97. Hancox JG, Shetty AK, Sangueza OP, et al. Perineal ulcers in an infant: an unusual presentation of postnatal cytomegalovirus infection. *J Am Acad Dermatol.* 2006;54(3):536-539.
98. Horwitz CA, Henle W, Henle G, et al. Clinical and laboratory evaluation of cytomegalovirus-induced mononucleosis in previously healthy individuals. Report of 82 cases. *Medicine (Baltimore).* 1986;65(2): 124-134.
99. Chen Y-C, Chiang H-H, Cho Y-T, et al. Human herpes virus reactivations and dynamic cytokine profiles in patients with cutaneous adverse drug reactions-a prospective comparative study. *Allergy.* 2015;70(5):568-575.
100. Klemola E. Hypersensitivity reactions to ampicillin in cytomegalovirus mononucleosis. *Scand J Infect Dis.* 1970;2(1):29-31.
101. Spear JB, Kessler HA, Dworin A, et al. Erythema nodosum associated with acute cytomegalovirus mononucleosis in an adult. *Arch Intern Med.* 1988; 148(2):323-324.
102. Asano Y, Yoshikawa T, Suga S, et al. Clinical features of infants with primary human herpesvirus 6 infection (exanthem subitum, roseola infantum). *Pediatrics.* 1994;93(1):104-108.
103. Kotton CN, Kumar D, Caliendo AM, et al. Updated international consensus guidelines on the management of cytomegalovirus in solid-organ transplantation. *Transplantation.* 2013;96(4):333-360.
104. Strauss RG. Optimal prevention of transfusion-transmitted cytomegalovirus (TTCMV) infection by modern leukocyte reduction alone: CMV sero/antibody-negative donors needed only for leukocyte products. *Transfusion.* 2016;56(8):1921-1924.
105. Cohen L, Yeshurun M, Shpilberg O, et al. Risk factors and prognostic scale for cytomegalovirus (CMV) infection in CMV-seropositive patients after allogeneic hematopoietic cell transplantation. *Transpl Infect Dis.* 2015;17(4):510-517.
106. Wood AJJ, Jacobson MA. Treatment of cytomegalovirus retinitis in patients with the acquired immunodeficiency syndrome. *N Engl J Med.* 1997;337(2): 105-114.
107. Karavellas MP, Plummer DJ, Macdonald JC, et al. Incidence of immune recovery vitreitis in cytomegalovirus retinitis patients following institution of successful highly active antiretroviral therapy. *J Infect Dis.* 1999;179(3):697-700.
108. Poizot-Martin I, Allavena C, Duvivier C, et al. CMV+ serostatus associates negatively with CD4:CD8 ratio normalization in controlled HIV-infected patients on cART. *PLoS One.* 2016;11(11):e0165774.
109. Choi Y-L, Kim J-A, Jang K-T, et al. Characteristics of cutaneous cytomegalovirus infection in non-acquired immune deficiency syndrome, immunocompromised patients. *Br J Dermatol.* 2006;155(5): 977-982.
110. Bhawan J, Gellis S, Ucci A, et al. Vesiculobullous lesions caused by cytomegalovirus infection in an immunocompromised adult. *J Am Acad Dermatol.* 1984;11(4, pt 2):743-747.
111. Feldman PS, Walker AN, Baker R. Cutaneous lesions heralding disseminated cytomegalovirus infection. *J Am Acad Dermatol.* 1982;7(4):545-548.
112. Lesher JL. Cytomegalovirus infections and the skin. *J Am Acad Dermatol.* 1988;18(6):1333-1338.
113. Shah T, Luck S, Sharland M, et al. Fifteen-minute consultation: diagnosis and management of congenital CMV. *Arch Dis Child Educ Pract Ed.* 2016;101(5): 232-235.
114. Genser B, Truschnig-Wilders M, Stünzner D, et al. Evaluation of five commercial enzyme immunoassays for the detection of human cytomegalovirus-specific IgM antibodies in the absence of a commercially available gold standard. *Clin Chem Lab Med.* 2001;39(1):62-70.
115. Walker JD, Chesney TM. Cytomegalovirus infection of the skin. *Am J Dermatopathol.* 1982;4(3):263-265.
116. James SH, Kimberlin DW. Advances in the prevention and treatment of congenital cytomegalovirus infection. *Curr Opin Pediatr.* 2016;28(1):81-85.
117. Zerr DM, Meier AS, Selke SS, et al. A population-based study of primary human herpesvirus 6 infection. *N Engl J Med.* 2005;352(8):768-776.

118. Krueger GR, Wassermann K, De Clerck LS, et al. Latent herpesvirus-6 in salivary and bronchial glands. *Lancet.* 1990;336(8725):1255-1256.
119. Santoro F, Kennedy PE, Locatelli G, et al. CD46 is a cellular receptor for human herpesvirus 6. *Cell.* 1999; 99(7):817-827.
120. Frenkel N, Katsafanas GC, Wyatt LS, et al. Bone marrow transplant recipients harbor the B variant of human herpesvirus 6. *Bone Marrow Transplant.* 1994;14(5):839-843.
121. Le J, Gantt S. AST Infectious Diseases Community of Practice. Human herpesvirus 6, 7 and 8 in solid organ transplantation. *Am J Transplant.* 2013;13(suppl 4): 128-137.
122. De Bolle L, Naesens L, De Clercq E. Update on human herpesvirus 6 biology, clinical features, and therapy. *Clin Microbiol Rev.* 2005;18(1):217-245.
123. Pruksananonda P, Hall CB, Insel RA, et al. Primary human herpesvirus 6 infection in young children. *N Engl J Med.* 1992;326(22):1445-1450.
124. Dulery R, Salleron J, Dewilde A, et al. Early human herpesvirus type 6 reactivation after allogeneic stem cell transplantation: a large-scale clinical study. *Biol Blood Marrow Transplant.* 2012;18(7):1080-1089.
125. Zahorsky J. Roseola infantum. *Arch Pediatr.* 1954;71(4): 124-128.
126. Levine PH, Jahan N, Murari P, et al. Detection of human herpesvirus 6 in tissues involved by sinus histiocytosis with massive lymphadenopathy (Rosai-Dorfman disease). *J Infect Dis.* 1992;166(2):291-295.
127. Luppi M, Barozzi P, Garber R, et al. Expression of human herpesvirus-6 antigens in benign and malignant lymphoproliferative diseases. *Am J Pathol.* 1998;153(3):815-823.
128. Suga S, Yoshikawa T, Asano Y, et al. IgM neutralizing antibody responses to human herpesvirus-6 in patients with exanthem subitum or organ transplantation. *Microbiol Immunol.* 1992;36(5):495-506.
129. Zerr DM, Corey L, Kim HW, et al. Clinical outcomes of human herpesvirus 6 reactivation after hematopoietic stem cell transplantation. *Clin Infect Dis.* 2005;40(7):932-940.
130. Yoshida M, Yamada M, Tsukazaki T, et al. Comparison of antiviral compounds against human herpesvirus 6 and 7. *Antiviral Res.* 1998;40(1-2):73-84.
131. Prichard MN, Whitley RJ. The development of new therapies for human herpesvirus 6. *Curr Opin Virol.* 2014;9:148-153.
132. Rapaport D, Engelhard D, Tagger G, et al. Antiviral prophylaxis may prevent human herpesvirus-6 reactivation in bone marrow transplant recipients. *Transpl Infect Dis.* 2002;4(1):10-16.
133. Hidaka Y, Okada K, Kusuhara K, et al. Exanthem subitum and human herpesvirus 7 infection. *Pediatr Infect Dis J.* 1994;13(11):1010-1011.
134. Emery VC, Clark DA. HHV-6A, 6B, and 7: persistence in the population, epidemiology and transmission. In: Arvin A, Campadelli-Fiume G, Mocarski E, et al, eds. *Human Herpesviruses: Biology, Therapy, and Immunoprophylaxis*. Cambridge, UK: Cambridge University Press; 2007:843-849. (Also available at https://www.ncbi.nlm.nih.gov/books/NBK47441/#c49upy-q8o-pd3-fg6.)
135. Smith C, Khanna R. Immune regulation of human herpesviruses and its implications for human transplantation. *Am J Transplant.* 2013;13(s3):9-23.
136. Hall CB, Caserta MT, Schnabel KC, et al. Characteristics and acquisition of human herpesvirus (HHV) 7 infections in relation to infection with HHV-6. *J Infect Dis.* 2006;193(8):1063-1069.
137. Drago F, Ranieri E, Malaguti F, et al. Human herpesvirus 7 in pityriasis rosea. *Lancet.* 1997;349(9062): 1367-1368.
138. Torigoe S, Koide W, Yamada M, et al. Human herpesvirus 7 infection associated with central nervous system manifestations. *J Pediatr.* 1996;129(2):301-305.
139. Sawyer MH. Enterovirus infections: diagnosis and treatment. *Semin Pediatr Infect Dis.* 2002;13(1):40-47.
140. Nassef C, Ziemer C, Morrell DS. Hand-foot-and-mouth disease: a new look at a classic viral rash. *Curr Opin Pediatr.* 2015;27(4):486-491.
141. Chang L-Y, Tsao K-C, Hsia S-H, et al. Transmission and clinical features of enterovirus 71 infections in household contacts in Taiwan. *JAMA.* 2004;291(2):222-227.
142. Ramers C, Billman G, Hartin M, et al. Impact of a diagnostic cerebrospinal fluid enterovirus polymerase chain reaction test on patient management. *JAMA.* 2000;283(20):2680-2685.
143. Kimura A, Abe M, Nakao T. Light and electron microscopic study of skin lesions of patients with the hand, foot and mouth disease. *Tohoku J Exp Med.* 1977;122(3):237-247.
144. Chang P-C, Chen S-C, Chen K-T. The current status of the disease caused by enterovirus 71 infections: epidemiology, pathogenesis, molecular epidemiology, and vaccine development. *Int J Environ Res Public Health.* 2016;13(9).
145. Bek EJ, McMinn PC. The pathogenesis and prevention of encephalitis due to human enterovirus 71. *Curr Infect Dis Rep.* 2012;14(4):397-407.
146. Puenpa J, Vongpunsawad S, Osterback R, et al. Molecular epidemiology and the evolution of human coxsackievirus A6. *J Gen Virol.* 2016;97(12):3225-3231.
147. Mathes EF, Oza V, Frieden IJ, et al. "Eczema coxsackium" and unusual cutaneous findings in an enterovirus outbreak. *Pediatrics.* 2013;132(1):e149-e157.
148. Downing C, Ramirez-Fort MK, Doan HQ, et al. Coxsackievirus A6 associated hand, foot and mouth disease in adults: clinical presentation and review of the literature. *J Clin Virol.* 2014;60(4):381-386.
149. Neri I, Dondi A, Wollenberg A, et al. Atypical forms of hand, foot, and mouth disease: a prospective study of 47 Italian children. *Pediatr Dermatol.* 2016;33(4):429-437.
150. Zeng H, Lu J, Zheng H, et al. The epidemiological study of coxsackievirus a6 revealing hand, foot and mouth disease epidemic patterns in Guangdong, China. *Sci Rep.* 2015;5:10550.
151. Laga AC, Shroba SM, Hanna J. Atypical hand, foot and mouth disease in adults associated with coxsackievirus A6: a clinico-pathologic study. *J Cutan Pathol.* 2016;43(11):940-945.
152. Miyamoto A, Hirata R, Ishimoto K, et al. An outbreak of hand-foot-and-mouth disease mimicking chicken pox, with a frequent association of onychomadesis in Japan in 2009: a new phenotype caused by coxsackievirus A6. *Eur J Dermatol.* 2014;24(1):103-104.
153. Cherry JD, Bobinski JE, Horvath FL, et al. Acute hemangioma-like lesions associated with ECHO viral infections. *Pediatrics.* 1969;44(4):498-502.
154. Prose NS, Tope W, Miller SE, et al. Eruptive pseudoangiomatosis: a unique childhood exanthem? *J Am Acad Dermatol.* 1993;29(5, pt 2):857-859.
155. Chuh A, Panzer R, Rosenthal A-C, et al. Annular eruptive pseudoangiomatosis and adenovirus infection:

a novel clinical variant of paraviral exanthems and a novel virus association. *Acta Derm Venereol.* 2017;97(3):354-357.
156. Henry M, Savaşan S. Eruptive pseudoangiomatosis in a child undergoing chemotherapy for Hodgkin lymphoma. *Pediatr Blood Cancer.* 2012;59(2):342-343.
157. Oka K, Ohtaki N, Kasai S, et al. Two cases of eruptive pseudoangiomatosis induced by mosquito bites. *J Dermatol.* 2012;39(3):301-305.
158. Pitarch G, Torrijos A, García-Escrivá D, et al. Eruptive pseudoangiomatosis associated to cytomegalovirus infection. *Eur J Dermatol.* 17(5):455-456.
159. McCuaig CC, Russo P, Powell J, et al. Unilateral laterothoracic exanthem. A clinicopathologic study of forty-eight patients. *J Am Acad Dermatol.* 1996;34(6):979-984.
160. Gutzmer R, Herbst RA, Kiehl P, et al. Unilateral laterothoracic exanthem (asymmetrical periflexural exanthem of childhood): report of an adult patient. *J Am Acad Dermatol.* 1997;37(3, pt 1):484-485.

Chapter 164 :: Herpes Simplex

:: Jeffrey I. Cohen

AT-A-GLANCE

- Herpes simplex viruses (HSVs) are common human DNA viral pathogens that intermittently reactivate. After replication in the skin or mucosa, the virus infects the local nerve endings and ascends to the ganglia where it becomes latent until reactivation.
- There are two types of HSV: HSV-1 and HSV-2. HSV-1 is mostly associated with orofacial disease, whereas HSV-2 usually causes genital infection, but both can infect oral and genital areas and cause acute and recurrent infections.
- Most of the adult population is seropositive for HSV-1, and the majority of infections are acquired in childhood. About one-fourth of adults are infected with HSV-2 in the United States. Acquisition of HSV-2 correlates with sexual behavior.
- Most primary HSV infections are asymptomatic or not recognized, but they can also cause severe disease. Most recurrences are not symptomatic and most transmissions occur during asymptomatic shedding.
- Genital herpes is the most prevalent sexually transmitted disease worldwide and is the most common cause of ulcerative genital disease; it is an important risk factor for acquisition and transmission of HIV.
- HSV can cause diseases involving the eye, CNS, and neonatal infection. Cellular immunity defects are a risk factor for severe and disseminated disease.
- Diagnosis is made by polymerase chain reaction, viral culture, or serology, depending on the clinical presentation.
- Treatment is with acyclovir, valacyclovir, or famciclovir. Regimens and dosages vary with the clinical setting. Resistance is rare, other than in immunocompromised patients.

Herpes simplex virus (HSV) infections are common worldwide and are caused by 2 closely related types of HSV. Their main clinical manifestations are mucocutaneous infections, with HSV Type 1 (HSV-1) being mostly associated with orofacial disease, and HSV Type 2 (HSV-2) usually being associated with genital infection. HSV-1 is increasingly becoming a more common cause of genital mucosal infections in young women in the United States than HSV-2.[1]

EPIDEMIOLOGY

The incidence of primary infection with HSV-1, which is responsible for the vast majority of recurring labial herpes, is greatest during childhood, when 30% to 60% of children are exposed to the virus. Rates of infection with HSV-1 increase with age and reduced socioeconomic status. From 20% to 40% of the population has had episodes of herpes labialis. The frequency of recurrent episodes is extremely variable, and, in some studies, averages approximately once per year. From 2005 to 2010 the seroprevalence of HSV-1 in the United States was 30% in persons 14 to 19 years of age, 50% in persons 20 to 29 years of age, and 62% in persons 30 to 39 years of age.[2] The rate of HSV-1 declined by 7% from 1999-2004 to 2005-2010.

Acquisition of HSV-2 correlates with sexual behavior and the prevalence of infection in one's potential sexual partners. Antibodies to HSV-2 are rare in people before the onset of intimate sexual activity and rise steadily thereafter. From 2005 to 2010 the seroprevalence of HSV-2 in the United States was 1.2% in persons 14 to 19 years of age, 9.9% in persons 20 to 29 years of age, and 19% in persons 30 to 39 years of age.[2] The rate of HSV-2 seropositivity did not change significantly from 1999-2004 to 2005-2010. Although most persons infected with HSV-1 or HSV-2 are asymptomatic, they still can transmit the virus.[3] Even though HSV-2–asymptomatic persons shed virus less frequently than symptomatic persons, the amount of HSV-2 shed during asymptomatic shedding is similar in symptomatic and asymptomatic groups.[4] In one study, 21% of genital swabs were positive for HSV by polymerase chain reaction (PCR) in persons who were HSV-2 seropositive, and 12% of oral swabs were positive for HSV by PCR in persons who were HSV-1 seropositive.[5] It is estimated that more than 70% of HSV-2 transmission is associated with asymptomatic shedding. The rate of transmission is no higher in persons with frequent symptomatic recurrences than it is in persons with infrequent recurrences. The average risk of transmission for couples discordant for genital herpes (ie, one partner has genital herpes and the other does not) varies from 5% to 10% per year.[6] As with other sexually-transmitted infections, the rate of acquisition of HSV-2 infection is higher for women than for men. Asymptomatic HSV-2 infection is more common among men and persons who are also seropositive for HSV-1, suggesting that prior infection with HSV-1 reduces one's likelihood of experiencing symptomatic HSV-2 infection.[7] Studies show that genital HSV infections significantly increase the risk for acquisition and transmission of HIV. Randomized trials with acyclovir reduced the frequency of genital ulcers and slightly

Figure 164-1 Primary herpetic gingivostomatitis. (Used with permission from Clyde S. Crumpacker, MD.)

reduced HIV viral loads, but did not reduce transmission of HIV.[8]

CLINICAL FINDINGS

CUTANEOUS FINDINGS

The clinical manifestations of HSV infection depend on the site of infection and the immune status of the host. Primary infections with HSV, namely those that develop in persons without preexisting immunity to either HSV-1 or HSV-2, are usually more severe, frequently involve systemic signs and symptoms, and have a higher rate of complications, compared to episodes associated with reactivation of HSV.

OROFACIAL INFECTIONS

Herpetic gingivostomatitis (Fig. 164-1) and pharyngitis are most commonly associated with a primary HSV-1 infection. The symptoms of primary oral herpes may resemble those of aphthous stomatitis and include ulcerative lesions involving the hard and soft palate, tongue, and buccal mucosa, as well as neighboring facial areas. Patients with pharyngitis exhibit ulcerative and exudative lesions of the posterior pharynx that can be difficult to differentiate from streptococcal pharyngitis. Other common symptoms include fever, malaise, myalgias, pain on swallowing, irritability, and cervical adenopathy.

Reactivation of virus from these primary infections involves the perioral facial area, mainly the lips, with the outer one-third of the lower lip being the most commonly affected area (Fig. 164-2). Other facial locations include the nose, chin, and cheek, and account for fewer than 10% of cases (Fig. 164-3). Two-thirds of labial lesions involve the vermilion border, and the rest occur at the junction of the border with the skin.

Figure 164-2 Herpes simplex virus infection. Erythema and early vesicles caused by recurrent herpes labialis of the upper lip. (Used with permission of the William Weston Collection.)

In patients with frequent recurrences, lesions may differ slightly in location with each episode. Immunocompetent patients tend not to experience recurrent intraoral lesions, but can present with clusters of tiny vesicles and ulcers, or linear fissures on the gingivae and anterior hard palate that are mildly symptomatic. Prodromal symptoms precede herpes labialis in 45% to 60% of episodes. Patients experience pain, burning, or itching at the site of the subsequent eruption. Even in the immunocompetent patient, the severity of recurrent herpes labialis is extremely variable and may vary from that of prodromal symptoms alone without the subsequent development of lesions (aborted episodes) to extensive disease induced by severe local sunburn.

The progression of classical herpes lesions has been divided according to the following stages based on their features: prodromal, erythema, and papule

Figure 164-3 Recurrent facial herpes simplex with grouped vesicles and crusting. (Used with permission from Clyde S. Crumpacker, MD.)

(the developmental stage); vesicle, ulcer, and hard crust (disease stage); followed by dry flaking and residual swelling (resolution stage). The lesions usually resolve within 5 to 15 days.

Triggers for oral herpes recurrences include emotional stress, illness, exposure to sun, trauma, fatigue, menses, chapped lips, and the season of the year. Other well-documented triggers include exposure to ultraviolet irradiation, trigeminal nerve surgery, oral trauma, epidural administration of morphine, and abrasive, laser, and chemical facial cosmetic procedures. The exact mechanism by which these diverse factors trigger HSV reactivation is unknown.

HSV-2 causes a primary orofacial infection that is indistinguishable from that associated with HSV-1, except that it is usually in adolescents and young adults, following genital–oral contact. HSV-2 orolabial infections are 120 times less likely to reactivate than orolabial HSV-1 disease.

GENITAL INFECTIONS

Genital herpes is the major clinical presentation of HSV-2 infection, but HSV-1 is becoming a more common cause of genital herpes in young women.[9,10] Because of their epidemiology, acquisition of HSV-1 in a person with prior HSV-2 infection is unusual, but HSV-2 acquisition in the presence of previous HSV-1 infection is common, and infection of the genital tract with both HSV-1 and HSV-2 has been described. Patients with previously known HSV-1 genital infection who develop frequent genital herpes recurrences should be tested for HSV-2 infection. Viremia occurs in approximately 25% of persons during primary genital herpes.

The clinical course of acute first-episode genital herpes among patients with HSV-1 and HSV-2 infections is similar. These infections are associated with extensive genital lesions in different stages of evolution, including vesicles, pustules, and erythematous ulcers that may require 2 to 3 weeks to resolve (Fig. 164-4). In males, lesions commonly occur on the glans penis or the penile shaft; in females, lesions may involve the vulva, perineum, buttocks, vagina, or cervix. There is accompanying pain, itching, dysuria, vaginal and urethral discharge, and tender inguinal lymphadenopathy. Systemic signs and symptoms are common and include fever, headache, malaise, and myalgias. Herpetic sacral radiculomyelitis with urinary retention, neuralgias, and constipation, can occur. HSV cervicitis occurs in more than 80% of women with primary infection. It can present as purulent or bloody vaginal discharge; examination reveals areas of diffuse or focal friability and redness, extensive ulcerative lesions of the exocervix, or, rarely, necrotic cervicitis. Cervical discharge is usually mucoid, but it is occasionally mucopurulent.

The rates of recurrence for genital HSV-2 infections vary greatly among individuals and over time within the same individual. Infections caused by HSV-2 reactivate approximately 16 times more frequently than HSV-1 genital infections, and average 3 to 4 times per year, but may appear virtually weekly. Recurrences tend to be more frequent in the first months to years after initial infection. The classical clinical manifestations of recurrent HSV-2 infection include multiple small, grouped, vesicular lesions in the genital area (Fig. 164-5), but which can occur anywhere in the perigenital region, including the groin, buttocks, and thighs; the lesions may recur at the same site or change

Figure 164-4 **A,** Primary genital herpes with vesicles. (Used with permission from Clyde S. Crumpacker, MD.) **B,** Primary herpetic vulvitis.

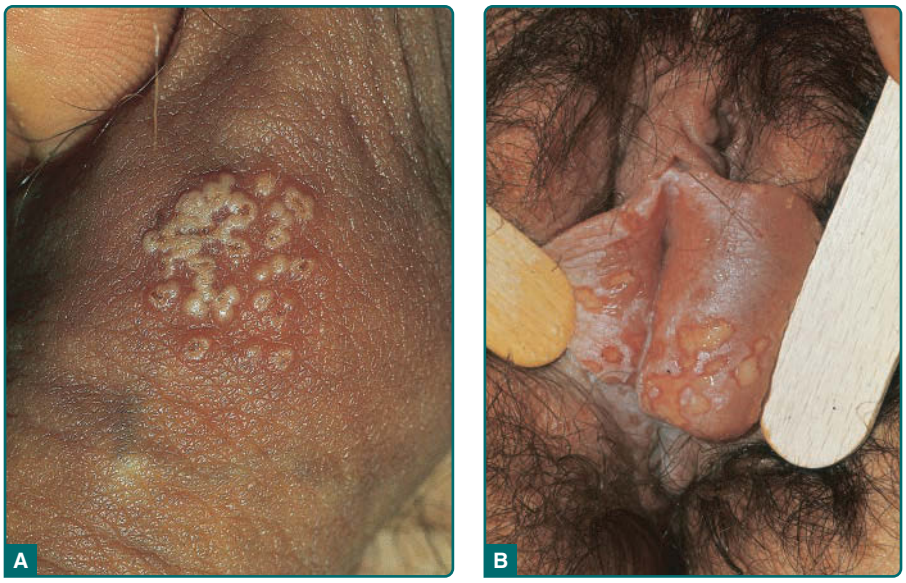

Figure 164-5 **A,** Genital herpes. Recurrent infection of the penis. Group of vesicles with early central crusting on a red base arising on the shaft of the penis. This "textbook" presentation, however, is much less common than small asymptomatic erosions or fissures. **B,** Genital herpes. Recurrent vulvar infection. Large, painful erosions on the labia. Extensive lesions such as these are uncommon in recurrent genital herpes in an otherwise healthy individual.

location. The recurrence of genital lesions may be heralded by a prodrome of tenderness, itching, burning, or tingling, and the outbreaks are less severe than primary infection. Without treatment, the lesions usually heal in 6 to 10 days. Herpetic cervicitis is less common in recurrent disease, occurring in 12% of patients. It may present without external lesions. Signs and symptoms that are less classical for genital HSV infection and that can divert one from the correct diagnosis include small erythematous lesions, fissures, pruritus, and urinary symptoms. HSV can cause urethritis, usually manifested only as a clear mucoid discharge, dysuria, and frequency. Occasionally, HSV can be associated with endometritis, salpingitis, or prostatitis. Symptomatic or asymptomatic rectal and perianal infections are common. Herpetic proctitis presents with anorectal pain, anorectal discharge, tenesmus, and constipation, with ulcerative lesions of the distal rectal mucosa. Genital herpes can recur at nongenital sites as well.

OTHER CUTANEOUS FINDINGS

HSV can infect any skin site (Fig. 164-6). The common theme among virtually all of these cutaneous presentations is the requirement that virus have penetrated otherwise normal and well-keratinized tissues. Herpetic whitlow (Fig. 164-7) is infection of the fingers by HSV acquired by direct inoculation or by direct spread from mucosal sites at the time of primary infection. Whitlow occurs in children who suck their fingers during a primary gingivostomatitis outbreak. It is also a well documented occupational hazard for medical personnel. It is usually caused by HSV-1, but HSV-2 whitlow may develop as a manifestation of primary inoculation following manual–genital contact with an infected partner. The infected region becomes erythematous and edematous. Lesions are usually present at the fingertip and can be pustular and very painful. Fever and local lymphadenopathy are common. Whitlow is often misdiagnosed as a bacterial paronychial infection, but surgical drainage, often needed for a bacterial infection, is unnecessary and potentially harmful, while antiviral therapy speeds healing. Whitlow may recur.

Cutaneous herpes can be transmitted between athletes involved in contact sports, such as wrestling (herpes gladiatorum) and rugby (herpes rugbiorum or scrum pox), and may occur as outbreaks or small epidemics among team members. In these instances, multiple herpetic lesions may appear across the thorax, ears, face, arms, and hands, in which infection is facilitated by trauma to the normally-keratinized skin during sport activities (Fig. 164-8). Concomitant ocular herpes can occur.

Figure 164-6 Recurrent genital herpes on the abdomen (zosteriform herpes simplex).

Figure 164-7 Herpes simplex virus infection. Herpetic whitlow. Painful, grouped, confluent vesicles on an erythematous, edematous base at the distal finger where the first (and presumed primary) symptomatic infection occurred.

Eczema herpeticum (Kaposi varicelliform eruption; Fig. 164-9) results from widespread infection following inoculation of virus to skin damaged by eczema. It is usually a manifestation of primary HSV-1 infection in a child with atopic dermatitis; the expression of antimicrobial peptides in the skin may be a factor in controlling susceptibility to eczema herpeticum in these patients. Cathelicidin and beta-defensins are antimicrobial peptides that inhibit HSV replication. Skin lesions from patients with eczema herpeticum have lower levels of cathelicidin and beta-defensins than do skin lesions from persons with atopic dermatitis or psoriasis.[11] Mycosis fungoides, Sézary syndrome, Darier disease, various bullous diseases of the skin (particularly if patients are receiving immunosuppressive therapy), and second-degree and third-degree burns also can be complicated by cutaneous dissemination of HSV. The severity of eczema herpeticum ranges from mild to fatal, with mortality rates of up to 10% being reported before antiviral therapy was available. Mortality was primarily caused by bacterial superinfection and bacteremia. Common pathogens include *Staphylococcus aureus*, beta-hemolytiic *Streptococcus*, and *Pseudomomas aerugionosa*. In a typical severe primary attack, vesicles develop in large numbers over areas of active or recently healed atopic dermatitis, particularly the face, several days after exposure and continue to appear in crops for several more days. The vesicles become pustular and markedly umbilicated and quickly progress to monomorphic erosions. Patients commonly have high fever and adenopathy. Viremia with infection of internal organs can be fatal. Recurrences are usually far milder than the first infection. Arriving at the correct diagnosis can be delayed

Figure 164-8 Herpes simplex gladiatorum with lesions on the neck.

Figure 164-9 Two examples of eczema herpeticum. Confluent and discrete crusted erosions associated with erythema and edema of the face of a child (**A**) and man (**B**) with atopic dermatitis. Note the monomorphic vesicles and punched out erosions. (Image **A,** Used with permission from Anna L. Bruckner, MD.)

because of secondary impetigo involving the lesions, but it should be considered in children with infected eczema, particularly if the child is more systemically ill than one might anticipate with impetigo. Eczema herpeticum of the young infant is a medical emergency, and early treatment with acyclovir can prove lifesaving.

Recurrent HSV infection is the most common precipitating event in cases of recurrent erythema multiforme (see Chap. 43). HSV-associated erythema multiforme is usually an acute, self-limited, recurrent disease, that lasts approximately 3 weeks. The lesions are usually symmetric, occurring on acral extremities and the face, and there is grouping of lesions over the elbow and knees as well as nailfold involvement. Mucosal involvement is usually mild and restricted to the mouth. Constitutional symptoms are rare, and the skin lesions heal without scarring.

NEONATAL HERPES

The neonate is a special category of immunodeficient host. The prevalence of neonatal herpes varies from 1 case per 12500 to 1700 live births.[12] Primary maternal genital herpes is associated with a risk of neonatal infection of 25% to 50% for vaginally-delivered babies, and accounts for 50% to 80% of cases of neonatal HSV infection. In contrast, recurrent maternal infection is associated with a risk of transmission of less than 3%, and transplacental antibodies likely play a role in decreasing the risk of infection.[13] Other risk factors for development of neonatal herpes include vaginal delivery, presence of cervical HSV infection, use of invasive monitors, isolation of HSV from the genital tract, and prolonged rupture of membranes.

Neonatal herpes infections manifest in 1 of 3 forms: skin, eye, and mouth involvement; encephalitis; or disseminated disease (Fig. 164-10). The encephalitic and disseminated disease forms account for more than 50% of cases of neonatal herpes. It is important to remember that more than 20% of neonates with neurologic and disseminated disease do not develop cutaneous vesicles. Without therapy, the overall mortality of neonatal herpes is 65%, and fewer than 10% of untreated neonates with CNS infection will develop normally. With current therapeutic modalities, most babies with skin, eye, and mouth disease survive and have normal development at age 1 year. For treated babies with encephalitis, mortality is 64%, with approximately 30% developing normally within 2 years after infection. Suppressive oral acyclovir for 6 months in neonates who survive CNS disease results in improved neurologic outcomes.[14] For treated babies with disseminated disease, mortality is 30%, with approximately 80% of the survivors apparently developing normally within 2 years after infection.[12]

Figure 164-10 Neonatal herpes simplex virus Type-2.

NONCUTANEOUS FINDINGS

OCULAR INFECTIONS

HSV is a leading cause of recurrent keratoconjunctivitis and its associated corneal opacification and visual loss. It is usually caused by HSV-1, except in neonates in whom HSV-2 is more prevalent. The majority of HSV eye disease is caused by reactivation of the virus in the trigeminal ganglia, but primary infections of the eye can also occur. Usually, the initial manifestation of herpetic eye disease is a superficial infection of the eyelids and conjunctiva (blepharoconjunctivitis), or corneal surface (dendritic or geographic epithelial ulcer with pain and blurred vision). Deeper involvement of the cornea (stromal keratitis) or anterior uvea (iritis) represents more serious forms of the disease and can cause permanent visual loss. Acute retinal necrosis is a rare but rapidly progressive disease characterized by retinal arteriolar sheathing, uveitis, and peripheral retinal opacification with variable pain and visual loss. Retinal detachment is common and it is usually associated with HSV-1 infection.

NEUROLOGIC DISORDERS

All HSV infections involve the nervous system, as neurons are the sole proven site of virus latency. HSV meningitis is manifested by headache, fever, stiff neck, and mild photophobia with lymphocytic pleocytosis in the cerebrospinal fluid. Most cases result from HSV-2 infection, which resolve spontaneously in 2 to 7 days. HSV infection may involve the sacral nerves with autonomic nervous system dysfunction, numbness, pelvic pain, tingling, urinary retention, constipation, and cerebrospinal fluid pleocytosis. Symptoms usually resolve in a few days, but in some cases, the neurologic residua take weeks to months to disappear, occasionally becoming permanent. Reactivation of HSV or varicella-zoster virus is associated with Bell's

palsy with acute, peripheral facial paresis caused by compression of the facial nerve in the temporal bone. HSV encephalitis is the most commonly identified acute, sporadic viral encephalitis in the United States, accounting for 10% to 20% of all cases. Nearly all of the cases arising after the neonatal period are caused by HSV-1. HSV encephalitis usually presents with acute focal neurologic symptoms, fever, and involvement of the temporal lobe. PCR of the cerebrospinal fluid for HSV DNA is the most common diagnostic technique.

COMPLICATIONS

All manifestations of HSV infection seen in the immunocompetent host also can be seen in immunocompromised patients, but they are usually more severe, more extensive, and more difficult to treat; for many of them, recurrences are more frequent. Patients with defects in T-cell immunity, such as those with AIDS or transplantation recipients, are at particular risk for progressive mucocutaneous or visceral infections, but the degree of dissemination depends on the level of immunodeficiency of the host. Recurrent and persistent ulcerative HSV lesions are among the most common and defining opportunistic infections in patients with AIDS.[15] Genital herpes is very common in patients with HIV and can be persistent and severe. Oropharyngeal HSV in immunocompromised patients can present with widespread involvement of skin (Fig. 164-11), the mucosa, and extremely painful, friable, hemorrhagic, and necrotic lesions, similar to mucositis caused by cytotoxic agents. The lesions can spread locally to involve the esophagus. Esophagitis presents with odynophagia, dysphagia, substernal pain, and multiple ulcerative lesions. Esophagitis can also arise directly by reactivation of HSV and its spread to the esophagus via the vagus nerve. Tracheobronchitis and pneumonitis can also occur by spreading of the virus from oropharyngeal HSV.

Figure 164-11 Herpes simplex virus infection. Chronic ulcer in an immunocompromised host. Multiple, slowly spreading, deep ulcers with central necrosis and hemorrhagic crusts on the lips, cheeks, and nose of a woman with leukemia.

HSV can reactivate from visceral ganglia of the autonomic nervous system or disseminate hematogenously to other visceral organs (causing pneumonitis, hepatitis, pancreatitis, or meningitis) and the GI tract. Most of these severe infections are caused by HSV-1, but HSV-2 can cause them as well.

ETIOLOGY AND PATHOGENESIS

RISK FACTORS

The risk of severe HSV disease and the recurrence rate correlate with the level of cellular immune competence of the host. Patients with mild decreases in cellular immunity may experience only an increased number of recurrences and a slower resolution of lesions, while severely compromised patients are more likely to develop disseminated, chronic, or drug-resistant infections. CD8+ and CD4+ T-lymphocyte subsets, natural killer cells, and inflammatory cytokines like interferon-γ are important in mediating protection against HSV. Innate immunity is also important and polymorphisms in TLR2 are associated with increased rates of genital lesions in seropositive persons.[16] Mutations in proteins important for interferon responses, including STAT1, TYK2, and UNC-93B, are associated with herpes simplex encephalitis.[17] Constant immune surveillance and engagement are required to maintain latency, mainly by HSV-specific CD8+ lymphocytes. T-cells reactive to HSV-1 are clustered around latently infected neurons in ganglia from HSV-1 seropositive persons. Dendritic cells and HSV-2–specific CD8+ lymphocytes localize to sites of reactivation, rapidly contain virus-infected cells,[18] and persist in the skin for weeks after lesions are cleared.[19] These virus-specific CD8 cells are oligoclonal CD8αα+ cells that persist in the dermal–epidermal junction, and produce cytotoxic granules.[20]

Patients with defects in humoral immunity have no increase in HSV disease severity, but the humoral immune response is important in reducing virus titers at the site of inoculation and in regional neural tissues during primary infection. The transfer of HSV-specific antibodies from mother to child is a key factor in protecting against neonatal herpes.

DIAGNOSIS

LABORATORY TESTING

The method of choice for diagnosis of HSV infection depends on the clinical presentation. In many instances,

the history and clinical findings may be sufficient, but the social, emotional, and therapeutic implications of a diagnosis dictate that it be confirmed by laboratory testing when possible. For patients with active lesions, virus can be isolated in cell culture. In culture, HSV causes typical cytopathic effects, and most specimens will prove positive within 48 to 96 hours after inoculation. The sensitivity of culture depends on the quantity of virus in the specimen. Even in the most experienced centers, only approximately 60% to 70% of fresh genital lesions are culture positive. Isolation of virus is most successful when lesions are cultured during the vesicular stage and when specimens are taken from immunocompromised patients or from patients suffering from a primary infection.

PCR is more sensitive than viral isolation and has become the preferred method for diagnosis. PCR has been extensively used for the diagnosis of CNS infections and neonatal herpes. It is also useful for the detection of HSV in late-stage ulcerative lesions. Both viral culture and PCR assays enable typing of the isolate as HSV-1 or HSV-2. This information helps to predict the frequency of reactivation after a first episode of HSV infection.

Serologic detection of IgG antibodies to HSV can be helpful in certain settings, but the results are often misinterpreted. The main function of serologic testing is to differentiate a primary episode from a recurrent infection (Table 164-1). A positive serologic test result can be useful in patients with recurrent, genital lesions that are not present at the time of examination, thereby making a positive culture unobtainable. Serologic testing also can be helpful for counseling patients with initial episodes of disease and their partners, especially during pregnancy, and in counseling partners of patients with genital herpes about their risk of acquiring HSV.

Type-specific serologic assays are based on antigenic differences between HSV-1 and HSV-2 glycoprotein G. These tests are often used to counsel patients about the meaning of the test results in terms of the natural history of the disease, disease transmission, and the emotional and social implications of the diagnosis.

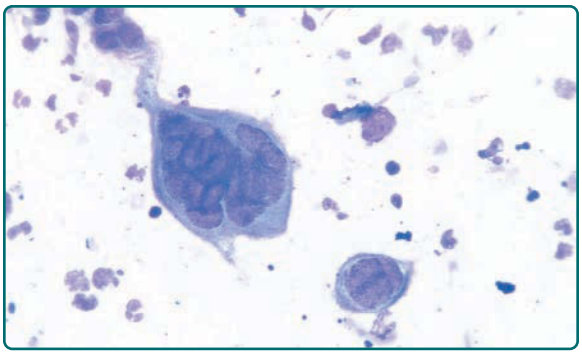

Figure 164-12 Herpes simplex virus: Positive Giemsa smear for Tzanck cells. A giant, multinucleated keratinocyte on a Giemsa-stained smear obtained from a vesicle base. Compare size of the giant cell to that of neutrophils also seen in this smear.

PATHOLOGY

Direct fluorescent antibody staining of lesion scrapings also can be used, but its sensitivity is lower than that of viral culture. The Tzanck test is helpful in rapid diagnosis of herpesvirus infections, but it is less sensitive than culture and staining with fluorescent antibody, with positive results in fewer than 40% of culture-proven cases. It is performed by scraping the base of a freshly-ruptured vesicle and staining the slides with Giemsa or Wright stain (the Papanicolaou staining method also can be used), followed by examination for multinucleated giant cells that are diagnostic of herpetic infection (Fig. 164-12). Both HSV and varicella-zoster virus will cause these changes. In skin biopsy specimens, epithelial cells are enlarged, swollen, and often separated. Multinucleated cells with intranuclear eosinophilic inclusion bodies can be seen.

DIFFERENTIAL DIAGNOSIS

The differential diagnosis of orolabial herpes includes aphthous ulcers, syphilis, and herpangina. Diseases that can mimic genital herpes include

TABLE 164-1
Classification of Herpes Simplex Infections According to Viral Isolation and Paired Serologic Test Results

		SEROLOGY (ACUTE)		SEROLOGY (CONVALESCENT)	
CLASSIFICATION	VIRUS ISOLATED	HSV-1 IgG	HSV-2 IgG	HSV-1 IgG	HSV-2 IgG
Primary HSV-1	HSV-1	–	–	+	–
Primary HSV-2	HSV-2	–	–	–	+
Primary HSV-1 plus previous HSV-2 infection (rare)	HSV-1	–	+	+	+
Primary HSV-2 plus previous HSV-1 infection	HSV-2	+	–	+	+
Recurrent HSV-1	HSV-1	+	– or +	+	– or +
Recurrent HSV-2	HSV-2	– or +	+	– or +	+

–, Negative; +, positive; HSV, herpes simplex virus.

TABLE 164-2
Differential Diagnosis of Orolabial and Genital Herpes

	DISEASE OR CONDITION	DIFFERENCES FROM HERPES
Orolabial	Aphthous ulcers	Not preceded by vesicles, located only on mucosa
	Syphilis	Painless, not preceded by vesicles
	Herpangina	Posterior portion of mouth (soft palate, tonsils)
	Erythema multiforme	Partial involvement of oral mucosa with targetoid plaques with vesicular or erosive centers; lesions may be confluent
	Stevens-Johnson syndrome	Diffuse erosive mucositis plus generalized skin lesions
Genital	Chancroid	Deep ulceration with exudate
	Syphilis	Painless, not preceded by vesicles
	Lymphogranuloma venereum	Painless ulcer, unimpressive primary lesions
	Granuloma inguinale	Painless ulcer, exuberant lesions

chancroid, syphilis, and lymphogranuloma venereum (Table 164-2).

CLINICAL COURSE AND PROGNOSIS

Although most patients with HSV infections are asymptomatic, primary infections can be severe. Most recurrences are asymptomatic, but symptomatic recurrences are milder than symptomatic primary infections. The frequency and severity of recurrent HSV-1 and HSV-2 disease decrease over time; therefore, the need for continued suppressive therapy should be reevaluated.

MANAGEMENT

INTERVENTIONS

COUNSELING

All sexually-active persons should be educated regarding the nature and risks of acquiring and transmitting sexually-transmitted infections, including HSV. Studies show that approximately one-half of patients with asymptomatic HSV-2 infection have mild, unrecognized disease and can be taught to recognize the symptoms and signs of genital herpes. Also, patients should be counseled regarding safer sex practices. It must be emphasized that the majority of transmission occurs in asymptomatic phases and from people who have no classical lesions. Patients with genital herpes should be counseled to refrain from sexual intercourse during outbreaks and for 1 to 2 days after, and to use condoms between outbreaks. Suppressive antiviral therapy is also an option for individuals concerned about transmission to a partner.

Pregnant women who are known to have genital herpes should be reassured that the risk of transmitting herpes to the baby during childbirth is extremely low. Recommendations for the management of pregnant women with recurrent genital herpes include clinical evaluation at delivery, with delivery by cesarean section indicated if there are signs and symptoms of active infection (including prodrome). But cesarean section delivery may not reliably prevent neonatal HSV infection when membranes are ruptured for long periods (≥24 hours). Women with primary HSV infection during pregnancy should be treated with antiviral therapy. For women at or beyond 36 weeks of gestation who are at risk for recurrent HSV infection, suppressive antiviral therapy has been recommended, as this decreases viral shedding, the incidence of active lesions near term, and the need for cesarean delivery because of HSV.[21] Close followup; sequential PCR or cultures for HSV of infants born to seropositive mothers who are shedding virus at the time of delivery; prophylactic therapy with intravenous acyclovir for infants born to mothers with primary infection; and intravenous acyclovir, if HSV is detected in infants of seropositive mothers, all have been suggested.[12]

Women who are known by history and serologic tests not to have genital herpes should be counseled about signs and symptoms of HSV and how to avoid acquiring the infection during pregnancy. Serology is helpful in counseling a couple in which the male partner has recurrent genital herpes and the pregnant wife is susceptible.

MEDICATIONS (SEE CHAP. 191)

Many HSV infections require no specific treatment. Keeping lesions clean and dry while they heal by themselves may be all that is required. Treatment is warranted for infections that are likely to prove protracted, highly symptomatic, or complicated. Acyclovir has a highly favorable therapeutic index because of its preferential activation in infected cells and preferential inhibition of the viral DNA polymerase. It must be phosphorylated to be active, and it requires the viral thymidine kinase for phosphorylation. Acyclovir inhibits HSV-1 and HSV-2 replication by 50% at a concentration of 0.1 and 0.3 μg/mL (range: 0.01 to 9.9 μg/mL), respectively, but is toxic at concentrations of greater than 30 μg/mL. Any strain that requires more than 3 μg/mL of acyclovir to be inhibited is said to be relatively drug resistant.

Valacyclovir, the L-valyl ester of acyclovir, is an oral prodrug of acyclovir that achieves 3- to 5-fold higher bioavailability after oral administration, and can be used in a more convenient dosage regimen. Famciclovir is the well absorbed oral form of penciclovir. Similar to acyclovir, famciclovir is converted by phosphorylation to its active metabolite penciclovir triphosphate. The efficacy and adverse effect profile of famciclovir is comparable to that of acyclovir. Penciclovir 1% cream is approved by the U.S. Food

TABLE 164-3
Recommended Regimens for the Treatment of Orofacial Herpes Simplex Infections

	ACCEPTABLE REGIMEN ALTERNATIVES			
DISEASE	**ADULTS**	**PEDIATRIC[a]**	**DURATION**	**COMMENTS**
Primary infection	Acyclovir, 200 mg orally 5 times a day Acyclovir, 400 mg orally 3 times a day Valacyclovir, 1 g orally twice a day Famciclovir, 250 mg orally 3 times a day	Acyclovir 15 mg/kg orally 5 times a day	7-10 days or until resolution of symptoms	IV acyclovir for severely ill individuals No studies have been done in adults; regimens are extrapolated from their effectiveness in primary genital herpes
Recurrent infection: episodic treatment	Topical penciclovir, 1% cream q2h while awake Topical docosanol, 10% cream 5 times a day Acyclovir, 400 mg orally 5 times a day Famciclovir, 500 mg orally 2 or 3 times a day Valacyclovir, 2 g orally twice a day for 1 day Famciclovir, 1500 mg single dose or 750 mg twice a day for 1 day		4-5 days or until lesions are healed	Treatment is generally not warranted
Recurrent infection: prophylaxis	Acyclovir, 400 mg orally twice a day			Start just before and during precipitating event, such as intensive ultraviolet light exposure
Recurrent infection: suppression of confirmed frequent recurrences	Acyclovir, 400 mg orally twice a day Valacyclovir, 500 mg once a day Valacyclovir, 1 g once a day	There are no pediatric studies, but children with confirmed frequent recurrences may benefit from suppressive oral acyclovir therapy		

[a]Oral dosage of acyclovir in children should not exceed 80 mg/kg/day. Children who weigh 40 kg or more should receive the adult dose.
Note: The doses are for patients with normal renal function. Neither valacyclovir nor famciclovir is approved by the U.S. Food and Drug Administration for use in children.

and Drug Administration (FDA) for the treatment of herpes simplex labialis. Docosanol 10% cream is approved by the FDA for nonprescription treatment of recurrent herpes labialis. Docosanol is a long-chain saturated alcohol that inhibits entry of lipid-enveloped virus into the cell. It decreases healing time by 18 hours when compared with placebo.

The current recommendations for antiviral treatment depend on the clinical disease, on host immune status, and whether one is treating a primary or recurrent episode or considering suppressive therapy (Tables 164-3 to 164-5).[22] For disseminated or severe herpes infections, the treatment of choice remains intravenous acyclovir 10 to 15 mg/kg every 8 hours. The dose of intravenous acyclovir for neonatal herpes is 20 mg/kg per dose given every 8 hours.

For first episodes of genital HSV-2 infections, oral acyclovir, famciclovir, or valacyclovir all speed healing and resolution of symptoms, and decrease viral shedding. When compared with placebo, acyclovir decreases time to healing from 16 to 12 days, the duration of pain from 7 to 5 days, and the duration of constitutional symptoms from 6 to 3 days. Valacyclovir was compared with acyclovir in the treatment of primary episodes and shown to be equivalent. Antiviral treatment of initial herpes episodes does not decrease subsequent recurrences, probably because HSV establishes latent infection within hours after infection and days before symptoms evolve.

Treatment of recurrent episodes of genital herpes with famciclovir, acyclovir, or valacyclovir reduces the time of healing from approximately 7 to 5 days, time of cessation of viral shedding from 4 to 2 days, and duration of symptoms from 4 to 3 days when compared with placebo. Valacyclovir and acyclovir are equivalent; valacyclovir was similar to famciclovir in one study, but slightly superior to famciclovir to suppress genital herpes in another study. For persons with frequent or complicated genital recurrences, long-term suppressive therapy with acyclovir or its analogs is the most effective management strategy. Suppressive therapy was effective during the first year after acquisition of genital herpes. Suppressive therapy reduces the rate of shedding in healthy persons and those with HIV. Suppressive therapy with valacyclovir was more effective to reduce the burden of genital herpes disease than episodic therapy. Because genital herpes is not progressive in the normal host and because the

TABLE 164-4
Recommended Regimens for the Treatment of Genital Herpes Simplex Infections

DISEASE	ACCEPTABLE REGIMEN ALTERNATIVES: ADULTS	ACCEPTABLE REGIMEN ALTERNATIVES: PEDIATRIC[a]	DURATION	COMMENTS
Primary infection	Acyclovir, 200 mg orally 5 times a day Acyclovir, 400 mg orally 3 times a day Valacyclovir, 1 g orally twice a day Famciclovir, 250 mg orally 3 times a day	Acyclovir, 40-80 mg/kg/day orally divided in 3 to 4 doses (maximum 1 g/day)	7–10 days or until clinical resolution occurs.	
Recurrent infection	Acyclovir, 400 mg orally 3 times a day Acyclovir, 200 mg orally 5 times a day Acyclovir, 800 mg orally twice a day Valacyclovir, 500 mg orally twice a day Valacyclovir, 1 g orally once a day Valacyclovir, 1 g orally twice a day[b] Famciclovir, 500 mg,[b] 250 mg, 125 mg orally twice a day Famciclovir, 1 g orally twice a day for 1 day (patient initiated) Famciclovir, 500 mg, then 250 mg twice daily for 2 days	For children ≥12 years of age: Acyclovir, 200 mg orally 5 times a day for 5 days Acyclovir, 800 mg orally twice a day for 5 days Acyclovir, 800 mg 3 times a day for 2 days		
Suppression of recurrences	Acyclovir, 400 mg orally twice a day Acyclovir, 800 mg orally once a day Valacyclovir, 500 mg, 1000 mg orally once a day[c] Valacyclovir, 250 mg orally twice a day[c] Valacyclovir, 500 mg twice a day or 1000 mg orally once a day[b] Famciclovir, 250 mg orally twice a day Famciclovir, 125 mg, 250 mg orally 3 times a day	For children ≥12 years of age: Acyclovir, 400 mg orally twice a day		Duration of the therapy is controversial; some authorities will offer treatment for 1 year and then reassess the need to resume it
Reduction of transmission	Valacyclovir, 500 mg orally once a day			Safer sex practices should continue to be used

[a]Oral dosage of acyclovir in children should not exceed 80 mg/kg/day. Children who weigh 40 kg or more should receive the adult dose.
[b]HIV patients.
[c]The high once-a-day and twice-daily doses of valacyclovir are more effective in patients who present with more than 10 recurrences per year.
Note: The doses are for patients with normal renal function. Neither valacyclovir nor famciclovir is approved by the U.S. Food and Drug Administration for use in children.

rate of recurrences varies over time and may decrease after some years, it is wise to recommend a "holiday" from treatment every year or so to reassess the continuing need for treatment. Sunscreen has shown benefit in some, but not all trials, but there is no evidence for lysine or gammaglobulin.[23] Novel antivirals that inhibit the HSV helicase–primase complex[24,25] were effective for treatment of recurrent genital herpes in Phase II trials, but are not licensed.

The use of antiviral suppressive therapy during the late phase of pregnancy to avoid neonatal herpes also has been advocated, but a formal study of the approach would require a very large number of participants because of the rare incidence of neonatal herpes. A more achievable goal is to decrease the need for cesarean deliveries caused by herpes recurrences during labor. Studies show that antiviral therapy in late pregnancy (beginning at 36 weeks) prevents clinical recurrences, cesarean sections associated with genital herpes, and the risk of HSV-viral shedding at delivery.

Orolabial HSV infections warrant antiviral treatment less often than do genital infections. Primary HSV gingivostomatitis should be treated with oral acyclovir. The pediatric dose is 15 mg/kg of acyclovir suspension orally 5 times a day for 7 days. When it is started within 3 days of onset of the disease, this regimen decreases the duration of oral and extraoral lesions, fever, and eating and drinking difficulties. Valacyclovir and famciclovir may be equally effective, but they have not been studied in this setting and are not currently approved for use in children. Severely ill children may need to be hospitalized for hydration, and IV acyclovir may be necessary.

Treatment of recurrent herpes labialis with antiviral drugs in immunocompetent hosts has shown only modest benefits.[23] Oral infections are inherently briefer and less symptomatic than genital herpes. Treatment is only effective if used very early in the disease, especially in the prodromal or erythema lesion stages. Patients who wish treatment should have the medication available and be vigilant for the earliest signs and symptoms of a recurrence. When treatment is thought to be required, penciclovir 1% cream every 2 hours while awake, for 4 days can be used. Treatment should be initiated as early as possible. When initiated within

TABLE 164-5
Recommended Regimens for Other Herpes Cutaneous Diseases

DISEASE	ACCEPTABLE REGIMEN ALTERNATIVES: ADULTS	ACCEPTABLE REGIMEN ALTERNATIVES: PEDIATRIC[a]	DURATION	COMMENTS
Neonatal herpes		IV acyclovir, 20 mg/kg every 8 h	14-21 days	For infants with CNS disease, 6 months of acyclovir suppression is effective (see text)
Disseminated infection	IV acyclovir, 10-15 mg/kg 3 times a day	IV acyclovir, 10 mg/kg 3 times a day	14-21 days	
Herpes gladiatorum, herpetic whitlow	Acyclovir, 200 mg orally 5 times per day Acyclovir, 400 mg orally 3 times a day Valacyclovir, 1 g orally twice a day Famciclovir, 250 mg orally 3 times a day	Acyclovir, 40-80 mg/kg/day orally divided into 3 to 4 doses (maximum: 1 g/day)	7-10 days or until resolution of symptoms	No studies have been done; regimens are extrapolated from the treatment of genital herpes. Consider suppressive antiviral therapy for patients with frequent recurrences
Eczema herpeticum	Acyclovir, 200 mg orally 5 times a day Acyclovir, 400 mg orally 3 times a day Valacyclovir, 1 g orally twice a day IV acyclovir, 10-15 mg/kg 3 times a day	Acyclovir, 40-80 mg/kg/day orally divided into 3 to 4 doses (maximum: 1 g/day); IV acyclovir 10-15 mg/kg 3 times daily	14-21 days	No studies have been done. Use IV acyclovir in severely ill individuals. Consider suppressive antiviral therapy for patients with recurrences. Ocular involvement should be treated in consultation with an ophthalmologist

[a]Oral dosage of acyclovir in children should not exceed 80 mg/kg/day. Children who weigh 40 kg or more should receive the adult dose.
Note: The doses are for patients with normal renal function. Neither valacyclovir nor famciclovir is approved by the U.S. Food and Drug Administration for use in children.

1 hour of first symptoms of recurrence, penciclovir sped the healing of lesions (4.8 days vs 5.5 days) and decreased the duration of pain (3.5 days vs 4.1 days). This regimen is approved by the FDA. Docosanol 10% cream is approved by the FDA for nonprescription treatment of herpes simplex labialis. It is applied 5 times a day at the first sign of recurrence of herpes simplex labialis. There has been no direct comparison with topical penciclovir. Oral acyclovir, 400 mg 5 times a day for 5 days, affords marginal benefit if begun in the earliest hour or two of the outbreak. Famciclovir, 500 mg 3 times a day for 5 days, when started within 48 hours after experimental ultraviolet radiation, decreased the median time to healing from 6 to 4 days, but is not useful for the more usual sporadic cases of herpes labialis. Valacyclovir (2 g twice daily for 1 day) decreased the mean duration of cold sore episodes by 1 day when compared with placebo, if started in the prodrome period. Similarly, a single dose of famciclovir (1500 mg) reduced time to healing of herpes labialis lesions by approximately 2 days compared with placebo. Creams and ointments containing 5% and 10% acyclovir are not beneficial in recurrent herpes labialis.

The use of suppressive acyclovir for herpes labialis is controversial. In one small study, oral acyclovir, 400 mg twice a day, was effective in decreasing recurrences of herpes labialis. In another study, suppressive therapy with valacyclovir was more effective than episodic therapy with valacyclovir for herpes labialis. In studies with skiers (who have significant sun exposures), acyclovir 400 mg twice a day, was shown to reduce recurrences in one study, whereas acyclovir, 800 mg twice daily, failed to prevent recurrences in another study. Both perioperative famciclovir (125 or 250 mg orally twice daily given 1 to 2 days before to 5 days after the procedure) and valacyclovir (500 mg twice daily for 14 days, starting either a day before or the day of the procedure) appeared to reduce the recurrence of orofacial HSV in patients undergoing facial laser resurfacing. Valacyclovir also suppresses recurrences of herpes gladiatorum.

Herpetic eye disease should always be treated in consultation with an ophthalmologist. Options usually involve topical antivirals, including vidarabine, trifluridine, acyclovir, or ganciclovir. Topical antivirals are effective in shortening the duration of dendritic and geographic keratitis, and are used to prevent corneal epithelial disease in patients with blepharitis and conjunctivitis, as well as patients on topical steroid therapy for corneal stromal inflammation and iridocyclitis. Oral acyclovir is also effective for dendritic and geographical epithelial keratitis. Suppressive antiviral therapy reduces the rates of all types of recurrent ocular HSV disease, and it is most important for patients with a history of HSV stromal keratitis because it can prevent additional episodes and potential loss of vision.

Antiviral Resistance: Virtually all clinically relevant drug resistance has been seen in immunocompromised patients. The primary mechanism of acyclovir resistance is selection of viral mutants defective or deficient in thymidine kinase expression. Most mutants that are thymidine kinase deficient are somewhat attenuated for virulence in vivo.

The treatment of resistant HSV infection is complicated. Very few people who claim to be "resistant"

to one of the antiviral drugs actually harbor resistant virus. There is a common misconception that treatment prevents all recurrences. One should suspect resistance only in people who continue to have culture-proven or PCR-proven outbreaks of unaltered frequency and severity, especially if the lesions do not heal by themselves. When resistance is suspected, virus should be cultured and tested for sensitivity to acyclovir. These tests are expensive but are available through commercial reference laboratories. Foscarnet does not require activation by HSV thymidine kinase and is usually effective in the treatment of acyclovir-resistant HSV. The drug requires IV therapy and can cause numerous adverse reactions, including nephrotoxicity, electrolyte disturbances, anemia, and seizures. Rare foscarnet-resistant HSV strains have been reported.

Cidofovir also does not require activation by HSV thymidine kinase. Cidofovir has been used in cases of acyclovir-resistant HSV and topical cidofovir has been used with success to treat progressive herpetic lesions. Intravenous cidofovir is associated with considerable nephrotoxicity and requires the coadministration of saline hydration and probenecid. A few patients with acyclovir-resistant genital herpes have responded to imiquimod 5% cream. Imiquimod causes severe inflammation in some patients with recurrent herpes labialis. Resiquimod reduced the rate of new lesions in 1 study of persons without drug-resistant virus, but had no effect on genital herpes in 4 other studies. Continuous intravenous acyclovir also has been used to treat acyclovir-resistant HSV. Long-term suppressive acyclovir therapy reduced the rate of drug-resistant HSV disease in hematopoietic stem cell transplant recipients.

PREVENTION

Strategies to prevent HSV infection have proved inadequate. HSV infection can be prevented by total abstinence, as indicated by very low seroprevalence rates in cloistered nuns. Condoms reduce rates of transmission if used routinely. Male circumcision reduced the rate of HSV-2 infection in one study, but not in another study. Other than these public health approaches, most efforts involve antiviral therapy and vaccines directed at genital herpes.

Antiviral Therapy: Acyclovir, famciclovir, and valacyclovir all decrease both symptomatic and subclinical shedding of HSV-2, from approximately 8% of the days in the placebo group to 0.3% to 0.6% of the days in the treatment group, when assessed by culture. Once-daily valacyclovir reduced shedding by PCR from 14% to 3% in patients with newly diagnosed genital herpes. Valacyclovir 500 mg once daily was effective in reducing the transmission of HSV-2 between partners by 48%, and reduced clinical disease in the susceptible partner by 7% in a randomized, placebo-controlled trial involving immunocompetent, heterosexual couples in stable relationships.[6] This therapy can be recommended for individuals concerned about transmission to a partner, in conjunction with the use of condoms. Frequency of HSV-2 shedding was reduced with high-dose acyclovir (800 mg 3 times daily) or high-dose valacyclovir (1 g 3 times daily) compared with standard dose valacyclovir (500 mg daily); however, the high-dose therapies did not reduce recurrence rates compared with standard dose valacyclovir.[26] Tenofovir gel applied vaginally within 12 hours before and 12 hours after coitus reduced the incidence of HSV-2 by approximately 50%.[27] Oral tenofovir and emtricitabine-tenofovir had a modest effect on reducing acquisition of HSV-2.[28] Vaginal microbicides are also being studied, mostly focusing on decreasing HIV transmission, but some of the compounds also have anti-HSV activity and may also affect HSV transmission.

Vaccines: No vaccine is licensed to protect against acquisition of HSV (prophylactic) or to reduce the number of recurrent episodes (therapeutic).[29] A recombinant HSV-2 glycoprotein D vaccine was ineffective at preventing genital herpes disease, infection, or HSV shedding.[30] Several candidate vaccines are under development to prevent recurrent genital HSV.[31] A replication-defective mutant, deleted for 2 essential viral proteins, is currently in a clinical trial. Initial results with a subunit vaccine containing HSV-2 gD2 and ICP4 protein showed a 50% reduction in HSV-2 genital shedding after vaccination. A Phase II study of a vaccine consisting of HSV-2 peptides linked to heat shock protein with an adjuvant, showed a 15% reduction in HSV-2 genital shedding.

ACKNOWLEDGMENTS

The author recognizes the contribution of Adriana Marques, who was a coauthor of this chapter in the previous edition. Much of the text is based on the chapter from the prior edition.

REFERENCES

1. Bernstein DI, Bellamy AR, Hook EW 3rd, et al. Epidemiology, clinical presentation, and antibody response to primary infection with herpes simplex virus type 1 and type 2 in young women. *Clin Infect Dis*. 2013;56:344-351.
2. Bradley H, Markowitz LE, Gibson T, et al. Seroprevalence of herpes simplex virus types 1 and 2—United States, 1999-2010. *J Infect Dis*. 2014;209:325-333.
3. Johnston C, Corey L. Current concepts for genital herpes simplex virus infection: diagnostics and pathogenesis of genital tract shedding. *Clin Microbiol Rev*. 2016;29:149-161.
4. Tronstein E, Johnston C, Huang ML, et al. Genital shedding of herpes simplex virus among symptomatic and asymptomatic persons with HSV-2 infection. *JAMA*. 2011;305:1441-1449.
5. Mark KE, Wald A, Magaret AS, et al. Rapidly cleared episodes of herpes simplex virus reactivation in immunocompetent adults. *J Infect Dis*. 2008;198:1141-1149.
6. Corey L, Wald A, Patel R, et al. Once-daily valacyclovir to reduce the risk of transmission of genital herpes. *N Engl J Med*. 2004;350:11-20.

7. Langenberg AG, Corey L, Ashley RL, et al. A prospective study of new infections with herpes simplex virus type 1 and type 2. Chiron HSV Vaccine Study Group. *N Engl J Med*. 1999;341:1432-1438.
8. Mujugira A, Magaret AS, Celum C, et al; Partners in Prevention HSV/HIV Transmission Study Team. Daily acyclovir to decrease herpes simplex virus type 2 (HSV-2) transmission from HSV-2/HIV-1 coinfected persons: a randomized controlled trial. *J Infect Dis*. 2013;208:1366-1374.
9. Horowitz R, Aierstuck S, Williams EA, et al. Herpes simplex virus infection in a university health population: clinical manifestations, epidemiology, and implications. *J Am Coll Health*. 2010;59:69-74.
10. Gupta R, Warren T, Wald A. Genital herpes. *Lancet*. 2007;370:2127-2137.
11. Hata TR, Kotol P, Boguniewicz M, et al. History of eczema herpeticum is associated with the inability to induce human β-defensin (HBD)-2, HBD-3 and cathelicidin in the skin of patients with atopic dermatitis. *Br J Dermatol*. 2010;163:659-661.
12. Corey L, Wald A. Maternal and neonatal herpes simplex virus infections. *N Engl J Med*. 2009;361:1376-1385.
13. James SH, Kimberlin DW. Neonatal herpes simplex virus infection: epidemiology and treatment. *Clin Perinatol*. 2015;42:47-59.
14. Kimberlin DW, Whitley RJ, Wan W, et al. Oral acyclovir suppression and neurodevelopment after neonatal herpes. *N Engl J Med*. 2011;365:1284-1292.
15. Wauters O, Lebas E, Nikkels AF. Chronic mucocutaneous herpes simplex virus and varicella zoster virus infections. *J Am Acad Dermatol*. 2012;66:e217-e227.
16. Bochud PY, Magaret AS, Koelle DM, et al. Polymorphisms in TLR2 are associated with increased viral shedding and lesional rate in patients with genital herpes simplex virus type 2 infection. *J Infect Dis*. 2007;196:505-509.
17. Sancho-Shimizu V, Perez de Diego R, Jouanguy E, et al. Inborn errors of anti-viral interferon immunity in humans. *Curr Opin Virol*. 2011;1:487-496.
18. Schiffer JT, Corey L. Rapid host immune response and viral dynamics in herpes simplex virus-2 infection. *Nat Med*. 2013;19:280-290.
19. Zhu J, Koelle DM, Cao J, et al. Virus-specific CD8+ T cells accumulate near sensory nerve endings in genital skin during subclinical HSV-2 reactivation. *J Exp Med*. 2007;204:595-603.
20. Zhu J, Peng T, Johnston C, et al. Immune surveillance by CD8αα+ skin-resident T cells in human herpes virus infection. *Nature*. 2013;497:494-497.
21. Money D, Steben M; Society of Obstetricians and Gynaecologists of Canada. SOGC clinical practice guidelines: guidelines for the management of herpes simplex virus in pregnancy. Number 208, June 2008. *Int J Gynaecol Obstet*. 2009;104:167-171.
22. Cernik C, Gallina K, Brodell RT. The treatment of herpes simplex infections: an evidence-based review. *Arch Intern Med*. 2008;168:1137-1144.
23. Chi CC, Wang SH, Delamere FM, et al. Interventions for prevention of herpes simplex labialis (cold sores on the lips). *Cochrane Database Syst Rev*. 2015;8:CD010095.
24. Tyring S, Wald A, Zadeikis N, et al. ASP2151 for the treatment of genital herpes: a randomized, double-blind, placebo- and valacyclovir-controlled, dose-finding study. *J Infect Dis*. 2012;205:1100-1110.
25. Wald A, Corey L, Timmler B, et al. Helicase-primase inhibitor pritelivir for HSV-2 infection. *N Engl J Med*. 2014;370:201-210.
26. Johnston C, Saracino M, Kuntz S, et al. Standard-dose and high-dose daily antiviral therapy for short episodes of genital HSV-2 reactivation: three randomised, open-label, cross-over trials. *Lancet*. 2012;379:641-647.
27. Abdool Karim SS, Abdool Karim Q, Kharsany AB, et al; CAPRISA 004 Trial Group. Tenofovir gel for the prevention of herpes simplex virus type 2 infection. *N Engl J Med*. 2015;373:530-539.
28. Celum C, Morrow RA, Donnell D, et al. Daily oral tenofovir and emtricitabine-tenofovir preexposure prophylaxis reduces herpes simplex virus type 2 acquisition among heterosexual HIV-1-uninfected men and women: a subgroup analysis of a randomized trial. *Ann Intern Med*. 2014;161:11-19.
29. Dropulic LK, Cohen JI. The challenge of developing a herpes simplex virus 2 vaccine. *Expert Rev Vaccines*. 2012;11:1429-1440.
30. Belshe RB, Leone PA, Bernstein DI, et al; Herpevac Trial for Women. Efficacy results of a trial of a herpes simplex vaccine. *N Engl J Med*. 2012;366:34-43.
31. Johnston C, Gottlieb SL, Wald A. Status of vaccine research and development of vaccines for herpes simplex virus. *Vaccine*. 2016;34:2948-2952.

Chapter 165 :: Varicella and Herpes Zoster

:: Myron J. Levin, Kenneth E. Schmader, & Michael N. Oxman

AT A GLANCE

VARICELLA

- Varicella (chickenpox) and herpes zoster (shingles) are distinct clinical entities caused by a single member of the herpesvirus family, varicella-zoster virus (VZV).
- Varicella, a highly contagious exanthem that occurs most often in childhood, is the result of primary VZV infection of a susceptible individual.
- The rash of varicella usually begins on the face and scalp and spreads rapidly to the trunk, with relative sparing of the extremities. Lesions are scattered, rather than clustered, reflecting viremic spread to the skin, and they progress sequentially from rose-colored macules to papules, vesicles, pustules, and crusts. Lesions in all stages are usually present at the same time.
- In immunocompetent children, systemic symptoms are usually mild and serious complications are rare. In adults and immunocompromised persons of any age, varicella is more likely to be severe and can be associated with life-threatening complications.
- Varicella results in lifelong latent VZV infection of sensory and autonomic neurons, and host immunity to VZV.
- Live attenuated Oka VZV varicella vaccines have virtually eliminated varicella in countries where they have been deployed.

HERPES ZOSTER

- Herpes zoster is characterized by unilateral dermatomal pain and rash that results from reactivation and multiplication of latent VZV that persisted within neurons following varicella.
- The erythematous maculopapular and vesicular lesions of herpes zoster are clustered within a single dermatome, because VZV reaches the skin via the sensory nerve from the single ganglion in which latent VZV reactivates, and not by viremia.
- Herpes zoster is most common in older adults and in immunocompromised individuals.
- Pain is an important manifestation of herpes zoster. The most common debilitating complication is chronic neuropathic pain that persists long after the rash resolves, a complication known as postherpetic neuralgia (PHN).
- Antiviral therapy and analgesics reduce the acute pain of herpes zoster. Lidocaine patch (5%), high-dose capsaicin patch, gabapentin, pregabalin, opioids, and tricyclic antidepressants may reduce the pain of PHN.
- A live attenuated Oka/Merck strain VZV herpes zoster vaccine (ZVL; Zostavax®) reduces the incidence of herpes zoster by one-half and the incidence of PHN by two-thirds. An adjuvanted recombinant glycoprotein E subunit herpes zoster vaccine (RZV; Shingrix®) has substantially greater efficacy for herpes zoster and PHN, but it requires 2 doses and is more reactogenic.

INTRODUCTION

Varicella (chickenpox) and herpes zoster (shingles, zoster) are distinct clinical entities caused by a single member of the herpesvirus family, varicella-zoster virus (VZV). The different clinical manifestations of these 2 diseases are the result of differences in the host immune response and in the pathogenesis of the VZV infection, and not due to differences in the etiologic agent. Varicella, a highly contagious vesicular exanthem that occurs most often in childhood, is the result of exogenous primary infection of a susceptible individual. In contrast, herpes zoster results from reactivation of endogenous virus that persists in latent form within ganglionic neurons following an earlier attack of varicella. Herpes zoster is a localized dermatomal disease characterized by unilateral radicular pain and a vesicular dermatomal eruption.

HISTORICAL PERSPECTIVE

There was a report in 1892 of 5 instances in which varicella occurred in children exposed to adults with herpes zoster, and in the ensuing half century, clinical and histologic evidence lent support to the suggestion that susceptible individuals could develop varicella after exposure to someone with herpes zoster.[1-5] This included the development of varicella by children without a prior history of varicella who were inoculated with vesicle fluid from herpes zoster. In the 1950s, viruses isolated from varicella and herpes zoster were shown to have similar properties in tissue culture, and when compared by complement fixation and immunofluorescence techniques.[6] Nucleic acid identification

methods subsequently demonstrated that the viruses isolated from a case of varicella and from a later case of herpes zoster in the same patient were identical.[7]

EPIDEMIOLOGY

EPIDEMIOLOGY OF VARICELLA

Varicella is distributed worldwide, but its age-specific incidence differs in temperate versus tropical climates, and in populations that have received varicella vaccine. In temperate climates, in the absence of varicella vaccination, varicella is endemic, with a regularly recurring seasonal prevalence in winter and spring, and periodic epidemics that reflect the accumulation of susceptible persons. In Europe and North America in the prevaccination era, 90% of cases occurred in children younger than 10 years of age and fewer than 5% in individuals older than the age of 15.[8] From 1988 to 1995, before varicella vaccine was introduced, there were approximately 11,000 hospitalizations and 100 deaths caused by varicella each year in the United States.[9,10] The risk of hospitalization and death was much higher in infants and adults than in children, and most varicella-related deaths occurred in previously healthy people. In tropical and semitropical countries, the mean age of varicella is higher, and susceptibility among adults is significantly greater, than in temperate climates. High levels of susceptibility to varicella among adult immigrants from tropical climates are well documented in the US military, for example, among recruits from Puerto Rico.[11] This geographical variation is important for hospitals, where susceptible health care workers from semitropical areas, such as the Philippines and Mexico, may pose a significant risk of nosocomial varicella.

Widespread use of varicella vaccine has markedly altered the epidemiology of varicella in the United States. Two-dose varicella vaccine coverage now exceeds 90% in young children.[12] This has resulted in a marked reduction in varicella-related morbidity. Varicella incidence and outpatient visits have declined by >85%, and hospitalizations have declined by ≥93%.[13-18] The decline is greatest among children aged 1 to 4 years who were targeted for vaccination, but cases have declined in all age groups, including unvaccinated infants and adults, reflecting herd immunity. Varicella-related mortality also declined substantially after the introduction of the varicella vaccine, and is now rare.[19] Varicella vaccine effectiveness has been demonstrated in a number of countries.[20]

Varicella is highly contagious. Attack rates of 87% among susceptible siblings in households and nearly 70% among susceptible patients on hospital wards have been reported.[21] More than 95% of cases of varicella are clinically apparent, although occasionally the exanthem may be so sparse and transient as to pass unnoticed. A typical patient is infectious for 1 to 2 days before the exanthem appears, and for 4 or 5 days thereafter, until the last crop of vesicles has crusted. Immunocompromised patients, who may experience successive crops of lesions for a week or more, are infectious longer. The mean incubation period of varicella is 14 to 17 days, with a range of 10 to 23 days, but it may be prolonged in patients who develop varicella after passive immunization with varicella-zoster immune globulin, or after postexposure immunization with varicella vaccine.[22]

The major route by which varicella is acquired and transmitted is from the respiratory tract by airborne droplets or aerosols, but infection also may be spread by direct contact. Varicella crusts are not infectious, and the duration of infectivity of droplets containing virus is probably quite limited. Although the infectiousness of patients with varicella is thought to depend largely on virus shed from the mucous membranes of the upper respiratory tract, VZV has rarely been cultured from pharyngeal secretions. However, VZV DNA can be detected in the oropharynx of most patients using polymerase chain reaction (PCR)–based assays.[23]

Varicella generally confers lifelong immunity, although subsequent exposure to VZV boosts humoral and cell-mediated immune responses, indicating subclinical reinfection.[24] Most reported second episodes of varicella represent incorrect diagnoses. Second episodes of varicella reported in immunocompromised patients usually represent cutaneous dissemination of herpes zoster.[25] Even severely immunocompromised patients very rarely develop second episodes of varicella after reexposure. Modified and breakthrough varicella now account for a significant proportion of the varicella occurring in the USA. Modified varicella occurs in individuals who develop varicella early in infancy in the presence of maternal antibody or following postexposure prophylaxis with varicella-zoster immune globulin or varicella vaccine. Breakthrough varicella occurs when vaccinated individuals are reinfected following exposure to wildtype VZV. Breakthrough varicella is frequently mild. However, both modified and breakthrough varicella are infectious for susceptible contacts.

EPIDEMIOLOGY OF HERPES ZOSTER

Herpes zoster occurs sporadically throughout the year without seasonal prevalence and independent of the prevalence of varicella. There is no convincing evidence that herpes zoster can be acquired by contact with persons with varicella or herpes zoster.[1] Rather, the incidence of herpes zoster is determined by factors that influence the host–virus relationship and the presence of immune responses necessary to prevent reactivation of latent VZV. The incidence of herpes zoster in community-dwelling populations ranges from 2 to 5 per 1000 person-years.[26,27]

A major risk factor for herpes zoster is age (Fig. 165-1A). The incidence of herpes zoster increases

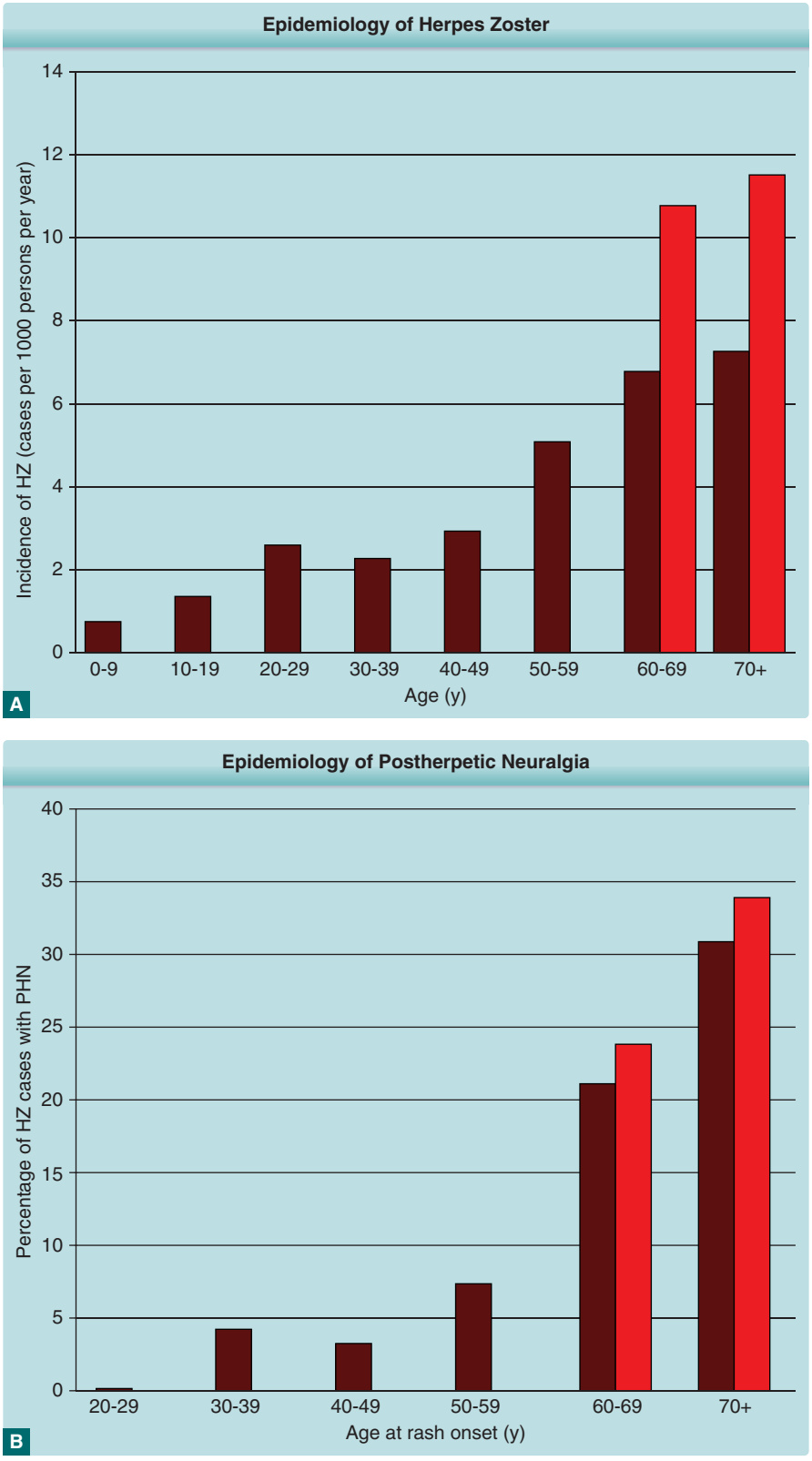

Figure 165-1 Epidemiology of Herpes Zoster (HZ) and Postherpetic Neuralgia (PHN). **A,** Incidence of herpes zoster (cases per 1000 persons per year) versus age. Dark red = data from Hope-Simpson RE. *Proc R Soc Med.* 1965;58:9.[1] Bright red = data for persons ≥60 years of age from the Shingles Prevention Study placebo recipients; Oxman MN et al. *N Engl J Med.* 1995;352:2271.[28] **B,** Percentage of cases of herpes zoster with postherpetic neuralgia. Postherpetic neuralgia is defined as clinically significant pain or discomfort due to herpes zoster persisting for ≥30 days after rash onset. Dark red = data from Hope-Simpson RE. Postherpetic neuralgia. *J R Coll Gen Pract.* 1975;25:571-575. Bright red = data for persons ≥60 years of age from the Shingles Prevention Study placebo recipients; Oxman MN et al: *N Engl J Med.* 1995;352:2271.[28]

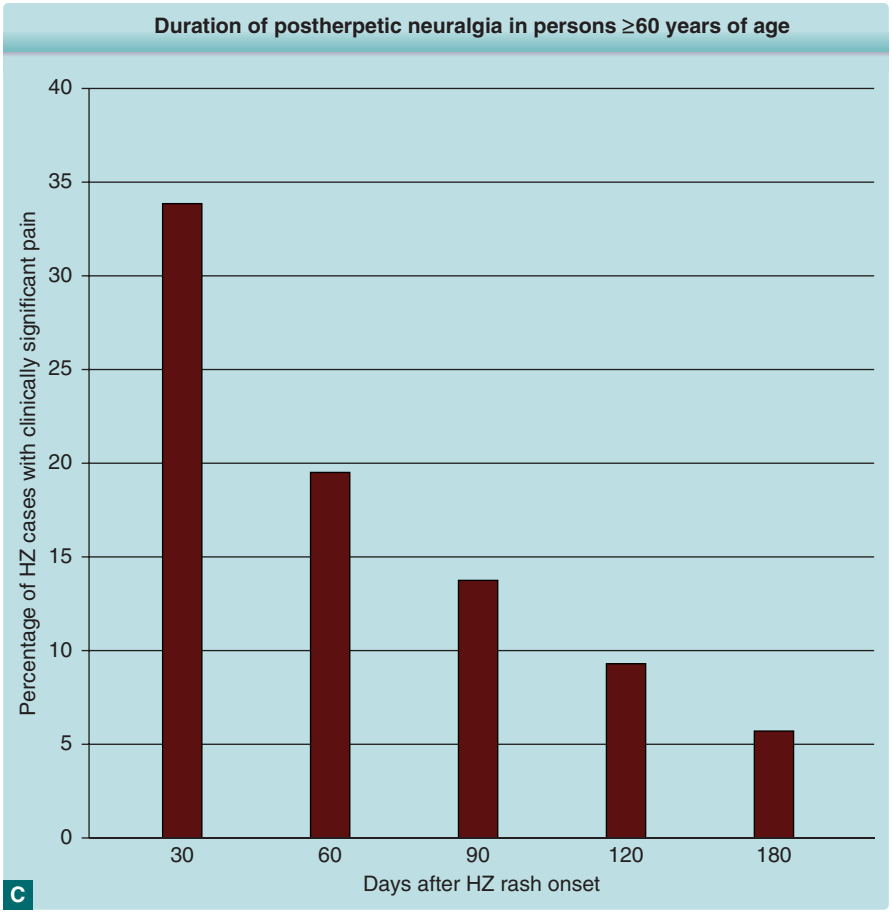

Figure 165-1 (*Continued*) **C,** Duration of postherpetic neuralgia in persons ≥60 years of age. Bright red = duration of clinically significant pain or discomfort due to herpes zoster among Shingles Prevention Study placebo recipients with confirmed herpes zoster; calculated from data in Oxman MN et al. *N Engl J Med.* 1995;352:2271.[28]

with increasing age; in older adults, it ranges from 8 to 12 per 1000 person-years in population-based and health care records–based studies on 4 continents.[1,27-34] We estimate that there are at least 1.5 million new cases of herpes zoster in the United States each year, more than half of which occur in persons ≥60 years of age; this number will increase dramatically as the population ages.[1,27-29,33,35-38]

Another major risk factor for herpes zoster is decreased VZV-specific cell-mediated immunity.[29,34,39] Immunocompromised patients have a significantly greater risk of herpes zoster (depending on their underlying condition) than immunocompetent individuals of the same age.[40-43] Ten percent of herpes zoster cases occur in immunocompromised patients.[33] Immunocompromising conditions associated with increased risk of herpes zoster include bone marrow and solid organ transplants, hematologic and solid tumor malignancies, and immune-mediated diseases (eg, systemic lupus erythematous, rheumatoid arthritis). Many cases of herpes zoster that occur in patients with immune-mediated diseases are the result of the use of chemotherapy or therapy with immune modulators or corticosteroids.[40-43] Herpes zoster is a prominent and early "opportunistic infection" in persons infected with HIV, in whom it is often the first sign of immune deficiency.[44,45] Thus, HIV infection should be considered in young individuals who develop herpes zoster.

Other factors reported to correlate with the risk of herpes zoster include female sex,[32] physical trauma in the affected dermatome,[46] IL-10 gene polymorphisms,[47] family history of herpes zoster,[48-50] and white race.[31,32,51] The likelihood of recurrent herpes zoster is reported to range from 1% to 6%.[1,27,30,32] Much of this variation is dependent on the observation interval after the first episode of herpes zoster, as well as the accuracy of the diagnosis; not all of the cases reported may have actually been herpes zoster. Among the 19,276 placebo recipients in the Shingles Prevention Study followed for a median of 3.12 years,[28] the incidence of second episodes of documented herpes zoster was less than 1/10th the incidence of documented first episodes. A large retrospective effectiveness study also indicated that the recurrence rate of herpes zoster in immunocompetent persons is low.[53] Recurrent herpes zoster is more common in patients who are immunocompromised, and they are more likely to have multidermatomal or bilateral disease.[52,54] Immunocompetent patients thought to be suffering multiple episodes of herpes zoster, especially when they occur in the same dermatome, are more likely to have recurrent zosteriform

herpes simplex.[55] Second episodes of herpes zoster in immunocompetent persons almost always involve a different dermatome than that involved in the first episode.

Patients with herpes zoster are less contagious than patients with varicella. The rate at which susceptible household contacts develop varicella after exposure to herpes zoster appears to be about one-third of the rate observed following exposure to varicella.[1,56] Virus can be isolated from vesicles and pustules in uncomplicated herpes zoster for up to 7 days after the appearance of the rash, and for much longer periods in immunocompromised individuals. Patients with uncomplicated herpes zoster appear to spread the infection by means of direct contact with their lesions, although airborne transmission also has been documented.[57,58] Patients with disseminated herpes zoster may also transmit the infection via aerosols, so that airborne precautions, as well as contact precautions, are required for such patients.

The effect on the epidemiology of herpes zoster of the marked reduction in endemic varicella, due to widespread varicella vaccination of children, is unclear. A recent study showed that the age-specific incidence of HZ has increased >4-fold over the last 6 decades.[59] However, this temporal increase began before the availability of varicella vaccine; has occurred in countries without varicella vaccination programs[60-62]; was not altered by the introduction of varicella vaccination programs[13,59,63,64]; and has occurred in states that had a relatively low inclusion of children in varicella vaccination programs. These observations indicate that the reduction in exposure of adults to exogenous VZV due to varicella vaccination does not explain the temporal increase in the incidence of herpes zoster.[13,65,66] They also suggest that reactivations of endogenous latent VZV, in which rapid mobilization of host immune responses limits replication of the reactivated virus and prevents progression to herpes zoster ("neutralized reversions"[1,67]), is the major factor slowing the age-related decline in VZV-specific cell-mediated immunity observed in immunocompetent persons.

CLINICAL FEATURES

VARICELLA

PRODROME

In young children, prodromal symptoms are uncommon. In older children and adults, the rash is often preceded by 2 to 3 days of mild fever, chills, malaise, headache, anorexia, backache and, in some patients, sore throat and dry cough.

RASH

In unvaccinated persons, the rash usually begins on the face and scalp and spreads rapidly to the trunk, with relative sparing of the extremities.[1,68,69] New lesions appear in successive crops, and are mainly distributed centrally (Fig. 165-2A,B). The rash tends to be denser on the back between the shoulder blades than on the scapulae and buttocks, and more profuse on the medial than on the lateral aspects of the limbs. It is not uncommon to have a few lesions on the palms and soles, and vesicles often appear earlier and in larger numbers in areas of inflammation, such as diaper rash or sunburn.

A characteristic feature of varicella lesions is their rapid progression, over as little as 12 hours, from rose-colored macules to papules, and then to vesicles, pustules, and crusts (Fig. 165-2A-D). The typical vesicle is 2 to 3 mm in diameter and elliptical, with its long axis parallel to the folds of the skin. The early vesicle is superficial and thin-walled, and surrounded by an irregular area of erythema (Fig. 165-2C), which gives the lesions the appearance of a "dewdrop on a rose petal."[70] The vesicular fluid soon becomes cloudy with the influx of inflammatory cells that converts the vesicle to a pustule, which then dries, beginning in the center, producing an umbilicated pustule (Fig. 165-2E) and then a crust. Crusts fall off spontaneously in 1 to 3 weeks, leaving shallow pink depressions that gradually disappear. Scarring is rare unless the lesions were traumatized by the patient or superinfected with bacteria. Healing lesions may leave hypopigmented macules that persist for weeks to months; if scars occur, they are depressed and poxlike. In immunocompromised patients, lesions may lack surrounding erythema, and progression of vesicles to pustules may be delayed or absent (Fig. 165-2F).

Vesicles also develop in the mucous membranes of the mouth, nose, pharynx, larynx, trachea, esophagus, GI tract, urinary tract, and vagina. These mucosal vesicles rupture so rapidly that only shallow 2- to 3-mm ulcers remain and the vesicular stage is typically missed.

A distinctive feature of varicella is the simultaneous presence, in any one area of the skin, of lesions in all stages of development (Fig. 165-2A and B). Careful prospective studies have shown that the average number of lesions in healthy children is 250 to 500; secondary cases resulting from household exposure are more severe than cases resulting from exposure at school, presumably because more intense and prolonged exposure at home results in a higher virus inoculum.[21]

FEVER

Fever usually persists as long as new lesions continue to appear, and its height is generally proportional to the severity of the rash. It may be absent in mild cases or rise to 40.5°C (105°F) in severe cases with extensive rash. Prolonged fever or recurrence of fever after defervescence may signify a secondary bacterial infection or another complication.

PRURITUS

The most distressing symptom is pruritus, which is usually present until all lesions are crusted.

Figure 165-2 Varicella. **A** and **B,** Typical cases of varicella in two 4-year-old children. Note the presence of lesions in all stages of development and erosions at sites of excoriation. **C,** Early vesicles with surrounding erythema ("dewdrops on rose petals") in an immunocompetent child with varicella. **D,** Crusted lesions in the same child on rash day 3. **E,** Many large pustules and umbilicated pustules in a 21-year-old woman who was febrile and "toxic" and had varicella pneumonia. **F,** Varicella in an immunocompromised bone marrow transplant recipient. There are large numbers of vesicles, many of which have fused to form larger vesicles; none have progressed to pustules and none are surrounded by erythema. (Images **A-D,** Used with permission from Dr. M.G. Myers.)

BREAKTHROUGH DISEASE

Approximately 10% to 15% of vaccinees immunized with a single dose of varicella vaccine develop "breakthrough" varicella after exposure to active VZV infections. Breakthrough varicella is usually atypical. The rash is predominantly maculopapular, with fewer lesions (less than 60) and fewer vesicles than the rash of unmodified varicella. These patients shed VZV, but are generally less contagious than patients who have not been immunized. The incidence and severity of fever is also less than that in natural varicella.[71] The routine administration of a second dose of varicella vaccine has further reduced the incidence of varicella and greatly reduced the incidence of breakthrough disease.[18,66]

COMPLICATIONS OF VARICELLA

In the normal child, varicella is rarely complicated. The most common complication is secondary bacterial infection of skin lesions, usually by *Staphylococci* or *Streptococci*, which may produce impetigo, cellulitis, erysipelas, and, rarely, necrotizing fasciitis.[72] These local infections often lead to scarring and, rarely, to septicemia and metastatic infection. Bullous lesions may develop when vesicles are superinfected by *Staphylococci* that produce exfoliative toxins. Varicella is frequently complicated by invasive group A streptococcal infections, which usually occur within 2 weeks of the onset of the varicella rash and are particularly virulent.[73] In the prevaccine era, 15% to 30% of invasive group A streptococcal infections were associated with varicella. Widespread varicella vaccination has reduced the proportion of invasive group A streptococcal hospitalizations associated with varicella in the United States to 2%.[74]

In adults, fever and constitutional symptoms are more prominent and prolonged, the rash of varicella is more profuse, and complications are more frequent. A small number of patients develop varicella pneumonia, which is the major severe complication of varicella in adults. Varicella pneumonia is characterized by cough, dyspnea, tachypnea, high fever, pleuritic chest pain, cyanosis, and hemoptysis beginning 1 to 6 days after rash onset. The severity of the symptoms usually exceeds the physical findings, but imaging typically reveals diffuse, peribronchial nodular densities throughout both lung fields with a tendency to concentrate in the perihilar regions and at the bases. The mortality in adults with frank varicella pneumonia is estimated to be between 10% and 30%, but it is less than 10% if immunocompromised patients are excluded and patients receive prompt antiviral therapy.[75]

Varicella during pregnancy is a threat to both mother and fetus.[76] Disseminated infection and varicella pneumonia may result in maternal death, but neither the incidence nor the severity of varicella pneumonia appear to be significantly increased by pregnancy.[77] The fetus may die as a consequence of premature labor or maternal death caused by severe varicella pneumonia, but varicella during pregnancy does not, otherwise, substantially increase fetal mortality. However, even in uncomplicated varicella, maternal viremia can result in intrauterine (congenital) VZV infection that results in a characteristic constellation of congenital abnormalities.[76] The overall risk of congenital varicella syndrome is about 1% when maternal varicella occurs during the first 20 weeks of gestation, with the highest risk (2%) when maternal varicella occurs between 13 and 20 weeks.[76] Perinatal varicella (occurring within 10 days of birth) is much more serious than varicella in infants infected even a few weeks later.[78]

The morbidity and mortality of varicella are markedly increased in immunocompromised patients. In these patients, continued virus replication and dissemination result in a prolonged high-level viremia, more extensive rash, prolongation of new vesicle formation, and clinically significant visceral involvement. Severe abdominal and back pain are common prodromal symptoms of severe varicella with visceral dissemination in immunocompromised patients.[79] Immunocompromised patients may also develop pneumonia, hepatitis, encephalitis, and hemorrhagic complications of varicella, which range in severity from mild febrile purpura to severe and often fatal purpura fulminans with disseminated intravascular coagulation.

CNS complications of varicella include several distinct syndromes. Formerly common, varicella-associated Reye syndrome (acute encephalopathy with fatty degeneration of the liver) is now very rare since the etiologic role of salicylates was recognized and their use in children with fever contraindicated.[80] Acute cerebellar ataxia is more common than other neurologic complications of varicella, occurring in 1 in 4000 cases, but it has an excellent prognosis.[81] Encephalitis is much less common (1 per 33,000 cases), but frequently causes death or permanent neurologic sequelae. The pathogenesis of cerebellar ataxia and encephalitis remains obscure, but in many cases it is possible to detect VZV antigens, VZV antibodies, and VZV DNA in the cerebrospinal fluid of patients, suggesting direct infection of the CNS.

Although mildly elevated aminotransferase levels are common during varicella, clinical hepatitis is rare, except as a complication in immunocompromised patients. Other rare complications of varicella include myocarditis, glomerulonephritis, orchitis, pancreatitis, gastritis and ulcerative lesions of the bowel, arthritis, Henoch-Schönlein vasculitis, optic neuritis, keratitis, and iritis. Most are likely due to parenchymal or endovascular VZV infection.

HERPES ZOSTER

PRODROME

Pain and paresthesia in the involved dermatome often precede the eruption by 1 to 3 days, but occasionally

by a week or longer. Abnormal sensations vary from superficial itching, tingling, or burning to severe, deep, boring, or lancinating pain. The pain may be constant or intermittent, and it is often accompanied by tenderness and hyperesthesia of the skin in the involved dermatome. The prodromal pain of herpes zoster may be confused with pain from disease in a visceral organ (such as myocardial infarction, cholecystitis, renal colic, prolapsed intervertebral disk), and this may lead to misdiagnosis and misdirected investigations and interventions.[68] Prodromal pain is uncommon in immunocompetent persons younger than 30 years, but it occurs in the majority of persons with herpes zoster over the age of 60 years. A few patients experience acute segmental neuralgia without ever developing a cutaneous eruption—a condition known as *zoster sine herpete*.[83]

RASH

The most distinctive feature of herpes zoster is the localization and distribution of the rash, which is unilateral and is generally limited to the area of skin innervated by a single sensory ganglion (Fig. 165-3A,B). The skin supplied by the trigeminal nerve, particularly the ophthalmic division (10%-15%), and the trunk from T3 to L2 (>50%), are most frequently affected; herpes zoster lesions are uncommon distal to the elbows or knees.[1,30,68,69]

Although the individual lesions of herpes zoster and varicella are histologically indistinguishable, those of herpes zoster tend to evolve more slowly and usually consist of closely grouped vesicles on an erythematous base, rather than the more discrete, randomly distributed vesicles of varicella (Fig. 165-3C,D). This difference reflects intraneural (axonal) spread of virus to the skin in herpes zoster, as opposed to viremic spread in varicella. Herpes zoster lesions begin as erythematous macules and papules in a dermatomal distribution. Vesicles form within 12 to 24 hours and evolve into pustules by the third day (Fig. 165-3E). These dry and crust in 7 to 10 days. The crusts generally persist for 2 to 3 weeks. In normal individuals, new lesions continue to appear for 1 to 4 days (occasionally for as long as 7 days). The rash is most severe and lasts longest in older people, and is least severe and of shortest duration in children.

Between 10% and 15% of cases of herpes zoster involve the ophthalmic division of the trigeminal nerve (Fig. 165-4A,B).[84] The rash of ophthalmic zoster may extend from the level of the eye to the vertex of the skull, but it terminates sharply at the midline of the forehead. When only the supratrochlear and supraorbital branches are involved, the eye is usually spared. Involvement of the nasociliary branch, which innervates the eye, as well as the tip and side of the nose, provides VZV with direct access to intraocular structures. Thus, when ophthalmic zoster involves the tip and the side of the nose (Hutchinson sign), careful attention must be given to the condition of the eye. Involvement of the nasociliary branch is frequently accompanied by unilateral conjunctivitis and impaired corneal sensation, which can lead to corneal ulceration and sight-threatening bacterial infection. The eye is involved in 20% to 70% of patients with ophthalmic zoster.

Herpes zoster affecting the second and third divisions of the trigeminal nerve (Fig. 165-4C,D), as well as other cranial nerves, may produce symptoms and lesions in the mouth (Fig. 165-4E,F), ears, pharynx, or larynx. The Ramsay Hunt syndrome (facial palsy in combination with herpes zoster of the external ear, ear canal, or tympanic membrane, with or without tinnitus, vertigo, and deafness) results from involvement of the facial and auditory nerves. The ear and external auditory canal are innervated by the 5th, 7th, 9th, and 10th cranial nerves and by the upper cervical nerves, and the facial nerve anastomoses with all of them. Thus, when herpes zoster involves the ganglia of any of these nerves it may cause facial paralysis and cutaneous lesions on or around the ear[68] (Fig. 165-4G,H).

PAIN

Although the rash is important, pain is the cardinal symptom of herpes zoster, especially in the elderly. Some patients with herpes zoster do not experience pain, but most (>85% over age 50) have dermatomal pain or discomfort during the acute phase (the first 30 days following rash onset) that ranges from mild to severe. Patients describe their pain or discomfort as "burning," "deep aching," "tingling," or "stabbing." In some patients, itching may be the predominant symptom. For some patients, the pain intensity is so great that words like "horrible" or "excruciating" are used to describe the experience. Acute herpes zoster pain is associated with decreased physical functioning, emotional distress, and decreased social functioning.[85,86]

PRURITUS

Itching is often a prominent and distressing symptom throughout the acute phase of herpes zoster. It frequently persists until all crusts have fallen off.

COMPLICATIONS OF HERPES ZOSTER

See Table 165-1.

The sequelae of herpes zoster include cutaneous, ocular, neurologic, and visceral complications.[68] Most are associated with the spread of VZV from the initially involved sensory ganglion, nerve, or skin, either via the bloodstream or by direct neural extension, including involvement of the spinal cord. The rash may disseminate after the initial dermatomal eruption has become apparent. When immunocompetent patients are carefully examined, it is not uncommon to identify a few vesicles in areas distant from the

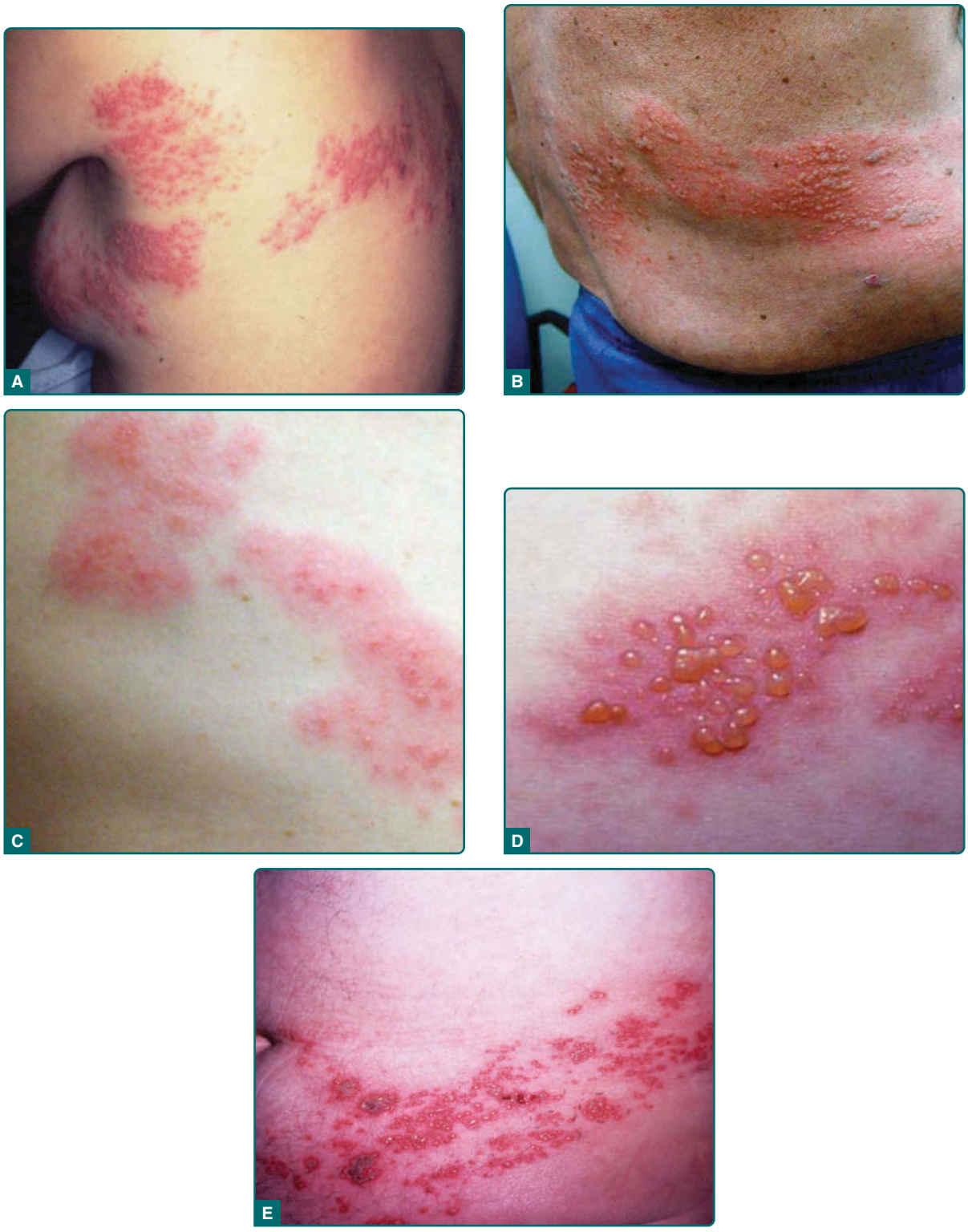

Figure 165-3 Herpes zoster. **A,** Classical herpes zoster in the left T4 dermatome. Note the concentration of lesions in areas of the dermatome innervated by the posterior primary division and the lateral branch of the anterior primary division of the left T4 spinal nerve. **B,** Right T10 herpes zoster with numerous pustular lesions. **C,** Early lesions of herpes zoster. Note the closely grouped vesicles on a confluent erythematous base, in contrast to the discrete randomly distributed vesicles of varicella (Fig. 165-2). **D,** Clustered vesicular lesions of herpes zoster. **E,** Left T8 herpes zoster with numerous pustular lesions and early crusting.

Figure 165-4 Herpes zoster involving cranial nerves. **A** and **B,** Ophthalmic herpes zoster involving the first (ophthalmic) division of the fifth cranial nerve (V1). Involvement of the nasociliary branch, as evidenced by lesions on the tip and side of the nose (Hutchinson sign), provides VZV with direct access to the eye. This is frequently accompanied by unilateral conjunctivitis and impaired corneal sensation, which can lead to corneal ulceration and sight-threatening bacterial infection. **A,** Left ophthalmic herpes zoster with involvement of the nasociliary branch, as evidenced by lesions on the tip and side of the nose (Hutchinson sign). **B,** Severe right ophthalmic herpes zoster with involvement of the nasociliary nerve and eye, as well as superficial gangrene. **C,** Herpes zoster involving the second division of the right fifth cranial nerve (V2). **D,** Herpes zoster involving the third division of the left fifth cranial nerve (V3). **E** and **F,** Cranial nerve herpes zoster in a 60-year-old woman with right-sided facial palsy (Hunt syndrome) and vesicles on her tongue (**E**) and palate (**F**). **G** & **H,** Ramsey Hunt Syndrome: An 83-year-old woman developed left ear pain and fever followed by an erythematous vesicular rash involving her left ear

Figure 165-4 (*Continued*) (**G**) with left-sided hearing loss and left facial paresis (**H**). She also had evidence of involvement of the other cranial nerves as indicated by difficulty swallowing, leftward tongue protrusion, hoarse dysphonia and absent palatal elevation on the left. Despite treatment with oral acyclovir, 800 mg 5 times daily for 10 days, she had no resolution of her left-sided hearing loss and facial paresis 4 months later. (Images G and H, Reproduced with permission from Espay AJ, Bull RL: *Arch Neurol*. 2005;62(11):1774-1775. Copyright © 2005 American Medical Association. All rights reserved.)

involved and immediately adjacent dermatomes, especially as age increases. The disseminated lesions usually appear within a week of the onset of the segmental eruption and, if few in number, are easily overlooked and are not problematic. More extensive dissemination (with 25-50 lesions or more), producing a varicella-like eruption (disseminated herpes zoster, Fig. 165-5), may occur in immunocompromised patients. If the rash spreads widely from a small, painless area of herpes zoster, the initial dermatomal presentation may go unnoticed, and the ensuing disseminated eruption may be mistaken for varicella.[25,68]

When the dermatomal rash is particularly extensive, as it often is in severely immunocompromised patients, there may be superficial gangrene with delayed healing and subsequent scarring (Fig. 165-3B). Secondary bacterial infection (usually with *Staphylococci* or *Streptococci*) may delay healing and cause scarring in both immunocompetent and immunocompromised patients.

Ophthalmic zoster may be accompanied by a wide range of complications.[84] Corneal sensation is generally impaired and, when that impairment is severe, it may lead to neurotrophic keratitis with chronic ulceration and bacterial infection.

Herpes zoster may be attended by a variety of neurologic complications, of which postherpetic neuralgia (PHN) is the most common and important.[87] PHN has been variably defined as pain after rash healing, or any pain 1 month, 3 months, 4 months, or 6 months after rash onset.[88-91] The prevalence of PHN was reported to be 5% to 30% in a systematic review of 49 studies published between 1945 and 2012 that encompassed a wide variety of PHN definitions and patient ages.[27] Age is the most significant risk factor for PHN (Fig. 165-1B). Clinically significant pain lasting 3 months or more is rare in immunocompetent persons younger than 50 years of age. In a large UK general practice database study, PHN defined as any pain ≥3 months from rash onset was 11%,

TABLE 165-1
Complications of Herpes Zoster

CUTANEOUS	VISCERAL	NEUROLOGIC
▪ Bacterial superinfection ▪ Scarring ▪ Zoster gangrenosum ▪ Cutaneous dissemination	▪ Pneumonitis ▪ Hepatitis ▪ Esophagitis ▪ Gastritis ▪ Pericarditis ▪ Cystitis ▪ Arthritis	▪ Postherpetic neuralgia ▪ Meningoencephalitis ▪ Transverse myelitis ▪ Peripheral nerve palsies Motor Autonomic ▪ Cranial nerve palsies ▪ Sensory loss ▪ Deafness ▪ Ocular complications ▪ Granulomatous angiitis (causing contralateral hemiparesis)

Figure 165-5 Disseminated herpes zoster. **A** and **B**, An immunocompromised adult with leukemia on treatment with disseminated herpes zoster and varicella-zoster virus pneumonia.

13%, 15%, 18%, and 21% in patients ages 60-64, 65-69, 70-74, 75-79, and 80-84 years, respectively.[92] A meta-analysis of 18 cohort studies found that the incidence of PHN increased by 1.22% to 3.11% for each 10-year increase in age.[93] Other risk factors for PHN include the presence of prodromal pain, severe pain during the acute phase of herpes zoster, extensive rash, and significant sensory abnormalities in the affected dermatome. PHN usually remits gradually over several months (Figs. 165-1C) but, as with the incidence of PHN, its duration increases with increasing age.

Patients with PHN may suffer from constant pain (described as "burning," "aching," or "throbbing"), intermittent lancinating pain ("stabbing," "shooting"), and/or stimulus-evoked pain, including allodynia ("tender," "burning," "stabbing"). Allodynia, which is pain elicited by stimuli that are normally not painful, is a particularly disabling component of the disease that is present in approximately 90% of patients with PHN.[94] Patients with allodynia may suffer severe pain after even the lightest touch to the affected skin, such as by a breeze or by contact with clothing. PHN often results in disordered sleep, depression, anorexia, weight loss, chronic fatigue, and social isolation, and it may interfere with dressing, bathing, general activity, traveling, shopping, cooking, and housework.[93]

Dorsal root ganglia contain visceral, as well as cutaneous, afferent neurons, which likely explains the occurrence of visceral as well as cutaneous lesions in patients with herpes zoster. The affected viscera usually have afferent innervation corresponding to the infected dermatome. Thus, herpes zoster lesions in the gastric mucosa are observed in patients with thoracic herpes zoster, hemicystitis is observed in patients with sacral herpes zoster, and herpes zoster in other dermatomes can result in mucosal lesions causing esophagitis, pleuritis, and peritonitis. Infection via visceral afferents originating in mechanoreceptors involved with GI and bladder motility and sphincter function can result in ileus, symptoms of GI obstruction, and dysfunction of the bladder and anus. Transmission of ganglionic infection via proprioceptive afferents can also result in myositis.[68] Latent VZV in enteric neurons provides another potential source of virus causing visceral complications, which may explain episodes of visceral herpes zoster in the absence of skin lesions.[95] Innervation of cerebral blood vessels by neurons in cranial and dorsal root ganglia accounts for a syndrome of ophthalmic herpes zoster and delayed contralateral hemiplegia.[96-98] VZV from infected neurons in the involved ganglion infects these cerebral arteries, causing segmental granulomatous angiitis that results in a contralateral stroke, which may occur weeks to months after the episode of ophthalmic herpes zoster (average interval = 7-8 weeks); the delayed onset of the contralateral stroke may obscure its relationship to the episode of ophthalmic herpes zoster.[96-98] Although most cases have followed ophthalmic herpes zoster and involved the ipsilateral middle and anterior cerebral arteries, some have followed herpes zoster in other cranial and cervical dermatomes. Evidence also has been presented associating temporal arteritis, myocardial infarction, and aortic aneurysms due to granulomatous angiitis with reactivation of latent VZV.[99,100] Other studies of this relationship have not always been confirmatory, and these associations remain controversial.[101-104]

Most serious complications of herpes zoster are more common in immunocompromised persons. These include necrosis of skin and scarring, and cutaneous dissemination (Fig. 165-5). Patients with cutaneous dissemination may also have widespread, often fatal, visceral dissemination, particularly to the lungs, liver, and brain.

Figure 165-6 Chronic disseminated herpes zoster caused by acyclovir-resistant varicella-zoster virus in an immunocompromised patient. Chronic verrucous lesions disseminated herpes zoster caused by acyclovir-resistant varicella-zoster virus in an immunocompromised patient with AIDS. (Used with permission from Dr. V. Asensi.)

HIV-infected patients who are not treated with combination antiretroviral therapy often suffer multiple recurrences of herpes zoster as their HIV infection progresses. Recurrences may be in the same or different dermatomes or in several contiguous or noncontiguous dermatomes. Cutaneous and visceral dissemination may also occur in patients with untreated HIV infection. In addition, patients with AIDS may develop chronic verrucous, hyperkeratotic, or ecthymatous cutaneous lesions caused by acyclovir-resistant VZV (Fig. 165-6) (see also Chap. 168). These manifestations of severe HIV infection are rare in the current era of effective antiretroviral therapy for HIV infection.

ETIOLOGY AND PATHOGENESIS

VZV is a member of the herpesvirus family. All herpesviruses are morphologically indistinguishable and share a number of properties, including the capacity to establish latent infections that persist for life. VZV and herpes simplex virus (Types I and II) are further classified as α-herpesviruses because they become latent in sensory neurons after primary infection.

The VZV genome contains at least 71 genes, most of which have functional and DNA- sequence homology to genes of other herpesviruses.[105] Immediate early gene products regulate VZV replication. Early gene products, such as VZV thymidine kinase and VZV DNA polymerase, support virus replication, whereas late genes encode virus structural proteins. There is only 1 VZV serotype. However, there are 7 or 8 VZV genotypes (clades) that display geographic segregation and recombination.[106,107] Variations in nucleotide sequences allow one to distinguish wildtype from vaccine virus strains, and to "fingerprint" viruses isolated from individual patients.[105,108-110]

PATHOGENESIS OF VARICELLA

Entry of VZV is through the mucosa of the upper respiratory tract and oropharynx, where VZV infects tonsillar T cells that disseminate virus via the blood and lymphatics (the primary viremia). Infected T cells carry virus to the reticuloendothelial system, the major site of virus replication during the remainder of the incubation period, and to the skin. Viremia occurs early in the incubation period, but VZV replication and rash formation are delayed by innate immune responses, for example, by interferon and natural killer cells, and by developing VZV-specific immune responses.[105,111,112]

Virus replication eventually overcomes these host defenses, so that some 10 to 14 days after infection a much larger (secondary) viremia occurs, resulting in systemic symptoms and skin lesions. In addition, immunopathology contributes to rash development. Skin lesions appear in successive crops, reflecting a cyclic viremia that in the normal host is terminated after about 3 to 5 days by VZV-specific immune responses, primarily VZV-specific T cell–mediated immune responses. Virus circulates in mononuclear leukocytes, primarily lymphocytes. Even in uncomplicated varicella, viremia results in subclinical infection of many organs in addition to the skin. T cell–mediated immunity to VZV is required for recovery from varicella. The immunologic memory that develops during varicella persists for life and is essential to protect against second episodes of varicella and against herpes zoster.[1,29,111,112]

PATHOGENESIS OF HERPES ZOSTER

During varicella, VZV passes from lesions in the skin and mucosal surfaces into contiguous endings of sensory nerves and is transported up the sensory fibers to the sensory ganglia. In the ganglia, the virus establishes latent infections in neurons that persist for life. The density of latent VZV is greatest in ganglia innervating areas of skin with the greatest density of

varicella lesions. Consequently, herpes zoster occurs most often in dermatomes where the rash of varicella is most dense-skin innervated by the first (ophthalmic) division of the trigeminal ganglion and by spinal sensory ganglia from T1 to L2.[1,68,69] The viremia that occurs during varicella may provide VZV with another means to access sensory neurons.

Latent VZV in ganglia produces a latency-associated transcript (LAT) homologous to that produced by latent HSV, but no infectious virus.[113] However, latent VZV may reactivate sporadically, producing infectious virus. The frequency and mechanism of these reactivations are unknown, but VZV reactivation and replication resulting in HZ has been associated most clearly with immunosuppression. VZV may also reactivate without producing overt disease; presumably, because replication and spread of the reactivated virus is terminated by preexisting or rapidly mobilized VZV-specific immunity. The small quantity of viral antigen released during such "contained reactivations" is postulated to stimulate and sustain host immunity to VZV.[1,67,114]

When VZV-specific T cell–mediated immunity falls below some critical level, reactivated virus can no longer be contained.[1,29] Virus multiplies and spreads within the ganglion, causing neuronal necrosis and intense inflammation, processes that are often accompanied by severe neuropathic pain.[115,116] VZV then spreads antidromically down the sensory nerve, and is released from the sensory nerve endings in the skin, where it produces the characteristic cluster of zoster vesicles. Spread of the ganglionic infection proximally along the posterior nerve root to the meninges and spinal cord may result in local leptomeningitis, cerebrospinal fluid pleocytosis, and segmental myelitis. Infection and destruction of neurons in the dorsal horn may play a role in persistent neuropathic pain (see section "Pathogenesis of Pain in Herpes Zoster and Postherpetic Neuralgia" below); infection of motor neurons in the anterior horn and inflammation of the anterior nerve root account for the local palsies that may accompany the cutaneous eruption.[115] Extension of infection within the CNS may result in rare complications of herpes zoster, such as meningoencephalitis or transverse myelitis. Viremia also occurs during herpes zoster.[23]

PATHOGENESIS OF PAIN IN HERPES ZOSTER AND POSTHERPETIC NEURALGIA

A number of different but overlapping mechanisms, which vary from patient to patient and over time in any individual patient, appear to be involved in the pathogenesis of pain in herpes zoster and in PHN.[91,117-119] Injury to the peripheral nerve and to neurons in the ganglion trigger afferent pain signals (neuropathic pain). Inflammation in the skin triggers nociceptive pain signals that further amplify this pain. Damage to neurons in the spinal cord and ganglion, and to the peripheral nerve, is important in the pathogenesis of PHN. Postmortem examination of patients with herpes zoster and severe PHN compared with patients with herpes zoster and no persistent pain demonstrated dorsal horn atrophy and cell, axon, and myelin loss with fibrosis in sensory ganglia only in patients with persistent pain.[115] Damaged primary afferent nerves may become spontaneously active and hypersensitive to peripheral stimuli, and also to sympathetic stimulation. Excessive nociceptor activity and ectopic impulse generation may, in turn, sensitize CNS neurons, augmenting and prolonging central responses to innocuous as well as noxious stimuli.[91,118-121] Clinically, these mechanisms result in allodynia.

DIAGNOSIS

CLINICAL DIAGNOSIS

VARICELLA

Varicella can usually be diagnosed by the appearance and evolution of the rash (see Fig. 165-2), particularly when there is a history of exposure within the preceding 2 to 3 weeks. The rapid evolution of lesions from macules to papules, to vesicles, to pustules and crusts, and the simultaneous presence of lesions at all stages of development, distinguish varicella from most other generalized rashes.

Disseminated herpes zoster may be mistaken for varicella, especially when there is widespread dissemination of VZV from a small, painless area of herpes zoster or from the affected sensory ganglion in the absence of an obvious dermatomal eruption. Although disseminated HSV infections may resemble varicella, this is a rare disease that is limited to severely immunocompromised patients. There is usually an obvious concentration of lesions at and surrounding the site of the primary or recurrent infection, for example, the mouth or external genitalia, and there is often marked toxicity and visceral involvement.

The remaining differential diagnoses of varicelliform rashes are listed in Table 165-2. The character, distribution, and evolution of the lesions, together with a careful epidemiologic history, usually differentiate these diseases from varicella. When any doubt exists, the clinical impression should be confirmed by laboratory testing.

HERPES ZOSTER

In the preeruptive stage, the prodromal pain of herpes zoster is often confused with other causes of localized pain. Once the eruption appears, the character and dermatomal location of the rash, coupled with dermatomal pain and localized sensory abnormalities, usually makes the diagnosis obvious (Figs. 165-3 and 165-4).[68]

TABLE 165-2
Differential Diagnosis of Varicella and Herpes Zoster

VARICELLA	HERPES ZOSTER
Most Likely	***Most Likely***
▪ Vesicular exanthems of Coxsackieviruses and echoviruses ▪ Eczema herpeticum ▪ Disseminated herpes zoster ▪ Impetigo ▪ Insect bites ▪ Contact dermatitis ▪ Rickettsialpox ▪ Disseminated herpes simplex[a]	▪ Zosteriform herpes simplex ▪ Contact dermatitis ▪ Insect bites ▪ Burns
Consider	***Consider***
▪ Papular urticaria ▪ Erythema multiforme ▪ Drug eruptions ▪ Disseminated herpes simplex ▪ Molluscum contagiosum ▪ PLEVA[b] ▪ Scabies ▪ Secondary syphilis ▪ Dermatitis herpetiformis ▪ Bullous pemphigoid ▪ Pemphigus vulgaris	▪ Papular urticaria ▪ Erythema multiforme[a] ▪ Drug eruptions[a] ▪ Scabies ▪ Molluscum contagiosum ▪ Bullous pemphigoid (isotopic response)

[a]May resemble disseminated herpes zoster.
[b]Pityriasis lichenoides et varioliformis acuta.

A cluster of vesicles, particularly near the mouth or genitals, may represent herpes zoster, but it also may be recurrent HSV infection (Fig. 165-7).[55] Zosteriform herpes simplex is often impossible to distinguish from herpes zoster on clinical grounds. In the absence of profound and clinically obvious immune deficiency, a history of multiple recurrences in the same dermatome distinguishes zosteriform herpes simplex from herpes zoster. Table 165-2 lists other considerations in the differential diagnosis of herpes zoster.

Figure 165-7 Zosteriform herpes simplex. This immunocompetent adult with no history of genital herpes or prior herpetic lesions presented with a 1-day history of mild tenderness of her left buttock, followed by the onset of the clustered vesicular lesions in her left S2/S3 dermatomes. They were mildly tender and pruritic. PCR assay and viral culture both revealed HSV-2.

LABORATORY DIAGNOSIS

The lesions of varicella and herpes zoster are indistinguishable by histopathology (Fig. 165-8). VZV infection of the skin is initiated by infection of epithelial cells in the basal layer (stratum germinativum) and the stratum spinosum. The resulting papular lesions evolve into intraepithelial vesicles within 12 to 24 hours as a result of infection of increasing numbers of epithelial cells, which show acanthosis, "ballooning degeneration," eosinophilic (acidophilic) intranuclear inclusion bodies, and multinucleated giant cell formation. An influx of edema fluid elevates the uninvolved stratum corneum to form a delicate clear vesicle containing large amounts of cell-free infectious virus and multinucleated giant cells with eosinophilic intranuclear inclusion bodies (Fig. 165-8A,B). The multinucleated giant cells form by fusion of infected epithelial cells with adjacent infected and uninfected cells at the base and periphery of the vesicle. The underlying dermis shows edema and mononuclear cell infiltration. The presence of multinucleated giant cells and epithelial cells containing acidophilic intranuclear inclusion bodies distinguishes the cutaneous lesions produced by VZV from all other vesicular eruptions, such as those caused by poxviruses, Coxsackieviruses, and echoviruses, except for those produced by HSV. These cells can be demonstrated in Tzanck smears prepared at the bedside from material scraped from the base of vesicular lesions and stained with hematoxylin and eosin, Giemsa, or similar stains (Fig. 165-8C). When virus-containing vesicle fluid is inoculated into human fibroblast tissue cultures, similar multinucleated giant cells containing acidophilic intranuclear inclusion bodies form by fusion of infected cells with adjacent infected and uninfected cells (Fig. 165-8D).

The best diagnostic test for detection of VZV is polymerase chain reaction (PCR) because of its very high sensitivity and specificity, ready availability, and relatively quick (1 day or less) turnaround time.[110,122,123] Vesicle fluid is the best specimen for PCR analysis, but lesion scrapings, crusts, tissue biopsy, or cerebrospinal fluid are equally useful. PCR can distinguish VZV from HSV, and wildtype VZV from Oka vaccine strains of VZV.[110] Isolation of virus is less sensitive and may take a week or more, but it is the only technique that yields infectious VZV for further analysis, such as determination of sensitivity to antiviral drugs. VZV is extremely labile, and only 30% to 60% of cultures from proven cases are generally positive. To maximize virus recovery, specimens should be inoculated into cell culture immediately. It is important to select new vesicles containing clear fluid for aspiration, because the probability of isolating VZV diminishes rapidly as lesions become pustular. VZV is almost never isolated from crusts.

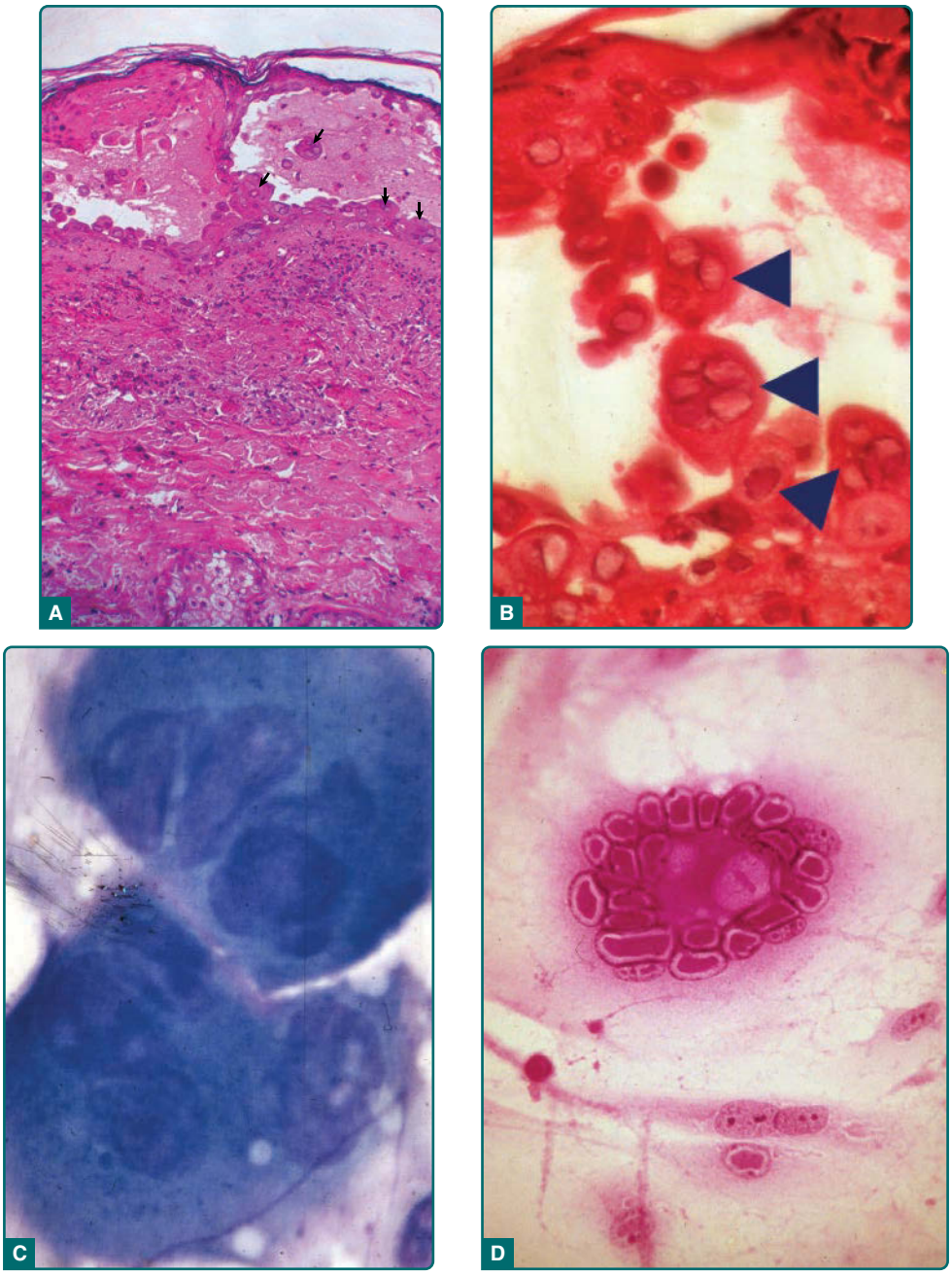

Figure 165-8. Varicella zoster histopathology. **A** and **B,** Papular lesions of varicella evolve into intraepithelial vesicles within 12 to 24 hours. An influx of edema fluid elevates the uninvolved stratum corneum to form a delicate clear vesicle containing large amounts of cell-free infectious virus and multinucleated giant cells, containing eosinophilic intranuclear inclusion bodies, formed by fusion of infected epithelial cells with adjacent infected and uninfected cells. The underlying dermis shows edema and mononuclear cell infiltration (**A,** H&E ×100; **B,** H&E ×400). **C,** The multinucleated giant cells are readily identified in Tzanck smears prepared from material scraped from the base of vesicular lesions and stained with H&E, Giemsa, or similar stains. Giemsa ×1000. **D,** Infected human fibroblast tissue cultures show similar multinucleated giant cells containing eosinophilic intranuclear inclusion bodies that are formed by fusion of infected cells with adjacent infected and uninfected cells. H&E ×1000. (Images **A** and **B,** Used with permission from Dr. R. J. Barr.)

Immunofluorescent or immunoperoxidase staining of cellular material from fresh vesicles or prevesicular lesions can detect VZV significantly more often and faster than virus culture.[124] Enzyme immunoassays provide another rapid and sensitive method for antigen detection. These techniques have a somewhat faster turnaround time than PCR, but lack the excellent sensitivity and specificity of PCR, which remains the diagnostic method of choice.[122,123]

Serologic tests permit the retrospective diagnosis of varicella and herpes zoster when acute and convalescent sera are available for comparison, but this is rarely done.[122,123] Serologic tests are more important to identify susceptible individuals who may be

candidates for isolation or prophylaxis. The technique most commonly used is a solid-phase enzyme-linked immunosorbent assay (ELISA). However, these assays (there are many commercial sources) often lack sensitivity, failing to detect antibody in a significant number of persons who are immune, especially those who received varicella vaccine. False-positive results in susceptible individuals are less common, but problematic, especially in health care workers in whom susceptibility to VZV is a risk for nosocomial varicella.

DIFFERENTIAL DIAGNOSIS

See Table 165-2.

MANAGEMENT

ANTIVIRAL AGENTS

Chapter 191 provides a detailed description of the treatment of varicella and herpes zoster. The nucleoside analogs acyclovir, famciclovir, valacyclovir, and brivudin, and the pyrophosphate analog foscarnet, are efficacious in treating VZV infections. Acyclovir and penciclovir are guanosine analogs that are selectively phosphorylated by VZV thymidine kinase; they are poor substrates for cellular thymidine kinase and thus are not activated in, and are not toxic for, uninfected cells. Cellular enzymes then convert acyclovir monophosphate and penciclovir monophosphate to the corresponding triphosphates, which interfere with viral DNA synthesis by inhibiting viral DNA polymerase. VZV is approximately tenfold less sensitive than HSV to acyclovir and penciclovir.

Two prodrugs, valacyclovir (for acyclovir) and famciclovir (for penciclovir), are better and more reliably absorbed than acyclovir following oral administration.[125] Thus, they produce much higher blood levels of antiviral activity and permit less frequent dosing than acyclovir. Valacyclovir is a valine ester of acyclovir that is converted enzymatically to acyclovir after absorption. Famciclovir is a prodrug of penciclovir, a nucleoside analog similar to acyclovir in mechanism of action and antiviral activity against VZV and HSV. Famciclovir is converted enzymatically to penciclovir after absorption. Brivudin is a thymidine analog, also activated by viral thymidine kinase, with very high activity against VZV. Although effective in the treatment of herpes zoster, it is not licensed in the United States, in part because of a potentially lethal interaction with 5-fluorouracil.[126]

Foscarnet, a second-line drug that is an analog of inorganic pyrophosphate, inhibits the replication of all known herpesviruses in vitro. It exerts its antiviral activity by selective inhibition at the pyrophosphate-binding site of virus-specific DNA polymerases at concentrations that do not greatly inhibit cellular DNA polymerases. Foscarnet does not require phosphorylation by thymidine kinase to be activated and is therefore active against nucleoside-resistant VZV mutants that have reduced or altered thymidine kinase activity, but it is more toxic than the nucleoside analogs. Cidofovir is another drug that directly inhibits viral DNA polymerase but, because of its toxicity, is considered a third-line drug. A new antiviral agent, amenamevir, is a potent helicase-primase inhibitor that is active against acyclovir-resistant VZV and HSV. A single dose of 400 mg daily was as effective and as well tolerated as valacyclovir 1 g 3 times daily in Japanese patients with proven herpes zoster.[127]

Topical antiviral therapy has no role in the treatment of varicella. It has limited efficacy against herpes zoster and is not recommended. Systemic therapy, either oral or parenteral, is the standard of care. Because of their superior pharmacokinetics and the reduced sensitivity of VZV compared to HSV to acyclovir and penciclovir, famciclovir, or valacyclovir are preferred over acyclovir for oral therapy of VZV infections. Acyclovir-resistant VZV has been documented in varicella and herpes zoster in severely immunosuppressed patients, such as patients with advanced AIDS. Because of the usual mechanism of acyclovir resistance (mutations in the viral thymidine kinase gene), these acyclovir-resistant mutants are cross-resistant to ganciclovir, valacyclovir, famciclovir, and penciclovir. They usually respond to foscarnet and are sensitive to amenamevir, an investigational helicase-primase inhibitor.

TREATMENT OF VARICELLA

TOPICAL THERAPY

In healthy children, varicella is generally benign and self-limited. Cool compresses, calamine lotion or Caladryl Clear (zinc acetate 0.1% + pramoxine 1%) locally, tepid baths with baking soda or colloidal oatmeal (3 cups per tub of water), and oral antihistamines may relieve itching. Creams and lotions containing glucocorticoids and occlusive ointments should not be used. Antipyretics may be needed, but salicylates must be avoided because of their association with Reye syndrome. Minor bacterial infections are treated with warm soaks. Bacterial cellulitis requires systemic antimicrobial therapy that is effective against *Staphylococcus aureus* and group A β-hemolytic streptococcus.

ANTIVIRAL THERAPY

Immunocompetent Children: See Table 165-3. A large randomized, controlled trial of acyclovir treatment of otherwise healthy children 2 to 12 years of age found that treatment with oral acyclovir (20 mg/kg 4 times per day for 5 days) initiated within 24 hours of rash onset modestly reduced the maximum number of lesions, the time to cessation of new lesion formation, and the duration of the rash, fever, and constitutional symptoms when compared to placebo.[128] Treatment initiated more than 24 hours after rash onset was not effective. Because varicella is a relatively benign

TABLE 165-3
Antiviral Treatment of Varicella in the Normal and Immunocompromised Host

PATIENT GROUP	REGIMEN
Normal[a]	
Neonate	Acyclovir 10 mg/kg or 500 mg/m^2 every 8 h for 10 d
Child (2 to <18 y of age)	Symptomatic treatment alone, or Valacyclovir 20 mg/kg every 8 h for 5 d[b] (not to exceed 3 g/d) or Acyclovir 20 mg/kg orally 4 times a day × 5 d (not to exceed 3200 mg/d)
Adolescent (≥40 kg) or adult, especially with mild immunocompromise (eg, use of inhaled glucocorticoids)	Valacyclovir 1 g orally every 8 h for 7 d or Famciclovir 500 mg orally every 8 h for 7 d or Acyclovir 800 mg orally 5 times a day for 7 d
Pneumonia	Acyclovir 10 mg/kg IV every 8 h × 7-10 d[b]
Pregnancy	Routine use of acyclovir is not recommended. If there are complications (eg, pneumonia) treat pneumonia as per recommendation above.
Immunocompromised	
Mild varicella or mild immunocompromise	Valacyclovir 1 g orally every 8 h for 7-10 d or Famciclovir 500 mg orally every 8 h for 7-10 d or Acyclovir 800 mg orally 5 times a day for 7-10 d
Severe varicella or severe immunocompromise	Acyclovir 10 mg/kg IV every 8 h for 7–10 d
Acyclovir resistant (advanced AIDS)	Foscarnet 40 mg/kg IV every 8 h until healed

[a]Oral acyclovir or preferably, famciclovir or valacyclovir, should be considered for otherwise healthy persons at increased risk for moderate-to-severe varicella (eg, persons aged >12 y, persons with chronic cutaneous or pulmonary disorders, persons receiving long-term salicylate therapy, and persons receiving short, intermittent, or aerosolized courses of corticosteroids). (From Marin M et al. Prevention of varicella: Recommendations of the Advisory Committee on Immunization Practices [ACIP]. *MMWR Recomm Rep.* 2007;56:1-40.)

[b]Must prepare suspension by grinding 500-mg valacyclovir caplets and suspending in cherry-flavored Suspension Structural Vehicle USP-NF (SSV) at 25 mg/mL or 50 mg/mL in lots of 100 mL at time of dispensing.

infection in children and the clinical benefits of treatment are modest, routine antiviral treatment is not recommended in immunocompetent children.[66,129,130] Some experts favor its use where cost is not a concern; when it can be begun in time to benefit the patient (within 24 hours of rash onset); and where there is a perceived need to speed resolution of the infection. Because secondary cases among susceptible children in the household are generally more severe than the index cases,[21] and because early initiation of treatment is more readily accomplished in that setting, treatment with acyclovir is an option for such secondary cases.

We recommend oral antiviral therapy, preferably valacyclovir or famciclovir, for persons >12 years of age, persons with chronic cutaneous or pulmonary disorders or other debilitating diseases, persons receiving long-term salicylate therapy, and persons receiving short, intermittent, or aerosolized courses of corticosteroids because these individuals are at increased risk for moderate-to-severe varicella.[130]

Immunocompetent Adolescents and Adults: A randomized, controlled trial of acyclovir treatment of healthy adolescents 13 to 18 years of age found that early treatment with oral acyclovir (800 mg 5 times a day for 5 days) reduced the maximum number of lesions and time to cessation of new lesion formation compared to placebo.[131] A randomized, placebo-controlled trial of oral acyclovir in healthy young adults with varicella showed that early treatment (within 24 hours of rash onset) with oral acyclovir (800 mg 5 times a day for 7 days) significantly reduced the time to crusting of lesions, the extent of disease, and duration of symptoms and fever.[75] Thus, routine treatment of varicella in adults seems reasonable, especially because varicella complications are more frequent in adults. Although not tested, famciclovir 500 mg orally every 8 hours or valacyclovir 1000 mg orally every 8 hours would be more convenient and appropriate substitutes for acyclovir in normal adolescents and adults. Many physicians do not prescribe oral acyclovir in uncomplicated varicella during pregnancy because the risk of treatment to the fetus is unknown. Other physicians recommend oral antiviral therapy for infections in the third trimester when organogenesis is complete, because of the risk of varicella pneumonia, and of spread of the infection to the newborn. Intravenous acyclovir is often considered for pregnant women with varicella who have extensive cutaneous and/or systemic disease. Though limited in size, registries of pregnant women treated with acyclovir did not reveal any toxicity for pregnant women or their fetuses,[132-134] and extensive, though unrecorded, clinical experience also confirms its safety in pregnant women. Consequently, we recommend treatment for pregnant women with varicella who have extensive rash, toxicity, any signs of systemic infection, or any risk factors such as the use of immunosuppressive medications.

Uncontrolled trials in immunocompetent adults with varicella pneumonia suggest that early treatment (within 36 hours of hospitalization) with IV acyclovir (10 mg/kg every 8 hours) reduces fever and tachypnea and improves oxygenation.[135] Other serious complications of varicella in the immunocompetent host, such as encephalitis, meningoencephalitis, myelitis, and ocular complications, should be treated with IV acyclovir.

Immunocompromised Patients: Controlled trials in immunocompromised patients with varicella demonstrated that treatment with IV acyclovir decreased the incidence of life-threatening visceral complications when treatment was initiated within 72 hours of rash onset.[136] Intravenous acyclovir has been the standard of care for varicella in patients with substantial immunodeficiency. Although oral therapy

with famciclovir or valacyclovir should suffice for patients with mild degrees of immunologic impairment, there are no controlled clinical trials to guide the decision. Patients who are started on IV therapy may be switched to oral therapy when new lesions cease to appear and the patient is stable.

TREATMENT OF HERPES ZOSTER

TOPICAL THERAPY

During the acute phase of herpes zoster, the application of cool compresses, calamine lotion or Caladryl Clear, cornstarch, or baking soda may lessen local symptoms and hasten the drying of vesicular lesions. Occlusive ointments and creams or lotions containing glucocorticoids should not be used. Topical treatment with antiviral agents is not effective. Bacterial superinfection of herpes zoster lesions is uncommon and should be treated with warm soaks; bacterial cellulitis requires systemic antibiotic therapy.

ANTIVIRAL THERAPY

The major goals of antiviral therapy in patients with herpes zoster are to limit the extent, duration, and severity of pain and rash in the primary dermatome and to prevent disease elsewhere.

Except for PHN, most complications of herpes zoster, including vasculopathy, result from continuing replication and spread of VZV from the affected ganglion, and may thus be prevented by early initiation of effective antiviral therapy.

Immunocompetent Adolescents and Adults: Table 165-4 lists current evidence-based recommendations for treatment of herpes zoster based on the results of randomized controlled trials. Recommended antivirals reduce the time to rash healing, and the duration and severity of acute pain in older adults with herpes zoster who are treated within 72 hours of rash onset.[137] In some studies, the duration of chronic pain was also reduced, but the FDA has not approved these agents for the prevention of PHN.[138] Randomized controlled trials comparing antivirals demonstrated equivalent results in rash healing, acute pain, and the duration of chronic pain.[139-141] Oral acyclovir, famciclovir, and valacyclovir are all acceptable antivirals for older adults. However, famciclovir or valacyclovir are preferred because of their thrice-daily dosing schedule, their greater oral bioavailability, and the higher and more reliable blood levels of antiviral activity achieved. This is important because of the reduced sensitivity to acyclovir of VZV compared with HSV, and the potential existence of barriers to the entry of antiviral agents into tissues that are sites of VZV replication.

The utility of antiviral agents is unproven if treatment is initiated more than 72 hours after rash onset.

TABLE 165-4
Antiviral Treatment of Herpes Zoster in the Normal and Immunocompromised Host

PATIENT GROUP	REGIMEN
Normal	
Age <50 y	Symptomatic treatment alone, or Famciclovir 500 mg orally every 8 h for 7 d or Valacyclovir 1 g orally every 8 h for 7 d or Acyclovir 800 mg orally 5 times a day for 7 d[a]
Age ≥50 y, and patients of any age with cranial nerve involvement (eg, ophthalmic zoster)	Famciclovir 500 mg orally every 8 h for 7 d or Valacyclovir 1 g orally every 8 h for 7 d or Acyclovir 800 mg orally 5 times a day for 7 d[a]
Immunocompromised	
Mild immunocompromise, including HIV-1 infection	Famciclovir 500 mg orally every 8 h for 7-10 d or Valacyclovir 1 g orally every 8 h for 7-10 d or Acyclovir 800 mg orally 5 times a day for 7-10 d[a]
Severe immunocompromise	Acyclovir 10 mg/kg IV every 8 h for 7-10 d
Acyclovir resistant (eg, advanced AIDS)	Foscarnet 40 mg/kg IV every 8 h until healed

[a]Famciclovir or valacyclovir are preferred because their greater and more reliable oral bioavailability result in higher blood levels of antiviral activity, the lower susceptibility of VZV (compared to HSV) to acyclovir and penciclovir, and the existence of barriers to the entry of antiviral agents into tissues that are sites of VZV replication.

Nevertheless, we believe that it is prudent to initiate antiviral therapy even if more than 72 hours have elapsed after rash onset in patients with herpes zoster involving cranial nerves (eg, ophthalmic zoster), in patients who continue to have new vesicle formation, or in patients who are of advanced age and may thus have a delay in development of effective immune responses.[135]

Ophthalmic zoster represents a special therapeutic challenge because of the risk of ocular complications. Examination by an ophthalmologist should be sought in most cases, for example, when there is any evidence of involvement of the eye and when the nasociliary nerve is involved. Oral acyclovir was effective in preventing ocular complications of ophthalmic zoster in a randomized, controlled trial.[142] Famciclovir and valacyclovir appear to have efficacy comparable to that of acyclovir in the treatment of ophthalmic zoster, and are preferred for the reasons cited above.[143,144]

Immunocompromised Patients: A randomized, double-blind, placebo-controlled trial in immunocompromised patients with herpes zoster showed that IV acyclovir (500 mg/m^2 every 8 hours for 7 days) halted progression of the disease, both in patients with localized herpes zoster and in patients with cutaneous dissemination.[145] Acyclovir accelerated the rate of

clearance of virus from vesicles and markedly reduced the incidence of subsequent visceral and progressive cutaneous dissemination. Pain subsided faster in acyclovir recipients, and fewer reported PHN, but these differences were not statistically significant. In patients with mild immunocompromise and localized herpes zoster, oral famciclovir or valacyclovir will usually suffice.[146,147] A randomized, controlled trial of oral famciclovir versus oral acyclovir in patients with localized herpes zoster following bone marrow or organ transplantation or cancer chemotherapy showed that both treatments were equivalent in rash healing and loss of acute pain, and were well tolerated.[147] However, oral famciclovir or valacyclovir are preferable to oral acyclovir.

ANTIINFLAMMATORY THERAPY

The possibility that inflammation within the sensory ganglion and contiguous neural structures contributes to PHN provided the rationale for the use of glucocorticoids during the acute phase of herpes zoster. Randomized controlled trials, however, showed that the addition of glucocorticoids to acyclovir did not change the incidence of chronic pain.[148-150] However, glucocorticoids did reduce acute pain in most trials, and in one trial of acyclovir and prednisone, the time to uninterrupted sleep, return to baseline daily activity, and cessation of analgesic therapy was reduced in patients who received glucocorticoids.[149] Consequently, some experts advocate oral glucocorticoids for otherwise healthy older adults whose rash is complicated by moderate-to-severe pain and who have no contraindications to glucocorticoids.[137] Others believe that the common adverse effects of glucocorticoids outweigh their benefits, and argue against their routine use in older patients with herpes zoster. We agree and do not recommend the use of glucocorticoids in this setting.

ANALGESICS

Greater severity of acute pain is a risk factor for PHN, and acute pain may contribute to central sensitization and the genesis of chronic pain. Therefore, aggressive pain control is both reasonable and humane.[137] The severity of acute herpes zoster pain should be determined using standardized pain scales. Clinicians should prescribe analgesics with the goal of limiting the severity of pain to less than 3 on a 0-to-10 scale, and to a level of pain that does not interfere with sleep. The choice, dosage, and schedule of drugs are governed by the patient's pain severity, underlying conditions, and response to and side effects of specific drugs. A randomized controlled trial of oxycodone, gabapentin, or placebo in older adults during the early phase of herpes zoster showed that oxycodone, but not gabapentin, provided significantly greater pain relief than placebo in patients with moderate-to-severe pain.[151] This trial was not powered to analyze PHN, and there are no other controlled trials of the effect of treatment with opioids or gabapentin during the acute phase of herpes zoster on the subsequent development of PHN. A crossover study of a single dose of 900 mg of gabapentin during the acute phase of herpes zoster showed greater pain relief than placebo.[152] If pain control remains inadequate, regional or local anesthetic nerve blocks should be considered for acute pain control.[137,153] A randomized controlled trial demonstrated that a single epidural injection of corticosteroids and local anesthetics in the acute phase of herpes zoster reduced acute pain but did not prevent the subsequent development of PHN.[153]

TREATMENT OF POSTHERPETIC NEURALGIA

PHN is difficult to treat. Fortunately, it resolves spontaneously in most patients, although this often requires several months (Fig. 165-1C). Severity and duration of PHN are a function of age. Clinicians have advocated a wide range of treatments, including many oral and topical medications, epidural injection of local anesthetic and glucocorticoids, acupuncture, biofeedback, subcutaneous injections of triamcinolone, transepidermal electrical nerve stimulation, spinal cord stimulators, and systemic administration of a variety of compounds, but most have not been validated by controlled trials. The results of randomized controlled trials demonstrated efficacy for pain relief in PHN for the following drugs: gabapentin, pregabalin, tricyclic antidepressants, opioid analgesics, tramadol, 5% lidocaine patch, and high-concentration capsaicin patch.[154-157] The choice among these medications should be guided by the adverse event profiles, potential for drug interactions, patient comorbidities, and treatment preferences. On average, these agents provide adequate pain relief (defined as reduction of pain to below 3 on a 0- to 10-point scale or by 50% on a visual analog scale) in 30% to 60% of patients. These modalities are now recommended as evidence-based pharmacotherapy for PHN as described in more detail in practice management guidelines.[154,155,158-160]

PREVENTION

PREVENTION OF VARICELLA

VARICELLA VACCINE

Live attenuated Oka VZV varicella vaccines are immunogenic and efficacious in protecting susceptible children against varicella. Similar results were obtained in susceptible adults when 2 doses were given 4 to 8 weeks apart. Vaccinated children and adults developed breakthrough varicella caused by wildtype VZV at a rate of 1% to 3% per year (cumulative ~15%) compared to an attack rate of 8% to 13% per year in unvaccinated children.[161] Breakthrough varicella is relatively mild, with fewer lesions and milder constitutional

symptoms. The FDA licensed the Oka/Merck varicella vaccine in the United States in 1995. In 2005, the FDA approved a combined measles, mumps, rubella, and varicella (MMRV) vaccine for routine immunization of children 12 months to 12 years of age.

Because of the frequency of breakthrough varicella, the CDC Advisory Committee on Immunization Practices (ACIP) now recommends two 0.5-mL doses of varicella vaccine for healthy children aged ≥12 months, and for all adolescents and adults without evidence of immunity.[162] Because of the increased severity of varicella in adults, all susceptible adults should be identified and vaccinated. Particular effort should be devoted to identifying and vaccinating susceptible adults who may be at increased risk for exposure or transmission, including (1) health care providers, (2) household contacts who might infect immunocompromised persons, or susceptible pregnant women, (3) persons who live or work in environments in which transmission of VZV is likely (eg, teachers, day care employees, residents, and staff in institutional settings), (4) persons who live or work in environments in which transmission has been reported (eg, college students, inmates and staff members of correctional institutions, and military personnel), (5) nonpregnant women of childbearing age, (6) adolescents and adults living in households with children, and (7) international travelers. Second-dose catch-up varicella vaccination is recommended for children, adolescents, and adults who previously received only 1 dose.[66,163]

The immunity to varicella induced by varicella vaccine is not as solid as that induced by wildtype VZV infection, and the duration of vaccine-induced immunity is not yet known. However, a high percentage of children followed long-term have remained seropositive.[164] Recent experience in clinical practice indicates that vaccine effectiveness in children is modestly lower than vaccine efficacy in clinical trials, and outbreaks of breakthrough varicella in schools and day care centers still occur.[163,165-167] Several studies have indicated that vaccine effectiveness declines over 10 years.[168] A CDC analysis of 10 years of surveillance data for varicella (1995-2004) showed that the annual rate of breakthrough varicella increased with time since vaccination, from 1.6 cases per 1000 person-years within 1 year after vaccination to 9.0 cases per 1000 person-years at 5 years and 58.2 cases per 1000 person-years at 9 years.[168] Although most breakthrough varicella in children is characterized by mild disease, more recent reports indicate that 25% to 30% of breakthrough cases are not mild, are clinically similar to varicella in unvaccinated children,[169] and are often as contagious as cases in unvaccinated persons.

Varicella vaccine is remarkably safe and well tolerated, causing mainly minor rashes and injection site reactions.[169] Serious adverse events have been rare (2.6/100,000 doses distributed) and, in the majority of cases, a causal relationship between the serious adverse event and varicella vaccine could not be established.

Herpes zoster occurs in vaccinees, but at a lower rate than herpes zoster following varicella caused by wildtype VZV. Cases of laboratory-confirmed herpes zoster in vaccinees include cases caused by reactivation of vaccine virus and many cases caused by reactivation of wildtype VZV that established latent infection during unrecognized varicella acquired prior to or after vaccination.[82]

Among children <18 years of age in a managed care plan, the incidence of herpes zoster was 79% lower among recipients of varicella vaccine than among unvaccinated children. Half of the cases of herpes zoster in vaccinated children were caused by Oka vaccine VZV and half were caused by wildtype VZV, whereas all cases of herpes zoster in unvaccinated children were caused by wildtype VZV.[82]

POSTEXPOSURE PROPHYLAXIS AND INFECTION CONTROL

Patients with varicella and herpes zoster often transmit VZV to susceptible individuals. When exposure is recognized (risk period of 1-2 days before rash until crusting is well under way), preventive measures include varicella vaccine, high-titer varicella-zoster immune globulin (VARIZIG), and postexposure chemoprophylaxis with acyclovir.

Active immunization with varicella vaccine is effective in preventing illness or modifying varicella severity in immunocompetent children if administered within 3 days after exposure.[170] Comparable information is not available for immunocompromised patients. An alternative for these patients is VARIZIG, a purified human immune globulin prepared from plasma containing high levels of immunoglobulin G antibody to VZV. This product may be considered for patients who have been exposed to varicella and are at increased risk for severe disease and complications.[171] It is dosed on a weight basis and should be given as soon as possible, preferably with 96 hours of exposure, although current recommendations permit an interval of up to 10 days.[172]

Whereas protection afforded by VARIZIG is transient, varicella vaccine induces long-lasting VZV immunity and protection against subsequent exposures. Therefore, the ACIP recommends varicella vaccine for postexposure prophylaxis in unvaccinated susceptible immunocompetent persons.[162] Varicella vaccine is also much less expensive than VARIZIG.

Chemoprophylaxis with acyclovir also has been studied in susceptible children following household exposure to varicella. Children who received postexposure treatment with acyclovir had either no varicella or experienced fewer and less severe cases of varicella than children in the control group.[173] However, appropriate timing is critical, and immunity to varicella may not be achieved, especially with early postexposure treatment. Reported experience with postexposure treatment with acyclovir is lacking in immunocompromised patients. Oral famciclovir or valacyclovir are preferable to oral acyclovir for postexposure chemoprophylaxis.

The importance of infection control practices for VZV varies with the age and immune status of the

exposed susceptible individual. It is not imperative to prevent exposure of susceptible normal children to VZV, but exposure of immunocompromised patients, newborn infants, and adults, particularly women of childbearing age, should be avoided. Exposure of susceptible immunocompromised patients to VZV warrants reduction in the dosage of glucocorticoids and other immunosuppressive drugs, and administration of VariZIG. Hospital and long-term care facility personnel without a clear history of varicella or herpes zoster should be tested for antibody to VZV prior to employment, and susceptible personnel vaccinated against varicella. Appropriate leave from work should be instituted following VZV exposure of any susceptible personnel who are not vaccinated. In hospitals, airborne and contact precautions are recommended for patients with varicella, immunocompromised patients with localized herpes zoster, and any patient with disseminated herpes zoster until all lesions are crusted.[174] Contact precautions are recommended for immunocompetent patients with localized herpes zoster.

PREVENTION OF HERPES ZOSTER

Until universal varicella vaccination greatly reduces the number of people latently infected with wildtype VZV, prevention of herpes zoster must be aimed at preventing reactivation of latent VZV that results in clinical disease. Long-term suppressive acyclovir treatment is only practical in immunocompromised patients at proven risk of developing herpes zoster within a defined time period, for example, in the year following bone marrow or solid organ transplantation.

LIVE ATTENUATED ZOSTER VACCINE

Live attenuated Oka VZV zoster vaccines (ZVL) boost VZV-specific cellular immunity in older adults sufficiently to prevent or attenuate herpes zoster.[108] The clinical rationale for zoster vaccine is the substantial morbidity of herpes zoster in older adults and the need to initiate antiviral therapy within 72 hours of rash onset for maximum benefit; even then, antiviral therapy does not prevent PHN. In addition, treatment of PHN is often ineffective and poorly tolerated by older adults.

In 2006, the ACIP recommended routine administration of live attenuated Oka/Merck strain VZV zoster vaccine (ZVL; Zostavax®) to adults 60 years of age and older for the prevention of herpes zoster and its complications, particularly PHN.[37] This recommendation is based on the results of the Shingles Prevention Study, a randomized, double-blind, placebo controlled VA Cooperative Study conducted in 38,546 community-dwelling adults ≥60 years of age at 22 study sites across the continental United States.[28] ZVL reduced the burden of illness due to herpes zoster (a clinically relevant measure of the adverse impact of herpes zoster) by 61.1%; reduced the incidence of clinically significant PHN by 66.5%; and reduced the incidence of herpes zoster by 51.3%. Clinically significant PHN is defined as pain and discomfort (eg, allodynia, severe pruritus) due to herpes zoster scored as ≥3 on a 0-10 scale that persists for more than 90 days after rash onset. ZVL also decreased the adverse impact of herpes zoster on capacity to perform activities of daily living and health-related quality of life.[175] Reactions at the injection site were more frequent among vaccine recipients but were generally mild. The proportion of subjects reporting serious adverse events, and rates of hospitalization and death were comparable in vaccine and placebo recipients.[28,176]

Long-term followup studies of Shingles Prevention Study participants demonstrated that ZVL efficacy for herpes zoster burden of illness and incidence of herpes zoster declined over time, but persisted through 5 to 7 years postvaccination, declining markedly thereafter.[177,178] ZVL efficacy for herpes zoster burden of illness was 61.1% from 0.0 to 4.9 years postvaccination, 50.1% from 3.3 to 7.8 years postvaccination, and 58.6% from 0.0 to 7.8 years postvaccination. Comparable figures for incidence of herpes zoster were 51.3%, 39.6%, and 48.7%, and for incidence of PHN were 66.5%, 60.1%, and 64.9%.

A number of retrospective reviews of the use of ZVL in "real world" practice settings using electronic records from large integrated health care organizations and administrative medical claims databases showed very similar results for vaccine effectiveness for the incidence of herpes zoster.[179-185] These studies confirmed declines in effectiveness of ZVL for incidence of herpes zoster similar to those demonstrated in the Shingles Prevention Study and its Persistence Substudies.[28,177,178] However, ZVL effectiveness in persons vaccinated when they were ≥70 years of age was similar to vaccine effectiveness in younger vaccinees; furthermore, ZVL effectiveness for PHN was higher and better preserved over time than for incidence of herpes zoster.[181-184] In addition, ZVL reduced the duration and severity of pain in vaccinees who developed herpes zoster, reduced the incidence of ophthalmic zoster, and reduced the incidence and severity of prodromal pain.[179,185] Although these data suggest that a second dose of ZVL may be needed, and a second dose of ZVL administered ≥10 years after the initial dose did significantly boost VZV-specific immune responses,[186] there is currently no recommendation for revaccination from the ACIP.[187] In a large, randomized, placebo-controlled trial, the efficacy of ZVL for incidence of herpes zoster in 50- to 59-year-old individuals was 69.8%, which led to expansion of FDA licensure to include this age group.[188] However, the ACIP did not modify the recommendation to administer ZVL at ≥60 years of age. Neither the FDA nor the ACIP have set an upper age limit for the use of ZVL. Older individuals are at highest risk for herpes zoster and PHN, and reduction in herpes zoster pain, severity, and duration occurs in very old recipients of ZVL even when herpes zoster is not prevented.[28,181]

Although highly attenuated, ZVL is contraindicated in immunocompromised persons.

Nevertheless, it has been administered to a number of immunocompromised patients, with very rare adverse events.[180,189-199] With more than 30 million doses administered to persons ≥60 years of age in the United States since 2006, more than 10 million doses administered to persons ≥70 years of age in the United Kingdom since 2010, and additional doses in Japan and other countries, ZVL has proven to have a remarkable safety profile.[184,200]

ZVL may be administered without screening for a history of varicella or herpes zoster, or serologic testing for varicella immunity.[37] Persons known to be VZV seronegative should be vaccinated against varicella according to current recommendations.[162] Older adults who have PHN or who have a current episode of herpes zoster may ask to be vaccinated, but ZVL is not indicated to treat acute herpes zoster or PHN. Some patients may want to receive ZVL after a recent episode of herpes zoster has resolved. The optimal time to immunize an individual after a recent episode of herpes zoster is unknown, and the clinical diagnosis of herpes zoster is not always correct. The authors believe that an interval of 2 to 3 years after onset of a well-documented case of herpes zoster is reasonable. Administration of ZVL to Shingles Prevention Study placebo recipients 5 to 85 months after documented herpes zoster was safe and well tolerated.[201]

When considering ZVL, older adults may express concerns about transmission of vaccine virus to other individuals, but transmission of vaccine virus from recipients of ZVL to susceptible household contacts has not been documented. Thus, immunocompetent older adults in contact with immunocompromised patients should receive ZVL to reduce the risk that they will develop herpes zoster and transmit wild-type VZV to their susceptible immunocompromised contacts.[37,108] For the same reasons, older adult contacts of susceptible pregnant women and infants should receive zoster vaccine. ZVL recipients with susceptible pregnant or immunocompromised contacts need not take any special precautions following vaccination, except in the rare situation that a vesicular rash develops, in which case standard contact precautions are adequate.[37] In the very unlikely event that an immunocompromised contact develops a significant illness caused by vaccine virus, he or she can be treated with antiviral agents.

ADJUVANTED GLYCOPROTEIN E SUBUNIT ZOSTER VACCINE

A new adjuvanted recombinant VZV subunit zoster vaccine (RZV; Shingrix®) consisting of recombinant VZV glycoprotein E (gE) and a powerful $AS01_B$ adjuvant system was approved in October 2017 by the US FDA for the prevention of herpes zoster in adults ≥50 years of age. RZV is administered intramuscularly on a 2-dose schedule with a 2- to 6-month interval.[202] The ACIP has recommended RZV for prevention of herpes zoster in immunocompetent adults ≥50 years of age, with preference for RZV over ZVL for initial immunization and for administration to older adults who have already received ZVL.[203] VZV gE is a major component of the virus envelope that is essential for virus replication and cell-to-cell spread and is a major target for VZV-specific $CD4^+$ T-cell responses. $AS01_B$ is a liposome-based adjuvant system that contains monophosphoryl lipid A (a Toll-like receptor 4 agonist) and the saponin QS21 (a purified extract from the *Quillaja saponaria* tree). QS21 stimulates strong humoral and $CD4^+$ T-cell responses to gE.[204] A number of Phase I, I/II, and II studies established that 2 doses of RZV formulated with 50 µg of gE and $AS01_B$ containing 50 µg monophosphoryl lipid A and 50 µg QS21 administered 2 months apart induced strong immune responses to gE that, on the basis of a small followup study, appear to decline significantly over the first 3 years postvaccination and then persist above baseline levels for at least 9 years.[205,206] The VZV/gE-specific $CD4^+$ T-cell and humoral responses induced by RZV were much more robust and long-lasting than those induced by ZVL, and addition of an Oka varicella vaccine did not increase the magnitude or durability of the immune responses to RZV.[204]

Two large blinded randomized placebo-controlled Phase III trials conducted concurrently at the same sites in 18 countries assessed the safety and efficacy of 2 doses of RZV administered intramuscularly 2 months apart in adults ≥50 years of age (ZOE-50; 15,411 participants) and ≥70 years of age (ZOE-70; 13,900 participants).[207,208] In ZOE-50 and ZOE-70, subjects were stratified into decades (50-59, 60-69, and ≥70 years) and (70-79 and ≥80 years), respectively; the study design was similar to that of the Shingles Prevention Study, except that T cell–mediated immune responses were measured by enumerating T cells expressing ≥2 of 4 activation markers: interferon-γ, interleukin-2, tumor necrosis factor-α, and CD40 ligand[207,208] rather than by responder cell frequency and ELISPOT.[28,209,210] In ZOE-50, during a mean followup of 3.2 years, RZV had an overall efficacy for incidence of herpes zoster of 97.2%, with no decrement in the ≥70-year age group.[207] Solicited and unsolicited adverse events were reported in 84.4% of RZV recipients and 37.8% of placebo recipients. Most were mild to moderate intensity, but 17.0% in RZV recipients and 3.2% in placebo recipients prevented normal everyday activities (grade 3). These were mostly injection-site reactions (pain, redness, swelling) in 81.5% of RZV recipients (9.5% grade 3) and 11.9% of placebo recipients (0.4% grade 3), and systemic reactions (myalgia, fatigue, headache, shivering, fever, and GI symptoms) in 66.1% of RZV recipients (11.4% grade 3) and 29.5% of placebo recipients (2.4% grade 3).[207]

In ZOE-70, during a mean followup of 3.7 years, RZV efficacy for incidence of herpes zoster was 89.8%; 90.0% in 70- to 79-year-olds and 89.1% in those ≥80 years of age.[208] In a pooled analysis of data from subjects ≥70 years of age in ZOE-50 and ZOE-70 (15,596 subjects), RZV efficacy for incidence of herpes zoster was 91.3% and for PHN was 88.8%. Adverse reactions were similar to those reported in ZOE-50, but tended

to be less frequent among subjects ≥80 years of age than among younger subjects. Incidence of serious adverse events and potential immune-mediated diseases were similar in the RZV and placebo recipients.[208] Most were mild to moderate intensity, but 11.9% in RZV recipients and 2.0% in placebo recipients prevented normal everyday activities (grade 3). These were mostly injection-site reactions (pain, redness, swelling) in 74.1% of RZV recipients (8.5% grade 3) and 9.9% of placebo recipients (0.2% grade 3), and systemic reactions (myalgia, fatigue, headache, shivering, fever, and GI symptoms) in 53.0% of RZV recipients (6.0% grade 3) and 25.1% of placebo recipients (2.0% grade 3).[208]

Because RZV contains only the gE subunit of VZV, it is incapable of replication, and there is no danger of vaccine virus replication causing disease. A number of Phase I, I/II, and small Phase III studies have demonstrated that RZV is safe and immunogenic in persons with various immunosuppressive conditions, including HIV infection and hematopoietic cell transplant recipients.[211,212] RZV can be safely coadministered with other vaccines,[213] to persons previously vaccinated with ZVL,[214] and to persons with previous herpes zoster.[215] Although no results are available from head-to-head studies, RZV appears to be substantially more immunogenic in persons previously immunized with ZVL than a booster dose of ZVL.[186,214] Table 165-5 summarizes the current ACIP recommendations.

The development and clinical evaluation of RZV are summarized in an excellent review by Cunningham and Heineman,[217] in which pooled data from ZOE-50 and ZOE-70 indicate that overall RZV efficacy for incidence of herpes zoster declines from 97.6% in year 1 to 87.9% in year 4 postvaccination. If that rate of decline continues, persons vaccinated with RZV at 50 years of age, as recommended by the ACIP may require additional immunization to ensure an adequate level of protection later in life when the incidence and severity of herpes zoster and PHN are markedly increased.

Although the absence of recognized autoimmune diseases in RZV recipients followed for approximately 4 years postvaccination is encouraging, it does not eliminate the theoretical concern that the powerful $AS01_B$ adjuvant system might induce or aggravate autoimmune diseases, especially because the interval between their initiation and clinical recognition may be many years. At this point, it is incumbent on the US FDA, to ensure that large, well-designed, and relevant Phase IV postmarketing studies are expeditiously completed.[218,219]

TABLE 165-5

Recommendations for the Use of Herpes Zoster Vaccines (2018 ACIP Recommendations)[203]

1. Recombinant zoster vaccine (RZV) is recommended for the prevention of herpes zoster and related complications for immunocompetent adults aged ≥50 y. RZV is administered in 2 doses 2-6 mo apart.
2. RZV is recommended for the prevention of herpes zoster and related complications for immunocompetent adults who previously received live attenuated zoster vaccine (ZVL). RZV should not be administered <2 mo after receipt of ZVL.
3. RZV is preferred over ZVL for the prevention of herpes zoster and related complications.

Note: These recommendations serve as a supplement to the existing recommendations for the use of ZVL in immunocompetent adults aged ≥60 y. RZV can be administered concomitantly, at different anatomic sites, with other adult vaccines.[216]

ACKNOWLEDGMENTS

Dedicated to the memory of Stephen E. Straus, a coauthor of this chapter in previous editions and to Michiaki Takahashi who developed the attenuated Oka strain of VZV used in all live attenuated zoster and varicella vaccines.

MNO is grateful to M. Ashbaugh and W. Buchanan for assistance with the figures, to R. Harbecke and D. Mussatto for useful discussion and invaluable assistance with manuscript preparation, and for the support of the Veterans Medical Research Foundation and the James R. and Jesse V. Scott Fund for Shingles Research.

REFERENCES

1. Hope-Simpson RE. The nature of herpes zoster: a long-term study and a new hypothesis. *Proc R Soc Med.* 1965;58:9-20.
2. Garland J. Varicella following exposure to herpes zoster. *N Engl J Med.* 1943;228:336-337.
3. Kundratitz K. Experimentelle Übertragung von Herpes zoster auf den Menschen und die Beziehungen von Herpes zoster zu Varicellen. *Monatsschrift für Kinderheilkunde.* 1925;129:516-22.
4. Lipschütz B, Kundratitz K. Über die Ätiologie des Zoster und über seine Beziehungen zu Varicellen. *Wien klin Wochenschr.* 1925;38:499-503.
5. Bruusgaard E. The mutual relation between zoster and varicella. *Br J Dermatol.* 1932;44:1-24.
6. Weller TH, Witton HM. The etiologic agents of varicella and herpes zoster; serologic studies with the viruses as propagated in vitro. *J Exp Med.* 1958;108(6):869-890.
7. Straus SE, Reinhold W, Smith HA, et al. Endonuclease analysis of viral DNA from varicella and subsequent zoster infections in the same patient. *N Engl J Med.* 1984;311(21):1362-1364.
8. Choo PW, Donahue JG, Manson JE, et al. The epidemiology of varicella and its complications. *J Infect Dis.* 1995;172(3):706-712.
9. Seward J, Galil K, Wharton M. Epidemiology of varicella. In: Arvin AM, Gershon AA, eds. *Varicella-Zoster Virus Virology and Clinical Management*. Cambridge, UK: Cambridge University Press; 2000:187.
10. Kilgore PE, Kruszon-Moran D, Seward JF, et al. Varicella in Americans from NHANES III: implications for control through routine immunization. *J Med Virol.* 2003;70(suppl 1):S111-S118.
11. Longfield JN, Winn RE, Gibson RL, et al. Varicella outbreaks in Army recruits from Puerto Rico. Varicella susceptibility in a population from the tropics. *Arch Intern Med.* 1990;150(5):970-973.
12. Seither R, Calhoun K, Street EJ, et al. Vaccination coverage for selected vaccines, exemption rates, and provisional enrollment among children in

kindergarten—United States, 2016–17 school year. *MMWR Morb Mortal Wkly Rep.* 2017;66(40):1073-1080.
13. Jumaan AO, Yu O, Jackson LA, et al. Incidence of herpes zoster, before and after varicella-vaccination-associated decreases in the incidence of varicella, 1992-2002. *J Infect Dis.* 2005;191(12):2002-2007.
14. Davis MM, Patel MS, Gebremariam A. Decline in varicella-related hospitalizations and expenditures for children and adults after introduction of varicella vaccine in the United States. *Pediatrics.* 2004;114(3): 786-792.
15. Bialek SR, Perella D, Zhang J, et al. Impact of a routine two-dose varicella vaccination program on varicella epidemiology. *Pediatrics.* 2013;132(5):e1134-e1140.
16. Leung J, Harpaz R. Impact of the maturing varicella vaccination program on varicella and related outcomes in the United States: 1994-2012. *J Pediatric Infect Dis Soc.* 2016;5(4):395-402.
17. Marin M, Zhang JX, Seward JF. Near elimination of varicella deaths in the US after implementation of the vaccination program. *Pediatrics.* 2011;128(2): 214-220.
18. Lopez AS, Zhang J, Marin M. Epidemiology of varicella during the 2-dose varicella vaccination program—United States, 2005-2014. *MMWR Morb Mortal Wkly Rep.* 2016;65(34):902-905.
19. Nguyen HQ, Jumaan AO, Seward JF. Decline in mortality due to varicella after implementation of varicella vaccination in the United States. *N Engl J Med.* 2005;352(5):450-458.
20. Marin M, Marti M, Kambhampati A, et al. Global varicella vaccine effectiveness: a meta-analysis. *Pediatrics.* 2016;137(3):e20153741.
21. Ross AH. Modification of chicken pox in family contacts by administration of gamma globulin. *N Engl J Med.* 1962;267:369-376.
22. White CJ, Kuter BJ, Hildebrand CS, et al. Varicella vaccine (VARIVAX) in healthy children and adolescents: results from clinical trials, 1987 to 1989. *Pediatrics.* 1991;87(5):604-610.
23. Levin MJ. Varicella-zoster virus and virus DNA in the blood and oropharynx of people with latent or active varicella-zoster virus infections. *J Clin Virol.* 2014;61(4):487-495.
24. Arvin AM, Korpchak CM, Wittek AE. Immunologic evidence of reinfection with varicella-zoster virus. *J Infect Dis.* 1983;148(2):200-205.
25. Schimpff S, Serpick A, Stoler B, et al. Varicella-Zoster infection in patients with cancer. *Ann Intern Med.* 1972;76(2):241-254.
26. Yawn BP, Gilden D. The global epidemiology of herpes zoster. *Neurology.* 2013;81(10):928-930.
27. Kawai K, Gebremeskel BG, Acosta CJ. Systematic review of incidence and complications of herpes zoster: towards a global perspective. *BMJ Open.* 2014;4(6):e004833.
28. Oxman MN, Levin MJ, Johnson GR, et al. A vaccine to prevent herpes zoster and postherpetic neuralgia in older adults. *N Engl J Med.* 2005;352(22):2271-2284.
29. Oxman MN. Immunization to reduce the frequency and severity of herpes zoster and its complications. *Neurology.* 1995;45:S41-S46.
30. Ragozzino MW, Melton LJ 3rd, Kurland LT, et al. Population-based study of herpes zoster and its sequelae. *Medicine (Baltimore).* 1982;61(5):310-316.
31. Schmader K, George LK, Burchett BM, et al. Racial differences in the occurrence of herpes zoster. *J Infect Dis.* 1995;171(3):701-704.
32. Thomas SL, Hall AJ. What does epidemiology tell us about risk factors for herpes zoster? *Lancet Infect Dis.* 2004;4(1):26-33.
33. Yawn BP, Saddier P, Wollan PC, et al. A population-based study of the incidence and complication rates of herpes zoster before zoster vaccine introduction. *Mayo Clin Proc.* 2007;82(11):1341-1349.
34. Schmader K, Gnann JW Jr, Watson CP. The epidemiological, clinical, and pathological rationale for the herpes zoster vaccine. *J Infect Dis.* 2008;197(suppl 2):S207-S215.
35. Insinga RP, Itzler RF, Pellissier JM, et al. The incidence of herpes zoster in a United States administrative database. *J Gen Intern Med.* 2005;20(8):748-753.
36. Donahue JG, Choo PW, Manson JE, et al. The incidence of herpes zoster. *Arch Intern Med.* 1995; 155(15):1605-1609.
37. Harpaz R, Ortega-Sanchez IR, Seward JF. Prevention of herpes zoster: recommendations of the Advisory Committee on Immunization Practices (ACIP). *MMWR Recomm Rep.* 2008;57(RR-5):1-30; quiz CE2-CE4.
38. Cohen JI. Herpes zoster. *N Engl J Med.* 2013;369(3): 255-263.
39. Cohen JI. A new vaccine to prevent herpes zoster. *N Engl J Med.* 2015;372(22):2149-2150.
40. Forbes HJ, Bhaskaran K, Thomas SL, et al. Quantification of risk factors for herpes zoster: population based case-control study. *BMJ.* 2014;348:g2911.
41. Yun H, Yang S, Chen L, et al. Risk of herpes zoster in autoimmune and inflammatory diseases: implications for vaccination. *Arthritis Rheumatol.* 2016;68(9): 2328-2337.
42. Kawai K, Yawn BP. Risk factors for herpes zoster: a systematic review and meta-analysis. *Mayo Clin Proc.* 2017;92(12):1806-1821.
43. Strangfeld A, Listing J, Herzer P, et al. Risk of herpes zoster in patients with rheumatoid arthritis treated with anti-TNF-alpha agents. *JAMA.* 2009;301(7):737-744.
44. Buchbinder SP, Katz MH, Hessol NA, et al. Herpes zoster and human immunodeficiency virus infection. *J Infect Dis.* 1992;166(5):1153-1156.
45. Engels EA, Rosenberg PS, Biggar RJ. Zoster incidence in human immunodeficiency virus-infected hemophiliacs and homosexual men, 1984-1997. District of Columbia Gay Cohort Study. Multicenter Hemophilia Cohort Study. *J Infect Dis.* 1999;180(6):1784-1789.
46. Thomas SL, Wheeler JG, Hall AJ. Case-control study of the effect of mechanical trauma on the risk of herpes zoster. *BMJ.* 2004;328(7437):439.
47. Haanpaa M, Nurmikko T, Hurme M. Polymorphism of the IL-10 gene is associated with susceptibility to herpes zoster. *Scand J Infect Dis.* 2002;34(2): 112-114.
48. Hicks LD, Cook-Norris RH, Mendoza N, et al. Family history as a risk factor for herpes zoster: a case-control study. *Arch Dermatol.* 2008;144(5):603-608.
49. Hernandez PO, Javed S, Mendoza N, et al. Family history and herpes zoster risk in the era of shingles vaccination. *J Clin Virol.* 2011;52(4):344-348.
50. Lai YC, Yew YW. Risk of herpes zoster and family history: a meta-analysis of case-control studies. *Indian J Dermatol.* 2016;61(2):157-162.
51. Joon Lee T, Hayes S, Cummings DM, et al. Herpes zoster knowledge, prevalence, and vaccination rate by race. *J Am Board Fam Med.* 2013;26(1):45-51.
52. Yawn BP, Wollan PC, Kurland MJ, et al. Herpes zoster recurrences more frequent than previously reported. *Mayo Clin Proc.* 2011;86(2):88-93.

53. Tseng HF, Chi M, Smith N, et al. Herpes zoster vaccine and the incidence of recurrent herpes zoster in an immunocompetent elderly population. *J Infect Dis.* 2012;206(2):190-196.
54. Sundriyal D, Kapoor R, Kumar N, et al. Multidermatomal herpes zoster. *BMJ Case Rep.* 2014;2014.
55. Kalman CM, Laskin OL. Herpes zoster and zosteriform herpes simplex virus infections in immunocompetent adults. *Am J Med.* 1986;81(5):775-778.
56. Viner K, Perella D, Lopez A, et al. Transmission of varicella zoster virus from individuals with herpes zoster or varicella in school and day care settings. *J Infect Dis.* 2012;205(9):1336-1341.
57. Lopez AS, Burnett-Hartman A, Nambiar R, et al. Transmission of a newly characterized strain of varicella-zoster virus from a patient with herpes zoster in a long-term-care facility, West Virginia, 2004. *J Infect Dis.* 2008;197(5):646-653.
58. Leclair JM, Zaia JA, Levin MJ, et al. Airborne transmission of chickenpox in a hospital. *N Engl J Med.* 1980;302(8):450-453.
59. Kawai K, Yawn BP, Wollan P, et al. Increasing incidence of herpes zoster over a 60-year period from a population-based study. *Clin Infect Dis.* 2016;63(2):221-226.
60. Brisson M, Edmunds WJ, Law B, et al. Epidemiology of varicella zoster virus infection in Canada and the United Kingdom. *Epidemiol Infect.* 2001;127(2):305-314.
61. Russell ML, Schopflocher DP, Svenson L, et al. Secular trends in the epidemiology of shingles in Alberta. *Epidemiol Infect.* 2007;135(6):908-913.
62. Toyama N, Shiraki K. Epidemiology of herpes zoster and its relationship to varicella in Japan: a 10-year survey of 48,388 herpes zoster cases in Miyazaki prefecture. *J Med Virol.* 2009;81(12):2053-2058.
63. Leung J, Harpaz R, Molinari NA, et al. Herpes zoster incidence among insured persons in the United States, 1993-2006: evaluation of impact of varicella vaccination. *Clin Infect Dis.* 2011;52(3):332-340.
64. Hales CM, Harpaz R, Joesoef MR, et al. Examination of links between herpes zoster incidence and childhood varicella vaccination. *Ann Intern Med.* 2013;159(11):739-745.
65. Mullooly JP, Riedlinger K, Chun C, et al. Incidence of herpes zoster, 1997-2002. *Epidemiol Infect.* 2005;133(2):245-253.
66. Marin M, Guris D, Chaves SS, et al. Prevention of varicella: recommendations of the Advisory Committee on Immunization Practices (ACIP). *MMWR Recomm Rep.* 2007;56(RR-4):1-40.
67. Malavige GN, Jones L, Black AP, et al. Varicella zoster virus glycoprotein E-specific $CD4^+$ T cells show evidence of recent activation and effector differentiation, consistent with frequent exposure to replicative cycle antigens in healthy immune donors. *Clin Exp Immunol.* 2008;152(3):522-531.
68. Oxman MN. Clinical manifestations of herpes zoster. In: Arvin AM, Gershon AA, eds. *Varicella-Zoster Virus: Virology and Clinical Management*. Cambridge, UK: Cambridge University Press; 2000:246.
69. Stern ES. The mechanism of herpes zoster and its relation to chickenpox. *Br J Dermatol Syphylol.* 1937;49:263-271.
70. Wesselhoeft C. The differential diagnosis of chicken pox and smallpox. *N Engl J Med.* 1944;230(1):15-19.
71. Johnson CE, Stancin T, Fattlar D, et al. A long-term prospective study of varicella vaccine in healthy children. *Pediatrics.* 1997;100(5):761-766.
72. Aebi C, Ahmed A, Ramilo O. Bacterial complications of primary varicella in children. *Clin Infect Dis.* 1996;23(4):698-705.
73. Kiska DL, Thiede B, Caracciolo J, et al. Invasive group A streptococcal infections in North Carolina: epidemiology, clinical features, and genetic and serotype analysis of causative organisms. *J Infect Dis.* 1997;176(4):992-1000.
74. Patel RA, Binns HJ, Shulman ST. Reduction in pediatric hospitalizations for varicella-related invasive group A streptococcal infections in the varicella vaccine era. *J Pediatr.* 2004;144(1):68-74.
75. Wallace MR, Bowler WA, Murray NB, et al. Treatment of adult varicella with oral acyclovir. A randomized, placebo-controlled trial. *Ann Intern Med.* 1992;117(5):358-363.
76. Enders G, Miller E, Cradock-Watson J, et al. Consequences of varicella and herpes zoster in pregnancy: prospective study of 1739 cases. *Lancet.* 1994;343(8912):1548-1551.
77. Zhang HJ, Patenaude V, Abenhaim HA. Maternal outcomes in pregnancies affected by varicella zoster virus infections: population-based study on 7.7 million pregnancy admissions. *J Obstet Gynaecol Res.* 2015;41(1):62-68.
78. Meyers JD. Congenital varicella in term infants: risk reconsidered. *J Infect Dis.* 1974;129(2):215-217.
79. Morgan ER, Smalley LA. Varicella in immunocompromised children. Incidence of abdominal pain and organ involvement. *Am J Dis Child.* 1983;137(9):883-885.
80. CDC. Reye syndrome—United States, 1984. *MMWR Morb Mortal Wkly Rep.* 1985;34(1):13-16.
81. Liu GT, Urion DK. Pre-eruptive varicella encephalitis and cerebellar ataxia. *Pediatr Neurol.* 1992;8(1):69-70.
82. Weinmann S, Chun C, Schmid DS, et al. Incidence and clinical characteristics of herpes zoster among children in the varicella vaccine era, 2005-2009. *J Infect Dis.* 2013;208(11):1859-1868.
83. Lewis GW. Zoster sine herpete. *Br Med J.* 1958;2(5093):418-421.
84. Liesegang TJ. Herpes zoster ophthalmicus natural history, risk factors, clinical presentation, and morbidity. *Ophthalmology.* 2008;115(2)(suppl):S3-S12.
85. Katz J, Cooper EM, Walther RR, et al. Acute pain in herpes zoster and its impact on health-related quality of life. *Clin Infect Dis.* 2004;39(3):342-348.
86. Schmader KE, Sloane R, Pieper C, et al. The impact of acute herpes zoster pain and discomfort on functional status and quality of life in older adults. *Clin J Pain.* 2007;23(6):490-496.
87. Gilden DH, Kleinschmidt-DeMasters BK, LaGuardia JJ, et al. Neurologic complications of the reactivation of varicella-zoster virus. *N Engl J Med.* 2000;342(9):635-645.
88. Jung BF, Johnson RW, Griffin DR, et al. Risk factors for postherpetic neuralgia in patients with herpes zoster. *Neurology.* 2004;62(9):1545-1551.
89. Drolet M, Brisson M, Schmader KE, et al. The impact of herpes zoster and postherpetic neuralgia on health-related quality of life: a prospective study. *CMAJ.* 2010;182(16):1731-1736.
90. Johnson RW, Bouhassira D, Kassianos G, et al. The impact of herpes zoster and post-herpetic neuralgia on quality-of-life. *BMC Med.* 2010;8:37.
91. Baron R, Binder A, Wasner G. Neuropathic pain: diagnosis, pathophysiological mechanisms, and treatment. *Lancet Neurol.* 2010;9(8):807-819.
92. Gauthier A, Breuer J, Carrington D, et al. Epidemiology and cost of herpes zoster and post-herpetic

neuralgia in the United Kingdom. *Epidemiol Infect.* 2009;137(1):38-47.
93. Forbes HJ, Thomas SL, Smeeth L, et al. A systematic review and meta-analysis of risk factors for postherpetic neuralgia. *Pain.* 2016;157(1):30-54.
94. Wood MJ. Herpes zoster and pain. *Scand J Infect Dis Suppl.* 1991;80:53-61.
95. Chen JJ, Gershon AA, Li Z, et al. Varicella zoster virus (VZV) infects and establishes latency in enteric neurons. *J Neurovirol.* 2011;17(6):578-589.
96. Rosenblum WI, Hadfield MG. Granulomatous angiitis of the nervous system in cases of herpes zoster and lymphosarcoma. *Neurology.* 1972;22(4):348-354.
97. Bourdette DN, Rosenberg NL, Yatsu FM. Herpes zoster ophthalmicus and delayed ipsilateral cerebral infarction. *Neurology.* 1983;33(11):1428-1432.
98. Hilt DC, Buchholz D, Krumholz A, et al. Herpes zoster ophthalmicus and delayed contralateral hemiparesis caused by cerebral angiitis: diagnosis and management approaches. *Ann Neurol.* 1983;14(5):543-553.
99. Nagel MA, Gilden D. Developments in varicella zoster virus vasculopathy. *Curr Neurol Neurosci Rep.* 2016;16(2):12.
100. Gilden D, Cohrs RJ, Mahalingam R, et al. Neurological disease produced by varicella zoster virus reactivation without rash. *Curr Top Microbiol Immunol.* 2010;342:243-253.
101. Kennedy PG, Grinfeld E, Esiri MM. Absence of detection of varicella-zoster virus DNA in temporal artery biopsies obtained from patients with giant cell arteritis. *J Neurol Sci.* 2003;215(1-2):27-29.
102. Muratore F, Croci S, Tamagnini I, et al. No detection of varicella-zoster virus in temporal arteries of patients with giant cell arteritis. *Semin Arthritis Rheum.* 2017;47(2):235-240.
103. Ing EB, Ing R, Liu X, et al. Does herpes zoster predispose to giant cell arteritis: a geo-epidemiologic study. *Clin Ophthalmol.* 2018;12:113-118.
104. Buckingham EM, Foley MA, Grose C, et al. Identification of herpes zoster-associated temporal arteritis among cases of giant cell arteritis. *Am J Ophthalmol.* 2018;187:51-60.
105. Arvin AM, Gilden D. Varicella-zoster virus. In: Knipe DM, Howley PM, eds. *Fields Virology*. 6th ed. Philadelphia, PA: Lippincott Williams & Wilkins; 2013:2015-2057.
106. Breuer J, Grose C, Norberg P, et al. A proposal for a common nomenclature for viral clades that form the species varicella-zoster virus: summary of VZV Nomenclature Meeting 2008, Barts and the London School of Medicine and Dentistry, 24-25 July 2008. *J Gen Virol.* 2010;91(pt 4):821-828.
107. Jensen NJ, Rivailler P, Tseng HF, et al. Revisiting the genotyping scheme for varicella-zoster viruses based on whole-genome comparisons. *J Gen Virol.* 2017;98(6):1434-1438.
108. Oxman MN. Zoster vaccine: current status and future prospects. *Clin Infect Dis.* 2010;51(2):197-213.
109. Depledge DP, Yamanishi K, Gomi Y, et al. Deep sequencing of distinct preparations of the live attenuated varicella-zoster virus vaccine reveals a conserved core of attenuating single-nucleotide polymorphisms. *J Virol.* 2016;90(19):8698-8704.
110. Harbecke R, Oxman MN, Arnold BA, et al. A real-time PCR assay to identify and discriminate among wild-type and vaccine strains of varicella-zoster virus and herpes simplex virus in clinical specimens, and comparison with the clinical diagnoses. *J Med Virol.* 2009;81(7):1310-1322.
111. Ku CC, Besser J, Abendroth A, et al. Varicella-Zoster virus pathogenesis and immunobiology: new concepts emerging from investigations with the SCIDhu mouse model. *J Virol.* 2005;79(5):2651-2658.
112. Arvin AM. Humoral and cellular immunity to varicella-zoster virus: an overview. *J Infect Dis.* 2008;197(suppl 2):S58-S60.
113. Depledge DP, Ouwendijk WJD, Sadaoka T, et al. A spliced latency-associated VZV transcript maps antisense to the viral transactivator gene 61. *Nature Communications.* 2018;9:1167. doi: 10.1038/s41467-018-03569-2
114. Krause PR, Klinman DM. Varicella vaccination: evidence for frequent reactivation of the vaccine strain in healthy children. *Nat Med.* 2000;6(4):451-454.
115. Watson CP, Deck JH, Morshead C, et al. Post-herpetic neuralgia: further post-mortem studies of cases with and without pain. *Pain.* 1991;44(2):105-117.
116. Head H, Campbell AW. The pathology of herpes zoster and its bearing on sensory localisation. *Brain.* 1900;23(3):353-523.
117. Kost RG, Straus SE. Postherpetic neuralgia—pathogenesis, treatment, and prevention. *N Engl J Med.* 1996;335(1):32-42.
118. Rowbotham M, Baron R, Petersen KI, et al. Spectrum of pain mechanisms contributing to PHN. In: Watson CP, Gershon AA, eds. *Herpes Zoster and Postherpetic Neuralgia*. 2nd ed. Amsterdam: Elsevier; 2001:167.
119. Wallace MS, Oxman MN. Acute herpes zoster and postherpetic neuralgia. *Anesthesiol Clin North America.* 1997;15:371-405.
120. Fields HL, Rowbotham M, Baron R. Postherpetic neuralgia: irritable nociceptors and deafferentation. *Neurobiol Dis.* 1998;5(4):209-227.
121. Rowbotham MC, Petersen KL, Fields HL. Is postherpetic neuralgia more than one disorder? *Pain Forum.* 1998;7(4):231-237.
122. Levin MJ, Weinberg A, Schmid DS. Herpes simplex virus and varicella-zoster virus. In: Hayden RT, Wolk DM, Carroll KC, et al, eds. *Diagnostic Microbiology of the Immunocompromised Host*. 2nd ed. Washington, DC: American Society for Microbiology; 2016:135-156.
123. Boivin G, Mazzulli T, Petric M, et al. Diagnosis of viral infections. In: Richman DD, Whitley RJ, Hayden FG, eds. *Clinical Virology.* 3rd ed. Washington, DC: ASM Press; 2009:265.
124. Schmidt NJ, Gallo D, Devlin V, et al. Direct immunofluorescence staining for detection of herpes simplex and varicella-zoster virus antigens in vesicular lesions and certain tissue specimens. *J Clin Microbiol.* 1980;12(5):651-655.
125. Stein GE. Pharmacology of new antiherpes agents: famciclovir and valacyclovir. *J Am Pharm Assoc (Wash).* 1997;NS37(2):157-163.
126. Keizer HJ, De Bruijn EA, Tjaden UR, et al. Inhibition of fluorouracil catabolism in cancer patients by the antiviral agent (E)-5-(2-bromovinyl)-2′-deoxyuridine. *J Cancer Res Clin Oncol.* 1994;120(9):545-549.
127. Kawashima M, Nemoto O, Honda M, et al. Amenamevir, a novel helicase-primase inhibitor, for treatment of herpes zoster: a randomized, double-blind, valaciclovir-controlled phase 3 study. *J Dermatol.* 2017;44(11):1219-1227.
128. Dunkle LM, Arvin AM, Whitley RJ, et al. A controlled trial of acyclovir for chickenpox in normal children. *N Engl J Med.* 1991;325(22):1539-1544.

129. Klassen TP, Hartling L, Wiebe N, et al. Acyclovir for treating varicella in otherwise healthy children and adolescents. Cochrane Database Syst Rev. 2005;(4):CD002980.
130. Non-HIV Antiviral Drugs (Table 4.9) in Red Book; 2015 Report of the Committee on Infectious Diseases 30th ed. In: Kimberlin DW, Brady MT, Jackson MA, et al, eds. Elk Grove Village, IL: American Academy of Pediatrics; 2015.
131. Balfour HH Jr, Rotbart HA, Feldman S, et al. Acyclovir treatment of varicella in otherwise healthy adolescents. The Collaborative Acyclovir Varicella Study Group. *J Pediatr.* 1992;120(4, pt 1):627-633.
132. Ratanajamit C, Vinther Skriver M, Jepsen P, et al. Adverse pregnancy outcome in women exposed to acyclovir during pregnancy: a population-based observational study. *Scand J Infect Dis.* 2003;35(4): 255-259.
133. Pasternak B, Hviid A. Use of acyclovir, valacyclovir, and famciclovir in the first trimester of pregnancy and the risk of birth defects. *JAMA.* 2010;304(8):859-866.
134. Stone KM, Reiff-Eldridge R, White AD, et al. Pregnancy outcomes following systemic prenatal acyclovir exposure: conclusions from the international acyclovir pregnancy registry, 1984-1999. *Birth Defects Res A Clin Mol Teratol.* 2004;70(4):201-207.
135. Haake DA, Zakowski PC, Haake DL, et al. Early treatment with acyclovir for varicella pneumonia in otherwise healthy adults: retrospective controlled study and review. *Rev Infect Dis.* 1990;12(5):788-798.
136. Nyerges G, Meszner Z, Gyarmati E, et al. Acyclovir prevents dissemination of varicella in immunocompromised children. *J Infect Dis.* 1988;157(2):309-313.
137. Dworkin RH, Johnson RW, Breuer J, et al. Recommendations for the management of herpes zoster. *Clin Infect Dis.* 2007;44(suppl 1):S1-S26.
138. Tyring S, Barbarash RA, Nahlik JE, et al. Famciclovir for the treatment of acute herpes zoster: effects on acute disease and postherpetic neuralgia. A randomized, double-blind, placebo-controlled trial. Collaborative Famciclovir Herpes Zoster Study Group. *Ann Intern Med.* 1995;123(2):89-96.
139. Beutner KR, Friedman DJ, Forszpaniak C, et al. Valaciclovir compared with acyclovir for improved therapy for herpes zoster in immunocompetent adults. *Antimicrob Agents Chemother.* 1995;39(7): 1546-1553.
140. Tyring SK, Beutner KR, Tucker BA, et al. Antiviral therapy for herpes zoster: randomized, controlled clinical trial of valacyclovir and famciclovir therapy in immunocompetent patients 50 years and older. *Arch Fam Med.* 2000;9(9):863-869.
141. Degreef H. Famciclovir, a new oral antiherpes drug: results of the first controlled clinical study demonstrating its efficacy and safety in the treatment of uncomplicated herpes zoster in immunocompetent patients. *Int J Antimicrob Agents.* 1994;4(4): 241-246.
142. Cobo LM, Foulks GN, Liesegang T, et al. Oral acyclovir in the treatment of acute herpes zoster ophthalmicus. *Ophthalmology.* 1986;93(6):763-770.
143. Colin J, Prisant O, Cochener B, et al. Comparison of the efficacy and safety of valaciclovir and acyclovir for the treatment of herpes zoster ophthalmicus. *Ophthalmology.* 2000;107(8):1507-1511.
144. Tyring S, Engst R, Corriveau C, et al. Famciclovir for ophthalmic zoster: a randomised aciclovir controlled study. Br J Ophthalmol. 2001;85(5):576-581.
145. Balfour HH Jr, Bean B, Laskin OL, et al. Acyclovir halts progression of herpes zoster in immunocompromised patients. *N Engl J Med.* 1983;308(24):1448-1453.
146. Gnann JW Jr, Crumpacker CS, Lalezari JP, et al. Sorivudine versus acyclovir for treatment of dermatomal herpes zoster in human immunodeficiency virus-infected patients: results from a randomized, controlled clinical trial. Collaborative Antiviral Study Group/AIDS Clinical Trials Group, Herpes Zoster Study Group. *Antimicrob Agents Chemother.* 1998;42(5):1139-1145.
147. Tyring S, Belanger R, Bezwoda W, et al. A randomized, double-blind trial of famciclovir versus acyclovir for the treatment of localized dermatomal herpes zoster in immunocompromised patients. *Cancer Invest.* 2001;19(1):13-22.
148. Wood MJ, Johnson RW, McKendrick MW, et al. A randomized trial of acyclovir for 7 days or 21 days with and without prednisolone for treatment of acute herpes zoster. *N Engl J Med.* 1994;330(13):896-900.
149. Whitley RJ, Weiss H, Gnann JW Jr, et al. Acyclovir with and without prednisone for the treatment of herpes zoster. A randomized, placebo-controlled trial. The National Institute of Allergy and Infectious Diseases Collaborative Antiviral Study Group. *Ann Intern Med.* 1996;125(5):376-383.
150. He L, Zhang D, Zhou M, et al. Corticosteroids for preventing postherpetic neuralgia. *Cochrane Database Syst Rev.* 2008;(1):CD005582.
151. Dworkin RH, Barbano RL, Tyring SK, et al. A randomized, placebo-controlled trial of oxycodone and of gabapentin for acute pain in herpes zoster. *Pain.* 2009;142(3):209-217.
152. Berry JD, Petersen KL. A single dose of gabapentin reduces acute pain and allodynia in patients with herpes zoster. *Neurology.* 2005;65(3):444-447.
153. van Wijck AJ, Opstelten W, Moons KG, et al. The PINE study of epidural steroids and local anaesthetics to prevent postherpetic neuralgia: a randomised controlled trial. *Lancet.* 2006;367(9506):219-224.
154. Dworkin RH, O'Connor AB, Backonja M, et al. Pharmacologic management of neuropathic pain: evidence-based recommendations. *Pain.* 2007;132(3):237-251.
155. Attal N, Cruccu G, Haanpaa M, et al. EFNS guidelines on pharmacological treatment of neuropathic pain. Eur J Neurol. 2006;13(11):1153-1169.
156. Backonja M, Wallace MS, Blonsky ER, et al. NGX-4010, a high-concentration capsaicin patch, for the treatment of postherpetic neuralgia: a randomised, double-blind study. *Lancet Neurol.* 2008;7(12):1106-1112.
157. Moulin DE, Clark AJ, Gilron I, et al. Pharmacological management of chronic neuropathic pain-consensus statement and guidelines from the Canadian Pain Society. *Pain Res Manag.* 2007;12(1):13-21.
158. Dubinsky RM, Kabbani H, El-Chami Z, et al. Practice parameter: treatment of postherpetic neuralgia: an evidence-based report of the Quality Standards Subcommittee of the American Academy of Neurology. *Neurology.* 2004;63(6):959-965.
159. Johnson RW, Rice AS. Clinical practice. Postherpetic neuralgia. *N Engl J Med.* 2014;371(16):1526-1533.
160. Finnerup NB, Attal N, Haroutounian S, et al. Pharmacotherapy for neuropathic pain in adults: a systematic review and meta-analysis. *Lancet Neurol.* 2015;14(2):162-173.
161. Baxter R, Ray P, Tran TN, et al. Long-term effectiveness of varicella vaccine: a 14-year, prospective cohort study. *Pediatrics.* 2013;131:e1389.

162. Marin M, Guris D, Chaves SS, et al. Prevention of varicella. Recommendations of the Advisory Committee on Immunization Practices (ACIP). June 22, 2007. Contract No. RR04.
163. Marin M, Nguyen HQ, Keen J, et al. Importance of catch-up vaccination: experience from a varicella outbreak, Maine, 2002-2003. *Pediatrics.* 2005;115(4):900-905.
164. Asano Y, Suga S, Yoshikawa T, et al. Experience and reason: twenty-year follow-up of protective immunity of the Oka strain live varicella vaccine. *Pediatrics.* 1994;94(4, Pt 1):524-526.
165. Galil K, Lee B, Strine T, et al. Outbreak of varicella at a day-care center despite vaccination. *N Engl J Med.* 2002;347(24):1909-1915.
166. Vazquez M, LaRussa PS, Gershon AA, et al. Effectiveness over time of varicella vaccine. *JAMA.* 2004;291(7):851-855.
167. Seward JF, Zhang JX, Maupin TJ, et al. Contagiousness of varicella in vaccinated cases: a household contact study. *JAMA.* 2004;292(6):704-708.
168. Chaves SS, Gargiullo P, Zhang JX, et al. Loss of vaccine-induced immunity to varicella over time. *N Engl J Med.* 2007;356(11):1121-1129.
169. Chaves SS, Zhang J, Civen R, et al. Varicella disease among vaccinated persons: clinical and epidemiological characteristics, 1997-2005. *J Infect Dis.* 2008;197 Suppl 2:S127-S131.
170. Watson B, Seward J, Yang A, et al. Postexposure effectiveness of varicella vaccine. *Pediatrics.* 2000;105(1, pt 1): 84-88.
171. CDC. A new product (VariZIG) for postexposure prophylaxis of varicella available under an investigational new drug application expanded access protocol. *MMWR Morb Mortal Wkly Rep.* 2006;55(8):209-210.
172. CDC. FDA approval of an extended period for administering VariZIG for postexposure prophylaxis of varicella. *MMWR Morb Mortal Wkly Rep.* 2012;61(12):212.
173. Asano Y, Yoshikawa T, Suga S, et al. Postexposure prophylaxis of varicella in family contact by oral acyclovir. *Pediatrics.* 1993;92(2):219-222.
174. Bolyard EA, Tablan OC, Williams WW, et al. Guideline for infection control in healthcare personnel, 1998. Hospital Infection Control Practices Advisory Committee. Infect Control Hosp Epidemiol. 1998;19(6):407-463.
175. Schmader KE, Johnson GR, Saddier P, et al. Effect of a zoster vaccine on herpes zoster-related interference with functional status and health-related quality-of-life measures in older adults. *J Am Geriatr Soc.* 2010;58(9):1634-1641.
176. Simberkoff MS, Arbeit RD, Johnson GR, et al. Safety of herpes zoster vaccine in the shingles prevention study: a randomized trial. *Ann Intern Med.* 2010;152(9):545-554.
177. Morrison VA, Johnson GR, Schmader KE, et al. Long-term persistence of zoster vaccine efficacy. *Clin Infect Dis.* 2015;60(6):900-909.
178. Schmader KE, Oxman MN, Levin MJ, et al. Persistence of the efficacy of zoster vaccine in the shingles prevention study and the short-term persistence substudy. *Clin Infect Dis.* 2012;55(10):1320-1328.
179. Tseng HF, Smith N, Harpaz R, et al. Herpes zoster vaccine in older adults and the risk of subsequent herpes zoster disease. *JAMA.* 2011;305(2):160-166.
180. Langan SM, Smeeth L, Margolis DJ, et al. Herpes zoster vaccine effectiveness against incident herpes zoster and post-herpetic neuralgia in an older US population: a cohort study. *PLoS Med.* 2013;10(4):e1001420.
181. Baxter R, Bartlett J, Fireman B, et al. Long-term effectiveness of the live zoster vaccine in preventing shingles: a cohort study. *Am J Epidemiol.* 2018;187(1):161-169.
182. Tseng HF, Harpaz R, Luo Y, et al. Declining effectiveness of herpes zoster vaccine in adults aged ≥60 years. *J Infect Dis.* 2016;213(12):1872-1875.
183. Izurieta HS, Wernecke M, Kelman J, et al. Effectiveness and duration of protection provided by the live-attenuated herpes zoster vaccine in the Medicare population ages 65 years and older. *Clin Infect Dis.* 2017;64(6):785-793.
184. Amirthalingam G, Andrews N, Keel P, et al. Evaluation of the effect of the herpes zoster vaccination programme 3 years after its introduction in England: a population-based study. *Lancet Public Health.* 2018;3(2):e82-e90.
185. Marin M, Yawn BP, Hales CM, et al. Herpes zoster vaccine effectiveness and manifestations of herpes zoster and associated pain by vaccination status. *Hum Vaccin Immunother.* 2015;11(5):1157-1164.
186. Levin MJ, Schmader KE, Pang L, et al. Cellular and humoral responses to a second dose of herpes zoster vaccine administered 10 years after the first dose among older adults. *J Infect Dis.* 2016;213(1):14-22.
187. Hales CM, Harpaz R, Ortega-Sanchez I, et al. Update on recommendations for use of herpes zoster vaccine. *MMWR Morb Mortal Wkly Rep.* 2014;63(33):729-731.
188. Schmader KE, Levin MJ, Gnann JW Jr, et al. Efficacy, safety, and tolerability of herpes zoster vaccine in persons aged 50-59 years. *Clin Infect Dis.* 2012; 54(7):922-928.
189. Tseng HF, Tartof S, Harpaz R, et al. Vaccination against zoster remains effective in older adults who later undergo chemotherapy. *Clin Infect Dis.* 2014;59(7):913-919.
190. Tseng HF, Luo Y, Shi J, et al. Effectiveness of herpes zoster vaccine in patients 60 years and older with end-stage renal disease. *Clin Infect Dis.* 2016;62(4): 462-467.
191. Shafran SD. Live attenuated herpes zoster vaccine for HIV-infected adults. *HIV Med.* 2016;17(4):305-310.
192. Bombatch C, Pallotta A, Neuner EA, et al. Evaluation of herpes zoster vaccination in HIV-infected patients 50 years of age and older. *Ann Pharmacother.* 2016;50(4):326-327.
193. Benson C, Hua L, Andersen J, et al. ZOSTAVAX is generally safe and immunogenic in HIV+ adults virologically suppressed on ART: results of a Phase 2, randomized, double-blind, placebo-controlled trial. Paper presented at the 19th Conference on Retroviruses and Opportunistic Infections, Seattle, WA, 5-8 March 2012.
194. Issa NC, Marty FM, Leblebjian H, et al. Live attenuated varicella-zoster vaccine in hematopoietic stem cell transplantation recipients. *Biol Blood Marrow Transplant.* 2014;20(2):285-287.
195. Naidus E, Damon L, Schwartz BS, et al. Experience with use of Zostavax(®) in patients with hematologic malignancy and hematopoietic cell transplant recipients. *Am J Hematol.* 2012;87(1):123-125.
196. Perry LM, Winthrop KL, Curtis JR. Vaccinations for rheumatoid arthritis. *Curr Rheumatol Rep.* 2014;16(8):431.
197. Tsigrelis C, Ljungman P. Vaccinations in patients with hematological malignancies. *Blood Rev.* 2016;30(2): 139-147.

198. Zhang J, Delzell E, Xie F, et al. The use, safety, and effectiveness of herpes zoster vaccination in individuals with inflammatory and autoimmune diseases: a longitudinal observational study. *Arthritis Res Ther.* 2011;13(5):R174.
199. Zhang J, Xie F, Delzell E, et al. Association between vaccination for herpes zoster and risk of herpes zoster infection among older patients with selected immune-mediated diseases. *JAMA.* 2012;308(1): 43-49.
200. Willis ED, Woodward M, Brown E, et al. Herpes zoster vaccine live: a 10 year review of post-marketing safety experience. *Vaccine.* 2017;35(52):7231-7239.
201. Morrison VA, Oxman MN, Levin MJ, et al. Safety of zoster vaccine in elderly adults following documented herpes zoster. *J Infect Dis.* 2013;208(4):559-563.
202. GlaxoSmithKline. Shingrix® Package Insert. https://www.fda.gov/downloads/biologicsbloodvaccines/vaccines/approvedproducts/ucm581605.pdf. Accessed March 8-, 2018.
203. Dooling KL, Guo A, Patel M, et al. Recommendations of the Advisory Committee on Immunization Practices for Use of Herpes Zoster Vaccines. *MMWR Morb Mortal Wkly Rep.* 2018;67(3):103-108.
204. Leroux-Roels I, Leroux-Roels G, Clement F, et al. A phase 1/2 clinical trial evaluating safety and immunogenicity of a varicella zoster glycoprotein e subunit vaccine candidate in young and older adults. *J Infect Dis.* 2012;206(8):1280-1290.
205. Chlibek R, Pauksens K, Rombo L, et al. Long-term immunogenicity and safety of an investigational herpes zoster subunit vaccine in older adults. *Vaccine.* 2016;34(6):863-868.
206. Schwarz TF, Volpe S, Catteau G, et al. Persistence of immune response to an adjuvanted varicella-zoster virus subunit vaccine for up to year nine in older adults. *Hum Vaccin Immunother.* 201;14(6):1370-1377.
207. Lal H, Cunningham AL, Godeaux O, et al. Efficacy of an adjuvanted herpes zoster subunit vaccine in older adults. *N Engl J Med.* 2015;372(22):2087-2096.
208. Cunningham AL, Lal H, Kovac M, et al. Efficacy of the herpes zoster subunit vaccine in adults 70 years of age or older. *N Engl J Med.* 2016;375(11):1019-1032.
209. Levin MJ, Oxman MN, Zhang JH, et al. Varicella-zoster virus-specific immune responses in elderly recipients of a herpes zoster vaccine. *J Infect Dis.* 2008;197(6):825-835.
210. Weinberg A, Zhang JH, Oxman MN, et al. Varicella-zoster virus-specific immune responses to herpes zoster in elderly participants in a trial of a clinically effective zoster vaccine. *J Infect Dis.* 2009;200(7):1068-1077.
211. Berkowitz EM, Moyle G, Stellbrink HJ, et al. Safety and immunogenicity of an adjuvanted herpes zoster subunit candidate vaccine in HIV-infected adults: a phase 1/2a randomized, placebo-controlled study. *J Infect Dis.* 2015;211(8):1279-1287.
212. Stadtmauer EA, Sullivan KM, Marty FM, et al. A phase 1/2 study of an adjuvanted varicella-zoster virus subunit vaccine in autologous hematopoietic cell transplant recipients. *Blood.* 2014;124(19):2921-2929.
213. Schwarz TF, Aggarwal N, Moeckesch B, et al. Immunogenicity and safety of an adjuvanted herpes zoster subunit vaccine coadministered with seasonal influenza vaccine in adults aged 50 years or older. *J Infect Dis.* 2017;216(11):1352-1361.
214. Grupping K, Campora L, Douha M, et al. Immunogenicity and safety of the HZ/su adjuvanted herpes zoster subunit vaccine in adults previously vaccinated with a live attenuated herpes zoster vaccine. *J Infect Dis.* 2017;216(11):1343-1351.
215. Godeaux O, Kovac M, Shu D, et al. Immunogenicity and safety of an adjuvanted herpes zoster subunit candidate vaccine in adults ≥ 50 years of age with a prior history of herpes zoster: a phase III, non-randomized, open-label clinical trial. *Hum Vaccin Immunother.* 2017;13(5):1051-1058.
216. Kroger AT, Duchin J, Vázquez M. General Best Practice Guidelines for Immunization. Best Practices Guidance of the Advisory Committee on Immunization Practices (ACIP). www.cdc.gov/vaccines/hcp/acip-recs/general-recs/downloads/general-recs.pdf. Accessed March 9, 2018.
217. Cunningham AL, Heineman T. Vaccine profile of herpes zoster (HZ/su) subunit vaccine. *Expert Rev Vaccines.* 2017;16(7):1-10.
218. Oxman MN, Harbecke R, Koelle DM. Clinical usage of the adjuvanted herpes zoster subunit vaccine (HZ/su): revaccination of recipients of live attenuated zoster vaccine and coadministration with a seasonal influenza vaccine. *J Infect Dis.* 2017;216(11):1329-1333.
219. Woloshin S, Schwartz LM, White B, et al. The Fate of FDA Postapproval Studies. *N Engl J Med.* 2017;377(12):1114-1117.

Chapter 166 :: Poxvirus Infections

:: Ellen S. Haddock &
Sheila Fallon Friedlander

AT-A-GLANCE

- Poxviruses are the largest animal viruses; they can cause disease of varying severity in humans.
- Smallpox is the only poxvirus whose sole reservoir is humans, which allowed its eradication.
- The virus used in smallpox vaccines, vaccinia, has its own adverse effects.
- Monkeypox is a zoonotic infection endemic in Africa.
- Milker's nodule and orf mainly cause localized cutaneous infections.
- Molluscum contagiosum is generally a benign cutaneous disease most frequently seen in children and immunocompromised individuals.
- Histopathologic features of poxviral cutaneous lesions include the presence of intracytoplasmic eosinophilic inclusion bodies.

Poxviruses are a family of double-stranded DNA viruses that replicate in the cytoplasm of host cells (Table 166-1). They are the largest known animal viruses and can be seen with light microscopy.[1] The poxvirus family is divided into multiple genera. Four genera affect humans: *Orthopoxvirus*, *Parapoxvirus*, *Molluscipoxvirus*, and *Yatapoxvirus*. The poxviruses that cause significant disease in humans are reviewed here. Their effects on humans range from systemic disease to localized infection to epithelial cell proliferation without other findings.

ORTHOPOXVIRUS INFECTIONS

Members of the *Orthopoxvirus* genus that cause disease in humans include variola (smallpox), vaccinia, cowpox, and monkeypox. Variola, vaccinia, and monkeypox are discussed in detail below. Cowpox, whose major reservoir is thought to be cats and small rodents rather than cows, rarely infects humans.

SMALLPOX (VARIOLA)

AT-A-GLANCE

- Mortality from the major form of smallpox is approximately 30%.
- Smallpox is transmitted mainly by the respiratory route; viremia leads to cutaneous and visceral involvement.
- The eruption consists of multiple papules in a centrifugal distribution that progress en masse through vesicular and pustular stages.
- The disease has not been seen since 1978, but concern exists about the potential use of variola virus for bioterrorism.
- Smallpox vaccination has been reinstituted on a selective basis for response in the case of an outbreak.

Variola virus is the pathogen responsible for smallpox, a disease that devastated humankind in catastrophic epidemics for more than 3000 years. This poxvirus scarred and killed millions of people in both the Old and New Worlds, affecting entire populations on every continent. It is estimated to have killed approximately 500 million people in the 20th century alone.[2] The practice of variolation, the intentional introduction of smallpox virus from a pustule of an infected person into a healthy nonimmune person to induce a mild form of the disease as prophylaxis against a full-scale infection, gained popularity in the 18th century.[3] This practice reduced mortality significantly but caused full-scale disease in a subset of individuals, resulting in 1% to 2% mortality.[3] Edward Jenner altered the course of history in 1796 when he created the first vaccine by inoculating patients with cowpox virus to protect them against the related smallpox virus. Later, vaccinia virus was used for vaccination, and smallpox was eradicated in the United States in 1949. The World Health Organization (WHO) launched a global campaign to eradicate smallpox in 1959,[3] and an intensive effort culminated in global eradication by 1980.[3,4]

TABLE 166-1
Poxviruses with Humans as Hosts

GENUS	SPECIES	HOSTS	MAIN PORTAL OF ENTRY	CLINICAL FEATURES	TREATMENT
Orthopoxvirus	Variola virus (smallpox)	Humans	Respiratory tract	High fever and myalgia precede oropharyngeal enanthem and centrifugal exanthem. Simultaneous progression of skin lesions from macules to papulovesicles, pustules, and crusts, resulting in significant scars. Last reported case in 1978; concern for use in bioterrorism.	Postexposure vaccination to reduce severity and disease occurrence (prior to onset of clinical symptoms) Tecovirimat (SIGA Technologies) Brincidofovir (CMX001, Chimerix)
	Vaccinia virus	Humans	Skin	Used as vaccine for smallpox. Also protects against monkeypox. Vaccination site progresses from papule to vesicle, pustule, and crust, leaving scar. Adverse events occur when virus spreads locally or in a generalized manner, more severe in individuals with disruption of the skin barrier or immune compromise.	Symptomatic treatment for minor local reactions, or for typical systemic symptoms Vaccinia immune globulin or cidofovir for extensive lesions distant from vaccination site Skin care Fluid and electrolyte repletion
	Monkeypox virus	Rodents, humans, monkeys, anteaters	Skin	Clinical presentation similar to that of smallpox but with more prominent lymphadenopathy and lower mortality.	Postexposure prophylaxis with vaccinia virus (4-14 days after exposure) Tecovirimat Cidofovir Brincidofovir
	Cowpox virus	Rodents, cats, humans, cattle	Skin	Contact with infected animal host gives rise to papule that becomes vesicular, hemorrhagic, pustular, and ulcerative; resulting eschar heals over 3-4 weeks with scarring. Constitutional symptoms and lymphangitis common. Can be extensive or severe if skin barrier is disrupted.	No known treatment
Parapoxvirus	Orf virus	Sheep, goats, humans	Skin	Contact with infected animal or fomite leads to 1 or more papules, usually on hand. Papule progresses into pustule or nodule with central umbilication and surrounding gray-white or violaceous ring and outer zone of erythema. Becomes weepy, then dries and crusts. Healing occurs over 4-8 weeks, usually without scarring. Constitutional symptoms are uncommon.	Resolves within 4-6 weeks Debridement, topical cidofovir, or topical imiquimod may speed resolution
	Pseudocowpox virus (paravaccinia virus)	Cattle, humans	Skin	Transmission by contact with infected teats/mouths of cattle. Causes milker's nodule. Clinical findings and course similar to orf; differentiated by animal hosts.	Disease is self-limited; symptomatic treatment only Curettage of large lesions may speed resolution
	Bovine papular stomatitis virus	Cattle, humans	Skin	Transmitted by contact with infected mouths of cattle. Clinical findings and course similar to orf and paravaccinia.	Similar to above

(*Continued*)

TABLE 166-1
Poxviruses with Humans as Hosts (*Continued*)

GENUS	SPECIES	HOSTS	MAIN PORTAL OF ENTRY	CLINICAL FEATURES	TREATMENT
Molluscipoxvirus	Molluscum contagiosum virus	Humans	Skin	Discrete firm, dome-shaped papules; may have central umbilication. Can be extensive in individuals with atopic dermatitis or immune compromise. Most cases resolve spontaneously in months to years, but lesions often are treated to reduce symptoms and minimize autoinoculation. Can be persistent/refractory in immunocompromised individuals.	Cantharidin 0.7% topically for 2-6 hours, before rinsing Imiquimod cream Intralesional candida antigen Oral cimetidine Podophyllotoxin Cidofovir Physically destructive therapies (curettage, cryotherapy, CO_2 laser, pulsed-dye laser, electrodessication)
Yatapoxvirus	Tanapox virus	Humans, monkeys	Possibly skin	Uncertain mode of transmission; possible mosquito vector from infected monkeys to humans. Short fever precedes eruption of 1 or more pruritic, indurated papules with surrounding edema. Become necrotic and/or ulcerative, then heal within 6 weeks with scarring.	Self-resolving within 6 weeks, with resulting lifelong immunity

After eradication, the WHO directed all laboratories other than the Centers for Disease Control and Prevention (CDC) in the United States and the Vector laboratory in Russia to destroy their smallpox samples. However, a misplaced vial of variola virus was discovered at the National Institutes of Health facility in Bethesda, Maryland in 2014,[5] raising the theoretical possibility that other unreported stocks of virus may exist and could be used as a biologic weapon. Concerns about bioterrorism have renewed the need for knowledge about smallpox and the development of improved vaccines and treatments in case the disease reemerges.

EPIDEMIOLOGY

Unlike other members of the poxvirus family, smallpox only affects humans and cannot be acquired from other species. Transmission is generally via respiratory droplets and requires close contact but aerosol spread also has been reported. Outbreaks occur in the winter and early spring seasons when conditions of low humidity and low temperature favor survival of the aerosolized virus.[6] Smallpox is less infectious than other diseases spread by the respiratory route, including measles, varicella, and influenza. The estimated rate of secondary infection of unvaccinated contacts is 37% to 88%.[7] Secondary cases are often limited to family members or health care workers. Spread of smallpox is facilitated by the large quantity of virus in the aerosolized droplets, high population density, and extensive contact between the infected individual and others. The very young, the elderly, and pregnant women are more susceptible to infection.[8] Individuals with more-severe clinical disease are reported to be more infectious, but these same people also tend to be toxemic and confined to bed.

There are 2 main strains of variola virus: (a) variola major, the more common, severe, and often lethal form, and (b) variola minor, a milder less-lethal form.

Today, the majority of the world's population is susceptible to smallpox disease, as routine vaccination of civilians was discontinued in the United States in 1971 and worldwide in the 1980s. Those vaccinated before 1972 have uncertain levels of immunity remaining. Until 2002, only laboratory workers handling non–highly attenuated orthopoxviruses still were advised to receive routine vaccination. Since that time, military personnel and a small group of U.S. civilians who would serve as first-line responders in a bioterrorism attack have been vaccinated.[9] The risk of adverse effects from the vaccine, particularly in immunocompromised patients and individuals with atopic dermatitis or other skin barrier defects, has prevented mass vaccination policies.

CLINICAL FEATURES

Prodrome: An infected individual is asymptomatic during the incubation period of viral replication. A prodrome of high fever (39°C to 41°C [102.2°F to 105.8°F]), chills, myalgia, and severe headache develops within 7 to 17 days of exposure, with an average incubation of 10 to 12 days.[7] The prodrome usually lasts 2 to 3 days, during which the affected individual is severely ill and often bedridden.

Cutaneous Findings: Approximately 1 day after the onset of fever, an enanthem of red macules develops on the mouth, tongue, and oropharynx and subsequently

vesiculates and ulcerates, releasing high concentrations of transmissible virus particles in respiratory secretions. A skin rash (exanthem) usually follows a day later.[7] The fever usually declines with appearance of the rash.[10]

The classic smallpox rash begins as macules on the face and extremities but quickly spreads to cover the body. Involvement of all parts of the body, including palms and soles, occurs within 24 to 48 hours. Smallpox tends to have a centrifugal distribution, meaning that lesions are most concentrated on the face and distal extremities. A key characteristic of smallpox is that all lesions progress synchronously through macular, papular, vesicular, and pustular stages. Each stage lasts 1 to 2 days. Macules become raised papules 2 to 3 mm in diameter within 1 or 2 days and then form vesicles 2 to 5 mm in diameter (Fig. 166-1) within another 1 or 2 days. Firm, deep-seated pustules 4 to 6 mm in diameter (Fig. 166-2) develop 4 to 7 days after the onset of the rash and may umbilicate or become confluent. After 8 to 10 days, the lesions begin to crust (Fig. 166-3). Fever may reoccur during the pustular stage, especially if a secondary bacterial infection has developed. Scabs begin separating 2 weeks after the onset of the rash and typically have all separated by 4 weeks. After their resolution, pitted scars ("pockmarks") remain on 65% to 80% of survivors and can be disfiguring (Fig. 166-4).[7] Scarring is most common on the face, where there are larger and more numerous sebaceous glands, which are particularly susceptible to infection and destruction by variola virus.[4]

Classic or ordinary smallpox, described above, is the most common type, accounting for 85% of smallpox outbreaks.[2,4]

In addition to ordinary smallpox, the WHO recognizes 3 other clinically recognizable forms of variola major, which differ in disease presentation and rash burden.[2,10] These are modified smallpox, flat smallpox, and hemorrhagic smallpox.

Modified smallpox (approximately 5% to 7% of all cases) is a mild, nonfatal form of variola major infection that occurs in previously vaccinated individuals. It has a milder prodrome, fewer lesions, and an accelerated and abbreviated course because the disease has been "modified" or attenuated by previous vaccination.[2] Lesions tend not to progress to vesicles or pustules, crusting by day 10.

Figure 166-2 Pustular smallpox lesions with characteristic highest density on the face and extremities. (From the Centers for Disease Control and Prevention [CDC] Public Health Image Library, Atlanta, GA, USA.)

Flat smallpox (also called *malignant smallpox*) is an uncommon form of variola major infection (approximately 5% of cases) in which lesions develop slowly and persist as soft, velvety vesicles that coalesce into confluent, edematous plaques with a flat appearance.[2] It usually occurs in children and unvaccinated individuals lacking cellular immunity. Affected individuals become severely ill with toxic fever, and most die with hemorrhagic lesions and pneumonia.[7]

Figure 166-1 Day 3 of rash in a young woman with smallpox, with fluid accumulating in several vesicles. (From the Centers for Disease Control and Prevention [CDC] Public Health Image Library, Atlanta, GA, USA.)

Figure 166-3 Crusted lesions on the foot at day 21 of the rash of smallpox. (From the Centers for Disease Control and Prevention [CDC] Public Health Image Library, Atlanta, GA, USA, and contributed by Paul B. Dean, MD.)

Figure 166-4 Scars and pockmarks remain after the crusts have fallen off. (From the Centers for Disease Control and Prevention [CDC] Public Health Image Library, Atlanta, GA, USA, and contributed by J. Noble, Jr., MD.)

Hemorrhagic smallpox, also known as *fulminant smallpox*, involves hemorrhage into the skin or mucous membranes and is the rarest (<1% of cases) and deadliest form of smallpox.[2] It is equally common in unvaccinated and vaccinated persons and is almost always fatal.[2] In the early hemorrhagic form, massive hemorrhage from mucosal surfaces occurs before any rash develops and leads to death before the sixth day of illness.[11] This form is more common in adults, and pregnant women are especially susceptible. In the late hemorrhagic form, hemorrhage occurs after onset of the typical rash and death occurs within 12 days.[11] This form affects women and men equally.[4]

Variola sine eruption, is a brief febrile illness (48 hours or less) without a rash that can occur when a vaccinated individual is exposed to someone infected with variola major. This brief illness can be confirmed by serologic studies showing a rise in antibody titers against smallpox virus.[7]

Infections with the variola minor strain, the milder strain of smallpox, are clinically indistinguishable from cases of modified smallpox and mild cases of ordinary smallpox. Historically, outbreaks were diagnosed retrospectively as variola minor if the fatality rate was low (1% or less). Minor and major strains can now be differentiated by polymerase chain reaction (PCR).[4]

Noncutaneous Findings: Variola virus spreads by the blood to noncutaneous systems. It can infect the metaphyses of growing bones and lead to arthritis in up to 2% of affected children. Osteomyelitis variolosa is less frequent but may also cause bone deformities.[12] Swelling of the eyelids and a mild conjunctivitis are common findings. Cough and bronchitis may be seen in some cases of smallpox. A degree of encephalopathy often occurs, with symptoms ranging from headache and hallucinations to delirium and psychosis.[4] Gross hematuria can occur with the hemorrhagic type of variola major.[13]

Complications: Secondary bacterial infection occurs commonly in skin lesions, as well as at regional lymph nodes, affecting 5% of individuals. Keratitis and corneal ulceration, common in malnourished individuals, result in blindness in 1% of cases. Variola virus or bacterial superinfection can lead to respiratory complications, including pneumonia, at days 8 to 10 of illness. Both arthritis and osteomyelitis can lead to limb deformities, including bone shortening, subluxation, and flail joints. Orchitis is less common and usually unilateral. Encephalitis is reported in 0.2% of cases.[4]

ETIOLOGY AND PATHOGENESIS

Smallpox is caused by the variola virus, a linear, double-stranded DNA virus of the genus *Orthopoxvirus*. Variola virus measures approximately 300 × 250 × 200 nm and has a brick-shaped appearance on electron microscopy (Fig. 166-5).

Although the 2 major forms, variola major and variola minor, have approximately 98% genetic homology, variola major is markedly more virulent, with significantly higher mortality.[14]

Humans are the only natural reservoir of the variola virus. Smallpox usually spreads by implantation of droplets containing virus on to nasal, oral, or pharyngeal mucous membranes or alveoli of the lung.[4] Household contacts of an infected individual and others with prolonged face-to-face exposure are at greatest risk of infection.[9] Variola virus is less commonly spread by accidental inoculation into the skin, through the conjunctiva, and through contact with infected body fluids or highly contaminated fomites. Rarely, it is transmitted transplacentally, by long-range

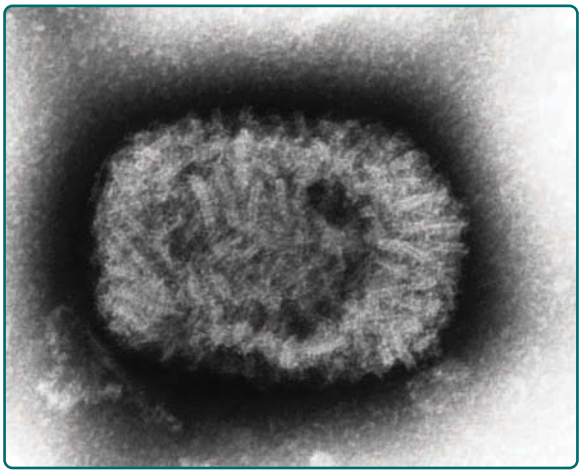

Figure 166-5 Electron micrograph of the variola virus. (From the Centers for Disease Control and Prevention [CDC] Public Health Image Library, Atlanta, GA, USA, and contributed by J. Nakano.)

airborne viral particles, or by viral particles suspended in enclosed areas.[15]

The virus attaches to respiratory epithelial cells, travels to regional lymph nodes, and replicates at these sites. Transient primary viremia with uptake of the virus by macrophages occurs, and the virus spreads to the reticuloendothelial organs, where asymptomatic replication continues. A massive secondary viremia follows and causes the onset of symptoms (the prodromal period). The virus spreads to the skin and mucosa, along with other organs and tissues such as the liver and kidneys.[7,16]

Variola virus is transmissible beginning in the late prodromal phase by aerosolization of viral particles from the oropharynx. It is most infectious during the first week of the rash, which is when enanthem lesions have ulcerated and are releasing virus into mouth and pharynx secretions.[4] The virus remains transmissible until all scabs have fallen off of skin lesions.[16]

DIAGNOSIS

An acute, generalized rash with characteristic well-circumscribed, firm, deep-seated vesicles or pustules should raise concern for smallpox.

The CDC protocol for evaluation of acute, generalized vesicular or pustular rashes, available on the CDC website (cdc.gov), should be consulted and followed whenever suspicion arises.[17] Airborne and contact precautions should be implemented immediately. The next step is defining the suspicion for smallpox as high, moderate, or low, based on the CDC's major and minor smallpox criteria.

Major criteria include (a) febrile prodrome 1 to 4 days before rash onset; (b) classic smallpox lesions, defined as deep-seated, firm/hard, round, well-circumscribed vesicles or pustules; and (c) lesions in the same stage of development (ie, all vesicles or all pustules) on any one part of the body.

Minor criteria include (a) centrifugal distribution, meaning that lesions are most concentrated on the face and distal extremities; (b) lesions first occurred on the oral mucosa/palate, face, or forearms; (c) patient appears toxic or moribund; (d) slow evolution of lesions, meaning that they evolve from macules to papules to pustules, with each stage lasting 1 to 2 days; and (e) lesions on palms and soles.

Risk for smallpox is considered to be high if patients meet all major criteria. Patients with febrile prodrome plus 1 other major criteria or 4 or more minor criteria are considered to have a moderate risk for smallpox. Patients with febrile prodrome but fewer than 4 minor criteria or no febrile prodrome are considered to have a low risk for smallpox.

The recommended workup depends on smallpox risk status. When the risk of smallpox is determined to be high, local and state health departments should be contacted immediately; they will lead diagnosis and management efforts, in coordination with the CDC. High-risk specimens should be tested only at laboratories with appropriate expertise and biosafety levels.

Moderate- and low-risk cases should be worked up for more common causes of febrile exanthema, such as varicella zoster virus (VZV), herpes simplex virus (HSV), and enterovirus. The CDC recommends Tzanck smear to evaluate for HSV as well as direct fluorescent antibody assay to evaluate for HSV and VZV. PCR for VZV, HSV, and enterovirus should be performed. If possible, electron microscopy to distinguish between poxvirus and VZV should be performed, and the virus can be cultured. Biopsy to evaluate for erythema multiforme also can be considered. PCR for nonvariola *Orthopoxvirus* should be conducted and can be coordinated by the CDC. PCR for all orthopoxviruses, including variola, also can be performed. Multiple diagnostic methods are used to improve diagnostic certainty.

For high-risk cases, the focus is on ruling out variola before any additional testing is performed. All testing should be performed by a biosafety level 3 laboratory. Electron microscopy can be performed under biosafety level 3 conditions at a local facility. All other testing should be performed by a Laboratory Research Network facility or by the CDC. These laboratories will perform variola-specific PCR, nonvariola *Orthopoxvir*us PCR, and PCR that tests for all orthopoxviruses. In high-risk cases, testing for VZV, HSV, and enterovirus will only be pursued once variola has been ruled out.[18]

Special Tests: Since the eradication of smallpox the positive predictive value of any one test is very low, so multiple methods of testing are used to confirm a diagnosis of smallpox.

Real-time PCR (RT-PCR) is the quickest and most sensitive assay for detecting and differentiating between orthopoxviruses. As mentioned above, 3 different assays are used to evaluate a possible smallpox infection: (a) *Orthopoxvirus* RT-PCR, which detects all *Orthopoxvirus* including variola; (b) nonvariola *Orthopoxvirus* RT-PCR, which detects all *Orthopoxvirus* except for variola; and (c) RT-PCR assay that detects only variola. PCR is very useful for distinguishing viral species but cannot determine whether a virus is viable.

Viral culture for virus isolation has the benefit of providing additional material for testing, but should only be performed by the CDC. Historically, orthopoxviruses could be differentiated by the morphology of the pocks they produced on the chorioallantoic membranes of chicken embryos, but this is not commonly performed today.[16]

Electron microscopy is most useful for confirming the presence of a virus and differentiating between poxvirus and varicella. It can distinguish between brick-shaped orthopoxviruses and icosahedral varicella viruses, but cannot distinguish among orthopoxviruses (ie, cannot distinguish variola from vaccinia, monkeypox, or cowpox).[19]

Serologic testing, including immunofluorescence and enzyme-linked immunosorbent assay, has limited usefulness in diagnosis of smallpox because orthopoxviruses are closely related and there is significant antibody cross-reactivity. Serologic testing cannot reliably distinguish between variola, vaccinia, and monkeypox

infection. However, it can be useful for confirming past exposure to *Orthopoxvirus*.[19]

As with serologic testing, current immunohistochemistry assays can identify *Orthopoxvirus* but cannot differentiate among species of *Orthopoxvirus*. However, immunohistochemistry can be helpful in identifying other microorganisms such as HSV, VZV, enterovirus, syphilis, and rickettsia.[19]

Laboratory Abnormalities: The white blood cell count may increase as the skin lesions of smallpox become pustular. Severe thrombocytopenia occurs in hemorrhagic smallpox, both early and late types. A marked decrease in the level of factor V (accelerator globulin) and increase in thrombin time are noted in the early hemorrhagic form, likely from disseminated intravascular coagulation. The late hemorrhagic form has a smaller degree of these coagulation disturbances.[4]

Pathology: Skin biopsy specimens from early papules show edema and dilation of the capillaries of the papillary dermis with a perivascular infiltrate of lymphocytes, histiocytes, and plasma cells. With progression, the cells of the epidermis become vacuolated and swollen and undergo ballooning degeneration. These vesicles have characteristic intracytoplasmic inclusion bodies called *Guarnieri bodies*. Pustules form with migration of polymorphonuclear cells into the vesicles. Eventually, the pustule becomes a crust, with new epithelium growing to repair the surface. Mucous membrane lesions show similar changes but also have extensive necrosis of the epithelial cells leading to rapid ulceration rather than vesiculation.[20]

The CDC algorithm recommends histopathologic and immunohistochemical analysis only after workup for VZV, HSV, and enterovirus and *Orthopoxvirus* PCR analysis are negative.[18]

DIFFERENTIAL DIAGNOSIS

Table 166-2 outlines the differential diagnosis of smallpox.

The exanthem of smallpox is most often confused with that of chickenpox (varicella). Smallpox lesions are deep-seated and firm, whereas chickenpox vesicles are more superficial ("dewdrops on a rose petal"). Smallpox lesions progress simultaneously, so all lesions on any one part of the body are in the same stage (eg, all papules or all vesicles), whereas chicken pox lesions appear in crops, so multiple different stages (a mix of papules, vesicles, pustules, and crusts) are seen at once. Chickenpox lesions progress more quickly than smallpox lesions, evolving from macule to papule to vesicle to crust in less than 24 hours. In contrast, each stage of smallpox lasts 1 to 2 days. Overall, chickenpox has a shorter disease course, with all lesions crusting within 4 to 6 days from initial appearance.[16] In contrast to smallpox, which is preceded by a severe febrile prodrome with prostration, headache, backache, chills, vomiting, or abdominal pain, chickenpox is not preceded by a significant prodrome, and patients do not appear toxic. Smallpox has a centrifugal distribution, with lesions most concentrated on the face and distal extremities. In contrast, chickenpox has a centripetal distribution, with lesions most concentrated on the trunk. Palms and soles may be affected in smallpox, but are rarely involved in chickenpox.[17]

Disseminated herpes zoster can appear similar to varicella but usually begins in a dermatomal distribution. The morbilliform prodromal rash of smallpox can be confused with coxsackievirus or measles infections.

Human monkeypox clinically resembles smallpox but often manifests with lymphadenopathy. It is a zoonotic disease and is not spread as easily between persons.

Secondary syphilis should be considered, especially when there are lesions on the palms and soles, but these lesions do not progress.

Table 166-2 lists other eruptions in the differential diagnosis.

TABLE 166-2
Differential Diagnosis of Smallpox and Monkeypox

Most Likely

- Papulovesicular eruption
  - Coxsackievirus infection
  - Extensive arthropod or mite infestation
  - Varicella
  - Disseminated zoster
  - Generalized vaccinia
  - Prodromal morbilliform eruption
  - Erythema multiforme
  - Drug eruption
- Hemorrhagic lesions (smallpox only)
  - Meningococcemia
  - Disseminated intravascular coagulation
- Mucosal lesions
  - Hand-foot-and-mouth disease
  - Stevens-Johnson syndrome

Consider

- Papulovesicular eruption
  - Kaposi varicelliform eruption
  - Eczema vaccinatum
  - Extensive molluscum contagiosum (in immunosuppressed patients)
  - Bullous impetigo
  - Pityriasis lichenoides et varioliformis acuta
  - Rickettsialpox
- Prodromal morbilliform eruption
  - Measles
  - Other viral infections
- Hemorrhagic lesions (smallpox only)
  - Acute leukemia
  - Viral hemorrhagic fevers
  - Mucosal lesions
  - Oral herpes simplex

Always Rule Out

- Papulovesicular eruption
  - Secondary syphilis
- Hemorrhagic lesions (smallpox only)
  - Acquired coagulopathy
- Mucosal lesions
  - Stevens-Johnson syndrome

The lesions of hemorrhagic smallpox can be similar to those of meningococcemia, viral hemorrhagic fevers such as Ebola, dengue or rift valley fever, severe acute leukemia, and other acute hemorrhagic eruptions, such as those associated with coagulopathies.

CLINICAL COURSE AND PROGNOSIS

Death from smallpox typically occurs during the second week of illness and is thought to be caused by toxemia associated with immune complexes with variola antigens, which induce hypotension/shock and multiorgan failure. Underlying host immune deficiencies likely play a role in the most severe flat and hemorrhagic forms of the disease.[2] Encephalitis is an important factor in death from variola minor but not from variola major.[4,7]

The overall mortality rate for variola major is 30%, compared to less than 1% for variola minor.[3,4] Mortality from ordinary smallpox ranges from less than 10% when lesions are discrete to 50% to 75% when lesions are confluent. Modified smallpox is associated with less than 10% mortality. In contrast, flat smallpox has a case fatality rate of more than 90%, and hemorrhagic forms have nearly 100% mortality. Those who survive the disease will have lifetime immunity.

MANAGEMENT

A patient suspected of having smallpox should be isolated in a negative-pressure room.

Postexposure vaccination before the development of clinical symptoms can reduce disease occurrence and severity, as discussed below; however, vaccination after the development of clinical symptoms does not appear to provide any benefit.[21]

Treatments for smallpox infection have not been studied in humans but have been investigated under the Animal Efficacy Rule, which allows the U.S. Food and Drug Administration (FDA) to grant approval based on animal model studies when studies in humans are not ethical or feasible.[22]

Tecovirimat (SIGA Technologies, New York, NY), an *Orthopoxvirus*-specific antiviral medication, was added to the U.S. Strategic National Stockpile in 2013 for treatment of smallpox.[23,24] In the event of a smallpox outbreak, it would be used under the Emergency Use Authorization. It works by targeting the *F13L* vaccinia gene that is highly conserved among orthopoxviruses and preventing viral egress from infected cells.[21] It reduces morbidity and mortality of variola infection in nonhuman primates in both prelesional and postlesional settings.[25]

Brincidofovir (CMX001; Chimerix, Durham, NC), a lipid conjugate of cidofovir with broad-spectrum in vitro activity against double-stranded DNA viruses, is being studied as a potential smallpox therapy under the Animal Efficacy Rule. Initial studies in a rabbit model of smallpox were promising, with a significant reduction in mortality when treated after the first sign of clinical disease.[25A]

A National Institutes of Health strategy for developing smallpox treatments is to identify broad-spectrum antivirals that have obtained regular FDA approval for other viral indications and then seek approval for use against orthopoxviruses under the Animal Efficacy Rule.[23]

Prevention: Vaccination with vaccinia virus (Table 166-3) is 90% to 96% effective in preventing smallpox disease when given before exposure to variola virus. For postexposure prophylaxis, vaccination within 2 to 3 days of exposure can protect against severe disease. Vaccination within 4 to 5 days may protect against death.[3]

Vaccination with vaccinia virus is not currently available to the general public, as the risk of smallpox outbreak is thought to be low, the risk of adverse effects is significant, particularly in the immunosuppressed and those with skin barrier defects, and postexposure prophylaxis is effective. However, vaccination is indicated for laboratory workers handling non–highly attenuated orthopoxviruses as well as individuals designated to respond to a suspected smallpox outbreak.[9]

In the event of an outbreak, the U.S. government has stockpiled enough smallpox vaccine to vaccinate the entire U.S. population.[2] The 3 currently stockpiled vaccines are: ACAM2000 (Emergent, Gaithersburg, MD), Aventis Pasteur Smallpox Vaccine (APSV; Sanofi Pasteur, Lyon, France), and Imvamune (Bavarian Nordic, Zealand, Denmark). ACAM2000 and APSV contain replication-competent virus, meaning that they can replicate in mammalian cells. ACAM2000 vaccine, grown in cell culture, was licensed by the FDA in 2007 and replaced the previously licensed Dryvax vaccine, made in calf skin, which was destroyed.[2,3,26] APSV, a calf-lymph-origin vaccine manufactured the 1950s, contains the same strain of virus used to produce Dryvax and ACAM2000. Imvamune contains a replication-deficient strain of vaccinia virus, which was attenuated by multiple passages through tissue

TABLE 166-3
Vaccination Against Smallpox Using Vaccinia Virus[a]

Indications

- Preexposure prevention of smallpox for laboratory workers, first responders, and some military personnel.
- Postexposure prophylaxis against severe disease and death.

Contraindications

- Contraindications in the preexposure setting:
  - History of atopic dermatitis or current disruption of the skin barrier in self or close contact.
  - Immunosuppression in self or close contact.
  - Heart disease or significant cardiac risk factors.
  - Serious allergy to vaccine component.
  - Age younger than 12 months.
  - Pregnancy, breastfeeding, or pregnant close contact.
- Contraindications in the postexposure setting:
  - No absolute contraindications in the case of an actual smallpox outbreak.

[a]Current (as of this writing) Centers for Disease Control and Prevention (CDC) recommendations were issued in 2016.[38]

culture and cannot replicate in mammalian cells. It was designed for individuals at high risk for complications from vaccination with replication-competent virus. In the event of an outbreak, APSV and Imvamune would be used under Investigational New Drug or Emergency Use Authorization regulatory mechanisms.[2]

The primary strategy for postexposure protection in an outbreak is vaccination with replication-competent ACAM2000 and APSV. These are derived from the strain used during the eradication campaign, so confidence in their efficacy is high. ACAM2000 will be used first, and the older APSV will be used after supplies of ACAM2000 run out. The viral strain used in the Imvamune vaccine was not used in the eradication campaign, so its efficacy is less certain, and it requires 2 doses (a primary–booster sequence), so it is not optimal for emergency treatment.[2]

In the event of an outbreak of smallpox, individuals with known exposure to smallpox should be vaccinated with replication-competent smallpox vaccine unless they are severely immunodeficient and not expected to benefit from vaccine, such as those who have received bone marrow transplants within the past 3 months, individuals infected with HIV with CD4 cell counts <50 cells/μL (or age-adjusted equivalent levels in children), and individuals with severe combined immunodeficiency or complete DiGeorge syndrome. When minimal benefit from vaccination is expected, treatment with antiviral therapy is preferred, but there is no absolute contraindication to vaccination during an outbreak, and Imvamune is a reasonable option if antivirals are not available. Pregnant and breastfeeding women should be vaccinated with replication-competent vaccine.[2]

Vaccination with replication-competent vaccine also may be advised for individuals with no known exposure but high risk for infection. However, in the absence of known exposure, vaccination with replication-competent vaccine is relatively contraindicated for individuals with atopic dermatitis and individuals with HIV infection with CD4 counts 50 to 199 cells/μL (or age-adjusted equivalent levels in children). Instead, these individuals should be vaccinated with Imvamune if availability and time allow.[2]

Vaccination does not provide lifelong immunity. Most estimates suggest that primary vaccination gives full protection for 3 to 5 years and waning immunity for at least another 10 years. Revaccination may give significant protection for at least 30 years.[27]

VACCINIA AND SMALLPOX VACCINATION

AT-A-GLANCE

- The smallpox vaccine contains live vaccinia virus.
- Smallpox vaccination is not currently available to the public.
- Smallpox vaccination can cause serious adverse effects in some individuals.
- Vaccination soon after exposure to smallpox can prevent severe disease and death.
- The U.S. government has stockpiled enough smallpox vaccine to immunize all U.S. citizens in case of an outbreak.

Discussion here focuses on the features of vaccinia virus used as a smallpox vaccine; vaccinia virus is not known to cause natural infection. The discussion pertains specifically to replication-competent vaccinia used in ACAM2000 and APSV, and Dryvax vaccines. The Imvamune vaccine, which contains highly attenuated vaccinia incapable of replicating in human cells, is not discussed here because it produces no skin reaction and has no risk of secondary transmission.[2]

EPIDEMIOLOGY

Vaccinia is member of the *Orthopoxvirus* genus with similarities to cowpox. Although the original smallpox vaccination contained cowpox, over time vaccination strains became contaminated with vaccinia, which was similarly effective and eventually replaced cowpox as the main vaccination agent during the 19th century.[3]

Routine smallpox vaccination was discontinued in the United States in 1972 and globally after 1980. Vaccination of the military and a small group of voluntary public health and health care workers who would be first-line responders in a possible outbreak was reinitiated in the United States in 2002.[2,9,28]

Vaccination with the replication-competent vaccinia virus causes a major local skin reaction, which indicates that the vaccination has been effective. It carries risk of more severe adverse effects in some individuals, including young children and individuals with atopic dermatitis.

Because of significant homology with other poxviruses, vaccination with vaccinia virus provides protection not only against smallpox but also against closely related orthopoxviruses including monkeypox and cowpox.[4]

CLINICAL FEATURES

Cutaneous Findings: The normal local skin reaction to vaccination begins 3 to 5 days after administration, starting with a papule that develops into a vesicle (Jennerian vesicle) and then a pustule around days 7 to 9. It crusts and scabs over during days 10 to 14, with the scab detaching at days 17 to 21 and leaving a residual scar (Fig. 166-6). A robust local cutaneous reaction 7.5 cm or larger in diameter occurs in up to 16% of vaccinations (Fig. 166-7). This can be mistaken for bacterial cellulitis, but it peaks 6 to 12 days after vaccination and improves spontaneously without antibiotic therapy in 24 to 72 hours.[29] In contrast, secondary bacterial infections usually occur within the first 5 days or 30 days after vaccination.

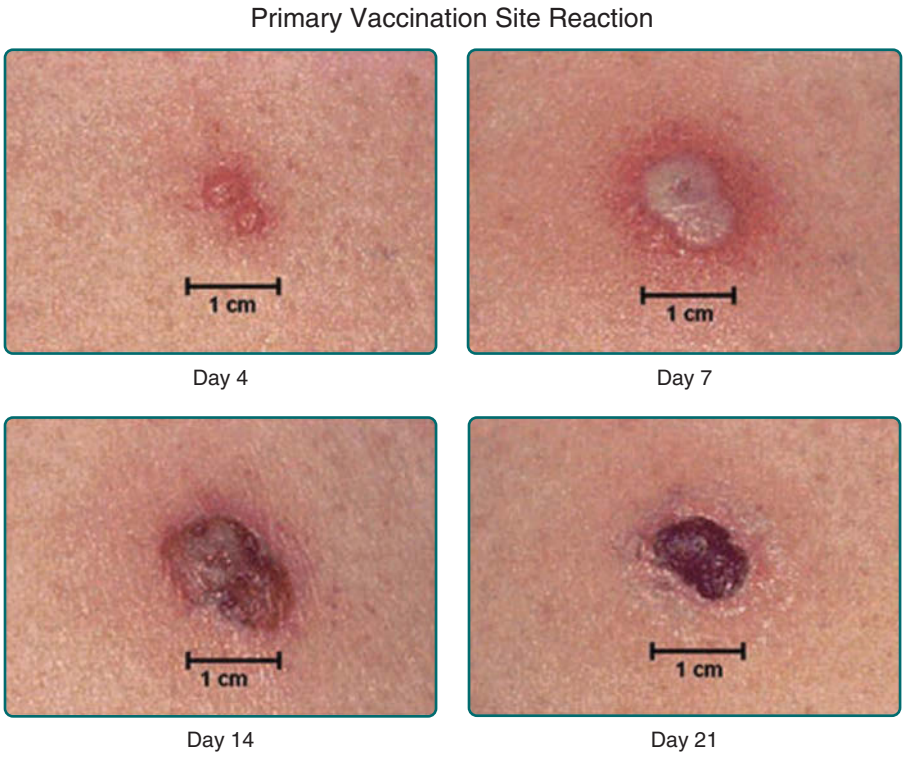

Figure 166-6 Normal progression seen at the smallpox vaccination site. (From the Centers for Disease Control and Prevention [CDC], Atlanta, GA, USA.)

Minor local reactions that can occur near the primary site include intense surrounding erythema or edema and nearby satellite lesions.[27]

Noncutaneous Findings: Soreness almost universally occurs at the vaccination site, and lymphadenopathy/lymphangitis also may be seen. Systemic symptoms can occur and are considered normal reactions. Systemic symptoms include fever (greater than 37.7°C [99.9°F] and more common in children), chills, headache, myalgias, and malaise. They generally peak at days 8 to 10 and last 1 to 3 days. Approximately 30% of vaccine recipients feel too ill to carry out normal activities.[30]

Figure 166-7 A robust take after smallpox vaccination. (From the Centers for Disease Control and Prevention [CDC], Atlanta, GA, USA.)

Cutaneous Complications: Adverse effects from vaccinia vaccinations were studied most extensively for the first-generation vaccine (Dryvax), which is no longer used. Fewer individuals have been vaccinated with the newer second-generation vaccines (ACAM2000, APSV, and Imvamune), so their adverse effects are less-well studied. However, because ACAM2000 is derived from the same viral strain used in manufacturing Dryvax, its safety profile is expected to be similar, if not identical.[2,3] With a larger population of immunosuppressed individuals and rising prevalence of atopic dermatitis, the potential for adverse effects from replication-competent vaccines is higher than it was historically.[3] Replication-competent vaccines are relatively contraindicated in these populations, and highly attenuated vaccinia vaccines like Imvamune have been developed for use in these populations.

Adverse cutaneous reactions associated with replication-competent smallpox vaccination can be localized or generalized. Adverse events can occur at any age, but infants and children younger than the age of 5 years tend to be particularly affected. Adverse reactions are 10 times more common with primary vaccination than revaccination. Secondary bacterial infection, usually by staphylococci or group A streptococci, can occur at the primary site.

Accidental vaccinia is the autoinoculation of vaccinia virus from the vaccination site to another area. It is the most common adverse event seen and accounts for about half of all adverse events. The most common sites of transfer are the eyelids (Fig. 166-8), nose, mouth, and genitalia. Lesions are seen at these areas

Figure 166-8 Inadvertent inoculation of vaccinia to the eyelid. (From the Centers for Disease Control and Prevention [CDC] Public Health Image Library, Atlanta, GA, USA, and contributed by Michael Lane, MD.)

7 to 10 days after vaccination, and they usually follow the time course of the original primary lesion. The lesions may be more attenuated if autoinoculation occurs more than 5 days after vaccination as the host immune response is developing.[28] Accidental inoculation to the eyes can lead to conjunctivitis, keratitis, or iritis. Vaccinia keratitis can cause corneal ulceration with scarring and visual loss.

Generalized, nonspecific, immune-mediated reactions, including morbilliform and roseola-like rashes, may develop. Vaccination can lead to generalized vaccinia, in which macular, papular, or, less commonly, vesicular lesions can be disseminated to normal skin without evidence of autoinoculation. Generalized vaccinia can be limited or extensive and can occur anywhere on the body (Fig. 166-9). It is thought to be caused by spread of vaccinia virus via the bloodstream and usually occurs 6 to 9 days after primary vaccination and progresses through the typical stages of vaccinia lesions. The condition is self-limited in immunocompetent individuals but is often more severe in the setting of immunodeficiency.[27]

Figure 166-9 Generalized vaccinia in an 8-month-old infant. (From the Centers for Disease Control and Prevention [CDC] Public Health Image Library, Atlanta, GA, USA, and contributed by Allen W. Mathies, MD of the California Emergency Preparedness Office, Immunization Branch.)

Hypersensitivity reactions such as erythema multiforme can also develop (Fig. 166-10). These rashes typically self-resolve over several days. In rare cases, Stevens-Johnson syndrome can develop and requires hospitalization and supportive care.

Eczema vaccinatum is the localized or generalized spread of vaccinia virus in individuals with atopic dermatitis or, less frequently, other chronic dermatoses such as Darier disease. An affected individual feels ill with fever, malaise, and lymphadenopathy. Eczema vaccinatum can occur in the primary vaccine recipient, with onset usually at the same time or soon after the appearance of lesions at the vaccination site. Papules, pustules, or vesicles can occur anywhere on the body, but have a predilection for areas with prior lesions of atopic dermatitis (Fig. 166-11). The number of lesions can range from several to hundreds; the most serious cases result in substantial loss of skin barrier.

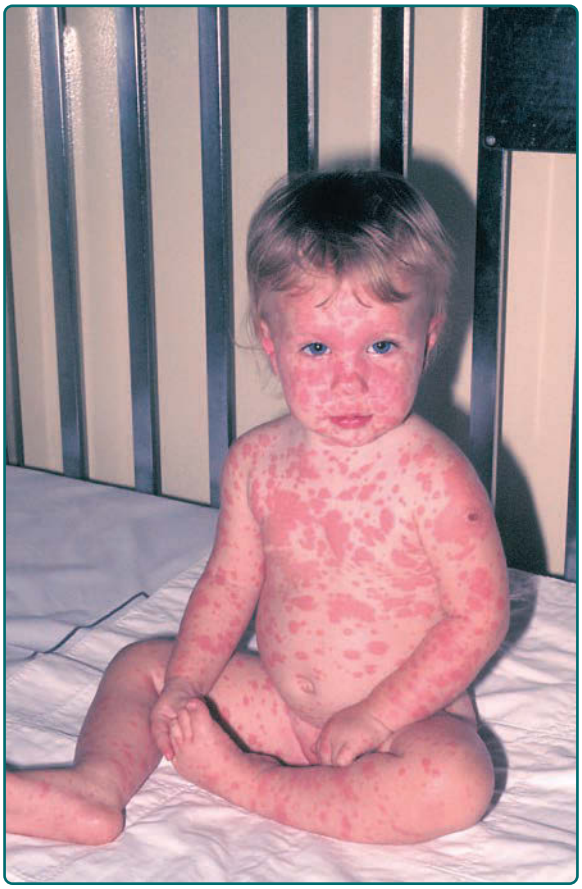

Figure 166-10 Erythema multiforme following vaccination in a 1-year-old child. (From the Centers for Disease Control and Prevention [CDC] Public Health Image Library, Atlanta, GA, USA, and contributed by Allen W. Mathies, MD and John Leedom, MD of the California Emergency Preparedness Office, Immunization Branch.)

Figure 166-11 Eczema vaccinatum with lesions in areas of active dermatitis.

The severity of eczema vaccinatum is independent of the severity or activity of the atopic dermatitis or other underlying skin disease. It also can be acquired by secondary transmission, usually by children in contact with a recently vaccinated family member.[31,32]

Vaccination of individuals with severe impairment of the immune system leads to progressive vaccinia, also called *vaccinia necrosum* and *vaccinia gangrenosa*. In these individuals, the primary lesion at the site of vaccination does not heal but instead enlarges and progresses to a painless ulcer with central necrosis (Fig. 166-12). Viral replication is not halted and viremia occurs, with similar metastatic lesions developing at distant sites in the skin, bone, and/or viscera. Most cases have occurred in individuals with defective cell-mediated immunity, but cases also have been described in those with humoral defects.[7] The degree of immune impairment may correlate with the risk for development of progressive vaccinia.[33]

Figure 166-12 A 22-month-old male with Bruton hypogammaglobulinemia developed progressive vaccinia. (From the Centers for Disease Control and Prevention [CDC] Public Health Image Library, Atlanta, GA, USA, and contributed by Arthur E. Kaye, MD.)

Noncutaneous Complications: CNS complications can occur in previously healthy individuals. Postvaccinial encephalopathy most commonly affects children younger than 2 years of age, causing cerebral edema without inflammation. Symptoms develop abruptly 6 to 10 days after vaccination and can include fever, headache, seizures, hemiplegia, aphasia, and transient amnesia. Postvaccinial encephalitis and encephalomyelitis occur 11 to 15 days after vaccination, with fever, malaise, vomiting, and headache that progress to confusion, seizures, amnesia, spinal cord signs, and coma.[34] These complications are thought to be autoimmune reactions, because vaccinia virus is not found in either sampled cerebrospinal fluid or tissue. Other neurologic events reported to occur in temporal association with smallpox vaccination include transverse myelitis, paralysis, seizures, and polyneuritis, but causality has not been established.[4,35]

Myocarditis/pericarditis is the most common serious adverse effect following immunization with ACAM2000. In Phase 3 clinical trials, the incidence was 5.7 per 1000 first-time vaccinees. The risk for myocarditis with APSV is expected to be similar.[2]

Smallpox vaccination of a woman during pregnancy can rarely lead to fetal or congenital vaccinia; approximately 50 cases are reported in the literature. Transmission to the fetus can occur at any time during the pregnancy and results in lesions on the skin, mucous membranes, and placenta. The appearance can be similar to that of generalized vaccinia or progressive vaccinia, and lesions can be extensive (Fig. 166-13). It is unknown whether infection is through the blood or by direct contact with infected amniotic fluid. No reliable intrauterine diagnostic test exists to confirm fetal infection. ACAM2000 has not been studied in pregnant women.[3]

ETIOLOGY AND PATHOGENESIS

Smallpox vaccination involves the introduction of vaccinia virus into the outer layers of the intact skin by multiple punctures (scarification) with a bifurcated needle that has been dipped in the vaccine (Fig. 166-14). Two to 3 punctures are recommended for primary vaccination and 15 punctures are recommended for revaccination.[9] After inoculation, the replication-competent virus rapidly multiplies locally and occasionally at regional lymph nodes. When replication-competent vaccine is administered, viable, transmissible vaccinia virus is present at the resulting skin lesion until the lesion scabs and separates. A major cutaneous reaction is expected and is the primary indication of an effective immune response. The area heals with scarring at the injection site. Infection is usually limited by the host response with the development of antibody-mediated and cell-mediated immunity.[16] Adverse events and complications occur when the virus spreads outside of the local area, either by transfer or because of host inability to contain the response.

Figure 166-13 Extensive scarring in an otherwise healthy infant from contracting vaccinia in utero. (From the Centers for Disease Control and Prevention [CDC] Public Health Image Library, Atlanta, GA, USA, and contributed by Arthur E. Kaye, MD.)

Studies suggest that immunoglobulin M antibodies, detected as early as day 4 of vaccination, may play a role in preventing potentially deadly early viral spread.[36] Neutralizing immunoglobulin G antibodies and cellular immunity start to become detectable around day 7 of vaccination and are responsible for maintaining the long-term host-immune response to the virus.

Figure 166-14 Bifurcated needle used for smallpox vaccination. (From the Centers for Disease Control and Prevention [CDC] Public Health Image Library, Atlanta, GA, USA, and contributed by James Gathany.)

DIAGNOSIS

Recent personal history of vaccinia vaccination supports the diagnosis. History of recent vaccinia vaccination of a close contact should raise suspicion for secondary transmission.

CLINICAL COURSE AND PROGNOSIS

Typically a papule develops at the inoculation site several days after administration and evolves into a vesicle and then a pustule. A scab typically forms within 2 weeks and falls off within 3 weeks, leaving a scar (see Fig. 166-6).

Potentially fatal adverse reactions from smallpox vaccination are eczema vaccinatum, progressive vaccinia, and postvaccinial CNS disease, described above. The mortality rate for eczema vaccinatum is 30% to 40%.[3] Progressive vaccinia is universally fatal if untreated. CNS complications have a 15% to 25% fatality rate. Individuals with postvaccinial encephalopathy, encephalitis, or encephalomyelitis may recover in approximately 2 weeks, but 25% of survivors are left with residual sequelae (eg, mental impairment, paralysis).[34]

Most fatalities from secondary transmission occur in infants younger than 1 year of age who develop eczema vaccinatum after contact with a recently vaccinated individual. Fetal vaccinia often results in fetal or neonatal death.[31,34]

Management: Symptomatic treatment alone is needed for minor local events (robust take, lymphangitis, intense erythema, or edema) and typical systemic symptoms (headache, malaise, myalgia, fever) occurring after vaccination. Secondary bacterial infections should be treated with appropriate antimicrobial therapy. Uncomplicated cases of accidental secondary transmission of vaccinia do not require therapy.

Extensive vaccinial lesions distant from the vaccination site and secondary transmission of vaccinia can be treated by IV administration of vaccinia immune globulin (VIG) or cidofovir to speed recovery. VIG is an FDA-approved sterile solution of the immunoglobulin fraction of plasma from persons vaccinated with vaccinia. The Strategic National Stockpile contains limited quantities of both VIG and cidofovir. Cidofovir is used under an Investigational New Drug protocol.

Generalized vaccinia usually requires only symptomatic treatment, but if severe, such as in those with immunodeficiency, VIG may be beneficial.

With severe eczema vaccinatum in which there is significant loss of the skin barrier, meticulous skin care and fluid and electrolyte repletion are needed. Early treatment with VIG has been shown to reduce mortality from eczema vaccinatum (from 30% to 40% down to 7%, based on preeradication era data).[33] VIG administration and care in an intensive care unit also reduces the case fatality rate of progressive vaccinia from 100% to 20% to 30%.[34]

Treatment of neurologic complications is supportive care; there is no evidence that VIG is effective in these cases.

Given the rarity of fetal vaccinia, inadvertent vaccination during pregnancy is not ordinarily a reason for termination. There is no indication for prophylactic administration of VIG to the pregnant woman, but it might be considered for a viable infant born with vaccinial lesions.[27,37]

Prevention: Vaccinia virus can be isolated from the vaccination site as soon as a papule forms and until the scab separates, approximately two week after vaccination.[9] To prevent inadvertent transmission of the live, replication-competent virus to other sites on the body or to unvaccinated individuals, the vaccination site should be covered with gauze and an overlying semipermeable membrane bandage until scabs have shed. Contact precautions and frequent hand washing are important when caring for the vaccination site.

As a consequence of elevated risks of adverse events, preevent vaccination is contraindicated for individuals who have a history of atopic dermatitis or a currently disrupted skin barrier, are immunosuppressed, are allergic to any component of the vaccine, or are pregnant or breastfeeding. Vaccination is also contraindicated for individuals with household contacts who have a history of atopic dermatitis or a currently disrupted skin barrier, are immunosuppressed, or are pregnant. Preevent vaccination of individuals younger than 18 years of age is not recommended, and preevent vaccination of children younger than 1 year of age is contraindicated. The CDC also recommends against vaccination of individuals with known cardiac disease.[38]

MONKEYPOX

AT-A-GLANCE

- Monkeypox is a member of the *Orthopoxvirus* genus, along with variola and vaccinia.
- Since the eradication of smallpox, monkeypox is the main *Orthopoxvirus* affecting human populations.[39]
- Its clinical presentation is similar to that of smallpox, with a key difference being that lymphadenopathy is more common in monkeypox.[39]

In contrast to smallpox, which was described in writings as far back as 340 AD, monkeypox is a relatively recently recognized disease. It was first identified in 1958 as an illness of cynomolgus monkeys, hence its name. Monkeypox was first documented to cause human illness in 1970 in Zaire (the present Democratic Republic of the Congo), when it was isolated from a patient with suspected smallpox infection.[39]

EPIDEMIOLOGY

Human monkeypox is a disease acquired mainly from infected animals. The disease is endemic to the Congo Basin of Central Africa, with the majority of human monkeypox infections occurring in the Democratic Republic of Congo, but cases are also reported in the Central African Republic, the Republic of Congo, and Sudan.[39] The majority of cases are in children. Transmission occurs mainly during handling of infected animals or contact with their body fluids. Person-to-person spread via respiratory droplets and close contact can occur as with smallpox, but usually in a more limited manner. Outbreaks in the Democratic Republic of Congo in 1996-1997 showed sustained human-to-human transmission for the first time, and the incidence of human monkeypox infection has been rising. This may reflect decreased immunity after the discontinuation of routine smallpox vaccination which is protective against monkeypox.[4,39] In spring 2003, the first cases of human monkeypox in the Western Hemisphere were identified in the Midwest region of the United States (72 reported cases, 37 laboratory confirmed). All cases were associated with contact with infected pet prairie dogs previously housed with rodents imported from Ghana.[40,41]

CLINICAL FEATURES

Prodrome: Similar to smallpox, symptoms of monkeypox manifest after a 7- to 17-day incubation period. A prodrome of fever, chills, malaise, headache, myalgias, and back pain occurs, lasting 1 to 4 days.[39] Some individuals experience sore throat, cough, or shortness of breath. Diarrhea and abdominal pain also may be reported.[4,42]

Cutaneous Findings: As with ordinary smallpox, a rash generally develops 1 to 3 days after the onset of fever, initially consisting of monomorphic macules and papules. Most commonly, the eruption begins on the face and/or trunk, with the lesions spreading in a centrifugal pattern to become generalized. They then progress over 14 to 21 days to vesicles and pustules that umbilicate, crust, and desquamate (Figs. 166-15 and 166-16). Dyspigmented and pitted scars result. Monkeypox lesions can involve the oral and genital mucous membranes.[43]

In the outbreak in the United States, only 1 patient (a child) had a generalized rash as extensive as those seen in cases in Africa. The other affected individuals had only localized lesions, mostly on the hands, that were associated with direct contact with the infected animals from Ghana (Figs. 166-17 and 166-18). This may indicate that West African strains of monkeypox virus are less virulent than those of Central Africa.[40,42]

Noncutaneous Findings: Significant lymphadenopathy develops 1 to 2 days before the onset of the rash, usually in submandibular, cervical, or inguinal areas (Fig. 166-19). Conjunctivitis and keratitis may occur. Confusion and seizures are rare.[44,45]

Figure 166-15 Umbilicated pustular lesions on the palm from monkeypox. (Used with permission from the Joint Pathology Center, Silver Spring, MD, USA.)

Complications: Secondary skin and soft-tissue infections may occur (approximately 20% of cases). Affected individuals may also develop pneumonitis (12%), encephalitis (less than 1%), and ocular complications, including scarring with corneal lesions.[43]

ETIOLOGY AND PATHOGENESIS

Monkeypox is caused by the monkeypox virus, a zoonotic virus. Like variola and vaccinia viruses, it is a type of *Orthopoxvirus* with a brick shape on electron microscopy. The monkeypox viral genome is 96% identical to that of the variola virus at the central region, which encodes essential enzymes and structural proteins. The end regions that encode virulence and host-range factors are substantially different, and the range of hosts for the monkeypox virus is much wider than that for variola virus.[46] In addition to humans, hosts for monkeypox include cynomolgus and other monkeys, other primates (apes, gorillas, chimpanzees, orangutans), and nonprimate animals such as rabbits, mice, guinea pigs, rats, squirrels, and giant anteaters.

Monkeypox is mainly transmitted through abraded skin after a bite or scratch from an infected animal or by contact with its infected bodily fluids. The virus multiplies locally at the site of injury and is rapidly transported to regional lymph nodes, where multiplication continues. Invasion of the bloodstream

Figure 166-17 The primary inoculation site of monkeypox virus in a 3-year-old child, 14 days after being bitten by a prairie dog. (Copyright © Marshfield Clinic, Inc. All rights reserved. Reprinted with permission from Marshfield Clinic, Inc., Marshfield, WI, USA.)

Figure 166-16 A 5-year-old male from the Democratic Republic of Congo with late desquamative monkeypox lesions. (Used with permission from the Joint Pathology Center, Silver Spring, MD, USA.)

Figure 166-18 Monkeypox lesions resolving in the same 3-year-old child. (Copyright © Marshfield Clinic, Inc. All rights reserved. Reprinted with permission from Marshfield Clinic, Inc., Marshfield, WI, USA.)

Figure 166-19 Significant postauricular lymphadenopathy with pustular skin lesions in a 2-year-old female with monkeypox. (Used with permission from the Joint Pathology Center, Silver Spring, MD, USA.)

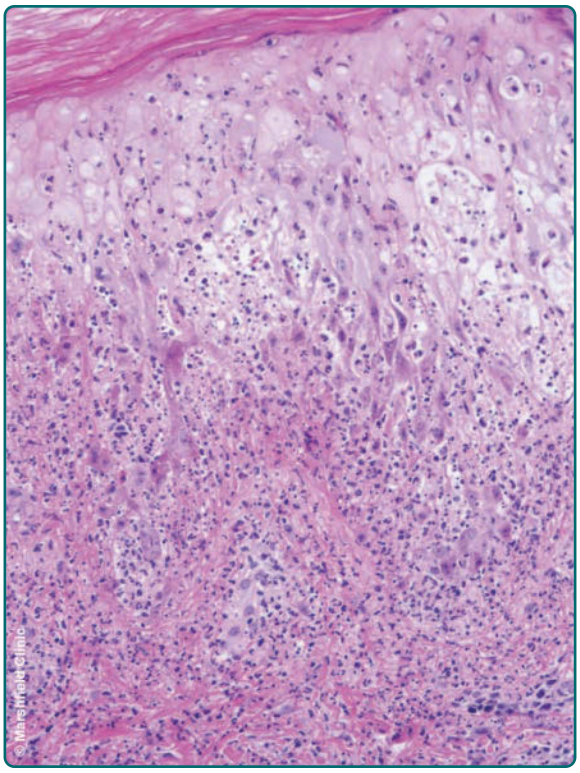

Figure 166-20 Histopathology of a monkeypox lesion with dermal papillary edema, acute inflammation, and ballooning degeneration of keratinocytes. (hematoxylin and eosin [H&E]. (Copyright © Marshfield Clinic, Inc. All rights reserved. Reprinted with permission from Marshfield Clinic, Inc., Marshfield, WI, USA.)

disseminates the virus to distant sites. The monkeypox virus is also transmissible from person to person via aerosolization of the virus or contact with lesions or body fluids during the first week of the rash, although its transmissibility is significantly lower than that of smallpox.[39] Monkeypox rarely may be transmitted by contaminated fomites.[47]

The longest documented chain of person-to-person spread is believed to have affected 6 individuals, which suggests that monkeypox has less potential for the type of epidemic spread seen with smallpox.[39]

DIAGNOSIS

Laboratory Testing: Leukocytosis, elevated transaminase levels, and low blood urea nitrogen levels are often seen. Lymphocytosis and thrombocytopenia occur less often.[48]

Pathology: On examination of skin biopsy specimens, features of monkeypox are indistinguishable from those of smallpox. There is similar dermal papillary edema, acute inflammation, and ballooning degeneration of keratinocytes (Fig. 166-20). Cytoplasmic eosinophilic inclusion bodies (Guarnieri bodies) are also seen. Focal necrosis may occur.[45]

Special Tests: PCR analysis of a swab, crust, or other material can confirm monkeypox virus infection. Electron microscopy and serologic tests can confirm *Orthopoxvirus* infection, but cannot distinguish monkeypox from variola or vaccinia.

DIFFERENTIAL DIAGNOSIS

Table 166-2 outlines the differential diagnosis of monkeypox virus infection.

The clinical features of monkeypox are similar to but less severe than those of ordinary smallpox. Lymphadenopathy is a distinctive hallmark of monkeypox not usually seen in smallpox. It is observed in 90% of unvaccinated individuals and 53% of vaccinated individuals.[4]

Varicella causes a milder and shorter/absent viral prodrome, has a centripetal distribution, and is not associated with lymphadenopathy.

Orf and bovine stomatitis, caused by poxviruses of the *Parapoxvirus* genus, can produce similar but more localized skin lesions.

Also in the differential diagnosis are drug eruptions, eczema herpeticum, and rickettsialpox (see Table 166-2). Immunocompromised individuals may develop extensive molluscum lesions that can look similar.

CLINICAL COURSE AND PROGNOSIS

In Africa, mortality ranges from 1% to 10% and mainly occurs in children. Death usually occurs during the

second week of disease and is secondary to bacterial superinfection, GI complications, or pulmonary complications. These are likely compounded by poor nutrition and inaccessibility of medical care.[4,40] All individuals affected by the 2003 outbreak in the United States survived.[49]

Scars left by the rash may improve over time.

MANAGEMENT

Contact and droplet precautions should be instituted, and suspected cases should be isolated in a negative air pressure room if possible.

Postexposure prophylaxis with vaccinia virus is the preferred treatment strategy.[46] It is recommended for those within 4 days of direct exposure to monkeypox virus and should be considered up to 14 days after exposure, including in children younger than 12 months of age, pregnant women, and people with skin conditions, as the risk of contracting monkeypox is considered greater for most individuals than the risk of developing complications from vaccination.[46]

However, vaccination is contraindicated in individuals with severe immunodeficiency in T-cell function, even if they have been directly exposed, as their risk of severe complications from vaccination approaches or exceeds their risk from monkeypox exposure.

Other treatment options include tecovirimat, which can be used under an Investigational New Drug protocol to treat monkeypox infection and is maintained in the U.S. Strategic National Stockpile.[50] Tecovirimat prevents death and reduces severity of monkeypox infection in nonhuman primate models, even when administered after the appearance of clinical symptoms.[21,51] Cidofovir and brincidofovir also can be used.[52] However, the efficacy of these drugs against monkeypox infection in humans has not been studied and is uncertain.

Prevention: Global eradication of monkeypox is more difficult than smallpox eradication, because of the wide range of animal hosts. Vaccination with the Dryvax smallpox vaccine containing vaccinia was found to be effective in preventing human monkeypox. Observation of cases in Africa showed that vaccination was 85% protective against monkeypox, and those who were not fully protected developed only mild disease.[45] The newer ACAM2000 vaccine has similar immunogenicity to Dryvax and showed equal protection against monkeypox virus in a nonhuman primate model.[53,54] However, vaccination with vaccinia virus is not currently in use in monkeypox-endemic areas because the risk of severe adverse events is thought to outweigh the potential benefit.[39]

The CDC currently recommends preexposure vaccination for laboratory workers, investigators of monkeypox cases, and health care providers who may care for patients with monkeypox, provided they have no contraindication to smallpox vaccination (Table 166-4).[46]

TABLE 166-4

Vaccination against Human Monkeypox Using Vaccinia Virus[a]

Indications

- Preexposure vaccination for laboratory workers, investigators of monkeypox cases, and health care providers who may care for patients with monkeypox.
- Postexposure vaccination for those within 4 days of direct exposure to monkeypox virus; should be considered up to 14 days after exposure.

Contraindications

- Contraindications in the preexposure setting:
  - Same as for vaccination against smallpox with vaccinia virus (see Table 166-3).
- Contraindications in the postexposure setting:
  - Severe immunodeficiency in T-cell function, defined as HIV-infected individuals with CD4 count <200 cells/μL (or age-adjusted equivalent level in children), recipients of high-dose immunosuppressive therapy, and people with lymphosarcoma, hematologic malignancies, or primary T-cell congenital immunodeficiencies.[46]

[a]Current Centers for Disease Control and Prevention (CDC) recommendations issued in 2003 and 2016.[38,36]

PARAPOXVIRUS INFECTIONS

The *Parapoxvirus* genus includes 3 viruses that produce disease in humans: pseudocowpox virus (the cause of milker's nodule), orf virus, and bovine papular stomatitis virus. These entities, sometimes grouped together as "barnyard pox," are clinically and histologically indistinguishable.[13] They are distinguished primarily by clinical history and PCR assay. Unlike the orthopoxviruses, parapoxviruses tend to cause localized rather than systemic disease in healthy individuals. Milker's nodule and orf are reviewed here.

MILKER'S NODULE

AT-A-GLANCE

- Milker's nodules are caused by pseudocowpox, also known as paravaccinia, a virus transmitted by cows.
- Lesions are clinically indistinguishable from orf and bovine papular stomatitis.
- Unlike the *Orthopoxvirus* cowpox, pseudocowpox does not immunize against smallpox.[1,55]

EPIDEMIOLOGY

Pseudocowpox is present worldwide, but disease develops only in individuals in close contact with

Figure 166-21 A milker's nodule on the hand. (From the National Institute for Occupational Safety and Health [NIOSH], Atlanta, GA, USA, with permission.)

cattle. It is an occupational disease of milkers, veterinarians, and meat industry workers. Most cases are in newly employed milkers who have not developed immunity.[1] Cases are mostly sporadic, but small epidemics have been reported. No natural cases of human-to-human transmission have been reported.

CLINICAL FEATURES

Paravaccinia inoculation usually occurs on the hands or, less commonly, the face. The incubation period for milker's nodule is 4 to 7 days. In a minority of cases, the infected individual develops mild systemic symptoms, such as a transient low-grade fever.[56]

Cutaneous Findings: After the incubation period, 1 to several lesions usually develop. In rare cases, numerous lesions may develop. Lesions progress through 6 typical stages, each lasting approximately a week. A lesion begins as a red, and occasionally pruritic, macule that develops into a raised papule (Fig. 166-21). It evolves into a papulovesicle with a target-like appearance—a red center surrounded by a white or gray ring and outer red halo. The lesions then develop into bluish or violaceous tender nodules. Some ulcerate or have a central depression (Fig. 166-22A), which results in formation of eschars with crust. Lesions usually heal in 4 to 8 weeks and typically resolve without scarring.[56]

The clinical presentation of milker's nodule is virtually identical to that of orf and bovine papular stomatitis.[13,57]

Noncutaneous Findings: Lymphangitis is often present in the skin surrounding the primary lesion(s). Lymphadenopathy is not common.

Complications: Secondary bacterial infection can occur but is rare. Erythema multiforme, morbilliform eruptions, and erythema nodosum have been reported in cases of milker's nodule.

Figure 166-22 **A,** Firm, eroded milker's nodule. **B,** Multiple lesions at the site of a second-degree scalding burn sustained in a milking barn.

ETIOLOGY AND PATHOGENESIS

Milker's nodule is caused by the pseudocowpox virus, also known as paravaccinia, which is a member of the *Parapoxvirus* genus. Although historically pseudocowpox and bovine papular stomatitis sometimes were considered to be the same entity, they are genetically distinct.[57] Pseudocowpox most commonly causes lesions on the teats of cows while bovine papular stomatitis most commonly causes lesions in the oral cavity.[13]

Humans can become accidental hosts for pseudocowpox after contacting infected animals or contaminated fresh meat. Pseudocowpox virus is transferred by direct inoculation into the skin, often through a break in the skin barrier.[58] Cases of transmission from contaminated fomites to individuals with burn injury have been reported (see Fig. 166-22B).[59]

DIAGNOSIS

Pathology: Histopathologic findings depend on the stage of the lesion. Early lesions show vacuolization and ballooning of cells in the upper third of the epidermis, which sometimes leads to multilocular vesicles. Intracytoplasmic inclusion bodies may be seen. Epidermal necrosis may be observed focally with ulceration and crust as the lesion progresses. Neutrophils are seen in the epidermis and superficial papillary dermis with epidermal necrosis. Mature lesions have finger-like

epidermal projections, papillary dermal edema, and a mixed inflammatory infiltrate that includes lymphocytes, histiocytes, and eosinophils. Regressing lesions have decreasing acanthosis and inflammation.[58,60]

Special Tests: When blister fluid or crusts are viewed with electron microscopy, *Parapoxvirus* virions typically are smaller than orthopoxviruses and have an ovoid (as opposed to brick-like) shape with a crisscross filament pattern.[57] Electron microscopy cannot differentiate among *Parapoxvirus* species. RT-PCR can confirm *Parapoxvirus* genus and distinguish between pseudocowpox, orf, and bovine papular stomatitis.[13,57]

DIFFERENTIAL DIAGNOSIS

Milker's nodules are clinically indistinguishable from orf and bovine papular stomatitis, but clinical history helps with differentiation: cattle are the source of infection for milker's nodules and bovine papular stomatitis while sheep or goats are the source of infection for orf. PCR can distinguish among the 3 viruses.

Milker's nodules must also be differentiated from the *Orthopoxvirus* cowpox. Cowpox is very rare in humans and, contrary to its name, is rarely transmitted from cows. It has a longer incubation period and causes more pain and lymphadenopathy. It is a more-severe infection that may cause death in individuals who have atopic dermatitis or are immunocompromised. Large lesions of milker's nodule also can be confused with anthrax, pyogenic granuloma, giant herpetic lesions, and keratoacanthoma (Table 166-5).

TABLE 166-5

Differential Diagnosis of Milker's Nodule and Orf

Most Likely

- Few to multiple lesions
  - Bovine papular stomatitis
  - Cowpox
  - Herpetic whitlow
- Solitary lesion
  - Pyogenic granuloma
  - Pyoderma

Consider

- Few to multiple lesions
  - Atypical mycobacterial infection
  - Sporotrichosis
- Solitary lesion
  - Tularemia
  - Giant herpetic lesion
  - Giant molluscum
  - Erysipeloid

Always Rule Out

- Few to multiple lesions
  - Anthrax
  - Primary inoculation tuberculosis
- Solitary lesion
  - Keratoacanthoma
  - Syphilitic chancre

CLINICAL COURSE AND PROGNOSIS

Milker's nodule is a self-limited illness. Most cases heal without scarring. Infection does not produce lifelong immunity; up to 12% of individuals have second infections.[57]

MANAGEMENT

Because the disease is self-limited, treatment, if needed, is symptomatic. Surgical curettage of large lesions may help speed healing.[61]

Prevention: As discussed above, there is no cross-immunity between orthopoxviruses and parapoxviruses, so smallpox vaccination does not prevent milker's nodules. Prevention mainly consists of isolation of infected animals and contact precautions.

ORF

AT-A-GLANCE

- Orf virus is usually transmitted to humans from sheep or goats.
- Orf infection looks similar to milker's nodule and progresses through similar clinical stages before resolving spontaneously.

Orf, also known as contagious pustular dermatosis, infectious pustular dermatitis, scabby mouth disease, and sore mouth disease, is a self-limited zoonotic viral infection that usually affects the hands of people handling infected animals. The disease is endemic in sheep and goats, and it is transmitted to humans through contact with infected tissue or fomites. Orf shares clinical characteristics with milker's nodule and bovine papular stomatitis. It may be mistaken for more serious and life-threatening disorders such as tularemia, anthrax, and erysipeloid (see Table 166-5).

The name *orf* is derived from the Nordic word *Hrufa*, meaning boil or scab.[59] Walley first identified orf as a contagious disease in sheep in 1890, and Newson and Cross first described the disease in humans in 1934.[59]

EPIDEMIOLOGY

Orf virus is a member of the *Parapoxvirus* genus, which also includes pseudocowpox and bovine papular stomatitis. Although sheep and goats are the most common sources of infection, the virus also has been found in mountain goats, gazelles, musk oxen, and reindeer. The nostrils and lips of infected animals are

affected, as well as the teats of ewes suckling young. Human disease is most often seen in farmers, shepherds, veterinarians, and butchers, but anyone who has contact with small ruminants is at risk.[62] The disease has been reported in children with exposure to farms or petting zoos.[63] Humans develop disease after contact with animals or fomites such as barn doors, feeding troughs, wire fencing, bottles, and harnesses. Multiple cases of orf infection following the Muslim feast of the sacrifice (Eid al-Adha), during which lambs are slaughtered, have been reported.[64] According to the CDC, the disease is not transmitted from human to human.

CLINICAL FEATURES

Cutaneous Findings: Orf lesions usually develop on the hands but can occur anywhere, including the face and perianal area.[61,65] A solitary lesion is the most common presentation, but multiple lesions are possible.[65]

As with milker's nodule lesions, orf lesions evolve through 6 clinical stages, each lasting roughly 1 week (Table 166-6).[65,66] A red macule appears a few days after inoculation and develops into a red papule by 1 week after the inoculation. During the second week, the lesion evolves into a targetoid nodule with a red papule surrounded by a white ring and enclosed by a peripheral halo of erythema (Fig. 166-23). During the third week, considered the acute stage, the lesion becomes weepy (Fig. 166-24). It may appear as a flat-topped, crusted, hemorrhagic pustule 2 to 3 cm in diameter (Fig. 166-25A).[59] During the fourth week, the lesion enters the regenerative stage, during which it dries out and black dots composed of pyknotic cells form on its surface (Fig. 166-25B). During the fifth week, papillomas develop on the surface of the lesion. In the final, regressive stage, a dry crust forms at the periphery of the lesion and gradually extends centrally. The crust may shed and reform several times before the lesion flattens and heals.[65] Lesions are typically painless.[59]

Noncutaneous Findings: Systemic findings are uncommon in immunocompetent individuals but can include lymphadenopathy and lymphangitis. Rarely, fever and malaise may occur.[65]

Complications: Orf lesions can become secondarily infected.[67] An estimated 7% to 18% of individuals with orf infections develop erythema multiforme.[68] Vesiculopapular, papular (see Fig. 166-25A), and bullous-pemphigoid like eruptions also may develop.[69,70]

TABLE 166-6
Clinical Manifestation of Orf

TIME AFTER EXPOSURE	CLINICAL MANIFESTATIONS
3-7 days	1-4 papules on hand (typically only 1 lesion): begin as a red maculopapular lesion
	↓
	Vesicle
	↓
10-14 days	Target lesion with red center, white middle ring, and red halo
	↓
14-21 days	Acute weeping stage
	↓
21-28 days	Regenerative dry stage with black dots
	↓
28-35 days	Papillomatous stage
	↓
35 days	Regressive stage with dry crust and eventual shedding of the scab

Adapted from Clark J, Diven D. Poxviruses. In: Tyring SK, Moore AY, Lupi O, eds. *Mucocutaneous Manifestations of Viral Diseases.* 2nd ed. London, UK: Informa Healthcare; 2010:51, with permission.

Figure 166-23 The target phase of orf shows a white circle with central and peripheral erythema.

Figure 166-24 In the acute phase, there is weeping of the surface overlying an elevated tumor.

Figure 166-25 **A,** Multiple orf papulonodules with unusually extensive hemorrhagic crust during the acute weeping stage, 16 days after a goat bite to multiple fingers. A diffuse papular eruption that developed after the primary orf lesions is also visible. **B,** Twenty-two days after the goat bite, the primary orf lesions have begun to dry out and flatten, and the secondary eruption is resolving. (Used with permission from Victoria R. Barrio, MD.)

Additionally, secondary spread within active atopic dermatitis skin lesions has been reported.[71] Rare complications include giant orf lesions and Stevens-Johnson syndrome.[62,72]

ETIOLOGY AND PATHOGENESIS

Orf is an ovoid crosshatched particle approximately 250 nm long × 150 nm wide.[64] The virus is very stable and can survive heating, drying, and solvents. It is transmitted to humans from animals or fomites through a crack in the skin and replicates within the epidermis.

Orf virus encodes immunomodulatory genes that interfere with host response and allow time for viral replication within epidermal cells. Orf virus interferon resistance protein and virus interleukin-10 inhibit interferon and inflammatory cytokine production. Additionally, granulocyte-macrophage colony-stimulating factor inhibitory factor inhibits the biologic activity of granulocyte-macrophage colony-stimulating factor and interleukin-2.[73] Clearance of the infection occurs when host immune response eventually overcomes orf's immunomodulatory proteins.

Risk Factors: Exposure to infected animals is the greatest risk factor for orf infection. Infections tend to occur most often during the spring and summer months, which is lambing season, as young animals are most susceptible to infection.[63] Vaccination of sheep with a commercially available unattenuated, live orf vaccine with the intent of conferring immunity is a risk factor for humans.[63]

Immunocompromised individuals have an increased risk of developing giant (greater than 3 cm in diameter) orf lesions and may have difficulty clearing them.[63,74]

DIAGNOSIS

Clinical appearance and history of ungulate exposure are usually diagnostic. Dermoscopy of orf lesions shows central ulceration surrounded by white structureless areas, white shiny streaks, dotted and hairpin vessels, and fine peripheral scale.[75]

Pathology: In the maculopapular and target stages, intranuclear and intracytoplasmic inclusions are present in vacuolated epidermal cells, with an accumulation of neutrophils, basophils, dendritic cells, and lymphocytes (Fig. 166-26). During the acute stage, multilocular vesicles form and the epidermis degenerates. Papillomatosis and acanthosis subsequently develop, and marked finger-like downward projections of the epidermis may be seen (Fig. 166-27).[65]

Special Tests: RT-PCR testing, which is available through the CDC, is the most rapid and accurate way

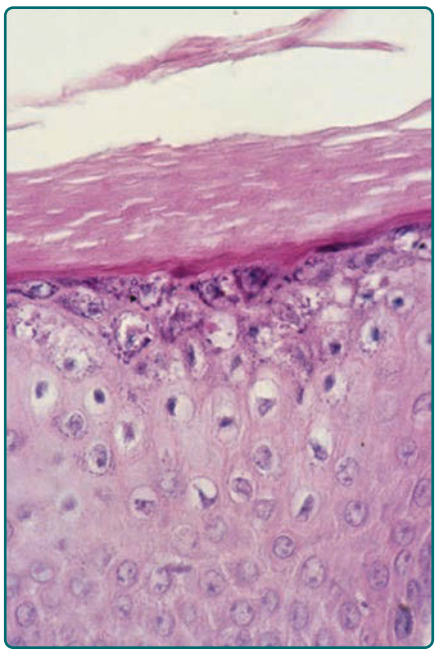

Figure 166-26 Orf histopathology. In the target phase, there are superficial vacuolated epidermal cells with inclusion bodies.

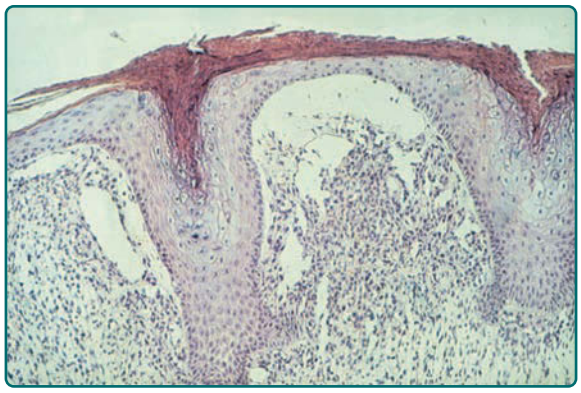

Figure 166-27 Orf histopathology. Later in the target stage, there are finger-like projections of the epidermis and a dense inflammatory infiltrate accompanied by massive edema in the papillary body.

to make the diagnosis when clinical uncertainty exists. Electron microscopy cannot definitively distinguish between *Orthopoxvirus* and *Parapoxvirus*.

DIFFERENTIAL DIAGNOSIS

A variety of bacterial and infectious diseases can present with findings similar to those of orf (see Table 166-5). Milker's nodule and bovine papular stomatitis are clinically and histologically indistinguishable from orf, but are associated with different animal exposure. The lesion of anthrax is more hemorrhagic with rapid progression to an eschar. Herpetic whitlow may resemble orf but tends to be more painful. Tularemia and syphilis are associated with chancres. Sporotrichosis begins as a single necrotic nodule but is followed by multiple nodules arising in a linear fashion along the lymphatics. Primary inoculation tuberculosis and atypical mycobacterial infection can give rise to ulcerative lesions that may take months to years to heal.

CLINICAL COURSE AND PROGNOSIS

Orf usually resolves within 4 to 6 weeks without treatment. Typically, scarring does not occur. Immunocompromised individuals can develop progressive, destructive lesions that may require interventions such as debridement, antiviral therapy such as cidofovir cream, or imiquimod topical immunomodulatory therapy.[63,74,76] Recurrence is uncommon but has been reported.[74]

MANAGEMENT

Supportive care is the most appropriate intervention for immunocompetent patients. Application of compresses, culture of lesion specimens, and antibiotic coverage may be appropriate if secondary bacterial infection is suspected. Immunocompromised patients may require medical intervention, as described above.

Prevention: Barrier precautions, such as use of gloves and good hand hygiene, help prevent orf infection. Individuals with an impaired skin barrier from either abrasions or intrinsic skin disease (eg, atopic dermatitis) should be particularly vigilant about avoiding contact with infected animals or potential fomites.

MOLLUSCIPOXVIRUS INFECTION: MOLLUSCUM CONTAGIOSUM

AT-A-GLANCE

- Molluscum contagiosum is a common benign cutaneous infection with associated signs isolated to the skin.
- Children are most commonly affected.
- Severe inflammatory responses can occur at the site of the lesions, which are sometimes mistaken for secondary bacterial infection or cellulitis.
- A number of associated skin findings, including eczematous reactions surrounding the lesions, more diffuse autoeczematization-type reactions, or lichenoid, Gianotti-Crosti type lesions may develop.

Molluscum contagiosum (MC) is a common benign cutaneous viral infection specific to humans that occurs worldwide and is transmitted by skin-to-skin-contact. Since the eradication of smallpox, MC virus is the primary poxvirus affecting humans.[77]

MC infection was first described clinically by Bateman in 1817. Henderson and Paterson identified its characteristic intracytoplasmic viral inclusion bodies in 1841.[78]

EPIDEMIOLOGY

MC infection most commonly affects children, sexually active adults, athletes participating in contact sports, and individuals with impaired cellular immunity.[77] The infection is most prevalent before the age of 14 years, with a median age of 5 years in a retrospective study of 170 children at Johns Hopkins.[79,80] A metaanalysis estimates that 5.1% to 11.5% of children ages 0 to 16 years are affected at any given time, but true prevalence is likely higher, as some infections may be subclinical.[79] Seropositivity to MC virion surface protein in unaffected individuals ranges from 6% in Japan to approximately 30% in the United Kingdom.[81,82]

MC lesions are mainly limited to the skin, but rarely develop on mucosal surfaces, including the eye.[77] In children, lesions are usually on exposed areas, whereas in adults, many cases are limited to the genital area,

suggesting sexual transmission.[83] Genital and perianal lesions can also develop in children, but are rarely associated with sexual transmission in this age group.[84] The prevalence of sexually transmitted MC infections in adults has risen over the past several decades, with a large Spanish study noting a threefold increase in the yearly incidence (from 1.3% to 4%) in a sexually transmitted disease unit between 1988 and 2007.[85] An earlier study showed an 11-fold increase in patient visits for MC in the United States between 1966 and 1983. One theorized explanation is that reduced transmission in childhood may result in more adults who are immunologically naïve and vulnerable to sexual transmission.[85]

MC infections are more common in individuals infected with HIV. Data from the 1980s and early 1990s suggested a prevalence of 5% to 18% in this population, but with the increased use of antiretroviral therapy, the rate may now be lower.[86]

Transmission may occur via direct skin or mucous membrane contact, or via fomites. Bath towels, swimming pools, and public or shared baths are reported as sources of infection.[87] Autoinoculation and koebnerization also play a role in the spread of lesions. Vertical transmission from mother to neonate during the intrapartum period has been reported.[88,89]

MC lives in the epidermis and does not remain latent in the body after the cutaneous lesions have cleared.[77]

CLINICAL FEATURES

Cutaneous Findings: MC often presents as small pink, pearly, or skin-colored papules that enlarge to 2 to 5 mm in size. As they enlarge they may become flat-topped, dome-shaped, and opalescent. Lesions may have a central dell or umbilication (Fig. 166-28A), from which a white curd-like substance containing the virus can be expressed with pressure. Children usually develop multiple papules, often in exposed sites like the face and extremities or intertriginous sites, such as the axillae and popliteal fossae. Lesions may be grouped in clusters or appear in a linear array. The latter often results from koebnerization or development of lesions at sites of trauma. In adults, lesions typically develop in the genital area.

Immunosuppressed patients typically have more-severe and extensive disease, and may develop giant molluscum as large as 2.5 cm in diameter.[90,91]

Noncutaneous Findings: MC is not associated with systemic complications.

Complications: Although many patients are asymptomatic, pruritus may be a significant problem, particularly in those patients with underlying atopic dermatitis. Chronic conjunctivitis and punctate keratitis may develop in patients with eyelid lesions. Secondary bacterial infection can occur, particularly if patients scratch their lesions.

Approximately 19% to 39% of children with MC develop an erythematous, eczematous dermatitis surrounding their molluscum lesions, known as *molluscum dermatitis*.[87,92] This is more common in children with atopic dermatitis; roughly half of children with both atopic dermatitis and MC develop molluscum dermatitis.[92]

In approximately 20% of patients, molluscum lesions may become inflamed, with erythema and swelling (see Fig. 166-28B), and these inflamed lesions may become pustular or fluctuant.[87,92] The development of inflamed MC lesions suggests a robust immune response and tends to be associated with a subsequent decline in the number of lesions.[92]

Figure 166-28 Molluscum contagiosum. **A,** Discrete, solid, skin-colored papules, 1 to 2 mm in diameter with central umbilication. **B,** Multiple, scattered, and discrete lesions, some of which are inflamed.

A small subset of individuals with MC develop a Gianotti-Crosti–like reaction consisting of pruritic monomorphous, edematous, erythematous papules or papulovesicles, centered on the elbows and knees, which lasts for several weeks. This eruption also tends to be followed by reduction in the number of MC lesions and may be considered a favorable prognostic sign.[92]

ETIOLOGY AND PATHOGENESIS

MC virus is a large, brick-shaped double-stranded DNA poxvirus with genomic similarities to other poxviruses. It shares two-thirds of the viral genes of vaccinia and variola viruses.[80] There are 4 clinically indistinguishable subtypes of MC virus. MC virus genotype 1 is responsible for 98% of disease in the United States.[93,94] MC virus genotype 2 is primarily seen in adults and immunocompromised individuals and is most commonly transmitted by sexual contact. The incubation period of the virus estimated to be approximately 2 to 6 weeks.[95]

MC virus replicates in the cytoplasm of epithelial cells. Viral inclusion bodies known as Henderson-Paterson bodies develop in the basal layer of the epidermis and enlarge as cells rise through the epidermis, pushing cellular organelles against the sides of the cell.[90] Proliferation and enlargement of the virion-packed cells causes disintegration of the stratum corneum and the formation of a dimple-like ostium through which the virions are released when the inclusion bodies rupture.[90]

Molluscum lesions can persist for a long time without significant inflammatory cell infiltration because the MC virus possesses multiple genes that impede host immune response.[90] These include genes coding for (a) a homolog of a major histocompatibility class 1 heavy chain, which may interfere with antigen presentation; (b) a chemokine homolog that inhibits chemotaxis; (c) a protein that inhibits apoptosis by preventing activation of the death effector domain of caspase 8; and (d) a glutathione peroxidase homolog that prevents apoptosis in cells damaged by ultraviolet radiation and hydrogen peroxide.[77,90,96] Eventually the immune system detects the virus and mounts a localized response involving plasmacytoid dendritic cells, interferon-induced dendritic cells, natural killer cells, and cytotoxic T lymphocytes, ultimately clearing the infection.[97]

Risk Factors: A 2014 metaanalysis of risk factors found an association between recent history of swimming and development of MC, with the relative risk of MC among swimmers approximately twice that of nonswimmers.[98]

Altered skin barrier function and immunity in atopic dermatitis may be a risk factor for MC, with 18% to 47% of MC patients having a history of atopic dermatitis.[80,92,99-101] Atopic dermatitis may be somewhat overrepresented because children with atopic dermatitis may be assessed by physicians more often than those without, in whom molluscum may go undiagnosed.[99] Individuals with atopic dermatitis may have more widespread involvement and pruritus, as well as increased risk of developing molluscum dermatitis.[80,101]

HIV is a risk factor for MC infection, and affected individuals are at higher risk for extensive prolonged disease.[102] MC infection is associated with a CD4+ count of <200 cells/μL.[103] Additionally, MC eruption can occur in association with immune reconstitution inflammatory syndrome after initiation of antiretroviral therapy.[104]

Individuals with a *DOCK8* (dedicator of cytokinesis 8) mutation, which results in T-cell and B-cell deficiency, are at risk for extensive molluscum infections.[90,105]

Patients receiving immunosuppressive medications for organ transplants or other indications also have increased risk. MC infections have been reported in patients taking methotrexate, alone or in combination with a tumor necrosis factor-α inhibitor or cyclosporine, for treatment of Crohn disease, mycosis fungoides, mixed connective tissue disease, psoriasis, and exfoliative dermatitis.[106] Additionally, treatment with Janus kinase inhibitors and fingolimod also are implicated in the development of MC virus infections.[107,108]

DIAGNOSIS

Clinical diagnosis is usually straightforward and can be aided by dermoscopic examination where MC lesions typically have a central polylobular white-yellow amorphous structure surrounded by a peripheral crown of blood vessels (red corona).[109,110] The appearance corresponds to hyperplastic squamous epithelium expanding into the dermis, separated by septae of compressed dermis.[109] Punctiform, radial, and mixed patterns also may be seen.[111]

Pathology: Evaluation of the central contents of the lesion using a crush preparation and Wright or Giemsa staining can be carried out when necessary (Fig. 166-29). Histopathologic examination reveals a hypertrophied and hyperplastic epidermis. Above the

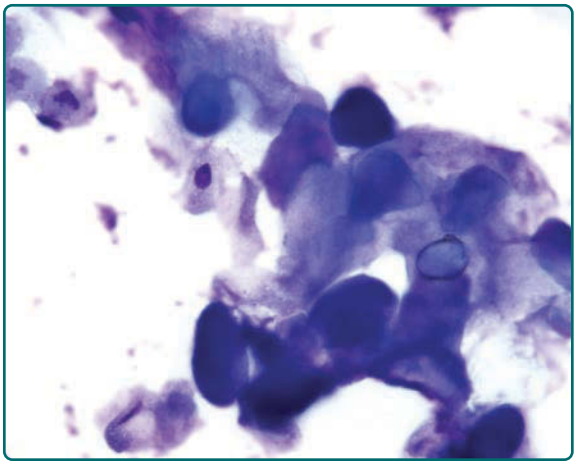

Figure 166-29 Microscopic examination (Giemsa stain) of cellular material from the area of central umbilication shows intracytoplasmic molluscum inclusion bodies.

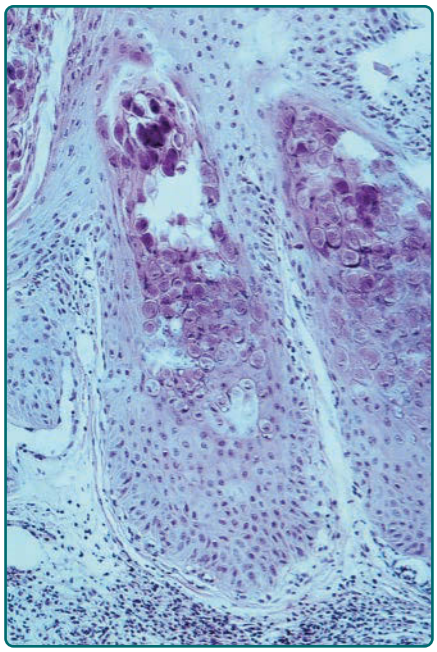

Figure 166-30 Molluscum contagiosum. Histopathology (skin biopsy, hematoxylin and eosin [H&E]) shows downgrowth of infected epidermal cells bearing large eosinophilic cytoplasmic inclusion bodies (Henderson-Paterson bodies).

basal layer, enlarged cells containing large, intracytoplasmic inclusions (Henderson-Paterson bodies) can be seen (Fig. 166-30).

Special Tests: PCR confirmation can be performed but is usually not necessary.

DIFFERENTIAL DIAGNOSIS

The differential diagnosis includes verrucae, pyogenic granulomas, amelanotic melanoma, basal cell carcinomas, and appendageal tumors. Fungal infections caused by *Cryptococcus*, histoplasmosis, and *Penicillium* must be considered in immunocompromised hosts (Table 166-7).

TABLE 166-7
Differential Diagnosis of Molluscum Contagiosum

Most Likely
- Verrucae

Consider
- Pyogenic granuloma
- Papular granuloma annulare
- Epidermal inclusion cyst
- Sebaceous hyperplasia

Always Rule Out
- Appendageal tumors
- Basal cell carcinoma
- Amelanotic melanoma
- Cryptococcosis/histoplasmosis/penicilliosis

CLINICAL COURSE AND PROGNOSIS

MC infections typically resolve spontaneously within months to years. Each individual lesion lasts approximately 2 months, but the total duration of infection is longer because lesions spread by autoinoculation.[90] In the largest prospective cohort of children with MC infection, the average duration was 13.3 months.[112] A retrospective review of 170 children with MC evaluated in the Division of Pediatric Dermatology at the Johns Hopkins Children's Center found that treatment did not shorten time to resolution.[80] Lesions typically resolve without scarring, but scratching or destructive treatments may result in scarring.

In patients infected with HIV, MC may resolve with initiation of antiretroviral therapy and improvement in CD4 cell counts.[102]

MANAGEMENT

It is important to discuss the risks and benefits of individual therapies with families before embarking on treatment of this essentially benign condition, which typically resolves without complication in the immunocompetent individual. For some children, no treatment is the best option as the child's native immune response may clear the MC without additional intervention. Nevertheless, treatment may be warranted for persistent, pruritic, spreading, or cosmetically undesirable lesions, as well as to prevent autoinoculation or transmission to others.[113] However, robust analysis of the comparative efficacy of treatments is lacking. A 2017 Cochrane Database analysis of treatments for MC identified only 22 randomized controlled trials of MC treatments and concluded that no single intervention is convincingly effective for the treatment of MC.[114] The analysis did not include several therapies commonly used by pediatric dermatologists because of insufficient data.[113,115]

In the absence of compelling evidence for the superiority of any particular treatment, multiple therapies are used, including destructive, immunomodulatory, cytotoxic, and antiviral therapies.[113]

Physically destructive therapies include curettage, cryotherapy, CO_2 laser, pulsed-dye laser, and electrodessication.[116] They may work by rupturing the intracytoplasmic sacs containing MC viral proteins and triggering an immunologic response that clears the infection.[77]

Chemically destructive therapies include potassium hydroxide, silver nitrate, trichloracetic acid, phenol, and the blistering agent cantharidin, which is likely the most commonly used therapy.[77,115,117] Cantharidin 0.7% in a collodion base is applied to the lesions and washed off after 2 to 6 hours.[118] This substance, which was originally extracted from the blister beetle, causes dissolution of desmosomal plaques, resulting in acantholysis and intraepidermal blistering, with extrusion of the molluscum bodies.[118,119] Cantharidin is the preferred treatment for children because it is painless at time of application, in contrast with curettage and cryotherapy, which are painful and may be traumatic for children. However, families must be counseled regarding the small risk of

extreme reaction or scarring, and cantharidin should not be used on the thin skin of the face and genital areas. MC typically resolves after an average of 2.1 treatments with cantharidin.[120] A randomized controlled trial of cantharidin treatment versus placebo for treatment of MC that was published in 2014 found no significant difference, but was limited by sample size and short duration of follow up.[117,121] Parent and physician satisfaction with the therapy is high; 78% to 95% of parents say they would use cantharidin treatment again for molluscum reoccurrence.[120,122,123]

Immunomodulatory therapies include intralesional interferon-α or interferon-β, intralesional *Candida* antigen injection, cimetidine, and imiquimod.[77,90] Oral cimetidine has been used with some success, although evidence is contradictory.[124,125] Although imiquimod cream is favored by some physicians and may be effective for genital lesions, randomized controlled trials have found it ineffective in children.[115,126-129]

The cytotoxic therapy podophyllotoxin and antiviral therapy cidofovir, which can be administered topically or IV, are also used.

For genital molluscum, the 2014 United Kingdom national guidelines recommend either nontreatment or treatment with podophyllotoxin 0.5%, imiquimod 5% cream, or liquid nitrogen therapy.[130] Podophyllotoxin and imiquimod should be avoided during pregnancy and breastfeeding.[130]

Immunosuppressed patients may be unresponsive to traditional therapies. Treatment of the underlying disease is thought to be the most effective therapy for resolving MC infection. In HIV patients, MC infection may improve as CD4 count rises. A recent systematic review of 13 studies found little evidence to support any particular intervention for MC in HIV.[102] Combination therapies may be tried.[77] Some clinicians recommend that adolescents and adults with new-onset MC infection undergo evaluation for HIV infection and/or other causes of an immunocompromised state.[83]

Medium-strength topical steroids sometimes are used to treat molluscum dermatitis and Gianotti-Crosti–like reactions. Data on whether treating these secondary eruptions raises the risk of MC recurrence are contradictory, and this issue needs further study.[87,92]

Prevention/Screening: Spread through autoinoculation can be reduced by treating existing lesions, avoiding scratching, and using antipruritics as necessary. As mentioned above, treating molluscum dermatitis with topical steroids may reduce autoinoculation via scratching but potentially raises the risk of relapse by dampening the immune response to molluscum, and should be considered on a case-by-case basis until studied further.[87,92]

MC infection should not prevent children from attending school or playing sports.[131] To prevent spread to others, the CDC advises covering lesions that could contact other individuals with clothing or bandages. This is especially important when participating in contact sports and sharing equipment like helmets and baseball gloves. The CDC recommends avoiding swimming unless all lesions can be covered by watertight bandages.

ACKNOWLEDGMENTS

The authors acknowledge the contributions of Drs. Caroline Piggott and Wynnis Tom, former authors of this chapter.

REFERENCES

1. Diven DG. An overview of poxviruses. *J Am Acad Dermatol*. 2001;44(1):1-16.
2. Petersen BW, Damon IK, Pertowski CA, et al. Clinical guidance for smallpox vaccine use in a postevent vaccination program. *MMWR Recomm Rep*. 2015; 64(2):1-32.
3. Voigt EA, Kennedy RB, Poland GA. Defending against smallpox: a focus on vaccines. *Expert Rev Vaccines*. 2016:1-15.
4. Fenner F, Henderson DA, Arita I, et al. *Smallpox and Its Eradication*. Geneva, Switzerland: World Health Organization; 1988.
5. Arita I. Discovery of forgotten variola specimens at the National Institutes of Health in the USA. *Expert Rev Anti Infect Ther*. 2014;12(12):1419-1421.
6. Huq F. Effect of temperature and relative humidity on variola virus in crusts. *Bull World Health Organ*. 1976;54(6):710-712.
7. Breman JG, Henderson DA. Diagnosis and management of smallpox. *N Engl J Med*. 2002;346(17): 1300-1308.
8. Kiang KM, Krathwohl MD. Rates and risks of transmission of smallpox and mechanisms of prevention. *J Lab Clin Med*. 2003;142(4):229-238.
9. Wharton M, Strikas RA, Harpaz R, et al. Recommendations for using smallpox vaccine in a pre-event vaccination program. Supplemental recommendations of the Advisory Committee on Immunization Practices (ACIP) and the Healthcare Infection Control Practices Advisory Committee (HICPAC). *MMWR Recomm Rep*. 2003;52(RR-7):1-16.
10. WHO Expert Committee on Smallpox Eradication. WHO Expert Committee on Smallpox Eradication. Second report. *World Health Organ Tech Rep Ser*. 1972; 493:1-64.
11. McKenzie PJ, Githens JH, Harwood ME, et al. Haemorrhagic smallpox. 2. Specific bleeding and coagulation studies. *Bull World Health Organ*. 1965;33(6):773-782.
12. Arora A, Agarwal A, Kumar S. Osteomyelitis variolosa: a report of two cases. *J Orthop Surg (Hong Kong)*. 2008; 16(3):355-358.
13. MacNeil A, Lederman E, Reynolds MG, et al. Diagnosis of bovine-associated parapoxvirus infections in humans: molecular and epidemiological evidence. *Zoonoses Public Health*. 2010;57(7-8):e161-e164.
14. Slifka MK, Hanifin JM. Smallpox: the basics. *Dermatol Clin*. 2004;22(3):263-274.
15. Henderson DA, Inglesby TV, Bartlett JG, et al. Smallpox as a biological weapon: medical and public health management. Working Group on Civilian Biodefense. *JAMA*. 1999;281(22):2127-2137.
16. Moore ZS, Seward JF, Lane JM. Smallpox. *Lancet*. 2006;367(9508):425-435.
17. Centers for Disease Control and Prevention (CDC). *Acute, Generalized Vesicular or Pustular Rash Illness Protocol*. https://www.cdc.gov/smallpox/clinicians/

algorithm-protocol.html. Published December 5, 2016. Accessed September 29, 2018.
18. Centers for Disease Control and Prevention (CDC). *Acute, Generalized Vesicular or Pustular Rash Illness Testing Protocol in the United States*. https://www.cdc.gov/smallpox/pdfs/rash-illness-protocol.pdf. Accessed September 29, 2018.
19. Centers for Disease Control and Prevention (CDC), Association of Public Health Laboratories. *Laboratory Approach to the Diagnosis of Smallpox*. July 2011. https://www.aphl.org/programs/preparedness/Smallpox/index.html.
20. Fenner F, Wittek R, Dumbell KR. *The Orthopoxviruses*. San Diego, CA: Academic Press; 1989.
21. Berhanu A, Prigge JT, Silvera PM, et al. Treatment with the smallpox antiviral tecovirimat (ST-246) alone or in combination with ACAM2000 vaccination is effective as a postsymptomatic therapy for monkeypox virus infection. *Antimicrob Agents Chemother.* 2015;59(7):4296-4300.
22. U.S. Department of Health and Human Services, Food and Drug Administration, Center for Drug Evaluation and Research (CDER), et al. *Product Development Under the Animal Rule—Guidance for Industry*. October2015.https://www.fda.gov/downloads/Drugs/GuidanceComplianceRegulatoryInformation/Guidances/UCM399217.pdf. Accessed September 29, 2018.
23. U.S. Department of Health and Human Services. *2014 Public Health Emergency Medical Countermeasures Enterprise (PHEMCE) Strategy and Implementation Plan*. February 2015. http://www.phe.gov/Preparedness/mcm/phemce/Documents/2014-phemce-sip.pdf. Accessed September 29, 2018.
24. U.S. Department of Health and Human Services. *2015 Public Health Emergency Medical Countermeasures Enterprise (PHEMCE) Strategy and Implementation Plan*. December 2015. https://www.phe.gov/Preparedness/mcm/phemce/Documents/2015-PHEMCE-SIP.pdf. Accessed September 29, 2018.
25. Mucker EM, Goff AJ, Shamblin JD, et al. Efficacy of tecovirimat (ST-246) in nonhuman primates infected with variola virus (smallpox). *Antimicrob Agents Chemother.* 2013;57(12):6246-6253.
25A. Trost LC, Rose ML, Khouri J, et al. The efficacy and pharmacokinetics of brincidofovir for the treatment of lethal rabbitpox virus infection: a model of smallpox disease. *Antiviral Res*. 2015;117:115-121.
26. Centers for Disease Control and Prevention (CDC). Notice to readers: newly licensed smallpox vaccine to replace old smallpox vaccine. *MMWR Morb Mortal Wkly Rep.* 2008;57(08);207-208. Available at https://www.cdc.gov/mmwr/preview/mmwrhtml/mm5708a6.htm
27. Fulginiti VA, Papier A, Lane JM, et al. Smallpox vaccination: a review, part I. Background, vaccination technique, normal vaccination and revaccination, and expected normal reactions. *Clin Infect Dis.* 2003;37(2):241-250.
28. Rotz LD, Dotson DA, Damon IK, et al; Advisory Committee on Immunization Practices. Vaccinia (smallpox) vaccine: recommendations of the Advisory Committee on Immunization Practices (ACIP), 2001. *MMWR Recomm Rep.* 2001;50(RR-10):1-25.
29. Casey C, Vellozzi C, Mootrey GT, et al. Surveillance guidelines for smallpox vaccine (vaccinia) adverse reactions. *MMWR Recomm Rep.* 2006;55(RR-1):1-16.
30. Frey SE, Couch RB, Tacket CO, et al. Clinical responses to undiluted and diluted smallpox vaccine. *N Engl J Med.* 2002;346(17):1265-1274.
31. Lupatkin H, Lupatkin JF, Rosenberg AD. Smallpox in the 21st century. *Anesthesiol Clin North America.* 2004;22(3):541-561.
32. Neff JM. Contact vaccinia—transmission of vaccinia from smallpox vaccination. *JAMA.* 2002;288(15):1901-1905.
33. Cono J, Casey CG, Bell DM; Centers for Disease Control and Prevention. Smallpox vaccination and adverse reactions. Guidance for clinicians. *MMWR Recomm Rep.* 2003;52(RR-4):1-28.
34. Tom WL, Kenner JR, Friedlander SF. Smallpox: vaccine reactions and contraindications. *Dermatol Clin.* 2004;22(3):275-289.
35. Bartlett J, Borio L, Radonovich L, et al. Smallpox vaccination in 2003: key information for clinicians. *Clin Infect Dis.* 2003;36(7):883-902.
36. Moyron-Quiroz JE, McCausland MM, Kageyama R, et al. The smallpox vaccine induces an early neutralizing IgM response. *Vaccine.* 2009;28(1):140-147.
37. Maurer DM, Harrington B, Lane JM. Smallpox vaccine: contraindications, administration, and adverse reactions. *Am Fam Physician.* 2003;68(5):889-896.
38. Petersen BW, Harms TJ, Reynolds MG, et al. Use of vaccinia virus smallpox vaccine in laboratory and health care personnel at risk for occupational exposure to orthopoxviruses—recommendations of the Advisory Committee on Immunization Practices (ACIP), 2015. *MMWR Morb Mortal Wkly Rep.* 2016;65(10):257-262.
39. McCollum AM, Damon IK. Human monkeypox. *Clin Infect Dis.* 2014;58(2):260-267.
40. Reed KD, Melski JW, Graham MB, et al. The detection of monkeypox in humans in the western hemisphere. *N Engl J Med.* 2004;350(4):342-350.
41. Reynolds MG, Carroll DS, Olson VA, et al. A silent enzootic of an orthopoxvirus in Ghana, West Africa: evidence for multi-species involvement in the absence of widespread human disease. *Am J Trop Med Hyg.* 2010;82(4):746-754.
42. Ligon BL. Monkeypox: a review of the history and emergence in the western hemisphere. *Semin Pediatr Infect Dis.* 2004;15(4):280-287.
43. Nalca A, Rimoin AW, Bavari S, et al. Reemergence of monkeypox: prevalence, diagnostics, and countermeasures. *Clin Infect Dis.* 2005;41(12):1765-1771.
44. Breman JG. Monkeypox: an emerging infection for humans? In: Scheld WM, Craig WA, Hughes JM, eds. Emerging infections. 4th ed. Washington DC: ASM Press; 2000:45-67.
45. Pattyn SR. Monkeypoxvirus infections. *Rev Sci Tech.* 2000;19(1):92-97.
46. Centers for Disease Control and Prevention (CDC). *Interim Centers for Disease Control and Prevention (CDC) Guidance for Use of Smallpox Vaccine, Cidofovir, and Vaccinia Immune Globulin (VIG) for Prevention and Treatment in the Setting of an Outbreak Monkeypox Infections*. June 11, 2003. CDC Stacks. https://www.cdc.gov/poxvirus/monkeypox/clinicians/smallpox-vaccine.html. Accessed September 29, 2018.
47. Cho CT, Wenner HA. Monkeypox virus. *Bacteriol Rev.* 1973;37(1):1-18.
48. Huhn GD, Bauer AM, Yorita K, et al. Clinical characteristics of human monkeypox, and risk factors for severe disease. *Clin Infect Dis.* 2005;41(12):1742-1751.

49. Centers for Disease Control and Prevention (CDC). Update: multistate outbreak of monkeypox—Illinois, Indiana, Kansas, Missouri, Ohio, and Wisconsin, 2003. *MMWR Morb Mortal Wkly Rep.* 2003;52(27):642-646.
50. Centers for Disease Control and Prevention (CDC). *Receiving, Distributing, and Dispensing Strategic National Stockpile Assets: A Guide to Preparedness, Version 11*. February 2014. http://ema.ohio.gov/Documents/Plans/ReceivingDistributingandDispensingStrategicNationalStockpileAssets_%20AGuidetoPreparedness_Version11.pdf. Accessed September 29, 2018.
51. Jordan R, Goff A, Frimm A, et al. ST-246 antiviral efficacy in a nonhuman primate monkeypox model: determination of the minimal effective dose and human dose justification. *Antimicrob Agents Chemother.* 2009;53(5):1817-1822.
52. Centers for Disease Control and Prevention (CDC). Monkeypox: treatment. http://www.cdc.gov/poxvirus/monkeypox/clinicians/treatment.html. Accessed August 14, 2016.
53. Marriott KA, Parkinson CV, Morefield SI, et al. Clonal vaccinia virus grown in cell culture fully protects monkeys from lethal monkeypox challenge. *Vaccine.* 2008;26(4):581-588.
54. Handley L, Buller RM, Frey SE, et al. The new ACAM2000 vaccine and other therapies to control orthopoxvirus outbreaks and bioterror attacks. *Expert Rev Vaccines.* 2009;8(7):841-850.
55. Wheeler CE, Cawley EP. The etiology of milker's nodules. *AMA Arch Derm.* 1957;75(2):249-259.
56. Adriano AR, Quiroz CD, Acosta ML, et al. Milker's nodule—case report. *An Bras Dermatol.* 2015;90(3):407-410.
57. Zhao H, Wilkins K, Damon IK, et al. Specific qPCR assays for the detection of orf virus, pseudocowpox virus and bovine papular stomatitis virus. *J Virol Methods.* 2013;194(1-2):229-234.
58. Groves RW, Wilson-Jones E, MacDonald DM. Human orf and milkers' nodule: a clinicopathologic study. *J Am Acad Dermatol.* 1991;25(4):706-711.
59. Tan ST, Blake GB, Chambers S. Recurrent orf in an immunocompromised host. *Br J Plast Surg.* 1991;44(6):465-467.
60. Barraviera SRCS. Diseases caused by poxvirus-orf and milker's nodules: a review. *J Venom Anim Toxins Incl Trop Dis.* 2005;11(2):1-7.
61. Kennedy C, Lyell A. Perianal orf. *J Am Acad Dermatol.* 1984;11(1):72-74.
62. Key SJ, Catania J, Mustafa SF, et al. Unusual presentation of human giant orf (ecthyma contagiosum). *J Craniofac Surg.* 2007;18(5):1076-1078.
63. Lederman ER, Austin C, Trevino I, et al. Orf virus infection in children: clinical characteristics, transmission, diagnostic methods, and future therapeutics. *Pediatr Infect Dis J.* 2007;26(8):740-744.
64. Nougairede A, Fossati C, Salez N, et al. Sheep-to-human transmission of orf virus during Eid al-Adha religious practices, France. *Emerg Infect Dis.* 2013;19(1):102-105.
65. Leavell UW, McNamara MJ, Muelling R, et al. Orf. Report of 19 human cases with clinical and pathological observations. *JAMA.* 1968;204(8):657-664.
66. Clark J, Diven D. Poxviruses. In: Tyring SK, Moore AY, Lupi O, eds. *Mucocutaneous Manifestations of Viral Diseases*. 2nd ed. London, UK: Informa; 2016:51.
67. Midilli K, Erkiliç A, Kuşkucu M, et al. Nosocomial outbreak of disseminated orf infection in a burn unit, Gaziantep, Turkey, October to December 2012. *Euro Surveill.* 2013;18(11):20425.
68. Joseph RH, Haddad FA, Matthews AL, et al. Erythema multiforme after orf virus infection: a report of two cases and literature review. *Epidemiol Infect.* 2014;143(2):385-390.
69. White KP, Zedek DC, White WL, et al. Orf-induced immunobullous disease: a distinct autoimmune blistering disorder. *J Am Acad Dermatol.* 2008;58(1):49-55.
70. Stewart AC. Epidemiology of orf. *N Z Med J.* 1983;96:100-101.
71. Dupre A, Christol B, Bonafe JL, et al. Orf and atopic dermatitis. *Br J Dermatol.* 1981;105:103-104.
72. Yirrell DL, Vestey JP, Norval M. Immune responses of patients to orf virus infection. *Br J Dermatol.* 1994;130(4):438-443.
73. Haig DM, Thomson J, McInnes C, et al. Orf virus immuno-modulation and the host immune response. *Vet Immunol Immunopathol.* 2002;87:395-399.
74. Geerinck K, Lukito G, Snoeck R, et al. A case of human orf in an immunocompromised patient treated successfully with cidofovir cream. *J Med Virol.* 2001;64(4):543-549.
75. Chavez-Alvarez S, Barbosa-Moreno L, Villarreal-Martinez A, et al. Dermoscopy of contagious ecthyma (orf nodule). *J Am Acad Dermatol.* 2016;74(5):e95-e96.
76. Lederman ER, Green GM, DeGroot HE, et al. Progressive orf virus infection in a patient with lymphoma: successful treatment using imiquimod. *Clin Infect Dis.* 2007;44(11):e100-e103.
77. Smith KJ, Skelton H. Molluscum contagiosum: recent advances in pathogenic mechanisms, and new therapies. *Am J Clin Dermatol.* 2002;3(8):535-545.
78. Meirowsky E, Keys S, Behr G. The cytology of molluscum contagiosum, with special regard to the significance of the so-called vacuoles. *J Invest Dermatol.* 1946;7(4):165-169.
79. Olsen JR, Gallacher J, Piguet V, et al. Development and validation of the Molluscum Contagiosum Diagnostic Tool for Parents: diagnostic accuracy study in primary care. *Br J Gen Pract.* 2014;64(625):e471-e476.
80. Basdag H, Rainer BM, Cohen BA. Molluscum contagiosum: to treat or not to treat? Experience with 170 children in an outpatient clinic setting in the northeastern United States. *Pediatr Dermatol.* 2015;32(3):353-357.
81. Sherwani S, Farleigh L, Agarwal N, et al. Seroprevalence of molluscum contagiosum virus in German and UK populations. *PLoS One.* 2014;9(2):e88734-e88711.
82. Konya J, Thompson CH. Molluscum contagiosum virus: antibody responses in persons with clinical lesions and seroepidemiology in a representative Australian population. *J Infect Dis.* 1999;179(3):701-704.
83. Gur I. The epidemiology of molluscum contagiosum in HIV-seropositive patients: a unique entity or insignificant finding? *Int J STD AIDS.* 2008;19(8):503-506.
84. Becker TM, Blount JH, Douglas J, et al. Trends in molluscum contagiosum in the United States, 1966-1983. *Sex Transm Dis.* 1986;13(2):88-92.
85. Villa L, Varela JA, Otero L, et al. Molluscum contagiosum: a 20-year study in a sexually transmitted infections unit. *Sex Transm Dis.* 2010;37(7):423-424.
86. Gottlieb SL, Myskowski PL. Molluscum contagiosum. *Int J Dermatol*. 1994;33(7):453-461.

87. Osio A, Deslandes E, Saada V, et al. Clinical characteristics of molluscum contagiosum in children in a private dermatology practice in the greater Paris area, France: a prospective study in 661 patients. *Dermatology.* 2011;222(4):314-320.
88. Luke JD, Silverberg NB. Vertically transmitted molluscum contagiosum infection. *Pediatrics.* 2010; 125(2):e423-e425.
89. Berbegal-DeGracia L, Betlloch-Mas I, DeLeon-Marrero F-J, et al. Neonatal molluscum contagiosum: five new cases and a literature review. *Australas J Dermatol.* 2015;56(2):e35-e38.
90. Chen X, Anstey AV, Bugert JJ. Review molluscum contagiosum virus infection. *Lancet Infect Dis.* 2013; 13(10):877-888.
91. Petersen CS, Gerstoft J. Molluscum contagiosum in HIV-infected patients. *Dermatology.* 1992;184(1):19-21.
92. Berger EM, Orlow SJ, Patel RR, et al. Experience with molluscum contagiosum and associated inflammatory reactions in a pediatric dermatology practice. *Arch Dermatol.* 2012;148(11):1257-1258.
93. Smith KJ, Col, Usa MC, et al. Molluscum contagiosum: its clinical, histopathologic, and immunohistochemical spectrum. *Int J Dermatol.* 1999;38(9):664-672.
94. Senkevich TG, Koonin EV, Bugert JJ, et al. The genome of molluscum contagiosum virus: analysis and comparison with other poxviruses. *Virology.* 1997;233(1):19-42.
95. Braue A, Ross G, Varigos G, et al. Epidemiology and impact of childhood molluscum contagiosum: a case series and critical review of the literature. *Pediatr Dermatol.* 2005;22(4):287-294.
96. Shisler JL. Immune evasion strategies of molluscum contagiosum virus. *Adv Virus Res*. 2015;92:201-252.
97. Vermi W, Fisogni S, Salogni L, et al. Spontaneous regression of highly immunogenic molluscum contagiosum virus (MCV)-induced skin lesions Is associated with plasmacytoid dendritic cells and IFN-DC infiltration. *J Invest Dermatol.* 2011;131(2):426-434.
98. Olsen JR, Gallacher J, Piguet V, et al. Epidemiology of molluscum contagiosum in children: a systematic review. *Fam Pract.* 2014;31(2):130-136.
99. Dohil MA, Lin P, Lee J, et al. The epidemiology of molluscum contagiosum in children. *J Am Acad Dermatol.* 2006;54(1):47-54.
100. Olsen JR, Piguet V, Gallacher J, et al. Molluscum contagiosum and associations with atopic eczema in children: a retrospective longitudinal study in primary care. *Br J Gen Pract.* 2015;66(642):e53-e58.
101. Seize MB, Ianhez M, Cestari Sda C. A study of the correlation between molluscum contagiosum and atopic dermatitis in children. *An Bras Dermatol.* 2011;86(4):663-668.
102. Martin P. Interventions for molluscum contagiosum in people infected with human immunodeficiency virus: a systematic review. *Int J Dermatol.* 2016;55(9):956-966.
103. Maurer T, Rodrigues LK, Ameli N, et al. The effect of highly active antiretroviral therapy on dermatologic disease in a longitudinal study of HIV type 1-infected women. *Clin Infect Dis.* 2004;38(4):579-584.
104. Drain PK, Mosam A, Gounder L, et al. Recurrent giant molluscum contagiosum immune reconstitution inflammatory syndrome (IRIS) after initiation of antiretroviral therapy in an HIV-infected man. *Int J STD AIDS.* 2014;25(3):235-238.
105. Chu EY. Cutaneous manifestations of DOCK8 deficiency syndrome. *Arch Dermatol.* 2012;148(1):79-15.
106. Beutler BD, Cohen PR. Molluscum contagiosum of the eyelid: case report in a man receiving methotrexate and literature review of molluscum contagiosum in patients who are immunosuppressed secondary to methotrexate or HIV infection. *Dermatol Online J.* 2016;22(3).
107. Kinoshita M, Ogawa Y, Kawamura T, et al. Case of disseminated molluscum contagiosum caused by ruxolitinib, a Janus kinase 1 and 2 inhibitor. *J Dermatol.* 2016;43(11):1387-1388.
108. Behle V, Wobser M, Goebeler M, et al. Extensive molluscum contagiosum virus infection in a young adult receiving fingolimod. *Mult Scler.* 2016;22(7): 969-971.
109. Morales A, Puig S, Malvehy J, et al. Dermoscopy of molluscum contagiosum. *Arch Dermatol.* 2005; 141(12):1644-1644.
110. Vazquez-Lopez F, Kreusch J, Marghoob AA. Dermoscopic semiology: further insights into vascular features by screening a large spectrum of nontumoral skin lesions. *Br J Dermatol.* 2004;150(2):226-231.
111. Ianhez M, Cestari Sda C, Enokihara MY, et al. Dermoscopic patterns of molluscum contagiosum: a study of 211 lesions confirmed by histopathology. *An Bras Dermatol.* 2011;86(1):74-79.
112. Olsen JR, Gallacher J, Finlay AY, et al. Time to resolution and effect on quality of life of molluscum contagiosum in children in the UK: a prospective community cohort study. *Lancet Infect Dis.* 2015;15(2): 190-195.
113. McCuaig C, Silverberg N, Santer M. Commentaries on "Interventions for cutaneous molluscum contagiosum." *Evid Based Child Health.* 2011;6(5):1602-1605.
114. van der Wouden JC, van der Sande R, Kruithof EJ, et al. Interventions for cutaneous molluscum contagiosum. *Cochrane Database Syst Rev*. 2017; (5):CD004767.
115. Coloe J, Morrell DS. Cantharidin use among pediatric dermatologists in the treatment of molluscum contagiosum. *Pediatr Dermatol.* 2009;26(4):405-408.
116. Griffith RD, Yazdani Abyaneh M-A, Falto-Aizpurua L, et al. Pulsed dye laser therapy for molluscum contagiosum: a systematic review. *J Drugs Dermatol.* 2014; 13(11):1349-1352.
117. Coloe Dosal J, Stewart PW, Lin J-A, et al. Cantharidin for the treatment of molluscum contagiosum: a prospective, double-blinded, placebo-controlled trial. *Pediatr Dermatol.* 2014;31(4):440-449.
118. Mathes EF, Frieden IJ. Treatment of molluscum contagiosum with cantharidin: a practical approach. *Pediatr Ann.* 2010;39(3):124-128, 130.
119. Moed L, Shwayder TA, Chang MW. Cantharidin revisited: a blistering defense of an ancient medicine. *Arch Dermatol.* 2001;137(10):1357-1360.
120. Silverberg NB, Sidbury R, Mancini AJ. Childhood molluscum contagiosum: experience with cantharidin therapy in 300 patients. *J Am Acad Dermatol.* 2000;43(3):503-507.
121. Osier E, Eichenfield LF. The utility of cantharidin for the treatment of molluscum contagiosum. *Pediatr Dermatol.* 2015;32(2):295-296.
122. Moye VA, Cathcart S, Morrell DS. Safety of cantharidin: a retrospective review of cantharidin treatment in 405 children with molluscum contagiosum. *Pediatr Dermatol.* 2014;31(4):450-454.
123. Cathcart S, Coloe J, Morrell DS. Parental satisfaction, efficacy, and adverse events in 54 patients treated with cantharidin for molluscum contagiosum infection. *Clin Pediatr (Phila).* 2008;48(2):161-165.

124. Dohil M, Prendiville JS. Treatment of molluscum contagiosum with oral cimetidine: clinical experience in 13 patients. *Pediatr Dermatol.* 1996;13(4):310-312.
125. Cunningham BB, Paller AS, Garzon M. Inefficacy of oral cimetidine for nonatopic children with molluscum contagiosum. *Pediatr Dermatol.* 1998;15(1):71-72.
126. Farhangian ME, Huang KE, Feldman SR, et al. Treatment of molluscum contagiosum with imiquimod in the United States: a retrospective cross-sectional study. *Pediatr Dermatol.* 2015;33(2):227-228.
127. Syed TA, Goswami J, Ahmadpour OA, et al. Treatment of molluscum contagiosum in males with an analog of imiquimod 1% in cream: a placebo-controlled, double-blind study. *J Dermatol.* 1998;25(5):309-313.
128. Katz KA. Dermatologists, imiquimod, and treatment of molluscum contagiosum in children. *JAMA Dermatol.* 2015;151(2):125-122.
129. Medicis Pharmaceutical Corp. Aldara Drug Label. 2010. https://www.accessdata.fda.gov/drugsatfda_docs/label/2010/020723s022lbl.pdf. Accessed September 29, 2018.
130. Fernando I, Pritchard J, Edwards SK, et al. UK national guideline for the management of genital molluscum in adults, 2014 Clinical Effectiveness Group, British Association for Sexual Health and HIV. *Int J STD AIDS.* 2015;26(10):687-695.
131. Kimberlin DW, Brady MT, Jackson MA, et al, eds. *Red Book:2015 Report of the Committee on Infectious Diseases*. 30th ed. 2015. http://ebooks.aappublications.org/content/red-book-30th-edition-2015. Accessed September 29, 2018.

Chapter 167 :: Human Papillomavirus Infections

:: Jane C. Sterling

AT-A-GLANCE

- Human papillomavirus (HPV) has a worldwide occurrence, affecting people of all ages and all races. It is most common in children and young adults.
- There are more than 150 genotypes of HPV, with some regional specificity. Low-risk types cause warts; high-risk types are associated with intraepithelial neoplasia and malignancy.
- The lesions are well-defined, raised papules or plaques with a rough or hard surface, usually without inflammation.
- The lesions are most common on the hands or feet, but any skin site may be affected, including the lower genital or oral mucosa.
- Treatments include destructive, antiviral, antiproliferative, and immunologic modalities.

INTRODUCTION

Human papillomavirus (HPV) infections are very common, occurring in a worldwide distribution, affecting all ages and lasting months or years. The majority of individuals will have at least one infection with the virus during the course of a lifetime, although the severity and duration of the disease will depend, to a large extent, on the immune response raised against the virus-infected cells.

The clinical disease caused by the virus is also dependent on the viral genotype and the body site. Whereas skin and mucosal warts are benign and induced by one of several different types according to body site, premalignancies and invasive cancer of the anogenital area or oropharynx are associated with other, so-called high-risk, HPV types (Table 167-1).

VIROLOGY

The papillomaviruses form a large group of closely related viruses, defined by their host range. HPVs only infect humans and, in particular, epithelial keratinocytes. In experimental systems, the virus does not infect keratinocytes in monolayer tissue culture.

Papillomaviruses are DNA viruses with each virus particle or virion consisting of a nonenveloped icosahedral capsid containing the double-stranded genetic material as a circular genome (Fig. 167-1). The virus is much smaller, both in particle size and length of genetic material, than other common viruses that infect skin such as herpes simplex virus and molluscum contagiosum virus. The genes are all transcribed in one direction from one DNA strand, leading to the production of 5 to 6 early (E) proteins involved in DNA replication, cell cycle control and immune evasion; and 2 late (L) proteins, L1 and L2, that form the outer shell or capsid (Fig. 167-2).

The virus is shed from the surface of the skin or mucosa within sloughed, dead keratinocytes. New infection occurs when the virus particle contacts the basal epidermal keratinocyte, presumed to be via small microabrasions in the skin or mucosa. Maceration of skin can increase the chance of infection because of impairment of barrier function. Cell entry depends on an initial adherence of the virion to the cell via heparin sulphate and α6-integrins,[1,2] although the full process of receptor binding leading to internalization by endocytosis has not yet been clarified. Within a stem cell or transit amplifying cell of the basal layer, the virus is maintained in low copy number. It is carried to the surface in daughter cells, producing, as it goes, the early viral proteins. High-volume viral DNA amplification and L1 and L2 protein production occurs in the upper layers, with formation of completely new virus particles in the granular layer. The switch to capsid protein production depends on a change in splice site usage in the early genes.[3] The E6 and E7 proteins are pivotal to the process of viral genome amplification, which also depends on the E1 and E2 proteins. The viral E1^E4 protein can interact with keratin filaments, weakening cytoplasmic structure and potentially facilitating virus particle release at the surface.[4]

There are more than 150 HPV types, defined according to the DNA sequence within the *L1* gene.[5] A virus is defined as a distinct type if there is greater than 10% dissimilarity from other known HPVs in the DNA of this region. The HPVs have been grouped, according to phylogeny, into five genera: alpha, beta, gamma, mu, and nu (see Table 167-1). HPVs that are not found in malignancies or premalignancies are termed *low-risk types*, and those found in invasive or preinvasive disease are called *high-risk types*. The high-risk anogenital HPVs fall into the large alpha genus. High-risk genital HPV types can integrate within the host cell genome, and the maintained expression of their E6 and E7 proteins has oncogenic effects on cell division and cell function. These E6 and E7 proteins affect cell cycle control and apoptosis via interaction with ubiquitin ligases, telomerase, and several other cellular pathways.[6] In the process of integration, the E2, E4, L2, and to a lesser extent the L1 regions of the genome are frequently disrupted. In malignant lesions, late proteins and virus particles are rarely, if ever found, although episomal (nonintegrated) viral DNA may be maintained in preinvasive disease.

TABLE 167-1
Diseases Caused by or Associated with Human Papillomavirus Infection

DISEASE	CLINICAL	MOST COMMONLY ASSOCIATED HPV TYPES[a]	PV GENUS
Cutaneous warts	Common warts, filiform warts, mosaic warts	2, 27, 57 (7) 4, (60) (48)	Alpha Mu Gamma
	Palmar and plantar warts	1, (63)	Nu
	Butchers' warts	2, 7	Alpha
	Plane warts	3, 10 (28)	Alpha
Anogenital warts	Vulval warts, vaginal warts, penile warts, perianal warts	6, 11 (and others)	Alpha
Oral warts		6, 11 (and others)	Alpha
EV and EV-like syndromes	Benign scaly or flaky lesions;	9, 12, 15, 19, 22-25, 36-38, 80	Beta
	Plane warts	3, 10	Alpha
	Skin SCC	5, 8, 14, 17, 20, 21, 47, 93, 96	Beta
Skin SCC	Periungual SCC	16	Alpha
	Carcinoma cuniculatum or verrucous carcinoma	(11, 6)	Alpha
AGIN	VIN, VaIN, CIN, PIN, AIN	16, (18, 31, 33, 35, 45, 52, 58 and others)	Alpha
Anogenital SCC	SCC of vulva, vagina, cervix, penis, anal area	16, 18, 31, 33, 35, 42 (and others)	Alpha
Oropharyngeal SCC	SCC of mouth, pharynx	16 (18, 31, 33, 35 and others)	Alpha

[a]Human papillomavirus (HPV) types in parentheses are found less commonly.

AGIN, anogenital intraepithelial neoplasia; AIN, anal and perianal intraepithelial neoplasia; CIN, cervical intraepithelial neoplasia; EV, epidermodysplasia verruciformis; PIN, penile intraepithelial neoplasia; PV, papilloma virus; SCC, squamous cell carcinoma; VaIN, vaginal intraepithelial neoplasia; VIN, vulval intraepithelial neoplasia.

EPIDEMIOLOGY

Infection with HPV occurs throughout the world and in all ages. Benign cutaneous warts are most common in childhood and into the 20s, with 30% to 70% of school-age children having skin warts,[7,8] but anogenital warts, which are usually spread via sexual contact, are most common in early adult life. In children, anogenital warts should raise consideration of sexual abuse, although HPV types that cause common warts may often be found in warts of prepubertal children.[9] Squamous cell malignancy, associated most strongly with the high-risk anogenital HPV types, usually only develops after an infection has persisted for several years.

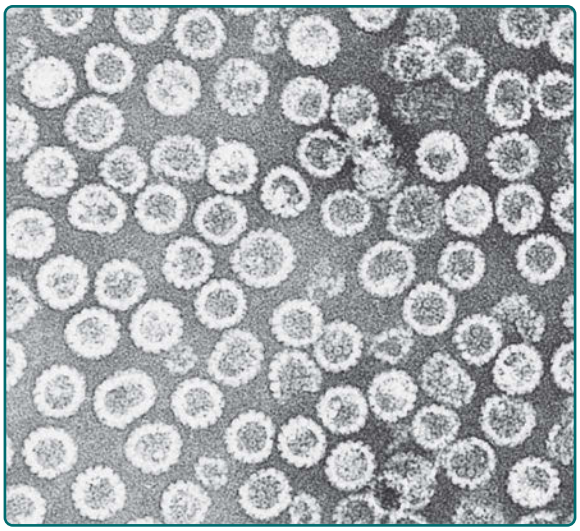

Figure 167-1 Papillomavirus virus–like particles. Transmission electron micrograph of human papillomavirus type 16 virus–like particles composed of the L1 and L2 proteins. These proteins were synthesized in cell culture and self-assembled into 55-nm particles that are morphologically similar to natural infectious virus except that they do not contain the viral DNA. The particles in the electron micrograph were purified from the cells. (Micrograph used with permission from Heather Greenstone. Courtesy of Prof. Elliot Androphy.)

Spread of infection can be via direct contact, but the virus particles, released from epithelial surfaces as keratinocytes are shed, can remain present in the environment for an unknown duration and may later lead to infection in another individual.[10] Even after infection, it can take months before a visible wart appears.[11] After being established, infection can spread on the surface to adjacent skin.

Protection against a new infection is via neutralizing antibodies. The anti-HPV vaccines, produced as the L1 capsid protein assembled into virus-like particles, lead to a humoral response against the virus particle. In natural infection, seroconversion also occurs, but in this situation, anti-HPV antibodies are not effective in

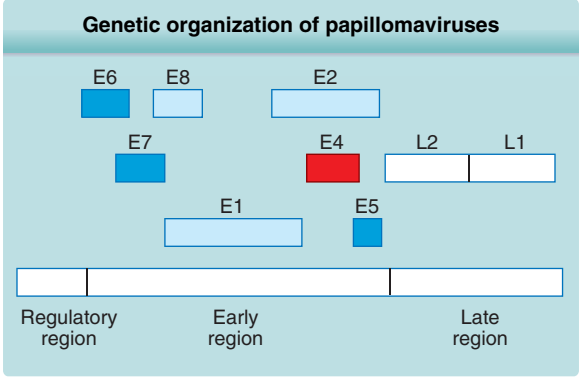

Figure 167-2 Genetic organization of papillomaviruses. The circular human papillomavirus genome of approximately 8000 nucleotide base pairs is represented here as a linear strand. (Used with permission from Prof. Elliot Androphy.)

the resolution of established infection. Clearance of the virus from infected tissue is dependent on a cell-mediated immune response, and as yet there is no available, effective therapeutic vaccine. Most warts in children will clear within 2 years,[8] but in a minority of otherwise well individuals, warts can spread and persist longer.[12]

In individuals with long-term immune compromise, especially those with inherited immunodeficiency and transplant recipients receiving high-dose immune suppression, warts and malignancy caused by HPVs can be a major problem. Five years after renal transplant, it is estimated that approximately 90% of patients have warts[13] caused by the HPV types that cause warts in healthy people.[14] Many other HPV types, mainly from the beta papilloma viruses (PVs), can be detected by polymerase chain reaction (PCR) on the skin (normal or lesional) of transplant recipients.[15-17] Using such sensitive methods, these virus types are also found on the skin and in the hair follicles of healthy individuals.[18])

SKIN HUMAN PAPILLOMAVIRUS INFECTIONS

CUTANEOUS WARTS

CLINICAL FEATURES

Viral warts are initially asymptomatic and often unnoticed but grow to form well-defined, thickened, hyperkeratotic lesions (Fig. 167-3). These are often unsightly and may cause pain if sited at pressure points or if they crack and bleed. Walking and use of the hands can be affected according to the site of the warts (Fig. 167-4). Common sites are the hands and feet, especially at areas of minor trauma, such as knuckles or around nails (Fig. 167-5). On the dorsal aspects of hands or feet or on the limbs, warts are exophytic or "cauliflower shaped" (Fig. 167-6), but on soles or palms, they are often relatively flat to the surface with a more

Figure 167-3 Well-defined wart on the finger. Small thrombosed capillaries are visible as black dots. (The nail had been damaged previously from trauma.)

Figure 167-4 Very hyperkeratotic warts over the Achilles tendon.

Figure 167-5 Multiple warts on the hand with periungual warts affecting nail growth.

Figure 167-6 Warts on the knee.

Figure 167-7 Mosaic warts on the sole.

endophytic growth pattern. The term *mosaic warts* is applied to a group of small adjacent but relatively flat warts on the sole (Fig. 167-7). Smaller and flatter warts, often on the backs of the hands or face, may be *plane warts* (also called *verruca plana*; see Fig. 167-8). On the face and limbs, warts can sometimes have a small base and longer, fingerlike projections, a morphological type called *filiform warts* (Fig. 167-9).

Warts are most common in children and young adults[19] but can occur at any age.

ETIOLOGY AND PATHOGENESIS

Common warts are caused most frequently by HPV-2/27/57, HPV-4, and HPV-1 (soles and palms) and less frequently by HPV-7 (called *butcher's warts*). Flat warts are usually caused by type 3 or 10 or very occasionally type 28.

Butchers' warts were originally described in meat workers, whose hands were in direct contact with wet meat. The finding of HPV-7 is not limited to these warts but has been reported rarely in hand warts, face warts, and HIV infection.

HPV-1 warts are found only on the palms and soles and may be called *myrmecia*. They produce higher amounts of new particles compared to other cutaneous types. Some unusual HPV types, HPV-57 and -60, have been found in epidermoid plantar cysts of Japanese patients.[20]

DIAGNOSIS AND HISTOLOGY

Warts can usually be diagnosed clinically without the need for histologic confirmation. Paring the surface of a

Figure 167-8 Plane warts (verruca plana). **A,** Multiple pink flat warts on the face of an 11-year-old girl. **B,** Many flat-topped papules occur in a linear configuration resulting from self-inoculation. (Used with permission from Prof. Elliot Androphy.)

Figure 167-9 Common warts. Filiform warts on the chin and lips of a child. (Used with permission from Prof. Elliot Androphy.)

Figure 167-10 Verruca vulgaris. The process is one of extensive hyperplasia, and the hyperplastic cells contain both intranuclear and intracytoplasmic inclusion bodies. (Used with permission from Prof. Elliot Androphy.)

wart will reveal capillary loops close to the surface and often causes bleeding. These capillaries often thrombose and then appear as black dots (see Fig. 167-3).

The histology is of acanthosis, hypergranulosis, and hyperkeratosis of the epidermis. The keratinocytes of the upper granular layer may show koilocytosis with clear cytoplasm and a dense twisted nucleus (Fig. 167-10). Detection of HPV DNA by PCR or in situ hybridization will confirm the diagnosis but is not in use for standard clinical care.

The differential diagnoses are listed in Table 167-2.

TABLE 167-2
Differential Diagnosis of Warts

COMMON WARTS	PLANE WARTS	GENITAL WARTS
Seborrheic keratosis	Seborrheic keratosis	Seborrheic keratosis
Actinic keratosis	Actinic keratosis	Vulval or penile papillomatosis
Bowen disease	Lichen planus	Lichen planus
SCC, keratoacanthoma	Adenoma sebaceum	VIN, PIN, AIN
Acrokeratosis verruciformis	Syringomas	Verrucous carcinoma
Epidermal naevus	Trichoepitheliomas	Condyloma acuminatum (secondary syphilis)
Pyogenic granuloma	Disseminated superficial actinic porokeratosis	Sebaceous gland hyperplasia
Fish tank granuloma		
Verrucous tuberculosis		
Callus		
Soles and Palms Only		
Palmoplantar keratoderma		
Corn		
Inclusion cyst		
Palmar pits (Darier disease, Gorlin syndrome)		
Carcinoma cuniculatum		

AIN, anal and perianal intraepithelial neoplasia; PIN, penile intraepithelial neoplasia; SCC, squamous cell carcinoma; VIN, vulval intraepithelial neoplasia.

CLINICAL COURSE, PROGNOSIS, AND MANAGEMENT

Untreated, warts in young people usually clear spontaneously within about 2 years, and only a few remain at 4 years.[21] In adults, clearance can often be very slow, with warts persisting for years. Large and widespread warts (Fig. 167-11) are common in immunosuppressed individuals such as transplant recipients and in children or adults with genetic immunodeficiency (Table 167-3). In these cases, large areas of skin may be affected as well as mucous membranes, and the condition may be called *generalized verrucosis*.[22]

Treatment can speed clearance in warts but often fails in immunosuppressed individuals.

There is no virus-specific anti-viral therapy for warts, so available treatments aim to (1) damage the infected epithelium and debulk the lesions, (2) have some effect on the virus life cycle, or (3) to stimulate an immune response (Table 167-4). It is possible that most treatments may have more than one effect. Recent reviews of treatments for warts give more detail of the spectrum and potential efficacy of the range of treatments used today.[38–40]

The most commonly used treatments for warts are destructive and include topical applications with salicylic acid and physical treatment with cryotherapy. For the greatest effect, treatment needs to be repeated and of long duration. It is worth informing patients that regular treatment for at least 3 months or longer is likely to be required. Even with assiduous treatment, the clearance rate for most common treatments is 60% to 70% compared with 30% clearing with placebo.[41]

Salicylic acid (12%–17% in a paint or up to 50% in plasters or an ointment) is applied to the wart, which can be rubbed down or pared gently beforehand. Occlusion with an adhesive dressing after application may improve clearance. Daily treatment is recommended, but as the salicylic acid gradually destroys and so removes the keratin layer, the wart or more likely surrounding tissue can become sore, and treatment may need to be reduced in frequency. For this reason, salicylic acid in these strengths is not recommended for facial or anogenital warts.

Figure 167-11 Leg with numerous warts. The large, scaly, and horny warts contain human papillomavirus (HPV)-2. The smaller, flatter, less scaly papules are warts that contain HPV-3. With extensive warts such as these, an assessment of immune function is indicated. (Used with permission from Prof. Elliot Androphy.)

Cryotherapy (see Chap. 206) with liquid nitrogen is best used as a double freeze, repeated every 3 weeks for at least 3 months. This is a painful treatment and often not tolerated to warts around nails, on the soles, or by children.

Other treatments that damage or destroy the infected epithelium include caustics such as silver nitrate, phenol, mono- or trichloroacetic acid, and surgical approaches with laser or excisional surgery.

Plane warts require less keratolysis, and treatment with other topical applications such as the immune modulator imiquimod can be effective.

Severe proliferative warts may be helped but sometimes only for the duration of the treatment by treatments that reduce or slow epidermal growth, such as podophyllotoxin or retinoids.

In immune compromise, clearance of warts, either spontaneously or with treatment, is rare and treatment is usually aimed at measures to reduce wart bulk, maintain function, and avoid pain.

EPIDERMODYSPLASIA VERRUCIFORMIS AND EPIDERMODYSPLASIA VERRUCIFORMIS–LIKE SYNDROMES

CLINICAL FEATURES

Epidermodysplasia verruciformis (EV) is a rare, heritable skin disorder with a mild underlying primary immunodeficiency. The signs of EV become apparent in late childhood or adolescence, but in the absence of a family history, diagnosis may be delayed until a decade or two later. Widespread flaky, scaly, or flat warty lesions are seen on the face, hands, and forearms and other sun-exposed sites (Fig. 167-12). There is often erythema, hyperpigmentation, or more rarely hypopigmentation of lesions, and there can be confusion with pityriasis versicolor and plane warts. In early adult life, actinic keratoses, Bowen disease, and invasive squamous cell carcinoma (SCC) can develop at affected sites (Fig. 167-13). Metastatic disease can follow.

TABLE 167-3
Syndromes of Immune Compromise in Which Warts May Be a Prominent Clinical Feature

ONSET	SYNDROME	FEATURES	REFERENCES
Infancy	SCID, both pre or post bone marrow transplant	Warts	23
Infancy	Wiskott Aldrich	Warts	24
Early childhood	Common variable immunodeficiency	Warts	25
Early childhood	Ataxia-telangiectasia	Warts	26
Childhood	Bittner syndrome	Warts of palms and soles, Bowen disease	27
Childhood or adult	GATA-2 deficiency (also called WILD syndrome)	Warts, anogenital SCC	28-30
Childhood or adult	DOCK-8 deficiency	Warts; atopic disease, bacterial and viral infections	31
Childhood or adult	Selective IgA deficiency	Warts	32
Childhood or adult	Intestinal lymphangiectasia, Waldman disease	Lymphedema and rarely warts of hands and feet	33
Adult	Idiopathic CD4 lymphocytopenia	Cutaneous warts, anogenital warts, AGIN, EV-like	34,35
Adult	IL-7 deficiency	Warts; Cryptococcus meningitis	36
Adult	WHIM syndrome	Warts, anogenital SCC	37

AGIN, anogenital intraepithelial neoplasia; EV, epidermodysplasia verruciformis; IgA, immunoglobulin A; SCC, squamous cell carcinoma; SCID, severe combined immunodeficiency; WHIM, warts, hypogammaglobulinemia, immunodeficiency, and myelokathexis.

TABLE 167-4
Commonly Used Treatments for Cutaneous and Anogenital Warts

Treatments Damaging or Destroying the Epithelium[a]
Topical
Salicylic acid
Cantharidin
Phenol
Monochloroacetic or trichloroacetic acid
Silver nitrate
5-Fluorouracil
Zinc oxide
Retinoid
Bleomycin (IL)
Physical
Cryotherapy
Cautery
Photodynamic therapy
Laser (pulsed dye)
Surgical removal
Reduction of Proliferation
Retinoid (topical or oral)
Podophyllotoxin
Cidofovir
Virucidal
Formalin
Glutaraldehyde
Immune Modulation
Imiquimod
Diphencyprone or squaric acid topical immunotherapy
Immunotherapy with *Candida* or mumps antigen (IL)
Interferon (IL)
Zinc sulphate (oral)
Cimetidine (oral)

Further details in References 37 to 39.
IL, intralesional.

Patients with EV have a mild cell-mediated immune impairment.[42] This is often not obvious on clinical grounds because widespread susceptibility to other infections is not a feature but can reduce susceptibility to contact allergy.

Figure 167-12 Epidermodysplasia verruciformis. Plane wart–like lesions on the dorsa of the hands and forearms associated with human papillomavirus-5 and -8. The lesions are numerous, flat, reddish, and partly confluent. (Used with permission from Prof. Elliot Androphy.)

Figure 167-13 Invasive cancer in an epidermodysplasia verruciformis patient infected with numerous human papillomavirus (HPV) types, including HPV-5, -8, -9, -14, and others. In the tumor cells, HPV-5 DNA was detected in a high copy number. This large squamous cell carcinoma did not metastasize and did not recur after surgery. There are numerous actinic keratoses on the forehead. (Used with permission from Prof. Elliot Androphy.)

A clinical appearance very similar to EV, called acquired EV, may be seen after long-term immunocompromise from several causes[43,44] (Table 167-5).

ETIOLOGY AND PATHOGENESIS

EV can be inherited, usually with an autosomal recessive pattern. The genes implicated most commonly are *EVER-1* and *-2*, which produce the transmembrane, zinc-containing proteins TMC6 and TMC8.[45]

A large number of HPV types are associated with EV lesions and the clinically unaffected skin of patients.[46] These include HPV-3 and -10, the cause of plane warts, as well as the beta PVs, some of which are found in SCCs and some of which are only found in benign lesions (see Table 167-1). Patients may also have warts harboring the usual HPV types found in common warts.

TABLE 167-5
Conditions That May Lead to Acquired Epidermodysplasia Verruciformis

Transplantation (organ or bone marrow)
HIV infection
Less Common Causes
Common variable immunodeficiency
Coronin-1-A deficiency
Connective tissue disease (eg, SLE treated with long-term immunosuppression)
Graft-versus-host disease
IgM deficiency
Leprosy
Lymphoma
Myasthenia gravis

IgM, immunoglobulin M; SLE, systemic lupus erythematosus.

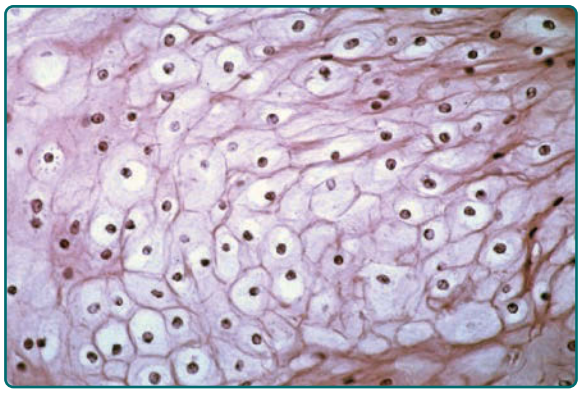

Figure 167-14 Characteristic cytopathic effect of epidermodysplasia verruciformis–specific human papillomavirus (HPV) in a patient found to be infected with HPV-5, -8, and -9. Very abundant clear large cells with small pyknotic nuclei replace almost the entire epidermis. (Used with permission from Prof. Elliot Androphy.)

DIAGNOSIS AND HISTOLOGY

Diagnosis may be made on a combination of clinical features and family history. Skin biopsy shows mild acanthosis and hyperkeratosis. In some lesions, there may also be pallor or clearing of the cytoplasm of the upper spinous layer keratinocytes, called ballooning, with small dense nuclei (so-called clear cells; see Fig. 167-14). With sensitive HPV detection, the beta PVs are found most commonly.

CLINICAL COURSE, PROGNOSIS, AND TREATMENT

Treatments usually make little lasting difference, but short-term, cosmetic improvement can be obtained by a number of approaches that remove the hyperkeratosis.[42,43] Cryotherapy, topical salicylic acid, 5-fluorourcil, and imiquimod have all been used with varying results.[47,48] Photodynamic therapy (PDT)[49] or an oral retinoid, such as acitretin,[50] can produce a useful improvement in lesions.

To reduce the risk of skin cancers, sun protection is important. Regular surveillance for SCC and early treatment of suspicious lesions may avoid metastatic disease.

SQUAMOUS CELL CARCINOMA AND HUMAN PAPILLOMAVIRUS

Common warts in immunocompetent individuals are not forerunners of skin cancer. However, there are a very few reports, usually in the setting of immunosuppression, of long-standing periungual warts progressing into Bowen disease (full-thickness dysplasia) or invasive SCC.[51] In such cases, the high-risk anogenital HPV type, HPV-16, is usually present. Long-standing and slowly enlarging warty areas on the soles, fingers, or anogenital skin can be a feature of carcinoma cuniculatum or verrucous carcinoma (Buschke-Löwenstein tumour), in which the HPV types usually associated with anogenital warts, HPV-6 or -11, are occasionally detected.[52,53]

Skin SCCs on sun exposed skin are also found to contain a number of EV-related beta HPV types, with a higher yield in the cancers of immunosuppressed individuals. These HPVs are often found in normal skin of both immunocompetent and immunocompromised individuals,[16,18] and the exact role they play in the steps of carcinogenesis is still under debate.[54]

MUCOSAL AND PERI-MUCOSAL HUMAN PAPILLOMAVIRUS INFECTIONS

ANOGENITAL WARTS

CLINICAL FEATURES

Warts can affect the vulva, vagina, cervix, penis, scrotum, perianal skin, and anal canal. They may present singly but are usually found as multiple, well-defined papules or as flat or filiform lesions and may grow into larger protuberant lesions (Fig. 167-15). The moist fold beneath an abdominal apron of an obese patient is another site for these warts.[55] On mucosal surfaces, they are often macerated and appear pale, but on drier skin, they can become more obviously hyperkeratotic and hard. They may be asymptomatic but can be itchy and uncomfortable and may be traumatized with movement or sexual activity.

DIAGNOSIS

HPV-6 or -11 are the most common causative agents, but other HPV types are found with PCR analysis. Anogenital warts produce less virus particles than cutaneous warts.

For differential diagnosis, see Table 167-2.

CLINICAL COURSE, PROGNOSIS, AND TREATMENT

Anogenital warts are usually treated with a topical application as first-line therapy.[56] Podophyllotoxin or imiquimod are both self-applied treatments with a 50% to 70% clearance rate.[57] Recurrence rates after imiquimod treatment are slightly less than after podophyllotoxin.[58]

Figure 167-15 Mucosal warts. **A,** Multiple condylomata acuminata on the shaft of the penis. **B,** Erythroplasia of the glans with exophytic squamous cell carcinoma extending onto prepuce. **C,** Multiple perianal condylomata in a child. Sexual abuse must be considered. **D,** Multiple confluent condylomata on the labia minora, majora, and fourchette. (Images **A, C,** Used with permission from Prof. Elliot Androphy. Image **B,** Used with permission from Reinhard Kirnbauer, MD.)

Other treatments in use include topical trichloroacetic acid,[59] sinecatechins from green tea,[60] and physical therapies with cryotherapy, PDT, laser, electrocautery, or surgery.

Since the introduction of the quadrivalent anti-HPV vaccine in 2007, there has been a recorded decrease in presentation of genital warts or prevalence of HPV-6 and -11.[61,62]

ORAL WARTS

Warts can develop on the lips, in the oral cavity, and in upper respiratory tract and are usually regarded as a sexually transmitted disease. Because of the moist site, they are usually macerated and can be flat or cauliflower shaped (Fig. 167-16). The low-risk genital HPV types are the usual cause. Laryngeal warts (laryngeal papillomatosis) can develop in childhood, probably caused by infection from the mother at birth, and can affect speech and breathing.

Oral warts are common in HIV infection and may worsen, rather than improve, during antiretroviral therapy.[63]

ANOGENITAL INTRAEPITHELIAL NEOPLASIA AND CANCER

CLINICAL FEATURES

Anogenital intraepithelial neoplasia (AGIN) includes dysplasia of the vulva (vulvar intraepithelial neoplasia; see Fig. 167-17), vagina (vaginal intraepithelial neoplasia), cervix (cervical intraepithelial neoplasia), penis (penile intraepithelial neoplasia), perianal skin, and anal canal (anal intraepithelial neoplasia). The term *Bowenoid papulosis* has been used to describe the disorder, especially when the lesions are pigmented and resemble seborrheic keratosis. AGIN may also present with velvety plaques, white macerated, warty lesions or less distinct erythematous areas.[64]

ETIOLOGY

The high risk HPV types, especially HPV-16, are associated with these disorders.

Figure 167-16 Multiple mucosal warts extending to the vermillion border, where they become highly keratinized. (Used with permission from Prof. Elliot Androphy.)

Biopsy is essential for diagnosis with the histology showing full-thickness epidermal dysplasia, classified as undifferentiated intraepithelial neoplasia. Differentiated intraepithelial neoplasia occurs in association with chronic inflammatory genital disease, such as lichen sclerosus, and histologically is a subtler basal dysplasia, often with acanthosis and hyperkeratosis, and is not associated with HPV infection (see Chap. 64).

CLINICAL COURSE, PROGNOSIS, AND MANAGEMENT

Surgery is the treatment of choice for single lesions if the site is easily operable but may not be best for multifocal or multicentric disease. Laser or topical immunotherapy with imiquimod offers an alternative approach.[65] Both the patient and physician need to be aware of the changes that could indicate malignant change, and these include a persistent area of discomfort, an ulcer, or a frank tumor. It is estimated that an individual with AGIN has an approximate 5% lifetime risk of developing cancer. Cancer can be the presenting feature.

Figure 167-17 Vulval intraepithelial neoplasia, grade III. Small area of raised and minimally pigmented skin near the posterior fourchette.

ORAL AND OROPHARYNGEAL SQUAMOUS CELL CARCINOMA

Silent infection with high risk HPVs within the mouth or throat can present later in life with oropharyngeal SCC. The traditional association of this malignancy with smoking and alcohol is being replaced with a stronger association with HPV infection, especially in younger male patients. The incidence of this malignancy is rising but should be reduced following the introduction of the anti-HPV vaccine to male patients.[66]

REFERENCES

1. Johnson KM, Kines RC, Roberts JN, et al. Role of heparan sulfate in attachment to and infection of the murine female genital tract by human papillomavirus. *J Virol.* 2009;83(5):2067-2074.
2. Raff AB, Woodham AW, Raff LM, et al. The evolving field of human papillomavirus receptor research: a review of binding and entry. *J Virol.* 2013;87(11):6062-6072.
3. Doorbar J, Egawa N, Griffin H, et al. Human papillomavirus molecular biology and disease association. *Rev Med Virol.* 2016;25(suppl 1):2-13.
4. Doorbar J. The E4 protein; structure, function and patterns of expression. *Virology.* 2013;445(1-2):80-98.
5. Bernard H-U, Burk RD, Chen Z, et al. Classification of papillomaviruses (PVs) based on 189 PV types and proposal of taxonomic amendments. *Virology.* 2010;401(1):70-79.
6. McLaughlin-Drubin ME, Meyers J, Munger K. Cancer associated human papillomaviruses. *Curr Opin Virol.* 2012;2(4):459-466.
7. van Haalen FM, Bruggink SC, Gussekloo J, et al. Warts in primary schoolchildren: prevalence and relation with environmental factors. *Br J Dermatol.* 2009;161(1):148-152.
8. Bruggink SC, Eekhof JAH, Egberts PF, et al. Natural course of cutaneous warts among primary schoolchildren: a prospective cohort study. *Ann Fam Med.* 2013;11(5):437-441.
9. Padel AF, Venning VA, Evans MF, et al. Human papillomaviruses in anogenital warts in children: typing by in situ hybridisation. *Br Med J.* 1990;300(6738):1491-1494.
10. Strauss S, Sastry P, Sonnex C, et al. Contamination of environmental surfaces by genital human papillomaviruses. *Sex Transm Infect.* 2002;78(2):135-138.
11. Bunney MH. *Viral Warts: Their Biology and Treatment.* Oxford: Oxford University Press; 1982.
12. Tomson N, Sterling J, Ahmed I, et al. Human papillomavirus typing of warts and response to cryotherapy. *J Eur Acad Derm Verereol.* 2010;25(9):1108-1111.
13. Leigh IM, Glover MT. Skin cancer and warts in immunosuppressed renal transplant recipients. *Recent Results Cancer Res.* Vol 139, *Skin Cancer: Basic Science, Clinical Research and Treatment.* Springer-Verlag; Berlin, Heidelberg; 1995:69-86.
14. Rüdlinger R, Smith IW, Bunney MH, et al. Human papillomavirus infections in a group of renal transplant recipients. *Br J Dermatol.* 1986;115(6):681-692.

15. Shamanin V, zur Hausen H, Lavergne D, et al. Human papillomavirus infections in nonmelanoma skin cancers from renal transplant recipients and nonimmunosuppressed patients. *J Natl Cancer Inst.* 1996;88(12): 802-811.
16. Boxman IL, Berkhout RJ, Mulder LH, et al. Detection of human papillomavirus DNA in plucked hairs from renal transplant recipients and healthy volunteers. *J Invest Dermatol.* 1997;108(5):712-715.
17. de Villiers EM, Lavergne D, McLaren K, et al. Prevailing papillomavirus types in non-melanoma carcinomas of the skin in renal allograft recipients. *Int J Cancer.* 1997;73(3):356-361.
18. de Koning MN, Struijk L, Bavinck JN, et al. Betapapillomaviruses frequently persist in the skin of healthy individuals. *J Gen Virol.* 2007;88(Pt 5):1489-1495.
19. Kyriakis K, Pagana G, Michailides C, et al. Lifetime prevalence fluctuations of common and plane viral warts. *J Eur Acad Dermatol Venereol.* 2007;21(2):260-262.
20. Egawa K, Kitasato H, Honda Y, et al. Human papillomavirus 57 identified in a plantar epidermoid cyst. *Br J Dermatol.* 1998;138(3):510-514.
21. Williams HC, Pottier A, Strachan D. The descriptive epidemiology of warts in British schoolchildren. *Br J Dermatol.* 1993;128(5):504-511.
22. Sri JC, Dubina MI, Kao GF, et al. Generalized verrucosis: a review of the associated diseases, evaluation, and treatments. *J Am Acad Dermatol.* 2012;66(2):292-311.
23. Laffort C, Le Deist F, Favre M, et al. Severe cutaneous papillomavirus disease after haemopoietic stem cell transplantation in patients with severe combined immune deficiency caused by common γc cytokine receptor subunit or JAK-3 deficiency. *Lancet.* 2004;363(9426):2051-2054.
24. Zinn KH, Belohradsky BH. Wiskott-Aldrich-Syndrom mit Verrucae vulgares. *Hautarzt.* 1977;28(12):664-667.
25. Reid TM, Fraser NG, Kernohan IR. Generalized warts and immune deficiency. *Br J Dermatol.* 1976;95(5):559-564.
26. Barnett N, Mak H, Winkelstein JA. Extensive verrucosis in primary immunodeficiency diseases. *Arch Dermatol.* 1983;119(1):5-7.
27. Stritzler C, Sawitsky A, Stritzler R. Bittner's syndrome. *Arch Dermatol.* 1971;103(5):548-549.
28. Kreuter A, Hochdorfer B, Brockmeyer NH, et al. A human papillomavirus-associated disease with disseminated warts, depressed cell-mediated immunity, primary lymphedema, and anogenital dysplasia: WILD syndrome. *Arch Dermatol.* 2008;144(3):366-372.
29. Hsu AP, Sampaio EP, Khan J, et al. Mutations in GATA2 are associated with the autosomal dominant and sporadic monocytopenia and mycobacterial infection (MonoMAC) syndrome. *Blood.* 2011;118(10): 2653-2655.
30. Dorn JM, Patnaik MS, Van Hee M, et al. WILD syndrome is GATA2 deficiency: a novel deletion in the GATA2 gene. *J Allergy Clin Immunol Pract.* 2017;5(4):1149-1152; e1.
31. Chu EY, Freeman AF, Jing H, et al. Cutaneous manifestations of *DOCK8* deficiency syndrome. *Arch Dermatol.* 2012;148(1):79-84.
32. Jorgensen GH, Gardulf A, Sigurdsson MI, et al. Clinical symptoms in adults with selective IgA deficiency: a case-control study. *J Clin Immunol.* 2013;33(4):742-747.
33. Lee SJ, Song HJ, Boo S-J, et al. Primary intestinal lymphangiestasia with generalized warts. *World J Gastrenterol.* 2015;21(27):8467-8472.
34. Stetson CL, Rapini RP, Tyring SK, et al. $CD4^+$ T lymphocytopenia with disseminated HPV. *J Cutan Pathol.* 2002;29(8):502-505.
35. Fischer LA, Norgaard A, Permin H, et al. Multiple flat warts associated with idiopathic CD4-positive T lymphocytopenia. *J Am Acad Dermatol.* 2008;58(suppl 2):S37-S38.
36. Horev L, Unger S, Molho-Pessach V, et al. Generalized verrucosis and HPV-3 susceptibility associated with CD4 T-cell lymphopenia caused by inherited human interleukin-7 deficiency. *J Am Acad Dermatol.* 2015;72(6):1082-1084.
37. Tarzi MD, Jenner M, Hattotuwa K, et al. Sporadic case of warts, hypogammaglobulinemia, immunodeficiency, and myelokathexis syndrome. *J Allergy Clin Immunol.* 2005;116(5):1101-1105.
38. Mulhem E, Pinelis S. Treatment of nongenital cutaneous warts. *Am Fam Physician.* 2011;84(3):288-293.
39. Kwok CS, Gibbs S, Bennett C, et al. Topical treatments for cutaneous warts. *Cochrane Database Syst Rev.* 2013;9:CD001781.
40. Sterling JC, Gibbs S, Haque Hussain S, et al. British Association of Dermatologists' Guidelines for the management of cutaneous warts 2014. *Br J Dermatol.* 2014;171(4):696-712.
41. Kwok CS, Holland R, Gibbs S. Efficacy of topical treatments for cutaneous warts: a meta-analysis and pooled analysis of randomized controlled trials. *Br J Dermatol.* 2011;165(2):233-246.
42. Patel T, Morrison K, Rady P, et al. Epidermodysplasia verruciformis and susceptibility to HPV. *Dis Mark.* 2010;29(3-4):199-206.
43. Rogers HD, Macgregor JL, Nord KM, et al. Acquired epidermodysplasia verruciformis. *J Am Acad Dermatol.* 2009;60(2):315-320.
44. Zampetti A, Giurdanella F, Manco S, et al. Acquired epidermodysplasia verruciformis: a comprehensive review and a proposal for treatment. *Dermatol Surg.* 2013;39(7):974-980.
45. Ramoz N, Rueda LA, Bouadjar B, et al. Mutations in two adjacent novel genes are associated with epidermodysplasia verruciformis. *Nat Genet.* 2002;32(4):579-581.
46. Dell'Oste V, Azzimonti B, De Andrea M, et al. High β-HPV DNA loads and strong seroreactivity are present in epidermodysplasia verruciformis. *J Invest Dermatol.* 2009;129(4):1026-1034.
47. Berthelot C, Dickerson MC, Rady P, et al. Treatment of a patient with epidermodysplasia verruciformis carrying a novel EVER2 mutation with imiquimod. *J Am Acad Dermatol.* 2007;56(5):882-886.
48. Janssen K, Lucker GP, Houwing RH, et al. Epidermodysplasia verruciformis: unsuccessful therapeutic approach with imiquimod. *Int J Dermatol.* 2007;46(suppl 3):45-47.
49. Karrer S, Szeimies R, Abels C, et al. Epidermodysplasia verruciformis treated using topical 5-aminolaevulinic acid photodynamic therapy. *Br J Dermatol.* 1999;140(5):935-938.
50. Nijhawan RI, Osei-Tutu A, Hugh JM. Sustained clinical resolution of acquired epidermodysplasia verruciformis in an immunocompromised patient after discontinuation of oral acitretin with topical imiquimod. *J Drugs Dermatol.* 2013;12(3):348-349.
51. Riddell C, Rashid R, Thomas V. Ungual and periungual human papillomavirus-associated squamous cell carcinoma: a review. *J Am Acad Dermatol.* 2011; 64(6):1147-1153.
52. Schwartz RA. Verrucous carcinoma of the skin and mucosa. *J Am Acad Dermatol.* 1995;32(1):1-21.
53. del Pino M, Bleeker MC, Quint WG, et al. Comprehensive analysis of human papillomavirus prevalence and

the potential role of low-risk types in verrucous carcinoma. *Mod Pathol.* 2012;25(10):1354-1363.
54. Quint KD, Genders RE, de Koning MNC, et al. Human *beta-papillomavirus* infection and keratinocyte carcinomas. *J Pathol.* 2015;235(2):342-354.
55. Staples CG, Henderson H, Tsongalis GJ. Condylomata of the pannus in 3 obese patients: a new location for a common disease. *Arch Dermatol.* 2012;146(5):572-574.
56. Park IU, Introcaso C, Dunne EF. Human papillomavirus and genital warts: a review of the evidence for the 2015 Centers for Disease Control and Prevention Sexually Transmitted Diseases Treatment Guidelines. *Clin Infect Dis.* 2015;61(suppl 8):S849-S855.
57. Werner RN, Westfechtel L, Dressler C, et al. Self-administered interventions for anogenital warts in immunocompetent patients: a systematic review and meta-analysis. *Sex Transm Infect.* 2017;93(3):155-161.
58. Moore RA, Edwards JE, Hopwood J, et al. Imiquimod for the treatment of genital warts: a quantitative systematic review. *BMC Infect Dis.* 2001;1:3.
59. Scheinfeld N. Update on the treatment of genital warts. *Dermatol Online J.* 2013;19(6):18559.
60. Stockfleth E, Meyer T. Sinecatechins (Polyphenon E) ointment for treatment of external genital warts and possible future indications. *Expert Opin Biol Ther.* 2014;14(7):1033-1043.
61. Ali H, Donovan B, Wand H, et al. Genital warts in young Australians five years into national human papillomavirus vaccination programme: national surveillance data. *Br Med J.* 2013;346:f2032.
62. Markowitz LE, Hariri S, Lin C, et al. Reduction in human papillomavirus (HPV) prevalence among young women following HPV vaccine introduction in the United States, National Health and Nutrition Examination Surveys, 2003-2010. *J Infect Dis.* 2013;208(3):385-393.
63. Shiboski CH, Lee A, Chen H, et al. Human papillomavirus infection in the oral cavity of HIV patients is not reduced by initiating antiretroviral therapy. *AIDS.* 2016;30(10):1573-1582.
64. Cararach M, Dexeus D. Preinvasive lesions of the vulva. *CME J Gynecol Oncol.* 2007;12:1466-1473.
65. van Seters M, van Beurden M, ten Kate FJ, et al. Treatment of vulvar intraepithelial neoplasia with topical imiquimod. *N Engl J Med.* 2008;358(14):1465-1473.
66. Gooi Z, Chan JY, Fakhry C. The epidemiology of the human papillomavirus related to oropharyngeal head and neck cancer. *Laryngoscope.* 2016;126(4):894-900.

Chapter 168 :: Cutaneous Manifestations of HIV and Human T-Lymphotropic Virus

:: Adam D. Lipworth, Esther E. Freeman, & Arturo P. Saavedra

MUCOCUTANEOUS MANIFESTATIONS OF HIV

AT-A-GLANCE

- HIV is a retrovirus that causes immune suppression and dysregulation primarily via depletion of CD4+ lymphocytes and CD4+ cells of monocytic lineage.
- In spite of better screening programs, availability of antiretroviral therapy (ART), and improved side-effect profiles, new infections continue to be documented.
- The range of dermatologic complications seen in HIV/AIDS relates to the evolving immunologic state of the patient, specific viral characteristics of the serotype causing infection, the period of time from infection to dermatologic complication, and the length of antiretroviral treatment.
- Acute HIV infection presents as a mononucleosis-like syndrome that can include a morbilliform exanthem 3 to 6 weeks after infection with HIV.
- In resource-limited areas, untreated infection may lead to progressive dermatologic disease.
- In reconstituted individuals and long-term viral suppression, sun-induced neoplasia and viral-induced neoplasia are significant burdens.

AN OVERVIEW OF HIV INFECTION

According to the World Health Organization (WHO), by the end of 2015, 36.7 million people worldwide were living with the HIV, lymphotropic human retrovirus. Approximately 2.1 million of those were newly diagnosed that year, and approximately 1.1 million died from complications of AIDS. CD4 count parameters that serve as guidelines for the initiation of treatment have increased from less than 200 cells/μL in 2003 to 500 cells/μL in 2011. As of 2015, all newly diagnosed HIV patients are candidates for antiretroviral therapy (ART); upwards of 30 million people will be eligible for treatment.[1] Nevertheless, infections continue to occur both locally and abroad despite prevention programs and newly developed recommendations from the Centers for Disease Control and Prevention for optout screening in all health care settings in the absence of written consent for screening.[2] These figures suggest that whereas progress has been made, a significant number of infections continue to occur, and the burden of disease will continue to exist as infected individuals live longer. Consequently, identification of HIV infection-associated diagnoses is relevant in both resource-limited settings and in resource-abundant zones. The field of HIV medicine continues to rapidly evolve, and excellent internet resources that are frequently updated include the U.S. Department of Health and Human Services' AIDS*info* (https://aidsinfo.nih.gov) and the Centers for Disease Control and Prevention's National Prevention Information Network (https://npin.cdc.gov/).

ETIOLOGY AND PATHOGENESIS

HIV is predominantly transmitted through sexual contact. Other important means of transmission include exposure to infected blood (including needles shared by injecting drug users and "skin popping") and transmission from an infected mother to her fetus during pregnancy, delivery, or breastfeeding. HIV-1 is the most common cause of HIV infection globally, while HIV-2 infection has been detected mainly in West Africa. Although both HIV subtypes cause clinically similar disease, HIV-2 is associated with slower progression of immunosuppression, decreased infectivity, and resistance to nonnucleoside reverse transcriptase inhibitors.[3]

The profound immunosuppression that defines HIV disease results from progressive depletion of CD4+ T lymphocytes. Efficient infection of a target cell by HIV requires not only expression of a CD4 molecule on that cell's surface, but also the presence of a coreceptor (such as chemokine receptor 5 [CCR5] or chemokine-related receptor 4 [CXCR4]). Although HIV infects primarily CD4+ T lymphocytes and CD4+ cells of monocytic lineage, any cell that expresses CD4 and an appropriate coreceptor may be infected by HIV.[4]

CLINICAL FEATURES

Cutaneous disorders occur in nearly every patient during the course of HIV disease, either as a result of acquired immunodeficiency or from treatment. HIV disease is a continuum that progresses from primary infection to death via a sequence of opportunistic infections and neoplasms that mark the gradual

deterioration of the immune system. *Acute HIV infection* or *acute retroviral syndrome* presents approximately 3 to 6 weeks following primary infection, with the majority of individuals developing an acute mononucleosis-like syndrome. Clinical manifestations include fever, lethargy, rash, myalgia/arthralgia, cervical and axillary lymphadenopathy, pharyngitis, mucosal ulcers, night sweats, nausea/vomiting/diarrhea, weight loss, and laboratory abnormalities including leukopenia, thrombocytopenia, and transaminitis.[5] The rash typically manifests as asymptomatic macules and papules on the face and upper trunk, although the eruption may be more diffuse and pruritic.[6] Urticaria and pustules also have been reported.[6,7] Symptoms generally last an average of 2 to 3 weeks and resolve gradually as levels of plasma viremia decrease. The presentation of acute retroviral syndrome provides a valuable opportunity for early diagnosis of HIV disease, during a particularly critical time when levels of viremia, and therefore the degree of infectivity, are at extremely high levels.[8]

Unfortunately, this diagnostic opportunity may be missed if clinical suspicion is not sufficiently high; recent estimates place the proportion of HIV patients in the United States who are currently undiagnosed at 14%,[9] and the diagnosis is often missed despite the suggestive symptoms of acute retroviral syndrome,[10] in part because the protean manifestations are easily mistaken for other infections such as Epstein-Barr virus.[11] Even when acute HIV infection is suspected, the diagnosis can be missed because patients may present prior to seroconversion, resulting in false-negative HIV antibody tests. When acute HIV infection is considered, clinicians should perform more sensitive direct tests for HIV viral RNA or for the p24 core structural protein (see section "Diagnosis").[5,10]

Individuals who have access to combination ART have a markedly altered course of disease if immune restoration is successfully achieved. In most cases, there is a marked reduction in the incidence of opportunistic infections, but certain neoplasms, particularly those induced by sun exposure or arising as a result of virus-induced dysplasia, now amount to a significant dermatologic burden. Globally, however, the majority of HIV-infected individuals lack access to ART and, consequently, many of the cutaneous manifestations associated with HIV disease become chronic and progressive.

TABLE 168-1
Correlation of Mucocutaneous Manifestations of HIV Infection with CD4 T-Cell Counts

CD4 T-CELL COUNT >500 CELLS/μL	CD4 T-CELL COUNT 250–500 CELLS/μL	CD4 T-CELL COUNT <200 CELLS/μL
Acute retroviral syndrome	Dermatophyte infections, recurrent or persistent	Bacillary angiomatosis
Herpes zoster infection (nondisseminated)	Oral candidiasis	Hyperkeratotic scabies
Seborrheic dermatitis	Oral hairy leukoplakia Herpes zoster infection, disseminated	Cutaneous military tuberculosis Eosinophilic folliculitis Herpes simplex virus infection (>1 month's duration) Idiopathic pruritus Invasive fungal infections Kaposi sarcoma Molluscum contagiosum, large facial lesions Papular pruritic eruption of HIV

DIAGNOSIS

Studies have documented that in the past, up to 25% of those with HIV infection were not tested, despite suggestive symptoms.[12] In fact, 2% of individuals thought to have Epstein-Barr virus were found to have HIV when tested retrospectively in one study, and approximately half of those had acute primary HIV infection.[13] The laboratory diagnosis of HIV-1 infection is typically made by either identification of antibodies to HIV or direct detection of HIV antigens or nucleic acids (Table 168-1). A delay of 3 to 4 weeks typically occurs between newly acquired HIV-1 infection and development of antibodies, which is referred to as the "window period." However, core structural protein p24 antigen may be detected several weeks prior to seroconversion. The viral-RNA assay detects infection up to 5 days earlier than the p24 assay, and appears to be more sensitive.[12]

AIDS is now designated by the Centers for Disease Control and Prevention as HIV stage 3. In this new staging system, an HIV-seropositive individual older than 6 years of age with a CD4+ T-cell count <200 cells/μL, a CD4+ T-cell percentage <14%, or with any of several diseases considered to be indicative of a severe defect in cell-mediated immunity is considered to have AIDS.[14] Table 168-2 lists the conditions deemed to be AIDS-defining in a patient with a confirmed HIV infection.

CLINICAL COURSE, PROGNOSIS, AND MANAGEMENT

The length of time between initial infection and the development of symptomatic disease varies significantly. This period of clinical latency does not necessarily imply disease latency. Viral replication may persist, and CD4+ T-cell levels progressively decline. Thus, between 2013 and 2015, after the completion of 3 randomized controlled trials, guidelines recommended therapy with ART upon diagnosis regardless of CD4 count.[15] The more severe and life-threatening complications of HIV disease typically occur when

TABLE 168-2
AIDS (HIV Stage 3)—Defining Illnesses

- Candidiasis of bronchi, trachea, or lungs
- Candidiasis of esophagus
- Cervical cancer, invasive
- Coccidioidomycosis, disseminated or extrapulmonary
- Cryptococcosis, extrapulmonary
- Cryptosporidiosis, chronic intestinal (>1 month's duration)
- Cytomegalovirus disease (other than liver, spleen, or nodes), onset at age >1 month
- Cytomegalovirus retinitis (with loss of vision)
- Encephalopathy attributed to HIV
- Herpes simplex: chronic ulcers (>1 month's duration) or bronchitis, pneumonitis, or esophagitis (onset at age >1 month)
- Histoplasmosis, disseminated or extrapulmonary
- Isosporiasis, chronic intestinal (>1 month's duration)
- Kaposi sarcoma
- Lymphoma, Burkitt (or equivalent term) or immunoblastic (or equivalent term)
- Lymphoma, primary, of brain
- *Mycobacterium avium* complex or *Mycobacterium kansasii*, disseminated or extrapulmonary
- *Mycobacterium tuberculosis* of any site, pulmonary, disseminated, or extrapulmonary
- *Mycobacterium*, other species or unidentified species, disseminated or extrapulmonary
- *Pneumocystis jirovecii* (previously known as *Pneumocystis carinii*) pneumonia
- Pneumonia, recurrent
- Progressive multifocal leukoencephalopathy
- *Salmonella* septicemia, recurrent
- Toxoplasmosis of brain, onset at age >1 month
- Wasting syndrome attributed to HIV

Adapted from Centers for Disease Control and Prevention (CDC). Appendix A: AIDS-defining conditions. *MMWR Recomm Rep*. 2008;57 (RR-10):9. Available at https://www.cdc.gov/mmwr/preview/mmwrhtml/rr5710a2.htm.

CD4+ T-cell counts fall below 200 cells/μL. As a consequence of accessibility to ART, patients with HIV are living longer. As a result, dermatologic complications from long-term well-controlled HIV disease, such as virus-induced and sun-induced neoplasias, are now increasingly recognized.

MEDICATIONS AND MEDICATION-RELATED EFFECTS IN THE SETTING OF HIV

AT-A-GLANCE

- There is nearly a 100-fold increase in adverse cutaneous drug reactions in the setting of HIV/AIDS.
- Sulfonamides and penicillins are common causes of these reactions.
- Antiretroviral medications themselves also frequently cause adverse reactions, including morbilliform, urticarial, retinoid-like, vasculitic or bullous eruptions. Chronically, they may cause alopecia, hirsutism, dyspigmentation, and lipodystrophy/lipoatrophy.
- Treatment includes supportive care, cessation of the etiologic agent when necessary, topical and oral corticosteroid use, and, less commonly, advanced immunosuppressants.

The incidence of adverse cutaneous drug eruptions is estimated to be as much as 100 times higher in individuals with untreated HIV disease than in the general population, and may rise further with advancing immunodeficiency.[16] Adverse reactions can complicate upwards of 20% of prescriptions. Sulfonamide drugs and penicillins are common causative agents of cutaneous drug eruptions, accounting for 75% of cases in one study.[17] Of note, individuals that are sulfa-allergic are at increased risk of more-severe reactions to sulfa drugs in the setting of immune reconstitution. Given the high incidence of sulfa-induced reactions, it is important to note that darunavir, tipranavir, amprenavir (no longer marketed in the United States), and fosamprenavir contain sulfa moieties. Drug reactions may present in the setting of immune restoration, and in the midst of immune reconstitution inflammatory syndrome (IRIS). In such cases, drug reactions are likely to be more severe than at other points in the HIV disease course.[17]

Drug interactions should also be considered when patients with HIV are treated for other dermatologic concerns. For instance, reports exist documenting iatrogenic Cushing syndrome in patients treated with topical, intranasal, and intramuscular steroids as a result of ritonavir-induced and atazanavir-induced inhibition of cytochrome P450.[18,19] (Refer to Table 168-3 for the various classes of ARTs and their most significant dermatologic manifestations.)

CLINICAL FEATURES

Morbilliform eruptions are by far the most common manifestation, accounting for approximately 75% to 95% of cases.[20] Urticaria, erythema multiforme (major and minor), lichenoid eruption, vasculitis, and fixed drug eruption are also reported. Approximately 20% of cases are associated with systemic symptoms, such as fever, headache, myalgia, and arthralgia.[17] In patients who are positive for HLA-B5701, drug reaction with eosinophilia and systemic syndrome may develop in patients treated with abacavir. Cardiovascular collapse has been reported in these cases. Severe bullous eruptions and desquamatory reactions appear to be more common in HIV disease (Fig. 168-1). In one study, the incidence of toxic epidermal necrolysis (TEN) in HIV-infected individuals was found to be 375 times greater than that in the general population.[21]

TABLE 168-3
Adverse Effects of Antiretroviral Drugs

DRUGS	SYSTEMIC SIDE EFFECTS	DERMATOLOGIC SIDE EFFECTS
Nucleoside Reverse Transcription Inhibitors (NRTIs)		
Abacavir (ABC) Didanosine (ddI) Emtricitabine (FTC) Lamivudine (3TC) Stavudine (d4T) Tenofovir (TDF) Tenofovir alafenamide fumarate (TAF) Zidovudine (AZT) Zalcitabine (ddC)*	Pancreatitis, peripheral neuropathy, lactic acidosis and hepatotoxicity (didanosine, stavudine, zalcitabine) Hepatotoxicity (emtricitabine, lamivudine) Renal toxicity (tenofovir) Anemia, granulocytopenia, myopathy, lactic acidosis, hepatotoxicity, and nausea (zidovudine) Oropharyngeal and esophageal ulcerations (zalcitabine)	Hypersensitivity, with rare instances of Stevens-Johnson syndrome/toxic epidermal necrolysis (SJS/TEN) Systemic hypersensitivity reactions in up to 8% of patients is associated with HLA-B5701/HLA-DR7/HLA-DQ3; incidence reduced by prescreening for HLA-B5701 (abacavir) Leukocytoclastic vasculitis (didanosine) Hyperpigmentation of the nail bed, palms, and soles (emtricitabine) Hyperpigmentation of the nails (including multiple longitudinal and transverse bands), diffuse hyperpigmentation of the skin and oral mucosa, leukocytoclastic vasculitis, and hypertrichosis (zidovudine) Lipohypotrophy with (stavudine, zidovudine) Paronychia with nailfold pyogenic granuloma (lamivudine, zidovudine)
Nonnucleoside Reverse Transcription Inhibitors (NNRTIs)		
Delavirdine Efavirenz Etravirine Nevirapine Rilpivirine	Hepatotoxicity (all) Depression and mood changes (efavirenz, rilpivirine)	Hypersensitivity reactions are common within the first 6 weeks of therapy, with rare progression to systemic hypersensitivity or SJS/TEN (highest incidence with nevirapine) Lipodystrophies with rilpivirine
Protease Inhibitors (PIs)[a]		
Amprenavir[b] Atazanavir Darunavir Fosamprenavir Indinavir Lopinavir Nelfinavir Ritonavir Saquinavir Tipranavir	Nausea, vomiting, diarrhea, headaches, lipid anomalies, and hyperglycemia PR prolongation and hyperbilirubinemia (atazanavir) Hepatotoxicity and intracranial hemorrhage (tipranavir) Nephrolithiasis and hyperbilirubinemia (indinavir) Ritonavir may affect levels of many other medications, including saquinavir and intralesional steroids (leading to the development of Cushing syndrome)[c]	Hypersensitivity reactions with rare progression to SJS (amprenavir, fosamprenavir, tipranavir) Acute exanthematous pustulosis Lipohypertrophy (indinavir) Dose-dependent retinoid-like effects (xerosis, cheilitis, alopecia, lateral nailfold pyogenic granuloma, curly hair, and recurrent paronychia), acute porphyria, "frozen shoulder," and venous thrombosis (indinavir) Spontaneous bleeding and hematomas (ritonavir) Rare cases of fixed drug eruptions (saquinavir) Darunavir, tipranavir, fosamprenavir, and amprenavir contain sulfa moieties and should be used with caution in sulfa-allergic patients
Fusion Inhibitors		
Enfuvirtide	Increased frequency of bacterial pneumonia	Systemic hypersensitivity reactions in <1% of patients Injection-site reactions in up to 98% of patients, requiring discontinuation in only 3%
Integrase Inhibitors		
Raltegravir Dolutegravir Elvitegravir	Well tolerated: nausea, diarrhea, headache, insomnia Hepatotoxicity	Pruritus Rare cases of skin hypersensitivity (dolutegravir)
Chemokine Receptor 5 (CCR5) Antagonist		
Maraviroc	Hepatotoxicity, nasopharyngitis, cough, abdominal pain, dizziness, musculoskeletal symptoms	

[a]Simeprevir, boceprevir, and ombitasvir/paritaprevir/dasabuvir are not included in this table even though they are protease inhibitors with activity against HIV because they are U.S. Food and Drug Administration–approved only for treatment of hepatitis C.

[b]Denotes that this medication is no longer marketed or has been discontinued by the manufacturer. Please note that in the case of amprenavir, a prodrug (fosamprenavir) is available.

[c]Cobicistat, a pharmacokinetic enhancer ("boosting agent") is used for its ability to increase the blood levels of agents such as atazanavir and darunavir. It does not have antiviral activity against HIV. Because this agent inhibits cytochrome P450, the risk of Cushing syndrome exists when corticosteroids are used concurrently.

Retinoid-like effects such as cheilitis, paronychia, and eruption of pyogenic granuloma are seen with some nucleoside reverse transcriptase inhibitors and protease inhibitors (Fig. 168-2). These effects are generally dose-dependent and can be managed if alternative regimens are not the best option for an individual patient. Other dermatologic manifestations that are specific to individual antiretroviral medications

Figure 168-1 Toxic epidermal necrolysis in an HIV-infected patient. (Used with permission from Dr. Anisa Mosam.)

include melanonychia (zidovudine), leukocytoclastic vasculitis (didanosine), and infection-site reactions (enfuvirtide) (see Table 168-3).

The lipodystrophy syndrome and its accompanying metabolic syndrome warrants specific mention (see Chap. 74). HIV-related lipodystrophy is characterized by abnormal fat distribution, which may include lipohypertrophy, lipoatrophy, or both. It generally arises from ART, but HIV infection itself may also cause lipodystrophy.[22] Lipohypertrophy is most commonly associated with protease inhibitor therapy, while lipoatrophy is frequently associated with nuclease reverse transcription inhibitors, particularly the thymidine analogs stavudine and zidovudine. Lipohypertrophy presents with central obesity, cushingoid habitus ("buffalo hump"), increased neck girth, increased abdominal girth from intraabdominal fat ("protease pouch" or "crix belly"), and breast enlargement (Fig. 168-3A). Lipoatrophy most commonly presents with flattening of convex contours of the face (Fig. 168-3B). Abnormal fat distribution is often accompanied by metabolic abnormalities, such as fasting glucose levels, fasting insulin levels, hypertriglyceridemia, hypercholesterolemia, and decreased high-density lipoprotein.

ETIOLOGY AND PATHOGENESIS

Factors associated with increased risk of drug eruptions include female gender, peripheral CD4+ T-cell count <200 cells/μL, CD8+ T-cell count >460 cells/μL, and a history of drug eruptions in the past.[23] Recently, the role of skin-directed lymphocytes has been studied as the skin-directed lymphocytes relate to the pathogenesis of TEN. In HIV-infected individuals, a relative decrease in tissue-specific CD4+ cells, with decreased CD4+/CD8+ ratio was noted in comparison to uninfected hosts. Specifically, a decrease in dermal CD3+ CD4+ CD25+ (and FoxP3+) regulatory T cells was noted, suggesting a role for regulatory T cells in prevention of adverse cutaneous drug reactions.[24]

DIAGNOSIS

Diagnosis of adverse cutaneous drug reactions remains largely clinical, and is often a diagnosis of exclusion. The most significant consideration is whether the correct culprit has been identified, understanding that some reactions can occur even 2 weeks after drug discontinuation. HIV-infection may itself lead to new-onset hypersensitivity to medications not previously noted by the patient. Identification of culprit medications prevents repeat exposures and is a determinant of morbidity, most notably in the case of Stevens-Johnson syndrome/TEN where drugs with longer half-life, such as nevirapine, have been correlated to more severe disease and duration.[25] Individuals commencing therapy with abacavir are now frequently prescreened for HLA-B5701 and other HLA subtypes to prevent hypersensitivity reactions. Significant controversy exists in the literature regarding the value of peripheral eosinophilia in evaluating drug reactions, and its absence does not exclude the diagnosis.[26]

DIFFERENTIAL DIAGNOSIS

The most difficult entity to exclude when a patient presents with a morbilliform exanthem is viral infection. Often, drug-induced vasculitis is difficult to differentiate from other causes of leukocytoclastic vasculitis, including infection, autoimmune disorders, and HIV itself, or from idiopathic subtypes.

CLINICAL COURSE, PROGNOSIS, AND MANAGEMENT

In the absence of mucosal involvement and systemic symptoms, a causative medication may often be continued with close clinical monitoring. However, if early symptoms of urticaria/angioedema or Stevens-Johnson syndrome/TEN are present, the drug should be immediately discontinued.

Short-term corticosteroid therapy appears to be safe in most HIV-infected individuals.[23] Desensitization is an option for individuals with a history of uncomplicated cutaneous drug eruptions.[27] The management of Stevens-Johnson syndrome and TEN remain controversial. Supportive care should be initiated in a supervised setting where hydration, followup of electrolyte abnormalities, wound care, and early recognition of infection can be delivered. Treatment with IV immunoglobulin, cyclosporine, and anti–tumor necrosis

Figure 168-2 Retinoid-like effects in a patient with HIV disease treated with indinavir. **A,** Eczematous dermatitis superimposed on severe asteatosis; **B,** cheilitis; **C,** paronychia; **D,** pyogenic granuloma. Pruritus and scalp defluvium are also commonly seen.

agents, among others has been reported, but large-scale, definitive trials are lacking.[28]

Management of lipodystrophy remains challenging. Substitution of ART regimens containing stavudine and zidovudine are of partial benefit for lipoatrophy.[29] Although switching individuals to nuclease reverse transcription inhibitor–sparing regimens have produced modest results in lipoatrophy, the improvement in fat distribution may come at the expense of lipid anomalies if patients are switched to protease inhibitors.[30] Facial lipoatrophy has been treated with soft-tissue fillers, such as poly-L-lactic acid or calcium hydroxylapatite, with varying degrees of success.[31] Liposuction has been used to treat the dorsocervical lipomatosis, but results are often unsatisfactory.

Figure 168-3 Antiretroviral therapy–induced lipodystrophy. **A,** Protease inhibitor–induced lipodystrophy; **B,** facial lipoatrophy. (Used with permission from Dr. Anisa Mosam.)

MUCOCUTANEOUS INFECTIONS IN HIV DISEASE

AT-A-GLANCE

- HIV patients are at elevated risk for a wide variety of infections, many of which affect the skin and mucous membranes. Coinfecting pathogens often interact with HIV in complex and potentially symbiotic ways that alter the course of both diseases.
- In well-controlled HIV with normal CD4+ T-cell counts, patients remain at risk for several specific persistent or newly acquired infections, such as staphylococcal pyodermas, herpes simplex and herpes zoster reactivation, syphilis, and a variety of human papillomavirus–related diseases.
- In advanced HIV disease, severe immunocompromise predisposes patients to opportunistic infections, often with high morbidity and potentially high mortality. Opportunistic infections include oral hairy leukoplakia, bacillary angiomatosis, cutaneous miliary tuberculosis, and invasive mycoses.
- AIDS patients are also at risk for infection with more typical human pathogens, but with unusually severe or atypical presentations, including severe dermatophytoses, giant molluscum contagiosum, crusted scabies, and atypical leishmaniasis.
- AIDS-defining infections should raise suspicion for HIV in patients whose HIV status is unknown.

In advanced HIV disease, the profoundly immunosuppressed state predisposes patients to opportunistic infections from organisms that are rarely pathogenic to immunocompetent individuals. Even after immune reconstitution, HIV patients remain at higher risk than seronegative individuals for a variety of cutaneous infections, such as staphylococcal pyodermas, herpes zoster reactivation, and various human papillomavirus (HPV)-related diseases. This section examines the mucocutaneous infections of advanced HIV/AIDS and then those infections with unique features in stable HIV disease. It focuses on those features of each infection that are specific to HIV disease, as general characteristics are presented elsewhere in this text. Nearly all of the infections presented can flare or manifest as part of the IRIS, discussed later in this chapter (see section "Immune Reconstitution Inflammatory Syndrome").

INFECTIONS IN ADVANCED HIV DISEASE (OPPORTUNISTIC INFECTIONS)

With the rise in access to effective ART, highly morbid opportunistic infections are becoming increasingly rare, but they remain quite common in the developing world. In developed countries, they pose outsized diagnostic and therapeutic challenges, because clinical familiarity with AIDS-associated infections has declined in step with their incidence.

Oral Hairy Leukoplakia and Other Epstein-Barr Virus–Related Disease: Chapter 163 discusses viral diseases like oral hairy leukoplakia in greater detail.

Oral hairy leukoplakia is a benign Epstein-Barr virus infection of oral mucosal epithelium in

immunosuppressed patients. Clinically, oral hairy leukoplakia presents on one or both lateral aspects of the tongue with asymptomatic, corrugated white plaques that cannot be removed by scraping with a tongue depressor.[32] Treatment is not required, but the lesions may resolve with antiretroviral drugs. Local therapies with reported efficacy include podophyllin,[33,34] gentian violet,[35] and cryotherapy.[36] HIV patients are also more susceptible to Epstein-Barr virus–associated malignancies with cutaneous manifestations including Burkitt lymphoma, diffuse large B-cell lymphoma, and leiomyosarcoma.[37,38]

Bacillary Angiomatosis: Chapter 154 discusses bacterial infections in greater detail.

Bacillary angiomatosis, caused by *Bartonella henselae* and *Bartonella quintana,* occurs most commonly in HIV patients with a CD4+ T-cell count <200 cells/μL.[39] Clinically, the cutaneous lesions of bacillary angiomatosis are red-to-violaceous, dome-shaped papules, nodules, or plaques that may resemble cherry angiomas, pyogenic granulomas, or Kaposi sarcoma,[40] although many atypical appearances have been reported.[41] Nearly any cutaneous site may be involved, but the palms, soles, and oral cavity are usually spared. Hematogenous or lymphatic dissemination of *B. henselae* and *B. quintana* can result in soft-tissue masses, osseous lesions, lymphadenopathy, splenomegaly, and hepatomegaly.[42,43]

The organism can be seen on tissue biopsy using a silver stain such as Warthin-Starry stain. The antibiotics of choice for bacillary angiomatosis are erythromycin (500 mg 4 times daily) or doxycycline (100 mg twice daily), for at least 4 weeks or until the lesions resolve.[44] Lifelong secondary prevention may be indicated in patients with recurrent bacillary angiomatosis. Bacillary angiomatosis has become rare in developed countries because of the widespread use of ART and macrolide prophylaxis for *Mycobacterium avium* complex.

Mycobacterial Infections: Tuberculosis is the most common opportunistic infection in HIV, but cutaneous manifestations are relatively rare even in this immunocompromised population.[45] Not surprisingly, of the many forms of cutaneous tuberculosis (see Chap. 157), the most commonly reported in AIDS are those associated with low levels of cell-mediated immunity to *Mycobacterium tuberculosis* or *Mycobacterium bovis*. These multibacillary presentations include scrofuloderma, gummatous tuberculosis, and, especially, cutaneous miliary tuberculosis.[46-49] Miliary tuberculosis was only rarely reported in adults prior to the AIDS epidemic. It presents with disseminated but asymmetric red-brown pinpoint macules, papules, and papulovesicles that may crust over.[49] Miliary tuberculosis is treated with multidrug antituberculosis therapy, but mortality rates are high (>50%), particularly in the case of multidrug-resistant organisms.[48]

Non-tuberculous mycobacterial infections (see Chap. 157), especially *M. avium* complex, may rarely disseminate to the skin in profoundly immunocompromised individuals. A wide variety of lesions have been described, including papules, plaques, nodules, abscesses, pustules, ulcers, and more. Cutaneous and blood cultures are key to diagnosis, as they are more sensitive than acid-fast stains of tissue alone, and in vitro susceptibility testing can guide selection of antibiotics.[50]

Most data, including a large 2015 cohort study, suggest that HIV infection does not substantially impact the prevalence or clinical course of concomitant leprosy infection (see Chap. 159).[51] However, a 13-year Brazilian longitudinal case series of coinfected patients made several provocative observations to the contrary.[52] These authors argue that an elevated prevalence of leprosy among HIV-infected individuals has been obscured by various diagnostic challenges, including atypical morphology of leprosy lesions on coinfected patients, conflation of HIV-related and leprosy-related neuropathy, and the limited window for diagnosis in patients with concomitant lepromatous leprosy and AIDS, which they observed to be rapidly fatal, as well as associated with other confounding severe comorbidities.[52] Both the 2015 cohort study and the Brazilian longitudinal case series observed upgrading reactions when coinfected patients began antiretroviral and antileprosy therapy.[51,52]

Invasive Mycoses: Chapter 162 discusses fungal infections in greater detail.

Disseminated fungal infections in advanced HIV disease may arise either by (a) local invasion of the skin or mucosa with secondary lymphatic or hematogenous dissemination or (b) reactivation of a latent pulmonary focus of infection. Cutaneous dissemination usually occurs in patients with a CD4+ T-cell count <50 cells/μL,[53-55] and may present with a wide variety of skin lesions shared by most of the opportunistic fungi, including cellulitis-like plaques, pink or skin-colored nodules, deep ulcerations, acneiform papules and pustules, and umbilicated papules that resemble molluscum.[56-62] These papules tend to favor the face and upper trunk, and they lack the white core of molluscum-infected keratinocytes at the base of a molluscum papule's dell. Fungal pathogens with potential for angioinvasion, such as *Aspergillus* species, may also present with purpuric papules and plaques of septic vasculitis.

Mortality is high for AIDS patients with systemic mycoses that have disseminated to the skin. Because the cutaneous lesions may develop prior to manifestations of internal organ involvement, they provide an opportunity for early diagnosis and intervention if the clinician maintains a sufficiently high index of suspicion. Cryptococcosis, histoplasmosis, and penicilliosis are a subset of deep fungal infections for which AIDS is the primary risk factor for cutaneous infection.

The yeast species *Cryptococcus neoformans* and *Cryptococcus gatti* are common worldwide, resulting in widespread pulmonary exposures that are rarely problematic for immunocompetent people.[63] However, the yeast may invade and disseminate in AIDS patients, most commonly to the CNS.[45] Skin lesions occur only in approximately 10% of AIDS patients with

Figure 168-4 Cryptococcosis in a child with congenital HIV and AIDS: pink plaques with crusted erosions on the face.

Figure 168-5 Disseminated histoplasmosis in AIDS. A young woman from South Africa with advanced untreated HIV/AIDS presented with cervical adenopathy and disseminated skin-colored papules (some umbilicated), pustules, and ulcerated nodules of varying sizes.

disseminated cryptococcosis, presenting with any of the various lesions described above, including umbilicated papules (Fig. 168-4). Diagnosis can be secured by a latex agglutination test for capsular antigen, culture, or staining with India ink or periodic acid–Schiff stains.[55,63] Treatment is typically with amphotericin-B and flucytosine in combination, followed by a long course of an oral azole antifungal medication.[64]

Histoplasma capsulatum var. *capsulatum* is a dimorphic soil fungus endemic to river valleys of the midwestern and southeastern United States, southeastern South America, and southern and eastern Africa. However, it may be found worldwide, especially in caves and other areas with bat and bird droppings.[65] Like the other fungal infections discussed in this section, pulmonary histoplasmosis is relatively common in exposed populations, but disseminated histoplasmosis is limited to profoundly immunosuppressed patients. Disseminated disease presents with fevers, weight loss, pulmonary symptoms, lymphadenopathy, hepatosplenomegaly, and the polymorphic mucocutaneous lesions common to all the invasive mycoses discussed in this section, again including umbilicated papules, nodules, and necrotic ulcers (Fig. 168-5).[58,59] Heavy involvement of the face, including nasal and oropharyngeal mucosa, is common.

Histopathologic examination demonstrates 2- to 4-µm intracellular yeast forms within parasitized macrophages; in central and western sub-Saharan Africa, some histoplasmosis patients will demonstrate larger, 8- to 15-µm intracellular pathogens, signaling infection with the related species *H. capsulatum* var. *duboisii*.[65] The African histoplasmosis variant *duboisii* appears far less prevalent among AIDS patients than the *capsulatum* variant, even in southern Africa. However, dermatologists should be familiar with it because disseminated African histoplasmosis favors cutaneous sites, along with lymph nodes and bone. Both forms are treated with long courses of itraconazole, sometimes after an initial course of amphotericin B.[66]

The dimorphic fungus *Penicillium marneffei* is a leading cause of mortality among AIDS patients in Southeast Asia.[62] Unlike cryptococcosis, disseminated penicilliosis involves the skin in the great majority of patients—more than 80% in a recent Vietnamese study.[62] Skin lesions, including umbilicated papules, often precede the dyspnea, fever, weight loss, anemia, and lymphadenopathy common to those with more advanced disease.[62] Like *Histoplasma* species, *P. marneffei* parasitizes macrophages, and is observed as 2- to 5-µm intracellular oval yeast forms with transverse septae.[65] Treatment with amphotericin or itraconazole is often effective, although relapse is common.[67]

Superficial Mycoses: Chapter 160 discusses superficial fungal infection in greater detail.

Unlike the opportunistic infections discussed thus far, superficial mycoses and the remaining infections discussed in this section are common in *both* AIDS *and* in well-controlled HIV. However, in immunocompromised patients, these common infections often present with atypical manifestations not seen in patients with stable HIV disease.

Candida colonization of the oropharynx is common in HIV-infected individuals, and has been reported in up to 90% of individuals with advanced disease.[68] Oropharyngeal candidiasis typically presents in 4 different clinical patterns: pseudomembranous (thrush), hyperplastic, erythematous (atrophic), and angular cheilitis. Pseudomembranous candidiasis typically involves the tongue, and presents with yellow-white plaques that are removable by scraping. Hyperplastic candidiasis usually involves the buccal mucosa, and consists of white plaques that are not removable by scraping. Erythematous candidiasis commonly presents with erythematous patches of the palate and the dorsal tongue with associated depapillation. Angular cheilitis manifests as erythema with curd-like flecks or painful fissures at the angles of the lips. Other forms of superficial mucocutaneous candidiasis also occur with greater incidence in advanced HIV disease, including vulvovaginal candidiasis in women,[69] and candida intertrigo in children.[70]

Fungal nail infections are particularly common in HIV disease, caused not only by dermatophytes,

Figure 168-6 Extensive tinea corporis in AIDS. This plaque extended to the chest and face as well.

Figure 168-7 Giant molluscum on the scalp in of a patient with AIDS.

but also by *Candida* and nondermatophyte molds.[71,72] Infection of the undersurface of the proximal nail plate is termed *proximal subungual onychomycosis*, and while relatively uncommon even in AIDS patients, it is highly *specific* for advanced immunocompromised patients and should prompt an HIV test in patients whose HIV status is unknown.[73] Antiretrovirals are sometimes effective in clearing onychomycosis,[74] although oral terbinafine or triazole antifungals often are required; drug–drug interactions should be checked carefully before commencing systemic antifungal therapy.

In HIV disease, dermatophyte infections of the epidermis, commonly caused by *Trichophyton rubrum* may be asymptomatic and extensive (Fig. 168-6). The morphology also may be atypical, often lacking the raised erythematous border and annular shape.[75] *Malassezia*-related diseases, including pityriasis versicolor, *Pityrosporum* folliculitis, and seborrheic dermatitis, are all far more prevalent, and often more severe, in HIV patients, particularly at low CD4 counts.[76]

Severe Molluscum Contagiosum: Chapter 166 discusses poxvirus infections in greater detail.

Approximately 33% of advanced HIV patients with CD4+ T-cell counts of <100 cells/μL have molluscum contagiosum.[77] In this population, the characteristic umbilicated papules with yellow-white cores often coalesce into large confluent plaques and nodules, particularly on the face (Fig. 168-7).[39,77] Whereas most molluscum papules resolve with effective immune reconstitution,[78,79] these giant molluscum lesions may persist for many months or years, and may worsen as part of IRIS.[80] In addition to commonly used treatments such as cantharidin, electrofulguration and curettage, extrusion of the papule cores, and imiquimod 5% cream,[81,82] severe cases can be treated with topical cidofovir, a nucleotide analog with activity against several DNA viruses.[83,84]

Scabies: Chapter 178 discusses scabies in greater detail.

Scabies usually presents in the typical manner in HIV patients, with pruritus, interdigital burrows, and excoriated papules favoring the genital region, finger webs, and axillae. However, individuals with advanced HIV disease are more likely to have severe hypersensitivities to the *Sarcoptes scabiei* mites, resulting in widespread scabetic nodules, as well as vesicles and pustules.[85] Advanced AIDS patients who are not able to control mite replication are at risk for developing crusted scabies, a highly infectious variant in which the presence of thousands or millions of mites (as opposed to the 10 to 15 typically harbored by immunocompetent hosts) produces extensive thick hyperkeratotic plaques with gray-brown scale, involving atypical locations such as the scalp, beard area, palms, and soles. The plaques may be nonpruritic or minimally pruritic.[86,87] For crusted scabies, multiple doses of ivermectin (200 μg/kg weekly for up to 7 weeks) may be and should be combined with a topical scabicide and a keratolytic cream to improve penetration.[88]

Atypical Leishmaniasis: Chapter 176 discusses leishmaniasis in greater detail.

HIV and *Leishmania* species are both intracellular pathogens in many of the same myeloid cells, including macrophages and dendritic cells. In coinfected patients, the 2 pathogens interact in complex and often symbiotic ways, substantially altering the course of both diseases.[89] Among the many pathophysiologic mechanisms, the HIV-induced shift in cytokines toward a TH2-dominant milieu impairs the TH1 response critical to controlling leishmaniasis. In turn, the *Leishmania*-induced activation of immune cells creates an abundance of target cells for HIV infection.[89] The result in coinfected patients is a more rapid progression to AIDS, higher HIV viral loads, and increased infectivity.[89,90] These patients also suffer more severe and persistent *Leishmania* infections; atypical and disseminated forms of cutaneous and mucocutaneous leishmaniasis are common, with widespread ulcers that are highly refractory to therapy.[89,91,92] Visceral leishmaniasis is of particular concern in HIV-infected patients, who are at 100 to 2320 times the risk of this often deadly variant.[90]

INFECTIONS IN WELL-CONTROLLED HIV

With access and adherence to ART, most patients can avoid or recover from the profound immunosuppressed state of advanced AIDS. These patients with chronic, stable, well-controlled HIV disease are, of course, susceptible to all typical infections that can affect any seronegative individual. In addition, certain infections remain more prevalent among these patients relative to the seronegative population, despite undetectable viral loads and normal CD4 counts. As patients live with stable HIV disease for decades, these conditions account for an increasing proportion of the care HIV patients receive from dermatologists.

Staphylococcal Infections: Chapters 150 to 152 discuss staphylococcal infections in greater detail.

HIV-infected individuals tend to present with the same wide range of primary *Staphylococcus aureus* skin and soft-tissue infections that are normally seen in seronegative individuals, as well as secondary *S. aureus* infection of molluscum, herpetic ulcers, atopic dermatitis, and other primary dermatoses. Despite normal CD4+ T-cell counts, even patients with well-controlled HIV remain at elevated risk for a number of clinically relevant *S. aureus*–related mucocutaneous complications.

At all stages of HIV, the prevalence of *S. aureus* nasal carriage exceeds that of the general population, with estimates as high as 30% to 50% colonization of HIV-infected individuals.[93,94] Colonization with methicillin-resistant *S. aureus* (MRSA) specifically is approximately 3 times more prevalent among even well-controlled HIV patients than among seronegative patients (16.8% vs 5.8% in a large, prospective, cohort study from 2009).[95] The relative risk of actual infection with community-associated MRSA among HIV patients is even higher, 6 times that of HIV-negative controls in a large 2010 population analysis.[96] Of those HIV patients who develop MRSA skin or soft-tissue infections, recurrences are extremely common, with estimates as high as 50% over the 9 months following the initial infection, and 71% over a 3-year period.[97]

Management of staphylococcal infections should be directed at treatment the acute infection, and treatment of any underlying dermatoses. Well-controlled HIV is not an indication for systemic antibiotics for pyodermas that could otherwise be treated adequately with local therapy, such as incision and drainage for most abscesses, or topical antibiotics for impetigo. The role of eradication of *S. aureus* nasal carriage, more extensive decolonization regimens, and chronic oral prophylaxis for recurrent *S. aureus* infections all remain controversial.

Herpes Simplex Viruses 1 and 2 Infections: Chapter 164 discusses herpes simplex in greater detail.

In advanced HIV disease, primary and recurrent herpes simplex virus (HSV) 1 and HSV-2 infections are often more severe, longer lasting and refractory to therapy, and recurrences are more frequent than in immunocompetent patients. A chronic herpetic ulcer lasting more than 1 month is a marker of profound immunosuppression and has been designated an AIDS-defining condition.[98] However, one uncommon form of chronic HSV, called *verrucous HSV* or *herpes vegetans*, occurs in patients with advanced AIDS and in patients with well-controlled HIV. In this variant, thick, proliferative, vegetative plaques and nodules may persist for months or years (Fig. 168-8). Most reported cases are resistant to thymidine kinase–dependent antivirals such as acyclovir and valacyclovir.[99] High doses of thymidine kinase–dependent antivirals can sometimes overcome this resistance mechanism, but when that fails, thymidine kinase–independent options include topical imiquimod, IV foscarnet, and cidofovir in topical, intralesional, or IV form.[100-102]

Figure 168-8 Herpes vegetans in well-controlled HIV. The verrucous weeping plaques and nodules had been present for longer than 5 years, despite continual adherence to antiretroviral therapy and a CD4+ T-cell count higher than 600 cells/μL.

The synergy between HSV and HIV also critically impacts the pathogenicity of HIV infection. HSV-2 imparts a twofold to threefold increased risk of HIV acquisition, which in areas of high HSV-2 prevalence might be responsible for up to 25% of HIV infections.[103] The pathophysiology of this increased HIV risk goes well beyond enhanced HIV entry through epithelium disrupted by HSV ulcers; local HSV-2 viral shedding occurs more frequently than recurrences of actual ulcers, and the resultant near continual subclinical inflammation increases the number of target cells for HIV to infect, even with the use of low-dose prophylactic acyclovir or valacyclovir. In people who are already coinfected, HSV-2 enhances HIV viral replication, thereby increasing HIV plasma viral load and HIV shedding in genital mucosa, further increasing the transmissibility of HIV.[103]

Varicella Zoster Virus Infection: Chapter 165 discusses varicella-zoster virus in greater detail.

In advanced HIV disease, atypical presentations of varicella-zoster virus reactivation are common, including recurrent dermatomal herpes zoster (HZ), disseminated HZ, and chronic HZ.[104,105] Individual

lesions may exhibit unusual morphology, such as ecthymatous ulcers, hyperkeratotic papules, or vegetative plaques.[106,107] Complications such as postherpetic neuralgia are common, despite the younger age of most HIV patients who develop HZ.[108,109]

The risk of HZ correlates inversely with CD4+ T-cell counts, except during the 6-month period after ART initiation, when the risk of HZ is actually highest, possibly because of IRIS.[110-112] At least for treated HIV patients younger than 65 years old, the risk of HZ never decreases to the level of the age-matched general population, even long after CD4+ T-cell count recovery. The risk is higher among those who ever experienced a low CD4+ T-cell count nadir.[110]

The HZ live vaccine can be safely administered to HIV patients who are not severely or moderately immunosuppressed.[113,114] Prophylactic oral acyclovir (400 mg twice daily) can also reduce the HZ risk in HIV patients—by 62% in one randomized controlled trial.[115] Acyclovir resistance has been reported but appears to be rare.[116,117] AIDS patients who develop dermatomal HZ or mild primary varicella may be treated with oral valacyclovir or famciclovir, but any evidence of disseminated disease, visceral involvement, or other severe complications should prompt initiation of IV acyclovir 10 mg/kg 3 times daily.

Human Papillomavirus Infections: Chapter 167 discusses HPV infections in greater detail.

While the introduction of effective ART has reduced the incidence of AIDS-defining malignancies including HPV-induced cervical cancer (see section "Human Papillomavirus–induced Dysplasia and Squamous Cell Carcinoma"), the incidence and burden of HPV disease overall may actually be increasing with the improving life expectancy of HIV patients.[118-121] HPV infections are far more prevalent in HIV-infected individuals than in the general population,[122,123] in part because both can be sexually transmitted, but also because HIV at all stages is associated with more-extensive and more-severe HPV lesions, lower clearance rates, and slower response to therapy.[124]

HIV patients are also at high risk for simultaneous infection with multiple HPV types, including high-risk oncogenic types, and the malignancies they cause may clinically resemble benign HPV lesions.[124,125] Even in the absence of malignancy, extensive and refractory warts can substantially impact the lives of patients with otherwise well-controlled HIV disease. The adverse medical and social impact is perhaps most pronounced from oral and anogenital condyloma, typically caused by HPV-6 and HPV-11. Oral florid papillomatosis and anogenital giant condyloma of Buschke and Lowenstein can be locally destructive and deforming, and are considered by some to be variants of verrucous carcinoma.

Cases of verruca and condyloma resolution with ART alone have been reported,[126,127] but many patients require therapy specifically targeting their warts. Immune-mediated treatments, such as imiquimod[128-133] and intralesional candida antigen,[134] appear to be safe and potentially effective in HIV patients.

Figure 168-9 Acquired epidermodysplasia verruciformis in a child with congenital HIV disease.

Other therapies with reported success for refractory warts include topical podophyllotoxin,[135] intralesional cidofovir,[136-138] intralesional bleomycin,[139] intralesional and systemic interferon,[140,141] CO_2 laser,[142] and photodynamic therapy,[142] potentially in combinations.

Another form of extensive HPV disease, acquired epidermodysplasia verruciformis, has been described in children with congenital HIV, and also reported in adults with well-controlled HIV. As in hereditary epidermodysplasia verruciformis, children with the acquired form develop extensive, thin, flat-topped papules resembling verruca plana or tinea versicolor from unusual susceptibility to the beta subtypes of HPV, including types HPV-5, HPV-8, and HPV-9 (Fig. 168-9).[143] Treatment of this stigmatizing disease is challenging; mixed success has been reported with topical cidofovir, topical imiquimod, oral retinoids, and interferon-α in combination with ribavirin.[144-147]

Syphilis: Chapter 170 discusses syphilis in greater detail.

Given that the vast majority of HIV infections are sexually transmitted, individuals with HIV infection should also be screened for other sexually transmitted diseases such as chlamydia, gonorrhea, and genital ulcerative diseases, including syphilis and chancroid.

Syphilis is a particularly important disease to consider in HIV-infected patients, because asymptomatic coinfections are curable if caught early and are more morbid than in seronegative patients if not adequately treated. Syphilis patients with HIV are at higher risk for multiple primary chancres, longer-lasting chancres, more-severe manifestations of secondary syphilis such as lues maligna and condyloma lata,[148] and early progression to neurosyphilis[149,150]; this heightened risk of neurosyphilis should prompt consideration of a lumbar puncture for any new diagnosis of syphilis in a patient with advanced HIV disease, or in a patient with well-controlled HIV disease who has syphilis of unknown stage, or a rapid plasma reagin titer of at least 1:32.[150]

HIV coinfection increases the risk of treatment failure from a single dose of intramuscular penicillin for primary and secondary syphilis, but treatment guidelines are the same for HIV seronegative and seropositive patients as alternative treatment regimens have

not been found to be more effective.[151] Adverse reactions to syphilis therapy, including drug eruptions and the Jarisch-Herxheimer reaction, are more common in HIV patients.[150]

Further complicating matters, testing for syphilis is less reliable in HIV patients. HIV patients with secondary syphilis may have falsely negative nontreponemal antibody (ie, rapid plasma reagin and Venereal Disease Research Laboratory) titers either from delayed antibody formation, or from the prozone phenomenon, in which HIV-related immune dysregulation causes massively elevated titers, high enough impair the assay.[152,153]

As in many other coinfections, the clinical impact of HIV and syphilis coinfection is bidirectional; just as HIV alters the course of syphilis infection, syphilis also appears to adversely impact HIV disease progression and transmissibility, and is associated with decreased CD4+ T-cell counts and increased HIV viral loads.[154]

CUTANEOUS MALIGNANCY IN HIV

AT-A-GLANCE

- Kaposi sarcoma remains one of the most common HIV-associated malignancies worldwide, even with reduction in incidence because of ART. Recently, a novel group of HIV-infected patients has been identified that develop new-onset Kaposi sarcoma while already virologically suppressed on ART.
- HPV-induced dysplasia and squamous cell carcinoma are more common in HIV-infected men and women than in the general population, with a high burden in men who have sex with men. Screening for anal and cervical dysplasia is particularly important for HIV-positive patients.
- Cutaneous lymphomas and other nonkeratinocyte cancers are also more prevalent in HIV-positive patients. Primary cutaneous lymphomas in HIV patients tend to be aggressive rather than indolent, with survival often less than 1 year.

KAPOSI SARCOMA

Kaposi sarcoma (KS) is vascular and lymphatic neoplasm caused by human herpesvirus-8. There are several subtypes of KS, including AIDS-related KS, classic/Mediterranean KS, endemic African KS, and transplant-associated KS. AIDS-related KS is an AIDS-defining malignancy. At the beginning of the HIV epidemic, KS was one of the first opportunistic sequela noted in what would later be defined as AIDS[155] and was a frequent presenting sign of HIV/AIDS.

Even though incidence of HIV-related KS in the United States and Europe has decreased with the advent of ART,[156-158] KS remains one of the most common HIV-associated cancers in sub-Saharan Africa, with an incidence among HIV-infected persons of 164 to 334 per 100,000 person-years.[159,160] This incidence is on par with the incidence of prostate cancer in the United States.[156,161]

Despite the successes of ART, ART is not tantamount to cure and not all ART-adherent patients have their health fully restored. In addition to KS that does not respond completely to ART, we are now faced with a new group of patients who develop KS for the first time while on ART, separate from unmasking IRIS. Dermatologists were at the forefront of identifying that a novel group of HIV-infected patients on ART with no prior KS were developing new-onset cutaneous KS despite virologic supression.[162] ART decreases KS incidence,[156] but does not bring it down to zero, even with ART adherence. Understanding why new KS develops despite ART is an area of active investigation in several research sites in Africa.

Diagnosis: KS diagnosis is made based on clinical appearance and biopsy. Tissue confirmation is strongly recommended, even in resource-poor settings.[163] When routine histology is indeterminate, or to confirm histologic findings, anti–latency-associated nuclear antigen staining can be used to establish the presence of human herpesvirus-8.

Differential Diagnosis: Differential diagnosis for KS includes other vascular lesions, postinflammatory hyperpigmentation, and scar, among others.[163] Oval plaques could be mistaken for lichen planus, pityriasis rosea, syphilis, or psoriasis. Violaceous or vascular lesions can mimic lichen planus, psoriasis, lichen simplex chronicus, acroangiodermatitis, and stasis dermatitis. Of particular importance, bacillary angiomatosis can mimic KS (Fig. 168-10), and mistaking bacillary angiomatosis for KS, without performing a biopsy, could lead to unnecessary chemotherapy with poor outcome.[40]

Figure 168-10 Bacillary angiomatosis mimicking Kaposi sarcoma in a Kenyan patient. Note the subcutaneous nodule of bacillary angiomatosis on the nose. (Used with permission from Toby Maurer.)

Clinical Course, Prognosis, and Management: Survival following diagnosis of KS remains poor in the areas hardest hit, such as sub-Saharan Africa, even in the era of available ART.[164] This poor survival despite ART has been speculated to be, at least in part, a consequence of late presentation and delayed diagnosis of the disease in resource-poor settings. For example, newer studies have found that 69% to 86% of KS patients in Africa are diagnosed only at an advanced stage of the disease.[165,166] Dermatologists can have a role in early diagnosis both in identifying cutaneous lesions and in asking about potentially dangerous symptoms that could be suggestive of systemic involvement worthy of further workup, such as unexplained GI bleeding or a persistent cough in the absence of tuberculosis.

Treatment of HIV-related KS in mild to moderate cases consists of ART; in more-severe cases, chemotherapy is also required. The distinction of what constitutes "mild" versus "severe" KS requiring chemotherapy is an area of debate. The 2014 WHO guidelines (Table 168-4) go beyond the AIDS Clinical Trials Group staging[167] and incorporate functional status, such as difficulty swallowing or difficulty walking, into the criteria for chemotherapy.[168]

In addition to ART and possibly systemic chemotherapy, local therapies such as radiation,[169] direct injections of chemotherapy agents such as bleomycin, vincristine, and vinblastine,[170-172] and topicals such as imiquimod[173] and alitretinoin gel[174] can be useful adjuvants for lesion control, localized edema, and cosmesis.

TABLE 168-4

HIV-Associated Kaposi Sarcoma Treatment According to World Health Organization Guidelines

MILD/MODERATE KS DISEASE	SEVERE/SYMPTOMATIC KS DISEASE
Immediate ART initiation is recommended	Immediate ART initiation in combination with systemic chemotherapy
WHO definition of mild/moderate:	WHO definition of severe:
▪ Confined to skin and/or lymph nodes ▪ No symptomatic visceral disease ▪ No significant oral disease (ie, does not interfere with chewing or swallowing) ▪ No significant edema affecting function ▪ Not functionally disabling or immediately life-threatening	▪ Symptomatic visceral disease (pulmonary or GI) ▪ Extensive oral KS lesions which interfere with chewing or swallowing ▪ Painful or disabling tumor-associated facial/genital/peripheral edema or ulcerated tumors ▪ Life-threatening or functionally disabling disease ▪ Progressive or persistent disease despite ART

ART, antiretroviral therapy; KS, Kaposi sarcoma; WHO, World Health Organization.

HUMAN PAPILLOMAVIRUS–INDUCED DYSPLASIA AND SQUAMOUS CELL CARCINOMA

Anal HPV infection is more prevalent in HIV-infected men and women than in the general population. In men who have sex with men (MSM), anal HPV infection is present in 40% to 60% of HIV-negative individuals, but in up to 94% of HIV-positive MSM.[175-178] Similarly, in HIV-negative women, HPV DNA can be detected anally in 42%, but in as many as 76% of HIV-positive women.[179] The relative risk of HPV-related invasive anal cancer is also much higher in HIV patients, with an age-, sex-, and race-standardized relative risk of invasive anal cancer in HIV-infected men compared to HIV-uninfected men of 37.9, and in HIV-infected women compared to uninfected women of 6.8.[180] In addition to higher levels of anal cancer in HIV-infected women, invasive cervical cancer is also increased in HIV infection, with a relative risk of 5.8.[180]

Clinical Features: The presence of anal or genital condyloma is suggestive of HPV infection, and warrants further screening for invasive disease. Perianal squamous cell carcinoma in situ (also known as Bowen disease) or invasive squamous cell carcinoma can present as pruritus, mass, bleeding, or pain.

Prevention, Screening, and Diagnosis: The quadrivalent or nonavalent HPV vaccine is recommended for all HIV-positive females 9 to 26 years of age and all males 9 to 21 years of age. Males 22 to 26 years of age should also be vaccinated if not vaccinated at younger ages.[181] Vaccination does not replace screening.

Screening for anal and cervical dysplasia is particularly important for HIV-positive patients. For anal dysplasia and cancer, at baseline and followup visits, both men and women should be asked about anal symptoms such as itching, bleeding, diarrhea, and pain. Dermatologists can also assist by performing a visual inspection of the perianal region.[182] There are no universally accepted guidelines on anal Papanicolaou tests for HIV patients. New York State Department of Health AIDS Institute recommends that anal cytology be obtained at baseline and annually in all HIV-positive MSM, any HIV patient with a history of anogenital condyloma/warts (men and women), and HIV-positive women with abnormal cervical and/or vulvar histology.[182] The Infectious Disease Society of America guidelines for HIV patients are similar, adding that women with a history of receptive anal intercourse should also be screened.[181] However, there also have been arguments for a more inclusive screening policy, that all HIV-positive patients, men and women, should receive cytologic screening starting at age 30 years.[183]

Clinical Course, Prognosis, and Management: HIV-positive patients with anal cancer treated with chemotherapy and radiation appear to have similar rates of tumor response and local control to HIV-negative counterparts.[184-186] However, overall survival

of HIV patients after a diagnosis of anal cancer is lower than in the general population with anal cancer, possibly because of coinfections and morbidities.[184,187]

CUTANEOUS LYMPHOMAS IN HIV

Epidemiology: In the ART era, the risk of lymphoma in HIV patients is at least 11 to 15 times that of the general population[23,188]; pre-ART it may have been as high as 352-fold.[189] Incidence of HIV-associated lymphomas is generally correlated with the degree of immunosuppression, however, with increasingly widespread and early initiation of ART, the incidence of non-Hodgkin lymphoma is declining and is increasingly noted at higher CD4+ counts.[190]

Cutaneous lymphomas, in particular, differ in their epidemiology in HIV-infected individuals as compared to uninfected individuals.[189,191,192] Infected individuals are at increased risk of developing CD30+ anaplastic large-cell lymphoma, diffuse B-cell lymphoma, and plasmablastic lymphoma, a malignancy that is virtually unseen outside of AIDS. Mycosis fungoides, however, has a similar presentation, clinical course, and management paradigm to that for uninfected individuals.[193]

Clinical Features: Cutaneous manifestations can vary widely. Primary cutaneous lymphomas have been described as singular nodules or tumors that can have ulceration.[38,189] Plasmablastic lymphomas may present in the oral mucosa.[194]

Diagnosis and Differential Diagnosis: Skin biopsy with histologic examination and immunohistochemical staining are the mainstays of diagnosis of cutaneous lesions suspicious for malignancy in the HIV patient.[189,195] Diagnosis on clinical grounds alone is difficult because of the diversity of presentations. In the clinical context of HIV, primary cutaneous lymphoma may be especially difficult to differentiate from systemic lymphoma because of the presence of systemic symptoms such as lymphadenopathy.[195] However, this distinction is of interest because of the differences in prognosis, clinical course, and management between primary cutaneous and systemic lymphoma.

Clinical Course, Prognosis, and Management: In HIV-negative individuals, primary cutaneous lymphomas typically have a more indolent course and better prognosis when compared to systemic lymphomas. In contrast, primary cutaneous lymphomas in HIV patients tend to be aggressive, with survival often less than 1 year.[189,192,194,195] Patients often die because of complications of immunosuppression, such as sepsis, rather than the lymphoma itself, although metastasis has been noted, especially with CD30+ anaplastic large-cell lymphoma.[189,192,196]

No guidelines exist for management of cutaneous lymphomas and other nonkeratinocytic malignancies in the setting of HIV. If amenable, lesions of some subtypes may be managed with excision and local radiotherapy.[38,195] Because of the high risk of sepsis and complications of immunosuppression, the literature suggests that chemotherapy is used best when in combination with ART and adequate HIV control. This is true in both resource-abundant as well as resource-poor settings.[196,197] Cyclophosphamide, hydroxydaunorubicin, vincristine, and prednisone (CHOP), and Adriamycin and vincristine monotherapy have been tried.[194] Reports of spontaneous clearance of lymphoma following HIV control exist.[195]

OTHER NONKERATINOCYTE CANCERS

HIV predisposes patients to other nonkeratinocytic cutaneous cancers as well. Merkel cell carcinoma and appendageal carcinoma have an increased incidence in this population.[198] Melanoma incidence is also slightly increased in HIV, with a recent metaanalysis showing a relative risk of 1.50 (95% confidence interval, 1.12 to 2.01) among studies in the ART era that accounted for ethnicity.[199] In pediatric patients, smooth muscle tumors are the second most common malignancy in patients with HIV and cutaneous variants have been observed.[38]

CUTANEOUS AND MUCOCUTANEOUS INFLAMMATORY CONDITIONS IN HIV

AT-A-GLANCE

- Plaque psoriasis is the most common variant of psoriasis in HIV patients, but unusual presentations of psoriasis should prompt HIV testing.
- Seborrheic dermatitis can be severe and extensive in HIV patients, with prevalence and severity increasing with worsening immunosuppression. Prolonged treatment may be required.
- Papular pruritic eruption (PPE) is characterized by pruritic, symmetric papules of the distal extremities, and is more commonly found in tropical and subtropical zones. Eosinophilic folliculitis (EF), in contrast, favors the midline. The mainstay of therapy for both PPE and EF is antiretroviral therapy.

PSORIASIS

While there has been debate regarding whether HIV infection may increase or decrease the prevalence of psoriasis, a recent large study of U.S. data found

no association.[200,201] Plaque psoriasis is still the most prevalent variant in HIV-associated psoriasis in U.S. studies, but the presence of rupioid psoriasis, sebopsoriasis, reactive arthritis with keratoderma blenorrhagica with palmoplantar manifestations, acute onset of severe psoriasis, severe exacerbation of existing psoriasis, or psoriasis with multiple morphologies in a single patient should raise concern for concomitant HIV infection.[200,202-204] Erythroderma has been reported as the most prevalent variant in small studies of the sub-Saharan African population.[205]

Although typical psoriasis presentations are diagnosed clinically, biopsy plays a greater role in diagnosing HIV-associated psoriasis because of the higher proportion of severe or atypical presentations, and because HIV confers a higher risk of clinical mimickers, such as lymphoma, tinea, and secondary syphilis.[200,206] In the pediatric population, HIV-associated psoriasis has been noted in infancy and may mimic, or complicate, a diaper rash.[207]

The pathogenesis of psoriasis in HIV infection is poorly understood, and generates several apparent paradoxes. Psoriasis is a disease of T-cell–mediated inflammation, and yet HIV, which destroys T cells, has been noted to worsen it.[208] Psoriasis sometimes emerges late in the course of HIV disease, when the patient is severely immunosuppressed,[200,203] although it also has been noted to regress before death in severe AIDS.[200,209]

As in HIV-negative patients, treatment of HIV-associated psoriasis depends on severity of disease and degree of skin involvement.[200,210] Guidelines for treatment are based on case series, reports, and small reviews. Topical therapies, including emollients, vitamin D analogs, and corticosteroids are recommended for mild disease, although as mentioned earlier, high-potency topical steroid use requires caution in the setting of ART regimens that include ritonavir or cobicistat. Phototherapy may be used for moderate-to-severe disease, after carefully weighing its benefits against the HIV-related increased risks of photosensitive eruptions and of skin cancer.[198-200] Acitretin may be used alone as a second-line therapy for moderate-to-severe disease or in combination with phototherapy.[200,210]

Given that psoriasis can be exacerbated by severity of concomitant HIV infection, ART is also first-line therapy for moderate-to-severe disease, and may be used as monotherapy.[210] Care must be taken to watch for severe exacerbations in the setting of IRIS.[211]

Refractory cases of psoriasis may respond to methotrexate, cyclosporine (especially when needing rapid response), and hydroxyurea. Tumor necrosis factor-α inhibitors, which are often a mainstay of treatment in HIV-negative patients, need to be approached very cautiously in HIV-positive patients.[200,210,212] Treatment with these agents may be complicated by worsening immunosuppression. In addition, HIV patients on biologic therapy are at higher risk for progressive multifocal leukoencephalopathy caused by reactivation of the John Cunningham (JC) virus.[213]

SEBORRHEIC DERMATITIS

In the general population, the prevalence of seborrheic dermatitis hovers around 3% to 5%. In HIV, the prevalence of seborrheic dermatitis can be as high as 83%, and both the prevalence and severity tend to increase with worsening immunosuppression.[214,215]

A case series of 20 HIV patients with seborrheic dermatitis from the United States, Botswana, and South Africa demonstrated that seborrheic dermatitis can be severe and extensive in HIV patients. The case series described extensive involvement of the scalp (Fig. 168-11), axillae, groin, and flexural extremities, with frequent bacterial superinfection, and with markedly thick and greasy yellow scaling of the scalp. Patients also exhibited extension beyond the typical seborrheic distribution, sometimes progressing to erythroderma.[216]

HIV patients are often refractory to standard seborrheic dermatitis treatments, and they experience frequent treatment failure and recurrence.[216,217] ART itself may improve seborrheic dermatitis, or may help its response to other treatments.[216,218,219] The mainstays of treatment are topical and systemic antifungals, topical or oral corticosteroids, and oral antibiotics when needed to address bacterial superinfection.[216] Ketoconazole may have more activity against *Malassezia furfur*, thought to be an underlying pathogen in seborrheic dermatitis, over other azoles such as fluconazole and itraconazole, although this has

Figure 168-11 Seborrheic dermatitis in HIV with extensive scalp involvement. This patient from Kenya was compliant with her antiretroviral therapy and had already failed topical antifungals.

primarily been demonstrated in the laboratory rather than in human studies.[220,221] The current WHO guidelines recommend topical ketoconazole as first-line therapy, with the addition of topical corticosteroids in severe or unresponsive cases.[168] Prolonged treatment courses are often required.

PAPULAR PRURITIC ERUPTION

Papular pruritic eruption (PPE) is a common HIV-associated skin condition, particularly in tropical and subtropical regions. Prevalence may be as high as 46% in adults and 42% in children, depending on geography.[222-228] PPE is characterized by pruritic, symmetric papules. The eruption favors the distal extremities (Fig. 168-12), but can also appear on the face and trunk. It generally spares the palms, soles, and mucous membranes.[168] Scabies, eosinophilic folliculitis, papulonecrotic tuberculid, and drug eruptions should be considered in the differential diagnosis of PPE.

The pathophysiology is poorly understood, but is proposed to be a hypersensitivity and/or recall reaction to arthropod assault in the setting of HIV.[229] Patients with PPE have significantly lower CD4+ T-cell counts than patients without PPE.[230] Independent of the CD4+ T-cell count, the development of PPE is also associated with greater HIV viral loads at ART commencement.[231]

PPE resolves with ART,[232] which is considered the mainstay of treatment. Initial worsening after ART initiation may occur as part of IRIS; one study found exacerbation of the dermatitis in 13% of patients after starting ART.[232] For symptomatic control, the current WHO recommendations include oral antihistamines and topical corticosteroids.[168] Other therapies that have been tried with some success include pentoxifylline[233,234] and oral promethazine.[235] Given the concern that PPE may represent a reaction to arthropod assault, mosquito repellant and other protective measures also have been suggested.[230]

Figure 168-12 Papular pruritic eruption in HIV. The eruption favors the distal extremities. (Used with permission from Serling Chua.)

EOSINOPHILIC FOLLICULITIS

Eosinophilic folliculitis (EF) comes in several forms, including HIV-associated, infancy-associated, and classic. With regard to HIV-associated EF specifically, prevalence varies widely in different studies from the United States and Asia, ranging from 4% to 19%.[236,237] Low CD4+ T-cell count and advanced immunosuppression are associated with the development of EF.[168,238]

EF is characterized by follicular pruritic papules and pustules, favoring the midline, of the face, neck, scalp, trunk, and proximal extremities (Fig. 168-13). This distribution stands in contrast to PPE, which favors the distal extremities, although the 2 entities can appear clinically similar. Both the distribution and morphology of EF lesions mimic those of acne; although sometimes challenging to distinguish, pruritus and sudden emergence at low CD4+ T-cell counts or after commencing ART are suggestive of EF over acne.

Similar to PPE, the mainstay of treatment is ART. Patients who develop EF IRIS should continue to be treated with ART.[168] Other therapeutic options include oral itraconazole,[239] oral isotretinoin,[240] and phototherapy.[241] Current WHO recommendations suggest, in addition to evaluating the patient for ART, (a) starting an oral antihistamine, followed by additional symptomatic control with (b) topical steroids, (c) oral itraconazole, and, finally, if no response to the above, trying (d) permethrin 5% applied above the waist.[168]

Figure 168-13 HIV-associated eosinophilic folliculitis, favoring the face. The eruption can appear acne-like, but is severely pruritic. (Used with permission from Toby Maurer.)

IMMUNE RECONSTITUTION INFLAMMATORY SYNDROME

AT-A-GLANCE

- Previously tolerated antigens may lead to robust inflammatory reactions in the setting of immune reconstitution following treatment with antiretroviral therapy (ART).
- Both inflammatory conditions and infections can flare in this setting.
- High viral load and low CD4 counts at the time of initiation of ART are risk factors.
- Most reactions eventually subside so treatment may range from supportive care to oral steroids in significant reactions; life-threatening reactions may require ART interruption.

As immune function is restored in HIV, previously unrecognized or tolerated antigens may lead to strong stimulation of the immune response. Commonly referred to as IRIS, this reaction has been reported in up to 20% of patients receiving ART and usually occurs in the first 2 to 3 months following the initiation of ART.[242] When a clinically unrecognized disease is noted after the initiation of ART, the term *unmasking IRIS* is used. In turn, when a previously recognized clinical entity flares, the term *paradoxical IRIS* applies.

CLINICAL FEATURES

Inflammatory disorders such as EF, adverse cutaneous drug reactions, sarcoid, connective tissue disorders, AIDS-related lymphoma, non-Hodgkin lymphoma, and neurologic disease may flare in the setting of IRIS. Other systemic symptoms may include fever and lymphadenopathy. Minor cognitive disorders are not uncommon. Infectious agents previously tolerated also can be increasingly recognized by the immune response. Mycobacteria (both tuberculous and nontuberculous), HSV, varicella zoster virus, *Cryptococcus*, hepatitides B and C viruses, molluscum virus, the progressive multifocal leukoencephalopathy (progressive multifocal leukoencephalopathy) virus, and cytomegalovirus are common agents known to "flare" in the setting of IRIS.[243]

ETIOLOGY AND PATHOGENESIS

The pathogenesis of IRIS is multifactorial and immunologic mechanisms suggest that 2 main factors are related to the likelihood of disease: (a) lower CD4+ count and/or percentage and (b) higher HIV RNA, prior to initiation of ART. Younger patients and male patients are disproportionately affected. Other risk factors include shorter interval between initiating treatment of an opportunistic infection and starting ART, and rapidly falling viral load.

TABLE 168-5
Immune Reconstitution Inflammatory Syndrome

Major Criteria
1. Atypical presentation of opportunistic infections or tumors in patients responding to antiretroviral therapy (ART).
2. Decrease in plasma HIV RNA level by at least 1 $\log^{10}$ copies/mL.

Minor Criteria
1. Increased blood CD4+ T-cell count after ART.
2. Increase in immune response specific to the relevant pathogen.
3. Spontaneous resolution of disease without specific antimicrobial therapy or tumor chemotherapy with continuation of ART.

DIAGNOSIS

IRIS is diagnosed clinically. Serologic tests, skin biopsy and radiographic studies may be helpful in uncovering culprits, but these do not diagnose IRIS. Case definition relies on a previous diagnosis of AIDS with low pretreatment count, a positive virology and immunologic response to ART, and a temporal association between the initiation of ART and disease development. In the case of unmasking IRIS, there must be solid reason to believe that the pathogen or antigen was present before it became manifest and before ART initiation. Table 168-5 reviews one published set of diagnostic criteria. This syndrome must be differentiated from patient nonadherence to ART (and progression of HIV), antimicrobial resistance, and tachyphylaxis.

CLINICAL COURSE, PROGNOSIS, AND MANAGEMENT

Most IRIS reactions are self-limited. Clinically significant dermatologic reactions that may lead to patient nonadherence may be treated with prednisone up to 1 mg/kg, rapidly tapered. One notable exception is KS, where systemic corticosteroids may lead to worse outcomes. Infectious agents are treated based on the extent of involvement and systemic disease (WHO guidelines for dermatologic disease). Rarely, the syndrome may be fatal if central neurologic structures are affected. Perhaps the most important aspect of treatment entails continuation of ART and educating the patient to understand that as the immune system recovers, most of these reactions improve. Notably, molluscum, PPE, and EF in the setting of IRIS are best treated in this fashion. Some physicians advocate for "slowing down" immune recovery in an effort to lessen the acute inflammatory responses, and to stop it only if life-threatening to the patient.[244] The AIDSinfo website (https://aidsinfo.nih.gov/guidelines/search/4/IRIS/0) has up-to-date information on each entity that flares with IRIS.

MUCOCUTANEOUS MANIFESTATIONS OF THE HUMAN T-LYMPHOTROPHIC VIRUS

AT-A-GLANCE

- Human T-cell lymphotropic virus (HTLV)-1 was the first retrovirus discovered.
- Seroprevalence is highest in Japan, the Caribbean, equatorial Africa, and South America.
- Because most infected hosts are asymptomatic carriers, screening protocols are necessary to prevent further transmission and disease development.
- Time from infection to development of disease can be up to 60 years.
- Transmission is mostly via breastfeeding, sexual intercourse, drug use and blood transfusion.
- Important dermatologic manifestations include infective dermatitis and cutaneous manifestations of acute T-cell leukemia/lymphoma.
- HTLV-1–associated diseases often respond poorly to treatment.

Human T-lymphotropic virus-1 (HTLV-1) was the first retrovirus discovered. Currently, more than 20 million people are thought to be infected worldwide, with highest prevalence in southern Japan (up to 37%), but it also has been reported in equatorial Africa, the Caribbean (prevalence of 5% in Jamaica), and in virtually every country in South America.[245] In Brazil, more than 2.5 million people are infected.[246] Although 3 more related viruses also have been reported in Central Africa (HTLV-2, HTLV-3, and HTLV-4), only HTLV-1 has been definitively linked to human disease.[247]

HTLV-1 is transmitted from mother-to-child with 20% efficiency, primarily through breastfeeding, although 5% of transmissions occur in the intrauterine or perinatal period. Transmission also has been documented via sexual intercourse (most commonly from male to female partner), blood transfusion, and IV drug use. More recently, transmission also has been documented after organ transplantation.[246] IV transmission is considered to be the most efficient route of infection. The period of seroconversion can be up to 65 days. Although infection with HTLV-1 is persistent in human CD4+ lymphocytes, more than 90% of hosts remain asymptomatic carriers. It is unclear how infected individuals develop disease.[247] The rate of coinfection with HIV among HTLV-1 patients is not clear but is estimated to be approximately 12.5%. Interestingly, HTLV-1 coinfected HIV patients have been observed to exhibit higher CD4+ T-cell counts than matched HTLV-1–negative patients infected by HIV, but have clinically more advanced HIV disease at any given CD4+ T-cell count.[248]

CLINICAL FEATURES

The most significant dermatologic manifestations of HTLV-1 infection include infective dermatitis and cutaneous adult T-cell leukemia (ATL). Other dermatologic conditions have been noted in asymptomatic carriers, particularly atopic dermatitis, seborrheic dermatitis, crusted scabies, dermatophytosis, and ichthyosis. These dermatologic diseases are considered important in the future development of systemic manifestations of HTLV-1.

Infective dermatitis is most common in tropical areas of high HTLV-1 seroprevalence such as Jamaica and Brazil, often among patients with high HTLV-1 viral loads.[246,249] The disease resembles seborrheic dermatitis and presents as recalcitrant, relapsing eczematous dermatitis, and blepharoconjunctivitis, usually in children and adolescents. The scalp and neck, as well as intertriginous areas, are particularly involved. Periorbital papules with seborrheic scale may be commonly seen near the eyebrows as well as retroauricular fissuring in a minority of patients (Fig. 168-14). Patients may also develop rhinorrhea, bacterial pustulosis, and a high nasal carrier rate of *Staphylococcus* and *Streptococcus* spp. The resulting exudative discharge is often foul smelling. Infective dermatitis is associated with a marked TH1 response, and can be severely pruritic.[246,249]

ATL develops in less than 5% of infected hosts, but in its acute form carries a poor prognosis. ATL can present in 4 systemic subtypes, some with cutaneous manifestations. The acute systemic fulminant type can present dermatologically as infiltration of skin by neoplastic cells, most commonly as papules and nodules. The chronic and smoldering subtypes are less common and show lesions similar to mycosis fungoides (Fig. 168-15). Lesions may be papulosquamous and nodular, but erythrodermic variants also have been described. The fourth subtype is a systemic lymphomatous presentation. HTLV-1 can also cause a progressive myeloneuropathy called HTLV-1–associated myelopathy/tropical spastic paraparesis. Whereas ATL has been associated with infection via breastfeeding, HTLV-1–associated myelopathy/tropical spastic paraparesis has been associated with transmission via blood transfusions.[247]

DIAGNOSIS

Infective dermatitis is usually diagnosed with serologic confirmation of HTLV-1 in at-risk patients with clinical manifestations of the disease, such as recalcitrant eczema in endemic zones. Histopathology is rarely necessary, and when obtained, it is nonspecific. ATL is diagnosed mostly by showing anti–HTLV-1 antibodies in patient's serum, initially with enzyme-linked immunosorbent assay testing, but Western blot is often used for confirmation. Proviral DNA insertion can be shown via polymerase chain reaction testing. The presence of ATL cells (flower cells), which in skin may be CD25+ or CD25−, is also helpful.

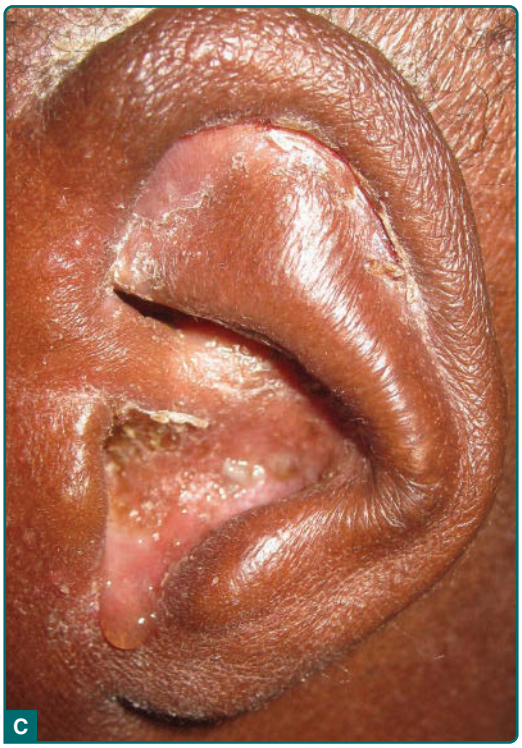

Figure 168-14 Infective dermatitis. **A,** Note atopic/seborrheic dermatitis-like eruption with notable areas of exudate and pyoderma, (**B**) blepharoconjunctivitis, and (**C**) retroauricular fissuring. (Images **A** and **B,** Used with permission from Dr. Anisa Mosam.)

Figure 168-15 Cutaneous adult T-cell leukemia/lymphoma, smoldering type. Note the mixture of disseminated papules, plaques, and violaceous nodules in this patient from Jamaica. (Used with permission from Dr. Thomas Kupper and Maryanne Tawa, NP.)

DIFFERENTIAL DIAGNOSIS

The most important considerations in infective dermatitis include seborrheic dermatitis, atopic dermatitis, folliculitis, contact dermatitis, ichthyosis, xerosis, and impetigo. Cutaneous ATL involvement is histopathologically differentiated from other forms of cutaneous T-cell lymphoma, psoriasis, nummular eczema, and, in rare instances, infiltrative disease such as sarcoid.

CLINICAL COURSE, PROGNOSIS, AND MANAGEMENT

Infective dermatitis is often treated with antibiotics. The disease is not curable and is chronically relapsing. Trimethoprim-sulfamethoxazole is the agent of choice and treats symptomatic staphylococcal infection and improves the eczematous dermatitis. In fact, it is often used as a diagnostic maneuver when the disease is in question. High-potency topical steroids and immunomodulators have been used for symptomatic control.

Prognosis of ATL is very poor, particularly in the acute form, where resistance to multiple chemotherapeutic agents is rapidly demonstrated. Symptomatic control of

cutaneous lesions in chronic and smoldering subtypes has been obtained with superpotent topical steroids, intralesional steroids and intralesional chemotherapy.

Because no vaccines are yet available for HTLV-1, screening programs are of paramount importance. In the case of HTLV-1 seropositivity, the use of cesarean section is recommended to prevent vertical transmission. Avoidance of breastfeeding and cross-feeding is also recommended, particularly if the serological status of the milk mother is unknown. Safe sexual intercourse methods are also recommended, as is counseling of IV drug users.[247]

REFERENCES

1. World Health Organization, 2016. Accessed August 29, 2016, at http://www.who.int/hiv/en/.
2. Centers for Disease Control and Prevention (CDC). HIV/AIDS: HIV Testing: Guidelines. http://www.cdc.gov/hiv/guidelines/testing.html
3. Campbell-Yesufu OT, Gandhi RT. Update on human immunodeficiency virus (HIV)-2 infection. *Clin Infect Dis.* 2010;52(6):780-787.
4. Fevrier M, Dorgham K, Rebollo A. CD4+ T cell depletion in human immunodeficiency (HIV) infection: role of apoptosis. *Viruses.* 2011;3(5):586-612.
5. Cohen MS, Shaw GM, McMichael AJ, et al. Acute HIV-1 infection. *N Engl J Med.* 2011;364:1943-1954.
6. Macneal RJ, Dinulos JG. Acute retroviral syndrome. *Dermatol Clin.* 2006;24:431-438, v.
7. Vanhems P, Dassa C, Lambert J, et al. Comprehensive classification of symptoms and signs reported among 218 patients with acute HIV-1 infection. *J Acquir Immune Defic Syndr.* 1999;21:99-106.
8. Quinn TC, Wawer MJ, Sewankambo N, et al. Viral load and heterosexual transmission of human immunodeficiency virus type 1. Rakai Project Study Group. *N Engl J Med.* 2000;342:921-929.
9. Hall HI, An Q, Tang T, et al. Prevalence of diagnosed and undiagnosed HIV infection—United States, 2008-2012. *MMWR Morb Mortal Wkly Rep.* 2015;64:657-662.
10. Kahn JO, Walker BD. Acute human immunodeficiency virus type 1 infection. *N Engl J Med.* 1998;339:33-39.
11. Rosenberg ES, Caliendo AM, Walker BD. Acute HIV infection among patients tested for mononucleosis. *N Engl J Med.* 1999;340:969.
12. Kahn JO, Walker BD. Acute human immunodeficiency virus type 1 infection. *N Engl J Med.* 1998;339(1):33-39.
13. Rosenberg ES, Caliendo AM, Walker BD. Acute HIV infection among patients tested for mononucleosis. *N Engl J Med.* 1999;340(12):969.
14. Centers for Disease Control and Prevention (CDC). About HIV/AIDS. http://www.cdc.gov/hiv/basics/whatishiv.html. Accessed August 29, 2016.
15. Eholie SP, Badje A, Kouame GM, et al. Antiretroviral treatment regardless of CD4 count: the universal answer to a contextual question. *AIDS Res Ther.* 2016;(13):27.
16. Roujeau JC, Stern RS. Severe adverse cutaneous reactions to drugs. *N Engl J Med.* 1994;331:1272-1285.
17. Smith KJ, Skelton HG, Yeager J, et al. Increased drug reactions in HIV-1-positive patients: a possible explanation based on patterns of immune dysregulation seen in HIV-1 disease. The Military Medical Consortium for the Advancement of Retroviral Research (MMCARR). *Clin Exp Dermatol.* 1997;22(3):118-123.
18. Levine D, Ananthakrishhnan S, Garg A. Iatrogenic Cushing syndrome after a single intramuscular corticosteroid injection and concomitant protease inhibitor therapy. *J Am Acad Dermatol.* 2011;65(4):877.
19. Tempark T, Phatarakijnirund V, Chatproedprai S, et al. Exogenous Cushing's syndrome due to topical corticosteroid application: case report and review literature. *Endocrine.* 2010;38:328-334.
20. Coopman SA, Johnson RA, Platt R, et al. Cutaneous disease and drug reactions in HIV infection. *N Engl J Med.* 1993;328(23):1670-1674.
21. Saiag P, Caumes E, Chosidow O, et al. Drug-induced toxic epidermal necrolysis (Lyell syndrome) in patients infected with the human immunodeficiency virus. *J Am Acad Dermatol.* 1992;26(4):567-574.
22. Miller J, Carr A, Emery S, et al. HIV lipodystrophy: prevalence, severity and correlates of risk in Australia. *HIV Med.* 2003;4(3):293-301.
23. Eliaszewicz M, Flahault A, Roujeau JC, et al. Prospective evaluation of risk factors of cutaneous drug reactions to sulfonamides in patients with AIDS. *J Am Acad Dermatol.* 2002;47(1):40-46.
24. Yang C, Mosam A, Mankahala A, et al. HIV Infection predisposes skin to toxic epidermal necrolysis via depletion of skin-directed CD4+ cells. *J Am Acad Dermatol.* 2014;70(6):1096-1102.
25. Garcia-Doval I, LeCleach L, Bocquet H, et al. Toxic epidermal necrolysis and Stevens-Johnson syndrome: does early withdrawal of causative drugs decrease the risk of death? *Arch Dermatol.* 2010;136(3):323-327.
26. Romagosa R, Kapoor S, Sanders J, et al. Inpatient adverse cutaneous drug eruptions and eosinophilia. *Arch Dermatol.* 2001;137(4):511-512.
27. Yoshizawa S, Yasuoka A, Kikuchi Y, et al. A 5-day course of oral desensitization to trimethoprim/sulfamethoxazole (T/S) in patients with human immunodeficiency virus type-1 infection who were previously intolerant to T/S. *Ann Allergy Asthma Immunol.* 2000;85(3):241-244.
28. Dodiuk-Gad RP, Olteanu C, Jeschke MG, et al. Treatment of toxic epidermal necrolysis in North America. *J Am Acad Dermatol.* 2015;73(5):876-877.
29. Carr A, Workman C, Smith DE, et al. Abacavir substitution for nucleoside analogs in patients with HIV lipoatrophy: a randomized trial. *JAMA.* 2002;288(2):207-215.
30. Tebas P, Zhang J, Yarasheski K, et al. Switching to a protease inhibitor-containing, nucleoside-sparing regimen (lopinavir/ritonavir plus efavirenz) increases limb fat but raises serum lipid levels: results of a prospective randomized trial (AIDS clinical trial group 5125s). *J Acquir Immune Defic Syndr.* 2007;45(2):193-200.
31. Silvers SL, Eviatar JA, Echavez MI, et al. Prospective, open-label, 18-month trial of calcium hydroxylapatite (Radiesse) for facial soft-tissue augmentation in patients with human immunodeficiency virus-associated lipoatrophy: one-year durability. *Plast Reconstr Surg.* 2006;118:34S-45S.
32. Hall LD, Eminger LA, Hesterman KS, et al. Epstein-Barr virus: dermatologic associations and implications: part I. Mucocutaneous manifestations of Epstein-Barr virus and nonmalignant disorders. *J Am Acad Dermatol.* 2015;72:1-19; quiz 19-20.
33. Lozada-Nur F, Costa C. Retrospective findings of the clinical benefits of podophyllum resin 25% sol on hairy leukoplakia. Clinical results in nine patients. *Oral Surg Oral Med Oral Pathol.* 1992;73:555-558.

34. Moura MD, Guimaraes TR, Fonseca LM, et al. A random clinical trial study to assess the efficiency of topical applications of podophyllin resin (25%) versus podophyllin resin (25%) together with acyclovir cream (5%) in the treatment of oral hairy leukoplakia. *Oral Surg Oral Med Oral Pathol Oral Radiol Endod.* 2007;103:64-71.
35. Bhandarkar SS, MacKelfresh J, Fried L, et al. Targeted therapy of oral hairy leukoplakia with gentian violet. *J Am Acad Dermatol.* 2008;58:711-712.
36. Goh BT, Lau RK. Treatment of AIDS-associated oral hairy leukoplakia with cryotherapy. *J Infect Dis.* 1994;5:60-62.
37. Eminger LA, Hall LD, Hesterman KS, et al. Epstein-Barr virus: dermatologic associations and implications: part II. Associated lymphoproliferative disorders and solid tumors. *J Am Acad Dermatol.* 2015;72:21-34; quiz 35-36.
38. Tetzlaff MT, Nosek C, Kovarik CL. Epstein-Barr virus-associated leiomyosarcoma with cutaneous involvement in an African child with human immunodeficiency virus: a case report and review of the literature. *J Cutan Pathol.* 2011;38:731-739.
39. Jung AC, Paauw DS. Diagnosing HIV-related disease: using the CD4 count as a guide. *J Gen Intern Med.* 1998;13:131-136.
40. Forrestel AK, Naujokas A, Martin JN, et al. Bacillary angiomatosis masquerading as Kaposi's sarcoma in East Africa. *J Int Assoc Provid AIDS Care*. 2015;14:21-25.
41. Schwartz RA, Nychay SG, Janniger CK, et al. Bacillary angiomatosis: presentation of six patients, some with unusual features. *Br J Dermatol.* 1997;136:60-65.
42. Plettenberg A, Lorenzen T, Burtsche BT, et al. Bacillary angiomatosis in HIV-infected patients—an epidemiological and clinical study. *Dermatology.* 2000;201:326-331.
43. Perkocha LA, Geaghan SM, Yen TS, et al. Clinical and pathological features of bacillary peliosis hepatis in association with human immunodeficiency virus infection. *N Engl J Med.* 1990;323:1581-1586.
44. Stevens DL, Bisno AL, Chambers HF, et al. Practice guidelines for the diagnosis and management of skin and soft tissue infections: 2014 update by the Infectious Diseases Society of America. *Clin Infect Dis.* 2014;59:e10-e52.
45. Chang CC, Crane M, Zhou J, et al. HIV and co-infections. *Immunol Rev.* 2013;254:114-142.
46. Santos JB, Figueiredo AR, Ferraz CE, et al. Cutaneous tuberculosis: epidemiologic, etiopathogenic and clinical aspects-part I. *An Bras Dermatol.* 2014;89:219-228.
47. Regnier S, Ouagari Z, Perez ZL, et al. Cutaneous miliary resistant tuberculosis in a patient infected with human immunodeficiency virus: case report and literature review. *Clin Exp Dermatol.* 2009;34:e690-e692.
48. High WA, Evans CC, Hoang MP. Cutaneous miliary tuberculosis in two patients with HIV infection. *J Am Acad Dermatol.* 2004;50:S110-S113.
49. Libraty DH, Byrd TF. Cutaneous miliary tuberculosis in the AIDS era: case report and review. *Clin Infect Dis.* 1996;23:706-710.
50. Endly DC, Ackerman LS. Disseminated cutaneous mycobacterium avium complex in a person with AIDS. *Dermatol Online J.* 2014;20:22616.
51. Pires CA, Juca Neto FO, de Albuquerque NC, et al. Leprosy reactions in patients coinfected with HIV: clinical aspects and outcomes in two comparative cohorts in the Amazon region, Brazil. *PLoS Negl Trop Dis.* 2015;9:e0003818.
52. Talhari C, Mira MT, Massone C, et al. Leprosy and HIV coinfection: a clinical, pathological, immunological, and therapeutic study of a cohort from a Brazilian referral center for infectious diseases. *J Infect Dis.* 2010;202:345-354.
53. Murakawa GJ, Kerschmann R, Berger T. Cutaneous *Cryptococcus* infection and AIDS. Report of 12 cases and review of the literature. *Arch Dermatol.* 1996; 132:545-548.
54. Nnoruka EN, Chukwuka JC, Anisuiba B. Correlation of mucocutaneous manifestations of HIV/AIDS infection with CD4 counts and disease progression. *Int J Dermatol.* 2007;46(suppl 2):14-18.
55. Warkentien T, Crum-Cianflone NF. An update on *Cryptococcus* among HIV-infected patients. *Int J STD AIDS.* 2010;21:679-684.
56. Supparatpinyo K, Khamwan C, Baosoung V, et al. Disseminated *Penicillium marneffei* infection in southeast Asia. *Lancet.* 1994;344:110-113.
57. Duong TA. Infection due to *Penicillium marneffei*, an emerging pathogen: review of 155 reported cases. *Clin Infect Dis.* 1996;23:125-130.
58. Angius AG, Viviani MA, Muratori S, et al. Disseminated histoplasmosis presenting with cutaneous lesions in a patient with acquired immunodeficiency syndrome. *J Eur Acad Dermatol Venereol.* 1998;10:182-185.
59. Laochumroonvorapong P, DiCostanzo DP, Wu H, et al. Disseminated histoplasmosis presenting as pyoderma gangrenosum-like lesions in a patient with acquired immunodeficiency syndrome. *Int J Dermatol.* 2001;40:518-521.
60. Ramos-e-Silva M, Lima CM, Schechtman RC, et al. Systemic mycoses in immunodepressed patients (AIDS). *Clin Dermatol.* 2012;30:616-627.
61. Crum-Cianflone N, Hullsiek KH, Satter E, et al. Cutaneous malignancies among HIV-infected persons. *Arch Intern Med.* 2009;169:1130-1138.
62. Larsson M, Nguyen LH, Wertheim HF, et al. Clinical characteristics and outcome of Penicillium marneffei infection among HIV-infected patients in northern Vietnam. *AIDS Res Ther.* 2012;9:24.
63. Antinori S. New insights into HIV/AIDS-associated cryptococcosis. *ISRN AIDS*. 2013;2013:471363.
64. Perfect JR, Dismukes WE, Dromer F, et al. Clinical practice guidelines for the management of cryptococcal disease:2010 update by the infectious diseases society of America. *Clin Infect Dis.* 2010;50:291-322.
65. Guarner J, Brandt ME. Histopathologic diagnosis of fungal infections in the 21st century. *Clin Microbiol Rev.* 2011;24:247-280.
66. Loulergue P, Bastides F, Baudouin V, et al. Literature review and case histories of *Histoplasma capsulatum* var. *duboisii* infections in HIV-infected patients. *Emerg Infect Dis.* 2007;13:1647-1652.
67. Supparatpinyo K, Perriens J, Nelson KE, et al. A controlled trial of itraconazole to prevent relapse of *Penicillium marneffei* infection in patients infected with the human immunodeficiency virus. *N Engl J Med.* 1998;339:1739-1743.
68. Laskaris G, Hadjivassiliou M, Stratigos J. Oral signs and symptoms in 160 Greek HIV-infected patients. *J Oral Pathol Med.* 1992;21:120-123.
69. Duerr A, Sierra MF, Feldman J, et al. Immune compromise and prevalence of *Candida* vulvovaginitis in human immunodeficiency virus-infected women. *Obstet Gynecol.* 1997;90:252-256.
70. Prose NS. HIV infection in children. *J Am Acad Dermatol.* 1990;22:1223-1231.

71. Gupta AK, Daigle D, Foley KA. The prevalence of culture-confirmed toenail onychomycosis in at-risk patient populations. *J Eur Acad Dermatol Venereol.* 2015;29:1039-1044.
72. Surjushe A, Kamath R, Oberai C, et al. A clinical and mycological study of onychomycosis in HIV infection. *Indian J Dermatol Venereol Leprol.* 2007;73:397-401.
73. Johnson RA. Dermatophyte infections in human immune deficiency virus (HIV) disease. *J Am Acad Dermatol.* 2000;43:S135-S142.
74. Moreno-Coutino G, Arenas R, Reyes-Teran G. Improvement in onychomycosis after initiation of combined antiretroviral therapy. *Int J Dermatol.* 2013;52: 311-313.
75. Aly R, Berger T. Common superficial fungal infections in patients with AIDS. *Clin Infect Dis.* 1996;22(suppl 2): S128-S132.
76. Di Silverio A, Brazzelli V, Brandozzi G, et al. Prevalence of dermatophytes and yeasts (*Candida* spp., *Malassezia furfur*) in HIV patients. A study of former drug addicts. *Mycopathologia.* 1991;114:103-107.
77. Koopman RJ, van Merrienboer FC, Vreden SG, et al. Molluscum contagiosum; a marker for advanced HIV infection. *Br J Dermatol.* 1992;126:528-529.
78. Hicks CB, Myers SA, Giner J. Resolution of intractable molluscum contagiosum in a human immunodeficiency virus-infected patient after institution of antiretroviral therapy with ritonavir. *Clin Infect Dis.* 1997;24:1023-1025.
79. Sen S, Bhaumik P. Resolution of giant molluscum contagiosum with antiretroviral therapy. *Indian J Dermatol Venereol Leprol.* 2008;74:267-268.
80. Drain PK, Mosam A, Gounder L, et al. Recurrent giant molluscum contagiosum immune reconstitution inflammatory syndrome (IRIS) after initiation of antiretroviral therapy in an HIV-infected man. *Int J STD AIDS.* 2014;25:235-238.
81. Strauss RM, Doyle EL, Mohsen AH, et al. Successful treatment of molluscum contagiosum with topical imiquimod in a severely immunocompromised HIV-positive patient. *Int J STD AIDS.* 2001;12:264-266.
82. Buckley R, Smith K. Topical imiquimod therapy for chronic giant molluscum contagiosum in a patient with advanced human immunodeficiency virus 1 disease. *Arch Dermatol.* 1999;135:1167-1169.
83. Toro JR, Wood LV, Patel NK, et al. Topical cidofovir: a novel treatment for recalcitrant molluscum contagiosum in children infected with human immunodeficiency virus 1. *Arch Dermatol.* 2000;136: 983-985.
84. Calista D. Topical cidofovir for severe cutaneous human papillomavirus and molluscum contagiosum infections in patients with HIV/AIDS. A pilot study. *J Eur Acad Dermatol Venereol.* 2000;14:484-488.
85. Thappa DM, Karthikeyan K. Exaggerated scabies: a marker of HIV infection. *Indian Pediatr.* 2002; 39:875-876.
86. Roberts LJ, Huffam SE, Walton SF, et al. Crusted scabies: clinical and immunological findings in seventy-eight patients and a review of the literature. *J Infect.* 2005;50:375-381.
87. Hengge UR, Currie BJ, Jager G, et al. Scabies: a ubiquitous neglected skin disease. *Lancet Infect Dis.* 2006;6:769-779.
88. Currie BJ, McCarthy JS. Permethrin and ivermectin for scabies. *N Engl J Med.* 2010;362:717-725.
89. Okwor I, Uzonna JE. The immunology of Leishmania/HIV co-infection. *Immunol Res.* 2013;56:163-171.
90. Alvar J, Aparicio P, Aseffa A, et al. The relationship between leishmaniasis and AIDS: the second 10 years. *Clin Microbiol Rev.* 2008;21:334-359.
91. Couppie P, Clyti E, Sobesky M, et al. Comparative study of cutaneous leishmaniasis in human immunodeficiency virus (HIV)-infected patients and non-HIV-infected patients in French Guiana. *Br J Dermatol.* 2004; 151:1165-1171.
92. Lindoso JA, Barbosa RN, Posada-Vergara MP, et al. Unusual manifestations of tegumentary leishmaniasis in AIDS patients from the New World. *Br J Dermatol.* 2009;160:311-318.
93. Nguyen MH, Kauffman CA, Goodman RP, et al. Nasal carriage of and infection with *Staphylococcus aureus* in HIV-infected patients. *Ann Intern Med.* 1999;130:221-225.
94. Ganesh R, Castle D, McGibbon D, et al. Staphylococcal carriage and HIV infection. *Lancet.* 1989;2:558.
95. Shet A, Mathema B, Mediavilla JR, et al. Colonization and subsequent skin and soft tissue infection due to methicillin-resistant *Staphylococcus aureus* in a cohort of otherwise healthy adults infected with HIV type 1. *J Infect Dis.* 2009;200:88-93.
96. Popovich KJ, Weinstein RA, Aroutcheva A, et al. Community-associated methicillin-resistant *Staphylococcus aureus* and HIV: intersecting epidemics. *Clin Infect Dis.* 2010;50:979-987.
97. Graber CJ, Jacobson MA, Perdreau-Remington F, et al. Recurrence of skin and soft tissue infection caused by methicillin-resistant *Staphylococcus aureus* in a HIV primary care clinic. *J Acquir Immune Defic Syndr.* 2008; 49:231-233.
98. From the Centers for Disease Control and Prevention. 1993 revised classification system for HIV infection and expanded surveillance case definition for AIDS among adolescents and adults. *JAMA.* 1993; 269:729-730.
99. Patel AB, Rosen T. Herpes vegetans as a sign of HIV infection. *Dermatol Online J.* 2008;14:6.
100. Gilbert J, Drehs MM, Weinberg JM. Topical imiquimod for acyclovir-unresponsive herpes simplex virus 2 infection. *Arch Dermatol.* 2001;137:1015-1017.
101. Lalezari J, Schacker T, Feinberg J, et al. A randomized, double-blind, placebo-controlled trial of cidofovir gel for the treatment of acyclovir-unresponsive mucocutaneous herpes simplex virus infection in patients with AIDS. *J Infect Dis.* 1997;176: 892-898.
102. Wanat KA, Gormley RH, Rosenbach M, et al. Intralesional cidofovir for treating extensive genital verrucous herpes simplex virus infection. *JAMA Dermatol.* 2013;149:881-883.
103. Barnabas RV, Celum C. Infectious co-factors in HIV-1 transmission herpes simplex virus type-2 and HIV-1: new insights and interventions. *Curr HIV Res.* 2012; 10:228-237.
104. Onunu AN, Uhunmwangho A. Clinical spectrum of herpes zoster in HIV-infected versus non-HIV infected patients in Benin City, Nigeria. *West Afr J Med.* 2004;23:300-304.
105. Nikkels AF, Snoeck R, Rentier B, et al. Chronic verrucous varicella zoster virus skin lesions: clinical, histological, molecular and therapeutic aspects. *Clin Exp Dermatol.* 1999;24:346-353.
106. Gilson IH, Barnett JH, Conant MA, et al. Disseminated ecthymatous herpes varicella-zoster virus infection in patients with acquired immunodeficiency syndrome. *J Am Acad Dermatol.* 1989;20:637-642.

107. Lokke Jensen B, Weismann K, Mathiesen L, et al. Atypical varicella-zoster infection in AIDS. *Acta Derm Venereol.* 1993;73:123-125.
108. Blank LJ, Polydefkis MJ, Moore RD, et al. Herpes zoster among persons living with HIV in the current antiretroviral therapy era. *J Acquir Immune Defic Syndr.* 2012;61:203-207.
109. Gebo KA, Kalyani R, Moore RD, et al. The incidence of, risk factors for, and sequelae of herpes zoster among HIV patients in the highly active antiretroviral therapy era. *J Acquir Immune Defic Syndr.* 2005;40: 169-174.
110. Grabar S, Tattevin P, Selinger-Leneman H, et al. Incidence of herpes zoster in HIV-infected adults in the combined antiretroviral therapy era: results from the FHDH-ANRS CO4 cohort. *Clin Infect Dis.* 2015;60:1269-1277.
111. Wood SM, Shah SS, Steenhoff AP, et al. Primary varicella and herpes zoster among HIV-infected children from 1989 to 2006. *Pediatrics.* 2008;121:e150-e156.
112. Shearer K, Maskew M, Ajayi T, et al. Incidence and predictors of herpes zoster among antiretroviral therapy-naive patients initiating HIV treatment in Johannesburg, South Africa. *Int J Infect Dis.* 2014;23: 56-62.
113. Shafran SD. Live attenuated herpes zoster vaccine for HIV-infected adults. *HIV Med.* 2016;17:305-310.
114. Weinberg A, Levin MJ, Macgregor RR. Safety and immunogenicity of a live attenuated varicella vaccine in VZV-seropositive HIV-infected adults. *Hum Vaccin.* 2010;6:318-321.
115. Barnabas RV, Baeten JM, Lingappa JR, et al. Acyclovir prophylaxis reduces the incidence of herpes zoster among HIV-infected individuals: results of a randomized clinical trial. *J Infect Dis.* 2016;213:551-555.
116. Bernhard P, Obel N. Chronic ulcerating acyclovir-resistant varicella zoster lesions in an AIDS patient. *Scand J Infect Dis.* 1995;27:623-625.
117. Saint-Leger E, Caumes E, Breton G, et al. Clinical and virologic characterization of acyclovir-resistant varicella-zoster viruses isolated from 11 patients with acquired immunodeficiency syndrome. *Clin Infect Dis.* 2001;33:2061-2067.
118. Greenspan D, Canchola AJ, MacPhail LA, et al. Effect of highly active antiretroviral therapy on frequency of oral warts. *Lancet.* 2001;357:1411-1412.
119. Meys R, Gotch FM, Bunker CB. Human papillomavirus in the era of highly active antiretroviral therapy for human immunodeficiency virus: an immune reconstitution-associated disease? *Br J Dermatol.* 2010;162:6-11.
120. Maurer T, Rodrigues LK, Ameli N, et al. The effect of highly active antiretroviral therapy on dermatologic disease in a longitudinal study of HIV type 1-infected women. *Clin Infect Dis.* 2004;38:579-584.
121. Palefsky J. Human papillomavirus infection in HIV-infected persons. *Top HIV Med.* 2007;15:130-133.
122. Kojic EM, Cu-Uvin S. Update: human papillomavirus infection remains highly prevalent and persistent among HIV-infected individuals. *Curr Opin Oncol.* 2007;19:464-469.
123. Palefsky JM, Holly EA, Efirdc JT, et al. Anal intraepithelial neoplasia in the highly active antiretroviral therapy era among HIV-positive men who have sex with men. *AIDS.* 2005;19:1407-1414.
124. Gormley RH, Kovarik CL. Dermatologic manifestations of HPV in HIV-infected individuals. *Curr HIV/AIDS Rep.* 2009;6:130-138.
125. Lissouba P, Van de Perre P, Auvert B. Association of genital human papillomavirus infection with HIV acquisition: a systematic review and meta-analysis. *Sex Transm Infect.* 2013;89:350-356.
126. Spach DH, Colven R. Resolution of recalcitrant hand warts in an HIV-infected patient treated with potent antiretroviral therapy. *J Am Acad Dermatol.* 1999;40:818-821.
127. Roark TR, Pandya AG. Combination therapy of resistant warts in a patient with AIDS. *Dermatol Surg.* 1998;24:1387-1389.
128. Cusini M, Salmaso F, Zerboni R, et al. 5% Imiquimod cream for external anogenital warts in HIV-infected patients under HAART therapy. *Int J STD AIDS.* 2004; 15:17-20.
129. Gilson RJ, Shupack JL, Friedman-Kien AE, et al. A randomized, controlled, safety study using imiquimod for the topical treatment of anogenital warts in HIV-infected patients. Imiquimod Study Group. *AIDS.* 1999;13:2397-2404.
130. Juschka U, Hartmann M. Topical treatment of common warts in an HIV-positive patient with imiquimod 5% cream. *Clin Exp Dermatol.* 2003;28(suppl 1): 48-50.
131. Kreuter A, Potthoff A, Brockmeyer NH, et al. Imiquimod leads to a decrease of human papillomavirus DNA and to a sustained clearance of anal intraepithelial neoplasia in HIV-infected men. *J Invest Dermatol.* 2008;128:2078-2083.
132. Saiag P, Bauhofer A, Bouscarat F, et al. Imiquimod 5% cream for external genital or perianal warts in human immunodeficiency virus-positive patients treated with highly active antiretroviral therapy: an open-label, noncomparative study. *Br J Dermatol.* 2009;161:904-909.
133. Walzman M. Successful treatment of profuse recalcitrant extra-genital warts in an HIV-positive patient using 5% imiquimod cream. *Int J STD AIDS.* 2009;20:657-658.
134. Wong A, Crawford RI. Intralesional *Candida* antigen for common warts in people with HIV. *J Cutan Med Surg.* 2013;17:313-315.
135. Kilewo CD, Urassa WK, Pallangyo K, et al. Response to podophyllotoxin treatment of genital warts in relation to HIV-1 infection among patients in Dar es Salaam, Tanzania. *Int J STD AIDS.* 1995;6:114-116.
136. Matteelli A, Beltrame A, Graifemberghi S, et al. Efficacy and tolerability of topical 1% cidofovir cream for the treatment of external anogenital warts in HIV-infected persons. *Sex Transm Dis.* 2001; 28:343-346.
137. Orlando G, Fasolo MM, Beretta R, et al. Combined surgery and cidofovir is an effective treatment for genital warts in HIV-infected patients. *AIDS.* 2002; 16:447-450.
138. Orlando G, Fasolo MM, Beretta R, et al. Intralesional or topical cidofovir (HPMPC, VISTIDE) for the treatment of recurrent genital warts in HIV-1-infected patients. *AIDS.* 1999;13:1978-1980.
139. Shah M, Murphy M, Price JD, et al. Intralesional bleomycin for the treatment of non-genital warts in HIV-infected patients. *Acta Derm Venereol.* 1996; 76:81-82.
140. Frega A, di Renzi F, Stentella P, et al. Management of human papilloma virus vulvo-perineal infection with systemic beta-interferon and thymostimulin in HIV-positive patients. *Int J Gynaecol Obstet.* 1994; 44:255-258.

141. Lozada-Nur F, Glick M, Schubert M, et al. Use of intralesional interferon-alpha for the treatment of recalcitrant oral warts in patients with AIDS: a report of 4 cases. *Oral Surg Oral Med Oral Pathol Oral Radiol Endod.* 2001;92:617-622.
142. Xu J, Xiang L, Chen J, et al. The combination treatment using CO(2) laser and photodynamic therapy for HIV seropositive men with intraanal warts. *Photodiagnosis Photodyn Ther.* 2013;10:186-193.
143. Moore RL, de Schaetzen V, Joseph M, et al. Acquired epidermodysplasia verruciformis syndrome in HIV-infected pediatric patients: prospective treatment trial with topical glycolic acid and human papillomavirus genotype characterization. *Arch Dermatol.* 2012;148:128-130.
144. Javelle E, Lightburne E, Dukan P, et al. Human immunodeficiency virus (HIV)-associated epidermodysplasia verruciformis eradicated after interferon-alpha and ribavirin treatment. *Int J Dermatol.* 2014;53: 487-489.
145. Haas N, Fuchs PG, Hermes B, et al. Remission of epidermodysplasia verruciformis-like skin eruption after highly active antiretroviral therapy in a human immunodeficiency virus-positive patient. *Br J Dermatol.* 2001;145:669-670.
146. Darwich E, Darwich L, Canadas MP, et al. New human papillomavirus (HPV) types involved in epidermodysplasia verruciformis (EV) in 3 HIV-infected patients: response to topical cidofovir. *J Am Acad Dermatol.* 2011;65:e43-e45.
147. Lee KC, Risser J, Bercovitch L. What is the evidence for effective treatments of acquired epidermodysplasia verruciformis in HIV-infected patients? *Arch Dermatol.* 2010;146:903-905.
148. Stevenson J, Heath M. Syphilis and HIV infection: an update. *Dermatol Clin.* 2006;24:497-507, vi.
149. Centers for Disease Control and Prevention (CDC). Symptomatic early neurosyphilis among HIV-positive men who have sex with men—four cities, United States, January 2002-June 2004. *MMWR Morb Mortal Wkly Rep.* 2007;56:625-628.
150. Kassutto S, Sax PE. HIV and syphilis coinfection: trends and interactions. *AIDS Clin Care*. 2003;15: 9-15.
151. Workowski KA, Bolan GA; Centers for Disease Control and Prevention. Sexually transmitted diseases treatment guidelines, 2015. *MMWR Recomm Rep.* 2015; 64(RR-03):1-137.
152. Jurado RL, Campbell J, Martin PD. Prozone phenomenon in secondary syphilis. Has its time arrived? *Arch Intern Med.* 1993;153:2496-2498.
153. Kingston AA, Vujevich J, Shapiro M, et al. Seronegative secondary syphilis in 2 patients coinfected with human immunodeficiency virus. *Arch Dermatol.* 2005;141:431-433.
154. Kofoed K, Gerstoft J, Mathiesen LR, et al. Syphilis and human immunodeficiency virus (HIV)-1 coinfection: influence on CD4 T-cell count, HIV-1 viral load, and treatment response. *Sex Transm Dis.* 2006;33: 143-148.
155. Centers for Disease Control (CDC). Kaposi's sarcoma and Pneumocystis pneumonia among homosexual men—New York City and California. *MMWR Morb Mortal Wkly Rep.* 1981;30:305-308.
156. Semeere AS, Busakhala N, Martin JN. Impact of antiretroviral therapy on the incidence of Kaposi's sarcoma in resource-rich and resource-limited settings. *Curr Opin Oncol.* 2012;24:522-530.
157. Lodi S, Guiguet M, Costagliola D, et al. Kaposi sarcoma incidence and survival among HIV-infected homosexual men after HIV seroconversion. *J Natl Cancer Inst.* 2010;102:784-792.
158. Clifford GM, Polesel J, Rickenbach M, et al. Cancer risk in the Swiss HIV Cohort Study: associations with immunodeficiency, smoking, and highly active antiretroviral therapy. *J Natl Cancer Inst.* 2005;97:425-432.
159. Rohner E, Valeri F, Maskew M, et al. Incidence rate of Kaposi sarcoma in HIV-infected patients on antiretroviral therapy in Southern Africa: a prospective multicohort study. *J Acquir Immune Defic Syndr.* 2014;67:547-554.
160. Semeere A, Wenger M, Busakhala N, et al. A prospective ascertainment of cancer incidence in sub-Saharan Africa: the case of Kaposi sarcoma. *Cancer Med.* 2016; 5:914-928.
161. Howlader N, Noone AM, Krapcho M, et al, eds. SEER Cancer Statistics Review, 1975-2011. Bethesda, MD: National Cancer Institute; 2014. https://seer.cancer.gov/csr/1975_2011/
162. Maurer T, Ponte M, Leslie K. HIV-associated Kaposi's sarcoma with a high CD4 count and a low viral load. *N Engl J Med.* 2007;357:1352-1353.
163. Amerson E BN, Buziba, N, Wabinga H, et al. Diagnosing Kaposi's Sarcoma (KS) in East Africa: how accurate are clinicians and pathologists? *Infect Agent Cancer*. 2012;7(suppl 1):P6.
164. Semeere AS, Freeman EE, Wenger M, et al. A more representative and less biased approach to estimating mortality after diagnosis of Kaposi's sarcoma among HIV-infected adults in sub-Saharan Africa in the era of antiretroviral therapy. Paper presented at: 15th International Conference on Malignancies in AIDS and Other Acquired Immunodeficiencies; October 26-27, 2015; Bethesda, MD.
165. Chu KM, Mahlangeni G, Swannet S, et al. Determinants of mortality and disease progression of Kaposi's sarcoma in the ART programme of Khayelitsha, South Africa. Paper presented at: 16th Conference on Retroviruses and Opportunistic Infections; 2009; Montreal, Canada.
166. Uldrick TS, Mosam A, Shaik F, et al. Prognosis of patients with AIDS-associated Kaposi's sarcoma receiving antiretroviral therapy +/– chemotherapy in Kwazulu-Natal, South Africa: an analysis of 1-yr survival data from NCT00380770. Paper presented at: 11th International Conference on Malignancies in AIDS and Other Acquired Immunodeficiencies; 2008; Bethesda, MD.
167. Krown SE, Metroka C, Wernz JC. Kaposi's sarcoma in the acquired immune deficiency syndrome: a proposal for uniform evaluation, response, and staging criteria. AIDS Clinical Trials Group Oncology Committee. *J Clin Oncol.* 1989;7:1201-1207.
168. World Health Organization. *Guidelines on the Treatment of Skin and Oral HIV-Associated Conditions in Children and Adults*. Geneva, Switzerland: World Health Organization;2014.Availableat:http://apps.who.int/iris/bitstream/handle/10665/136863/9789241548915_eng.pdf;jsessionid=AB011C11883345F328CD821A271B8608?sequence=1
169. Swift PS. The role of radiation therapy in the management of HIV-related Kaposi's sarcoma. *Hematol Oncol Clin North Am.* 1996;10:1069-1080.
170. Brambilla L, Boneschi V, Beretta G, et al. Intralesional chemotherapy for Kaposi's sarcoma. *Dermatologica.* 1984;169:150-155.

171. Brambilla L, Bellinvia M, Tourlaki A, et al. Intralesional vincristine as first-line therapy for nodular lesions in classic Kaposi sarcoma: a prospective study in 151 patients. *Br J Dermatol.* 2010;162:854-859.
172. Flaitz CM, Nichols CM, Hicks MJ. Role of intralesional vinblastine administration in treatment of intraoral Kaposi's sarcoma in AIDS. *Eur J Cancer B Oral Oncol.* 1995;31B:280-285.
173. Rosen T. Limited extent AIDS-related cutaneous Kaposi's sarcoma responsive to imiquimod 5% cream. *Int J Dermatol.* 2006;45:854-856.
174. Bodsworth NJ, Bloch M, Bower M, et al; International Panretin Gel KS Study Group. Phase III vehicle-controlled, multi-centered study of topical alitretinoin gel 0.1% in cutaneous AIDS-related Kaposi's sarcoma. *Am J Clin Dermatol.* 2001;2:77-87.
175. Goldstone S, Palefsky JM, Giuliano AR, et al. Prevalence of and risk factors for human papillomavirus (HPV) infection among HIV-seronegative men who have sex with men. *J Infect Dis.* 2011;203: 66-74.
176. Chin-Hong PV, Vittinghoff E, Cranston RD, et al. Age-specific prevalence of anal human papillomavirus infection in HIV-negative sexually active men who have sex with men: the EXPLORE study. *J Infect Dis.* 2004;190:2070-2076.
177. Schofield AM, Sadler L, Nelson L, et al. A prospective study of anal cancer screening in HIV-positive and negative MSM. *AIDS.* 2016;30:1375-1383.
178. Blas MM, Brown B, Menacho L, et al. HPV prevalence in multiple anatomical sites among men who have sex with men in Peru. *PLoS One.* 2015;10:e0139524.
179. Palefsky JM, Holly EA, Ralston ML, et al. Prevalence and risk factors for anal human papillomavirus infection in human immunodeficiency virus (HIV)-positive and high-risk HIV-negative women. *J Infect Dis.* 2001;183:383-391.
180. Frisch M, Biggar RJ, Goedert JJ. Human papillomavirus-associated cancers in patients with human immunodeficiency virus infection and acquired immunodeficiency syndrome. *J Natl Cancer Inst.* 2000;92:1500-1510.
181. Aberg JA, Gallant JE, Ghanem KG, et al. Primary care guidelines for the management of persons infected with HIV:2013 update by the HIV Medicine Association of the Infectious Diseases Society of America. *Clin Infect Dis.* 2014;58:1-10.
182. Clinical Guidelines: Adult HIV Care—Anal Dysplasia and Cancer. 2007.
183. Panther L. *HPV-Related Complications. HIV Update Course*. Boston, MA: Beth Israel Deaconess Medical Center; 2016.
184. Edelman S, Johnstone PA. Combined modality therapy for HIV-infected patients with squamous cell carcinoma of the anus: outcomes and toxicities. *Int J Radiat Oncol Biol Phys.* 2006;66:206-211.
185. Blazy A, Hennequin C, Gornet JM, et al. Anal carcinomas in HIV-positive patients: high-dose chemoradiotherapy is feasible in the era of highly active antiretroviral therapy. *Dis Colon Rectum.* 2005;48:1176-1181.
186. Das P, Crane CH, Eng C, et al. Prognostic factors for squamous cell cancer of the anal canal. *Gastrointest Cancer Res.* 2008;2:10-14.
187. Das P, Bhatia S, Eng C, et al. Predictors and patterns of recurrence after definitive chemoradiation for anal cancer. *Int J Radiat Oncol Biol Phys.* 2007; 68:794-800.
188. Gibson TM, Morton LM, Shiels MS, et al. Risk of non-Hodgkin lymphoma subtypes in HIV-infected people during the HAART era: a population-based study. *AIDS.* 2014;28:2313-2318.
189. Wilkins K, Turner R, Dolev JC, et al. Cutaneous malignancy and human immunodeficiency virus disease. *J Am Acad Dermatol.* 2006;54:189-206; quiz 207-210.
190. Yanik EL, Achenbach CJ, Gopal S, et al. Changes in clinical context for Kaposi's Sarcoma and non-Hodgkin lymphoma among people with HIV infection in the United States. *J Clin Oncol.* 2016;34(27): 3276-3283.
191. Cerroni L. Cutaneous lymphomas in HIV-infected individuals. In: *Skin Lymphoma: The Illustrated Guide.* 4th ed. Hoboken, NJ: Wiley-Blackwell; 2014:275-280.
192. Beylot-Barry M, Vergier B, Masquelier B, et al. The spectrum of cutaneous lymphomas in HIV infection: a study of 21 cases. *Am J Surg Pathol.* 1999;23:1208-1216.
193. Wilkins K, Dolev JC, Turner R, et al. Approach to the treatment of cutaneous malignancy in HIV-infected patients. *Dermatol Ther.* 2005;18:77-86.
194. Jambusaria A, Shafer D, Wu H, et al. Cutaneous plasmablastic lymphoma. *J Am Acad Dermatol.* 2008;58:676-678.
195. Saggini A, Anemona L, Chimenti S, et al. HIV-associated primary cutaneous anaplastic large cell lymphoma: a clinicopathological subset with more aggressive behavior? Case report and review of the literature. *J Cutan Pathol.* 2012;39:1100-1109.
196. Baptista MJ, Garcia O, Morgades M, et al. HIV-infection impact on clinical-biological features and outcome of diffuse large B-cell lymphoma treated with R-CHOP in the combination antiretroviral therapy era. *AIDS.* 2015;29:811-818.
197. Bateganya MH, Stanaway J, Brentlinger PE, et al. Predictors of survival after a diagnosis of non-Hodgkin lymphoma in a resource-limited setting: a retrospective study on the impact of HIV infection and its treatment. *J Acquir Immune Defic Syndr.* 2011;56:312-319.
198. Lanoy E, Dores GM, Madeleine MM, et al. Epidemiology of nonkeratinocytic skin cancers among persons with AIDS in the United States. *AIDS.* 2009;23:385-393.
199. Olsen CM, Knight LL, Green AC. Risk of melanoma in people with HIV/AIDS in the pre- and post-HAART eras: a systematic review and meta-analysis of cohort studies. *PLoS One.* 2014;9:e95096.
200. Morar N, Willis-Owen SA, Maurer T, et al. HIV-associated psoriasis: pathogenesis, clinical features, and management. *Lancet Infect Dis.* 2010;10:470-478.
201. Kanada KN, Schupp CW, Armstrong AW. Association between psoriasis and viral infections in the United States: focusing on hepatitis B, hepatitis C and human immunodeficiency virus. *J Eur Acad Dermatol Venereol.* 2013;27:1312-1316.
202. Obuch ML, Maurer TA, Becker B, et al. Psoriasis and human immunodeficiency virus infection. *J Am Acad Dermatol.* 1992;27:667-673.
203. Fernandes S, Pinto GM, Cardoso J. Particular clinical presentations of psoriasis in HIV patients. *Int J STD AIDS.* 2011;22:653-654.
204. Tull TJ, Noy M, Bunker CB, et al. Sebopsoriasis in HIV positive patients: a case series of twenty patients. *Br J Dermatol.* 2017;176(3):813-815.
205. Kassi K, Mienwoley OA, Kouyate M, et al. Severe skin forms of psoriasis in black Africans: epidemiological, clinical, and histological aspects related to 56 cases. *Autoimmune Dis*. 2013;2013:561032.

206. Bittencourt Mde J, Brito AC, Nascimento BA, et al. A case of secondary syphilis mimicking palmoplantar psoriasis in HIV infected patient. *An Bras Dermatol.* 2015;90:216-219.
207. Carnero L, Betlloch I, Ramon R, et al. Psoriasis in a 5-month-old girl with HIV infection. *Pediatr Dermatol.* 2001;18:87-89.
208. Fife DJ, Waller JM, Jeffes EW, et al. Unraveling the paradoxes of HIV-associated psoriasis: a review of T-cell subsets and cytokine profiles. *Dermatol Online J.* 2007;13:4.
209. Colebunders R, Blot K, Mertens V, et al. Psoriasis regression in terminal AIDS. *Lancet.* 1992;339:1110.
210. Menon K, Van Voorhees AS, Bebo BF, et al. Psoriasis in patients with HIV infection: from the medical board of the National Psoriasis Foundation. *J Am Acad Dermatol.* 2010;62:291-299.
211. Tripathi SV, Leslie KS, Maurer TA, et al. Psoriasis as a manifestation of HIV-related immune reconstitution inflammatory syndrome. *J Am Acad Dermatol.* 2015;72:e35-e36.
212. Lee ES, Heller MM, Kamangar F, et al. Hydroxyurea for the treatment of psoriasis including in HIV-infected individuals: a review. *Psoriasis Forum*. 2011;17:180-187.
213. Di Lernia V. Progressive multifocal leukoencephalopathy and antipsoriatic drugs: assessing the risk of immunosuppressive treatments. *Int J Dermatol.* 2010;49:631-635.
214. Mathes BM, Douglass MC. Seborrheic dermatitis in patients with acquired immunodeficiency syndrome. *J Am Acad Dermatol.* 1985;13:947-951.
215. Wiwanitkit V. Prevalence of dermatological disorders in Thai HIV-infected patients correlated with different CD4 lymphocyte count statuses: a note on 120 cases. *Int J Dermatol.* 2004;43:265-268.
216. Forrestel AK, Kovarik CL, Mosam A, et al. Diffuse HIV-associated seborrheic dermatitis—a case series. *Int J STD AIDS*. 2016;27(14):1342-1345.
217. Buchness MR. Treatment of skin diseases in HIV-infected patients. *Dermatol Clin.* 1995;13:231-238.
218. Dunic I, Vesic S, Jevtovic DJ. Oral candidiasis and seborrheic dermatitis in HIV-infected patients on highly active antiretroviral therapy. *HIV Med.* 2004;5:50-54.
219. Hengge UR, Franz B, Goos M. Decline of infectious skin manifestations in the era of highly active antiretroviral therapy. *AIDS.* 2000;14:1069-1070.
220. Zissova LG, Kantarjiev TB, Kuzmanov AH. Drug susceptibility testing of *Malassezia furfur* strains to antifungal agents. *Folia Med (Plovdiv)*. 2001;43:10-12.
221. Miranda KC, de Araujo CR, Costa CR, et al. Antifungal activities of azole agents against the *Malassezia* species. *Int J Antimicrob Agents.* 2007;29:281-284.
222. Bason MM, Berger TG, Nesbitt LT Jr. Pruritic papular eruption of HIV-disease. *Int J Dermatol.* 1993; 32:784-789.
223. Boonchai W, Laohasrisakul R, Manonukul J, et al. Pruritic papular eruption in HIV seropositive patients: a cutaneous marker for immunosuppression. *Int J Dermatol.* 1999;38:348-350.
224. Rosatelli JB, Machado AA, Roselino AM. Dermatoses among Brazilian HIV-positive patients: correlation with the evolutionary phases of AIDS. *Int J Dermatol.* 1997;36:729-734.
225. Sivayathorn A, Srihra B, Leesanguankul W. Prevalence of skin disease in patients infected with human immunodeficiency virus in Bangkok, Thailand. *Ann Acad Med Singapore.* 1995;24:528-533.
226. Smith KJ, Skelton HG 3rd, James WD, et al. Papular eruption of human immunodeficiency virus disease. A review of the clinical, histologic, and immunohistochemical findings in 48 cases. The Military Medical Consortium for Applied Retroviral Research. *Am J Dermatopathol.* 1991;13: 445-451.
227. Panya MF, Mgonda YM, Massawe AW. The pattern of mucocutaneous disorders in HIV-infected children attending care and treatment centres in Dar es Salaam, Tanzania. *BMC Public Health.* 2009;9:234.
228. Lowe S, Ferrand RA, Morris-Jones R, et al. Skin disease among human immunodeficiency virus-infected adolescents in Zimbabwe: a strong indicator of underlying HIV infection. *Pediatr Infect Dis J.* 2010; 29:346-351.
229. Penneys NS, Nayar JK, Bernstein H, et al. Chronic pruritic eruption in patients with acquired immunodeficiency syndrome associated with increased antibody titers to mosquito salivary gland antigens. *J Am Acad Dermatol.* 1989;21:421-425.
230. Farsani TT, Kore S, Nadol P, et al. Etiology and risk factors associated with a pruritic papular eruption in people living with HIV in India. *J Int AIDS Soc*. 2013;16:17325.
231. Chua SL, Amerson EH, Leslie KS, et al. Factors associated with pruritic papular eruption of human immunodeficiency virus infection in the antiretroviral therapy era. *Br J Dermatol.* 2014;170:832-839.
232. Colebunders R, Moses KR, Laurence J, et al. A new model to monitor the virological efficacy of antiretroviral treatment in resource-poor countries. *Lancet Infect Dis.* 2006;6:53-59.
233. Lakshmi SJ, Rao GR, Ramalakshmi, et al. Pruritic papular eruptions of HIV: a clinicopathologic and therapeutic study. *Indian J Dermatol Venereol Leprol.* 2008;74:501-503.
234. Berman B, Flores F, Burke G 3rd. Efficacy of pentoxifylline in the treatment of pruritic papular eruption of HIV-infected persons. *J Am Acad Dermatol.* 1998;38:955-959.
235. Navarini AA, Stoeckle M, Navarini S, et al. Antihistamines are superior to topical steroids in managing human immunodeficiency virus (HIV)-associated papular pruritic eruption. *Int J Dermatol.* 2010;49:83-86.
236. Goldstein B, Berman B, Sukenik E, et al. Correlation of skin disorders with CD4 lymphocyte counts in patients with HIV/AIDS. *J Am Acad Dermatol.* 1997; 36:262-264.
237. Kim TG, Lee KH, Oh SH. Skin disorders in Korean patients infected with human immunodeficiency virus and their association with a CD4 lymphocyte count: a preliminary study. *J Eur Acad Dermatol Venereol.* 2010;24:1476-1480.
238. Rajendran PM, Dolev JC, Heaphy MR Jr, et al. Eosinophilic folliculitis: before and after the introduction of antiretroviral therapy. *Arch Dermatol.* 2005;141: 1227-1231.
239. Berger TG, Heon V, King C, et al. Itraconazole therapy for human immunodeficiency virus-associated eosinophilic folliculitis. *Arch Dermatol.* 1995;131: 358-360.
240. Otley CC, Avram MR, Johnson RA. Isotretinoin treatment of human immunodeficiency virus-associated eosinophilic folliculitis. Results of an open, pilot trial. *Arch Dermatol.* 1995;131:1047-1050.

241. Lim HW, Vallurupalli S, Meola T, et al. UVB phototherapy is an effective treatment for pruritus in patients infected with HIV. *J Am Acad Dermatol.* 1997;37:414-417.
242. French MA, Lenzo N, John M, et al. Immune restoration disease after the treatment of immunodeficient HIV-infected patients with highly active antiretroviral therapy. *HIV Med.* 2000;1(2):107-115.
243. French MA. Immune reconstitution inflammatory syndrome: a reappraisal. *Clin Infect Dis.* 2009; 48(1):101-107.
244. French MA, Price P, Stone SF. Immune restoration after antiretroviral therapy. *AIDS.* 2004;18(12):1615-1627.
245. Cook LB, Elemans M, Rowan AG, et al. HTLV-1: persistence and pathogenesis. *Virology.* 2013;435: 131-140.
246. Ferreira LC, Caramelli P, Carneiro-Proietti AB. Human T-cell lymphotropic virus type 1 (HTLV-1): when to suspect infection? *Rev Assoc Med Bras.* 2010;56(3):340-347.
247. Goncalves DU, Proietti FA, Ribas JG, et al. Epidemiology, treatment and prevention of human T-cell leukemia virus type 1-associated diseases. *Clin Microbiol Rev.* 2010;23(3):577-589.
248. Schechter M, Harrison LH, Halsey NA, et al. Coinfection with human T-cell lymphotropic virus type I and HIV in Brazil. Impact on markers of HIV disease progression. *JAMA.* 1994;271(5):353-357.
249. Oliveria MF, Brites C, Ferraz N, et al. Infective dermatitis associated with the human T-cell lymphotropic virus type 1 in Salvador, Bahia, Brazil. *Clin Infect Dis.* 2005;40(11):90-96.

Chapter 169 :: Mosquito-Borne Viral Diseases

:: Edwin J. Asturias & J. David Beckham

INTRODUCTION

DEFINITIONS

Mosquito-borne viral diseases are also called arbovirus (**ar**thropod-**bo**rne) infections. They are considered zoonotic diseases that are transmitted to humans indirectly via mosquitos or ticks from primates to humans, or humans to humans. An overview of mosquito-borne diseases is shown in Table 169-1.

HISTORICAL PERSPECTIVE

Since the arrival of the Spanish into the Americas in 1495, the "Black Death" or "Blood Vomit" (Xekik in Mayan) was a feared disease that affected people in the Caribbean and on the American continent. Outbreaks along the Mediterranean coast were suspected to have been brought from Africa.[1] However, the connection between arthropods and disease was not postulated until 1881 when Cuban doctor and scientist Carlos Finlay proposed that yellow fever (YF) may be transmitted by mosquitoes instead of human contact, a reality that was verified by Major Walter Reed in 1901.[2] By 1930, besides YF, dengue was the other important arbovirus infection that had been described.[3] From 1950 on, the use of vertebrate tissue culture and mosquito cell lines led to the discovery of many more arbovirus pathogens that are important in humans.[4]

FLAVIVIRUS INFECTIONS

AT-A-GLANCE

- Most common mosquito-borne infections worldwide
- Febrile illness associated with rash, conjunctivitis, or both
- Hemorrhagic or neurologic disease as complications
- Zika virus is transmitted from a mother to her child and through human secretions.

INTRODUCTION

The *Flaviviridae* (Latin, *flavus,* yellow) are a family of positive sense, single-stranded, enveloped RNA viruses, commonly found in mosquitos and ticks that can infect primates and humans. As transmission occurs via mosquitos, the skin is the primary site of infection. Flavivirus of human importance include dengue virus (DENV), Japanese encephalitis virus (JEV), Murray Valley encephalitis virus (MVEV), St. Louis encephalitis virus (SLEV), West Nile virus (WNV), Spondweni virus (SPOV), Zika virus (ZIKV), Wesselsbron virus (WESSV), and yellow fever virus (YFV). Of these, only DENV, WNV, SPOV, ZIKV, and YFV have demonstrated skin tropism with cutaneous manifestations. Epidermal Langerhans cells (LCs) along with dermal dendritic cells (DCs), macrophages, and T cells provide the first line of defense against these viruses.[5] The local trauma and inflammation resulting from the mosquito bite might enhance the recruitment of many of these cells.

DENGUE VIRUS

ETIOLOGY AND PATHOGENESIS

Dengue is a flaviviral disease caused by the four dengue virus serotypes (DENV 1–4) and transmitted by *Aedes* mosquitoes. Dengue is endemic in more than 100 countries in southeast Asia, the Americas, the western Pacific, Africa, and the eastern Mediterranean regions. It is estimated to cause an estimated 390 million human infections per year globally, of which 96 million manifests with symptoms.[6] After the initial acute infection and peak viremia, release of inflammatory mediators leads to endothelial dysfunction and vascular leak in severe dengue. Vascular leak is typically evident 3 to 6 days after the onset of illness, lasts for 24 to 48 hours, and usually shows rapid and complete reversal.[7]

CLINICAL FEATURES

After an incubation period of 3 to 10 days, infection by any dengue virus can produce a wide spectrum of illness, most being asymptomatic or subclinical. Around 10% to 15% will manifest as a self-limited febrile illness classically characterized by elevated temperature (≤40°C), severe headache, retro-orbital pain, malaise, severe joint and muscle pain, nausea, and vomiting, with a rash appearing after 3 to 4 days of fever onset.[8] In about 5% of symptomatic patients, especially after a second infection with dengue, severe dengue will be complicated by plasma leakage with or without bleeding. This critical phase occurs around defervescence from the initial fever and can lead to hypovolemic shock, organ failure, metabolic acidosis,

TABLE 169-1
An Overview of Mosquito-Borne Viral Diseases

CONDITION	VIRAL FAMILY	INCUBATION PERIOD (DAYS)	PRODROMAL SYMPTOMS	DERMATOLOGIC MANIFESTATIONS	LABORATORY TESTS	COMMENTS AND OTHER DIAGNOSTIC FEATURES
Dengue virus	Flavivirus	3–10	Usually none; 70% asymptomatic	Erythema early on ("islands of white in a sea of red"), maculopapular or urticarial exanthem in febrile phase (50%–80%)	Leukopenia, thrombocytopenia, elevated transaminases Dengue PCR or NS1 Ag positive in first 7 days of illness; dengue IgM positive after 5 days of illness in 80%	**Second infections carry 5% risk of hospitalization and severe dengue (hemorrhagic or third spacing); infants at high risk of severe dengue because of maternal antibodies**
Zika virus	Flavivirus	3–7	Variable; 80% asymptomatic	Common (70%–85%); erythema, macular, or maculopapular and very pruritic	Leukocytosis, thrombocytopenia, elevated transaminases Zika blood PCR diagnostic in first 5–10 days; Zika IgM positive in 5–15 days; false-positives occur in dengue endemic areas	**Nonpurulent conjunctivitis (60%), facial and neck edema (70%)**
Yellow Fever virus	Flavivirus	3–6	Fever, muscle pain, backache, headache, shivers, vomiting in acute phase	Acute phase: facial flushing, conjunctival hyperemia Toxic phase (15%): jaundice, petechiae, hemorrhage	Leukopenia, thrombocytopenia, elevated transaminases and bilirubin; blood PCR positive in first 5–7 days, IgM positive in 5–15 days	**40%–50% mortality rate in those progressing to "toxic" stage** **Vaccine confers lifelong immunity**
West Nile virus	Flavivirus	3–14 (≤28)	70% symptomatic; high fever (>39°C), headache, severe polyarthralgia, myalgia	Affects ~20%; small pink to red macules and papules on the torso and proximal extremities	Mild leukocytosis and hyponatremia PCR positive in first 3–5 days of illness but usually negative when presenting IgM and IgG serology most helpful	**Hospitalization in 30%; fatigue for 1 mo in 95%; neuroinvasive disease in 1%**
Chikungunya virus	Alphavirus	2–6	Fever, headache, flulike symptoms, myalgia, GI symptoms	Variable: morbilliform, vesiculobullous, and psoriatic-like presentations; postinflammatory hyperpigmentation	Leucopenia and lymphopenia PCR positive first in 3 days of illness IgM and IgG serology after 1 week of illness	**Symmetric arthralgia and arthritis in 70% (can last 6–12 mo)**
Mayaro virus	Alphavirus	Unknown	Acute febrile illness with headache, malaise; red eyes in 45%	Rash with pruritus in 30%–50%	Leucopenia IgM and IgG ELISA	**Endemic in South America and the Caribbean** **Arthralgia and arthritis in 50%–90% (can last 6–12 months)**
O'nyong-nyong virus	Alphavirus	Unknown	Acute febrile illness in 80%–100%, headache, myalgia	Rash in 70%–90%	Leucopenia IgM and IgG ELISA	**Outbreaks in Africa** **Arthralgia and arthritis in 60%–100% (can last 6–12 mo)**
Ross River virus	Alphavirus	7–9	Acute febrile illness in 20%–60%, headache, photophobia	Rash in 40%–50%	Leucopenia IgM and IgG ELISA	**Endemic in Australia** **Arthralgia and arthritis in 80%–100% (can last 6–12 mo)**
Sindbis virus	**Alphavirus**	**2–10**	**Acute febrile illness in 15%–40%, headache, malaise, and arthralgia**	**Rash in 80%–90%**	**Leucopenia** **IgM and IgG ELISA**	**Endemic in Eurasia, Africa, and Oceania** **Arthralgia and arthritis in 90% (can last 6–12 mo)**

Ag, antigen; ELISA, enzyme-linked immunosorbent assay; GI, gastrointestinal; IgG, immunoglobulin G; IgM, immunoglobulin M; NS1, nonstructural protein 1; PCR, polymerase chain reaction.

Figure 169-1 Rash of classical dengue. (Reproduced from Carod-Artal FJ, Wichmann O, Farrar J, et al. Neurological complications of dengue virus infection. *Lancet Neurol*. 2013;12(9):906-919; with permission. Copyright © Elsevier.)

disseminated intravascular coagulation (DIC), and severe hemorrhage.[9,10]

CUTANEOUS FINDINGS

A skin exanthem is present in 50% to 80% of patients who have symptomatic dengue. In the first 24 to 48 hours of the febrile episode, erythematous flushing of the face, neck, and chest is common, likely caused by capillary dilation. By day 3 to 5 of illness, a generalized morbilliform dark erythematous eruption with areas of clearing described as "islands of white in a sea of red" is seen in 70% of patients presenting with rash (Fig. 169-1). This rash frequently involves the palms and soles and commonly is associated with mild edema of the hands and feet. Other less common presentations include maculopapular eruptions, petechiae, purpura, and in 15% to 30% mucosal involvement with oral or genital bleeding, which signals dengue hemorrhagic fever. The typical cutaneous maculopapular eruption lasts up to 5 days. Involvement of the palms and soles may be followed by desquamation. There may be cutaneous hyperesthesia with alteration of the sense of touch.

NONCUTANEOUS FINDINGS

Only one of every 7 to 14 dengue infections is symptomatic. Clinical manifestations vary from self-limited fever to severe hemorrhagic fever and shock syndrome. Although rare, oral mucosal manifestations of dengue include acute gingival and palate bleeding, dryness of the mouth, taste changes, and erythematous plaques and vesicles on the tongue and palate.[11]

COMPLICATIONS

Between 10% and 20% of children confirmed with dengue will be hospitalized.[12] Besides dengue hemorrhagic fever and plasma leakage, severe dengue can also lead to hepatitis, neurologic disorders, and myocarditis. If untreated, the mortality rate can be as high as 20%.

DIAGNOSIS

Acute dengue infection can be confirmed by virus isolation in culture, detection of viral genomic RNA, viral products (capture and detection of the secreted NS1 protein), or the host immune response to virus infection (immunoglobulin [Ig] M). Reverse transcriptase polymerase chain reaction (RT-PCR) is the preferred method of virologic confirmation and can detect 69% to 82% of cases in the first 3 days of illness. NS1 antigen parallels viremia, and testing can detect 84% to 90% of cases in the first 5 to 7 days of illness.[13] Dengue IgM is positive in 10% to 20% of dengue cases by day 5 of illness but becomes progressively positive up to 80% to 90% of cases after 10 days of illness onset.[8]

Supportive Studies: Laboratory abnormalities include leukopenia, thrombocytopenia (platelets <100,000 × mm^3), elevated transaminases, elevated hematocrit, and hyponatremia.

DIFFERENTIAL DIAGNOSIS

In endemic areas, approximately 10% of the febrile episodes in children are caused by dengue.[12] The fever and rash of dengue must be differentiated from other flavivirus infections as well as other conditions, including typhoid fever, rickettsiosis, secondary syphilis, chikungunya, primary HIV infection, drug reactions, and other common viral exanthems (enterovirus, measles, rubella, human herpesvirus 6 [HHV6], and parvovirus B19 infections).

CLINICAL COURSE, PROGNOSIS, MANAGEMENT, AND PREVENTION

Most cases of dengue are self-limited, and most patients recover without sequelae. Fatigue can last for several weeks, leading to absenteeism and loss of productivity. No specific antiviral therapy is available for dengue. Treatment of patients with dengue with warning signs and severe dengue includes rehydration, supportive care, avoidance of nonsteroidal and steroidal antiinflammatory therapy, and transfusion if needed. A recently licensed live attenuated recombinant vaccine containing the four dengue serotypes has been shown to reduce severe dengue by 90%, hospitalization by 80%, and clinical dengue by 50% to 60%.[14]

ZIKA VIRUS

ETIOLOGY AND PATHOGENESIS

ZIKV is an emerging mosquito-borne virus belonging to the genus *Flavivirus* and initially discovered in the Zika Forest of Uganda in 1947 in rhesus monkeys and in humans in 1952. Primarily transmitted by the *Aedes* mosquito, ZIKV became a pandemic of emergency proportions after its spread to Brazil in 2015.

Since 2013, 84 countries have been affected. Unique to ZIKV is its ability to be transmitted from human to human through body fluids, sexual contact, and vertically from mother to fetus. ZIKV RNA persists in semen longer than in blood, saliva, or urine for up to 6 months after the onset of illness. Tissue pathology in congenital Zika syndrome is caused by direct viral infection of neural structures but in Guillain-Barré syndrome (GBS) is likely caused by postinfectious host-directed immune response.[15]

CLINICAL FEATURES

Most ZIKV infections in humans are asymptomatic (~80%). In 20% of infected patients, a mild febrile illness is associated with nonpurulent conjunctivitis, rash, malaise, and arthralgia, which will resolve within 2 to 7 days, and rarely requires hospitalization.

CUTANEOUS FINDINGS

The classic ZIKV exanthema appears within 1 to 2 days of illness and is associated with low-grade fever in 55% of patients. Distributed mainly on the trunk and extremities, it affects the palms and soles rarely. The rash is described as micropapular, descending, and pruritic in adults and children (Fig. 169-2B). Itching is the main reason for consultation due to severity associated with insomnia in 20% of cases.[16] Biopsies of the skin demonstrate a nonspecific perivascular lymphocytic infiltrate in the upper dermis.

NONCUTANEOUS FINDINGS

Associated mucous lesions include conjunctival hyperemia without purulence in 56% (Fig. 169-2A), facial and neck edema (60%–70%) (Fig. 169-2A), and acral edema that affects adults (50%) more than children (15%).

COMPLICATIONS

ZIKV congenital syndrome is characterized by microcephaly, chorioretinitis, hearing loss, irritability, hypertonia, and esophageal dysfunction.[17-20] GBS can occur 2 to 6 weeks after a ZIKV infection.[21,22]

DIAGNOSIS

Symptomatic patients infected with ZIKV are viremic for a mean of 3 days, and the virus can be detected in blood or serum samples using RT-PCR assays for at least 1 week. Serologic diagnosis using ZIKV IgM and IgG production with paired acute and convalescent serum can be used after 5 days of illness. However, given its commonality with other flaviviruses such

Figure 169-2 Presentation of Zika virus infection. **A,** Edema and erythema of the malar region of the face and conjunctival injection. **B,** Macular rash on the abdomen. **C,** Hyperemia and petechiae in the hard palate. **D,** Tender, mobile, soft lymph node, about 15 mm in diameter, behind the left ear. (Reproduced from Brasil P, Calvet GA, de Souza RV, et al. Exanthema associated with Zika virus infection. *Lancet Infect Dis*. 2016;16(7):866; with permission. Copyright © Elsevier.)

as dengue or Japanese encephalitis, a high degree of serologic cross-reactivity to ZIKV serology is usually observed. More specific tests such as the plaque reduction neutralization test can improve differentiation between flaviviruses in endemic areas.[23,24]

Supportive Studies: Head ultrasonography, magnetic resonance imaging, and hearing and ophthalmologic examinations should be considered in any child exposed to ZIKV during pregnancy.

DIFFERENTIAL DIAGNOSIS

The clinical manifestations of ZIKV infection resemble other mosquito-transmitted diseases such as Chikungunya (CHIKV) and Dengue, but in comparison, ZIKV-related symptoms are usually milder and shorter and rarely lead to hospitalization.[25] The rare Spowendi virus infection in Africa can present with a rash similar to Zika but is characterized by a sunburn-like appearance.[26]

CLINICAL COURSE, PROGNOSIS, MANAGEMENT, AND PREVENTION

In pregnant women with laboratory evidence of recent ZIKV infection, approximately 5% of their fetuses or infants will demonstrate birth defects potentially associated with ZIKV infection.[27] No specific antiviral therapy is available for ZIKV, and several ZIKV vaccines are under development.[28]

YELLOW FEVER VIRUS

ETIOLOGY AND PATHOGENESIS

Endemic in Africa and South America, YF is caused by a RNA virus member of the family Flaviviridae. YF virus is maintained in nature by transmission between nonhuman primates and blood-feeding mosquitoes mainly belonging to the genera *Haemagogus* in Africa and *Aedes* in South America.[29] After inoculation by the vector, YF virus replicates within the endoplasmic reticulum of hepatocytes and other organs such as the kidneys, heart, and the gastrointestinal (GI) tract. Jaundice, the hallmark of this infection, arises from hepatocellular necrosis and the formation of intracellular hyaline deposits within the hepatic lobules.

CLINICAL FEATURES

YF incubates in humans for 3 to 6 days followed by infection that can occur in one or two phases. The first "acute" phase usually causes fever, muscle pain with prominent backache, headache, shivers, loss of appetite, and nausea or vomiting. Most patients improve after 3 to 4 days of illness. In 15% of patients, a second "toxic" phase ensues within 24 hours of the initial remission with high fever, jaundice, abdominal pain, vomiting, mucosal bleeding, and GI hemorrhage. Renal failure and shock can lead to death.

CUTANEOUS FINDINGS

In the mild acute phase of the disease, facial flushing and conjunctival hyperemia are common. In severe "toxic" forms of disease, jaundice can be accompanied by petechiae, and skin hemorrhage from thrombocytopenia and DIC is common.[30]

DIAGNOSIS

YF should be suspected in any person from or returning from an endemic area with acute onset of fever and jaundice appearing within 14 days of onset of the first symptoms.

Supportive Studies: Laboratory diagnosis of YF is generally accomplished by serologic testing for virus-specific IgM and neutralizing antibodies.[31] Sometimes the virus can be detected by RT-PCR in blood samples taken early in the illness.[32,33] In severe or fatal cases, RT-PCR, histopathology with immunohistochemistry and virus culture of biopsy or autopsy tissues can also be positive.

DIFFERENTIAL DIAGNOSIS

Mild YF infections may mimic any of the acute febrile illnesses in the tropics, including dengue, Zika, chikungunya, influenza, and other viral infections. Severe YF hemorrhagic fever should be differentiated from Lassa, Crimean-Congo, Ebola, and other South American hemorrhagic fevers.

CLINICAL COURSE, PROGNOSIS, MANAGEMENT, AND PREVENTION

The majority of individuals recover fully from the acute phase of illness, with no consequences and lifelong immunity to YF. Of the 15% who will progress to severe disease, half will recover fully with lifelong immunity, and 40% to 50% will die. No antivirals are approved for treatment of YF, yet nitazoxanide has been shown to interfere with its replication.[34] A very effective vaccine against YF exists, and only one dose is required to protect thru life.[35] Since 2006, more than 105 million people have been vaccinated in mass campaigns in West Africa with dramatic reduction in outbreaks.

WEST NILE VIRUS

First isolated in 1937 from a woman in Uganda, WNV disease caused sporadic outbreaks in Africa, Asia, and Europe. In the summer of 1999, it emerged in North America and by 2003 caused the largest outbreak of WNV ever reported with 9862 confirmed cases, of

which 2866 (29%) were neuroinvasive.[36] WNV is now considered endemic in most of the United States and is maintained in an enzootic cycle between birds and mosquitoes. It is known to infect more than 300 species of birds, but in the Western Hemisphere, American crows and robins as well as sparrows, finches, grackles, jays, and magpies are the most common reservoirs.[37]

CLINICAL FEATURES

Transmission of WNV to humans occurs predominantly through the bite of the Culex family of mosquitos. Rare cases occur as a consequence of blood transfusion or organ transplantation, and infection can occur in utero or postnatally from breastfeeding.[38] After a typical incubation period of 3 to 14 days but as long as 28 days after infection, systemic symptoms can develop. WNV infection is asymptomatic in about 80% of cases, and many additional patients with mild infection never seek medical attention.

CUTANEOUS FINDINGS

A maculopapular rash appears in 5% to 22% of patients as a roseola-like, nonpruritic eruption, characterized by pink macules or papules, 5 to 10 mm in diameter, frequently affecting the torso and proximal extremities but sparing the palms and soles and lasting 5 to 7 days (Fig. 169-3). Younger patients, as well as those without neuroinvasive disease, are frequently affected.[39-41] Other skin manifestations may include roseola-like eruptions, a punctate exanthem, and rarely purpura fulminans.[42]

NONCUTANEOUS FINDINGS

One in five WNV-infected patients have symptoms characterized as nonspecific "flulike" symptoms consisting of fever, headache, malaise, anorexia, abdominal pain, sore throat, back pain, or diarrhea.[38,43,44] In one series of patients, it was noted that the most commonly reported symptoms were fever (100%), generalized fatigue (74%), nausea or vomiting (44%), headache (48%), and back or limb pain (35%).[45]

Figure 169-3 Diffuse maculopapular rash associated with West Nile virus infection. (Reproduced from Sejvar JJ. Clinical manifestations and outcomes of West Nile virus infection. *Viruses*. 2014;6(2):606-623. Licensed under CC BY 3.0.)

COMPLICATIONS

Fatigue is a common complication reported in 96% of patients for a median of 36 days. Hospitalization occurs in 30% for a median stay of 5 days, and 57 of 72 (79%) patients who normally attended school or work could not do so with a mean absence of 10 days. Fewer than 1% of patients develop neuroinvasive disease, classified as meningitis, encephalitis, or acute flaccid paralysis.[46] Older age, chronic medical conditions, and immunosuppression increase the likelihood of complications. Cranial nerve palsies are found in about 10% of patients and most commonly involve the second and seventh cranial nerves, causing optic neuritis (see later) or peripheral facial palsy, respectively. Involvement of lower cranial nerves can result in vertigo, dysphagia, or dysarthria. Brainstem involvement can be extensive enough that some patients develop bulbar dysfunction, leading to subsequent respiratory failure.[43] Aside from optic neuritis, other neuro-ophthalmologic manifestations of WNV infection include chorioretinitis, uveitis, and vitreitis.[47,48]

DIAGNOSIS

Specific testing for WNV usually involves RT-PCR and serologies. RT-PCR testing from serum is generally not as helpful as serologic testing because the majority of patients will no longer have detectable viremia by the time they develop neuroinvasive symptoms. WNV-specific immunoglobulin (IgM) in cerebrospinal fluid (CSF) with confirmatory plaque reduction neutralization is the test of choice for neuroinvasive disease.[49] CSF IgM can persist for up to 199 days. WNV IgM or IgG can cross-react with other flaviviruses and results in patients with other flavivirus exposure are only indicative of recent or previous flavivirus infection (eg, West Nile, dengue, Japanese encephalitis, or ZIKV) or vaccination (eg, Japanese encephalitis or YF vaccine).

Supportive Studies: Patients with WNV typically have a normal complete blood cunt or a mild leukocytosis. Hyponatremia can be seen, as well as elevation of liver enzymes. Neuroinvasive WNV shows a lymphocytic pleocytosis of less than 500 cells/mm^3 in the CSF.

DIFFERENTIAL DIAGNOSIS

The rash of WNV must be differentiated from primary HIV infection, drug reactions, and other common viral exanthems (enterovirus, measles, rubella, HHV6, and parvovirus B19 infections). In returning travelers, other flavivirus (dengue) and alphavirus infections (CHIKV), as well as other conditions, including typhoid fever, rickettsiosis, and secondary syphilis, should be thought of.

CLINICAL COURSE, PROGNOSIS, MANAGEMENT, AND PREVENTION

Most WNV infections are asymptomatic or mildly symptomatic. Hospitalization and death are rare but are more frequent in older adults and those affected by chronic conditions or immunosuppression. The mortality rate in neuroinvasive disease has been 9% from 1999 and 2015.

The mainstay of prevention revolves around avoiding mosquito bites with insect repellants that contain DEET, picaridin, IR3535, or oil of lemon eucalyptus. It is recommended to wear long clothing and to make home modifications to prevent mosquito accessibility and breeding by installing screens on windows or using air conditioning. It is important to eliminate sources of standing water, including pots, bowls, and rubber tires. If sleeping outside, the use of a mosquito bed net is recommended. No antiviral treatments for WNV infection are available, and there are not yet vaccines approved for human use.[50]

ALPHAVIRUSES

AT-A-GLANCE

- Mosquito-borne infections causing rheumatologic and neurologic diseases
- Chikungunya, Mayaro, Ross River, Sindbis and O'nyong-nyong viruses manifest as febrile illness associated with rash, conjunctivitis, or both.
- Arthralgia and arthritis are common complications.

INTRODUCTION

Alphaviruses are a genus of enveloped, positive-sense, single-stranded RNA viruses, usually transmitted by mosquitoes, and together with the genus Rubivirus belong to the Togaviridae family. Alphaviruses are commonly referred to as "Old World" and "New World" viruses, with Old World viruses generally associated with dermatologic and rheumatic disease in humans (CHIKV and Mayaro virus [MAYV]) and "New World" viruses (Venezuelan, Eastern, Western, and Venezuelan equine encephalitis) primarily associated with potentially fatal encephalitic disease in the Americas.[51]

CHIKUNGUNYA

ETIOLOGY AND PATHOGENESIS

Chikungunya fever is caused by CHIKV, an alphavirus from the Togaviridae family transmitted by the *Aedes aegypti* and *albopictus* mosquitos. First described in Tanzania in 1952, epidemics subsequently occurred in Africa, Asia, and India and in 2013 to 2014 emerged in the Caribbean and Latin America.[52] Since 2000, the virus has been reemerging, causing several outbreaks of more severe forms of the disease in southeast Asia, the Caribbean, and Latin America. Most of the manifestations of chikungunya infection are caused by high levels of viremia present in the blood during early stages of infection. This high viremia correlates with an intense inflammatory response that results in infiltration of immune cells into infected joints and surrounding tissues, producing arthritis. Direct infection of osteoblasts may explain the arthritis and arthralgia during infection.

CLINICAL FEATURES

After the bite of an infectious mosquito, the incubation period is 2 to 4 (≤10) days. Chikungunya means "that which bends up" in Swahili or Makonde for the posture assumed by affected patients. Approximately 70% of acute CHIKV infections are symptomatic, presenting with abrupt onset of high fever (>39°C), headache, severe polyarthralgia and myalgia, and an erythematous maculopapular rash (Fig. 147-4B), which varies in severity from mild and localized to generalized.[52]

CUTANEOUS FINDINGS

A variety of mucocutaneous lesions occur in 40% to 50% of patients with CHIKV infection. Morbilliform exanthem is the most common presentation, but pigmented, vesiculobullous, and psoriatic-like lesion are also described in children.[53,54] Postinflammatory hyperpigmentation may appear soon after the evanescence of the rash. Facial flushing, xerosis of skin with scaling, desquamation of palms, acute intertrigo-like lesions with genital or perianal ulceration, aphthous-like ulcers, and lymphedema in an acral distribution have also been reported. Hemorrhagic skin lesions and purpura are more typical of dengue but are occasionally reported with CHIKV infection. Rarely, CHIKV infection can mimic atypical Kawasaki syndrome in young children.[54-59]

NONCUTANEOUS FINDINGS

Most patients have joint pain and swelling with severe morning stiffness, consistent with in inflammatory arthritis (Fig. 147-4A). The joint pain is typically symmetrical, and almost any joint can be affected, especially during the acute phase, although the distal extremities are affected more frequently.

COMPLICATIONS

CHIKV antigen and RNA has been shown to persist in macrophages for up to 90 days, and in one patient, CHIKV RNA and protein was found in synovial macrophages 18 months after infection. Chronic, episodic, often debilitating, polyarthralgia or polyarthritis associated with fatigue is the most common and feared

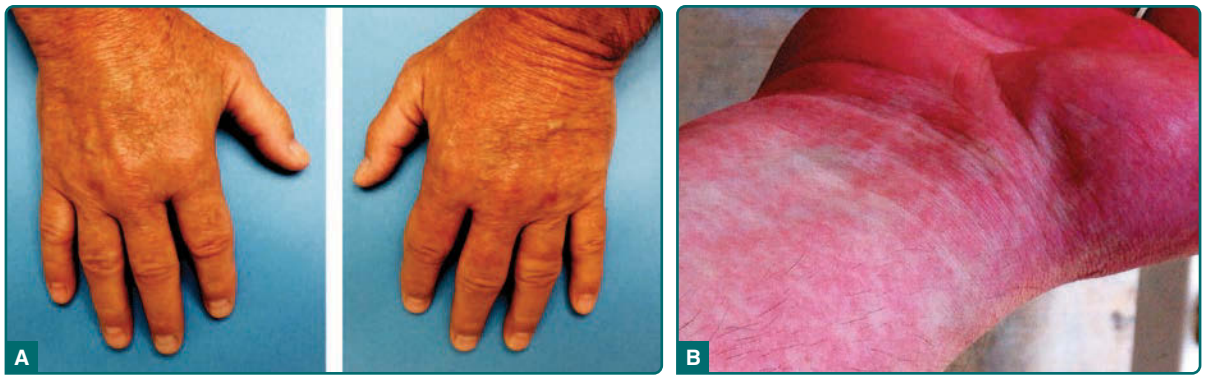

Figure 169-4 Clinical features of disease in patients with chikungunya virus infection. **A,** Active symmetric synovitis in the metacarpophalangeal and proximal interphalangeal joints during the chronic phase of chikungunya-associated arthritis. The patient was a white man aged 57 years. The patient developed high fever, a diffuse maculopapular rash, joint pain, stiffness, and swelling consistent with an acute pattern. **B,** Maculopapular rash during the acute infectious phase. The rash was distributed over the entire body, resolved after a few days and was followed by desquamation. The patient was a white woman aged 33 years. The patient developed fever, diffuse arthritis, and an erythematous, maculopapular rash over her entire body. Both individuals traveled to Haiti during a chikungunya virus outbreak. (Reproduced from Miner JJ, Aw-Yeang HX, Fox JM, et al. Chikungunya viral arthritis in the United States: a mimic of seronegative rheumatoid arthritis. *Arthritis Rheumatol*. 2015;67:1214-1220; with permission. Copyright © 2015 John Wiley & Sons.)

complication. Currently, no strong evidence exists that CHIKV arthritis can predispose to autoimmune disease.[60]

DIAGNOSIS

CHIKV infection should be considered in patients with acute onset of fever and polyarthralgia, especially travelers returning from endemic or outbreak areas. Laboratory diagnosis is best accomplished by testing serum or plasma to detect virus, viral nucleic acid, or virus-specific IgM and neutralizing antibodies. Viral culture may detect virus in the first 3 days of illness; however, CHIKV should be handled under biosafety level conditions. In the first week of illness, RNA detection using RT-PCR is preferable. IgM antibodies normally develop toward the end of the first week of illness.

Supportive Studies: Leucopenia and lymphopenia are common during CHIKV infection but less pronounced than with dengue. Thrombocytopenia and hemorrhagic manifestations are rare.

DIFFERENTIAL DIAGNOSIS

Pruritus, although rarely pronounced, can help distinguish CHIKV from ZIKV infection because this symptom is more common in the later. Petechiae and purpura are rare with CHIKV and more common with dengue. Mayaro, Sindbis, O'nyong-nyong, and rubella virus infections can mimic CHIKV, especially in female patients.

CLINICAL COURSE, PROGNOSIS, MANAGEMENT, AND PREVENTION

No licensed vaccine or antiviral drug is available against CHIKV. Current treatment mainly involves the use of antiinflammatory drugs for symptomatic relief. No specific treatment or vaccine is currently available to prevent infection.

MAYARO, O'NYONG-NYONG, ROSS RIVER, AND SINDBIS GROUP VIRUSES

ETIOLOGY AND PATHOGENESIS

MAYV was first isolated from sick forest workers in Trinidad in 1954, and it is now endemic in South America, where is causes periodic outbreaks, most recently Haiti. O'nyong-nyong virus first emerged in Uganda in 1959 and so far has caused at least three outbreaks in Africa. Ross River virus (RRV) was first isolated in 1959 from mosquitoes trapped in Queensland, Australia, where it is endemic, causing an average of 4000 cases per year. Sindbis virus was first isolated from mosquitoes in 1952 in Egypt and is the most widely distributed arbovirus found in Eurasia, Africa, and Oceania.[51,61]

CLINICAL FEATURES

Illnesses caused by MAYV, RRV, O'nyong-nyong, and the Sindbis virus group commonly present with an acute febrile illness of 3 to 5 days' duration after a 2- to 7-day incubation period. Most patients present with headache, myalgia, rash, and arthralgia that may last for weeks or months.

CUTANEOUS FINDINGS

Rash occurs in 30% to 50% of cases in MAYV and RRV infections but is almost universal (≤90%) with Sindbis

and O'nyong-nyong viruses. The morphology is either maculopapular or micropapular, and the exanthema usually appears by the fifth day and fades within 3 to 4 days. The incidence of rash is higher in children than in adults.

NONCUTANEOUS FINDINGS

Arthralgia, accompanied by joint edema in 20% of cases, is a very prominent sign that causes temporary incapacity in many patients. Arthralgia is present in virtually all confirmed cases and persists in some for at least 2 months but with decreasing severity.

COMPLICATIONS

Arthritis, similar to CHIKV, is the most common complication. Protracted disease—primarily arthralgia—is well documented for Sindbis virus, RRV, and MAYV disease and can be persistent and incapacitating for up to 12 months. Fatalities are rare.

DIAGNOSIS

Serologies, including IgM and IgG enzyme-linked immunosorbent tests, are used as standard for laboratory-based diagnoses of arthritogenic alphavirus disease. MAYV, RRV, Sindbis, and O'nyong-nyong infection can be confirmed by RT-PCR or virus isolation, but the viremic phase is short.

Supportive Studies: Leucopenia is a constant finding in all cases. Mild albuminuria and slight thrombocytopenia are occasionally seen.

DIFFERENTIAL DIAGNOSIS

Rubella virus and CHIKV infection should be considered in the differential diagnosis of these viruses. The geographical location and travel exposure of the patient should help differentiate these viruses.

MANAGEMENT AND PREVENTION

No antiviral therapy or vaccines are available for these infections. Avoiding mosquito bites by wearing protective clothing and ng repellents and insecticide-impregnated mosquito nets is important for prevention.

REFERENCES

1. Holbrook MR. Historical perspectives on flavivirus research. *Viruses*. 2017;9(5).
2. Reed W, Carroll J, Agramonte A, et al. The etiology of yellow fever—a preliminary note. *Public Health Pap Rep*. 1900;26:37-53.
3. Cleland JB, Bradley B. Dengue fever in Australia: its history and clinical course, its experimental transmission by Stegomyia fasciata, and the results of inoculation and other experiments. *J Hyg (Lond)*. 1918;16(4):317-418.
4. Shope RE. The discovery of arbovirus diseases. *Ann N Y Acad Sci*. 1994;740:138-145.
5. Briant L, Despres P, Choumet V, et al. Role of skin immune cells on the host susceptibility to mosquito-borne viruses. *Virology*. 2014;464-465:26-32.
6. Bhatt S, Gething PW, Brady OJ, et al. The global distribution and burden of dengue. *Nature*. 2013;496(7446):504-507.
7. Malavige GN, Ogg GS. Pathogenesis of vascular leak in dengue virus infection. *Immunology*. 2017;151(3):261-269.
8. Muller DA, Depelsenaire AC, Young PR. Clinical and laboratory diagnosis of dengue virus infection. *J Infect Dis*. 2017;215(suppl 2):S89-S95.
9. Guzman MG, Harris E. Dengue. *Lancet*. 2015;385(9966):453-465.
10. Carod-Artal FJ, Wichmann O, Farrar J, et al. Neurological complications of dengue virus infection. *Lancet Neurol*. 2013;12(9):906-919.
11. Pedrosa MS, de Paiva M, Oliveira L, et al. Oral manifestations related to dengue fever: a systematic review of the literature. *Aust Dent J*. 2017;62(4):404-411.
12. L'Azou M, Moureau A, Sarti E, et al. Symptomatic dengue in children in 10 Asian and Latin American countries. *N Engl J Med*. 2016;374(12):1155-1166.
13. Hunsperger EA, Munoz-Jordan J, Beltran M, et al. Performance of dengue diagnostic tests in a single-specimen diagnostic algorithm. *J Infect Dis*. 2016;214(6):836-844.
14. Malisheni M, Khaiboullina SF, Rizvanov AA, et al. Clinical efficacy, safety, and immunogenicity of a live attenuated tetravalent dengue vaccine (CYD-TDV) in children: a systematic review with meta-analysis. *Front Immunol*. 2017;8:863.
15. Ritter JM, Martines RB, Zaki SR. Zika virus: pathology from the pandemic. *Arch Pathol Lab Med*. 2017;141(1):49-59.
16. Cordel N, Birembaux X, Chaumont H, et al. Main characteristics of zika virus exanthema in Guadeloupe. *JAMA Dermatol*. 2017;153(4):326-328.
17. Krauer F, Riesen M, Reveiz L, et al. Zika virus infection as a cause of congenital brain abnormalities and Guillain-Barré syndrome: systematic review. *PLoS Med*. 2017;14(1):e1002203.
18. de Paula Freitas B, de Oliveira Dias JR, Prazeres J, et al. Ocular findings in infants with microcephaly associated with presumed zika virus congenital infection in Salvador, Brazil. *JAMA Ophthalmol*. 2016 Feb 9. doi: 10.1001/jamaophthalmol.2016.0267. [Epub ahead of print].
19. Ventura CV, Maia M, Ventura BV, et al. Ophthalmological findings in infants with microcephaly and presumable intra-uterus Zika virus infection. *Arq Bras Oftalmol*. 2016;79(1):1-3.
20. Miranda-Filho Dde B, Martelli CM, Ximenes RA, et al. Initial description of the presumed congenital Zika syndrome. *Am J Public Health*. 2016;106(4):598-600.
21. Oehler E, Watrin L, Larre P, et al. Zika virus infection complicated by Guillain-Barre syndrome—case report, French Polynesia, December 2013. *Euro Surveill*. 2014;19(9).
22. Araujo LM, Ferreira ML, Nascimento OJ. Guillain-Barre syndrome associated with the Zika virus outbreak in Brazil. *Arq Neuropsiquiatr*. 2016;74(3):253-255.
23. Eppes C, Rac M, Dunn J, et al. Testing for Zika virus infection in pregnancy: key concepts to deal

with an emerging epidemic. *Am J Obstet Gynecol*. 2017;216(3):209-225.
24. Landry ML, St George K. Laboratory diagnosis of Zika virus infection. *Arch Pathol Lab Med*. 2017;141(1):60-67.
25. Waggoner JJ, Gresh L, Vargas MJ, et al. Viremia and clinical presentation in nicaraguan patients infected with Zika Virus, chikungunya virus, and dengue virus. *Clin Infect Dis*. 2016;63(12):1584-1590.
26. Wolfe MS, Calisher CH, McGuire K. Spondweni virus infection in a foreign resident of Upper Volta. *Lancet*. 1982;2(8311):1306-1308.
27. Shapiro-Mendoza CK, Rice ME, Galang RR, et al. Pregnancy outcomes after maternal Zika Virus infection during pregnancy—U.S. territories, January 1, 2016-April 25, 2017. *MMWR Morb Mortal Wkly Rep*. 2017;66(23):615-621.
28. Focosi D, Maggi F, Pistello M. Zika virus: implications for public health. *Clin Infect Dis*. 2016;63(2):227-233.
29. Monath TP, Vasconcelos PF. Yellow fever. *J Clin Virol*. 2015;64:160-173.
30. Carneiro SC, Cestari T, Allen SH, et al. Viral exanthems in the tropics. *Clin Dermatol*. 2007;25(2):212-220.
31. Niedrig M, Kursteiner O, Herzog C, et al. Evaluation of an indirect immunofluorescence assay for detection of immunoglobulin M (IgM) and IgG antibodies against yellow fever virus. *Clin Vaccine Immunol*. 2008;15(2):177-181.
32. Domingo C, Escadafal C, Rumer L, et al. First international external quality assessment study on molecular and serological methods for yellow fever diagnosis. *PLoS One*. 2012;7(5):e36291.
33. Domingo C, Patel P, Yillah J, et al. Advanced yellow fever virus genome detection in point-of-care facilities and reference laboratories. *J Clin Microbiol*. 2012;50(12):4054-4060.
34. Boldescu V, Behnam MAM, Vasilakis N, et al. Broad-spectrum agents for flaviviral infections: dengue, Zika and beyond. *Nat Rev Drug Discov*. 2017;16(8):565-586.
35. Barrett ADT. Yellow fever live attenuated vaccine: a very successful live attenuated vaccine but still we have problems controlling the disease. *Vaccine*. 2017;35(44):5951-5955.
36. Tyler KL. Current developments in understanding of West Nile virus central nervous system disease. *Curr Opin Neurol*. 2014;27(3):342-348.
37. Hollidge BS, Gonzalez-Scarano F, Soldan SS. Arboviral encephalitides: transmission, emergence, and pathogenesis. *J Neuroimmune Pharmacol*. 2010;5(3):428-442.
38. Debiasi RL, Tyler KL. West Nile virus meningoencephalitis. *Nat Clin Pract Neurol*. 2006;2(5):264-275.
39. Sejvar JJ, Marfin AA. Manifestations of West Nile neuroinvasive disease. *Rev Med Virol*. 2006;16(4):209-224.
40. Ferguson DD, Gershman K, LeBailly A, et al. Characteristics of the rash associated with West Nile virus fever. *Clin Infect Dis*. 2005;41(8):1204-1207.
41. Del Giudice P, Schuffenecker I, Zeller H, et al. Skin manifestations of West Nile virus infection. *Dermatology*. 2005;211(4):348-350.
42. Shah S, Fite LP, Lane N, et al. Purpura fulminans associated with acute West Nile virus encephalitis. *J Clin Virol*. 2016;75:1-4.
43. Davis LE, DeBiasi R, Goade DE, et al. West Nile virus neuroinvasive disease. *Ann Neurol*. 2006;60(3):286-300.
44. Hayes EB, Sejvar JJ, Zaki SR, et al. Virology, pathology, and clinical manifestations of West Nile virus disease. *Emerg Infect Dis*. 2005;11(8):1174-1179.
45. Jeha LE, Sila CA, Lederman RJ, et al. West Nile virus infection: a new acute paralytic illness. *Neurology*. 2003;61(1):55-59.
46. Patel H, Sander B, Nelder MP. Long-term sequelae of West Nile virus-related illness: a systematic review. *Lancet Infect Dis*. 2015;15(8):951-959.
47. Davis LE, Beckham JD, Tyler KL. North American encephalitic arboviruses. *Neurol Clin*. 2008;26(3):727-757, ix.
48. Khairallah M, Ben Yahia S, Ladjimi A, et al. Chorioretinal involvement in patients with West Nile virus infection. *Ophthalmology*. 2004;111(11):2065-2070.
49. Tardei G, Ruta S, Chitu V, et al. Evaluation of immunoglobulin M (IgM) and IgG enzyme immunoassays in serologic diagnosis of West Nile Virus infection. *J Clin Microbiol*. 2000;38(6):2232-2239.
50. Biedenbender R, Bevilacqua J, Gregg AM, et al. Phase II, randomized, double-blind, placebo-controlled, multicenter study to investigate the immunogenicity and safety of a West Nile virus vaccine in healthy adults. *J Infect Dis*. 2011;203(1):75-84.
51. Suhrbier A, Jaffar-Bandjee MC, Gasque P. Arthritogenic alphaviruses—an overview. *Nat Rev Rheumatol*. 2012;8(7):420-429.
52. Burt FJ, Chen W, Miner JJ, et al. Chikungunya virus: an update on the biology and pathogenesis of this emerging pathogen. *Lancet Infect Dis*. 2017;17(4):e107-e117.
53. Nawas ZY, Tong Y, Kollipara R, et al. Emerging infectious diseases with cutaneous manifestations: viral and bacterial infections. *J Am Acad Dermatol*. 2016;75(1):1-16.
54. Seetharam KA, Sridevi K, Vidyasagar P. Cutaneous manifestations of chikungunya fever. *Indian Pediatr*. 2012;49(1):51-53.
55. Bandyopadhyay D, Ghosh SK. Mucocutaneous manifestations of Chikungunya fever. *Indian J Dermatol*. 2010;55(1):64-67.
56. Bandyopadhyay D, Ghosh SK. Mucocutaneous features of Chikungunya fever: a study from an outbreak in West Bengal, India. *Int J Dermatol*. 2008;47(11):1148-1152.
57. Bhat RM, Rai Y, Ramesh A, et al. Mucocutaneous manifestations of chikungunya fever: a study from an epidemic in coastal karnataka. *Indian J Dermatol*. 2011;56(3):290-294.
58. Kumar V, Jain R, Kumar A, et al. Chikungunya fever presenting as life threatening thrombotic thrombocytopenic purpura. *J Assoc Physicians India*. 2017;65(7):96-100.
59. Lee YS, Quek SC, Koay ES, et al. Chikungunya mimicking atypical Kawasaki disease in an infant. *Pediatr Infect Dis J*. 2010;29(3):275-277.
60. Goupil BA, Mores CN. A Review of Chikungunya Virus-induced arthralgia: clinical manifestations, therapeutics, and pathogenesis. *Open Rheumatol J*. 2016;10:129-140.
61. Tesh RB, Watts DM, Russell KL, et al. Mayaro virus disease: an emerging mosquito-borne zoonosis in tropical South America. *Clin Infect Dis*. 1999;28(1):67-73.

Sexually Transmitted Diseases

PART 26

Chapter 170 :: Syphilis

:: Susan A. Tuddenham & Jonathan M. Zenilman

AT-A-GLANCE

- A disease caused by the spirochete *Treponema pallidum* subspecies *pallidum* that is almost exclusively sexually transmitted.
- In the United States, syphilis disproportionately affects men who have sex with men and African American heterosexual communities.
- The most common and recognizable manifestations are usually cutaneous.
- Syphilis passes through 4 distinct clinical phases:
  - Primary stage, characterized by a chancre.
  - Secondary stage, characterized typically by skin eruption(s) with or without lymphadenopathy and organ disease.
  - A latent period of varied duration, characterized by the absence of signs or symptoms of disease, with only reactive serologic tests as evidence of infection.
  - Tertiary stage, with cutaneous, neurologic, or cardiovascular manifestations.
- Neurosyphilis and ophthalmic syphilis can occur at any stage.
- The recommended treatment for most types of syphilis is benzathine penicillin G, with dose and administration schedule determined by disease stage.
- Any patient diagnosed with syphilis should be tested for other sexually transmitted infections, including HIV.

DEFINITIONS

Syphilis is a sexually transmitted infection caused by *Treponema pallidum* subspecies *pallidum*. Many of its manifestations are cutaneous, making it of interest and importance to dermatologists, especially as morbidity from syphilis rises in the developed world and continues in the developing world.

HISTORICAL PERSPECTIVE

Whether syphilis arose in the New World, the Old World, or both remains a controversial subject.[1-3] Pandemics of syphilis began in the Old World in Naples, Italy, 1 year after Columbus returned from the New World.[2,4,5] Syphilis earned the monicker "great pox,"[5] to distinguish it from another virulent disease with cutaneous manifestations, smallpox. The disease takes its name from a poem, called *Syphilis, Sive Morbus Gallicus* (*Syphilis*, or *the French Disease*), written in 1530 by Giralomo Fracastoro, a physician and poet of Verona. Part of the poem recounts the story of a shepherd, named Syphilus, who, as punishment for angering Apollo, was afflicted with the disease known as syphilis.[4] Other names besides Morbus Gallicus and the Great Pox by which the disease has been known include lues, the Great Mimic, the Great Masquerader, the Great Imitator, and the Neapolitan disease.[4] The cause of syphilis, the bacterium *T. pallidum*, was discovered by Schaudinn and Hoffman in 1905.[6] Darkfield microscopy was pioneered in 1906 by Landsteiner, and serologic testing for syphilis was pioneered in 1910 by Wasserman.[5]

Because of the skin manifestations, syphilis historically has been of major interest to dermatologists, who were leaders in syphilis research and treatment in Europe and the United States, especially in the prepenicillin era.[7-12] One of the leading American dermatology journals, currently called *Archives of Dermatology*, was before 1955 called *Archives of Dermatology and Syphilology*. An editorial explaining

the jettisoning of "Syphilology" from the journal's title stated:

> The diagnosis and treatment of patients with syphilis is no longer an important part of dermatologic practice. The papers on syphilis that are now submitted to the Archives are few and far between. Few dermatologists now have patients with syphilis; in fact, there are decidedly fewer patients with syphilis, and so continuance of the old label, "Syphilology," on this publication seems no longer warranted.

Elsewhere in the world, however, the link between dermatology and syphilology (and other sexually transmitted diseases) remains stronger.[13,14]

Treatments for syphilis in the prepenicillin era included burning sores with hot irons, rubbing mercury-containing ointments (calomel) on lesions, administering mercury orally, and treating with arsenicals, including salvarsan (also called "606" or arsphenamine), which was the first systemic treatment and was discovered by Ehrlich and Hata in 1909.[5] Arsenical and other heavy metal-based therapies required multiple injections for at least a year, and were highly toxic. Recognition that *T. pallidum* was heat sensitive led the Viennese psychiatrist Julius Wagner von Jauregg to develop syphilis malariotherapy in 1917,[15] an accomplishment for which he received the Nobel Prize in Medicine in 1927.[16] That therapy involved inoculating syphilis patients with malaria, allowing them to experience, optimally, between 10 and 12 febrile episodes, and then treating them with quinine.[10,16-18] The treatment reportedly led to complete or partial remission of neurosyphilis (general paresis) in a substantial proportion of patients, although it killed an estimated 10% of those receiving the therapy.[17]

Two studies have provided the most insight into the natural history of syphilis. The first was a retrospective study of approximately 2000 persons with syphilis in Oslo, where mercury treatments standard in other places were not used.[18] The second was the infamous Tuskegee syphilis study, in which 399 black men from Alabama who had late syphilis were prospectively followed from 1932 to 1972.[19] The men were denied treatment for syphilis, even after the discovery of the effectiveness of penicillin for the disease. There were multiple other serious ethical lapses in the study. The aftermath of the study led to major changes in ethical requirements for conducting clinical research in the United States.[20]

Of historical interest, persons said to have suffered from syphilis include Ivan the Terrible, Henry VIII, Henri de Toulouse-Lautrec, and Al Capone,[5] among many others.[21] Osler, aware of the high prevalence and protean manifestations of syphilis, has been quoted as saying, "He who knows syphilis knows medicine."[5] By the early 1930s, it was estimated that approximately 10% of Americans had syphilis, with 500,000 new infections and 60,000 cases of congenital syphilis per year.[22] In 1937, Surgeon General Thomas Parran, keenly interested in syphilis, published a book, titled *Shadow on the Land*,[23] that focused on the substantial public health harms of the then-prevalent disease.[22] Parran developed and implemented a national program for syphilis prevention and control, emphasizing screening, treatment, community involvement, and education.[22,24] Penicillin was first used to treat syphilis in 1943, and became widely available in the postwar era.[5] As a result of effective treatment, syphilis incidence then declined sharply in the 1950s, followed by a modest rebound through the mid-1980s. In the late 1980s and early 1990s syphilis reemerged in the United States in the South and in large cities, disproportionately affecting black Americans, and associated with crack cocaine and commercial sex workers.[2,25] The waning of the crack epidemic and development of the National Plan to Eliminate Syphilis from the United States, released in 1999 by the Centers for Disease Control and Prevention (CDC), resulted in declining rates in heterosexuals.[26] However, since the late 1990s, there has been a dramatic increase in incidence in men who have sex with men in the United States and other developed countries.

EPIDEMIOLOGY

In 2000 and 2001, the rate of reported primary and secondary syphilis in the United States was the lowest it had been since reporting began in 1941, at 2.1 cases per 100,000 population. Unfortunately, syphilis incidence in the United States has been increasing steadily since 2001; the rate of primary and secondary syphilis (which is indicative of incident infection) was 6.3 cases per 100,000 population in 2014, the highest rate reported since 1994.[27] The current syphilis epidemic in the United States has been primarily driven by increasing cases among gay, bisexual, and other men who have sex with men (MSM). Of 19,999 reported cases of primary and secondary syphilis in 2014, 12,226 (61.1%) were among MSM and 3,407 (17.0%) were among men without information about the gender of the sex partner. Among male cases with information on gender of sex partner, 82.9% occurred in MSM.[27] Incidence of syphilis and other sexually transmitted infections among MSM had declined during the AIDS epidemic, and the subsequent increased incidence among MSM has been attributed to a number of factors, including a decrease in safe sex practices resulting from successful HIV treatments, use of the internet to meet sex partners, serosorting (ie, attempting to choose sex partners who share the same HIV status), and an increase in use of recreational drugs, including methamphetamine and erectile dysfunction medicines.[2,28,29] Studies that led to the approval, in 2012, for the use of oral antiretroviral medications for pre-exposure prophylaxis to prevent HIV acquisition in high-risk individuals generally did not report increased sexual risk behavior or acquisition of sexually transmitted infections.[30] However, how widespread rollout of preexposure prophylaxis may affect syphilis rates, particularly in MSM, remains to be seen.[31] The epidemics of HIV and syphilis in the United States MSM population have been intimately linked. Not only are a high proportion of patients coinfected (in 2014, 51.2% of cases

of reported primary and secondary syphilis among MSM were also HIV-positive),[27] but incident syphilis infection also is associated with a significantly increased risk of HIV acquisition.[32-34] All patients diagnosed with syphilis should be tested for the other sexually transmitted infections, including HIV. Conversely, all patients diagnosed with HIV should also be tested for the other sexually transmitted infections, including syphilis.[35]

Although rising syphilis incidence in the United States is primarily attributable to cases in MSM, the general male and female populations are affected as well. During 2013-2014, the primary and secondary syphilis rate increased 14.4% in men and 22.7% in women.[27] The increase in women has been particularly concerning because of a concomitant rise in reported cases of congenital syphilis. In 2015, the CDC released a report warning of a 38% increase in reported cases of congenital syphilis between 2012 and 2014. Although rates in all ethnic groups increased, the rate of congenital syphilis in blacks remained approximately 10 times the rate among whites in 2014.[36]

Rates of primary and secondary syphilis nationwide are highest in persons 20 to 29 years old. There is a major health disparity; blacks are disproportionately affected by primary and secondary syphilis, with rates in 2014 more than 5 times higher than rates among non–Hispanic whites overall.[27]

Recently, there has been an increase in reported cases of ocular syphilis. Between December 2014 and March 2015, 12 cases of ocular syphilis were reported from San Francisco, California, and Seattle, Washington. Several of these patients suffered severe sequelae, including permanent vision loss. Subsequent case finding indicated more than 200 cases reported over the past 2 years from 20 states. As a result, in October 2015, the CDC released a clinical advisory calling for vigilance and careful screening for visual complaints in any patient at risk for syphilis.[37,38]

Internationally, morbidity from syphilis remains substantial. Each year an estimated 12 million new cases of syphilis occur, and 1 million pregnancies are complicated by syphilis.[2]

CLINICAL FEATURES

When considering syphilis in the differential diagnosis in a patient, clinicians should take into account the epidemiology and routes of transmission of the disease. This requires taking a complete sexual history. Patients should be asked about partners (including gender and number of recent sexual partners), sexual practices (including anatomic exposure site and use of condoms), and past history of sexually transmitted infections. Effective interviewing skills characterized by respect and a nonjudgmental attitude are critical to obtaining an accurate assessment of behavioral risk.[35]

Untreated syphilis is characterized by multiple distinct stages of disease, each of which is associated with different clinical (including cutaneous) manifestations. Table 170-1 outlines the natural history of syphilis.

TABLE 170-1
Stages of Syphilis

Contact (one-third become infected)	
↓ (10-90 days)	
Primary (chancre)	
↓ (3-12 weeks)	
Secondary (mucocutaneous lesions, organ involvement)	Neurosyphilis can occur (including ocular syphilis)
↓ (4-12 weeks)	
Early latent → Relapsing (1/4) (1 year from contact)	
↓	
Late latent (more than 1 year)	
Continue late latent (two-thirds)	Tertiary (one-third) ▪ Late benign (16%) ▪ Cardiovascular (10%) ▪ Neurosyphilis (5% to 10%)

EXPOSURE AND INCUBATING SYPHILIS

Syphilis in adults is almost exclusively sexually acquired, when a person comes in contact with infectious lesions of syphilis on another person. Of note, these lesions are only present during primary or secondary syphilis, so the infection is considered sexually transmissible solely in these stages. Importantly, patients with early latent syphilis (within the first year of infection) can relapse into secondary syphilis and become infectious again.[16] Infectious lesions of syphilis in adults, which include chancres, condyloma lata, and mucous patches, can be present anywhere on the body but are typically located in or around the genital, anal, or oral area. Direct contact with infectious lesions during oral, vaginal, or anal sex, or during other sexual activities, can result in inoculation and infection. Lesions on keratinized skin (eg, secondary syphilis palmoplantar lesions and maculopapular rash on the trunk) typically do not contain sufficient treponemes to be infectious, and prophylaxis for persons exposed to noninfectious lesions such as those is neither necessary nor indicated. Infectious lesions of congenital syphilis include discharge from rhinitis ("snuffles") and bullous lesions on the skin.

Nonsexually acquired syphilis rarely occurs[39] and when it does, it is usually via blood transfusion (of unscreened blood),[40] accidental inoculation in an occupational setting (eg, laboratory or health care worker)[41] or nonoccupational setting (eg, tattooing),[42] or through exposure in utero.[43] Transmission to the fetus may occur at any stage of maternal infection, although it is far more likely in the early stages of disease.[16,44]

Estimates of the risk of acquisition ("transmission efficiency") of syphilis following sexual exposure to a person with infectious syphilis are varied and have been derived in 2 types of sources.[45] The first source are data from 3 prospective placebo-controlled trials of prophylactic treatment, in which 9%,[46] 28%,[47] or 63%[48] of sexual contacts to syphilis acquired syphilis. The second source is from studies of persons identified as sex contacts in contact-tracing interviews of persons diagnosed with syphilis, in which 18% to 88% of contacts acquired syphilis.[45] Nevertheless, the relatively high estimates of syphilis acquisition following exposure underscores the importance of prompt treatment and testing of sexual contacts, as discussed 'Disease Reporting and Management of Persons Exposed to Syphilis' section. Persons recently exposed to and infected with syphilis who have yet to manifest signs or symptoms of the disease are said to have incubating syphilis.

PRIMARY SYPHILIS

Primary syphilis is the first stage of syphilis, and is characterized by the appearance of 1 or more chancres. Treponemes in the cerebrospinal fluid (CSF) can be demonstrated in up to 30% of primary and secondary syphilis cases.[49] There may be overlap of secondary syphilis or even neurosyphilis manifestations with primary syphilis.

CUTANEOUS FINDINGS

At the inoculation site, a chancre develops after an incubation period that ranges from 10 to 90 days (average: 3 weeks). The chancre starts as a dusky red macule that evolves into a papule and then a round-to-oval ulcer (Figs. 170-1 to 170-4). The typical chancre, also called a *Hunterian chancre* or *ulcus durum* (hard ulcer), ranges in diameter from a few millimeters to 2 cm and is sharply demarcated with regular, raised borders that are indurated, giving the lesion a cartilaginous feel. The base is usually clean, and the chancre is classically painless. Pain can be reported,[50] and

Figure 170-2 Early chancre on the penile shaft, demonstrating a clean base.

multiple chancres have been reported in 32% to 47% of cases.[51] The absence of any of the typical features of a chancre does not rule out syphilis, however. Variations in clinical presentation can result from the number of spirochetes inoculated, the patient's immune status, concurrent antibiotic therapy, and impetiginization.[52-54] Because they are typically painless, patients might not be aware of chancres, especially if painless and located in areas that are not visible, such as the ventral uncircumcised penis, anus, vagina, cervix, or oral cavity.[55,56]

Common genital locations for a chancre in men include the glans, the coronal sulcus, and the foreskin.[57,58] Retraction of the foreskin when a chancre is present on the underside causes the foreskin to flip suddenly, a sign known as the *dory flop*, after the movement of a dory, a small wooden fishing boat, which flips suddenly when overturned.[57] The dory flop sign can help distinguish chancres from other nonindurated causes of genital ulcer disease, such as herpes simplex virus infection and chancroid, that present without the induration that leads to the sudden flip of the foreskin. Uncommon presentations include giant necrotic chancre, phagedenic chancre (a deep, bright-red, necrotic ulcer with a soft base and exudate, resulting from secondary bacterial infection associated with immunosuppression), phimosis resulting from

Figure 170-1 Early chancre presenting as a large oval ulcer with elevated borders on the shaft of the penis.

Figure 170-3 Chancre on the penile shaft, demonstrating a clean base and elevated borders

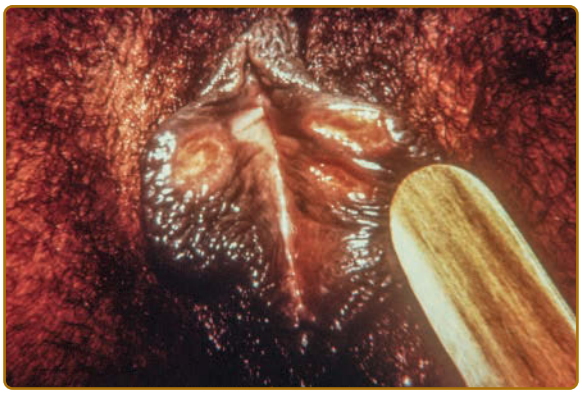

Figure 170-4 Chancres on the labia in a female.

adherence of a chancre on the foreskin to the glans, endourethral ulcers leading to swelling or serosanguinous discharge, and balanitis.[56,58]

Common genital locations in women include the cervix, labia majora, labia minora, fourchette, urethra and perineum (see Fig. 170-4).[58,59] Chancres in women, especially labial ones, can be more edematous than indurated.[58] *Edema indurativum* is a unilateral labial swelling with rubbery consistency and intact surface, indicative of a deep-seated chancre.

Extragenital chancres occur where there may be exposure, and are most frequent in the oropharyngeal cavity.[60,61] Syphilis can be transmitted via either receptive or active oral sexual exposure, and is seen in both heterosexual and MSM.[62,63] Oral lesions are often larger and may lack the indurated borders that are more typical in keratinized tissues (Fig. 170-5). Anal sex can lead to development of chancres in the perianal (Fig. 170-6) or anal areas that can be difficult to detect on routine physical examination.[50,64] Digital or other[65,66] contact with the oral, genital, or anal areas, or receiving a bite (eg, on the nipple during sex)[67] can also lead to infection and chancre on the exposed area.

The chancre heals in 3 to 6 weeks without treatment and 1 to 2 weeks with treatment. Scarring typically does not occur, although thin atrophic scars may occur.[55] Coinfection with herpes simplex virus or *Haemophilus ducreyi*, the causative organism of chancroid, can be present in rare cases.[68-70] Relapses of primary syphilis, called *monorecidive syphilis* or *chancre redux*, arise in the setting of untreated or inadequately treated syphilis and are rare.[71]

Table 170-2 outlines the differential diagnosis of chancres.

Figure 170-5 Chancre on the tongue.

Figure 170-6 Chancre in the perianal area. Fecal material is also present in the area.

NONCUTANEOUS FINDINGS

In 60% to 70% of cases of primary syphilis, painless regional lymphadenopathy arises 7 to 10 days after the chancre appears, especially when the chancre's location is genital. Unilateral lymphadenopathy is more common earlier in the course of disease, with bilateral involvement later in the course.[71]

SECONDARY SYPHILIS

Secondary syphilis is essentially an infectious vasculitis, characterized by localized or diffuse mucocutaneous lesions, often with generalized lymphadenopathy, in the presence of laboratory evidence from tissues or sera consistent with syphilis.[72] Cutaneous and mucosal locations are most common.[73]

TABLE 170-2
Differential Diagnosis of Primary Syphilis

Infectious
- Aphthous ulcer
- Chancroid
- Erosive candidal vulvitis or balanitis
- Granuloma inguinale
- Herpes simplex
- Lymphogranuloma venereum
- Vaccinia

Noninfectious
- Basal cell carcinoma
- Behçet disease
- Fixed-drug eruption
- Squamous cell carcinoma
- Traumatic erosion or ulcer

Figure 170-7 Rash of secondary syphilis with nonscaling, oval pink, ill-defined macules and patches on the trunk.

CUTANEOUS FINDINGS

Lesions of secondary syphilis, classically called *syphilids* or, when affecting the skin, *syphiloderms*,[58] typically erupt 3 to 12 weeks after the chancre appears (up to 6 months after exposure). In some cases lesions of the secondary syphilis develop while the chancre is still present,[51,53] with overlap more common among HIV-infected persons.[53] Rash is present in nearly all cases of secondary syphilis, although the specific type of rash varies.[51,52,74] Erythematous macules (*roseola syphilitica*) or maculopapules are commonly present symmetrically on the trunk and extremities in 40% to 70% of cases (Fig. 170-7), with papular, papulosquamous, or lichenoid presentations less common.[51,74] A white scaly ring on the surface of papulosquamous lesions, called the *Biett collarette* (Fig. 170-8), is characteristic of, but

Figure 170-8 Papulosquamous syphilitic eruption with erythematous, well-demarcated, flattened plaques covered with scales (Biett collarette).

Figure 170-9 Secondary syphilis lesions: multiple, hyperpigmented scaly papules on the palms.

not pathognomonic for, syphilis. The face is typically spared in these generalized syphilids, although seborrheic dermatitis–like lesions around the hairline, termed the *Crown of Venus* or *corona veneris*, can form a crown-like pattern.[55] Lesions are not usually pruritic,[58] although pruritus was reported in up to 40% of patients in one study.[58] The presentation of the rash overall can be subtle or florid, or can develop from subtle macules to more florid papules over time.[75] Erythematous to copper-colored round papules or macules, well demarcated and sometimes with an annular scale, are present on the palms and soles in nearly 75% of cases (Figs. 170-9 to 170-12) and classically cross the palmar creases.[51] Plantar lesions can be variously mistaken for calluses (*clavi syphilitici*). Plantar lesions can also extend to the lateral and posterior aspects of the foot (Fig. 170-13).

Other dermatologic manifestations include a patchy nonscarring alopecia, described as *moth-eaten* (see Fig. 170-11) or, less commonly, a diffuse alopecia of the scalp. Loss of lateral third of the eyebrows can occur. Annular papules and plaques can be present around the mouth and nose, in a presentation colloquially referred to as "nickels and dimes"

Figure 170-10 Secondary syphilis lesions: multiple, hyperpigmented papules with more pronounced scale on the palms.

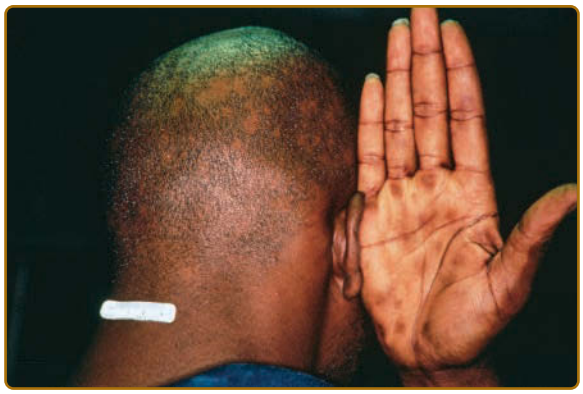

Figure 170-11 Secondary syphilis lesions on palm and moth-eaten alopecia of secondary syphilis.

Figure 170-12 Secondary syphilis lesions on sole of foot.

Figure 170-13 Plantar lesions of secondary syphilis extending to the lateral aspect of the foot.

Figure 170-14 Annular plaques of secondary syphilis on the face, colloquially referred to as "nickels and dimes."

Figure 170-15 Papules of secondary syphilis on the penis.

(Fig. 170-14).[58] Papules and plaques, sometimes annular and occasionally papulosquamous, also can be present on the penis and scrotum (Fig. 170-15). Mucous patches are white-to-yellow erosions on the tongue that efface lingual papillae (Fig. 170-16).[58] Confluence of mucous patches on the tongue has been termed *plaques fauchée en prairie*. Mucous patches can be present elsewhere in the oral cavity (Fig. 170-17), on other mucous membranes (such as on the genitalia), or at the corners of the mouth, where they appear as "split papules," with an erosion traversing the center (Fig. 170-18). Mucous patches are teeming with

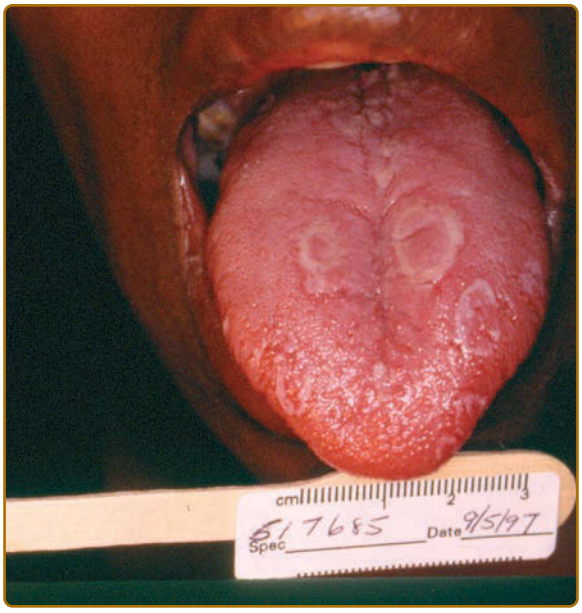

Figure 170-16 Mucous patches of the tongue in secondary syphilis. Note lack of typical lingual papillae in affected areas.

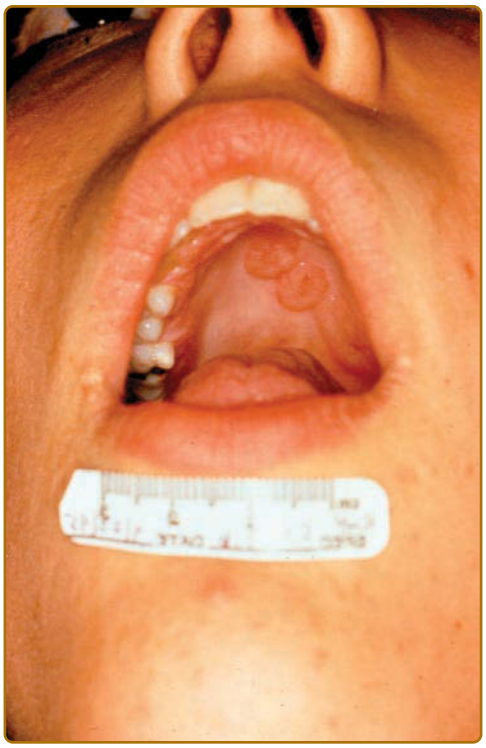

Figure 170-17 Mucous patches on hard palate.

spirochetes and, hence, highly infectious. Also highly infectious are condyloma lata, which present as moist, flat, well-demarcated papules or plaques with macerated or eroded surfaces in intertriginous areas, commonly in the labial folds in females or in the perianal region in all patients (Figs. 170-19 to 170-21).[58] However, any moist intertriginous area of the body can harbor condyloma lata, including the axillae, web spaces between toes, and the folds under breasts, umbilicus (Fig. 170-22) or an abdominal panniculus. Mucous patches and condyloma lata have been reported in 8% and 17% of patients with secondary

Figure 170-18 Split papule, a type of mucous patch of secondary syphilis that can be present at the angle of the mouth, with a characteristic slit traversing its center.

Figure 170-19 Condyloma lata, presenting as moist papules in the perineum.

Figure 170-20 Condyloma lata, presenting as moist, flat-topped plaques on the buttocks.

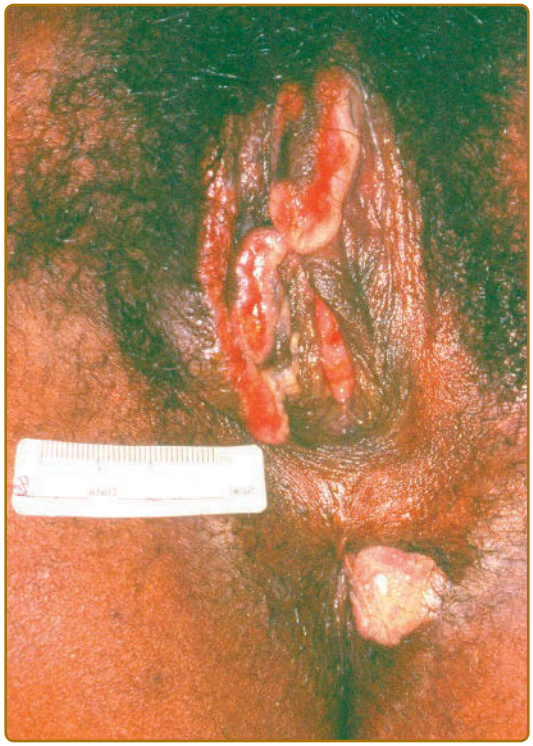

Figure 170-21 Condyloma lata in a female.

Figure 170-22 Moist papule in the umbilicus in secondary syphilis.

Figure 170-24 Multiple hyperpigmented papules of secondary syphilis on the arm.

syphilis, respectively.[51] Malignant lues is a rare manifestation that presents as crusted or scaly papules and plaques that can ulcerate or become necrotic, with an oyster shell-like surface (Fig. 170-23). These lesions, described as rupioid, are often seen in association with high nontreponemal titers and systemic symptoms.[76] Nail changes including fissuring, onycholysis, Beau lines, and onychomadesis have been reported.[55] Less-common presentations of secondary syphilis include hyperkeratotic, lichenoid, nodular, follicular, pustular, frambesiform, and corymbose eruptions and palmoplantar keratodermas (Figs. 170-24 to 170-26).[56,77-80] With the exception of mucous patches and condyloma lata, cutaneous manifestations of secondary syphilis do not contain a substantial number of treponemes and, therefore, are not typically infectious.

The maculopapular rash of secondary syphilis can resemble almost any generalized or localized maculopapular eruption (Table 170-3); mucous membrane lesions resemble mucosal manifestations of other dermatoses, and syphilitic hair loss has to be separated from other etiologies of alopecias.

Figure 170-23 Sharply marginated, necrotic ulcers of secondary syphilis described as "rupioid," covered by thick, dirty crusts (like oyster shells).

Without treatment, the secondary stage typically recedes 4 to 12 weeks after it appears. Scarring typically does not occur, although pigmentary changes (leukoderma colli syphiliticum or, if on the neck, "necklace of Venus") can result[55] from inhibition of melanogenesis. Dermal atrophy, possibly related to elastin degradation, may occur. Absence of syphilids in cinnabar-containing red tattoos has been reported as well, possibly resulting from the antitreponemal effect of mercury in cinnabar.[81]

NONCUTANEOUS FINDINGS

In addition to neurosyphilis (including ocular syphilis),[82] discussed in section "Neurosyphilis" patients with secondary syphilis may experience systemic symptoms that include sore throat, malaise, headache, weight loss, fever, musculoskeletal aches, pruritus, and hoarseness.[74] Pharyngitis and tonsillitis,[83] laryngitis,[84] gastritis,[85] hepatitis,[85] renal disease (membranous glomerulopathy),[86] and periostitis[87] have all been reported in secondary syphilis, as have hematologic abnormalities including lymphopenia, anemia, and elevated erythrocyte sedimentation rate.[88] Lymphadenopathy is common, and is often bilateral and symmetric in distribution.[58]

Figure 170-25 Hyperkeratotic lesions of secondary syphilis on the soles.

Figure 170-26 Psoriaform lesions of secondary syphilis on the arm.

LATENT SYPHILIS

The secondary stage is followed by an asymptomatic stage with no clinical findings, with seroreactivity by definition the only evidence of infection. So-called latent syphilis is a diagnosis of exclusion, after primary, secondary, and tertiary syphilis (including neurosyphilis) have been ruled out. Asymptomatic patients who have acquired syphilis within the last year are classified as having "early latent" infection.[35] The distinction between *early latent* and asymptomatic syphilis acquired more than 1 year ago (often termed *late latent syphilis*), is important for 2 reasons. First, up to 25% of patients with early latent syphilis may relapse into secondary syphilis, leading to possible sexual transmission.[16] Second, clinical management of patients with early latent syphilis differs from management of patients with late latent syphilis.[16,35] The treatment of early latent syphilis is the same as that of primary and secondary (collectively termed *early syphilis*), whereas late syphilis requires an extended therapeutic course.[35]

Persons who acquired syphilis during the preceding year can be diagnosed with *early* latent syphilis. A patient can be classified as having early latent syphilis if, within the year preceding discovery of the reactive serologic test, the patient had 1 of the following:

1. Documented seroconversion or a sustained (longer than 2 weeks) fourfold or greater increase in nontreponemal test titers;
2. Unequivocal symptoms of primary or secondary syphilis;
3. A sex partner documented to have primary, secondary, or early latent syphilis; or
4. Reactive nontreponemal and treponemal tests if the patient's only possible exposure occurred within the previous 12 months.[35]

To make a diagnosis of early latent syphilis based on the first or third criterion above, clinicians often need, and should seek, the assistance of the local health department. Because syphilis diagnoses and results of reactive serologic tests for syphilis are reportable in every state and territory of the United States, local or state health departments compile (or attempt to compile) records of all syphilis diagnoses and reactive serologic titers for persons residing in the jurisdiction. Clinicians can contact the "reactor desk" of their local or state health jurisdiction, where syphilis diagnostic and titer histories are maintained, to inquire about a patient's titer history and prior diagnoses and treatments, so that a patient can be staged as having early latent syphilis according to the first criterion above. Public health workers can also search diagnostic and titer histories in their databases for the names of sex partners identified by seroreactive patients, to enable staging patients with early latent syphilis under the third criteria above.

Patients in whom the duration of infection cannot be established based on the criteria reference above should be assumed to have late latent syphilis and must be managed accordingly. Latent syphilis may remain indefinitely or progress to the tertiary stage.

TABLE 170-3

Differential Diagnosis of the Maculopapular Rash of Secondary Syphilis

Most Likely

- Drug eruption
- Pityriasis rosea
- Psoriasis
- Viral eruption
- Differential for condyloma lata: Condyloma acuminata

Consider

- Balanitis
- Cutaneous T-cell lymphoma
- Dermatophytosis
- Eczema
- Erythema multiforme
- Granuloma annulare
- Lichen planus
- Lupus erythematosus
- Sarcoid
- Vasculitis
- Vulvitis

TERTIARY SYPHILIS

Late manifestations of syphilis are rarely seen. However, historically, on the basis of information from the Oslo and Tuskegee studies, approximately one-third of patients with untreated latent syphilis progress to tertiary syphilis, typically after 15 to 40 years, while the other two-thirds remain in latency.[16] Tertiary syphilis manifestations may include gummas (granulomatous, erosive, nodular lesions which most commonly affect the skin and bones), and cardiovascular syphilis.[35] Although neurosyphilis can occur at any stage of disease (see "Neurosyphilis" later), late manifestations of neurosyphilis are also considered to be a manifestation of tertiary syphilis.

CUTANEOUS FINDINGS

The signs and symptoms of syphilis that occur after secondary syphilis that do not involve the cardiovascular or nervous systems have historically been referred to as *late benign syphilis*. Lesions of late benign syphilis are caused by delayed-type hypersensitivity responses to the small number of treponemes present in the involved tissue or organ.[54] The hallmark of late benign syphilis is the *gumma*, a granulomatous nodular lesion with variable central necrosis, which most commonly affect the skin or mucous membranes (80% of gummas).[54] Gummas are nontender pink to dusky-red nodules or plaques that vary in size from millimeters to many centimeters in diameter. They favor sites of previous trauma and may arise anywhere on the body, but are more common on the scalp, forehead (Fig. 170-27), buttocks, and presternal, supraclavicular, or pretibial areas. The nodule is initially firm but develops a gummy consistency from accumulation of necrotic tissue. Gummas may grow both horizontally and vertically, and many assume geometric configurations. Small ulcers and abscesses may be present within the lesions. As the central gumma heals, new lesions may develop on the periphery, forming scalloped borders. In contrast to noduloulcerative lesions, gummas are deeper and more destructive (Fig. 170-28). Tissue necrosis eventuates in cylindrical, punched-out ulcers with clean granulomatous bases covered with adherent yellow-white slough (Fig. 170-29). The ulcer may enlarge, remain unchanged, or heal spontaneously, even as the gumma enlarges. Superficial gummas heal with atrophic scars, whereas deeper lesions leave thickened, pitted, ridged scars. Pseudochancre redux refers to a solitary gumma of the penis.

Figure 170-28 Aggressive gumma of the forehead causing destruction of the calvarium, mimicking advanced, destructive basal cell carcinoma.

Gummas involving the mucous membranes typically affect the palate, nasal mucosa, tongue, tonsils, and pharynx. The lesions ulcerate and can be disfiguring, as when they cause a saddle-nose deformity from destruction of nasal cartilage and bone, or perforation

Figure 170-27 Disfiguring gummatous infiltration of the glabella and forehead with scattered ulcerations in a 60-year-old woman with late benign syphilis.

Figure 170-29 Two deep, punched-out ulcers in the popliteal fossa covered with an adherent yellow slough at the base. This is the classical appearance of nodular gummas.

Figure 170-30 Destruction of the nasal cartilage and bone by a gumma leads to a saddle nose (**A**) and to the perforation of the nasal cartilage and skin and thus to considerable mutilation (**B**).

of the nose or palate (Fig. 170-30).[54] Gummas do not heal without appropriate antibiotic therapy, but in the setting of appropriate therapy respond briskly, leaving scars.[16] Chronic interstitial glossitis can develop even after penicillin treatment and may undergo malignant degeneration (Fig. 170-31).

Other manifestations of late benign syphilis affecting the skin include granulomatous nodular and noduloulcerative lesions and psoriasiform plaques.[55] Nodular and noduloulcerative lesions are superficial, firm, painless, dull-red, shiny, flat nodules that range in size from several millimeters to 2 cm. They appear in a grouped configuration, can coalesce into large plaques or ulcerate, and can resemble granuloma annulare.[89,90] Psoriasiform plaques are most commonly seen on the arms, back, and face.

Table 170-4 outlines the differential diagnosis of dermatologic manifestations of tertiary syphilis.

NONCUTANEOUS FINDINGS

Besides the skin and mucous membranes, gummas can affect practically any organ, but especially the bones, as well as the liver, heart, brain, stomach, and upper respiratory tract.[16] When they involve critical organs such as the brain, gummas can have serious complications.[91]

Historically, cardiovascular manifestations of tertiary syphilis affected 10% to 40% of those infected and were thought to be responsible for most deaths caused by syphilis.[16] Syphilis typically causes syphilitic aortitis, leading to aortic regurgitation in 10% of individuals with untreated disease,[92] and can also cause coronary ostial stenosis and saccular aneurysm.[93] *T. pallidum* DNA has been detected in an aortic aneurysm, demonstrating that infection of the aorta leads to direct damage to the tissue.[94]

Figure 170-31 Premalignant, chronic, interstitial glossitis secondary to gummatous infiltration of the tongue.

TABLE 170-4
Differential Diagnosis of Tertiary Syphilis

Consider
- Deep fungal infections
- Granulomatosis with polyangiitis (Wegener polyangiitis)
- Leishmaniasis
- Lupus vulgaris
- Lymphomas
- Metastatic carcinoma
- Psoriasis
- Sarcoid
- Sarcomas
- Vasculitis

NEUROSYPHILIS

Infection of the CNS by *T. pallidum* can occur during any stage of infection. "Neuroinvasion," in which *T. pallidum* disseminates to CSF and meninges, occurs very early in syphilis.[95] Neuroinvasion can be transient, with the body clearing the infection, or more sustained, in which case it is called asymptomatic neurosyphilis, defined by CSF abnormalities. Asymptomatic neurosyphilis, if discovered, is usually treated to prevent progression to symptomatic neurosyphilis, although benefits of treatment for asymptomatic neurosyphilis are not well documented.

Early symptomatic neurosyphilis typically manifests as meningitis, resulting in meningismus, fever, or cranial nerve abnormalities (especially cranial nerves II, III, IV, VI, VII, and VIII), or meningovasculitis, resulting in meningitis with stroke, usually affecting the portion of the brain supplied by the middle cerebral artery.[95] Uveitis is the most common ophthalmic manifestation of early neurosyphilis (see "Ocular Syphilis" below), presenting as eye pain, redness, and photophobia, and sensorineural hearing loss is the most common manifestation of otologic syphilis. Ophthalmic and otologic manifestations of early neurosyphilis are managed in the same way as neurologic manifestations.[35,95]

Early symptomatic neurosyphilis is not uncommon. A review of syphilis cases among HIV-infected men in 4 large U.S. cities during 2002 to 2004 showed that almost 2%, including persons at each stage of infection, had symptomatic early neurosyphilis. Ocular abnormalities were most common among those affected, followed by other cranial nerve involvement, acute meningitis, other syndromes (headache, altered mental status, or both), and cerebrovascular accidents. Of those with symptomatic early neurosyphilis, nearly one-third had persistent neurologic deficits 6 months after receiving appropriate treatment.[96]

The 2 syndromes commonly associated with late neurosyphilis are general paresis of the insane, also known as dementia paralytica, and tabes dorsalis.[95] General paresis presents as a rapidly progressive dementia, accompanied by personality changes. Tabes dorsalis presents with sensory ataxia and bowel and bladder dysfunction, resulting from damage to the posterior columns of the spinal cord. Tabes dorsalis can be accompanied by an Argyll Robertson pupil (which accommodates, but does not react to, light) and optic atrophy. These syndromes are now very rare in the developed world.

Clinicians diagnosing a person with syphilis should perform a neurologic review of systems and perform a neurologic examination. According to CDC recommendations, indications for CSF examination in persons with syphilis include neurologic, ophthalmic, or otologic signs or symptoms; evidence of active tertiary syphilis; or treatment failure. HIV infection in-and-of-itself is not an indication for CSF examination.[35]

OCULAR SYPHILIS

Although the syndromes may not always overlap, ocular syphilis has generally been considered to be a subset of neurosyphilis, and as per CDC recommendations should be clinically managed as such.[35] Given the recent increase in reported cases, clinicians should be careful to ask about eye symptoms in evaluating any patient suspected to have syphilis. Ocular syphilis may occur during any stage of infection, and may involve almost any portion of the eye. Chancres or gummas of the conjunctiva, conjunctivitis, and scleroconjunctivitis; syphilitic interstitial keratitis; anterior, posterior, and pan uveitis; multiple retinal complications including retinal detachment, cataracts, and glaucoma, as well as optic nerve involvement (including papillitis, retrobulbar neuritis, optic atrophy, optic nerve gumma, and various stroke syndromes) are among the clinical syndromes that have been described. Furthermore, multiple manifestations of syphilis can be observed in the eye, such as pupillary abnormalities (including the Argyll Robertson pupil), palsies of the third, fourth and sixth nerve, usually from syphilitic basilar meningitis, and focal gummas along the nerves, brainstem infarction, or syphilitic aneurysmal compression or hemorrhage that may involve the optic and oculomotor nerves. Syphilitic basilar meningitis or gummas may cause a chiasmal syndrome with bitemporal hemianopia. Finally, eyelid chancres or condyloma lata of the eyelids have been described, although these do not directly involve the eye.[37,97-99]

CONGENITAL SYPHILIS

Congenital syphilis results from infection in utero with *T. pallidum*. Transplacental fetal infection can occur at any time during pregnancy and at any stage of maternal infection.[100] Probability of transmission of infection depends on the stage of infection in an untreated mother, ranging from 70% to 100% in primary syphilis, 40% for early latent syphilis, and 10% for late latent syphilis.[101] Because infection is spread hematogenously, a chancre is not present on the fetus or infant.[100] In 30% to 40% of cases, congenital syphilis results in stillbirth.[43] Of infants who survive, two-thirds are asymptomatic at delivery and only later develop symptoms.[100]

Clinical findings in symptomatic infants are similar to congenital infections caused by cytomegalovirus, toxoplasmosis, herpes simplex virus, rubella, and other infections.[43] The most prominent manifestations of early congenital syphilis, defined as syphilis in a child younger than 2 years of age, include fever, rash, hepatosplenomegaly, and persistent rhinitis ("snuffles").[100] Hydrops fetalis (edema), lymphadenopathy, neurosyphilis, leukocytosis, thrombocytopenia, periostitis, and osteochondritis also may be present, with the pain associated with osteochondrotic lesions causing the infant to refuse to move the affected anatomic area ("pseudoparalysis of

Figure 170-32 Bullous eruptions on the soles of a newborn with early prenatal syphilis. Bullae have ruptured and now present as erosions ("syphilitic pemphigus").

Parrot").[43,100] If present at delivery, the rash is usually bullous ("syphilitic pemphigus"; Fig. 170-32) and very infectious.[100] Rash that presents at 2 weeks or more after birth, however, is typically maculopapular, with small copper-red lesions similar to lesions of secondary syphilis most commonly affecting the hands and feet.[43] Desquamation and crusting can then occur.[102] Other cutaneous lesions present can include condyloma lata (Fig. 170-33), mucous patches, fissures around the lips, nares, or anus, and petechiae from thrombocytopenia.[43] The skin of the syphilitic neonate is often dry and wrinkled and, in newborns with fair skin, may have a café-au-lait hue (Fig. 170-34).

Late congenital syphilis is defined as disease occurring in a child who is at least 2 years old that typically manifests over the first 2 decades of life.[43] Many manifestations of late congenital syphilis result from damage caused during early infection and are not reversible with treatment. Those manifestations include scars (*rhagades*; Fig. 170-35) resulting from cutaneous fissures; a saddle-nose deformity, resulting from destruction of nasal cartilage; frontal bossing (Olympian brow), thickening of the sternoclavicular portion of the clavicle (Higoumenakia sign), anterior bowing of the midtibia (saber shins), and scaphoid scapula, all resulting from chronic periostitis; and

Figure 170-33 Hyperpigmented papules of syphilis in a neonate.

Figure 170-34 Early prenatal syphilis in a newborn. The skin is dry and wrinkled, with a yellowish-brownish hue. There is hemorrhagic rhinitis. This is what Diday described as "a little wrinkled potbellied *(not seen here)* old man with a cold in his head." Note also the aged appearance of the fingers in this newborn.

peg-shaped notched central incisors (Hutchinson teeth; Fig. 170-36) and mulberry molars, resulting from syphilis vasculitis in developing tooth buds. Other manifestations include eighth nerve deafness and eye abnormalities, including interstitial keratitis, glaucoma, or corneal scarring. The Hutchinson triad refers to Hutchinson teeth, interstitial keratitis, and eighth nerve deafness.[43]

Of note, as with any sexually transmitted disease, the diagnosis of syphilis in a child beyond the neonatal period should raise the question of child abuse.[35]

Figure 170-35 Perioral rhagades are linear scars that result from ulcerations that appear during early congenital syphilis and persist to adulthood.

Figure 170-36 The presence of small, notched, peg-shaped upper incisors (Hutchinson teeth) is also part of the late congenital syphilis triad.

SYPHILIS AND HIV INFECTION

Chap. 168 discusses cutaneous manifestations of the HIV.

The interaction of syphilis and HIV infection is complex.[29] The clinical presentation of syphilis varies in minor ways between HIV-infected and HIV-uninfected persons.[29] HIV-infected persons are more likely to present with more than 1 chancre and with larger and deeper chancres in primary syphilis,[53,103] and are more likely to manifest signs of secondary syphilis while at least 1 chancre is present.[53,104] Atypical and aggressive presentations of syphilis in HIV-infected persons might also be more common, although those presentations are not thought to be unique to HIV coinfection.[29,103]

Some studies have shown syphilis to transiently increase HIV viral load and decrease CD4+ T-cell count during infection, with resolution following treatment.[105-111] Those changes might facilitate HIV transmission by HIV-infected patients coinfected with syphilis.[29,109] An effect of syphilis on progression to AIDS or mortality has not been found.[112] Syphilis also is associated with HIV acquisition,[113] and all persons presenting with syphilis who are not known to be infected with HIV should be tested for HIV.[35] The disruption of epidermal or mucosal barriers caused by syphilis ulcers, and the migration to these lesions of inflammatory cells that are targets for HIV are 2 biologic mechanisms that might account for the synergy between the 2 infections. Common behavioral factors (eg, lack of condom use) also likely contribute to risk of coinfection. All HIV-infected persons entering HIV care should have a serologic test for syphilis, which should be repeated yearly thereafter in all those who are sexually active, or more frequently (every 3 to 6 months) if indicated (depending on risk behaviors).[114] HIV infection also is associated with repeat syphilis infection.[115]

Because of its effect on the immune system, HIV infection is thought to increase risk of neurosyphilis.[29,95] This is based on studies correlating abnormal CSF findings with advanced HIV disease[116] and failure to normalize CSF–VDRL (Venereal Disease Research Laboratory) test results in the presence of HIV infection,[117] especially with lower CD4 cell counts. Additionally, HIV-infected persons with syphilis can experience "neurorelapse," meaning the development of neurosyphilis following appropriate treatment for primary, secondary, or early latent syphilis, and declines in nontreponemal titers consistent with cure.[95]

HIV infection can sometimes complicate serologic diagnosis of syphilis and subsequent followup, as unusual serologic responses have been observed in HIV-infected persons with syphilis.[35] False-negative serologic test results in the setting of the prozone phenomenon[118] and seronegative syphilis[119] have been reported. Also, serofast reactions (ie, persistently reactive nontreponemal test results, even following appropriate treatment) can occur.[120] When syphilis is suspected clinically and serology is nonreactive, skin biopsy can be useful diagnostically, as can darkfield microscopy[35,121] or polymerase chain reaction (PCR)-based assays for *T. pallidum*,[68] if available.

CDC treatment recommendations for syphilis do not depend on HIV infection status, and are supported by limited data indicating that outcomes are not improved with more intense or prolonged treatment.[29,35,122] Titers might decline more slowly in appropriately treated HIV-infected persons,[29,35,123] particularly in those who have lower titers on initial diagnosis.[124] Compared with HIV-uninfected persons, HIV-infected persons with primary or secondary syphilis should have more frequent followup (Table 170-5).[35]

ETIOLOGY AND PATHOGENESIS

T. pallidum subspecies *pallidum* is a motile, spiral-shaped bacterium for which humans are the only natural host.[16] *T. pallidum* ranges in size from 5 to 16 µm in length and is 0.2 to 0.3 µm in diameter.[121] The bacterium is surrounded by a cytoplasmic membrane, which is itself enclosed by a loosely associated outer membrane. Between those membranes lies a thin layer of peptidoglycan, which provides structural stability and houses endoflagella, organelles that are responsible for *T. pallidum*'s characteristic corkscrew motility. Microscopically the bacterium is indistinguishable from other pathogenic treponemes that cause nonvenereal diseases, including *T. pallidum* subspecies *endemicum* (bejel), *T. pallidum* subspecies *pertenue* (yaws), and *T. pallidum* subspecies *carateum* (pinta). The *T. pallidum* genome, sequenced in 1998,[125] is 1.14 Mb in length, relatively small for a bacterium.[16]

The bacterium has very limited metabolic capabilities, making it reliant on host pathways for many of its metabolic needs.[16,73] *T. pallidum* does not survive more than a few hours to days outside its host and cannot be cultured easily in vitro for sustained periods, complicating efforts to understand the organism.[16,73] Instead, it must be propagated in mammals, with rabbits the preferred species because, following testis inoculation, rabbits, unlike mice, experience disease

TABLE 170-5

Centers for Disease Control and Prevention Recommendations for Treatment and Followup of Adults with Primary, Secondary, Early Latent, or Late Latent Syphilis.[35]

STAGE OF DISEASE	HIV STATUS OF PERSON	RECOMMENDED TREATMENT[a]	ALTERNATIVE TREATMENT FOR PENICILLIN-ALLERGIC PERSONS (NONPREGNANT WOMEN ONLY[b])	SCHEDULE FOR FOLLOWUP AFTER TREATMENT[c]	TIME FRAME TO EXPECT FOURFOLD DECLINE IN TITER[d]
Primary or secondary	HIV-uninfected	Benzathine penicillin G, 2.4 million units, administered IM in a single dose	Doxycycline 100 mg orally twice daily for 14 days	6 and 12 months	6 to 12 months
	HIV-infected	Benzathine penicillin G, 2.4 million units, administered IM in a single dose	Doxycycline 100 mg orally twice daily for 14 days	3, 6, 9, 12, and 24 months	6 to 12 months
Early latent	HIV-uninfected	Benzathine penicillin G, 2.4 million units, administered IM in a single dose	Doxycycline 100 mg orally twice daily for 14 days	6, 12, and 24 months after treatment	12 to 24 months
	HIV-infected	Benzathine penicillin G, 2.4 million units, administered IM in a single dose	Doxycycline 100 mg orally twice daily for 14 days	6, 12, 18, and 24 months	12 to 24 months
Late latent (>1 year), or latent of unknown duration	HIV-uninfected	Benzathine penicillin G: 3 doses of 2.4 million units IM given at 1 week intervals	Doxycycline 100 mg orally twice daily for 28 days	6, 12, and 24 months after treatment	12 to 24 months
	HIV-infected	Benzathine penicillin G: 3 doses of 2.4 million units IM given at 1 week intervals	Doxycycline 100 mg orally twice daily for 28 days	6, 12, 18, and 24 months	12 to 24 months

[a]Initial treatment is the same for HIV-uninfected and HIV-infected persons.

[b]Pregnant women must not be treated with doxycycline. If allergic to penicillin, pregnant women must be desensitized and then treated with benzathine penicillin G.

[c]Some persons (eg, men who have sex with men or women who become pregnant) should be screened appropriately in addition to being followed at the recommended intervals to assess clinical and serologic response to treatment.

[d]If titers have not declined fourfold after the stated time frame, consider reinfection or treatment failure (including treatment failure because of neurosyphilis). If at any time after treatment signs or symptoms of syphilis appear, also consider those same possibilities.

manifestations.[16,73] *T. pallidum* divides slowly, taking from 30 to 50 hours in vitro. That slow reproduction rate has important implications for treatment, which must be present in the body for a long period to assure effectiveness against the bacterium.[16]

Following inoculation, *T. pallidum* attaches to host cells, including epithelial, fibroblast-like, and endothelial cells, likely by binding to fibronectin, laminin, or other components of host serum, cell membranes, and the extracellular matrix.[16] It can invade rapidly into the bloodstream—within minutes of inoculation, based on rabbit models—and can cross many barriers in the body, such as the blood–brain barrier and the placental barrier, to infect many tissues and organs. That dissemination leads ultimately to manifestations of syphilis distant from the site of the initial chancre(s) in an infected person and in a developing fetus.[16]

T. pallidum lacks virulence factors common to many other bacteria, including lipopolysaccharide endotoxin.[16] It does, however, produce a brisk immune response, mediated by membrane lipoproteins,[126] that begins shortly after infection. Infection at all stages leads to infiltration by lymphocytes, macrophages, and plasma cells.[73] CD4+ T cells predominate in chancres, and CD8+ T cells predominate in lesions of secondary syphilis.[73] Infection leads also to elaboration of T-helper (Th)-1 cytokines, including interleukin-2 and interferon-γ, although downregulation of the Th1 response during secondary syphilis, coincident with the peaking of antibody titers,[73] might contribute to the organism's ability to evade the host immune response.[54,127] Subtyping studies of *T. pallidum* have linked certain strains of the organism to neurosyphilis.[128]

The humoral immune response begins with production of immunoglobulin (Ig) M antibodies approximately 2 weeks after exposure, followed 2 weeks thereafter by IgG antibodies.[126] IgM, in addition to IgG, continues to be produced during infection and can lead to immune-complex formation.[126] Antibody titers peak during bacterial dissemination in secondary syphilis.[73] Some antibodies cross-react with other treponemal species, and some are specific for *T. pallidum* subspecies *pallidum*. The immune response is somewhat active against the organism, helping block attachment of the organism to host cells, conferring passive immunity in rabbit models, and enhancing phagocytosis in vitro.[73]

The immune response is sufficient to prevent syphilis reinfection in persons who have untreated syphilis.

In other words, in what is called the *law of Colles* or *chancre immunity*, persons with untreated syphilis will not experience another episode of primary syphilis as long they remain untreated.[73] However, the immune response is insufficient to eradicate *T. pallidum* from the host. In addition to suppressing the Th1 response, the organism is thought to evade those host defenses by taking harbor in immune-privileged tissues (eg, CNS, eye, and placenta), failing to be present in sufficient quantities (eg, during latent infection) to trigger a host response, varying its surface proteins during infection through gene conversion, and overcoming host attempts to prevent bacterial access to iron, which is necessary for bacterial growth.[16,73] The immune response is also inadequate to prevent reinfection after a person is cured of syphilis, although it might modify the course of reinfection. Compared with persons with syphilis for the first time, for example, reinfected persons may be more likely to be asymptomatic.[129]

The immune response is also likely responsible for the tissue damage caused in syphilis.[16] Damage to axons located near the site of a chancre might explain why that lesion, although ulcerative, is typically painless.[130]

Interest in a vaccine for syphilis continues, with focus on using outer membrane protein antigens to elicit an immunoprotective response.[131] However, a number of barriers to vaccine development exist. Those include variability in outer membrane protein antigens, the limited number of antigens on *T. pallidum* to which immunoprotective antibodies could bind, the possibility that the formation of a host protein coat around *T. pallidum* might prevent antibody binding, and a potential lack of commercial incentive to produce a vaccine.[131]

DIAGNOSIS

Diagnosis of syphilis depends on clinical suspicion combined with laboratory testing to directly or indirectly detect infection with *T. pallidum*. Of note, in cases where clinical suspicion for syphilis is high, clinicians should not wait for the results of laboratory testing before administering appropriate treatment. Clinicians should also remember that serologies can be negative in up to 30% of patients with primary syphilis.[132]

DIRECT DETECTION OF *T. PALLIDUM*

Direct detection of *T. pallidum*, provides definitive evidence of infection, and is particularly important in primary syphilis, given that serologies may be negative. However, these tests, including darkfield microscopy, which has been a mainstay of diagnosis for decades, are rarely available outside of specialized settings.[133]

DARKFIELD MICROSCOPY

When available, darkfield microscopic examination is the diagnostic test of choice in chancres, moist lesions of secondary syphilis (condylomata lata and mucous patches), and the discharge from rhinitis in congenital syphilis. Darkfield examination (Fig. 170-37) will often be positive before serologic tests become reactive.[134] Importantly, because nonpathogenic treponemes are normally present in the oral cavity and can be mistaken for *T. pallidum*, darkfield microscopy cannot be used to test oral lesions.[135] The number of *T. pallidum* organisms in secondary syphilis lesions except for mucous patches and condyloma lata is generally not sufficient to allow darkfield diagnosis.

Figure 170-37 Darkfield microscopy showing a treponeme.

Universal precautions must be used when collecting and handling darkfield specimens, as lesions of syphilis suitable for darkfield examination are very infectious. Darkfield specimens are prepared by removing crusts from the surface of the lesion, cleaning the surface of the lesion with a sterile saline-soaked gauze, squeezing the base of the lesion with 2 gloved fingers to induce the presence of a serous exudate on the surface, and collecting the exudate with a glass slide, cover slip, or bacteriologic loop. Only if the amount of exudate is insufficient to prevent the slide from drying out prior to microscopic examination should a drop of nonbacteriostatic normal saline be added before covering the slide with a cover slip. The slide is examined within 5 to 20 minutes by a trained microscopist, using a darkfield microscope, for the presence of organisms with the characteristic morphology and motility of *T. pallidum*.[121] Sensitivity is approximately 74% to 79%, but declines as minutes elapse, as dead treponemes cannot exhibit the motility required for diagnosis.[121] Of note, prior application of a topical antibiotic to a lesion can yield a false-negative darkfield specimen.

DIRECT FLUORESCENCE ANTIBODY TEST

The lesional exudate is smeared on a glass slide and stained with fluorescein-labeled anti–*T. pallidum* immunoglobulin. In contrast to darkfield microscopic examination, the smear can be held for later evaluation and oral or anal lesions can be examined because only *T. pallidum* is stained. The sensitivity of the test is 73% to 100%.[121]

MOLECULAR TESTS

In research settings, PCR-based methods have been used to detect *T. pallidum* DNA from lesions.[68]

HISTOPATHOLOGIC EXAMINATION

Histopathologic examination is not essential for a diagnosis of syphilis, which can in many cases be made on the basis of clinical findings, serologic testing, and, for appropriate lesions, and if available, darkfield microscopy. In unusual or questionable cases, however, histopathologic examination can be useful.

PRIMARY SYPHILIS

At the edge of a chancre, the epidermis shows changes similar to those of secondary syphilis, discussed later.[136] The papillary dermis shows edema and a perivascular and interstitial infiltrates characterized by lymphocytes (predominantly CD4+ T cells), histiocytes, and plasma cells, with neutrophils admixed. *T. pallidum* organisms can be visualized along the dermal–epidermal junction and in and around blood vessels, using Livaditis or Warthin-Starry stains or by immunofluorescent techniques.[136]

SECONDARY SYPHILIS

Although clinically different in appearance, lesions of primary and secondary syphilis share many histologic features, with changes more marked in papular lesions and less so in macular lesions.[136] In the epidermis those changes include psoriasiform hyperplasia, exocytosis of lymphocytes, spongiform pustulation, and parakeratosis; in the dermis those changes include marked papillary dermal edema and perivascular and/or periadnexal infiltrate composed of lymphocytes and/or histiocytes, sometimes granulomatous, and most intense in the papillary dermis. Plasma cells are present in three-fourths of cases, and *T. pallidum* organisms can be seen on appropriately stained sections in one-third of cases, usually in the epidermis and less commonly around superficial dermal blood vessels.[136]

TERTIARY SYPHILIS

Histopathologically, gummatous lesions are characterized by granulomas with central zones of acellular necrosis. Endarteritis obliterans and angiocentric plasma cell infiltrates of dermal blood vessels also can be present. Nodular lesions show small granulomas in the dermis, accompanied by islands of epithelioid cells, multinucleated giant cells, lymphocytes, and plasma cells.[136]

SEROLOGY

Serologic tests for syphilis include nontreponemal tests, which detect IgG and IgM antibodies to lipoidal material released from damaged host cells and possibly from *T. pallidum,* and treponemal tests, which detect antibodies to *T. pallidum* itself. Accurate serologic diagnosis of syphilis requires both types of test. Table 170-6 outlines the sensitivity and specificity of selected serologic tests for syphilis.[121,126,137-139]

NONTREPONEMAL SEROLOGIC TESTS

The 2 most widely used nontreponemal tests are the VDRL and rapid plasma reagin (RPR) tests. These

TABLE 170-6
Sensitivity and Specificity of Selected Serologic Tests for Syphilis[121,137-139]

	SENSITIVITY (%)				
TEST	PRIMARY SYPHILIS	SECONDARY SYPHILIS	LATENT SYPHILIS	TERTIARY SYPHILIS	SPECIFICITY (%)
Nontreponemal Tests					
RPR	86 (77-99)	100	98 (95-100)	73	98 (93-99)
VDRL	78 (74-87)	100	96 (88-100)	71 (37-94)	98 (96-99)
Treponemal Tests					
TPPA	88 (86-100)	100	97 (97-100)	94	96 (95-100)
MHA-TP	76 (69-90)	100	97 (97-100)	94	99 (98-100)
FTA-ABS	84 (70-100)	100	100	96	97 (94-100)
TPHA	77 (53-86)	100	99 (99-100)	100	96-99
EIA[a]	85-97	97-100	100 (early latent) 75-100 (late latent)	NA	99-100

[a]Various EIAs from different manufacturers were tested. See Ref. 137 for details.

EIA, enzyme immunoassay; FTA-ABS, fluorescent treponemal antibody absorption assay; MHA-TP, microhemagglutination assay for *Treponema pallidum*; RPR, rapid plasma reagin; TPHA, *T. pallidum* hemagglutination; TPPA, *T. pallidum* particle agglutination; VDRL, Venereal Disease Research Laboratory.

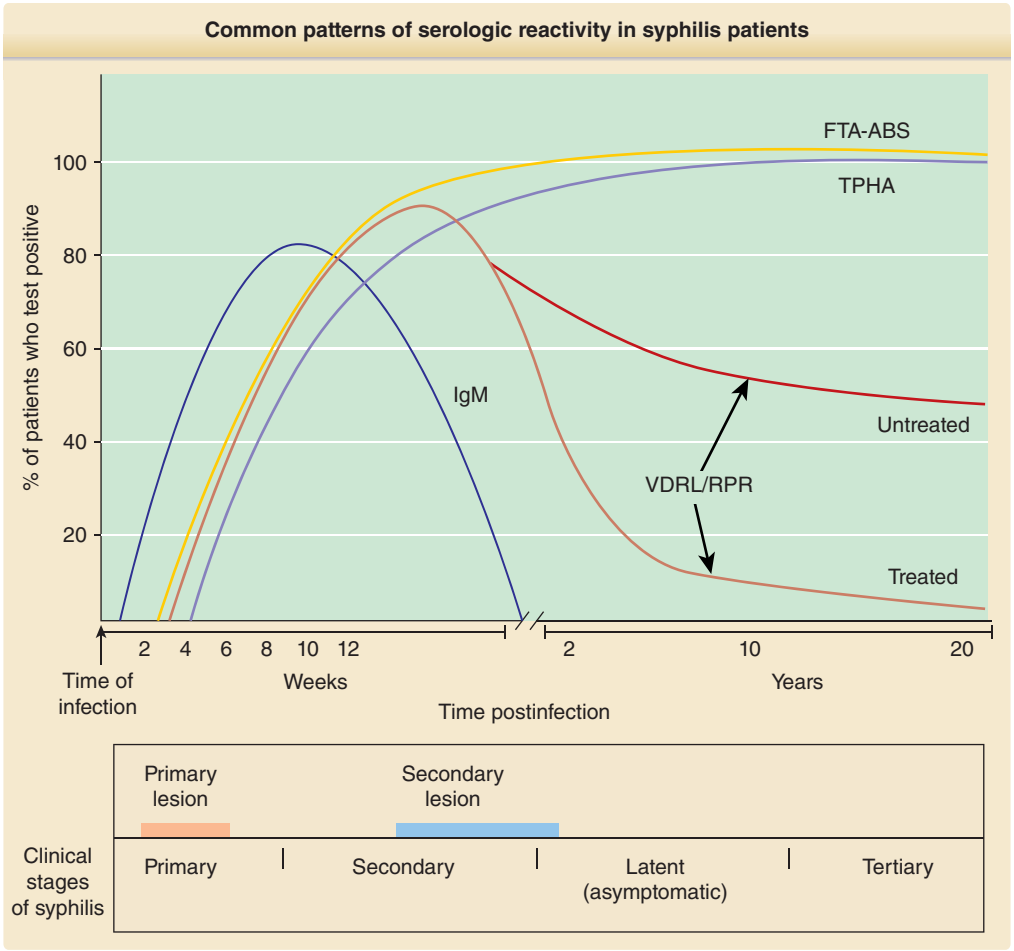

Figure 170-38 Common patterns of serologic reactivity in syphilis patients. FTA-ABS, Fluorescent treponemal antibody absorption assay; IgM, immunoglobulin M; RPR, rapid plasma reagin; TPHA, *Treponema pallidum* hemagglutination test; VDRL, Venereal Disease Research Laboratory. (From Peeling RW, Ye H. Diagnostic tools for preventing and managing maternal and congenital syphilis: an overview. *Bull World Health Organ*. 2004;82(6):439-446. By permission of World Health Organization.)

tests are used both to diagnose syphilis, and to monitor response to treatment. The VDRL and RPR begin to become reactive 4 to 5 weeks after infection, with 100% sensitivity by approximately 12 weeks, and revert to nonreactive in 25% to 30% of cases during late latent syphilis (Fig. 170-38).[140] Cases of seronegative secondary syphilis in HIV-infected persons have been reported.[119] Results can be qualitative (reactive/nonreactive) or quantitative. Quantitative results are reported as titer, which refers to serial dilutions of serum by a factor of 2 (1:2, 1:4, 1:8, and so on). The reported titer represents the most dilute sample that gives a reactive result. RPR and VDRL titers cannot be directly compared, and even for the same test, reported titers may differ slightly between laboratorians and laboratories. Because of the importance of using nontreponemal titers to assess response to treatment, a titer for each person diagnosed with syphilis must be obtained on the day-of-treatment. Without a day-of-treatment titer, it is very difficult to interpret subsequent titers to determine whether the person has responded to treatment appropriately.

Treatment success is defined serologically as a fourfold (two-dilution) decline in nontreponemal test titer (see section "Management"), although in many persons, following appropriate treatment nontreponemal titers will revert to nonreactive. In persons treated for primary syphilis, nontreponemal tests become nonreactive in 60% by 4 months, and in nearly all patients by 12 months.[141] In persons treated for secondary syphilis, the tests usually become nonreactive 12 to 24 months after treatment. However, in some cases, more frequently if therapy is administered in the latent stage, nontreponemal tests may remain reactive in low titers for up to 5 years or longer. In some persons nontreponemal antibodies can persist at a low titer for long periods, and sometimes for life.[142] Both patients who fail to achieve a fourfold decline in titer, as well as those who have adequate serologic decline but whose nontreponemal test titers do not become undetectable, have been referred to as *serofast*. However, current CDC guidelines recommend additional followup and testing only for the group of serofast patients who do not achieve a fourfold decline in titer (see section "Management").[35,133]

False-negative results occur during very early infection or in latent and late syphilis. In a small percent of secondary syphilis cases, very high antibody titers inhibit test reactivity, producing a false-negative result,

called the prozone phenomenon. To exclude the prozone phenomenon, the test must be repeated with diluted serum. Many laboratories do not routinely check for the prozone phenomenon, so clinicians must request a ruling out of the prozone phenomenon in the appropriate setting (eg, a patient with a suspicious rash and a negative nontreponemal test result). Importantly, nontreponemal titers may decline over time even in the absence of treatment, so persons with late latent syphilis who have never been treated may have nonreactive nontreponemal test results (see "The Reverse Sequence Algorithm" below).[133]

Biologic false-positive results constitute approximately 1% of reactive nontreponemal tests and usually have low titers (<1:8). Table 170-7 outlines the causes of biologic false-positive results.

In the traditional algorithm for diagnosis of syphilis, the nontreponemal test is performed first, followed by a treponemal test for confirmation if the nontreponemal test is positive.

TREPONEMAL SEROLOGIC TESTS

Examples of treponemal serologic tests include the *T. pallidum* particle agglutination (TPPA) test, the microhemagglutination assay for *T. pallidum* (MHA-TP), the fluorescent treponemal antibody absorption assay (FTA-ABS), the *T. pallidum* hemagglutination test (TPHA), and various treponemal enzyme immunoassays (EIAs) and immunochemiluminescence assays. These tests, which use whole or fragments of *T. pallidum* as antigen, detect the presence of antibodies to *T. pallidum*. Compared with nontreponemal tests, they are more cumbersome to perform—except for treponemal EIAs—but have greater sensitivity in the primary and late stages and slightly higher specificity. They have historically been used, and in many settings are still used, to confirm syphilis, because a reactive treponemal test result essentially rules out the possibility of a biologic false-positive reaction on a nontreponemal test. Consequently, a reactive nontreponemal test result followed by a reactive treponemal test result confirms a diagnosis of syphilis. The test results must be interpreted in light of clinical findings and prior serologic test results to determine whether the case of syphilis is new or old, and if old, previously treated successfully or unsuccessfully.

Persons who have had syphilis usually will have reactive treponemal test results for life, even after successful treatment, making a reactive treponemal test in a person with a history of syphilis generally not useful clinically. However, 15% to 25% of treponemal tests become nonreactive between 2 and 3 years after treatment of primary syphilis.[143] The tests are highly specific and sensitive during the secondary and the late phases of the disease. Treponemal test titers do not correlate with, and are not used to monitor, disease activity. Sensitivity is low in the weeks after infection, but is nearly 100% by 12 weeks (see Fig. 170-38). False-positive results in treponemal tests are also rare, but are associated with infections, autoimmune or connective tissue disease, and narcotic addiction.[126,143,144]

TABLE 170-7
Causes of Biologic False-Positive Nontreponemal Tests

	ACUTE	CHRONIC
Physiologic	Pregnancy[a]	Advanced age
Spirochete	Leptospirosis	Endemic syphilis
Infection	Lyme disease Rat-bite fever Relapsing fever	Pinta Yaws
Viral infection	Cytomegalovirus Infectious mononucleosis Hepatitis Herpes simplex Herpes zoster-varicella infection Measles Mumps *Mycoplasma* pneumonia Toxoplasmosis Viral sepsis	Human T-cell leukemia/lymphoma virus 1 HIV infection
Bacterial infection	Pneumonia	Lepromatous leprosy Lymphogranuloma venereum Tuberculosis
Protozoan infection	Malaria	Kala azar Trypanosomiasis
Autoimmune		Autoimmune hemolytic syndrome
Disease		Autoimmune thyroiditis Idiopathic thrombocytopenic purpura Mixed connective tissue disease Polyarteritis nodosa Primary biliary cirrhosis Rheumatoid arthritis Sjögren syndrome Systemic lupus erythematosus
Other		Drug abuse Dysproteinemias Hepatic cirrhosis Malnutrition Malignancy Lymphoproliferative disorders

[a]Evidence for pregnancy as a cause of biologic false-positive reactions is limited and concern persists for clinicians failing to diagnosis syphilis in pregnancy.

THE REVERSE SEQUENCE ALGORITHM

The automation of EIA tests, a form of treponemal test, has made EIAs less expensive for large-volume laboratories to perform.[126,145] As a result, many large-volume

laboratories have begun to use EIAs rather than nontreponemal tests as the first step of the algorithm for laboratory diagnosis of syphilis.[39] In this "reverse sequence" algorithm, a treponemal EIA is performed first. If and only if the EIA result is reactive, is a nontreponemal test is performed. Reactive results on both tests confirm a diagnosis of syphilis. In approximately 3% of cases, a reactive treponemal EIA result is followed by a nonreactive nontreponemal test result. In those cases, a tie-breaker test, consisting of an alternate treponemal test, can be performed, with data combined with clinical suspicion to determine diagnosis and treatment.[145]

The use of the reverse sequence algorithm does lead to the identification of a number of serodiscordant patients in whom both the initial and "tie-breaker" treponemal tests are positive, but the nontreponemal test is negative. This can occur in the setting of the prozone phenomenon, early primary syphilis, adequately treated past syphilis, or untreated syphilis of long duration. Patients with a history of treatment will require no further management unless the sexual history suggests recent reexposure. Those without a history of treatment should be treated. Knowledge of sexual history, clinical findings and results of prior serologic tests for syphilis is therefore necessary to appropriately interpret the results of serologic testing.[35,133] Figure 170-39 illustrates the interpretation of reverse sequence algorithm results.

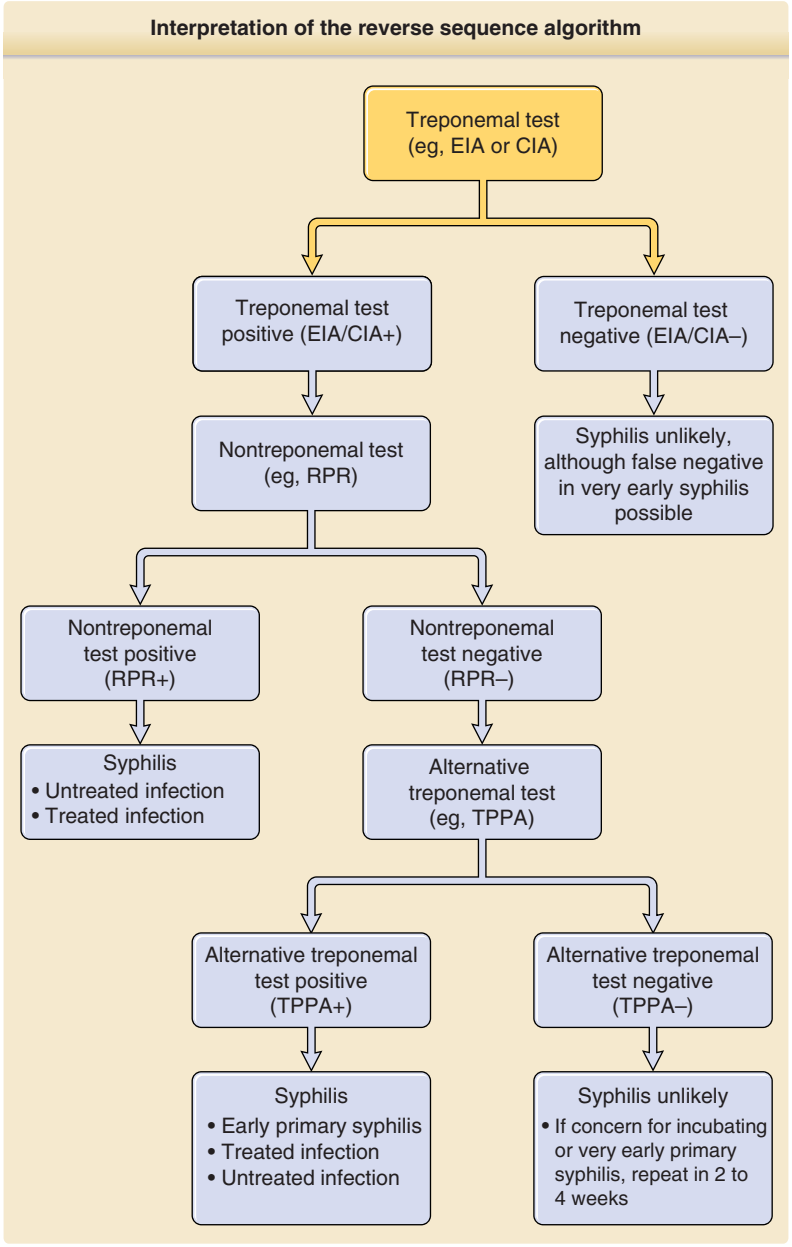

Figure 170-39 Interpretation of the reverse sequence algorithm.[133,145] CIA, Chemiluminescent immunoassay; EIA, enzyme immunoassay; RPR, rapid plasma reagin; TPPA, *Treponema pallidum* particle agglutination.

RAPID SEROLOGIC TESTS

Of note, several rapid, point-of-care serologic tests for syphilis are in use or under development internationally. One has been cleared for use outside of laboratory settings in the United States, and others are under development.[146]

CONGENITAL SYPHILIS

Transplacental transfer of maternal nontreponemal and treponemal IgG antibodies to the fetus complicates serologic diagnosis of congenital syphilis.[35] Infants born to mothers with reactive nontreponemal and treponemal tests should be evaluated with a quantitative nontreponemal serologic test performed on infant serum, as umbilical cord blood might be contaminated with maternal blood, yielding a false-positive result. Treponemal tests are difficult to interpret in this setting and are not recommended by the CDC. All infants whose mothers have reactive serologic tests should be examined carefully for evidence of congenital syphilis. If possible, suspicious lesions or body fluids (eg, nasal discharge) should be tested using darkfield microscopy or PCR testing. Pathologic examination of the placenta using specific staining or a *T. pallidum* PCR test should be considered.[35] Any neonate with proven, highly probable or possible congenital syphilis (based on assessment of physical examination, serologic tests, darkfield microscopy or PCR of lesions or body fluid, and adequacy of maternal treatment) should have CSF tested for VDRL reactivity, white blood cell count, and protein level, as well as other tests that would suggest other diseases in the differential diagnosis. Other tests, such as long-bone radiographs, chest radiographs, liver function tests, neuroimaging, ophthalmologic examination, and auditory brainstem response may be necessary as clinically indicated.[35]

CLINICAL COURSE AND PROGNOSIS

Despite decades of use, *T. pallidum* has remained sensitive to penicillin. Although treatment failures do occur, and may be more common in HIV-infected patients, penicillin treatment is generally very effective at eradicating the infection in all stages of syphilis. Although severe, and in a few rare cases, life-threatening complications of secondary syphilis can occur,[147] the vast majority of patients with primary and secondary syphilis will have resolution of symptoms with no permanent sequelae (even without treatment). The goal of antibiotic therapy, then, is not only to address the immediate syndrome, but also to prevent transmission to sexual partners, and progression to tertiary syphilis. Unfortunately, in tertiary syphilis, irreversible damage to vital structures may occur through gummas or cardiovascular or CNS involvement. Neurosyphilis, which can occur at any stage, can be life-threatening. Of note, several patients in the recently reported cluster of 12 ocular syphilis cases developed permanent sequelae despite appropriate treatment; 2 of the 12 became legally blind.[37]

MANAGEMENT

Based on data from case series and clinical trials and long clinical experience,[148] penicillin is the recommended treatment for all stages of syphilis, with the preparation, dose, and length of treatment dependent on the clinical manifestations, stage of disease, and age of the patient.[35] Benzathine penicillin G, the recommended preparation of penicillin for most stages of syphilis, has a long half-life, which is critical therapeutically because of the slow dividing time of *T. pallidum*. The choice of penicillin formulation is important in assuring adequate treatment. In the United States, the only penicillin product that is appropriate for treatment of primary, secondary, or latent syphilis is Bicillin L-A, which contains only benzathine penicillin G. Another similarly packaged product, Bicillin C-R, contains procaine penicillin G in addition to benzathine penicillin G and is not an appropriate treatment. Substantial confusion and errors relating to those 2 products have been reported.[149,150]

Penicillin-allergic persons with syphilis who are not pregnant and do not have neurosyphilis may be treated with doxycycline. Pregnant women who are penicillin-allergic must be desensitized to and treated with penicillin, which is the only drug that is known to prevent maternal transmission and to treat infection in the fetus.[35] Reports of treatment failures and emergence in *T. pallidum* of resistance to macrolides, including azithromycin, at one point a convenient alternative to penicillin because of its oral formulation, now precludes use of that class of drug in the United States and much of the world,[151-153] although it may still be used with caution in some areas.[137] As discussed previously, CDC-recommended treatment regimens do not differ on the basis of a person's HIV infection status.[35]

Table 170-5 outlines the CDC recommendations for treatment and followup of adults with primary, secondary, early latent or late latent syphilis. For information on children and for congenital syphilis, as well as neurosyphilis and ocular syphilis (which require IV penicillin), CDC treatment guidelines should be consulted.[35]

Clinical and serologic followup is important to monitor response to treatment (see Table 170-5). Treatment success is generally defined as a fourfold decline in serologic nontreponemal titer (or reversion to nonreactive result) following appropriate treatment, in the absence of persistent signs or symptoms of syphilis, and within a specified time frame depending on stage of infection and HIV infection status of the infected person.[35] An example of a fourfold decline in titer is a 1:64 titer declining to 1:16, or a 1:16 titer declining to 1:4. The CDC recommends followup at 6-month intervals until a fourfold decline is documented, except for HIV-infected persons with

primary or secondary syphilis, for whom followup at 3, 6, 9, 12, and 24 months is recommended, and congenital syphilis, for whom followup every 2 to 3 months is recommended.[35] Approximately 15% to 20% of persons with primary and secondary syphilis who are treated appropriately will remain serofast and will not achieve the fourfold decline in titer. The CDC guidelines recommend additional clinical followup, and in some cases, retreatment or CSF evaluation to rule out CNS infection.[35]

A fourfold titer increase following appropriate treatment indicates reinfection or treatment failure—the latter in some cases associated with neurosyphilis—with treatment depending on which of those is believed to have caused the increase. Reinfection must be assessed by clinical history and physical examination. If treatment failure cannot be ruled out, the patient should be treated with 7.2 million units of benzathine penicillin G (divided into 3 weekly doses); CSF examination should be performed to determine whether neurosyphilis is present, and, if it is, the patient also should be treated for neurosyphilis.[35]

COMPLICATIONS OF TREATMENT

The Jarisch-Herxheimer reaction is a self-limited clinical syndrome consisting of fever, headache, flare of mucocutaneous lesions, tender lymphadenopathy, pharyngitis, malaise, myalgia, and leukocytosis. It occurs within the first 24 hours after initiating therapy. The fever peaks 6 to 8 hours after the onset, usually around 39°C (102.2°F), but it can be as high as 42°C (107.6°F). Patients should be warned about the possibility of developing this reaction before receiving treatment. Acetaminophen can be used to attempt to diminish the reaction, although very little evidence of its effectiveness exists.[35] The patient should be encouraged to rest, maintain fluid intake, and seek medical attention if symptoms are severe. The pathogenesis of the Jarisch-Herxheimer reaction is unknown, but is thought to result from cytokine release mediated by the release of lipoproteins from dying *T. pallidum* organisms.[154] In pregnant patients, the Jarisch-Herxheimer reaction may lead to premature labor or fetal distress, events that should prompt the patient to seek evaluation. However, given the potentially devastating effects of congenital syphilis, prompt treatment of maternal syphilis is critical.[35]

Anaphylaxis from administration of penicillin injection is a life-threatening emergency that is managed by epinephrine and other medications, such as antihistamines, along with emergent transfer to a monitored setting.[155]

At the time of initial treatment, patients should be educated to distinguish an allergic reaction, which precludes further treatment with penicillin or related drugs, from a Jarisch-Herxheimer reaction, which does not.

DISEASE REPORTING AND MANAGEMENT OF PERSONS EXPOSED TO SYPHILIS

As reflected by the efforts to eliminate syphilis in the United States, prevention and control of syphilis are of substantial public health interest in the United States and worldwide.[2,35] Syphilis is a nationally notifiable disease in the United States, meaning that both clinicians and laboratories are mandated by law to report cases or laboratory results diagnostic of or suspicious for syphilis to their local or state public health authorities. Clinicians should contact their local or state health department to familiarize themselves with local reporting requirements, including required forms and need for paper-based or electronic reports, for syphilis and other reportable diseases.[35]

Local or state public health authorities maintain databases of syphilis diagnoses, laboratory results, and treatments for persons diagnosed with syphilis. That information is available to clinicians taking care of persons with suspected syphilis and can be helpful in staging infections (eg, determining if criteria for early latent syphilis are met) and assuring appropriate treatment. Clinicians should routinely encourage persons diagnosed with syphilis to inform their sex partners of exposure to syphilis and followup with patients to assure that disclosure has occurred. Identifying which sex partners are at risk of infection depends both on the elapsed time since last exposure and stage of infection in the source patient. This risk period is 3 months plus duration of symptoms for primary syphilis, 6 months plus duration of symptoms for secondary syphilis, and 1 year for early latent syphilis and latent syphilis of unknown duration. Clinicians should also inform persons they diagnose with syphilis that the case will be reported to the public health authority and that, in many cases, health department workers (sometimes called Communicable Disease Investigators or Disease Intervention Specialists) will contact the person to ensure that treatment was adequate, provide education about syphilis, solicit contact information for sex partners, and inquire about sexual behaviors so that prevention and control resources can be targeted to affected populations. It is a principle of public health practice, including in syphilis contact-tracing investigations, to protect the confidentiality of the source partner.[35]

Management of at-risk sex partners of persons diagnosed with syphilis also depends on elapsed time since exposure. Sex partners exposed during the 90 days preceding the diagnosis of primary, secondary, or early latent syphilis should be examined and tested for syphilis. However, regardless of results of the physical examination and laboratory tests, those partners should be treated presumptively because of the high efficacy of prophylactic

treatment and the likelihood (up to 63%) that they been infected but have yet to show clinical or laboratory evidence of disease. Persons exposed more than 90 days before the diagnosis of primary, secondary, or early latent syphilis should also be examined and tested and treated presumptively if serologic test results are not available immediately and the opportunity for followup is uncertain. Sex partners of persons with late latent syphilis should be evaluated and tested, and then managed on the basis of those findings.[35]

PREVENTION AND SCREENING

Safer sex practices are critical for prevention of syphilis transmission. Screening also may be important in identifying asymptomatic patients who should be treated. The CDC recommends that all pregnant women be screened at the first prenatal visit, with retesting early in the third trimester and at delivery if at high risk for syphilis. Sexually active MSM should be screened at least annually, and every 3 to 6 months if at increased risk (eg, patient or sexual partner has multiple partners). Persons with HIV who are sexually active should be screened at first HIV evaluation and then at least annually thereafter, with more frequent screening depending on individual risk behaviors and the local epidemiology.[35]

ACKNOWLEDGMENTS

We appreciate the significant contributions of Dr. Kenneth Katz to this chapter. We also thank Dr. Gerald Lazarus for his help in reviewing and selecting the images for this chapter.

REFERENCES

1. de Melo FL, de Mello JC, Fraga AM, et al. Syphilis at the crossroad of phylogenetics and paleopathology. *PLoS Negl Trop Dis.* 2010;4(1):e575.
2. Fenton KA, Breban R, Vardavas R, et al. Infectious syphilis in high-income settings in the 21st century. *Lancet Infect Dis.* 2008;8(4):244-253.
3. Rothschild BM. History of syphilis. *Clin Infect Dis.* 2005;40(10):1454-1463.
4. Glickman FS. Syphilus. *J Am Acad Dermatol.* 1985;12(3):593-596.
5. Sefton AM. The great pox that was...syphilis. *J Appl Microbiol.* 2001;91(4):592-596.
6. Waugh M. The centenary of *Treponema pallidum*: on the discovery of *Spirochaeta pallida*. *Int J STD AIDS.* 2005;16(9):594-595.
7. Arnold HL Jr. Dermatology, 50 years ago. *JAMA.* 1989;262(6):824-825.
8. Dunst KM, Gurunluoglu R, Aubock J, et al. Adolf Jarisch (1850-1902): an important contributor to Austrian dermatology. *Arch Dermatol Res.* 2006;297(9):383-388.
9. Leslie KS, Levell NJ. Dermatologists, beacons of epidemics; past, present and future! *Int J Dermatol.* 2004;43(6):468-470.
10. Sartin JS, Perry HO. From mercury to malaria to penicillin: the history of the treatment of syphilis at the Mayo Clinic—1916-1955. *J Am Acad Dermatol.* 1995;32(2, pt 1):255-261.
11. Steffen C. Why a historical approach has clinical benefits: John Hinchman Stokes and George Miller MacKee. *Skinmed.* 2006;5(1):31-36.
12. Wallach D, Tilles G. First International Congress of Dermatology and Syphilology, Paris, Aug. 5-10, 1889. *J Am Acad Dermatol.* 1992;26(6):995-1001.
13. Gruber F. History of venereology in Croatia. *Acta Dermatovenerol Croat.* 2009;17(4):247-262.
14. Thappa DM. Evolution of venereology in India. *Indian J Dermatol Venereol Leprol.* 2006;72(3):187-196; quiz 197.
15. Albert MR. Fever therapy for general paresis. *Int J Dermatol.* 1999;38(8):633-637.
16. Lafond RE, Lukehart SA. Biological basis for syphilis. *Clin Microbiol Rev.* 2006;19(1):29-49.
17. Whitrow M. Wagner-Jauregg and fever therapy. *Med Hist.* 1990;34(3):294-310.
18. Harrison LW. The Oslo study of untreated syphilis, review and commentary. *Br J Vener Dis.* 1956; 32(2):70-78.
19. Jones JH, Tuskegee Institute. *Bad Blood: The Tuskegee Syphilis Experiment.* New and expanded ed. New York, NY: Free Press; 1993.
20. The National Commission for the Protection of Human Subjects of Biomedical and Behavioral Research. *The Belmont Report: Ethical Principles and Guidelines for the Protection of Human Subjects of Research.* Bethesda, MD: U.S. Department of Health, Education, and Welfare; 1978. Available at https://videocast.nih.gov/pdf/ohrp_belmont_report.pdf
21. Hayden D. *Pox: Genius, Madness, and the Mysteries of Syphilis.* New York, NY: Basic Books; 2003.
22. Brandt AM. *No Magic Bullet: A Social History of Venereal Disease in the United States Since 1880.* New York, NY: Oxford University Press; 1985.
23. Parran T. *Shadow on the Land: Syphilis.* New York, NY: Reynal & Hitchcock; 1937.
24. Hook EW 3rd. Elimination of syphilis transmission in the United States: historic perspectives and practical considerations. *Trans Am Clin Climatol Assoc.* 1999;110:195-203; discussion 203-204.
25. Nakashima AK, Rolfs RT, Flock ML, et al. Epidemiology of syphilis in the United States, 1941-1993. *Sex Transm Dis.* 1996;23(1):16-23.
26. Division of STD Prevention, National Center for HIV, STD and TB Prevention, Centers for Disease Control and Prevention, Department of Health and Human Services. *The National Plan to Eliminate Syphilis From the United States.* Atlanta, GA: Division of STD Prevention, National Center for HIV, STD, and TB Prevention, Centers for Disease Control and Prevention; 2006. Available at https://www.cdc.gov/stopsyphilis/SEEPlan2006.pdf.
27. Centers for Disease Control and Prevention (CDC). *2014 Sexually Transmitted Diseases Surveillance.* Archived at http://www.cdc.gov/std/stats14/syphilis.htm. Last accessed September 18, 2018.
28. Peterman TA, Furness BW. The resurgence of syphilis among men who have sex with men. *Curr Opin Infect Dis.* 2007;20(1):54-59.

29. Zetola NM, Klausner JD. Syphilis and HIV infection: an update. *Clin Infect Dis.* 2007;44(9):1222-1228.
30. Fonner VA, Dalglish SL, Kennedy CE, et al. Effectiveness and safety of oral HIV pre-exposure prophylaxis (PrEP) for all populations: a systematic review and meta-analysis. *AIDS.* 2016;30(12):1973-1983.
31. Chen YH, Snowden JM, McFarland W, et al. Pre-exposure prophylaxis (PrEP) Use, seroadaptation, and sexual behavior among men who have sex with men, San Francisco, 2004-2014. *AIDS Behav.* 2016;20(12):2791-2797.
32. Solomon MM, Mayer KH, Glidden DV, et al. Syphilis predicts HIV incidence among men and transgender women who have sex with men in a preexposure prophylaxis trial. *Clin Infect Dis.* 2014;59(7):1020-1026.
33. Pathela P, Braunstein SL, Blank S, et al. The high risk of an HIV diagnosis following a diagnosis of syphilis: a population-level analysis of New York City men. *Clin Infect Dis.* 2015;61(2):281-287.
34. Peterman TA, Newman DR, Maddox L, et al. High risk for HIV following syphilis diagnosis among men in Florida, 2000-2011. *Public Health Rep.* 2014;129(2):164-169.
35. Workowski KA, Bolan GA. Centers for Disease Control and Prevention. Sexually transmitted diseases treatment guidelines, 2015. *MMWR Recomm Rep.* 2015;64(RR-03):1-137.
36. Bowen V, Su J, Torrone E, et al. Increase in incidence of congenital syphilis—United States, 2012-2014. *MMWR Morb Mortal Wkly Rep.* 2015;64(44):1241-1245.
37. Woolston S, Cohen SE, Fanfair RN, et al. A cluster of ocular syphilis cases—Seattle, Washington, and San Francisco, California, 2014-2015. *MMWR Morb Mortal Wkly Rep.* 2015;64(40):1150-1151.
38. Centers for Disease Control and Prevention (CDC). Clinical Advisory: Ocular Syphilis in the United States. Updated March 24, 2016. https://www.cdc.gov/std/syphilis/clinicaladvisoryos2015.htm. Last accessed October 6, 2016.
39. Ozturk F, Gurses N, Sancak R, et al. Acquired secondary syphilis in a 6-year-old girl with no history of sexual abuse. *Cutis.* 1998;62(3):150-151.
40. Orton S. Syphilis and blood donors: what we know, what we do not know, and what we need to know. *Transfus Med Rev.* 2001;15(4):282-291.
41. Meyer GS. Occupational infection in health care. The century-old lessons from syphilis. *Arch Intern Med.* 1993;153(21):2439-2447.
42. Kazandjieva J, Tsankov N. Tattoos: dermatological complications. *Clin Dermatol.* 2007;25(4):375-382.
43. Woods CR. Syphilis in children: congenital and acquired. *Semin Pediatr Infect Dis.* 2005;16(4):245-257.
44. Wicher V, Wicher K. Pathogenesis of maternal-fetal syphilis revisited. *Clin Infect Dis.* 2001;33(3):354-363.
45. Garnett GP, Aral SO, Hoyle DV, et al. The natural history of syphilis. Implications for the transmission dynamics and control of infection. *Sex Transm Dis.* 1997;24(4):185-200.
46. Moore MB Jr, Price EV, Knox JM, et al. Epidemiologic treatment of contacts to infectious syphilis. *Public Health Rep.* 1963;78:966-970.
47. Schroeter AL, Turner RH, Lucas JB, et al. Therapy for incubating syphilis. Effectiveness of gonorrhea treatment. *JAMA.* 1971;218(5):711-713.
48. Alexander LJ, Schoch AG. Prevention of syphilis; penicillin calcium in oil and white wax, U.S. P., bismuth ethylcamphorate and oxophenarsine hydrochloride in treatment, during incubation stage, of persons exposed to syphilis. *Arch Derm Syphilol.* 1949;59(1):1-10.
49. Lukehart SA, Hook EW 3rd, Baker-Zander SA, et al. Invasion of the central nervous system by *Treponema pallidum*: implications for diagnosis and treatment. *Ann Intern Med.* 1988;109(11):855-862.
50. Hourihan M, Wheeler H, Houghton R, et al. Lessons from the syphilis outbreak in homosexual men in east London. *Sex Transm Infect.* 2004;80(6):509-511.
51. Rompalo AM, Joesoef MR, O'Donnell JA, et al. Clinical manifestations of early syphilis by HIV status and gender: results of the syphilis and HIV study. *Sex Transm Dis.* 2001;28(3):158-165.
52. Golden MR, Marra CM, Holmes KK. Update on syphilis: resurgence of an old problem. *JAMA.* 2003;290(11):1510-1514.
53. Rompalo AM, Lawlor J, Seaman P, et al. Modification of syphilitic genital ulcer manifestations by coexistent HIV infection. *Sex Transm Dis.* 2001;28(8):448-454.
54. Zeltser R, Kurban AK. Syphilis. *Clin Dermatol.* 2004;22(6):461-468.
55. Lautenschlager S. Cutaneous manifestations of syphilis: recognition and management. *Am J Clin Dermatol.* 2006;7(5):291-304.
56. Dourmishev LA, Dourmishev AL. Syphilis: uncommon presentations in adults. *Clin Dermatol.* 2005;23(6):555-564.
57. Katz KA. Dory flop sign of syphilis. *Arch Dermatol.* 2010;146(5):572.
58. Crissey JT, Denenholz DA. Syphilis. *Clin Dermatol.* 1984;2(1):1-166.
59. Davies T. *Primary Syphilis in the Female [thesis (MD)]*. London, UK: Oxford University Press; 1931.
60. Ramoni S, Cusini M, Gaiani F, et al. Syphilitic chancres of the mouth: three cases. *Acta Derm Venereol.* 2009;89(6):648-649.
61. Allison SD. Extragenital syphilitic chancres. *J Am Acad Dermatol.* 1986;14(6):1094-1095.
62. Emerson CR, Lynch A, Fox R, et al. The syphilis outbreak in Northern Ireland. *Int J STD AIDS.* 2007;18(6):413-417.
63. Centers for Disease Control and Prevention (CDC). Transmission of primary and secondary syphilis by oral sex—Chicago, Illinois, 1998-2002. *MMWR Morb Mortal Wkly Rep.* 2004;53(41):966-968.
64. Gunn RA. Expedited intervention services for possible occult primary syphilis among MSM with asymptomatic incident syphilis. *Sex Transm Dis.* 2009;36(9):594-595.
65. Ramoni S, Cusini M, Boneschi V, et al. Primary syphilis of the finger. *Sex Transm Dis.* 2010;37(7):468.
66. Bernabeu-Wittel J, Rodriguez-Canas T, Conejo-Mir J. Primary syphilitic chancre on the hand with regional adenopathy. *Sex Transm Dis.* 2010;37(7):467.
67. Oh Y, Ahn SY, Hong SP, et al. A case of extragenital chancre on a nipple from a human bite during sexual intercourse. *Int J Dermatol.* 2008;47(9):978-980.
68. Scott LJ, Gunson RN, Carman WF, et al. A new multiplex real-time PCR test for HSV1/2 and syphilis: an evaluation of its impact in the laboratory and clinical setting. *Sex Transm Infect.* 2010;86(7):537-539.
69. Lai W, Chen CY, Morse SA, et al. Increasing relative prevalence of HSV-2 infection among men with genital ulcers from a mining community in South Africa. *Sex Transm Infect.* 2003;79(3):202-207.
70. Hope-Rapp E, Anyfantakis V, Fouere S, et al. Etiology of genital ulcer disease. A prospective study of 278 cases seen in an STD clinic in Paris. *Sex Transm Dis.* 2010;37(3):153-158.

71. Eccleston K, Collins L, Higgins SP. Primary syphilis. *Int J STD AIDS.* 2008;19(3):145-151.
72. Centers for Disease Control and Prevention (CDC). *2014 Sexually Transmitted Diseases Surveillance. Appendix C1. Case Definitions for Nationally Notifiable Infectious Diseases.* 2014. Archived at https://www.cdc.gov/std/stats14/appendixc.htm. Last accessed October 16, 2016.
73. Peeling RW, Hook EW 3rd. The pathogenesis of syphilis: the Great Mimicker, revisited. *J Pathol.* 2006;208(2):224-232.
74. Chapel TA. The signs and symptoms of secondary syphilis. *Sex Transm Dis.* 1980;7(4):161-164.
75. Baughn RE, Musher DM. Secondary syphilitic lesions. *Clin Microbiol Rev.* 2005;18(1):205-216.
76. Watson KM, White JM, Salisbury JR, et al. Lues maligna. *Clin Exp Dermatol.* 2004;29(6):625-627.
77. Lejman K, Starzycki Z. Keratopustular variety of framboesiform syphilis: a case report. *Br J Vener Dis.* 1977;53(3):195-199.
78. Kirby JS, Goreshi R, Mahoney N. Syphilitic palmoplantar keratoderma and ocular disease: a rare combination in an HIV-positive patient. *Cutis.* 2009;84(6):305-310.
79. Tham SN, Ng SK. Secondary syphilis with framboesiform lesions. *Genitourin Med.* 1990;66(2):99-100.
80. Beck MH, Hubbard HC, Dave VK, et al. Secondary syphilis with framboesiform facial lesions: a case report. *Br J Vener Dis.* 1981;57(2):103-105.
81. Goldman L. Macular syphilides absent in red tattoo. *Cutis.* 1989;44(4):313.
82. Fonollosa A, Giralt J, Pelegrin L, et al. Ocular syphilis—back again: understanding recent increases in the incidence of ocular syphilitic disease. *Ocul Immunol Inflamm.* 2009;17(3):207-212.
83. Kolios AG, Weber A, Sporri S, et al. Syphilitic pharyngitis. *Arch Dermatol.* 2010;146(5):570-572.
84. Brass LS, White JA. Granulomatous disease of the larynx. *J La State Med Soc.* 1991;143(1):11-14.
85. Mylona EE, Baraboutis IG, Papastamopoulos V, et al. Gastric syphilis: a systematic review of published cases of the last 50 years. *Sex Transm Dis.* 2010;37(3):177-183.
86. Hunte W, al-Ghraoui F, Cohen RJ. Secondary syphilis and the nephrotic syndrome. *J Am Soc Nephrol.* 1993;3(7):1351-1355.
87. Middleton S, Rowntree C, Rudge S. Bone pain as the presenting manifestation of secondary syphilis. *Ann Rheum Dis.* 1990;49(8):641-642.
88. Cruz AR, Pillay A, Zuluaga AV, et al. Secondary syphilis in Cali, Colombia: new concepts in disease pathogenesis. *PLoS Negl Trop Dis.* 2010;4(5):e690.
89. Wu SJ, Nguyen EQ, Nielsen TA, et al. Nodular tertiary syphilis mimicking granuloma annulare. *J Am Acad Dermatol.* 2000;42(2, pt 2):378-380.
90. Sule RR, Deshpande SG, Dharmadhikari NJ, et al. Late cutaneous syphilis. *Cutis.* 1997;59(3):135-137.
91. Horowitz HW, Valsamis MP, Wicher V, et al. Brief report: cerebral syphilitic gumma confirmed by the polymerase chain reaction in a man with human immunodeficiency virus infection. *N Engl J Med.* 1994;331(22):1488-1491.
92. Roberts WC, Ko JM, Vowels TJ. Natural history of syphilitic aortitis. *Am J Cardiol.* 2009;104(11):1578-1587.
93. Jackman JD Jr, Radolf JD. Cardiovascular syphilis. *Am J Med.* 1989;87(4):425-433.
94. O'Regan AW, Castro C, Lukehart SA, et al. Barking up the wrong tree? Use of polymerase chain reaction to diagnose syphilitic aortitis. *Thorax.* 2002;57(10):917-918.
95. Marra CM. Update on neurosyphilis. *Curr Infect Dis Rep.* 2009;11(2):127-134.
96. Centers for Disease Control and Prevention (CDC). Symptomatic early neurosyphilis among HIV-positive men who have sex with men—four cities, United States, January 2002-June 2004. *MMWR Morb Mortal Wkly Rep.* 2007;56(25):625-628.
97. Moradi A, Salek S, Daniel E, et al. Clinical features and incidence rates of ocular complications in patients with ocular syphilis. *Am J Ophthalmol.* 2015;159(2):334-343;e1.
98. Li JZ, Tucker JD, Lobo AM, et al. Ocular syphilis among HIV-infected individuals. *Clin Infect Dis.* 2010;51(4):468-471.
99. Margo CE, Hamed LM. Ocular syphilis. *Surv Ophthalmol.* 1992;37(3):203-220.
100. Jenson HB. Congenital syphilis. *Semin Pediatr Infect Dis.* 1999;10(3):183-194.
101. Doroshenko A, Sherrard J, Pollard AJ. Syphilis in pregnancy and the neonatal period. *Int J STD AIDS.* 2006;17(4):221-227; quiz 228.
102. Lugo A, Sanchez S, Sanchez JL. Congenital syphilis. *Pediatr Dermatol.* 2006;23(2):121-123.
103. Schofer H, Imhof M, Thoma-Greber E, et al. Active syphilis in HIV infection: a multicentre retrospective survey. The German AIDS Study Group (GASG). *Genitourin Med.* 1996;72(3):176-181.
104. Hutchinson CM, Hook EW 3rd, Shepherd M, et al. Altered clinical presentation of early syphilis in patients with human immunodeficiency virus infection. *Ann Intern Med.* 1994;121(2):94-100.
105. Buchacz K, Patel P, Taylor M, et al. Syphilis increases HIV viral load and decreases CD4 cell counts in HIV-infected patients with new syphilis infections. *AIDS.* 2004;18(15):2075-2079.
106. Dyer JR, Eron JJ, Hoffman IF, et al. Association of CD4 cell depletion and elevated blood and seminal plasma human immunodeficiency virus type 1 (HIV-1) RNA concentrations with genital ulcer disease in HIV-1-infected men in Malawi. *J Infect Dis.* 1998;177(1):224-227.
107. Kofoed K, Gerstoft J, Mathiesen LR, et al. Syphilis and human immunodeficiency virus (HIV)-1 coinfection: influence on CD4 T-cell count, HIV-1 viral load, and treatment response. *Sex Transm Dis.* 2006;33(3):143-148.
108. Manfredi R, Sabbatani S, Pocaterra D, et al. Syphilis does not seem to involve virological and immunological course of concurrent HIV disease. *AIDS.* 2006;20(2):305-306.
109. Modjarrad K, Vermund SH. Effect of treating co-infections on HIV-1 viral load: a systematic review. *Lancet Infect Dis.* 2010;10(7):455-463.
110. Palacios R, Jimenez-Onate F, Aguilar M, et al. Impact of syphilis infection on HIV viral load and CD4 cell counts in HIV-infected patients. *J Acquir Immune Defic Syndr.* 2007;44(3):356-359.
111. Sadiq ST, McSorley J, Copas AJ, et al. The effects of early syphilis on CD4 counts and HIV-1 RNA viral loads in blood and semen. *Sex Transm Infect.* 2005;81(5):380-385.
112. Weintrob AC, Gu W, Qin J, et al. Syphilis co-infection does not affect HIV disease progression. *Int J STD AIDS.* 2010;21(1):57-59.
113. Tobian AA, Quinn TC. Herpes simplex virus type 2 and syphilis infections with HIV: an evolving synergy in transmission and prevention. *Curr Opin HIV AIDS.* 2009;4(4):294-299.

114. Aberg JA, Gallant JE, Ghanem KG, et al. Primary care guidelines for the management of persons infected with HIV: 2013 update by the HIV Medicine Association of the Infectious Diseases Society of America. *Clin Infect Dis.* 2014;58(1):1-10.
115. Katz KA, Lee MA, Gray T, et al. Repeat syphilis among men who have sex with men—San Diego County, 2004-2009. *Sex Transm Dis.* 2011;38(4):349-352.
116. Marra CM, Maxwell CL, Smith SL, et al. Cerebrospinal fluid abnormalities in patients with syphilis: association with clinical and laboratory features. *J Infect Dis.* 2004;189(3):369-376.
117. Marra CM, Maxwell CL, Tantalo L, et al. Normalization of cerebrospinal fluid abnormalities after neurosyphilis therapy: does HIV status matter? *Clin Infect Dis.* 2004;38(7):1001-1006.
118. Smith G, Holman RP. The prozone phenomenon with syphilis and HIV-1 co-infection. *South Med J.* 2004;97(4):379-382.
119. Kingston AA, Vujevich J, Shapiro M, et al. Seronegative secondary syphilis in 2 patients coinfected with human immunodeficiency virus. *Arch Dermatol.* 2005;141(4):431-433.
120. Agmon-Levin N, Elbirt D, Asher I, et al. Syphilis and HIV co-infection in an Israeli HIV clinic: incidence and outcome. *Int J STD AIDS.* 2010;21(4):249-252.
121. Larsen SA, Pope V, Johnson RE, et al, eds. *A Manual of Tests for Syphilis.* 9th ed. Washington, DC: American Public Health Association; 1998.
122. Rolfs RT, Joesoef MR, Hendershot EF, et al. A randomized trial of enhanced therapy for early syphilis in patients with and without human immunodeficiency virus infection. The Syphilis and HIV Study Group. *N Engl J Med.* 1997;337(5):307-314.
123. Gonzalez-Lopez JJ, Guerrero ML, Lujan R, et al. Factors determining serologic response to treatment in patients with syphilis. *Clin Infect Dis.* 2009;49(10):1505-1511.
124. Yinnon AM, Coury-Doniger P, Polito R, et al. Serologic response to treatment of syphilis in patients with HIV infection. *Arch Intern Med.* 1996;156(3):321-325.
125. Fraser CM, Norris SJ, Weinstock GM, et al. Complete genome sequence of *Treponema pallidum*, the syphilis spirochete. *Science.* 1998;281(5375):375-388.
126. Sena AC, White BL, Sparling PF. Novel *Treponema pallidum* serologic tests: a paradigm shift in syphilis screening for the 21st century. *Clin Infect Dis.* 2010;51(6):700-708.
127. Fitzgerald TJ. The Th1/Th2-like switch in syphilitic infection: is it detrimental? *Infect Immun.* 1992;60(9):3475-3479.
128. Marra C, Sahi S, Tantalo L, et al. Enhanced molecular typing of *Treponema pallidum*: geographical distribution of strain types and association with neurosyphilis. *J Infect Dis.* 2010;202(9):1380-1388.
129. Kenyon C, Lynen L, Florence E, et al. Syphilis reinfections pose problems for syphilis diagnosis in Antwerp, Belgium—1992 to 2012. *Euro Surveill.* 2014;19(45):20958.
130. Wrzolkowa T, Kozakiewicz J. Ultrastructure of vascular and connective tissue changes in primary syphilis. *Br J Vener Dis.* 1980;56(3):137-143.
131. Cullen PA, Cameron CE. Progress towards an effective syphilis vaccine: the past, present and future. *Expert Rev Vaccines.* 2006;5(1):67-80.
132. Huber TW, Storms S, Young P, et al. Reactivity of microhemagglutination, fluorescent treponemal antibody absorption, Venereal Disease Research Laboratory, and rapid plasma reagin tests in primary syphilis. *J Clin Microbiol.* 1983;17(3):405-409.
133. Tuddenham S, Ghanem KG. Emerging trends and persistent challenges in the management of adult syphilis. *BMC Infect Dis.* 2015;15:351.
134. Wheeler HL, Agarwal S, Goh BT. Dark ground microscopy and treponemal serological tests in the diagnosis of early syphilis. *Sex Transm Infect.* 2004;80(5):411-414.
135. Tsang RS, Morshed M, Chernesky MA, et al. Canadian Public Health Laboratory Network laboratory guidelines for the use of direct tests to detect syphilis in Canada. *Can J Infect Dis Med Microbiol.* 2015;26 (suppl A):13A-17A.
136. Crowson AN, Magro C, Martin M Jr., Treponemal diseases. In: Elder DE, Elenitsas R, Johnson B Jr, et al, eds. *Lever's Histopathology of the Skin.* 10th ed. Philadelphia, PA: Lippincott Williams & Wilkins; 2009:579-591.
137. Cole MJ, Perry KR, Parry JV. Comparative evaluation of 15 serological assays for the detection of syphilis infection. *Eur J Clin Microbiol Infect Dis.* 2007;26(10):705-713.
138. Lesinski J, Krach J, Kadziewicz E. Specificity, sensitivity, and diagnostic value of the TPHA test. *Br J Vener Dis.* 1974;50(5):334-340.
139. Cantor AG, Pappas M, Daeges M, et al. Screening for syphilis: updated evidence report and systematic review for the US Preventive Services Task Force. *JAMA.* 2016;315(21):2328-2337.
140. Peeling RW, Ye H. Diagnostic tools for preventing and managing maternal and congenital syphilis: an overview. *Bull World Health Organ.* 2004;82(6):439-446.
141. Baker-Zander SA, Roddy RE, Handsfield HH, et al. IgG and IgM antibody reactivity to antigens of *Treponema pallidum* after treatment of syphilis. *Sex Transm Dis.* 1986;13(4):214-220.
142. Clement ME, Okeke NL, Hicks CB. Treatment of syphilis: a systematic review. *JAMA.* 2014;312(18):1905-1917.
143. Romanowski B, Sutherland R, Fick GH, et al. Serologic response to treatment of infectious syphilis. *Ann Intern Med.* 1991;114(12):1005-1009.
144. Larsen SA, Hambie EA, Pettit DE, et al. Specificity, sensitivity, and reproducibility among the fluorescent treponemal antibody-absorption test, the microhemagglutination assay for *Treponema pallidum* antibodies, and the hemagglutination treponemal test for syphilis. *J Clin Microbiol.* 1981;14(4):441-445.
145. Centers for Disease Control and Prevention (CDC). Syphilis testing algorithms using treponemal tests for initial screening—four laboratories, New York City, 2005-2006. *MMWR Morb Mortal Wkly Rep.* 2008;57(32):872-875.
146. Peterman TA, Fakile YF. What is the use of rapid syphilis tests in the United States? *Sex Transm Dis.* 2016;43(3):201-203.
147. Ridruejo E, Mordoh A, Herrera F, et al. Severe cholestatic hepatitis as the first symptom of secondary syphilis. *Dig Dis Sci.* 2004;49(9):1401-1404.
148. Kampmeier RH. The introduction of penicillin for the treatment of syphilis. *Sex Transm Dis.* 1981;8(4):260-265.
149. Centers for Disease Control and Prevention (CDC). Inadvertent use of Bicillin C-R for treatment of syphilis—Maryland, 1998. *MMWR Morb Mortal Wkly Rep.* 1999;48(35):777-779.

150. Centers for Disease Control and Prevention (CDC). Inadvertent use of Bicillin C-R to treat syphilis infection—Los Angeles, California, 1999-2004. *MMWR Morb Mortal Wkly Rep.* 2005;54(9):217-219.
151. Zhou P, Qian Y, Xu J, et al. Occurrence of congenital syphilis after maternal treatment with azithromycin during pregnancy. *Sex Transm Dis.* 2007;34(7):472-474.
152. Zhou P, Li K, Lu H, et al. Azithromycin treatment failure among primary and secondary syphilis patients in Shanghai. *Sex Transm Dis.* 2010;37(11):726-729.
153. Katz KA, Klausner JD. Azithromycin resistance in *Treponema pallidum*. *Curr Opin Infect Dis.* 2008;21(1):83-91.
154. Pound MW, May DB. Proposed mechanisms and preventative options of Jarisch-Herxheimer reactions. *J Clin Pharm Ther.* 2005;30(3):291-295.
155. Zilberstein J, McCurdy MT, Winters ME. Anaphylaxis. *J Emerg Med.* 2014;47(2):182-187.

Chapter 171 :: Endemic (Nonvenereal) Treponematoses

:: Francisco G. Bravo, Carolina Talhari, & Khaled Ezzedine

INTRODUCTION

The endemic treponematoses are infectious diseases caused by microorganisms that are closely related to *Treponema pallidum*, the causative agent of syphilis. This group of entities includes (1) pinta, caused by *Treponema carateum*; (2) yaws, caused by *T. pallidum* ssp. *pertenue*; and (3) bejel, caused by *T. pallidum* ssp. *endemicum.* Although all these entities are caused by *Treponema* species, there are important differences between the endemic treponematoses and syphilis, including a nonvenereal form of transmission, an endemic occurrence in very specific geographic areas, a tendency to affect children rather than sexually active adults, and a less likely risk for congenital transmission to occur. In common with syphilis, every endemic treponematosis goes through an early stage (including primary and secondary), a period of latency, and a late stage. Significant morbidity is associated with progression of the disease, mainly affecting the skin, bone, and cartilage, leading to significant disfigurement, pain, disability, and social isolation, causing more suffering to already disadvantaged populations living in poverty.

From an epidemiologic point of view, global efforts commanded by the World Health Organization (WHO) from 1952 through 1964 resulted in more than 50 million individuals who were treated for endemic treponematosis, with special attention to yaws. The global incidence of endemic treponematoses was reduced significantly, by 95%, from 50 million cases worldwide to a merely 2.5 million cases.[1] However, after all the efforts of such campaign, the sustainability of the control program was transferred to local primary care systems in endemic areas. Because of waning and poor commitment in such surveillance programs, there has been a resurgence in the incidence of the endemic treponematoses. A recent study estimates that at least 89 million people are living in yaws-endemic areas.[2] The WHO now recognizes all endemic treponematosis as neglected tropical diseases.[3] The current WHO goal is to eliminate yaws by 2020; stricter and more sensitive surveillance programs are required to reach such goal. Table 171-1 shows a quick comparison among the three diseases.

PINTA

AT-A-GLANCE

- Pinta is a chronic infectious and contagious disease recognized by the World Health Organization as a neglected tropical disease.
- It is the most benign form of endemic treponematosis, with clinical manifestations limited to the skin, including vitiligo-like achromic lesions as well as hyperpigmented lesions.
- It affects people of all ages.
- It is neither sexually transmitted nor congenitally acquired.
- Treatment includes single or divided dose of long-acting benzathine penicillin (1.2 MU for adults; 0.6 MU for children).

INTRODUCTION

DEFINITIONS

Pinta, also known as azula (blue), carate, and mal de pinto (pinto sickness), is the most benign of the endemic treponematosis because it affects only the skin. The word pinta comes from Spanish for painted, spot, or mark.[4]

The etiologic agent of pinta, *Treponema carateum*, cannot be distinguished morphologically or serologically from the not-yet-cultivable *T. pallidum* subspecies that cause venereal syphilis, yaws, and bejel.[1,2]

HISTORICAL PERSPECTIVE

Pinta is considered the first treponematosis to occur in humans. It was described in Aztec and Caribbean Amerindians in the early years of the 16th century.[5,6] Initially, it was thought that a pathogenic fungus caused pinta. However, two observations suggested otherwise. First, laboratory studies of pinta patients'

TABLE 171-1
Clinical Aspect of the Endemic Treponematosis

FEATURE	PINTA	YAWS	BEJEL
Etiology	*Treponema carateum*	*Treponema pallidum* ssp. *pertenue*	*Treponema pallidum* ssp. *endemicum*
World distribution, main areas	Probably present focally in Brazilian and Venezuelan green forest	Papua New Guinea, Solomon Islands, and Ghana	African Sahel and Saudi Arabia
Climate conditions	Tropical green forest	Tropical humid	Hot and dry climate
Population affected	Children and adults	Mostly children	Mostly children
Transmission	Close contact	Close contact	Close contact and fomites
Primary lesion	Evident, can be multiple, several locations	One to several, lower extremities	Rarely evident
Predominant lesion	Vitiligo-like and hyperchromic lesions	Exudative, papillomatous or papulo-squamous lesions	Moist lesions near mucosal surface or intertriginous areas
Nonskin involvement	None	Periositis, osteitis	Periositis, osteitis

sera showed that result for the Wassermann test, an early serology test for syphilis (STS), was positive in the majority of cases. Second, treatments that were effective against syphilis (ie, mercury and arsenicals) were also effective against pinta.[7] In 1938, Armenteros and Triana (Cuba)[6] recognized *Treponema carateum* as the causative agent of pinta. Leon Blanco, in Mexico, reproduced the disease by inoculating exudates on himself and human volunteers in 1942. The same author also demonstrated that patients with late-stage pinta could not be reinfected, but patients whose early-stage pinta had been cured could be reinfected.[8,9] Padilha-Gonçalves established that pinta was a different treponematosis from syphilis or yaws.[10,11]

EPIDEMIOLOGY

Most patients acquire the infection during childhood. There is no difference between the two sexes. The indigenous population is the most affected.[3]

In the 1950s, pinta existed in Mexico, Central America, and the northern countries of South America. The WHO then considered the disease endemic in 15 Latin American countries, including Brazil, Colombia, Ecuador, Peru, and Venezuela. Lower numbers of cases were seen in Bolivia, Dominican Republic, El Salvador, Guatemala, Haiti, Honduras, and Nicaragua. The disease was occasionally seen in Cuba, Guadeloupe, Panama, Puerto Rico, and the Virgin Islands.[12] The last report of cases from Colombia was in 1977.[12] Although Cuba had reported its last case in 1975, in 1998, a patient who had lived in Cuba for 7 years was diagnosed with pinta in Austria.[13] In 1982 and 1983, clinical evidence of pinta was discovered in 20% of the examined inhabitants of a remote village of Panama.[14]

In Brazil, the disease was supposed to be extinct until 1975, when 265 new cases of pinta were diagnosed among Indians from Baniwas, Canamari, Paumari, and Tikuna ethnic groups.[4,5,15] These Indians lived in small communities on the banks of the Amazon river, including the Içana, Juruá, Purus, and upper Negro rivers as well as in some tributaries of the western Amazon river. Since 1979, no further cases of pinta have been reported to the WHO from previously Brazilian endemic areas.[5,15]

Because of the lack of surveillance data, the current prevalence of pinta is unknown; it is believed that the disease still exists in very isolated communities in remote rural areas of Mexico and South America, especially in a few scattered areas in the Brazilian Amazon rainforest. Nonpublished cases have been reported affecting the Yaruro community in Venezuela by R. Hernandez-Perez (FB, personal communication), near the border with Brazil.

There is no proof of a spontaneous cure for the disease; because cell-mediated immunity is not completely effective, the infection persists indefinitely. Patients may harbor subclinical disease and be contagious for a long time. It has been said that pinta was man's best friend: it follows him to the grave.[12]

CLINICAL FEATURES

CUTANEOUS FINDINGS

The disease is classified into two different clinical stages, the primary and late stages.

The primary stage is characterized by two phases, an early phase or initial period, and a secondary phase or period of cutaneous dissemination. According to Padilha-Gonçalves,[10,11] the initial period appears 7 to 20 days after the treponema inoculation. The primary lesions consist of one to several erythematous scaly papules (Fig. 171-1) affecting most commonly the face, upper and lower extremities, or other exposed areas. These lesions tend to grow in extension, producing erythematosquamous or erythematous, hyperpigmented plaques, varying in size and shape (arciform, circinate, polycyclic, and serpiginous) (Fig. 171-2). Generally, the lesions are asymptomatic, but eventually patients may complain of pruritus (Fig. 171-3). Regional lymphadenopathy is common. During early infection, the STS

Figure 171-1 Pinta. Early phase in a Tikuna Indian presenting with an erythematous scaly plaque on the abdomen.

Figure 171-2 Pinta. Early phase in a Tikuna Indian presenting with multiple erythematosquamous papules.

Figure 171-3 Lichenification and dyschromic changes in early pinta.

result may be negative for antibodies to nontreponemal (cardiolipin) and treponemal antigens. Within 6 months to 2 to 3 years of the first lesions' appearance, hypochromic, erythematous, or erythematohypochromic patches appear, initiating the period of cutaneous dissemination (secondary phase). Those lesions present variable degrees of hyperkeratosis.[5,12] The lesions are small and occasionally nummular in morphology. They gradually enlarge and coalesce, affecting large areas of the body; the centers of the lesions look like normal skin. These lesions are referred to as pintides and are initially red to violaceous and later become slate-blue, brown, gray, or black. Lesions from different periods may be present in a single patient, giving a polymorphic clinical picture.[1,3,4]

The late or tertiary stage, which appears 2 to 5 years after the first lesion, is characterized by the appearance of achromic patches, especially over body prominences, such as the dorsum of the hands, wrist, elbows, anterior aspect of the tibia, ankles, and dorsal and plantar areas of the foot. In this period, large hypochromic areas commonly appear on the upper extremities, trunk, and thighs. One may observe cutaneous atrophy, achromic dotlike lesions, and multiple hyperchromic lesions, producing a mottled pattern. The presence of hypochromic patches with irregular borders and hypochromic macules is quite frequent on buttocks (Fig. 171-4). Curiously, the groin, genital area, and the inner and upper parts of the thighs are often spared. Another very important aspect of the late phase of pinta is the appearance of hyperchromic and hyperkeratotic patches most commonly on exposed areas of the upper and lower extremities. On the palmar surfaces, hyperpigmented and achromic patches associated with hyperkeratosis are usually observed (Fig. 171-5). Plantar hyperkeratosis is quite frequent. In some patients, even with a prolonged history of the disease, the cutaneous lesions may be confined to a limited area of the body.[5,12]

NONCUTANEOUS FINDINGS

There is no evidence of involvement of other organs, even after many years of evolution.[2,5,8]

Figure 171-4 Dissemination period in a Tikuna child and his mother. The child (the pictures shows his back, held by the mother) presents with hypochromic scaly patches, and the mother shows achromic lesions on the elbows (late pinta).

COMPLICATIONS

Although early pinta lesions heal within several months after specific treatment, the therapy cannot reverse the skin changes of late pinta that can stigmatize those who were infected.[8] Unlike the other treponematoses, neither destructive skin and bone lesions nor cardiovascular and neurologic manifestations are seen in patients with pinta.[3]

Figure 171-5 Vitiligoid and hyperchromic changes in late pinta.

ETIOLOGY AND PATHOGENESIS

The disease is caused by *T. carateum*, an organism that is morphologically and antigenically identical to the etiologic agents of syphilis and yaws.[3,12,15] However, *T. carateum* has not been propagated in experimentally infected animals and has not been characterized genetically.[16]

The disease is found in warm and humid environments and is usually acquired during early childhood. Pinta is thought to spread mostly via direct contact with an infected person, although it is said that transmission may occur via fomites. The treponema enters the skin through small cuts, scratches, or other skin damage. The only known reservoir is human beings.[3,12,15]

DIAGNOSIS

LABORATORY TESTING

Dark-field microscopy can be used to identify viable spirochetes from lesion swabs; however, in most settings where pinta is still prevalent, this technique is not routinely available. Therefore, serology remains the cornerstone of diagnosis. The *T. pallidum* particle agglutination (TPPA) and hemagglutination (TPHA) assays are used to detect *Treponema*-specific antibodies; when the result is positive, it usually remains positive for life. The venereal disease research laboratory (VDRL) and rapid plasma reagin (RPR) tests are nonspecific tests. Although these tests are less specific, they are more accurate to reflect disease activity than TPPA or TPHA, with titers falling rapidly after successful treatment.[3] However, serologic techniques cannot distinguish pinta from syphilis or any of the other nonvenereal treponematoses.

PATHOLOGY

The histopathologic examination is important for the diagnosis of pinta. The primary lesions are characterized by mild acanthosis and spongiosis, with lymphocyte migration and vacuolar degeneration of the basal cell layer, but in the dermis, the changes consist of a slight lymphohistiocytic and plasmocytic infiltrate and mild vascular reaction.[5,15] The hypochromic lesions from the secondary phase present with moderate hyperkeratosis, acanthosis, and spongiosis, plus a superficial infiltrate around the thickened vessels. In the erythematous and squamous lesions, acanthosis, hyperkeratosis, and spongiosis are seen in the epidermis plus a lymphohistiocytic infiltrate in the dermis with edema and vascular proliferation in the papillary dermis. In the achromic lesions, there are hyperkeratosis, atrophy of the epidermis, and complete absence of melanin in the basal layer but some perivascular

TABLE 171-2
Differential Diagnosis of Pinta

Primary Stage
- Tinea
- Psoriasis
- Erythema dyschromicum perstans
- Tinea versicolor
- Eczema
- Leprosy
- Cutaneous tuberculosis

Late Stage
- Vitiligo

inflammatory infiltrate. It is possible to demonstrate the presence of treponema in the epidermis through special stains such as Warthin-Starry, in all lesions, except for those that are already achromic.[4,6,12]

DIFFERENTIAL DIAGNOSIS

See Table 171-2.

CLINICAL COURSE AND PROGNOSIS

Primary and secondary lesions of pinta may resolve spontaneously. However, despite treatment, patients may present with lifelong late lesions.[3,12,15]

MANAGEMENT

MEDICATIONS

The recommended treatment for pinta, irrespective of the stage of the disease, is a single or divided dose of long-acting benzathine penicillin (1.2 MU for adults; 0.6 MU for children), which renders the lesions non-infectious in less than 24 hours. Within a few days, the hypochromic and erythematosquamous lesions disappear. Later, the hyperpigmented and recent achromic lesions disappear. The old achromic patches do not usually respond to the treatment and persist for life, giving a vitiligo-like clinical aspect in some patients.[5,12,17]

PREVENTION AND SCREENING

At present, the WHO has not developed a specific strategy for the control or eradication of pinta. However, it has launched a campaign to eradicate yaws by 2020. The strategy is based on mass treatment of endemic communities with an oral dose of azithromycin, a macrolide antibiotic with demonstrated efficacy against yaws.[1,2,7,18] If *T. carateum* is sensitive to azithromycin, this treatment strategy could have a concomitant effect on pinta in areas of Latin America where yaws and pinta may be coendemic.[7]

YAWS

AT-A-GLANCE

- Yaws is the most prevalent of the endemic treponematosis.
- It is most commonly seen in children.
- Countries with the largest number of cases are Papua New Guinea, the Solomon Islands, and Ghana.
- Primary lesions are either papillomatous or ulcerated lesion on the lower extremities.
- Secondary lesions are multiple, bilateral, and symmetrical. They are either moist and papillomatous (raspberry-like) or dry and papulosquamous.
- Eroded or hyperkeratotic palmoplantar lesions with fissuring induce a crablike gait (crab yaws).
- Periostitis and dactylitis are common.
- Penicillin and azithromycin are both effective in the treatment of patients with yaws.

INTRODUCTION

DEFINITION

Yaws is an infectious disease caused by *T. pallidum* ssp. *pertenue*. The term *yaws* probably originates either from the Carib word *yaya* (sore) or from the African word *yaw* (berry). The clinical appearance of a typical lesion of yaws, resembling a raspberry, explains also one of the names given to the disease, *framboesia tropica* (*framboesia* is the French word for raspberry). Other names used to refer to the same disease include pian, buba, bouba, parangui, and paru.

HISTORICAL PERSPECTIVE

Yaws was the 17th century term used by the Dutch physician Willen Piso when he wrote one of the first clinical descriptions of the disease in South America. In 1679, Thomas Sydenham described classical yaws in African slaves and thought it was the same disease as syphilis. In 1905, Castellani found spirochetes in the ulcers of patients with yaws from Ceylon.[18]

Some phylogenetic analyses identify yaws as the oldest of the treponemal diseases and suggest that syphilis and bejel evolved subsequently. The Unitarian hypothesis proposed by Hudson stated that syphilis, as a venereal disease, arose from yaws brought to

Europe by the slave trade. However, recent genetic studies by Gray and Mulligan[19] support the idea of a parallel evolution of the three subspecies of *T. pallidum* responsible for yaws, syphilis, and bejel.

EPIDEMIOLOGY

The geographical distribution of yaws has changed dramatically since the 1950s following the very successful programs developed by the WHO and UNICEF to eradicate the disease. Those programs were directed to identify active disease as well as latent disease and to treat them with long-acting penicillin. Furthermore, the programs were also intended to establish alert systems for early detection of any new cases. In 1950, yaws was still present in tropical and subtropical areas around the world, including Central and South America, most of Central Africa, India, Southeast Asia, and the Western Pacific region. Since then, the map has changed drastically; the disease has almost disappeared from the Americas. Ecuador was the last country reporting elimination of the disease; Guyana reported residual cases in 2003. India also reported elimination of the disease by the year 2003. The number of affected African countries has diminished, and the disease is now confined to few countries of East Central Africa. On the contrary, yaws is still clearly present in Western Pacific countries, such as Papua New Guinea, the Solomon Islands, and Vanuatu. A recent systematic review published in 2015 identified 256,343 cases reported to the WHO in 13 endemic countries in the 2010 to 2013 period.[2,3] The prevalence of active disease in such endemic areas ranged from 0.31% to 14%, and the prevalence of latent disease ranged from 2.4% to 31%. Near 84% of reported cases came from three countries, Papua New Guinea, the Solomon Islands, and Ghana.

CLINICAL FEATURES

CUTANEOUS FINDINGS

Yaws is transmitted by direct skin contact with an infectious lesion and facilitated by abrasion or erosion of the skin. Children are most commonly affected, up to 15 years of age, with a peak incidence between 6 and 10 years. The disease affects people living in rural communities under poor sanitary condition in tropical areas of the world with an average temperature over 27°C (80°F) and heavy rainfall.

The primary lesion of yaws is usually a papule that develops 21 days (range, 9 to 90 day) after initial contact. The papule evolves into a proliferative, exudative, papillomatous lesion 2 to 5 cm in diameter or evolves into a crusted, nontender ulcer, most commonly located on the legs. Genital location is extremely uncommon. This primary lesion is known under different names, including "mother yaws," "maman pian," or "buba madre" (Fig. 171-6A). Even if left untreated, the lesion resolves spontaneously over a 3- to 6-month period, leaving a pigmented scar. A patient may have primary and secondary lesions simultaneously.[20]

Secondary lesions appear after 1 to 2 months (up to 24 months). They represent hematogenous and lymphatic spreading to the skin and bone. In the skin, the lesions can be exudative, proliferative, and papillomatous (Fig. 171-6B) (*pianomes* in French) or dry

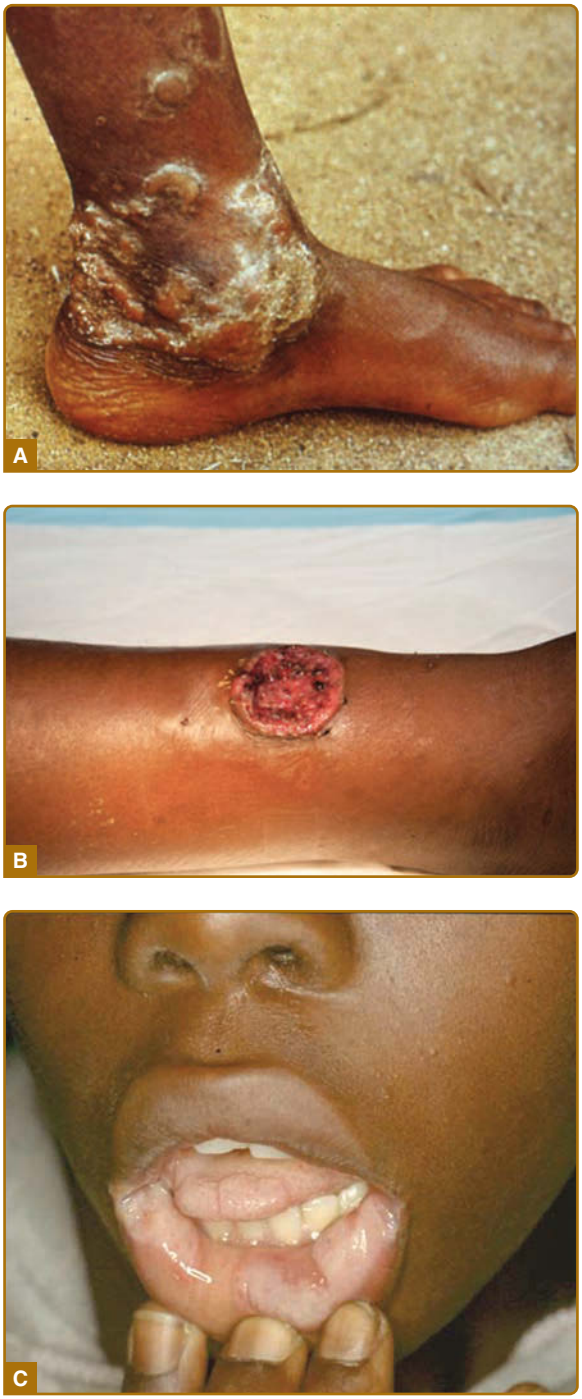

Figure 171-6 **A,** Primary lesion in yaws, also known as maman pian. **B,** The secondary, exudative lesion, known as pianome. **C,** Mucosal and perioral lesion of yaws, quite similar to the mucosal condylomas of syphilis.

and papulosquamous (*pianides* in French). The exudative papules (*pianomes* or *frambresiomas*) are usually generalized, bilateral, and symmetrical, from a few millimeters to 2 cm in diameter, soft, wet, red yellowish in color, with either a moist surface or a crust. By resembling raspberries, they are the most representative lesions of yaws. They can affect scalp and folds; in the latter location, they may resemble condyloma lata of syphilis. Mucosal lesions tend to be located around natural orifices, presenting as a bilateral exudative, angular cheilitis (Fig. 171-6C). The dry, papulosquamous papules (*pianides*) are multiple and generalized, and they can have annular or discoid morphology, with a squamous collaret (tinea yaws), grouped in a corymbose pattern. On the face, lesions may resemble psoriasis or seborrheic dermatitis. Multiple, florid lesions are associated with the wet seasons; they become scarce and restricted to intertriginous areas in dry climate.

On the palms and soles, the lesions can be also exudative papules or papulosquamous plaques, keratodermic, with a tendency to form fissures (Fig. 171-7). Because the acral lesions are tender or painful, patients develop a peculiar gait, known as crab yaws. Pianic onychia is a paronychia that originates from hyperkeratotic lesions in the nail folds.[21]

All secondary yaws resolves, either spontaneously or after treatment, healing with or without scarring. If left untreated, the patient will enter the latent phase and remain as such for the rest of her or his life. Relapsing yaws tend to localize in perioral, perianal, and axillary areas. Relapses may occur for as long as 5 years after the initial infection.

About 10% of untreated patients progress to the tertiary sate. Late-stage lesions are subcutaneous gummatous nodules with massive tissue destruction and necrosis, sometimes resulting in large serpiginous ulcerations, followed by debilitating deformity and contractures. The most common manifestations associated with this state are a result of simultaneous involvement of the skin and bone structures .The complete destruction of the nasal cartilage and the collapse of the nasal pyramid results in a deformity known as gangosa (Fig. 171-8). Pintoid dyschromia and palmoplantar hyperkeratosis have been described at this late stage (Fig. 171-9).

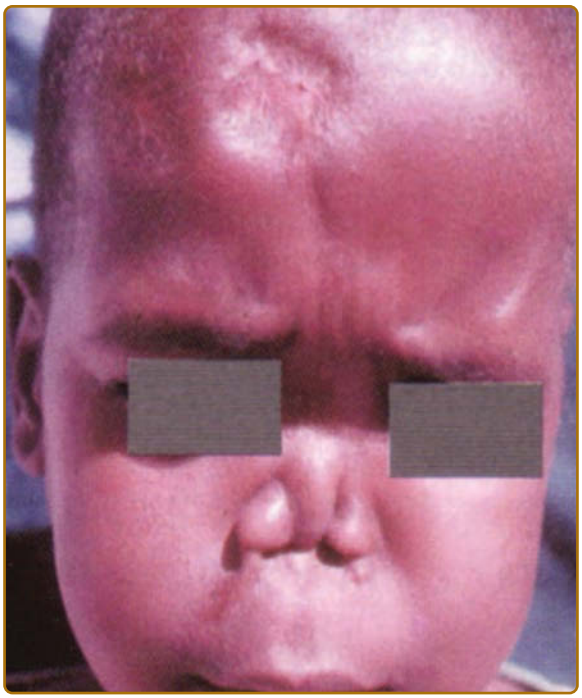

Figure 171-8 Gangosa seen in yaws. See the significant destruction of nasal cartilage.

In areas of reduced transmission, because of climate condition or after mass treatment, a milder form of disease can be seen, associated with few lesions (attenuated yaws).

NONCUTANEOUS FINDINGS

Arthralgia, generalized lymphadenopathy, headaches, and malaise are common, as well as asymptomatic cerebrospinal fluid changes.

The most important noncutaneous findings refer to the involvement of osteoarticular structures. In secondary yaws, early osteoperiostitis of fingers (dactylitis) or long bones (forearm, fibula, and tibia) might result in nocturnal bone pain swelling. Early bone changes can be visualized on radiography, and the

Figure 171-7 Crab yaws: plantar keratoderma with fissuring.

Figure 171-9 Pintoid dyschromia and hyperkeratosis seen in late yaws.

thickened periosteum can be palpated clinically; a fusiform swelling of a finger affecting the two proximal phalanges is a common expression of this dactylitis (ghoul hand). The average number of bones involved is three, with common involvement of hand and feet. A specific hypertrophic bone exostosis of the paranasal area known as goundou is rarely seen nowadays.

In late yaws, besides the destructive central face involvement known as rhinopharyngitis obliterans or gangosa, patients may also develop a saddle-nose deformity, bowing of the tibia, or sabre shins. Another manifestation includes the presence of juxtaarticular nodes. Opposite of tertiary syphilis, late yaws is not associated with cardiovascular or neurologic disease. Optic atrophy, however, has been reported in the tertiary stage.[21] *T. pallidum* spp. *pertenue* is not associated with congenital transmission.

ETIOLOGY AND PATHOGENESIS

T. pallidum ssp. *pertenue* is a spiral-shaped, gram-negative bacteria that belongs to the family Spirochaetaceae, closely related to other subspecies of *T. pallidum,* from which it is morphologically and serologically identical. *T. pallidum* ssp. *pertenue* is 10 to 15 μm long and has a diameter of 0.2 μm; it is not seen on regular microscopy but can be seen on dark-light microscopy. A cytoplasmic membrane enclosed by a loosely associated outer membrane surrounds the bacterium. Some proteins of this outer membrane are able to induce opsonic activity.[18] *Treponema* has a characteristic corkscrew motility and can swim efficiently in gel-like media or environment, such as the connective tissue, a factor that contributes to its virulence. The microorganism multiplies very slowly, at a rate of 1 every 30 to 33 hours. It does not grow on culture media but can be isolated and reproduced in experimental animals, such as rabbits and golden hamsters. In vitro assays based on *Treponema* protein synthesis have demonstrated that *T. pallidum* ssp. *pertenue* is sensitive to penicillin, tetracycline, and erythromycin.

T. pallidum ssp. *pertenue* is 99.8% identical in its genomic sequence to *T. pallidum* ssp. *pallidum.* Established differences between the two microorganisms include a one pair base difference in the *tpp15* gene, one nucleotide difference in the *gpd* gene, a base pair deletion in the *tpr* gene, sequence variation in the *arp* gene, and sequence variation of the intergenic spacer IGR19.[18]

The microorganism enters the skin by small abrasions. After penetrating the epidermis, it reaches the extracellular matrix and attaches to fibronectin-coated surfaces. After minutes, the spirochetes reach lymph nodes and disseminate extensively in hours. The lymph node enlarges and teems with treponemas for several weeks. In the skin, the initial reaction is mainly neutrophilic and later composed mainly of plasma cell. *T. pallidum* ssp. *pertenue* is seen as extracellular clusters in upper regions of the epidermis on immunohistochemistry staining. The immune response to the microorganism is both humoral and cellular. The organism, because of its low metabolic rate, is able to maintain infection with few viable cells, avoiding the stimulation of the immune system in the latent state. Adults rarely develop new skin lesions, suggesting that untreated individuals can develop immunity to reinfection.

DIAGNOSIS

The diagnosis is easy in the endemic areas, although attenuated yaws may be more challenging. Health care workers not familiar with the disease may need laboratory methods to confirm the diagnosis

LABORATORY TESTING

Treponemas can be detected in a wet preparation using dark-field microscopy. However, the scarce availability of the method in rural setting makes it unpractical. The best diagnostic aid is serology testing using the same techniques as in syphilis. Nontreponemal agglutination tests, such as the RPR and the VDRL, can be used for diagnosis and follow-up after treatment, as they are used in syphilis. False positives can be seen in patients with other tropical diseases such as malaria and leprosy, as well as in rheumatic diseases. Results of treponemal tests, such as TPHA, TPPA, and fluorescent treponemal antibody absorption (FTA-ABS) are also positive, but as in syphilis, they remain positive forever and are not useful for follow-up.

The new rapid diagnostic test, including the immunochromatographic strips developed for syphilis, are also very useful and easy to use in the primary care setting. Differential diagnosis with syphilis itself might be tricky; real-time polymerase chain reaction remains, in such cases, the technique of choice, although it is expensive and limited to research centers. In such cases, epidemiologic and clinical data need to be carefully evaluated to establish the correct diagnosis.

PATHOLOGY

The histologic findings of yaws is quite similar to those of syphilis and include epidermal hyperplasia, focal spongiosis, and a dermal infiltrate. Some authors describe an early accumulation of neutrophils in the epidermis,[18] but others state that is mainly plasmocytic from the beginning.[1] Plasma cells predominate in all evolved lesions. An important difference with syphilis is that yaws does not induce vascular changes or endothelial proliferation. The same immunohistochemistry staining used in syphilis is quite useful in yaws by demonstrating the spirochetes in large numbers at the epidermal level.

Figure 171-10 Radiographic evidence of periosteitis of yaws.

IMAGING

Radiographic studies are particularly valuable in cases of periostitis and bone involvement; onion layering periosteal reaction and loss of clarity of the cortex are seen on plain radiographs (Fig. 171-10). Bowing of the tibia, destructive osteitis of facial bones (such as seen in gangosa), and the hypertrophic periostitis and exostosis seen in gondou are quite evident on radiology studies.

DIFFERENTIAL DIAGNOSIS

See Table 171-3.

TABLE 171-3
Differential Diagnosis of Yaws

Primary Lesion
- Leishmaniasis
- Tropical phagedenic ulcer
- Ecthyma
- Tuberculosis
- Buruli ulcer
- Sickle cell anemia

Secondary Lesions
- Eczema
- Psoriasis
- Syphilis
- Disseminated leishmaniasis
- Superficial mycosis
- Infective dermatitis of HTLV-1
- Leprosy
- Impetigo
- Pyoderma vegetans

Facial Lesions
- Leishmaniasis
- Lupus vulgaris
- Leprosy
- Paracoccidioidomycosis
- Rhinoscleroma
- Rhinosporidiosis
- Rhinoentomophthoromycosis
- T-NK lymphomas

Pintoid Lesions
- Vitiligo
- Pinta

HTLV, human T-lymphotropic virus; T-NK, it is a type of extranodal lymphoma caused by a proliferation of Natural Killer cells or T lymphocytes.

CLINICAL COURSE AND PROGNOSIS

Primary and secondary lesions may resolve spontaneously. Up to 10% of patients in a latent stage may evolve into the most disfiguring, disabling late stage after 5 years of an untreated infection.

MANAGEMENT

MEDICATIONS

Single-dose, long-acting penicillin has been the treatment of choice for yaws and the base of the successful eradication program. A dose of 1.2 million units for patients older than 10 years and a dose of 0.6 million units for those younger than 10 years is still the recommended regimen. Cure rates are above 95% for early active yaws.

One oral dose of azithromycin (30 mg/kg, to a maximal dose of 2 g) is considered as effective as penicillin. Since 2012, the WHO considers the one single dose of azithromycin equivalent to the standard penicillin regimen. Oral tetracyclines, doxycycline, and erythromycin are considered alternative drugs for adults who are allergic to penicillin; erythromycin is the choice for children younger than 12 years of age.

Oral therapy with azithromycin has many advantages over intramuscular penicillin therapy. When it is used in massive control programs, it can be administrated by less skilled health workers, and there is a reduced risk of anaphylaxis. However, a higher potential risk of developing resistance does exist when macrolides are used. In such cases, follow-up is recommended, allowing early retreatment with penicillin when needed.

The effectiveness of therapy is expressed by several facts. Yaws lesions become noninfectious in 24 hours after therapy. Joint pain disappears in 24 to 48 hours. All clinical lesions resolve within 2 to 4 weeks after therapy. However, therapy will not resolve the destruction and deformities seen in the tertiary stage, thus justifying the importance of early intervention. RPR and VDRL testing titers decrease to a minimum within 6 to 12 months and become negative or remain at low titers in the next 2 years.

PREVENTION AND SCREENING

The success of the WHO eradication effort in the 1950s was followed by a loss of continuity of such a program. The responsibility of maintaining the program was rapidly transferred to primary care systems that were either too weak or nonexistent in many endemic areas; this lack of continuity translated into a resurge of yaws in the past decades. Of note, the success of this program in India and Ecuador remain an exception because both countries have now been declared free of yaws. One of the conclusions of the 1950s efforts was the importance of subclinical or latent cases as a source of reinfection. The initial program was directed to treat active disease cases; resurveys of the treated communities showed that all new cases were individuals in the latent stage who did not receive treatment.

In 2012, the WHO endorsed the commitment to eradicate yaws by the year 2020. This time, the strategy includes some variations. Surveys are directed to detect precisely the villages and communities affected by yaws. Oral azithromycin instead of intramuscular penicillin is the treatment of choice. The aim of the program is the treatment of the whole community, which will be repeated if the first attempt did not cover 90% of the population. The follow-up surveillance program will include passive and active search of new cases, tracing and treating contacts, intensive information and educational efforts, and monthly reporting of case (including no new cases) and yearly serologic surveys in children younger than 5 years. Indeed, improvement of education and sanitary conditions in affected communities are important factors that will facilitate the success of the eradication program.[18]

BEJEL

AT-A-GLANCE

- Bejel is most commonly seen in children.
- Transmission routes include direct contact and fomites by sharing utensils.
- Countries and regions with the largest number of cases are the African Sahelian countries and Saudi Arabia (dry, hot climates).
- Primary lesions are not easily identified or seen.
- Secondary lesions are represented by moist plaques on mucosal and perioral areas, mimicking condyloma lata or angular stomatitis.
- Gummas and gangosa represent tertiary lesions.
- Involvement of the nasopharynx and larynx is common.
- Periostitis and saber shins may be seen.
- The treatment of choice is penicillin.

INTRODUCTION

DEFINITIONS

The name *bejel* has been coined from Arabic and is the term used for nonvenereal (endemic) treponematoses. Other names have been used to designate the disease, including *njovera* in Zimbabwe, *belesch* or *bishel* in Saudi Arabia, and *dichuchwa* in Botswana. The causative agent is the spirochete *T. pallidum* ssp. *endemicum.* Bejel is a disease of countries of dry and arid climate and is often found in isolated communities with poor hygiene. The disease mainly involves children from 2 to 15 years of age, but it can also be seen in adults belonging to nomadic people. This treponematosis is likely transmitted not only by nonvenereal direct mucosal or skin contact but also by sharing utensils and drinking vessels. Bejel is therefore often considered as a "familial" disease.

HISTORICAL PERSPECTIVE

Endemic syphilis or bejel has been described in many European countries since the 16th century. The first description appeared in 1575 in Brno, Czech Republic, where it was called *morbus Brunogallicus*. It was associated with the use of communal bath and bloodletting. A similar disease was described in southwest Scotland and received the name of *sibbens* or *sivvens*. In Croatia in the 1800s, an entity named *morbus Skrljevo* sharing similar clinical features with nonvenereal syphilis was commonly seen and clearly associated with poverty and poor hygiene. The republic of Bosnia and Herzegovina were a site of endemic syphilis for centuries. By the 20th century, additional cases were seen in Russia and Bulgaria. Europe was able to eliminate the disease basically by improving sanitary conditions, and the few persistent endemic areas disappeared with the massive use of penicillin in the 1950s.[22]

EPIDEMIOLOGY

As with the other endemic treponematosis, bejel was once described as endemic in many areas of the world, such as Northern Europe, the Balkans, Russia, Mongolia, the near East, the eastern Mediterranean, and southern and northern Africa, affecting mainly those living in poverty. Improvements in the social and economic status in many of these populations have led to a marked reduction in the prevalence of the infection, even preceding the massive campaigns efforts of the 1950s by the WHO. However, there are still areas of the world where the disease is yet prevalent, mostly in the Near East (rural areas of Saudi Arabia) and the African Sahel, the geographic area between the southern border of the Sahara desert and the Sudanese sabana. In the 1980s, bejel was reported in Burkina

Faso and Mali. In the 1990s, cases were reported in Niger and Mauritania. It is an interesting observation that bejel predominates in countries with dry climate, but in the nearby countries with more humid climates, yaws is the predominant disease.[1]

Few additional cases have been reported in Turkey, Mozambique, and, most recently, Iran but only as isolated cases.[23]

CLINICAL FEATURES

CUTANEOUS FINDINGS

The main population affected are children younger than 15 years of age. Overcrowding, poor sanitary conditions, and poor personal hygiene seem to facilitate the infection. Distinctly in bejel, the primary lesion is infrequently observed. When the lesion has been noted, it is described as a painless and superficial mucosal ulceration in the mouth or the nasopharynx. An anecdotal report of a primary lesion in the nipple of a nursing woman has been reported that tended to simulate the genital primary chancre of syphilis.

The secondary lesions are quite similar also to what is seen in syphilis in the oral mucosae, tonsils, tongue, lips, and nasopharynx. They are oval, almost painless patches, with a whitish, slightly elevated cap. Lesions of angular stomatitis can be part of bejel, similar to what is seen in yaws. Patients also may have generalized, nonitchy skin eruptions, generalized lymphadenopathy, and laryngitis. Condylomata lata-like lesions (Fig. 171-11) may also be present in mucosal and intertriginous areas. On hairless skin, circinate papules may appear (Fig. 171-12). The secondary lesions take 6 to 9 months to heal, and then the disease enters the latency period.

The tertiary stage may develop earlier than in yaws, as early as 6 months or taking several years to show. The lesions are gummas that can progress to very destructive ulcerations. They may heal spontaneously, but leave significant scars, surrounded by hyperpigmentation. Involvement of central face and nasal cartilage and bone may result in the picture of gangosa, as described in yaws.

Figure 171-11 Cheilitis and angular stomatitis, representing secondary lesions of bejel.

Figure 171-12 Dry and exudative lesions of bejel.

NONCUTANEOUS FINDINGS

Patients with bejel may develop the same osteitis and periostitis of long bones and hands seen in patients with yaws. Such patients will complain of nocturnal pain. The bone changes may evolve into saber tibias, although it is said that such involvement is less severe than in yaws.

Neurologic and cardiovascular involvement, as well as congenital transmission are all said to be rare in bejel, but there is a report that mentioned uveitis, optic atrophy, and choroidal atrophic scar. An attenuated form of bejel, manifested mainly as leg pain and radiographic evidence of periostitis. has been described in Saudi Arabia.[1]

ETIOLOGY AND PATHOGENESIS

The disease is caused by *T. pallidum* ssp. *endemicum*. The microorganism is morphologically identical to all spirochetes of the genus *Treponema*. There is a 99.7 genome sequence identity with the genome of *T. pallidum ssp pallidum*[24]; its genome size is 1137.7 kbp.

As the other endemic treponematosis, acquiring the disease during childhood and a direct transmission through the skin seem to be the classical scenario. However, bejel is the disease in which more emphasis should be put on the risk of transmission by fomites transported in utensils and drinking vessels.

DIAGNOSIS

Most cases of bejel are diagnosed on the basis of clinical findings. Among all the nonvenereal treponematosis,

bejel is the one with which the differential diagnosis with venereal syphilis might be tricky.

LABORATORY TESTING

Results of the nontreponemal agglutination tests, such as the RPR and VDRL, as well as the most specific treponemal tests, TPHA, TPPA and FTA-ABS, are positive, as in yaws. Clear distinction with venereal syphilis is most difficult and should be based on a careful history and evaluation of the mother and siblings, as illustrated by a recent case seen in Canada.[25] In a small number of cases, the final diagnosis may require molecular studies that, unfortunately, are only available in research centers.

PATHOLOGY

The cutaneous lesions show a superficial dermal lymphoplasmacytic infiltrate. In early lesions, epidermal changes such hyperplasia and spongiosis are expected. Treponemas can be then visualized with the aid of immunohistochemistry. Additional findings that may be seen include a lichenoid pattern of the infiltrate and endothelial swelling in superficial capillary plexus, as in venereal syphilis. Tuberculoid granulomas are described occasionally.[20]

IMAGING

Periostitis as well as bone involvement can be seen on radiographs, very much as they are seen in yaws.

DIFFERENTIAL DIAGNOSIS

See Table 171-4.

TABLE 171-4
Differential Diagnosis of Bejel

Primary and Secondary Cutaneous Lesions
▪ Syphilis
▪ Condyloma acuminatum
▪ Molluscum contagiosum
▪ Seborrheic dermatitis
▪ Psoriasis dermatophytosis
Tertiary Gummatous Lesions
▪ Syphilis
▪ Gummas of tuberculosis
▪ Deep fungal infections
▪ Rhinosporidiosis
▪ Rhinoscleroma
Mucosal and Perioral Lesions
▪ Syphilis
▪ Angular cheilitis
▪ Herpes simplex
▪ Aphthous disease

MANAGEMENT

MEDICATIONS

Penicillin remains the treatment of choice for bejel. As in yaws, the WHO recommends 1.2 million units of benzathine penicillin for treatment of all stages in adults; half the dose is used in children younger than 10 years.

Strategies for eradication are the same as proposed by the WHO in the case of yaws. Accessibility to health care for deprived populations is an important part of any future effort to control and elimination of bejel.

ACKNOWLEDGMENTS

Figures 171-6A to C and 171-8 to 171-12 were obtained by one of the authors (KE) while working at the NGOs Centre René Labusquière and the Réseau Dermatrop, from patients from Mali, Senegal, and Ghana.

REFERENCES

1. Giacani L, Lukehart SA. The endemic treponematoses. *Clin Microbiol Rev.* 2014;27(1):89-115.
2. Mitjà O, Marks M, Konan DJ, et al. Global epidemiology of yaws: a systematic review. *Lancet Glob Health.* 2015; 3(6):e324-e331.
3. Marks M, Solomon AW, Mabey DC. Endemic treponemal diseases. *Trans R Soc Trop Med Hyg.* 2014; 108(10):601-607.
4. Talhari S, Dourado HV, Alecrim WD, et al. Pinta em população nativa do estado do Amazonas. *Acta Amazônica.* 1975;5:199-202.
5. Talhari S. Pinta. In: Talhari S, Neves RG, eds. *Dermatologia Tropical.* Rio de Janeiro: Medsi; 1995:291-300.
6. Engelkens HJ, Vuzevski VD, Stolz E. Nonvenereal treponematoses in tropical countries. *Clin Dermatol.* 1999; 17:143-152.
7. Stamm LV. Pinta: Latin America's forgotten disease? *Am J Trop Med Hyg.* 2015;93(5):901-903.
8. Carrillo AM. From badge of pride to cause of stigma: combating mal del pinto in Mexico. *Endeavor.* 2013;37: 13-20.
9. Pardo-Castello V, Ferrer I. Pinta. Mal del pinto; carate. *Arch Dermatol Syph.* 1942;45:843-864.
10. Gonçalves AP. Pinta: presentation of 2 patients. *An Bras Derm Sifilogr.* 1950;25:185-186.
11. Gonçalves AP. Immunologic aspects of pinta. *Dermatologica.* 1967;135:199-204.
12. Medina R. Pinta: an endemic treponematoses in the Americas. *Bol Oficina Sanit Panam.* 1979;86:242-255
13. Woltsche-Kahr I, Schmidt B, Aberer W, et al. Pinta in Austria (or Cuba?). Import of an extinct disease? *Arch Dermatol.* 1999;135(6):685-688.
14. Fohn MJ, Wignall S, Baker-Zander SA, et al. Specificity of antibodies from patients with pinta for antigens of Treponema pallidum subspecies pallidum. *J Infect Dis.* 1988;157(1):32-37.
15. Talhari S. Pinta: aspectos clínicos, laboratoriais e situação epidemiológica no estado do Amazonas

(Brasil). PhD thesis. São Paulo, Brazil: Escola Paulista de Medicina; 1988.
16. Čejková D, Strouhal M, Norris SJ, et al. A retrospective study on genetic heterogeneity within Treponema Strains: subpopulations are genetically distinct in a limited number of positions. *PLoS Negl Trop Dis.* 2015; 9(10):e0004110.
17. Carrillo AM. From badge of pride to cause of stigma: combating mal del pinto in Mexico. *Endeavor.* 2013; 37:13-20.
18. Mitjà O, Asiedu K, Mabey D. Yaws. *Lancet.* 2013; 381(9868):763-773.
19. Gray RR, Mulligan CJ, Molini BJ, et al. Molecular evolution of the tprC, D, I, K, G, and J genes in the pathogenic genus Treponema. *Mol Biol Evol.* 2006; 23(11):2220-2233.
20. Padilha-Goncalves A, Basset A, Maleville J. Tropical treponematosis. In: Canizares O, Harman RM, eds. *Clinical Tropical Dermatology.* 2nd ed. Boston: Blackwell Scientific Publications; 1992:129-150.
21. Farnsworth N, Rosen T. Endemic treponematosis: review and update. *Clin Dermatol.* 2006;24(3):181-190.
22. Lipozencic J, Marinovic B, Gruber F. Endemic syphilis in Europe. *Clin Dermatol.* 2014;32(2):219-226.
23. Abdolrasouli A, Croucher A, Hemmati Y, et al. A case of endemic syphilis, Iran. *Emerg Infect Dis.* 2013; 19(1):162-163.
24. Mitja O, Smajs D, Bassat Q. Advances in the diagnosis of endemic treponematosis: yaws, bejel and pinta. *PLoS Negl Trop Dis.* 2013;7(10):e2283.
25. Fanella S, Kadkhoda K, Tsang R. Local transmission of imported endemic syphilis, Canada, 2011. *Emerg Infect Dis.* 2012;18(6):1002-1004.

Chapter 172 :: Chancroid

:: Stephan Lautenschlager & Norbert H. Brockmeyer

AT-A-GLANCE

- Chancroid is a sexually transmitted acute ulcerative disease usually localized at the anogenital area and often associated with inguinal adenitis or bubo.
- *Haemophilus ducreyi*—a Gram-negative, facultative anaerobic coccobacillus—is the causative agent.
- Chancroid is disappearing even from most countries where *H. ducreyi* was previously epidemic, with the exception of North India and Malawi. Nevertheless, recent sporadic case reports from Western Europe have been described, often initially misdiagnosed as genital herpes.
- Painful, soft ulcers with ragged undermined margins develop 1 to 2 weeks after inoculation (usually prepuce and frenulum in men and vulva, cervix, and perianal areas in women).
- *H. ducreyi* facilitates the transmission of HIV.
- In contrast to a sustained reduction in the proportion of genital ulcer disease caused by *H. ducreyi*, the bacterium is increasingly found in the South Pacific region and in Africa as a common cause of nongenital cutaneous ulcers especially in children.
- Laboratory culture of *H. ducreyi* is problematic, but greater sensitivity can be expected by nucleic acid amplification methods, which are not routinely available.
- Azithromycin and ceftriaxone are recommended as single-dose treatment, enhancing compliance.

EPIDEMIOLOGY

Until the 1990s chancroid was seen most commonly in developing countries, especially in Africa and Asia, where it was isolated from more than 50% of patients with genital ulcers.[1-3] A systematic review analyzed 49 studies (35 were published during 1980-1999 and 14 during 2000-2014) on chancroid.[4] During 1980-1999, the percentage of genital ulcers caused by *Haemophilus ducreyi* ranged from 0% in Thailand and China to 69% in South Africa. During 2000-2014, the percentage of genital ulcers caused by H. ducreyi was low (<10%) except for Malawi with 15% of genital ulcer disease[5] and North India with 24% of genital ulcer disease.[6] A recent report from Cuba described no infection with *H. ducreyi* in genital ulcer disease patients.[7] In the United States, only 11 cases of chancroid were reported in 2015.[8] In Europe, chancroid is restricted to rare sporadic cases, often misdiagnosed as genital herpes.[9,10] The distinct decrease in prevalence has followed the introduction by the World Health Organization (WHO) of syndromic management for treating genital ulcer disease.[4] Nevertheless, the global epidemiology of *H. ducreyi* is poorly documented because of difficulties in confirming a microbiologic diagnosis. As a result, this condition may be substantially underdiagnosed.[8]

Lower-class prostitutes appeared to be a reservoir in all previously reported outbreaks of this disease where men had a markedly higher incidence than women. Male circumcision is associated with a reduced risk of contracting chancroid.[11] Several studies in Africa show that chancroid ulcer was an important risk factor for the heterosexual spread of HIV.[12,13] In West Africa, it has been shown that 2% of female sex workers carry the organism asymptomatically.[14] The duration of infectivity in the absence of treatment is estimated to be 45 days for women. The transmission rate from females to males is not known, in contrast to a reported transmission rate from males to females of 70% per sex act.[15] Nonsexual transmission leading to nongenital skin ulcers mostly in children in the Asia Pacific region has been recently reported.[16,17] Based on sequencing of whole genomes and defined genetic loci, it appears that the cutaneous *H. ducreyi* strains (Class II) diverged from the class I genital strains relatively recently.[18]

CLINICAL FINDINGS

The incubation period is between 3 and 7 days, rarely more than 10 days. No prodromal symptoms are known. The chancre begins as a soft papule surrounded by erythema. After 24 to 48 hours it becomes pustular, then eroded and ulcerated (Fig. 172-1); vesicles are not seen. The edges of the ulcers are often ragged and undermined (Fig. 172-2). The ulcer is usually covered by a necrotic, yellowish-gray exudate (Fig. 172-3), and its base is composed of granulation tissue that bleeds readily on manipulation. In contrast to syphilis, chancroid ulcers are usually tender and/or painful, not indurated (soft chancre). The diameter varies from 1 mm to 2 cm. Half of the males present with a single ulcer, and most lesions are found on the external or internal surface of the prepuce, on the frenulum, or on the glans (Fig. 172-4). Lesions may spread by extension and autoinoculation, leading to "kissing ulcers" (Fig.172-5) or large serpiginous ulcers involving the groin or thigh. Meatus and shaft of the penis and the anus (Fig. 172-6) are involved less frequently.

Figure 172-1 Early sharply circumscribed ulcer in the coronal sulcus.

Figure 172-3 Chancroid with necrotic, yellowish-gray exudates.

Edema of the prepuce is often seen. Rarely, if the chancre is localized in the urethra, *H. ducreyi* causes purulent urethritis.[19]

In females, the lesions are mostly localized on the vulva (Fig. 172-7), especially on the fourchette, the labia minora, and the vestibule. Vaginal, cervical, and perianal ulcers also have been described. Extragenital lesions of chancroid have been reported on the breasts, fingers, thighs, and inside the mouth. Trauma and abrasion may be important for such extragenital manifestations.

Painful inguinal adenitis (bubo) occurs in up to 50% of patients within a few days to 2 weeks (average: 1 week) after onset of the primary lesion (Fig. 172-8). The adenitis is unilateral in most patients, and erythema of the overlying skin is typical. Buboes can become fluctuant and may rupture spontaneously. The pus of bubo is usually thick and creamy. Buboes are less common in female patients. Besides the common types of chancroid described above, a number of clinical variants have been reported (Table 172-1). Mild systemic symptoms can rarely accompany chancroid, but systemic infection by *H. ducreyi* has never been observed. The significance of the recent detection of

Figure 172-4 Isolated small soft chancre on the glans.

Figure 172-2 Ragged edges of a soft ulcer.

Figure 172-5 Spreading of *Haemophilus ducreyi* by autoinoculation ("kissing ulcer") from the frenulum to the glans.

Figure 172-6 Anal chancroid.

Figure 172-7 Vulvar chancroid with undermined edges.

Figure 172-8 Small soft ulcer on the internal surface of the prepuce with painful, fluctuant inguinal adenitis (bubo).

TABLE 172-1
Clinical Variants of Chancroid

Giant chancroid	Single lesion extends peripherally and shows extensive ulceration.
Large serpiginous ulcer	Lesion that becomes confluent, spreading by extension and autoinoculation. The groin or thigh may be involved (*Ulcus molle serpiginosum*).
Phagedenic chancroid	Variant caused by superinfection with fusospirochetes. Rapid and profound destruction of tissue can occur (*Ulcus molle gangrenosum*).
Transient chancroid	Small ulcer that resolves spontaneously in a few days may be followed 2 to 3 weeks later by acute regional lymphadenitis (French: *chancre mou volant*).
Follicular chancroid	Multiple small ulcers in a follicular distribution.
Papular chancroid	Granulomatous ulcerated papule may resemble donovanosis or condylomata lata (*Ulcus molle elevatum*).

genetic material of *H. ducreyi* in oesophageal lesions of HIV patients[20] is not yet clear.

DIFFERENTIAL DIAGNOSIS

The 3 classic etiologic agents for genital ulceration are (a) *H. ducreyi*, (b) *Treponema pallidum*, and (c) herpes simplex. The clinical appearance of the diseases caused by these 3 organisms can be extremely variable in both men and women, making clinical diagnosis of genital ulcer disease with reasonable certainty possible only for a minority of patients.[21] The etiology of genital ulcers (Table 172-2)[22] also differs considerably by geographic region. In industrialized countries, isolated painful chancres are most likely caused by herpes simplex virus.[23] In a high percentage of genital ulcers, no pathogen can be isolated but coinfections with syphilis (*Ulcus mixtum*) or herpes simplex are not uncommon.[24,25]

DIAGNOSIS

H. ducreyi appears as small Gram-negative rods. Microscopy may be done on ulcer swabs, but because of low sensitivity and specificity, microscopy is not routinely recommended for diagnosis. A definitive diagnosis of chancroid requires the identification of *H. ducreyi* on culture media; however, the advent of more-sensitive DNA amplification techniques has demonstrated that the sensitivity of culture of *H. ducreyi* reaches only 75% at best. Culture is particularly important when testing of antimicrobial susceptibility pattern is needed, such as in cases of therapeutic failure. *H. ducreyi* will only survive a few hours on the swab, and bedside inoculation of culture plates (2 different selective, enriched culture media) followed by immediate incubation can be done to reduce loss of viable bacteria during transportation.[26]

TABLE 172-2
Differential Diagnosis of Chancroid

	DISEASE	ETIOLOGIC AGENT
Most Likely	Genital herpes	Herpes simplex virus Type 1 and Type 2
	Syphilis	*Treponema pallidum*
	Lymphogranuloma venereum	*Chlamydia trachomatis* serovars L1 to L3
Consider	Other bacterial sexually transmitted infection:	
	Donovanosis (formerly granuloma inguinale)	*Klebsiella granulomatis* (formerly *Calymmatobacterium granulomatis*)
	Other bacterial infections	*Streptococcus* species, staphylococcal and fusospirillary infections, *Mycobacterium tuberculosis, Corynebacterium diphtheriae* (very rare)
	Viral infections:	
	Acute HIV infection	HIV
	Chronic anogenital ulcers in HIV-positive patients	Cytomegalovirus
	Ulcus vulvae acutum	Epstein-Barr virus, cytomegalovirus, adenovirus, and others
	Genital herpes zoster	Varicella-zoster virus
	Parasitic infections:	
	Amebiasis	*Entamoeba histolytica*
	Leishmaniasis	*Leishmania* species
	Scabies	*Sarcoptes scabiei*
	Inflammatory diseases:	
	Behçet disease	
	Aphthosis	
	Crohn disease	
	Pyoderma gangraenosum	
	Drug induced:	
	Fixed drug eruption	For example, Trimethoprim-sulfamethoxazole
	Toxic	For example, Foscarnet
	Traumatic and self-induced genital ulcers and neoplasms	
Always Rule Out	Genital herpes	Herpes simplex virus Type 1 and Type 2
	Syphilis	*T. pallidum*
	HIV infection	

Specimens taken for culture also may be used for nucleic acid amplification techniques. These are excellent for demonstrating *H. ducreyi* in clinical sample material with higher detection rates than culture. Various different in-house polymerase chain reaction methods have been described, some of which have the advantage of simultaneously testing for other relevant pathogens, in particular *T. pallidum* and herpes simplex virus.[26]

TABLE 172-3
Complications of Chancroid

- Painful inguinal adenitis (up to 50%)[27] (see Fig. 172-8)
- Spontaneous ruptures of inguinal buboes with occurrence of large abscesses and fistula formation (rare)
- Spreading of *Haemophilus ducreyi* to distant sites ("kissing ulcers" [see Fig. 172-5] and/or extragenital lesions resulting from autoinoculation; the phenomenon of spreading of Hd through autoinoculation occurs in 50% of male patients)
- Esophageal lesions in HIV patients[20]
- Acute conjunctivitis (very rare)[28]
- Bacterial superinfection (including anaerobes) leading to extensive destruction (rare)
- Scarring leading to phimosis (rare)
- Erythema nodosum (very rare)[29]
- Enhanced HIV transmission (3-fold to 10-fold increased risk)

COMPLICATIONS

In about half of the untreated patients, the course is that of spontaneous resolution without complications. As a consequence of delay in treatment, various complications may occur (Table 172-3).

PROGNOSIS AND CLINICAL COURSE

The disease is usually self-limited. Occasionally, without treatment, genital ulcer and inguinal abscess have been reported to persist for years. Local pain is the most frequent complaint. If no clinical improvement is evident 1 week after the start of therapy, incorrect diagnosis, coinfection with another sexually transmitted infection, concomitant HIV infection, poor compliance, or a resistant strain of *H. ducreyi* must be considered.

Infections do not confer immunity and reinfections are possible. To avoid reinfections, patients must be instructed to use condoms properly.

TREATMENT

Beginning in the 1970s with the emergence of β-lactamase–producing strains of *H. ducreyi* treatment failures became common. Plasmid-mediated resistance to tetracycline, sulfonamides, chloramphenicol, and aminoglycosides also has been reported.[30,31] Little is known about chromosomally mediated resistance in *H. ducreyi*, but decreased susceptibilities to various antibiotics in the absence of identifiable resistant plasmids suggests such mechanisms.[30] Based on in vitro susceptibility, the most active drugs against *H. ducreyi* are azithromycin, ceftriaxone, ciprofloxacin, and erythromycin. Worldwide, several isolates with intermediate

TABLE 172-4

Regimens Recommended by the Centers for Disease Control and Prevention, the World Health Organization,[a] and the *European STI Guidelines* (2017)[b]

ANTIBIOTICS	DOSAGE	LIMITATIONS
Azithromycin	1 g orally in a single dose	High cost, limited availability
or		
Ceftriaxone[a]	250 mg IM in a single dose	Parenterally, may perform less well in HIV-positive patients
or		
Ciprofloxacin	500 mg orally twice daily for 3 days	High cost, compliance, pregnancy
or		
Erythromycin base	500 mg orally q.i.d. for 7 days	Compliance, GI intolerance, QT interval prolongation

[a]WHO recommends as alternative therapy only.

[b]Lautenschlager S, Kemp M, Christensen JJ, et al. 2017 European guideline for the management of chancroid. *Int J STD AIDS.* 2017;28(4):324-329.

Q.i.d., quarter in die sumendus (which is same as q.d.s.)

resistance to either ciprofloxacin or erythromycin have been reported.[31] Although no antimicrobial susceptibility data for *H. ducreyi* have been published for 2 decades, it is still assumed that the infection will respond successfully to treatment with recommended cephalosporin-, macrolide-, or fluoroquinolone-based regimens.[32] Table 172-4 lists the regimens recommended by the Centers for Disease Control and Prevention, the WHO, and the *European STI Guidelines* (2017).[26,33,34] Antibiotic combinations (eg, ceftriaxone and streptomycin) showed synergy in an animal model and may be promising to improve single-dose treatment, but clinical evaluation is needed.[35] Local treatment consists of antiseptic dressings (eg, povidone-iodine). Suppurative nodes should not be incised; if necessary, they can be punctured to prevent spontaneous rupture and sinus tract formation. A large syringe should be used and the fluctuant buboes entered laterally through normal skin. In patients with phimosis, a circumcision may be necessary when all active lesions have healed. In pregnancy, ceftriaxone is the preferred drug, but azithromycin also can be used.[36]

Even after correct treatment, relapses occur in approximately 5% of patients and retreatment with the original regimen is recommended. Usually reinfection by an untreated sexual partner is the suspected cause of relapse.

HIV infection and lack of circumcision appear to be associated with increased likelihood of infection with *H. ducreyi* and treatment failure.[11] In resource-poor areas of the world, syndromic management can be recommended, but local epidemiology must be considered.[18,34] Flow charts for the management of genital ulcers have been developed that do not require laboratory identification of the causative pathogen.[37] If a patient complains of one or more small blisters or an ulcer with a history of recent blisters, then herpes management should be followed. If an isolated small ulcer and painful matted gland is present, lymphogranuloma venereum, chancroid, and syphilis should be treated, and if only an ulcer is present, syphilis and chancroid should be treated.[37]

RELATION BETWEEN HIV INFECTION AND CHANCROID

During the 1990s, renewed interest in chancroid led to evidence that genital ulcers promote the heterosexual transmission and acquisition of HIV.[38-42] During this time it was shown that effective treatment of genital ulcers reduced the incidence of HIV.[43]

Furthermore, it was shown that concomitant HIV infection has clinically significant effects on the course of the chancroid disease, and failure of single-dose[12] or short-course[40] therapy for chancroid in men is associated with HIV-1 seropositivity. A wide variation of the clinical picture of chancroid has been observed in HIV-infected patients.[40] As in every patient with a sexually transmitted infection, patients with chancroid should also be tested for HIV antibodies and HIV-seropositive patients with chancroid should be monitored closely and treated with a multiday regimen.

PREVENTION

The augmentation of the HIV epidemic by *H. ducreyi*, especially in Africa, has made chancroid control an urgent priority. As a result of the widespread syndromic treatment of genital ulcers combined with behavioral change within communities in response to the global HIV epidemic, chancroid has been nearly eliminated in many countries where it was previously endemic. In the rare case of diagnosis of chancroid nowadays,[4,9,10] patients should be advised to abstain from sexual activity until all clinical lesions have cleared. Sexual contacts of the patient (within 10 days of symptom presentation) should be examined and treated regardless of whether symptoms of the disease are present, as asymptomatic carriage of *H. ducreyi* is possible.[14] Antibiotics may provide some protection from reinfection; a single dose of azithromycin lasted as long as 2 months after treatment.[44] Chancroid survives in populations in which many men are having sex with a few women. As a result of the dramatic decrease of the incidence of chancroid with only a few exceptions,[4] eradication seems to be a feasible public health objective.[45] Nevertheless, *H. ducreyi* should be considered as a cause of chronic limb ulcers in adults, and especially in children, in the Pacific region and Africa.[16-18] The reservoir for *H. ducreyi* cutaneous infection remains to be elucidated.

REFERENCES

1. Behets FM, Liomba G, Lule G, et al. Sexually transmitted diseases and human immunodeficiency virus control in Malawi: a field study of genital ulcer disease. *J Infect Dis*. 1995;171:451-455.
2. D'Costa LJ, Plummer FA, Bowmer I, et al. Prostitutes are a major reservoir of sexually transmitted diseases in Nairobi, Kenya. *Sex Transm Dis*. 1985;12:64-67.
3. Totten PA, Kuypers JM, Chen CY, et al. Etiology of genital ulcer disease in Dakar, Senegal, and comparison of PCR and serologic assays for detection of *Haemophilus ducreyi*. *J Clin Microbiol*. 2000;38:268-273.
4. Gonzalez-Beiras C, Marks M, Chen CY, et al. Epidemiology of *Haemophilus ducreyi* infections. *Emerg Infect Dis*. 2016;22:1-8.
5. Phiri S, Zadrozny S, Weiss HA, et al. Etiology of genital ulcer disease and association with HIV infection in Malawi. *Sex Transm Dis*. 2013;40:923-928.
6. Hassan I, Anwar P, Rather S, et al. Pattern of sexually transmitted infections in a Muslim majority region of North India. *Indian J Sex Transm Dis*. 2015;36: 30-34.
7. Noda AA, Blanco O, Correa C, et al. Etiology of genital ulcer disease in male patients attending a sexually transmitted diseases clinic: first assessment in Cuba. *Sex Transm Dis*. 2016;43:494-497.
8. Centers for Disease Control and Prevention, National Center for HIV/AIDS, Viral Hepatitis, STD, and TB Prevention, Division of STD Prevention. *Sexually Transmitted Disease Surveillance 2016*. Atlanta, GA: U.S Department of Health and Human Services; 2017. https://www.cdc.gov/std/stats16/CDC_2016_STDS_Report-for508WebSep21_2017_1644.pdf.
9. Fouéré S, Lassau F, Rousseau C, et al. First case of chancroid in 14 years at the largest STI clinic in Paris, France. *Int J STD AIDS*. 2016;27:805-807.
10. Barnes P, Chauhan M. Chancroid-desperate patient makes own diagnosis. *Int J STD AIDS*. 2014; 25:768-770.
11. Weiss HA, Thomas SL, Munabi SK, et al. Male circumcision and risk of syphilis, chancroid, and genital herpes: a systematic review and meta-analysis. *Sex Transm Infect*. 2006;82:101-109.
12. Jessamine PG, Plummer FA, Ndinya Achola JO, et al. Human immunodeficiency virus, genital ulcers and the male foreskin: synergism in HIV-1 transmission. *Scand J Infect Dis Suppl*. 1990;69:181-186.
13. Mohammed TT, Olumide YM. Chancroid and human immunodeficiency virus infection—a review. *Int J Dermatol*. 2008;47:1-8.
14. Hawkes S, West B, Wilson S, et al. Asymptomatic carriage of *Haemophilus ducreyi* confirmed by the polymerase chain reaction. *Genitourin Med*. 1995;71:224-227.
15. Plummer FA, D'Costa LJ, Nsanze H, et al. Epidemiology of chancroid and *Haemophilus ducreyi* in Nairobi, Kenya. *Lancet*. 1983;2:1293-1295.
16. Ussher JE, Wilson E, Campanella S, et al. *Haemophilus ducreyi* causing chronic skin ulceration in children visiting Samoa. *Clin Infect Dis*. 2007;44:e85-e87.
17. McBride WJ, Hannah RC, Le Cornec GM, et al. Cutaneous chancroid in a visitor from Vanuatu. *Australas J Dermatol*. 2008;49:98-99.
18. Lewis DA, Mitja O. *Haemophilus ducreyi*: from sexually transmitted infection to skin ulcer pathogen. *Curr Opin Infect Dis*. 2016;29:52-57.
19. Kunimoto DY, Plummer FA, Namaara W, et al. Urethral infection with *Haemophilus ducreyi* in men. *Sex Transm Dis*. 1988;15:37-39.
20. Borges MC, Colares JK, Lima DM, et al. *Haemophilus ducreyi* detection by polymerase chain reaction in oesophageal lesions of HIV patients. *Int J STD AIDS*. 2009;20:238-240.
21. DiCarlo RP, Martin DH. The clinical diagnosis of genital ulcer disease in men. *Clin Infect Dis*. 1997; 25:292-298.
22. Lautenschlager S. Cutaneous manifestations of syphilis: recognition and management. *Am J Clin Dermatol*. 2006;7:291-304.
23. Lautenschlager S, Eichmann A. The heterogeneous clinical spectrum of genital herpes. *Dermatology*. 2001;202:211-219.
24. Chen CY, Ballard RC, Beck-Sague CM, et al. Human immunodeficiency virus infection and genital ulcer disease in South Africa: the herpetic connection. *Sex Transm Dis*. 2000;27:21-29.
25. O'Farrell N. Increasing prevalence of genital herpes in developing countries: implications for heterosexual HIV transmission and STI control programmes. *Sex Transm Infect*. 1999;75:377-384.
26. Lautenschlager S, Kemp M, Christensen JJ, et al. 2017 European guideline for the management of chancroid. *Int J STD AIDS*. 2017;28:324-329.
27. Lagergard T. *Haemophilus ducreyi*: pathogenesis and protective immunity. *Trends Microbiol*. 1995;3:87-92.
28. Gregory JE, Henderson RW, Smith R. Conjunctivitis due to *Haemophilus ducreyi* infection. *Br J Vener Dis*. 1980;56:414.
29. Kaur C, Thami GP. Erythema nodosum induced by chancroid. *Sex Transm Infect*. 2002;78:388-389.
30. Erbelding E, Quinn TC. The impact of antimicrobial resistance on the treatment of sexually transmitted diseases. *Infect Dis Clin North Am*. 1997;11:889-903.
31. Dangor Y, Ballard RC, Miller SD, et al. Antimicrobial susceptibility of *Haemophilus ducreyi*. *Antimicrob Agents Chemother*. 1990;34:1303-1307.
32. Lewis DA. Epidemiology, clinical features, diagnosis and treatment of *Haemophilus ducreyi*-a disappearing pathogen? *Expert Rev Anti Infect Ther*. 2014;12:687-696.
33. Centers for Disease Control and Prevention: Sexually Transmitted Treatment Guidelines, 2015. *MMWR Recomm Rep*. 2015;64:26-27.
34. World Health Organisation. *Guidelines for the Management of Sexually Transmitted Infections*. 2003. http://apps.who.int/iris/bitstream/handle/10665/42782/9241546263_eng.pdf;jsessionid=71C39D6930AA74D06292B34123ACC5DD?sequence=1.
35. Roy-Leon JE, Lauzon WD, Toye B, et al. In vitro and in vivo activity of combination antimicrobial agents on *Haemophilus ducreyi*. *J Antimicrob Chemother*. 2005;56:552-558.
36. Geisler WM. Diagnosis and management of uncomplicated *Chlamydia trachomatis* infections in adolescents and adults: summary of evidence reviewed for the 2015 Centers for Disease Control and Prevention Sexually Transmitted Diseases Treatment Guidelines. *Clin Infect Dis*. 2015;61(suppl 8):S774-S784.
37. Lewis DA. Chancroid: clinical manifestations, diagnosis, and management. *Sex Transm Infect*. 2003;79:68-71.
38. Wasserheit JN. Epidemiological synergy. Interrelationships between human immunodeficiency virus infection and other sexually transmitted diseases. *Sex Transm Dis*. 1992;19:61-77.

39. Telzak EE, Chiasson MA, Bevier PJ, et al. HIV-1 seroconversion in patients with and without genital ulcer disease. A prospective study. *Ann Intern Med*. 1993;119:1181-1186.
40. Abeck D, Ballard RC. Chancroid. *Curr Probl Dermatol*. 1996;24:90-96.
41. Royce RA, Sena A, Cates W Jr, et al. Sexual transmission of HIV. *N Engl J Med*. 1997;336:1072-1078.
42. Fleming DT, Wasserheit JN. From epidemiological synergy to public health policy and practice: the contribution of other sexually transmitted diseases to sexual transmission of HIV infection. *Sex Transm Infect*. 1999;75:3-17.
43. Grosskurth H, Mosha F, Todd J, et al. Impact of improved treatment of sexually transmitted diseases on HIV infection in rural Tanzania: randomised controlled trial. *Lancet*. 1995;346:530-536.
44. Thornton AC, O'Mara EM Jr, Sorensen SJ, et al. Prevention of experimental *Haemophilus ducreyi* infection: a randomized, controlled clinical trial. *J Infect Dis*. 1998;177:1608-1613.
45. Steen R. Eradicating chancroid. *Bull World Health Organ*. 2001;79:818-826.

Chapter 173 :: Lymphogranuloma Venereum

:: Norbert H. Brockmeyer
& Stephan Lautenschlager

AT-A-GLANCE

- Lymphogranuloma venereum is a sexually transmitted infection caused by L serovars (serologic variants) of *Chlamydia trachomatis*.
- Endemic in Africa, Southeast Asia, and South and Central America, and rare in developed countries.
- Outbreaks have occurred among men who have sex with men in Europe, Australia, and North America.
- Clinically manifests as inguinal and anorectal syndromes, in 3 stages.
- Hematogenous spread with manifestations of systemic infection.
- Diagnosis is by identification of organism and by serology or genotyping.
- Doxycycline or azithromycin (second-line) treatment is curative if given early in the infection course.

EPIDEMIOLOGY

Lymphogranuloma venereum (LGV) is a sexually transmitted infection caused by specific *Chlamydia* variants that is rare in developed countries. It is endemic in East and West Africa, India, Southeast Asia, South and Central America, and some Caribbean Islands; LGV accounts for 7% to 19% of genital ulcer diseases in areas of Africa and India.[1,2] The peak incidence occurs in sexually active persons 15 to 40 years of age, in urban areas, and in individuals of lower socioeconomic status. Men are 6 times more likely than women to manifest clinical infection.[3] The incidence of LGV is low in the developed world where cases are usually limited to travelers or military personnel returning from endemic areas. Since 2003, however, outbreaks of LGV have appeared in Europe, Australia, and North America, particularly in the form of proctitis, among HIV-positive men who have sex with men (MSM).[4-8] In 2013, more than 1000 cases were reported to the European Centre for Disease Prevention and Control, approximately 50% of them from the United Kingdom[9]; however, the real number is likely to be higher, as LGV is not routinely recorded in many European countries. In addition, a cluster of 38 LGV cases among MSM was reported in the United States in Michigan for the period August 2015 thru April 2016[10]; the true incidence of LGV in the United States, however, is unknown because national reporting of LGV ended in 1995.

LGV is contracted by direct contact with infectious secretions, usually through any type of unprotected intercourse, whether oral, vaginal, or anal. Transmission efficiency is unknown.[11] Asymptomatic rectal infection and/or penile and oral infection is the likely source of onward transmission.[12] Sexual practices, such as fisting and sex-toy sharing, may be other routes of transmission. In a study that compared sexual behaviors in men with LGV and men with non-LGV chlamydial proctitis, fisting was a major predisposing factor.[13] An epidemic of LGV has been reported among "crack" cocaine users in the Bahamas.[14]

As a consequence of underdiagnosis and underreporting, the epidemiology of LGV remains poorly understood. Common diagnostic laboratory methods are nonspecific and not readily available in endemic areas. Even in industrialized countries, only a few laboratories offer specific assays to LGV serovars (serologic variants).[15] Without such assays, many LGV cases are misdiagnosed as common chlamydial urogenital infection. Underdiagnosis of LGV is also largely a result of the presence of an asymptomatic carrier state. Women, in particular, may harbor asymptomatic persistent infection in the cervical epithelium, thus serving as reservoirs of the infection as they do for other urogenital chlamydial infections and gonorrhea. A large study conducted in the United Kingdom found that only 6% of MSM were asymptomatic carriers of LGV *Chlamydia* serovars; the majority of cases of LGV in the rectum and urethra were symptomatic,[16] whereas a recent study reported a prevalence of asymptomatic rectal infection of 19%.[17] Infectivity in men usually ceases after healing of the primary mucosal lesion. Interestingly, most of the detected cases in the recent outbreaks are in men who practice receptive anal sex, suggesting that a high proportion of men who practice insertive anal sex are misdiagnosed or undiagnosed. The reasons behind this are unclear but may be organism-related, host-related (eg, sexual practices such as fisting and the use of sex toys, IV drug use, HIV status) or physician-related (failure to diagnose genital LGV). The resurgence of LGV as a health problem may simply reflect increased awareness rather than increased incidence.

ETIOLOGY AND PATHOGENESIS

LGV (tropical or climatic bubo, lymphopathia venerea, Nicolas-Favre disease) is caused by *Chlamydia trachomatis* serovars L1, L2, and L3.[18] Most of the recent outbreaks are caused by a number of strains of

Figure 173-1 Lymphogranuloma venereum.

C. trachomatis L2 serovar (L2b), suggesting that these outbreaks most likely represent increased awareness of a slowly evolving endemic.[5,6,16,19] There are new cases in Spain, Finland, Czech Republic, and The Netherlands (where the first case of a female patient with bubonic LGV caused by a serovar L2b was reported).[20-23] In France, a change in epidemiology since 2013 has been reported with declining infections of the L2b type and increasing numbers of the L2 type.[24] Case reports with infection of the L2c variant suggest a more aggressive clinical course, causing severe proctitis.[25]

Chlamydiae are obligate intracellular bacteria characterized by 2 distinct morphologic forms: (a) the small metabolically inactive and infectious elementary body, and (b) the larger metabolically active and noninfectious reticulate body (Fig. 173-1). *C. trachomatis* has been subdivided into several serovars that differ in their major outer membrane proteins, and which are associated with several diseases. Serovars A, B, and C are the causes of trachoma ocular infections. These infections are rarely seen in North America and Europe, but are quite frequently seen in Africa and Asia, where they represent an important cause of blindness.[26] Serovars D to K are responsible for ocular, genital, and respiratory tract infections.[15,27,28] In contrast to the A-to-K serovars that remain confined to the mucosa, LGV serovars are more invasive and have a high affinity for macrophages.[18] After being inoculated onto the mucosal surface, the organisms replicate within macrophages, and find their way to the draining lymph nodes, and cause lymphadenitis.

CLINICAL FINDINGS

CUTANEOUS LESIONS AND RELATED PHYSICAL FINDINGS

Clinical manifestations are protean, depending on the sex of the patient, acquisition mode, and the infection stage. Three clinical stages characterize LGV. Nonspecific cutaneous lesions such as erythema nodosum, erythema multiforme, urticaria, and scarlatiniform exanthema may occur with any of these stages.[29]

Figure 173-2 Lymphogranuloma venereum: soft painless erosion on the prepuce.

PRIMARY STAGE

Three to 30 days after infection, 5- to 8-mm painless erythematous papule(s) or small herpetiform ulcers appear at the site of inoculation (Fig. 173-2). Painful ulcerations[30] and nonspecific urethritis are less common. Thus, the initial lesions may be differentiated from the more common herpetic lesions by the lack of pain associated with the lesions. In males, the lesion is usually found on the coronal sulcus, prepuce, or glans penis, and in females, on the posterior wall of the vagina, vulva, or, occasionally, the cervix. Inoculation also may be rectal, at the lip, or pharyngeal.[15,31] The primary lesion is transient, often heals within a few days, and may go unnoticed.[25]

SECONDARY STAGE

A few weeks after the primary lesion appears, marked lymph node involvement and hematogenous dissemination occur, manifested by variable signs and symptoms, including fever, myalgia, decreased appetite, and vomiting. Photosensitivity may develop in up to 35% of the patients, often 1 to 2 months after bubo formation (painful inflammation of lymph node, characterized by a unilateral enlargement, suppuration, and abscesses, also firm and tender immovable mass).[32] Less commonly, patients may develop meningoencephalitis, hepatosplenomegaly, arthralgia, and iritis.[33,34] The lymphadenitis episodes often resolve spontaneously in 8 to 12 weeks. Depending on the mode of transmission, 2 major syndromes are seen.

Figure 173-3 Lymphogranuloma venereum: lymph node involvement. Initially, the overlying skin is erythematous and indurated.

Figure 173-5 Lymphogranuloma venereum: bilateral, firm, immovable masses above the Poupart ligament.

The acute genital syndrome or inguinal syndrome is characterized by inguinal and/or femoral lymph node involvement and is the major presentation in men in developing countries. Initially, the skin overlying the affected lymph node is erythematous and indurated (Fig. 173-3). Over the subsequent 1 to 2 weeks, the lymph node enlarges and coalesces to form a firm and tender immovable mass (bubo; Fig. 173-4), which may rupture and drain through the skin, forming sinus tracts. Bilateral involvement occurs in one-third of the cases (Fig. 173-5). Nodal enlargement on either side of the inguinal ligament, the "groove sign," is pathognomonic of LGV, but only presents in 10% to 20% of cases[35] and is rarely bilateral.[15] In women, inguinal lymphadenitis is unusual because the lymphatic drainage of the vagina and cervix is to the deep pelvic/retroperitoneal lymph nodes. When these nodes are involved, low abdominal/back pain that exacerbates upon lying supine and pelvic adhesions may ensue.

Figure 173-4 Early bubo consisting of unilateral enlargement and coalescence of inguinal lymph nodes. Note the absence of the primary lesion in this case. (Used with permission of Shukrallah Zaynoun, MD.)

The acute anorectal syndrome is characterized by perirectal nodal involvement, acute hemorrhagic proctitis, and pronounced systemic symptoms. It is the most common presentation in women and in homosexual men who practice anal sex. The major source of rectal spread in women is the internal lymphatic drainage of the lower two-thirds of the vagina. Patients may complain of anal pruritus, bloody and/or purulent rectal discharge, tenesmus, diarrhea, constipation, and lower abdominal pain.[36] In a recent outbreak of LGV in Western Europe, 96% of MSM patients presented with signs and symptoms of proctitis.[37] LGV proctitis mimics chronic inflammatory bowel disease, both clinically and in pathologic substrate. These cases may present with an incomplete or undisclosed history of proctosigmoiditis, without the characteristic adenopathy syndrome.[38] Reactive arthritis in MSM following LGV proctitis has been reported in several cases in recent years.[34] Despite affecting mostly HIV-positive MSM, LGV has not behaved as an opportunistic infection in the recent outbreak, and clinical features have not differed between HIV-positive and HIV-negative cases.[39]

TERTIARY STAGE

This stage is seen more often in women with untreated anorectal syndrome than in men, although it is also seen in homosexual men, because of the location of the involved lymphatics. It includes rectal strictures (most common) and abscesses, perineal sinuses, rectovaginal fistulae (leading to "watering can perineum"), and "lymphorrhoids" (perianal outgrowths of lymphatic tissue). Esthiomene (Greek for "eating away") is a rare primary infection of the external genitalia (mostly in women), leading to progressive lymphangitis and genital destruction. Infertility and "frozen pelvis" are potential sequelae of ruptured deep pelvic nodes in women. Late sequelae of the genital syndrome are less common and include urethral strictures and

genital elephantiasis with ulcers and fistulas (in 4% of patients).[40] Penile deformities, such as the saxophone penis, may also occur.[41]

OTHER UNUSUAL MANIFESTATIONS

Extragenital-anal inoculation of LGV is rare. Oropharyngeal infection may manifest initially as pinhead-sized vesicles on the lip, and later on as cervical lymphadenopathy with constitutional symptoms, closely mimicking lymphoma. Tonsillitis, supraclavicular and mediastinal lymphadenopathy, and pericarditis rarely occur.[42-44] Ocular autoinoculation of infected discharges may lead to conjunctivitis with marginal corneal perforation, often with preauricular lymphadenopathy.[45] Although most rectal LGV among MSM appears to be symptomatic, some investigators have noted that asymptomatic infections can occur.[46]

LABORATORY TESTS

Diagnosis of LGV may be difficult, but LGV should be suspected in any patient with infected sexual contacts, genital ulcer, perianal fistula, or bubo. The accuracy of clinical diagnosis has been reported to be as low as 20%.[47] Consequently, laboratory tests are important to establish the diagnosis and are usually divided into 2 broad categories: (a) nonspecific tests that do not distinguish between LGV and non-LGV serovars, and (b) specific LGV tests. In practice, a positive test on lymph node aspirate is considered diagnostic of LGV, in contrast to a positive test on a primary genital or anorectal lesion where further specific testing is required to rule out common chlamydial urogenital infections.

SPECIFIC TESTS FOR LYMPHOGRANULOMA VENEREUM

Confirmation of LGV requires identification of the genotype L1, L2 or L3. Typing is important because the recommended antibiotic treatment for LGV is longer than for non-LGV cases.[25,48] Nucleic acid amplification tests (NAAT), like polymerase chain reaction (PCR), may be performed on all specimens, and has been the diagnostic method of choice in recent outbreaks. Several currently available commercial NAATs allow sensitive and specific detection of *C. trachomatis*, but do not provide any information about the underlying genotype(s).[49,50] Using these tests identification of LGV in positive specimens would require a separate analysis.

Methods for typing include genotype-specific PCRs, multiplex-nested PCR and RFLP- or sequence analysis of appropriate omp1 gene regions.[51-54] LGV- and non LGV strains can also be differentiated by real time PCR tests based on pmpH or omp1 gene regions that contain specific deletions or single nucleotide polymorphisms.[53,55,56]

A real-time quadriplex PCR assay has been developed that is capable of detecting LGV, non-LGV, or mixed infections simultaneously in rectal specimens. The assay also contains a supplemental amplification target for the confirmation of *C. trachomatis* infection as well as a human DNA control for monitoring sample adequacy and PCR inhibition.[55]

Another assay described by Twin et al.[56] targets a 61-bp PCR fragment of the omp1 gene, where LGV and non LGV serovars deviate from each other by one nucleotide that allows differentiation by high resolution melting analysis (HRMA). The assay correctly identifies LGV and non LGV types in 44/47 (93,6%) specimens previously analyzed by a multiplex real time PCR assay published from the same group.[54]

A dual target PCR assay based on the cryptic plasmid for highly sensitive detection of *C. trachomatis* and pmpH to differentiate between LGV and non LGV strains in a single reaction has been shown to distinguish LGV and non LGV infection in 95% of 156 analyzed *C. trachomatis* positive samples, including 65/67 (97%) anorectal smears.[57] The advantage of this test is to use a second target recommended to prevent missed infections due to target sequence variation[49] and to differentiate LGV and non-LGV genotypes simultaneously in a single reaction.

All these assays are commercially unavailable in-house developments that are not FDA approved. Nevertheless, these tests may be used for laboratory testing after evaluation of test performance characteristics according to quality assurance of microbiological diagnostics, such as CLIA (Clinical Laboratory Improvement Amendments).[15]

NONSPECIFIC CHLAMYDIAL TESTS

The complement fixation test is the most commonly used test. Titers greater than 1:64 are considered diagnostic, titers greater than 1:256 are highly suggestive of LGV, and titers below 1:32 exclude the diagnosis unless the infection is in its early stages.[58] The microimmunofluorescence test for the L-type serovar is more sensitive and specific, but less readily available.[59] The use of species-specific proteins and peptides in immunoblots or line assays further improves the specificity of serologic testing,[60] but as of this writing no LGV-specific serologic marker has been identified.

In addition, direct fluorescence microscopy using conjugated monoclonal antibody against *C. trachomatis* on smears from bubo material or genital swab can be done.[61] Serology assays are sensitive but nonspecific because of cross-reactivity with other chlamydial infections. In addition, the assays do not differentiate current

from prior infection. The Frei test, the earliest diagnostic modality to identify LGV, consists of an intradermal skin test assessing delayed hypersensitivity to chlamydial antigens. It is no longer used because of its low sensitivity and limited specificity, a consequence of cross-reaction with *C. trachomatis* serovars D to K.[17] Finally, other nonspecific laboratory findings include mild leukocytosis, false-positive Venereal Disease Research Laboratory, cryoprecipitates, rheumatoid factor, and high serum levels of immunoglobulin A and immunoglobulin G.[62]

DIAGNOSTIC PROCEDURES

Proctoscopic examination reveals, in the setting of the anorectal syndrome, multiple discrete and irregular superficial ulcerations and friable granulation tissue, usually confined to the distal 10 cm of the anorectal canal.[63,64]

To confirm clinically suspected LGV the detection of *C. trachomatis* genotypes specific for LGV by laboratory methods is required. Today PCR-based assays, as described above, are preferred over culture because of their higher sensitivity. Clinical material suitable for testing includes anorectal swabs and genital swabs from suspicious epithelial lesions or bubo aspirates. According to the European guideline, anorectal swabs from mucosal lining taken during proctoscopy are recommended, but blind swabs are also acceptable. Commercial *C. trachomatis* nucleic acid amplification tests are not approved for testing anorectal sample types, but several studies have shown that nucleic acid amplification test–based testing of such specimens is superior to other direct detection procedures.[65,66] When the test is positive for *C. trachomatis* a second assay to identify the presence of an LGV genotype or detection of *C. trachomatis* and differentiation of LGV/non-LGV genotypes in a single assay (as described above) is required. If no epithelial lesion is present and lymph node aspirates cannot be obtained, serology may be applied for evaluation. A high complement fixation titer or detection of immunoglobulin A against *C. trachomatis* support LGV diagnosis, but represent no definite proof. On the other hand, serology has a high negative predictive value. Antibody-negative results largely rule out LGV, as the inguinal stage usually takes several weeks to appear.

HISTOPATHOLOGIC EXAMINATION

Primary lesions reveal nonspecific ulceration with granulation tissue, and endothelial swelling. Organisms are rarely demonstrated using Giemsa stain. Biopsy of affected lymph nodes reveals suppurative granulomatous inflammation. Necrotic foci may enlarge into stellate abscesses, which, in turn, may coalesce into discharging sinuses. These histopathologic findings are not specific to LGV and can be found in chancroid, cat-scratch disease, tularemia, and some deep fungal infections. The pathology of LGV-proctocolitis is similar to that of Crohn disease and includes crypt distortion, submucosal fibrosis, and follicular inflammation with occasional granuloma formation.[63] The LGV-proctocolitis will be also similar to syphilitic proctocolitis.[67]

DIFFERENTIAL DIAGNOSIS

Table 173-1 outlines the differential diagnosis of LGV.

In contrast to LGV primary stage, chancroid ulcers are usually larger and more painful, and donovanosis (granuloma inguinale) ulcers have abundant friable granulation tissue without associated lymphadenitis. Acute genital syndrome may be hard to differentiate from chancroid. Buboes containing little or no pus are, however, more likely to be caused by LGV. Suspecting LGV proctitis in HIV-positive MSM who present with signs and symptoms of Crohn disease (Fig. 173-6) or malignancy (Fig. 173-7) is important, even in the absence of LGV pathognomonic findings.[68] Both conditions have similar proctoscopic findings; however, Crohn disease is more proximally localized. Studies from The Netherlands, the United Kingdom, and

TABLE 173-1

Differential Diagnosis of Lymphogranuloma Venereum (Stage Specific)

- Primary stage
  - Ulcerogenital diseases (herpes simplex virus, syphilis, chancroid, donovanosis)
  - *Neisseria gonorrhoeae* and/or common chlamydial urogenital infection
  - Noninfectious causes: trauma, balanitis, fixed drug eruption
- Secondary stage
  - Acute genital syndrome
  - Ulcerogenital diseases with lymphadenopathy (syphilis, chancroid, herpes simplex virus)
  - Incarcerated inguinal hernia
  - Reactive inguinal lymphadenitis to a lower-extremity focus of infection
  - Bubonic plague (in endemic areas)
  - AIDS
  - Kaposi sarcoma
  - Tularemia
  - Mycobacterial infections
  - Acute anorectal syndrome
  - Inflammatory bowel disease
  - Oropharyngeal lymphogranuloma venereum
  - Lymphoma
  - Infectious mononucleosis
  - Cat-scratch disease
- Tertiary stage
  - Malignancy
  - Filariasis and other parasitic infections
  - Pseudoelephantiasis (no lymphadenitis) of tuberculosis and donovanosis
  - Deep fungal infection
  - Hidradenitis suppurativa
  - Trauma

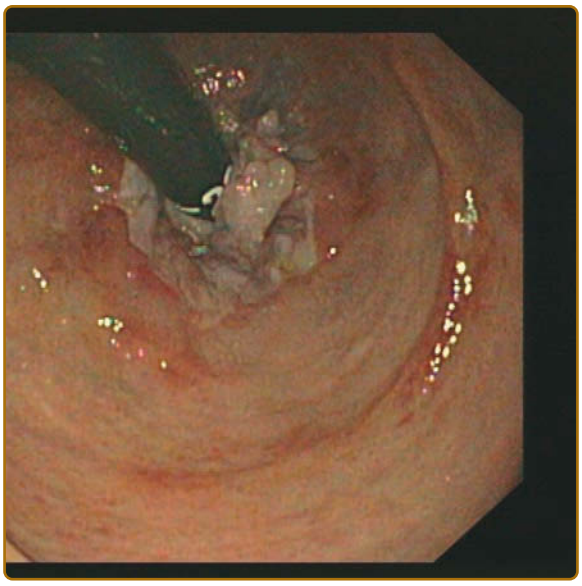

Figure 173-6 Lymphogranuloma venereum imitating Crohn disease.

Australia show that 7% to 23% of patients with rectal chlamydial infection and signs or symptoms of proctitis have LGV.[46,69,70]

COMPLICATIONS

In addition to the complications seen in the tertiary stage, the ulcerative nature of LGV may facilitate the acquisition and transmission of bloodborne pathogens such as HIV[71] and hepatitis C.[18] In addition, several case reports have described an association between LGV and sexually acquired reactive arthritis in HLA-B27–positive individuals.[34,72]

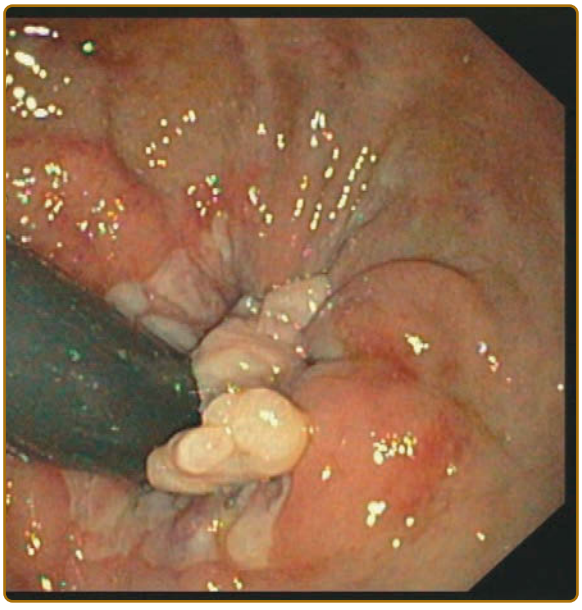

Figure 173-7 Exophytic tumor caused by lymphogranuloma venereum.

PROGNOSIS AND CLINICAL COURSE

Antibiotic treatment, if given early, is curative, with acute anorectal syndrome responding more dramatically than acute genital syndrome.

TREATMENT

Oral doxycycline, 100 mg twice daily for 3 weeks, is the treatment of choice.[73] When contraindicated, oral azithromycin, 1 to 1.5 g once weekly for 3 weeks or as a third-line erythromycin base, at a dose of 500 mg 4 times a day for 3 weeks, may be given.[15,48,74] Pregnant and lactating women can be treated with azithromycin or erythromycin. Doxycycline should be avoided in the second and third trimester of pregnancy because of the risk for discoloration of teeth and bones; doxycycline is, however, compatible with breastfeeding.[75] It should be noted that the duration of treatment needed to eradicate *C. trachomatis* is longer for the LGV serovars compared with the other less-invasive serovars of *C. trachomatis*. Therefore, when in doubt about the *Chlamydia* serovar, a 3-week course of antibiotics is advised.[76] Therapy may be prolonged in HIV-positive patients and, in general, should not be stopped until the complete resolution of all signs and symptoms (Table 173-2).

Surgery is often required in the late stages of LGV and includes lateral aspiration of buboes through intact skin (direct incision has a high risk of fistula formation), rectal stricture dilation, abscess drainage, rectovaginal fistula repair, genital reconstruction, and colostomy. Avoidance of sexual activity until complete resolution of signs and symptoms is important.[48,74]

PREVENTION

LGV seems to be a rapidly spreading universal problem. Effective control should include periodic evaluation of high-risk individuals, reinforcement of health education aiming at early recognition and counseling, improving community and clinician awareness of LGV, and increasing the availability of specific diagnostic tests. All sexual contacts should be traced and

TABLE 173-2
Treatment of Lymphogranuloma Venereum

	DRUG	DOSE	LENGTH OF TREATMENT
First-line	Oral doxycycline	100 mg twice daily	3 weeks
Second-line	Oral azithromycin	1 to 1.5 g once weekly	3 weeks
Third-line	Oral erythromycin	500 mg 4 times daily	3 weeks

treated. Persons who have had sexual contacts with a patient who has LGV within the 60 days before onset of the patient's symptoms should be examined and tested for urethral, cervical, or rectal chlamydial infection, depending on a anatomic site of exposure. They should be presumptively treated with a *Chlamydia* regimen.[74] The role of screening in asymptomatic patients is not yet clear and cannot be recommended. LGV case reporting should be mandatory by law for more reliable monitoring of prevalence trends. To exclude reinfections, retesting by nuclear amplification tests (also including HIV, syphilis, and hepatitis C) during a followup test 3 months after an LGV diagnosis should be offered.[25] It is assumed that in a reasonable period of time a *Chlamydia*-vault vaccine will be available to eradicate infections.[77,78]

REFERENCES

1. Memish ZA, Osoba AO. International travel and sexually transmitted diseases. *Travel Med Infect Dis.* 2006;4(2):86-93.
2. Goeman J, Piot P. The epidemiology of sexually transmitted diseases in Africa and Latin America. *Semin Dermatol.* 1990;9(2):105-108.
3. Simms I, Ward H, Martin I, et al. Lymphogranuloma venereum in Australia. *Sex Health.* 2006;3(3):131-133.
4. Sethi G, Allason-Jones E, Richens J, et al. Lymphogranuloma venereum presenting as genital ulceration and inguinal syndrome in men who have sex with men in London, UK. *Sex Transm Infect.* 2009;85(3):165-170.
5. Stark D, van Hal S, Hillman R, et al. Lymphogranuloma venereum in Australia: anorectal *Chlamydia trachomatis* serovar L2b in men who have sex with men. *J Clin Microbiol.* 2007;45(3):1029-1031.
6. Meyer T, Arndt R, von Krosigk A, et al. Repeated detection of lymphogranuloma venereum caused by *Chlamydia trachomatis* L2 in homosexual men in Hamburg. *Sex Transm Infect.* 2005;81(1):91-92.
7. Kropp RY, Wong T. Emergence of lymphogranuloma venereum in Canada. *CMAJ.* 2005;172(13):1674-1676.
8. Rönn MW, Ward H. The association between LGV and HIV among MSM: systematic review and metaanalysis. *BMC Infect Dis.* 2011;11:70.
9. European Centre for Disease Prevention and Control. *Sexually Transmitted Infections in Europe 2013*. Stockholm, Sweden: ECDC; 2015.
10. de Voux A, Kent JB, Macomber K, et al. Notes from the field: cluster of lymphogranuloma venereum cases among men who have sex with men—Michigan, August 2015-April 2016. *MMWR Morb Mortal Wkly Rep.* 2016;65(34):920-921.
11. Stein RO. Conjugal lymphogranulomatosis inguinalis. *Z Haut Geschlechtskr.* 1950;9(5):208-215.
12. Haar K, Dudareva-Vizule S, Wisplinghoff H, et al. Lymphogranuloma venereum in men screened for pharyngeal and rectal infection, Germany. *Emerg Infect Dis.* 2013;19(3):488-492.
13. Hamill M, Benn P, Carder C, et al. The clinical manifestations of anorectal infection with lymphogranuloma venereum (LGV) versus non-LGV strains of *Chlamydia trachomatis*: a case-control study in homosexual men. *Int J STD AIDS.* 2007;18(7):472-475.
14. Bauwens JE, Orlander H, Gomez MP, et al. Epidemic lymphogranuloma venereum during epidemics of crack cocaine use and HIV infection in the Bahamas. *Sex Transm Dis.* 2002;29(5):253-259.
15. Stoner BP, Cohen SE. Lymphogranuloma venereum 2015: clinical presentation, diagnosis, and treatment. *Clin Infect Dis.* 2015;61(8):865-873.
16. Ward H, Alexander S, Carder C, et al. The prevalence of lymphogranuloma venereum infection in men who have sex with men: results of a multicentre case finding study. *Sex Transm Infect.* 2009;85(3):173-175.
17. Pallawela S, Bradshaw D, Hodson L, et al. Screening for asymptomatic lymphogranuloma venereum co-infection in men who have sex with men newly diagnosed with HIV, hepatitis C or syphilis. *Int J STD AIDS.* 2015;27(8):625-627.
18. Kapoor S. Re-emergence of lymphogranuloma venereum. *J Eur Acad Dermatol Venereol.* 2008;22(4):409-416.
19. Wang SP, Kuo CC, Barnes RC, et al. Immunotyping of *Chlamydia trachomatis* with monoclonal antibodies. *J Infect Dis.* 1985;152(4):791-800.
20. Korhonen S, Hiltunen-Back E, Puolakkainen M. Genotyping of *Chlamydia trachomatis* in rectal and pharyngeal specimens: identification of LGV genotypes in Finland. *Sex Transm Infect.* 2012;88:465-469.
21. Cabello Úbeda A, Fernández Roblas R, García Delgado R, et al. Anorectal lymphogranuloma venereum in Madrid: a persistent emerging problem in men who have sex with men. *Sex Transm Dis.* 2016;43(7):414-419.
22. Vanousova D, Zakoucka H, Jilich D, et al. First detection of *Chlamydia trachomatis* LGV biovar in the Czech Republic, 2010-2011. *Euro Surveill.* 2012;17(2):20055.
23. Verweij SP, Ouburg S, de Vries H, et al. The first case record of a female patient with bubonic lymphogranuloma venereum (LGV), serovariant L2b. *Sex Transm Infect.* 2012;88(5):219-220.
24. Peuchant O, Touati A, Sperandio C, et al. Changing pattern of *Chlamydia trachomatis* strains in lymphogranuloma venereum outbreak, France, 2010-2015. *Emerg Infect Dis.* 2016;22(11):1945-1947.
25. De Vries HJ, Zingoni A, Kreuter A, et al. 2013 European guideline on the management of LGV. *J Eur Acad Dermatol Venereol.* 2015;29:1-6.
26. Taylor HR, Burton MJ, Haddad D, et al. Trachoma. *Lancet.* 2014;384(9960):2142-2152.
27. Lanjouw E, Ouburg S, de Vries HJ, et al. 2015 European guideline on the management of *Chlamydia trachomatis* infections. *Int J STD AIDS.* 2016;27:333-348.
28. Geisler WM, Suchland RJ, Whittington WL, et al. The relationship of serovar to clinical manifestations of urogenital *Chlamydia trachomatis* infection. *Sex Transm Dis.* 2003;30(2):160-165.
29. Marchand C, Granier F, Cetre JC, et al. Anal lymphogranuloma venereum with erythema nodosa. Apropos of a case [in French]. *Ann Dermatol Venereol.* 1987;114(1):65-69.
30. Sturm PD, Moodley P, Govender K, et al. Molecular diagnosis of lymphogranuloma venereum in patients with genital ulcer disease. *J Clin Microbiol.* 2005;43(6):2973-2975.
31. Dosekun O, Edmonds S, Stockwell S, et al. Lymphogranuloma venereum detected from pharynx in four London men who have sex with men. *Int J STD AIDS.* 2013;24(6):495-496.
32. Sonck C. On the occurrence of solar dermatitis in lymphogranuloma inguinale. *Acta Derm Venereol.* 1939;20:529.
33. Myhre EB, Mardh PA. Unusual manifestations of *Chlamydia trachomatis* infections. *Scand J Infect Dis Suppl.* 1982;32:122-126.

34. Perry ME, White SA. Three causes of reactive arthritis secondary to LGV. *J Clin Rheumatol.* 2015;21:33-34.
35. Schachter J, Osoba AO. Lymphogranuloma venereum. *Br Med Bull.* 1983;39(2):151-154.
36. Van der Bij AK, Spaargaren J, Morré SA, et al. Diagnostic and clinical implications of anorectal lymphogranuloma venereum in men who have sex with men: a retrospective case-control study. *Clin Infect Dis.* 2006; 42(2):186-194.
37. Ward H, Martin I, Macdonald N, et al. Lymphogranuloma venereum in the United Kingdom. *Clin Infect Dis.* 2007;44(1):26-32.
38. Høie S, Knudsen LS, Gerstoft J. Lymphogranuloma venereum proctitis: a differential diagnose to inflammatory bowel disease. *Scand J Gastroenterol.* 2011; 46(4):503-510.
39. White JA. Manifestations and management of lymphogranuloma venereum. *Curr Opin Infect Dis.* 2009; 22(1):57-66.
40. Hopsu-Havu VK, Sonck CE. Infiltrative, ulcerative, and fistular lesions of the penis due to lymphogranuloma venereum. *Br J Vener Dis.* 1973;49(2):193-202.
41. Kumaran MS, Gupta S, Ajith C, et al. Saxophone penis revisited. *Int J STD AIDS.* 2006;17(1):65-66.
42. Trebing D, Brunner M, Kröning Y, et al. Tumorous extragenital manifestation of lymphogranuloma venereum [in German]. *J Dtsch Dermatol Ges.* 2005;3(6):445-447.
43. Andrada MT, Dhar JK, Wilde H. Oral lymphogranuloma venereum and cervical lymphadenopathy. Case report. *Mil Med.* 1974;139(2):99-101.
44. Albay DT, Mathisen GE. Head and neck manifestations of lymphogranuloma venereum. *Ear Nose Throat J.* 2008;87(8):478-480.
45. Buus DR, Pflugfelder SC, Schachter J, et al. Lymphogranuloma venereum conjunctivitis with a marginal corneal perforation. *Ophthalmology.* 1988;95(6):799-802.
46. de Vrieze NH, van Rooijen M, Schim van der Loeff MF, et al. Anorectal and inguinal lymphogranuloma venereum among men who have sex with men in Amsterdam, The Netherlands: trends over time, symptomatology and concurrent infections. *Sex Transm Infect.* 2013;89:548-552.
47. Dangor Y, Ballard RC, da L Exposto F, et al. Accuracy of clinical diagnosis of genital ulcer disease. *Sex Transm Dis.* 1990;17(4):184-189.
48. Bremer V, Brockmeyer NH, Frobenius W et al. S2k-Leitlinie: Infektionen mit *Chlamydia trachomatis*. AWMF-Register Nr. 2016;059/005. https://www.awmf.org/uploads/tx_szleitlinien/059-005l_S2k_Chlamydia-trachomatis_Infektionen_2016-12.pdf. Accessed Aug, 2016.
49. Papp JR, Schachter J, Gaydos CA, et al. Recommendations for the laboratory-based detection of Chlamydia trachomatis and Neisseria gonorrhoeae. *MMWR Recomm Rep*. 2014;63:1-19.
50. Meyer T. Diagnostic procedures to detect Chlamydia trachomatis infections. *Microorganisms*. 2016;4,pii:E25. doi: 10.3390/microorganisms4030025.
51. White JA. Manifestations and management of lymphogranuloma venereum. *Curr Opin Infect Dis*. 2009;22:57-66.
52. Meyer T, Arndt R, von Krosigk A, et al. Repeated detection of lymphogranuloma venereum caused by Chlamydia trachomatis L2 in homosexual men in Hamburg. *Sex Transm Infect*. 2005;81:91-92.
53. Morre SA, Spaargaren J, Fennema JS, et al. Real-time polymerase chain reaction to diagnose lymphogranuloma venereum. *Emerg Infect Dis* 11: 2005;1311-1312.
54. Stevens MP, Twin J, Fairley CK, et al. Development and evaluation of an ompA quantitative real-time PCR assay for Chlamydia trachomatis serovar determination. *J Clin Microbiol*. 2010;48: 2060-2065.
55. Chen CY, Chi KH, Alexander S, et al. The molecular diagnosis of lymphogranuloma venereum: evaluation of a real time multiplex polymerase chain reaction test using rectal and urethral specimens. *Sex Transm Dis*. 2007;34:451-455.
56. Twin J, Stevens MP, Garland SM. et al. Rapid determination of lymphogranuloma venereum serovars of Chlamydia trachomatis by quantitative high-resolution melt analysis (HRMA). *J Clin Microbiol*. 2012;50:3751-3753.
57. Meyer T, Brockmeyer NH. Implementation of Lymphgranuloma venereum identification in Chlamydia trachomatis testing by nucleic acid amplification. *Clin Microbiol*. 2017;6:1. DOI: 10.4172/2327-5073.1000274.
58. van Dyck E, Piot P. Laboratory techniques in the investigation of chancroid, lymphogranuloma venereum and donovanosis. *Genitourin Med.* 1992;68(2): 130-133.
59. Clad A, Freidank HM, Kunze M, et al. Detection of seroconversion and persistence of *Chlamydia trachomatis* antibodies in five different serological tests. *Eur J Clin Microbiol Infect Dis.* 2000;19(12):932-937.
60. Forsbach-Birk V, Simnacher U, Pfrepper KI, et al. Identification and evaluation of a combination of chlamydial antigens to support diagnosis of severe and invasive *Chlamydia trachomatis* infections. *Clin Microbiol Infect.* 2009;16:1237-1244.
61. Viravan C, Dance DA, Ariyarit C, et al. A prospective clinical and bacteriologic study of inguinal buboes in Thai men. *Clin Infect Dis.* 1996;22(2):233-239.
62. Sonck CE, Räsänen JA, Mustakallio KK, et al. Autoimmune serum factors in active and inactive lymphogranuloma venereum. *Br J Vener Dis.* 1973;49(1):67-68.
63. Greaves AB. The frequency of lymphogranuloma venereum in persons with perirectal abscesses, fistulae in ano, or both. With particular reference to the relationship between perirectal abscesses of lymphogranuloma origin in the male and inversion. *Bull World Health Organ.* 1963;29:797-801.
64. Quinn TC, Goodell SE, Mkrtichian E, et al. *Chlamydia trachomatis* proctitis. *N Engl J Med.* 1981;305(4):195-200.
65. Schachter J, Moncada J, Liska S, et al. Nucleic acid amplifications tests in the diagnosis of chlamydial and gonococcal infections of the oropharynx and rectum of men who have sex with men. *Sex Transm Dis.* 2008;35(7):637-642.
66. Ota KV, Tamari IE, Smieja M, et al. Detection of *Neisseria gonorrhoeae* and *Chlamydia trachomatis* in pharyngeal and rectal specimens using the BD Probetec ET system, the Gen-Probe Aptima Combo 2 assay and culture. *Sex Transm Infect.* 2009;85(3): 182-18.
67. Arnold CA, Limketkai BN, Illei PB, et al. Syphilitic and lymphogranuloma venereum (LGV) proctocolitis: clues to a frequently missed diagnosis. *Am J Surg Pathol.* 2013;37(1):38-46.
68. Rob F, Kašpírková J, Jůzlová K, et al. Lymphogranuloma venereum with only proximal rectal involvement mimicking inflammatory bowel disease: a potential diagnostic pitfall. *J Eur Acad Dermatol Venereol.* 2017;31(5):e264-e265.
69. Hill SC, Hodson L, Smith A. An audit on the management of lymphogranuloma venereum in a sexual health clinic in London, UK. *Int J STD AIDS.* 2010;21: 772-776.

70. Bissesor M. Characteristics of LGV infection among homosexual men in Melbourne. Abstracts of the 19th Biennial Conference of the International Society for Sexually Transmitted Diseases Research, Quebec City, Canada, 2011. *Sex Transm Infect.* 2011;87(1):A139.
71. Fleming DT, Wasserheit JN. From epidemiological synergy to public health policy and practice: the contribution of other sexually transmitted diseases to sexual transmission of HIV infection. *Sex Transm Infect.* 1999;75(1):3-17.
72. El Karoui K, Méchaï F, Ribadeau-Dumas F, et al. Reactive arthritis associated with L2b lymphogranuloma venereum proctitis. *Sex Transm Infect.* 2009;85(3):180-181.
73. Leeyaphan C, Ong JJ, Chow EP, et al. Systematic review and meta-analysis of doxycycline efficacy for rectal lymphogranuloma venereum in men who have sex with men. *Emerg Infect Dis.* 2016;22(10):1778-1784.
74. Workowski KA, Bolan GA; Centers for Disease Control and Prevention. Sexually transmitted diseases treatment guidelines, 2015. *MMWR Recomm Rep.* 2015;64(RR-03):1-137.
75. Briggs GC, Freeman RK, Yaffe SJ. *Drugs in Pregnancy and Lactation*. 9th ed. Philadelphia, PA: Lippincott Williams & Wilkins; 2011.
76. Mohrmann G, Noah C, Sabranski M, et al. Ongoing epidemic of lymphogranuloma venereum in HIV-positive men who have sex with men: how symptoms should guide treatment. *J Int AIDS Soc.* 2014;17(4)(suppl 3):19657.
77. Poston TB, Gottlieb SL, Darville T. Status of vaccine research and development of vaccines for *Chlamydia trachomatis* infection. *Vaccine.* 2017 [Epub ahead of print].
78. Jiang J, Liu G, Kickhoefer VA, et al. A protective vaccine against *Chlamydia* genital infection using vault nanoparticles without an added adjuvant. *Vaccines (Basel).* 2017;5(1):3.

Chapter 174 :: Granuloma Inguinale

:: Melissa B. Hoffman & Rita O. Pichardo

AT-A-GLANCE

- Granuloma inguinale (GI) is a rare, chronic, progressive ulcerative disease that mainly affects the genital and perigenital skin.
- GI is primarily contracted through sexual transmission.
- GI is caused by infection with *Klebsiella granulomatis*, a gram-negative bacteria.
- It affects mostly people of lower socioeconomic status living in tropical or subtropical areas.
- Diagnosis confirmed by demonstrating intracellular Donovan bodies on histology.

INTRODUCTION

Granuloma inguinale (GI), or donovanosis, is a rare chronic ulcerative disease affecting mainly genital and perigenital skin. The microorganism was first identified in 1905 by Donovan, who noted the characteristic Donovan bodies in macrophages. In 1955, the name "donovanosis" was proposed.[1] The prevalence of GI has decreased markedly in recent times, and it can now be considered a sporadic disease. Despite its rarity, GI can have an aggressive clinical course so prompt recognition and treatment are necessary.

EPIDEMIOLOGY

GI is typically found in warm, moderately humid tropical and subtropical climates. GI has characteristically been reported in specific endemic areas, including Papua New Guinea, South Africa, parts of India and Brazil, and among the Aboriginal community of Australia.[2]

Sporadic cases have been reported elsewhere in southern Africa, the West Indies, and South America.[3] The disease is very rare in Europe and North America. Since 1989, fewer than 10 cases per year have been reported in the United States.[4] Recent epidemiologic data is limited, but overall, the incidence of GI is decreasing, especially in previously endemic areas such as Papua New Guinea and Australia.[3,5] The disease has nearly been eradicated from Australia, with only five cases reported in 2004.[5] GI is most commonly seen in individuals with lower socioeconomic status and sexually active adults between ages 20 and 40 years. No true race or gender predilection has been determined.

MODE OF TRANSMISSION

Although the mode of transmission is generally thought to be sexual, this is controversial. The consensus that donovanosis is transmitted sexually has been predominant since the middle of the 20th century. The majority of cases of GI occur in patients who have a history of sexual activity, and there is an increased incidence of the disease in age groups with the highest sexual activity. Often individuals with GI have history of sexual contact with sex professionals and concurrent sexually transmitted infections (STIs).[6] The predominance of genital lesions and lesions on the cervix only or on the anus in men involved with receptive anal intercourse all favor venereal origin. However, GI has occurred in young children and sexually inactive adults, challenging the idea that all cases are sexually transmitted. Furthermore, transmission rate between sexual partners is lower compared with other STIs.[2] The incidence of GI is also relatively low among sex workers and their conjugal partners. In rare cases, transvaginal transmission of GI during delivery can occur.[7]

CLINICAL FEATURES

The incubation period is uncertain, with estimates ranging between 1 and 360 days.[8] Most often the incubation period is stated to be about 2 to 3 weeks, which is based on human experimental data in which lesions appeared on average 50 days after exposure in a group of volunteers.[9] GI usually first presents as a single firm papule or subcutaneous nodule that later ulcerates and gradually increases in size. Four clinical types have been described—ulcerogranulomatous, hypertrophic, necrotic, and sclerotic. The most common presentation is the ulcerogranulomatous type, which presents as highly vascular, beefy-red ulcers that are nontender but bleed to the touch (Fig. 174-1). If untreated, the ulcers may extend to adjacent tissues via self-inoculation and form multiple ulcers. These ulcers are often mirror images of each other and have been described as "kissing lesions" (Fig. 174-2). The ulcers of GI may have a smooth border or a hypertrophic or verrucous border resembling condyloma acuminatum in the hypertrophic type (Fig. 174-3). The necrotic type often occurs in long-standing donovanosis and presents as a foul-smelling, deep ulcer with copious gray exudate and extensive destruction to surrounding tissues (Fig. 174-4). In the rare dry sclerotic type, lesions are nonbleeding ulcers that form fibrous band–like scars.

The genital region is affected in 90% of cases and the inguinal area in 10%. The most common locations

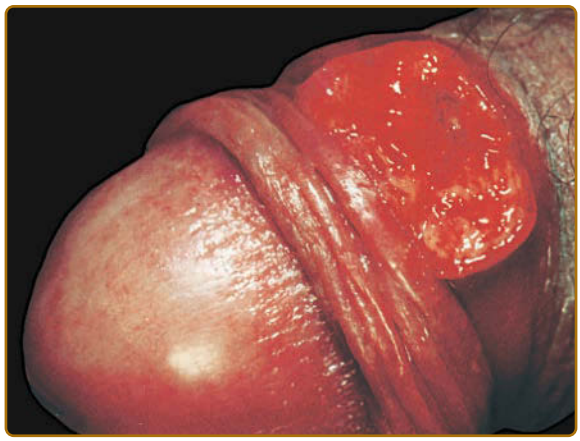

Figure 174-1 Granuloma inguinale, ulcerogranulomatous type. Beefy red, ulcerated plaque that bleeds easily. (Used with permission from A. Eichmann, MD.)

involved in men are the coronal sulcus, prepuce, and glans penis and in women are the labia minora, fourchette, and perineum.[10] Occasionally, GI presents as a mass in the vagina or cervix and can mimic a carcinoma.[11] The anus and colon may be involved, especially in homosexual men. GI may spread to the tissue overlying the regional lymph nodes and present as abscess or subcutaneous granuloma called a pseudobubo that later ulcerates.[10] The lymph nodes themselves are rarely involved unless there is an overlying bacterial superinfection. Rarely, pseudoelephantiasis of the genitals has occurred because of cicatrization and blockage of the lymph channels.[12]

Although rare, extragenital lesions account for about 6% of cases. Sites of involvement include the lips,

Figure 174-2 Granuloma inguinale, kissing lesions. Two adjacent ulcers that are essentially mirror images of each other. (Used with permission from Shukrallah Zaynoun, MD.)

Figure 174-3 Granuloma inguinale. Long-standing hypertrophic lesion causing significant destruction to surrounding tissue. (Reproduced with permission from the Graham Library of Wake Forest Department of Dermatology.)

gums, cheek, palate, pharynx, neck, nose, larynx, and chest.[6,8,13] Even more rare is disseminated donovanosis with spread to bone (causing osteomyelitis) or liver.[14,15] GI takes on an aggressive course during gestation and should be considered in women with atypical lesions living in high-risk areas.[16] Although no congenital infections have been reported, there are cases in which the infection was passed to the infant during vaginal delivery. The presentation of exposed infants has varied from otitis media and lymphadenitis to mastoiditis and meningitis.[7,17]

As with other STIs, patients with GI may be coinfected with HIV. HIV/AIDS-related immune alteration may alter the clinical manifestations of GI.[18] The natural history is usually more rapid, extragenital dissemination may occur more frequently, and ulcers may persist for prolonged periods, leading to more tissue

Figure 174-4 Granuloma inguinale. Large ulcerative lesion with destruction to surrounding tissues.

destruction. HIV-infected patients with GI also have high failure rates to first-line therapy.[19]

ETIOLOGY AND PATHOGENESIS

GI is caused by the organism *Klebsiella granulomatis*, previously called *Calymmatobacterium granulomatis*. The name was changed after sequencing the phoE and 16S ribosomal RNA genes and demonstrating close homology with *Klebsiella pneumoniae* and *Klebsiella rhinoscleromatis*.[20] *K. granulomatis* is a facultative gram-negative, nonmotile, pleomorphic bacteria that resides in the cytoplasm of large mononuclear cells. Although the mature form is encapsulated, it can be unencapsulated and demonstrates a closed safety pin appearance in its immature form.[2] Infection leads to a granulomatous inflammatory response, causing local tissue destruction and cutaneous ulceration.

DIAGNOSIS

Clinical suspicion of GI can be confirmed by the demonstration of the characteristic inclusion bodies called Donovan bodies within large mononuclear cells either in smears obtained directly from tissue or biopsy samples (Fig. 174-5). Whereas the cells are 25 to 90 µm in diameter, the Donovan bodies are 0.5 to 0.7 µm by 1 to 1.5 µm and may or may not be encapsulated.[3] Rarely, the Donovan bodies are found extracellularly or within neutrophils.[21] Both tissue smears and biopsies can be stained with Giemsa, Wright, silver or Gram stains to demonstrate the Donovan bodies. The bodies are more easily visualized with properly done smears than with biopsy. If GI is suspected and multiple swabs are being taken from an ulcer for detection of other organisms, the swab for GI should be taken first so that an adequate amount of cellular material can be obtained. It is also recommended that the ulcer not be cleaned with topical antimicrobials or saline because this may lead to negative smears.[18] The ulcer should be gentle wiped with a cotton swab only before taking the smear. Tissue smears should be prepared by rolling a swab firmly across lesion and then rolling this swab evenly across glass slide to deposit the material. A rapid Giemsa method such as Rapi-Diff can then be used to stain tissue smears for rapid diagnosis. Tissue for biopsy should be taken from the advancing edge of the ulcer.

Histologically, the epidermis may exhibit pseudoepitheliomatous hyperplasia or ulcerations (or both) depending on the site biopsied. The dermis often contains a dense mixed inflammatory infiltrate composed of histiocytes, plasma cells, and rare lymphocytes. The hypertrophic and cicatricial forms of GI may exhibit fibrosis. The clusters of Donovan bodies appear as safety pin–like structures inside vacuolated cytoplasms of large mononuclear cells.

Neither cultures nor serology play a major role in diagnosis. *K. granulomatis* is difficult to culture and store; however, successful culture has been accomplished by two laboratories using human peripheral blood mononuclear cells and in HEp-2 cells.[22,23] A polymerase chain reaction (PCR) test using a colorimetric detection system has been developed but is currently only in use for research purposes.[24] No commercial PCR test for GI is available currently. Serologic tests have been developed but are not reliable.

DIFFERENTIAL DIAGNOSIS

The clinical differential diagnosis of GI includes several other disorders that cause genital ulcers. Distinguishing features of GI ulcers include the lack of pain, beefy-red appearance, and presence of "kissing lesions." Table 174-1 reviews the most common differential diagnoses (organized by clinical presentation of genital ulcers, necrotic lesions, or extragenital involvement).

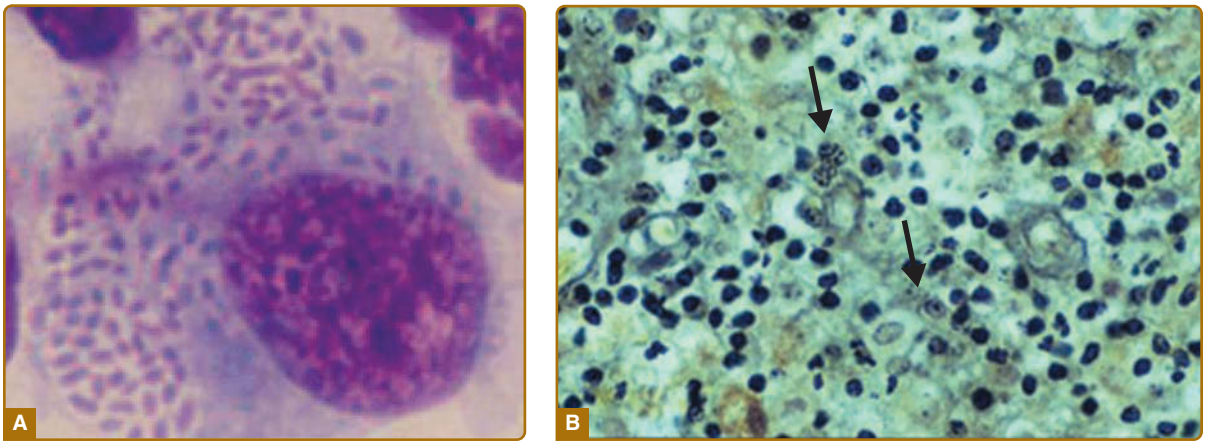

Figure 174-5 Granuloma inguinale. **A,** Large, mononuclear cell demonstrating multiple Donovan bodies. **B,** Donovan bodies (arrows) readily stained with Giemsa stain (Image **A,** From O'Farrell N. Donovanosis. In: Longo, DL, Fauci AS, Kasper DL, et al, eds. *Harrison's Principles of Internal Medicine*. 18th ed. New York: McGraw-Hill; 2012:1321; with permission.)

TABLE 174-1
Differential Diagnosis of Granuloma Inguinale

DISORDER	CONSIDERATIONS
Genital Ulcers	
Primary syphilis	Chancre: painless, punched-out, pink ulcer with nonpurulent clean base and indurated raised border; usually hard and firm
Secondary syphilis	Condyloma lata: present as pale, white, moist warty plaque but may rarely ulcerate
Lymphogranuloma venereum	Initially presents as an asymptomatic, genital papule or pustule or a symptomatic ulceration; later inguinal buboes form
Chancroid	Painful ulcers, often yellow in color, with surrounding erythema and painful lymphadenopathy
Condyloma acuminatum	White, gray, or skin-colored warty papules or may be giant cauliflower-like lesions
Malacoplakia	Solitary or multiple soft papules and nodules, often in urinary tract
Long-Standing Necrotic Lesions	
Squamous cell carcinoma	Important to rule out malignancy in long-standing necrotic lesions, especially those that do not respond to conventional therapy
Genital amebiasis	Painful genital ulcers with or without genitourinary discharge
Chronic herpes simplex in immunosuppressed	May present with chronic nonhealing genital ulcers with exuberant granulation tissue or with more verrucous growth
Extragenital Involvement	
Leishmaniasis	Often starts as nonhealing papule or nodule that enlarges slowly and may develop central ulceration or raised, indurated border
Paracoccidiomycosis	Red painful plaques and nodules on oral and nasal mucosa
Pyoderma gangrenosum	Painful solitary nodule or pustule than transforms into ulcer with dusky, undermined border
Cutaneous tuberculosis	Tuberculous chancres: firm shallow ulcer with granular base; may also have dissemination to organs such as liver or bone

CLINICAL COURSE AND PROGNOSIS

Treatment has been shown to halt progression of lesions, and healing typically proceeds inward from the ulcer margins. GI shows no tendency for spontaneous healing. If left untreated, GI may disseminate to internal organs, including the liver, ovaries, and uterus or to bone. If not correctly diagnosed, systemic dissemination can be fatal.[20] If left untreated, genital complications include genital swelling that may progress to pseudoelephantiasis, phimosis, paraphimosis, and progressive tissue destruction that may lead to destruction of the whole penis or other involved organs.[25] Another major risk of untreated GI is the presence of painless ulcers that bleed easily upon contact greatly increases the risk of HIV transmission. Development of carcinoma is another serious but rare complication that is predicted to occur in 0.25% of cases. A recent case report demonstrated coexisting squamous cell carcinoma and GI in an HIV-infected patient.[25] Malignancies should always be ruled out in cases of long-standing ulcers not responsive to treatment. Despite these complications, if proper treatment is initiated early in the course of disease, the prognosis is generally good.

MANAGEMENT

The optimal way to manage a possible case of GI is to establish diagnosis as soon as possible so appropriate antibiotics and specific patient education can be given. The patient should be educated about the complications of untreated GI and the risk for acquiring other STIs, including HIV. Several antimicrobial regimens have proven effective, but only a limited number of controlled trials have been published. Prolonged therapy is usually required to permit granulation and reepithelialization of the ulcers. It should be noted that standard treatment regimens used for other STIs such as chancroid may not be adequate in both dose and duration for GI, highlighting the importance of appropriate diagnosis. Table 174-2 outlines the most current treatment recommendations by both the Centers for Disease Control and World Health Organization.[26,27] Duration of treatment should be for at least 3 weeks and until complete healing is achieved. The addition of another antibiotic to these regimens, specifically an aminoglycoside (gentamicin 1 mg/kg IV every 8 hours), can be considered if improvement is not evident within the first few days of therapy. The addition of aminoglycosides is particularly important in patients who are pregnant or HIV positive, given the aggressive clinical course in these subsets of patients. Children with GI should receive a short course of azithromycin 20 mg/kg. Children born to mothers with GI should receive prophylaxis with a 3-day course of azithromycin 20 mg/kg once daily.[28]

Relapse may occur 6 to 18 months after apparently effective therapy, thus requiring follow-up by the physician. Long-standing cases may be complicated by secondary bacterial infections or by fistula and abscess formation, which require surgical intervention and render antibiotic treatment alone ineffective.[29] Patients with GI should be screened for other STIs, notably HIV and syphilis. Although donovanosis is uncommon in partners of index cases, all sexual contacts in the previous 6 months should be examined. Treatment of sexual partners is not necessary unless they develop signs and symptoms of GI.

ACKNOWLEDGMENTS

The authors acknowledge the contributions of Abdul-Ghani Kibbi, Ruba F. Bahhady, and Myrna El-Shareef, the former authors of this chapter.

TABLE 174-2
Treatment of Granuloma Inguinale

	CDC (2015)	WHO (2003)
Recommendations[a]	Azithromycin 1 g orally once weekly or 500 mg/day	Azithromycin 1 g orally once; then 500 mg/day or Doxycycline 100 mg orally twice daily
Alternatives	Doxycycline 100 mg orally twice daily or Ciprofloxacin 750 mg orally twice daily or Erythromycin base 500 mg orally four times daily or Trimethoprim-sulfamethoxazole one double-strength (160 mg/800 mg) tablet orally twice daily	Erythromycin 500 mg four times daily or Tetracycline 500 mg four times daily or Trimethoprim 80 mg/sulfamethoxazole 400 mg, 2 tablets, twice daily for a minimum of 14 days
Pregnancy	Macrolide antibiotic (azithromycin or erythromycin) as dosed above	

[a]Duration of treatment with any regimen is for at least 3 weeks and until all lesions have completely epithelialized.
CDC, Centers for Disease Control and Prevention; WHO, World Health Organization.

REFERENCES

1. Marmell M, Santora E. Donovanosis; granuloma inguinale; incidence, nomenclature, and diagnosis. *Am J Syph Gonorrhea Vener Dis*. 1950;34(1):83-90.
2. Basta-Juzbasic A, Ceovic R. Chancroid, lymphogranuloma venereum, granuloma inguinale, genital herpes simplex infection, and molluscum contagiosum. *Clin Dermatol*. 2014;32(2):290-298.
3. O'Farrell N. Donovanosis. *Sex Transm Infect*. 2002;78(6):452-457.
4. Lupi O, Madkan V, Tyring SK. Tropical dermatology: bacterial tropical diseases. *J Am Acad Dermatol*. 2006;54(4):559-578; quiz 578-580.
5. Bowden FJ. Donovanosis in Australia: going, going. *Sex Transm Infect*. 2005;81(5):365-366.
6. Veeranna S, Raghu TY. A clinical and investigational study of donovanosis. *Indian J Dermatol Venereol Leprol*. 2003;69(2):159-162.
7. Ahmed N, Pillay A, Lawler M, et al. Donovanosis causing lymphadenitis, mastoiditis, and meningitis in a child. *Lancet*. 2015;385(9987):2644.
8. O'Farrell N. Donovanosis: an update. *Int J STD AIDS*. 2001;12(7):423-427.
9. Greenblatt RB, Dienst RB, Pund ER, et al. Experimental and clinical granuloma inguinale. *JAMA*. 1939;113(12):1109-1116.
10. Velho PE, Souza EM, Belda Junior W. Donovanosis. *Braz J Infect Dis*. 2008;12(6):521-525.
11. Taneja S, Jena A, Tangri R, et al. Case report. MR appearance of cervical donovanosis mimicking carcinoma of the cervix. *Br J Radiol*. 2008;81(966):e170-e172.
12. Narang T, Kanwar AJ. Genital elephantiasis due to donovanosis: forgotten but not gone yet. *Int J STD AIDS*. 2012;23(11):835-836.
13. Veeranna S, Raghu TY. Oral donovanosis. *Int J STD AIDS*. 2002;13(12):855-856.
14. Fletcher HM, Rattray CA, Hanchard B, et al. Disseminated donovanosis (granuloma inguinale) with osteomyelitis of both wrists. *West Indian Med J*. 2002;51(3):194-196.
15. Paterson DL. Disseminated donovanosis (granuloma inguinale) causing spinal cord compression: case report and review of donovanosis involving bone. *Clin Infect Dis*. 1998;26(2):379-383.
16. Liverani CA, Lattuada D, Mangano S, et al. Hypertrophic donavanosis in a young pregnant woman. *J Pediatr Adolesc Gynecol*. 2012;25(4):e81-e83.
17. Govender D, Naidoo K, Chetty R. Granuloma inguinale (donovanosis): an unusual cause of otitis media and mastoiditis in children. *Am J Clin Pathol*. 1997;108(5):510-514.
18. Marfatia YS, Menon DS, Jose S, et al. Nonhealing genital ulcer in AIDS: a diagnostic dilemma! *Indian J Sex Transm Dis*. 2016;37(2):197-200.
19. Jamkhedkar PP, Hira SK, Shroff HJ, et al. Clinico-epidemiologic features of granuloma inguinale in the era of acquired immune deficiency syndrome. *Sex Transm Dis*. 1998;25(4):196-200.
20. Hart G. Donovanosis. *Clin Infect Dis*. 1997;25(1):24-30; quiz 31-22.
21. Richens J. The diagnosis and treatment of donovanosis (granuloma inguinale). *Genitourin Med*. 1991;67(6):441-452.
22. Carter J, Hutton S, Sriprakash KS, et al. Culture of the causative organism of donovanosis (Calymmatobacterium granulomatis) in HEp-2 cells. *J Clin Microbiol*. 1997;35(11):2915-2917.
23. Kharsany AB, Hoosen AA, Kiepiela P, et al. Growth and cultural characteristics of Calymmatobacterium granulomatis—the aetiological agent of granuloma inguinale (Donovanosis). *J Med Microbiol*. 1997;46(7):579-585.
24. Carter JS, Kemp DJ. A colorimetric detection system for Calymmatobacterium granulomatis. *Sex Transm Infect*. 2000;76(2):134-136.
25. Sardana K, Garg VK, Arora P, et al. Malignant transformation of donovanosis (granuloma inguinale) in a HIV-positive patient. *Dermatol Online J*. 2008;14(9):8.
26. Centers for Disease Control and Prevention. 2015 sexually transmitted diseases treatment guidelines, granuloma inguinale (donovanosis). 2015. https://www.cdc.gov/std/tg2015/donovanosis.htm.
27. World Health Organization. Guidelines for the management of sexually transmitted infections 2001:44. http://www.who.int/hiv/hiv_aids_2001_01.pdf.
28. Bowden FJ, Bright A, Rode JW, et al. Donovanosis causing cervical lymphadenopathy in a five-month-old boy. *Pediatr Infect Dis J*. 2000;19(2):167-169.
29. Bozbora A, Erbil Y, Berber E, et al. Surgical treatment of granuloma inguinale. *Br J Dermatol*. 1998;138(6):1079-1081.

Chapter 175 :: Gonorrhea, Mycoplasma, and Vaginosis

:: Lindsay C. Strowd, Sean McGregor, & Rita O. Pichardo

AT-A-GLANCE

- More than 20 million new sexually transmitted diseases (STDs) occur annually in the United States.
- In the United States, chlamydia is currently the most common reported STD. It is also the most common cause of pelvic inflammatory disease in women.
- Urethritis is a common presenting symptom of STDs in both men and women.
- High-risk patients often have coinfection with multiple STDs.
- Diagnosis can usually be made through direct microscopy, culture, or newer diagnostic methods such as nucleic acid amplification tests.
- Early and appropriate antimicrobial therapy of STDs results in good prognosis.

GONORRHEA

INTRODUCTION

Gonorrhea is a bacterial infection by *Neisseria gonorrhoeae*, a gram-negative, aerobic coccus-shaped bacterium found in pairs. The organisms are usually visualized intracellularly, located within polymorphonuclear leukocytes (Fig. 175-1). Gonorrhea is a common sexually transmitted disease (STD) affecting both men and women, particularly teenagers and young adults. In adult patients, gonococcal infection can affect the genitals, anus, or pharynx and can be acquired through vaginal, anal, or oral intercourse. It can also be transmitted vertically from mother to child during vaginal birth, manifesting as an inflammatory eye infection (ophthalmia neonatorum).

Albert Ludwig Sigismund Neisser first discovered the causative agent of gonorrhea in 1879. The origins of gonococcal infections are unknown, but references to gonorrhea, or "the clap" as it has been termed, go back to the 16th century in Europe.[1] Before the advent of antibiotics, silver preparations including silver nitrate and silver proteinate (Protargol) were used to treat gonorrhea in the 19th and 20th centuries.

EPIDEMIOLOGY

More than 820,000 people are estimated to acquire new gonococcal infections in the United States yearly according to the Centers for Disease Control and Prevention (CDC), although only about half are actually reported through the public health system. This makes gonorrhea the second most commonly reported infectious disease in the United States, second only to chlamydia. Higher endemic areas of the country include the southern United States and Alaska, with the lowest prevalence being in the northwestern states.[2] The rate of new infections declined after the implementation of a national gonorrhea control program in the United States during the mid-1970s and continued to decrease through the late 1990s. The yearly prevalence of gonococcal infections reached an all-time low in 2009. It has risen every year since 2009, with the exception of 2013, when it decreased slightly.[2] Newer epidemiologic data from the CDC and state registries indicates that there is increasing heterosexual transmission that may explain the increasing prevalence. The highest rate of reported gonococcal infections is among sexually active teenagers and young adults, aged 15 to 24 years. There is notable ethnic disparity, with the reported gonorrhea rate in African Americans being twenty times higher and in Hispanics twice as high compared with whites.[2] Such racial disparity is multifactorial and may be attributable to differences in accessibility to health care, lack of use of available resources, and sexual partner preferences. Risk factors for acquisition of gonorrheal infection include new or multiple sex partners, younger age, unmarried status, commercial sex work, minority ethnicity, substance and alcohol abuse, lower socioeconomic and educational levels, inconsistent condom use, and any previous STD infection. Prior gonorrhea is an especially important risk factor for acquisition of a new gonococcal infection because recidivism is particularly common.[3] As is true of most STDs, alcohol ingestion to the point of inebriation is associated with risky sexual behavior, including unprotected intercourse and sex with multiple partners, and is thus a major factor in acquisition of gonorrhea.[4]

Since the 1980s, prevalence rates among men and women have been similar in all age categories, although for any given age range, the prevalence will be slightly higher in women. Recent data indicate larger increases in infection among women compared with men. Although men having sex with men (MSM) is traditionally thought to be a high-risk group for

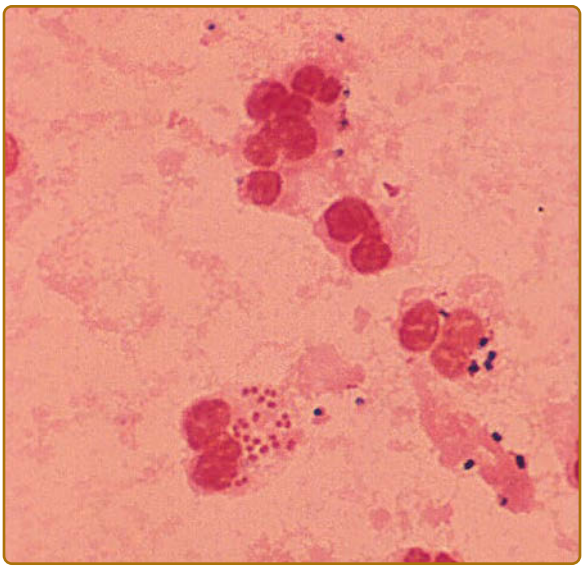

Figure 175-1 Diagnostic Gram-stained smear of urethral discharge of a man with acute gonorrhea. Gonococci (*red*) within a polymorphonuclear leukocyte. There are also some gram-positive cocci in this smear (*dark blue*). (Used with permission from Angelika Stary, MD.)

gonorrhea, heterosexual women and men show an increasing prevalence of infection.[5] A relatively high divorce rate and the wide availability of drugs to treat erectile dysfunction have both contributed to a resurgence of STDs (including gonorrhea) among middle-aged and older individuals living in industrialized countries.[6]

CLINICAL FEATURES

CUTANEOUS FINDINGS

Cutaneous Disease (Men): The incubation period in men is typically from 2 to 8 days, although it may rarely be longer because most infections are symptomatic by 2 weeks after exposure. Only about 10% of infections are asymptomatic in men. The most common manifestation of gonococcal infection in men is urethritis, characterized by a spontaneous, often profuse, cloudy or purulent discharge from the penile meatus (Fig. 175-2). Mucosal membrane inflammation in the anterior urethra leads to pain or burning upon urination and meatal erythema and swelling (Fig. 175-3). In some cases, there is so much soft tissue inflammation that the entire distal penis becomes swollen, so-called "bull head clap" (Fig. 175-4). Testicular pain and swelling may indicate epididymitis or orchitis and may be the only presenting symptom. However, epididymitis is more commonly caused by *Chlamydia trachomatis* or by combined infection with *N. gonorrhoeae*. There have been rare instances of genital skin furuncles caused by gonorrhea.[7]

Cutaneous Disease (Women): Fifty percent of women infected with *N. gonorrhoeae* are asymptomatic.

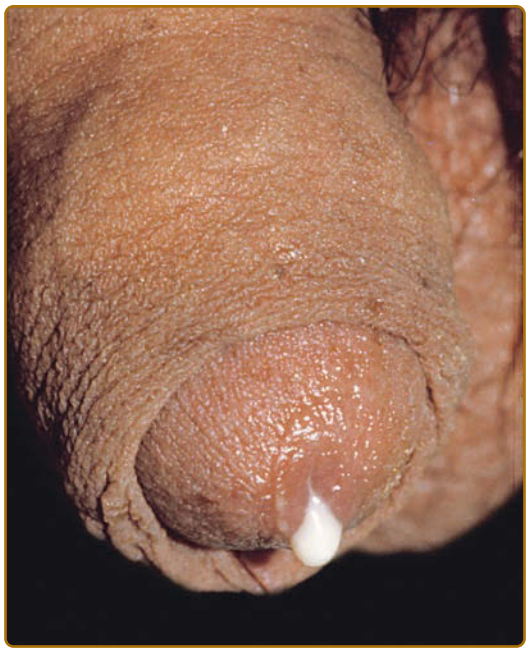

Figure 175-2 Acute gonorrhea in a male manifesting as creamy purulent discharge from the urethra. (Used with permission from Dr. Ted Rosen.)

Appropriate screening, prompt diagnosis, and treatment are crucial in women because of serious complications that can result in sterility. The endocervix is a common site of local infection. Symptoms of urethritis include mucopurulent discharge, vaginal pruritus, and dysuria. However, vaginitis does not occur except in prepuberal girls and postmenopausal women because the vaginal epithelium of sexually mature women does not support growth of *N. gonorrhoeae*. Other sites of infection include the Bartholin and Skene glands, which results in swelling and tenderness.[7]

Proctitis: Proctitis is a manifestation of gonococcal infection manifesting in those who practice unprotected

Figure 175-3 Acute gonorrhea in an uncircumcised male. There is a purulent discharge from the urethra and concomitant inflammation of the prepuce and glans. (Used with permission from Dr. Ted Rosen.)

Figure 175-4 Swelling of the distal shaft characterizes "bull head clap," which is actually a manifestation of urethral gonococcal infection. (Used with permission from Dr. Ted Rosen.)

Figure 175-5 Disseminated gonococcal infection. Tender, hemorrhagic, and necrotic pustules on the fingers and palms. (Used with permission from Dr. Ted Rosen.)

anoreceptive intercourse. Thus, it is most common in MSM. As a result of gonococcal proctitis, MSM are at a higher risk of acquiring HIV infection because of both damaged anorectal epithelial integrity and local recruitment of HIV-target cell types (CCR5/CD4$^+$ T cells and DC-SIGN [DC-specific intercellular adhesion molecule 3 grabbing nonintegrin] + dendritic cells).[8] Women may also develop proctitis through autoinoculation from cervical discharge or from anoreceptive intercourse. Proctitis symptoms include rectal mucopurulent discharge, pain on defecation, constipation, and tenesmus.

Disseminated Disease: Spread of infection from the primary site of inoculation to other parts of the body through the bloodstream leads to disseminated gonococcal infection (DGI), also known as gonococcemia. Disseminated disease occurs in 0.5% to 3% of cases and is associated with a classic triad of dermatitis, migratory polyarthritis, and tenosynovitis. Skin findings consist of small- to medium-sized macules or, most typically, hemorrhagic vesicopustules on an erythematous base located on palms and soles (Fig. 175-5) or on the trunk and elsewhere on the extremities. Skin lesions may develop necrotic centers. The concurrence of some degree of hemorrhage and necrosis led to the term "gun metal gray" to describe the cutaneous lesions of DGI. On the palms and soles, lesions may be tender, but in other sites, they tend to be both nonpruritic and painless. Skin lesions disappear after appropriate treatment has been administered. Cutaneous lesions may be present in 40% to 70% of cases of disseminated disease. Histologically, perivascular neutrophilia, dermal vasculitis, and epidermal neutrophil infiltration may be seen.

NONCUTANEOUS FINDINGS

Pharyngitis: Pharyngitis caused by *N. gonorrhoeae* was once thought to be rare. However, the common practice of fellatio among heterosexual adolescents and young adults, as well as among MSM, often in lieu of penetrative intercourse, has made pharyngeal gonorrhea much more common.[9] It is estimated that in adolescent women, 11% to 26% of cases of gonorrhea are composed solely of asymptomatic pharyngeal infection.[9] Although it may be asymptomatic, pharyngeal disease may serve as a source for disseminated gonococcal disease. When present, symptoms range from cervical lymphadenopathy and mild to moderate pharyngeal erythema to severe ulceration with pseudomembrane formation.[10]

Pelvic Inflammatory Disease: Organisms may invade the upper genital tract, including the uterus, fallopian tubes, and ovaries, resulting in pelvic inflammatory disease (PID). PID occurs in about 10% to 40% of uncomplicated gonorrheal infections in women and is characterized by fever, lower abdominal pain, back pain, vomiting, vaginal bleeding, dyspareunia, and adnexal or cervical tenderness during movement associated with a pelvic examination. Sequelae of untreated infection include tubo-ovarian abscesses, subsequent ectopic pregnancies, chronic pelvic pain, and infertility caused by chronic inflammation with resultant scarring. Symptoms tend to occur or worsen at the time of menses and cannot be distinguished from nongonococcal causes.[11,12] Fitz-Hugh–Curtis syndrome, involving inflammation of the liver capsule, is associated with genitourinary tract infection and may be present in up to one fourth of women with PID caused by either *N. gonorrhoeae* or *C. trachomatis*. Presenting symptoms include right upper quadrant pain and tenderness with abnormal liver function test results.[13] This syndrome must be distinguished from acute viral hepatitis.

Disseminated Disease: Tenosynovitis is defined as pain and swelling of the synovium, or a fluid-filled capsule that surrounds a tendon. With regards to the arthritis seen in disseminated disease, pain and

swelling may occur in a single joint or in multiple joints asymmetrically. Whereas true septic arthritis caused by gonorrhea is more typically monoarticular or pauciarticular, polyarticular disease is most often associated with active bacteremia.[14] *Neisseria meningitidis* infection is highly associated with meningitis, but *N. gonorrhoeae* infection can also rarely lead to meningitis in disseminated disease. Gonococcal meningitis tends to be less severe than meningococcal meningitis because several cases in the literature describe patients who spontaneously recovered without treatment.[15] Gonococcal endocarditis represents a rare complication of disseminated disease, affecting 1% to 2% of those with disseminated gonococcus. Vegetations preferentially affect the aortic valve in young male patients with no prior history of cardiac or valvular disease. Gonococcal endocarditis is a serious complication that often fails antimicrobial therapy and requires surgical intervention in approximately 50% of cases and carries a mortality rate of up to 19%.[16]

Newborns and Children: Neonates may acquire *N. gonorrhoeae* during passage through the birth canal from contact with infected secretions. Such ocular infections are known as ophthalmia neonatorum and are characterized by profuse, purulent ocular discharge[17] and can lead to severe corneal perforation or scarring. Most states, by law, require the prophylactic use of silver nitrate drops, erythromycin, or tetracycline ophthalmic ointment for prevention of ophthalmia neonatorum (Table 175-1). However, the efficacy of prophylactic ocular antibiotics has been recently questioned, and its use in low-risk patient populations may someday be discontinued.[18] Pharyngeal or genital gonococcal infection in children is often a sign of sexual abuse and warrants further investigation.[17]

COMPLICATIONS

Permanent sequelae of gonococcal infection in women may be infertility and increased risk of ectopic pregnancy as a result of untreated PID. Untreated DGI can lead to septic arthritis, yielding permanent joint damage. Meningitis and endocarditis are rare manifestations of DGI, which can lead to death or permanent disability caused by central nervous system or cardiac damage. Neonatal infection can lead to growth retardation, low birth weight, prematurity, blindness, and sometimes even infant death.[19]

TABLE 175-1

Prophylaxis for Gonococcal Infection in Neonates

- Erythromycin 0.5% ophthalmic ointment to both eyes immediately after birth
  Or
- Ceftriaxone 25–50 mg/kg IV or IM in a single dose, not to exceed 125 mg

IM, intramuscular; IV, intravenous.

ETIOLOGY AND PATHOGENESIS

Gonorrhea is a bacterial infection caused by *N. gonorrhoeae*, a gram-negative, aerobic coccus-shaped bacterium transmitted via mucosal secretions. Pathogenesis involves bacterial attachment to columnar epithelial cells via pili or fimbriae. The most common sites of attachment include the mucosal cells of the male and female urogenital tracts. Outer membrane proteins, PilC and Opa, on the bacteria aid in attachment and local invasion. Invasion is mediated by bacterial adhesins and sphingomyelinase, which contribute to the process of endocytosis. Gonococci also induce upregulated target cell integrins, which prevent mucosal cell shedding, a natural defense mechanism. Certain gonococcal strains produce immunoglobulin A proteases that cleave the heavy chain of the human immunoglobulin and block the host's normal bactericidal immune response. When inside the cell, the organism undergoes replication and can grow in both aerobic and anaerobic environments. After cellular invasion, the organism replicates and proliferates locally, inducing an inflammatory response. Outside the cell, the bacteria are susceptible to temperature changes, ultraviolet light, drying, and other environmental factors. The outer membrane contains lipooligosaccharide endotoxin, which is released by the bacteria during periods of rapid growth and contributes to its pathogenesis in disseminated infection. Delays in proper antibiotic treatment, physiologic changes in host defenses, resistance to immune responses, and highly virulent strains of bacteria contribute to hematogenous spread and disseminated infection. Humans are the only natural hosts of *N. gonorrhoeae*.[20]

RISK FACTORS

The prevalence of gonococcal infection amongst patient populations considered high risk varies by geographic location within the United States. Risk factors of infection include having multiple sex partners; sex partners with known sexually transmitted infections (STIs); engaging in unprotected oral, vaginal, or anal intercourse; and engaging in other risky sexual practices such as exchanging sex for money or drugs.[5] With respect to other STIs being a risk factor, there is frequent coinfection of patients with both *N. gonorrhoeae* and *C. trachomatis*. Patients with HIV are also at increased risk for other STIs, including gonorrhea. Studies have examined factors that may facilitate spread of asymptomatic gonococcal infection, including pregnancy, viral hepatitis, menstruation, and alcoholism.[21]

DIAGNOSIS

LABORATORY TESTING

Syndromic treatment is widely regarded as unacceptable practice because a majority of gonococcal

infections are asymptomatic.[19] Because of high specificity (>99%) and sensitivity (>95%), a Gram stain of a urethral specimen that demonstrates polymorphonuclear leukocytes with intracellular gram-negative diplococci can be considered diagnostic for infection with *N. gonorrhoeae* in symptomatic men.[18] However, because of lower sensitivity, a negative Gram stain result cannot be considered sufficient for ruling out gonococcal infection in asymptomatic men at high risk for infection. In contrast to urethral Gram stains, the sensitivity of Gram stain in endocervical swabs is less than 35% and should not be used a screening tool in women.[18] Vaginal specimens are never recommended for diagnostic purposes because the vaginal mucosa resists gonococcal invasion.

Bacterial culture has been the "gold standard" diagnostic test for years, although newer and more specific tests are now being widely used. Culturing *N. gonorrhoeae* requires media containing heme, nicotinamide adenine dinucleotide, yeast extract, carbon dioxide, and other supplements required for isolation. Culture can be performed on modified Thayer-Martin medium. In men, culture is performed on secretions or urethral swabs. Endocervical and endourethral specimens for culture yield accurate results in women. Cultures on pharyngeal and rectal swabs may also be performed if infection is suspected in these areas.

There is a growing trend among health departments and STI clinics to use nucleic acid amplification tests (NAATs) to provide more rapid diagnosis. These tests use methods such as polymerase chain reaction (PCR); transcription-mediated amplification; and strand displacement amplification on urine, urethral, pharyngeal, or rectal samples. Overall, NAATs are highly sensitive and specific and may be able to detect even the presence of one organism, and some can provide point of care testing with rapid turnaround time in 30 to 60 minutes.[19] However, there is much variability in the cost, sensitivity, and indicated anatomic testing sites, so these tests are subject to ongoing controversy.[20] In addition, diagnosis via any nonculture method does not allow for antibiotic sensitivity testing.

In DGI, cultures, and if available, NAAT, should be done on blood, joint fluid, and skin lesions. Synovial fluid from affected joints must be analyzed for cell count, Gram stain, and culture. Of necessity, diagnosis may rely on clinical suspicion and pertinent findings because tests for DGI yield positive results only in a small number of cases.

PROGNOSIS AND CLINICAL COURSE

The prognosis is excellent if infection is treated early with appropriate antibiotics. Previously treated gonococcal infection does not reduce the risk of reinfection. DGI has a good prognosis if treated appropriately and before permanent damage to joints or organs occurs.

TREATMENT

The Gonococcal Isolate Surveillance Project was established in 1986 by the CDC with the purpose of tracking antimicrobial susceptibilities to *N. gonorrhoeae* strains in the United States. These data have been used to help inform CDC recommendations regarding treating for gonococcal infections. Strains of *N. gonorrhoeae* with increasing resistance to cefixime increased in 2009 and 2010 and subsequently decreased in 2012 and 2013 after the CDC changed its treatment recommendations to dual therapy. The most current CDC guidelines for first-line treatment of patients with *N. gonorrhoeae* are a combination of ceftriaxone and azithromycin.[22] Of concern are more recent studies that show emerging gonococcal isolates resistant to azithromycin in some areas of Europe.[23] About 10% to 30% of people with gonococcal infection are coinfected with *Chlamydia*. Table 175-2 shows current CDC recommendations, as revised in 2015, for uncomplicated cervical, urethral, pharyngeal, and rectal gonococcal infections.[5] Because of the increased prevalence of antimicrobial resistance of tetracyclines, fluoroquinolones, and penicillin, these antibiotics are not recommended for the routine treatment of any gonococcal infections.[24]

Studies show that provider adherence to current CDC treatment recommendations varies between 76% and 88%, with two main areas of nonadherence identified as lack of dual therapy and incorrect dosing. Only about one third of patients had appropriate posttreatment follow-up, and there is large variation in the percentage of partners who receive treatment.[25]

Patients with DGI may require hospitalization caused by septic arthritis, meningitis, or endocarditis. The recommended regimen for DGI affecting the joints is ceftriaxone, 1 g intramuscularly (IM) or intravenously (IV) every 24 hours, continuing for 7 days. The CDC also recommends a single dose of azithromycin 1 g by mouth. The treatment is similar for gonococcal meningitis and endocarditis, but the ceftriaxone is dosed as 1 to 2 g IV every 12 to 24 hours for 10 to 14 days, as well as the single 1 g of azithromycin

TABLE 175-2

Treatment of Localized, Uncomplicated Gonococcal Infection of the Cervix, Rectum, Pharynx, or Urethra (2015 CDC Guidelines)

First-Line Treatment

- Ceftriaxone 250 mg IM single dose *plus*
- Azithromycin 1 g PO single dose

Alternative Therapy

- Cefixime 400 mg PO single dose *plus*
- Azithromycin 1 g PO single dose

Single-dose injectable cephalosporin regimens (other than ceftriaxone 250 mg IM) that are safe and generally effective against uncomplicated urogenital and anorectal gonococcal infections include ceftizoxime (500 mg IM), cefoxitin (2 g IM with probenecid 1 g PO), and cefotaxime (500 mg IM)

IM, intramuscular; IV, intravenous; PO, oral.

TABLE 175-3
Treatment of Disseminated Gonococcal Infection

Treatment of Arthritis and Arthritis-Dermatitis Syndrome
- Ceftriaxone 1 g IV every 24 hours for 7 days *plus*
- Azithromycin 1 g PO single dose

Treatment of Meningitis and Endocarditis
- Ceftriaxone 1–2 g IV every 12–24 hours for 10–14 days *plus*
- Azithromycin 1 g PO single dose

IV, intravenous; PO, oral.

orally (Table 175-3). Therapy for gonococcal infections in neonates is shown in Table 175-4. Gonococcal ophthalmia neonatorum should be treated with ceftriaxone, 25 to 50 mg/kg IV or IM, not to exceed 125 mg in a single dose. For treatment regimens for PID and epididymitis, readers are referred to the CDC's website.[5]

Sexual partners of those found to have gonococcal infections should be evaluated. However, because this is not always feasible, empiric treatment may be advisable. In general, treatment of partners of female or heterosexual male patients diagnosed with gonorrhea empirically is as or more effective than the traditional reliance on referral, testing, and as-needed treatment.[21] One way of doing this is via expedited partner therapy (having the index patient deliver therapy to the partner); such expedited therapy decreases the risk of persistent or recurrent infection in the index patient.[26] No studies have evaluated empiric treatment of gonorrhea (or chlamydia) in MSM. State laws vary with regard to expedited partner therapy and must be considered. Moreover, this type of empiric therapy misses the opportunity to counsel partners and treat comorbid disease when detected.

CONTRAINDICATIONS

Allergic reactions are uncommon with third-generation cephalosporins. Use of ceftriaxone or cefixime is contraindicated in persons with a history of an immunoglobulin (Ig) E–mediated penicillin allergy. Other regimens include dual treatment with single doses of oral gemifloxacin 320 mg plus oral azithromycin 2 g or dual treatment with single doses of intramuscular gentamicin 240 mg plus oral azithromycin 2 g. Providers treating persons with cephalosporin or IgE-mediated penicillin allergy should consult an infectious disease specialist.

TABLE 175-4
Treatment of Gonococcal Infection in Neonates

- Ceftriaxone, 25–50 mg/kg/day IV or IM in a single daily dose for 7 days or for 10–14 days if meningitis is documented
  Or
- Cefotaxime, 25 mg/kg IV or IM every 12 hours for 7 days, or for 10–14 days if meningitis is documented

IM, intramuscular; IV, intravenous.

SCREENING RECOMMENDATIONS

The CDC currently recommends yearly screening of men who engage in receptive anal intercourse, all sexually active women younger than 25 years old, any woman with a new sex partner, multiple sex partners, or a sex partner with a known STI. Other at-risk populations include those who are not in monogamous relationships, have a current or past history of STIs, or who exchange sex for money or drugs.[5]

Epidemiologic studies have indicated most providers screen for gonococcal infection with pharyngeal or urethral swabs, but far fewer providers do anal screening. One study looking at gonococcal screening results of more than 52,000 men in the United States between January 2013 and May 2015 showed that only about 4% of patients had a rectal screen, but of those who underwent rectal screening, 17% had a positive test result.[27] Other studies have shown that there is a percentage of patients who only have extragenital infection and therefore would be missed if they did not receive pharyngeal or anal testing. Any patient who is being tested for gonococcal infection should also undergo testing for other STIs, especially chlamydia, given it high rate of coinfection and for HIV.[28]

GENITAL MYCOPLASMAS

INTRODUCTION

Mycoplasma are the smallest free-living, self-replicating bacteria. These organisms developed by degenerative evolution from lactobacilli and lack a cell wall (Fig. 175-6). These organisms routinely colonize the respiratory and urogenital tracts of humans. *Mycoplasma* spp. and other *Ureaplasma* spp. are referred to as the genital mycoplasmal organisms and may be found in the lower urogenital tracts of

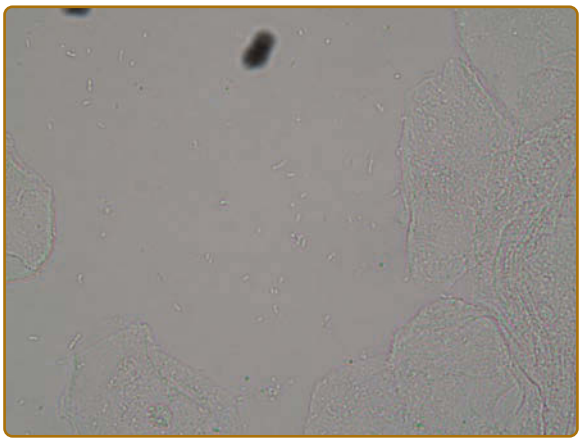

Figure 175-6 Lactobacilli from genital mycoplasma infection. (Used with permission from Dr. Libby Edwards.)

sexually active adults. Seven mycoplasmal strains have been isolated from the genital tract. The most common strains include *Mycoplasma hominis* and *Mycoplasma genitalium. M. genitalium* was identified first in the 1980s and is now thought to be responsible for 30% of persistent urethritis.[29] Less common strains include *Mycoplasma fermentans, Mycoplasma penetrans, Mycoplasma pneumoniae, Mycoplasma primatum,* and *Mycoplasma spermatophilum.*[30]

EPIDEMIOLOGY

The global prevalence of *M. genitalium* among all sexually active women ranges from 1% to 6.4%. About 40% to 80% of sexually active women in the United States have urogenital colonization with *Ureaplasma* organisms. *M. hominis* has also been isolated in 20% to 50% of sexually active women. Rates of colonization tend to be lower in men, except in the setting of HIV coinfection. The rates of colonization in children and nonsexually active adults are even lower. Newborns may be infected by passage through the birth canal of an infected mother. Although the most common cause of symptomatic non-gonococcal urethritis (NGU) remains *Chlamydia* spp., the genital mycoplasmas also cause this disorder. *Ureaplasma* organisms have been found to be the cause of more than 20% of nonchlamydial NGU, and *M. genitalium* accounts for 10% to 20% of cases of nonchlamydial NGU.[31] The detection of *M. hominis* in a urethral smear is irrelevant to NGU because numerous studies have isolated *M. hominis* independently of symptoms and in most cases is thought to be a commensal organism with low virulence.[32]

CLINICAL FEATURES

CUTANEOUS FINDINGS

Cutaneous Disease (Men): The most common cutaneous disease in men with mycoplasma infection is urethritis, although is less commonly implicated than gonococcal and chlamydial urethritis. Urethritis presents with dysuria, urethral pain and pruritus, and a mucopurulent discharge. Occasionally, men have urethral discharge but are otherwise asymptomatic. Physical findings and symptomatology are indistinguishable from those seen with chlamydial NGU.

Cutaneous Disease (Women): The most common cutaneous disease in women with mycoplasma infection is cervicitis, although is less commonly implicated than gonococcal and chlamydial cervicitis. Cervicitis presents with mucopurulent exudate visible in the endocervical canal, a friable cervical os that bleeds with minimal manipulation, abnormal vaginal discharge, and intermenstrual vaginal bleeding.[29]

NONCUTANEOUS FINDINGS

As with gonorrhea and chlamydia, various genital mycoplasmas infections can result in noncutaneous disease such as urethritis, cervicitis, PID, endometritis, salpingitis, and chorioamnionitis. Other species can cause respiratory infection, septic arthritis, surgical wound infections, neonatal pneumonia, and meningitis. Infection with these organisms needs to be considered if workup results for the more commonly isolated organisms are negative. There is no clear relationship between genital mycoplasma and epididymitis or prostatitis. In cases of bacterial vaginitis, coinfection with *Mycoplasma* spp. (particularly *M. hominis*) may worsen the condition.

COMPLICATIONS

Invasion by different species of *Mycoplasma* and *Ureaplasma* spp. can cause disseminated disease, especially in immunocompromised hosts who have deficiencies in antibody production. Disseminated disease may result in respiratory tract invasion, osteomyelitis, or infectious arthritis. Bacteremia as a result of *M. hominis* has been shown after renal transplantation. *M. hominis* has also be found in surgical wound infections, pericardial effusions, prosthetic heart valves, and subcutaneous abscesses, as well as in synovial fluid of people with rheumatoid arthritis.

There is an increased frequency of *M. hominis* and *Ureaplasma* spp. in cervical cultures from women who are unable to conceive, suggesting a causative role in infertility. The role of *M. genitalium* in infertility is not well studied in this regard. Although this may represent an overinterpretation, for some cases of premature rupture of the fetal membranes, preterm labor, intraamniotic infection, and chorioamnionitis, the presence of genital mycoplasmas suggests that these organisms may play a role in the pathogenesis of these complications of pregnancy.[33] *Ureaplasma* spp. and *M. hominis* have been isolated from the blood of febrile women postpartum and postabortion. Some studies have suggested infection with *M. genitalium* may facilitate coinfection with another sexually transmitted pathogen.[34] It is not currently known if infection with *M. genitalium* leads to male infertility or can be responsible for proctitis from anal infection.

ETIOLOGY AND PATHOGENESIS

The bacteria can attach to and penetrate epithelial cells by adhesion proteins on the back of the cell body. The structure and function of adhesion proteins for *M. genitalium* (P110 and P140) and *M. hominis* (P100) are well characterized. The abundance of urea to metabolize predisposes *Ureaplasma* spp. to the urinary tract. The specific adhesion proteins for *Ureaplasma* spp. are still unknown. All genital mycoplasmas multiply as

parasites because they are unable to complete various metabolic reactions. Cholesterol is required for growth and is taken from the epithelial cell; *Ureaplasma* spp. need urea as well. Because of their parasitic nature and specific nutritional requirements, *Mycoplasma* spp. tend to remain localized to mucosal surfaces. Disseminated infection is rare and tends to occur only in immunocompromised hosts or in cases of epithelium severely traumatized by instrumentation.

RISK FACTORS

Risk factors for genital mycoplasmas include multiple partners, younger age, ethnic minority, presence of other STIs, and past or present bacterial vaginosis (BV).

DIAGNOSIS

LABORATORY TESTING

Mycoplasmas are slow-growing organisms, and culture can take up to 6 months to speciate. Culture specimens should be obtained from the urethra or first voided urine in men and from the cervix, urethra, and vagina in women. *M. hominis* and *U. urealyticum* can be cultured on special media, which is enriched with horse serum as a nutrient source. Because of this, the preferred method of testing involves NAAT. First-voided urine is actually the preferred specimen to submit when the reference laboratory plans to use NAAT.[30] There is currently no Food and Drug Administration (FDA)–approved diagnostic laboratory test for detection of Mycoplasma spp. The standard of care is empiric treatment for mycoplasma infection in cases of persistent or recurrent urethritis, cervicitis, and PID.[29]

Laboratory tests for genital mycoplasmas may be limited because most specimens must be sent to reference laboratories. PCR assay is required to detect *M. genitalium* and may also optionally be used by laboratories to identify other *Mycoplasma* spp. Although various commercial tests are available for antibodies (complement-binding reaction [CBR], hemagglutination, immunofluorescence), the mere detection of *Mycoplasma* antibodies is not sufficient to verify infection because of the possibility of prior colonization and cross reactions. Increased titer levels may be a sign of acute infection. Because *Mycoplasma* spp. do not possess a cell wall, Gram stain will not detect these organisms.

PROGNOSIS AND CLINICAL COURSE

The prognosis in immunocompetent hosts is excellent with prompt diagnosis and appropriate treatment.

TABLE 175-5
Treatment of Mycoplasma Urethritis

- Azithromycin 1 g PO single dose *or*
- Azithromycin 500 mg PO on day 1 + 250 mg PO for 4 days
  Or
- Moxifloxacin 400 mg/day for 7–14 days

PO, oral.

TREATMENT

Because these organisms lack a cell wall, they are inherently resistant to β-lactam and cephalosporin antibiotics because these drugs target cell wall synthesis. Urethritis is often treated with 7 days of doxycycline, but this only provides effective treatment in about one third of mycoplasma infections. A single high dose of azithromycin or a 5-day course of azithromycin provides significantly higher cure rates than doxycycline. Patients who fail azithromycin usually have a macrolide-resistant strain of mycoplasma, and in some areas of the world, these emerging resistant strains can represent up to 50% of isolates. In macrolide-resistant mycoplasma infection, consider a course of oral moxifloxacin and retesting of patients 3 to 4 weeks after therapy completion to assess for clearance (Table 175-5).[35]

Current CDC guidelines for empiric treatment of PID do not recommend antibiotics that are effective against mycoplasma, particularly *M. genitalium*. If *M. genitalium* is isolated or if the patient does not respond to treatment on standard PID regimens, the CDC recommends consideration of treatment with moxifloxacin 400 mg/day for 14 days.[34]

SCREENING RECOMMENDATIONS

The CDC does not currently recommend routine screening for mycoplasma infection, and there are no FDA-approved diagnostic screening tests available in the United States.

CHLAMYDIA

INTRODUCTION

Chlamydia is a common STI that has implications in a variety of organ systems. The disease primary affects the mucous membranes of the ophthalmic, genitourinary, and respiratory systems. Depending on the organ system affected, there are clinically distinct manifestations that occur. However, common themes, including an enduring nature and inflammatory sequelae, are noted throughout each infection.[36] This chapter highlights some of those manifestations but focuses mainly on genitourinary infections.

EPIDEMIOLOGY

In the United States, *C. trachomatis* remains the most frequently reported STI, with more than 1.4 million cases reported in 2012.[37] The National Health and Nutrition Examination Survey (NHANES) is used by the CDC to monitor the population prevalence of chlamydial infections.[37] According to NHANES data, the overall prevalence of chlamydia infections between 2007 and 2012 was 1.7% (95% confidence interval [CI], 1.4%–2.0%), and the highest prevalence was seen in non-Hispanic blacks (5.2%).[37] Prevalence among US patients with at least two sexual partners was 3.2% (CI, 2.2%–4.2%).[37] In comparison, the prevalence of chlamydia infections in patients with one sexual partner was 1.4% (CI, 1.1%–1.7%).[37] The prevalence of chlamydia in sexually active women is inversely proportional to age, with the highest rates of infection occurring between the ages of 14 and 24 years.[37] Additionally, 1 in 7 non-Hispanic black women and 1 in 22 Mexican American women between the ages of 14 to 24 years were infected with chlamydia compared with 1 in 55 non-Hispanic white women.[37] The reason for such racial disparities is unknown but may be due to differences in sexual networks, decreased access to care, and untimely partner treatment.

CLINICAL FEATURES

CUTANEOUS FINDINGS

The clinical manifestations of *C. trachomatis* infections vary based on the site of involvement, the sex and age of the patient, and the serovar responsible for infection. Urogenital infections are the most common manifestations of *C. trachomatis* infections. The most common site of infection in men is the urethra. In comparison, the urethra and cervix are the most common sites in women.[37] In men, urethritis is the most common manifestation of infection and is characterized by dysuria and a watery or mucoid discharge from the urethra. The discharge may be scant, and some patients may only complain of stained underwear. In comparison, the discharge in gonococcal urethritis is more purulent and profuse. However, there is considerable clinical overlap, and neither the nature of the discharge nor the severity of accompanying dysuria can be reliably used to make a specific diagnosis. *C. trachomatis* may also cause epididymitis in males and proctitis in both sexes. *C. trachomatis* and *N. gonorrhoeae* are the most common causes of epididymitis in male patients younger than 35 years of age.[36] Epididymitis presents as unilateral testicular pain and swelling accompanied by dysuria and fever. Proctitis is caused by direct inoculation of serovars D to K and presents as pruritus, pain, and a mucopurulent discharge. The infection is limited to the rectum and not as severe as proctitis due to serovars L1 to L3 in lymphogranuloma venereum. Cervicitis caused by *C. trachomatis* is the female counterpart to urethritis in men. The classic presentation is mucopurulent cervicitis with discharge from the cervical os. However, the majority of women with urogenital *C. trachomatis* infections are asymptomatic. Patients may complain of vaginal discharge, bleeding, or abdominal pain. If dysuria is present, it may indicate concomitant urethritis.

COMPLICATIONS

PID is a complication of *C. trachomatis* infection as well as gonococcal infections. PID is the overarching clinical presentation encompassing combinations of endometritis, salpingitis, and peritonitis. The diagnosis of acute PID is typically clinical, and patients present with fever; lower abdominal pain; vomiting; and cervical, uterine, and adnexal motion tenderness. Patients may also have an indolent or "silent" form of the disease with similar degrees of inflammation. The sequelae of both forms of PID include infertility, ectopic pregnancy, and chronic pelvic pain resulting from inflammation and scarring.

Perinatal infections may result in conjunctivitis and pneumonia. Neonatal conjunctivitis or ophthalmia neonatorum is acquired during birth from an infected birth canal. It may result from either gonorrhea or chlamydia infections. It typically presents 1 to 2 weeks after birth and is characterized by a purulent ocular discharge with erythema and swelling of the eyelids. Neonatal chlamydial pneumonia typically presents within 8 weeks of birth and is characterized by nasal symptoms, tachypnea, and cough. The cough is staccato in nature, and patients are typically symptomatic for at least 3 weeks before presentation. Cultures positive for *C. trachomatis* can be obtained from nasopharyngeal specimens. Wheezing is typically absent. However, a peripheral eosinophilia may be observed, and patients may be prone to developing asthma later in life.

Genital infections with *C. trachomatis* may also result in reactive arthritis. Reactive arthritis is an immune-mediated arthritis resulting from a mucosal infection, urethritis in the case of chlamydia, with concomitant conjunctivitis and cutaneous lesions involving the genitals. Individuals with the histocompatibility marker HLA-B27 are at increased risk of developing reactive arthritis.

ETIOLOGY AND PATHOGENESIS

RISK FACTORS

C. trachomatis is a nonmotile, gram-negative, obligate intracellular bacteria that replicates within human cells. Its replication is characterized by a two-phase life cycle that begins with an infectious form known as the elementary body (EB). The EB enters the host epithelial cell via endocytosis, resulting in

the formation of a chlamydial inclusion. The Greek-derived word *chlamys* means "cloak draped around the shoulder." This refers to the draping of intracytoplasmic inclusions containing *C. trachomatis* around the nucleus of an infected cell. Six to 8 hours after entry, the EB converts into the reticulate body (RB), which replicates via binary fission. The RBs are then converted back into EBs and released from the cell to infect other cells. Recently, extrusion of chlamydial inclusions with subsequent phagocytosis by macrophages has been implicated as a means of immune evasion and ultimately dissemination of infectious particles.[38]

C. trachomatis strains are classified into 15 serovars with different clinical presentations. Serovars A through C cause chronic conjunctivitis and trachoma and are endemic in Africa and Asia, D through K cause urogenital tract infections, and L1 though L3 cause lymphogranuloma venereum. The target cells of *C. trachomatis* include the epithelial cells of the endocervix, conjunctiva, urethra, rectum, and epididymis. Infected cells release interleukin-8 and other proinflammatory cytokines that recruit neutrophils to the site of infection. This is followed by lymphocytes, macrophages, plasma cells, and eosinophils. Upon resolution, fibrosis and scarring ensue, which are increased in response to repeated infections. Transmission is through oral, anal, or vaginal intercourse with symptoms occurring 1 to 3 weeks after exposure. Coinfection with other STDs occurs frequently, most commonly with gonorrhea. Additionally, there is an association between positive *C. trachomatis* testing and the presence of high-risk human papilloma virus (HPV).[39] Various serotypes have been associated with an increased risk of cervical squamous cell carcinoma, suggesting that *Chlamydia* spp. may act as a cofactor with oncogenic, high-risk HPV in neoplastic transformation.[40,41]

DIAGNOSIS

Traditionally, chlamydial infection was diagnosed by cell culture with specimens obtained from the endocervix, urethra, rectum, or conjunctiva, as indicated. Modern techniques have largely replaced this method of diagnosis. Specifically, the nucleic acid amplification test (NAAT) is the preferred method of testing (Fig. 175-7). Although specific symptoms may suggest infection with *C. trachomatis*, laboratory confirmation is necessary for diagnosis. Urogenital infections may be diagnosed by collecting endocervical or vagina specimens in women, urethral specimens in men, or a first-catch urine specimen in either sex. NAATs are the most sensitive tests available and are almost as specific as culture. They are approved by the FDA for the diagnosis of urogenital infections caused by *C. trachomatis*. Although rectal and oropharyngeal specimens may be obtained, NAATs are not FDA approved for the diagnosis of infection at such sites. NAATs offer some advantages over prior diagnostic strategies in that they are relatively noninvasive and easy to perform. However, they are expensive and unable to differentiate among different serovars *of C. trachomatis*. Additionally, they only detect the DNA or RNA of chlamydial species and may remain positive up to 3 weeks after treatment.[42]

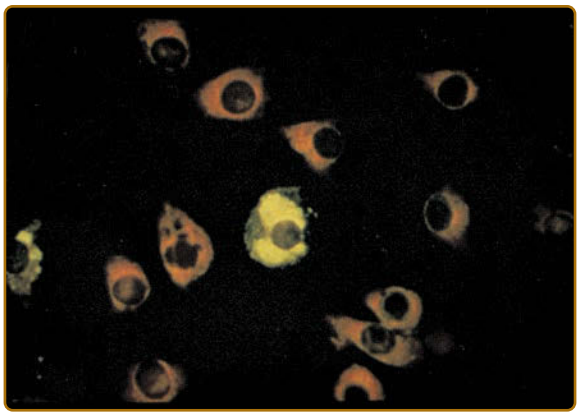

Figure 175-7 Detection of *Chlamydia trachomatis* by direct immunofluorescence with monoclonal antibodies. (Used with permission from Dr. Ted Rosen.)

DIFFERENTIAL DIAGNOSIS

Table 175-6 shows the differential diagnosis for all mucosal-oriented venereal diseases.

TABLE 175-6

Differential Diagnosis for All Mucosal-Based Venereal Diseases

LOCALIZED	SYSTEMIC	ALWAYS RULE OUT
▪ Urinary tract infection ▪ Chlamydia ▪ Gonorrhea ▪ Pelvic inflammatory disease ▪ Trichomoniasis ▪ Herpes simplex virus ▪ Bacterial vaginosis ▪ Vaginitis ▪ Endometriosis ▪ Mycoplasmal infection ▪ Orchitis and epididymitis ▪ Lymphatic occlusion caused by pelvic neoplasm	▪ Septic arthritis ▪ Rheumatoid arthritis ▪ Psoriatic arthritis ▪ Bowel-bypass syndrome ▪ Hepatitis B and C ▪ Behçet disease ▪ Reiter syndrome ▪ Lyme disease ▪ Rheumatic fever	▪ Tubo-ovarian abscess ▪ Ectopic pregnancy ▪ Pregnancy ▪ Appendicitis ▪ Meningococcemia ▪ Coinfection with syphilis and HIV ▪ Sexual abuse (in children)

CLINICAL COURSE, PROGNOSIS, AND MANAGEMENT

The treatment of infection due to *C. trachomatis* is summarized in Table 175-7. The first-line treatment of chlamydial infections are doxycycline 100 mg orally twice daily for 7 days or azithromycin given orally as a single 1-g dose.[37] Single-dose therapy with azithromycin is advantageous because it can be administered as directly observed therapy minimizing issues with adherence and follow-up. In comparison with doxycycline, single-dose therapy with azithromycin appears to be equally effective. This was demonstrated in a meta-analysis of the treatment of chlamydial infections in which azithromycin provided a 97% cure rate compared with a 98% cure rate with doxycycline.[43] There are studies that question the efficacy of azithromycin, particularly when rectal infection is present.[44,45] In a recent study of men who had sex with women, the failure rate of single-dose azithromycin was 12.8%.[46] The failure rate was 6.2% when adjusted for false positives and reinfection.[46]

PREVENTION AND SCREENING

If the symptoms persist or there is concern for reinfection, repeat testing can be indicated. However, it should be performed at least 3 weeks after therapy if NAAT is used to prevent false-positive results. In a study comparing pregnant and nonpregnant women with chlamydial infections, NAAT test results after single-dose treatment were negative in all women at 4 weeks.[47] Additionally, routine testing for cure is not recommended in the early treatment period unless the aforementioned criteria are met, lack of adherence to therapy is suspected, or the patient is pregnant. It is recommended that both men and women should be retested at 3 months or within at least 1 year of treatment. Notably, most recurrences are the result of reinfection rather than treatment failure. As a result, the CDC recommends abstinence from sexual activity until the patient and all partners are treated.[37] Additionally, patients are often coinfected with other STIs and should be tested for gonorrhea, HIV, and syphilis.

Early treatment with appropriate antibiotic therapy results in excellent prognosis and reduces the risk of long-term complications such as infertility from PID. The CDC recommends annual screening of all sexually active women younger than the age of 25 years and for older women with risk factors (eg, those who have a new sex partner or multiple sex partners).[37] The primary goals of screening are to detect infection and prevent complications. Similar to early treatment, screening has been shown to decrease the chance of developing PID.[48,49] Additionally, the CDC recommends annual screening at areas of contact for MSM.[37] A large study of male patients between 15 and 60 years of age indicated that 17.1% of rectal specimens were positive for *N. gonorrhea*, *C. trachomatis*, or both and provides support of these recommendations.[50] Evidence is insufficient to recommend routine screening for *C. trachomatis* in sexually active young men, based on feasibility, efficacy, and cost-effectiveness. However, screening in young men should be considered in high-prevalence clinical settings.[37]

TABLE 175-7
Treatment of *Chlamydia* Infection

- Azithromycin, 1 g PO in a single dose
  Or
- Doxycycline, 100 mg PO twice a day for 7 days

Alternative regimens:

- Erythromycin base 500 mg PO, four times daily for 7 days
  Or
- Erythromycin ethylsuccinate 800 mg PO, four times daily for 7 days
  Or
- Ofloxacin 300 mg PO, twice daily for 7 days
  Or
- Levofloxacin 500 mg/day for 7 days

Recommended treatment for pregnant women:

- Azithromycin 1 g PO as a single dose

Recommended treatment for ophthalmia neonatorum:

- Erythromycin base or ethylsuccinate 50 mg/kg/day PO, divided into four doses daily, for 14 days

PO, oral.

BACTERIAL VAGINOSIS

EPIDEMIOLOGY

Bacterial vaginosis (BV) is the most common vaginal infection in women ages 15 to 44 years. BV occurs in one third of adult women in the United States. It is an unpleasant, mild infection of the vagina caused by bacteria. It is sometimes asymptomatic and self-resolving but can lead to more serious problems. It is estimated that approximately 10% to 30% of pregnant women in the United States may have BV during their pregnancy because of the hormonal changes that occur during this period. BV is twice as common in African American women as in white women.[51] The reasons are not entirely clear. Incidence rates are difficult to determine because of the high prevalence of asymptomatic infection but it is approximately 10% to 25% in patients attending obstetric clinics and as high as 30% to 65% in patients attending STD clinics. Having sex at an early age and new or multiple sex partners are the most common risk factors for BV infection. Others include smoking, pregnancy, use of intrauterine devices, douching, tub bathing (bubble bath), and use of bidet toilets.[52-54] These factors may contribute to the development of BV because of the disruption of normal bacterial flora.

BV may rarely occur in prepubertal or virginal girls and boys. Most of the cases are related to vaginal, oral, and anal sex. Some studies have shown an increased prevalence among women who have sex with women,

perhaps based on transfer of pathogenic vaginal flora related to frequent use of lubricant and shared vaginal sex toys.[55] There is evidence that shows that hormonal contraception (both combined estrogen–progestin and progestin only) is protective against development of BV.

ETIOLOGY AND PATHOGENESIS

BV is a synergistic polymicrobial infection caused by an imbalance of the bacterial flora normally present in the vagina. Although the exact causative pathogen has not been established, it has been observed that there is a corresponding decrease in the population of the lactobacilli species. Lactobacilli are large rod-shaped organisms that help maintain the acidic pH of healthy vaginas and inhibit other anaerobic microorganisms. Normally, lactobacilli are found in high concentrations in healthy vaginas. This change in the population of lactobacilli results in the increase in the pH of the vaginal lumen because of the reduction in the lactic acid production. Apart from the lactic acid, the production of Lactocin and H_2O_2 also contributes to the disease state. In general, the lactobacilli is replaced with the increased population of pathogenic gram-negative anaerobic bacteria such as *Gardnerella vaginalis*; *M. hominis*; *Mycoplasma curtisii*; anaerobic gram-negative rods belonging to the genera *Prevotella*, *Porphyromonas*, and *Bacteroides*; and *Peptostreptococcus* spp.[56,67]

CLINICAL PRESENTATION

The number of asymptomatic infections is as high as 84%.[58] Women with BV report an increased volume of white or gray vaginal discharge and a fishy odor, especially after contact with alkaline semen during intercourse.[59] Vulvovaginal pruritus and inflammation are generally absent or mild. On physical examination, a milky, homogenous vaginal coating may be seen adherent to the vaginal wall. This infection is not common in men; however, the urethras of men whose sexual partners have symptoms of BV are frequently colonized with the same strain of *G. vaginalis*.

DIAGNOSIS

According to the Amsel criteria for diagnosing BV, three of the following four findings must be present:

1. Profuse milky vaginal discharge
2. A positive whiff test result (presence of a fishy odor when secretions are exposed to 10% or 20% potassium hydroxide)
3. A vaginal fluid pH greater than 4.5
4. Presence of clue cells greater than 20% on microscopic examination (Fig. 175-8)

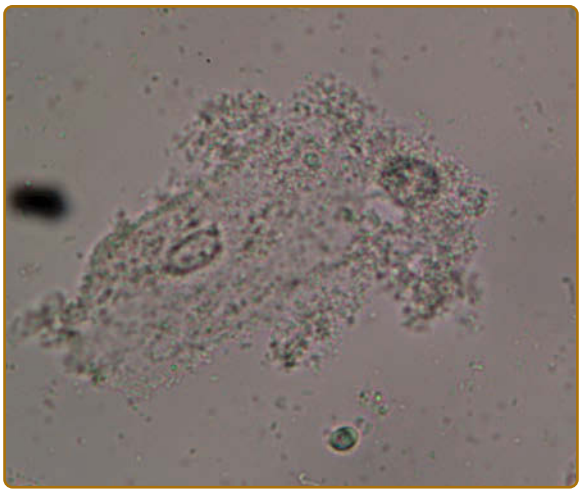

Figure 175-8 Bacterial vaginosis. Clue cells are large epithelial cells covered with bacteria. (Used with permission from Dr. Libby Edwards.)

Clue cells are squamous epithelial cells covered by coccobacilli that give the cytoplasm a ground-glass appearance and obscure the crisp margins of the cell, leaving ragged borders.[38] The presence of clue cells representing at least 20% of the epithelial cells on saline wet mount is the most reliable indicator of BV. Other important considerations are the absence of lactobacilli and no increase in white blood cells.

In the Nugent method, the swab was obtained from the lateral vaginal wall and rolled on a glass slide. This method involves the use of Gram staining to distinguish between the normal bacterial flora of gram-positive rods and lactobacilli from the gram-negative morphotypes seen in BV. Because of the variety of bacterial species, culture is not a reliable diagnostic test. A DNA probe-based test (16SrRNA gene) has a sensitivity of 92.8% and a specificity of 85.7% on a study comparing the utility of microscopic techniques.[60] The AmpliSens Florocenosis/Bacterial vaginosis-FRT multiplex real-time PCR (Florocenosis-BV) assay results in 100% sensitivity compared with Amsel's criteria.[61] The immunochromatographic test, OSOM BVBlue, showed a sensitivity of 100.0%, specificity of 98.3%, positive predictive value of 94.4%, and negative predictive value of 100.0% compared with Gram stain (Nugent's method).[62]

COMPLICATIONS

BV has been shown to be a risk factor in pregnancy for premature deliveries and babies with low birth weight.[63] Having BV makes women more susceptible to acquiring HIV, as well as other STDs such as herpes simplex virus, chlamydia, and gonorrhea.[64] BV may increase the risk of developing a postsurgical infection after procedures such as hysterectomy or dilation and curettage. BV can sometimes cause PID, increasing the risk of infertility.

Studies have produced conflicting data as to whether BV is associated with a higher risk of acquiring cervical intraepithelial neoplasia.[65] There are some studies that have linked BV to postpartum fever, postpartum endometritis, and postabortal infections; however, further studies are needed to investigate the relationship between BV and these complications.[66]

PROGNOSIS AND CLINICAL COURSE

Uncomplicated cases of BV resolve after appropriate treatment. There are reports of cases that may resolve on their own without therapy. Complications are rare, but long-standing or untreated BV may lead to more serious sequelae. Recurrent infections have been reported. Providers should suspect concomitant infections such as candidiasis if symptoms do not resolve after treatment.

TREATMENT

Treatment of patients with BV is summarized in Table 175-8. Treatment in asymptomatic BV is not necessary in women who are not pregnant. The established benefits of therapy for BV in symptomatic nonpregnant women are to (1) relieve vaginal symptoms and signs of infection and (2) reduce the risk for infectious complications after a variety of gynecologic procedures (endometrial biopsy, hysterectomy, hysterosalpingography, placement of an IUD, cesarean section, uterine curettage, and abortion). In pregnant women, treatment of BV also reduces the risk of postpartum infectious complications as well as the risk of preterm labor.[67,78]

Probiotics sometimes are used for BV, mainly to help with repopulation of normal lactobacilli to prevent recurrence.[69] Although the optimal treatment for recurrent disease is not yet established, the recommendation is to use longer courses of medications.

TABLE 175-8
Treatment of Bacterial Vaginosis

- Metronidazole 500 mg PO twice daily for 7 days
  Or
- Tinidazole 2 g PO once daily for 3 days
  Or
- Metronidazole gel, 075%, 5 g intravaginally once daily for 5 days
  Or
- Clindamycin cream, 5%, 5 g intravaginally once a day for 7 days

In pregnant women:

- Metronidazole 250 mg PO three times daily for 7 days
  Or
- Metronidazole 500 mg PO twice daily for 7 days
  Or
- Clindamycin 300 mg twice daily for 7 days

Alternative regimen:

- Tinidazole 1 g PO once daily for 5 days
  Or
- Metronidazole 2 g PO in a single dose
  Or
- Clindamycin ovules 100 g intravaginally once a day for 3 days

PO, oral.

PREVENTION

Given the prevalence of the STIs discussed in this chapter, it is important for clinicians to discuss safe sex practices with all patients, especially patients who fall into one of the high-risk demographic groups. Educating patients on transmission methods, STD complications, and treatment options is critical in raising awareness of these disease entities. The CDC provides comprehensive and unbiased information for both providers and patients. Physicians should be aware of the available screening tests for each STD and the limitations of these tests. Routine screening and empiric treatment in high-risk groups or when there is a high clinical suspicion will aid in reducing transmission rates and disease burden.

ACKNOWLEDGMENTS

The authors thank Dr. Ted Rosen, who was the author of this chapter in the eighth edition.

REFERENCES

1. Higgins J. *The Mirror for Magistrates* as cited in the *Oxford English Dictionary* entry for "clap." 1587.
2. Centers for Disease Control and Prevention. Sexually transmitted diseases in the United States, 2009. http://www.cdc.gov/std/stats09/trends.pdf.
3. Fowler T, Caley M, Johal R, et al. Previous history of gonococcal infection as a risk factor in patients presenting with gonorrhea. *Int J STD AIDS*. 2010;21:277.
4. Nicoletti A. The STD/alcohol connection. *J Pediatr Adolesc Gynecol*. 2010;23:53.
5. Workowski KA, Bolan GA. Sexually transmitted diseases treatment guidelines. *MMWR Recommend Rep*. 2015;64(RR3):1-137.
6. Fang L, Oliver A, Jayaraman GC, et al. Trends in gender disparities between younger and middle-age adults among reported rates of Chlamydia, gonorrhea and infectious syphilis in Canada: findings from 1997dispari *Sex Transm Dis*. 2010;37:18.
7. Rosen T. Unusual presentations of gonorrhea. *J Am Acad Dermatol*. 1982;6:369.
8. Kaul R, Pettengell C, Sheth PM, et al. The genital tract immune milieu: an important determinant of HIV susceptibility and secondary transmission. *J Reprod Immunol*. 2008;77:32.
9. Giannini CM, Kim HK, Mortensen J, et al. Culture of non-genital sites increases the detection of gonorrhea in women. *J Pediatr Adolesc Gynecol*. 2010;23:246.

10. Little JW. Gonorrhea: update. *Oral Surg Oral Med Oral Pathol Oral Radiol Endod*. 2006;101:137.
11. Crossman SH. The challenge of pelvic inflammatory disease. *Am Fam Physician*. 2006;73:859.
12. Judlin P. Current concepts in managing pelvic inflammatory disease. *Curr Opin Infect Dis*. 2010;23:83.
13. Peter NG, Clark LR, Jaeger JR. Fitz-Hugh-Curtis syndrome: a diagnosis to consider in women with right upper quadrant pain. *Cleve Clin J Med*. 2004;71:233.
14. Rice PA. Gonococcal arthritis (disseminated gonococcal infection). *Infect Dis Clin North Am*. 2005;19:853.
15. Knapp JS, Holmes KK. Disseminated gonococcal infections caused by Neisseria gonorrhoeae with unique nutritional requirements. *J Infect Dis*. 1975;132(2): 204-208.
16. Shetty A, Ribeiro D, Evans A, et al. Gonococcal endocarditis: a rare complication of a common disease. *J Clin Pathol*. 2004;57(7):780-781.
17. Woods CR. Gonococcal infections in neonates and young children. *Semin Pediatr Infect Dis*. 2005;16:258.
18. Darling EK, McDonald H. A meta-analysis of the efficacy of ocular prophylactic agents used for the prevention of gonococcal and chlamydial ophthalmia neonatorum. *J Midwifery Womens Health*. 2010;55:319.
19. Herbst de Cortina S, Bristow CC, Joseph Davey D, et al. A systematic review of point of care testing for Chlamydia trachomatis, Neisseria gonorrhoeae, and Trichomonas vaginalis. *Infect Dis Obstet Gynecol*. 2016;2016:4386127.
20. Todar K. The pathogenic Neisseriae. In: *Todarer Online Textbook of Bacteriology*. Madison, WI: University of Wisconsin-Madison Department of Bacteriology; 2008.
21. Martin MC, Pérez F, Moreno A, et al. Neisseria gonorrhoeae meningitis in pregnant adolescent. *Emerg Infect Dis*. 2008;14(10):1672-1674.
22. Watson J, Carlile J, Dunn A, et al. Increased gonorrhea cases—Utah, 2009-2014. *MMWR Morb Mortal Wkly Rep*. 2016;65:889-893.
23. Brunner A, Nemes-Nikodem E, Jeney C, et al. Emerging azithromycin-resistance among the Neisseria gonorrhoeae strains isolated in Hungary. *Ann Clin Microbiol Antimicrob*. 2016;15(1):53.
24. Skinner JM, Distefano J, Warrington J, et al. Trends in reported syphilis and gonorrhea among HIV-infected people in Arizona: implications for prevention and control. *Public Health Reports*. 2014;129 (suppl 1):85-94.
25. Boyajian AJ, Murray M, Tucker M, et al. Identifying variations in adherence to the CDC sexually transmitted disease treatment guidelines of Neisseria gonorrhoeae. *Public Health*. 2016;136:161-165.
26. Tabrizi SN, Chen S, Tapsall J, et al. Evaluation of opa-based real-time PCR for detection of Neisseria gonorrhoeae. *Sex Transm Dis*. 2005;32:199.
27. Tao G, Hoover KW, Nye MB, et al. Rectal infections with Neisseria gonorrhoeae and Chlamydia trachomatis in men in the United States. *Clin Infect Dis*. 2016;63(10):1325-1331.
28. Nall J, Barr B, McNeil CJ, et al. Implementation of oral and rectal gonococcal and chlamydial nucleic acid amplification-based testing as a component of local health department activities. *Sex Transm Dis*. 2016;43(10):605-607.
29. Centers for Disease Control and Prevention. Sexually transmitted diseases treatment guidelines 2006; diseases characterized by urethritis and cervicitis. http://www.cdc.gov/std/treatment/2006/ urethritis-and-cervicitis.htm#uc6.
30. Hartmann J. Genital mycoplasmas. *J Dtsch Dermatol Ges*. 2009;7:371.
31. Martin DH. Nongonococcal urethritis: new views through the prism of modern molecular microbiology. *Curr Infect Dis Rep*. 2008;10:128.
32. Stirling KM, Hussain N, Sanders MM, et al. Association between maternal genital mycoplasma colonization and histologic chorioamnionitis in preterm births. *J Neonatal Perinatal Med*. 2016;9(2):201-209.
33. Larsen B, Hwang J. Mycoplasma, ureaplasma, and adverse pregnancy outcomes: a fresh look. *Infect Dis Obstet Gynecol*. 2010;2010. pii: 521921.
34. Ona S, Molina RL, Diouf K. Mycoplasma genitalium: an overlooked sexually transmitted pathogen in women? *Infect Dis Obstet Gynecol*. 2016;2016:4513089.
35. Bjornelius E, Magnusson C, Jensen JS. Mycoplasma genitalium macrolide resistance in Stockholm, Sweden. *Sex Transm Infect*. 2017;93(3):167-168.
36. Batteiger BE, Tan M. Chlamydia trachomatis (trachoma, genital infections, perinatal infections, and lymphogranuloma venereum). In: *Mandell, Douglas, and Bennett's Principles and Practice of Infectious Diseases*. 8th ed. Philadelphia: Elsevier Saunders; 2015: 2154-2170.
37. Workowski KA, Bolan GA, Centers for Disease Control and Prevention. Sexually transmitted diseases treatment guidelines, 2015. *MMWR Recomm Rep*. 2015;64(RR-03):1-137. Erratum in: *MMWR Recomm Rep*. 2015;64(33):924.
38. Zuck M, Ellis T, Venida A, et al. Extrusions are phagocytosed and promote Chlamydia survival within macrophages. *Cell Microbiol*. 2017 Apr;19(4). doi: 10.1111/cmi.12683. Epub 2016 Nov 21.
39. Bianchi S, Boveri S, Igidbashian S, et al. Chlamydia trachomatis infection and HPV/Chlamydia trachomatis co-infection among HPV-vaccinated young women at the beginning of their sexual activity. *Arch Gynecol Obstet*. 2016;294(6):1227-1233.
40. Anttila T, Saikku P, Koskela P, et al. Serotypes of Chlamydia trachomatis and risk for development of cervical squamous cell carcinoma. *JAMA*. 2001;285(1): 47-51.
41. Madeleine MM, Anttila T, Schwartz SM, et al. Risk of cervical cancer associated with Chlamydia trachomatis antibodies by histology, HPV type and HPV cofactors. *Int J Cancer*. 2007;120(3):650-655.
42. Dukers-Muijrers NH, Morr Schwartz SM, et al. Risk of cervical cancer associated with Chlamydia trachomatis antibodies by histology, HPV type and Ht taken at least 3 weeks after treatment. *PLoS One*. 2012;7(3):e34108.
43. Lau CY, Qureshi AK. Azithromycin versus doxycycline for genital chlamydial infections: a meta-analysis of randomized clinical trials. *Sex Transm Dis*. 2002;29(9): 497-502.
44. Kong FY, Tabrizi SN, Fairley CK, et al. The efficacy of azithromycin and doxycycline for the treatment of rectal chlamydia infection: a systematic review and meta-analysis. *J Antimicrob Chemother*. 2015;70(5):1290-1297.
45. Geisler WM, Uniyal A, Lee JY, et al. Azithromycin versus doxycycline for urogenital chlamydia trachomatis infection. *N Engl J Med*. 2015;373(26):2512-2521.
46. Kissinger PJ, White S, Manhart LE, et al. Azithromycin treatment failure for chlamydia trachomatis among heterosexual men with nongonococcal urethritis. *Sex Transm Dis*. 2016;43(10):599-602.
47. Lazenby GB, Korte JE, Tillman S, et al. A recommendation for timing of repeat Chlamydia trachomatis test following infection and treatment in

pregnant and nonpregnant women. *Int J STD AIDS*. 2017;28(9):902-909.
48. Scholes D, Stergachis A, Heidrich FE, et al. Prevention of pelvic inflammatory disease by screening for cervical chlamydial infection. *N Engl J Med*. 1996;334(21):1362-1366.
49. Kamwendo F, Forslin L, Bodin L, et al. Decreasing incidences of gonorrhea- and chlamydia-associated acute pelvic inflammatory disease. A 25-year study from an urban area of central Sweden. *Sex Transm Dis*. 1996;23(5):384-391.
50. Tao G, Hoover KW, Nye MB, et al. Rectal infection with Neisseria gonorrhoeae and Chlamydia trachomatis in men in the United States. *Clin Infect Dis*. 2016;63(10):1325-1331.
51. Ness RB, Hillier S, Richter HE, et al. Can known risk factors explain racial differences in the occurrence of bacterial vaginosis? *J Natl Med Assoc*. 2003 Mar;95(3):201-212.
52. Madden T, Grentzer JM, Secura GM, et al. Risk of bacterial vaginosis in users of the intrauterine device: a longitudinal study. *Sex Transm Dis*. 2012;39(3):217-222.
53. Ogino M, Iino K, Minoura S. Habitual use of warm water cleaning toilets is related to aggravation of the vaginal microflora. *J Obstet Gynaecol*. 2010;36(5):1071-1074.
54. Ness RB, Hillier SL, Richter HE, et al. Douching in relation to bacterial vaginosis, lactobacilli, and facultative bacteria in the vagina. *Obstet Gynecol.* 2002 Oct;100(4):765.
55. Marrazzo JM, Thomas KK, Agnew K, et al. Prevalence and risks for bacterial vaginosis in women who have sex with women. *Sex Transm Dis*. 2010;37:335.
56. Hillier S. The complexity of microbial diversity in bacterial vaginosis. *N Eng J Med*. 2005;353:1886-1887.
57. Hill GB. The microbiology of bacterial vaginosis. *Am J Obstet Gynecol*. 1993;169:450-454.
58. Centers for Disease Control and Prevention. Sexually Transmitted diseases treatment guidelines 2006; bacterial vaginosis. http://www.cdc.gov/mwr/preview/mmwrhtml/rr5511a1.
59. Edwards L, Lynch PJ. *Genital Dermatology Atlas*. 2nd ed. St. Louis: Lippincott Williams & Wilkins; 2011:268-288.
60. Rumyantseva TA, Bellen G, Romanuk TN, et al. Utility of microscopic techniques and quantitative real-time polymerase chain reaction for the diagnosis of vaginal microflora alterations. *J Low Genit Tract Dis*. 2015;19(2):124-128.
61. Rumyantseva T, Shipitsvna E, Guschin A, et al. Evaluation and subsequent optimizations of the quantitative AmpliSens Florocenosis/Bacterial vaginosis-FRT multiplex real-time PCR assay for diagnosis of bacterial vaginosis. *APMIS*. 2016;124(12):1099-1108.
62. Kampan NC, Suffian SS, Ithnin NS, et al. Evaluation of BV(SZ, Jamil MS, in A, Unemo M. Evaluation and subsequent opt *Sex Reprod Healthc*. 2011;2(1):1-5.
63. Klebanoff MA, Hillier SL, Nugent RP, et al. Is bacterial vaginosis a stronger risk factor for preterm birth when it is diagnosed earlier in gestation? *Am J Obstet Gynecol*. 2005;192:470.
64. Myer L, Denny L, Telerant R, et al. Bacterial vaginosis and susceptibility to HIV infection in South African women: a nested case-control study. *J Infect Dis*. 2005; 192:1372.
65. Boyle DC, Barton SE, Uthayakumar S, et al. Is bacterial vaginosis associated with cervical intraepithelial neoplasia? *Int J Gynecol Cancer*. 2003;13:159.
66. Uthayakumar S, Boyle DC, Barton SE, et al. Bacterial vaginosis and cervical intraepithelial neoplasiaecause or coincidence? *J Obstet Gynecol*. 1998;18:572.
67. Hay P, Ugwumadu AHN, Manyonda IT. Oral clindamycin prevents spontaneous preterm birth and mid trimester miscarriage in pregnant women with bacterial vaginosis. *Int J STD AIDS*. 2001;12(suppl 2):70.
68. Ugwumadu A, Reid F, Hay P, et al. Natural history of bacterial vaginosis and intermediate flora in pregnancy and effect of oral clindamycin. *Obstet Gynecol*. 2004;104:114.
69. Larsson PG, Stray-Pedersen B, Ryttig KR, et al. Human lactobacilli as supplementation of clindamycin to patients with bacterial vaginosis reduce the recurrence rate; a 6-month, double-blind, randomized, placebo-controlled study. *BMC Womens Health*. 2008 Jan 15;8:3.

This page intentionally left blank

Infestations, Bites, and Stings

PART 27

Chapter 176 :: Leishmaniasis and Other Protozoan Infections

:: Esther von Stebut

Protozoa are considered to be zoonotic, eukaryotic, single-celled organisms. They possess a cellular membrane and, in contrast to bacteria, a nucleus. Many protozoa have different proliferative stages and undergo substantial changes during their life cycle. As a consequence of their size, which ranges from 10 µm to greater than 50 µm, they can very often easily be found in various tissues (eg, stool, other body fluids). Protozoa are widely distributed throughout the world.

A number of protozoan pathogens are human parasites and can induce severe courses of disease, especially as inducers of opportunistic disease (eg, in patients with HIV/AIDS). Treatment of protozoan infections is often difficult and prophylaxis through vaccination, for example, does not exist yet.

Among the protozoan infections (Table 176-1), leishmaniasis, trichomoniasis, and (rarely) amebiasis, as well as rhinosporidiosis, primarily manifest in the skin. The other protozoan infections are associated with (transient) skin affection and are only briefly mentioned in this chapter.

LEISHMANIASIS

AT-A-GLANCE

- Leishmaniasis is a complex of diseases caused by the protozoa *Leishmania* and transmitted by the bite of infected phlebotomine sandflies.
- Four major human diseases: (a) localized cutaneous leishmaniasis, (b) diffuse cutaneous leishmaniasis, (c) mucocutaneous leishmaniasis, and (d) visceral leishmaniasis.
- Which of the 4 diseases results depends mainly on the interaction between *Leishmania* species and the immunologic status of the host.
- Diagnosis is by organism isolation or serology, but species identification is only possible with isoenzyme analysis and new molecular techniques.
- Management ranges from observation to systemic therapy, primarily with antimonials, and vaccines in development.

EPIDEMIOLOGY

Together with malaria and dengue, leishmaniasis is the third most frequent infectious disease transmitted by a vector. Annually, approximately 1.6 million new cases are reported; among these, it is estimated that approximately 200,000 to 400,000 cases represent visceral leishmaniasis, and 700,000 to 1.2 million cases represent cutaneous leishmaniasis. Around 12 million individuals are currently infected worldwide.[1-3]

The World Health Organization (WHO) considers leishmaniasis to belong among the so-called neglected tropical diseases. Neglected tropical diseases are poverty-associated infectious diseases that are primarily prevalent in subtropical and tropical regions, and for which there is little to no public interest, little research activity, high morbidity and mortality, and no safe and long-lasting therapies (as of this writing).

Leishmaniasis is endemic in 90 countries around the world, mainly in tropical and subtropical regions (excluding Australia and Southeast Asia). The different clinical presentations, cutaneous, mucocutaneous

TABLE 176-1
Protozoan Infections Important for Humans

MODE OF TRANSMISSION	PATHOGEN	DISEASE	MAIN ORGAN INVOLVED
Insect bite	*Leishmania* spp.	(Muco-)cutaneous, and visceral leishmaniasis	Skin, lymph nodes, mucous membranes, visceral organs
	Trypanosoma brucei	African trypanosomiasis (sleeping sickness)	Blood, lymph nodes, liquor
	Trypanosoma cruzi	American trypanosomiasis (Chagas disease)	
	Plasmodium spp.	Malaria	Liver, blood
Sexually transmitted	*Trichomonas vaginalis*	Trichomoniasis	Genital tract
Water	*Rhinosporidium seeberi*	Rhinosporidiosis	Nasal/oral mucosa, rarely skin
Food/water ingestion	*Cryptosporidium* spp.	Cryptosporidiosis	Intestine
	Giardia lamblia	Giardiasis	Intestine
	Entamoeba histolytica	Amebiasis	Intestine, (skin)
	Toxoplasma gondii	Toxoplasmosis	Intestine Cysts in various organs

and visceral disease, have a distinct distribution as shown in Figs. 176-1 (cutaneous leishmaniasis) and 176-2 (visceral leishmaniasis):

- Cutaneous leishmaniasis (CL) is widely distributed, with approximately one-third of cases occurring in each of 3 epidemiologic regions: the Americas, the Mediterranean basin, and western Asia from the Middle East to Central Asia. The 10 countries with the highest case counts are Afghanistan, Algeria, Brazil, Colombia, Costa Rica, Ethiopia, Iran, Peru, Sudan, and Syria. Together these 10 countries account for 70% to 75% of all CL cases.[4]
- More than 90% of global visceral leishmaniasis (VL) cases occur in 6 countries: Bangladesh, Brazil, Ethiopia, India, South Sudan, and Sudan.
- Close to 90% of mucocutaneous leishmaniasis (MCL) cases occur in Bolivia, Brazil, and Peru.

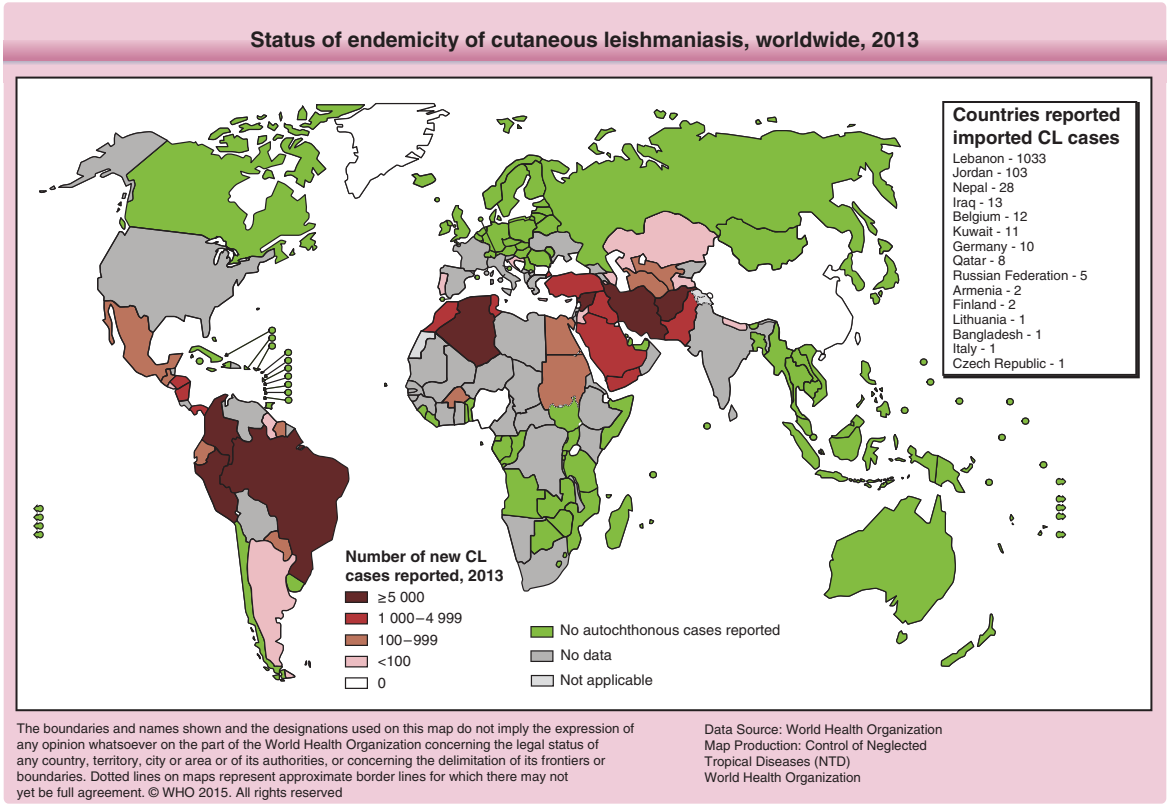

Figure 176-1 Geographic distribution of cutaneous leishmaniasis according to the World Health Organization. (Copyright 2015 by the World Health Organization [WHO]. All rights reserved. Used with permission.)

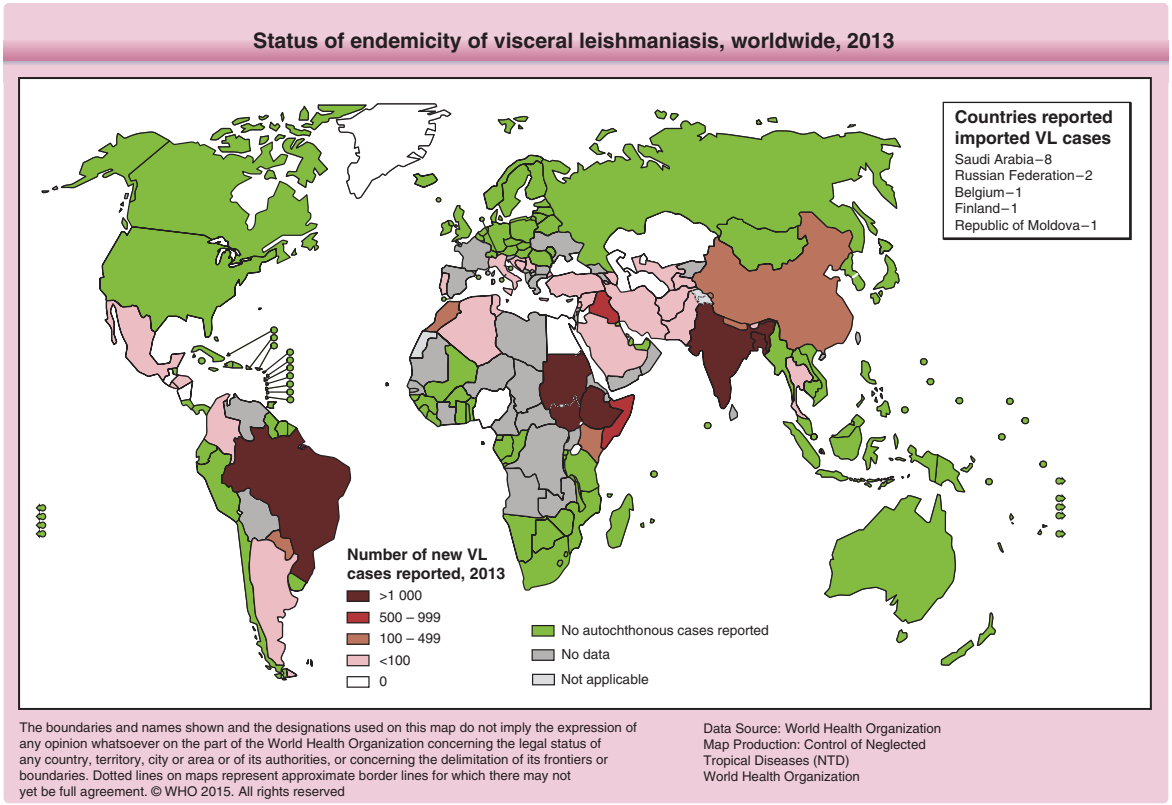

Figure 176-2 Geographic distribution of visceral leishmaniasis. (Copyright 2015 by the World Health Organization [WHO]. All rights reserved. Used with permission.)

The distribution of disease is strongly associated with the distribution of its vector, the sand fly. Outside of endemic regions, the disease is very often only recognized by travelers after their return home.

In recent years, coinfections of *Leishmania* with HIV have become a major concern. Because HIV-infected individuals have longer periods of parasitemia, humans potentially become reservoirs for the parasite as well. This is one possible explanation for the increased rate of leishmaniasis cases in some regions that reportedly have high numbers of HIV/*Leishmania* coinfected patients (eg, Southern Europe; Fig. 176-3).

ETIOLOGY

PARASITE AND LIFE CYCLE

The genus *Leishmania* consists of parasitic protozoa of the phylum *Sarcomastigophora*, order Kinetoplastida, and family Trypanosomatidae. Two subgenera, *Leishmania* and *Viannia,* exist.[5-7] For clinical purposes, a nomenclature omitting the subgenus is often used. More than 20 species are pathogenic for humans, which are transmitted by the bite of an infected female phlebotomine sand fly (Table 176-2). Cases of venereal and vertical transmission, as well as transmission from infected blood transfusion or needles have, however, been reported.

Leishmania are dimorphic parasites (Fig. 176-4). In the gut of the sand fly or in culture, they exist in a spindle-shaped motile (single anterior flagellum) promastigote form (10 to 20 µm). Upon transmission to the host, *Leishmania* parasites are ingested by macrophages and neutrophil granulocytes and—as a consequence of the shift toward a low pH in phagolysosomes—transform into the obligate intracellular, oval, nonmotile amastigote form (2 to 6 µm) that has a relatively large basophilic nucleus and a smaller rod-shaped kinetoplast at the base of the lost flagellum.

After ingestion during a blood meal of a sand fly, infected macrophages are ruptured and the amastigotes are released into the stomach of the insect where they immediately transform into the promastigote form. The promastigotes subsequently migrate to the alimentary tract of the fly, multiply extracellularly by binary fission, and, in a few days, reach the esophagus and the salivary glands of the fly, where they change into infective metacyclic promastigotes, which will be released into the skin at next bite. Promastigotes are then phagocytosed by resident host (skin) macrophages and neutrophils, where they transform into amastigotes that multiply by binary fission and get released following cellular burst to infect other cells of the host.

RESERVOIR HOST

Leishmaniasis is mostly zoonotic, being incidentally transmitted to humans from wild and domestic animals (primary reservoir hosts) (see Table 176-2). The main reservoir hosts are the great gerbil, the fat

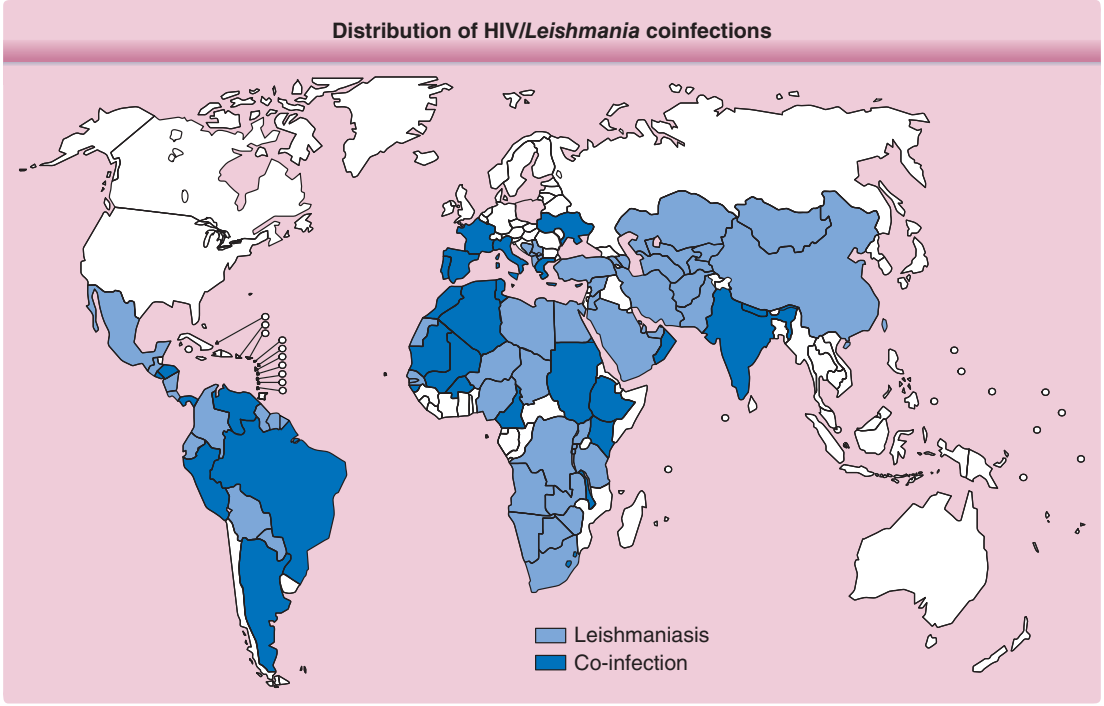

Figure 176-3 Distribution of HIV/*Leishmania* coinfections.

sand rat, *Meriones* spp., and other rodents, as well as dogs, the opossum, sloths, and others. In several regions, however, the zoonotic host is not even fully characterized, leading to difficulties in reservoir and vector control strategies.

VL caused by *Leishmania donovani* and Old Word CL caused by some *Leishmania tropica* strains are anthroponotic diseases (ie, humans are the primary reservoir hosts). Additional factors that may contribute to the increasing relevance of humans as reservoir hosts are alterations in the natural habitats (eg, human settlements in close proximity to forests, restrictions in the diversity and distribution of mammals available for sand fly feeding).

TABLE 176-2
***Leishmania* Species and Geographic Distribution**

LEISHMANIA SPECIES	VECTOR	TRANSMISSION	GEOGRAPHIC LOCATION
Old World			
L. (L.) major	*Phlebotomus*	Zoonotic	Central Asia, West Asia, North Africa
L. (L.) tropica		Anthroponotic	
L. (L.) infantum		Zoonotic	Mediterranean basin, North Africa
L. (L.) aethiopica			Ethiopia, Kenya, Yemen, Sudan
L. (L.). chagasi			Brazil
L. (L.) donovani		Anthroponotic	India, Bangladesh, Nepal, Sudan
New World			
L. (V.) braziliensis	*Lutzomyia*	Zoonotic	Central and South America
L. (L.) mexicana	*Psychodopygus*		
L. (L.) amazonesis			
L. (V.) panamensis			
L. (V.) peruviana			
L. (V.) venezuelensis			
L. (V.) guyanensis			

L., *Leishmania*; (L.), subgenus *Leishmania*, (V.) subgenus *Viannia*.

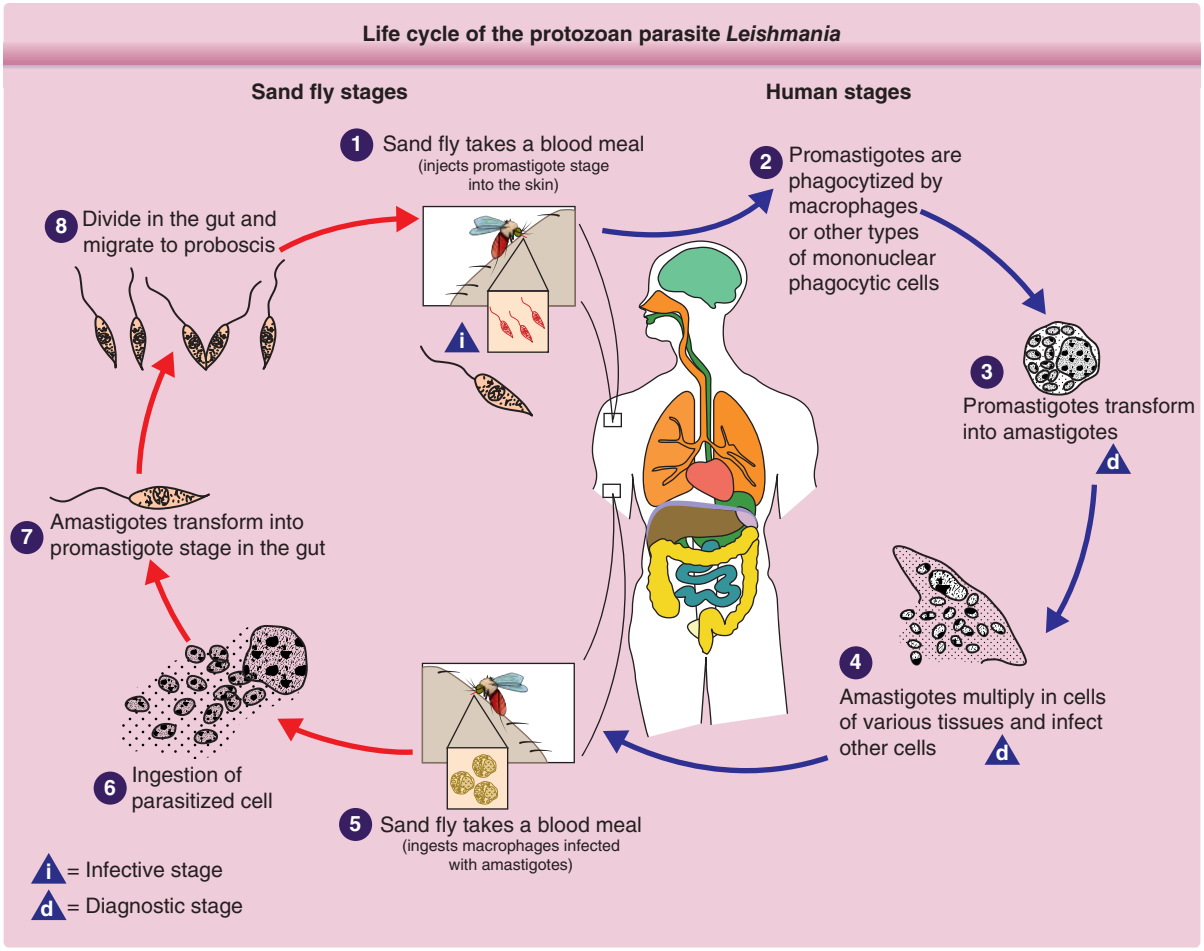

Figure 176-4 Life cycle of the protozoan parasite *Leishmania*. (From the Centers for Disease Control and Prevention [CDC].)

INSECT VECTOR

The insect vector of leishmaniasis, the female phlebotomine sand fly, is grouped under the suborder *Nematocera* of the order Diptera.[1] Three genera (*Phlebotomus* in the Old World, and *Lutzomyia* and *Psychodopygus* in the New World), and approximately 70 species are implicated as vectors (see Table 176-2). They are widely distributed and have predilection to intertropical and warm temperate zones. Presumably as a consequence of globalization and global warming, Phlebotominae have been spreading into, for example, northern European regions in recent years.

Only the female sand fly is hematophagus. They live for approximately 40 days and are known as pool feeders, because they tear open the skin with their wide mouthparts and suck the blood as it collects.

Phlebotomine sandflies are small (<3 mm), and do not fly far from their breeding site. Their activity is mostly crepuscular or nocturnal while the host is asleep. They rest during the day and lay their eggs in dark, cool, humid, and organic matter-rich places, such as rodent burrows, bird's nests, and house wall fissures. Being exophilic and exophagic, they prefer to rest and to have their meal outdoors, which limits their control through house spraying.

PATHOGENESIS

The resulting disease depends on the fate of the phagocytosed amastigotes. This, in turn, is a function of numerous parasite-related and host-related factors, as well as other factors that may account for geographical differences. In general, parasites interfere with the signaling pathways, intracellular kinases, transcription factors, and gene expression of macrophages, compromising their ability to generate leishmanicidal substances. In addition, they impair dendritic cell activation, migration, and the ability to secrete T-helper 1 (Th1) cytokines.

PARASITE-RELATED FACTORS[7]

Sand fly saliva is increasingly recognized as an essential element in the pathogenesis of the disease. Besides containing vasodilators, anticoagulants, and immunomodulators, it may also increase the inoculum size and the diameter of the lesion in previously unexposed individuals. Intraspecific variations of sand fly saliva may even affect the overall clinical outcome of *Leishmania infantum*–induced disease by

shifting the adaptive immunity from a Th1 to a Th2 immune response. The development of antisaliva antibodies after exposure may account for the decline with age of susceptibility to the infection in endemic areas.

Other parasite-related factors include infectivity, pathogenicity, virulence, and tissue tropism. These differ from one species to the other. For example, lipophosphoglycan and gp63 are 2 important promastigote virulence factors that impair the overall functions of infected cells, with lipophosphoglycan being clearly involved in *Leishmania major* disease, but absent in *Leishmania mexicana*. Although viscerotropic species tend to spread to the reticuloendothelial system, they may become dermotropic as a consequence of treatment such as seen in post–kala-azar dermal leishmaniasis (PKDL). Similarly, *L. tropica*, classically dermotropic, may cause visceral disease.

HOST-RELATED FACTORS[7]

Malnutrition, immunosuppression, and the host genetic background influence host susceptibility as well as resistance to disease.

The output of acquired T-cell immunity, which depends on the net effect of the opposing Th1 and Th2 responses, largely determines the course and the therapeutic response of the infection. A dominant Th1/cytotoxic T-cell Type 1 response resulting in the production of interferon-γ and nitric oxide leads to a leishmanicidal state of macrophages, and accounts for subclinical infection or self-healing LCL and the positive Montenegro skin test (that assesses delayed-type hypersensitivity to leishmanial antigen). A dominant Th2 response accounts for progressive disease such as diffuse cutaneous leishmaniasis (DCL), and is characterized by anergy to leishmanial antigen (negative Montenegro skin test). In addition, regulatory T cells, as well as the so-called Th17 cells producing interleukin-17A, contribute to disease susceptibility. The majority of parasite-specific T cells home to the site of infection, thus, cytokine profiles of T cells in peripheral blood may not reflect the actual immune status well. Mucosal leishmaniasis patients will have both Th1 and Th2 responses, with slight predominance of Th2 immunity, explaining persistence of the disease. To summarize, T-cell immunity would be intact in localized cutaneous leishmaniasis (LCL), defective in DCL, and pathologically exuberant in MCL. Humoral immunity seems to play a role during parasite opsonization, but little or no role in determining the course of the infection. High titers of antileishmanial immunoglobulin (Ig) G correlate more with chronic, nonhealing, and visceral disease.

HIV coinfection of individuals both leads to a more-severe course of infection with *Leishmania*, but also worsens disease outcome of the HIV infection. Other coinfections prevalent in endemic countries, such as malaria, also are known to have an effect on the course of disease.

TABLE 176-3
Leishmaniasis Disease Forms and Causative *Leishmania* Species

	LEISHMANIA SPP.	
DISEASE PRESENTATION	**OLD WORLD**	**NEW WORLD**
Localized cutaneous leishmaniasis	*L. (L.) major* *L. (L.) tropica* *L. (L.) infantum* *L. (L.) aethiopica*	*L. (V.). braziliensis* *L. (L.) mexicana* *L. (L.) amazonensis* *L. (V.) panamensis* *L. (V.) guyanensis*
Diffuse cutaneous leishmaniasis (rare)	*L. (L.) aethiopica* *L. (L.) major*[a]	*L. (L.). mexicana* *L. (L.) amazonensis* *L. (V.) braziliensis*[a]
Mucocutaneous leishmaniasis (rare)		*L. (V.) braziliensis* *L. (V.) guyanesis (rare)* *L. (V.) panamensis (rare)*
Visceral leishmaniasis	*L. (L.) donovani* *L. (L.) infantum*	*L. (L.) chagasi*
Post–kala-azar dermal leishmaniasis	*L. (L.) donovani*	

[a]Upon immunosuppression of the human host.
L., *Leishmania*; (L.), subgenus *Leishmania*, (V.) subgenus *Viannia*.

CLINICAL FINDINGS

Depending on host factors and the parasites species, leishmaniasis primarily presents as CL, whereas other (sub-)species have the tendency to spread across mucosal membranes to induce MCL or spread into visceral organs (VL) (Table 176-3).[2-7]

The clinical spectrum ranges from CL to MCL or VL, and cryptic infections.

CUTANEOUS LEISHMANIASIS

Localized Cutaneous Leishmaniasis: LCL constitutes 50% to 75% of all incident cases. It is the mildest form of *Leishmania* diseases and the one that prevails in the Old World. It can be caused by all *Leishmania* species.

Old World LCL (Aleppo boil, Baghdad boil, Oriental sore, leishmaniasis tropica, Biskra button, Delhi boil, Bouton d'Orient, Lahore sore, Rose of Jericho, Kandahar sore, the little sister) is caused mainly by *L. major*, *L. tropica*, *Leishmania aethiopica*, and to a lesser extent *L. infantum* (see Table 176-3). The morphologic spectrum of Old World LCL is wide. Lesions start as erythematous papules that enlarge over a few weeks to form nodules/plaques and often ulcerate and become crusted (Figs. 176-5 to 176-9). The "volcanic" nodulo-ulcerative morphology is characteristic and consists of a painless crateriform ulcer with a rolled margin and a necrotic base that is often covered with an adherent crust (Fig. 176-5). Two major types, (a) the moist type (mainly caused by *L. major*) (Fig. 176-5) and (b) the dry

Figure 176-5 Old World localized cutaneous leishmaniasis on the arm ("moist type").

Figure 176-6 Acute Old World localized cutaneous leishmaniasis: multiple nodules on the arm and trunk caused by *Leishmania major*.

Figure 176-7 Acute Old World localized cutaneous leishmaniasis. Single crusted erythematous plaque on the forehead.

Figure 176-8 Old World localized cutaneous leishmaniasis of the left cheek.

type (primarily caused by *L. tropica*) (Fig. 176-6), are identified. Both types may coexist in the same patient. Other presentations include "iceberg nodules," and eczematoid, psoriasiform, erysipeloid, zosteriform, paronychial, chancriform, annular, palmoplantar, verrucous, and keloidal lesions.

Depending on the causing subspecies, the following characteristics also may be noted:

- *L. major* tends to cause multiple, moist ulcerations resembling furuncles with lymphadenopathy.
- *L. tropica*–associated lesions are fewer, mainly in the face, without lymph node involvement. Recurrences are found in approximately 10% of patients close to the original lesions.
- *L. infantum*, the causative agent of Mediterranean VL in children, may cause a self-limited skin disease in adults with rare ulceration.
- *L. aethiopica* may cause a similar cutaneous disease to *L. tropica*, but carries a higher risk of evolving into DCL in up to 20% of affected individuals.

Species identification cannot be made clinically and requires biochemical/molecular techniques.

Satellitosis, regional lymphadenopathy, localized lymphadenitis, sporotrichoid lymphatic spread, subcutaneous lymphatic nodules, and localized hypoesthesia may occur. Mature lesions may be elongated and oriented parallel to skin creases.

Figure 176-9 Acute Old World localized cutaneous leishmaniasis. Crusted erythematous nodule underneath the right perioral area.

Figure 176-10 Acute Old World localized cutaneous leishmaniasis ("moist type") on the forearm.

New World LCL (Valley sickness, Andean sickness, white leprosy, chiclero ulcer, uta, pian bois, and bay sore) is caused by *L. mexicana* and *Leishmania (Viannia) braziliensis* complexes mainly (see Table 176-3). Pure cutaneous disease is very similar to Old Word LCL and isolated ulcers in exposed areas are the most common presentations (Figs. 176-10 to 176-14). The progression of the lesions gives rise to a characteristic scar consisting of thin pale skin at the ulcer site with a hyperpigmented border.

Infection with *L. mexicana* or *L. (V.) Leishmania (Viannia) guyanensis* causes only cutaneous disease in contrast to infection with *L. (V) braziliensis* and *Leishmania (Viannia) panamensis*, which may, in 40% to 80% of cases, progress to MCL. Approximately 50% of the lesions caused by *L. mexicana* heal within 3 months, whereas those caused by *L. braziliensis* persist much longer and are often associated with lymphadenopathy. Sporotrichoid lymphatic spread (see Fig. 176-12C)

Figure 176-11 Acute New World localized cutaneous leishmaniasis acquired in Costa Rica. Classical noduloulcerative lesion on the forehead. Note that the ulcerated nodules look similar to volcanoes seen from above ("volcano sign").

Figure 176-12 Acute New World localized cutaneous leishmaniasis with large volcaniform lesions on the dorsum of the right foot (**A**) and the ankle of the left foot (**B**) caused by *Leishmania guyanensis* infection of a young boy. **C,** Sporotrichoid extension of the lesion into the lymphatic system with erythematous papules on the outside of the left lower leg.

Figure 176-13 New World localized cutaneous leishmaniasis chiclero ulcer. A deep ulcer on the helix at the site of a sand fly bite. (From Wolff K, Johnson R, Saavedra AP, et al. *Fitzpatrick's Color Atlas and Synopsis of Clinical Dermatology*, 8th ed. New York, NY: McGraw-Hill; 2017, with permission.)

can be found more frequently, especially in children and immunosuppressed patients. Mature lesions may be elongated and oriented parallel to skin creases.

Disease caused by certain subspecies has the following specific presentations:

- *L. mexicana* is the causative organism of chiclero ulcer, a chronic mutilating infection of the pinna of the ear of forest workers in Mexico and Central America (see Fig. 176-13). *Lutzomyia flaviscutellata* is the major vector.
- In Brazil, the lower limbs are commonly affected, causing the typical Bauru ulcers.

Figure 176-14 Chronic-localized cutaneous leishmaniasis. Verrucous, scaly, erythematous plaque with focal ulceration and crusting. (Used with permission from Raj Kubba, MD.)

- Uta, the Andean cutaneous form of leishmaniasis, is caused by *L. braziliensis* and predominantly affects exposed areas in children. Its principal vector is *Lutzomyia peruensis*.

An atypical nodular form of New World CL caused by *Leishmania donovani chagasi* has been reported from Honduras and Nicaragua. Unusual clinical pictures have been reported, especially in immunosuppressed patients.

Complications of Localized Cutaneous Leishmaniasis: Secondary bacterial infection is common. Additional complications include permanent scarring, disfigurement, and social stigma. Autoinoculation or koebnerization following trauma, tattooing, or surgery has been reported. Major complications of LCL include chronic LCL, DCL, and MCL (in New World LCL). AIDS and other immunosuppressive conditions increase the risk of mucocutaneous and visceral dissemination, and of recurrence following therapy. Disseminated CL, defined as more than 10 pleomorphic lesions in noncontiguous areas of the body, has been reported in increasing frequency, complicating New World LCL and HIV-associated Old World LCL.

Other Forms of Localized Cutaneous Leishmaniasis: Most cases of LCL heal spontaneously within 1 year and are characterized as acute LCL. Disease lasting more than 1 year is termed *chronic LCL*. Typically, the lesions evolve from papules to chronic disfiguring indurated nodules/plaques that are larger than average acute LCL lesions and may exhibit variable degrees of scaling, ulceration, verrucosity, and scarring (see Fig. 176-14). The diagnosis may be challenging because of the paucity of organisms seen on histologic examination.

Leishmaniasis recidivans is a rare form of chronic LCL and accounts for 3% to 10% of all LCL cases. It is caused mostly by *L. tropica* in the Old World, and less commonly by *L. (V) braziliensis* in the New World as well as by *Leishmania amazonensis*, *L. (V) panamensis*, and *L. (V) guyanensis*. Erythematous scaly papules, often with an apple jelly appearance, at the borders of a completely or partially healed CL lesion, are characteristic. It may complicate vaccination with a live strain of *Leishmania* and usually occurs in the setting of hyperactive T-cell immunity and low antibody titers.

Reactivation of dormant infection (up to 15 years after apparent resolution) after an unknown stimulus such as trauma or topical corticosteroids, rather than reinfection with different strains, is believed to account for most of the cases. In fact, several studies have demonstrated persistence of the intracellular living organisms in "healed" *Leishmania* lesions, this being more likely to occur if therapy was incomplete or deficient. Approximately 6% of all untreated, primary LCL cases develop leishmaniasis recidivans.

Lupoid leishmaniasis shares a similar etiology and clinical picture with leishmaniasis recidivans; lupoid leishmaniasis, however, is not a recurrent lesion. The lesion characteristically occurs over the face and may clinically resemble lupus vulgaris or discoid lupus

Figure 176-15 Disfiguring lupoid leishmaniasis of several years duration in a Middle Eastern man.

Figure 176-16 Diffuse cutaneous leishmaniasis with multiple, nodular lesions on the arms, trunk, and face of a patient from Mexico. (Used with permission from Dr. Sven Krengel, Lübeck, Germany.)

erythematosus. In the absence of molecular identification of parasites, the diagnosis may be delayed for several years leading to mutilation (Fig. 176-15).

DCL, also called *pseudolepromatous leishmaniasis*, is an anergic rare form of CL that occurs in the setting of deficient cell-mediated immunity, and clinically and histologically mimics lepromatous leprosy. It is usually caused by *L. aethiopica* in the Old World and by *L. amazonensis, L. braziliensis, L. guyanensis,* and *L. mexicana* in the New World. In North Brazil, DCL develops in approximately 0.2% of *L. braziliensis* infections. In Sudan and Ethiopia, 20% of cases develop DCL. Immunosuppressed patients, especially HIV-infected individuals, may develop a severe form of DCL (>200 lesions) with no species-specific relation.

Following a classical LCL lesion, dissemination occurs (immediately in 30% of cases, but up to 11 years in others) in the form of nonulcerated and parasite-laden nodules (Fig. 176-16) with a predilection for exposed areas of the body such as the face, where lesions may coalesce leading to leonine facies. Viscera are not involved. A progressive/chronic course with relapse after therapy is classical.

MUCOCUTANEOUS LEISHMANIASIS

MCL may complicate up to 10% of LCL patients and is characterized by the chronic and progressive spread of lesions to the nasal, pharyngeal, and buccal mucosa. Lesions appear 1 to 5 years after resolution of the primary lesion(s), or, less commonly, while they are still present. It is often a complication of New World LCL caused by *L. (V) braziliensis*, *L. (V) panamensis*, *L. amazonensis*, and *L. (V) guyanensis*. Ninety percent of cases occur in Bolivia, Brazil, and Peru. In the Old World, similar mucosal lesions caused by *L. aethiopica* may be seen but have a better prognosis.

MCL results from direct extension or hematogenous/lymphatic spread to the upper respiratory tract, and, rarely, ocular and genital mucosa, and liver. Bony structures are usually spared. Stuffy nose, epistaxis, coryza, hyperemia, and nasal septum crusting and ulceration are frequent presenting symptoms and signs. If untreated, the disease evolves into either septal perforation with resulting collapse of the nasal bridge and free hanging nose (tapir nose or parrot beak) or partial/total nasooropharyngeal mutilating ulceration (espundia; Fig. 176-17). In rare cases, the lips, cheeks, soft palate, or larynx is involved. Lymphadenopathy is common in *L. braziliensis*–induced disease and may be associated with hepatomegaly and systemic symptoms.

The major causes of mortality are secondary infection, pharyngeal obstruction, and respiratory failure. Cure rates decrease with advanced disease.

VISCERAL LEISHMANIASIS

VL (Sikari disease, Burdwan fever, Shahib disease, tropical splenomegaly, kala-azar, death fever, dumdum fever) is endemic in the tropical and subtropical parts of the world. Ninety percent of cases occur in Bangladesh, Ethiopia, India, Nepal, Brazil, and Sudan. The causative agents are *L. donovani* and *Leishmania chagasi/L. infantum* and to a lesser extent *L. amazonensis*, and *Leishmania (Viannia) colombiensis*. Infection with *L. donovani* occurs in the Old World (India and Sudan), is anthroponotic and highly

Figure 176-17 Mucocutaneous leishmaniasis, South American. Painful, mutilating ulceration with destruction of portion of the nose. (Used with permission from Eric Kraus, MD.)

endemic, and involves *Phlebotomus argentipes* as a vector. Other infections are zoonotic, and dogs are the major reservoir hosts. *L. infantum* afflicts mainly malnourished children in China, Africa, the Middle East, and the Mediterranean basin.

Hematogenous dissemination of the parasite to the reticuloendothelial system follows skin inoculation. However, congenital (transplacental) transmission may occur. Most infections remain subclinical. The incubation period and the duration of the disease are variable. The cardinal features of VL are persistent, high, undulating fever; leucopenia; anemia; splenomegaly; and hypergammaglobulinemia. Other findings include emaciation, burning feet (peripheral neuropathy), hepatogastrointestinal disturbances, epistaxis, thrombocytopenia, and lymphadenopathy.

Skin lesions develop later in the course of the disease and consist of ashy hyperpigmented patches on the temple, around the mouth, and on the abdomen, hands, and feet in light skin persons; hence, the name kala-azar (*black sickness* in Hindi). Other findings include hair and skin depigmentation (in Kenyan patients), cutaneous nodules and mucosal ulcers (in Sudanese patients), trichomegaly (Pitalugo sign), petechiae, and jaundice.

Without treatment, the fatality rate in developing countries approaches 100% in 2 years with the major complications being cachexia, secondary infections, enteritis, and pneumonia. Hemolytic anemia, acute renal damage, and severe mucosal hemorrhage are less common.

Visceral Leishmaniasis/HIV Coinfection: Most coinfection cases have IV drug use as a common denominator and represent diagnostic and therapeutic challenges, as VL precipitates the onset of AIDS and HIV increases the risk of VL. The problem is mostly described in Spain, Italy, France, and Portugal. *L. infantum* is the major causative agent; however, other *Leishmania* species that do not normally visceralize have been isolated.

MCL-like, PKDL-like, and DCL-like pictures may result and cutaneous lesions are highly variable. Multiple dermatofibroma-like and Kaposi sarcoma–like papulonodular lesions may occur, and should be differentiated from parasitic colonization of Kaposi sarcoma. The presence of amastigotes in atypical locations tends to correlate with the degree of immunosuppression.

People with both conditions have a worse prognosis, shortened survival time, higher relapse rate, and inferior response to treatment compared with HIV-negative patients. VL is now being proposed to be integrated into the Centers for Disease Control and Prevention clinical category C as an AIDS-defining illness.

OTHER FORMS OF LEISHMANIASIS

Post–Kala-Azar Dermal Leishmaniasis: PKDL is extremely rare in the New World and is mostly seen, in 2 major forms, in Sudan and India. As the name implies, it is a cutaneous manifestation of VL that usually develops months to years after resolution of VL, and rarely during its treatment. In India, PKDL is the most common skin manifestation of leishmaniasis presenting as polymorphic or macular lesions (Fig. 176-18).

Affected patients are the major reservoirs of the infection. High blood concentration of the immunosuppressive cytokine interleukin-10 in VL patients is predictive of PKDL development. The parasite count is low and detection of organisms is not always possible. With polymerase chain reaction (PCR) technique, however, *Leishmania* parasites are recovered in skin lesions in up to 83% and 94% of Sudanese and Indian PKDL patients, respectively. The development of skin lesions in PKDL is closely linked to *Leishmania*-specific lymphocyte reactivity, or in HIV patients, to immune reconstitution during highly active antiretroviral therapy treatment. The reason behind the 2 major clinical forms of PKDL remains essentially unclear.

Viscerotropic Leishmaniasis: Caused by *L. tropica*, viscerotropic leishmaniasis has been described among American veterans of Operation Desert Storm. Visceral infection manifests as fever, malaise, and variable hematologic and hepatogastrointestinal findings. Classic signs of VL are absent and the skin is usually not involved; however, a recent report in a young Afghani refugee living in the United States demonstrated cutaneous lesions. Positive culture from bone marrow aspirates and good response to antimonials are typical.

Leishmanid: Leishmanid refers to an id reaction consisting of a diffuse, asymptomatic, and symmetric papular eruption in the setting of acute LCL or leishmaniasis recidivans. It typically resolves within 8 weeks of its appearance. Leishmanid may develop during treatment and is not an indication to withhold therapy.

Figure 176-18 **A,** Polymorphic and (**B**) macular post–kala-azar dermal leishmaniasis. (Used with permission from Prof. Mitali Chatterjee, Calcutta, India.)

Cryptic Leishmaniasis: Both cutaneous and visceral infection can remain subclinical or manifest with mild, nonspecific, and transient symptoms.

DIAGNOSIS

Given the potential treatment toxicity, confirmation of the diagnosis is always mandatory. Parasite subspecies determination is important for treatment decisions.[7-14] Even when smear, histology, and culture results are combined, the parasite may not be detected in 10% to 20% of cases. The diagnostic challenge is often greater in New World disease and in chronic lesions. The sensitivity of both tissue smear and culture approaches 90% when specimens are taken during the first weeks of infection. The best approach is to use several diagnostic methods.

Taken from the infiltrated margin, a skin biopsy may be divided into 3 parts: one for an impression smear, one for histologic examination, and another for culture.

IMPRESSION SMEAR

Several smear techniques may be used with a success rate ranging between 50% and 80%. They are obtainable from fine-needle aspirates or tissue scrapings, air-dried, fixed with methyl alcohol, stained with Giemsa stain, and viewed under oil-immersion microscopy. Impression smears, made by gently pressing the skin biopsy against a glass slide 2 to 5 times, provide better sensitivity than hematoxylin-and-eosin examination.

HISTOLOGY

The histopathologic examination of early lesions of LCL reveals a dense and diffuse mixed inflammatory cell infiltrate composed predominantly of histiocytes, and scattered multinucleated giant cells, lymphocytes, and plasma cells (sometimes with intracytoplasmic homogenous eosinophilic immunoglobulin material called *Russell bodies*). The hallmark of the disease (in approximately 70% of the cases) is the presence of numerous extracellular and intracellular (within histiocytes) amastigotes (also known as *Leishman-Donovan bodies*) (Fig. 176-19A). Giemsa stain stains the parasite nonmetachromatically and the kinetoplast bright red (Fig. 176-19B). The organisms also may be highlighted by the Wright and Feulgen stains. Monoclonal antibodies can identify amastigotes and promastigotes in smear, biopsy, or culture specimens, constituting a rapid screening test for leishmaniasis; however, they are not commercially available.

The histologic differential diagnosis includes diseases characterized by parasitized macrophages. The presence of halo surrounding the yeasts in histoplasmosis, safety pin-like encapsulated Donovan bodies in granuloma inguinale, and Mikulicz cells in rhinoscleroma distinguishes these conditions from leishmaniasis. Other considerations are blastomycosis, paracoccidiomycosis, toxoplasmosis, and trypanosomiasis. As the lesion evolves, the number of amastigotes per section decreases and the histology approaches that of a chronic LCL, where the predominant histologic pattern is nodular/diffuse noncaseating tuberculoid granulomatous dermatitis. Epidermal hyperplasia and ulceration are variable. Scarring with marked loss of elastic fibers may be seen.

In DCL, a diffuse infiltrate composed of vacuolated macrophages with numerous intracellular and extracellular amastigotes is characteristic. The major differential diagnosis is lepromatous leprosy.

In MCL, the histopathologic findings are similar to those of LCL but organisms are usually sparse.

In PKDL, Pautrier-like epidermal microabscesses and a dense lymphoplasmacytic infiltrate with papillary dermal edema (in early lesions) are characteristic.

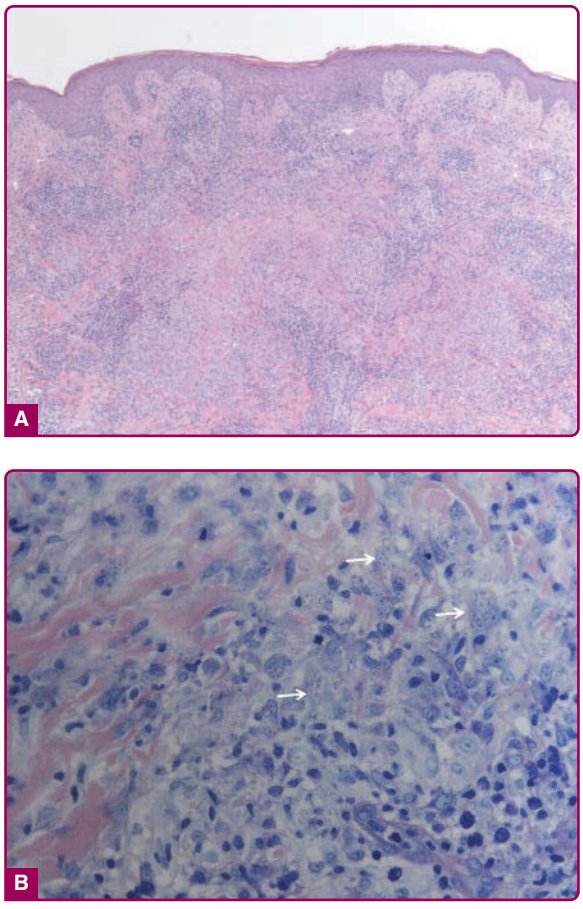

Figure 176-19 A Histologic examination (hematoxylin and eosin). Cutaneous leishmaniasis with tuberculoid granulomatous dermatitis. Note the presence of multinucleated giant cells and the surrounding lymphoplasmacytic infiltrate.

CULTURE

Culture (at room temperature), by means of a biphasic medium such as Novy-MacNeal-Nicolle or chick embryo medium, is the gold standard of diagnosis, but with a sensitivity of only approximately 50%, depending on the experience of the laboratory. It can be performed using aspirates, scrapings, or fresh skin biopsies. Promastigotes often appear after several days, but occasionally may take few weeks. Species identification is not possible based on their morphology.

MOLECULAR ANALYSES

Molecular techniques using species-specific oligonucleotide probes for kinetoplast DNA may be used on all specimens. PCR methods are particularly useful and offer superior specificity and sensitivity in the diagnosis of CL, MCL, and VL, especially in cases where organisms are scarce. False-positive reactions and species identification in New World CL can be problematic.

Together with PCR, isoenzyme analysis is currently considered to be the gold standard for *Leishmania* specification. It consists of enzyme electrophoresis of cultured promastigotes and is based on the fact that morphologically similar promastigotes of different species have different enzyme profiles; however, it is lengthy and costly.

DIAGNOSIS IN VISCERAL LEISHMANIASIS

In VL, microscopic detection and/or culture of parasites in tissue aspirates from spleen (sensitivity >97%), lymph nodes (sensitivity 60%), or bone marrow (sensitivity 55% to 97%) is diagnostic. However, as these techniques are invasive, several serologic and molecular methods have been developed. Anti-K39 antibody based on a recombinant antigen from *L. chagasi* has high sensitivity and specificity. It is an immunochromatographic strip test using fingerprick blood and is helpful in resource-poor regions. As a last resort, PCR of peripheral blood or tissue aspirate can be done, and it is extremely sensitive.

MONTENEGRO SKIN TEST (LEISHMANIN)

The Montenegro skin test is analogous to the tuberculin test and consists of phenol-killed promastigotes injected in the dermis. This allows the detection of exposure to *Leishmania* without distinguishing between past and active infection. Up to 50% of people living in endemic areas may test positive without a history of previous or active disease. The test is positive once crusting has developed, and negative in anergic states such as DCL and PKDL or often in lesions (less than 3 months old). In most countries, the antigen for the test is not available.

TECHNIQUES WITH LIMITED VALUE

Serology is not useful because of its low sensitivity (antibodies present in low titer) and specificity (because of cross-reaction with leprosy, malaria, and other trypanosomal infections). Laboratory animal inoculation (xenodiagnosis) is useful when the parasite load is low. Electron microscopy offers no advantage over light microscopy and its use is limited.

DIFFERENTIAL DIAGNOSIS

Depending on the form of leishmaniasis, different disease entities need to be considered (Table 176-4).

TREATMENT

Given the clinical diversity of leishmaniasis and the lack of adequately controlled therapeutic trials, each case needs to be individualized based on the parasite species, extent of the disease, host immune and nutritional status, presence of intercurrent diseases, geographic region, and cost, availability, and toxicity of the various therapeutic options.[7-14]

TABLE 176-4
Differential Diagnosis for Cutaneous and Visceral Leishmaniasis

LEISHMANIASIS FORM	DIFFERENTIAL DIAGNOSIS
Localized cutaneous leishmaniasis	Arthropod bite Infections: pyoderma, Majocchi granuloma, tuberculosis, atypical mycobacterial and deep fungal infections), lupus, leprosy Sarcoidosis, foreign-body granulomas, discoid lupus Pyoderma gangrenosum Malignancy: basal cell/squamous cell carcinoma, keratoacanthoma, lymphoma, pseudolymphoma
Diffuse cutaneous leishmaniasis	Infections: lepromatous leprosy, deep fungal infections Xanthomas Lymphoma
Mucocutaneous leishmaniasis	Infections: leprosy, syphilitic gumma, yaws, tuberculosis, deep fungal infections (eg, paracoccidioidomycosis) Granulomatosis with polyangiitis (Wegener) Malignancy: nasopharyngeal carcinoma, squamous cell carcinoma and lymphoma
Visceral leishmaniasis	Infections: malaria, syphilis, tuberculosis, typhoid fever, brucellosis, histoplasmosis, schistosomiasis Systemic lupus erythematosus Leukemia/lymphoma Tropical splenomegaly syndrome
Post–kala-azar dermal leishmaniasis	Infections: syphilis, yaws, leprosy

THERAPEUTIC OPTIONS

Local Therapy: Various regimens have shown some efficacy (Table 176-5). Long-term experience exists regarding intralesional application of antimony. Excision of single lesions can be considered. The combination of paromomycin with methylbenzethonium chloride was shown to be effective mainly against Old World CL. Application of photodynamic therapy resulted in the ablation of affected tissue leading to good clinical results. Moist wound treatment with sodium chloride is low priced and effective.

TABLE 176-5
Local Therapy Against Cutaneous Leishmaniasis

- Excision/curettage or laser ablation
- Cryotherapy, thermotherapy, electrotherapy, photodynamic therapy
- Intralesional antimonial, combined with cryotherapy
- Paromomycin ointment alone or combined with 12% methylbenzethonium chloride
- Sodium chloride (moist wound treatment)

Others:
Topical azoles, topical amphotericin B, topical glyceryl trinitrate or nitric oxide donor, intralesional metronidazole, intralesional interferon-γ

Systemic Therapy: Table 176-6 summarizes the systemic therapies used for leishmaniasis. Sodium stibogluconate and meglumine antimoniate are pentavalent antimony derivatives with slightly differing antimony concentrations and comparable efficacy and safety profiles. They are the mainstay of systemic treatment. Indian VL is treated with 20 mg/kg/day IM or IV once daily for 40 days versus 28 days if the disease is contracted elsewhere. Antimony resistance is a serious issue in India and Iran. Resistant cases may benefit from combining antimonials with pentoxifylline, allopurinol, paromomycin, azithromycin, interferon-γ, granulocyte-macrophage colony-stimulating factor, and topical imiquimod.

Recently, treatment with liposomal amphotericin B or miltefosine has proven to be efficacious for many CL and VL cases. Side effects are less severe and transient.

Other reported systemic therapies include terbinafine, metronidazole, dapsone, interferon-γ, allopurinol, trimethoprim-sulfamethoxazole, rifampin, nifurtimox, quinolones, pyrimethamine, anti–interleukin-10 (experimentally lead to sterile cure), and azithromycin.

CHOICE OF TREATMENT

Species determination is important for the choice of the systemic drug. Resistance and drug ineffectiveness for distinct subspecies is an increasing problem. None of the drugs has universal anti-*Leishmania* activity. Current guidelines aid the decision about the choice of drug. Table 176-7 summarizes current recommendations about the treatment of CL, MCL, and VL caused by different subspecies.

In general, New World CL tends to be more severe and progressive than Old World CL. In addition, New World CL caused by *L. braziliensis* may progress into MCL ("espundia"), thus necessitating systemic therapy. As a rule, patients should be monitored until the lesions have completely healed. Follow up at 6 months is appropriate.

Because many lesions caused by *L. major* and *L. mexicana* heal spontaneously within 4 months, a less-aggressive approach can be favored. Local therapy (see Table 176-5) is appropriate for small, noninflamed and localized lesions that are not at risk to progress to MCL. Patients with uncomplicated CL can be treated with local therapy. Pregnancy may favor local treatment because of the toxicity of the drugs.

Patients exhibiting "complex" lesions should receive systemic therapy. *Complex lesions* have more than 3 lesions or at least one larger than 4 cm and localized on cosmetically or functionally important sites such as the joints or face. In addition, patients with persistent, diffuse, progressive, recurrent, satellite, and sporotrichoid lesions and/or MCL and VL should receive systemic treatment. Patients with immunosuppression (eg, as a result of HIV infection or medication) have an increased risk for parasite persistence and recurrences and should thus be treated systemically. In general, Old World CL requires shorter courses compared to New World CL.

TABLE 176-6
Systemic Drugs Available Against Leishmaniasis

DRUG/DOSE	MECHANISM OF ACTION	ADVERSE EVENTS
Pentavalent antimonials: ▪ sodium stibogluconate (Pentostam) IV ▪ meglumine antimoniate (Glucantime) IM/IV 20 mg/kg/day for 20 to 30 days	Inhibition of glycolysis and oxidation of fatty acids of the parasite	Dose dependent and resolve after discontinuation of drug Pain at injection site, myalgia (68%), pancreatitis (18%), hepatitis, marrow suppression, QT prolongation, fatigue, headache, rash, and nausea
Pentoxifylline (with pentavalent antimony) 400 mg orally 2 to 3 times/day	Inhibits tumor necrosis factor-α	No significant side effects related to pentoxifylline
Pentamidine 2 to 4 mg/kg/day IM or IV every other day for 4 to 7 days	Not established yet	Risk of diabetes mellitus in high-dose course, nephrotoxicity, hypotension, arrhythmias, nausea, vomiting, diarrhea, pancytopenia, cough, bronchospasm, confusion, and hallucinations
Amphotericin B 1 mg/kg every other day for up to 30 days IV (15 mg/kg total dose)	Binding to sterols present in parasite's membrane causing a change in permeability	Hyperpyrexia, hypotension, thrombophlebitis, renal complications, anemia, and hepatitis
Liposomal amphotericin 2 to 3 mg/kg/day IV for 5 to 14 days		Less renal toxicity than amphotericin B
Miltefosine 1.5 to 2.5 mg/kg/day for 28 days orally	Inhibits phosphatidylcholine biosynthesis in parasites	Diarrhea, vomiting, reproductive toxicity in animals
Imidazoles	Inhibition of demethylation of lanosterol, blocking ergosterol synthesis	No significant side effects, hepatotoxicity
Paromomycin sulfate 15 mg/kg daily IM for 21 days	Inhibition of protein synthesis	Rarely: nephrogenic, ototoxic, hepatotoxic
Zinc sulfate 2.5 to 10 mg/kg/day orally for 30 to 40 days	Boosting of Th1 reaction as well as phagocytosis of parasites	Necrosis at injection site

TABLE 176-7
Systemic Treatment Recommendations for Leishmaniasis

PATHOGEN	RECOMMENDED DRUGS (ORDER OF CHOICE)
Old World	
Leishmania major	1. Miltefosine, fluconazole, ketoconazole 2. Liposomal amphotericin B 3. Antimony IV (+ pentoxifylline)
Leishmania tropica	1. Azoles (oral) 2. Liposomal amphotericin B 3. Antimony IV (± allopurinol)
Leishmania infantum	1. Liposomal amphotericin B 2. Miltefosine or antimony IV (± pentoxifylline)
Leishmania aethiopica	Liposomal amphotericin B, miltefosine, Antimony IV (+ pentoxifylline)
New World	
Leishmania braziliensis	1. Antimony IV (+ pentoxifylline) 2. Miltefosine 3. Liposomal amphotericin B
Leishmania guyanensis	1. Miltefosine 2. Pentamidine 3. Antimony IV (+ pentoxifylline)
Leishmania mexicana	1. Ketoconazole 2. Miltefosine 3. Antimony IV (+ pentoxifylline)

PREVENTION AND VACCINE

Essential to prevention is the promotion of personal protective measures through the use of protective clothing, insect repellents containing 30% to 35% *N*, *N*-diethyl-3-methylbenzamide (DEET), and permethrin-treated bed nets; the avoidance of endemic areas; and staying on higher floors of buildings in the evening.

One method of reservoir control of *L. major* was achieved by destroying burrows made by the rodent host. In endemic areas where dogs could be hosts of parasites, a dog collar coated with deltamethrin could be a useful way to control transmission. Targeting anthroponotic foci that are at the origin of deadly epidemics, suspecting leishmaniasis in persons with skin lesions or febrile illnesses returning from endemic areas, and deferring prospective blood donors from donating blood for at least 1 year after their return are other measures. Control of HIV in southern Europe where leishmaniasis is closely associated with HIV has generated positive outcome.

New diagnostic tests, drugs, and vaccines are in development. Vaccine development for tropical diseases is often limited by the lack of financial return. "Leishmanization," the self-inoculation of the live parasite in inconspicuous areas of the body, has been practiced in endemic areas to prevent disfiguring

facial lesions, but was later abandoned because of its complications. Killed promastigotes vaccines with and without adjuvant bacille Calmette-Guérin seem to be useful in some endemic areas. Adjuvants such as bacille Calmette-Guérin are important to prime a Th1 response. Attenuated live parasites–based and plasmid DNA–based vaccines using leishmanial antigens have shown efficacy in mouse models. Experimental vaccines containing a component of sand fly saliva proteins appear to be promising. Despite being experimentally successful, a safe nonliving prophylactic vaccine has not yet been able to confer significant protection in humans. A vaccine for dogs has been approved. The sequencing of the *Leishmania* genome in 2007 might lead the way to new ways for prevention, control, and treatment of the condition.

AFRICAN TRYPANOSOMIASIS (SLEEPING SICKNESS)

EPIDEMIOLOGY

African trypanosomiasis afflicts humans (sleeping sickness) and cattle (nagana), and affects up to half a million people every year in the middle latitudes of Africa, where the vector is found.[2] The fatality rate is close to 100% in untreated patients. The disease is very rare in the United States.

African trypanosomiasis is caused by infections with *Trypanosoma brucei*. Depending on the species involved, African trypanosomiasis presents in 2 distinct forms:

- West African or Gambian trypanosomiasis (caused by *Trypanosoma brucei gambiense*) is a chronic predominantly anthroponotic disease present in rural areas west of the Rift Valley.
- East African or Rhodesian trypanosomiasis (caused by *Trypanosoma brucei rhodesiense*) is an acute fatal disease (within weeks, if untreated) that infects mainly livestock/game animals east of the Rift Valley, and sporadically herdsmen, hunters, photographers, and tourists.

Water requirements of the *Glossina palpalis* group of tsetse flies and the savannah habitat of *Glossina morsitans* determine the geographic distribution of Gambian trypanosomiasis and Rhodesian trypanosomiasis, respectively. This ecologic separation, however, is not as strict as it was in the past, with an overlap of the 2 forms of the disease in Uganda.

ETIOLOGY AND PATHOGENESIS

T. brucei, a unicellular organism, enters the bloodstream of a mammalian host via the bite of a blood-feeding infected male or female tsetse fly of the genus *Glossina*.[15] Other uncommon ways to contract the disease include placental transmission, blood transfusion, and sexual contact.

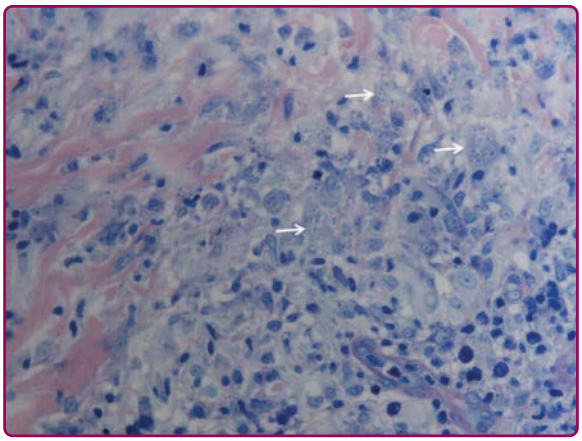

Figure 176-20 Giemsa stain of skin biopsy with cutaneous leishmaniasis. Moderately dense lymphohistiocytic infiltrate with numerous parasitized macrophages containing amastigotes (Leishman bodies, marked with white arrows).

The tsetse flies are attracted by dust clouds of moving objects and animals, as well as black and blue colors. They bite most during early daylight and at dusk, and ingest trypomastigotes from infected blood meals (Fig. 176-20).

Trypomastigotes have a glycoprotein-coated surface that is protective against lytic factors in human plasma. Furthermore, the extensive antigenic variation of the glycoprotein present on the parasite's surface allows evasion from humoral immunity,[16] which explains why a vaccine targeting trypanosomes is extremely difficult to develop.[17]

CLINICAL FINDINGS

In Rhodesian trypanosomiasis, a painful chancre develops at the site of the tsetse bite and resolves within 1 to 3 weeks leaving no scar. It consists of a circumscribed, rubbery, indurated, 2- to 5-cm dusky red nodule, often with a central eschar (Fig. 176-21).[17-19] In Gambian trypanosomiasis, however, the initial lesion consists of a single, nonspecific nodule that is often mistaken for an insect bite or a folliculitis.

Afterward, African trypanosomiasis will evolve in 2 stages: the hemolymphatic or early stage and the meningoencephalitic or late stage. In contrast to the late stage, when the skin is not involved, cutaneous changes may be seen in the early stage and are more commonly observed in Rhodesian trypanosomiasis and in light-skin patients. Perhaps for this reason, skin lesions are rarely reported in native Africans.

EARLY STAGE

The hemolymphatic stage occurs 3 to 10 days after the initial bite, with the parasites entering the

Figure 176-21 East African trypanosomiasis. The trypanosome chancre consists of erythematous nodule with central bulla and ulceration. This patient was treated with suramin and survived. (From Moore AC, Ryan ET, Waldron MA. Case Records of the Massachusetts General Hospital. Weekly clinicopathological exercises. Case 20-2002. A 37-year-old man with fever, hepatosplenomegaly, and a cutaneous foot lesion after a trip to Africa. *N Engl J Med*. 2002;346[26]:2069-2076, with permission of the Massachusetts Medical Society. Copyright © 2002 Massachusetts Medical Society.)

circulation and causing irregularly spiking fever. Hepatosplenomegaly, constitutional symptoms, normocytic anemia, thrombocytopenia, and pruritus (especially presternal) develop, and may be related to circulating immune complexes. Local lymphadenopathy progresses to generalized lymphadenopathy in virtually all African natives and in about half of European patients. Involvement of the posterior cervical (Winterbottom sign) and supraclavicular lymph node is characteristic only of Gambian trypanosomiasis. The disease is more severe in Rhodesian trypanosomiasis where severe parasitemia, myocarditis, and, rarely, fatal disseminated intravascular coagulopathy develop.[18] Trypanids are distinctive eruptions that develop 6 to 8 weeks after the onset of fever in approximately half the light-skin patients, and consist of poorly defined, centrally pale, evanescent, annular, targetoid, or blotchy erythematous macular, hemorrhagic, urticarial, or erythema nodosum-like lesions, commonly on the trunk.[19] These lesions might be the result of a Type III hypersensitivity reaction.[2] A sensation of formication may be associated. The eruption waxes and wanes over weeks with accentuation upon exposure to cold, heat, or sweat. Painless swelling of the face (imparting a sad look), and of the hands and feet may occur. Other findings include ichthyosis, acroparesthesias, icterus, petechiae, and generalized flushing.

LATE STAGE

The late stage is characterized by CNS involvement weeks to months after exposure in Rhodesian trypanosomiasis, and months to years after exposure in Gambian trypanosomiasis, and occurs when parasites cross the blood–brain barrier. Severe headache develops followed by chronic meningoencephalitis, somnolence, coma, and death. Delayed bilateral pain disproportionate to a sharp squeeze applied to soft tissues, known as the Kerandel sign (deep, delayed hyperesthesia), is characteristically found in European patients, but is uncommon in African patients.[20] Patients may also develop behavioral changes, psychosis, and focal neurologic symptoms. Marked weight loss can ensue.

DIAGNOSIS

Diagnosis of African trypanosomiasis is via detection of trypanosomes in blood film or Giemsa-stained thick smears, chancre/lymph node aspirate, buffy coat, bone marrow, or cerebrospinal fluid. Histologically, long, thin trypanosomes are best seen using Giemsa stain, in the midst of a perivascular lymphoplasmacytic infiltrate.[20] Because of antigenic variability, serologic tests lack sensitivity and specificity. Differentiation of Rhodesian trypanosomiasis from Gambian trypanosomiasis is usually based on epidemiology. PCR is the method of choice, but cost limits its use in African countries. New diagnostic tools are being developed.

TREATMENT

A lumbar puncture is essential for the differentiation between the early and late stages because treatment varies based on stage. Four registered drugs are currently provided free of charge by the WHO. Table 176-8 outlines the drugs and the stages for which the drugs

TABLE 176-8
Treatment Options against African Trypanosomiasis

DRUG	EARLY STAGE	LATE STAGE
Pentamidine	Rhodesian trypanosomiasis (RT), Gambian trypanosomiasis (GT)	
Suramin	RT, GT	
Melarsoprol	RT, GT	RT, GT Effective against CNS life forms, neurotoxic
Eflornithine	GT	GT Effective against CNS life forms, neurotoxic
Nifurtimox		RT, GT

are given. Of concern, HIV-positive patients receiving treatment for Rhodesian trypanosomiasis may succumb to full-blown AIDS.

Combination therapy using the available drugs was investigated and all trials showed better results than monotherapy.[21,22] Of note, combination therapy containing melarsoprol leads to severe drug reactions. A multicountry study comparing nifurtimox (registered for the treatment of Chagas disease) and eflornithine to eflornithine alone was undertaken for late-stage Gambian trypanosomiasis. The combination therapy resulted in fewer infusions, shorter treatment duration, and fewer adverse effects.

Various small molecules of diverse chemical nature are currently being investigated in clinical trials.

PREVENTION

Control of African trypanosomiasis in endemic areas is highly cost-effective and entails case detection and treatment, keeping tsetse populations at low levels,[2,21] and mass screening of at-risk populations.

CHAGAS DISEASE (AMERICAN TRYPANOSOMIASIS)

EPIDEMIOLOGY

American trypanosomiasis is a zoonotic disease caused by *Trypanosoma cruzi* and transmitted to humans by blood-sucking triatomine bugs (kissing bugs, assassin bugs, reduviid bugs).[1,2] It is endemic in many rural areas of Central and South America and Mexico. In the United States, as many as 300,000 individuals are affected and as many as 45,000 individuals have the clinical disease.

ETIOLOGY AND PATHOGENESIS

Triatomine bugs are large (3 to 4 cm), "cone-nosed" bedbugs that thrive in poor housing conditions and become infected with *T. cruzi* by feeding on contaminated blood. An infected triatomine bug takes a blood meal usually at night, and releases trypomastigotes in its feces near the site of the bite wound, usually a mucocutaneous junction. Human infection occurs when mucous membranes, especially the conjunctiva, or skin breaks are contaminated with the feces upon rubbing/scratching (Fig. 176-22). Other reported ways of transmission of the disease seem to be via the intake of reduviid feces–contaminated fruits and fruit products. Congenital (transplacental) transmission and transmission by blood transfusion and organ transplantation may also occur.

CLINICAL FINDINGS

American trypanosomiasis progresses in 3 stages.[23-25]

ACUTE PHASE (FIRST STAGE)

Transient parasitemia is usually asymptomatic or associated with fever, lymphadenopathy, mild hepatosplenomegaly, and morbilliform/urticarial rash; it can last for as long as 8 weeks. This stage may be fatal in young children or immunosuppressed individuals.

Other dermatologic manifestations seen in the first stage include:

- *Chagoma*, a painful inflammatory reaction at the site of inoculation, approximately 1- to 3-cm in size, erythematous, often ulcerated nodule with a surrounding pale halo. Local lymphadenopathy often present.
- *Schizotrypanides*, a generalized morbilliform eruption, or transient skin rash resembling measles.
- *Romaña sign* (or ophthalmoganglionar complex), which manifests as unilateral conjunctivitis with palpebral edema (from conjunctival inoculation).

INDETERMINATE PHASE (SECOND STAGE)

During this chronic, asymptomatic, but infectious stage, low levels of the parasite are found in blood. Reactivation of the infection may occur following organ transplantation (disseminated, painful, subcutaneous and/or ulcerated nodules).

SYMPTOMATIC CHRONIC PHASE (THIRD STAGE)

The third stage is characterized by lethal, dilated cardiomyopathy, arrhythmias, megaesophagus, and megacolon. It occurs in 10% to 30% of patients, often many years after initial infection. Genetic variability of *T. cruzi* might determine the clinical presentation of chronic disease. The pathogenesis was thought to be mediated by molecular mimicry; however, parasites persistence in tissues were recently demonstrated by PCR and in situ hybridization.

DIAGNOSIS

Diagnosis and treatment are problematic. In the first stage, diagnosis involves microscopic demonstration of trypomastigotes in blood specimens, especially thin smears, hemoculture, or xenodiagnosis. Thereafter,

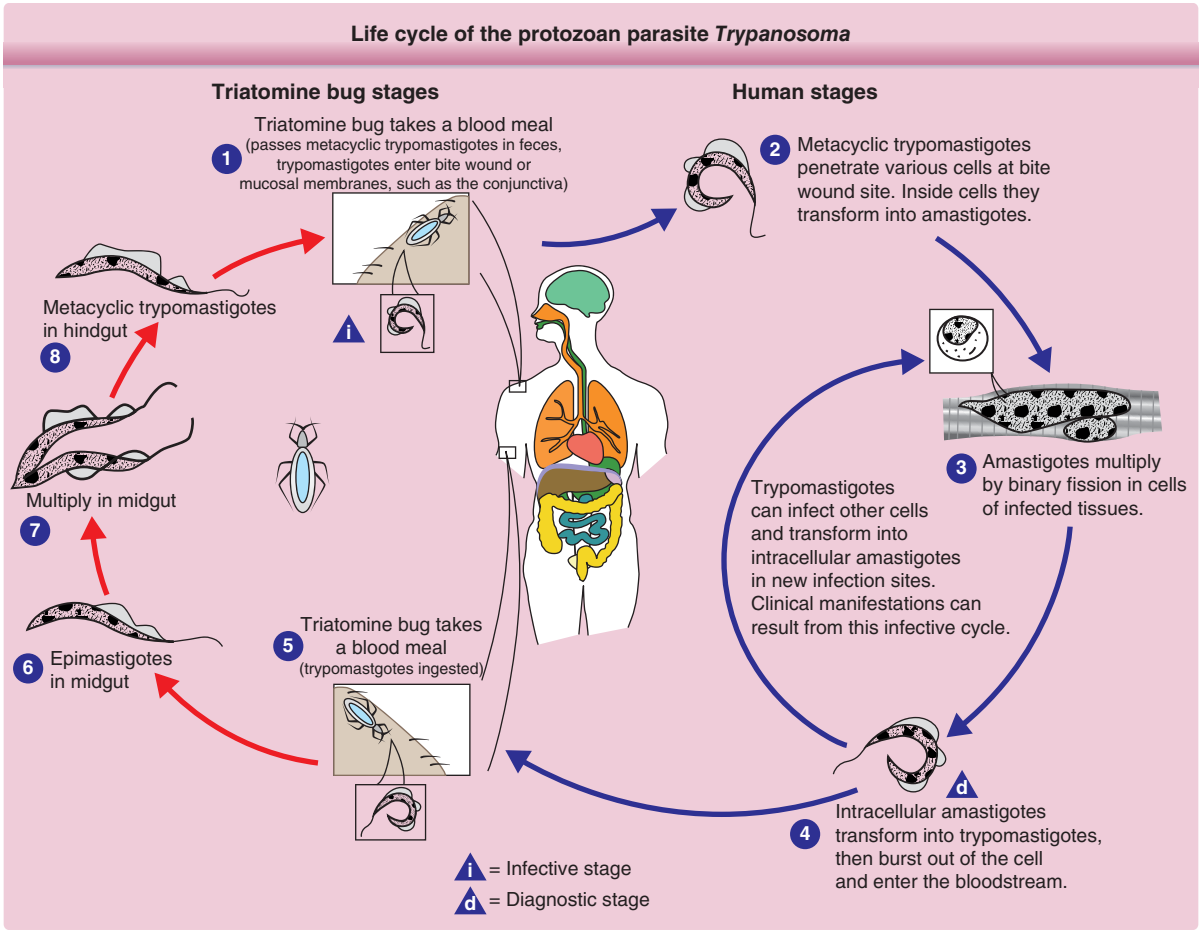

Figure 176-22 Life cycle of the protozoan parasite *Trypanosoma*. (From the Centers for Disease Control and Prevention [CDC].)

detection of organisms becomes difficult, and diagnosis relies more on serologic testing or PCR. The WHO recommends using at least 2 antigen detection tests for confirmation of the disease.[2,26]

TREATMENT

Treatment is indicated for acute infections, congenital infections, patients who are immunosuppressed, and children with chronic disease.[2,27-29] Both drugs that are available, benznidazole and nifurtimox, are toxic and most effective when given during the first stage of the infection or in congenital infections.

Because of their toxicity, potential carcinogenic risk, decreased efficacy in chronic disease, and the presumably autoimmune nature of the latter, treatment of chronic disease has long been considered controversial. Later studies, however, revealed the persistence of the parasite in heart muscle as well as digestive tissue in patients with the chronic condition. In addition, patients with chronic cardiomyopathy who were given benznidazole had less clinical deterioration a decade later as well as lower serologic titers. Consequently, chemotherapeutic intervention at any stage of the disease is currently recommended.

Allopurinol and itraconazole also have been tried for chronic disease.

PREVENTION

Preventive measures are aimed at eradicating the vectors, improving diagnostic tests, developing less toxic and more efficient drugs, and implementing serologic screening of organ donors and recipients. Control programs have reduced the incidence of American trypanosomiasis by 70% in some countries of South America.[2]

MALARIA

EPIDEMIOLOGY

Malaria transmission occurs in 95 countries/territories; 3.2 billion people (half of the world's population) are at risk of acquiring malaria. Sub-Saharan Africa

carries the largest burden with 88% of malaria cases and 90% of malaria-associated deaths. However, Asia, Latin America and, to a lesser extent, the Middle East also are at risk.[30]

According to the WHO, in 2015, 214 million patients with malaria were reported together with approximately 450,000 fatal cases. Between 2000 and 2015, the global burden has fallen by approximately 40% as a result of efficient control programs; however, in sub-Saharan Africa the decline has lagged behind.

The exact incidence of cutaneous lesions in malaria is not known, but it appears to be rare.

ETIOLOGY AND PATHOGENESIS

Malaria is caused by infection with the protozoan parasite of the genus *Plasmodium*. Malaria is spread by the bite of infected, female *Anopheles* mosquitoes (Fig. 176-23). The mosquitos bite between dusk and dawn. Transmission efficacy depends on parasite, vector, environmental (temperature, humidity and habitat conditions), and host factors.

Human malaria is caused by 5 species of *Plasmodium*, among which *Plasmodium falciparum* and *Plasmodium vivax* are most threatening. *P. falciparum* is the most prevalent species on the African continent with the most malaria-related deaths globally. *P. vivax* is the dominant parasite outside of sub-Saharan Africa.

Patients at higher risk to develop malaria are mainly infants, children ages 5 years and younger, pregnant women, patients with immunosuppression (eg, HIV/AIDS), and nonimmune immigrants and travelers. Partial immunity after years of exposure does not provide complete protection, but it reduces the risk for severe disease.

Skin manifestations in malaria are rare[31]; their type appears to depend on the immunopathologic mechanism:

1. IgE antibodies against the parasite are found in individuals from endemic areas. Mast cell activation in malaria plays a central role in the pathophysiology. The precise mechanism for mast cell activation is unknown; clinically, it presents as urticaria.
2. IgG antimalarial antibodies are known to be protective against infection. IgG and IgE containing immune complexes are elevated in malaria. Purpura and petechiae may result from cytoadherence, vasculitis, and immune-complex–associated vessel damage.

Figure 176-23 *Anopheles* mosquito. (Image from Centers for Disease Control and Prevention [CDC] and James Gathany.)

CLINICAL FINDINGS

Malaria is characterized by an acute febrile disease. Symptoms appear, starting with fever, headache, chills and vomiting, 7 to 14 days after the infective mosquito bite. The initial symptoms may be mild and nonspecific, leaving it difficult to recognize as malaria. If not treated early, *P. falciparum* can progress to severe illness that is often associated with death. Severe malaria (mainly seen in children) is characterized by severe anemia, respiratory distress with metabolic acidosis, and cerebral malaria. Multiorgan involvement in adults is frequent. Asymptomatic infections in endemic areas in individuals with partial immunity may occur.

Cutaneous manifestations are rarely reported and are not specific for malaria.[31] Their onset appears to occur at the time systemic symptoms develop. If reported, they are described as urticaria/angioedema, petechiae/purpura, or disseminated intravascular coagulopathy.

DIAGNOSIS

The diagnosis is made by investigation, blood count, hemogram, and liver function assessment.

TREATMENT

Symptomatic treatment can be initiated to mitigate skin symptoms (eg, antihistamines, corticosteroids). However, upon initiation of antimalarial systemic treatment, skin lesions appear to resolve within a few days.

A vaccine against malaria is under development, but not available yet.

Prevention methods can be highly effective, ranging from utilization of vector-control measures (insecticide-treated mosquito nets, indoor spraying with insecticides) to chemoprophylaxis for travelers. However, malaria-endemic areas such as sub-Saharan Africa and India are causing significant concern because of high levels of malaria transmission and widespread reports of insecticide resistance.

TRICHOMONIASIS

EPIDEMIOLOGY

Trichomoniasis is considered the most prevalent nonviral sexually transmitted disease worldwide. It appears that millions of *Trichomonas vaginalis* infections remain undiagnosed and untreated.[32] *T. vaginalis* infections affect approximately 3% of all females (ages 14 to 49 years), and are mostly asymptomatic. Approximately 20% of all females between 16 and 35 years of age suffer at least 1 *T. vaginalis* infection.

T. vaginalis is most often transmitted during sexual contact. It remains viable for 24 hours in a humid and warm milieu, and transmission through contaminated objects is possible. Females are more often affected and symptomatic than males. Female sex workers have the highest incidence at 50% to 70%. Approximately 70% of all females with gonorrhea suffer from trichomoniasis.

Spontaneous remission is frequent (about one-third of cases). Only approximately 5% of male patients in a sexually transmitted disease outpatient clinic are positive for *T. vaginalis*. Approximately 15% of non–gonorrhea urethritis in males is caused by *T. vaginalis*, however.

ETIOLOGY AND PATHOGENESIS

Three species of *Trichomonas* are pathogenic for humans exhibiting specific localizations. The most common, *T. vaginalis*, prefers cornified mucosa such as the urethra. Other species, such as *Trichomonas tenax*, are found in the oral cavity and can cause gingivitis and other infections. *Pentatrichomonas hominis* is associated with GI symptoms.

T. vaginalis is 4 to 45 µm in length and 2 to 14 µm wide. It contains 4 frontal and 1 larger back flagella, which is embedded into an undulating membrane. Because of its characteristic twitching movements, the pathogen is easy to recognize under the microscope.

CLINICAL FINDINGS

T. vaginalis prefers the epithelia of the vagina and the urethra, and less of the cervix. Rarely, bladder and ureter are affected.[32] Only 15% to 20% of all infected females are symptomatic and suffer from diffuse, malodorous, yellow-green vaginal discharge with or without vulvar involvement. Sexual intercourse may be painful. An untreated trichomoniasis of a female can be associated with inflammatory pelvic disease, neoplasia of the cervix and premature labor. *T. vaginalis* carriers are more prone to acquire HIV, human papillomavirus, and herpes virus infections.

Infection of the prostate, ureter, and foreskin of males is most often asymptomatic. Dysuria and ureter discharge with balanoposthitis are possible. Ascending infections of the prostate and epididymis are very rare.

DIAGNOSIS

WET-MOUNT MICROSCOPY

Swabs of vagina, cervix, or ureter can be examined for the typically large, moving pathogen. This is the most commonly used method, and it has a relatively low cost. The sensitivity is low (51% to 65% in vagina secretions; even lower in male specimens). The sensitivity declines dramatically with a delayed evaluation of the sample.

CULTURE

Before molecular testing methods became available, culture was considered the gold standard for diagnosing *T. vaginalis* infections. It has a sensitivity of 75% to 95% and a high specificity. Several culture media are available.

MOLECULAR TESTS

Nucleic acid amplification tests are available for detection of *T. vaginalis* in vaginal, endocervical, and urine specimens of women. The specificity is very high; the sensitivity is 95% to 100%.[33]

SEROLOGY

The antibody response is variable and not reliable; a routine test for antibodies against *T. vaginalis* is not recommended.

TREATMENT

Treatment reduces both symptoms and transmission.[34]

Systemic treatment consists of metronidazole, 2 g orally in a single dose, or tinidazole 2 g can be given in a single dose. The cure rates after metronidazole regimens were 84% to 98%, those after tinidazole 92% to 100%. An alternative regimen, metronidazole 500 mg orally twice a day for 7 days, can be administered. The response rate is considered to be 90% to 95%. One study showed that topical metronidazole 750 mg combined with 200 mg miconazole twice daily for 7 days was as effective as systemic treatment with metronidazole alone.

Long-term treatment with metronidazole should be avoided. During pregnancy, treatment options are limited. Topical metronidazole can be considered.

RHINOSPORIDIOSIS

EPIDEMIOLOGY

Rhinosporidium seeberi is an aquatic pathogen; it is still unclear if it can be classified as protozoan or a fungus.[35,36] It can be found in America, Europe, Africa, and Asia, mainly in tropical regions (predominantly in South India, Sri Lanka, and South America).

ETIOLOGY AND PATHOGENESIS

The mode of transmission is largely unknown, but appears to be associated with spore transmission during fresh water contact (eg, during bathing). Within the inoculated tissue, the organisms replicate locally with hyperplasia, followed by a localized immune response resulting in a granulomatous disease.

CLINICAL FINDINGS

Rhinosporidiosis is mainly seen in males at the nasal, nasopharyngeal, and oral mucosa. Symptoms present as painless nodules that slowly grow to large, hyperplastic polyps with irregular, erythematous surfaces.

The external skin is only rarely affected. Conjunctiva, rectum and external genitalia can be involved.

DIAGNOSIS

The protozoan cannot be cultured yet, thus the diagnosis is based on biopsy specimen followed by histology. A large sporangium (mature form of the pathogen, 100 to 400 µm in size) is seen with thousands of endospores inside.

TREATMENT

Removal of the affected tissue is the main therapy; however, recurrences are frequent. Injection of amphotericin B appears to minimize development of recurrences. Long-term treatment with dapsone has been reported.

CRYPTOSPORIDIOSIS

EPIDEMIOLOGY

Cryptosporidiosis is a disease caused by the protozoan parasite *Cryptosporidium*. Both giardiasis and cryptosporidiosis belong to the most common intestinal parasitic infections worldwide.[37,38]

Children and people taking care of infected individuals have an increased risk of acquiring the infection. In addition, travelers (especially backpackers, campers), swimmers, people who handle infected cattle, and individuals exposed to human feces during sexual contact are more likely to get infected.

ETIOLOGY AND PATHOGENESIS

The life cycle of *Cryptosporidium* can be completed in humans and many animals. *Cryptosporidium parvum* infects humans and animals, whereas *Cryptosporidium hominis* is only found in humans.

Oral infection is established through uptake of *Cryptosporidium* oocysts via contaminated earth, water, uncooked food or after contact with feces of an infected individual or animal. Oocysts are highly resistant to disinfectants; they remain viable and infective for long periods.

After ingestion, oocysts exist in the small intestine and release sporozoites that attach to the microvilli of the intestinal epithelial cells. Then then develop into trophozoites, reproduce by multiple fission, and become merozoites. Released merozoites attach to epithelial cells and become macrogamonts (female sexual form) or microgamonts (male form). Finally, zygotes form after the microgamont penetrates the macrogamont. Zygotes then develop into oocysts, which are then released with the feces.

CLINICAL FINDINGS

After 2 to 10 days of parasite ingestion, watery diarrhea, abdominal cramps/pain, dehydration, nausea and vomiting, fever, weight loss, and lack of appetite develop. The symptoms last for about a week with cycles of transient improvement. Extraintestinal symptoms are arthralgia, headache, and drowsiness. Pulmonary involvement shows unspecific symptoms such as coughing.

Some individuals may be asymptomatic. However, young children and severely immunosuppressed patients (eg, those with HIV/AIDS) have a higher risk for developing severe disease forms.

Spontaneous (chronic) urticaria and angioedema are associated with *Cryptosporidium*-associated diarrhea.[37,38]

DIAGNOSIS

Stool specimens can be investigated for the presence of oocysts. At least 3 different stool samples should be inspected. Antibody detection in serum and molecular methods are available.[39]

TREATMENT

A specific treatment is not available. Paromomycin and other drugs reduce the symptoms of cryptosporidiosis.

GIARDIASIS

EPIDEMIOLOGY

Giardia lamblia (synonyms: *Giardia intestinalis* and *Giardia duodenalis*) is a flagellated protozoan parasite. Infections with *G. lamblia* are the most common intestinal infection in the United States, especially in children.[38,40] In the United States, 5 to 6 cases per 100,000 population are reported. Annually, 1.2 million cases are estimated for the United States.

ETIOLOGY AND PATHOGENESIS

G. lamblia cysts are highly infectious; approximately 10 cysts are sufficient to cause an infection. Transmission occurs mainly by consumption of contaminated water (pools, lakes, inadequately purified drinking water, seasonal), but less frequently also via contaminated food, or fecal–oral transmission (nonseasonal) (Fig. 176-24).

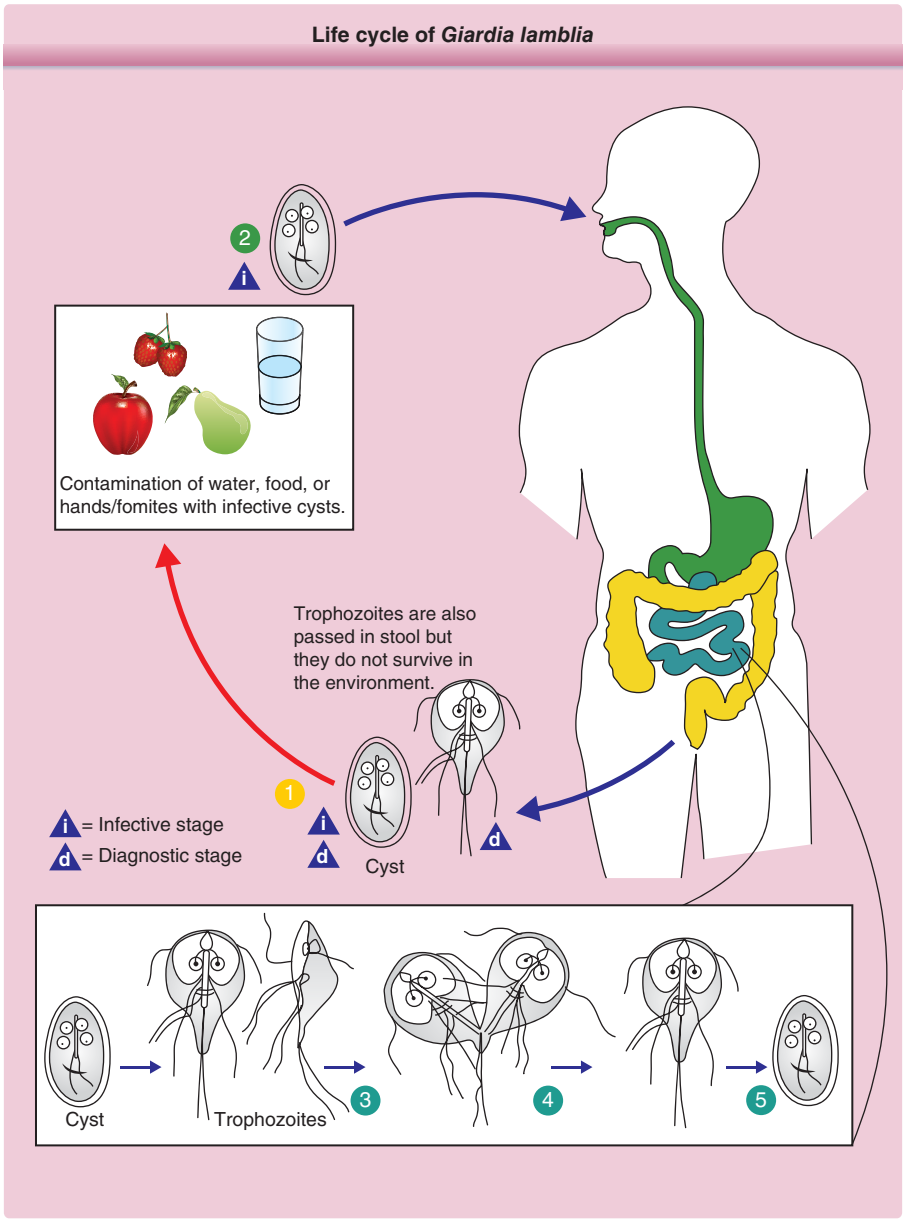

Figure 176-24 Life cycle of *Giardia lamblia*. (From the Centers for Disease Control and Prevention [CDC].)

CLINICAL FINDINGS

Giardiasis is a self-limited disease characterized by diarrhea, abdominal cramps, bloating, dehydration, weight loss, and malabsorption. Symptoms vary and can last for up to 2 weeks; asymptomatic cases are reported.

Skin symptoms of giardiasis are less common and most often present as acute urticaria and/or as angioedema. Giardiasis is also known as pathogen causing chronic urticaria.[41]

DIAGNOSIS

The diagnosis is made by microscopic identification of *Giardia* cysts in stool.

TREATMENT

Systemic treatment with metronidazole, tinidazole, and nitazoxanide is effective.[42] Alternative drugs that can be used to treat giardiasis are paromomycin, quinacrine, albendazole, and furazolidone.

AMEBIASIS

EPIDEMIOLOGY

Amebiasis is the second leading cause of death from parasitic diseases. Annually, 50 million individuals are affected by the infection, and approximately 100,000 deaths are reported. A higher incidence is reported in Mexico and in developing tropical countries.[2,43]

In developed countries, risk groups include male homosexuals, travelers, immigrants, and institutionalized patients. In Europe, asymptomatic intestinal infections are seen in 1% of the population; in homosexuals, asymptomatic intestinal infections are seen in approximately 20% of individuals.

ETIOLOGY AND PATHOGENESIS

Only a few ameba are pathogenic for humans. Within the genus *Entamoeba*, *Entamoeba histolytica* is a pathogenic ameba that can cause intestinal and extraintestinal diseases. Nonpathogenic ameba can be found in the colon. Within the genus *Acanthamoeba*, some facultatively pathogenic species are relevant as inducers of opportunistic infections.

E. histolytica exists in 2 forms: (a) the capsuled cyst (10 to 15 µm) or infective stage, and (b) the mobile trophozoite or tissue-invasive stage. Cysts are known to remain viable for several months in a cold, humid milieu, but they are labile to heat and dryness.

Both forms are passed in the feces. Human beings are the only natural hosts and asymptomatic carriers are the main risk for infection. Infection generally occurs by ingestion of mature cysts in fecally contaminated food, water, or hands. In industrial countries, anal sex and contaminated enema equipment are the main modes of transmission.[2,43]

Trophozoites have marked phagocytic, proteolytic, and cytolytic capabilities, releasing proteases, collagenase, hyaluronidase, *N*-acetylglucosaminidase, phospholipase A, and secretagogues.[2,44] Consequently, they can invade human colonic mucosa and occasionally penetrate through to the portal circulation, reaching the liver and other organs, causing fatal lesions. Some mammalian cells are resistant to trophozoite adherence.

Most cases of asymptomatic noninvasive "luminal amebiasis" are caused by *Entamoeba dispar*, rather than *E. histolytica*.

CLINICAL FINDINGS

Depending on the extent of invasion and the transmission mode, the clinical spectrum includes 3 major presentations[2,43-45]:

1. Invasive intestinal disease (dysentery, colitis, and amebomas).
2. Invasive extraintestinal disease (liver abscess, peritonitis, and pleuropulmonary abscess).
3. Cutaneous disease is rare and can be either primary or secondary:
   - In primary cutaneous amebiasis, an extremely rare condition, the skin is affected without underlying intestinal or extraintestinal disease. It is thought to be secondary to direct inoculation from scratching with contaminated fingers in areas with poor hygiene. Penile lesions are often acquired through anal intercourse with infected individuals.
   - In secondary cutaneous amebiasis, the skin can be infected following extension from an underlying/contiguous intestinal or extraintestinal abscess, draining catheter, fistula, colostomy or laparotomy incision. Trophozoites can also spread through contaminated stool to the anogenital skin. This is often seen in children with diarrhea following direct and prolonged contact with infected feces in their diapers. Autoinoculation via contaminated hands may account for more distal lesions.

     Both types of cutaneous transmissions are rare and result in rapidly progressive, foul smelling, and painful punched-out ulcers with a hemopurulent, raw beef-like base; necrotic, cord-like, and undermined borders; and surrounding erythema (Fig. 176-25). Lesions may reach up to 20 cm in diameter and are often destructive if untreated. Chronic urticaria may be associated and local lymphadenopathy is common. Without prompt diagnosis and treatment, the prognosis is poor. In rare cases, even primary cutaneous amebiasis has a fatal outcome.

Figure 176-25 Cutaneous amebiasis. (From Kristal L, Prose NS: *Color Atlas of Pediatric Dermatology*, 5th ed. New York, NY: McGraw-Hill; 2017, with permission.)

DIAGNOSIS

The diagnosis relies on identification of cysts and/or trophozoites in infected stool, mucosa, or skin. This method cannot distinguish between *E. histolytica* and *E. dispar.* For this, enzyme-linked immunosorbent assays are useful. Stool culture and PCR are only available as research tools. Serology may be helpful, but false-negativity may occur in early infection.

Skin biopsy reveals ulceration, mixed inflammatory cell infiltrate, and areas of necrosis where trophozoites may be identified as round or oval cells (20 to 50 µm) with basophilic cytoplasm, an eccentric nucleus with central karyosome, and often displaying erythrophagocytosis (sign of pathogenicity).

TREATMENT

For symptomatic intestinal or extraintestinal disease, the drug of choice is oral or IV metronidazole (250 to 800 mg every 8 to 12 hours for 10 days), followed by treatment with one of the luminal agents: iodoquinol, paromomycin, diloxanide furoate, dehydroemetine, or chloroquine.

OPPORTUNISTIC AMEBAS

EPIDEMIOLOGY AND ETIOLOGY

The free-living amebas belonging to the genera *Naegleria, Acanthamoeba, Balamuthia*, and lately described *Sappinia* are ubiquitous in air, soil, and water; they rarely cause disease in immunocompetent patients; reported presentations include acanthamebic keratitis (in contact lens wearers) and primary amebic meningoencephalitis (caused by *Naegleria fowleri*). Immunocompromised AIDS and organ transplantation patients are at risk of disseminated disease, as well as at risk of developing granulomatous amebic encephalitis, a rare, gradually progressive, fatal neurologic disease caused by *Acanthamoeba* species. Free-living amebas can also harbor bacteria, such as *Legionella*, *Mycobacterium avium*, *Burkholderia* spp., *Escherichia coli*, and *Vibrio cholerae*, possibly serving as vectors of bacterial infections in humans.

The portal of entry of the amebas is usually the nasal mucosa, from which they can reach the CNS. They can also enter through a skin break or through the respiratory tract with subsequent hematogenous dissemination to the CNS.

CLINICAL FINDINGS

Cutaneous lesions have been mainly reported in *Acanthamoeba*-induced disease, mostly in HIV-positive patients.[43-45] *Balamuthia mandrillaris*–related skin involvement, however, is being increasingly reported. In HIV-positive patients, skin lesions are the most common (75% to 90% of the cases) and sometimes the sole manifestation of disseminated disease. The extremities (lower more than upper) and the face are commonly involved. Numerous widely distributed papules, plaques, nodules, and pustules, as well as cellulitis, nonhealing ulcers with rolled borders, eschars, and palatal ulceration have been described. Lymphadenopathy may be present. An asymptomatic plaque over the central face with possible satellite lesions along with neurologic symptoms is a characteristic presentation of *B. mandrillaris* disease.

One study suggested that the immunologic state of the patient determines the clinical outcome of cutaneous acanthamebiasis. On the one hand, immunocompromised patients were unexpectedly found to develop multiple subacute skin lesions without CNS involvement and to respond better to therapy. On the other hand, immunocompetent patients had a worse prognosis with slowly progressive cutaneous lesions and more CNS involvement.

DIAGNOSIS

Histopathologically, a dermal and/or subcutaneous predominantly neutrophilic infiltrate is present, sometimes with vasculitic, and granulomatous changes. The identification of 20- to 30-µm trophozoites with abundant vacuolated cytoplasm, and central nuclear karyosome is diagnostic but may be difficult because of their macrophage-like appearance. Gomori methenamine silver and periodic acid–Schiff stains may highlight the organisms. *B. mandrillaris* may occasionally exhibit more than 1 nucleolus, distinguishing it from *Acanthamoeba*. Definite diagnosis

and speciation is possible using indirect immunofluorescence, culture or PCR.

TREATMENT

The disease is often fatal, but early treatment using a combination of IV pentamidine and oral fluconazole, sulfadiazine, isethionate, or 5-fluorocytosine may improve the outcome. HIV patients may benefit from antiretroviral therapy.

ACANTHAMOEBA KERATITIS

EPIDEMIOLOGY AND ETIOLOGY

Acanthamoeba is a ubiquitous protozoan parasite among which 8 species can cause keratitis.[46] Main risk factors are contact lens wear, poor hygiene, and contact with contaminated water.

CLINICAL FINDINGS

The keratitis has can acute onset showing a painful keratitis with destruction of the epithelial layer of the cornea. Secondary scleritis can occur. Typically, only 1 eye is affected. The course can be potentially sight-threatening.

DIAGNOSIS

A corneal scraping can be analyzed by histology, tissue culture, and/or PCR. In scraping material, *Acanthamoeba* can be detected after addition of 10% potassium hydroxide.

TREATMENT

Various local treatments using topical antiseptics, neomycin, paromomycin, polymyxin B, azole antimycotics, and antiinflammatory steroids are effective.

The prognosis is poor because of an often delayed diagnosis, and frequently a lack of effective medical management.

TOXOPLASMOSIS

EPIDEMIOLOGY

Toxoplasmosis, caused by the parasitic protozoan *Toxoplasma gondii* (class Sporozoa), is one of the most common human infections worldwide[47]; approximately 50% of the world's population is infected without symptoms (in United States, it is approximately 23% of the population; in some areas it is as much as 95%).

ETIOLOGY

The main reservoirs of *T. gondii* infection are members of the cat family (Felidae), which become infected by carnivorism; dogs and rabbits can also host the parasite. Viable organisms invade the feline intestinal epithelium, where they undergo an asexual cycle followed by a sexual cycle and then form oocysts, which are excreted in large numbers and are resistant to harsh environmental conditions and disinfectants. Human infection results mainly from ingestion of cyst-containing undercooked meat or milk, but can also result from ingestion of the oocytes from fecally contaminated hands or food, organ transplantation, blood transfusion, or transplacental transmission.

The parasites become tachyzoites and form tissue cysts, mostly in skeletal muscle, myocardium, brain, eye, and placenta, and may remain asymptomatic. Invasion of the reticuloendothelial/endothelial systems results in suppuration and granuloma formation.

CLINICAL DIAGNOSIS

The 3 major clinical forms are congenital, acquired, and disseminated.[2,48-50]

CONGENITAL TOXOPLASMOSIS

It occurs in 1 per 1000 live births in the United States. The risk of transmission is highest in the third trimester; however, the disease is more severe if transmitted in early pregnancy. Approximately 10% of affected newborns will have chorioretinitis and blindness, and 20% will have generalized or CNS disease. Infection may manifest as abortion, stillbirth, microcephaly, tram-track intracerebral calcifications, deafness, hydrocephalus, mental retardation, or seizures.

Skin lesions include purpura, jaundice, blueberry muffin lesions (dermal erythropoiesis), and erythroderma. Untreated subclinical infection may reactivate during the second to third decade of life, mostly in the form of retinochoroiditis.

ACQUIRED TOXOPLASMOSIS

In immunocompetent persons, it is often asymptomatic in 80% to 90% of cases. However, 10% to 20% of patients, preferentially including pregnant women, develop cervical or occipital lymphadenopathy and a flu-like illness. Rarely, myocarditis, pneumonitis, encephalitis, and polymyositis may occur.

TABLE 176-9
Spectrum of Cutaneous Lesions Seen in Acquired Toxoplasmosis in Immunocompetent Persons[48-50]

- Dermatomyositis-like syndrome.
- Pityriasis lichenoides
- Cellulitis
- Others: Sweet syndrome; cold urticaria; erythroderma; palmoplantar maculopapular rash; morphea; mastocytosis; lichen planus pilaris; pityriasis rubra pilaris; capillaritis; papular acantholytic dermatosis; keratosis lichenoides chronica; chronic prurigo; scarlatiniform eruption; panniculitis; erythema multiforme; roseola; papular urticaria

Cutaneous manifestations are protean reflecting the heterogeneous immune responses to the organism, and include among others dermatomyositis-like syndrome and pityriasis lichenoides (Table 176-9). Toxoplasmosis should be sought in patients with an acute dermatomyositis-like picture. Both conditions share a common underlying pathogenic mechanism related to the expression on muscle fibers of human leukocyte antigen class I, as well as production of certain cytokines.[3]

TOXOPLASMOSIS IN IMMUNODEFICIENT PATIENTS

This is often secondary to reactivation of latent infection and presents as disseminated disease. Toxoplasmic encephalitis is the most common cause of intracerebral lesions in AIDS patients.

Disseminated papular/nodular eruption may occur. Rare cases of graft-versus-host disease–like rash have been reported in patients who underwent hematopoietic stem cell transplantation. Histology may not be helpful in differentiating between the 2 conditions. A high degree of suspicion of toxoplasmosis and molecular confirmation are important to distinguish between the 2 conditions.

DIAGNOSIS

Diagnosis is routinely made by serology.

Protozoa may be identified in bronchoalveolar lavage, lymph node specimens, or skin biopsies. Tachyzoites, visualized with Wright or Giemsa stains, are crescent-shaped and have a prominent, centrally placed nucleus. The most common histologic finding is subacute histiolymphocytic vasculitis with demonstration of trophozoites within macrophages. Epidermotropic infection and neural infiltration may occur. Immunoperoxidase stains are specific and are particularly helpful when small tissue specimens are submitted.

PCR-based testing has a high diagnostic value in acute disease and has become the preferred method of diagnosis, particularly in prenatal diagnosis of toxoplasmosis and in immunocompromised patients with disseminated toxoplasmosis. PCR detection of the parasite in fluid specimens (blood, amniotic fluid, cerebrospinal fluid, urine, vitreous, and aqueous fluid), as well as fetal and brain tissues, is indicative of active infection.

TREATMENT

Treatment should be initiated in all patients with acute or active disease or congenital infection, and in immunosuppressed individuals.[3] Sulfadiazine and pyrimethamine act synergistically and together provide effective therapy. Clindamycin can be used in sulfonamide-allergic patients. Cotrimoxazole was recently reported to be effective in the treatment of toxoplasmic lymphadenitis.

ACKNOWLEDGMENTS

The author acknowledges the contributions of Joelle M. Malek and Samer H. Ghosn, the previous authors of this chapter.

REFERENCES

1. Esch KJ, Petersen CA. Transmission and epidemiology of zoonotic protozoal diseases of companion animals. *Clin Microbiol Rev.* 2013;26(1):58-85.
2. Lupi O, Bartlett BL, Haugen RN, et al. Tropical dermatology: tropical diseases caused by protozoa. *J Am Acad Dermatol.* 2009;60(6):897-925.
3. Kollipara R, Peranteau AJ, Nawas ZY, et al. Emerging infectious diseases with cutaneous manifestations: fungal, helminthic, protozoan and ectoparasitic infections. *J Am Acad Dermatol.* 2016;75(1):19-30.
4. David CV, Craft N. Cutaneous and mucocutaneous leishmaniasis. *Dermatol Ther (Heidelb).* 2009;22(6):491-502.
5. Reithinger R, Dujardin JC, Louzir H, et al. Cutaneous leishmaniasis. *Lancet Infect Dis.* 2007;7(9):581-596.
6. Bailey MS, Lockwood DN. Cutaneous leishmaniasis. *Clin Dermatol.* 2007;25(2):203-211.
7. von Stebut E. Leishmaniasis. *J Dtsch Dermatol Ges.* 2015;13(3):191-200.
8. González U, Pinart M, Reveiz L, et al. Interventions for Old World cutaneous leishmaniasis. *Cochrane Database Syst Rev.* 2008;(4):CD005067.
9. Khatami A, Firooz A, Gorouhi F, et al. Treatment of acute Old World cutaneous leishmaniasis: a systematic review of the randomized controlled trials. *J Am Acad Dermatol.* 2007;57(2):335.e1-e29.
10. Palumbo E. Current treatment for cutaneous leishmaniasis: a review. *Am J Ther.* 2009;16(2):178-182.
11. Barrett MP, Croft SL. Management of trypanosomiasis and leishmaniasis. *Br Med Bull.* 2012;104:175-196.
12. Aronson N, Herwaldt BL, Libman M, et al. Diagnosis and treatment of leishmaniasis: clinical practice guidelines by the Infectious Diseases Society of America (IDSA) and the American Society of Tropical Medicine and Hygiene (ASTMH). *Am J Trop Med Hyg.* 2016;63(12):e202-e264.

13. Copeland NK, Aronson NE. Leishmaniasis: treatment updates and clinical practice guidelines review. *Curr Opin Infect Dis.* 2015;28(5):426-437.
14. Blum J, Buffet P, Visser L, et al. LeishMan recommendations for treatment of cutaneous and mucosal leishmaniasis in travelers, 2014. *J Travel Med.* 2014;21(2):116-129.
15. Wamwiri FN, Changasi RE. Tsetse flies (*Glossina*) as vectors of human African trypanosomiasis: a review. *Biomed Res Int.* 2016;2016:6201350.
16. Geiger A, Bossard G, Sereno D, et al. Escaping deleterious immune response in their hosts: lessons from trypanosomatids. *Front Immunol.* 2016;7:212.
17. Brun R, Blum J. Human African trypanosomiasis. *Infect Dis Clin North Am.* 2012;26(2):261-273.
18. Moore AC, Ryan ET, Waldron MA. Case records of the Massachusetts General Hospital. Weekly clinicopathological exercises. Case 20-2002. A 37-year-old man with fever, hepatosplenomegaly, and a cutaneous foot lesion after a trip to Africa. *N Engl J Med.* 2002;346(26):2069-2076.
19. Ezzedine K, Darie H, Le Bras M, et al. Skin features accompanying imported human African trypanosomiasis: hemolymphatic *Trypanosoma gambiense* infection among two French expatriates with dermatologic manifestations. *J Travel Med.* 2007;14(3):192-196.
20. Kennedy PG. The continuing problem of human African trypanosomiasis (sleeping sickness). *Ann Neurol.* 2008;64(2):116-126.
21. Singh Grewal A, Pandita D, Bhardwaj S, et al. Recent updates on development of drug molecules for human African trypanosomiasis. *Curr Top Med Chem.* 2016;16(20):2245-2265.
22. Priotto G, Kasparian S, Mutombo W, et al. Nifurtimox-eflornithine combination therapy for second-stage African *Trypanosoma brucei* gambiense trypanosomiasis: a multicentre, randomised, phase III, non-inferiority trial. *Lancet.* 2009;374(9683):56-64.
23. Benziger CP, do Carmo GA, Ribeiro AL. Chagas cardiomyopathy: clinical presentation and management in the Americas. *Cardiol Clin.* 2017;35(1):31-47.
24. Andrade DV, Gollob KJ, Dutra WO. Acute Chagas disease: new global challenges for an old neglected disease. *PLoS Negl Trop Dis.* 2014;8(7):e3010.
25. Kransdorf EP, Zakowski PC, Kobashigawa JA. Chagas disease in solid organ and heart transplantation. *Curr Opin Infect Dis.* 2014;27(5):418-424.
26. Rodriguez JB, Falcone BN, Szajnman SH. Detection and treatment of *Trypanosoma cruzi*: a patent review (2011-2015). *Expert Opin Ther Pat.* 2016;26(9):993-1015.
27. Nabavi SF, Sureda A, Daglia M, et al. Flavonoids and Chagas' disease: the story so far! *Curr Top Med Chem.* 2017;17(4):460-466.
28. Wiens MO, Kanters S, Mills E, et al. Systematic review and meta-analysis of the pharmacokinetics of benznidazole in the treatment of Chagas disease. *Antimicrob Agents Chemother.* 2016;60(12):7035-7042.
29. Salomao K, Menna-Barreto RF, de Castro SL. Stairway to heaven or hell? Perspectives and limitations of Chagas disease chemotherapy. *Curr Top Med Chem.* 2016;16(20):2266-2289.
30. Cullen KA, Mace KE, Arguin PM; Centers for Disease Control and Prevention (CDC). Malaria surveillance—United States, 2013. *MMWR Surveill Summ.* 2016;65(2):1-22.
31. Vaishnani JB. Cutaneous findings in five cases of malaria. *Indian J Dermatol Venereol Leprol.* 2011;77(1):110.
32. Leitsch D. Recent advances in the *Trichomonas vaginalis* field. *F1000Res.* 2016;5.
33. Hollman D, Coupey SM, Fox AS, et al. Screening for *Trichomonas vaginalis* in high-risk adolescent females with a new transcription-mediated nucleic acid amplification test (NAAT): associations with ethnicity, symptoms, and prior and current STIs. *J Pediatr Adolesc Gynecol.* 2010;23:312-316.
34. de Brum Vieira P, Tasca T, Secor WE. Challenges and persistent questions in treatment of trichomoniasis. *Curr Top Med Chem.* 2017;17(11):1249-1265.
35. Das S, Kashyap B, Barua M, et al. Nasal rhinosporidiosis in humans: new interpretations and a review of the literature of this enigmatic disease. *Med Mycol.* 2011;49(3):311-315.
36. Lupi O, Tyring SK, McGinnis MR. Tropical dermatology: fungal tropical diseases. *J Am Acad Dermatol.* 2005;53(6):931-951.
37. Cacciò SM, Chalmers RM. Human cryptosporidiosis in Europe. *Clin Microbiol Infect.* 2016;22(6):471-480.
38. Huang DB, White AC. An updated review on *Cryptosporidium* and *Giardia*. *Gastroenterol Clin North Am.* 2006;35(2):291-314, viii.
39. Chalmers RM, Katzer F. Looking for *Cryptosporidium*: the application of advances in detection and diagnosis. *Trends Parasitol.* 2013;29(5):237-251.
40. Painter JE, Gargano JW, Collier SA, et al; Centers for Disease Control and Prevention. Giardiasis surveillance—United States, 2011-2012. *MMWR Suppl.* 2015;64(3):15-25.
41. McKnight JT, Tietze PE. Dermatologic manifestations of giardiasis. *J Am Board Fam Pract.* 1992;5(4):425-428.
42. Escobedo AA, Lalle M, Hrastnik NI, et al. Combination therapy in the management of giardiasis: what laboratory and clinical studies tell us, so far. *Acta Trop.* 2016;162:196-205.
43. Stanley SL Jr. Amoebiasis. *Lancet.* 2003;361(9362):1025-1034.
44. Parshad S, Grover PS, Sharma A, et al. Primary cutaneous amoebiasis: case report with review of the literature. *Int J Dermatol.* 2002;41(10):676-680.
45. Fernández-Díez J, Magaña M, Magaña ML. Cutaneous amebiasis: 50 years of experience. *Cutis.* 2012;90(6):310-314.
46. Maycock NJ, Jayaswal R. Update on *Acanthamoeba* keratitis: diagnosis, treatment, and outcomes. *Cornea.* 2016;35(5):713-720.
47. Flegr J, Prandota J, Sovičková M, et al. Toxoplasmosis—a global threat. Correlation of latent toxoplasmosis with specific disease burden in a set of 88 countries. *PLoS One.* 2014;9(3):e90203.
48. Rand AJ, Buck AB, Love PB, et al. Cutaneous acquired toxoplasmosis in a child: a case report and review of the literature. *Am J Dermatopathol.* 2015;37(4):305-310.
49. Mawhorter SD, Effron D, Blinkhorn R, et al. Cutaneous manifestations of toxoplasmosis. *Clin Infect Dis.* 1992;14(5):1084-1088.
50. Leyva WH, Santa Cruz DJ. Cutaneous toxoplasmosis. *J Am Acad Dermatol.* 1986;14(4):600-605.

Chapter 177 :: Helminthic Infections

:: Kathryn N. Suh & Jay S. Keystone

AT-A-GLANCE

- Helminthic infections are a major cause of morbidity and mortality, particularly in tropical and developing countries.
- The majority of infected individuals has a low worm burden and is asymptomatic.
- Dermatologic symptoms and cutaneous findings may be associated with or present features of many helminthic infections.
- Returned travelers and immigrants from endemic areas may differ in the dermatologic manifestations of helminthic infection.
- Migratory lesions, subcutaneous masses, papular eruptions, urticaria, and pruritus are the most common presenting symptoms of helminthic infections.
- Cutaneous larva migrans is the most common helminthic dermatosis identified.
- Recognition of skin findings or helminthic infections and an appropriate epidemiologic history can guide appropriate investigations and effective therapy.

Helminths (worms) are variably sized multicellular parasites that can infect a wide range of mammals, including humans. Those causing human disease belong to 3 groups: nematodes (roundworms), trematodes (flukes), and cestodes (tapeworms); trematodes and cestodes are collectively referred to as platyhelminths (flatworms). A variety of helminths can infect humans and cause cutaneous findings (Table 177-1).[1,2] This chapter focuses on those helminths that are notable for causing dermatologic disease.

EPIDEMIOLOGY

Globally, helminthic infections are among the most common diseases of humans. However, the true prevalence of helminthiases is difficult to determine, particularly as the majority of infected individuals harbor relatively few worms and are asymptomatic. Large worm burdens and symptomatic disease affect a relatively small proportion of those who are infected.

While some helminths such as *Enterobius vermicularis* and *Toxocara canis* are found worldwide, others are more geographically restricted. Most infections occur in developing tropical or subtropical countries, where environmental conditions are conducive to the completion of the life cycle of many helminths, and the requisite animal hosts and vectors for ongoing transmission exist. In addition, the high population density, poverty, and poor sanitation commonly found in these areas further facilitate the transmission of these diseases. Knowledge of the geographic distribution of specific helminths is important for the clinician, and will help to direct appropriate investigations and management.

Helminthic infections are less prevalent in temperate and northern climates, although some diseases are endemic even in these regions. In developed countries and colder climates, helminthic diseases are more often imported by travelers to or immigrants from endemic areas. Less frequently, helminthic infections in developed nations can be locally acquired (eg, trichinellosis resulting from improperly prepared food) or transmitted via person-to-person spread (eg, enterobiasis).

SKIN DISEASES IN TRAVELERS

Dermatologic disorders are the third most common illness in travelers.[3] Observational studies over the past decade have consistently demonstrated that between 10% and 23% of travelers develop a dermatologic condition during or after travel.[4-11] These figures cannot be generalized to all travelers, however, as studies included only individuals assessed in specialty (travel and tropical medicine) clinics and may also have been subject to geographic biases (because of the specific populations studied and/or the destinations of these individuals).

Infections, including tropical skin diseases, are common causes of dermatoses among travelers. Insect bites, allergic reactions, and other rashes are among the most prevalent noninfectious dermatologic diagnoses in travelers. Of the helminthic skin infections, cutaneous larva migrans (CLM) is by far the most commonly reported in travelers and accounts for up to 25% of all skin diseases in this group.[7-11] Most other helminthic infections that may be associated with dermatologic findings are relatively rare in travelers.

SKIN DISEASES IN IMMIGRANTS AND REFUGEES

The prevalence of dermatologic conditions in immigrants and refugees has not been exhaustively studied,[5,6,9,10] but in general they appear to occur no more frequently than in travelers. These observations are subject to the same biases noted above. The helminths that cause skin findings in this population, and the clinical presentations,

TABLE 177-1

Helminths Causing Cutaneous Disease: Common Dermatologic Findings

SPECIES	LOCALIZED EDEMA	MIGRATORY SKIN LESIONS	NODULES OR MASSES	PAPULES	PETECHIAE	PRURITUS	URTICARIA	ULCER	VESICLE/BULLA
Nematodes (Roundworms)									
Ancylostoma braziliense, Ancylostoma caninum		X		X		X	X		X
Ancylostoma duodenale, Necator americanus (human hookworm)		X				X	X		X
Ascaris lumbricoides						X	X		
Dirofilaria spp.		Rare	X						
Dracunculus medinensis	X[a]	X						X	X
Enterobius vermicularis						X			
Filariae									
Brugia malayi, Brugia timori	X[b]		X						
Loa loa	X[a]	X	X			X	X		
Mansonella ozzardi, Mansonella perstans, Mansonella streptocerca	X[b]			X		X			
Onchocerca volvulus	Rare[a]		X	X		X	X		X
Wuchereria bancrofti	X[b]		X						
Gnathostoma spinigerum, others	X[a]	X	X			X	X		
Strongyloides stercoralis		X		X	X[c]	X	X		
Toxocara canis, Toxocara cati						X	X		
Trichinella spiralis	X[a]		X		X	X	X		
Trematodes (Flukes)									
Fasciola hepatica		X				X	X		
Paragonimus westermani		X	X			X	X		
Schistosoma spp. (human and avian)			X	X		X	X		
Cestodes (Tapeworms)									
Echinococcus granulosis, Echinococcus multilocularis			X						
Spirometra mansonoides, others (sparganosis)		X	X						
Taenia multiceps, others (coenurosis)			X						
Taenia solium (cysticercosis)			X						

[a]Focal or localized edema.

[b]Lymphedema with filarial infections.

[c]Disseminated strongyloidiasis.

Figure 177-1 Onchocercal dermatitis. (Used with permission from Herman Zaiman, MD.)

may differ from those in travelers, however. For example, filarial infections are more commonly encountered in individuals who have resided in endemic areas for prolonged periods rather than in travelers, because they usually require repeated exposures to insect vectors for effective transmission to occur. Strongyloidiasis is also more prevalent in immigrants from endemic areas, particularly southeast Asia, and often presents with eosinophilia and few, if any, abdominal symptoms; most are asymptomatic. Onchocerciasis rarely occurs in short-term (at least 1 month) visitors to endemic areas and characteristically presents as an acute dermatitis with a hyperimmune response manifested by pruritus and rash (Fig. 177-1), despite low parasite loads. In contrast, infected immigrants more commonly have chronic onchodermatitis, with chronic skin changes, including atrophy, hypopigmentation, and lichenification, and onchocercal nodules (Fig. 177-2).

Figure 177-2 Onchocercal nodule over iliac crest. (Used with permission from Jay S. Keystone, MD, FRCPC.)

LIFE CYCLE AND TRANSMISSION OF HELMINTHS

All helminths have complex life cycles that include maturation from eggs (or other infective forms) to larvae (or other immature forms) to adults. Human disease results from ingestion of eggs or other infective forms, or, alternatively, exposure of the skin to infective forms (larvae or cercariae) by direct contact or via the bite of an insect vector. Humans may be the primary hosts for some helminths (eg, *Strongyloides stercoralis*), or may be incidental or accidental hosts (eg, avian schistosomes, animal hookworm, and *T. canis*). Helminths that are well adapted to humans can mature from the infective stage into adult forms in the human host; infection generally persists for the life span of the adult worm, which in some cases can be for many years. In contrast, animal helminths cannot mature into adult forms in humans (who in this setting are therefore "dead-end" hosts), although infection can still cause tissue damage and clinical findings.

In general, helminths do not multiply in the human host. Most helminths (with the notable exception of *S. stercoralis*) are incapable of completing an entire life cycle in the human host, and depend on the environment (eg, soil, water), plants, or other animal hosts or insects, for their survival. Consequently, transmission of infection requires the presence of appropriate environmental conditions, specific intermediate hosts (in whom only the asexual reproductive cycle occurs), and/or specific insect vectors, explaining in large part the localized geographic distributions of many helminthic diseases.

Examples of helminthic diseases acquired by ingestion of infective forms (eggs or metacercariae) in contaminated food or water include *Ascaris lumbricoides* and *Fasciola hepatica*. In ascariasis, swallowed eggs are consumed, larvae are released within the GI tract, and migrate through the portal–systemic circulation to the lungs, from which they are swallowed. Skin disease, such as urticaria, may occur during the larval migration phase. Once in the GI tract, larvae mature into adult worms where sexual reproduction may take place; either eggs or adult worms can be shed in stool. Eggs must mature in soil before releasing infective larvae. In fascioliasis, infective metacercariae ingested on watercress excyst in the small intestine and migrate through the intestinal wall and peritoneum to their target tissue, the biliary tract, where they become adults. Again, skin findings typically occur as immature forms migrate. Eggs produced by adult flukes are passed in feces and become infective for humans only after maturation in a suitable (intermediate) snail host.

Schistosomiasis results from penetration of intact skin by infective cercariae. Dermatologic findings in early disease manifest either at the time of cercarial penetration (swimmer's itch or cercarial dermatitis), or during migration of immature forms (schistosomulae)

from the skin and through tissue to the venous systems of their target organs (bladder or bowel, depending on the infecting species), where they mature into adults. Sexual reproduction leads to the release of eggs into the local circulation. En route to the bladder or bowel, eggs may sometimes become trapped in ectopic tissues, including skin, where they cause a granulomatous reaction. Eggs hatch in fresh water, releasing cercariae that must undergo further maturation in one of several intermediate snail hosts in order to infect humans.

Infection can also result from penetration of intact skin by larvae, as exemplified by human hookworm infection. Larvae then migrate to the circulatory system where they are carried to the lungs, penetrate the alveoli and ascend the bronchial tree, are swallowed, and enter the GI tract. Skin findings may occur during larval migration to the lungs. Maturation into adult worms occurs in the small intestine, where they reproduce and release eggs into stool. Under the appropriate environmental conditions, eggs mature into infective larvae in soil. In contrast, larvae of animal hookworms (eg, *Ancylostoma braziliense*) cannot mature beyond the larval stage in humans and tunnel aimlessly in the skin before the infection eventually extinguishes itself.

Larvae also can be introduced through intact skin by insect bites (eg, in filarial infections). The insect vector and the target tissue both vary according to the infecting species; cutaneous disease may be seen during either migration of larval forms through tissue, or as a result of adult worms in tissue. Microfilariae (larvae) released from mature adult worms are taken up by an insect during a subsequent blood meal, and then undergo maturation to infective forms within the insect before being introduced into another human host.

CLINICAL FEATURES

APPROACH TO THE PATIENT

With the exception of CLM, most travelers and immigrants who present with dermatologic complaints will not have a diagnosis attributable to a helminthic infection. However, clearly these must be considered if the epidemiologic and exposure history and clinical findings are consistent with a helminthic infection, as these are treatable infections that have important clinical implications, such as disseminated strongyloidiasis in an immunocompromised host.

As with all diseases of travelers and immigrants, a thorough history is essential in order to direct the clinician toward the correct diagnosis. The history should focus on aspects related to travel (or residence in endemic areas), general medical conditions, and medications. In addition, specific details of the dermatologic complaints must also be obtained. Finally, the clinician should be knowledgeable about (or know how to find out about) outbreaks of disease that may have been ongoing during an individual's travel or residence in a given area.

EXPOSURE HISTORY: TRAVEL AND AREAS OF RESIDENCE

The travel history (or history of residence in endemic areas) must be thorough in order to elucidate likely exposures to helminths. Specific details may be more readily obtained in recently returned travelers than immigrants, although immigrants are much more likely to be aware of local and endemic diseases (albeit often by local names). Details to be obtained include the exact dates, durations, and locations of travel or residence; purpose of travel; activities or occupations, inquiring specifically about those that would increase exposure to specific helminths; dietary intake; a history of similar signs and symptoms in other family members or fellow travelers; and the use of preventive measures.

The exact destinations of travel (urban versus rural), not only the country or countries visited, are important to obtain. While some diseases may be endemic throughout a world region or area, the prevalence of others may vary greatly, sometimes within a given country. For example, onchocerciasis and loaisis are endemic in Central and West Africa, but generally not in other parts of Africa; and both infections are found only in rural areas, unlike bancroftian filariasis (*Wuchereria bancrofti*) that is often transmitted in urban centers. The risk of disease may not be present in all areas of a country in which a disease is considered to be endemic; for example, schistosomiasis is found in Brazil, but predominantly in the eastern and northeastern regions. Duration of travel or residence in an endemic area (and hence duration of exposure) is relevant for some diseases; schistosomiasis can be acquired after a single exposure to infective cercariae in freshwater, whereas filariasis is often acquired only after numerous bites, and therefore is rare among short-term travelers to endemic areas.

The purpose of travel is also correlated with the likelihood of exposure to specific pathogens. Rural and adventure travelers are more likely to be exposed to helminthic infections than are business travelers, travelers whose itineraries are limited to urban areas, and those whose travels are of shorter durations.

Certain activities and occupations will place individuals at greater risks of helminthic infections while abroad. Examples of common exposures and associated diseases include barefoot walking or walking in open shoes (sandals) (eg, CLM; strongyloidiasis); freshwater swimming in Africa (eg, schistosomiasis); and dietary indiscretions such as consumption of salads or undercooked or contaminated meat or fish (eg, ascariasis, echinococcosis, fascioliasis, gnathostomiasis). Although direct exposure to animals is not a risk factor for helminthic infections, the risk of CLM is greater in areas with a higher prevalence of stray dogs and cats. For those infections that are vector borne, such as filarial infections transmitted by mosquitoes, black flies and deer flies, the use of preventive measures such as appropriate clothing, insect repellent and bed nets can reduce the risk of infection.

GENERAL MEDICAL HISTORY

In addition to the travel history, a general medical history should be obtained. Skin findings may be related to underlying medical conditions, or to any associated treatment for these. The differential diagnosis of skin lesions in a returned traveler or immigrant also includes noninfectious disorders such as contact dermatitis (including to jewelry), drug eruptions, and photosensitivity reactions (that may be precipitated by travel-related medications such as doxycycline). A list of prescription and nonprescription medications or supplements should be obtained, in particular those that may have been started recently and/or prescribed abroad, as well as any recent use of topical medications or products.

DERMATOLOGIC HISTORY

The dermatologic history should include details regarding the initial presentation, morphology, and anatomic distribution of skin lesions; the progression and duration of lesions; time of onset relative to potential exposures; and any associated local and systemic signs and symptoms. While some manifestations of helminthic infections, such as urticaria or maculopapular eruptions, are nonspecific, the differential diagnosis of helminthic dermatoses can often be narrowed based on the description and morphology of the lesion(s) present. For some diseases such as CLM, skin findings are virtually pathognomonic and the diagnosis can be established by history and careful examination of skin lesions, often without the need for additional investigations.

CUTANEOUS FINDINGS OF HELMINTHIC INFECTIONS

Skin lesions caused by helminthic infections can assume a variety of morphologies. The most commonly encountered problem is that of migratory skin lesions. CLM is the most common cause of migratory lesions in general. Subcutaneous nodules, papular eruptions, and urticaria and pruritus are also common manifestations of helminthic infections.

MIGRATORY SKIN LESIONS

Migratory lesions can be caused by multiple helminths. Migratory lesions can be linear (serpiginous) or may be more ill-defined areas of erythema and swelling, and may be painless, painful, or pruritic. Table 177-2 lists the most common helminthic causes of migratory lesions, as well as characteristic features of these lesions.

Serpiginous and linear lesions are most commonly caused by CLM (most frequently caused by *A. braziliense*

TABLE 177-2
Differential Diagnosis of Migratory Skin Lesions

HELMINTH	MORPHOLOGY OF LESION	DESCRIPTION	MOST COMMON LOCATION
Ancylostoma braziliense, Ancylostoma caninum	Serpiginous (cutaneous larva migrans [CLM])	Typically 1 to 3 serpiginous lesions, 3 mm wide and up to 20 cm in length; intensely pruritic, may be vesicobullous; movement up to several cm per day	Feet, buttocks
Ancylostoma duodenale, Necator americanus (human hookworm)	Serpiginous	Pruritic tracks from larval migration	Feet
Dracunculus medinensis	Localized area of edema or swelling with movement beneath	Moving mass may be seen just before emergence of adult worm through skin	Feet
Fasciola hepatica	Migratory subcutaneous swellings	Erythematous, painful, pruritic subcutaneous nodules may have a migratory component; larval track marks also may be seen	Abdomen, back, extremities
Loa loa	Migratory subcutaneous swelling or serpiginous	Migration of adult worm across conjunctivae or under skin	Skin, eye
Gnathostoma spinigerum	Serpiginous (CLM)	Migration of larvae can cause creeping eruption; movement 1 cm per hour	Trunk, upper body
	Migratory subcutaneous swellings (eosinophilic panniculitis)	Intermittent single or multiple erythematous swellings; may be migratory, pruritic or painful; last 1 to 4 weeks, with recurrences in different anatomic areas after variable asymptomatic periods	Thighs
Paragonimus westermani	Migratory subcutaneous swellings or nodules	Firm migratory swellings or nodules, may be migratory; slightly tender and slightly mobile, up to 6 cm in diameter; swellings contain immature flukes	Lower abdomen, inguinal region
Spirometra mansonoides, others (sparganosis)	Migratory subcutaneous swellings	Slow growing, typically painful swellings that may be migratory; may be pruritic	Abdomen, lower extremities
Strongyloides stercoralis (larva currens)	Serpiginous (larva currens)	Movement at 5 to 10 cm per hour; intensely pruritic, transient, but recurrent	Buttocks, groin, trunk, thighs

Figure 177-3 Cutaneous larva migrans. (Used with permission from Jay S. Keystone, MD, FRCPC.)

and *Ancylostoma caninum*; see also "Cutaneous Larva Migrans Syndrome"). Usually 1 to 3 (or more) erythematous, serpiginous, and intensely pruritic lesions caused by intradermal larval migration are present (Fig. 177-3). Serpiginous skin lesions in *S. stercoralis* infection, a pathognomonic manifestation of strongyloidiasis known as larva currens, typically present as recurrent, transient, and rapidly moving skin lesions (Fig. 177-4). Larval migration may occur at rates of 5 to 10 cm per hour, and the lesions usually disappear within hours only to recur over subsequent weeks to years. Linear migratory lesions also can be seen occasionally in human hookworm infection (*Ancylostoma duodenale* and *Necator americanus*) at the site of larval penetration, and in gnathostomiasis (usually relatively slow migration at 1 cm per hour). Linear migratory lesions also can be seen in loaiasis, and result from movement of the adult worm (not larvae) in tissue, typically under the skin or also across the bulbar conjunctivae (Fig. 177-5).

Figure 177-4 Larva currens in chronic strongyloidiasis. Multiple serpiginous, inflammatory lesions are visible on the buttocks.

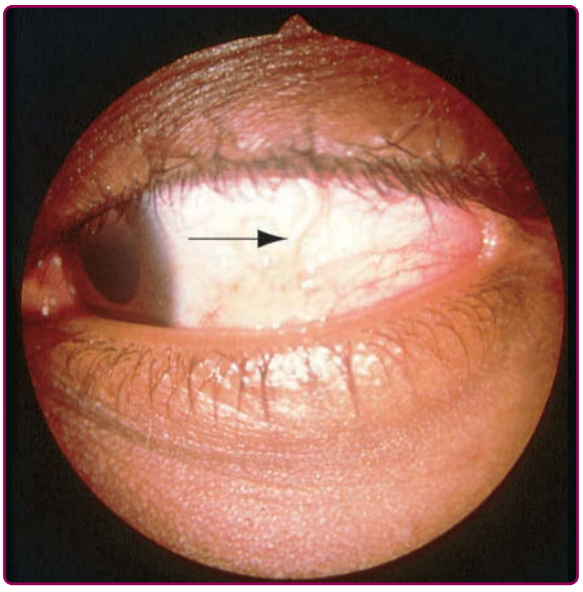

Figure 177-5 Loiasis. Adult worm crossing bulbar conjunctiva of the eye (*arrow*). (Used with permission from Murray Wittner, MD, PhD.)

Migratory subcutaneous swellings and nodules are characteristic of infections caused by *Loa loa*, *Fasciola*, *Gnathostoma*, and *Paragonimus*, and in sparganosis (*Spirometra* spp.). Lesions may be painful or pruritic. Migratory swelling resulting from the movement of adult worms is also seen in dracunculiasis, in which movement within a bullous, vesicular, or edematous lesion on the foot is often noted prior to eruption of the skin lesion and egress of the adult worm (Fig. 177-6). Since the implementation of a global eradication and drinking water monitoring program in endemic

Figure 177-6 Dracunculiasis. (Used with permission from Jay S. Keystone, MD, FRCPC.)

countries, cases of dracunculiasis have decreased dramatically and the disease has almost been eliminated.

SUBCUTANEOUS NODULES AND MASSES

Subcutaneous and soft-tissue masses may have variable characteristics, including overlying erythema, pain or tenderness, and pruritus. They may be single or multiple, and fixed or mobile. Table 177-3 lists the more common etiologies of nodular lesions.

Solitary nodules or masses are found in echinococcosis, filariasis caused by *Brugia malayi* and *W. bancroftii* (both of which may cause scrotal masses in men from lymphatic obstruction), dirofilariasis, and coenurosis (*Taenia multiceps*). *Multiple nodules* are typical of cysticercosis (*Taenia solium* infection), in which small, painless subcutaneous or intramuscular nodules are present, although single nodules can also occur. Subcutaneous cysticercosis, reported commonly in infected individuals in older case series, currently occurs in less than 10% of cases. Most other helminths that manifest as subcutaneous nodules or masses may present with single or multiple lesions. *Painless nodules* are most characteristic of coenurosis, cysticercosis, dirofilariasis, echinococcus, and onchocerciasis. *Painful nodules* are seen in paragonimiasis and sparganosis. Transient painful lesions that resolve and subsequently recur in different anatomic areas are characteristic of *Gnathostoma* infection and loiasis. *Fixed lesions* are typical of cysticercosis, echinococcosis, and onchocerciasis.

PAPULAR AND MACULAR LESIONS

Papules and macules occur in relatively few helminthic infections (Table 177-4). Papular lesions may occur at sites of skin penetration by infective larvae or cercariae in CLM and schistosomiasis. In CLM, papules are typically in the feet or buttocks, similar to the distribution of migratory lesions. In schistosomiasis, exposure to infected freshwater (for avian or human schistosomes) or salt water (avian schistosomes) may cause pruritus, which is followed rapidly by a papular eruption in previously sensitized individuals. Chronic

TABLE 177-3
Differential Diagnosis of Nodular Skin and Subcutaneous Lesions

HELMINTH	DESCRIPTION OF NODULAR LESION	MOST COMMON LOCATION
Brugia malayi	Hydrocele/scrotal mass caused by lymphatic obstruction	Scrotum
Dirofilaria spp.	Single erythematous, well-defined, firm nodule or mass, usually 1 to 5 cm in diameter; usually asymptomatic but may be tender; rarely may be migratory	Head and neck, breasts, extremities, scrotum
Dracunculus medinensis	Edematous lesion/mass may be seen just before emergence of adult worm through skin; movement underneath lesion due to movement of adult worm	Feet
Echinococcus spp.	Firm subcutaneous (or muscular) nodules or masses; usually single but may be multiple; may feel fluctuant; nontender. Rarely with fistulization and inflammation of skin (*Echinococcus multilocularis*). True cutaneous lesions are rare	Abdomen
Gnathostoma spinigerum	Intermittent single or multiple erythematous swellings; may be migratory, pruritic or painful; last 1 to 4 weeks, with recurrences in different anatomic areas after variable asymptomatic periods	Trunk, upper body, thighs
Loa loa	Calabar swellings–localized angioedema, 5 to 20 cm in diameter, usually lasting 2 to 4 days but recurrent; caused by migration of adult worms	Eyelid, upper extremities, periarticular regions (especially knee, wrist)
Mansonella perstans	Calabar swellings–localized swellings lasting 1 to 4 days, recurrent	Face, upper extremities (especially forearms), hands
Onchocerca volvulus	Well-defined, fixed, painless nodules containing adult worms in deep dermis and subcutaneous tissue	Over bony prominences including skull (South America), ribs, iliac crest (Africa), others
Paragonimus westermani	Firm swellings or nodules, may be migratory; slightly tender and slightly mobile, up to 6 cm in diameter; swellings contain immature flukes	Lower abdomen, inguinal region
Spirometra mansonoides, others (sparganosis)	Slow growing, typically painful swellings that may be migratory; may be pruritic	Abdomen, lower extremities
Taenia multiceps, others (coenurosis)	Solitary subcutaneous (or muscular) nodule, usually 2 to 6 cm in diameter; painless	Trunk (especially intercostal regions), anterior abdominal wall; head, neck, extremities less commonly
Taenia solium (cysticercosis)	Painless, fixed, well-circumscribed rubbery subcutaneous nodules in 50% of patients with cysticercosis; may be single or multiple; average size 2 cm in diameter	Trunk, extremities
Wuchereria bancrofti	Hydrocele/scrotal mass caused by lymphatic obstruction	Scrotum

TABLE 177-4
Differential Diagnosis of Papular and Macular Lesions

HELMINTH	DESCRIPTION	MOST COMMON LOCATION
Ancylostoma *braziliense, Ancylostoma caninum* (CLM)	Pruritic erythematous papule(s) within days of larval penetration; may be vesicular; also papular larva migrans	Feet, buttocks
Ancylostoma duodenale, Necator americanus (human hookworm)	Ground itch: in sensitized individuals, pruritic papular lesions at sites of larval entry; may be vesicular	Feet, hands
perstans, Mansonella streptocerca	Multiple pruritic papules; hypopigmented and hyperpigmented macules and lichenification may be present	Upper chest (*M. streptocerca*)
Onchocerca volvulus	*Acute:* multiple pruritic papules, may become vesicular or pustular; may be erythematous and edema may be present	Face, trunk, extremities
	Chronic: intensely pruritic, flat papules (3 to 9 mm) or macules, may be hyperpigmented or lichenified	Shoulders, buttocks, waist, extremities
Schistosoma spp. (avian)	Erythematous papular or maculopapular lesions, may be vesicular or urticarial; intensely pruritic; onset within 24 hours of saltwater or freshwater exposure, lasts 1 to 3 weeks	Any surface exposed to water
Schistosoma spp. (human)	*Acute:* erythematous papular and urticarial lesions in previously sensitized individuals; onset within hours of freshwater exposure, lasting 1 week	Any surface exposed to water
	Chronic: bilharziasis cutanea tarda; slightly pigmented, 2- to 4-mm, firm, pruritic, oval papules or papulonodular lesions, may be verrucous or polypoid; may appear in crops; caused by granulomatous reaction to eggs in skin	Trunk, especially periumbilical region; buttocks, genitalia

papular lesions (bilharziasis cutanea tarda) may be present in chronic schistosomiasis. Papular lesions also may be manifestations of acute or chronic infection with *Onchocerca volvulus*, and have been reported in disseminated and chronic strongyloidiasis.

URTICARIA AND PRURITUS

Pruritus (Table 177-5) may be present in the absence of skin findings, either as a primary symptom of infection (eg, filariasis caused by *Mansonella perstans* or *O. volvulus*),

TABLE 177-5
Helminthic Infections Causing Urticaria and Pruritus

HELMINTH	COMMENTS
Nematodes (Roundworms)	
Ancylostoma braziliense, Ancylostoma caninum	Pruritus and urticaria after skin penetration and during larval migration
Ancylostoma duodenale, Necator americanus (human hookworm)	Pruritus and urticaria after skin penetration and during larval migration
Ascaris lumbricoides	Pruritus and urticaria during larval migration (with Loeffler syndrome)
Enterobius vermicularis	Pruritus ani
Filariae	
Loa loa	Pruritus and urticaria
Mansonella ozzardi, Mansonella perstans, Mansonella streptocerca	Pruritus occurs early, may be only symptom
Onchocerca volvulus	Pruritus and urticaria in acute or chronic disease
Gnathostoma spinigerum, others	Pruritus and urticaria during larval migration
Strongyloides stercoralis	Pruritus and urticaria after skin penetration and during larval migration, including chronic infection; pruritus ani
Toxocara canis, Toxocara cati	Pruritus and urticaria during larval migration
Trichinella spiralis	Pruritus and urticaria during larval migration
Trematodes (Flukes)	
Fasciola hepatica	Urticaria during migration of adult flukes
Paragonimus westermani	Urticaria during larval migration
Schistosoma spp. (human and avian)	Transient urticaria with pruritus within 24 hours of exposure to cercariae; urticaria with Katayama fever (acute schistosomiasis)

or before the onset of skin lesions (eg, schistosomiasis). Pruritus is a common feature of many helminthic infections, with the noteworthy exceptions of lymphatic filariasis (eg, caused by *Brugia* spp. and *W. bancrofti*) and tapeworm infections. *Pruritus ani* is characteristic of strongyloidiasis and enterobiasis (pinworm infection).

Urticaria are often present in the acute phase of infection, during which larvae or other immature forms actively invade human tissues. Helminths that infect humans by penetration of skin may cause a local urticarial rash at the sites of penetration. Migration of immature forms in the circulation may cause a generalized hypersensitivity reaction; urticaria is common during this phase of infection by many helminths (see Table 177-5). Chronic spontaneous urticaria, recurrent episodes of wheals, and/or angioedema lasting 6 weeks or longer, is associated with parasitic infections, including *T. canis* and *Anisakis simplex*.[12]

LOCALIZED EDEMA

Although edema or swelling may be an associated feature of many helminthic skin lesions, localized edema may is highly suggestive of the presence of certain infections.

Eyelid edema in particular may be seen in gnathostomiasis and loiasis (Calabar swelling), and violaceous periorbital edema is characteristic of trichinosis. *Limb edema* is highly suggestive of lymphatic filariasis (caused by *Brugia* spp. and *W. bancrofti*). Rarely, limb edema ("gros bras camerounais") may occur with acute onchocerciasis.[13]

CHANGES IN SKIN TEXTURE OR PIGMENTATION

Hypopigmentation of skin can be a feature of chronic infection caused by *O. volvulus* ("leopard skin"), *M. perstans*, and *Mansonella streptocerca*. Hypopigmented macules are the most common cutaneous findings in streptocerciasis. In onchocerciasis, depigmentation is characterized by perifollicular pigmentation within macular or minimally depressed areas, with yellow-brown hypopigmentation, and is particularly noticeable in dark-skinned individuals. *Hyperpigmentation* can also occur with mansonellosis caused by *M. streptocerca*, as well as in chronic schistosomiasis and onchocerciasis. *Lichenification* is a feature of onchocerciasis ("sowda" in Arabic), and to a lesser extent mansonellosis; hyperpigmented plaques eventually coalesce and become lichenified over time, particularly over the lower extremities and in young adults in Yemen and Sudan. *Verrucous lesions* may be seen in chronic schistosomiasis (bilharziasis cutanea tarda). *Ichthyosis* also may be present in chronic onchocerciasis.

OTHER CUTANEOUS MANIFESTATIONS

Petechiae may be present with trichinellosis and are frequently seen in disseminated strongyloidiasis, in which they are particularly prominent on the trunk. *Vesicles* or *bullae* may be seen at the site of larval skin penetration in up to 15% of patients with CLM, in human hookworm infection, and occasionally in dracunculiasis, onchocerciasis, and strongyloidiasis. *Ulcers* are uncommon findings in most helminthiases, with the exception of dracunculiasis; multiple ulcers are common. Ulcerative genital lesions, particularly in women, may occasionally be present in schistosomiasis and tend to occur more often with acute disease (eg, in travelers).

Erythema nodosum is rare in helminthic infections, but has been described as a clinical finding with hookworm infection, visceral larva migrans, sparganosis, and lymphatic filariasis. It also has been reported in 1 patient in conjunction with ascariasis,[14] although erythema nodosum in this patient may also have been caused by concomitant *Chlamydia pneumoniae* pneumonia. *Erythema multiforme* has been reported in CLM. *Eosinophilic panniculitis* has been documented in gnathostomiasis and toxocariasis. *Eosinophilic cellulitis* (Wells syndrome) may occur in ascariasis, onchocerciasis, and toxocariasis. *Eosinophilic folliculitis* has been rarely described in CLM and in toxocariasis. *Exfoliative dermatitis* of the affected limb may occur during the resolution phase of acute adenolymphangitis or following secondary bacterial-mediated cellulitis in *W. bancrofti* infection.

INTERVAL BETWEEN EXPOSURE AND ONSET OF SYMPTOMS

The time of onset of skin disease (and other key symptoms) relative to travel and likely exposures can be helpful in establishing a diagnosis (Table 177-6). Some infections, such as cercarial dermatitis in schistosomiasis or CLM, become evident within hours to days of exposure, whereas others may not present until months to years after infection.

PROGRESSION AND DURATION OF SKIN LESIONS

Skin lesions resulting from helminthic infections can persist for variable durations (see Table 177-6). For helminths that cause infection by penetration of skin, local dermatologic findings last only for a short time during infection by human helminths, but may persist longer with animal helminths (eg, CLM). During the chronic phase of infection, however, the duration of cutaneous manifestations varies depending on the infecting helminth. For infections in which skin findings are the result of inflammatory reactions to larvae (eg, onchocerciasis) or eggs (eg, schistosomiasis) in tissues, clinical manifestations can persist for the life span of the adult worms, which in some cases may be years. Even with appropriate therapy for chronic infections, chronic skin changes may not resolve completely.

TABLE 177-6
Interval from Exposure to Onset, and Duration, of Cutaneous Symptoms

SPECIES	TYPICAL INTERVAL BETWEEN EXPOSURE AND ONSET OF CUTANEOUS SYMPTOMS (RANGE)	TYPICAL DURATION OF SYMPTOMS (RANGE)
Nematodes (Roundworms)		
Ancylostoma braziliense, Ancylostoma caninum	Usually 1 to 5 days, typically within 1 month	2 to 14 weeks, rarely longer (up to 2 years)
Ancylostoma duodenale, Necator americanus (human hookworm)	Ground itch: 1 to 2 days Urticaria: 1 to 3 weeks	1 to 2 weeks
Ascaris lumbricoides	Urticaria: 10 to 14 days	Several weeks
Dirofilaria spp.	Subcutaneous nodules: several months	
Dracunculus medinensis	Edema, vesicle or bulla formation, ulceration with worm protrusion: 1 year	Several weeks
Enterobius vermicularis	Pruritus ani: weeks to months	30 to 45 days (self-limited) or until treated
Filariae		
Brugia malayi, Brugia timori	Hydrocele: years	Years
Loa loa	Calabar swelling, urticaria: >6 months to years Adult worm migration: years	Several days to weeks Years
Mansonella ozzardi, Mansonella perstans, Mansonella streptocerca	Pruritus, dermatitis, hypopigmentation: unknown	Years
Onchocerca volvulus	Onchodermatitis: months to years Onchocercoma: years	Years Years
Wuchereria bancrofti	Hydrocele: years	Years
Gnathostoma spinigerum, others	Creeping eruption: 1 to 2 days Migratory masses: 3 to 4 weeks	Up to 3 months 1 to 2 weeks, but recur for years
Strongyloides stercoralis	Larva currens: months to years Chronic urticaria, larva currens: years Petechiae, purpura (in disseminated disease): variable	Hours, but recur for years Years —
Toxocara canis, Toxocara cati	Urticaria: weeks to months	Years
Trichinella spiralis	Eyelid edema, petechiae: 1 to 3 weeks	2 to 3 weeks
Trematodes (Flukes)		
Fasciola hepatica	Urticaria: 6 to 12 weeks (with abdominal pain, fever, weight loss)	Several weeks to months
Paragonimus westermani	Urticaria: 2 days to 2 weeks Subcutaneous nodules: 2 to 3 weeks	Several weeks Years
Schistosoma spp. (human and avian)	Swimmer's itch: <24 hours Urticaria: 2 weeks to months Bilharzia cutanea tarda: years	Days to 3 weeks 2 to 10 weeks Years
Cestodes (Tapeworms)		
Echinococcus granulosis, Echinococcus multilocularis	Years	Years
Spirometra mansonoides, others (sparganosis)	20 days to 3 years	Years
Taenia multiceps, others (coenurosis)	Months to years	Years
Taenia solium (cysticercosis)	Variable—months to years	Years

NONCUTANEOUS FINDINGS

Apart from the skin, symptoms of helminthic infections tend to most frequently involve the respiratory, GI, and neurologic systems, and the eye. Disease may also occur in many other tissues as a consequence of aberrant migration of larvae and adult worms.

Because the skin lesions of many helminthic infections tend to occur in acute (larval) infection, and nondermatologic symptoms often result from the presence of adult helminths or their products of reproduction, it is important to appreciate that skin findings often precede other manifestations of disease. However, dermatologic and nondermatologic symptoms may coexist in some acute infections, as well as in chronic infections.

PULMONARY DISEASE

Loeffler syndrome, a hypersensitivity syndrome consisting of dyspnea, wheezing, cough, and fever, typically

results from larval migration through lung tissue and may be seen in infection caused by human hookworms, *Ascaris*, and *Strongyloides*. Because these symptoms are a result of larval migration, they begin shortly after infection and may occur coincidentally with an urticarial rash. Loeffler syndrome typically lasts for 1 to 2 weeks. Diffuse pulmonary infiltrates and nodules may be seen during larval migration in acute schistosomiasis (Katayama syndrome) that occurs several weeks after exposure.[15]

Other pulmonary symptoms are generally not simultaneous with dermatologic symptoms, occurring after larvae have matured into adult forms. *Hemoptysis* is uncommon; among helminthic infections it is most frequently a feature of paragonimiasis, but also can be a symptom of echinococcal disease and disseminated strongyloidiasis. *Pulmonary nodules* may be seen in dirofilariasis, a zoonotic filariasis transmitted by mosquitoes, in conjunction with subcutaneous swellings and ocular lesions. *Pleural effusions* also occur rarely, and in helminthic infections are more likely to be eosinophilic. The most common parasitic etiology is *Paragonimus*, but effusions also can be caused by a variety of other helminths.[16]

GASTROINTESTINAL DISEASE

Abdominal pain is most commonly seen in ascariasis and human hookworm infection, after dermatologic manifestations have resolved, and in strongyloidiasis. Abdominal pain in strongyloidiasis is typically epigastric. Because *S. stercoralis* can complete its entire life cycle within the human host, larvae and adult worms may coexist simultaneously, and thus abdominal symptoms may be coincident with larva currens and pruritus ani. Right-upper-quadrant abdominal pain also may be a manifestation of acute fascioliasis, caused by larval penetration of the hepatic capsule; urticaria also may be present during this phase. *Diarrhea* can be a symptom with heavy *Strongyloides* or *Schistosoma* infections, and rarely hookworm infection. *Hepatitis* may be seen in acute fascioliasis. *Liver masses* or abdominal masses may be the presenting symptom of echinococcosis; hypodense liver lesions are commonly seen in fascioliasis as well. *Hepatomegaly* is one of the classic findings of visceral larva migrans (toxocariasis), typically occurring in children and usually in conjunction with fever, respiratory symptoms (wheezing) and occasionally urticaria. Hepatomegaly also has been reported as a finding of several other helminthiases including fascioliasis. *Granulomatous hepatitis* may also cause hepatomegaly, and is most commonly encountered in schistosomiasis (the result of granuloma formation around eggs in the periportal circulation), but also can be a feature of ascariasis (eggs), strongyloidiasis (larvae), and toxocariasis (larvae). *Biliary disease* may be a result of either occlusion of the biliary tract by adult worms or flukes (eg, ascariasis, fascioliasis) or from compression of the biliary tract by a mass lesion (eg, echinococcosis). *Hepatic fibrosis* can be a complication of chronic schistosomiasis.

NEUROLOGIC DISEASE

Helminthic infections most commonly affecting the CNS include neurocysticercosis and strongyloidiasis. *Seizures*, typically focal but sometimes generalized, are the most common presentation of neurocysticercosis. Neurocysticercosis should be considered in the presence of subcutaneous cysticercosis. The clinical presentation of neurocysticercosis is determined by the number, size, and location of intracranial lesions, as well as the viability of cysts (dying cysts produce more inflammation and are more likely to be associated with seizures). Globally, neurocysticercosis is among the most common causes of seizure disorders. Seizures may also occur with infection caused by *Schistosoma* spp. and *Paragonimus*, and in sparganosis. *Meningitis* can be seen in strongyloidiasis. *S. stercoralis* larvae may be visualized in cerebrospinal fluid, but more commonly meningitis is a result of Gram-negative bacteremia caused by enteric organisms that are carried across the bowel mucosa during larval penetration in disseminated disease; abdominal petechiae or purpura are often present. *Eosinophilic meningitis* or *meningoencephalitis* may be a feature of cysticercosis, gnathostomiasis, paragonimiasis, schistosomiasis, toxocariasis, angiostrongyliasis, baylisascariasis, and, less commonly, strongyloidiasis, among others.[17] *Mass lesions* or *cysts* can be caused by *Echinococcus* spp., *Paragonimus, Taenia* spp. causing coenurosis, and *Toxocara*. In schistosomiasis, intracranial infection is most commonly associated with *Schistosoma japonicum* infection and may result from the development of granulomas around ectopic eggs. Other CNS manifestations of helminthic infections, including brain abscesses, transverse myelitis and myelopathy, and intracranial hemorrhage, may occasionally be seen.

OCULAR DISEASE

Although ocular involvement is most frequently associated with infections caused by *Loa loa* and *O. volvulus* (river blindness), disease involving the conjunctiva, sclera, and all chambers of the eye can be occasional features of many helminthic infections. Onchocerciasis is a major cause of blindness worldwide. Ocular symptoms and findings are often related to the presence of larvae or microfilariae migrating through and causing inflammatory reactions in various chambers of the eye and the retina. Onchodermatitis is common in chronic infection, and skin findings and eye disease may be present simultaneously. Ocular disease is also one of the most frequent presentations of sparganosis.

Conjunctivitis is the typical ocular manifestation of gnathostomiasis and sparganosis, but also has been reported in a variety of other infections. *Keratitis* is most commonly present in onchocerciasis and coenurosis. *Uveitis* is characteristic of onchocerciasis and schistosomiasis. *Retinitis* or *chorioretinitis* may be present in onchocerciasis and toxocariasis. *Migration of adult worms* through the eye may be seen in loiasis and dirofilariasis, and less commonly in fascioliasis and gnathostomiasis,

and gives rise to a foreign-body sensation in the eye. *Granulomatous nodules* in the eye or conjunctivae may be present in toxocariasis, schistosomiasis and *M. perstans* infection. *Eyelid swelling* (Calabar swelling) may be the result of infection by *Loa loa* and *M. perstans.*

LYMPHADENOPATHY

Lymphadenopathy is an uncommon finding in helminthic infections, with the exception of filarial infections. *Regional lymphadenopathy* can be present with lymphatic filariasis (caused by infection with *Brugia* spp. and *W. bancrofti*), as well in loiasis, *M. streptocerca* infection, and onchocerciasis. *Generalized lymphadenopathy* may be present in lymphatic filariasis, and in acute schistosomiasis (Katayama fever).

OTHER SYMPTOMS

Fever and urticaria can be features of Loeffler syndrome, which may be the initial manifestation of infection due to *A. lumbricoides*, human hookworm, *S. stercoralis*, and in toxocariasis. Fever in acute trichinellosis usually occurs in conjunction with other symptoms including myalgias, cough, facial edema, and splinter hemorrhages in the nails. Fever is also a finding in acute schistosomiasis (Katayama fever) and fascioliasis, and also may be present in other helminthiases, typically during larval migration. *Gram-negative sepsis* may occur in disseminated strongyloidiasis, a result of translocation of enteric bacteria as *Strongyloides* larvae penetrate the intestinal lumen; a petechial or purpuric eruption, particularly on the trunk, has been well reported in disseminated strongyloidiasis (see section "Strongyloidiasis").

COMPLICATIONS

Secondary complications including excoriation and secondary superinfection are not uncommon, especially when pruritic lesions are present. Skin changes, such as lichenification and pigment changes, as noted above, may be persistent. Other significant complications of specific cutaneous helminthic diseases are discussed below.

ETIOLOGY AND PATHOGENESIS

Cutaneous manifestations can be seen at every phase of the helminth life cycle in humans: by larvae or cercariae during skin penetration; during larval migration and tissue invasion; and because of the presence of eggs and adult worms in skin and soft tissues. Skin lesions also may occur during either early (acute) or chronic infection.

The pathogenesis of skin lesions in helminthic infections is varied. Direct penetration of skin may lead to a localized immune response, as seen in CLM or cercarial dermatitis. Migration of helminths can cause a generalized immune response (urticaria, maculopapular eruptions), particularly from migration of larvae or immature forms (eg, with *Ascaris* or *Toxocara* infection); a local inflammatory reaction to adult worms or eggs may also develop, as occurs with cutaneous nodules caused by *O. volvulus* and in schistosomiasis and cysticercosis, or subcutaneous swellings caused by *Loa loa* and *Gnathostoma*. Skin changes can also result from disruption of the normal skin structures because of lymphedema, as with filarial infections. Finally, ill-defined systemic immune reactions, such as erythema nodosum or erythema marginatum, rarely reported manifestations of several helminthic infections, also may be present. Skin findings of helminthic infections do not generally result from hematogenous spread of parasites, in contrast to many bacterial and viral infections.

Helminths induce a dramatic expansion of the T helper 2 (Th2) lymphocyte subset, with elevated levels of immunoglobulin E (IgE), peripheral eosinophilia, and an increase in tissue mast cells. It is unclear whether these Th2-derived responses are important in the protective immune response against the parasite or are responsible for immune-mediated pathology, or both.[12] Despite high levels of IgE and other features of Th2 cell activation, allergic responses are rarely observed in infected individuals except during the invasive phase of infection, when pruritus and/or urticaria may occur. Infected hosts have evolved elaborate immune evasion strategies to permit long-lived helminthic infections, including the induction of tolerance to parasite antigens.

DIAGNOSIS

The definitive diagnosis of most helminthic infections rests on identification of 1 or more of the various stages of the helminth (eg, larvae, eggs, adult worms) in tissue specimens, blood, or excretions (stool or urine). Occasionally, adult worms may be observed during medical procedures (eg, endoscopy or surgery). In many helminthic infections causing skin disease, however, cutaneous findings occur during the larval migration phase, and hence precede the presence of adult worms and the production of eggs or larvae that may not be detectable for weeks or months. The diagnosis of a helminthic infection is therefore often difficult during the penetration and acute phase of the disease; the diagnosis may be suspected because of associated epidemiologic and clinical findings. In chronic infection, the diagnosis can be established based on the identification of parasite eggs or larvae, or occasionally adult worms, but the sensitivity of stool examination can also vary depending on the parasite.

SUPPORTIVE STUDIES

Results of routine blood tests, including eosinophilia, are neither sensitive nor specific for diagnosing helminthic infections. While most hematologic

and biochemical tests are nonspecific, the presence of eosinophilia can suggest specific diseases when combined with clinical findings and/or the exposure history, and should prompt additional investigations.[18,19] Diagnosis of helminthic infections also may be aided by results of ancillary investigations (eg, chest radiography; abdominal imaging).

LABORATORY TESTING

Eosinophilia: Eosinophilia, defined as an absolute eosinophil count of greater than 500 eosinophils per mm^3, is not typical of infections caused by most pathogens other than helminths; helminth antigens are effective stimuli for inducing eosinophilia. Levels of eosinophils in the blood can be affected by host factors, including the response to other bacterial, viral, or fungal coinfections (which lower eosinophil counts), the use of systemic steroids (which lower eosinophil counts), and an immunosuppressed state. In helminthic infection, eosinophil counts vary according to the stage of infection and the infecting helminth. Tissue invasion is the key factor in the development of eosinophilia. For example, eosinophilia is not a feature of intestinal lumen-dwelling helminths, except during the larval migration phase for those helminths in which this occurs; in contrast, helminthic infections in which adults, larvae, or eggs persist in tissues are typically associated with eosinophilia. Eosinophil counts are usually normal during the penetration phase and reach their highest levels (often markedly elevated) during the invasive phase of the cycle. Eosinophilia often accompanies the urticarial rash during the invasive stage of infection; thereafter, the eosinophil count often decreases slowly and may fluctuate more or less above the normal value during the chronic phase of infection. However, the detection of helminthic infection in returned travelers who present with asymptomatic eosinophilia is often very low. A transient hypereosinophilia may be also observed approximately 10 days after the start of effective antihelminthic treatment, and eosinophilia may persist for one to two months after successful helminth eradication.

Table 177-7 lists the helminths that typically cause eosinophilia. Severe or high-grade eosinophilia (an eosinophil count of >3000/mm^3) is suggestive of infection caused by relatively few of these parasites (Table 177-7).

Additional Laboratory Tests: Other laboratory tests may be abnormal but may not aid with establishing a specific diagnosis. Other than leukocytosis, which may reflect only the presence of eosinophilia, hematologic studies obtained when skin lesions are present are unlikely to be helpful. Evidence of disseminated intravascular coagulation may be present in disseminated strongyloidiasis. Iron-deficiency anemia is a feature of established hookworm infection, but occurs well after the resolution of cutaneous disease.

Biochemical testing may reveal abnormal liver function tests and enzymes in acute fascioliasis and toxocariasis, when urticaria may be present. Granulomatous hepatitis may be associated with a disproportionately elevated alkaline phosphatase. Most biochemical tests are otherwise nonspecific and are of limited use in determining the correct diagnosis.

TABLE 177-7
Helminthic Infections That May Be Associated with Eosinophilia

DISEASE	COMMENTS
Ascariasis[a]	Marked eosinophilia in early infection
Cysticercosis	
Dirofilariasis	
Dracunculiasis	
Fascioliasis[a]	Marked eosinophilia in early infection
Filariasis[a]	Eosinophilia may be marked especially in loiasis and with pulmonary symptoms
Gnathostomiasis[a]	
Hookworm infection (CLM)[a]	Can be marked during larval migration
Paragonimiasis[a]	Marked eosinophilia in early infection
Schistosomiasis[a]	Especially during early infection (Katayama fever)
Sparganosis	
Strongyloidiasis[a]	Eosinophilia may be moderate in chronic infection
Toxocariasis (VLM)[a]	

[a]Marked eosinophilia (eosinophil count >3000/mm^3) may be present.
CLM, cutaneous larva migrans; VLM, visceral larva migrans.

Serology: Serologic assays are available for many helminthic infections, but vary greatly in their sensitivity and specificity. Their utility is also limited by cross-reactivity of tests among the various helminths, especially with filarial antibodies. Another significant limitation to serologic testing relates to the delayed appearance of antibodies after acute infection. Antibody production typically begins during the invasive (acute) phase of disease, when skin lesions are clinically apparent, but titers may be negative at this time. Serologic tests may not become positive for 2 months or more after the onset of infection. Although the presence of antibodies often supports or establishes the clinical diagnosis, antibodies may reflect prior infection and do not necessarily imply active or acute disease, and titers often remain positive for years after helminthic infections have been eradicated. The exception is strongyloidiasis, where a decrease in antibody titer is often used as a test of cure.

Molecular Testing: Molecular testing by polymerase chain reaction is highly sensitive and specific, and may be especially useful in the diagnosis of mixed infections.[20,21] However, its use is limited by the technical requirements of testing and cost, and it is not readily available in many diagnostic laboratories in North America.

Pathology: Additional diagnostic tests may include pathologic examination of tissue specimens or blood (for microfilariae), or microscopic examination of other specimens (eg, bronchoscopy specimens in disseminated strongyloidiasis).

RADIOLOGIC INVESTIGATIONS

Symptomatic patients with Loeffler syndrome and acute schistosomiasis will typically have diffuse patchy infiltrates or nodules on chest radiographs; urticaria may be present at this time. Radiologic findings consistent with acute respiratory distress syndrome may be present in disseminated strongyloidiasis. Chest radiographs also may be abnormal in paragonimiasis (cystic lesions, pleural effusion). Pleural effusions may be present in infection caused by other helminths, as previously noted. A solitary pulmonary nodule may be noted in dirofilariasis.

Abdominal imaging (ultrasonography, CT, or MRI) should be directed by abdominal symptoms and is suggestive of a diagnosis in relatively few helminthic infections. Septated hepatic cysts are characteristic of cystic echinococcosis, whereas in alveolar hydatid disease hepatic lesions are usually solid. Hepatic masses or nodules (hypodense lesions up to 10 mm in size) may be visualized on ultrasonography or CT scan in fascioliasis. Tracts or tunnels representing migration of immature flukes through the liver also may be noted in fascioliasis.

Imaging studies of the CNS are diagnostic in neurocysticercosis, in which CT or MRI usually reveals parenchymal cysts and occasionally intraventricular or subarachnoid cysts. In cerebral gnathostomiasis, worm-like tracts have been noted.

MANAGEMENT

Treatment varies depending on the specific diagnosis. Recommended and alternate therapies for treatment of helminthic infections causing cutaneous findings can be found in recent reviews and guidelines.[22] Table 177-8 lists treatment of selected infections that are discussed in detail below.

SPECIFIC HELMINTHIC DISEASES OF MAJOR IMPORTANCE

The sections that follow describe key features of the most important helminthic infections. CLM syndrome and enterobiasis (pinworm infection) are encountered relatively frequently by clinicians in developed countries. In comparison, filariasis and schistosomiasis are uncommon, but may lead to chronic dermatologic complications. Strongyloidiasis, also seen relatively infrequently, must be considered in the appropriate clinical context; failure to diagnose and treat the infection may have significant clinical consequences for immunocompromised patients in particular, in whom disseminated strongyloidiasis carries a significant mortality risk. For these reasons, these 5 infections are described below.

CUTANEOUS LARVA MIGRANS SYNDROME

The terms *CLM* and *creeping eruption* are often used interchangeably when referring to disease caused by animal hookworms. Even though CLM is the most common cause of creeping eruption,[23] technically CLM refers to a syndrome in which the larvae of any animal nematode infect humans *and* in which the infected human is a dead-end host. These nematodes include animal hookworms (mostly from dogs and cats), *Gnathostoma* species, and agents of zoonotic filariases including Spirurina type X, *Pelodera strongyloides*, and zoonotic *Strongyloides* species. By definition, CLM syndrome does *not* include diseases in which creeping eruption is the result of: (a) nonlarval forms of parasites (eg, dracunculiasis, loiasis); (b) larval forms of human nematodes such as *S. stercoralis* (larva currens); or (c) larval forms of trematodes such as *Fasciola gigantica*. Creeping eruption refers to the clinical finding (sign) of a migratory serpiginous lesion, but does not denote the etiology of the lesion.

Hookworm-related CLM (creeping verminous dermatitis, sand-worm eruption, plumber's itch, duck hunter's itch), is most commonly caused by animal hookworms, and in particular *A. braziliense*. Other skin-penetrating hookworm larvae that produce similar disease include *A. caninum, Uncinaria stenocephala* (hookworm of European dogs), and *Bunostomum phlebotomum* (hookworm of cattle). *A. caninum* causes eosinophilic enteritis as well as cutaneous disease. Cats and dogs are hosts for *Ancylostoma ceylanicum* and *A. caninum*.

Clinically, the hallmark of CLM is a creeping eruption. The different helminthic diseases causing creeping eruption can often be distinguished based on the epidemiologic and exposure history, the characteristics of the cutaneous trail(s) (location, number, width and length, rate of movement) (see Table 177-2), and the duration of symptoms (see Table 177-6), in addition to other clinical and laboratory findings. The correct diagnosis is required for appropriate treatment.

EPIDEMIOLOGY

Hookworm-related CLM is widely distributed but is most commonly found in tropical and subtropical areas, especially the southeastern United States, Caribbean, Africa, Central and South America, India, and Southeast Asia. Contact with sand or soil contaminated with animal feces is required for infection to occur; infection can be prevented by avoiding skin contact with fecally contaminated soil.

CLINICAL FEATURES

Infection results from direct skin penetration by infective larvae of animal hookworms. Larvae migrate up to several centimeters a day, usually between the stratum germinativum and stratum corneum, and induce a localized eosinophilic inflammatory reaction.

TABLE 177-8

Treatment of Selected Helminthic Infections Causing Cutaneous Diseases

DISEASE	PRIMARY THERAPY (ADULT DOSES)	ALTERNATE THERAPY (ADULT DOSES)	COMMENTS
Cutaneous larva migrans	Albendazole 400 mg by mouth daily × 3 days	Ivermectin 200 µg/kg daily × 1 to 2 days Thiabendazole, topical 10% Albendazole, topical	
Enterobiasis	Albendazole 400 mg by mouth once	Mebendazole 100 mg once Pyrantel pamoate 11 mg/kg (maximum: 1 g) once	Treatment should be repeated 2 weeks after the first treatment, regardless of the agent used. Treatment of household contacts recommended
Filariasis	Endosymbiotic *Wolbachia* bacteria may play a role in filarial development and host response for all filariasis except loiasis. Doxycycline 100 to 200 mg by mouth daily × 6 to 8 weeks can reduce *Wolbachia* and block microfilariae production Antihistamines or glucocorticoids may be required to reduce the allergic reaction secondary to microfilariae disintegration during the treatment of filarial infections In patients with microfilariae in the blood, diethylcarbamazine (DEC) may cause severe allergic or febrile reactions. When microfilariae are present, it is advisable to start with a low dose and escalate (eg, 50 mg on day 1; 50 mg thrice daily on day 2; 100 mg by mouth thrice daily on day 3; then full dose)		
Brugia malayi, Brugia timori	DEC 2 mg/kg by mouth thrice daily × 12 days		In chronic disease, elevation of the affected limb, compression stockings, good skin care, treatment of superficial fungal and bacterial infections are important. Surgical treatment can sometimes be considered
Loa loa	DEC 3 mg/kg by mouth thrice daily × 21 days		Surgical removal of adult worm may be required
Mansonella ozzardi	Ivermectin 200 µg/kg by mouth once		Ivermectin reduces microfilarial burden. DEC is ineffective. Doxycycline may be effective
Mansonella perstans	Doxycycline 100 to 200 mg daily × 6 to 8 weeks		DEC, mebendazole. and ivermectin are ineffective
Mansonella streptocerca	DEC 2 mg/kg by mouth thrice daily × 12 days	Ivermectin 150 µg/kg by mouth once	
Onchocerca volvulus	Ivermectin 150 µg/kg by mouth once, then every 6 months until asymptomatic		DEC must not be used as rapid killing of worms can cause ocular side effects
Wuchereria bancrofti	DEC 2 mg/kg by mouth thrice daily × 12 days		Single-dose combination of albendazole 400 mg plus either ivermectin 200 µg/kg or diethylcarbamazine 6 mg/kg is effective in suppressing *W. bancrofti* microfilaremia. Chronic disease: see *Brugia* spp.
Schistosomiasis			Systemic steroids (eg, prednisone) may be helpful during acute disease
Schistosoma haematobium, Schistosoma intercalatum, Schistosoma mansoni	Praziquantel 40 mg/kg/day in 1 or 2 doses × 1 day	Oxamniquine 15 mg/kg by mouth once (***S. mansoni* only**)	Oxamniquine unavailable in the United States, and is generally not as effective as praziquantel, but has been effective in some areas when praziquantel is less effective. In East Africa, increase oxamniquine dose to 30 mg/kg. In Egypt and South Africa, increase oxamniquine dose to 30 mg/kg/day × 2 days. Oxamniquine is contraindicated in pregnancy
Schistosoma japonicum, Schistosoma mekongi	Praziquantel 60 mg/kg/day in 2 or 3 doses × 1 day		
Strongyloidiasis	Ivermectin 200 µg/kg/day × 2 days	Albendazole 400 mg by mouth twice daily × 7 days	In immunocompromised patients or disseminated disease, it may be necessary to prolong or repeat therapy. Combination therapy (ivermectin plus albendazole) may be indicated in disseminated disease

DEC, diethylcarbamazine.

Figure 177-7 Cutaneous larva migrans with vesicular and bullous lesions. (Used with permission from Jay S. Keystone, MD, FRCPC.)

In contrast to human hookworm infection, animal hookworm larvae cannot mature beyond the larval stage in humans; they are unable to invade deeper tissues and die after days to months.

Typical skin lesions appear 1 to 5 days after exposure. The characteristic lesion of hookworm-related CLM is an erythematous, raised, and vesicular, linear, or serpentine cutaneous trail that progresses at a rate of 2 to 3 cm per day (see Fig. 177-6). Vesicular, papular or bullous lesions may be seen at the site of larval skin penetration in up to 15% of patients with CLM (Fig. 177-7). Lesions are approximately 3 mm wide and may reach 15 to 20 cm in length. They can be single or multiple, are intensely pruritic, and may be painful. The hookworm larvae advance a few millimeters to a few centimeters daily. The most common anatomic sites (usually 3 to 4 cm from the penetration site) include the feet (see Fig. 177-3) and buttocks (Fig. 177-8), although other sites may be affected. Excoriation and impetiginization are uncommon (10% of cases). Skin lesions usually last between 2 and 8 weeks, but have been reported to last for as long as 2 years. Systemic signs and symptoms (wheezing, dry cough, urticaria) are rare.

Figure 177-8 Cutaneous larva migrans of the buttocks. (Used with permission from Jay S. Keystone, MD, FRCPC.)

A less frequent but well-reported clinical presentation is that of hookworm folliculitis, consisting of 20 to 100 eosinophilic follicular papules and pustules confined to a particular area of the body, usually the buttocks. Patients with folliculitis usually also have creeping eruption. Papular lesions without CLM (papular larva migrans) are a less-common presentation. Other cutaneous signs related to the subcutaneous migration of helminth larvae have been occasionally described, such as urticaria and panniculitis.

DIAGNOSIS

The diagnosis of hookworm-related CLM is based on clinical findings. Hookworm folliculitis also can be diagnosed clinically when creeping eruption is also present; if not, skin biopsy may be required. Histopathologic findings include larvae trapped within the follicular canal, the stratum corneum, or the dermis, together with an inflammatory eosinophilic infiltrate.[24] Skin scrapings in patients with folliculitis may reveal live and dead larvae when examined by light microscopy with mineral oil.

MANAGEMENT

Both albendazole (400 mg by mouth daily for 3 days) and ivermectin (200 µg/kg daily for 1 or 2 days) are effective therapies for hookworm-related CLM[25,26] (see Table 177-8). Treatment of hookworm folliculitis may require repeated treatments. Topical therapy with thiabendazole, 10% albendazole, or ivermectin also may be used, but may be less effective than oral therapy. Thiabendazole is often not readily available. Because larvae have usually migrated beyond the end of the visible skin lesion and their location cannot be reliably determined, surgical excision or cryotherapy is not recommended.

ENTEROBIASIS (PINWORM INFECTION)

EPIDEMIOLOGY

Enterobiasis (threadworm, pinworm, or seatworm infection; oxyuriasis) is caused by *E. vermicularis*. It is among the most widely distributed helminthic infections and is found worldwide. Transmission is by the fecal–oral route; infection results from ingestion of *E. vermicularis* eggs (eg, by contact with contaminated fomites or via contaminated fingers) and rarely by inhalation and ingestion of aerosolized eggs in dust. The highest rates of infection are among children. Infection can be prevented by treatment of infected cases and good personal hygiene.

CLINICAL FEATURES

Nocturnal anal and perianal pruritus is the primary clinical feature. The worm may be seen around the anus. The skin may become impetiginized, and cellulitis may occur as a complication.

Women may rarely develop vulvovaginitis; vulvar granuloma and an association with Bartholin cysts also have been described. Nondermatologic extraintestinal manifestations are rare but have been reported. Epidemiologically, enterobiasis is often associated with an intestinal protozoan, *Dientamoeba fragilis*, which may produce GI upset. A recent study detected *D. fragilis* DNA on washed pinworm ova.[27]

DIAGNOSIS

The diagnosis is established by identification of *E. vermicularis* eggs in the perianal area, most effectively by the sticky-tape method. A piece of tape, sticky side out, can be attached to a wooden tongue depressor and firmly pressed against the perianal skin immediately on waking in the morning, before defecation or bathing. The tape is removed and placed sticky side down on a slide, and examined under a microscope. Sensitivity of this method is 70% with 3 specimens and increases to almost 100% with 7 specimens. Eggs are found in stool in only 10% to 15% of infections. Occasionally, the adult worm (white, up to 4 mm in length) is found in the perianal area, vulva, vagina, or underclothes. When ectopic sites are involved, the parasite may be identified in tissue sections.

DIFFERENTIAL DIAGNOSIS

The differential diagnosis includes strongyloidiasis, atopic dermatitis, contact dermatitis, and neurodermatitis.

MANAGEMENT

Enterobiasis is self-limited if reinfection does not occur. Treatment with 1 dose of albendazole 400 mg, mebendazole 100 mg, or pyrantel pamoate 11 mg/kg, is effective (see Table 177-8). Treatment of household members is also recommended, as household transmission is common. Treatment should be repeated once, 2 weeks after the first course of therapy, as medications are relatively ineffective against developing larvae and newly ingested eggs. Specific personal hygiene measures are also important for eradication of infection; these include wearing underwear and pajamas to sleep, bathing in the morning, keeping fingernails short, changing underwear daily and bedsheets weekly, and dusting the environment to remove eggs.

FILARIASIS

Filarial infections have been broadly grouped into 3 categories of disease based on the location of disease: lymphatic, cutaneous, and body cavity. Morbidity is almost entirely attributable to those species that cause lymphatic disease, and to a lesser extent cutaneous disease. Body cavity infection, caused by *Mansonella ozzardi*, is usually asymptomatic and is not discussed further.

EPIDEMIOLOGY

Lymphatic filariasis is caused mainly by *W. bancrofti* (bancroftian filariasis), which causes 90% of disease, and *B. malayi* (Malayan filariasis), which accounts for only 10% of all cases.[28] Infection caused by *Brugia timori* is rare. Lymphatic filariasis is widely distributed in both urban and rural areas of tropical and subtropical areas, with the largest number of infections occurring in India, South Asia, East Asia, and the Pacific Islands, and sub-Saharan Africa. *W. bancrofti* is also endemic in northern parts of South America (Guyana, Surinam, and some coastal regions of Brazil). In developed countries, infections are seen primarily in immigrants and persons with prolonged visits to endemic areas. Infection is transmitted to humans by mosquitoes, and can be prevented by avoidance of mosquito bites. The incubation period is usually 5 to 18 months, during which time microfilariae migrate to the lymphatic system, mature into adults, mate, and release microfilariae (larvae); occasionally symptoms develop within 3 months of exposure. Lymphatic filariasis is first acquired in childhood, often with as many as one-third of children in endemic areas infected before the age of 5 years.[29] The characteristic symptoms typically occur years after infection and the prevalence of clinical disease increases after age 20 years in endemic areas. Adult worms live an average of 10 to 15 years, and microfilariae probably 6 to 12 months.

Cutaneous filariasis is caused by *Loa loa*, *M. perstans*, *M. streptocerca*, and *O. volvulus*. Loiasis is endemic in rural areas of Central and West Africa, affecting an estimated 3 to 13 million residents. *Loa loa* is transmitted by the day-biting *Chrysops* fly; infection can be prevented by avoiding bites from *Chrysops* in endemic areas, diethylcarbamazine chemoprophylaxis, and treatment of infected humans to reduce the source of parasites. Symptoms usually begin an average of 24 months after exposure, but can begin as early as 4 months or as late as a decade or more after infection. The adult worm can live longer than 20 years in the human host.

Infection caused by both *M. perstans* and *M. streptocerca* is often asymptomatic. *M. perstans* is endemic in sub-Saharan Africa, as well as parts of Central and South America, where it is transmitted by *Culicoides* midges. Like lymphatic filariasis, infection during childhood is common, and reinfection may occur.[30] In highly endemic areas, the prevalence of infection may be as high as 80%. *M. streptocerca* is endemic in forested areas of West and Central Africa. Transmission is also by infected midges.

Onchocercosis (river blindness; erysipelas de la costa in Mexico and Guatemala; sowda in Arabic speaking areas; craw-craw in West Africa) is concentrated in rural areas of equatorial Africa and the Arabian peninsula,

and in Latin America. Onchocerciasis is transmitted by black-flies of the genus *Simulium.* In the human, infective larvae mature to adult worms that are encapsulated in fibrous tissue and reside in nodules in the subcutaneous tissue and deep fascia. The incubation period is usually 1 to 2 years with a range of months to several years, although microfilariae may first appear 3 to 15 months after exposure; symptoms may precede microfilaremia but often develop only after months or years of infection. Microfilariae can survive in humans for up to 2 to 3 years, and adult worms for 10 to 15 years. The primary means of preventing onchocerciasis are through vector control and mass treatment with ivermectin of the population in endemic areas.

CLINICAL FEATURES

Lymphatic Filariasis (*Brugia malayi, Brugia timori; Wuchereria bancrofti*): Clinical manifestations may be acute, chronic, or recurrent. Initial infection may be subclinical but may also cause recurrent lymphangitis with characteristic retrograde progression (beginning in the affected lymph node and moving distally), lymphadenitis, orchitis, epididymitis, or, occasionally, fever. Lymphangitis typically recurs 6 to 10 times per year, with each episode lasting 3 to 7 days. The affected body part clinically appears normal between early episodes, although during the resolution of the acute phase of *W. bancrofti* filariasis, there may be extensive exfoliation of the skin of the affected limb. Intermittent fevers and adenolymphangitis can recur for the lifetime of the adult worm. Travelers (>1 month) to endemic areas less frequently acquire infection but may present with more intense inflammatory reactions to filarial parasites. The findings may include lymphangitis, lymphadenitis, groin pain from the associated lymphatic inflammation, urticaria, and peripheral eosinophilia.

Chronic disease with sequelae of lymphatic obstruction (lymphedema, elephantiasis, hydrocele, and chyluria) becomes evident 10 to 15 years after infection. The skin over the involved area can become hypertrophic, verrucous, and fibrotic with redundant skin folds (Fig. 177-9). Fissures, ulceration, secondary bacterial infection, and gangrene may occur. The lower extremity, scrotum, and penis are most commonly affected, and less frequently the upper extremity, breast, and vulva are involved. Although antiparasitic treatment does not reverse the late findings of scarring and lymphatic obstruction, a 6-week course of doxycycline can reduce mild-to-moderate lymphedema independent of active filarial infection by reducing vascular endothelial growth factor.[31]

The differential diagnosis for lymphatic filariasis includes acute infection that can resemble bacterial lymphangitis and other causes of nodular lymphangitis (eg, sporotrichosis, leishmaniasis). Other causes of lymphedema and elephantiasis must also be considered during evaluation of chronic disease.

Cutaneous Filariasis: Loaisis (*Loa loa*): The characteristic finding of loiasis is the Calabar swelling (Fig. 177-10), a localized area of angioedema caused by migration of adult worms through subcutaneous tissues. Calabar swellings usually begin years after infection, typically around joints of the upper extremities, generally last 2 to 4 days, and may be associated with pruritus or pain. They range in size from 5 to 20 cm in diameter and may recur in different locations. Fatigue, myalgias, arthralgias, and fever are rare. Adult worms may be seen moving across the bulbar conjunctiva of the eye (see Fig. 177-5) and eyelid. Pruritus may also occur. High-grade peripheral eosinophilia, leukocytosis, and elevated IgE levels are often present.

The differential diagnosis includes other causes of migratory and nodular skin lesions (see Tables 177-2 and 177-3).

Figure 177-9 Lymphatic filariasis. (Used with permission from Jay S. Keystone, MD, FRCPC.)

Cutaneous Filariasis: Mansonelliasis (*Mansonella perstans, Mansonella streptocerca*): Cutaneous manifestations of *M. perstans* infection include Calabar-like swellings, typically in the

Figure 177-10 Calabar swelling in loiasis. (Used with permission from Jay S. Keystone, MD, FRCPC.)

forearms, hands and face, and pruritus with or without a papular rash. The exact interval between infection and onset of symptoms is unclear. Pruritus, papular lesions, and hypopigmented, hyperpigmented, or lichenified macules, typically found on the upper chest, are seen with *M. streptocerca* infection. Eosinophilia is often present in *Mansonella* infections, but also may be from the high prevalence of coinfection with other filarial or helminthic infections.

Cutaneous Filariasis: Onchocerciasis (*Onchocerca volvulus*): Individuals with onchocerciasis may be asymptomatic. Clinical manifestations most commonly involve the skin and eye. Heavy infections can result in blindness from chronic keratitis or retinitis. Six different patterns of skin changes have been described in onchocerciasis: acute and chronic papular onchodermatitis (see Fig. 177-1), lichenified onchodermatitis, atrophy, depigmentation, and onchocercal nodules (see Fig. 177-2). More than one pattern of skin involvement may be present simultaneously, or one pattern of skin involvement may evolve into another pattern.

Pruritus is the most prominent and persistent symptom of infection. Acute papular onchodermatitis most often involves the face, extremities, and trunk, and includes widespread small pruritic papules, vesicles and pustules, sometimes with associated erythema and edema. Short-term visitors to endemic regions typically present with acute pruritus and rash (see Fig. 177-1),[32] and demonstrate immune hyperresponsiveness despite low levels of parasites[33]; skin nodules and eye involvement are usually absent. After exposures in forested areas of West and Central Africa, travelers and expatriates may have an acute form of onchocerciasis characterized by acute pruritic and erythematous swelling of a limb known as *gros bras camerounais*[13] or onchocerciasis-associated limb swelling.[34]

The skin lesions of chronic papular onchodermatitis are macules and lichenoid papules varying in size from 3 to 9 mm in diameter. Pruritus is common, and postinflammatory hyperpigmentation may be present. The most commonly affected anatomic areas are the buttocks, shoulders, and waist (see Fig. 177-1). Palpable asymptomatic onchocercal nodules containing the adult worm involve the deep dermis and subcutaneous tissue (see Fig. 177-2), and occur over bony prominences such as the skull, iliac crest, knee, rib, sacrum, scapula, and trochanter.

Diagnosis is made by finding microfilariae in the skin by biopsy or skin snips (superficial 2- to 4-mm snips of the upper dermis placed in saline and incubated for 24 hours; the fluid is then examined for microfilariae). Peripheral eosinophilia and elevated IgE levels are common findings.

The differential diagnosis for onchocercal nodules includes other parasitic causes of nodules (see Table 177-3) and epidermal inclusion cysts. Acute onchodermatitis may resemble miliaria, insect bites, scabies or eczema. Chronic onchodermatitis may resemble a chronic or lichenoid eczema or atopic dermatitis. Skin changes resembling lichenified onchodermatitis can be the result of conditions causing significant pruritus or rubbing. Atrophic changes resemble those associated with aging. Onchocercal depigmentation may be confused with postinflammatory hypopigmentation or depigmentation.

DIAGNOSIS

Eosinophilia, sometimes high-grade, and elevated IgE levels are common in filarial infections. Diagnosis rests primarily on demonstration of microfilariae in blood (for lymphatic filariasis, loiasis, and cutaneous filariasis caused by *Mansonella* species; note that daytime blood specimens are appropriate for all except bancroftian filariasis, which requires nocturnal specimens for diagnosis) or in skin snips (for *Mansonella* and *Onchocerca* infections). However, persons with active filarial infection may not be microfilaremic. Microfilariae may not appear in blood until 5 to 6 months after infection in loiasis. Diagnosis also can be established through identification of the adult worm.

Filarial serology is often very sensitive but is nonspecific because of cross-reaction with other helminthiases. A positive serologic test for bloodborne species should be followed by both a blood examination for larvae and test for filarial antigen, to confirm whether serology represents an active infection or a previous one.

Infiltrates may be present on chest radiography in individuals with lymphatic filariasis and tropical pulmonary eosinophilia, an aberrant immune response to the infection. Inguinal lymph node ultrasonography may show active adult worms ("filarial dance sign"), more commonly seen in men than in women. Lymph node biopsy is contraindicated.

MANAGEMENT

Management of filariasis depends on the infecting species. Table 177-8 summarizes treatment of filariasis.

SCHISTOSOMAL INFECTIONS

EPIDEMIOLOGY

Cercarial dermatitis (swimmer's itch) occurs worldwide and may be acquired by contact with infective cercariae of many species of nonhuman schistosomal parasites in both freshwater and salt water. Attack rates during outbreaks usually range from 55% to 100% of those exposed, with highest attack rates in those with a history of previous cercarial dermatitis.

An estimated 200 million people worldwide have schistosomiasis (bilharziasis) and over half a billion live in endemic areas. Infection can be caused by *Schistosoma haematobium*, *Schistosoma intercalatum*, *Schistosoma japonicum*, *Schistosoma mansoni*, and *Schistosoma mekongi*. Humans are the only important reservoir

for *S. haematobium*, which is prevalent in Africa and the Middle East. *Schistosoma mansoni* is endemic in the same areas, as well as parts of the Caribbean and South America; *S. intercalatum* in central Africa; *S. japonicum* in China, Indonesia, and the Philippines; and *S. mekongi* primarily in Cambodia and Laos.

Infection can be acquired after a brief exposure in an endemic area, often in travelers,[35-37] typically after swimming, wading, rafting, or bathing in slow-moving freshwater in endemic areas. Attack rates in nonimmune, exposed persons (eg, travelers) can be as high as 100%. Cutaneous manifestations can be seen at every phase of the infection.

CLINICAL FEATURES

Clinical findings of cercarial dermatitis are confined to the skin and are usually distributed on skin surfaces exposed directly to water. Pruritus may begin while swimming, followed rapidly by the appearance of an erythematous macular rash that persists for several hours. Ten to 15 hours after exposure, papules, vesicles, and urticaria develop. Marked pruritus is characteristic. Symptoms peak 48 to 72 hours after exposure, and gradually resolve spontaneously over the next several weeks.

Cercariae of *S. haematobium, S. intercalatum, S. japonicum, S. mansoni,* and *S. mekongi* can penetrate intact skin within 30 seconds to 10 minutes and may elicit a local inflammatory response (penetration phase). The first exposure to cercariae typically results in erythema and pruritus that resolve within hours. In those previously sensitized, a pruritic, erythematous, papular, and urticarial rash develops, usually lasting 1 week. Migration of the larvae (schistosomulae) usually occurs 2 to 6 weeks after exposure and leads to an acute parasitic hypersensitivity reaction with circulating immune complexes. This invasive phase (Katayama fever or acute schistosomiasis) has historically been described with *S. japonicum* (Katayama fever, sensu stricto), *S. mansoni,* and, to a lesser extent, with *S. haematobium*. Symptoms of acute schistosomiasis are most prominent in primary infection in nonimmune persons and include fever, fatigue, myalgia, cough, and headache that may persist for several weeks. Abdominal symptoms and diarrhea also may be present. Urticaria, purpura, subungual hemorrhages, and edema of the face, the extremities, genitals, and trunk may be seen during the invasive phase.

Chronic infection may be asymptomatic, or associated with abdominal pain (*S. mansoni*, *S. japonicum*) or hematuria (*S. haematobium*). Chronic dermal schistosomiasis (bilharziasis cutanea tarda) may begin after years of infection and result from a granulomatous inflammatory reaction to the deposition of eggs in the dermis (Fig. 177-11), which may continue for the life span of the adult worm (10 years or more). It is seen primarily in persons who have lived in endemic regions. Lesions are skin-colored or slightly pigmented, 2- to 4-mm firm, pruritic, oval papules that appear in crops and clusters, typically on the trunk and especially the periumbilical region, and remain unchanged without treatment. Lesions also appear in the genital and buttocks areas, especially on the vulva in women and the scrotum and penis in men. Chronic lesions may also include painless, skin-colored, pink, or brown eroded papules and warty, vegetative, polypoid lesions that may be ulcerated and necrotic, with fistulous tracts. Chronic skin disease can be complicated by lymphedema and elephantiasis, secondary bacterial infection, and squamous cell carcinoma.

Figure 177-11 Ectopic deposition of *Schistosoma mansoni* eggs.

DIFFERENTIAL DIAGNOSIS

The differential diagnosis of acute schistosomiasis includes other causes of urticaria. Bilharziasis cutanea tarda of the genitals and buttocks must be differentiated from syphilis, condyloma latum, condyloma acuminatum, other granulomatous diseases, malignancy, and hemorrhoids.

DIAGNOSIS

Cercarial dermatitis is largely a clinical and epidemiologic diagnosis. In schistosomiasis, prominent eosinophilia may be present in early infection, especially during the invasive phase, and subsequently fluctuates more or less above the normal value during the chronic phase. Onset of eosinophilia may lag behind appearance of clinical symptoms. Acute disease can be suspected based on the history of exposure and cercarial dermatitis, although many patients do not develop the dermatitis. Identification of eggs in the stool or urine occurs only after the acute phase of infection, generally 2 to 3 months after the onset of infection. Similarly, serology does not become positive until approximately 2 months after infection.

MANAGEMENT

Cercarial dermatitis is self-limited and does not require specific therapy. Table 177-8 outlines management of schistosomiasis.

STRONGYLOIDIASIS

EPIDEMIOLOGY

Strongyloidiasis is caused by *S. stercoralis*, which is endemic to Africa, Asia, Southeast Asia, and Central and South America. Disease is also found in the Caribbean, and to a much lesser extent in Europe, Japan, Australia, and parts of the southern United States. Humans are the only hosts. Infection caused by *Strongyloides fuelleborni*, found sporadically in Africa and Papua New Guinea, is relatively rare. The prevalence of infection can be high in endemic areas, as well as among institutionalized mentally impaired persons, in former prisoners of war, and in refugees and immigrants from endemic areas. Most infected persons have low worm burdens and are persistently infected for life, often with minimal or no symptoms.

The life cycle of *Strongyloides* helminths differs from that of most other helminths in that an entire parasite life cycle may be completed within the human host. Infection typically results from penetration of skin or mucous membranes by infective larvae, usually from soil; the risk of infection is high for persons with frequent soil contact (eg, walking barefoot) in warm, moist areas contaminated by human feces. Filariform larvae travel via the circulatory system to the lungs where they penetrate the alveoli, ascend the trachea, are swallowed, and then mature into adult worms in the small intestine. Although sexual reproduction does take place within the intestine, adult females are also parthenogenetic (capable of reproduction without males). Eggs are deposited in the intestinal mucosa, hatch, and release rhabditiform larvae, which are excreted in the stool to begin another "free-living" cycle, developing into adults in soil where they reproduce sexually and give rise to infective filariform larvae. However, rhabditiform larvae in the bowel may also transform directly into filariform larvae (the "parasitic cycle") that penetrate the perianal skin and/or intestinal mucosa and enter the circulation, and begin another cycle of infection (autoinfection). In the appropriate clinical setting this may lead to disseminated disease (hyperinfection syndrome).

Appropriate sanitation and avoidance of soil contact by skin in endemic areas reduce the risk of infection. Persons with a history of prior residence or activities that place them at an increased risk for strongyloidiasis should be evaluated for presence of the infection, and should be treated even if asymptomatic. This is especially important in persons who receive or will receive immune suppressing therapy.

CLINICAL FEATURES

Cutaneous manifestations may be seen at any phase of infection. Following skin penetration, an urticarial eruption or larva currens may develop. Larva currens, a migratory serpiginous and intensely pruritic lesion caused by intradermal migration of larvae, can be differentiated from CLM by the high rate of movement (up to 5 to 10 cm per hour). Larva currens typically disappears within a few hours, only to recur over the course of weeks to years. Perianal larva currens may be present (see Fig. 177-4) and is pathognomonic of chronic infection. Lesions on the buttocks and in the perianal region result from larvae exiting the GI tract and reinfecting the host by penetrating the perianal skin. Persons chronically infected with *Strongyloides* may also experience pruritus ani and chronic urticaria, which may be complicated by prurigo nodularis or lichen simplex chronicus. The dermatologic manifestation of hyperinfection and disseminated strongyloidiasis is a rapidly and progressively diffuse petechial and purpuric eruption, often with a reticular pattern, typically involving the trunk and proximal extremities (Fig. 177-12).[38,39] The "thumbprint sign," a unique pattern of periumbilical purpura resembling multiple thumbprints,[40] also may be seen.

During the invasive phase of the infection, transient pulmonary manifestations (cough, wheezing, infiltrates) are manifestations of pulmonary migration and may be associated with urticaria. Chronic strongyloidiasis gives rise to nonspecific GI complaints (epigastric pain, nausea, vomiting, diarrhea, constipation, malabsorption, weight loss).

COMPLICATIONS

Hyperinfection syndrome is the most severe complication, typically occurring in the presence of impaired cellular immunity as seen with use of systemic steroids but also with other immunocompromised states, including human T-cell lymphotropic virus (HTLV)-1

Figure 177-12 Disseminated strongyloidiasis, with nonpalpable purpura on the abdominal wall. (Reprinted with permission from Grossman ME, Roth J. *Cutaneous Manifestations of Infection in the Immunocompromised Host*. Baltimore, MD: Lippincott, Williams & Wilkins; 1995.)

infection. Interestingly, HIV infection is not associated with an increased risk of disseminated disease.

Insidious GI symptoms may be present in hyperinfection syndrome. Pulmonary disease is the most common extraintestinal manifestation of hyperinfection syndrome and is characterized by diffuse pulmonary infiltrates with dyspnea, cough, wheezing, or hemoptysis. Diarrhea and abdominal pain occur frequently, with inflammation leading to small-bowel-wall edema; ileus may develop in late stages. In uncontrolled hyperinfection, filariform larvae also penetrate organs not normally involved in the life cycle, including the urinary tract, liver, brain, and skin. The finding of filariform larvae in stool may be an early sign of hyperinfection even in those with minimal symptoms. Gram-negative bacillary infections including bacteremia, peritonitis, meningitis and sepsis may result from the concurrent migration of bacteria and larvae across the bowel wall. The mortality rate for disseminated disease is approximately 50%.

DIAGNOSIS

Peripheral eosinophilia is present in up to 80% of patients with intestinal disease. Eosinophilia may be high grade during larval migration, but is rarely a feature of disseminated infection (although pulmonary eosinophilia may be noted in the latter), and may be absent in patients on systemic steroids and who are otherwise severely immunocompromised. In chronic disease, the eosinophil level fluctuates and is often mildly elevated (mild to moderate increase) but may be normal. Hence, the absence of eosinophilia does not rule out strongyloidiasis.

The diagnosis of larva currens is based on its characteristic clinical features. The identification of larvae in the stool, small bowel contents, and, rarely, in other body fluids confirms the diagnosis. Larvae first appear in the stool 2 to 4 weeks after exposure. Multiple stool examinations are often necessary to make the diagnosis; a single stool specimen may fail to detect larvae in up to 70% of cases, although sensitivity approaches 100% with 7 consecutive stool samples. Although the agar plate method is a very good test that has a sensitivity of 90%,[41] it is not readily available. A stool sample is placed on solid bacterial medium, incubated, and subsequently examined for bacterial tracks created by larvae dragging enteric bacteria as they migrate across the plate. Serology has become the test of choice, with a sensitivity of approximately 90%, but lacks specificity and may cross-react with other helminthic infections (in particular filariasis, ascariasis, and acute schistosomiasis). However, because strongyloidiasis is potentially fatal, and most individuals are not infected with other helminths, except in the tropics, the lack of sensitivity is not clinically relevant. Because studies show that antibody levels drop significantly over the first year following successful therapy, serology is often used as a test of cure.[42] Skin biopsy of the larva currens eruption often fails to reveal larvae, whereas they may be visualized in biopsy specimens of purpuric and petechial lesions with hyperinfection.

MANAGEMENT

Treatment of strongyloidiasis in asymptomatic individuals is often successful. Ivermectin 200 µg/kg daily for 2 days is the recommended therapy (see Table 177-8). Albendazole 400 mg twice daily for 7 days appears to be a less-effective alternative, although data are more limited; the drug is not approved by the U.S. Food and Drug Administration for this indication.

In contrast, patients with disseminated disease may require prolonged or repeated courses of therapy; some experts also suggest that combination therapy with ivermectin and albendazole be used in this setting. Patients with concurrent HTLV-1 infection may require lifetime therapy, given intermittently, owing to the inability of the host to eliminate the parasite. If possible, immunosuppressant therapy should be discontinued in those with hyperinfection.

For patients in whom strongyloidiasis is suspected epidemiologically or clinically and who require immunosuppression therapy, *Strongyloides* therapy should be given "on spec" if the diagnosis cannot be ruled out in a timely manner prior to initiating immunosuppressants.

REFERENCES

1. Lupi O, Downing C, Lee M, et al. Mucocutaneous manifestations of helminth infections: nematodes. *J Am Acad Dermatol*. 2015;73:929.
2. Lupi O, Downing C, Lee M, et al. Mucocutaneous manifestations of helminth infections: trematodes and cestodes. *J Am Acad Dermatol*. 2015;73:947.
3. Caumes E. Skin diseases. In: Keystone JS, Freedman DO, Kozarsky PE, eds, et al. *Travel Medicine, Third Edition*. e Philadelphia, PA: Elsevier; 2013:487-500.
4. Ansart S, Perez L, Vergely O, et al. Illness in travelers returning from the tropics: a prospective study of 622 patients. *J Travel Med*. 2005;12:312.
5. Freedman DO, Weld LH, Kozarsky PE, et al. Spectrum of disease and relation to place of exposure among ill returned travelers. *N Engl J Med*. 2006;354:119.
6. O'Brien DP, Leder K, Matchett E, et al. Illness in returned travelers and immigrants/refugees: the 6 year experience of two Australian infectious diseases units. *J Travel Med*. 2006;13:145.
7. Ansart S, Perez L, Jaureguiberry S, et al. Spectrum of dermatoses in 165 travelers returning from the tropics with skin diseases. *Am J Trop Med Hyg*. 2007;76:184.
8. Lederman ER, Weld LH, Elyazar IR, et al. Dermatologic conditions of the ill returned traveler: an analysis from the GeoSentinel Surveillance Network. *Int J Infect Dis*. 2008;12:593.
9. Herbinger KH, Seiss C, Nothdurft HD, et al. Skin disorders among travellers returning from tropical and non-tropical countries consulting a travel medicine clinic. *Trop Med Int Health*. 2011;16:1457.
10. Stevens MS, Geduld J, Libman M, et al. Dermatoses among returned Canadian travellers and immigrants: surveillance report based on CanTravNet data, 2009-2012. *CMAJ Open*. 2015;3:E119-E126.

11. Herbinger KH, Alberer M, Berens-Riha N, et al. Spectrum of imported infectious diseases: a comparative prevalence study of 16,817 German travelers and 977 immigrants from the tropics and subtropics. *Am J Trop Med Hyg*. 2016;94:757.
12. Kohlkir P, Balakirski G, Merk HF, et al. Chronic spontaneous urticaria and internal parasites—a systematic review. *Allergy*. 2016;71:308.
13. Nozais JP, Caumes E, Datry A, et al. Apropos of 5 new cases of onchocerciasis edema [in French]. *Bull Soc Pathol Exot*. 1997;90:335.
14. Bergler-Czop B, Lis-Swiety A, Kamińska-Winciorek G, et al. Erythema nodosum caused by ascariasis and *Chlamydophila pneumoniae* pulmonary infection—a case report. *FEMS Immunol Med Microbiol*. 2009;57:236.
15. Pavlin BI, Kozarsky P, Cetron MS. Acute pulmonary schistosomiasis: case report and review of the literature. *Travel Med Infect Dis*. 2012;10:209.
16. Martin GJ. Approach to the patient in the tropics with pulmonary disease. In: Guerrant RL, Walker DH, Weller PF, eds. *Tropical Infectious Diseases: Principles, Pathogens and Practice, Third Edition*. Philadelphia, PA: Elsevier; 2011:982-990.
17. Graeff-Teixiera C, Ara'mburu da Silva AC, Yoshimura K. Update on eosinophilic meningoencephalitis and its clinical relevance. *Clin Microbiol Rev*. 2009;22:322.
18. Schulte C, Krebs B, Jelinek T, et al. Diagnostic significance of blood eosinophilia in returning travelers. *Clin Infect Dis*. 2007;34:407.
19. O'Connell EM, Nutman TB. Eosinophilia in infectious diseases. *Immunol Allergy Clin North Am*. 2015;35:493.
20. Llewellyn S, Inpankaew T, Nery SV, et al. Application of a multiplex quantitative PCR to assess prevalence and intensity of intestinal parasite infections in a controlled clinical trial. *PLoS Negl Trop Dis*. 2016;10::e0004380.
21. Utzinger J, Becker SL, van Lieshout L, et al. New diagnostic tools in schistosomiasis. *Clin Microbiol Infect*. 2015;21:529.
22. Drugs for parasitic infections. *Med Lett Drugs Ther*. 2013;11(suppl):e1.
23. Vanhaecke C, Perignon A, Monsel G, et al. Aetiologies of creeping eruption: 78 cases. *Br J Dermatol*. 2014;170:1166.
24. Caumes E, Ly F, Bricaire F. Cutaneous larva migrans with folliculitis: report of seven cases and review of the literature. *Br J Dermatol*. 2002;146:1.
25. Hochedez P, Caumes E. Hookworm-related cutaneous larva migrans. *J Travel Med*. 2007;14:326.
26. Kincaid L, Klowak M, Klowak S, et al. Management of imported cutaneous larva migrans: a case series and mini-review. *Travel Med Infect Dis*. 2015;13:382.
27. Ögren J, Dienus O, Löfgren S, et al. *Dientamoeba fragilis* DNA detection in *Enterobius vermicularis* eggs. *Pathog Dis*. 2013;69:157.
28. Mendoza N, Li A, Gill A, et al. Filariasis: diagnosis and treatment. *Dermatol Ther*. 2009;22:475.
29. Witt C, Ottesen EA. Lymphatic filariasis: an infection of childhood. *Trop Med Int Health*. 2001;6:582.
30. Asio SM, Simonsen PE, Onapa AW. *Mansonella perstans* filariasis in Uganda: patterns of microfilaraemia and clinical manifestations in two endemic communities. *Trans R Soc Trop Med Hyg*. 2009;103:266.
31. Mand S, Debrah AY, Klarmann U, et al. Doxycycline improves filarial lymphedema independent of active filarial infection: a randomized controlled clinical trial. *Clin Infect Dis*. 2012;55:621.
32. Nguyen JC, Murphy ME, Nutman TB, et al. Cutaneous onchocerciasis in an America traveler. *Int J Dermatol*. 2004;4;125.
33. Henry NL, Law M, Nutman TB, et al. Onchocerciasis in a nonendemic population: clinical and immunologic assessment before treatment and at the time of presumed care. *J Infect Dis*. 2001;183:512.
34. Chakvetadze C, Bani-Sadr F, Develoux M, et al. Limb swelling and hypereosinophilia. *Lancet*. 2006;368:1126.
35. Leshem E, Maor Y, Meltzer E, et al. Acute schistosomiasis outbreak: clinical features and economic impact. *Clin Infect Dis*. 2008;47:1499.
36. Clerinx J, Van Gompel A. Schistosomiasis in travellers and migrants. *Travel Med Infect Dis*. 2011;9:6.
37. Coltart CE, Chew A, Storrar N, et al. Schistosomiasis presenting in travellers: a 15 year observational study at the Hospital for Tropical Diseases, London. *Trans R Soc Trop Med Hyg*. 2015;109:214.
38. von Kuster LC, Genta RM. Cutaneous manifestations of strongyloidiasis. *Arch Dermatol*. 1988;124:1826.
39. Basile A, Simzar S, Bentow J, et al. Disseminated *Strongyloides stercoralis* hyperinfection during medical immunosuppression. *J Am Acad Dermatol*. 2010;63:896.
40. Bank DE, Grossman ME, Kohn SR, et al. The thumbprint sign: rapid diagnosis of disseminated strongyloidiasis. *J Am Acad Dermatol*. 1990;23:324.
41. Sato Y, Kobayashi J, Toma H, et al. Efficacy of stool examination for detection of *Strongyloides* infection. *Am J Trop Med Hyg*. 1996;53:248.
42. Loutfy MR, Wilson M, Keystone JS, et al. Serology and eosinophil count in the diagnosis and management of strongyloidiasis in a non-endemic area. *Am J Trop Med Hyg*. 2002;66:749.

Chapter 178 :: Scabies, Other Mites, and Pediculosis

:: Chikoti M. Wheat, Craig N. Burkhart, Craig G. Burkhart, & Bernard A. Cohen

SCABIES

AT-A-GLANCE

- Human infestation caused by the *Sarcoptes scabiei* var. *hominis* mite that lives its entire life cycle within the epidermis.
- Causes a diffuse, pruritic eruption after an incubation period of 4 to 6 weeks.
- Is transmitted by close physical contact or by fomites.
- Topical therapy with permethrin 5% cream is most effective topical therapy, but oral ivermectin, although off-label, is also effective.
- Because of the common occurrence of asymptomatic mite carriers in the household, all family members and close contacts should be treated simultaneously.

EPIDEMIOLOGY

Scabies is a worldwide issue that affects all ages, races, and socioeconomic levels. Prevalence varies considerably with some underdeveloped countries having rates from 4% to 100% of the general population.[1] In the developing world the populations affected include children, the elderly, and immunosuppressed individuals. An infested host usually harbors between 3 and 50 oviparous female mites,[2] but the number may vary considerably among individuals. For example, patients with crusted, formerly "Norwegian," scabies (Fig. 178-1) who have a defective immunologic or sensory response (ie, leprosy, paraplegic, or HIV-infected patients) harbor millions of mites on their skin surface, with minimal pruritus. Infants and the elderly may not be effective scratchers and harbor intermediate numbers between 50 and 250 mites.

It is well established that close personal contact is a prime route of transmission. Although sometimes considered a sexually transmitted disease, the equally high prevalence in children attests that close nonsexual contact among children and other family members is also sufficient to transmit the infestation. Transmission via inanimate objects has been best demonstrated with crusted scabies but is much less likely to occur in normal hosts. Crusted scabies is notoriously contagious, and anyone roaming within the general vicinity of these patients risks acquiring the infestation. Indeed, 6000 mites/g of debris from sheets, floor, screening curtains, and nearby chairs have been detected.[3] Mites are also prevalent in the personal environment of normal scabies patients.[4,5] In one study, live mites were recovered from dust samples taken from bedroom floors, overstuffed chairs, and couches in every patient's dwelling.[5]

ETIOLOGY AND PATHOGENESIS

Scabies is an infestation by the highly host-specific mite, *Sarcoptes scabiei* var. *homini*, family Sarcoptidae, class Arachnida. The mite is pearl-like, translucent, white, eyeless, and oval in shape with 4 pairs of short stubby legs. The adult female mite is 0.4×0.3 mm with the male being slightly smaller—just slightly too small to be seen by the naked eye. The scabies mite is able to live for 3 days away from the host in a sterile test tube, and for 7 days if placed in mineral oil mounts.[4,6] Mites cannot fly or jump.

The life cycle of mites is completed entirely on human skin. The female mite, by a combination of chewing and body motions, is able to excavate a sloping burrow of 0.5 to 5 mm/day in the stratum corneum to the boundary of the stratum granulosum.[7,8] Along this path, which can be 1 cm long, she lays anywhere from 0 to 4 eggs a day, or up to 50 eggs during her life span of 30 days. Eggs hatch in 10 to 12 days and larvae leave the burrow to mature on the skin surface. After the larvae molt, they become nymphs which can only survive 2 to 5 days off host. The male mite lives on the surface of the skin and enters burrows to procreate.

CLINICAL FINDINGS

The diagnosis of scabies is suspected by pruritus associated with a characteristic distribution of lesions and epidemiologic history. Onset is typically insidious, with the patient complaining of intense nocturnal pruritus. Pruritus typically appears 4 to 6 weeks after initial infestation, although many patients may not develop symptoms for 3 months and some patients are never sensitized. With subsequent reinfestations, symptoms develop within 2 to 3 days.[9]

Figure 178-1 Crusted scabies. Hyperkeratotic plaques populated with thousands of mites.

Similar to the human response to other insects such as fleas, yellow jackets, and mosquitoes, there is a wide range of clinical responses to an infestation with scabies and some individuals remain asymptomatic despite being infested. These individuals are considered "carriers."

On physical examination, patients display excoriations and eczematous dermatitis that favors the interdigital webs (see Fig. 178-1), sides of fingers, volar aspects of the wrists and lateral palms (Fig. 178-2), elbows, axillae, scrotum, penis (Fig. 178-3), labia, and areolae in women. The head and neck are usually spared in healthy adults, but in infants, elderly, and immunocompromised individuals, all skin surfaces are susceptible. Indurated, crusted nodules can be seen in infants and young children on intertriginous areas as well as on the trunk. In crusted scabies (see Fig. 178-1), hyperkeratotic plaques develop diffusely on the palmar and plantar regions, with thickening and dystrophy of the toenails and fingernails. Although, patients with crusted type have an enormous mite burden they have few or no symptoms.

Figure 178-3 Scabies. Microscopic examination of a mineral oil preparation after scraping a burrow reveals a gravid female mite with oval, gray eggs and fecal pellets.

The pathognomonic lesion is a burrow, which is a thin, thread-like, linear, or often J-shaped structure (see Figs. 178-2 and 178-4) 1 to 10 mm in length. It is a tunnel caused by the movement of the mite in the stratum corneum. When present, the burrow is best seen in the interdigital webs and wrists; however, it can be difficult to find in early stages of the condition, or after the patient has extensively excoriated the lesions. In infants and young children who are less-effective scratchers, burrows can be identified on palms and soles as well as intertriginous areas and the trunk. Identification of a burrow can be facilitated by rubbing a black felt-tip marker across an affected area. After the excess ink is wiped away with an alcohol pad, the burrow appears darker than the surrounding skin because of ink accumulation in the burrow.

Figure 178-2 Scabies. Several thread-like burrows are present in the web spaces of the fingers and on the knuckles, a common location for these lesions in scabies. Longitudinal scraping of a burrow will often reveal the mite or mite products under microscopic examination.

Figure 178-4 A dermoscopic image of triangle or "delta-wing jet" sign of dense scabies head parts (*long red arrow*), relatively translucent scabies body (*long black arrow*), scabies eggs (*short red arrows*), and classic S-shaped burrow. Heine Delta 20× dermatoscope with Nikon Coolpix 4500 camera. (From Fox G. Diagnosis of scabies by dermoscopy. *BMJ Case Rep*. 2009;2009. Reproduced by permission from BMJ Publishing Group Ltd.)

A definitive diagnosis is made by microscopic identification of the scabies mites, eggs, or fecal pellets (scybala). This is accomplished by placing a drop of mineral oil over a burrow and then scraping longitudinally with a number 15 scalpel blade along the length of the burrow or a suspicious skin area, being careful not to cause bleeding. Scrapings are best taken from a burrow, papule, or vesicle that is not excoriated. The scrapings are then applied to a glass slide and examined under low power (see Fig. 178-3). Confocal microscopy and dermoscopy also can be used to examine the mite in vivo.[10,11] The classic dermoscopic finding is the "delta-wing jet" sign of dense scabies head parts and body, eggs, and a burrow (see Fig. 178-4). A skin biopsy can be diagnostic, if the mite happens to be transected in the stratum corneum (Fig. 178-5).

An enzyme-linked immunosorbent assay has been developed for serologic testing of other mite infestations in animals; however, no serologic tests for scabies exist for humans.[12] Despite the possibility of confirming the presence of mites via multiple methods of testing, the diagnosis usually is based on clinical impression, and solidified by response to treatment.

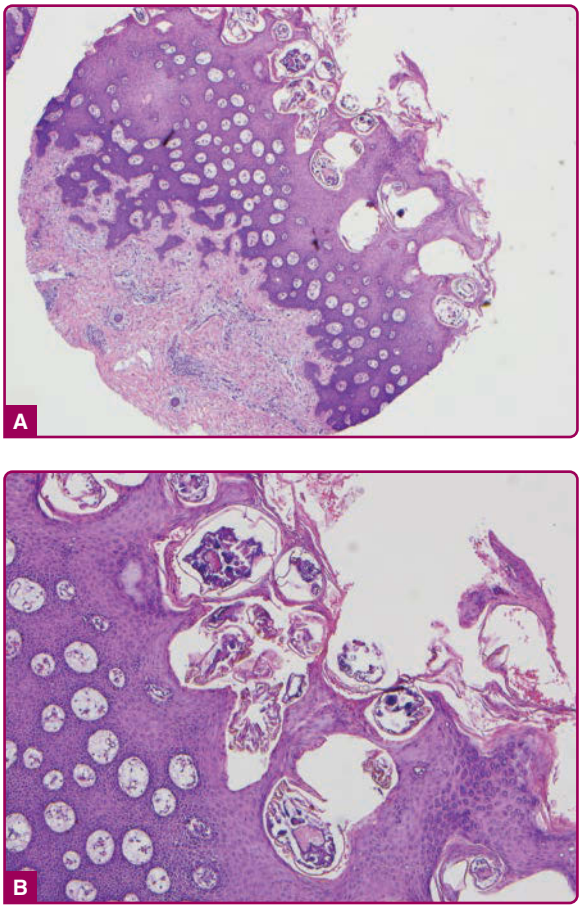

Figure 178-5 A skin biopsy can be diagnostic, if the mite happens to be transected in the stratum corneum. Images show (**A**) ×4 magnification and (**B**) ×10 magnification of scabies mite within the stratum corneum.

DIFFERENTIAL DIAGNOSIS

Table 178-1 outlines the differential diagnosis of scabies.

COMPLICATIONS

Secondary impetiginization may occur and poststreptococcal glomerulonephritis has resulted from scabies-induced pyodermas caused by *Streptococcus pyogenes*. Lymphangitis and septicemia also have been reported in crusted scabies. Finally, scabies infestation can also trigger bullous pemphigoid.[13,14]

TREATMENT

Scabies is treated by a combination of a scabicide and fomite control. With all insecticidal therapies, a second application, usually a week after the initial treatment, is required to reduce the potential for reinfestation from fomites as well as to kill any nymphs that may have hatched after treatment as a result of a semiprotective environment within the egg. All household and close contacts must be simultaneously treated to prevent reinfestation from mildly symptomatic and asymptomatic carriers.

Topical scabicides are applied overnight to the entire skin surface with special attention to finger and toe creases, cleft of the buttocks, belly button, and beneath the fingernails and toenails. In adults, one can exclude treating the scalp and face. Most treated individuals experience relief from symptoms within 3 days, but patients must be informed that even after adequate scabicidal therapy, the rash and pruritus may persist for up to 4 weeks. The itching experienced during this time period is commonly referred to as "postscabetic itch."

TABLE 178-1
Differential Diagnosis of Scabies

Most Likely
- Atopic dermatitis
- Dyshidrotic eczema
- Pyoderma
- Contact dermatitis
- Insect bite reaction
- Id reaction
- Varicella
- Miliaria

Consider
- Dermatitis herpetiformis
- Psoriasis
- Bullous pemphigoid
- Linear immunoglobulin A bullous dermatosis
- Drug eruption
- Systemic causes of pruritus
- Delusions of parasitosis

TABLE 178-2
Treatment of Scabies

DRUG	DOSE	COMMENTS
Permethrin 5% cream	Apply to entire body (neck down) for 8 to 14 hours then wash off, repeat in 7 days; if crusted scabies use daily for 7 days then twice weekly until cured	Most common treatment presently; pregnancy category B, tolerance seems to be developing
Lindane 1% lotion	Apply for 8 hours, repeat in 7 days	U.S. Food and Drug Administration "black box" warning now in effect[a]; banned in California
Crotamiton 10% cream	Apply for 8 hours on days 1, 2, 3, and 8	Has antipruritic qualities; effectiveness is marginal
Precipitated sulfur 5% to 10%	Apply for 8 hours on days 1, 2, and 3	Considered safe in neonates and during pregnancy; limited efficacy data; inexpensive
Benzyl benzoate 10% lotion	Apply for 24 hours	Not available in United States
Ivermectin 200 µg/kg	Taken orally on days 1 and 8; if crusted scabies take on days 1, 2, 8, 9, and 15	Highly effective with good safety profile; not recommended for children who weigh less than 15 kg (33 lb) or for pregnant or lactating women; wash sheets and clothing at 60°C (140°F) and dry in a hot dryer; items that cannot be placed in a washer can be placed in a sealed plastic bag in a warm area for 2 weeks

[a]"Black box" warning warns against usage in premature infants and individuals with known uncontrolled seizure disorders, as well as cautious usage in infants, children, and the elderly including people who weigh less than 50 kg (110 pounds) and over 65 years old may be at risk of serious neurotoxicity.

Patients should be educated that excessive washing of the skin with harsh soaps will aggravate their skin irritation. Instead, oral antihistamines and emollients can be beneficial. Table 178-2 summarizes the treatments for scabies, but a few comments are warranted:

- Lindane has received a "black box" warning as well as restrictive labeling changes from the U.S. Food and Drug Administration (FDA) to greatly restrict its usage.[15,16] Moreover, it is banned in California.[17] A physician should write a prescription for lindane only when cognizant of all the caveats noted by the FDA (see the footnote to Table 178-2).[18]
- There are no documented cases of scabies resistance to permethrin, but tolerance is beginning to develop.[19] Pregnant females, breastfeeding mothers, and children younger than age 2 years should limit their 2 applications (1 week apart) to 2 hours only when using permethrin.
- Crotamiton is considerably less effective than all other options offered.
- Five percent to 10% sulfur is messy, malodorous, tends to stain, and can produce irritant dermatitis, but is inexpensive and may be the only choice in areas of the world in which a lack of funds dictates therapy.[20] The efficacy and toxicity of sulfur has not been critically evaluated in recent years, but many believe that it is the safest choice for neonates and pregnant females.[21]

Ivermectin is an anthelmintic agent derived from a class of compounds known as avermectins. It has been used in veterinary medicine since 1981, and has excellent antiparasitic properties.[22-24] Ivermectin has been approved since 1996 by the FDA for treatment of 2 diseases, namely onchocerciasis and strongyloides. Clinical efficacy for scabies has been impressive at a dosage of 200 µg/kg given twice 1 week apart.[25,26] Given that millions of people have been treated for onchocerciasis worldwide without significant side effects including pregnant women, it appears to be extremely safe. Nevertheless, because the drug acts on nerve synpases that utilize glutamate or γ-aminobutyric acid, and because the blood–brain barrier is not fully developed in young children, it is not recommended for use in children who weigh less than 15 kg (33 lbs) or in pregnant or lactating women. Success rates approach 100% in studies where entire households and close contacts of infested individuals are treated while maintaining strict fomite controls.[24,27]

In crusted scabies, the combination of oral ivermectin and a topical scabicide is recommended as the oral medication will not penetrate into the thickness of the keratinous debris under the nails.

PREVENTION

Several measures should be considered to reduce the potential of reinfestation by fomite transmission. Because of the common occurrence of asymptomatic mite carriers in the household, all family members and close contacts should be treated simultaneously. After treatment, treated individuals should wear clean clothing, and all clothing, pillow cases, towels and bedding used during the previous week should be washed in hot water and dried at high heat. Nonwashables should be dry-cleaned, ironed, put in the clothes dryer without washing, or stored in a sealed plastic bag in a warm area for 2 weeks. Floors, carpets, upholstery (in both home and car) play areas, and furniture should

be carefully vacuumed. Fumigation of living spaces is not recommended. Pets also do not need to be treated because they do not harbor the human scabies mite.

OTHER MITES BESIDES SCABIES

AT-A-GLANCE

- Scabies and *Demodex* live in the skin, most other mites drop off human host after feeding.
- Some species are vectors of human disease.
- Chiggers can cause pruritic vesicular, papular, or granulomatous lesions.

There are 45,000 described species of mites that belong to the subclass Acarina and the class Arachnida. Table 178-3 lists some of the mites that can affect humans. Human infestation by these mites occurs only accidentally (save for *Demodex* species).

Demodex folliculorum hominis and *Demodex brevis* are the only mites that routinely live on humans; *D. folliculorum* resides in the hair follicle and *D. brevis* resides in the infundibulum of the sebaceous gland. Their presence has been linked with rosacea, perioral dermatitis, and suppurative folliculitis; however, a causal role for mites in these diseases has not been established.

Although animal and fowl mites are not primary parasites of humans, *Pyemotes* sp. can cause straw itch, oak leaf eruption, or itch mite eruptions. These mites can cause epidemics of dermatitis with outbreaks in the last decade occurring in several Midwestern States. *Pyemotes ventricosus* and *Pyemotes tritici* occur in animal handlers, farmers participating in harvesting of grain, and those exposed to decorative grain.[28,29] *Pyemotes herfsi*'s normal host is the leaf galls on oak trees, and therefore this eruption characteristically occurs in people who spend time outdoors in or near wooded areas. Typical bites appear on exposed skin as red macules with a small blister center 10 to 16 hours after contact.

Harvest mites (also called berry bugs, red bugs, scrub-itch mites, and chiggers) are in the family Trombiculidae and are distributed worldwide.[30] In the United States, they inhabit mostly the southeast, south, and midwest, in areas of grasslands and forest, and damp areas along lakes and streams. Humans are susceptible to the larvae from April until the first frost. The minute, reddish larvae of *Trombicula* are less than 0.5 mm long and feed on skin cells of animals, including humans. Rather than sucking blood, these mites inject digestive enzymes into the skin breaking down cells, which can subsequently cause severe reactions and swelling. Each bite has a characteristic red papule with a white, hard central area. After feeding, they drop off their hosts and mature into adults, which are harmless to humans. Rarely does a victim realize when the bite is occurring, as itching from a chigger bite does not develop until 1 to 2 days after the bite. Chiggers prefer warm, covered areas of the body, and thus the bites are often clustered behind the knees, or beneath tight undergarments such as socks, underwear, and brassieres.

The house dust mite is a cosmopolitan guest in human habitation and feeds off flakes of shed human skin. The mites are harmless, but their bodies and excreta are believed to play a role in human disease. They are a common precipitant of asthma, hay fever, and allergic respiratory symptoms worldwide. In addition, atopic dermatitis may be exacerbated in some patients by dust mite allergens.[31,32]

PEDICULOSIS

Pediculosis, the infestation of humans by lice, has been a human affliction since antiquity. Three species of lice infest humans: (a) *Pediculus humanus capitis*, the head louse, (b) *Pediculus humanus humanus*, the body or clothing louse, and (c) *Phthirus pubis*, the pubic, or crab, louse. Patients present with pruritus secondary to a delayed hypersensitivity reaction. After the initial exposure, it may take 2 to 6 weeks for the pruritus to occur. Subsequent exposure results in symptoms within 1 to 2 days of exposure.[33]

TABLE 178-3
Mites Other Than Scabies

TYPE OF MITE	SCIENTIFIC NAME	CLINICAL FEATURES/DISEASE ASSOCIATION
Follicle	*Demodex folliculorum hominis* and *Demodex brevis*	Associated with rosacea, idiopathic facial burning
Fowl	*Dermanyssus gallinae* and *Demodex avium*	Pruritic papules, sometimes with a hemorrhagic center
Straw itch	*Pyemotes tritici, Pyemotes ventricosus,* and *Pyemotes herfsi*	Patchy dermatitis on trunk and arms during and after harvesting
Harvest or red (chiggers)	Genus *Trombicula: Eurotrombicula alfreddugesi* and *Eurotrombicula splendens*	Scrub typhus vector; papular to vesicular lesions found on ankles, waist, or warm skinfolds; most common in United States
Animal	*Ornithonyssus bacoti, Liponyssoides sanguineus, Cheyletiella* sp. (Cheyletielosis)	Endemic/murine typhus vector; rickettsialpox vector; nonspecific pruritic eruption on body parts in close contact with infested pets
House dust	*Dermatophagoides* sp.	Atopic dermatitis, allergies

PEDICULOSIS CAPITIS (HEAD LICE)

AT-A-GLANCE

- Infestation occurs worldwide affecting hairs of the scalp most commonly in children between the ages of 3 and 12 years.
- Presence of 0.8-mm eggs (nits) firmly attached to scalp hairs is most common sign of infestation.
- Spread by close physical contact and sharing of headgear, combs, brushes, and pillows.
- Resistance to traditional nonprescription preparations is growing; topical malathion and ivermectin should be considered in resistant cases.

EPIDEMIOLOGY

Head lice infestations occur worldwide and are most common in children between the ages of 3 and 12 years.[34] Based on pediculicide sales in the United States, an estimated 10 to 12 million children are infected each year. Head lice affect all levels of society, and all ethnic groups; however, the incidence is low among African Americans in the United States, possibly as a consequence of an anatomic inability of female lice in America to deposit eggs on coarse curly hair.[35] A recent study by Koch and associates showed an increase in trend in the number of prescriptions suggesting either an increase in the number of infestations or increased failure rates of nonprescription home regimens.[36]

Transmission occurs primarily by means of direct head-to-head contact and less commonly by indirect (fomite) transmission through combs, brushes, blow-dryers, hair accessories, upholstery, pillows, bedding, helmets, or other headgear.[37-42] Lice can be dislodged by air movement, blow-dryers, combs, and towels, and passively transferred to fabric, facilitating new infestations.[30-32,34,35]

ETIOLOGY AND PATHOGENESIS

Head lice are blood-sucking, wingless, highly host-specific insects belonging to the order Anoplura. They are almost 2 mm long with 3 pairs of claw-like legs that are well adapted for grasping hair. Their entire life cycle is on the scalp (Fig. 178-6). More than 95% of infested individuals have fewer than 100 adult lice in their scalps. The female louse lays 5 to 10 eggs per day during her 30-day life span. After 10 days, the eggs

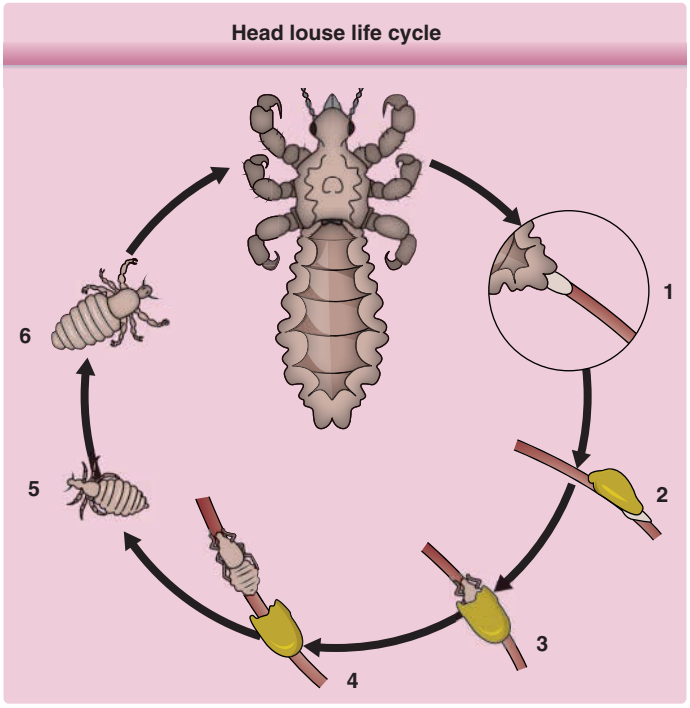

Figure 178-6 Head louse life cycle. During egg laying, the female louse secretes a proteinaceous cement that flows from the genital opening to adhere the egg tightly onto the hair shaft (*1* and *2*). The hatch-ready louse uses its mouthparts to cut a circular hole in the operculum and sucks in air, which is expelled from its posterior, causing it to be quickly ejected from the egg, typically 5 to 10 days after the egg was first laid (*3* and *4*). The emerged instar requires a blood meal soon after hatching, and completes 3 molts, taking a blood meal between each, before developing into an adult 9 to 12 days after hatching (*4*, *5*, and *6*). (Adapted from Figure 1 in Koch E, Clark JM, Cohen B, et al. Management of head louse infestations in the United States—a literature review. *Pediatr Dermatol*. 2016;33:466-472, with permission. Copyright © 2016, John Wiley and Sons.)

hatch producing larvae, which are referred to as nymphs or "instars." Instars look like miniature adult louse and go through 3 stages of development that take 14 days for full maturation. The eggs are laid approximately 1 cm from the scalp surface, firmly attached to individual hairs with a proteinaceous glue secreted by the female louse and that closely resembles the amino acid composition of the human hair shaft itself.[43,44]

Lice typically survive less than 2 days away from the scalp, although under favorable conditions of heat and humidity, survival has been reported at 4 days. Nits can survive for 10 days away from the scalp.

CLINICAL FINDINGS

Pediculosis capitis is confined to the scalp with nits (Fig. 178-7) found most readily in the occipital and retroauricular regions. Most patients experience pruritus. The average incubation before symptoms is 4 to 6 weeks. Some individuals remain asymptomatic despite infestation, and can be considered "carriers."

Mite bites may produce 2-mm erythematous macules or papules, but usually an examiner only finds excoriations, erythema, and scaling. Other findings may include a low-grade fever, regional lymphadenopathy, and irritability.

Infestations are diagnosed by demonstrating egg capsules (nits) and live lice. Nits are readily seen by the naked eye and are an efficient marker of past or present infestation. They can be differentiated from dandruff, hair casts, and the like, as nits are not easily removed from the hair shaft.[45] The color of newly laid or viable eggs is tan to brown; the remains of eggs that have hatched are clear, white, or light in color. Moreover, newly laid eggs are usually identified within a few millimeters of the scalp and lice embryos can be seen on dermoscopy, while hatched nits are usually further from the scalp. The presence of adult lice confirms active infestation. However, lice are fast, avoid light, and blend in with the hair, making them difficult to find. Finding live adult lice or immature nymphs is best achieved with fine combing the hair with a nit comb. Wet combing, in which water and conditioner are applied to the hair prior to using the nit comb, increases the yield by prying the adult lice from the hair follicles.[44,45]

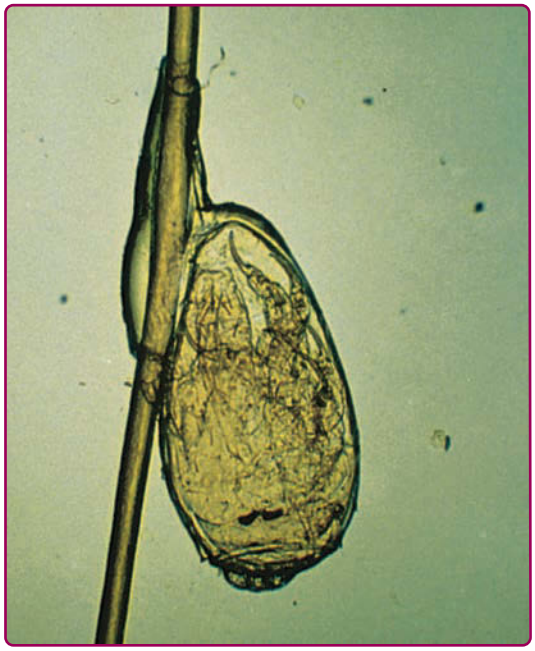

Figure 178-7 Nit sheath. Microscopic view of an egg, containing an unhatched louse, attached to a hair shaft.

DIFFERENTIAL DIAGNOSIS

Table 178-4 outlines the differential diagnosis of head lice.

COMPLICATIONS

Although head lice have never been identified as a source of transmission of infection, secondary bacterial infections can occur with pediculosis capitis. In fact, head lice are thought to be the most common cause of pyodermas of the scalp in the developed world.[46]

Head lice and body lice are closely related, so it is not surprising that head lice can serve as host for rickettsiae and have the potential of transmitting diseases.[47,48] Head lice in laboratory experiments have been readily infected with *Rickettsia prowazekii*.[49] *Bartonella quintana*, which causes trench fever, also has been isolated in head lice.[50-53] Transmission of these infections to humans by pediculosus capitis, however, has never been described and it is highly unlikely to occur outside of experimental conditions.

TREATMENT

Standard treatment recommendations for pediculosis capitis utilize a 2-step process of confirming active infestation with live lice and then treating the infestation with a nonprescription or prescription pediculicidal therapy. Pediculicide choice is typically based on local resistance patterns and access of patients to a physician for prescription medications.[54] However, with increasing resistance to pediculicides, a multimodal approach, similar to *Staphylococcus aureus*

TABLE 178-4
Differential Diagnosis of Head Lice

- Seborrheic dermatitis (dandruff)
- Insect bites
- Eczema
- Psoriasis
- Hair gel hair spray
- Piedra (a fungal infection)
- Pseudonits (desquamated epithelial cells with sebaceous plugs encircling the hair)
- Delusions of parasitosis

therapy, is warranted to prevent widespread resistance to currently available products.[55] This is especially important when treating with prescription pediculicides.

Physical methods to treat infestations, including shaving one's head to avoid infestation, dates back to the 6th century BC, when priests and wealthy Egyptians removed scalp hair and wore wigs. The routine of head shaving for military services today was founded on the same principle. While a buzz haircut may be a solution for boys, such an approach would be traumatic psychologically for girls. Another method is to comb the nits out after application of a hair moisturizer such as Cetaphil. The moisturizer is applied, left in for 2 minutes, then all the lotion is combed out. The hair is then dried with a hair dryer. This can be done every few days, with the best results showing cure rates of 95% if done over a 24-day period.[56] However, combing out nits is difficult, tedious, time-consuming, and somewhat painful. Although wet combing can be an adjuvant to topical insecticidal therapy, it is not, by itself, sufficient in most situations.[47]

Pediculicides remain the most effective treatment for head lice.[57-64] Given (a) variable ovicidal activity, (b) possible lack of patient compliance, (c) growing resistance to pediculicides, and (d) the potential of fomite reinfestation, it is recommended to repeat treatment with all insecticidal treatments in 1 week.

Table 178-5 summarizes the array of treatments for head lice. One of the leading factors for the increasing number of infestations is resistance of lice to topical therapies.[65-70] Since the introduction of insecticides years ago, the louse has adapted by several genetic alterations. The agents with the highest success rates, namely malathion and ivermectin, are prescription products. One trial has shown oral ivermectin given twice at a 7-day interval to be more effective than topical malathion lotion.[71] However, both pediculicides are highly effective and treatment decisions should be based on local resistance patterns and individual patient characteristics.

There are a number of anecdotal and market-driven reports with occlusive and suffocation methods (such as with application of petrolatum, mayonnaise, dimethicone, vegetable oil, mineral oil, hair pomade, and olive oil).[72,73] However, there are no studies establishing the safety and efficacy.[36] To accurately evaluate pediculicidal activity of any compound, one must appreciate that head lice have the ability to "resurrect" from a state of seeming death, in which respiratory and motor function appear to have ceased.[74,75] These insects are less dependent than mammals for continuous nervous control of respiration and circulation, and the

TABLE 178-5
Treatment of Head Lice and Crab Lice

	ADMINISTRATION	RISK FACTORS
Pyrethrins synergized (RID, Pronto, etc.)[a]	Topically for 10 minutes[b]	Allergy to chrysanthemums, ragweed, or related plants; increased resistance with steep decline in effectiveness
Permethrin 1%[a] lotion (Nix)	Topically to damp hair for 10 minutes, rinse then repeat in 7 days[b]	First-choice treatment except in places with known resistance; approved for patients older than age 2 months
Permethrin 5% cream	Topically overnight[b]	None; if used for "resistant" head lice, no evidence that it is more effective than permethrin 1% lotion
Malathion 0.5% (Ovide) shampoo	Topically to dry hair and leave on for 8 to 12 hours allowing to dry naturally; then shampoo and use a lice comb	High flammability so avoid hair dryer or open flame while wet; burning/stinging at sites of eroded skin; approved for patients older than age 6 years
Carbaryl 0.5%	Topically overnight	Not available in United States
Lindane 1%	Topically for 4 minutes[b]	U.S. Food and Drug Administration (FDA) "black box" warning now in effect[c]; banned in California
Benzyl alcohol 5% lotion	Topically to dry hair for 10 minutes, rinse then repeat in 7 days	Dosed by hair length so can be costly; can be used in pregnant and lactating women; approved for children older than age 6 months; minor side effects
Topical ivermectin 0.5% lotion	Topically to hair once although most experts recommend reapplication a week later	Approved for patients older than age 6 months
Ivermectin (Stromectol), oral 200 µg/kg	Orally on days 1, 8, and 15	Very good efficacy on adult lice although inferior to permethrin; not ovicidal, hence nits are safe until they hatch; not recommended for pregnant females or children weighing less than 15 kg (33 lbs); not FDA approved for pediculosis
Spinosad 0.9% suspension	Topically to dry hair for 10 minutes then rinse; repeat in 7 days	Do not use in infants younger than age 6 months because of benzyl alcohol content; minor side effects

[a]Available in nonprescription form.
[b]Apply to dry scalp and hair followed by adequate washing out with nonmedicated shampoo (head lice).
[c]See footnote to Table 178-2. "Black box" warning: Lindane is still available for patients weighing more than 50 kg (110 lbs) and younger than age 65 years, but is cautioned against use because of neurotoxicity.

exact point of death is not readily defined. Indeed, the World Health Organization recommends pediculicidal testing to be read 24 hours after application of insecticide because doing otherwise results in overestimation of mortality rates.[52] Not following these guidelines has led to overestimates of the efficacy of several alternative treatments with occlusive agents and essential oils from health food stores. Such products slow the movements of adult lice and may allow them to be more easily combed out of the scalp, but these substances are usually not lethal to lice.

Patients should be counseled in at least some effective measures to prevent reinfestation by fomite transmission. After treatment, treated individuals should wear clean clothing, and all clothing, hats, pillow cases, towels, and bedding used during the previous week should be washed in hot water and dried at high heat. Nonwashables should be dry-cleaned, ironed, put in the clothes dryer without washing, or stored in a sealed plastic bag in a warm area for 2 weeks. Combs and brushes may be washed in very hot water (65°C [149°F]) or may be coated with the pediculicide for 15 minutes. Floors, carpets, upholstery (in both home and car), play areas, and furniture should be carefully vacuumed to remove any hairs with viable eggs attached. Fumigation of living spaces is not recommended and pets do not need to be treated because they do not harbor the human head louse. Despite treatment, nits can remain on the hair for months. Therefore a strict "no nit" policy will only result in significant absence from school.[76] As a result, the American Academy of Pediatrics does not recommend a "no nit" policy.

PEDICULOSIS CORPORIS (BODY LICE)

AT-A-GLANCE

- Infestations most commonly found in homeless individuals, refugees, and victims of war and natural disasters.
- Diagnosis made by presence of nits in lining of clothing, particularly the seams.
- Infections transmitted by body lice include epidemic typhus, trench fever, and relapsing fever.

ETIOLOGY AND PATHOGENESIS

P. humanus humanus, body lice, have a very similar morphology to head lice, except they are 30% larger. The body louse's life span is 20 days during which the female may lay up to 300 eggs. The lice lay their eggs in the seams of clothing, while obtaining their blood meals from the host. The body louse can survive without a blood meal for up to 3 days.

EPIDEMIOLOGY

Pediculosis corporis requires exposure to the louse and favors an inability to wash and change clothing. Consequently, it is most commonly found on homeless individuals, refugees, victims of war and natural disasters, or those forced into crowded living conditions with poor hygiene. The infestation is usually transmitted by contaminated clothing or bedding. After exposure, the inability to wash or change clothes allows the infestation to persist.

CLINICAL FINDINGS

Symptomatically, patients complain of pruritus. Most commonly, the only sign of body lice is excoriations, often linear and primarily on the back, neck, shoulders, and waist. Postinflammatory pigmentation is seen in chronic cases. Adult lice are not easily seen except in heavy infestations. Diagnosis is made by closely examining the lining of the clothing, particularly at the seams, for the presence of nits. The clothing also may be shaken over a sheet of white paper, at which time the lice may be seen moving about on the paper.

DIFFERENTIAL DIAGNOSIS

Table 178-6 outlines the differential diagnosis of body lice.

COMPLICATIONS

Several important human diseases are transmitted by the body louse. The major diseases include epidemic typhus (caused by a rickettsiae, *R. prowazekii*), murine typhus (caused by *Rickettsia typhi*), trench fever (caused by *B. quintana*), and relapsing fever (caused by a spirochete, *Borrelia recurrentis*).[77-81] Lice obtain organisms, such as rickettsiae and spirochetes, from ingestion of blood meals from infested hosts. Transmission of microorganisms from body lice is not from the louse bite, but rather by (a) contaminated fecal material being scratched into excoriated skin of bite sites, (b) inhalation of dry, powdery louse feces from handling typhus-contaminated bedding or clothing, or (c) an infected louse having its gut ruptured, allowing an infective blood meal to enter

TABLE 178-6
Differential Diagnosis of Body Lice

- Scabies
- Atopic dermatitis
- Contact dermatitis
- Drug reaction
- Viral exanthem
- Other animal parasites
- Systemic causes of pruritus
- Delusions of parasitosis

excoriations on the skin. In addition, excoriation can lead to secondary infection with *S. aureus*, *S. pyogenes*, and other bacteria.

TREATMENT

The most important treatment for body lice is disinfestation of all clothing and bedding. Beds should be burned or sprayed with lice sprays, because the body louse may lay eggs on the seams of the mattress or couch. Clothing is best treated like biohazardous waste, bagged, and tightly sealed in specially marked, plastic, biohazard bags. The waste is handled separately from other trash until it can be incinerated, maintaining a temperature of 65°C (149°F) for 30 minutes. If this is not possible, clothing and bedding should be fumigated, machine washed in hot water, and dried on high heat or dry-cleaned. Hot ironing of the seams of upholstered furniture should also be performed and exposure to infested items should be strictly avoided for 2 weeks. The patient should be treated from head to toe with a topical insecticide or given oral ivermectin.

PEDICULOSIS PUBIS (CRAB LICE)

AT-A-GLANCE

- Best to call "crab lice" (rather than "pubic lice") as infestations may involve other hair-bearing sites such as mustache, beard, axillae, eyelashes, eyebrows, and scalp hair.
- Transmitted by sexual or close contact, as well as via fomites (contaminated clothing, towels, and bedding).
- Topical therapy options similar to pediculosis capitis, but oral ivermectin is the preferred treatment for this infestation.

ETIOLOGY AND PATHOGENESIS

Pediculosis pubis is caused by infestation of the body with *P. pubis*. Crab lice range from 0.8 to 1.2 mm in length and have wide, short bodies resembling tiny crabs. They have a serrated edge on their first claw, which gives them traction on flat, hairless, surfaces; thus, they can navigate across the entire body surface. They most commonly are found in the pubic and perianal region, but occasionally they also reside in mustache, beard, axillae, eyelashes, eyebrows, and scalp hair. In hirsute individuals, they are also found on the short hairs of the thighs and trunk. The louse has a life span of less than 3 weeks, during which time the female will lay approximately 25 eggs on human hairs. The adult crab louse can survive for 36 hours off the human host, and the eggs are viable for up to 10 days.

EPIDEMIOLOGY

Crab lice can be found in all levels of society and all ethnic groups. Patients with crab lice often have another concurrent sexually transmitted disease. Although pediculosis pubis is considered a sexually transmitted disease, transmission has been documented to occur from contaminated clothing, towels, and bedding.

CLINICAL FINDINGS

In the case of crab lice, all hairy parts of the body should be examined, especially the eyelashes, eyebrows, and perianal area. Many individuals have 2 different hair-bearing sites infested.[82] These lice can be mistaken for scabs or moles, or can blend in with skin color, making them difficult to detect. Infested patients have an average of 10 to 25 adult organisms on their body. Nits also can be identified near the base of hairs (Fig. 178-8). The diagnosis can be confirmed by microscopic examination of the plucked hair to identify the nits and/or adult lice. Although rare, skin lesions named maculae caerulea, representing hemorrhage, can be seen with pubic lice, with slate gray to bluish, irregular-shaped macules approximately 1 cm in diameter. Pediculosis palpebrarum, or phthiriasis palpebrarum, is the infestation of the eyelashes with crab lice.

DIFFERENTIAL DIAGNOSIS

Table 178-7 outlines the differential diagnosis of crab lice.

Figure 178-8 Pediculosis pubis. Several lice and their dot-like nits attached to the hair shafts can be seen in the pubic area of this patient. (Used with permission from D.A. Burns, MD.)

TABLE 178-7
Differential Diagnosis of Crab Lice

- Excoriations
- Scabies
- Contact dermatitis
- Piedra
- Trichomycosis pubis
- Hair casts
- Nevi

TREATMENT

Shaving is not curative as the louse will seek another hairy area of the body to reside. Crab lice are treated with the same topical therapy as that for pediculosis capitis (see Table 178-5).[83] In vitro and in vivo resistance to pyrethrins have been shown.[84] There is a lack of appreciation for their tendency to inhabit rectal hair.[82] Unless the physician is certain that only one body area is involved, all hairy areas of the body should be treated because (a) it is not uncommon to have other areas infested, and (b) lice can migrate away from a treated areas to other hair-bearing locations. For this reason, oral ivermectin is recommended for this entity.[52] However, as ivermectin treatment relies on the insect obtaining a blood meal, so the nits are not affected and the patient requires repeat oral ivermectin on day 8 and day 15.

Phthiriasis palpebrarum (Fig. 178-9) has traditionally been treated with petrolatum (Vaseline), but this treatment is slow and needs to be applied at least 5 times a day for weeks. Ivermectin is the first-line therapy for this condition.[85]

Fomite precautions mirror those discussed previously for pediculosis capitis. Treatment failure is usually a result of failure to treat all hairy areas (especially perirectally) or reinfestation from neglecting to treat sexual contacts. Other household members are also infested occasionally and should be carefully questioned for symptoms and/or examined.

Figure 178-9 Pediculosis pubis. Eyelash infestation with *Pthirus pubis*. Nits can be seen attached to the eyelashes. (Used with permission from D.A. Burns, MD.)

REFERENCES

1. Burkhart CG. Scabies: an epidemiologic reassessment. *Ann Intern Med.* 1983;98:498-503.
2. Mellanby K. *Scabies*. 2nd ed. Hampton, England: E.W. Classey Ltd; 1972.
3. Carslaw RW, Dobson RM, Hood AJ. Mites in the environment of cases of Norwegian scabies. *Br J Dermatol.* 1975;92:333-337.
4. Estes SA, Arlian L. Survival of *Sarcoptes scabiei*. *J Am Acad Dermatol.* 1981;5:343-345.
5. Arlian LG, Estes SA, Vyszenski-Moher DL. Prevalence of *Sarcoptes scabiei* in the environment of scabietic patients. *J Am Acad Dermatol.* 1988;1:806-811.
6. Arlian LG, Runyan RA, Achar S. Survival and infectivity of *Sarcoptes scabiei* var. *canis* and var. *hominis*. *J Am Acad Dermatol.* 1984;11:210-215.
7. Burgess I. *Sarcoptes scabiei* and scabies. *Adv Parasitol.* 1994;33:235-293.
8. Fimiani M, Mazzatenta C, Alessandrini C, et al. The behaviour of Sarcoptes scabiei var. hominis in human skin: an ultrastructural study. *J Submicrosc Cytol Pathol.* 1997;29(1):105-113.
9. Bergström FC, Reynolds S, Johnstone M, et al. Scabies mite inactivated serine protease paralogs inhibit the human complement system. *J Immunol.* 2009;182:7809-7817.
10. Prins C, Stucki L, French L. Dermoscopy for the in vivo detection of *Sarcoptes scabiei*. *Dermatology.* 2004;208:241-243.
11. Argenziano G, Fabbrocini G, Delfino M. Epiluminescence microscopy. A new approach to in vivo detection of *Sarcoptes scabiei*. *Arch Dermatol.* 1997;133:751-753.
12. van der Heijden HM, Rambags PG, Elbers AR. Validation of ELISAs for the detection of antibodies to *Sarcoptes scabiei* in pigs. *Vet Parasitol.* 2000;89:95-107.
13. Chung SD, Lin HC, Wang KH. Increased risk of pemphigoid following scabies: a population-based matched-cohort study. *J Eur Acad Dermatol Venereol.* 2014;28:558-564.
14. Bornhövd E, Partscht K, Flaig MJ, et al. Bullous scabies and scabies triggered bullous pemphigoid [in German]. *Hautarzt.* 2001;52:56-61.
15. Labeling changes for Lindane. *FDA Consum.* 2003;37:6.
16. Center for Drug Evaluation and Research. *FDA Public Health Advisory. Safety of Topical Lindane Products for the Treatment of Scabies and Lice*. http://www.fda.gov/cder/drug/infopage/lindane/default.htm. Accessed Jun 5, 2003.
17. California Department of Health Services. State Health Director Offers Tips for Protecting Children From Head Lice. Sacramento, CA: California Department of Health Services; October 10, 2000. News Release No. 54-00.
18. Burkhart CG, Burkhart CN. Safety and efficacy of pediculicides for head lice. *Expert Opin Drug Saf.* 2006;5:169-176.
19. Pasay C, Arlian L, Morgan M, et al. The effect of insecticide synergists on the response of scabies mites to pyrethroid acaricides. *PLoS Negl Trop Dis.* 2009;3:e354.
20. Pruksachatkunakorn C, Damrongsak M, Sinthupuan S. Sulfur for scabies outbreaks in orphanages. *Pediatr Dermatol.* 2002;19:448-453.
21. Diaz M, Cazorla D, Acosta M. Efficacy, safety, and acceptability of precipitated sulphur petrolatum for topical treatment of scabies at the city of Coro, Falcon State, Venezuela. *Rev Invest Clin.* 2004;56:615-622.

22. Pulliam JD, Preston JM. Safety of ivermectin in target animals. In: Campbell WC, ed. *Ivermectin and Abamectin*. New York, NY: Springer-Verlag; 1989:149-161.
23. Benz GW, Roncalli RA, Gross SJ. Use of ivermectin in cattle, sheep, goats, and swine. In: Campbell WC, ed. *Ivermectin and Abamectin*. New York, NY: Springer-Verlag; 1989:215-229.
24. Burkhart CN. Ivermectin: an assessment of its pharmacology, microbiology, and safety. *Vet Hum Toxicol.* 2000; 42:30-35.
25. Meinking TL, Taplin D, Hermida JL. The treatment of scabies with ivermectin. *N Engl J Med.* 1996;333:26-30.
26. Aubin F, Humbert P. Ivermectin for crusted (Norwegian) scabies. *N Engl J Med.* 1995;332:1995.
27. Marty P, Gari-Toussaint M, LeFichoux Y. Efficacy of ivermectin in the treatment of an epidemic of *Sarcoptes scabiei*. *Ann Trop Med Parasitol.* 1994;88:433.
28. Grob M, Dorn K, Lautenschlager S. Grain mites: a small epidemic caused by *Pyemotes* species [in German]. *Hautarzt.* 1998;49:838-843.
29. Kunkle GA, Greiner EC. Dermatitis in horses and man caused by the straw itch mite. *J Am Vet Med Assoc.* 1982; 181:467-469.
30. Elston DM. What's eating you? Chiggers. *Cutis.* 2006; 77:350-352.
31. Jeong SK, Kim HJ, Youm JK. Mite and cockroach allergens activate protease-activated receptor 2 and delay epidermal permeability barrier recovery. *J Invest Dermatol.* 2008;128:1930-1939.
32. Bussmann C, Böckenhoff A, Henke H, et al. Does allergen-specific immunotherapy represent a therapeutic option for patients with atopic dermatitis? *J Allergy Clin Immunol.* 2006;118:1292-1298.
33. Gunning K, Pippitt K, Kiraly B, et al. Pediculosis and scabies: treatment update. *Am Fam Physician.* 2012;15; 86(6):535-541.
34. Mumcuoglu KY, Klaus S, Kafka D. Clinical observation related to head lice infestation. *J Am Acad Dermatol.* 1991;25:248-251.
35. Carter D. *Insect egg glue* [doctoral thesis]. Cambridge, UK: Department of Applied Biology, Cambridge University; 1990.
36. Koch E, Clark JM, Cohen B, et al. Management of head louse infestations in the United States—a literature review. *Pediatr Dermatol.* 2016;33(5):466-472.
37. Burkhart CN. Fomite transmission with head lice: a continuing controversy. *Lancet.* 2003;361:99-100.
38. Takano-Lee M, Edman JD, Mullens BA, et al. Transmission potential of the human head louse, *Pediculus capitis* (Anoplura: Pediculidae). *Int J Dermatol.* 2005; 44:811-816.
39. Burkhart CN, Burkhart CG. Fomite transmission in head lice. *J Am Acad Dermatol.* 2007;56:1044-1047.
40. Burgess IF. Human lice and their management. *Adv Parasitol.* 1995;36:271-342.
41. Mauder JW. An update on head lice. *Health Visit.* 1993;66:317-318.
42. Speare R, Cahill C, Thomas G. Head lice on pillows, and strategies to make a small risk even less. *Int J Dermatol.* 2003;42:626-629.
43. Burkhart CN, Stankiewicz BA, Pchalek I, et al. Molecular composition of the louse sheath. *J Parasitol.* 1999; 85:559-561.
44. Burkhart CN. *Nit Sheath and Bacterial Symbiotes of the Human Head Louse (Pediculus Humanus Capitis)* [master's thesis]. Toledo, OH: Medical College of Ohio; 2003.
45. Burkhart CN, Burkhart CG, Pchalak I. The adherent cylindrical nit structure and its chemical denaturation in vitro: an assessment with therapeutic implication for head lice. *Arch Pediatr Adolesc Med.* 1998; 1152:711-712.
46. Dodd C. Treatment of head lice: choice of treatment will depend on local patterns of resistance. *BMJ.* 2001; 323(7321):1084.
47. Roberts RJ, Casey D, Morgan DA, et al. Comparison of wet combing with malathion for treatment of head lice in the UK: a pragmatic randomized controlled trial. *Lancet.* 2000;356:540-544.
48. Jahnke C, Bauer E, Hengge UR, et al. Accuracy of diagnosis of pediculosis capitis: visual inspection vs wet combing. *Arch Dermatol.* 2009;145:309-313.
49. Fournier A. Human pathogens in body and head lice. *Emerg Infect Dis.* 2002;8:1515-1518.
50. Robinson B. Potential role of head lice, *Pediculus humanus capitis*, as vectors of *Rickettsia prowazekii*. *Parasitol Res.* 2003;90:209-211.
51. Weyer KF. Biological relationships between lice and microbial agents. *Annu Rev Entomol.* 1960;5:405-420.
52. World Health Organization. *Instructions for Determining the Susceptibility or Resistance of Body Lice and Head Lice to Insecticides*. Geneva, Switzerland: WHO;1981. Available at http://apps.who.int/iris/bitstream/handle/10665/70733/WHO_VBC_81.808_eng.pdf?sequence=1&isAllowed=y
53. Sasaki T, Poudel SK, Isawa H, et al. First molecular evidence of *Bartonella quintana* in *Pediculus humanus capitis* (Phthiraptera: Pediculidae) collected from Nepalese children. *J Med Entomol.* 2006;43:110-112.
54. Frankowski BL, Weiner LB; Committee on School Health the Committee on Infectious Diseases, American Academy of Pediatrics. Head lice. *Pediatrics.* 2002;110(3): 638-643.
55. Grayson ML. The treatment triangle for staphylococcal infections. *N Engl J Med.* 2006;355(7):724-727.
56. Tebrueggge M, Runnuacles J. Is wet combing effective in children with pediculosis capitis infestation? *Arch Dis Child.* 2007;92(9):818-820.
57. Meinking TL, Serrano L, Hard B, et al. Comparative in vitro pediculicidal efficacy of treatments in a resistant head lice population in the United States. *Arch Dermatol.* 2002;138:220-224.
58. Meinking TL, Taplin D, Kalter DC, et al. Comparative efficacy of treatments for pediculosis capitis infestations. *Arch Dermatol.* 1986;122:267-271.
59. Meinking TL, Entzel P, Villar ME, et al. Comparative efficacy of treatments for pediculosis capitis infestations: update 2000. *Arch Dermatol.* 2001;137(3):287-292.
60. Downs AM, Stafford KA, Hunt LP, et al. Widespread insecticide resistance in head lice to over-the-counter pediculocides in England, and the emergence of carbaryl resistance. *Br J Dermatol.* 2002;146:88-89.
61. Burkhart CN, Burkhart CG. Topical pyrethroids: assessment of function and efficacy in head lice. *Int J Pediatr.* 2002;17:209-212.
62. Chosidow O, Chastang C, Brue C. Controlled study of malathion and d-phenothrin lotions for *Pediculus humanus* var *capitis*-infested school children. *Lancet.* 1994;344:1724-1727.
63. Meinking TL, Serrano L, Hard B. Comparative in vitro pediculocidal efficacy of treatments in a resistant head lice population. *Arch Dermatol.* 2002;138:220-224.
64. Meinking TL, Vicaria M, Eyerdam DH, et al. Efficacy of a reduced application time of Ovide lotion (0.5% malathion) compared to Nix crème rinse (1% permethrin) for the treatment of head lice. *Pediatr Dermatol.* 2004;21:670-674.

65. Burgess IF, Brown CM, Peck S. Head lice resistant to pyrethroid insecticides in Britain. *Br Med J*. 1995; 311:752.
66. Downs AM, Stafford KA, Coles GC. Head lice: prevalence in school children and insecticide resistance. *Parasitol Today*. 1999;15:1-5.
67. Bailey AM, Prociv P. Persistent head lice following multiple treatments: evidence for insecticide resistance in *Pediculus humanus capitis*. *Australas J Dermatol*. 2001;42:146-149.
68. Mumcuoglu KY, Hemingway J, Miller J. Permethrin resistance in the head louse *Pediculus capitis* from Israel. *Med Vet Entomol*. 1995;9:427-432.
69. Rupes V, Moravek J, Shmela J. A resistance of head lice, *Pediculus capitis*, to permethrin in the Czech Republic. *Cent Eur J Public Health*. 1995;3:30-32.
70. Gellatly KJ, Krim S, Palenchar DJ, et al. EXpansion of the knockdown resistance frequency map for human head lice (Phthiraptera: Pediculidae) in the United States using quantitative sequencing. *J Med Entomol*. 2016; 53:653-659.
71. Chosidow O, Giraudeau B, Cottrell J, et al. Oral ivermectin versus malathion lotion for difficult-to-treat head lice. *N Engl J Med*. 2010;362:896-905.
72. Burkhart CN, Burkhart CG. Recommendation to standardize pediculicidal and ovicidal testing for head lice (Anoplura: Pediculidae). *J Med Entomol*. 2001; 38(2):127-129.
73. Burkhart CG, Burkhart CN. Asphyxiation of lice with topical agents, not a reality…yet. *J Am Acad Dermatol*. 2006;54:721-722.
74. Narahashi T. Neuronal ion channels as the target sites of insecticides. *Pharmacol Toxicol*. 1996;79:1-14.
75. Adams ME, Miller TA. Neural and behavioral correlates of pyrethroid and DDT type poisoning in the house fly *Musca domestica*. *Pestic Biochem Physiol*. 1980;13:137-147.
76. Frankowski BL, Bocchini JA Jr; Council on School Health and Committee on Infectious Diseases. Head lice. *Pediatrics*. 2010;126(2):392-403.
77. Bonilla DL, Kabeya H, Henn J, et al. *Bartonella quintana* in body lice and head lice from homeless persons, San Francisco, California, USA. *Emerg Infect Dis*. 2009; 15:912-915.
78. Fang R, Houhamdi L, Raoult D. Detection of *Rickettsia prowazekii* in body lice and their feces by using monoclonal antibodies. *J Clin Microbiol*. 2002;40: 3358-3363.
79. Houhamdi L, Fournier PE, Fang R, et al. An experimental model of human body louse infection with *Rickettsia prowazekii*. *J Infect Dis*. 2002;186:1639-1646.
80. Raoult D, Roux V. The body louse as a vector of reemerging human diseases. *Clin Infect Dis*. 1999;29: 888-911.
81. Alcantara V, Rolain JM, Eduardo AG, et al. Molecular detection of *Bartonella quintana* in human body lice from Mexico City. *Clin Microbiol Infect*. 2009;15: 93-94.
82. Burkhart CG, Burkhart CN. Oral ivermectin for *Phthirus pubis*. *J Am Acad Dermatol*. 2004;51:1038.
83. Kalter DC, Sperber J, Rosen T. Treatment of pediculosis pubis: clinical comparison of efficacy and tolerance of 1% lindane shampoo vs. 1% permethrin crème rinse. *Arch Dermatol*. 1987;123:1315-1319.
84. Speare R, Koehler JM. A case of pubic lice resistant to pyrethrins. *Aust Fam Physician*. 2001;30:572-574.
85. Burkhart CG, Burkhart CN. Oral ivermectin therapy for phthiriasis palpebrum. *Arch Ophthal*. 2000; 118:134-135.

Chapter 179 :: Lyme Borreliosis

:: Roger Clark & Linden Hu

AT-A-GLANCE

- Lyme disease is caused by *Borrelia burgdorferi*, a tickborne spirochete.
- Clinical course can be prolonged and may involve multiple organ systems.
- The most common cutaneous finding is the erythema migrans rash. Other cutaneous manifestations include lymphocytoma and acrodermatitis chronica atrophicans, which are only seen in European disease.
- Diagnosis is typically made on clinical identification of the erythema migrans rash and/or serologic testing.
- Early treatment with antibiotics (doxycycline, amoxicillin, or cefuroxime) is highly successful.

HISTORICAL PERSPECTIVE

Lyme borreliosis, or Lyme disease, is the most commonly reported arthropod-borne illness in both the United States and Europe.[1] The disease acquired its name from epidemiologic investigations in the 1970s of cases of oligoarticular arthritis among children in and around the town of Lyme, Connecticut.[2] Certain features, including the tight clustering of cases in a heavily wooded area, and a rash that preceded arthritis that occurred predominantly in the summer, were suggestive that this was an arthropod-borne infectious disease.

In 1981, Burgdorfer isolated a new spirochetal bacterium, *Borrelia burgdorferi*, from the midgut of the *Ixodes dammini* tick (now *Ixodes scapularis*).[3] Recovery of the organism from cutaneous lesions, cerebrospinal fluid, and blood specimens of patients with Lyme disease in both the United States[4,5] and Europe[6-8] definitively linked the disease with *B. burgdorferi*. Subsequently, additional genospecies causing Lyme disease were recognized. The original North American genospecies was designated *B. burgdorferi* sensu stricto and other species (including the 2 most prominent genospecies in other parts of the world, *Borrelia garinii* and *Borrelia afzelii*) were considered part of the *B. burgdorferi* sensu lato group. Recently, a change in the genus of Lyme disease causing *Borrelia* to *Borreliella* has been proposed to recognize significant differences with relapsing fever *Borrelia*. *Borreliella* encompasses all the genospecies that were originally designated as part of the sensu lato group. However, this has not been fully accepted so we will continue to use the *Borrelia* designation conventions.

EPIDEMIOLOGY

Lyme disease occurs in the northern hemisphere in North America, Europe and Asia. The prevalence of strains differs between the continents, with *B. burgdorferi* being the predominant species in North America, *B. garinii* and *B. afzelii* being predominant in Asia, and all three present in Europe. Disease is often focal with high rates in some countries/states but not others. In Europe, the incidence is highest in the Austria, Belgium, Estonia, Lithuania, The Netherlands, Slovenia, and Sweden, with approximately 120,000 reported cases per year in Europe. The disease is less common in Asia, but has been reported in Russia, China, Korea, and Japan. In the United States, the majority of the cases are reported from the Northeast and mid-Atlantic areas and the North Central part of the country. There is also a smaller foci of disease in the Northwestern United States.

Lyme disease *Borrelia* are transmitted by ticks in the *Ixodes ricinus* group. In the United States, the major tick vector is *I. scapularis*. *Ixodes pacificus* serves as the vector in the western United States. The white-footed mouse is the primary amplifying host of *B. burgdorferi*, with other small mammals, such as voles, shrews, chipmunks, and birds, playing a lesser role. *B. burgdorferi* sensu stricto is by far the dominant genospecies in the United States, although there have been recent reports of other species causing human disease (*Borrelia bissettii, Borrelia mayonii*).[9-11]

In Europe, the disease is transmitted by the *I. ricinus* tick, which feeds on more than 300 species of animals. Birds, shrews, voles, and other small mammals serve as the major amplifying hosts of *Borrelia* species in Europe.[12] Three genospecies constitute the majority of human-infecting organisms in Europe: *B. burgdorferi* sensu stricto, *B. afzelii*, and *B. garinii*.

Ixodes persulcatus is the main vector of *B. burgdorferi* in Asia. Human infections are less common throughout most of Asia and correspondingly, less is understood about the epidemiology. *I. persulcatus* is only known to transmit *B. garinii* and *B. afzelii*.

B. burgdorferi has an enzootic cycle that involves the *Ixodes* ticks and small mammals and birds, as noted above. *Ixodes* ticks undergo 4 stages during a 2-year cycle: egg, larva, nymph, and adult. There is no transovarial (ie, transmission of disease from the adult tick to the larva via the eggs) passage of *B. burgdorferi*. Ticks must acquire the bacterium by taking a blood meal from an animal that can maintain the living organism. Once acquired, there is transstadial transmission (passage from one stage in the tick lifecycle to the next). The majority of human transmission is from infected nymphal stage ticks, although infected adult ticks are also able to transmit disease.

In the United States, the incidence and range of the organism has steadily grown over the last several decades. Deer, which do not get infected with *B. burgdorferi* but can transport infected ticks, and birds are thought to be the primary drivers in dispersal of infected ticks into new areas. In the United States, the Centers for Disease Control and Prevention initiated surveillance for Lyme disease in 1982, and the Council of State and Territorial Epidemiologists made Lyme disease a nationally notifiable disease in 1991. From 1992 to 2006 the number of cases reported annually doubled, from 9908 cases to 19,931 cases.[13] By 2015, the number of new cases reported annually in the United States was 34,390.[12] In 2015, accounting for unreported cases, the Centers for disease control and prevention estimated that the incidence of Lyme disease in the U.S. was approximately 300,000 cases per year.[14,15] During the period 2005 to 2014, approximately 96% of reported cases occurred in 14 states located in the Northeastern, mid-Atlantic, and North Central regions: Connecticut, Delaware, Maine, Maryland, Massachusetts, Minnesota, New Hampshire, New Jersey, New York, Pennsylvania, Rhode Island, Vermont, Virginia, and Wisconsin (Fig. 179-1).[16] Disease in many of the states with low incidence represents travelers infected during travel to more endemic regions.

In the United States, Lyme disease is slightly more prevalent in males (53.1%) than in females, and whites are disproportionately represented at 94.1% of cases. Two-thirds of cases of have onset in the summer months of June, July, and August. There is a bimodal age distribution of Lyme disease in the United States, with peaks at ages 5 to 9 years (8.6 cases per 100,000 population) and 55 to 59 years (7.8 cases per 100,000 population).[13]

CLINICAL FEATURES

CUTANEOUS FINDINGS

EARLY CUTANEOUS FINDINGS

Erythema Migrans: Lyme disease initiates with movement of bacteria from the tick to the patient during tick attachment. Bacteria first multiply locally in the skin. The erythema migrans (EM) rash, which is typically the first symptom to develop with infection, begins 3 to 30 days (average: 7 days)[17] after completion of tick feeding.

EM is thought to be present in 70% to 80% of those individuals infected, with estimates reported to be as high as 90% in patients diagnosed with Lyme disease.[5,17,18] EM rash is a result of the host inflammatory response to the nascent infection. The histopathologic description of EM is a superficial and deep perivascular infiltrate of eosinophils at the center of the lesion and plasma cells, lymphocytes, and histiocytes peripherally (Fig. 179-2).[19] Immunohistochemical studies indicate the infiltrate to be composed of CD4+ T lymphocytes, with the exception of those seen

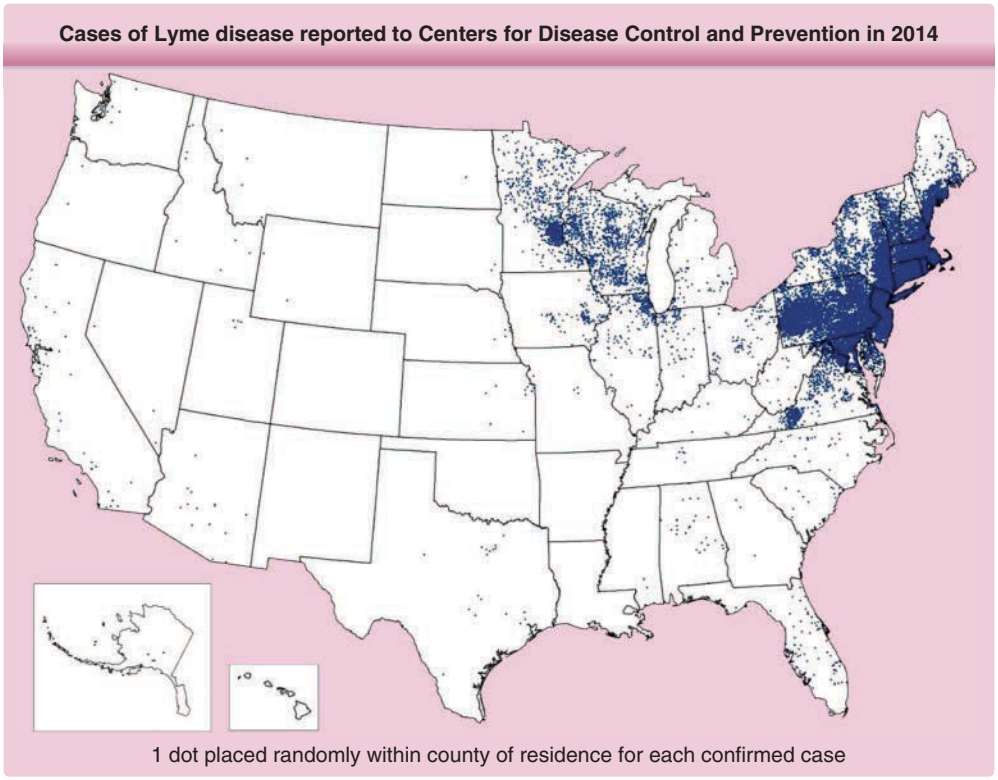

Figure 179-1 Cases of Lyme disease reported to Centers for Disease Control and Prevention in 2014. Cases shown indicate the county or residence of the infected individuals, and do not necessarily indicate where the infection occurred.

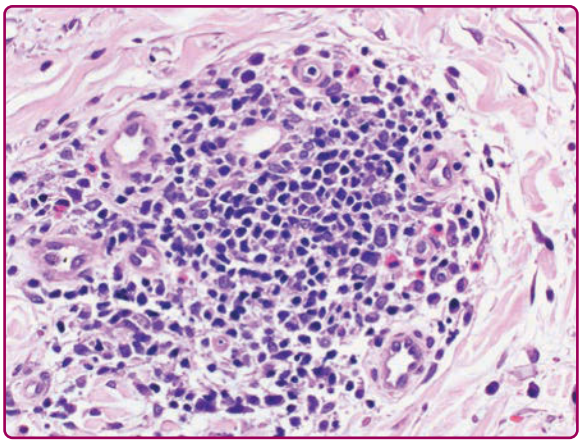

Figure 179-2 Histopathology of erythema migrans. Dense nodular perivascular lymphoid cell infiltrate with many plasma cells and few eosinophils in a biopsy from a later stage of erythema migrans. (Hematoxylin and eosin stain, ×40 magnification.)

Figure 179-3 Erythema migrans with the classic "bull's-eye" appearance with a dark center, surrounding area of clearance, and a darker, advancing border. While this represents the classic appearance, it occurs only in a minority of cases.

in association with HIV infection in which the infiltrate is mainly CD8+ T lymphocytes, reflective of the CD4 lymphopenia of HIV infection.[20] The organism can be readily cultured from biopsy of the EM lesion and can be seen in tissue samples by immunofluorescence.[21]

Solitary EM rash typically occurs at the site of the tick bite, although in many cases, a definite history of a tick bite at the site of the lesion is not obtained.[22] Certain areas on the body are more likely to sustain tick bites long enough to allow for transmission of the spirochete, which is typically thought to require a minimum of 36 hours. Ticks may go unnoticed in the popliteal fossa, the groin, axilla, back, and on the head; likewise EM rash may also go unobserved in these areas. In small children, solitary EM rash occurs more often on the head and neck than in older children or adults, where these areas are seldom affected.[18]

EM rash is classically described as a large (>5 cm), expanding, erythematous, round or oval lesion, with the longer axis along the lines of least skin tension (Langer lines) and central clearing, often with a darker punctate center at the site of the tick bite (so-called Bull's-eye rash) (Figs. 179-3 and 179-4). However, this classic appearance only occurs in a minority of cases. In one observational study of 118 microbiologically proven cases of Lyme disease, only 9% of EM rash had this appearance, whereas 59% had a homogeneous appearance.[23] In another study of 14 patients with microbiologically proven Lyme disease, 10 (71%) of 14 EM rashes lacked the classic central clearing (Fig. 179-5).[24] Central clearing may be more common in *B. garinii* than with *B. burgdorferi*. Strle and others compared characteristics of culture-proven EM rash from *B. garinii* in Slovenia and *B. burgdorferi* in the United States. Central clearing was found in 71% of those with *B. garinii* versus 35.3% with *B. burgdorferi* (p = 0.0002) (Table 179-1).[25]

The lesion in itself is usually asymptomatic, but approximately 30% to 50% of patients report mild tingling, itching, or burning.[25,26] Systemic manifestations, reported in approximately 50% of patients, may appear before, during, or after the classic lesion.[27,28] Uncommon presentations of EM rash include forms with marked central necrosis, EM of minimal size (size of the ring less than 5 cm at initial presentation) (2%), and the vesicular variant (5%).[29-31]

The bacteria can disseminate from the inoculation site as early as 3 days after the presence of the original EM lesion. The most common manifestation of hematogenous dissemination of the spirochete are multiple EM rashes, which are scattered over the body. These are randomly distributed and do not represent multiple localized infections at individual tick bite sites. The appearance of multiple EM lesions appears to have become less common, as Lyme disease is more widely recognized and treated early in the disease process. As of this writing, it is estimated that multiple EM lesions occur approximately 10% to 18% of the time in those infected with *B. burgdorferi*.[5,32,33] Secondary EM lesions

Figure 179-4 Erythema migrans lesion. Note the relative central clearing. This lesion lacks the darker punctate center sometimes found in the classic "bull's-eye" lesion. (From Clark RP. Tickborne infections. In: McKean S, Ross J, Dressler D, et al, eds. *Principles and Practice of Hospital Medicine*. 2nd ed. New York NY: McGraw-Hill; 2017, with permission.)

Figure 179-5 Erythema migrans. Note the lack of central clearance. This is the most common form of EM rash in the United States, appearing as an expanding, homogeneous, round or oval erythematous rash.

Figure 179-6 Disseminated erythema migrans. These are often smaller than the primary EM rash noted at the site of the tick bite.

are generally smaller than the primary EM lesions, but are otherwise indistinguishable, either visually or histologically (Figs. 179-6 to 179-8).

LATE CUTANEOUS FINDINGS

There are several dermatologic findings of Lyme disease that occur months to years after the initial infection. The majority of these are reported only in European infections and have not been seen in North American or Asian cases of disease.

Acrodermatitis Chronica Atrophicans: Observed mainly in elderly patients in Europe, acrodermatitis chronica atrophicans (ACA) has an insidious onset and appears to have a predilection for females.[34] Rare cases of ACA have been reported in children.[35] The time interval from the spirochete inoculation to the onset of symptoms of ACA is extremely difficult to evaluate. Most patients do not recall the specific tick bite that initiated the disease.[8,36] That the spirochete can survive for decades is favored by reports indicating recovery of the spirochete from biopsies of skin from ACA patients even after 20 years.[8]

TABLE 179-1
Characteristics of Erythema Migrans

CHARACTERISTICS	FREQUENCY (%) LYME—U.S. (N = 79)	FREQUENCY (%) LYME—EUROPE (N = 231)
Patients:		
Median Age (years)	38	46.7
(range in years)	(16-76)	(15-83)
Male	62%	43%
Female	38%	57%
Median diameter at presentation	13 cm	26 cm
Multiple EM lesions	18%	6%
"Bull's-eye" or central clearing	37%	71%

Data from Nadelman RB, Nowakowski J, Forseter G, et al. The clinical spectrum of early Lyme borreliosis in patients with culture-confirmed erythema migrans. *Am J Med*. 1996;100(5):502-508; and Strle F, Nelson JA, Ruzic-Sabljic E, et al. European Lyme borreliosis: 231 culture-confirmed cases involving patients with erythema migrans. *Clin Infect Dis*. 1996; 23(1):61-65.

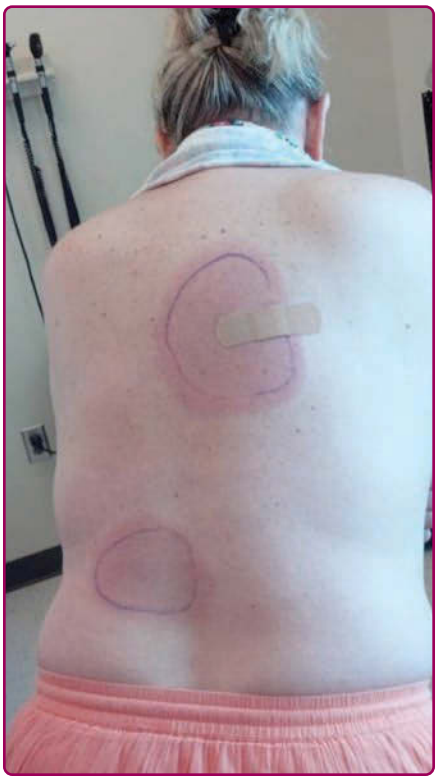

Figure 179-7 Disseminated erythema migrans lesions with uniformly erythematous, round, or oval morphology. This does not represent multiple tick bites; rather, it represents hematogenous spread of the spirochete in a random distribution on the skin. This patient also had lesions present in multiple other locations. (From Clark RP. Tickborne infections. In: McKean S, Ross J, Dressler D, et al, eds. *Principles and Practice of Hospital Medicine*. 2nd ed. New York NY: McGraw-Hill; 2017, with permission.)

Figure 179-8 Disseminated erythema migrans. The lesion on the left is elongated, almost linear in appearance, whereas the one on the right is almost elliptical, with a "bull's-eye" morphology.

Figure 179-10 Acrodermatitis chronica atrophicans with bluish-red discoloration and cutaneous atrophy as evidenced by the "tissue paper" appearance of the dorsum of the right hand. (Image used with permission of Franc Strle, MD.)

An inflammatory phase characterizes the early clinical stages of this biphasic disease.[37] The inflammatory phase presents as a bluish-red discoloration on the extensor aspect of fingers, hands, joints, and lower extremities (Fig. 179-9). Joints usually involved include the elbows and knees. Infiltrated purple bands of varying widths may be observed adjacent to involved joint(s). Associated findings include a cushion-like ("doughy") swelling of the dorsum of the hands and feet.[37] The extremities are most commonly involved, although extensive lesions on the trunk also have been documented. Lesions typically extend from the distal to the proximal portion of the extremity involved. Although the erythema and swelling initially vary in intensity ("waxes and wanes"), swelling of the posterior aspect of the lower extremities is believed by some to be particularly indicative of Lyme disease.[38]

Cutaneous atrophy characteristic of the later clinical stage is not an obligatory sequel to the inflammatory phase of ACA.[37] Rarely, coexistence of both kinds of lesions at different sites in the same patient has been documented. The atrophic phase is characterized by lesions with a "cigarette paper-like" appearance and a prominence of superficial veins (Fig. 179-10).

CNS and peripheral nervous system involvement also have been documented in approximately 45% of patients with ACA. Thirty percent to 45% of patients suffer from a polyneuropathy, often most pronounced in the limb with cutaneous involvement.[39] Chronic joint and bone involvement, attributed to persistence of spirochetes in cutaneous lesions, is most often seen in patients with longstanding ACA or an untreated lesion of EM or ACA and is typically restricted to the extremity involved. The characteristic symptom, exhibited in approximately one-third of patients in one study, was a swollen or painful foot and heel.[39] Other symptoms include subluxation of small joints, bursitis, arthritis, and cortical thickening of bone. Solitary or multiple fibrotic lesions near joints, particularly in the olecranon area, may develop in some patients.[37]

All 3 species of *B. burgdorferi* that infect humans have been found in ACA lesions.[40] Histopathologic features of biopsied lesions vary with the clinical phase of ACA. In inflammatory lesions, 3 layers are typically described: an atrophic epidermis, a zone of uninvolved papillary dermis, and a layer of inflammatory cells composed of lymphocytes and plasma cells.[41] The presence of plasma cells in the infiltrate is documented mainly from studies from Europe, as American reports indicate that few or no plasma cells are found.[36] The infiltrate may be deep with extension into the subcutis.[38] Occasionally, interface dermatitis has been reported. Unusual findings include the presence of vacuoles, either singly or in groups, at different levels of the dermis.[42] Although some believe these represent mature adipocytes, others believe them to be an expression of lymphedema, given that they are mainly observed from biopsies of markedly edematous sites. In favor of the expression-of-lymphedema hypothesis is the absence of such vacuoles from the same site after treatment.

Figure 179-9 Acrodermatitis chronica atrophicans. Note the classical "tissue paper–like" cutaneous atrophy. (Image used with permission of Franc Strle, MD.)

Phenotypic studies indicate the lymphocytes in the infiltrate are mainly of the CD4 phenotype, favoring the concept that ACA is a T-cell–mediated immune response.[43] Further in support of this theory is the expression of adhesion molecules, such as intracellular adhesion molecule-1, on endothelial cells, lymphocytes, and basal keratinocytes in the inflammatory infiltrate.[44] Chronicity of the lesions may be partially explained by downregulation of major histocompatibility complex class II molecules on Langerhans cells.[45]

Cutaneous Scleroborrelioses: Sclerotic skin lesions clinically indistinguishable from primary lichen sclerosus et atrophicus or morphea develop not only in association with other dermatoborrelioses (approximately 10% of patients with ACA and borrelial lymphocytoma [see below]) but also in the absence of other cutaneous manifestations of Lyme disease.[29,46,47]

Periarticular ("ulnar") fibrous nodules described in association ACA, may also occur in the absence of dermatoborrelioses.[48] They usually present as hard nodules on the elbows and knees, and on the lateral aspect of the digits near joints, and have been reported to be provoked by trauma, surgery, and electromagnetic radiation.[49]

Uncommon sclerotic disorders associated with Lyme disease include progressive facial hemiatrophy (Parry-Romberg syndrome) and eosinophilic fasciitis (Shulman syndrome) (see Chap. 64).[50] In support of an infectious etiology is the clinical similarity of the cutaneous lesions, positive history of tick bite, and, in rare cases, antiborrelial serologic evidence and positive culture and polymerase chain reaction (PCR) from lesions.[51,52] Eosinophilic fasciitis associated with borrelial infection has been termed *borrelial fasciitis*, reflective of the infectious nature of these lesions.[52] However, patients with borrelial fasciitis lack the peripheral blood eosinophilia typical of patients with Shulman disease.

A unifying feature of lichen sclerosus et atrophicus–like and morphea-like scleroborrelioses is the abundance of plasma cells in the inflammatory infiltrate.[37] Unusual histologic findings include a scleromyxedema-like picture with increased dermal mucin and fibroblast proliferation.[48]

Histopathologic examination of a periarticular fibrous nodule reveals relatively well-circumscribed nodules of broad hyalinized bundles of collagen with macrophages and plasma cells.[49,53] Adjacent capillaries may be occluded by similar deposits.

Progressive facial hemiatrophy and eosinophilic fasciitis show variable dermal sclerosis, loss of appendages, and a perivascular infiltrate composed predominantly of lymphocytes and plasma cells with scattered histiocytes.[38] In borrelial fasciitis, eosinophilic infiltration of the fascial planes is not as impressive as in "idiopathic" Shulman disease.[50]

Cutaneous Atrophoborrelioses: Atrophic lesions indistinguishable from primary anetoderma (see Chap. 70) may also occur in the absence of other dermatoborrelioses.[37,54] When associated with ACA, these lesions are usually seen at the periphery of an extensive lesion.[55]

Biopsy specimens from atrophic or anetoderma-like skin lesions show abnormal elastic tissue fibers in association with a perivascular infiltrate of lymphocytes with occasional histiocytes, neutrophils, or eosinophils.[37] Spirochetes are found with difficulty in histologic sections.

Cutaneous Lymphoborrelioses (B-Cell and T-Cell Lymphoid Hyperplasias): Lymphocytic infiltrates associated with *Borrelia* are the least common of the cutaneous hallmarks of Lyme disease (1%) and may present either as single borrelial lymphocytoma (lymphadenosis benigna cutis) or as multiple lesions.[38] The coexistence of lymphocytoma with other dermatoborrelioses led to the suggestion of a unifying causative organism, favored by the development of EM-like lesions following passive inoculation of an infiltrate from a lesion of lymphadenosis benigna cutis.[8,56] Lymphocytoma has been reported solely in Europe. However, all 3 species of *B. burgdorferi* sensu lato are associated with lymphocytoma, so it is unclear whether the lack of U.S. cases is related to strain differences.[40]

More common in children than in adults, lymphocytoma clinically presents as a nodulopapular lesion in the ear lobes (Fig. 179-11) and scrotum in children and the nipple-areolar area (Fig. 179-12) in adults.[29] The precise reason for this predilection is not known but is believed to be tissue temperature related.[38] As with the other dermatoborrelioses, most patients are not aware of a preceding tick bite. The incubation period varies anywhere from a few weeks to 10 months. The duration of an untreated solitary lesion can vary from months to years (average: 5 years). Spontaneous resolution may occur, but typically lesions resolve more rapidly with antibiotic therapy.[39] Lesions of multiple lymphocytomas can be entirely subcutaneous, may last for decades, and typically have no specific site predilection or associations with other dermatoborrelioses.

Direct evidence of an infective etiology has been provided from studies demonstrating the presence of

Figure 179-11 Borrelial lymphocytoma in a young adult with an erythematous nodulopapular lesion of the ear lobe. (Image used with permission of Franc Strle, MD.)

Figure 179-12 Borrelial lymphocytoma involving the left nipple. (Photograph used with permission of Franc Strle, MD.)

fragmented spiral forms suggestive of *B. burgdorferi* in lesions of benign lymphocytic infiltrates,[57] and has been confirmed by immunofluorescence using species-specific monoclonal antibodies. Spirochetes may be cultured directly from biopsy specimens or *B. burgdorferi* DNA may be detected by PCR. High titers of antiborrelial antibodies have been reported in more than 50% of patients with lymphadenosis benigna cutis solitaria.[56] The common denominator in patients with *Borrelia*-associated lymphoma appears to be a high titer of antibodies, typical of the chronic stage of the infection, against *B. burgdorferi*.[56]

Discoid lesions "starting as small papules and expanding peripherally with central clearance" that wax and wane also have been described in association with borrelial infection.[57] The name given for these lesions is *benign lymphocytic infiltrates* of the skin (Jessner-Kanof) (see Chap. 120). More common in men, they tend to be located on the face, neck, and upper trunk. Annular lesions clinically resembling EM also have been described.

Several reports suggest an association of low-grade cutaneous B-cell lymphoma with *B. burgdorferi* infection.[58,59] Clinical presentation of *Borrelia*-ssociated B-cell lymphoproliferative disease is varied and consists of multiple ill-defined, slowly progressive plaques and nodules presenting on the trunk, extremities, or both, of usually older patients. The highest frequency of infection with *Borrelia* has been found in marginal zone lymphoma (20% to 52%), followed by follicular center lymphoma (15% to 26%) and diffuse large B-cell lymphoma (15% to 16%; see Chaps. 119 and 120).[58,60] That antigenic drive by *Borrelia* may be a pathogenic factor in more than 1 subtype is supported by the association of *B. burgdorferi* with multiple subtypes of cutaneous B-cell lymphoma. Demonstration of the organism in the skin before development of overt cutaneous B-cell lymphoma serves to confirm the temporal progression of *B. burgdorferi*–associated B-cell lymphoproliferative disease. Clinical regression of marginal zone lymphoma after eradication of *B. burgdorferi* argues in favor of a benign process.[59,61,62]

Histopathologic findings of benign B-cell– and T-cell–dominant hyperplasias are essentially similar to benign lymphoid hyperplasias secondary to an arthropod bite, vaccination, or other causes (see Chap. 120). Definitive classification of *Borrelia*-associated B-cell lymphoma is confounded by the immunohistochemical profile: expression of CD5 and CD10 (common acute lymphoblastic leukemia antigen), antigens typically associated with centrocytic lymphoma, are absent in *Borrelia*-associated B-cell lymphoma.[58]

Other Cutaneous Lesions: Other cutaneous lesions reported in patients with documented Lyme disease include panniculitis, vasculitis, granuloma annulare, erythema multiforme, and a syphilis-like papulosquamous eruption, but *B. burgdorferi* has not been directly recovered from any of these lesions (Table 179-2).

NONCUTANEOUS FINDINGS

After the initial inoculation into skin and resultant EM lesion, *B. burgdorferi* quickly disseminates to other parts of the body causing site-specific manifestations. Common areas for dissemination include the central and peripheral nervous system, the heart and the joints. Often in early Lyme disease there are multiple, nonspecific symptoms in addition to rash. The frequency of these symptoms appears to vary depending on the genospecies is involved (Table 179-3).

NERVOUS SYSTEM MANIFESTATIONS

B. burgdorferi can cause neurologic disease in 10% to 15% of patients in the United States who have not received antibiotics. Meningitis, cranial neuropathy, and radiculopathy are the most common neurologic manifestations and can manifest as soon as 1 week after EM.[63] Facial palsy is the most characteristic neuropathy of early Lyme disease in the United States, occurring in 40% to 50% of patients with borrelial neurologic involvement, usually within 4 weeks after onset of EM. Bilateral facial palsy should immediately raise suspicion for Lyme disease, as it is uncommon in most other causes of facial palsy. Involvement of other cranial nerves has been reported, but is relatively rare.[63] The triad of lymphocytic meningitis, cranial palsy (often facial), and radiculoneuritis, known as Bannwarth syndrome, is pathognomonic for Lyme disease. It is frequently reported in Europe but is rare in the United States.[64,65] It is thought that *B. garinii* causes meningitis and radiculopathy more frequently than *B. burgdorferi*.[66] Acute or subacute myelitis leading to spastic paraparesis and cerebrospinal fluid pleocytosis, mononeuritis, and a Guillain-Barré–like syndrome may also occur in early disseminated disease.[67,68] Late neurologic manifestations include encephalomyelitis, encephalopathy, and chronic polyneuropathies.[69,70]

TABLE 179-2
Cutaneous Manifestations of Lyme Disease

	ONSET	DIAGNOSIS/DIFFERENTIAL DIAGNOSIS
Common Manifestations		
Erythema migrans	Weeks to months (early)	Arthropod bite, erythema multiforme granuloma annulare, urticaria, erysipelas, brown recluse spider bite, fixed drug eruption
Acrodermatitis chronica atrophicans	Months to years (late)	Venous insufficiency, lichen sclerosus, scleroderma, physiologic age-related atrophy, corticosteroid-induced atrophy
Uncommon Manifestations		
Cutaneous scleroborrelioses	Months to years (late)	
▪ Morphea		▪ Primary morphea
▪ Lichen sclerosus et atrophicus		▪ Primary lichen sclerosus et atrophicus
▪ Periarticular fibrous nodules		▪ Rheumatoid nodule, gouty tophi
▪ Progressive facial hemiatrophy		▪ Primary progressive facial hemiatrophy/Parry-Romberg syndrome
▪ Eosinophilic fasciitis		▪ Primary eosinophilic fasciitis/Shulman syndrome
Cutaneous atrophoborrelioses	Months to years (late)	
▪ Anetoderma		▪ Primary anetoderma
Cutaneous lymphoborrelioses	Months to years (late)	
▪ B-cell dominant (including B-cell lymphoma)		▪ Arthropod bite reaction, response to vaccination, granulomas, neoplasm
▪ T-cell dominant		▪ Pityriasis lichenoides, polymorphous light eruption
Other cutaneous lesions	Weeks to months to years (early or late)	
▪ Panniculitis		▪ Erythema nodosum
▪ Granuloma annulare		▪ Insect bite reaction
▪ Erythema multiforme		▪ Drug eruption
▪ Syphilis-like papulosquamous eruption		▪ Secondary syphilis

CARDIAC MANIFESTATIONS

Cardiac involvement occurs in anywhere from 1% to 10% of untreated patients in the United States[71,72] and in 0.3% to 4% of European patients.[73,74] The wide ranges probably reflect the fact that in recent years, Lyme disease is recognized and treated sooner, resulting in lower incidence than in the past. It usually occurs within several weeks after the onset of infection, although it can occur as early as 1 week and as late as 7 months into the infection.[71,75] Within the heart, *B. burgdorferi* has a predilection for the atrioventricular node, resulting in atrioventricular block. Acute myopericarditis and left ventricular dysfunction can also occur, but are usually self-limited and mild, only sometimes resulting in transient cardiomegaly or pericardial effusion.[76] *B. burgdorferi* has been isolated from endomyocardial biopsy samples from several European patients with chronic dilated cardiomyopathy, a complication observed less frequently in the United States.[77,78] In the United States, there have been cases of cardiac sudden death where autopsies have revealed myocarditis caused by undiagnosed Lyme disease.[72]

TABLE 179-3
Clinical Manifestations of Early Lyme Disease

SYMPTOM OR LABORATORY ABNORMALITY	FREQUENCY (%) LYME U.S. (N = 79)	FREQUENCY (%) LYME EUROPE (N = 231)	FREQUENCY (%) *B. MAYONII* (N = 6)
Fatigue	54	10	67
Arthralgia	44	25	17
Myalgia	44	11	67
Headache	42	20	83
Neck stiffness/ meningeal signs	35	1	50
GI symptoms	26	0.4	67
Regional lymph-adenopathy	23	7	N/A
Fever	16	4	83

MUSCULOSKELETAL MANIFESTATIONS

Early musculoskeletal manifestations of *B. burgdorferi* infection are typically nonspecific. Inflammatory arthritis is the most frequent clinical sign of late-disseminated Lyme disease in the United States, occurring in approximately 60% of patients with untreated or incompletely treated infection.[62,79] It usually presents 1 or more months

after the onset of Lyme disease as asymmetric monoarthritis or oligoarthritis of large joints, most often of the knee. Migratory arthralgia is also relatively common, especially during disseminated Lyme disease. Bouts of arthritis are generally frequent and short at first, becoming longer and less frequent with time, each lasting from several days to 1 year.[79]

OTHER MANIFESTATIONS OF LYME DISEASE

Ophthalmic complications in the form of conjunctivitis, keratitis, iridocyclitis, retinal vasculitis, chorioiditis, and optic neuropathy are rare manifestations of Lyme disease. They are thought to be the direct result of tissue inflammation by *B. burgdorferi* and are usually associated with other signs and symptoms of disease. The eye also may be affected by extraocular manifestations of Lyme disease, such as cranial nerve pareses and orbital myositis. Findings in other organ systems (GI, lymphatic, respiratory, urinary, and genital) have been reported, but the associations with borrelial infection are loose.

PERINATAL LYME DISEASE

Studies in both human and animal models indicate that *B. burgdorferi* can cross the placenta during the initial spirochetemia, but evidence of a fetal immune response or an adverse neonatal outcome are not definitively established. Several studies have found no link between maternal infection with Lyme and subsequent birth defects.[80-84]

LYME DISEASE IN CHILDREN

Other than differences in localization of EM lesions (more typically in the head and neck), pediatric Lyme disease is similar to that of adults. Of note, however, optic nerve involvement may lead to blindness in children.[85]

COMPLICATIONS

All manifestations of Lyme disease resolve over time, even in the absence of antibiotic therapy. Antibiotic therapy can hasten resolution of some (EM, arthritis), but not all (facial palsy, radiculitis) manifestations, and antibiotic therapy can clearly abort late manifestations.

Coinfection with *B. burgdorferi* and either (or both) of *Babesia microti* or *Anaplasma phagocytophilum* occurs at different frequencies depending on the geographic location, and may alter the clinical presentation of Lyme disease in some patients. Some studies suggest more-severe disease in patients who are coinfected, but this remains uncertain.[86-89]

A small number of patients have symptoms that persist for years despite appropriate antibiotic therapy. Up to 10% of patients with Lyme arthritis who are treated with appropriate antibiotics may have continued arthritis that persists for years.[90,91] Arthritis in these patients does typically respond to immunosuppressive agents (methotrexate, anti–tumor necrosis factor therapies), which has led to suggestions that these patients may have an autoimmune syndrome. Molecular mimicry of borrelial antigens with host proteins has been proposed as one possible mechanism, but this remains unproven.[92,93]

There are many reports of patients who continue to have symptoms beyond a standard treatment course for Lyme disease of 2 to 4 weeks, including profound fatigue, depression, myalgia, polyarthralgias without arthritis, and paresthesias, as well as neurocognitive difficulties involving memory, concentration (particularly auditory), and decreased mental flexibility (ie, impaired verbal fluency) after infection with *B. burgdorferi*.[92] This syndrome is often referred to as posttreatment Lyme disease syndrome. The linkage of these symptoms with *B. burgdorferi* infection remains controversial and several large epidemiologic studies have shown that patients who have contracted Lyme disease are no more likely to suffer from these symptoms than persons in the general population.[94-96] There are numerous studies demonstrating that longer-than-standard courses of antibiotics for Lyme disease do not improve long-term symptoms.[97-99] However, prolonged courses of antibiotics for Lyme disease do have serious adverse effects.[100,101] At this time, courses of antibiotics exceeding the standard duration are not recommended.

ETIOLOGY AND PATHOGENESIS

RISK FACTORS

The risk of acquiring Lyme disease is almost completely dependent on exposure to the tick vector in areas where Lyme disease is prevalent. These areas are detailed in section "Epidemiology". Avoidance of environments where ticks are likely to be found is an effective strategy to prevent disease. Other methods to reduce the risk of acquiring Lyme disease and coinfecting organisms are found in section "Prevention".

PATHOGENESIS

B. burgdorferi sensu lato, the agent of Lyme borreliosis, belongs to the eubacterial phylum of *Spirochaetales*, which are vigorously motile, corkscrew-shaped bacteria. Recently, it has been proposed that *B. burgdorferi* sensu lato be renamed as *Borreliella burgdorferi* to distinguish it from relapsing fever *Borrelia*. Here we will continue to use the *Borrelia* designation. The borrelial genome is made up of a linear chromosome and more than 20 circular and linear plasmids, the largest number

known for any bacteria.[102,103] Some of the plasmids can be considered minichromosomes, as they are required for survival of the organism. Among the interesting characteristics of the organism are the large number of lipoproteins (more than 150) encoded by the genome. *Borrelia* lack biosynthetic machinery to produce many essential nutrients (eg, amino acids, fatty acids), suggesting that *B. burgdorferi* is highly dependent on its hosts for obtaining crucial nutrients.[102,103]

Ixodes ticks have a 2-year, 3-stage (larval, nymphal, and adult) life cycle. Larval ticks acquire *B. burgdorferi* organisms by taking a blood meal from an infected animal and maintain the infection during the subsequent molting to the nymphal and adult stages. *B. burgdorferi* remain dormant in the tick's midgut between feedings.[104] Each tick life stage takes 1 blood meal: larval ticks feed in late summer, nymphal ticks feed the subsequent spring and early summer, and adult ticks feed in the fall and early winter.[104] The major reservoirs for *B. burgdorferi* are small rodents and birds that are fed on by larval and nymphal ticks. Adult ticks feed on larger mammals (eg, deer) that are not important reservoirs for *B. burgdorferi* but are an important feeding source for adult ticks. Reductions in deer populations can lead to significant decreases in the tick population.[105] Humans are incidental hosts not important in maintaining *B. burgdorferi* in the wild. Most cases of human illness occur in the late spring and summer months when the nymphs are most active and human outdoor activity is greatest.

Of clinical relevance, certain *Ixodes* ticks are vectors of other tick-borne illnesses in addition to Lyme disease: *I. scapularis* ticks in the United States and *I. ricinus* ticks in Europe may transmit *B. microti* (a red blood cell parasite), *A. phagocytophilum* (formerly referred to as the agent of human granulocytic ehrlichiosis) and *Borrelia miyamotoi* (a relapsing fever type *Borrelia*).[86,102,103] *I. ricinus* in Europe and *I. persulcatus* in Asia are also vectors of tick-borne encephalitis virus, whereas *I. scapularis* transmits a related Powassan family virus (deer tick virus).[106,107] Patients who have been bitten by *Ixodes* ticks may be coinfected with multiple organisms.

B. burgdorferi rapidly adapt to different host environments by changing protein expression.[104] There are multiple levels of control of gene expression but 2 of the major regulators of borrelial gene expression are the histidine kinase-1 (HK1)/response regulator-1 (Rrp1) pathway and the Response regulator-2 (Rrp2)/RNA polymerase, sigma S (RpoS)/RNA polymerase, sigma N (RpoN) pathway. The HK1/Rrp1 pathway becomes activated as bacteria exit a mammalian host and enter a tick host. The Rrp2/RpoS/RpoN system becomes activated as the bacteria readies itself for entry into a mammalian host. Other regulatory factors such as BosR, a Fur-like transcription factor, and RpoD, a sigma factor, also help to control expression of genes upon tick feeding and transition to the mammalian host. Genes upregulated by Rrp2/RpoS/RpoN include those that may assist with immune evasion and cellular adhesion, as well as genes identified as essential for establishment of initial infection whose functions are unknown.

At the tick bite site, the spirochete is injected along with tick saliva into the skin. The presence of the tick salivary protein, Salp15, on the surface of the spirochete is instrumental in helping the organism evade the mammalian immune system during early infection.[108] After a latency period of 3 days to 1 month, the organism spreads through the skin. The immune response to the bacteria causes the characteristic EM rash. The bacteria enter the blood circulation and disseminate hematogenously. This generally occurs within days to weeks after infection. This dissemination is caused by both host and pathogen factors. For instance, it has been found that in North America, infection with certain strains of *B. burgdorferi,* such as OspC type A (RST 1), are particularly likely to result in hematogenous spread of the organism.[109] Host proteases, such as plasmin and matrix metalloproteinases, may assist the bacteria as it moves through tissues.

With its ability to establish long-term infection in mammalian hosts, several important factors in escaping immune defenses have been identified. Motility is a critical element of *B. burgdorferi* survival.[110] *B. burgdorferi* move very quickly within tissues and have been clocked at up to 4 μM/s which is faster than neutrophils or macrophages can travel. Another important element is antigenic variation. *B. burgdorferi* have the ability to change the antigenic composition of a dominant protein expressed during mammalian infection, VlsE, through recombination into a portion of the gene from silent cassettes.[106,107] Finally, *B. burgdorferi* have been shown to express proteins that bind a host complement inhibitory protein, factor H. Binding of factor H by specific *B. burgdorferi* has been shown in vitro to help it evade complement mediated killing.[111-113] However, the importance of individual factor H–binding proteins in vivo is not known, possibly a consequence of redundancy among the proteins.

DIAGNOSIS

Physical findings, a history of potential exposure, known tick bites, or symptoms consistent with the typical multisystem presentation of Lyme disease can all be helpful in making a diagnosis. In the presence of classic EM or of Bannwarth syndrome, the diagnosis of Lyme disease can be made on clinical grounds alone. Diagnostic conundrums arise in presentations that involve other compatible skin, cardiac, neurologic, or musculoskeletal symptoms in the absence of a history of EM or tick exposure. In these cases, laboratory testing can aid in making the diagnosis.

DIRECT DETECTION OF *BORRELIA BURGDORFERI*

The gold standard for diagnosis of most infectious diseases is culture. However, the need for specialized media and the slow growth of the organism make it impractical in most clinical settings. *B. burgdorferi* can

be readily cultured from biopsies of EM and ACA,[21] but rarely grows in synovial fluid in patients with Lyme arthritis or cerebrospinal fluid samples in patients with meningitis.[7,114] Studies also have demonstrated that the organism can be recovered from the blood in up to 50% of untreated adult patients with multiple EM.[115] However, cultures are generally insensitive in patients with extracutaneous manifestations of Lyme borreliosis, particularly in later-stage disease.

PCR assays are very sensitive in detecting *B. burgdorferi* DNA in skin biopsy and synovial fluid specimens from patients with EM and Lyme arthritis, respectively.[116] PCR testing for *B. burgdorferi* DNA has not been approved by the U.S. Food and Drug Administration (FDA), and its main use is in detecting *B. burgdorferi* in synovial fluid where Lyme arthritis is suspected. In this setting its sensitivity is between 70% and 85%,[116-118] but a positive test does not necessarily mean there are living organisms.

SEROLOGIC DIAGNOSIS OF LYME DISEASE

Immunologic diagnosis is the main laboratory modality used to support a clinical diagnosis of Lyme disease. In the United States, the FDA has approved more than 70 different immunoassays for Lyme disease—mainly enzyme-linked immunoabsorbent (ELISA) and Western immunoblot assays.[119] ELISA tests use whole-cell lysates of *B. burgdorferi* sensu lato or purified *B. burgdorferi* antigens to capture either anti-*B. burgdorferi* immunoglobulin (Ig) G and/or IgM antibodies present in a given sample. Although relatively sensitive, ELISA tests are associated with a high rate of false-positive results.[120,121] Patients with autoimmune diseases (lupus, rheumatoid arthritis), Epstein-Barr virus, bacterial endocarditis, and other tick-borne diseases appear to be at an increased risk for false-positive IgM serologic testing; syphilis, *Helicobacter pylori*, systemic lupus erythematosus, ehrlichiosis, and babesiosis cause false-positive IgG serologic testing.[120,121] A newer ELISA test that uses only a small peptide of the constant region of *B. burgdorferi* VlsE protein appears to have greater specificity than traditional whole-cell ELISA testing. This test, also known as the *C6 peptide test*, measures only IgG antibody, but IgG antibody to the C6 peptide develops early in the course of disease and the sensitivity of the assay in patients with early disease has been equivalent to that seen with IgM whole-cell ELISA tests.[121,122] Western immunoblot assays are more specific because they enable detection of antibodies to individual components of *B. burgdorferi*. Currently, there are no widely accepted standard tests or criteria for serodiagnosis of Lyme disease in either Europe or Asia, in part because of the presence of multiple strains of *B. burgdorferi* that have only partial antigen cross-reactivity.

Because of its limitations, particularly high false-positive results within the general population, serologic testing should be initiated based on the pretest probability of disease and serve only to support a clinical diagnosis.[7] It is most helpful in patients with an intermediate pretest probability of Lyme disease—namely those who reside in endemic areas and who present with signs and symptoms consistent with, but not diagnostic of, Lyme disease (eg, facial palsy, arthritis, or atrioventricular nodal conduction abnormalities in the absence of an EM lesion). Patients who reside in areas of high endemicity and have clear EM lesions should be diagnosed on clinical grounds alone without laboratory testing. Testing should be avoided in patients with low suspicion for disease (patients not living in endemic areas, or with nonspecific systemic symptoms, or after a tick bite) as the rates of false-positive tests greatly outnumber true positive tests in this setting. Figure 179-13 shows one algorithm for the workup of patients presenting with an eruption suspicious for EM.

Once the decision is made to obtain serologic testing, current recommendations are for 2-stage testing, starting with a highly sensitive ELISA test first.[123] If the ELISA is negative, the likelihood of Lyme disease is low, and further testing is not generally recommended. However, if the test is positive or indeterminate, a Western immunoblot assay with high specificity should be used to confirm the results. The specificity of this 2-step approach is thought to be 99% to 100% in late-stage Lyme disease.[119] If testing is negative early in the course of disease, the tests can be repeated in 3 to 4 weeks (antibiotic therapy, if given very early, may abort antibody development). It is important to note that in patients with disease untreated for longer than 1 month, IgM testing should not be performed. A positive IgM Western blot with a negative IgG Western blot in this setting is considered a negative result owing to the high false-positivity rate of IgM testing. Misuse or misinterpretation of the IgM tests is a major factor in over diagnosis of Lyme disease. Seronegativity in patients suspected of having late Lyme disease practically excludes the diagnosis.[124] Finally, because IgG and IgM antibody titers may persist for years despite antibiotic therapy, persistent seropositivity is not in itself an indication of treatment failure, nor is it proof of recent infection or reinfection. Currently, there is no test that allows confirmation of successful clearance of the organism after treatment.

Some recent studies suggest that the use of 2-step testing for Lyme disease may result in underdiagnosis of Lyme disease. The performance of traditional ELISA tests against nonisogenic genotypes of *B. burgdorferi* is reduced and results in lower sensitivity in patients infected with these strains early in the course of disease.[119] The C6 antibody test appears to function better across genotypes of *B. burgdorferi* sensu stricto and with the European strains *B. garinii* and *B. afzelii*. Newer strategies using the C6 ELISA as the second step (dual enzyme immunoassay), replacing Western blot testing[125] or using a C6 band in the second step Western blot IgG test[126] show promising results but require further confirmation before they can be recommended.

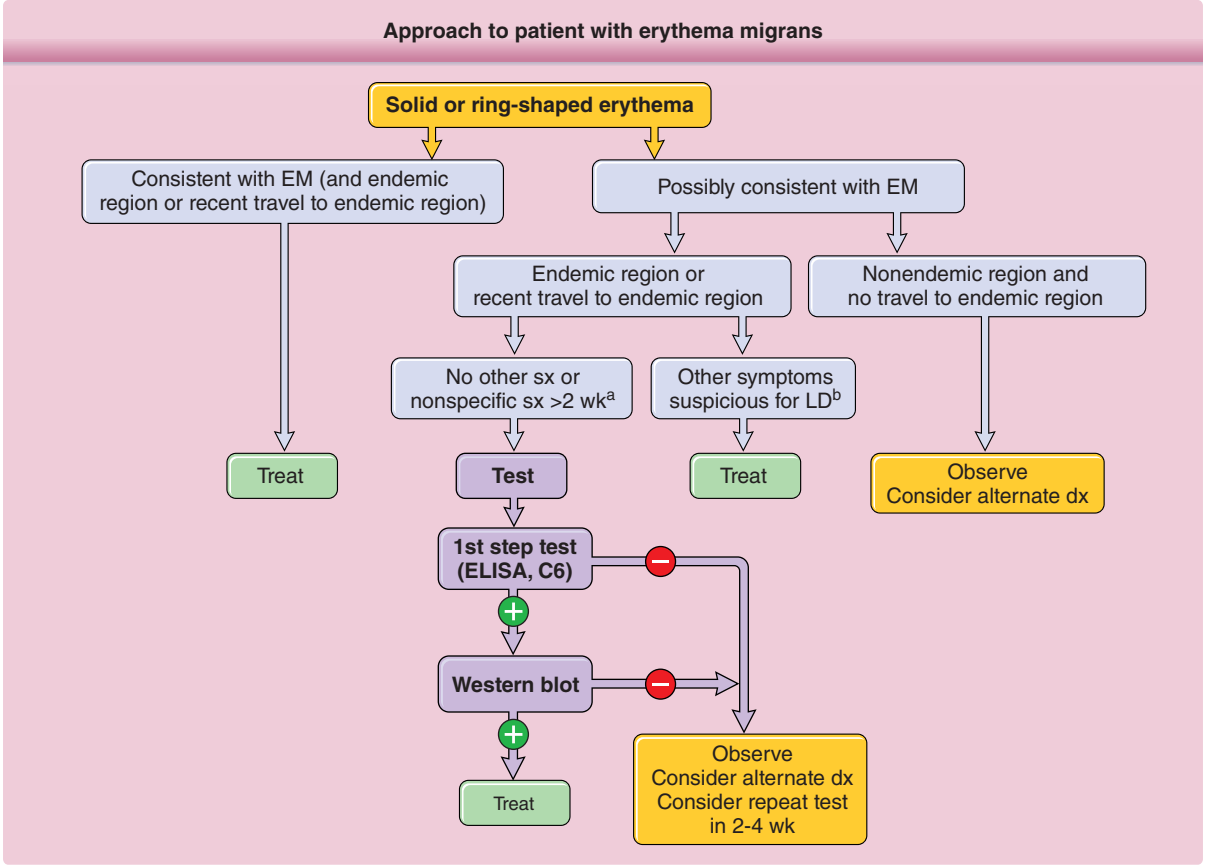

Figure 179-13 Approach to patient with erythema migrans (EM). [a]Fever, chills, fatigue. [b]Bell palsy, radiculoneuritis, meningitis, arthritis. dx, Diagnosis; ELISA, enzyme-linked immunosorbent assay; LD, Lyme disease; sx, symptoms.

DIFFERENTIAL DIAGNOSIS

The differential diagnosis of Lyme disease is dependent upon the specific manifestation. Early, nonspecific systemic symptoms (fevers, myalgia, headache, lymphadenopathy) have often been described as "viral-like" and cannot be distinguished from many infectious and noninfectious causes of these types of symptoms.

EM is the most distinctive clinical manifestation of infection. The differential diagnosis for EM includes cellulitis or erysipelas, tinea, insect bites, fixed drug eruptions, and erythema multiforme. EM can usually be distinguished from other conditions by its size, onset, duration, local symptoms (eg, itching, pain at site) or presence of systemic symptoms. A newer inclusion in the differential diagnosis is another tick-associated disease called southern tick-associated rash illness (STARI). STARI is associated with the bite of a different tick, *Amblyomma americanum*, but the causative agent has not been identified. Most cases of STARI have occurred in the southern United States where Lyme disease is uncommon. However, as *A. americanum* has spread northward and Lyme disease has expanded southward, there is now overlap in the geographic regions where STARI and Lyme occur. STARI is typically a self-limited disease that does not require treatment.

Table 179-4 lists the differential diagnoses for other cutaneous manifestations of Lyme disease. For many of the cutaneous manifestations of borreliosis, the clinical and histologic appearances are insufficient to make a definitive diagnosis. Obtaining a good clinical history is important. Lesions of ACA are notoriously overlooked or misinterpreted. In those with a relevant clinical history, the onset appears to be related to an untreated lesion of EM and/or neurologic manifestations. In one study, a history of EM months to years earlier on the same side was found in approximately 18% of patients.[45] Serologic testing is typically positive in patients with ACA, but are more variable with other cutaneous manifestations.[47] Direct identification of the spirochete in the affected skin by immunofluorescence, culture or PCR is often necessary to make a definitive diagnosis.

MANAGEMENT

Antibiotic treatment is indicated for all stages of Lyme disease, even though most manifestations resolve over time without therapy. Patients may not be asymptomatic at the time of completion of the antibiotic course but this is not an indication for extending length of therapy; symptoms generally continue to improve steadily over time. Of note, Jarisch-Herxheimer reactions (fevers, chills, and worsening arthralgia and

TABLE 179-4
Differential Diagnosis of Erythema Migrans

DIAGNOSTIC ENTITY	DESCRIPTION	DISTINGUISHING FEATURES TO DIFFERENTIATE FROM ERYTHEMA MIGRANS
Single Lesions		
Cellulitis, erysipelas	Erythematous painful, spreading rash, often with associated edema, most commonly on lower extremity	Generally painful, seldom round or ovoid
Hypersensitivity to tick bite	Red papule at bite site with surrounding pruritic erythema, edema, urticaria	Typically pruritic, seldom exceeds 5 cm
Tinea corporis	Erythematous, annular lesions	Scaly, often with tiny vesicles at the border
Contact dermatitis	Acute erythematous rash which may form papules, vesicles, scale; in chronic cases lichenification, fissuring and erosions may occur	Generally in areas exposed to jewelry, clothing, often with unusual patterns; often pruritic
Southern tick-associated rash illness (STARI)	Clinically indistinguishable from erythema migrans rash	Generally occurs in the South and Southwestern United States, but the geographic range is spreading to overlap with Lyme disease
Multiple Lesions		
Urticaria	Multiple, small, localized cutaneous edema with blanching erythema, generally pruritic	Usually presents as a pruritic, erythematous wheal; lesions generally last for minutes to hours
Tinea corporis	Erythematous, annular lesions	Scaly, often with tiny vesicles at the border
Pityriasis rosea	Multiple, small 2- to 4-cm oval lesions, often preceded by a larger "Herald patch"	Scaly, often appear in a classic "Christmas tree" pattern, generally on the trunk
Erythema annulare centrifugum	Expanding erythematous, annular, migrating lesions	Generally chronic, with waxing/waning course
Erythema multiforme	Circular, erythematous plaques, generally not exceeding 3 cm, sometimes with wheal with dark center; lesions often become confluent	Acral distribution, may involve mucous membranes; sometimes follows herpes simplex virus or *Mycoplasma pneumoniae* infection

myalgia) are sometimes reported after the initial dose of antibiotics; the reaction is thought to be caused by host reaction to the dying organisms.

The Infectious Disease Society of America has published guidelines for the treatment of all manifestations of Lyme disease,[127] although many of the recommendations are based on expert opinion and not on rigorously controlled clinical trials. Treatment patterns differ in different countries, but no data suggest differences in either the efficacy of specific antibiotics or in the optimal duration of therapy between patients in North America and Europe.

Treatment of all of the cutaneous manifestations of Lyme disease should initially be with oral antibiotics. Doxycycline is generally considered as first-line therapy, because it has excellent penetration into the CNS and is also effective against *A. phagocytophilum*, the agent of human granulocytic ehrlichiosis. Doxycycline should be used in children and pregnant women.[128] Cefuroxime is an alternative first-line agent. These 3 agents have been found to be equally effective.[129-131] Macrolides are second-line agents and should only be used in those who cannot tolerate the other agents. If macrolides are used to treat Lyme disease, close monitoring and follow up should take place.[127] Duration of therapy for EM is generally recommended to be 10 to 14 days; a randomized, double-blinded, placebo-controlled study showed similar outcomes in patients with EM treated with either a 10-day or a 20-day course of oral doxycycline.[131-133]

IV antibiotics (ceftriaxone, cefotaxime, or penicillin G) may be recommended for patients with cutaneous manifestations that are accompanied by neurologic disease (meningitis, encephalopathy) or high-degree heart block. However, multiple recent studies suggest that outcomes for treatment of neurologic disease with either oral doxycycline or IV ceftriaxone are similar. IV antibiotics are also sometimes used for patients with refractory ACA or arthritis.

Table 179-5 outlines the choice of antibiotics and duration of treatment of the major cutaneous and noncutaneous manifestations of Lyme disease.

Treatment of patients with nonspecific fibromyalgia-like disease after infection with *B. burgdorferi* is controversial. There are multiple controlled trials showing no benefit to prolonging therapy with currently recommended oral or IV antibiotics.[127,134]

PREVENTION

Prevention of Lyme disease on a personal level can be approached in many ways, including avoidance of environments where ticks which can carry *B. burgdorferi* are likely to reside. However, in some areas of the United States with a high prevalence of Lyme disease, avoidance may not be possible, as ticks are found in and around human habitations.

REPELLANTS AND ACARICIDES

The evidence for performing tick checks and bathing after engaging in activities where exposure to ticks is expected is mixed.[135,136] However, these are simple and reasonable measures and removal of crawling or even attached ticks can prevent disease as it is thought that there is minimal transmission of spirochetes before 36 hours of attachment and feeding.[127] Under certain conditions (see footnote for Table 179-5) if an attached tick is found, a single dose of oral doxycycline may be recommended as prophylaxis against the development of Lyme disease.[137]

There are several commercially available products marketed as insect repellants that have activity in preventing tick bites. The active ingredients, DEET

TABLE 179-5

Treatment Recommendations for Adults in the United States with Lyme Disease, by Clinical Findings

CLINICAL FINDING	ANTIBIOTIC	DURATION	ALTERNATIVE	REFERENCES
Prophylaxis[a]	Doxycycline 200 mg × 1 dose		Watchful waiting	127,137
Skin Manifestations				
Erythema migrans	Doxycycline 100 mg by mouth twice daily Amoxicillin 500 mg by mouth three times daily Cefuroxime axetil 500 mg by mouth twice daily	10 days 14 days 14 days	Azithromycin 500 mg by mouth daily for 7-10 days	131-133
Acrodermatitis chronica atrophicans	See regimen for erythema migrans	21 days		127
Borrelial lymphocytoma	See regimen for erythema migrans	14-21 days	Azithromycin 500 mg by mouth daily for 7 to 10 days	127
Musculoskeletal Manifestations				
Lyme arthritis	Doxycycline 100 mg by mouth twice daily	28 days	Amoxicillin 500 mg by mouth 3 times daily × 28 days Cefuroxime axetil 500 mg by mouth twice daily × 28 days	127
Failure/recurrence after initial treatment	Doxycycline 100 mg by mouth twice daily *or* Ceftriaxone 2 g IV daily	28 days 14-28 days	Amoxicillin 500 mg by mouth 3 times daily × 28 days Cefuroxime axetil 500 mg by mouth twice daily × 28 days	127
Cardiac Manifestations				
Lyme carditis	**Nonhospitalized** Doxycycline 100 mg by mouth twice daily Amoxicillin 500 mg by mouth 3 times daily Cefuroxime axetil 500 mg by mouth twice daily **Hospitalized[b]** Ceftriaxone 2 g IV daily until stable/discharge, then complete course with antibiotics listed above for nonhospitalized	 14-21 days 14-21 days		127
Neurologic Manifestations				
Cranial neuropathy/ radiculopathy	Doxycycline 100 mg by mouth twice daily or 200 mg by mouth daily	14 days	Amoxicillin 500 mg by mouth three × daily for 14 days Cefuroxime axetil 500 mg by mouth twice daily for 14 days	127, 144-148
Meningitis	**Nonhospitalized** Doxycycline 100 mg by mouth twice daily **Hospitalized[c]** Ceftriaxone 2 g IV daily[d]	 14 days 14 days	Penicillin G 18 to 24 million units IV divided in 6 daily doses (every 4 hours)	127, 144-149

[a]Prophylaxis should only be offered when all of the following conditions are met[114]:
The attached tick can be reliably identified as an adult or nymphal *Ixodes scapularis*
Tick that is estimated to have been attached for >36 hours
Prophylaxis can be started within 72 hours

[b]Ecologic information indicates that the local rate of infection of these ticks with *Borrelia burgdorferi* is >20%; *and*
Doxycycline treatment is not contraindicated.

[c]Hospitalization recommended for patients who are symptomatic, who have first-degree atrioventricular block with PR interval exceeding 30 msec, or with second- or third-degree atrioventricular block

[d]Many European studies have shown that oral doxycycline is as efficacious as IV beta-lactam therapy in treating Lyme meningitis. Some U.S. experts are similarly using oral doxycycline for this indication, although no U.S. studies have been reported at the time of the preparation of this manuscript. Consider deescalation to oral doxycycline upon discharge from the hospital to complete therapy.

(*N,N*-diethyl-meta-toluamide), IR3535, paramenthane-3,8-diol (PMD, which is refined from the oil of lemon eucalyptus), and picaridin are generally considered to have the greatest efficacy. However, because the duration of efficacy of each of these agents for repelling ticks is less than 2 hours, they require frequent reapplication. DEET has been in use for 70 years and has a strong safety record. DEET-treated clothing has been demonstrated to provide up to 92% protection against tick bites when applied to military clothing.[138]

Acaricides have potent acaricidal and insecticidal properties. The efficacy in actually reducing human infection with Lyme disease and other tick-borne illnesses through applying pyrethrins to the environment (such as spraying residential lawns) has been unclear. Recently, however, a large, randomized, double-blinded, placebo-controlled trial was conducted over 2 years in 3 states in the Northeast. The trial showed a 63% decrease in the number of ticks found, but no difference in tick-borne infections, based on both self-report and medical record review, by applying pyrethrins to the environment.[139] Certain pyrethrins, such as permethrin, can be applied to clothing as an effective acaricide against some species of ticks which carry Lyme disease.[140]

VACCINATION

An effective human vaccine against Lyme disease was developed against the outer-surface protein A antigen and introduced in the United States in 1998. This was shown to reduce the risk of infection by approximately 76% in those who were vaccinated.[141] However, a series of factors lead to its voluntary withdrawal from the market in 2002, a result of low demand.[142,143] There is currently no human vaccine available against Lyme disease. Vaccination for dogs is currently available.

ACKNOWLEDGMENTS

This chapter is based on a previous version of the chapter written by Drs. Meera Mahalingam, Jag Bhawan, Daniel Eisen, and Linden Hu.

REFERENCES

1. Centers for Disease Control and Prevention. Lyme disease—United States, 2001-2002. *MMWR Morb Mortal Wkly Rep.* 2004;53(17):365-369.
2. Steere AC, Malawista SE, Snydman DR, et al. Lyme arthritis: an epidemic of oligoarticular arthritis in children and adults in three Connecticut communities. *Arthritis Rheum.* 1977;20(1):7-17.
3. Burgdorfer W, Barbour AG, Hayes SF, et al. Lyme disease-a tick-borne spirochetosis? *Science.* 1982;216(4552):1317-1319.
4. Benach JL, Bosler EM, Hanrahan JP, et al. Spirochetes isolated from the blood of two patients with Lyme disease. *N Engl J Med.* 1983;308(13):740-742.
5. Steere AC, Bartenhagen NH, Craft JE, et al. The early clinical manifestations of Lyme disease. *Ann Intern Med.* 1983;99(1):76-82.
6. Ackermann R, Kabatzki J, Boisten HP, et al. *Ixodes ricinus* spirochete and European erythema chronicum migrans disease. *Yale J Biol Med.* 1984;57(4):573-580.
7. Aguero-Rosenfeld ME, Wang G, Schwartz I, et al. Diagnosis of lyme borreliosis. *Clin Microbiol Rev.* 2005;18(3):484-509.
8. Asbrink E. Erythema chronicum migrans Afzelius and acrodermatitis chronica atrophicans. Early and late manifestations of *Ixodes ricinus*-borne *Borrelia* spirochetes. *Acta Derm Venereol Suppl (Stockh).* 1985;118:1-63.
9. Golovchenko M, Vancova M, Clark K, et al. A divergent spirochete strain isolated from a resident of the southeastern United States was identified by multilocus sequence typing as *Borrelia bissettii*. *Parasit Vectors.* 2016;9:68.
10. Rudenko N, Golovchenko M, Vancova M, et al. Isolation of live *Borrelia burgdorferi sensu lato spirochaetes* from patients with undefined disorders and symptoms not typical for Lyme borreliosis. *Clin Microbiol Infect.* 2016;22(3):267.e9-267.e15.
11. Pritt BS, Mead PS, Johnson DK, et al. Identification of a novel pathogenic *Borrelia* species causing Lyme borreliosis with unusually high spirochaetaemia: a descriptive study. *Lancet Infect Dis.* 2016;16(5):556-564.
12. Gern L, Estrada-Pena A, Frandsen F, et al. European reservoir hosts of *Borrelia burgdorferi sensu lato*. *Zentralbl Bakteriol.* 1998;287(3):196-204.
13. Bacon RM, Kugeler KJ, Mead PS; Centers for Disease Control and Prevention (CDC). Surveillance for Lyme disease—United States, 1992-2006. *MMWR Surveill Summ.* 2008;57(10):1-9.
14. Nelson CA, Saha S, Kugeler KJ, et al. Incidence of clinician-diagnosed Lyme disease, United States, 2005-2010. *Emerg Infect Dis.* 2015;21(9):1625-1631.
15. Hinckley AF, Connally NP, Meek JI, et al. Lyme disease testing by large commercial laboratories in the United States. *Clin Infect Dis.* 2014;59(5):676-681.
16. Centers for Disease Control and Prevention (CDC). Lyme Disease Data Tables. 2006-2016. http://www.cdc.gov/lyme/stats/tables.html. Accessed October 5, 2016.
17. Steere AC, Sikand VK. The presenting manifestations of Lyme disease and the outcomes of treatment. *N Engl J Med.* 2003;348(24):2472-2474.
18. Gerber MA, Shapiro ED, Burke GS, et al. Lyme disease in children in southeastern Connecticut. Pediatric Lyme Disease Study Group. *N Engl J Med.* 1996;335(17):1270-1274.
19. Wilson TC, Legler A, Madison KC, et al. Erythema migrans: a spectrum of histopathologic changes. *Am J Dermatopathol.* 2012;34(8):834-837.
20. Berger BW. Erythema migrans in Lyme disease: a correction. *JAMA.* 1992;268(7):874.
21. Berger BW, Johnson RC, Kodner C, et al. Cultivation of *Borrelia burgdorferi* from erythema migrans lesions and perilesional skin. *J Clin Microbiol.* 1992;30(2):359-361.
22. Shapiro ED, Gerber MA. Lyme disease. *Clin Infect Dis.* 2000;31(2):533-542.
23. Smith RP, Schoen RT, Rahn DW, et al. Clinical characteristics and treatment outcome of early Lyme disease in patients with microbiologically confirmed erythema migrans. *Ann Intern Med.* 2002;136(6):421-428.
24. Schutzer SE, Berger BW, Krueger JG, et al. Atypical erythema migrans in patients with PCR-positive Lyme disease. *Emerg Infect Dis.* 2013;19(5):815-817.

25. Strle F, Ruzic-Sabljic E, Logar M, et al. Comparison of erythema migrans caused by *Borrelia burgdorferi* and *Borrelia garinii*. *Vector Borne Zoonotic Dis.* 2011; 11(9):1253-1258.
26. Duray PH, Asbrink E, Weber K. The cutaneous manifestations of human Lyme disease: a widening spectrum. *Adv Dermatol.* 1989;4:255-275; discussion 276.
27. Berger BW. Cutaneous manifestations of Lyme borreliosis. *Rheum Dis Clin North Am.* 1989;15(4):627-634.
28. Berger BW, Clemmensen OJ, Ackerman AB. Lyme disease is a spirochetosis. A review of the disease and evidence for its cause. *Am J Dermatopathol.* 1983; 5(2):111-124.
29. Goldberg NS, Forseter G, Nadelman RB, et al. Vesicular erythema migrans. *Arch Dermatol.* 1992;128(11): 1495-1498.
30. Malane MS, Grant-Kels JM, Feder HM Jr, et al. Diagnosis of Lyme disease based on dermatologic manifestations. *Ann Intern Med.* 1991;114(6):490-498.
31. Wu YS, Zhang WF, Feng FP, et al. Atypical cutaneous lesions of Lyme disease. *Clin Exp Dermatol.* 1993; 18(5):434-436.
32. Strle F, Nadelman RB, Cimperman J, et al. Comparison of culture-confirmed erythema migrans caused by *Borrelia burgdorferi sensu stricto* in New York State and by *Borrelia afzelii* in Slovenia. *Ann Intern Med.* 1999; 130(1):32-36.
33. Nadelman RB, Nowakowski J, Forseter G, et al. The clinical spectrum of early Lyme borreliosis in patients with culture-confirmed erythema migrans. *Am J Med.* 1996;100(5):502-508.
34. Kaufman LD, Gruber BL, Phillips ME, et al. Late cutaneous Lyme disease: acrodermatitis chronica atrophicans. *Am J Med.* 1989;86(6, pt 2):828-830.
35. Gellis SE, Stadecker MJ, Steere AC. Spirochetes in atrophic skin lesions accompanied by minimal host response in a child with Lyme disease. *J Am Acad Dermatol.* 1991;25(2, pt 2):395-397.
36. DiCaudo DJ, Su WP, Marshall WF, et al. Acrodermatitis chronica atrophicans in the United States: clinical and histopathologic features of six cases. *Cutis.* 1994; 54(2):81-84.
37. Burgdorf WH, Worret WI, Schultka O. Acrodermatitis chronica atrophicans. *Int J Dermatol.* 1979;18(8): 595-601.
38. Mullegger RR, McHugh G, Ruthazer R, et al. Differential expression of cytokine mRNA in skin specimens from patients with erythema migrans or acrodermatitis chronica atrophicans. *J Invest Dermatol.* 2000; 115(6):1115-1123.
39. Duray PH. Clinical pathologic correlations of Lyme disease. *Rev Infect Dis.* 1989;11(suppl 6):S1487-S1493.
40. Duray PH. The surgical pathology of human Lyme disease. An enlarging picture. *Am J Surg Pathol.* 1987; 11(suppl 1):47-60.
41. Asbrink E, Brehmer-Andersson E, Hovmark A. Acrodermatitis chronica atrophicans—a spirochetosis. Clinical and histopathological picture based on 32 patients; course and relationship to erythema chronicum migrans Afzelius. *Am J Dermatopathol.* 1986;8(3):209-219.
42. Buechner SA, Rufli T, Erb P. Acrodermatitis chronic atrophicans: a chronic T-cell-mediated immune reaction against *Borrelia burgdorferi*? Clinical, histologic, and immunohistochemical study of five cases. *J Am Acad Dermatol.* 1993;28(3):399-405.
43. Ilowite NT. Muscle, reticuloendothelial, and late skin manifestations of Lyme disease. *Am J Med.* 1995; 98(4A):63S-68S.
44. Silberer M, Koszik F, Stingl G, et al. Downregulation of class II molecules on epidermal Langerhans cells in Lyme borreliosis. *Br J Dermatol.* 2000;143(4):786-794.
45. Kaya G, Berset M, Prins C, et al. Chronic borreliosis presenting with morphea- and lichen sclerosus et atrophicus-like cutaneous lesions. a case report. *Dermatology.* 2001;202(4):373-375.
46. Tuffanelli D. Do some patients with morphea and lichen sclerosis et atrophicans have a *Borrelia* infection? *Am J Dermatopathol.* 1987;9(5):371-373.
47. Espana A, Torrelo A, Guerrero A, et al. Periarticular fibrous nodules in Lyme borreliosis. *Br J Dermatol.* 1991; 125(1):68-70.
48. Marsch WC, Mayet A, Wolter M. Cutaneous fibroses induced by *Borrelia burgdorferi*. *Br J Dermatol.* 1993; 128(6):674-678.
49. Granter SR, Barnhill RL, Duray PH. Borrelial fasciitis: diffuse fasciitis and peripheral eosinophilia associated with *Borrelia* infection. *Am J Dermatopathol.* 1996; 18(5):465-473.
50. Stanek G, Konrad K, Jung M, et al. Shulman syndrome, a scleroderma subtype caused by *Borrelia burgdorferi*? *Lancet.* 1987;1(8548):1490.
51. Abele DC, Anders KH. The many faces and phases of borreliosis. I. Lyme disease. *J Am Acad Dermatol.* 1990;23(2, pt 1):167-186.
52. Marsch WC, Wolter M, Mayet A. Juxta-articular fibrotic nodules in *Borrelia* infection—ultrastructural details of therapy-induced regression. *Clin Exp Dermatol.* 1994;19(5):394-398.
53. Hofer T, Goldenberger D, Itin PH. Anetoderma and borreliosis: is there a pathogenetic relationship? *Eur J Dermatol.* 2003;13(4):399-401.
54. Aberer E, Stanek G. Histological evidence for spirochetal origin of morphea and lichen sclerosus et atrophicans. *Am J Dermatopathol.* 1987;9(5):374-379.
55. Hovmark A, Asbrink E, Olsson I. The spirochetal etiology of lymphadenosis benigna cutis solitaria. *Acta Derm Venereol.* 1986;66(6):479-484.
56. Abele DC, Anders KH, Chandler FW. Benign lymphocytic infiltration (Jessner-Kanof): another manifestation of borreliosis? *J Am Acad Dermatol.* 1989;21(4, pt 1): 795-797.
57. Garbe C, Stein H, Dienemann D, et al. *Borrelia burgdorferi*-associated cutaneous B cell lymphoma: clinical and immunohistologic characterization of four cases. *J Am Acad Dermatol.* 1991;24(4):584-590.
58. Goodlad JR, Davidson MM, Hollowood K, et al. *Borrelia burgdorferi*-associated cutaneous marginal zone lymphoma: a clinicopathological study of two cases illustrating the temporal progression of *B. burgdorferi*-associated B-cell proliferation in the skin. *Histopathology.* 2000; 37(6):501-508.
59. Slater DN. *Borrelia burgdorferi*-associated primary cutaneous B-cell lymphoma. *Histopathology.* 2001; 38(1):73-77.
60. Roggero E, Zucca E, Mainetti C, et al. Eradication of *Borrelia burgdorferi* infection in primary marginal zone B-cell lymphoma of the skin. *Hum Pathol.* 2000; 31(2):263-268.
61. Kutting B, Bonsmann G, Metze D, et al. *Borrelia burgdorferi*-associated primary cutaneous B cell lymphoma: complete clearing of skin lesions after antibiotic pulse therapy or intralesional injection of interferon alfa-2a. *J Am Acad Dermatol.* 1997;36(2, pt 2): 311-314.
62. Steere AC. Lyme disease. *N Engl J Med.* 1989;321(9): 586-596.

63. Pachner AR, Steere AC. The triad of neurologic manifestations of Lyme disease: meningitis, cranial neuritis, and radiculoneuritis. *Neurology.* 1985;35(1):47-53.
64. Bannwarth A. Chronische lymphocytare Meningitis, entzundliche Polyneuritis und "Rheumatismus." Ein beitrag zum Problem "Allergie und Nervensystem. *Arch Psychiatr Nervenkr.* 1941;113:284.
65. Oschmann P, Dorndorf W, Hornig C, et al. Stages and syndromes of neuroborreliosis. *J Neurol.* 1998; 245(5):262-272.
66. Stanek G, Strle F. Lyme disease: European perspective. *Infect Dis Clin North Am.* 2008;22(2):327-339, vii.
67. Garin C, Bujadoux A. Paralysis by ticks. 1922. *Clin Infect Dis.* 1993;16(1):168-169.
68. Logigian EL, Steere AC. Clinical and electrophysiologic findings in chronic neuropathy of Lyme disease. *Neurology.* 1992;42(2):303-311.
69. Kaplan RF, Meadows ME, Vincent LC, et al. Memory impairment and depression in patients with Lyme encephalopathy: comparison with fibromyalgia and nonpsychotically depressed patients. *Neurology.* 1992; 42(7):1263-1267.
70. Cox J, Krajden M. Cardiovascular manifestations of Lyme disease. *Am Heart J.* 1991;122(5):1449-1455.
71. Steere AC, Batsford WP, Weinberg M, et al. Lyme carditis: cardiac abnormalities of Lyme disease. *Ann Intern Med.* 1980;93(1):8-16.
72. Forrester JD, Meiman J, Mullins J, et al. Notes from the field: update on Lyme carditis, groups at high risk, and frequency of associated sudden cardiac death—United States. *MMWR Morb Mortal Wkly Rep.* 2014; 63(43):982-983.
73. Grzesik P, Oczko-Grzesik B, Kepa L. Cardiac manifestations of Lyme borreliosis [in Polish]. *Przegl Epidemiol.* 2004;58(4):589-596.
74. Mayer W, Kleber FX, Wilske B, et al. Persistent atrioventricular block in Lyme borreliosis. *Klin Wochenschr.* 1990;68(8):431-435.
75. van der Linde MR, Crijns HJ, Lie KI. Transient complete AV block in Lyme disease. Electrophysiologic observations. *Chest.* 1989;96(1):219-221.
76. Stanek G, Klein J, Bittner R, et al. Isolation of *Borrelia burgdorferi* from the myocardium of a patient with longstanding cardiomyopathy. *N Engl J Med.* 1990; 322(4):249-252.
77. Sonnesyn SW, Diehl SC, Johnson RC, et al. A prospective study of the seroprevalence of *Borrelia burgdorferi* infection in patients with severe heart failure. *Am J Cardiol.* 1995;76(1):97-100.
78. Mikkila HO, Seppala IJ, Viljanen MK, et al. The expanding clinical spectrum of ocular lyme borreliosis. *Ophthalmology.* 2000;107(3):581-587.
79. Steere AC, Schoen RT, Taylor E. The clinical evolution of Lyme arthritis. *Ann Intern Med.* 1987;107(5):725-731.
80. Walsh CA, Mayer EW, Baxi LV. Lyme disease in pregnancy: case report and review of the literature. *Obstet Gynecol Surv.* 2007;62(1):41-50.
81. Strobino BA, Williams CL, Abid S, et al. Lyme disease and pregnancy outcome: a prospective study of two thousand prenatal patients. *Am J Obstet Gynecol.* 1993; 169(2, pt 1):367-374.
82. Maraspin V, Cimperman J, Lotric-Furlan S, et al. Treatment of erythema migrans in pregnancy. *Clin Infect Dis.* 1996;22(5):788-793.
83. Strobino B, Abid S, Gewitz M. Maternal Lyme disease and congenital heart disease: a case-control study in an endemic area. *Am J Obstet Gynecol.* 1999;180(3, pt 1): 711-716.
84. Gerber MA, Zalneraitis EL. Childhood neurologic disorders and Lyme disease during pregnancy. *Pediatr Neurol.* 1994;11(1):41-43.
85. Rothermel H, Hedges TR 3rd, Steere AC. Optic neuropathy in children with Lyme disease. *Pediatrics.* 2001; 108(2):477-481.
86. Krause PJ, Telford SR 3rd, Spielman A, et al. Concurrent Lyme disease and babesiosis. Evidence for increased severity and duration of illness. *JAMA.* 1996;275(21): 1657-1660.
87. Horowitz HW, Aguero-Rosenfeld ME, Holmgren D, et al. Lyme disease and human granulocytic anaplasmosis coinfection: impact of case definition on coinfection rates and illness severity. *Clin Infect Dis.* 2013; 56(1):93-99.
88. Krause PJ, McKay K, Thompson CA, et al. Disease-specific diagnosis of coinfecting tickborne zoonoses: babesiosis, human granulocytic ehrlichiosis, and Lyme disease. *Clin Infect Dis.* 2002;34(9):1184-1191.
89. Diuk-Wasser MA, Vannier E, Krause PJ. Coinfection by *Ixodes* tick-borne pathogens: ecological, epidemiological, and clinical consequences. *Trends Parasitol.* 2016; 32(1):30-42.
90. Steere AC, Levin RE, Molloy PJ, et al. Treatment of Lyme arthritis. *Arthritis Rheum.* 1994;37(6):878-888.
91. Gross DM, Forsthuber T, Tary-Lehmann M, et al. Identification of LFA-1 as a candidate autoantigen in treatment-resistant Lyme arthritis. *Science.* 1998; 281(5377):703-706.
92. Weinstein A, Britchkov M. Lyme arthritis and post-Lyme disease syndrome. *Curr Opin Rheumatol.* 2002; 14(4):383-387.
93. Brown CR, Reiner SL. Clearance of *Borrelia burgdorferi* may not be required for resistance to experimental lyme arthritis. *Infect Immun.* 1998;66(5):2065-2071.
94. Wormser GP, Weitzner E, McKenna D, et al. Long-term assessment of fatigue in patients with culture-confirmed Lyme disease. *Am J Med.* 2015;128(2): 181-184.
95. Kalish RA, Kaplan RF, Taylor E, et al. Evaluation of study patients with Lyme disease, 10-20-year follow-up. *J Infect Dis.* 2001;183(3):453-460.
96. Seltzer EG, Gerber MA, Cartter ML, et al. Long-term outcomes of persons with Lyme disease. *JAMA.* 2000; 283(5):609-616.
97. Klempner MS, Hu LT, Evans J, et al. Two controlled trials of antibiotic treatment in patients with persistent symptoms and a history of Lyme disease. *N Engl J Med.* 2001;345(2):85-92.
98. Krupp LB, Hyman LG, Grimson R, et al. Study and treatment of post Lyme disease (STOP-LD): a randomized double masked clinical trial. *Neurology.* 2003; 60(12):1923-1930.
99. Fallon BA, Keilp JG, Corbera KM, et al. A randomized, placebo-controlled trial of repeated IV antibiotic therapy for Lyme encephalopathy. *Neurology.* 2008; 70(13):992-1003.
100. Patel R, Grogg KL, Edwards WD, et al. Death from inappropriate therapy for Lyme disease. *Clin Infect Dis.* 2000;31(4):1107-1109.
101. Ettestad PJ, Campbell GL, Welbel SF, et al. Biliary complications in the treatment of unsubstantiated Lyme disease. *J Infect Dis.* 1995;171(2):356-361.
102. Casjens S, Palmer N, van Vugt R, et al. A bacterial genome in flux: the twelve linear and nine circular extrachromosomal DNAs in an infectious isolate of the Lyme disease spirochete *Borrelia burgdorferi*. *Mol Microbiol.* 2000;35(3):490-516.

103. Fraser CM, Casjens S, Huang WM, et al. Genomic sequence of a Lyme disease spirochaete, *Borrelia burgdorferi*. *Nature.* 1997;390(6660):580-586.
104. Radolf JD, Caimano MJ, Stevenson B, et al. Of ticks, mice and men: understanding the dual-host lifestyle of Lyme disease spirochaetes. *Nat Rev Microbiol.* 2012; 10(2):87-99.
105. Telford SR 3rd, Mather TN, Moore SI, et al. Incompetence of deer as reservoirs of the Lyme disease spirochete. *Am J Trop Med Hyg.* 1988;39(1):105-109.
106. El Khoury MY, Camargo JF, White JL, et al. Potential role of deer tick virus in *Powassan* encephalitis cases in Lyme disease-endemic areas of New York, U.S.A. *Emerg Infect Dis.* 2013;19(12):1926-1933.
107. Henningsson AJ, Lindqvist R, Norberg P, et al. Human tick-borne encephalitis and characterization of virus from biting tick. *Emerg Infect Dis.* 2016;22(8): 1485-1487.
108. Dai J, Wang P, Adusumilli S, et al. Antibodies against a tick protein, Salp15, protect mice from the Lyme disease agent. *Cell Host Microbe.* 2009;6(5):482-492.
109. Wormser GP, Brisson D, Liveris D, et al. *Borrelia burgdorferi* genotype predicts the capacity for hematogenous dissemination during early Lyme disease. *J Infect Dis.* 2008;198(9):1358-1364.
110. Sultan SZ, Manne A, Stewart PE, et al. Motility is crucial for the infectious life cycle of *Borrelia burgdorferi*. *Infect Immun.* 2013;81(6):2012-2021.
111. Kraiczy P, Skerka C, Kirschfink M, et al. Immune evasion of *Borrelia burgdorferi* by acquisition of human complement regulators FHL-1/reconectin and factor H. *Eur J Immunol.* 2001;31(6):1674-1684.
112. Stevenson B, El-Hage N, Hines MA, et al. Differential binding of host complement inhibitor factor H by *Borrelia burgdorferi* Erp surface proteins: a possible mechanism underlying the expansive host range of Lyme disease spirochetes. *Infect Immun.* 2002;70(2): 491-497.
113. McDowell JV, Wolfgang J, Tran E, et al. Comprehensive analysis of the factor h binding capabilities of *Borrelia* species associated with lyme disease: delineation of two distinct classes of factor h binding proteins. *Infect Immun.* 2003;71(6):3597-3602.
114. Wormser GP, Bittker S, Cooper D, et al. Comparison of the yields of blood cultures using serum or plasma from patients with early Lyme disease. *J Clin Microbiol.* 2000; 38(4):1648-1650.
115. Wormser GP, Nowakowski J, Nadelman RB, et al. Improving the yield of blood cultures for patients with early Lyme disease. *J Clin Microbiol.* 1998;36(1): 296-298.
116. Nocton JJ, Dressler F, Rutledge BJ, et al. Detection of *Borrelia burgdorferi* DNA by polymerase chain reaction in synovial fluid from patients with Lyme arthritis. *N Engl J Med.* 1994;330(4):229-234.
117. Li X, McHugh GA, Damle N, et al. Burden and viability of *Borrelia burgdorferi* in skin and joints of patients with erythema migrans or lyme arthritis. *Arthritis Rheum.* 2011;63(8):2238-2247.
118. Persing DH, Rutledge BJ, Rys PN, et al. Target imbalance: disparity of *Borrelia burgdorferi* genetic material in synovial fluid from Lyme arthritis patients. *J Infect Dis.* 1994;169(3):668-672.
119. Wormser GP, Liveris D, Hanincova K, et al. Effect of *Borrelia burgdorferi* genotype on the sensitivity of C6 and 2-tier testing in North American patients with culture-confirmed Lyme disease. *Clin Infect Dis.* 2008;47(7):910-914.
120. Magnarelli LA, Miller JN, Anderson JF, et al. Cross-reactivity of nonspecific treponemal antibody in serologic tests for Lyme disease. *J Clin Microbiol.* 1990; 28(6):1276-1279.
121. Nocton JJ, Steere AC. Lyme disease. *Adv Intern Med.* 1995;40:69-117.
122. Goettner G, Schulte-Spechtel U, Hillermann R, et al. Improvement of Lyme borreliosis serodiagnosis by a newly developed recombinant immunoglobulin G (IgG) and IgM line immunoblot assay and addition of VlsE and DbpA homologues. *J Clin Microbiol.* 2005; 43(8):3602-3609.
123. Sanchez E, Vannier E, Wormser GP, et al. Diagnosis, treatment, and prevention of Lyme disease, human granulocytic anaplasmosis, and babesiosis: a review. *JAMA.* 2016;315(16):1767-1777.
124. Avery RA, Frank G, Eppes SC. Diagnostic utility of *Borrelia burgdorferi* cerebrospinal fluid polymerase chain reaction in children with Lyme meningitis. *Pediatr Infect Dis J.* 2005;24(8):705-708.
125. Branda JA, Linskey K, Kim YA, et al. Two-tiered antibody testing for Lyme disease with use of 2 enzyme immunoassays, a whole-cell sonicate enzyme immunoassay followed by a VlsE C6 peptide enzyme immunoassay. *Clin Infect Dis.* 2011;53(6):541-547.
126. Branda JA, Aguero-Rosenfeld ME, Ferraro MJ, et al. 2-Tiered antibody testing for early and late Lyme disease using only an immunoglobulin G blot with the addition of a VlsE band as the second-tier test. *Clin Infect Dis.* 2010;50(1):20-26.
127. Wormser GP, Dattwyler RJ, Shapiro ED, et al. The clinical assessment, treatment, and prevention of lyme disease, human granulocytic anaplasmosis, and babesiosis: clinical practice guidelines by the Infectious Diseases Society of America. *Clin Infect Dis.* 2006; 43(9):1089-1134.
128. Steere AC. Lyme disease. *N Engl J Med.* 2001;345(2): 115-125.
129. Nadelman RB, Luger SW, Frank E, et al. Comparison of cefuroxime axetil and doxycycline in the treatment of early Lyme disease. *Ann Intern Med.* 1992;117(4): 273-280.
130. Dattwyler RJ, Volkman DJ, Conaty SM, et al. Amoxycillin plus probenecid versus doxycycline for treatment of erythema migrans borreliosis. *Lancet.* 1990;336(8728): 1404-1406.
131. Wormser GP, Ramanathan R, Nowakowski J, et al. Duration of antibiotic therapy for early Lyme disease. A randomized, double-blind, placebo-controlled trial. *Ann Intern Med.* 2003;138(9):697-704.
132. Stupica D, Lusa L, Ruzic-Sabljic E, et al. Treatment of erythema migrans with doxycycline for 10 days versus 15 days. *Clin Infect Dis.* 2012;55(3):343-350.
133. Kowalski TJ, Tata S, Berth W, et al. Antibiotic treatment duration and long-term outcomes of patients with early lyme disease from a lyme disease-hyperendemic area. *Clin Infect Dis.* 2010;50(4):512-520.
134. Auwaerter PG, Bakken JS, Dattwyler RJ, et al. Scientific evidence and best patient care practices should guide the ethics of Lyme disease activism. *J Med Ethics.* 2011;37(2):68-73.
135. Connally NP, Durante AJ, Yousey-Hindes KM, et al. Peridomestic Lyme disease prevention: results of a population-based case-control study. *Am J Prev Med.* 2009;37(3):201-206.
136. Vazquez M, Muehlenbein C, Cartter M, et al. Effectiveness of personal protective measures to prevent Lyme disease. *Emerg Infect Dis.* 2008;14(2):210-216.

137. Nadelman RB, Nowakowski J, Fish D, et al. Prophylaxis with single-dose doxycycline for the prevention of Lyme disease after an *Ixodes scapularis* tick bite. *N Engl J Med.* 2001;345(2):79-84.
138. Schreck CE, Snoddy EL, Spielman A. Pressurized sprays of permethrin or DEET on military clothing for personal protection against *Ixodes dammini* (Acari: Ixodidae). *J Med Entomol.* 1986;23(4):396-399.
139. Hinckley AF, Meek JI, Ray JA, et al. Effectiveness of residential acaricides to prevent Lyme and other tick-borne diseases in humans. *J Infect Dis.* 2016;214(2):182-188.
140. Lane RS. Treatment of clothing with a permethrin spray for personal protection against the western black-legged tick, Ixodes pacificus (Acari: Ixodidae). *Exp Appl Acarol.* 1989;6(4):343-352.
141. Steere AC, Sikand VK, Meurice F, et al. Vaccination against Lyme disease with recombinant *Borrelia burgdorferi* outer-surface lipoprotein A with adjuvant. Lyme Disease Vaccine Study Group. *N Engl J Med.* 1998;339(4):209-215.
142. Poland GA. Vaccines against Lyme disease: What happened and what lessons can we learn? *Clin Infect Dis.* 2011;52(suppl 3):s253-s258.
143. Nigrovic LE, Thompson KM. The Lyme vaccine: a cautionary tale. *Epidemiol Infect.* 2007;135(1):1-8.
144. Karlsson M, Hammers-Berggren S, Lindquist L, et al. Comparison of intravenous penicillin G and oral doxycycline for treatment of Lyme neuroborreliosis. *Neurology.* 1994;44(7):1203-1207.
145. Dotevall L, Hagberg L. Successful oral doxycycline treatment of Lyme disease-associated facial palsy and meningitis. *Clin Infect Dis.* 1999;28(3):569-574.
146. Borg R, Dotevall L, Hagberg L, et al. Intravenous ceftriaxone compared with oral doxycycline for the treatment of Lyme neuroborreliosis. *Scand J Infect Dis.* 2005; 37(6-7):449-454.
147. Ljostad U, Skogvoll E, Eikeland R, et al. Oral doxycycline versus intravenous ceftriaxone for European Lyme neuroborreliosis: a multicentre, non-inferiority, double-blind, randomised trial. *Lancet Neurol.* 2008; 7(8):690-695.
148. Bremell D, Dotevall L. Oral doxycycline for Lyme neuroborreliosis with symptoms of encephalitis, myelitis, vasculitis or intracranial hypertension. *Eur J Neurol.* 2014;21(9):1162-1167.
149. Ljostad U, Henriksen TH. Management of neuroborreliosis in European adult patients. *Acta Neurol Scand Suppl.* 2008;188:22-28.

Chapter 180 :: The Rickettsioses, Ehrlichioses, and Anaplasmoses

:: Maryam Liaqat, Analisa V. Halpern, Justin J. Green, & Warren R. Heymann

AT-A-GLANCE

- *Rickettsiae* primarily target vascular endothelial cells, causing febrile illness and rash in the mammalian host.
- Transmission is predominantly via tick bites, with certain pathogens transmitted by human body lice and mites.
- Fever, headache, myalgia, and malaise are common to rickettsial, ehrlichial, and *Anaplasma* infections; rash is common in rickettsial disease, occasional in ehrlichial infection, and rare in anaplasmosis.
- The early signs and symptoms of infection are often nonspecific and can mimic self-limited viral illnesses or other life-threatening illnesses.
- Early empiric treatment with doxycycline should be considered in highly suspicious cases until rickettsial infection is definitively ruled out, as delayed treatment can lead to severe sequelae and high mortality rates.

Rickettsial diseases are curable infections that, if unrecognized, can be readily lethal. Early nonspecific symptoms can mimic benign viral illnesses and should be considered in any patient who presents with constitutional symptoms, fever, headache, and a characteristic petechial rash. The advent of modern molecular technologies, including genetic analysis, has allowed for significant taxonomic reclassification of the rickettsiae, including moving the family *Bartonella* (see Chap. 154) and the genus *Coxiella* out of the order Rickettsiales to the orders Rhizobiales (*Bartonella*) and Legionellales (*Coxiella*). "Rickettsiae" now includes a polyphyletic group of microorganisms in the class Proteobacteria, comprising species belonging to the genera *Rickettsia*, *Orientia*, *Ehrlichia*, *Anaplasma*, and *Neorickettsia*. Several nonrickettsial agents that were historically included in the group of infections loosely termed the *rickettsioses* remain incorporated in the discussion of rickettsial disease herein to reflect that precedent.[1]

Historically rickettsiae and *Rickettsia*-like organisms (eg, *Coxiella burnetii*) were endemic pathogens; the rise of international travel, however, has allowed for the spread of rickettsial infections to nonendemic areas.

ETIOLOGY AND PATHOGENESIS OF SPOTTED FEVER AND TYPHUS GROUPS

Rickettsiae are obligate, intracellular, Gram-negative bacteria. They are pleomorphic 0.3 to 1 µm coccobacilli composed of DNA and RNA and reproduce through binary fission. Rickettsiae are propagated by arthropod vectors that use mammals (and sometimes the arthropods themselves) as reservoirs of infection. Rickettsiae are separated into the spotted fever group and the typhus group on the basis of common genetics, immunologic patterns, and intracellular growth characteristics. The typhus group lives entirely within the cell cytoplasm, whereas the spotted fever group can reside within the cytoplasm or nucleus. Rickettsiae are differentiated by unique antigenic structures on cell surface proteins. *Rickettsia rickettsii* has 2 major surface proteins, outer membrane protein A (OmpA) and outer membrane protein B (OmpB), which are the main targets for serologic testing. Additionally, Sca1 and Sca2 are autotransporter proteins that play a role in actin-based mobility and induction of phagocytosis of host cells.

Infection occurs through arthropod-induced breaks in the skin allowing access of the pathogen to the blood and lymph. Spotted fever rickettsiae are injected into the host through the saliva of the feeding tick, whereas typhus group rickettsiae enter through the feces of infected human body lice or fleas. Manipulation of the bite site, a long attachment of the arthropod, and exposure to arthropod hemolymph during tick removal aid in the transmission of pathogenic organisms. The rickettsial organisms then spread via the hematogenous and lymphatic systems, attach to endothelial cell membranes, and are phagocytosed. Spotted fever group rickettsiae stimulate host cells to produce reactive oxygen species and cause actin polymerization that aid in bacterial extrusion. In contrast, typhus group rickettsiae replicate intracellularly until the host cell bursts.[2] The severe clinical manifestations of rickettsial infection (eg, hypovolemia, purpura, pulmonary and cerebral edema) are caused by proliferation of bacteria within the vascular endothelium resulting in a multifocal, systemic vasculitis and microvascular leakage.[3]

SPOTTED FEVER GROUP

ROCKY MOUNTAIN SPOTTED FEVER

Rocky Mountain Spotted Fever (RMSF) was first recognized in 1896 in the Snake River Valley of Idaho and was originally called *black measles* because of the characteristic appearance of the rash. Caused by the tick-borne *R. rickettsii*, it is the most frequently reported rickettsial infection in the United States. Incidence has increased from less than 2 cases per million persons in 2000 to over 11 cases per million in 2014.[4] However, according to the Centers for Disease Control and Prevention, associated mortality has declined to less than 0.5%.[5]

EPIDEMIOLOGY

The vector largely responsible for RMSF in the eastern two-thirds of the United States is the American dog tick, *Dermacentor variabilis*. Rocky Mountain wood tick, *Dermacentor andersoni*, is prevalent in the Western United States and *Rhipicephalus sanguineus*, in Mexico and Arizona (Fig. 180-1). RMSF is most prevalent in the Southeastern and South Central states, during spring and early summer. Surveillance data in the United States during 2008-2012 demonstrates highest incidence in persons 60 to 69 years of age; the highest case-fatality rate, however, is among children younger than age 10 years.[6] Table 180-1 outlines the principal epidemiologic characteristics of RMSF.

CLINICAL AND LABORATORY FINDINGS

A high index of suspicion is important to the diagnosis of RMSF. One or 2 classic symptoms, as outlined in Table 180-2, may be seen at presentation, but only approximately 60% of patients will have the complete clinical triad of fever (>39.5°C [102°F]), headache, and rash. Fever usually presents within the first 3 days of the illness, followed by a characteristic rash 2 to 4 days after the onset of fever. The rash usually starts on the wrists and ankles, spreading centripetally over the next 6 to 18 hours. Palms and soles are typically involved with relative sparing of the face.[6] Cutaneous lesions are initially blanchable red macules that become papular and display evidence of petechiae or purpura (Fig. 180-2). Atypical "spotless" fever, seen in approximately 20% of cases does not imply milder disease, and is more common in the elderly and darker-skinned individuals.[3] Periorbital edema, confusion, abdominal pain mimicking an acute abdomen, conjunctival injection, palatal petechiae, edema of dorsal hands, and calf pain are sometimes appreciated. Necrosis from overwhelming vasculitis is rare and preferentially occurs in peripheral locations such as the digits, penis, and scrotum (Fig. 180-3).[7] Such episodes of gangrene may ultimately require amputation.

Thrombocytopenia, anemia, mild hyponatremia, and mild transaminitis may be present. Even though the white blood cell count is typically normal, an increase in bands may be observed.[6] Severe and life-threatening cardiac, GI, hepatic, neurologic, ophthalmologic, renal, and pulmonary manifestations can occur with delayed or inadequate treatment. In patients with severe RMSF who survive the acute illness, long-term sequelae are usually the result of neurologic deficits or acral necrosis. In a case series by Buckingham and colleagues of 92 children diagnosed with RMSF, the median delay between seeking medical attention and antibiotic therapy was 6 days, with only 49% reporting a tick bite.[8] Table 180-2 outlines the cutaneous and systemic manifestations of RMSF, as well as common laboratory abnormalities.

PATHOLOGY

Histopathologic examination shows a septic vasculitis (Fig. 180-4). Early lesions demonstrate dermal edema with a predominantly perivascular lymphohistiocytic infiltrate and extravasated erythrocytes. Lymphohistiocytic vasculitis can progress to leukocytoclastic vasculitis. Basal cell vacuolization, lymphocytic exocytosis, fibrin thrombi, and capillary wall necrosis also can be appreciated. Immunohistology reveals positive staining for *R. rickettsii* in infected endothelial cells and tick hemolymph (Fig. 180-5). Most rickettsial diseases share a similar histology.

DIAGNOSIS AND DIFFERENTIAL DIAGNOSIS

Serologic examination using the indirect immunofluorescence assay (IFA) is the gold standard for diagnosis of RMSF. It detects convalescent antibodies (at a diagnostic titer of ≥64 immunoglobulin [Ig] G and ≥32 IgM) but is seldom diagnostic before the seventh day of disease, and often not until far into the second week. An effective treatment of RMSF should begin by the fifth day of illness. The causative *Rickettsia* species is not determined unless Western immunoblotting and cross-absorption with appropriately selected antigens are performed. It is vital to begin empiric therapy while awaiting serologies. Because of inferior sensitivity and specificity, the Weil-Felix test (agglutination of certain *Proteus* sp.) and complement fixation tests have been largely supplanted by newer diagnostic methods. Immunohistochemical staining of skin or organ tissue biopsy and polymerase chain reaction (PCR) may also confirm the diagnosis.[9]

When a patient presents without a rash, the differential diagnosis for RMSF is broad (Tables 180-3 and 180-4). Macules and papules, petechiae, or purpuric lesions may sometimes develop in these diseases as well, further precluding the ability to distinguish them from RMSF on clinical grounds alone.



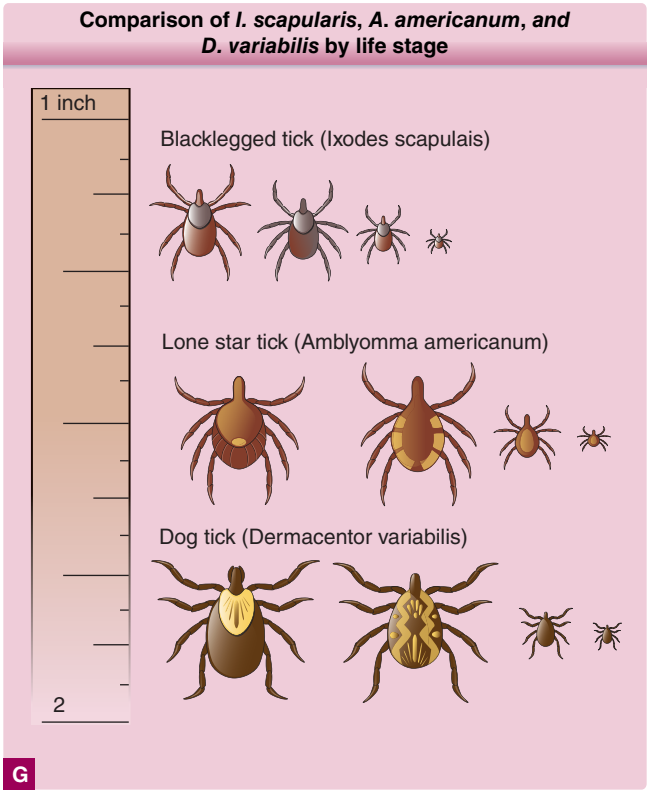

Figure 180-1 Tick species responsible for transmission of rickettsia, ehrlichia, and anaplasma. **A,** *Dermacentor variabilis*. **B,** *Dermacentor andersoni*. **C,** *Amblyomma americanum*. **D,** *Ixodes scapularis*. **E,** *Ixodes pacificus*. **F,** *Rhipicephalus sanguineus*. **G,** Comparison of *I. scapularis*, *A. americanum*, and *D. variabilis* by life stage. (From the Centers for Disease Control and Prevention. https://www.cdc.gov/ticks/tickbornediseases/tickID.html.)

TABLE 180-1

Epidemiologic Features, Prognosis, and Treatment of *Rickettsia*, *Ehrlichia*, and *Anaplasma* Infection

DISEASE (AGENT)	PRIMARY VECTOR(S)	EPIDEMIOLOGY	INCUBATION PERIOD	RISK FACTORS[a]	PROGNOSIS	FIRST-LINE TREATMENT	SECOND-LINE TREATMENTS
Rocky Mountain spotted fever (*Rickettsia rickettsii*)	*Dermacentor variabilis* (American dog tick), *Dermacentor andersoni* (Rocky Mountain wood tick), *Amblyomma americanum* (lone star tick), *Rhipicephalus sanguineus* (brown dog tick), *Amblyomma cajennense* (Central and South America), *Haemaphysalis leporispalustris* ticks	Widespread in the United States, concentrated in South Atlantic and South-Central states; Argentina, Brazil, Columbia, Costa Rica, Mexico, Panama, Canada Spring–Summer	2 to 14 days	Males; adults 40 to 64 years of age, children <10 years of age; rural dwelling	Severe disease: glucose-6-phosphate dehydrogenase (G6PD) deficiency (rapid decompensation, fulminant disease with higher incidence of necrosis), males, elderly, neurologic disease, hepatitis, jaundice, thrombocytopenia, acute renal failure, sulfa medications, delayed diagnosis and treatment	Adults[b]: doxycycline 100 mg by mouth q12h × 5 to 10 days Children[c]: doxycycline 2.2 mg/kg by mouth q12h × 5 to 10 days Pregnancy[c]: doxycycline 100 mg by mouth q12h for 5 to 10 days	Adults: chloramphenicol, 50 to 75 mg/kg by mouth q6h × 5 to 10 days *or* tetracycline 500 mg by mouth q6h × 5 to 10 days Children: chloramphenicol, 12.5 to 25 mg/kg by mouth q6h × 5 to 10 days Pregnancy[d]: chloramphenicol
Mediterranean spotted fever (*Rickettsia conorii*)	*Rhipicephalus sanguineus* (brown dog tick)	Endemic to Southern Europe, Middle East, Southwest Asia, India, and Africa Summer	5 to 7 days	Exposure to dogs	Mild disease (mainly in children) has good prognosis. Severe disease "malignant Mediterranean spotted fever: alcoholics, elderly, G6PD deficiency, diabetes mellitus, heart disease, delayed diagnosis and treatment	Adults: doxycycline 200 mg by mouth q12h × 1 day *or* 100 mg by mouth q12h for 2 to 5 days Children[c]: doxycycline 2.2 mg/kg by mouth q12h × 5 to 10 days Pregnancy: azithromycin 500 mg by mouth daily × 3 days	Adults: tetracycline 500 mg by mouth q6h × 10 days *or* ciprofloxacin 750 mg q12h for 8 days Children: clarithromycin, 15 mg/kg/day divided q12h for 7 days *or* azithromycin, 10 mg/kg/day daily × 3 days Pregnancy[d]: chloramphenicol
Rickettsialpox (*Rickettsia akari*)	*Liponyssoides sanguineus (Allodermanyssus sanguineus)* (house mouse, *Mus musculus,* mite)	United States (mainly eastern seaboard), South Africa, Korea, Ukraine, Croatia Sporadic	~7 days (eschar), ~7 to 24 days (systemic symptoms and rash)	Males; urban dwellers (likely from mice exposure); IV drug users	Excellent	Self-limiting	Doxycycline can be used for severe cases

TABLE 180-1

Epidemiologic Features, Prognosis, and Treatment of *Rickettsia*, *Ehrlichia*, and *Anaplasma* Infection (*Continued*)

DISEASE (AGENT)	PRIMARY VECTOR(S)	EPIDEMIOLOGY	INCUBATION PERIOD	RISK FACTORS[a]	PROGNOSIS	FIRST-LINE TREATMENT	SECOND-LINE TREATMENTS
Endemic typhus (*Rickettsia typhi; Rickettsia felis*)	*Xenopsylla cheopis* (rat flea), *Ctenocephalides felis* (cat flea)	Southeast United States, Gulf region, Southern California; worldwide most cases in Africa (reported on all continents except Antarctica) Summer	1 to 2 weeks (~12 days)	Exposure to fleas, poverty, poor hygiene	Excellent prognosis with treatment. Complicated disease occurs with alcoholism, elderly, hematologic disorders, and exposure to sulfa-containing drugs	Adults: doxycycline 100 mg by mouth q12h for 7 to 14 days Children[c]: doxycycline 2.2 mg/kg by mouth q12h × 5 to 10 days Pregnancy[c,d]: chloramphenicol *or* doxycycline	Adults: chloramphenicol, 80 to 100 mg/kg/day by mouth divided q6h Children: chloramphenicol, 12.5 to 25 mg/kg by mouth q6h for 5 to 10 days Pregnancy: azithromycin
Epidemic typhus (*Rickettsia prowazekii*)	*Pediculus humanus* var. *corporis* (human body louse), *Neohaematopinus sciuropteri* lice, *Orchopeas howardi* fleas	United States, Eastern Europe, Africa, Central and South America, China, Himalayan region Sporadic (increased in winter)	~1 to 2 weeks (average: 8 days)	Wartime, poor hygiene, natural disasters, cold weather	Good prognosis with treatment. Fever abates in 2 weeks without treatment and in 48 hours with treatment. Recovery of strength in 2 to 3 months	Adults[e]: doxycycline 200 mg single dose (or until afebrile for 24 hours) Children[c]: doxycycline 2.2 mg/kg by mouth q12h × 5 to 10 days Pregnancy[c,d]: chloramphenicol *or* doxycycline	Adults: chloramphenicol, 80 to 100 mg/kg/day by mouth divided q6h Children: chloramphenicol, 12.5 to 25 mg/kg by mouth q6h for 5 to 10 days Pregnancy: azithromycin
Human monocytic ehrlichiosis (*Ehrlichia chaffeensis*)	*Amblyomma americanum* (lone star tick), *Dermacentor variabilis* (American dog tick), *Ixodes pacificus* ticks	South and Mid-Atlantic, North-/South-Central United States, isolated areas of New England[f] Spring and summer (peak in May to July	5 to 14 days	Males; adults older than age 70 years	Poor prognosis: immunosuppression (HIV, transplantation, glucocorticoids); cough, lymphadenopathy, diarrhea; use of trimethoprim-sulfamethoxazole	Adults: doxycycline 100 mg by mouth q12h for 5 to 14 days Children[c]: doxycycline 2.2 mg/kg by mouth q12h × 5 to 14 days Pregnancy[c]: doxycycline 100 mg by mouth q12h for 5 to 14 days	Adults: tetracycline 500 mg by mouth q6h × 5 to 14 days *or* Rifampin 300 mg by mouth q12h × 7 to 10 days Children: tetracycline 25 to 50 mg/kg/day by mouth divided q6h × 5 to 14 days *or* Rifampin 10 mg/kg by mouth q12h × 7 to 10 days Pregnancy: rifampin 300 mg by mouth q12h × 7 to 10 days

(*Continued*)

Human granulocytic anaplasmosis (*Anaplasma phagocytophilum*)	*Ixodes scapularis* (Eastern United States) and *Ixodes pacificus* (Western United States), *Ixodes ricinus* (Europe) (black-legged ticks)	New England, upper Midwest Mid-Atlantic, and northern California in United States and Europe[g] Spring and summer (peaks in July and November)	5 to 21 days	Males; adults 60 to 69 years of age	Poor prognosis: elderly, marked lymphopenia, anemia, immunosuppression (HIV, transplantation, glucocorticoids); development of opportunistic infections (eg, aspergillosis, disseminated candidiasis)	Adults[h]: doxycycline 100 mg by mouth q12h for 5 to 14 days Children[c,h]: doxycycline 2.2 mg/kg by mouth q12h × 5 to 14 days Pregnancy[c,h]: doxycycline 100 mg by mouth q12h for 5 to 14 days	Adults: tetracycline 500 mg by mouth q6h × 5 to 14 days *or* rifampin 300 mg by mouth q12h × 7 to 10 days Children: tetracycline 25 to 50 mg/kg/day by mouth divided q6h × 5 to 14 days *or* rifampin 10 mg/kg by mouth q12h × 7 to 10 days Pregnancy: rifampin 300 mg by mouth q12h × 7 to 10 days

Children are defined as persons who weigh less than 45 kg (99 lbs). The maximum daily dose for tetracycline is 2 g and for chloramphenicol it is 4 g.

[a]Males appear to be at higher risk of all tick-borne rickettsial diseases, presumably because of greater recreational and occupational exposure. Disease occurs in all age groups; numbers reflect highest age-specific incidence.

[b]Treat for 3 days after fever subsides and until clinical improvement is noted, typically for a minimum of 5 to 7 days. More-severe illness may require longer duration of therapy.

[c]In severe, life-threatening cases, or when Rocky Mountain spotted fever cannot be ruled out, doxycycline should be considered first-line therapy for individuals of any age and during pregnancy.

[d]Use with caution in the third trimester of pregnancy as chloramphenicol may cause gray baby syndrome in neonates (abdominal distension, pallor, cyanosis, vasomotor collapse). Doxycycline should be considered in near-term gravidas.

[e]For recrudescent disease (Brill-Zinsser), a second course of antibiotics is usually curative.

[f]In 2016, four states (Missouri, Arkansas, New York, and Virginia) accounted for 50% of all reported cases of ehrlichiosis.

[g]In 2016, eight states (Vermont, Maine, Rhode Island, Minnesota, Massachusetts, Wisconsin, New Hampshire, and New York) account for 90% of all reported cases of anaplasmosis.

[h]Treatment is extended to treat potential coinfection with Lyme disease.

Data from Parola P, Paddock CD, Raoult D. Tick-borne rickettsioses around the world: emerging diseases challenging old concepts. *Clin Microbiol Rev*. 2005;18:719; and Dana AN. Diagnosis and treatment of tick infestation and tick-borne diseases with cutaneous manifestations. *Dermatol Ther*. 2009;22:293-326.

TABLE 180-2

Clinical and Diagnostic Findings in Rocky Mountain Spotted Fever, Human Monocytic Ehrlichiosis, and Human Granulocytic Anaplasmosis

	ROCKY MOUNTAIN SPOTTED FEVER	HUMAN MONOCYTIC EHRLICHIOSIS	HUMAN GRANULOCYTIC ANAPLASMOSIS
Tropism	▪ Endothelial cells	▪ Monocytes	▪ Granulocytes
Common initial signs and symptoms	▪ Fever to 38.9°C (102°F), chills, malaise, myalgia, nausea, vomiting, anorexia, headache ▪ Periorbital edema, abdominal pain mimicking appendicitis (children > adults), conjunctival injection, palatal petechiae, edema of dorsal hands, calf pain	▪ Fever, chills, headache, malaise, myalgia, nausea, vomiting, anorexia, photophobia ▪ Abdominal pain mimicking appendicitis (children > adults), conjunctival injection, palatal petechiae, edema of dorsal hands, calf pain	▪ Malaise, fever, myalgia, headache ▪ Less common: arthralgia, nausea, vomiting, diarrhea, cough
Rash	▪ Erythematous blanching macules and/or papules 2 to 4 days after fever onset; starts at wrists/ankles and spreads centripetally; may involve palms, soles; rash evolves over a few days to petechial and purpuric lesions	▪ Erythematous macules and/or papules, petechiae, or diffuse erythema approximately 5 days after onset of systemic symptoms	▪ Rare
Common laboratory abnormalities	▪ Common: thrombocytopenia, anemia, mild hyponatremia ▪ Variably elevated: liver transaminases, lactate dehydrogenase, creatine kinase, bilirubin, alkaline phosphatase, blood urea nitrogen, creatinine ▪ Cerebrospinal fluid: leukocytosis, moderately elevated protein, and a normal glucose level	▪ Leukopenia, lymphopenia, thrombocytopenia, transaminitis, and anemia	▪ Thrombocytopenia, transaminitis, leukopenia, anemia, elevated creatinine ▪ Neutropenia is more common than lymphopenia
Systemic sequelae	▪ Cardiovascular: hypotension, hypovolemia, peripheral edema, inappropriate tachycardia, myocarditis, arrhythmias ▪ GI: bleeding, perforation, hepatomegaly, jaundice ▪ Neurologic: confusion, delirium, stupor, meningismus, coma, motor deficits, cranial nerve palsy, deafness, photophobia, hallucinations, seizures, Guillain-Barré syndrome ▪ Other: conjunctivitis, acute renal failure, adult respiratory distress syndrome	▪ Respiratory: cough, dyspnea, respiratory insufficiency/adult respiratory distress syndrome ▪ Neurologic: Meningoencephalitis, altered mental status, cranial or peripheral motor nerve paralysis, sudden transient deafness ▪ Other: acute renal failure, disseminated intravascular coagulation, and pericarditis	▪ General: septic or toxic shock–like syndrome (see Chap. 172), coagulopathy, disseminated intravascular coagulation (see Chap. 140), rhabdomyolysis, pancreatitis ▪ Respiratory: adult respiratory distress syndrome ▪ Neurologic: brachial plexopathy, demyelinating polyneuropathy, cranial nerve paralysis ▪ Other: acute abdominal syndrome, myocarditis, acute renal failure, hemorrhage, opportunistic infections

TREATMENT

Tetracyclines, specifically doxycycline, are the drugs of choice for all rickettsial diseases in patients of all ages, even during pregnancy. Although repeated exposure to tetracycline increases the risk of tooth staining, studies suggest that limited use of this antibiotic in children during the first 6 to 7 years of life has a negligible effect on the color of permanent incisors.[10] Sulfa-based medications are not recommended, as they may result in a more complicated disease course.[11]

Chloramphenicol may be used if tetracyclines are contraindicated because of allergies. Side effects include aplastic anemia, reversible bone marrow suppression, and gray baby syndrome in near-term gravidae.[12] Aggressive supportive care is crucial, with particular attention to electrolyte and fluid balance. Treatment and management strategies for RMSF are listed in Tables 180-1 and 180-5.

Fulminant RMSF leading to more rapid decompensation has characteristically been reported in chronic alcoholics and black males with glucose-6-phosphate dehydrogenase deficiency. These patients have a higher risk of cutaneous necrosis.[3] Prompt empiric administration of appropriate antibiotic therapy is recommended, as it is the most important factor affecting survival.

PREVENTION

Avoiding tick exposure, wearing protective clothing, performing tick checks regularly while in tick-infested areas, and proper tick extractions are important for lowering the risk of infection. Chemical repellants, such as diethyltoluamide (DEET) in concentrations up to 35%, are safe for use in adults and children. Prophylactic antibiotics after tick exposure are not recommended.

Figure 180-2 **A,** Early macular blanchable macules and papules on the ankle and sole. No truncal lesions were present at this time. **B,** Truncal and facial hemorrhagic macules and papules 7 days after the onset of the rash. **C,** Erythematous macular lesions on the palm may develop into a petechial rash that spreads centrally. **D,** Petechial lesions on the arm of a child with fulminant Rocky Mountain spotted fever. (Image C, Used with permission from Daniel Noltkamper, MD. Reprinted from Hardin JM. Cutaneous conditions. In: Knoop KJ, Stack LB, Storrow AB, et al, eds. *The Atlas of Emergency Medicine*, 4th ed. New York, NY: McGraw-Hill, 2016; Image D, Used with permission from Chapman AS, Bakken JS, Folk SM, et al; Tickborne Rickettsial Diseases Working Group; CDC. Diagnosis and management of tickborne rickettsial diseases: Rocky Mountain spotted fever, ehrlichioses, and anaplasmosis—United States: a practical guide for physicians and other health-care and public health professionals. *MMWR Recomm Rep*. 2006;55(RR-4):1-27, available at http://www.cdc.gov/mmwr/preview/mmwrhtml/rr5504a1.htm.)

Figure 180-3 Gangrene of the toes in Rocky Mountain spotted fever. (From Chapman AS, Bakken JS, Folk SM, et al; Tickborne Rickettsial Diseases Working Group; CDC. Diagnosis and management of tickborne rickettsial diseases: Rocky Mountain spotted fever, ehrlichioses, and anaplasmosis—United States: a practical guide for physicians and other health-care and public health professionals. *MMWR Recomm Rep*. 2006;55(RR-4):1-27, Figure 18, available at http://www.cdc.gov/mmwr/preview/mmwrhtml/rr5504a1.htm. Used with permission from Gary Marshall, MD).

TICK-BITE ASSOCIATED: MEDITERRANEAN SPOTTED FEVER AND AFRICAN TICK BITE FEVER

Several other tick-borne rickettsial species are pathogenic to humans. Mediterranean spotted fever (MSF), also known as *Boutonneuse fever* or *Marseille fever*, caused by *Rickettsia conorii*, was first documented as a cause of human rickettsial disease is 1932. MSF is the prototypical illness of the non-RMSF spotted fever group. African tick bite fever (ATBF), caused by *Rickettsia africae*, is a distinct clinical entity.

EPIDEMIOLOGY

R. conorii is transmitted by an infected *R. sanguineus* tick (see Fig. 180-1) and is endemic throughout Africa, the Middle East, South Asia, and Eastern Europe. Contact with dogs is reported in up to 90% of cases of MSF. Table 180-1 summarizes the epidemiologic characteristics of MSF. *R. africae* is transmitted by an infected *Amblyomma* tick endemic to sub-Saharan Africa.

CLINICAL AND LABORATORY FINDINGS

The constitutional symptoms, systemic complications, and laboratory abnormalities of the tick-bite–associated spotted fevers are similar to those of RMSF. The classic cutaneous hallmark of this group is the tache noir, occurring in approximately 13% to 68% of patients with *R. conorii* infection (Fig. 180-6A).[13] The tache noir occurs at the site of inoculation as an erythematous, indurated papule with a central necrotic eschar that represents locally aggressive endothelial invasion by

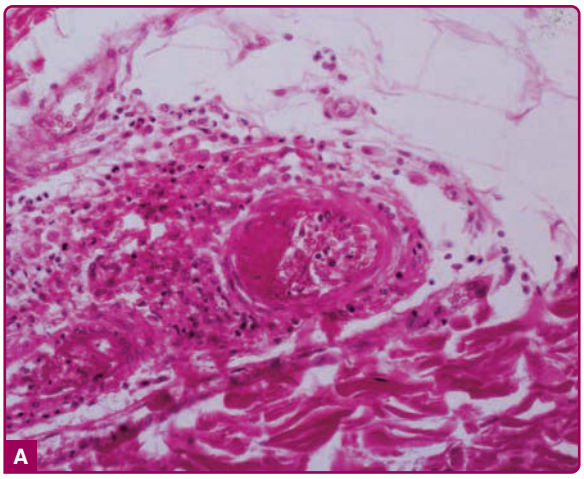

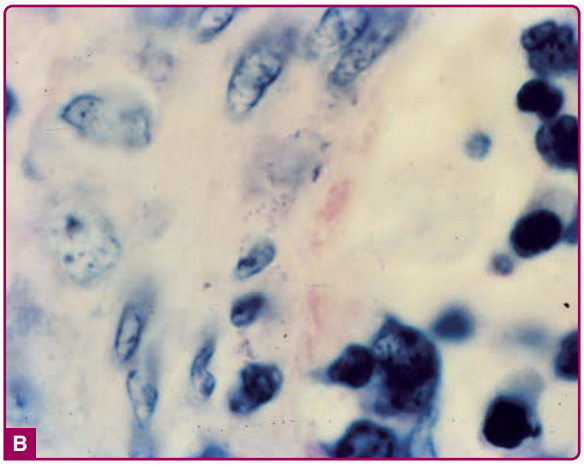

Figure 180-4 **A,** Vascular lesion of Rocky Mountain spotted fever as seen in an arteriole in the skin. An early thrombus is present. **B,** Rickettsiae are seen in endothelial cells from a biopsy of a cutaneous lesion.

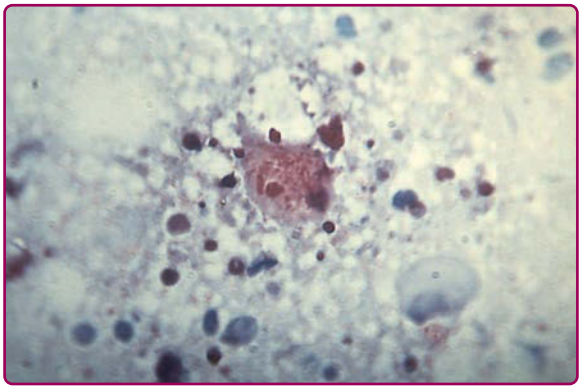

Figure 180-5 Giemsa stain of Rocky Mountain spotted fever in tick lymph cells. (From the Centers for Disease Control and Prevention. http://www.cdc.gov/ncidod/dvrd/rmsf/organism.htm.)

TABLE 180-3
Differential Diagnosis of Rickettsial and Ehrlichial Diseases

Most Likely
- Enteroviral infection (eg, coxsackievirus, echovirus)
- Roseola infantum (human herpesvirus 6)
- Drug eruption
- Group A streptococcal pharyngitis
- Vasculitis
- Kawasaki disease
- Measles (coryza, Koplik spots, cough)
- Epstein-Barr virus/infectious mononucleosis

Consider
- Viral meningoencephalitis
- *Mycoplasma pneumoniae* infection
- Parvovirus B19
- Tularemia
- Leptospirosis
- Immune complex–mediated illness
- Atypical erythema multiforme
- Typhoid fever
- Dengue
- Viral hemorrhagic fevers (Ebola, Marburg, Lassa)

Always Rule Out
- Meningococcemia (more rapid-onset rash and leukocytosis, but both may show gangrenous lesions)
- Disseminated gonococcal infection
- Lyme disease
- Tick-borne viral fevers (eg, Colorado tick fever)
- Thrombotic thrombocytopenic purpura and immune thrombocytopenic purpura
- Toxic shock syndrome
- Stevens-Johnson syndrome
- Secondary syphilis

rickettsiae. Temporal and morphologic pattern of the rash in this group of spotted fevers is similar to RMSF; however, the eruption may be more diffuse and is less frequently petechial or purpuric (Fig. 180-6B). The presence of multiple tick bites, multiple eschars (seen in 50% of patients with ATBF), and lymphadenitis, distinguish ATBF from MSF,[1] although children with MSF may have cervical lymphadenopathy.[13]

DIAGNOSIS AND DIFFERENTIAL DIAGNOSIS

Like RMSF, diagnosis of MSF or ATBF is by IFA. Biopsy from an eschar for immunohistochemistry is particularly sensitive in MSF. PCR or Western blot analysis can be used to differentiate between *R. conorii* and *R. africae*. The addition of shell-vial culture along with real-time PCR is purported to improve diagnosis of MSF.[14] Newer serologic assays and PCR have been useful in identifying the numerous emerging agents of spotted fever around the globe, including *Rickettsia japonica* (Japanese spotted fever) and *Rickettsia slovaca*.[1] *R. slovaca*, along with *Rickettsia raoultii* are associated with TIBOLA/DEBONEL (tick-borne lymphadenopathy/*Dermacentor*-borne necrosis erythema and lymphadenopathy), a recently recognized rickettsial disease associated with eschar formation at the tick-bite site and painful lymphadenopathy. TIBOLA/DEBONEL is usually seen in the pediatric population with tick-bites involving the scalp.[15]

The rash of MSF generates a similar differential diagnosis as that of RMSF. If a tache noir is seen, one must also consider brown recluse spider bite, cutaneous anthrax, scrub typhus, rickettsialpox, aspergillosis, or mucormycosis.

TREATMENT

Table 180-1 outlines the guidelines for treatment of MSF. Overall, non-RMSF spotted fevers run a less-aggressive course than RMSF. However, MSF has been reported to cause severe cardiac, renal, and neurologic complications, as well as death in approximately 1% of cases.[13] In general, all non-RMSF spotted fevers are treated similarly to MSF. Even though macrolide antibiotics may offer a better risk-to-benefit ratio than tetracyclines in the pediatric age group, doxycycline is still first-line therapy.[16]

MITE-BITE ASSOCIATED: RICKETTSIALPOX

Rickettsialpox is an acute, self-limited, febrile disease so named because of its clinical resemblance to varicella (chickenpox). Its etiologic agent is *Rickettsia akari*. *Mus musculus*, the house mouse, is the reservoir, and the vector is the rodent mite, *Liponyssoides sanguineus* (formerly *Allodermanyssus sanguineus*).[17] The colorless rodent mite inflicts a painless bite and is too small to be readily recognized by the victim.

EPIDEMIOLOGY

Most cases of rickettsialpox in the United States have occurred in large metropolitan areas of the Northeastern United States. Anthrax attacked raised attention of physicians to skin eschars and rash and allowed the identification of 34 cases of rickettsialpox in New York City between 2001 and 2002.[18] Table 180-1 describes the salient epidemiologic features of rickettsialpox.

CLINICAL AND LABORATORY FINDINGS

A primary lesion occurs at the site of the mite bite as early as 1 to 2 days after transmission. It consists of a painless, erythematous, indurated papule ranging in size from 0.5 to 3 cm. Vesicle formation is followed by desiccation, which produces an eschar to form the characteristic tache noir (Fig. 180-7). Regional lymphadenopathy is common. Resolution of the primary lesion occurs within 1 month.

Approximately 7 days after the primary lesion appears, fever, chills, diaphoresis, myalgia (often

TABLE 180-4
Selected Differential Diagnosis of Fever and Erythematous or Petechial Rash

DISEASE	AGENT	SEASON	ONSET	CLINICAL FEATURES
Rocky Mountain spotted fever	*Rickettsia rickettsii*	Spring to summer	Fever, headache, malaise, GI symptoms, rash after 2 to 4 days; rapid progression to severe systemic illness	Rash starting on ankles/wrists, spreads centripetally, may involve palms/soles, progresses from erythematous macules to petechiae
Endemic (murine) typhus	*Rickettsia typhi*	Sporadic	Fever, malaise, headache, rash after 4 to 5 days	Erythematous macules and/or papules involving trunk > extremities
Human monocytic ehrlichiosis	*Ehrlichia chaffeensis*	Spring to summer	Fever malaise, headache, rash in ~30% of patients	Erythematous macules and/or papules, or petechial rash; more common in children > adults
Meningococcal disease	*Neisseria meningitidis*	Year-round, but more common late winter to early spring	Fever and rash within 24 h, rapid progression to severe systemic illness	Erythematous macules and/or papules, petechiae usually beginning on lower extremities and spreading centripetally; toxic appearing
Group A streptococcal pharyngitis	*Streptococcus pyogenes*	Fall to winter	Abrupt onset of fever and sore throat, malaise; rash follows acute illness	May cause petechial rash in children who appear well
Fifth disease (erythema infectiosum)	Human parvovirus B19	Late winter to early summer	Low fever and mild constitutional signs before rash onset	"Slapped cheek"–appearing erythematous rash on face, lacy erythematous rash on trunk; papular-purpuric gloves-and-socks syndrome—young adults
Roseola infantum	Human herpesvirus 6	Year-round	Fever for 3 to 5 days, then rash; commonly in children <2 years of age	Morbilliform rash begins on trunk, spreads and fades rapidly
Enteroviral infection	Echovirus, coxsackie viruses, other non-polio enteroviruses	Summer to early fall most commonly, but occurs year-round	Nonspecific febrile illness, with or without rash	Fine morbilliform rash at fever onset; begins on face and spreads caudally; occasionally petechial

Adapted from Chapman AS, Bakken JS, Folk SM, et al; Tickborne Rickettsial Diseases Working Group; CDC. Diagnosis and management of tickborne rickettsial diseases: Rocky Mountain spotted fever, ehrlichioses, and anaplasmosis—United States: a practical guide for physicians and other health-care and public health professionals. *MMWR Recomm Rep*. 2006;55(RR-4):1-27, available at http://www.cdc.gov/mmwr/preview/mmwrhtml/rr5504a1.htm.

manifesting as backache), malaise, and headache begin. The fever persists with remissions for approximately 1 week before abating. Two to 3 days after the onset of systemic symptoms, a generalized papulovesicular eruption occurs (see Fig. 180-7B). Small vesicles or pustules appear with subsequent central crust formation. Roughly 5 to 40 lesions may be found, typically resolving in 1 week. Less frequently, an enanthem characterized

TABLE 180-5
Management of Rickettsial, Ehrlichial, and *Anaplasma* Infections

- Delays in treatment can lead to severe sequelae and fatal outcome.
- Clinical history, symptoms, physical examination, and laboratory findings should guide approach to management and treatment.
- Clinicians may consider a "watch-and-wait" approach for 24 to 48 hours for patients early in the course of illness who have nonsupporting history, nonspecific clinical signs, and normal laboratory findings.
- Doxycycline is the drug of choice for the treatment of presumptive or confirmed rickettsial disease in both adults and children.
- Limited courses of tetracycline-class antibiotics (eg, doxycycline) do not pose a substantial threat of tooth staining in children.
- Tetracyclines are typically contraindicated in pregnancy but are warranted in life-threatening cases of Rocky Mountain spotted fever when clinical suspicion arises.
- When early invasive meningococcal infection cannot be ruled out, antibiotics for *Neisseria meningitides* must be started.
- Prophylactic use of antibiotics after a tick bite is not recommended, as atypical presentations may result, delaying adequate diagnosis and treatment. If prophylaxis is given, a full 10-day course should be administered.
- In patients for whom tetracyclines are absolutely contraindicated, chloramphenicol can be used for rickettsial disease; rifampin or rifabutin may be considered for the ehrlichioses/anaplasmosis.
- When treating ehrlichial infections, consider continuation for 14 to 21 days to allow for adequate treatment of concomitant Lyme disease in areas endemic for *Borrelia burgdorferi*.

Adapted from Chapman AS, Bakken JS, Folk SM, et al; Tickborne Rickettsial Diseases Working Group; CDC. Diagnosis and management of tickborne rickettsial diseases: Rocky Mountain spotted fever, ehrlichioses, and anaplasmosis—United States: a practical guide for physicians and other health-care and public health professionals. *MMWR Recomm Rep*. 2006;55(RR-4):1-27, available at http://www.cdc.gov/mmwr/preview/mmwrhtml/rr5504a1.htm.

Figure 180-6 **A,** Mediterranean spotted fever. Tache noire with eschar at the site of the mite bite. **B,** Multiple disseminated red papules in the same patient. (Used with permission from VisualDx. Copyright Logical Images, Inc.)

by small erosions on the tongue, palate and pharynx, photophobia, generalized lymphadenopathy, and GI symptoms may be noted. Thrombocytopenia is common during the acute febrile illness, and a mild leukopenia with a relative lymphocytosis may be seen.

PATHOLOGY

In contrast to RMSF, MSF, ATBF, and typhus group Rickettsioses, the perivascular macrophage, not the endothelial cell, appears to be the target of *R. akari*. Primary lesions are characterized by extensive necrosis and an acute inflammatory infiltrate. Secondary papulovesicular lesions display a subepidermal split with superficial edema, and a perivascular lymphohistiocytic infiltrate that can become vasculitic.

DIAGNOSIS AND DIFFERENTIAL DIAGNOSIS

Antibody titers peak after 3 to 4 weeks and could be delayed for up to 8 weeks with antibiotic use. Biopsy for direct immunofluorescence with anti–*R. rickettsii* immunoglobulin is highly sensitive; however, because of cross-reactivity among the spotted fever group rickettsiae, confirmatory cross-adsorption testing may be considered with *R. akari* and *R. rickettsii* antigens. The preferred method to identify the organism is by swabbing eschar or vesicles of patients with rickettsioses allowing DNA detection by PCR. The use of multiplex real-time PCR offers greater sensitivity than nested PCR assays to distinguish various rickettsial species.[19]

The differential diagnosis includes varicella, smallpox, gonococcemia, infectious mononucleosis, echovirus (Types 9 and 16), and coxsackievirus infection (A9, A16, and B5), in addition to those diseases discussed under the differential diagnosis of MSF. In varicella, one observes a "dewdrop on a rose petal," referring to a primarily vesicular lesion surrounded by macular erythema. This is distinct from the erythematous papule surmounted by a vesicle seen with rickettsialpox.[17] Fever occurs with the rash of varicella but precedes the eruption of rickettsialpox.

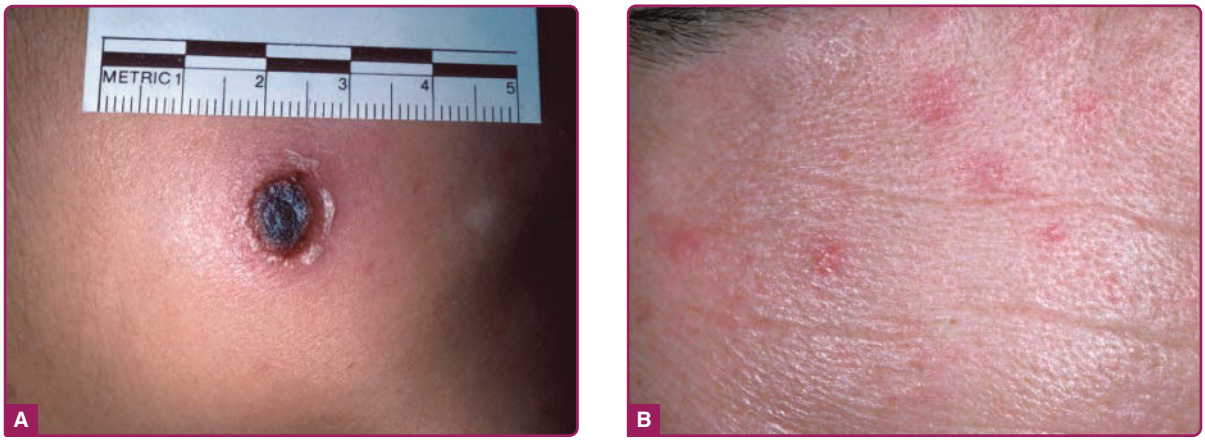

Figure 180-7 **A,** Rickettsialpox: tache noir. A crusted, ulcerated lesion with eschar and a faint red halo at the site of the mite bite. **B,** Mediterranean spotted fever: 32-year-old white male with eschar on thigh, followed by fever, and erythematous papules and small pustules. (Used with permission from VisualDx. Copyright Logical Images, Inc.)

TREATMENT

Rickettsialpox is self-limited. Even without antibiotics, it will resolve within 2 weeks. In the rare severe case, tetracycline antibiotics continued for up to 5 days are the most effective therapy; defervescence is typical within 48 hours.[17]

TYPHUS GROUP

ENDEMIC TYPHUS (MURINE OR FLEA-BORNE TYPHUS)

Endemic typhus is caused mainly by *Rickettsia typhi*, and is classically transmitted to humans by the rat flea (*Xenopsylla cheopis*), with rats serving as the reservoir. *Rickettsia felis* has emerged as an important agent of endemic typhus with characteristics of both the typhus and spotted fever group rickettsiae. *R. felis* has been identified in peridomestic cats, dogs, opossums, and their fleas (eg, cat flea, *Ctenocephalides felis*) in parts of southern Texas, southern California, and Mexico.[20,21]

EPIDEMIOLOGY

Murine typhus has been reported from all continents except Antarctica, although most cases today occur in Africa. It is most likely underdiagnosed and mistaken for a viral illness because flea bites are not usually recalled and most cases are self-limited.[22] Table 180-1 outlines the epidemiologic characteristics of murine typhus.

CLINICAL AND LABORATORY FINDINGS

Most infected persons experience fever, headache, backache, and joint pain 6 to 14 days after contact with an infected flea. Nonspecific GI symptoms may be present, especially in children.[23] Extremely high fever, 41.1°C (106°F), may last up to 2 weeks. Commonly, a rash begins on the chest and spreads to the sides and back. The palms and soles are rarely involved. The rash may last only a few hours and consists of erythematous macules and/or papules. Petechiae are found infrequently. Rash is seen in less than 20% of patients at presentation. Fifty percent to 60% of patients will develop a rash over the course of the illness, with a median onset of 6 days after the onset of fever.[20] More-severe complications are uncommon but may include seizures, meningoencephalitis, retinitis, acute hepatitis, splenic rupture, endocarditis, renal insufficiency, pneumonia, and respiratory failure. Thrombocytopenia, transaminitis, and hyponatremia are common, although usually mild.

DIAGNOSIS AND DIFFERENTIAL DIAGNOSIS

Diagnostic IFA titers are present in 50% of patients by day 7, and in virtually 100% of patients by day 15; however, these may not distinguish between endemic and epidemic typhus. Although Western blot and cross-adsorption studies can differentiate the 2 diseases, they require expensive, specialized laboratories.[23] The differential diagnosis of endemic typhus is broad as a result of the nonspecific nature of the cutaneous eruption (see Table 180-3).

TREATMENT

Treatment of endemic typhus is similar to that of RMSF (see Table 180-1). With institution of appropriate antibiotics, fever typically resolves in 2 to 3 days. Spontaneous recovery often occurs within 2 weeks in untreated patients. Prior infection with *R. typhi* provides lifelong immunity to subsequent infection.

EPIDEMIC (LOUSE-BORNE) TYPHUS

Epidemic typhus (also called *prison fever, famine fever*, and *ship fever*) is caused by *Rickettsia prowazekii*, and is transmitted to humans primarily via the body louse (*Pediculus humanus* var. *corporis*). Epidemic typhus may result in long-term latent asymptomatic infection. A reemergence of the illness known as Brill–Zinsser disease (BZD) can occur in survivors who may suffer recrudescent infection, even decades after the initial infection.

EPIDEMIOLOGY

Louse infestation occurs when cold weather, poor hygiene, crowding, and poverty are prevalent. These conditions are most commonly found today in refugee camps, and among the homeless and imprisoned. The most recent outbreak of epidemic typhus occurred during the mid-1990s in rural highlands of Central and South America (especially Peru) and Africa (including Burundi), with smaller outbreaks in Russia and Kazakhstan.[24] Table 180-1 details the epidemiologic characteristics of epidemic typhus.

The major reservoir for disease is humans, with lice acquiring the infection by feeding on persons with primary illness or BZD. The lice are spread through close personal contact or infested clothing. The infected louse will defecate while taking a blood meal, and the organisms in the feces are then scratched into the skin, enabling transmission. Lice die of infection within 3 weeks, however, their feces can be infectious for up to 100 days, thereby allowing human-to-human transmission through clothes or close contact. Contact with

southern flying squirrels (*Glaucomys volans*) is associated with outbreaks of epidemic typhus in the Eastern United States, where the fleas or lice from these rodents can be important vectors.[25]

CLINICAL AND LABORATORY FINDINGS

After an incubation period of 1 to 2 weeks, abrupt onset of intractable headache, fever (to 40°C [104°F]), chills, and myalgia occurs. If left untreated, prostration resulting from overwhelming hypotension and vascular collapse may ensue. Typically, a rash begins in the axillary folds and upper trunk on the fifth day of illness. Initial lesions consist of erythematous macules that become papular and petechial over several days. In contrast with most rickettsial diseases, the eruption spreads centrifugally but spares the face, palms, and soles. Complications include acral gangrene, cerebral thrombosis, and other neurologic sequelae, multiorgan system failure, and death. Laboratory abnormalities include thrombocytopenia, elevated transaminases, and elevated lactate dehydrogenase. Leukocytosis is seen in a minority of patients.

BZD occurs as a recrudescence of previous infection with *R. prowazekii*. Provocation by immunologic stress induced by poor living conditions may play a role. The illness is usually milder than the primary disease. In the United States it was most commonly seen in those who were exposed to epidemic typhus in World War II.

DIAGNOSIS AND DIFFERENTIAL DIAGNOSIS

Techniques for diagnosis are identical to those used for other rickettsial diseases, with the IFA test the most widely used method. The differential diagnosis is similar to that of endemic typhus. The diagnosis of epidemic typhus should be considered when the appropriate clinical characteristics are seen in the setting of known or suspected louse infestation, or, in the United States, when a history of an exposure to flying squirrels is elicited. The centrifugal spread, lack of eschar, and predilection for colder months helps differentiate epidemic typhus from other rickettsial infections. Endemic typhus is typically less severe than epidemic typhus. When lice and rats are both prevalent (eg, poor hygienic conditions, prison), a risk exists for both diseases. In such situations, it is critical to discriminate between *R. typhi* and *R. prowazekii* infections, as *R. prowazekii* has markedly greater epidemic potential.

TREATMENT

Fatal illness is rare if proper therapy is initiated early (see Table 180-1). Although a single dose of doxycycline may be curative, optimal therapy should be continued for 2 to 3 days after defervescence. BZD is treated identically to primary epidemic typhus. Therapy failures have been documented with azithromycin for BZD.[26]

PREVENTION

Prevention begins with regular bathing and clothes washing. Delousing with appropriate agents, such as permethrin, malathion, lindane or dichlorodiphenyltrichloroethane (DDT), is effective.

SCRUB TYPHUS

Scrub typhus (*tsutsugamushi fever* or *chigger fever)*, is a mite-transmitted zoonosis caused by *Orientia tsutsugamushi*. The vector is the larval stage (chigger) of the trombiculid mite (*Leptotrombidium deliense* and other *Leptotrombidium* sp.). The mites and the rodents that carry them serve as the major reservoirs.

EPIDEMIOLOGY

Named for the type of vegetation that harbors the mite vector, scrub typhus is endemic to a region spanning the Indian subcontinent to Eastern Asia and the Western Pacific Rim (Japan, Korea, India, Pakistan, Taiwan, Southeast Asia, and Australia). Scrub vegetation is a transitional terrain between tall forests and cleared land, composed of plantations, fields, groves, and tall grass. Accordingly, the illness is more common in rural settings and is a common occupational disease. Because of the long incubation period, scrub typhus can present in travelers returning to nonepidemic areas.

CLINICAL AND LABORATORY FINDINGS

An erythematous papule appears within 2 days of the chigger bite and undergoes ulceration and eschar formation in one-half to two-thirds of patients. The eschar may be absent in intertriginous areas. Regional lymphadenopathy is followed by generalized lymphadenopathy. One to 2 weeks after the bite, there is a sudden onset of high fever (40°C to 40.6°C [104°F to 105°F]). Chills, headache, cough, myalgia, anorexia, nausea, diarrhea, dyspnea, ocular pain, and conjunctival injection are variably present. Approximately 4 to 5 days after the fever begins a centrifugal macular followed by papular eruption occurs in approximately 35% of cases. The eruption starts on the trunk, spreads to the extremities, and fades within a few days. Hepatosplenomegaly and a relative bradycardia may be appreciated. Severe complications include adult respiratory distress syndrome, myocarditis, pericarditis, disseminated intravascular coagulation, hemophagocytic syndrome, retinal vein occlusion, renal failure, and hepatitis. Nuchal rigidity, meningoencephalitis, tremors, slurred speech, deafness, and tinnitus are seen rarely. Examination of the cerebrospinal fluid in these cases reveals only a slight monocytosis.

DIAGNOSIS AND DIFFERENTIAL DIAGNOSIS

The differential diagnosis is similar to that for endemic typhus. Enzyme-linked immunosorbent assay, dot blot urine immunoassay, rapid immunochromatographic flow assay, and PCR have the greatest sensitivity and specificity but are limited by their availability in endemic areas. Diagnostically, IFA remains the gold standard. Conclusive diagnosis is based on a fourfold increase in titer of paired samples drawn at least 2 weeks apart. A single acute titer of greater than 1:50 can be used as a preliminary diagnostic cutoff in travelers returning from endemic areas.[27] In 2009, an association was reported between high *O. tsutsugamushi* DNA loads determined by PCR and disease severity.[28] However, newer evidence suggests IgM enzyme-linked immunosorbent assay has higher diagnostic accuracy and may be used as alternative reference to the IgM IFA.[29]

TREATMENT

Although single dose or short courses (3 days) of doxycycline may prove to be efficacious, treatment is recommended for 14 days. Naturally occurring doxycycline-resistant and chloramphenicol-resistant strains of *O. tsutsugamushi* have been found in northern Thailand; azithromycin, rifampin, and ciprofloxacin are alternatives in this setting.[30] With the institution of proper antibiotics, defervescence occurs abruptly, usually within 24 hours. In untreated patients, fever lasts for approximately 2 weeks. While vaccine development has yielded disappointing results further research is crucial as prevention given increasing resistance to available antibiotic therapies.[31]

PREVENTION

DEET applied to the skin or impregnated into clothing is effective at preventing transmission. Chemoprophylaxis with weekly doxycycline may be efficacious when traveling to endemic areas. Paradoxically, rodent control may increase the risk of human disease as chiggers lose their natural host and target humans.

THE EHRLICHIOSES

The ehrlichial pathogens were reclassified in 1994 based on distinct phylogenetic and pathogenic characteristics. Disease previously known as Human granulocytic ehrlichiosis is now called Anaplasmosis or Human granulocytic Anaplasmosis (HGA) and is caused by organism in the Anaplasma genus. In contrast, Human monocytic ehrlichiosis (HME) is attributed to the Ehrlichia species.[6]

EPIDEMIOLOGY

Human disease attributed to ehrlichial organisms has been reported in the United States since 1986. The causative agent of HME is *Ehrlichia chaffeensis*, and the main reservoirs are deer, dogs, and coyote. The white-footed mouse (*Peromyscus leucopus*) and white-tailed deer (*Odocoileus virginianus*) are the principal reservoirs for *Anaplasma phagocytophilum*, the causative agent of HGA. Table 180-1 describes the principal epidemiologic characteristics of HME and HGA.

HGA infection occurs in a geographic pattern identical to that of Lyme disease (*Borrelia burgdorferi*; see Chap. 179), namely in the Northeast, parts of the Pacific Northwest, and the upper Midwest United States. The vector for both HGA and Lyme is the *Ixodes* tick (see Fig. 180-1D and E). In addition to *A. phagocytophilum* and *B. burgdorferi*, *Ixodes* ticks can transmit *Babesia microti*, *Borrelia afzelii*, and *Borrelia garinii*. Not surprisingly, most cases of HGA are found in areas with high incidences of Lyme disease and babesiosis.

The lone star tick (*Amblyomma americanum*) and the American dog tick (*D. variabilis*), the vectors of *E. chaffeensis*, also transmit *R. rickettsii* and *Francisella tularensis*, the causative agents of RMSF and tularemia (see Chap. 156), respectively (see Fig. 180-1). It is essential to consider possible coinfection with these potentially life-threatening organisms in patients with known or suspected ehrlichial disease. Although mainly a tick-borne disease, HGA has been reported after blood transfusions, as well as after contact with contaminated animal tissue.[32,33]

ETIOLOGY AND PATHOGENESIS

Ehrlichiae and Anaplasmodiae are small, obligate intracellular bacteria. *E. chaffeensis* is trophic for monocytic cells, whereas *A. phagocytophilum* prefer myeloid or granulocytic cells. The organisms grow within membrane-bound vacuoles, and form intracytoplasmic microcolonies called morulae, which may be seen in peripheral blood smears.[6,34]

CLINICAL AND LABORATORY FINDINGS

There is substantial overlap in the clinical presentation and laboratory evaluation of patients with HME, HGA, and RMSF (see Table 180-2). Patients give a history of a tick bite in only approximately 68% of cases of ehrlichiosis. The clinical course ranges from asymptomatic seroconversion to multisystem organ failure and death (see Table 180-2) The rash of HME is often indistinguishable from that of RMSF, and can present as erythematous macules and papules, petechiae, or as a diffuse erythema. It is observed in approximately 33% of adults and 66% of children with HME. Rash is rare in HGA; the absence of a rash in a patient with systemic findings suggestive of RMSF should prompt consideration of anaplasmosis. Conversely, if a rash is present in a patient with anaplasmosis, coinfection with meningococcus, *R. rickettsii*, or *B. burgdorferi* should be considered. Laboratory abnormalities include leukopenia (often with a left shift), thrombocytopenia, and elevated transaminases. Despite similar

presentations, HME usually has a more-severe progression and higher case fatality ratio, where as HGA has a high prevalence of opportunistic infections.[35]

PATHOLOGY

In contrast to the rickettsioses, neither endothelial cell injury nor frank vasculitis is a typical feature. A single retrospective case study suggests HME rarely may be associated with cutaneous vasculitis such as polyarteritis nodosa.[36]

DIAGNOSIS AND DIFFERENTIAL DIAGNOSIS

Clinical illness nearly always precedes laboratory diagnosis by any method. Morulae stained with Wright or Giemsa stains are occasionally observed inside the leukocytes in peripheral blood smears, buffy coat preparations, or cerebrospinal fluid, usually during the first week of infection (Fig. 180-8). Smear sensitivities are low and variably dependent upon the experience of the microscopist.[34] Consequently, a negative smear

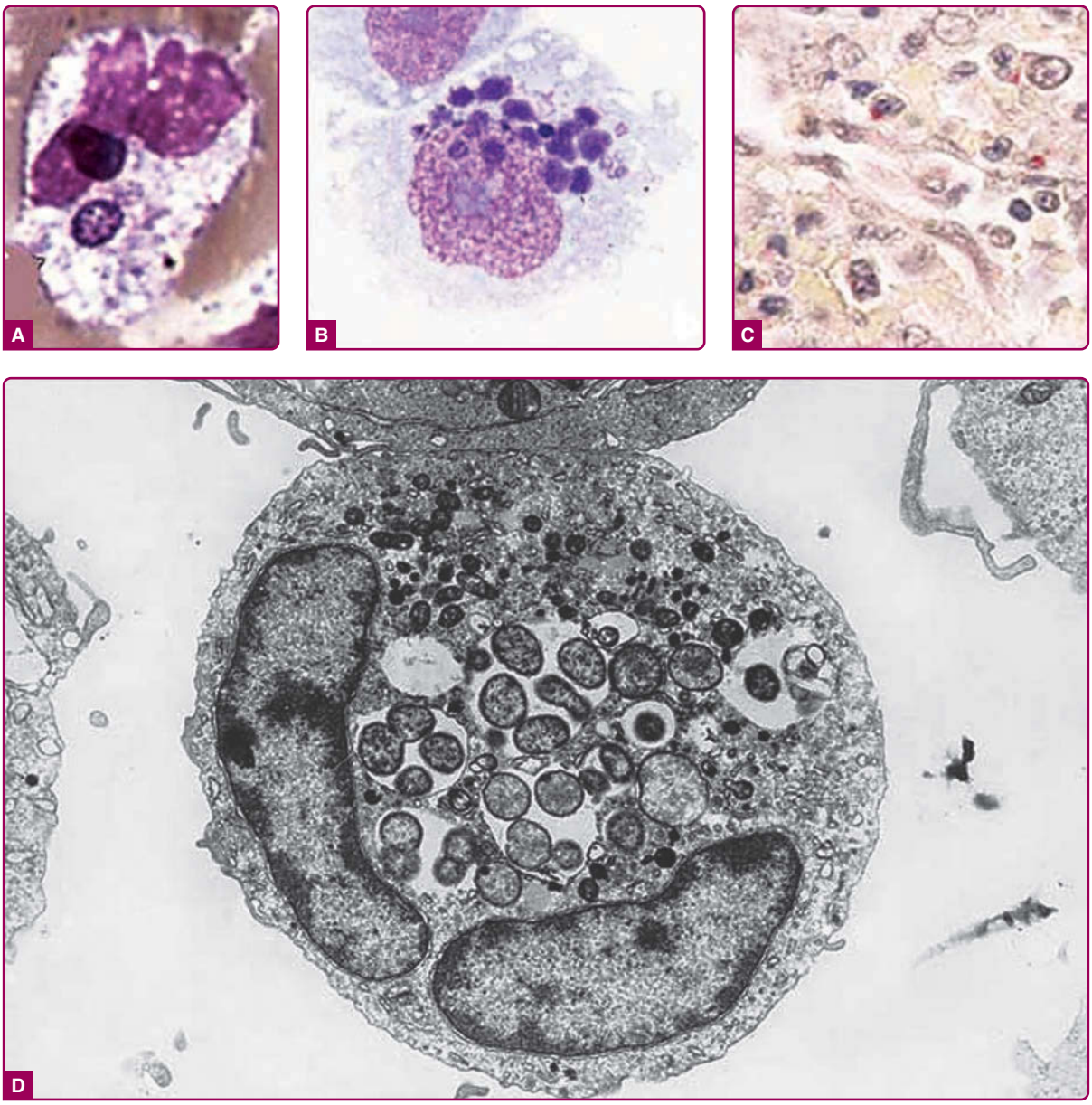

Figure 180-8 **A,** *Anaplasma phagocytophilum* in human peripheral blood band neutrophil (Wright stain, original magnification ×1000). **B,** *A. phagocytophilum* in THP-1 myelomonocytic cell culture (Leukostat stain, original magnification ×400). **C,** *A. phagocytophilum* in neutrophils infiltrating human spleen (immunohistochemistry with hematoxylin counterstain; original magnification ×100). **D,** *A. phagocytophilum* ultrastructure by transmission electron microscopy in HL-60 cell culture (original magnification ×21,960). (Used with permission from Dumler JS, Choi KS, Garcia-Garcia JC, et al. Human granulocytic anaplasmosis and *Anaplasma phagocytophilum*. *Emerg Infect Dis*. 2005;11(12):1828-1834, Fig. 1. Available at https://wwwnc.cdc.gov/eid/article/11/12/05-0898_article.)

should not delay treatment. False-positives can occur with toxic granulation, superimposed platelets, and Döhle bodies.

Confirmatory testing should be performed with serologic assays available through commercial and state public health laboratories. The sensitivity of the IFA is dependent on the timing of collection and is estimated to be 94% to 100% sensitive after 14 days. Antibody titers are typically as high as 1:640 during acute infection.[37] Paired serum samples taken 2 to 3 weeks apart should demonstrate a fourfold rise in titers. PCR of whole blood may be more useful than tissue biopsy in HME and HGA, as these pathogens are trophic for circulating leukocytes. Immunohistochemical staining of formalin-fixed, paraffin-embedded tissue may be useful for documenting infection in the first 48 hours of disease.[6]

The differential diagnosis is extensive and similar to RMSF (see Tables 180-3 and 180-4). The presence of a rash, normal white blood cell count, lack of morulae, and pathologic evidence of vasculitis is more consistent with RMSF.

TREATMENT

The median duration of disease is 1 to 2 weeks with treatment. Defervescence usually occurs within 1 to 2 days. Tables 180-1 and 180-5 detail appropriate therapy. Treatment with doxycycline for 5 to 14 days is generally effective, but continued therapy for 14 to 21 days is indicated if coinfection with *B. burgdorferi* is suspected.[6,34] Rifampin has been successfully used to treat HGA in pregnant women and young children.

PREVENTION

Preventive measures include avoidance of tick exposure, use of chemical repellants such as DEET, light-colored clothing (to visualize ticks), and careful removal of attached ticks.

ACKNOWLEDGMENTS

We would like to thank Sandra A. Kopp, who contributed to this chapter in the previous edition of *Fitzpatrick's Dermatology in General Medicine*.

REFERENCES

1. Parola P, Paddock CD, Raoult D. Tick-borne rickettsioses around the world: emerging diseases challenging old concepts. *Clin Microbiol Rev.* 2005;18:719.
2. Todar K. Rickettsial diseases, including typhus and rocky mountain spotted fever. *Todar's Online Textbook of Bacteriology*. 2008-2012:2-6. http://textbookofbacteriology.net/Rickettsia.html. Accessed July 20, 2018.
3. Walker DH, Raoult D. *Rickettsia rickettsii* and other spotted fever group rickettsiae (Rocky Mountain spotted fever and other spotted fever). In: Mandell GL, Bennett JE, Dolin R, eds. *Principles and Practice of Infectious Diseases*. Vol 2. 8th ed. Philadelphia, PA: Churchill Livingstone; 2015:2198.
4. Chapman AS, Bakken JS, Folk SM, et al; Tickborne Rickettsial Diseases Working Group; CDC. Diagnosis and management of tickborne rickettsial diseases: Rocky Mountain spotted fever, ehrlichioses, and anaplasmosis—United States: a practical guide for physicians and other health-care and public health professionals. *MMWR Recomm Rep.* 2006;55(RR-4):1-27.
5. Centers for Disease Control and Prevention (CDC). Rocky Mountain Spotted Fever (RMSF). Statistics and Epidemiology. https://www.cdc.gov/rmsf/stats/index.html. Accessed July 31, 2018.
6. Biggs HM, Behravesh CB, Bradley KK, et al. Diagnosis and management of tickborne rickettsial diseases: Rocky Mountain spotted fever and other spotted fever group rickettsioses, ehrlichioses, and anaplasmosis—United States. *MMWR Recomm Rep.* 2016;65(RR-2):1-44.
7. Kirkland KB, Marcom KP, Sexton DJ, et al. Rocky Mountain spotted fever complicated by gangrene: report of six cases and review. *Clin Infect Dis.* 1993;16:629.
8. Buckingham SC, Marshall GS, Gordon ES, et al. Clinical and laboratory features, hospital course, and outcome of Rocky Mountain spotted fever in children. *J Pediatr.* 2007;150:180-184.
9. Dana AN. Diagnosis and treatment of tick infestation and tick-borne diseases with cutaneous manifestations. *Dermatol Ther.* 2009;22:293-326.
10. Lochary ME, Lockhart PB, Williams WT Jr. Doxycycline and staining of permanent teeth. *Pediatr Infect Dis J.* 1998;17:429.
11. Elston DM. Rickettsial skin disease: uncommon presentations. *Clin Dermatol.* 2005;23:541.
12. Stallings SP. Rocky Mountain spotted fever and pregnancy: a case report and review of the literature. *Obstet Gynecol Surv.* 2001;155:37.
13. Rovery C, Raoult D. Mediterranean spotted fever. *Infect Dis Clin North Am.* 2008;22:515-530.
14. Segura F, Pons I, Sanfeliu I, et al. Shell-vial culture, coupled with real-time PCR, applied to *Rickettsia conorii* and *Rickettsia massiliae*-Bar29 detection, improving the diagnosis of the Mediterranean spotted fever. *Ticks Tick Borne Dis.* 2016;7(3):457-461.
15. Parola P, Rovery C, Rolain J, et al. *Rickettsia slovaca* and *R. raoultii* in tick-bourne Rickettsioses. *Emerg Infect Dis.* 2009;15:105-108.
16. Cascio A, Colomba C, Di Rosa D, et al. Efficacy and safety of clarithromycin as treatment for Mediterranean spotted fever in children: a randomized controlled trial. *Clin Infect Dis.* 2001;33:409.
17. Heymann WR. Rickettsialpox. *Clin Dermatol.* 1996;14:279.
18. Didier R. Rickettsialpox. In: Mandell GL, Bennett JE, Dolin R, eds. *Principles and Practice of Infectious Diseases*. Vol 2. 8th ed. Philadelphia, PA: Churchill Livingstone; 2015:2206.
19. Denison A, Amin B, Nicholson W, et al. Detection of *Rickettsia rickettsii*, *Rickettsia parkeri*, and *Rickettsia akari* in skin biopsy specimens using multiplex real-time polymerase chain reaction assay. *Clin Infect Dis.* 2014;59:635.
20. Dumler JS. *Rickettsia typhi* (murine typhus). In: Mandell GL, Bennett JE, Dolin R, eds. *Principles and Practice of Infectious Diseases*. Vol 2. 8th ed. Philadelphia, PA: Churchill Livingstone; 2015: 2221.
21. Zavala-Velazquez JE, Zavala-Castro JE, Vado-Solís I, et al. Identification of *Ctenocephalides felis* fleas as a

host of *Rickettsia felis*, the agent of a spotted fever rickettsiosis in Yucatan, Mexico. *Vector Borne Zoonotic Dis.* 2002;2:69.
22. Purcell K, Fergie J, Richman K, et al. Murine typhus in children, South Texas. *Emerg Infect Dis.* 2007; 13:926-927.
23. Whiteford SF, Taylor JP, Dumler JS. Clinical, laboratory and epidemiologic features of murine typhus in 97 Texas children. *Arch Pediatr Adolesc Med.* 2001;155:396.
24. Raoult DA, Roux V, Ndihokubwayo JB, et al. Jail fever (epidemic typhus) outbreak in Burundi. *Emerg Infect Dis.* 1997;3(3):357-360.
25. Walker DH. *Rickettsia prowazekii* (epidemic or louse-borne typhus). In: Mandell GL, Bennett JE, Dolin R, eds. *Principles and Practice of Infectious Diseases*. Vol 2. 8th ed. Philadelphia, PA: Churchill Livingstone; 2015:2217.
26. Turcinov D, Kuzman I, Herendic B. Failure of azithromycin in treatment of Brill-Zinsser disease. *Antimicrob Agents Chemother.* 2000;44:1737.
27. Blacksell SD, Bryant N, Paris D, et al. Scrub typhus serologic testing with the indirect immunofluorescence method as a diagnostic gold standard: a lack of consensus leads to a lot of confusion. *Clin Infect Dis.* 2007;44:391.
28. Sonthayanon P, Chierakul W, Wuthiekanun V, et al. Association of high *Orientia tsutsugamushi* DNA loads with disease of greater severity in adults with scrub typhus. *J Clin Microbiol.* 2009;47:430-434.
29. Blacksell SD, Lim C, Tanganuchitcharnchai A, et al. Optimal cutoff and accuracy of an IgM enzyme-linked immunosorbent assay for diagnosis of acute scrub typhus in northern Thailand: an alternative reference method to the IgM immunofluorescence assay. *J Clin Microbiol*. 2016;54(6):1472-1478.
30. Watt G, Kantipong P, Jongsakul K, et al. Doxycycline and rifampicin for mild scrub-typhus infections in northern Thailand: a randomised trial. *Lancet.* 2000; 356:1057.
31. Chattopadhyay S, Richards AL. Scrub typhus vaccines: past history and recent developments. *Hum Vaccin.* 2007;3(3):73-80.
32. Bakken JS, Krueth J, Lund T, et al. Exposure to deer blood may be a cause of human granulocytic ehrlichiosis. *Clin Infect Dis.* 1996;23:198.
33. Centers for Disease Control and Prevention (CDC). *Anaplasma phagocytophilum* transmitted through blood transfusion—Minnesota. *MMWR Morb Mortal Wkly Rep.* 2008;57:1145-1148.
34. Dumler JS, Choi KS, Garcia-Garcia JC, et al. Human granulocytic anaplasmosis and *Anaplasma phagocytophilum*. *Emerg Infect Dis.* 2005;11(12):1828-1834.
35. Dumler SJ, Madigan JE, Pusterla N, et al. Ehrlichioses in humans: epidemiology, clinical presentation, diagnosis, and treatment. *Clin Infect Dis.* 2007;45(suppl 1): S45-S51.
36. Pick N, Potasman I, Strenger C, et al. Ehrlichiosis associated vasculitis. *J Intern Med.* 2000;247:674.
37. Sanchez E, Vannier E, Wormser GP, et al. Diagnosis, treatment and prevention of lyme disease, human granulocytic anaplasmosis, and babesiosis: a review. *JAMA*. 2016;315:1767.

Chapter 181 :: Arthropod Bites and Stings

:: Robert A. Schwartz & Christopher J. Steen

AT-A-GLANCE

- Many arthropod species are capable of inflicting bites and stings on humans.
- Reactions to arthropod assaults can range from mild to life threatening.
- Arthropods also serve as vectors for systemic diseases.
- The terrestrial arthropods of medical importance include the orders Arachnida (arachnids), Chilopoda (centipedes), Diplopoda (millipedes), and Insecta (insects).

Arthropod bites and stings are a significant cause of morbidity worldwide. Although many arthropod attacks produce only mild, transient cutaneous changes, more severe local and systemic sequelae can occur, including potentially fatal toxic and anaphylactic reactions. Arthropods also serve as vectors for numerous systemic diseases. The medically significant classes of nonaquatic arthropods are Arachnida, Chilopoda, Diplopoda, and Insecta (Fig. 181-1).[1]

HISTOPATHOLOGY

Many arthropod bites produce a similar histologic reaction pattern. In the acute phase, there is a superficial and deep, perivascular, and interstitial inflammatory infiltrate, which is characteristically wedge shaped. The infiltrate is usually mixed in composition with an abundance of lymphocytes and eosinophils, although neutrophils and histiocytes also can be seen. Neutrophils may predominate in reactions to fleas, mosquitoes, fire ants, and brown recluse spiders. Over the most prominent superficial infiltrates, spongiosis can be seen, sometimes with progression to vesicle formation or epidermal necrosis. Older, excoriated areas are usually altered by the effects of scratching, with the development of parakeratosis, serum exudates, and a dermal infiltrate with neutrophils and more abundant lymphocytes. Although not commonly seen on histology, insects or insect parts, including burrowed scabies mites, eggs, feces, or the retained mouthparts of ticks, may be visible. Chronic lesions, which most often result when arthropod parts are retained in the skin, may have a pseudolymphomatous appearance (Chap. 120).

TREATMENT PRINCIPLES

The morbidity from arthropod bites and stings varies with the species inflicting the injury. Although species-specific clinical findings and treatment will be discussed in further detail, there are several applicable general treatment principles (Table 181-1). Local wound care is essential following arthropod assault. Wounds should be cleansed; any remaining arthropod parts, including stingers, should be removed expeditiously. Patient discomfort should be addressed and can involve a variety of treatment modalities, including the use of ice packs, application of topical corticosteroids and antipruritics, injection of local anesthetics, and, less frequently, the use of systemic analgesics. Supportive measures for systemic toxic and allergic reactions, including anaphylaxis, should be instituted when necessary. Secondary infection should be treated with appropriate antibiotics. Bites from several terrestrial arthropods species may require tetanus prophylaxis. Severe envenomation from particular species, such as the black widow spider, may require antivenom administration. Documented hypersensitivity to some species can be treated with desensitization immunotherapy. Awareness of the potential arthropod-borne illnesses spread by each species is also important.

DIFFERENTIAL DIAGNOSIS

See Table 181-2.

ARACHNIDA

The class Arachnida contains 3 orders of medical significance: (1) Araneae (spiders), (2) Acarina (ticks and mites), and (3) Scorpiones (scorpions). Arachnids are distinguished anatomically from other arthropods by a lack of wings or antennae and the presence of 4 pairs of legs and 2 body segments. Larval ticks, which only have 3 pairs of legs, are an exception to this rule (Fig. 181-1).

ARANEAE

Spiders are carnivorous members of the animal kingdom that use webs and venom to capture and kill prey. Within the United States, 3 genera contain species whose bites are toxic to man: (1) *Latrodectus*, (2) *Loxosceles*, and (3) *Tegenaria*. The American Association of Poison Control Centers reported more than 15,000 spider bites in the United States in 2004.[2] In the same year, only 1 death was attributed to spider envenomation in the United States.

LATRODECTUS

Members of the *Latrodectus* genus, or widow spiders, are often black in color and have a red, hourglass-shaped marking on their abdomens (Fig. 181-2). Although there are more than 20 species of widow

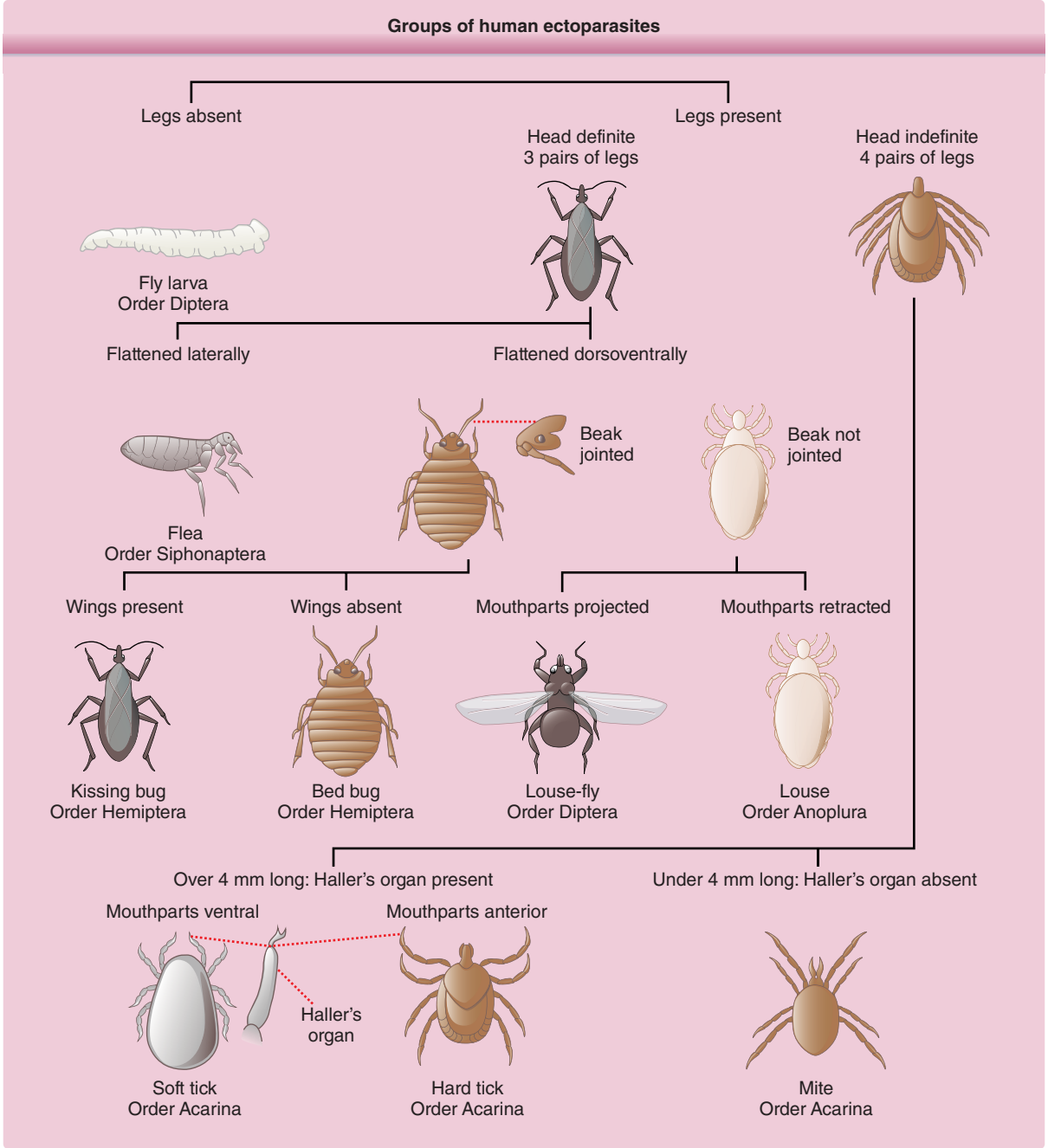

Figure 181-1 Pictorial key to groups of human ectoparasites. (Used with permission from C. J. Stojanovich and H. G. Scott, US Department of Health, Education, and Welfare, Public Health Service.)

TABLE 181-1

General Treatment Principles for Arthropod Bites

Local wound care–cleansing, removal of any remaining arthropod parts
Ice packs
Topical corticosteroid application
Topical antipruritic agents
Injection of local anesthetics
Systemic analgesic agents
Tetanus prophylaxis (as necessary)

spiders, *Latrodectus mactans*, the Southern black widow spider, is the most common and notorious in the United States and can be found in all but the most northern parts of the country. Other widow spiders encountered in the United States include *Latrodectus various* (Northern black widow), *Latrodectus hesperus* (Western black widow), *Latrodectus bishopi* (red-legged widow), and *Latrodectus geometricus* (brown widow). Members of the *Latrodectus* genus are nonaggressive, trapping spiders that spin webs in protected areas and await their prey. Human bites are often the result of accidental or deliberate provocation. Webs are

TABLE 181-2
Differential Diagnosis of Arthropod Bites and Stings

- Black widow bite: acute abdomen (appendicitis, etc.), meningitis, tetanus, drug withdrawal, acute renal failure, acute myocarditis, acute coronary syndrome, other arthropod bite
- Brown recluse bite: hobo spider bite, chemical burn, Lyme disease, cutaneous anthrax infection, pyoderma gangrenosum, ecthyma, trauma, vasculitis, neoplasm, other arthropod bite
- Scorpion sting: other arthropod bite, tetanus, botulism, Guillain–Barré, organophosphate toxicity, medication overdose
- Centipede bite: other arthropod bite, cellulitis
- Millipede "burn": contact dermatitis, conjunctivitis
- Insect bites (flies, fleas, bedbugs, kissing bugs): other arthropod bites (scabies, lice), atopic dermatitis, contact dermatitis, papular urticaria, delusions of parasitosis
- Hymenoptera bite/sting: other arthropod bite, anaphylaxis
- Lepidopterism: other arthropod bite, contact dermatitis, atopic dermatitis, phytodermatitis

typically found on the corners of doors and windows, underneath woodpiles, in garages and sheds, and on the undersides of eaves. Webs also can be found around outdoor toilet seats, a location that has led to bites on or near the genitalia.[3]

Clinical Findings: Bites of the black widow spider (*L. mactans*), which are often painful, usually only result in mild dermatologic manifestations. Within the first 30 minutes, localized erythema, piloerection, and sweating may appear at the wound site. A sensation of numbness or aching pain may develop shortly after the bite. Urticaria and cyanosis may occur at the bite site. Black widow venom contains the neurotoxin α-latrotoxin, which acts by opening ion channels at presynaptic nerve terminals, thereby causing an irreversible release of acetylcholine at motor nerve endings and catecholamines at adrenergic nerve endings.[4] Consequently, black widow bites may produce agonizing crampy abdominal pain and muscle spasm that may mimic an acute abdomen.[4] Other signs and symptoms include headache, paresthesias, nausea, vomiting, hypertension, lacrimation, salivation, seizures, tremors, acute renal failure, and sometimes, paralysis; fortunately, death is uncommon. Based on the spectrum of symptoms, black widow bite may be misdiagnosed as drug withdrawal, appendicitis, meningitis, or tetanus, to name a few.[4]

Management: Although many widow spider bites require only local wound care, more serious reactions may necessitate hospitalization. Those patients at increased risk for serious complications include the very young, very old, and those with underlying cardiovascular disease. Current treatments for black widow envenomation include intravenous calcium gluconate (10%), narcotic analgesics, muscle relaxants, and benzodiazepines.[5] *L. mactans* antivenom prepared from equine serum is also available. Additionally, there appears to be an effective cross-reactivity among antivenom for a number of other *Latrodectus* species.[6-8] The benefits of the antivenom in treating complications of widow bites should be weighed against the potential for allergic reaction to the antivenom. Patients should also be up to date on tetanus immunization.

LOXOSCELES

Members of the *Loxosceles* genus, also called *recluse spiders* or *fiddle-back spiders*, are nonaggressive spiders characterized by a dark brown marking on their cephalothorax in the shape of a fiddle or violin (Fig. 181-3). The brown recluse spider, *Loxosceles reclusa*, is the most well-known member of this genus and is most abundant in the American Midwest and Southeast. Other medically significant members of this genus include *Loxosceles deserta* (desert recluse), *Loxosceles rufescens*

Figure 181-2 Black widow spider with characteristic red hourglass marking on the underside of its abdomen.

Figure 181-3 Brown recluse spider with characteristic fiddle-shaped marking on cephalothorax.

(Mediterranean recluse), *Loxosceles kaiba* (Grand Canyon recluse), and *Loxosceles arizonica* (Arizona recluse). Recluse spiders are so named because they will often seek out shelter in undisturbed places such as closets, attics, and storage areas for bedding and clothing. Bites usually occur when the spider feels threatened or provoked, such as when someone tries to put on clothing that contains the spider.[1]

Clinical Findings: Bites of the brown recluse spider (*L. reclusa*) vary from mild, local reactions to severe ulcerative necrosis, a reaction known as *necrotic arachnidism*. After a bite, transient erythema may develop, with the formation of a central vesicle or papule. The hallmark "red, white, and blue" sign of a brown recluse bite is characterized by a central violaceous area surrounded by a rim of blanched skin that is further surrounded by a large asymmetric erythematous area (Fig. 181-4A). In a small percentage of cases, the initial wound may progress to necrosis (Fig. 181-4B), which usually begins 2 to 3 days after the bite, with eschar formation occurring between the fifth and seventh days.[9] Eventually deep ulcers develop. The bite reaction may mimic pyoderma gangrenosum or erythema migrans of Lyme disease.[10] Cutaneous anthrax and chemical burns have been mistaken for a brown recluse spider bite.[11,12] The potential for misdiagnosis has led to the development of a sensitive enzyme-linked immunosorbent assay for *Loxosceles* species venom that may eventually be available for clinical application.[13]

Brown recluse venom contains a number of proteins, including sphingomyelinase D, esterase, hyaluronidase, and alkaline phosphatase, which all contribute to tissue destruction. Sphingomyelinase D, the major component of the venom, cleaves sphingomyelin to form cermade-1-phosphate and choline and also hydrolyzes lysophosphatidylcholine to produce lysophosphatidic acid.[14] Lysophosphatidic acid then triggers a proinflammatory response and causes platelet aggregation and increased vascular permeability.[14] Sphingomyelinase D is also capable of inducing complement-mediated hemolysis.[15] Systemic symptoms may develop within 1 to 2 days after envenomation and include nausea, vomiting, headache, fever, and chills. Rare but serious sequelae of brown recluse bites include renal failure, hemolytic anemia, hypotension, and disseminated intravascular coagulation.[16,17]

Management: General treatment measures for recluse bites include cleansing the bite site and the application of cold compresses. Patients may also require analgesics to control pain. Antibiotics may be useful in reducing secondary bacterial infection of the wound site. Warm compresses and strenuous exercise should be avoided. Although *Loxosceles* antivenoms have been developed and are frequently used in South America, there is little evidence to support their effectiveness, particularly against local cutaneous effects.[8] A number of treatment modalities have been suggested, including hyperbaric oxygen, dapsone, intralesional and systemic corticosteroids, colchicine, and diphenhydramine.[18,19] However, one study that used a rabbit model to compare dapsone, colchicine, intralesional triamcinolone, and diphenhydramine showed no effect on eschar size from any of these medications.[18] Necrotic wounds heal slowly, sometimes over many months, and may require surgical excision and reconstruction to close the resulting defect. Surgical interventions should be delayed until the wound has stabilized.

TEGENARIA

Tegenaria agrestis, the hobo spider or "aggressive house spider," is the predominant cause of necrotic arachnidism in the Pacific Northwest of the United States and can be found in an area ranging from Alaska to Utah.[20] Although *Loxosceles* species are not typically found in the same geographic distribution, bites from hobo spiders are often mistaken for brown recluse bites. These spiders are brown in color with a gray herringbone pattern on the abdomen.[21] The hobo spider typically builds funnel-shaped webs in crawl spaces, basements, wood piles, and bushes. Most hobo spider bites occur from July to September when the more venomous male spiders are seeking mates.

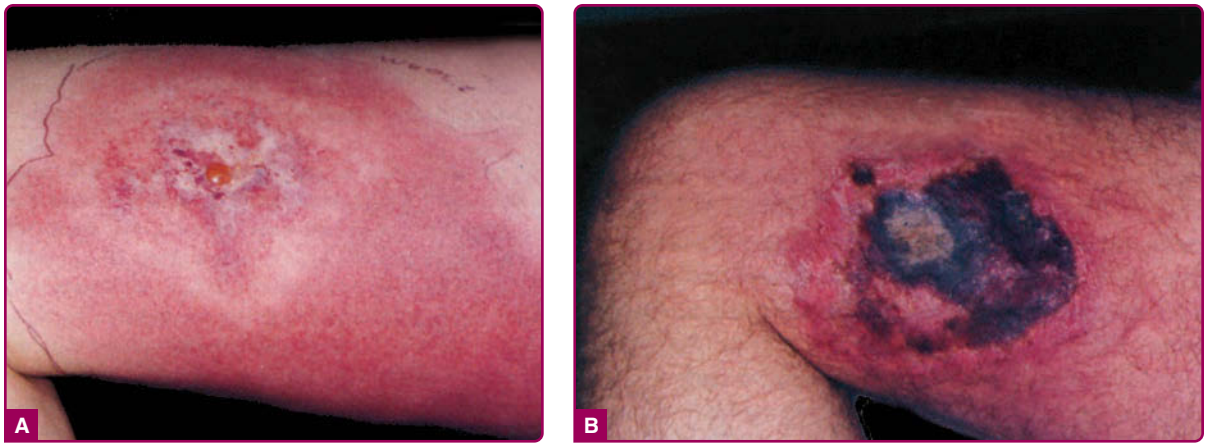

Figure 181-4 **A,** Clinically typical brown recluse spider bite showing the "red, white, and blue" sign. **B,** Late brown recluse spider bite with overlying eschar.

Clinical Findings: The local cutaneous effects after envenomation by the hobo spider, which can range from mild to serious, are similar to those caused by the brown recluse.[22] The initial bite is often painless. Induration and paresthesia of the bite site may develop within 30 minutes, and a large erythematous area may form around the site. Vesicle formation often occurs during the first 36 hours. Eschar formation may follow in severe cases, with necrosis and sloughing of the underlying tissue.

Management: Wounds usually heal within several weeks. The most common systemic symptom after a hobo spider bite is a severe headache, which can persist for up to 1 week.[23] Other symptoms may include fatigue, nausea, vomiting, diarrhea, paresthesias, and memory impairment. Although rare, death may ensue due to severe systemic effects, including aplastic anemia.[23]

TARANTULA

Tarantulas are indigenous to certain regions of the United States and are also kept as exotic pets. Tarantulas are members of the family Theraphosidae and are hair covered and larger than many other types of spider, with leg spans of up to 12 inches reported in certain species. Unlike the other venomous spiders discussed, tarantula bites generally only produce mild local symptoms. However, more serious reactions can be caused by urticating hairs on the spider's abdomen. When threatened, tarantulas may rub their back legs together in a motion that flicks these hairs off. These hairs may become embedded in the skin or eyes. Cutaneous responses to the hairs range from mild, local pruritus to granulomatous reactions. Ocular sequelae from hairs embedded in the cornea range from conjunctivitis and keratouveitis to corneal granulomas and chorioretinitis.[24-27] Although cutaneous reactions can be treated with topical corticosteroids, ocular involvement requires ophthalmologic evaluation.

SCORPIONES

The order Scorpiones (scorpions) comprises terrestrial arachnids most commonly encountered in tropical or arid regions, including the southwestern United States, northern Africa, Mexico, and the Middle East. These nocturnal creatures seek shelter under stones and tree barks during the day. As with other arachnids, scorpions are generally shy and sting humans only when provoked. Although capable of producing significant local wounds, the potential for serious, even lethal, cardiovascular complications following a scorpion sting remains of primary concern.[1] The scorpion of principal interest in the United States is *Centruroides exilicauda* (formerly *Centruroides sculpturatus*), whose sting is potentially fatal (Fig. 181-5). *Centruroides* species possess a small spine at the base of the stinger, a feature that may help distinguish them from other species of scorpion.[28,29]

Figure 181-5 *Centruroides* scorpion.

CLINICAL FINDINGS

Scorpion stings usually produce an immediate, sharp, burning pain. This may be followed by numbness extending beyond the sting site. Regional lymph node swelling, and, less commonly, ecchymosis and lymphangitis, may develop. *C. exilicauda* venom contains a powerful neurotoxin, capable of producing muscle spasticity, nystagmus, blurred vision, slurred speech, excessive salivation, respiratory distress, pulmonary edema, and myocarditis.[30-35] Infants and young children are at the greatest risk for serious complications.[29]

MANAGEMENT

Mild scorpion envenomations may only require symptomatic treatment, including analgesics and local ice compresses. Any child stung by a scorpion, especially if identified as *C. exilicauda*, should be hospitalized for close monitoring of respiratory, cardiac, and neurologic status.[36] Specific antivenom is the treatment of choice for severe envenomation. Critically ill children with neurotoxic effects of scorpion envenomation can benefit greatly and promptly with intravenous administration of scorpion-specific F(ab')(2) antivenom.[29] Lack of it may have serious consequences. Studies indicate that *C. exilicauda* antivenom is safe, with a low incidence of anaphylactic reaction following infusion and a rapid onset of symptom relief.[34,37] Although serum sickness is common after antivenom infusion, it is usually self-limited and can be managed with antihistamines and corticosteroids.[34,37]

ACARINA

The order Acarina contains ticks and mites (Fig. 181-1). Ticks are the most numerous members of this order, with approximately 800 known species. They are important worldwide as vectors of systemic disease, capable of transmitting viruses, rickettsia, spirochetes, bacteria, and parasites to humans.

MITES

See Chap. 178.

TICKS

Ticks are divided into 2 families: (1) Ixodidae (hard ticks) and (2) Argasidae (soft ticks). Hard ticks are responsible for the majority of tick-related disease. Ticks pass through multiple stages during their life cycle, including egg, larva, nymph, and adult, and require blood meals for transition between the latter 3 stages. Ticks are distinguished from other mites by the presence of a barbed hypostome, which is inserted into the skin for feeding (Fig. 181-6). Ticks ingest blood from a diversity of vertebrate hosts, including birds, reptiles, and mammals.[38] Adult hard ticks are capable of ingesting several hundred times their unfed body weight when taking a blood meal and may survive for months without feeding. When searching for a suitable host, hard ticks exhibit a unique behavior called "questing" during which the tick crawls to the edge of a leaf or blade of grass and holds its front pair of legs stretched out to grab onto a passing host.[39-41] Humans often become infested by contact with tall grass or brush that harbors the unfed ticks or by their association with domestic animals like cats or dogs. Ticks are attracted to the smell of sweat, the color white, and body heat. Once on a host, a tick may spend up to 24 hours in search of a protected site to feed, such as a skin fold or the hairline. Tick feeding time ranges from 2 hours to 7 days, with the tick dropping off of the host once fully engorged.

Figure 181-6 *Dermatocentor variabilis* feeding. The tick has been attached for 24 hours.

Many different tick species are responsible for local tick bite reactions and transmission of disease in human hosts. In the United States, *Ixodes scapularis* (deer tick or black-legged tick), *Dermacentor andersoni* (American wood tick), *Dermacentor variabilis* (American dog tick), *Ixodes pacificus* (Western black-legged tick), and *Amblyomma americanum* (Lone Star tick) are among the most common. In the Eastern Hemisphere, important tick species include *Ixodes ricinus* (castor bean tick or sheep tick) and *Ixodes persulcatus* (Taiga tick). Among the diseases transmitted by ticks are Lyme disease (Chap. 179), ehrlichiosis, babesiosis, Rocky Mountain spotted fever (Chap. 180), Colorado tick fever, Q fever, and tularemia (Chap. 156).

Clinical Findings: The majority of tick bites occur in the spring and summer, coinciding with the life cycle of the tick. Tick bites are usually painless, as the tick introduces an anesthetic and anticoagulant substance when biting. Often, a person will not even know he or she has been bitten, but will see or feel an attached tick while scratching or bathing. Tick bites may incite foreign body granuloma formation, reactions to injected toxins and salivary secretions, and other hypersensitivity responses. Rarely, delayed hypersensitivity reactions occur with fever, pruritus, and urticaria.[42] A red papule is usually seen at the bite site, and may progress to localized swelling and erythema.[42,43] A cellular response to the bite can lead to induration and nodularity after a few days. Foreign-body reactions may occur when mouthparts are retained in skin after incomplete removal of the tick. Chronic tick bite granulomas may present diagnostic problems and persist for months to years.

Tick paralysis is a potentially lethal complication of tick infestation and is thought to be caused by a neurotoxin contained within tick salivary secretions. The illness may start with headache and malaise and rapidly progress to an acute ascending lower motor neuron paralysis, similar to that of Guillain–Barré syndrome, which may result in respiratory failure and death.[44,45] Several species of tick are capable of causing tick paralysis, including *D. andersoni*, *D. variabilis*, and *A. americanum*. Typically, the onset of symptoms occurs 4 to 6 days after attachment of the tick. Symptoms resolve once the tick is removed from the patient. Supportive measures, including mechanical ventilation, may be required until symptoms resolve.

Management: After potential exposure, the skin should be inspected for ticks to remove them before they begin feeding and risk transmitting disease. Once a tick has inserted its hypostome into the skin, it must be forcibly removed. Although many methods have

been suggested for removing ticks, physical methods, such as slow, steady pulling on the tick, are probably the safest and most useful. Retained tick parts should be removed surgically if necessary to prevent development of foreign body granulomas. Antibiotic prophylaxis after tick bites is controversial. Although there is some evidence that prophylaxis may help prevent acquisition of Lyme disease and other vector-borne illnesses, the risks of antibiotic therapy must be weighed against the risks and prevalence of vector-borne illnesses in a particular region. In areas highly endemic for Lyme disease, the benefits of prophylactic treatment may outweigh the risks, especially in cases in which the tick has been attached to the host for an extended period of time and can accurately be identified as a vector for Lyme borreliosis. In these cases, the authors suggest a course of oral doxycycline (Chap. 179).

CHILOPODA AND DIPLOPODA

The arthropod classes Chilopoda and Diplopoda are composed of centipedes and millipedes, respectively. Centipedes and millipedes are terrestrial arthropods with multiple body segments.

CENTIPEDES

Centipedes, which have one pair of legs per body segment, are nocturnal carnivores that may produce extremely painful bites with a pair of poisonous claws. The *Scolopendra* species is found throughout the southwestern United States and may attack when its habitat is disturbed. In addition to severe pain and erythema following a bite, localized sweating, edema, secondary infection, and ulceration may be seen. There are also case reports of proteinuria, acute coronary ischemia, and myocardial infarction following centipede bite.[46-50] Treatment consists of analgesia, including injection of local anesthetics, antihistamines, and tetanus prophylaxis. Antibiotics may be required to treat secondary infection.

MILLIPEDES

Millipedes, which have 2 pairs of legs per body segment, usually feed on living and dead plant matter. They lack poison claws and neither bite nor sting. However, millipedes possess repugnatorial glands on either side of each segment and may emit a toxic substance if threatened. The oily, viscous liquid can cause a brownish discoloration of the skin that can persist for months and may produce burning and blistering.[51-53] Severe reactions are mainly seen in tropical species. Some species are capable of squirting the toxin several inches. This can result in various eye lesions, including periorbital edema, periorbital discoloration, conjunctivitis, and keratitis.[54] Although ophthalmologic evaluation should be considered for eye exposures, thorough immediate cleansing with soap and water is usually adequate for skin contact.

INSECTA

The class Insecta contains several orders of medical importance: Anoplura (lice; Chap. 178), Diptera (flies, mosquitoes), Coleoptera (beetles), Hemiptera (bedbugs, kissing bugs), Siphonaptera (fleas), Hymenoptera (ants, bees, wasps), and Lepidoptera (butterflies and moths). Insects can be distinguished from other arthropods by the presence of 3 body segments, a pair of compound eyes, paired antennae, and 6 legs.

DIPTERA

The order Diptera, or true flies, contains several important families: Culicidae (mosquitoes), Simuliidae (black flies), Ceratopogonidae (biting midges), Tabanidae (horse flies and deer flies), Psychodidae subfamily Phlebotominae (sandflies), and Glossinidae (tsetse flies). Not only do members of this order inflict cutaneous injury with their bites, they are also, collectively, responsible for the transmission of more disease worldwide than any other arthropod order.

The family Culicidae contains more than 2000 species of mosquito, many of which transmit disease. Several genera of mosquito, including *Anopheles*, *Culex*, and *Aedes*, serve as vectors for malaria, yellow fever, dengue fever, filariasis, and encephalitis viruses, including West Nile virus, which caused the largest arboviral meningoencephalitis outbreak ever recorded in North America.[55] *Aedes aegypti* mosquitoes, which are most active during daylight hours, are linked with infections by both dengue and zika viruses. Personal protection technologies such as insecticide-treated clothing using permethrin provides some individual protection. The efficacy of permethrin-treated clothing on personal protection has been assessed in the laboratory setting.[56] Because male mosquitoes lack piercing mouthparts, female mosquitoes inflict all human bites. Mosquito bites incite the formation of pruritic wheals and papular lesions, which form in response to irritating salivary secretions that are injected by the mosquito to prevent coagulation. Mosquito bites may have an urticarial, vesicular, eczematous, or granulomatous appearance. Bite reactions usually subside over several days.

Other biting flies include midges, black flies, horseflies, tsetse flies, and sandflies. Black flies of the family Simuliidae are vectors for onchocerciasis (African river blindness; Chap. 177) and tularemia (Chap. 156). Within the Tabanidae family, *Tabanus* species (horse flies) also serve as vectors for tularemia, and *Chrysops* species (deer flies or mango flies) are responsible for transmission of *Loa loa* filariasis (Chap. 177) and tularemia.

Figure 181-7 Cutaneous myiasis: a domed nodule resembling a furuncle at the site of deposition of a botfly larva. The lesion has a central pore through which the posterior end of the larva intermittently protrudes. The inset shows the larva that has been extracted.

Cutaneous myiasis (Fig. 181-7) may be caused by the deposition of fly larvae into intact skin or open wounds by several species, including *Dermatobia hominis* (human botfly).[57] Numerous species of sandflies also spread disease, with *Phlebotomus* species transmitting Old World leishmaniasis (Chap. 176) and *Lutzomyia* species transmitting New World leishmaniasis and Carrión disease/verruca peruana (bartonellosis; Chap. 176). *Glossina* species (tsetse flies) serve as vectors for African trypanosomiasis (Chap. 176).

Diptera bites should be cleansed thoroughly with soap and water to avoid secondary infection. A short course of topical steroids and systemic antihistamines may be used to control pruritus. Rare allergic reactions should be treated aggressively. Cutaneous myiasis is often best treated with local surgical excision of the larva and involved surrounding tissue. The antihistamines cetirizine or ebastine taken prophylactically as a single 10-mg dose have been demonstrated in studies to decrease wheal formation and subsequent pruritus following mosquito bites.[58,59]

COLEOPTERA

The Coleoptera order is the largest order in the animal kingdom, containing more than 300,000 species of beetles. Although beetles generally do not bite or sting humans, many species of beetle contain chemicals that can cause blistering of human skin.[60] Although some beetles are capable of emitting these chemicals, most cases of blister beetle dermatosis are the result of a beetle being crushed against the skin. The most well-known beetle to cause blister beetle dermatosis is *Lytta vesicatoria*, the Spanish fly, which is found in Southern Europe and contains the chemical cantharidin. Cantharidin, which causes vesiculation of the skin, is used in the treatment of warts and molluscum contagiosum. Several other species of beetle found in different regions of the world, including the central and southeastern United States, contain similar chemicals and can cause blistering.[61,62] *Paederus* species (rove beetles) contain the vesicant pederin and are another cause of beetle dermatitis.[62] Washing of affected areas immediately after exposure may help prevent vesiculation. Blisters should be treated with local wound care until resolved.

Another beetle with dermatologic significance is the carpet beetle. The most common species found in the United States are *Attagenus megatoma* (black carpet beetle) and *Anthrenus scrophulariae* (common carpet beetle). Although adult carpet beetles are of little clinical importance, cutaneous exposure to carpet beetle larvae, which feed on wool, carpets, clothing, and other organic material, can cause an allergic papulovesicular dermatitis.[63]

HEMIPTERA

The Hemiptera order encompasses 2 families of clinical significance: (1) the Cimicidae, which includes *Cimex lectularius* (bedbugs), and (2) the Reduviidae, which includes *Triatoma* species (kissing bugs). Although most members of this order are herbivores, these 2 families are frequent human parasites.

CIMICIDAE

The common bedbug (*C. lectularius*; see Fig. 181-1) has been a scourge of mankind for centuries. The bedbug is a nocturnal feeder that stays hidden during the day in cracks and crevices of headboards, in picture frames, behind loose wallpaper, or any other dark place that accommodates its flattened body.[1] After a potential victim has gone to bed, the insects come out of hiding for a blood meal. They are attracted to the warmth and carbon dioxide production of their victim. Bedbugs usually complete their meal in a matter of minutes and then return to hiding. Although bedbugs can survive for 1 year or more without feeding, they usually seek a blood meal every 5 to 10 days.[1] Bedbugs are common and are distributed worldwide. They can be spread in clothing and baggage of travelers and visitors, on secondhand mattresses, and via laundry.

Along with other blood-sucking arthropods, the role of bedbugs in infectious disease transmission has gained increasing interest in recent years. Although laboratory studies have shown that these insects are capable of incubating and shedding pathogens such as hepatitis B virus for several weeks after feeding on an infected bloodmeal, there is currently no convincing evidence that *Cimex* species act as vectors in their natural state.[64]

Bedbug bites are usually painless and may be overlooked unless large numbers of bites are present. Bites are usually multiple and may be grouped in a linear fashion. A row of 3 bedbug bites is sometimes referred to as *breakfast, lunch, and dinner*[65] (Fig. 181-8). Reactions to the bites consist of wheals and papules, often with a small hemorrhagic punctum at the center. Bullous reactions to bites are also possible in sensitized

Figure 181-8 Papular urticaria: bedbug bites. These are pruritic urticarial papules, arranged in a row (breakfast, lunch, and dinner).

individuals, and hypersensitivity reactions have been reported.[65-67] Flecks of blood also may be found on bed linens. Minimal symptomatic treatment of bites and good local wound care to prevent pruritus and secondary infection are sufficient in most cases.[67] In the presence of a secondary infection, topical antiseptic lotion or antibiotic cream should be applied.[66] Topical corticosteroids and oral antihistamines may be used for pruritus. Once a bedbug infestation has been diagnosed, a professional exterminator is often necessary to eradicate the insects. Evidence for disease transmission is lacking.

REDUVIIDAE

The kissing bug, or assassin bug, belongs to the family Reduviidae and is distinguished by a triangular shape on its back formed by the meeting of the membranous wings. All reduviid bugs possess piercing mouthparts used to feed on blood. Most species of Reduviidae are found in the Americas, with a few species located in Africa, Asia, and Europe. Within the United States, these insects are found in the Southwest from Texas to California.[68] Reduviidae are of great clinical significance because they act as vectors for *Trypanosoma cruzi*, the causative agent of Chagas disease, which affects an estimated 15 to 20 million people living in South America and Central America (Chap. 176). Kissing bugs earned their name for their predilection to bite on or near the lips. After taking a blood meal, reduviids characteristically turn around and defecate immediately. The trypanosomes are inoculated when the victim subsequently scratches the infected feces into the wound.[1]

Although they are nocturnal feeders and usually prey on rodents, during periodic flights they move toward the lights of desert homes. Defensive bites of reduviids are extremely painful. The painless bite of a feeding reduviid occurs only while the host is sleeping, because the blood meal takes several minutes to complete. Bites have been associated with papular, urticarial, and bullous reactions. A small proportion of victims may develop generalized, acute allergic reactions that cause the victim to awaken with sudden-onset anaphylactic signs and symptoms.[69] Defensive bites may incite more severe local cutaneous reactions, including necrosis and ulceration.

SIPHONAPTERA

Fleas belong to the insect order Siphonaptera (Fig. 181-1). These small bloodsucking insects are wingless and are capable of jumping to a height of 18 cm. Members of the family Pulicidae, most notably the rat fleas (*Xenopsylla cheopis* and *Xenopsylla brasiliensis*), transmit bubonic plague (*Yersinia pestis*) (Chap. 154). Other members of this family are also capable of transmitting disease, including the cat flea (*Ctenocephalides felis*), which is a vector for bubonic plaque and endemic typhus (*Rickettsia prowazekii*).

Fleabites produce minimal irritation in nonsensitized individuals, typically resulting in linear or clustered urticarial papules, frequently found on the lower legs (Fig. 181-9). In sensitized individuals, most often young children, the antigenic saliva is capable of producing papular urticaria, an eruption characterized by recurrent or chronic pruritic papules occurring on exposed skin areas.[1,70] Bullous reactions to fleabites may also develop in patients with hypersensitivity. Conservative topical therapy with corticosteroids and antipruritics, along with oral antihistamines, is usually sufficient for most fleabites. Antibiotics may be necessary should secondary bacterial infection develop. Once a flea infestation occurs, complete eradication of the insects is necessary to prevent additional bites.

Figure 181-9 Papular urticaria: fleabites. Multiple, pruritic urticarial papules, usually <1 cm in diameter; they may be topped by a vesicle. Here, they occur on the legs of a child.

Figure 181-10 Tungiasis: a necrotic periungual papule on the fifth toe. The larva can be visualized by removing the overlying crust.

The Tungidae family contains a tropical flea species called *Tunga penetrans* (the sand flea, chigoe flea, or jigger) that is the etiologic agent of tungiasis, an infestation caused by penetration of the adult female flea into human skin to lay eggs.[71] The usual sites of attachment are feet, particularly plantar surface, subungual or periungual skin or web spaces, and legs, but any body surface in contact with the ground can be affected. Solitary or multiple erythematous papules slowly enlarge over a few weeks to 4 to 10 mm in diameter (Fig. 181-10). A fully developed white or yellowish, firm, somewhat translucent nodule may be painful, especially if subungual, or the pain may reflect secondary impetigo and rarely lymphangitis and septicemia. Dermoscopy facilitates visualization of ovoid eggs, and thus the diagnosis of tungiasis.[72] Tungiasis may be also be associated with pain, pruritus, and, sometimes, autoamputation of toes.[73] Death from tetanus also has been reported. One need elicit a history of travel or residence in an endemic area. Treatment options include surgical excision of the affected area or killing the adult female flea with cryotherapy or topical agents. Tetanus prophylaxis is recommended, and systemic antibiotics should be used when necessary. Prevention can be enhanced in endemic areas by avoiding walking along beaches barefoot or in sandals and not sitting or lying in the sand in parts of Nigeria, the Caribbean, India, and Brazil.

HYMENOPTERA

The order Hymenoptera contains the families Apidae and Bombidae (bees), Vespidae (wasps), and Formicidae (ants). Many members of this order have evolved poison glands used for defense and/or hunting. Aside from local cutaneous reactions, Hymenoptera stings are an important problem because of their high incidence and ability to produce fatal anaphylactic reactions.[74]

All Hymenoptera stings are inflicted by female insects via a modified ovipositor or egg-laying apparatus. Most Hymenoptera stings occur when the nest or individual insects are threatened. The honeybee stings with a barbed ovipositor, which it leaves impaled into the skin. The honeybee dies after stinging because it eviscerates itself to expel its paired venom sacs. The stinger should be removed as swiftly as possible after a sting because the musculature attached to the stinger can continue to pump venom into the skin. If possible, the stinger should not be squeezed during removal with fingers or tweezers as additional venom can be injected into the victim. One method for removal is to scrape the edge of a credit card or the dull blade of a butter knife along the skin at an angle almost parallel to the surface. This will dislodge the stinger while minimizing the injection of additional venom. Other Hymenoptera species lack a barbed stinger and may sting repeatedly.

Imported fire ants (*Solenopsis invicta*), originally from Brazil, are an aggressive species that has become well established in the southeastern United States. *Solenopsis* venom contains a nonproteinaceous, hemolytic factor identified as a dialkylpiperidine, solenopsin D, which induces mast cell degranulation.[75] Imported fire ants often attack in groups. Their sting results in an intense inflammatory, wheal-and-flare reaction that becomes a sterile pustule and may progress to localized necrosis and scarring. Sensitized individuals may experience significant bullous reactions following a sting. When attacking, the ants tend to bite the flesh with their powerful jaws and then pivot and sting in a circular pattern, resulting in ring-shaped lesions.

CLINICAL MANIFESTATIONS

Hymenoptera stings typically produce immediate burning and pain, followed by the development of an intense, local, erythematous reaction with swelling and urticaria. This "typical" reaction to hymenoptera stings usually subsides within several hours. However, more severe local reactions can occur, including extensive swelling at the sting site and prolonged induration lasting for up to 1 week. A cell-mediated immune response also has been implicated in these reactions.[76] Generalized systemic reactions to hymenoptera stings occur in approximately 0.4% to 3.0% of patients. Anaphylactic reactions may be evident as generalized urticaria, angioedema, and bronchospasm.

MANAGEMENT

Treatment of a Hymenoptera sting is governed by the severity of the reaction. Mild local cutaneous reactions may only require local cleansing, application of ice, and possible injection of local anesthetic to control pain. Oral or parenteral diphenhydramine may help control urticaria and pruritus. Anaphylaxis must be treated vigorously with subcutaneous epinephrine (0.5 mL of 1:1000 dilution) and the institution of intramuscular epinephrine, exit to an emergency room, and the supportive measures. Individuals with known Hymenoptera hypersensitivity should always carry a preloaded epinephrine-filled syringe

for emergency self-administration. Desensitization therapy should be considered for any patient with a positive intradermal skin test to Hymenoptera venom and a history of sting-induced anaphylaxis. Fire ant hypersensitivity is a potentially deadly condition for which rush immunotherapy may be a good option to achieve protection quickly.

LEPIDOPTERA

The Lepidoptera order is the second largest order of insects and contains more than 100,000 species of caterpillars, moths, and butterflies. An estimated 100 to 150 species within this order are thought to produce *lepidopterism*, the term used to describe the aggregate of medical effects caused by caterpillars, moths, and butterflies.[77,78] Multiple theories regarding the mechanisms of lepidopterism have been proposed, including mechanical irritation by pointed hairs (setae), toxin injection through hollow setae, and cell-mediated hypersensitivity to the hairs. One well-known cause of erucism or caterpillar dermatitis is *Lymantria dispar* (gypsy moth caterpillar).[79,80] Cutaneous contact with hairs from this caterpillar may produce a pruritic dermatitis characterized by multiple erythematous papules often arranged in linear streaks. Urticaria, angioedema, and anaphylaxis may occur with processionary caterpillars (genus *Thaumetopoea*). Wind-borne hairs may produce keratoconjunctivitis and respiratory symptoms. *Megalopyge opercularis* (asp or puss caterpillar), which can inject venom through its hollow syringe-like hairs, is capable of inflicting an intensely painful sting, and may produce a characteristic train-track pattern of purpura at the sting site (Fig. 181-11).[81,82] Other species that cause lepidopterism in the Americas include *Automeris io* (io moth), *Euproctis chrysorrhoea* (brown-tailed moth), *Sibine stimulate* (saddleback moth), and *Hemerocampa pseudotsugata* (Douglas-fir tussock moth).

Treatment for lepidopterism is largely symptomatic. Systemic antihistamines, topical preparations containing menthol and camphor, and moderate- to high-potency topical corticosteroids can be used to control pruritus. Systemic steroids may be beneficial for severe reactions. The intractable pain caused by the sting of the puss caterpillar may require oral or parenteral narcotic analgesics. Embedded setae can be removed from the skin by "stripping" with adhesive tape. There is an antivenom available that should be employed for potentially fatal Lonomia genus caterpillar envenomation, still responsible for deaths in southern Brazil.[83]

PREVENTION

Several relatively simple steps can be taken to minimize the occurrence of arthropod bites. Spider bites can be reduced by wearing gloves while working in crawl spaces, garages, or basements or when manipulating woodpiles or rubbish piles. In scorpion-endemic areas, shaking out clothing and footwear before putting them on is advisable. Wearing appropriate clothing with good coverage and avoiding rubbing against high brush and grass may help avoid tick bites. Bright colors and artificial scents like perfume, which are attractants for mosquitoes and other flying insects, are best avoided on warm summer nights. In tropical regions, proper footwear is essential to preventing tungiasis. Infestations of living areas by arthropods, including fleas and bedbugs, are difficult to eliminate and may require the assistance of a professional exterminator.

Chemical repellents are also useful in preventing arthropod bites. Several different chemical compounds have been studied, including *N,N*-diethyl-3-methylbenzamide (DEET, previously diethyltoluamide), picaridin (KBR 3203), and *p*-menthane-3,8-diol (Eucalyptus oil). The most effective repellent for all biting flies, including mosquitoes, is DEET, which is available in many products in concentrations up to 100%. Generally, a product containing 10% to 30% DEET provides adequate protection for

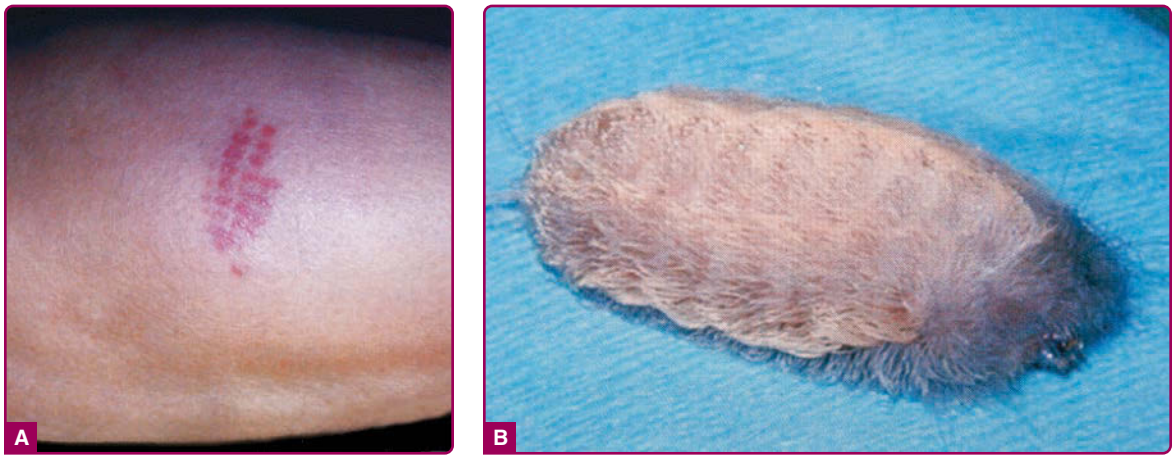

Figure 181-11 **A,** Cutaneous reaction from contact with a puss caterpillar showing the typical grid-like pattern. **B,** Pus caterpillar (*Megalopyge opercularis*) demonstrating the corresponding gridlike pattern of its hairs.

most outdoor activities, with higher concentrations of DEET providing longer protection times. Although DEET has an excellent safety record, there are reports of encephalopathy developing, particularly in children, after exposure to this chemical.[84,85] For this reason, only products with DEET concentrations of less than 10% should be used on children. Permethrin, an insecticide often used to treat pediculosis and scabies, is available as a tick repellent that can be sprayed on or impregnated into clothing and fabrics, including tents, bed nets, and sleeping bags, and remains effective through several wash cycles.[86] Combined use of permethrin-treated clothing and DEET applied to the skin provides the maximum protection. Long-lasting insecticidal nets and indoor residual spraying can be effective indoors, but significant exposure occurs outdoors. Accordingly, an outdoor mosquito control device, a synthetic human odor–baited mosquito device with multiple electrocuting grids, has been devised to attract and kill outdoor host-seeking mosquitoes, including important malaria vectors *An. arabiensis* and *An. funestus* sensu stricto, and shows considerable promise.[87] Rapid, noninvasive mass screening and posttherapeutic followup for scabies and selected other cutaneous infestations can be facilitated by use of videodermatoscopy, dermatoscopy, reflectance confocal microscopy, and optical coherence tomography.[88]

REFERENCES

1. Steen CJ, Carbonaro PA, Schwartz RA. Arthropods in dermatology. *J Am Acad Dermatol.* 2004;50(6):819-842; quiz 842-844.
2. Mowry JB, Spyker DA, Brooks DE, et al. 2014 Annual Report of the American Association of Poison Control Centers' National Poison Data System (NPDS): 32nd Annual Report. *Clin Toxicol (Phila).* 2015;53(10): 962-1147.
3. Kang J, Bhate C, Schwartz RA. Spiders in dermatology. *Semin Cutan Med Surg.* 2014;33(3):123-127.
4. Elston DM. What's eating you? *Latrodectus mactans* (the black widow spider). *Cutis.* 2002;69(4):257-258.
5. Monte AA. Black widow spider (*Latrodectus mactans*) antivenom in clinical practice. *Curr Pharm Biotechnol.* 2012;13(10):1935-1939.
6. Daly FF, Hill RE, Bogdan GM, et al. Neutralization of *Latrodectus mactans* and *L. hesperus* venom by redback spider (*L. hasseltii*) antivenom. *J Toxicol Clin Toxicol.* 2001;39(2):119-123.
7. Graudins A, Padula M, Broady K, et al. Red-back spider (*Latrodectus hasselti*) antivenom prevents the toxicity of widow spider venoms. *Ann Emerg Med.* 2001; 37(2):154-160.
8. Isbister GK, Graudins A, White J, et al. Antivenom treatment in arachnidism. *J Toxicol Clin Toxicol.* 2003; 41(3):291-300.
9. Sams HH, Dunnick CA, Smith ML, et al. Necrotic arachnidism. *J Am Acad Dermatol.* 2001;44(4):561-573; quiz 573-576.
10. Hoover EL, Williams W, Koger L, et al. Pseudoepitheliomatous hyperplasia and pyoderma gangrenosum after a brown recluse spider bite. *South Med J.* 1990; 83(2):243-246.
11. Roche KJ, Chang MW, Lazarus H. Images in clinical medicine. Cutaneous anthrax infection. *N Engl J Med.* 2001; 345(22):1611.
12. Vetter RS, Bush SP. Chemical burn misdiagnosed as brown recluse spider bite. *Am J Emerg Med.* 2002;20(1): 68-69.
13. Gomez HF, Krywko DM, Stoecker WV. A new assay for the detection of *Loxosceles* species (brown recluse) spider venom. *Ann Emerg Med.* 2002;39(5):469-474.
14. van Meeteren LA, Frederiks F, Giepmans BN, et al. Spider and bacterial sphingomyelinases D target cellular lysophosphatidic acid receptors by hydrolyzing lysophosphatidylcholine. *J Biol Chem.* 2004; 279(12):10833-10836.
15. Tambourgi DV, Pedrosa MF, de Andrade RM, et al. Sphingomyelinases D induce direct association of C1q to the erythrocyte membrane causing complement mediated autologous haemolysis. *Mol Immunol.* 2007; 44(4):576-582.
16. da Silva PH, da Silveira RB, Appel MH, et al. Brown spiders and loxoscelism. *Toxicon.* 2004;44(7): 693-709.
17. Elbahlawan LM, Stidham GL, Bugnitz MC, et al. Severe systemic reaction to *Loxosceles reclusa* spider bites in a pediatric population. *Pediatr Emerg Care.* 2005; 21(3):177-180.
18. Elston DM, Miller SD, Young RJ 3rd, et al. Comparison of colchicine, dapsone, triamcinolone, and diphenhydramine therapy for the treatment of brown recluse spider envenomation: a double-blind, controlled study in a rabbit model. *Arch Dermatol.* 2005;141(5): 595-597.
19. Wilson JR, Hagood CO Jr, Prather ID. Brown recluse spider bites: a complex problem wound. A brief review and case study. *Ostomy Wound Manage.* 2005; 51(3):59-66.
20. Centers for Disease Control and Prevention (CDC). Necrotic arachnidism—Pacific Northwest, 1988–1996. *MMWR Morb Mortal Wkly Rep.* 1996;45(21):433-436.
21. Sadler MA, Force RW, Solbrig RM, et al. Suspected *Tegenaria agrestis* envenomation. *Ann Pharmacother.* 2001;35(11):1490-1491.
22. Wasserman GS, Anderson PC. Loxoscelism and necrotic arachnidism. *J Toxicol Clin Toxicol.* 1983;21(4-5): 451-472.
23. Vest DK. Necrotic arachnidism in the northwest United States and its probable relationship to *Tegenaria agrestis* (Walckenaer) spiders. *Toxicon.* 1987;25(2):175-184.
24. Bernardino CR, Rapuano C. Ophthalmia nodosa caused by casual handling of a tarantula. *Clao J.* 2000; 26(2):111-112.
25. Choi JT, Rauf A. Ophthalmia nodosa secondary to tarantula hairs. *Eye (Lond).* 2003;17(3):433-434.
26. Sandboe FD. Spider keratouveitis. A case report. *Acta Ophthalmol Scand.* 2001;79(5):531-532.
27. Watts P, McPherson R, Hawksworth NR. Tarantula keratouveitis. *Cornea.* 2000;19(3):393-394.
28. Skolnik AB, Ewald MB. Pediatric scorpion envenomation in the United States: morbidity, mortality, and therapeutic innovations. *Pediatr Emerg Care.* 2013; 29(1):98-103.
29. Coorg V, Levitan RD, Gerkin RD, et al. Clinical presentation and outcomes associated with different treatment modalities for pediatric bark scorpion envenomation. *J Med Toxicol.* 2017;13(1):66-70.
30. Amitai Y. Clinical manifestations and management of scorpion envenomation. *Public Health Rev.* 1998;26(3):257-263.

31. Amitai Y, Mines Y, Aker M, et al. Scorpion sting in children. A review of 51 cases. *Clin Pediatr (Phila).* 1985; 24(3):136-140.
32. Bhadani UK, Tripathi M, Sharma S, et al. Scorpion sting envenomation presenting with pulmonary edema in adults: a report of seven cases from Nepal. *Indian J Med Sci.* 2006;60(1):19-23.
33. Elston DM, Stockwell S. What's eating you? *Centruroides exilicauda*. *Cutis.* 2002;69(1):16, 20.
34. LoVecchio F, McBride C. Scorpion envenomations in young children in central Arizona. *J Toxicol Clin Toxicol.* 2003;41(7):937-940.
35. Carbonaro PA, Janniger CK, Schwartz RA. Scorpion sting reactions. *Cutis.* 1996;57(3):139-141.
36. Shah N, Martens MG. Scorpion envenomation in pregnancy. *South Med J.* 2016;109(6):338-341.
37. LoVecchio F, Welch S, Klemens J, et al. Incidence of immediate and delayed hypersensitivity to Centruroides antivenom. *Ann Emerg Med.* 1999;34(5):615-619.
38. Eisen L, Eisen RJ, Lane RS. The roles of birds, lizards, and rodents as hosts for the western blacklegged tick *Ixodes pacificus*. *J Vector Ecol.* 2004;29(2):295-308.
39. Daniel M, Zitek K, Danielová V, et al. Risk assessment and prediction of *Ixodes ricinus* tick questing activity and human tick-borne encephalitis infection in space and time in the Czech Republic. *Int J Med Microbiol.* 2006;296(suppl 40):41-47.
40. Mays SE, Houston AE, Trout Fryxell RT, et al. Comparison of novel and conventional methods of trapping ixodid ticks in the southeastern U.S.A. *Med Vet Entomol.* 2016;30(2):123-134.
41. Tsunoda T, Tatsuzawa S. Questing height of nymphs of the bush tick, *Haemaphysalis longicornis*, and its closely related species, *H. mageshimaensis*: Correlation with body size of the host. *Parasitology.* 2004;128(pt 5):503-509.
42. Krinsky WL. Dermatoses associated with the bites of mites and ticks (Arthropoda: Acari). *Int J Dermatol.* 1983;22(2):75-91.
43. Bhate C, Schwartz RA. Lyme disease: part I. Advances and perspectives. *J Am Acad Dermatol.* 2011;64(4): 619-636; quiz 637-638.
44. Li Z, Turner RP. Pediatric tick paralysis: Discussion of two cases and literature review. *Pediatr Neurol.* 2004; 31(4):304-307.
45. Pek CH, Cheong CS, Yap YL, et al. Rare cause of facial palsy: case report of tick paralysis by *Ixodes holocyclus* imported by a patient travelling into Singapore from Australia. *J Emerg Med.* 2016;51(5):e109-e114.
46. Bouchard NC, Chan GM, Hoffman RS. Vietnamese centipede envenomation. *Vet Hum Toxicol.* 2004; 46(6):312-313.
47. Hasan S, Hassan K. Proteinuria associated with centipede bite. *Pediatr Nephrol.* 2005;20(4):550-551.
48. Ozsarac M, Karcioglu O, Ayrik C, et al. Acute coronary ischemia following centipede envenomation: case report and review of the literature. *Wilderness Environ Med.* 2004;15(2):109-112.
49. Yildiz A, Biçeroglu S, Yakut N, et al. Acute myocardial infarction in a young man caused by centipede sting. *Emerg Med J.* 2006;23(4):e30.
50. Elston DM. What's eating you? Centipedes (Chilopoda). *Cutis.* 1999;64(2):83.
51. Hendrickson RG. Millipede exposure. *Clin Toxicol (Phila).* 2005;43(3):211-212.
52. De Capitani EM, Vieira RJ, Bucaretchi F, et al. Human accidents involving *Rhinocricus* spp., a common millipede genus observed in urban areas of Brazil. *Clin Toxicol (Phila).* 2011;49(3):187-190.
53. Elston DM. What's eating you? Millipedes (Diplopoda). *Cutis.* 2001;67(6):452.
54. Hudson BJ, Parsons GA. Giant millipede "burns" and the eye. *Trans R Soc Trop Med Hyg.* 1997;91(2):183-185.
55. Petersen LR, Marfin AA, Gubler DJ. West Nile virus. *JAMA.* 2003;290(4):524-528.
56. Orsborne J, DeRaedt Banks S, Hendy A, et al. Personal protection of permethrin-treated clothing against *Aedes aegypti*, the vector of dengue and zika virus, in the laboratory. *PLoS One.* 2016;11(5):e0152805.
57. Hohenstein EJ, Buechner SA. Cutaneous myiasis due to *Dermatobia hominis*. *Dermatology.* 2004;208(3): 268-270.
58. Karppinen A, Kautiainen H, Petman L, et al. Comparison of cetirizine, ebastine and loratadine in the treatment of immediate mosquito-bite allergy. *Allergy.* 2002; 57(6):534-537.
59. Karppinen A, Petman L, Jekunen A, et al. Treatment of mosquito bites with ebastine: a field trial. *Acta Derm Venereol.* 2000;80(2):114-116.
60. Elston DM. What's eating you? Blister beetles. *Cutis.* 2004;74(5):285-286.
61. Brazzelli V, Martinoli S, Prestinari F, et al. Staphylinid blister beetle dermatitis. *Contact Dermatitis.* 2002;46(3): 183-184.
62. Claborn DM, Polo JM, Olson PE, et al. Staphylinid (rove) beetle dermatitis outbreak in the American southwest? *Mil Med.* 1999;164(3):209-213.
63. Ahmed AR, Moy R, Barr AR, et al. Carpet beetle dermatitis. *J Am Acad Dermatol.* 1981;5(4):428-432.
64. Silverman AL, Qu LH, Blow J, et al. Assessment of hepatitis B virus DNA and hepatitis C virus RNA in the common bedbug (*Cimex lectularius* L.) and kissing bug (*Rodnius prolixus*). *Am J Gastroenterol.* 2001;96(7):2194-2198.
65. Elston DM, Stockwell S. What's eating you? Bedbugs. *Cutis.* 2000;65(5):262-264.
66. Leverkus M, Jochim RC, Schäd S, et al. Bullous allergic hypersensitivity to bed bug bites mediated by IgE against salivary nitrophorin. *J Invest Dermatol.* 2006; 126(1):91-96.
67. Thomas I, Kihiczak GG, Schwartz RA. Bedbug bites: A review. *Int J Dermatol.* 2004;43(6):430-433.
68. Lynch PJ, Pinnas JL. "Kissing bug" bites. Triatoma species as an important cause of insect bites in the southwest. *Cutis.* 1978;22(5):585-591.
69. Anderson C, Belnap C. The kiss of death: a rare case of anaphylaxis to the bite of the "red margined kissing bug." *Hawaii J Med Public Health.* 2015;74(9)(suppl 2): 33-35.
70. Stibich AS, Schwartz RA. Papular urticaria. *Cutis.* 2001;68(2):89-91.
71. Heukelbach J. Tungiasis. *Rev Inst Med Trop Sao Paulo.* 2005;47(6):307-313.
72. Cabrera R, Daza F. Dermoscopy in the diagnosis of tungiasis. *Br J Dermatol.* 2009;160(5):1136-1137.
73. Sunenshine PJ, Janniger CK, Schwartz RA. Tungiasis. In: Demis DJ, ed. *Clinical Dermatology*. Philadelphia, PA: Lippincott & Williams Wilkins; 1999, Unit 18-33:1-10.
74. Steen CJ, Janniger CK, Schutzer SE, et al. Insect sting reactions to bees, wasps, and ants. *Int J Dermatol.* 2005; 44(2):91-94.
75. Yi GB, McClendon D, Desaiah D, et al. Fire ant venom alkaloid, isosolenopsin A, a potent and selective inhibitor of neuronal nitric oxide synthase. *Int J Toxicol.* 2003; 22(2):81-86.
76. Case RL, Altman LC, VanArsdel PP Jr. Role of cell-mediated immunity in Hymenoptera allergy. *J Allergy Clin Immunol.* 1981;68(5):399-405.

77. Diaz JH. The epidemiology, diagnosis, and management of caterpillar envenoming in the southern US. *J La State Med Soc.* 2005;157(3):153-157.
78. Dunlop K, Freeman S. Caterpillar dermatitis. *Australas J Dermatol.* 1997;38(4):193-195.
79. Allen VT, Miller OF 3rd, Tyler WB. Gypsy moth caterpillar dermatitis—revisited. *J Am Acad Dermatol.* 1991; 24(6, pt 1):979-981.
80. Wills PJ, Anjana M, Nitin M, et al. Population explosions of tiger moth lead to lepidopterism mimicking infectious fever outbreaks. *PLoS One.* 2016;11(4):e0152787.
81. Gardner TL, Elston DM. Painful papulovesicles produced by the puss caterpillar. *Cutis.* 1997;60(3):125-126.
82. Pinson RT, Morgan JA. Envenomation by the puss caterpillar (*Megalopyge opercularis*). *Ann Emerg Med.* 1991; 20(5):562-564.
83. Hossler EW. Caterpillars and moths. Part II. Dermatologic manifestations of encounters with Lepidoptera. *J Am Acad Dermatol.* 2010;62(1):13-28.
84. Hampers LC, Oker E, Leikin JB. Topical use of DEET insect repellent as a cause of severe encephalopathy in a healthy adult male. *Acad Emerg Med.* 1999; 6(12):1295-1297.
85. Sudakin DL, Trevathan WR. DEET: a review and update of safety and risk in the general population. *J Toxicol Clin Toxicol.* 2003;41(6):831-839.
86. Alpern JD, Dunlop SJ, Dolan BJ, et al. Personal protection measures against mosquitoes, ticks, and other arthropods. *Med Clin North Am.* 2016;100(2):303-316.
87. Matowo NS, Koekemoer LL, Moore SJ, et al. Combining synthetic human odours and low-cost electrocuting grids to attract and kill outdoor-biting mosquitoes: field and semi-field evaluation of an improved mosquito landing box. *PLoS One.* 2016; 11(1):e0145653.
88. Micali G, Lacarrubba F, Verzì AE, et al. Scabies: advances in noninvasive diagnosis. *PLoS Negl Trop Dis.* 2016;10(6):e0004691.

Chapter 182 :: Bites and Stings of Terrestrial and Aquatic Life

:: Camila K. Janniger, Robert A. Schwartz, Jennifer S. Daly, & Mark Jordan Scharf

AT-A-GLANCE

- Dog bites account for 80% to 90% of all mammalian bites involving humans, but cat bites are more likely to become infected.
- Whether or not postexposure prophylaxis with rabies immunoglobulin and human diploid cell rabies vaccine is needed depends on the circumstances surrounding the bite.
- In the United States, there are approximately 5 to 6 deaths from snakebites and probably 6000 to 7000 snakebite envenomations each year.
- Most stingray injuries occur when bathers, waders, or fishermen accidentally step on rays as they lie partially covered with sand in shallow waters. The extreme pain caused by the venom may be relieved by soaking the affected body part in very warm water.
- Cnidarian envenomations cause more annual deaths than do shark attacks.

Humans are a part of the environment and ideally live peacefully with other animals and plants. However, sometimes the interactions between man and the environment prove harmful to one or the other. The first 2 sections of this chapter consider the harmful effects of land-borne animal bites, as well as the bacterial and viral infections they may transmit. The last section reviews bites and stings and other forms of injury that may be inflicted by marine life.

BITES OF LAND ANIMALS

EPIDEMIOLOGY

Dog bites account for 80% to 90% of all mammalian bites involving humans. Four to 5 million dog bites are estimated to occur each year in the United States. In 2001, it was estimated that 368,245 persons were treated for dog bite–related injuries.[1] The human victim is often a 5- to 9-year-old boy who may have been teasing or playing with a dog. Sometimes the bite occurs when a person is trying to break up a pair of fighting dogs or trying to aid an animal. In the United States, 4% to 5% of dog bites are work related and include bites sustained by postal carriers. Overseas, a higher percentage are produced by untamed animals.[2-4] Most dog bite injuries involve the upper extremities, especially the hands. Cat bites are the second most common type of mammalian bite after dog bites, but the wounds following a cat's bite are nearly twice as likely to become infected as wounds from dog bites.[5] In addition, millions of exotic pets are transported legally and illegally into the United States and Europe annually. The approximately 1 million iguanas in America today may bite.[6]

CLINICAL APPROACH (PATHOGENESIS AND TREATMENT)

The evaluation and treatment of all bite wounds should include taking a careful history of the incident, the type of animal, the site of the bite, and the geographic setting. Hand wounds, puncture wounds, and crush injuries are likely to become infected. Specimens from infected bites should be cultured and a Gram-stained smear prepared; the wound should then be washed, well irrigated, and left open. Most patients with bites on the hands, deep cat bites (Table 182-1), deep cat scratches, and sutured wounds should be treated with amoxicillin/clavulanic acid or ceftriaxone because of the risk of *Pasteurella multocida* infection; if the patient is allergic to these agents, a quinolone or a tetracycline should be used. Evidence that the use of prophylactic antibiotics is of benefit exists only for bites of the hand. However, once the patient has an infection, intravenous antibiotics and surgical drainage are often required.[4,6-8] Tetanus immune status should be evaluated, and rabies prophylaxis should be considered, depending on the type of animal, local epidemiologic factors, and ability to quarantine the animal for 10 days.[9]

Human bites and monkey bites deserve special mention, because 30% become infected with aerobic or anaerobic mouth organisms. Infection caused by anaerobes may spread through the metacarpal–phalangeal space and causes severe damage. The same procedure should be followed as for other animal bites, that is, culture and Gram stain, thorough washing, and debridement. Wounds, especially hand wounds, should be left open if possible. Evidence suggests that patients with human bites that penetrate the epidermis should be treated prophylactically with amoxicillin/clavulanic acid for 7 to 10 days or, if the patient is allergic to

TABLE 182-1
Standard Management for Dog/Cat Bites

Culture and Gram stain
Wash wound and irrigate well
Ideally, wounds should be left open
Amoxicillin/clavulanic acid *or* ceftriaxone for prophylaxis* for 7-10 d
Intravenous antibiotics and surgical drainage for active infections
Evaluate tetanus immune status
Consider rabies prophylaxis or treatment

*Quinolone or tetracycline, if patient is allergic.

penicillins, with a fluoroquinolone plus an antianaerobic agent such as clindamycin.[7,10] Clenched-fist injuries should be evaluated by a hand surgeon because of the high likelihood of infectious complications, including septic arthritis and osteomyelitis.[2]

SPECIFIC BACTERIAL INFECTIONS CAUSED BY ANIMAL BITES

PASTEURELLA MULTOCIDA INFECTION

(See Chap. 156). An organism commonly infecting bite wounds is *P. multocida*, a bacterium present in the nasopharynx in 50% to 66% of dogs and 70% to 90% of cats. The most common pattern is that of local infection with adenitis after a dog or cat bite or scratch. *P. multocida* is the most common pathogen in cat bite infections and may also complicate 26% of dog bite wounds.[5] The infection usually presents within 24 to 48 hours, often within several hours. In patients with a cat bite, the infection may be followed by tenosynovitis or osteomyelitis as a result of inoculation of the organism into the periosteum by the long, sharp tooth of the animal. *Pasteurella* infections also have been reported after bites of large cats such as lions and tigers.

Systemic infection may also occur as bacteria may enter the respiratory tract through the inspiration of contaminated barn dust, or by inhalation of infectious droplets sprayed by the sneeze of an animal. In such cases, the bacteria probably colonize the respiratory tract and in some patients cause active infection. Bronchiectasis, emphysema, peritonsillar abscess, and sinusitis have all been described with this organism. Finally, systemic infection with bacteremia or meningitis may occur.

P. multocida is a small, gram-negative, ovoid bacillus that grows well on blood agar but does not grow on selective gram-negative media such as MacConkey agar. Because of the superficial resemblance of *P. multocida* to *Haemophilus influenzae* and *Neisseria* organisms, infections of the respiratory tract and CNS with this bacillus may be misdiagnosed initially.

Treatment of the patient with presumptive *P. multocida* infection should consist of careful washing of the wound and an attempt to leave it open. The empiric antibiotic of choice is amoxicillin/clavulanic acid orally for 7 to 10 days, with careful followup examination of the wound. *P. multocida* is susceptible to penicillin alone, and patients may be switched to penicillin if they have a pure infection with this organism. A fluoroquinolone, a tetracycline, and a trimethoprim-sulfamethoxazole are alternatives. In most patients, the antibiotic is aimed at both the patient's skin flora (such as *Staphylococcus aureus*) and organisms from the animal's mouth. Given the increasing prevalence of community acquired methicillin-resistant *S. aureus* (MRSA), patients should be treated with vancomycin, clindamycin, tetracycline, or trimethoprim-sulfamethoxazole if MRSA is suspected (Chaps. 154 and 156).[11]

STAPHYLOCOCCUS INTERMEDIUS INFECTION

S. intermedius is an organism associated with dogs weighing more than 40 lb. It is more commonly found in canine gingival flora than is *S. aureus* (39% vs 10%).[12] It is a gram-positive, coagulase-positive coccus that can be differentiated from *S. aureus* in the laboratory by biochemical testing. In comparison with *S. aureus*, *S. intermedius* does not produce acetoin from glucose and has β-galactosidase activity. If these tests are not performed (ie, if only a latex assay is used to identify *Staphylococci*), the laboratory may incorrectly report an isolate as *S. aureus* or unspecified *Staphylococcus*. Antibiotic treatment is the same as that for infections with *S. aureus*, although resistance to oxacillin is uncommon in *S. intermedius* and is growing in importance for *S. aureus*.[11]

CAPNOCYTOPHAGA CANIMORSUS INFECTION

C. canimorsus is a capnophilic ("carbon dioxide–loving"), facultatively anaerobic, slow-growing, gram-negative rod associated with dog bites.[13-16] The organism has been found in the oral cavity of 17% of cats and 24% of dogs. Most infections occur in splenectomized or immunocompromised hosts, although fatal infections including meningitis have been reported in immunocompetent hosts and present as overwhelming sepsis.

INFECTION BY *PORPHYROMONAS* SPECIES

Porphyromonas sp. are slow-growing anaerobic bacteria found in the deep gingival pockets of animal and humans. The organism is difficult to culture, requiring 4 to 6 days for colony formation as well as vitamin K and hemin in the media.[17,18] Citron and coworkers[19] found *Porphyromonas* sp. in 28% of culture specimens from patients with infected dog and cat bite wounds.

CAT SCRATCH DISEASE

Bartonella henselae is the most common etiologic agent of cat scratch disease. *Afipia felis* and other *Bartonella* species may cause some cases (Chap. 154).

Serratia marcescens may induce an unpleasant cellulitis in iguana bites in pet owners.[6] The treatment is trimethoprim-sulfamethoxazole or a quinolone antibiotic.

PLAGUE

(See Chap. 156).

TULAREMIA

(See Chap. 156).

RAT-BITE FEVER

(See Chap. 156).

SPECIFIC VIRAL INFECTIONS CAUSED BY ANIMAL BITES

RABIES

Epidemiology: The most notorious viral disease to occur after an animal bite is rabies, which is caused by a Rhabdovirus. Its epidemiology has changed in the past few years as a result of improved control of rabies in the domestic animal population. Now, nonimmune dogs and domestic animals account for only 8% of cases, whereas sylvatic animals, such as skunks, raccoons, red and gray foxes, and bats, represent the greatest potential danger. Rodents, such as squirrels and hamsters, are probably inconsequential as sources of rabies. However, cases of rabies in cattle are increasing.[20] Postexposure prophylaxis, which is nearly 100% effective, has reduced the number of cases of human rabies from more than 100/year a century ago to an average of 1 to 4 cases a year in the United States today. In 2004, of the 8 cases in the 49 states and Puerto Rico, 4 were acquired as a result of patients' receiving transplanted organs from an infected donor.[20,21] Although in the United States death in humans from rabies is rare, WHO estimates that 55,000 deaths occur each year in developing countries, half in children under 15 years.[22]

Live virus is introduced into nerve tissue at the time of the bite, multiplies at the site, and then spreads to the CNS. It replicates in gray matter and then spreads along autonomic nerves to the salivary glands, adrenal glands, and heart. The incubation period varies with the site of the bite from 5 days to as long as several years. Clinical features include a prodromal period of 1 to 4 days, followed by high fever, headache, and malaise. Paresthesia at the site of inoculation occurs in 80% of patients. The next sequence of events is familiar: agitation, hyperesthesia, dysphagia, excessive thirst, paralysis, and death.

Diagnosis: The diagnosis of clinical rabies is difficult and is often not made until after the death of the patient. Viral isolation methods may yield positive results for specimens of saliva or cerebral spinal fluid during the first 2 weeks of the illness, and saliva is infectious, so isolation precautions are needed. Serum antibodies may be detected as early as day 6 and usually by day 13. The fluorescent antibody method for detection of the viral antigen is the most rapid and sensitive means of making the diagnosis, and no matter where the actual bite site is, once patients have CNS disease, the diagnosis can be made from a biopsy of skin from the highly innervated hair-covered area of the neck or from brain tissue.

Prevention and Treatment: The most effective prevention for rabies is to avoid contact with any wild animal or any unfamiliar domestic animal. Persons at risk of unavoidable contact with rabies, such as spelunkers, veterinarians, virologists, and travelers spending time in countries where rabies is enzootic, should receive preexposure prophylaxis with the human diploid cell rabies vaccine (HDRV) series (3 intramuscular injections on days 0, 7, and 21 or 28) given in the deltoid muscle and repeated every 2 years. In persons vaccinated intradermally (using a lower intradermal dose), the neutralizing antibody titer should be performed, because the immune response may not be fully protective.[23]

The need for postexposure prophylaxis can be determined by the answers to the following questions: (1) What is the status of animal rabies in the locale where the exposure took place? (2) Was the attack provoked or unprovoked? (3) Of what species and size was the animal? (4) What was the state of health and vaccination record of the animal? (5) Will the brain of the animal be examined within 48 hours? (6) Can the animal be effectively quarantined? Most animals transmit rabies virus in saliva only a few days before becoming ill themselves; bats, however, may harbor the virus for many months.

Bites by Household Pets: If the dog or cat responsible for the bite is healthy and available for observation for 10 days, the patient should not be treated unless the animal develops rabies. At the first sign of rabies in the animal, the patient should be treated with rabies immunoglobulin (RIG) and the vaccine HDRV. The symptomatic animal should be killed and tested as soon as possible. If the animal is rabid or suspected of being rabid, or if it does not have up-to-date vaccination records, the patient should be treated with RIG and HDRV (see section "Specifics of Treatment").[24]

Bites by Wild Animals: All skunks, bats, groundhogs, foxes, coyotes, raccoons, bobcats, and other carnivores should be regarded as rabid unless laboratory test results prove negative. The patient should be treated with RIG and HDRV.

Bites by Other Animals: Bites by other animals (livestock, rodents, lagomorphs such as rabbits and hares, and ferrets) should be considered individually.[23] Local and state public health officials should be consulted about the need for prophylaxis. Bites by squirrels, hamsters, guinea pigs, gerbils, chipmunks, rats, mice, and other small rodents almost never call for anti-rabies prophylaxis.

Specifics of Treatment: The most important step is to cleanse the wound immediately with a brush and soap to remove as much virus as possible. The wound should be rinsed well and then scrubbed a second time with green soap or 70% alcohol, which is rabicidal. If vaccine treatment is indicated, both RIG and HDRV should be given as soon as possible, regardless of the interval after exposure, unless the patient has been previously vaccinated and a serologic assay shows current immunity. In this case, only HDRV is needed and should be given on day 0 and day 3. For nonimmune hosts, administration of RIG is the most urgent. If HDRV is not immediately available, RIG should be started and HDRV given as soon as it is obtained. RIG (20 IU/kg) should be given immediately—50% around the site of the bite and 50% in the thigh or the arm. This passive immunization not only will result in the early appearance of antibody but will also inhibit development of the active antibody from HDRV, hence the need for a 28-day series. Active immunization is accomplished using HDRV, given intramuscularly for a total of 5 doses on days 0, 3, 7, 14, and 28. Serum for rabies antibody testing should be collected 2 weeks after the fifth dose. If there is no antibody response, an additional booster should be given.

Management of the Patient with Clinical Rabies: In the rare cases in which a patient is admitted with the clinical diagnosis of rabies, several steps should be taken immediately. First, the diagnosis must be suspected and the patient placed on isolation precautions while the diagnosis is made rapidly by fluorescent antibody staining of specimens from various tissues, as well as immunofluorescence staining of the source animal's brain tissue. Elevated antibody titers in the absence of immunization are clear evidence of infection. The first signs of clinical rabies are usually nonspecific, such as malaise, anorexia, fatigue, headache, and fever. The acute neurologic illness that follows is most commonly characterized by intermittent episodes of hyperactivity. In some cases, however, a progressive paralysis occurs. The usual period from onset of symptoms to onset of coma is 10 days. Risk of exposure for hospital staff includes contact with open wounds or mucous membranes with saliva or other potentially infectious material such as neurologic tissue, spinal fluid, or urine. Blood, serum, and stool are not considered infectious.

Basic clinical management consists of anticipating and preventing all treatable complications of the rabies infection and induction of coma to manage the patient until the patient generates an immune response.[25] Pulmonary hypoxia should be prevented by tracheostomy at the first sign of respiratory difficulty, monitoring of actual partial pressure of oxygen, and use of supplemental oxygen. There are no specific antiviral treatments for rabies, although ribavirin has been tried.[25] Anticonvulsant therapy should also be instituted. Extreme increases in intracranial pressure may be prevented by insertion of a cerebrospinal fluid reservoir that allows withdrawal of the intraventricular fluid and measurement of intracranial pressure. Cardiac arrhythmias may be anticipated with careful monitoring. Rabies had been regarded as uniformly fatal, but there have been patients who have survived with prolonged cardiorespiratory support, and there is serologic evidence that some animals have survived. An aggressive approach to treatment of the patient with known rabies infection is worthwhile. In 2004, a 15-year-old girl without a history of prior rabies vaccination survived after her physicians used a treatment based on induced coma as well as other supportive measures and antiviral agents.[20,25] The World Health Organization has complied information regarding treatment and prevention accessible on their website.[22]

HERPESVIRUS SIMIAE (B VIRUS) INFECTION

Herpesvirus simiae (B virus) is enzootic in Old World monkeys, especially rhesus, cynomolgus, and other macaques. The illness in monkeys is similar to that caused by herpes simplex in humans, and asymptomatic monkeys may shed the virus in saliva. Most cases in humans have occurred after direct exposure to macaque monkeys or monkey tissue through bites, scratches, or cuts.[26] A vesicular lesion develops at the wound site with progressive lymphadenitis and fever. Over the next few days to weeks, patients develop a severe illness, which is characterized by rapidly progressive ascending neuropathy and encephalitis. The illness is rare and before the availability of antiviral therapy, 72% of cases were fatal. A cluster of 4 cases occurring in 1987 in Pensacola, Florida, were treated with acyclovir. The 2 patients who received acyclovir when their infections were localized responded well to therapy and were maintained on oral acyclovir. All macaques should be presumed to be shedding B virus and should be handled accordingly. All monkey-inflicted injuries should be cleansed, specimens should be collected for viral culture, and a physician should evaluate the patient. Clinical and serologic monitoring is critical, and high-risk or infected patients should be treated according to established guidelines. The use of acyclovir or ganciclovir initially and acyclovir for years has led to improved survival in infected patients.

SNAKEBITES

In the United States, there are approximately 5 to 6 deaths from snakebites and probably 6000 to 7000 snakebite envenomations each year.[26] The largest number of venomous snakebites occur in the Southwestern States.

Worldwide as many as 125,000 fatal snakebites may occur each year.[27] Because of regional differences in varieties of snakes, management recommendations including specific antivenom recommendations differ by geographic area. The World Health Organization has published guidelines to help ensure the quality and availability of antivenom immunoglobulins worldwide, and has an online database that can be used to explore the global distributions of venomous snake species, and access information on antivenom products and their manufacturers.[28]

The 2 major poisonous snakes in the Americas are the pit viper (family Viperidae, subfamily Crotalinae, which includes the rattlesnake, water moccasin, and copperhead) and the coral snake (family Elapidae). Poisonous snakes are found in all states of the United States except Maine, Hawaii, and Alaska.[29] The northern copperhead, also called the highland moccasin, is pink or reddish brown and is marked with large chestnut brown barrels resembling dumbbells or hourglasses (Fig. 182-1). The bite is painful but rarely fatal. The timber rattler is dark brown with chevrons of black and brown (Fig. 182-2).

The degree of toxicity of a snakebite depends on the potency of the venom, the amount injected, the size and condition of the snake, and the size of the person bitten. Pain occurs at the site of the bite (usually within 5 minutes). Signs and symptoms at the bite site include wheal with local edema, numbness, and, within moments, ecchymosis and painful lymphadenopathy (Fig. 182-3).

Nausea, vomiting, sweating, fever, drowsiness, and slurred speech may develop. Bleeding of the gums and hematemesis are common hemorrhagic manifestations. If edema and erythema have not developed within 8 hours after the bite, it can be assumed that significant envenomation did not occur. Estimated mortality rates for victims who receive antivenom in a health care facility are less than 1% and probably less than 0.1%.

For proper treatment, it is extremely important to establish that the bite is from a poisonous snake. Many patients experience symptoms related to fear that may mimic symptoms from venom. The patient should have distinct fang punctures and immediate local pain, followed by edema and discoloration



Figure 182-2 Timber rattlesnake.

within 30 minutes. It is helpful to inspect the snake, because those that are poisonous may be differentiated from those that are not by the presence of fangs and the shape of the pupils (Fig. 182-4). Availability of a photograph of snakes common to a specific geographic area is important for all hospital emergency wards to aid practitioners in deciding if the patient has been bitten by a poisonous snake.

Although there are still insufficient evidence-based criteria for first aid and out-of-hospital treatment for snakebite envenomations, a rational approach is outlined in Table 182-2.[30] In summary, the patient should be stabilized and transported as rapidly as possible to a health care facility capable of administering antivenom, and the affected site should be immobilized below the level of the heart. Constricting bands such as watches or jewelry should be removed; the routine use of venous compression bands is not recommended.[29] The patient should be kept as immobilized as possible.[29] Venous compression techniques are designed to impede the return of venous and lymphatic flow from the bite site without sacrificing blood flow to the extremity. In cases in which there is likely to be a significant delay in transport and the victim is developing systemic signs of envenomation such as hypotension, these techniques may be of value.[30] Arguments against the use of venous compression techniques include the time that it takes to apply the treatments, which may further delay transport time. Additional arguments against the use of these techniques include the potential for concentrating the venom in the affected limb, which may worsen local

Figure 182-1 Northern copperhead.

Figure 182-3 Copperhead snakebite.

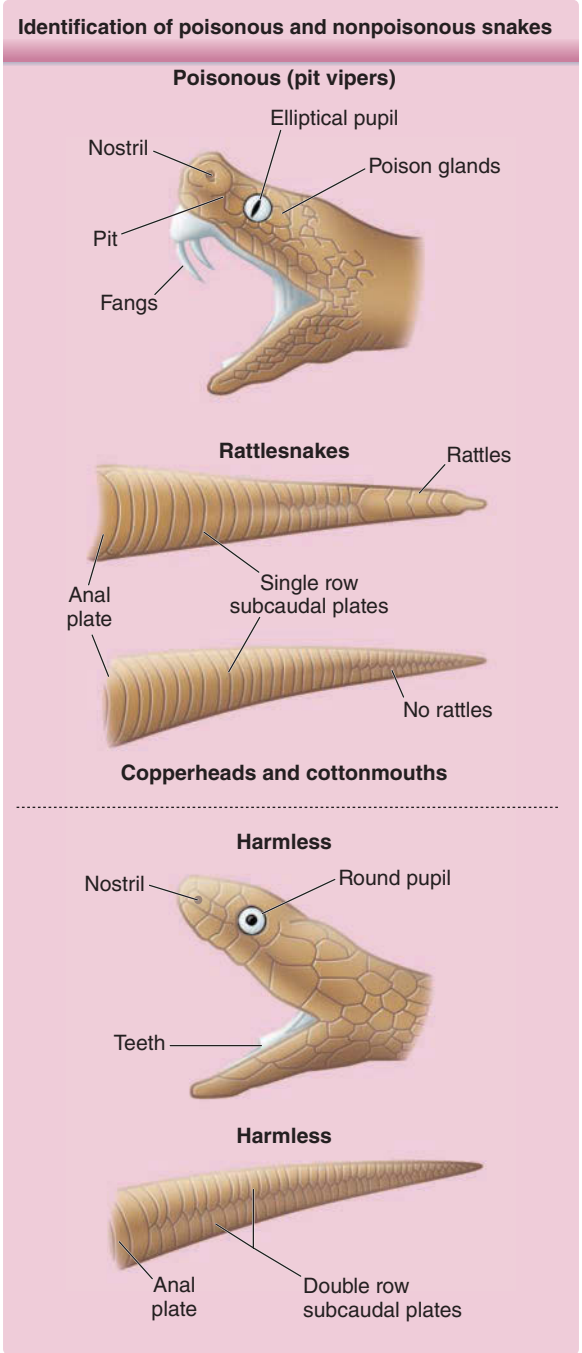

Figure 182-4 Identification of poisonous and nonpoisonous snakes. (From Wingert WA, Wainschel J: A quick handbook on snake bites. *Resid Staff Physician*, 1977, p. 56, with permission.)

necrosis, along with the possibility of a bolus effect when the compression is released.[30] Another possible disadvantage of the use of these compression techniques is the potential for them to cause arterial compression if the affected limb swells in reaction to the toxin. If a decision is made to use a venous compression band in the field, arterial pulses should be palpable distal to the ligature, and the dressing should be checked frequently to make sure that it is has not become too tight. If a venous compression dressing has been applied in the field and

TABLE 182-2
First Aid and Out-of-Hospital Treatment for Snakebite Envenomation

1. The patient should be stabilized and transported as rapidly as possible to a health care facility capable of administering antivenom. Consult the CDC and WHO websites for updated information on antivenom availability and use.[28]
2. The affected site should be immobilized below the level of the heart, constricting bands such as watches or jewelry should be removed, and the patient should be kept as immobile as possible.[29]
3. The use of venous compression bands or pressure immobilization is not recommended,[29] although there is controversy surrounding their use if there is likely to be a significant delay in transport and the victim is developing systemic signs of envenomation such as hypotension, and in such a case these techniques may be of value.[30]
4. The value of using a suction device to extract venom is debated in the literature.[29] If such a device is applied in the field and fluid is accumulating in the suction cup, it can be left in place until the patient reaches a medical facility.[30]
5. The use of cryotherapy, incision, or excision of the bite site, arterial tourniquets, and electroshock therapy as part of emergency field therapy should be discouraged.

CDC, Centers of Disease Control and Prevention; WHO, World Health Organization.

is not causing vascular compromise, it should be left in place until the patient reaches a health care facility and antivenom is at the bedside.[30]

The role of surgical intervention in the treatment of snakebite envenomations is limited in most cases. Surgery is appropriate only if medical treatment fails. This includes elevation of the bitten body part in conjunction with the administration of 4 to 6 vials of Crotalidae polyvalent immune Fab (ovine) (FabAV) over the course of 1 hour.[29] Debridement of truly necrotic skin and subcutaneous tissues is recommended 4 to 5 days after envenomation. In cases of bites to a digit, if there is severe swelling and the finger is tense, blue, or pale, a digit dermotomy may be of use. True compartment syndrome involving an extremity is a rare complication of snakebite envenomation. Fasciotomy should be used only in cases of increased compartment pressure that has not responded to prompt and sufficient treatment with antivenom.[31]

The primary treatment for crotaline snake venom poisoning is prompt and adequate dosing with antivenom. Antivenom is most effective if given within 4 hours of the snakebite (Table 182-3).

TABLE 182-3
Antivenom for Crotaline Snake Bites

- Emergency information and antivenom are available in the United States through the New Jersey Poison Control Center Network, which can be reached 24 hours a day by calling 800-222-1222.[29]
- The World Health Organization website has a database with information and pictures to aid providers in finding the correct antivenom[28]: http://apps.who.int/bloodproducts/snakeantivenoms/database/.

FabAV should be used for all severe American crotaline snakebites, but not those of the coral snake. The dosage should be guided by the severity and progression of local changes and systemic clinical signs. Because some patients develop recurrent manifestations of envenomation after initial treatment, both a loading dose of 4 to 6 vials of FabAV and then, once initial control has been achieved, 3 maintenance doses 6, 12, and 18 hours later are recommended.[29]

Supportive treatment is indicated, including hospitalization with careful evaluation of baseline hematocrit, platelet count, and prothrombin time. Coagulopathy should be corrected by using antivenin, because fresh-frozen plasma is ineffective.[29] The wound should be cleansed and covered. Antitetanus therapy and antibiotic prophylaxis with penicillin, ampicillin/sulbactam, or tetracycline should be initiated for severe bites.

BITES AND STINGS OF AQUATIC ORGANISMS

SEAL BITE

Normally, a seal bite occurs on the finger of a trainer or a seal hunter—thus the term *seal finger* or *spaek finger*.[32,33] Bites and contact abrasions also occur in in open-water swimmers from harbor seals, are uncommon, and usually involve the lower extremities.[33] An infection may ensue, the etiologic agent of which may be unclear. One study suggests that a virus similar to that causing Orf may be the culprit,[33] although *Mycoplasma* sp. have been isolated, and some patients respond to tetracycline (Chap. 156). The incubation period of 4 to 8 days is followed by throbbing pain, erythema at the site, and swelling of the joint proximal to the bite. Untreated, seal finger progresses to cellulitis, tenosynovitis, and arthritis Tetracycline, 500 mg orally 4 times a day for 10 days, remains the antibiotic of choice.[30,32] It is also helpful to immobilize and elevate the finger as well as soak it several times a day (Chap. 156).

INJURIES CAUSED BY JELLYFISH, PORTUGUESE MAN-OF-WAR, SEA ANEMONES, AND CORALS

Stings caused by jellyfish, Portuguese man-of-war, sea anemones, and corals are the most common envenomations experienced by humans in marine environments. All of these creatures are members of the phylum Cnidaria, formerly known as *Coelenterata*. They are divided into 3 major classes. The first class, Hydrozoa, includes the Portuguese man-of-war, fire corals, and hydroids. Jellyfish belong to the second class, Scyphozoa. The third class, Anthozoa, encompasses sea anemones and true corals. Approximately 100 of the 9000 species of Cnidaria that have been identified may cause injury to humans.[34]

Cnidarians are radially symmetric animals with body walls formed by an inner and outer layer of cells enclosing a jellylike substance. They may be either free floating in the water like jellyfish or sessile like corals.[34] Almost all cnidarians possess nematocysts, or stinging capsules, which are usually concentrated on some form of tentacle. Each nematocyst contains a toxin or group of toxins and a coiled thread-like apparatus with a barbed end that functions like a flexible hypodermic syringe (Fig. 182-5). When the nematocyst comes into contact with a victim, the barbed end is discharged, and the toxin is injected into the skin.

Cnidarian stings range from mild, self-limited irritations to extremely painful and serious injuries, depending on the toxin of the species involved and the magnitude of the envenomation. Stings from certain species such as the cubomedusae, or box jellyfish, can be fatal.

In most cases, jellyfish stings elicit toxic reactions that may be localized and/or systemic. Although immediate-type hypersensitivity reactions, including urticaria, angioedema, and anaphylaxis, occur less frequently, they require prompt medical intervention, because shock and death may ensue in highly sensitized individuals. Allergic contact dermatitis, delayed and persistent hypersensitivity reactions, granuloma annulare, and erythema nodosum are other possible cutaneous reactions to jellyfish stings.[35]

INJURIES CAUSED BY JELLYFISH

Sea Nettles: Among the organisms most commonly causing jellyfish stings are the sea nettles, which comprise 2 different species, both of which inhabit Atlantic as well as Indo-Pacific waters. *Cyanea capillata* and its relatives are the larger of the 2 species, with a bell measuring up to 1 m and numerous tentacles reaching 30 m in length (Fig. 182-6).[36] *Chrysaora fuscescens* (Fig. 182-7) is found in the Pacific waters off the coast of California. *Chrysaora quinquecirrha* is smaller, with a white or rusty bell that may reach 30 cm with 4 digestive tentacles hanging from it. Although sea nettle stings are seldom lethal, they can be quite painful.[37] Initially the victim experiences a sharp burning pain in the area contacted by the tentacles. Within minutes, the sting area develops a zigzag, whip-like pattern of raised red welts 2 to 3 mm wide (Fig. 182-8). The duration of acute pain may vary, but the pain often begins to abate in 30 minutes. The wheals usually subside by 1 hour, but purplish brown petechial and postinflammatory pigmentation may persist for several days.

Portuguese Man-of-War: *Physalia physalis* is the species name for the Portuguese man-of-war, which is a member of the class Hydrozoa and is therefore not a true jellyfish. *P. physalis* is encountered in both Atlantic and Mediterranean waters, and is easily recognized by its translucent blue to pink or purple bladderlike

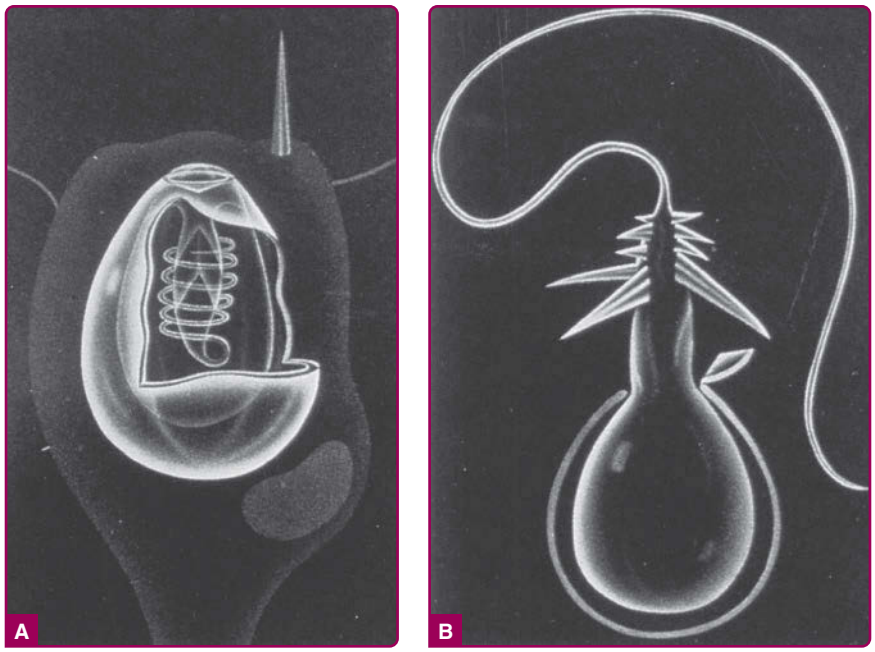

Figure 182-5 From left to right, a diagrammatic view of an intact and discharged coelenterate nematocyst. (R. Kreuzinger, used with permission from World Life Research Institute.)

float with multiple tentacles (Fig. 182-9). *P. physalis* is distinguished from its Pacific ocean relative *Physalia utriculus*, commonly known as the *blue bottle*, by its larger bell, which ranges in size from 10 to 30 cm, and multiple fishing tentacles extending up to 30 m; in contrast, *P. utriculus* has only a single tentacle that rarely exceeds 5 m.[38] These tentacles are armed along their entire length with hundreds of thousands of nematocysts arranged in stinging batteries, with each battery containing hundreds of nematocysts. The nematocysts remain active even after portions of the tentacles are broken off in storms or when these animals are stranded on the shoreline by high winds or waves. A beached Portuguese man-of-war can cause a severe

Figure 182-6 *Cyanea capillata*, also known as *sea nettle* or *lion's mane*, is a common cause of jellyfish stings. (B.W. Halstead, used with permission from World Life Research Institute.)

Figure 182-7 *Chrysaora achlyos*, commonly known as the black sea nettle, ranges from Monterey Bay to southern Baja California. This giant jelly sting causes consternation and painful stings that rarely need medical attention. (Used with permission from Jeffery Lee, D.D.S., Monte Sereno, CA.)

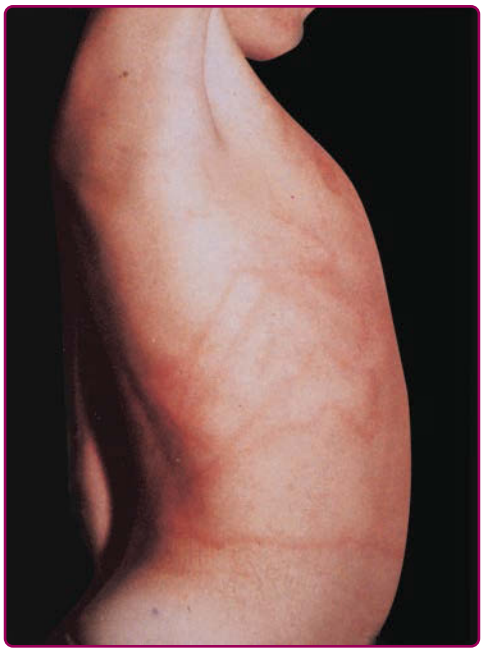

Figure 182-8 Whiplike sting pattern caused by *Cyanea capillata* in a young boy. (J.H. Barnes, used with permission from World Life Research Institute.)

sting when stepped on or touched. Children who are stung after handling these animals and then cry and rub their eyes may develop an acute conjunctivitis.

Stings of *P. physalis* are more painful and severe than those caused by sea nettles and are more extensive and serious than those caused by *P. utriculus*. At the moment of contact with the tentacles of *P. physalis*, the victim experiences a sharp, shocklike, burning pain. There may be painful paresthesias or numbness in the sting area. Initially, the sting area appears as an irregular single line or multiple lines composed of red papules, beaded streaks, or erythematous welts that correspond to the areas of tentacle contact. The wheals resolve in hours but may progress to vesicular, hemorrhagic, necrotic, or ulcerative stages before healing (Fig. 182-10).[39]



Figure 182-9 *Physalia physalis*, the Portuguese man-of-war, is distinguished by its bladder-like float and numerous trailing tentacles. (B.W. Halstead, used with permission from World Life Research Institute.)

Figure 182-10 This diver surfaced directly under a large Portuguese man-of-war and suffered a severe sting with bulla formation and tissue necrosis. (S. Anderson, used with permission from World Life Research Institute.)

Postinflammatory striae may persist for weeks to months. Severe localized complications of *P. physalis* stings may also include arterial spasm in the sting site that can result in distal digital gangrene.[40,41]

Within 10 to 15 minutes of a *Physalia* sting, the victim may develop symptoms of an envenomation reaction characterized by nausea, abdominal cramps, muscular pains, backache, irritability, dyspnea, and chest tightness. Intravascular hemolysis and acute renal failure were reported in a 4-year-old girl after a severe sting by *P. physalis*.[42] Most reports of death due to stings of *P. physalis* are not well documented, but well-substantiated case reports of human fatalities do exist.[43-45]

Cubomedusae (Class Cubozoa): Box Jellyfish: Of all the species of jellyfish that cause painful stings and distress to swimmers, the species with the most established record of lethality are the cubozoans. *Chironex fleckeri* or box jellyfish causes at least one death each year in Australia.[46] The fatality is usually a child, presumably because the size of the victim and the total area of the sting determine the likelihood of death. Until recently, most of the published cases of *C. fleckeri* stings involved fatal or nearly fatal envenomations, but less serious stings do occur in endemic areas.[47-49]

Figure 182-11 The deadly box jellyfish, *Chironex fleckeri*, is found in Indo-Pacific waters off the coast of Northern Australia. (Used with permission from R. Hartwick.)

Figure 182-12 Characteristic frosted cross-hatched tentacle marks diagnostic of a sting caused by *Chironex fleckeri*. (Used with permission from Townsville General Hospital, Department of Medical Illustration, Townsville, Queensland, Australia.)

C. fleckeri (commonly known as the *sea wasp*) is an advanced species of jellyfish, with a semitransparent cubic bell that may grow to a volume of 9 L and weigh more than 6 kg (Fig. 182-11).[46] Trailing from the bell are up to 60 stinging tentacles, which may reach 2 to 3 m in length. When a human comes into contact with a box jellyfish, some of the tentacles are torn off and adhere to the skin. Rescuers of *C. fleckeri* sting victims must exercise caution, because they also are at risk of envenomation until the tentacles have been neutralized and removed.

The stings appear initially as linear welts that give the patient the appearance of having been whipped.[46] Fresh stings of *C. fleckeri* are easily recognized because they have a diagnostic, frosted, cross-hatched, or ladderlike appearance (Fig. 182-12). Microscopic diagnosis is also possible from blade scrapings or tape-strippings from the sting site. The intense pain may persist for many hours. Severely stung areas of skin take on a dusky cyanotic appearance, and blister formation and necrosis may occur. The healing process is slow and may be complicated by bacterial superinfection and scarring.

Death may ensue within minutes due to cardiotoxic and neurotoxic agents in the venom that can produce ventricular arrhythmias and cardiac arrest, and respiratory failure, respectively.[48] Intravascular hemolysis caused by the toxin can precipitate acute renal failure. First aid for these victims frequently involves cardiopulmonary resuscitation. Intravenous verapamil has been proposed for both treatment and prophylaxis of ventricular arrhythmias.[50,51] Antivenom is available for *C. fleckeri* stings, and its early use in severe envenomations may be lifesaving and significantly reduces the pain and inflammation at the sting site.[47]

Irukandji syndrome is a severe and delayed response (usually 30 minutes but between 5 and 40 minutes) to the sting of a small box jellyfish, termed the *Irukandji jellyfish*, that has resulted in the death of 2 tourists in the Cairns–Port Douglas region of Australia.[52] The classic syndrome consists of local signs of inflammation together with severe back pain, excruciating muscle cramps, piloerection, sweating, nausea, vomiting, headache, and palpitations. The most severe cases may progress to include extreme hypertension and cardiac failure. Only one species, *Carukia barnesi*, has been clearly linked to this syndrome, but it is thought that at least 6 different species of small jellyfish, each with only 1 tentacle arising from each corner of the bell (carybdeids), may be etiologic agents. The stings most often occur in deep water. Treatment includes application of vinegar to discharge nematocysts and victim transport for medical attention including pain control and α-blockade, because the venom is thought to act as a presynaptic neuronal sodium agonist and to stimulate norepinephrine release.

Prevention and Treatment of Jellyfish Stings: Cnidarian envenomations cause more deaths than shark attacks annually.[53] Tables 182-4 through 182-6 give details on the prevention of jellyfish stings and first aid for and treatment of the stings. Systemic reactions may occur, and the treatment for these includes support of vital functions with cardiopulmonary resuscitation, oxygen, and intravenous fluids.[54] Application of a venous-lymphatic constriction bandage proximal to the wound site should be considered in the case of severe stings when systemic reactions

TABLE 182-4
Prevention of Jellyfish Stings

1. Swim only at patrolled beaches with properly trained lifeguards and adequate treatment facilities.
2. Avoid swimming in infested waters, especially after a storm, because stings may result from remnants of floating damaged tentacles.
3. Beware of apparently dead or beached jellyfish.
4. When snorkeling or scuba diving, wear protective clothing such as a wet suit, long-sleeved shirt, pants, or long woolen underwear, and gloves. In areas where Irukandji syndrome occurs, wear a Lycra stinger suit.
5. Use sunblock containing jellyfish and "sea lice" repellent.
6. Bathing beaches should be closed during periods of high jellyfish infestation.

are present or likely to occur, when topical deactivation of tentacles is not possible, and when transport to receive specific antivenin for *C. fleckeri* stings is available. The antivenin is prepared from sheep serum and may therefore pose a risk of allergic reaction in sensitive individuals.[35,37] The preferred route of administration is intravenous, but the antivenin may be given intramuscularly. In severe stinging, it has proved lifesaving. It is also the only treatment that can alleviate the intense pain and may reduce inflammation at the sting site and decrease the chance of scarring. Intravenous administration of verapamil has been advocated for both treatment and prophylaxis of arrhythmias.[50,51] For pain in severe stinging, parenteral narcotic analgesics and ice packs, as well as antivenin, should be considered. Local reactions may be treated with topical anesthetic ointments, creams, lotions, or sprays to relieve itching or burning pain.[34] Hot-water immersion as first aid enhances pain relief and has been judged better than ice packs.[53] For delayed-type hypersensitivity reactions, which may occur days to weeks after the stinging (Fig. 182-13), topical glucocorticoids, topical tacrolimus, antihistamines, and systemic glucocorticoids should be used as necessary.[36]

Secondary infections should be treated with the appropriate parenteral antibiotics, and antitetanus therapy should be considered. Application of ice or cold packs can relieve the pain of mild to moderate

TABLE 182-5
First-Aid Treatment of Jellyfish Stings

1. Remove or rescue the victim from the water.
2. Stabilize vital functions: Airway, breathing, circulation.
3. Immobilize the affected part to prevent further envenomation by adherent tentacles.
4. Identify the type of jellyfish sting by considering locale, time of year, and indigenous species and by observing the sting pattern. Preserve a portion of the tentacle for future identification. Tape-strip or scrape the sting site for microscopic analysis of the nematocysts if no tentacles are available.
5. To prevent further envenomation of the victim and to reduce the chance of a sting to the rescuer, disarm the nematocysts before removing the adherent tentacles.

TABLE 182-6
Organism-Specific and Followup Treatment of Jellyfish Stings

1. If *Chironex fleckeri* or other box jellyfish species that cause the Irukandji syndrome are suspected, douse or spray dilute acetic acid (3%-10%) or household vinegar over all areas of tentacle contact for at least 30 s.
2. For sea nettles, mix sodium bicarbonate (baking soda) with water to form a slurry and pour over the affected area or apply the powder directly to the tentacles.
3. For *Physalia physalis* stings, a slurry of baking soda is indicated. Vinegar had been reported to neutralize nematocysts of *P. physalis*, but work with species from Australia indicate that it may cause a discharge of nematocysts in some cases.
4. If vinegar or baking soda is unavailable, papain, available as a powdered meat tenderizer, may be applied directly as a powder or mixed in water as a slurry to sting areas and tentacles of both sea nettles and Portuguese man-of-war.
5. If nothing else is available, the tentacles can be rinsed off with seawater.
6. Do not use fresh water, methylated spirits, or alcohol in any form to deactivate tentacles, because these all may cause a rapid massive discharge of nematocysts.
7. After the tentacles have been disarmed, they may be carefully removed with a forceps or gently scraped away from the skin with shaving cream and a razor or a plastic card, shell, or knife.
8. Consider use of hot-water immersion rather than ice packs as first aid to enhance pain relief.

stings of many types of jellyfish, and aspirin or acetaminophen, alone or in combination with codeine, can be used to relieve persistent pain.

SEA ANEMONE DERMATITIS

Sea anemones are members of the phylum Cnidaria, class Anthozoa. They are sessile creatures with flowery tentacles armed with nematocysts (Fig. 182-14). The stings of sea anemones may cause dermatitis in

Figure 182-13 Delayed-type hypersensitivity reaction occurring about 2 weeks after jellyfish stings on the leg.



Figure 182-14 The elongated tentacles of the sea anemone cause can envenomations similar to shellfish stings. (Used with permission from Jeffery Lee, D.D.S., Monte Sereno, CA.)

sponge fishermen, sponge divers, and beachcombers who gather snails and crabs from rocky hollows along the shore. Their toxicity to humans depends on the species. After the immediate reaction has subsided, delayed-type hypersensitivity reactions can develop at the site of a sting from a sea anemone (Fig. 182-15).

The genus *Sagartia* is the cause of sponge fisherman's disease.[34] This anemone lives at the base of sponges sought by commercial fishermen. When they harvest or sort the sponges with their bare hands or forearms, they are likely to come into contact with the tentacles of *Sagartia*. Itching and burning occur at the sting site within minutes, accompanied by erythema, edema, and vesicles.[34]

Treatment of sea anemone stings is similar to that of jellyfish envenomations (see section "Prevention and Treatment of Jellyfish Stings").[55] The tentacles should be removed carefully.[34] Both vinegar and Stingose (an aqueous solution of 20% aluminum sulfate and 11% surfactant) have been suggested for application to neutralize the sites of anemone stings.[56] Sea anemone sting sites often heal slowly and may require treatment with antibiotics.

INJURIES CAUSED BY FIRE CORAL AND CORAL CUTS

Corals are colonial organisms belonging to the phylum Cnidaria. Coral injuries may be caused by nematocyst stings or lacerations. Both injuries may occur at the same time and may be complicated by foreign-body reactions, bacterial infections, and localized eczematous reactions.

Figure 182-15 Delayed-type hypersensitivity reaction to a presumed sea anemone sting. This 11-year-old girl stepped into a hole while wading in shallow waters on the South Carolina coast. She experienced an immediate burning pain with erythema and swelling of both lower legs that subsided within a day. Several days later, she developed a pruritic linear eruption. A diagnosis was made of a delayed-type hypersensitivity reaction that developed in the sting site and corresponded with the tentacle marks from what was presumed to be a sea anemone envenomation.

For most true corals, nematocyst envenomation is a relatively innocuous experience, resulting in mild pruritic erythema that requires little if any treatment. Calamine lotion or antipruritic lotions may bring relief.[57]

In contrast to the stings of true corals, the sting of the fire coral, *Millepora alcicornis*, is quite painful, as many scuba divers and snorkelers from the Florida Keys to the Caribbean will attest (Fig. 182-16). The wet mucous membrane or slime surrounding the organism

Figure 182-16 The mustard-colored finger-like outcropping in the upper left quadrant of this formation of coral and hydroids is a typical example of fire coral.

contains numerous nematocysts that readily discharge on contact with the skin, causing immediate burning and stinging pain. Within 1 to several hours a pruritic erythematous papular eruption appears, which in severe cases may become pustular and, in rare cases, may progress to necrosis and eschar formation.[57] Lesions heal in 1 to 2 weeks, often with postinflammatory hyperpigmentation. A delayed and persistent allergic contact dermatitis also has been reported to occur from a fire coral sting in the Red Sea.[58]

Fire coral stings should be rinsed with seawater to remove undischarged nematocysts. The sting area can then be compressed with either 5% acetic acid (vinegar) or 40% to 70% isopropyl alcohol for 15 to 30 minutes or until the pain is relieved.[37,59] Seawater compresses, hot to the point of tolerance, are also reported to inactivate the toxin. A topical steroid cream or ointment may relieve pruritus and promote healing.

Coral cuts—lacerations caused by the razor-sharp exoskeletons of coral—are notorious for their slow healing and propensity for secondary infection. Factors that complicate healing include the following: (1) wounds often involve the lower extremities and these generally heal more slowly because of decreased tissue blood supply; (2) wound edges are often irregular, contused, crushed, and abraded; (3) contamination of wounds is likely because of pathogenic bacteria in shore waters; and (4) foreign bodies, including marine algae growing on the coral or portions of the coral itself, may be implanted in the wound.

Treatment of coral cuts should begin with vigorous cleansing of the wound with soap and water with a soft brush or rough towel, followed by copious irrigation with saline to remove foreign bodies. If the wound is extensive, local anesthesia may be required to allow adequate cleansing, exploration, and debridement and to achieve good hemostasis. Hydrogen peroxide washing of the wound before dressing it is recommended.

The decision whether to perform primary closure of a coral cut wound or to allow it to heal by secondary intention depends on the location of the wound, the degree of tissue trauma at the wound margins, and the likelihood of subsequent infection. Tape-stripping is preferable to suturing of leg wounds, because sutured leg wounds have a high chance of abscess formation. Once the wound is closed, antibiotic ointment and rest are advisable. Tetanus prophylaxis should be given according to immunization history.

DERMATITIS FROM SPONGES

Sponges are members of the phylum Porifera, class Desmospongiae. They are simple multicellular animals that live attached to the sea bottom. Sponges grow by forming a series of hollow-centered branching tubes composed of a fibrous material called *spongin*, which contains spicules of calcium carbonate or silica.[34,60,61] Spicules of certain species of sponges are capable of penetrating the skin, causing a localized irritant or foreign-body reaction. Treatment of sponge spicule dermatitis involves tape-stripping of the affected area.

Figure 182-17 The poison bun sponge, *Fibula nolitangere*, can cause a severe irritant or toxin-induced contact dermatitis.

At least 13 species of sponges can cause a toxic dermatitis. Of these, the most commonly encountered are the West Indian and Hawaiian fire sponge, *Tedania ignis*; the poison bun sponge, *Fibula nolitangere* (Fig. 182-17); and the red sponge, *Microciona prolifera*, found in the northeastern United States.[62] These creatures are covered by a surface secretion, or slime, that produces an irritant or toxin-induced dermatitis when contacted by bare skin.[61]

Symptoms of itching, prickling, stinging, or burning appear within minutes of exposure and are followed within a few hours by pain, swelling, and stiffness. If the fingers are involved, they often become immobile within 24 hours. The first cutaneous sign of sponge poisoning is local erythema, which progresses to a papular, vesicular, or bullous eruption with weeping of a serous or purulent fluid.[61,62] Desquamation of the site occurs within several days. Erythema multiforme and anaphylactoid reactions have been reported in highly sensitized individuals. Treatment of sponge dermatitis is similar to that of severe poison ivy.[62]

INJURIES CAUSED BY ECHINODERMS: SEA URCHINS, STARFISH, AND SEA CUCUMBERS

SEA URCHINS

Sea urchins are spiny creatures that belong to the phylum Echinodermata, class Echinoidea. They are encased in a fragile, roughly spherical, calcareous shell, which is protected by a formidable array of mobile spines and pincer-like organs known as *pedicellariae* (Fig. 182-18).[63,64]

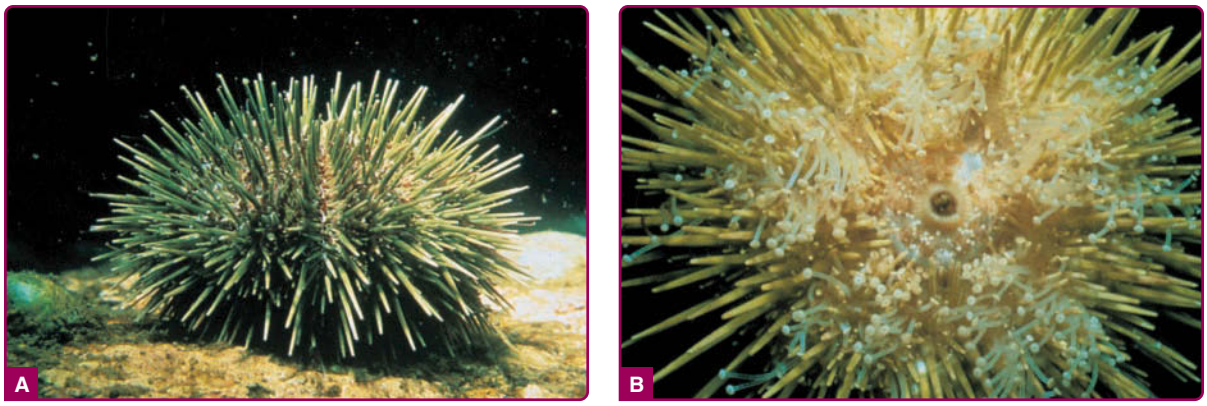

Figure 182-18 Lateral (**A**) and ventral (**B**) views of a sea urchin demonstrate this animal's protective spines and venomous pedicellaria underneath. (Used with permission from Marty Gilman, Worcester, MA.)

Bathers, surfers, divers, and fishermen are all at risk for sea urchin injuries. These creatures, such as the purple sea urchin, hide in rocks in low-tide zones along the Pacific coast between Alaska and Mexico (Fig. 182-19). Injuries may occur when the victim steps on an urchin, driving the spines into an unprotected foot, or as a result of loss of balance or wave action, in which case the hands or other body parts may be impaled. Sea urchin spines are composed of calcium carbonate and are covered with a proteinaceous membrane.[61] Injuries from sea urchins may be inflicted either by penetrating wounds from the animals' spines, which often break off and become imbedded in the wound, or by bites from the pedicellaria. In certain species, the spines or pedicellaria are venomous. This fact may explain why the pain of some sea urchin wounds is so excruciating and disproportionate to the apparent injury.

Encounters with sea urchins can result in both immediate and delayed reactions. Immediate reactions are usually localized and are initially manifested by a severe burning pain at the wound site, which quickly becomes red and swollen and may bleed profusely. There may be a black or purple discoloration at the site of the spine penetration due to either retained spines in the wound or to a tattoolike effect from dye released by spines that have exited intact, but this discoloration will likely disappear within 48 to 72 hours.[59] Paresthesias may develop at the wound area. Systemic symptoms are not common but can occur in injuries due to particularly venomous species. Symptoms may include nausea, syncope, paresthesias, ataxia, muscle cramps, paralysis, and respiratory distress.[62]



Figure 182-19 Purple sea urchin, *Strongylocentrotus purpuratus*, commonly found along the Pacific coast of the United States.

Delayed-type hypersensitivity reactions may occur with erythema and intense pruritus days after the initial injury.[65] In one of these cases, the diagnosis was confirmed by patch testing with extracts of the ground sea urchin spines.[66] Nodular reactions are localized to the area of spine penetration and are not usually painful. Nodules may take on colors from the dye in the spines[63] and may have a central umbilication or a keratotic surface[63] (Fig. 182-20).

The diffuse form more commonly involves the fingers or toes and is manifested by a fusiform swelling of the affected digit with accompanying pain and loss of function.[62,63] In addition to joint synovitis and arthritis, osteoarticular complications of sea urchin spine penetration may include tenosynovitis with or without destruction of the underlying bone, fasciitis, and bursitis.[67] Sea urchin spine wounds may also cause direct mechanical injuries to nerves and may be complicated by secondary infection.[68]

Initial first aid for the pain from immediate reactions is to soak the affected area in hot water (43°C-46°C [110°F-115°F]) for 30 to 90 minutes until maximal relief is obtained. Infiltration of the wound site with 1% to 2% lidocaine without epinephrine may be required in some cases to produce significant pain relief.[69] Spines protruding from the wound may be carefully removed. They are very fragile; therefore, it is difficult to extract the entire spine intact. Tumescence of the skin with a local anesthetic may allow superficially imbedded spines to be extracted when radiographs demonstrate no evidence of joint or bony impingement.[64] More invasive attempts at spine removal should not

Figure 182-20 **A** and **B,** Nodular reactions to imbedded sea urchin spines. (Used with permission from Karen Rothman, MD.)

be made without the benefit of aseptic surgical facilities and radiographs to confirm the spine locations. Removal of the spines may be aided by the use of an operating microscope. Antibiotics are indicated for secondary infections, and tetanus prophylaxis should be given if indicated.

STARFISH

Certain species of starfish may produce puncture wound injuries similar to those caused by sea urchins. The crown-of-thorns starfish, *Acanthaster planci*, accounts for most severe starfish envenomations.[62] The ice pick–like spines of *A. planci*, which may reach 4 to 6 cm in length, are covered with a thin skin and glandular tissue that produce a poisonous slime.[69] The resulting wound is quite painful and may be accompanied by numbness and paresthesias. Systemic symptoms including nausea, vomiting, and muscle weakness are infrequent and short-lived.[62] Fragments of spines and their surrounding integument may become imbedded in the wounded area, resulting in granulomatous reactions.

Treatment is similar to that of sea urchin wounds.

SEA CUCUMBERS

Sea cucumbers are sausage-shaped, bottom-feeding echinoderms that can produce a papular contact dermatitis by means of a toxic liquid substance, known as *holothurin*, that is secreted from their body walls.[34] Conjunctivitis, even blindness, can result from corneal involvement if the toxin comes in contact with the eyes.[62] Prevention of sea cucumber dermatitis involves protecting the skin and eyes from contact with these creatures and educating children and curious divers about the risk of handling them. Treatment consists of washing the affected area with soap and water to remove the toxin and then treating as for a mild contact dermatitis.

DERMATITIS AND BITES FROM MARINE WORMS

BRISTLEWORM DERMATITIS

Bristleworms are multisegmented marine worms of the phylum Annelida, class Polychaeta (which means "many bristles"; Fig. 182-21). Each segment of the worm is armed with rows of silky or bristle-like, hollow, venom-filled setae that can easily penetrate and break off in the unprotected skin of a victim as do cactus spines.[69] Contact with the bristleworm results in an erythematous papular or urticarial eruption at the site, accompanied by symptoms of paresthesias, intense itching, or burning pain.[34,69] The bristles are too small and fragile in most cases to be removed with a forceps; however, tape-stripping

Figure 182-21 *Hermodice carunculata*, the West Indian bristleworm, can inflict a painful wound with its hollow, venom-filled bristle-like setae. (Used with permission from Marty Gilman, Worcester, MA.)

with cellophane adhesive tape can be effective. After the setae have been removed, the application of ammonia soaks or alcohol or water compresses may bring symptomatic relief.

LEECH BITES

Leeches are another class of segmental worms whose bites may be encountered in freshwater or saltwater as well as on land. Although freshwater leeches are capable of attaching painlessly to their human hosts, saltwater leeches produce bites with pain similar to that of a bee sting. Leeches inject a powerful anticoagulant, hirudin, into the wound, as well as other antigenic substances that are capable of eliciting allergic reactions (including anaphylaxis) in sensitized individuals. Local symptoms of leech bites include bleeding from the puncture marks, pain, swelling, redness, and severe pruritus; urticarial, bullous, or necrotic reactions may occur in sensitized persons.[34] Leech bites and medical leech therapy result in infection by *Aeromonas hydrophila*.

Severe ulcerations may result if the leech is removed forcibly and its mouth parts are left behind in the bite site. Leeches must be induced to fall off by applying a noxious agent (such as alcohol, vinegar, brine, or a match flame) to their site of attachment.

CERCARIAL DERMATITIS (CLAM DIGGER'S ITCH)

Cercarial dermatitis, also known as *schistosome dermatitis* or *swimmer's* or *clam digger's itch*, is an acute pruritic eruption resulting from penetration of the skin by the cercarial forms of certain parasitic flatworms of the family Schistosomatidae.

Symptoms of cercarial dermatitis begin with urticaria-like lesions and a prickling sensation of the skin, which lasts about half an hour after exposure to cercaria-infested waters. Severe pruritus of the affected area occurs 10 to 12 hours later. Within 24 hours, erythematous papules appear that may progress to vesicles and later to pustules. Pain and swelling of the area accompanies the intense itching, which usually peaks in 48 to 72 hours. Headache, fever, and superinfection with lymphangitis are occasionally present.

In the Great Lakes region, several species of *Schistosoma cercariae* that cause swimmer's itch have been reported, and many other such species have been discovered throughout the world in both freshwater and saltwater.[70,71] A severely disabling form of cercarial dermatitis affects the paddy workers and rice farmers of the Far East. Cercarial dermatitis also has been described in individuals exposed to shallow coastal waters, notably on Long Island Sound where the condition affects clam diggers, giving rise to the name, *clam digger's itch* (Fig. 182-22). There is one reported case of cercarial dermatitis occurring on the hands and arms of a patient after he cleaned the aquarium in which he kept native water snails.[72]

Figure 182-22 Intensely pruritic papulovesicles suggestive of a severe reaction to flea bites in a patient with clam digger's itch. The left hand, which was not in the water and was holding the pail for collecting the clams, was spared.

Humans are accidental hosts in the life cycle of dermatitis-producing schistosomes. The cycle begins when the primary host, a waterfowl, marsh bird, finch, muskrat, mouse, or deer, passes schistosomal eggs in its feces into a body of water. Each egg hatches in 10 to 15 minutes, releasing a secondary stage miracidium. The miracidia are free-swimming and must locate and infect their definitive snail host within 12 hours or they will die. The miracidia migrate to the snail's digestive gland, where they develop into multiple sporocysts. In about 5 weeks, the sporocysts give rise to hundreds of fork-tailed cercariae that measure 0.75 mm in length. The cercariae are released from the snail under favorable conditions of light and heat, and are carried toward the shore by prevailing winds and currents.[71] When an appropriate host is encountered, the cercaria attach to the skin with their oral suckers and penetrate the epidermis and dermis by means of histolytic enzymes. They lose their tails in this process and are now called schistosomula. The schistosomula migrate via the blood vessels through the heart and lungs to the intrahepatic veins, where they mature into adult male and female trematode flukes. When the worms mate, they pass in pairs through the mesenteric venules of the intestinal wall where the female lays hundreds of eggs.[71] The eggs then penetrate the gut wall and are discharged in the feces, and the cycle is repeated.

When cercariae that do not cause schistosomiasis in humans accidentally attach to the skin, they may penetrate the epidermis but are unable to reach the bloodstream. The organisms die in the superficial papillary dermis and undergo total histolysis within 3 to 4 days. The cercarial protein residua stimulate a delayed-type hypersensitivity response, which may increase in

severity with repeated exposures. Skin biopsies taken at 3 to 4 days reveal an amorphous eosinophilic mass at the site of the dissolved cercaria, with an intense lymphocytic infiltrate. Later, histiocytes appear in the middle and deep papillary dermis.

The differential diagnosis of cercarial dermatitis includes insect bites from chiggers, mosquitoes, and fleas; contact dermatitis from poison ivy; and the stings of other marine coelenterates. In Africa, Asia, South America, and Puerto Rico, swimmer's itch must be distinguished from the dermatitis associated with human schistosomiasis, which produces an eruption with very similar but milder and more transient symptoms.[73] Swimmer's itch must also be distinguished from sea bather's eruption (SE), which is discussed in the next section.

Prevention of cercarial dermatitis in waters where swimmer's itch is known to be a problem is difficult. Coating the skin with petrolatum and various chemical repellents has been tried, but the effectiveness of these methods remains unproven. Clothing barriers may be of some help.

Treatment of cercarial dermatitis is largely symptomatic. In mild cases, antipruritic or drying lotions, oatmeal or starch baths, and antihistamines may alleviate pruritus. Aspirin may be helpful for the pain and swelling, and a bedtime sedative may be required to allow the patient much-needed sleep. Proper washing and hygiene should be maintained to prevent bacterial superinfection. In severe cases, potent topical glucocorticoids and occasionally systemic glucocorticoids may be required.

SEA BATHER'S ERUPTION

SE, also known as *marine dermatitis* and often misnamed *sea lice infestation*, is an acute dermatitis that begins shortly after bathing in seawater. SE is often confused with swimmer's itch (cercarial dermatitis, see previous section), not only because they both occur after exposure to water but also because the common names of these 2 conditions are easily confused. For many years, the cause of SE remained a mystery, but it is now known that the responsible agents in at least 2 types of SE are the larval forms of marine coelenterates. In waters off the coast of Florida and in the Caribbean, the tiny larvae of the thimble jellyfish, *Linuche unguiculata*, are to blame.[74] Off the coast of Long Island, New York, researchers found that the larval forms of the sea anemone *Edwardsiella lineata* were responsible for the eruption.

In addition to having a different etiology, SE can be distinguished from cercarial dermatitis by several other characteristics: SE primarily involves areas of the body covered by bathing suits from which water evaporates slowly, as opposed to uncovered areas as is typical of swimmer's itch. Most symptoms are not noted until the bather has left the water (although some of those affected have complained of a prickling sensation while still in the water).

The eruption is caused by minute stings from the nematocysts of the coelenterate larvae, which become trapped underneath swimwear or may adhere to hairy areas of the body. In addition to SE after contact with the larvae, which are most abundant in May and June, swimmers and bathers may also develop SE after contact with the other 2 free-swimming stages of *L. unguiculata*, the ephyrae and medusae stages.[75]

Figure 182-23 Sea bather's eruption in a young girl after a swim at a Florida beach. (Used with permission from Karen Rothman, MD.)

The lesions begin within 4 to 24 hours after exposure as erythematous macules, papules, or wheals that may itch or burn (Fig. 182-23).[34] These lesions may progress to vesiculopapules, which crust over and heal in 7 to 10 days. Associated systemic symptoms may include chills and a low-grade fever as well as nausea, vomiting, diarrhea, headache, weakness, muscle spasms, and malaise. Febrile and systemic symptoms are more common in children and adolescents.[76] In the presence of such constitutional symptoms, caregivers who fail to recognize the pattern of the eruption or who fail to take a history of exposure to saltwater may mistakenly make the diagnosis of a viral syndrome.

In waters along the coast of South Florida, the season for SE is between March and August with a peak in May. The incidence among bathers during May and June 1993 in Palm Beach County was reported to be 16%.[76] The strongest risk factor for developing SE is a previous history of the condition, which is consistent with the theory that SE represents a hypersensitivity response to the nematocyst stings. Other risk factors include age younger than 16 years and surfing. Showering with swimwear removed was found to be a protective measure.[76]

Prevention of SE includes the measures listed in Table 182-7. Treatment of SE is symptomatic and includes the use of antipruritic lotions, colloidal baths with starch or oatmeal, antihistamines, and topical glucocorticoids. Severe unremitting cases may warrant systemic glucocorticoid therapy.[74] Secondary bacterial infections may complicate the condition and should be diagnosed and treated appropriately.

TABLE 182-7
Prevention of Seabather's Eruption

1. Bathers should remove their swimwear and shower as soon as possible after leaving the water. Because fresh water may cause discharge of the nematocysts, it is important that the suits be removed before showering begins.
2. Bathing suits should be rinsed with soap and water and heat dried, because the eruption can recur when the suit is air-dried.
3. T-shirts should not be worn in the water. Women may consider wearing a 2-piece suit to reduce the surface area under which larvae may be trapped.
4. Whole-body Lycra swimsuits or wet suits with snug-fitting collars and cuffs may be protective, but the eruption may still occur along the collar or cuff edges.
5. Highly sensitized individuals should avoid swimming in infested waters during outbreaks of seabather's eruption.

INJURIES CAUSED BY MOLLUSKS

CONE SNAIL ENVENOMATIONS

Venomous marine snails are univalvular gastropods whose ornate cone-shaped shells (Fig. 182-24) are highly prized by shell collectors and divers. A number of species have a highly developed venom apparatus that can inflict a lethal sting. Most of the dangerous cone shell species are found in the shallow waters of the Indo-Pacific. Cone shells are carnivorous. They live on the ocean bottom and, depending on the species, may hunt worms, other mollusks, or fish. Cone shells kill their prey by means of a spear-like venomous radular tooth that is thrust out from the animal's proboscis. Cone shell venom contains several different kinds of neurotoxins; death may result from respiratory paralysis. There is so far no antivenin for cone shell toxin; mortality rates after envenomations from the more dangerous species (*Conus geographicus* and *C. magus*) may be as high as 15% to 20%.[34]

Figure 182-24 Cone shells collected digging in sand by one of the authors (R.A.S.) on Naples, Florida, beach.

Injuries from cone shells are of the puncture wound variety. The degree of pain is variable, ranging from a mild stinging sensation, similar to that of an insect bite, to excruciating pain. Early symptoms may include edema, ischemia, numbness, and paresthesias of the wound site. Paresthesias may become widespread, with the lips and mouth commonly affected.[34,62] Localized muscular paralysis may progress to generalized weakness or paralysis with eventual respiratory distress and cardiopulmonary failure.[77] Neurotoxic symptoms that indicate severe envenomation include diplopia, blurred vision, aphonia, dysphagia, and coma. Rare cases of disseminated intravascular coagulation have been reported after cone shell envenomation.

Great care must be exercised in handling live cone shells. Thick protective gloves should be worn, and the soft underportion of the animal should be avoided. Cone shells should never be placed in pockets of clothing or swimwear, because they have been known to sting through clothing.[78]

Treatment of cone shell envenomations is supportive. The victim should be kept at rest and the sting area kept dependent and immobilized. A compression dressing should be applied to occlude lymphatic-venous, but not arterial, flow.[78] Local suction may be helpful if it can be applied immediately to the wound site with a plunger device, such as the Extractor Vacuum Pump (Sawyer Products, Safety Harbor, Florida).

OCTOPUS BITES

Octopuses are an advanced group of mollusks belonging to the class Cephalopoda. The octopus bites with a parrotlike chitinous beak located on the ventral side of the head in the middle of its 8 tentacles (Fig. 182-25). Species of octopi range in size from a few centimeters to 1 to 2 m in diameter.[79] They are shy and reclusive

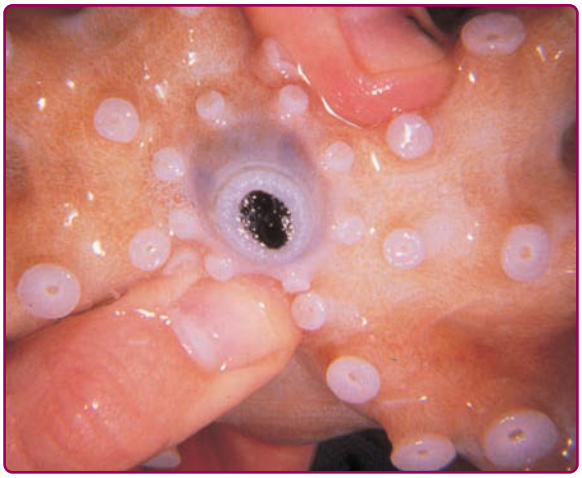

Figure 182-25 Ventral view of the underside of an octopus exposing the animal's centrally located mouth and parrotlike beak. (From Fulghum DD. Octopus bite resulting in granuloma annulare. *South Med J.* 1986;79:1434, with permission.)

creatures that tend to avoid encounters with humans; however, bites can occur when curious divers, fishermen, or beachgoers encounter these animals and handle them carelessly. Most octopus bites are not life-threatening to humans. The bite site may be immediately painful, as after a bee sting, and is recognized by the presence of 2 small puncture wounds, which may bleed profusely.[78] Symptoms from octopus bites are usually mild and transient and consist of redness, swelling, and itching.[79]

The most dangerous species of octopus, the Australian blue-ringed octopus, *Hapalochlaena maculosa*, is found in Australian coastal waters. Mortality rates after bites from *H. maculosa* may be as high as 25%. *H. maculosa* produces a toxin in its salivary glands that is introduced into the bite site by the animal's powerful beak and contains a fraction identical to tetrodotoxin; this toxin blocks peripheral nerve conduction and results in paralysis of the victim with subsequent respiratory failure. The bite of the blue-ringed octopus may or may not be painful, so that victims may not realize they have been bitten until neurologic symptoms develop.[62]

There is no antivenin for bites of *H. maculosa.* Treatment is supportive and similar to that recommended in the previous section for severe cone shell envenomations.

INJURIES CAUSED BY VENOMOUS FISH SPINES

Ichthyoacanthotoxicosis is the proper term for envenomations as a result of puncture wounds or lacerations inflicted by the spines of venomous fish. There are more than 200 species of venomous fish in the world that can cause injury to humans.[62] The most notorious of these species are the stingrays, catfish, lionfish, scorpionfish, stonefish, weevers, toadfish, and spiny dogfish. All of these fish have in common a venom apparatus consisting of a single spine or multiple spines, in various locations, which are covered by an integumentary sheath enclosing various forms of venom glands. When the spine of the animal penetrates the victim, the sheath is torn and the venom glands release their toxins into the wound. The toxins from some of these fish may remain potent for 24 to 48 hours after the death of the fish.[80]

STINGRAYS

Stingrays are one of the most common causes of venomous fish stings confronting humans, with as many as 1500 to 2000 stingray attacks reported each year in the United States alone.[69,81] Rays are grouped into one of 4 categories: (1) gymnurid (butterfly rays), (2) urolophid (round stingrays), (3) myliobatid (bat or eagle rays), and (4) dasyatid (proper stingrays). The groupings are based on their relative stinging ability, which depends on the size, number, and location of the caudal stinging appendages. The most dangerous group, the dasyatid or true stingrays, have the largest spines located further out on their tails, which makes them the most potent striking weapons. The spines have retroserrated teeth, so that removal is difficult (Fig. 182-26).

Figure 182-26 A close-up view of a stingray stinger without its outer membrane and venom glands, demonstrating the retroserrated spine. (Used with permission from David Fulghum, MD.)

Most stingray injuries occur when bathers, waders, or fishermen accidentally step on rays as they lie partially covered with sand in shallow waters.[82,83] Severe lacerations and puncture wounds are inflicted by the ray as it defensively whips its tail upward and forward when stepped on or threatened (Fig. 182-27).[82,83] The majority of wounds, therefore, are located on the dorsum of the foot or lower leg. Penetrating wounds to other locations have occurred to fishermen stung while attempting to remove rays from their lines or nets. Rarely these injuries are fatal. Soaking in warm water relieves the pain.

Figure 182-27 Stingrays reflexively swing their barbed tails up when stepped on, causing painful lacerations and puncture wounds. (The leg used for this photograph was a prosthesis; the stingray was alive.) (Used with permission from David Fulghum, MD.)

CATFISH

Both freshwater and saltwater catfish are armed with stout, sharp spines located immediately in front of the soft rays of their dorsal and pectoral fins. Catfish defensively lock these spines into an extended position when they are handled or threatened. Bathers may sustain stings on their feet or legs if they step on a catfish, but most catfish stings involve the hand or upper extremity of fishermen or seafood processors.[84] To prevent these injuries, it has been suggested that the offending spines be removed with a pair of pliers before cleaning of the fish is attempted. Empiric intravenous antibiotics may be required to cover common aquatic bacteria.

Swimmers and bathers in the Amazon River are at risk for urologic injuries if they encounter a very small species of catfish called the *candiru*, which has the ability to enter the human urethra. Barbs on the head of this fish prevent it from swimming backward out of the orifice, and surgical intervention is often required to extract the fish.

SCORPIONFISH

Scorpionfish, family Scorpaenidae, are divided into 3 main groups on the basis of their stinging apparatus. All have venomous spines of varying sizes and toxicity, which may be found in dorsal, pelvic, and anal locations, depending on the species.

Scorpionfish, genus *Scorpaena*, have stings that are of intermediate severity. They are bottom dwellers with superior camouflage abilities that allow them to blend in almost invisibly with their surroundings (Fig. 182-28). Their spines are long and heavy and have moderate-sized venom glands.

Stonefish, genus *Synanceja*, are the most dangerous members of the scorpionfish family. They live in shallow waters, sometimes partially buried in sand or mud, or in holes of rocky shoals, reef areas, or tidal pools.[69] Injuries occur when a wader steps on the erect venomous dorsal spine that the stonefish raises in defense. Stonefish spines are short and thick and have very large and well-developed venom glands. The wounds caused by stonefish are quite severe and may be fatal. A stonefish antivenin is available.

Figure 182-28 *Scorpaena plumieri*, a species of scorpionfish, is found in the waters of the West Indies. Its camouflage abilities are exceeded only by its painful sting.

WEEVERFISH

In European coastal waters, the weeverfish is one of the most common and serious causes of venomous fish spine injuries.[85] These fish are equipped with between 5 and 8 venomous dorsal spines and 2 venomous opercular spines (one on each side of the head near the gill plate).[86] Waders and bathers are at risk when they step on weeverfish that lie partly buried in mud or sand in shallow waters.

LOCAL AND SYSTEMIC SYMPTOMS OF FISH SPINE ENVENOMATIONS

The toxicity of a given venomous fish sting depends on a number of factors, including the species of fish involved, the location and severity of the wound, the amount of venom released, and the first aid and subsequent medical care provided to the victim. In general, these wounds produce pain disproportionate to the apparent severity of the injury. The pain is immediate and intense. In the case of scorpionfish stings, the pain may be so severe as to cause the victim to thrash about wildly, scream, and finally lose consciousness.

Initially, the sting site may appear pale or cyanotic. The area around the wound may be anesthetic or hyperesthetic. Erythema and edema soon develop, giving the appearance of a cellulitis. Vesicles may form. In severe stinging, especially those caused by stonefish, the wounded area may become indurated and develop areas of ischemic necrosis with subsequent sloughing and ulcer formation.

Systemic effects from toxic fish spine envenomations may range from mild to severe, depending on the species involved and the amount of venom entering the wound. They can include headache, nausea, vomiting, diarrhea, abdominal cramps and pain, fever, local lymphangitis and lymphadenitis, joint aches, muscle weakness, diaphoresis, peripheral neuropathy, limb paralysis, restlessness, delirium, seizures, cardiac arrhythmias, myocardial ischemia, pericarditis, hypotension, and respiratory distress, and can lead to death.[84,87,88]

PREVENTION

Prevention of toxic fish spine wounds begins with knowledge of and appreciation for the various venomous species that may be encountered in a given area. Waders and bathers should shuffle their feet to scare away and avoid stepping on rays or scorpionfish. Fishermen must exercise care when removing rays or catfish from their fishing lines or when cleaning fish with venomous spines. Fish hobbyists and divers should wear protective clothing and avoid handling venomous species.

TREATMENT

Puncture wounds and lacerations from venomous fish spines should be irrigated immediately with sterile saline or water, if available, and with seawater as a last resort.[78] The wounded area should then be soaked as quickly as possible in hot (not scalding) water of approximately 43°C to 46°C (110°F-115°F) for 30 to 90 minutes or until maximal pain relief is achieved. Hot soaks may be repeated if the pain returns. Because the wound or extremity may be partially anesthetic, the person administering first aid must test the water's temperature for the victim.[53,89] One source of hot water that is often overlooked and may be useful in an emergency is hot seawater from a boat motor's cooling system.

Local infiltration of the wound with 1% to 2% lidocaine without epinephrine may bring about significant pain relief and allow exploration of the wound after radiographs have been obtained to locate retained portions of spines.[59,69] Longer-acting anesthetics such as procaine and bupivacaine may be chosen to provide a longer period of pain relief. The wound should be thoroughly cleaned to remove any remnants of integumentary sheath. Abdominal and thoracic wounds and deep wounds to the hands, feet, or fascial compartments of the legs should be explored in the operating room.[69] Debridement of necrotic tissues may be required at the time of exploration, and sequential debridement may be necessary. In general, these wounds should be left open or closed loosely with tape or suture to allow for adequate drainage and to prevent abscess formation.

Tetanus prophylaxis should be administered if indicated, and antibiotics are recommended if the wound is more than 6 hours old, is extensive, or involves deep puncture injuries to the hand or foot. The choice of antibiotic should be based on the bacteriology of the marine environment in which the wound occurred and, subsequently, on results of deep wound or tissue cultures. Empiric antibiotic therapy for infections of wounds occurring in saltwater should include coverage for *Vibrio* species. Before final wound culture results are known, initial choices of parenteral antibiotics include intravenous ciprofloxacin, imipenem-cilastatin, a third-generation cephalosporin, gentamicin, tobramycin, or trimethoprim-sulfamethoxazole.

Stonefish stings complicated by severe reactions may be treated with antivenin by slow intravenous infusion. Antivenom is not usually required for the stings of lionfish and other species of scorpionfish except for stonefish.[69] Stonefish antivenom is available from the Australian Commonwealth Serum Laboratory, Melbourne, Australia.

FISH BITES

There are many species of fish whose bites are dangerous to humans. Among the best known are the sharks and barracudas, whose bites may cause severe injuries.

Although they are well publicized by the news media, shark attacks are relatively rare events. The average number of unprovoked shark attacks worldwide in 2012-2016 was 83 incidents annually.[90] Only 32 of the 400 known species of sharks have been reported to attack humans. Most shark attacks involve surfers, scuba divers, and swimmers. Because sharks are attracted to bright or shiny objects, as well as to those with contrasting colors, these items should not be worn in the water. Sharks are also attracted by any sort of blood in the water; therefore, women who are menstruating should refrain from water sports in areas in which sharks may be prevalent, and no one should swim with an open bleeding wound. Spear fishermen should never tie their catch to themselves, and should place their catch in the dive boat as soon as possible. Although most shark bites are not life-threatening, more severe attacks may cause extensive soft-tissue loss with massive hemorrhage, which, in the worst cases, can result in amputation of a limb or death.[91,92]

Barracuda attacks are even rarer than shark bites. They tend to occur in turbid waters where these predators may mistake jewelry or other brightly colored objects worn by bathers for the baitfish on which they feed. Barracuda bites typically produce straight or V-shaped lacerations.

Divers and aquarium hobbyists must be careful when feeding or handling moray eels, which have powerful jaws and knife-like teeth. Although they are not considered venomous by most sources, they can produce deep puncture wounds and lacerations (Fig. 182-29).[78] When biting, moray eels tend to lock onto their prey; decapitation of the eel or disarticulation of its jaw may be required to release the victim.[93] As with all deep puncture wounds

Figure 182-29 California Moray eel (*Gymnothorax mordax*), ranging from Point Conception to southern Baja California, with bites uncommon, but their incidence is rising because divers feed them at popular dive sites. (Used with permission from Jeffery Lee, D.D.S., Monte Sereno, CA.)

or lacerations, victims of moray eel bites should receive tetanus prophylaxis. Empiric antibiotic therapy for prophylaxis or treatment can include ciprofloxacin or cefuroxime for coverage of *Vibrio* or *Pseudomonas* species.[93]

WATERBORNE INFECTIONS

A variety of infections may result from exposures to aquatic environments. Pathogenic organisms may be actively introduced into the bite, sting, or laceration wounds caused by marine life; preexisting wounds may be passively infected when exposed to contaminated waters. *V. carchariae*, a halophilic (saltwater-loving) gram-negative bacillus, was reported as the cause of a wound infection after a shark bite.[94] Table 182-8 lists those organisms commonly associated with waterborne infections (see also Chap. 156). A host of other agents, such as *Streptococcus* and *Staphylococcus* sp., *Bacteroides fragilis*, *Clostridium perfringens*, *Escherichia coli*, *Salmonella enteritidis*, marine *Vibrio* sp., *Chromobacterium violaceum*, and *Chlorella*, also require consideration when dealing with infections associated with aquatic settings.[69] Life-threatening saltwater necrotizing fasciitis may result from a minor skin wound infected with a Vibrio species.[95]

TABLE 182-8
Wound Infections Associated with Waterborne Organisms

ORGANISM	CLINICAL FEATURES
Aeromonas hydrophilia	Cellulitis (may be bullous), fasciitis, myonecrosis, bacteremia.
Edwardsiella tarda	Cellulitis, abscess, osteomyelitis, bacteremia.
Erysipelothrix rhusiopathiae	Slowly progressive cellulitis without adenopathy or lymphangitis, almost always involving the hand; septic arthritis; subacute bacterial endocarditis.
Mycobacterium balnei or *Mycobacterium marinum*	Swimming pool granuloma; fish fancier's finger; chronic cellulitis and culture-negative ulcers; often the primary lesion is on the hand and then a series of lesions develop in draining lymphatics.
Pfiesteria piscicida	Raw, red pock-marked lesions in fish in polluted waterways; in humans, rashes, respiratory problems, and memory deficits.
Protothecosis	Papular or eczematoid dermatitis in immunosuppressed patients; localized infection of the olecranon bursa.
Pseudomonas species	Trench foot; gram-negative toe web space infections; swimmer's ear; hot tub folliculitis.
Streptococcus iniae	Cellulitis and bacteremia after skin injuries during the handling of fresh fish raised by aquaculture.
Vibrio vulnificus, other *Vibrio* sp.	Cellulitis, sometimes with bulla formation; may progress to septicemia, especially in alcoholics, diabetics, and immunosuppressed patients; metastatic cellulitis, meningitis, and death may result from fulminant infections.

CUTANEOUS MANIFESTATIONS OF SEAFOOD INGESTION AND SEAFOOD POISONING

Allergy to fish and crustaceans, such as shrimp, lobster, crab, and crawfish, is common, with most seafood allergies being lifelong.[96] Dermatologic reactions may appear after the ingestion of seafood. Urticaria, angioedema, and, rarely, leukocytoclastic vasculitis may occur in individuals sensitized to fish or shellfish. Many seafoods, such as kelp, contain large amounts of iodine, which may cause acneiform eruptions.

Scombroid food poisoning involves the ingestion of spoiled fish from the Scombridae family of fish, such as tuna, mackerel, and Bonita.[97] If these fish are not kept cold enough after being caught, their flesh develops scombrotoxins as a consequence of the bacterial breakdown of histidine into histamine, saurine, and possibly other toxic by-products. These can cause striking erythema and flushing of the face, neck, and upper trunk, as well as pruritus and urticarial and angioedematous eruptions. Oral antihistamines are the usual therapeutic option.

Ciguatera toxin, which is produced during blooms of toxic dinoflagellates, is incorporated into the marine food chain and concentrated in the flesh of a variety of fish. It is heat stable. Symptoms may occur after eating cooked or raw fish containing the toxin. Dermatologic symptoms of ingesting these fish may include generalized pruritus and diffuse erythematous macular and papular exanthems, which may progress to blister formation and desquamation.

ACKNOWLEDGMENTS

We thank Dr Bruce Halstead of the World Life Research Institute, Colton, California, for allowing us to reprint the photographs from the first and second editions of *Poisonous and Venomous Marine Animals of the World*. We also thank the legendary Professor Rajendra Kapila, who is in his 52nd year at Rutgers New Jersey Medical School, for his assistance.

REFERENCES

1. CDC. Nonfatal dog bite–related injuries treated in hospital emergency departments—United States, 2001. *MMWR Morb Mortal Wkly Rep.* 2003;52(26):605-610.
2. Aziz H, Rhee P, Pandit V, et al. The current concepts in management of animal (dog, cat, snake, scorpion) and human bite wounds. *J Trauma Acute Care Surg.* 2015;78(3):641-648.

3. Tuncali D, Bingul F, Terzioglu A, et al. Animal bites. *Saudi Med J.* 2005;26(5):772-776.
4. Benson LS, Edwards SL, Schiff AP, et al. Dog and cat bites to the hand: treatment and cost assessment. *J Hand Surg Am.* 2006;31(3):468-473.
5. Garcia VF. Animal bites and Pasteurella infections. *Pediatr Rev.* 1997;18(4):127-130.
6. Grim KD, Doherty C, Rosen T. Serratia marcescens bullous cellulitis after iguana bites. *J Am Acad Dermatol.* 2010;62(6):1075-1076.
7. Rittner AV, Fitzpatrick K, Corfield A. Best evidence topic report. Are antibiotics indicated following human bites? *Emerg Med J.* 2005;22(9):654.
8. Chaudhry MA, MacNamara AF, Clark S. Is the management of dog bite wounds evidence based? A postal survey and review of the literature. *Eur J Emerg Med.* 2004;11(6):313-317.
9. Mansfield KL, Andrews N, Goharriz H, et al. Rabies preexposure prophylaxis elicits long-lasting immunity in humans. *Vaccine.* 2016;34(48):5959-5967.
10. Talan DA et al. Clinical presentation and bacteriologic analysis of infected human bites in patients presenting to emergency departments. *Clin Infect Dis.* 2003;37(11):1481-1489.
11. Suchard JR. "Spider bite" lesions are usually diagnosed as skin and soft-tissue infections. *J Emerg Med.* 2011;41(5):473-481.
12. Barnham M, Holmes B. Isolation of CDC group M-5 and *Staphylococcus intermedius* from infected dog bites. *J Infect.* 1992;25(3):332-334.
13. Blanche P, Meyniard O, Ratovohery D, et al. *Capnocytophaga canimorsus* lymphocytic meningitis in an immunocompetent man who was bitten by a dog. *Clin Infect Dis.* 1994;18(4):654-655.
14. Linton DM, Potgieter PD, Roditi D, et al. Fatal *Capnocytophaga canimorsus* (DF-2) septicaemia. A case report. *S Afr Med J.* 1994;84(12):857-860.
15. Deshmukh PM, Camp CJ, Rose FB, et al. *Capnocytophaga canimorsus* sepsis with purpura fulminans and symmetrical gangrene following a dog bite in a shelter employee. *Am J Med Sci.* 2004;327(6):369-372.
16. van de Ven AR, van Vliet AC, Maraha B, et al. Fibrinolytic therapy in *Capnocytophaga canimorsus* sepsis after dog bite. *Intensive Care Med.* 2004;30(10):1980.
17. Elliott DR, Wilson M, Buckley CM, et al. Cultivable oral microbiota of domestic dogs. *J Clin Microbiol.* 2005; 43(11):5470-5476.
18. Summanen PH, Durmaz B, Väisänen ML, et al. *Porphyromonas somerae* sp. nov., a pathogen isolated from humans and distinct from *Porphyromonas levii*. *J Clin Microbiol.* 2005;43(9):4455-4459.
19. Citron DM, Hunt Gerardo S, Claros MC, et al. Frequency of isolation of *Porphyromonas* species from infected dog and cat bite wounds in humans and their characterization by biochemical tests and arbitrarily primed-polymerase chain reaction fingerprinting. *Clin Infect Dis.* 1996;23(suppl 1):S78-S82.
20. Krebs JW, Mandel EJ, Swerdlow DL, et al. Rabies surveillance in the United States during 2004. *J Am Vet Med Assoc.* 2005;227(12):1912-1925.
21. Burton EC, Burns DK, Opatowsky MJ, et al. Rabies encephalomyelitis: clinical, neuroradiological, and pathological findings in 4 transplant recipients. *Arch Neurol.* 2005;62(6):873-882.
22. World Health Organization (WHO). *Rabies and Envenomings: A Neglected Public Health Issue: Report of a Consultative Meeting*, 2007. http://www.who.int/bloodproducts/animal_sera/Rabies.pdf. Accessed July 25, 2018.
23. Kositprapa C, Limsuwun K, Wilde H, et al. Immune response to simulated postexposure rabies booster vaccinations in volunteers who received preexposure vaccinations. *Clin Infect Dis.* 1997;25(3):614-616.
24. Fishbein DB, Robinson LE. Rabies. *N Engl J Med.* 1993; 329(22):1632-1638.
25. Willoughby RE Jr, Tieves KS, Hoffman GM, et al. Survival after treatment of rabies with induction of coma. *N Engl J Med.* 2005;352(24):2508-2514.
26. Holmes GP, Chapman LE, Stewart JA, et al. Guidelines for the prevention and treatment of B-virus infections in exposed persons. The B virus Working Group. *Clin Infect Dis.* 1995;20(2):421-439.
27. WHO Guidelines for the Production, Control and Regulation of Snake Antivenom Immunoglobulins, 2018. http://www.who.int/bloodproducts/snake_antivenoms/snakeantivenomguide/en/. Accessed July 25, 2018.
28. World Health Organization (WHO). *Venomous snakes and antivenoms search interface*, 2018. http://apps.who.int/bloodproducts/snakeantivenoms/database/default.htm. Accessed 2018.
29. Gold BS, Dart RC, Barish RA. Bites of venomous snakes. *N Engl J Med.* 2002;347(5):347-356.
30. McKinney PE. Out-of-hospital and interhospital management of crotaline snakebite. *Ann Emerg Med.* 2001; 37(2):168-174.
31. Hall EL. Role of surgical intervention in the management of crotaline snake envenomation. *Ann Emerg Med.* 2001;37(2):175-180.
32. Eadie PA, Lee TC, Niazi Z, et al. Seal finger in a wildlife ranger. *Ir Med J.* 1990;83(3):117-118.
33. Nuckton TJ, Simeone CA, Phelps RT. California sea lion (*Zalophus californianus*) and Harbor seal (*Phoca vitulina richardii*) bites and contact abrasions in open-water swimmers: a series of 11 cases. *Wilderness Environ Med.* 2015;26(4):497-508.
34. Fisher AA. Aquatic dermatitis, Part I. Dermatitis caused by coelenterates. *Cutis.* 1999;64(2):84-86.
35. Auerbach PS, Hays, JT. Erythema nodosum following a jellyfish sting. *J Emerg Med.* 1987;5(6):487.
36. Lakkis NA, Maalouf GJ, Mahmassani DM. Jellyfish stings: a practical approach. *Wilderness Environ Med.* 2015; 26(3):422-429.
37. Auerbach PS. Envenomations from jellyfish and related species. *J Emerg Nurs.* 1997;23(6):555-565; quiz 566-567.
38. Burnett JW, Calton GJ. Jellyfish envenomation syndromes updated. *Ann Emerg Med.* 1987;16(9):1000-1005.
39. Halstead BW. Coelenterate (cnidarian) stings and wounds. *Clin Dermatol.* 1987;5(3):8-13.
40. Williamson JA, Burnett JW, Fenner PJ, et al. Acute regional vascular insufficiency after jellyfish envenomation. *Med J Aust.* 1988;149(11-12):698-701.
41. Giordano AR, Vito L, Sardella PJ. Complication of a Portuguese man-of-war envenomation to the foot: a case report. *J Foot Ankle Surg.* 2005;44(4):297-300.
42. Guess HA, Saviteer PL, Morris CR. Hemolysis and acute renal failure following a Portuguese man-of-war sting. *Pediatrics.* 1982;70(6):979-981.
43. Burnett JW, Gable WD. A fatal jellyfish envenomation by the Portuguese man-o'war. *Toxicon.* 1989;27(7): 823-824.
44. Stein MR, Marraccini JV, Rothschild NE, et al. Fatal Portuguese man-o'-war (*Physalia physalis*) envenomation. *Ann Emerg Med.* 1989;18(3):312-315.
45. Bengtson K, Nichols MM, Schnadig V, et al. Sudden death in a child following jellyfish envenomation by

Chiropsalmus quadrumanus. Case report and autopsy findings. *JAMA*. 1991;266(10):1404-1406.
46. Sutherland S. Lethal jellyfish. *Med J Aust*. 1985; 143(12-13):536.
47. Fenner PJ, Harrison SL. Irukandji and *Chironex fleckeri* jellyfish envenomation in tropical Australia. *Wilderness Environ Med*. 2000;11(4):233-240.
48. Bailey PM, Little M, Jelinek GA, et al. Jellyfish envenoming syndromes: unknown toxic mechanisms and unproven therapies. *Med J Aust*. 2003;178(1): 34-37.
49. O'Reilly GM, Isbister GK, Lawrie PM, et al. Prospective study of jellyfish stings from tropical Australia, including the major box jellyfish *Chironex fleckeri*. *Med J Aust*. 2001; 175(11-12):652-655.
50. Burnett JW, Calton GJ. The case for verapamil use in alarming jellyfish stings remains. *Toxicon*. 2004;44(8):817-818; author reply 819-820.
51. Burnett JW. The case for the use of verapamil in alarming Chironex stings. *Anaesth Intensive Care*. 1998; 26(4):461-464.
52. Collated by CRC Reef on behalf of the Queensland Government Irukandji Jellyfish Response Task Force, current status of knowledge and action on Irukandji, v.8.3. 6/1/2006:6/1/2006. http://www.reef.crc.org.au/iscover/plantsanimals/pdf/StatusofKnowledgeandActionPaperSep2002.pdf. Accessed November 22, 2011.
53. Wilcox CL, Yanagihara AA. Heated debates: hot-water immersion or ice packs as first aid for cnidarian envenomations? *Toxins (Basel)*. 2016;8(4):97.
54. Fenner PJ, Williamson JA. Worldwide deaths and severe envenomation from jellyfish stings. *Med J Aust*. 1996;165(11-12):658-661.
55. Garcia PJ, Schein RM, Burnett JW. Fulminant hepatic failure from a sea anemone sting. *Ann Intern Med*. 1994; 120(8):665-666.
56. Nicholls D. Sea anemone sting while SCUBA diving. *N Z Med J*. 1992;105(936):245.
57. Sagi A, Rosenberg L, Ben-Meir P, et al. "The fire coral" (*Millepora dichotoma*) as a cause of burns: a case report. *Burns Incl Therm Inj*. 1987;13(4):325-326.
58. Camarasa JG, Nogues Antich E, Serra-Baldrich E. Red Sea coral contact dermatitis. *Contact Dermatitis*. 1993; 29(5):285-286.
59. Auerbach PS. *Diving Medicine Articles: I Have Been Stung: What Should I Do?* [updated 2004], 2004, Divers Alert Network. Accessed July 26, 2018.
60. Isbister GK, Hooper JN. Clinical effects of stings by sponges of the genus Tedania and a review of sponge stings worldwide. *Toxicon*. 2005;46(7):782-785.
61. Burnett JW, Calton GJ, Morgan RJ. Dermatitis due to stinging sponges. *Cutis*. 1987;39(6):476.
62. Kizer KW. Marine envenomations. *J Toxicol Clin Toxicol*. 1983;21(4-5):527-555.
63. Baden HP. Injuries from sea urchins. *Clin Dermatol*. 1987;5(13):112-117.
64. Burnett JW, Burnett MG. Sea urchins. *Cutis*. 1999; 64(1):21-22.
65. Burke WA, Steinbaugh JR, O'Keefe EJ. Delayed hypersensitivity reaction following a sea urchin sting. *Int J Dermatol*. 1986;25(10):649-650.
66. Asada M, Komura J, Hosokawa H, et al. A case of delayed hypersensitivity reaction following a sea urchin sting. *Dermatologica*. 1990;180(2):99-101.
67. Guyot-Drouot MH, Rouneau D, Rolland JM, et al. Arthritis, tenosynovitis, fasciitis, and bursitis due to sea urchin spines. A series of 12 cases in Reunion Island. *Joint Bone Spine*. 2000;67(2):94-100.
68. De La Torre C, Toribio J. Sea-urchin granuloma: histologic profile. A pathologic study of 50 biopsies. *J Cutan Pathol*. 2001;28(5):223-228.
69. Auerbach PS. Marine envenomations. *N Engl J Med*. 1991;325(7):486-493.
70. Verbrugge LM, Rainey JJ, Reimink RL, et al. Prospective study of swimmer's itch incidence and severity. *J Parasitol*. 2004;90(4):697-704.
71. Hoeffler DF. "Swimmers' itch" (cercarial dermatitis). *Cutis*. 1977;19(4):461-465, 467.
72. Folster-Holst R, Disko R, Röwert J, et al. Cercarial dermatitis contracted via contact with an aquarium: case report and review. *Br J Dermatol*. 2001;145(4): 638-640.
73. Gonzalez E. Schistosomiasis, cercarial dermatitis, and marine dermatitis. *Dermatol Clin*. 1989;7(2):291-300.
74. Rossetto AL, Da Silveira FL, Morandini AC, et al. Seabather's eruption: report of fourteen cases. *An Acad Bras Cienc*. 2015;87(1):431-436.
75. Segura-Puertas L, Ramos ME, Aramburo C, et al. One Linuche mystery solved: All 3 stages of the coronate scyphomedusa *Linuche unguiculata* cause seabather's eruption. *J Am Acad Dermatol*. 2001;44(4):624-628.
76. Kumar S, Hlady WG, Malecki JM. Risk factors for seabather's eruption: a prospective cohort study. *Public Health Rep*. 1997;112(1):59-62.
77. Halford ZA, Yu PY, Likeman RK, et al. Cone shell envenomation: epidemiology, pharmacology and medical care. Diving Hyperb Med 2015;45(3):200-207.
78. Halstead BW, Auerbach PS, eds. *Dangerous Aquatic Animal of the World: A Color Guide, With Prevention, First Aid, and Emergency Treatment Procedures*. Princeton, NJ: Darwin Press; 1990.
79. Burnett JW. Aquatic adversaries: human injuries induced by octopi. *Cutis*. 1998;62(3):124.
80. Soppe GG. Marine envenomations and aquatic dermatology. *Am Fam Physician*. 1989;40(2):97-106.
81. Germain M, Smith KJ, Skelton H. The cutaneous cellular infiltrate to stingray envenomization contains increased TIA+ cells. *Br J Dermatol*. 2000;143(5):1074-1077.
82. Meyer PK. Stingray injuries. *Wilderness Environ Med*. 1997;8(1):24-28.
83. Fenner PJ, Williamson JA, Skinner RA. Fatal and non-fatal stingray envenomation. *Med J Aust*. 1989;151(11-12): 621-625.
84. Das SK, Johnson MB, Cohly HH. Catfish stings in Mississippi. *South Med J*. 1995;88(8):809-812.
85. Davies RS, Evans RJ. Weever fish stings: a report of two cases presenting to an accident and emergency department. *J Accid Emerg Med*. 1996;13(2): 139-141.
86. Borondo JC, Sanz P, Nogué S, et al. Fatal weeverfish sting. *Hum Exp Toxicol*. 2001;20(2):118-119.
87. Trestrail JH III, Al-Mahasneh QM. Lionfish string experiences of an inland poison center: a retrospective study of 23 cases. *Vet Hum Toxicol*. 1989;31(2): 173-175.
88. Perkins RA, Morgan SS. Poisoning, envenomation, and trauma from marine creatures. *Am Fam Physician*. 2004;69(4):885-890.
89. Atkinson PR, Boyle A, Hartin D, et al. Is hot water immersion an effective treatment for marine envenomation? *Emerg Med J*. 2006;23(7):503-508.
90. Burgess GH, Piercy A. International Shark Attack File: 2018 Worldwide Shark Attack Summary, Florida Museum of Natural History, University of Florida. http://www.flmnh.ufl.edu/fish/sharks/isaf/graphs.htm#trends. Accessed June 2018.

91. Woolgar JD, Cliff G, Nair R, et al. Shark attack: review of 86 consecutive cases. *J Trauma.* 2001;50(5):887-891.
92. Byard RW, Gilbert JD, Brown K. Pathologic features of fatal shark attacks. *Am J Forensic Med Pathol.* 2000; 21(3):225-229.
93. Erickson T, Vanden Hoek TL, Kuritza A, et al. The emergency management of Moray eel bites. *Ann Emerg Med.* 1992;21(2):212-216.
94. Pavia AT, Bryan JA, Maher KL, et al. *Vibrio carchariae* infection after a shark bite. *Ann Intern Med.* 1989; 111(1):85-86.
95. Schwartz RA, Kapila R. Dermatologic manifestations of necrotizing Fasciitis Medscape Reference. http://emedicine.medscape.com/article/1054438-overview. Updated June 21, 2018.
96. Husain Z, Schwartz RA. Food allergy update: more than a peanut of a problem. *Int J Dermatol.* 2013; 52(3):286-294.
97. Guergué-Díaz de Cerio O, Barrutia-Borque A, Gardeazabal-García J. Scombroid poisoning: a practical approach. *Actas Dermosifiliogr.* 2016;107(7):567-571.

Topical and Systemic Treatments

PART 28

Chapter 183 :: Principles of Topical Therapy

:: Mohammed D. Saleem, Howard I. Maibach, & Steven R. Feldman

AT-A-GLANCE

- Efficacy of a topically applied drug depends on three things: whether the drug is applied, the delivery of the active molecule by its vehicle, and the inherent potency of the active molecule.
- Adherence to topical treatment is often poor and decreases over time.
- Factors that affect penetration of applied drug include soluble medication concentration, regional variations in skin barrier properties, application frequency, and effects of the vehicle on barrier function.
- The primary barrier that limits the percutaneous absorption of compounds is the stratum corneum.
- The delivery of a topical agent is highly dependent on the physicochemical properties of the vehicle; this influences the kinetics of release and absorption and the onset, duration, and extent of a biologic response.
- Either the vehicle or its active ingredient(s) may cause local toxicity, systemic toxicity, or both.

INTRODUCTION

Topical therapy involves three key steps: topical application, percutaneous absorption, and binding of the active molecule to its target site. Sensible topical drug therapy involves selection of an appropriate agent that patients are able and willing to procure and apply (which may depend on the areas of the body affected), a vehicle that will effectively deliver the active molecule without irritation, and an active drug of the appropriate potency, along with a defined duration of use that maximizes efficacy and minimizes adverse side effects. Behind each of these considerations are basic principles that help guide the practitioner toward a rational plan of therapy.

ADHERENCE

The first principle of topical treatment is the ubiquity of poor adherence. Adherence is an often-ignored aspect of medication efficacy. Nonadherence to prescribed medicines in chronic conditions is between 30% and 50%.[1,2] Poor adherence to topical treatment is a common cause of poor response to drugs and is linked with poor outcomes in diseases such as psoriasis, atopic dermatitis, and acne.[3]

Poor adherence may be intentional or unintentional. Intentional nonadherence is driven by the patient's perception of the need for treatment weighed against their concern for toxicities and other costs. Unintentional nonadherence results from forgetfulness or lack of knowledge on prescribed regimens. Depression, socioeconomic status, single marital status, complicated treatment regimens, and high prescription costs are associated with nonadherence.[1,4-6]

There are varying patterns of poor adherence. Primary nonadherence refers to when patients do not fill their prescription or initiate treatment. Secondary nonadherence occurs when patients initiate treatment but use the medication poorly. Secondary nonadherence includes both poor execution (using the medication intermittently) and early discontinuation of treatment.

A variety of approaches have been promoted and tested as means to promote better adherence to topical treatment. Written instructions, discussing treatment expectations, and early follow-up visits after receiving

a prescription can improve adherence and decrease the overall required visits. Simplifying treatment regimens, prescribing patient preferred vehicles, treatment reminders, and support groups also improve adherence.[1,4] Last, a trusting and supportive doctor–patient relationship is critical to achieving adequate adherence.[7]

Nonadherence is often mistaken for treatment resistant disease. Adherence to topical therapies is often overestimated, resulting in switches to more costly and riskier alternative therapies.[8] Tachyphylaxis, defined as the decrease in drug response over time, is often a result of nonadherence rather than loss of corticosteroid receptor function.[9,10]

CUTANEOUS DELIVERY OF APPLIED DRUGS

Therapeutic efficacy of a topical drug relates to its inherent potency and the ability of the drug to penetrate the skin.[11] Many potent agents, such as hydrocortisone and fluocinolone acetonide, are poorly absorbed after topical application. Conversely, many well-absorbed agents with weak potency have negligible therapeutic use.

In contrast to many orally administered drugs that are nearly completely absorbed within a few hours, topical medicines generally have a poor total absorption and a slow absorption rate. For example, less than 1% of a topically applied corticosteroid such as hydrocortisone is absorbed after a single application left on the skin for more than 1 day. Furthermore, peak rates of absorption are reached up to 12 to 24 hours after application. Fortunately, low absorption does not necessarily translate into low efficacy. Drugs such as topical corticosteroids are effective because of their inherent potency and can exert clinically significant effects despite low absorption. In this light, absorption represents only one of many facets of efficacy.

DIFFUSION

LAWS OF DIFFUSION

Compounds applied topically to the skin surface migrate along concentration gradients according to well-described laws governing diffusion of solutes in solutions or their diffusion across membranes. For a detailed discussion of relevant equations, readers are referred to comprehensive reviews.[12]

FICK'S LAWS

Diffusion of uncharged compounds across a membrane or any homogeneous barrier is described by Fick's first and second laws. The first law states that the steady-state flux of a compound (J = moles/cm/s) per unit path length (δ, cm) is proportional to the concentration gradient (ΔC) and the diffusion coefficient (D, cm^2/s). The negative sign indicates that the net flux is in the direction of the lower concentration. This equation applies to diffusion-mediated processes in isotropic solutions under steady-state conditions. Fick's second law predicts the flux of compounds under non–steady-state conditions. Diffusion is an effective transport mechanism over very short distances but not over long ones. The relationship between the time (Δt) it takes for a molecule to migrate along a path length (x) and its diffusion coefficient is governed by the equation:

$$J = -D\,(\Delta C/\Delta\delta)$$

$$\Delta t = x^2/2D.$$

For example, diffusion coefficient for water in an aqueous solution is: $2.5 \times 10^{-5}\ cm^2/s$, suggesting that a water molecule would migrate over a 10-µm path (the equivalent of the width of the stratum corneum) in 0.4 ms. However, because diffusion depends on the square of the distance, longer distances are not efficiently covered; a 100-µm path would take 40 ms.

THREE-COMPARTMENT MODEL

Although pharmacokinetic analysis of topical preparations may require the description of a relatively large number of compartments, this discussion is confined to the three outlined in Fig. 183-1: (1) skin surface, (2) stratum corneum, and (3) viable tissue. The formulation itself forms a reservoir, from which the compound must be released; to undergo percutaneous absorption, the compound then must penetrate the stratum corneum; diffuse into and through the viable epidermis into the dermis; and, finally, gain access to the systemic compartment through the vascular system. In addition, the substance may diffuse through the dermal and hypodermal layers to reach underlying tissues. As summarized in Table 183-1, within each compartment, the compound may diffuse down along its concentration gradient, bind to specific components, or be metabolized. The size or characteristics of each compartment may alter with time, and the factors determining diffusion within each compartment may be affected by disease state as well as the nature or the pharmacologic or biologic activity of the drug or its excipients. Table 183-2 lists the parameters that affect the amount of drug in the skin compartments.

SKIN SURFACE

SURFACE APPLICATIONS OF FORMULATIONS

Formulations differ in their physicochemical properties, and, as discussed in section "Formulations", this

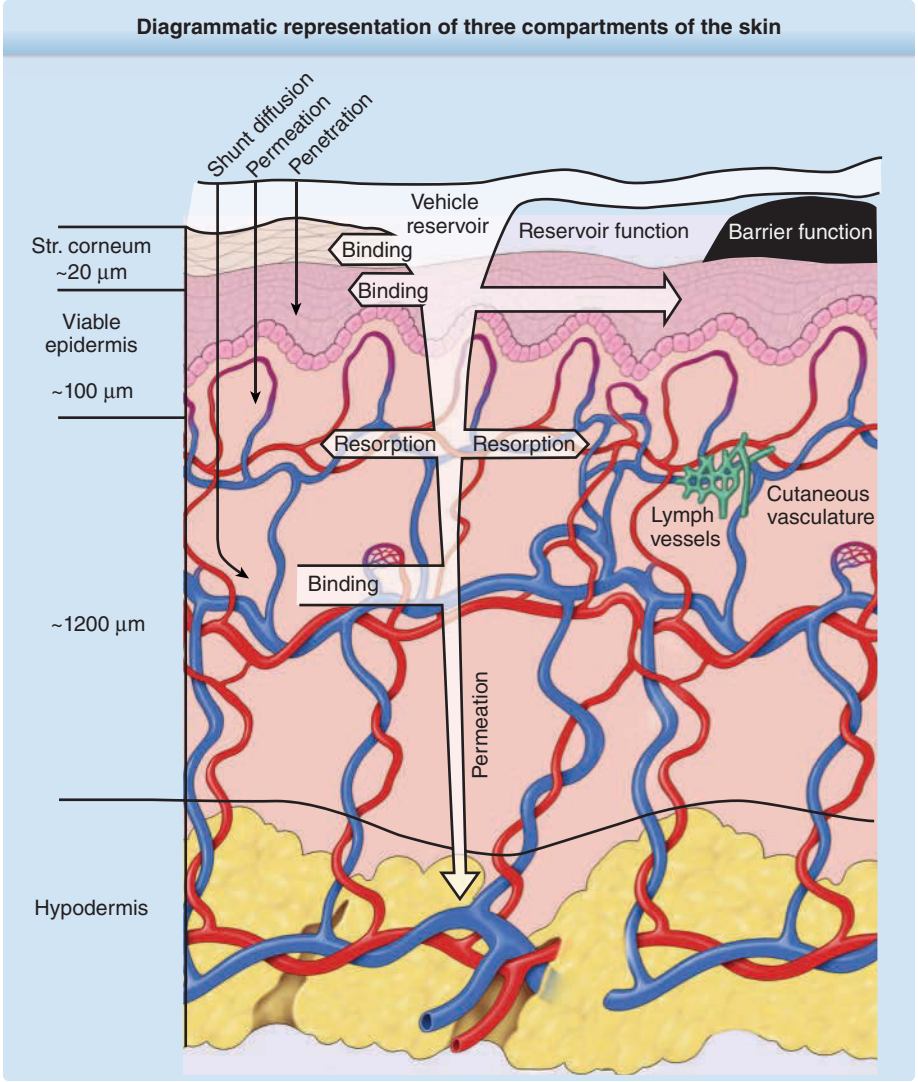

Figure 183-1 Diagrammatic representation of three compartments of the skin: surface, stratum (Str.) corneum, and viable tissues. Topical medication efficacy is a multifactorial process that involves the selection of a medication, adequate adherence, and drug delivery to the skin. Adequate adherence is a prerequest for successful drug delivery and can be classified as primary (filling a prescription and initiating treatment) or secondary (correct administration and continuation after initiation). Drug delivery can be simplified to three compartments of the skin: surface, stratum corneum, and viable tissues. After surface applications, evaporation and structural or compositional alterations in the applied formulation may play important roles in determining the bioavailability of drugs. Stratum corneum, the outermost layer, plays the most significant role in determining the diffusion of compounds into the body. After absorption, compounds may bind or diffuse within the viable tissues or become resorbed by the cutaneous vasculature.

influences the kinetics of release, absorption, or both. However, the principal consideration is that topically applied drug products represent a physically small compartment, which limits the amount of compound that can be applied to the skin surface. When a patient applies a dermatologic preparation, the layer of a formulation covering the skin is thin (~0.5 to 2.0 mg/cm^2). Thicker layers are felt as "unpleasant" and are consciously or subconsciously rubbed off or spread to larger surfaces. This restricts the amount of an active compound that can effectively come in contact with the skin surface to approximately 5 to 20 µg/cm^2 for a 1% (wt/wt) topical formulation.

However, even after being rubbed in, formulations do not remain homogeneous over the time course of penetration. For example, topical applications containing water, alcohol, or similar solvents undergo rapid evaporation.[13] This phenomenon, readily recognized by patients as a cooling sensation, results in rapidly increasing concentrations of nonvolatile substances on the skin surface, which may result in the formation of supersaturated "solutions" or, alternatively, precipitation of active ingredients. Formulations may also mix with skin-surface lipids or undergo time-dependent changes in their composition as excipients and drugs undergo absorption.

TABLE 183-1

Compartments Encountered by Substances Undergoing Percutaneous Absorption: General Relevance of Processes to Bioavailability

COMPARTMENT	PROCESSES	GENERAL RELEVANCE TO BIOAVAILABILITY
Vehicle	Diffusion	++
	Thermodynamic activity	++
	Evaporation	+
	Precipitation	±
Stratum corneum	Reservoir function	+++
	Diffusion	+++
	Binding	+
	Metabolism	–
Epidermis	Diffusion	±
Cutaneous vasculature	Metabolism	±
	Binding	++
	Resorption	+
Underlying tissues including dermis	Diffusion	±
	Metabolism	±
	Binding	–

–, although theoretically possible, this process is probably not of general relevance; ±, this process is of direct relevance but only in a restricted number of cases; +, the process is in general relevant but not as important as ++ or +++.

Altogether, these considerations suggest that dramatic changes in the composition and structure of formulations may occur after surface application, all of which may determine the subsequent bioavailability of active ingredients.

TABLE 183-2

Parameters That Affect Drug Amounts in Skin Compartments

- As applied products dry on the skin, the formulations may undergo drastic changes in composition and structure. Increasing concentration of drug may result in greater drug delivery or, if the active drug precipitates at high concentration, a reduction in drug delivery.
- Drug or formulation may affect the skin barrier, resulting in time-dependent changes of the barrier function.
- Skin barrier may be affected by the type and progression of a disease.
- There may be regional variations in the barrier properties of the skin.
- The therapeutic response to a topical drug can enhance or retard percutaneous absorption.
- Metabolic capacity of skin may lead to exposure of skin or systemically to both parent drug and pharmacologically active metabolite(s).

RESERVOIR

The reservoir function, first described by Vickers,[14] describes that simple occlusion leads to the renewed onset of a glucocorticoid-mediated vasoconstriction several hours after it had declined. He interpreted this effect as renewed liberation of the glucocorticoid from a "reservoir" stored in the upper skin layers.

We define as *reservoir* the amount of an active ingredient that is still in contact with the nonvolatile constituents of its formulation after the latter had been massaged into the skin surface. The compound has not yet penetrated, but it cannot be removed by simple rubbing or contact with clothing or other tissues. The reservoir thus adheres to the skin surface and resides in the wrinkles and layers of the stratum corneum. Reservoirs on eczematous skin may become even more prominent because of the scaliness of the skin. The upper volume of the follicular channels also serves as a reservoir, which may result in a relative increase in absorption through appendages. In vivo laser scanning microscopy measurements found that the hair follicles represent an efficient reservoir for topically applied formulations, which can be compared with the reservoir of the stratum corneum on several body sites.[15,16] This phenomenon may be increased in formulations that contain particles or precipitates, given the evidence that appropriately sized particles can rapidly penetrate along the shafts of hair follicles to a depth of up to 100 to 500 µm.[17-19]

Optimum size of the particles for penetration into hair follicles is between 300 and 600 nm, which corresponds to the cuticular structure of the hairs.[20,21] The rigid hair shaft acts as a geared pump because this effect could only be observed in the case of moving hairs.[20] The follicular reservoir may result in a relative increase in the absorption of topically applied substances. No evidence has been found that topically applied substances penetrate efficiently into the sweat glands. This may be caused by sweat outflow or other, unknown reasons.

FORMULATIONS

Formulations can be differentiated on the basis of whether they are designed to remain on the skin surface (sunscreen products and cosmetics), to be delivered to compartments in the skin (topical formulations), or to migrate across the skin into the central compartment (transdermal formulations).

Formulations may affect the kinetics and the degree of percutaneous absorption and, subsequently, the onset, duration, and extent of a biologic response. In the context of percutaneous absorption, several parameters should be considered when selecting a formulation:[22] the thermodynamic activity of the active ingredient,[23] amount of compound that can be incorporated into the formulation,[24] stability of the formulation on the skin surface (eg, emulsions may break easily),[25] partition coefficient of the active ingredient between the vehicle and the stratum corneum,[26] and enhancer activity.

In general, percutaneous absorption is proportional to the thermodynamic activity of the compound. Thus, the greatest flux is observed at the active ingredient's maximum solubility in a vehicle.

The physical chemical properties of the formation have critical importance when considering compounding medications. Drug compounding is the process of combining or altering ingredients to create tailored medication and are widely used by dermatologists. Dermatologists may tailor therapies to patients' specific needs; for example, they can be designed with less irritating vehicles or excluding specific allergenic components. Compounded drugs are not approved by the U.S. Food and Drug Administration (FDA), and their safety, effectiveness, or quality are not verified by the FDA. When a topical product is mixed with another product—for example, mixing 0.1% triamcinolone cream with a moisturizing cream or other product—the activity of the resulting product is not predictable. Although a 1:1 mixture would reduce the concentration of triamcinolone from 0.1% to 0.05%, the physical chemical properties of the vehicle will have changed. The resulting compounded product could be more effective, equally effective, or less effective than the original 0.1% triamcinolone cream depending on how well the modified vehicle delivers triamcinolone past the cutaneous barrier.

SKIN BARRIER

See Chap. 14.

The primary compartment that limits percutaneous absorption of compounds is the stratum corneum. This thin (10 to 20 µm) layer effectively surrounds the body and represents a highly differentiated structure that determines the diffusion of compounds across the skin. The physical description of the stratum corneum is well documented,[27] and it can be accurately described as "bricks" of bundled, water-insoluble proteins, embedded in a "mortar" of intercellular lipid, and water.

Stratum corneum is a highly organized, differentiated structure. To participate fully in forming an effective barrier to diffusion, the biogenesis of the corneocytes as well as the synthesis and processing of the intercellular lipid must proceed in an orderly manner. Disruption in the kinetics of skin barrier formation by accelerating the division of the keratinocytes in the underlying layers will lead to a disruption in its barrier properties.[28] Thus, the concept of dead or dying skin forming a passive barrier to diffusion is now replaced by a model of the stratum corneum as a highly differentiated structure with unique properties that are particularly suited for its role in forming the skin barrier.[29]

APPENDAGES

Appendages penetrate stratum corneum and epidermis, facilitating thermal control and providing a protective covering. Appendages are potential sites of discontinuity in the integrity of the skin barrier. The density of the hair follicles varies on different body sites. Hair follicles represent a reservoir that may store topically applied substances. A detailed analysis of the reservoir of the hair follicles showed that the highest reservoir is on the scalp followed by the forehead and the calf.[30] On the forehead, there are a high number of small follicles; the calf contains fewer but larger hair follicles. These reservoirs are comparable to the reservoir of the stratum corneum on these body sites. The percentage of the hair follicles on the total skin surface varies between 0.2% and 1.3%, depending on body site.[30] Differences in the follicular penetration were observed in different ethnic groups.[31] Hair follicles present an important pathway for percutaneous absorption in nondiseased skin.[26,32] This can be explained by the fact that only the upper wall of the follicular apparatus (the acroinfundibulum) is protected by a coherent stratum corneum, but in the lower part (infrainfundibulum), the corneocytes appear undifferentiated, and protection is incomplete, if not absent. Even solid particles may enter deep into the follicular orifice,[17,27,33] a phenomenon that lends itself to the concept of follicular targeting of drugs.[27]

It follows that in relationship to the integral protection against the passage of xenobiotics in general, and drugs specifically, the barrier function of the interfollicular stratum corneum is even more potent than previously believed, but more research is needed relative to the follicular pathway. Recent investigations hint to the presence of active follicles (open to penetration) and passive ones.[18]

PENETRATION PATHWAYS

In principle, three penetration pathways are possible: (1) intercellular penetration, inside the lipid layers around the corneocytes; (2) follicular penetration; and (3) intracellular penetration. Although in the past, the transcorneal penetration was assumed to be the only penetration pathway, recent investigations, as cited earlier in section "Appendages", demonstrate that penetration via the hair follicles should be taken into consideration.[30,31]

Up to the present time, no evidence is available that topically applied substances pass the skin barriers by means of the intracellular route.

Pathways Across the Stratum Corneum:

Studies have directly visualized penetration pathways across the stratum corneum by electron microscopy. For example, osmium vapor can be used to precipitate *n*-butanol that has penetrated stratum corneum.[34] After a brief (5 to 60 s) exposure of murine or human stratum corneum, the alcohol was found to be enriched in the intercellular spaces (threefold), although significant levels were also found in the corneocytes. By using a different approach that involved rapid freezing, water, ethanol, and cholesterol were

also found preferentially concentrated in the intercellular lipid spaces.[35] Similarly, the penetration of mercury chloride through the intercellular lipid can be detected after precipitation with ammonium sulfide vapor.

However, in most of these investigations, there was also significant localization of compounds in the corneocytes, more prevalent in the upper layers (stratum disjunctum). Thus, corneocytes undergoing desquamation appear to be relatively permeable, even to rather bulky ions such as mercury. There is additional evidence that other compounds can and do penetrate corneocytes. It is well established, for example, that occlusion or immersion of skin in a bath leads to swelling of the corneocytes, consistent with the entry of water. Other compounds have also been localized in corneocytes, such as the anionic surfactants that are bound to keratins. Low-molecular-weight moisturizers such as glycerol are likely to partition into the corneocytes and alter their water-binding capacity. Thus, the penetration of compounds into corneocytes cannot be excluded from considerations of percutaneous absorption pathways. Relevance of this step relates to whether it is rate determining (ie, whether the diffusion of compounds within the intercellular lipid is restricted by the corneocytes).

Pathways Across Hair Follicles: Using the method of differential stripping—a combination of tape stripping with cyanoacrylate surface biopsies—the amount of formulation stored in the hair follicles can be quantified.[36] Nanoparticles are stored 10 times longer in hair follicles than in the stratum corneum.[20] Note that when topically applied substances penetrate into hair follicles, they do not necessarily penetrate through the skin barrier into the living tissue because hair follicles also have barrier properties.

On the other hand, the particles can be used as efficient carrier systems for drug delivery into hair follicles. The hair follicles represent an important target structure because they are surrounded by a close network of blood capillaries. Additionally, they host stem and dendritic cells, which are important for regenerative medicine and immunomodulation.

For optimal action, drug should be released from the particles after having penetrated deep into the hair follicles. The pharmacokinetics is determined mainly by the process of the drug release from the particles in this case.

There have been attempts to detect follicular penetration.[37-39] Experiments were performed on animal and human skin, with different densities of the hair follicles. Unfortunately, in all cases, the properties of the stratum corneum had also changed.

Analysis of follicular penetration became possible after the development of a method that artificially closes the hair follicles in vivo.[40] Using this method, it was demonstrated that the small molecules, such as caffeine, may penetrate through the skin barrier not only by the transcorneal but also by follicular routes.[41]

INTER- AND INTRAINDIVIDUAL VARIATION IN SKIN BARRIER FUNCTION

Finally, it is worthwhile to consider the level of inter- and intraindividual variation in skin barrier activity, including that of follicles. An accurate and reproducible measurement of skin barrier activity is transepidermal water loss.[42] The extent of variation of this parameter for the same individual is estimated to be 8% by site and 21% according to the day of measurement. Variations among individuals are reported to be somewhat larger, ranging from 35% to 48%.[43] There appear to be no significant gender- or ethnic-dependent differences in skin barrier activity. Skin barrier activity of premature babies[44] is markedly impaired, although skin barrier function appears normal for full-term infants. Differences in skin barrier activity among different sites have been observed; barrier function can be ranked as arm ~ abdomen > postauricular > forehead.[42]

VIABLE TISSUE

Although the primary barrier to percutaneous absorption lies within the stratum corneum, diffusion within the viable tissue, as well as metabolism and resorption, also influence the bioavailability of compounds in specific skin compartments. These processes are interrelated, and factors that increase the rate of one of these processes inevitably influence the others. Because the development of dermatologic formulations is often focused on "targeted" delivery to living tissues, manipulation of these processes offers a clear-cut rationale for increasing the therapeutic efficacy of dermatologic drugs.

The passage of compounds from the stratum corneum into the viable epidermis results in a substantial dilution. This is not only the relatively larger volume of the epidermis compared with that of the stratum corneum but also the lower resistance to diffusion within viable tissues, approximately corresponding to that of an aqueous protein gel.[43] Drug concentrations of 10^{-4} to 10^{-6} M may be attained in the epidermis and dermis for substances that permeate readily. Although the actual concentration gradient of a compound is affected by the physicochemical properties of the compounds as well as by the duration of application, a concentration gradient is present at all times. In other words, strategies to enhance percutaneous absorption generally result in a relatively uniform and parallel increase in the concentration of compounds in all compartments.

SKIN METABOLISM

Skin contains a wide range of enzymatic activities, including phase I oxidative, reductive, hydrolytic, and phase II conjugation reactions, as well as a full

complement of drug-metabolizing enzymes.[45,46] Metabolic activity is a primary consideration in the design of prodrugs and may influence the bioavailability of drugs delivered via dermatologic or transdermal formulations. Alterations in skin metabolism have been implicated in a range of diseases, including hirsutism and acne, and they may be relevant to the risk of topical exposure to carcinogens. Metabolic processing of antigens by Langerhans cells is involved in the presentation of allergens to the immune system. Thus, metabolism in skin compartments plays a significant role in determining the fate of a topically applied active compound.

A variety of compounds of differing physicochemical properties—including estrone, estradiol, and estriol, as well as glucocorticoids, prostaglandins, retinoids, benzoyl peroxide, aldrin, anthralin, 5-fluorouracil, nitroglycerin, theophylline, and propranolol—are metabolized in the skin.[47] Arylamine-type hair dye ingredients are also subject to metabolism in human and animal skin, resulting in *N*-acetylated metabolites.[48-50] The enzyme responsible is believed to be epidermal *N*-acetyltransferase-1.[48] For example, cutaneous metabolism reduces the systemic bioavailability of nitroglycerin administered in a transdermal drug formulation in rhesus monkeys by 16% to 21% and hydrolyzes virtually 100% of a salicylate diester.[51] It is convenient to classify metabolic reactions in terms of their cofactor dependence.[52] Processes that require cofactors are likely to be energy dependent, and these are located within viable tissues. Among the best-studied examples are the interconversion of steroids (eg, estrone and estradiol) and oxidation of polycyclic aromatic hydrocarbons with mixed-function monooxygenases. In contrast, cofactor-independent processes involve catabolism and may be located outside of viable tissues (ie, in the transition region between the stratum corneum and stratum granulosum). The best characterized of these involve hydrolytic reactions such as nonspecific ester hydrolysis.

Metabolic activity is found in (1) skin-surface microorganisms, (2) appendages, (3) stratum corneum, (4) viable epidermis, and (5) dermis. In considering the site of the most significant metabolism, one has to consider the relevant enzymes and their specific activity, as well as their capacity relative to the size of the compartment. Thus, although the level of many enzymes is highest in the epidermis, the relatively large size of the dermal compartment may result in a significant role in the metabolism of topically applied substances. A further consideration is that enzymes involved in cutaneous metabolism may be induced upon exposure to xenobiotics. This has been well described for various mixed-function monooxygenases.[53] Finally, the qualitative and quantitative extrapolation of results from animal models to humans is uncertain, owing to the significant species differences in the metabolism of compounds.

Percutaneous absorption and metabolism of compounds can be viewed as two events in kinetic competition with each other. Generally, compounds that remain in the skin for longer periods of time undergo significantly more metabolism. Furthermore, the type of metabolism of a substance may also be influenced by the nature of its formulation, as illustrated by investigations on the metabolism of several transdermal nitroglycerin formulations.[54] The inclusion of enhancers in the formulation not only increased the bioavailability of the nitroglycerin but also the ratio of one metabolic compound (1,2-glyceryl dinitrate) in relation to another (1,3-glyceryl dinitrate). This may limit suitability of in vitro experiments for estimating the significance of cutaneous metabolism because the vasculature is not functional in vitro. It is difficult to extrapolate quantitatively the level of metabolism obtained for different formulations. This has significant implications for the estimation of bioequivalence.

However, despite the variety of skin-associated metabolic processes, the extent of metabolism is normally modest (ie, 2% to 5% of the absorbed compounds), although for *N*-acetylation of arylamines, metabolism may be quantitative.[50] Metabolism is limited not only by the relatively short period that a compound spends in the viable layers of the skin but also by the overall low level of enzyme activity. Thus, under many circumstances, the available enzymes are saturated by the level of compound undergoing percutaneous absorption.[45]

RESORPTION

Resorption, defined as the uptake of compounds by the cutaneous microvasculature, is directly related to the surface area of the exchanging capillaries as well as their blood flow. Total blood flow to the skin may vary up to 100-fold, a process primarily regulated by vascular shunts, but also by recruitment of new capillary beds. It is estimated that under resting conditions, only 40% of the blood flow passes via exchanging capillaries capable of acting as a sink for absorbed compounds. However, this value demonstrates considerable variation among body sites, individuals, and species and is influenced by disease states and environmental conditions. In particular, changes in temperature and humidity as well as the presence of vasoactive compounds may directly influence skin blood flow.[55]

For most compounds and situations, resorption does not change the rate of diffusion to the central compartment after topical applications. This is a result of the relatively high resistance to diffusion within the stratum corneum compared with uptake by the vasculature. However, for compounds or situations in which diffusion across the stratum corneum is rapid, resorption limits the maximum rate of absorption.[55] Evidence that resorption can limit the delivery of compounds to the central compartment comes primarily from studies that examined the influence of blood flow on this process. The percutaneous absorption of methyl salicylate is increased by elevated ambient temperature or strenuous exercise, an observation consistent with increased resorption as a result of cutaneous blood flow.[56] Moreover, intravenously administered nicotine (a vasoconstrictor) reduces the percutaneous

absorption of topically applied nicotine.[50] Regional differences in the percutaneous absorption of piroxicam, a nonsteroidal antiinflammatory drug, depend on the local vasculature rather than on skin barrier function.[57]

An additional consideration is that the rate of resorption may indirectly influence the diffusion of compounds to the underlying musculature, tissues, and joints.[58] The principle of locally enhanced delivery to underlying musculature has been demonstrated for piroxicam as well as several local anesthetic preparations.[59]

INFLUENCE OF PATHOLOGIC PROCESSES ON SKIN BARRIER FUNCTION

Reduced skin barrier function has been observed in pathologic conditions, including the ichthyoses,[60] psoriasis,[27] atopic dermatitis,[61] and contact dermatitis.[61] It is generally accepted that this is attributable to structural alterations in the stratum corneum. These structural deficiencies may arise from an absence of an enzyme or structural protein in the underlying viable tissues or may be related to the improper formation of the stratum corneum resulting from an increase in keratinocyte proliferation. Thus, in individuals predisposed to a defective barrier, a minor perturbation may become amplified as the skin "attempts to compensate" by increasing keratinocyte proliferation.[62] A further consideration is that the homeostatic mechanisms responsible for recovery of barrier activity after perturbation may be altered in some diseases or physiologic states.

For example, whereas the skin of aged people exhibits normal barrier function, the recovery of barrier activity after perturbation is markedly reduced.[63] This kinetic basis for reduced barrier function may also account for interindividual variation in barrier function or the apparently increased susceptibility of certain individuals to contact dermatitis.[64]

OTHER FACTORS THAT AFFECT ABSORPTION

STRATUM CORNEUM

Stratum corneum, the rate-limiting barrier to percutaneous drug delivery, is composed of ceramides, free fatty acids, and cholesterol in a 1:1:1 molar ratio. By weight, the stratum corneum consists of 50% ceramides (acylceramides being the most abundant), 35% cholesterol, and 15% free fatty acids. Stratum corneum thickness and thus drug penetration vary depending on body site (Fig. 183-2).[65]

There are two main routes for permeation through the stratum corneum: the (1) transepidermal and (2) transappendageal pathways (Fig. 183-3). The transappendageal, or shunt, route involves the flow of molecules through eccrine glands and hair follicles via the associated sebaceous glands.[66] In the transepidermal route, molecules pass between the corneocytes via the intercellular micropathway or through the cytoplasm of dead keratinocytes and intercellular lipids, defined as the *transcellular micropathway*.[66,67] The intercellular pathway is considered the most important route for cutaneous drug delivery.

An important consideration in topical therapy is that diseased skin may have an altered (increased,

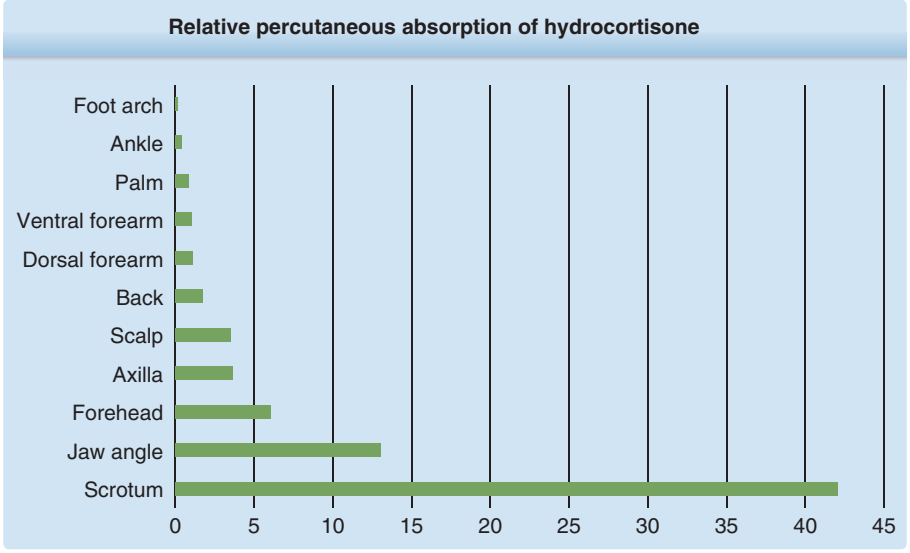

Figure 183-2 Relative percutaneous absorption of hydrocortisone. Regional variation was measured in males using carbon[14]-labeled hydrocortisone dissolved in acetone solvent. Values depicted are relative to the percutaneous absorption of topical applied to the ventral forearm. (Adapted from Feldman RJ, Maibach HI. Regional variation in percutaneous penetration of 14C cortisol in man. *J Invest Dermatol*. 1967;48(2):181-83.)

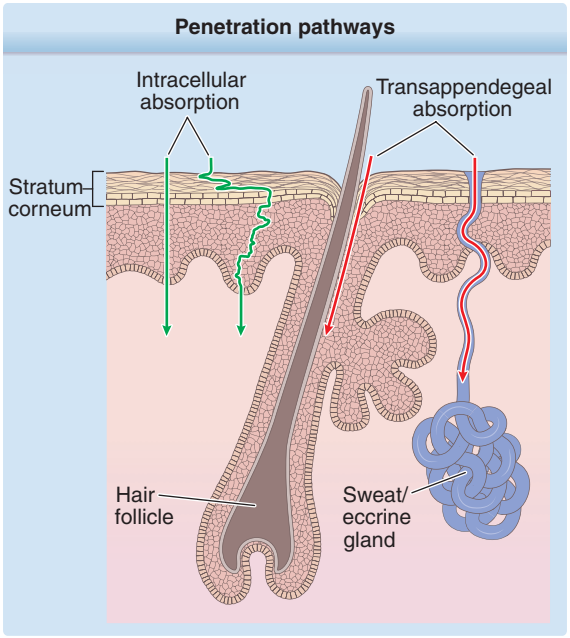

Figure 183-3 Penetration pathways.

decreased, or absent) stratum corneum, thus changing the body site's barrier function.[68] Abraded or eczematized skin presents less of a barrier. Solvents, surfactants, and alcohols can denature the cornified layer and increase penetration; as a result, topical medications with these components may enhance absorption.[69] Importantly, simple hydration of the stratum corneum enhances the absorption of topically applied steroids by four to five times.[10] Abnormal epidermal proliferation disrupts the skin barrier architecture, enhancing percutaneous absorption.

OCCLUSION

Occlusion via closed, airtight dressings or greasy ointment bases increases stratum corneum hydration; limits rub-off and wash-off of the drug; and, consequently, enhances penetration. Occlusion techniques range from application under an airtight dressing such as vinyl gloves, plastic wrap, and hydrocolloid dressings to occlusion at night for treatment of hands and feet, to application of a medication already impregnated into an airtight dressing, as seen in flurandrenolide tape. With many drugs, occlusion increases drug delivery by 10 times the amount of drug delivered when not occluded.[70] This approach can lead to more rapid onset times and increased efficacy when compared with topical application alone. On the other hand, occlusion may also lead to a more rapid appearance of the drug's adverse effects, such as the ability of topical corticosteroids to induce local skin atrophy or suppression of the hypothalamus–pituitary–adrenal axis. Occlusion may promote infection, folliculitis, or miliaria. In the case of topical anesthetics such as lidocaine and prilocaine, occlusion hastens absorption into both the skin and the bloodstream, which has led in rare cases to cardiac complications from lidocaine toxicity or methemoglobinemia from prilocaine toxicity.

APPLICATION FREQUENCY

The frequency of topical application for some drugs, such as corticosteroids, appear to saturate the stratum corneum so that multiple daily application yields minimum penetration increases compared with once-daily application.[71,72] Clinical studies support the same conclusion, so many topical package inserts are labeled for once-daily use.

QUANTITY OF APPLICATION

The quantity of the drug applied likely has a negligible effect on drug absorption. Obviously, enough drug must be dispensed and spread to cover the affected areas. Furthermore, the quantity of drug applied might affect patient adherence to the prescribed regimen. For example, too much applied drug might negatively alter the subjective experience of having a medication on the skin, that is, the drug may feel "wrong" (greasy, caked, chalky, and so on) or is cosmetically unattractive (shiny, white color). Regardless, the amount prescribed must be adequate to treat the affected body surface area (BSA) for the necessary length of time. In this regard, patient education is critical to prevent wasteful overuse or ineffective underuse of the medication. The amounts of topical medications to dispense is based on the estimated BSA, frequency of application, and duration of therapy. For topical medications such as sunscreens that are used over large areas, underapplication is a problem for most patients. However, for smaller areas, patients may apply a large amount of an ointment, for example, leading to complaints of greasiness or rubbing off on clothing, which can be minimized by using an appropriate amount. The finger-tip unit (FTU) is a measurement that allows health care providers and patients to easily communicate about treatment application. An FTU is the amount of topical dispensed from a 5-mm-diameter nozzle onto the tip of the palmar aspect of the index finger to the distal interphalangeal joint skin crease. One FTU is equivalent to approximately 500 mg of the topical agent, which can cover about 2% of the BSA.

MISCELLANEOUS FACTORS

Vigorous rubbing or massaging of the drug into the skin not only increases the surface area of skin covered but also increases blood supply to the area locally, augmenting systemic absorption. It may cause a local

exfoliative effect that also enhances penetration. The presence of hair follicles on a particular body site also enhances drug delivery, with the scalp and beard areas presenting less of a barrier compared with the relatively hairless body sites.

Reducing the particle size of the active ingredient increases its surface area–volume ratio, allowing for a greater solubility of the drug in its vehicle. This forms the basis for the increased absorption of certain micronized drugs.[73]

CLASSIFICATION AND CLINICAL APPLICATION OF TOPICAL FORMULATIONS

The vehicle is the inactive part of a topical preparation that brings a drug into contact with the skin. Before the mid-1970s, pharmaceutical companies performed limited testing of the impact of vehicle on the potency of a given formulation. Lack of a scientific analysis of the vehicle led to the marketing of topical drugs that, although having different concentrations of the same active ingredient, nevertheless exhibited similar bioavailability and potency. For example, older preparations of triamcinolone acetonide showed no real differences in potency among the 0.025%, 0.1%, and 0.5% concentrations. By contrast, modern drug development attempts to maximize drug bioavailability by optimizing vehicle formulation. Additionally, during the current drug development process, dose–response studies determine the maximal effective concentration within a given vehicle, above which any further increase in concentration serves no therapeutic benefit.

Vehicle of a topical formulation often has beneficial nonspecific effects by possessing cooling, protective, emollient, occlusive, or astringent properties. Rational topical therapy matches an appropriate vehicle that contains an effective concentration of the drug. The vehicle functions optimally when it is stable both chemically and physically and does not inactivate the drug. The vehicle also should be nonirritating, nonallergenic, cosmetically acceptable, and easy to use. Additionally, the vehicle must release the drug into the pharmacologically important compartment of the skin. Finally, the patient must accept using the vehicle or else compliance will be poor. For example, although ointments are often pharmacodynamically more effective than creams, patients generally prefer creams to ointments, and thus, more prescriptions are written for cream-based formulations. Table 183-3 lists many commonly used ingredients in topical preparations. Many of these compounds serve more than one function in a particular formulation.

TOPICAL FORMULATIONS

See Table 183-4.

TABLE 183-3

Vehicle Ingredients Commonly Used In Topical Preparations

Emulsifying Agents
- Cholesterol
- Disodium mono-oleamidosulfosuccinate
- Emulsifying wax
- Polyoxyl 40 stearate
- Polysorbates
- Sodium laureth sulfate
- Sodium lauryl sulfate

Auxiliary Emulsifying Agents or Emulsion Stabilizers
- Carbomer
- Catearyl alcohol
- Cetyl alcohol
- Glyceryl monostearate
- Lanolin and lanolin derivatives
- Polyethylene glycol
- Stearyl alcohol

Stabilizers
- Benzyl alcohol
- Butylated hydroxyanisole
- Butylated hydroxytoluene
- Chlorocresol
- Citric acid
- Edetate disodium
- Glycerin
- Parabens
- Propyl gallate
- Propylene glycol
- Sodium bisulfite
- Sorbic acid or potassium sorbate

Solvents
- Alcohol
- Diisopropyl adipate
- Glycerin
- 1,2,6-Hexanetriol
- Isopropyl myristate
- Propylene carbonate
- Propylene glycol
- Water

Thickening Agents
- Beeswax
- Carbomer
- Petrolatum
- Polyethylene
- Xanthan gum

Emollients
- Caprylic or capric triglycerides
- Cetyl alcohol
- Glycerin
- Isopropyl myristate
- Isopropyl palmitate
- Lanolin and lanolin derivatives
- Mineral oil
- Petrolatum
- Squalene
- Stearic acid
- Stearyl alcohol

Humectants
- Glycerin
- Propylene glycol
- Sorbitol solution

TABLE 183-4
Summary of Topical Formulations

FORMULATION	COMMON COMPONENTS	DESCRIPTION
Powders	Zinc oxide, talc (magnesium silicate)	Cosmetic, hygienic purposes; ideal for intertriginous areas and feet
Poultice	Dextranomer beads	Wound cleansers, absorptive agents; applied on decubiti or leg ulcers
Ointments		
Hydrocarbon base (ointments; oleaginous bases; emollients)	Petrolatum most commonly used Silicon ointments	Prevent evaporation of moisture from the skin; contain no preservatives; not for water-soluble drug use; ideal for diaper rash, incontinence, bedsores, colostomy sites
Absorption base	Lanolin and lanolin derivatives Cholesterol and cholesterol derivatives Sorbitan monostearate	Lubricating and hydrophilic substances; can form emulsions; emollients and protectants; easier to remove than hydrocarbon bases
Emulsions (water in oil; <25% water) (creams)	Sodium lauryl sulfate, quaternary ammonium compounds, spans, tweens	Less greasy; easy to spread on film; provide a protective film of oil as an emollient with a cooling effect
Emulsions (oil in water; >31% water) (creams)	Glycerin, propylene glycol, PEG, paraffin alcohols	Most commonly used to deliver a drug; easily spread, water washable and less greasy; easily removed from the skin; preservative containing (parabens)
Water-soluble bases	PEGs (liquid or solid)	No preservatives or additives; less occlusive, nonstaining, greaseless, easily washed off from the skin; poor absorption into the skin but maintains a high surface concentration; ideal for topical antifungals and topical antibiotics
Gels	Water, propylene glycol, PEGS with a cellulose derivative or Carbopol	Organic molecules uniformly distributed in a lattice throughout the liquid; deposits drug in concentrated form; ideal for use in facial or hair bearing areas; lack protective or emollient effects; may cause drying or stinging
Pastes (up to 50% powder in ointment base)	Zinc oxide, starch, calcium carbonate, talc	Less greasy than ointments; more drying and less occlusive; used as protectants, sunblocks, or for localizing a drug that may be staining or irritating
Liquids		
Solutions	Liquid vehicle may be aqueous, hydroalcoholic, or nonaqueous ▪ Tincture: hydroalcoholic solution with 50% alcohol; collodion: nonaqueous solution of pyroxylin with ether and ethanol ▪ Liniments: nonaqueous solutions or drugs in oil or alcoholic soap solutions	Function as astringents, counterirritants, antipruritics, emollients
Suspensions	Biphasic solution: insoluble drug in up to 20% concentration dispersed in liquid	Cooling effect; easier to apply and allows for uniform coating of larger affected areas; more drying than ointments
Shake lotions	Solutions with added powder; zinc oxide, talc, calamine, glycerol, alcohol, and water	Used to dry and cool wet and weeping skin
Foams	Triphasic solution with oil, organic solvents, and water, formulated with a hydrocarbon propellant	Deliver a greater amount of drug at an increased rate; especially useful for scalp application
Aerosols	Drug in a solution mixed with a pure propellant (nonpolar hydrocarbons)	Deliver drugs formulated as solutions, suspensions, emulsions, powders, and semisolids; ease of application to hair-bearing areas

PEG, polyethylene glycol.

POWDERS

Powders absorb moisture and decrease friction. Because they adhere poorly to skin, their use is mainly limited to cosmetic and hygienic purposes. Generally, powders are used in the intertriginous areas and on the feet. Adverse effects of powders include caking (especially if used on weeping skin), crusting, irritation, and granuloma formation. Furthermore, powders may be inhaled by the user. Most powders contain zinc oxide for antiseptic and covering properties, talc (primarily composed of magnesium silicate) for lubricating and drying properties, and a stearate for improved

adherence to the skin. Calamine is a popular skin-colored powder composed of 98% zinc oxide and 1% ferric oxide and acts as an astringent to relieve pruritus. Other drugs formulated as powders include some over-the-counter antifungals.[73]

POULTICES

A poultice, also referred to as a *cataplasm*, is a wet solid mass of particles, sometimes heated, that is applied to diseased skin. Historically, poultices contained meal, herbs, plants, and seeds. The modern poultice often consists of porous beads of dextranomer. Poultices are used as wound cleansers and absorptive agents in exudative lesions such as decubiti and leg ulcers.[73]

OINTMENTS

Ointments, semisolid preparations that spread easily, are petrolatum-based vehicles capable of providing occlusion, hydration, and lubrication. Drug potency often is increased by an ointment vehicle because of its ability to enhance permeability.[5] Ointment bases used in dermatology can be classified into five categories: (1) hydrocarbon bases, (2) absorption bases, (3) emulsions of water-in-oil, (4) emulsions of oil-in-water, and (5) water-soluble bases. Dermatologists commonly refer to the hydrocarbon bases and absorption bases as *ointments* and the water-in-oil and oil-in-water emulsion bases as *creams*. In pharmaceutical terms, all of these preparations are ointments and are specifically indicated for conditions affecting the glabrous skin (palms and soles) and lichenified areas.[10]

HYDROCARBON BASES

Also called *oleaginous bases*, hydrocarbon bases are often referred to as *emollients* because they prevent the evaporation of moisture from skin, are composed of a mixture of hydrocarbons of varying molecular weights, with petrolatum being the most commonly used (white petrolatum, except for being bleached, is identical to yellow petrolatum). They are greasy and can stain clothing. Silicon ointments are composed of alternating oxygen and silicon atoms bonded to organic groups, such as phenyl or methyl, and are excellent skin protectants. They can be used for diaper rash, incontinence, bedsores, and colostomy sites. Hydrocarbon bases are generally stable and do not contain preservatives. They cannot absorb aqueous solutions and thus are not used for water-soluble drugs.[73]

ABSORPTION BASES

Absorption bases contain hydrophilic substances that allow for the absorption of water-soluble drugs. The hydrophilic (polar) compounds may include lanolin and its derivatives, cholesterol and its derivatives, and partial esters of polyhydric alcohols such as sorbitan monostearate. These ointments are lubricating and hydrophilic, and they can form emulsions. They function well as emollients and protectants. They are greasy to apply but are easier to remove than hydrocarbon bases. They do not contain water. Examples include anhydrous lanolin and hydrophilic petrolatum.[73]

WATER-IN-OIL EMULSIONS (CREAMS)

Emulsions are two-phase systems involving one or more immiscible liquids dispersed in another, with the assistance of one or more emulsifying agents. A water-in-oil emulsion, by definition, contains less than 25% water, with oil being the dispersion medium. The two phases may separate unless shaken. The emulsifier (or surfactant) is soluble in both phases and surrounds the dispersed drops to prevent their coalescence. Examples of surfactants used include sodium lauryl sulfate, quaternary ammonium compounds, Spans (sorbitan fatty acid esters), and Tweens (polyoxyethylene sorbitan fatty acid esters). Preservatives are frequently added to increase emulsion's shelf life. Water-in-oil emulsions are less greasy, spread easily on the skin, and provide a protective film of oil that remains on the skin as an emollient, and the slow evaporation of the water phase provides a cooling effect.[5]

OIL-IN-WATER EMULSIONS

An oil-in-water emulsion contains greater than 31% water. In fact, the aqueous phase may constitute up to 80% of the formulation. This type of formulation is most commonly chosen to deliver a dermatologic drug. Clinically, oil-in-water emulsions spread easily, are water washable and less greasy, and are easily removed from the skin and clothing. Invariably, they contain preservatives, such as the parabens, to inhibit mold growth. Additionally, oil-in-water emulsions contain a humectant (an agent that draws moisture into the skin), such as glycerin, propylene glycol, or polyethylene glycol (PEG), to prevent the cream from drying out. The oil phase may contain either cetyl or stearyl alcohol (paraffin alcohols) to impart a stability and velvety smooth feel upon application to the skin. After application, the aqueous phase evaporates, leaving behind a small hydrating oil layer and a concentrated drug deposit.[73]

WATER-SOLUBLE BASES

Water-soluble bases consist either primarily or completely of various PEGs. Depending on their molecular weight, PEGs are either liquid (PEG 400) or solid (PEG 4000). These formulations are water soluble, do not decompose, and do not support mold growth and therefore require no preservative additives. They are much less occlusive than water-in-oil emulsions and are nonstaining, greaseless, and easily washed off of the skin. Without water, the ointment poorly delivers

its coformulated drug. Therefore, it is useful in scenarios when the practitioner desires a high surface concentration and low percutaneous absorption of drug. For example, topical antifungal drugs and topical antibiotics (eg, mupirocin) are formulated in this base.

Gels are made from water-soluble bases by formulating water, propylene glycol, and/or PEGs with a cellulose derivative or Carbopol. A gel consists of organic macromolecules uniformly distributed in a lattice throughout the liquid. After application, the aqueous or alcoholic component evaporates, and the drug is deposited in a concentrated form. This provides a faster release of the drug independent of its water solubility. Gels are popular because of their clarity and ease of both application and removal. They are suitable for facial or hairy areas because after application, little residue remains.[10] Nevertheless, they lack protective or emollient properties. If they contain high concentrations of alcohol or propylene glycol, they tend to be drying or cause stinging. Gels require preservatives.[12] Newer gel formulations may contain the humectant glycerin, the emollient dimethicone, or the viscoelastic polysaccharide hyaluronic acid, which can mitigate some of the associated irritation. Nonaqueous gels, with bases such as glycerol, may be used for poorly solubilized therapeutics such as 5-aminolevulonic acid.[74]

Microspheres, or microsponges, are formulated in an aqueous gel. Medication, in this case tretinoin, is combined into porous beads 10 to 25 µm in diameter. The beads are made up of methyl methacrylate and glycol dimethacrylate.

PASTES

Pastes are simply the incorporation of high concentrations of powders (up to 50%) into an ointment such as a hydrocarbon base or a water-in-oil emulsion. The powder must be insoluble in the ointment. Invariably, they are "stiffer" than the original ointment. Powders commonly used are zinc oxide, starch, calcium carbonate, and talc. Pastes function to localize the effect of a drug that may be staining or irritating (ie, anthralin). They also function as impermeable barriers that serve as protectants or sunblocks. Pastes are less greasy than ointments, more drying, and less occlusive.[73]

LIQUIDS

Liquids can be subdivided into solutions, suspensions, emulsions (discussed in section "Ointments"), and foams.

SOLUTIONS

A solution involves the dissolution of two or more substances into homogenous clarity. The liquid vehicle may be aqueous, hydroalcoholic, or nonaqueous (alcohol, oils, or propylene glycol). An example of an aqueous solution is aluminum acetate or Burow solution. A hydroalcoholic solution with a concentration of alcohol of approximately 50% is called a *tincture*. A collodion is a nonaqueous solution of pyroxylin in a mixture with ether and ethanol and is applied to the skin with a soft brush. Flexible collodions have added castor oil and camphor and are used, for example, to deliver 10% salicylic acid as a keratolytic agent. Liniments are nonaqueous solutions of drugs in oil or alcoholic solutions of soap. The base of oil or soap facilitates application to the skin with rubbing or massage. Liniments can be used as counterirritants, astringents, antipruritics, emollients, and analgesics.[73]

SUSPENSIONS (LOTIONS)

A suspension, or lotion, is a two-phase system consisting of a finely divided, insoluble drug dispersed into a liquid in a concentration of up to 20%. Nonuniform dosing can result if the suspended particles coalesce and separate out of a homogeneous mixture, therefore shaking of the lotion before application may be required. Examples include calamine lotion, steroid lotions, and emollients containing urea or lactic acid. The applied lotion leaves skin feeling cooler via evaporation of the aqueous component. Lotions are easier to apply and allow for uniform coating of the affected area and are often the favorite preparation in treating children. Lotions are more drying than ointments, and preparations with alcohol tend to sting eczematized or abraded skin. Lotions are suitable for application to large surface areas because of their ability to spread easily.[73]

SHAKE LOTIONS

Shake lotions are lotions to which a powder is added to increase the surface area of evaporation. As a result of increased evaporation, application of shake lotions effectively dries and cools wet and weeping skin. Generally, shake lotions consist of zinc oxide, talc, calamine, glycerol, alcohol, and water, to which specific drugs and stabilizers may be added. Shake lotions tend to sediment and derive their name from the need to shake the preparation before each use to obtain a homogeneous suspension. In addition, after water has evaporated from the lotion, the powder component may clump together and become abrasive. Therefore, patients should be instructed to remove the residual particles before the reapplication of shake lotions.[73]

FOAMS

Foams are triphasic liquids composed of oil, organic solvents, and water, kept under pressure in aluminum cans. Foams are formulated with a hydrocarbon propellant, either butane or propane.[75] The foam lattice is formed when the valve is activated. When in contact with skin, the lattice breaks down, the alcohol evaporates within 30 seconds and leaves minimal residue

in the skin. The alcohol component of the foam is thought to act as a penetration enhancer, momentarily altering the barrier properties of the stratum corneum and increasing drug delivery through the intercellular route.[75] Foam vehicles are highly effective in delivering greater amount of active drug at an increased rate compared with other vehicles that traditionally depend on hydration of the intercellular spaces within the stratum corneum. Foams have not been associated with an increase in the adverse events, and compliance seems to be better with this formulation, especially for localized conditions affecting the scalp.[75]

AEROSOLS

Topical aerosols may be used to deliver drugs formulated as solutions, suspensions, emulsions, powders, and semisolids. Aerosols involve formulating the drug in a solution within a pure propellant. Usually, the propellant is a blend of nonpolar hydrocarbons. When applied to abraded or eczematized skin, aerosols lack the irritation of other formulations, especially when the quality of the skin makes direct application painful or difficult. Furthermore, aerosols dispense a drug as a thin layer with minimal waste, and the unused portion cannot be contaminated. Aerosol foams, a relatively new vehicle for drug delivery, are commonly used to deliver corticosteroids such as betamethasone valerate and clobetasol propionate. The foam contains the drug within an emulsion formulated with a foaming agent (a surfactant), a solvent system (eg, water and ethanol), and a propellant. On application, a foam lattice forms transiently until it is broken by both the heat of the skin and the heat of rubbing the foam onto skin. Foams that are alcohol based leave little residue within seconds of application. Furthermore, a given corticosteroid formulated in a foam vehicle demonstrates comparable potency compared with the same corticosteroid in other vehicles.[11,76] Although aerosols allow for the ease of application (especially to hair-bearing areas) and high patient satisfaction, they suffer from the disadvantages of being expensive and potentially ecologically damaging.[73]

LIPOSOMES AS TRANSDERMAL DELIVERY SYSTEMS

Liposomes are microscopic spheres consisting of a bilayer that encloses an inner aqueous core. A wide variety of cosmetics contain liposomes. Liposome-based formulations are safe, cosmetically attractive, and well accepted. There is considerable evidence that, at least for some preparations, application of liposomes is mildly occlusive and improves stratum corneum hydration. Interest in the use of liposomes to enhance the delivery of drugs across the skin has been spurred by observations in animal models: liposome formulations were believed to enhance the penetration of compounds across the skin or to optimize the retention of bioactive compounds in target tissues.[32] However, these early studies, which relied largely on animal models, were followed by relatively few in vivo studies for humans conducted under standard conditions.[69]

Action mechanism of liposomes is based on a partly damaged liquid layer of the stratum corneum, so that the liposomes can penetrate efficiently into the skin barrier. Deep in the stratum corneum, the liposomes get damaged and release their drug, which has to pass through the last cell layers of the stratum corneum by itself to reach the living cells.

There is no clear evidence that liposomes can pass the skin barrier as intact structures, but intact liposomes can penetrate along the hair shaft, and this route may be appropriate for delivery of bioactive compounds into sebaceous glands or hair follicles.[16,66] Rigid liposomes penetrate better into the hair follicles than flexible liposomes, which supports the assumption that the moving hairs act as a geared pump.[52,66]

PENETRATION ENHANCERS

CHEMICAL ENHANCERS

A penetration enhancer is a compound that is able to promote drug transport through skin. Skin hydration and interaction with the polar head group of the lipids are mechanisms for increasing penetration. Water, alcohols (mainly ethanol), sulphoxides (dimethylsulphoxide), decylmethylsulphoxide, azones (laurocapram), and urea are some commonly used compounds.[67] Urea is thought to act as a penetration enhancer because of its keratolytic properties and by increasing the water content in the stratum corneum. Other substances that may also act as enhancers include propylene glycol, surfactants, fatty acids, and esters.[69]

Vesicular systems are widely used in dermatologic and cosmetic fields to enhance drug transport into the skin through the transcellular and follicular pathways. Examples of vesicular systems include liposomes (phospholipid-based vesicles), niosomes (nonionic surfactant vesicles), proliposomes, and proniosomes, which, respectively, are converted to liposomes and niosomes upon hydration.[77]

PHYSICAL ENHANCERS

Physical methods such as the application of a small electric current (iontophoresis), ultrasound energy (phono- or sonophoresis), and the use of microneedles increase cutaneous drug penetration.[67] Microdermoabrasion is the application of crystals (generally aluminum oxide) on the skin and the collection of such crystals and skin debris under vacuum suction. This technique enhances drug permeation and facilitates drug absorption by altering the architecture of the stratum corneum.[78]

STABILIZERS

Stabilizers are nontherapeutic ingredients and include the preservatives, antioxidants, and chelating agents. Preservatives protect the formulation from microbial growth. The ideal preservative is effective at a low concentration against a broad spectrum of organisms, nonsensitizing, odor free, color free, stable, and inexpensive. Unfortunately, the ideal preservative does not exist. The parabens are the most frequently added preservatives and are active against molds, fungi, and yeasts but less effective against bacteria. Alternative agents include the halogenated phenols, benzoic acid, sodium benzoate, formaldehyde-releasing agents, and previously, thimerosal. Most commonly used preservatives may act as contact sensitizers.

Antioxidants or preservatives prevent the drug or vehicle from degrading via oxidation. Examples include butylated hydroxyanisole and butylated hydroxytoluene, used in oils and fats. Ascorbic acid, sulfites, and sulfur-containing amino acids are used in water-soluble phases. Chelating agents, such as sodium EDTA (ethylenediaminetetraacetic acid) and citric acid, work synergistically with antioxidants by complexing heavy metals in aqueous phases.

THICKENING AGENTS

Thickening agents increase the viscosity of products or suspend ingredients in a formulation. Examples include beeswax and carbomers. In addition to functioning as an ointment vehicle, petrolatum may be added to an emulsion to increase its viscosity. As in this example, an ingredient may have a therapeutic effect as well as acting as part of a vehicle.

SIDE EFFECTS AND PRECAUTIONS

LOCAL EFFECTS

Either the vehicle or its active ingredients may cause local toxicity to the applied site. Local adverse effects are usually minor and reversible. Major cutaneous side effects include irritation, allergenicity, atrophy, comedogenicity, formation of telangiectases, pruritus, stinging, and pain. The mechanism of toxicity may be as simple as the desiccation of the stratum corneum (eg, the removal of sebum and oils by the preparation's emulsifiers) or involve a more complex effect on either the cells of the epidermis or dermis and the structures these cells comprise (ie, epidermis, adnexae). Local damage may occur either directly at or within close proximity to the treated site. Furthermore, irritation and damage may appear even after a drug has been discontinued. Often the therapeutic effects of the active ingredient mask or immediately treat the toxic effects of the formulation so that acutely toxic effects are transient.[79] For example, allergic contact dermatitis to a preservative in a topical steroid may be masked by the effects of the glucocorticoid itself.

IRRITANT CONTACT DERMATITIS

Irritation is driven less by drug penetration and more by drug concentration. Thus, lowering the concentration of an irritating drug may lower the risk of side effects. However, a change in formulation may reduce the preparation's efficacy. Nevertheless, often using a less concentrated preparation over a greater period of time is as therapeutically efficacious while minimizing adverse effects (eg, the use of benzoyl peroxide 2% to 5% preparations in contrast to 10% preparations).[79] In some instances, though, skin irritancy might be central to drug efficacy. For example, although not conclusively shown, the power of immunomodulating agents such as imiquimod might rely on an increased innate (inflammatory or irritant) immune response.

SUBJECTIVE OR SENSORY IRRITANT CONTACT DERMATITIS

Patients may detect burning or stinging sensations without any signs of cutaneous irritation after applying a topical medication. Several compounds, such as tacrolimus, sorbic acid, propylene glycol, benzoyl peroxide hydroxy acids, mequinol, ethanol, lactic acid, azelaic acid, benzoic acid, and tretinoin, may induce sensory irritant contact dermatitis in predisposed individuals.[80,81]

ALLERGIC CONTACT DERMATITIS

Contact allergy development depends on local penetration. Allergy is driven by antigen recognition and presentation, so percutaneous absorption of the drug must be at a level that guarantees interaction with the immune effector cells of the skin. Therefore, the contact allergenicity of a drug relates significantly to percutaneous absorption. In some instances, cutaneous allergy may be therapeutic, for example, the treatment of patients with cutaneous T-cell lymphoma with topical nitrogen mustard. The shift in malignant T cells from T helper (Th) 2 to Th1-type cytokine expression is believed to lead to apoptosis of the malignant T cells and tumor regression.[82]

MALIGNANCIES

Rarely, topical therapy may result in neoplasia. For example, the risk of secondary malignancies, such as keratoacanthomas, basal and squamous cell carcinomas, lentigo maligna, and primary melanoma, have been reported with the long-term use of nitrogen mustard.[82]

OTHERS

The application of topical corticosteroids to the periorbital skin has been suggested to induce cataracts and increase intraocular pressure.[10]

SYSTEMIC EFFECTS

One should be aware of the potential systemic toxicities of topical drugs. Although generally safer than the other administration routes, topical application can result in systemic toxicities ranging from end-organ toxicity (central nervous system, cardiac, renal, and so on), teratogenicity, and carcinogenicity to drug interactions. These outcomes may relate to the drug itself, its metabolites, or even a component of the vehicle.

The kinetics of topically applied drugs differ significantly from those administered by other routes. An important consideration is the lack of hepatic first-pass metabolism of a topical drug. This is especially relevant to drugs such as salicylic acid that are relatively innocuous when given enterally but may manifest central nervous system toxicity when applied topically. Additionally, acting as a reservoir, the stratum corneum may store large amounts of a topical drug, and a subsequently long diffusion period of many days may ensue, delivering a steady supply of drug to the systemic circulation.

Percutaneous toxicity directly relates to percutaneous absorption. Therefore, factors that modulate absorption also influence toxicity: concentration of drug, its vehicle, use of occlusion, body site and area treated, frequency of use, duration of therapy, and nature of the diseased skin. For example, 6% salicylic acid in Eucerin used for 11 days in the treatment of psoriasis has been associated with epistaxis and deafness, and the same concentration of salicylic acid in hydrophilic cream under occlusion for 4 days for the treatment of dermatitis (involving the same amount of BSA) may result in hallucination.[79] Similar to their effect on systemically administered drugs, renal and hepatic diseases, by influencing drug clearance, also contribute to an increased potential for drug toxicity.

Infants and young children have a greater surface area–volume ratio and thus are at greater risk of percutaneous toxicity than adults. This phenomenon necessitates alternative drugs, formulations, and dosing schedules for children with widespread cutaneous disease. Patients with acute flares of cutaneous illness (eg, psoriasis or atopic dermatitis) may require treatment of a larger BSA in a relatively abbreviated period. These patients may also increase their dose and frequency of application during such flares. Coupled with the likely increased percutaneous absorption of the diseased skin, these scenarios exponentially increase the possibility of systemic toxicity, and patient education is vital to prevent adverse outcomes.[73] To reduce the risk of toxicity from topical drugs and to increase treatment efficacy, many practitioners will rationally advocate systemic approaches (ie, methotrexate, cyclosporine, injectable or infusable biologics, or ultraviolet radiotherapy) to patients whose disease involves an extensive BSA. Nonimmunologic acute toxicity results from substances such as pesticides and chemical warfare agents that rapidly diffuse through the skin and reach target organs.

IMMUNOLOGIC CONTACT URTICARIA

In rare instances, anaphylactic shock can be precipitated by topical drug application. For example, when applied to diseased or abraded skin, bacitracin ointment can induce an immediate-type (Type I) hypersensitivity reaction in susceptible individuals. Such reactions might be represented by a local and then subsequently generalized pruritus, leading to cardiopulmonary arrest.[73]

MALIGNANCIES

Systemic calcineurin inhibitors have been associated with increased risk of lymphoma and nonmelanoma skin cancer. But the topical use of such drugs does not yet appear to induce cancer.[83] In fact, the risk for lymphoma with the use of topical calcineurin inhibitors was assessed in animal studies that demonstrated an increased risk only when blood levels were 30 times higher than those measured after topical application in human subjects.[83] More than 50 cases of lymphoma have been reported, although the topical calcineurin inhibitor use may be coincidental. Nevertheless, there is a need for additional follow-up information to establish the long-term safety profile of these drugs.[83]

ENDOCRINE SYSTEM

Topical corticosteroids can rarely cause hypothalamic–pituitary–adrenal axis suppression, growth retardation, hyperglycemia, iatrogenic Cushing syndrome, and femoral head osteonecrosis.[10] Factors that enhance drug absorption are directly related to an increase in these side effects; therefore, careful monitoring must be ensured when prescribing usage in large surfaces areas, prolonged use of potent corticosteroids, usage under occlusion, high-potency corticosteroids, or use for the pediatric age group (because of their increased surface–body mass ratio).

TRANSDERMAL DRUGS

Transdermal drug delivery, in contrast to topical drug delivery, uses topical application of therapeutic drug as a delivery system for systemic therapy. Transdermal patches have been approved by the FDA since 1981 (scopolamine being the first) for the delivery of numerous medications, with more seeking approval. Advantages of this approach include controlled release, a steady blood-level profile with zero-order kinetics, lack of a plasma peak, and, in some cases, improved patient compliance. These patches remain on the skin for

12 hours to 1 week. A patch consists of a plastic backing, a reservoir of medication, and either a rate-controlling membrane or a polymer matrix system for controlled diffusion followed by an adhesive facing the skin. The most common adhesives used are acrylates, silicones, and polyisobutylenes. These patches have been tested and are approved for use on the thighs, buttocks, lower abdomen, upper arms, and chest; application to other sites can lead to either sub- or supratherapeutic blood levels. Adverse effects of patches include local irritation and allergic contact dermatitis to either an adhesive or to the drug itself and may necessitate discontinuation.

CONCLUSIONS

Topical therapies are a mainstay of treatment for the dermatologist. An understanding of the interactions between a drug's concentration, penetration, availability, and treatment of diseased skin allows physicians to maximize both efficacy and tolerability of topical therapy. An understanding of local and systemic toxicities allows selection of appropriate, safe therapy for patients and minimizes unwanted effects. Appropriate selection of topical agents and patient education on proper use can optimize therapeutic outcomes.

ACKNOWLEDGMENTS

Previous authors were Aieska De Souza, Bruce E. Strober, Hans Schaefer, Thomas E. Redelmeier, Gerhard J. Nohynek, and Jürgen Lademann.

REFERENCES

1. Feldman SR, Vrijens B, Gieler U, et al. Treatment adherence intervention studies in dermatology and guidance on how to support adherence. *Am J Clin Dermatol.* 2017;18(2):253-271.
2. Foley P, Stockfleth E, Peris K, et al. Adherence to topical therapies in actinic keratosis: a literature review. *J Dermatolog Treat.* 2016;27(6):538-545.
3. Lee IA, Maibach HI. Pharmionics in dermatology: a review of topical medication adherence. *Am J Clin Dermatol.* 2006;7(4):231-236.
4. Anderson KL, Dothard EH, Huang KE, et al. Frequency of primary nonadherence to acne treatment. *JAMA Dermatol.* 2015;151(6):623.
5. Zaghloul SS, Goodfield MJD. Objective assessment of compliance with psoriasis treatment. *Arch Dermatol.* 2004;140(4):408-414.
6. Kulkarni AS, Balkrishnan R, Camacho FT, et al. Medication and health care service utilization related to depressive symptoms in older adults with psoriasis. *J Drugs Dermatol.* 3(6):661-666.
7. Molassiotis A, Morris K, Trueman I. The importance of the patient–clinician relationship in adherence to antiretroviral medication. *Int J Nurs Pract.* 2007;13(6):370-376.
8. Snyder A, Farhangian M, Feldman SR. A review of patient adherence to topical therapies for treatment of atopic dermatitis. *Cutis.* 2015;96(6):397-401.
9. Feldman SR. Tachyphylaxis to topical corticosteroids: the more you use them, the less they work? *Clin Dermatol.* 2006;24(3):229-230; discussion 230.
10. Tadicherla S, Ross K, Shenefelt PD, et al. Topical corticosteroids in dermatology. *J Drugs Dermatol.* 2009;8(12):1093-1105.
11. Franz TJ. Kinetics of cutaneous drug penetration. *Int J Dermatol.* 1983;22(9):499-505.
12. Bronaugh RL, Maibach HI, eds. *Percutaneous Absorption: Drugs, Cosmetics, Mechanisms, Methodology (Drugs and the Pharmaceutical Sciences).* 4th ed. Abingdon, UK: Taylor & Francis; 2005.
13. Flynn G. General introduction and conceptual differentiation of topical and transdermal drug delivery systems. In: Shah VP, Maibach HI, eds. *Topical Drug Bioavailability: Bioequivalence and Penetration.* New York: Plenum: Springer; 1993:369.
14. Vickers CF. Existence of reservoir in the stratum corneum. Experimental proof. *Arch Dermatol.* 1963;88:20-23.
15. Lademann J, Lange-Asschenfeldt S, Ulrich M, et al. Application of laser scanning microscopy in dermatology and cutaneous physiology. In: *Non Invasive Diagnostic Techniques in Clinical Dermatology.* Berlin: Springer Berlin Heidelberg; 2014:101-113.
16. Otberg N, Richter H, Schaefer H, et al. Visualization of topically applied fluorescent dyes in hair follicles by laser scanning microscopy. *Laser Phys.* 2003;13(5):761-764.
17. Rolland A. Particulate carriers in dermal and transdermal drug delivery: myth or reality. In: Walters K, Hadgraft J, eds. *Pharmaceutical Particulate Carriers: Therapeutic Applications.* New York: Marcel Dekker; 1993:367.
18. Lademann J, Otberg N, Richter H, et al. Investigation of follicular penetration of topically applied substances. *Skin Pharmacol Appl Skin Physiol.* 2001;14(suppl 1):17-22.
19. Schaefer H, Lademann J. The role of follicular penetration. A differential view. *Skin Pharmacol Appl Skin Physiol.* 2001;14(suppl 1):23-27.
20. Toll R, Jacobi U, Richter H, et al. Penetration profile of microspheres in follicular targeting of terminal hair follicles. *J Invest Dermatol.* 2004;123(1):168-176.
21. Lademann J, Richter H, Schaefer UF, et al. Hair follicles—a long-term reservoir for drug delivery. *Skin Pharmacol Physiol.* 2006;19(4):232-236.
22. Higuchi T. Physical chemical analysis of percutaneous absorption process from creams and ointments. *J Soc Cosmet Chem.* 1960;11(85).
23. Guy R, Hadgraft J, Maibach H. A pharmacokinetic model for percutaneous absorption. *Int J Pharm.* 1982;11(119).
24. Gupta SK, Bashaw E, Hwang S. Pharmacokinetic and pharmacodynamic modeling of transdermal products: in vivo methods, problems, and pitfalls. In: Shah V, Maibach H, eds. *Topical Drug Bioavailability: Bioequivalence and Penetration.* New York, Plenum; 1993.
25. Kubota K, Sznitowska M, Maibach HI. Percutaneous absorption: a single-layer model. *J Pharm Sci.* 1993;82(5):450-456.
26. Williams PL, Riviere JE. A biophysically based dermatopharmacokinetic compartment model for quantifying percutaneous penetration and absorption of topically applied agents. I. Theory. *J Pharm Sci.* 1995;84(5):599-608.
27. Schaefer H (Hans), Redelmeier TE. *Skin Barrier: Principles of Percutaneous Absorption.* Basel, Switzerland: Karger; 1996.

28. Elias PM, Menon GK. Structural and lipid biochemical correlates of the epidermal permeability barrier. *Adv Lipid Res.* 1991;24:1-26.
29. Elias PM, Feingold KR. Coordinate regulation of epidermal differentiation and barrier homeostasis. *Skin Pharmacol Appl Skin Physiol.* 2001;14(suppl 1):28-34.
30. Otberg N, Richter H, Schaefer H, et al. Variations of hair follicle size and distribution in different body sites. *J Invest Dermatol.* 2004;122(1):14-19.
31. Mangelsdorf S, Otberg N, Maibach HI, et al. Ethnic variation in vellus hair follicle size and distribution. *Skin Pharmacol Physiol.* 2006;19(3):159-167.
32. Egbaria K, Weiner N. Liposomes as a drug delivery system. *Adv Drug Deliv Rev.* 1990;(5):287-300.
33. Rolland A, Wagner N, Chatelus A, et al. Site-specific drug delivery to pilosebaceous structures using polymeric microspheres. *Pharm Res.* 1993;10(12):1738-1744.
34. Nemanic MK, Elias PM. In situ precipitation: a novel cytochemical technique for visualization of permeability pathways in mammalian stratum corneum. *J Histochem Cytochem.* 1980;28(6):573-578.
35. Squier CA, Lesch CA. Penetration pathways of different compounds through epidermis and oral epithelia. *J Oral Pathol.* 1988;17(9-10):512-516.
36. Teichmann A, Jacobi U, Ossadnik M, et al. Differential stripping: determination of the amount of topically applied substances penetrated into the hair follicles. *J Invest Dermatol.* 2005;125(2):264-269.
37. Maibach HI, Feldman RJ, Milby TH, et al. Regional variation in percutaneous penetration in man. Pesticides. *Arch Environ Health.* 1971;23(3):208-211.
38. Hueber F, Besnard M, Schaefer H, et al. Percutaneous absorption of estradiol and progesterone in normal and appendage-free skin of the hairless rat: lack of importance of nutritional blood flow. *Skin Pharmacol.* 1994;7(5):245-256.
39. Hueber F, Schaefer H, Wepierre J. Role of transepidermal and transfollicular routes in percutaneous absorption of steroids: in vitro studies on human skin. *Skin Pharmacol.* 1994;7(5):237-244.
40. Teichmann A, Otberg N, Jacobi U, et al. Follicular penetration: development of a method to block the follicles selectively against the penetration of topically applied substances. *Skin Pharmacol Physiol.* 2006;19(4):216-223.
41. Otberg N, Teichmann A, Rasuljev U, et al. Follicular penetration of topically applied caffeine via a shampoo formulation. *Skin Pharmacol Physiol.* 2007;20(4):195-198.
42. Pinnagoda J, Tupker RA, Agner T, et al. Guidelines for transepidermal water loss (TEWL) measurement. A report from the Standardization Group of the European Society of Contact Dermatitis. *Contact Dermatitis.* 1990; 22(3):164-178.
43. Scheuplein RJ. Mechanism of percutaneous absorption. II. Transient diffusion and the relative importance of various routes of skin penetration. *J Invest Dermatol.* 1967;48(1):79-88.
44. Rutter N. Clinical consequences of an immature barrier. *Semin Neonatol.* 2000;5(4):281-287.
45. Kao J, Carver MP. Cutaneous metabolism of xenobiotics. *Drug Metab Rev.* 1990;22(4):363-410.
46. Rolsted K, Benfeldt E, Kissmeyer A-M, et al. Cutaneous in vivo metabolism of topical lidocaine formulation in human skin. *Skin Pharmacol Physiol.* 2009;22(3):124-127.
47. Jacobi U, Toll R, Sterry W, et al. Do follicles play a role as penetration pathways in in vitro studies on porcine skin? An optical study. *Las Phys.* 2005;15:1594.
48. Nohynek GJ, Skare JA, Meuling WJA, et al. Urinary acetylated metabolites and N-acetyltransferase-2 genotype in human subjects treated with a para-phenylenediamine-containing oxidative hair dye. *Food Chem Toxicol.* 2004;42(11):1885-1891.
49. Dressler WE, Appelqvist T. Plasma/blood pharmacokinetics and metabolism after dermal exposure to para-aminophenol or para-phenylenediamine. *Food Chem Toxicol.* 2006;44(3):371-379.
50. Nohynek GJ, Duche D, Garrigues A, et al. Under the skin: biotransformation of para-aminophenol and para-phenylenediamine in reconstructed human epidermis and human hepatocytes. *Toxicol Lett.* 2005; 158(3):196-212.
51. Guzek DB, Kennedy AH, McNeill SC, et al. Transdermal drug transport and metabolism. I. Comparison of in vitro and in vivo results. *Pharm Res.* 1989;6(1):33-39.
52. Novotný J, Kovaríková P, Novotný M, et al. Dimethylaminoacid esters as biodegradable and reversible transdermal permeation enhancers: effects of linking chain length, chirality and polyfluorination. *Pharm Res.* 2009; 26(4):811-821.
53. Mukhtar H, Khan WA. Cutaneous cytochrome P-450. *Drug Metab Rev.* 1989;20(2-4):657-673.
54. Higo N, Hinz RS, Lau DT, et al. Cutaneous metabolism of nitroglycerin in vitro. II. Effects of skin condition and penetration enhancement. *Pharm Res.* 1992;9(3):303-306.
55. Riviere JE, Sage B, Williams PL. Effects of vasoactive drugs on transdermal lidocaine iontophoresis. *J Pharm Sci.* 1991;80(7):615-620.
56. Danon A, Ben-Shimon S, Ben-Zvi Z. Effect of exercise and heat exposure on percutaneous absorption of methyl salicylate. *Eur J Clin Pharmacol.* 1986; 31(1):49-52.
57. Monteiro-Riviere NA, Inman AO, Riviere JE, et al. Topical penetration of piroxicam is dependent on the distribution of the local cutaneous vasculature. *Pharm Res.* 1993;10(9):1326-1331.
58. Singh P, Roberts MS. Blood flow measurements in skin and underlying tissues by microsphere method: application to dermal pharmacokinetics of polar nonelectrolytes. *J Pharm Sci.* 1993;82(9):873-879.
59. Kushla GP, Zatz JL, Mills OH, et al. Noninvasive assessment of anesthetic activity of topical lidocaine formulations. *J Pharm Sci.* 1993;82(11):1118-1122.
60. Williams ML. Ichthyosis: mechanisms of disease. *Pediatr Dermatol.* 1992;9(4):365-368.
61. Werner Y, Lindberg M. Transepidermal water loss in dry and clinically normal skin in patients with atopic dermatitis. *Acta Derm Venereol.* 1985;65(2):102-105.
62. Ghadially R, Brown BE, Sequeira-Martin SM, et al. The aged epidermal permeability barrier. Structural, functional, and lipid biochemical abnormalities in humans and a senescent murine model. *J Clin Invest.* 1995;95(5):2281-2290.
63. Lavrijsen AP, Bouwstra JA, Gooris GS, et al. Reduced skin barrier function parallels abnormal stratum corneum lipid organization in patients with lamellar ichthyosis. *J Invest Dermatol.* 1995;105(4):619-624.
64. Wilhelm KP, Surber C, Maibach HI. Effect of sodium lauryl sulfate-induced skin irritation on in vivo percutaneous penetration of four drugs. *J Invest Dermatol.* 1991;97(5):927-932.
65. Feldman RJ, Maibach HI. Regional variation in percutaneous penetration of 14C cortisol in man. *J Invest Dermatol.* 1967;48(2):181-183.
66. El Maghraby GM, Barry BW, Williams AC. Liposomes and skin: from drug delivery to model membranes. *Eur J Pharm Sci.* 2008;34(4-5):203-222.

67. Trommer H, Neubert RHH. Overcoming the stratum corneum: the modulation of skin penetration. A review. *Skin Pharmacol Physiol.* 2006;19(2):106-121.
68. Chiang A, Tudela E, Maibach HI. Percutaneous absorption in diseased skin: an overview. *J Appl Toxicol.* 2012;32(8):537-563.
69. Dragicevic N, Maibach HI, eds. *Percutaneous Penetration Enhancers Chemical Methods in Penetration Enhancement: Modification of the Stratum Corneum.* Springer-Verlag: Berlin Heidelberg; 2016.
70. Ryan T, ed. Beyond occlusion: dermatology proceedings. In: *No. 137 of International Congress Symposium Series.* London: Royal Society of Medicine Services; 1988.
71. Wester RC, Noonan PK, Maibach HI. Frequency of application on percutaneous absorption of hydrocortisone. *Arch Dermatol.* 1977;113(5):620-622.
72. Eaglstein WH, Farzad A, Capland L. Editorial: topical corticosteroid therapy: efficacy of frequent application. *Arch Dermatol.* 1974;110(6):955-956.
73. Ricciatti-Sibbald D, Sibbald RG. Dermatologic vehicles. *Clin Dermatol.* 7(3):11-24.
74. McCarron PA, Donnelly RF, Andrews GP, et al. Stability of 5-aminolevulinic acid in novel non-aqueous gel and patch-type systems intended for topical application. *J Pharm Sci.* 2005;94(8):1756-1771.
75. Huang X, Tanojo H, Lenn J, et al. A novel foam vehicle for delivery of topical corticosteroids. *J Am Acad Dermatol.* 2005;53(1 suppl 1):S26-S38.
76. Franz TJ, Parsell DA, Halualani RM, et al. Betamethasone valerate foam 0.12%: a novel vehicle with enhanced delivery and efficacy. *Int J Dermatol.* 1999; 38(8):628-632.
77. Choi MJ, Maibach HI. Liposomes and niosomes as topical drug delivery systems. *Skin Pharmacol Physiol.* 2005;18(5):209-219.
78. Karimipour DJ, Karimipour G, Orringer JS. Microdermabrasion: an evidence-based review. *Plast Reconstr Surg.* 2010;125(1):372-377.
79. Zesch A. Short and long-term risks of topical drugs. *Br J Dermatol.* 1986;115 suppl:63-70.
80. Farage MA, Katsarou A, Maibach HI. Sensory, clinical and physiological factors in sensitive skin: a review. *Contact Dermatitis.* 2006;55(1):1-14.
81. Kligman AM, Sadiq I, Zhen Y, et al. Experimental studies on the nature of sensitive skin. *Skin Res Technol.* 2006;12(4):217-222.
82. Kim YH. Management with topical nitrogen mustard in mycosis fungoides. *Dermatol Ther.* 2003;16(4):288-298.
83. Thaçi D, Salgo R. Malignancy concerns of topical calcineurin inhibitors for atopic dermatitis: facts and controversies. *Clin Dermatol.* 28(1):52-56.

Chapter 184 :: Glucocorticoids

:: Avrom Caplan, Nicole Fett, & Victoria Werth

SYSTEMIC GLUCOCORTICOIDS

AT-A-GLANCE

- Systemic glucocorticoids are potent immunosuppressive and antiinflammatory agents that are frequently used for severe dermatologic diseases.
- Complications are increased with fluorinated compounds, higher doses, longer duration of therapy, and more frequent administration.
- Intralesional, IM, IV, topical, and oral routes of administration can be used.
- Careful monitoring of systemic and cutaneous side effects is an essential component of therapy.
- Glucocorticoid-induced osteoporosis begins early in treatment and should be aggressively managed in all patients on long-term therapy.

Glucocorticoids are a mainstay of dermatologic therapy because of their potent immunosuppressive and antiinflammatory properties. By understanding the properties and mechanisms of action of glucocorticoids, one can maximize their efficacy and safety as therapeutic agents.

PHARMACOLOGY AND MECHANISM OF ACTION

The major naturally occurring glucocorticoid is cortisol (hydrocortisone). It is synthesized from cholesterol by the adrenal cortex. Normally, less than 5% of circulating cortisol is unbound; this free cortisol is the active therapeutic molecule. The remainder is inactive because it is bound to cortisol-binding globulin (also called transcortin) or to albumin. Daily cortisol production is 5 to 7 mg/m^2, with a diurnal peak around 8:00 AM.[1] Cortisol has a plasma half-life of 90 minutes. It is metabolized primarily by the liver, although it exerts hormonal effects on virtually every tissue in the body. The metabolites are excreted by the kidney and the liver.

The mechanism of glucocorticoid action involves passive diffusion of the glucocorticoids through the cell membrane, followed by binding to soluble receptor proteins in the cytoplasm.[2] This hormone-receptor complex then moves to the nucleus and regulates the transcription of a limited number of target genes. There are 3 main mechanisms of glucocorticoid action. The first is direct effects on gene expression by the binding of glucocorticoid receptors to glucocorticoid-responsive elements, leading to the induction of proteins like annexin I and MAPK (mitogen-activated protein kinase) phosphatase 1. Annexins reduce phospholipase A_2 activity, which reduces the release of arachidonic acid from membrane phospholipids, limiting the formation of prostaglandins and leukotrienes.[3-5] The second mechanism is indirect effects on gene expression through the interactions of glucocorticoid receptors with other transcription factors. For example, inhibitory effects on AP-1 and nuclear factor κB, coupled with increased inhibitor of nuclear factor κB (IκB), decreases the synthesis of a number of proinflammatory molecules, including cytokines, interleukins, adhesion molecules, and proteases.[6] The third is glucocorticoid receptor–mediated effects on second messenger cascades through nongenomic pathways such as the phosphatidylinositol 3′-kinase (PI3K)-Akt-endothelial nitric oxide synthase (eNOS) pathway.[7,8]

There is usually a delay in the onset of pharmacologic activity of glucocorticoids relative to their peak blood concentrations, which is probably consequent to altering the transcription of genes,[7] although some actions appear to be independent of transcription. Some effects of glucocorticoids are too rapid to be mediated by genomic glucocorticoid action,[9] which might explain the additive benefits of very-high-pulse glucocorticoids.

CELLULAR EFFECTS OF CORTICOSTEROIDS

Glucocorticoids profoundly affect the replication and movement of cells. They induce monocytopenia, eosinopenia, and lymphocytopenia, and have a greater effect on T cells than on B cells.[10] The lymphocytopenia appears to be caused by a redistribution of cells as they migrate from the circulation to other lymphoid tissues. The increase in circulating polymorphonuclear leukocytes is related to demargination of cells from the bone marrow and a diminished rate of removal from the circulation, at least partially mediated by the increase in annexin 1[11]; there also appears to be inhibition of neutrophil apoptosis.[12]

Glucocorticoids affect cell activation, proliferation, and differentiation. They modulate the levels of mediators of inflammation and immune reactions, as seen with the inhibition of cytokines and tumor

necrosis factor synthesis or release.[13,14] Additionally, macrophage functions, including phagocytosis, antigen processing, and cell killing, are decreased by cortisol, and this decrease affects immediate and delayed hypersensitivity.[15,16]

Glucocorticoids suppress monocyte and lymphocyte function (both Th1 and Th2 cells) more than polymorphonuclear leukocyte function.[17] This effect is clinically important because granulomatous infectious diseases, such as tuberculosis, are prone to exacerbation and relapse during prolonged glucocorticoid therapy. The antibody-forming cells, B lymphocytes and plasma cells, are relatively resistant to the suppressive effects of glucocorticoids.

INDICATIONS

There is a long list of indications for skin disorders (Table 184-1). In addition, short courses of glucocorticoids may be used for a variety of forms of severe dermatitis, including contact dermatitis, atopic dermatitis, photodermatitis, exfoliative dermatitis, and erythrodermas. The use of glucocorticoids is controversial in the treatment of erythema nodosum, lichen planus, cutaneous T-cell lymphoma, and discoid lupus erythematosus.

DOSING REGIMEN

Systemic glucocorticoids can be administered intralesionally, orally, intramuscularly, and intravenously. The route and regimen are determined by the nature and extent of the disease being treated.

Intralesional glucocorticoid administration allows direct access to either a relatively few lesions or a particularly resistant lesion. The concentration depends on the site of injection and the nature of the lesion. Lower concentrations are used on the face to prevent atrophy of the skin. In conditions requiring sustained effects, such as keloids and alopecia areata, longer-acting glucocorticoids, such as triamcinolone diacetate (Aristospan), can be administered alone or mixed with the more typically used triamcinolone acetonide (Kenalog). It is best to limit the total monthly dose of Kenalog to 20 mg to ensure that the hypothalamic–pituitary–adrenal (HPA) axis will not be suppressed.[18]

IM administration of glucocorticoids is associated with variable benefits and challenges. Although IM administration removes concerns for compliance and is not affected by nausea, vomiting, or inability to achieve intravenous access, potential drawbacks include erratic absorption and lack of daily control of the dose. Furthermore, IM injections may result in lipoatrophy or sterile abscesses.[19] Long-acting formulations such as triamcinolone acetonide have increased side effects over short-acting formulations, including increased potential of HPA axis suppression. Because this medication produces effects lasting up to 3 weeks, IM administration of triamcinolone acetonide should not be given more than a few times per year to avoid adrenal suppression.[19]

Intravenous glucocorticoids are used in 2 situations: The first is to provide stress coverage for patients who are acutely ill or are undergoing surgery (see below in section on Adrenal Suppression for discussion on glucocorticoids and surgery) and who have adrenal suppression from daily glucocorticoid therapy. The second is for patients with certain diseases—such as resistant pyoderma gangrenosum, severe pemphigus or bullous pemphigoid, serious systemic lupus erythematosus, or dermatomyositis—so as to gain rapid control of the disease and minimize the need for long-term, high-dose, oral steroid therapy.[20] Methylprednisolone is used at a dose of 500 mg to 1 g daily because of its high potency and low sodium-retaining activity. Serious side effects associated with IV administration include anaphylactic reactions, seizures, arrhythmias, and sudden death. Other, less serious adverse reactions include hypotension, hypertension, hyperglycemia, electrolyte shifts, and acute psychosis. Slower administration over 2 to 3 hours minimizes many of the serious side effects. Patients without underlying renal or cardiac disease do not need to be treated in a monitored bed, although vital signs should be monitored regularly during administration.[19] It is important to monitor serum electrolytes before and after pulse therapy, particularly when patients are on concomitant diuretic therapy.

Prednisone is the most commonly prescribed oral glucocorticoid. The initial dose is most often daily to control the disease process and can range from 2.5 mg to several hundred milligrams daily.

TABLE 184-1
Most Common Indications of Systemic Steroids

- Serious blistering diseases (pemphigus, bullous pemphigoid, cicatricial pemphigoid, linear immunoglobulin A bullous dermatoses, epidermolysis bullosa acquisita, herpes gestationis, erythema multiforme, toxic epidermal necrolysis)
- Connective tissue diseases (dermatomyositis, systemic lupus erythematosus, mixed connective tissue disease, eosinophilic fasciitis, relapsing polychondritis)
- Vasculitis
- Neutrophilic dermatoses (pyoderma gangrenosum, acute febrile neutrophilic dermatosis, Behçet disease)
- Sarcoidosis
- Type I reactive leprosy
- Hemangioma of infancy
- Panniculitis
- Urticaria/angioedema

INITIATING THERAPY

FUNDAMENTAL PRINCIPLES

Before therapy with glucocorticoids is begun, the benefit that can realistically be expected should be weighed

TABLE 184-2
Glucocorticoid Equivalencies

	EQUIVALENT DOSE (mg)	GLUCOCORTICOID POTENCY	HPA SUPPRESSION	MINERALOCORTICOID POTENCY	PLASMA HALF-LIFE (min)	BIOLOGIC HALF-LIFE (h)
Short-acting Glucocorticoids						
Cortisol	20	1.0	1.0	1.0	90	8-12
Cortisone	25	0.8		0.8	80-118	8-12
Intermediate-acting Glucocorticoids						
Prednisone	5	4.0	4.0	0.3	60	18-36
Prednisolone	5	5.0		0.3	115-200	18-36
Triamcinolone	4	5.0	4.0	0	30	18-36
Methylprednisolone	4	5.0	4.0	0	180	18-36
Long-acting Glucocorticoids						
Dexamethasone	0.75	30	17	0	200	36-54
Betamethasone	0.6	25-40		0	300	36-54
Mineralocorticoids						
Fludrocortisone	2	10	12.0	250	200	18-36
Desoxycorticosterone acetate		0		20	70	

HPA, hypothalamic–pituitary–adrenal axis.

From Chrousos G, Pavlaki AN, Magiakou MA. Glucocorticoid therapy and adrenal suppression. [Updated January 11, 2011.] In: De Groot LJ, Chrousos G, Dungan K, et al., eds. *Endotext [Internet]*. South Dartmouth, MA: MDText.com, Inc; 2000. https://www.ncbi.nlm.nih.gov/books/NBK279156/, with permission.

Copyright © 2000-2018, MDText.com, Inc.

against the potential side effects. Alternative or adjunctive therapies should be considered, especially if long-term treatment is contemplated. Coexisting illnesses such as diabetes, hypertension, and osteoporosis need to be considered. The predisposition of the patient to side effects should be included in an assessment of risk.

CHOOSING AMONG GLUCOCORTICOIDS

A number of considerations bear on the choice of glucocorticoids (Table 184-2). First, a preparation with minimal mineralocorticoid effect is usually picked to decrease sodium retention. Second, the long-term oral use of prednisone or a similar drug, with an intermediate half-life and relatively weak steroid-receptor affinity, may reduce side effects. Long-term use of drugs like dexamethasone, which has a longer half-life and high glucocorticoid-receptor affinity, may produce more side effects without additional therapeutic effects. Third, if a patient does not respond to cortisone or prednisone, the substitution of the biologically active form, cortisol or prednisolone, should be considered. However, even in severe liver disease, substitution has not proved to be very important.

EVALUATION BEFORE TREATMENT

To minimize potential problems, the baseline evaluation should include a personal and family history, with special attention to predisposition to diabetes, hypertension, hyperlipidemia, glaucoma, and associated diseases that could be affected by steroid therapy. Side-effect-specific evaluation and monitoring recommendations during glucocorticoid therapy are discussed below in the section "Adverse Effects".

SIDE EFFECTS AND PRECAUTIONS

Table 184-3 outlines side effect preventive measures for systemic glucocorticoid therapy.

DIET

Diet should be low in calories, fat, and sodium, and high in protein, potassium, and calcium as tolerated, also considering any associated comorbidities. Protein intake is important to reduce steroid-induced nitrogen wasting.[21] Use of alcohol, coffee, and nicotine should be minimized. Exercise should be encouraged.

INFECTIONS

Glucocorticoid therapy increases the risk to patients for common and uncommon infections.[22] All patients anticipated to be on glucocorticoid doses of 15 mg or greater for 1 month or longer should be screened for tuberculosis with either a tuberculin

TABLE 184-3
Side Effects and Preventive Measures for Systemic Glucocorticoid Therapy

SIDE EFFECT	PREVENTIVE MEASURES
Hypertension	Blood pressure (baseline; repeat with each visit)
Weight gain	Weight (baseline; repeat with each visit)
Reactivation of infection	Purified protein derivative or interferon-gamma release assay; hepatitis screen; consider *Pneumocystis jiroveci* pneumonia prophylaxis
Metabolic abnormalities	Electrolytes, lipids, glucose (baseline; repeat early after starting therapy; repeat annually; more frequent monitoring with known factors [eg, diabetes, hyperlipidemia])
Osteoporosis	Bone density (baseline; repeat annually); instruct about diet, exercise; initiate calcium and vitamin D supplementation; start bisphosphonate for men, postmenopausal women based on bone mineral density evaluation
Eyes	Refer for ophthalmologic evaluation and consider more frequent screening if history of cataracts or glaucoma
Peptic ulcer	In patients on concomitant nonsteroidal antiinflammatory drugs, initiate prophylaxis with a proton pump inhibitor; with 2 or more risk factors, consider prophylaxis with proton pump inhibitor
Suppression of hypothalamic–pituitary–adrenal axis	Single, early morning doses, preferably every other day

skin test by injecting a purified protein derivative or an interferon-gamma release assay (QuantiFERON-TB Gold In-Tube Test or T-SPOT.TB). Patients with a positive screening test should have chest radiography to evaluate for active tuberculosis. Patients with a negative chest radiograph require treatment for latent tuberculosis. Anergic patients should have a baseline chest radiograph to search for evidence of previous tuberculosis. Of note, glucocorticoids downregulate delayed-type hypersensitivity and may suppress the purified protein derivative response. A positive purified protein derivative in this population is considered 5 mm or more of induration. Attention must also be paid to patients on high doses of glucocorticoids with underlying lung disease, low lymphocyte counts, underlying conditions further contributing to immunosuppression, and/or patients on concomitant cytotoxic therapies, as these patients are at increased risk for development of *Pneumocystis* pneumonia. Some advocate use of trimethoprim-sulfamethoxazole prophylaxis against *Pneumocystis jiroveci* for high-risk patients who are on high doses of glucocorticoids. Examination for other covert infections should be based on history and physical examination. For instance, a stool culture for *Strongyloides* should be performed for those who have lived in tropical countries and for Vietnam veterans.[23]

IMMUNIZATIONS

Immunization with live vaccines can be done if the duration of glucocorticoid use is less than 2 weeks at any dose, if the dose of glucocorticoid is less than 20 mg/day of any duration or less than 2 mg/kg in patients who weigh less than 10 kg, and if long-term alternate-day treatment with short-acting preparations is used. Immunization with live vaccines should not be done for at least 1 month after receiving high doses of glucocorticoids (>20 mg/day) for more than 2 weeks.[24]

ADRENAL SUPPRESSION

Patients receiving daily glucocorticoid therapy for longer than 3 to 4 weeks must be assumed to have adrenal suppression that requires tapering of the glucocorticoids to allow for recovery of the HPA axis. Prescribers may choose from among a variety of tapering algorithms and may choose to test the HPA axis to guide the need for short-term maintenance therapy at the low end of the taper.

If a prescriber chooses to test the HPA axis, it should be done with an 8 AM cortisol (to time the test when physiologic cortisol production peaks) prior to taking the daily steroid dose and after tapering that daily dose to a dose less than or equal to the daily physiologic cortisol level (<5 mg prednisone/day; or 15 to 20 mg hydrocortisone/day). If the 8 AM plasma cortisol levels are 5 µg/dL or less, then continued glucocorticoid therapy and rechecking of the serum cortisol every 3 to 6 months until levels are higher than 10 µg/dL is required. If levels are 5 µg/dL or higher but 20 µg/dL or less, prescribers may choose to perform further testing, such as a corticotropin-releasing hormone stimulation test; it is reasonable, however, to continue maintenance therapy with a very gradual taper.[25] At any point during tapering or within a year of stopping glucocorticoids, a stress caused, for example, by trauma, surgery, diarrhea, or fever can precipitate adrenal insufficiency related to an inadequate stress response. During such situations, it may be necessary to give higher doses of glucocorticoids in divided doses. Patients must be educated about the need for stress coverage and should wear bracelets or carry cards indicating that they are receiving glucocorticoids.

Most patients can be maintained on their regular dose of glucocorticoids in preparation for surgery. Prior guidelines for preoperative and perioperative management were based on cortisol response to severity of surgery.[26] However, expert opinion demonstrates a shifting paradigm.[27,28] Consideration may be given to high-dose glucocorticoids (50 mg hydrocortisone every 8 hours until tolerating oral intake) for patients undergoing major surgical procedures or patients with primary adrenal failure, congenital adrenal hyperplasia, or hypopituitarism.[28] Few randomized controlled trials have been done, and data is sparse. Clinicians must remain vigilant for intraoperative hypotension or

other signs of adrenal insufficiency for at-risk patients undergoing surgical procedures and treat appropriately if acute adrenal insufficiency is the etiology.

ADVERSE EFFECTS

Complications associated with systemic glucocorticoid therapy (Table 184-4) increase with higher doses, longer duration of therapy, and more frequent administration.[19,29] However, osteoporosis and cataracts develop with alternate-day dosing, and avascular necrosis (AVN) can be seen after only short courses of glucocorticoids.

TABLE 184-4
Complications Associated with Systemic Glucocorticoid Therapy

Bone health
▪ Avascular necrosis of bone
▪ Osteoporosis
Cardiovascular
▪ Atherosclerosis
▪ Dislipidemia
▪ Hypertension
▪ Sodium and fluid retention
Cutaneous
▪ Fibroblast inhibition
▪ Inhibition of wound healing
▪ Subcutaneous tissue atrophy (striae, purpura, ecchymoses)
Endocrine/Metabolic
▪ Alterations of fat distribution (typical cushingoid appearance)
▪ Fatty infiltration of the liver
▪ Growth failure
▪ Hyperglycemia and unmasking genetic predisposition to diabetes mellitus
▪ Secondary amenorrhea
▪ Suppression of hypothalamic–pituitary–adrenal axis
Gastrointestinal
▪ GI bleeding
▪ Intestinal perforation
▪ Pancreatitis
▪ Peptic ulcer
Immunity
▪ Effects on phagocyte kinetics and function
▪ Immunosuppression, anergy
▪ Increased incidence of infections
▪ Suppression of host defenses
Miscellaneous
▪ Anaphylaxis
▪ Drug interactions (for example, increased INR on patients on both prednisone and coumadin)
▪ Hypersensitivity reactions
▪ Myopathy
▪ Urticaria
Ophthalmologic
▪ Cataracts
▪ Glaucoma
Psychiatric/Mood disturbances
▪ Depression, mania
▪ Sleep disturbances
▪ Thoughts of self-harm

OSTEOPOROSIS

Osteoporosis occurs in 40% of individuals treated long-term with systemic glucocorticoids.[30,31] Bone loss occurs most rapidly in the first few months of glucocorticoid use, but continues at a slower rate after that.[30,32] Even low doses of prednisone (2.5 mg per day) adversely affect bone and increase vertebral and hip fractures.[33]

Glucocorticoids have both direct and indirect effects on bone. They decrease bone formation and increase resorption by inhibiting osteoblasts and increasing activity of osteoclasts.[30] Indirectly, glucocorticoids increase calcium excretion by the kidney, decrease intestinal calcium absorption, and reduce estrogen and testosterone levels.

Any patient anticipated to be on glucocorticoid therapy for 3 months or longer should receive calcium 1200 mg/day and vitamin D 800 International Units/day through diet and supplement.[34] Patients with comorbidities, such as patients with sarcoidosis or renal stones, may require close monitoring or adjustment of this recommendation. Clinicians may consider checking vitamin D levels and repleting prior to initiating maintenance therapy. Patients anticipated to be on prednisone 5 mg or more per day for 3 months or longer and all patients considered at high risk for osteoporosis should be evaluated with dual-energy x-ray absorptiometry or by the World Health Organization (WHO)'s fracture risk assessment tool, the FRAX equation (http://www.shef.ac.uk/FRAX/), for consideration of initiation of bisphosphonates. Rare side effects of bisphosphonates include osteonecrosis of the jaw and atypical femoral fractures. Additionally, bisphosphonates are contraindicated in patients with creatinine clearance below 30 mL/min. Oral bisphosphonates are contraindicated for patients who cannot sit upright for 30 minutes after swallowing a pill and for patients with esophageal disorders that impact swallowing, such as achalasia, strictures, reflux, or varices. Initiating bisphosphonates in women of childbearing potential should be considered case-by-case. In general, these women should avoid bisphosphonates in the absence of fragility fractures or ongoing bone loss.[35] Long-term use of glucocorticoids and/or high-risk patients may be evaluated for initiation of teriparatide. Secondary causes for osteoporosis should be considered and evaluated in all patients.

AVASCULAR NECROSIS

AVN is manifest by pain and limitation of motion in one or more joints. Various mechanisms have been postulated to explain AVN. Early detection is important because early intervention may prevent progression to degenerative joint disease requiring

joint replacement. Patients should be regularly questioned about pain and limitation of motion of joints. If abnormalities develop, a radiograph, bone scan, or MRI should be ordered. Because radiographs can be normal in AVN, if suspicion for this side effect is high, clinicians should consider evaluation by MRI. If multiple joints may be involved, then a bone scan may be needed. If imaging shows AVN, an orthopedic surgeon skilled in early intervention with core decompression may be able to halt progression of the disease.

CARDIOVASCULAR DISEASE

Glucocorticoid use is associated with an increased risk for ischemic heart disease and heart failure,[36,37] although these risks appear to be greatest in patients with iatrogenic Cushing syndrome.[38,39] Various mechanisms may contribute to this increased risk for cardiovascular events among patients with hypercortisolism, including hypercortisolism-induced hypertension, increased atherosclerosis, structural changes such as ventricular hypertrophy and myocardial fibrosis, and electrocardiographic changes. However, data is limited. Many studies excluded patients with iatrogenic Cushing syndrome, and comorbidities such as glucose intolerance, weight gain, and dyslipidemia may have resulted in confounding of study results.[40-43]

Increased cardiovascular risk may persist for years after normalization of the serum cortisol level in Cushing disease.[44,45] Although studies primarily address Cushing disease, it is prudent to remain aware of this increased risk for patients on glucocorticoids or with iatrogenic Cushing syndrome, as metabolic syndrome may persist after removal of glucocorticoids contributing to ongoing risk for cardiovascular disease.

Cardiovascular risk factors should be aggressively managed. Blood pressure, diet, serum lipids, and glucose levels should be measured serially. Abnormalities should be treated with dietary manipulation and medication as necessary and according to current guidelines.

GASTROINTESTINAL COMPLICATIONS

There is a significantly increased risk for peptic ulcer disease and GI bleeding in patients taking both glucocorticoids and nonsteroidal antiinflammatory agents, although it is unclear whether glucocorticoids independently increase this risk.[46-48] In patients on combined therapy with a nonsteroidal antiinflammatory agent and glucocorticoid, prophylaxis with a proton pump inhibitor should be initiated. Prophylaxis should be highly considered in patients with 2 or more risk factors (such as those with a previous history of peptic ulceration or advanced malignant disease).

SUPPRESSION OF THE HYPOTHALAMIC–PITUITARY–ADRENAL AXIS AND THE STEROID WITHDRAWAL SYNDROME

The HPA axis is rapidly suppressed after the onset of glucocorticoid therapy. However, if therapy is limited to 1 to 3 weeks, the recovery of the HPA axis is rapid. As noted above, longer daily glucocorticoid therapy is associated with suppression of the HPA axis. Symptoms of adrenal insufficiency include lethargy, weakness, nausea, anorexia, fever, orthostatic hypotension, hypoglycemia, and weight loss.

There also exists a steroid withdrawal syndrome, in which patients experience symptoms of adrenal insufficiency despite having an apparently normal cortisol response to adrenocorticotropic hormone. Symptoms most commonly include anorexia, lethargy, malaise, nausea, weight loss, desquamation of the skin, headache, and fever. Less commonly, vomiting, myalgia, and arthralgia occur.[49] These patients have adjusted to high levels of glucocorticoids, and symptoms disappear after the glucocorticoids are restarted. This problem can be treated by slower tapering of the glucocorticoids or by temporarily increasing the dose.[25,49]

PSYCHIATRIC EFFECTS

Mood and cognitive changes are dose dependent and can appear shortly after the start of glucocorticoids. Age and gender appear to be risk factors for specific side effects. Women may be more likely to develop depression, whereas men may be more likely to develop mania.[50] The risk of depression, mania, delirium, confusion, and disorientation increases with age, but the opposite is true of suicidal behavior and panic disorder. The incidence of neuropsychiatric events is highest in the first 3 months of therapy. Prednisone doses greater than 80 mg/day place patients at increased risk for steroid psychosis.[50]

CONCERNS DURING LACTATION AND PREGNANCY

Glucocorticoids cross the placenta, but they are not teratogenic. Even though glucocorticoids are secreted into breastmilk, no adverse effect has been reported among breastfed infants of mothers taking glucocorticoids. Prednisolone instead of prednisone and avoiding breastfeeding for 4 hours after a dose may decrease the amount of drug transferred during breastfeeding.[51]

ISSUES SPECIFIC TO PEDIATRICS

In the pediatric population, glucocorticoids cause growth suppression and early osteoporosis.[52] Glucocorticoids inhibit bone formation, affect calcium and phosphorus metabolism, and interfere with growth hormone via affects on growth hormone secretion, growth hormone receptor expression and signal

transduction from growth hormone to target tissuess.[52] These effects can be reversed by treatment with growth hormone. Osteoporosis can reverse after glucocorticosteroids are stopped.

TOPICAL GLUCOCORTICOIDS

AT-A-GLANCE

- Topical glucocorticoids are the most frequently prescribed of all dermatologic drug products.
- They are effective at reducing the symptoms of inflammation, but do not address the underlying cause of the disease.
- Topical glucocorticoid research has focused on strategies to optimize potency while minimizing side effects.
- As with systemic glucocorticoids, careful monitoring of side effects is an essential component of therapy.

MECHANISM OF ACTION

The mechanism of action, antiinflammatory effects, and immunosuppressive effects are as described in "Systemic Glucocorticoids" above. Topical steroids are also notable for their antiproliferative effect and their vasoconstrictive effect on dermal capillaries.

ANTIPROLIFERATIVE EFFECTS

This effect of topical corticosteroids is mediated by inhibition of DNA synthesis and mitosis, partly explaining the therapeutic action of these drugs in scaling dermatoses.[53] They are known to reduce the keratinocyte size and proliferation. Fibroblast activity and collagen formation are also inhibited by topical corticosteroids.[54]

VASOCONSTRICTION

Topical steroids cause capillaries in the superficial dermis to constrict, thus reducing erythema. The mechanism by which corticosteroids induce vasoconstriction is not yet completely clear. It is thought to be related to inhibition of natural vasodilators such as histamine, bradykinins, and prostaglandins, and possibly via augmentation of vascular tone.[55-58] Vasoconstriction assays are used to predict the clinical activity of an agent. These assays have been used to separate the topical corticosteroids into 7 classes based on potency according to the United States' classification system and 4 classes according to the United Kingdom and France's classification systems. In the U.S. system, Class 1 includes the most potent, while Class 7 contains the least potent topical corticosteroids. Table 184-5 lists many of the available topical corticosteroids according to this classification.

TABLE 184-5
Potency Ranking of Selected Topical Corticosteroid Preparations

Class 1—Superpotent
- Betamethasone dipropionate 0.05% optimized vehicle
- Clobetasol propionate 0.05%
- Diflorasone diacetate 0.05%
- Fluocinonide 0.1% optimized vehicle
- Flurandrenolide 4 μg/cm²
- Halobetasol propionate 0.05%

Class 2—Potent
- Amcinonide 0.1%
- Betamethasone dipropionate 0.05%
- Desoximetasone 0.25%
- Desoximetasone 0.05%
- Diflorasone diacetate 0.05%
- Fluocinonide 0.05%
- Halcinonide 0.1%
- Mometasone furoate 0.1%

Class 3—Potent, Upper Midstrength
- Amcinonide 0.1%
- Betamethasone dipropionate 0.05%
- Betamethasone valerate 0.1%
- Diflorasone diacetate 0.05%
- Fluocinonide 0.05%
- Fluticasone propionate 0.005%
- Triamcinolone acetonide 0.5%

Class 4—Midstrength
- Betamethasone valerate 0.12%
- Clocortolone pivalate 0.1%
- Desoximetasone 0.05%
- Fluocinolone acetonide 0.025%
- Flurandrenolide 0.05%
- Hydrocortisone probutate 0.1%
- Hydrocortisone valerate 0.2%
- Mometasone furoate 0.1%
- Prednicarbate 0.1%
- Triamcinolone acetonide 0.1%

Class 5—Lower Midstrength
- Betamethasone dipropionate 0.05%
- Betamethasone valerate 0.1%
- Fluocinolone acetonide 0.025%
- Fluocinolone acetonide 0.01%
- Flurandrenolide 0.05%
- Fluticasone propionate 0.05%
- Hydrocortisone butyrate 0.1%
- Hydrocortisone valerate 0.2%
- Prednicarbate 0.1%
- Triamcinolone acetonide 0.1%
- Triamcinolone acetonide 0.025%

Class 6—Mild Strength
- Alclometasone dipropionate 0.05%
- Desonide 0.05%
- Fluocinolone acetonide 0.01%
- Triamcinolone acetonide 0.025%

Class 7—Least Potent
- Topicals with dexamethasone, flumethasone, hydrocortisone, methylprednisolone, prednisolone

PHARMACOKINETICS

Before choosing a topical glucocorticoid preparation, one must consider patient-related factors such as age, extent and location of body surface area, and presence or absence of inflammation, as well as drug-related factors such as concentration, duration, vehicle, and intrinsic characteristics of the agent.

Penetration of the glucocorticoid varies according to the skin site, which, in turn, is related to the thickness of the stratum corneum and the vascular supply to the area. For example, penetration of topical steroids through the eyelids and scrotum is greater than through the forehead and significantly greater than through the palms and soles. Inflamed, moist, and denuded skin also shows increased penetration. Potent topical steroids (Classes 1 and 2) should rarely, if ever, be used in the areas with the highest level of penetration.

The target site for topical corticosteroids is the viable epidermis or dermis, and clinical response to a formulation is directly proportional to the concentration of corticosteroid achieved at the target site.

Topical corticosteroids are compounded in several formulations and with varying strengths. Treatment adherence in the management of skin conditions is vital, as such, formulations including spray, foam, lotion, hydrogel, and shampoo have been developed to improve patient convenience and acceptance.

Both increasing hydration of the stratum corneum and using occlusive dressings may enhance absorption of topical corticosteroids. Expert consensus recommends soak and smear methods for treating atopic dermatitis, which consists of a warm bath followed by a generous application of topical corticosteroids, though evidence from studies remains limited.

INDICATIONS

Topical corticosteroids are used for an antiinflammatory activity in inflammatory skin diseases, antimitotic effects, and for their capacity to decrease the synthesis of connective tissue molecules.[55] The responsiveness of diseases to topical glucocorticoids varies and thus must be considered when prescribing topical corticosteroids. Diseases can be divided into the 3 categories shown in Table 184-6: (a) highly responsive, (b) moderately responsive, and (c) least responsive.

TABLE 184-6
Responsiveness of Dermatoses to Topical Application of Corticosteroids

Highly responsive	▪ Atopic dermatitis (children) ▪ Intertrigo ▪ Psoriasis (intertriginous) ▪ Seborrheic dermatitis
Moderately responsive	▪ Atopic dermatitis (adults) ▪ Lichen simplex chronicus ▪ Nummular eczema ▪ Papular urticaria ▪ Parapsoriasis ▪ Primary irritant dermatitis ▪ Psoriasis
Least responsive	▪ Allergic contact dermatitis, acute phase ▪ Dyshidrotic eczema ▪ Granuloma annulare ▪ Insect bites ▪ Lichen planus ▪ Lupus erythematosus ▪ Necrobiosis lipoidica diabeticorum ▪ Palmoplantar psoriasis ▪ Pemphigus ▪ Psoriasis of nails ▪ Sarcoidosis

PEDIATRIC USES

Children and, in particular, infants, are at an increased risk of absorbing topical corticosteroids for several reasons. They have a higher body-surface-area-to-weight ratio, and thus have a higher degree of absorption for the same amount applied as an adult,[59] and they also have thinner skin. Infants also may be less able to metabolize potent glucocorticoids rapidly.[60] Application of topical steroids to the diaper area results in occlusion of the steroid by the diaper, and increased penetration occurs. As with other skin conditions, selecting the appropriate strength according to the body site, the extent of involvement, and the flare intensity is essential for treatment success.

Concerns for atrophy, hypopigmentation, osteoporosis, and telangiectasias are minimized when topical steroids are used in accordance with guidelines.[61] High-potency newer formulations of corticosteroids are effective in pediatric atopic dermatitis and may be considered for short courses, although the highest potency steroids may not be recommended by all experts for pediatric use.[59,62,63] Rarely, high-potency applications can result in systemic absorption and cutaneous side effects. The low risk for side effects and highly effective treatment modality should be carefully explained to parents to maximize compliance and understanding and minimize undertreatment. Results from numerous surveys demonstrate a "corticosteroid phobia" among patients/caregivers that leads to treatment noncompliance.[64-67]

GERIATRIC USES

Elderly patients may have thin skin, which allows for increased penetration of topical glucocorticoids. They are also more likely to have preexisting skin atrophy secondary to aging and may be diaper dependent. Similar precautions used in the treatment of infants should be used when treating elderly patients.

USES IN PREGNANCY

Most topical steroids are rated by the U.S. Food and Drug Administration as category C drugs. Best

available evidence suggests no significant effects for pregnant women who use mild or moderate topical corticosteroids during pregnancy. A risk for low birth weight is associated with high-potency topical steroids, although the risk is small if used in the short term and increases with heavier use of strong topical corticosteroids.[68] However, studies are observational and imprecision was noted in regard to the outcome of low birth weight.[69] Topical corticosteroids have not been studied during breastfeeding; however, based on National Institutes of Health recommendations, it is recommended to limit long-term exposure to high-potency corticosteroids while breastfeeding. In addition, use only water-miscible cream or gel products to limit exposure of infants to mineral paraffins while breastfeeding. Topical corticosteroids should be wiped off prior to breastfeeding.[51]

DOSING REGIMEN

The frequency of topical application of corticosteroids was developed in an empirical manner, with most textbooks and physicians recommending twice-daily use. For superpotent corticosteroids once-daily application is considered as beneficial as twice-daily application. Observations suggest once-daily dosing also may be beneficial when using lesser-potency corticosteroids.

Tachyphylaxis has been demonstrated in experimental conditions by diminished vasoconstriction, rebound of DNA synthesis, and recovery of histamine wheals after application of topical steroids in patients with a history of long-term topical steroid usage.[70] Whether this tachyphylaxis is clinically relevant remains unclear. For example, patient adherence to therapy may explain what could be seen clinically as tachyphylaxis in pediatric eczema treated with appropriate topical corticoisteroids.[61]

SIDE EFFECTS AND PRECAUTIONS

Both local and systemic side effects have been documented with the use of topical corticosteroids. Application of corticosteroids to large surface areas, occlusion, higher concentrations, or more potent derivatives directly increases the risk of systemic absorption and subsequent side effects. Side effect–specific monitoring parameters are discussed below.

Under normal conditions, up to 99% of the applied topical corticosteroid is cleared from the skin, and only 1% is therapeutically active. Cutaneous adverse effects can result from the small percentage of percutaneously absorbed corticosteroid or also may result from its transient presence onto the skin. Continued use of topical corticosteroids also may lead to tachyphylaxis, as noted above.

Table 184-7 outlines some general principles that should be remembered when initiating topical corticosteroids.[55] Considerations for prescribing topical corticosteroids to prevent side effects should be followed (Table 184-8).[54,71]

TABLE 184-7
Principles When Initiating Topical Steroid Therapy

- Initiate lowest potency to sufficiently control disease.
- Topical corticosteroids should be avoided on ulcerated or atrophic skin, and on skin with coexistent infectious dermatoses.
- Prolonged use of insufficiently potent agent should be avoided.
- Treatment with low to medium potency preparations is recommended for large surface areas.
- Highly responsive diseases will usually respond to weak steroid preparations, whereas less-responsive diseases require medium-potency or high-potency topical steroids.
- Low-potency, ideally nonhalogenated, preparations should be used on the face and intertriginous areas.
- Very potent steroid therapy, frequently under occlusion, is usually required for hyperkeratotic or lichenified dermatoses and for involvement of palms and soles.
- Because of the increased body-surface-area-to-body-mass-index ratio and increased risk of systemic absorption, high-potency preparations and halogenated–medium-potency preparations, should be avoided in infants and young children, other than for short-term application.

ADVERSE EFFECTS

Local adverse effects of topical corticosteroid use are more prevalent than systemic reactions.

ATROPHIC CHANGES

Skin atrophy is a prominent and potential cutaneous adverse effect, and involves both the epidermis and dermis. Dermal atrophy develops from the direct antiproliferative effects of topical corticosteroids on

TABLE 184-8
Continuing Use of Topical Steroids

- Highly potent formulations should be used for short periods (2 to 3 weeks) or intermittently.
- Once disease control is partially achieved, the use of a less-potent compound should be initiated.
- Reduce frequency of application (eg, application only in the morning, alternate-day therapy, weekend use) once disease control is partially achieved.
- Sudden discontinuation should be avoided after prolonged use to prevent rebound phenomena.
- Special guidelines should be followed when treating certain body areas (eg, intertriginous areas) or certain populations (eg, children or the elderly) to prevent the occurrence of local or systemic adverse effects.
- Close monitoring and further evaluation is recommended if systemic absorption of corticosteroids is suspected.
- Use combination therapy when clinically indicated (eg, addition of topical calcineurin inhibitor, tretinoin or calcipotriene).

TABLE 184-9
Classification of Corticosteroids by Cross-reactivity

STRUCTURAL CLASS	A	B	C	D1	D2
Type	Hydrocortisone	Triamcinolone Acetonide	Betamethasone	Betamethasone dipropionate	Methylprednisolone aceponate
Structure	C16—no methyl substitution		C16 methyl substitution	C16 methyl substitution	C16—no methyl substitution, no halogenation
	Probable C21—short-chain ester			C17/21 long-chain ester	
Cross-reactions	Cross-reacts with D2	Budesonide specifically cross-reacts with D2			Cross-reacts with A and budesonide
Patch-test substance	Tixocortol-21-pivalate	Budesonide		Clobetasol-17-propionate	Hydrocortisone-17-butyrate
		Triamcinolone acetonide			

Adapted from Jacob SE, Steele T. Corticosteroid classes: a quick reference guide including patch test substances and cross-reactivity. *J Am Acad Dermatol.* 2006;54(4):723-27.

fibroblasts, with inhibition of collagen and mucopolysaccharide synthesis, resulting in loss of dermal support. Reduction of glycosaminoglycan production and changes to structure and proportion has been described, though of note, low-potency therapy may have a lesser effect.[72] Levels of hyaluronan, the major glycosaminoglycan in the skin, are also rapidly decreased after short-term glucocorticoid treatment.[73,74] Fragmentation and thinning of elastic fibers develop in the upper layers of the dermis, whereas deeper fibers form a compact and dense network. As a result of these atrophic changes, there is vascular dilation, purpura, easy bruising, stellate pseudoscars (purpuric, irregularly shaped, and hypopigmented atrophic scars), and ulceration. Atrophy is more likely to occur with high-potency topical corticosteroids, but this effect has been clinically reversed by reduction of potency.[75] Clinicians must consider these findings when prescribing corticosteroids and use appropriate doses, formulations, and durations to minimize risk for skin atrophy and reverse this side effect if it develops.

ACNEIFORM REACTIONS

The development or exacerbation of dermatoses of the face, including steroid rosacea, acne, and perioral dermatitis, is a well-known side effect of topical corticosteroids.[76] Although steroids initially lead to the suppression of inflammatory papules and pustules, patients may flare when treatment is withdrawn, thus leading to continued use of greater potency topical corticosteroids. For these reasons, steroid use should be discouraged in the treatment of rosacea and perioral and periocular dermatitis.

OTHER CUTANEOUS EFFECTS

Decreased pigmentation and hypertrichosis are reported with use of topical corticosteroid therapy.[76] Patients may also experience a burning sensation primarily on the face after withdrawal from continuous high dose steroid therapy.[77] Even though data regarding this reaction is limited, clinicians may consider this in the differential for such reactions.

DEVELOPMENT OF INFECTIONS

Topical corticosteroids may exacerbate and/or mask cutaneous infectious diseases including tinea versicolor, disseminated *Alternaria* infection, and dermatophytosis. Granuloma gluteale infantum, characterized by reddish-purplish granulomatous lesions on the diaper area, is a well-known complication of diaper dermatitis during treatment with corticosteroids.[76]

ALLERGIC REACTIONS

Allergic contact dermatitis from steroids should be suspected when dermatitis worsens with corticosteroid therapy, does not lead to improvement, or changes the clinical pattern of disease. In a 6-year retrospective study, 127 patients (10.69%) had an allergic reaction to at least one corticosteroid. Among the 1188 patients, 71 (5.98%) reacted to 1 corticosteroid, 28 (2.36%) to 2 corticosteroids, 6 (0.51%) to 3 corticosteroids, 6 (0.51%) to 4 corticosteroids, and 16 (1.35%) to more than 4 corticosteroids.[78] Patients suspected of having an allergy to a topical corticosteroid should undergo patch testing to determine whether the vehicle or the steroid is causing the contact dermatitis.[79] If patch testing is unavailable, the clinician should prescribe a Class C steroid (from a classification A through D of steroids according to cross-reactivity in association with allergic contact dermatitis; Table 184-9 outlines the classification of corticosteroids by cross-reactivity). Table 184-10 outlines potential allergens in topical corticosteroids.

TABLE 184-10
Potential Allergens in Topical Corticosteroids Vehicles

- Formaldehyde-releasing preservatives (imidazolidinylurea/diazolidinylurea)
- Fragrance
- Lanolin
- Methylchloroisothiazolinone/methylisothiazolinone
- Parabens
- Propylene glycol
- Sorbitan sesquioleate

SYSTEMIC ADVERSE EFFECTS

Topical glucocorticoids, especially high-potency Class 1 agents, may result in HPA axis suppression and, rarely, other systemic adverse effects. Clinicians should be aware of this possibility when using high-potency topical corticosteroids or when patients report inappropriate use of high-potency corticosteroids.

ACKNOWLEDGMENTS

We would like to thank Isabel C. Valencia and Francisco A. Kerdel, who contributed to the previous version of this chapter in the 8th edition.

REFERENCES

1. Esteban NV, Loughlin T, Yergey AL, et al. Daily cortisol production rate in man determined by stable isotope dilution/mass spectrometry. *J Clin Endocrinol Metab*. 1991;72(1):39-45.
2. Bloom E, Matulich DT, Lan NC, et al. Nuclear binding of glucocorticoid receptors: Relations between cytosol binding, activation and the biological response. *J Steroid Biochem*. 1980;12:175-184.
3. Flower RJ, Rothwell NJ. Lipocortin-1: cellular mechanisms and clinical relevance. *Trends Pharmacol Sci*. 1994;15(3):71-76.
4. Pepinsky RB, Tizard R, Mattaliano RJ, et al. Five distinct calcium and phospholipid binding proteins share homology with lipocortin I. *J Biol Chem*. 1988;263(22):10799-10811.
5. Wallner BP, Mattaliano RJ, Hession C, et al. Cloning and expression of human lipocortin, a phospholipase A2 inhibitor with potential anti-inflammatory activity. *Nature*. 1986;320(6057):77-81.
6. Adcock IM, Caramori G, Ito K. New insights into the molecular mechanisms of corticosteroids actions. *Curr Drug Targets*. 2006;7(6):649-660.
7. Rhen T, Cidlowski JA. Antiinflammatory action of glucocorticoids—new mechanisms for old drugs. *N Engl J Med*. 2005;353(16):1711-1723.
8. Buttgereit F, Saag KG, Cutolo M, et al. The molecular basis for the effectiveness, toxicity, and resistance to glucocorticoids: Focus on the treatment of rheumatoid arthritis. *Scand J Rheumatol*. 2005;34(1):14-21.
9. Groner B, Hynes NE, Rahmsdorf U, et al. Transcription initiation of transfected mouse mammary tumor virus LTR DNA is regulated by glucocorticoid hormones. *Nucleic Acids Res*. 1983;11(14):4713-4725.
10. Cupps TR, Fauci AS. Corticosteroid-mediated immunoregulation in man. *Immunol Rev*. 1982;65:133-155.
11. Goulding NJ, Euzger HS, Butt SK, et al. Novel pathways for glucocorticoid effects on neutrophils in chronic inflammation. *Inflamm Res*. 1998;47(suppl 3):S158-S165.
12. Liles WC, Dale DC, Klebanoff SJ. Glucocorticoids inhibit apoptosis of human neutrophils. *Blood*. 1995;86(8):3181-3188.
13. Amano Y, Lee SW, Allison AC. Inhibition by glucocorticoids of the formation of interleukin-1 alpha, interleukin-1 beta, and interleukin-6: Mediation by decreased mRNA stability. *Mol Pharmacol*. 1993;43(2):176-182.
14. Kitajima T, Ariizumi K, Bergstresser PR, et al. A novel mechanism of glucocorticoid-induced immune suppression: the inhibition of T cell-mediated terminal maturation of a murine dendritic cell line. *J Clin Invest*. 1996;98(1):142-147.
15. Balow JE, Rosenthal AS. Glucocorticoid suppression of macrophage migration inhibitory factor. *J Exp Med*. 1973;137(4):1031-1041.
16. Hogan MM, Vogel SN. Inhibition of macrophage tumoricidal activity by glucocorticoids. *J Immunol*. 1988;140(2):513-519.
17. Parrillo JE, Fauci AS. Mechanisms of glucocorticoid action on immune processes. *Annu Rev Pharmacol Toxicol*. 1979;19:179-201.
18. Franchin G, Diamond B. Pulse steroids: how much is enough? *Autoimmun Rev*. 2006;5(2):111-113.
19. Jackson S, Gilchrist H, Nesbitt LT Jr. Update on the dermatologic use of systemic glucocorticosteroids. *Dermatol Ther*. 2007;20(4):187-205.
20. Sabir S, Werth VP. Pulse glucocorticoids. *Dermatol Clin*. 2000;18(3):437-446, viii-ix.
21. Cogan MG, Sargent JA, Yarbrough SG, et al. Prevention of prednisone-induced negative nitrogen balance. Effect of dietary modification on urea generation rate in patients on hemodialysis receiving high-dose glucocorticoids. *Ann Intern Med*. 1981;95(2):158-161.
22. Youssef J, Novosad SA, Winthrop KL. Infection risk and safety of corticosteroid use. *Rheum Dis Clin North Am*. 2016;42(1):157-176, ix-x.
23. Genta RM. Global prevalence of strongyloidiasis: critical review with epidemiologic insights into the prevention of disseminated disease. *Rev Infect Dis*. 1989;11(5):755-767.
24. National Center for Immunization and Respiratory Diseases. General recommendations on immunization—recommendations of the Advisory Committee on Immunization Practices (ACIP). *MMWR Recomm Rep*. 2011;60(2):1-64.
25. Nieman LK, Biller BM, Findling JW, et al. Treatment of Cushing's syndrome: an Endocrine Society clinical practice guideline. *J Clin Endocrinol Metab*. 2015;100(8):2807-2831.
26. Salem M, Tainsh RE Jr, Bromberg J, et al. Perioperative glucocorticoid coverage. A reassessment 42 years after emergence of a problem. *Ann Surg*. 1994;219(4):416-425.
27. Axelrod L. Perioperative management of patients treated with glucocorticoids. *Endocrinol Metab Clin North Am*. 2003;32(2):367-383.
28. MacKenzie CR, Goodman SM. Stress dose steroids: myths and perioperative medicine. *Curr Rheumatol Rep*. 2016;18(7):47.
29. Vittorio CC, Werth VP. Preventive techniques to limit glucocorticoid-induced side effects. *Adv Dermatol*. 2000;16:273-297; discussion 298.

30. Whittier X, Saag KG. Glucocorticoid-induced osteoporosis. *Rheum Dis Clin North Am*. 2016;42(1):177-189, x.
31. Dykman TR, Gluck OS, Murphy WA, et al. Evaluation of factors associated with glucocorticoid-induced osteopenia in patients with rheumatic diseases. *Arthritis Rheum*. 1985;28(4):361-368.
32. LoCascio V, Bonucci E, Imbimbo B, et al. Bone loss in response to long-term glucocorticoid therapy. *Bone Miner*. 1990;8(1):39-51.
33. Van Staa TP, Leufkens HG, Abenhaim L, et al. Use of oral corticosteroids in the United Kingdom. *Q J Med*. 2000;93(2):105-111.
34. Grossman JM, Gordon R, Ranganath VK, et al. American college of rheumatology 2010 recommendations for the prevention and treatment of glucocorticoid-induced osteoporosis. *Arthritis Care Res (Hoboken)*. 2010;62(11):1515-1526.
35. Abraham A, Cohen A, Shane E. Premenopausal bone health: osteoporosis in premenopausal women. *Clin Obstet Gynecol*. 2013;56(4):722-729.
36. Souverein PC, Berard A, Van Staa TP, et al. Use of oral glucocorticoids and risk of cardiovascular and cerebrovascular disease in a population based case-control study. *Heart*. 2004;90(8):859-865.
37. Wei L, MacDonald TM, Walker BR. Taking glucocorticoids by prescription is associated with subsequent cardiovascular disease. *Ann Intern Med*. 2004;141(10):764-770.
38. Fardet L, Petersen I, Nazareth I. Risk of cardiovascular events in people prescribed glucocorticoids with iatrogenic Cushing's syndrome: cohort study. *BMJ*. 2012;345:e4928.
39. Etxabe J, Vazquez JA. Morbidity and mortality in Cushing's disease: an epidemiological approach. *Clin Endocrinol (Oxf)*. 1994;40(4):479-484.
40. Alexandraki KI, Kaltsas GA, Vouliotis AI, et al. Specific electrocardiographic features associated with Cushing's disease. *Clin Endocrinol (Oxf)*. 2011;74(5):558-564.
41. Muiesan ML, Lupia M, Salvetti M, et al. Left ventricular structural and functional characteristics in Cushing's syndrome. *J Am Coll Cardiol*. 2003;41(12):2275-2279.
42. Yiu KH, Marsan NA, Delgado V, et al. Increased myocardial fibrosis and left ventricular dysfunction in Cushing's syndrome. *Eur J Endocrinol*. 2012;166(1):27-34.
43. Neary NM, Booker OJ, Abel BS, et al. Hypercortisolism is associated with increased coronary arterial atherosclerosis: analysis of noninvasive coronary angiography using multidetector computerized tomography. *J Clin Endocrinol Metab*. 2013;98(5):2045-2052.
44. Colao A, Pivonello R, Spiezia S, et al. Persistence of increased cardiovascular risk in patients with Cushing's disease after five years of successful cure. *J Clin Endocrinol Metab*. 1999;84(8):2664-2672.
45. Dekkers OM, Horvath-Puho E, Jorgensen JO, et al. Multisystem morbidity and mortality in Cushing's syndrome: a cohort study. *J Clin Endocrinol Metab*. 2013;98(6):2277-2284.
46. Hernandez-Diaz S, Rodriguez LA. Steroids and risk of upper gastrointestinal complications. *Am J Epidemiol*. 2001;153(11):1089-1093.
47. Piper JM, Ray WA, Daugherty JR, et al. Corticosteroid use and peptic ulcer disease: role of nonsteroidal anti-inflammatory drugs. *Ann Intern Med*. 1991;114(9):735-740.
48. Luo JC, Chang FY, Chen TS, et al. Gastric mucosal injury in systemic lupus erythematosus patients receiving pulse methylprednisolone therapy. *Br J Clin Pharmacol*. 2009;68(2):252-259.
49. Dixon RB, Christy NP. On the various forms of corticosteroid withdrawal syndrome. *Am J Med*. 1980;68(2):224-230.
50. Fardet L, Petersen I, Nazareth I. Suicidal behavior and severe neuropsychiatric disorders following glucocorticoid therapy in primary care. *Am J Psychiatry*. 2012;169(5):491-497.
51. Sammaritano LR, Bermas BL. Rheumatoid arthritis medications and lactation. *Curr Opin Rheumatol*. 2014;26(3):354-360.
52. Allen DB. Growth suppression by glucocorticoid therapy. *Endocrinol Metab Clin North Am*. 1996;25(3):699-717.
53. Almawi WY, Saouda MS, Stevens AC, et al. Partial mediation of glucocorticoid antiproliferative effects by lipocortins. *J Immunol*. 1996;157(12):5231-5239.
54. Smith EW. Do we need new and different glucocorticoids? A re-appraisal of the various congeners and potential alternatives. *Curr Probl Dermatol*. 1993;21:1-10.
55. Brazzini B, Pimpinelli N. New and established topical corticosteroids in dermatology: clinical pharmacology and therapeutic use. *Am J Clin Dermatol*. 2002;3(1):47-58.
56. Altura BM. Role of glucocorticoids in local regulation of blood flow. *Am J Physiol*. 1966;211(6):1393-1397.
57. Juhlin L, Michaelsson G. Cutaneous vascular reactions to prostaglandins in healthy subjects and in patients with urticaria and atopic dermatitis. *Acta Derm Venereol*. 1969;49(3):251-261.
58. Ullian ME. The role of corticosteroids in the regulation of vascular tone. *Cardiovasc Res*. 1999;41(1):55-64.
59. Eichenfield LF, Tom WL, Berger TG, et al. Guidelines of care for the management of atopic dermatitis: section 2. Management and treatment of atopic dermatitis with topical therapies. *J Am Acad Dermatol*. 2014;71(1):116-132.
60. West DP, Worobec S, Solomon LM. Pharmacology and toxicology of infant skin. *J Invest Dermatol*. 1981;76(3):147-150.
61. Mooney E, Rademaker M, Dailey R, et al. Adverse effects of topical corticosteroids in paediatric eczema: Australasian consensus statement. *Australas J Dermatol*. 2015;56(4):241-251.
62. Woods MT, Brown PA, Baig-Lewis SF, et al. Effects of a novel formulation of fluocinonide 0.1% cream on skin barrier function in atopic dermatitis. *J Drugs Dermatol*. 2011;10(2):171-176.
63. Wollenberg A, Oranje A, Deleuran M, et al. ETFAD/EADV eczema task force 2015 position paper on diagnosis and treatment of atopic dermatitis in adult and paediatric patients. *J Eur Acad Dermatol Venereol*. 2016;30(5):729-747.
64. Zuberbier T, Orlow SJ, Paller AS, et al. Patient perspectives on the management of atopic dermatitis. *J Allergy Clin Immunol*. 2006;118(1):226-232.
65. Charman CR, Morris AD, Williams HC. Topical corticosteroid phobia in patients with atopic eczema. *Br J Dermatol*. 2000;142(5):931-936.
66. Lee JY, Her Y, Kim CW, et al. Topical corticosteroid phobia among parents of children with atopic eczema in Korea. *Ann Dermatol*. 2015;27(5):499-506.
67. Aubert-Wastiaux H, Moret L, Le Rhun A, et al. Topical corticosteroid phobia in atopic dermatitis: a study of its nature, origins and frequency. *Br J Dermatol*. 2011;165(4):808-814.
68. Chi CC, Wang SH, Mayon-White R, et al. Pregnancy outcomes after maternal exposure to topical corticosteroids: a UK population-based cohort study. *JAMA Dermatol*. 2013;149(11):1274-1280.

69. Chi CC, Wang SH, Wojnarowska F, et al. Safety of topical corticosteroids in pregnancy. *Cochrane Database Syst Rev*. 2015;(10):CD007346.
70. Singh G, Singh PK. Tachyphylaxis to topical steroid measured by histamine-induced wheal suppression. *Int J Dermatol*. 1986;25(5):324-326.
71. Fusaro RM, Kingsley DN. Topical glucocorticoids. how they are used and misused. *Postgrad Med*. 1986;79(1):283-291.
72. Sarnstrand B, Brattsand R, Malmstrom A. Effect of glucocorticoids on glycosaminoglycan metabolism in cultured human skin fibroblasts. *J Invest Dermatol*. 1982;79(6):412-417.
73. Gebhardt C, Averbeck M, Diedenhofen N, et al. Dermal hyaluronan is rapidly reduced by topical treatment with glucocorticoids. *J Invest Dermatol*. 2010;130(1):141-149.
74. Zhang W, Watson CE, Liu C, et al. Glucocorticoids induce a near-total suppression of hyaluronan synthase mRNA in dermal fibroblasts and in osteoblasts: a molecular mechanism contributing to organ atrophy. *Biochem J*. 2000;349(pt 1):91-97.
75. Lee A, Bradford J, Fischer G. Long-term management of adult vulvar lichen sclerosus: a prospective cohort study of 507 women. *JAMA Dermatol*. 2015;151(10):1061-1067.
76. Hengge UR, Ruzicka T, Schwartz RA, et al. Adverse effects of topical glucocorticosteroids. *J Am Acad Dermatol*. 2006;54(1):1-15; quiz 16-18.
77. Hajar T, Leshem YA, Hanifin JM, et al. A systematic review of topical corticosteroid withdrawal ("steroid addiction") in patients with atopic dermatitis and other dermatoses. *J Am Acad Dermatol*. 2015;72(3):541-549.e2.
78. Davis MD, el-Azhary RA, Farmer SA. Results of patch testing to a corticosteroid series: a retrospective review of 1188 patients during 6 years at Mayo Clinic. *J Am Acad Dermatol*. 2007;56(6):921-927.
79. Coloe J, Zirwas MJ. Allergens in corticosteroid vehicles. *Dermatitis*. 2008;19(1):38-42.

Chapter 185 :: Retinoids

:: Anna L. Chien, Anders Vahlquist, Jean-Hilaire Saurat, John J. Voorhees, & Sewon Kang

AT-A-GLANCE

- A retinoid is any molecule that by itself or through metabolic conversion binds to and activates retinoic acid receptors.
- Retinoid receptors are ligand-dependent transcription factors.
- The predominant retinoid receptors in human skin are retinoic acid receptor α (RAR-α), RAR-γ, retinoid X receptor α (RXR-α), and RXR-β. RAR-γ/RXR-α heterodimers bind to retinoic acid–responsive elements and are responsible for retinoid signaling.
- Clinical use of topical retinoids:
  - Approved indications: acne, psoriasis, cutaneous T-cell lymphoma, Kaposi sarcoma, melasma, photoaged skin
  - Unapproved indications with clinical studies supporting benefit: postinflammatory hyperpigmentation, and early stretch marks
- Clinical use of oral retinoids:
  - Approved indications: acne, chronic hand eczema, psoriasis, and cutaneous T-cell lymphoma
  - Unapproved indications with clinical studies supporting benefit: pityriasis rubra pilaris, premalignancies, photoaging, ichthyosis, and Darier White disease
- Teratogenicity is the most concerning side effect. Mucocutaneous (cheilitis, xerosis, skin peeling, conjunctivitis) involvements are common, as are reversible abnormal results on laboratory tests (hyperlipidemia, increased liver enzyme levels, and hypothyroidism [bexarotene/alitretinoin]). Musculoskeletal and central nervous system side effects are rare.

INTRODUCTION AND BACKGROUND

Retinoids are widely used as prescription drugs as well as cosmeceuticals. They are able to elicit skin responses by mediating their effects through their intranuclear retinoid receptors, acting as transcription factors. Indeed, the discovery of retinoic acid receptors (RARs) and retinoid X receptors (RXRs) have been pivotal to our understanding of the retinoid action mechanism.[1,2] In 1976, Michael Sporn and his colleagues originally defined retinoids as both the naturally occurring compounds with vitamin A activity and the synthetic analogs of retinol. This concept is no longer adequate. Now, retinoid is defined as any molecule that, by itself or through metabolic conversion, binds to and activates the RARs, thereby eliciting transcriptional activation of retinoic acid–responsive genes, resulting in specific biologic responses. Our understanding of retinoid mechanism, as highlighted in this chapter, is primarily based on action of topical natural retinoids in vivo. Mechanism for oral retinoids is less clear, and further elucidation is needed.

PHARMACOLOGY AND MECHANISM OF ACTION

STRUCTURE

NOMENCLATURE

All-*trans*-retinoic acid (tretinoin), which binds to and activates RARs, is derived from sequential oxidation of all-*trans*-retinol (or vitamin A) and all-*trans*-retinaldehyde. It is a 20-carbon molecule that consists of a cyclohexenyl ring, a side chain with four double bonds (all arranged in *trans*-configuration), and a carboxylic-acid end group (Fig. 185-1). The numbering of the carbon atoms is as shown in Fig. 185-1. The terms *9-cis-* (alitretinoin) and *13-cis-retinoic acid* (isotretinoin) refer to stereoisomers of all-*trans*-retinoic acid in which the double bond that begins with the 9th and 13th carbon atoms, respectively, is in the *cis-* rather than *trans-*configuration. The fourth carbon atom is located in the cyclohexenyl ring of retinoic acid and is involved in a hydroxylation reaction to generate 4-hydroxy-retinoic acid (see Fig. 185-1). The addition of a hydroxyl group to the cyclohexenyl ring renders the molecule more polar, making it more amenable to excretion/elimination.[3,4]

A group of compounds referred to as *retinyl esters* functions as the molecular storage form of retinol. The compounds are formed by esterification of retinol with fatty acids (see Fig. 185-1), which specify the ester. Hydrolysis of retinyl esters regenerates retinol (see Fig. 185-1).

Retinoids are also classified into first, second, and third generations. First-generation retinoids include all-*trans*-retinoic acid (tretinoin), 13-*cis*-retinoic acid (isotretinoin), and 9-*cis*-retinoic acid (alitretinoin).

Nomenclature of natural retinoids

Sequential oxidation of retinol

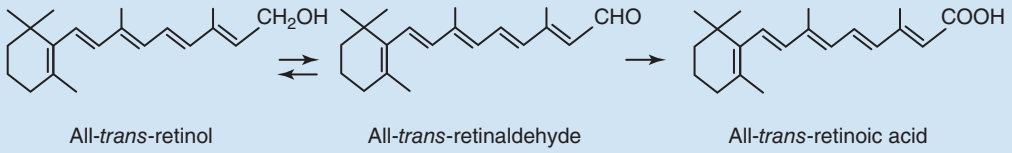

All-*trans*-retinol — All-*trans*-retinaldehyde — All-*trans*-retinoic acid

All-*trans*-retinoic acid and its stereoisomers

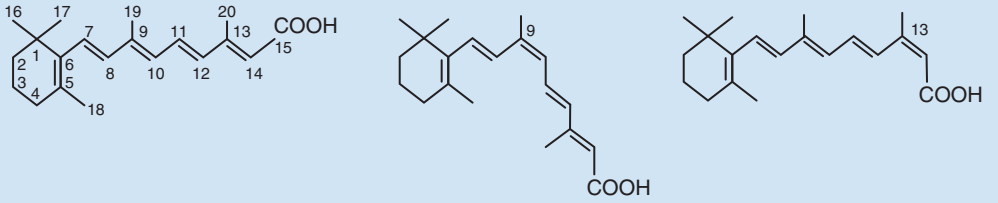

All-*trans*-retinoic acid — 9-*Cis*-retinoic acid — 13-*Cis*-retinoic acid

Hydroxylation of all-*trans*-retinoic acid and subsequent oxidation

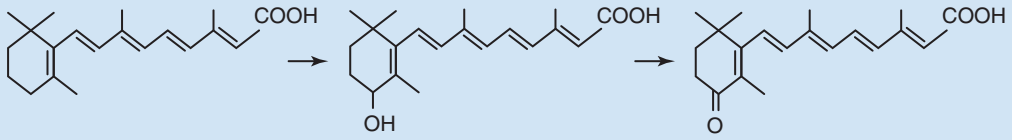

All-*trans*-retinoic acid — 4-Hydroxy all-*trans*-retinoic acid — 4-Oxo-all-*trans*-retinoic acid

Esterification of retinol

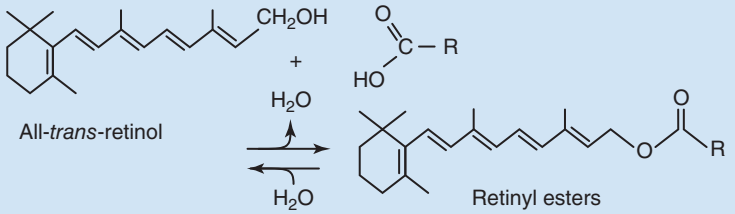

All-*trans*-retinol — Retinyl esters

Structural relationship of β-carotene and 14-hydroxy 4, 14-retro-retinol to retinol

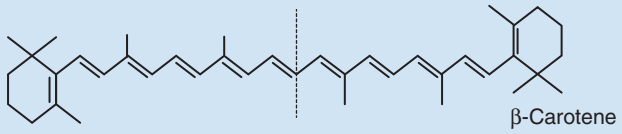

β-Carotene

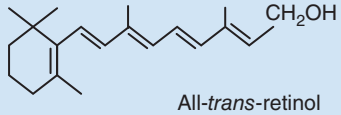

All-*trans*-retinol

Figure 185-1 Nomenclature of natural retinoids.

Through replacement of the β-ionone ring in all-*trans*-retinoic acid with an aromatic structure, newer retinoids, also known as second-generation of retinoids, were synthesized in the 1970s. These include etretinate, which is an ethyl ester, and its free acid metabolite, acitretin. With the discovery of retinoic acid receptors, receptor-specific, third-generation retinoids adapalene, tazarotene, and bexarotene were developed (Fig. 185-2). In fact, the second- and third-generation retinoids are also known as synthetic retinoids. They bear no structural similarities to all-*trans*-retinol or retinoic acid yet are still considered retinoids by virtue of their ability to activate the receptor(s), therefore mediating the retinoid effect.

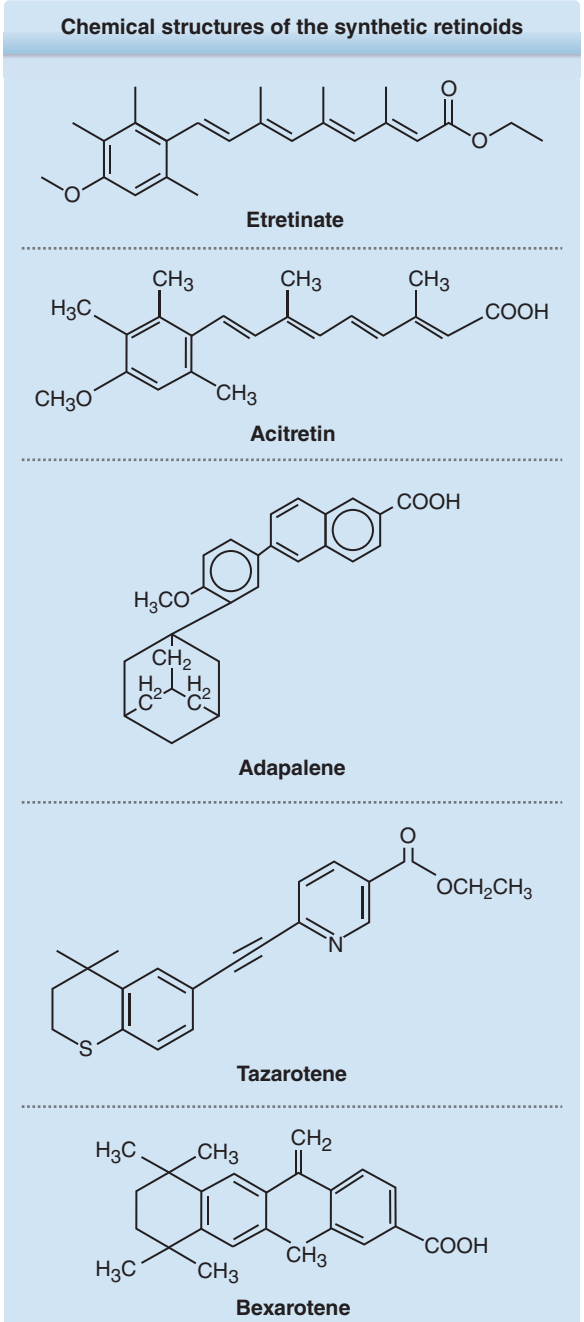

Figure 185-2 Chemical structures of the synthetic retinoids etretinate, acitretin, adapalene, tazarotene, and bexarotene.

RETINOID RECEPTORS

The discovery and characterization of RARs as having molecular features that are similar to steroid and thyroid hormone receptors were landmark findings.[1,2] A characteristic common to these receptors is that they bind to regulatory regions in DNA called *hormone response elements*, or *target sequences*, and activate gene transcription in a ligand-dependent manner. These receptors bind to specific DNA sequences as dimers. The critical partner for heterodimerization and functioning of RAR is the RXR,[5] whose physiologic ligand is 9-*cis*-retinoic acid.[3] There are three different members of RAR (α, β, and γ) and RXR (α, β, and γ), each encoded by different genes. When the heterodimer binds to the hormone response element, specifically the retinoic acid–responsive element (RARE) in the gene promoter, the basal transcriptional machinery is stimulated. In skin, cellular retinoic acid binding protein (CRABP) II, cellular retinol binding protein (CRBP), retinoic acid 4-hydroxylase (CYP26), and keratin 6—all of which contain RAREs—are regulated by all-*trans*-retinoic acid.[6-9] These protein products, in turn, activate other non–RARE-containing genes in a cascading reaction to produce the clinical features of retinoid action in skin (Fig. 185-3). Please see Table 185-1 for additional genes regulated by topical retinoids.

METABOLISM

ESTERIFICATION AND OXIDATION OF RETINOL

Treatment of human skin with all-*trans*-retinol or retinaldehyde increases retinyl ester levels in the epidermal layer by more than 10-fold.[6] This reaction is catalyzed by two enzymes: (1) lecithin/retinol acyltransferase and (2) acyl-coenzyme A/retinol acyltransferase. In human keratinocytes, lecithin/retinol acyltransferase has the predominant retinol-esterifying activity.[10]

Sequential oxidation of all-*trans*-retinol forms all-*trans*-retinoic acid, with all-*trans*-retinaldehyde as the intermediate metabolite. The first step (oxidation of all-*trans*-retinol to all-*trans*-retinaldehyde) is rate limiting for all-*trans*-retinoic acid formation. Application of all-*trans*-retinol or retinaldehyde to human skin results in histologic and molecular alterations that mimic those after all-*trans*-retinoic acid treatment.[6] These include epidermal hyperplasia; epidermal spongiosis; compaction of the stratum corneum; and induction of CRBP, CRABP-II, and CYP26.[10,11]

HYDROXYLATION OF ALL-*TRANS*-RETINOIC ACID

In human skin, all-*trans*-retinoic acid is catabolized primarily to the more polar 4-hydroxy-all-*trans*-retinoic

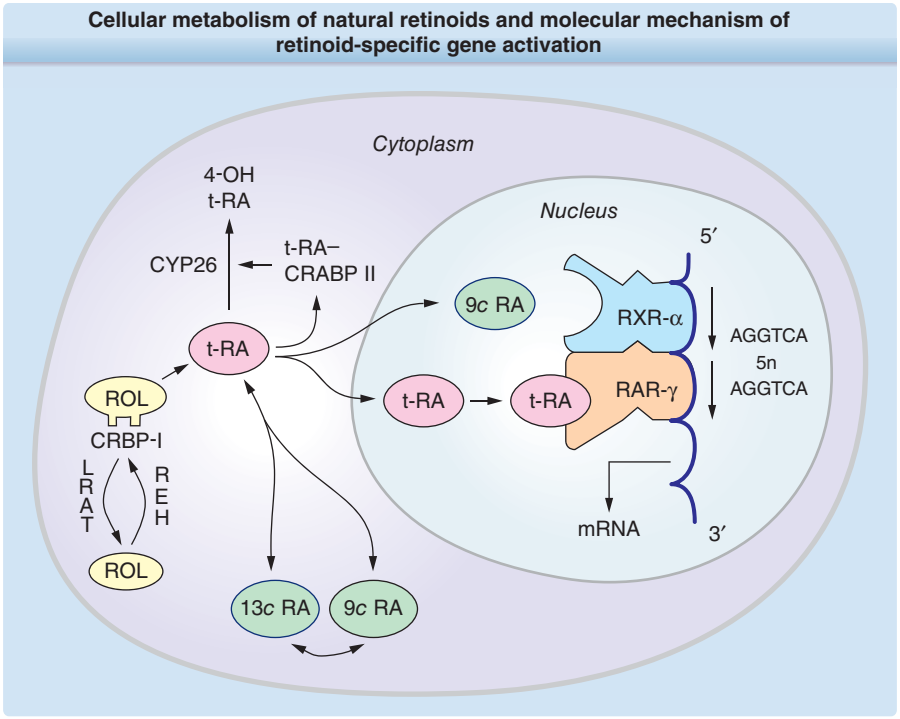

Figure 185-3 Cellular metabolism of natural retinoids and molecular mechanism of retinoid-specific gene activation. Retinol (ROL) delivered to a cell is bound to cellular retinol binding protein-I (CRBP-I). ROL can be esterified, via lecithin:retinol acyltransferase (LRAT), and stored as ROL esters. Hydrolysis of ROL ester by its hydrolase (REH) yields free ROL. Sequential oxidation of ROL generates retinoic acid (RA), which is bound to cellular retinoic acid binding protein (CRABP). All-*trans*-RA (*t*-RA) can be isomerized to 9-*cis*-RA (9*c* RA). Hydroxylation of *t* RA by cytochrome-P_{450} enzyme CYP26 generates 4-OH RA, which is relatively inactive. Retinoic acid receptors (RARs) and retinoid X receptors (RXRs) are intranuclear receptors for retinoids. In human skin, RAR-γ and RXR-α heterodimers bound to RA-response elements (such as AGGTCA direct repeats) transduce retinoid effects in the presence of RAR ligands. mRNA, messenger RNA.

TABLE 185-1
Retinoid Target Genes

GENE[a]	ROLE
Cellular retinol binding protein (CRBP)	Intracellular transport protein for retinol
Cellular retinoic acid binding protein (CRABP) II	Intracellular transport protein for retinoic acid
Retinoic acid 4-hydroxylase (CYP26)	Cytochrome P450 enzyme that inactivates all-*trans*-retinoic acid by hydroxylation at the fourth carbon molecule; this CYP26 is inducible by retinoic acid
Keratin 6	An intermediate filament; pairs with keratin 16 or 17
Heparin-binding (HB)-EGF	Induced by retinoic acid; stimulates basal cell growth via EGF receptor activation; neither HB-EGF nor AR possesses RARE; thus, RAR/RXR is likely regulating other transcription factor(s) that would, in turn, regulate AR and HB-EGF gene expression
Amphiregulin (AR)	

[a]Genes known to be regulated by topical retinoids.
(HB)-EGF, heparin binding-epidermal growth factor; RARE, retinoic acid–responsive element; RXR, retinoid X receptor.

acid, which is further metabolized to 4-oxo-retinoic acid. In untreated normal human skin, CYP26 activity is minimally detectable. Administration of all-*trans*-retinoic acid, all-*trans*-retinol or retinaldehyde to human skin, however, increases its activity several fold.[11,12] The CYP26 activity can be effectively inhibited by ketoconazole and a related azole, liarozole.[12,13] By blocking this major inactivation pathway of all-*trans*-retinoic acid, topical liarozole can serve as a retinoic acid mimetic amplifying human skin responses to all-*trans*-retinol and all-*trans*-retinoic acid.[13] This approach of targeting CYP26 has given rise to a novel class of new chemical entities referred to as *retinoic acid metabolism blocking agents* (RAMBAs). The drug development progress for RAMBA, however, has been slow.

ORAL RETINOIDS

Metabolism and pharmacokinetics for oral retinoids share similarities as topical retinoids but also exhibit differences. Because of their lipophilicity, the oral bioavailability of all retinoids is markedly enhanced when they are administrated with food, especially with fatty meals. Retinoids are metabolized mainly by oxidation and chain shortening to biologically inactive and

hydrophilic metabolites, which facilitate biliary or renal elimination (or both).

Isotretinoin and Other First-Generation Retinoids: Isotretinoin and alitretinoin are partially interconvertible isomers that differ in their elimination half-lives. Isotretinoin undergoes first-pass metabolism in the liver and subsequent enterohepatic recycling. The major metabolite is 4-oxoisotretinoin, which has reduced bioactivity; both compounds are excreted in urine and feces. After the end of treatment, endogenous concentrations of isotretinoin and its major metabolite are reached within 2 weeks. Therefore, a 1-month posttherapy period of contraception provides an adequate safety margin.[14]

Acitretin and Etretinate: Etretinate is a prodrug of acitretin that undergoes extensive hydrolysis in the body to yield the corresponding acid metabolite. Acitretin has a great pharmacokinetic advantage because it is eliminated more rapidly than etretinate.[15] Whereas etretinate is approximately 50 times more lipophilic than acitretin and binds strongly to plasma lipoproteins, acitretin binds to albumin. Thus, after etretinate is taken, it is stored in adipose tissue from which it is released slowly; it has a half-life of up to 120 days. In contrast, acitretin has a half-life of only 2 days.[15] However, small amounts of etretinate can be formed in patients receiving acitretin if it is taken simultaneously with alcohol.[16] This has prompted the manufacturer to extend the time of compulsory contraception in patients taking acitretin to 2 years (3 years in the United States).[17] Acitretin still has a pharmacokinetic advantage over etretinate; however, all women must strictly avoid alcohol consumption during treatment and for 2 months thereafter.[16] Acitretin metabolism primarily involves isomerization instead of oxidation. The major metabolite of acitretin is its 13-cis-isomer, which is inactive.

Bexarotene: Bexarotene is approximately 100-fold more potent in activating retinoid X receptors than RARs. The half-life for this drug is between 7 and 9 hours.[18] Bexarotene is metabolized by CYP 3A4 and generates its own inactive oxidative metabolites via hepatic CYP 3A4 induction. Neither bexarotene nor its metabolites are excreted in urine; thus, elimination is believed to occur primarily via the hepatobiliary system.[19]

INDICATIONS AND CONTRAINDICATIONS

TOPICAL RETINOIDS

Until recently, clinical use of topical retinoids has been limited to all-*trans*-retinoic acid, which is approved in the United States for the treatment of acne, photoaged skin, and melasma. Topical adapalene and tazarotene have also received approval for acne; tazarotene has received approval for psoriasis and photoaging. Bexarotene is approved for management of cutaneous T-cell lymphoma, and alitretinoin is approved for patients with Kaposi sarcoma (KS).

It is widely accepted that topical retinoids are extremely effective for acne therapy, especially for comedonal lesions. Of the different antiacne medications, retinoids are thought to be the best, if not the only, agents to normalize the abnormal follicular epithelial differentiation and desquamation that occur in acne. Therefore, the use of retinoids can also provide protection against the development of new lesions. This prophylactic property is the basis for including topical retinoid in almost all antiacne regimens. Moreover, in an era in which antibiotic stewardship has come to the forefront, retinoid is playing an even more important role in acne treatment in place of antibiotics.

Fine wrinkles and dyspigmentation are two features of photoaged skin that are improved by topical tretinoin or tazarotene. Several weeks of treatment are required before clinical improvement is appreciated.[20-22] For the effacement of fine wrinkles by topical tretinoin, partial restoration of markedly reduced levels of collagen in sun-exposed skin toward those seen in sun-protected skin appears to be responsible.[21,23]

Primary cutaneous T-cell lymphoma (CTCL) is characterized by clonal proliferation of skin-homing malignant T lymphocytes. As an RXR-selective retinoid, topical bexarotene inhibits tumor cell growth, encourages terminal differentiation, and induces apoptosis.[24] It may also play a role in chemoprophylaxis.[25,26]

Alitretinoin gel was approved in 1999 for the management of cutaneous KS, which is caused by human herpes virus 8 (HHV-8). Alitretinoin's mechanism of action in KS is not entirely clear, but it presumably relates to inhibition of cellular proliferation as well as induction of apoptosis seen with other retinoids. Furthermore, alitretinoin and tretinoin have been reported to inhibit herpes simplex virus replication; thus, alitretinoin may have an antiviral role against HHV-8.[27] In clinical trials, most patients saw improvement after 4 to 8 weeks of treatment with the most significant response occurring after 14 weeks of therapy.[28]

Besides the approved indications, topical retinoids have been demonstrated to be effective in the treatment of several other conditions. These include, but are not limited to, postinflammatory hyperpigmentation in blacks,[29] actinic dyspigmentation in Chinese and Japanese individuals,[30] and early stretch marks.[31] The controlled studies show more than therapeutic efficacies. They also provide valuable information to dispel some of the myths about retinoid use in humans. For example, African Americans and Asians tolerate topical tretinoin as well as, if not better than,[29,30,32] whites.[21,33] Furthermore, the often observed retinoid dermatitis does not usually lead to postinflammatory hyperpigmentation in those with greater constitutive pigmentation.

Many other skin disorders have been reported to be improved by topical retinoids, but most of them have not been rigorously studied; thus, their therapeutic claims should be interpreted with caution. Molluscum contagiosum, warts, and various forms of ichthyosis

may be improved by topical retinoids to a variable degree. In psoriasis, especially, irritation of treated skin has limited the use. Topical tazarotene, which is approved for psoriasis, does not appear to have fully overcome the irritation problem[34]; thus, it is typically used in combination with topical steroids.

With such a wide variety of skin conditions treatable by topical retinoids, their use has included all age groups, perhaps with the exception of neonates. The use of topical retinoids in pregnancy is an emotional issue. As discussed later, teratogenicity is not caused by topical retinoids. However, because none of the dermatologic conditions seen in pregnancy that may respond to topical retinoids (ie, acne, melasma, stretch marks) is life threatening to the mother or the fetus, it seems prudent to delay the treatment until after delivery.

ORAL RETINOIDS

Isotretinoin is remarkably effective in treating acne, possibly because it affects majority of etiologic factors implicated in the pathogenesis of acne: sebum production (caused by atrophy of sebaceous glands not achievable by topical retinoids or other systemic retinoids), comedogenesis, and colonization with *Propionibacterium acnes*.[35] In the early 1980s, isotretinoin treatment was restricted to patients with severe nodulocystic acne. Its use now has extended to patients with less severe disease who respond unsatisfactorily to conventional therapies or who have extensive scarring.[36,37] Lastly, in the age of antibiotic stewardship, isotretinoin has also been explored for the treatment of rosacea in an off-label manner.[38,39]

In addition to acne, oral retinoid is also used to manage psoriasis and the retinoid of choice is acitretin. The best results have been obtained in pustular psoriasis of the palmoplantar or generalized (von Zumbusch) type.[40-42] Rebound does not usually occur after cessation of treatment, and reintroduction of the drug produces a beneficial response.[43] Although complete clearing of plaque-type psoriasis is achieved in only approximately 30% of treated patients, significant improvement is obtained in a further 50%.[44-46] The decrease in the psoriasis area and severity index is approximately 60% to 70%, depending on the dosage.[44,47] Combination of acitretin with other antipsoriatic agents may be required.

Oral retinoid can also be used to manage chronic hand eczema. Alitretinoin is approved in Europe and Canada for treatment-resistant chronic hand eczema. Between 3 and 6 months of therapy is usually required to fully appreciate the effect.[48] This medication is not yet available in the United States.

In 1999, the U.S. Food and Drug Administration (FDA) approved bexarotene as oral therapy for the treatment of CTCL that is refractory to at least one systemic therapy. In early (IA–IIA) and advanced (IIB–IVB) stages of CTCL, oral bexarotene monotherapy produced approximately 60% and 50% response rates, respectively, at a dosage of 300 mg/m^2 or more per day within the first 2 months in most patients.[49,50]

Multiple other skin disorders respond to oral retinoids but for only a few of them is the effect established in controlled studies.[51] In pityriasis rubra pilaris, early treatment with acitretin appears to offer the best chance for clearing of this eruption. In extensive cases, concomitant use of methotrexate may be advantageous, but this combination carries an increased risk for toxicity.[52]

Acitretin is effective in the treatment of premalignancies, including human papillomavirus–induced tumors and actinic keratoses. In basal cell nevus syndrome and xeroderma pigmentosum, these drugs dramatically reduce the incidence of malignant degeneration of the precancers. A double-blind study demonstrated that acitretin at a dosage of 30 mg/day for 6 months prevented the development of premalignant and malignant skin lesions in renal transplant recipients.[53]

More recently, there is an increase in usage of low-dose oral retinoids for photoaging, especially outside of the United States. However, data regarding this indication are mixed. In one study, isotretinoin significantly improved the clinical features of photoaging and increased collagen as well as elastic fiber density.[54] In contrast, other studies found no significant differences in clinical and histologic improvement of photoaging when comparing isotretinoin to topical retinoic acid 0.05%. No significant differences were also seen when comparing isotretinoin to daily sunscreen use.[55,56] More rigorous studies are needed to further elucidate these effects. Furthermore, one must also consider the potential adverse effects of oral retinoids when choosing this treatment modality for skin aging.

Oral retinoid therapy has also been used in various forms of ichthyosis. The best results are obtained with acitretin for autosomal recessive congenital ichthyoses such as lamellar ichthyosis. Moderate to severe forms of Darier-White disease have also been shown to respond to retinoid therapy. Care should be taken to initiate therapy with a low dosage, such as 10 mg/day of acitretin, to prevent initial exacerbation of the disease; usually 20 mg/day is sufficient for significant improvement. Long-term treatment is usually needed to prevent relapse.

DOSING REGIMEN

TOPICAL RETINOIDS

For decades, tretinoin was the only topical retinoid available for clinical use sold under the trade name Retin-A. Now, tretinoin is also available in other formulations (Table 185-2). Adapalene is also available in varying formulations, and more recently, combination medications have been introduced (see Table 185-2). For acne and psoriasis, topical tazarotene is available and for photoaging treatment, tretinoin and tazarotene are

TABLE 185-2
Dosing Regimen of Topical Retinoids

TOPICAL RETINOID	DOSAGE SCHEDULES AND EXAMPLE FORMS
Tretinoin	Avita (0.025% cream and gel) Atralin (0.05% gel) Refissa (0.05% cream) Renova (0.02% cream) Retin-A (0.025%, 0.05%, 0.1% cream; 0.01%, 0.025% gel) Retin-A Micro (0.04% and 0.1% microsphere gel) Tretin-X (0.025%, 0.05%, 0.1% cream; 0.01%, 0.025% gel) TriLuma (tretinoin 0.05%/hydroquinone 4%–fluocinolone 0.1% cream) Ziana (tretinoin 0.025%/clindamycin 1.2% gel)
Adapalene	Differin 0.1% cream; 0.1%, 0.3% gel) Epiduo (adapalene 0.1%/benzoyl peroxide 2.5% gel)[a]
Tazarotene	Tazorac 0.05%, 0.1% gel and cream Avage (0.1% cream)
Bexarotene	Targretin gel
Alitretinoin	Panretin gel

[a]The chemical structure of adapalene renders it more resistant to oxidation (thus permitting its combination with benzoyl peroxide) and ultraviolet degradation frequently seen with retinoids.

approved for use. Tretinoin 0.05%/hydroquinone 4%–fluocinolone 0.1% is a topical combination approved for the treatment of melasma. Different formulations allow some flexibility in terms of tailoring the therapy to an individual's skin dryness or oiliness. Finally, more recently approved topical retinoids, including bexarotene and alitretinoin, are sold in gel formulations.

The most important element in topical retinoid therapy is patient education. It must be explained to each patient that local skin irritation, characterized by redness and peeling, can be expected. The concept that clinical improvement correlates with the degree of irritation has been erased through a large, controlled clinical study in which 0.025% and 0.1% tretinoin were shown to be equally efficacious, but the former was significantly less irritating than the latter.[22] Therefore, unlike most medications for which the dosing schedule may be set as once or twice daily, administration of a topical retinoid should be individualized and titrated depending on the skin reaction.

Under the nonprescription category, there are countless "natural retinoid" preparations with various claims (mostly antiaging). Most of these contain retinyl esters, which are less active than retinol and retinaldehyde. Whether any of these products can deliver retinoid activity to human skin should be established in every case and formulation. Current experts' views are that, with appropriate dosing and formulation, some preparations do induce biological effects that may reverse and partially prevent skin aging.

ORAL RETINOIDS

The consensus is that optimal benefit in acne would be achieved with a daily dose of isotretinoin, approximately 0.5 to 1 mg/kg of body weight per day (Table 185-3).[35] Posttherapy relapse is minimized by administering a cumulative dose of at least 120 mg/kg.[57] This implies 6 to 8 months of therapy. A lag period of 1 to 3 months may occur before the onset of the therapeutic effect, and a flare-up of disease during the first few weeks may be observed. Continued healing of acne after the discontinuation of therapy regularly occurs. Approximately one third of patients with acne require a second course of therapy for either persistent disease or relapse.

The recommended alitretinoin dose in treatment of chronic hand eczema is 10 to 30 mg/day. Treatment periods of up to 6 months are often needed before a full evaluation of the therapeutic effects can be made.

In psoriasis, patients are typically given an initial low dose of 10 to 25 mg/day of acitretin followed by progressively increasing doses.[58] Total clearing of the lesions may require a combination of treatments, such as retinoids plus topical glucocorticoids, topical vitamin D derivatives, dithranol (anthralin), ultraviolet B irradiation, or photochemotherapy (psoralen and ultraviolet A light [PUVA] treatment).[59-63]

TABLE 185-3
Dosing Regimens of Retinoids in Major Indications

DRUG	INDICATION	INITIALLY (mg/kg/day)	SUSTAINED (mg/kg/day)	LENGTH OF THERAPY (months)
Isotretinoin	Acne	0.3–0.5	0.5–1.0	4–6
Acitretin	Psoriasis	0.2–0.5	0.3–0.8	>3
	DOK[a]	0.3–0.6	0.5–1.0	>3
Alitretinoin	Hand eczema	10–30[b]	10–30[b]	>6
Bexarotene	CTCL	4–8	2–4 (8)	>2

[a]Lower dosing is recommended for Darier-White disease and epidermolytic ichthyosis.
[b]Daily dose in milligrams.
CTCL, cutaneous T-cell lymphoma; DOK, disorders of keratinization (genetic).

The recommended initial dosage of bexarotene is 300 mg/m^2/day, administered as a single oral dose with meals. Based on the severity of adverse effects, the dosage may be adjusted down to 100 or 200 mg/m^2/day, or administration may be suspended temporarily. If CTCL does not respond after 8 weeks of therapy, the dosage may be increased to 400 mg/m^2/day with careful monitoring.[49,50]

SIDE EFFECTS AND PRECAUTIONS

ADVERSE EFFECTS

TOPICAL RETINOIDS

The most common adverse effect associated with topical retinoid use is local skin irritation. This predictable skin response is temporary, but troubling, for many patients. It tends to peak within the first month of treatment and diminishes thereafter. It responds to a temporary reduction in the frequency or amount of retinoid application and to liberal use of emollients.

For bexarotene and alitretinoin, local irritation is also the most common side effect. With alitretinoin, the local erythema can increase to edema and vesiculation with continued use. However, most reactions are mild to moderate with only 7% of patients requiring treatment withdrawal in clinical trials.[28] Finally, the central hypothyroidism seen with systemic bexarotene is not observed when used in the gel formulation.[64,65]

Systemic retinoid exposure, as discussed later, has been well established as a cause of embryonic death and congenital malformation, and understandably, there is concern about potential teratogenicity from long-term topical retinoid use. Systemic absorption of retinoids from topical application is negligible, and the levels of endogenous retinoic acid in the blood are not increased by twice-daily application of 0.025% tretinoin to more than 40% of body area over 1 month. Furthermore, controlled topical administration of tretinoin at doses used for acne therapy (2 g of 0.025% gel applied daily to the face, neck, and upper part of the chest for 14 days) has less influence on plasma levels of endogenous retinoids than diurnal and nutritional factors.[66] Indeed, a large, population-based study demonstrated no excess risk of birth defects in offspring born to mothers who were exposed to topical tretinoin during pregnancy.[67] Therefore, no evidence exists for teratogenicity of topical tretinoin in humans.

ORAL RETINOIDS

See Table 185-4.

Teratogenesis as alluded to earlier is the most serious adverse effect of oral retinoids. Retinoid-induced birth defects include auditory, cardiovascular, craniofacial, ocular, axial and acral skeletal, central nervous system (hydrocephalus, microcephaly), and thymus gland abnormalities.[68] In men, retinoid therapy does not appear to produce abnormalities in spermatogenesis, sperm morphology, or sperm motility.[69] However, it is usually recommended that men who are actively trying to father children avoid systemic retinoid therapy.

Most patients receiving oral retinoids will also develop dryness of the lips, skin, and mucous membranes. More severe cases can lead to significant retinoid dermatitis, which can be misdiagnosed as an allergic reaction to the drug with resulting inappropriate discontinuation of the retinoid medication. Bexarotene appears to induce fewer mucocutaneous and ocular side effects than other classes of retinoids; localized or extensive exfoliative dermatitis is the most common cutaneous side effect with bexarotene.[18] *Staphylococcus aureus* colonization tends to correlate with isotretinoin-induced reduction in sebum production and may lead to overt cutaneous infections.[70] Various ill-defined skin eruptions, called *retinoid dermatitis*, are also observed frequently.

Blepharoconjunctivitis occurs with varying severity in about one third of patients treated with isotretinoin, likely related to its effects on meibomian glands. If artificial tears fail to alleviate the conjunctivitis, ophthalmologic consultation should be sought. Alterations in

TABLE 185-4
Adverse Effects of Systemic Retinoids: A Summary

	ISOTRETINOIN	ALITRETINOIN	ACITRETIN	BEXAROTENE
Teratogenicity	+	+	+	+
Mucocutaneous	+	+	+	+
Ocular	++	+	+	+
Alopecia	(+)	+	+	+
Headache	+	++	+	+
Musculoskeletal	++	+	+	+
Hepatotoxicity	(+)	(+)	+	+
Neutropenia	–	–	–	+
Hyperlipidemia	++	+	+	++
Hypothyroidism	–	+	–	+

visual function, mainly poor night vision, excessive glare sensitivity, and changes in color perception, also have been reported.[71]

Diffuse or localized hair loss (telogen effluvium), which is more severe during treatment with acitretin than with isotretinoin, is a common complaint, although objective alopecia tends to occur only at higher dosage levels and after several months of therapy. Nail thinning and paronychia-like changes with periungual granulation tissue may occur.

Bone pain without objective evidence of any abnormalities and without sequelae is frequent in retinoid-treated patients. Several reports with conflicting results have implicated synthetic retinoids in the formation of diffuse idiopathic skeletal hyperostosis (DISH) syndrome–like bone changes and calcification of tendons and ligaments.[72-74] Prospective studies have shown that the hyperostotic effects of retinoids are mostly asymptomatic and likely involve worsening of preexisting skeletal overgrowth rather than de novo changes.[75,76] No baseline radiographs are required, although monitoring patients at high risk who receive prolonged high-dose retinoid treatment may be useful.

Muscle pain and cramps rarely occur in patients taking etretinate or acitretin; however, these muscle effects are frequent with isotretinoin, particularly in individuals involved in vigorous physical activity. Increased muscle tone, axial muscle rigidity, and myopathy were reported to be related to etretinate and acitretin therapy.[77]

Central nervous system side effects are rare. Although signs of increased intracranial pressure are observed occasionally, the complete syndrome with papilledema (pseudotumor cerebri) and impaired vision is exceptional.[78] Concomitant use of isotretinoin and tetracyclines, which rarely produce increased intracranial hypertension, is the major risk factor for development of pseudotumor cerebri.

Anecdotal reports suggest a causal association between isotretinoin therapy and severe depression with suicide attempts.[79] However, large-scale epidemiologic studies provide no evidence that isotretinoin exposure is associated with any greater risk of psychiatric disorders than is antibiotic use in patients with acne.[80]

Clinical and biochemical central hypothyroidism occurred in 40% of patients in the trials of bexarotene therapy for CTCL. It was rapidly and completely reversible with cessation of therapy without any clinical sequelae.[49,81] The same adverse effect has been noted with alitretinoin, which is expected because both drugs bind to RXR that dimerizes with the nuclear thyroid receptor.

In very rare cases, isotretinoin has been linked to exacerbation of inflammatory bowel disease. A 5-year prospective study did not demonstrate an increased risk of inflammatory bowel disease or of cancer, diabetes, or cardiovascular disease in association with long-term etretinate use for psoriasis[82]; similar safety of long-term acitretin, bexarotene, or alitretinoin therapy has not been established.

Serum lipid changes are the most frequent abnormalities in laboratory test results seen with retinoid therapy. Interestingly, retinoid-induced hyperlipidemia is not associated with accelerated atherosclerosis or increased risk of cardiovascular disease with prolonged therapy. Depending on the type and dosage of retinoid, triglyceride levels are elevated in 50% to 80% and cholesterol levels in 30% to 50% of treated patients.[49,73,83] Disturbance of blood lipid levels is generally higher with isotretinoin and bexarotene than with acitretin. In cases of severe retinoid-induced hypertriglyceridemia, eruptive xanthomas and acute pancreatitis may occur. Discontinuation of therapy is required if the triglyceride level reaches 800 mg/dL. A less severe increase may be treated by dosage reduction or lifestyle changes. In some instances, use of lipid-lowering agents may be indicated.[84] Coadministration of atorvastatin with bexarotene is recommended.[18]

Transient abnormal elevations in serum transaminase levels have been reported in approximately 20% of patients treated with etretinate or acitretin and occur much less frequently with other retinoids. Increases in serum alkaline phosphatase levels have been reported infrequently with isotretinoin and are clinically insignificant. Transaminase elevations of more than three times the upper normal range should lead to discontinuation of retinoid therapy. It is believed that in patients with hepatic insufficiency, there is impaired retinoid drug elimination.[85]

A high incidence (28%) of dose-related neutropenia has been reported with the use of bexarotene therapy for CTCL, occurring as early as 2 to 4 weeks after initiation of treatment.[49] Hematologic abnormalities are much less common with other retinoids. Bleeding complications caused by isotretinoin-induced fibrinolysis has been reported.[86]

MONITORING OF THERAPY

Most adverse effects associated with retinoids are preventable and manageable with proper patient selection, dosage adjustments, discontinuation of treatment, and routine monitoring for potential toxicity. With isotretinoin, women with childbearing potential must have two negative results on a pregnancy test spaced 30 days apart and must practice effective contraception during treatment and for 1 month (2 months in some countries) after the completion of therapy.[87] The iPLEDGE program (http://www.ipledgeprogram.com) has been put into effect by the FDA and the manufacturer to minimize the risk of isotretinoin teratogenicity. Similar but less strict programs exist in Europe and elsewhere.

Ensuring that the patient avoids pregnancy during therapy is as imperative when prescribing acitretin and etretinate as when prescribing isotretinoin. However, because of the frequent prospect of long-term treatment of more chronic diseases (eg, psoriasis and ichthyosis) and the slow elimination of aromatic retinoids from the body after interruption of therapy, acitretin (or etretinate) therapy is usually not recommended for female patients with childbearing potential. Additional precautions before oral retinoid therapy include measurement of baseline serum lipid, complete blood count, thyroid function (bexarotene, alitretinoin), and liver enzyme levels. Laboratory studies are also

performed during therapy. Providers should also assess for any history of skeletal abnormalities.

DRUG INTERACTIONS

The major avenue of tretinoin inactivation is through CYP26. Ketoconazole and liarozole are effective inhibitors of CYP26 and thus concurrent use of these azoles and topical tretinoin can prolong the half-life of tretinoin locally in the skin, thereby aggravating local side effect. Other than retinoids, no other compounds have been shown to induce CYP26.

The concurrent use of oral retinoids with other therapies having similar side effects may increase the risk of these adverse events. Tetracyclines (increased intracranial pressure, phototoxicity), alcohol (increased conversion of acitretin to etretinate, hepatoxicity), methotrexate (hepatoxicity), and vitamin A supplements (hypervitaminosis A) should be avoided. The concomitant administration of bexarotene and gemfibrozil may result in increased plasma concentrations of bexarotene.

ACKNOWLEDGMENTS

We would like to acknowledge the contributions of Laura Vangoor, BFA, for the graphic illustrations.

REFERENCES

1. Petkovich M, Brand NJ, Krust A, et al. A human retinoic acid receptor which belongs to the family of nuclear receptors. *Nature.* 1987;330(6147):444-450.
2. Giguere V, Ong ES, Segui P, et al. Identification of a receptor for the morphogen retinoic acid. *Nature.* 1987;330(6149):624-629.
3. Levin AA, Sturzenbecker LJ, Kazmer S, et al. 9-cis retinoic acid stereoisomer binds and activates the nuclear receptor RXRa. *Nature.* 1992;355(6358):359-361.
4. Heyman RA, Mangelsdorf DJ, Dyck JA, et al. 9-cis retinoic acid is a high affinity ligand for the retinoid X receptor. *Cell.* 1992;68(2):397-406.
5. Yu VC, Delsert C, Andersen B, et al. RXR beta: a coregulator that enhances binding of retinoic acid, thyroid hormone, and vitamin D receptors to their cognate response element. *Cell.* 1991;67(6):1251-1266.
6. Kang S, Duell EA, Fisher GJ, et al. Application of retinol to human skin in vivo induces epidermal hyperplasia and cellular retinoid binding proteins characteristic of retinoic acid but without measurable retinoic acid levels or irritation. *J Invest Dermatol.* 1995;105(4):549-556.
7. Aström A, Pettersson U, Chambon P, et al. Retinoic acid induction of human cellular retinoic acid-binding protein-II gene transcription is mediated by retinoic acid receptor retinoid X receptor heterodimers bound to one far upstream retinoic acid-responsive element with 5-base pair spacing. *J Biol Chem.* 1994; 269(35):22334-22339.
8. Fisher GJ, Reddy AP, Datta SC, et al. All-trans retinoic acid induces cellular retinol-binding protein in vivo. *J Invest Dermatol.* 1995;105(1):80-86.
9. Rosenthal DS, Griffiths CE, Yuspa SH, et al. Acute or chronic topical retinoic acid treatment of human skin in vivo alters the expression of epidermal transglutaminase, loricrin, involucrin, filaggrin, and keratins 6 and13 but not keratins 1, 10, and 14. *J Invest Dermatol.* 1992;98(3):343-350.
10. Kurlandsky SB, Duell EA, Kang S, et al. Auto-regulation of retinoic acid biosynthesis through regulation of retinol esterification in human keratinocytes. *J Biol Chem.* 1996;28;271(26):15346-15352.
11. Duell EA, Kang S, Voorhees JJ. Retinoic acid isomers applied to human skin in vivo each induce a4-hydroxylase that inactivates only trans retinoic acid. *J Invest Dermatol.* 1996;106(2):316-320.
12. Duell EA, Aström A, Griffiths CE, et al. Human skin levels of retinoic acid and cytochrome P-450-derived 4-hydroxyretinoicacid after topical application of retinoic acid in vivo compared to concentrations required to stimulate retinoic acid receptor-mediated transcription in vitro. *J Clin Invest.* 1992;90(4):1269-1274.
13. Kang S, Duell EA, Kim KJ, et al. Liarozole inhibits human epidermal retinoic acid 4-hydroxylase activity and differentially augments human skin responses to retinoic acid and retinol in vivo. *J Invest Dermatol.* 1996;107(2):183-187.
14. Wiegand UW, Chou RC. Pharmacokinetics of oral isotretinoin. *J Am Acad Dermatol.* 1998;39(2 Pt 3): S8-S12.
15. Wiegand UW, Chou RC. Pharmacokinetics of acitretin and etretinate. *J Am Acad Dermatol.* 1998;39(2 Pt 3): S25-S33.
16. Gronhoj Larsen F, Steinkjer B, Jakobsen P, et al. Acitretin is converted to etretinate only during concomitant alcohol intake. *Br J Dermatol.* 2000;143(6):1164-1169.
17. Saurat JH. Systemic retinoids. What's new? *Dermatol Clin.* 1998;16(2):331-340.
18. Nguyen E-QH, Wolverton SE. Systemic retinoids. In: Wolverton SE, ed. *Comprehensive Dermatologic Drug Therapy.* Philadelphia: WB Saunders; 2001:269.
19. Howell SR, Shirley MA, Grese TA, et al. Bexarotene metabolism in rat, dog, and human, synthesis of oxidative metabolites, and in vitro activity at retinoid receptors. *Drug Metab Dispos.* 2001;29(7):990-998.
20. Kang S, Leyden JJ, Lowe NJ, et al. Tazarotene cream for the treatment of facial photodamage: a multicenter, investigator-masked, randomized, vehicle-controlled, parallel comparison of 0.01%, 0.025%, 0.05%, and 0.1% tazarotene creams with tretinoin emollient cream applied once daily for 24 weeks. *Arch Dermatol.* 2001;137(12):1597-1604.
21. Cho S, Loew L, Hamilton TA, et al. Long term treatment of photoaged human skin with topical retinoic acid improves epidermal cell atypia and thickens collagen band in the papillary dermis. *J Am Acad Dermatol.* 2005;53(5):769-774.
22. Griffiths CE, Kang S, Ellis CN, et al. Two concentrations of topical tretinoin (retinoic acid) cause similar improvement of photoaging but different degrees of irritation: a double-blind, vehicle controlled comparison of 0.1% and 0.025% tretinoin creams. *Arch Dermatol.* 1995;131(9):1037-1044.
23. Griffiths CE, Russman AN, Majmudar G, et al. Restoration of collagen formation in photodamaged human skin by tretinoin (retinoic acid). *N Engl J Med.* 1993;329(8):530-535.
24. Querfeld C, Nagelli LV, Rosen ST, et al. Bexarotene in the treatment of cutaneous T-cell lymphoma. *Expert Opin Pharmacother.* 2006;7(7):907-915.

25. Wu K, Kim HT, Rodriguez JL, et al. Suppression of mammary tumorigenesis in transgenic mice by RXR-selective retinoid, LGD 1069. *Cancer Epidemiol Biomarkers Prev.* 2002;11(5):467-474.
26. Rizvi NA, Marshall JL, Dahut W, et al. Phase I study of LGD 1069 in adults with advanced cancer. *Clin Cancer Res.* 1999;5(7):1658-1664.
27. Issacs CE, Kascsak R, Pullarkat RK, et al. Inhibition of herpes simplex virus replication by retinoic acid. *Antiviral Res.* 1997;33(2):117-127.
28. Cheer SM, Foster RH. Alitretinoin. *Am J Clin Dermatol.* 2000;1(5):307-314.
29. Bulengo-Ransby SM, Griffiths CE, Kimbrough-Green CK, et al. Topical tretinoin (retinoic acid) therapy for hyperpigmented lesions caused by inflammation of the skin in black patients. *N Engl J Med.* 1993;328(20):1438-1443.
30. Griffiths CE, Goldfarb MT, Finkel LJ, et al. Topical tretinoin (retinoic acid) treatment of hyperpigmented lesions associated with photoaging in Chinese and Japanese patients: a vehicle-controlled trial. *J Am Acad Dermatol.* 1994;30(1):76-84.
31. Kimbrough-Green CK, Griffiths CE, Finkel LJ, et al. Topical retinoic acid (tretinoin) for melasma in black patients: a vehicle-controlled clinical trial. *Arch Dermatol.* 1994;130(6):727-733.
32. Kang S, Kim KJ, Griffiths CE, et al. Topical tretinoin (retinoic acid) improves early stretch marks. *Arch Dermatol.* 1996;132(5):519-526.
33. Griffiths CE, Finkel LJ, Ditre CM, et al. Topical tretinoin (retinoic acid) improves melasma: a vehicle-controlled clinical trial. *Br J Dermatol.* 1993;129(4):415-421.
34. Esgleyes-Ribot T, Chandraratna RA, Lew-Kaya DA, et al. Response of psoriasis to a new topical retinoid, AGN 190168. *J Am Acad Dermatol.* 1994;30(4):581-590.
35. Layton AM, Knaggs H, Taylor J, et al. Isotretinoin for acne vulgaris: 10 years later: a safe and successful treatment. *Br J Dermatol.* 1993;129(3):292-296.
36. Eady EA, Jones CE, Tipper JL, et al. Antibiotic resistant propionibacteria in acne: need for policies to modify antibiotic usage. *Br Med J.* 1993;306(6877):555-556.
37. Cunliffe WJ, van de Kerkhof PC, Caputo R, et al. Roaccutane treatment guidelines: results of an international survey. *Dermatology.* 1997;194(4):351-357.
38. Park H, Del Rosso JQ. Use of oral isotretinoin in the management of rosacea. *J Clin Aesthet Dermatol*. 2011 Sep;4(9):54-61.
39. Asai Y, Tan J, Baibergenova A, et al. Canadian Clinical Practice Guidelines for Rosacea. *J Cutan Med Surg*. 2016 Sep;20(5):432-445.
40. Lassus A, Geiger JM. Acitretin and etretinate in the treatment of palmoplantar pustulosis: a double-blind comparative trial. *Br J Dermatol.* 1988;119(6):755-759.
41. Ozawa A, Ohkido M, Haruki Y, et al. Treatments of generalized pustular psoriasis: a multicenter study in Japan. *J Dermatol.* 1999;26(3):141-149.
42. Wolska H, Jablonska S, Langner A, et al. Etretinate therapy in generalized pustular psoriasis (Zumbusch type). Immediate and long-term results. *Dermatologica.* 1985;171(5):297-304.
43. Dubertret L, Chastang C, Beylot C, et al. Maintenance treatment of psoriasis by Tigason: a double-blind randomized clinical trial. *Br J Dermatol.* 1985;113(3):323-330.
44. van de Kerkhof P, Verfaille C. Retinoids and retinoic acid metabolism blocking agents in psoriasis. In: Vahlquist A, Duvic, eds. *Retinoids and Carotenoids in Dermatology.* New York: Informa Healthcare; 2007:125.
45. Ellis CN, Voorhees JJ. Etretinate therapy. *J Am Acad Dermatol.* 1987;16(2 Pt 1):267-291.
46. Lowe NL. When systemic retinoids fail to work in psoriasis. In: Saurat JH, eds. *Retinoids: 10 Years On.* Basel, Switzerland: Karger; 1991:341.
47. Geiger JM, Czarnetzki BM. Acitretin (Ro 10-1670, etretin): overall evaluation of clinical studies. *Dermatologica.* 1988;176(4):182-190.
48. Ruzika T, Larsen FG, Galewicz D, et al. Oral alitretinoin (9-cis retinoic acid) therapy for chronic hand dermatitis in patients refractory to standard therapy: results of a randomized, double-blind, placebo-controlled, multicenter trial. *Arch Dermatol.* 2004;140(12):1453-1459.
49. Duvic M, Martin AG, Kim Y, et al. Phase 2 and 3 clinical trial of oral bexarotene (Targretin capsules) for the treatment of refractory or persistent early-stage cutaneous T-cell lymphoma. *Arch Dermatol.* 2001;137(5):581-593.
50. Duvic M, Hymes K, Heald P, et al. Bexarotene is effective and safe for treatment of refractory advanced-stage cutaneous T-cell lymphoma: multinational phase II-III trial results. *J Clin Oncol.* 2001;19(9):2456-2471.
51. Arechalde A, Saurat JH. Retinoids: unapproved uses or indications. *Clin Dermatol.* 2000;18(1):63-76.
52. Clayton BD, Jorizzo JL, Hitchcock MG, et al. Adult pityriasis rubra pilaris: a 10-year case series. *J Am Acad Dermatol.* 1997;36(6 Pt 1):959-964.
53. Bavinck JN, Tieben LM, Van der Woude FJ, et al. Prevention of skin cancer and reduction of keratotic skin lesions during acitretin therapy in renal transplant recipients: a double-blind, placebo-controlled study. *J Clin Oncol.* 1995;13(8):1933-1938.
54. Bravo BS, Azulay DR, Luiz RR, et al. Oral isotretinoin in photoaging: objective histological evidence of efficacy and durability. *An Bras Dermatol.* 2015;90(4):479-486.
55. Bagatin E, Guadanhim LR, Enokihara MM, et al. Low-dose oral isotretinoin versus topical retinoic acid for photoaging: a randomized, comparative study. *Int J Dermatol.* 2014;53(1):114-122.
56. Bagatin E, Parada MO, Miot HA, et al. A randomized and controlled trial about the use of oral isotretinoin for photoaging. *Int J Dermatol.* 2010;49(2):207-214.
57. Lehucher-Ceyrac D, Weber-Buisset MJ. Isotretinoin and acne: a prospective analysis of 188 cases over 9 years. *Dermatology.* 1993;186(2):123-128.
58. Geiger JM, Saurat JH. Acitretin and etretinate. How and when they should be used. *Dermatol Clin.* 1993; 11(1):117-129.
59. Lauharanta J, Juvakoski T, Lassus A. A clinical evaluation of the effects of an aromatic retinoid (Tigason), combination of retinoid and PUVA and PUVA alone in severe psoriasis. *Br J Dermatol.* 1981;104(3):325-332.
60. Saurat JH, Geiger JM, Amblard P, et al. Randomized double-blind multicenter study comparing acitretin-PUVA, etretinate-PUVA and placebo-PUVA in the treatment of severe psoriasis. *Dermatologica.* 1988;177(4): 218-224.
61. Tanew A, Guggenbichler A, Hönigsmann H, et al. Photochemotherapy for severe psoriasis without or in combination with acitretin: a randomized, double-blind comparison study. *J Am Acad Dermatol.* 1991;25(4):682-684.
62. Roenigk HH Jr. Acitretin combination therapy. *J Am Acad Dermatol.* 1999;41(3 Pt 2):S18-S21.
63. Lebwohl M. Acitretin in combination with UVB or PUVA. *J Am Acad Dermatol.* 1999;41(3 Pt 2):S22-S24.
64. Breneman D, Duvic M, Kuzel T, et al. Phase 1 and 2 trial of bexarotene gel for skin-directed treatment of patients with cutaneous T-cell lymphoma. *Arch Dermatol.* 2002;138(3):325-332.
65. Heald P, Mehlmauer M, Martin AG, et al. Worldwide Bexarotene Study Group. Topical bexarotene therapy

for patients with refractory or persistent early-stage cutaneous T-cell lymphomas: results of the phase III clinical trial. *J Am Acad Dermatol.* 2003;49(5):801-815.
66. Buchan P, Eckhoff C, Caron D, et al. Repeated topical administration of all-trans-retinoic acid and plasma levels of retinoic acids in humans. *J Am Acad Dermatol.* 1994;30(3):428-434.
67. Jick SS, Terris BZ, Jick H. First trimester topical tretinoin and congenital disorders. *Lancet.* 1993;341(8854): 1181-1182.
68. Lammer EJ, chen DT, Hoar RM, et al. Retinoic acid embryopathy. *N Engl J Med.* 1985;313(14):837-841.
69. Koo J, Nguyen Q, Gambla C. Advances in psoriasis therapy. *Adv Dermatol.* 1997;12:47-72.
70. Williams RE, Doherty VR, Perkins W, et al. Staphylococcus aureus and intranasal mupirocin in patients receiving isotretinoin for acne. *Br J Dermatol.* 1992;126(4): 362-366.
71. Safran AB, Halioua B, Roth A, et al. Ocular side-effects of oral treatment with retinoids. In: Saurat JH, eds. *Retinoids: 10 Years On.* Basel, Switzerland: Karger; 1991:315.
72. Carey BM, Parkin GJ, Cunliffe WJ, et al. Skeletal toxicity with isotretinoin therapy: a clinico-radiological evaluation. *Br J Dermatol.* 1988;119(5):609-614.
73. Tfelt-Hansen P, Knudsen B, Petersen E, et al. Spinal cord compression after long-term etretinate. *Lancet.* 1989;2(8658):325-326.
74. Kilcoyne RF. Effects of retinoids in bone. *J Am Acad Dermatol.* 1988;19(1 Pt 2):212-216.
75. van Dooren-Greebe RJ, Lemmens JA, De Boo T, et al. Prolonged treatment with oral retinoids in adults: no influence on the frequency and severity of spinal abnormalities. *Br J Dermatol.* 1996;134(1):71-76.
76. Ling TC, Parkin G, Islam J, et al. What is the cumulative effect of long-term, low-dose isotretinoin on the development of DISH? *Br J Dermatol.* 2001;144(3):630-632.
77. Lister RK, Lecky BR, Lewis-Jones MS, et al. Acitretin-induced myopathy. *Br J Dermatol.* 1996;134(5): 989-990.
78. Bonnetblanc JM, Hugon J, Dumas M, et al. Intracranial hypertension with etretinate. *Lancet.* 1983;2(8356):974.
79. Chu A, Cunliffe WJ. The inter-relationship between isotretinoin/acne and depression. *J Eur Acad Dermatol Venereol.* 1999;12(3):263.
80. Jick SS, Kremers HM, Vasilakis-Scaramozza C. Isotretinoin use and risk of depression, psychotic symptoms, suicide, and attempted suicide. *Arch Dermatol.* 2000;136(10):1231-1236.
81. Sherman SI, Gopal J, Haugen BR, et al. Central hypothyroidism associated with retinoid X receptor-selective ligands. *N Engl J Med.* 1999;340(14):1075-1079.
82. Katz HL, Waalen J, Leach EE. Acitretin in psoriasis: an overview of adverse effects. *J Am Acad Dermatol.* 1999;41(3 Pt 2):S7-S12.
83. David M, et al. Adverse effects of retinoids. *Med Toxicol.* 1998;3:273.
84. Vahlquist C, Olsson AG, Lindholm, et al. Effects of gemfibrozil (Lopid) on hyperlipidemia in acitretin-treated patients. Results of a double-blind cross-over study. *Acta Derm Venereol.* 1995;75(5):377-380.
85. Vahlquist A, Lööf L, Nordlinder H, et al. Differential hepatotoxicity of two oral retinoids (etretinate and isotretinoin) in a patient with palmoplantar psoriasis. *Acta Derm Venereol.* 1985;65(4):359-362.
86. Bäck O, Nilsson TK. Retinoids and fibrinolysis. *Acta Derm Venereol.* 1995;75(4):290-292.
87. Leyden JL, Del Rosso JQ, Baum EW. The Use of Isotretinoin in the Treatment of Acne Vulgaris: Clinical Considerations and Future Directions. *J Clin Aesthet Dermatol.* 2014 Feb;7(2 Suppl):S3–S21.

Chapter 186 :: Systemic and Topical Antibiotics

:: Sean C. Condon, Carlos M. Isada, & Kenneth J. Tomecki

AT-A-GLANCE

- Empiric therapy for skin and soft-tissue infections (SSTIs) is usually successful.
- β-Lactam antibiotics (penicillins and cephalosporins) and clindamycin are first line options for empiric therapy for mild and moderate nonpurulent SSTIs.
- Antibiotic resistance is a growing concern. Culture and sensitivity help to define better management.
- Empiric therapy for moderate and severe purulent SSTIs should cover methicillin-resistant *Staphylococcus aureus* (MRSA).
- β-Lactam antibiotics and vancomycin inhibit bacterial cell wall synthesis.
- Several antibiotic classes interfere with bacterial protein synthesis by binding ribosomal subunits: tetracyclines at 30S; lincosamides (clindamycin), macrolides, streptogramins, and oxazolidinones (linezolid) at 50S.
- New agents for SSTIs include ceftaroline, lipoglycopeptides (dalbavancin, oritavancin, and telavancin), and oxazolidinones (tedizolid).
- Topical antibiotics may negate the need for systemic antibiotics in the treatment of impetigo; they are unnecessary as postsurgical prophylaxis to prevent wound infection.

BACKGROUND

Antibiotics are soluble compounds usually produced by organisms that inhibit bacterial growth, and also include synthetic compounds. The majority of skin and soft tissue infections (SSTIs) are caused by Gram-positive organisms, most of which are susceptible to agents with a relatively narrow spectrum of antimicrobial activity. β-Lactams have been the mainstay of therapy for SSTIs.[1] Increased use and misuse of antibiotics have led to selection and propagation of resistant bacteria. Community-acquired resistant pathogens such as methicillin-resistant *Staphylococcus aureus* (MRSA) have increased in recent years and MRSA now accounts for 50% of all SSTIs with significant morbidity, mortality, and health-care cost.[2-5] The therapeutic approach should be guided by the type of SSTI (purulent or nonpurulent) and clinical severity (mild, moderate, or severe). Empiric therapy for moderate or severe purulent SSTIs should include coverage for MRSA.[6] β-Lactams remain the recommended empiric therapy for mild or moderate nonpurulent SSTIs. The emergence of complicated SSTIs with resistant pathogens, for example, MRSA and vancomycin-resistant *Enterococcus* (VRE) are even more ominous; such complicated infections involve deeper tissues or occur in patients with underlying disease, and may necessitate surgical intervention.

Most SSTIs respond to antibiotic monotherapy (Table 186-1). Combination therapy may be necessary in severe situations such as necrotizing fasciitis. Increasing pathogen resistance and the relative paucity of new antimicrobials may pose therapeutic challenges for physicians. Understanding the pharmacologic properties of antibiotics ensures judicious use of these agents, and familiarity with antibiotic dosing schedules and adverse events will lead to therapeutic choices that achieve the highest degree of patient compliance.

PENICILLINS

PHARMACOLOGY AND MECHANISM OF ACTION

STRUCTURE

Penicillins are members of the β-lactam family, one of the oldest and largest groups of antibiotics widely used throughout medical practice. Antibiotic activity originates with the thiazolidine ring nucleus and β-lactam ring; different side chains alter activity and resistance to degradation.[7] However, all β-lactams share a similar mechanism of action: they bind to specific penicillin-binding proteins; inhibit cell wall peptidoglycan synthesis; and inactivate an inhibitor of autolytic enzymes present on bacterial cell walls.

Penicillins are grouped by their chemical structure and resistance to bacterial degradation and can be broadly classified as natural or semisynthetic. In common practice, they are classified as natural, aminopenicillins, antistaphylococcal, or extended-spectrum penicillins.

Natural penicillins are susceptible to β-lactamases and thus have a narrow spectrum of activity. Penicillin G is the best example in this group. Administered parenterally, penicillin G is active against *Streptococcus* spp., *Clostridium* spp., spirochetes, *Pasteurella multocida*, *Eikenella corrodens*, *Erysipelothrix rhusiopathiae*, and non–β-lactamase producing staphylococci. It is the treatment of choice for all *Treponema pallidum* infections. Penicillin V is adminstered orally, is less potent than penicillin G, and is indicated for minor infections.

Aminopenicillins (ampicillin, amoxicillin) are oral agents with a broad spectrum of activity. However,

TABLE 186-1
Recommended Therapies

ORGANISM	DISEASE	FIRST-LINE THERAPY	ALTERNATIVE THERAPY
Actinomyces israelii	Actinomycosis	Penicillin or amoxicillin	Doxycycline, clindamycin, erythromycin
Bacillus anthracis	Cutaneous anthrax	Doxycycline, ciprofloxacin, levofloxacin, or moxifloxacin	Penicillin or amoxicillin (if sensitive)
Bartonella spp.	Cat-scratch disease, bacillary angiomatosis, Carrion disease, trench fever	Azithromycin (cat-scratch) Aminoglycosides (other *Bartonella*)	Clarithromycin, rifampin, ciprofloxacin, TMP-SMX Erythromycin or doxycycline (BA)
Borrelia burgdorferi	Lyme disease	Doxycycline or amoxicillin	Ceftriaxone, cefuroxime axetil, cefotaxime
Borrelia recurrentis	Relapsing fever	Doxycycline	Penicillin, erythromycin
Chlamydia trachomatis	Chlamydia	Doxycycline or azithromycin	Erythromycin, ofloxacin, levofloxacin
Clostridium perfringens	Gas gangrene	Penicillin G ± clindamycin	Doxycycline, chloramphenicol, metronidazole
Coxiella burnetii	Q fever	Doxycycline	Clarithromycin, TMP-SMX (pregnancy)
Ehrlichia spp.	Ehrlichiosis	Doxycycline	Tetracycline, rifampin, ciprofloxacin
Eikenella corrodens	Human bite infection	Penicillin or ampicillin	Amoxicillin-clavulanate (empiric), TMP-SMX, cefuroxime, doxycycline
Erysipelothrix rhusiopathiae	Erysipeloid	Penicillin	Cephalosporins, clindamycin, fluoroquinolones
Francisella tularensis	Tularemia	Streptomycin	Gentamicin, doxycycline, ciprofloxacin, chloramphenicol
Haemophilus ducreyi	Chancroid	Azithromycin or ceftriaxone	Erythromycin, ciprofloxacin
Klebsiella granulomatis	Granuloma inguinale	Azithromycin	Doxycycline, ciprofloxacin, erythromycin, TMP-SMX
Klebsiella rhinoscleromatis	Rhinoscleroma	Fluoroquinolones	Rifampin[a] + TMP-SMX
Neisseria gonorrhoeae	Gonorrhea	Ceftriaxone + azithromycin	Ceftriaxone + doxycycline, cefixime + azithromycin
Nocardia spp.	Nocardiosis	TMP-SMX	Susceptibility recommended
Pasteurella multocida	Animal bite infections	Penicillin, ampicillin, or amoxicillin	Doxycycline, TMP-SMX
Pseudomonas aeruginosa	Pseudomonas	Ciprofloxacin	Antipseudomonal penicillin or cephalosporin
Rickettsia spp.	Typhus, Rickettsialpox, RMSF	Doxycycline	Chloramphenicol, fluoroquinolone
Staphylococcus aureus	MSSA	Oxacillin or nafcillin	Clindamycin, macrolides
Staphylococcus aureus	HA-MRSA	Vancomycin, ceftaroline, oritavancin, dalbavancin, linezolid, tedizolid, quinupristin/dalfopristin, tigecycline	
Staphylococcus aureus	CA-MRSA	TMP-SMX, doxycycline, clindamycin	Minocycline, rifampin[a]
Streptococcus pyogenes	Erysipelas	Penicillin	Other β-lactams, clindamycin, macrolides
Treponema pallidum	Syphilis	Penicillin	Doxycycline, tetracycline
Vibrio vulnificus	Necrotizing wound infection	Doxycycline + ceftazidime	Cefotaxime, fluoroquinolones

[a]Rifampin is not recommended as monotherapy because of significant development of resistance.

BA, bacillary angiomatosis; CA-MRSA, community-acquired methicillin-resistant *Staphylococcus aureus*; HA-MRSA, healthcare–acquired methicillin-resistant *S. aureus*; MSSA, methicillin-sensitive *S. aureus*; RMSF, Rocky Mountain spotted fever; TMP-SMZ, trimethoprim-sulfamethoxazole.

they are still susceptible to β-lactamase, have limited activity against staphylococci and enteric organisms, and lack activity against *Pseudomonas*. Aminopenicillins are commonly used for community-acquired infections of the upper airway and head and neck (bronchitis, sinusitis, otitis).

Extended-spectrum penicillins include carboxypenicillins (carbenicillin, ticarcillin) and ureidopenicillins (piperacillin), which also have a broad spectrum and susceptibility to β-lactamase. Carboxypenicillins have some activity against *Pseudomonas* spp. and *Proteus* spp., and are often administered concomitantly with aminoglycosides for serious pseudomonal infections. The ureidopenicillins, derived from ampicillin with similar Gram-positive coverage, have greater activity against Gram-negative organisms including *Pseudomonas*. Amoxicillin, ticarcillin, and piperacillin are often combined with β-lactamase inhibitors (tazobactam, clavulanic acid, sulbactam) to increase activity against *Staphylococcus aureus*.

Lastly, the antistaphylococcal penicillins (oxacillin, dicloxacillin, nafcillin) are β-lactamase resistant with good activity against *S. aureus*, but without activity against enterococci or Gram-negative organisms. β-Lactamase–resistant penicillins remain the drug of choice for methicillin-sensitive *S. aureus* SSTIs and are a good empiric therapeutic choice for mild nonpurulent SSTIs such as cellulitis where community-acquired MRSA is not suspected.

METABOLISM, ABSORPTION, AND DISTRIBUTION

Penicillin absorption is variable and depends on each compound's stability in an acidic environment and presence of food in the stomach. Most oral penicillins should be taken at least 1 hour before or after meals to avoid food binding. Amoxicillin absorption is unaffected by food. Penicillin G, nafcillin, carbenicillin, ticarcillin, and piperacillin are unstable at low pH and poorly absorbed; as such they are given parenterally. Once absorbed, penicillins are widely distributed in body fluids except for cerebrospinal fluid, prostate, and intraocular fluid where concentration is lower. Penicillins typically do not cross the blood–brain barrier, but meningitis can enhance permeability, allowing for therapeutic drug levels. Natural penicillins form low-solubility salts with amines (procaine, benzathine) that are added to penicillin and administered intramuscularly to allow for slower release and prolonged drug delivery. Unabsorbed penicillin is degraded by colonic bacteria, and the majority of free penicillin is excreted renally. Nafcillin, oxacillin, and ureidopenicillins are excreted via the hepatobiliary system and dose adjustment is not required in patients with renal failure. Penicillins are pregnancy category B; although excreted in breastmilk in low quantity, they are considered safe to use during breastfeeding.

INDICATIONS AND CONTRAINDICATIONS

Table 186-2 outlines the indications for penicillin therapy.

TABLE 186-2
Indications for Penicillin Therapy

- Syphilis and nonvenereal treponematoses
- Skin and soft tissue infections (SSTIs) caused by *Streptococcus* spp. (erysipelas, scarlet fever, impetigo, etc.)
- Empiric treatment of mild or moderate nonpurulent SSTIs
- Infected human and animal bites
- Erysipeloid (*Erysipelothrix rhusiopathiae*)
- Listeriosis
- Actinomycosis
- Lyme disease (when tetracyclines are contraindicated)
- Leptospirosis (alternative to tetracyclines; pregnant woman and children <9 years old)
- Anthrax (alternative, if sensitive)

TABLE 186-3
Contraindications and Precautions of Penicillin Therapy

- Known hypersensitivity to penicillin
- Increased penicillin levels with probenecid and disulfiram
- Enhanced effect of methotrexate and warfarin
- Use with caution in patients with renal impairment

Table 186-3 outlines the contraindications and precautions for penicillin therapy.

DOSING REGIMEN

Table 186-4 outlines the dosing regimens of commonly prescribed antibiotics for the treatment of SSTIs.

SIDE EFFECTS AND PRECAUTIONS

Hypersensitivity reactions are the most common adverse events reported with penicillins with manifestations ranging from mild to severe (Table 186-5).[8] Reported incidence varies and prevalence is unknown because of a lack of prospective studies. However, penicillin is the leading cause of drug-induced anaphylaxis, accounting for approximately 1% to 10% of all cases of anaphylaxis.[9] Approximately 5% to 10% of the general population reports an allergy to penicillin, but such hypersensitivity is probably overreported. If penicillin allergy is uncertain and if penicillin treatment is required, skin prick testing can detect Type I hypersensitivity, followed by intradermal testing if negative. Negative testing may allow a challenge dose of oral penicillin under observation. Approximately 10% to 20% of patients with a reported history of penicillin allergy have a positive skin test, and approximately 3% of those with a negative skin and history of allergy have an allergic response after a challenge dose of penicillin. The majority of these reactions tend to be mild. If a β-lactam is necessary for a patient with a positive skin test, desensitization is recommended.

CEPHALOSPORINS

PHARMACOLOGY AND MECHANISM OF ACTION

STRUCTURE

Cephalosporins, like penicillins, are β-lactams and inhibit bacterial cell wall synthesis by blocking peptidoglycan incorporation.[10] However, cephalosporins

TABLE 186-4

Dosing Regimens of Commonly Prescribed Antibiotics for the Treatment of Skin and Soft Tissue Infections[6]

CLASS	GENERIC NAME	ROUTE	ADULT DOSING
β-Lactam	Penicillin G	IV	1 to 4 million units q4-6h[a]
			(18 to 24 million units daily for neurosyphilis)
	Benzathine penicillin G	IM	2.4 million units × 1 dose (primary, secondary, and early latent [<1 year] syphilis)[a]
			2.4 million units weekly × 3 doses (late latent [<1 year]/unknown duration syphilis)
	Dicloxacillin	By mouth	250 to 500 mg q6h
	Nafcillin or oxacillin	IV	1 to 2 g q4-6h
	Amoxicillin	By mouth	500 mg q8h[a]
	Amoxicillin-clavulanate	By mouth	875 mg q12h[a]
	Cephalexin	By mouth	250 to 500 mg q6h
	Cefdinir	By mouth	300 mg q12h
	Cefprozil	By mouth	250 mg q12h or 500 mg q24h
	Cefazolin	IV	1 g q8h
Tetracycline	Tetracycline	By mouth	500 mg q6h (twice daily for acne)[a]
	Doxycycline	By mouth	100 mg q12-24h
	Minocycline	By mouth	100 mg q12h[a]
Macrolide	Erythromycin base	By mouth	250 to 500 mg q6 or 12h
		IV	500 mg to 1 g q6h[a]
	Clarithromycin	By mouth	250 to 500 mg q12h
	Azithromycin	By mouth	500 mg on day 1, then 250 mg daily × 2 to 5 days
			Chlamydia: 1 g single dose
		IV	500 mg q24h
Fluoroquinolone	Ciprofloxacin	By mouth, IV	Chancroid: 500 mg q12h × 3 days
			Cutaneous anthrax: 500 mg q12h × 60 days
	Levofloxacin	By mouth, IV	Uncomplicated SSTI: 500 mg q24h[a]
			Complicated SSTI: 750 mg q24 h[a]
Lincosamide	Clindamycin	By mouth	300 to 450 mg q6h
		IV	600 to 900 mg q8h
Trimethoprim-sulfamethoxazole		By mouth	1 to 2 double-strength tablets (180 mg/800 mg) q12-24h[a]

[a]Adjustments in dose or frequency of administration may be required in patients with renal impairment.

[b]Centers for Disease Control and Prevention recommendations for the treatment of gonococcal urethritis/cervicitis include concomitant therapy with azithromycin or doxycycline.

[c]Following a single dose of ceftriaxone 1 g IM or IV.

differ from penicillins in their structural nucleus, which has a dihydrothiazine and not a thiazolidine ring like penicillins. The dihydrothiazine ring provides resistance to some, but not all, β-lactamases. Most cephalosporins have some activity against both Gram-positive (excluding enterococci) and Gram-negative organisms, but the spectrum of activity varies widely within the group. The cephalosporins have 5 "generations" based on spectrum of activity and evolution of development. The first generation includes cephalexin, cefadroxil, and the parenteral agent cefazolin; all of which have good activity against methicillin-sensitive *S. aureus* and *Streptococcus* spp. with limited activity against Gram-negative organisms such as *Escherichia coli* and *Klebsiella spp*. Second-generation cephalosporins include cefprozil, cefaclor, cefuroxime axetil, and the parenteral agents cefotetan, cefoxitin, and cefuroxime, offering expanded Gram-negative activity over the first-generation agents, namely *Haemophilus influenzae* and *Moraxella catarrhalis*. Third-generation agents include cefdinir and the parenteral agents cefotaxime, ceftriaxone, and ceftazidime. Gram-negative coverage is expanded with the third generation but less effective against Gram-positive organisms. Thus, third-generation cephalosporins are effective in treating Gram-negative nosocomial infections. Cefotaxime and ceftriaxone cross the blood–brain barrier; as such, they are effective treatment for meningitis caused by *H. influenzae*, *Neisseria meningitidis*, and penicillin-sensitive *Streptococcus pneumoniae*. Ceftazidime is active against *Pseudomonas aeruginosa*, and cefdinir is useful in the treatment of SSTIs because of its activity against *S. aureus* and *Streptococcus* spp. Fourth-generation cephalosporins include cefepime, which has increased activity against Gram-positive

TABLE 186-5
Adverse Effects

ANTIBIOTIC CLASS	PREGNANCY CLASS	COMMON ADVERSE EFFECTS	UNCOMMON ADVERSE EFFECTS
Penicillins	B	Hypersensitivity reactions: ▪ Exanthem, urticaria ▪ Diarrhea	Hypersensitivity reactions: ▪ Exfoliative dermatitis, SJS, vasculitis, AGEP ▪ Angioedema, anaphylaxis, serum sickness ▪ Anaphylactoid reaction ▪ Hepatitis, interstitial nephritis ▪ Neurotoxicity (high dose) ▪ Pulmonary infiltrate with eosinophilia (PIE) ▪ Immune-mediated hematologic reactions ▪ Pseudomembranous colitis
Cephalosporins	B	▪ Hypersensitivity as above ▪ Diarrhea	▪ Hypersensitivity as above ▪ Renal tubular necrosis ▪ Disulfiram-like reaction (specific) ▪ Thrombophlebitis (IV site) ▪ Serum sickness-like reaction (cefaclor, cefprozil) ▪ Pseudocholelithiasis (ceftriaxone)
Tetracyclines	D	▪ Skin and nail hyperpigmentation (minocycline) ▪ Dental hyperpigmentation (infants, children) ▪ GI irritation	▪ Photosensitivity (doxycycline) ▪ Photoonycholysis ▪ Fixed drug eruption ▪ Pseudotumor cerebri ▪ Esophageal erosion/stricture ▪ Skeletal hypoplasia ▪ Serum sickness ▪ Renal toxicity ▪ Vestibular toxicity (minocycline) ▪ Fanconi syndrome (outdated tetracycline) ▪ Thyroid discoloration ▪ SJS, TEN ▪ Pancreatitis ▪ Blood dyscrasias (long-term use) ▪ Hypersensitivity reactions (various) ▪ Pseudomembranous colitis
Fluoroquinolones	C	▪ Nausea, vomiting ▪ Cephalgia, dizziness	▪ Exanthem, photosensitivity ▪ Delirium, seizure ▪ Tendon rupture, arthropathy (in the immature) ▪ QT prolongation ▪ Hepatitis (trovafloxacin–withdrawn from United States)
Trimethoprim-sulfamethoxazole	D	▪ Exanthem, photosensitivity ▪ Nausea, vomiting, anorexia ▪ Glossitis, stomatitis ▪ (Rare/severe reactions are more common in HIV/AIDS patients)	▪ SJS, TEN, vasculitis, urticaria ▪ Pustular eruption, Sweet syndrome ▪ Cholestatic hepatitis, hepatic necrosis ▪ Blood dyscrasias ▪ Severe hypersensitivity reaction ▪ Cephalgia, hallucination, tremor ▪ Nephrolithiasis, interstitial nephritis

(*Continued*)

TABLE 186-5
Adverse Effects (*Continued*)

ANTIBIOTIC CLASS	PREGNANCY CLASS	COMMON ADVERSE EFFECTS	UNCOMMON ADVERSE EFFECTS
Lincosamides (clindamycin)	B	▪ Diarrhea ▪ Exanthem, urticaria	▪ Pseudomembranous colitis ▪ Erythema multiforme, SJS, TEN ▪ Elevated hepatic transaminases (reversible) ▪ Blood dyscrasias ▪ Neuromuscular blockade
Macrolides	B/C	▪ Nausea, diarrhea, abdominal pain ▪ Dysgeusia (clarithromycin)	▪ Cholestatic hepatitis ▪ Pseudomembranous colitis ▪ Prolonged QT/torsades de pointes ▪ Anaphylaxis ▪ SJS

AGEP, acute generalized exanthematous pustulosis; SJS, Stevens-Johnson syndrome; TEN, toxic epidermal necrolysis.

bacteria compared to third-generation cephalosporins. Cefepime is active against Gram-negative bacteria such as *Pseudomonas*, *Enterobacteriaceae*, *Neisseria*, and *H. influenzae* but has greater activity against Gram-negative organisms that produce extended-spectrum β-lactamase.[11] Fifth-generation agents, or advanced-generation cephalosporins, are relatively new and include only ceftaroline. Ceftaroline is given parenterally with broad-spectrum activity against Gram-positive organisms, including MRSA, resistant *S. pneumoniae*, and Gram-negative organisms such as *H. influenzae* and *M. catarrhalis*, but not *P. aeruginosa*. Ceftaroline is indicated for the use of complicated SSTIs, including those caused by MRSA and is an option for empiric therapy for severe purulent SSTIs.[12]

METABOLISM, ABSORPTION, AND DISTRIBUTION

Cephalosporins are a chemically diverse class of antibiotics with unique pharmacokinetic and pharmacodynamic properties. Most oral cephalosporins can be taken without food, but the esterified cephalosporins (cefuroxime, cefpodoxime) require food to extend mucosal contact time and allow enzymatic cleavage. Medications that lower the gastric pH may reduce absorption of these 2 cephalosporins. Cefaclor is an extended release formulation and requires food. Most cephalosporins are renally excreted. Cephalosporins are pregnancy category B and excreted in breastmilk to varying degrees.

INDICATIONS AND CONTRAINDICATIONS

Table 186-6 outlines the indications for cephalosporin therapy.

Table 186-7 outlines the contraindications and precautions of cephalosporin therapy.

DOSING REGIMEN

Table 186-4 outlines the dosing regimens of commonly prescribed antibiotics for the treatment of SSTIs.

SIDE EFFECTS AND PRECAUTIONS

Table 186-5 outlines the adverse events.

First- and second-generation cephalosporins cross-react with penicillin in approximately 10% of penicillin-allergic patients, whereas third-generation cephalosporins cross-react in 2% to 3% of penicillin-allergic patients.[9] Although penicillins and cephalosporins share a common β-lactam ring, the side chains tend to predict cross-reactivity. For example, cefoxitin, cefamandole, and cephaloridine have side chains similar to penicillin, while cefaclor, cephalexin, and cefadroxil have structural side chains similar to amoxicillin. Some oral agents lack side chain similarity to penicillin, ampicillin, or amoxicillin, including cefdinir, cefpodoxime, and cefuroxime, and may be safer

TABLE 186-6
Indications of Cephalosporin Therapy

- Uncomplicated skin and soft tissue infections (SSTIs) caused by *Staphylococcus aureus* and *Streptococcus pyogenes* (first- and second-generation agents, plus cefdinir)
- Empiric therapy for mild or moderate nonpurulent SSTIs
- Empiric therapy for severe purulent SSTIs (ceftaroline)
- Complicated SSTIs caused by *S. aureus* (including methicillin-resistant *S. aureus*) and *S. pyogenes* (ceftaroline)
- Gonorrhea
- Lyme disease (ceftriaxone: meningitis and late disease; cefuroxime: early disease)
- Bacterial meningitis (ceftriaxone, cefotaxime)

TABLE 186-7
Contraindications and Precautions of Cephalosporin Therapy

- Known hypersensitivity to cephalosporin or penicillin (see the section "Side Effects and Precautions")
- Reduced absorption of cefdinir with antacids and iron salts
- Increased cyclosporine levels with ceftriaxone and ceftazidime
- Altered effect of warfarin with cefotetan, cefamandole, cefoperazone, cefixime, and cefaclor
- Impaired renal excretion of most cephalosporins with probenecid

for use in patients with a penicillin allergy. Patients reporting a penicillin allergy with a negative penicillin allergy skin test have no greater risk of allergic reaction to β-lactams than the general population. Cephalosporins are also able to elicit cephalosporin-specific allergic reactions as a result of their metabolite profile.

TETRACYCLINES

PHARMACOLOGY AND MECHANISM OF ACTION

STRUCTURE

Tetracyclines inhibit bacterial protein synthesis by binding to the 30S ribosomal subunit and blocking transfer RNA binding to the messenger RNA–ribosome complex.[13] Doxycycline and minocycline are semisynthetic second-generation tetracyclines that are more lipophilic and thus have greater activity than tetracycline, especially against *S. aureus* and community-acquired strains of MRSA; they may be used as empiric therapy for moderate purulent SSTIs.[6,14] As a class, tetracyclines have a broad spectrum of activity, including many Gram-positive and Gram-negative bacteria, spirochetes, *Mycoplasma*, *Rickettsia*, *Chlamydia*, and even some protozoa. Doxycycline is the preferred therapy for infections caused by *Borrelia* spp., *Chlamydia* spp., *Ehrlichia* spp. (monocytic and granulocytic ehrlichiosis), *Coxiella burnetii* (Q fever), *Leptospira* spp., *Mycoplasma* spp., and *Rickettsia* spp. Doxycycline is also used to treat infections caused by *Actinomyces* spp., *Bacillus anthracis*, *Mycobacterium marinum*, *Klebsiella granulomatis* (granuloma inguinale), and *Vibrio vulnificus*. In patients allergic to penicillin, doxycycline is an acceptable treatment for animal bites and syphilis. The activity is variable for *Streptococcus pyogenes*. For nonpurulent SSTIs, among which *S. pyogenes* is common, tetracyclines are not recommended as empiric monotherapy. A tetracycline combined with a β-lactam such as amoxicillin or doxycycline can be used for empiric treatment of SSTIs when both *S. pyogenes* and MRSA are considered. Tetracyclines can be helpful for many inflammatory diseases, for example, acne, rosacea, perioral dermatitis, some autoimmune blistering diseases (bullous pemphigoid, linear immunoglobulin A bullous dermatosis, and dermatitis herpetiformis), and confluent and reticulated papillomatosis.

METABOLISM, ABSORPTION, AND DISTRIBUTION

Tetracycline is absorbed incompletely, primarily in the stomach and small intestine, necessitating its ingestion on an empty stomach. Doxycycline and minocycline are unaffected by the presence or absence of food and have longer half-lives than tetracycline, requiring less-frequent dosing. They also have much greater lipid solubility than tetracycline, allowing for good tissue penetration with rapid availability in secretions in the prostate, respiratory tract, female reproductive tract, and bile. However, patients should avoid concurrent ingestion of iron preparations, aluminum hydroxide gels, calcium and magnesium salts, or milk products, as these significantly lower absorption of all tetracyclines. Tetracycline is excreted primarily by the kidneys, and therefore dosing should be adjusted in patients with renal failure. Doxycycline is excreted in the feces and does not require adjustments in patients with hepatic or renal failure. Minocycline is largely metabolized before excretion, and does not accumulate in patients with hepatic failure. Tetracyclines can accumulate in developing bone and teeth, cross the placenta, and appear in high concentrations in breastmilk. They are pregnancy category D and should be avoided during pregnancy, while nursing, and throughout childhood.

INDICATIONS AND CONTRAINDICATIONS

Table 186-8 outlines the indications for for tetracycline therapy.

TABLE 186-8
Indications for Tetracycline Therapy

First-Line Therapy
- *Borrelia* spp. infections
- *Chlamydia* spp. infections
- Ehrlichiosis
- Empiric treatment of moderate purulent skin and soft-tissue infections
- Methicillin-resistant *Staphylococcus aureus* infections
- Lyme disease
- Rickettsial diseases
- Mild to moderate tularemia
- *Mycobacterium marinum*
- Lymphogranuloma venereum
- Alternative therapy

Actinomycosis (Penicillin Allergic)
- Animal bites (*Pasteurella multocida*)
- Granuloma inguinale
- Syphilis (penicillin allergic)
- Bacillary angiomatosis
- Anthrax (*Bacillus anthracis*)
- *Yersinia pestis* infections
- Rhinoscleroma

TABLE 186-9
Contraindications and Precautions of Tetracycline Therapy

- Patients with renal failure (impaired excretion and antianabolic properties)
- Photosensitivity (doxycycline)
- Nursing, pregnancy, and childhood years (<9 years of age)
- Impaired absorption by calcium, magnesium, aluminum (other cations), iron, sodium bicarbonate, and cimetidine
- Increased metabolism of doxycycline with the use of phenytoin, carbamazepine, barbiturates, and alcohol
- Reduced insulin requirements in diabetic patients
- Increased serum levels of digoxin, lithium, and warfarin
- Methoxyflurane anesthesia (renal failure)

Table 186-9 outlines the contraindications and precautions of tetracycline therapy.

DOSING REGIMEN

Table 186-4 outlines the dosing regimens of commonly prescribed antibiotics for the treatment of SSTIs.

SIDE EFFECTS AND PRECAUTIONS

Table 186-5 outlines the adverse events of tetracycline therapy and Table 186-9 outlines the contraindications and precautions of tetracycline therapy.

CLINDAMYCIN

PHARMACOLOGY AND MECHANISM OF ACTION

STRUCTURE

Clindamycin is a lincosamide antibiotic derived through chemical modification of lincomycin.[15] Its absorption and spectrum are much better than lincomycin, a now obsolete medication. Clindamycin binds to the bacterial 50S ribosomal subunit and inhibits protein synthesis through blockade of peptide chain initiation. The binding site overlaps the sites of other antibiotics that bind the 50S subunit such as macrolides (erythromycin), accounting for antagonism between the drugs. Clindamycin facilitates opsonization and phagocytosis and decreases bacterial adhesion to host cells and production of staphylococcal exotoxin. Clindamycin has antiparasitic activity by targeting protein synthesis of the apicoplast, an organelle essential for parasite survival.[16]

Clindamycin is effective against most Gram-positive cocci, anaerobes, and some protozoa. In dermatologic practice, it is active against most *Streptococcus* species (including *Streptococcus viridans*), *S. aureus*, *Staphylococcus epidermidis*, *B. anthracis*, and *Nocardia* spp., but is ineffective against *Enterococcus*, Gram-negative aerobes, *Clostridium difficile*, and *T. pallidum*. Its anaerobic spectrum includes *Bacteroides fragilis*, fusobacterium, *Peptostreptococcus*, and *Clostridium perfringens*. Its protozoal spectrum includes *Toxoplasma gondii*, *Babesia* spp., and *Plasmodium falciparum*. Clindamycin is an option for mild and moderate nonpurulent SSTIs, but is not recommended as empiric therapy for purulent SSTIs because of the possibility of clindamycin resistance in MRSA.

METABOLISM, ABSORPTION, AND DISTRIBUTION

Clindamycin reaches therapeutic levels in most tissues except cerebrospinal fluid, and preferentially accumulates in polymorphonuclear leukocytes, which may explain its impact on abscesses. Clindamycin is not inhibited by food intake and is primarily metabolized by the liver and excreted in the bile with some (~10%) excretion in the urine. Dosing adjustments are necessary for patients with hepatic failure or combined hepatic and renal failure. Clindamycin is not effectively removed by dialysis.

INDICATIONS AND CONTRAINDICATIONS

Table 186-10 outlines the indications clindamycin therapy.

Table 186-11 outlines the contraindications and precautions of clindamycin therapy.

DOSING REGIMEN

Table 186-4 outlines the dosing regimens of commonly prescribed antibiotics for the treatment of SSTIs.

TABLE 186-10
Indications for Clindamycin Therapy

- Uncomplicated skin and soft-tissue infections (SSTIs) caused by susceptible bacteria and protozoa
- Empiric treatment of mild and moderate nonpurulent SSTIs
- Deep tissue infections: streptococcal myositis, necrotizing fasciitis, or infections with *Clostridium perfringens* in conjunction with penicillin and surgical debridement
- Surgical prophylaxis in penicillin-allergic patients
- Prophylaxis for recurrent staphylococcal infection
- Foot ulcers (in combination with agents for Gram-negative infection) in diabetic patients
- Hidradenitis suppurativa
- Bacterial vaginosis

TABLE 186-11
Contraindications and Precautions of Clindamycin Therapy

- Hepatic failure
- Colitis
- Enhancement of neuromuscular blockade with tubocurarine and pancuronium
- Possible antagonism with erythromycin

SIDE EFFECTS AND PRECAUTIONS

Table 186-5 outlines the adverse events.

Clindamycin frequently causes GI upset and diarrhea, the latter in 20% to 35% of patients. *C. difficile*–associated diarrhea and pseudomembranous colitis are life threatening complications that may occur in clindamycin therapy, albeit infrequently. Despite the well-known association with clindamycin, comparative studies have shown equivalent or even higher risk of *C. difficile*–associated diarrhea with other antibiotics.[16]

MACROLIDES

PHARMACOLOGY AND MECHANISM OF ACTION

STRUCTURE

Macrolide antibiotics are a diverse family with a large macrolactam ring.[17] Erythromycin is the prototypical macrolide with newer derivatives that include clarithromycin and azithromycin. Macrolides reversibly bind to the 50S ribosomal subunit and inhibit RNA-dependent protein synthesis as well as inhibit neutrophil chemotaxis and interleukin-8 secretion.[18] Macrolides have good but varied activity against Gram-positive pathogens: clarithromycin > erythromycin > azithromycin. *S. aureus* has variable susceptibility to erythromycin and resistance to *Streptococcus* species is increasing—approximately 50% of group A streptococci isolates were resistant to erythromycin in a recent pediatric population study.[18] Streptococcal resistance to macrolides is not drug specific; it occurs throughout the class. Erythromycin has poor Gram-negative coverage and its systemic use has largely been replaced by clarithromycin and azithromycin, which have good activity against *H. influenzae*, *Neisseria gonorrhoeae*, *M. catarrhalis*, *Chlamydia*, *Mycoplasma pneumoniae*, *Helicobacter pylori*, *T. gondii*, *T. pallidum*, *Borrelia burgdorferi*, and nontuberculous mycobacteria. Azithromycin has good activity against *P. multocida* and *E. corrodens*, making it a useful alternative in the treatment of infected animal bites. Clarithromycin is the most active macrolide against *Mycobacterium leprae* and is widely used for skin infections with several other nontuberculous mycobacteria, notable *Mycobacterium chelonae*, *Mycobacterium abscessus*, and *Mycobacterium fortuitum*.

METABOLISM, ABSORPTION, AND DISTRIBUTION

Macrolides accumulate intracellularly in polymorphonuclear leukocytes and macrophages, which accounts for their activity against intracellular pathogens. Erythromycin base is absorbed in the small intestine and inactivated by gastric acidity, hence the need for enteric-coated tablets or capsules. Erythromycin esters (erythromycin estolate, stearate, and ethylsuccinate) are less acid labile than the base form and can be taken without food. Structural modifications of clarithromycin and azithromycin confer increased acid stability, tissue penetration and spectrum of activity compared to erythromycin. Food decreases the absorption of azithromycin and has no effect on clarithromycin. Tissue concentrations of macrolides typically exceed plasma levels. Clarithromycin and azithromycin have longer half-lives than erythromycin, which allows for less-frequent dosing (see Table 186-4). Azithromycin remains in tissue longer and accumulates at high levels intracellularly allowing for daily short-term dosing after a loading dose. Erythromycin and azithromycin are metabolized by the liver, whereas clarithromycin is metabolized by the kidneys, thus requiring dose adjustment in patients with renal failure. Erythromycin and clarithromycin interact with the cytochrome P450 system, which poses numerous potential drug interactions (see Table 186-13). Clarithromycin is pregnancy category C, whereas erythromycin and azithromycin are category B.

INDICATIONS AND CONTRAINDICATIONS

Table 186-12 outlines the indications for macrolide therapy.

Table 186-13 outlines the contraindications and precautions of macrolide therapy.

TABLE 186-12
Indications for Macrolide Therapy

- Granuloma inguinale
- Chlamydia
- Uncomplicated nonpurulent skin and soft tissue infections (folliculitis, erysipelas, cellulitis, etc)
- Bites—animal and human (*Pasteurella multocida*, *Eikenella corrodens*—azithromycin)
- Lyme disease
- *Bartonella* infections (except Oroya fever—*Bartonella bacilliformis*)
- Nontuberculous mycobacterial skin disease (clarithromycin)
- Lymphogranuloma venereum (alternative)

TABLE 186-13
Contraindications and Precautions of Macrolide Therapy

- CYP3A4 inhibition:
  - Increased drug toxicity (increased serum levels)
  - Warfarin, carbamazepine, buspirone, benzodiazepines, corticosteroids (methylprednisolone), HMG-CoA reductase inhibitors, oral contraceptives, cyclosporine, tacrolimus, disopyramide, felodipine, ergot alkaloids
- CYP1A2 inhibition:
  - Increased drug toxicity (increased serum levels)
  - Theophylline, omeprazole
- Other:
  - Digoxin (levels elevate because of change in drug metabolism by gut flora)
  - Fluconazole (increased clarithromycin levels)

DOSING REGIMEN

Table 186-4 outlines the dosing regimens of commonly prescribed antibiotics for the treatment of SSTIs.

SIDE EFFECTS AND PRECAUTIONS

Table 186-5 outlines the adverse events.

The most common side effects are abdominal pain, nausea, vomiting, and diarrhea as well as drug interactions. Macrolides may produce cardiac conduction defects and arrhythmias. A recent metaanalysis determined that macrolide therapy may be associated with increased risk of sudden cardiac death or ventricular tachyarrhythmias and cardiovascular death, but without increased all-cause mortality.[19] At present, there is no significant difference related to all-cause mortality with the use of macrolide antibiotics.

FLUOROQUINOLONES

PHARMACOLOGY AND MECHANISM OF ACTION

STRUCTURE

Fluoroquinolones are fluorinated derivatives of the first quinolone, nalidixic acid, which was originally isolated from the antimalarial agent chloroquine.[20] Fluoroquinolones inhibit the action of bacterial topoisomerase II (DNA gyrase) and topoisomerase IV, leading to disruption of DNA replication, transcription, and repair. In Gram-positive organisms, the primary target is topoisomerase IV; in Gram-negative organisms, the primary target is topoisomerase II. Fluoroquinolones in the United States include ciprofloxacin, levofloxacin, moxifloxacin, ofloxacin, and gemifloxacin. All have a broad-spectrum of activity with appreciable bacteriocidal activity against many Gram-negative organisms, including *Salmonella, Shigella, Enterobacter,* and *Campylobacter*. Ciprofloxacin is most active against *P. aeruginosa*. As a class, the fluoroquinolones have limited anaerobic activity, but gemifloxacin and moxifloxacin exhibit lower minimum inhibitory concentrations against anaerobic organisms and have better activity against Gram-positive organisms. Moxifloxacin is approved therapy for uncomplicated SSTIs. Levofloxacin and moxifloxacin have good activity against *Streptococcus*. Levofloxacin is better than moxifloxacin for *S. aureus* infections, but resistance may develop. Neither should be first line therapy for uncomplicated SSTIs, but each is helpful in the treatment of complicated, polymicrobial, and/or Gram-negative infections, such as diabetic ulcers and severe nosocomial infections. Ciprofloxacin and levofloxacin are effective agents for *Chlamydia*, erysipeloid, granuloma inguinale, and chancroid (see Table 186-14 below). Fluoroquinolones are no longer recommended as treatment of gonococcal disease. Fluoroquinolones also can be effective against some *Mycobacterium* species including *M. tuberculosis, M. chelonae, M. fortuitum*, and *M. kansasii*.[21-23]

METABOLISM, ABSORPTION, AND DISTRIBUTION

Fluoroquinolones are rapidly absorbed after ingestion with a large volume of distribution. Food does not inhibit absorption, but antacids or products containing divalent cations, such as milk, may reduce absorption. Unlike β-lactams, fluoroquinolones act in a concentration-dependent manner and can be administered once or twice daily. Except for moxifloxacin, which is eliminated by the liver, most fluoroquinolones are excreted by the kidneys with adjustment needed in patients with renal failure. None of the fluoroquinolones are removed by dialysis. Most are excreted in breastmilk in small, almost negligible quantities.

TABLE 186-14
Indications for Fluoroquinolone Therapy

First-Line Therapy
- Skin and soft tissue infections (SSTIs) caused by Gram-negative pathogens (see section "Mechanism of Action")
- *Pseudomonas aeruginosa* infections (otitis externa, ecthyma gangrenosum, SSTI) (ciprofloxacin)
- Rhinoscleroma
- Chancroid
- Anthrax

Alternative Therapy
- *Bartonella* spp. infections
- *Chlamydia* (levofloxacin, ofloxacin)
- Granuloma inguinale
- Erysipeloid (*Erysipelothrix rhusiopathiae*)

TABLE 186-15
Contraindications and Precautions of Fluoroquinolone Therapy

- Decreased bioavailability with antacids (aluminum, magnesium, alum), iron, zinc, and sucralfate
- Inhibited theophylline and aminophylline metabolism (ciprofloxacin)
- Tendon rupture (in patients with renal disease, hemodialysis, or steroid use)
- Decreased seizure threshold
- Decreased warfarin and cyclosporine metabolism

INDICATIONS AND CONTRAINDICATIONS

Table 186-14 outlines the indications for fluoroquinolone therapy.

Table 186-15 outlines the contraindications and precautions of fluoroquinolone therapy.

DOSING REGIMEN

Table 186-4 outlines the dosing regimens of commonly prescribed antibiotics for the treatment of SSTIs.

SIDE EFFECTS AND PRECAUTIONS

Table 186-5 outlines the adverse events.

TRIMETHOPRIM-SULFAMETHOXAZOLE

PHARMACOLOGY AND MECHANISM OF ACTION

STRUCTURE

Trimethoprim-sulfamethoxazole (cotrimoxazole, TMP-SMX) is a combination of trimethoprim and a sulfamethoxazole in a 1:5 ratio, which work synergistically to inhibit bacterial nucleic acid synthesis by inhibiting dihydrofolate reductase (trimethoprim) and dihydropteroate synthetase (sulfamethoxazole). These 2 enzymes are involved in the synthesis of tetrahydrofolic acid.[24]

TMP-SMX is a broad spectrum antibiotic with good activity against many aerobic Gram-positive cocci including *S. aureus*, *S. viridans*, and community-acquired MRSA.[14] It is also effective against: *H. influenzae*, *E. coli*, *Proteus mirabilis*, *Klebsiella pneumoniae*, *Shigella*, *Yersinia*, *Vibrio cholera*, *Nocardia* spp., *M. marinum*, *M. fortuitum*, and *Brucella*. The use of TMP-SMX for SSTIs caused by *S. pyogenes* is controversial because of concern for resistance, which may result from laboratory testing techniques.[25] Nonetheless, TMP-SMX is not recommended for nonpurulent SSTIs. However, TMP-SMX is active against most community-acquired MRSA and can be used for empiric therapy for moderate purulent SSTIs. The following organisms are resistant to TMP-SMX: *Mycoplasma* spp., *Rickettsia* spp., *M. tuberculosis*, and *T. pallidum*. *P. aeruginosa* is not sensitive to TMP-SMX, but other pseudomonal species are susceptible. TMP-SMX is occasionally effective for *Nocardia* infections and nontuberculous mycobacteria infections. TMP-SMX is not active against anaerobes.

METABOLISM, ABSORPTION, AND DISTRIBUTION

TMP and SMX are well absorbed, but achieve different serum concentrations following administration of equal quantities of drug. A serum ratio of 1:20 (TMP:SMX) is necessary for optimal synergy against most pathogens, which can be achieved by administration of the compound in a fixed 1:5 ratio. Both drugs are rapidly distributed to tissues including cerebrospinal fluid and sputum. Excretion is via the kidneys.

INDICATIONS AND CONTRAINDICATIONS

Table 186-16 outlines the indications for TMP-SMX therapy.

Table 186-17 outlines the contraindications and precautions of TMP-SMX therapy.

DOSING REGIMEN

Table 186-4 outlines the dosing regimens of commonly prescribed antibiotics for the treatment of SSTIs.

SIDE EFFECTS AND PRECAUTIONS

Table 186-5 outlines the adverse events.

TABLE 186-16
Indications for Trimethoprim-Sulfamethoxazole Therapy

- Community-acquired methicillin-resistant *S. aureus*
- *Nocardia asteroides* infections
- Empiric therapy for moderate purulent skin and soft tissue infections (SSTIs)
- Uncomplicated SSTIs caused by susceptible pathogens (see section "Mechanism of Action")
- Granuloma inguinale (alternative)

TABLE 186-17
Contraindications and Precautions of Trimethoprim-Sulfamethoxazole Therapy

- Severe reactions in patients with HIV/AIDS
- Prolonged prothrombin time in patients on warfarin
- Contraindicated for patients on methotrexate

TMP-SMX is pregnancy category D and should be avoided for breastfeeding women, especially during the first 6 weeks of the newborn's life.[24]

OTHER AGENTS

Even though the aforementioned drugs are most of the antibiotics used in dermatologic practice, several new or infrequently used medications deserve attention for the treatment of complicated SSTIs or systemic infections caused by resistant pathogens. Most have restricted use, predicated on approval by an infectious disease specialist.

VANCOMYCIN

Vancomycin is a glycopeptide antibiotic effective against Gram-positive bacteria; specifically, Gram-positive infections resistant to β-lactams or when β-lactam use is contraindicated. Vancomycin is a first line therapy for complicated and/or severe SSTIs caused by hospital-acquired MRSA. Vancomycin is an option for empiric therapy for severe purulent and nonpurulent (plus piperacillin and tazobactam) SSTIs. Vancomycin inhibits bacterial cell wall peptidoglycan synthesis. Dosing is determined by the patient's weight (15 to 20 mg/kg), and frequency of administration by the patient's creatinine clearance, which necessitates renal function monitoring during therapy. Potential adverse reactions include nephrotoxicity, ototoxicity, phlebitis at the injection site, hypersensitivity reactions, and leukopenia. "Red man syndrome," secondary to histamine release, is an uncommon reaction thought to be caused by drug impurities; it can be minimized by more refined preparations and slower infusions. Drug-induced linear immunoglobulin A disease is a rare cutaneous side effect. There are isolated reports of vancomycin-resistant *S. aureus* and *Enterococcus faecium*.

LIPOGLYCOPEPTIDES: DALBAVANCIN, ORITAVANCIN, AND TELAVANCIN

The lipoglycopeptides, semisynthetic derivatives of glycopeptides (vancomycin), disrupt bacterial cell wall integrity and/or inhibit bacterial cell wall synthesis.[26] They are recommended for treatment of complicated SSTIs, especially infections with Gram-positive organisms, including *S. aureus*, streptococci, and clostridia, as well as MRSA, VRE, and multidrug-resistant pneumococci. Telavancin is an option for empiric therapy for severe purulent SSTIs. Lipoglycopeptides are administered intravenously. Long half-lives for oritavancin and dalbavancin allow infrequent dosing, for example, a single-dose (oritavancin) or two-dose (dalbavancin) regimen, which is useful in outpatient therapy. Telavancin and dalbavancin require dose adjustment in patients with renal failure, whereas oritavancin does not. Lipoglycopeptides are pregnancy category C and should not be administered to breastfeeding mothers. As a class, these drugs can induce a hypersensitivity reaction similar to vancomycin-related "red man syndrome," suggesting a possible cross-allergy. Oritavancin may lead to an increased risk of osteomyelitis. Patients treated with telavancin have an increased risk of taste disturbances, nephrotoxicity, and QT prolongation. Transaminitis may occur with dalbavancin and oritavancin, while oritavancin and telavancin can interfere with coagulation studies. Oritavancin inhibits CYP2C9 and 2C19 and induces CYP3A4 and 2D6, which suggests that caution should be exercised when coadministering oritavancin and warfarin.[26]

OXAZOLIDINONES: LINEZOLID, TEDIZOLID

Until recently, linezolid was the only available oxazolidinone approved for the treatment of complicated SSTIs caused by MRSA, VRE, and vancomycin-resistant *S. aureus*. Tedizolid was approved in 2014 and early experience has shown advantages compared to linezolid.[27] Oxazolidinones inhibit protein synthesis by binding to the 23S portion of the 50S ribosomal subunit, a unique mechanism that minimizes cross-resistance to other antibiotics. Oxazolidinones are active against Gram-positive organisms (including anaerobes) and nontuberculous mycobacteria such as *M. chelonae* and *M. fortuitum*. Tedizolid and linezolid have a similar spectrum of activity, but tedizolid is 2-fold to 8-fold more potent against Gram-positive bacteria. Linezolid is generally well tolerated and side effects are infrequent. Reversible thrombocytopenia and leukopenia occur in 2% of patients and correlates with duration of therapy, which necessitates complete blood cell count monitoring during therapy. High oral bioavailability allows identical oxazolidinone dosing intravenously or orally; Linezolid dosing is 600 mg twice daily and tedizolid is 200 mg once daily. GI side effects and thrombocytopenia tend to occur less frequently in tedizolid-treated patients. Given its broader spectrum of coverage and better safety profile, tedizolid may be more efficacious than linezolid. The ability to convert to oral administration is an attractive component of oxazolidinone treatment. Linezolid is recommended as a first-line option as empiric treatment of severe purulent SSTIs.

QUINUPRISTIN-DALFOPRISTIN

Quinupristin and dalfopristin are streptogramin antibiotics combined in a fixed ratio of 3:7.[28] Both quinupristin and dalfopristin irreversibly inhibit bacterial protein translation by binding to different sites of the 50S ribosomal subunit. They exhibit synergistic activity against a variety of multidrug-resistant Gram-positive organisms, including MRSA, VRE, and vancomycin-resistant *S. aureus*. The recommended dose is 7.5 mg/kg IV twice daily for at least 7 days, with lower dosing for patients with hepatic insufficiency. Patient tolerability can be a problem, especially if phlebitis (75%), arthralgia, or myalgia occurs. Quinupristin-dalfopristin is metabolized by the liver and excreted in the bile. Elevation of hepatic transaminases and bilirubin can occur. Concomitant administration with drugs metabolized by the CYP3A4 system is contraindicated. Quinupristin-dalfopristin should be used in caution in patients taking cyclosporine or agents that prolong the QT interval.

DAPTOMYCIN

Daptomycin, a member of the lipopeptide antibiotic class derived from the fermentation of *Streptomyces roseosporus*, exerts its activity via a multistep process involving the disruption of bacterial cell wall function.[29] It is approved for the treatment of complicated SSTIs caused by *S. aureus* (including MRSA), penicillin-resistant *S. pneumoniae*, and VRE. Dosing is typically 4 mg/kg IV every 24 hours for 7 to 14 days, with excretion primarily by the kidneys, which requires dosage adjustments for patients with renal impairment. The drug is generally well tolerated, with headache and GI complaints reported most commonly. The primary serious adverse event is myopathy, which is usually transient and reversible, without progression to rhabdomyolysis.

ERTAPENEM

Ertapenem is a β-lactam member of the carbapenem family, which also includes imipenem and meropenem. Carbapenems are unique among β-lactams in their stability and resistance to extended-spectrum β-lactamases. Ertapenem is long acting with a broad spectrum of antimicrobial activity similar to the older carbapenems, but with poor activity against *Pseudomonas, Acinetobacter*, and enterococci. Although comparable to piperacillin-tazobactam in the treatment of complicated SSTIs, and active against both Gram-positive and Gram-negative aerobes and anaerobes, ertapenem use should be reserved for polymicrobial infections not otherwise sensitive to agents with more narrow spectra of activity. Compared to other carbapenems, ertapenem has a long half-life, which allows for once daily intravenous administration (1 g/day for 7 to 14 days) but should be used cautiously in patients with renal impairment. CNS effects and hypersensitivity reactions may occur.[30]

TIGECYCLINE

Tigecycline is a glycylcycline antibiotic with broad-spectrum activity indicated for the treatment of complicated SSTIs caused by susceptible organisms, including MRSA, VRE, *Acinetobacter*, and Gram-negatives that produce extended-spectrum β-lactamase.[31] A derivative of minocycline, tigecycline shares the same 30S ribosomal binding site and has a spectrum of activity similar to the classic tetracyclines. Compared to tetracyclines, tigecycline has a greater volume of distribution, better activity against organisms with tetracycline resistance, and better activity against *Streptococcus* spp. Tigecycline dosing is 50 mg IV twice daily following a 100-mg loading dose. Lower dosing is necessary for patients with hepatic disease. Tigecycline has a similar side effect profile to the tetracycline family and the same precautions should be taken.

TOPICAL ANTIBIOTICS

Topical antibiotics (Table 186-18) play an important role in the management of many common dermatologic conditions. For localized superficial infections, such as impetigo, a topical antibiotic may eliminate the need for systemic therapy. Extensive impetigo, infection on the legs, or infection in immunocompromised individuals deserve treatment with systemic antibiotics. Topical antibiotics are still prescribed as prophylactic therapy after minor surgical or cosmetic procedures to decrease postoperative wound infections and speed wound healing. But such use is unnecessary and perhaps counterproductive, given the expense and the risk of inducing allergy. For most surgical procedures, petrolatum is adequate postsurgical care.[32] Burns are unique in that they produce a fertile ground for secondary infection and prophylactic treatment with topical antibiotics is often reasonable.

CLINDAMYCIN

Clindamycin is primarily used for the treatment of acne and is available as a 1% gel, solution, lotion, foam, and swab. It is also available in a preparation with benzoyl peroxide. The addition of benzoyl peroxide may slow development of antibiotic resistance to clindamycin. Pseudomembranous colitis rarely has been reported to occur with the topical use of clindamycin.[33] Clindamycin is safe to use during pregnancy.

TABLE 186-18
Topical Antibiotics

TOPICAL AGENT (FORMULATION)	MECHANISM OF ACTION	ANTIBACTERIAL COVERAGE AND INDICATION	APPLICATION	SAFETY	ADVERSE EFFECTS
Clindamycin (1% gel, solution, lotion, foam, swab)	Binds to bacterial 50S ribosomal subunit; inhibits protein synthesis	Gram-positive cocci, anaerobes; *Propionibacterium acnes* (acne vulgaris)	Once per day	Category B	Pseudomembranous colitis (rare)
Mupirocin (2% ointment)	Reversibly binds to isoleucyl-transfer RNA synthetase; inhibits protein synthesis	Gram-positive bacteria: staphylococci, most streptococci (impetigo); also for eradication of methicillin-resistant *Staphylococcus aureus* (MRSA) from colonized sites	3 times per day	Category B	Avoid application with polyethylene glycol-based preparations to large open wounds to prevent toxic absorption
Retapamulin	Inhibits peptidyl transferase via 50S bacterial ribosomes at protein L3; inhibits protein synthesis	*S. aureus,* excluding MRSA; *Streptococcus pyogenes* (impetigo)	Twice per day × 5 days	For use in children >9 months of age only; Category B	Allergic contact dermatitis (rare)
Bacitracin	Interferes with bacterial cell-wall synthesis	Gram-positive cocci (staphylococci, streptococci)	1 to 3 times per day	Category C	Allergic contact sensitization; anaphylactic shock (rare)
Polymyxin B (ointment)	Cationic detergent; disrupts bacterial membrane integrity	Gram-negative organisms (*Pseudomonas aeruginosa*, *Enterobacter*, *Escherichia coli*)	1 to 3 times per day	Category C	Allergic contact dermatitis
Aminoglycosides (neomycin, gentamicin)	Binds to 30S ribosomal subunit; inhibits protein synthesis	Neomycin: aerobic, Gram-negative bacteria Gentamicin: prophylactic for *P. aeruginosa*	Neomycin: 1 to 3 times per day Gentamicin: 3 to 4 times per day	Neomycin: Category D Gentamicin: Category C	Allergic contact dermatitis (neomycin)
Silver sulfadiazine	Targets bacterial cell wall and membrane integrity	Broad spectrum; useful in the treatment of burns	1 to 2 times per day	Category B	Transient leukopenia
Fusidic acid (2% cream, ointment)	Interrupts elongation factor G; inhibits protein synthesis	*S. aureus* (including MRSA), *Staphylococcus epidermidis, Corynebacterium minutissimum, S. pyogenes, P. acnes*	2 to 3 times per day for up to 2 weeks	Safe to use during pregnancy	Allergic contact dermatitis

MUPIROCIN

Mupirocin, formerly known as *pseudomonic acid A*, a topical agent derived from *Pseudomonas fluorescens*, reversibly binds to isoleucyl-transfer RNA synthetase and inhibits protein synthesis. Activity is limited to Gram-positive bacteria, particularly staphylococci and most streptococci. Activity is enhanced with an acid pH (5.5), the normal pH of skin. Mupirocin may lose efficacy when exposed to high temperatures. Treatment with mupirocin ointment 2% is 3 times daily, principally for localized impetigo caused by *S. aureus* and *S. pyogenes*. Prolonged use can lead to resistance.[34] Formulations with calcium salts (to aid in stability) are available. The ointment can be used intranasally twice daily in each nostril for 5 days to eradicate MRSA colonization.

RETAPAMULIN

Retapamulin, a semisynthetic pleuromutilin antibiotic isolated from *Clitopilus scyphoides*, inhibits protein synthesis via 50S bacterial ribosomes at protein L3, near the peptidyl transferase center.[35] Retapamulin binding inhibits peptidyl transferase and partial inhibition of binding of initiator transfer RNA to the P-site of the ribosome. It is approved for the topical treatment of impetigo caused by *S. aureus* (excluding MRSA) and *S. pyogenes* in patients older than 9 months of age.

Allergic contact dermatitis to the active ingredient may occur, but is uncommon.

BACITRACIN

Bacitracin, a polypeptide antibiotic originally isolated from the Tracy-I strain of *Bacillus subtilis*, is a cyclic polypeptide with multiple components (A, B, and C). Bacitracin A is the major component of commercial products and often used as the zinc salt. It interferes with bacterial cell-wall synthesis by binding to the well and inhibiting the dephosphorylation of a membrane-bound lipid pyrophosphate; is active against Gram-positive cocci such as staphylococci and streptococci, but inactive against most Gram-negative organisms and yeasts. Available as bacitracin ointment and zinc bacitracin, with 400 to 500 units/g, topical bacitracin is effective treatment of impetigo, furunculosis and pyodermas. It is often combined with polymyxin B and neomycin as a triple antibiotic. Unfortunately, the topical application carries the risk of allergic contact sensitization and, rarely, anaphylactic shock.[36]

POLYMYXIN B

Polymyxin B, a topical antibiotic derived from a spore-forming soil aerobe *Bacillus polymyxa*, is a mixture of cyclic polypeptides (polymyxin B1 and polymyxin B2) that functions as a cationic detergent to disrupt the integrity of the membrane. Polymyxin B is active against a wide range of Gram-negative organisms including *P. aeruginosa, Enterobacter*, and *E. coli*. It is available in ointment form (5000 to 10,000 units/g) in combination with bacitracin or as a triple antibiotic ointment with bacitracin and neomycin. Recommended use is 1 to 3 times per day.

AMINOGLYCOSIDES: NEOMYCIN AND GENTAMICIN

Aminoglycosides exert their antibacterial effects by binding to the 30S ribosomal subunit and interfering with protein synthesis. Neomycin, isolated from *Streptomyces fradiae*, has activity against aerobic Gram-negative bacteria, and is commonly packaged in combination with other antibiotics. The risk of allergic contact dermatitis is high—9% of patients who undergo patch testing.[37]

Gentamicin, isolated from *Micromonospora purpurea*, is available as a 0.1% cream or ointment and used by some surgeons for operations on the ear, especially in diabetic or immunocompromised patients, to provide prophylaxis against malignant otitis externa caused by *P. aeruginosa*. The ophthalmic formulation can be used for operative wounds in the periorbital area.

SILVER SULFADIAZINE

Silver sulfadiazine is a topical product that releases silver slowly and exerts its effect on the bacterial cell wall and membranes. It has broad-spectrum activity and is useful in the treatment of burns.

FUSIDIC ACID

Fusidic acid, a fusidate antibiotic that inhibits bacterial protein synthesis translocation by interrupting elongation factor G, is active against *S. aureus* (including MRSA), *S. epidermidis, Corynebacterium minutissimum, S. pyogenes*, and *Propionibacterium acnes*.[38] Typically applied 2 to 3 times per day for up to 2 weeks, fusidic acid is available at 2% in a cream or ointment; it is unavailable in the United States. Allergic contact dermatitis is uncommon (<1%) and cross-resistance with other antibiotics is uncommon. In some locales, fusidic acid is combined with steroids for the treatment of atopic dermatitis.

ACKNOWLEDGMENTS

The authors thank Drs. Gasbarre, Schmitt, Bonner, and James for their work on this chapter in previous editions.

REFERENCES

1. Rosen T. Update on treating uncomplicated skin and skin structure infections. *J Drugs Dermatol*. 2005;4(6)(suppl):s9-s14.
2. Esposito S, Noviello S, Leone S. Epidemiology and microbiology of skin and soft tissue infections. *Curr Opin Infect Dis*. 2016;29(2):109-115.
3. Fritsche TR, Jones RN. Importance of understanding pharmacokinetic/pharmacodynamic principles in the emergence of resistances, including community-associated staphylococcus aureus. *J Drugs Dermatol*. 2005;4(6)(suppl):s4-s8.
4. Moran GJ, Krishnadasan A, Gorwitz RJ, et al. Methicillin-resistant *S. aureus* infections among patients in the emergency department. *N Engl J Med*. 2006;355(7):666-674.
5. Guillamet CV, Kollef MH. How to stratify patients at risk for resistant bugs in skin and soft tissue infections? *Curr Opin Infect Dis*. 2016;29(2):116-123.
6. Stevens DL, Bisno AL, Chambers HF, et al. Practice guidelines for the diagnosis and management of skin and soft tissue infections: 2014 update by the Infectious Diseases Society of America. *Clin Infect Dis*. 2014;59(2):e10-e52.
7. Kadurina M, Bocheva G, Tonev S. Penicillin and semi-synthetic penicillins in dermatology. *Clin Dermatol*. 2003;21(1):12-23.

8. Thethi AK, Van Dellen RG. Dilemmas and controversies in penicillin allergy. *Immunol Allergy Clin North Am*. 2004;24(3):445-461, vi.
9. Mirakian R, Leech SC, Krishna MT, et al. Management of allergy to penicillins and other beta-lactams. *Clin Exp Allergy*. 2015;45(2):300-327.
10. Del Rosso JQ. Cephalosporins in dermatology. *Clin Dermatol*. 2003;21(1):24-32.
11. Yahav D, Paul M, Fraser A, et al. Efficacy and safety of cefepime: a systematic review and meta-analysis. *Lancet Infect Dis*. 2007;7(5):338-348.
12. Frampton JE. Ceftaroline fosamil: a review of its use in the treatment of complicated skin and soft tissue infections and community-acquired pneumonia. *Drugs*. 2013;73(10):1067-1094.
13. Klein NC, Cunha BA. Tetracyclines. *Med Clin North Am*. 1995;79(4):789-801.
14. Klein NC, Cunha BA. New uses of older antibiotics. *Med Clin North Am*. 2001;85(1):125-132.
15. Falagas ME, Gorbach SL. Clindamycin and metronidazole. *Med Clin North Am*. 1995;79(4):845-867.
16. Guay D. Update on clindamycin in the management of bacterial, fungal and protozoal infections. *Expert Opin Pharmacother*. 2007;8(14):2401-2444.
17. Alzolibani AA, Zedan K. Macrolides in chronic inflammatory skin disorders. *Mediators Inflamm*. 2012;2012:159354.
18. Scheinfeld NS, Tutrone WD, Torres O, et al. Macrolides in dermatology. *Dis Mon*. 2004;50(7):350-368.
19. Cheng YJ, Nie XY, Chen XM, et al. The role of macrolide antibiotics in increasing cardiovascular risk. *J Am Coll Cardiol*. 2015;66(20):2173-2184.
20. Sable D, Murakawa GJ. Quinolones in dermatology. *Clin Dermatol*. 2003;21(1):56-63.
21. Saravolatz LD, Leggett J. Gatifloxacin, gemifloxacin, and moxifloxacin: the role of 3 newer fluoroquinolones. *Clin Infect Dis*. 2003;37(9):1210-1215.
22. Suh B, Lorber B. Quinolones. *Med Clin North Am*. 1995;79(4):869-894.
23. Blondeau JM. The role of fluoroquinolones in skin and skin structure infections. *Am J Clin Dermatol*. 2002;3(1):37-46.
24. Michalek K, Lechowicz M, Pastuszczak M, et al. The use of trimethoprim and sulfamethoxazole (TMP-SMX) in dermatology. *Folia Med Cracov*. 2015;55(1):35-41.
25. Bowen AC, Lilliebridge RA, Tong SY, et al. Is *Streptococcus pyogenes* resistant or susceptible to trimethoprim-sulfamethoxazole? *J Clin Microbiol*. 2012;50(12):4067-4072.
26. Van Bambeke F. Lipoglycopeptide antibacterial agents in Gram-positive infections: a comparative review. *Drugs*. 2015;75(18):2073-2095.
27. Rybak JM, Roberts K. Tedizolid phosphate: a next-generation oxazolidinone. *Infect Dis Ther*. 2015 [Epub ahead of print].
28. Allington DR, Rivey MP. Quinupristin/dalfopristin: a therapeutic review. *Clin Ther*. 2001;23(1):24-44.
29. Lee SY, Fan HW, Kuti JL, et al. Update on daptomycin: the first approved lipopeptide antibiotic. *Expert Opin Pharmacother*. 2006;7(10):1381-1397.
30. Congeni BL. Ertapenem. *Expert Opin Pharmacother*. 2010;11(4):669-672.
31. Stein GE, Babinchak T. Tigecycline: an update. *Diagn Microbiol Infect Dis*. 2013;75(4):331-336.
32. Smack DP, Harrington AC, Dunn C, et al. Infection and allergy incidence in ambulatory surgery patients using white petrolatum vs bacitracin ointment. A randomized controlled trial. *JAMA*. 1996;276(12):972-977.
33. Parry MF, Rha CK. Pseudomembranous colitis caused by topical clindamycin phosphate. *Arch Dermatol*. 1986;122(5):583-584.
34. Vasquez JE, Walker ES, Franzus BW, et al. The epidemiology of mupirocin resistance among methicillin-resistant *Staphylococcus aureus* at a veterans' affairs hospital. *Infect Control Hosp Epidemiol*. 2000;21(7):459-464.
35. Yang LP, Keam SJ. Retapamulin: a review of its use in the management of impetigo and other uncomplicated superficial skin infections. *Drugs*. 2008;68(6):855-873.
36. Sood A, Taylor JS. Bacitracin: allergen of the year. *Am J Contact Dermat*. 2003;14(1):3-4.
37. Warshaw EM, Belsito DV, Taylor JS, et al. North American Contact Dermatitis Group patch test results: 2009 to 2010. *Dermatitis*. 2013;24(2):50-59.
38. Schofer H, Simonsen L. Fusidic acid in dermatology: an updated review. *Eur J Dermatol*. 2010;20(1):6-15.

Chapter 187 :: Dapsone

:: Chee Leok Goh & Jiun Yit Pan

AT-A-GLANCE

- Dapsone (4,4′-diaminodiphenylsulfone) is a sulfonamide with unique pharmacologic action.
- It is used as an antiinfective in particular against Hensen disease and selected fungal infections such as actinomycetoma and rhinosporidiosis. It is also used for the treatment of malaria and as a prophylaxis for toxoplasmosis.
- It is also an antiinflammatory agents and is effective against dermatitis herpetiformis, erythema elevatum diutinum, linear immunoglobulin A dermatosis and chronic bullous disease of childhood, and bullous eruption of systemic lupus erythematosus.
- It has antineutrophilic effect and used against collagen vascular and autoimmune diseases and recently topically for acne.
- It is often used as corticosteroid-sparing agent.
- Significant side effects to watch for include hemolysis and methemoglobinemia, which are frequently observed in patient with glucose-6-phosphate dehydrogenase (G6PD) deficiency. Dapsone should only be given with great caution and in very special circumstances to patients with G6PD deficiency when the benefits outweigh the risks when constant hemoglobin and monitoring of reticulocyte counts is essential.
- Other serious side effects include drug hypersensitivity syndrome (sulphone syndrome), Stevens-Johnson syndrome, and agranulocytosis.
- Dapsone is classified as C Pregnancy Category (ie, risk not ruled out).

INTRODUCTION

Dapsone is 4,4′-diaminodiphenylsulfone,[1,2] an aniline derivative belonging to the group of synthetic sulfones. Although dapsone is classified as a sulfonamide, cross-reactions occur in only 7% to 22% of sulfa-allergic patients. They are usually mild.[3,4]

The molecule was synthesized in 1908, but research into dapsone as an antimicrobial agent started only in 1937.[5,6] Later it was recognized to possess antiinflammatory effects, and it was investigated predominantly by in vitro studies aiming to get more information on the effect of dapsone on inflammatory effector cells, cytokines, and mediators, such as cellular toxic oxygen metabolism, myeloperoxidase-halogenid system, adhesion molecules, chemotaxis, membrane-associated phospholipids, prostaglandins, leukotrienes, interleukin-8, tumor necrosis factor-α (TNF-α), lymphocyte functions, and tumor growth. The latter capabilities primarily were used in treating chronic inflammatory disorders.

Hence, dapsone has dual functions, combining antimicrobial, antiprotozoal, and antiinflammatory effects resembling those of the nonsteroidal antiinflammatory drugs (NSAIDs).

MECHANISM OF ACTION

DAPSONE AS A BACTERIOSTATIC ANTIBIOTIC AGENT

Dapsone acts by interfering in the folate biosynthetic pathway. It inhibits the synthesis of dihydrofolic acid by competing with para-aminobenzoic acid for the active site of dihydropteroate synthetase.[7,8] It has been used for the treatment of Hensen disease since 1945 (often in combination with other antibiotics, eg, rifampicin and clofazimine). It is also used to treat toxoplasmosis and is used for pneumocystis pneumonia (PCP) prophylaxis in immunocompromised patients in whom it is often prescribed in combination with pyrimethamine and leucovorin. It is also used as chemoprophylaxis for Plasmodium falciparum malaria.

In the early 2000s, a topical 5% dapsone gel was reported to be effective against acne without causing clinically significant declines in hemoglobin levels, even in patients with glucose-6-phosphate dehydrogenase (G6PD) deficiency.[9] In February 2016, the U.S. Food and Drug Administration (FDA) approved a 7.5% dapsone gel for once-daily application versus twice-daily application of the 5% formulation for acne vulgaris.[10] The mechanism of action of topical dapsone here is likely to result from its combined antiinflammatory and antimicrobial activities.

DAPSONE AS AN ANTIINFLAMMATORY AGENT

The antiinflammatory effects of dapsone was studied in animals in the 1970s. Studies showed wide variations in dapsone antiinflammatory properties. The conclusion then was that dapsone can be attributed as an antiinflammatory potential comparable to the NSAIDs. But its exact antiinflammatory mechanism

remains unknown. Since then it has been used for its antiinflammatory action on selected dermatologic disorders, especially in those with neutrophilic chemotaxis (eg, dermatitis herpetiformis and leukocytoclastic vasculitis).

Dapsone inhibits migration of neutrophils to areas of inflammation by inhibiting neutrophil chemotaxis to the chemoattractant signals F-met-leu-phe[6,11] and leukotriene B_4 (LTB_4).[12-14] Dapsone also inhibits the adherence of neutrophils to skin-localized immunoglobulin A (IgA)[15] and endothelium.[16] Additionally, dapsone inhibits the release of inflammatory mediators, including interleukin (IL)-8,[17] prostaglandin D_2, and TNF-α.[18] Dapsone also inhibit the myeloperoxidase H_2O_2-halide–mediated cytotoxic system,[19,20] likely via the inhibition of the calcium flux necessary for these events.[21] Myeloperoxidase is the enzyme in the azurophilic granules of neutrophils and in the lysosomes of monocytes that catalyzes the conversion of hydrogen peroxide and chloride ions into hypochlorous acid, a potent oxidant that causes cell damage.[22]

The dual antimicrobial and antiinflammatory functions and the long-term usage safety profile of dapsone place it in a unique position as a therapeutic agent different from other drugs. First, its antimicrobial effects can be used in immunocompromised conditions to prevent and treat opportunistic infections in patients (eg, against bacterial and protozoal infection). Second, it is safe for use in long-term treatment (eg, lifelong use in leprosy, long-term intermittent therapy in inflammatory dermatoses). Third, it has unique powerful disease-specific antiinflammatory activities (eg, prompt decrease of pruritus and control of skin lesions in dermatitis herpetiformis to the extent that the disease rapid and dramatic response to dapsone is sometime used as a diagnostic test of the disease).

CHEMISTRY AND PHARMACOLOGY OF DAPSONE

Chemically, dapsone is an aniline derivative. As a sulfone, it shows the structure of a sulphur atom linking to two carbon atoms (Fig. 187-1). The solubility of dapsone varies over a wide range depending on the solvent used (eg, water, 0.2 mg/mL vs methanol, 52 mg/mL). After oral administration, dapsone is almost completely absorbed from the gut with bioavailability exceeding 86%. Peak serum concentrations are attained within 2 to 8 hours. After ingestion of a single 50- to 300-mg dose of dapsone, maximum serum concentrations range from 0.63 to 4.82 mg/L.[23,24] Under steady-state conditions, 100 mg/day (the dose most frequently used) results in serum concentrations of 3.26 mg/L (maximum) and 1.95 mg/L (after 24 hours).[8,23,24] These dapsone serum concentrations attained in vivo must be kept in mind when interpreting the results of in vitro investigations.

After absorption, dapsone undergoes enterohepatic circulation. It is metabolized by the liver but also by

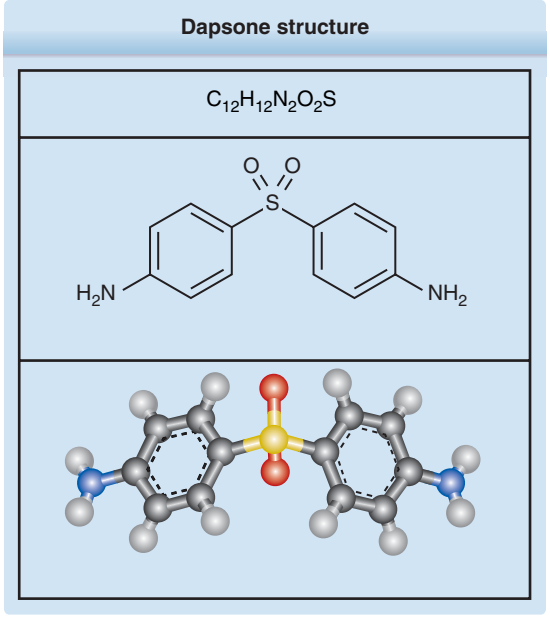

Figure 187-1 Dapsone structure.

activated polymorphonuclear leukocytes (PMNs) and mononuclear cells.[25] In the liver, dapsone is metabolized primarily through acetylation by *N*-acetyltransferase to monacetyl-dapsone (MADDS) and through hydroxylation by cytochrome P-450 enzymes, resulting in the generation of dapsone hydroxylamine (DDS-NOH). In fact, administration of dapsone has been used to determine the acetylation phenotype (rapid vs slow acetylator). In terms of both efficacy and induction of adverse effects, the most important issue is the generation of DDS-NOH. This metabolic pathway also occurs in lesional skin of inflammatory dermatoses and is thought to be mediated by activated PMN.[25] Dapsone is distributed to virtually all organs and retained in the skin, muscle, kidneys, and liver. Trace concentrations of the drug may be presented in these tissues up to 3 weeks after discontinuation of dapsone treatment. The drug is also distributed into sweat, saliva, sputum, tears, and bile. Dapsone is 50% to 90% bound to plasma proteins, but MADDS is almost completely bound to plasma proteins. It crosses the blood–brain barrier and placenta and is detectable in breast milk.[26,27] Cases have been reported in which dapsone therapy of the mother resulted in neonatal hemolysis and cyanosis.[28]

Approximately 20% of dapsone is excreted as unchanged drug via urine, and 70% to 85% is eliminated as water-soluble metabolites after conjugation with glucuronic acid. This step is mediated by uridine diphosphate glucuronosyltransferase. Additionally, a small amount might be excreted in faeces, including some yet unidentified metabolites. The complex metabolic pathway of dapsone has been reviewed.[24,25,29]

When dapsone is administered, there is equilibrium between acetylation and deacetylation. Thus, there is the possibility that PMNs in peripheral blood are exposed both to dapsone and its metabolites. These metabolites, such as DDS-NOH, have been shown to be pharmacologically active. However, they are believed

to be responsible for its antiinflammatory mechanisms (eg, inhibition of chemotaxis) but also for a number of side effects. This has been clearly documented for DDS-NOH. Interestingly, Khan and coworkers[30] recently demonstrated that human keratinocytes that had been stimulated by various cytokines such as TNF-α, IL-1β, and interferon γ (INF-γ) can produce DDS-NOH as well.

Dapsone tablets are available in 25- and 100-mg sizes; therapeutic doses for various conditions range from 25 mg to approximately 400 mg. Dapsone is well absorbed from the gut with peak levels being reached 2 to 6 hours after a single dose. The half-life, approximately 30 hours because of enterohepatic recirculation.[24] This allows for once-daily dosing and explains the utility of activated charcoal in reducing drug levels during accidental or intentional overdose.[31] Dapsone and its metabolites may be transmitted through human milk, and hemolysis has occurred in nursing infants.[27,32,33] No teratogenicity has been observed, but no controlled studies have been performed in humans, and it is classified as Pregnancy Category C.[34,35]

Topical dapsone in a 5% gel formulation was approved in 2005 for the treatment of acne vulgaris.[36,37] Twice-daily application on up to 22% of patients' body surface area resulted in systemic levels of dapsone and its metabolites that were 100-fold less than oral dapsone at a therapeutic dose. There was no hemolytic anemia or methemoglobinemia, even in patients who were G6PD deficient.[9,38-40] Therefore, in 2008, the FDA removed the requirement for pretreatment G6PD testing. Overall, topical dapsone gel has a favorable short- and long-term safety profile.

A higher concentration of 7.5% dapsone gel as a once-daily application has shown to be effective in multiple subgroups of patients.[41-44] It was well tolerated, with a low incidence of treatment-related adverse events, with the majority of adverse events being administration site related and mild or moderate in severity.[42,45] Topical dapsone has also been shown in a case report to be effective in the treatment of leukocytoclastic vasculitis.[46,47]

Dapsone is metabolized in the liver. The two major metabolic pathways involve acetylation[48,49] and *N*-hydroxylation.[43-45] Dapsone is acetylated polymorphically; that is, some patients rapidly acetylate dapsone to MADDS, but others acetylate dapsone slowly. However, in all patients, MADDS is rapidly deacetylated. Thus, equilibrium between MADDS and dapsone is quickly reached and sustained. Dapsone's efficacy, half-life, and toxicities appear unrelated to the rate of acetylation, and checking the acetylator phenotype is unnecessary before use of dapsone.

The most clinically significant metabolic pathway of dapsone involves hydroxylation of one of the amino groups by cytochrome 2C19,[43] 3A4, and 2C9 and 2C8[44] to form dapsone hydroxylamine. Dapsone hydroxylamine is a potent oxidant that is responsible for development of methemoglobinemia, hemolysis, and liver damage.[45,47,50,51] Dapsone hydroxylamine is reduced back to dapsone by methemoglobin reductase in erythrocytes and cytochrome b_5 reductase and cytochrome P2D in hepatocytes. Reduced levels of these enzymes have been detected in dapsone-treated patients who developed symptomatic methemoglobinemia. Genetic variability in detoxifying enzymes may therefore explain patients' differential development of methemoglobinemia.[52] Recent studies have also shown that dapsone can be hydroxylated by keratinocytes themselves. These hydroxylated metabolites then form drug–protein adducts that generate stress signals, which are delivered to draining lymph nodes. This may be responsible for the pathogenesis of some of the cutaneous side effects of dapsone.[53-55]

Dapsone is predominantly metabolized by the hepatocytes, but a small study indicated that there is no need to adjust dapsone doses in patients with cirrhosis.[56] However, it is prudent to exercise caution when prescribing dapsone in patients with hepatic disease.

Probenecid[57] and trimethoprim[58] have been shown to lead to higher blood levels of dapsone (Table 187-1), hence the need to exercise caution when prescribing them concurrently. Conversely, rifampicin reduces dapsone blood levels by upregulating the P_{450} system.[59] Cimetidine and omeprazole, which block *N*-hydroxylation of dapsone, have been used to mitigate some of the side effects of dapsone. Cimetidine dosed 400 mg three times a day has reduced methemoglobin levels in reported patients by 27% to 60%.[60-63]

Dapsone and its metabolites are excreted by the kidneys; therefore, it is important to check renal functions before prescribing dapsone to patients. Dapsone should be avoided in patients with significant renal dysfunction.

TABLE 187-1
Common Drug Interactions

Increase Blood Levels of Dapsone (Greater Chance of Adverse Events)
▪ Probenecid
▪ Trimethoprim
Reduces Blood Levels of Dapsone (Lowers Effectiveness)
▪ Rifampicin
Block N-Hydroxylation of Dapsone (Lessening Side Effects)
▪ Cimetidine
▪ Omeprazole

MEDICAL INDICATIONS OF DAPSONE

Since its introduction, dapsone has had therapeutic trials and anecdotal successes in a multitude of diseases (Table 187-2). However, there are only a few conditions for which dapsone is considered the drug of choice.

ANTIMICROBIAL ACTION

Dapsone is most commonly used in combination with rifampicin and clofazimine for the treatment of leprosy.[64] It is also used to both treat and prevent PCP,[65]

TABLE 187-2
Therapeutic Indications for Dapsone[1,22,226]

As an Antiinfective Drug

Infections diseases: Hensen disease, malaria, leishmaniasis, nocardiosis, *Pneumocystis* prophylaxis

As an Antiinflammatory Drug

Consistently responsive: dermatitis herpetiformis, erythema elevatum diutinum, linear IgA dermatosis and chronic bullous dermatosis of childhood (idiopathic or drug induced), bullous SLE, prurigo pigmentosa, acropustulosis infantalis

Used as an Adjunctive Combination Treatment

Autoimmune blistering diseases: pemphigus (foliaceus, vulgaris and IgA variants), bullous pemphigoid, epidermolysis bullosa acquisita, mucous membrane pemphigoid

Neutrophilic dermatosis: subcorneal pustular dermatosis (idiopathic and drug induced), acute febrile neutrophilic dermatosis (Sweet syndrome), pyoderma gangrenosum

Autoimmune diseases: rheumatoid papules, relapsing polychondritis, subacute lupus erythematosus, chronic cutaneous lupus erythematosus, lupus panniculitis, vasculitides, cutaneous polyarteritis nodosa, urticarial vasculitis, Henoch-Schönlein purpura, chronic leukocytoclastic vasculitis

Others: Behçet disease, acne and related disorders, hidradenitis suppurativa, granuloma faciale, perifolliculitis capitis abscedens et suffodiens, brown recluse spider bites that becomes necrotic, generalized granuloma annulare, chronic idiopathic thrombocytopenia purpura, chronic urticaria, aphthous stomatitis, psoriasis, Melkersson-Rosenthal syndrome, eosinophilic fasciitis, α_1-antitrypsin deficiency–related panniculitis, neutrophilic eccrine hidradenitis, insect bite–like reactions in patients with leukemia, erythema multiforme, Rosai-Dorfman disease, idiopathic angioedema, eosinophilic folliculitis (Ofuji disease)

Used in Nondermatologic Disorders

Rheumatoid arthritis, eosinophilic fasciitis, immune thrombocytopenia, stroke, asthma, seizure disorders, glioblastoma

especially in immunocompromised hosts. It is also used for toxoplasmosis in people who are unable to tolerate trimethoprim with sulfamethoxazole.[65]

ANTIINFLAMMATORY ACTION

Other indications include dermatitis herpetiformis (in combination with a gluten-free diet),[66,67] erythema elevatum diutinum (effective in 80% of early cases of the disease),[68,69] linear IgA dermatosis and chronic bullous dermatosis of childhood,[70-73] and the bullous eruption of systemic lupus erythematosus.[74,75] Patients with these disorders achieve a clinical response within 24 to 48 hours, and their conditions flare over the same time course with drug withdrawal. In 2015, dapsone was reported to be effective against generalized granuloma annulare.[76]

Other noninfectious conditions in which dapsone has found sporadic success span the spectrum of dermatologic disease (see Table 187-2).[75,77-147] As a unifying feature, most of these diseases have granulocytes (neutrophils or eosinophils) as the predominant infiltrating cell, especially early in the pathologic process. The response to dapsone therapy is not as rapid, regular, or predictable in these diseases. However, dapsone may have a role as a second-line or steroid-sparing agent.

DOSAGES

A therapeutic dose of dapsone varies from 25 mg to 200 mg/day, usually in a single dose. Rarely, patients may require 300 mg/day before a response is seen. The recommended starting dose is between 50 and 100 mg/day to minimize potential pharmacologic adverse effects, in particular hemolysis. If a therapeutic trial of dapsone is successful, the dose of dapsone should be decreased to a point at which lesions recur to be sure that the improvement was indeed caused by dapsone and that there is a continuing need for the drug. Reducing the dose of dapsone to the lowest effective dose is an important means to minimize potential side effects.

TOPICAL DAPSONE

Topical dapsone (5% gel) is FDA approved for acne vulgaris in adults[9,36-40] and adolescents[77] up to 12 years old. It has not been reported to cause hemolysis even in patients with G6PD deficiency.[9] Clinical trials showed that it can reduce the mean total lesion count by 39% and 49%.[9,36,40,77] It can be used in conjunction with other acne medications, including adapalene and benzoyl peroxide gel.[78]

Topical dapsone, when applied together with benzoyl peroxide, may cause yellow-orange discoloration of the skin; it is washable from skin but may stain clothing.[79] Dapsone 7.5% gel has been FDA approved for the treatment of mild to moderate acne vulgaris as a single daily application since 2016.[80]

ADVERSE REACTIONS FROM DAPSONE (TABLE 187-3)

HEMATOLOGY

HEMOLYSIS

The commonest side effects of dapsone is dose-related hemolysis. Hemolysis may lead to hemolytic anemia and methemoglobinemia. About 20% of patients receiving dapsone treatment develop hemolysis.[22] The side effect is more common and severe in those with G6PD deficiency. G6PD deficiency should be ruled out before initiating therapy in all patients.[148] Hemolysis is more profound at the initiation of

TABLE 187-3
Adverse Effects of Dapsone[a]

Hematology
- Hemolysis
- Methemoglobinemia

Liver
- Toxic hepatitis
- Cholestatic jaundice
- Transaminitis
- Hypoalbuminemia

Skin
- Exfoliative dermatitis
- Erythema multiforme
- Urticaria
- Erythema nodosum
- Morbilliform exanthem
- Scarlatiniform exanthem
- Photosensitivity

Others
- Gastrointestinal upset (nausea)
- *Headache*
- *Fatigue*
- *Insomnia*
- *Psychosis*
- Peripheral neuropathy
- Motor neuropathy

Life-Threatening Side Effects
- *Dapsone hypersensitivity syndrome*
- Hemolysis
- Methemoglobinemia
- *Agranulocytosis*
- *Aplastic anemia*
- Hemophagocytic syndrome
- *Toxic epidermal necrolysis, Stevens-Johnson syndrome*[194]

[a]Italicized adverse effects are idiosyncratic and not dose dependent.

therapy and is often accompanied by a compensatory reticulocytosis. However, G6PD-deficient patients are less susceptible to methemoglobinemia production, but more susceptible to hemolysis.[22] A case of hemolysis in a neonate from dapsone in breast milk has been reported.[27,32]

METHEMOGLOBINEMIA

Methemoglobinemia is a predictable consequence of dapsone therapy caused by dapsone hydroxylamine's generation of reactive oxygen species (ROS).[149-156] Methemoglobinemia usually occurs only with the intake of oral dapsone; however, a single case of methemoglobinemia has been reported in a patient using topical 5% dapsone.[49] Methemoglobin is the form of hemoglobin in which the iron molecule is in the oxidized ferric (Fe^{3+}) state rather than in the ferrous state (Fe^{2+}). As such, the molecule itself is unable to carry oxygen or carbon dioxide.[151] The signs and symptoms of methemoglobinemia are those of poor oxygenation, including cyanosis, headache, shortness of breath, chest pain, and fatigue. And although some degree of methemoglobinemia occurs in most patients, symptomatic methemoglobinemia is rare. Symptoms usually occur with methemoglobin levels of 20% to 30%.[155,156] Pulse oximetry is a reasonable screening test for methemoglobinemia because a normal value excludes significant methemoglobin levels. However, an abnormal value must be followed up with a direct methemoglobin determination.[152-157] Cimetidine, which blocks the hydroxylation of dapsone, has been used intentionally to lower methemoglobin levels in dapsone-treated patients by 27% to 60%.[60-63,158] Lipoic acid, a dietary supplement with antioxidant properties, has also been shown in vitro to decrease methemoglobin formation, and 90 mg/day of lipoic acid daily has been suggested for dapsone-treated patients.[159]

Although G6PD-deficient individuals are at greater risk for hemolytic anemia and methemoglobinemia, the clinician should remember that these events are also seen in patients without G6PD deficiency.[160]

LIVER

Toxic hepatitis and cholestatic jaundice from dapsone have been reported. Hepatitis and jaundice may also occur as part of the dapsone hypersensitivity reaction or syndrome. Dapsone is metabolized by the cytochrome P450 system. Dapsone metabolites produced by the cytochrome P450 2C19 isozyme are associated with the methemoglobinemia side effect of the drug.

SKIN

Various skin eruptions from dapsone have been described.[161] They include exfoliative dermatitis, erythema multiforme, urticaria, erythema nodosum, morbilliform and scarlatiniform exanthema, and Stevens-Johnson syndrome or toxic epidermal necrolysis. Dapsone-induced photosensitivity is quite rare but usually not dose dependent. When used topically, dapsone can cause mild skin irritation, redness, dry skin, burning, and itching.

OTHER ADVERSE EFFECTS

These include nausea, headache, fatigue, insomnia, psychosis, and peripheral neuropathy. Also reported are varied neurologic side effects, including a distal motor neuropathy, most often without a sensory component.[162-164] These are usually reversible with dose decrease or discontinuation of dapsone. Checking a patient's distal motor strength at follow-up visits may alert the clinician to such side effects.

Effects on the lung occur rarely and may be serious, although they are generally reversible.[165]

SERIOUS ADVERSE REACTIONS TO DAPSONE

DAPSONE HYPERSENSITIVITY SYNDROME

Hypersensitivity reactions to dapsone occur in some patients. This reaction may be more frequent in patients receiving multiple-drug therapy.[166-168] The reaction manifests with a rash and may also present with fever, jaundice, and eosinophilia.[169-173] In general, these symptoms occur within the first 6 weeks of therapy and may be ameliorated by corticosteroid therapy.

This reaction appears to be more frequent in patients receiving multiple-drug therapy.[168] Latencies of the hypersensitivity syndrome after initiation of dapsone treatment were less than 20 days, 24.5%; 21 to 28 days, 35.0%; 29 to 35 days, 20.9%; and more than 36 days, 19.6%. Maximum latency was 20 weeks; 91% and 97% of patients presented with a rash and fever respectively, and 73.7% had lymphadenopathy. Hepatic dysfunction could be detected in the majority of cases, its severity ranging from abnormal liver test results over hepatosplenomegaly and jaundice to hepatic coma. About half of the patients demonstrated hematologic changes (leucocytosis in 56.6%, eosinophilia in 43.8%). After withdrawal of dapsone (and in most cases, steroid therapy), the majority of patients (82.3%) recovered, but nearly 10% had a fatal outcome, hepatic coma being the most frequent cause of death. Early discontinuation of dapsone was associated with a better prognosis.[22,174] Corticosteroids have proved helpful, but dosages up to 1g/day of methylprednisolone for 3 days may be required followed by a prednisone taper over 4 to 6 weeks.

Clinicians should be alert for rashes that present with fever and other systemic symptoms because these may be manifestations of the dapsone hypersensitivity syndrome.[175-190] The incidence of this syndrome ranges from 0.2% to 5% of treated patients.[175-178] It is similar to hypersensitivity syndrome seen with some anticonvulsants and other medications.[179,180] These syndromes are postulated to be due to drug-allergy-induced immunosuppression[53,54,178,179] leading to a reactivation of human herpesvirus 6 (HHV6) or other latent viruses such as cytomegalovirus and Epstein-Barr virus. They develop between 2 and 7 weeks after initiating the medication and inevitably include the triad of fever, rash, and hepatitis. The rash is most often an exfoliative dermatitis,[180] but maculopapular and Stevens-Johnson–like lesions have occurred. It is the reactivation of HHV6 that is thought to cause the late flaring of rash, fever, and hepatitis characteristically seen in this class of drug reactions, necessitating such a long steroid taper.[178] The hepatitis has a mixed hepatocellular and cholestatic picture with elevations in both transaminases[181-186] and alkaline phosphatase.[187] Additionally, any other end-organ damage must be managed supportively.[175,176] Plasma exchange has also been successfully used in a patient in whom tapering of steroids led to recrudescence of symptoms.[190]

HEMOLYSIS AND METHEMOGLOBINEMIA

Dapsone therapy is often associated with hemolysis and sometimes methemoglobinemia in a dose-dependent fashion.[191] These adverse effects are caused by the hydroxylated metabolite, dapsone hydroxylamine, a potent oxidant.[45,47,192-197] Within the erythrocytes, dapsone hydroxylamine generates ROS, which oxidize oxyhemoglobin into methemoglobin. Acute methemoglobinemia occurs rarely but may result in dyspnea, anemia, and vascular collapse; in serious cases, it may result in death. The oxidized hemoglobin becomes microscopically visible as Heinz bodies. These Heinz bodies and hydroxylated metabolite/cellular protein adducts may label the red blood cells (RBCs) as senescent, targeting them for removal by the spleen. Glutathione within the erythrocytes is responsible for reversing oxidative damage; however, production of glutathione depends on G6PD. Patients with G6PD deficiency are less tolerant of pharmacologic oxidative stress and are at risk for substantial hemolysis. There are two types of G6PD deficiency that are screened for with the same laboratory assay: "A-type" G6PD deficiency occurs in African Americans and is milder than the type seen in patients of Mediterranean heritage.[198] G6PD deficiency should be ruled out before initiating dapsone therapy in all patients.[148] Baseline anemias should be worked up before starting patients on dapsone. The frequency of symptomatic anemia is 10%,[199] but it might be higher in certain populations such as solid organ allograft recipients (23%).[200,201] This higher rate of hemolysis may be attributable to the greater frequency of renal insufficiency in this patient population or a potential interaction with medicines such as sirolimus. If dapsone therapy is efficacious but hemolysis is limiting therapy, coadministration of darbepoetin may allow continuation of drug at therapeutic doses.[202,203]

AGRANULOCYTOSIS

Agranulocytosis is another rare, idiosyncratic side effect and has been estimated to occur in 0.2% to 0.4% of treated patients.[148,159,191,204-209] It usually occurs during the first 3 months of therapy. Although usually reversible within days when patients stop therapy, it may be fatal because of superseding infection. Symptoms of agranulocytosis include fever, pharyngitis, dysphagia, and oral ulcerations.[148,191] Patients should be warned to seek medical care immediately if these symptoms develop. Recombinant granulocyte colony-stimulating factor has been used to produce a more rapid resolution of agranulocytosis.[210]

APLASTIC ANEMIA

Individual case reports of other hematologic sequelae of dapsone include two cases of pure RBC aplasia[211] and a single case of hemophagocytic syndrome induced by dapsone.[212] Abnormalities in white blood cell formation, including aplastic anemia, are rare yet are the cause of the majority of deaths attributable to dapsone therapy.[213-215]

INITIATING AND MONITORING OF DAPSONE THERAPY

Before starting patients on dapsone, a targeted history and physical examination to screen for significant preexisting anaemia, cardiopulmonary disease, and peripheral neuropathy should be performed. Laboratory tests (Table 187-4) should include a complete blood cell count and reticulocytes counts to determine baseline white blood cell count, hemoglobin, and reticulocytes. G6PD deficiency should be ruled out, as should significant hepatic or renal dysfunction. After therapy has begun, a white blood cell count with differential and hemoglobin levels and reticulocytes count should be obtained weekly for the first month and then twice a month during the next 2 months.[148,191] A drop in hemoglobin of 1 to 2 g/dL should be anticipated and, in the absence of symptoms, should not prompt drug discontinuation. Monitoring reticulocyte counts also provide an estimation of the adequacy of compensation for hemolysis. A profoundly elevated reticulocyte count suggests that erythropoiesis is at its maximum and that further dose increases are not likely to be well tolerated. Even during long-term therapy, complete blood cell counts should be obtained periodically. Checking methemoglobin levels is unnecessary in the absence of symptoms. Patients should also be told to carry a medication card so that in an emergency, treating physicians will know they are taking a drug with hemolytic and methemoglobin-generating potential. It is important that all patients be made aware of the potential clinical manifestations of adverse events. Especially during the first 3 months of therapy when the risk of agranulocytosis and the dapsone hypersensitivity syndrome is highest, patients should be reminded to seek medical attention immediately for significant fever, pharyngitis, dysphagia, swollen lymph nodes, oral ulcerations, and rash.[148,191] Patients with diabetes should also be made aware that dapsone causes falsely low hemoglobin A1c values because of the accelerated RBC turnover; monitoring fructosamine levels avoids this potential confounder.[216] It might be suggested to patients who have mild symptoms of anemia or methemoglobinemia to take cimetidine 400 mg three times daily and lipoic acid 90 mg/day to see if these might ameliorate symptoms enough for dapsone administration to continue.[60-63,169]

Dapsone is contraindicated in patients who are allergic to the drug. It should not be administered to patients with severe anaemia. Dapsone must be used with caution in the following conditions: G6PD deficiency, methemoglobinemia reductase deficiency, severe hepatopathy, cardiac insufficiency or heart failure, and pulmonary diseases as well as comedication with methemoglobinemia-inducing drugs or compounds.

TABLE 187-4
Laboratory Monitoring

Before Initiation of Therapy
- Glucose-6-phosphate dehydrogenase
- CBC
- Reticulocyte count
- Hepatic function tests
- Renal function tests

During Therapy
- CBC (with WBC differential) weekly for the first month and twice a month for the next 2 months; periodically thereafter
- Reticulocyte count weekly for the first month and twice a month for the next 2 months; periodically thereafter

CBC, complete blood count; G6PD, glucose-6-phosphate dehydrogenase; WBC, white blood cell.

TREATING OVERDOSE

In the case of accidental or intentional dapsone overdose, the clinician should be prepared for significant hemolysis (which may be delayed by up to 9 days because of enterohepatic recirculation) and methemoglobinemia.[217-219] Massive intravascular hemolysis seen in dapsone overdose has been linked to optic ischemic injury.[220-222] Although dapsone is 50% to 80% protein bound in the circulation, the unbound portion can be dialyzed off, and repeated dialysis has been helpful in the case of overdose.[223] Because of dapsone's enterohepatic recirculation, administration of activated charcoal will reduce drug levels by removing drug from the gut. Methylene blue, 1% solution given 1 to 2 mg/kg slowly intravenously,[224,225] can be used to decrease the degree of methemoglobinemia. Methylene blue is a cofactor for methemoglobin reductase after first being reduced by cellular stores of NADPH (nicotinamide adenine dinucleotide phosphate hydrogen) to leukomethylene blue. G6PD-deficient patients should not be given methylene blue because they may have insufficient NADPH, and unreduced methylene blue is its own direct hemolytic agent. Ascorbic acid 1000 mg intravenously every 12 hours has also been used in a case of overdose and certainly could be used until G6PD status is reviewed so that methylene blue can be administered. Ascorbic acid's effect is caused by its ability to increase methemoglobin reductase activity.[218]

ACKNOWLEDGMENTS

We acknowledge Joni G. Sago and Russell P. Hall III, who wrote the previous version of this chapter. The new version is adapted from the previous version.

REFERENCES

1. Lang PG. Sulfones and sulfonamides in dermatology today. *J Am Acad Dermatol*. 1979;1:479.
2. Zhu YI, Stiller MJ. Dapsone and sulfones in dermatology: overview and update. *J Am Acad Dermatol* 2001;45:420.
3. Holtzer CD, Flaherty JFJ, Coleman RL. Crossreactivity in HIV-infected patients switched from trimethoprim-sulfamethoxazole to dapsone. *Pharmacotherapy*. 1998;18:831.
4. Beumont MG, Graziani A, Ubel PA, et al. Safety of dapsone as Pneumocystis carinii pneumonia prophylaxis in human immunodeficiency virus-infected patients with allergy to trimethoprim/sulfamethoxazole. *Am J Med*. 1996;100:611.
5. Buttle GAH, Stephenson D, Smith T, et al. The treatment of streptococcal infections in mice with 4:20diaminodiphenylsulfone. *Lancet*. 1937;229:1331-1334.
6. Debol SM, Herron MJ, Nelson RD. Anti-inflammatory action of dapsone: inhibition of neutrophil adherence is associated with inhibition of chemoattractant-induced signal transduction. *J Leukoc Biol*. 1997;62:827-836.
7. Coleman MD. Dapsone: modes of action, toxicity and possible strategies for increasing patient tolerance. *Br J Dermatol*. 1993;129:507-513.
8. Dapsone In: McEvoy GK (ed). *AHFS Drug Information*. Bethesda, MD: American Society of Health-System Pharmacists; 2011:622-626.
9. Stotland M, Shalita AR, Kissling RF. Dapsone 5% gel: a review of its efficacy and safety in the treatment of acne vulgaris. *Am J Clin Dermatol*. 2009;10(4): 1594-1602.
10. Allergan. Aczone (dapsone) 7.5% Gel prescribing information (PDF). Allergan USA, Inc.; Madison, NJ: February 2016.
11. Harvath L, Yancey KB, Katz SI. Selective inhibition of human neutrophil chemotaxis to N-formylmethionyl-leucyl-phenylalanine by sulfones. *J Immunol*. 1986; 137:1305.
12. Maloff BL, Fox D, Bruin E, et al. Dapsone inhibits LTB4 binding and bioresponse at the cellular and physiologic levels. *Eur J Pharmacol*. 1988;158:85.
13. Wozel G, Blasum C, Winter C, et al. Dapsone hydroxylamine inhibits the LTB4-induced chemotaxis of polymorphonuclear leukocytes into human skin: results of a pilot study. *Inflamm Res*. 1997;46:420.
14. Wozel G, Lehmann B. Dapsone inhibits the generation of 5-lipoxygenase products in human polymorphonuclear leukocytes. *Skin Pharmacol*. 1995;8:196.
15. Thuong-Nguyen V, Kadunce DP, Hendrix JD, et al. Inhibition of neutrophil adherence to antibody by dapsone: a possible therapeutic mechanism of dapsone in the treatment of IgA dermatoses. *J Invest Dermatol*. 1993;100:349.
16. Coleman MD, Smith JK, Perris AD, et al. Studies on the inhibitory effects of analogues of dapsone on neutrophil function in-vitro. *J Pharm Pharmacol*. 1997;49:53.
17. Schmidt E, Reimer S, Kruse N, et al. The IL-8 release from cultured human keratinocytes, mediated by antibodies to bullous pemphigoid autoantigen 180, is inhibited by dapsone. *Clin Exp Immunol*. 2001; 124:157.
18. Abe M, Shimizu A, Yokoyama Y, et al. A possible inhibitory action of diaminodiphenyl sulfone on tumour necrosis factor-alpha production from activated mononuclear cells on cutaneous lupus erythematosus. *Clin Exp Dermatol*. 2008;33(6): 759-763.
19. Stendahl O, Dahlgren C. The inhibition of polymorphonuclear leukocyte cytotoxicity by dapsone; a possible mechanism in the treatment of dermatitis herpetiformis. *J Clin Invest*. 1977;62:214.
20. Kazmierowski JA, Ross JE, Peizner DS, et al. Dermatitis herpetiformis: effects of sulfones and sulfonamides on neutrophil myeloperoxidase-mediated iodination and cytotoxicity. *J Clin Immunol*. 1984;4:55.
21. Suda T, Suzuki Y, Matsui T, et al. Dapsone suppresses human neutrophil superoxide production and elastase release in a calcium-dependent manner. *Br J Dermatol*. 2005;152:887.
22. Wozel G, Blasu C. Dapsone in dermatology and beyond. *Arch Dermatol Res*. 2014;306:103-124.
23. Ahmad RA, Rogers HJ. Pharmacokinetics and protein binding interactions of dapsone and pyrimethamine. *Br J Clin Pharmacol*. 1980;10:519-524.
24. Zuidema J, Hilbers-Modderman ES, Merkus FW. Clinical pharmacokinetics of dapsone. *Clin Pharmacokinet*. 1986;11:299-315.
25. Uetrecht J, Zahid N, Shear NH, et al. Metabolism of dapsone to a hydroxylamine by human neutrophils and mononuclear cells. *J Pharmacol Exp Ther*. 1988;245:274-279.
26. Branski D, Kerem E, Gross-Kieselstein E, et al. A Bloody diarrhea—a possible complication of sulfasalazine transferred through human breast milk. *J Pediatr Gastroenterol Nutr*. 1986;5:316-317.
27. Sanders SW, Zone JJ, Foltz RL, et al. Hemolytic anemia induced by dapsone transmitted through breast milk. *Ann Intern Med*. 1982;96:465-466.
28. Lowe J. Studies in sulphone therapy. *Lepr Rev*. 1952; 23:4-29.
29. Wolf R, Tuzun B, Tuzun Y. Dapsone: unapproved uses or indications. *Clin Dermatol*. 2000;18:37-53.
30. Khan FD, Roychowdhury S, Nemes R, et al. Effect of pro-inflammatory cytokines on the toxicity of the arylhydroxylamine metabolites of sulpha-methoxazole and dapsone in normal human keratinocytes. *Toxicology*. 2006;218:90-99.
31. Endre ZH, Charlesworth JA, Macdonald GJ, et al. Successful treatment of acute dapsone intoxication using charcoal hemoperfusion. *Aust N Z J Med*. 1983;13:509.
32. Edstein MD, Veenendaal JR, Newman K, et al. Excretion of chloroquine, dapsone and pyrimethamine in human milk. *Br J Clin Pharmacol*. 1986;22:733.
33. Hocking DR. Neonatal haemolytic disease due to dapsone. *Med J Aust*. 1968;1:1130.
34. Maurus JN. Hansen's disease in pregnancy. *Obstet Gynecol*. 1978;52:22.
35. Collier PM, Kelly SE, Wojnarowska F. Linear IgA disease and pregnancy. *J Am Acad Dermatol*. 1994;30:407.
36. Draelos Z, Carter E, Maloney J, et al. Two randomized studies demonstrate the efficacy and safety of dapsone gel 5% for the treatment of acne vulgaris. *J Am Acad Dermatol*. 2007;56:439.e1-e10.
37. Scheinfeld N. Aczone, a topical gel formulation of the antibacterial, anti-inflammatory dapsone for the treatment of acne. *Curr Opin Investig Drugs*. 2009;10(5): 474-481.
38. Thiboutot D, Willmer J, Sharata H, et al. Pharmacokinetics of dapsone gel, 5% for the treatment of acne vulgaris. *Clin Pharmaokinet*. 2007;46(8): 697-712.

39. Piette W, Taylor S, Pariser D, et al. Hematologic safety of dapsone gel 5% for topical treatment of acne vulgaris. *Arch Dermatol*. 2008;144(12):1564-1570.
40. Lucky A, Maloney JM, Roberts J, et al. Dapsone gel 5% for the treatment of acne vulgaris: safety and efficacy of long-term (1 year) treatment. *J Drugs Dermatol*. 2007;6(10):981-987.
41. Al-Salama ZT, Deeks ED. Dapsone 7.5% gel: a review in acne vulgaris. *Am J Clin Dermatol*. 2017;18(1):139-145.
42. Draelos ZD, Rodriguez DA, Kempers SE, et al. Treatment response with once-daily topical dapsone gel, 7.5% for acne vulgaris: subgroup analysis of pooled data from two randomized, Double-blind studies. *J Drugs Dermatol*. 2017;16(6):591-598.
43. Caraco Y, Wilkinson GR, Wood AJ. Differences between white subjects and Chinese subjects in the in vivo inhibition of cytochrome P450s 2C19, 2D6 and 3A by omeprazole. *Clin Pharmacol Ther*. 1996;60:396.
44. Gill JP, Gil Berglund E. CYP2C8 and antimalaria drug efficacy. *Pharmacogenomics*. 2007;8(2):187-198.
45. Cucinell SA, Israili ZH, Dayton PG. Microsomal N-oxidation of dapsone as a cause of methemoglobin formation in human red cells. *Am J Trop Med Hygiene*. 1972;21:322.
46. Pate DA, Johnson LS, Tarbox MB. Leukocytoclastic vasculitis resolution with topical dapsone. *Cutis*. 2017;99(6):426-428.
47. Hjelm M, DeVerdier CH. Biochemical effects of aromatic amines-I. Methaemoglobinaemia, haemolysis and Heinz-body formation induced by 4,4′-diaminodiphenylsulphone. *Biochem Pharmacol*. 1965;14:1119.
48. Ellard GA, Gammon PT, Savin JA, et al. Dapsone acetylation in dermatitis herpetiformis. *Br J Dermatol*. 1974;90:441.
49. Ellard GA, Gammon PT, Helmy HS, et al. Dapsone acetylation and the treatment of leprosy. *Nature*. 1972; 239:159.
50. Clement B, Helmy HS, Rees RJ. et al. Reduction of sulfamethoxazole and dapsone hydroxylamines by a microsomal enzyme system purified from pig liver and pig and human liver microsomes. *Life Sci*. 2005;77:205.
51. Ganesan S, Sahu R, Walker LA, et al. Cytochrome P450-dependent toxicity of dapsone in human erythrocytes. *J Appl Toxicol*. 2010;30(3):271-275.
52. Eichelbaum M, Evert B. Influence of pharmacogenetics on drug disposition and response. *Clin Exp Pharmacol Physiol*. 1996;23:983.
53. Roychowdhury S, Vyas PM, Reilly TP, et al. Characterization of the formation and localization of sulfamethoxazole and dapsone-associated drug-protein adducts in human epidermal keratinocytes. *J Pharmacol Exp Ther*. 2005;314:43.
54. Roychowdhury S, Cram AE, Aly A, et al. Detection of haptenated proteins in organotypic human skin explant cultures exposed to dapsone. *Drug Metab Dispos*. 2007;35:1463-1465.
55. Khan F, Vyas PM, Gaspari AA, et al. Effect of arylhydroxylamine metabolites of sulfamethoxazole and dapsone on stress signal expression in human keratinocytes. *J Pharm Exp Ther*. 2007;323(3):771-777.
56. May DG, Arns PA, Richards WO, et al. The disposition of dapsone in cirrhosis. *Clin Pharmacol Ther*. 1992;51:689.
57. Goodwin CS, Sparell G. Inhibition of dapsone excretion by probenecid. *Lancet*. 1969;294:884.
58. Lee BL, Medina I, Benowitz NL, et al. Dapsone, trimethoprim, and sulfamethoxazole plasma levels during treatment of Pneumocystis pneumonia in patients with the acquired immunodeficiency syndrome (AIDS). Evidence of drug interactions. *Ann Intern Med*. 1989;110:606.
59. Balakrishnan SPS. Drug interactions—The influence of rifampicin and clofazimine on the urinary excretion of DDS. *Lepr India*. 1981;53:17.
60. Rhodes LE, Tingle MD, Park BK, et al. Cimetidine improves the therapeutic/toxic ratio of dapsone in patients on chronic dapsone therapy. *Br J Dermatol*. 1995;132:257.
61. Coleman M. Improvement of patient tolerance to dapsone: current and future developments. *Dermatol Online J*. 2007;13(4):18.
62. Mehta M. Cimetidine and dapsone-mediated methaemoglobinaemia. *Anaesthesia*. 2007;62:1188.
63. Goolamali S, Macfarlane C. The use of cimetidine to reduce dapsone-dependent haematological side-effects in a patient with mucous membrane pemphigoid. *Clin Exp Dermatol*. 2009;34:e1025-e1026.
64. Grunwald MH, Amichai B. Dapsone—the treatment of infectious and inflammatory diseases in dermatology. *Int J Antimicrob Agents*. 1996;7:187-192.
65. Rossi S, ed. *Australian Medicines Handbook*. Adelaide, Australian Medicines Handbook; 2006.
66. Kruizinga EE, Hamminga H. Treatment of dermatitis herpetiformis with diaminodiphenylsulphone (DDS). *Dermatologica*. 1953;106:386.
67. Katz SI. Treatment: drugs and diet, in dermatitis herpetiformis: the skin and the gut. *Ann Intern Med*. 1980;93:857.
68. Katz SI, Gallin JI, Hertz KC, et al. Erythema elevatum diutinum: skin and systemic manifestations, immunologic studies, and successful treatment with dapsone. *Medicine (Baltimore)*. 1977;56:443.
69. Farley-Loftus R, Dadlani C, Wang N, et al. Erythema elevatum diutinum. *Dermatol Online J*. 2008;14(10):13.
70. Leonard JN, Haffenden GP, Ring NP, et al. Linear IgA disease in adults. *Br J Dermatol*. 1982;107:301.
71. Jablonska S, Chorzelski TP, Rosinska D, et al. Linear IgA bullous dermatosis of childhood (chronic bullous dermatosis of childhood). *Clin Dermatol*. 1992;9:393.
72. Wojnarowska F, Marsden RA, Bhogal B, et al. Chronic bullous disease of childhood, childhood cicatricial pemphigoid and linear IgA disease of adults: a comparative study demonstrating clinical and immunopathologic overlap. *J Am Acad Dermatol*. 1988;19:792.
73. Nanda A, Dvorak R, Al-Sabah H, et al. Linear IgA bullous disease of childhood: an experience from Kuwait. *Pediatr Dermatol*. 2006;23(5):442-447.
74. Hall RP, Lawley TJ, Smith HR, et al. Bullous eruption of systemic lupus erythematosus. Dramatic response to dapsone therapy. *Ann Intern Med*. 1982;97:165.
75. Callen JP. Treatment of cutaneous lesions in patients with lupus erythematosus. *Dermatol Clin* 1994;12:201.
76. Lukács J, Schliemann S, Elsner P. Treatment of generalized granuloma annulare—a systematic review. *J Eur Acad Dermatol Venereol*. 2015;29(8): 1467-1480.
77. Raimer S, Maloney JM, Bourcier M, et al. Efficacy and safety of dapsone gel 5% for the treatment of acne vulgaris in adolescents. *Cutis*. 2008;81:171-178.
78. Fleischer A, Shalita A, Eichenfield LF, et al. Dapsone gel 5% in combination with Dapalene Gel 0.1%, benzoyl peroxide gel 4% or moisturizer for the treatment of acne vulgaris: a 12-week, randomized, double-blind study. *J Drugs Dermatol*. 2010;9(1):33-40.

79. Dubina M, Fleischer A. Interaction of topical sulfacetamide and topical dapsone with benzoyl peroxide. *Arch Dermatol*. 2009;145(9):1027-1029.
80. Marcus KA. Office of Drug Evaluation III Center for Drug Evaluation and Research FDA. Federal Food, Drug, and Cosmetic Act (FDCA) for ACZONE (dapsone) Gel, 7.5%. 2016.
81. Yasuda H, Kobayashi H, Hashimoto T, et al. Subcorneal pustular dermatosis type of IgA pemphigus: demonstration of autoantibodies to desmocollin-1 and clinical review [review]. *Br J Dermatol*. 2000;143:144.
82. Heaphy MR, Kobayashi H, Hashimoto T, et al. Dapsone as a glucocorticoid-sparing agent in maintenance-phase pemphigus vulgaris. *Arch Dermatol*. 2005;141:699.
83. Martin LK, Agero AL, Werth V, et al. Interventions for pemphigus vulgaris and pemphigus foliaceus. Cochrane Database of Systematic Reviews 2009, Issue 1. Art. No.: CD006263. doi: 10.1002/14651858.CD006263.pub2.
84. Gurcan H, Ahmed R. Efficacy of dapsone in the treatment of pemphigus and pemphigoid: analysis of current data. *Am J Clin Dermatol*. 2009;10(6):383-396.
85. Person JR, Rogers RS. Bullous pemphigoid responding to sulfapyridine and the sulfones. *Arch Dermatol*. 1977;113:610.
86. Venning VA, Millard PR, Wojnarowska F. Dapsone as first line therapy for bullous pemphigoid. *Br J Dermatol*. 1989;120:83.
87. Bouscarat F, Chosidow O, Picard-Dahan C, et al. Treatment of bullous pemphigoid with dapsone: retrospective study of thirty-six cases. *J Am Acad Dermatol*. 1996;34:683.
88. Schmidt E, Kraensel R, Goebeler M, et al. Treatment of bullous pemphigoid with dapsone, methylprednisolone, and topical clobetasol propionate: a retrospective study of 62 cases. *Cutis*. 2005;76:205.
89. Motegi S, Abe M, Tamura A, et al. Childhood bullous pemphigoid successfully treated with diaminodiphenyl sulfone. *J Dermatol*. 2005;32:809-812.
90. Kirtschig G, Murrell D, Wojnarowska F, et al. Interventions for mucous membrane pemphigoid/cicatricial pemphigoid and epidermolysis bullosa acquisita: a systematic literature review. *Arch Dermatol*. 2002;138:380.
91. Rogers RS, Mehregan DA. Dapsone therapy of cicatricial pemphigoid. *Semin Dermatol*. 1998;7:201.
92. Miserocchi E, Baltatzis S, Roque MR, et al. The effect of treatment and its related side effects in patients with severe ocular cicatricial pemphigoid. *Ophthalmology*. 2002;109:111.
93. Cohen D, Ben-Amitai D, Feinmesser M, et al. Childhood lichen planus pemphigoides: a case report and review of the literature. *Pediatr Dermatol*. 2009;26(5):569-574.
94. Cheng S, Edmonds E, Ben-Gashir M, et al. Subcorneal pustular dermatosis: 50 years on. *Clin Dermatol*. 2007;33:229-233.
95. Aram H. Acute febrile neutrophilic dermatosis (Sweet's syndrome). Response to dapsone. *Arch Dermatol*. 1984;120:245.
96. Walling HW, Snipes CJ, Gerami P, et al. The relationship between neutrophilic dermatosis of the dorsal hands and Sweet syndrome: report of 9 cases and comparison to atypical pyoderma gangrenosum. *Arch Dermatol*. 2006;142:57.
97. Cohen P. Neutrophilic dermatoses: a review of current treatment options. *Am J Clin Dermatol*. 2009;10(5):301-312.
98. Callen JP, Taylor WB. Pyoderma gangrenosum—a literature review. *Cutis*. 1978;21:61.
99. Teasley L, Foster C, Baltatzis S. Sclerokeratitis and facial skin lesions: a case report of pyoderma gangrenosum and its response to dapsone therapy. *Cornea*. 2007;26:215-219.
100. Chang DJ, Lamothe M, Stevens RM, et al. Dapsone in rheumatoid arthritis [review]. *Semin Arthritis Rheum*. 1996;25:390.
101. Martin JA, Jarrett P. Rheumatoid papules treated with dapsone. *Clin Exp Dermatol*. 2004;29:387.
102. Barranco VP, Minor DB, Soloman H. Treatment of relapsing polychondritis with dapsone. *Arch Dermatol*. 1976;112:1286.
103. Damiani JM, Levine HL. Relapsing polychondritis—report of ten cases. *Laryngoscope*. 1979;89(6 Pt 1):929-946.
104. Walling H, Sontheimer R. Cutaneous lupus erythematosus: issues in diagnosis and treatment. *Am J Clin Dermatol*. 2009;10(6):365-381.
105. Ujiie H, Shimizu T, Ito M, et al. Lupus erythematosus profundus successfully treated with dapsone: review of the literature. *Arch Dermatol*. 2006;142:399.
106. Guillevin L. Treatment of polyarteritis nodosa with dapsone. *Scand J Rheumatol*. 1986;15(1):95-96.
107. Fortson JS, Zone JJ, Hammond ME, et al. Hypocomplementemic urticarial vasculitis syndrome responsive to dapsone. *J Am Acad Dermatol*. 1986;15:1137.
108. Iqbal H, Evans A. Dapsone therapy for Henoch-Schönlein purpura: a case series. *Arch Dis Child*. 2005;90:985.
109. Shin J, Lee J, Chung K. Dapsone therapy for Henoch-Schonlein purpura. *Arch Dis Child*. 2006;91(8):714.
110. Fredenberg MF, Malkinson FD. Sulfone therapy in the treatment of leukocytoclastic vasculitis. Report of three cases. *J Am Acad Dermatol*. 1987;16:772.
111. Sunderkötter C, Pappelbaum KI, Ehrchen J. Management of leukocytoclastic vasculitis. *J Dermatol Treat*. 2005;16:193.
112. Chen K, Carlson J. Clinical approach to cutaneous vasculitis. *Am J Clin Dermatol*. 2008;9(2):71-92.
113. Sharquie KE. Suppression of Behçet's disease with dapsone. *Br J Dermatol*. 1984;110:493.
114. Sharquie KE, Najim RA, Abu-Raghif AR. Dapsone in Behçet's disease: a double-blind, placebo-controlled, cross-over study. *J Dermatol*. 2002;29:267.
115. Prendiville JS, Logan RA, Russell-Jones R. A comparison of dapsone with 13-cis retinoic acid in the treatment of nodular cystic acne. *Clin Exp Dermatol*. 1988;13:67.
116. Kaur M, Lewis H. Hidradenitis suppurativa treated with dapsone: a case series of five patients. *J Dermatol Treat*. 2006;17:211-213.
117. van de Kerkhof P. On the efficacy of dapsone in granuloma faciale. *Acta Derm Venereol*. 1994;74:61.
118. Bolz S, Jappe U, Hartschuh W. Successful treatment of perifolliculitis capitis abscedens et suffodiens with combined isotretinoin and dapsone. *J German Soc Dermatol*. 2007;6(1):44-47.
119. Godeau B, Durand JM, Roudot-Thoraval F, et al. Dapsone for chronic autoimmune thrombocytopenic purpura: a report of 66 cases. *Br J Haematol*. 1997;97:336.
120. Damodar S, Viswabandya A, George B, et al. Dapsone for chronic idiopathic thrombocytopenic purpura in children and adults—a report on 90 patients. *Eur J Haematol*. 2005;75:328-331.

121. Cassano N, D'Argento V, Filotico R, et al. Low-dose dapsone in chronic idiopathic urticaria: preliminary results of an open study. *Acta Dermato Venereol*. 2005;85:254.
122. Criado R, Criado PR, Martins JE, et al. Urticaria unresponsive to antihistaminic treatment: an open study of therapeutic options based on histopathologic features. *J Dermatol Treat*. 2008;19(2):92-96.
123. Engin B, Ozdemir M. Prospective randomized nonblinded clinical trial on the use of dapsone plus antihistamine vs. antihistamine in patients with chronic idiopathic urticaria. *J Eur Acad Dermatol Venereol*. 2007;22(4):481-486.
124. Letsinger JA, McCarty MA, Jorizzo JL. Complex aphthosis: a large case series with evaluation algorithm and therapeutic ladder from topicals to thalidomide. *J Am Acad Dermatol*. 2005;52:500.
125. Mimura M, Hirota SK, Sugaya NN, et al. Systemic treatment in severe cases of recurrent aphthous stomatitis: an open trial. *Clinics*. 2009;64(3):193-198.
126. Lynde C, Bruce A, Rogers R. Successful treatment of complex aphthosis with colchicine and dapsone. *Arch Dermatol*. 2009;145(3):273-276.
127. Steiner A, Pehamberger H, Wolff K. Sulfone treatment of granuloma annulare. *J Am Acad Dermatol* 1985;13:1004.
128. Cyr P. Diagnosis and management of granuloma annulare. *Am Fam Physician*. 2006;74(10):1729-1734.
129. Halverstam C, Lebwohl M. Nonstandard and off-label therapies for psoriasis. *Clin Dermatol*. 2009;26(5):546-553.
130. Rees R, Campbell D, Rieger E, et al. The diagnosis and treatment of brown recluse spider bites. *Ann Emerg Med*. 1987;16:945.
131. Rees RS, Altenbern DP, Lynch JB, et al. Brown recluse spider bites. A comparison of early surgical excision versus dapsone and delayed surgical excision. *Ann Surg*. 1985;202:659.
132. Cole HP, Wesley RE, King LEJ. Brown recluse spider envenomation of the eyelid: an animal model. *Ophthalmol Plast Reconstr Surg*. 1994;11:153.
133. Elston DM, Miller SD, Young RJ, et al. Comparison of colchicine, dapsone, triamcinolone, and diphenhydramine therapy for the treatment of brown recluse spider envenomation: a double-blind, controlled study in a rabbit model. *Arch Dermatol*. 2005;141:595.
134. Mold JW, Thompson DM. Management of brown recluse spider bites in primary care. *J Am Board Fam Pract*. 2004;17:347.
135. Peterson MD. Brown spider envenomation. *Clin Tech Small Anim Pract*. 2006;21(4):191-193.
136. Tan J, Rao B. Mesotherapy-induced panniculitis treated with dapsone: case report and review of reported adverse effects of mesotherapy. *J Cut Med Surg*. 2006;10(2):92-95.
137. Gokdemir G, Kucukunal A, Sakiz D. Cutaneous granulomatous reaction from mesotherapy. *Dermatol Surg*. 2009;35(2):291-293.
138. Sobjanek M, Włodarkiewicz A, Zelazny I, et al. Successful treatment of Melkersson-Rosenthal syndrome with dapsone and triamcinolone injections. *J Eur Acad Dermatol Venereol*. 2008;22(8):1029.
139. Smith L, Cox N. Dapsone treatment for eosinophilic fasciitis. *Arch Dermatol*. 2008;144(7):845-847.
140. Pittelkow MR, Smith KC, Su WP. Alpha-1-antitrypsin deficiency and panniculitis. Perspectives on disease relationship and replacement therapy. *Am J Med*. 1988;84:80.
141. Korver G, Liu C, Peterson M. Alpha-1-antitrypsin deficiency presenting with panniculitis and incidental discovery of chronic obstructive pulmonary disease. *Int J Dermatol*. 2007;46(10):1078-1090.
142. Lee S, In SG, Shin JH, et al. Neutrophilic eccrine hidradenitis in non-small cell lung cancer. *Int J Dermatol*. 2007;46(1):59-60.
143. Ulmer A, Metzler G, Schanz S, et al. Dapsone in the management of "insect bite-like reaction" in a patient with chronic lymphocytic leukemia. *Br J Dermatol*. 2007;156:163.
144. Mahendran R, Grant JW, Norris PG. Dapsone-responsive persistent erythema multiforme. *Dermatology*. 2000; 200:281-282.
145. Hoffman L, Hoffman M. Dapsone in the treatment of persistent erythema multiforme. *J Drugs Dermatol*. 2006;5(4):375-377.
146. Chan CC, Chu CY. Dapsone as a potential treatment for cutaneous Rosai-Dorfman disease with neutrophilic predominance. *Arch Dermatol*. 2006;142:428-430.
147. González P, Soriano V, Caballero T, et al. Idiopathic angioedema treated with dapsone. *Allergol Immunopathol (Madr)*. 2005;33:54.
148. Wolverton S, Remlinger K. Suggested guidelines for patient monitoring: hepatic and hematologic toxicity attributable to systemic dermatologic drugs. *Dermatol Clin*. 2007;25(2):195-205.
149. Coleman MD, Coleman NA. Drug-induced methaemoglobinaemia. Treatment issues. *Drug Safe*. 1996; 14:394.
150. Williams S, MacDonald P, Hoyer JD, et al. Methemoglobinemia in children with acute lymphoblastic leukemia (ALL) receiving dapsone for Pneumocystis carinii pneumonia (PCP) prophylaxis: a correlation with cytochrome b5 reductase (CB5R) enzyme levels. *Pediatr Blood Cancer*. 2005;44:55.
151. Zosel A, Rychter K, Leikin J. Dapsone-induced methemoglobinemia: case report and literature review. *Am J Ther*. 2007;14:585-587.
152. Salamat A, Watson HG. Drug-induced methaemoglobinaemia presenting with angina following the use of dapsone. *Clin Lab Haem*. 2003;25:327.
153. Groeper K, Katcher K, Tobias JD. Anesthetic management of a patient with methemoglobinemia. *South Med J*. 2003;96:504.
154. Ashurst J, Wasson MN, Hauger W, et al. Pathophysiologic mechanisms, diagnosis, and management of dapsone-induced methemoglobinemia. *J Am Osteopath Assoc*. 2010;110(1):18-20.
155. Choi A, Sarang A. Drug-induced methaemoglobinaemia following elective coronary artery bypass grafting. *Anaesthesia*. 2007;62:737-740.
156. Orion E, Matz H, Wolf R. The life-threatening complications of dermatologic therapies. *Clin Dermatol*. 2005;23:182-192.
157. Rausch-Madison S, Mohsenifar Z. Methodologic problems encountered with cooximetry in methemoglobinemia. *Am J Med Sci*. 1997;314:203-206.
158. Coleman MD, Rhodes LE, Scott AK, et al. The use of cimetidine to reduce dapsone-dependent methaemoglobinaemia in dermatitis herpetiformis patients. *Br J Clin Pharmacol*. 1992;34:244.
159. Coleman M, Taylor C. Effects of dihydrolipoic acid (DHLA), α-lipoic acid. N-acetyl cysteine and ascorbate on xenobiotic-mediated methaemoglobin formation in human erythrocytes in vitro. *Environ Toxicol Pharmacol*. 2003;14(3):121-127.

160. Ranawaka R, Mendis S, Weerakoon HS. Dapsone-induced haemolytic anaemia, hepatitis and agranulocytosis in a leprosy patient with normal glucose-6-phosphatedehydrogenase activity. *Lepr Rev*. 2008;79:436-440.
161. Kar BR. Dapsone-induced photosensitivity: a rare clinical presentation. *Photodermatol Photoimmunol Photomed*. 2008;24:270-271.
162. Saqueton AC, Lorincz AL, Vick NA, et al. Dapsone and peripheral motor neuropathy. *Arch Dermatol*. 1969;100:214.
163. Daneshmend TK, Homeida M. Dapsone-induced optic atrophy and motor neuropathy. *Br Med J (Clin Res Ed)*. 1981;283:311.
164. Daneshmend TK. The neurotoxicity of dapsone. *Adv Drug React Ac Pois Rev*. 1984;3:43.
165. Jaffuel D, Lebel B, Hillaire-Buys D, et al. Eosinophilic pneumonia induced by dapsone. *BMJ*. 1998; 317(7152):181.
166. Richardus JH, Smith TC. Increased incidence in leprosy of hypersensitivity reactions to dapsone after introduction of multidrug therapy. *Lepr Rev*. 1989;60(4):267-273.
167. Kumar RH, Kumar MV, Thappa DM. Dapsone syndrome—a five year retrospective analysis. *Indian J Lepr*. 1998;70(3):271-276.
168. Rao PN, Lakshmi TS. Increase in the incidence of dapsone hypersensitivity syndrome—an appraisal. *Lepr Rev*. 2001;72(1):57-62.
169. Joseph MS. Hypersensitivity reaction to dapsone. Four case reports. *Lepr Rev*. 1985;56(4):315-320.
170. Jamrozik K. Dapsone syndrome occurring in two brothers. *Lepr Rev*. 1986;57(1):57-62.
171. Hortaleza AR, Salta-Ramos NG, Barcelona-Tan J, et al. Dapsone syndrome in a Filipino man. *Lepr Rev*. 1995;66(4):307-313.
172. Tomecki KJ, Catalano CJ. Dapsone hypersensitivity. The sulfone syndrome revisited. *Arch Dermatol*. 1981;117(1):38-39.
173. Zhang F-R, Liu H, Irwanto A, et al. *HLA-B*13:01* and the dapsone hypersensitivity syndrome. *N Eng J Med*. 2013;369(17):1620-1628.
174. Lorenz M, Wozel G, Schmitt J. Hypersensitivity reactions to dapsone: a systematic review. *Acta Derm Venereol*. 2012;92:194-199.
175. Teo R, Tay YK, Tan CH, et al. Presumed dapsone-induced hypersensitivity syndrome causing reversible hypersensitivity myocarditis and thyrotoxicosis. *Ann Acad Med Singapore*. 2006;35:833-836.
176. Alves-Rodrigues E, Ribero LC, Silva MD, et al. Dapsone syndrome with acute renal failure during leprosy treatment: case report. *Braz J Infect Dis*. 2005;9(1):84-86.
177. Alves-Rodrigues EN, Ribeiro LC, Silva MD, et al. Renal hypersensitivity vasculitis associated with dapsone. *Am J Kidney Dis*. 2005;46:E51.
178. Tohyama M, Hashimoto K, Yasukawa M, et al. Association of human herpesvirus 6 reactivation with the flaring and severity of drug-induced hypersensitivity syndrome. *Br J Dermatol*. 2007;157:934-940.
179. Takahashi H, Tanaka M, Tanikawa A, et al. A case of drug-induced hypersensitivity syndrome showing transient immunosuppression before viral reactivation during treatment for pemphigus foliaceus. *Clin Exp Dermatol*. 2006;31:33.
180. Agrawal S, Agrawal A. Dapsone hypersensitivity syndrome: a clinico-epidemiological review. *J Dermatol*. 2005;32:883.
181. Frey HM, Gershon AA, Borkowsky W, et al. Fatal reaction to dapsone during treatment of leprosy. *Ann Intern Med*. 1981;94:777.
182. Prussick R, Shear NH. Dapsone hypersensitivity syndrome. *J Am Acad Dermatol*. 1996;35:346.
183. McKenna KE, Robinson J. The dapsone hypersensitivity syndrome occurring in a patient with dermatitis herpetiformis [letter]. *Br J Dermatol*. 1997;137:657.
184. Leslie K, Gaffney K, Ross CN, et al. A near fatal case of the dapsone hypersensitivity syndrome in a patient with urticarial vasculitis. *Clin Exp Dermatol*. 2003;28:496-498.
185. Kosseifi S, Guha B, Nassour DN, et al. The dapsone hypersensitivity syndrome revisited: a potentially fatal multisystem disorder with prominent hepatopulmonary manifestations. *J Occup Med Toxicol*. 2006;1:9.
186. Johnson DA, Cattau EL Jr, Kuritsky JN. Liver involvement in the sulfone syndrome. *Arch Intern Med*. 1986;46:875.
187. Itha S, Kumar A, Dhingra S, et al. Dapsone induced cholangitis as a part of dapsone syndrome: a case report. *BMC Gastroenterol*. 2003;3:21.
188. Dhanya N, Shanmuga Sundaram V, Rai R, et al. Dapsone syndrome with leukemoid reaction. *Indian J Lepr*. 2006;78(4):359-363.
189. Zhu K, He FT, Jin N, et al. Complete atrioventricular block associated with dapsone therapy: a rare complication of dapsone-induced hypersensitivity syndrome. *J Clin Pharm Ther*. 2009;34:489-492.
190. Higuchi M, Agatsuma T, Iizima M, et al. A case of drug-induced hypersensitivity syndrome with multiple organ involvement treated with plasma exchange. *Ther Apheresis Dialysis*. 2005;9(5):412-416.
191. Hall RP. Dapsone. In: Wolverton SE, ed. *Comprehensive Dermatologic Drug Therapy*. Philadelphia: WB Saunders; 2001:230.
192. DeGowin RL. A review of the therapeutic and hemolytic effects of dapsone. *Arch Intern Med*. 1967;120:242-248.
193. Graham WR. Adverse effects of dapsone. *Int J Dermatol*. 1975;14:494-500.
194. Stroupe J, Stephens JR, Reust R, et al. Adverse reactions associated with dapsone therapy in HIV-positive patients: a case presentation and review. *The AIDS Reader*. 2006;16:47-48, 53-55.
195. McMillan DC, Simson JV, Budinsky RA, et al. Dapsone-induced hemolytic anemia: effect of dapsone hydroxylamine on sulfhydryl status, membrane skeletal proteins and morphology of human and rat erythrocytes. *J Pharmacol Exp Ther*. 1995;274:540.
196. Jollow DJ, Bradshaw TP, McMillan DC. Dapsone-induced hemolytic anemia. *Drug Metab Rev*. 1995; 27:107.
197. McMillan DC, Powell CL, Bowman ZS, et al. Lipids versus proteins as major targets of pro-oxidant, direct-acting hemolytic agents. *Toxicol Sci*. 2005;88:274.
198. Motulsky AG, Yoshida A. Stametoyannopoulos G. Variants of glucose-6-phosphate dehydrogenase. *Ann N Y Acad Sci*. 1971;179:636.
199. Wertheim M, Males JJ, Cook SD, et al. Dapsone induced haemolytic anaemia in patients treated for ocular cicatricial pemphigoid. *Br J Ophthalmol*. 2006;90(4):516.
200. Lee I, Barton TD, Goral S, et al. Complications related to dapsone use for pneumocystis jirovecii pneumonia prophylaxis in solid organ transplant patients. *Am J Transplant*. 2005;5:2791-2795.

201. Naik P, Lyon GM 3rd, Ramirez A, et al. Dapsone-induced hemolytic anemia in lung allograft recipients. *J Heart Lung Transplant*. 2008;27:1198-1202.
202. Flosadottir E, Bjarnason B. Full dapsone dose made possible by control of anaemia with darbepoetin-alpha. *Acta Derm Venereol*. 2008;88:540-541.
203. Mobacken H. Commentary to a paper by Flosadottir & Bjarnason on full dapsone dose made possible by control of anaemia with darbepoetin alpha. *Acta Derm Venereol*. 2008;88:639.
204. Hornsten P, Keisu M, Wiholm BE. The incidence of agranulocytosis during treatment of dermatitis herpetiformis with dapsone as reported in Sweden, 1972 through 1988. *Arch Dermatol*. 1990;126:919.
205. Andersohn F, Konzen C, Garbe E. Systematic review: agranulocytosis induced by nonchemotherapy drugs. *Ann Intern Med*. 2007;146(9):657-665.
206. Ognibene AJ. Agranulocytosis due to dapsone. *Ann Intern Med*. 1970;72:521.
207. Potter MN, Yates P, Slade R, et al. Agranulocytosis caused by dapsone therapy for granuloma annulare. *J Am Acad Dermatol*. 1989;20:87.
208. Cockburn EM, Wood SM, Waller PC, et al. Dapsone-induced agranulocytosis: spontaneous reporting data [letter]. *Br J Dermatol*. 1993;128:702.
209. Coleman MD. Dapsone-mediated agranulocytosis: risks, possible mechanisms and prevention. *Toxicology*. 2001;162:53.
210. Miyagawa S, Shiomi Y, Fukumoto T, et al. Recombinant granulocyte colony-stimulating factor for dapsone-induced agranulocytosis in leukocytoclastic vasculitis. *J Am Acad Dermatol*. 1993;28:659.
211. Borrás-Blasco J, Conesa-García V, Navarro-Ruiz A, et al. Pure red cell aplasia associated with dapsone therapy. *Ann Pharmacother*. 2005;39:1137.
212. Hiura Y, Kawabata H, Kanekura T, et al. Hemophagocytic syndrome induced by diaminodiphenylsulfone. *J Dermatol*. 2007;34:730-731.
213. Foucauld J, Uphouse W, Berenberg J. Dapsone and aplastic anemia. *Ann Intern Med*. 1985;102(1):139.
214. Meyerson MA, Cohen PR. Dapsone-induced aplastic anemia in a woman with bullous systemic lupus erythematosus. *Mayo Clin Proc*. 1994;69(12):1159-1162.
215. Björkman A, Phillips-Howard PA. Adverse reactions to sulfa drugs: implications for malaria chemotherapy. *Bull World Health Organ*. 1991;69(3):297-304.
216. Froud T, Faradji RN, Gorn L, et al. Dapsone-induced artifactual A1c reduction in islet transplant recipients. *Transplantation*. 2007;83(6):824-825.
217. Dawson AH, Whyte IM. Management of dapsone poisoning complicated by methaemoglobinaemia. *Med Toxicol Adverse Drug Exp*. 1989;4:387.
218. Shadnia S, Rahimi M, Moeinsadat M, et al. Acute methemoglobinemia following attempted suicide by dapsone. *Arch Med Res*. 2006;37:410-414.
219. Ferguson J, Lavery G. Deliberate self-poisoning with dapsone—a case report and summary of relevant pharmacology and treatment. *Anaesthesia*. 1997;52:359-363.
220. Kenner DJ, Holt K, Agnello R, et al. Permanent retinal damage following massive dapsone overdose. *Br J Ophthalmol*. 1980;64:741.
221. Leonard JN, Tucker WF, Fry L, et al. Dapsone and the retina [letter]. *Lancet*. 1982;1:453.
222. Hussain N, Agrawal S. Optical coherence tomographic evaluation of macular infarction following dapsone overdose. *Indian J Ophthalmol*. 2006;54(4):271-272.
223. Thunga G, Sam KG, Patel D, et al. Effectiveness of hemodialysis in acute dapsone overdose—a case report. *Am J Emerg Med*. 2008;26:1070.e1-1070.e4.
224. Clifton J, Leikin JB. Methylene blue. *Am J Ther*. 2003;10:289.
225. Prasad R, Singh R, Mishra OP, et al. Dapsone induced methemoglobinemia: intermittent vs continuous intravenous methylene blue therapy. *Indian J Pediatr*. 2008;75(3):245-247.
226. Wozel G. Innovative use of dapsone. *Dermatol Clin*. 2010;28(3):599-610.

Chapter 188 :: Antifungals

:: Mahmoud Ghannoum, Iman Salem, & Luisa Christensen

AT-A-GLANCE

- Topical agents should be used for superficial fungal infections of limited extent.
- Topical agents have the advantage of low cost, nonprescription availability, ease of use, and high patient compliance.
- Topical antifungals include imidazoles, allylamines, benzylamines, polyenes, and ciclopirox.
- A number of new carrier vehicles have been investigated to improve the bioavaliabilty of topical antifungals.
- Systemic agents should be used to treat onychomycosis and tinea capitis, or when superficial fungal infection affects a large surface area.
- Attention should be paid to drug–drug interactions when prescribing systemic antifungals.
- Combination therapy with topical and systemic drugs presents several advantages.

INTRODUCTION/ BACKGROUND

Superficial mycoses, caused mainly by dermatophytes and yeast, are among the most frequent infections worldwide, affecting approximately 20% to 25% of the world's population.[1] Topical antifungals are the preferred option for the treatment of most of these infections, achieving high patient compliance. Moreover, many topical drugs have additional antibacterial action, which is beneficial in cases of superimposed bacterial infections. Further, many also possess anti-inflammatory properties, which are advantageous in minimizing the effects of the host local inflammatory reactions to mycotic infection.[2] Systemic antifungals are the mainstay treatment of tinea capitis and onychomycosis; also, dermatologists tend to reserve them for extensive, recurrent, or recalcitrant dermatomycosis.[3,4] Despite the diversity in the structure of the fungal cell membrane and the unique existence of the mycotic cell wall compared to mammalian cells, the similarities in the metabolic profile between both kingdoms allow for limited numbers of organism-specific targets. Overall, the main target of both systemic and topical antifungals is ergosterol (Fig. 188-1), the fundamental mycotic cell membrane sterol. As of this writing, the 3 main antifungal categories targeting ergosterol are (1) allylamines and benzylamines, (2) azoles (imidazole and triazoles), and (3) polyenes. Whereas allylamines, benzylamines, and azoles block the biosynthesis of ergosterol, polyenes bind the molecule with high affinity, creating cell membrane pores. Other systemic antifungal agents (griseofulvin and flucytosine) act on intracellular structures via mechanisms similar to cancer chemotherapeutic agents.[5,6] Although both are clinically effective, azoles exhibit superior activity against yeasts compared to allylamines, but less activity against dermatophytes.[7] Although the most common adverse effects associated with topical therapy are mild, transient, and localized hypersensitivity skin reactions, systemic antifungals demonstrate various degrees of organ toxicity and possible serious drug interactions.[3] This chapter aims to discuss the main topical and systemic antifungal agents currently in clinical use (Tables 188-1 through 188-4).

ALLYLAMINES

Two agents represent this family: terbinafine, available in both topical and oral forms, and naftifine, available only for topical application.[8]

MECHANISM OF ACTION

Allylamines exhibit differential antifungal activity against *Candida* species (fungistatic), and dermatophytes (fungicidal). They act through the suppression of ergosterol synthesis by inhibiting the action of squalene epoxidase enzyme, the enzyme that catalyzes the conversion of squalene precursors into ergosterol. The resultant deficiency of ergosterol is responsible for the fungistatic effect, while the buildup of squalene accounts for fungicidal activity.[8]

NAFTIFINE

Naftifine is a broad-spectrum topical allylamine.

MECHANISM OF ACTION

In addition to its antifungal activity, naftifine has antibacterial activity (gram-positive and gram-negative) as well as antiinflammatory properties secondary to its ability to suppress the synthesis of leukotrienes and prostaglandins.[9]

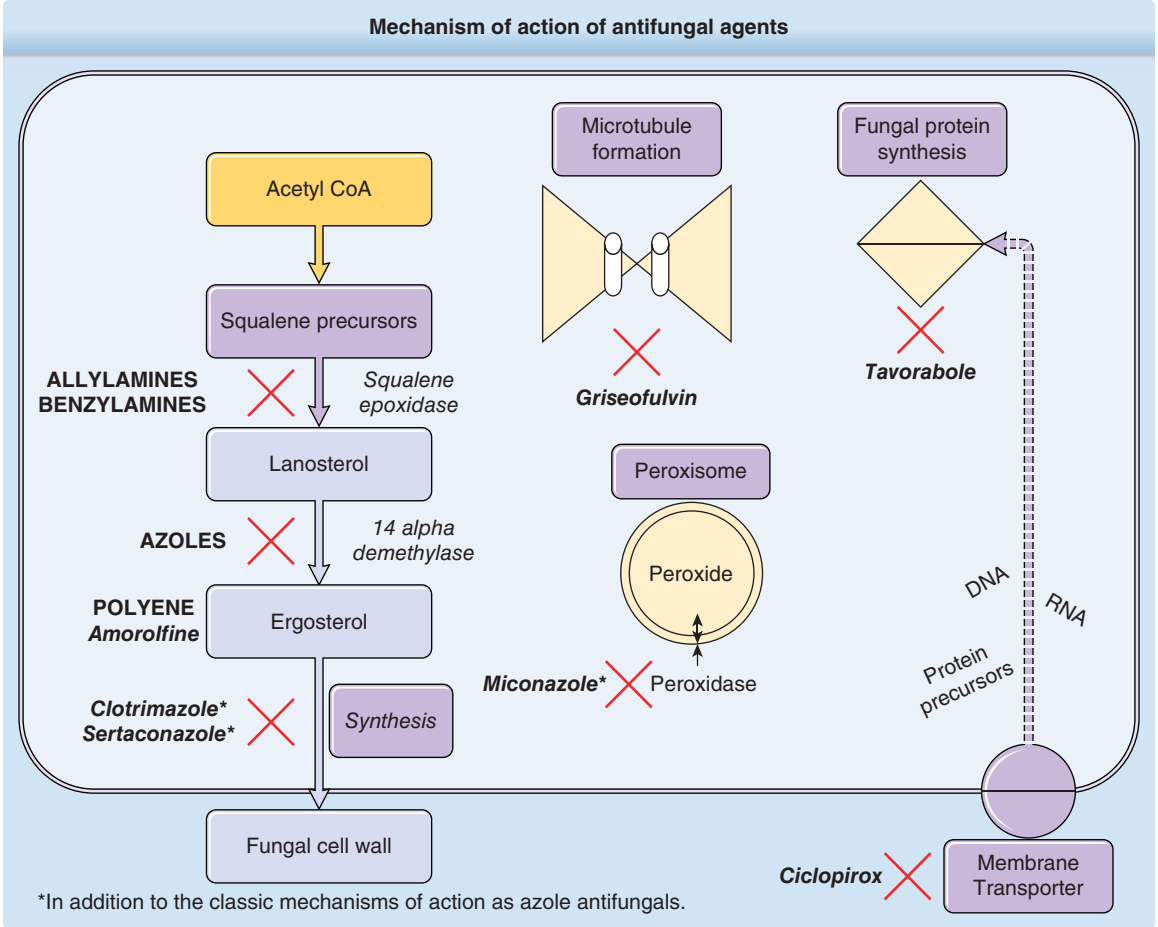

Figure 188-1 Mechanism of action of antifungal agents.

PHARMACOKINETICS

The lipophilic properties of naftifine account for its efficient penetration through the stratum corneum. Therapeutic drug levels can persist in stratum corneum up to 5 days following a single application. Only 3% to 6% of the applied drug can be systemically absorbed.[9-11]

CLINICAL INDICATIONS

Naftifine is indicated for the treatment of interdigital tinea pedis, tinea cruris, tinea corporis, tinea versicolor, and *Candida* infections.[8]

DOSAGE AND FORMULATIONS

Naftifine is commercially available as 1% gel and cream. A single daily application of naftifine is usually recommended for 2 to 4 weeks according to the indication (Table 188-1).[12]

SIDE EFFECTS

The side effects of naftifine are generally minor and include dryness, pruritus, local irritation, and erythema.[8]

TERBINAFINE

MECHANISM OF ACTION

Terbinafine works through the suppression of squalene epoxidase enzyme, blocking the formation of ergosterol.[13]

PHARMACOKINETICS

The systemic absorption of topical terbinafine is inconsequential (3%-5%).[8] The oral absorption of the drug is not influenced by food intake and, owing to its lipophilic properties, tends to rapidly distribute and accumulate in hair follicles, nails, and skin with minimal concentrations in plasma. It has a long half-life of 17 hours. The oxidative biotransformation of the drug takes place in the liver by the means of CYP2D6 enzyme. Most of the drug is eliminated in urine. A dose adjustment is necessary in patients with advanced renal or liver diseases.[8,13-15]

INDICATIONS

Topical terbinafine is efficacious in the treatment of all superficial mycoses, including tinea versicolor.[8,13] Unless contraindicated, terbinafine is the first line

TABLE 188-1
Trade Names and Formulations of Representative Topical Antifungals

DRUG/CLASS	TRADE NAMES	USUAL FORMULATION	INDICATIONS	DOSING REGIME	PREGNANCY CATEGORY
Polyenes					
Nystatin	Mycostatin Nystop Pedi-Dri (Rx)	Cream, powder, ointment	Mucosal and cutaneous candidiasis	Twice daily	B
Azoles					
Imidazoles					
Clotrimazole	Clotrim, Cruex Lotrimin, Mycelex (OTC)	Cream, solution, lotion	Tinea corporis/cruris/pedis	Twice daily for 2-4 wk	B
Econazole	Spectazole, Ecoza (Rx)	Cream, powder, foam, solution	Dermatophytoses, tinea versicolor, cutaneous candidiasis	Once daily (twice for candidiasis) for 2 wk	C
Oxiconazole	Oxistat (Rx)	Cream, lotion	Dermatophytoses, tinea versicolor	Once-twice daily for 2 wk	B
Miconazole	Miconazole OTC	Cream, ointment, powder or spray	Dermatophytoses	Twice daily for 2-4 wk	C
Sertaconazole	Ertaczo (Rx)	Cream, lotion, gel, powder, solution	Interdigital tinea pedis	Twice daily for 4 wk	C
Ketoconazole	Ketoconazole (Rx)	Cream, shampoo	Dermatophytoses, tinea versicolor, cutaneous candidiasis	Once daily for 2-6 wk	C
Triazoles					
Efinaconazole	Jublia (Rx)	Solution	Onychomycosis	Once daily for 48 wk	C
Allylamines					
Terbinafine	Lamisil (OTC)	Cream, powder, solution, spray, gel	Dermatophytoses, tinea versicolor	Once or twice daily for 2-4 wk	B
Naftifine	Naftin (Rx)	Cream, gel	Dermatophytoses	Once-twice daily for 2-6 wk	B
Benzylamines					
Butenafine	Lotrimin Ultra (OTC), Mentax (Rx)	Cream, spray, powder	Dermatophytoses, tinea versicolor	Once-twice daily for 2 wk	C
Hydroxypyridones					
Ciclopirox olamine	Loprox (Rx)	Cream, suspension, gel, nail lacquer solution	Dermatophytoses, onychomycosis	Twice daily for 2-4 wk; nail lacquer—apply once daily for 48 wk	B
Morolphines					
Amorolfine	Loceryl (Rx) Not available in the USA	Nail lacquer solution	Onychomycosis	Apply once daily for 48 wk	D
Oxaborole					
Tavaborole	Kerydin (Rx)	Nail lacquer solution	Onychomycosis	Apply once daily for 48 wk	C

of treatment of dermatophytosis owing to its fungicidal activity, high efficacy, tolerability, single daily dose, better pharmacokinetic profile, and high affinity to stratum corneum.[16] Oral terbinafine exhibits a potent fungicidal action, superior to griseofulvin and itraconazole, against *Trichophyton rubrum* and *T. mentagrophytes*. Although considered the first treatment option in dermatophyte onychomycosis, terbinafine does not demonstrate efficacy against nondermatophyte and *Candida* onychomycosis.[15]

Terbinafine and griseofulvin are the only FDA-approved drugs for the treatment of tinea capitis in children. However, terbinafine is less effective than griseofulvin in eradicating ectothrix tinea capitis in the pediatric population, particularly, that caused by *Microsporum canis* and *Trichophyton tonsurans*, because of its high tendency to accumulate in sebum. Immature preadolescent sebaceous glands produce less sebum, thus resulting in lower drug concentrations.[17-19] Many clinical studies have shown efficacy of terbinafine in the treatment

TABLE 188-2
Trade Names and Formulations of Representative Systemic Antifungals

DRUG/CLASS	TRADE NAMES	USUAL FORMULATION	INDICATIONS	DOSING REGIME		PREGNANCY CATEGORY
				ADULT	PEDIATRIC	
Allylamines						
Terbinafine	Lamisil, Terbinex	1. Tablets 250 mg 2. Oral granules	Tinea unguium[a]	Continuous 250 mg/d >20 kg Fingernail for 6 wk Toenail for 9-12 wk Pulse 500 mg/d for 1 wk/m for same duration	Continuous >20 kg 62.5 mg/d 20-40 kg 125 mg/d for same duration	B
			T. capitis[a]	250 mg/d for 2-8 wk	5 mg/kg/d[c] for 2-4 wk	
			T. pedis, cruris, corporis[b]	250 mg/d 2-4 wk		
			Seborrheic dermatitis[b]	250 mg/d 4-6 wk		
Azoles						
Triazoles						
Fluconazole	Diflucan	1. Capsule 150 mg 2. Tablets 150 mg 3. Solution for IV infusion	1. Esophageal candidiasis[a]	150 mg/d for 2-3 wk after clinical improvement	6 mg/kg/d until clinical improvement, then 3 mg/kg/d for 2 wk	C
			2. Vaginal candidiasis[a]	150 mg once Recurrence 150 mg/wk for 6 mo		
			3. Cutaneous, mucocutaneous candidiasis[a]	300 mg/wk for 2 wk		
			4. T. capitis[b]		6 mg/kg/d *Trichophyton tonsurans* for 20 d *Microsporum canis* 2 wk	
			5. Onychomycosis[b]	150-300 mg/wk Fingernail for 6-9 mo Toenail for 9-15 mo	3-6 mg/kg/d Fingernail 12-16 wk Toenail 18-26 wk	
			6. Tinea pedis, cruris, corporis, barbae[b]	150 mg/wk for 2-6 wk		
			7. Tinea versicolor[b]	300 mg/wk for 2 wk		
Itraconazole	Sporanox		1. Onychomycosis[a]	**Continuous**		C
	Sporanox pluspak Onmel	1. Capsules 100 mg 2. Cyclodextrin oral solution		200 mg/d Fingernail for 6 wk Toenail for 12 wk **Pulse** 400 mg/d for 1 wk/mo Fingernail 2 pulses Toenail 3 pulses	**Pulse** 5 mg/kg/d for 1 wk/mo Fingernail 2 pulses Toenail 3 pulses	
			2. Oropharyngeal candidiasis[a]	Oral solution 100-200 mg/d for 1-2 wk after clinical improvement	>15 kg 100 mg/d 15-30 kg 100 mg/d alternating with 200 mg/d 30-45 kg 200 mg/d same duration as adults	

(*Continued*)

TABLE 188-2
Trade Names and Formulations of Representative Systemic Antifungals (*Continued*)

DRUG/CLASS	TRADE NAMES	USUAL FORMULATION	INDICATIONS	DOSING REGIME		PREGNANCY CATEGORY
				ADULT	PEDIATRIC	
			3. T. capitis[b]	200 mg/d for 2-8 wk	5 mg/kg/d *T. tonsurans* for 2-4 wk *M. canis* for 4-8 wk	
			4. T. pedis, cruris, corporis[b]	200 mg/d for 1 wk		
			5. Pityriasis versicolor[b]	TTT 200 mg/d for 1 wk Prophylaxis 400 mg once every month		
Other						
Griseofulvin	Griseofulicin Griseofulvic Gris-PEG Grifulvin V	1. Tablets Microsize 250, 500 mg Ultramicro-size 125, 165, 250 mg 2. Oral suspension 125 mg/5 mL	1. T. capitis[a]	Microsize 500 mg/d or ultramicrosize 300-375 mg/d for 4-8 wk	Microsize 15-2 0 mg/kg/d or ultramicrosize 5-10 mg/kg/d for 6-12 wk	C
			2. T. cruris,[a] corporis	Same doses as above for 2-4 wk	Same doses as above for 2-4 wk	
			3. T. pedis[a]	Microsize 750-1000 mg/d or ultramicrosize 660-750 mg/d for 4-8 wk	Microsize 10-20 mg/kg/d or ultramicro-size 5-10 mg/kg/d for 4-8 wk	

[a]FDA-approved indications.
[b]Off-label indications.
[c]Indicated for children older than 4 years.

of cutaneous and lymphocutaneous sporotrichosis at a dose of 500 mg twice daily for 2 to 4 weeks beyond the clinical resolution. Terbinafine has also shown efficacy in the treatment of phaeohyphomycosis, chromoblastomycosis, mucormycosis, and maduromycosis.[17]

DOSAGE AND FORMULATIONS

The following terbinafine formulations are available for topical use—cream, powder, solution, spray, and gel 1% (Table 188-1). Oral terbinafine formulations include 250-mg tablets and oral granules. Because terbinafine can persist in keratinized tissue up to 6 months after the last dose,[19] a pulse regimen could represent an alternate treatment strategy for onychomycosis. A daily dose of 250 mg for 1 week monthly continued for 1 year has shown a mycological cure rate of 90% compared to 75% achieved with itraconazole pulse dosage.[17] Terbinafine at a daily dose of 250 mg for a period ranging from 2 to 4 weeks is effective in the management of tinea barbae, tinea corporis, tinea cruris, tinea faciei, and moccasin-type tinea pedis (Table 188-2).[12]

SIDE EFFECTS

The side effects of the topical application are not common (6%) and are typically limited to mild localized cutaneous reaction. In general, the oral route is well tolerated, with fewer side events reported with the pulse regimen compared to continuous dosing. Minimal GI tract upset (eg, abdominal pain, nausea, vomiting, diarrhea), appetite changes, and weight gain are the most common terbinafine adverse effects. A unique side effect is altered taste, which can last up to 6 weeks with or without loss of smell and tongue discoloration. Severe but rare adverse events are hepatotoxicity leading to possible organ failure and hematologic disorders including pancytopenia; these are usually reversible after drug stoppage. Cutaneous hypersensitivity eruptions as severe as Stevens–Johnson syndrome and toxic epidermal necrolysis have been reported, mainly within 4 to 5 weeks of treatment. Drug discontinuation may result in GI and cutaneous adverse events, and headaches, vertigo, and transient optic neuropathy may also occur (Table 188-3).[20]

DRUG–DRUG INTERACTIONS

Terbinafine exhibits a potent inhibitory effect on CYP2D6, and therefore increases the potential toxicity of drugs metabolized by this enzyme, including nortriptyline, amitriptyline, venlafaxine, and desipramine. In addition, terbinafine reduces the elimination of caffeine and cyclosporine. The concomitant administration of terbinafine with rifampicin or cimetidine

TABLE 188-3
Side Effects, Contraindications, and Monitoring of Representative Systemic Antifungals

DRUG	SIDE EFFECTS	PRECAUTIONS/CONTRAINDICATIONS	MONITORING
Terbinafine	1. Ageusia (altered taste), loss of smell, and tongue discoloration+ 2. Hepatotoxicity, hematologic disorders ++ 3. GIT upset, aggravate psoriasis, lupus erythematosus	1. Hepatic disease (chronic or active) 2. Renal impairment (creatinine clearance <50 mL/min)	1. Baseline LFTs 2. Full CBC 3. BUN, creatinine 4. Plasma level of CYP2D6-metabolized drugs
Fluconazole	1. Cardiac abnormalities (torsade de pointes), exfoliative skin reactions, anaphylactic reactions++ 2. Headache, myalgia, dizziness, GIT upset+++ 3. Hepatic, renal functions abnormalities	1. Hepatic and renal impairment 2. In patients with risk for arrhythmias 3. Coadministration with astemizole, terfenadine, cisapride (increased risk of developing torsade de pointes) 4. Coadministration with statins (increased myopathy)	1. Baseline LFTs 2. Full CBC 3. Regular LFTs 4. Close monitor of oral hypoglycemic, and blood glucose
Itraconazole	1. Triad of hypertension, hypokalemia, &edema in elderly+ 2. Negative inotropic fulminant hepatitis, Stevens–Johnson syndrome; Anaphylaxis++ 3. GIT upset, esp. odious taste with cyclodextrin solution+++ 4. Headache, rhinitis, sinusitis, hepatic, renal impairment	1. Heart failure 2. Liver disease 3. Patients with hypersensitivity to other azoles (use with caution)	1. Patients with risk factors for CHF for developing signs or symptoms of CHF 2. Baseline LFTs 3. Regular LFTs 4. Blood glucose in patients using oral hypoglycemic 5. Plasma level of drugs metabolized with by CYP3A4
Griseofulvin	1. Hetaotoxicity, pancytopenia++ 2. Hypersensitivity skin eruptions, Photosensitivity, 3. GIT upset+++ 4. Neurologic problems	1. Porphyria 2. LCF 3. Patients with penicillin sensitivity (use with cautious) 4. Females using OCP should change the contraceptive method or add another form	1. Liver enzymes after 8 wk of continuous use 2. BUN, creatinine after 8 wk of continuous use

+, Most unique; ++, most serious; +++, most common; LFTs, liver function tests; BUN, blood urea nitrogen; CBC, complete blood picture; CHF, chronic heart failure; CYP, cytochrome P; GIT, gastrointestinal tract; LCF, liver cell failure; OCP, oral contraceptive pills.

should be avoided as well, as they are known to increase its toxicity and decrease its efficacy, respectively (Table 188-4).[8,13,20]

BENZYLAMINES

Benzylamines are structurally and functionally related to allylamines.[8]

BUTENAFINE

Butenafine is the only available antifungal derivative of benzylamine, and has a chemical formula *N*-(4-*tert*-butylbenzyl)-*N*-methyl-1-naphthalenemethylamine hydrochloride.[8]

MECHANISM OF ACTION

Similar to allylamines, butenafine inhibits the synthesis of ergosterol, with subsequent enhancement in membrane permeability and leakage of important cellular components, resulting in mycotic cell death.[8]

INDICATIONS

Butenafine is indicated for the treatment of dermatophyte infections, with efficacy superior to that of the allylamines; additionally, it can be used in cases of pityriasis versicolor (PV) and candidiasis (Table 188-1).[8,13]

DOSAGE AND FORMULATIONS

The only available commercial formulation is a 1% cream,[9] applied once daily for 2 to 4 weeks.[8]

SIDE EFFECTS

Side effects of butenafine are minimal and include itching, burning, erythema, and contact dermatitis.

AZOLES

The azoles are group of antifungals characterized by 1 or more azole rings. They can be further subclassified into imidazoles, which include ketoconazole, butoconazole, clotrimazole, econazole, luliconazole, miconazole, and sertaconazole, and triazoles, which

TABLE 188-4
Drug–Drug Interactions of Representative Systemic Antifungals

ANTIFUNGAL AGENT	INTERACTING DRUG/CLASS	MECHANISM OF INTERACTION	RESULTING EFFECTS	RECOMMENDATION
Terbinafine	1. CYP2D6 metabolizing agents (TCAs, SSRI haloperidol, some BB)	Terbinafine is a CYP2D6 isoenzyme inhibitor ++	Inhibition of their breakdown, and increase their toxicity	Cautious coadministration
	2. Warfarin	Terbinafine is a potential *CYP*-450 2C9 inducer	Decrease the anticoagulant activity and increase the risk of thrombosis	Close monitoring of anticoagulation parameters (ie, INR, PT)
	3. Rifampicin, phenytoin	CYP-450 enzyme inducer	Induce the metabolism of terbinafine, decrease its level	Avoid combination, or increase the dose of terbinafine
	4. Cimetidine	CYP2D6 enzyme inhibitor	Inhibit the metabolism of terbinafine, decrease its clearance	Avoid combination, or decrease the dose of terbinafine
Fluconazole	1. Terfenadine, astemizole, cisapride	Synergism (prolongation of QT interval)	Serious arrhythmias (torsades de pointes)	Coadministration is contraindicated
	2. CYP3A4-metabolizing agents (eg, CCBs, benzodiazepines, SSRIs, TCA, phenytoin, carbamazepine, cyclosporine, PDIs, warfarin)	Fluconazole is CYP3A4 inhibitor +	Increase the plasma level and decrease the clearance of coadministered drug	Monitor the level of coadministrated drug or their effects, or consider terbinafine as alternative
	3. CYP2C9 metabolizing agents, phenytoin, oral hypoglycemic agents, (eg, sulfonylurea, rosiglitazone, and nateglinide)	Fluconazole is a CYP2C9 isoenzyme inhibitor	Clinically evident phenytoin toxicity, hypoglycemia respectively	Consider other alternatives (terbinafine, itraconazole, griseofulvin)
	4. 4.CYP3A4 inducers (eg, phenytoin, carbamazepine, phenobarbital, rifampin, rifabutin, INH, nevirapine)	Induce the metabolism of fluconazole	Decrease its therapeutic effects	Avoid combination, or increase the dose of fluconazole
	5. CYP3A4 inhibitors (clarithromycin, indinavir, ritonavir)	Decrease the metabolism of fluconazole	Increase its therapeutic and side effects	Avoid combination, or decrease the dose of fluconazole
Itraconazole	1. H2 blocker antihistamines (eg, cimetidine, ranitidine) antacids, proton pump inhibitors (eg, omeprazole pantoprazole), oral didanosine	Decrease gastric acidity	Decrease itraconazole absorption and bioavailability	Itraconazole capsules can be taken 2 h after the concurrent drug, or consider alternatives not affected by gastric acidity(eg, itraconazole solution, terbinafine or fluconazole)
	2. Drug metabolized by cytochrome 3A4 (CYP3A4) isoenzyme (eg, statins, darunavir, CCBs, benzodiazepines, warfarin)	Itraconazole is a CYP3A4 inhibitor ++	Decrease the metabolism of these drugs; hence increase their therapeutic and side effects	Monitor the level of coadministrated drug or their effects (eg, close. monitoring of the level of myopathy and myoglobinuria in case of statins), or consider terbinafine as alternative
	3. Digoxin, quinidine	Itraconazole is a P gp and CYP3A4 inhibitor	Digoxin toxicity	Terbinafine, fluconazole, or griseofulvin can be safely administered
	4. CYP3A4 inducers	Increases the hepatic metabolism of itraconazole	Accelerate the clearance of itraconazole	Avoid combination, or increase the dose of itraconazole
	5. CYP3A4 inhibitors (clarithromycin, indinavir, ritonavir)	Decreases the hepatic metabolism of itraconazole	Decrease the clearance of itraconazole	Avoid combination, or decrease the dose of itraconazole

(*Continued*)

TABLE 188-4
Drug–Drug Interactions of Representative Systemic Antifungals (*Continued*)

ANTIFUNGAL AGENT	INTERACTING DRUG/CLASS	MECHANISM OF INTERACTION	RESULTING EFFECTS	RECOMMENDATION
Griseofulvin	1. Warfarin, phenobarbital, and estrogens	Griseofulvin is an enzymatic inducer	Increase the metabolism of these drugs	Dose adjustment of the concurrent drugs
	2. Phenobarbitone	Decrease the oral absorption and induces metabolism of Griseofulvin.	Failure in griseofulvin therapy	Avoid coadministration

+, mild potency or needs high doses; ++, high potency; CYP, cytochrome P; BB, beta blockers; CCBs, calcium channel blockers; INH, isoniazid; INR, International Normalized Ratio; PDIs, phosphodiesterase inhibitors; PT, prothrombin time; SSRI, selective serotonin-reuptake inhibitors; TCAs, tricyclic antidepressants.

include fluconazole, itraconazole, efinaconazole, and isavuconazole.[5]

MECHANISM OF ACTION

Azoles act through the inhibition of lanosterol demethylase enzyme (14α-demethylase), a fungal cytochrome P450 (CYP)–dependent enzyme that catalyzes the conversion step of lanosterol into ergosterol, thereby blocking the biosynthesis of ergosterol. Subsequently, the reduced level of ergosterol disrupts the membrane permeability. Additionally, the buildup of the 14α-methylated sterols precursors will interfere with cell growth, leading eventually to cell death. Azoles in normal concentrations are typically fungistatic agents; however, high concentrations of azoles can be fungicidal. The heme-containing pocket is the binding site of azoles on the lanosterol demethylase enzyme and variations in its conformation, together with variation in the drug structure, are the determinants of the azole binding affinity and cross resistance.[21]

IMIDAZOLES

CLOTRIMAZOLE

Mechanism of Action: Clotrimazole is the first developed topical imidazole that can disrupt mycotic phospholipids, resulting in leakage of intracellular iron, degradation of nucleic acids, and suppression of cell respiration.[8]

Pharmacokinetics: Application of clotrimazole is associated with negligible systemic absorption (0.5%).[13]

Indications: Clotrimazole can be used for all superficial mycoses, achieving mycological cure rates ranging from 60% to 100% in dermatophytosis, and 80% to 100% in cutaneous candidiasis.[13]

Dosage and Formulations: Clotrimazole is available as cream, lotion, spray, powder, lozenge, suppository, and 1% solution (Table 188-1). As with most azoles, clotrimazole is applied twice daily for 2 to 4 weeks according to the indication.[8]

Side Effects: Similar to other topical antifungals, clotrimazole can result in local skin reaction in the form of itching, erythema, and rash.[8,13]

Pregnancy Category: B.

KETOCONAZOLE

Ketoconazole was the first marketed oral broad-spectrum antifungal agent.[13]

Mechanism of Action: Ketoconazole inhibits 14α-demethylase, blocking the conversion of lanosterol into ergosterol. It has fungicidal activity at high concentrations.[3] Possible antiinflammatory activity of topical ketoconazole has been postulated.[22]

Pharmacokinetics: Systemic absorption of topical ketoconazole is negligible, whereas 5% of the drug reaches the hair keratin 12 hours from the first shampoo application.[8] The absorption of oral ketoconazole is enhanced by acidic beverages, and decreases with the increase in gastric pH.[13]

Indications: Ketoconazole is used topically for the treatment of all dermatomycoses and its shampoo formulation is effective in the treatment of seborrheic dermatitis (Table 188-1). However, the prescription of oral preparations has now been markedly restricted by the FDA and other health organizations due to drug interaction and serious side effects on the liver and adrenal glands.[23-25]

Dosage and Formulations: The commercial formulations in the United States include 5% shampoo, 2% cream, and 200-mg tablets. Ketoconazole shampoo is applied once daily (left for 5-10 minutes) for 1 to 4 weeks in the treatment of PV, and once weekly for prophylaxis (Table 188-1).[26] In cases of scalp seborrheic dermatitis, the shampoo is used twice a week for 4 weeks. Oral ketoconazole is used once daily for 10 to 20 days in cases of superficial mycosis.[13]

Side Effects: The adverse effects of the topical drug are generally minimal and uncommon, including itching, allergic reactions, and contact dermatitis. Serious side effects have been recorded with the oral formulation, encompassing liver toxicity, anaphylactic reactions, and marked depression. More common but less serious side effects include nausea, vomiting, diarrhea, abdominal pain, headache, sleeping disturbances, dizziness, and pancytopenia, as well as impotence, gynecomastia, and decreased libido owing to its androgen-opposing properties at both the adrenal and testicular levels.[8]

Drug–Drug Interactions: Ketoconazole is a strong inhibitor of CYP3A4 and can increase the serum concentrations of coadministered drugs foremost metabolized by this enzyme, leading to a decrease in therapeutic efficacy and increase in adverse effects.[8]

MICONAZOLE

Mechanism of Action: In addition to the mechanism inherent to azoles, miconazole is capable of blocking the mycotic peroxidase enzyme, leading to the accumulation of toxic peroxide and subsequent cell death.[8]

Pharmacokinetics: Miconazole efficiently penetrates the stratum corneum, with <1% absorbed to systemic circulation.[8]

Indications: Miconazole cream is an efficacious treatment for tinea cruris, tinea corporis, and tinea pedis, in addition to its efficacy in treating PV and cutaneous candidiasis (Table 188-1).

Dosage and Formulations: The commercial preparations of miconazole include vaginal suppositories (100 mg, 200 mg), gel (2%), cream (2%), ointment, lotion, and powder.[8,13]

Side Effects: Miconazole side effects include those inherent to topical azoles, with cross-sensitivity recorded with the majority.[8]

LULICONAZOLE

Luliconazole and sertaconazole are the most recently developed imidazoles.

Mechanism of Action: Luliconazole mechanism of action is the same as azoles, though the modification of its structure renders it less liable to keratin binding and more available for penetration into deeper nail layers. Therefore, many studies are now investigating the use of luliconazole for treating onychomycosis.[27]

Pharmacokinetics: Luliconazole is characterized by second meta-replaced chlorine on its benzene ring, which is responsible for its superior potency over lanoconazole.[28]

Indications: Luliconazole is FDA approved for the treatment tinea cruris, tinea pedis, and tinea corporis (Table 188-1).[12]

Dosage and Formulations: Luliconazole 1% cream is the only available formulation in the United States.[29]

Side Effects: Mild cutaneous irritation is uncommonly reported with luliconazole.[29]

SERTACONAZOLE

Sertaconazole is a benzothiophene imidazole derivative.[28]

Mechanism of Action: Sertaconazole, in addition to the typical action of azoles, is capable of exhibiting fungicidal action at high concentration through binding to nonsterol lipids in the mycotic cell wall, increasing its permeability and resulting in cell lysis. In addition, sertaconazole has antiinflammatory, antibacterial, and antipruritic properties.[28]

Pharmacokinetics: Insignificant amounts of sertaconazole may reach the systemic circulation after topical application; additionally, sertaconazole forms a drug depot that can persist in the stratum corneum up to 48 hours after the last dose.[28]

Indications: In the EU, sertaconazole is approved for all dermatomycoses (PV, seborrheic dermatitis, cutaneous candidiasis, and dermatophytosis), whereas in the United States, its license is limited to tinea pedis.[28]

Dosage and Formulations: Sertaconazole is available as 2% cream and solution (Table 188-1).[28]

Side Effects: Topical application can result in mild local dryness, burning sensation, and dermatitis.[28]

Pregnancy Category: C.

EFINACONAZOLE

Mechanism of Action: Efinaconazole reduces the ergosterol synthesis in a dose-dependent manner.[30] It inhibits lanosterol 14-alphademethylase, which prevents transformation of lanosterol into ergosterol.

Pharmacokinetics: Less efinaconazole is bound to keratin compared to amorolfine and ciclopirox, which allows more drug to penetrate the nail plate. In addition, its lipophilic ester component reduces the surface tension, allowing more nail penetration.[28]

Indications: Efinaconazole is FDA licensed for the topical treatment of onychomycosis.[28]

Dosage and Formulations: Efinaconazole 10% solution is applied as a single daily application for 48 weeks (Table 188-1).[27,28]

Side Effects: Local eczema and ingrown nails have been reported with efinaconazole use.[27,28]

Pregnancy Category: C.

TRIAZOLES

Both triazoles and imidazoles are 5-membered ring heterocycles. Imidazoles have 2-ring nitrogen atoms, whereas triazoles contain 3 and are less prone to metabolic degradation.

FLUCONAZOLE

Fluconazole is a water-soluble *bis*-triazole that became FDA approved in the early 1990s.[8]

Mechanism of Action: Fluconazole inhibits lanosterol 14-demethylase and prevents conversion of lanosterol to ergosterol.[27,31]

Pharmacokinetics: Fluconazole has an excellent oral bioavailability, attaining nearly 90% (comparable to that achieved by intravenous route). Its pharmacokinetics are linear, predictable, and independent of gastric acidity, food intake, or disease activity. Unlike most other antifungal agents, only a small percentage of fluconazole is bound to plasma protein, resulting in greater amounts of free drug for therapeutic activity.[6,32] The drug is also characterized by a long half-life of 25 to 30 hours.[4] In addition, the wide distribution in various tissues including skin, nail, vitreous chamber of the eye, and cerebral spinal fluid (CSF), together with a good safety profile especially in immunocompromised patients, have qualified the use of fluconazole for the treatment of invasive fungal infections for almost 3 decades. The drug is poorly metabolized by the liver, and hence the kidney is the main route of drug elimination; therefore, dose adjustment is required with renal insufficiency.[6,32]

Indications: Fluconazole is one of the most commonly used antifungals in the treatment of esophageal, vaginal, and oropharyngeal candidiasis, and cryptococcal meningitis. It is efficacious against all *Candida* except *C. krusei*. Additionally, fluconazole is used as an off-label treatment for onychomycosis, tinea infections, PV, and chronic mucocutaneous candidiasis when itraconazole and terbinafine are contraindicated (Table 188-2).[8,13]

Dosage and Formulation: Fluconazole is available in the following formulations: 150 mg capsules, tablet, liquid, and solution for intravenous infusion. Fluconazole is used in the treatment of onychomycosis in adults at a weekly dose of 150 to 450 mg for 3 and 6 months for finger and toe nail onychomycosis, respectively. In children, the dose is calculated based on body weight, 3-6 mg/kg/wk for 6 to 12 weeks in cases of finger onychomycosis extended to 9 to 15 weeks in cases of toe nail involvement. The recommended dose in cases of dermatophytosis is 150 mg once a week for 2 to 4 weeks in cases of tinea barbae, tinea pedis, and tinea corporis, and 4 to 6 weeks in tinea cruris and tinea capitis. Fluconazole is effective in the treatment of cutaneous and chronic mucocutaneous candidiasis and PV at a dose of 300 mg/wk for 2 weeks and once monthly for prophylaxis (Table 188-2).[3,26,33]

Side Effects: In general, fluconazole has fewer side effects than other antifungals. The most frequent drug side effects are headache, myalgia, dizziness, nausea, dyspepsia, diarrhea, and abdominal pain. In addition, cardiac abnormalities such as prolonged QT intervals and torsade de pointes are uncommonly reported with fluconazole. Exfoliative cutaneous reactions including Stevens–Johnson syndrome and toxic epidermal necrolysis were rarely described with the drug. Other adverse events include anaphylactic reactions, angioedema, acneform eruption, eye hemorrhage, and neutropenia (Table 188-3).[8]

Drug–Drug Interactions: Fluconazole is a substrate of the CYP3A hepatic isoenzyme. In addition, it has a moderate suppressing effect on CYP3A and CYP2C9, and a weak inhibitory effect on CYP2C19; therefore, the concurrent administration with drugs metabolized by any of these enzymes could result in deleterious drug interactions. An example would be fatal arrhythmias with the concomitant administration of astemizole, cisapride, pimozide, and terfenadine (Table 188-4).[3,8,32]

Pregnancy Category: C

ITRACONAZOLE

Itraconazole is a broad-spectrum fungistatic triazole, synthetically derived from ketoconazole through the prolongation of its hydrophobic side chains, promoting the binding of the drug to the apoprotein of the 14α-demethylase enzyme.[3]

Mechanism of Action: Like other azoles, itraconazole acts through the inhibition of 14-α-demethylase, suppressing the conversion of lanosterol to ergosterol.[3]

Pharmacokinetics: Itraconazole is a highly lipophilic agent. The capsule formulation requires gastric acidity for optimum absorption, as it delays the gastric emptying and increases the drug dissolution; therefore, it is best administrated after a meal. In contrast, a cyclodextrin oral solution of itraconazole is not influenced by gastric acidity, and is best absorbed when taken on an empty stomach. Like terbinafine, itraconazole has a high affinity to nail and can accumulate there, forming a drug reservoir for 6 to 9 months after discontinuation of the drug. The half-life of itraconazole is typically 21 hours, and it has been postulated that its efficacy as a prophylactic agent is directly proportional to its plasma level, but should not, however, exceed 17 μg/mL by bioassay measurement to avoid drug toxicity. A twice-daily scheduling of doses is required in children because of drug lower plasma concentrations compared to adults.[3] Itraconazole undergoes an extensive hepatic metabolism by cytochrome CYP3A4

enzyme; as a result, a dose adjustment is required in patients with progressive liver disease. Renal insufficiency and renal dialysis have no influence on the drug plasma concentration. An exception is the intravenous formulation, which should be avoided when the creatinine clearance is less than 30 mL/min.[13]

Indications: Itraconazole is considered the best choice in treatment of *Candida* and nondermatophyte onychomycosis; its short course of treatment and good tolerability make it an especially good treatment choice for children.[15] Itraconazole is also used as an off-label treatment for many dermatophytoses, including tinea corporis, tinea capitis, tinea pedis, tinea cruris, tinea manuum, and PV (Table 188-2).

Dosage and Formulations: The recommended dose for tinea infections and PV is 100 mg twice daily for 5 days (Table 188-2). For the treatment of onychomycosis, itraconazole is prescribed as a continuous regimen (a daily dose of 200 mg for 6 weeks) or a monthly pulse dose (400 mg/d for 1 week). The dosage of the drug in children is calculated based on body weight (5 mg/kg/d) and both continuous or pulse regimens can be followed (Table 188-2).[8,13]

Side Effects: The most frequent side effects of itraconazole are GI disorders, especially the characteristic unpleasant taste associated with the hydroxypropyl-*b*-cyclodextrin vehicle, which can lead to patient noncompliance. Elderly patients on itraconazole often experience a triad of edema, hypertension, and hyperkalemia. In addition, itraconazole has a negative inotropic effect that can predispose to complete heart failure; therefore, it should be avoided in patients with a history of heart disease. Side effects such as hepatitis, jaundice, Stevens–Johnson syndrome, peripheral neuropathy, and adrenal suppression have been infrequently reported (Table 188-3).[3]

Drug–Drug Interactions: Itraconazole is a hepatic CYP3A4 enzyme substrate and inhibitor, and thus can affect the serum level, efficacy, and toxicity of drugs metabolized by the same enzyme. Similarly, CYP3A4 enzyme inducers and other inhibitors can increase or decrease the metabolism of the drug, respectively, and special considerations should be taken when combining itraconazole with one or more of these drugs. Given the necessity of gastric acidity for the optimum absorption of itraconazole, drugs such as H2 receptor blockers and proton pump blockers will decrease the drug absorption and subsequently its therapeutic effect (Table 188-4).[8]

Pregnancy Category: C.

POLYENES

NYSTATIN

Nystatin is a topical polyene derived from *Streptomyces* spp.[8]

MECHANISM OF ACTION

Nystatin has both fungistatic and fungicidal activity. It acts through binding to the mycotic ergosterol, for which its affinity is higher than that of the cholesterol found in mammalian cells. This binding will result in creation of pores in the cell membrane with subsequent leakage of essential fungal intracellular components, resulting in cell death.[34]

PHARMACOKINETICS

Because of the high toxicity associated with its intravenous administration, nystatin is confined to topical use only. Systemic absorption after cutaneous or mucous membrane application is insignificant.[8]

INDICATIONS

Nystatin is commonly used in the treatment of cutaneous, oropharyngeal, and vaginal candidiasis. The drug is not effective against dermatophytes or *Malassezia* spp. (Table 188-1).[8,34,35]

DOSAGE AND FORMULATIONS

Nystatin is available in cream, ointment, liquid, suspension, powder, and lozenge formulations. A twice-daily application for 4 to 5 days is the recommended dose for cutaneous infections, while the regimen for the treatment of oral candidiasis is a rinse 4 times daily for 14 days (Table 188-1).[8,35,36]

SIDE EFFECTS

Few side effects were reported with all formulations of nystatin; these include localized hypersensitivity reactions associated with the cutaneous application and manifested as allergic contact dermatitis, erythema, itching, and edema. Nausea, vomiting, and diarrhea have been reported with large doses of oral formulations.[8,25]

Pregnancy Category: B.

OTHER ANTIFUNGALS

CICLOPIROX

Ciclopirox olamine is a synthetic ethanolamine salt derivative of hydroxypyridone.[37]

MECHANISM OF ACTION

Ciclopirox exhibits broad-spectrum fungicidal and fungistatic, antibacterial, and antiinflammatory activities. It acts through the inhibition of the transmembrane uptake of RNA, DNA, and protein precursors. High drug concentrations (>50 µg/mL) alter the integrity of the cell membrane, leading to leakage of K ions, peptides, and amino acids. Ciclopirox also suppresses

aerobic glycolysis in the yeast cell, and subinhibitory concentrations decrease the adherence of *Candida albicans* to both vaginal and buccal epithelial cells. The drug is capable of chelating trivalent molecules as Al^{3+} and Fe^{3+}, cofactors for the enzymes involved in detoxification of hazardous metabolites, mitochondrial electron transport chain, and energy production. The antiinflammatory effect of ciclopirox is attributed to its ability to reduce the synthesis and release of the proinflammatory prostaglandin E_2.[38]

PHARMACOKINETICS

The vaginal application of ciclopirox was associated with 15% to 20% systemic absorption, whereas the systemic absorption from other routes was insignificant.[38] Compared to efinaconazole and luliconazole, ciclopirox exhibits the least nail permeation. Ciclopirox is metabolized by glucuronidation and its metabolites are eliminated mainly by the kidney.[39]

INDICATIONS

Ciclopirox is used in the treatment of various dermatophytoses.[11] A ciclopirox monotherapy of onychomycosis has been associated with a cure rate of 5.5% to 8.5% after 48 weeks,[40] whereas a combination with oral terbinafine increased the cure rate to 88.2% compared to 64.7% achieved by terbinafine alone.[41] Ciclopirox also can be used in the treatment of cutaneous candidiasis, tinea versicolor, and scalp seborrheic dermatitis (Table 188-1).[38]

DOSAGE AND FORMULATIONS

Ciclopirox can be incorporated in one of the following formulations with either isopropyl or benzyl alcohol as a vehicle: 0.77% cream, gel, 1% shampoo, and 8% nail lacquer solution. For most indications, twice-daily application is required and should be continued for 4 weeks, regardless of clinical improvement. The ciclopirox shampoo should be left for 3 minutes before rinsing. The nail lacquer, on the other hand, should be applied on a daily basis and removed with alcohol once a week before reapplication (Table 188-1).[38,42]

SIDE EFFECTS

Side effects include mild erythema and itching of the skin adjacent to the application site and infrequent nail alterations.[42]

AMOROLFINE

MECHANISM OF ACTION

Amorolfine interrupts the ergosterol synthesis at the 14-reduction and the 7-8 isomerization in the ergosterol pathway, resulting in the depletion of ergosterol as well as the accumulation of 24-methylene ignosterol.[43]

PHARMACOKINETICS

The nail lacquer tends to build a reservoir that continues to release the drug to the nail plate in an exponential pattern. Negligible systemic absorption is associated with topical application. The drug is generally eliminated in urine and stool at a very slow rate.[43]

INDICATIONS

Amorolfine has both fungistatic and concentration- and time-dependent fungicidal action against yeasts, and exhibits fungicidal activity against most dermatophytes and other filamentous fungi. Amorolfine nail lacquer is approved for the treatment of onychomycosis in the absence of matrix involvement in Europe but not in the United States. The use of amorolfine vaginal tablets has been associated with high clinical cure rates of vulvovaginal candidiasis (90%-95%), though with a high recurrence rate (Table 188-1).

DOSAGE AND FORMULATIONS

Amorolfine is available as a 0.25% cream and 5% nail lacquer. For superficial dermatomycosis, cream is applied once daily for 2 to 4 weeks, whereas the regimen for onychomycosis is a weekly application of nail lacquer until the regeneration of nail (approximately 6 or 12 months in finger- and toenail onychomycosis, respectively) (Table 188-1).[44]

SIDE EFFECTS

Side effects include mild allergic reaction of adjacent skin.[43]

Pregnancy Category: D.

TAVABOROLE

Tavaborole is a novel oxaborole antifungal drug that encloses a fluorine atom, decreasing the pH of the boronic center, which inhibits fungal peptide synthesis. Tavaborole exhibits broad-spectrum activity against a variety of fungi, including the dermatophytes (*Trichophyton rubrum, Trichophyton mentagrophytes, T. tonsurans,* and *Epidermophyton floccosum*), some *Microsporum* species, and *C. albicans*.[45]

MECHANISM OF ACTION

Tavaborole acts through inhibiting a new target, aminoacyl transfer RNA synthetase (AARS), for which its affinity is a thousand times that of the mammalian cell and thereby selectively inhibits the mycotic protein synthesis.[27]

PHARMACOKINETICS

Tavaborole is incorporated in an alcohol-based solution and is therefore not suitable for ophthalmic, oral, or intravaginal use. It is characterized by low molecular weight, which accounts for enhanced nail penetration. Tavaborole usually undergoes extensive metabolism before finally being eliminated in the urine.[27]

INDICATIONS

Tavaborole is approved for the topical treatment of onychomycosis (Table 188-1).[27]

DOSAGE AND FORMULATIONS

Tavaborole is available as a 5% topical solution, applied once daily for 48 weeks (Table 188-1).[46]

SIDE EFFECTS

The most common side effects are exfoliation, erythema, and dermatitis.[47]

Pregnancy Category: C.

GRISEOFULVIN

Griseofulvin is a metabolic derivative of *Penicillium griseofulvum*, classically used for the treatment of dermatophytes. It has no activity against yeast and molds.[8]

MECHANISM OF ACTION

Griseofulvin is a fungistatic drug, blocking the growth and proliferation of the fungal cell. Griseofulvin binds tubulin- and microtubule-associated proteins (MAPs) along the polymerized microtubules, suppressing the formation of the mitotic spindle at the G2/M phase of the cell cycle. This inhibits cell division and forces the cell to undergo apoptosis.[48]

PHARMACOKINETICS

Griseofulvin is a water-insoluble drug, known for its low bioavailability profile. Most of the drug absorption occurs in the duodenum, and better absorption of griseofulvin can occur either when coated with polyethylene glycol or on coadministration with fatty meals.[49,50] Griseofulvin is characterized by its accumulation in the keratin-producing tissues, where it is adherently bound to newly formed keratin, rendering it resistant to fungal penetration. The 6-desmethyl enzyme is responsible for the metabolism of griseofulvin in the liver. The cutaneous elimination of the drug is slower than its elimination from plasma, allowing for extended drug activity even after its discontinuation. Griseofulvin is eliminated from the body mainly through the kidney in the form of metabolites.[3]

INDICATIONS

Griseofulvin remains the first line of treatment for tinea capitis caused by *Microsporum* species owing to its higher efficacy compared to terbinafine, and similar efficiency yet lower cost compared to itraconazole and fluconazole.[19] It is also the only FDA-approved treatment for pediatric onychomycosis, though its efficacy is limited to dermatophytes only (Table 188-2).[15]

DOSAGE AND FORMULATIONS

Griseofulvin is available in the following formulations: 250- and 500-mg microsize and 125-, 165-, and 250-mg ultramicrosize tablets, and 125-mg/5-mL oral suspensions.[8] Griseofulvin is recommended at a daily dose of 1-g microsize, or 660- to 750-mg ultramicrosize for 4 to 8 weeks in the treatment of tinea pedis and half of these doses for the treatment of tinea cruris and corporis. The recommended daily dosing of griseofulvin for the treatment of tinea capitis in children is dependent on their body weight and is as follows: ultramicrosize 10 to 15 mg/kg, oral suspension 15 to 25 mg/kg, microsize 20 to 25 mg/kg, continued for 1 to 2 months (Table 188-2).[3]

SIDE EFFECTS

The main side effects associated with griseofulvin are related to hypersensitivity, which ranges from mild urticaria, serum sickness, acute generalized exanthematous pustulosis, subacute cutaneous lupus erythematous, Stevens–Johnson syndrome, and toxic epidermal necrolysis. Photosensitivity, including photo-toxic and photo-allergic reactions, also has been commonly reported with griseofulvin.[51] Other cutaneous eruptions include lichenoid eruption, porphyria, and pityriasis rosea.[12,13] Rare but serious side effects include hepatotoxicity, leukopenia, thrombocytopenia, and anemia.[51] Neurologic problems such as peripheral neuritis, memory loss, confusion, and insomnia were uncommonly recorded in some patients (Table 188-3).[52,53]

DRUG–DRUG INTERACTIONS

Griseofulvin should not be prescribed concurrently with phenobarbitone because it decreases the absorption and increases the metabolism of griseofulvin.[44] Interactions with alcohol, cyclosporine, oral contraceptives, aspirin, and warfarin also have been reported (Table 188-4).[54-56]

Pregnancy Category: C.

NEW CARRIER VEHICLES AND FORMULATIONS

A number of new carrier vehicles have been investigated to improve the bioavailability of topical antifungals and enhance their therapeutic effects. Different mechanisms include incorporation of the drug in

a lipid core matrix to achieve a maintained drug release up to 24 hours and to prevent light degradation of the drug. New carriers include micelles, solid lipid nanoparticles and nanostructured lipid carriers, and drug microemulsions. Vesicular carrier systems include liposomes, niosomes, transferosomes, ethosomes, and penetration enhancer vesicles.[57,58]

COMBINATION THERAPY

For the treatment of onychomycosis, combination therapy of a topical agent with a systemic antifungal provides several advantages, including higher rates of fungal killing, prevention of drug resistance, and expansion of spectrum activity.[3,15,59] Further, because the duration of therapy is shorter and oral medications can be used at lower doses, combination therapy decreases drug-related toxicity.[15,59,60] A case in which combination therapy can be of particular use is in onycholysis secondary to onychomycosis, as the separation of the nail plate from the subungual tissue interrupts the transport of drug from the nail plate to the nail bed and vice-versa. Using topical as well as oral therapy would ensure the nail plate and nail bed both are in contact with the antifungal agent.[3,59-61]

In the case of superficial skin infections, the addition of topical steroids to antifungal therapy, either in the same formulation or separately, is controversial. Because of the concern about the side effects associated with the abuse of topical steroids, many studies have discouraged this combination and suggested the use of topical antifungals with antiinflammatory properties instead.[12]

REFERENCES

1. Havlickova B, Czaika VA, Friedrich M. Epidemiological trends in skin mycoses worldwide. *Mycoses.* 2008;51(suppl 4):2-15.
2. Weinstein A, Berman B. Topical treatment of common superficial tinea infections. *Am Fam Physician.* 2002; 65(10):2095-2102.
3. Gupta AK, Cooper EA. Update in antifungal therapy of dermatophytosis. *Mycopathologia.* 2008;166(5-6): 353-367.
4. Gupta AK, Foley KA, Versteeg SG. New antifungal agents and new formulations against dermatophytes. *Mycopathologia.* 2017;182(1-2):127-141.
5. Dismukes WE. Antifungal therapy: lessons learned over the past 27 years. *Clin Infect Dis.* 2006;42(9):1289-1296.
6. Lewis RE. Current concepts in antifungal pharmacology. *Mayo Clin Proc.* 2011;86(8):805-817.
7. Del Rosso JQ, Kircik LH. Optimizing topical antifungal therapy for superficial cutaneous fungal infections: Focus on topical naftifine for cutaneous dermatophytosis. *J Drugs Dermatol.* 2013;12(11)(suppl):s165-s171.
8. Zhang A, Camp W, Elewski B. Advances in topical and systemic antifungals. *Dermatol Clin*. 2007;25(2): 165-183.
9. Gupta AK, Ryder JE, Cooper EA. Naftifine: a review. *J Cutan Med Surg.* 2008;12(2):51-58.
10. Nigam PK. Antifungal drugs and resistance: current concepts. *Our Dermatol Online.* 2015;6(2):212-221.
11. High WA, Fitzpatrick JE. Topical antifungal agents. In: Fitzpatrick TB, Wolff K, eds. *Fitzpatrick's Dermatology in General Medicine*. 7th ed. New York, NY: McGraw-Hill; 2008.
12. Sahoo AK, Mahajan R. Management of tinea corporis, tinea cruris, and tinea pedis: a comprehensive review. *Ind Dermatol Online J.* 2016;7(2):77-86.
13. Dias MFRG, Bernardes-Filho F, Quaresma-Santos MVP, et al. Treatment of superficial mycoses: review—part II. *An Bras Dermatol.* 2013;88(6):937-944.
14. Leyden J. Pharmacokinetics and pharmacology of terbinafine and itraconazole. *J Am Acad Dermatol.* 1998; 38(5):S42-S47.
15. Ameen M, Lear JT, Madan V, et al. British association of dermatologists' guidelines for the management of onychomycosis 2014. *Br J Dermatol.* 2014; 171(5):937-958.
16. Van Duyn Graham L, Elewski BE. Recent updates in oral terbinafine: its use in onychomycosis and tinea capitis in the US. *Mycoses.* 2011;54(6):e679-e685.
17. Hossain MA, Ghannoum MA. New developments in chemotherapy for non-invasive fungal infections. *Exp Opin Invest Drugs.* 2001;10(8):1501-1511.
18. Kakourou T, Uksal U. Guidelines for the management of tinea capitis in children. *Pediatr Dermatol.* 2010; 27(3):226-228.
19. Michaels BD, Del Rosso JQ. Tinea capitis in infants: recognition, evaluation, and management suggestions. *J Clin Aesthet Dermatol.* 2012;5(2):49-59.
20. Newland JG, Abdel-Rahman SM. Update on terbinafine with a focus on dermatophytoses. *Clin Cosmet Investig Dermatol.* 2009;2:49-63.
21. Mast N, Zheng W, Stout C, et al. Antifungal azoles: structural insights into undesired tight binding to cholesterol-metabolizing CYP46A1. *Mol Pharmacol.* 2013;84(1):86-94.
22. Del Rosso JQ. Adult seborrheic dermatitis. *J Clin Aesthet Dermatol.* 2011;4(5):32-38.
23. Greenblatt HK, Greenblatt DJ. Liver injury associated with ketoconazole: review of the published evidence. *J Clin Pharmacol.* 2014;54(12):1321-1329.
24. Banankhah PS, Garnick KA, Greenblatt DJ. Ketoconazole. Associated liver injury in drug-drug interaction studies in healthy volunteers. *J Clin Pharmacol.* 2016; 56(10):1196-1202.
25. Gupta AK, Daigle D, Foley KA. Drug safety assessment of oral formulations of ketoconazole. *Expert Opin Drug Saf.* 2015;14(2):325.
26. Renati S, Cukras A, Bigby M. Pityriasis versicolor. *BMJ.* 2015;350:h1394.
27. Saunders J, Maki K, Koski R, et al. Tavaborole, efinaconazole, and luliconazole: three new antimycotic agents for the treatment of dermatophytic fungi. *J Pharm Pract.* 2017;30(6):621-630.
28. Del Rosso JQ. The role of topical antifungal therapy for onychomycosis and the emergence of newer agents. *J Clin Aesthet Dermatol.* 2014;1;7(7):10-18.
29. Scher RK, Nakamura N, Tavakkol A. Luliconazole: a review of a new antifungal agent for the topical treatment of onychomycosis. *Mycoses*. 2014;57(7): 389.
30. Tatsumi Y, Nagashima M, Shibanushi T, et al. Mechanism of action of efinaconazole, a novel triazole antifungal agent. *Antimicrob Agents Chemother.* 2013;57(5): 2405-2409.
31. Lyon JP, Carvalho CR, Rezende RR, et al. Synergism between flucon azole and methylene blue-photodynamic therapy against fluconazole-resistant candida strains. *Ind J Med Microbiol.* 2016;34(4):506-508.

32. Ashley ES, Lewis R, Lewis JS, et al. Pharmacology of systemic antifungal agents. *Clin Infect Dis.* 2006;43(suppl 1): S28-S39.
33. Cornely OA, Bassetti M, Calandra T, et al. ESCMID* Guideline for the diagnosis and management of Candida diseases 2012: non-neutropenic adult patients. *Clin Microbiol Infect.* 2012;18(suppl 7):19-37.
34. Vandeputte P, Ferrari S, Coste A. Antifungal resistance and new strategies to control fungal infections. *Int J Microbiol.* 2012;2012:713687.
35. Darwazeh AM, Darwazeh TA. What makes oral candidiasis recurrent infection? A clinical view. *J Mycology.* 2014;2014:758394.
36. Akpan A, Morgan R. Oral candidiasis. *Postgrad Med J.* 2002;78(922):455-459.
37. Gupta AK. Ciclopirox: an overview. *Int J Derm.* 2001;40(5): 305-310.
38. Subissi A, Monti D, Togni G, et al. Ciclopirox. *Drugs.* 2010;70(16):2133-2152.
39. Matsuda Y, Sugiura K, Hashimoto T, et al. Efficacy coefficients determined using nail permeability and antifungal activity in keratin-containing media are useful for predicting clinical efficacies of topical drugs for onychomycosis. *PLoS One.* 2016;21;11(7):e0159661.
40. Gupta AK, Skinner AR. Ciclopirox for the treatment of superficial fungal infections: a review. *Int J Dermatol.* 2003;42(suppl 1):3-9.
41. Avner S, Nir N, Henri T. Combination of oral terbinafine and topical ciclopirox compared to oral terbinafine for the treatment of onychomycosis. *J Dermatol Treat.* 2005;16(5-6):327-330.
42. Gupta AK, Bluhm R. Ciclopirox (Loprox) gel for superficial fungal infections. *Skin Therapy Lett.* 2004;9(7):4-5, 9.
43. Rotta I, Sanchez A, Gonçalves PR, et al. Efficacy and safety of topical antifungals in the treatment of dermatomycosis: a systematic review. *Br J Dermatol.* 2012; 166(5):927-933.
44. Polak AM. Preclinical data and mode of action of amorolfine. *Clin Exp Dermatol.* 1992;17(suppl 1):8-12.
45. Gupta AK, Daigle D, Foley KA. Topical therapy for toenail onychomycosis: an evidence-based review. *Am J Clin Dermatol.* 2014;15(6):489-502.
46. Gupta G, Foley KA, Gupta AK. Tavaborole 5% solution: a novel topical treatment for toenail onychomycosis. *Skin Therapy Lett.* 2015;20(6):6-9.
47. Markham A. Tavaborole: first global approval. *Drugs.* 2014;74(13):1555-1558.
48. Rathinasamy K, Jindal B, Asthana J, et al. Griseofulvin stabilizes microtubule dynamics, activates p53 and inhibits the proliferation of MCF-7 cells synergistically with vinblastine. *BMC Cancer.* 2010;10(1):213.
49. Debruyne D, Coquerel A. Pharmacokinetics of antifungal agents in onychomycoses. *Clin Pharmacokinet.* 2001;40(6):441-472.
50. Elewski B, Tavakkol A. Safety and tolerability of oral antifungal agents in the treatment of fungal nail disease: a proven reality. *Ther Clin Risk Manag.* 2005;1(4):299-306.
51. Iorizzo M, Piraccini BM, Tosti A. Today's treatments options for onychomycosis. *J Dtsch Dermatol Ges.* 2010; 8(11):875-879.
52. Moossavi M, Bagheri B, Scher RK. Systemic antifungal therapy. *Dermatol Clin.* 2001;19(1):35-52.
53. Zuber TJ, Baddam K. Superficial fungal infection of the skin: where and how it appears help determine therapy. *Postgrad Med.* 2001;109(1):117-120, 123-126, 131-132.
54. Himanshu B, Shyam M, Yatin M. Drug-drug interactions in medical ICU. *Ind J Pharm.* 2015;2(1):62-69.
55. Katz HI. Possible drug interactions in oral treatment of onychomycosis. *J Am Pod Med Assoc.* 1997; 87(12):571-574.
56. Brodell RT, Elewski B. Antifungal drug interactions. Avoidance requires more than memorization. *Postgrad Med.* 2000;107(1):41-43.
57. Güngör S, Erdal M, Aksu B. New formulation strategies in topical antifungal therapy. *J Cosmetics Dermatol Sci Appl.* 2013;3(1):56-65.
58. Bseiso E, Nasr M, Abd El Gawad N, et al. Recent advances in topical formulation carriers of antifungal agents. *Ind J Dermatol Venereol Leprol.* 2015;81(5):457-463.
59. Baran R, Kaoukhov A. Topical antifungal drugs for the treatment of onychomycosis: an overview of current strategies for monotherapy and combination therapy. *J Eur Acad Dermatol Venereol.* 2005;19(1):21-29.
60. Hay RJ. The future of onychomycosis therapy may involve a combination of approaches. *Br J Dermatol.* 2001;145(suppl 60):3-8.
61. Lecha M, Effendy I, Feuilhade de Chauvin M, et al. Treatment options—development of consensus guidelines. *J Eur Acad Dermatol Venereol.* 2005;19(suppl 1):25-33.

Chapter 189 :: Antihistamines

:: Michael D. Tharp

AT-A-GLANCE

- H_1 antihistamines are first-line therapy for chronic idiopathic and physical urticarials.
- H_1 agents may be useful in treating conditions with histamine-associated pruritus.
- Limited evidence supports the use of H_1 in the treatment of atopic dermatitis.
- Certain special patient populations, including children, the elderly, and patients with renal or hepatic impairment, may require dosage adjustments when using antihistamines.
- H_2 antihistamines may be a useful adjunct to H_1 antihistamine therapy in refractory cases of chronic idiopathic urticaria/angioedema.

Histamine is a low-molecular-weight amine that is synthesized from L-histidine by histidine decarboxylase, an enzyme expressed by numerous cells throughout the body. Histamine exerts its effects through 4 different receptors that play a role in embryonic development, cellular growth and proliferation, hematopoiesis and immunity, inflammation, and wound healing. This amine is an important neurotransmitter in the CNS and is produced in neurons located in the tuberomammillary nucleus of the posterior hypothalamus. Nerves arising from this area regulate the sleep–wake cycle, endocrine homeostasis, cognition and memory. Histamine also exerts anticonvulsant effects. Histamine is metabolized by 2 major pathways: diamine oxidase and histamine methyl transferase.[1,2]

Histamine receptors are heptahelical transmembrane molecules that transmit extracellular signals to intracellular second messengers via G proteins. These receptors have constitutive activity, and thus are able to trigger downstream events in the absence of ligand stimulation. Active and inactive states of histamine receptors exist in equilibrium and can be shifted to a greater proportion of active or inactive states by histamine and antihistamines, respectively.[3,4] Both H_1 and H_2 histamine receptors are widely expressed on neurons, smooth muscle, epithelium, endothelium, and multiple immune cells. H_2 receptors also exist on gastric mucosal parietal cells; consequently, occupation by specific H_2 antihistamines inhibits gastric acid secretion. H_3 and H_4 receptors have more limited expression in the body with H_3 receptors occurring primarily on histaminergic neurons and immune cells, whereas H_4 receptors are highly expressed in the bone marrow and on peripheral hematopoietic cells.[2,5]

H_1 ANTIHISTAMINES

The first H_1 antihistamines were introduced in the 1940s after groundbreaking work by Bovet in the 1930s. The H_1 antihistamines—diphenhydramine, chlorpheniramine, and promethazine—all became available for clinical use during this time, and these and other agents were the primary source of antihistamine therapy until the 1980s when less-sedating, second-generation antihistamines were developed. First-generation antihistamines are divided into 6 groups on the basis of chemical structure: (a) ethylenediamines, (b) ethanolamines, (c) alkylamines, (d) phenothiazines, (e) piperazines, and (f) piperidines. The presence of multiple aromatic or heterocyclic rings and alkyl substituents enhances the lipophilicity of these compounds, permitting penetration of the blood–brain barrier, thereby leading to sedation. Second-generation antihistamines are less capable of accumulating in the CNS, and thus are less sedating. Compared to first-generation antihistamines, these second-generation agents also have the added advantage of longer half-lives, thus requiring for less-frequent dosing. Today, more than 45 H_1 antihistamines exist worldwide as prescription and nonprescription medications, and are used for the treatment of allergic reactions, urticaria, pruritus, nausea, vertigo, sleep, and anxiety.[4,6]

MECHANISM OF ACTION

H_1 antihistamines are inverse agonists that reversibly bind and stabilize the inactive form of the H_1 receptor, thereby favoring the inactive state (Table 189-1). By means of the H_1 receptor, H_1 antihistamines decrease the production of proinflammatory cytokines, the expression of cell-adhesion molecules, and chemotaxis of eosinophils and other immune cells (Fig. 189-1).[1,4] H_1 antihistamines may also decrease mediator release from mast cells and basophils through inhibition of calcium ion channels. In addition to binding to histamine receptors, first-generation H_1 antihistamines also act on muscarinic, α-adrenergic, and serotonin receptors, as well as cardiac ion channels. Some of the more significant side effects associated with first-generation H_1 antihistamines, such as urinary retention, hypotension, and cardiac arrhythmias, are mediated through these nonhistamine receptors.

Many of the low-sedating, second-generation H_1 antihistamines are chemically derived from first-generation agents.[1,2] For example, cetirizine is a metabolite of hydroxyzine and loratadine is related to azatadine. The second-generation H_1 antihistamines bind noncompetitively to the H_1 receptor, and thus are not easily displaced by histamine. They

TABLE 189-1
Basic Pharmacology of Antihistamines

- Both H_1 and H_2 antihistamines are inverse agonists that reversibly bind and stabilize the inactive form of the histamine receptor, thereby favoring the inactive state.
- First-generation H_1 agents are relatively lipophilic, which enhances penetration of the blood–brain barrier and leads to sedation.
- First-generation H_1 antihistamines may interact with other drugs metabolized by the hepatic cytochrome P450 system leading to drug–drug interactions.
- Second-generation H_1 antihistamines have poor penetration of the blood–brain barrier and thus are less sedating.
- Second-generation H_1 antihistamines bind selectively to peripheral H_1 receptors and have fewer CNS effects.
- Second-generation H_1 antihistamines require less hepatic metabolism and thus are less likely to interact with other medications.
- There is no evidence of tolerance or tachyphylaxis to first-generation or second-generation antihistamines.

dissociate slowly, and have a longer duration of action than first-generation H_1 antihistamines. As a result of the selectivity of second-generation antihistamines for the H_1 receptor and their reduced lipophilicity, these agents are far less likely to cause sedation and have fewer side effects than the first-generation antihistamines.[1,3,6]

Some low-sedating H_1 antihistamines affect cell trafficking in the skin and other tissues, presumably by modulating the release of inflammatory mediators and the expression of adhesion molecules. In a skin chamber model, cetirizine administration reduced eosinophil influx after allergen challenge; however, similar effects have not been seen in the nasal mucosa following allergen exposure. In vitro studies demonstrate that cetirizine inhibits eosinophil, monocyte, and T-lymphocyte chemotaxis to *N*-formyl-methionyl-leucyl-phenylalanine and platelet-activating factor.[7] H_1 antihistamines may also modulate the expression of cellular adhesion molecules such as antigen-induced intercellular adhesion molecule 1 that exists on keratinocytes, Langerhans cells, and endothelial cells These antihistamines also may influence the release of inflammatory mediators from leukocytes.[8] In vitro, desloratadine and emedastine inhibit platelet-activating factor–induced eosinophil chemotaxis, tumor necrosis factor-α–induced eosinophil adhesion, and spontaneous and phorbol myristate–induced superoxide generation.[9,10]

PHARMACOKINETICS

FIRST-GENERATION H_1 ANTIHISTAMINES

After oral administration, the sedating effects of first-generation H_1 antihistamines can be observed within

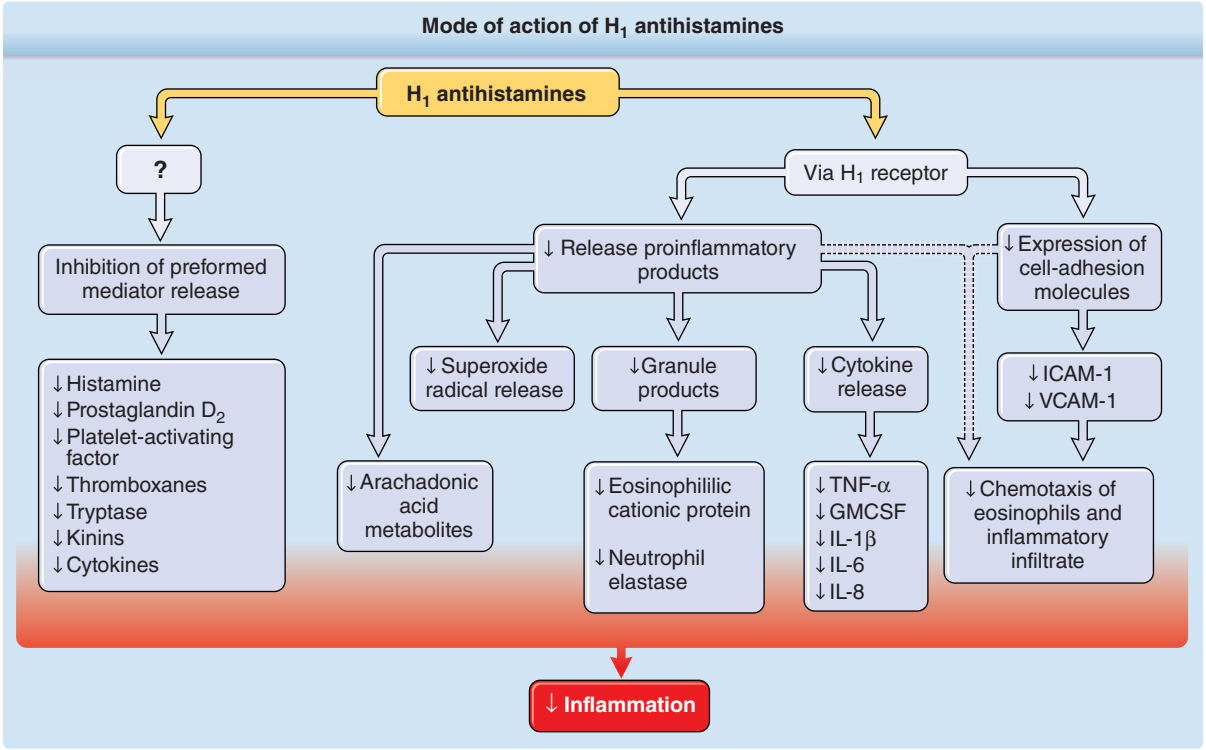

Figure 189-1 Mode of action of H_1 antihistamines. By means of the H_1 receptor, H_1 antihistamines inhibit the release of preformed mediators and decrease the production of proinflammatory cytokines, the expression of cell-adhesion molecules, and chemotaxis of eosinophils and other cells. ↓, Decreased; GMCSF, granulocyte-macrophage colony-stimulating factor; ICAM-1, intercellular adhesion molecule 1; IL, interleukin; TNF-α, tumor necrosis factor-α; VCAM-1, vascular cellular adhesion molecule 1.

30 minutes to 1 hour and generally persist for 4 to 6 hours. However, sedation may last for 24 hours or longer for some agents in some individuals. For example, after the oral administration of a single dose, the serum half-lives of brompheniramine, chlorpheniramine, and hydroxyzine exceed 20 hours in adults. First-generation H_1 antihistamines are metabolized by hepatic cytochrome P450 (CYP) enzyme 3A4, forming glucuronides before excretion in urine.[1,4]

The potency and relative concentration of H_1 antihistamines in the skin can be compared by their inhibition of the cutaneous wheal-and-flare response induced by intradermal histamine. First-generation H_1 antihistamines are typically administered in divided doses at intervals of 4 to 8 hours (see section "Dosing Regimens"), although once-daily dosing may suffice for agents with longer serum half-lives. In placebo-controlled, double-blind studies, there is no evidence of tolerance or tachyphylaxis to these antihistamines over a 3-month period. Interestingly, despite the relatively short half-lives of first-generation antihistamines, suppression of allergen-induced wheal-and-flare reactions may persist for up to 7 days after discontinuation.[1,4]

Topical H_1 antihistamine formulations for dermatologic use are available, although these preparations tend to be less effective and are associated with the potential for delayed allergic contact reactions.

SECOND-GENERATION H_1 ANTIHISTAMINES

Most second-generation, H_1 antihistamines are low sedating. They are administered once or twice daily and generally achieve peak plasma concentrations within 1 to 2 hours, These drugs achieve higher concentrations in the skin than first-generation antihistamines, and a single dose can suppress the wheal-and-flare reaction from 1 to 24 hours. Regular use prolongs this effect; for example, 6 days of daily cetirizine use results in 7 days of wheal-and-flare suppression.[11-15]

The second-generation antihistamines—loratadine, acrivastine, mizolastine, ebastine, and oxatomide—are metabolized in the liver via the hepatic enzyme CYP 3A4. Cetirizine, fexofenadine, levocabastine, desloratadine, and levocetirizine undergo minimal hepatic metabolism, which reduces the likelihood of interactions with other drugs. In general, most of these antihistamines are excreted in the urine and thus dosages need to be adjusted for patients with renal insufficiency.[1,4]

In healthy adults, cetirizine and levocetirizine reach peak concentrations approximately 1 hour after administration, with elimination half-lives of 6.5 to 10 hours. Fexofenadine generally reaches a peak concentration at 2 to 3 hours, with an elimination half-life of 14 hours.[5] While dosage adjustments are recommended for patients with decreased creatinine clearance, this is usually unnecessary for patients with hepatic disease because fexofenadine undergoes minimal hepatic metabolism.[1,4] Loratadine's half-life ranges on average from 8 to 24 hours, depending on hepatic function. Ebastine, which is metabolized to form its carboxylic acid metabolite, and carebastine, has a half-life of 15 hours.[1,4] In a single-dose study, normal subjects were treated with cetirizine (10 mg), fexofenadine (60 mg), or loratadine (10 mg) prior to repeated intradermal histamine injections over 24 hours. In the study, cetirizine proved to be more potent than fexofenadine, which was more effective than loratadine in suppressing these histamine reactions.[16] Similar studies also have demonstrated that levocetirizine (5 mg) and fexofenadine (180 mg) are more potent than desloratadine (5 mg) in suppressing histamine's effects in the skin.[17] Pharmacogenetics may also influence drug metabolism and clearance of antihistamines. In a series of pharmacokinetic studies, approximately 7% of all subjects and 20% of African Americans were slow metabolizers of desloratadine. Comparable differences may exist for other H_1 antihistamines.[4,18]

INDICATIONS

Table 189-2 outlines the indications for treatment with H_1 antihistamines.

H_1 antihistamines appear to be effective in treating up to 50% of patients with chronic idiopathic urticaria (CIU), angioedema, and dermatographism. They are not as effective in treating physical urticarias, hereditary and acquired angioedema, urticarial vasculitis, and pruritus unrelated to histamine. Comparative studies of different groups of first-generation H_1 antihistamines are few; however, in general, these agents appear to have equal efficacy in the treatment of CIU. If an agent from one class of H_1 antihistamines proves ineffective, then an agent from another antihistamine group should be considered.[4,19]

Studies comparing the efficacy of second-generation antihistamines, on the other hand, are numerous. Double-blind, placebo-controlled, or parallel studies, have demonstrated that low-sedating H_1 antihistamines (cetirizine, loratadine, fexofenadine, desloratadine, levocetirizine, acrivastine, mizolastine, azelastine, ebastine, and oxatomide) are superior to placebo in the treatment of urticaria and angioedema.[20-26] Trials comparing different second-generation antihistamines with one another have not shown any one agent to be consistently superior, although cetirizine and levocetirizine have fared best overall in comparative trials.[1,26-29]

Even though both first-generation and second-generation H_1 antihistamines are used to treat pruritus in patients with atopic dermatitis, their efficacy

TABLE 189-2
Indications for Treatment with H_1 Antihistamines

- Acute urticaria
- Chronic idiopathic urticarial
- Physical urticarias and dermatographism
- Pruritus associated with histamine release
- Symptoms of mastocytosis

has not been proved by rigorous clinical trials. In the 18-month Early Treatment of the Atopic Child study, cetirizine afforded a steroid-sparing benefit to children with severe atopic dermatitis, but no consistent benefit was observed in children with moderate disease.[30,31] A meta-analysis of 16 studies conducted from 1966 through 1999 failed to demonstrate a major role for either first-generation or second-generation H_1 antihistamines in the treatment of atopic dermatitis.[31]

Mastocytosis represents an uncontrolled proliferation of tissue mast cells, and histamine is believed responsible for many of the symptoms associated with this disorder; H_1 antihistamines are commonly used to treat symptomatic mastocytosis patients.[32-34] In general, higher doses of H_1 antihistamines than normally employed for allergic disorders may be necessary for symptom control in mastocytosis patients. For example, fexofenadine 360 mg in the morning and cetirizine 40 mg at night may be necessary for some symptomatic mastocytosis patients.

DOSING REGIMENS

The H_1 antihistamines are considered first-line therapy in the treatment of CIU and physical urticarials, and may be useful in treating other conditions in which histamine-driven pruritus is a major feature. The lowest effective dosage is preferred to minimize dose-related side effects, such as sedation. Table 189-3 outlines the dosing regimens for H_1 antihistamines. After several days of therapy, the dosage may be increased if symptom control is inadequate. Occasionally, gradual escalation of dosing permits the development of tolerance to sedation, which allows higher dosages to be used to treat certain conditions, such as refractory CIU. Doses up to 4 times that normally recommended for second-generation H_1 antihistamines may be necessary in the treatment of some CIU patients.[19,35] In a retrospective study of 368 CIU patients treated with either first-generation or second-generation H_1 antihistamines, 276 (75%) increased their dose by 2 to 4 times the normal recommended dose. Half of these patients experienced a clinical benefit from the medication increase. Those patients treated with second-generation H_1 antihistamines also experienced less sedation and other side effects compared to patients treated with first-generation H_1 agents.[35]

Ingestion of the medication with food may alleviate the GI discomfort that sometimes can accompany antihistamine use. Patients, however, should be advised to avoid taking fexofenadine with antacids because this can interfere with drug absorption. Individuals with comorbid conditions, such as hepatic or renal disease, may require lower dosages as a result of impaired metabolism or excretion of these drugs. Certain special patient populations, including children, the elderly, and pregnant or breastfeeding women, may also need antihistamine dosage adjustments (Table 189-4). Therapeutic end points are usually dictated by improvement in histamine-related signs and symptoms (eg, severity of pruritus; wheal number, size, and frequency). As for drug toxicity, no particular monitoring beyond the usual surveillance for adverse effects is required in most cases. Because of reports of hepatotoxicity, some sources recommend periodic liver transaminase evaluation when cyproheptadine is prescribed.[1,4,6]

RISKS AND PRECAUTIONS

Sedation is the most commonly reported problem, primarily with first-generation H_1 antihistamines

TABLE 189-3
Dosing Regimens for H_1 Antihistamines[1,6,15,18,33,81]

DRUG	FORMULATION	DOSAGE	CONDITIONS REQUIRING DOSAGE ADJUSTMENT
First-generation H_1 Antihistamines			
Chlorpheniramine	2-, 4-, 8-, 12-mg tablet	Adult: 4 mg thrice daily, 4 times daily; 8-12 mg twice daily	Hepatic impairment
	2 mg/5 mL syrup	Age 6-11 years: 2 mg q4-6h	
Cyproheptadine	4-mg tablet	Adult: 4 mg thrice daily, 4 times daily	Hepatic impairment
	2 mg/5 mL syrup	Age 7-14 years: 4 mg twice daily, thrice daily	
Diphenhydramine	25-, 50-mg tablet	Adult: 25-50 mg q4-6h	Hepatic impairment
	12.5 mg/5 mL syrup	Age 6-12 years: 12.5-25 mg q4-6h	
	50 mg/15 mL syrup	Age <6 years: 6.25-12.5 mg q4-6h	
	6.25 mg/5 mL syrup		
	12.5 mg/5 mL syrup		
Hydroxyzine	10-, 25-, 50-, 100-mg tablet	Age ≥6 years: 25-50 mg q6-8h or at bedtime	Hepatic impairment
	10 mg/5 mL syrup	Age <6 years: 25-50 mg daily	
Tripelennamine	25-, 50-, 100-mg tablets	Adult: 25-50 mg q4-6h	Hepatic impairment

(*Continued*)

TABLE 189-3
Dosing Regimens for H_1 Antihistamines[1,6,15,18,33,81] (*Continued*)

DRUG	FORMULATION	DOSAGE	CONDITIONS REQUIRING DOSAGE ADJUSTMENT
Second-generation H_1 Antihistamines			
Acrivastine[a]	8-mg tablet	Adult: 8 mg thrice daily	Renal impairment
Azelastine	2-mg tablet[b]	Adult: 2-4 mg twice daily	Renal and hepatic impairment
	0.1% nasal spray	Age 6-12 years: 1-2 mg twice daily	
		2 sprays/nostril twice daily	
Cetirizine	5-, 10-mg tablet	Age ≥6 years: 5-10 mg daily	Renal and hepatic impairment
	5 mg/mL syrup	Age 2-6 years: 5 mg daily	
		Age 6 months to 2 years: 2.5 mg daily	
Desloratadine	2.5-, 5-mg tablet	Age ≥12 years: 5 mg daily	Renal and hepatic impairment
	5 mg/mL syrup	Age 6-12 years: 2.5 mg daily	
		Age 1-6 years: 1.25 mg daily	
		Age 6-12 months: 1 mg daily	
Ebastine[b]	10-mg tablet	Age ≥6 years: 10-20 mg daily	Renal impairment
		Age 6-12 years: 5 mg daily	
		Age 2-5 years: 2.5 mg daily	
Fexofenadine	30-, 60-, 120-, 180-mg tablet	Age ≥12 years: 60 mg daily, twice daily; 120-180 mg daily	Renal impairment
		Age 6-12 years: 30 mg daily, twice daily	
Levocetirizine	5-mg tablet	Age ≥6 years: 5 mg daily	Renal and hepatic impairment
Loratadine	10-mg tablet	Age ≥6 years: 10 mg daily	Renal and hepatic impairment
	5 mg/mL suspension	Age 2-9 years: 5 mg daily	
Mizolastine[b]	10-mg tablet	Adult: 10 mg daily	Hepatic impairment

[a]Available in the United States only as a fixed-dose combination with pseudoephedrine hydrochloride, 120 mg.
[b]Not currently available in the United States.

(Table 189-5).[1,4] The sedative effect is much more pronounced with first-generation H_1 antihistamines, especially in the ethanolamine and phenothiazine groups, and is less marked with the alkylamine group antihistamines. The use of first-generation H_1 antihistamines is associated with an increase in occupational injuries and automobile accidents.[36] Sedating H_1 antihistamines are sometimes used for their somnolent effects at night; however, these agents actually delay the onset of rapid eye movement sleep, leading to poor sleep quality and impaired memory, attention capabilities, and sensory-motor performance the following day.[37] Other CNS effects of sedating antihistamines include dizziness, tinnitus, disturbed coordination, inability to concentrate, blurred vision, and diplopia. Stimulatory CNS effects, which occur especially with the alkylamine group, include nervousness, irritability,

TABLE 189-4
Factors for Risk-to-Benefit Assessment of First-generation H_1 Antihistamine Therapy

- Risks
  - History of cardiac arrhythmias, particularly ventricular arrhythmias
  - First trimester of pregnancy
  - Prostatic hypertrophy
- Contraindications
  - Narrow-angle glaucoma
  - Concomitant use of monoamine oxidase inhibitors

TABLE 189-5
Adverse Effects of H_1 Antihistamines

- Sedation[a]
- Other CNS disturbances[a]
  - Dizziness
  - Tinnitus
  - Blurred vision
  - Irritability or nervousness
  - Insomnia
  - Tremor
- GI complaints (rare)[a]
  - Nausea and vomiting
  - Diarrhea or constipation
  - Anorexia
- Anticholinergic effects[a]
  - Dry mucous membranes
  - Urinary retention
  - Postural hypotension
- Cardiac arrhythmias (particularly prolongation of the QT interval, ventricular arrhythmias, torsades de pointes) (rare)[a]
- Hypersensitivity reactions (rare)

[a]More common in first-generation H_1 antihistamines.

insomnia, and tremor.[1,4] Most second-generation H_1 antihistamines, except for cetirizine and levocetirizine, are low sedating and thus better tolerated than first-generation agents.[37-41] Although far less soporific than its parent compound hydroxyzine, cetirizine causes sedation in approximately 10% to 15% of users, and appears to be dose dependent.[38,39] At doses of 10 mg and 20 mg, cetirizine occupies 12% and 25% of H_1 receptors in the human brain, respectively, as assessed by positron emission tomography scan.[40] Fexofenadine and loratadine/desloratadine, on the other hand, are least likely to enter the brain, and consequently have few if any CNS effects.[4,41]

Anticholinergic side effects are much more common with first-generation H_1 antihistamines as they have an affinity for cholinergic receptors.[4,42,43] These anticholinergic side effects include dry mucous membranes, urinary retention and hesitancy, postural hypotension, dizziness, erectile dysfunction, and constipation. These effects are often associated with the ethanolamine, phenothiazine, and piperazine groups. The anticholinergic effects of H_1 antihistamines preclude their use in patients with narrow-angle glaucoma and require close monitoring in patients with prostatic hypertrophy.[4,42] Most second-generation H_1 antihistamines are selective for H_1 receptors, and thus lack these anticholinergic side effects.[1,4,41]

GI complaints, including anorexia, nausea, vomiting, epigastric distress, diarrhea, and constipation, are uncommon side effects. The administration of these agents with food frequently reduces/eliminates these symptoms.[1,6]

Arrhythmias, particularly prolongation of the QT interval and torsades de pointes, are the most serious, but fortunately rare, cardiac side effects.[1,6] These dose-dependent effects are mediated through blockade of potassium channels unrelated to the H_1 histamine receptor. Transient hypotension may develop after intravenous therapy, especially if the drug is administered rapidly.[43] Two early second-generation H_1 antihistamines, terfenadine and astemizole, were removed from the world market because of risk of QT interval prolongation and torsades de pointes. Other second-generation agents have an approximately 1000-fold lower affinity for cardiac ion channels than terfenadine and astemizole. Evidence for ventricular arrhythmias have been extensively investigated and found to be absent in the newer second-generation H_1 antihistamines currently available in the United States.[4,5,42]

The occurrence of cutaneous reactions after the administration of oral H_1 antihistamines is extremely uncommon. Reported reactions include eczematous dermatitis, allergic contact dermatitis, urticaria, petechiae, fixed drug eruptions, and photosensitivity. Some of these reactions may be secondary to excipients in the drug.[44]

DRUG INTERACTIONS

The H_1 antihistamines may interact with other drugs metabolized by the hepatic CYP system, such as imidazole antifungals, cimetidine, and macrolide antibiotics.[4,6] The first-generation H_1 antihistamines—diphenhydramine, chlorpheniramine, clemastine, promethazine, hydroxyzine, and tripelennamine—inhibit the hepatic enzyme CYP 2D6 in vitro.[45,46] In vivo, diphenhydramine has been noted to increase levels of other drugs metabolized by the CYP 2D6 system, including metoprolol and venlafaxine. First-generation H_1 antihistamines are contraindicated for patients receiving monoamine oxidase inhibitors as these medications may interfere with the metabolism of monoamine oxidase inhibitors.[6,46,47]

Central depressive effects may be accentuated when sedating H_1 antihistamines are combined with alcohol or other CNS depressants such as benzodiazepines. These interactions are generally not observed with second-generation H_1 antihistamines. In rare circumstances, antihistamines of the phenothiazine group may block and reverse the vasopressor effect of epinephrine. If individuals receiving a phenothiazine require a vasopressor agent, norepinephrine or phenylephrine should be used.[1,6,42]

SPECIAL PATIENT POPULATIONS

CHILDREN

Many of the sedating and low-sedating H_1 antihistamines can be safely used in children with appropriate dosing. Children may be more susceptible to certain side effects, such as excitation and insomnia, especially with first-generation H_1 antihistamines. Acute poisoning may develop with first-generation agents, but this is rare. Hallucinations, ataxia, incoordination, athetosis, and convulsions are the major features. The second-generation H_1 antihistamines cetirizine, levocetirizine, and loratadine have been extensively studied in children from 6 to 36 months of age with long-term safety profiles equal to placebo.[4,48,49]

ELDERLY

Caution should be used when treating elderly patients who may have renal insufficiency, cardiac disease, chronic hepatic disease, and/or CNS or balance comorbidities with first-generation H_1 antihistamines. Older individuals may be more susceptible to anticholinergic effects, particularly urinary retention and hesitancy, constipation, and postural hypotension.[4,6,42]

PREGNANT WOMEN

There are limited guidelines for the use of H_1 antihistamines in pregnant women. Most H_1 antihistamines are classified as U.S. Food and Drug Administration (FDA) pregnancy category B or category C. Based on earlier reports linking H_1 antihistamines to fetal malformations, particularly cleft palate defects, these agents have been

customarily avoided in the first trimester of pregnancy. However, newer studies, including a metaanalysis of 200,000 first-trimester exposures to first-generation antihistamines, did not demonstrate an increased risk of congenital malformations.[50] In a prospective trial, astemizole administered to pregnant women was not associated with intrauterine growth retardation or perinatal complications, and the rate of congenital abnormalities was identical to the control group and general population.[51-53]

BREASTFEEDING WOMEN

No formal studies have been performed on the safety of H_1 antihistamines during breastfeeding. Theoretically, these drugs may diminish milk supply via anticholinergic effects. Clemastine, diphenhydramine, promethazine, triprolidine, cetirizine, loratadine, fexofenadine, desloratadine, and levocetirizine are all known to be excreted in breastmilk; however, their effects on the nursing infants has not been studied. When antihistamine therapy is necessary for the nursing mother, second-generation agents, which have fewer side effects and toxicities, are preferred.[4,6,52]

H_2 ANTIHISTAMINES

MECHANISM OF ACTION

H_2 antihistamines also are inverse agonists and include cimetidine, ranitidine, famotidine, and nizatidine. These agents bind to H_2 receptors located throughout the body, including epithelial cells, endothelial cells, and chondrocytes, as well as lymphocytes, neutrophils, eosinophils, monocytes, mast cells and dermal dendritic cells. In addition to their association with gastric acid secretion, H_2 receptors, and thus H_2 antihistamines, appear to play some role in antigen presentation, cellular recruitment, cutaneous vascular permeability, and local release of inflammatory mediators.[54] These complex immune events, however, remain poorly defined.

PHARMACOKINETICS

H_2 antihistamines are rapidly absorbed from the GI tract with peak levels occurring between 1 and 2 hours after administration. They are eliminated primarily unchanged through renal excretion with only 10% to 35% undergoing hepatic metabolism. The half-life of cimetidine in plasma is 2 hours, and approximately 70% is excreted unchanged in the urine.[54,55] The plasma half-life of ranitidine is 2 to 3 hours in healthy adults, and longer in elderly individuals and those with liver or kidney disease.[55,56] Famotidine has a plasma half-life of 3 to 8 hours, but may exceed 20 hours in patients with renal failure.[57] Nizatidine has a plasma half-life of 1 to 2 hours, and its duration of action is up to 10 hours.[51] The oral bioavailability of nizatidine is not affected by food and this antihistamine is primarily eliminated by the kidneys within 16 hours. In general, H_2 antihistamines have limited penetration of the blood–brain barrier.[55-58]

TABLE 189-6
Dermatologic Indications for Treatment with H_2 Antihistamines

- Acute allergic reactions
- Chronic urticaria (as a second-line agent)
- Systemic symptoms associated with mastocytosis (especially GI related)

INDICATIONS IN DERMATOLOGY

There are few data from controlled studies supporting the use of H_2 antihistamines to treat dermatologic conditions (Table 189-6). Several studies demonstrate that H_2 antihistamines have a limited role in blocking histamine-induced wheal-and-flare reactions in the skin. Compared to H_1 antihistamines alone, the addition of an H_2 antihistamine further reduces this reaction by only 5% to 15%.[59] Most often, H_2 antihistamines are used in combination with H_1 agents in refractory cases of CIU and angioedema. In a double-blind crossover study, greater reductions in pruritus and wheal number, size, and severity were observed when cimetidine was combined with hydroxyzine versus hydroxyzine alone.[59] Similar observations have been made for when cimetidine was combined with chlorpheniramine.[60] Combination H_1 and H_2 antihistamine therapy also may be helpful in reducing GI symptoms associated with mastocytosis.[34] High doses of cimetidine also have been reported successful in the treatment of verruca vulgaris in some individuals.[61]

INITIATION OF THERAPY

For treatment of dermatologic conditions, H_2 antihistamines are generally used following an unsuccessful trial of H_1 antihistamines alone. In most cases, treatment with H_2 antihistamines may be initiated without any particular laboratory screening. The inhibition of the hepatic CYP system and the potential for drug interactions is usually the greatest concern, and patients' medication lists should be reviewed carefully before initiating therapy. Ranitidine is less inhibitory of the CYP system than cimetidine and may be the preferred H_2 antihistamine in situations in which drug interactions are a particular concern.[56] Also, patients with decreased creatinine clearance may require dosage adjustments.[62] In patients taking the cardiac drug dofetilide, cimetidine is contraindicated because of the risk of prolongation of the QT interval and life-threatening cardiac arrhythmias.[63] Therapeutic end points for H_2 antihistamines are determined by improvements in

TABLE 189-7
Dosing Regimens for H_2 Antihistamines[46,47,50,82]

DRUG	FORMULATION	DOSAGE	CONDITIONS REQUIRING DOSAGE ADJUSTMENT
Cimetidine	100-, 200-, 300-, 400-, 800-mg tablet	Adult: 400-800 mg twice daily	Renal or hepatic impairment
	300 mg/5 mL syrup		
	200 mg/20 mL syrup		
Ranitidine	75-, 150-, 300-mg tablet	Adult: 75-150 mg twice daily	Renal impairment
	15 mg/5 mL syrup	Pediatric: 5-10 mg/kg/day divided in 2 doses	
	150-mg granules		
Famotidine	10-, 20-, 40-mg tablet	Adult: 20-40 mg twice daily	Renal impairment
	40 mg/5 mL syrup	Age 1-16 years: 1 mg/kg/day	
		Divided in 2 doses, up to 40 mg twice daily	
Nizatidine	150-, 300-mg capsule	Age ≥12 years: 150 mg daily, twice daily	Renal impairment
	15 mg/5 mL syrup		

histamine-related signs and symptoms (eg, pruritus; flushing, wheal size/frequency/intensity). Table 189-7 lists the dosing regimens for H_2 antihistamines.

RISKS AND PRECAUTIONS

In general, H_2 antihistamines are safe and rarely cause significant side effects. However, in patients with hepatic or renal disease, there is a greater risk for adverse effects. H_2 antihistamines may have CNS effects, including confusion, headache, and dizziness (Table 189-8). These effects seem to be partly dose-related. Other, less-common side effects include drowsiness, malaise, muscular pain, diarrhea, and constipation. There are rare reports of granulocytopenia.[56-58] For patients with a history of thrombocytopenia, a complete blood count may be warranted once H_2 antihistamine therapy is initiated, because thrombocytopenia has been reported as an idiosyncratic effect in a few individuals.[64] By their suppression of gastric acid secretion, H_2 antihistamines may facilitate oral infections and increase the risk of pneumonia in immunocompromised individuals.[65] As a class, these drugs may mask symptoms of gastric carcinoma. Also, cimetidine and ranitidine inhibit alcohol dehydrogenase activity, which can lead to increased blood alcohol levels.[56]

Uncommon side effects of cimetidine include gynecomastia with or without elevated prolactin levels in men; galactorrhea with elevated prolactin levels in women; and loss of libido, impotence, and reduction of sperm counts in young men.[56] Modest elevations in serum creatinine levels and hepatic transaminase levels have been reported and are reversible after the drug is withdrawn.[56,66] Rare dermatologic adverse effects, including alopecia and urticarial vasculitis, also have been reported.[66-68]

Ranitidine does not bind to androgen receptors and unlike cimetidine, does not enhance cell-mediated immune responses.[56] Ranitidine may affect the cardiovascular system by altering parasympathetic and sympathetic control functions. This altered cardiac sympathovagal balance may lead to a susceptibility to arrhythmias, particularly bradyarrhythmias, after intravenous infusion.[68]

Famotidine and nizatidine are associated with few side effects. They cause less inhibition of the CYP system, and therefore have fewer reported drug interactions.[57,58]

TABLE 189-8
Adverse Effects of H_2 Antihistamines

- CNS disturbances
  - Confusion
  - Dizziness
  - Drowsiness
  - Headache
- GI effects
  - Abdominal pain
  - Diarrhea or constipation
  - Increased transaminases and hepatitis (rare)
  - Nausea or vomiting
- Gynecomastia
- Hematologic (rare)
  - Anemia
  - Thrombocytopenia
- Hypersensitivity to H_2 (uncommon)
- Drug interactions
- Cardiac effects (with concomitant administration of dofetilide; dofetilide use is therefore a contraindication)

DRUG INTERACTIONS

Through inhibition of the CYP system, cimetidine increases the serum levels of numerous drugs, including some commonly prescribed medications.[68,69] Cimetidine increases levels of warfarin potentially leading to an increased risk of bleeding. This agent

also interacts with cardiac drugs, including β blockers, calcium channel blockers, amiodarone, and antiarrhythmic agents. As already mentioned, cimetidine use is contraindicated in patients taking dofetilide. Both cimetidine and ranitidine also can reduce the urinary excretion of procainamide and quinidine. Other common drugs with which cimetidine interacts are phenytoin, benzodiazepines, metformin, sulfonylureas, and selective serotonin reuptake inhibitors.[56,68,69]

Although ranitidine interacts with other medications less frequently than cimetidine, significant interactions with fentanyl, metoprolol, midazolam, nifedipine, theophylline, and warfarin have been observed. Ranitidine may decrease the absorption of diazepam and reduce its plasma concentration by 25%.[56]

SPECIAL PATIENT POPULATIONS

CHILDREN

Of the H_2 antihistamines, ranitidine and famotidine have pharmacokinetics that have been relatively well studied in children, and these drugs have acceptable safety profiles with appropriate dosing. Cimetidine and nizatidine are not recommended for children for uses other than reducing gastric acidity. One adverse effect unique to children is an uncommon but drug class–wide risk of necrotizing enterocolitis in neonates.[70]

ELDERLY

Older patients may require a reduction in dosage to accommodate decreased renal function, as well as careful review of medication lists. Elderly patients also appear more susceptible to H_2 antihistamine–induced CNS disturbances, such as confusion and dizziness.[56-58]

PREGNANT WOMEN

The H_2 antihistamines are classified as FDA pregnancy category B drugs. Cimetidine, ranitidine, famotidine, and nizatidine are all excreted in breastmilk; however, the potential effects on the nursing infant have not been studied.[56-58]

OTHER THERAPEUTIC AGENTS WITH ANTIHISTAMINIC ACTIVITY

TRICYCLIC ANTIDEPRESSANTS

Tricyclic antidepressants bind to both H_1 and H_2 receptors. The tricyclic antidepressant most commonly used in dermatology is doxepin, which is 800 times more potent than diphenhydramine.[71] Oral doxepin has been used successfully in the treatment of refractory CIU, physical urticarials, and pruritus associated with systemic conditions.[72,73] In a double-blind, crossover study, doxepin proved more efficacious than diphenhydramine in the treatment of CIU.[72] Topical doxepin cream has proven effective for the treatment of pruritus in patients with atopic dermatitis and lichen simplex chronicus.[73]

Sedation is the most common adverse effect with both oral and topical doxepin, although some patients may develop tolerance with regular use.[72-74] Oral doxepin has been classified by the FDA as a pregnancy category C drug; topical doxepin is classified as a pregnancy category B drug.[74] Use of both oral and topical forms is contraindicated during breastfeeding. The safety and efficacy of doxepin therapy in children younger than age 12 years has not been established. This drug also should be used with caution in elderly patients, who may be more susceptible to its anticholinergic effects, including urinary retention and blurred vision. Doxepin should not be used concurrently with monoamine oxidase inhibitors, and all patients with underlying depression should be closely monitored for signs of suicidal ideation when initiating therapy. Doxepin also can cause a sudden increase in intraocular pressure and should not be used in patients with glaucoma.[71-74] Although doxepin has the potential to alter myocardial function, several studies have shown this medication to be safe in depressed patients with and without underlying heart disease.[75]

KETOTIFEN

Ketotifen, a benzocycloheptathiophene derivative, is an H_1 antihistamine with additional mast cell– and basophil-stabilizing properties.[3,76,77] Ketotifen has been used successfully in the treatment of CIU, physical urticaria, and symptoms associated with mastocytosis.[76-79] In a double-blind trial in CIU patients, ketotifen alleviated pruritus more effectively than clemastine or placebo.[79] Studies comparing ketotifen with low-sedating H_1 antihistamines have not been performed. Sedation and atropine-like side effects have been reported with this medication.[80] There are no studies evaluating the safety of ketotifen in pregnant or breastfeeding women. Ketotifen is available in the United States only as an ophthalmic solution.[80]

REFERENCES

1. Simons FE. Advances in H_1-antihistamines. *N Engl J Med.* 2004;351:2203-2217.
2. Parsons ME, Ganellin R. Histamine and its receptors. *Br J Pharmacol.* 2006:147:S127-S135.
3. Leurs R, Church MK, Taglialatela M. H_1 antihistamines: inverse agonism, anti-inflammatory actions and cardiac effects. *Clin Exp Allergy.* 2002;32:489.
4. Simons EF, Simons KJ. Histamine and H_1 antihistamines: celebrating a century of progress. *Clin Rev Allergy Immunol.* 2011;128:1139-1150.

5. Simons EF, Simons KJ. H_1 antihistamines. Current status and future directions. *World Allergy Organ J.* 2008;1:145-155.
6. Passalacqua G, Canonica GW. Structure and classification of H_1-antihistamines and overview of their activities. In: Simons FER. *Histamine and H_1-Antihistamines in Allergic Disease*, 2nd ed. New York, NY: Marcel Dekker; 2002:65.
7. Jinquan T, Reimert CM, Deleuran B, et al. Cetirizine inhibits the in vitro and ex vivo chemotactic response of T lymphocytes and monocytes. *J Allergy Clin Immunol.* 1995;95(5, pt 1):979-086.
8. Marone G, Granata F, Spadaro G, et al. Antiinflammatory effects of oxatomide. *J Investig Allergol Clin Immunol.* 1999;9(4):207-214.
9. el-Shazly AE, Masuyama K, Samejima Y, et al. Inhibition of human eosinophil chemotaxis in vitro by the antiallergic agent emedastine difumarate. *Immunopharmacol Immunotoxicol.* 1996;18(4):587-595.
10. Agrawal DK, et al. Desloratadine attenuation of eosinophil chemotaxis, adhesion, and superoxide generation. *Allergy.* 2000;55(suppl 63):276.
11. Jansen B, Graselli U, Dallinger S, et al. Pharmacokinetics and pharmacodynamics of the novel H_1-receptor antagonist emedastine in healthy volunteers. *Eur J Clin Pharmacol.* 2000;55(11-12):837-841.
12. Deschamps C, Dubruc C, Mentre F, et al. Pharmacokinetic and pharmacodynamic modeling of mizolastine in healthy volunteers with an indirect response model. *Clin Pharmacol Ther.* 2000;68(6):647-657.
13. Grant JA, Riethuisen JM, Moulaert B, et al. A double-blind, randomized, single-dose, crossover comparison of levocetirizine with ebastine, fexofenadine, loratadine, mizolastine, and placebo: suppression of histamine-induced wheal-and-flare response during 24 hours in healthy male subjects. *Ann Allergy Asthma Immunol.* 2002;88(2):190-197.
14. Devalia JL, De Vos C, Hanotte F, et al. A randomized, double-blind, crossover comparison among cetirizine, levocetirizine, and ucb 28557 on histamine-induced cutaneous responses in healthy adult volunteers. *Allergy.* 2001;56(1):50-57.
15. Cetirizine. In: DRUGDEX System. Greenwood Village, CO: Thomson Micromedex [updated periodically].
16. Grant JA, Danielson L, Rihoux JP, et al. A double-blind, single-dose, crossover comparison of cetirizine, ebastine, epinastine, fexofenadine, terfenadine and loratadine versus placebo: suppression of histamine-induced wheal and flare response during 24 hours in healthy male subjects. *Allergy.* 1999;54:700-707.
17. Meltzer EO, Gillman SA. Efficacy of fexofenadine versus desloratadine in suppressing histamine-induced wheal and flare. *Allergy Asthma Proc.* 2007;28:67-73.
18. Geha RS, Meltzer EO. Desloratadine: a new, nonsedating, oral antihistamine. *J Allergy Clin Immunol.* 2001;107:751.
19. Morgan M, Khan DA. Therapeutic alternatives for chronic urticaria: an evidence-based review, part 1. *Ann Allergy Asthma Immunol.* 2008;100:403-412.
20. Breneman D, Bronsky EA, Bruce S, et al. Cetirizine and astemizole therapy for chronic idiopathic urticaria: A double-blind, placebo-controlled comparative trial. *J Am Acad Dermatol.* 1995;33(2, pt 1):192-198.
21. Ring J, Hein R, Gauger A, et al. Once-daily desloratadine improves the signs and symptoms of chronic idiopathic urticaria: a randomized, double-blind, placebo-controlled study. *Int J Dermatol.* 2001;40(1):72-76.
22. Leynadier F, Duarte-Risselin C, Murrieta M. Comparative therapeutic effect and safety of mizolastine and loratadine in chronic idiopathic urticaria: URTILOR study group. *Eur J Dermatol.* 2000;10:205.
23. Lorette G, Giannetti A, Pereira RS, et al. One-year treatment of chronic urticaria with mizolastine: Efficacy and safety. URTOL study group. *J Eur Acad Dermatol Venereol.* 2000;14(2):83-90.
24. Camarasa JM, Aliaga A, Fernández-Vozmediano JM, et al. Azelastine tablets in the treatment of chronic idiopathic urticaria. Phase III, randomised, double-blind, placebo and active controlled multicentric clinical trial. *Skin Pharmacol Appl Skin Physiol.* 2001;14(2):77-86.
25. LaRosa M, Leonardi S, Marchese G, et al. Double-blind multicenter study on the efficacy and tolerability of cetirizine compared to oxatomide in chronic idiopathic urticaria in preschool children. *Ann Allergy Asthma Immunol.* 2001;87(1):48-53.
26. Breneman DL. Cetirizine versus hydroxyzine and placebo in chronic idiopathic urticaria. *Ann Pharmacother.* 1996;30:1075.
27. Potter PC, Kapp A, Maurer M, et al. Comparison of the efficacy of levocetirizine 5 mg and desloratadine 5 mg in chronic idiopathic urticaria patients. *Allergy.* 2009;64(4):596-604.
28. Handa S, Dogra S, Kumar B. Comparative efficacy of cetirizine and fexofenadine in the treatment of chronic idiopathic urticaria. *J Dermatolog Treat.* 2004;15(1):55-57.
29. Garg G, Thami GP. Comparative efficacy of cetirizine and levocetirizine in chronic idiopathic urticaria. *J Dermatolog Treat.* 2007;18:23.
30. Diepgen TL; Early Treatment of the Atopic Child Study Group. Long-term treatment with cetirizine of infants with atopic dermatitis: a multi-country, double-blind, randomized, placebo-controlled trial (the ETAC trial) over 18 months. *Pediatr Allergy Immunol.* 2002;13(4):278-286.
31. Klein PA, Clark RA. An evidence-based review of the efficacy of antihistamines in relieving pruritus in atopic dermatitis. *Arch Dermatol.* 1999;135(12):1522-1555.
32. Tefferi A, Pardanani A. Clinical, genetic, and therapeutic insights into systemic mast cell disease. *Curr Opin Hematol.* 2004;11:58.
33. Frieri M, Alling DW, Metcalfe DD. Comparison of the therapeutic efficacy of cromolyn sodium with that of combined chlorpheniramine and cimetidine in systemic mastocytosis. Results of a double-blind clinical trial. *Am J Med.* 1985;78:9.
34. Friedman BS, Santiago ML, Berkebile C, et al. Comparison of azelastine and chlorpheniramine in the treatment of mastocytosis. *J Allergy Clin Immunol.* 1993;92(4):520-526.
35. Weller K, Ziege C, Staubach P, et al. H_1 antihistamine up dosing in chronic spontaneous urticaria: patients' perspective of effectiveness and side effects—a retrospective study. *PLoS One.* 2011;6(9):e23931.
36. Casale TB, Blaiss MS, Gelfand E, et al. First do no harm: managing antihistamine impairment in patients with allergic rhinitis. *J Allergy Clin Immunol.* 2003;111(5):S835-S842.
37. Kay GG, Berman B, Mockoviak SH, et al. Initial and steady-state effects of diphenhydramine and loratadine ion sedation, cognition, mood and psychomotor performance. *Arch Intern Med.* 1997;157:2350-2356.

38. Aaronson DW. Evaluation of cetirizine in patients with allergic rhinitis and perennial asthma. *Ann Allergy Asthma Immunol.* 1996;76:440.
39. Mansmann HC Jr, Altman RA, Berman BA, et al. Efficacy and safety of cetirizine therapy in perennial allergic rhinitis. *Ann Allergy.* 1992;68(4):348-353.
40. Tashiro M, Kato M, Miyake M, et al. Dose dependency of brain histamine H_1 receptor occupancy following oral administration of cetirizine hydrochloride measured using PET with [11C]doxepin. *Hum Psychopharmacol.* 2009;24:540-548.
41. Horak F, Stübner UP. Comparative tolerability of second generation antihistamines. *Drug Saf.* 1999;20:385.
42. Church DS, Church MK. Pharmacology of antihistamines. *World Allergy Organ J.* 2011;4:S22-S27.
43. Lauria JI, Markello R, King BD. Circulatory and respiratory effects of hydroxyzine in volunteers and geriatric patients. *Anesth Analg.* 1968;47:378.
44. Sharkouri AA, Bahan SL. Hypersensitivity to antihistamines. *Allergy Asthma Proc.* 2013;34:488-496.
45. Mann RD, Pearce GL, Dunn N, et al. Sedation with "non-sedating" antihistamines: four prescription-event monitoring studies in general practice. *BMJ.* 2000;320(7243):1184-1186.
46. Hamelin BA, Bouayad A, Drolet B, et al. In vitro characterization of cytochrome P450 206 inhibition by classic histamine H_1 receptor antagonists. *Drug Metab Dispos.* 1998;26(6):536-539.
47. Hamelin BA, Bouayad A, Méthot J, et al. Significant interaction between the nonprescription antihistamine diphenhydramine and the CYP2D6 substrate metoprolol in healthy men with the high or low CYP2D6 activity. *Clin Pharmacol Ther.* 2000;67(5):466-477.
48. Simons FE; Early Prevention of Asthma in Atopic Children (EPAAC) Study Group. Safety of levocetirizine treatment in young atopic children; an 18-month study. *Pediatr Allergy Immunol.* 2007;18:535-542.
49. Church MK, Maurer M, Simons FE, et al. Risk of first generation H_1 antihistamines: a GA(2)LEN position paper. *Allergy.* 2010;65(4):459-466.
50. Gilbert C, Mazzotta P, Loebstein R, et al. Fetal safety of drugs used in the treatment of allergic rhinitis: a critical review. *Drug Saf.* 2005;28(8):707-719.
51. Seto A, Einarson T, Koren G. Pregnancy outcome following first trimester exposure to antihistamines: meta-analysis. *Am J Perinatol.* 1997;14:119.
52. Pastuszak A, Schick B, D'Alimonte D, et al. The safety of astemizole in pregnancy. *J Allergy Clin Immunol.* 1996;98(4):748-750.
53. Gilboa SM, Alles EC, Rai RP, et al. Antihistamines and birth defects; a systemic review of the literature. *Expert Opin Drug Saf.* 2014;13:1667-1698.
54. Panula P, Chazot PL, Cowart M, et al. International union of basic and clinical pharmacology. XCVVIII. Histamine receptors. *Pharmacol Rev.* 2015;67:601-655.
55. Simons FE, Sussman GL, Simons KJ. Effect of the H_2-antagonist cimetidine on the pharmacokinetics and pharmacodynamics of the H_1-antagonists hydroxyzine and cetirizine in patients with chronic urticaria. *J Allergy Clin Immunol.* 1995;95:685.
56. Cimetidine, Ranitidine. In: DRUGDEX System. Greenwood Village, CO: Thomson Micromedex [updated periodically].
57. Famotidine. In: DRUGDEX System. Greenwood Village, CO: Thomson Micromedex [updated periodically].
58. Nizatidine. In: DRUGDEX System. Greenwood Village, CO: Thomson Micromedex [updated periodically].
59. Thomas RH, Browne PD, Kirby JD. The influence of ranitidine, alone and in combination with clemastine, on histamine-mediated cutaneous weal and flare reactions in human skin. *Br J Clin Pharmacol.* 1985;20:377-382.
60. Bleehen SS, Thomas SE, Greaves MW, et al. Cimetidine and chlorpheniramine in the treatment of chronic idiopathic urticaria: a multi-centre randomized double-blind study. *Br J Dermatol.* 1987;117(1):81-88.
61. Leman JA, Benton EC. Verrucas. Guidelines for management. *Am J Clin Dermatol.* 2000;1:143.
62. Drayer DE, Romankiewicz J, Lorenzo B, et al. Age and renal clearance of cimetidine. *Clin Pharmacol Ther.* 1982;31(1):45-50.
63. Yamreudeewong W. Potentially significant drug interactions of class III antiarrhythmic drugs. *Drug Saf.* 2003;26:421.
64. Gafter U, Zevin D, Komlos L, et al. Thrombocytopenia associated with hypersensitivity to ranitidine: possible cross-reactivity with cimetidine. *Am J Gastroenterol.* 1989;84(5):560-562.
65. Laheij RJ, Sturkenboom MC, Hassing RJ, et al. Risk of community-acquired pneumonia and use of gastric acid-suppressive drugs. *JAMA.* 2004;292(16):1955-1960.
66. Tullio CJ, Roberts MA. Cimetidine-induced alopecia. *Clin Pharm.* 1985;4:145.
67. Nault MA, Milne B, Parlow JL. Effects of the selective H_1 and H_2 histamine receptor antagonists loratadine and ranitidine on autonomic control of the heart. *Anesthesiology.* 2002;96:336.
68. Penston J, Wormsley KG. Adverse reactions and interactions with H_2 receptor antagonists. *Med Toxicol.* 1986;3:192-216.
69. Jensen RT, Collen MJ, Pandol SJ, et al. Cimetidine-induced impotence and breast changes in patients with gastric hypersecretory states. *N Engl J Med.* 1983;308(15):883-887.
70. Guillet R, Stoll BJ, Cotten CM, et al. Association of H_2-blocker therapy and higher incidence of necrotizing enterocolitis in very low birth weight infants. *Pediatrics.* 2006;117(2):e137-e142.
71. Richelson E. Tricyclic antidepressants and histamine H_1 receptors. *Mayo Clin Proc.* 1979;54:669-674.
72. Greene SL, Reed CE, Schroeter AL. Double-blind crossover study comparing doxepin with diphenhydramine for the treatment of chronic urticaria. *J Am Acad Dermatol.* 1985;12:669.
73. Drake LA, Fallon JD, Sober A. Relief of pruritus in patients with atopic dermatitis after treatment with topical doxepin cream. The Doxepin Study Group. *J Am Acad Dermatol.* 1994;31:613.
74. Doxepin. In: DRUGDEX System. Greenwood Village, CO: Thomson Micromedex [updated periodically].
75. Veith RC, Raskind MA, Caldwell JH, et al. Cardiovascular effects of tricyclic antidepressants in depressed patients with chronic heart disease. *N Engl J Med.* 1982;306:954-59.
76. Egan C, Rallis TM. Treatment of chronic urticaria with ketotifen. *Arch Dermatol.* 1997;133:147.
77. Phanuphak P. Double-blind, placebo-controlled study of ketotifen in chronic urticaria. *Immunol Allerg Pract.* 1987;9:138.
78. Mansfield LE, Taistra P, Santamauro J, et al. Inhibition of dermographia, histamine, and dextromethorphan skin tests by ketotifen. A possible effect on cutaneous vascular response to mediators. *Ann Allergy.* 1989;63(3):201-206.

79. Kamide R, Niimura M, Ueda H, et al. Clinical evaluation of ketotifen for chronic urticaria: Multicenter double-blind comparative study with clemastine. *Ann Allergy.* 1989;62(4):322-325.
80. Ketotifen. In: DRUGDEX System. Greenwood Village, CO: Thomson Micromedex [updated periodically].
81. Simons FE, Simons KJ. Clinical pharmacology of H_1-antihistamines. In: Simons FE, ed. *Histamine and H_1-Antihistamines in Allergic Disease*. 2nd ed. New York, NY: Marcel Dekker; 2002:141.
82. Lessard E, Yessine MA, Hamelin BA, et al. Diphenhydramine alters the disposition of venlafaxine through inhibition of CYP2D6 activity in humans. *J Clin Psychopharmacol.* 2001;21(2):175-184.

Chapter 190 :: Cytotoxic and Antimetabolic Agents

:: Jeremy S. Honaker & Neil J. Korman

AT-A-GLANCE

- Cytotoxic and antimetabolic agents are used in dermatology to treat serious, life-threatening, and recalcitrant disease.
- Methotrexate and azathioprine are commonly used in dermatology whereas thioguanine, hydroxyurea, cyclophosphamide, chlorambucil, and liposomal doxorubicin are occasionally used.
- Methotrexate is U.S. Food and Drug Administration (FDA) approved for treatment of psoriasis and advanced mycosis fungoides, whereas cyclophosphamide is FDA approved for advanced mycosis fungoides only, and liposomal doxorubicin is approved for AIDS-related Kaposi sarcoma; other uses of the agent in this chapter occur on an "off-label" basis.
- Cytotoxic and antimetabolic agents act through inhibition and/or interruption of the cell cycle.
- Side effects and complications with these potentially dangerous medications are numerous, and close clinical followup and laboratory evaluation is necessary.
- Cytotoxic agents used in dermatology, as well as those initiated for other purposes, may yield distinctive cutaneous eruptions and cutaneous sequelae.

Cytotoxic and antimetabolic agents may be used to treat severe or refractory skin disease. The toxicities of such agents are significant and must be balanced against their therapeutic advantages. In treating skin disease, most of these agents are utilized at the lower immunomodulatory doses rather than at the higher cytotoxic doses.

Cytotoxic and antimetabolic drugs modulate the behavior of inflammatory and other cells through inhibition of cell growth and development. The cell cycle represents a conceptual schema for the sequence of growth experienced by essentially all cells (Chap. 5). Specific cytotoxic drugs may be effective at different stages of the cell cycle.

The cytotoxic drugs commonly used in dermatology fall into 2 classes: (1) antimetabolites and (2) alkylating agents. Antimetabolites mimic natural molecules and are most active while DNA is being synthesized (S phase). Alkylating agents exert effect through physicochemical interactions with DNA, such as alkylation, crosslinking, and carbamylation. The effects of alkylating agents are generally independent of the cell cycle.

The immunosuppressive properties of cytotoxic agents (see also Chap. 192) provide benefit in immunologically mediated disease, yet these agents may predispose to infection as well. Potentially lethal infections may arise quickly in an immunosuppressed patient. Those placed on cytotoxic agents should be queried at each visit for symptoms of infection, such as fever, chills, sweating, shortness of breath, cough, headache, dysuria, and arthritis. Prompt reporting of symptoms should be encouraged.

We have organized these medications into 3 groups, Antiproliferative, Cytotoxic, and Immunosuppressive/antiinflammatory.

ANTIPROLIFERATIVE AGENTS

METHOTREXATE

Methotrexate (MTX) is one of the most frequently employed antimetabolic agents in dermatology. An impressive record of safety with MTX has accumulated, though patient selection and monitoring is crucial for its safe use.

Discovered in 1948, MTX was initially used as a chemotherapeutic agent to treat hematologic malignancies. In dermatology, low doses of MTX are given for the treatment of nonneoplastic diseases including psoriasis, psoriatic arthritis, and dermatomyositis. It also has been used for the treatment of a wide variety of cutaneous disease (Table 190-1), including sarcoidosis, lymphomatoid papulosis, and pyoderma gangrenosum, among others.

In the treatment of psoriasis and psoriatic arthritis, MTX is considered the "gold standard" for the treatment of severe psoriasis and psoriatic arthritis. Based on a meta-analysis of several studies of psoriasis patients treated with MTX, approximately 45% of patients reach a 75% improvement in their Psoriasis Area and Severity Index (PASI) score.[1] Furthermore, the combination of MTX with biologics in the treatment of psoriasis has improved efficacy compared to either drug alone.[2]

MECHANISM OF ACTION

MTX is a synthetic analog of folate that competitively and irreversibly inhibits dihydrofolate reductase, thereby inhibiting folic acid metabolism and acting as an immunosuppressant/antiinflammatory medication (Fig. 190-1). MTX also partially inhibits thymidylate synthetase. Inhibition of these enzymes reduces

TABLE 190-1
Uses for Methotrexate in Dermatology

- U.S. Food and Drug Administration–approved indications
  - Severe psoriasis (± psoriatic arthritis)
  - Mycosis fungoides
- "Off-label" uses
  - Dermatomyositis
  - Cutaneous lupus erythematosus
  - Scleroderma
  - Pemphigus vulgaris
  - Bullous pemphigoid
  - Mucous membrane pemphigoid
  - Cutaneous polyarteritis nodosa
  - Behçet disease
  - Pyoderma gangrenosum
  - CD30+ lymphoproliferative disease lymphomatoid papulosis; anaplastic large cell lymphoma)
  - Pityriasis lichenoides et varioliformis acuta
  - Pityriasis rubra pilaris
  - Sarcoidosis
  - Alopecia areata
  - Atopic dermatitis
  - Lichen planus

availability of purine nucleotides and thymidylate, required for RNA and DNA synthesis. Of note, it was recently discovered that MTX also can inhibit DNA methylation via decreasing cellular levels of *S*-adenyl methionine.[3]

All folate antagonists (eg, trimethoprim-sulfamethoxazole) share the same basic properties as MTX and concomitant use may potentiate the toxicity of MTX (see section "Drug Interactions").

PHARMACOKINETICS

Oral MTX is absorbed rapidly through the GI tract. In children, absorption is decreased by concurrent ingestion of food and milk, but this has not been observed in adults. In adults, the mean bioavailability is 67% of the administered dose. Peak plasma levels occur 1 to 3 hours after administration and remain greater than 0.1 µM, the level at which inhibition of protein synthesis ends, for about 6 hours. The half-life of the drug is 4 to 5 hours. For doses higher than 20 mg/wk, GI absorption is more erratic, and subcutaneous (SC) dosing is recommended.[4] A head-to-head, randomized, crossover study of oral versus SC MTX in 47 patients with rheumatoid arthritis revealed that SC administration had a 14% to 40% higher bioavailability than oral MTX, with a linear dose-proportional increase up to 25 mg/wk.[5] Therefore, patients treated with MTX may have improved efficacy with SC MTX, in comparison to oral MTX, due to improved bioavailability.

Methotrexate is eliminated chiefly by the kidneys, with 60% to 95% excreted unchanged. Decreases in glomerular filtration or tubular secretion may lead to MTX toxicity. Approximately 50% of MTX within the blood is protein bound. Weak organic acids, such as aspirin or many other nonsteroidal antiinflammatory agents, may displace MTX, altering blood levels and renal excretion (see section "Drug Interactions").

INDICATIONS

Methotrexate may be used for several diseases in dermatology (Table 190-1), but its chief indication is for treatment of severe psoriasis and psoriatic arthritis. The effects of MTX in psoriasis were first recognized in the late 1950s and 1960s,[6] and in 1972, MTX was approved by the U.S. Food and Drug Administration (FDA) for psoriasis at the same time the initial psoriasis guidelines were published. The listed indication was for the treatment of severe, recalcitrant, disabling psoriasis.[7] By the later 1980s, more than one-half of dermatologists reported using MTX to treat severe psoriasis.[8] MTX has been used to treat all of the psoriasis subtypes, including plaque, guttate, pustular, and erythrodermic forms of the disease.

The impact of an increasing number of systemic treatments for psoriasis (the "biologics"; Chap. 193) on the use of MTX has not been fully studied, although MTX is significantly less expensive than the biologics, even after including the costs of laboratory monitoring and liver biopsies.[9] Unfortunately many insurance companies require an inadequate response to or intolerance to MTX as a prerequisite to biologic approval.

Many patients with lymphomatoid papulosis are treated with MTX.[10] Fewer patients with mycosis fungoides/Sezary syndrome are treated with MTX, but higher doses of MTX have been associated with improvements in all primary CD30+ lymphoproliferative disorders.[11]

Topical MTX is available; its successful use has been reported in stage IA or IB mycosis fungoides and in lymphomatoid papulosis (1% MTX compounded in a hydrophilic gel containing laurocapram to enhance percutaneous absorption).[12]

DOSING REGIMEN

Methotrexate is available in 2.5-mg tablets. Subcutaneous solution (25 mg/mL) is less expensive, and may have better efficacy and less adverse effects compared with the oral form. Although a single weekly dose of MTX is the typical regimen used, some prefer the older regimen of a weekly dose divided into 3 equal parts and separated by 12 hours. These dosing regimens are equally efficacious, but split dosing may lessen GI upset.

Typical oncologic doses of MTX (100-250 mg/m^2/wk) are cytotoxic; however, lower doses (7.5-25.0 mg/wk) are immunomodulatory. In dermatology, MTX doses are typically less than 30 mg/wk; most psoriasis patients are controlled and tolerate 15 mg/wk. For CTCL, MTX is usually administered at a dose of 10 to 25 mg per week, although higher doses have been used.[11] Lymphomatoid papulosis is sensitive to MTX and may respond well to weekly doses as low as 5 mg.[10] Higher doses (60-240 mg^2/m^2 IV) of MTX, given with folinic acid (leucovorin) to minimize damage to normal

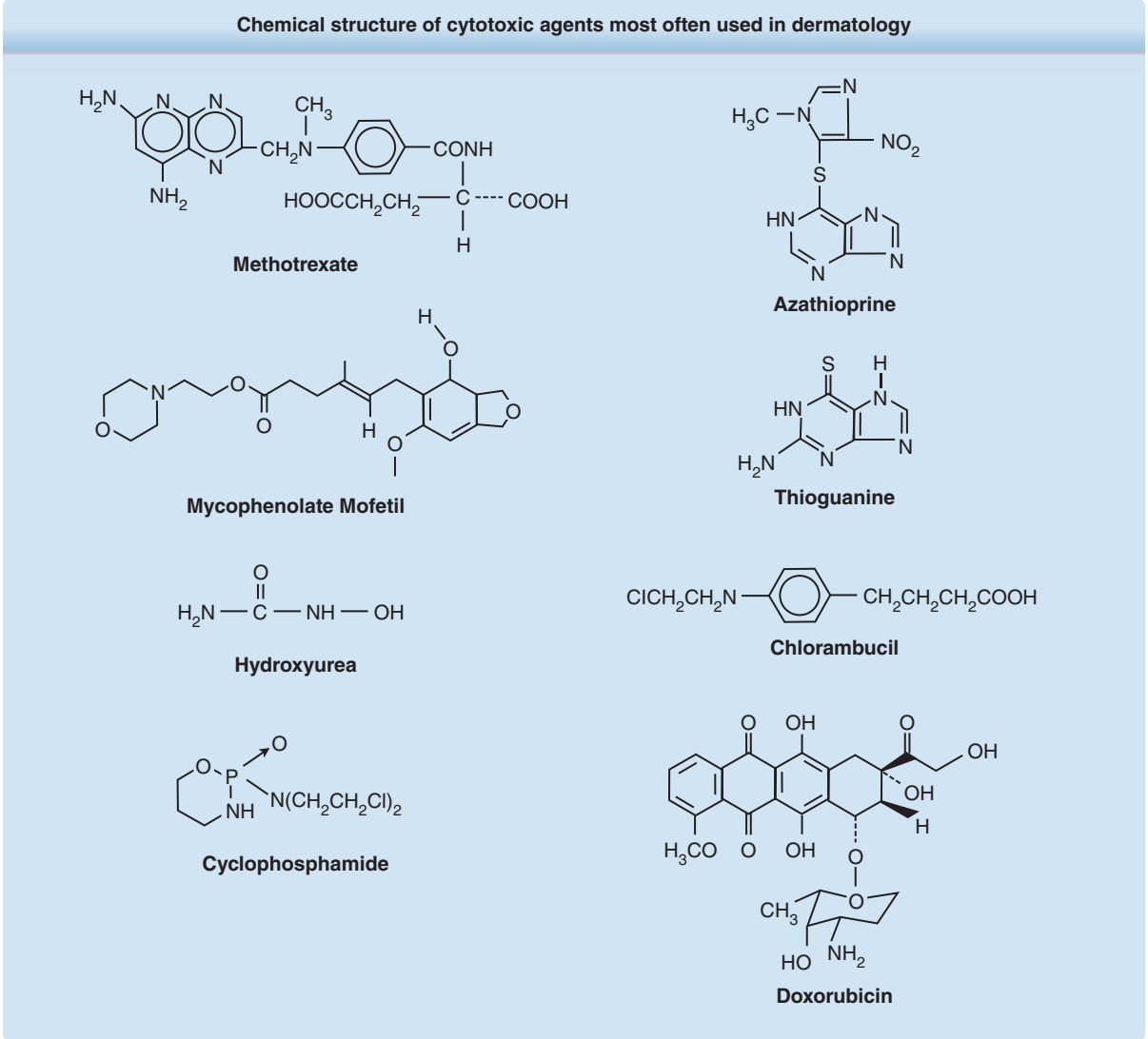

Figure 190-1 Chemical structure of cytotoxic agents most often used in dermatology.

tissues, have been used to treat advanced mycosis fungoides.[11]

Despite its longstanding use in CTCL patients, relatively few clinical studies of MTX have been published. The response of patients with mycosis fungoides to low-dose MTX (defined commonly as <100 mg/wk but often limited to <30 mg/wk) ranges from "definite improvement" in 9 of 16 patients to an overall response in 17 of 29 patients with erythrodermic MF and 20 of 60 with plaque MF (median dose of 25 mg/wk).[13]

Cumulative dose should be tracked and recorded, as this may impact monitoring (particularly liver function) with continued use (see section "Monitoring Therapy").

INITIATING THERAPY

Evaluation before MTX use includes a careful history and physical examination, and assessment of concomitant conditions or medications that may limit MTX use. Exclusion of patients inappropriate for MTX therapy is an important first step in management. Absolute contraindications to the use of MTX include pregnancy, lactation, and bone marrow suppression as evidenced by significant anemia, leukopenia, or thrombocytopenia.

Relative contraindications to MTX use include abnormalities in renal or liver function (including viral hepatitis), cirrhosis, excessive alcohol consumption, concomitant use of hepatotoxic drugs, active infection, immunosuppression, recent vaccination with a live vaccine, obesity (body mass index >30), diabetes mellitus, poor reliability, and an active desire to conceive (men and women) (Table 190-2).[7] Although the elderly are often less amenable to MTX therapy because of declining renal function, elderly patients may tolerate MTX at lower doses, and titration of the medication should be approached cautiously. Although use of MTX is typically avoided in the setting of HIV, it may be appropriate in select circumstances; caution is advised.[14]

TABLE 190-2
Risks and Precautions With Methotrexate Use

- Absolute contraindications
  - Pregnancy (category X)
  - Lactation
  - Significant anemia, leukopenia, or thrombocytopenia
- Relative contraindications
  - Renal dysfunction (dose may be reduced)
  - Hematologic disease (dose may be reduced)
  - Hepatic disease or hepatic dysfunction
  - Unreliable patient
  - Excessive alcohol consumption
  - Diabetes mellitus and/or obesity
  - Active infection and/or potential reactivation of infection (tuberculosis)
  - HIV infection
  - Man or woman contemplating impending conception
- Common adverse effects
  - GI distress (minimized with folate supplementation)
  - Myelosuppression (acute)
  - Toxic hepatitis
  - Liver fibrosis/cirrhosis (chronic)

Baseline laboratory studies (Table 190-3) include a complete blood cell count with differential (CBC/diff), liver function testing, serologic assessment for hepatitis B and C antibodies, renal function assessment, and pregnancy and HIV screening (where indicated).[14] Although a baseline screen for tuberculosis using purified protein derivative (PPD) or one of the interferon gamma release assays (such as QuantiFERON GOLD) is not expressly mandated, the Centers of Disease Control and Prevention recommends consideration of such testing for any patient placed on long-term immunosuppressive medication.[15]

Initiation of MTX therapy in a psoriasis patient typically involves use of a single 2.5- to 5-mg test dose, which is particularly important in patients with declining renal function or other risk factors for hematologic toxicity.[16] Repeat laboratory studies, a skin examination, and a review of systems are conducted 1 week later. Performance of repeat laboratory studies sooner than 5 to 6 days after dosing yields only expected elevated liver transaminases and may confound interpretation.

If the test dose is tolerated and laboratory studies are unremarkable, weekly therapy may commence using a typical starting dose of 5 to 15 mg/wk, depending on the severity of disease, overall health, and ideal body weight of the patient. The dose may be increased by 2.5 to 5.0 mg every 4 to 8 weeks until adequate control is achieved or toxicity ensues up to a dose of 25 mg per week as a maximum (management of toxicity discussed below).[7] When improvement has stabilized, the dose may be tapered in 2.5-mg decrements to a point at which disease activity is stable. For those patients in whom the plan is to treat with long-term MTX, the goal is to allow for mild- or low-grade psoriasis to minimize the cumulative dose. It is important to discuss this expectation with the patient. Concomitant topical therapy may also lower the MTX dose needed for satisfactory control.

If a patient does not demonstrate satisfactory improvement on a dose of 20 to 25 mg/wk, consideration of alternative agents is indicated. Some patients with refractory disease may respond better to SC MTX. In psoriasis, MTX can be combined with ultraviolet B (UVB) phototherapy, or biologics to enhance efficacy.[7]

TABLE 190-3
Laboratory Monitoring for Methotrexate[a]

CBC, platelets	7-14 d after drug initiation, then every 2-4 wk for the first few months, then every 1-3 mo, depending on leukocyte count and patient stability
Renal function studies	Serum BUN and Cr levels at 1- to 2-mo intervals: GFR for patients at risk for decreased renal function
Liver chemistries: AST, ALT alkaline phosphatase, serum albumin	Every 4-8 wk (more frequent liver chemistry monitoring in lieu of an initial liver biopsy for patients with hepatic risk factors)
Pregnancy test	Women of childbearing potential

[a]More frequent monitoring may be required under certain circumstances such as dosage changes or if there are concomitant medications.
Adapted from Kalb RE, Strober B, Weinstein G, et al. Methotrexate and psoriasis: 2009 National Psoriasis Foundation Consensus Conference. J Am Acad Dermatol. 2009;60(5):824-837.

MONITORING THERAPY

It can take 4 to 8 weeks to see a response to changes in MTX dosage.[7] Ongoing laboratory evaluation during MTX therapy (Table 190-3) should include a CBC with differential and liver function tests weekly for 2 to 4 weeks for the first few months, then every 1 to 3 months.[7] It is recommended to repeat testing with any decreased oral intake, dose escalation or intercurrent illness. Liver function testing should not be performed earlier than 5 days after dosing to avoid confounded results. Renal function tests should be performed every 1 to 2 months,[7] or with any suspicion of altered renal function.

For patients without risk factors for liver injury (Table 190-2), current recommendations suggest consideration of liver biopsy after 3.5 to 4 g total cumulative dosage. However, for patients with risk factors for MTX-induced liver injury, a delayed baseline liver biopsy should be considered (after 2-6 months of use, when it is apparent the medication is efficacious, well tolerated, and likely to be continued), and again at a cumulative dose of 1.0 to 1.5 g.

The gold standard for assessing MTX-induced liver fibrosis is percutaneous needle biopsy. The procedure is not without risk; minor bleeding occurs in 1 in 1000 patients, and the risk of death is estimated at 1 in 10,000.[17] Liver specimens are assessed for lobular architecture, inflammation and fibrosis, and fat infiltration and graded using a scale of I to IV (Table 190-4).

TABLE 190-4

Guidelines for MTX Therapy Based on Roenigk Scale for Histopathologic Evaluation for Liver Biopsy Findings

Roenigk Scale for Histopathologic Evaluation of liver biopsy findings	Guidelines for MTX therapy
Grade 1: Normal; fatty infiltration, mild; nuclear variability, mild; portal inflammation, mild	Continue MTX
Grade 2: Fatty infiltration, moderate to severe; nuclear variability, moderate to severe; portal tract expansion, portal tract inflammation and necrosis, moderate to severe	Continue MTX
Grade IIIA: Fibrosis, mild (portal fibrosis here denotes formation of fibrotic septa extending into the lobules; slight enlargement of portal tracts without disruption of limiting plates or septum formation does not classify the biopsy as grade III)	Continue MTX Repeat biopsy after approximately 6 mo of MTX therapy Consider alternate prescription
Grade IIIB: Fibrosis, moderate to severe	Stop MTX. Exceptional circumstances may require continued MTX with thorough followup liver biopsies.
Grade IV: Cirrhosis (regenerating nodules as well as bridging of portal tracts must be demonstrated)	Stop MTX. Exceptional circumstances, however, may require continued MTX therapy with thorough followup liver biopsies

Adapted from Kalb RE, Strober B, Weinstein G, Lebwohl M. Methotrexate and psoriasis: 2009 National Psoriasis Foundation Consensus Conference. *J Am Acad Dermatol*. 2009;60(5):824-837, with permission. Copyright © American Academy of Dermatology.

Patients with grades I and II histology may continue MTX, those with grade IIIA histology may continue with a repeat liver biopsy in 6 months, and those with grades IIIB and IV histology (moderate to severe fibrosis or cirrhosis) should discontinue MTX.[7]

Noninvasive serum biomarkers, including procollagen (PIIINP) and FibroTest/FibroSURE, and ultrasound diagnostics have been used to evaluate liver fibrosis as an alternative to liver biopsy. Measurement of the amino terminal peptide of procollagen III (PIIINP) is popular in some European countries, but the test is not approved in the United States.[7] Serum assay of the PIIINP may suggest fibrosis; however, specificity is limited. PIIINP is a marker of fibrogenesis, and it may be elevated in any organ system PIIINP as it is a marker of fibrogenesis.[18-21] It is unreliable in patients with psoriatic arthritis. The FibroTest, also known as FibroSURE in the United States, uses a patented validated artificial intelligence algorithm of indirect serum markers for fibrosis that is corrected for age and sex. The 5 serum markers used in the FibroSURE test are γ-glutamyltranspeptidase, total bilirubin, haptoglobin, apolipoprotein A-I, and α_2-macroglobulin. The composite FibroSURE score ranges from 0-1 with higher scores associated with higher levels of liver fibrosis.[22] A systemic review of studies evaluating the use of FibroTest in hepatitis C–related fibrosis revealed a specificity and sensitivity of 90% and 47%, respectively.[23]

In addition to serum markers, ultrasonography of the liver has been used to monitor hepatotoxicity without any helpful results.[24,25] However, transient elastography (TE), which is measured by using pulse-echo ultrasonography of the liver, is capable of one-dimensional evaluation of liver fibrosis by measuring the propagation and velocity of the wave in the liver. A meta-analysis of 9 TE studies for the detection of liver fibrosis in hepatitis C patients identified a sensitivity of 87% and specificity of 91%.[26] Although a few small studies comparing TE to liver biopsy have been conducted in psoriasis patients treated with MTX,[22,27,28] the consensus finding is that TE, when used in conjunction with other biomarkers (FibroSURE, PIIINP), may be helpful in monitoring for liver toxicity, and therefore reduce unnecessary liver biopsies. However, at present, percutaneous liver biopsy remains the gold standard for evaluation when MTX-induced liver disease is suspected.[29,30]

RISKS AND PRECAUTIONS

Absolute and relative contraindications and common adverse effects of MTX are summarized in Table 190-2.

COMPLICATIONS

Adverse reactions to MTX can range from the trivial to life threatening.[1]

Hematologic Effects: The most important acute adverse effect of MTX is myelosuppression. Neutropenia with life-threatening bone marrow toxicity can occur. Leukocyte and platelet counts are decreased maximally approximately 7 to 10 days after treatment. Risk factors for bone marrow toxicity include advanced age, poor renal function, hypoalbuminemia, lack of folate supplementation, and concurrent administration of conflicting medications (see section "Drug Interactions"). Blood counts should be monitored after changes in therapy, especially in patients with impaired renal function (eg, the elderly). Trimethoprim-sulfamethoxazole and other folate antagonists should be avoided entirely as they compete with MTX for renal tubular secretion and when coadministered with MTX are commonly associated with severe toxicity.

GI Effects: Nausea and vomiting with oral administration is common (10%-30% of all patients) and dose-related. Such effects may be seen with parenteral dosing as well. Symptoms may even occur before dosing or 24 to 36 hours afterward, suggesting a psychosomatic or anticipatory basis in select cases. Supplementation with folate (1-5 mg/d) reduces GI symptoms without compromising efficacy.[31-34] A study on folate supplementation (5 mg daily) suggested a slight decrease in MTX efficacy,[35] but others questioned

the methodology,[16] and most authorities continue to advocate strongly for supplementation.[7]

Hepatic Effects: MTX is hepatotoxic, and induction of liver fibrosis is a major concern with long-term MTX use. The drug should be avoided in patients with liver disease and active alcoholics. Some elevation in liver transaminases is expected with use; these occur near the time of drug administration. Therefore, monitoring labs should be performed at least 5 to 6 days after the last dose. These elevations are not strictly predictive of those predisposed to fibrosis. Dose reduction is indicated if transaminases exceed 2- to 3-fold normal values and discontinuance is indicated if transaminases exceed 5-fold normal values when measured at least 5 to 6 days after the last dose. It is recommended to withhold MTX for 1 to 2 weeks and then repeating liver function tests before reintroducing the drug. Indications for liver biopsy are described before ("Monitoring therapy").

Mucosal and Cutaneous Effects: Oral ulcerations or stomatitis may occur with MTX use. Skin ulceration, particularly of the lower legs, may herald bone marrow suppression. In patients treated with MTX for psoriasis, rapid ulceration of psoriatic plaques may also suggest toxicity.[36] Laboratory studies and dose reduction or complete discontinuance is indicated when mucocutaneous ulcerations or skin ulcerations develop, respectively. Methotrexate may also engender a cutaneous "recall reaction" in areas of prior irradiation or recent sunburn.[25] In patients with coexistent renal failure, MTX excretion is reduced and can lead to prolonged blood and skin levels of MTX. Mild alopecia may uncommonly occur with MTX use. "Methotrexate-induced rheumatoid papular eruption" occurs in patients with rheumatoid arthritis and presents with erythematous indurated papules usually on the proximal extremities that develop shortly after MTX administration and resolve upon MTX discontinuation.[37] Other cutaneous manifestations include acral erythema, epidermal necrosis, and vasculitis.

Carcinogenicity: It is not clear that MTX increases the risk for malignancy or lymphoproliferative disease. One study showed that MTX was associated with a small increased risk of nonmelanoma skin cancers in rheumatoid arthritis and psoriatic arthritis patients.[38] Another study of patients taking MTX for rheumatoid arthritis demonstrated a 50% increased risk of malignancy relative to the general population, with a 3-fold increased risk in melanoma, a 5-fold increased risk in non-Hodgkin lymphoma, and a nearly 3-fold increase in lung cancer.[39] Conversely, another study revealed a slight increase in lymphoma among psoriatic patients, but use of MTX was not discriminatory.[40] A systematic review of 88 studies revealed there was insufficient evidence to fully evaluate the risk of lymphoma and malignancies, but there was no strong evidence of increased risk identified.[41] Furthermore, a nested case control of 5,757 rheumatoid arthritis patients treated with MTX found that high disease activity, but not MTX dose, was a risk factor for lymphoproliferative disorders.[42]

Mutagenicity and Teratogenicity: MTX is a category X agent during pregnancy and administration is absolutely contraindicated (Table 190-2). Reliable contraception is requisite while taking MTX.[7] Pregnancies that occur after the discontinuation of MTX appear unaffected, but it is generally advocated that men wait 3 months after discontinuance before attempting conception and women wait 1 complete menstrual cycle.[7]

Pulmonary Effects: Acute pneumonitis and pulmonary fibrosis have been reported with MTX use in psoriasis, although such reactions are more common in rheumatoid arthritis patients.[43] Pulmonary toxicity likely represents an idiosyncratic reaction. MTX-induced lung injury can be sudden and severe with a 17% mortality rate.[44] However, the process is usually subacute and presents as a new onset of cough and shortness of breath. A meta-analysis demonstrated that MTX was not associated with an increased risk of adverse respiratory events, respiratory infections, or noninfectious respiratory events in those with psoriasis, psoriatic arthritis, and inflammatory bowel disease.[45] The strongest predictors of lung injury are older age, diabetes, rheumatoid pleuropulmonary involvement, hypoalbuminemia, and previous use of disease-modifying antirheumatic drugs (DMARDs). A chest radiograph should be performed in those with symptoms of pneumonitis. Discontinuance is recommended if examination findings are concerning. Pulmonary function testing is not helpful in screening for the detection or prevention of pulmonary toxicity.[46]

Opportunistic Infections: Opportunistic infections (eg, *Pneumocystis* pneumonia, cryptococcosis, and histoplasmosis) have been reported in otherwise healthy individuals receiving low-dose MTX.[47-51] However, affected patients were often being concurrently treated with other immunosuppressive medications as well, with prednisone being the most common agent.

Anaphylaxis: Systemic anaphylaxis with low-dose MTX has been reported.[52] Many patients with anaphylaxis had received MTX before, at comparable doses, without untoward effects.

Folate and Folinic Acid Supplementation: Daily supplementation with 1 to 5 mg of folate has reduced adverse effects and toxicities without compromising the efficacy of MTX.[28,31] Nausea, vomiting, diarrhea, alopecia, stomatitis and oral ulceration, elevated transaminases, and mild myelosuppression may be prevented. Folic acid supplementation ranges from 1 to 5 mg daily or skipped on the day MTX is taken.[53] Elevated homocysteine levels—common with MTX use and an independent risk factor for coronary artery disease—are decreased with folate supplementation.[54] Pneumonitis and moderate to severe myelosuppression are not mitigated by folate supplementation.

Folinic acid (leucovorin) also may be used if folic acid does not sufficiently control MTX toxicities. Folinic acid should be given at least 24 hours after the dose of weekly MTX, because unlike folate, it competes with MTX for cellular uptake. Folinic acid is prescribed as 5 mg by mouth every 12 hours for 3 doses.[55]

One theoretical risk that may occur with folate supplementation is the potential masking of vitamin B_{12} deficiency (macrocytosis). Progressively increasing mean corpuscular volume is common in patients on MTX and signals the onset of macrocytic anemia.

Overdose: MTX overdose should be treated promptly (within 24-36 hours after overdose) with folinic acid (leucovorin). Folinic acid is metabolized in vivo to tetrahydrofolate in the absence of dihydrofolate reductase, providing an alternative supply of DNA and RNA precursors.

Folinic acid should be given early, preferably within the first 24 to 36 hours after overdose. Folinic acid itself has very little toxicity. An oral dose of 10 mg/m^2, or 15 to 25 mg every 6 hours for 6 to 10 doses should be given on first suspicion of MTX overdose without delay for a serum assay.[7] If serum assay is available, oral or parenteral doses may be continued every 6 hours until the serum concentration of MTX falls to less than 10^{-8} M.

Drug Interactions: Although any drug that may enhance MTX toxicity should be avoided during therapy, there are several near-absolute contraindications (Table 190-5), including aspirin, many nonsteroidal antiinflammatory agents, probenecid, and trimethoprim-sulfamethoxazole.[56] Conversely, many cyclooxygenase-2 selective inhibitors, such as celecoxib, do not impact the pharmacokinetics of MTX.[7] Patients with psoriatic arthritis can be safely treated with ketoprofen, flurbiprofen, and piroxicam. In addition, patients receiving warfarin should have plasma prothrombin times monitored.

HYDROXYUREA

Hydroxyurea is an antiproliferative medication. Hydroxyurea was first synthesized in 1869 and has been used to treat hematologic malignancies, sickle cell anemia, and psoriasis among others.

MECHANISM OF ACTION

Hydroxyurea impairs DNA synthesis through inhibition of ribonucleotide diphosphate reductase, an enzyme that reduces nucleotides to deoxynucleotides. This inhibition limits the supply of DNA bases available for synthesis; strand breakage and cell death result. Hydroxyurea also prevents cells from repairing damage from UV or ionizing radiation, acting as a radiosensitizer. Finally, hydroxyurea yields hypomethylation of genes, altering expression,[57] and this may contribute to normalization of psoriatic skin through improved keratinocyte differentiation. Hydroxyurea is most active in cells with a high proliferative index. It is preferentially concentrated within leukocytes.

PHARMACOKINETICS

Hydroxyurea is a small molecule that is well absorbed after oral administration. Serum levels peak within 2 hours of dosing. Hydroxyurea has a rapid onset of action, with tissue effects noted within 5 hours. The metabolism of hydroxyurea is incompletely understood, but at least 80% is excreted by the kidney. With 24 hours of dosing, negligible amounts of hydroxyurea remain in the body.

INDICATIONS

In dermatology, hydroxyurea has been used chiefly for the treatment of psoriasis (Table 190-6) but also has been used as an adjuvant treatment in metastatic melanoma and in the treatment of erythromelalgia. Although there are no randomized clinical trials on hydroxyurea's use in psoriasis, studies suggest it has a beneficial effect. Efficacy has been demonstrated in plaque, pustular, and erythrodermic forms.

In 2 large series of 60 and 85 patients treated with hydroxyurea for severe psoriasis, 50% to 60% achieved a response.[58] One study compared use of MTX (15-20 mg/wk) and lower dose hydroxyurea (3-4.5 g/wk) and found a 77% reduction versus a 49%

TABLE 190-5
Drug Interactions of Methotrexate

- Aspirins[a]
- Nonsteroidal antiinflammatory agents[a]
- Probenecid[a]
- Trimethoprim-sulfamethoxazole
- Sulfonamides
- Penicillins
- Minocycline
- Ciprofloxacin
- Thiazide diuretics
- Furosemide
- Phenytoin
- Sulfonylureas
- Barbiturates
- Phenytoin
- Dipyridamole
- Ethanol
- Trimethoprim-sulfamethoxazole[a]

[a]Near absolute contraindications.

TABLE 190-6
Uses for Hydroxyurea in Dermatology

- U.S. Food and Drug Administration–approved indications
  - Squamous cell carcinoma of the head and neck (rare use)
  - Metastatic melanoma and GI melanoma (rare use)
- "Off-label" uses
  - Severe psoriasis (often an option for those with liver disease that limits other options)
  - Pyoderma gangrenosum
  - Sweet syndrome
  - Cryoglobulinemia
  - Scleromyxedema
  - Hypereosinophilic syndrome update

reduction in the PASI score, respectively.[59] In another nonrandomized study of 31 patients with recalcitrant psoriasis, 75% of patients treated with 1 to 1.5 g/d of hydroxyurea showed at least a 35% reduction in PASI score and 55% had a more than 70% reduction in PASI.[60] When hydroxyurea is effective, a response generally occurs within 2 to 3 weeks, with maximal improvement at 6 to 8 weeks. Because hydroxyurea has relatively little hepatotoxicity, it may be a viable alternative for those with liver disease, which precludes use of MTX.

DOSING REGIMEN

Hydroxyurea is available as 200-, 400-, and 500-mg tablets. Typical doses range from 1 to 2 g daily, usually as a divided dose. Doses above 2 g daily are unlikely to yield additional benefit and are increasingly toxic.[61] Hydroxyurea is usually well tolerated, but if dyspepsia occurs, it may be taken with food, milk, or antacids. There is limited data on the use of hydroxyurea in the pediatric population.

INITIATING THERAPY

Patients placed on hydroxyurea should have a complete history and physical examination. Exclusion of patients with severe comorbidities or active infections is indicated. All women of childbearing age should receive a pregnancy test. Baseline laboratory evaluation should include a CBC with differential, a serum chemistry evaluation, and urinalysis. Older patients and those with renal impairment are more susceptible to toxicity with hydroxyurea and should receive starting doses of only 500 mg/d.

MONITORING THERAPY

It is recommended that CBC with differential should be repeated weekly during the first month of therapy until stable, then monthly; this may be increased to biweekly, and, later, to monthly if results remain stable. Liver function studies and serum chemistry should be monitored monthly until stable, then every 3 to 6 months. Close surveillance for nonmelanoma skin cancer at followup visits is indicated. Discontinuance of hydroxyurea is indicated if a satisfactory response is not achieved with 8 weeks of therapy. Safety guidelines used during hydroxyurea therapy are summarized in Table 190-7.

RISKS AND PRECAUTIONS

Absolute and relative contraindications and common adverse effects of hydroxyurea are summarized in Table 190-8.

COMPLICATIONS

Approximately 18% of patients discontinued hydroxyurea because of side effects whereas 57% of patients experienced no side effects.[62] All patients on hydroxyurea develop megaloblastosis. Between 10% and 35% of patients given hydroxyurea develop anemia, whereas approximately 7% develop leukopenia, and 2% to 3% develop thrombocytopenia. Hydroxyurea should be discontinued if the hemoglobin declines by more than 3 g or the WBC declines to <4000 to 4500 cells/mm, or the platelet count declines to <100,000.[6] The most common adverse effect with hydroxyurea is myelosuppression. Myelosuppression due to hydroxyurea usually resolves rapidly on discontinuation.

Transient, reversible hepatitis occurs occasionally and is associated with an acute "flulike" syndrome. Sporadic elevations of blood urea nitrogen (BUN) and serum creatinine have been reported, but frank renal failure is rare.

Cutaneous side effects include diffuse reversible hyperpigmentation including the buccal mucosa and

TABLE 190-7
Safety Monitoring for Hydroxyurea Use

- Initial evaluation
  1. Careful history and physical examination
  2. Identification of proper patient characteristics and risk factors
- Survey for interacting medications (cytarabine)
- Baseline laboratory tests:
  1. CBC with differential/platelets
  2. Basic serum chemistry profile
  3. Urinalysis
  4. Renal function testing (creatinine/blood urea nitrogen)
- Ongoing laboratory monitoring
  1. CBC with differential/platelets
     Perform weekly initially, then
     a. transition to biweekly or monthly after 1 mo,
     b. perform testing with any dose escalation, and
     c. decrease/discontinue if hemoglobin decreases by 3 g/dL, white blood cell count <4000/mm^3, or platelets <100,000/mm^3
  2. Serum chemistry
     Perform monthly initially, then
     a. transition to every 3-6 mo if stable,
     b. perm testing with any dose escalation, and
     c. physical exam (focus on SCCs in particular)

CBC, complete blood cell count.

TABLE 190-8
Risks and Precautions With Hydroxyurea Use

- Absolute contraindications
  1. Hypersensitivity to hydroxyurea
- Relative contraindications
  1. Pregnancy/lactation (category D)
  2. History of hepatovenular occlusive disease
  3. Chronic anemia
  4. Renal disease
- Common adverse effects
  1. Myelosuppression (most common side effect)
  2. Dermatomyositis-like eruption
  3. Renal toxicity (elevated creatinine/blood urea nitrogen, hematuria, proteinuria)
  4. Increased risk of secondary hematologic malignancies when used for polycythemia vera

tongue) and ulcers over pressure points, often on the malleolus or tibial crest and on the back. Nail changes consist of longitudinal transverse or diffuse melanonychia, lunular pigmentation. The drug is also associated with hydroxyurea-associated vascular occlusion in patients with myeloproliferative disease. Other side effects include dermatomyositis-like eruptions.[63,64] lichenoid drug eruptions, ulcerations of the lower leg, alopecia, cutaneous vasculitis, photosensitivity, and radiation recall. In patients treated with hydroxyurea for myeloproliferative disorders, nonmelanoma skin cancer has been reported as an association.[65,66] Patients on hydroxyurea with atrophie-blanch-like lesions may need a trial off the drug, because hydroxyurea can mimic this syndrome through unknown mechanisms. Hydroxyurea may cause serpentine supravenous hyperpigmentation.

Other reported side effects of hydroxyurea include lupus erythematosus, mild GI distress (anorexia, nausea, vomiting, diarrhea, and constipation), and secondary malignancies when used in patients with primary hematologic disorders, such as polycythemia vera. Elevations in transaminases have been observed. A rare but important adverse effect of hydroxyurea is fever with a flulike illness. Hydroxyurea is a category D agent during pregnancy, and its use should be avoided. Males should use adequate contraception.

Drug Interactions: Hydroxyurea appears to have few significant drug interactions, with the exception of coadministration with other myelosuppressive agents and cytarabine. Use of such agents with hydroxyurea may lead to additive bone marrow toxicity.

IMMUNOSUPPRESSIVE/ ANTIINFLAMMATORY AGENTS

AZATHIOPRINE

Azathioprine is a synthetic analog of natural purine bases used in RNA and DNA synthesis (Fig. 190-1). Although many thiopurine derivatives exist, azathioprine is the agent most often used in dermatology.

MECHANISM OF ACTION

Azathioprine is a prodrug that is metabolized to 6-mercaptopurine (6-MP) and acts as an immunosuppressant/antiinflammatory. It was first synthesized in the 1950s and has better availability when given by mouth than 6-MP. 6-MP is further anabolized via hypoxanthine-guanine phosphoribosyl transferase (HGPRT), ultimately to a purine analog, 6-thioguanine (6-TG), which inhibits RNA and DNA synthesis and repair, yielding immunosuppression. HGPRT activation is critical. Interestingly, however, patients with Lesch-Nyhan syndrome (HGPRT deficiency) experience no immunosuppression or untoward effects while taking azathioprine.[67]

PHARMACOKINETICS

Azathioprine and its metabolite, 6-MP, are equally potent when administered parenterally, but azathioprine has improved bioavailability, with 88% of the oral dose being absorbed through the GI tract. After absorption, azathioprine is converted to 6-MP, mostly within erythrocytes. The fate of 6-MP is determined by one of 3 competing metabolic pathways: (1) it may be anabolized to an ultimate active form (6-TG) via HGPRT, (2) it may be catabolized to an inactive form via xanthine oxidase (XO), or (3) it may be catabolized to an inactive form by thiopurine methyltransferase (TPMT).[68]

Elucidation of the TPMT-dependent catabolic pathway has revolutionized the clinical use of azathioprine. In humans, expression of TPMT is variable as a result of genetic polymorphisms. Patients may be categorized into 3 subgroups: (1) a large majority possesses high levels of TPMT expression (~90%), (2) intermediate expression is found in ~10%, and (3) less than 1% demonstrate very low TPMT activity (about 1 in 300 persons).[69] Commercial assays for TPMT activity allow for graduated azathioprine dosing, with improved efficacy and a lesser incidence of unforeseen side effects (see section "Dosing Regimen").[70,71]

XO is another enzyme involved in the catabolism of 6-MP. Allopurinol, used in the treatment of gout, is a potent inhibitor of XO; toxicity may result in those taking both medications.[72] Unlike TPMT, there is very little genetic variation in XO expression, and it is unnecessary to assess innate XO expression before azathioprine dosing. A careful medication history, however, is critical (see section "Drug Interactions").

INDICATIONS

Azathioprine is licensed for 3 major indications: pemphigus vulgaris, systemic lupus erythematosus, and dermatomyositis. It is used for many other dermatologic conditions "off-label" (Table 190-9).[73]

TABLE 190-9
Uses for Azathioprine in Dermatology

- U.S. Food and Drug Administration–approved indications
  - Dermatomyositis
  - Pemphigus vulgaris
  - Systemic lupus erythematosus
- "Off-label" uses
  - Scleroderma
  - Atopic dermatitis
  - Psoriasis
  - Bullous pemphigoid
- Mucous membrane pemphigoid
  - Pityriasis rubra pilaris
  - Wegener granulomatosis
  - Cutaneous vasculitis
  - Relapsing polychondritis
  - Behçet disease
  - Sarcoidosis
  - Lichen planus
  - Polymorphous light eruption

A randomized clinical trial in adjuvant immunosuppressants in the treatment of pemphigus vulgaris, azathioprine was the most efficacious of the immunosuppressive medications.[74] Of the 4 medications (mycophenolate mofetil, azathioprine, cyclophosphamide, prednisolone), azathioprine remains a common regimen among practicing dermatologists.[75] Another study found no difference between mycophenolate mofetil (MMF) and azathioprine efficacy in the treatment of bullous pemphigoid, yet MMF had a lower liver toxicity profile.[76] In addition to bullous pemphigoid, azathioprine has been shown to be effective in treating moderate-to-severe, refractory atopic dermatitis.[77,78]

DOSING REGIMEN

Azathioprine is supplied as 50-mg tablets and also as an injectable solution for subcutaneous delivery. It is strongly recommended that dosing be based on the patient's TPMT expression (Table 190-10).[70,79] Acute severe neutropenia is the most feared complication and may occur in 86% of patients receiving a standard dosing of azathioprine in patients with 2 TPMT variant alleles.[80] Patients with one variant allele also may be at risk for greater toxicity, but this is controversial.[80] Dosing azathioprine should be approached with caution because of the potential for great toxicity in the following conditions: older adults, impaired renal or hepatic function, and concomitant treatment with allopurinol.[80]

Insufficient data exists to recommend an optimal dose, duration of therapy, or to predict the relapse rate upon discontinuation in the pediatric population. Doses up to 3 mg/kg/d have been used. TPMT levels should be repeated in cases of nonresponse or change in response. For pediatric patients with atopic dermatitis, safe and successful treatment has been described with a recommended starting dose of 2.0 to 2.5 mg/kg (1.0-1.5 mg/kg when TPMT levels are reduced).[81,82]

INITIATING THERAPY

Azathioprine can be initiated as monotherapy; however, concomitant bridge therapy with prednisone is often used in steroid-responsive bullous disorders.[80] Azathioprine should not be used in patients with severe comorbidities, active infections, or the possibility of reactivation of an infection (tuberculosis).

Baseline laboratory tests include a CBC with differential, renal and liver function testing, and an erythrocyte TPMT activity assay. Mycobacterial infections have occurred in patients taking azathioprine. Tuberculin skin testing or QuantiFERON gold should be considered in high-risk populations prior to initiating therapy.

MONITORING THERAPY

During therapy, a CBC with differential should be obtained biweekly for the first 2 months, monthly for the next 2 months, and every 2 months thereafter; liver function testing should occur every month for 3 months and then bimonthly thereafter, unless abnormalities are noted.[83] Laboratory monitoring may not need to be this frequent. Additional laboratory evaluation to rule out hepatitis B and C, HIV, and tuberculosis is also recommended.

Additional laboratory testing is necessary with dosage increases or if an initial TPMT level cannot be determined. Biannual physical examinations should pay particular attention to evidence of possible lymphoreticular disease and skin cancer, particularly squamous cell carcinoma (SCC). Safety guidelines used during azathioprine therapy are summarized in Table 190-11.

TABLE 190-10
Dosing of Azathioprine Based on Thiopurine Methyltransferase (TPMT) Enzyme Assay

TPMT ERYTHROCYTE ASSAY	DOSING RANGE
>19.0 U (high expression)	2.0-3.0 mg/kg
13.7-19.0 U (intermediate expression)	1.0-1.5 mg/kg
5.0-13.7 U (low expression)	Could consider 0.5 mg/kg or select alternative medication
<5.0 U (very low expression)	Do not use

TABLE 190-11
Safety Monitoring for Azathioprine Use

- Initial evaluation
- Careful history and physical examination
- Identification of proper patient characteristics and risk factors
- Survey for interacting medications (allopurinol, aminosalicylates)
- Baseline laboratories:
  - Thiopurine methyltransferase erythrocyte assay
  - CBC with differential
  - Basic serum chemistry profile
  - Liver function tests
  - Urinalysis
  - Pregnancy testing for women of child-bearing age
  - Tuberculin testing (if indicated)
  - Consider TPMT genotype assay if borderline intermediate/high expression by erythrocyte measurement
- Ongoing laboratory monitoring
  - CBC with differential
  - Biweekly for 2 mo, monthly for 2 mo, then bimonthly thereafter
- Liver function testing
  - Monthly for 3 mo, then bimonthly monthly thereafter
- Consider erythrocyte 6-TG level, repeat TPMT (to check for induction)
- Followup clinical evaluation
  - Biannual complete physical examinations
  - Particular attention to possible lymphoreticular disease (adenopathy)
  - Careful survey for nonmelanoma skin cancer (squamous cell carcinoma)

CBC, complete blood cell count.

TABLE 190-12
Risks and Precautions With Azathioprine Use

- Absolute contraindications
  - Hypersensitivity to azathioprine
  - Active or ongoing infection
- Relative contraindications
  - Pregnancy/lactation (category D, but myelosuppression of fetus/infant common—avoid)
  - Allopurinol use (dose must be reduced by 75%)
  - Prior lymphoproliferative disease or prior use of alkylating agents
- Common adverse effects
  - GI distress (minimized by administration with food)
  - Myelosuppression
  - Possible increased risk of lymphoproliferative disease or skin cancer
  - Possible opportunistic infections

RISK FACTORS AND PRECAUTIONS

Absolute and relative contraindications and common adverse effects of azathioprine are summarized in Table 190-12.

COMPLICATIONS

With careful monitoring, azathioprine is generally safe. Adverse effects tend to occur in those patients with lower TPMT activity levels, higher doses of azathioprine, or concomitant use of allopurinol. Specifically, overall adverse reactions and bone marrow toxicity have been found to be associated with TMPT polymorphisms, but hepatotoxicity has not.[84]

Hematologic Effects: Myelosuppression is a major side effect of azathioprine use. Higher rates of myelosuppression have been seen in patients without *TMPT* variations; therefore, pretreatment TPMT measurement should not be a substitute for regular hematologic surveillance during azathioprine treatment. In a large prospective study, the probability of myelotoxicity in the normal TPMT activity group was 3.5% compared with 14.3% in the intermediate TPMT activity group (95% CI 1.37-14.99, OR 4.5).[85] Generalized depression of all blood cell lines is most common,[86] but depression of any single lineage may be observed. Thrombocytopenia is a common initial presentation of bone marrow toxicity. Bone marrow suppression tends to occur at higher doses,[87] and in those with lower TPMT expression. Discontinuance usually results in complete marrow recovery.

Infections: Most patients treated with azathioprine also receive large doses of glucocorticoids. Therefore, it is often difficult to quantify the independent role of azathioprine in any predisposition toward infection. Herpes virus infections, human papilloma infection among others, have been reported in patients taking azathioprine.[87] However, there is not a general increased incidence of infection in cohorts of inflammatory bowel disease or atopic dermatitis patients.[88] Nevertheless, proper screening and selection of patients is warranted because of potential risk.

GI Effects: GI side effects are the most common side effects leading to drug discontinuation and are dose dependent.[89] Patients receiving high doses of azathioprine may experience nausea, vomiting, and diarrhea. Such symptoms are not usually treatment limiting and may be reduced by gradual dose escalation over weeks, administration with food, splitting the daily dose, or concomitant dosing with antiemetics. Pancreatitis is a separate established adverse effect, is rare, and is limited to patients with Crohn disease.[80]

Hepatic Effects: Mild imbalances in liver transaminases, bilirubin, and alkaline phosphatase are not uncommon, may be transient, and are typically without serious clinical implications. Toxic hepatitis (drug-induced hepatotoxicity, nodular regenerative hyperplasia) has developed in approximately 1% of patients treated with azathioprine for rheumatoid arthritis, and it is usually reversible.[90] Other adverse effects include hepatic veno-occlusive disease and associated pancreatitis. Discontinuation is warranted with evidence of liver toxicity.

Anaphylaxis: Azathioprine-induced shock and hypersensitivity reactions have been reported in patients with cutaneous disease. In most cases, hypotensive collapse occurred within hours of the initial dose. Several cases of drug fever also have been reported with azathioprine (Chap. 45).

Carcinogenesis: Azathioprine has been associated with increased risk for skin cancer and lymphoma. The increased number and aggressive behavior of SCCs may occur because of increased absorption of UVA radiation by 6-TG. As a result of increased UVA radiation absorption, increased reactive oxygen species develop and result in mutagenic DNA damage that is conducive for skin cancer development.[91-93] One small case series confirmed a reduced minimal erythema dose to UVA irradiation with coadministration of azathioprine.[91] Azathioprine increases the risk of squamous cell carcinoma by 56% (95% CI 1.11-2.18, OR 1.56),[94] and is associated with >12 months of use in patients with inflammatory bowel disease (95% CI 3.1-6.0, OR 4.3).[95] As UVA radiation is an important carcinogenic hazard for patients taking azathioprine, efforts (sun avoidance, broad spectrum sunscreen) to mitigate UVA exposure are paramount. Furthermore, for organ transplant patients, skin cancer screening at baseline and every 6 months, is advised. For patients who are developing multiple SCC, switching from azathioprine to medications with lower photocarcinogenesis potential (such as mycophenolate mofetil or sirolimus) may be considered.[80]

An increased risk of lymphoproliferative disease occurs in renal transplant recipients, rheumatoid arthritis patients, and inflammatory bowel disease patients treated with chronic azathioprine.[96-98] In one study, the relative risk was increased 10- to 13-fold, or

1 lymphoma per 1000 patient-years of azathioprine treatment. Dermatologic doses of azathioprine are often lower and the duration of treatment shorter than those used in other conditions, suggesting that the risk of lymphoma is probably lower in those treated for cutaneous disease. However, a meta-analysis of patients treated with azathioprine for inflammatory bowel disease who developed lymphoma included those on "low-dose" regimens.[98] In light of this information, it seems prudent to inform patients that the exact magnitude of any increased risk for lymphoma with "low-dose" azathioprine is not known.

Mutagenicity and Teratogenicity: Azathioprine is a category D agent during pregnancy. The prodrug and the active metabolites readily cross the placenta. The rate of congenital malformation is low (4.3%), but myelosuppression and immunosuppression are significant occurrences in neonates and breastfed infants. Fertility of men or women appears unaffected by azathioprine.[99]

Drug Interactions: A major drug interaction occurs between azathioprine and allopurinol. When allopurinol must be used concurrently with azathioprine, the azathioprine dose should be decreased by 75%. The aminosalicylates may inhibit TPMT activity, and it is prudent to minimize or avoid such medications in patients using azathioprine.

THIOGUANINE

Thioguanine (Fig. 190-1) is a less used member of the thiopurine family of drugs. It is the natural metabolite of AZA and appears to be more effective than its parent compound. It has a metabolism and mechanism of action similar to that of azathioprine.

MECHANISM OF ACTION

Thioguanine is a prodrug and member of the thiopurine family; its metabolism and mechanism of action is via inhibition of purine synthesis. Thioguanine produces nucleotide analogs that ultimately yield cytotoxic activity via incorporation into cellular DNA. Apoptosis is induced preferentially against activated T lymphocytes.[100]

PHARMACOKINETICS

Thioguanine is given orally, but it has incomplete and unpredictable absorption with variations of 10-fold seen in plasma concentrations. Peak plasma concentrations occur 2 to 4 hours after ingestion.[101]

INDICATIONS

In dermatology, thioguanine has been used chiefly for the treatment of psoriasis, particularly in those with recalcitrant disease or with contraindications to other systemic therapies (Table 190-13). A small retrospective study of patients with recalcitrant psoriasis, demonstrated that 14 of 18 patients experienced significant improvement with thioguanine, including patients with psoriatic arthritis, palmoplantar disease, or scalp involvement.[102] Two additional open-label studies on the drug used in psoriasis showed response rates of 78% and 49%, respectively,[103,104] In a longer-term study, 58% of 76 patients with psoriasis were effectively maintained at 24 months, and the drug was safely used up to 145 months. Thioguanine has been used effectively, although infrequently, to treat lupus and atopic dermatitis. There is limited data available regarding the use of thioguanine in the pediatric population.

TABLE 190-13
Uses for Thioguanine in Dermatology

- U.S. Food and Drug Administration–approved indications
  - None
- "Off-label" uses
  - Severe psoriasis
  - Severe cutaneous lupus erythematosus
  - Severe atopic dermatitis

DOSING REGIMEN

Thioguanine is supplied as 40-mg tablets. Guidelines suggest beginning with a dose of 80 mg twice weekly with possible advancement by 20 mg every 2 to 4 weeks, to a maximum dose of 160 mg 3 times weekly.[83]

Similar to azathioprine, use of commercial assays for TPMT activity improves thioguanine dosing. The latest review of thioguanine use in severe psoriasis recommends an assessment of TPMT levels before treatment so as to guide the selection of an adequate starting dose.[102]

Pulse dosing, either twice or 3 times per week (120 mg twice per week up to 160 mg 3 times per week), may confer a reduced risk of bone marrow toxicity, as compared to daily dosing.[83]

INITIATING THERAPY

Patients with severe comorbidities, particularly hematologic disturbances, active infection, or who are pregnant or wish to become pregnant should be excluded, and males must also use adequate contraception. Recommended baseline laboratory studies include a CBC with differential, liver function studies, and a TPMT activity assay.

MONITORING THERAPY

Repeat blood counts and liver function tests should be followed weekly at first, transitioning to biweekly as the dose stabilizes, then monthly for 3 months, and quarterly thereafter and always with dose escalation (Table 190-14).

TABLE 190-14
Safety Monitoring for Thioguanine Use

- Initial evaluation
  - Careful history and physical examination
  - Identification of proper patient characteristics and risk factors
  - Survey for interacting medications (aminosalicylates)
- Baseline laboratories:
  - Thiopurine methyltransferase erythrocyte assay
  - CBC with differential/platelets
  - Liver function tests
  - Renal function testing (creatinine/blood urea nitrogen)
- Ongoing laboratory monitoring
- CBC with differential/platelets and liver function tests
  - Perform weekly initially, then
    - Transition to biweekly as the dose stabilizes, then
    - Monthly for 3 mo and quarterly thereafter
    - Perform laboratory testing with any dose escalation

CBC, complete blood cell count.

RISKS AND PRECAUTIONS

Absolute and relative contraindications and common adverse effects of thioguanine are summarized in Table 190-15.

COMPLICATIONS

Common adverse effects of thioguanine include myelosuppression and GI disturbances. In the largest series of patients using thioguanine for psoriasis, 49% experienced myelosuppression, yet only 20% required complete discontinuance.[104] In one series, thrombocytopenia was the earliest indicator of myelosuppression.[102] Pulsed dosing of thioguanine has been associated with a lower rate of myelosuppression, but TPMT testing was not performed in this study.[105]

GI disturbances include nausea, excessive flatulence, taste changes, esophageal reflux, and diarrhea, symptoms that are often tolerated without discontinuance. In a single study, elevated liver transaminases occurred in 25% of patients, but many had been taking MTX prior to the study.[104] Generally, thioguanine is not considered particularly hepatotoxic; liver biopsy is not indicated during treatment. Rare cases of toxic hepatic veno-occlusive disease have occurred in patients using thioguanine for psoriasis.[106] Low-dose thioguanine use in pregnant women has been reported with inflammatory bowel disease; however, use during pregnancy is generally avoided.[107]

TABLE 190-15
Risks and Precautions With Thioguanine Use

- Absolute contraindications
  - Hypersensitivity to thioguanine
- Relative contraindications
  - Pregnancy/lactation (category D)
  - History of hepatovenular occlusive disease
  - Hematologic disorders
- Common adverse effects
  - Myelosuppression (most common side effect)
  - GI distress (often tolerated)
  - Toxic hepatitis (less common than with other cytotoxic agents)

Drug Interactions: Thioguanine metabolism is not dependent on XO; it may be administered concurrently with allopurinol without dose reduction. Aminosalicylates may inhibit TPMT activity, and it is prudent to minimize or avoid such medications in patients taking thioguanine.

MYCOPHENOLIC ACID AND MYCOPHENOLATE MOFETIL

Mycophenolic acid (MPA) (Fig. 190-1) is a lipid-soluble, weak organic acid with antifungal, antibacterial, antiviral, and immunosuppressive properties. MPA was first used as an oral agent for moderate-to-severe psoriasis in the 1970s, but use was discontinued because of intolerability. Mycophenolate mofetil (MMF) represents a derivative of MPA, with greater bioavailability, improved tolerance, and enhanced immunosuppression. Properties and use of this agent are discussed in detail in Chap. 192.

CYCLOSPORINE

Cyclosporine is a neutral cyclic peptide that suppresses T lymphocyte function via inhibition of intracellular calcineurin, resulting in decreased IL-2 and interferon γ production. As a result of decreased IL-2 and interferon γ production, there is decreased activation and proliferation of helper and cytotoxic lymphocytes. Cyclosporine was discovered while searching for new antifungal agents and it was later found to have potent immunosuppressive effects. Although cyclosporine is not routinely used by most US dermatologists, it is approved for the treatment of psoriasis and also has been used to treat many other inflammatory dermatoses. Properties and use of this agent are discussed in detail in Chap. 192.[108,109]

TACROLIMUS

Tacrolimus is a macrolide that inhibits calcineurin by binding to the FK506 binding protein. As a result of binding the FK506 binding protein, gene encoding via calcineurin is inhibited leading to decreased IL-2 and interferon γ production.[110] This leads to decreased proliferation and activation of T lymphocytes. Tacrolimus is available in topical and oral formulations. Although oral tacrolimus is commonly used in the prevention of organ transplant rejection, topical tacrolimus is indicated for the treatment of atopic dermatitis and also has been used to treat many other inflammatory

dermatoses. Properties and use of this agent is discussed in detail in Chap. 192.[110]

THALIDOMIDE

Thalidomide is a nonpolar glutamic acid derivative with hypnosedative, immunomodulatory, and neural/vascular tissue effects. Initially removed from the market because of severe teratogenic effects (phocomelia) in 1961, thalidomide was later found to be effective in treating erythema nodosum leprosum.[111] The FDA approval of thalidomide for erythema nodosum leprosum resulted in the opportunity for off-label use treating dermatoses including AIDS-related Kaposi sarcoma, pyoderma gangrenosum, bullous pemphigoid, prurigo nodularis, uremic pruritus, and Jessner lymphocytic infiltrate of the skin among others. The mechanism of action of thalidomide is not well understood. Properties and use of this agent is discussed in detail in Chap. 195.[111]

CYTOTOXIC AGENTS

CYCLOPHOSPHAMIDE

Cyclophosphamide (Fig. 190-1) was originally derived from nitrogen mustard in 1958, then combined with phosphoric acid in an effort to make an inert drug capable of entering and releasing active nitrogen mustard within target cells.[77] Cyclophosphamide is an alkylating agent and acts primarily by crosslinking DNA. In oncology, cyclophosphamide is used as an antineoplastic agent. In dermatology, it is used as an immunosuppressive and steroid-sparing agent, particularly for autoimmune blistering disorders and systemic vasculitis.

MECHANISM OF ACTION

Cyclophosphamide is a classic cell cycle–nonspecific drug; its cytotoxic effect is independent of the proliferative index. Active metabolites of cyclophosphamide form covalent bonds with the nucleophilic centers of DNA. This alkylation leads to DNA crosslinking, abnormal base-pair formation, imidazole ring cleavage with depurination, and chain scission. Ultimately, these mutations lead to cell death and possibly mutagenesis and carcinogenesis. Cyclophosphamide has a greater effect on B lymphocytes than T lymphocytes and a greater effect on suppressor T cells than helper T cells.[112] Resistance to cyclophosphamide may occur as a result of decreased cellular penetration, increased competition from other nucleophilic substances, improved DNA repair, or increased drug metabolism.

PHARMACOKINETICS

Oral cyclophosphamide has a bioavailability of 74%. Peak plasma levels are achieved within 1 hour of administration. The half-life of the drug is between 2 and 10 hours. Cyclophosphamide is initially inactive, but undergoes hepatic metabolism via the cytochrome P_{450} (CYP) system into the active metabolite nitrogen mustard, which can then be converted into the other active metabolite phosphoramide mustard.[93] It is first converted to 4-hydroxycyclophosphamide, an active molecule that exists in equilibrium with aldophosphamide. Aldophosphamide may be cleaved to phosphoramide mustard, another active metabolite, and acrolein, an inactive metabolite. Aldehyde dehydrogenase may also convert aldophosphamide into a second inactive metabolite, carboxyphosphamide. The kidneys excrete just 10% to 20% of the drug unchanged but excrete 50% of the active metabolites.

INDICATIONS

In dermatology, cyclophosphamide is used as a steroid-sparing agent in only the most serious diseases. In particular, patients with pemphigus vulgaris may be treated with cyclophosphamide in combination with steroids, and evidence supports its steroid-sparing benefits.[113] Cyclophosphamide also has been used for the treatment of mucous membrane pemphigoid and has been inconsistently reported as beneficial in Stevens–Johnson syndrome and toxic epidermal necrolysis.[114,115]

Other diseases that may respond to cyclophosphamide include pyoderma gangrenosum, necrobiotic xanthogranuloma, cutaneous amyloidosis, lichen myxedematosus, giant cell reticulohistiocytoma, primary cutaneous diffuse large B-cell lymphoma, and mycosis fungoides. However, with the availability of safer immunosuppressive agents, cyclophosphamide is not an agent that is routinely used for the enormous majority of cutaneous inflammatory diseases.

DOSING REGIMEN

Cyclophosphamide is available as 25- and 50-mg tablets and also in an injectable form. Oral doses are typically 1 to 3 mg/kg/d either divided or as a single morning dose. Intravenous pulse dosing of 0.5 to 1.0 g/m^2 monthly provides an alternative therapeutic approach that has been associated with fewer side effects than daily oral dosing. Vigorous hydration, beginning 24 hours before and continuing throughout therapy, is recommended to minimize bladder toxicity. Although pulse dosing may be efficacious in achieving disease control in pemphigus vulgaris, bullous pemphigoid, systemic sclerosis, and ANCA positive vasculitis, patients may have a slightly increased risk of disease relapse in comparison to oral cyclophosphamide following completion of therapy.[116]

INITIATING THERAPY

Patients being considered for cyclophosphamide therapy should have a thorough history and physical examination. Cyclophosphamide is contraindicated in patients with a history of transitional cell carcinoma

of the bladder.[117] Patients with a history of a lymphoproliferative disorder must be treated with extreme caution. Use in pregnant or lactating patients is contraindicated. Baseline laboratory evaluations should include a CBC with differential, serum chemistry profile, liver function testing, and urinalysis. Initiation of cyclophosphamide therapy is contraindicated if the total white blood cell count is less than 5000/mm^3 or if the absolute neutrophil is less than 1000/mm^3.[116]

MONITORING THERAPY

Blood counts and urinalysis with microscopic examination to look for red blood cells in the urine should be repeated weekly initially but may be reduced to biweekly or monthly over the first few months as long as the results remain in the normal range. Liver function testing should be performed monthly, but over time if the results remain in the normal range liver function testing may be reduced to every 2 to 3 months. Urine cytology is indicated when the cumulative dose exceeds 50 g and every 6 months thereafter, or on any occasion of hemorrhagic cystitis. Some authorities recommend a chest radiograph every 6 months. Followup physical examination should pay particular attention for any evidence of lymphoproliferative disease (lymphadenopathy). Patients taking cyclophosphamide should have all age-appropriate cancer screening, including stool guaiac examination and Papanicolaou smears for women. Safety guidelines used during cyclophosphamide therapy are summarized in Table 190-16.[116]

TABLE 190-16
Safety Monitoring for Cyclophosphamide Use

- Initial evaluation
  - Careful history and physical examination
  - Identification of proper patient characteristics and risk factors
  - Survey for interacting medications (allopurinol, cimetidine)
- Baseline laboratories:
  - CBC with differential
  - Basic serum chemistry profile
  - Urinalysis with microscopic exam for red blood cells in the urine
  - Renal function testing (creatinine/blood urea nitrogen)
- Ongoing laboratory monitoring
- CBC with differential and urinalysis with microscopic exam for red blood cells
  - Perform weekly initially, then
    - Transition to biweekly or monthly after 2-3 mo
    - Perform testing with any dose escalation
    - Decrease/discontinue if white blood cell count <4000/mm^3, or platelets <100,000/mm^3
    - Discontinue and refer to urologist if red blood cells appear in urine
- Basic serum chemistry and liver function tests
  - Perform monthly initially, then
    - Transition to every 2-3 mo if stable
- Urine cytology testing
  - Perform when cumulative dose >50 g or if patient has hemorrhagic cystitis

CBC, complete blood cell count.

TABLE 190-17
Risks and Precautions With Cyclophosphamide Use

- Absolute contraindications
  - Hypersensitivity to cyclophosphamide (can cross-react with chlorambucil)
- Relative contraindications
  - Pregnancy/lactation (category D; fetal loss common)
  - History of transitional cell carcinoma of the bladder
  - Depressed bone marrow function
  - Impaired hepatic or renal function
- Common adverse effects
  - GI distress (minimized with antiemetic medications)
  - Myelosuppression (often dose limiting)
  - Hemorrhagic cystitis due to elimination of toxic metabolites (minimized with mesna)
  - Carcinogenicity (transitional cell carcinoma of bladder, lymphoproliferative disease)
  - Reproductive consequences (amenorrhea, azoospermia, gonadal failure)

RISKS AND PRECAUTIONS

Absolute and relative contraindications and common adverse effects of cyclophosphamide are summarized in Table 190-17.

COMPLICATIONS

Because of its activity independent of the cell cycle, the toxic effects of cyclophosphamide are significant and numerous.

GI Effects: Nausea and vomiting are the most common GI side effects associated with cyclophosphamide use. Coadministration of ondansetron and dexamethasone reduces these side effects. The addition of aprepitant to this combination therapy may provide even greater antiemetic action.[118]

Hematologic Effects: Hematologic disturbances are frequent with cyclophosphamide, especially leukopenia and thrombocytopenia. A nadir in blood counts occurs 8 to 12 days after initiation of therapy. Myelosuppression is not requisite to immunosuppression, but it often represents a dose-limiting side effect.

Genitourinary Effects: Bladder toxicity is a well-recognized consequence of cyclophosphamide use. Patients should be counseled to ensure vigorous hydration throughout the day and to empty their bladder before bed and cyclophosphamide should be given in the early morning to allow for vigorous hydration throughout the day.[116] Hemorrhagic cystitis can occur in up to 40% of patients treated with oral cyclophosphamide.[119] This cystitis occurs during therapy and is believed to be caused by the metabolite, acrolein. A scavenging agent, mesna (sodium 2-mercaptoethane sulfonate), binds acrolein in the bladder and may be used to reduce the incidence of cystitis. Mesna is used primarily with high-dose

intravenous cyclophosphamide regimens, but it also may be used in low-dose oral cyclophosphamide therapy.[120] Mesna may be administered orally or intravenously. In the rheumatologic literature, a cumulative dose of >36 g, concomitant hemorrhagic cystitis during treatment and untreated bladder toxicity are thought to be responsible for the markedly increased risk of transitional cell carcinoma of the bladder (8- to 10-fold increased risk) among those taking chronic oral cyclophosphamide. Bladder cancer may arise years after cyclophosphamide therapy, and ongoing monitoring of the lower urinary tract (by urinalysis and cystoscopy when necessary) should be considered.[116]

Infectious Disease: Because of the potent immunosuppressant effects of cyclophosphamide, patients may be at an increased risk of developing opportunistic infections, including *Pneumocystis jirovecii* (formerly *Pneumocystis carinii*) pneumonia, especially when patients are treated with additional immunosuppressive medications (eg, systemic corticosteroids). Prophylaxis should be considered based on a cumulative dose of cyclophosphamide (>7.5 g) and concomitant therapy with other immunosuppressive medications. Prophylactic treatment options to prevent *P. jirovecii* include trimethoprim-sulfamethoxazole, aerosolized pentamidine, oral dapsone, or oral atovaquone).[116]

Carcinogenicity: Treatment with cyclophosphamide has been associated with an increased risk of various solid organ tumors, non-Hodgkin lymphoma, leukemia, transitional cell carcinoma of the bladder, and squamous cell carcinoma. Most of these associations are derived from organ transplant and oncology patients who have been exposed to chronic use or higher doses of cyclophosphamide, and who often are on other concurrent immunosuppressive agents. There is also a slight increased risk of non-Hodgkin lymphoma in patients with rheumatologic disorders who are treated with cyclophosphamide.[121,122] Because cyclophosphamide dosing tends to be of shorter duration and of lower dose for patients who are receiving the drug for dermatologic disorders than for patients with organ transplants, cancer, or rheumatologic disorders, it seems reasonable to conclude that the risk of cancer is likely lower in dermatology patients than in patients who receive cyclophosphamide for other indications.

Cutaneous Effects: Anagen effluvium can occur in up to 30% of those treated with cyclophosphamide.[123] This alopecia typically resolves after therapy is completed. Diffuse brown hyperpigmentation of the skin and mucosa, as well as transverse, longitudinal, or diffuse melanonychia, may occur. Cutaneous hyperpigmentation usually resolves within 6 to 12 months after therapy is discontinued. Toxic acral erythema of chemotherapy has been described, as well as radiation recall.[124] Similar to other chemotherapeutic agents that are secreted in the eccrine glands, cyclophosphamide may induce neutrophilic eccrine hidradenitis.[125] Urticaria, dermatomyositis, cutaneous vasculitis, and induction of Stevens–Johnson syndrome may occur.[88]

Mutagenicity and Teratogenicity: Cyclophosphamide is a category D agent during pregnancy. Therefore, adequate contraception is necessary while on cyclophosphamide. Four pregnant women exposed to cyclophosphamide during treatment for systemic lupus resulted in pregnancy loss in all cases.[126] Azoospermia and amenorrhea may also occur with cyclophosphamide use. Amenorrhea may occur in up to 60% of women treated with cyclophosphamide, with up to 80% of those experiencing premature ovarian failure.[127] Age and cumulative dose are most determinative of the risk of gonadal failure. In men, testosterone administration may lessen the risk of gonadal failure, whereas in women, leuprolide acetate may provide a similar partial protection.[128,129] These observations make it clear that cyclophosphamide should not be a first-line therapy for men or women who wish to conceive after treatment.

Cardiac/Pulmonary Toxicity: Cardiac and pulmonary are rare complications that typically only occur when cyclophosphamide is used in high doses for chemotherapy.[116]

Drug Interactions: Because the microsomal enzyme system responsible for activation of cyclophosphamide is involved in the metabolism of many other drugs, the potential for multiple drug interactions exists. Allopurinol, cimetidine, and chloramphenicol all increase cyclophosphamide toxicity. The effects of succinylcholine are potentiated by cyclophosphamide. Digoxin absorption is diminished with coadministration of oral cyclophosphamide.

CHLORAMBUCIL

Chlorambucil is another alkylating agent derived from nitrogen mustard. In comparison to cyclophosphamide, chlorambucil is used infrequently in dermatology.

MECHANISM OF ACTION

Like cyclophosphamide, chlorambucil exerts its effects independent of the cell cycle through crosslinking of DNA.

PHARMACOKINETICS

Chlorambucil is well absorbed, with 87% bioavailability after oral administration. The drug is 99% protein bound in plasma. It has a plasma half-life of approximately 1.5 hours. Less than 1% of the drug is excreted by the kidney. Although the drug is extensively metabolized by the liver, it does not require hepatic activation. In comparison to cyclophosphamide, chlorambucil has a slower onset of effect.

INDICATIONS

Isolated reports detail use of chlorambucil as a steroid-sparing agent in pemphigus vulgaris, bullous

TABLE 190-18
Uses for Chlorambucil in Dermatology

- U.S. Food and Drug Administration–approved indications
  - None
- "Off-label" uses
  - Granulomatosis with polyangiitis (Wegener)
  - Lymphomatoid granulomatosis
  - Dermatomyositis
  - Scleroderma
  - Relapsing polychondritis
  - Severe cutaneous lupus erythematosus
  - Pemphigus vulgaris
  - Bullous pemphigoid
  - Epidermolysis bullosa acquisita
  - Pyoderma gangrenosum
  - Langerhans cell histiocytosis
  - Necrobiotic xanthogranuloma with paraproteinemia
  - Sarcoidosis
  - Severe disseminated granuloma annulare

pemphigoid, primary cutaneous B-cell lymphoma, aggressive pyoderma gangrenosum, and Behçet disease (Table 190-18). Chlorambucil use also has been described in erythrodermic cutaneous T-cell lymphoma and necrobiotic xanthogranuloma.[130,131] Complicating management decisions, the U.S. FDA–approved package insert states that chlorambucil should not be used for nonmalignant diseases.

DOSING REGIMEN

Chlorambucil is supplied as 2-mg tablets. The recommended dosage is 0.05 to 0.2 mg/kg/d. Doses for cutaneous disease should remain toward the lower end of this range.

INITIATING THERAPY

Patients being considered for chlorambucil therapy should have a thorough history and physical examination. When considering chlorambucil use, patients with a history of a lymphoproliferative disorder must be approached with extreme caution. Use in pregnant or lactating patients is contraindicated. Baseline laboratory evaluations should include a CBC with differential, serum chemistry profile, liver function testing, and urinalysis.

MONITORING THERAPY

Blood counts should be repeated weekly initially but may be reduced to biweekly or monthly over time in patients whose blood counts remain stable. Liver function testing and urinalysis should continue monthly but may be reduced to every 3 months if stable. Some authorities recommend a chest radiograph every 6 months. followup physical examination should pay particular attention to any evidence

TABLE 190-19
Safety Monitoring for Chlorambucil Use

- Initial evaluation
  - Careful history and physical examination
  - Identification of proper patient characteristics and risk factors
  - Survey for interacting medications (vaccinations, other immunosuppressives)
- Baseline laboratories:
  - CBC with differential
  - Serum chemistry profile
  - Urinalysis
  - Renal function testing (creatinine/blood urea nitrogen)
- Ongoing laboratory monitoring
  - Complete blood count with differential and urinalysis
  - Perform weekly initially, then
    - Transition to biweekly or monthly after 2-3 mo
    - Repeat with any dose escalation
    - Decrease or discontinue dosing if white blood cell count $<4000/mm^3$, or platelets $<100,000/mm^3$
- Basic serum chemistry and liver function tests
  - Perform monthly initially, then
    - Transition to every 3-6 mo if stable

of lymphoproliferative disease (lymphadenopathy). Patients taking chlorambucil should have all age-appropriate cancer screening, including stool guaiac examinations and Papanicolaou smears for women. Safety guidelines during chlorambucil therapy are summarized in Table 190-19.

RISKS AND PRECAUTIONS

Absolute and relative contraindications and common adverse effects of chlorambucil are summarized in Table 190-20.

COMPLICATIONS

Common side effects of chlorambucil include nausea and vomiting, azoospermia, amenorrhea, pulmonary fibrosis, seizures, anemia, thrombocytopenia, neutropenia, pancytopenia, and hepatotoxicity. Chlorambucil

TABLE 190-20
Risks and Precautions With Chlorambucil Use

- Absolute contraindications
  - Hypersensitivity to chlorambucil (can cross-react with cyclophosphamide)
- Relative contraindications
  - Pregnancy/lactation (category D)
  - Active infection (dependent on severity)
  - Impaired hepatic function
  - Childhood (possible increased risk of seizures)
- Common adverse effects
  - Myelosuppression (often dose-limiting)
  - GI distress (minimized with antiemetic medications)
  - Carcinogenicity (lymphoproliferative disease, squamous cell carcinoma)
  - Reproductive consequences (amenorrhea, azoospermia)

increases the risk of lymphoproliferative disorders and squamous cell carcinoma of the skin among organ transplant recipients. Other cutaneous side effects include alopecia, a morbilliform rash, urticaria, and mucosal ulcerations. Chlorambucil is pregnancy category D.

Drug Interactions: Through strong immunosuppression, chlorambucil may decrease the efficacy of viral vaccinations. Concomitant use of additional immunosuppressive drugs may potentiate any risk of infection or carcinogenesis.

ANTHRACYCLINES

Anthracyclines are antibiotic molecules that possess potent antineoplastic properties.

These agents act specifically during the S phase of cell division. Pegylated liposomal doxorubicin (PLD) (Fig. 190-1) is an anthracycline that is sometimes used in the treatment of Kaposi sarcoma.[132,133]

MECHANISM OF ACTION

Anthracyclines, such as doxorubicin, are intercalated within DNA and RNA. Through template disorder and steric obstruction, this incorporation leads to defective synthesis. Cell death typically results, but mutagenesis and carcinogenesis may also occur.

PHARMACOKINETICS

PLD has pharmacokinetic properties similar to standard doxorubicin; however, the liposomal formulation results in improved tolerance. Encapsulating liposomes have a diameter of approximately 100 nm and are designed to prevent phagocytosis of the agent by the reticuloendothelial system. The result is a plasma half-life of more than 55 hours and improved tumor penetrance.

INDICATIONS

PLD is approved by the U.S. FDA for the treatment of AIDS-related Kaposi sarcoma. PLD also has been used to treat cutaneous T-cell lymphoma mycosis fungoides and Sezary syndrome types.

DOSING REGIMEN

PLD is administered at a dose of 20 to 30 mg/m^2 infused intravenously over 30 to 60 minutes once every 2 to 3 weeks.

INITIATING THERAPY

A thorough history and physical examination is required before initiation of therapy with PLD. Prior use of anthracyclines is an indication for caution, as additive cardiotoxicity may occur. Physical evidence of existing cardiac failure should be sought. Baseline laboratory studies should include a complete blood count with differential, a CD4 count, an HIV viral load assay, and liver function studies, including a total bilirubin.

MONITORING THERAPY

Before each dose of PLD, all patients should have a repeat blood count, CD4 count, and liver function tests with total bilirubin. Specific tests for cardiotoxicity, such as a multiple-gated acquisition scan, are indicated for cumulative doses greater than 450 mg/m^2 or if signs or symptoms of congestive heart failure develop.

RISKS AND PRECAUTIONS

Absolute and relative contraindications and common adverse effects of doxorubicin are summarized in Table 190-21.

COMPLICATIONS

Myelosuppression is the most common side effect of PLD. A nadir in blood counts is expected during the second week of therapy. Neutropenia should be treated with granulocyte-macrophage colony-stimulating factor or granulocyte colony-stimulating factor. The HIV viral load does not change substantially during treatment, but CD4 counts may be lowered slightly. Abrupt or precipitous decreases in a CD4 count may require treatment discontinuation.

Although it is known that PLD has myocardial toxicity, it seems to have less cardiotoxicity with nonliposomal forms of doxorubicin. Although testing for congestive heart failure with cumulative doses in excess of 450 mg/m^2 is suggested, multiple studies show no adverse cardiac impact with cumulative doses of up to 1040 mg/m^2. Hepatotoxicity may occur with PLD, and this may be additive to any such toxicity caused by antiretroviral medications. Nausea and vomiting with dosing is also common. Doxorubicin is pregnancy category D. It is embryotoxic and an abortifacient and should be avoided in women who are pregnant or who are planning to conceive during treatment.

TABLE 190-21
Risks and Precautions With Doxorubicin Use

- Absolute contraindications
  - Hypersensitivity to anthracyclines
- Relative contraindications
  - Pregnancy/lactation (category D)
- Common adverse effects
  - Myelosuppression
  - GI distress
  - Toxic hepatitis
  - Hyperpigmentation of the skin and nails

A small percentage of patients may experience an initial infusion reaction, which typically resolves and does not occur with later dosing. Other effects include hyperpigmentation of the skin and nails, alopecia, acral erythema and dysesthesias, urticaria, radiation recall reactions, or a pustular psoriasiform drug eruption.

Drug Interactions: Although no drug interaction studies have been conducted with PLD, it is reasonable to conclude it may interact with drugs known to interact with conventional doxorubicin, which includes digoxin, cyclosporine, calcium channel blockers, and ciprofloxacin.

Despite continued introduction of highly targeted immunomodulating drugs ("biologics"; (Chap. 194), cytotoxic agents remain as important medications in the therapeutic arsenal of dermatologists. Table 190-22 summarizes the major indications, principal mechanism of action, and common toxicities of these agents.

MUCOCUTANEOUS REACTIONS TO CYTOTOXIC AGENTS

Specific cytotoxic agents may be used by dermatologists for the treatment of severe and recalcitrant dermatologic disease, but typically only certain agents are employed, and dosages are typically less than those used for other indications. Mucocutaneous reactions to these medications initiated by other providers are commonly seen in patients during consultation. A morphologic approach to those reactions is useful. To this end, subcategories of mucocutaneous reactions to various cytotoxic agents are examined, paying particular attention to those that may provoke characteristic mucocutaneous reactions.

HAIR FOLLICLE COMPLICATIONS

Alopecia: One of the most widely recognized cutaneous effects of cytotoxic agents is alopecia. Cytotoxic agent–induced alopecia is a form of anagen effluvium caused by interruption of the rapidly dividing cells of the hair matrix. The particular agent, dose, schedule, and route of administration impact the degree of hair loss, yet at equivalent dosages, intravenous administration is generally more deleterious than oral administration. Numerous cytotoxic agents produce alopecia, but doxorubicin, cyclophosphamide, and vincristine are most often implicated (Table 190-23).[134,135]

Cytotoxic agent–induced alopecia usually begins 2 to 4 weeks after therapy and may progress for several months. Up to 85% to 90% of the hair may be lost; the remaining fraction spared is that normally in telogen. Loss of hair on the scalp and eyebrows is most noticeable, but eyelashes and body hair may be shed as well (Fig. 190-2). The alopecia typically resolves with cessation of treatment, although regrowth may occur with a different color, quality, or texture. Permanent alopecia has occurred most often with high-dose busulfan.[136]

TABLE 190-22
Summary of Cytotoxic Agents Commonly Used in Dermatology

DRUG	COMMON INDICATIONS	MECHANISM OF ACTION	TYPICAL DOSE	KEY SIDE EFFECTS
Methotrexate	Psoriasis Connective tissue disease	Inhibition of dihydrofolate reductase	7.5-25	Myelosuppression Toxic hepatitis Liver fibrosis/cirrhosis
Azathioprine	Bullous disorders Connective tissue disease	Forms purine analogs that interrupt DNA/RNA synthesis	0.5-3.0 mg/kg/d (dependent on innate TPMT expression)	Myelosuppression GI distress Increased risk of malignancy
Thioguanine	Psoriasis	Forms purine analogs that interrupt DNA/RNA synthesis	80-120 mg/d or 120-160 mg 3×/wk (dependent on innate TPMT expression)	Myelosuppression
Hydroxyurea	Psoriasis	Inhibition of ribonucleotide diphosphate reductase	1-2 g/d	Myelosuppression Dermatomyositis-like reaction
Cyclophosphamide	Vasculitis Connective tissue disease Advanced cutaneous T-cell lymphoma	Metabolites undergo physiochemical reactions with DNA (alkylation)	1-3 mg/kg/d or 0.5-1.0 g/monthly	GI distress Myelosuppression Hemorrhagic cystitis Bladder carcinogenesis
Chlorambucil	Vasculitis Connective tissue disease	Physiochemical reactions with DNA (alkylation)	0.05-0.2 mg/kg/d	GI distress Myelosuppression Increased risk of malignancy
Doxorubicin (liposomal)	AIDS-related Kaposi sarcoma	Intercalation into DNA with termination of synthesis	20-30 mg/m^2 every 2-3 wk	GI distress Toxic hepatitis Possible cardiotoxicity Infusion site reactions

TPMT, thiopurine methyltransferase.

TABLE 190-23
Cytotoxic Agents Associated With Alopecia

- Bleomycin
- Busulfan (significant risk of permanent loss)
- Cytarabine
- Dacarbazine
- Daunorubicin
- Docetaxel
- **Doxorubicin**
- Etoposide
- Fluorouracil
- **Hydroxyurea**
- **Methotrexate**
- Nitrogen mustard derivatives (**cyclophosphamide, chlorambucil**)
- Nitrosoureas
- Paclitaxel
- Procarbazine
- Thiotepa
- Vinca alkaloids

Agents in bold represent medications more often used by dermatologists in treating patients with skin disease.

Scalp cooling has been used with limited success to minimize hair loss, likely by reducing biochemical activity, but it may create a haven for malignant cells and it therefore remains a controversial intervention, particularly for hematologic malignancies.[134,137] Topical minoxidil shortened the duration of alopecia in breast cancer patients receiving adjuvant chemotherapy and in patients with gynecologic malignancies who received cyclophosphamide, doxorubicin, or *cis*-platinum, but it did not induce significant regrowth in patients with permanent alopecia due to busulfan or cyclophosphamide.[134,138]

TABLE 190-24
Cytotoxic Agents Associated With Nail Plate Malformations (Dystrophy)

- Bleomycin
- **Cyclophosphamide**
- Daunorubicin
- Docetaxel
- **Doxorubicin**
- Fluorouracil
- **Hydroxyurea**
- Mitoxantrone

Acneiform Eruption: Classic cytotoxin-induced folliculitis begins as erythematous macules, followed in days by the appearance of papules, and then pustules. Lesions predominate on the face and upper trunk. The eruption typically resolves over 2 weeks, but comedones may persist, or postinflammatory hyperpigmentation may result. Simple acne vulgaris also may be aggravated by androgens used in conjunction with chemotherapeutic agents in some multidrug regimens. Folliculitis is most often associated with actinomycin D and less often with MTX or cisplatin.[139]

NAIL COMPLICATIONS

Malformed Nail Plates (Dystrophy): Nail changes may sometimes occur in patients treated with cytotoxic agents (Table 190-24). Mild nail reactions produce Beau lines, for example, typically seen following trauma. Severe reactions may produce onycholysis or onychomadesis (Fig. 190-3). The great toenail is most

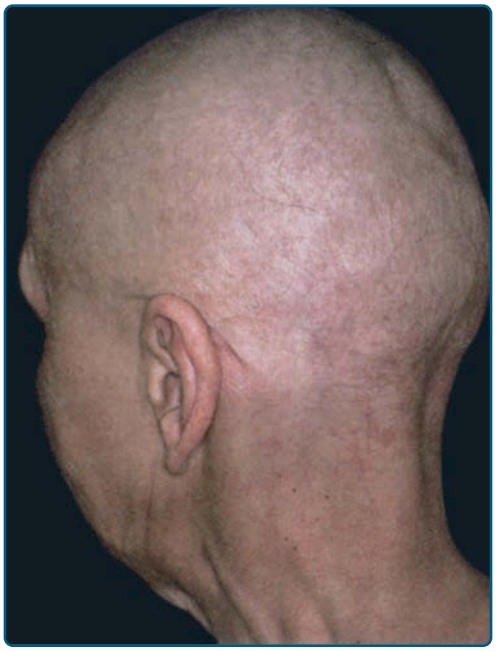

Figure 190-2 Alopecia after the administration of combined chemotherapy with cyclophosphamide, doxorubicin, and vincristine.

Figure 190-3 Presence of proximal indented Beau line and distal band of leukonychia due to cyclophosphamide 3 months after bone marrow transplantation.

often affected.[104] Less common nail problems caused by cytotoxic drugs include nail bed pain, thickening or thinning of the nail plate, and splinter hemorrhage or subungual hemorrhage. Anthracyclines (doxorubicin) and taxanes (paclitaxel, docetaxel) most often yield onychodystrophy, with paclitaxel and docetaxel producing nail changes in up to 30% to 40% of those treated.[135,140]

Nail Pigmentation: Treatment with cytotoxic agents may lead to leukonychia or hyperpigmentation of the nail plate. Leukonychia is characterized by a white discoloration in the nail; although the mechanism is unknown, it is presumed to be cytotoxic in nature. Mees lines is a type of patterned leukonychia that was described in 1919 as transverse white lines after arsenic exposure.[141] Cytotoxic agents that most often lead to leukonychia include doxorubicin, vincristine, cyclophosphamide, MTX, and 5-fluorouracil.[142]

Nail hyperpigmentation usually develops weeks or months after chemotherapy. Hyperpigmentation of the nail may be oriented longitudinally, horizontally, diffusely, or in a perilunar fashion.[143] Various mechanisms have been proposed, including genetic predisposition, toxic effect on the nail matrix, photosensitization, or focal stimulation of melanocytes. Blacks are more often affected, presumably due to increased numbers of melanocytes within the nail matrix.[144] Cyclophosphamide, doxorubicin, hydroxyurea, and bleomycin are most often implicated in nail hyperpigmentation.[145] Typically, leukonychia or nail hyperpigmentation due to cytotoxic agents resolves with cessation of therapy.

ECCRINE GLAND COMPLICATIONS

Neutrophilic Eccrine Hidradenitis: Neutrophilic eccrine hidradenitis (NEH) consists of tender, erythematous macules, papules, and plaques on the trunk, neck, and extremities that develop after exposure to cytotoxic agents (Fig. 190-4).[146,147] Lesions resolve spontaneously over a period of days. Histologic changes include a characteristically perieccrine neutrophilic infiltrate. Apocrine gland involvement also has been identified.[148] Concentration of the cytotoxic agent within sweat is the likely mechanism of injury. NEH is most often associated with cytarabine, but other agents have been implicated (Table 190-25). A similar condition unassociated with cytotoxic agents is recognized, suggesting the lesions represent a final common pathway of adnexal injury. In a single case report, prophylactic dosing of dapsone prevented NEH in a patient who had had multiple prior eruptions due to lomustine, an alkylating agent.[149]

Figure 190-4 Neutrophilic eccrine hidradenitis (*arrow*). (From the Archives of Fitzsimmons Army Medical Center.)

TABLE 190-25
Cytotoxic Agents Associated With Adnexal Toxicity

NEUTROPHILIC ECCRINE HIDRADENITIS	ECCRINE SYRINGOSQUAMOUS METAPLASIA
Bleomycin	Bleomycin
Chlorambucil	Cytarabine (common)
Cytarabine (common)	Daunorubicin
Daunorubicin	**Doxorubicin**
Doxorubicin (common)	Mitoxantrone
Mitoxantrone	Suramin
Vincristine	

Agents in bold represent medications more often used by dermatologists in treating patients with skin disease.

Syringosquamous Metaplasia: Chemotherapy-induced syringosquamous metaplasia (CISM) is closely related to NEH. Like neutrophilic hidradenitis, direct cytotoxic injury of sweat ducts is implicated. Clinically, CISM presents as erythematous papular eruptions, similar to miliaria, which erupt 2 to 39 days after administration of the cytotoxic agent.[150,151] The papules resolve approximately 4 weeks after discontinuance. Histologic examination demonstrates prominent squamous metaplasia of the upper sweat duct, with necrotic ductal epithelial cells; inflammation is minimal. On occasion, CISM may even mimic SCC.[152] Cytarabine has been most often associated with CISM.

CHEMOTHERAPY-INDUCED EPIDERMAL COMPLICATIONS

Acral Erythema: Multiple cytotoxic agents may yield a distinct cutaneous reaction known as toxic *acral erythema*. The reaction usually develops 4 to 23 days after initiation of chemotherapy as painful, sharply demarcated erythema of the palmoplantar surfaces, with associated edema (Fig. 190-5).[153] In severe cases, large bullae may extend over the dorsum of the hands and feet.[154] Pain may limit ambulation or use of the hands. Therapy is limited mostly to analgesics and emollients, although pyridoxine supplementation may improve dysesthesias. The reaction is self-limited and resolves over 2 to 4 weeks. Recurrence with subsequent exposure is highly variable. Although the etiology of acral erythema is unknown, the elevated levels

Figure 190-5 Cytarabine-induced painful acral erythema with edema.

Figure 190-6 Flagellate hyperpigmentation occurs 2 weeks after administration of bleomycin.

of cytotoxic agents within eccrine glands of acral skin has been proposed to play a role. In support of such a theory, coexistent syringosquamous metaplasia has been demonstrated.[155,156] Acral erythema is most common with cytarabine, doxorubicin, fluorouracil, and MTX (Table 190-26). Long-term hydroxyurea therapy may produce a unique form of acral erythema that is linear and resembles dermatomyositis, without any corresponding muscle findings (drug-induced pseudodermatomyositis); rarely, the face may be involved.[63,157]

Inflammation of Actinic Keratoses: A number of different cytotoxic agents and chemotherapeutic protocols yield inflammation of actinic keratoses. Systemic fluorouracil is the most common cause of inflamed actinic keratoses, and this should come as no surprise to dermatologists.[158] The reaction usually develops within 1 week of initiating chemotherapy. The actinic keratoses may resolve or remain after completion of the therapy. A similar reaction within seborrheic keratoses has been reported to occur with cytarabine and may mimic the sign of Leser-Trélat or herpes zoster.[159,160]

TABLE 190-26
Cytotoxic Agents Associated With Acral Erythema

- Bleomycin
- **Cyclophosphamide**
- Cytarabine
- Daunorubicin
- Docetaxel
- **Doxorubicin**
- Etoposide
- Fluorouracil
- **Hydroxyurea** (dermatomyositis-like eruption possible)
- Lomustine
- Mercaptopurine
- **Methotrexate**
- Paclitaxel
- Suramin
- Vinblastine

Agents in bold represent medications more often used by dermatologists in treating patients with skin disease.

Cutaneous Hyperpigmentation: Bleomycin may produce a unique form of flagellate (linear) hyperpigmentation of the skin in those exposed; typically after cumulative doses of 90 to 285 mg.[157,161] Lesions begin as linear, erythematous, pruritic lesions that are slowly replaced by hyperpigmentation and are present hours to weeks after dosing (Fig. 190-6). The eruption usually resolves without treatment over weeks to months. The pathogenesis of bleomycin-induced flagellate hyperpigmentation is unknown.

Bleomycin may also produce patchy pigmentation in areas of pressure, within the palmar creases, or within striae distensae. Other unique forms of cutaneous hyperpigmentation are recognized, such as the serpentine supravenous hyperpigmentation that may accompany fluorouracil infusions[162] or the polycyclic bands of pigmentation on the scalp occurring with daunorubicin.[144]

Many antineoplastic drugs may lead to other forms of hyperpigmentation, including patchy, acral, photoaccentuated, polycyclic, occlusion-accentuated, pressure-accentuated (Fig. 190-7), or generalized patterns (Table 190-27).[139] Although the cause of cutaneous hyperpigmentation is unknown, postulated mechanisms include a toxic effect on melanocytes, increased drug deposition due to increased blood flow,

Figure 190-7 Hyperpigmentation at sites of occlusion during administration of thiotepa.

TABLE 190-27
Cytotoxic Agents Associated With Skin Hyperpigmentation

DRUG	PATTERN OF PIGMENTATION
Bleomycin	Flagellate
Busulphan	Dusky, may appear similar to Addison disease
Cisplatin	Pressure-induced
Cyclophosphamide	May be localized to palms, soles, or nails
Dactinomycin	Diffuse
Daunorubicin	Sun-exposed areas
Doxorubicin	Diffuse, particularly nails
Etoposide	Occluded areas
Fluorouracil	Sun-exposed areas, areas of prior irradiation, nails
Hydroxyurea	Diffuse, particularly nails
Ifosfamide	Hands, feet, and occluded areas
Methotrexate	Sun-exposed areas, hair may develop "flag sign"
Nitrosoureas	Occluded areas
Paclitaxel	Localized
Plicamycin	Localized
Procarbazine	Diffuse
Tamoxifen	Hair pigmentation
Thiotepa	Occluded areas
Vinca alkaloids	Localized

Agents in bold represent medications more often managed by dermatologists in treating patients with skin disease.

TABLE 190-28
Cytotoxic Agents With Radiation Reactions

- Photosensitivity
  - Dacarbazine
  - Fluorouracil
  - **Hydroxyurea**
  - **Methotrexate**
  - Mitomycin
  - **Thioguanine**
  - Vinblastine
- Radiation enhancement
  - Bleomycin
  - Cisplatin
  - Dactinomycin
  - **Doxorubicin**
  - Fluorouracil
  - **Hydroxyurea**
  - **Methotrexate**
- Radiation recall reaction
  - Bleomycin
  - Cytarabine (common)
  - Dactinomycin
  - **Doxorubicin**
  - Etoposide 1
  - Fluorouracil
  - **Hydroxyurea**
  - Lomustine
  - **Methotrexate**
  - Melphalan
  - Mitomycin
  - Paclitaxel
- Sunburn recall reaction
  - **Methotrexate**
  - Suramin

Agents in bold represent medications more often used by dermatologists in treating patients with skin disease.

local toxicity due to concentration in sweat, associated endocrinologic abnormalities, and drug-induced depletion of tyrosinase inhibitors.[143]

Photosensitivity: Most chemotherapy-induced photosensitivity is phototoxic rather than photoallergic in nature (Table 190-28; see also Chap. 97). Phototoxic reactions begin rapidly after administration and often mimic sunburns, with burning, erythema, and even vesicles or bullae. Photoallergic reactions typically present as an eczematous process whereas photoallergic processes are dependent on sensitization and may be delayed weeks or months after an initial exposure.

Radiation Recall Reaction: Recall reactions consist of erythema confined to an area of prior radiation exposure or sunburn. Severe cases may develop vesiculation (Fig. 190-8). Radiation recall may occur years after irradiation, and the pathogenesis is unknown. It has been postulated that radiation-damaged keratinocytes are further damaged by the administration of the cytotoxic agent (Table 190-28).[163] Methotrexate often engenders a unique recall reaction to sunburn when dosed 1 to 3 days after exposure.[164] Folinic acid supplementation (leucovorin rescue) does not prevent UV sunburn recall reactions due to MTX.

Figure 190-8 Reactivation of solar erythema 2 days after high-dose methotrexate administration to a young woman with choriocarcinoma. (From Bronner AK, Hood AF. Cutaneous complications of chemotherapeutic agents. J Am Acad Dermatol 1983;9:645, with permission.)

Radiation Enhancement Reactions: Radiation enhancement is a synergistic reaction between an antineoplastic agent and irradiation. This radiosensitization is often desired in antineoplastic treatment, but it may lead to adverse effects on the skin. The result may be radiation dermatitis that presents initially as pain and erythema followed by desquamation and hyperpigmentation. Although a number of chemotherapeutic agents may produce this reaction, doxorubicin and dactinomycin are most often implicated (Table 190-28).[139]

CHEMOTHERAPY-INDUCED DERMAL COMPLICATIONS

Local Injury: Extravasation of chemotherapeutic agents may occur in up to 6% of adults treated with infusions and is likely an even more common occurrence among pediatric patients.[143,165] As expected, the degree of injury is related to the drug used, the rate of delivery, the concentration of the agent, and the amount extravasated.

Agents with minimal toxicity on extravasation may produce only a chemical cellulitis or phlebitis and are classified as irritants. Chemical cellulitis manifests as erythema, induration, and pain at the injection site. Sometimes it may follow the course of a vein. It is often of short duration and resolves without treatment. Chemotherapy-induced phlebitis manifests as linear cords, often with accompanying discomfort.

Vesicants are agents, which on extravasation yield direct-tissue necrosis. Chemotherapy-induced tissue necrosis can be a devastating complication. Extravasation should always be treated by immediate discontinuance of the infusion and the application of either hot or cold packs. Cold packs are used for all chemotherapeutic agents except vinca alkaloids to localize the drug and promote degradation. Vinca alkaloids are treated with hot packs because application of cold promotes tissue necrosis.[166] Doxorubicin is perhaps the most dangerous of all vesicants, and extravasation of this agent may yield ulcers that progress for months that may even erode into tendon or bone (Fig. 190-9). Severe ulcerations caused by extravasation of doxorubicin may require wide excision and skin grafting.

Figure 190-9 Severe tissue necrosis after extravasation of doxorubicin.

Other treatments advocated for specific situations include (1) topical dimethyl sulfoxide (DMSO); (2) local injection of hyaluronidase; or (3) potent topical, intralesional, or oral steroids. DMSO is a topical solvent that has free radical scavenging and antioxidant properties; it may hasten removal of extravasated drugs. Topical DMSO may have benefit in anthracycline-induced skin ulceration.[167,168] Hyaluronidase degrades hyaluronic acid, breaking down subcutaneous tissue, and promoting drug diffusion through the interstitial space. It appears effective in vinca alkaloid, epipodophyllotoxin, and paclitaxel extravasations, but should not be used in anthracycline extravasation.[169,170] Hyaluronidase is contraindicated in sites involved with malignancy or superinfection. Finally, histologic examination of extravasation injuries has demonstrated surprisingly few inflammatory cells in areas of tissue damage, perhaps explaining why corticosteroids are, in general, of little value in management.[167,170]

Sclerotic Dermal Reactions: Bleomycin and docetaxel produce sclerotic tissue reactions that may be localized, regional, or diffuse in extent.[171,172] Localized tissue reactions may mimic morphea or systemic sclerosis. Melphalan may produce a unique form of reticulate scleroderma after limb perfusion. The mechanism of tissue sclerosis is unknown. Biopsies of cytotoxic agent–induced dermal sclerosis may be indistinguishable from morphea or systemic sclerosis. In some cases, the sclerosis resolved after withdrawal of the offending agent.

Raynaud Phenomenon: Secondary Raynaud phenomenon, with or without digital ulceration, is most often associated with bleomycin, vincristine, cisplatin, or cisplatin with gemcitabine.[173-175] This reaction may occur with systemic chemotherapy or after intralesional injection to treat verruca vulgaris. The mechanism of development is unknown, but bleomycin is known to be toxic to endothelial cells. In one study of 90 patients receiving bleomycin for testicular cancer, 37% developed Raynaud phenomenon, with 7% having transient disease.[173] Risk factors for the development of Raynaud phenomenon include combination therapy with vinblastine or high cumulative doses of bleomycin.

CHEMOTHERAPY-INDUCED MUCOSAL COMPLICATIONS

Oral complications may occur in up to 40% of those receiving chemotherapy. Because of a high inherent proliferative index, the mucosa is susceptible to the effects of multiple cytotoxic agents. Young patients and those with preexisting oral disease appear even more susceptible.[143]

Mucositis/Stomatitis: A wide range of cytotoxic agents may induce stomatitis (Table 190-29). Patients with cytotoxic agent–induced stomatitis usually

TABLE 190-29
Cytotoxic Agents Associated With Mucositis

- Bleomycin
- **Cyclophosphamide**
- Cytarabine
- Dactinomycin
- Daunorubicin
- Docetaxel
- **Doxorubicin**
- Fluorouracil
- **Hydroxyurea**
- Mercaptopurine
- **Methotrexate**
- Mitomycin
- Nitrosoureas
- Paclitaxel
- Plicamycin
- Procarbazine
- Vinblastine

Agents in bold represent medications more often used by dermatologists in treating patients with skin disease.

experience burning and mucosal erythema days after administration. Painful erosions and ulcerations often follow (Fig. 190-10). The mouth is most often affected, especially the buccal mucosa and tongue, but any mucosal surface may be involved. Mucositis may be complicated by secondary bacterial or fungal infection. Meticulous, but not overly aggressive, hygiene may reduce the incidence of secondary infection, and antibiotics and antifungal agents are often used. A meta-analysis of treatments for cytotoxic agent–induced mucositis suggested that simple modalities, such as ice chips, had equivalent benefit as more aggressive interventions.[176,177] Oral hemorrhage may be secondary to chemotherapy-induced thrombocytopenia, and a careful clinical examination is always required.

Mucosal Hyperpigmentation: Many cytotoxic agents induce mucosal hyperpigmentation. Mucosal hyperpigmentation may manifest as various patterns, including linear, patchy, and macular forms. Some agents tend to affect certain anatomic areas such as the gingival margin (cyclophosphamide) or tongue (fluorouracil). The mechanism of mucosal hyperpigmentation is not well understood. Typically, cytotoxic agent–induced hyperpigmentation resolves slowly over weeks to months after discontinuance. One notable exception is mucosal hyperpigmentation caused by cyclophosphamide, which may be permanent. Cyclophosphamide may also produce a permanent pigmented band on the teeth.

Figure 190-10 Stomatitis induced by combined chemotherapy with cytarabine, doxorubicin, and methotrexate. (Used with permission from Allan C. Harrington, MD.)

ACKNOWLEDGMENTS

We would like to thank Drs Aieska De Souza, Megan M. Moore, and Bruce E. Strober, the authors of the previous version of this chapter. Many of the display items have been reused from the previous version.

REFERENCES

1. West J, Ogston S, Foerster J. Safety and efficacy of methotrexate in psoriasis: a meta-analysis of published trials. *PLoS One.* 2016;11(5):e0153740.
2. Armstrong AW, Bagel J, Van Voorhees AS, et al. Combining biologic therapies with other systemic treatments in psoriasis: evidence-based, best-practice recommendations from the Medical Board of the National Psoriasis Foundation. *JAMA Dermatol.* 2015; 151(4):432-438.
3. Cronstein BN. The mechanism of action of methotrexate. *Rheum Dis Clin North Am.* 1997;23(4):739-755.
4. Said S, Jeffes EW, Weinstein GD. Methotrexate. *Clin Dermatol.* 1997;15(5):781-797.
5. Schiff MH, Jaffe JS, Freundlich B. Head-to-head, randomised, crossover study of oral versus subcutaneous methotrexate in patients with rheumatoid arthritis: drug-exposure limitations of oral methotrexate at doses ≥15 mg may be overcome with subcutaneous administration. *Ann Rheum Dis.* 2014;73(8):1549-1551.
6. Rees RB, Bennett JH. Methotrexate vs. aminopterin for psoriasis. *Arch Dermatol.* 1961;83:970-972.
7. Kalb RE, Strober B, Weinstein G, et al. Methotrexate and psoriasis: 2009 National Psoriasis Foundation Consensus Conference. *J Am Acad Dermatol.* 2009; 60(5):824-837.
8. Peckham PE, Weinstein GD, McCullough JL. The treatment of severe psoriasis. A national survey. *Arch Dermatol.* 1987;123(10):1303-1307.
9. Beyer V, Wolverton SE. Recent trends in systemic psoriasis treatment costs. *Arch Dermatol.* 2010; 146(1):46-54.
10. Newland KM, McCormack CJ, Twigger R, et al. The efficacy of methotrexate for lymphomatoid papulosis. *J Am Acad Dermatol.* 2015;72(6):1088-1090.
11. Wood GS, Wu J. Methotrexate and Pralatrexate. *Dermatol Clin.* 2015;33(4):747-755.
12. Demierre M-F, Vachon L, Ho V, et al. Phase 1/2 pilot study of methotrexate-laurocapram topical gel for the treatment of patients with early-stage mycosis fungoides. *Arch Dermatol.* 2003;139(5):624-628.
13. Zackheim HS, Kashani-Sabet M, McMillan A. Low-dose methotrexate to treat mycosis fungoides:

a retrospective study in 69 patients. *J Am Acad Dermatol.* 2003;49(5):873-878.
14. Menon K, Van Voorhees AS, Bebo BF, et al. Psoriasis in patients with HIV infection: from the medical board of the National Psoriasis Foundation. *J Am Acad Dermatol.* 2010;62(2):291-299.
15. Targeted Tuberculin Testing and Treatment of Latent Tuberculosis Infection ATS/CDC Statement Committee on Latent Tuberculosis Infection Membership List. https://www.cdc.gov/mmwr/preview/mmwrhtml/rr4906a1.htm.
16. Gutierrez-Ureña S, Molina JF, García CO, et al. Pancytopenia secondary to methotrexate therapy in rheumatoid arthritis. *Arthritis Rheum.* 1996;39(2):272-276.
17. Tugwell P, Bennett K, Bell M, et al. Methotrexate in rheumatoid arthritis. Feedback on American College of Physicians guidelines. *Ann Intern Med.* 1989;110(8):581-583.
18. Zachariae H, Aslam HM, Bjerring P, et al. Serum aminoterminal propeptide of type III procollagen in psoriasis and psoriatic arthritis: relation to liver fibrosis and arthritis. *J Am Acad Dermatol.* 1991;25(1, pt 1): 50-53.
19. Nagy Z, Czirják L. Increased levels of amino terminal propeptide of type III procollagen are an unfavourable predictor of survival in systemic sclerosis. *Clin Exp Rheumatol.* 2005;23(2):165-172.
20. Teppo A-M, Törnroth T, Honkanen E, et al. Urinary amino-terminal propeptide of type III procollagen (PIIINP) as a marker of interstitial fibrosis in renal transplant recipients. *Transplantation.* 2003;75(12): 2113-2119.
21. dos Santos Moreira C, Serejo F, Alcântara P, et al. Procollagen type III amino terminal peptide and myocardial fibrosis: a study in hypertensive patients with and without left ventricular hypertrophy. *Rev Port Cardiol.* 2015;34(5):309-314.
22. Lynch M, Higgins E, McCormick PA, et al. The use of transient elastography and FibroTest for monitoring hepatotoxicity in patients receiving methotrexate for psoriasis. *JAMA Dermatol.* 2014;150(8):856-862.
23. Shaheen AAM, Wan AF, Myers RP. FibroTest and FibroScan for the prediction of hepatitis C-related fibrosis: a systematic review of diagnostic test accuracy. *Am J Gastroenterol.* 2007;102(11):2589-2600.
24. Coulson IH, Mckenzie J, Neild VS, et al. A comparison of liver ultrasound with liver biopsy histology in psoriatics receiving long-term methotrexate therapy. *Br J Dermatol.* 1987;116(4):491-495.
25. Miller JA, Dodd H, Rustin MH, et al. Ultrasound as a screening procedure for methotrexate-induced hepatic damage in severe psoriasis. *Br J Dermatol.* 1985;113(6):699-705.
26. Talwalkar JA, Kurtz DM, Schoenleber SJ, et al. Ultrasound-based transient elastography for the detection of hepatic fibrosis: systematic review and meta-analysis. *Clin Gastroenterol Hepatol.* 2007;5(10):1214-1220.
27. Berends MA, Snoek J, de Jong EM, et al. Biochemical and biophysical assessment of MTX-induced liver fibrosis in psoriasis patients: FibroTest predicts the presence and Fibroscan predicts the absence of significant liver fibrosis. *Liver Int.* 2007;27(5):639-645.
28. Bray AP, Barnova I, Przemioslo R, et al. Liver fibrosis screening for patients with psoriasis taking methotrexate: a cross-sectional study comparing transient elastography and liver biopsy. *Br J Dermatol.* 2012;166(5):1125-1127.
29. Zachariae H. Liver biopsies and methotrexate: a time for reconsideration? *J Am Acad Dermatol.* 2000;42(3):531-534.
30. Osuga T, Ikura Y, Kadota C, et al. Significance of liver biopsy for the evaluation of methotrexate-induced liver damage in patients with rheumatoid arthritis. *Int J Clin Exp Pathol.* 2015;8(2):1961-1966.
31. Endresen GK, Husby G. Folate supplementation during methotrexate treatment of patients with rheumatoid arthritis. An update and proposals for guidelines. *Scand J Rheumatol.* 2001;30(3):129-134.
32. Ortiz Z, Shea B, Suarez-Almazor ME, et al. The efficacy of folic acid and folinic acid in reducing methotrexate gastrointestinal toxicity in rheumatoid arthritis. A metaanalysis of randomized controlled trials. *J Rheumatol.* 1998;25(1):36-43.
33. Duhra P. Treatment of gastrointestinal symptoms associated with methotrexate therapy for psoriasis. *J Am Acad Dermatol.* 1993;28(3):466-469.
34. Morgan S l, Alarcón GS, Krumdieck CL. Folic acid supplementation during methotrexate therapy: it makes sense. *J Rheumatol.* 1993;20(6):929-930.
35. Salim A, Tan E, Ilchyshyn A, et al. Folic acid supplementation during treatment of psoriasis with methotrexate: a randomized, double-blind, placebo-controlled trial. *Br J Dermatol.* 2006;154(6):1169-1174.
36. Pearce HP, Wilson BB. Erosion of psoriatic plaques: an early sign of methotrexate toxicity. *J Am Acad Dermatol.* 1996;35(5)(pt 2):835-838.
37. Goerttler E, Kutzner H, Peter HH, et al. Methotrexate-induced papular eruption in patients with rheumatic diseases: a distinctive adverse cutaneous reaction produced by methotrexate in patients with collagen vascular diseases. *J Am Acad Dermatol.* 1999;40(5, pt 1): 702-707.
38. Scott FI, Mamtani R, Brensinger CM, et al. Risk of nonmelanoma skin cancer associated with the use of immunosuppressant and biologic agents in patients with a history of autoimmune disease and nonmelanoma skin cancer. *JAMA Dermatol.* 2016;152(2):164-172.
39. Buchbinder R, Barber M, Heuzenroeder L, et al. Incidence of melanoma and other malignancies among rheumatoid arthritis patients treated with methotrexate. *Arthritis Rheum.* 2008;59(6):794-799.
40. Gelfand JM, Berlin J, Van Voorhees A, et al. Lymphoma rates are low but increased in patients with psoriasis: results from a population-based cohort study in the United Kingdom. *Arch Dermatol.* 2003;139(11):1425-1429.
41. Salliot C, van der Heijde D. Long-term safety of methotrexate monotherapy in patients with rheumatoid arthritis: a systematic literature research. *Ann Rheum Dis.* 2009;68(7):1100-1104.
42. Shimizu Y, Nakajima A, Inoue E, et al. Characteristics and risk factors of lymphoproliferative disorders among patients with rheumatoid arthritis concurrently treated with methotrexate: a nested case-control study of the IORRA cohort. *Clin Rheumatol.* 2017;36(6):1237-1245.
43. McKenna KE, Burrows D. Pulmonary toxicity in a patient with psoriasis receiving methotrexate therapy. *Clin Exp Dermatol.* 2000;25(1):24-27.
44. Kremer JM, Alarcón GS, Weinblatt ME, et al. Clinical, laboratory, radiographic, and histopathologic features of methotrexate-associated lung injury in patients with rheumatoid arthritis: a multicenter

study with literature review. *Arthritis Rheum.* 1997;40(10):1829-1837.
45. Conway R, Low C, Coughlan RJ, et al. Risk of liver injury among methotrexate users: a meta-analysis of randomised controlled trials. *Semin Arthritis Rheum.* 2015;45(2):156-162.
46. Cottin V, Tébib J, Massonnet B, et al. Pulmonary function in patients receiving long-term low-dose methotrexate. *Chest.* 1996;109(4):933-938.
47. Basile A, Simzar S, Bentow J, et al. Disseminated *Strongyloides stercoralis*: hyperinfection during medical immunosuppression. *J Am Acad Dermatol.* 2010;63(5): 896-902.
48. Kaneko Y, Suwa A, Ikeda Y, et al. *Pneumocystis jiroveci* pneumonia associated with low-dose methotrexate treatment for rheumatoid arthritis: report of two cases and review of the literature. *Mod Rheumatol.* 2006;16(1):36-38.
49. Duncan KO, Imaeda S, Milstone LM. *Pneumocystis carinii* pneumonia complicating methotrexate treatment of pityriasis rubra pilaris. *J Am Acad Dermatol.* 1998;39(2, pt 1):276-278.
50. Witty LA, Steiner F, Curfman M, et al. Disseminated histoplasmosis in patients receiving low-dose methotrexate therapy for psoriasis. *Arch Dermatol.* 1992; 128(1):91-93.
51. Altz-Smith M, Kendall LG, Stamm AM. Cryptococcosis associated with low-dose methotrexate for arthritis. *Am J Med.* 1987;83(1):179-181.
52. Alkins SA, Byrd JC, Morgan SK, et al. Anaphylactoid reactions to methotrexate. *Cancer.* 1996;77(10):2123-2126.
53. Menting SP, Dekker PM, Limpens J, et al. Methotrexate dosing regimen for plaque-type psoriasis: a systematic review of the use of test-dose, start-dose, dosing scheme, dose adjustments, maximum dose and folic acid supplementation. *Acta Derm Venereol.* 2016;96(1):23-28.
54. van Ede AE, Laan RF, Blom HJ, et al. Homocysteine and folate status in methotrexate-treated patients with rheumatoid arthritis. *Rheumatology (Oxford).* 2002;41(6):658-665.
55. Strober BE, Menon K. Folate supplementation during methotrexate therapy for patients with psoriasis. *J Am Acad Dermatol.* 2005;53(4):652-659.
56. Thomas DR, Dover JS, Camp RD. Pancytopenia induced by the interaction between methotrexate and trimethoprim-sulfamethoxazole. *J Am Acad Dermatol.* 1987;17(6):1055-1056.
57. Nyce J, Liu L, Jones PA. Variable effects of DNA-synthesis inhibitors upon DNA methylation in mammalian cells. *Nucleic Acids Res.* 1986;14(10):4353-4367.
58. Moschella SL, Greenwald MA. Psoriasis with hydroxyurea. An 18-month study of 60 patients. *Arch Dermatol.* 1973;107(3):363-368.
59. Ranjan N, Sharma NL, Shanker V, et al. Methotrexate versus hydroxycarbamide (hydroxyurea) as a weekly dose to treat moderate-to-severe chronic plaque psoriasis: a comparative study. *J Dermatol Treat.* 2007;18(5):295-300.
60. Kumar B, Saraswat A, Kaur I. Rediscovering hydroxyurea: its role in recalcitrant psoriasis. *Int J Dermatol.* 2001;40(8):530-534.
61. Smith CH. Use of hydroxyurea in psoriasis. *Clin Exp Dermatol.* 1999;24(1):2-6.
62. Layton AM, Sheehan-Dare RA, Goodfield MJ, et al. Hydroxyurea in the management of therapy resistant psoriasis. *Br J Dermatol.* 1989;121(5):647-653.
63. Elliott R, Davies M, Harmse D. Dermatomyositis-like eruption with long-term hydroxyurea. *J Dermatol Treat.* 2006;17(1):59-60.
64. Dacey MJ, Callen JP. Hydroxyurea-induced dermatomyositis-like eruption. *J Am Acad Dermatol.* 2003;48(3):439-441.
65. Pata O, Tok CE, Yazici G, et al. Polycythemia vera and pregnancy: a case report with the use of hydroxyurea in the first trimester. *Am J Perinatol.* 2004;21(3): 135-137.
66. Callot-Mellot C, Bodemer C, Chosidow O, et al. Cutaneous carcinoma during long-term hydroxyurea therapy: a report of 5 cases. *Arch Dermatol.* 1996;132(11):1395-1397.
67. Chan GL, Canafax DM, Johnson CA. The therapeutic use of azathioprine in renal transplantation. *Pharmacotherapy.* 1987;7(5):165-177.
68. Lennard L. The clinical pharmacology of 6-mercaptopurine. *Eur J Clin Pharmacol.* 1992;43(4):329-339.
69. Weinshilboum RM, Sladek SL. Mercaptopurine pharmacogenetics: monogenic inheritance of erythrocyte thiopurine methyltransferase activity. *Am J Hum Genet.* 1980;32(5):651-662.
70. Jackson AP, Hall AG, McLelland J. Thiopurine methyltransferase levels should be measured before commencing patients on azathioprine. *Br J Dermatol.* 1997;136(1):133-134.
71. Snow JL, Gibson LE. A pharmacogenetic basis for the safe and effective use of azathioprine and other thiopurine drugs in dermatologic patients. *J Am Acad Dermatol.* 1995;32(1):114-116.
72. Kennedy DT, Hayney MS, Lake KD. Azathioprine and allopurinol: the price of an avoidable drug interaction. *Ann Pharmacother.* 1996;30(9):951-954.
73. Schram ME, Borgonjen RJ, Bik CMJM, et al. Off-label use of azathioprine in dermatology: a systematic review. *Arch Dermatol.* 2011;147(4):474-488.
74. Chams-Davatchi C, Esmaili N, Daneshpazhooh M, et al. Randomized controlled open-label trial of four treatment regimens for pemphigus vulgaris. *J Am Acad Dermatol.* 2007;57(4):622-628.
75. Bystryn JC, Steinman NM. The adjuvant therapy of pemphigus. An update. *Arch Dermatol.* 1996;132(2): 203-212.
76. Beissert S, Werfel T, Frieling U, et al. A comparison of oral methylprednisolone plus azathioprine or mycophenolate mofetil for the treatment of bullous pemphigoid. *Arch Dermatol.* 2007;143(12):1536-1542.
77. Berth-Jones J, Takwale A, Tan E, et al. Azathioprine in severe adult atopic dermatitis: a double-blind, placebo-controlled, crossover trial. *Br J Dermatol.* 2002; 147(2):324-330.
78. Meggitt SJ, Gray JC, Reynolds NJ. Azathioprine dosed by thiopurine methyltransferase activity for moderate-to-severe atopic eczema: a double-blind, randomised controlled trial. *Lancet.* 2006;367(9513):839-846.
79. Relling MV, Gardner EE, Sandborn WJ, et al. Clinical pharmacogenetics implementation consortium guidelines for thiopurine methyltransferase genotype and thiopurine dosing: 2013 update. *Clin Pharmacol Ther.* 2013;93(4):324-325.
80. Meggitt SJ, Anstey AV, Mohd Mustapa MF, et al. British Association of Dermatologists' guidelines for the safe and effective prescribing of azathioprine 2011. *Br J Dermatol.* 2011;165(4):711-734.
81. Fuggle NR, Bragoli W, Mahto A, et al. The adverse effect profile of oral azathioprine in pediatric atopic

dermatitis, and recommendations for monitoring. *J Am Acad Dermatol.* 2015;72(1):108-114.
82. Sidbury R, Davis DM, Cohen DE, et al. Guidelines of care for the management of atopic dermatitis: section 3. Management and treatment with phototherapy and systemic agents. *J Am Acad Dermatol.* 2014;71(2):327-349.
83. Menter A, Korman NJ, Elmets CA, et al. Guidelines of care for the management of psoriasis and psoriatic arthritis: section 4. Guidelines of care for the management and treatment of psoriasis with traditional systemic agents. *J Am Acad Dermatol.* 2009;61(3):451-485.
84. Liu Y-P, Xu H-Q, Li M, et al. Association between thiopurine *S*-methyltransferase polymorphisms and azathioprine-induced adverse drug reactions in patients with autoimmune diseases: a meta-analysis. *PLoS One.* 2015;10(12):e0144234.
85. el-Azhary RA, Farmer SA, Drage LA, et al. Thioguanine nucleotides and thiopurine methyltransferase in immunobullous diseases: optimal levels as adjunctive tools for azathioprine monitoring. *Arch Dermatol.* 2009;145(6):644-652.
86. Bacon BR, Treuhaft WH, Goodman AM. Azathioprine-induced pancytopenia. Occurrence in two patients with connective-tissue diseases. *Arch Intern Med.* 1981;141(2):223-226.
87. Younger IR, Harris DW, Colver GB. Azathioprine in dermatology. *J Am Acad Dermatol.* 1991;25(2, pt 1): 281-286.
88. Lawson DH, Lovatt GE, Gurton CS, et al. Adverse effects of azathioprine. *Adverse Drug React Acute Poisoning Rev.* 1984;3(3):161-171.
89. Pasadhika S, Kempen JH, Newcomb CW, et al. Azathioprine for ocular inflammatory diseases. *Am J Ophthalmol.* 2009;148(4):500-509.e2.
90. Whisnant JK, Pelkey J. Rheumatoid arthritis: treatment with azathioprine (Imuran(R)). Clinical side-effects and laboratory abnormalities. *Ann Rheum Dis.* 1982;41(suppl 1):44-47.
91. Perrett CM, Walker SL, O'Donovan P, et al. Azathioprine treatment photosensitizes human skin to ultraviolet A radiation. *Br J Dermatol.* 2008;159(1): 198-204.
92. Brem R, Li F, Karran P. Reactive oxygen species generated by thiopurine/UVA cause irreparable transcription-blocking DNA lesions. *Nucleic Acids Res.* 2009;37(6):1951-1961.
93. O'Donovan P, Perrett CM, Zhang X, et al. Azathioprine and UVA light generate mutagenic oxidative DNA damage. *Science.* 2005;309(5742):1871-1874.
94. Jiyad Z, Olsen CM, Burke MT, et al. Azathioprine and risk of skin cancer in organ transplant recipients: systematic review and meta-analysis. *Am J Transplant.* 2016;16(12):3490-3503.
95. Long MD, Herfarth HH, Pipkin CA, et al. Increased risk for non-melanoma skin cancer in patients with inflammatory bowel disease. *Clin Gastroenterol Hepatol.* 2010;8(3):268-274.
96. Wilkinson AH, Smith JL, Hunsicker LG, et al. Increased frequency of posttransplant lymphomas in patients treated with cyclosporine, azathioprine, and prednisone. *Transplantation.* 1989;47(2):293-296.
97. Silman AJ, Petrie J, Hazleman B, et al. Lymphoproliferative cancer and other malignancy in patients with rheumatoid arthritis treated with azathioprine: a 20 year follow up study. *Ann Rheum Dis.* 1988;47(12):988-992.
98. Kandiel A, Fraser AG, Korelitz BI, et al. Increased risk of lymphoma among inflammatory bowel disease patients treated with azathioprine and 6-mercaptopurine. *Gut.* 2005;54(8):1121-1125.
99. Roubenoff R, Hoyt J, Petri M, et al. Effects of antiinflammatory and immunosuppressive drugs on pregnancy and fertility. *Semin Arthritis Rheum.* 1988;18(2): 88-110.
100. Murphy FP, Coven TR, Burack LH, et al. Clinical clearing of psoriasis by 6-thioguanine correlates with cutaneous T-cell depletion via apoptosis: evidence for selective effects on activated T lymphocytes. *Arch Dermatol.* 1999;135(12):1495-1502.
101. LePage GA, Whitecar JP. Pharmacology of 6-thioguanine in man. *Cancer Res.* 1971;31(11):1627-1631.
102. Mason C, Krueger GG. Thioguanine for refractory psoriasis: a 4-year experience. *J Am Acad Dermatol.* 2001; 44(1):67-72.
103. Zackheim HS, Maibach HI. Treatment of psoriasis with 6-thioguanine. *Australas J Dermatol.* 1988; 29(3):163-167.
104. Zackheim HS, Glogau RG, Fisher DA, et al. 6-Thioguanine treatment of psoriasis: experience in 81 patients. *J Am Acad Dermatol.* 1994;30(3):452-458.
105. Silvis NG, Levine N. Pulse dosing of thioguanine in recalcitrant psoriasis. *Arch Dermatol.* 1999;135(4):433-437.
106. Romagosa R, Kerdel F, Shah N. Treatment of psoriasis with 6-thioguanine and hepatic venoocclusive disease. *J Am Acad Dermatol.* 2002;47(6):970-972; author reply 972.
107. de Boer NKH, Van Elburg RM, Wilhelm AJ, et al. 6-Thioguanine for Crohn's disease during pregnancy: thiopurine metabolite measurements in both mother and child. *Scand J Gastroenterol.* 2005;40(11):1374-1377.
108. Amor KT, Ryan C, Menter A. The use of cyclosporine in dermatology: part I. *J Am Acad Dermatol.* 2010;63(6):925-946; quiz 947-948.
109. Ryan C, Amor KT, Menter A. The use of cyclosporine in dermatology: part II. *J Am Acad Dermatol.* 2010;63(6):949-972; quiz 973-974.
110. Nghiem P, Pearson G, Langley RG. Tacrolimus and pimecrolimus: from clever prokaryotes to inhibiting calcineurin and treating atopic dermatitis. *J Am Acad Dermatol.* 2002;46(2):228-241.
111. Tseng S, Pak G, Washenik K, et al. Rediscovering thalidomide: a review of its mechanism of action, side effects, and potential uses. *J Am Acad Dermatol.* 1996;35(6): 969-979.
112. Rapini RP. Cytotoxic drugs in the treatment of skin disease. *Int J Dermatol.* 1991;30(5):313-322.
113. Martin LK, Werth V, Villanueva E, et al. Interventions for pemphigus vulgaris and pemphigus foliaceus. *Cochrane Database Syst Rev.* 2009;(1):CD006263.
114. Sacher C, Hunzelmann N. Cicatricial pemphigoid (mucous membrane pemphigoid): current and emerging therapeutic approaches. *Am J Clin Dermatol.* 2005; 6(2):93-103.
115. Trautmann A, Klein CE, Kämpgen E, et al. Severe bullous drug reactions treated successfully with cyclophosphamide. *Br J Dermatol.* 1998;139(6):1127-1128.
116. Kim J, Chan JJ. Cyclophosphamide in dermatology. *Australas J Dermatol.* 2017;58(1):5-17.
117. Volkmer BG, Seidl-Schlick EM, Bach D, et al. Cyclophosphamide is contraindicated in patients with a history of transitional cell carcinoma. *Clin Rheumatol.* 2005;24(4):319-323.
118. Herrstedt J, Muss HB, Warr DG, et al. Efficacy and tolerability of aprepitant for the prevention of

chemotherapy-induced nausea and emesis over multiple cycles of moderately emetogenic chemotherapy. *Cancer.* 2005;104(7):1548-1555.
119. Foad BS, Hess EV. Urinary bladder complications with cyclophosphamide therapy. *Arch Intern Med.* 1976;136(5):616-619.
120. Martin-Suarez I, D'Cruz D, Mansoor M, et al. Immunosuppressive treatment in severe connective tissue diseases: effects of low dose intravenous cyclophosphamide. *Ann Rheum Dis.* 1997;56(8):481-487.
121. Baltus JA, Boersma JW, Hartman AP, et al. The occurrence of malignancies in patients with rheumatoid arthritis treated with cyclophosphamide: a controlled retrospective follow-up. *Ann Rheum Dis.* 1983;42(4): 368-373.
122. Baker GL, Kahl LE, Zee BC, et al. Malignancy following treatment of rheumatoid arthritis with cyclophosphamide. Long-term case-control follow-up study. *Am J Med.* 1987;83(1):1-9.
123. DeSpain JD. Dermatologic toxicity of chemotherapy. *Semin Oncol.* 1992;19(5):501-507.
124. Borroni G, Vassallo C, Brazzelli V, et al. Radiation recall dermatitis, panniculitis, and myositis following cyclophosphamide therapy: histopathologic findings of a patient affected by multiple myeloma. *Am J Dermatopathol.* 2004;26(3):213-216.
125. Wenzel FG, Horn TD. Nonneoplastic disorders of the eccrine glands. *J Am Acad Dermatol.* 1998;38(1):1-17; quiz 18-20.
126. Clowse MEB, Magder L, Petri M. Cyclophosphamide for lupus during pregnancy. *Lupus.* 2005;14(8):593-597.
127. Wetzels JFM. Cyclophosphamide-induced gonadal toxicity: a treatment dilemma in patients with lupus nephritis? *Neth J Med.* 2004;62(10):347-352.
128. Masala A, Faedda R, Alagna S, et al. Use of testosterone to prevent cyclophosphamide-induced azoospermia. *Ann Intern Med.* 1997;126(4):292-295.
129. Somers EC, Marder W, Christman GM, et al. Use of a gonadotropin-releasing hormone analog for protection against premature ovarian failure during cyclophosphamide therapy in women with severe lupus. *Arthritis Rheum.* 2005;52(9):2761-2767.
130. Coors EA, von den Driesch P. Treatment of erythrodermic cutaneous T-cell lymphoma with intermittent chlorambucil and fluocortolone therapy. *Br J Dermatol.* 2000;143(1):127-131.
131. Torabian SZ, Fazel N, Knuttle R. Necrobiotic xanthogranuloma treated with chlorambucil. *Dermatol Online J.* 2006;12(5):11.
132. Hengge UR, Esser S, Rudel HP, et al. Long-term chemotherapy of HIV-associated Kaposi's sarcoma with liposomal doxorubicin. *Eur J Cancer.* 2001;37(7): 878-883.
133. Di Lorenzo G, Kreuter A, Di Trolio R, et al. Activity and safety of pegylated liposomal doxorubicin as first-line therapy in the treatment of non-visceral classic Kaposi's sarcoma: a multicenter study. *J Invest Dermatol.* 2008;128(6):1578-1580.
134. Trüeb RM. Chemotherapy-induced alopecia. *Semin Cutan Med Surg.* 2009;28(1):11-14.
135. Hussain S, Anderson DN, Salvatti ME, et al. Onycholysis as a complication of systemic chemotherapy: report of five cases associated with prolonged weekly paclitaxel therapy and review of the literature. *Cancer.* 2000;88(10):2367-2371.
136. Tosti A, Piraccini BM, Vincenzi C, et al. Permanent alopecia after busulfan chemotherapy. *Br J Dermatol.* 2005;152(5):1056-1058.
137. Grevelman EG, Breed WP. Prevention of chemotherapy-induced hair loss by scalp cooling. *Ann Oncol.* 2005;16(3):352-358.
138. Duvic M, Lemak NA, Valero V, et al. A randomized trial of minoxidil in chemotherapy-induced alopecia. *J Am Acad Dermatol.* 1996;35(1):74-78.
139. Koppel RA, Boh EE. Cutaneous reactions to chemotherapeutic agents. *Am J Med Sci.* 2001;321(5):327-335.
140. Nicolopoulos J, Howard A. Docetaxel-induced nail dystrophy. *Australas J Dermatol.* 2002;43(4):293-296.
141. Rümke CL. An observation in Broek in Waterland in 1919 [in Dutch]. *Ned Tijdschr Geneeskd.* 1985;129(51): 2469-2471.
142. Benatti C, Gnocchi M, Travaglino E, et al. Chemotherapy-induced leukonychia. *Haematologica.* 2004;89(7):ElM16.
143. Susser WS, Whitaker-Worth DL, Grant-Kels JM. Mucocutaneous reactions to chemotherapy. *J Am Acad Dermatol.* 1999;40(3):367-398; quiz 399-400.
144. Anderson LL, Thomas DE, Berger TG, et al. Cutaneous pigmentation after daunorubicin chemotherapy. *J Am Acad Dermatol.* 1992;26(2, pt 1):255-256.
145. Dave S, Thappa DM. Peculiar pattern of nail pigmentation following cyclophosphamide therapy. *Dermatol Online J.* 2003;9(3):14.
146. Flynn TC, Harrist TJ, Murphy GF, et al. Neutrophilic eccrine hidradenitis: a distinctive rash associated with cytarabine therapy and acute leukemia. *J Am Acad Dermatol.* 1984;11(4, pt 1):584-590.
147. Thorisdottir K, Tomecki KJ, Bergfeld WF, et al. Neutrophilic eccrine hidradenitis. *J Am Acad Dermatol.* 1993; 28(5, pt 1):775-777.
148. Brehler R, Reimann S, Bonsmann G, et al. Neutrophilic hidradenitis induced by chemotherapy involves eccrine and apocrine glands. *Am J Dermatopathol.* 1997;19(1):73-78.
149. Shear NH, Knowles SR, Shapiro L, et al. Dapsone in prevention of recurrent neutrophilic eccrine hidradenitis. *J Am Acad Dermatol.* 1996;35(5, pt 2):819-822.
150. Bhawan J, Malhotra R. Syringosquamous metaplasia. A distinctive eruption in patients receiving chemotherapy. *Am J Dermatopathol.* 1990;12(1):1-6.
151. Valks R, Fraga J, Porras-Luque J, et al. Chemotherapy-induced eccrine squamous syringometaplasia. A distinctive eruption in patients receiving hematopoietic progenitor cells. *Arch Dermatol.* 1997;133(7): 873-878.
152. El Darouti MA, Marzouk SA, El Hadidi HA, et al. Eccrine syringosquamous metaplasia. *Int J Dermatol.* 2001;40(12):777-781.
153. Burgdorf WH, Gilmore WA, Ganick RG. Peculiar acral erythema secondary to high-dose chemotherapy for acute myelogenous leukemia. *Ann Intern Med.* 1982; 97(1):61-62.
154. Werchniak AE, Chaffee S, Dinulos JGH. Methotrexate-induced bullous acral erythema in a child. *J Am Acad Dermatol.* 2005;52(5)(suppl 1):S93-S95.
155. Rongioletti F, Ballestrero A, Bogliolo F, et al. Necrotizing eccrine squamous syringometaplasia presenting as acral erythema. *J Cutan Pathol.* 1991;18(6): 453-456.
156. Tsuboi H, Yonemoto K, Katsuoka K. A case of bleomycin-induced acral erythema (AE) with eccrine squamous syringometaplasia (ESS) and summary of reports of AE with ESS in the literature. *J Dermatol.* 2005;32(11):921-925.
157. Guillet G, Guillet MH, de Meaux H, et al. Cutaneous pigmented stripes and bleomycin treatment. *Arch Dermatol.* 1986;122(4):381-382.

158. Omura EF, Torre D. Inflammation of actinic keratoses due to systemic fluorouracil therapy. *JAMA.* 1969 ;208(1):150-151.
159. Patton T, Zirwas M, Nieland-Fisher N, et al. Inflammation of seborrheic keratoses caused by cytarabine: a pseudo sign of Leser-Trelat. *J Drugs Dermatol.* 2004;3(5):565-566.
160. Williams JV, Helm KF, Long D. Chemotherapy-induced inflammation in seborrheic keratoses mimicking disseminated herpes zoster. *J Am Acad Dermatol.* 1999;40(4):643-644.
161. Kumar R, Pai V. Bleomycin induced flagellate pigmentation. *Indian Pediatr.* 2006;43(1):74-75.
162. Jain V, Bhandary S, Prasad GN, et al. Serpentine supravenous streaks induced by 5-fluorouracil. *J Am Acad Dermatol.* 2005;53(3):529-530.
163. Yeo W, Johnson PJ. Radiation-recall skin disorders associated with the use of antineoplastic drugs. Pathogenesis, prevalence, and management. *Am J Clin Dermatol.* 2000;1(2):113-116.
164. Westwick TJ, Sherertz EF, McCarley D, et al. Delayed reactivation of sunburn by methotrexate: sparing of chronically sun-exposed skin. *Cutis.* 1987; 39(1):49-51.
165. Ener RA, Meglathery SB, Styler M. Extravasation of systemic hemato-oncological therapies. *Ann Oncol.* 2004;15(6):858-862.
166. Dorr RT, Alberts DS. Vinca alkaloid skin toxicity: antidote and drug disposition studies in the mouse. *J Natl Cancer Inst.* 1985;74(1):113-120.
167. Dorr RT. Antidotes to vesicant chemotherapy extravasations. *Blood Rev.* 1990;4(1):41-60.
168. Svingen BA, Powis G, Appel PL, et al. Protection against adriamycin-induced skin necrosis in the rat by dimethyl sulfoxide and alpha-tocopherol. *Cancer Res.* 1981;41(9, pt 1):3395-3399.
169. Laurie SW, Wilson KL, Kernahan DA, et al. Intravenous extravasation injuries: the effectiveness of hyaluronidase in their treatment. *Ann Plast Surg.* 1984;13(3):191-194.
170. Bertelli G. Prevention and management of extravasation of cytotoxic drugs. *Drug Saf.* 1995;12(4):245-255.
171. Cohen IS, Mosher MB, O'Keefe EJ, et al. Cutaneous toxicity of bleomycin therapy. *Arch Dermatol.* 1973;107(4):553-555.
172. Hassett G, Harnett P, Manolios N. Scleroderma in association with the use of docetaxel (Taxotere) for breast cancer. *Clin Exp Rheumatol.* 2001;19(2):197-200.
173. Berger CC, Bokemeyer C, Schneider M, et al. Secondary Raynaud's phenomenon and other late vascular complications following chemotherapy for testicular cancer. *Eur J Cancer.* 1995;31A(13-14):2229-2238.
174. Gottschling S, Meyer S, Reinhard H, et al. First report of a vincristine dose-related Raynaud's phenomenon in an adolescent with malignant brain tumor. *J Pediatr Hematol Oncol.* 2004;26(11):768-769.
175. Vanhooteghem O, Richert B, de la Brassinne M. Raynaud phenomenon after treatment of verruca vulgaris of the sole with intralesional injection of bleomycin. *Pediatr Dermatol.* 2001;18(3):249-251.
176. Worthington HV, Clarkson JE, Bryan G, et al. Interventions for preventing oral mucositis for patients with cancer receiving treatment. *Cochrane Database Syst Rev.* 2011;(4):CD000978.
177. Riley P, Glenny A-M, Worthington HV, et al. Interventions for preventing oral mucositis in patients with cancer receiving treatment: oral cryotherapy. *Cochrane Database Syst Rev.* 2015;(12):CD011552.

Chapter 191 :: Antiviral Drugs

:: Zeena Y. Nawas, Quynh-Giao Nguyen, Khaled S. Sanber, & Stephen K. Tyring

AT-A-GLANCE

- Antivirals are approved for treatment of a variety of viral infections.
- Antiviral resistance is a growing concern, especially in the treatment of HIV infection.
- Antivirals work in a number of different ways, and their spectra of activity can be very specific (amantadine) or quite broad (ribavirin).
- The use of prodrugs of acyclovir and ganciclovir has greatly increased the oral bioavailability of these agents, which allows outpatient treatment of many herpesvirus infections.

The pace of development of new antiviral drugs has been accelerated by the HIV (HIV) epidemic. Progress in our understanding of the molecular biology and pathogenesis of viral diseases has been remarkable. This chapter focuses on the antiviral drugs most likely to be used by dermatologists, as well as those that cause cutaneous side effects. The age of effective antiviral therapy is here, and they are used throughout all disciplines of medicine. We need to be prepared to evaluate patients on a wide variety of antiviral drugs, especially those currently used to treat HIV.

DRUGS FOR THE TREATMENT OF HERPESVIRUS INFECTIONS

See Chaps. 164 and 165.

ACYCLOVIR

MECHANISM OF ACTION

See Fig. 191-1. Acyclovir, 9-[(2-hydroxyethoxy)methyl] guanine, was the first orally available drug to be widely used for the treatment of herpes simplex virus (HSV) and varicella-zoster virus (VZV) infections. The triphosphate form of the drug is the active form, which has a potent inhibitory effect on herpesvirus-induced DNA polymerases but relatively little effect on host cell DNA polymerase. As such, it has a tremendous margin of safety when used to treat herpetic infections. Acyclovir triphosphate causes premature termination of the nascent viral DNA chain. HSV- and VZV-induced thymidine kinases result in efficient phosphorylation of acyclovir to acyclovir monophosphate, the first step in drug metabolism. This step is not accomplished efficiently by normal cellular kinases, resulting in greater concentrations of active drug in infected cells.

PHARMACOKINETICS

Although acyclovir is available in oral, IV, and topical formulations, the oral bioavailability is only in the range of 15% to 30%, with the topical even less. Excretion is almost entirely renal, with approximately 62% of the drug remaining unmetabolized. Because of its reliance on renal excretion, the dose must be reduced for patients with a creatinine clearance of less than 50 mL/min. Acyclovir is water-soluble and distributes widely throughout the body, including into the contents of vesicles, cerebrospinal fluid (1:2 ratio from serum concentration), and vaginal secretions. Its half-life is 4 hours in neonates, 2 to 3 hours in children 1 to 12 years old, 2 to 3.5 hours in adults, and approximately 5 hours in hemodialysis patients.

INDICATIONS

- Symptomatic primary or recurrent HSV1/2 infections
- Chronic suppression of HSV1/2 infections
- HSV encephalitis
- Primary VZV infection, including HIV associated acute retinal necrosis
- Herpes zoster (shingles)
- Prevention of perinatal and treatment of neonatal HSV infection
- HSV gingivostomatitis and orolabial cold sores (off-label)
- Prevention of HSV, CMV, or VZV reactivation in hematopoietic stem cell transplant and HIV patients (off-label)
- New onset Bell palsy (off-label)

Acyclovir is indicated for a variety of infections, including that of primary HSV1/2 as well as VZV. In general, treatments for herpes viral infections are most effective when initiated as early as possible, within 24 hours for varicella and 72 hours for herpes zoster onset. A buccal tablet formulation of acyclovir was approved by the FDA in 2013 for treatment of recurrent herpes labialis in immunocompetent adults. Acyclovir given in late pregnancy to women with

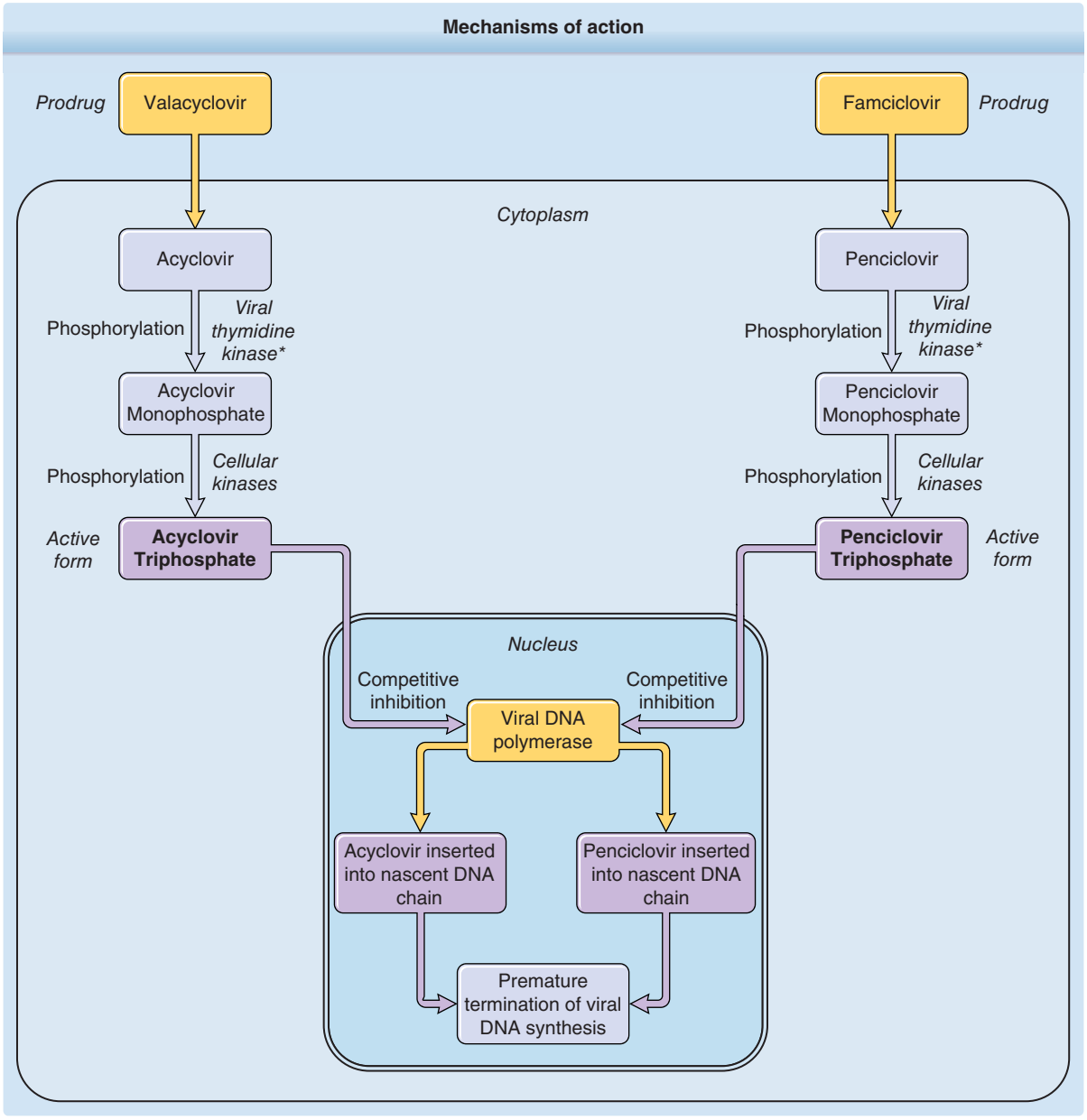

Figure 191-1. Mechanisms of action.

recurrent genital herpes has been shown to decrease the frequency of genital lesions, though there is some evidence that suggests standard oral dosing of acyclovir results in insufficient levels to prevent viral shedding on delivery.[1] As a result, acyclovir treatment is still recommended to neonates of mothers with recent genital HSV infection.

In addition, acyclovir has been shown to select for HIV-1 V85I reverse transcriptase variant in vitro,[2] which suggests a possible role in reducing HIV viral load. However, it was shown that acyclovir did not significantly prevent transmission of HIV despite a reduction of 0.25log(10) copies per milliliter in HIV RNA in those treated for genital HSV.[3] In fact, herpes virus infections in HIV patients is not yet well understood, and the only indicated treatment for HSV that is independent of HIV status is that of HSV encephalitis. All other indications, while useful on many occasions, remain off-label.

Despite its high efficacy, resistance to acyclovir remains an issue with herpes infections. Data from corneal HSV-1 isolates suggests that infections commonly represent mixtures of acyclovir-sensitive and resistant viruses with different *thymidine kinase* gene sequences. The acyclovir-resistant HSV-1 can establish latency and reactivate intermittently to cause acyclovir-refractory disease.[4]

DOSING REGIMENS

Treatment regimens with acyclovir vary depending on the indication and route of administration. An

TABLE 191-1A
Commonly Used Dosing Regimens for Acyclovir—Adults and Adolescents ≥12 Years

CONDITION	DOSAGE	ROUTE	DURATION
Primary HSV infection, immunocompetent host	5 mg/kg every 8 h *or* 400 mg 3×/d	IV Oral	5-7 d 7-10 d
Recurrent genital HSV infection, immunocompetent host	400 mg 3×/d *or* 800 mg 3×/d	Oral Oral	5 d 2 d[4]
Recurrent oral labial HSV infection, immunocompetent host	400 mg 5×/d *or* 5% cream 6×/d	Oral Topical	5 d 7 d
Mucocutaneous HSV infection, immunocompromised host[6]	5 mg/kg every 8 h *or* 400 mg 5×/d	IV Oral	7 d 14-21 d
Perinatal HSV infection	10-20 mg/kg every 8 h	IV	10-21 d
Chronic suppression of HSV infection	400 mg 2×/d *or* 800 mg every day	Oral	<12 mo
HSV encephalitis	10 mg/kg every 8 h	IV	14-21 d
Varicella: adolescent >40 kg/adult	800 mg 4×/d	Oral	5 d
Varicella: pneumonia or third-trimester pregnancy	800 mg 5×/d *or* 10 mg/kg every 8 h	Oral IV	5 d 5 d
Herpes zoster: normal host or not severe disease in immunocompromised host	800 mg 5×/d	Oral	7-10 d
Herpes zoster: severe disease or immunocompromised host	10-12 mg/kg every 8 h	IV	7-14 d

IV dose of 5 mg per kg every 8 hours or oral dose of 400 mg 3 times daily is generally recommended and more successful for patient compliance than 200 mg 5 times daily.[5] Chronic suppression requires an oral dose of 400 mg 3 times daily for up to 12 months (Table 191-1A).[6] The dose should be adjusted for patients with a creatinine clearance level of less than 50 mL/min, but drug level assays are not routinely performed. Data for pediatric dosing for <12 years of age is limited but available, particularly recommended for HSV-related neonatal and encephalitis infections (Table 191-1B).[7]

TABLE 191-1B
Commonly Used Dosing Regimens for Acyclovir—Pediatrics <12 Years

CONDITION	DOSAGE	ROUTE	DURATION
Primary HSV infection, immunocompetent host	40-80 mg/kg divided into 3-4 doses	Oral	5-10 d
Recurrent genital HSV infection, immunocompetent host[7]	20-25 mg/kg 2×/d	Oral	—
Primary HSV, immunocompromised host	20 mg/kg 3×/d *or* 5-10 mg/kg every 8 h	Oral IV	5-10 d
Mucocutaneous HSV infection, immunocompromised host[6]	5 mg/kg every 8 h *or* 400 mg 5×/d	IV Oral	7 d 14-21 d
Neonatal HSV infection	20 mg/kg every 8 h	IV	14-21 d
Chronic suppression of HSV infection	20 mg/kg 2×/d	Oral	5-14 d
HSV encephalitis	10-15 mg/kg every 8 h	IV	14-21 d
Varicella: >1 y old and <41 kg	20 mg/kg 4x/d	Oral	5 d
Herpes zoster: <1 y old ≥1 y old	10 mg/kg every 8 h *or* 500 mg every 8 h	Oral	7-10 d

HSV, herpes simplex virus.

SIDE EFFECTS AND PRECAUTIONS

Acyclovir is generally very well tolerated with uncommon reactions such as renal impairment (5% incidence). The major risk for impairment is renal tubular crystallization with rapid IV administration, though interstitial nephritis also has been reported. CNS toxicity is uncommon, but may manifest as lethargy, tremors, or seizures. Patients with these side effects commonly have underlying diseases involving the CNS. Thrombophlebitis is a known complication of infusion, and appears to be related to the high pH of the reconstituted solution (pH 11).

It should be warned that acyclovir crosses the human placenta and is excreted in breastmilk. However, it has been determined safe for use (pregnancy category B; see Table 191-2) and recommended for herpes treatment during pregnancy. The drug is also safe for administration during active breast-feeding, so long as the nursing mother does not have active lesions near or on the breast.[8] It has been shown to increase the risk of toxicity of foscarnet, mycophenolate, tenofovir, and zidovudine and decrease the therapeutic effects of talimogene laherparepvec, varicella vaccine, and zoster vaccine.

VALACYCLOVIR

MECHANISM OF ACTION AND PHARMACOKINETICS

See Fig. 191-1. Valacyclovir, the L-valine ester of acyclovir, was developed to provide increased oral bioavailability of the active drug acyclovir.[9] Valacyclovir is readily absorbed from the GI tract and almost entirely converted to acyclovir by intestinal and hepatic esterases. The mechanism of action and spectrum of activity of valacyclovir are identical to those of acyclovir, though improved from its predecessor. Valacyclovir has an oral bioavailability of 55%. Following a 1-g oral dose of valacyclovir, peak plasma concentrations of acyclovir in the range of 5.7 µg/mL are achieved in 1.75 hours, and area-under-the-curve (AUC) concentrations are similar to those achieved with 5 mg/kg of acyclovir given IV. Its half-life ranges from 1.3 to 2.5 hours in children to approximately 30 minutes in adults. Excretion is primarily renal, with 89% metabolized to acyclovir. Like acyclovir, the dose must be adjusted for those with underlying renal impairment.

TABLE 191-2
Pregnancy Categories of Systemic Antiviral Agents

AGENT	PREGNANCY CATEGORY
Acyclovir	B
Valacyclovir	B
Famciclovir	B
Ganciclovir and valganciclovir	C
Foscarnet	C
Cidofovir	C

INDICATIONS

- Initial and recurrent HSV genital infections
- Suppression and reduction of transmission of genital HSV infections
- Herpes zoster (shingles)
- Herpes labialis (cold sores)
- Varicella (chickenpox)

Valacyclovir therapy should be initiated at the earliest symptom of an HSV or VZV infection, within 72 hours of first diagnosis or 24 hours of onset of recurrent episode. It is preferred by patients due to its oral efficacy, compared to acyclovir, and ease of use in the outpatient setting. Treatment with valacyclovir has been suggested to decrease the frequency of clinical outbreaks as well as the incidence of viral shedding. Early studies showed a 30% reduction in viral shedding from valacyclovir-treated genital herpes compared to placebo-treated (P <.001).[10,11] Recent data showed even more promising results, where valacyclovir given 1 g daily resulted in a 78% reduction in viral shedding compared to placebo, and 79% of subjects had no clinical recurrences while receiving valacyclovir compared with 52% of subjects receiving placebo (P <.01).[12] Though less commonly, the drug has further been used to suppress recurrence of ocular herpes disease.[13]

In the setting of oral herpes simplex, valacyclovir has been used alone or combined with oral corticosteroids. In one study, there were more aborted lesions in the valacyclovir-clobetasol arm than in the placebo group (50% vs 15.8%, P = .04),[14] but further study is needed to assess the independent contribution of the corticosteroid.

Valacyclovir demonstrates in vitro activity against Epstein-Barr virus (EBV). It is being studied in the settings of infectious mononucleosis, hepatitis, encephalopathy, and posttransplant lymphoproliferative disease. Unfortunately, in a recent trial, valacyclovir treatment was not effective in decreasing peripheral blood EBV viral loads in pediatric liver transplantation patients.[15] In healthy volunteers, long-term administration of valacyclovir effectively reduces the number of EBV-infected B cells, although it does not reduce the number of EBV DNA copies per B cell.[16]

DOSING REGIMENS

Standard doses for adults with herpetic infections range from 0.5 to 1 g 2 to 3 times daily, as listed in Table 191-3.[17] The drug also has been evaluated in children with malignancy.[18] In this setting, valacyclovir (15 mg/kg) was well tolerated and demonstrated excellent bioavailability.[19] Those less than 3 months of age demonstrate decreased clearance of the drug. Among children 3 months through 11 years of age, a 20-mg/kg dose of an extemporaneously compounded

TABLE 191-3
Dosing Regimens for Valacyclovir

CONDITION	DOSAGE	ROUTE	DURATION
Primary HSV infection, immunocompetent host	1000 mg 2×/d	Oral	10 d
Recurrent genital HSV infection, immunocompetent host	500 mg 2×/d	Oral	3 d
Recurrent oral labial HSV infection, immunocompetent host	2000 mg 2×/d	Oral	1 d
Oral labial HSV infection, immunocompromised host	500 mg 2×/d	Oral	5-10 d
Chronic suppression of HSV infection	1000 mg every day	Oral	Undefined/ indefinite
Varicella: adolescent/ adult	1000 mg 3×/d	Oral	5 d
Herpes zoster: normal host or not severe disease in immunocompromised host	1000 mg 3×/d	Oral	7 d

HSV, herpes simplex virus.

valacyclovir oral suspension produced favorable acyclovir blood levels and was well tolerated. The authors noted that among children 2 through 5 years of age, a dose increase from 20 to 25 mg/kg resulted in near doubling of the peak concentration [C(max)] and the area under the curve (AUC).[20]

SIDE EFFECTS AND PRECAUTIONS

Most adverse effects are similar to those with acyclovir, including a potential for acute renal failure as well as CNS effects of agitation, hallucinations, seizures, and encephalopathy.[21] Additionally, the drug has been reported to produce both immediate hypersensitivity and a symmetrical drug-related intertriginous and flexural exanthem.[22,23] Severe effects of thrombotic thrombocytopenic purpura/hemolytic uremic syndrome (TTP/HUS) have been reported in patients with AIDS as well as in transplant recipients receiving dosages of 8 g/d. TTP/HUS has not been reported in patients in patients taking conventional dosages (up to 3 g/d) of valacyclovir. It is labeled as pregnancy category B risk.

Valacyclovir has been shown to precipitate in renal tubules and should be used with caution in those with renal impairment. Its most severe effects have been observed in elderly and immunocompromised patients, for which it is recommended to give the lowest dose possible. Given its metabolism to acyclovir, which can be detected in breastmilk, breast-feeding mothers should be aware that their nursing infants may receive small, though clinically insignificant, amounts of acyclovir. Common drug interactions include increased toxicity risk of foscarnet, mycophenolate, tenofovir, zidovudine, and decreased therapeutic effects of talimogene laherparepvec, varicella vaccine, and zoster vaccine.

FAMCICLOVIR AND PENCICLOVIR

MECHANISM OF ACTION

See Fig. 191-1. Famciclovir, [9-(4-hydroxy-3-hydroxymethylbut-1-yl)guanine], is biotransformed to the active compound penciclovir, [9-(4-hydroxy-3-hydroxy-3-hydroxymethylbut-1-yl)guanine], which is phosphorylated to penciclovir triphosphate to eventually inhibit HSV-2 polymerase. The initial phosphorylation of penciclovir to penciclovir monophosphate is efficiently carried out by HSV- or VZV-induced thymidine kinases with subsequent phosphorylation to diphosphate and triphosphate forms occurring via cellular kinases. The mechanism by which penciclovir triphosphate competitively inhibits viral DNA polymerases is similar to that of acyclovir, though more DNA chain extension may occur with penciclovir because of its hydroxyl group on the acyclic side chain.

PHARMACOKINETICS

Famciclovir is marketed as an oral formulation, which is converted to penciclovir by deacetylation and oxidation in the liver and intestine. The bioavailability of oral famciclovir is 77%, with a peak plasma concentration of 3.3 µg/mL reached 1 hour after oral administration of 500 mg of famciclovir. The plasma half-life of the converted penciclovir is 2 to 4 hours, with 60% to 70% of the drug excreted in urine unchanged. As with acyclovir, the dose of penciclovir should be reduced in patients with advanced renal dysfunction. Compared with the intracellular half-life of acyclovir triphosphate, that of penciclovir triphosphate is markedly prolonged in both HSV-infected cells (10 to 20 hours) and VZV-infected cells (7 hours), allowing the drug to be administered 2 to 3 times daily. Penciclovir is available as a 1% ointment for the treatment of recurrent oral HSV. At least in some vehicles, topical penetration of penciclovir is superior to that of acyclovir.[24] Microemulsion and nanoparticle formulations investigations concluded that these could be a promising vehicle for topical delivery of penciclovir.[25-27]

INDICATIONS

- Initial and recurrent HSV genital infections
- Suppression of frequently recurring genital HSV infections
- Initial and recurrent HSV labialis (cold sores) infections
- Herpes zoster (shingles)
- Varicella infection (chickenpox) in HIV patients (off-label)

As with acyclovir and valacyclovir, famciclovir and penciclovir should be initiated as soon as possible after diagnosis, ideally within 72 hours of rash onset. Famciclovir also has been shown to be an effective, well-tolerated option for the suppression of genital herpes among individuals with multiple recurrences.[28] Famciclovir is also equivalent to acyclovir for treatment of ophthalmic zoster.[29]

DOSING REGIMENS

Famciclovir is available as an oral agent and penciclovir as a topical cream. Standard adult doses are given in Table 191-4.[30] Pediatric doses are generally of increased treatment duration though with similar amount per dose, for example, 500 mg twice daily. In one study of recurrent genital HSV, a 2-day course of 500 mg initially, then 250 mg twice daily, was noninferior to the standard 5-day course of 125 mg twice daily.[31] In another study, single-day famciclovir (1000 mg administered twice daily) was similar in efficacy to 3-day valacyclovir (500 mg administered twice daily) for the treatment of recurrent genital herpes.[32] Single-day treatment is associated with high patient satisfaction.[33] Some data suggest that suppressive treatment may be superior to episodic treatment.[34] Studies in children are ongoing, and currently the drug is used less commonly in this population.[35,36] Although famciclovir has shown efficacy in general populations, one study of patient-initiated episodic treatment of recurrent genital herpes in immunocompetent black patients showed efficacy similar to that of placebo.[37]

TABLE 191-4
Dosing Regimens for Famciclovir and Penciclovir

CONDITION	DOSAGE	ROUTE	DURATION
Primary HSV infection, immunocompetent host	250 mg 3×/d	Oral	7-10 d
Recurrent genital HSV infection, immunocompetent host	125 mg 2×/d *or* 1000 mg 2×/d	Oral Oral	5 d 1 d
Recurrent oral labial HSV infection, immunocompetent host	1500 mg every day *or* 1% penciclovir cream every 2 h	Oral Topical	1 d 5 d or until lesions healed
Oral labial HSV infection, immunocompromised host	500 mg 2×/d	Oral	7 d
Chronic suppression of HSV infection	250 mg 2×/d	Oral	Up to 1 y
Varicella: adolescent/adult	500 mg 3×/d	Oral	5-7 d
Herpes zoster: normal host or not severe disease in immunocompromised host	500 mg 3×/d	Oral	7 d

HSV, herpes simplex virus.

SIDE EFFECTS AND PRECAUTIONS

Like acyclovir and valacyclovir, famciclovir is generally well tolerated.[38] The dose should be reduced for patients with a creatinine clearance less than 60 mL/min. The drug has been used safely along with hydration in patients with prior renal toxicity related to acyclovir.[39] Leukocytoclastic vasculitis has been reported with the drug.[40] Common side effects include:

- headache,
- nausea,
- diarrhea, and
- dizziness.

Serious toxicity is uncommon and the drug is labeled a pregnancy risk factor B. Famciclovir has been shown to diminish the therapeutic effect of talimogene laherparepvec, varicella virus vaccine, and zoster vaccine.

TRIFLURIDINE

MECHANISM OF ACTION AND PHARMACOKINETICS

Trifluridine, 5-trifluoromethyl-2′-deoxyuridine, is a pyrimidine nucleoside analog. Trifluridine monophosphate acts as an irreversible competitive inhibitor of thymidylate synthetase, and trifluridine triphosphate inhibits HSV DNA polymerase. Trifluridine triphosphate also inhibits cellular DNA polymerases, although it does so to a lesser extent than viral DNA polymerases. Because of its mechanism, it is considered a potent drug with expected response to treatment within 2 to 7 days. Because of systemic toxicity, trifluridine is approved only for topical application in the form of a 1% ophthalmic aqueous solution. The elimination half-life for the ophthalmic solution is 12 minutes.

INDICATIONS

- Primary and recurrent HSV keratoconjunctivitis, keratitis
- Acyclovir-resistant mucocutaneous HSV infections in patients with AIDS (off-label)

Trifluridine is indicated for the treatment of primary keratoconjunctivitis and recurrent epithelial keratitis caused by HSV types 1 and 2. It also has been suggested to benefit acyclovir-resistant HSV infections in AIDS patients. The drug offers a unique and effective delivery route that has similar efficacy to others of its class. A meta-analysis data from 99 randomized trials of 5363 total participants showed no significant difference between topical trifluridine, vidarabine, acyclovir, or ganciclovir in treatment of dendritic epithelial

TABLE 191-5
Dosing Regimens for Trifluridine

CONDITION	DOSAGE	ROUTE	DURATION
HSV keratoconjunctivitis/ keratitis	Induction: 1 drop every 2 h (maximum, 9 drops/24 h) Maintenance: 1 drop every 4 h (maximum, 6 drops/24 h)	Topical	Maximum, 21 d
Acyclovir-resistant HSV infection in AIDS	1 drop every 8 h	Topical	10-14 d or until lesions resolve

HSV, herpes simplex virus.

keratitis within 1 week of therapy.[41] A 2010 systematic review of 106 trials found that use of any of 4 topical antiviral agents (trifluridine, acyclovir ganciclovir, or brivudine) were equally effective and resulted in healing of 90% of the eyes within 2 weeks.[42] However, other authors have suggested that although the drug is effective, it may result in delays in reepithelialization of corneal ulcers.[43] As a result, there may be additional benefit from topical interferon in those treated with this agent.[44]

DOSING REGIMENS

Standard dosing regimens consist of 1 drop of 1% solution every 2 hours until reepithelialization of ulcer occurs, followed by 1 drop every 4 hours for another 7 days. Regimens are provided in Table 191-5. It is recommended to consider another form of therapy if no clinical improvement is seen at 7 to 14 days.

SIDE EFFECTS AND PRECAUTIONS

Adverse reactions to trifluridine are generally minor, mainly manifesting as transient local burning or stinging (5%), palpebral edema (3%), epithelial and punctate keratopathy, and stromal edema. It is considered a pregnancy category C risk with systemic application, but the amount available systemically following topical application of the ophthalmic drops has been considered negligible.

DRUGS FOR THE TREATMENT OF CYTOMEGALOVIRUS INFECTIONS

GANCICLOVIR AND VALGANCICLOVIR

MECHANISM OF ACTION AND PHARMACOKINETICS

Ganciclovir, 9-(1,3-dihydroxy-2-propoxymethyl)guanine, is phosphorylated by viral kinases to a substrate that competitively inhibits the binding of deoxyguanosine triphosphate to DNA polymerase, thereby inhibiting viral DNA synthesis. It is effective in treating cytomegalovirus infections intravenously, though oral bioavailability is only 5%. Valganciclovir, L-valine 2-[(2-amino-1,6-dehydro-6-*oxo*-9*H*-purin-9-yl) methoxy]-3-hydroxypropyl ester, is the L-valyl ester of ganciclovir that is more bioavailable. After oral administration, valganciclovir is converted to ganciclovir by intestinal and hepatic esterases with an oral availability of approximately 60% that is increased by 30% when administered with a high-fat meal. After a 900-mg dose of valganciclovir, the maximum plasma concentration of ganciclovir is 5.61 µg/mL, and the plasma concentration–time curve is similar to that achieved with ganciclovir given intravenously at a dose of 5 mg/kg. The elimination half-life is approximately 4 hours, though delayed in those with renal impairment.

INDICATIONS

- CMV retinitis in immunocompromised patients
- Suppression and prevention of CMV disease in transplant recipients
- CMV esophagitis, colitis, or neurologic disease in HIV patients (off-label)

Intravenous ganciclovir and oral valganciclovir are both approved for use in the treatment of cytomegalovirus in immunocompromised patients as well as in prevention of CMV disease in transplant patients.[45-47]

DOSING REGIMENS

Standard dosing regimens include 5 mg/kg/dose of ganciclovir every 12 hours for induction followed by every 24 hours for maintenance therapy. The equivalent dosing of valganciclovir is 900 mg twice daily induction followed by once-daily maintenance. Dosing summary is provided in Table 191-6. Pediatric dosing regimens also have been published and are similar to adult dosing.[48]

SIDE EFFECTS AND PRECAUTIONS

Potential side effects include a variety of GI (ie, diarrhea, nausea, and loss of appetite) as well as hematologic side effects (ie, anemia, thrombocytopenia, neutropenia, bone marrow aplasia, and aplastic anemia). Acute

TABLE 191-6
Dosing Regimens for Ganciclovir/Valganciclovir

CONDITION	DOSAGE	ROUTE	DURATION
CMV retinitis	Induction:		
	900 mg 2×/d	Oral	21 d
	5 mg/kg every 12 h	IV	14-21 d
	Maintenance:		
	900 mg every day	Oral	Until CD4 count >100 after 6 mo of HAART
	5 mg/kg every day	IV	

CMV, cytomegalovirus; HAART, highly active antiretroviral therapy.

renal failure may occur, for which doses should be immediately adjusted to half the regular dose. Nonspecific adverse reactions include headache, dizziness, confusion, nervousness, vivid dreams, tremor, weakness, peripheral edema, and pain at the injection site.

Known drug interactions include potentiation of imipenem, mycophenolate, probenecid, reverse transcriptase inhibitors, and tenofovir. It is labeled as pregnancy category C and recommended to use contraception during and 30 to 90 days post treatment. Breast-feeding is not recommended, since it is not known if ganciclovir or valganciclovir are excreted into breastmilk.

FOSCARNET

MECHANISM OF ACTION

Foscarnet, trisodium phosphonoformate, is a pyrophosphate-containing antiviral drug that noncompetitively inhibits viral DNA polymerases at the pyrophosphate binding site. In contrast to the nucleoside analogs, foscarnet does not require phosphorylation and is therefore active against many strains of virus that are resistant to acyclovir, famciclovir, or ganciclovir as a result of absent or reduced kinase activity.[49-51] Salvage therapy with foscarnet plus a thymidine analog has been shown to be effective in patients with advanced-stage HIV disease and viruses harboring multiple drug-resistance mutations including thymidine-associated mutations.[52] Unfortunately, resistance to combined ganciclovir and foscarnet therapy has been reported in the setting of dual-strain cytomegalovirus coinfection.[53] Valproic acid has been reported to impair the antiviral activity of ganciclovir, cidofovir, and foscarnet.[54]

PHARMACOKINETICS

Foscarnet is available as an IV preparation that has poor solubility and must be administered by an infusion pump in a dilute solution over 1 to 2 hours. The drug has a half-life of 3 to 4 hours initially with a terminal component of 88 hours or longer, for which up to 20% of the cumulative dose may be deposited in bone. Twenty-eight percent of the dose is excreted unaltered by the kidney.

INDICATIONS

- CMV retinitis
- Acyclovir-resistant HSV infections
- CMV esophagitis or colitis (off-label)
- Ganciclovir-resistant CMV infections (off-label)

DOSING REGIMENS

Standard dosing schedules consist of induction therapy of 40 to 90 mg/kg/dose every 8 to 12 hours followed by maintenance therapy of 90 to 120 mg/kg/d. Specific regimens are provided in Table 191-7. The dose must be adjusted accordingly in patients with renal dysfunction.

SIDE EFFECTS AND PRECAUTIONS

Renal toxicity (30%) is the major risk with foscarnet, for which close monitoring of renal function is required. Impairment of renal function typically occurs during the second week of induction therapy and is reversible within 1 week following dose adjustment or discontinuation of therapy. Saline hydration before administration and slow infusion of the drug may reduce nephrotoxicity risk. In addition, the drug has been associated with electrolyte and metabolic abnormalities including hypocalcemia, hyper/hypophosphatemia, hypomagnesaemia, and hypokalemia, described with up to 48% incidence. Other common adverse reactions include nausea/vomiting with diarrhea (<47%), anemia (33%), granulocytopenia (17%), fever (65%), and headache (26%).

TABLE 191-7
Dosing Regimens for Foscarnet

CONDITION	DOSAGE	ROUTE	DURATION
CMV retinitis	Induction: 90 mg/kg every 12 h	IV	14-21 d
	Maintenance: 90 mg/kg every 24 h	IV	Until CD4 count >100 on 6 mo of HAART
Acyclovir-resistant HSV infection	40 mg/kg every 8 h *or* 60 mg/kg every 12 h	IV	14-21 d 2-3 wk or until clinical resolution
CMV esophagitis/colitis	90 mg/kg every 12 h	IV	21-42 d or until clinical resolution

CMV, cytomegalovirus; HAART, highly active antiretroviral therapy; HSV, herpes simplex virus.

Careful monitoring for renal impairment and seizures is recommended because of foscarnet's effects on renal function and electrolytes, respectively. Because of its sodium content, foscarnet use is cautioned in patients with underlying heart failure. It has been determined as pregnancy category C risk, for which ultrasonographic monitoring of amniotic fluid volumes is recommended after 20 weeks to detect oligohydramnios. It not known whether foscarnet is excreted in breastmilk. Known drug interactions include potentiation of adverse side effects of acyclovir/valacyclovir, aminoglycosides, amphotericin B, cyclosporine, QTc-prolonging agents, methotrexate, and tacrolimus. Conversely, loop diuretics and pentamidine have been shown to enhance the toxic effect of foscarnet.

CIDOFOVIR

MECHANISM OF ACTION AND PHARMACOKINETICS

Cidofovir, (*S*)-1-[3-hydroxy-2(phosphonylmethoxy)-propyl]cytosine, is a phosphonate nucleotide analog.[55] Unlike other nucleoside analogs, it does not require initial phosphorylation by virus-induced kinases and can be converted by host cell enzymes to cidofovir diphosphate, a competitive inhibitor of viral DNA polymerases. Cidofovir is officially approved for IV administration, though a topical formulation can be compounded for off-label usage. It has a volume of distribution of 0.31 L per kg with low CSF penetration; therefore, an IV dose of 5 mg/kg results in a peak plasma concentration of 11.5 µg/mL. Plasma half-life is approximately 2.6 hours with markedly longer intracellular half-life of 24 to 87 hours. Excretion is mainly renal, which can be facilitated by the addition of concomitant probenecid.

INDICATIONS AND CONTRAINDICATIONS

- CMV retinitis
- Acyclovir-resistant HSV infections (off-label)

Cidofovir is approved for IV treatment of CMV retinitis particularly in those with AIDS, though it has been shown in multiple incidences to be effective in acyclovir-resistant HSV infections,[5,56] both via IV and topical routes, as well as in topical treatments for human papillomavirus infections, Kaposi sarcoma, and molluscum contagiosum.[57-65] Given its significant renal metabolism, cidofovir is contraindicated in those with preexisting renal impairment, as evidenced by serum creatinine >1.5 or >2+ proteinuria.

DOSING REGIMENS

For adults, cidofovir may be given at an induction dose of 5 mg/kg once weekly for the first 2 weeks, followed by a 5-mg/kg dose once every 2 weeks (Table 191-8).

TABLE 191-8
Dosing Regimens for Cidofovir

CONDITION	DOSAGE	ROUTE	DURATION
CMV retinitis	Induction: 5 mg/kg every week	IV	2 wk
	Maintenance: 5 mg/kg every 2 wk	IV	Until CD4 count >00 after 6 mo on HAART

CMV, cytomegalovirus; HAART, highly active antiretroviral therapy.
Note: Cidofovir IV administration must be accompanied by prehydration and probenecid.

Data regarding the use in pediatric patients are accumulating.[66]

SIDE EFFECTS AND PRECAUTIONS

Common adverse effects consist of renal impairment (59% incidence), which consists of:

- renal tubular damage,
- dose-dependent proximal tubular injury (Fanconi-like),
- proteinuria, and
- elevated serum creatinine levels.

Other common effects include nausea (48%), alopecia (16%), rash, fever, myalgias, asthenia, headache, abdominal pain, diarrhea, nausea, dyspepsia, flatulence, increased creatinine, pancreatitis, and hypophosphatemia. The incidence of nephrotoxicity can be reduced by vigorous hydration before and after infusion, in addition to coadministration of probenecid. In addition to close monitoring of renal function, the drug should not be used concurrently with tenofovir disoproxil fumarate (TDF) because of a risk of increased tenofovir levels and toxicity. The following rare but possible effects can occur: squamous cell carcinoma associated with intralesional injection of cidofovir to treat human papillomavirus (HPV)–related recurrent respiratory papillomatosis,[67-69] and herpes simplex stomatitis associated with prophylactic cidofovir therapy.[70]

Cidofovir has been labeled pregnancy category C, suggesting possible teratogenic risk. It is thus recommended that women of childbearing potential use effective contraception during and for 1 month following treatment and that men use barrier contraception during and for 3 months following treatment. The indications for treating CMV retinitis during pregnancy are the same as in nonpregnant HIV-infected women; however, therapy with cidofovir should be avoided during the first trimester when possible. It is not known whether cidofovir is excreted in breastmilk, but generally breast-feeding on cidofovir is not recommended because of the potential for serious adverse reactions in the nursing infant.

OTHER INFECTIONS

MECHANISM OF ACTION

Interferons are cytokines derived from a variety of cells that interact through high-affinity cell surface receptors. They have broad antiviral and immunomodulating effects that include induction of gene transcription, inhibition of cellular growth, interference with oncogene expression, alteration of cell surface antigen expression, increased phagocytic activity of macrophages, and cytotoxicity of lymphocytes.

PHARMACOKINETICS

Interferon is commonly given subcutaneously, but also may be administered intravenously, intralesionally, or intramuscularly. It has a plasma half-life of 2 to 3 hours after IV administration, and 4 to 6 hours after subcutaneous or intramuscular administration. A prolonged half-life can be obtained with pegylated interferon.

INDICATIONS

Interferon therapy has been approved for a variety of viral infections (IFN-alpha), for multiple sclerosis (IFN-beta), for chronic granulomatous disease (IFN-gamma), as well as for a number of neoplastic diseases (IFN-alpha), including melanoma. It also has been useful as off-label therapies for chronic myelogenous leukemia, cutaneous T-cell lymphoma, Behçet disease, desmoid tumor, multiple myeloma, neuroendocrine tumors, renal cell carcinoma, and West Nile virus. In the setting of viral infections, interferon-α has been studied most extensively and includes alphacon-1, alpha-2a/b, and alpha-n3.

VIRAL DISEASES TREATED WITH INTERFERON

- Condylomata acuminata (intralesional)
- Chronic hepatitis C infection +/− in combination with ribavirin (IM, subcutaneous [SC])
- Chronic hepatitis B infection (IM, SC)
- AIDS-related Kaposi sarcoma (IM, SC)

DOSING REGIMENS

Common dosing regimens are provided in Table 191-9. Pediatric dosing is adjusted by one-third to one-half of adult dosing with recommendation to consider acetaminophen premedication prior to interferon administration to reduce the incidence of some adverse reactions.

TABLE 191-9
Dosing Regimens for the Interferons

CONDITION	DOSAGE	ROUTE	DURATION
Kaposi sarcoma	IFNα-2b 30 million units 3×/wk	IM, Subcutaneous	Dependent on response
Condyloma acuminata	IFNα-2b 1 million units 3×/wk *or* IFNα-n3 250k units 2×/wk	Intralesional	3 wk Up to 8 wk
Chronic hepatitis C (with ribavirin)	PEG-IFNα-2a 180 µg once a week *or* PEG-IFNα-2b 1.5 µg/kg once a week *or* IFN-alfacon-1 15 µg/d *or* IFNα-2b 3 million units 3×/wk	Subcutaneous IM, Subcutaneous	Dependent on response and genotype Up to 48 wk 18-24 mo
Chronic hepatitis B	PEG-IFNα-2a 180 µg once a week *or* IFNα-2b 10 million units 3×/wk	Subcutaneous IM, Subcutaneous	48 wk 16 wk

IFN, interferon; PEG-IFN, peginterferon.

SIDE EFFECTS AND PRECAUTIONS

Side effects with interferon are common and often result in discontinuation of the drug. In a majority of patients, flulike symptoms of fever, chills, tachycardia, malaise, myalgia, and headache may occur within 1 to 2 hours of administration. The most common cutaneous side effects include injection site reactions, alopecia, psoriasis, fixed drug eruptions, eczematous drug reactions, sarcoidosis,[71] lupus, pigmentary changes, and lichenoid eruptions.[72,73] Other adverse effects include bone marrow suppression as well as GI- and hepatotoxicity for which blood counts and metabolic panels should be monitored. Interferon-α has further been shown to cause or aggravate neuropsychiatric events for which patients should be monitored for depression psychosis, cognitive changes, and suicidal and homicidal ideation. Interferon-α should not be used to treat hepatitis B–related cirrhosis or decompensated liver disease because hepatitis flares could lead to further decompensation.

Precaution should be taken in prescribing interferon to patients with underlying eye, autoimmune, cardiovascular, ischemic, infectious, or lung disease. Alone, interferon is labeled as pregnancy risk factor C.

Combination therapy of interferon-α with ribavirin is associated with birth defects (category X) and is contraindicated in pregnant women as well as males of pregnant partners. Interferon may enhance the activity of aldesleukin, clozapine, deferiprone, dypnone, methadone, ribavirin, theophylline, tizanidine, zidovudine, and telbivudine.

DRUGS FOR THE TREATMENT OF HIV INFECTION

Drug treatment of HIV infection requires specialized training and experience. The US Department of Health and Human Services (HHS) and the World Health Organization (WHO) publish guidelines for the treatment of HIV. Both sets of guidelines are updated regularly as evidence from ongoing clinical trials emerges and therefore should be consulted routinely. The DHHS guidelines are available at http://aidsinfo.nih.gov/guidelines, and the WHO guidelines are available at http://www.who.int/hiv/pub/guidelines.

INTRODUCTION

HIV infection is treated with antiretroviral therapy (ART) which involves the use of multidrug regimens to reduce HIV-associated morbidity, prolong the duration and quality of survival, and prevent HIV transmission.

As of June 2016, there are more than 25 available antiretroviral (ARV) drugs in 6 major classes (Table 191-10). Multiple comparative clinical trials have shown that combination therapy involving multiple drugs from different classes is most effective. However, eradication of HIV infection cannot be achieved with available ARV regimens, primarily because the pool of latently infected CD4 T cells is established during the earliest stages of acute HIV infection and persists with a long half-life.[74]

ARV drugs work by blocking the virus at various points in its 7-stage life cycle. The stages of the HIV life cycle and the classes of ARV drugs that block them are as follows[74,75]:

1. Binding (also called Attachment): The viral envelope glycoprotein binds to the host receptors (CD4) and coreceptors (CC-chemokine receptor 5 (CCR5) or CXC-chemokine receptor 4 (CXCR4)). Entry inhibitors target this stage. The only FDA-approved drug that targets this stage is a CCR5 inhibitor.
2. Fusion: The HIV envelope and the host cell membrane fuse enabling the entry of the viral capsid in the host cell. Fusion inhibitors target this stage.
3. Reverse Transcription: The viral reverse transcriptase converts its genetic material (HIV RNA) into HIV double-stranded DNA. Nucleoside/nucleotide analog reverse transcriptase inhibitors (NRTIs) and nonnucleoside reverse transcriptase inhibitors (NNRTIs) target this stage.
4. Integration: The viral integrase integrates the viral DNA into the host DNA. Integrase strand transfer inhibitors (INSTIs) target this stage.
5. Replication: HIV protein chains and RNA are produced using the host cell machinery.
6. Assembly: The newly replicated proteins and RNA move to the surface of the host cell and assembly into immature virions.
7. Budding and Maturity: The newly formed virion buds out of the host cell and releases protease that breaks up the viral protein chains, ultimately resulting in mature virions. Protease inhibitors (PIs) target this stage, which results in inhibition of reverse transcription and possibly other downstream stages in the life cycle, including integration.

In addition, 2 drugs are pharmacokinetic (PK) enhancers/boosters used solely to improve the

TABLE 191-10
Available Antiretroviral Therapy and Their Abbreviations

Entry Inhibitor
Maraviroc (MVC)
Fusion Inhibitor
Enfuvirtide (T-20)
Nucleoside and Nucleotide Reverse Transcriptase Inhibitors (NRTIs)
Abacavir (ABC)
Didanosine (ddI)
Emtricitabine (FTC)
Lamivudine (3TC)
Stavudine (d4T)
Tenofovir disoproxil fumarate (TDF)
Zidovudine (ZDV, AZT)
Nonnucleoside Reverse Transcriptase Inhibitors (NNRTIs)
Delavirdine (DLV)
Efavirenz (EFV)
Etravirine (ETR)
Nevirapine (NVP)
Rilpivirine (RPV)
Integrase Strand Transfer Inhibitors (INSTIs)
Dolutegravir (DTG)
Elvitegravir (EVG)
Raltegravir (RAL)
Protease Inhibitors (PIs)
Atazanavir (ATV)
Atazanavir/ritonavir (ATV/r)
Atazanavir/cobicistat (ATV/c)
Darunavir (DRV)
Darunavir/cobicistat (DRV/c)
Fosamprenavir (FPV)
Indinavir (IDV)
Lopinavir/ritonavir (LPV/r)
Nelfinavir (NFV)
Saquinavir (SQV)
Tipranavir (TPV)
Pharmacokinetic Enhancers/Boosters
Ritonavir (RTV)
Cobicistat (COBI)

pharmacokinetic profiles of some ARV. These are listed in Table 191-10.[74]

ART was shown to reduce HIV-related morbidity and mortality, and reduce perinatal and behavior-associated transmission of HIV. HIV suppression with ART may also decrease inflammation and immune activation thought to contribute to higher rates of cardiovascular and other end-organ damage reported in HIV-infected cohorts. Maximal and durable suppression of plasma viremia delays or prevents the selection of drug-resistance mutations, preserves CD4 T-cell numbers, and confers substantial clinical benefits, all of which are important treatment goals.[74]

THERAPY INITIATION RECOMMENDATIONS

Antiretroviral therapy (ART) is recommended for all HIV-infected individuals to reduce the risk of disease progression, regardless of CD4 count, age group or pregnancy/lactation. Both the HHS and WHO expanded the recommendation of ART to *all* HIV-infected individuals in 2015. In January 2016, based on new findings, the HHS gave the highest strength and evidence rating for this recommendation.[74,76,77]

For most patients, ART is initiated soon after the initial diagnosis. However, several conditions increase the urgency for therapy, these include pregnancy, presence of HIV-related complications, opportunistic infections, chronic hepatitis B and C infection, acute symptomatic HIV infection, and CD4 ≤200 cells/μL, rapidly declining CD4 counts, and higher viral loads (eg, >100,000 copies/mL).[74]

THERAPY REGIMEN RECOMMENDATIONS

The initial ART regimen for a treatment-naive patient generally consists of 2 NRTIs, combined with an INSTI, an NNRTI, or a pharmacologically boosted PI. This strategy has resulted in decreased HIV RNA and increase in CD4 T lymphocyte (CD4) cell in most patients. However, on the basis of individual patient characteristics and needs, an alternative regimen may in some instances be the optimal regimen.[74,76] Table 191-11 shows the recommended and alternative first-line regimens based on the latest WHO guidelines.

Given the large number of excellent options for initial therapy, selection of a regimen for a particular patient should be guided by factors such as viral load, CD4 count, virologic efficacy, side-effect profile, toxicity, pill burden, dosing frequency, previous exposure to drugs, drug–drug interaction potential, resistance testing results, comorbid conditions, and cost. When initiating a combination ART, all drugs should be started simultaneously rather than sequentially.[74]

When initial suppression is not achieved or is lost, rapidly changing to a new regimen with at least 2 active drugs is required. Thus, when prescribing a first-line regimen, second- and third-line strategies should be formulated, keeping in mind the high-level cross-resistance seen among the same class of drugs. Indiscriminate use of the drugs will lead to minimal options for the future. The increasing number of drugs and drug classes makes viral suppression below detection limits an appropriate goal in all patients.[74]

Viral load reduction to below limits of assay detection in an ART-naive patient usually occurs within the first 12 to 24 weeks of therapy.[74]

TABLE 191-11
Preferred and Alternative First-Line ART Regimens

POPULATION	PREFERRED FIRST-LINE REGIMEN	ALTERNATIVE FIRST-LINE REGIMENS
Adults	TDF + 3TC (or FTC) + EFV	AZT + 3TC + EFV (or NVP) TDF + 3TC (or FTC) + DTG TDF + 3TC (or FTC) + EFV TDF + 3TC (or FTC) + NVP
Pregnant/ breastfeeding women	TDF + 3TC (or FTC) + EFV	AZT + 3TC + EFV (or NVP) TDF + 3TC (or FTC) + NVP
Adolescents	TDF + 3TC (or FTC) + EFV	AZT + 3TC + EFV (or NVP) TDF (or ABC) + 3TC (or FTC) + DTG TDF (or ABC) + 3TC (or FTC) + EFV TDF (or ABC) + 3TC (or FTC) + NVP
Children 3 y to less than 10 y	ABC + 3TC + EFV	ABC + 3TC + NVP AZT + 3TC + EFV (or NVP) TDF + 3TC (or FTC) + EFV (or NVP)
Children less than 3 y	ABC (or AZT) + 3TC + LPV/r	ABC (or AZT) + 3TC + NVP

Note: For expansions of the abbreviations used, please refer to Table 191-10.

PREVENTION

PREEXPOSURE PROPHYLAXIS (PrEP)

Oral PrEP of HIV is the use of ARV drugs by HIV-negative people before potential exposure to prevent infection.[78] The WHO recommends oral PrEP containing TDF for all populations with substantial risk of HIV infection (defined by an incidence of HIV infection in the absence of PrEP greater than 3%). For such populations, oral PrEP should be offered as an additional prevention choice as part of combination of prevention approaches, including regular HIV testing and counseling, provision of condoms, screening and treatment

TABLE 191-12
WHO Guidelines for Use of ARV Drugs for HIV Prevention

PROPHYLAXIS TYPE	POPULATION	REGIMEN			
Preexposure prophylaxis (PrEP)	All populations at substantial risk	TDF (alone or in combination with FTC)			
		Recommended 2-Drug Regimen	**Alternative 2-Drug Regimen**	**Preferred Additional 3rd Drug**	**Preferred Additional 3rd Drug Alternative**
Postexposure prophylaxis (PEP)	Adults and adolescents	TDF + 3TC (or FTC)	N/A	LPV/r or ATV/r	RAL, DRV/r or EFV
	Children	ZDV + 3TC	ABC + 3TC TDF + 3TC (or FTC)	LPV/r	Age-appropriate selection from ATV/r, RAL, DRV, EFV, and NVP

Note: For expansions of the abbreviations used, please refer to Table 191-10.

for sexually transmitted infections, and adherence counseling.[74,78] Furthermore, HIV testing is required before PrEP is offered and regularly while PrEP is taken. Renal function testing using serum creatinine testing is preferred before starting PrEP and quarterly during PrEP use for the first 12 months then annually thereafter. These populations may include people engaging in high-risk sexual behaviors, people who inject drugs, people in prisons and closed settings, and sex workers.[78,79] Table 191-12 shows the WHO's recommend regimen for PrEP.

POSTEXPOSURE PROPHYLAXIS (PEP)

PEP of HIV is the use of ARV drugs by HIV-negative people after exposure to a known or suspected (high-risk) source of HIV infection. PEP should be prescribed following occupational exposure to HIV by health workers and following non-occupational exposures, including unprotected sexual exposure, injecting drug use and exposure following sexual assault. The WHO recommends at least a 2-drug PEP regimen, but prefers 3 drugs. A full 28-day prescription of antiretrovirals should be provided for HIV PEP following initial risk assessment, and enhanced adherence counseling is suggested for all individuals initiating HIV PEP. Data from animal studies suggest that the efficacy of PEP in preventing transmission is time dependent, and every effort should be made to provide PEP as soon as possible following exposure.[79] Table 191-13 shows the WHO's recommended regimens for PEP.

ADVERSE EFFECTS

Adverse effects have been reported with the use of all antiretroviral (ARV) drugs and are among the most common reasons cited for switching or discontinuing therapy and for medication nonadherence. Fortunately, newer ARV regimens are less toxic than regimens used in the past. Generally less than 10% of antiretroviral therapy (ART)-naive patients enrolled in randomized trials have treatment-limiting adverse events.[74]

Several factors may predispose individuals to adverse effects of ARV medications, these include[74]

- concomitant use of medications with overlapping and additive toxicities,
- comorbid conditions that increase the risk of or exacerbate adverse effects,
- drug–drug interactions that may lead to an increase in drug toxicities, and
- genetic factors that predispose patients to abacavir (ABC) hypersensitivity reaction.

In general, the overall benefits of ART outweigh its risks and that some non–AIDS-related conditions (eg, anemia, cardiovascular disease, renal impairment) may be more likely in the absence of ART.[74]

TABLE 191-13
WHO Guidelines for Postexposure Prophylaxis

POPULATION	RECOMMENDED 2-DRUG REGIMEN	ALTERNATIVE 2-DRUG REGIMEN	PREFERRED ADDITIONAL THIRD DRUG	PREFERRED ADDITIONAL THIRD DRUG ALTERNATIVE
Adults and adolescents	TDF + 3TC (or FTC)	N/A	LPV/r or ATV/r	RAL, DRV/r, or EFV
Children	ZDV + 3TC	ABC + 3TC TDF + 3TC (or FTC)	LPV/r	Age-appropriate selection from ATV/r, RAL, DRV, EFV, and NVP

Note: For expansions of the abbreviations used, please refer to Table 191-10.

DRUG INTERACTIONS

Pharmacokinetic (PK) drug–drug interactions between antiretroviral (ARV) drugs and concomitant medications are common, and may lead to increased or decreased drug exposure. In some instances, changes in drug exposure may increase toxicities or affect therapeutic responses. When prescribing or switching one or more drugs in an ARV regimen, clinicians must consider the potential for drug–drug interactions—both those that affect ARVs and those that ARVs affect on other drugs a patient is taking. The magnitude and significance of interactions are difficult to predict when several drugs with competing metabolic pathways are prescribed concomitantly. When prescribing interacting drugs is necessary, clinicians should be vigilant in monitoring for therapeutic efficacy and/or concentration-related toxicities.[74]

The following gives an overview of the pharmacology, mechanism of action, and side effects, particularly mucocutaneous adverse effects, of each class of drugs.

ENTRY INHIBITOR

The only FDA-approved fusion inhibitor is maraviroc.

PHARMACOLOGY AND MECHANISM OF ACTION

Maraviroc selectively binds to the human chemokine receptor CCR5 present on the cell membrane, preventing the interaction of HIV-1 gp120 and CCR5 necessary for CCR5-tropic HIV-1 to enter cells. Maraviroc is a substrate of CYP3A and P-glycoprotein (P-gp) and its pharmacokinetics are likely to be modulated by inhibitors and inducers of these enzymes/transporters.

SIDE EFFECTS AND PRECAUTIONS

Mucocutaneous Side Effects: Severe and potentially life-threatening skin and hypersensitivity reactions have been reported in patients taking maraviroc. This includes cases of Stevens–Johnson syndrome, hypersensitivity reaction, and toxic epidermal necrolysis.

Other Side Effects:

- Abdominal pain
- Cough
- Dizziness
- Musculoskeletal symptoms
- Pyrexia
- Upper respiratory tract infections
- Hepatotoxicity, which may be preceded by severe rash or other signs of systemic allergic reactions
- Orthostatic hypotension, especially in patients with severe renal insufficiency

FUSION INHIBITOR

The only FDA-approved fusion inhibitor is enfuvirtide.

PHARMACOLOGY AND MECHANISM OF ACTION

Enfuvirtide is a synthetic peptide that mimics a portion of glycoprotein 41 (gp41), HR1, an HIV envelope glycoprotein required for fusion of the viral envelope with the host cell membrane.[80] The drug blocks the formation of a 6-helix bundle structure that is critical for the fusion process.

Enfuvirtide is administered via subcutaneous injection. Pharmacokinetics are linear up to a dose of 180 mg. Enfuvirtide does not influence concentrations of drugs metabolized by CYP 3A4, CYP 2D6, or *N*-acetyltransferase, and has only minimal effects on those metabolized by CYP 1A2, CYP 2E1, or CYP 2C19.

SIDE EFFECTS AND PRECAUTIONS

Mucocutaneous Side Effects:

- Local injection site reactions
- Induration
- Erythema
- Nodules
- Cysts

Other Side Effects:

- GI upset
- Increased risk of bacterial pneumonias

Injection site reactions occur in nearly all patients. Patients should be alert for signs or symptoms of pneumonia.

NUCLEOSIDE AND NUCLEOTIDE REVERSE TRANSCRIPTASE INHIBITORS (NRTIs)

FDA-approved NRTIs are abacavir, didanosine, emtricitabine, lamivudine, stavudine, tenofovir disoproxil fumarate, and zidovudine.

PHARMACOLOGY AND MECHANISM OF ACTION

NRTIs compete with the naturally occurring deoxynucleoside substrates for binding to reverse transcriptase (RT). After diffusing into the cytoplasm, they are phosphorylated by intracellular kinases to their active triphosphate forms. The triphosphate form is incorporated into DNA, resulting in chain termination. This group of agents demonstrates activity against HIV-1 and HIV-2, as well as other retroviruses.

NRTIs are well absorbed from the GI tract, although there are differences in bioavailability when they are administered with and without food as well as differences in both serum and intracellular half-lives. The volume of distribution, metabolism, and excretion also vary considerably among the different agents.

SIDE EFFECTS AND PRECAUTIONS

Mucocutaneous Side Effects: Serious and sometimes fatal hypersensitivity reactions can occur with abacavir. Patients who carry the HLA-B*5701 allele are at a higher risk of experiencing a hypersensitivity reaction to abacavir.

Fat redistribution has been seen in some patients taking emtricitabine. These changes may include an increased amount of fat in the upper back and neck ("buffalo hump"), breast, and around the trunk. Loss of fat from the legs, arms, and face may also happen. Hyperpigmentation primarily of palms and/or soles, but also possibly the tongue, arms, lip, and nails, also have been seen with this medication. Rash is common and includes hypersensitivity reaction, maculopapular rash, pustular rash, and vesiculobullous rash.

Rash, pruritus, xerostomia, alopecia, lipodystrophy, Stevens–Johnson syndrome, and vasculitis can occur with didanosine.

Alopecia, rash, pruritus, and fat redistribution can be seen with lamivudine.

Fat redistribution can be seen with stavudine.

Rash, including macular, papular, pustular, vesiculobullous, or urticarial, as well as pruritus and diaphoresis, can be seen with tenofovir.

Lipodystrophy, skin/nail pigmentation changes (blue), Stevens–Johnson syndrome, toxic epidermal necrolysis, urticarial, and morbilliform eruption can be seen with zidovudine.

Other Side Effects: The hallmark toxicity of the NRTI class is mitochondrial toxicity, which may manifest as hepatic steatosis, peripheral neuropathy, pancreatitis, dyslipidemia, fat maldistribution, and lipoatrophy. All NRTIs have "black box" warnings in their product labeling regarding the possibility of lactic acidosis syndrome, which is potentially fatal.

Common side effects of zidovudine include bone marrow suppression and GI intolerance. Stavudine is associated with lipoatrophy and lactic acidosis. Didanosine can cause pancreatitis and peripheral neuropathy, whereas abacavir is associated with life-threatening hypersensitivity reactions. Tenofovir is associated with headache and nausea. It can elevate didanosine levels and lower those of atazanavir. Lamivudine is generally well tolerated but may produce neutropenia. Onset of bullous pemphigoid has been reported with the combination of lamivudine + didanosine + nelfinavir.[81]

NONNUCLEOSIDE REVERSE TRANSCRIPTASE INHIBITORS (NNRTIs)

FDA-approved NNRTIs are delavirdine, efavirenz, etravirine, nevirapine, and rilpivirine.

PHARMACOLOGY AND MECHANISM OF ACTION

Drugs in this class are structurally different from the NRTIs. The NNRTIs bind near the catalytic site of reverse transcriptase and alter the enzymes' ability to change conformation. This increased enzyme rigidity prevents its normal polymerization function and therefore the replication rate of the virus reduces.

Nevirapine has greater than 90% bioavailability and a plasma half-life of 24 hours. It is metabolized in the liver and induces its own metabolic pathway. As the metabolism of the drug increases, the dose is increased from once a day during the first 2 weeks to twice per day thereafter. Delavirdine has a bioavailability of 85%. It requires an acidic environment for absorption and should not be given with antacids, H_2 blockers, or proton pump inhibitors. Its plasma half-life is 6 hours, and it is metabolized in the liver. The absorption of efavirenz is increased by food. However, it is generally administered on an empty stomach to minimize side effects. The half-life of efavirenz is 40+ hours, and it is metabolized in the liver.[82]

SIDE EFFECTS AND PRECAUTIONS

Mucocutaneous Side Effects: Nevirapine is associated with rash in about 20% of patients and may cause Stevens–Johnson syndrome.[83,84] Among HIV-infected patients with CD4 counts <250 cells/μL, higher baseline counts are associated with a higher incidence of rash, requiring discontinuation of the drug.[85] The rash appears to be related to the quinone methide formed in the skin by sulfation of the 12-OH metabolite followed by loss of the sulfate.[86] Mucosal side effects include whitish plaques, burning, taste disturbance, and xerostomia.[87] Treatment with nevirapine

should be initiated slowly to minimize the incidence of cutaneous reactions. If the rash is extensive, or if mucous membranes are involved, the drug should be discontinued. Nevirapine is generally not recommended for women with $CD4^+$ T-cell counts higher than 250 cells/mm^3 or for men with $CD4^+$ T-cell counts above 400/mm^3 because of an increased risk of hepatitis in these patients.

Etravirine is associated with a self-limiting rash in 19% of patients.[88] Delavirdine is also commonly associated with drug rash.

Other Side Effects:

- Hepatitis
- CNS abnormalities
- Efavirenz is teratogenic

INTEGRASE STRAND TRANSFER INHIBITORS (INSTIs)

FDA-approved INSTIs are dolutegravir, elvitegravir, and raltegravir.

PHARMACOLOGY AND MECHANISM OF ACTION

INSTIs inhibit HIV integrase and thus prevent the integration of HIV-1 DNA into host genomic DNA, blocking the formation of the HIV-1 provirus and propagation of the viral infection.

SIDE EFFECTS AND PRECAUTIONS

Mucocutaneous Side Effects: Severe, potentially life-threatening and fatal skin reactions have been reported with the use of raltegravir. This includes cases of Stevens–Johnson syndrome, hypersensitivity reaction, and toxic epidermal necrolysis.

Hypersensitivity reactions characterized by rash, constitutional findings, and sometimes organ dysfunction, including liver injury, have been reported with the use of dolutegravir.

Other Side Effects: The most common adverse reactions include insomnia, headache, dizziness, nausea, diarrhea, and fatigue.

PROTEASE INHIBITORS (PIs)

FDA-approved protease inhibitors are atazanavir, atazanavir-cobicistat, darunavir, darunavir-cobicistat, fosamprenavir, indinavir, lopinavir/ritonavir boosting, nelfinavir, ritonavir (used as a pharmacokinetic boosting agent), saquinavir, and tipranavir.

PHARMACOLOGY AND MECHANISM OF ACTION

Protease inhibitors target an enzyme responsible for the proteolytic cleavage of viral polypeptide precursors. They demonstrate activity against HIV-1 and HIV-2 and may be active against other viruses as well.

Oral bioavailability and first-pass hepatic metabolism vary among the protease inhibitors and formulations have been altered to provide greater absorption. Saquinavir and lopinavir have poor oral availability and are administered in combination with low-dose ritonavir to improve drug levels. Ritonavir has good oral bioavailability, but side effects limit the dose in most patients. It is often used at low doses to boost blood levels of other protease inhibitors.

All protease inhibitors are metabolized via the hepatic cytochrome P_{450} (CYP) system. This makes them prone to interactions with drugs that induce, inhibit, or are themselves metabolized by CYP enzymes. Ritonavir is used primarily for its CYP effect to inhibit the metabolism of other agents and thus raise their blood levels.

SIDE EFFECTS AND PRECAUTIONS

Mucocutaneous Side Effects: The most common side effect of the protease inhibitors to present to dermatologists is lipodystrophy.[89,90] The lipodystrophy may relate to inhibition of ZMPSTE24, an enzyme that removes the farnesylated tail of prelamin A. Buildup of this protein appears to be related to acquired lipodystrophy, possibly through an interaction with a transcription factor called sterol regulatory element–binding protein 1.[91] Fat distribution may improve with L-acetylcarnitine therapy, and fillers have been employed to reduce the social stigma associated with therapy.[92]

Other mucocutaneous side effects:

- Morbilliform rash, generalized erythema, SJS
- Striae
- Paronychia, ingrown toenails
- Pruritus, xerosis
- Desquamative cheilitis
- Icterus (especially with atazanavir as it is associated with unconjugated hyperbilirubinemia)

Other Adverse Effects:

- GI upset
- Nausea
- Vomiting
- Diarrhea
- Hepatitis
- Occasional hepatic failure
- Dyslipidemias (except atazanavir)
- Alteration in glucose metabolism
- Significant drug–drug interactions

INVESTIGATIONAL DRUGS

The guidelines are continuously being adjusted and improved based on the latest available research. The currently available drugs are safer, simpler to use, and more potent than previous drugs. These improvements are expected to continue given the current crop of investigational drugs. Table 191-14 summarizes the current investigational drugs.

DRUGS FOR THE TREATMENT OF HEPATITIS C

Hepatitis C virus (HCV) infection is a major global health problem with 130 to 150 million people estimated to be chronically infected individuals worldwide.[93] Up to 85% of patients with acute HCV infection are unable to clear the infection, and become chronically infected if left untreated. For these patients, the risk of progression to liver cirrhosis is estimated to be 15% to 30% within 20 years. These patients are at higher risk of subsequently developing hepatocellular carcinoma.[94]

HCV belongs to the Flaviviridae family. It is an enveloped, positive-sense RNA virus.[95] The lack of a proofreading mechanism during the replication of the HCV RNA genome leads to significant variation. Thus, HCV has been divided into 7 genotypes with distinct geographic distribution. Genotype 1 is the most common genotype worldwide and in the United States. Genotypes 1, 2, 4, and 5 are endemic in Africa, whereas genotypes 3 and 6 are mostly found

TABLE 191-14
Investigational Drugs

DRUG CLASS	DRUG NAME	MECHANISM OF ACTION
Entry inhibitor	AMD-070	Selective, reversible, small molecule CXCR4 chemokine coreceptor antagonist
	Cenicriviroc	Small-molecule CCR5 coreceptor antagonist
	Fostemsavir	Binds to the viral envelope gp120 and interfering with virus attachment to the host CD4 receptor
	INCB-9471	Small-molecule CCR5 coreceptor antagonist
	Ibalizumab	Humanized monoclonal antibody that binds to extracellular domain 2 of the CD4 receptor and causes conformational changes
	Monomeric DAPTA	Selective CCR5 coreceptor antagonist
	PRO-140	Humanized IgG4 monoclonal antibody (mAb) that binds to hydrophilic extracellular domains on CCR5
	Vicriviroc	Reversible, small-molecule CCR5 coreceptor antagonist
Nucleoside reverse transcriptase inhibitors (NRTIs)	Amdoxovir	Inhibits the activity of HIV-1 reverse transcriptase
	Apricitabine	
	Censavudine	
	Elvucitabine	
	PSI-5004	
	Tenofovir Alafenamide	A prodrug of the nucleotide analog tenofovir
Nonnucleoside reverse transcriptase inhibitor (NNRTI)	Doravirine	Noncompetitive inhibitors of HIV-1 reverse transcriptase
Integrase strand transfer inhibitors (INSTI)	Cabotegravir	Prevents viral DNA integration into the host genome
Protease Inhibitor (PI)	TMC-310v911	PIs bind the HIV-1 protease enzyme to inhibit cleavage of viral Gag and Gag-Pol polyproteins, thereby preventing the formation of mature, infectious virus particles.[5-7] TMC-310911 is characterized as having a broader in vitro resistance profile than that of currently approved PIs, including darunavir.
Maturation Inhibitor	BMS-955176	Binds to HIV-1 Gag, inhibiting the final protease-mediated cleavage event
Gene Therapy Product	SB-728-T	May provide HIV-infected individuals with a reproducible pool of CD4 T cells permanently resistant to HIV entry, potentially improving immune restoration and leading to functional control of HIV
Histone deacetylase inhibitors	Valproic Acid Vorinostat	HDAC inhibitors reactivate latent HIV within resting CD4 T cells. When latent HIV is reactivated, it is once again able to produce new virus and replicate. It is hoped that after latent HIV is reactivated, the CD4 T cells in which the virus was hiding are more likely to die off on their own or be recognized and killed by the body's immune system.[8,9] In addition, any new virus that is produced during reactivation can then be prevented from infecting other cells with the use of ongoing ART.[8,9] Recent research has shown that additional therapies, together with HDAC inhibitors, may be needed to fully eliminate latent HIV from the body.
Immune modulator	Tucaresol	Enhances costimulatory signaling to CD4-positive T cells
Microbicides	Astodrimer	Blocks HIV attachment to and entry into host CD4 cells
	Dapivirine Tenofovir	Developed as a preexposure prophylaxis. Topical microbicide that inhibit the infection process at the vaginal or rectal mucosa and directly interfere with the HIV replication cycle

in Asia. Genotype 7 was only recently identified and is thought to have originated in Africa.[96]

Knowledge of the HCV life cycle paved the way for the development of direct-acting antivirals (DAAs) that have revolutionized the treatment of HCV infection. Briefly, the HCV life cycle consists of the following steps[97]:

1. Attachment: This involves the binding of HCV particles onto hepatocytes and is mediated by multiple cellular factors and components of the enveloped virions.
2. Cell entry: Clathrin-mediated endocytosis allows the HCV particles to enter early endosomes.
3. Fusion: pH-dependent membrane fusion is induced by the acidic environment in early endosomes. This releases the HCV genome into the cytosol.
4. Translation and Replication: The viral genome in the cytosol becomes available for translation by cellular ribosomes into a single polyprotein that is subsequently cleaved by cellular and viral proteases (NS2, NS3/4A) into the 10 mature viral proteins including structural proteins (core, E1, E2, p7) and nonstructural proteins (NS2, NS3, NS4A, NS4B, NS5A, and NS5B). The replication complex is subsequently assembled at the cellular ER membrane in association with the viral genomic RNA and nonstructural viral proteins (a process thought to be coordinated by NS4B and NS5A). Viral RNA replication is thought to occur at these complexes where NS5B (the viral RNA–dependent RNA polymerase) uses the viral genomic RNA as a template to synthesize a negative-sense intermediate strand. The negative sense intermediate strand is then used as a template to synthesize nascent genomic RNA strands that can be translated into viral proteins, used as templates for further RNA replication, or assembled in virions.
5. Assembly: This step is not fully understood but is thought to be dependent on cellular lipid metabolism as well as viral proteins.
6. Release: HCV virions are released as lipoviral particles with associated apoE and/or apoB, which are essential for viral infectivity.

DAAs target specific viral proteins with the aim of interrupting critical stages of the HCV life cycle. Approved DAAs as of this writing can be classified based on their mechanism of action as follows:

1. Protease (NS3/4A) inhibitors: boceprevir (discontinued), telaprevir (discontinued), paritaprevir, simeprevir, elbasvir, grazoprevir
2. NS5A inhibitors: daclatasvir, ledipasvir, ombitasvir
3. Polymerase (NS5B) inhibitor, nucleot(s)ide analog: sofosbuvir
4. Polymerase (NS5B) inhibitor, nonnucleoside analog: dasabuvir

The goal of HCV is sustained virologic response (SVR), which is defined as undetectable HCV RNA levels at a specified end point after completion of therapy. This end point has historically been set at 24 weeks from completion of therapy, but SVR at 12 weeks post-treatment has been shown to correlate closely to that at 24 weeks.[98] Thus, SVR at 12 weeks has been adopted as the primary efficacy endpoint in more recent clinical trials and clinical practice.[99]

The exact treatment chosen depends several factors that can affect responses, which include genotype, coinfection with HIV-1, comorbidities, cirrhosis, and prior treatment. This is an area of active research and as new results from clinical trials become available, guidelines outlining the preferred regimens for different patient populations are being updated.[93,100] The following website is a useful resource: http://www.hepatitisc.uw.edu/page/treatment/drugs.

PEG-IFNα AND RIBAVIRIN COMBINATION THERAPY

HCV virus is able to suppress the innate and adaptive immune and proinflammatory responses of the host by various mechanisms. Exogenous PEG-IFNα is used in an attempt to counteract that suppression. Ribavirin has an unclear mechanism of action against HCV, but there is evidence to suggest that it may have an immunomodulatory effect that mediates increased sensitivity to PEG-IFNα.[101]

PEG-IFNα is administered subcutaneously and is associated with localized injection site reactions in the majority of treated patients. These include erythema, tenderness, pruritus, and rashes at the site of injection.[102] The latter most commonly present as pruritic, erythematous patches or plaques with ill-defined borders. These reactions usually resolve spontaneously without treatment. Less commonly (<4%), cutaneous necrosis can occur at the injection site, which can be managed with local wound care and usually resolve in 1 to 2 months. Alternative injection sites can be used for future doses. Other miscellaneous localized skin reactions have been reported, including blistering reactions, granulomatous and suppurative dermatitis, lupus-like reactions, embolia cutis medicamentosa, and localized alopecia.[103]

Generalized dermatologic adverse events also have been associated with the use of PEG-IFNα, and the addition of ribavirin further increases their incidence. These adverse events can affect compliance and may lead to premature discontinuation of antiviral therapy. The most commonly encountered generalized dermatologic adverse events seen with the combination of PEG-IFNα and ribavirin include alopecia (28% to 36%) and skin rash (21%).[104] The skin rash most commonly seen with PEG-IFNα and ribavirin combination therapy has been characterized as eczematous dermatitis (erythematous papules and microvesicles often with excoriation) that is predominantly located over friction sites on the extremities and trunk. It can be associated with generalized pruritis and xerosis. Symptomatic patients can be treated with topical steroids and emollients without discontinuation of antiviral treatment. Steroids can be tapered off once the rash resolves.

Systemic anti-histamines and hydroxyzine also can be used for pruritis.[102,103]

Other forms of dermatitis also have been reported including nummular dermatitis and Meyerson phenomenon, an eczematous eruption centered around preexisting melanocytic nevi. Fixed drug eruptions and lichenoid eruptions (most commonly lichen planus) also have been described in association with PEG-IFNα and ribavirin therapy in HCV-infected patients.

PEG-IFNα and ribavirin also have been associated with the exacerbation or unmasking of various autoimmune disorders, many of which have skin manifestations that are important to recognize. These disorders include psoriasis, alopecia aerata, vitiligo, sarcoidosis, systemic lupus erythematosus, systemic sclerosis, polyarteritis nodosa. Some of these conditions were successfully treated with systemic corticosteroids but they often necessitate the discontinuation of antiviral therapy. Topical options for the treatment of psoriasis include steroids, calcipotriol, and PUVA.[103]

Other side effects of PEG-IFNα include flulike symptoms, fatigue, bone marrow suppression/cytopenias, and mood disturbances. Interferon is contraindicated for patients with liver failure and should be used with caution in patients with compensated cirrhosis. Other contraindications for PEG-IFNα include cytopenias, severe cardiac disease, uncontrolled seizures, uncontrolled psychiatric disease, and pregnancy.

Ribavirin also has "black box" warnings for hemolytic anemia and teratogenicity. The former can be severe and most often occurs within 1 to 2 weeks after starting therapy. Therefore, hemoglobin/hematocrit level should be checked at baseline and then 2 and 4 weeks after starting therapy. Given its teratogenicity, ribavirin is contraindicated in pregnancy and in male partners of pregnant women. Pregnancy should also be avoided (by using 2 forms of contraception) during therapy with ribavirin and for at least 6 months after completion of therapy (WHO).

FIRST-GENERATION DAAs

The first-generation protease inhibitors include boceprevir and telaprevir. They were initially used for the treatment of genotype 1 in combination with PEG-IFNα and ribavirin, since they were associated with higher SVR rates. However, compared to PEG-IFNα plus ribavirin alone, these agents were more expensive and were associated with a higher incidence of clinically significant adverse events leading to poor adherence and higher rates of premature discontinuation of therapy. This can subsequently lead to higher rates of resistance and treatment failure.[99] Therefore, these regimens are no longer recommended by the most recent guidelines as they have been replaced by safer and more efficacious second-generation DAAs.[100]

The most notable adverse events with boceprevir were anemia, neutropenia, and dysgeusia. However, the latter was not a common cause of discontinuation of therapy. When compared to PEG-IFNα and ribavirin alone, the use of boceprevir was not associated with a significantly increased incidence of serious skin rash.

On the other hand, the most notable adverse events associated with telaprevir were rash, pruritis, anorectal discomfort, diarrhea, and anemia. Around 6% to 7% of patients receiving telaprevir discontinued therapy due to skin rash. The rash can occur at any time during treatment with telaprevir, but 50% of the cases occurred within the first 4 weeks of initiation of therapy. Around 90% were classified as Grade 1 or 2 and did not progress. The rash most commonly associated with telaprevir was described as eczematous dermatitis that usually resolved with the discontinuation of therapy. However, telaprevir has been associated with more serious dermatologic adverse reactions, including drug rash with eosinophilia and systemic symptoms (DRESS) and Stevens–Johnson syndrome (SJS).

Therefore, patients receiving telaprevir should be instructed to report any skin or mucosal lesions, and any patient with such lesions should be questioned about systemic symptoms. In patients with systemic symptoms or involvement of mucous membranes or a significant portion of body surface area then discontinuation of therapy should be considered. Although the efficacy has not been fully established, mild to moderate rash can be managed with topical steroids and/or oral antihistamines. Systemic corticosteroids should be avoided.[105,106]

SECOND-GENERATION DAAs

Different combinations of the second-generation DAAs have been approved for HCV treatment.[93] There is a trend toward using interferon-free and, whenever possible, ribavirin-free regimens for the shortest effective treatment duration. Indicated and preferred treatment regimens are being actively updated as results of recent and ongoing trials get reported (useful resource: http://www.hepatitisc.uw.edu/page/treatment/drugs). This section attempts to provide an account of the dermatologic adverse events (exclusive of infectious complications like cellulitis) as well as the most common adverse events reported in recent clinical trials using FDA-approved DAA-based regimens without ribavirin when used over a duration of 12 weeks. It should be noted that the dermatologic side effects previously associated with ribavirin (including rash and pruritis) had higher incidence in patients who received DAA-based regimens that included ribavirin (mostly for treatment-experienced patients with cirrhosis).

- Simeprevir (Olysio): It is only indicated in combination with sofosbuvir or PEG-IFNα plus ribavirin. The most common adverse events associated with simeprevir were rash, photosensitivity, pruritis, nausea, and transient hyperbilirubinemia. However, the rates of discontinuation of therapy were comparable to those with PEG-IFNα plus ribavirin alone. The skin rash can develop at any time during treatment but most commonly begins within 4 weeks from the initiation of therapy.

A photosensitivity reaction with skin rash can also occur and patients should be instructed to minimize exposure to sunlight.[107,108]

- Sofosbuvir (Sovaldi): When used in combination with PEG-IFNα plus ribavirin, the most common adverse events include fatigue, nausea, anemia, and neutropenia. There was no significant increase in rate of discontinuation of therapy when compared with PEG-IFNα plus ribavirin alone. When used in combination with ribavirin alone, the most common adverse effects reported were fatigue, headache, nausea and pruritis. However, the rate of discontinuation of this regimen was relatively low (≤1%).[107]
- Ledipasvir and sofosbuvir (Harvoni): The most common adverse events were fatigue, headache, nausea, and diarrhea. In the ION-1 Study, up to 7% of patients had rash.[109] Mild rash and pruritis were reported in 1% to 2% of patients in the ION-2 and 3 studies.[110,111] However, none of the dermatologic adverse events required discontinuation of treatment. No rash was reported in ION-4 study wherein Harvoni was used to treat patients with HCV/HIV-1 coinfection.[112]
- Daclatasvir (Daklinza) and sofosbuvir: The most common adverse events were fatigue, headache, nausea, and diarrhea. This combination can also cause bradycardia in patients taking amiodarone (especially if they also take a beta-blocker). Rash was reported in 2% and pruritis in 5% of patients in the 12-week treatment groups.[113]
- Elbasvir and grazoprevir: The most common adverse observed in patients were fatigue, headache, and nausea. Skin rash (that did not require discontinuation of therapy) was reported in 2 of 33 patients (6%) in the group receiving elbasvir and grazoprevir without ribavirin.[114,115]
- Ombitasvir-paritaprevir-ritonavir and dasabuvir (Viekira Pak): The most common adverse events were fatigue and nausea. Pruritis was reported in 5% to 6% of patients, and skin rash was reported in up to 4% to 5% of patients. The latter did not warrant discontinuation of therapy in any of the treated patients.[116,117]
- Sofosbuvir and velpatasvir (Epclusa): The most common adverse effects were headache, fatigue, and nausea. Pruritis was reported in 3% to 4% of patients. However, there were no reports of serious skin rash after 12 weeks of treatment with sofosbuvir and velpatasvir in the clinical trials that have been published as of this writing.[118,119]

DRUGS FOR THE TREATMENT OF HEPATITIS B

Hepatitis B virus (HBV) infection is most commonly treated with a nucleoside/tide reverse transcriptase inhibitor (NRTI). Generally, these agents are mostly given orally once daily, with dose adjustment for patients with impaired renal function (creatinine clearance <50 mL/min). NRTIs act by inhibiting the polymerase activity of HBV. However, their low-level activity against the human mitochondrial DNA polymerase gamma and can lead to mitochondrial toxicity, for which a "Black Box" warning is included in the product labeling of all NRTIs. This may be manifested as myopathy, peripheral neuropathy, hepatic steatosis, pancreatitis, dyslipidemia, lipoatrophy, and lactic acidosis.[120]

Currently, the preferred agents for HBV treatment are either entecavir or tenofovir based on a favorable side effect profile and lower rates of resistance. The other NRTIs approved for treatment of HBV include lamivudine, adefovir, and telbivudine. Tenofovir and adefovir have been associated with nephrotoxicity and Fanconi syndrome as well as rashes with variable morphology (including maculopapular, urticarial, vesiculobullous, pustular, and lichenoid rashes). Telbivudine has been reported to cause myopathy and peripheral neuropathy. Pancreatitis has been reported with lamivudine. Entecavir is generally well tolerated.[121,122]

PEG-IFNα-2a also can be used in patients without cirrhosis who are HBeAg positive with good efficacy (27% rate of seroconversion at 1 year) but poor tolerability due to side effects as discussed previously. Of note, PEG-IFNα-2a is contraindicated in patients with decompensated cirrhosis, cytopenias, severe cardiac disease, uncontrolled seizures, and uncontrolled psychiatric disease. It should be used with caution in patients with compensated cirrhosis.

For persons with HDV coinfection, the only effective treatment is PEG-IFNα. For persons with HIV coinfection, treatment of HBV and HIV need to be coordinated to utilize drugs active against both viruses (tenofovir, entecavir, lamivudine, and telbivudine).[121]

Indications for initiation of treatment include the following:

1. ALF or decompensated cirrhosis (NRTIs only)
2. The presence of significant liver injury or fibrosis, as reflected by elevated ALT levels or biopsy-proven inflammation and/or fibrosis plus active HBV viremia (HBV DNA >2000 IU/mL if HBeAg negative, or >20,000 IU/mL if HBeAg positive).
3. Immunosuppressive therapy.

For patients treated with PEG-IFNα, the recommended duration of treatment is 48 weeks. For patients treated with NRTIs, the exact duration of therapy varies and depends on multiple factors including HBeAg status, duration of HBV DNA suppression, and presence of cirrhosis/decompensation (AASLD Guidelines for Treatment of Chronic Hepatitis B). If seroconversion of HBeAg or hepatitis B surface antigen (HBsAg) is observed, then treatment can be discontinued. However, the latter is only rarely observed.[121,123]

DRUGS TO TREAT OTHER VIRAL INFECTIONS

Neuraminidase inhibitors can be used to treat patients presenting with severe influenza infection or those at

high risk for severe infection or complications (such as pregnant women and elderly patients). Neuraminidase inhibitors include oseltamivir, zanamivir, and peramivir. Oseltamivir and peramivir have been associated with serious skin adverse events, including cases of Stevens–Johnson syndrome and erythema multiforme. Other skin side effects have been reported with peramivir including urticaria and maculopapular rash.

Ribavirin is used to treat respiratory syncytial virus infection. The dermatologic side effects were discussed in the HCV section.

ACKNOWLEDGMENTS

The authors thank Drs Hay, Reichman, and Elston for their work on this chapter in previous editions. The authors also thank M. Liu for her contribution to this chapter.

REFERENCES

1. Leung DT, Henning PA, Wagner EC, et al. Inadequacy of plasma acyclovir levels at delivery in patients with genital herpes receiving oral acyclovir suppressive therapy in late pregnancy. *J Obstet Gynaecol Can.* 2009;31(12):1137-1143.
2. Vanpouille C, Lisco A, Margolis L. Acyclovir: a new use for an old drug. *Curr Opin Infect Dis.* 2009;22(6):583-587.
3. Celum C, Wald A, Lingappa JR, et al. Acyclovir and transmission of HIV-1 from persons infected with HIV-1 and HSV-2. *N Engl J Med.* 2010;362(5):427-439.
4. Duan R, de Vries RD, van Dun JM, et al. Acyclovir susceptibility and genetic characteristics of sequential herpes simplex virus type 1 corneal isolates from patients with recurrent herpetic keratitis. *J Infect Dis.* 2009;200(9):1402-1414.
5. Workowski KA, Bolan GA; Centers for Disease Control and Prevention (CDC). Sexually transmitted diseases treatment guidelines, 2015. *MMWR Recomm Rep.* 2015;64(RR-03):1-137.
6. Leflore S, Anderson PL, Fletcher CV. A risk-benefit evaluation of acyclovir for the treatment and prophylaxis of herpes simplex virus infections. *Drug Saf.* 2000: 23(2):131-142.
7. Bradley JS, Nelson JD, Kimberlin DK, et al, eds. *Nelson's Pocket Book of Pediatric Antimicrobial Therapy*. 18th ed. Philadelphia, PA: Lippincott Williams & Wilkins; 2011.
8. Gartner LM, Morton J, Lawrence RA, et al. Breastfeeding and the use of human milk. *Pediatrics.* 2005; 115(2):496-506.
9. Yadav M, Upadhyay V, Singhal P, et al. Stability evaluation and sensitive determination of antiviral drug, valacyclovir and its metabolite acyclovir in human plasma by a rapid liquid chromatography-tandem mass spectrometry method. *J Chromatogr B Analyt Technol Biomed Life Sci.* 2009;877(8-9):680-688.
10. Corey L, Wald A, Patel R, et al. Once-daily valacyclovir to reduce the risk of transmission of genital herpes. N Engl J Med. 2004;350(1):11-20.
11. Sperling RS, Fife KH, Warren TJ, et al. The effect of daily valacyclovir suppression on herpes simplex virus type 2 viral shedding in HSV-2 seropositive subjects without a history of genital herpes. *Sex Transm Dis.* 2008;35(3):286-290.
12. Martens MG, Fife KH, Leone PA, et al. Once daily valacyclovir for reducing viral shedding in subjects newly diagnosed with genital herpes. *Infect Dis Obstet Gynecol.* 2009;2009:105376.
13. Miserocchi E, Modorati G, Galli L, et al. Efficacy of valacyclovir vs acyclovir for the prevention of recurrent herpes simplex virus eye disease: a pilot study. *Am J Ophthalmol.* 2007;144(4):547-551.
14. Hull C, McKeough M, Sebastian K, et al. Valacyclovir and topical clobetasol gel for the episodic treatment of herpes labialis: a patient-initiated, double-blind, placebo-controlled pilot trial. *J Eur Acad Dermatol Venereol.* 2009;23(3):263-267.
15. Ozçay F, Arslan H, Bilezikçi B, et al. The role of valacyclovir on Epstein-Barr virus viral loads in pediatric liver transplant patients. *Transplant Proc.* 2009;41(7): 2878-2880.
16. Hoshino Y, Katano H, Zou P, et al. Long-term administration of valacyclovir reduces the number of Epstein-Barr virus (EBV)-infected B cells but not the number of EBV DNA copies per B cell in healthy volunteers. *J Virol.* 2009;83(22):11857-11861.
17. Aoki FY. Contemporary antiviral drug regimens for the prevention and treatment of orolabial and anogenital herpes simplex virus infection in the normal host: four approved indications and 13 off-label uses. *Can J Infect Dis.* 2003;14(1):17-27.
18. Zeng L, Nath CE, Blair EY, et al. Population pharmacokinetics of acyclovir in children and young people with malignancy after administration of intravenous acyclovir or oral valacyclovir. *Antimicrob Agents Chemother.* 2009;53(7):2918-2927.
19. Bomgaars L, Thompson P, Berg S, et al. Valacyclovir and acyclovir pharmacokinetics in immunocompromised children. *Pediatr Blood Cancer.* 2008;51(4):504-508.
20. Kimberlin DW. Pharmacokinetics and safety of extemporaneously compounded valacyclovir oral suspension in pediatric patients from 1 month through 11 years of age. *Clin Infect Dis.* 2010;50(2):221-228.
21. Asahi T, Tsutsui M, Wakasugi M, et al. Valacyclovir neurotoxicity: clinical experience and review of the literature. *Eur J Neurol.* 2009;16(4):457-460.
22. Daito J, Hanada K, Katoh N, et al. Symmetrical drug-related intertriginous and flexural exanthema caused by valacyclovir. *Dermatology.* 2009;218(1):60-62.
23. Ebo DG, Bridts CH, De Clerck LS, et al. Immediate allergy from valacyclovir. *Allergy.* 2008;63(7): 941-942.
24. Hasler-Nguyen N, Shelton D, Ponard G, et al. Evaluation of the in vitro skin permeation of antiviral drugs from penciclovir 1% cream and acyclovir 5% cream used to treat herpes simplex virus infection. *BMC Dermatol.* 2009;9:3.
25. Zhu W, Guo C, Yu A, et al. Microemulsion-based hydrogel formulation of penciclovir for topical delivery. *Int J Pharm.* 2009;378(1-2):152-158.
26. Lv Q, Yu A, Xi Y, et al. Development and evaluation of penciclovir-loaded solid lipid nanoparticles for topical delivery. *Int J Pharm.* 2009;372(1-2):191-198.
27. Zhu W, Yu A, Wang W, et al. Formulation design of microemulsion for dermal delivery of penciclovir. *Int J Pharm.* 2008;360(1-2):184-90.
28. Tyring SK, Diaz-Mitoma F, Shafran SD, et al. Oral famciclovir for the suppression of recurrent genital herpes: the combined data from two randomized controlled trials. *J Cutan Med Surg.* 2003;7(6):449-454.

29. Tyring S, Berger T, Yen-Moore A, et al. Single-day therapy for recurrent genital herpes. *Am J Clin Dermatol.* 2006;7(4):209-211.
30. Harpaz R, Ortega-Sanchez IR, Seward JF; Advisory Committee on Immunization Practices (ACIP) Centers for Disease Control and Prevention (CDC). Prevention of herpes zoster: recommendations of the Advisory Committee on Immunization Practices (ACIP). *MMWR Recomm Rep.* 2008;57(RR-5):1-30.
31. Bodsworth N, Bloch M, McNulty A, et al; Australo-Canadian FaST Famciclovir Short-Course Herpes Therapy Study Group. 2-day versus 5-day famciclovir as treatment of recurrences of genital herpes: Results of the FaST study. *Sex Health.* 2008;5(3):219-225.
32. Abudalu M, Tyring S, Koltun W, et al. Single-day, patient-initiated famciclovir therapy versus 3-day valacyclovir regimen for recurrent genital herpes: a randomized, double-blind, comparative trial. *Clin Infect Dis.* 2008;47(5):651-658.
33. Aoki FY. The continuing evolution of antiviral therapy for recurrent genital herpes: 1-day patient-initiated treatment with famciclovir. *Herpes.* 2007;14(3):62-65.
34. Bartlett BL, Tyring SK, Fife K, et al. Famciclovir treatment options for patients with frequent outbreaks of recurrent genital herpes: The RELIEF trial. *J Clin Virol.* 2008;43(2):190-195.
35. Ogungbenro K, Matthews I, Looby M, et al. Population pharmacokinetics and optimal design of paediatric studies for famciclovir. *Br J Clin Pharmacol.* 2009;68(4):546-560.
36. Sáez-Llorens X, Yogev R, Arguedas A, et al. Pharmacokinetics and safety of famciclovir in children with herpes simplex or varicella-zoster virus infection. *Antimicrob Agents Chemother.* 2009;53(5):1912-1920.
37. Leone P, Abudalu M, Mitha E, et al. One-day famciclovir vs. placebo in patient-initiated episodic treatment of recurrent genital herpes in immunocompetent Black patients. *Curr Med Res Opin.* 2010;26(3):653-661.
38. Tyring S, Richwald G, Hamed K. Single-day therapy: an expert opinion on a recent development for the episodic treatment of recurrent genital herpes. *Arch Gynecol Obstet.* 2007;275(1):1-3.
39. Htwe TH, Bergman S, Koirala J. Famciclovir substitution for patients with acyclovir-associated renal toxicity. *J Infect.* 2008;57(3):266-268.
40. Te CC, Le V, Allee M. Famciclovir-induced leukocytoclastic vasculitis. *Ann Pharmacother.* 2008;42(9):1323-1326.
41. Wilhelmus KR. Therapeutic interventions for herpes simplex virus epithelial keratitis. *Cochrane Database Syst Rev.* 2008;(1):CD002898.
42. Wilhelmus KR. Antiviral treatment and other therapeutic interventions for herpes simplex virus epithelial keratitis. *Cochrane Database Syst Rev.* 2010;(12):CD002898.
43. Kaufman HE, Varnell ED, Gebhardt BM, et al. Efficacy of a helicase-primase inhibitor in animal models of ocular herpes simplex virus type 1 infection. *J Ocul Pharmacol Ther.* 2008;24(1):34-42.
44. Guess S, Stone DU, Chodosh J. Evidence-based treatment of herpes simplex virus keratitis: a systematic review. *Ocul Surf.* 2007;5(3):240-250.
45. Perrottet N, Manuel O, Lamoth F, et al. Variable viral clearance despite adequate ganciclovir plasma levels during valganciclovir treatment for cytomegalovirus disease in D+/R- transplant recipients. *BMC Infect Dis.* 2010;10(1):2.
46. Perrottet N, Decosterd LA, Meylan P, et al. Valganciclovir in adult solid organ transplant recipients: pharmacokinetic and pharmacodynamic characteristics and clinical interpretation of plasma concentration measurements. *Clin Pharmacokinet.* 2009;48(6):399-418.
47. Simon P, Sasse M, Laudi S, et al. Two strategies for prevention of cytomegalovirus infections after liver transplantation. *World J Gastroenterol.* 2016;22(12):3412-3417.
48. Marshall BC, Koch WC. Antivirals for cytomegalovirus infection in neonates and infants: focus on pharmacokinetics, formulations, dosing, and adverse events. *Paediatr Drugs.* 2009;11(5):309-321.
49. Duan R, de Vries RD, Osterhaus AD, et al. Acyclovir-resistant corneal HSV-1 isolates from patients with herpetic keratitis. *J Infect Dis.* 2008;198(5):659-663.
50. Hatchette T, Tipples GA, Peters G, et al. Foscarnet salvage therapy for acyclovir-resistant varicella zoster: report of a novel thymidine kinase mutation and review of the literature. *Pediatr Infect Dis.* 2008;27(1):75-77.
51. Wang H, Zhu L, Xue M, et al. Low-dose foscarnet preemptive therapy for cytomegalovirus viremia after haploidentical bone marrow transplantation. *Biol Blood Marrow Transplant.* 2009;15(4):519-520.
52. Charpentier C, Laureillard D, Sodqi M, et al. Foscarnet salvage therapy efficacy is associated with the presence of thymidine-associated mutations (TAMs) in HIV-infected patients. *J Clin Virol.* 2008;43(2):212-215.
53. Rodriguez J, Casper K, Smallwood G, et al. Resistance to combined ganciclovir and foscarnet therapy in a liver transplant recipient with possible dual-strain cytomegalovirus coinfection. *Liver Transpl.* 2007;13(10):1396-1400.
54. Michaelis M, Ha TA, Doerr HW, et al. Valproic acid interferes with antiviral treatment in human cytomegalovirus-infected endothelial cells. *Cardiovasc Res.* 2008;77(3):544-550.
55. De Clercq E. Emerging antiviral drugs. *Expert Opin Emerg Drugs.* 2008;13(3):393-416.
56. Andrei G, Fiten P, Goubau P, et al. Dual infection with polyomavirus BK and acyclovir-resistant herpes simplex virus successfully treated with cidofovir in a bone marrow transplant recipient. *Transpl Infect Dis.* 2007;9(2):126-131.
57. Jesus DM, Costa LT, Gonçalves DL, et al. Cidofovir inhibits genome encapsidation and affects morphogenesis during the replication of vaccinia virus. *J Virol.* 2009;83(22):11477-11490.
58. Sonvico F, Colombo G, Gallina L, et al. Therapeutic paint of cidofovir/sucralfate gel combination topically administered by spraying for treatment of orf virus infections. *AAPS J.* 2009;11(2):242-249.
59. Van Pachterbeke C, Bucella D, Rozenberg S, et al. Topical treatment of CIN 2+ by cidofovir: results of a phase II, double-blind, prospective, placebo-controlled study. *Gynecol Oncol.* 2009;115(1):69-74.
60. Coremans G, Snoeck R. Cidofovir: clinical experience and future perspectives on an acyclic nucleoside phosphonate analog of cytosine in the treatment of refractory and premalignant HPV-associated anal lesions. *Expert Opin Pharmacother.* 2009;10(8):1343-1352.
61. Calista D. Topical 1% cidofovir for the treatment of vulvar intraepidermal neoplasia (VIN1) developed on lichen sclerosus. *Int J Dermatol.* 2009;48(5):535-536.
62. Amine A, Rivera S, Opolon P, et al. Novel anti-metastatic action of cidofovir mediated by inhibition of

E6/E7, CXCR4 and Rho/ROCK signaling in HPV tumor cells. *PLoS One.* 2009;4(3):e5018.
63. Field S, Irvine AD, Kirby B. The treatment of viral warts with topical cidofovir 1%: our experience of seven paediatric patients. *Br J Dermatol.* 2009;160(1): 223-224.
64. De Socio GV, Simonetti S, Rosignoli D, et al. Topical cidofovir for severe warts in a patient affected by AIDS and Hodgkin's lymphoma. *Int J STD AIDS.* 2008;19(10):715-716.
65. Cusack C, Fitzgerald D, Clayton TM, et al. Successful treatment of florid cutaneous warts with intravenous cidofovir in an 11-year-old girl. *Pediatr Dermatol.* 2008;25(3):387-389.
66. Bhadri VA, Lee-Horn L, Shaw PJ. Safety and tolerability of cidofovir in high-risk pediatric patients. *Transpl Infect Dis.* 2009;11(4):373-379.
67. Tchernev G. Sexually transmitted papillomavirus infections: epidemiology pathogenesis, clinic, morphology, important differential diagnostic aspects, current diagnostic and treatment options. *An Bras Dermatol.* 2009;84(4):377-389.
68. Lott DG, Krakovitz PR. Squamous cell carcinoma associated with intralesional injection of cidofovir for recurrent respiratory papillomatosis. *Laryngoscope.* 2009;119(3):567-570.
69. Donne AJ, Hampson L, He XT, et al. Potential risk factors associated with the use of cidofovir to treat benign human papillomavirus-related disease. *Antivir Ther.* 2009;14(7):939-952.
70. Dvorak CC, Cowan MJ, Horn B, et al. Development of herpes simplex virus stomatitis during receipt of cidofovir therapy. *Clin Infect Dis.* 2009;49(8):e92-e95.
71. Shuja F, Kavoussi SC, Mir MR, et al. Interferon induced sarcoidosis with cutaneous involvement along lines of venous drainage in a former intravenous drug user. *Dermatol Online J.* 2009;15(12):4.
72. Mistry N, Shapero J, Crawford RI. A review of adverse cutaneous drug reactions resulting from the use of interferon and ribavirin. *Can J Gastroenterol.* 2009;23(10):677-683.
73. Sato M, Sueki H, Iijima M. Repeated episodes of fixed eruption 3 months after discontinuing pegylated interferon-alpha-2b plus ribavirin combination therapy in a patient with chronic hepatitis C virus infection. *Clin Exp Dermatol.* 2009;34(8):e814-e817.
74. Panel on Antiretroviral Guidelines for Adults and Adolescents. Guidelines for the use of antiretroviral agents in HIV-1-infected adults and adolescents. https://aidsinfo.nih.gov/contentfiles/lvguidelines/adultandadolescentgl.pdf. Accessed June 21, 2016.
75. Laskey SB, Siliciano RF. A mechanistic theory to explain the efficacy of antiretroviral therapy. *Nat Rev Micro.* 2014;12(11):772-780.
76. WHO. *Policy Brief: Consolidated Guidelines on the Use of Antiretroviral Drugs for Treating and Preventing HIV Infection: What's New*. Geneva, Switzerland: WHO; 2015. http://www.who.int/hiv/pub/arv/policy-brief-arv-2015/en/.
77. Panel on Antiretroviral Therapy and Medical Management of HIV-Infected Children. Guidelines for the use of antiretroviral agents in pediatric HIV infection. https://aidsinfo.nih.gov/contentfiles/lvguidelines/pediatricguidelines.pdf. Accessed January 14, 2016.
78. WHO. *Guideline on When to Start Antiretroviral Therapy and on Pre-exposure Prophylaxis for HIV*. Geneva, Switzerland: WHO; 2015. http://www.who.int/hiv/pub/guidelines/earlyrelease-arv/en/.
79. United States Public Health Service, Centers for Disease Control and Prevention (US), National Center for HIV/AIDS, Viral Hepatitis, STD, and TB Prevention (US), et al. Preexposure prophylaxis for the prevention of HIV infection—2014: a clinical practice guideline. http://stacks.cdc.gov/view/cdc/23109.
80. WHO. *News and Events Topics Publications Data and Statistics About US Guidelines on Post-exposure Prophylaxis for HIV and the Use of Co-trimoxazole Prophylaxis for HIV-Related Infections among Adults, Adolescents and Children*. Geneva, Switzerland: WHO; 2014. http://www.who.int/hiv/pub/guidelines/arv2013/arvs2013upplement_dec2014/en/.
81. Atzori L, Pinna AL, Pilloni L, et al. Bullous skin eruption in an HIV patient during antiretroviral drugs therapy. *Dermatol Ther.* 2008;21(suppl 2):S30-S34.
82. Maggiolo F. Efavirenz: a decade of clinical experience in the treatment of HIV. *J Antimicrob Chemother.* 2009;64(5):910-928.
83. Vemula S, Kerr S, Pancharoen C, et al. Incidence and risk factors for non-nucleoside reverse transcriptase inhibitors (NNRTI)-related rash in Thai children with HIV infection. *J Med Assoc Thai.* 2007;90(11):2437-2441.
84. Hall DB, Macgregor TR. Case-control exploration of relationships between early rash or liver toxicity and plasma concentrations of nevirapine and primary metabolites. *HIV Clin Trials.* 2007;8(6):391-399.
85. Manosuthi W, Sungkanuparph S, Tansuphaswadikul S, et al. Incidence and risk factors of nevirapine-associated skin rashes among HIV-infected patients with CD4 cell counts <250 cells/microL. *Int J STD AIDS.* 2007;18(11):782-786.
86. Chen J, Mannargudi BM, Xu L, et al. Demonstration of the metabolic pathway responsible for nevirapine-induced skin rash. *Chem Res Toxicol.* 2008;21(9):1862-1870.
87. Moura MD, Senna MI, Madureira DF, et al. Oral adverse effects due to the use of Nevirapine. *J Contemp Dent Pract.* 2008;9(1):84-90.
88. Fulco PP, McNicholl IR. Etravirine and rilpivirine: nonnucleoside reverse transcriptase inhibitors with activity against human immunodeficiency virus type 1 strains resistant to previous nonnucleoside agents. *Pharmacotherapy.* 2009;29(3):281-294.
89. Mercier S, Gueye NF, Cournil A, et al. Lipodystrophy and metabolic disorders in HIV-1-infected adults on 4- to 9-year antiretroviral therapy in Senegal: a case-control study. *J Acquir Immune Defic Syndr.* 2009;51(2):224-230.
90. Sarni RO, Souza FI, Battistini TR, et al. Lipodystrophy in children and adolescents with acquired immunodeficiency syndrome and its relationship with the antiretroviral therapy employed [in Portuguese]. *J Pediatr (Rio J).* 2009;85(4):329-334.
91. Goulbourne CN, Vaux DJ. HIV protease inhibitors inhibit FACE1/ZMPSTE24: A mechanism for acquired lipodystrophy in patients on highly active antiretroviral therapy? *Biochem Soc Trans.* 2010;38 (pt 1):292-296.
92. Benedini S, Perseghin G, Terruzzi I, et al. Effect of L-acetylcarnitine on body composition in HIV-related lipodystrophy. *Horm Metab Res.* 2009;41(11):840-845.
93. World Health Organization. *Guidelines for the Screening Care and Treatment of Persons with Chronic Hepatitis C Infection: Updated Version*. Geneva: World Health Organization; 2016.
94. Webster DP, Klenerman P, Dusheiko GM. Hepatitis C. *Lancet.* 2015;385(9973):1124-1135.

95. Simmonds P. Reconstructing the origins of human hepatitis viruses. *Philos Trans R Soc Lond B Biol Sci.* 2001;356(1411):1013-1026.
96. Smith DB, Bukh J, Kuiken C, et al. Expanded classification of hepatitis C virus into 7 genotypes and 67 subtypes: updated criteria and genotype assignment web resource. *Hepatology.* 2014;59(1):318-327.
97. Kim CW, Chang KM. Hepatitis C virus: virology and life cycle. *Clin Mol Hepatol.* 2013;19(1):17-25.
98. Yoshida EM, Sulkowski MS, Gane EJ, et al. Concordance of sustained virological response 4, 12, and 24 weeks post-treatment with sofosbuvir-containing regimens for hepatitis C virus. *Hepatology.* 2015; 61(1):41-45.
99. FakhriRavari A, Malakouti M, Brady R. Interferon-free treatments for chronic hepatitis C genotype 1 infection. *J Clin Transl Hepatol.* 2016;4(2):97-112.
100. AASLD/IDSA HCV Guidance Panel. Hepatitis C guidance: AASLD-IDSA recommendations for testing, managing, and treating adults infected with hepatitis C virus. *Hepatology.* 2015;62(3):932-954.
101. Chung RT, Gale M Jr, Polyak SJ, et al. Mechanisms of action of interferon and ribavirin in chronic hepatitis C: summary of a workshop. *Hepatology.* 2008;47(1):306-320.
102. Negro F. Adverse effects of drugs in the treatment of viral hepatitis. *Best Pract Res Clin Gastroenterol.* 2010; 24(2):183-192.
103. Mistry N, Shapero J, Crawford RI. A review of adverse cutaneous drug reactions resulting from the use of interferon and ribavirin. *Can J Gastroenterol.* 2009;23(10):677-683.
104. Fried MW. Side effects of therapy of hepatitis C and their management. *Hepatology.* 2002;365(suppl 1): S237-S244.
105. Cacoub P, Bourlière M, Lübbe J, et al. Dermatological side effects of hepatitis C and its treatment: patient management in the era of direct-acting antivirals. *J Hepatol.* 2012;56(2):455-463.
106. Jacobson IM, Pawlotsky JM, Afdhal NH, et al. A practical guide for the use of boceprevir and telaprevir for the treatment of hepatitis C. *J Viral Hepat.* 2012;19(suppl 2):1-26.
107. Kohli A, Shaffer A, Sherman A, et al. Treatment of hepatitis C: a systematic review. *JAMA.* 2014; 312(6):631-640.
108. Manns MP, Fried MW, Zeuzem S, et al. Simeprevir with peginterferon/ribavirin for treatment of chronic hepatitis C virus genotype 1 infection: pooled safety analysis from Phase IIb and III studies. *J Viral Hepat.* 2015;22(4):366-375.
109. Afdhal N, Zeuzem S, Kwo P, et al. Ledipasvir and sofosbuvir for untreated HCV genotype 1 infection. *N Engl J Med.* 2014;370(20):1889-1898.
110. Afdhal N, Reddy KR, Nelson DR, et al. Ledipasvir and sofosbuvir for previously treated HCV genotype 1 infection. *N Engl J Med.* 2014;370(16):1483-1493.
111. Kowdley KV, Gordon SC, Reddy KR, et al. Ledipasvir and sofosbuvir for 8 or 12 weeks for chronic HCV without cirrhosis. *N Engl J Med.* 2014;370(20):1879-1888.
112. Naggie S, Cooper C, Saag M, et al. Ledipasvir and sofosbuvir for HCV in Patients Coinfected with HIV-1. *N Engl J Med.* 2015;373(8):705-713.
113. Sulkowski MS, Gardiner DF, Rodriguez-Torres M, et al. Daclatasvir plus sofosbuvir for previously treated or untreated chronic HCV infection. *N Engl J Med.* 2014;370(3):211-221.
114. Lawitz E, Gane E, Pearlman B, et al. Efficacy and safety of 12 weeks versus 18 weeks of treatment with grazoprevir (MK-5172) and elbasvir (MK-8742) with or without ribavirin for hepatitis C virus genotype 1 infection in previously untreated patients with cirrhosis and patients with previous null response with or without cirrhosis (C-WORTHY): a randomised, open-label phase 2 trial. *Lancet.* 2015;385(9973):1075-1086.
115. Sulkowski M, Hezode C, Gerstoft J, et al. Efficacy and safety of 8 weeks versus 12 weeks of treatment with grazoprevir (MK-5172) and elbasvir (MK-8742) with or without ribavirin in patients with hepatitis C virus genotype 1 mono-infection and HIV/hepatitis C virus co-infection (C-WORTHY): a randomised, open-label phase 2 trial. *Lancet.* 2015;385(9973):1087-1097.
116. Andreone P, Colombo MG, Enejosa JV, et al. ABT-450, ritonavir, ombitasvir, and dasabuvir achieves 97% and 100% sustained virologic response with or without ribavirin in treatment-experienced patients with HCV genotype 1b infection. *Gastroenterology.* 2014;147(2):359-365.e1.
117. Ferenci P, Bernstein D, Lalezari J, et al. ABT-450/r-ombitasvir and dasabuvir with or without ribavirin for HCV. *N Engl J Med.* 2014;370(21):1983-1992.
118. Feld JJ, Jacobson IM, Hézode C, et al. Sofosbuvir and velpatasvir for HCV Genotype 1, 2, 4, 5, and 6 Infection. *N Engl J Med.* 2015;373(27):2599-2607.
119. Foster GR, Afdhal N, Roberts SK, et al. Sofosbuvir and Velpatasvir for HCV Genotype 2 and 3 Infection. *N Engl J Med.* 2015;373(27):2608-2617.
120. Fontana RJ. Side effects of long-term oral antiviral therapy for hepatitis B. *Hepatology.* 2009;49 (5 suppl):S185-S195.
121. Terrault NA, Bzowej NH, Chang KM, et al; American Association for the Study of Liver Diseases. AASLD guidelines for treatment of chronic hepatitis B. *Hepatology.* 2016;63(1):261-283.
122. Borras-Blasco J, Navarro-Ruiz A, Borras C, et al. Adverse cutaneous reactions associated with the newest antiretroviral drugs in patients with human immunodeficiency virus infection. *J Antimicrob Chemother.* 2008;62(5):879-888.
123. Trepo C, Chan HL, Lok A. Hepatitis B virus infection. *Lancet.* 2014;384(9959):2053-2063.

Chapter 192 :: Immunosuppressive and Immunomodulatory Drugs

:: Drew Kurtzman, Ruth Ann Vleugels, & Jeffrey Callen

AT-A-GLANCE

- Immunosuppressants and immunomodulators represent an indispensable group of antiinflammatory medications that are capable of treating a wide array of inflammatory skin conditions.
- The immunosuppressive and immunomodulatory drugs covered in this chapter include mycophenolate mofetil, the calcineurin inhibitors (cyclosporine, tacrolimus, and pimecrolimus), and the mammalian target of rapamycin (mTOR) inhibitor everolimus.
- The primary goal of therapy with immunosuppressants and immunomodulators is to effectively treat an inflammatory condition while maintaining patient safety.
- By working in an additive or synergistic fashion, combination regimens have the potential for greater efficacy and may allow for decreased doses of individual drugs, which may enhance overall safety and reduce medication-related side effects.
- A comprehensive understanding of the pathophysiology of the disease being treated as well as the pharmacokinetic and pharmacodynamic properties of each immunosuppressant and immunomodulator is fundamental to favorable patient outcomes.

INTRODUCTION

There has been significant progress in the field of antiinflammatory therapy. A critical advance has been the successful effort to reduce the use of systemic corticosteroids by the early or concomitant introduction of immunosuppressive or immunomodulatory therapy (or both). Before a detailed discussion of these agents is provided, an important distinction between immunosuppressants and immunomodulators must be made. Immunosuppressants are characterized by a low therapeutic index (narrow window between the therapeutic and toxic range) and significant intra- and interindividual pharmacokinetic variability. These shortcomings are circumvented by precise drug dosing (based on ideal or lean body weight) as well as by screening for end-organ toxicity and, in some cases, close monitoring of plasma drug levels (parent or metabolite peak and trough levels). Immunomodulators, by contrast, have a wider therapeutic index, a greater safety margin, more predictable pharmacokinetic properties, and less interindividual variability. In addition, although immunosuppressants appear to globally impair the host immune response typically in a dose-dependent fashion, immunomodulators may act more selectively by targeting only specific portions of the immune system and therefore pose a lower risk of complications related to immune dysfunction. Whether immunosuppressants or immunomodulators are selected, the primary goals of immunotherapy are safety and efficacy. These goals are best accomplished by using the lowest effective drug doses to achieve disease remission and, in certain scenarios, by using combination therapy (Fig. 192-1).[1,2] Among dermatologists, immunosuppressants and immunomodulators are frequently used as corticosteroid-sparing agents.[3] This chapter reviews the key pharmacologic properties and prescribing principles of some of the major immunosuppressants and immunomodulators used in dermatology, including mycophenolate mofetil (MMF), the calcineurin inhibitors (CNIs; cyclosporine, tacrolimus, and pimecrolimus), and the mammalian target of rapamycin (mTOR) inhibitor everolimus. Other immunosuppressants, antimetabolites, and cytotoxic agents are discussed in Chap. 190.

MYCOPHENOLATE MOFETIL

MMF is an ethyl ester of its active metabolite, mycophenolic acid (MPA), a biological product of several *Penicillium* species. Because of its enhanced bioavailability, MMF is the more widely available drug formulation.

PHARMACOLOGY AND MECHANISM OF ACTION

MECHANISM OF ACTION

MPA reversibly inhibits the type II isoform of inosine monophosphate dehydrogenase, which is a key enzyme in the de novo purine synthesis pathway. As a result, the proliferation of both T and B lymphocytes is selectively reduced because of their impaired ability to use the hypoxanthine-guanine phosphoribosyl transferase–dependent purine salvage pathway. Decreased delayed hypersensitivity reactions and

A modified, median-effect formula

$$CI = \frac{\text{A combined with B}}{\text{A}} + \frac{\text{B combined with A}}{\text{B}}$$

CI: index inhibition (eg, immunglobulins, disease activity)

CI: = 1 additive
< 1 synergistic
> 1 antagonistic

Figure 192-1 A modified, median-effect formula is widely used in organ transplantation, which helps in finding the therapeutic windows of immunosuppressive drugs as well as the synergistic, additive, or antagonistic effect of a postulated drug combination. CI, combination index. (Data from Chou TC, Talalay P. Quantitative analysis of dose-effect relationships: the combined effects of multiple drugs or enzyme inhibitors. *Adv Enzyme Regul*. 1984;22:274.)

immunoglobulin levels have been observed in individuals treated with MMF, which is attributable to its effect on T and B lymphocytes, respectively.

ABSORPTION, DISTRIBUTION, METABOLISM, AND EXCRETION

MMF is rapidly absorbed after oral administration and is presystemically hydrolyzed to form MPA, the active metabolite. At clinically relevant concentrations, 97% of MPA is bound to plasma albumin. MPA is metabolized by hepatic glucuronyl transferases to form the inactive glucuronide of MPA (MPAG), which is almost exclusively excreted by the kidneys. In the setting of renal failure, increased serum levels of MPAG displace MPA from albumin binding sites and lead to elevated free concentrations of MPA, which can result in supratherapeutic drug concentrations. Secondary peaks of serum MPA levels are seen 6 to 12 hours after ingestion, suggesting that enterohepatic circulation contributes to steady-state serum MPA concentrations. As with other immunosuppressive agents, doses of MMF up to 20% higher may be required in children because of increased hepatic metabolism. An enteric-coated oral formulation of mycophenolate (MP-EC) is available and exhibits fewer gastrointestinal (GI) side effects than MMF. This formulation is as effective as MMF at the following conversion rate: 250 mg of MMF is equivalent to 180 mg of MP-EC, and 500 mg of MMF is equivalent to 360 mg of MP-EC.

INDICATIONS AND CONTRAINDICATIONS

INDICATIONS

There are currently no licensed indications for MMF in dermatology. However, MMF is frequently used to treat immunobullous disorders (especially pemphigus), connective tissue diseases (including cutaneous lupus erythematosus, dermatomyositis, and systemic sclerosis), papulosquamous disorders (including lichen planus, lichen planopilaris, and psoriasis), pyoderma gangrenosum, cutaneous vasculitis, sarcoidosis, and chronic atopic dermatitis, among other conditions.[3-5] Despite the wide spectrum of inflammatory disorders effectively treated with MMF, high-quality studies supporting its use for these conditions are limited. MMF may be combined with other immunosuppressants and immunomodulators, but an increased risk of infection, malignancy, and other serious adverse effects may discourage this practice. Combination regimens, however, may allow for dose reduction of individual drugs and may decrease the incidence of dose-dependent adverse side effects.

CONTRAINDICATIONS

Absolute contraindications to using MMF include known hypersensitivity and pregnancy. Relative contraindications include severe renal dysfunction and deficiency of the hypoxanthine-guanine phosphoribosyl transferase enzyme (see Other Considerations).

DOSING REGIMEN

Depending on the condition being treated, dosing of MMF varies (Table 192-1). Most patients with skin disease respond to 1 to 1.5 g given twice daily. In pediatric patients, the recommended starting dose of MMF is 600 mg/m^2. Children with a body surface area of 1.5 m^2 or greater should receive adult-equivalent doses or more, particularly if augmented hepatic metabolism is a concern.

MMF is frequently and safely co-prescribed with corticosteroids and can be continued while corticosteroid therapy is tapered or withdrawn. Depending on the condition being treated, MMF may display a steroid-sparing effect. The full therapeutic benefit of MMF is seen after 3 months of use, and judging its success should be reserved until after adequate time on medication has been allotted.

THERAPEUTIC MONITORING

No guidelines for preventing or screening for MMF toxicity exist. At the outset of therapy, blood counts

TABLE 192-1
Mycophenolate Mofetil Dosing Regimen[a]

	DAILY ORAL DOSE (mg/kg)
Cytotoxic T cell–mediated diseases	25–35
Antibody-mediated diseases	35–55

[a]180 mg of enteric-coated mycophenolate sodium is the equivalent of 250 mg of mycophenolate mofetil; 360 mg of enteric-coated mycophenolate sodium is the equivalent of 500 mg of mycophenolate mofetil.

and serum chemistries, including liver and kidney function testing, should be obtained on a regular basis. When patients are receiving stable doses and have no signs of toxicity, the frequency of monitoring can be extended to 3-month intervals.

Measuring serum MPA concentrations to achieve a target trough level has been advocated for in the transplantation literature because this practice appears to improve allograft survival in transplant recipients receiving MMF therapy.[6,7] Small prospective studies have shown similar benefit of monitoring serum MPA levels for systemic lupus erythematosus and certain systemic vasculitides.[8,9] A major hindrance to routinely measuring serum MPA levels is the time-sensitive nature of the assay—trough levels need to be taken 12 hours after the last dose, which is not always feasible for patients, and drug kinetics are highly influenced by enterohepatic recirculation, which may vary by individual and is affected by certain medications. The utility of monitoring serum MPA levels has not been established for any dermatologic condition and is therefore not presently recommended.

SIDE EFFECTS AND PRECAUTIONS

Dose-dependent GI side effects, occasionally with intractable diarrhea, are common, but in the vast majority of cases, these symptoms diminish with continuation of therapy. Further dividing the total daily dose (eg, three or four times a day) and taking the medication with food may improve tolerability. If such measures fail, switching to MP-EC is recommended. An increased risk of herpes zoster virus reactivation is seen during treatment with MMF, particularly among older adult patients.

SERIOUS ADVERSE EFFECTS (TABLE 192-2)

Significant cytopenias rarely complicate treatment with MMF but are more common when maximum dose therapy is used in conjunction with other immunosuppressants. An increased incidence of lymphoma and skin cancer has been reported in MMF users and appears to be related to the intensity and duration of immunosuppression. In children using MMF, lymphoproliferative disorders have also occurred. The risk of serious infection is increased during treatment with MMF, and some infections (eg, JC virus–associated progressive multifocal leukoencephalopathy [PML]) may have fatal outcomes.

TABLE 192-2
Serious Adverse Effects of Mycophenolate Mofetil

Embryotoxicity
Lymphoma and other malignancies
Serious and opportunistic infections, including progressive multifocal leukoencephalopathy
Severe cytopenias, including neutropenia and pure red cell aplasia
Skin cancer

DRUG INTERACTIONS

Simultaneous administration of MMF with antacids, cholestyramine, and proton pump inhibitors (PPIs) decreases its absorption. Whereas cholestyramine disrupts enterohepatic circulation, PPIs impair absorption by increasing gastric pH. Spacing the administration of PPIs by a period of 2 hours before or after MMF may circumvent this interaction. Cyclosporine also interferes with the enterohepatic circulation of MPA, and coadministration of the two agents may result in decreased serum concentrations of MPA, although the clinical significance of this specific interaction has not been shown to be meaningful.[10] There is no increase in nephrotoxicity, hepatotoxicity, hypertension, or neurotoxicity when MMF is combined with cyclosporine and corticosteroids. Despite an unknown influence on the ovulation-suppressing actions of certain oral contraceptives, MMF has been shown to decrease mean plasma concentrations of levonorgestrel and ethinylestradiol. For this reason, reliable forms of contraception are recommended in women of childbearing potential who use MMF (see Other Considerations).

OTHER CONSIDERATIONS

Because MMF decreases host immunity, age-appropriate vaccinations are recommended before starting and during therapy, but live attenuated vaccines should be avoided after treatment has been initiated. Individuals with preexisting renal disease might require lower doses of MMF as a result of impaired drug excretion, and more frequent toxicity monitoring may be necessary in these instances. Judicious use of MMF is warranted in the setting of hepatic insufficiency, although even in cases of advanced liver disease (eg, alcoholic cirrhosis), conversion to active MPA and enterohepatic recirculation appear unaffected. MMF is a Pregnancy Category D medication because it has been shown to increase the risk of first trimester pregnancy loss and cause congenital malformations. Therefore, women of reproductive potential using MMF require contraception, and because of an unknown effect on the efficacy of oral contraceptive pills, if a hormone-based contraceptive is selected, concurrent use of a barrier contraceptive is recommended.[10] Active contraception should continue for 6 to 8 weeks after discontinuation of MMF. Because MMF inhibits the de novo synthesis of purines, deficiency of hypoxanthine-guanine phosphoribosyl transferase (eg, Lesch-Nyhan syndrome) is a relative contraindication to its use.

CALCINEURIN INHIBITORS

The CNIs are a versatile class of immunomodulators that were originally discovered as microorganism fermentation products. The CNIs selectively

suppress T-cell responses and have synergistic therapeutic effects when they are combined with most other immunosuppressive drugs.[1,2] Despite established efficacy for a number of inflammatory conditions, the use of cyclosporine and other systemic CNIs to treat skin disease has declined with the advent of biologic agents that exert more targeted effects.

CYCLOSPORINE

Cyclosporine is a lipophilic cyclic polypeptide metabolite produced by the fungal species *Beauveria nivea*.

PHARMACOLOGY AND MECHANISM OF ACTION (FIG. 192-2)

Mechanism of Action: Cyclosporine, also known as cyclosporine A (CsA), and other CNIs inhibit T-cell activation by several mechanisms. Of these, disruption of T-cell receptor signaling is the best understood mechanism and is thought to be the most important in terms of antiinflammatory activity.[11] Cyclosporine binds the intracytoplasmic, high-affinity immunophilin receptor cyclophilin and forms a drug–receptor complex that binds to calcineurin, a serine/threonine protease composed of two subunits, CnA and CnB. CnA constitutes the catalytic unit possessing binding sites for CnB and calmodulin (Fig. 192-2). Cyclophilin activity strongly correlates with increased interleukin (IL)-2 production via activation of the CD3 domain of the T-cell receptor. Cyclophilin is also involved in the induction of apoptosis and degranulation of cytotoxic T-lymphocytes. Experimental data has shown that the CsA–cyclophilin complex inhibits the nuclear translocation of the nuclear factor of activated T cells (NFAT) molecule by blocking its dephosphorylation. This is thought to be a key step by which CsA and other CNIs uncouple T-cell receptor activation from IL-2 and other inflammatory cytokine transcription.

In summary, CsA inhibits T-cell activation mediated by antigens by blocking the downstream signaling cascade of the T-cell receptor, but it does not inhibit the early phases of T-lymphocyte signal transduction.

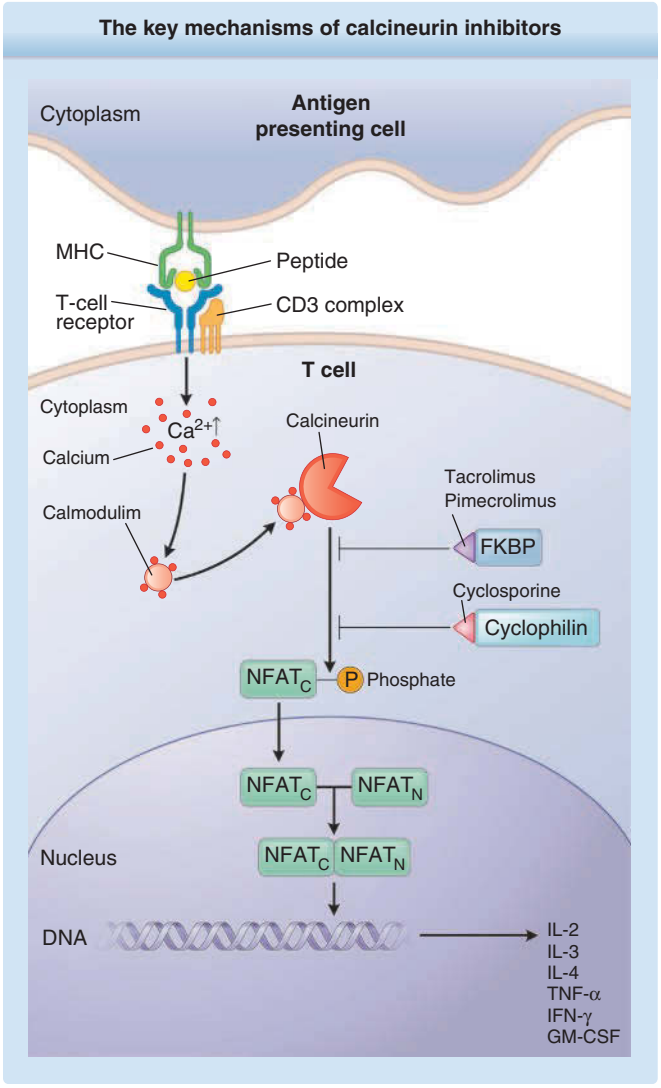

Figure 192-2 The key mechanisms by which calcineurin inhibitors disrupt T-cell activation triggered by the presentation of antigen via the T-cell receptor (TCR). The first step in antigen presentation involves the presentation of a peptide that is bound within the peptide-binding groove of the major histocompatibility complex (MHC) class II molecule. This complex is then presented to the TCR. This causes transmembrane signaling that increases intracellular calcium concentrations. The liberated calcium, bound to calmodulin, interacts with calcineurin, a calcium-dependent serine/threonine phosphatase that dephosphorylates nuclear factor of activated T cells (shown here as NFATc), and this causes NFAT to translocate to the nucleus. There it binds to other nuclear components of NFAT (shown here as NFATn). This complex regulates the transcription of many cytokine genes, shown in the diagram. Cyclosporine, tacrolimus, and pimecrolimus diffuse freely into the cytoplasm of T cells and bind with their respective immunophilins (eg, cyclosporine with cyclophilin, and tacrolimus/pimecrolimus with FK506 binding protein [FKBP-506] or macrophilin 506). This drug–immunophilin complex binds to calcineurin and blocks its ability to dephosphorylate NFAT, preventing translocation into the nucleus and blocking the production of cytokines, chemokines, and growth factors (eg, interleukin [IL]-2, IL-3, IL-4, tumor necrosis factor-α [TNF-α], interferon-γ [IFN-γ], granulocyte macrophage colony-stimulating factor [GM-CSF]) that would normally be induced after T-cell activation via the TCR. APC, antigen-presenting cell. (Figure modified from Nghiem P, Pearson G, Langley RG. Tacrolimus and pimecrolimus: from clever prokaryotes to inhibiting calcineurin and treating atopic dermatitis. *J Am Dermatol*. 2002;46:228-241.)

The immunosuppressive effects of CsA and the CNIs are intricate and subject to constant discoveries. A simplified explanation of the mechanism of action of these drugs is illustrated in Fig. 192-2.

Absorption, Distribution, Metabolism, and Excretion: After oral administration, absorption of CsA follows a predictable trajectory but is heavily influenced by the formulation chosen as well as patient-specific characteristics. Peak plasma drug concentrations occur 1 to 4 hours after administration, but co-ingestion with food can delay or even reduce total drug absorption. After entry into the circulation, CsA distributes into a variety of tissues and displays a large volume of distribution (13 L/kg). Notably, unlike most other medications, CsA binds to cellular elements of whole blood, including lymphocytes, granulocytes, and erythrocytes, and only a fraction remains bound to plasma lipoproteins. If monitoring drug levels, whole blood levels are preferred to plasma measurements because of the drug's accumulation in erythrocytes and leukocytes.[12] Cyclosporine is metabolized into more than 30 partially active byproducts primarily by the hepatic cytochrome P450 3A4 enzyme (CYP3A4).[13,14] Medications that compete for binding to CYP3A4 will increase CsA levels, and drugs that induce P450 will accelerate its metabolism and decrease blood levels (see Drug Interactions and Table 192-3). In addition, certain foods rich in bioflavonoids, such as grapefruit, appear to increase CsA bioavailability through an interaction with hepatic and enteric cytochromes. The elimination half-life of CsA is 6 to 12 hours in the absence of severe hepatic disease, and biliary excretion accounts for more than 90% of its elimination. Renal failure does not substantially alter CsA clearance.

A microemulsion formulation of CsA (Neoral, Novartis) is available and has greater bioavailability than the standard formulation.[12] Because the two preparations are not bioequivalent, lower doses of microemulsion CsA appear to have comparable efficacy to standard doses of the nonemulsified formulation. An intravenous preparation of CsA is also available. Topical CsA solution has limited utility for treating inflammatory skin conditions, owing to its poor penetration across cornified epithelia, but recently, a liposomal gel of CsA was developed and has shown efficacy for treating plaque psoriasis.[15] Further studies are needed to determine whether CsA gel is useful for other inflammatory skin conditions.

INDICATIONS AND CONTRAINDICATIONS

Indications: Cyclosporine is approved for treating moderate to severe plaque psoriasis. The dosage for optimal disease control is 4 to 5 mg/kg/day. The use of CsA in combination with methotrexate appears beneficial, but combination with biologics (eg, tumor necrosis factor-α [TNF-α] inhibitors and IL-12/23 and IL-17 blockers) has not been adequately studied and should be avoided, apart from short periods of overlap when de-escalation followed by discontinuation of CsA is planned. Although approved for psoriasis, use of CsA has decreased owing to the availability of more targeted agents as well as the predictable toxicity associated with long-term administration.

Although CsA is only licensed for psoriasis, it appears efficacious for treating a variety of dermatologic conditions, including pyoderma gangrenosum, pemphigus and its variants, palmoplantar pustulosis, lichen planus, atopic dermatitis, Behçet disease, alopecia areata, and epidermolysis bullosa acquisita, among others.[16-18] Despite historically mixed outcomes, more recent data supports that CsA may improve mortality in patients with Stevens-Johnson syndrome and toxic epidermal necrolysis.[19]

Contraindications: Contraindications to using CsA include known hypersensitivity, severe renal

TABLE 192-3
Drugs that Interact with Cyclosporine[a]

DRUG CLASS	SPECIFIC DRUGS
Drugs That May Increase the Risk of Nephrotoxicity	
Antibiotics	Ciprofloxacin, gentamycin, tobramycin, vancomycin, trimethoprim with sulfamethoxazole
Antimetabolites	Melphalan
Antifungals	Amphotericin B, ketoconazole
Antiinflammatory drugs	Colchicine, diclofenac, naproxen, sulindac
Gastrointestinal agents	Cimetidine, ranitidine
Immunosuppressives	Tacrolimus
Other drugs	Fibrates, methotrexate
Drugs That Increase Cyclosporine Concentrations	
Calcium channel blockers	Diltiazem, nicardipine, verapamil
Antibiotics	Azithromycin, clarithromycin, erythromycin, quinupristin–dalfopristin
Antifungals	Fluconazole, itraconazole, ketoconazole, voriconazole
Antivirals	Boceprevir, indinavir, nelfinavir, ritonavir, telaprevir, saquinavir
Glucocorticoids	Methylprednisolone
Other drugs and supplements	Allopurinol, amiodarone, bromocriptine, colchicine, danazol, grapefruit juice, imatinib, metoclopramide, oral contraceptives
Drugs That Decrease Cyclosporine Concentrations	
Antibiotics	Nafcillin, rifampin
Anticonvulsants	Carbamazepine, oxcarbazepine, phenobarbital, phenytoin
Other drugs and supplements	Bosentan, octreotide, orlistat, sulfinpyrazone, St. John's wort, terbinafine, ticlopidine

[a]Neoral (cyclosporine) prescribing information. [Medication prescribing guide]. 2015; https://www.pharma.us.novartis.com/sites/www.pharma.us.novartis.com/files/neoral.pdf.

TABLE 192-4
Calcineurin Inhibitor Dosing Regimen

DRUG	ADULT DOSAGE	PEDIATRIC DOSAGE[a]
Cyclosporine—oral	2.5–5.0 mg/kg/day	5–7 mg/kg/day
Cyclosporine—intravenous	2–3 mg/kg/day	3–5 mg/kg/day
Tacrolimus—oral	150–200 µg/kg/day	200–300 µg/kg/day
Tacrolimus—intravenous	25–50 µg/kg/day	50–100 µg/kg/day
Tacrolimus—topical	2×/day	2×/day[b]
Pimecrolimus—topical	2×/day	2×/day

[a]Initiating therapy at adult-equivalent doses may be the most prudent approach with dose escalation as tolerated or to effect.
[b]Only the 0.03% ointment is approved for children.

dysfunction, uncontrolled hypertension, and malignancy. Patients with psoriasis who are receiving CsA should not undergo phototherapy because of an increased risk of cutaneous malignancy.

DOSING REGIMEN (TABLE 192-4)

The recommended starting dosage of CsA is 2.5 mg/kg/day, which can be increased by 0.5 to 1.0 mg/kg/day at 2-week intervals until the desired outcome is achieved. If rapid disease control is needed, initiation of CsA at 4 to 5 mg/kg/day is acceptable because most patients with dermatologic conditions respond to doses within this range. Dosages greater than 5 mg/kg/day are not advisable other than for very short periods of time. Dose reductions are permissible at any time, although judicious decreases are recommended to prevent a disease flare. Intravenous CsA can be infused slowly over a period of 2 to 6 hours at about one third of the usual oral dose, or about 2 mg/kg/day. Because nephrotoxicity complicates long-term use, courses of CsA should typically not exceed 6 to 12 months.

Therapeutic Monitoring: Before initiating CsA, baseline laboratory studies should be obtained, including blood counts; comprehensive serum chemistries, including tests for renal function and electrolytes (including magnesium); uric acid; lipids; and urinalysis. These studies should be repeated every 2 weeks at the outset of therapy, and if stable, the assessment intervals can be extended at the discretion of the prescriber. During CsA therapy, if serum creatinine increases 25% above the pretreatment level on two consecutive occasions, the CsA dose should be reduced, and if it remains persistently elevated despite dose modification, CsA should be discontinued (Fig. 192-3). Blood pressure measurements should also be performed before and regularly during treatment with CsA because elevations in blood pressure may be the first sign of nephrotoxicity.

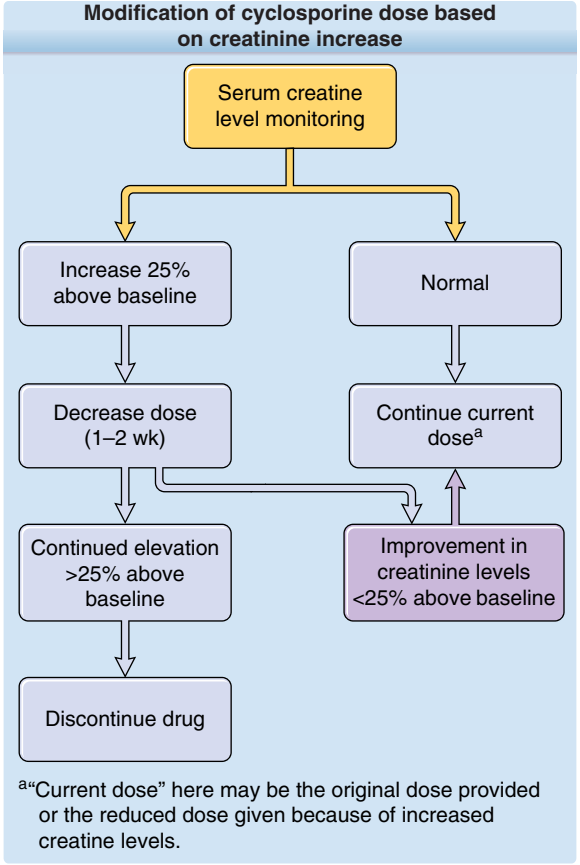

Figure 192-3 Modification of cyclosporine dose based on creatinine increase.

Although targeting a specific trough level is useful for preventing organ rejection in transplant recipients, this practice has not been shown to be beneficial in individuals with psoriasis or other inflammatory skin conditions who receive CsA and is therefore not recommended. In patients who are not responsive to CsA or drug compliance is in question, checking a trough level may be warranted because it can distinguish between primary noncompliance and lack of efficacy. The two most common commercially available assays—high-performance liquid chromatography (HPLC) and radioimmunoassay—are performed on EDTA (ethylenediaminetetraacetic acid)-containing whole blood.

SIDE EFFECTS AND PRECAUTIONS

Nausea, vomiting, anorexia, and diarrhea are common side effects of CsA. These symptoms tend to subside with ongoing use, although dose reduction may be necessary. Headache is another common side effect of CsA, especially in patients with a history of migraine. Cyclosporine-induced seizures are uncommon but are associated with hypomagnesemia and the concomitant use of systemic corticosteroids. For this reason, serum magnesium levels should be monitored closely during treatment, and caution should be exercised in individuals receiving CsA and corticosteroids. Lethargy,

confusion, tremors, and paresthesias are uncommon side effects of CsA.[20]

Overall, one in four patients taking CsA develops clinical or laboratory evidence of altered renal function. Two types of CsA-induced nephrotoxicity are seen. The first type typically begins within 2 to 3 weeks after drug initiation, and it is associated with high CsA blood levels. A decrease in glomerular filtration rate is seen, along with hypertension and tubular dysfunction. Upon dose reduction or discontinuation, there is complete reversal of this type of nephrotoxicity. The second type of CsA-associated nephrotoxicity is likely a result of cumulative, subclinical chronic renal toxicity. This type tends to occur with long-term therapy (>6 months) and is typically irreversible. Notably, it may occur in the absence of any detectable elevation of creatinine or blood pressure. When individuals experience this form of chronic nephrotoxicity, kidney biopsies characteristically show interstitial fibrosis, tubular atrophy, and vasculopathy. The pathogenesis underlying both types of CsA-mediated nephrotoxicity is poorly understood, but several mediators, including endothelin-1, angiotensin II, osteopontin, and transforming growth factor-β, have been implicated. Calcium channel blockers; angiotensin-converting enzyme inhibitors; angiotensin receptor blockers; and newer drugs, including endothelin A receptor blockers (eg, bosentan) and renin inhibitors (eg, aliskiren), appear to be beneficial for attenuating CsA-induced hypertension and nephrotoxicity.[20] Because of the risk of nephrotoxicity, diuretics and other nephrotoxic drugs should be used cautiously in individuals treated with CsA (see Table 192-3). Importantly, in patients undergoing long-term CsA therapy, serum creatinine and its clearance may not be reliable indicators of altered renal function, and more sensitive tests (eg, renal biopsy) may be needed to detect deleterious changes.

There is evidence of impaired fibrinolysis and endothelial damage and proliferation after CsA use. Hypercoagulability seems to contribute to the progression of atherosclerosis and glomerular damage in CsA-treated patients. In addition to renal artery vasoconstriction, CsA may cause peripheral vasoconstriction and precipitate attacks of Raynaud phenomenon.

Hypercholesterolemia, elevation of low-density lipoproteins, and hypertriglyceridemia may be seen during treatment with CsA. Electrolyte perturbations, most commonly hypomagnesemia and hyperkalemia (less so, hypokalemia), occur in up to 15% of CsA users. Close electrolyte monitoring is needed, particularly if medications that alter potassium balance (eg, triamterene and spironolactone) are co-prescribed. Hyperuricemia can also be seen during CsA therapy, and CsA should therefore be administered cautiously in individuals with a known history of gout. Hyperuricemia may also be an early indicator of CsA-induced nephrotoxicity.

Osteoporosis can complicate CsA treatment and appears to result from its action on osteoblasts and osteoclasts and from its ability to alter lymphocyte-derived cytokines. Myopathy has been reported in transplant recipients receiving high doses of CsA; therefore, caution should be exercised with the concomitant use of statins.

Mucocutaneous side effects from CsA therapy are common. Hypertrichosis occurs in virtually all patients on long-term CsA. It is not limited to androgen-dependent, hair-bearing areas and shows no tendency for spontaneous remission. Gingival hypertrophy is reported in up to 70% of CsA users. It is more common in children; in individuals with poor oral hygiene; and with the concomitant use of calcium channel blockers, particularly nifedipine. Improvement of this complication can be seen with the administration of oral metronidazole or azithromycin. An acneiform eruption, indistinguishable from that seen in steroid-induced acne, is frequently reported with CsA use. Disseminated comedonal or cystic acneiform eruptions can also occur. Keratosis pilaris, sebaceous hyperplasia, warts, and epidermal inclusion cysts occur in up to one third of CsA-treated patients. Eruptive nevi may also develop during CsA use.[21]

Serious Adverse Effects (Table 192-5): Significant cytopenias rarely occur during treatment with CsA. An uncommon but serious adverse complication is the development of thrombotic microangiopathy–hemolytic uremic syndrome, the risk of which is greatest in allogeneic bone marrow transplant patients receiving CsA for acute graft-versus-host disease (GVHD).[22] Hepatotoxicity with a risk of liver failure is rare but appears to be more common in patients with significant comorbidities and in those concurrently taking hepatotoxic medications.

As in other patients receiving immunosuppressants, individuals treated with CsA have a higher risk of malignancy, particularly lymphoma and skin cancers. Cyclosporine-treated transplant recipients have a relative risk of all skin cancers of 6.8 compared with 2.2 to 5.5 in those receiving other immunosuppressants, such as azathioprine. Cyclosporine-treated dermatologic patients also have an elevated risk of skin cancer, including squamous cell carcinoma, basal cell carcinoma, human papilloma virus–associated anogenital carcinoma, and Kaposi sarcoma. Approximately 25% of nonvisceral Kaposi sarcomas that develop in the setting of CsA use can be expected to undergo complete or partial remission following cessation or reduction of CsA. Epstein-Barr virus–associated post-transplant lymphoproliferative disorder (PTLD) is exceedingly rare among individuals receiving CsA for

TABLE 192-5
Serious Adverse Effects of Cyclosporine

Fulminant hepatotoxicity
Hyperkalemia
Lymphoma and other malignancies, including skin cancer
Nephrotoxicity
Neurotoxicity
Serious and opportunistic infections, including polyoma virus infection (eg, progressive multifocal leukoencephalopathy)
Thrombotic microangiopathy/hemolytic uremic syndrome

inflammatory skin conditions. PTLD frequently fails to respond to chemotherapy, but it may regress after reduction or cessation of immunosuppression. The incidence of lymphoma in CsA-treated dermatologic patients appears to be less than 0.2%, and lymphomas developing in CsA-treated patients appear to have a better prognosis despite having a shorter latency period. Other neoplasms, such as melanoma, have also been reported in patients on CsA, although their true incidence is unknown.

Patients receiving CsA are at risk for serious and opportunistic infections, which can have fatal outcomes. JC virus-associated PML and polyoma virus–associated nephropathy have been reported in renal, hepatic, and cardiac transplant recipients receiving CsA.

Neurotoxicity, including serious complications such as cortical blindness and hemiplegia, has been reported in association with CsA use. The posterior reversible encephalopathy syndrome (PRES), which is characterized by impaired consciousness, visual changes, movement disorders, and psychiatric disturbance, has been described in postmarketing reports. Hypomagnesemia and the concomitant use of high-dose systemic corticosteroids appear to be associated with these serious neurotoxic sequelae.

Drug Interactions: A variety of drugs interact with CsA and either increase or decrease its therapeutic effect by inhibiting or accelerating CYP3A4-mediated metabolism, respectively. Table 192-3 provides a detailed list of drugs that interact with CsA.

Other Considerations: During treatment with CsA, vaccination may be less effective, and live attenuated vaccines should be avoided. Children and adults have similar bioavailability of oral CsA, but children usually exhibit a higher degree of renal clearance and have shorter blood level half-lives. Children may therefore require higher doses of CsA or more frequent administration to achieve comparable serum drug concentrations and beneficial therapeutic outcomes. Cyclosporine is a Pregnancy Category C medication, so it should only be used when the potential benefits outweigh the risks.[12] It does not appear to be mutagenic or teratogenic, although there is a higher than expected incidence of preterm birth, fetal growth retardation, abortions, preeclampsia, and hypertension in mothers taking CsA during pregnancy. There are no reports of neonatal complications in children born to fathers taking CsA. Adequate contraceptive measures are recommended in women of childbearing potential. Cyclosporine is excreted in breast milk and should be avoided in nursing mothers.

TACROLIMUS

Tacrolimus, a CNI formerly known as FK506, is a macrolide immunosuppressant that was first isolated from *Streptomyces tsukubaensis*.

PHARMACOLOGY AND MECHANISM OF ACTION

Mechanism of Action (see Fig. 192-2): The postulated mechanism of action of tacrolimus is similar to that of CsA. Instead of binding to cyclophilin, however, tacrolimus binds to FK506 binding protein (FKBP), but the downstream effect is similar—inhibition of the calcium-dependent phosphatase, calcineurin, which disrupts nuclear translocation of NFAT and uncouples T-cell receptor activation from inflammatory cytokine transcription (eg, IL-2, IL-3, IL-4, IL-12, and TNF-α).[11]

Absorption, Distribution, Metabolism, and Excretion: Tacrolimus can be administered orally, topically, and intravenously. The pharmacokinetics of systemic tacrolimus are understood as a two-compartment model with a rapid initial drop in plasma concentrations after entry into the circulation followed by a long elimination half-life of 12 to 21 hours when equilibrium is achieved. Tacrolimus is primarily metabolized by the hepatic cytochrome P450 system (CYP3A4), and less than 1% of the drug is excreted unchanged in the urine. Tacrolimus has not demonstrated superiority to CsA for the prophylaxis of organ rejection or for treating inflammatory conditions, but it appears to have better bioavailability, higher potency, and a lower molecular weight, the latter of which confers enhanced skin penetration. These pharmacologic properties provided the rationale for experiments that demonstrated attenuation of contact hypersensitivity after topical application of tacrolimus and subsequent development of tacrolimus ointment for atopic dermatitis.[23,24]

Pharmacokinetic studies of topical tacrolimus have shown low percutaneous absorption in individuals with atopic dermatitis. Although the initial systemic absorption may be as high as 10% to 20%, blood levels become undetectable by 1 week as healing and reestablishment of the skin barrier occurs. In clinical trials, detection of blood levels of tacrolimus greater than 2 ng/mL were exceedingly rare, in contrast with trough levels of 5 to 15 ng/mL in transplant patients receiving oral tacrolimus.[25] The notable exception is when topical tacrolimus is used in patients with Netherton syndrome, in whom blood levels within or above the established therapeutic trough range for oral tacrolimus in organ transplant recipients may be observed, owing to poor barrier function inherent to this syndrome.[26]

INDICATIONS AND CONTRAINDICATIONS

Topical Indications: Tacrolimus ointment (Protopic, Astellas), available in 0.03% and 0.1%, is approved by the U.S. Food and Drug Administration (FDA) for use in adults with moderate to severe atopic dermatitis. In children aged 2 to 15 years with moderate to severe atopic dermatitis, only the 0.03% ointment is approved.

Off-label use of tacrolimus ointment has been employed for a number of other inflammatory skin conditions, including seborrheic dermatitis, cutaneous lupus erythematosus, pyoderma gangrenosum, and vitiligo, among others.

Oral and Intravenous Indications: There are no labeled indications for the use of systemic tacrolimus for any dermatologic condition. It is currently approved only for the prophylaxis of organ rejection in renal, hepatic, and cardiac transplant recipients. Its mechanism of action suggests that any patient who is responsive to CsA will also respond to tacrolimus. Beneficial outcomes using tacrolimus have been reported for psoriasis, pyoderma gangrenosum, lupus erythematosus, GVHD, and atopic dermatitis, among others.

Contraindications: Tacrolimus is contraindicated in individuals with known hypersensitivity, and the intravenous formulation should be avoided in those with allergy to hydrogenated castor oil because it represents the main excipient. Other contraindications to systemic tacrolimus are similar to CsA and include active infection, malignancy, and severe hepatic or renal dysfunction. Topical tacrolimus is contraindicated in patients with Netherton syndrome.

DOSING REGIMEN (SEE TABLE 192-4)

The recommended doses of topical and systemic tacrolimus are outlined in Table 192-4. The use of topical tacrolimus deserves special mention. Currently, there is an FDA-issued boxed warning for topical tacrolimus that outlines a lack of long-term safety data and that new malignancies (eg, skin cancer and lymphoma) have been reported in individuals treated with topical tacrolimus. In light of this warning, initiation of tacrolimus and other topical CNIs should begin by addressing parental and patient concerns. These agents should be considered second-line treatments and are typically indicated when standard therapy, including emollients and topical corticosteroids, have failed or resulted in deleterious side effects. Topical CNIs should be applied sparingly to affected areas of skin twice daily using the smallest effective amount. Therapy should be discontinued where signs of prior skin inflammation have subsided. Adjunctive measures, such as emollients, should be continued. When the skin barrier is restored and inflammation is quiescent, two or three weekly applications to sites of prior involvement appear to decrease the requirement for topical steroid use.[27] Importantly, the application of tacrolimus ointment should be restricted to small areas of inflamed skin because large application quantities have been associated with increased percutaneous absorption and a higher risk of systemic side effects.[28] Application under occlusion should be avoided, except for short periods when rapid disease control is desired.

Therapeutic Monitoring: Monitoring for adverse effects and end-organ toxicity with an approach similar to that used for CsA (eg, blood counts, hepatic and renal function tests, electrolytes [including magnesium], uric acid levels, and lipid panels) is strongly recommended for individuals receiving systemic tacrolimus. In renal, hepatic, and cardiac transplant recipients, measuring trough levels to a target plasma concentration between 5 and 15 ng/mL is recommended to prevent organ rejection during treatment with oral tacrolimus. This practice has not been established for any dermatologic condition.

During treatment with topical tacrolimus, patients should be evaluated for signs of cutaneous infection with particular vigilance for eczema herpeticum, the risk of which is increased among atopic patients treated with topical tacrolimus. Any evidence of lymphadenopathy should be documented and closely followed. Skin examinations for cutaneous malignancy should also be conducted at regular intervals, although a causal link between topical tacrolimus use and skin cancer development has not been established. No routine serologic monitoring is necessary. If there is clinical evidence of systemic absorption, serum levels of tacrolimus, as assessed by enzyme-linked immunosorbent assay or HPLC on whole blood, should be obtained.

SIDE EFFECTS AND PRECAUTIONS

The side effects of tacrolimus are similar to those of CsA (see earlier discussion). Neurotoxicity and glucose intolerance are somewhat higher than with CsA, however, so close monitoring of magnesium and glucose levels is strongly recommended. Nephrotoxicity, as with CsA, is a predictable side effect, particularly when high doses or prolonged courses are used. Acute nephrotoxicity appears to be the result of afferent renal arteriole vasoconstriction and is characterized by elevated serum creatinine, hyperkalemia, or a decrease in urine output and is typically reversible.[29] Chronic nephrotoxicity from tacrolimus, which is a result of long-term use, is progressive and irreversible. Caution should be exercised when administering other nephrotoxic agents with tacrolimus. Mucocutaneous side effects appear to be less frequent with tacrolimus than CsA.

Users of topical tacrolimus may experience application site stinging and burning, which is typically more pronounced in excoriated skin. Efforts to limit exposure to denuded areas by pretreating with a topical steroid may ameliorate this side effect and improve adherence to therapy. Pretreatment with oral aspirin before application of tacrolimus has also been shown to reduce symptoms of skin irritation.[30] Refrigeration before application may also mitigate these side effects. Topical tacrolimus has been associated with exacerbations of rosacea, including the granulomatous subtype, and it should therefore be used cautiously in individuals with this condition.[31] Tacrolimus ointment should be avoided on premalignant skin lesions, on infected skin, and in those receiving phototherapy, owing to a theoretically increased susceptibility to skin cancer.

SERIOUS ADVERSE EFFECTS (REFER TO TABLE 192-4)

Similar to CsA, the use of systemic tacrolimus has been associated with lymphoma and other malignancies; serious infections, including those secondary to opportunistic organisms (eg, polyoma virus); irreversible nephrotoxicity; severe neurotoxicity; and pure red cell aplasia as well as other clinically significant cytopenias. Notably, tacrolimus may have a reduced risk for predisposition to skin cancer compared with CsA because in vitro studies have shown that CsA facilitates malignant keratinocyte survival, an attribute that tacrolimus has failed to demonstrate.[32] Tacrolimus may prolong the QT interval and result in torsades de pointes and should therefore be avoided in patients with long QT syndrome. GI perforation has been reported as a rare complication of tacrolimus use.

Drug Interactions: Hepatic cytochrome CYP3A4 enzymes metabolize tacrolimus, and therefore medications or other substances that inhibit or induce these enzymes may increase or decrease whole blood concentrations of tacrolimus, respectively. The relevant food and drug interactions are similar to those for CsA (see Table 192-3) and include grapefruit juice, certain antivirals (eg, protease inhibitors), azole antifungals, calcium channel blockers, select antibiotics, anticonvulsants, and St. John's wort. Understanding these interactions is critical to avoid supratherapeutic or subtherapeutic blood concentrations of tacrolimus. Tacrolimus should not be combined with CsA because their mechanisms of action and toxicity profiles overlap. Unlike CsA, tacrolimus does not interfere with enterohepatic circulation, so lower doses of MMF should be used when the two medications are co-prescribed.

Other Considerations: Individuals with impaired hepatic function should receive a reduced dose of systemic tacrolimus, concordant with the degree of liver dysfunction. Closer monitoring of tacrolimus trough levels may be warranted in such scenarios. Because tacrolimus is minimally metabolized and excreted by the kidneys, dose adjustments are typically not necessary in individuals with preexisting renal disease, but increased surveillance for tacrolimus-induced nephrotoxicity is recommended. Tacrolimus is a Pregnancy Category C medication, and its use in pregnant women should be restricted to scenarios in which known or perceived benefit outweighs its risk. Similar to CsA, tacrolimus is excreted in breast milk, so caution is advised in nursing mothers. Live attenuated vaccines should be avoided during treatment with systemic tacrolimus.

PIMECROLIMUS

Pimecrolimus is a topical, synthetic CNI modified from the macrolide immunosuppressant, ascomycin. Pimecrolimus is formulated exclusively in a cream vehicle (Elidel, Valeant).

PHARMACOLOGY AND MECHANISM OF ACTION

After topical application, pimecrolimus remains largely confined to the skin and has poor percutaneous absorption. In the rare event that clinically significant systemic absorption occurs, as with other CNIs, pimecrolimus is metabolized and excreted primarily by the liver.

Mechanism of Action: Pimecrolimus acts similarly to the other CNIs and functions by inhibiting calcineurin, uncoupling T-cell receptor activation from inflammatory cytokine production (see Fig. 192-2 and Mechanism of Action for CsA and tacrolimus for more detail). The clinical efficacy of pimecrolimus is slightly lower than that of topical tacrolimus as a result of decreased binding avidity to FKBP.[33]

INDICATIONS AND CONTRAINDICATIONS

Indications: Pimecrolimus 1% cream is indicated as a second-line treatment for mild to moderate atopic dermatitis in individuals aged 2 years and older.

Contraindications: Pimecrolimus is contraindicated in patients with a known hypersensitivity. As with topical tacrolimus, pimecrolimus is also contraindicated in patients with Netherton syndrome.

DOSING REGIMEN (SEE TABLE 192-4)

Pimecrolimus should be applied to affected areas of skin twice daily, using the smallest effective amount, and it should be discontinued after cutaneous inflammation has subsided. Emollients should be continued even after cessation of pimecrolimus. Continuous long-term use of pimecrolimus is not recommended. Selecting pimecrolimus over topical tacrolimus is often a matter of prescriber and patient preference because pimecrolimus and tacrolimus are formulated in different vehicles, which may influence compliance. Furthermore, because of its occlusive vehicle, topical tacrolimus appears to have greater potency than pimecrolimus, which may also influence which drug is preferred.

SIDE EFFECTS AND PRECAUTIONS

In general, pimecrolimus is very well tolerated. Intense burning and itching may occur at application sites, particularly in areas of eroded or excoriated skin. If these symptoms develop, they tend to subside with continued use and may also be ameliorated with refrigeration before use. Acneiform eruptions may develop in areas of application. Uncommonly, cutaneous infections complicate its use, and a slightly increased risk of eczema herpeticum has been observed in atopic patients treated with topical pimecrolimus compared with the baseline incidence typically seen in atopic patients.

TABLE 192-6
Serious Adverse Effects of Tacrolimus and Pimecrolimus

FORMULATION	SPECIFIC SIDE EFFECTS
Tacrolimus	
Systemic	Hyperkalemia Lymphoma and other malignancies Nephrotoxicity Neurotoxicity QT prolongation Serious and opportunistic infections Severe cytopenias, including pure red cell aplasia
Topical	Theoretical risk of lymphoma and skin malignancy[a]
Pimecrolimus	
Theoretical risk of lymphoma and skin malignancy[a]	

[a]Long-term safety data have not been established, although there are studies that refute this theoretical risk (see text for full details).

Pimecrolimus should not be applied to premalignant or malignant skin lesions, in areas of active infection, or to skin exposed to phototherapy. Rarely, flulike symptoms and headache may develop and may be a result of systemic absorption.[23] If percutaneous absorption does occur, pimecrolimus appears to have little systemic immunosuppressive effects, and therefore a wider margin of safety compared with other CNIs.

Serious Adverse Effects (Table 192-6): Similar to topical tacrolimus, the labeling of pimecrolimus contains an FDA-issued boxed warning regarding rare reports of malignancy developing during use. Treatment with topical pimecrolimus, therefore, should be limited to short treatment periods with the least amount of drug used to attain a clinical response. A recent case-control study evaluated the association between topical immunomodulator therapy and lymphoma in a cohort of patients with atopic dermatitis and found no increased risk with the use of topical CNIs.[34]

Drug Interactions: Because percutaneous absorption is limited, there are no substantial drug interactions with topical pimecrolimus.

Other Considerations: There are insufficient studies reporting pregnancy outcomes in women using topical pimecrolimus, but as with other medications, use during pregnancy should be approached circumspectly and, if used, the potential benefit should outweigh any perceived risk.

mTOR INHIBITORS

EVEROLIMUS

Everolimus belongs to a class of medications that inhibit mTOR, a key serine-threonine kinase in the PI3K/AKT pathway that governs cellular metabolism, differentiation, and proliferation. Rapamycin (sirolimus) was the first mTOR inhibitor discovered and was first isolated from *Streptomyces hygroscopicus*. Everolimus and temsirolimus are synthetic rapamycin analogues with greater bioavailability.

PHARMACOLOGY AND MECHANISM OF ACTION

Mechanism of Action (Fig. 192-4): Everolimus and other mTOR inhibitors bind to the intracellular protein FKBP-12 (macrophilin-12) to form an aggregate with mTOR complex 1 (mTORC1) that disrupts mTOR kinase activity. In mammalian cells, mTOR inhibitors abrogate the activity of S6 ribosomal protein kinase (S6K) and eukaryotic initiation factor 4E-binding protein (4E-BP1), which are downstream effectors of mTOR involved in protein synthesis.[35] In T lymphocytes, mTOR inhibitors also block cell cycle progression from G1 to S phase and therefore exhibit potent immunosuppressive effects.[36]

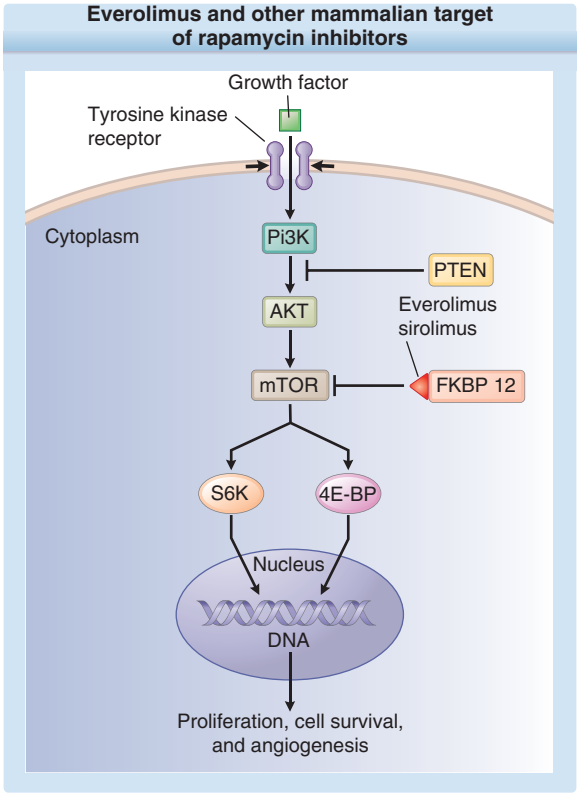

Figure 192-4 Everolimus and other mammalian target of rapamycin (mTOR) inhibitors (eg, sirolimus) bind to FK binding protein (FKBP)-12, forming a complex that inhibits mTOR kinase activity. The downstream effect is reduced activity of S6 ribosomal protein kinase (S6K) and eukaryotic initiation factor 4E–binding protein (4E-BP), which results in decreased cellular proliferation, survival, and angiogenesis. In T cells, mTOR inhibitors also block cell cycle progression from G1 to S phase. AKT, serine/threonine kinase; Pi3K, phosphatidylinositol-3-kinase; PTEN, phosphate and tensin homolog. (Adapted by permission from Springer Nature: Atkins MB, Yasothan U, Kirkpatrick P. Everolimus. *Nat Rev Drug Discov*. 2009;8:535-536. Copyright © 2009.)

Absorption, Distribution, Metabolism, and Excretion: After oral administration, peak serum everolimus concentrations occur within 1 to 2 hours. Consumption with high fat meals appears to reduce total drug absorption.[35] Approximately 75% of everolimus is protein bound within the circulation, and the majority of drug metabolism occurs in the liver because it is a substrate for the hepatic cytochrome CYP3A4 enzyme. Importantly, everolimus is also a competitive inhibitor of CYP3A4 and may increase the concentration of medications that are also metabolized by this enzyme (see Drug Interactions). After conversion into inactive moieties, excretion occurs primarily in the feces, with only 5% of drug excreted unchanged in the urine.

INDICATIONS AND CONTRAINDICATIONS

Indications: There are no labeled dermatologic indications for everolimus. Everolimus is currently indicated to treat hormone receptor–positive breast cancer; neuroendocrine tumors of pancreatic, GI, or lung origin; advanced renal cell carcinoma; and angiomyolipoma and subependymal giant cell astrocytoma that develop in individuals with tuberous sclerosis complex (TSC). Off-label use of everolimus has shown efficacy for treating psoriasis, atopic dermatitis, Kaposi sarcoma, chronic GVHD, and morphea.[37-42] Topical everolimus has also been used to treat facial angiofibromas in individuals with TSC.[43] This beneficial outcome is not surprising, given that constitutive mTOR signaling represents the key pathogenic perturbation underlying TSC. Of note, compared with CNIs, especially CsA, when used as allograft-preserving immunosuppressants, mTOR inhibitors, including everolimus, appear to reduce the long-term risk of cutaneous malignancy in transplant recipients.[44,45]

Contraindications: Everolimus is contraindicated in individuals with known hypersensitivity to the active ingredient or any of its excipients.

DOSING REGIMEN

No established dosing regimen for treating dermatologic conditions exists, although everolimus dosages between 0.5 and 1.5 mg twice daily have been reportedly successful for controlling certain inflammatory and neoplastic skin diseases.

Therapeutic Monitoring: Routine laboratory testing, including blood counts, serum chemistries, assessment of hepatic and renal function, and lipid quantification, is recommended during treatment with everolimus.

Titrating drug doses to achieve a trough concentration between 5 and 15 ng/mL is recommended for individuals receiving everolimus for certain malignancies,[35] but this practice has not been established for any dermatologic condition.

SIDE EFFECTS AND PRECAUTIONS

Mucocutaneous side effects are common during everolimus treatment and tend to occur within the first month of initiating therapy. Common reactions include aphthous stomatitis, acneiform and morbilliform eruptions, folliculitis, and pruritus; less common reactions include erythroderma, onychodystrophy, cutaneous small vessel vasculitis, and symmetrical drug-related intertriginous and flexural exanthema (SDRIFE).[46,47] Other side effects from everolimus are diarrhea, fatigue, headache, peripheral edema, and impaired wound healing. Treatment-induced diabetes mellitus is an uncommon but important potential side effect of everolimus.

mTOR inhibitors should be used cautiously when co-prescribed with MMF or CNIs. Cytopenias, hypercholesterolemia, electrolyte disturbances, elevation of liver enzymes, and thrombotic microangiopathy–hemolytic uremic syndrome are observed more frequently when these drugs are coadministered.

Serious Adverse Effects (Table 192-7): Noninfectious pneumonitis is a potentially serious side effect seen during treatment with everolimus. Nonspecific signs and symptoms such as cough, dyspnea, and hypoxia should raise suspicion for the possibility of this complication, and treatment should be discontinued if radiologic imaging is confirmatory. Corticosteroid therapy may be required if symptoms are severe. Everolimus has been associated with serious, potentially fatal infections, including opportunistic infections. In addition, severe renal and hepatic dysfunction may complicate everolimus therapy. Of note, malignancy is a much less common adverse effect seen during everolimus therapy, likely related to the antiproliferative and antineoplastic properties of mTOR inhibitors. Capillary leak syndrome has been observed during oral sirolimus treatment for psoriasis, but this complication has never been reported for everolimus.[48]

Drug Interactions: Everolimus is both a substrate for and a competitive inhibitor of CYP3A4. Therefore, plasma concentrations of everolimus and drugs metabolized by this enzyme may be affected by concurrent use and should be cautiously co-prescribed. Whereas medications that inhibit CYP3A4 activity (eg, ketoconazole, erythromycin, verapamil) increase plasma concentrations of everolimus, CYP3A4 inducers (eg, rifampin, St. John's wort) reduce concentrations.[35]

TABLE 192-7
Serious Adverse Effects of Everolimus

Embryotoxicity
Hepatotoxicity
Nephrotoxicity
Noninfectious pneumonitis
Serious and opportunistic infections

Other Considerations: Renal impairment does not influence the metabolism or excretion of everolimus, and therefore no dosage adjustment is necessary for individuals with renal dysfunction. Liver dysfunction, however, appears to increase drug levels, and reduced doses of everolimus are warranted in such scenarios, commensurate with the degree of hepatic impairment. Based on preclinical and small clinical studies, everolimus appears to cause fetal harm and is therefore categorized as a Pregnancy Category D medication. It should not be used during pregnancy, but its use may be justified in very limited clinical settings when known benefit outweighs the risk. Although it is unknown whether everolimus passes into breast milk, lactating women should avoid nursing while using everolimus. Everolimus may acutely impair both male and female fertility, although its long-term effect on fertility has not been established.[35]

REFERENCES

1. Madan V, Griffiths CE. Systemic ciclosporin and tacrolimus in dermatology. *Dermatol Ther.* 2007;20(4): 239-250.
2. Kahan BD, Kramer WG. Median effect analysis of efficacy versus adverse effects of immunosuppressants. *Clin Pharmacol Ther*. 2001;70(1):74-81.
3. Kalajian AH, Van Meter Jr, Callen JP. Sarcoidal anemia and leukopenia treated with methotrexate and mycophenolate mofetil. *Arch Dermatol.* 2009;145(8):905-909.
4. Edge JC, Outland JD, Dempsey JR, et al. Mycophenolate mofetil as an effective corticosteroid-sparing therapy for recalcitrant dermatomyositis. *Arch Dermatol.* 2006;142(1):65-69.
5. Eaton PA, Callen JP. Mycophenolate mofetil as therapy for pyoderma gangrenosum. *Arch Dermatol.* 2009;145(7):781-785.
6. Figurski MJ, Pawinski T, Goldberg LR, et al. Pharmacokinetic monitoring of mycophenolic acid in heart transplant patients: correlation the side-effects and rejections with pharmacokinetic parameters. *Ann Transplant*. 2012;17(1):68-78.
7. Le Meur Y, Buchler M, Thierry A, et al. Individualized mycophenolate mofetil dosing based on drug exposure significantly improves patient outcomes after renal transplantation. *Am J Transplant*. 2007;7(11):2496-2503.
8. Djabarouti S, Breilh D, Duffau P, et al. Steady-state mycophenolate mofetil pharmacokinetic parameters enable prediction of systemic lupus erythematosus clinical flares: an observational cohort study. *Arthritis Res Ther*. 2010;12(6):R217.
9. Djabarouti S, Lazaro E, Breilh D, et al. Lower 12-hour trough concentrations of mycophenolic acid in patients with active systemic vasculitides taking mycophenolate mofetil. *J Rheumatol*. 2012;39(11):2222-2223.
10. CellCept (mycophenolate mofetil) prescribing information. [Medication prescribing guide]. 2015; https://http://www.gene.com/download/pdf/cellcept_prescribing.pdf.
11. Nghiem P, Pearson G, Langley RG. Tacrolimus and pimecrolimus: from clever prokaryotes to inhibiting calcineurin and treating atopic dermatitis. *J Am Acad Dermatol*. 2002;46(2):228-241.
12. Neoral (cyclosporine) prescribing information. [Medication prescribing guide]. 2015; https://http://www.pharma.us.novartis.com/sites/www.pharma.us.novartis.com/files/neoral.pdf.
13. Kovarik JM, Mueller EA, Richard F, et al. Evidence for earlier stabilization of cyclosporine pharmacokinetics in de novo renal transplant patients receiving a microemulsion formulation. *Transplantation*. 1996; 62(6):759-763.
14. Lee CS KJ. Cyclosporine. In: Wolverton S, ed. *Comprehensive Dermatologic Drug Therapy*. 2nd ed. Philadelphia: Elsevier; 2007:219-237.
15. Kumar R, Dogra S, Amarji B, et al. Efficacy of novel topical liposomal formulation of cyclosporine in mild to moderate stable plaque psoriasis: a randomized clinical trial. *JAMA Dermatol.* 2016;152(7):807-815.
16. Matis WL, Ellis CN, Griffiths CE, et al. Treatment of pyoderma gangrenosum with cyclosporine. *Arch Dermatol.* 1992;128(8):1060-1064.
17. Mendes D, Correia M, Barbedo M, et al. Behcet's disease—a contemporary review. *J Autoimmun*. 2009; 32(3-4):178-188.
18. Lebwohl M, Ellis C, Gottlieb A, et al. Cyclosporine consensus conference: with emphasis on the treatment of psoriasis. *J Am Acad Dermatol*. 1998;39(3):464-475.
19. Lee HY, Fook-Chong S, Koh HY, et al. Cyclosporine treatment for Stevens-Johnson syndrome/toxic epidermal necrolysis: retrospective analysis of a cohort treated in a specialized referral center. *J Am Acad Dermatol*. 2017;76(1):106-113.
20. Dubertret L. Retinoids, methotrexate and cyclosporine. *Curr Probl Dermatol*. 2009;38:79-94.
21. Lopez V, Molina I, Martin JM, et al. Eruptive nevi in a patient receiving cyclosporine A for psoriasis treatment. *Arch Dermatol.* 2010;146(7):802-804.
22. Woo M, Przepiorka D, Ippoliti C, et al. Toxicities of tacrolimus and cyclosporin A after allogeneic blood stem cell transplantation. *Bone Marrow Transplant*. 1997;20(12):1095-1098.
23. Hanifin JM, Paller AS, Eichenfield L, et al. Efficacy and safety of tacrolimus ointment treatment for up to 4 years in patients with atopic dermatitis. *J Am Acad Dermatol*. 2005;53(2 suppl 2):S186-S194.
24. Saripalli YV, Gadzia JE, Belsito DV. Tacrolimus ointment 0.1% in the treatment of nickel-induced allergic contact dermatitis. *J Am Acad Dermatol*. 2003;49(3):477-482.
25. Pascual JC, Fleisher AB. Tacrolimus ointment (Protopic) for atopic dermatitis. *Skin Therapy Lett.* 2004;9(9):1-5.
26. Allen A, Siegfried E, Silverman R, et al. Significant absorption of topical tacrolimus in 3 patients with Netherton syndrome. *Arch Dermatol.* 2001;137(6):747-750.
27. Breneman D, Fleischer AB Jr, Abramovits W, et al. Intermittent therapy for flare prevention and long-term disease control in stabilized atopic dermatitis: a randomized comparison of 3-times-weekly applications of tacrolimus ointment versus vehicle. *J Am Acad Dermatol*. 2008;58(6):990-999.
28. Teshima D, Ikesue H, Itoh Y, et al. Increased topical tacrolimus absorption in generalized leukemic erythroderma. *Ann Pharmacother.* 2003;37(10):1444-1447.
29. PROGRAF (tacrolimus) prescribing information. Medication prescribing guide. 2015; https://www.astellas.us/docs/prograf.pdf.
30. Mandelin J, Remitz A, Reitamo S. Effect of oral acetylsalicylic acid on burning caused by tacrolimus ointment in patients with atopic dermatitis. *Arch Dermatol.* 2010;146(10):1178-1180.

31. Hu L, Alexander C, Velez NF, et al. Severe tacrolimus-induced granulomatous rosacea recalcitrant to oral tetracyclines. *J Drugs Dermatol*. 2015;14(6):628-630.
32. Norman KG, Canter JA, Shi M, et al. Cyclosporine A suppresses keratinocyte cell death through MPTP inhibition in a model for skin cancer in organ transplant recipients. *Mitochondrion*. 2010;10(2):94-101.
33. Paller AS, Lebwohl M, Fleischer AB Jr, et al. Tacrolimus ointment is more effective than pimecrolimus cream with a similar safety profile in the treatment of atopic dermatitis: results from 3 randomized, comparative studies. *J Am Acad Dermatol*. 2005;52(5):810-822.
34. Arellano FM, Wentworth CE, Arana A, et al. Risk of lymphoma following exposure to calcineurin inhibitors and topical steroids in patients with atopic dermatitis. *J Invest Dermatol*. 2007;127(4):808-816.
35. AFINITOR (everolimus) prescribing information. Medication prescribing guide. 2016; https://http://www.pharma.us.novartis.com/sites/www.pharma.us.novartis.com/files/afinitor.pdf.
36. Magnuson B, Ekim B, Fingar DC. Regulation and function of ribosomal protein S6 kinase (S6K) within mTOR signalling networks. *Biochem J*. 2012;441(1):1-21.
37. Frigerio E, Colombo MD, Franchi C, et al. Severe psoriasis treated with a new macrolide: everolimus. *Br J Dermatol*. 2007;156(2):372-374.
38. Van Velsen SG, Haeck IM, Bruijnzeel-Koomen CA. Severe atopic dermatitis treated with everolimus. *J Dermatolog Treat*. 2009;20(6):365-367.
39. Wei KC, Lai PC. Combination of everolimus and tacrolimus: a potentially effective regimen for recalcitrant psoriasis. *Dermatol Ther*. 2015;28(1):25-27.
40. Mourah S, Porcher R, Battistella M, et al. Paradoxical simultaneous regression and progression of lesions in a phase II study of everolimus in classic Kaposi sarcoma. *Br J Dermatol*. 2015;173(5):1284-1287.
41. Jedlickova Z, Burlakova I, Bug G, et al. Therapy of sclerodermatous chronic graft-versus-host disease with mammalian target of rapamycin inhibitors. *Biol Blood Marrow Transplant*. 2011;17(5):657-663.
42. Frumholtz L, Roux J, Bagot M, et al. Treatment of generalized deep morphea with everolimus. *JAMA Dermatol*. 2016;152(10):1170-1172.
43. Dill PE, De Bernardis G, Weber P, et al. Topical everolimus for facial angiofibromas in the tuberous sclerosis complex. A first case report. *Pediatr Neurol*. 2014;51(1):109-113.
44. Feldmeyer L, Hofbauer GF, Boni T, et al. Mammalian target of rapamycin (mTOR) inhibitors slow skin carcinogenesis, but impair wound healing. *Br J Dermatol*. 2012;166(2):422-424.
45. Holdaas H, De Simone P, Zuckermann A. Everolimus and malignancy after solid organ transplantation: a clinical update. *J Transplant*. 2016;2016:4369574.
46. Campistol JM, de Fijter JW, Flechner SM, et al. mTOR inhibitor-associated dermatologic and mucosal problems. *Clin Transplant*. 2010;24(2):149-156.
47. Kurtzman DJ, Oulton J, Erickson C, et al. Everolimus-Induced Symmetrical Drug-Related Intertriginous and Flexural Exanthema (SDRIFE). *Dermatitis*. 2016;27(2):76-77.
48. Kaplan MJ, Ellis CN, Bata-Csorgo Z, et al. Systemic toxicity following administration of sirolimus (formerly rapamycin) for psoriasis: association of capillary leak syndrome with apoptosis of lesional lymphocytes. *Arch Dermatol*. 1999;135(5):553-557.

Chapter 193 :: Immunobiologics: Targeted Therapy Against Cytokines, Cytokine Receptors, and Growth Factors in Dermatology

:: Andrew Johnston, Yoshikazu Takada, & Sam T. Hwang

AT-A-GLANCE

- Immunobiologics are drugs defined as antibodies and proteins engineered from living organisms that induce or alter immune responses by interacting with specific biologic targets.
- Those used to treat cutaneous disease and cancer include recombinant cytokines and growth factors, monoclonal antibodies, and fusion proteins.
- Targeting the immune system with biologics may result in an increased risk of infections and malignancies.

Immunobiologics are compounds synthesized in living organisms that exhibit immune modulatory properties for therapeutic purposes. They consist of recombinant cytokines, growth factors, antibody-based agents, and fusion proteins. Many cytokines are known to play critical roles in the most common of dermatologic conditions, including psoriasis and atopic dermatitis, and, as of this writing, more than 10 immunobiologic agents, mostly humanized monoclonal antibodies, have been approved or will soon be approved for these conditions since the last version of this chapter. Herein, we briefly discuss cytokines as it is difficult to discuss immunobiologics that target specific cytokines without understanding the fundamental role of the cytokine in biologic or immunologic processes. Besides tumor necrosis factor (TNF)-α, interleukin (IL)-4, and IL-1, some of the first cytokines to be recognized as central to immunopathogenesis of common skin diseases, cytokines such as IL-18, IL-22, and IL-23, are now seen to play critical roles in Still disease (IL-18), epidermal psoriatic hyperproliferation (IL-22), and T-helper cell type 17 (Th17) maintenance (IL-23). We emphasize the newer cytokines and treatments that are in development and refer to excellent reviews to highlight the clinical usefulness of older agents. Lastly, we point out some of the unique side effects that are sometimes observed with the new biologic agents as these (often rare) side effects take time to recognize and to characterize in the literature. When possible, we depict the cellular events that mediate cutaneous inflammation and identify the molecular interactions affected by specific immunobiologic agents in relevant figures.

INTERLEUKIN 1

IL-1 was the first cytokine to be detected in skin[1] and is now regarded as the prototypical member of a family of 11 structurally related cytokines (Fig. 193-1). IL-1 is a fundamental cytokine for directing epidermal responses to injury and infection. Although pro-IL-1α is active as a cell membrane–associated cytokine, under conditions of cell stress, cytoplasmic pro-IL-1α also can be rapidly processed and secreted.[2,3] In contrast, pro-IL-1β is inactive and always requires the action of a protease for activity. A diverse array of stimuli, including cell stress, infection, and local danger signals, trigger the assembly of macromolecular inflammasome complexes that activate caspase-1, which then cleaves pro-IL-1β to its active form.[4] Once activated, both IL-1α and IL-1β can bind IL-1 receptor 1 (R1) on the surface on target cells, driving signal transduction (Fig. 193-2). A decoy receptor, IL-1R2, that has a shorter cytoplasmic tail devoid of signaling domains and unable to initiate signal transduction, can be expressed on the cell surface. IL-1 signaling is also controlled by the expression of the IL-1 receptor antagonist (IL-1Ra), which limits IL-1 receptor activation by competitive inhibition (Fig. 193-2). Once secreted, IL-1α and IL-1β have similar functions, acting on keratinocytes, fibroblasts, vascular endothelium, and lymphocytes. IL-1 has rapid and profound effects on keratinocytes, inducing a range of gene transcripts involved in inflammatory and antimicrobial responses. IL-1 also appears to be a key cytokine in the development of Th17 T-cell responses.[5]

A critical step in the activation of IL-1β is the assembly of inflammasome complexes, which are a combination of a molecular sensor (eg, MEFV [pyrin], NLRP1, NLRP3 [cryopyrin], NLRP12, and AIM2), combined with an adaptor molecule (apoptosis-associated speck-like protein containing a CARD [ASC]), and an effector molecule (caspase-1). These complexes transduce the detection of a variety of cellular danger signals into IL-1 cytokine activity. A number of sterile autoinflammatory conditions are associated with mutations in genes encoding inflammasome components.[6] In particular, the cryopyrin-associated periodic syndromes, a collection of diseases including familial cold autoinflammatory syndrome, Muckle-Wells syndrome, and neonatal-onset multisystem inflammatory disorder

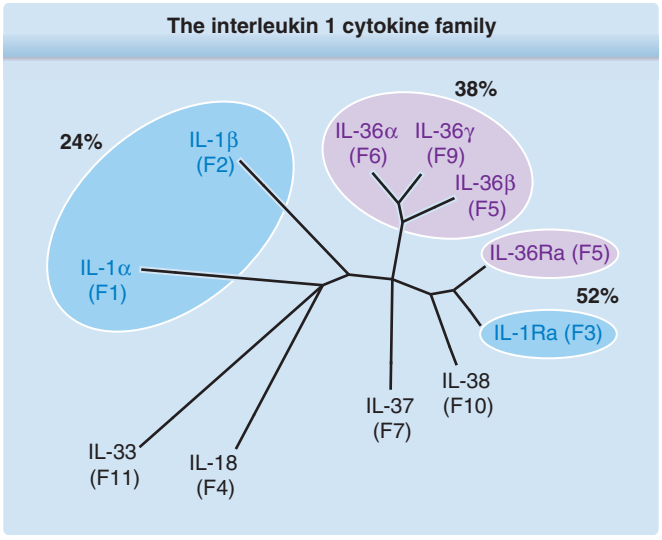

Figure 193-1 The interleukin (IL)-1 family consists of 11 cytokine ligands. A high degree of homology is shared between IL-1α/β, IL-36α/β/γ, and their respective receptor antagonists.

(also known as chronic infantile neurologic cutaneous and articular syndrome) are associated with gain-of-function mutations in *NLRP3*, encoding cryopyrin, leading to increased inflammasome activation and IL-1β processing and activity.[7,8] Pyrin (*MEFV*) mutations are the cause of familial Mediterranean fever[9] and the recently described disease, pyrin-associated autoinflammation with neutrophilic dermatosis.[10]

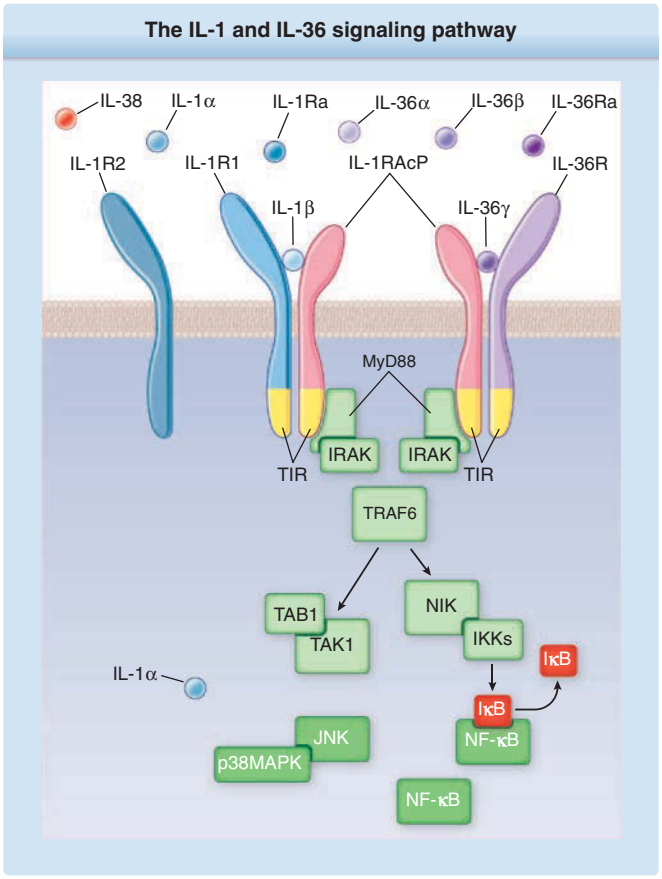

Figure 193-2 The interleukin (IL)-1 and IL-36 signaling pathways. IκB, inhibitor of nuclear factor κB; IKK, inhibitor of nuclear factor κB kinase; IRAK, interleukin-1 receptor-associated kinase; JNK, c-Jun N-terminal kinase; MyD88, myeloid differentiation 88; NF-κB, nuclear factor κB; NIK, nuclear factor κB–inducing kinase; TIR, Toll interleukin-1 receptor; TRAF, tumor necrosis factor receptor-associated factor.

Another condition arising because of elevated IL-1 activity is caused by a deficiency of the IL-1 receptor antagonist, an autosomal recessive, genetic, autoinflammatory syndrome resulting from mutations in *IL1RN*.[11] The mutations result in an abnormal protein that is not secreted, exposing the cells to unopposed IL-1 activity. This results in pustular rash, joint swelling, oral mucosal lesions, multifocal osteomyelitis, and periostitis.[11]

ANAKINRA

Anakinra was the first biologic developed to specifically target IL-1. It is a recombinant, nonglycosylated version of IL-1Ra that competitively inhibits both IL-1α and IL-1β activity at the IL-1 receptor. Anakinra has proved useful in treating a number of joint, bone, and muscle diseases.[12] Several case reports and clinical trials have demonstrated the efficacy of anakinra for treating the cryopyrin-associated periodic syndromes and deficiency of the IL-1 receptor antagonist.[11] Anakinra has a short half-life of 4 to 6 hours and therefore requires daily subcutaneous injections. IL-1β is elevated in hidradenitis suppurativa,[13] and encouraging data from small studies support the use of anakinra for hidradenitis suppurativa.[14,15] Several reports describe the use of anakinra to treat pustular psoriasis where anakinra appears to induce a rapid normalization of systemic inflammatory symptoms followed by improvement of the pustular skin eruption. However, the response in the skin tends to be incomplete with erythema and hyperkeratosis remaining in some cases.[16-18] Clinical trials to assess the efficacy of anakinra for pustular skin diseases are ongoing (NCT01794117).

RILONACEPT

Rilonacept is a dimeric fusion protein consisting of the IL-1-binding domains of the extracellular portions of human IL-1R1 and IL-1RAcP fused to the Fc portion of human immunoglobulin (Ig) G_1. Thus rilonacept functions as a soluble IL-1 decoy receptor binding IL-1α and IL-1β. Rilonacept is indicated for the treatment of cryopyrin-associated periodic syndromes, including familial cold autoinflammatory syndrome and Muckle-Wells syndrome.[19,20]

CANAKINUMAB

Canakinumab is a fully human monoclonal IgG_1 antibody that neutralizes IL-1β. Canakinumab is U.S. Food and Drug Administration (FDA) approved for use in cryopyrin-associated periodic syndromes[20] and recently approved for tumor necrosis factor receptor–associated periodic syndrome, hyperimmunoglobulin D syndrome/mevalonate kinase deficiency, and familial Mediterranean fever. Canakinumab has a been used in cases of pustular psoriasis[21]; however, the relevance of using IL-1 antagonism to tackle a disease that may be primarily driven by deviations in IL-36 signaling, particularly when *IL36RN* mutations are present, has been questioned.[22]

INTERLEUKIN-18

IL-18 is an IL-1 family member and like IL-1β, IL-18 always requires posttranslational cleavage of the pro protein for activity either by caspase-1,[23] mast cell chymase,[24] or granzyme B.[25] IL-18 is broadly expressed by epithelia, blood mononuclear cells, and keratinocytes.[26] IL-18 acts via its dimeric receptor, IL18Rα-IL18Rβ, to induce p38 mitogen-activated protein kinase and AP-1 signaling, but unlike IL-1, no nuclear factor κB (NF-κB) activation.[27] IL-18 activity is mainly regulated by the expression of soluble IL-18 binding protein (IL-18BP). IL-18 is best understood for its ability, in combination with IL-12, for the induction of Th1 T-cell responses.[28] However, since pro-IL-18 is also activated by inflammasomes, a contributing role for IL-18 in the cryopyrin-associated periodic syndromes has been suggested.[29] Increased IL-18 expression is seen in acute atopic dermatitis and psoriasis,[30] and heightened responses of keratinocytes to IL-18 have been observed in cutaneous lupus erythematosus lesions, thus roles for IL-18 in chronic or autoimmune inflammatory skin conditions have been proposed.[31] Elevated levels of free IL-18 (not bound to neutralizing IL-18BP) have been detected in the serum of patients with adult-onset Still disease,[32] thus following Phase II trials, tadekinig alfa, a recombinant human IL-18BP, was granted orphan drug and breakthrough therapy status by the FDA in 2017 for adult-onset Still disease.

INTERLEUKIN-33

IL-33 is an IL-1 family cytokine broadly expressed by endothelia and epithelia, but typically absent from leukocytes. IL-33 signals through a complex containing the receptor ST2 (IL-33R) coupled with IL-1RAcP,[33] and like IL-1, IL-33 signaling activates NF-κB, as well as c-Jun N-terminal kinase and p38 mitogen-activated protein kinase.[28] IL-33 activity is controlled by a soluble alternatively spliced form of ST2 forming a decoy receptor[34] and also a single immunoglobulin IL-1-related receptor, an IL-1 family receptor that interacts with ST2 on the cell surface to reduce responses to IL-33.[35] Unlike IL-1β and IL-18, IL-33 is not a substrate for caspase-1 activation; rather, IL-33 is inactivated by the apoptosis-associated caspases 3 and 8, as a means of reducing cell death-related inflammation.[36] Likely as a consequence of its ability to promote Th2 responses, disruptions in IL-33 or soluble ST2 expression have

been linked with allergic inflammation,[37] but there are no ongoing clinical trials assessing the use of IL-33 or ST2.

INTERLEUKIN-36

The cytokines IL-36α, IL-36β, and IL-36γ are a trio of homologous proinflammatory cytokines, and due to their sequence similarities to IL-1α and IL-1β, are members of the IL-1 superfamily (see Fig. 193-1). The 3 IL-36 cytokines are expressed primarily by epithelial tissues, including skin, with IL-36α and IL-36β expression detectable only in inflamed skin, whereas IL-36γ expression is present in normal skin and strongly upregulated in inflammatory skin conditions, including psoriasis,[38-40] hidradenitis suppurativa,[41] and pustular disease.[42] All 3 IL-36 isoforms are highly inducible by proinflammatory stimuli such as IL-1, TNF, and IL-17A,[39] and work synergistically with these cytokines.[43] The IL-36 cytokines are overexpressed in both chronic plaque and pustular psoriasis skin lesions[38,39,42,44] where they drive keratinocyte inflammatory responses,[39] synergize with other proinflammatory cytokines,[43] and promote activation of dendritic cells,[45,46] macrophages and Langerhans cells.[47] Like IL-1β and IL-18, the IL-36 cytokines require posttranslational *N*-terminal peptide cleavage for full activity,[48] with recent data indicating the activity of the neutrophil proteases elastase and cathepsin G,[42,49] as well as keratinocyte-derived cathepsin S,[50] may be critical for IL-36 activation. Once activated, IL-36 has powerful effects on epithelial cell gene expression, with the induction of a range of chemokine and proinflammatory cytokines by keratinocytes, and as such may help drive the vicious inflammatory cycle seen in a number of skin diseases. IL-36 cytokines signal via the IL-36R coupled to the IL-1RAcP (see Fig. 193-2), which appear to be widely expressed in tissues, including lung epithelium, dendritic cells, keratinocytes, fibroblasts, and some endothelia.

Analogous to IL-1β, IL-36 activity is limited by the presence of the IL-36 receptor antagonist (IL-36RA) encoded by *IL36RN*. Missense mutations in *IL36RN* are associated with a number of inflammatory skin diseases,[51] including the severe episodic skin disease generalized pustular psoriasis (GPP),[52,53] impetigo herpetiformis,[54] and acute generalized exanthematous pustulosis.[55,56] Mutations in *IL36RN* account for between 46% and 82% of cases of GPP without concomitant plaque psoriasis.[57] The disease-associated missense mutations in *IL36RN* affect the structure and function of IL-36RA, leading to unchecked activity at the IL-36 receptor. In skin, this results in keratinocyte IL-1β, IL-6, IL-8, and chemokine production, promoting neutrophil infiltration.[52,53] The identification of a role for the IL-36 cytokines in inflammatory skin diseases has prompted interest in targeting this pathway therapeutically and clinical trials of IL-36 receptor antagonists may be on the horizon in the near future.[58]

IL-37 and IL-38 data are scarce but these cytokines appear to be antiinflammatory in nature,[59,60] although their receptors, disease associations, and mechanisms of action have yet to be defined.

CYTOKINES OF THE TH17 AXIS (IL-17A, IL-22, AND IL-23)

INTERLEUKIN-17

The homodimeric cytokine IL-17A is the best-studied of the 6-member IL-17 cytokine family (IL-17A through IL-17F, and reviewed by Monin and Gaffen[61]) and is the signature cytokine of Th17 cells, a T-cell phenotype recognized both for being essential for immune defense at epithelial barriers and implicated in a number of inflammatory immune diseases,[62] including psoriasis,[63] rheumatic diseases,[64] and systemic lupus erythematosus.[65] IL-17A has wide-ranging proinflammatory effects and it induces the secretion of cytokines such as IL-6, IL-8, CCL20, and granulocyte-macrophage colony-stimulating factor by keratinocytes and fibroblasts, resulting in recruitment of T cells, macrophages, and neutrophils to the skin. Furthermore, IL-17A synergizes with other proinflammatory cytokines such as interferon (IFN)-γ,[5,66] TNF-α,[67-69] and IL-36,[43] among others. There are multiple cellular sources of IL-17A in the skin. Immunohistochemistry demonstrates that the major portion of staining for IL-17A in lesional psoriasis skin is associated with mast cells and neutrophils,[70] CD4+ and CD8+ T cells,[71] mucosal-associated invariant T cells[72] and Type 3 innate lymphoid cells.[73] Around 50% of epidermal T cells are capable of secreting IL-17A.[5] IL-17A signals via ubiquitously expressed IL-17RA–IL-17RC receptor complexes transducing signals via ACT1/tumor necrosis factor receptor-associated factor-6 and activate multiple pathways including NF-κB, extracellular signal-regulated kinase, p38, and c-Jun N-terminal kinase.[61] Mutations in a number of components of this pathway are associated with chronic mucocutaneous candidiasis[74] and variants in several genes involved in IL-17A responses are associated with increased genetic risk for psoriasis[75,76] revealing critical roles for IL-17A in psoriasis.

SECUKINUMAB

Secukinumab is a fully human anti–IL-17A $IgG_1\kappa$ monoclonal antibody that, following demonstration of efficacy in 2 Phase III trials[77] became the first anti–IL-17A biologic FDA approved for plaque psoriasis.[78] The proportion of patients attaining a 75% reduction in their disease from baseline (ie, PASI75 [Psoriasis Area and Severity Index 75] response) at week 12 of treatment was greater than 80% (ERASURE [Efficacy of Response and Safety of Two Fixed Secukinumab

Regimens in Psoriasis] study NCT01365455) and greater than 70% (FIXTURE [Full Year Investigative Examination of Secukinumab vs Etanercept Using Two Dosing Regimens to Determine Efficacy in Psoriasis] study NCT01358578) showing better efficacy than etanercept (44% of etanercept recipients achieved a PASI75 response) or placebo (<5%).[77] Secukinumab also rapidly improves both systemic and skin symptoms in GPP patients.[79-81] A recent study of secukinumab for moderate to severe palmoplantar pustulosis demonstrated a 50% improvement in disease severity and significant improvements in quality-of-life scores.[81] Secukinumab is also undergoing, as of this writing, clinical trials for hidradenitis suppurativa (NCT03099980), psoriatic arthritis (NCT02854163, NCT02745080, NCT01989468), and allergic contact dermatitis (NCT02778711).

IXEKIZUMAB

Ixekizumab is a humanized IgG_4 monoclonal antibody that neutralizes IL-17A. Data from 3 Phase III clinical trials (UNCOVER-1, UNCOVER-2, and UNCOVER-3) indicate that ixekizumab 80 mg every 2 or 4 weeks, is effective for plaque psoriasis with more than 80% of patients achieving PASI75 at 12 weeks.[82,83] These Phase III trials also indicated that ixekizumab was superior to the anti-TNF agent etanercept for plaque psoriasis[84] and had beneficial effects on scalp involvement,[85] nail involvement,[86] and itch.[87] A recent small trial also suggested that ixekizumab may be useful for treating erythrodermic psoriasis and GPP.[88] Clinical trials are ongoing for psoriatic arthritis (NCT01695239, NCT03151551, NCT02349295, NCT02584855), rheumatoid arthritis (NCT00966875), and bullous pemphigoid (NCT03099538).

BRODALUMAB

Brodalumab, is a human anti–IL-17RA monoclonal antibody targeting the IL-17 receptor A chain. Brodalumab was recently FDA approved for moderate-to-severe plaque psoriasis in adult patients who are candidates for systemic therapy or phototherapy and have failed to respond or have lost response to other systemic therapies. Three Phase III studies have been conducted and generated some very promising results for plaque psoriasis (AMAGINE-1, AMAGINE-2 and AMAGINE-3).[89,90] At week 12, 60% (brodalumab 140 mg) and 83% (brodalumab 210 mg) versus 3% (placebo) patients achieved a PASI75 (AMAGINE-1[89]). In the second 2 trials, at week 12, the PASI75 response rates were 86% (210 mg) and 67% (140 mg) versus 8% (placebo) (AMAGINE-2) and 85% (210 mg) and 69% (140 mg) versus 6% (placebo) (AMAGINE-3).[90] Moreover, brodalumab 210 mg every 2 weeks was shown to be superior to ustekinumab and placebo in treating plaque psoriasis.[90] In a smaller study, brodalumab was also shown to induce clinical improvement in 11 (92%) of 12 GPP patients.[91] There are also ongoing clinical trials examining the efficacy of brodalumab for psoriatic arthritis (NCT02029495, NCT02024646).

INTERLEUKIN-22

IL-22 is a member of the IL-10 family of cytokines (along with IL-19, IL-20, IL-24, and IL-26), members of which are related by their sequence and structural similarities as well as their shared receptor usage. Each IL-10 family cytokine uses a heterodimeric receptor with IL-22 using the ubiquitously expressed IL-10R2 in conjunction with IL-22R1, a receptor with a highly specific tissue expression pattern, being expressed only by the skin, lung, and gut epithelia, and liver and pancreas cells, but not lymphocytes.[92] IL-22 production has been detected from Th1 and Th17 T-cells, as well as Tc22 (IL-22+ CD8+) T cells, Th22 cells that produce IL-22 in the absence of IFN-γ, IL-4, or IL-17.[93] In addition, several phenotypes of innate immune cells have been reported to produce IL-22, including natural killer (NK) cells, γδ T cells, lymphoid tissue inducer cells, and Type 3 innate lymphoid cells. As such, Th17, Th22, Tc22 T cells, Type 3 innate lymphoid cells, and NK cells (reviewed in Sabat et al[92]) have all been reported to be increased in number in psoriasis plaques. IL-22 has profound effects on epidermal keratinocytes, driving hyperplasia, keratinocyte migration, and disruption of epidermal differentiation.[94] IL-22, along with the other IL-20 subfamily members is abundantly overexpressed in lesional psoriasis epidermis, as well as in the blood of psoriasis patients,[95] and is restored back to normal levels during effective treatments.[96] Consequently, IL-22 has long been suspected of playing a crucial role in the development of psoriasis skin lesions. The effects of IL-22 on skin are further heightened by powerful synergies with IL-17 and TNF, promoting IL-22 as an attractive cytokine target for inflammatory skin diseases. A number of targeted IL-22/IL-22R therapeutics have been investigated for psoriasis and atopic dermatitis, but as of this writing there are no agents approved nor in ongoing trials.

INTERLEUKIN-12

IL-12 is a heterodimeric cytokine composed of IL-12p35 and IL-12p40 subunits. IL-12 is a major inducer of IFN-γ-producing (Th1) T cells (Fig. 193-3), activates NK and CD8+ T cells, and has the ability to induce skin-homing characteristics (cutaneous lymphocyte-associated antigen expression) on memory T cells.[97] Activated antigen-presenting cells are the chief source of IL-12 and skin macrophages are the main source of IL-12 in psoriasis,[98] but the functional role of IL-12 in psoriasis is uncertain in light of the dominance of the Th17 pathway in this disease. IL-12 uses the dimeric receptor IL-12Rβ1–IL-12Rβ 2, signaling via Jak2/Tyk2 promoting the formation of STAT4 homodimers. IL-12 expression is increased in psoriasis lesions[98] and chronic, but not acute, atopic dermatitis skin.[99] Several genetic polymorphisms conferring risk or protection for

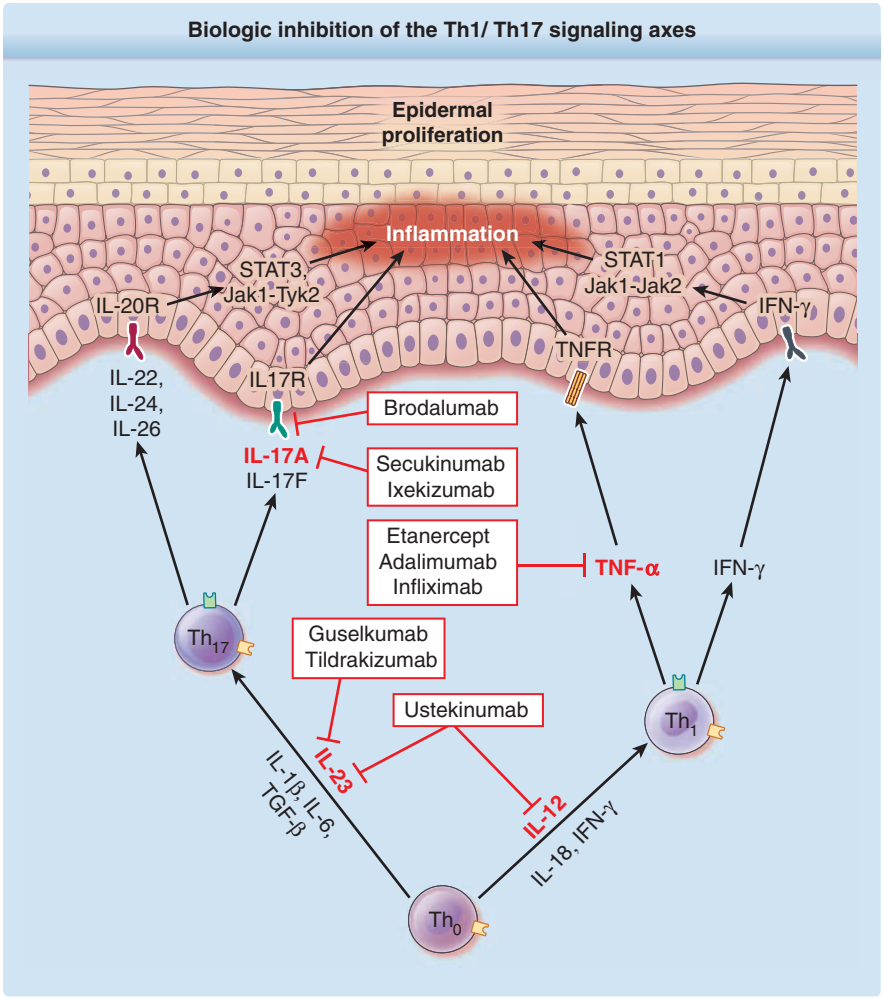

Figure 193-3 Biologic inhibition of the IL-23/IL-17 (Th1/Th17) signaling axes. IFN, interferon; IL, interleukin; STAT, signal transducer and activator of transcription; TGF, transforming growth factor; Th, T-helper; TNFR, tumor necrosis factor receptor.

psoriasis have been identified near the *IL12B* gene,[100-102] which may enhance Th1 T-cell responses in psoriasis.[103]

USTEKINUMAB

Ustekinumab is an $IgG_1\kappa$ human monoclonal antibody directed at IL-12p40 (the shared subunit of IL-12 and IL-23) that is FDA approved for use in psoriasis, psoriatic arthritis, and Crohn disease. Phase III clinical trial data for plaque psoriasis highlighted the efficacy of ustekinumab with more than 66% of patients using ustekinumab 45 mg and more than 75% of patients using ustekinumab 90 mg attaining a PASI75 by week 12.[104,105] Although ustekinumab is effective, subsequent research identified IL-23, rather than IL-12, as the more important driver of psoriasis pathogenesis, leading to a focus on specifically blocking the IL-23/IL-17 inflammatory axis, detailed below (see "Interleukin-23"). A number of case reports and a small uncontrolled study show the potential of ustekinumab for treating hidradenitis suppurativa[106] although TNF antagonists have shown greater efficacy.[107] The efficacy of ustekinumab in severe atopic dermatitis was suggested from multiple case reports, however data from recent randomized controlled trials do not support this use.[108-110]

INTERLEUKIN-23

IL-23 is a heterodimeric cytokine composed of 1 IL-23p19 and 1 IL-12p40 subunit; the IL-12p40 subunit is also used by IL-12 (IL-12p40 + IL-12p35). IL-23 is expressed by dendritic cells[111] and epidermal keratinocytes.[112] IL-23 binds the dimeric receptor IL-23R–IL-12Rβ1 (shared with IL-12) on the cell surface and signals via Jak2/Tyk2, and signal transducer and activator of transcription (STAT) 3/STAT4 heterodimers.[113] The importance of IL-23 in immune-mediated inflammatory skin diseases stems from its key functions as a master regulator of Th17 T-cell responses.[114,115] This role is highlighted by several

disease-associated polymorphisms in *IL23R* encoding one of the IL-23 receptor subunits in Crohn disease, psoriasis, and psoriatic arthritis.[100-102,116] Targeting IL-23 is attractive as it is deemed upstream of the Th17 cells implicated in multiple inflammatory diseases (see Fig. 193-3). A number of biologics designed to inhibit IL-23 are, as of this writing, showing promise in the clinic. Approaches targeting the IL-23 receptor itself are also in development.[117,118] The first biologic used to target IL-23 was the anti–IL-12p40 biologic ustekinumab (see "Ustekinumab"), which has been used with success for treating psoriasis.[104,105]

GUSELKUMAB

Specific targeting the IL-23p19 subunit with guselkumab, a fully human $IgG_1\lambda$ antibody, is showing clinical promise. Guselkumab (see Fig. 193-3) was FDA approved in 2017 for the treatment of moderate to severe plaque psoriasis after the completion of 2 Phase III clinical trials.[119,120] Both clinical trials used guselkumab 100 mg, at weeks 0 and 4 and then every 8 weeks, and found this was superior to placebo at week 16 as more than 70% of patients reached a 90% improvement in their disease (PASI90). Guselkumab was also found to be superior to the anti-TNF agent adalimumab with respect to PASI90 measurements at weeks 16 (73.3% vs 49.7%), week 24 (80.2% vs 53.0%), and week 48 (76.3% vs 47.9%).[120] Guselkumab is, as of this writing, also in Phase III trials for palmoplantar pustulosis (NCT02641730), GPP, and erythrodermic psoriasis (NCT02343744), and Phase IIa trials for psoriatic arthritis (NCT02319759), although results of a Phase II study on rheumatoid arthritis treated with guselkumab were negative.[121]

TILDRAKIZUMAB

Tildrakizumab is a humanized monoclonal $IgG_1\kappa$ antibody targeting IL-23p19 (see Fig. 193-3). Results from multicenter Phase III trials (reSURFACE 1 and reSURFACE 2) for moderate-to-severe chronic plaque psoriasis showed tildrakizumab (100 and 200 mg) effective with more than 60% of patients achieving a PASI75 compared with placebo (6%) and the anti-TNF agent etanercept (48%).[122]

RISANKIZUMAB

Risankizumab is a fully human IgG1 monoclonal antibody against IL-23p19. Results from a Phase II trial (NCT02054481) with moderate-to-severe chronic plaque psoriasis are promising, with 77% of risankizumab-treated patients (pooled 90-mg and 180-mg treated groups) attaining a PASI90 at week 12, compared with 40% of patients at PASI90 with ustekinumab (45 or 90 mg).[123] In addition, a Phase III trial examining risankizumab for GPP or erythrodermic psoriasis is, as of this writing, ongoing in Japan (NCT03022045).

TUMOR NECROSIS FACTOR-α

TNF-α is a homotrimeric cytokine expressed by a wide array of cell types, including most phenotypes of activated T cells, neutrophils, mast cells, NK cells, antigen-presenting cells, adipocytes, fibroblasts, and keratinocytes.[124] TNF triggers its effects by binding to its p55 and p75 receptors expressed primarily on the surface of keratinocytes, neutrophils, endothelial cells, and fibroblasts. TNF has strong synergistic interactions with other proinflammatory cytokines such as IL-17A.[67] TNF is regarded as a central cytokine in the development of several autoimmune diseases, including psoriatic arthritis, rheumatoid arthritis, and inflammatory bowel disease. TNF-α is a significant participant in skin inflammation, involved in the recruitment of immune cells to the cutaneous microenvironment,[125,126] inhibiting keratinocyte apoptosis, and promoting keratinocyte proliferation in psoriasis.[124,127] Following the successful targeting TNF-α in arthritis,[128] this approach was taken in psoriasis where treatments targeting TNF-α (such as etanercept, adalimumab, and infliximab) were shown to be effective. Although all 3 drugs inhibit TNF-α, they are structurally different and have unique pharmacodynamic and pharmacokinetic profiles. Furthermore, not all psoriasis patients show a significant response to the anti-TNF biologics,[129] suggesting that there may be differences in inflammatory signaling in skin lesions possibly as a consequence of heterogeneity in genetic background.[130] Some loss of efficacy of the anti-TNF biologics has been reported over time,[131] even with fully humanized antibodies, suggesting the production of antiidiotype antibodies.[132,133] Other TNF inhibitors, without dermatologic indications, also have been approved by the FDA, including golimumab (for the treatment of rheumatoid arthritis, psoriatic arthritis, and ankylosing spondylitis) and certolizumab pegol (for the treatment of Crohn disease and rheumatoid arthritis).

ETANERCEPT

Etanercept is a fusion protein consisting of the Fc region of IgG_1 fused to the soluble TNF receptor 2 (p75 TNFR) extracellular domain. Etanercept is FDA approved for rheumatoid arthritis, polyarticular juvenile idiopathic arthritis, psoriatic arthritis, ankylosing spondylitis, and plaque psoriasis. Psoriasis dosing is 50 mg twice weekly for 3 months, followed by 50 mg once weekly.

ADALIMUMAB

Adalimumab is a recombinant humanized monoclonal antibody engineered with a human variable domain

(compared with infliximab's mouse variable domain [see "Infliximab" below]). Adalimumab is FDA approved for plaque psoriasis, Crohn disease, ulcerative colitis, and uveitis. For psoriasis, the initial dose is 80 mg, followed by 40 mg every 2 weeks starting 1 week after the initial dose. There is mounting evidence of the efficacy of adalimumab for hidradenitis suppurativa,[134] and the drug is now FDA approved for this indication.

INFLIXIMAB

Infliximab is a chimeric monoclonal antibody containing a mouse variable domain. Infliximab is FDA approved for plaque psoriasis, psoriatic arthritis, Crohn disease, ulcerative colitis, ankylosing spondylitis, and rheumatoid arthritis. Psoriasis dosing is 5 mg/kg given as an IV infusion, followed by additional doses at 2 and 6 weeks after the first infusion, then every 8 weeks thereafter. Of the 3 TNF biologics in use for plaque psoriasis, infliximab has most commonly been used for pustular forms of psoriasis[135,136] and as such has become one of the recommended treatment options for severe acute GPP despite the lack of adequate clinical trials.[137] Infliximab has been reported to have a rapid effect, with systemic inflammation and skin pustules starting to recede in as little as 2 days from the first infusion. The risk of development of antidrug antibodies is higher with infliximab than with other anti-TNF agents because of the presence of the mouse variable domain.

PARADOXICAL PSORIASIS

Although TNF antagonists are effective for the treatment of various rheumatic and nonrheumatic diseases, including psoriasis, there are many case reports describing several paradoxical cutaneous adverse effects during their use. New-onset or exacerbation of cutaneous psoriasis, a lupus-like syndrome,[138] cutaneous vasculitis, and sarcoidosis have been described,[139] with increased IFN-α production[140] and disruption in the cytokine balance in the skin implicated in its pathogenesis.[141]

INFECTIONS

TNF inhibitors are associated with serious infections, including pneumonia, sepsis, tuberculosis, histoplasmosis, coccidioidomycosis, and other invasive fungal infections. Labeling also indicates that for patients who have resided in regions where histoplasmosis and coccidioidomycosis are endemic, the risks and benefits of TNF inhibitor therapy should be carefully considered. A metaanalysis of rheumatoid arthritis patients treated with infliximab or adalimumab in randomized controlled trials suggested that use of these agents result in 1 excess serious infection for every 59 patients treated for a period of 3 to 12 months.[142] Use of etanercept with anakinra is associated with an increased risk of serious infections; consequently, it is recommended that anakinra not be used concurrently with any TNF inhibitor. One prospective study reported an increased incidence of herpes zoster among rheumatoid arthritis patients treated with anti-TNF monoclonal antibodies (adalimumab, infliximab) compared to conventional disease-modifying antirheumatic drugs.[143] A metaanalysis addressing the risk of serious infections (infection requiring antibiotic treatment and/or hospitalization) among rheumatoid arthritis patients treated with adalimumab and infliximab reported a significantly increased risk for such infections compared to placebo.[142] Another metaanalysis addressing the risk of serious infections among rheumatoid arthritis patients treated with adalimumab, etanercept, or infliximab, with and without adjustment for exposure, reported no increased risk of serious infection at manufacturer-recommended doses; however, there was a twofold increased risk of serious infection among patients treated with higher doses (2 to 3 times the recommended dose).[144]

MALIGNANCY

A metaanalysis of data from 9 randomized controlled trials of 3493 rheumatoid arthritis patients treated with adalimumab or infliximab demonstrated an increased risk of solid-organ malignancies.[142] This increased risk proved to be dose dependent. Nonmelanoma skin cancers accounted for the majority of reported malignancies followed by lymphoma in this study. Infliximab was associated with aggressive hepatosplenic T-cell lymphomas in postmarketing surveillance of patients with Crohn disease treated with concomitant azathioprine or 6-mercaptopurine. Additionally, aggressive cutaneous T-cell lymphomas have been reported in patients receiving TNF inhibitors.[145] A metaanalysis of data from 18 randomized control trials, involving 8808 rheumatoid arthritis patients, reported no increased risk for lymphoma, nonmelanoma skin cancer, and melanoma among patients treated with adalimumab, etanercept, and infliximab.[144] The largest observational study as of this writing suggests a slightly higher risk of lymphoma associated with adalimumab and infliximab compared to etanercept.[146] It remains unclear whether the excess risk of lymphoma reported in observational studies is a result of the TNF inhibitor or the severity of the underlying disease (eg, rheumatoid arthritis), which itself may portend a greater risk of lymphoma. Psoriasis patients may also have an increased risk of lymphoma, independent of biologic therapy, making additional studies necessary to determine if long-term exposure to biologics impacts lymphoma risk in psoriasis patients.[147]

RECOMBINANT CYTOKINES AND GROWTH FACTORS

Cytokines, including the interleukins, are low-molecular-weight polypeptides that exhibit paracrine and/or autocrine activity in the mediation of immune responses. They may act as growth factors by inducing the proliferation of specific immune cell populations. A particular cytokine may also influence the production of other cytokines and the behavior of cellular populations that express its receptor. Since the molecular cloning of the first cytokines in the early 1980's, recombinant cytokines have proven to be invaluable for the treatment of conditions in which immunologic aberrations exist or among which some clinical benefit might be derived from augmentation or suppression of the host immune response.

RECOMBINANT INTERLEUKINS AND INTERFERONS

INTERLEUKIN-2

IL-2 is a Th1 cytokine with antitumor activity produced by CD4+ lymphocytes in response to activation by antigen-presenting cells.[148] IL-2 promotes the proliferation and maintenance of helper T-cell populations, but is also key to the proliferation and activation of regulatory T cells. In addition, it enhances both NK cell cytotoxicity and lymphokine-activated cell activity.[149] In the dermatologic setting, recombinant human IL-2 has been used for the treatment of melanoma. Although described as the first true immunotherapy,[148] its use as a single agent has been largely supplanted by checkpoint inhibitors such as anti-CTLA4 and anti-PD1/PD-L1, as well as by drugs such as vemurafenib (which is FDA-approved for melanoma) and dabrafenib, which target small molecules. IL-2 may have a role in stimulating autoreactive antitumor T cells in vitro to proliferate prior to reintroducing these cells back into patients, after which IL-2 is administered to maintain proliferation of the adoptively transferred antitumor T cells in vivo.

Several studies, particularly those that combine IL-2 with adoptive cell transfer, have reported durable clinical responses among melanoma patients, and it has FDA approval for the treatment of patients with metastatic disease.[150]

At high doses, serious adverse effects associated with infused IL-2 include fever, chills, hypotension, thrombocytopenia, vascular leak syndrome, pulmonary edema, cardiac arrhythmias, renal compromise, and exfoliative erythroderma.[151,152]

INTERFERONS

Interferons are small proteins produced by many cells in response to viral and other injury. Key components of the innate immune response, they have cytostatic and immunoregulatory properties in addition to interfering with viral replication. Three major types of IFN—α, β, and γ—are commercially approved by the FDA for treatment of a number of indications, primarily in the treatment of cancers and lymphomas. IFN-α and IFN-β bind the same receptor and are termed Type I IFN, whereas IFN-γ binds to a different receptor and is classified as a Type II IFN.[153]

IFN-α and IFN-β, Type I interferons, are produced by a variety of leukocytes as well plasmacytoid dendritic cells. Imiquimod, a potent Toll-like receptor 7 agonist that is used for the treatment of viral warts and skin cancer, stimulates the production of IFN-α by plasmacytoid dendritic cells in the skin. IFN-α is useful in the treatment of hepatitis C but has good activity in the treatment of cutaneous T-cell lymphomas (CTCLs), including mycosis fungoides and Sézary syndrome.[153] Until 2009 both recombinant IFN-α2a (Roferon) and IFN-α2b (Intron-A) were available in the United States, but as of this writing only the Intron-A is available in the United States. Similar in structure, they have similar biologic properties. Pegylated, longer-lasting formations (once a week) of IFN-α are also available.[154]

The interferons help to reverse some of the immune dysfunction that are found in CTCL, which have been reported to be increased Th2 cytokine activity (increased IL-4 and IL-13) and function (increased eosinophilia) that is triggered by the malignant, pathogenic CD4+ helper T cells. The interferons stimulate a Th1-mediated immune environment by activation of CD8+ T cells and shifting the Th2 environment toward a Th1 environment that has increased levels of IFN-γ and IL-12. IL-5, a potent stimulator of eosinophil proliferation, levels decrease in the blood of patients who are treated with Type I interferons.[155] Indeed type I interferons have been recognized as key cytokines that portend effective antitumor responses.

There has been abundant experience using interferons in CTCL.[153] Recombinant IFN is generally administered via subcutaneous or IM injection from 1 to 3 times a week at doses ranging from 1 to 3 million units. It appears to be particularly effective in Sézary syndrome where it can be highly effective in reducing pruritus, and clinical responses up to 75% have been observed in CTCL patients at various stages of disease. Combining IFN with other agents, such as bexarotene and psoralen and ultraviolet A therapy, may increase the overall efficacy of the Type I interferons. Side effects, particularly at the high dosing ranges, are common and include "flu-like" symptoms (arthralgia and myalgia), which can be managed by acetaminophen, and fatigue. Other common side effects include weight loss, sexual dysfunction, and depression. Laboratory monitoring, particularly at the initiation of therapy and with increased dosing, that includes hepatic function tests (aspartate aminotransferase/alanine aminotransferase) and complete blood cell count is commonly performed in light of abnormalities that include leukopenia. Care should be exercised in using interferons in patients with preexisting autoimmune disease because these agents may worsen or

precipitate a number of autoimmune events, including thyroid disease and connective tissue disorders. IFN-α has been reported to worsen CD8+ CTCL, an uncommon variant of CTCL, perhaps because of its ability to enhance Th1 immunity.

IFN-α has also had wide application as adjuvant therapy for high-risk melanoma in which patients may not have detectable systemic disease, but have known high-risk biomarkers such as tumor depth and regional lymph node metastases. Despite initial enthusiasm for the use of this agent, large clinical trials have not conclusively demonstrated a clinical benefit for IFN and its use in the adjuvant setting is decreasing.[156] Besides CTCL and melanoma, the ability of the Type I interferons to stimulate antiviral and antitumor immunity have resulted in a large number of non–FDA-approved uses, including viral warts, Behçet disease, Kaposi sarcoma, and nonmelanoma skin cancer.[157]

The use of IFN-γ for CTCL and other dermatologic conditions has been reported but not at the level of the Type I interferons. Approved by the FDA for chronic granulomatous disease and osteoporosis, IFN-γ1b (Actimmune) is the only form available. Mechanistically, IFN-γ is a hallmark Th1 cytokine and potently stimulates Th1 immunity against cancer cells and virally infected cells. It can enhance the ability of macrophages and dendritic cells to produce costimulatory molecules and present viral and other antigens on their cell surface. In the context of CTCL, it tips the balance of the immune environment toward a Th1 environment and possibly enhances adaptive immune responses against CTCL cells.

IFN-γ1b is administered similarly to IFN-α1a and IFN-α1b, via subcutaneous injection. Dosing is based on body surface area, and this agent is usually given 1 to 3 times a week. A limited number of studies involving small numbers of patients between 1990 and 2013 (delivered IV)[158] suggest that high-dose IFN-γ1b can have objective responses in 30% to 66% of patients, depending on the stage of the patient. In general, early-stage (IA to IIA) patients had an impressive partial response rate of approximately 90% in the 2013 study.[158] In general, the adverse effects of IFN-γ1b are similar to those of recombinant Type I interferons, although it may have less of a tendency to impair the mood or cognitive faculties of older patients.[159]

GROWTH FACTORS

THE EPIDERMAL GROWTH FACTOR RECEPTOR FAMILY

The epidermal growth factor receptor (EGFR; ErbB1; HER1 in humans), a member of the ErbB family of receptors, is a transmembrane protein that is a receptor for members of the epidermal growth factor (EGF) family of extracellular protein ligands.[160] Mutations affecting EGFR expression or activity can result in cancer.[161]

EGFR ligands are initially synthesized as membrane-bound precursors consisting of an EGF motif flanked by an N-terminal extension and a C-terminal membrane-anchoring region. The EGF-like domain, characterized by a consensus sequence composed of 6 conserved cysteines forming 3 intramolecular disulfide bonds, can be cleaved (shed) to release the mature, circulating form. Seven EGFR ligands (amphiregulin, betacellulin, heparin-binding EGF-like growth factor, transforming growth factor [TGF]-α, epiregulin, epigen, and EGF) bind to EGFR.

Ligand binding to EGFR induces the formation of receptor homodimers (EGFR/EGFR) and heterodimers with other ErbB family members (EGFR/ErbB2, EGFR/ErbB3, and EGFR/ErbB4), and the activation of the intrinsic kinase domain, resulting in phosphorylation of specific tyrosine residues within the cytoplasmic tail. Phosphorylated tyrosine residues act as binding sites for a variety of intracellular signal inducers, and stimulate multiple pathways of signal transduction including the Ras/Raf/mitogen activated protein/extracellular signal-related kinase kinase (MEK)/extracellular signal-regulated kinase, the phospholipase Cγ/protein kinase C, the phosphoinositide-3 kinase (PI3K)/AKT, STAT, and NF-κB cascades (Fig. 193-4).[162] Thus, the EGF receptor/ligand system comprises expression of EGFR-ligand precursors, their processing by metalloproteases, ligand binding to EGFR, and subsequent activation of EGFR signaling.

RELEVANCE OF EPIDERMAL GROWTH FACTOR RECEPTOR SIGNALING TO HUMAN SKIN HOMEOSTASIS AND DISEASES

EGFR signaling is essential for epidermal and hair follicle homeostasis, and dysregulation of the EGFR/ligand system and aberrant activation of EGFR signaling is involved in nonmelanoma skin cancer and chronic inflammatory disorders, such as psoriasis, atopic dermatitis, and allergic contact dermatitis.[163-165] Excessive activation of EGFR signaling by overexpression of, or mutations in, EGFR is also found in various types of human tumors, making EGFR a target for cancer therapy (see Fig. 193-4). Although humanized neutralizing antibodies and synthetic small compounds against EGFR are in clinical use today, these drugs are known to cause a variety of skin toxicities, including acneiform skin rash, skin dryness (xerosis), itching (pruritus), paronychia, nail changes, hair abnormalities, mucositis, and increased growth of the eyelashes (trichomegaly) or facial hair.[166] These side effects derive from the impairment of the multiple EGFR-dependent homeostatic functions of the skin. EGFR signaling is involved in reepithelialization of epidermal wound healing[163] and proliferation of keratinocyte stem cells in vivo.[167]

Reduced expression of EGFR or its ligand TGF-α results in impaired epidermal and hair follicle differentiation, delayed hair development, and multiple hair shaft abnormalities.[165] Reduced expression of TGF-α

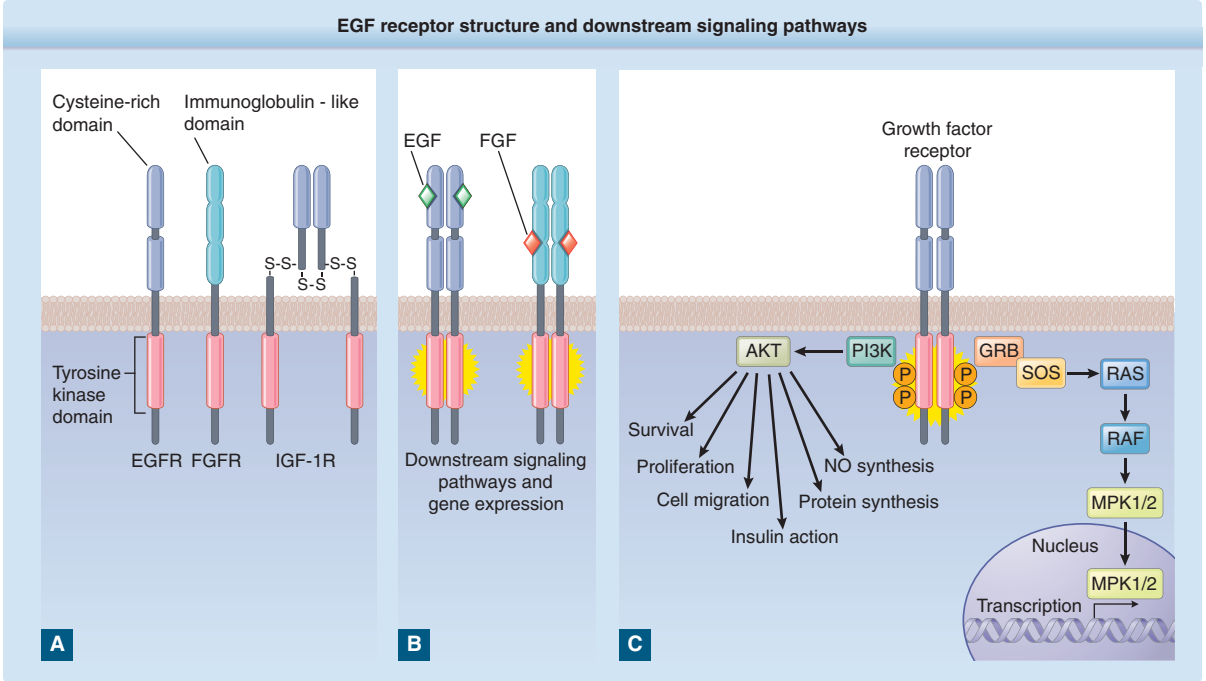

Figure 193-4 Growth factor receptor tyrosine kinases and signaling cascades. **A** and **B,** Epidermal growth factor receptor (EGFR) and fibroblast growth factor receptor (FGFR) are monomeric and upon binding to growth factors they dimerize and the kinase domains phosphorylate to each other (transphosphorylation). Insulin-like growth factor (IGF)-1R and insulin receptor are $\alpha\alpha\beta\beta$ tetrameric and it has not been fully established how growth factor binding to the ectodomain induces kinase activation. **C,** Ligand binding to receptor tyrosine kinases (RTK), including EGFR and FGFR, induces kinase activation and subsequently induces signaling pathways inside the cells through signaling cascades (eg, PI3K/AKT and MAPK pathways), leading to cell proliferation, survival, transcription and many other biologic processes. GRB, growth factor receptor bound protein; PI3K, phosphoinositide 3 kinase; MAPK, mitogen-activated protein kinase; NO, nitrous oxide; SOS, son of sevenless.

leads to impaired wound healing, wavy hair, curly whiskers, defective outer root sheath (ORS), altered hair follicle structure, and impaired early wound epithelialization.[165] Although mutations that lead to EGFR overexpression (known as upregulation) or overactivity are associated with many cancers, including squamous cell carcinoma of the lung (80% of cases) and anal cancers,[168] aberrant EGFR signaling is implicated in psoriasis, eczema, and atherosclerosis.[169]

CLINICAL USE OF EPIDERMAL GROWTH FACTOR LIGANDS AND ANTAGONISTS

Recombinant human EGF (Heberprot-P) is used to treat diabetic foot ulcers, with preliminary data showing improved wound healing.[170] It can be given by injection into the wound site,[171] or may be used topically.

The ErbB receptors are aberrantly activated in a wide range of human tumors, and as such they are excellent candidates for selective anticancer therapies. Several antibodies directed against the extracellular domain of ErbBs and tyrosine kinase inhibitors that target the kinase domain are in clinical use or at advanced developmental stages. The treatment of tumor cells with these agents affects many of the intracellular pathways that are essential for cancer development and progression. In preclinical models, treatment of tumor cells with ErbB-targeted tyrosine kinase inhibitors and antibodies rapidly downregulates PI3K/AKT, mitogen-activated protein kinase, Src, and STAT signaling, and blocks the proliferation of tumor cell lines and xenografts in nude mice.[172]

Cetuximab and panitumumab are examples of monoclonal antibody inhibitors. Other monoclonals in clinical development are zalutumumab, nimotuzumab, and matuzumab. The monoclonal antibodies block the extracellular ligand-binding domain. With the binding site blocked, signal molecules can no longer attach there and activate the tyrosine kinase.

Another method is using small molecules to inhibit the EGFR tyrosine kinase, which is on the cytoplasmic side of the receptor. Without kinase activity, EGFR is unable to activate itself, which is a prerequisite for binding of downstream adaptor proteins. Ostensibly by halting the signaling cascade in cells that rely on this pathway for growth, tumor proliferation and migration is diminished. Gefitinib, erlotinib, brigatinib, and lapatinib (mixed EGFR and ErbB2 inhibitor) are examples of small-molecule kinase inhibitors. Many patients, however, develop resistance via mutations in the *EGFR* gene.

The most common adverse effect of EGFR inhibitors, found in more than 90% of patients, is a papulopustular

rash that spreads across the face and torso. The rash's presence is correlated with the drug's antitumor effect.[173] In 10% to 15% of patients the effects can be serious and require treatment.

FIBROBLAST GROWTH FACTORS

Fibroblast growth factors (FGFs) are a family of growth factors with members involved in angiogenesis, wound healing, embryonic development, and various endocrine-signaling pathways. The FGFs are heparin-binding proteins and interactions with cell-surface-associated heparan sulfate proteoglycans are essential for FGF signal transduction. FGFs are key players in developmental processes that include mesoderm induction, anteroposterior patterning, limb development, neural induction, and neural development, and in mature tissues/systems, angiogenesis, keratinocyte organization, and wound healing processes.

The mammalian FGF receptor family has 4 members: FGFR1, FGFR2, FGFR3, and FGFR4. The FGFRs consist of 3 extracellular immunoglobulin-type domains (D1 to D3), a single-span transmembrane domain, and an intracellular tyrosine kinase domain. FGFs interact with the D2 and D3 domains, with the D3 interactions primarily responsible for ligand-binding specificity.[174,175] Alternate messenger RNA splicing gives rise to "b" and "c" variants of FGFRs 1, 2, and 3. Through this mechanism 7 different signaling FGFR subtypes can be expressed at the cell surface. Each FGFR binds to a specific subset of the FGFs. Similarly, most FGFs can bind to several different FGFR subtypes. FGF1 is sometimes referred to as the "universal ligand" as it activates all 7 different FGFRs. In contrast, FGF7 (keratinocyte growth factor) binds only to FGFR2b (keratinocyte growth factor receptor), and FGF5 binds to FGFR1. The signaling complex at the cell surface is believed to be a ternary complex formed between 2 identical FGF ligands, 2 identical FGFR subunits, and either 1 or 2 heparan sulfate chains.

FGF1 through FGF10 (called *paracrine FGF*) all bind FGFRs. FGF1 is also known as acidic, and FGF2 is also known as *basic fibroblast growth factor*. FGF1 and FGF2 promote endothelial cell proliferation and the physical organization of endothelial cells into tube-like structures. They thus promote angiogenesis, the growth of new blood vessels from the preexisting vasculature. FGF1 and FGF2 are more potent angiogenic factors than vascular endothelial growth factor or platelet-derived growth factor. FGF1 has been shown in clinical experimental studies to induce angiogenesis in the heart. Exogenous FGF2 stimulates migration and proliferation of endothelial cells in vivo, has antiapoptotic activity, and encourages mitogenesis of smooth muscle cells and fibroblasts, which induces the development of large collateral vessels with adventitia. Gene therapy using FGF1 in nonviral expression vector has been studied in diabetic limb ischemia patients in clinical trials.[176]

As well as stimulating blood vessel growth, FGFs are important players in wound healing. FGF1 and FGF2 stimulate angiogenesis and the proliferation of fibroblasts that give rise to granulation tissue, which fills up a wound space/cavity early in the wound-healing process. FGF7 (keratinocyte growth factor) and FGF10 (keratinocyte growth factor-2) stimulate the repair of injured skin and mucosal tissues by stimulating the proliferation, migration, and differentiation of epithelial cells, and they have direct chemotactic effects on tissue remodeling. Dysregulation of the FGF signaling system underlies a range of diseases, where inhibitors of FGF signaling have shown clinical efficacy. Some FGF ligands (particularly FGF2) enhance tissue repair (eg, skin burns and ulcers) in a range of clinical settings.[177]

FGF4 plays a particularly unique role in the hair cycle. This gene was initially identified as an oncogene, which confers transforming potential when transfected into mammalian cells. Targeted disruption of the homolog of this gene in mouse resulted in the phenotype of abnormally long hair, which suggested a function as an inhibitor of hair elongation. The disruption of FGF5 expression in mammals increases the length of the anagen (growth) phase of the hair cycle, resulting in a phenotype of extremely long hair in many species, including humans. Blocking FGF5 in the human scalp (by applying herbal extract that blocked FGF5) extends the hair cycle, resulting in less hair fallout and increased hair length.[178]

INSULIN-LIKE GROWTH FACTOR/INSULIN

The insulin-like growth factor (IGF)/insulin family consists of insulin, IGF-1, and IGF-2. IGF-1 is specific to IGFR Type I (IGF-1R); insulin is specific to insulin receptor (IR); and IGF-2 bind to IGF-1R; and IR. Insulin is composed of B-chain and A-chain, which are disulfide-linked. IGF-1 and IGF-2 have B-chain, A-chain, and C-chain, which connects B-chains and A-chains. B-chains and A-chains are involved in receptor binding. Insulin is synthesized as a single chain with the C-peptide (B-C-A) (proinsulin). The C-peptide is cleaved upon maturation. Insulin is released when any of several stimuli are detected. These stimuli include ingested protein and glucose in the blood produced from digested food.

IGF-1 is produced primarily by the liver as an endocrine hormone, as well as in target tissues in a paracrine/autocrine fashion. Production is stimulated by growth hormone. IGF-1 is always bound to 1 of 6 binding proteins (IGF-BP). IGF-BP3, the most abundant protein, accounts for 80% of all IGF binding. IGF-1 binds to IGF-BP3 in a 1:1 molar ratio.

IGF-2 is imprinted, with expression resulting favorably from the paternally inherited allele. The major role of IGF-2 is as a growth-promoting hormone during fetal development. IGF-2 exerts its effects by binding to the IGF-1 receptor and to the short isoform of the IR (IR-A).

Insulin is produced by the beta cells of the pancreatic islet. It regulates the metabolism of carbohydrates, fats and protein by promoting the absorption of, especially, glucose from the blood into fat, liver, and skeletal muscle cells.

IR, under normal insulin stimulation, activates 2 major intracellular signaling cascades. The PI3K/AKT pathway has a predominant metabolic effect and is activated by the IR phosphorylation of IR substrate 1/2. The Ras/Raf/MEK/extracellular signal-regulated kinase pathway has predominant mitogenic effects and is activated by the IR phosphorylation of Shc. When the metabolic signaling pathway is partially impaired (insulin resistance), a compensatory increase of insulin occurs to maintain the metabolic homeostasis. Under this condition, the mitogenic pathway, which is not affected by specific impairment, is over stimulated.

Diabetes mellitus is one of the most common and best-known metabolic disorders affecting the wound healing process. Hyperglycemia reduces collagen deposits and delays wound remodeling. Wounds of diabetic patients respond poorly to conventional treatment. This delay in wound healing has been associated with increased morbidity and mortality rates in this patient population. The use of local injection of long-acting insulin-zinc suspension accelerates wound healing without any major side effects. Intralesional insulin administration restores collagen synthesis and formation of granulation tissue to normal values when administered during the early stages of the healing process.[179]

OTHER IMMUNOBIOLOGIC AGENTS

ALEFACEPT

Alefacept is a bioengineered protein consisting of the human IgG_1 antibody Fc region fused to the first extracellular domain of human lymphocyte function-associated antigen-3 (CD58). Lymphocyte function-associated antigen-3 is a member of the immunoglobulin superfamily and is expressed on the surface of antigen presenting cells. It normally binds to CD2, which is preferentially expressed on the surface of effector/memory T cells, an interaction that plays an important role in the activation of T cells in response to antigen. Although alefacept was the first biologic agent FDA-approved for the treatment of psoriasis in 2003, monoclonal antibodies that target TNF-α or components of the IL-17 signaling pathway (see section "Cytokines of the Th17 axis (IL-17A, IL-22, and IL-23)" above) have better efficacy (50% to 90% PASI75 vs. 21% PASI75 for alefacept) and thus dominate the therapeutic agents that are used for psoriasis.

DENILEUKIN DIFTITOX

Denileukin diftitox (DAB389–IL-2) is a ligand-toxin fusion protein consisting of a fragment of diphtheria toxin fused to IL-2. DAB389–IL-2 is believed to associate with malignant cells expressing the high-affinity IL-2 receptor. Upon binding to the receptor, it is internalized within endosomes, where its adenosine diphosphate–ribosyltransferase region is cleaved and translocated into the cytoplasm. In the cytoplasm, it interrupts protein synthesis, eventually leading to apoptosis of the affected cell.

CD25 is the α chain of the IL-2 receptor, which, when bound to the β and common γ chain, forms the high-affinity IL-2 receptor. CD25 serves both as a marker of activated T cells, as well as for regulatory CD4+ T cells that express the transcription factor, FoxP3 (ie, CD4+CD25+FoxP3+ T-regs). Naturally occurring T-regs exhibit immunosuppressive properties and have been shown to play an important role in the induction of immune tolerance. Thus, elimination of T-reg cells may increase antitumor immunity, similar to the concept employed by checkpoint inhibitors such as anti–PD-1. Because of its ability to deplete CD25+ T cells, DAB389–IL-2 may contribute to antitumor immunity by eliminating T-reg cells in addition to malignant cells that express the CD25 component of the IL-2 receptor.

While clinical data do not indicate that DAB389-IL-2 is helpful in the treatment of metastatic melanoma, use of this agent resulted in a 10% complete response rate in heavily pretreated CTCL patients. Patient numbers, however, were small, but the relatively long mean duration of response (9 months) in complete responders suggests that this agent may be useful in some patients with CTCL.[180] These data led to the approval by the FDA for DAB389–IL-2 in patients with detectable CD25 expression. Isolated reports have also suggested that this agent may be useful in some patients with psoriasis although it is not approved for this indication.

DAB389–IL-2 is administered IV over at least 15 minutes. Doses at 9 µg/kg/day and 18 µg/kg/day have been used for the treatment of CTCL. Infusion reactions represent the most common adverse effect associated with DAB389–IL-2 treatment, but reversible transaminitis and vascular leak syndrome and morbilliform skin rash also represent known adverse effects.

MOGAMULIZUMAB (ANTI-CCR4)

Chemokines are small (approximately 10 kDa) chemoattractant cytokines that are released by keratinocytes, endothelial cells, leukocytes, dendritic cells, and many other cell types. As their name implies, the binding of a chemokine (3 principal structural classes with approximately 50 known chemokines) to its appropriate cell surface receptor (approximately 20 known receptors) triggers a G-protein–coupled signaling pathway that affects cellular migration as well as

multiple other complex intracellular signals via PI3K and AKT.

CCR4 is a chemokine receptor (binds to CCL22 and CCL17) that is highly expressed by skin-homing T cells (Th2 > Th1 cells) at the cell surface.[181] CCR4+ skin-homing T cells are abundant in many inflammatory skin conditions, including CTCLs such as mycosis fungoides and Sézary syndrome. With that in mind, mogamulizumab is a humanized, defucosylated monoclonal antibody that binds to CCR4 and induces antibody-dependent cellular cytotoxicity of the target cell. In the case of CTCL, that target cell is frequently a clonal CCR4+, CD4+ T-cell population with Th2 characteristics.

In Japan, mogamulizumab is already approved for the treatment of adult T-cell leukemia/lymphoma. A Phase I/II clinical trial of IV administered agent in previous treated mycosis fungoides and Sézary syndrome patients revealed an overall 37% response rate with better response rates among the Sézary syndrome patients.[182] Treatment side effects consisted of nausea (31%) and other nonspecific events that were mostly grade 1 or grade 2 in severity, suggesting that this agent has a good safety profile. Interestingly, several patients on this agent have exhibited a morbilliform skin eruption. This may be related to the high expression of CCR4 on regulatory skin T cells. Depletion of this population of cells may increase the possibility of inflammatory, and potentially antitumor, skin responses that are suppressed by skin T-regs, adding another mechanism of action for its therapeutic benefit in CTCL.[183]

RITUXIMAB

Rituximab is a humanized chimeric monoclonal antibody against CD20, a cell surface protein expressed by mature and pre-B cells. It induces the depletion of B cells in vivo. CD20 expression is lost during the differentiation of B cells to plasma cells. Aside from playing a crucial role in antibody production, B cells may also serve as antigen-presenting cells and provide costimulatory signals, which promote CD4+ T-cell expansion and effector cell function.[184]

Rituximab is FDA approved for the treatment of patients with moderate-to-severe rheumatoid arthritis and for the treatment of relapsed or chemorefractory (low-grade or follicular) CD20+ non-Hodgkin B-cell lymphomas, and transiently reduces the population of CD20+ cells in the circulation.[185] This effect is achieved by its ability to enhance antibody and complement-mediated cytotoxicity, and promote the apoptosis of malignant CD20+ cells.[186] Aside from its role in the treatment of lymphoma and rheumatoid arthritis, rituximab is increasingly used off-label for the management of other autoimmune diseases. More specifically, reports have suggested its efficacy for the treatment of paraneoplastic and refractory pemphigus, autoimmune hemolytic anemia, granulomatosis with polyangiitis (Wegener) hypocomplementemic urticarial vasculitis, systemic lupus erythematosus, cutaneous B-cell lymphoma, chronic graft-versus-host disease, and epidermolysis bullosa acquisita.

Caution, however, should be taken before initiating therapy with rituximab for off-label use. Two cases of progressive multifocal leukoencephalopathy were reported to the FDA in 2006 involving patients who received rituximab for the treatment of systemic lupus erythematosus.[85] Recent reports have also noted marked progression of Kaposi sarcoma among patients treated for autoimmune hemolytic anemia and Castleman disease.[187,188]

In a case series of patients receiving rituximab for autoimmune bullous disorders (pemphigus vulgaris, bullous pemphigoid, and mucous membrane pemphigus), severe adverse reactions were noted in 3 (43%) of 7 patients.[189] These reactions, which consisted of serious infections, enteropathy, and pulmonary embolism, were thought to be associated with concurrent high-dose adjuvant immunosuppression and underlying malignancy among the affected individuals. In a study involving 11 patients with refractory pemphigus vulgaris treated with rituximab and IV immunoglobulin, no infections or other clinically significant adverse effects were noted.[190] Additionally, no severe adverse effects were reported in case series and open-label studies among patients treated with intralesional and/or IV rituximab for cutaneous B-cell lymphoma and dermatomyositis.[191] A study addressing the safety of rituximab for the treatment of diffuse cutaneous systemic sclerosis (among 15 patients) reported mild infusion reactions (affecting 7 [46%] patients), urinary tract infection and a dental abscess affecting a single patient, and 1 case of prostate cancer at 6-month followup.[192]

INDICATIONS

Rituximab is FDA approved for the treatment of CD20+ non-Hodgkin B-cell lymphomas and moderate-to-severe rheumatoid arthritis.

INITIATING THERAPY AND MONITORING

No specific dosing regimen has been established for the off-label use of this medicine in the dermatologic setting. Rituximab is usually administered at a standard dose of 375 mg/m^2 body surface area at weekly intervals. Premedication with acetaminophen and antihistamines should be considered to decrease the risk for infusion reactions. Monitoring of blood cell counts and serum antibody levels may be pursued every 2 to 3 months while on therapy. A rapid depletion of CD20+ B cells occurs after treatment and may last from 2 to 6 months before recovery. Live vaccines should not be administered to patients prior to and during therapy.

Rituximab is a pregnancy category C medication with unknown safety during lactation.

RISKS, PRECAUTIONS, AND COMPLICATIONS

Reported adverse effects associated with rituximab therapy include fatal infusion reactions, vasculitis, hepatitis B reactivation, tumor lysis syndrome, renal toxicity, severe mucocutaneous reactions, cardiac arrhythmias/angina and bowel obstruction/perforation. Cases of progressive multifocal leukoencephalopathy have been reported among patients with lymphoid malignancies and systemic lupus erythematosus treated with rituximab.[92]

Besides efficacy in pemphigus vulgaris[190] and foliaceus,[193] rituximab is reported to be beneficial in immune thrombocytopenia[194] and antineutrophilic cytoplasmic antibody–associated vasculitis, a historically difficult-to-control disease with potentially very significant skin ulceration.[195] Regarding antineutrophilic cytoplasmic antibody–associated vasculitis, a 2014 study compared the efficacy of azathioprine with rituximab to maintain patients in remission following treatment with cyclophosphamide and glucocorticoids. Importantly, only 5% of the patients in the rituximab group (vs 29% of patients in the azathioprine group) relapsed during the followup period, suggesting that anti-CD20 therapy is more effective in keeping patients in remission. Side effects were similar in both arms.[195]

Other anti-CD20 therapies also in development as of this writing include ocrelizumab, ofatumumab, and obinutuzumab, with obinutuzumab having glycosylation properties that increase antibody-dependent cellular cytotoxicity.[196]

DUPILUMAB

While treatment of psoriasis with biologic agents has made great strides with the development of agents such as etanercept, adalimumab, and infliximab, the use of biologics to treat eczematous and atopic disorders has lagged far behind. This has changed with the development of dupilumab, a humanized monoclonal antibody that targets the IL-4Rα subunit that is shared between the IL-4 and the IL-13 receptors (Fig. 193-5). Because this target is critical for both IL-4 and IL-13 signaling, dupilumab is expected to block the binding and signaling of both these classic Th2 cytokines. Even though the efficacy of dupilumab suggests that IL-4 and IL-13 have critical roles in asthma and atopic disease, IL-4 itself may be a counterregulatory cytokine

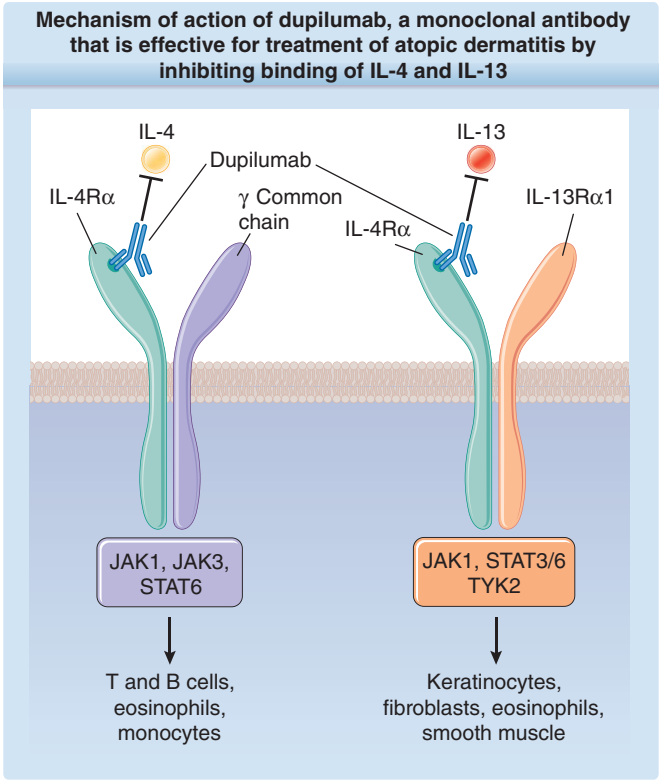

Figure 193-5 Dupilumab blocks a cell member receptor subunit that is essential for signaling via interleukin (IL)-4 as well as IL-13. The IL-4 and IL-13 receptors are 2 subunit receptors that share the common IL-4Rα subunit, which is the target for dupilumab. Downstream signaling through Janus kinase (JAK) and signal transducer and activator of transcription (STAT) proteins are attenuated in the presence of dupilumab. Note that the IL-4 and IL-13 receptors are distributed among different cell types that are likely to play roles in both skin and airway allergic inflammation and asthma. TYK, tyrosine kinase.

in other diseases, such as psoriasis, as local injection of IL-4 in human psoriatic plaques results in reduction of skin inflammation by silencing IL-23 in antigen-presenting cells.[197]

Dupilumab was initially approved for asthma, but in early 2017 the FDA approved it as the first biologic agent for the treatment of moderate-to-severe atopic dermatitis that is not adequately controlled by topical treatments. Although structural integrity via a defect in the keratinocyte protein, filaggrin, clearly does play a role in a sizeable proportion of patients with atopic dermatitis, a shift in the immune environment toward a Th2-skewed milieu has been observed in acute atopic dermatitis, although a Th1 alteration in chronic atopic dermatitis also has been reported.

Traditional treatments for atopic dermatitis include ultraviolet-B light, topical steroids, cyclosporine, and calcineurin inhibitors. In patients with severe disease, none of these agents can uniformly achieve desirable results. The largest clinical trial as of this writing enrolled 380 patients with at least moderate disease, assigning them to either dupilumab at one of several dosing schemes or placebo. Patients receiving the highest doses (300 mg) either once a week or every 2 weeks achieved a reduction in a standardized atopic dermatitis EASI score of at least 68% versus only 17% for patients on placebo. Interestingly, itching, a primary component of atopic dermatitis symptoms, was reduced very quickly in many patients on active drug and the greatest improvement in symptoms was seen in just 4 weeks of treatment. In terms of safety, patients in the dupilumab group had the same frequency of adverse events. Importantly the number of infectious adverse events, except for an increase in herpes virus infection in the dupilumab group, was similar and low in both groups. The safety profile of this agent thus is at least as good as, if not better than, systemic agents such as cyclosporine.

BRENTUXIMAB VEDOTIN

CD30 is a cell-surface activation marker that is frequently expressed by malignant B cells in Hodgkin disease as well as in T-cell neoplasms such as most anaplastic large-cell lymphoma (systemic as well as primary skin-localized), a minority of mycosis fungoides neoplasms and indolent cutaneous lymphoid proliferation such as lymphomatoid papulosis. The CD30 engagement to its ligand, CD30L, is thought to normally lead to cellular inactivation via NF-κB pathways and tumor necrosis factor receptor-associated factor-2 degradation, perhaps explaining why lymphomatoid papulosis has a waxing-and-waning characteristic. It has been proposed that CD30, however, does not function in this manner in anaplastic large-cell lymphoma, but instead causes further cell activation and proliferation.[198]

Brentuximab vedotin is a novel biologic agent in which a monoclonal antibody to CD30 is conjugated to monomethyl auristatin E, a potent disruptor of cell microtubules (Fig. 193-6).[199] Binding of this agent to the cell surface results in internalization and eventual release of the toxin intracellular, resulting in cell division arrest and cell death.[199] Brentuximab vedotin was found to be very effective in CD30+ Hodgkin disease, and it was also very effective in a small number of CD30+ anaplastic large-cell lymphoma patients.[200] Based on that positive result, it was tested in a large clinical trial of mycosis fungoides and anaplastic large-cell lymphoma patients who compared it to a physician's choice of either bexarotene or methotrexate.[201] Interestingly, there was very little correlation with CD30 expression levels (ie, some patients had only 10% detectable CD30+ cells) and efficacy, suggesting that specific depletion of other CD30+ cells (possibly a CD30+ regulatory T cell[202]) besides the tumor cells may contribute to this agent's mechanism of action.[201] Treatment with 1.8 mg/kg once every 3 weeks with brentuximab vedotin yielded impressive results, with almost 5 times as many patients who were assessed with an objective global response lasting at least 4 months compared to the other arm of standard agents. Even though 1 on-study death was attributed to this agent in the brentuximab group (none in the other group), serious grade 3 to grade 4 adverse events were fewer in the brentuximab group, and overall side effects were similar. Peripheral neuropathy, an adverse event related to the monomethyl auristatin, was frequently observed, but reversible, in most of the patients who developed it.[201] Given the poor response of patients with advanced CTCL to many chemotherapies and biologic agents, the remarkable and somewhat durable response that was observed with brentuximab vedotin make it a promising agent for patients who have failed other therapies.

TOCILIZUMAB

IL-6 is a pleiotropic, 21 kDa (in humans), single-chain, nonglycosylated protein cytokine with diverse functions in inflammation, neurologic function, and endocrine activity.[203] Depending on the cell type and the timing of exposure to IL-6, it can act as both a proinflammatory and an antiinflammatory cytokine. It is produced by T cells and macrophages (often in response to pathogen-associated molecular patterns) following infection, injury, and burns and helps to mobilize neutrophils from the bone marrow. Its functions in skin are many but help shape the inflammatory response to viral, parasitic, and particularly bacterial infections. For example, it has been reported that individuals who develop autoantibodies to IL-6 have repeated episodes of staphylococcal cellulitis and skin abscesses.[204]

The IL-6 receptor is comprised of a specific 80-kDa chain known as IL-6R that is required to bind IL-6 and a widely expressed universal signaling subunit known as gp130, or CD130, that is organized as a dimeric structure. Neutrophils also express the IL-6 receptor,

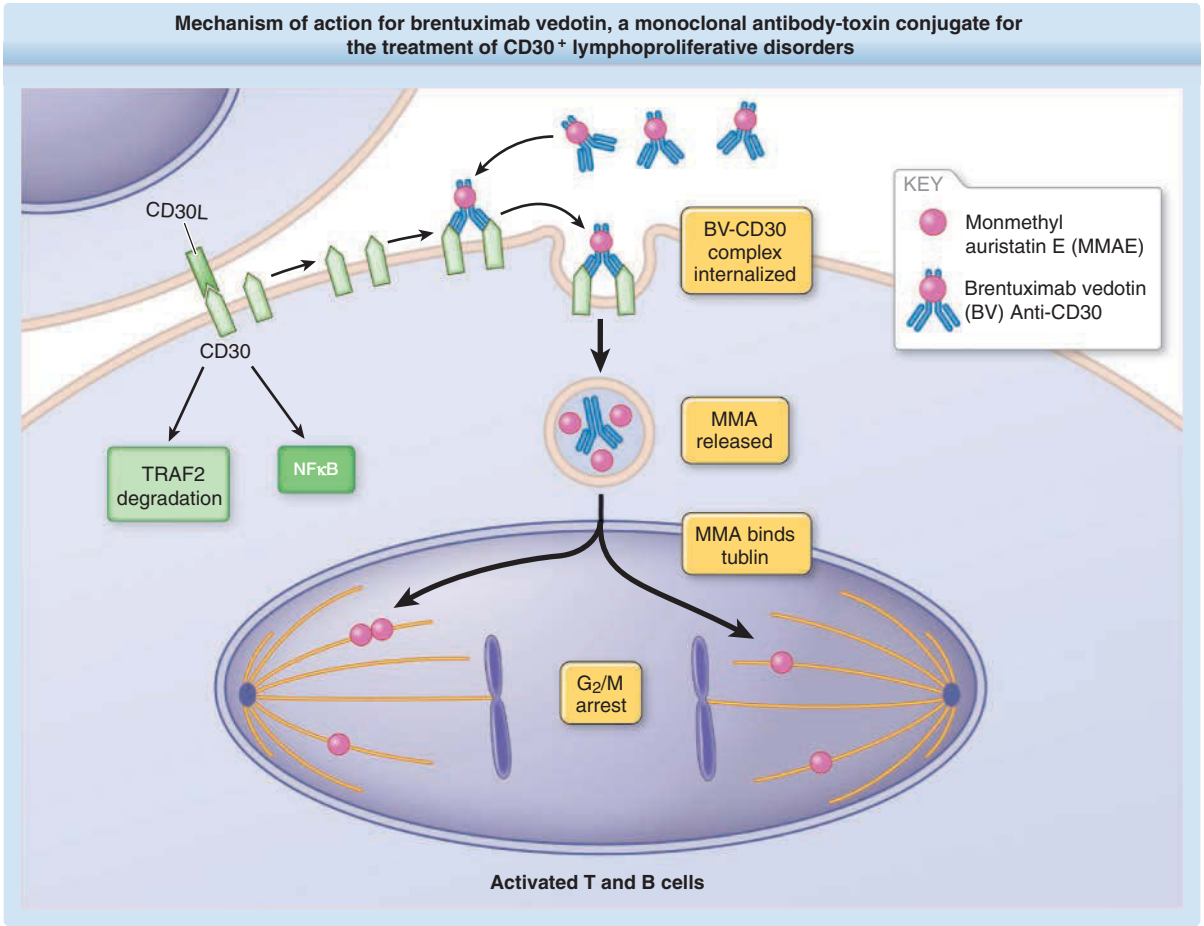

Figure 193-6 CD30 as a biologic target in cutaneous T-cell lymphoma (CTCL). Activated T and B cells express CD30. Brentuximab vedotin (BV) is conjugated to a potent microtubule disruptor, monomethyl auristatin E (MMAE). Following binding of BV to CD30, it is internalized, and eventually MMAE is released from CD30 in lysosomes. MMAE then binds tublin and causes G_2/M arrest and cell death. CD30L, CD30 ligand; NFκB, nuclear factor κB; TRAF, tumor necrosis factor receptor-associated factor.

which when engaged, stimulates production of key Th17 cytokines such as IL-17 and IL-23.

Tocilizumab, a humanized monoclonal antibody, targeted at IL-6R, has shown efficacy in rheumatoid arthritis, juvenile arthritis, and other conditions. IL-6 is undoubtedly involved in our cutaneous response to pathogens as well as in a number of inflammatory skin disease including lupus, and its pleotropic contributions to skin inflammation are complex, which can be illustrated from human psoriasis and murine models.[205] IL-6 and STAT3 polymorphisms have been found that link predisposition with the development of psoriasis as well as predict response to TNF antagonists.[205] Clinically, IL-6 serum levels correlate with skin disease activity in psoriasis,[206] and IL-6 knockout mice have reduced dermal inflammation and epidermal hyperplasia in response to IL-23.[207] IL-6 is a downstream cytokine produced by a number of cells, particularly keratinocytes, in the skin in response to Th17 cytokines such as IL-1, IL-17, and IL-36, as well as TNF-α. Together with IL-17, IL-6 likely contributes to neutrophil recruitment in psoriasis vulgaris, as well as in pustular psoriasis. Despite the evidence, however, that IL-6 is easily detectable in skin and blood of psoriasis patients, clinical trials with tocilizumab have not shown sufficient efficacy to warrant treatment of patients with psoriasis vulgaris, although it has been reported that a limited number of patients with the pustular psoriasis variant have responded to this agent.[208]

SUMMARY

Table 193-1 summarizes the immunobiologic agents discussed above.

ACKNOWLEDGMENTS

The authors wish to thank and acknowledge Drs. Stephen K. Richardson and Dr. Joel M. Gelfand for their excellent chapter on immunobiologics, cytokines, and growth factors in dermatology in the 8th edition of this text, which helped to shape this chapter for the 9th edition.

TABLE 193-1
A Summary of Immunobiologic Agents

DRUG	PROTEIN STRUCTURE	INDICATIONS	MECHANISM OF ACTION	DOSE[a]	COMMON SIDE EFFECTS & SPECIAL CONSIDERATIONS
Interleukin-1 Inhibitors					
Anakinra	Recombinant, nonglycosylated IL-1RA	▪ CAPS[b] ▪ DIRA ▪ *Pustular psoriasis*[c] ▪ *Hidradenitis suppurativa*	Competitive inhibition of IL-1α and IL-1β activity at IL-1 receptor level	*Off-label use*	▪ Injection-site reaction ▪ Upper respiratory tract infection ▪ Headache ▪ Diarrhea ▪ Flu-like symptoms ▪ Abdominal pain[1]
Rilonacept	Dimeric fusion protein	▪ CAPS ▪ FCAS ▪ MWS	Soluble IL-1 decoy receptor binding IL-1α and IL-1	*Off label use*	▪ Injection site reactions ▪ Upper respiratory tract infections[2]
Canakinumab	Human monoclonal IgG_1 antibody	▪ CAPS ▪ FCAS ▪ MWS[3] ▪ TRAPS ▪ HIDS ▪ MKD ▪ FMF ▪ Pustular psoriasis	Neutralizes IL-1β	*Off-label use*	▪ Nasopharyngitis ▪ Diarrhea ▪ Influenza ▪ Headache ▪ Nausea[3]
Interleukin-17					
Secukinumab	Human anti–IL-17A $IgG_1κ$ monoclonal antibody	▪ Plaque psoriasis ▪ Psoriatic arthritis ▪ Ankylosing spondylitis[4] ▪ Generalized pustular psoriasis ▪ palmoplantar pustulosis	Anti–IL-17A $IgG_1κ$	Plaque Psoriasis: 300 mg SQ weekly for 4 weeks and then every 4 weeks thereafter[4]	▪ Increased risk for serious infections, tuberculosis ▪ Inflammatory bowel disease ▪ Nasopharyngitis ▪ Diarrhea ▪ Upper respiratory tract infection[4]
Ixekizumab	Humanized IgG_4 monoclonal antibody	▪ Plaque psoriasis ▪ Erythrodermic psoriasis ▪ Generalized pustular psoriasis	Neutralizes IL-17A	Plaque Psoriasis: two 80-mg (total dose: 160 mg) SQ injections every 2 to 4 weeks, then 80 mg every 4 weeks[5]	▪ Increased risk for serious infections, tuberculosis ▪ Inflammatory bowel disease ▪ Injection-site reactions ▪ Nausea ▪ Upper respiratory tract infection[5]
Brodalumab	Human anti–IL-17RA monoclonal antibody	▪ Moderate to severe plaque psoriasis	Targets IL-17 receptor A chain	Plaque psoriasis: 210 mg SQ at weeks 0, 1, and 2, followed by 210 mg every 2 weeks[6]	▪ Suicidal ideation ▪ Increased risk for serious infections, tuberculosis ▪ Crohn disease ▪ Arthralgia ▪ Headache ▪ Injection-site reactions ▪ Neutropenia[6]
Interleukin-12					
Ustekinumab	$IgG_1κ$ human monoclonal antibody	▪ Psoriasis ▪ Psoriatic arthritis ▪ Crohn disease	Targets IL-12p40 subunit	Plaque psoriasis: 45 to 90 mg SQ and 4 weeks later, followed by 45 mg administered SQ every 12 weeks[7]	▪ Increased risk for serious infections, tuberculosis ▪ Malignancies ▪ Hypersensitivity reactions ▪ Reversible posterior leukoencephalopathy syndrome[7]

(*Continued*)

TABLE 193-1
A Summary of Immunobiologic Agents (*Continued*)

DRUG	PROTEIN STRUCTURE	INDICATIONS	MECHANISM OF ACTION	DOSE[a]	COMMON SIDE EFFECTS & SPECIAL CONSIDERATIONS
Interleukin-23					
Guselkumab	Human $IgG_1\lambda$ antibody	▪ Moderate to severe plaque psoriasis	Targets IL-23p19 subunit	Psoriasis: 100 mg SQ at weeks 0 and 4, then every 8 weeks	▪ Increased risk for infection, tuberculosis ▪ Upper respiratory tract infections ▪ Headache ▪ Injection-site reactions[8]
Tildrakizumab	Humanized monoclonal $IgG_1\lambda$ antibody	▪ *Moderate to severe chronic plaque psoriasis*	Targets IL-23p19 subunit	Psoriasis: 100 mg at weeks 0 and 4 and then every 12 weeks thereafter	
Risankizumab	Fully human IgG_1 monoclonal antibody	▪ *Moderate to severe plaque psoriasis* ▪ *Generalized pustular psoriasis* ▪ *Erythrodermic psoriasis*	Targets IL-23p19 subunit	Psoriasis: 90 and 180 mg[d]	
Tumor Necrosis Factor-α					
Etanercept	Fusion protein (Fc region of IgG_1 fused to soluble TNF receptor 2	▪ Rheumatoid arthritis ▪ Polyarticular juvenile idiopathic arthritis ▪ Psoriatic arthritis ▪ Ankylosing spondylitis ▪ Plaque psoriasis	Binds to TNF-α and inhibits activity	Psoriasis: 50 mg twice weekly × 3 months, followed by 50 mg once weekly	▪ New-onset/exacerbation of cutaneous psoriasis ▪ Lupus-like syndrome ▪ Cutaneous vasculitis ▪ Sarcoidosis ▪ Infections (pneumonia, sepsis, tuberculosis, histoplasmosis, coccidioidomycosis, invasive fungal infection) ▪ Solid-organ malignancies (dose-dependent risk)
Adalimumab	Recombinant humanized monoclonal antibody with a human variable domain	▪ Plaque psoriasis ▪ Crohn disease ▪ Ulcerative colitis ▪ Uveitis ▪ Hidradenitis suppurativa	Binds to TNF-α and inhibits activity	Psoriasis: 80 mg initial dose, then 40 mg every 2 weeks starting 1 week after initial dose	
Infliximab	Chimeric monoclonal antibody containing a mouse variable domain	▪ Plaque psoriasis ▪ Psoriatic arthritis ▪ Crohn disease ▪ Ulcerative colitis ▪ Ankylosing spondylitis ▪ Rheumatoid arthritis ▪ *Generalized pustular psoriasis*	Binds to TNF-α and inhibits activity	Psoriasis: 5 mg/kg IV, followed by additional doses at 2 and 6 weeks after the first infusion, then every 8 weeks thereafter	
Recombinant Interleukins and Interferons					
IL-2	Recombinant interleukin	▪ Metastatic melanoma	Antitumor activity; promotes proliferation and maintenance of helper and regulatory T cells; enhances NK cell cytotoxicity	Metastatic melanoma: 600,000 IU/kg every 8 hours for not more than 14 doses; course repeated after 9 days rest, for a maximum of 28 doses per course[9]	▪ Fever, chills, hypotension ▪ Thrombocytopenia, vascular leak syndrome ▪ Pulmonary edema ▪ Cardiac arrhythmias ▪ Renal compromise ▪ Exfoliative erythroderma

(*Continued*)

TABLE 193-1

A Summary of Immunobiologic Agents (*Continued*)

DRUG	PROTEIN STRUCTURE	INDICATIONS	MECHANISM OF ACTION	DOSE[a]	COMMON SIDE EFFECTS & SPECIAL CONSIDERATIONS
▪ IFN-α ▪ IFN-α2a ▪ IFN-α2b ▪ Pegylated IFN-α	Recombinant interferon	▪ Hepatitis C ▪ CTCL: Mycosis fungoides; Sézary syndrome ▪ *Viral warts* ▪ *Behçet disease* ▪ *Kaposi sarcoma* ▪ *Nonmelanoma skin cancer*	Stimulate Th1-mediated immune environment, activate CD8+ T cells and shift the Th2 environment toward a Th1 environment	CTCL: 1 to 3 million units SQ or IM 1 to 3 times/week	▪ Flu-like symptoms (arthralgia, myalgia) ▪ Fatigue ▪ Weight loss ▪ Sexual dysfunction ▪ Depression ▪ Leukopenia ▪ Worsening of preexisting autoimmune disease (thyroid, connective tissue disorders)
▪ IFN-γ ▪ IFN-γ1b	Recombinant interferon	▪ Chronic granulomatous disease[10] ▪ CTCL	Stimulates Th1 immunity against cancer cells and virally infected cells	*Off-label use*	▪ Exacerbation of preexisting cardiac conditions ▪ Bone marrow toxicity ▪ Hepatic toxicity ▪ Renal toxicity ▪ Flu-like symptoms[10]
Epidermal Growth Factor Ligands and Antagonists					
Cetuximab	Monoclonal antibody inhibitors	▪ Head and neck cancers ▪ Colorectal cancers[11] ▪ Tumors (especially nonmelanoma skin cancers)	Blocks the extracellular ligand-binding domain and inhibits activation of tyrosine kinase; blocks tumor growth and proliferation via these pathways	*Off-label use*	▪ Acneiform papulopustular rash (facial, trunk) ▪ Xerosis ▪ Pruritus ▪ Paronychia ▪ Nail changes ▪ Hair abnormalities ▪ Mucositis ▪ Trichomegaly (eyelashes) ▪ Facial hair
Panitumumab	Monoclonal antibody inhibitors	▪ Metastatic colorectal carcinoma[12]	Blocks the extracellular ligand-binding domain and inhibits activation of tyrosine kinase	*Off-label use*	
Other Agents					
Alefacept	Human IgG_1 antibody Fc region fused to LFA-3, CD58	▪ Psoriasis	Disrupts activation of effector/memory T cells	Psoriasis: 15 mg once weekly as IM injection for 12 weeks[13]	▪ Lymphopenia ▪ Increased risk of serious infections ▪ Pharyngitis[13]
Denileukin Diftitox	Ligand toxin fusion protein	▪ CTCL with CD25 expression ▪ *Metastatic melanoma*	Associates with malignant cells expressing IL-2	CTCL: 9 to 18 μg/kg/day IV over 15 minutes	▪ Infusion reactions ▪ Reversible transaminitis ▪ Vascular leak syndrome ▪ Morbilliform skin rash
Mogamulizumab (anti-CCR4)	Humanized, defucosylated monoclonal antibody	▪ CTCL ▪ *Adult T-cell leukemia/lymphoma*	Binds to CCR4, induced antibody-dependent cellular cytotoxicity of the target cell		▪ Nausea ▪ Morbilliform skin eruption
Rituximab	Humanized chimeric monoclonal antibody against CD20	▪ Moderate to severe rheumatoid arthritis ▪ CD20+ non-Hodgkin B-cell lymphomas ▪ *Paraneoplastic and refractory pemphigus* ▪ *Autoimmune hemolytic anemia* ▪ *Granulomatosis*	Induces depletion of B cells in vivo	*Off-label use*	▪ Infusion reactions ▪ Vasculitis ▪ Hepatitis B reactivation ▪ Tumor lysis syndrome ▪ Renal toxicity

(*Continued*)

TABLE 193-1
A Summary of Immunobiologic Agents (*Continued*)

DRUG	PROTEIN STRUCTURE	INDICATIONS	MECHANISM OF ACTION	DOSE[a]	COMMON SIDE EFFECTS & SPECIAL CONSIDERATIONS
		▪ *Wegener polyangiitis* ▪ *Hypocomplementemic urticarial vasculitis* ▪ *Systemic lupus erythematosus* ▪ *Cutaneous B-cell lymphoma* ▪ *Chronic GVHD* ▪ *EBA*			▪ Severe mucocutaneous reactions ▪ Cardiac arrhythmias/angina ▪ Bowel obstruction/perforation ▪ PML
Dupilumab	Humanized monoclonal antibody	▪ Moderate to severe atopic dermatitis ▪ Asthma	Targets IL-4Rα subunit	Moderate to severe atopic dermatitis: 300 mg once a week or every 2 weeks	▪ Increased risk for herpes virus infection
Brentuximab vedotin	Monoclonal antibody to CD30 conjugated to monomethyl auristatin E	▪ CD30+ Hodgkin disease ▪ Mycosis fungoides ▪ Anaplastic large-cell lymphoma	Binding to cell surface results in internalization and eventual release of the toxin intracellularly, leading to cell division arrest and cell death	Mycosis fungoides: 1.8 mg/kg once every 3 weeks	▪ Peripheral neuropathy (reversible) ▪ Neutropenia ▪ Infusion reactions ▪ PML[14]
Tocilizumab	Humanized monoclonal antibody	▪ Rheumatoid arthritis ▪ Juvenile arthritis ▪ *Pustular psoriasis*	IL-6 receptor binding with effects on cutaneous inflammation	*Off-label use*	▪ Increased risk for serious infections ▪ Increased liver function enzymes ▪ Nasopharyngitis ▪ Hypertension[15]

[a]Recommended doses are based on U.S. Food and Drug Administration (FDA)-approved indications.
[b]Underlining indicates FDA approved.
[c]Italicizing indicates small trials and/or case reports.
[d]Final FDA-approved dosing interval not yet available.
[1]https://www.accessdata.fda.gov/drugsatfda_docs/label/2016/103950s5175lbl.pdf
[2]https://www.accessdata.fda.gov/drugsatfda_docs/label/2008/125249lbl.pdf
[3]https://www.accessdata.fda.gov/drugsatfda_docs/label/2012/125319s047lbl.pdf
[4]https://www.accessdata.fda.gov/drugsatfda_docs/label/2016/125504s001s002lbl.pdf
[5]https://www.accessdata.fda.gov/drugsatfda_docs/label/2016/125521s000lbl.pdf
[6]https://www.accessdata.fda.gov/drugsatfda_docs/label/2017/761032lbl.pdf
[7]https://www.accessdata.fda.gov/drugsatfda_docs/label/2016/761044lbl.pdf
[8]https://www.accessdata.fda.gov/drugsatfda_docs/label/2017/761061s000lbl.pdf
[9]https://www.accessdata.fda.gov/drugsatfda_docs/label/2012/103293s5130lbl.pdf
[10]https://www.accessdata.fda.gov/drugsatfda_docs/label/2015/103836s5182lbl.pdf
[11]https://www.accessdata.fda.gov/drugsatfda_docs/label/2012/125084s0228lbl.pdf
[12]https://www.accessdata.fda.gov/drugsatfda_docs/label/2009/125147s080lbl.pdf
[13]https://www.accessdata.fda.gov/drugsatfda_docs/label/2012/125036s0144lbl.pdf
[14]https://www.accessdata.fda.gov/drugsatfda_docs/label/2011/125388s000,125399s000lbl.pdf
[15]https://www.accessdata.fda.gov/drugsatfda_docs/label/2013/125276s092lbl.pdf

CAPS, cryopyrin-associated periodic syndromes; CTCL, cutaneous T-cell lymphoma; DIRA, deficiency of interleukin-1-receptor antagonist; EBA, epidermolysis bullosa acquisita; FCAS, familial cold autoinflammatory syndrome; FMF, familial Mediterranean fever; GVHD, graft-versus-host-disease; HIDS, hyperimmunoglobulin D syndrome; IFN, interferon; Ig, immunoglobulin; IL, interleukin; IM, intramuscular; LFA, leukocyte function–associated antigen; MKD, mevalonate kinase deficiency; MWS, Muckle-Wells syndrome; NK, natural killer; PML, progressive multifocal leukoencephalopathy; SQ, subcutaneous; TNF, tumor necrosis factor; TRAPS, tumor necrosis factor receptor-associated periodic syndrome.

REFERENCES

1. Luger TA, Stadler BM, Luger BM, et al. Murine epidermal cell-derived thymocyte-activating factor resembles murine interleukin 1. *J Immunol.* 1982; 128(5):2147-2152.
2. Kondo S, Sauder DN, Kono T, et al. Differential modulation of interleukin-1 alpha (IL-1 alpha) and interleukin-1 beta (IL-1 beta) in human epidermal keratinocytes by UVB. *Exp Dermatol.* 1994;3(1): 29-39.
3. Afonina IS, Tynan GA, Logue SE, et al. Granzyme B-dependent proteolysis acts as a switch to enhance the proinflammatory activity of IL-1α. *Mol Cell.* 2011;44(2):265-278.
4. Franchi L, Eigenbrod T, Muñoz-Planillo R, et al. The inflammasome: a caspase-1-activation platform that regulates immune responses and disease pathogenesis. *Nat Immunol.* 2009;10(3):241-247.
5. Kryczek I, Bruce AT, Gudjonsson JE, et al. Induction of IL-17+ T cell trafficking and development by IFN-gamma: mechanism and pathological relevance in psoriasis. *J Immunol.* 2008;181(7):4733-4741.
6. Broderick L, De Nardo D, Franklin BS, et al. The inflammasomes and autoinflammatory syndromes. *Annu Rev Pathol.* 2015;10:395-424.
7. Aksentijevich I, Nowak M, Mallah M, et al. De novo CIAS1 mutations, cytokine activation, and evidence for genetic heterogeneity in patients with neonatal-onset multisystem inflammatory disease (NOMID): a new member of the expanding family of pyrin-associated autoinflammatory diseases. *Arthritis Rheum.* 2002;46(12):3340-3348.
8. Hoffman HM, Mueller JL, Broide DH, et al. Mutation of a new gene encoding a putative pyrin-like protein causes familial cold autoinflammatory syndrome and Muckle-Wells syndrome. *Nat Genet.* 2001;29(3):301-305.
9. Ancient missense mutations in a new member of the RoRet gene family are likely to cause familial Mediterranean fever. The International FMF Consortium. *Cell.* 1997;90(4):797-807.
10. Masters SL, Lagou V, Jéru I, et al. Familial autoinflammation with neutrophilic dermatosis reveals a regulatory mechanism of pyrin activation. *Sci Transl Med.* 2016;8(332):332ra45.
11. Aksentijevich I, Masters SL, Ferguson PJ, et al. An autoinflammatory disease with deficiency of the interleukin-1-receptor antagonist. *N Engl J Med.* 2009;360(23):2426-2437.
12. Dinarello CA, van der Meer JW. Treating inflammation by blocking interleukin-1 in humans. *Semin Immunol.* 2013;25(6):469-484.
13. van der Zee HH, de Ruiter L, van den Broecke DG, et al. Elevated levels of tumour necrosis factor (TNF)-α, interleukin (IL)-1β and IL-10 in hidradenitis suppurativa skin: a rationale for targeting TNF-α and IL-1β. *Br J Dermatol.* 2011;164(6):1292-1298.
14. Leslie KS, Tripathi SV, Nguyen TV, et al. An open-label study of anakinra for the treatment of moderate to severe hidradenitis suppurativa. *J Am Acad Dermatol.* 2014;70(2):243-251.
15. Zarchi K, Dufour DN, Jemec GB. Successful treatment of severe hidradenitis suppurativa with anakinra. *JAMA Dermatol.* 2013;149(10):1192-1194.
16. Rossi-Semerano L, Piram M, Chiaverini C, et al. First clinical description of an infant with interleukin-36-receptor antagonist deficiency successfully treated with anakinra. *Pediatrics.* 2013;132(4): e1043-e1047.
17. Huffmeier U, Wätzold M, Mohr J, et al. Successful therapy with anakinra in a patient with generalized pustular psoriasis carrying IL36RN mutations. *Br J Dermatol.* 2014;170(1):202-204.
18. Viguier M, Guigue P, Pagès C, et al. Successful treatment of generalized pustular psoriasis with the interleukin-1-receptor antagonist anakinra: lack of correlation with IL1RN mutations. *Ann Intern Med.* 2010;153(1):66-67.
19. McDermott MF. Rilonacept in the treatment of chronic inflammatory disorders. *Drugs Today (Barc).* 2009;45(6):423-430.
20. Kone-Paut I, Galeotti C. Current treatment recommendations and considerations for cryopyrin-associated periodic syndrome. *Expert Rev Clin Immunol.* 2015; 11(10):1083-1092.
21. Skendros P, Papagoras C, Lefaki I, et al. Successful response in a case of severe pustular psoriasis after interleukin-1β inhibition. *Br J Dermatol.* 2017; 176(1):212-215.
22. Tauber M, Viguier M, Le Gall C, et al. Is it relevant to use an interleukin-1-inhibiting strategy for the treatment of patients with deficiency of interleukin-36 receptor antagonist? *Br J Dermatol.* 2014;170(5): 1198-1199.
23. Dinarello CA, Novick D, Kim S, et al. Interleukin-18 and IL-18 binding protein. *Front Immunol.* 2013;4:289.
24. Omoto Y, Tokime K, Yamanaka K, et al. Human mast cell chymase cleaves pro-IL-18 and generates a novel and biologically active IL-18 fragment. *J Immunol.* 2006;177(12):8315-8319.
25. Omoto Y, Yamanaka K, Tokime K, et al. Granzyme B is a novel interleukin-18 converting enzyme. *J Dermatol Sci.* 2010;59(2):129-135.
26. Naik SM, Cannon G, Burbach GJ, et al. Human keratinocytes constitutively express interleukin-18 and secrete biologically active interleukin-18 after treatment with pro-inflammatory mediators and dinitrochlorobenzene. *J Invest Dermatol.* 1999;113(5):766-772.
27. Lee JK, Kim SH, Lewis EC, et al. Differences in signaling pathways by IL-1beta and IL-18. *Proc Natl Acad Sci U S A.* 2004;101(23):8815-8820.
28. Smith DE. The biological paths of IL-1 family members IL-18 and IL-33. *J Leukoc Biol.* 2011;89(3): 383-392.
29. Brydges SD, Broderick L, McGeough MD, et al. Divergence of IL-1, IL-18, and cell death in NLRP3 inflammasomopathies. *J Clin Invest.* 2013;123(11): 4695-4705.
30. Ohta Y, Hamada Y, Katsuoka K. Expression of IL-18 in psoriasis. *Arch Dermatol Res.* 2001;293(7):334-342.
31. Wittmann M, Macdonald A, Renne J. IL-18 and skin inflammation. *Autoimmun Rev.* 2009;9(1):45-48.
32. Girard C, Rech J, Brown M, et al. Elevated serum levels of free interleukin-18 in adult-onset Still's disease. *Rheumatology (Oxford).* 2016;55(12):2237-2247.
33. Schmitz J, Owyang A, Oldham E, et al. IL-33, an interleukin-1-like cytokine that signals via the IL-1 receptor-related protein ST2 and induces T helper type 2-associated cytokines. *Immunity.* 2005;23(5): 479-490.
34. Hayakawa H, Hayakawa M, Kume A, et al. Soluble ST2 blocks interleukin-33 signaling in allergic airway inflammation. *J Biol Chem.* 2007;282(36):26369-26380.

35. Bulek K, Swaidani S, Qin J, et al. The essential role of single Ig IL-1 receptor-related molecule/Toll IL-1R8 in regulation of Th2 immune response. *J Immunol.* 2009;182(5):2601-2609.
36. Luthi AU, Cullen SP, McNeela EA, et al. Suppression of interleukin-33 bioactivity through proteolysis by apoptotic caspases. *Immunity.* 2009;31(1):84-98.
37. Smith DE. IL-33: a tissue derived cytokine pathway involved in allergic inflammation and asthma. *Clin Exp Allergy.* 2010;40(2):200-208.
38. Debets R, Timans JC, Homey B, et al. Two novel IL-1 family members, IL-1 delta and IL-1 epsilon, function as an antagonist and agonist of NF-kappa B activation through the orphan IL-1 receptor-related protein 2. *J Immunol.* 2001;167(3):1440-1446.
39. Johnston A, Xing X, Guzman AM, et al. IL-1F5, -F6, -F8, and -F9: a novel IL-1 family signaling system that is active in psoriasis and promotes keratinocyte antimicrobial peptide expression. *J Immunol.* 2011;186(4):2613-2622.
40. D'Erme AM, Wilsmann-Theis D, Wagenpfeil J, et al. IL-36γ (IL-1F9) is a biomarker for psoriasis skin lesions. *J Invest Dermatol.* 2015;135(4):1025-1032.
41. Thomi R, Kakeda M, Yawalkar N, et al. Increased expression of the interleukin-36 cytokines in lesions of hidradenitis suppurativa. *J Eur Acad Dermatol Venereol.* 2017;31(12):2091-2096.
42. Johnston A, Xing X, Wolterink L, et al. IL-1 and IL-36 are dominant cytokines in generalized pustular psoriasis. *J Allergy Clin Immunol.* 2017;140(1):109-120.
43. Carrier Y, Ma HL, Ramon HE, et al. Inter-regulation of Th17 cytokines and the IL-36 cytokines in vitro and in vivo: implications in psoriasis pathogenesis. *J Invest Dermatol.* 2011;131(12):2428-2437.
44. Blumberg H, Dinh H, Trueblood ES, et al. Opposing activities of two novel members of the IL-1 ligand family regulate skin inflammation. *J Exp Med.* 2007;204(11):2603-2614.
45. Foster AM, Baliwag J, Chen CS, et al. IL-36 promotes myeloid cell infiltration, activation, and inflammatory activity in skin. *J Immunol.* 2014;192(12):6053-6061.
46. Mutamba S, Allison A, Mahida Y, et al. Expression of IL-1Rrp2 by human myelomonocytic cells is unique to DCs and facilitates DC maturation by IL-1F8 and IL-1F9. *Eur J Immunol.* 2012;42(3):607-617.
47. Dietrich D, Martin P, Flacher V, et al. Interleukin-36 potently stimulates human M2 macrophages, Langerhans cells and keratinocytes to produce pro-inflammatory cytokines. *Cytokine.* 2016;84:88-98.
48. Towne JE, Renshaw BR, Douangpanya J, et al. Interleukin-36 (IL-36) ligands require processing for full agonist (IL-36α, IL-36β and IL-36γ) or antagonist (IL-36Ra) activity. *J Biol Chem.* 2011;286(49):42594-42602.
49. Henry CM, Sullivan GP, Clancy DM, et al. Neutrophil-derived proteases escalate inflammation through activation of IL-36 family cytokines. *Cell Rep.* 2016;14(4):708-722.
50. Ainscough JS, Macleod T, McGonagle D, et al. Cathepsin S is the major activator of the psoriasis-associated proinflammatory cytokine IL-36γ. *Proc Natl Acad Sci U S A.* 2017;114(13):E2748-E2757.
51. Setta-Kaffetzi N, Navarini AA, Patel VM, et al. Rare pathogenic variants in IL36RN underlie a spectrum of psoriasis-associated pustular phenotypes. *J Invest Dermatol.* 2013;133(5):1366-1369.
52. Marrakchi S, Guigue P, Renshaw BR, et al. Interleukin-36-receptor antagonist deficiency and generalized pustular psoriasis. *N Engl J Med.* 2011;365(7):620-628.
53. Onoufriadis A, Simpson MA, Pink AE, et al. Mutations in IL36RN/IL1F5 are associated with the severe episodic inflammatory skin disease known as generalized pustular psoriasis. *Am J Hum Genet.* 2011;89(3):432-437.
54. Sugiura K, Oiso N, Iinuma S, et al. IL36RN mutations underlie impetigo herpetiformis. *J Invest Dermatol.* 2014;134(9):2472-2474.
55. Navarini AA, Valeyrie-Allanore L, Setta-Kaffetzi N, et al. Rare variations in IL36RN in severe adverse drug reactions manifesting as acute generalized exanthematous pustulosis. *J Invest Dermatol.* 2013;133(7):1904-1907.
56. Nakai N, Sugiura K, Akiyama M, et al. Acute generalized exanthematous pustulosis caused by dihydrocodeine phosphate in a patient with psoriasis vulgaris and a heterozygous IL36RN mutation. *JAMA Dermatol.* 2015;151(3):311-315.
57. Capon F. IL36RN mutations in generalized pustular psoriasis: just the tip of the iceberg? *J Invest Dermatol.* 2013;133(11):2503-2504.
58. Ganesan R, Raymond EL, Mennerich D, et al. Generation and functional characterization of anti-human and anti-mouse IL-36R antagonist monoclonal antibodies. *MAbs.* 2017;9(7):1143-1154.
59. Dinarello CA, Nold-Petry C, Nold M, et al. Suppression of innate inflammation and immunity by interleukin-37. *Eur J Immunol.* 2016;46(5):1067-1081.
60. van de Veerdonk FL, Stoeckman AK, Wu G, et al. IL-38 binds to the IL-36 receptor and has biological effects on immune cells similar to IL-36 receptor antagonist. *Proc Natl Acad Sci U S A.* 2012;109(8):3001-3005.
61. Monin L, Gaffen SL. Interleukin 17 family cytokines: signaling mechanisms, biological activities, and therapeutic implications. *Cold Spring Harb Perspect Biol.* 2018;10(4).
62. Beringer A, Noack M, Miossec P. IL-17 in chronic inflammation: from discovery to targeting. *Trends Mol Med.* 2016;22(3):230-241.
63. Lowes MA, Suarez-Farinas M, Krueger JG. Immunology of psoriasis. *Annu Rev Immunol.* 2014;32:227-255.
64. Lubberts E. The IL-23-IL-17 axis in inflammatory arthritis. *Nat Rev Rheumatol.* 2015;11(7):415-429.
65. Li D, Guo B, Wu H, et al. Interleukin-17 in systemic lupus erythematosus: a comprehensive review. *Autoimmunity.* 2015;48(6):353-361.
66. Teunissen MB, Koomen CW, de Waal Malefyt R, et al. Interleukin-17 and interferon-gamma synergize in the enhancement of proinflammatory cytokine production by human keratinocytes. *J Invest Dermatol.* 1998;111(4):645-649.
67. Chiricozzi A, Guttman-Yassky E, Suárez-Fariñas M, et al. Integrative responses to IL-17 and TNF-α in human keratinocytes account for key inflammatory pathogenic circuits in psoriasis. *J Invest Dermatol.* 2011;131(3):677-687.
68. Wang CQF, Akalu YT, Suarez-Farinas M, et al. IL-17 and TNF synergistically modulate cytokine expression while suppressing melanogenesis: potential relevance to psoriasis. *J Invest Dermatol.* 2013;133(12):2741-2752.
69. Johnston A, Guzman AM, Swindell WR, et al. Early tissue responses in psoriasis to the antitumour necrosis factor-α biologic etanercept suggest reduced interleukin-17 receptor expression and signalling. *Br J Dermatol.* 2014;171(1):97-107.

70. Lin AM, Rubin CJ, Khandpur R, et al. Mast cells and neutrophils release IL-17 through extracellular trap formation in psoriasis. *J Immunol.* 2011; 187(1):490-500.
71. Res PC, Piskin G, de Boer OJ, et al. Overrepresentation of IL-17A and IL-22 producing CD8 T cells in lesional skin suggests their involvement in the pathogenesis of psoriasis. *PLoS One.* 2010;5(11):e14108.
72. Teunissen MBM, Yeremenko NG, Baeten DLP, et al. The IL-17A-producing CD8+ T-cell population in psoriatic lesional skin comprises mucosa-associated invariant T cells and conventional T cells. *J Invest Dermatol.* 2014;134(12):2898-2907.
73. Villanova F, Flutter B, Tosi I, et al. Characterization of innate lymphoid cells in human skin and blood demonstrates increase of NKp44+ ILC3 in psoriasis. *J Invest Dermatol.* 2014;134(4):984-991.
74. Okada S, Puel A, Casanova JL, et al. Chronic mucocutaneous candidiasis disease associated with inborn errors of IL-17 immunity. *Clin Transl Immunology.* 2016;5(12):e114.
75. Elder JT, Bruce AT, Gudjonsson JE, et al. Molecular dissection of psoriasis: integrating genetics and biology. *J Invest Dermatol.* 2010;130(5):1213-1226.
76. Das S, Stuart PE, Ding J, et al. Fine mapping of eight psoriasis susceptibility loci. *Eur J Hum Genet.* 2015;23(6):844-853.
77. Langley RG, Elewski BE, Lebwohl M, et al. Secukinumab in plaque psoriasis—results of two phase 3 trials. *N Engl J Med.* 2014;371(4):326-338.
78. Armstrong AW, Papp K, Kircik L. Secukinumab: review of clinical evidence from the pivotal studies ERASURE, FIXTURE, and CLEAR. *J Clin Aesthet Dermatol.* 2016;9(6)(suppl 1):S7-S12.
79. Bohner A, Roenneberg S, Eyerich K, et al. Acute generalized pustular psoriasis treated with the IL-17A antibody secukinumab. *JAMA Dermatol.* 2016;152(4):482-484.
80. Imafuku S, Honma M, Okubo Y, et al. Efficacy and safety of secukinumab in patients with generalized pustular psoriasis: a 52-week analysis from phase III open-label multicenter Japanese study. *J Dermatol.* 2016;43(9):1011-1017.
81. Gottlieb A, Sullivan J, van Doorn M, et al. Secukinumab shows significant efficacy in palmoplantar psoriasis: results from GESTURE, a randomized controlled trial. *J Am Acad Dermatol.* 2017;76(1):70-80.
82. Gordon KB, Blauvelt A, Papp KA, et al. Phase 3 trials of ixekizumab in moderate-to-severe plaque psoriasis. *N Engl J Med.* 2016;375(4):345-356.
83. Farahnik B, Beroukhim K, Zhu TH, et al. Ixekizumab for the treatment of psoriasis: a review of phase III trials. *Dermatol Ther (Heidelb).* 2016;6(1):25-37.
84. Griffiths CE, Reich K, Lebwohl M, et al. Comparison of ixekizumab with etanercept or placebo in moderate-to-severe psoriasis (UNCOVER-2 and UNCOVER-3): results from two phase 3 randomised trials. *Lancet.* 2015;386(9993):541-551.
85. Reich K, Leonardi C, Lebwohl M, et al. Sustained response with ixekizumab treatment of moderate-to-severe psoriasis with scalp involvement: results from three phase 3 trials (UNCOVER-1, UNCOVER-2, UNCOVER-3). *J Dermatolog Treat.* 2017;28(4):282-287.
86. van de Kerkhof P, Guenther L, Gottlieb AB, et al. Ixekizumab treatment improves fingernail psoriasis in patients with moderate-to-severe psoriasis: results from the randomized, controlled and open-label phases of UNCOVER-3. *J Eur Acad Dermatol Venereol.* 2017;31(3):477-482.
87. Kimball AB, Luger T, Gottlieb A, et al. Impact of ixekizumab on psoriasis itch severity and other psoriasis symptoms: results from 3 phase III psoriasis clinical trials. *J Am Acad Dermatol.* 2016;75(6): 1156-1161.
88. Saeki H, Nakagawa H, Ishii T, et al. Efficacy and safety of open-label ixekizumab treatment in Japanese patients with moderate-to-severe plaque psoriasis, erythrodermic psoriasis and generalized pustular psoriasis. *J Eur Acad Dermatol Venereol.* 2015;29(6):1148-1155.
89. Papp KA, Reich K, Paul C, et al. A prospective phase III, randomized, double-blind, placebo-controlled study of brodalumab in patients with moderate-to-severe plaque psoriasis. *Br J Dermatol.* 2016;175(2):273-286.
90. Lebwohl M, Strober B, Menter A, et al. Phase 3 studies comparing brodalumab with ustekinumab in psoriasis. *N Engl J Med.* 2015;373(14):1318-1328.
91. Yamasaki K, Nakagawa H, Kubo Y, et al. Efficacy and safety of brodalumab in patients with generalized pustular psoriasis and psoriatic erythroderma: results from a 52-week, open-label study. *Br J Dermatol.* 2017;176(3):741-751.
92. Sabat R, Ouyang W, Wolk K. Therapeutic opportunities of the IL-22–IL-22R1 system. *Nat Rev Drug Discov.* 2014;13(1):21-38.
93. Duhen T, Geiger R, Jarrossay D, et al. Production of interleukin 22 but not interleukin 17 by a subset of human skin-homing memory T cells. *Nat Immunol.* 2009;10(8):857-863.
94. Boniface K, Bernard FX, Garcia M, et al. IL-22 inhibits epidermal differentiation and induces proinflammatory gene expression and migration of human keratinocytes. *J Immunol.* 2005;174(6):3695-3702.
95. Boniface K, Guignouard E, Pedretti N, et al. A role for T cell-derived interleukin 22 in psoriatic skin inflammation. *Clin Exp Immunol.* 2007;150(3):407-415.
96. Wolk K, Sabat R. Interleukin-22: a novel T- and NK-cell derived cytokine that regulates the biology of tissue cells. *Cytokine Growth Factor Rev.* 2006;17(5):367-380.
97. Sigmundsdóttir H, Johnston A, Gudjónsson JE, et al. Differential effects of interleukin 12 and interleukin 10 on superantigen-induced expression of cutaneous lymphocyte-associated antigen (CLA) and alphaEbeta7 integrin (CD103) by CD8+ T cells. *Clin Immunol.* 2004;111(1):119-125.
98. Yawalkar N, Karlen S, Hunger R, et al. Expression of interleukin-12 is increased in psoriatic skin. *J Invest Dermatol.* 1998;111(6):1053-1057.
99. Hamid Q, Naseer T, Minshall EM, et al. In vivo expression of IL-12 and IL-13 in atopic dermatitis. *J Allergy Clin Immunol.* 1996;98(1):225-231.
100. Capon F, Di Meglio P, Szaub J, et al. Sequence variants in the genes for the interleukin-23 receptor (IL23R) and its ligand (IL12B) confer protection against psoriasis. *Hum Genet.* 2007;122(2):201-206.
101. Cargill M, Schrodi SJ, Chang M, et al. A large-scale genetic association study confirms IL12B and leads to the identification of IL23R as psoriasis-risk genes. *Am J Hum Genet.* 2007;80(2):273-290.
102. Nair RP, Ruether A, Stuart PE, et al. Polymorphisms of the IL12B and IL23R genes are associated with psoriasis. *J Invest Dermatol.* 2008;128(7):1653-1661.
103. Johnston A, Xing X, Swindell WR, et al. Susceptibility-associated genetic variation at IL12B enhances

Th1 polarization in psoriasis. *Hum Mol Genet.* 2013;22(9):1807-1815.
104. Papp KA, Langley RG, Lebwohl M, et al. Efficacy and safety of ustekinumab, a human interleukin-12/23 monoclonal antibody, in patients with psoriasis:52-week results from a randomised, double-blind, placebo-controlled trial (PHOENIX 2). *Lancet.* 2008;371(9625):1675-1684.
105. Leonardi CL, Kimball AB, Papp KA, et al. Efficacy and safety of ustekinumab, a human interleukin-12/23 monoclonal antibody, in patients with psoriasis:76-week results from a randomised, double-blind, placebo-controlled trial (PHOENIX 1). *Lancet.* 2008;371(9625):1665-1674.
106. Blok JL, Li K, Brodmerkel C, et al. Ustekinumab in hidradenitis suppurativa: clinical results and a search for potential biomarkers in serum. *Br J Dermatol.* 2016;174(4):839-846.
107. Eisen DB. Ustekinumab, another biologic with potential to help patients with hidradenitis suppurativa? *Br J Dermatol.* 2016;174(4):718-719.
108. Weiss D, Schaschinger M, Ristl R, et al. Ustekinumab treatment in severe atopic dermatitis: down-regulation of T-helper 2/22 expression. *J Am Acad Dermatol.* 2017;76(1):91-97; e3.
109. Khattri S, Brunner PM, Garcet S, et al. Efficacy and safety of ustekinumab treatment in adults with moderate-to-severe atopic dermatitis. *Exp Dermatol.* 2017;26(1):28-35.
110. Saeki H, Kabashima K, Tokura Y, et al. Efficacy and safety of ustekinumab in Japanese patients with severe atopic dermatitis: a randomized, double-blind, placebo-controlled, phase II study. *Br J Dermatol.* 2017;177(2):419-427.
111. Hoebeeck J, van der Luijt R, Poppe B, et al. Rapid detection of VHL exon deletions using real-time quantitative PCR. *Lab Invest.* 2005;85(1):24-33.
112. Piskin G, Sylva-Steenland RM, Bos JD, et al. In vitro and in situ expression of IL-23 by keratinocytes in healthy skin and psoriasis lesions: enhanced expression in psoriatic skin. *J Immunol.* 2006;176(3):1908-1915.
113. Robinson RT. IL12Rbeta1: the cytokine receptor that we used to know. *Cytokine.* 2015;71(2):348-359.
114. Di Meglio P, Nestle FO. The role of IL-23 in the immunopathogenesis of psoriasis. *F1000 Biol Rep.* 2010;2.
115. Langrish CL, McKenzie BS, Wilson NJ, et al. IL-12 and IL-23: master regulators of innate and adaptive immunity. *Immunol Rev.* 2004;202:96-105.
116. Nair RP, Duffin KC, Helms C, et al. Genome-wide scan reveals association of psoriasis with IL-23 and NF-kappaB pathways. *Nat Genet.* 2009;41(2):199-204.
117. Desmet J, Verstraete K, Bloch Y, et al. Structural basis of IL-23 antagonism by an Alphabody protein scaffold. *Nat Commun.* 2014;5:5237.
118. Quiniou C, Domínguez-Punaro M, Cloutier F, et al. Specific targeting of the IL-23 receptor, using a novel small peptide noncompetitive antagonist, decreases the inflammatory response. *Am J Physiol Regul Integr Comp Physiol.* 2014;307(10):R1216-R1230.
119. Reich K, Armstrong AW, Foley P, et al. Efficacy and safety of guselkumab, an anti-interleukin-23 monoclonal antibody, compared with adalimumab for the treatment of patients with moderate to severe psoriasis with randomized withdrawal and retreatment: results from the phase III, double-blind, placebo- and active comparator-controlled VOYAGE 2 trial. *J Am Acad Dermatol.* 2017;76(3):418-431.
120. Blauvelt A, Papp KA, Griffiths CE, et al. Efficacy and safety of guselkumab, an anti-interleukin-23 monoclonal antibody, compared with adalimumab for the continuous treatment of patients with moderate to severe psoriasis: results from the phase III, double-blinded, placebo- and active comparator-controlled VOYAGE 1 trial. *J Am Acad Dermatol.* 2017;76(3):405-417.
121. Smolen JS, Agarwal SK, Ilivanova E, et al. A randomised phase II study evaluating the efficacy and safety of subcutaneously administered ustekinumab and guselkumab in patients with active rheumatoid arthritis despite treatment with methotrexate. *Ann Rheum Dis.* 2017;76(5):831-839.
122. Reich K, Papp KA, Blauvelt A, et al. Tildrakizumab versus placebo or etanercept for chronic plaque psoriasis (reSURFACE 1 and reSURFACE 2): results from two randomised controlled, phase 3 trials. *Lancet.* 2017;390(10091):276-288.
123. Papp KA, Blauvelt A, Bukhalo M, et al. Risankizumab versus ustekinumab for moderate-to-severe plaque psoriasis. *N Engl J Med.* 2017;376(16):1551-1560.
124. LaDuca JR, Gaspari AA. Targeting tumor necrosis factor alpha. New drugs used to modulate inflammatory diseases. *Dermatol Clin.* 2001;19(4):617-635.
125. Indhumathi S, Rajappa M, Chandrashekar L, et al. Pharmacogenetic markers to predict the clinical response to methotrexate in south Indian Tamil patients with psoriasis. *Eur J Clin Pharmacol.* 2017;73(8):965-971.
126. Gottlieb AB, Masud S, Ramamurthi R, et al. Pharmacodynamic and pharmacokinetic response to anti-tumor necrosis factor-alpha monoclonal antibody (infliximab) treatment of moderate to severe psoriasis vulgaris. *J Am Acad Dermatol.* 2003;48(1):68-75.
127. Hancock GE, Kaplan G, Cohn ZA. Keratinocyte growth regulation by the products of immune cells. *J Exp Med.* 1988;168(4):1395-1402.
128. Keffer J, Probert L, Cazlaris H, et al. Transgenic mice expressing human tumour necrosis factor: a predictive genetic model of arthritis. *EMBO J.* 1991;10(13):4025-4031.
129. Papp KA, Poulin Y, Bissonnette R, et al. Assessment of the long-term safety and effectiveness of etanercept for the treatment of psoriasis in an adult population. *J Am Acad Dermatol.* 2012;66(2): e33-e45.
130. Tsoi LC, Spain SL, Knight J, et al. Identification of 15 new psoriasis susceptibility loci highlights the role of innate immunity. *Nat Genet.* 2012;44(12):1341-1348.
131. Gniadecki R, Bang B, Bryld LE, et al. Comparison of long-term drug survival and safety of biologic agents in patients with psoriasis vulgaris. *Br J Dermatol.* 2015;172(1):244-252.
132. Carrascosa JM, van Doorn MB, Lahfa M, et al. Clinical relevance of immunogenicity of biologics in psoriasis: implications for treatment strategies. *J Eur Acad Dermatol Venereol.* 2014;28(11):1424-1430.
133. van Schouwenburg PA, van de Stadt LA, de Jong RN, et al. Adalimumab elicits a restricted anti-idiotypic antibody response in autoimmune patients resulting in functional neutralisation. *Ann Rheum Dis.* 2013;72(1):104-109.
134. Ingram JR. Interventions for hidradenitis suppurativa: updated summary of an original Cochrane review. *JAMA Dermatol.* 2017;153(5):458-459.
135. Elewski BE. Infliximab for the treatment of severe pustular psoriasis. *J Am Acad Dermatol.* 2002;47(5):796-797.

136. Newland MR, Weinstein A, Kerdel F. Rapid response to infliximab in severe pustular psoriasis, von Zumbusch type. *Int J Dermatol.* 2002;41(7):449-452.
137. Robinson A, Van Voorhees AS, Hsu S, et al. Treatment of pustular psoriasis: from the Medical Board of the National Psoriasis Foundation. *J Am Acad Dermatol.* 2012;67(2):279-288.
138. Williams VL, Cohen PR. TNF alpha antagonist-induced lupus-like syndrome: report and review of the literature with implications for treatment with alternative TNF alpha antagonists. *Int J Dermatol.* 2011;50(5):619-625.
139. Viguier M, Richette P, Bachelez H, et al. Paradoxical adverse effects of anti-TNF-alpha treatment: onset or exacerbation of cutaneous disorders. *Expert Rev Clin Immunol.* 2009;5(4):421-431.
140. Collamer AN, Battafarano DF. Psoriatic skin lesions induced by tumor necrosis factor antagonist therapy: clinical features and possible immunopathogenesis. *Semin Arthritis Rheum.* 2010;40(3):233-240.
141. Swindell WR, Xing X, Stuart PE, et al. Heterogeneity of inflammatory and cytokine networks in chronic plaque psoriasis. *PLoS One.* 2012;7(3):e34594.
142. Bongartz T, Sutton AJ, Sweeting MJ, et al. Anti-TNF antibody therapy in rheumatoid arthritis and the risk of serious infections and malignancies: systematic review and meta-analysis of rare harmful effects in randomized controlled trials. *JAMA.* 2006;295(19):2275-2285.
143. Strangfeld A, Listing J, Herzer P, et al. Risk of herpes zoster in patients with rheumatoid arthritis treated with anti-TNF-alpha agents. *JAMA.* 2009;301(7):737-744.
144. Leombruno JP, Einarson TR, Keystone EC. The safety of anti-tumour necrosis factor treatments in rheumatoid arthritis: meta and exposure-adjusted pooled analyses of serious adverse events. *Ann Rheum Dis.* 2009;68(7):1136-1145.
145. Adams AE, Zwicker J, Curiel C, et al. Aggressive cutaneous T-cell lymphomas after TNFalpha blockade. *J Am Acad Dermatol.* 2004;51(4):660-662.
146. Mariette X, Tubach F, Bagheri H, et al. Lymphoma in patients treated with anti-TNF: results of the 3-year prospective French RATIO registry. *Ann Rheum Dis.* 2010;69(2):400-408.
147. Gelfand JM, Shin DB, Neimann AL, et al. The risk of lymphoma in patients with psoriasis. *J Invest Dermatol.* 2006;126(10):2194-2201.
148. Rosenberg SA. IL-2: the first effective immunotherapy for human cancer. *J Immunol.* 2014;192(12):5451-5458.
149. Asadullah K, Sterry W, Trefzer U. Cytokine therapy in dermatology. *Exp Dermatol.* 2002;11(2):97-106.
150. Goff SL, Dudley ME, Citrin DE, et al. Randomized, prospective evaluation comparing intensity of lymphodepletion before adoptive transfer of tumor-infiltrating lymphocytes for patients with metastatic melanoma. *J Clin Oncol.* 2016;34(20):2389-2397.
151. Rook AH, Kuzel TM, Olsen EA. Cytokine therapy of cutaneous T-cell lymphoma: interferons, interleukin-12, and interleukin-2. *Hematol Oncol Clin North Am.* 2003;17(6):1435-1448, ix.
152. Holman DM, Kalaaji AN. Cytokines in dermatology. *J Drugs Dermatol.* 2006;5(6):520-524.
153. Spaccarelli N, Rook AH. The use of interferons in the treatment of cutaneous T-cell lymphoma. *Dermatol Clin.* 2015;33(4):731-745.
154. Schiller M, Tsianakas A, Sterry W, et al. Dose-escalation study evaluating pegylated interferon alpha-2a in patients with cutaneous T-cell lymphoma. *J Eur Acad Dermatol Venereol.* 2017;31(11):1841-1847.
155. Suchin KR, Cassin M, Gottleib SL, et al. Increased interleukin 5 production in eosinophilic Sezary syndrome: regulation by interferon alfa and interleukin 12. *J Am Acad Dermatol.* 2001;44(1):28-32.
156. Sabel MS, Sondak VK. Pros and cons of adjuvant interferon in the treatment of melanoma. *Oncologist.* 2003;8(5):451-458.
157. Stadler R. Interferons in dermatology. Present-day standard. *Dermatol Clin.* 1998;16(2):377-398.
158. Sugaya M, Tokura Y, Hamada T, et al. Phase II study of i.v. interferon-gamma in Japanese patients with mycosis fungoides. *J Dermatol.* 2014;41(1):50-56.
159. Olsen EA, Rook AH, Zic J, et al. Sezary syndrome: immunopathogenesis, literature review of therapeutic options, and recommendations for therapy by the United States Cutaneous Lymphoma Consortium (USCLC). *J Am Acad Dermatol.* 2011;64(2):352-404.
160. Herbst RS. Review of epidermal growth factor receptor biology. *Int J Radiat Oncol Biol Phys.* 2004;59(2)(suppl):21-26.
161. Zhang H, Berezov A, Wang Q, et al. ErbB receptors: from oncogenes to targeted cancer therapies. *J Clin Invest.* 2007;117(8):2051-2058.
162. Bublil EM, Yarden Y. The EGF receptor family: spearheading a merger of signaling and therapeutics. *Curr Opin Cell Biol.* 2007;19(2):124-134.
163. Pastore S, Mascia F, Mariani V, et al. The epidermal growth factor receptor system in skin repair and inflammation. *J Invest Dermatol.* 2008;128(6):1365-1374.
164. Sibilia M, Kroismayr R, Lichtenberger BM, et al. The epidermal growth factor receptor: from development to tumorigenesis. *Differentiation.* 2007;75(9):770-787.
165. Schneider MR, Werner S, Paus R, et al. Beyond wavy hairs: the epidermal growth factor receptor and its ligands in skin biology and pathology. *Am J Pathol.* 2008;173(1):14-24.
166. Lacouture ME. Mechanisms of cutaneous toxicities to EGFR inhibitors. *Nat Rev Cancer.* 2006;6(10):803-812.
167. Nanba D, Toki F, Barrandon Y, et al. Recent advances in the epidermal growth factor receptor/ligand system biology on skin homeostasis and keratinocyte stem cell regulation. *J Dermatol Sci.* 2013;72(2):81-86.
168. Walker F, Abramowitz L, Benabderrahmane D, et al. Growth factor receptor expression in anal squamous lesions: modifications associated with oncogenic human papillomavirus and human immunodeficiency virus. *Hum Pathol.* 2009;40(11):1517-1527.
169. Jost M, Kari C, Rodeck U. The EGF receptor—an essential regulator of multiple epidermal functions. *Eur J Dermatol.* 2000;10(7):505-510.
170. Yang S, Geng Z, Ma K, et al. Efficacy of topical recombinant human epidermal growth factor for treatment of diabetic foot ulcer: a systematic review and meta-analysis. *Int J Low Extrem Wounds.* 2016;15(2):120-125.
171. Berlanga J, Fernández JI, López E, et al. Heberprot-P: a novel product for treating advanced diabetic foot ulcer. *MEDICC Rev.* 2013;15(1):11-15.
172. Hynes NE, Lane HA. ERBB receptors and cancer: the complexity of targeted inhibitors. *Nat Rev Cancer.* 2005;5(5):341-354.
173. Liu HB, Wu Y, Lv TF, et al. Skin rash could predict the response to EGFR tyrosine kinase inhibitor and the prognosis for patients with non-small cell lung

cancer: a systematic review and meta-analysis. *PLoS One.* 2013;8(1):e55128.
174. Ornitz DM, Xu J, Colvin JS, et al. Receptor specificity of the fibroblast growth factor family. *J Biol Chem.* 1996;271(25):15292-15297.
175. Zhang X, Ibrahimi OA, Olsen SK, et al. Receptor specificity of the fibroblast growth factor family. The complete mammalian FGF family. *J Biol Chem.* 2006;281(23):15694-15700.
176. Belch J, Hiatt WR, Baumgartner I, et al. Effect of fibroblast growth factor NV1FGF on amputation and death: a randomised placebo-controlled trial of gene therapy in critical limb ischaemia. *Lancet.* 2011;377(9781):1929-1937.
177. Nunes QM, Li Y, Sun C, et al. Fibroblast growth factors as tissue repair and regeneration therapeutics. *PeerJ.* 2016;4:e1535.
178. Maeda T, Yamamoto T, Isikawa Y. Sanguisorba officinalis root extract has FGF-5 inhibitory activity and reduces hair loss by causing prolongation of the anagen period. *Nishi Nihon Hifuka.* 2007; 69(1):81-86.
179. Martínez-Jiménez MA, Aguilar-García J, Valdés-Rodríguez R, et al. Local use of insulin in wounds of diabetic patients: higher temperature, fibrosis, and angiogenesis. *Plast Reconstr Surg.* 2013;132(6): e1015-e1019.
180. Olsen E, Duvic M, Frankel A, et al. Pivotal phase III trial of two dose levels of denileukin diftitox for the treatment of cutaneous T-cell lymphoma. *J Clin Oncol.* 2001;19(2):376-388.
181. Gehad A, Al-Banna NA, Vaci M, et al. Differing requirements for CCR4, E-selectin, and $\alpha 4\beta 1$ for the migration of memory CD4 and activated T cells to dermal inflammation. *J Immunol.* 2012;189(1):337-346.
182. Duvic M, Pinter-Brown LC, Foss FM, et al. Phase 1/2 study of mogamulizumab, a defucosylated anti-CCR4 antibody, in previously treated patients with cutaneous T-cell lymphoma. *Blood.* 2015;125(12):1883-1889.
183. Ni X, Langridge T, Duvic M. Depletion of regulatory T cells by targeting CC chemokine receptor type 4 with mogamulizumab. *Oncoimmunology.* 2015;4(7):e1011524.
184. Dorner T, Burmester GR. The role of B cells in rheumatoid arthritis: mechanisms and therapeutic targets. *Curr Opin Rheumatol.* 2003;15(3):246-252.
185. Edwards JC, Cambridge G. Sustained improvement in rheumatoid arthritis following a protocol designed to deplete B lymphocytes. *Rheumatology (Oxford).* 2001;40(2):205-211.
186. Cerny T, Borisch B, Introna M, et al. Mechanism of action of rituximab. *Anticancer Drugs.* 2002;13(suppl 2):S3-S10.
187. Marcelin AG, Aaron L, Mateus C, et al. Rituximab therapy for HIV-associated Castleman disease. *Blood.* 2003;102(8):2786-2788.
188. Clifford KS, Demierre MF. Progression of classic Kaposi's sarcoma with rituximab. *J Am Acad Dermatol.* 2005;53(1):155-157.
189. Schmidt E, Seitz CS, Benoit S, et al. Rituximab in autoimmune bullous diseases: mixed responses and adverse effects. *Br J Dermatol.* 2007;156(2):352-356.
190. Ahmed AR, Spigelman Z, Cavacini LA, et al. Treatment of pemphigus vulgaris with rituximab and intravenous immune globulin. *N Engl J Med.* 2006;355(17):1772-1779.
191. Kerl K, Prins C, Saurat JH, et al. Intralesional and intravenous treatment of cutaneous B-cell lymphomas with the monoclonal anti-CD20 antibody rituximab: report and follow-up of eight cases. *Br J Dermatol.* 2006;155(6):1197-1200.
192. Lafyatis R, Kissin E, York M, et al. B cell depletion with rituximab in patients with diffuse cutaneous systemic sclerosis. *Arthritis Rheum.* 2009;60(2):578-583.
193. Loh TY, Paravar T. Rituximab in the management of juvenile pemphigus foliaceus. *Dermatol Online J.* 2017;23(6).
194. Salama A. Emerging drugs for immune thrombocytopenia (ITP). *Expert Opin Emerg Drugs.* 2017;22(1):27-38.
195. Guillevin L, Pagnoux C, Karras A, et al. Rituximab versus azathioprine for maintenance in ANCA-associated vasculitis. *N Engl J Med.* 2014;371(19):1771-1780.
196. Maverakis E, Kim K, Shimoda M, et al. Glycans in the immune system and The Altered Glycan Theory of Autoimmunity: a critical review. *J Autoimmun.* 2015;57:1-13.
197. Guenova E, Skabytska Y, Hoetzenecker W, et al. IL-4 abrogates T(H)17 cell-mediated inflammation by selective silencing of IL-23 in antigen-presenting cells. *Proc Natl Acad Sci U S A.* 2015;112(7):2163-2168.
198. El-Mallawany NK, Frazer JK, Van Vlierberghe P, et al. Pediatric T- and NK-cell lymphomas: new biologic insights and treatment strategies. *Blood Cancer J.* 2012;2(4):e65.
199. Berger GK, McBride A, Lawson S, et al. Brentuximab vedotin for treatment of non-Hodgkin lymphomas: a systematic review. *Crit Rev Oncol Hematol.* 2017;109:42-50.
200. Younes A, Bartlett NL, Leonard JP, et al. Brentuximab vedotin (SGN-35) for relapsed CD30-positive lymphomas. *N Engl J Med.* 2010;363(19):1812-1821.
201. Prince HM, Kim YH, Horwitz SM, et al. Brentuximab vedotin or physician's choice in CD30-positive cutaneous T-cell lymphoma (ALCANZA): an international, open-label, randomised, phase 3, multicentre trial. *Lancet.* 2017;390(10094):555-566.
202. de Kleer I, Vercoulen Y, Klein M, et al. CD30 discriminates heat shock protein 60-induced FOXP3+ CD4+ T cells with a regulatory phenotype. *J Immunol.* 2010;185(4):2071-2079.
203. Hunter CA, Jones SA. IL-6 as a keystone cytokine in health and disease. *Nat Immunol.* 2015;16(5):448-457.
204. Puel A, Picard C, Lorrot M, et al. Recurrent staphylococcal cellulitis and subcutaneous abscesses in a child with autoantibodies against IL-6. *J Immunol.* 2008;180(1):647-654.
205. Saggini A, Chimenti S, Chiricozzi A. IL-6 as a druggable target in psoriasis: focus on pustular variants. *J Immunol Res.* 2014;2014:964069.
206. Neuner P, Urbanski A, Trautinger F, et al. Increased IL-6 production by monocytes and keratinocytes in patients with psoriasis. *J Invest Dermatol.* 1991;97(1):27-33.
207. Lindroos J, Svensson L, Norsgaard H, et al. IL-23-mediated epidermal hyperplasia is dependent on IL-6. *J Invest Dermatol.* 2011;131(5):1110-1118.
208. Younis S, Rimar D, Slobodin G, et al. Tumor necrosis factor-associated palmoplantar pustular psoriasis treated with interleukin 6 blocker. *J Rheumatol.* 2012;39(10):2055-2056.

Chapter 194 :: Molecular Targeted Therapies

:: David Michael Miller, Bobby Y. Reddy, & Hensin Tsao

The treatment strategy for human disease has evolved dramatically since 2000 as a result of advances in molecular genetics, cell biology, and pharmacology. Increased understanding of molecular pathophysiology has allowed for the development of therapeutics that interact with specific molecular targets associated with disease. Agents that are the product of rational drug design, in which compounds are deliberately designed to interact with a biologic target, are often referred to as "targeted therapy" and form one of the cornerstones of "precision medicine." The potential of targeted therapy is perhaps best exemplified with oncologic disease, but the promise of rational drug design is beginning to be seen across all fields of medicine.

Discussing all targeted therapies in medicine is beyond the scope of this chapter. Consequently, we focus on those molecular targeted therapies that have the most overlap with dermatology in either their indication or the adverse effects caused by their use (Table 194-1). Thus we review targeted therapies designed to interact with the tyrosine kinases BCR-ABL, c-KIT, PDGFR and EGFR; smoothened; histone deacetylases; and proteins of the MAP kinase pathway. We finish with a section on the future directions in melanoma targeting AKT and ERK proteins.

Of note, marketing indications, contra-indications and warnings are dynamic and constantly evolving. Thus, those covered in this chapter are current as of the writing. Please refer to the FDA product label for the most up-to-date information.

KIT, BCR-ABL, AND PDGFR INHIBITORS

AT-A-GLANCE

- The small-molecule tyrosine kinase inhibitors imatinib, nilotinib, dasatinib, bosutinib, and ponatinib are indicated for Philadelphia chromosome–positive leukemia.
- Imatinib also has indications for dermatofibrosarcoma protuberans, a soft-tissue sarcoma, driven in part by alterations in platelet-derived growth factor receptor signaling.
- Cutaneous adverse effects of these multityrosine kinase inhibitors include edema, morbilliform eruptions, bullous eruptions, dyspigmentation, keratosis-pilaris–like eruptions and neutrophilic dermatoses.

BACKGROUND

Tyrosine kinases are key components of numerous cellular pathways involved in cell growth, proliferation, migration, angiogenesis, differentiation, and survival. Drug development focusing on tyrosine kinases began after the initial discovery in 1980 that the oncogene associated with Abelson murine leukemia virus, ABL1, was a tyrosine kinase.[1] This finding led to the understanding that a fusion protein, which resulted from a translocation of the *Abl1* gene on chromosome 9 to a part of the breakpoint cluster region (*BCR*) gene on chromosome 22, was the driving event in the majority of chronic myeloid leukemias (CMLs).[2] The protein product of this fusion oncogene, known as the Philadelphia chromosome, was one of the first targets for rational drug design. Cells that express the Philadelphia chromosome are transformed as a result of constitutive activation of the BCR-ABL kinase, which mediates oncogenesis through a variety of transduction pathways including the mitogen-activated protein kinase (MAPK), Janus kinase (JAK)/signal transducer and activator of transcription (STAT), and phosphatidylinositol-4,5-bisphosphate 3-kinase (PI3K) (Fig. 194-1).

One of the earliest proof of principles of "targeted therapy" came via the demonstration that a small molecular inhibitor of the BCR-ABL fusion oncoprotein—imatinib mesylate—inhibited the growth of BCR-ABL–expressing cells[3] and exhibited substantial clinical activity in patients with Philadelphia chromosome–expressing CML and acute lymphoblastic leukemia.[4,5] These data revolutionized the approach to cancer therapy and shifted the drug development paradigm toward identifying disease-causing targets. In dermatofibrosarcoma protuberans, a fusion between the collagen gene (COL1A1) and the platelet-derived growth factor (PDGFR) β-chain gene produces a constitutively active mitogen driven by paracrine and autocrine ligands.[6] Imatinib inhibits the tyrosine kinase associated with PDGFRβ and its use in patients with dermatofibrosarcoma protuberans yields a clinical benefit.[7]

Despite the breakthrough impact that imatinib has had on the field of oncology in general and in several malignancies in particular, nearly one-third of patients with CML require other therapies. Most commonly the reason for alternate treatment is the development of resistance mutations in BCR-ABL1 that affect the ability of imatinib to interact with the adenosine triphosphate (ATP)-binding pocket. Consequently, second-generation and third-generation tyrosine

TABLE 194-1
Molecular Target Therapies

GENERIC NAME	BRAND NAME	MOLECULAR TARGET	INDICATION
Imatinib	Gleevec	BCR-ABL, c-KIT, PDGFR	Ph⁺-CML, GIST, ASM, DFSP, Ph⁺-ALL, HES/CEL
Nilotinib	Tasigna	BCR-ABL, c-KIT, PDGFR	Ph⁺-CML
Dasatinib	Sprycel	BCR-ABL, c-KIT, PDGFR	Ph⁺-CML, Ph⁺-ALL
Bosutinib	Bosulif	BCR-ABL	Ph⁺-CML
Ponatinib	Iclusig	BCR-ABL, c-KIT, PDGFR	Ph⁺-CML, Ph⁺-ALL
Cetuximab	Erbitux	EGFR	CRC, SCCHN
Panitumumab	Vectibix	EGFR	CRC
Gefitinib	Iressa	EGFR	NSCLC
Erlotinib	Tarceva	EGFR	EGFR-mutated NSCLC, Pancreatic Cancer
Afatinib	Gilotrif	EGFR	EGFR-mutated NSCLC
Osimertinib	Tagrisso	EGFR	EGFR-mutated (T790M) NSCLC
Vismodegib	Erivedge	SMO	BCC
Sonidegib	Odomzo	SMO	BCC
Vorinostat	Zolinza	HDACs	CTCL
Romidepsin	Istodax	HDACs	CTCL, PTCL
Belinostat	Beleodaq	HDACs	PTCL
Panobinostat	Farydak	HDACs	Multiple Myeloma
Vemurafenib	Zelboraf	$BRAF^{V600E}$	Melanoma
Dabrafenib	Tafinlar	$BRAF^{V600E}$	Melanoma
Trametinib	Mekinist	MEK	Melanoma
Cobimetinib	Cotellic	MEK	Melanoma

ASM, aggressive systemic mastocytosis; BCC, basal cell carcinoma; CEL, chronic eosinophilic leukemia; CRC, colorectal cancer; CTCL, cutaneous T-cell lymphoma; DFSP, dermatofibrosarcoma protuberans; EGFR, epidermal growth factor receptor; GIST, GI stromal tumor; HDAC, histone deacetylases; HES, hypereosinophilic syndrome; NSCLC, non-small cell lung cancer; PDGFR, platelet-derived growth factor receptor; Ph⁺-ALL, Philadelphia chromosome-positive acute lymphoblastic leukemia; Ph⁺-CML, Philadelphia chromosome-positive chronic myeloid leukemia; PTCL, peripheral T-cell lymphoma; SCCHN, squamous cell carcinoma, head and neck; SMO, smoothened.

kinase inhibitors (TKIs) have been developed with enhanced affinity for BCR-ABL. These TKIs include nilotinib, dasatinib, bosutinib, and ponatinib.

IMATINIB MESYLATE (GLEEVEC)

PHARMACOLOGY AND MECHANISM OF ACTION

Structure: Imatinib, 4-[(4-methyl-1-piperazinyl) methyl]-*N*-[4-methyl-3-[[4-(3-pyridinyl)-2-pyrimidinyl] amino]-phenyl]benzamide methanesulfonate, has the molecular formula $C_{29}H_{31}N_7O \bullet CH_4SO_3$ and a molecular weight of 589.7 daltons. Figure 194-2 shows its structure.

Metabolism: Imatinib is predominantly metabolized by cytochrome P450 (CYP) 3A4 and the main active metabolite is a *N*-demethylated piperazine derivative. The drug and its metabolites are primarily excreted in the feces. The elimination half-life is approximately 18 hours for the unchanged form and 40 hours for the *N*-desmethyl derivative.[8]

Absorption and Distribution: Imatinib is absorbed orally with bioavailability of 98%. The compound has high levels of binding to circulating plasma proteins, mainly albumin and α_1-acid glycoprotein.

Mechanism of Action: Imatinib mesylate is a small-molecule TKI with activity against BCR-ABL, c-KIT, and PDGFR (see Fig. 194-1). Imatinib binds near the ATP-binding site of the inactive, unphosphorylated confirmation of these kinases, inhibiting the enzyme activity of the protein. In cells with constitutively active BCR-ABL, imatinib induces apoptosis and inhibits proliferation. Imatinib also downregulates cell proliferation triggered by aberrant c-KIT and platelet-derived growth factor (PDGF) signaling.

INDICATIONS AND CONTRAINDICATIONS

Imatinib mesylate was initially approved in 2001 for use in CML. In 2002, the label was updated to include

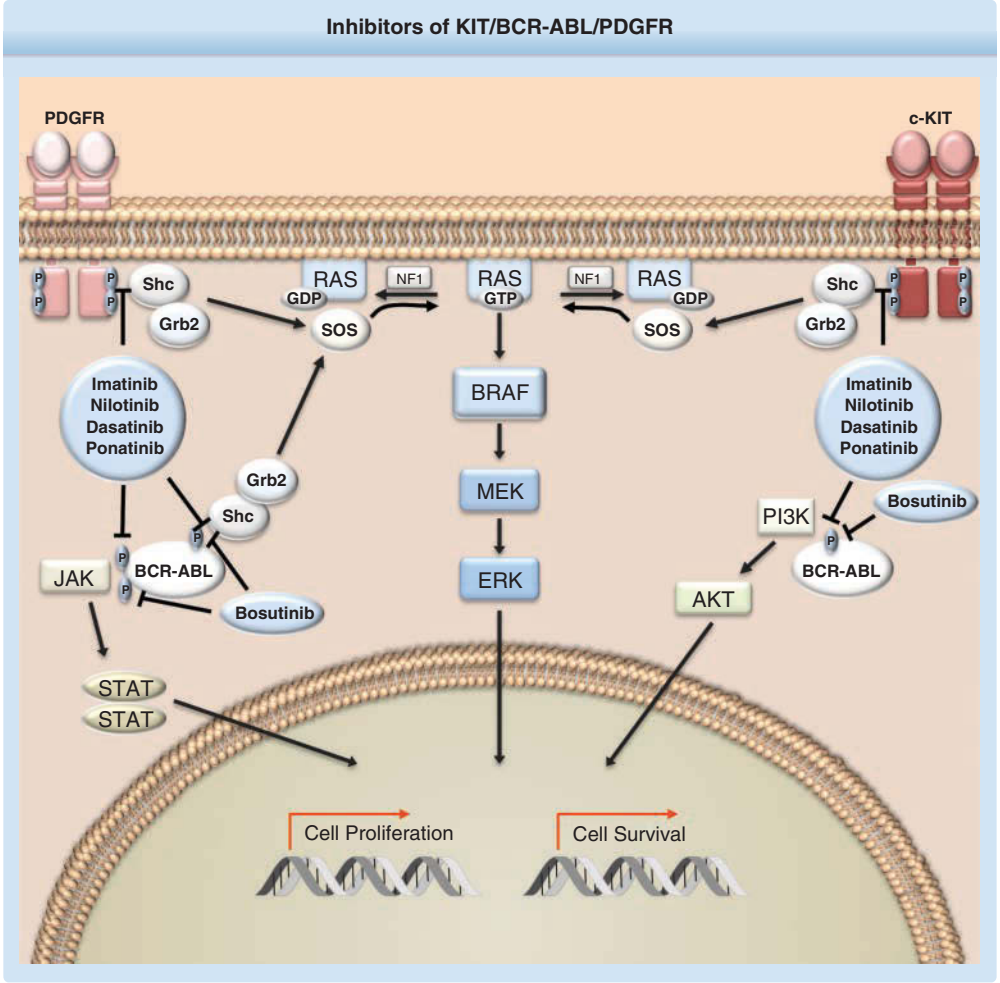

Figure 194-1 Inhibitors of KIT/BCR-ABL/PDGFR. Imatinib, nilotinib, dasatinib, and ponatinib are multi–tyrosine kinase inhibitors that modulate autophosphorylation of tyrosine residues associated with BCR-ABL (breakpoint cluster region–Abelson murine leukemia virus), c-KIT, and PDGFR (platelet-derived growth factor receptor). c-KIT and PDGFR are receptor tyrosine kinases and BCR-ABL is a nonreceptor tyrosine kinase. Bosutinib is an inhibitor of BCR-ABL, but not of c-KIT or PDGFR. The signal transduction pathways downstream of these tyrosine kinases, such as MAPK (mitogen-activated protein kinase) cascade, Janus kinase (JAK)/signal transducer and activator of transcription (STAT), and phosphatidylinositol-4,5-bisphosphate 3-kinase (PI3K) regulate the expression of genes involved in cell growth, proliferation, and cell survival.

advanced or metastatic GI stromal tumors. In 2006, the U.S. Food and Drug Administration (FDA) further expanded the approval to include dermatofibrosarcoma protuberans, aggressive systemic mastocytosis, myelodysplastic/myeloproliferative diseases with PDGFR gene rearrangements, relapsed/refractory Philadelphia chromosome–positive acute lymphocytic leukemia, and hypereosinophilic syndrome/chronic eosinophilic leukemia with FIP1L1-PDGFR fusion kinase rearrangements.

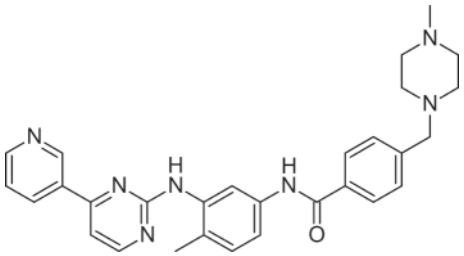

Figure 194-2 Structure of Imatinib.

Off-label uses of imatinib have been reported for melanomas harboring KIT alterations, which occur at a higher frequency in melanomas arising from mucosal, acral and chronically sun-damaged skin. Data from several newer trials suggest a modest clinical benefit as a single agent in c-KIT–mutated melanoma and newer National Comprehensive Cancer Network (NCCN) guidelines include imatinib as a treatment option for metastatic melanoma.[9-11] Clinical activity of imatinib is also being investigated for desmoid tumors and for advanced or metastatic chordomas expressing PDGFRβ and/or PDGFβ.

There are no contraindications on the manufacturer's label.

TABLE 194-2
Dosing for Imatinib

DISEASE	DOSE
Chronic myeloid leukemia, chronic phase	400 mg daily
Chronic myeloid leukemia, accelerated phase or blast crisis	600 mg daily
GI stromal tumors	400 mg daily
Dermatofibrosarcoma protuberans	400 mg twice daily
Aggressive systemic mastocytosis	400 mg daily
Myelodysplastic/myeloproliferative diseases	400 mg daily
Relapsed/refractory Philadelphia chromosome–positive acute lymphocytic leukemia	600 mg daily
Hypereosinophilic syndrome/chronic eosinophilic leukemia	400 mg daily
Melanoma[a]	400 mg twice daily

[a]Use of imatinib for melanoma is not FDA approved; off-label dosing based on NCT00470470.[11]

DOSING REGIMEN

Table 194-2 outlines the dosing regimens for imatinib.

Dosing adjustments for hepatic and renal impairment are recommended. For patients with mild renal impairment (creatinine clearance [CrCl] = 40 to 59 mL/min), doses of greater than 600 mg are not recommended. A 50% reduction in the starting dose is recommended for patients with moderate renal impairment (CrCl = 20 to 39 mL/min), with subsequent dose increases given as tolerated to a maximum recommended dose of 400 mg. Use imatinib with caution in patients with several renal impairment (CrCl <20 mL/min); no specific recommendations have been defined. Dose reductions of 25% are recommended for patients with severe hepatic impairment (total bilirubin >3 times to 10 times the upper limits of normal [ULN]).

SIDE EFFECTS AND PRECAUTIONS

Adverse Effects: The most common adverse effects include edema, nausea, vomiting, muscle cramps, myalgias, diarrhea, bone pain, fatigue, and abdominal pain. Less common but serious adverse effects include severe fluid retention (eg, pericardial effusion, pulmonary edema, pleural effusions, and ascites), hematologic toxicity (eg, anemia, neutropenia, and thrombocytopenia), congestive heart failure, liver failure, and hemorrhage.

A wide variety of cutaneous side effects have been reported in patients taking imatinib, including periorbital edema, dyspigmentation, morbilliform eruption, pityriasis rosea-like eruption, acute generalized exanthematous pustulosis, exacerbation of psoriasis, drug rash with eosinophilia and systemic symptoms, pseudoporphyria, mycosis fungoides–like eruption, acute neutrophilic dermatosis, erythroderma, Stevens-Johnson syndrome, perforating folliculitis, and urticaria.[12]

Women of reproductive age should be counseled that imatinib is a pregnancy category D drug as it was teratogenic when tested in rodents and there have been postmarket reports of congenital anomalies from pregnant women on imatinib. Thus, patients should be advised to use highly effective contraception and avoid pregnancy while taking imatinib.

Nursing mothers should be counseled that imatinib and its metabolites have been detected in human breastmilk and nursing infants could receive up to 10% of the maternal dose. Given the risk to infants, breastfeeding is not recommended while taking imatinib.

Drug Interactions: Because of its metabolism by CYP3A4, drug concentrations of imatinib are affected by agents that inhibit or induce CYP3A4. Furthermore, studies demonstrate that imatinib is a moderate inhibitor of CYP3A4 and weakly inhibits CYP2D6; therefore, caution should be used when prescribing imatinib with CYP3A4 and CYP2D6 substrates with a narrow therapeutic window.

Please see the Gleevec package insert for full drug–drug interactions and adverse effects.[8]

NILOTINIB (TASIGNA)

PHARMACOLOGY AND MECHANISM OF ACTION

Structure: Nilotinib, 4-methyl-*N*-[3-(4-methyl-1H-imidazol-1-yl)-5-(trifluoromethyl)phenyl]-3-[[4-(3-pyridinyl)-2-pyrimidinyl]amino]-benzamide, monohydrochloride, monohydrate, has the molecular formula $C_{28}H_{22}F_3N_7O \bullet HCl \bullet H_2O$ and molecular weight of 584 daltons. Figure 194-3 shows the structure of nilotinib.

Metabolism: Nilotinib is metabolized by CYP3A4 and metabolism is predominantly by oxidation and hydroxylation. The vast majority of the dose (93%) is eliminated in the feces. The elimination half-life is estimated at 17 hours.[13]

Absorption and Distribution: Nilotinib is absorbed orally and absorption is increased when given 30 minutes after a meal. Of the circulating compound, 98% is bound to serum protein.

Mechanism of Action: Similar to its forerunner imatinib, nilotinib is a multityrosine kinase inhibitor. The compound binds and stabilizes the inactive

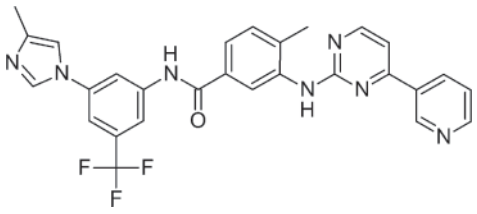

Figure 194-3 Structure of Nilotinib.

conformation of the kinase domain of its target proteins (BCR-ABL, KIT, PDGFR, discoidin domain receptor). It was rationally designed based on the structure of its predecessor to overcome resistance in CML to imatinib. Rational designs of the compound yield a significantly higher affinity and inhibitor activity of nilotinib against BCR-ABL compared with imatinib, while maintaining its activity against PDGFR and KIT.

INDICATIONS AND CONTRAINDICATIONS

Nilotinib is indicated for adult patients with either newly diagnosed Philadelphia chromosome–positive (Ph^+) CML in chronic phase or accelerated-phase CML that is resistant or intolerant to prior treatment with imatinib. Nilotinib does not have any current FDA-approved indications for dermatologic disease.

However, the results with imatinib in c-KIT–mutated melanoma have provided the rationale for early phase trials exploring the usefulness of nilotinib in these subsets. Similar to imatinib, the results have been modest. In one trial, 7 (16.7%) of 42 patients with metastatic KIT-altered melanoma achieved a response with single-agent nilotinib.[14] In a second trial of patients with advanced melanoma harboring KIT mutations or amplifications who had received prior KIT inhibitor therapy, 4 (21%) of 19 patients experienced a response.[15]

Nilotinib is contraindicated for use in patients with long QT syndrome, hypokalemia, or hypomagnesemia.

DOSING REGIMEN

The recommended dose for newly diagnosed Ph^+ chronic-phase CML is 300 mg by mouth twice daily; for resistant or intolerant Ph^+ chronic-phase CML and accelerated-phase CML, 400 mg by mouth twice daily is recommended.

Nilotinib should not be taken with food. It is recommended to avoid food for at least 2 hours before and 1 hour after the dose is taken. Foods that inhibit CYP3A4 should be avoided.

Dose adjustments are recommended for a variety of indications, including impaired hepatic function, QT interval, and hematologic toxicity. See the Tasigna product label for full dose adjustment recommendations.

SIDE EFFECTS AND PRECAUTIONS

Adverse Effects: The most common adverse effects include cutaneous toxicities (see below), thrombocytopenia, neutropenia, anemia, constipation, nausea, vomiting, hyperbilirubinemia, fatigue, elevated lipase, and elevated transaminases.

Serious adverse effects include a boxed warning for QT prolongation and sudden death. Thus, nilotinib is not recommended for use in patients with hypokalemia, hypomagnesemia, or long QT syndrome. Medications known to prolong the QT interval or that strongly inhibit CYP3A4 should also be avoided. Potassium, calcium, magnesium, phosphate, or sodium electrolyte abnormalities should be corrected prior to initiation and should be periodically monitored during therapy.

In the initial trial of nilotinib in CML, cutaneous toxicities were the most common adverse effects noted and included rash (specific morphologies not described), pruritus, dry skin, and alopecia. Postmarket reports have included a case of bullous Sweet syndrome.[12]

Nilotinib is a pregnancy category D drug, based on its mechanism of action and data in animal studies that the compound may cause fetal harm. Women with reproductive potential should be advised to use highly effective contraception during therapy. Findings in animal studies demonstrate that nilotinib may be unsafe during nursing. It is recommended to consider alternatives to breastfeeding or to weigh the risks against the benefits of use during nursing.

Drug Interactions: As nilotinib is a substrate of CYP3A4, inhibitors and inducers of CYP3A4 may affect serum concentrations. Nilotinib is an inhibitor of CYP3A4, CYP2C8, CYP2C9, and CYP2D6, and may also induce CYP2B6, CYP2C8, and CYP2C9. Thus, coadministration of nilotinib with substrates of these enzymes may affect the serum concentrations.

See the Tasigna product label for full drug–drug interactions and adverse effects.[13]

DASATINIB (SPRYCEL)

PHARMACOLOGY AND MECHANISM OF ACTION

Structure: Dasatinib,*N*-(2-chloro-6-methylphenyl)-2-[[6-[4-(2-hydroxyethyl)-1-piperazinyl]-2-methyl-4-pyrimidinyl]amino]-5-thiazolecarboxamide, monohydrate, has the molecular formula $C_{22}H_{26}ClN_7O_2S \cdot H_2O$, which corresponds to a formula weight of 506.02 daltons for the monohydrate form and 488.01 daltons for the anhydrous free base.[16] Figure 194-4 shows the structure of dasatinib.

Metabolism: Dasatinib is predominantly metabolized by CYP3A4. Dasatinib metabolites are also produced by uridine diphosphate-glucuronosyltransferase (UGT) and flavin-containing monooxygenase 3 (FMO-3) enzymes. The estimated elimination half-life is 3 to 5 hours. Dasatinib is primarily excreted through the feces.

Absorption and Distribution: Following oral administration, peak plasma concentrations are reached between 30 minutes and 6 hours. The apparent volume of distribution is 2505 L.

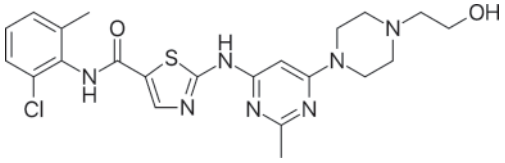

Figure 194-4 Structure of Dasatinib.

Mechanism of Action: Dasatinib is a small molecule kinase inhibitor. It inhibits numerous kinases, including BCR-ABL, c-KIT, PDGFRβ, SRC family (SRC, LCK, YES, FYN), and EPHA2. In preclinical in vitro studies, dasatinib inhibited the growth of BCR-ABL overexpressing CML and acute lymphoblastic leukemia (ALL) cell lines.[16] In these assays, dasatinib was effective in cell lines that possess BCR-ABL kinase mutations that conferred resistance to imatinib.

INDICATIONS AND CONTRAINDICATIONS

Dasatinib has FDA approval for adults with (a) newly diagnosed Ph^+ chronic-phase CML, (b) chronic, accelerated, or myeloid or lymphoid blast-phase Ph^+-CML with intolerance or resistance to previous therapy including imatinib, and (c) adults with Ph^+-ALL with intolerance or resistance to previous therapy.

In melanoma, early-phase investigations with dasatinib have shown only a modest clinical benefit when used a monotherapy[17] or in combination with systemic chemotherapy.[18]

There are no contraindications listed on the manufacturer's label.

DOSING REGIMEN

The recommended oral dose is 100 mg daily for chronic-phase CML and 140 mg once daily for accelerated-phase CML, myeloid or lymphoid blast-phase CML, or Ph^+-ALL.

Please see the manufacturer's label for dose modification for neutropenia, thrombocytopenia, and concomitant use of CYP3A4 modifiers. Studies were not performed in patients with impaired renal function, thus there are no specific dose modifications for patients with renal impairment.

SIDE EFFECTS AND PRECAUTIONS

Adverse Effects: For newly diagnosed chronic-phase CML, the most common adverse effects are myelosuppression, diarrhea, and fluid retention. Patients who have previously progressed, or were intolerant to prior imatinib therapy, commonly experience myelosuppression, fluid retention, diarrhea, headache, fatigue, dyspnea, nausea, hemorrhage, musculoskeletal pain, and skin toxicity.

Cutaneous adverse effects include neutrophilic dermatosis,[19] keratosis pilaris–like lesions and pustules, white keratotic papules, and milia.[20]

Drug Interactions: Caution is advised when dasatinib is used concomitantly with strong CYP3A4 inducers (including, but not limited to phenytoin, rifampin, phenobarbital, carbamazepine, dexamethasone, rifabutin) and strong CYP3A4 inhibitors (ketoconazole, voriconazole, itraconazole, atazanavir, nelfinavir, indinavir, ritonavir, saquinavir, nefazodone, telithromycin, and clarithromycin). It is recommended to avoid St. John's wort and grapefruit juice while taking dasatinib.

It is recommended to advise women of reproductive potential to avoid pregnancy during treatment with dasatinib and for at least 30 days following the final dose. Breastfeeding is not recommended while taking dasatinib and for at least 2 weeks after the final dose.

Use with caution in patients with hepatic impairment.

See the Sprycel package insert for full drug–drug interactions and adverse effects.[16]

BOSUTINIB (BOSULIF)

PHARMACOLOGY AND MECHANISM OF ACTION

Structure: Bosutinib, 3-Quinolinecarbonitrile, 4-[(2,4-dichloro-5-methoxyphenyl)amino]-6-methoxy-7-[3-(4-methyl-1-piperazinyl) propoxy]-, hydrate (1:1), has the chemical formula $C_{26}H_{29}Cl_2N_5O_3 \bullet H_2O$ (monohydrate); its molecular weight is 548.46 (monohydrate), equivalent to 530.46 (anhydrous).[21] Figure 194-5 shows the structure of bosutinib.

Metabolism: Bosutinib is predominantly metabolized by CYP3A4 and primarily excreted through the feces.

Absorption and Distribution: Oral bioavailability is 34% when taken with food and following oral administration; peak plasma concentrations are reached between 4 and 6 hours. The apparent volume of distribution is 6080 L ± 1230 L.

Mechanism of Action: Bosutinib is a small-molecular-weight kinase inhibitor. It inhibits numerous kinases, including BCR-ABL and the SRC family kinases SRC, LCK, and FYN. In preclinical in vitro studies, bosutinib inhibited the growth of 16 of 18 BCR-ABL overexpressing murine myeloid cell lines that were resistant to imatinib. Bosutinib did not inhibit the mutant cell lines that expressed the T315I and V299L resistance mutations.[21]

INDICATIONS AND CONTRAINDICATIONS

Bosutinib has FDA approval for adults with chronic-phase, accelerated-phase, or blast-phase Ph^+-CML with

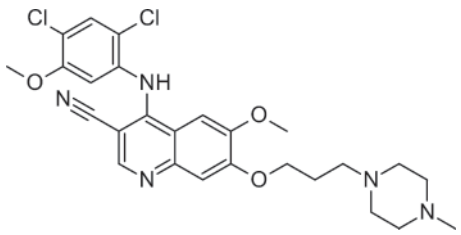

Figure 194-5 Structure of Bosutinib.

intolerance or resistance to previous therapy. Bosutinib does not have any current FDA-approved indications for dermatologic disease.

Bosutinib is contraindicated in patients with a known hypersensitivity to the drug.

DOSING REGIMEN

The recommended oral dose is 500 mg once daily with food.

See the manufacturer's label for dose modifications for neutropenia, thrombocytopenia, renal impairment, hepatic impairment, and concomitant use of CYP3A4 modifiers.

SIDE EFFECTS AND PRECAUTIONS

Adverse Effects: The most common adverse effects are diarrhea, nausea, thrombocytopenia, vomiting, abdominal pain, rash (not otherwise specified), anemia, pyrexia, and fatigue.

Bosutinib is a pregnancy category D drug, and it is recommended to advise women of reproductive potential to avoid pregnancy during treatment. As to breastfeeding, bosutinib may be excreted in human milk and thus the risk of harm to a nursing infant must be weighed with the importance of the drug to the mother.

Drug Interactions: Caution is advised when bosutinib is used concomitantly with strong CYP3A4 inducers (including, but not limited to, phenytoin, rifampin, phenobarbital, carbamazepine, dexamethasone, rifabutin) and strong CYP3A4 inhibitors (ketoconazole, voriconazole, itraconazole, atazanavir, nelfinavir, indinavir, ritonavir, saquinavir, nefazodone, telithromycin, and clarithromycin). It is recommended to avoid St. John's wort and grapefruit juice while taking bosutinib. Proton pump inhibitors can reduce exposure to bosutinib and should be avoided if possible. Consider H_2 blockers or short-acting antacids.

See the Bosulif package insert for full drug–drug interactions and adverse effects.[21]

PONATINIB (ICLUSIG)

PHARMACOLOGY AND MECHANISM OF ACTION

Structure: Ponatinib, 3-(imidazo[1,2-b]pyridazin-3-ylethynyl)-4-methyl-*N*-{4-[(4-methylpiperazin-1-yl)methyl]-3-(trifluoromethyl)phenyl}benzamide hydrochloride, has the chemical formula $C_{29}H_{28}ClF_3N_6O$, which corresponds to a molecular weight of 569.02 daltons.[22] Figure 194-6 shows the structure of ponatinib.

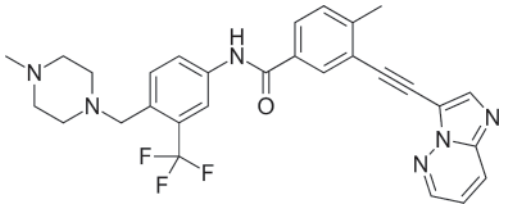

Figure 194-6 Structure of Ponatinib.

Metabolism: Ponatinib is metabolized by CYP3A4, and to a lesser degree by CYP2C8, CYP2D6, and CYP3A5. It is also metabolized by amidases and/or esterases. Ponatinib is primarily excreted through the feces.

Absorption and Distribution: Following oral administration, peak plasma concentrations are reached within 6 hours. The apparent volume of distribution is 1223 L.

Mechanism of Action: Ponatinib is a small-molecular-weight kinase inhibitor. It inhibits a variety of kinases, including BCR-ABL, VEGFR (vascular endothelial growth factor receptor), PDGFR, FGFR (fibroblast growth factor receptor), EPH (ephrin), KIT, RET, TIE2 (TEK receptor tyrosine kinase), FLT3 (fms-related tyrosine kinase 3), and the SRC family kinases. Ponatinib also inhibits the T315I mutation that confers resistance to imatinib.

INDICATIONS AND CONTRAINDICATIONS

Ponatinib has FDA approval for adults with T315I-mutant-positive chronic-phase, accelerated-phase, or blast-phase CML or T315I-mutant-positive Ph^+-ALL. It is also approved for adults with chronic-phase, accelerated-phase, or blast-phase CML or Ph^+-ALL in which no other TKI treatment is indicated. Ponatinib does not have any current FDA-approved indications for dermatologic disease.

There are no contraindications listed on the manufacturer's label.

DOSING REGIMEN

The recommended oral dose is 45 mg once daily taken with or without food.

Please see the manufacturer's label for dose modification for neutropenia, thrombocytopenia, renal impairment, hepatic impairment, and concomitant use of CYP modifiers.

SIDE EFFECTS AND PRECAUTIONS

Adverse Effects: The most common nonhematologic adverse effects include hypertension, rash (not otherwise specified), fatigue, xerosis, headache, abdominal pain, constipation, nausea, arthralgia, and pyrexia. Hematologic toxicities include

myelosuppression including leukopenia, neutropenia and thrombocytopenia, anemia, and lymphopenia.

Ponatinib has a boxed warning for vascular occlusion, including arterial and venous thrombosis, which occurred in at least 27% of patients, heart failure and hepatotoxicity.

Ponatinib is a pregnancy category D drug and it is recommended to advise women of reproductive potential to avoid pregnancy during treatment. With considerations to breastfeeding, it is unknown if ponatinib is excreted in human milk and thus the risk of harm to a nursing infant must be weighed with the importance of the drug to the mother.

Drug Interactions: Caution is advised when ponatinib is used concomitantly with strong CYP3A inducers and inhibitors.

See the Iclusig package insert for full drug–drug interactions and adverse effects.[22]

EPIDERMAL GROWTH FACTOR RECEPTOR INHIBITORS

AT-A-GLANCE

- The epidermal growth factor receptor (EGFR) is found on the cell surface of a variety of epithelial cells and is dysregulated in numerous malignancies.
- Monoclonal antibodies that block epidermal growth factor binding to EGFR and small-molecular-weight inhibitors of the EGFR intracellular tyrosine kinase have been approved as therapy for several types of cancer.
- Although there are no FDA-approved dermatologic indications at the time of publication of this book, clinical investigations in cutaneous oncology are ongoing.
- EGFR inhibitors commonly have skin toxicities that include papulopustular eruptions, pruritus, xeroderma, and paronychia.

BACKGROUND

Drug development focused on the EGFR (also known as ErbB1 or HER1) showcases the potential of targeted therapy, rational drug design and personalized medicine. Although agents that inhibit EGFR signaling do not currently have any FDA-approved dermatologic indications, investigations into their use in cutaneous malignancy are ongoing. In addition these agents, which include cetuximab, panitumumab, gefitinib, erlotinib, afatinib, and osimertinib have significant cutaneous adverse effects and thus knowledge of their indication, mechanism of action, and associated toxicities is relevant to all dermatologists.

EGFR is a member of the ErbB family of tyrosine kinase receptors, which also includes ErbB2 (HER2/neu), ErbB3 (HER3), and ErbB4 (HER4). These cell-surface proteins possess an extracellular ligand-binding domain, a transmembrane domain and an intracellular tyrosine kinase domain (Fig. 194-7). EGFR, which is found on a variety of cell types, including keratinocytes and cells of various solid tumors, is activated following binding of epidermal growth factor (EGF) and other growth factors. Ligand binding to the extracellular domain of EGFR results in dimerization in which the receptor either binds with another EGFR protein or heterodimerizes with an additional monomer of the ErbB family. Dimerization triggers the intracellular tyrosine kinase to autophosphorylate several tyrosine residues. Subsequent recognition of the phosphorylated tyrosine residues on the C-terminal domain of the receptor by various adaptor proteins initiates downstream signal transduction signaling. EGFR activation can trigger networks involved in tumor growth and proliferation, inhibition of apoptosis and metastases such as the MAPK, STAT, PI3K, and phospholipase pathways.

Dysregulation of EGFR signaling is common in several epithelial cancers and can occur through multiple mechanisms including gene amplification and activating mutations. In 2004, the discovery of in-frame activating deletions in exon 19 and the L858R substitution in exon 21 of EGFR profoundly changed the therapeutic landscape in non–small-cell lung cancer (NSCLC) and provided an additional early rationale for precision medicine in oncology.[23,24]

Two distinct mechanisms have been developed to interrupt EGFR signaling as a therapeutic strategy in cancer: (a) targeting of the extracellular ligand binding domain via monoclonal antibodies and (b) inhibition of intracellular tyrosine kinase via small molecules.

The monoclonal antibodies cetuximab and panitumumab have demonstrated efficacy in several carcinomas. Cetuximab holds approval for colorectal and head and neck cancer and panitumumab is indicated in combination with systemic chemotherapy for colorectal cancer.

During the 1990s a concerted effort began to develop small-molecular-weight compounds that inhibit various tyrosine kinases. The first-generation TKIs against EGFR, gefitinib and erlotinib, were designed as competitive inhibitors of ATP binding to the intracellular kinase domain. Despite promising preclinical data, early clinical studies in lung cancer with gefitinib were discouraging as ISEL (Iressa Survival Evaluation in Lung Cancer), a large trial of unselected, heavily pretreated patients, did not show an overall survival benefit in patients with NSCLC.[25] Interestingly, subgroup analysis revealed that never-smokers and Asian patients achieved better overall survival with gefitinib. Translational studies subsequently demonstrated the importance of the exon 19 and exon 21 EGFR mutations as predictive biomarkers. These somatic mutations,

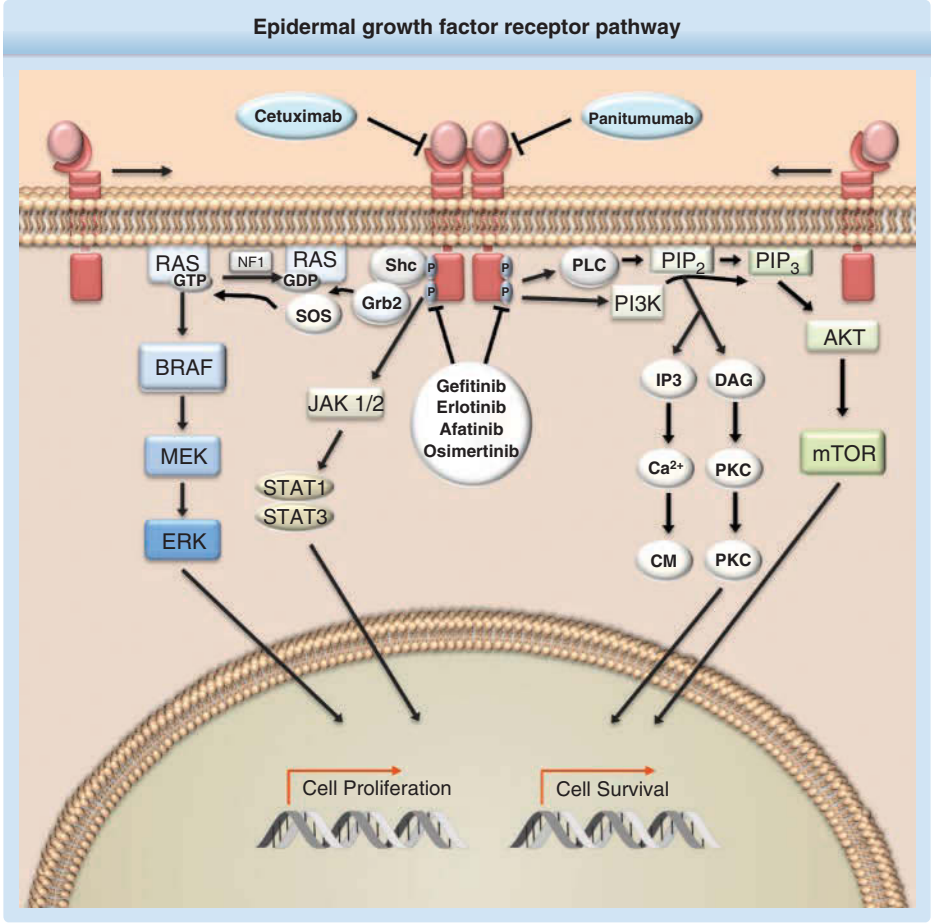

Figure 194-7 Epidermal growth factor receptor (EGFR) pathway. The human epidermal growth receptor is a cell-surface protein comprised of an extracellular ligand-binding domain, a transmembrane domain, and an intracellular tyrosine kinase domain. Binding of the epidermal growth factor and other ligands to the extracellular domain results in dimerization in which the receptor either binds with another EGFR protein (seen above) or heterodimerizes with an additional monomer of the ErbB family. Dimerization triggers the intracellular tyrosine kinase to autophosphorylate several tyrosine residues. Subsequent recognition of the phosphorylated tyrosine residues on the C-terminal domain of the receptor by various adaptor proteins initiates downstream signal transduction signaling. EGFR activation can trigger networks involved in cell proliferation, cell survival and metastases such as the mitogen-activated protein kinase (MAPK), Janus kinase(JAK)/signal transducer and activator of transcription (STAT), phosphatidylinositol-4,5-bisphosphate 3-kinase (PI3K), and phospholipase C (PLC) pathways.

which encode the tyrosine kinase domain of EGFR (encoded by exons 18 to 24), occur at higher frequency in adenocarcinomas, nonsmokers, and Asians. These alterations reduce the affinity of the tyrosine kinase to ATP and thus confer enhanced sensitivity to EGFR TKIs. Followup studies in NSCLC with gefitinib and erlotinib incorporating EGFR-mutation biomarkers have demonstrated superior clinical benefit in patients with exon 19 and exon 21 alterations.[26,27] As a result, erlotinib and the second-generation TKI afatinib are indicated only for NSCLC patients with tumors that possess exon 19 or exon 21 alterations.

Despite initial response to monotherapy EGFR TKI, resistance emerges for the majority of patients within the first 1 to 2 years following initiation of treatment. Secondary mutations in the tyrosine kinase domain of EGFR are associated with the development of resistance to reversible TKIs in the majority of patients. The most clinically relevant secondary mutation, the T790M of exon 20, has been detected in nearly 60% of patients who have become resistant while taking gefitinib or erlotinib.[28] The T790M mutation replaces threonine with a larger methionine residue, simultaneously enhancing the affinity of the EGFR kinase for ATP and sterically impeding drug binding.[29] Showcasing the success of rational drug development, osimertinib, a small molecule inhibitor with activity against EGFR possessing T790M, was shown to be highly active in lung cancer patients with the T790M resistance mutation.[30] This sequence of developmental successes, beginning with the identification a disease-causing protein, demonstrating the clinical efficacy with disruption of that target, followed by second-generation and third-generation modifications of therapies to overcome mechanisms of resistance, exemplifies the goal of targeted therapy.

CETUXIMAB (ERBITUX)

PHARMACOLOGY AND MECHANISM OF ACTION

Structure: Cetuximab is a recombinant, human/mouse chimeric monoclonal antibody. It is a composite of the Fv region of a murine anti-EGFR antibody with a human immunoglobulin G_1 heavy-chain and kappa light-chain constant regions.[31] It has an approximate molecular weight of 152,000 daltons.

Metabolism: The estimated elimination half-life of cetuximab is approximately 112 hours. Clearance of cetuximab appears to be similar to pathways of metabolism for other biologics, including internalization of the ligand-receptor complex with subsequent removal from the circulation.[32]

Absorption and Distribution: Cetuximab is administered intravenously and exhibits nonlinear pharmacokinetics. The volume of distribution appeared to be independent of dose and approximated 2 to 3 L/m^2. Cetuximab reaches steady-state plasma concentrations by the third weekly infusion.

Mechanism of Action: Cetuximab is a monoclonal antibody with affinity for the extracellular ligand-binding portion of EGFR. Cetuximab acts as a competitive inhibitor for EGF and other ligands on normal epithelium as well as tumor cells. Preclinical studies have demonstrated that cetuximab binding to EGFR precludes receptor-associated kinase activation and downregulates signal transduction pathways associated with cell growth, proliferation, angiogenesis, and metastases.[31]

INDICATIONS AND CONTRAINDICATIONS

Cetuximab is FDA approved for use in colorectal and head and neck cancer. Initial approval in 2004 was granted for use in metastatic colorectal cancer (mCRC) in combination with irinotecan in patients who are refractory to irinotecan-based therapy. On March 1, 2006, the FDA expanded approval for use in combination with radiotherapy for patients with local or regionally advanced squamous cell carcinoma of the head and neck (SCCHN) or as monotherapy for patients with recurrent or metastatic SCCHN whose tumors were refractory to platinum-based chemotherapy. In 2011, cetuximab was approved for patients with recurrent locoregional or metastatic SCCHN in combination with platinum-based therapy plus 5-fluorouracil. On July 6, 2012, the FDA granted approval to cetuximab for first-line therapy in combination with FOLFIRI (irinotecan, 5-fluorouracil, and leucovorin) in patients with wildtype K-ras mCRC that expresses EGFR. Erbitux is not indicated for use in patients with RAS-mutated colorectal cancer.

Cetuximab has been investigated for use in cutaneous squamous cell carcinoma (cSCC), although the totality of the efficacy data to date are limited. A Phase II, uncontrolled trial of 36 chemotherapy-naïve patients with unresectable or metastatic cSCC who were treated with an initial dose of 400 mg/m^2 body surface area of cetuximab, followed by weekly doses of 250 mg/m^2 for at least 6 weeks, was published in 2011.[33] This small study reported a complete response in 2 (6%), a partial response in 8 (22%), and stable disease in 15 (42%) of the 36 patients at 6 weeks. Nevertheless, responses were limited in duration, with the median duration of response for the responders of 5 months. Additional prospective studies with larger number of patients are needed to better assess the efficacy of cetuximab in cSCC.

There are no contraindications on the manufacturer's label.

DOSING REGIMEN

Cetuximab is given as an IV infusion. The initial dose is 400 mg/m^2 infused over 120 minutes, followed by weekly infusions at 250 mg/m^2. See the manufacturer's label for premedication recommendations and additional dose and infusion rate modifications.

SIDE EFFECTS AND PRECAUTIONS

Adverse Effects: The most common adverse reactions are cutaneous toxicity, headache, diarrhea, and infection. Cetuximab carries a boxed warning for serious, potentially fatal, infusion reactions that occurred in approximately 3% of patients and for cardiopulmonary arrest and/or sudden death. Close monitoring of serum electrolytes during and after infusion is strongly recommended. Other serious adverse effects include interstitial lung disease and hypomagnesemia.

Similar to other agents that disrupt EGFR signaling, skin toxicities are common with cetuximab and include a papulopustular eruption, xerosis, pruritus, mucositis, alopecia, trichomegaly, paronychia, and onycholysis.[34] The development of an acne-like eruption occurs typically within 1 to 2 weeks of initiation of cetuximab therapy and also is associated with improved clinical outcomes.[35]

Cetuximab is a pregnancy category C drug, and should be used during pregnancy only if the potential harms to the fetus are outweighed by the potential benefit to the mother. Immunoglobulin G antibodies, such as cetuximab, are secreted in human milk; consequently, breastfeeding should be avoided during and at least up to 60 days after treatment, if possible, to prevent potential adverse reactions to nursing infants.

Drug Interactions: No drug interactions are listed on the manufacturer's label.

PANITUMUMAB (VECTIBIX)

PHARMACOLOGY AND MECHANISM OF ACTION

Structure: Panitumumab is a recombinant, human immunoglobulin G_2 kappa monoclonal antibody with a molecular weight of 147,000 daltons.[36] It is engineered in Chinese hamster ovary cells.

Metabolism: The mean estimated elimination half-life is 7.5 days.

Absorption and Distribution: Administration of the recommended dose will result in reaching steady-state concentrations by the third infusion.

Mechanism of Action: Panitumumab is a monoclonal antibody with affinity for the extracellular ligand-binding portion of EGFR. Panitumumab, like cetuximab, functions as a competitive inhibitor for EGF and other ligands on both normal epithelium and tumor cells. Preclinical studies have demonstrated that binding to EGFR by panitumumab decreases receptor-associated kinase activation, resulting in downregulated signal transduction pathways that are associated with cell growth, proliferation, angiogenesis, and metastases.

INDICATIONS AND CONTRAINDICATIONS

Panitumumab is indicated for the treatment of mCRC that is wildtype for KRAS as determined by an FDA-approved test. It has FDA approval as first-line therapy in combination with FOLFOX and as monotherapy following progression after treatment with a regimen incorporating fluoropyrimidine, oxaliplatin, and irinotecan. Panitumumab is not approved for use in mCRC patients who possess a KRAS mutation or for whom the mutation status of KRAS is unknown.

Panitumumab is currently in development for head and neck cancer.

Use of panitumumab has been reported in locally advanced cSCC with promising results. The successful use of panitumumab in an elderly patient who had an anaphylactic reaction to cetuximab[37] and in a small Phase II trial of 16 patients who produced a best overall response rate by RECIST criteria of 31% have been reported.[38] Although promising, pivotal Phase III trials are needed to confirm these early investigational results.

There are no contraindications on the manufacturer's label.

DOSING REGIMEN

Panitumumab is administered as an IV infusion and the recommended dose is 6 mg/kg every 14 days.

There are no specific dosing adjustments for renal or hepatic impairment.

SIDE EFFECTS AND PRECAUTIONS

Adverse Effects: The most common adverse effects are skin toxicity, fatigue, nausea, and diarrhea. Serious adverse effects include electrolyte disturbance, infusion reactions, pulmonary fibrosis/interstitial lung disease, and keratitis. Panitumumab carries a box warning for dermatologic toxicity. Skin adverse events were common in the registration trial, with 90% of patients experiencing toxicity of any grade, while 15% suffered from severe skin toxicity. The cutaneous manifestations include, but are not limited to, papulopustular eruptions, exfoliation, pruritus, erythema, photosensitivity, xeroderma, and paronychia. Fatal bullous disease and life-threatening necrotizing fasciitis, abscesses and sepsis have been observed in patients on panitumumab.[36]

Panitumumab is a pregnancy category C drug. No studies have been performed in pregnant women, although Cynomolgus monkeys treated with 1.25 to 5 times the recommended human dose did demonstrate evidence of embryo lethality and abortions. Consequently, extreme caution is recommended with administration during pregnancy and the risks to the fetus must be weighed against the potential benefit to the mother.

It is recommended that breastfeeding by avoided during treatment of at least 2 months following completion of treatment.

Drug Interactions: No specific drug interactions are listed on the manufacturer's label.

GEFITINIB (IRESSA)

PHARMACOLOGY AND MECHANISM OF ACTION

Structure: Gefitinib, 4-quinazolinamine *N*-(3-chloro-4-uorophenyl)-7-methoxy-6-[3-(4-morpholinyl) propoxy], has the molecular formula $C_{22}H_{24}ClFN_4O_3$ and a molecular mass of 446.9 daltons.[39] Figure 194-8 shows the structure of gefitinib.

Metabolism: Gefitinib is metabolized predominantly by CYP3A4 and to a lesser degree by CYP2D6. The estimated elimination half-life is 48 hours after intravenous administration.

Absorption and Distribution: The oral bioavailability of gefitinib is approximately 60% and peak plasma levels are reached 3 to 7 hours after dosing.

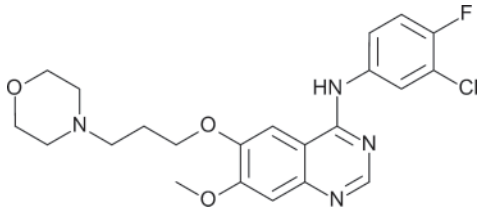

Figure 194-8 Structure of gefitinib.

Food does not significantly affect absorption. The volume of distribution is 1400 L.

Mechanism of Action: Gefitinib is a small-molecule TKI. It reversibly binds and inhibits the kinase domain of EGFR. Gefitinib has a higher affinity for EGFR harboring exon 19 deletions or the exon 21 point mutation L858R, as compared with the wild-type EGFR protein.

INDICATIONS AND CONTRAINDICATIONS

Gefitinib has limited indication in the United States to patients with NSCLC who are currently receiving and benefitting from gefitinib or have previously benefited from therapy with gefitinib. Gefitinib was initially granted accelerated approval by the FDA in May 2003 for patients with NSCLC tumors that were refractory to a platinum-based regimen and docetaxel. However, after 2 studies demonstrated a lack of efficacy, the FDA changed the label in 2005, withdrawing approval for new patients. Subsequent studies have demonstrated clinical effectiveness of gefitinib in patients with tumors harboring EGFR mutations and the drug is indicated for use in advanced NSCLC in Europe. Gefitinib does not have any current FDA-approved indications for dermatologic disease.

There are no contraindications on the manufacturer's label.

DOSING REGIMEN

Recommended dosing is 250 mg once daily by mouth, with or without food.

SIDE EFFECTS AND PRECAUTIONS

Adverse Effects: Skin toxicities and diarrhea are the most common adverse effects. Cutaneous toxicities are common and share the characteristics of other agents targeting EGFR. A papulopustular eruption, xeroderma, and pruritus are all common. The papulopustular eruption typically develops 1 to 2 weeks following treatment initiation and has been associated with improved overall survival.[40] Other adverse cutaneous manifestations include photosensitivity, mucositis as well as nail and hair changes. Nail effects include onycholysis, paronychia, and pyogenic granulomalike lesions of the nailfold. Hair changes include alopecia, trichomegaly and hirsutism.[12]

Based on preclinical animal studies, gefitinib may produce fetal harm when administered to pregnant women. Thus, it is recommended to strongly advise avoidance of gefitinib during pregnancy. Gefitinib has been detected in rat milk and thus lactating women should be made aware of the potential harm to infants during nursing.

Drug Interactions: Caution is advised when gefitinib is administered concomitantly with inhibitors and inducers of CYP3A4. It is also recommended to avoid compounds that can affect gastric pH such as proton pump inhibitors. Close monitoring of the prothrombin time and/or international normalized ratio when used with warfarin is warranted.

See the Iressa package insert for full drug–drug interactions and adverse effects.[39]

ERLOTINIB HYDROCHLORIDE (TARCEVA)

PHARMACOLOGY AND MECHANISM OF ACTION

Structure: Erlotinib, *N*-(3-ethynylphenyl)-6,7-*bis*(2-methoxyethoxy)-4-quinazolinamine, has the molecular formula $C_{22}H_{23}N_3O_4 \bullet HCl$ and a molecular weight of 429.90 daltons.[41] Figure 194-9 shows the structure of erlotinib.

Metabolism: Erlotinib is predominantly metabolized by CYP3A4 and to a lesser degree by CYP1A2 and CYP1A1. The elimination half-life is estimated to be 36.2 hours. Time to steady-state in the plasma is 7 to 8 days.

Absorption and Distribution: Peak plasma levels are reached after 4 hours of an oral dose. Oral absorption is 60%, which is increased to approximately 100% if administered with food. The volume of distribution is 232 L.

Mechanism of Action: Erlotinib is a reversible small-molecule inhibitor of EGFR. It competes with the binding of ATP to the intracellular domain of EGFR, thus preventing autophosphorylation of the tyrosine residues and precluding downstream signal transduction. Erlotinib exhibits preferential binding to EGFR proteins that possess the exon 19 deletion or exon 21 (L858R) mutations as compared to the wildtype EGFR protein.

INDICATIONS AND CONTRAINDICATIONS

Erlotinib has FDA approval for use in NSCLC and pancreatic carcinoma. In NSCLC its approval extends to first-line, maintenance, or second-line or greater therapy after progression following at least 1 regimen of chemotherapy in patients with metastatic tumors that

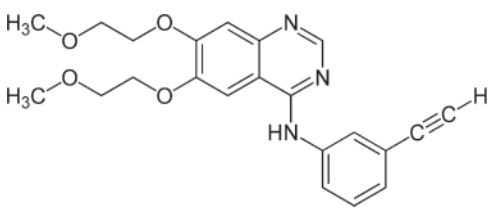

Figure 194-9 Structure of erlotinib.

possess either exon 19 deletions or exon 21 (L858R) substitution mutations in EGFR, as detected by an FDA-approved test.

Erlotinib is also indicated for patients with locally advanced, unresectable or metastatic pancreatic carcinoma as frontline therapy in combination with gemcitabine.

Erlotinib is being investigated in combination with radiotherapy and other systemic agents in cSCC. In melanoma, a Phase II trial of erlotinib and bevacizumab for patients with metastatic disease demonstrated disappointing results, with a progression-free survival (PFS) of only 2 months.[42]

There are no contraindications listed on manufacturer's label.

DOSING REGIMEN

For NSCLC, the recommended dose of erlotinib is 150 mg by mouth administered once daily until disease progression or unacceptable toxicity. The dose for pancreatic cancer is 100 mg once daily, in combination with gemcitabine, until disease progression or unacceptable toxicity. It is recommended that erlotinib be taken on an empty stomach.

No dose adjustments are provided in the manufacturer's labeling during initial treatment in patients with renal impairment. Monitoring of renal function is recommended while taking erlotinib and the drug should be stopped in patients developing renal impairment until toxicity has resolved.

Specific dosing for hepatic impairment has not been defined. See the manufacturer's label for adjustments in patients with baseline liver abnormalities.

SIDE EFFECTS AND PRECAUTIONS

Adverse Effects: The most common adverse effects include cutaneous toxicity, diarrhea, fatigue, anorexia, dyspnea, cough, nausea, and vomiting. Serious drug toxicities include interstitial lung disease, which occurs in 1.1% of patients who are taking erlotinib, hepatotoxicity, GI perforations, myocardial ischemia/infarction, microangiopathic hemolytic anemia, cerebrovascular accident, corneal perforations/ulcerations, and persistent severe keratitis.

Skin toxicities are very common and occur to some degree in most patients receiving erlotinib. The most common include the development of a papulopustular eruption, xeroderma, and pruritus. The papulopustular eruption often develops 1 to 2 weeks following treatment initiation and has been associated with improved overall survival.[40] Other adverse cutaneous manifestations include bullous eruptions, photosensitivity, and mucositis, as well as nail and hair changes. Nail effects include onycholysis, paronychia, and pyogenic granuloma-like lesions of the nailfold. Hair changes include alopecia, trichomegaly, and hirsutism.[12]

Erlotinib can cause fetal harm and women of reproductive potential should be advised to use highly effective contraception. In regards to breastfeeding, it is not known if erlotinib is found in breastmilk, but based on the potential for serious harm, it is recommended that the risks and benefits of taking Tarceva be weighed carefully.

Drug Interactions: Caution should be advised when erlotinib is administered with inhibitors or inducers of CYP3A4 and CYP1A2 as they can affect the plasma concentrations. Cigarette smoking can accelerate clearance of erlotinib, potentially decreasing its antitumor effects. Caution is also advised with concomitant use of compounds such as proton pump inhibitors, H_2-receptor antagonists, and antacids, which increase gastric pH and can decrease erlotinib plasma concentrations.

See the Tarceva package insert for full drug–drug interactions and adverse effects.

AFATINIB DIMALEATE (GILOTRIF)

PHARMACOLOGY AND MECHANISM OF ACTION

Structure: Afatinib dimaleate, 2-butenamide, *N*-[4-[(3-chloro-4-fluorophenyl)amino]-7-[[(3*S*)-tetrahydro-3-furanyl]oxy]-6-quinazolinyl]-4-(dimethylamino)-,(2*E*)-,(2*Z*)2-butenedioate (1:2), has the molecular formula $C_{32}H_{33}ClFN_5O_{11}$ and a molecular weight of 718.1 daltons.[43] Figure 194-10 shows the structure of afatinib.

Metabolism: Enzymatic metabolism of afatinib is minimal and the compound is principally excreted in the feces following covalent adducts to circulating proteins. The elimination half-life is estimated to be 37 hours. Time to steady-state in the plasma is approximately 8 days.

Absorption and Distribution: Peak plasma levels are reached 2 to 5 hours after an oral dose. Oral absorption is approximately 92%, and a high-fat meal decreased maximal plasma concentrations by 50%.

Mechanism of Action: Afatinib is a second-generation small-molecule kinase inhibitor with activity against all 4 ErbB family members. Unlike

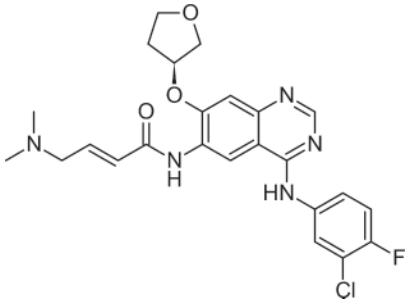

Figure 194-10 Structure of afatinib.

the first-generation EGFR TKIs gefitinib and erlotinib, which reversibly inhibit EGFR, afatinib covalently binds the kinase domain of the receptor. Consequently, afatinib irreversibly inhibits autophosphorylation of associated tyrosine residues, resulting in downregulation of cell growth and survival signal transduction pathways.

INDICATIONS AND CONTRAINDICATIONS

Afatinib has FDA approval for use as a first-line agent in metastatic NSCLC that possesses either exon 19 deletions or exon 21 (L858R) substitution mutations in EGFR, as detected by an FDA-approved test. Afatinib does not have any current FDA-approved indications for dermatologic disease.

There are no contraindications listed on manufacturer's label.

DOSING REGIMEN

The recommended dose for afatinib is 40 mg by mouth administered once daily until disease progression or unacceptable toxicity. It is recommended that afatinib be taken at least 1 hour before or 2 hours after a meal.

For patients with renal impairment (estimated glomerular filtration rate: 15 to 29 mL/min), a reduction to 30 mg by mouth daily is recommended. Afatinib has not been studied in patients with glomerular filtration rates of <15 mL/min; consequently, no specific dose adjustments are recommended.

Afatinib has not been studied in patients with severe (Child-Pugh grade C) hepatic impairment. For patients with mild-to-moderate hepatic impairment, no specific dose modifications are given.

SIDE EFFECTS AND PRECAUTIONS

Adverse Effects: The most common adverse effects of afatinib include diarrhea, cutaneous toxicity, anorexia, nausea, and vomiting. Serious drug toxicities include interstitial lung disease, which occurs in 1.6% of patients who are taking afatinib, hepatotoxicity, keratitis, and embryofetal toxicity.[43]

Skin toxicities are common and include the development of a papulopustular eruption, xeroderma, pruritus, stomatitis, and nail changes. Correlative studies suggest that the development of the papulopustular eruption might be predictive of tumor response, similar to that seen in other EGFR inhibitors.[44] When compared to gefitinib and erlotinib, afatinib has been shown to induce paronychia at a higher frequency and with accelerated onset.[45] Although the mechanism for this difference has not been elucidated, the fact that afatinib is an irreversible inhibitor while both gefitinib and erlotinib are both reversible inhibitors, has been cited as a possible explanation.[45] There is a report of afatinib-associated Stevens-Johnson syndrome.[46] Other cutaneous effects include hypertrichosis of the eyelashes and eyebrows.[47]

Afatinib can cause fetal harm and women of reproductive potential should be recommended to use highly effective contraception during treatment and for at least 2 weeks after the last dose. In regards to breastfeeding, it is not known if afatinib is found in human breastmilk, but based on the potential for serious harm, it is recommended that breastfeeding be avoided in women taking Gilotrif and for 2 weeks following the final dose.

Drug Interactions: Caution is advised when afatinib is used with agents that modify P-glycoprotein. Coadministration of inhibitors of P-glycoprotein—including, but not limited to, ketoconazole, itraconazole, ritonavir, cyclosporine, tacrolimus, erythromycin, verapamil, quinidine, nelfinavir, saquinavir, and amiodarone—can increase afatinib concentrations. Conversely, afatinib exposure can be decreased when coadministered with inducers of P-glycoprotein, such as phenytoin, rifampicin, phenobarbital, carbamazepine, and St. John's wort.[43]

See the Gilotrif package insert for full drug–drug interactions and adverse effects.

OSIMERTINIB (TAGRISSO)

PHARMACOLOGY AND MECHANISM OF ACTION

Structure: Osimertinib (AZD9291), *N*-(2-{2-dimethylaminoethyl-methylamino}-4-methoxy-5-{[4-(1-methylindol-3-yl)pyrimidin-2-yl]amino}phenyl) prop-2-enamide mesylate salt, has the molecular formula $C_{28}H_{33}N_7O_2 \bullet CH_4O_3S$, and the molecular weight of 596 daltons.[48] Figure 194-11 shows the structure of osimertinib.

Metabolism: Osimertinib is metabolized primarily by oxidation via CYP3A and dealkylation. It is excreted primarily in the feces and the estimated elimination half-life is 48 hours.

Absorption and Distribution: Following administration, the median time to maximum concentration is 6 hours, with a range of 3 to 24 hours. The mean volume of distribution at steady-state is 986 L.

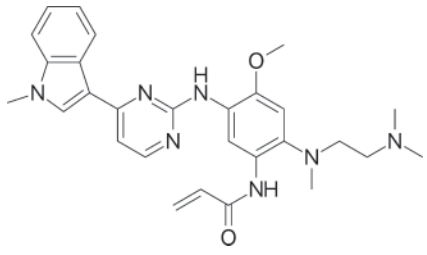

Figure 194-11 Structure of osimertinib.

Mechanism of Action: Osimertinib is a small-molecule kinase inhibitor of the EGFR. It binds irreversibly to certain mutant forms of EGFR, such as T790M, L858R, and exon 19 deletion, and with a higher affinity as compared with the wildtype EGFR protein. In vitro, osimertinib has been shown to inhibit ACK1, BLK, and HER2, HER3, and HER4, the other 3 ERbB members.

INDICATIONS AND CONTRAINDICATIONS

Osimertinib received accelerated approval in November 2015 for patients with metastatic NSCLC that possess a T790M mutation in EGFR and have progressed on prior EGFR TKI therapy. Approval was based on data from the 2 AURA Phase II studies (AURA extension and AURA2). These were multicentered single-arm trials of 411 patients with T790M-mutant EGFR NSCLC who had progressed on prior EGFR TKI therapy and in aggregate osimertinib-treated patients had a 59% overall objective response rate.[30] Osimertinib does not have any current FDA-approved indications for dermatologic disease. In 2018, the FDA granted an approval for first-line treatment in patients with metastatic NSCLC with exon 19 deletions or exon 21 L858R mutations.

There are no contraindications on the manufacturer's label.

DOSING REGIMEN

The recommended dosing in patients with a confirmed T790M EGFR mutation is 80 mg once daily by mouth, with or without food.

SIDE EFFECTS AND PRECAUTIONS

Adverse Effects: Similar to other EGFR kinase inhibitors, osimertinib commonly causes diarrhea, rash, xerosis, nail changes, nausea, and anorexia. Serious toxicities include interstitial lung disease/pneumonitis, QTc interval prolongation, cardiomyopathy, and embryofetal toxicity.

Based on the mechanism of action and animal studies, osimertinib can cause harm to a developing fetus when administered to a pregnant woman. It is recommended to advise females of reproductive age to use effective contraception during treatment and for 6 weeks after the final dose of osimertinib. Additionally, it is recommended to advise males to use highly effective contraception for 4 months after the final dose if they are sexually active with females of reproductive potential.

Breastfeeding while taking osimertinib and for the 2 weeks following the final dose is not recommended.

Drug Interactions: Caution is advised when osimertinib is administered concomitantly with strong inducers of CYP3A (eg, phenytoin, rifampin, carbamazepine, St. John's wort). Coadministering osimertinib with rosuvastatin (a breast cancer resistance protein [BRCP] substrate) increased plasma concentrations of rosuvastatin, whereas coadministration with simvastatin (a CYP3A4 substrate) had no clinically significant effect on simvastatin concentrations. Thus, close monitoring for adverse effects is recommended when osimertinib is used with BRCP substrates (eg, rosuvastatin, sulfasalazine, topotecan).

See the Tagrisso package insert for full drug–drug interactions and adverse effects.

SMOOTHENED INHIBITORS

AT-A-GLANCE

- The hedgehog pathway is disrupted in the vast majority of basal cell carcinomas.
- Loss of the tumor-suppressor PTCH1 or activating mutations in smoothened leads to unregulated cell growth and oncogenesis.
- The small molecules vismodegib and sonidegib are inhibitors of smoothened and are approved for the treatment of unresectable and advanced basal cell carcinoma.
- Vismodegib and sonidegib carry boxed warnings for embryofetal toxicity.

BACKGROUND

The hedgehog (HH) pathway, a cascade vital for embryonic development, is now known to be critical in the molecular pathogenesis of basal cell carcinoma (BCC). In the 1990s, mutations in the tumor-suppressor patched 1 (*PTCH1*) gene were found in both BCCs arising in basal cell nevus syndrome[49] and in sporadic cases.[50] Loss of *PTCH1*, an inhibitor of the downstream protein smoothened (SMO), results in constitutive upregulation of HH signaling and overexpression of genes responsible for cell survival, growth, proliferation, vascularization and healing (Fig. 194-12). Nearly all sporadic BCCs have a disease-promoting mutation in HH signaling, with approximately 90% possessing a loss of at least 1 allele PTCH1 and 10% having activating mutations in SMO.[51] Molecularly targeted therapy for BCC emerged in 2012 with the first-in-class SMO inhibitor vismodegib (Erivedge). In 2015, the second-in-class inhibitor sonidegib (Odomzo) was approved.

VISMODEGIB (ERIVEDGE)

PHARMACOLOGY AND MECHANISM OF ACTION

Structure: Vismodegib, 2-Chloro-*N*-[4-chloro-3-(2-pyridinyl)phenyl]-4-(methylsulfonyl)benzamide, has the molecular formula $C_{19}H_{14}Cl_2N_2O_3S$ and molecular weight of 421.3 g/mol.[52] Figure 194-13 shows the structure of vismodegib.

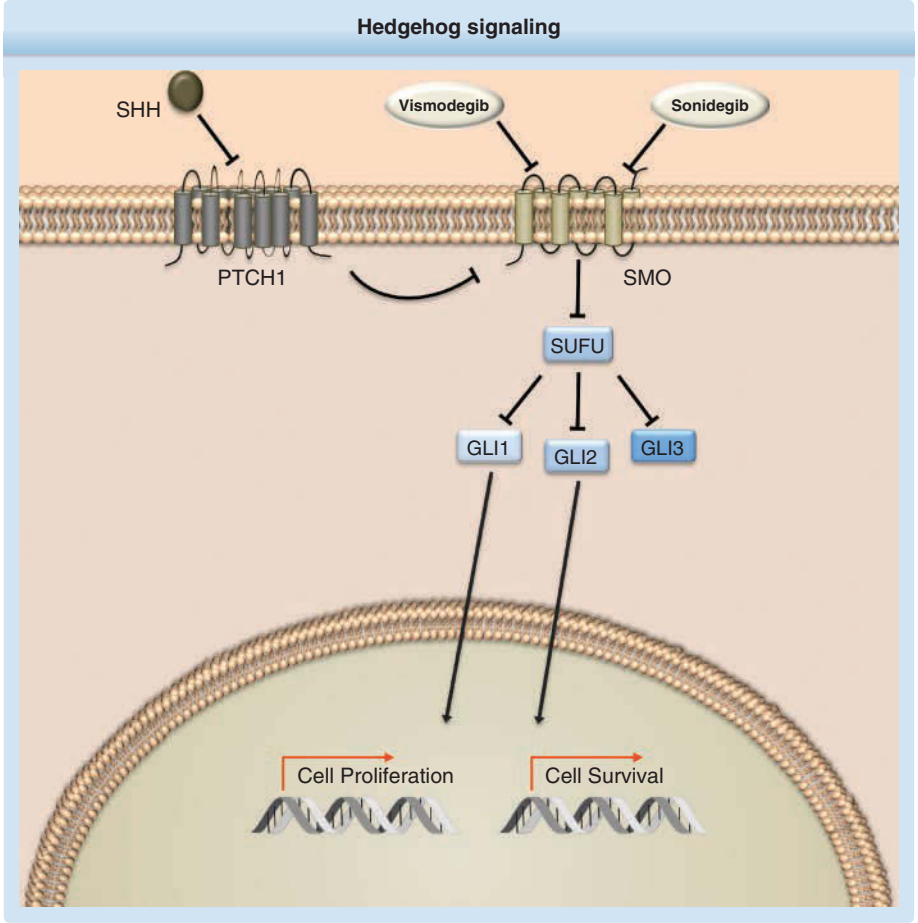

Figure 194-12 Hedgehog signaling. Hedgehog (HH) signaling is initiated by binding of 1 of 3 extracellular HH ligands, sonic hedgehog (SHH), Indian hedgehog (IHH) and desert hedgehog (DHH). These ligands bind to 12-pass transmembrane protein receptors Patched 1 (PTCH1) and Patched 2 (PTCH2). When unbound, Patched receptors interact and inhibit the 7-pass transmembrane transduction protein Smoothened (SMO). Following ligand binding to Patched, the inhibition of SMO is relieved and transduction through a series of interacting proteins, including suppressor of fused (SUFU), results in translocation of the glioma-associated oncogene homolog (GLI) transcription factors: GLI1, GLI2, and GLI3. GLI1 functions exclusively as an activator of transcription, while the actions of GLI2 and GLI3 are dependent on the signaling context. In the absence of HH ligands, GLI3 functions as the primary repressor of the transduction cascade. Following nuclear translocation, GLI transcription factors modulate the expression on numerous cell programs including those involved in cell growth, proliferation, epithelial–mesenchymal transition, angiogenesis, inhibition of apoptosis, and stem cell maintenance. The small molecules vismodegib and sonidegib bind to SMO and impair signaling through the HH pathway.

Metabolism: Vismodegib is metabolized via oxidation and glucuronidation primarily by CYP2C9 and CYP3A4/5, although it is excreted predominantly in its unchanged form.[52] The estimated half-life is 12 days following a single dose and 4 days with continuous daily dosing.

Absorption and Distribution: Vismodegib is absorbed orally and has a bioavailability of 31.8%.

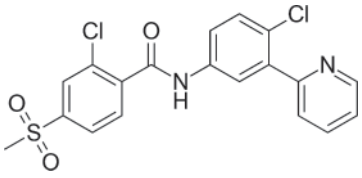

Figure 194-13 Structure of vismodegib.

The volume of distribution is 16.4 L to 26.6 L. Vismodegib binds to serum albumin and α_1-acid glycoprotein.

Mechanism of Action: Vismodegib is a first-in-class small-molecule inhibitor of the 7-pass transmembrane protein SMO, a key member of the HH signal-transduction pathway. Inhibition of SMO precludes activation and translocation of the transcription factor GLI (glioma-associated oncogene homolog), thereby decreasing the induction of genes involved with cell proliferation and survival.

INDICATIONS AND CONTRAINDICATIONS

Vismodegib was approved by the FDA on January 30, 2012, for treatment of adult patients with metastatic or

unresectable BCC. Approval stemmed from data from the ERIVANCE BCC trial, a multicenter, Phase II, single-arm, two-cohort, open-label II trial of 104 patients with locally advanced (n = 63) or metastatic BCC (n = 33).[53] Vismodegib taken orally produced objective responses in 10 (30.3%) patients with metastatic BCC and 27 (42.8%) patients with locally advanced BCC. Median duration of response was 7.6 months.

There are no contraindications on the manufacturer's label.

DOSING REGIMEN

Recommended dosing for vismodegib is 150 mg daily by mouth for metastatic and locally advanced BCC. It is usually continued until disease progression or the development of unacceptable adverse effects. The safety and effectiveness of vismodegib has not been established in patients with hepatic or renal impairment.

SIDE EFFECTS AND PRECAUTIONS

Adverse Effects: Treatment-emergent adverse effects are commonly experienced with vismodegib. In the STEVIE (Safety Events in Vismodegib) study, a multicenter, open-label trial of 499 patients with metastatic BCC or locally advanced BCC, 491 patients had at least 1 adverse effect.[54] Common adverse effects include muscle spasms, dysgeusia, asthenia, decrease in weight, fatigue, nausea, decrease in appetite, and diarrhea. Cutaneous adverse effects are common. Alopecia occurs in the majority of patients (58% to 63%).[55] Keratoacanthomas and well-differentiated squamous cell carcinomas occurring during treatment also have been described.[55] Roughly one-third of patients in STEVIE discontinued treatment because of unacceptable toxicity. Grade 5 adverse effects have been reported in patients using vismodegib, although according to the trial investigators, those events were thought to be unrelated to vismodegib.[53,54] Premature fusion of the epiphyses has been reported in pediatric patients exposed to Erivedge, and in some cases, the fusion progressed after discontinuation of the drug.[52]

Animal reproductive studies demonstrated that vismodegib is teratogenic, embryotoxic, and fetotoxic. In rats, doses approximately 0.2 times the area under the curve of the recommended dose in humans resulted in malformation, retardations, or variations in skeletal and visceral structures. As a result, the Erivedge product label contains a boxed warning of embryofetal toxicity. Women should be screened for pregnancy 7 days prior to starting and it is recommended that females avoid pregnancy during treatment and for up to 24 months after the last dose. It is recommended that male patients use condoms with spermicide during treatment and for 3 months after discontinuation. Women should be counseled not to breastfeed during treatment and for 24 months after the last dose.

Patients are advised not to donate blood products during treatment and for 24 months after completing treatment.

Drug Interactions: There is little definitive evidence at this time of drug interactions with vismodegib. Data indicates that vismodegib is a substrate of the P-glycoprotein efflux transporter; consequently, coadministration with inhibitors of P-glycoprotein, such as macrolide antibiotics, may increase drug levels and systemic toxicity. Medications that affect gastric pH may reduce the drug's bioavailability, but there are no formal studies evaluating the effect of pH-altering drugs on vismodegib.

See the Erivedge package insert for full drug–drug interactions and adverse effects.[52]

SONIDEGIB (ODOMZO)

PHARMACOLOGY AND MECHANISM OF ACTION

Structure: Sonidegib, *N*-[6-(*cis*-2,6-dimethylmorpholin-4-yl)pyridine-3-yl]-2-methyl-4′-(trifluoromethoxy)[1,1′-biphenyl]-3-carboxamide diphosphate, has the molecular formula $C_{26}H_{26}F_3N_3O_3 \bullet 2H_3PO_4$ and molecular weight of 681.49 daltons. Figure 194-14 shows the structure of sonidegib.

Metabolism: Sonidegib is metabolized by CYP3A, and the compound and its metabolites are primarily excreted via the enterohepatic circulation. The elimination half-life is approximately 28 days and 70% of the absorbed dose is eliminated in the feces and 30% is excreted in the urine.[56]

Absorption and Distribution: When given orally, less than 10% of the dose is absorbed. Consumption of a high-fat meal results in an increased systemic exposure of the drug. Steady-state volume of distribution is 9166 L with the compound exhibiting high binding to plasma proteins.

Mechanism of Action: Sonidegib, like vismodegib, is a small-molecule inhibitor of the 7-pass, transmembrane protein SMO. Consequently, exposure to the compound is thought to attenuate the expression of HH signaling genes involved with cell proliferation and survival.

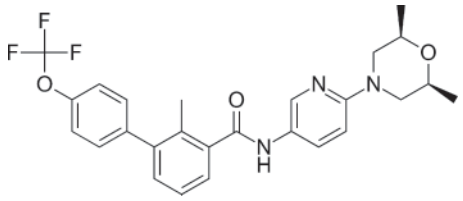

Figure 194-14 Structure of sonidegib.

INDICATIONS AND CONTRAINDICATIONS

Sonidegib was approved by the FDA on July 24, 2015, for treatment of adults patients with locally advanced BCC that recurs following surgical excision or radiotherapy, and for those patients who are not candidates for surgery or radiotherapy. The approval was based on data from the BOLT (Basal Cell Carcinoma Outcomes With LDE225 Treatment) trial, an international multicenter, randomized, 2-arm, noncomparative trial of 230 patients.[57] Daily administration of 200 mg of sonidegib produced objective responses in 43% of patients, and 800 mg daily achieved objective responses of 38%.

The drug has no contraindications on the product label.

DOSING REGIMEN

Recommending dosing is 200 mg by mouth daily, taken at least 1 hour prior to or 2 hours after a meal, until disease progression or unacceptable adverse effects.

Prior to starting treatment, it is recommended to obtain verification of the pregnancy status of women with reproductive potential, and serum creatinine kinase and kidney function tests for all patients.

There are no recommended dose adjustments for patients with mild-to-moderate renal impairment (CrCl 30 to 59 mL/min) or for patients with mild hepatic impairment. Data is lacking in patients with more significant liver impairment.

SIDE EFFECTS AND PRECAUTIONS

Adverse Effects: The most common adverse events include muscle spasms, alopecia, dysgeusia, nausea, elevated creatinine kinase, fatigue, weight loss, anorexia, myalgia, headache, and pruritus. Adverse effects limit the duration of treatment in roughly one-third of patients. One case of rhabdomyolysis was reported by the study investigators, although upon independent review, the case was deemed not to be consistent with rhabdomyolysis. Nevertheless, baseline creatinine kinase levels are suggested and dose interruptions are recommended for the first occurrence of serum creatinine kinase elevation between 2.5 and 10 times the ULN.

Although there are no data from pregnant women, animal toxicity studies demonstrated that sonidegib, like vismodegib, is teratogenic, embryotoxic, and fetotoxic. As a result, there is a boxed warning on the Odomzo package label for embryofetal toxicity. Consequently, women with childbearing potential should be warned of the potential embryofetal death and severe birth defects and should be advised to avoid pregnancy during treatment and for at least 20 months after the last dose. Although the concentration of sonidegib in semen has not been evaluated, it is recommended that male patients use condoms with spermicide during treatment and for at least 8 months after discontinuation. There is inadequate literature to assess the safety of sonidegib in regards to lactation; consequently, it is recommended that women avoid breastfeeding during treatment with sonidegib for at least 20 months after the last dose. There are no data regarding the effects of sonidegib on human reproduction; however, the compound did decrease fertility in female rodents at doses 1 to 2 times the recommended human dose.

Patients are advised not to donate blood products during treatment and for 20 months after completing treatment.

Drug Interactions: Given that sonidegib is metabolized by CYP3A, inhibitors and inducers of CYP3A can affect drug concentrations and such agents should be used with caution. Preclinical studies suggest that sonidegib inhibits CYP2B6 and CYP2C9 and thus can affect drug levels of those substrates.

See the Odomzo package insert for full drug–drug interactions and adverse effects.[56]

HISTONE DEACETYLASE INHIBITORS

AT-A-GLANCE

- Histone modification is a key epigenetic phenomena that regulates gene expression.
- Abnormalities in the acetylation of histone proteins is a common occurrence in several malignancies.
- Regulation of histone acetylation is controlled by histone acetyltransferases and histone deacetylases (HDACs).
- Inhibitors of HDACs have demonstrated efficacy as cancer therapy and their administration is thought to induce differentiation, cell-cycle arrest and apoptosis through restoration of normal acetylation of histone and nonhistone proteins.
- Of the 4 HDAC inhibitors currently approved, 2—vorinostat and romidepsin—have FDA approval for the treatment of cutaneous T-cell lymphoma.

BACKGROUND

Dysregulated gene expression is a hallmark of oncogenesis. Aberrant expression of genes can result from mutations of the DNA nucleotide sequence or via epigenetic modulations, such as chromatin modification. DNA and histone complexes form the basic structural unit of chromatin, the nucleosome. The conformational structure of nucleosomes and chromatin is regulated, in part, by acetylation of histone proteins. In its condensed form, negatively charged DNA is wrapped tightly around positively charged histone proteins, limiting the ability of transcription factors to access DNA promoter

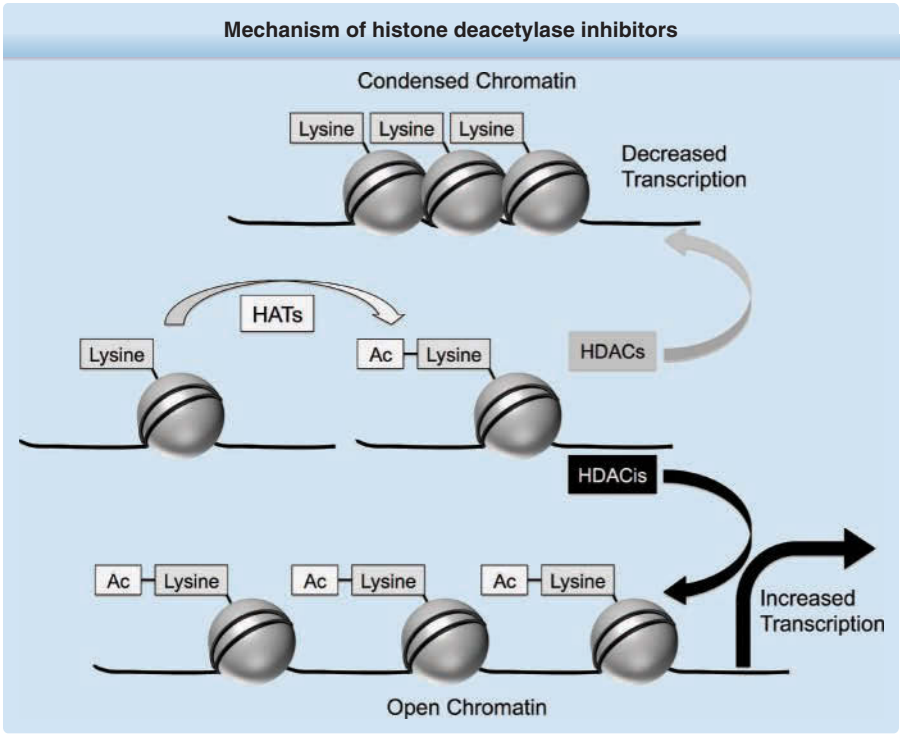

Figure 194-15 Mechanism of histone deacetylase inhibitors. In its condensed form, negatively charged DNA (*black lines*) is wrapped tightly around positively charged histone proteins (*gray spheres*), limiting the ability of transcription factors to access DNA promoter regions. Histone acetyltransferases (HATs) neutralize the positive charge on histones by the addition of acetyl groups to the lysine residues in the tails of histones. Acetylation of these residues results in a more relaxed structure for chromatin and permits greater access to gene promoters by transcription factors, facilitating gene expression. In contrast, the activity of histone deacetylases (HDACs) promotes an underacetylated state, contributing to transcriptional silencing by impairing nucleosome accessibility (*upper panel*). Agents that inhibit HDACs (HDACis) are thought to restore normal acetylation, resulting in increased transcription of genes that regulate differentiation, cell-cycle arrest, and apoptosis (*bottom panel*).

regions. The acetylation of lysine residues in the tails of histones by histone acetyltransferases neutralizes the positive charge on histones (Fig. 194-15). This results in a more relaxed structure for chromatin and permits greater access to gene promoters by transcription factors, facilitating gene expression. In contrast, the activity of histone deacetylases (HDACs) promotes an underacetylated state, contributing to transcriptional silencing by impairing nucleosome accessibility. The fine balance between acetylation and deacetylation is disrupted in several human diseases. In cancer cells, histone deacetylation is associated with the downregulation of proapoptotic genes as well as of genes critical for differentiation.[58] In addition to chromatin modulation, histone acetyltransferases and HDACs have been shown to be involved in the regulation of nonhistone proteins involved in oncogenesis, such as p53, nuclear factor κB, E2F, and hypoxia-inducible factor 1α.[58,59] Consequently, inhibitors of HDACs have been developed for therapeutic use and have shown promise in several malignancies, including cutaneous T-cell lymphoma. Although the exact therapeutic mechanism is unknown, drugs that inhibit HDACs are thought to induce differentiation, cell-cycle arrest and apoptosis through restoration of normal acetylation.[58] The FDA has approved 4 HDAC inhibitors for cancer therapy: vorinostat, romidepsin, belinostat, and panobinostat. Vorinostat and romidepsin have approval for use in cutaneous T-cell lymphoma, while romidepsin and belinostat are indicated to treat peripheral T-cell lymphoma. Panobinostat is approved for use in multiple myeloma.

VORINOSTAT (ZOLINZA)

PHARMACOLOGY AND MECHANISM OF ACTION

Structure: Vorinostat, suberanilohydroxamic acid or *N*-hydroxy-*N'*-phenyloctanediamide, is a hydroxamic acid derivative with the empirical formula $C_{14}H_{20}N_2O_3$ and molecular weight of 264.32 daltons. Figure 194-16 shows the structure of vorinostat.

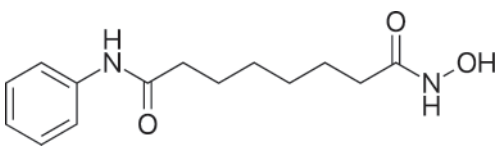

Figure 194-16 Structure of vorinostat.

Metabolism: Glucuronidation and hydrolysis are the major metabolic pathways of vorinostat. There is negligible biotransformation by CYP. The mean terminal half-life is approximately 2 hours.

Absorption and Distribution: When taken orally with a high-fat meal, the median time to maximum concentration is 4 hours. Steady-state concentrations after multiple doses in the fed-state are achieved in 4 hours (range: 0.5 to 14 hours).

Mechanism of Action: Vorinostat is an inhibitor of the several HDACs including HDAC1, HDAC2, HDAC3, and HDAC6. In vitro, vorinostat results in the accumulation of acetylated histones, and in some transformed cells, induces apoptosis and/or arrest of the cell cycle.[60]

INDICATIONS AND CONTRAINDICATIONS

Vorinostat was approved in 2006 for treatment of cutaneous T-cell lymphoma in patients with persistent, recurrent, or progressive disease on or following 2 systemic therapies. Approval was based on 2 Phase II trials that demonstrated overall objective response rates ranging from 24% to 30% in heavily pretreated patients.[61,62] Improvement in baseline pruritus was also noted in 32% to 45% of patients.[61,62] Although vorinostat demonstrates efficacy in patients with refractory disease, it is typically regarded as beyond second-line therapy.

There are no specific contraindications on the drug label.

DOSING REGIMEN

The recommended dose of vorinostat is 400 mg by mouth once daily with food.

Vorinostat has not been adequately studied in patients with renal impairment. Although renal excretion does not play a role in the elimination of vorinostat, caution is advised in patients with preexisting renal impairment.

Compared to patients with normal renal function, patients with mild (bilirubin >1 to 1.5 times ULN or aspartate aminotransferase > ULN but bilirubin ≤ ULN) and moderate (bilirubin 1.5 to ≤3 times ULN) hepatic impairment has mean area-under-the-curve levels that were increased by 50%. Therefore, it is recommended to reduce the dose in patients with mild-to-moderate hepatic impairment, although no specific recommendations are made on the package label because of insufficient data.

SIDE EFFECTS AND PRECAUTIONS

Adverse Effects: The most common adverse reactions (incidence ≥20%) are fatigue, diarrhea, nausea, dysgeusia, thrombocytopenia, anorexia, and weight loss. Alopecia was observed in 18.6% of patients in the clinical trials leading to the drug's approval.[60] The most common serious adverse reactions in the clinical trials that led to approval were pulmonary embolism, squamous cell carcinoma, and anemia.

Vorinostat is a pregnancy category D medication. Although there are no adequate studies in pregnant women, preclinical animal studies demonstrated that vorinostat may cause fetal harm. Thus, it is recommended to advise avoidance of vorinostat during pregnancy. The safety of vorinostat during breastfeeding is unknown. However, because it is possibly unsafe for use, lactating women should be made aware of the potential harm to infants during nursing.

Drug Interactions: GI bleeding and severe thrombocytopenia have been observed when vorinostat is used concurrently with other HDAC inhibitors such as valproic acid.

Prolongation of prothrombin time and international normalized ratio were observed when vorinostat was coadministered with coumarin-derivative anticoagulants. Close monitoring of prothrombin time and international normalized ratio is recommended with concurrently administered vorinostat and coumarin derivatives such as warfarin.

See the Zolinza package insert for full drug–drug interactions and adverse effects.[60]

ROMIDEPSIN (ISTODAX)

PHARMACOLOGY AND MECHANISM OF ACTION

Structure: Romidepsin, (1*S*,4*S*,7*Z*,10*S*,16*E*,21*R*)-7-ethylidene-4,21-bis(1-methylethyl)-2-oxa-12,13-dithia-5,8,20,23-tetraazabicyclo[8.7.6]tricos-16-ene-3,6,9,19,22-pentone, has the empirical formula $C_{24}H_{36}N_4O_6S_2$ and a molecular weight of 540.71 daltons.[63] Figure 194-17 shows the structure of romidepsin.

Metabolism: Romidepsin is principally metabolized by CYP3A4 with partial contribution by CYP3A5, CYP2B6, CYP2C19, and CYP1A1. The elimination half-life is approximately 3 hours.

Absorption and Distribution: When given intravenously in concentrations ranging from 1 to 24 mg/m^2 romidepsin exhibits linear pharmacokinetics.

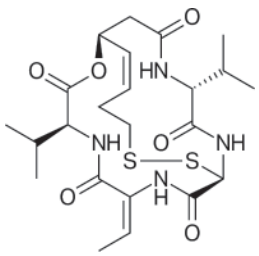

Figure 194-17 Structure of romidepsin.

The drug is a substrate for the P-glycoprotein ABCB1 efflux transporter.

Mechanism of Action: Romidepsin acts as a HDAC inhibitor. In preclinical studies, romidepsin was shown to induce cell-cycle arrest and apoptosis in some cancer cell lines.[63] The full mechanism of action, however, has not been fully elucidated.

INDICATIONS AND CONTRAINDICATIONS

Romidepsin was approved by the FDA in 2009 for treatment of cutaneous T-cell lymphoma in patients who have received at least 1 previous systemic therapy. Approval was based on 2 Phase II clinical trials. Clinical benefit was noted across all stages of disease, with overall response rates of 34%, including 38% in patients with advanced disease (Stage IIB or greater). Complete responses were noted in 5.6% to 7% of patients.[64,65]

In 2011, the FDA expanded approval for treatment of peripheral T-cell lymphoma in patients who have received at least 1 prior therapy.

There are no specific contraindications on the drug label.

DOSING REGIMEN

Romidepsin is administered as an IV infusion. The recommended dose is 14 mg/m^2 given over 4 hours on days 1, 8, and 15 of a 28-day cycle. Cycles are repeated for as long as the patient tolerates the treatment and continues to demonstrate a clinical benefit.

Although there have been no dedicated hepatic or renal impairment studies with romidepsin, caution is advised in patients with moderate-to-severe hepatic impairment and endstage renal impairment.

SIDE EFFECTS AND PRECAUTIONS

Adverse Effects: The most common adverse effects are nausea, asthenia/fatigue, thrombocytopenia, vomiting, diarrhea, diarrhea, pyrexia, constipation, neutropenia, and electrocardiogram T-wave changes. The most common serious adverse effect observed in trials leading to romidepsin's approval was infection. Additional serious adverse effects that occurred in at least 2% of patients included pyrexia, vomiting, cellulitis, deep vein thrombosis, febrile neutropenia, abdominal pain, chest pain, pulmonary embolism, dyspnea, and dehydration. One case of grade IV "dermatitis medicamentosa" and a single case of oral candidiasis were noted in the pivotal Phase II trial.[65] Several treatment-emergent changes in the morphology of electrocardiograms were observed in the clinical studies. Thus, the package label recommends considering cardiovascular monitoring in patients with congenital long QT syndrome, patients taking QT-prolonging medications, and in patients with a history of significant cardiovascular disease.

Based on the mechanism of action and preclinical animal studies, romidepsin may produce fetal harm when administered to pregnant women. Thus, it is recommended to advise avoidance of romidepsin during pregnancy. Romidepsin is possibly unsafe for use during breastfeeding, and lactating women should be made aware of the potential harm to infants during nursing.

Drug Interactions: Concomitant use of strong CYP3A4 inducers such as rifampin is not recommended. Close monitoring of toxicities is recommended when coadministering strong CYP3A4 inhibitors and warfarin and coumarin derivatives.

See the Istodax package insert for full drug–drug interactions and adverse effects.[63]

BELINOSTAT (BELEODAQ)

PHARMACOLOGY AND MECHANISM OF ACTION

Structure: Belinostat, (2E)-*N*-hydroxy-3-[3-(phenylsulfamoyl)phenyl]prop-2-enamide, has the molecular formula $C_{15}H_{14}N_2O_4S$ and the molecular weight is 318.35 g/mol.[66] Figure 194-18 shows the structure of belinostat.

Metabolism: Belinostat is primarily metabolized by UGT1A1, but also undergoes hepatic metabolism by CYP3A4, CYP2A6, and CYP2C9. The elimination half-life is 1.1 hours.

Absorption and Distribution: After intravenous injection, the mean volume of distribution of belinostat approaches total body water.

Mechanism of Action: Belinostat inhibits the activity of HDACs. In preclinical studies, belinostat was shown to induce cell-cycle arrest and apoptosis in some cancer cells. Compared to normal cells, belinostat demonstrates preferential cytotoxicity to transformed cells.[66]

INDICATIONS AND CONTRAINDICATIONS

Beleodaq was granted FDA approval in 2014 for treatment of relapsed or refractory peripheral T-cell lymphoma. Approval was based on a pivotal Phase II trial of 120 patients with relapsed or refractory disease. Overall response rates were 25.8%, including a complete response in 13 patients (10.8%).[67]

There are no specific contraindications on the drug label.

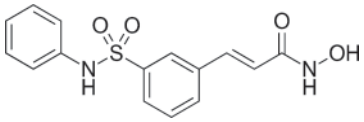

Figure 194-18 Structure of belinostat.

DOSING REGIMEN

The recommended dosing and schedule of Beleodaq is 1000 mg/m^2 administered IV on days 1 to 5 of a 21-day cycle.

Patients with moderate-to-severe hepatic impairment were not included in the pivotal clinical trials; as a result, there is insufficient data to recommend a dose of Beleodaq in patients with hepatic impairment.

The exposure to Beleodaq was not altered in patients with a CrCl of greater than 39 mL/min. There is insufficient data to recommend a dose of Beleodaq in patients with a CrCl of less than 39 mL/min.

SIDE EFFECTS AND PRECAUTIONS

Adverse Effects: The most common adverse effects of belinostat are nausea, fatigue, pyrexia, anemia, vomiting, constipation, diarrhea, dyspnea, rash, and peripheral edema. The most common serious adverse effects include pneumonia, pyrexia, infection, anemia, increased creatinine, thrombocytopenia, and multiorgan failure.

Belinostat is a pregnancy category D medication. It may cause embryofetal lethality as it targets actively dividing cells and is genotoxic.[66] Thus, it is recommended to advise avoidance of belinostat during pregnancy. The safety of belinostat during breastfeeding is unknown. However, because it is possibly unsafe for use, nursing women should be made aware of the potential harm to infants during breastfeeding.

Drug Interactions: It is recommended to avoid concomitant use of belinostat with strong UGT1A1 inhibitors.

See the Beleodaq package insert for full drug–drug interactions and adverse effects.[66]

PANOBINOSTAT (FARYDAK)

PHARMACOLOGY AND MECHANISM OF ACTION

Structure: Panobinostat, (2*E*)-*N*-hydroxy-3-[4- [[[2-(2-methyl-1*H*-indol-3-yl)ethyl]amino]methyl]phenyl]-2-propenamide, has the molecular formula $C_{21}H_{23}N_3O_2 \bullet C_3H_6O_3$ and molecular weight of 439.51 daltons (as a lactate), which is equivalent to 349.43 of free base.[68] Figure 194-19 shows the structure of panobinostat.

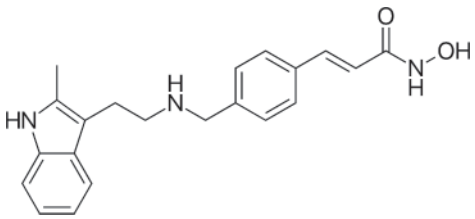

Figure 194-19 Structure of panobinostat.

Metabolism: Panobinostat is metabolized via oxidation, reduction, hydrolysis, and glucuronidation. Approximately 40% of the compound is metabolized by CYP3A. Minor contributions come via CYP2D6 and CYP2C19. Glucuronidation occurs via UGT1A1, UGT1A3, UGT1A7, UGT1A8, UGT1A9, and UGT2B4. The elimination half-life is approximately 37 hours.

Absorption and Distribution: The oral bioavailability of panobinostat is approximately 21% and peak plasma concentrations are achieved within 2 hours of oral administration. In vitro, panobinostat is approximately 90% bound to plasma proteins.

Mechanism of Action: Panobinostat is an HDAC inhibitor. In vitro, panobinostat was shown to induce cell-cycle arrest and apoptosis in some transformed cells. Panobinostat demonstrates preferential cytotoxicity to transformed cells compared to normal cells.

INDICATIONS AND CONTRAINDICATIONS

Farydak was approved by the FDA in 2015 for use in combination with bortezomib and dexamethasone as treatment of multiple myeloma in patients who have received at least 2 prior regimens. Panobinostat does not have any current FDA-approved indications for dermatologic disease, although there is an ongoing Phase Ib/II trial exploring the treatment of resistant metastatic melanoma with panobinostat and the epigenetic modifier decitabine along with temozolomide (NCT00925132).

There are no specific contraindications on the drug label.

DOSING REGIMEN

The recommended dose of panobinostat is 20 mg, taken by mouth once every other day for 3 doses per week (on days 1, 3, 5, 8, 10, 12) of weeks 1 and 2 of each 21-day cycle for 8 cycles.

It is recommended to reduce the starting dose of panobinostat to 15 mg for patients with mild hepatic impairment and to 10 mg in patients with moderate hepatic impairment. Use in patients with severe hepatic impairment is not recommended.

The exposure to Farydak was not altered in patients with mild or severe renal impairment. It was not studied in patients with end stage renal disease or those on dialysis.

Dose and/or schedule modifications of Farydak may be required based on toxicity. See the Farydak package insert for the appropriate dose reduction.

SIDE EFFECTS AND PRECAUTIONS

Adverse Effects: The most common adverse effects (incidence of at least 20%) in clinical studies are

diarrhea, fatigue, nausea, peripheral edema, anorexia, pyrexia, and vomiting. The most common hematologic adverse effects (≥60% incidence) include thrombocytopenia, lymphopenia, leukopenia, neutropenia, and anemia. Electrolyte abnormalities, such as hypophosphatemia, hypokalemia, and hyponatremia, occur in 40% or more of patients. Farydak possesses a boxed warning for severe diarrhea and severe and fatal cardiac ischemic events, severe arrhythmias, and electrocardiogram changes. Severe diarrhea occurred in 25% of patients receiving Farydak. Fatal and serious cases of GI and pulmonary hemorrhage have been reported.

Farydak may cause fetal harm if administered during pregnancy. In preclinical studies, panobinostat was teratogenic in rabbits and rats. Patients should be advised to avoid getting pregnant while taking Farydak. It is also recommended that women use highly effective contraception for at least 1 month after the last dose of Farydak. Men should be advised to use condoms while on treatment and for 3 months after the last dose of Farydak. The safety of panobinostat during breastfeeding is unknown. However, because it is possibly unsafe for use, nursing women should be made aware of the potential harm to infants during breastfeeding.

Drug Interactions: It is recommended to avoid concomitant use of Farydak with strong inducers of CYP3A4, CYP2D6 substrates, and antiarrhythmic/QT-prolonging drugs. The dose of Farydak should be reduced with concomitant use of strong inhibitors of CYP3A4.

See the Farydak package insert for full drug–drug interactions and adverse effects.[68]

MITOGEN-ACTIVATED PROTEIN KINASE INHIBITORS

AT-A-GLANCE

- Between 75% and 85% of melanomas harbor oncogenic mutations in the mitogen-activated protein kinase (MAPK) pathway, including BRAF (v-raf murine sarcoma viral oncogene homolog B), RAS, and neurofibromin 1 (NF1).
- Activating mutations in BRAF, such as V600E and V600K, can trigger unregulated cell growth and promote melanocyte transformation.
- Vemurafenib and dabrafenib are inhibitors of certain mutated forms of BRAF, including V600E and V600K.
- Trametinib and cobimetinib are inhibitors of mitogen-activated extracellular signal-regulated kinase (MEK).
- Combination BRAF and MEK inhibition can lead to clinical benefit, including improved overall survival, in patients with unresectable or metastatic melanoma in patients harboring BRAF V600E or V600K mutations.

BACKGROUND

Melanomagenesis results from the dysregulation of a number of cellular circuits including the PI3K pathway, telomerase promoter, the retinoblastoma pathway, and the MAPK pathway. Targeted therapy in melanoma became a possibility following the 2002 discovery that activating mutations of the protooncogene v-raf murine sarcoma viral oncogene homolog B (BRAF) drive nearly half of melanomas.[69] BRAF, a serine-threonine kinase in the MAPK pathway, is normally activated by RAS, resulting in signal transduction via the phosphorylation of mitogen-activated extracellular signal-regulated kinase (MEK) (Fig. 194-20). Mutations in BRAF—usually V600E, but occasionally V600K and other substitutions—result in constitutive activation of the kinase domain, leading to RAS-independence and hyperactivation of downstream mediators such as MEK and extracellular signal-regulated kinase (ERK). Aberrant activation of the MAPK pathway can lead to cell-cycle dysregulation, resistance to apoptosis, immune evasion, and increased invasion and metastases. The discovery that gain-of-function alterations in BRAF were a key determinant in melanomagenesis drove the development of therapeutic strategies to intervene at multiple nodes in the MAPK pathway.

Precision medicine in melanoma became a possibility with the demonstration that the small-molecule inhibitors of mutant BRAF, vemurafenib and dabrafenib, could prolong disease-free and overall survival when used as monotherapy.[70-72] In addition, inhibition of MEK with trametinib monotherapy improves PFS in patients with BRAF-mutant melanoma.[73] Although initially promising, it became evident that the acquisition of resistance to single-agent therapy precludes durable responses in advanced disease. Building off of preclinical data that showed dual-targeting of BRAF and MEK cooperate to reduce MAPK output, clinical trials have subsequently validated the safety and superior efficacy of combined BRAF/MEK inhibition in BRAF-mutant melanoma.[74-77] Indeed, many of the dermatologic toxicities seen with single-agent BRAF inhibition, such as cSCC and keratoacanthomas, are attenuated with dual BRAF inhibition/MEK inhibition. However, despite reducing many of the adverse effects and delaying the emergence of therapeutic resistance, combined BRAF inhibition/MEK inhibition does not entirely circumvent mechanisms of resistance and the vast majority of patients progress on treatment. In addition, 20% to 25% of patients have mutations in MAPK signaling

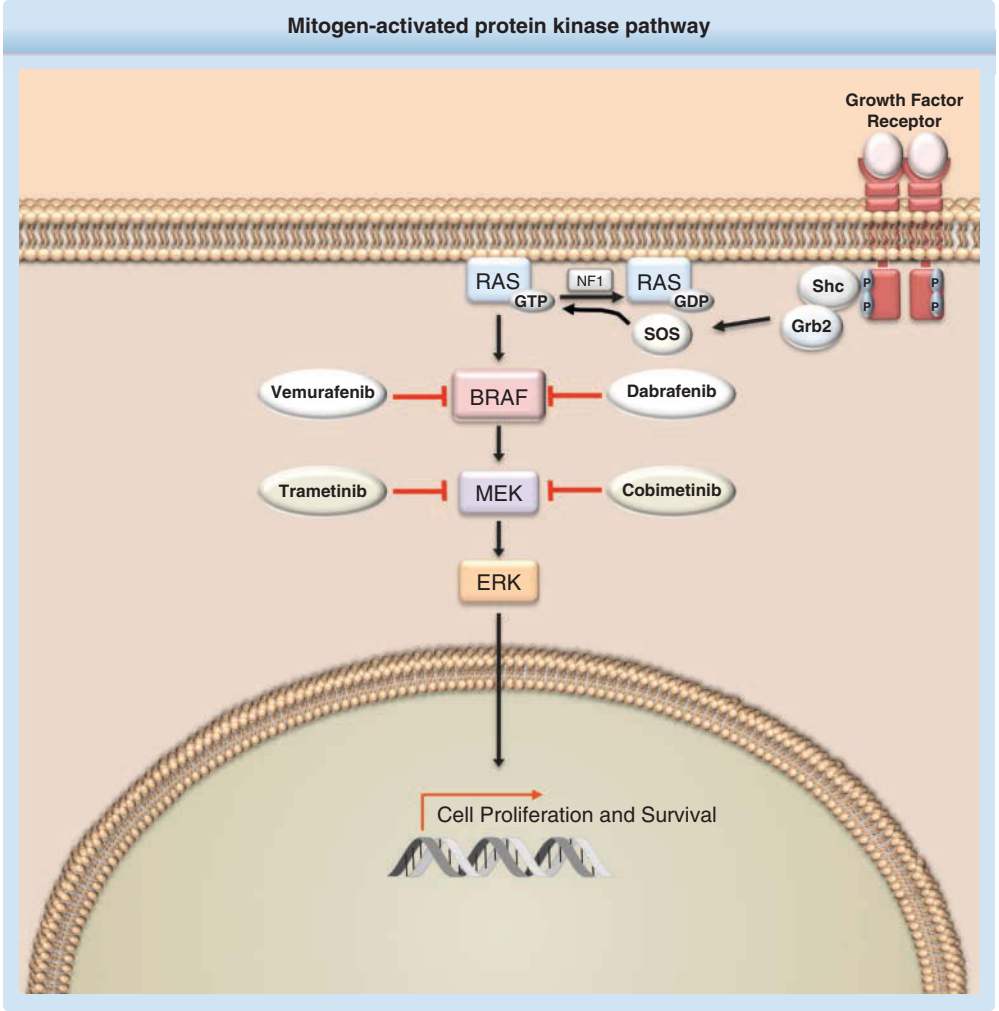

Figure 194-20 Mitogen-activated protein kinase (MAPK) pathway. Activation of receptor tyrosine kinases, such as c-KIT initiates signaling through the MAPK pathway. The action of guanine nucleotide exchange factors (GEFs), such as son of sevenless (*SOS*), accelerates the exchange of guanosine diphosphate (*GDP*) for guanosine triphosphate (*GTP*) by RAS. Activated RAS triggers the MAPK cascade, which includes BRAF, MEK, and ERK, leading to cell proliferation and survival. The activity of RAS is attenuated by guanosine triphosphatase–activating proteins such as neurofibromin 1 (*NF1*). The small molecules vemurafenib and dabrafenib inhibit the activity of BRAF, whereas trametinib and cobimetinib inhibit MEK.

proteins that are not currently druggable, such as RAS and neurofibromin 1. Consequently, additional targets and approaches are being explored such as AKT and ERK, as well as immune checkpoint blockade.

VEMURAFENIB (ZELBORAF)

PHARMACOLOGY AND MECHANISM OF ACTION

Structure: Vemurafenib, propane-1-sulfonic acid {3-[5-(4-chlorophenyl)-1H-pyrrolo[2,3-b]pyridine-3-carbonyl]-2,4-difluoro-phenyl}-amide, has the molecular formula $C_{23}H_{18}ClF_2N_3O_3S$ and molecular weight of 489.92 daltons. Figure 194-21 shows the structure of vemurafenib.

Metabolism: In vitro studies demonstrate that vemurafenib is a substrate of CYP3A4. Following oral administration, 94% of the dose of vemurafenib was recovered in the feces, while approximately 1% was found in the urine. The median elimination half-life is 57 hours.[78]

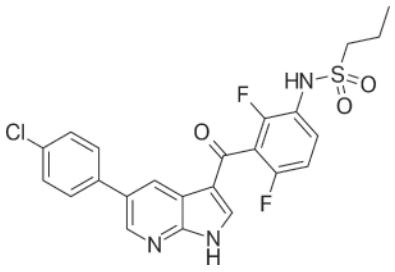

Figure 194-21 Structure of vemurafenib.

Absorption and Distribution: The bioavailability of vemurafenib has not been determined; however, following multiple doses, the median time to maximum plasma concentration was approximately 3 hours. In the clinical trials leading to its approval, Zelboraf was taken without regard to food.

Mechanism of Action: Vemurafenib is a small-molecular-weight inhibitor of certain mutated forms of the serine-threonine kinase BRAF, including V600E. In addition, vemurafenib inhibits wildtype BRAF, CRAF, ARAF, SRMS, ACK1, MAP4K5, and FGR. In cells with V600E-mutated BRAF, vemurafenib has antitumor effects.

INDICATIONS AND CONTRAINDICATIONS

The FDA approved Zelboraf in 2011 for use as monotherapy in the treatment of unresectable or metastatic melanoma with the $BRAF^{V600E}$ mutation, as detected by an FDA-approved test. Approval was based on 2 trials that demonstrated improved response rates and survival rates as compared to dacarbazine.[70,71] The median PFS was 5.3 months and 1.6 months, and the objective response rates were 48% and 5% in the vemurafenib-treated and dacarbazine-treated groups, respectively.[71] The median overall survival in patients treated with vemurafenib was 15.9 months in the single-arm Phase II trial.[70]

When used in combination with the MEK inhibitor cobimetinib (Cotellic), vemurafenib demonstrated improved efficacy, achieving an overall response rate of 68% and a PFS of 9.9 months.[77]

Zelboraf is also indicated to treat patients with Erdhiem-Chester disease harboring V600 mutations. There are no contraindications listed on the drug label.

DOSING REGIMEN

The recommended dose of vemurafenib is 960 mg, taken by mouth with or without a meal, twice daily administered approximately 12 hours apart.

No formal studies have been conducted to evaluate the effects of renal or hepatic impairment on the pharmacokinetics of Zelboraf. No dose adjustments are recommended for patients with mild and moderate renal or hepatic impairment. Caution is advised for severe renal or hepatic impairment.

SIDE EFFECTS AND PRECAUTIONS

Adverse Effects: The most common noncutaneous adverse effects of Zelboraf include arthralgia, fatigue, and nausea. Zelboraf is associated with a variety of skin toxicities, including rash, alopecia, photosensitivity, pruritus, and new primary malignancies. Skin eruptions occurred in up to 68% of the patients taking vemurafenib.[70,71,79] The rashes have been described as folliculocentric, toxic erythema–like, or exaggerated keratosis pilaris–like.[80] The toxic erythema–like rash has been described as having a morphology similar to a classic maculopapular drug hypersensitivity rash with histopathologic features suggestive of an exanthematous drug eruption.[80] Squamous proliferations ranging from benign papillomas and verrucous keratoses to keratoacanthomas and squamous cell carcinomas are commonly seen in patients taking single-agent vemurafenib. Papillomas were reported in 29% of patients and cSCCs and keratoacanthomas were described in 26% of patients in the Phase II trial.[70] In a newer prospective study of the cutaneous adverse effects of vemurafenib, verrucous papillomas occurred in 79% of patients, with nearly half of the patients developing between 4 and 20 efflorescent and verruciform lesions.[81] A hand–foot skin reaction characterized by hyperkeratotic plaques located on pressure points of the sole was observed in 60% of patients.[81] Additional skin toxicities that have been described with monotherapy include hair growth modification, hyperkeratotic follicular rash, xerosis, cystic lesions, facial erythema, cheilitis, nipple hyperkeratosis, Stevens-Johnson syndrome, toxic epidermal necrolysis, drug rash with eosinophilia and systemic symptoms syndrome, nevi efflorescence, and radiodermatitis.[81] Several of the cutaneous adverse effects appear to be dependent on MEK output via paradoxical activation of MAPK signaling, as concomitant use of the MEK inhibitor cobimetinib was associated with lower rates of keratoacanthomas, cSCCs, and alopecia.[77]

Additional adverse effects of Zelboraf include hepatoxicity, QT prolongation, uveitis, photophobia, and renal injury, including interstitial nephritis and acute tubular necrosis.

Based on its mechanism of action, Zelboraf may cause fetal harm and women should be made aware of the potential risk to a fetus. It is recommended that women of reproductive age be advised to use highly effective contraception during treatment and for 2 weeks after the final dose of Zelboraf. Although there is no information available regarding the presence of vemurafenib in human milk, the potential for harm to nursing infants exists; therefore, women should be advised to avoid breastfeeding during treatment and for at least 2 weeks following the last dose of Zelboraf.

Drug Interactions: It is recommended to avoid concomitant use of strong CYP3A4 inhibitors or inducers and CYP1A2 substrates with a narrow therapeutic window.

See the Zelboraf package insert for full drug–drug interactions and adverse effects.[78]

DABRAFENIB (TAFINLAR)

PHARMACOLOGY AND MECHANISM OF ACTION

Structure: Dabrafenib mesylate, *N*-{3-[5-(2-amino-4-pyrimidinyl)-2-(1,1-dimethylethyl)-1,3-thiazol-4-yl]-

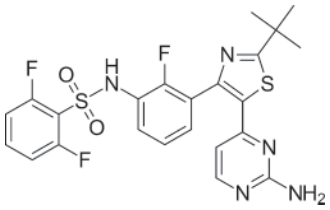

Figure 194-22 Structure of dabrafenib.

2-fluorophenyl}-2,6-difluorobenzene sulfonamide, methanesulfonate salt, has the molecular formula $C_{23}H_{20}F_3N_5O_2S_2$ CH_4O_3S and a molecular weight of 615.68 daltons.[82] Figure 194-22 shows the structure of dabrafenib mesylate.

Metabolism: Dabrafenib is primarily metabolized by CYP2C8 and CYP3A4. Excretion through the feces is the main route of elimination (71%) of dabrafenib, while urinary excretion accounts for 23% of its elimination. After oral administration, the half-life of dabrafenib is 8 hours.

Absorption and Distribution: Dabrafenib exhibits 95% bioavailability and peak plasma concentrations are reached in 2 hours after oral administration; 99.7% of dabrafenib is bound to plasma proteins and its volume of distribution is 70.3 L.

Mechanism of Action: Dabrafenib is a small-molecular-weight inhibitor of certain mutated forms of the BRAF, including V600E, V600K, and V600D. It is a reversible ATP-competitive inhibitor, with a concentration required for 50% inhibition that is 5 times lower for $BRAF^{V600E}$ than for wildtype BRAF.[72] In addition, dabrafenib inhibits wildtype BRAF, CRAF, SIK1, NEK11, and LIMK1. In melanoma cells with V600-mutated BRAF, dabrafenib inhibits cell growth.

INDICATIONS AND CONTRAINDICATIONS

Tafinlar was given FDA approval in 2013 for treatment of unresectable or metastatic melanoma with BRAF V600E mutation, as detected by an FDA-approved test. Approval was based on data from a multicenter, open-label, randomized trial of 250 patients that demonstrated improved PFS as compared to dacarbazine (5.1 months vs. 2.7 months).[72] Tafinlar was also given accelerated approval in 2014 and full approval in 2015 for use in combination with the MEK inhibitor trametinib (Mekinist) in unresectable or metastatic BRAF V600E or V600K mutated melanoma. Approval was given after the combination demonstrated objective response rates of 64% to 76% and PFS of 9.3 to 11.4 months.[74-76] Long-term followup of patients from that cohort demonstrated on overall survival of 25 months and a 3-year overall survival of 38%.[83]

Tafinlar is also indicated in combination with Mekinist as: 1) adjuvant treatment for patients with V600 mutant melanoma involving lymph nodes following complete resection;2) treatment for metastatic V600 mutant NSCLC; and 3) metastatic or locally advanced V600 mutant anaplastic thyroid cancer with no satisfactory locoregional treatment options. There are no specific contraindications on the drug label.

DOSING REGIMEN

The recommend dose of Tafinlar is 150 mg taken by mouth twice daily at least 1 hour before or at least 2 hours after a meal. An FDA-approved test must be performed that confirms either the presence of a BRAF V600E mutation prior to monotherapy with Tafinlar, or the presence of a BRAF V600E or V600K mutation prior to combined therapy with trametinib.

No formal studies have been conducted to evaluate the effects of renal or hepatic impairment on the pharmacokinetics of Tafinlar. No specific dose adjustments are recommended for patients with mild hepatic or mild or moderate renal impairment. An appropriate dose has not been determined for moderate to severe hepatic or severe renal impairment.

Dose modifications of Tafinlar may be required based on toxicity. See the Tafinlar product label for the appropriate dose reduction.

SIDE EFFECTS AND PRECAUTIONS

Adverse Effects: The most common noncutaneous adverse effects include headache, pyrexia, and arthralgia. Cutaneous toxicities are similar to those seen with vemurafenib and include verruciform keratotic squamoproliferative lesions, papillomas, alopecia, rash, Grover disease, plantar hyperkeratosis, cSCC, keratoacanthoma, increased incidence of melanoma, seborrheic dermatitis–like eruption and palmar-plantar erythrodysesthesia syndrome.[82,84] New primary malignancies, cutaneous and noncutaneous, have been reported during treatment with Tafinlar. Additional toxicities include hemorrhage, cardiomyopathy, uveitis (including iritis and iridocyclitis), hyperglycemia, and hemolytic anemia in patients with glucose-6-phosphate dehydrogenase deficiency.

Based on data from animal studies and its mechanism of action, Tafinlar may cause fetal harm and women should be made aware of the potential risk to a fetus. It is recommended that women of reproductive age be advised to use highly effective contraception during treatment and for 2 weeks after the final dose of Tafinlar. Although there is no information available regarding the presence of dabrafenib in human milk, there is a potential for serious adverse reactions to nursing infants; consequently, women should be advised to avoid breastfeeding during treatment and for at least 2 weeks following the last dose of Tafinlar.

Drug Interactions: It is recommended to avoid concurrent use of strong inhibitors or inducers of CYP3A4 or CYP2C8. Coadministration of compounds that are sensitive substrates of CYP3A4, CYP2B6,

CYP2C8, CYP2C9, or CYP2C19 may result in decreased efficacy of these agents.

See the Tafinlar package insert for full drug–drug interactions and adverse effects.[82]

TRAMETINIB (MEKINIST)

PHARMACOLOGY AND MECHANISM OF ACTION

Structure: Trametinib dimethyl sulfoxide, or acetamide, *N*-[3-[3-cyclopropyl-5-[(2-fluoro-4-iodophenyl) amino]-3,4,6,7-tetrahydro-6,8-dimethyl-2,4,7-trioxopyrido[4,3-*d*]pyrimidin-1(2*H*)-yl]phenyl]-, compound with 1,1′-sulfinylbis[methane] (1:1), has the molecular formula $C_{26}H_{23}FIN_5O_4 \bullet C_2H_6OS$ and molecular mass of 693.53 daltons. Figure 194-23 shows the structure of trametinib dimethyl sulfoxide.

Metabolism: Trametinib is primarily metabolized by non–CYP-mediated deacetylation alone or in combination with monooxygenation or glucuronidation biotransformation pathways. The estimated elimination half-life is 3.9 to 4.8 hours. Greater than 80% is excreted through the feces, while less than 20% is eliminated through the urine.

Absorption and Distribution: Trametinib is 72% bioavailable and the volume of distribution is 214 L.

Mechanism of Action: Trametinib is a reversible, small-molecule inhibitor of activation and kinase activity of MEK1 and MEK2.[85] Trametinib inhibits the in vitro and in vivo cell growth of BRAF V600 mutation-positive melanoma.

INDICATIONS AND CONTRAINDICATIONS

Mekinist is indicated for use as a single agent or in combination with dabrafenib for the treatment of unresectable or metastatic BRAF V600E–mutated or BRAF V600K–mutated melanoma, as determined by an FDA-approved test. Approval as monotherapy was given in 2013 based on the Phase III METRIC (MEK Versus Dacarbazine [DTIC] or Paclitaxel [Taxol] in Metastatic Melanoma) study which demonstrated improved PFS in patients receiving trametinib 2 mg once daily (4.8 months) as compared to those receiving either dacarbazine or paclitaxel (1.5 months).[73] As stated above, Mekinist is synergistic when used in combination with Tafinlar resulting in superior objective response rates (64% to 76%) and PFS (9.3 to 11.4 months) compared to monotherapy.[74-76]

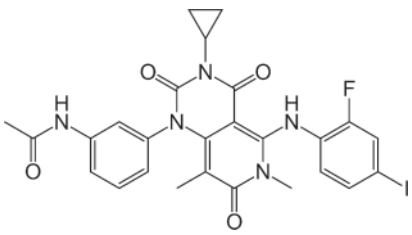

Figure 194-23 Structure of trametinib.

Mekinist is also indicated in combination with Tafinlar as: 1) adjuvant treatment for patients with V600 mutant melanoma involving lymph nodes following complete resection;2) treatment for metastatic V600 mutant NSCLC; and 3) metastatic or locally advanced V600 mutant anaplastic thyroid cancer with no satisfactory locoregional treatment options.

There are no specific contraindications on the product label.

DOSING REGIMEN

The recommend dose of trametinib is 2 mg taken by mouth once daily at least 1 hour before or at least 2 hours after a meal.

No dedicated studies have been conducted to evaluate the effects of renal or hepatic impairment on the pharmacokinetics of Mekinist. No specific dose adjustments are recommended for patients with mild hepatic or mild or moderate renal impairment. An appropriate dose of Mekinist has not been determined for moderate to severe hepatic or severe renal impairment.

Dose modifications of Mekinist may be required based on toxicity. See the Mekinist package insert for the appropriate dose reduction.

SIDE EFFECTS AND PRECAUTIONS

Adverse Effects: The most common adverse effects include rash, diarrhea, and lymphedema. When used in combination with Tafinlar, the most common toxicities include pyrexia, nausea, rash, diarrhea, vomiting, chills, hypertension, and peripheral edema. The most common cutaneous toxicity is a papulopustular eruption similar to those seen with inhibitors of EGFR, occurring in 40% to 93% of patients.[86] Other skin changes include pruritus, xerosis, alopecia, paronychia, and eruptions described as maculopapular and urticarial-to-targetoid with central duskiness.[86] Other adverse effects include venous thromboembolism, cardiomyopathy, retinal vein occlusion, retinal pigment epithelial detachment, interstitial lung disease, and hyperglycemia.

Based on data from animal studies and its mechanism of action, Mekinist may cause fetal harm and women should be made aware of the potential risk to a fetus. It is recommended that women of reproductive age be advised to use highly effective contraception during treatment and for 4 months after the final dose of Mekinist. Increased follicular cysts and decreased corpora lutea were observed in animal studies; thus, women should be advised that Mekinist may impair fertility. Although there is no information available regarding the presence of trametinib in human milk,

there is a potential for serious adverse reactions to nursing infants; consequently, women should be advised to avoid breastfeeding during treatment and for at least 4 months following the last dose of Mekinist.

Drug Interactions: Trametinib is not a substrate of CYP enzymes and at the clinically relevant systemic concentration of 0.04 µM, it is not an inhibitor of CYP1A2, CYP2A6, CYP2B6, CYP2C9, CYP2C19, CYP2D6, or CYP3A4.

See the Mekinist package insert for full drug–drug interactions and adverse effects.[82]

COBIMETINIB (COTELLIC)

PHARMACOLOGY AND MECHANISM OF ACTION

Structure: Cobimetinib fumarate, (*S*)-[3,4-difluoro-2-(2-fluoro-4-iodophenylamino)phenyl] [3-hydroxy-3-(piperidin-2-yl)azetidin-1-yl]methanone hemifumarate, has the molecular formula $C_{46}H_{46}F_6I_2N_6O_8$ and molecular mass of 1178.71 daltons. Figure 194-24 shows the structure of cobimetinib fumarate.

Metabolism: Cobimetinib is primary metabolized by oxidization via CYP3A and glucuronidation by way of UGT2B7. The elimination half-life following oral administration is 44 hours. Excretion is primarily via the fecal route (76%).

Absorption and Distribution: The bioavailability of cobimetinib is 46% and its volume of distribution is 806 L.

Mechanism of Action: Cobimetinib fumarate is a reversible inhibitor of MEK1 and MEK2. The compound inhibits BRAF V600E–mutant murine cells transplanted into mice.[87]

INDICATIONS AND CONTRAINDICATIONS

Cotellic is indicated for the treatment of unresectable or metastatic BRAF V600E–mutant or BRAF V600K–mutant melanoma, in combination with vemurafenib. Approval was based on results from the coBRIM (Cobimetinib Combined with Vemurafenib in Advanced BRAF V600–mutant Melanoma) trial which showed that the combination of vemurafenib and cobimetinib produced improved PFS and response rates compared to single-agent vemurafenib in patients with previously untreated, unresectable or metastatic BRAF V600 mutation-positive melanoma (PFS: 9.9 months vs. 6.2 months; objective response rate 68% vs. 45%).[77]

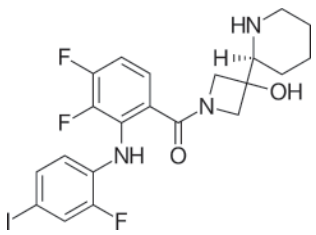

Figure 194-24 Structure of cobimetinib.

There are no specific contraindications on the product label.

DOSING REGIMEN

The recommended dose of Cotellic is 60 mg by mouth once daily, with or without food, for the first 21 days of a 28-day cycle.

No dedicated studies have been conducted to evaluate the effects of renal or hepatic impairment on the pharmacokinetics of Cotellic. No specific dose adjustments are recommended for patients with mild hepatic or mild or moderate renal impairment. An appropriate dose of Cotellic has not been determined for moderate to severe hepatic or severe renal impairment.

Dose modifications of Cotellic may be required based on toxicity. See the Cotellic package insert for the appropriate dose reduction.[87]

SIDE EFFECTS AND PRECAUTIONS

Adverse Effects: The most common adverse reactions for Cotellic are diarrhea, photosensitivity reaction, nausea, pyrexia, and vomiting. The most common grade 4 event (4%) was elevated creatinine kinase, a known class effect of MEK blockade.[77] Other serious laboratory abnormalities include increased γ-glutamyl transferase, hypophosphatemia, increased alanine aminotransferase and aspartate aminotransferase, lymphopenia, increased alkaline phosphatase, and hyponatremia. Although squamoproliferative events are seen with combination therapy, cSCC and keratoacanthomas appear to be less common with the dual therapy cobimetinib and vemurafenib compared with single-agent vemurafenib.[77] A grade 3 to grade 4 rash was seen in 16% of patients receiving dual therapy compared with 17% receiving single agent vemurafenib. Other noncutaneous adverse effects include cardiomyopathy, hemorrhage, noncutaneous malignancies, retinopathy, and rhabdomyolysis.

Based on data from animal studies and its mechanism of action, Cotellic may cause fetal harm and women should be made aware of the potential risk to a fetus. It is recommended that women of reproductive age be advised to use highly effective contraception during treatment and for 2 weeks following the final dose of Cotellic. Patients should be advised that Cotellic may impair fertility in both females and males. Although there is no information available regarding the presence of cobimetinib in human milk, there is a potential for serious adverse reactions to nursing infants; therefore, women should be advised to avoid breastfeeding during treatment and for at least 2 weeks following the last dose of Cotellic.

Drug Interactions: Moderate or strong inhibitor or inducers of CYP3A should be avoided when taking Cotellic.

See the Cotellic package insert for full drug–drug interactions and adverse effects.

FUTURE DIRECTIONS IN MELANOMA: AKT AND ERK INHIBITION

AKT INHIBITORS

PI3K–AKT–mTOR (mammalian target of rapamycin) signaling is an important oncogenic pathway in melanoma development and progression. The hyperactivation of this pathway is associated with activation of receptor tyrosine kinases, somatic mutations in key signaling genes such as *PIK3CA*, or inactivation of the tumor-suppressor gene *PTEN*.[88] Preclinical studies with AKT inhibitors have demonstrated the usefulness of AKT inhibitors in melanoma treatment. Conjunctival melanoma is a rare, but deadly, variant of melanoma with limited effective treatment options. Preclinical in vitro studies demonstrate that the AKT inhibitor, MK2206, suppresses growth in conjunctival melanoma cell lines, and furthermore, a synergistic effect was observed when combined with the MEK inhibitor MEK162.[89] These preliminary findings have supported the rationale for a recently initiated Phase II clinical trial studying the efficacy of the MEK inhibitor trametinib, with or without the AKT inhibitor GSK2141795, for treatment of patients with stage IV uveal melanoma (NCT01979523). Also, in a Phase I trial investigating the oral AKT inhibitor MK2206 combined with chemotherapy for solid tumors, 2 patients with stage IV *BRAF WT* melanoma tolerated and experienced disease-free progression with MK2206 combined with carboplatin and paclitaxel.[90]

More recently, another Phase I study revealed that the AKT inhibitor ipatasertib (GDC-0068) is capable of safe and robust targeting of AKT in patients with solid tumors.[91] These preliminary studies are paving the way for larger randomized, controlled clinical trials, which may result in the addition of AKT inhibitors to the armamentarium of therapeutics for advanced melanoma.

EXTRACELLULAR SIGNAL-REGULATED KINASE INHIBITORS

The MAPK (RAS-RAF-MEK-ERK) pathway is hyperactivated in more than 90% of melanomas.[92] RAF and MEK inhibitors were the first clinically available therapeutics aimed at targeting the MAPK pathway for advanced melanoma patients. However, acquired resistance to BRAF and MEK inhibitors proves to be a major limitation to sustainable outcomes.[93] One well-characterized mechanism of resistance is the reactivation of the downstream MAPK pathway target ERK; hence, investigators are focusing on the development of ERK inhibitors.[93] Preclinical studies show that ERK inhibition is more effective, compared to MEK inhibition, in suppressing MAPK activity and tumor growth in multiple BRAF inhibitor–resistant melanoma cell lines.[94] Also, in vitro data demonstrates that MEK inhibitor–resistant melanoma cell lines are sensitive to ERK inhibition, and that combined treatment with MEK and ERK inhibitors is synergistic and overcomes acquired resistance to MEK inhibition.[95] Although the preclinical data is promising, ERK inhibitors are capable of targeting a wide range of kinases, hence a potential narrow therapeutic index is a major concern. Currently, there are Phase I clinical trials underway exploring safety and tolerability of the ERK inhibitors, BVD-523 and LTT462, in patients with advanced solid malignancies (NCT01781429, NCT02711345).

REFERENCES

1. Goff SP, Gilboa E, Witte ON, et al. Structure of the Abelson murine leukemia virus genome and the homologous cellular gene: studies with cloned viral DNA. *Cell.* 1980;22(3):777-785.
2. Ben-Neriah Y, Daley GQ, Mes-Masson AM, et al. The chronic myelogenous leukemia-specific P210 protein is the product of the bcr/abl hybrid gene. *Science.* 1986;233(4760):212-214.
3. Druker BJ, Tamura S, Buchdunger E, et al. Effects of a selective inhibitor of the Abl tyrosine kinase on the growth of Bcr-Abl positive cells. *Nat Med.* 1996;2(5):561-566.
4. Druker BJ, Sawyers CL, Kantarjian H, et al. Activity of a specific inhibitor of the BCR-ABL tyrosine kinase in the blast crisis of chronic myeloid leukemia and acute lymphoblastic leukemia with the Philadelphia chromosome. *N Engl J Med.* 2001;344(14):1038-1042.
5. Druker BJ, Talpaz M, Resta DJ, et al. Efficacy and safety of a specific inhibitor of the BCR-ABL tyrosine kinase in chronic myeloid leukemia. *N Engl J Med.* 2001;344(14):1031-1037.
6. Simon MP, Pedeutour F, Sirvent N, et al. Deregulation of the platelet-derived growth factor B-chain gene via fusion with collagen gene COL1A1 in dermatofibrosarcoma protuberans and giant-cell fibroblastoma. *Nat Genet.* 1997;15(1):95-98.
7. McArthur GA, Demetri GD, van Oosterom A, et al. Molecular and clinical analysis of locally advanced dermatofibrosarcoma protuberans treated with imatinib: Imatinib Target Exploration Consortium Study B2225. *J Clin Oncol.* 2005;23(4):866-873.
8. *Gleevec (imatinib)* [package insert]. Stein, Switzerland: Novartis; 2016.
9. Guo J, Si L, Kong Y, et al. Phase II, open-label, single-arm trial of imatinib mesylate in patients with metastatic melanoma harboring c-Kit mutation or amplification. *J Clin Oncol.* 2011;29(21):2904-2909.
10. Hodi FS, Corless CL, Giobbie-Hurder A, et al. Imatinib for melanomas harboring mutationally activated or

amplified KIT arising on mucosal, acral, and chronically sun-damaged skin. *J Clin Oncol.* 2013;31(26):3182-3190.
11. Carvajal RD, Antonescu CR, Wolchok JD, et al. KIT as a therapeutic target in metastatic melanoma. *JAMA.* 2011;305(22):2327-2334.
12. Macdonald JB, Macdonald B, Golitz LE, et al. Cutaneous adverse effects of targeted therapies: part I: inhibitors of the cellular membrane. *J Am Acad Dermatol.* 2015;72(2):203-218; quiz 219-220.
13. *Tasigna (nilotinib)* [package insert]. Stein, Switzerland: Novartis; 2010.
14. Lee SJ, Kim TM, Kim YJ, et al. Phase II trial of nilotinib in patients with metastatic malignant melanoma harboring KIT gene aberration: a multicenter trial of Korean Cancer Study Group (UN10-06). *Oncologist.* 2015;20(11):1312-1319.
15. Carvajal RD, Lawrence DP, Weber JS, et al. Phase II study of nilotinib in melanoma harboring KIT alterations following progression to prior KIT inhibition. *Clin Cancer Res.* 2015;21(10):2289-2296.
16. *Sprycel (dasatinib)* [package insert]. Princeton, NJ: Bristol-Myers Squibb Company; 2016.
17. Kluger HM, Dudek AZ, McCann C, et al. A phase 2 trial of dasatinib in advanced melanoma. *Cancer.* 2011;117(10):2202-2208.
18. Algazi AP, Weber JS, Andrews SC, et al. Phase I clinical trial of the Src inhibitor dasatinib with dacarbazine in metastatic melanoma. *Br J Cancer.* 2012;106(1):85-91.
19. Ainechi S, Carlson JA. Neutrophilic dermatosis limited to lipo-lymphedematous skin in a morbidly obese woman on dasatinib therapy. *Am J Dermatopathol.* 2016;38(2):e22-e26.
20. Drucker AM, Wu S, Busam KJ, et al. Rash with the multitargeted kinase inhibitors nilotinib and dasatinib: metaanalysis and clinical characterization. *Eur J Haematol.* 2013;90(2):142-150.
21. *Bosulif (bosutinib)* [package insert]. New York, NY: Pfizer Inc; 2016.
22. *Iclusig (ponatinib)* [package insert]. Cambridge, MA: Ariad Pharmaceuticals, Inc; 2016.
23. Paez JG, Janne PA, Lee JC, et al. EGFR mutations in lung cancer: correlation with clinical response to gefitinib therapy. *Science.* 2004;304(5676):1497-1500.
24. Lynch TJ, Bell DW, Sordella R, et al. Activating mutations in the epidermal growth factor receptor underlying responsiveness of non-small-cell lung cancer to gefitinib. *N Engl J Med.* 2004;350(21):2129-2139.
25. Thatcher N, Chang A, Parikh P, et al. Gefitinib plus best supportive care in previously treated patients with refractory advanced non-small-cell lung cancer: results from a randomised, placebo-controlled, multicentre study (Iressa Survival Evaluation in Lung Cancer). *Lancet.* 2005;366(9496):1527-1537.
26. Fukuoka M, Wu YL, Thongprasert S, et al. Biomarker analyses and final overall survival results from a phase III, randomized, open-label, first-line study of gefitinib versus carboplatin/paclitaxel in clinically selected patients with advanced non-small-cell lung cancer in Asia (IPASS). *J Clin Oncol.* 2011;29(21):2866-2874.
27. Rosell R, Carcereny E, Gervais R, et al. Erlotinib versus standard chemotherapy as first-line treatment for European patients with advanced EGFR mutation-positive non-small-cell lung cancer (EURTAC): a multicentre, open-label, randomised phase 3 trial. *Lancet Oncol.* 2012;13(3):239-246.
28. Yu HA, Arcila ME, Rekhtman N, et al. Analysis of tumor specimens at the time of acquired resistance to EGFR-TKI therapy in 155 patients with EGFR-mutant lung cancers. *Clin Cancer Res.* 2013;19(8):2240-2247.
29. Carrera S, Buque A, Azkona E, et al. Epidermal growth factor receptor tyrosine-kinase inhibitor treatment resistance in non-small cell lung cancer: biological basis and therapeutic strategies. *Clin Transl Oncol.* 2014;16(4):339-350.
30. Janne PA, Yang JC, Kim DW, et al. AZD9291 in EGFR inhibitor-resistant non-small-cell lung cancer. *N Engl J Med.* 2015;372(18):1689-1699.
31. *Erbitux (cetuximab)* [package insert]. Branchburg, NJ: ImClone LLC; 2012.
32. Tan AR, Moore DF, Hidalgo M, et al. Pharmacokinetics of cetuximab after administration of escalating single dosing and weekly fixed dosing in patients with solid tumors. *Clin Cancer Res.* 2006;12(21):6517-6522.
33. Maubec E, Petrow P, Scheer-Senyarich I, et al. Phase II study of cetuximab as first-line single-drug therapy in patients with unresectable squamous cell carcinoma of the skin. *J Clin Oncol.* 2011;29(25):3419-3426.
34. Garden BC, Wu S, Lacouture ME. The risk of nail changes with epidermal growth factor receptor inhibitors: a systematic review of the literature and metaanalysis. *J Am Acad Dermatol.* 2012;67(3):400-408.
35. Perez-Soler R, Saltz L. Cutaneous adverse effects with HER1/EGFR-targeted agents: is there a silver lining? *J Clin Oncol.* 2005;23(22):5235-5246.
36. *Vectibix (panitumumab)* [package insert]. Thousand Oaks, CA: Amgen Inc; 2015.
37. Marti A, Fauconneau A, Ouhabrache N, et al. Complete remission of squamous cell carcinoma after treatment with panitumumab in a patient with cetuximab-induced anaphylaxis. *JAMA Dermatol.* 2016;152(3):343-345.
38. Foote MC, McGrath M, Guminski A, et al. Phase II study of single-agent panitumumab in patients with incurable cutaneous squamous cell carcinoma. *Ann Oncol.* 2014;25(10):2047-2052.
39. *Iressa (gefitinib)* [package insert]. Wilmington, DE: AstraZeneca Pharmaceuticals LP; 2015.
40. Wacker B, Nagrani T, Weinberg J, et al. Correlation between development of rash and efficacy in patients treated with the epidermal growth factor receptor tyrosine kinase inhibitor erlotinib in two large phase III studies. *Clin Cancer Res.* 2007;13(13):3913-3921.
41. *Tarceva (erlotinib)* [package insert]. Northbrook, IL: OSI Pharmaceuticals, LLC; 2016.
42. Mudigonda TV, Wyman K, Spigel DR, et al. A phase II trial of erlotinib and bevacizumab for patients with metastatic melanoma. *Pigment Cell Melanoma Res.* 2016;29(1):101-103.
43. *Gilotrif (afatinib dimaleate)* [package insert]. Ridgefield, CT: Boehringer Ingelheim International GmbH; 2016.
44. Kudo K, Hotta K, Bessho A, et al. Development of a skin rash within the first week and the therapeutic effect in afatinib monotherapy for EGFR-mutant non-small cell lung cancer (NSCLC): Okayama Lung Cancer Study Group experience. *Cancer Chemother Pharmacol.* 2016;77(5):1005-1009.
45. Chen KL, Lin CC, Cho YT, et al. Comparison of skin toxic effects associated with gefitinib, erlotinib, or afatinib treatment for non-small cell lung cancer. *JAMA Dermatol.* 2016;152(3):340-342.
46. Doesch J, Debus D, Meyer C, et al. Afatinib-associated Stevens-Johnson syndrome in an EGFR-mutated lung cancer patient. *Lung Cancer.* 2016;95:35-38.

47. Miguel-Gomez L, Vano-Galvan S, Garrido-Lopez P, et al. Afatinib-induced hypertrichosis of the eyelashes and eyebrows. *Indian J Dermatol Venereol Leprol.* 2016;82(2):192-193.
48. *Tagrisso (osimertinib mesylate)* [package insert]. Wilmington, DE: AstraZeneca Pharmaceuticals LP; 2016.
49. Johnson RL, Rothman AL, Xie J, et al. Human homolog of patched, a candidate gene for the basal cell nevus syndrome. *Science.* 1996;272(5268):1668-1671.
50. Gailani MR, Stahle-Backdahl M, Leffell DJ, et al. The role of the human homologue of *Drosophila* patched in sporadic basal cell carcinomas. *Nat Genet.* 1996;14(1):78-81.
51. Epstein EH. Basal cell carcinomas: attack of the hedgehog. *Nat Rev Cancer.* 2008;8(10):743-754.
52. *Erivedge (vismodegib)* [package insert]. South San Francisco, CA: Genetech; 2016.
53. Sekulic A, Migden MR, Oro AE, et al. Efficacy and safety of vismodegib in advanced basal-cell carcinoma. *N Engl J Med.* 2012;366(23):2171-2179.
54. Basset-Seguin N, Hauschild A, Grob JJ, et al. Vismodegib in patients with advanced basal cell carcinoma (STEVIE): a preplanned interim analysis of an international, open-label trial. *Lancet Oncol.* 2015;16(6):729-736.
55. Macdonald JB, Macdonald B, Golitz LE, et al. Cutaneous adverse effects of targeted therapies: part II: inhibitors of intracellular molecular signaling pathways. *J Am Acad Dermatol.* 2015;72(2):221-236; quiz 237-228.
56. *Odomzo (sonidegib)* [package insert]. East Hanover, NJ: Novartis; 2016.
57. Migden MR, Guminski A, Gutzmer R, et al. Treatment with two different doses of sonidegib in patients with locally advanced or metastatic basal cell carcinoma (BOLT): a multicentre, randomised, double-blind phase 2 trial. *Lancet Oncol.* 2015;16(6):716-728.
58. Minucci S, Pelicci PG. Histone deacetylase inhibitors and the promise of epigenetic (and more) treatments for cancer. *Nat Rev Cancer.* 2006;6(1):38-51.
59. Lane AA, Chabner BA. Histone deacetylase inhibitors in cancer therapy. *J Clin Oncol.* 2009;27(32):5459-5468.
60. *Zolinza (vorinostat)* [package insert]. Whitehouse Station, NJ: Merck & Co., Inc; 2015.
61. Duvic M, Talpur R, Ni X, et al. Phase 2 trial of oral vorinostat (suberoylanilide hydroxamic acid, SAHA) for refractory cutaneous T-cell lymphoma (CTCL). *Blood.* 2007;109(1):31-39.
62. Olsen EA, Kim YH, Kuzel TM, et al. Phase IIb multicenter trial of vorinostat in patients with persistent, progressive, or treatment refractory cutaneous T-cell lymphoma. *J Clin Oncol.* 2007;25(21):3109-3115.
63. *Istodax (romidepsin)* [package insert]. Summit, NJ: Celgene Corporation; 2016.
64. Piekarz RL, Frye R, Turner M, et al. Phase II multiinstitutional trial of the histone deacetylase inhibitor romidepsin as monotherapy for patients with cutaneous T-cell lymphoma. *J Clin Oncol.* 2009;27(32):5410-5417.
65. Whittaker SJ, Demierre MF, Kim EJ, et al. Final results from a multicenter, international, pivotal study of romidepsin in refractory cutaneous T-cell lymphoma. *J Clin Oncol.* 2010;28(29):4485-4491.
66. *Beleodaq (belinostat)* [package insert]. Irvine, CA: Spectrum Pharmaceuticals; 2014.
67. O'Connor OA, Horwitz S, Masszi T, et al. Belinostat in patients with relapsed or refractory peripheral T-cell lymphoma: results of the pivotal phase II BELIEF (CLN-19) study. *J Clin Oncol.* 2015;33(23):2492-2499.
68. *Farydak (panobinostat)* [package insert]. East Hanover, NJ: Novartis Pharmaceuticals Corporation; 2015.
69. Davies H, Bignell GR, Cox C, et al. Mutations of the BRAF gene in human cancer. *Nature.* 2002;417(6892):949-954.
70. Sosman JA, Kim KB, Schuchter L, et al. Survival in BRAF V600-mutant advanced melanoma treated with vemurafenib. *N Engl J Med.* 2012;366(8):707-714.
71. Chapman PB, Hauschild A, Robert C, et al. Improved survival with vemurafenib in melanoma with BRAF V600E mutation. *N Engl J Med.* 2011;364(26):2507-2516.
72. Hauschild A, Grob JJ, Demidov LV, et al. Dabrafenib in BRAF-mutated metastatic melanoma: a multicentre, open-label, phase 3 randomised controlled trial. *Lancet.* 2012;380(9839):358-365.
73. Flaherty KT, Robert C, Hersey P, et al. Improved survival with MEK inhibition in BRAF-mutated melanoma. *N Engl J Med.* 2012;367(2):107-114.
74. Robert C, Karaszewska B, Schachter J, et al. Improved overall survival in melanoma with combined dabrafenib and trametinib. *N Engl J Med.* 2015;372(1):30-39.
75. Flaherty KT, Infante JR, Daud A, et al. Combined BRAF and MEK inhibition in melanoma with BRAF V600 mutations. *N Engl J Med.* 2012;367(18):1694-1703.
76. Long GV, Stroyakovskiy D, Gogas H, et al. Combined BRAF and MEK inhibition versus BRAF inhibition alone in melanoma. *N Engl J Med.* 2014;371(20):1877-1888.
77. Larkin J, Ascierto PA, Dreno B, et al. Combined vemurafenib and cobimetinib in BRAF-mutated melanoma. *N Engl J Med.* 2014;371(20):1867-1876.
78. *Zelboraf (vemurafenib)* [package insert]. South San Francisco, CA: Genentech; 2016.
79. Flaherty KT, Puzanov I, Kim KB, et al. Inhibition of mutated, activated BRAF in metastatic melanoma. *N Engl J Med.* 2010;363(9):809-819.
80. Sinha R, Edmonds K, Newton-Bishop JA, et al. Cutaneous adverse events associated with vemurafenib in patients with metastatic melanoma: practical advice on diagnosis, prevention and management of the main treatment-related skin toxicities. *Br J Dermatol.* 2012;167(5):987-994.
81. Boussemart L, Routier E, Mateus C, et al. Prospective study of cutaneous side-effects associated with the BRAF inhibitor vemurafenib: a study of 42 patients. *Ann Oncol.* 2013;24(6):1691-1697.
82. *Tafinlar (dabrafenib)* [package insert]. East Hanover, NJ: Novartis Pharmaceuticals Corporation; 2016.
83. Long GV, Weber JS, Infante JR, et al. Overall survival and durable responses in patients with BRAF V600-mutant metastatic melanoma receiving dabrafenib combined with trametinib. *J Clin Oncol.* 2016;34(8):871-878.
84. Anforth RM, Blumetti TC, Kefford RF, et al. Cutaneous manifestations of dabrafenib (GSK2118436): a selective inhibitor of mutant BRAF in patients with metastatic melanoma. *Br J Dermatol.* 2012;167(5):1153-1160.
85. *Mekinist (trametinib)* [package insert]. East Hanover, NJ: Novartis Pharmaceuticals Corporation; 2015.
86. Patel U, Cornelius L, Anadkat MJ. MEK inhibitor-induced dusky erythema: characteristic drug hypersensitivity manifestation in 3 patients. *JAMA Dermatol.* 2015;151(1):78-81.
87. *Cotellic (cobimetinib)* [package insert). South San Francisco, CA: Genentech; 2015.

88. Jokinen E, Koivunen JP. MEK and PI3K inhibition in solid tumors: rationale and evidence to date. *Ther Adv Med Oncol.* 2015;7(3):170-180.
89. Cao J, Heijkants RC, Jochemsen AG, et al. Targeting of the MAPK and AKT pathways in conjunctival melanoma shows potential synergy. *Oncotarget*. 2016.
90. Molife LR, Yan L, Vitfell-Rasmussen J, et al. Phase 1 trial of the oral AKT inhibitor MK-2206 plus carboplatin/paclitaxel, docetaxel, or erlotinib in patients with advanced solid tumors. *J Hematol Oncol.* 2014;7:1.
91. Saura C, Roda D, Rosello S, et al. A first-in-human phase I study of the ATP-competitive Akt inhibitor ipatasertib (GDC-0068) demonstrates robust and safe targeting of Akt in patients with solid tumors. *Cancer Discov.* 2017;7(1):102-113.
92. Wellbrock C, Arozarena I. The complexity of the ERK/MAP-kinase pathway and the treatment of melanoma skin cancer. *Front Cell Dev Biol.* 2016;4:33.
93. Welsh SJ, Rizos H, Scolyer RA, et al. Resistance to combination BRAF and MEK inhibition in metastatic melanoma: where to next? *Eur J Cancer.* 2016;62:76-85.
94. Carlino MS, Todd JR, Gowrishankar K, et al. Differential activity of MEK and ERK inhibitors in BRAF inhibitor resistant melanoma. *Mol Oncol.* 2014;8(3):544-554.
95. Hatzivassiliou G, Liu B, O'Brien C, et al. ERK inhibition overcomes acquired resistance to MEK inhibitors. *Mol Cancer Ther.* 2012;11(5):1143-1154.

Chapter 195 :: Antiangiogenic Agents

:: Adilson da Costa, Michael Y. Bonner, & Jack L. Arbiser

AT-A-GLANCE

- "Direct" antiangiogenic agents act directly on untransformed endothelial cells to prevent proliferation, migration, and survival.
- "Indirect" antiangiogenic agents inhibit tumor-produced oncogene proteins that promote a proangiogenic state.
- Antiangiogenic agents are a promising class of drugs because they are effective against slow-growing tumors.

In 1971, Judah Folkman published a landmark paper hypothesizing that all tumor growth is dependent on angiogenesis and that inhibitors of angiogenesis could be used to treat cancers.[1] The ensuing years have proven him correct and have seen the development of new agents that, either alone or in adjunct, have shown promise not only in oncology but in a variety of dermatologic conditions as well.[2]

Antiangiogenic drugs can be classified as either "direct" or "indirect;" the direct act directly on untransformed endothelial cells to prevent proliferation, migration, or survival, a process that normally occurs upon stimulation by proangiogenic molecules; the indirect act indirectly by inhibition of tumor-produced oncogenic protein products that promote proangiogenic states. Angiogenesis inhibitors as a drug class provide a unique approach to cancer treatment because they are also effective against slow-growing tumors, whereas traditional therapies, such as chemotherapy and radiation, work best on rapidly-dividing cells. In the future, the switch to an angiogenic phenotype may be able to be blocked in clinically undetectable cancers, thereby preventing disease progression using therapies directed, in part, by angiogenesis biomarkers.[3,4] Although application of these agents center so far on oncologic and ophthalmologic diseases, promising and new dermatologic indications are sure to come.[2]

Figure 195-1 better illustrates the mechanisms of action of some of the drugs described in this chapter, helping to elucidate how they work as antiangiogenic agents.

BECAPLERMIN (REGRANEX)

With the rise in incidence of diabetes and the increasingly aging population, chronic wounds have become increasingly prevalent. Treatment of these wounds is particularly challenging because normal wound-healing processes have been disrupted.[2]

MECHANISM OF ACTION

Becaplermin (recombinant human platelet-derived growth factor BB) is the first FDA-approved angiogenesis-stimulating therapy. Endogenous platelet-derived growth factor (PDGF) is chemotactic for several cell types necessary for wound healing, and is also a mitogen for fibroblasts, the source for extracellular matrix components like glycosaminoglycans and fibronectin. Thus, PDGF is an important factor in the formation of granulation tissue.[5]

INDICATIONS

Becaplermin gel is currently indicated for the treatment of lower extremity, diabetic, neuropathic ulcers which must be adequately vascularized and reach to at least the level of subcutaneous tissue.[5-7] Off-label uses include the application of becaplermin to ulcerated hemangiomata, surgical wounds, grafts, pyoderma gangrenosum, calciphylaxis, ulcerated necrobiosis lipoidica, and flaps.[8-11] However, cost-effectiveness of this form of therapy in the treatment of diabetic foot ulcers is also outlined.[12]

CONTRAINDICATIONS

Becaplermin gel is contraindicated in patients with known cancer within the treatment area or a history of hypersensitivity.[2] Efficacy has not been established for pressure and venous stasis ulcers. Efficacy has also

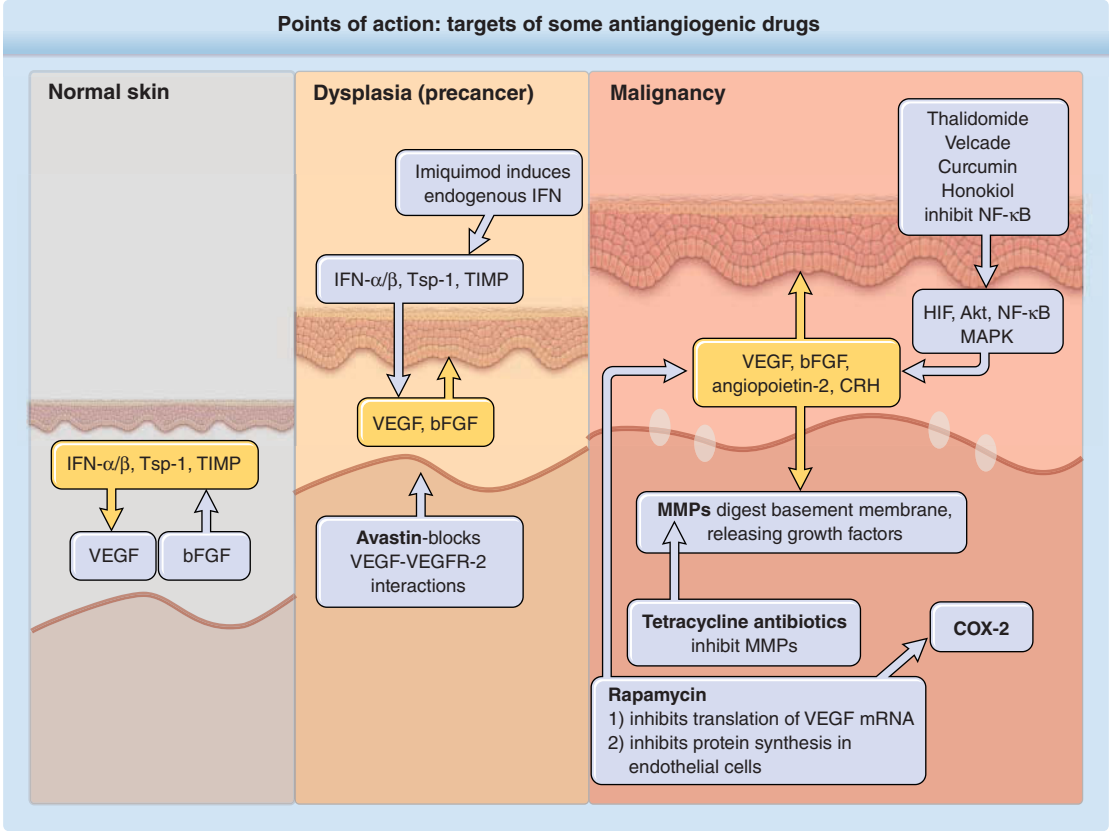

Figure 195-1 Points of action of some of the antiangiogenic drugs. Schematic depiction of the key points of action of some of the antiangiogenic drugs discussed in this chapter in normal skin, precancerous lesions, and malignancy. bFGF, basic fibroblast growth factor; COX-2, cyclooxygenase 2; CRH, corticotropin-releasing hormone; HIF, histoplasma inhibitory factor; IFN, interferon; MAPK, mitogen-activated protein kinase; MMP, matrix metalloproteinase; mRNA, messenger RNA; NF-κB, nuclear factor κB; TIMP, tissue inhibitor of metalloproteinases; Tsp-1, thrombospondin 1; VEGF, vascular endothelial growth factor; VEGFR-2, vascular endothelial growth factor receptor 2.

not been evaluated for diabetic neuropathic ulcers that do not extend through the dermis into subcutaneous tissue or for ischemic diabetic ulcers.[5]

DOSING REGIMEN

Becaplermin gel should be applied topically once daily with dose depending on the size of the lesion; generally, every square inch of ulcer requires two-thirds inch of gel from a 15-g tube or one-and-one-third inches of gel from a 2-g tube. After application, the area should be covered with a saline-moistened dressing, then left in place for approximately 12 hours. The dose should be recalculated every 1 to 2 weeks to ensure accurate dosing as the wound changes size. Becaplermin gel should be used in conjunction with standard proper ulcer care.[5]

MONITORING THERAPY

If there is less than a 30% decrease in size after 10 weeks or if the wound has not completely healed after 20 weeks of treatment, the treatment plan should be reevaluated.[5]

RISKS AND PRECAUTIONS[5,13,14]

- Because becaplermin gel is nonsterile, it should not be applied to wounds closed by primary intention.
- An increased rate of mortality because of malignancy has been observed in patients treated with 3 or more tubes of becaplermin gel. Consequently, caution should be used in patients with a known history of malignancy. However, a newer cohort study has shown that such malignancy association is not yet completely established.
- *Pregnancy category:* C.
- The safety and efficacy of becaplermin have not been evaluated in children younger than 16 years of age.

COMPLICATIONS (SOME EXAMPLES)[5]

- Rash
- Hypersensitivity reaction (most often to the paraben or m-cresol components)
- Ulcer-related complications (incidence was similar in becaplermin vs placebo groups)

BEVACIZUMAB (AVASTIN)

MECHANISM OF ACTION

Bevacizumab is a recombinant, humanized immunoglobulin G_1 monoclonal antibody against vascular endothelial growth factor (VEGF). VEGF is a growth factor that promotes angiogenesis by supporting endothelial cell replication and survival as well as vascular permeability. This potent proangiogenic molecule is upregulated in a majority of human tumors and serves to alter tumor vasculature.[2]

Binding of bevacizumab to VEGF is direct and specific. The antibody also competitively binds VEGF receptor 1 (VEGFR-1) and VEGFR-2, preventing VEGF from binding to its receptors and initiating the signaling cascade. It also reduces and normalizes tumor vascularity.[15] In addition, changes in interleukin (IL)-8 or soluble VEGFR-2 levels at second cycle appear predictive for response.[16] Specifically talking about metastatic colorectal cancer, a recent report suggests that NOTCH1 hyperexpression is a detrimental prognostic factor in patients treated with chemotherapy plus bevacizumab.[17]

INDICATIONS

In February 2004, bevacizumab became the first antiangiogenesis drug approved by the U.S. Food and Drug Administration (FDA) for first-line treatment of metastatic colorectal carcinoma when given in combination with intravenous 5-fluorouracil–based chemotherapy. Bevacizumab also has indications for non–small-cell lung cancer, cervical cancer (including metastatic), glioblastoma, ovarian (epithelial), fallopian tube, primary peritoneal cancer (platinum-resistant/sensitive recurrent), metastatic renal cell carcinoma, head and neck squamous cell carcinoma, gastric cancer, and renal carcinoma.[18-25] Bevacizumab, in combination either with other antiangiogenic agents or with chemotherapy, even if isolated, is currently being investigated in metastatic melanoma, hemangioendothelioma, angiosarcoma, metastatic colorectal cancer, age-related macular degeneration, retinoblastoma, corneal neovascularization, and ovary tumor.[17,18,26-32] Other than a history of hypersensitivity, no known contraindications to bevacizumab therapy exist.[18]

Bevacizumab-induced inhibition of angiogenesis promotes a more homogeneous intratumoral distribution of paclitaxel, improving the antitumor response.[33] In general, bevacizumab prolongs progression-free survival and overall survival, and increases the 1-year survival rate in cancer patients as compared with control therapy.[34]

COMPLICATIONS (SOME EXAMPLES)[18,35,36]

- GI perforation with associated intraabdominal abscess or fistula formation.
- Wound dehiscence (incisions should be healed completely before treatment initiation; drug should be held for at least 28 days prior to elective surgery).
- Serious hemorrhagic events including hemoptysis, GI bleeding, CNS hemorrhaging, epistaxis, vaginal bleeding, and pulmonary hemorrhage. Use in patients with active hemorrhaging or recent history of hemoptysis is not advised.
- Arterial thromboembolic events, including cerebral infarction, transient ischemic attacks, myocardial infarction, and angina.
- Reversible posterior leukoencephalopathy syndrome, a neurologic disorder characterized by headache, seizure, lethargy, confusion, blindness, and other visual or neurologic disturbances, that is diagnosed and confirmed by MRI.
- Hypertension (monitoring every 2 to 3 weeks during course of treatment is advised).
- Proteinuria.
- Infusion reactions.

BORTEZOMIB (VELCADE)

MECHANISM OF ACTION

Bortezomib is the first proteasome inhibitor to gain FDA approval. This novel class of drugs acts by impairing the ability of the proteasome to degrade a variety of ubiquitinated proteins. Proteasome inhibitors may promote a proapoptotic state by preventing the degradation of tumor-suppressor proteins, such as p53 and inhibitors of nuclear factor κB (NF-κB). NF-κB upregulates the transcription of genes involved in neoplastic progression including VEGF.[37] Bortezomib also acts directly to inhibit chemotaxis, capillary formation, and transcription of VEGF, IL-6, insulin-like growth factor-1, ang-1, and ang-2.[38,39] Because it has been shown to correlate with NF-κB activity, chemoresistance might also be lessened in the presence of bortezomib. Moreover, bortezomib inhibits the angiogenesis mediated by mesenchymal stem cells.[40]

INDICATIONS

Bortezomib is currently indicated for the treatment of recurrent or refractory multiple myeloma and mantle cell lymphoma.[38] Investigational applications include cutaneous T-cell lymphoma, squamous cell carcinoma, and metastatic melanoma.[41] It has been reported that the combination of bortezomib, melphalan, dexamethasone, and intermittent thalidomide is an effective regimen for relapsed/refractory myeloma and is associated with improvement of abnormal bone metabolism and angiogenesis.[42] Good results can be obtained when bortezomib is combined with bevacizumab to treat temozolomide-resistant malignant gliomas.[43]

CONTRAINDICATIONS[39]

- Hypersensitivity to bortezomib, boron, or mannitol.

COMPLICATIONS (SOME EXAMPLES)[39]

- Hypotension
- Peripheral neuropathy
- Acute respiratory distress syndrome
- Blood dyscrasias (neutropenia, thrombocytopenia)
- Fatigue, malaise, and weakness
- Cytochrome P450 (CYP) 3A4 drug metabolism interactions
- Skin rash

CETUXIMAB (ERBITUX)

MECHANISM OF ACTIONS

Cetuximab is a chimeric, human–murine monoclonal antibody against the epithelial growth factor receptor (EGFR), and, as such, competitively inhibits the binding of epithelial growth factor (EGF), transforming growth factor, and other associated ligands. Downstream signaling blockade results in myriad antitumor properties, including decreased proliferation, cellular motility, and invasive potential via downregulation of signaling molecules such as basic fibroblast growth factor (bFGF, a product of keratinocytes) and IL-8.[44,45] Angiogenesis is also inhibited through decreased EGFR-mediated VEGF expression. When combined with irinotecan, cetuximab has synergistic antiangiogenesis and anti-invasion activities mediated by downregulation of phosphatidylinositol-3-kinase (PI3K)/Akt and mitogen-activated protein kinase/extracellular signal-regulated kinase (ERK) pathways[46]; such combination seems to induce a sudden, long-lasting reduction in VEGF-circulating levels, as well as an increase in interferon (IFN)-γ.[44] In addition, cetuximab may inhibit tumor growth and angiogenesis induced by ionizing radiation.[47]

INDICATIONS

Cetuximab is currently indicated for the treatment of metastatic colorectal carcinoma and squamous cell carcinoma of the head and neck, either alone or in combination with radiation or chemotherapy.[48] Additionally, its use in squamous cell carcinoma of the skin is currently under investigation. Given the demonstrated role of EGFR in melanoma, cetuximab may also play an eventual role in melanoma treatment. Be aware, however, that EGFR inhibitors are contraindicated in organ transplantation, as they can stimulate immunity. The subconjunctival use of cetuximab and bevacizumab to inhibit corneal angiogenesis has been reported in the literature.[29]

COMPLICATIONS (SOME EXAMPLES)[48]

- Serious infusion reactions
- Acneiform neutrophilic folliculitis—appearance correlates with clinical response
- Pruritus
- Electrolyte disturbances
- Abdominal pain and upset
- Infections associated with neutropenia

CORTICOSTEROIDS

The role of corticosteroids in angiogenesis is a bit of a mixed picture, with neutral, antiangiogenic, and pro-angiogenic effects having been observed in various cases. In the setting of uveal melanoma, El Filali and colleagues demonstrated no significant differences in levels of VEGF, PDGF, or thrombospondin 1 (TSP-1) in in vitro models treated with triamcinolone acetate.[49] In vivo and in vitro models of prostate cancer have shown potentiation of antiangiogenesis by docetaxel when concurrently exposed to dexamethasone as measured by levels of VEGF, IL-8, and chemokine ligand-1.[50] Contrastingly, sequential delivery of dexamethasone followed by VEGF showed an increase in vascularity in a biosensor-model implant into murine subcutaneous fat.[51] Whatever the ultimate mechanism and role, the clinical usefulness of steroids as antiinflammatory and antiangiogenic agents is readily apparent.

ERLOTINIB (TARCEVA)

MECHANISM OF ACTION

Erlotinib is a small-molecule phosphorylation inhibitor that specifically inhibits the EGFR tyrosine kinase. Acting intracellularly, erlotinib downregulates the expression of VEGF via the PI3K/Akt signaling pathway.[2] When combined with cisplatin, erlotinib inhibits growth and angiogenesis through c-MYC and hypoxia inducible factor (HIF)-1α in EGFR-mutated lung cancer.[52]

INDICATIONS

Erlotinib is currently indicated for the treatment of non–small-cell lung cancer and pancreatic cancer.[53] There is an ongoing clinical trial investigating using the combination of erlotinib and bevacizumab in stage 4 melanoma. Other than a history of hypersensitivity, there are no known contraindications.[2] Preliminary clinical trials have shown that association of erlotinib with pazopanib, an oral angiogenesis inhibitor, can work perfectly together to obtain better results against angiogenesis.[54]

COMPLICATIONS (SOME EXAMPLES)[53]

- Acneiform rash
- GI upset
- CYP450, CYP1A2, and CYP3A4 drug metabolism interactions

EVEROLIMUS (AFINITOR)

MECHANISM OF ACTION

Everolimus is another mammalian target of rapamycin (mTOR) inhibitor classified as semisynthetic because it is derived from sirolimus; it has a shorter half life than sirolimus, but better oral bioavailability and less frequent toxic side effects.[55] This agent also complexes with FK-binding protein 2 to inhibit mTOR, suppress HIF-1α, and block VEGF-mediated vascular endothelial cell stimulation, bFGF-induced angiogenesis, and T-cell activation and proliferation.[56,57] Nevertheless, a few years ago, everolimus was linked with lymphangiogenesis, after causing hyperexpression of prospero homeobox protein 1, podoplanin, VEGFR-C, and VEGFR-3 in chick chorioallantoic membranes treated with it.[58]

INDICATIONS

Everolimus is indicated for the treatment of advanced renal cell carcinoma after failure of sunitinib or sorafenib, and as an agent in drug-eluting stents.[59] Everolimus is approved for astrocytoma and breast, neuroendocrine, renal angiomyolipoma with tuberous sclerosis complex, and renal cancers.[58,59] Some other commercial brands are also approved for liver and renal transplantation.[59] Dermatologic, off-label applications are limited to a case report of its use in psoriasis.[60] Recently, it was shown that immune modulatory oligonucleotide, a toll-like receptor 9 agonist, cooperates with everolimus in renal cell carcinoma by interfering with tumor growth and angiogenesis.[61]

COMPLICATIONS (SOME EXAMPLES)[59]

- Noninfectious pneumonitis
- Susceptibility to infections
- Oral ulceration and mucositis
- Blood dyscrasias
- Musculoskeletal pain
- CYP3A4 drug metabolism interactions

IMIQUIMOD (ALDARA)

MECHANISM OF ACTION

Imiquimod (imidazoquinoline) is both the first immune response modifier and the first topical anti-angiogenic agent for dermatologic use. Imiquimod acts by inducing the activation of toll-like receptor 7 in immune cells. Toll-like receptor 7 activation enhances the innate immune response by increasing endogenous IFN and interleukin production, including IFN-α, IFN-β, IFN-γ, IL-10, IL-12, and IL-18; these cytokines also function as endogenous angiogenesis inhibitors.[62,63] The upregulation of these cytokines, as well as of other endogenous angiogenesis inhibitors, such as IFN-inducible protein 10, tissue inhibitor of metalloproteinases, and TSP-1, is the basis for imiquimod's antiangiogenic activity.[64] Additionally, imiquimod also downregulates proangiogenic factors such as bFGF and matrix metalloproteinase 9. In vivo, imiquimod has been shown to inhibit angiogenesis in human bowenoid papulosis, hemangioendothelioma, cutaneous melanoma, and murine lung sarcoma cells.[64-66] A topical combination therapy of imiquimod and gentian violet for cutaneous melanoma metastases has been reported[67]; recently, we have observed that such combination can be helpful for plantar warts as well (unpublished data).

INDICATIONS

Imiquimod is currently approved for the treatment of clinically typical, nonhyperkeratotic, nonhypertrophic actinic keratosis on the face or scalp, and biopsy-confirmed, primary, superficial basal cell carcinoma located on the trunk, neck, or extremities (maximum tumor diameter of 2 cm) in immunocompetent adults. It is also approved for the treatment of external genital and perianal condyloma acuminata.[68] Several studies have shown efficacy in squamous cell carcinoma, lentigo maligna, hemangiomas, Kaposi sarcoma, pyogenic granuloma, discoid lupus erythematosus, and port-wine stain in combination with pulsed-dye laser.[69-74] Other than a history of hypersensitivity, there are no known contraindications.[2]

PHARMACOKINETICS

Imiquimod is only minimally absorbed transdermally, with less than 0.9% of the topical dose being excreted in the urine or feces.[68]

DOSING REGIMEN[68]

- *Actinic keratosis:* Patients are to apply the cream 2 times per week to the face or scalp but not both concurrently, preferably before sleeping hours. The area should be washed with a mild soap and water and allowed to dry before application. After approximately 8 hours following application, the area should again be washed with mild soap and water to remove the agent. Treatment should continue for a full 16 weeks, and should not be extended because of missed doses or skip periods.
- *Superficial basal cell carcinoma:* Following biopsy confirmation, patients are to apply the cream 5 times per week to the affected area plus 1 cm around the lesion, preferably before sleeping hours. The area should be washed with a mild soap and water and allowed to dry before application. After approximately 8 hours following application, the area should again be washed with mild soap and water to remove the agent.
- *External genital and perianal condyloma acuminate:* Patients are to apply the cream 3 times per week to the affected area, preferably before sleeping hours. The area should be washed with a mild soap and water and allowed to dry before application. After approximately 6 to 10 hours following application, the area should again be washed with mild soap and water to remove the agent. Treatment should continue until the lesion(s) completely resolve or until a maximum course of 16 weeks.

RISKS AND PRECAUTIONS[68]

- *Immunosuppression:* The safety and efficacy of imiquimod has not been established in immunosuppressed patients.
- *Photosensitivity:* Patients should be instructed to avoid or minimize exposure to sunlight or sunlamps during the treatment course.
- *Pregnancy class:* C.
- *Pediatrics:* The safety and efficacy of imiquimod has not been established in the treatment of external genital and perianal condyloma acuminate in children younger than 12 years of age, or in the treatment of actinic keratosis or superficial basal cell carcinoma in children younger than 18 years of age.

COMPLICATIONS (SOME EXAMPLES)[68]

- *Local skin toxicities:* Frequency of local skin toxicities include: erythema (97%), flaking/scaling/dryness (93%), scabbing crusting (79%), induration (78%), edema (71%), erosion/ulceration (54%), vesicles (29%), and weeping or exudates (22%). Patients should be instructed to contact their health care provider if they experience any sign or symptom in the treatment area that restricts or prohibits daily activity or makes continued application of the cream difficult; a rest period of a few days may be necessary. Additionally, to reduce the likelihood of an adverse reaction, the agent should not be applied under occlusion other than porous gauze or cotton underwear. Health care providers should evaluate for possible bacterial superinfection when assessing reactions to imiquimod.
- *Decreased wound healing:* Recent wounds should be allowed to heal completely prior to initiating treatment.
- GI upset.
- Upper respiratory tract infection, coughing, sinusitis.
- Musculoskeletal pain.
- Headache.

INTERFERON-α2b (INTRON A)

IFN-α made history in 1988 as the first antiangiogenic therapy used in humans for the successful treatment of pulmonary hemangiomatosis in a pediatric patient. IFN-α2b is a synthetic cytokine made from the bacterium *Escherichia coli* transformed with recombinant DNA and has similar actions to its natural endogenous counterpart, IFN-α, a type I IFN produced endogenously by the immune system.[2]

MECHANISM OF ACTION

The IFNs act through the Janus kinase–signal transducers and activators of transcription (JAK-STAT) pathway. IFN-α, which is both a direct-on-endothelial-cells agent, including impairment of their proliferation and migration[75] as a result of delayed progression from the S-phase to the G_2-phase of the cell cycle and resulting in the inhibition of Cdc2 kinase activity,[76] and an indirect-on-endothelial-cells antiangiogenic agent, was first observed to impair capillary endothelial cell migration. Its properties as an indirect antiangiogenic agent include the ability to decrease tumor cell production of bFGF, which may explain its success in treating hemangiomata.[4] Further actions, such as downregulation of IL-8 and VEGF gene expression,[75] work together

to interfere with both blood vessels and tumor cell proliferation, leading to regression of tumors without necrosis.[75] IFN-α has well-known antiviral activity and antitumor activity, which may be mediated in part by upregulating major histocompatibility complex Class I antigen expression, activating natural killer cells, controlling progression through cell-cycle checkpoints, and activating apoptosis.[2] In vitro assays also demonstrate ability for IFN-α to inhibit osteoclast differentiation and renal cell carcinoma-induced angiogenesis by reducing calcium-phosphate resorption activity and expression of proteoclastic transcription factor c-Fos; by inhibiting bone endothelial cell proliferation and the expression of FGF-2; and by inhibiting secretion of FGF-2.[77]

INDICATIONS

INF-α2b is currently indicated for the treatment of chronic hepatitis B (which may be chemopreventive against hepatocellular carcinoma), chronic hepatitis C, AIDS-associated Kaposi sarcoma, and condylomata acuminata. It is also indicated in malignant melanoma (adjuvant to surgical therapy in patients who are at high-risk of systemic recurrence; must be administered within 56 days postoperatively), hairy cell leukemia, and follicular lymphoma.[78] Off-label uses in dermatology include cutaneous T-cell lymphoma (mycosis fungoides) and basal and squamous cell skin cancers. It also has been used in the treatment of infantile hemangiomas along with corticosteroids or in the event of corticosteroid resistance; however, given rising concerns over the risk of spastic diplegia (especially in children younger than 1 year of age), its usefulness in this setting has been somewhat tempered.[79] Early reports had shown that combination therapy of IFN-α and 5-fluorouracil inhibits tumor angiogenesis in human hepatocellular carcinoma cells by regulating VEGF and angiopoietins.[76]

CONTRAINDICATIONS[78]

- Hypersensitivity to IFN-α or any drug components
- Combination IFN-α and ribavirin therapy in pregnancy or in males whose female partners are pregnant
- Autoimmune hepatitis
- Personal history of a hemoglobinopathy (eg, sickle cell disease, thalassemia major)
- Renal insufficiency (creatinine clearance <50 mL/min)

PHARMACOKINETICS

IFN-α2b comes as a powder that, upon reconstitution, should be used immediately but may be stored up to 24 hours at 2°C to 8°C (36°F to 46°F). It can be given by subcutaneous, IM, IV, or intralesional routes. Its half-life is 3 to 12 hours when given subcutaneously or IM and 30 minutes when given IV. The drug is likely metabolized by the kidneys. Polyethylene glycol IFN-α2b has a 10-fold increase in half life, decreased toxicity, and increased compliance.[78,80] Table 195-1 outlines dosing regimens.

TABLE 195-1
Interferon-α2b Dosing[78,81]

DISEASE	DOSE
Malignant melanoma high-dose regimen	Induction: 20 million IU/m² IV infusion over 20 minutes, 5 consecutive days/week for 4 weeks Maintenance: 10 million IU/m² subcutaneously 3 times/week for 48 weeks
Malignant melanoma adjuvant low-dose regimen (in clinical trials)	Maintenance: 3 million IU/m² subcutaneously 3 times/week for 1 year
AIDS-related Kaposi sarcoma	30 million IU/m² subcutaneously or IM 3 times/week until disease progression or maximal response has been achieved after 16 weeks
Condylomata acuminata	1 million IU per lesion (maximum of 5 lesions per course) 3 times/week on alternate days for 3 weeks; may administer additional courses at 12- to 16-week intervals
Hemangiomas	3 million U/m²/day for at least 6 months

COMPLICATIONS (SOME EXAMPLES)[78,79]

- Flu-like symptoms (headache, fatigue, fever, chills, tachycardia, myalgia, and anorexia)
- Depression (new-onset depression or worsening of preexisting depression; patients should be monitored during therapy for severe depression, and therapy should be discontinued if necessary)
- Sarcoidosis (observed in combination IFN-α-ribavirin therapy)
- Spastic diplegia (a form of cerebral palsy that is a neuromuscular condition characterized by hypertonia and spasticity in the muscles of the lower extremities; Little disease)

INITIATING THERAPY

Hemoglobin, complete blood cell count with differential, electrolytes, liver function tests, thyroid-stimulating hormone, chest radiography, and eye examination should be obtained before initiation of

and during therapy on a routine basis. Patients with prior cardiac disease or advanced cancer require a baseline electrocardiogram and routine reevaluation thereafter. Therapy should not be initiated in patients with a history of depression or severe psychiatric disorder because of the risk of worsening psychiatric symptoms and suicide. Patients with thyroid disorders that cannot be corrected with medication should not be treated. The development of spastic diplegia in patients with hemangiomas who are taking IFN seems to correlate with age and severe hypothyroidism (caused by the presence of ectopic thyroxine–degrading enzymes produced by the hemangiomas). Thus, thyroid monitoring is mandatory in all patients with large hemangiomas.[78,79]

MONITORING THERAPY

Treatment should be discontinued if the absolute neutrophil count reaches less than 0.5×10^9/L or the platelet count reaches less than 25×10^9/L. Other symptoms warranting discontinuation include new-onset or worsening eye symptoms, the development of thyroid dysfunction not correctable by medication, and the development of severe depression or other psychiatric disorder during therapy.[78]

RISKS AND PRECAUTIONS[78]

- *Pregnancy category:* C.
- *Pediatrics:* The safety and efficacy in children have not established for any indications other than chronic hepatitides B and C.

PANITUMUMAB (VECTIBIX)

MECHANISM OF ACTION

Panitumumab is an entirely human monoclonal antibody directed against EGFR. Like cetuximab, it blocks ligand interactions associated with the EGFR (EGF, transforming growth factor) and downstream signaling molecules like VEGF, bFGF, and IL-8; however, because panitumumab is not chimeric, the hypothesized benefit is better overall efficacy and immunologic tolerance.[82]

INDICATIONS

Panitumumab is currently indicated for progressing, metastatic colorectal carcinoma in combination with or as a single agent following chemotherapy.[83] No known dermatologic uses or investigations into potential uses exist at this time, but, given its similarity to cetuximab, possible investigations into panitumumab's usefulness in cutaneous squamous cell carcinoma and melanoma are warranted. Other than a history of hypersensitivity, there are no known contraindications.[2]

COMPLICATIONS (SOME EXAMPLES)[83]

- Severe dermatologic toxicities (acneiform dermatitis, pruritus, erythema, rash, skin exfoliation, paronychia, dry skin, skin fissures)
- Photosensitivity
- Pulmonary fibrosis
- Electrolyte disturbances
- Infusion reactions

PEGAPTANIB (MACUGEN)

MECHANISM OF ACTION

Pegaptanib is a short peptide strand, or aptamer, directed against a specific isomer of secreted VEGF, namely, VEGF165, which is thought to play a particular role in endothelial cell proliferation.[84]

INDICATIONS

Like ranibizumab, pegaptanib is currently indicated for the treatment of neovascular, or wet, age-related macular degeneration[85-87]; however, no known dermatologic uses or investigations into potential uses exist at this time.[2] New reports have presented benefits in other oculovasculopathies, for instance, ischemic diabetic macular edema,[88,89] choroidal neovascularization,[90] retinal ischemic diseases,[91] and myopic choroidal neovascularization.[92]

CONTRAINDICATIONS[85]

- Ocular or periocular infection

COMPLICATIONS (SOME EXAMPLES)[85]

- Endophthalmitis, retinal detachment, and traumatic cataract formation associated with intravitreal administration
- Hypertension
- Dizziness, headache, and vertigo

PROPRANOLOL (HEMANGEOL)

MECHANISM OF ACTION

The effectiveness of propranolol in the treatment of hemangioma was discovered by chance in 2008[93] and is considered relatively safe for this usage.[94] Given to infants who are at least 5-weeks old, propranolol, a beta-blocker, can be used in the treatment of infantile hemangioma (Fig. 195-2).[95,96] Propanolol is not only successfully used for cutaneous hemangioma, but also for liver infantile hemangioma;[97] some incomplete responses have been described, such as in focal subglottic hemangioma.[98] In general, beta-blockers, whether systemic or topical, have better long-term results when compared to corticosteroids,[99-101] but when beta-blockers and corticosteroids are used together, there is a faster positive outcome.[102]

Propranolol works in the treatment of hemangioma, by blocking both β_1- and β_2-adrenegric receptors in hemangioma endothelial cells; it also reduces levels without transactivating VEGF-2 signaling, and without promoting G_0/G_1-phase cell-cycle arrest—indeed, G_0/G_1-phase cell-cycle arrest has been associated with decreased cyclin D_1, CDK-4, CDK-6, phospho-Rb expression, and with cessation of cell proliferation.[35] Moreover, propranolol reduces the expression of HIF-1α in a dose-dependent and a time-dependent manner, mainly by acting on β_2-adrenegric receptors, in addition to blocking both STAT-3 and proapoptotic Bcl-2 pathways.[103] In fact, newer studies point to better results when propranolol is prescribed to infants older than 6 months of age; propranolol also reduces plasma VEGF levels in a posttreatment long-term manner.[104]

INDICATIONS[95]

- Tremors
- Angina
- Hypertension
- Heart rhythm disorders
- Treatment and prevention of myocardial infarction
- Reduction of the severity and frequency of migraine
- Infantile hemangioma

CONTRAINDICATIONS[95]

- Muscle disorder
- Bronchitis, emphysema, or other breathing disorders
- Low blood glucose or diabetes
- Slow heartbeats, low blood pressure

Figure 195-2 Posterior fossa brain malformations, hemangiomas of the face, arterial anomalies, cardiac anomalies, and eye abnormalities (PHACE) syndrome patient whose cranial hemangioma was treated with systemic propranolol. **A,** Patient before treatment, at age 45 days; (**B**) same patient at age 5 years. (Images used with permission from Dr. Caroline Romanelli Tiburcio Alves Zelenika, Pontifical Catholic University of Campinas, Campinas/SP, Brazil.)

- Congestive heart failure
- Depression
- Liver or kidney disease
- Thyroid disorder
- Pheochromocytoma
- Problems with circulation (eg, Raynaud syndrome)

DOSING REGIMEN

Chapter 118 provides dosing regimen information for propranolol.

COMPLICATIONS (SOME EXAMPLES)[95]

- Nausea, vomiting, diarrhea, constipation, or stomach cramps
- Decreased sex drive, impotence, or difficulty having an orgasm
- Sleep problems (insomnia)
- Tired feeling
- Hypoglycemia
- Asthma attack

RANIBIZUMAB (LUCENTIS)

MECHANISM OF ACTION

Ranibizumab is an antibody fragment related to bevacizumab that similarly competitively binds VEGF and inhibits its interactions with VEGFR-1 and VEGFR-2; it acts to block endothelial proliferation and survival. Smaller in size than bevacizumab (a full-length antibody), ranibizumab is thought to have better tissue absorption and fewer inflammatory reactions.[105]

INDICATIONS

Ranibizumab is currently indicated for the treatment of patients with neovascular, or wet, age-related macular degeneration, as well as diabetic retinopathy, macular edema, and choroidal neovascularization secondary to pathologic myopia;[28,106-108] clinical trials looking into its use in combination with pulsed-dye laser in cutaneous neurofibroma and port-wine stain are ongoing.[2]

CONTRAINDICATIONS[106]

- Ocular or periocular infection
- Hypersensitivity

COMPLICATIONS (SOME EXAMPLES)[106]

- Endophthalmitis and retinal detachment associated with intravitreal administration
- Increase in intraocular pressures
- Arterial thromboembolic events

SIROLIMUS (RAPAMUNE)

MECHANISM OF ACTION

Isolated from the bacterium *Streptomyces hygroscopicus*, sirolimus is a macrocyclic lactone antibiotic with immunosuppressant, antifungal, and antineoplastic properties. After forming a complex with FK-binding protein-12, sirolimus acts by inhibiting the interaction of the mTOR with its substrates; mTOR is a serine–threonine protein kinase activated by several growth factors whose downstream targets affect cell-cycle control and angiogenesis in normal and neoplastic cells.[109] Sirolimus decreases levels of hypoxia HIF-1α and significantly inhibits VEGF-mediated vascular endothelial cell stimulation, bFGF-induced angiogenesis, and T-cell activation and proliferation.[110] By suppressing mTOR complex 2, sirolimus also inhibits Akt activation.[111] Of the drugs used in the solid-organ transplantation setting, including cyclosporine and tacrolimus, rapamycin has the greatest antiangiogenic activity. To that effect, it may be useful for the prevention of squamous cell carcinoma and lymphoma in the immunosuppressed transplantation population.[2]

INDICATIONS

Rapamycin is currently approved for prophylaxis against renal transplant rejection as well as lymphangioleiomyomatosis.[112] Off-label uses in dermatology include the treatment of psoriasis, Kaposi sarcoma, tuberous sclerosis, and angiofibromatosis.[113-117] There are also case reports of its efficacy in nephrogenic systemic fibrosis, scleroderma, and dermatomyositis.[118-120] Ongoing clinical trials are looking into the usefulness of sirolimus in the prevention of nonmelanoma skin cancer in patients following kidney transplantation, that of topical sirolimus in basal cell nevus syndrome (Gorlin-Goltz syndrome), and in combination with pulsed-dye laser in port-wine stain. Other than a history of hypersensitivity to it or other rapamycin derivatives, there are no known contraindications.[2] A new generation of sirolimus-based compounds, phosphorus-containing sirolimus (FIM-A), inhibit the angiogenesis and proliferation of osteosarcomas, as they arrest cells in the G_1-phase of the cell cycle, accompanied by reduction of VEGF and HIF-1α; as well as they also inhibit mTORC1 signaling as demonstrated by decreased phosphorylation of p70S6K1 and 4E-BP1.[121]

COMPLICATIONS (SOME EXAMPLES)[112,122]

- *Systemic toxicities:* Complications that may occur include headache, thrombocytopenia, arthralgia, interstitial pneumonitis, and hypercholesterolemia.
- *Cutaneous toxicities:* Cutaneous side effects of therapy include angioedema, leukocytoclastic vasculitis, xerosis, and aphthous ulceration, which all resolve with discontinuation of therapy.
- Increased susceptibility to infections and malignancies.

SORAFENIB (NEXAVAR)

MECHANISM OF ACTION

Sorafenib is a small-molecule, phosphorylation inhibitor of several tyrosine kinase receptors, including PDGF-β, VEGFR-1, VEGFR-2, VEGFR-3, and RAF kinase,[123,124] thereby contributing to RAF/MEK/ERK pathway blockage.[125,126] Like sunitinib, sorafenib inhibition of multiple points of downstream signaling by tyrosine kinase receptors results in tumor growth inhibition and regression.[2] Furthermore, it has been reported, in preclinical models, that sorafenib blocks tumor growth, angiogenesis, and metastatic potential of osteosarcoma through a mechanism potentially involving the inhibition of the ERK1/ERK2, MCL-1, and ezrin pathways.[127]

INDICATIONS

Sorafenib is currently indicated for the treatment of advanced renal cell carcinoma, unresectable hepatocellular carcinoma, and differentiated thyroid cancer.[128] Ongoing clinical trials are looking into the use of sorafenib in the treatment of metastatic melanoma, both alone and in combination with chemotherapy (carboplatin and paclitaxel). Other than a history of hypersensitivity, there are no known contraindications.[128]

It has been observed in patients who use sorafenib for cancer treatment that progression-free survival was significantly shorter in patients with high levels of Ang-2, granulocyte colony-stimulating factor, hematopoietic growth factor, and leptin.[129] Interestingly, expression levels of many angiogenesis-related genes in the cutaneous metastasis of sarcomatoid-changed and rhabdoid features of an advanced renal cell carcinoma were relatively higher than those of the primary sorafenib-resistant tumor.[130]

A plethora of different sorafenib derivatives with good clinical and in vitro profiles have been presented in recent years. DCT015, a new sorafenib derivate, inhibits tumor growth and angiogenesis in gastric cancer models by inhibiting proliferation, inducing the morphologic changes of apoptosis, increasing the apoptosis percentage, as well as increasing the sub-G_1 population in gastric cancer cells, once it inhibits both MEK/ERK and PI3K/Akt signaling pathways, VEGF-induced migration, and tube formation in human umbilical vein endothelial cells. In addition, DCT015 downregulates VEGF-induced VEGFR-2 phosphorylation with the decreased phosphorylation of the downstream key protein.[131] Such suppression of VEGFR-2/EGFR–mediated angiogenesis can be also observed with NSK-01105, another novel sorafenib derivative, in human prostate tumor growth.[132] Another sorafenib derivative, SL1122-37, has greater effects than sorafenib on human hepatocellular carcinoma growth and prevention of angiogenesis.[133]

COMPLICATIONS (SOME EXAMPLES)[128]

- Dermatologic toxicities (rash, hand–foot syndrome, alopecia, pruritus)
- Multiple blood dyscrasias
- Hypertension, cardiac ischemia
- GI upset, perforation
- CYP2B6, CYP2C8, and CYP3A4 drug metabolism interactions
- Nephrotic syndrome[134]

SUNITINIB (SUTENT)

MECHANISM OF ACTION

Sunitinib is a small-molecule, phosphorylation inhibitor of several tyrosine kinase receptors, including PDGF-α, PDGF-β, VEGFR-1, VEGFR-2, and VEGFR-3; tumor growth inhibition and tumor regression result due to a variety of downstream mechanisms.[55,135,136]

INDICATIONS

Sunitinib is currently indicated for the treatment of GI stromal tumors, advanced renal cell carcinoma, and pancreatic neuroendocrine tumors.[137] Indeed, patients with AA/AC alleles of the VEGFR-1 single-nucleotide polymorphism rs9582036 as well as expression of phosphorylated VEGFR-2 in tumor stroma may carry a good prognosis for sunitinib-treated metastatic renal cell carcinoma.[138,139] Clinical trials are ongoing as to the efficacy of sunitinib in metastatic melanoma, but case reports exist of sunitinib efficacy in treating metastatic melanomas, as well as in treating skin ulcers associated with angioosteohypertrophy syndrome (or Klippel-Trénaunay syndrome, hemangiectatic hypertrophy).[140] Other than a history of hypersensitivity, there are no known contraindications.[2]

COMPLICATIONS (SOME EXAMPLES)[137,141]

- Dermatologic toxicities (rash, skin discoloration, hand–foot syndrome, alopecia)
- Hypertension
- Adrenal insufficiency
- CYP3A4 drug metabolism interactions (monitor with concurrent use of CYP3A4 inducers and/or inhibitors)

TEMSIROLIMUS (TORISEL)

MECHANISM OF ACTION

Like sirolimus, temsirolimus is an mTOR inhibitor that downregulates production of HIF-1α and blocks VEGF-mediated vascular endothelial cell stimulation, bFGF-induced angiogenesis, and T-cell activation and proliferation. The increased water solubility of temsirolimus allows for both oral and IV administration.[55]

INDICATIONS

Temsirolimus is currently indicated for the treatment of advanced renal cell carcinoma[142] and is being evaluating in clinical trials for the treatment of metastatic melanoma in combination with either sorafenib or bevacizumab.[2] Preliminary data show that metformin, another mTOR inhibitor, might enhance temsirolimus activity.[136] Preclinical studies show that good synergistic effect can be obtained by combining temsirolimus and cetuximab in head and neck squamous cell carcinoma,[143] in which baseline detection of caspase-3 activity may be useful for early identification of therapy success.[144] Promising results may also be obtained when temsirolimus is combined with bevacizumab and cetuximab for solid tumor treatment.[145] Other than a history of hypersensitivity to it or other rapamycin derivatives, there are no known contraindications.[2]

COMPLICATIONS (SOME EXAMPLES)[142]

- Rash
- Mucositis, GI upset, and bowel perforation
- Metabolic derangements (hyperglycemia, hyperlipidemia)
- Interstitial lung disease
- Renal toxicity
- CYP3A4 drug metabolism interactions
- Diarrhea and stomatitis[146]
- Fatigue[147]

THALIDOMIDE (THALOMID)

Thalidomide was first released in Europe and several other regions in the late 1950s and quickly became a popular sedative used for the treatment of nausea in pregnancy. It was not approved in the United States at that time because of its questionable safety in pregnancy and emerging evidence of peripheral neuropathy as a side effect; the drug was, however, approved for use in clinical trials in the United States and was given to more than a thousand physicians in the United States for this purpose before its eventual banning. It was soon discovered that thalidomide caused severe embryopathy, resulting in phocomelia, amelia, or other severe birth defects when taken during pregnancy. The tragic experience with thalidomide prompted dramatic changes in drug regulation and approval.[2] Recently, it was shown in zebrafish and chickens that thalidomide teratogenicity occurs due to thalidomide binding to the *cereblon (CRBN)* gene, which inhibits ubiquitin ligase activity.[148]

In 1965, Sheskin prescribed thalidomide for psychosis in one of his patients and accidentally discovered that thalidomide effectively treated her erythema nodosum leprosum. The FDA approved thalidomide in 1998 for the treatment of erythema nodosum leprosum and currently classifies it as an orphan drug.[2]

As interest in thalidomide's ability to treat a wide variety of refractory diseases grows, a promising class of drugs named IMiDs (thalidomide and its derivatives lenalidomide and pomalidomide) or immunomodulatory thalidomide analogs, are under development and investigation. One member of this new class of drugs, lenalidomide (CC-5013, Revlimid), has been approved for the treatment of multiple myeloma, myelodysplastic syndromes, and chronic lymphocytic leukemia. However, Phase III clinical studies of lenalidomide for the treatment of metastatic melanoma did not show a significant effect.[149]

MECHANISM OF ACTION

Thalidomide exhibits a wide range of effects in vitro and in vivo. Its mechanisms of action are still unclear, but, exhibiting antineoplastic, immunomodulatory, and antiangiogenic properties, thalidomide downregulates the expression of VEGF, bFGF, and possibly tumor necrosis factor-α, IFN-α insulin-like growth factor-1, NF-κB, IL-6, IL-12, IL-8, and matrix metalloproteinase-2.[150-152] Recently, it was described that Slit2/Robo1 endothelial signaling plays a role in angiogenesis, which can be blocked by thalidomide, once it blocks the PI3K/Akt pathway.[153] Thalidomide's antiangiogenic properties may be the basis for its antineoplastic activity, but its myriad other effects likely account for its teratogenicity.[154] Apart from its hypnosedative properties, thalidomide's eventual effects on the immune

system result in a reduction in the helper T-cell–to–suppressor T-cell ratio, and a decrease in leukocyte chemotaxis and in monocyte phagocytosis.[155] Additionally, human keratinocytes demonstrate increased migration and proliferation when exposed to thalidomide.[156]

INDICATIONS

Thalidomide is currently approved and considered first-line therapy for the acute treatment of the cutaneous manifestations of moderate to severe erythema nodosum leprosum as well as maintenance therapy for prevention and suppression of the cutaneous manifestations of erythema nodosum leprosum recurrence. In combination with dexamethasone, thalidomide is also approved for the treatment of newly-diagnosed multiple myeloma.[157] Off-label uses include Kaposi sarcoma, hemangioendotheliomas, severe aphthous stomatitis (especially in patients with AIDS), psoriasis, and a variety of other dermatologic conditions.[151]

CONTRAINDICATIONS[157]

- *Pregnancy class:* X
- Hypersensitivity to the drug or its components

PHARMACOKINETICS

Thalidomide has low water solubility and slow absorption from the GI tract, reaching peak plasma levels 0.5 to 4 hours after administration; it is only available in an oral form. A delay in absorption of up to 2 hours may occur if given in conjunction with foods high in fat.[157]

Thalidomide's half-life is approximately 5 to 7 hours, with renal clearance estimated to be 1.15 mL/min. Thalidomide's main route of elimination remains unknown, but it undergoes nonenzymatic hydrolysis in the serum to a variety of metabolites. Because hepatic metabolism appears to play an insignificant role, thalidomide is unlikely to affect levels of CYP-metabolized drugs such as oral contraceptives. Acetylcholine, prostaglandins, histamine, and serotonin are antagonized by thalidomide in vitro; alcohol, barbiturates, chlorpromazine, and reserpine have enhanced hypnosedative activity in the presence of thalidomide.[157]

DOSING REGIMEN

Because thalidomide may induce drowsiness, guidelines for dosing include initiation at 100 to 300 mg/day with a full glass of water at bedtime or at least 1 hour after the evening meal. Therapy should be continued until improvement is noted, at which point the physician can begin tapering the dose by 50 mg every 2 to 4 weeks. In the case of maintenance therapy, an attempt at tapering should occur every 3 to 6 months (Table 195-2).[157]

TABLE 195-2
Thalidomide Dosing for Selected Dermatologic Diseases[157,159]

DISEASE	DOSE
Erythema nodosum leprosum	Initial dose: 100-300 mg/day, preferably 1 hour after the evening meal with a full glass of water Maintenance dose: 50-100 mg/day Tapering recommendations: 50-mg decrements every 2-4 weeks once symptoms subside (usually after 2 weeks); in patients requiring prolonged treatment, attempt tapering schedule every 3-6 months
Severe cutaneous erythema nodosum leprosum reaction	Initial dose: 400 mg/day
Chronic graft-versus-host disease	Initial dose: 100 mg 4 times daily Maintenance dose: 200 to 400 mg 4 times daily Pediatric dose: 3-9.5 mg/kg twice daily to 4 times daily
Cutaneous lupus erythematosus	Initial dose: 400 mg/day Maintenance dose: 25-50 mg/day
Recurrent aphthous stomatitis	100 mg/day
Behçet syndrome	Initial dose: 400 mg/day Maintenance dose: 200 mg/day

INITIATING THERAPY

Thalidomide therapy should be reserved for patients with debilitating, serious diseases that have proven refractory to other therapies. The manufacturer of thalidomide has developed a restricted distribution program called System for Thalidomide Education and Prescribing Safety (S.T.E.P.S.), which requires both prescribers and dispensing pharmacists to be registered. It is mandatory for patients to be informed about the program, adhere to its requirements, and demonstrate in writing an understanding of these warnings. Female patients of childbearing potential (defined by the program as sexually mature women who have not undergone a hysterectomy or who have not been postmenopausal for at least 24 consecutive months) must have a negative pregnancy test (with a β-human chorionic gonadotropin sensitivity of at least 50 mU/mL) within 24 hours of treatment initiation. Patients must use reliable contraception (2 effective methods unless using the abstinence method) for a period of at least 1 month before initiating therapy and must continue

this practice during and for 1 month after therapy is completed. Male patients are required to use latex condoms, including those patients who have had a vasectomy.[157]

MONITORING THERAPY

S.T.E.P.S. requires patient monitoring during therapy. Strict guidelines for pregnancy testing are outlined for males and females of childbearing potential to prevent possible fetal damage. If, during the course of therapy, a patient becomes pregnant, the drug should be stopped immediately and the exposure reported to the FDA and the manufacturer (Celgene; Summit, New Jersey, USA). Patients should then see an obstetrician/gynecologist with experience in reproductive toxicity.[157]

RISKS AND PRECAUTIONS[157]

- Hypersensitivity
- Bradycardia
- Stevens-Johnson syndrome and toxic epidermal necrolysis
- Seizures
- *Pregnancy category:* X

COMPLICATIONS (SOME EXAMPLES)

- *Teratogenicity:* Thalidomide's embryopathy is well documented. Thalidomide is pregnancy category X, and patients selected for therapy must follow strict contraceptive measures as directed by the program. Thalidomide-induced defects in limb formation may be a consequence of bFGF inhibition, as bFGF induces embryologic limb formation.[158]
- *Peripheral neuropathy:* Thalidomide is neurotoxic and may result in a sensory, symmetrical distal polyneuropathy, which may later evolve to include motor symptoms as well. Neurotoxicity can be permanent. Incidence of peripheral neuropathy in patients receiving thalidomide ranges from 0.5% to 25%. Patients with preexisting peripheral neuropathy should not begin treatment. Baseline nerve conduction studies should be obtained before treatment initiation along with monthly monitoring during the first 3 months decreasing to 6-month intervals thereafter during treatment. A 40% decrease in nerve conduction necessitates treatment discontinuation.[157]
- *Neutropenia:* Because of the risk of neutropenia, baseline measurements should be obtained (including a white blood cell count with differential) and monitored regularly during the treatment course. Treatment should not be initiated in patients with an absolute neutrophil count of less than 750/mm.[157]
- *Other side effects:* Other side effects include drowsiness, orthostatic hypotension, rash, fever, and increases in HIV viral loads.[157,159]

TRASTUZUMAB (HERCEPTIN)

MECHANISM OF ACTION

Trastuzumab is a human, monoclonal antibody directed against the human estrogen receptor 2 (HER-2). Blockade of HER-2 results in downregulation of angiopoeitin-1, plasminogen-activator inhibitor-1, VEGF, and transforming growth factor-α but upregulation of TSP-1, an inhibitor of angiogenesis.[160]

INDICATIONS

Trastuzumab is currently indicated for the treatment of HER-2 overexpression, lymph node–positive breast cancer, or breast cancer that is node-negative and is estrogen receptor/progesterone receptor–negative or has 1 high-risk feature,[2] sometimes associated with another chemotherapy, such as paclitaxel, doxorubicin, cyclophosphamide, or docetaxel, as well as for treatment of metastatic gastric or gastroesophageal junction adenocarcinoma (in combination with cisplatin and either capecitabine or 5-fluorouracil).[161] No known dermatologic uses or investigations into potential uses exist at this time. Other than a history of hypersensitivity, there are no known contraindications.[2]

COMPLICATIONS (SOME EXAMPLES)[161]

- Cardiomyopathy (requires a baseline measurement of left ventricular ejection fraction and monitoring every 3 months during treatment)
- Pulmonary toxicities (interstitial pneumonitis, acute respiratory distress syndrome)
- Worsening of chemotherapy-induced neutropenia
- Infusion reactions

Table 195-3 summarizes the most important aspects of some experimental drugs that are still in experimental use and that may be helpful as antiangiogenic agents in the future.

TABLE 195-3
Antiangiogenic Properties of Selected Experimental Drugs

DRUG	ANTIANGIOGENIC EFFECTS
ABT-510	Synthetic TSP-1 analog; inhibits actions of VEGF-A, VEGF-C, and bFGF[162-166]
Calcium dobesilate	Binds and antagonizes bFGF[167,168]
Curcumin (diferuloylmethane)	Decreases proangiogenic factors, decreases endothelial cell proliferation, decreases neovascularization[169-173]
Fulvene-5	Fulvene-5 inhibits Nox4 and NADP-oxidase, as well as downregulates expression of ANG-2[174]
Gentian violet	Triphenylmethane dye; downregulates expression of ANG-2[175]
Honokiol	Inhibits VEGFR-2 autophosphorylation, blocks activation of Rac (necessary for endothelial cell migration and proliferation) in response to vascular endothelial growth factor, interferes with the expression of Bcl-2, caspase-3, and TNF-α[176-178]
Interleukin-12	Decreases bFGF-mediated angiogenesis, stimulates natural killer cells to exhibit cytotoxicity against endothelial cells, acts through interferon-γ to induce interferon-inducible protein 10, an antiangiogenic chemokine, and downregulates matrix metalloproteinase synthesis[179]

ANG, angiopoietin; bFGF, basic fibroblast growth factor; NADP, nicotinamide adenine dinucleotide phosphate; TNF, tumor necrosis factor; TSP, thrombospondin; VEGFR, vascular endothelial growth factor receptor.

ACKNOWLEDGMENTS

We thank Ricard L. Berrios, MD, and Jonathan Hofmekler, BSc, who contributed to the equivalent chapter in the 7th edition.

REFERENCES

1. Folkman J. Tumor angiogenesis: therapeutic implications. *N Engl J Med.* 1971;285(21):1182-1186.
2. Berrios RL, Bonner MY, Hofmekler J, et al. Antiangiogenic agents. In: Goldsmith LA, Katz SI, Gilchrest BA, et al. *Fitzpatrick's Dermatology in General Medicine*. 7th ed. New York, NY: McGraw-Hill; 2008:2827-2833.
3. Folkman J. Angiogenesis. *Annu Rev Med.* 2006;57:1-18.
4. Kerbel R, Folkman J. Clinical translation of angiogenesis inhibitors. *Nat Rev Cancer.* 2002;2(10):727-739.
5. Drugs.com. Becaplermin. http://www.drugs.com/ppa/becaplermin.html. Accessed March 2016.
6. Goldman R. Growth factors and chronic wound healing: past, present, and future. *Adv Skin Wound Care.* 2004;17(1):24-35.
7. Gilligan AM, Waycaster CR, Motley TA. Cost-effectiveness of becaplermin gel on wound healing of diabetic foot ulcers. *Wound Repair Regen.* 2015;23(3):353-360.
8. Cohen MA, Eaglstein WH. Recombinant human platelet-derived growth factor gel speeds healing of acute full-thickness punch biopsy wounds. *J Am Acad Dermatol.* 2001;45(6):857-862.
9. Metz BJ, Rubenstein MC, Levy ML, et al. Response of ulcerated perineal hemangiomas of infancy to becaplermin gel, a recombinant human platelet-derived growth factor. *Arch Dermatol.* 2004;140(7):867-870.
10. Twu O, Mednik S, Scumpia P, et al. Use of becaplermin for nondiabetic ulcers: pyoderma gangrenosum and calciphylaxis. *Dermatol Ther.* 2016;29(2):104-108.
11. Tauveron V, Rosen A, Khashoggi M, et al. Long-term successful healing of ulcerated necrobiosis lipoidica after topical therapy with becaplermin. *Clin Exp Dermatol.* 2013;38(7):745-747.
12. Fang RC, Galiano RD. A review of becaplermin gel in the treatment of diabetic neuropathic foot ulcers. *Biologics*. 2008;2(1):1-12.
13. Ziyadeh N, Fife D, Walker AM, et al. A matched cohort study of the risk of cancer in users of becaplermin. *Adv Skin Wound Care.* 2011;24(1):31-39.
14. Papanas N, Maltezos E. Benefit-risk assessment of becaplermin in the treatment of diabetic foot ulcers. *Drug Saf.* 2010;33(6):455-461.
15. Jain RK, Duda DG, Clark JW, et al. Lessons from phase III clinical trials on anti-VEGF therapy for cancer. *Nat Clin Pract Oncol.* 2006;3(1):24-40.
16. Lam SW, Nota NM, Jager A, et al. Angiogenesis- and hypoxia-associated proteins as early indicators of the outcome in patients with metastatic breast cancer given first-line bevacizumab-based therapy. *Clin Cancer Res.* 2016;22(7):1611-1620.
17. Paiva TF Jr, de Jesus VH, Marques RA, et al. Angiogenesis-related protein expression in bevacizumab-treated metastatic colorectal cancer: NOTCH1 detrimental to overall survival. *BMC Cancer.* 2015;15:643.
18. Drugs.com. Bevacizumab. http://www.drugs.com/ppa/bevacizumab.html. Accessed March 2016.
19. Tredan O, Lacroix-Triki M, Guiu S, et al. Angiogenesis and tumor microenvironment: bevacizumab in the breast cancer model. *Target Oncol*. 2015;10(2):189-198.
20. Rinne ML, Lee EQ, Nayak L, et al. Update on bevacizumab and other angiogenesis inhibitors for brain cancer. *Expert Opin Emerg Drugs*. 2013;18(2):137-153.
21. Veytsman I, Aragon-Ching JB, Swain SM. Bevacizumab and angiogenesis inhibitors in the treatment of CNS metastases: the road less travelled. *Curr Mol Pharmacol.* 2013 [Epub ahead of print].
22. Yamatodani T, Holmqvist B, Kjellen E, et al. Using intravital microscopy to observe bevacizumab-mediated anti-angiogenesis in human head and neck squamous cell carcinoma xenografts. *Acta Otolaryngol.* 2012;132(12):1324-1333.
23. Seystahl K, Weller M. Is there a world beyond bevacizumab in targeting angiogenesis in glioblastoma? *Expert Opin Investig Drugs.* 2012;21(5):605-617.
24. Deguchi T, Shikano T, Kasuya H, et al. Combination of the tumor angiogenesis inhibitor bevacizumab and intratumoral oncolytic herpes virus injections as a treatment strategy for human gastric cancers. *Hepatogastroenterology.* 2012;59(118):1844-1850.
25. Gerger A, El-Khoueiry A, Zhang W, et al. Pharmacogenetic angiogenesis profiling for first-line Bevacizumab plus oxaliplatin-based chemotherapy in patients with metastatic colorectal cancer. *Clin Cancer Res.* 2011;17(17):5783-5792.

26. Hu CC, Chaw JR, Chen CF, et al. Controlled release bevacizumab in thermoresponsive hydrogel found to inhibit angiogenesis. *Biomed Mater Eng*. 2014;24(6): 1941-1950.
27. Kuo CN, Chen CY, Chen SN, et al. Inhibition of corneal neovascularization with the combination of bevacizumab and plasmid pigment epithelium-derived factor-synthetic amphiphile INTeraction-18 (p-PEDF-SAINT-18) vector in a rat corneal experimental angiogenesis model. *Int J Mol Sci*. 2013;14(4):8291-8305.
28. Dursun A, Arici MK, Dursun F, et al. Comparison of the effects of bevacizumab and ranibizumab injection on corneal angiogenesis in an alkali burn induced model. *Int J Ophthalmol*. 2012;5(4):448-451.
29. Tunik S, Nergiz Y, Keklikci U, et al. The subconjunctival use of cetuximab and bevacizumab in inhibition of corneal angiogenesis. *Graefes Arch Clin Exp Ophthalmol*. 2012;250(8):1161-1167.
30. Del Vecchio M, Mortarini R, Canova S, et al. Bevacizumab plus fotemustine as first-line treatment in metastatic melanoma patients: clinical activity and modulation of angiogenesis and lymphangiogenesis factors. *Clin Cancer Res*. 2010;16(23):5862-5872.
31. Lee SY, Kim DK, Cho JH, et al. Inhibitory effect of bevacizumab on the angiogenesis and growth of retinoblastoma. *Arch Ophthalmol*. 2008;126(7):953-958.
32. Tao X, Sood AK, Deavers MT, et al. Anti-angiogenesis therapy with bevacizumab for patients with ovarian granulosa cell tumors. *Gynecol Oncol*. 2009;114(3): 431-436.
33. Cesca M, Morosi L, Berndt A, et al. Bevacizumab-induced inhibition of angiogenesis promotes a more homogeneous intratumoral distribution of paclitaxel, improving the antitumor response. *Mol Cancer Ther*. 2016;15(1):125-135.
34. Su Y, Yang WB, Li S, et al. Effect of angiogenesis inhibitor bevacizumab on survival in patients with cancer: a meta-analysis of the published literature. *PLoS One*. 2012;7(4):e35629.
35. Chen XL, Lei YH, Liu CF, et al. Angiogenesis inhibitor bevacizumab increases the risk of ischemic heart disease associated with chemotherapy: a meta-analysis. *PLoS One*. 2013;8(6):e66721.
36. Ranpura V, Hapani S, Chuang J, et al. Risk of cardiac ischemia and arterial thromboembolic events with the angiogenesis inhibitor bevacizumab in cancer patients: a meta-analysis of randomized controlled trials. *Acta Oncol*. 2010;49(3):287-297.
37. Ludwig H, Khayat D, Giaccone G, et al. Proteasome inhibition and its clinical prospects in the treatment of hematologic and solid malignancies. *Cancer*. 2005;104(9):1794-1807.
38. Roccaro AM, Hideshima T, Raje N, et al. Bortezomib mediates antiangiogenesis in multiple myeloma via direct and indirect effects on endothelial cells. *Cancer Res*. 2006;66(1):184-191.
39. Drugs.com. Bortezomib. http://www.drugs.com/ppa/bortezomib.html. Accessed March 2016.
40. Wang X, Zhang Z, Yao C. Bortezomib inhibits the angiogenesis mediated by mesenchymal stem cells. *Cancer Invest*. 2012;30(9):657-662.
41. Zinzani PL, Musuraca G, Tani M, et al. Phase II trial of proteasome inhibitor bortezomib in patients with relapsed or refractory cutaneous T-cell lymphoma. *J Clin Oncol*. 2007;25(27):4293-4297.
42. Terpos E, Kastritis E, Roussou M, et al. The combination of bortezomib, melphalan, dexamethasone and intermittent thalidomide is an effective regimen for relapsed/refractory myeloma and is associated with improvement of abnormal bone metabolism and angiogenesis. *Leukemia*. 2008;22(12):2247-2256.
43. Bota DA, Alexandru D, Keir ST, et al. Proteasome inhibition with bortezomib induces cell death in GBM stem-like cells and temozolomide-resistant glioma cell lines, but stimulates GBM stem-like cells' VEGF production and angiogenesis. *J Neurosurg*. 2013;119(6):1415-1423.
44. Vincenzi B, Santini D, Russo A, et al. Angiogenesis modifications related with cetuximab plus irinotecan as anticancer treatment in advanced colorectal cancer patients. *Ann Oncol*. 2006;17(5):835-841.
45. Perrotte P, Matsumoto T, Inoue K, et al. Anti-epidermal growth factor receptor antibody C225 inhibits angiogenesis in human transitional cell carcinoma growing orthotopically in nude mice. *Clin Cancer Res*. 1999;5(2):257-265.
46. Pham MH, Delestre L, Dewitte A, et al. Synergistic effect of SN-38 in combination with cetuximab on angiogenesis and cancer cell invasion. *Anticancer Res*. 2015;35(11):5983-5991.
47. Pueyo G, Mesia R, Figueras A, et al. Cetuximab may inhibit tumor growth and angiogenesis induced by ionizing radiation: a preclinical rationale for maintenance treatment after radiotherapy. *Oncologist*. 2010;15(9):976-986.
48. Drugs.com. Cetuximab. http://www.drugs.com/ppa/cetuximab.html. Accessed March 2016.
49. El Filali M, Homminga I, Maat W, et al. Triamcinolone acetonide and anecortave acetate do not stimulate uveal melanoma cell growth. *Mol Vis*. 2008;14:1752-1759.
50. Wilson C, Scullin P, Worthington J, et al. Dexamethasone potentiates the antiangiogenic activity of docetaxel in castration-resistant prostate cancer. *Br J Cancer*. 2008;99(12):2054-2064.
51. Sung J, Barone PW, Kong H, et al. Sequential delivery of dexamethasone and VEGF to control local tissue response for carbon nanotube fluorescence based micro-capillary implantable sensors. *Biomaterials*. 2009;30(4):622-631.
52. Lee JG, Wu R. Erlotinib-cisplatin combination inhibits growth and angiogenesis through c-MYC and HIF-1alpha in EGFR-mutated lung cancer in vitro and in vivo. *Neoplasia*. 2015;17(2):190-200.
53. Drugs.com. Erlotinib. http://www.drugs.com/ppa/erlotinib.html. Accessed March 2016.
54. Dy GK, Infante JR, Eckhardt SG, et al. Phase Ib trial of the oral angiogenesis inhibitor pazopanib administered concurrently with erlotinib. *Invest New Drugs*. 2013;31(4):891-899.
55. Nguyen A, Hoang V, Laquer V, et al. Angiogenesis in cutaneous disease: part I. *J Am Acad Dermatol*. 2009;61(6):921-942; quiz 943-944.
56. Bianco R, Garofalo S, Rosa R, et al. Inhibition of mTOR pathway by everolimus cooperates with EGFR inhibitors in human tumours sensitive and resistant to anti-EGFR drugs. *Br J Cancer*. 2008;98(5):923-930.
57. Cejka D, Preusser M, Woehrer A, et al. Everolimus (RAD001) and anti-angiogenic cyclophosphamide show long-term control of gastric cancer growth in vivo. *Cancer Biol Ther*. 2008;7(9):1377-1385.
58. Ceausu RA, Cimpean AM, Dimova I, et al. Everolimus dual effects of an area vasculosa angiogenesis and lymphangiogenesis. *In Vivo*. 2013;27(1):61-66.
59. Drugs.com. Everolimus. http://www.drugs.com/ppa/everolimus.html. Accessed March 2016.

60. Frigerio E, Colombo MD, Franchi C, et al. Severe psoriasis treated with a new macrolide: everolimus. *Br J Dermatol.* 2007;156(2):372-374.
61. Damiano V, Rosa R, Formisano L, et al. Toll-like receptor 9 agonist IMO cooperates with everolimus in renal cell carcinoma by interfering with tumour growth and angiogenesis. *Br J Cancer.* 2013;108(8):1616-1623.
62. Testerman TL, Gerster JF, Imbertson LM, et al. Cytokine induction by the immunomodulators imiquimod and S-27609. *J Leukoc Biol.* 1995;58(3):365-372.
63. Majewski S, Marczak M, Mlynarczyk B, et al. Imiquimod is a strong inhibitor of tumor cell-induced angiogenesis. *Int J Dermatol.* 2005;44(1):14-19.
64. Hesling C, D'Incan M, Mansard S, et al. In vivo and in situ modulation of the expression of genes involved in metastasis and angiogenesis in a patient treated with topical imiquimod for melanoma skin metastases. *Br J Dermatol.* 2004;150(4):761-767.
65. Miller RL, Gerster JF, Owens ML, et al. Imiquimod applied topically: a novel immune response modifier and new class of drug. *Int J Immunopharmacol.* 1999;21(1):1-14.
66. Suzuki H, Wang B, Shivji GM, et al. Imiquimod, a topical immune response modifier, induces migration of Langerhans cells. *J Invest Dermatol.* 2000;114(1):135-141.
67. Arbiser JL, Bips M, Seidler A, et al. Combination therapy of imiquimod and gentian violet for cutaneous melanoma metastases. *J Am Acad Dermatol.* 2012;67(2):e81-e83.
68. Drugs.com. Imiquimod cream (Aldara). http://www.drugs.com/pro/imiquimod.html. Accessed March 2016.
69. Ezzell TI, Fromowitz JS, Ramos-Caro FA. Recurrent pyogenic granuloma treated with topical imiquimod. *J Am Acad Dermatol.* 2006;54(5)(suppl):S244-S245.
70. Li VW, Li WW, Talcott KE, et al. Imiquimod as an antiangiogenic agent. *J Drugs Dermatol.* 2005;4(6):708-717.
71. Sidbury R, Neuschler N, Neuschler E, et al. Topically applied imiquimod inhibits vascular tumor growth in vivo. *J Invest Dermatol.* 2003;121(5):1205-1209.
72. Gul U, Gonul M, Cakmak SK, et al. A case of generalized discoid lupus erythematosus: successful treatment with imiquimod cream 5%. *Adv Ther.* 2006;23(5):787-792.
73. Chang CJ, Hsiao YC, Mihm MC Jr, et al. Pilot study examining the combined use of pulsed dye laser and topical Imiquimod versus laser alone for treatment of port wine stain birthmarks. *Lasers Surg Med.* 2008;40(9):605-610.
74. Tremaine AM, Ortiz A, Armstrong J, et al. Combined therapy for enhanced microvascular destruction in port wine stains: pulsed dye laser photothermolysis and imiquimod. *Lasers Surg Med.* 2009:22-23.
75. Indraccolo S. Interferon-alpha as angiogenesis inhibitor: learning from tumor models. *Autoimmunity.* 2010;43(3):244-247.
76. Rosewicz S, Detjen K, Scholz A, et al. Interferon-alpha: regulatory effects on cell cycle and angiogenesis. *Neuroendocrinology.* 2004;80(suppl 1):85-93.
77. Avnet S, Cenni E, Perut F, et al. Interferon-alpha inhibits in vitro osteoclast differentiation and renal cell carcinoma-induced angiogenesis. *Int J Oncol.* 2007;30(2):469-476.
78. Drugs.com. Interferon alfa-2b. http://www.drugs.com/ppa/interferon-alfa-2b.html. Accessed March 2016.
79. Michaud AP, Bauman NM, Burke DK, et al. Spastic diplegia and other motor disturbances in infants receiving interferon-alpha. *Laryngoscope.* 2004;114(7):1231-1236.
80. Tagliaferri P, Caraglia M, Budillon A, et al. New pharmacokinetic and pharmacodynamic tools for interferon-alpha (IFN-alpha) treatment of human cancer. *Cancer Immunol Immunother.* 2005;54(1):1-10.
81. Arbiser JL. Antiangiogenic therapy and dermatology: a review. *Drugs Today (Barc).* 1997;33(10):687-696.
82. Cohenuram M, Saif MW. Panitumumab the first fully human monoclonal antibody: from the bench to the clinic. *Anticancer Drugs.* 2007;18(1):7-15.
83. Drugs.com. Panitumumab. http://www.drugs.com/ppa/panitumumab.html. Accessed March 2016.
84. Ferrara N, Houck KA, Jakeman LB, et al. The vascular endothelial growth factor family of polypeptides. *J Cell Biochem.* 1991;47(3):211-218.
85. Drugs.com. Pegaptanib sodium. http://www.drugs.com/ppa/pegaptanib-sodium.html. Accessed March 2016.
86. Manresa N, Mulero J, Losada M, et al. Effect of pegaptanib and ranibizumab on plasma and vitreous homocysteine in patients with exudative age-related macular degeneration. *Retina.* 2015;35(9):1765-1771.
87. Inoue M, Kadonosono K, Arakawa A, et al. Long-term outcome of intravitreal pegaptanib sodium as maintenance therapy in Japanese patients with neovascular age-related macular degeneration. *Jpn J Ophthalmol.* 2015;59(3):173-178.
88. Kiire CA, Morjaria R, Rudenko A, et al. Intravitreal pegaptanib for the treatment of ischemic diabetic macular edema. *Clin Ophthalmol.* 2015;9:2305-2311.
89. Basile AS, Hutmacher MM, Kowalski KG, et al. Population pharmacokinetics of pegaptanib sodium (Macugen(®)) in patients with diabetic macular edema. *Clin Ophthalmol.* 2015;9:323-335.
90. Lytvynchuk L, Sergienko A, Lavrenchuk G, et al. Antiproliferative, apoptotic, and autophagic activity of ranibizumab, bevacizumab, pegaptanib, and aflibercept on fibroblasts: implication for choroidal neovascularization. *J Ophthalmol*. 2015;2015:934963.
91. Hussain RM, Harris A, Siesky B, et al. The effect of pegaptanib (Macugen(®)) injection on retinal and retrobulbar blood flow in retinal ischaemic diseases. *Acta Ophthalmol.* 2015;93(5):e399-e400.
92. Rinaldi M, Chiosi F, Dell'Omo R, et al. Intravitreal pegaptanib sodium (Macugen) for treatment of myopic choroidal neovascularization: a morphologic and functional study. *Retina.* 2013;33(2):397-402.
93. Delmotte N, Curti C, Montana M, et al. News on infantile hemangioma therapy by beta-blocker [in French]. *Therapie.* 2012;67(3):257-265.
94. Chang L, Ye X, Qiu Y, et al. Is propranolol safe and effective for outpatient use for infantile hemangioma? A prospective study of 679 cases from one center in China. *Ann Plast Surg.* 2016;76(5):559-563.
95. Drugs.com. Propranolol. http://www.drugs.com/propranolol.html. Accessed March 2016.
96. Phillips CB, Pacha O, Biliciler-Denkta G, et al. A review of beta antagonist treatment for infantile hemangioma. *J Drugs Dermatol.* 2012;11(7):826-829.
97. Marsciani A, Pericoli R, Alaggio R, et al. Massive response of severe infantile hepatic hemangioma to propranolol. *Pediatr Blood Cancer.* 2010;54(1):176.
98. Canadas KT, Baum ED, Lee S, et al. Case report: treatment failure using propranolol for treatment of focal subglottic hemangioma. *Int J Pediatr Otorhinolaryngol.* 2010;74(8):956-958.
99. Xu SQ, Jia RB, Zhang W, et al. Beta-blockers versus corticosteroids in the treatment of infantile hemangioma: an evidence-based systematic review. *World J Pediatr.* 2013;9(3):221-229.

100. Chinnadurai S, Fonnesbeck C, Snyder KM, et al. Pharmacologic interventions for infantile hemangioma: a meta-analysis. *Pediatrics.* 2016;137(2):1-10.
101. Sawa K, Yazdani A, Rieder MJ, et al. Propranolol therapy for infantile hemangioma is less toxic but longer in duration than corticosteroid therapy. *Plast Surg (Oakv)*. 2014;22(4):233-236.
102. Aly MM, Hamza AF, Abdel Kader HM, et al. Therapeutic superiority of combined propranolol with short steroids course over propranolol monotherapy in infantile hemangioma. *Eur J Pediatr.* 2015;174(11):1503-1509.
103. Li P, Guo Z, Gao Y, et al. Propranolol represses infantile hemangioma cell growth through the beta2-adrenergic receptor in a HIF-1alpha-dependent manner. *Oncol Rep.* 2015;33(6):3099-3107.
104. Ozeki M, Nozawa A, Hori T, et al. Propranolol for infantile hemangioma: effect on plasma vascular endothelial growth factor. *Pediatr Int.* 2016;58(11):1130-1135.
105. Million RP. Therapeutic area crossroads: anti-angiogenesis. *Nat Rev Drug Discov.* 2008;7(2):115-116.
106. Drugs.com. Ranibizumab. http://www.drugs.com/ppa/ranibizumab.html. Accessed March 2016.
107. Figurska M, Robaszkiewicz J, Wierzbowska J. Safety of ranibizumab therapy in wet AMD and the role of vascular endothelial growth factors in physiological angiogenesis. *Klin Oczna*. 2010;112(4-6):147-150.
108. Barzelay A, Lowenstein A, George J, et al. Influence of non-toxic doses of bevacizumab and ranibizumab on endothelial functions and inhibition of angiogenesis. *Curr Eye Res.* 2010;35(9):835-841.
109. Rao RD, Buckner JC, Sarkaria JN. Mammalian target of rapamycin (mTOR) inhibitors as anti-cancer agents. *Curr Cancer Drug Targets.* 2004;4(8):621-635.
110. Kwon YS, Kim JC. Inhibition of corneal neovascularization by rapamycin. *Exp Mol Med*. 2006;38(2):173-179.
111. Sarbassov DD, Ali SM, Sengupta S, et al. Prolonged rapamycin treatment inhibits mTORC2 assembly and Akt/PKB. *Mol Cell.* 2006;22(2):159-168.
112. Drugs.com. Sirolimus. http://www.drugs.com/ppa/sirolimus.html. Accessed March 2016.
113. Chumsri S, Zhao M, Garofalo M, et al. Inhibition of the mammalian target of rapamycin (mTOR) in a case of refractory primary cutaneous anaplastic large cell lymphoma. *Leuk Lymphoma.* 2008;49(2):359-361.
114. Zhang Q, Nowak I, Vonderheid EC, et al. Activation of Jak/STAT proteins involved in signal transduction pathway mediated by receptor for interleukin 2 in malignant T lymphocytes derived from cutaneous anaplastic large T-cell lymphoma and Sezary syndrome. *Proc Natl Acad Sci U S A*. 1996;93(17):9148-9153.
115. Saggar S, Zeichner JA, Brown TT, et al. Kaposi's sarcoma resolves after sirolimus therapy in a patient with pemphigus vulgaris. *Arch Dermatol.* 2008;144(5):654-657.
116. Hofbauer GF, Marcollo-Pini A, Corsenca A, et al. The mTOR inhibitor rapamycin significantly improves facial angiofibroma lesions in a patient with tuberous sclerosis. *Br J Dermatol.* 2008;159(2):473-475.
117. Reitamo S, Spuls P, Sassolas B, et al. Efficacy of sirolimus (rapamycin) administered concomitantly with a subtherapeutic dose of cyclosporin in the treatment of severe psoriasis: a randomized controlled trial. *Br J Dermatol.* 2001;145(3):438-445.
118. Swaminathan S, Arbiser JL, Hiatt KM, et al. Rapid improvement of nephrogenic systemic fibrosis with rapamycin therapy: possible role of phospho-70-ribosomal-S6 kinase. *J Am Acad Dermatol.* 2010;62(2):343-345.
119. Lapidoth M, Ben-Amitai D, Bhandarkar S, et al. Efficacy of topical application of eosin for ulcerated hemangiomas. *J Am Acad Dermatol.* 2009;60(2):350-351.
120. Nadiminti U, Arbiser JL. Rapamycin (sirolimus) as a steroid-sparing agent in dermatomyositis. *J Am Acad Dermatol.* 2005;52(2)(suppl 1):17-19.
121. Liu WN, Lin JH, Cheng YR, et al. FIM-A, a phosphorus-containing sirolimus, inhibits the angiogenesis and proliferation of osteosarcomas. *Oncol Res.* 2013;20(7):319-326.
122. Warino L, Libecco J. Cutaneous effects of sirolimus in renal transplant recipients. *J Drugs Dermatol.* 2006;5(3):273-274.
123. Ng R, Chen EX. Sorafenib (BAY 43-9006): review of clinical development. *Curr Clin Pharmacol.* 2006;1(3):223-228.
124. Plaza-Menacho I, Mologni L, Sala E, et al. Sorafenib functions to potently suppress RET tyrosine kinase activity by direct enzymatic inhibition and promoting RET lysosomal degradation independent of proteasomal targeting. *J Biol Chem.* 2007;282(40):29230-29240.
125. Liu L, Cao Y, Chen C, et al. Sorafenib blocks the RAF/MEK/ERK pathway, inhibits tumor angiogenesis, and induces tumor cell apoptosis in hepatocellular carcinoma model PLC/PRF/5. *Cancer Res.* 2006;66(24):11851-11858.
126. Murphy DA, Makonnen S, Lassoued W, et al. Inhibition of tumor endothelial ERK activation, angiogenesis, and tumor growth by sorafenib (BAY43-9006). *Am J Pathol.* 2006;169(5):1875-1885.
127. Pignochino Y, Grignani G, Cavalloni G, et al. Sorafenib blocks tumour growth, angiogenesis and metastatic potential in preclinical models of osteosarcoma through a mechanism potentially involving the inhibition of ERK1/2, MCL-1 and ezrin pathways. *Mol Cancer.* 2009;8:118.
128. Drugs.com. SORAfenib. http://www.drugs.com/ppa/sorafenib.html. Accessed March 2016.
129. Miyahara K, Nouso K, Tomoda T, et al. Predicting the treatment effect of sorafenib using serum angiogenesis markers in patients with hepatocellular carcinoma. *J Gastroenterol Hepatol.* 2011;26(11):1604-1611.
130. Karashima T, Fukuhara H, Tamura K, et al. Expression of angiogenesis-related gene profiles and development of resistance to tyrosine-kinase inhibitor in advanced renal cell carcinoma: characterization of sorafenib-resistant cells derived from a cutaneous metastasis. *Int J Urol.* 2013;20(9):923-930.
131. Wang W, Wang H, Ni Y, et al. DCT015, a new sorafenib derivate, inhibits tumor growth and angiogenesis in gastric cancer models. *Tumour Biol.* 2016;37(7):9221-9232.
132. Yu P, Ye L, Wang H, et al. NSK-01105, a novel sorafenib derivative, inhibits human prostate tumor growth via suppression of VEGFR2/EGFR-mediated angiogenesis. *PLoS One.* 2014;9(12):e115041.
133. Qin Y, Lu Y, Wang R, et al. SL1122-37, a novel derivative of sorafenib, has greater effects than sorafenib on the inhibition of human hepatocellular carcinoma (HCC) growth and prevention of angiogenesis. *Biosci Trends*. 2013;7(5):237-244.
134. Overkleeft EN, Goldschmeding R, van Reekum F, et al. Nephrotic syndrome caused by the angiogenesis inhibitor sorafenib. *Ann Oncol.* 2010;21(1):184-185.
135. Roskoski R Jr. Sunitinib: a VEGF and PDGF receptor protein kinase and angiogenesis inhibitor. *Biochem Biophys Res Commun.* 2007;356(2):323-328.

136. Cabebe E, Wakelee H. Sunitinib: a newly approved small-molecule inhibitor of angiogenesis. *Drugs Today (Barc).* 2006;42(6):387-398.
137. Drugs.com. Sunitinib malate. http://www.drugs.com/ppa/sunitinib-malate.html. Accessed March 2016.
138. Dornbusch J, Walter M, Gottschalk A, et al. Evaluation of polymorphisms in angiogenesis-related genes as predictive and prognostic markers for sunitinib-treated metastatic renal cell carcinoma patients. *J Cancer Res Clin Oncol.* 2016;142(6):1171-1182.
139. del Puerto-Nevado L, Rojo F, Zazo S, et al. Active angiogenesis in metastatic renal cell carcinoma predicts clinical benefit to sunitinib-based therapy. *Br J Cancer.* 2014;110(11):2700-2707.
140. Nguyen S, Franklin M, Dudek AZ. Skin ulcers in Klippel-Trenaunay syndrome respond to sunitinib. *Transl Res.* 2008;151(4):194-196.
141. Zhu X, Stergiopoulos K, Wu S. Risk of hypertension and renal dysfunction with an angiogenesis inhibitor sunitinib: systematic review and meta-analysis. *Acta Oncol.* 2009;48(1):9-17.
142. Drugs.com. Temsirolimus. http://www.drugs.com/ppa/temsirolimus.html. Accessed March 2016.
143. Lattanzio L, Milano G, Monteverde M, et al. Schedule-dependent interaction between temsirolimus and cetuximab in head and neck cancer: a preclinical study. *Anticancer Drugs.* 2016;27(6):533-539.
144. John K, Rosner I, Keilholz U, et al. Baseline caspase activity predicts progression free survival of temsirolimus-treated head neck cancer patients. *Eur J Cancer.* 2015;51(12):1596-1602.
145. Liu X, Kambrick S, Fu S, et al. Advanced malignancies treated with a combination of the VEGF inhibitor bevacizumab, anti-EGFR antibody cetuximab, and the mTOR inhibitor temsirolimus. *Oncotarget.* 2016;7(17):23227-23238.
146. Abdel-Rahman O, Fouad M. Risk of oral and gastrointestinal mucosal injury in patients with solid tumors treated with everolimus, temsirolimus or ridaforolimus: a comparative systematic review and meta-analysis. *Expert Rev Anticancer Ther.* 2015;15(7):847-858.
147. Abdel-Rahman O, Fouad M. Risk of fatigue in patients with solid tumors treated with everolimus, temsirolimus or ridaforolimus: a comparative meta-analysis. *Expert Rev Anticancer Ther.* 2015;15(4):477-486.
148. Ito T, Ando H, Suzuki T, et al. Identification of a primary target of thalidomide teratogenicity. *Science.* 2010;327(5971):1345-1350.
149. Bartlett JB, Tozer A, Stirling D, et al. Recent clinical studies of the immunomodulatory drug (IMiD) lenalidomide. *Br J Cancer.* 2005;93(6):613-619.
150. Li X, Liu X, Wang J, et al. Thalidomide down-regulates the expression of VEGF and bFGF in cisplatin-resistant human lung carcinoma cells. *Anticancer Res.* 2003;23(3B):2481-2487.
151. Rosenbach M, Werth VP. Dermatologic therapeutics: thalidomide. A practical guide. *Dermatol Ther.* 2007;20(4):175-186.
152. Gelati M, Corsini E, Frigerio S, et al. Effects of thalidomide on parameters involved in angiogenesis: an in vitro study. *J Neurooncol.* 2003;64(3):193-201.
153. Li Y, Fu S, Chen H, et al. Inhibition of endothelial Slit2/Robo1 signaling by thalidomide restrains angiogenesis by blocking the PI3K/Akt pathway. *Dig Dis Sci.* 2014;59(12):2958-2966.
154. D'Amato RJ, Loughnan MS, Flynn E, et al. Thalidomide is an inhibitor of angiogenesis. *Proc Natl Acad Sci U S A.* 1994 26;91(9):4082-4085.
155. Fuchida SI, Shimazaki C, Hirai H, et al. The effects of thalidomide on chemotactic migration of multiple myeloma cell lines. *Int J Lab Hematol.* 2008;30(3):220-229.
156. Nasca MR, O'Toole EA, Palicharla P, et al. Thalidomide increases human keratinocyte migration and proliferation. *J Invest Dermatol.* 1999;113(5):720-724.
157. Drugs.com. Thalidomide. http://www.drugs.com/ppa/thalidomide.html. Accessed March 2016.
158. Stephens TD, Bunde CJ, Fillmore BJ. Mechanism of action in thalidomide teratogenesis. *Biochem Pharmacol.* 2000;59(12):1489-1499.
159. Faver IR, Guerra SG, Su WP, et al. Thalidomide for dermatology: a review of clinical uses and adverse effects. *Int J Dermatol.* 2005;44(1):61-67.
160. Izumi Y, Xu L, di Tomaso E, et al. Tumour biology: Herceptin acts as an anti-angiogenic cocktail. *Nature.* 2002;416(6878):279-280.
161. Drugs.com. Trastuzumab. http://www.drugs.com/ppa/trastuzumab.html. Accessed March 2016.
162. Hoekstra R, de Vos FY, Eskens FA, et al. Phase I safety, pharmacokinetic, and pharmacodynamic study of the thrombospondin-1-mimetic angiogenesis inhibitor ABT-510 in patients with advanced cancer. *J Clin Oncol.* 2005;23(22):5188-5197.
163. Markovic SN, Suman VJ, Rao RA, et al. A phase II study of ABT-510 (thrombospondin-1 analog) for the treatment of metastatic melanoma. *Am J Clin Oncol.* 2007;30(3):303-309.
164. Baker LH, Rowinsky EK, Mendelson D, et al. Randomized, phase II study of the thrombospondin-1-mimetic angiogenesis inhibitor ABT-510 in patients with advanced soft tissue sarcoma. *J Clin Oncol.* 2008;26(34):5583-5588.
165. Punekar S, Zak S, Kalter VG, et al. Thrombospondin 1 and its mimetic peptide ABT-510 decrease angiogenesis and inflammation in a murine model of inflammatory bowel disease. *Pathobiology.* 2008;75(1):9-21.
166. Anderson JC, Grammer JR, Wang W, et al. ABT-510, a modified type 1 repeat peptide of thrombospondin, inhibits malignant glioma growth in vivo by inhibiting angiogenesis. *Cancer Biol Ther.* 2007;6(3):454-462.
167. Arbiser JL, Byers HR, Cohen C, et al. Altered basic fibroblast growth factor expression in common epidermal neoplasms: examination with in situ hybridization and immunohistochemistry. *J Am Acad Dermatol.* 2000;42(6):973-977.
168. Lameynardie S, Chiavaroli C, Travo P, et al. Inhibition of choroidal angiogenesis by calcium dobesilate in normal Wistar and diabetic GK rats. *Eur J Pharmacol.* 2005 7;510(1-2):149-156.
169. Arbiser JL, Klauber N, Rohan R, et al. Curcumin is an in vivo inhibitor of angiogenesis. *Mol Med.* 1998;4(6):376-383.
170. Sharma RA, Gescher AJ, Steward WP. Curcumin: the story so far. *Eur J Cancer.* 2005;41(13):1955-1968.
171. Wang F, He Z, Dai W, et al. The role of the vascular endothelial growth factor/vascular endothelial growth factor receptors axis mediated angiogenesis in curcumin-loaded nanostructured lipid carriers induced human HepG2 cells apoptosis. *J Cancer Res Ther.* 2015;11(3):597-605.

172. Zhang JR, Lu F, Lu T, et al. Inactivation of FoxM1 transcription factor contributes to curcumin-induced inhibition of survival, angiogenesis, and chemosensitivity in acute myeloid leukemia cells. *J Mol Med (Berl).* 2014;92(12):1319-1330.
173. Das L, Vinayak M. Long term effect of curcumin in regulation of glycolytic pathway and angiogenesis via modulation of stress activated genes in prevention of cancer. *PLoS One.* 2014;9(6):e99583.
174. Bhandarkar SS, Jaconi M, Fried LE, et al. Fulvene-5 potently inhibits NADPH oxidase 4 and blocks the growth of endothelial tumors in mice. *J Clin Invest.* 2009;119(8):2359-2365.
175. Perry BN, Govindarajan B, Bhandarkar SS, et al. Pharmacologic blockade of angiopoietin-2 is efficacious against model hemangiomas in mice. *J Invest Dermatol.* 2006;126(10):2316-2322.
176. Bai X, Cerimele F, Ushio-Fukai M, et al. Honokiol, a small molecular weight natural product, inhibits angiogenesis in vitro and tumor growth in vivo. *J Biol Chem.* 2003;278(37):35501-35507.
177. Ma L, Chen J, Wang X, et al. Structural modification of honokiol, a biphenyl occurring in *Magnolia officinalis*: the evaluation of honokiol analogues as inhibitors of angiogenesis and for their cytotoxicity and structure-activity relationship. *J Med Chem.* 2011;54(19):6469-6481.
178. Li Z, Liu Y, Zhao X, et al. Honokiol, a natural therapeutic candidate, induces apoptosis and inhibits angiogenesis of ovarian tumor cells. *Eur J Obstet Gynecol Reprod Biol.* 2008;140(1):95-102.
179. Yao L, Sgadari C, Furuke K, et al. Contribution of natural killer cells to inhibition of angiogenesis by interleukin-12. *Blood.* 1999;93(5):1612-1621.

Chapter 196 :: Other Topical Medications

:: Shawn G. Kwatra & Manisha Loss

AT-A-GLANCE

Topical medications discussed in this chapter include:

- Analgesics
- Antiinflammatory agents
- Antimicrobial and antiparasitic agents
- Antiperspirants, antipruritics, and astringents
- Bleaching and keratolytic agents
- Topical psoriasis and wart therapies
- Compounding medications

This chapter reviews topical therapies that are used to treat dermatologic diseases but that are not discussed elsewhere in the text. When applied to large areas of skin, particularly in the presence of skin disease, or to infants and children, all topical medications have the potential to cause systemic side effects.

ANALGESICS

CAPSAICIN

Capsaicin is the active ingredient responsible for the "hotness" in chili peppers. Initial topical application results in itching, pricking, and burning as a result of activation of the transient receptor potential vanilloid-1.[1] Repeated application depletes substance P from cutaneous nerve endings and leads to desensitization of epidermal nerve fibers, thereby producing hypoalgesia.

Topical capsaicin has been used to treat postherpetic neuralgia, diabetic neuropathy, reflex sympathetic dystrophy, Raynaud phenomenon, osteoarthritis, plantar warts, and diabetic neuralgia.[2] A recent metaanalysis of 6 randomized controlled trials found high efficacy of topical capsaicin in the treatment of postherpetic neuralgia.[3] In addition, capsaicin is also an effective antipruritic agent for localized areas of pruritus of neuropathic origin, such as in brachioradial pruritus and notalgia paresthetica.[4]

The chief side effect of capsaicin is irritation and an intense burning sensation. Thus, capsaicin should not be applied to a large area of the body and may not be tolerated by children.

TOPICAL ANESTHETICS

Numerous topical anesthetic formulations are available. Eutectic mixture of local anesthetics (EMLA) cream and topical lidocaine are two of the most frequently employed topical anesthetics and are discussed in further detail below.

EUTECTIC MIXTURE OF LOCAL ANESTHETICS CREAM

EMLA cream contains the sodium channel-blocking amide anesthetics lidocaine 2.5% and prilocaine 2.5%. Application under occlusion to intact skin or genital mucous membranes for at least 1 hour before performance of a painful procedure, including debridement of venous leg ulcers,[5] can provide local anesthesia that may persist for up to 2 hours. In addition, EMLA is effective in cases of postburn pruritus[6] and notalgia paresthetica.

The cream may cause transient local blanching followed by transient local erythema. Like all products containing lidocaine, it should not be used in patients with hypersensitivity to amide anesthetics. Side effects to EMLA are usually limited to mild skin reactions. Rare severe complications include CNS toxicity, cardiotoxicity, and methemoglobinemia.[7] The prilocaine component of EMLA has been linked to cases of methemoglobinemia in patients for whom applications exceeded the recommended dose, application area, or application time.[8] Those particularly susceptible to methemoglobinemia include patients who are very young, those with glucose-6-phosphate dehydrogenase deficiency, and those taking oxidizing drugs such as sulfonamides and antimalarials.

Caution regarding dosing should also be used in patients susceptible to systemic effects of lidocaine or prilocaine, including acutely ill, debilitated, and elderly patients. In addition, factors that increase risk of systemic toxicity include application of excessive amounts of EMLA, longer application time, and application to inflamed skin.[7] Finally, as EMLA is ototoxic, it should not be used if there is a concern that it could penetrate or migrate beyond the tympanic membrane to the middle ear. EMLA is a pregnancy category B drug.

LIDOCAINE

Various topical anesthetic products contain only lidocaine, typically at concentrations of 4% or 5%, which may be applied with or without occlusion. Lidocaine 5% medicated plaster is commonly used to treat localized neuropathic pain, in particular postherpetic neuralgia and diabetic polyneuropathy.[9]

Lidocaine can result in local skin irritation, such as erythema, edema, or bruising. Systemic toxicity from topical lidocaine prepared in a 30% concentration has been reported. Systemic effects may include CNS and cardiac effects, including seizure, coma, arrhythmia, apnea, and death. Lidocaine is a pregnancy category B drug.

ANTIINFLAMMATORY AGENTS

COAL TAR

Coal tar has been used in the treatment of inflammatory dermatoses, including psoriasis and atopic dermatitis. In 1925, Goeckerman pioneered the concomitant use of coal tar and ultraviolet B therapy for psoriasis. Coal tar inhibits DNA synthesis and mitosis in epidermal cells, an effect potentiated by ultraviolet A exposure.[10] Coal tar also has antiinfective, antipruritic, photosensitizing, and vasoconstrictive effects. Coal tar works by activating the aryl hydrocarbon receptor, which results in induction of epidermal differentiation. Coal tar also counteracts T-helper type-2 cytokine-mediated downregulation of skin barrier proteins.[11]

Coal tar has historically been messy to use, has an unpleasant odor, and can stain clothing, making its use challenging for some. Newer formulations may be better tolerated. Systemic adverse effects are uncommon, whereas local adverse effects can include tar folliculitis, acneiform eruptions, irritant dermatitis, burning, stinging, allergic contact dermatitis, atrophy, telangiectases, pigmentation, exfoliative dermatitis, and keratoacanthomas.[12] Although animal experiments have shown coal tar to induce skin cancers, a large cohort study among patients with psoriasis and eczema revealed that coal tar is not associated with an increased risk of skin cancer.[13]

WOOD TAR

Wood tar (or pine tar) is produced by distillation of wood and roots of pine under controlled conditions, and can be added to arachis oil (peanut oil) or other bases. Wood tar is thought to work through reducing DNA synthesis and mitotic activity and has been found to have antibacterial, antiinflammatory, antifungal, and antipruritic activity. Wood tar can be used for atopic dermatitis, psoriasis (especially of the scalp), and seborrheic dermatitis, among other inflammatory skin conditions. Although most commonly derived from juniper (oil of cade), wood tar also may be derived from beech, birch, and pine. Wood tar may result in contact sensitivity.

SHALE OIL

Shale oil (also referred to as *ammonium bituminosulfonate*, *ichthyol*, *ichthammol*, or *black salve*) is derived from oil shale, a sulfur-rich sedimentary rock. Further processing of extracted shale oil yields light-colored and dark-colored components. Shale oil decreases inflammation by inhibiting leukotriene B_4 lipoxygenase.[14,15] A randomized, controlled trial showed that pale sulfonated shale oil cream 4% is more effective than placebo in the treatment of mild to moderate atopic dermatitis.[16] Pale sulfonated shale oil also has been used to treat venous leg ulcers, acne, psoriasis, seborrhea, eczema, rosacea, and pruritus.[17] Shale oil is generally well tolerated and the most common side effect is skin irritation.

CRISABOROLE

Crisaborole is a boron-containing, novel, small molecule that reduces skin inflammation by inhibiting phosphodiesterase 4. Two double-blind, randomized, controlled trials found crisaborole to be more effective than vehicle in reducing disease severity and improving pruritus in patients with mild to moderate atopic dermatitis.[18] Crisaborole is generally well tolerated and no severe adverse effects have been reported as of this writing.

ANTIMICROBIAL AGENTS

Table 196-1 outlines the topical antimicrobials and astringents discussed in this section of the chapter.

CHLORHEXIDINE

Chlorhexidine gluconate is a bisbiguanide with rapid onset that binds to the stratum corneum. Chlorhexidine provides sustained fungicidal and broad-spectrum bactericidal activity (Gram-negative and Gram-positive organisms). Although it does not kill bacterial spores or mycobacteria, it does inhibit their growth. Chlorhexidine has residual activity for longer than 6 hours, even when wiped from the field. A metaanalysis found chlorhexidine had reduced bacterial colonization and surgical site infections as compared to povidone iodine.[19] Because chlorhexidine does not lose its effectiveness in the presence of organic material, such as whole blood, it is an important antiseptic, disinfectant, antibacterial dental rinse, and preservative. Because of ototoxicity and the risk of conjunctivitis and corneal ulceration, chlorhexidine is not recommended for preoperative preparation of the face or head.

DYES

Dyes are useful topical treatments because they are inexpensive and chemically and physically stable. The topical antiseptic dyes used in dermatology—gentian violet (methylrosaniline chloride), brilliant green, malachite green, and fuchsine—are all derivatives or metabolites. The dyes are effective against *Candida* species and several aerobic Gram-positive bacteria, including methicillin-resistant *Staphylococcus aureus*. Gentian violet is a known contact sensitizer and may cause skin necrosis in concentrations greater than 2% aqueous solution or when used undiluted in skin folds.[20]

TABLE 196-1
Topical Antimicrobials and Astringents

DRUG	GROUP	ANTIBACTERIAL MECHANISM	ANTIMICROBIAL SPECTRUM	MAJOR SIDE EFFECTS OR CONTRAINDICATIONS	USE (SELECTED)	U.S. FOOD AND DRUG ADMINISTRATION PREGNANCY CATEGORY
Chlorhexidine	Bisbiguanide	(1) Binds to negatively charged bacterial cell wall and cytoplasmic components leading to altered osmotic equilibrium (2) Precipitation of cytoplasmic components	Gram-positive, Gram-negative bacteria, enveloped viruses, and fungi	Keratitis, ototoxicity	Antiseptic surgical hand scrub and surgical site preparation	B
Gentian violet	Dye	Unknown	Some vegetative Gram-positive bacteria (eg, *Staphylococcus* sp.) and yeast	Potential skin necrosis at high concentrations or when occluded; stains skin and clothing; tattooing when applied over granulation tissue; mutagenic	Impetiginized eczema; mycotic skin infections; oral candidiasis; superficial skin infections	C
Brilliant green	Dye	Unknown	Similar to gentian violet	Potential skin necrosis; stains skin and clothing	Similar to gentian violet	Not used in Western medicine
Hydrogen peroxide	Peroxide	Oxidizes microbial molecules	Broad-spectrum antimicrobial	Avoid in abscesses; bleaches hair	Cleansing of wounds, suppurating ulcers, and local infections	—
Povidone-iodine	Iodophor	Oxidation and release of free iodine	Gram-positive, Gram-negative, enveloped viruses, fungi, sporicidal, *Mycobacterium tuberculosis*	Caution in patients with thyroid disorders; potential systemic toxicity in neonates or when applied to large body surface area; neutralized by blood, serum proteins, and sputum	Antiseptic surgical hand scrub, prevention or treatment of topical site infection associated with surgery, burns, minor cuts/scrapes	C
Clioquinol	Iodophor	Oxidation and release of free iodine; chelates bacterial surface and trace metals needed for bacterial growth	Gram-positive, Gram-negative, enveloped viruses, fungi, sporicidal, *M. tuberculosis*	Possible irreversible optic atrophy and peripheral neuropathy (oral); contraindicated in children <2 years of age; contraindicated for diaper rash; stains skin yellow; neutralized by blood, serum proteins, and sputum	Approved for fungal infections; also used for pyoderma, folliculitis, and impetigo	—
Metronidazole	Imidazole	Creation of reduced intermediate compounds and free radicals	Anaerobes, protozoa, and microaerophilic bacteria	Contraindicated during first trimester of pregnancy	Rosacea	B

(*Continued*)

TABLE 196-1
Topical Antimicrobials and Astringents (*Continued*)

DRUG	GROUP	ANTIBACTERIAL MECHANISM	ANTIMICROBIAL SPECTRUM	MAJOR SIDE EFFECTS OR CONTRAINDICATIONS	USE (SELECTED)	U.S. FOOD AND DRUG ADMINISTRATION PREGNANCY CATEGORY
Mupirocin	Fermentation product of *Pseudomonas fluorescens*	Inhibits bacterial isoleucyl-tRNA synthetase	Gram-positive, some Gram-negative, spares normal flora	Potentially toxic amounts of polyethylene glycol contained in vehicle may be absorbed in patients with extensive burns or open wounds	Nonbullous impetigo, eradication of nasal carriage of *Staphylococcus aureus*	B
Retapamulin	Pleuromutilin	Inhibits 50S subunit of prokaryotic ribosome	Gram-positive	Allergic contact dermatitis	Nonbullous impetigo	B
Azelaic acid	Dicarboxylic acid	Possibly through inhibition of microbial respiratory chain	*Propionibacterium acnes* and *Staphylococcus epidermidis*	Hypopigmentation	Acne	B
Benzoyl peroxide	Peroxide	Oxidizes microbial molecules	Broad-spectrum antimicrobial	Bleaches dark clothing	Acne	C
Aluminum salts	Astringent	Coagulation of proteins	Broad-spectrum antimicrobial	Do not use under impervious material to prevent evaporation	Weeping, impetiginized skin disorders	—
Potassium permanganate	Astringent	Oxidizes microbial molecules	Broad-spectrum antimicrobial	Skin discoloration; caustic at high concentrations or with contact of undissolved crystals	Weeping, impetiginized skin disorders	—
Silver nitrate	Astringent	Precipitation of bacterial proteins by free silver ions	Gram-positive and Gram-negative bacteria	Black skin discoloration, caustic at high concentrations; potential methemoglobinemia	Weeping, impetiginized skin disorders, cauterization of wounds, removal of granulation tissue, aseptic prophylaxis of burns	C

HYDROGEN PEROXIDE

Hydrogen peroxide has been used for a number of years as a cleansing agent and for the removal of debris. It has antibacterial properties against both Gram-positive and Gram-negative bacteria, and its effervescent quality helps debride wounds.

IODINATED COMPOUNDS

Iodine solution is bactericidal, sporicidal, and viricidal. Iodophors are complexes of iodine with a carrier that slowly liberates inorganic iodine on contact with reducing substances. This preserves the antimicrobial activities of iodine while minimizing the irritant effects of the free tincture. Iodophors must be applied to dry skin as they are inactivated by contact with blood and sputum.

POVIDONE-IODINE

Povidone iodine has a wide spectrum of in vitro activity against Gram-negative and Gram-positive bacteria, fungi, and viruses. Systemic absorption can occur with resultant renal and thyroid dysfunction if large or prolonged quantities are used.

CLIOQUINOL

Clioquinol, 5-chloro-8-hydroxy-7-iodoquinoline, is weakly antifungal and antibacterial. It is effective alone or combined with a topical steroid to treat inflammatory dermatoses, especially in intertriginous areas. Adverse

reactions include a yellowish discoloration on clothing or skin, delayed contact hypersensitivity, and contact dermatitis. In the early 1970s, it was linked to subacute myelooptic neuropathy in Japan,[21] and was banned in many countries, including the United States. This link was questioned by subsequent epidemiologic studies,[22] but product labeling still warns of possible irreversible optic atrophy and peripheral neuromuscular disease.

METRONIDAZOLE

Metronidazole is an imidazole with activity against anaerobic bacteria and protozoa that is most often used in dermatology for rosacea. In addition to its antibiotic properties, its mode of action in rosacea may involve the impedance of leukocyte chemotaxis and selective suppression of cellular immunity.

MUPIROCIN

Mupirocin was initially isolated by *Pseudomonas fluorescens* and is bactericidal at the concentration achieved with topical application to the skin and mucous membranes. As mupirocin has a unique mechanism of action, in which it prevents the incorporation of isoleucine into proteins by inhibiting bacterial isoleucyl-tRNA synthetase, there is no cross-resistance with other antimicrobials. It has activity against staphylococci, streptococci, and certain Gram-negative bacteria, but is not effective against *Pseudomonas* and is inactive against much of the normal skin flora. It is the treatment of choice for nonbullous impetigo, and is effective in the elimination of *S. aureus* nasal colonization. Mupirocin is a pregnancy category B drug.

RETAPAMULIN

Retapamulin is a member of the pleuromutilin class of antibiotics and is derived from *Clitopilus scyphoides*. It is bacteriostatic and inhibits the elongation phase of protein synthesis through selective binding to the 50S subunit of prokaryotic ribosomes. It is effective against certain Gram-positive bacteria and is approved by the U.S. Food and Drug Administration (FDA) for the treatment of methicillin-sensitive *S. aureus* and *Streptococcus pyogenes*. It is prescribed as a 1% topical ointment. Side effects can include irritant and contact dermatitis. Retapamulin is a pregnancy category B drug.

AZELAIC ACID

Azelaic acid is a naturally occurring aliphatic dicarboxylic acid that is a competitive inhibitor of tyrosinase. Azelaic acid is a reversible inhibitor of cytochrome P450 reductase and 5α-reductase in microsomes as well as a reversible inhibitor of some enzymes in the respiratory chain. In vitro azelaic acid has antimicrobial effects against *Propionibacterium acnes* and *Staphylococcus epidermidis*. Its efficacy against acne and rosacea is attributed to activity against *P. acnes*, normalization of keratinization, and a direct antiinflammatory effect. Azelaic acid is a pregnancy category B drug and is often a preferred treatment of acne or rosacea in pregnant patients.

BENZOYL PEROXIDE

Benzoyl peroxide is an organic compound that is commonly used in the treatment of acne vulgaris. Benzoyl peroxide functions by reducing and decreasing the size of comedones, increasing the sebum excretion rate, and through its bactericidal effects. Benzoyl peroxide is directly toxic to *P. acnes* and effective against resistant strains of *P. acnes*. To limit antibiotic resistance, it is suggested that topical benzoyl peroxide be added when a long-term oral antibiotic is used.[23] In addition, benzoyl peroxide is frequently combined with topical antibiotics, as combination therapy may reduce the development of antibiotic resistance by *P. acnes*. Benzoyl peroxide is a pregnancy category C drug.

ANTIPARASITIC AGENTS

Table 196-2 outlines the topical antiparasitic agents discussed in this section. Chapter 178 provides detailed discussions of scabies, other mites, and pediculosis.

CROTAMITON

Crotamiton (crotonyl-*N*-ethyl-*o*-toluidine) is a colorless or pale yellow oil used in the treatment of scabies, pediculosis capitis, and, occasionally, pruritus. Its mode of action is unknown. Other antiparasitic formulations, such as topical permethrin and ivermectin cream, have been found in head-to-head controlled trials to be superior to crotamiton in the treatment of scabies.[24,25] It is approved for use in infants and children, but is a pregnancy category C drug.

LINDANE (γ-BENZENE HEXACHLORIDE)

Lindane, also known as γ-*benzene hexachloride* or *hexachlorocyclohexane*, is a chlorinated hydrocarbon pesticide that is effective against lice, scabies, and fleas as a 1% lotion or shampoo. There are multiple side effects of topical lindane application, including CNS toxicity, seizures, and aplastic anemia. The use of lindane is limited given this potential for lindane toxicity, in addition to the fact that safer and more effective alternative agents

TABLE 196-2
Topical Antiparasitic Agents

TREATMENT	GROUP OR COMPOSITION	MECHANISM	MAJOR SIDE EFFECTS OR CONTRAINDICATIONS	USE	U.S. FOOD AND DRUG ADMINISTRATION PREGNANCY CATEGORY
Permethrin (1% or 5%)	Synthetic pyrethroid	Inhibits nerve cell sodium ion influx	Itching and stinging on application; contraindicated for infants <2 months of age	Lice and scabies; used on clothing as an insect repellant	B
Ivermectin	Avermectin	Binding to glutamate- and γ-aminobutyric acid–gated chloride ion channels	Skin irritation upon application	Scabies, head lice, rosacea	C
Synergized pyrethrins	Natural botanical	Pyrethrins inhibit nerve cell sodium ion influx; piperonyl butoxide inhibits cytochrome P450	Itching and stinging on application; ragweed or chrysanthemum allergy	Lice	C
Malathion (0.5%)	Organophosphate	Cholinesterase inhibitor	Flammable; not approved for children <6 years of age	Lice	B
Crotamiton (10%)	Crotonyl-*N*-ethyl-*o*-toluidine	Unknown	Poor efficacy	Scabies	C
Lindane (1%)	Organochlorine	Cholinesterase inhibitor	May cause seizures, muscle spasms, aplastic anemia; not for use in children <3 years of age, pregnant or breast-feeding women, patients with underlying neurologic disorders, or over broken skin	Lice and scabies	C
Spinosad (0.9%)	Fermentation product	Generalized CNS excitation leading to paralysis	No major side effects in preclinical trials	Lice	Not rated

are available.[26] Patients with seizure disorders, children who weigh less than 50 kg, and patients with acutely inflamed or raw skin should avoid using lindane.

IVERMECTIN

Ivermectin is a derivative of the avermectin family of macrocyclic lactone parasiticides. It is a broad-spectrum anti parasitic agent and also displays antiinflammatory properties. Ivermectin's antiparasitic mechanism of action is through binding to glutamate-gated and γ-aminobutyric acid–gated chloride ion channels of parasite nerve and muscles cells, leading to increased permeability of chloride ions and later paralysis and death. Topical ivermectin can be used to treat scabies, head lice, as well as rosacea. Topical 1% ivermectin was found to be as effective as 2.5% permethrin cream in scabies patients when applied with 2 applications and a 1-week interval between applications.[27] Two multisite, randomized, double-blinded studies showed that a single, 10-minute, at-home application of topical 0.5% ivermectin is effective in eliminating head-louse infestations.[28] For the treatment of rosacea, in an investigator-blinded, randomized trial, once-daily ivermectin 1% cream displayed superior efficacy to twice-daily metronidazole 0.75% cream in the treatment of inflammatory lesions in patients with moderate to severe papulopustular rosacea.[29]

MALATHION

Malathion is an organophosphate insecticide that acts by irreversibly binding to acetylcholinesterase. It is approved in the United States as a 0.5% lotion for the treatment of head and body lice and is an alternative agent for the treatment of scabies. The lotion, containing 78% isopropyl alcohol, is flammable. Safety for children younger than 6 years of age has not been established, and it is a pregnancy category B drug.

PERMETHRIN

Permethrin is a synthetic pyrethroid modeled after the natural insecticide found in the pyrethrum flower, *Chrysanthemum cinerariifolium*. It acts by disabling sodium transport channels on parasitic nerve cell

membranes, causing paralysis and death. It is available as a nonprescription 1% cream rinse, which is left on dry hair for 10 minutes. There is a lack of safety data for its use in children younger than 2 months of age, and in pregnant and breastfeeding women. Prescription-strength permethrin 5% cream is also effective against pediculosis capitis resistant to the 1% cream, pediculosis pubis, and scabies. The 5% cream is applied to dry skin from the neck down with a repeat application 1 week later. Application of 5% permethrin cream twice (1 week apart) was found to be superior to a single dose of oral ivermectin in scabies patients. In addition, permethrin-treated patients recovered earlier.[30] Permethrin is a pregnancy category B drug.

PYRETHRINS

Pyrethrins are the naturally occurring esters of chrysanthemumic acid. In combination with piperonyl butoxide, it is available as a liquid, gel, oil, aerosol spray, foam, and shampoo, and is used in the treatment of lice. Pyrethrins are neurotoxins, and piperonyl butoxide inhibits pyrethrin metabolism, potentiating the effects of pyrethrins. It is also effective against fleas, mosquitoes, and houseflies. As it is derived from the extract of chrysanthemums, individuals who are sensitive to chrysanthemum or ragweed should avoid this medication. The aerosol spray should never be prescribed to patients with a history of asthma.

SPINOSAD

Spinosad is a fermentation product of the soil bacterium *Saccharopolyspora spinosa* that causes widespread excitation of the insect CNS and leads to paralysis. In particular, spinosad disrupts acetylcholine transmission and acts as a γ-aminobutyric acid agonist. Spinosad 0.9% cream was found to be superior to 1% permethrin cream in the treatment of head lice and is both pediculicidal and ovicidal with a 10-minute application.[31]

ANTIPERSPIRANTS

ALUMINUM COMPOUNDS

Aluminum chloride solutions are typically used as a first-line therapy for hyperhidrosis in 15% to 20% solutions in the axilla and up to 30% on the palms and soles. Aluminum chloride is thought to work though obstructing the distal portion of eccrine sweat gland ducts. The solution is applied topically for 1 week at night, when eccrine glands are less active, and if tolerated up to twice daily. After control is achieved, it can be applied every 1 to 3 weeks as maintenance therapy. Skin irritation is a common adverse effect with aluminum chloride that may limit its use. Application to dry skin may reduce local irritation from aluminum chloride.

GLYCOPYRROLATE

Glycopyrrolate is an anticholinergic agent that blocks muscarinic receptors and inhibits cholinergic transmission. It is often used as a systemic therapy for hyperhidrosis. Topical glycopyrrolate is increasingly being used as a therapy, particularly for facial and axillary hyperhidrosis. A 2% glycopyrrolate spray applied twice daily to the axillae was found to have similar efficacy as a single session of botulinum toxin type-A injection when the two treatments were evaluated at 6 weeks.[32] In addition, 2% topical glycopyrrolate impregnated in cotton pads significantly reduced sweat production on the forehead as compared to placebo in a split-face, randomized, double-blinded study.[33]

IONTOPHORESIS

Iontophoresis is a procedure in which electric current is used to transport ions through the skin. The mechanism by which iontophoresis acts to decrease sweating is not fully understood, although there are several hypotheses. The hypotheses include a disruption of ion channels resulting in obstruction of the sweat gland, inhibition of sympathetic nerve transmission, and local alterations in pH that affect the sweat gland.[34] In an iontophoretic treatment, a hyperhidrotic area of skin to be treated is covered with lukewarm tap water. Electrodes are then inserted into the water and a direct current delivered, usually at 8 to 20 amperes. The amperage is increased until a tingling sensation is experienced and then applied for 10 to 20 minutes 3 to 4 times weekly. The effect of iontophoresis can be enhanced with the addition of glycopyrrolate to the trays before initiation of iontophoresis. Iontophoresis works best on palmar and plantar surfaces. Adverse effects may include irritation, hyperesthesia, and blisters.

ANTIPRURITIC AGENTS

Table 196-3 outlines the topical antipruritics discussed in this section.

DOXEPIN

Doxepin is a tricyclic antidepressant that is a potent antagonist of histamine H_1 and histamine H_2 receptors. Doxepin's antipruritic effects also may be secondary to modulation of adrenergic, muscarinic, and serotonergic receptors. In its topical form, 5% doxepin cream may be effective in treating neuropathic itch, lichen simplex chronicus, and nummular eczema. Exposure to topical doxepin cream has been reported to result in systemic contact dermatitis upon exposure to oral doxepin.[35]

TABLE 196-3
Topical Antipruritics

DRUG	GROUP	MECHANISM	PRECAUTIONS	U.S. FOOD AND DRUG ADMINISTRATION PREGNANCY CATEGORY
Diphenhydramine	Antihistamine	Local anesthesia; histamine antagonism	Significant percutaneous absorption; potential sensitization with cross-sensitization to oral diphenhydramine and related compounds	B
Doxepin	Tricyclic antidepressant	Histamine antagonism, interference with neuronal synaptic communication; decreased awareness through production of drowsiness	Potential contact sensitization; significant systemic absorption resulting in drowsiness and drug interactions; contraindicated in patients taking monoamine oxidase inhibitors	B
Menthol	Cyclic terpene alcohol	Counter irritant. Cooling sensation in the skin via transient receptor potential melastatin 8 (TRPM8) receptors in the skin	—	C when combined with camphor (ie, Sarna)
Phenol	—	Local anesthesia	Avoid in pregnant women and infants; irritant in diaper area and skin folds	Should be avoided
Pramoxine hydrochloride	Surface anesthetic	Local anesthesia	—	C

MENTHOL

Menthol is a highly lipid-soluble cyclic terpene alcohol that is often used with camphor. It is derived from naturally occurring plant oils or prepared synthetically. Menthol is a counterirritant that, by induction of a cool sensation via transient receptor potential melastatin 8 (TRPM8) receptors in the skin, overwhelms the sensation of itch.

PHENOL

Phenol in low concentrations (0.5% to 2%) acts as an antipruritic agent through its anesthetic effect. It is percutaneously absorbed and should be avoided in pregnant women and infants. In higher concentrations, it is caustic and is used for deep chemical peels.

PRAMOXINE HYDROCHLORIDE

Pramoxine hydrochloride is effective in cases of mild to moderate pruritus. As with other local anesthetics, it inhibits conduction of nerve impulses by altering the cell membrane permeability to ions. The onset of action of pramoxine products is 2 to 5 minutes. A double-bind, randomized-controlled trial showed that pramoxine 1% lotion significantly decreased itch as compared to a control lotion in patients with uremic pruritus and hemodialysis-dependent end-stage renal disease.[36]

ASTRINGENTS

In medical practice, astringents are agents that cause contraction or shrinking of the tissues, arrest of secretion, or control of bleeding.

ALUMINUM SALTS

Aluminum acetate tablets diluted 1:10 to 1:40 (Burow solution) are an effective astringent and germicidal agent. Nonprescription aluminum sulfate and calcium acetate (Domeboro) are available and, when dissolved in water, a chemical reaction occurs forming aluminum acetate and a precipitate of calcium sulfate (modified Burow solution). These solutions may be used as wet dressings, compresses, or soaks, and can be used in a variety of skin conditions, such as insect bites and poison ivy, oak, sumac, and allergic contact dermatitis.

POTASSIUM PERMANGANATE

Potassium permanganate is an oxidizing agent, astringent, antiseptic, and antifungal that may be used to clean or deodorize wounds. Solutions of 1:4000 to

1:16,000 may be used as wet compresses to reduce weeping, or at 1:25,000 as a medicated bath. This agent may cause permanent staining of clothing and ceramics and temporary brown or bright purple staining of the skin, which may be removed with a weak solution of oxalic acid or sodium thiosulfate.

SILVER NITRATE

Silver nitrate in 0.5% aqueous solution is an astringent and antimicrobial that is applied as a wet dressing in the treatment of infected eczema, gravitational ulcers, and other weeping and/or infected skin lesions caused by Gram-positive or Gram-negative bacteria. It is also available in a solid form that may be used as a hemostat. At low concentration (0.5% formulation, used clinically), it is bacteriostatic, while bactericidal at higher concentrations (10%). As methemoglobinemia has been noted secondary to topical treatment, methemoglobin levels should be followed with prolonged use.[37]

BLEACHING AGENTS

HYDROQUINONE

Usually used in concentrations of 2% to 5%, hydroquinone decreases pigmentation by inhibiting tyrosinase, thereby blocking the conversion of dopa to melanin. It may also act by inhibiting DNA and RNA synthesis, degrading melanosomes, and destroying melanocytes.[38] Combination therapy consisting of hydroquinone, a retinoid, and a topical steroid has shown efficacy in the treatment of melasma. In particular, once-daily application of hydroquinone 4% in combination with tretinoin 0.05% and fluocinolone acetonide 0.01% showed superior efficacy as compared to twice-daily application of hydroquinone 4% cream in the treatment of moderate to severe facial melasma.[39] Side effects include irritant dermatitis, contact dermatitis, postinflammatory pigmentation, and cutaneous ochronosis.

TRETINOIN (RETINOIC ACID)

Tretinoin's mechanism of action involves inhibition of transcription of tyrosinase, stimulation of keratinocyte turnover, and decreased melanosome transfer,[38] leading to decreased pigmentation.[40] It is typically used in concentrations of 0.05% to 0.1% to treat melasma. Local adverse effects include erythema and desquamation; postinflammatory hyperpigmentation has been reported. Adapalene may be used as an alternative, milder retinoid for patients who do not tolerate tretinoin.[38]

AZELAIC ACID

Azelaic acid is a dicarboxylic acid derived from *Pityrosporum ovale*. It is a weak, competitive, reversible inhibitor of tyrosinase.[41] Treatment of melasma is typically with concentrations of 15% to 20%. Side effects include burning, itching, and erythema.

MONOBENZYL ETHER OF HYDROQUINONE

Occasionally used to depigment skin in individuals with widespread vitiligo, monobenzyl ether of hydroquinone typically causes irreversible depigmentation by causing melanocyte necrosis.[42]

KERATOLYTIC AGENTS

Table 196-4 outlines the topical keratolytic agents discussed in this section.

Keratolytics are agents that cause keratolysis, or peeling, of the epidermis. At low concentrations, most keratolytics act as humectants, or moisturizing agents, and can be used to soften keratin.

α-HYDROXY ACIDS

Chapter 213 discusses chemical peels and dermabrasion in greater detail.

α-Hydroxy acids (lactic acid, glycolic acid, citric acid, glucuronic acid, and pyruvic acid) reduce the thickness of the hyperkeratotic stratum corneum by an incompletely understood mechanism wherein the acids may directly solubilize the protein components of desmosomes or activate endogenous hydrolytic enzymes by changing the pH of the stratum corneum, resulting in keratolysis. Also, by diffusing into the stratum corneum and binding water, the acids act as humectants increasing the water content of the stratum corneum. This decreases the formation of dry scales on the skin surface and allows gentle rubbing of the skin during bathing to mechanically remove cornified tissue. The concentration of α-hydroxy acid, pH of the preparation, and composition of the base in which it is compounded are important in determining their efficacy. In general, more anhydrous preparations are less irritating, allowing higher concentrations of acid to be tolerated.

PROPYLENE GLYCOL

Propylene glycol is a humectant, occlusive, and keratolytic agent. It is often combined with other medications to enhance their penetration. A combination of

TABLE 196-4
Topical Keratolytic Agents

AGENT	DOSAGE	INDICATIONS (SELECTED)	SIDE EFFECTS/ COMMENTS	U.S. FOOD AND DRUG ADMINISTRATION PREGNANCY CATEGORY
α-Hydroxy acids	2% to 20% as nonpeeling agent, >20% as peeling agent	Photoaging, scaling, hyperkeratosis, acne, hyperpigmentation	Increased photosensitivity	Not contraindicated in pregnancy
Propylene glycol	40% to 60% under occlusion at bedtime; may be combined with salicylic acid (Keralyt gel) or lactic acid (Epilyt); 2% vehicle in many preparations	Ichthyosis, hyperkeratosis, psoriasis	Enhances absorption of other topical agents; possible CNS effects	—
Salicylic acid	Scaly dermatoses: FDA-approved twice daily to 4 times daily at 1.8% to 3%; calluses, corns, and warts: FDA-approved at 12% to 40% for plaster vehicles, 12% to 17.6% in collodion-like vehicles	Hyperkeratosis, scaling	Salicylism (headache, drowsiness, and tinnitus); maximum topical dose of 2 g/24 hours in adults	C
Urea	Twice daily to 4 times daily in 10% to 40% creams and lotions	Xerosis, pruritus, hyperkeratosis, eczema, ichthyosis, psoriasis, nail avulsion	Some patients experience burning; enhances absorption of other topical agents	C
Lactic acid (an α-hydroxy acid)	Twice daily to 4 times daily in 5% to 12% preparations	Ichthyosis, xerosis, eczema, photoaging	Hypothetical risk of metabolic acidosis	Not contraindicated in pregnancy

20% propylene glycol with 5% lactic acid in a semiocclusive cream base is used as a highly effective and well-tolerated keratolytic in patients with lamellar ichthyosis and may be used in various other hyperkeratotic diseases.[43]

SALICYLIC ACID

Salicylic acid has been used in concentrations ranging from 0.5% to 60% in almost any base. In concentrations of 3% to 6%, it causes shedding of scales by softening the stratum corneum, dissolving the intracellular matrix, and loosening connections between corneocytes. In concentrations higher than 6%, salicylic acid is destructive to tissue. Salicylism has been reported with widespread and prolonged use, especially in children, who should apply no more than 2 g (33 mL of a 6% solution) to their skin in a 24-hour period. Sensitization is rare, and irritation can be minimized if introduced at lower concentrations. Salicylic acid is often used to treat warts, psoriasis, and acne.

UREA

Urea is a humectant that is proteolytic at high concentrations. Urea has been added to some topical glucocorticoid preparations to possibly increase their penetration. Urea preparations have been used to treat psoriasis, dry skin, onychomycosis, and eczema.

LACTIC ACID

Lactic acid is a humectant and keratolytic that is available at concentrations up to 12%. In addition to being a keratolytic, lactic acid increases ceramide production by keratinocytes, improving water barrier function.[44]

CALCIPOTRIENE

Calcipotriol is a vitamin D analog that inhibits epidermal proliferation, induces epidermal differentiation, and exerts antiinflammatory effects. Hypercalcemia may occur if more than 100 g is used per week. It is applied initially twice daily, and maximal improvement can be expected within 6 to 8 weeks. Cutaneous irritation may occur in up to 20% of patients, particularly when used on the face or in intertriginous areas. Of note, calcipotriene and betamethasone dipropionate are more effective when combined together than either is individually when treating scalp and body psoriasis.[40]

Please see Chap. 28 for additional information on calcipotriene.

WART THERAPIES

CANTHARIDIN

Cantharidin is a naturally occurring terpenoid that is secreted by blister beetles. Cantharidin application causes acantholysis and blistering of the skin.

Cantharidin solutions are used to treat warts and molluscum contagiosum. Cantharidin is a pregnancy category C drug.

DIPHENYLCYCLOPROPENONE

Diphenylcyclopropenone (DPCP), also known as *diphencyprone*, is a potent contact allergen used in the treatment of viral warts and alopecia areata. Theories for its mechanism of action include alterations in cytokine levels, nonspecific inflammation causing wart regression, and binding of DPCP to wart protein inducing a specific immune response.[45] Many clinics recommend avoiding DPCP in children younger than 12 years of age, although children with alopecia areata who are younger than 12 years of age have been successfully treated with DPCP.[45]

SQUARIC ACID DIBUTYL ESTER

Squaric acid dibutyl ester is a potent topical sensitizer with a similar mechanism of action and use as DPCP. It has been used in the treatment of warts and alopecia areata and involves the production of an allergic dermatitis. As squaric acid functions through eliciting an inflammatory response, the most common side effects include eczematous reactions, blistering, and swelling of regional lymph nodes.[46]

DINITROCHLOROBENZENE

Dinitrochlorobenzene is a potent sensitizer with a similar mechanism of action and use as DPCP and squaric acid. Of note, dinitrochlorobenzene is not commonly used given the agent was found to be mutagenic by the Ames test and genotoxic through the exchange of sister chromatids in human fibroblasts.[47]

FORMALDEHYDE

Formaldehyde is a powerful disinfectant that causes anhidrosis, desiccation, and, sometimes, hypersensitivity when applied to skin. It can cause hardening and fissuring of the skin, so normal surrounding skin should be protected from it by petrolatum, zinc paste, or meticulous application. Individuals with eczema or allergies should avoid formaldehyde as sensitization is problematic given that it is a ubiquitous component of many personal products.

GLUTARALDEHYDE

Glutaraldehyde is viricidal. It also combines chemically with keratin-producing polymers that harden the wart surface thereby facilitating paring.

IMIQUIMOD

Imiquimod is a topically applied medication that stimulates the innate immune system through toll-like receptor 7. Imiquimod is used to treat genital warts, actinic keratoses, and superficial basal cell carcinoma. Side effects commonly include local skin irritation and systemic reactions are uncommon but can include symptoms such as fever and fatigue. Imiquimod is a pregnancy category C drug.

MONOCHLOROACETIC, DICHLOROACETIC, AND TRICHLOROACETIC ACIDS

Monochloroacetic acid, dichloroacetic acid, and trichloroacetic acid in concentrations of 50% to 90% are all effective in the management of warts. Trichloroacetic acid is also commonly used at lower concentrations (10% to 35%) for facial peels. Anal and vaginal lesions are occasionally treated with trichloroacetic acid, whereas monochloroacetic acid is most commonly used on plantar warts under salicylic acid plaster occlusion. The application needs to be repeated at 1- to 2-week intervals until complete resolution.

PODOFILOX

Podofilox is podophyllotoxin, the active ingredient of podophyllin, and is used to treat warts and molluscum contagiosum. It should not be used during pregnancy unless the potential benefit justifies the potential risk to the fetus.

SALICYLIC ACID

The effectiveness of salicylic acid in treating warts is thought to be related to keratolysis and local irritation of the skin in which the virus is present. Salicylic acid is the most established agent in terms of consistency of data regarding efficacy as well as safety in the treatment of viral warts.[48]

SINECATECHINS

Sinecatechins originate from green tea leaves of *Camellia sinensis*. A 15% sinecatechins ointment is available for the treatment of external genital warts and is applied 3 times daily until all warts are cleared, for up to a maximum of 16 weeks.[49] The mechanism of clearance may be related to the immunostimulatory, antiproliferative, antiangiogenic, and antitumor properties of catechins within the sinecatechins ointment. It appears to have a clinical efficacy comparable to other currently available topical therapies for external genital warts.[50]

COMPOUNDING MEDICATIONS

Compounding medications allows physicians to tailor a specific mixture of an active drug or drugs to an appropriate vehicle. While pharmaceutical companies decide how to compound standardized topical agents, there are instances where it may be appropriate to compound different formulations based on individual patient needs or if there is treatment failure to respond to commercially available products.

ACKNOWLEDGMENTS

The authors would like to acknowledge Drs. Craig Burkhart and Kenneth Katz for their contributions to a previous version of this chapter.

REFERENCES

1. Caterina MJ, Schumacher MA, Tominaga M, et al. The capsaicin receptor: a heat-activated ion channel in the pain pathway. *Nature.* 1997;389(6653):816-824.
2. Bode AM, Dong Z. The two faces of capsaicin. *Cancer Res.* 2011;71(8):2809-2814.
3. Yong YL, Tan LT, Ming LC, et al. The effectiveness and safety of topical capsaicin in postherpetic neuralgia: a systematic review and meta-analysis. *Front Pharmacol.* 2016;7:538.
4. Steinke S, Gutknecht M, Zeidler C, et al. Cost-effectiveness of an 8% capsaicin patch in the treatment of brachioradial pruritus and notalgia paraesthetica, two forms of neuropathic pruritus. *Acta Derm Venereol.* 2017;97(1):71-76.
5. Briggs M, Nelson EA, Martyn-St James M. Topical agents or dressings for pain in venous leg ulcers. *Cochrane Database Syst Rev.* 2012;11:Cd001177.
6. Kopecky EA, Jacobson S, Bch MB, et al. Safety and pharmacokinetics of EMLA in the treatment of postburn pruritus in pediatric patients: a pilot study. *J Burn Care Rehabil.* 2001;22(3):235-242.
7. Tran AN, Koo JY. Risk of systemic toxicity with topical lidocaine/prilocaine: a review. *J Drugs Dermatol.* 2014;13(9):1118-1122.
8. Guay J. Methemoglobinemia related to local anesthetics: a summary of 242 episodes. *Anesth Analg.* 2009;108(3):837-845.
9. de Leon-Casasola OA, Mayoral V. The topical 5% lidocaine medicated plaster in localized neuropathic pain: a reappraisal of the clinical evidence. *J Pain Res.* 2016;9:67-79.
10. Stoughton RB, DeQuoy P, Walter JF. Crude coal tar plus near ultraviolet light suppresses DNA synthesis in epidermis. *Arch Dermatol.* 1978;114(1):43-45.
11. van den Bogaard EH, Bergboer JG, Vonk-Bergers M, et al. Coal tar induces AHR-dependent skin barrier repair in atopic dermatitis. *J Clin Invest.* 2013;123(2):917-927.
12. Paghdal KV, Schwartz RA. Topical tar: back to the future. *J Am Acad Dermatol.* 2009;61(2):294-302.
13. Roelofzen JH, Aben KK, Oldenhof UT, et al. No increased risk of cancer after coal tar treatment in patients with psoriasis or eczema. *J Invest Dermatol.* 2010;130(4):953-961.
14. Rabe KF, Perkins RS, Dent G, et al. Inhibitory effects of sulfonated shale oil fractions on the oxidative burst and Ca++ mobilization in stimulated macrophages. *Arzneimittelforschung.* 1994;44(2):166-170.
15. Diezel W, Schewe T, Rohde E, et al. Ammonium bituminosulfonate (Ichthyol). Anti-inflammatory effect and inhibition of the 5-lipoxygenase enzyme [in German]. *Hautarzt.* 1992;43(12):772-774.
16. Korting HC, Schollmann C, Cholcha W, et al. Efficacy and tolerability of pale sulfonated shale oil cream 4% in the treatment of mild to moderate atopic eczema in children: a multicentre, randomized vehicle-controlled trial. *J Eur Acad Dermatol Venereol.* 2010;24(10):1176-1182.
17. Boyd AS. Ichthammol revisited. *Int J Dermatol.* 2010;49(7):757-760.
18. Paller AS, Tom WL, Lebwohl MG, et al. Efficacy and safety of crisaborole ointment, a novel, nonsteroidal phosphodiesterase 4 (PDE4) inhibitor for the topical treatment of atopic dermatitis (AD) in children and adults. *J Am Acad Dermatol.* 2016;75(3):494-503.e494.
19. Privitera GP, Costa AL, Brusaferro S, et al. Skin antisepsis with chlorhexidine versus iodine for the prevention of surgical site infection: a systematic review and meta-analysis. *Am J Infect Control.* 2017;45(2):180-189.
20. Balabanova M, Popova L, Tchipeva R. Dyes in dermatology. *Clin Dermatol.* 2003;21(1):2-6.
21. Tsubaki T, Honma Y, Hoshi M. Neurological syndrome associated with clioquinol. *Lancet.* 1971;1(7701):696-697.
22. Meade TW. Subacute myelo-optic neuropathy and clioquinol. An epidemiological case-history for diagnosis. *Br J Prev Soc Med.* 1975;29(3):157-169.
23. Walsh TR, Efthimiou J, Dreno B. Systematic review of antibiotic resistance in acne: an increasing topical and oral threat. *Lancet Infect Dis.* 2016;16(3):e23-e33.
24. Pourhasan A, Goldust M, Rezaee E. Treatment of scabies, permethrin 5% cream vs. crotamiton 10% cream. *Ann Parasitol.* 2013;59(3):143-147.
25. Goldust M, Rezaee E, Raghiafar R. Topical ivermectin versus crotamiton cream 10% for the treatment of scabies. *Int J Dermatol.* 2014;53(7):904-908.
26. Koch E, Clark JM, Cohen B, et al. Management of head louse infestations in the United States—a literature review. *Pediatr Dermatol.* 2016;33(5):466-472.
27. Goldust M, Rezaee E, Raghifar R, et al. Treatment of scabies: the topical ivermectin vs. permethrin 2.5% cream. *Ann Parasitol.* 2013;59(2):79-84.
28. Pariser DM, Meinking TL, Bell M, et al. Topical 0.5% ivermectin lotion for treatment of head lice. *N Engl J Med.* 2012;367(18):1687-1693.
29. Taieb A, Ortonne JP, Ruzicka T, et al. Superiority of ivermectin 1% cream over metronidazole 0.75%

cream in treating inflammatory lesions of rosacea: a randomized, investigator-blinded trial. *Br J Dermatol.* 2015;172(4):1103-1110.
30. Goldust M, Rezaee E, Hemayat S. Treatment of scabies: comparison of permethrin 5% versus ivermectin. *J Dermatol.* 2012;39(6):545-547.
31. Stough D, Shellabarger S, Quiring J, et al. Efficacy and safety of spinosad and permethrin creme rinses for pediculosis capitis (head lice). *Pediatrics.* 2009;124(3):e389-e395.
32. Baker DM. Topical glycopyrrolate reduces axillary hyperhidrosis. *J Eur Acad Dermatol Venereol.* 2016; 30(12):2131-2136.
33. Hyun MY, Son IP, Lee Y, et al. Efficacy and safety of topical glycopyrrolate in patients with facial hyperhidrosis: a randomized, multicentre, double-blinded, placebo-controlled, split-face study. *J Eur Acad Dermatol Venereol.* 2015;29(2):278-282.
34. Grabell DA, Hebert AA. Current and emerging medical therapies for primary hyperhidrosis. *Dermatol Ther (Heidelb).* 2017;7(1):25-36.
35. Brancaccio RR, Weinstein S. Systemic contact dermatitis to doxepin. *J Drugs Dermatol.* 2003;2(4):409-410.
36. Young TA, Patel TS, Camacho F, et al. A pramoxine-based anti-itch lotion is more effective than a control lotion for the treatment of uremic pruritus in adult hemodialysis patients. *J Dermatolog Treat.* 2009;20(2):76-81.
37. Chou TD, Gibran NS, Urdahl K, et al. Methemoglobinemia secondary to topical silver nitrate therapy—a case report. *Burns.* 1999;25(6):549-552.
38. Sheth VM, Pandya AG. Melasma: a comprehensive update: part II. *J Am Acad Dermatol.* 2011;65(4): 699-714; quiz 715.
39. Ferreira Cestari T, Hassun K, Sittart A, et al. A comparison of triple combination cream and hydroquinone 4% cream for the treatment of moderate to severe facial melasma. *J Cosmet Dermatol*. 2007;6(1):36-39.
40. Kin KC, Hill D, Feldman SR. Calcipotriene and betamethasone dipropionate for the topical treatment of plaque psoriasis. *Expert Rev Clin Pharmacol*. 2016;9(6):789-797.
41. Kim YJ, Uyama H. Tyrosinase inhibitors from natural and synthetic sources: structure, inhibition mechanism and perspective for the future. *Cell Mol Life Sci.* 2005;62(15):1707-1723.
42. Hariharan V, Klarquist J, Reust MJ, et al. Monobenzyl ether of hydroquinone and 4-tertiary butyl phenol activate markedly different physiological responses in melanocytes: relevance to skin depigmentation. *J Invest Dermatol.* 2010;130(1):211-220.
43. Ganemo A, Virtanen M, Vahlquist A. Improved topical treatment of lamellar ichthyosis: a double-blind study of four different cream formulations. *Br J Dermatol.* 1999;141(6):1027-1032.
44. Rawlings AV, Davies A, Carlomusto M, et al. Effect of lactic acid isomers on keratinocyte ceramide synthesis, stratum corneum lipid levels and stratum corneum barrier function. *Arch Dermatol Res.* 1996;288(7):383-390.
45. Buckley DA, Du Vivier AW. The therapeutic use of topical contact sensitizers in benign dermatoses. *Br J Dermatol.* 2001;145(3):385-405.
46. Micali G, Cicero RL, Nasca MR, et al. Treatment of alopecia areata with squaric acid dibutylester. *Int J Dermatol.* 1996;35(1):52-56.
47. DeLeve LD. Dinitrochlorobenzene is genotoxic by sister chromatid exchange in human skin fibroblasts. *Mutat Res.* 1996;371(1-2):105-108.
48. Kwok CS, Gibbs S, Bennett C, et al. Topical treatments for cutaneous warts. *Cochrane Database Syst Rev.* 2012(9):Cd001781.
49. Tatti S, Swinehart JM, Thielert C, et al. Sinecatechins, a defined green tea extract, in the treatment of external anogenital warts: a randomized controlled trial. *Obstet Gynecol.* 2008;111(6):1371-1379.
50. De Clercq E, Li G. Approved antiviral drugs over the past 50 years. *Clin Microbiol Rev.* 2016;29(3):695-747.

Chapter 197 :: Photoprotection

:: Jin Ho Chung

AT-A-GLANCE

- Photoprotection measures include seeking shade during the peak ultraviolet (UV) B hours of 10:00 AM to 2:00 PM and the use of high sun protection factor (SPF) broad spectrum sunscreen, clothing, wide-brimmed hat, and sunglasses.
- UV induces skin aging and skin cancer, but using sunscreen may slow down skin aging and reduce the risk of developing skin cancer.
- Photoprotection in children is essential and its importance should be taught from childhood.
- Although oral photoprotection cannot substitute for topical sunscreen, it may serve as a secondary measure to prevent skin damage from solar radiation.
- UV protection factor is a UV protection rating for fabrics. Several chemical treatments can increase a fabric's natural UV protection factor.
- Many types of glass have very good UVA2 and UVA1 protection (up to 380 nm).
- Sunglass standards, mandatory in Australia and voluntary in the United States, specify a maximum percentage of light allowed to be transmitted and a minimum vertical dimension of sunglasses.

The earth is constantly exposed to radiation from the sun, which is indispensable for life. Radiation includes ultraviolet, visible, and infrared rays. Ultraviolet (UV) light B, which accounts for 5% to approximately 10% of the UV light that reaches the surface of the earth, is high in energy and induces erythema. UVA is composed of UVA2 (320 nm to approximately 340 nm) and UVA1 (340 nm to approximately 400 nm). UVA1 is low energy and accounts for 95% of the UV that reaches the surface of the earth because it can penetrate through clouds and glass windows, and is not obstructed by the ozone layer For this reason, UVA1 is present all the time, regardless of cloud cover or other obstruction. Although UVA1 may not cause erythema, it is more likely to cause pigmentation than any other wavelength. In addition, it induces reactive oxygen species (ROS), which cause damage to blood vessels, collagen fibers, and elastic fibers located deep under the skin, and are involved in skin aging. Infrared rays also affect skin and trigger skin aging by increasing skin temperature.[1]

With increased attention to physical fitness and outdoor recreational activities, daily exposure to sunlight is common. In addition, longer life expectancy has increased the amount of lifetime exposure to sunlight. Although sun exposure may have beneficial effects, such as mood elevation and vitamin D_3 photosynthesis, unwanted effects are well known. Acute effects of sun exposure include sunburn and delayed tanning. Acute responses to sunlight result from the direct influence on biologic chromophores like DNA. These responses release proinflammatory cytokines, enzymes, and immunosuppressive factors. These effects are mediated by ROS, which are generated by UVB, UVA and visible light as well as and infrared rays. Chronic responses to sunlight are a result of accumulation of damage and decreased ability to repair. Chronic sun exposure is strongly associated with photoaging, actinic keratoses, and skin cancers. Complete avoidance of sun exposure is neither necessary, practical, nor would it be generally acceptable to the general public. As such, behavioral modifications such as seeking shade during peak UVB hours of 10:00 AM and 2:00 PM, the use of photoprotective measures, such as sunscreen, clothing, wide-brimmed hat, and sunglasses, and, when appropriate, intake of vitamin D supplements, have become the public health message to deliver. This chapter discusses the currently available (as of this writing), commonly used photoprotective measures, as well as oral photoprotection, which is gaining increasing attention.

AVOIDANCE OF SUN EXPOSURE

An ideal photoprotection method is to avoid sunlight. Therefore, it is recommended to stay indoors when the UV rays are strong. The amount of UV that reaches human skin is influenced by the changes in environment. Sunlight is absorbed when entering the atmosphere. The ozone (O_3) layer, the stratosphere layer at 10 to 50 km above the surface of the earth, absorbs all of the UVC, most of the UVB and barely any UVA. When the sun is at its highest above the horizon, the distance UV penetrates the atmosphere is relatively shorter, and thus less is absorbed in the atmosphere and more reaches the surface of the earth. Therefore, between 10:00 AM and 2:00 PM, when UV is strongest, the sun is best avoided. Also, UV decreases by 3% as the latitude increases by 1°. Because atmosphere becomes thinner as altitude increases, UV increases by 4% every 300 meters from the horizon. Snow, sand, and metal can reflect up to 90% of UV. UV is reduced by 50% to approximately 95% under the shade; hence, one should stay in the shade if possible.

SUNSCREEN

Sunscreen is used to prevent the detrimental effects of UV, and should not be used to prevent sunburn simply to stay longer outside under the sun. People generally

apply sunscreen less than the recommended amount, and do not reapply it every 2 hours. Furthermore, the amount of UV required for DNA damage is far less than the amount of UV needed to induce erythema. Therefore, application of sunscreen does not preclude sun damage, and one should continuously take all measures to prevent UV irradiation.

HISTORY

The first UVB filter, PABA (*para*-aminobenzoic acid), was patented in 1943, and the first UVA filter, a benzophenone, was introduced in 1962. In 1972, the U.S. Food and Drug Administration (FDA) reclassified sunscreens from cosmetics to nonprescription drugs, resulting in more stringent regulation. In 1979, long UVA filters, dibenzoylmethane derivatives, became available. In the 1990s, the need for protection against UVA, as well as against UVB, was recognized, which led to further development of UVA filters. In 2001, the FDA defined 16 active sunscreen ingredients with maximum concentrations, and in 2011, established labeling and effectiveness testing for broad-spectrum protection and water resistance.[2]

SUN PROTECTION FACTOR

The sun protection factor (SPF) was first developed by an Austrian, Franz Greiter, in 1962, and was adopted by the FDA in 1978.[3] Current FDA guidelines specifically require that products be tested using a solar simulator with emission spectrum covering the wavelength range of 290 nm to 400 nm, and that the sunscreen product be applied at a concentration of 2 mg/cm^2.

By definition, SPF is the ratio of the minimal erythema dose (MED) of a subject's sunscreen-protected skin over the MED of the unprotected skin:

$$\text{SPF} = \frac{\text{MED of sunscreen-protected skin}}{\text{MED of unprotected skin}}$$

Because the end point is erythema, SPF is a reflection of sun protection against the biologic effect of UVB (290 nm to 320 nm), and, to a lesser extent, UVA2 (320 nm to 340 nm). In other words, SPF15 does not mean that the exposure time to solar radiation is extended by 15 times, but that the amount of radiation required to cause erythema is increased by 15 times after the use of sunscreen. Figure 197-1 shows the effect of sunscreens with different SPFs on the transmission of erythemogenic rays.[4] If an individual develops slight erythema after 10 minutes of sun exposure, 30 minutes of unprotected sun exposure will result in a 3 MED sunburn. In contrast, when wearing an SPF15 or SPF30 sunscreen, the same 30-minute exposure would result in only 20% or 10%, respectively, of an MED. With chronic exposure, the added protection from an SPF30 sunscreen halves the cumulative UV damage

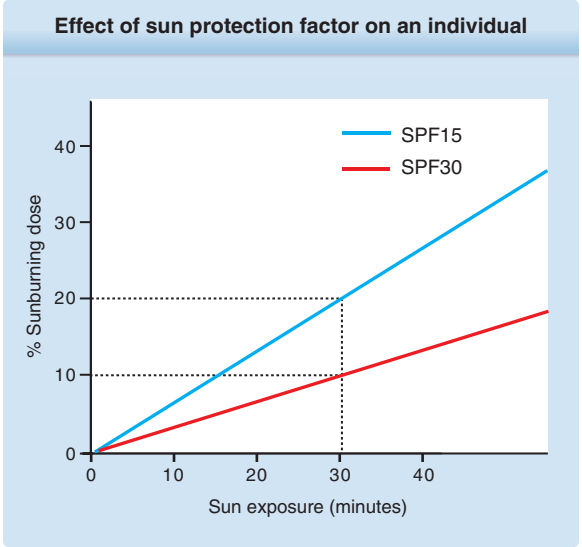

Figure 197-1 Effect of sun protection factor (SPF) 15 and SPF-30 sunscreens on an individual who would develop minimal erythema after 10 minutes of unprotected sun exposure. After a 30-minute sun exposure, 20% of a sunburning dose is achieved after the application of SPF15 sunscreen; after the application of SPF30 sunscreen, only 10% of a sunburning dose reaches the skin.

compared to the SPF15 sunscreen, even though both products prevent sunburn.

The concentration of sunscreen specified for SPF testing (2 mg/cm^2) is the equivalent of 1 oz (30 mL) of sunscreen to cover the entire body surface. Studies of the actual sunscreen usage by individuals have consistently demonstrated that the amount of sunscreen applied is closer to 0.5 to 0.8 mg/cm^2, so that the actual in-use SPF is significantly lower than the label SPF.[5] The relationship is not linear, and an SPF30 product (at 2 mg/cm^2) has an SPF of only 3 if applied at 0.5 mg/cm^2 (Fig. 197-2).[6]

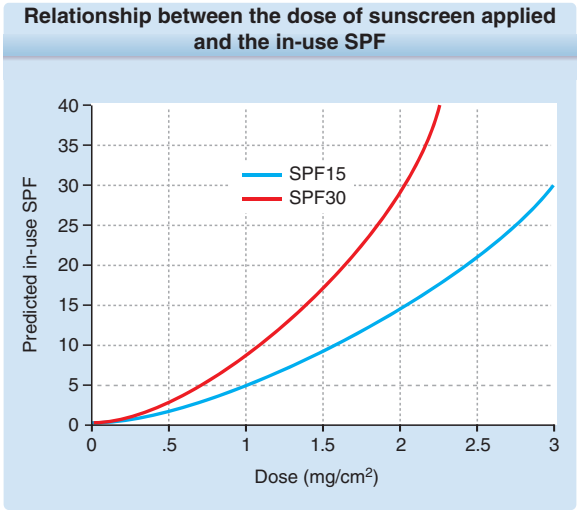

Figure 197-2 Relationship between the dose of sunscreen applied and the in-use sun protection factor (SPF). (Used with permission from JF Nash, Procter & Gamble, Cincinnati, OH.)

SPF2 products absorb 50% of the UVB when applied at 2 mg/cm^2 and the other 50% is absorbed into skin. SPF15 blocks 93.3% of UVB and 6.7% is absorbed into skin. SPF30 blocks 96.7% of UVB and 3.3% is absorbed into skin. It may appear that this difference is not significant as SPF15 blocks 93.3% and SPF30 blocks 96.7% of UVB; however, this is not true. In fact, the important factor in photoprotection is not how much is blocked by sunscreen, but how much is prevented from being absorbed into skin. For SPF15, 6.7% is absorbed into skin, whereas for SPF30, 3.3% is absorbed, which is only half the amount. Also, the amount of UVB needed to cause DNA damage that results in skin cancer is less than the amount needed to cause erythema. Moreover, the amount of sunscreen people use is always less than 2 mg/cm^2. Therefore, it is more helpful to choose sunscreen with the highest SPF available.

ASSESSMENT OF ULTRAVIOLET A PROTECTION

SPF is accepted as the worldwide standard for the assessment of protection against the erythemogenic effects of UVB and UVA2. Among the several methods to evaluate protection against UVA, the persistent pigment darkening (PPD) method has become the most widely used in the past years.[6,7] In the PPD method, the dose of UVA required to induce PPD observed 2 to 24 hours after exposure of sunscreen-protected skin is compared to that of sunscreen-unprotected skin; the ratio is then expressed as the UVA protection factor. In many countries, including Japan and Korea, the UVA protection of sunscreen products is then classified as PA+, PA++, or PA+++ (where PA indicates protection for UVA). The European Union requires UVA protection factor to be at least one-third of the labeled SPF, with the PPD method as the assessment of the UVA protection. For example, a SPF30 sunscreen must have a UVA protection factor of at least 10.[8]

In June 2011, the FDA decided to use an in vitro critical wavelength test (broad-spectrum test) to assess UVA protection of sunscreens sold in the United States.[9] The broad-spectrum test measures a sunscreen product's absorbance of UV radiation across both the UVA and UVB regions of the spectrum. To label a sunscreen product as "broad spectrum," it should have a critical wavelength of at least 370 nm. The critical wavelength is the wavelength at which the area-under-the-absorbance-curve represents 90% of the total area-under-the-curve in the UV region. For SPF15 or higher sunscreen products that are broad spectrum, use of the following statement is optional: "if used as directed with other sun protection measures, decreases the risk of skin cancer and early skin aging caused by the sun." In addition, in vivo PPD testing is no longer required in the United States according to this rule.

IMMUNE PROTECTION FACTOR

SPF for a sunscreen product correlates poorly with its ability to protect against immunosuppression. This has resulted in the development of the concept of immune protection factor to quantify the ability of sunscreen products to prevent immunosuppression.[10] Several different methods have been used, including contact sensitization and intradermal injection, all of which are quite laborious and time consuming to perform. Until a simple and reliable method that can be easily performed in a large number of test persons is developed, it is unlikely that immune protection factor will be used to rate commercial products.

ULTRAVIOLET FILTERS

There are 3 different nomenclatures used by the sunscreen industry and regulatory agencies around the world: (a) International Nomenclature of Cosmetic Ingredients (INCI), (b) United States Adopted Name (USAN), and (c) trade name. USAN is the nomenclature used in the FDA Sunscreen Monograph. For example, for a widely used UVA1 filter, the INCI name is butyl methoxydibenzoylmethane, the USAN is avobenzone, and a trade name is Parsol 1789. In this chapter, when available, the USAN nomenclature is used.

The term *sunblock* is commonly used to refer to sunscreens and their active ingredients, but it is a misnomer, and the FDA Sunscreen Monograph does not sanction the term. All sunscreen active ingredients are filters that absorb part of the incident UV radiation, but a portion of the radiation is always transmitted. Microfine inorganic filters additionally reflect and scatter UV radiation.

In the United States, all active sunscreen ingredients are regulated by the FDA as nonprescription drugs.[9] Only UV filters listed in the Sunscreen Monograph issued by the FDA may be marketed in the United States (16 active ingredients; Table 197-1). In addition, filters approved by the FDA as active ingredients of final products through the New Drug Application (NDA) process also can be marketed in the United States, as was done for the latest UVA filter available in the U.S. market, ecamsule (Mexoryl SX). In 2002, the FDA instituted the Time and Extend Application process as an alternate to filing the NDA.[11] With the Time and Extend Application process, data generated outside the United States can, for the first time, be used for the application, provided that the sunscreen product has been marketed for nonprescription purchase for a minimum of 5 years in the country where testing was performed. In the European Union, South America, many Asian countries, and Africa, sunscreens are regulated as cosmetics, resulting in a simpler and more expeditious approval process compared to the United States, usually resulting in approval within 1 to 2 years

TABLE 197-1
Ultraviolet (UV) Filters Listed in the U.S. Food and Drug Administration Sunscreen Monograph

U.S. ADOPTED NAME[a]	INTERNATIONAL NOMENCLATURE OF COSMETIC INGREDIENTS	λ_{max} (nm); OR ABSORPTION RANGE	COMMENT
Organic Filters: UVB			
▪ PABA derivatives			
▪ PABA	PABA	283	Stains clothing; not widely used
▪ Padimate O	Ethylhexyl dimethyl PABA	311	Most commonly used PABA derivative; photounstable
▪ Cinnamates			
▪ Octinoxate	Ethylhexyl methoxycinnamate	311	Most widely used UVB filter; photounstable
▪ Cinoxate	Cinoxate	289	—
▪ Salicylates			
▪ Octisalate	Ethylhexyl salicylate	307	Weak UVB absorbers; improves photostability of other filters
▪ Homosalate	Homosalate	306	
▪ Trolamine salicylate	Triethanolamine salicylate	260 to 355	Weak UVB absorbers; good substantivity—used in water-resistant sunscreens and hair-care products
▪ Others			
▪ Octocrylene	Octocrylene	303	Photostable; improves photostability of photolabile filters
▪ Ensulizole	Phenylbenzimidazole sulfonic acid	310	Water soluble; enhances sun protection factor of the final product
Organic Filters: UVA			
▪ Benzophenones			
▪ Oxybenzone	Benzophenone-3	288, 325	Most commonly used UVA filter; most common cause of photoallergic contact dermatitis to UV filters
▪ Sulisobenzone	Benzophenone-4	366	—
▪ Dioxybenzone	Benzophenone-8	352	—
▪ Others			
▪ Avobenzone	Butyl methoxydibenzoylmethane	360	Photounstable; enhances the photodegradation of octinoxate
▪ Meradimate	Menthyl anthranilate	340	A weak UVA filter; no sensitization reaction reported
Inorganic Filters			
▪ Titanium dioxide	Titanium dioxide	See below[b]	No report of sensitization reaction; photostable; used to enhance photostability of the final product; micronized zinc oxide has better UVA1 protection compared to microfine titanium dioxide; micronized zinc oxide has lower refractive index compared to microfine titanium dioxide and thus appears less white; commonly coated with dimethicone or silica to maintain effectiveness as sunscreen
▪ Zinc oxide	Zinc oxide	See below[b]	

[a]This is the name used by the U.S. Food and Drug Administration in the listing.

[b]λ_{max} ranges from visible to UVA to UVB range, depending on the particle size. As titanium dioxide is micronized (10 nm to 50 nm in diameter), λ_{max} shifts toward UVB; microfine zinc oxide maintains a flat absorption profile spanning from UVB to UVA.

PABA, *para*-aminobenzoic acid.

Data from Kullavanijaya P, Lim HW. Photoprotection. *J Am Acad Dermatol*. 2005;52:937; and Department of Health and Human Services, Food and Drug Administration. Sunscreen drug products for nonprescription human use; final monograph. *Fed Regist*. 1999;64:27666.

of filing. Currently, there are at least 34 approved active ingredients in Australia and 26 in the European Union.

UV filters can be divided into 2 categories: *organic* and *inorganic*. These terms are recommended by the FDA to replace the terms *chemical* and *physical* filters, respectively. Organic filters can be subdivided further into UVB filters and UVA filters. The most widely used UVB filter worldwide is octinoxate (ethylhexyl methoxycinnamate), whereas the most widely used UVA filter is oxybenzone (benzophenone-3).

Titanium dioxide (TiO_2) and zinc oxide (ZnO) are inorganic filters that are snowy white in color and insoluble in water. They are photostable and do not react with organic filters. When their size is larger than 200 nm, inorganic filters can protect skin from all the wavelengths of UV. Also, visible rays and infrared rays may be reflected

and scattered. Depending on the size, the properties of reflection or absorption change. Inorganic filters are not allergenic and do not react with skin, and are thus recommended for children and adults with allergies. However, inorganic filters are not preferred and are restricted in use because they leave a white coating behind. If applied too often, they may be comedogenic. On the other hand, micronized titanium dioxide is 10 nm to 100 nm in size. Because titanium dioxide scatters less visible light, it does not leave a white coating behind. However, its ability to block UV radiation decreases, leading to declined effect of photoprotection. Also, titanium dioxide may have negative effects on health if absorbed into skin. Therefore, more studies are required to elucidate whether inorganic filters actually penetrate into the skin, especially if they are used on inflamed skin or infants.

Sunscreen products combine ingredients in a variety of combinations to produce a product that confers stability and optimal UV protection. Currently, unless products are approved as new drugs through the NDA process, the FDA guidelines do not allow avobenzone to be combined with PABA, padimate O, or inorganic filters (titanium dioxide, zinc oxide).

ULTRAVIOLET FILTERS AND PHOTOSTABILITY

Avobenzone (butyl methoxydibenzoylmethane; Parsol 1789) is an excellent UVA1 filter but is photounstable and degrades during UV exposure. There are several other UV filters with this characteristic, including UVB filters padimate O (ethylhexyl dimethyl PABA) and octinoxate (ethylhexyl methoxycinnamate).[12] It is possible to incorporate other agents to increase the photostability of the final product (Fig. 197-3). Most of these agents are photostable UV filters (eg, octocrylene, salicylates, oxybenzone) that absorb photons to minimize the effect on the photounstable UV filter; they also serve as receptor molecules for energy transfer from excited state photounstable filter, hence minimizing the photodegradation of the latter (Fig. 197-3).[5,13]

In vitro, sunscreens containing photostabilized avobenzone have been shown to retain up to 90% of the active filter following 25 MED (50 J/cm^2) of solar-simulated radiation, the equivalent of approximately 5 hours of sun exposure.[13] Under ideal circumstance this would allow the user to apply sunscreen only once daily. However, it should be noted that sunscreens do migrate on the skin surface toward follicular orifices, resulting in an uneven distribution of UV filters; furthermore, sunscreens do get removed by rubbing and from water or sweat exposure. This is the reason that the FDA, in the final rule, advises that sunscreen should be reapplied every 2 hours.[9]

ULTRAVIOLET FILTERS AND PHOTOALLERGY

Octocrylene, oxybenzone (benzophenonone-3), and avobenzone (butyl methoxydibenzoylmethane) are

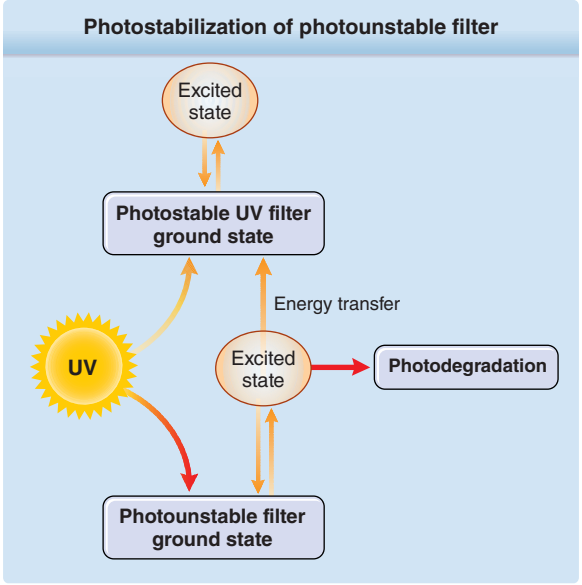

Figure 197-3 Photostabilization of photounstable filter. Photostable ultraviolet (UV) filter absorbs a portion of incident photons, hence decreasing the number of photons absorbed by the photounstable filter. Photostable UV filter also serves as a receptor for energy transfer from the excited-state photounstable filter, minimizing the photodegradation of the latter.

the most common causes of UV filter photoallergy.[14] It should be noted that although UV filters are the most common cause of photoallergy in many studies in the United States and the United Kingdom, considering the number of individuals using sunscreens, the prevalence of photoallergy to UV filters is very low (much less than 1%). No photoallergy has been reported with inorganic UV filters (titanium dioxide and zinc oxide).

SUNSCREEN USE IN CHILDREN

Because of the concern about percutaneous absorption of sunscreens, the 1999 FDA Sunscreen Monograph recommends that the physician should be consulted on the use of sunscreens in children younger than age 6 months.[9] For this group of patients, it is prudent to use other means of photoprotection, such as clothing.[15] Children younger than 2 years old should use inorganic sunscreen rather than organic sunscreen.

SUNSCREEN USE IN PREGNANCY

During pregnancy, sunscreen is also recommended to prevent skin damage from UV radiation, such as pigmentary disorders, especially melasma. Sunscreen has been proven safe by toxicology tests, including

teratogenic tests; however, studies regarding safety of nanoparticulate inorganic ingredients during pregnancy are not available.[16]

CONTROVERSIES

POTENTIAL SYSTEMIC ABSORPTION

Organic Ultraviolet Filters: Systemic absorption of some organic UV filters following topical application to the skin has been reported.[17] In humans, up to 2% of an applied dose of benzophenone-3 and its metabolites were excreted in the urine following topical application of a commercially available product. The chemical characteristics of organic UV filters, such as molecular weight and solubility in fluids, as well as vehicle and viscosity of the sunscreen products, influence skin penetration.

Inorganic Nanoparticles: Metal oxide inorganic UV filters (titanium dioxide and zinc oxide) have been widely used in the form of nanoparticles. This is to minimize the reflection of visible light, thereby enhancing the aesthetic appearance of the final product. Nanoparticles are defined as particles less than 100 nm. In vitro, these particles can induce free radical formation in the presence of UV radiation, resulting in cell damage. Multiple studies have shown that neither nanostructured titanium dioxide nor zinc oxide penetrates beyond the stratum corneum of skin.[18] The risk for humans from using sunscreens that contain nanostructured titanium dioxide or zinc oxide is considered negligible.

NONMELANOMA SKIN CANCER AND MELANOMA

Although there have been questions in the past, the protective role of sunscreens in the prevention of skin cancer development has now been established. In a 4.5-year study with an 8-year followup of more than 1600 individuals in Australia, it was shown that the group that was assigned to use SPF16 broad-spectrum sunscreen had a decreased incidence of squamous cell carcinoma and basal cell carcinoma by 38% and 25%, respectively.[19] In a 10-year followup, 11 melanomas developed in the sunscreen group, compared to 22 in the control group.[20]

VITAMIN D

Another area of controversy is the concern that photoprotection may compromise health by decreasing a person's serum vitamin D level, specifically the level of the highly variable "storage form" (25-OH-vitamin D) that is the precursor to the tightly regulated active form [1,25-$(OH)_2$-vitamin D]. There are only 3 sources of vitamin D. Exposure to the UVB spectrum of sunlight converts 7-dehydrocholesterol in the skin to previtamin D by photoisomerization. Also, previtamin D converts to vitamin D by heat isomerization. Subsequently, vitamin D is hydroxylated in the liver and kidneys to its active form. The peak action spectrum for previtamin D synthesis is 300 ± 5 nm. However, previtamin D_3 and vitamin D_3 are sensitive to UV radiation. If they are constantly exposed to sunlight in the skin, they will be photodegraded and become inactive. Therefore, continuous exposure to sunlight does not produce vitamin D proportionally. It is the reason why vitamin D intoxication does not occur with excessive sun exposure. The amount of UVB required to produce daily needed vitamin D in humans is not so much; exposure of 0.33 or 0.5 MED 2 or 3 times a week to arms, hands, and face is sufficient. In other words, a person with skin type II who lives in Boston needs only 5 minutes at noon in July.[21] According to another study, arms and legs can create 3000 IU by being exposed to 0.5 MED of UVB. Therefore, light-skinned people can produce sufficient vitamin D by staying under midday sunlight for 5 to approximately 30 minutes, twice a week.[22]

Another source is dietary intake, although only a few naturally-occurring foods contain a significant amount of vitamin D (eg, oily salt water fish [herring, salmon, and sardines], cod liver oil, and egg yolk). In the United States, milk, orange juice, margarine, butter, cereals, and chocolate mixes are fortified with vitamin D. Lastly, vitamin D supplements are readily available as vitamin D_3 (cholecalciferol, the form produced in skin) or vitamin D_2 (ergocalciferol); as of this writing, vitamin D_3 is more commonly used than vitamin D_2 because vitamin D_3 is considered to be more stable.[22]

The effect of application of sunscreens on vitamin D levels has been evaluated. A relatively recent review of all the published evidence concluded that normal usage of sunscreens does not generally result in vitamin D insufficiency.[23] This is primarily a result of the inadequate application of sunscreens—applying an insufficient amount of sunscreen or not reapplying sunscreen every 2 hours—and sunscreen users may expose themselves to more sun than nonusers. Hence, in these cases, even when sunscreen is applied, daily required UVB for vitamin D production is achieved. However, among patients who practiced diligent photoprotection (eg, those with lupus erythematosus or erythropoietic protoporphyria), a large percentage were found to have inadequate serum vitamin D levels.[24,25] A comprehensive review by the U.S. Institute of Medicine, released in November 2010, concluded that the strongest evidence for the beneficial effect of vitamin D on health is for bone health; in contrast, for extraskeletal outcomes, the Institute of Medicine review indicated that the current evidence is inconsistent and inconclusive and as such is insufficient to make public health recommendation.[26] Because the action spectrum for cutaneous vitamin D synthesis (ie, UVB) is the same as for DNA damage and photocarcinogenesis, it is not advisable to use sun exposure as a means of obtaining vitamin D. For those individuals who are concerned or are at risk for vitamin D insufficiency, a balanced diet and a daily 600 IU vitamin D_3 supplement, along with 1 g of calcium,

is recommended.[26] This recommendation applies especially to elderly individuals who are homebound dark-skinned individuals with modest sun exposure, and those who practice rigorous photoprotection.

ORAL PHOTOPROTECTION

Oral photoprotection refers to consumption of one or more active ingredients to minimize skin damage caused by solar radiation. However, by definition an oral substance cannot replace topical sunscreen, because consumption of the substance is incapable of physically blocking UVR penetration into skin. Instead, it can be used as a complement to prevent or reduce skin damage caused by solar radiation absorption. Oral photoprotection is convenient and useful, assuming that it is effective. It is not influenced by external environments, such as swimming and sweating, and it is not affected by the need to penetrate through the horny layer of skin. However, systemic adverse effects may be present. The action mechanisms by which active ingredients for oral photoprotection prevent skin damage from UV radiation are diverse. The substances react with various targets in UV-induced signaling pathways, exerting antioxidant, antiinflammatory, and immunomodulating actions. The most common substance used for oral photoprotection is an antioxidant, which should be stable and highly capable of eliminating ROS. Its end products after reaction as an antioxidant should not be converted into free radicals.

Oral photoprotection alone, without topical sunscreen, is insufficient to adequately protect skin from solar radiation. Nevertheless, its effectiveness is evident. Vitamins, such as vitamin C and vitamin E, as well as extracts or purified substances from certain plants (phytochemicals) can prevent skin damage from solar radiation. Hence, they may be used topically or as oral supplements to maintain healthy skin. Such active phytochemicals include polyphenols, which are either flavonoids or nonflavonoids, and nonpolyphenols, such as carotenoids and caffeine (Table 197-2).

TABLE 197-2
Active Ingredients for Oral Photoprotection

Vitamins
- L-Ascorbic acid (vitamin C)
- Tocopherol (vitamin E)
- Nicotinamide

Polyphenol
- Flavonoids
  - Catechins
  - Isoflavones (genistein, silymarin)
  - Proanthocyanidins
- Nonflavonoids
  - Phenolic acid (benzoic, gallic, and cinnamic [caffeic, ferulic, and *p*-coumaric] acids)
  - Resveratrol

Nonpolyphenols
- Carotenoids
  - Beta-carotene
  - Lycopene
  - Astaxanthin
- Caffeine

VITAMINS

L-ASCORBIC ACID (VITAMIN C)

Because of its water soluble properties L-ascorbic acid is the most important antioxidant in the hydrophilic phase. As it is not naturally synthesized in humans, daily intake is best be achieved through food. Studies have not yet proven that oral supplementation of vitamin C alone can protect human skin from sunlight exposure. However, some studies have demonstrated that combined use of vitamin C and vitamin E has positive effects.[27]

TOCOPHEROL (VITAMIN E)

Along with vitamin C, tocopherol is a natural antioxidant, but is lipid soluble. Having affinity mainly with cell membrane lipids and intercellular cement lipids, tocopherol plays an important role in protection from oxidative damage by eliminating ROS. α-Tocopherol is oxidized to tocoferoxyl radical by ROS and, in turn, regenerated by vitamin C. Along with vitamin C, glutathione and coenzyme Q10 can recycle tocopherol. Although controversial, high dose oral vitamin E appears effective at reducing UVB-induced damage in human skin.[28]

NICOTINAMIDE

Nicotinamide (or niacinamide) is an amide form of vitamin B_3, which is an essential water-soluble vitamin. Oral nicotinamide is photoprotective. Nicotinamide prevents adenosine triphosphate depletion induced by UV radiation, thereby boosting cellular energy and enhancing DNA repair. Oral nicotinamide is safe and effective in reducing the rates of new nonmelanoma skin cancers and actinic keratoses in high-risk patients.[29]

POLYPHENOL

Polyphenols are mainly found in fruits, vegetables, coffee, tea, red wine, nuts, cereal, and chocolate. Polyphenols are chemicals that have more than one phenolic ring per molecule. A phenolic ring has a hydroxyl group bound to an aromatic ring. The intrinsic antioxidant activity of polyphenols resides in this hydroxyl (–OH) group that acts as a hydrogen or electron donor to a free radical or other reactive species. The typical classification of these molecules depends on the number and type of phenolic rings, which determine their biologic properties. Polyphenols are classified

as flavonoids or nonflavonoids and are being proven effective for cutaneous inflammation, oxidative stress, UV-induced DNA damage, and carcinogenesis in vivo.[30]

FLAVONOIDS

The flavonoids include catechins, isoflavones, and proanthocyanidins.

Catechins: The catechins are mainly present in tea leaves and are made up of catechin, epicatechin, galactocatechin, epicatechingallate, and epigallocatechin-3-gallate. A double-blind, placebo-controlled study revealed that consuming green tea polyphenols decreased UV-induced erythema in women.[31]

Isoflavones: The most well-known isoflavones are genistein, derived from soybean, and silymarin, derived from the milk thistle (*Silybum marianum*). Genistein exerts a photoprotective effect in animal models.[32] The major active component of silymarin is silibinin, which has been shown to protect against photocarcinogenesis in animals.[33]

Proanthocyanidins: The proanthocyanidins are also known as condensed tannins; this is a group of substances widely present in grape seeds. Oral administration of an extract of grape seeds is effective in preventing the UV-induced pigmentation of guinea pig skin[34] and inhibiting tumor induction in response to UV radiation in mice.[35]

NONFLAVONOIDS

The nonflavonoids include the phenolic acids and resveratrol.

Phenoic Acid: The phenolic acids include benzoic, gallic, and cinnamic (caffeic, ferulic, and *p*-coumaric) acids. They appear mostly in red wine and tea. They exhibit antioxidant properties. Caffeic acid has been shown to protect against UVA-induced photodamage by ROS in mice.[36]

Resveratrol: Resveratrol, a stilbene found in grapes, red wine, and nuts, is also a potential polyphenolic antioxidant. Resveratrol suppresses UV-induced malignant tumor progression in mice.[37]

NONPOLYPHENOLS

The nonpolyphenolic phytochemicals include carotenoids and caffeine.

CAROTENOIDS

Carotenoids, which are vitamin A derivatives, include beta-carotene, lycopene, and astaxanthin. They are effective antioxidants for photoprotection. Lycopene and beta-carotene are relatively abundant in the human skin.[38]

Beta-Carotene: Fruits and vegetables (eg. carrot, pumpkin, sweet potato, mango) are rich in beta-carotene. As an endogenous photoprotector, it prevents erythema formation resulting from UV radiation.[39] The effect of photoprotection is dependent on treatment dosages and duration.

Lycopene: Lycopene, a bright red carotenoid pigment, exists in tomatoes and red vegetables or fruits, such as red carrots, watermelons, and papayas, and is a very efficient singlet oxygen quencher. Research has proven its effectiveness in reduction of erythema resulting from UV radiation.[40]

Astaxanthin: Microalgae, salmon, trout, shrimp, and crayfish contain astaxanthin. Astaxanthin has proven photoprotective activity against UVA.[41]

GARMENTS

CLOTHING AS A PHOTOPROTECTIVE MEASURE

Clothing, including hats, is an integral part of photoprotection. Compared to sunscreens, clothing is easy to put on, durable, and a social necessity. However, in most cultures, there are body sites that are infrequently covered by clothing, such as the face, the V area of the neck, and the dorsal hands. During hot (and sunny) weather, garments tend to cover even less skin.

When performing outdoor activities, it is crucial that one wear clothing that provides protection against the sun, especially children. Parents should educate their children about proper clothing before going outdoors. A wide-brimmed hat is highly recommended as it can protect wider areas, including the forehead, eyes, and nose.

ULTRAVIOLET PROTECTION FACTOR

UV protection factor (UPF) is the in-vitro measurement used in many countries, including the United States, Australia, and the European Union, to quantify the ability of fabrics to protect against UV. The amount to which 290 to 400-nm wavelengths penetrate through clothing is measured by spectrophotometric technique. The higher UPF, the less UV penetrates through fabrics. Because erythema is the factor considered, similar to the SPF, UPF is a better reflection of UVB than UVA protection.[42] In the United States, garments are classified as having good protection (UPF15 to UPF24), very good protection (UPF25 to UPF39), or excellent protection (UPF40 to UPF50+).

Several factors affect the UV protectiveness of garments.[5,42] Polyester fibers are the best UV absorber, whereas cotton and rayon are the poorest. Laundering garments made from cotton or rayon increases the UPF because of shrinkage, causing a decrease in the porosity of the fabrics. Wetness decreases the UV protection of a light-colored (especially white) garment. This is because the protective effect of white cotton fabric is mainly from light-scattering at the fiber–air interface: when wet, the fabric no longer scatters light and the garment becomes more transparent to both UV and visible light. In contrast, dark-colored garments absorb light and thus do not become see-through or provide less UV protection when wet. Chemical treatments include the incorporation of UV absorbers in fabrics during the manufacturing (mill finishing) process; the addition of UV absorber as laundry additives, and the addition of optical whitening agents, which are widely incorporated in many laundry detergents in the United States and Europe. These optical whitening agents absorb UV radiation at 360 nm and convert it to a visible light wavelength of 430 nm, thereby decreasing UV transmission through the fabric. The emission of visible light from the fabric makes the fabric look "brighter."

It is a common misperception that color of the fabric linearly correlates with the UPF. In experiments with cotton fabric with a UPF of 4.1, red fabric with the same dye concentration had UPF of 41, 31, and 20, depending on the type of red dye used. A yellow fabric had UPF of 25, whereas a violet one had UPF of 24.[42] This is because color is a reflection of the *visible light* that the eye would see and the brain would perceive; it does not necessarily correlate with the transmission of UV rays through the fabric.

GLASS

GLASS USED IN BUILDINGS AND CARS

Transmission of UV radiation through windows depends on glass type, thickness, and color. It is well known that UVB is effectively filtered by glass. Many types of glass now also have very good UVA2 and UVA1 protection (up to 380 nm). It should be noted that car windshields are made of laminated glass, which allows less than 1% of UV (300 nm to 380 nm) to pass through, whereas side and rear windows are usually made from nonlaminated glass that allows a higher level of UVA transmission. This explains why common sites of involvement for patients with a photodermatosis are the side of the face and forearm closest to the side window of the car.[43]

SUNGLASSES

Sunglasses protect eyes and skin near eyes from the sunlight, as UV radiation damages cornea, conjunctiva, lens, and retina. Acute UV damage includes photokeratitis, mainly caused by UVB, and solar retinitis, caused by visible light. Chronic damage include cataract, pterygium, and macular degeneration. Mainly UVB is absorbed by the cornea to damage it; in addition, UVA, the longer UV wavelengths, damages the lens and further provokes cataracts. Visible and infrared rays impair the retina. Consequently to protect the retina, yellow-colored or red-colored sunglasses, which can block blue or purple light, are preferred.[44] Sunglasses are especially important for children because their clear ocular lenses transmit more visible light when compared to adult lenses.[45] Lenses with darker colors may induce greater exposure to UV as a consequence of pupil dilation, unless the lenses offer good UV protection. Also, the shape of the lenses should such that they block light entering from the side. Sunglasses are also recommended during morning and afternoon hours when sunlight is parallel with eye levels. The time of maximum UV exposure to the eye is not from 10:00 AM to 2:00 PM as in the case of the skin, but is between 8:00 and 10:00 AM and 2:00 and 4:00 PM, when solar radiation is parallel to the eye.[46]

Australia has led the world in sunglass standards, developing the world's first national mandatory standard for sunglasses for general use in 1971; it was last revised in 2003 (AS/NZ 1067:2003). The amount of visible light transmitted through the lens is called *luminous transmittance*; a lens with 20% luminous transmittance would allow 20% of the visible light to pass through. Lenses are grouped into 5 categories (0 to 4), ranging from fashion sunglasses (lens category 0) to special-purpose sunglasses for very high sun-glare reduction (lens category 4); category 4 lenses are not to be worn during driving. Category 0 lenses are allowed to have luminous transmission of 80% to 100%, whereas category 4 transmission is limited to 3% to 8%. The standard requires that the UVB transmittance be 5% of the luminous transmittance. Specifically, if the luminous transmittance is 20%, then the allowed UVB transmittance is 5% of 20%, which is 1%. The UVA transmittance for lens categories 0 to 2 must be no more than the luminous transmittance, while for lens categories 3 and 4, it must be no more than 50% of the luminous transmittance. The standard also mandates that the minimum vertical diameter for adult sunglasses is 28 mm, and for children, 24 mm. The 2003 Australian Standard is similar to the European Standard EN 1836:2005. The 2 standards differ in the maximum amount of UVB transmission allowed and the definition of UVA.[47]

The U.S. sunglass standard was first published in 1972 by the American National Standards Institute (ANSI) and last revised in 2010 (ANSI Z80.3). However, unlike the Australian standard, compliance with the U.S. standard is voluntary and is not followed by all manufacturers. The U.S. standard classified sunglasses as *Normal Use* (eg, from home to the car to the office) or *High* or *Prolonged Exposure* (eg, at the beach, fishing, skiing). Lenses are classified by intended function as cosmetic purpose, general purpose, special purpose very dark, and special purpose strongly colored.[47] For example, for general purpose sunglasses, ANSI Z80.3

requires less than 1% of the wavelengths below 310 nm to be transmitted. No minimum vertical dimension of the sunglasses is stated in the U.S. standard.

PHOTOPROTECTIVE CARE FOR PHOTOSENSITIVE SKIN DISEASES

Photosensitivity is generally defined as an abnormal reaction of the skin to sunlight and other sources of UV light. In patients with photosensitive skin diseases, it is important to provide them with specific instructions and guidelines regarding how to incorporate photoprotection in daily life (Table 197-3). Individuals with limited sun exposure because of rigorous practice of photoprotection and patients with photosensitive skin diseases are known to be at risk for vitamin D insufficiency. In a newer study with cutaneous lupus erythematosus patients, 25-hydroxyvitamin D levels were found to be significantly lower among sun avoiders and daily sunscreen users than among individuals who did not avoid the sun.[24] Dietary supplementation with at least 400 IU/day of vitamin D_3 (cholecalciferol) is thus recommended for all patients with photosensitive disorders who avoid sun and use sunscreens. Vitamin D_3 (cholecalciferol, the natural form produced endogenously) is superior to vitamin D_2 (ergocalciferol).

LUPUS ERYTHEMATOSUS

As UV-induced skin lesions in patients with cutaneous lupus erythematosus could develop up to several weeks after UV exposure, a relationship between sun exposure and exacerbation of cutaneous lupus erythematosus does not seem obvious to the patient. Consequently, patients must be informed about the relationship of UV exposure to their disease. The use of a broad-spectrum sunscreen with high UVB and UVA protection factors prevents skin lesions in all patients with photosensitive cutaneous lupus erythematosus.[48]

TABLE 197-3

Ultraviolet Protection in Patients with Photosensitive Diseases

- Strict avoidance of sunlight exposure and other sources of ultraviolet
- Physical protection including clothing, hat, umbrella, and sunglasses
- Broad-spectrum sunscreens (sun protection factor ≥50)
- Oral antioxidants
- Removal of photosensitizing drugs
- Vitamin D supplementation

XERODERMA PIGMENTOSUM

Xeroderma pigmentosum is a rare autosomal recessive disease of DNA repair, characterized by severe UV sensitivity with greatly increased risk for skin cancer. The goal of UV protection is to significantly lessen the amount of UV radiation reaching the skin and eyes of xeroderma pigmentosum patients. Special UV-blocking clothing treated with UV absorbers and blockers is recommended. Xeroderma pigmentosum patients should wear large-brimmed sun hats (made with UV blocking material), and may use a UV-blocking plastic shield attached to the hat that covers the whole face. Xeroderma pigmentosum patients should wear UVA-blocking and UVB-blocking sunglasses that provide full eye coverage, as well as a highly effective sunscreen on a daily basis. During the day, sunscreen should be reapplied every 2 to 3 hours.

ERYTHROPOIETIC PROTOPORPHYRIA

Erythropoietic protoporphyria is a rare, autosomal recessive inborn error of metabolism that is associated with severe painful photosensitivity. When the skin is exposed to sunlight, the accumulated phototoxic protoporphyrin is activated by blue light, resulting in singlet oxygen free radical reactions that lead to severe neuropathic pain, often followed by swelling and redness. Although several treatments (including beta-carotene, *N*-acetyl-L-cysteine, and vitamin C) have been described in the literature, a systematic review of more than 20 studies showed little to no benefit.[49] Afamelanotide (analog of human α-melanocyte–stimulating hormone) provided safe and effective photoprotection through eumelanin synthesis in patients with erythropoietic protoporphyria.[50]

ACKNOWLEDGMENTS

This chapter has been revised from its previous version written by Dr. Henry W. Lim.

REFERENCES

1. Krutmann J, Morita A, Chung JH. Sun exposure: what molecular photodermatology tells us about its good and bad sides. *J Invest Dermatol*. 2012;132(3, pt 2): 976-984.
2. Department of Health and Human Services, Food and Drug Administration. Labeling and effectiveness testing; sunscreen drug products for over-the-counter human use. Final rule. *Fed Regist*. 2011;76(117):35620-35665.

3. Department of Health, Education and Welfare, Food and Drug Administration. Sunscreen drug products for over-the-counter human use. *Fed Regist*. 1978;43:38206-38269.
4. Australian/New Zealand Standard. Sunscreen products—evaluation and classification. AS/NZS 2604; 1998.https://www.scribd.com/document/102213663/As-NZS-2604-1998-Sunscreen-Products-Evaluation-and-Classification.
5. Kullavanijaya P, Lim HW. Photoprotection. *J Am Acad Dermatol*. 2005;52(6):937-958.
6. Diffey BL, Ferguson J. Assessment of photoprotective properties of sunscreens. In: Lim HW, Draelos ZD, eds. *Clinical Guide to Sunscreens and Photoprotection*. New York, NY: Informa Healthcare; 2009:53-63.
7. Lim HW, Naylor M, Honigsmann H, et al. American Academy of Dermatology Consensus Conference on UVA protection of sunscreens: summary and recommendations. *J Am Acad Dermatol*. 2001;44(3):505-508.
8. Jansen R, Osterwalder U, Wang SQ, et al. Photoprotection: part II. Sunscreen: development, efficacy, and controversies. *J Am Acad Dermatol*. 2013;69(6):867.e1-e14; quiz 881-882.
9. Wang SQ, Lim HW. Current status of the sunscreen regulation in the United States: 2011 Food and Drug Administration's final rule on labeling and effectiveness testing. *J Am Acad Dermatol*. 2011;65(4):863-869.
10. Fourtanier A, Moyal D, Maccario J, et al. Measurement of sunscreen immune protection factors in humans: a consensus paper. *J Invest Dermatol*. 2005;125(3):403-409.
11. Department of Health and Human Services, Food and Drug Administration. Additional criteria and procedures for classifying over-the-counter drugs as generally recognized as safe and effective and not misbranded. *Fed Regist*. 2002;67(15):3060-3076.
12. Maier H, Schauberger G, Brunnhofer K, et al. Change of ultraviolet absorbance of sunscreens by exposure to solar-simulated radiation. *J Invest Dermatol*. 2001;117(2):256-262.
13. Cole CA, Vollhardt J, Mendrok C. Formulation and stability of sunscreen products. In: Lim HW, Draelos ZD, eds. *Clinical Guide to Sunscreens and Photoprotection*. New York, NY: Informa Healthcare; 2009:39-51.
14. European Multicentre Photopatch Test Study (EMCPPTS) Taskforce. A European multicentre photopatch test study. *Br J Dermatol*. 2012;166(5):1002-1009.
15. Quatrano NA, Dinulos JG. Current principles of sunscreen use in children. *Curr Opin Pediatr*. 2013;25(1):122-129.
16. Schalka S, Steiner D, Ravelli FN, et al. Brazilian consensus on photoprotection. *An Bras Dermatol*. 2014;89(6)(suppl 1):1-74.
17. Gonzalez H. Percutaneous absorption with emphasis on sunscreens. *Photochem Photobiol Sci*. 2010;9(4):482-488.
18. Burnett ME, Wang SQ. Current sunscreen controversies: a critical review. *Photodermatol Photoimmunol Photomed*. 2011;27(2):58-67.
19. van der Pols JC, Williams GM, Pandeya N, et al. Prolonged prevention of squamous cell carcinoma of the skin by regular sunscreen use. *Cancer Epidemiol Biomarkers Prev*. 2006;15(12):2546-2548.
20. Green AC, Williams GM, Logan V, et al. Reduced melanoma after regular sunscreen use: randomized trial follow-up. *J Clin Oncol*. 2011;29(3):257-263.
21. Holick MF. Sunlight "D"ilemma: risk of skin cancer or bone disease and muscle weakness. *Lancet*. 2001;357(9249):4-6.
22. Holick MF. Vitamin D deficiency. *N Engl J Med*. 2007;357(3):266-281.
23. Norval M, Wulf HC. Does chronic sunscreen use reduce vitamin D production to insufficient levels? *Br J Dermatol*. 2009;161(4):732-736.
24. Cusack C, Danby C, Fallon JC, et al. Photoprotective behaviour and sunscreen use: impact on vitamin D levels in cutaneous lupus erythematosus. *Photodermatol Photoimmunol Photomed*. 2008;24(5):260-267.
25. Holme SA, Anstey AV, Badminton MN, et al. Serum 25-hydroxyvitamin D in erythropoietic protoporphyria. *Br J Dermatol*. 2008;159(1):211-213.
26. Ross AC, Manson JE, Abrams SA, et al. The 2011 report on dietary reference intakes for calcium and vitamin D from the Institute of Medicine: what clinicians need to know. *J Clin Endocrinol Metab*. 2011;96(1):53-58.
27. Placzek M, Gaube S, Kerkmann U, et al. Ultraviolet B-induced DNA damage in human epidermis is modified by the antioxidants ascorbic acid and D-alpha-tocopherol. *J Invest Dermatol*. 2005;124(2):304-307.
28. Eberlein-Konig B, Ring J. Relevance of vitamins C and E in cutaneous photoprotection. *J Cosmet Dermatol*. 2005;4(1):4-9.
29. Chen AC, Martin AJ, Choy B, et al. A phase 3 randomized trial of nicotinamide for skin-cancer chemoprevention. *N Engl J Med*. 2015;373(17):1618-1626.
30. Nichols JA, Katiyar SK. Skin photoprotection by natural polyphenols: anti-inflammatory, antioxidant and DNA repair mechanisms. *Arch Dermatol Res*. 2010;302(2):71-83.
31. Heinrich U, Moore CE, De Spirt S, et al. Green tea polyphenols provide photoprotection, increase microcirculation, and modulate skin properties of women. *J Nutr*. 2011;141(6):1202-1208.
32. Terra VA, Souza-Neto FP, Frade MA, et al. Genistein prevents ultraviolet B radiation-induced nitrosative skin injury and promotes cell proliferation. *J Photochem Photobiol B*. 2015;144:20-27.
33. Mallikarjuna G, Dhanalakshmi S, Singh RP, et al. Silibinin protects against photocarcinogenesis via modulation of cell cycle regulators, mitogen-activated protein kinases, and Akt signaling. *Cancer Res*. 2004;64(17):6349-6356.
34. Yamakoshi J, Otsuka F, Sano A, et al. Lightening effect on ultraviolet-induced pigmentation of guinea pig skin by oral administration of a proanthocyanidin-rich extract from grape seeds. *Pigment Cell Res*. 2003;16(6):629-638.
35. Mittal A, Elmets CA, Katiyar SK. Dietary feeding of proanthocyanidins from grape seeds prevents photocarcinogenesis in SKH-1 hairless mice: relationship to decreased fat and lipid peroxidation. *Carcinogenesis*. 2003;24(8):1379-1388.
36. Yamada Y, Yasui H, Sakurai H. Suppressive effect of caffeic acid and its derivatives on the generation of UVA-induced reactive oxygen species in the skin of hairless mice and pharmacokinetic analysis on organ distribution of caffeic acid in ddY mice. *Photochem Photobiol*. 2006;82(6):1668-1676.
37. Kim KH, Back JH, Zhu Y, et al. Resveratrol targets transforming growth factor-beta2 signaling to block UV-induced tumor progression. *J Invest Dermatol*. 2011;131(1):195-202.
38. Scarmo S, Cartmel B, Lin H, et al. Significant correlations of dermal total carotenoids and dermal lycopene

with their respective plasma levels in healthy adults. *Arch Biochem Biophys*. 2010;504(1):34-39.
39. Kopcke W, Krutmann J. Protection from sunburn with beta-carotene—a meta-analysis. *Photochem Photobiol*. 2008;84(2):284-288.
40. Stahl W, Heinrich U, Aust O, et al. Lycopene-rich products and dietary photoprotection. *Photochem Photobiol Sci*. 2006;5(2):238-242.
41. Yoshihisa Y, Rehman MU, Shimizu T. Astaxanthin, a xanthophyll carotenoid, inhibits ultraviolet-induced apoptosis in keratinocytes. *Exp Dermatol*. 2014;23(3):178-183.
42. Hatch KL, Block L, Gies P. Photoprotection by fabric. In: Lim HW, Draelos ZD, eds. *Clinical Guide to Sunscreens and Photoprotection*. New York NY: Informa Healthcare; 2009:223-241.
43. Hampton PJ, Farr PM, Diffey BL, et al. Implication for photosensitive patients of ultraviolet A exposure in vehicles. *Br J Dermatol*. 2004;151(4):873-876.
44. Wu J, Seregard S, Algvere PV. Photochemical damage of the retina. *Surv Ophthalmol*. 2006;51(5):461-481.
45. Roberts JE. Ultraviolet radiation as a risk factor for cataract and macular degeneration. *Eye Contact Lens*. 2011;37(4):246-249.
46. Sasaki H, Sakamoto Y, Schnider C, et al. UV-B exposure to the eye depending on solar altitude. *Eye Contact Lens*. 2011;37(4):191-195.
47. Almutawa F, Vandal R, Wang SQ, et al. Current status of photoprotection by window glass, automobile glass, window films, and sunglasses. *Photodermatol Photoimmunol Photomed*. 2013;29(2):65-72.
48. Kuhn A, Gensch K, Haust M, et al. Photoprotective effects of a broad-spectrum sunscreen in ultraviolet-induced cutaneous lupus erythematosus: a randomized, vehicle-controlled, double-blind study. *J Am Acad Dermatol*. 2011;64(1):37-48.
49. Minder EI, Schneider-Yin X, Steurer J, et al. A systematic review of treatment options for dermal photosensitivity in erythropoietic protoporphyria. *Cell Mol Biol (Noisy-le-grand)*. 2009;55(1):84-97.
50. Langendonk JG, Balwani M, Anderson KE, et al. Afamelanotide for erythropoietic protoporphyria. *N Engl J Med*. 2015;373(1):48-59.

Physical Treatments PART 29

Chapter 198 :: Phototherapy

:: Tarannum Jaleel, Brian P. Pollack, & Craig A. Elmets

AT-A-GLANCE

The main wavelengths used for phototherapy include broadband ultraviolet B (BB-UVB), narrowband UVB (NB-UVB), ultraviolet A (UVA) 1, and UVA for psoralen photochemotherapy (PUVA); these have different depths of penetration and interact with a specific range of molecules rendering unique photobiologic properties with respect to potency, side effects, and diseases in which they are effective.

Targeted therapy devices can deliver distinct wavelengths of ultraviolet radiation to **only** lesional skin. Such devices that can deliver wavelengths of UVR at or close to those that are most effective at clearing localized atopic dermatitis, psoriasis, vitiligo, and cutaneous T-cell lymphoma have been evaluated, and are being used clinically.

Sunburn-like reactions are the most common short term adverse effect of phototherapy. UVB phototoxicity usually peaks at 12 to 24 hours and PUVA reaction manifests at 24 to 48 or even 72 hours. Importantly, except for PUVA therapy for which formal long term follow up studies established an increased risk of lentigines, squamous cell carcinoma, and possibly melanoma, other forms of phototherapy appear to be remarkably safe.

MECHANISMS OF PHOTOTHERAPY

Phototherapy is the use of ultraviolet radiation or visible light for therapeutic purposes. Its beneficial effects in vitiligo were first recognized thousands of years ago in India and Egypt and its activity is now well-established for a variety of other dermatologic conditions. The enduring appeal of phototherapy is based on its relative safety coupled with an ongoing interest in its molecular and biologic effects. The expanded use of phototherapy for dermatologic and nondermatologic conditions can be attributed to the following factors: identification of photosensitizers with unique photochemical properties; development of novel methods for the delivery of light to cutaneous and noncutaneous surfaces; and manufacture of light sources that emit selective wavelengths of radiant energy. The main phototherapeutic devices that are in use today (aside from lasers, high-output incoherent light sources, and visible light sources employed for photodynamic therapy) include broadband ultraviolet B (BB-UVB), narrowband UVB (NB-UVB), ultraviolet A (UVA) 1, and UVA for psoralen photochemotherapy (PUVA). Ideally, these devices used for therapeutic ultraviolet radiation (UVR) should be safe, efficient, and cost-effective. Therefore, understanding the basic principles of these devices is important for dermatologists and other providers using phototherapy for the management of dermatologic diseases.[1,2]

The distinct wavelengths of UVR used for phototherapy have different depths of penetration and interact with a specific range of molecules. As a consequence, each form of phototherapy has unique photochemical and photobiologic properties with respect to potency, side effects, and diseases in which they are effective (Fig. 198-1).

Most UVB radiation (290 to 320 nm) is absorbed superficially by the epidermis and superficial dermis (Fig. 198-2). In white skin, less than 10% of UVB radiation is transmitted beyond 14 microns.[3] This particular wavelength of radiant energy produces many different types of DNA damage, including pyrimidine dimers and 6,4-pyrimidine-pyrimidone photoproducts. These by-products are thought to be particularly important for both UVB's efficacy and toxicity.[4] UVB also causes

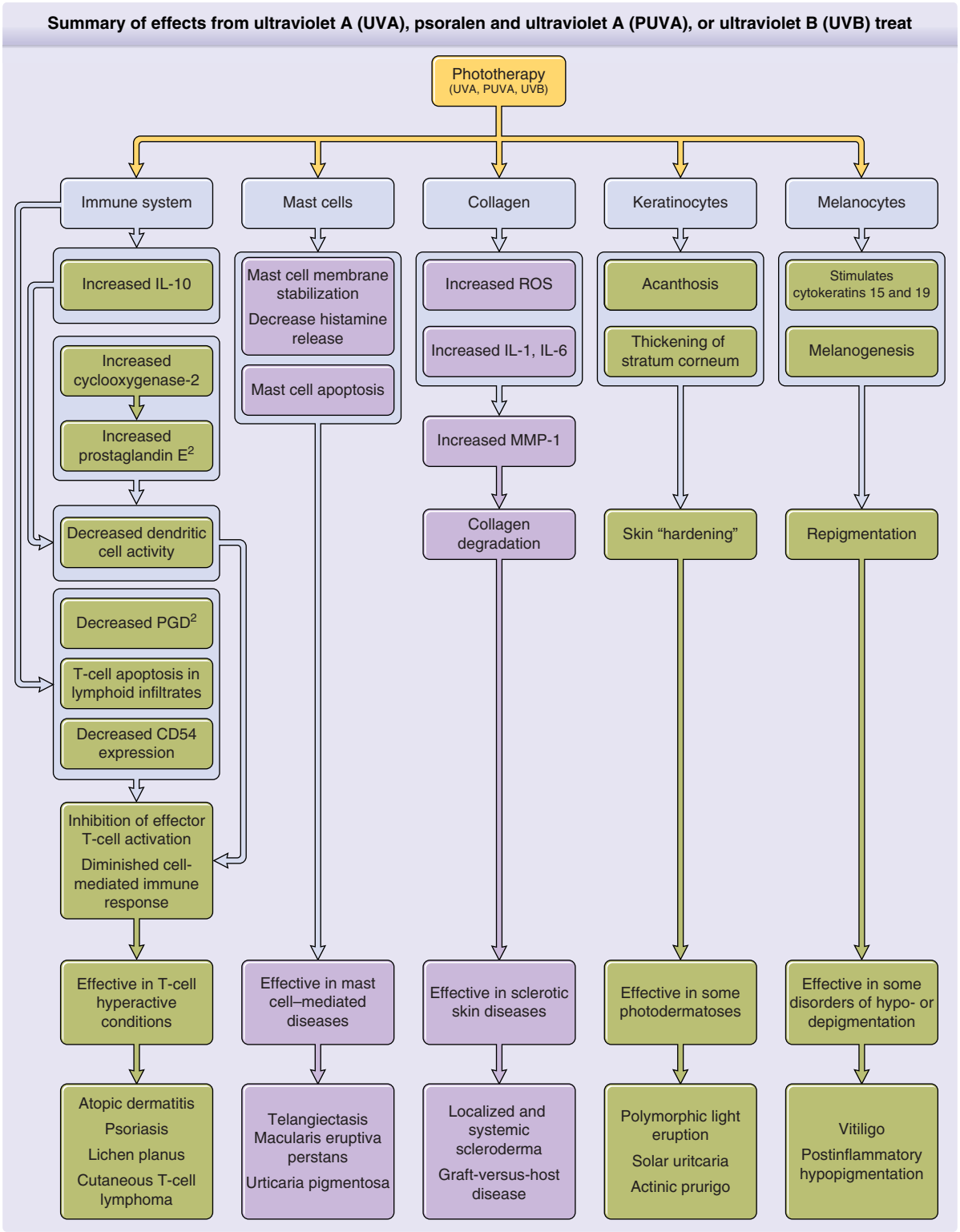

Figure 198-1 Summary of effects from ultraviolet A (UVA), psoralen and ultraviolet A (PUVA), or ultraviolet B (UVB) treatment. Detailed discussion in text. Boxes in *purple* indicate effects of either UVA and/or PUVA only, boxes in *green* indicate effects of both UVB and UVA and/or PUVA. The bottom two rows of boxes indicate clinical relevance of and application of skin changes induced by phototherapy. IL, interleukin; MMP, matrix metalloproteinase; PGD_2, prostaglandin D_2; ROS, reactive oxygen species.

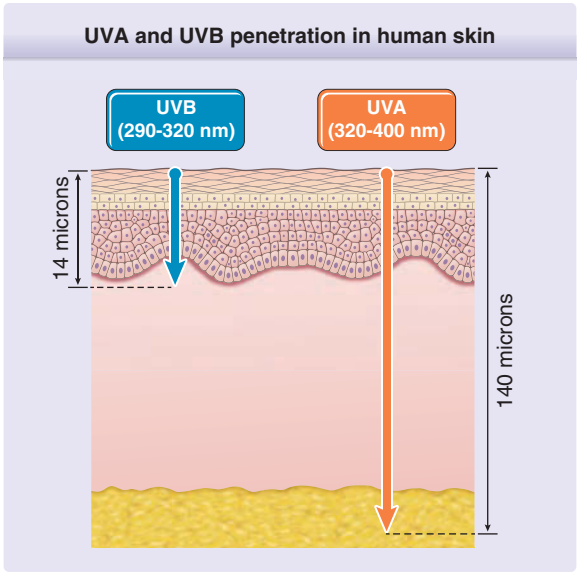

Figure 198-2 Depth of penetration in human skin for ultraviolet B (UVB) and ultraviolet A (UVA).

photochemical changes in *trans*-urocanic acid, converting it into the *cis* form of the molecule. Urocanic acid is a breakdown product of histidine and is present in large amounts in the stratum corneum. Originally considered to be a natural photoprotectant, there is now substantial evidence that *cis*-urocanic acid is a mediator of UVB-induced immunosuppression.[5] In addition, urocanic acid levels can also affect vitamin D production. Specifically, upon NB-UVB exposure, there is an accompanied increase in hydroxyvitamin D synthesis that inversely correlates with the baseline levels of *trans*-urocanic acid.[6] A third direct target of UVB radiation is the amino acid tryptophan. UVB converts tryptophan into 6-formylindololo[3,2-b]carbazole, which binds to the intracellular aryl hydrocarbon hydroxylase receptor, initiating a series of events that culminates in activation of signal transduction pathways. One such pathway results in expression of cyclooxygenase-2, an enzyme required for synthesis of prostaglandin E_2.[7] Finally, there is evidence that UVB exposure leads to the generation of reactive oxygen intermediates, which has downstream effects such as DNA damage in the form of 8-oxo-deoxyguanosine, lipid peroxidation, activation of signal transduction pathways, and stimulation of cytokine production.[8]

In contrast to UVB radiation which has a relatively superficial depth of penetration, UVA radiation (320 to 400 nm) can reach the mid- or lower dermis to a depth of 140 microns (see Fig. 198-2).[3] It is therefore more effective than UVB for skin diseases in which the cutaneous pathology lies deeper than the superficial dermis. Like UVB, UVA radiation can produce pyrimidine dimers in DNA, but, on a per-photon basis, it is much less effective at doing so.[9] In most situations, the major biologic effects of UVA radiation are from the generation of reactive oxygen intermediates.[10] Following UVA exposure, reactive oxygen intermediates are formed in mitochondrial enzyme complexes during oxidative phosphorylation. Although the skin contains antioxidants, reactive oxygen intermediates formed during phototherapy exceed the amount that can be neutralized by endogenous photoprotective activities. UVA-induced oxidants are capable of harming DNA, lipids, structural and nonstructural proteins, and organelles such as mitochondria. The generation of oxidants following UV exposure also has been implicated in photoaging of the skin and skin cancer. Interestingly, animal studies show that exposure to UVA's longer wavelength (UVA1, 340-400 nm) has immunoprotective properties via the generation of heme oxygenase-1, which exerts antioxidant and antiinflammatory effects while also decreasing UVB-induced damage.[11]

In psoralen photochemotherapy, psoralen photosensitizers are activated by UVA radiation, and the depth of penetration of PUVA is the mid-dermis. The major photochemical effect of psoralen photochemotherapy is damage to DNA. Psoralen photochemotherapy–induced changes in DNA differ from those of UVB and UVA without psoralens.[12] Psoralens used for photochemotherapy have 2 double bonds that can absorb UVA radiation. When administered to an individual, these compounds intercalate with DNA. Following UVA exposure, they form a single adduct with DNA and then become a bifunctional adduct, crosslinking the DNA strands in the double helix, when a second photon is absorbed. There is also some evidence that photochemotherapy augments the production of reactive oxygen intermediates such as singlet oxygen. This effect has been implicated in induction of the cyclooxygenase enzyme and activation of arachidonic acid pathways.[13]

EFFECTS ON THE IMMUNE SYSTEM

The photoimmunologic effects of phototherapy are thought to provide an explanation, at least in part, for phototherapy's efficacy in cutaneous diseases in which T-cell hyperactivity predominates (eg, psoriasis, atopic dermatitis, lichen planus). Under normal circumstances, both effector and regulatory T cells are generated, with the overall intensity of the immune response dependent on the relative proportion of effector and regulatory T-cell populations that are present. UVB exposure inhibits activation of effector T cells, whereas it leaves the development of regulatory T cells unaltered.[14] Consequently, the equilibrium of effector and regulatory T cells is biased toward a diminished cell-mediated immune response. This perturbation in the balance of effector and regulatory T cells reflects disruption of the activities of dendritic cells within the skin, the major function of which is to present antigen to T-lymphocytes. This is a result of the direct effects of UVB on dendritic cells and indirectly through the production of interleukin (IL)-10 and prostaglandin E_2, both of which diminish the capacity of dendritic cells to present antigen to effector T cells leading to suppressed T-cell responses.[15] Increased levels of IL-10 have been found after UVB, UVA1, and PUVA exposure. Prostaglandin E_2 production occurs through

UVB effects on keratinocytes[16-18]; UVB is an inductive stimulus for cyclooxygenase-2, which is important for prostaglandin E_2 production. UV exposure also significantly lowers levels of immunomodulatory factors such as prostaglandin D_2, possibly reflecting a loss of Langerhans cells from the epidermis upon UV exposure.[19]

Other immunosuppressive soluble mediators that are reported to be increased following UVB exposure include agonists of the platelet activating factor receptor,[20] melanocyte-stimulating hormone, and calcitonin gene–related peptide.[21] In addition, in the setting of inflammation, FoxP3-positive regulatory T cells can convert into IL-17–producing cells and lose FoxP3. UVB radiation, however, increases FoxP3 expression by binding the transcription factor, p53, and stabilizing the FoxP3-positive regulatory T-cell population.[22,23] The epidermal growth factor–like growth factor amphiregulin influences the activity of regulatory T cells and basophil-derived amphiregulin is implicated in mediating UVB-induced immune suppression in murine models, which supports the notion that growth factors have immunomodulatory properties relevant to skin biology and disease.[24,25]

PUVA has effects that are similar to UVB with respect to antigen-presenting cells within the skin, the balance between effector and regulatory T cells, and the production of soluble immunosuppressive mediators.[14] However, there is limited information on the effect of UVA1 on antigen-presenting cells and on effector and regulatory T cells. In acute skin lesions of atopic dermatitis, UVA1 appears to increase IL-4 and thymus-regulated and activation-regulated chemokine messenger RNA expression, but has little effect on expression of human beta defensin-1, thymic stromal lymphopoietin, IL-5, IL-10, IL-13, or IL-31.[26,27]

In addition to its actions on cutaneous antigen-presenting cells, phototherapy causes cell death by apoptosis of T cells in cutaneous lymphoid infiltrates. This has been demonstrated for UVA1 phototherapy in the lymphocytic infiltrate in atopic dermatitis,[28] and for NB-UVB in psoriasis.[29] Another immunologic effect of phototherapy is on expression of CD54 (intercellular adhesion molecule-1) and other adhesion molecules. Intercellular adhesion molecule-1 is not normally present on epidermal keratinocytes, but can be induced in a variety of inflammatory skin conditions. It facilitates T-cell binding to keratinocytes, through its interaction with lymphocyte function–associated antigen-1 that is present on T cells. Because UVB, UVA1, and PUVA all interfere with keratinocyte expression of CD54, this effect of phototherapy may contribute to phototherapy's efficacy in diseases that have increased keratinocyte CD54 expression.[14]

EFFECTS ON MAST CELLS

Both UVA1 and PUVA have deleterious effects on mast cells, although the mechanisms of action differ.[30,31] PUVA is not cytotoxic for mast cells, and because of this, there is little reduction in mast cell concentrations in the dermis. However, PUVA does stabilize mast cell membranes and, as a result, limits the release of histamine and other mediators when these cells are stimulated to degranulate.[31] In contrast, chronic therapy with UVA1 results in apoptosis of mast cells with a marked reduction in their concentrations that can last for several months.[30] Both PUVA and UVA1 have been employed to treat selective mast cell–mediated diseases.

EFFECTS ON COLLAGEN

One of the downstream effects of UVA-induced generation of reactive oxygen intermediates is activation of matrix metalloproteinase (MMP)-1,[32,33] the major biologic activity of which is degradation of collagen. UVA radiation increases the production of IL-1 and IL-6, which are stimuli for MMPs.[34] PUVA also increases MMPs.[35] These effects of UVA1 and PUVA on MMP-1 and collagen degradation provide the rationale for its use in sclerotic skin diseases.

EFFECTS ON KERATINOCYTES

UVB, PUVA, and UVA all cause acanthosis of the epidermis and thickening of the stratum corneum.[36] This effect accentuates light scattering and increases its absorption by the upper levels of the epidermis. Therefore, phototherapy treatment doses must be progressively increased so that an equivalent number of photons can reach the lower levels of the epidermis and dermis where therapeutic targets lie. Alternatively, this attribute of phototherapy has been exploited for the management of chronic photosensitivity disorders because this "hardens" the skin, permitting individuals afflicted with these disorders to tolerate greater amounts of sun exposure.

EFFECTS ON MELANOCYTES

Exposure to UVR is also known to stimulate melanogenesis,[37] which is, at least in part, a consequence of DNA damage and/or its repair.[38-41] Experimental studies have shown that treatment of melanocytes with DNA repair enzymes increases the melanin content of melanocytes,[42] and application of small fragments of thymidine dinucleotides to guinea pig skin produces a tanning response.[39-41] The stimulatory effects on melanogenesis decrease the efficacy of phototherapy unless the doses of UVR are gradually

increased, but in patients with some photosensitivity disorders, this biologic effect can be exploited therapeutically, allowing them to tolerate greater amounts of ambient sun exposure.

Narrowband UVB and PUVA are also employed to repopulate vitiliginous skin with melanocytes. The mechanism by which phototherapy stimulates repigmentation of vitiliginous skin is incompletely understood, but may involve stimulation of hair follicle melanocyte proliferation and migration.[43] Cytokines and other inflammatory mediators released from other cells, such as keratinocytes, are thought to stimulate inactive melanocytes in the outer root sheath of hair follicles to proliferate, mature, and migrate to repopulate the interfollicular epidermis.[44] Increased expression of cytokeratins 15 and 19, markers for stem cell activation in the follicular and interfollicular epithelium, is also seen in response to phototherapy.[45]

PHOTOTHERAPY DEVICES

In an ideal situation, the wavelengths that are most effective for the treatment (ie, the action spectrum) for every dermatologic condition would be known and there would be a device capable of delivering those wavelengths specifically to lesional skin. For some skin diseases, such as psoriasis, great strides have been made toward this ideal; targeted therapy using devices that can deliver wavelengths of UVR at or close to those that are most effective at clearing psoriatic plaques have been evaluated and are being used clinically. Unfortunately, for most dermatologic conditions this information is still unknown. However, the increased availability of improved phototherapy devices and novel treatment approaches is providing new options for patients and clinicians. In addition, as studies are conducted that use phototherapy, there is a better understanding of how best to use these technologies. Many different types of phototherapy devices exist and more are currently under development. Phototherapy devices are varied and can be booth-like devices that patients enter to receive their treatment, smaller stationary devices that can deliver UVR to a specific anatomic region (such as the hands and/or feet) while sparing uninvolved areas, or handheld devices that can be maneuvered to deliver UVR to lesional skin. The type of device used needs to be individually tailored to a given patient. Some patients may have trouble standing for the required amount of time needed for therapy, whereas others may have difficulty maneuvering themselves. It is important to note that phototherapy can be delivered in the setting of a dermatology practice or in the home. Numerous changes are being made to phototherapy devices to make them safer and more convenient. For example, a "digital phototherapy device" has been developed that integrates a camera, computer hardware and software, a digital mirror device, and other components that only delivers UVR specifically to diseased skin while sparing surrounding normal skin.[46,47]

BASIC PRINCIPLES OF PHOTOTHERAPY DEVICES AND TYPES OF LAMPS

Phototherapy devices generate light by the conversion of electrical energy into electromagnetic energy. Filters and fluorophores are used to modify the output such that the desired wavelengths are emitted. There are several types of lamps (or bulbs) used to generate therapeutic UVR. These include incandescent lamps, arc lamps, and fluorescent lamps.

Incandescent lamps generate UVR by passing an electric current through a thin tungsten filament, which, in turn, generates heat and light. Because much of the electrical energy is converted to heat, these lamps are relatively inefficient light sources and have relatively short life spans. By sealing the tungsten filament in a quartz envelope that contains a halogen (bromine or iodine), the filament can be made to emit more energetic photons without reducing the longevity of the bulb. These lamps are called quartz halogen lamps and can emit wavelengths within the UV, visible, and infrared ranges. In clinical dermatology, these lamps are employed primarily in situations that require visible light such as phototesting and photodynamic therapy.

Arc or gas discharge lamps were the first effective artificial UVR sources used for phototherapy. Arc lamps take advantage of the fact that when a high voltage is passed across 2 electrodes in the presence of a gas, the electrons of the gas atoms become excited. The "arc" of an arc lamp refers to the electric arc generated when the gas is ionized (ionized gas is also known as plasma) by a high electric current. When the gas electrons return to their ground state, light is emitted. The type of gas incorporated into the lamp determines the wavelengths that are emitted (ie, spectral output). The output of arc lamps can be modulated by altering the gas pressure within the bulb such that at high pressures, the peak wavelength output broadens. High-pressure arc lamps typically contain mercury or xenon gas, whereas low-pressure arc lamps use fluorescent material. In addition to altering the gas pressure to modify the spectral output of arc discharge lamps, the addition of metal halides broadens the output spectrum such that it becomes nearly continuous across the UV spectrum. For example, when mercury arc lamps are operated at high pressures, they have output emission peaks (so-called mercury lines) seen at 297, 302, 313, 334, and 365 nm. In contrast, if a metal halide is added to the mercury, the output between these peaks is increased and is thus more continuous. The use of optical filters can then further refine the output of these lamps such that only the desired wavelengths are emitted. The advantage of metal halide lamps is the high output that allows for shorter treatment times. However, they are costlier and more difficult to operate than fluorescent lamps. One example of a metal halide lamp currently in clinical use is the UVA1 light source.

Fluorescent lamps are the most commonly used sources of therapeutic UVR. These lamps take advantage of the fact that chemicals called phosphors (a specific type of chromophore also called a fluorophore) absorb and then reemit light. The light that is reemitted is of lower energy (and thus longer wavelength) than the inciting light. Using this principle, the ultraviolet C irradiation (which peaks at 254 nm) generated from a low-pressure mercury lamp can be converted to the longer UVB and UVA wavelengths of light that are desirable for phototherapy. The final output of a fluorescent lamp is dictated by the specific phosphor of the bulb. An important advance in photodermatology came with the development of a modified fluorescent lamp that emits largely at 311 nm.[48] Broadband UVB and UVA light sources used for PUVA are other examples of fluorescent lamps.

Because different forms of phototherapy are used to treat different diseases, it is important and practical to divide devices based upon wavelength. Devices that deliver BB-UVB, 311-nm NB-UVB, UVA (for use in psoralen photochemotherapy), and UVA1 (340 to 400 nm) are available in the United States and in most other countries. In addition to differing by spectral output, phototherapy devices range in the surface area that they are designed to treat (whole body, localized regions, or only lesional skin). Devices used for large body surface areas resemble booths, which patients enter for each treatment. These devices come in a variety of styles, from round cylinders to folding units that can be unfolded for treatments and then collapsed while not in use. Devices have been developed to treat more limited areas (such as the palms and soles) and are substantially smaller in size. Finally, targeted therapy uses devices that can deliver therapeutic UVR only to lesional skin range in size from small handheld units to larger devices with a handheld wand attached.

BROADBAND AND NARROWBAND ULTRAVIOLET B

Originally used for psoriasis therapy, artificial sources of BB-UVB have been used therapeutically since the early 20th century. In particular, UVB combined with the topical application of coal tar (as developed initially by William Goeckerman) had been a mainstay of psoriasis treatment for many decades.[49] With the development and availability of NB-UVB, some dermatologists have concluded that BB-UVB is obsolete.[50] However, BB-UVB is still widely used in the United States for a variety of conditions.

The most commonly employed devices that deliver BB-UVB use fluorescent lamps. These devices emit UVR over a broad spectral range. Approximately two-thirds of the output is in the UVB range and the rest is primarily in the UVA. Because wavelengths within the UVB spectrum have higher energy than those within the UVA, the UVA component generally contributes little to the therapeutic efficacy, assuming the patient is not taking a photosensitizing medication. BB-UVB and NB-UVB devices are specifically designed to limit output below 290 nm (ie, in the ultraviolet C range).

The wavelengths that most efficiently clear psoriasis are approximately around 313 nm.[51] In contrast, wavelengths less than 300 nm are the most efficient at causing erythema and nonmelanoma skin cancer. Based on this knowledge, light sources, termed NB-UVB, have been produced.[48] These light sources emit only wavelengths between 308 and 313 nm, and have largely supplanted BB-UVB UV radiation sources for phototherapy. Although originally employed to treat psoriasis, they are now used to treat several other inflammatory skin diseases as well.

The initial starting dose of both BB-UVB and NB-UVB is determined in one of two ways (Tables 198-1 and 198-2). In the first, the minimal erythema dose (MED) is determined by exposing six 1-cm^2 areas of skin on the inner aspect of the forearm or lower back to gradually increasing amounts of UV radiation from the same device that will be used for phototherapy. Twenty-four hours later, the UV-exposed areas of skin are examined and phototherapy is initiated at 50% to 70% of the smallest UV dose that results in uniform erythema over the entire area (ie, the MED). A semiautomated handheld device to determine MED has shown high correlation with the conventional method with low interobserver variability. This may be a faster, more reproducible alternative to conventional MED testing.[52] Alternatively, the initial dose of phototherapy is established empirically based on Fitzpatrick skin phototype (Tables 198-1 and 198-2). Subsequent exposures are given 2 to 5 times per week and the dose is

TABLE 198-1
Narrowband Ultraviolet B Phototherapy

I. MED based
   A. MED determination
      Expose 1-cm^2 areas on the lower back or inner aspect of the forearm to 200, 400, 600, 800, 1000, 1200 mJ/cm^2; read at 24 hours
   B. Initial exposure: 50% to 70% of MED
   C. Subsequent exposures: 2 to 5 times per week
      Increase UV dose by 10% to 20% with each treatment

II. Skin phototype based
   Initial exposure based on Fitzpatrick skin phototype; subsequent exposures as above

SKIN PHOTOTYPE	INITIAL NB-UVB DOSE (MJ/CM^2)	MAXIMUM DOSE (MJ/CM^2)
I	130	2000
II	220	2000
III	260	3000
IV	330	3000
V	350	5000
VI	400	5000

MED, minimal erythema dose; NB-UVB, narrowband ultraviolet B.
Modified from Menter et al[1] and Krutmann et al.[374]

TABLE 198-2
Broadband Ultraviolet B Phototherapy

I. MED based
  A. MED determination
    Expose 1-cm² areas on the lower back or inner aspect of the forearm to 20, 40, 60, 80, 100, 120 mJ/cm²; read at 24 hours
  B. Initial exposure: 50% to 70% of MED
  C. Subsequent exposures: 2 to 5 times per week
    Increase UV dose by 25% with each treatment for the first 10 treatments; 10% per treatment thereafter
II. Skin phototype based
  Initial exposure based on Fitzpatrick skin phototype; subsequent exposures as above

SKIN PHOTOTYPE	INITIAL BB-UVB DOSE (MJ/CM²)
I	20
II	25
III	30
IV	40
V	50
VI	60

MED, minimal erythema dose; BB-UVB, broadband ultraviolet B.
Modified from Menter et al[1] and Krutmann et al.[374]

increased at each treatment, assuming the patient has not developed an erythema response. If an erythema response has occurred, then, depending on its severity, the dose is either reduced or the treatment is delayed (Tables 198-1 and 198-2). Interestingly, NB-UVB is considerably less photoadaptive in comparison to BB-UVB, demonstrating the importance of wavelength on epidermal thickening and need for higher subsequent MEDs when treated with BB-UVB in comparison to NB-UVB.[53] The maximum NB-UVB dose that should be administered is 2000 to 5000 mJ/cm², depending on the photoreactive skin type. If patients miss treatments, dosage modifications should be made to avoid a phototoxic response (see Table 198-5).

PSORALEN AND ULTRAVIOLET A

PUVA photochemotherapy combines the oral ingestion or topical application of psoralens with exposure to UVR in the UVA range. Although psoralens and sunlight had been employed for thousands of years for the treatment of vitiligo, it was not until 1947 that PUVA in its modern form was described, initially for the treatment of vitiligo, and subsequently for the treatment of psoriasis.[54]

Three forms of psoralen are used in photochemotherapy regimens: 8-methoxypsoralen (8-MOP), 5-methoxypsoralen (5-MOP), and 4,5′,8-trimethylpsoralen. In the United States, only 8-MOP is available. There are 2 oral formulations of 8-MOP, a micronized form that is typically given at a dose of 0.6 mg/kg 120 minutes prior to UVA exposure or a dissolved form that is given at a dose of 0.4 to 0.6 mg/kg 90 minutes before UVA exposure. Because the dissolved preparation is absorbed faster and yields higher and more reproducible serum levels, it is more commonly employed in PUVA phototherapy regimens.

The most common sources of radiation for PUVA therapy are UVA fluorescent lamps, which have a maximum emission at 352 nm, near the absorption maximum for psoralens. For oral PUVA therapy, UVA radiation is usually initiated at a dose that corresponds to either the skin phototype or to 50% to 70% of the minimum phototoxic dose (Table 198-3). The minimum phototoxic dose is determined by having the patient take the dose of the oral psoralen to be used for the photochemotherapy treatment and exposing six 1-cm² areas of skin to the gradually increasing doses of UVA. The minimum phototoxic dose is evaluated 72 hours after UVA exposure and is the lowest amount of UVA that produces a uniform erythema over the entire area. In the United States, it is more common to initiate therapy based on the skin phototype (Table 198-3). Treatments are usually given 2 to 4 times per week, avoiding consecutive days. The amount of UVA that is to be given is increased with each treatment. UVA dose modifications are made if an erythema response develops or if treatments are missed (Table 198-3).

Delivery of psoralens in bathwater is popular in some areas of the world because it provides a uniform drug distribution over the skin surface, is associated

TABLE 198-3
Oral Psoralen and Ultraviolet A Photochemotherapy

I. Psoralen dose
  8-MOP micronized 0.6 mg/kg; 120 minutes before UVA
  8-MOP dissolved 0.4-0.6 mg/kg; 90 minutes before UVA
MPD based
  A. MPD determination
    Expose 1 cm² areas on the lower back or inner aspect of the forearm to 0.5, 1, 2, 3, 4, 5 J/cm² UVA; read 72 hours after UVA exposure
  B. Initial exposure: 50% to 70% of MPD
  C. Subsequent exposures: 2 to 4 times per week
    Increase UVA dose per table entries each week (not each exposure)
II. Skin phototype based
  A. Initial exposure based on Fitzpatrick skin phototype; subsequent exposures as above

SKIN PHOTOTYPE	INITIAL PUVA DOSE (J/CM²)	DOSE INCREASES (PER WEEK AFTER THE FIRST WEEK)
I	0.5	0.5
II	1.0	0.5
III	1.5	1.0
IV	2.0	1.0
V	2.5	1.5
VI	3.0	1.5

8-MOP, 8-methoxypsoralen; MPD, minimum phototoxic dose; PUVA, psoralen and ultraviolet A; UVA, ultraviolet A.
Modified from Menter et al[1] and Krutmann et al.[374]

TABLE 198-4
Bath Psoralen and Ultraviolet A Photochemotherapy

I. Psoralen dose
8-MOP dissolved in bath water for a final concentration of 1 mg/L
Bath water is at body temperature (37°C [98.6°F])
Duration of bath is 15 to 20 minutes
II. UVA Exposure
A. MPD Determination
Expose 1-cm² areas on the lower back or inner aspect of the forearm; read 72 hours after UVA exposure
Skin phototype I or II: 0.5, 1, 2, 3, 4, and 5 J/cm² UVA
Skin phototype III or IV: 1, 2, 4, 6, 8, or 10 J/cm² UVA
B. UVA exposure immediately after bathing
C. Initial exposure: 30% of MPD
D. Subsequent exposures: 2 times per week
Increase UVA dose by 20% each week

8-MOP, 8-methoxypsoralen; MPD, minimum phototoxic dose; PUVA, psoralen and ultraviolet A; UVA, ultraviolet A.
Modified from Menter et al[1] and Krutmann et al.[374]

TABLE 198-5
Modification of Phototherapy Dose for Erythema or Missed Sessions

REASON FOR MODIFICATION	MODIFICATION OF DOSE
No erythema	Increase by 25%
Erythema with no pain	No increase
Erythema with pain	Hold treatment until symptoms subside
Erythema with pain and blistering	Hold treatment until symptoms subside and then reduce dose by 50% from last dose
Modification of Phototherapy Dose for Missed Treatments	
<1 week	No increase in dose
1 to 2 weeks	Decrease dose by 50% (BB-UVB) or 25% (NB-UVB or PUVA)
2 to 3 weeks	Decrease dose by 75% (BB-UVB) or 50% (NB-UVB or PUVA)
>3 weeks	Restart at initial exposure dose

BB-UVB, broadband ultraviolet B; NB-UVB, narrowband ultraviolet B; PUVA, psoralen and ultraviolet A.
Modified from Menter et al[1] and Krutmann et al.[374]

with very low psoralen plasma levels, and results in a rapid elimination of free psoralens from the skin. This form of psoralen delivery circumvents GI side effects and possible phototoxic hazards to the eyes that are associated with the oral form. Skin psoralen levels are highly reproducible, and photosensitivity lasts for no more than 2 hours. Bath PUVA consists of 15 to 20 minutes of whole-body immersion in solutions of 1 mg 8-MOP per liter of body temperature bathwater (Table 198-4). 5-MOP and trimethylpsoralen are also employed for bath PUVA. Irradiation is performed immediately after bathing, as photosensitivity decreases rapidly. Bath PUVA is started at 30% of the minimum phototoxic dose. Treatments are typically given twice weekly. Guidelines for bath, local immersion, and other topical PUVA forms have been published by the British Photodermatology Group.[55] A cost-effectiveness analysis of data collected across 4 centers in Scotland revealed that courses of both bath PUVA and other topical PUVA treatments were consistently more expensive than oral PUVA.[55] This is related predominantly to the increased nursing time required.

More recently, cream PUVA has been developed which can be used to treat local and more widespread disease.[55A] Thirty minutes following the application of a psoralen-containing cream, patients are exposed to UVA irradiation.

AVOIDANCE AND MANAGEMENT OF PHOTOTOXIC REACTIONS

Sunburn-like reactions are the most common short-term adverse effect of phototherapy. UVB phototoxicity usually peaks at 12 to 24 hours and PUVA reaction manifests at 24 to 48 or even 72 hours. Severe burns over a large portion of the skin surface produce systemic toxicity with fever and malaise in addition to pain. Severe PUVA burns, which extend well into the dermis, can lead to epidermal sloughing and are an indication for admission to a burn care hospital facility. To avoid exacerbating a still-developing PUVA burn it is recommended that PUVA treatments not be given on consecutive days. Table 198-5 specifies the UVB or UVA dose adjustments in the event of a burn reaction during phototherapy. A burn reported by the patient at the next visit, even if no longer visible, should be managed in the same manner as a still-visible reaction. Burns over limited body areas, such as just the face or breasts, can be managed by local application of an appropriate sunscreen before or part way through subsequent treatments, especially if the area is not affected by the disease being treated. However, care must be taken to consistently protect the same area(s) to avoid a sudden full treatment to previously shielded skin.

Repeated UV-irradiated skin develops tolerance to subsequent exposures, allowing and, indeed, mandating progressively larger doses for optimal therapeutic effect. However, this tolerance is rapidly lost when exposures cease, requiring downward adjustments of dose after as little as 1 week (see Table 198-5) to avoid burns.

ULTRAVIOLET A1

Because of its longer wavelength, UVA1 phototherapy (340 to 400 nm) can penetrate deeper into the skin than UVB or shorter-range UVA called UVA2

(ie, 320 to 340 nm). The first report describing a device capable of emitting UVA1 occurred in 1981.[56] It was not until 1992 when the therapeutic benefit of UVA1 was demonstrated for atopic dermatitis that greater interest in its therapeutic properties occurred.[57,58] Initially, one obstacle to the widespread use of first-generation UVA1 devices was the intense heat that they produced. Although not widely available in the United States, these light sources are useful for the management of a variety of dermatologic conditions for which other forms of phototherapy are not helpful.[59,60]

UVA1 is administered 3 to 5 times per week. Three dosing regimens have been used: low dose (10 to 30 J/cm^2), medium dose (40 to 70 J/cm^2), and high dose (130 J/cm^2). In general, patients are started at 20 to 30 J/cm^2 and increased to the full dose within 3 to 5 treatments. The risk of burns is far less than with UVB or PUVA therapy.

TARGETED PHOTOTHERAPY

Targeted phototherapy is also called focused phototherapy, concentrated phototherapy, and microphototherapy. Unlike the previously described phototherapy devices that expose both lesional and uninvolved skin to UVR, targeted phototherapy delivers therapeutic doses of UVR only to lesional skin. Several devices are available to deliver targeted phototherapy, including both monochromatic (1 wavelength) and polychromatic systems. As of this writing, there is also a new therapeutic device in development that provides digital UV phototherapy that can be used to institute either targeted UVA or UVB therapy.[47] There are several advantages to targeted phototherapy. These devices spare normal skin, thereby allowing higher fluences to be delivered to diseased skin while decreasing the risk of acute and chronic side effects to normal skin. Targeted therapy can be used on treatment-resistant lesions and in difficult anatomic locations (such as the scalp, chin, and nails). The handheld nature of a targeted phototherapy device may have increased feasibility for young children compared to receiving treatments in a phototherapy booth that can be large and intimidating. The limitations of targeted phototherapy are device expense and that it may not be practical to treat for patients with greater than 10% to 20% body surface area involvement.

Targeted phototherapy devices have been used to administer targeted therapy to patients with psoriasis, vitiligo, and cutaneous T-cell lymphoma.[61,62] Monochromatic light sources, which include excimer lasers, monochromatic UVA1 lasers,[63] and nonlaser devices known as monochromatic excimer light devices, have been developed for this purpose. They differ in several respects. Lasers typically treat smaller areas, but can emit higher amounts of radiation over a shorter period. In contrast, monochromatic excimer light devices deliver monochromatic irradiation to a larger area but with a lower power density. There are also several devices that emit polychromatic UVA or UVB (BB-UVB or NB-UVB) to targeted areas. These devices typically use fiberoptic systems coupled with UVB-generating sources. They have spot sizes from 1 to 3 cm. In addition, these devices have multiple delivery programs and automatic calibration which makes treatment with predetermined dosages possible. These devices are smaller, less expensive, and have fewer maintenance problems than lasers.[64,65] Treatment protocols with targeted phototherapy vary depending on the type of device that is employed. A novel cream that selectively filters solar UVB may be a cheaper and more convenient alternative to traditional phototherapy in certain cases. This cream has been shown to improve symptoms of chronic pruritus after 3 months of treatment (3 sessions per week).[66]

SAFETY OF PHOTOTHERAPY

Safety principles are common to most phototherapy devices. Equipment should be checked on a regular basis by the clinical staff or the manufacturer's engineer, since bulb output may change over time and internal dosimetry components may fail. While phototherapy is usually delivered without incident, the risk of overtreatment is real, although the exact incidence of adverse events attributable to phototherapy is unknown and varies depending on the device. Importantly, except for PUVA therapy for which formal long-term followup studies established an increased risk of lentigines, squamous cell carcinoma, and possibly melanoma, other forms of phototherapy appear to be remarkably safe.[62,67] Newer therapies, such as NB-UVB and UVA1 appear to be relatively safe especially compared to nonphototherapeutic options for the same diseases.

ULTRAVIOLET B

Repeated exposure of the skin to UV irradiation does result in cumulative actinic damage regardless of the source. With respect to nonmelanoma skin cancer, most studies show that there is little risk beyond that associated with habitual sun exposure with either BB-UVB or NB-UVB phototherapy.[68,69] More than 300 BB-UVB treatments is associated with a modest, but significant, increase in squamous cell carcinoma (SCC) and basal cell carcinoma.[70] However, the carcinogenic risk of a single PUVA treatment is approximately 7 times greater than a single UVB treatment.[71] As a result of its safety profile and efficacy, NB-UVB has emerged as a leading therapy for a number of skin diseases. Several studies also show that long-term exposure to BB-UVB combined with topical tar preparations is not associated with an increased risk of SCC.[72]

PSORALEN AND ULTRAVIOLET A

ACUTE SIDE EFFECTS

Potential side effects of PUVA include drug intolerance in addition to the adverse reactions resulting from the combined action of psoralens plus UVA radiation. Oral 8-MOP may cause nausea (10% of patients) and vomiting, which occasionally necessitates discontinuation of treatment. These side effects are more common with liquid preparations than with crystalline preparations, probably because of higher psoralen serum levels. The nausea may be minimized or avoided by instructing the patient to take 8-MOP with milk, food, or ginger, or to divide the dose into 2 portions, taken approximately 30 minutes apart. Other reported effects include nervousness, insomnia, and depression. With 5-MOP, nausea is rare, even with doses up to 1.8 mg/kg/body weight.

Following exposure to UVA, approximately 10% of patients undergoing PUVA therapy will experience pruritus. In most cases, this can be alleviated by bland emollients. Some patients with severe pruritus require systemic treatment. A stinging pain may rarely occur; the mechanism for this is unknown. These symptoms are usually unresponsive to antihistamines, and, in most instances, subside when the treatment is discontinued.

Mild and often transient focal erythema after PUVA therapy occurs frequently. Any area showing erythema with tenderness or blistering should be shielded during subsequent UVA exposures until the erythema has resolved. As noted above, erythema appearing within 24 hours may signal a potentially severe phototoxic reaction, and may worsen progressively over the next 24 hours, as peak erythema with PUVA characteristically occurs at least 48 hours after the treatment. In that situation, patients should be protected from further UVA exposures and sunlight, and should be monitored closely until the erythema has resolved.

Very rare side effects of PUVA include polymorphous light eruption-like rashes, acneiform eruptions, subungual hemorrhages caused by phototoxic reactions of the nail beds, onycholysis, and occasionally hypertrichosis of the face. These disappear when treatment is discontinued. Analysis of laboratory data in several large studies revealed no significant abnormal findings in patients receiving PUVA over prolonged periods of time.[73-75]

CHRONIC ACTINIC DAMAGE

Chronic exposure to PUVA may result in skin changes that resemble photoaging, which is aggravated by chronic natural sun exposure. PUVA lentigines are small brown macules with irregular borders and uneven pigmentation[76] and are histologically characterized by proliferation of large melanocytes.[77] In contrast to solar lentigines, melanocytes in PUVA lentigines often display an increased size of melanosomes, clustering and binucleation with nuclear hyperchromatism, and cellular pleomorphism. BRAF (v-raf murine sarcoma viral oncogene homolog B) mutations have been found to be present in PUVA lentigines,[78] but the full significance of this is not yet understood, as both cutaneous malignant melanoma and benign melanocytic nevi often have BRAF mutations.[79-82] The presence of these lesions is directly related to the number of PUVA treatments and total UVA dose that has been administered. The absence of PUVA lentigines serves as a useful indicator of a lower risk of PUVA malignancy.[83]

CARCINOGENESIS

Cutaneous malignancies are the major concern of long-term and repeated PUVA treatments. The risk of nonmelanoma skin cancer and possibly malignant melanoma increases in a dose-dependent manner. In laboratory animals, 8-MOP and 5-MOP have unequivocally induced skin cancer at levels of drug and UVA irradiation comparable to those used in PUVA therapy.[84] Cancer development is thought to stem from both DNA damage and downregulation of the immune system. The PUVA Follow-up Study, which evaluated 1380 patients who began PUVA treatment for psoriasis in 1975 and 1976 has documented major health events in these individuals in a prospective manner. Overall, patients who were treated with at least 337 PUVA treatments exhibited a 100-fold increased risk of SCC compared to that expected from population incidence rates.[85] Moreover, almost 4% of patients with SCC developed metastases, most commonly originating in the genital area. There is uncertainty about PUVA being the sole factor as many of the patients in the long-term followup studies also had significant exposure to sunlight and to treatments with carcinogenic potential, including arsenic, UVB, and methotrexate. The risk of developing SCC with PUVA may be further potentiated by the use of cyclosporine and for this reason cyclosporine is contraindicated in individuals who have been treated with PUVA.[86] Oral retinoids used concurrently with PUVA, on the other hand, reduce the risk of SCC.[87]

Individuals treated with PUVA are at increased risk of cutaneous malignancies of the genitalia, and this has led to standard protection of the genitalia during phototherapy.[88] The risk is dose-dependent, with a 90-fold increased risk of genital tumors among patients exposed to high doses of PUVA compared with that expected in the general population. Men treated with high-dose exposures to both PUVA and topical tar/UVB have the greatest risk of genital tumors.[88,89] There is currently no standardized regimen for genital shielding. Commonly used protective agents include commercially available pouches for genital shielding, surgical masks, paper towels, blue surgical towels, and underwear. The efficacy of these materials has been studied, and surgical masks were found to provide insufficient protection against UV irradiation, most likely because of increased porosity (looser weave) and decreased mass.[90]

The relationship between PUVA and melanoma also has been examined in detail. The PUVA Follow-Up Study has provided evidence that individuals with at least 250 treatments and at least 15 years from the first PUVA treatment were at increased risk of developing melanoma.[91] Patients who developed a phototoxic reaction more easily were at higher risk for melanoma than those with darker skin.[92] As a result of those studies, a personal or family history of melanoma or a history of more than 200 PUVA treatments is considered to be a relative contraindication to further PUVA therapy.[92]

In patients employing PUVA therapy in combination with methotrexate for at least 36 months, the incidence of lymphoma was more than 7 times higher than that of cohort members earlier in the study who had not taken methotrexate.[93]

OPHTHALMOLOGIC EFFECTS

UVA is absorbed in the lens and in the presence of UVA, psoralens can bind protein, DNA, and RNA. Because the lens never sheds its cells, protein-bound 8-MOP accumulates in the lens, increasing the risk of irreversible opacification.[94] There have been reports of various ocular problems in patients on PUVA including cataracts,[95,96] conjunctival hyperemia,[97] and decreased lacrimation.[97]

A 25-year prospective study[98] sought to evaluate the effect of PUVA on the eyes. Participants were instructed to use UVA-blocking eyewear when outside or looking outside through window glass during daylight for a minimum of 12 hours, although current labeling calls for 24 hours of eye protection. This study found no relationship between increasing numbers of PUVA sessions and visual impairment or cataracts, and demonstrates that increasing exposure to PUVA does not increase cataract risk among middle-aged and older persons using eye protection as practiced by this cohort.[98] Other smaller studies also have found no increase in cataract formation or visual impairment.[99-102]

ULTRAVIOLET A1

UVA1 phototherapy is generally well tolerated.[103,104] Reported side effects include intense tanning, erythema, pruritus, urticaria, tenderness, a burning sensation, polymorphous light eruption, eczema herpeticum, and bacterial superinfection.[59,60,105] However, because UVA1 phototherapy has only been available since the 1990s', the long-term effects are still under investigation.

SPECIAL CONSIDERATIONS

HIV

The safety of phototherapy and photochemotherapy in HIV-positive patients has been debated. UVR may activate HIV by the induction of nuclear factor κB,[106-108] and UVB therapy increases HIV-1 gene expression in the skin.[109-111] However, BB-UVB phototherapy does not appear to affect plasma HIV levels nor does it have an effect on CD4 counts.[110,112,113] In general, phototherapy is thought to be safe for HIV patients.[114] A consensus statement published by the American Academy of Dermatology in 2010 concluded that for moderate to severe psoriasis in HIV-positive patients, phototherapy and antiretrovirals are the recommended first-line therapeutic agents.[115]

CHILDREN

NB-UVB is now preferred to PUVA in children for most skin conditions, because of concern about PUVA side effects, including phototoxicity, carcinogenicity, photoaging, and the potential development of cataracts.

PREGNANCY

NB-UVB in a high mean cumulative dose (>118.16 J/cm^2 in 36 treatments) and BB-UVB (110 to 220 mJ/cm^2 in 7 to 22 treatments) can cause a proportionate decrease in serum folic acid levels. Although there are no specific guidelines, dermatologists should consider measuring folic acid levels intermittently, especially during the first trimester.[116-118]

ELDERLY

Phototherapy should be considered in patients older than 65 years of age if there are no physical and cognitive disabilities impairing use of phototherapy. However, it is important to be aware that UVB-induced erythema lasts longer and peaks later in the elderly.[119] Also, photoadaptation may be decreased in the elderly secondary to decreased epidermal turnover, melanocyte number, and tanning response. Hence, it is important to consider initiating phototherapy at a lower dose and increasing dose levels more slowly to limit the number of phototoxic events.[120]

MISCELLANEOUS

Patients who have had arsenic exposure are at increased risk for cutaneous malignancies and should avoid phototherapy. Transplantation patients have a much higher risk of skin cancer compared to the general population because of the medications they are taking to prevent rejection of their transplanted organ. Consequently, there is a relative contraindication to phototherapy in transplantation patients. Photosensitizing medications should theoretically be avoided during phototherapy treatment, although in practice many patients receive phototherapy while taking tetracycline, hydrochlorothiazide, or other photosensitizing drugs without adverse consequences. There are reports of an association between chronic use of voriconazole and the development of aggressive cutaneous malignancies, including melanoma.[121-123]

TABLE 198-6
Diseases Amenable to Phototherapy

	NB-UVB/ BB-UVB	PUVA	UVA1
Aquagenic pruritus	–	+	–
Atopic dermatitis	+	+	+ (acute flares)
Cholestatic pruritus	+	–	–
Chronic graft-versus-host disease	+	+	+
Chronic hand eczema	+	+	+
Chronic urticaria	+	+/–	+/–
Cutaneous T-cell lymphoma	+	+	+
Granuloma annulare	–	+	+
Indolent systemic mastocytosis	+	+	–
Lichen planus	+	+	–
Localized and systemic scleroderma	–	+	+
Lymphomatoid papulosis	–	+	+
Perforating disorders	+	+	–
Photodermatoses	+	+	–
Pityriasis lichenoides	+	+	–
Pruritus of chronic renal failure	+	–	–
Pruritus of polycythemia vera	+	+	–
Psoriasis	+	+	–
Telangiectasis macularis eruptiva perstans	–	+	+
Urticaria pigmentosa	–	+/–	+
Vitiligo	NB-UVB	+	–

BB-UVB, broadband ultraviolet B; NB-UVB, narrowband ultraviolet B; PUVA, psoralen and ultraviolet A; UVA, ultraviolet A.

DISEASES AMENABLE TO PHOTOTHERAPY

Table 198-6 summarizes the diseases amenable to phototherapy.

PHOTOTHERAPY OF PSORIASIS

BROADBAND AND NARROWBAND ULTRAVIOLET B

Both BB-UVB and NB-UVB have been employed to treat psoriasis. Their presumptive mechanisms of action in this disease include its effects on DNA, antimicrobial actions that may alter the microbial flora of the skin,[124] induction of anti-inflammatory and immunosuppressive cytokines,[125-127] augmentation of vitamin D levels,[128,129] alterations in antimicrobial peptides,[129] modulation of vascular endothelial growth factor expression,[130] restoration of Th17/Treg imbalance as well as function,[131] suppression of Type I interferon signaling,[132] a reduction in C-reactive protein,[133] and decrease in serum plasmin.[134]

Clinical trials[48] supporting the research findings[51] that wavelengths in the range of 313 nm are most effective at clearing psoriasis have led to broad use of NB-UVB for psoriasis (Fig. 198-3). NB-UVB has thus become first-line therapy for chronic plaque psoriasis, and is considered to be superior to conventional BB-UVB with respect to both clearing and remission times.[48,135] The difference in efficacy may be related to more efficient clearing of T cells by NB-UVB from the epidermis and dermis of psoriatic plaques compared with conventional BB-UVB.[29] The end point of phototherapy is complete clearance of all psoriatic skin lesions. Psoriasis, however, is a chronic disease and the remission induced by UVB phototherapy is often short-lived. In a randomized, prospective, multicentered trial, investigators found that continuing UVB phototherapy, after initial clearing, contributes to control of the disease and is justified for many patients.[136] The frequency of UVB treatments is reduced while maintaining the last dose given at the time of clearing. NB-UVB can be used safely in pregnancy and in children.

Other agents (topical and oral) combined with UVB phototherapy may clear psoriatic skin lesions in a shorter period of time. Combined therapies may thus allow for fewer treatments and potentially less photoaging and fewer other risks. Often combination regimens are administered when phototherapy alone is no longer effective. Oral retinoids, such as acitretin,[137] increase efficacy, particularly in patients with chronic plaque-type psoriasis.[138-140] Addition of oral acitretin to either NB-UVB or the Goeckerman regimen (see next paragraph) reduces the total number of treatments necessary.[141] Although fewer sessions may be required with combination therapy, the rate of relapse may be slightly higher. Methotrexate (15 mg/week) administered 3 weeks before starting NB-UVB can also enable quicker results in fewer phototherapy sessions.[142] Biologic therapies are being evaluated in conjunction with phototherapy. Treatment with NB-UVB significantly accelerated the clearance of psoriatic lesions in patients responding slowly to etanercept.[143]

BB-UVB and NB-UVB phototherapy can be combined with topical agents to achieve higher clearance rates, longer disease-free intervals, and a lower risk of side effects. The Goeckerman regimen consists of the application of tar-containing topical agents with subsequent UV irradiation. The use of liquid carbonis detergens with NB-UVB is one example of a modified form of this regimen. The regimen is safe, convenient, effective, and leads to a more rapid improvement of psoriasis than light therapy alone.[144] The antipsoriatic vitamin D analogs calcipotriol and calcitriol, used in conjunction

Figure 198-3 **A,** Psoriasis prior to narrowband ultraviolet B (NB-UVB) phototherapy. **B,** At the completion of NB-UVB therapy. (Photos used with permission from Herbert Hönigsmann, MD.)

with NB-UVB, provide additional benefit compared to either the drugs or the phototherapy alone.[145-150] Application of calcipotriol prior to phototherapy leads to unwanted degradation of vitamin D_3, and calcipotriene increases the MED in patients, suggesting that it has a photoprotective effect.[151] For these reasons, when used in combination with phototherapy, vitamin D analogs must be applied after the light treatment. Tazarotene 0.1% gel has an additive or synergistic effect when combined with NB-UVB.[152] Because retinoids can cause photosensitivity, it is common practice to initiate phototherapy at 50% to 75% of the usual starting dose when tazarotene is used with UVB.[153] Topical bexarotene gel 1% also has been combined with NB-UVB for the treatment of psoriasis and has greater efficacy than either alone.[154] By decreasing scatter from scales in the stratum corneum, lubricants improve transmission of UVB, and a combination of topical lubricants with UVB therapy increases efficacy.[155-157] The use of topical salicylic acid with UVB has not been found to increase the efficacy of UVB phototherapy because it blocks UVB penetration.[157A]

TARGETED PHOTOTHERAPY

Targeted phototherapy using a monochromatic 308-nm excimer laser or monochromatic excimer light is effective and safe for psoriasis. A large, multicenter study found that fewer patient visits were required with targeted phototherapy compared to conventional phototherapy.[158] The use of monochromatic excimer compared to cream PUVA has been found to have equivalent efficacy for palmoplantar psoriasis.[159] Calculating the dose that induces blistering on a psoriatic plaque and treating the plaques at just below that dose can lead to clearance in significantly fewer sessions.[160]

PSORALEN AND ULTRAVIOLET A PHOTOCHEMOTHERAPY

Oral PUVA has consistently induced remission of psoriasis in clinical studies.[73,161,162] At least a 75% improvement in the Psoriasis Area and Severity Index score can be expected after 12 weeks of PUVA treatments in 60% of patients.[161] In some studies, oral PUVA has been observed to be more efficacious in clearing plaque psoriasis than NB-UVB, and the duration of remission is more prolonged,[162] whereas other studies have found the 2 treatments to be comparable, particularly when NB-UVB is administered 3 times per week.[163-166] It must be noted here that unlike drug administration, the success of PUVA and phototherapy generally depends in large part on physician-determined patient-specific subtle modifications of the regimen, such as dose increments between treatments, that optimize therapeutic response while avoiding burns or other adverse

effects. Hence, the response to phototherapy may vary greatly among studies and among practitioners. Additionally, polymorphisms in genes encoding glutathione *S*-transferases are associated with PUVA sensitivity and these may have implications for treatment response.[167]

Repeated exposures are required to clear PUVA-responsive diseases, with gradual increments in dose as pigmentation and epidermal thickness increase. Upon clearing, patients are often transitioned to maintenance therapy, during which the frequency of treatments is gradually reduced. There are various maintenance algorithms. One regimen consists of 1 month of twice-weekly treatments, at the last UVA dose used for clearing, followed by another month of once-weekly exposures.

A combination of PUVA and methotrexate can reduce the duration of treatment, number of exposures, and total UVA dose required for clearing. It is also effective in clearing patients unresponsive to PUVA alone.[168] This combination appears to be safe if used during the clearing phase. However, long-term methotrexate, defined as 36 or more months of use, in combination with PUVA may increase the risk of lymphoma.[93]

The combination of cyclosporine with PUVA is not recommended because of the greatly increased risk of squamous cell carincoma.[86] There are no published clinical trials combining PUVA with biologic agents.

PUVA therapy is more efficacious when combined with a daily oral retinoid (etretinate, acitretin, isotretinoin; 1 mg/kg), a treatment regimen that has been referred to as RePUVA. The addition of an oral retinoid can bring patients into remission, even if they have not responded to PUVA alone.[169] The oral retinoid is typically administered 5 to 10 days before initiating PUVA, and is continued throughout the clearing phase. RePUVA can often reduce the number of PUVA exposures by one-third and the total cumulative UVA dose by more than one-half. Oral retinoids when combined with PUVA have been shown to reduce the risk of SCC by 30%, although it does not alter the incidence of basal cell carcinoma.[87] The mechanism of the synergistic action of retinoids and PUVA is unknown, but has been postulated to result in part from accelerated desquamation that optimizes the optical properties of the skin.

Topical tazarotene gel 0.1% combined with oral PUVA accelerates the response to treatment.[170] This may decrease exposure to UVA and thus the long-term hazards associated with PUVA therapy. Because of the photosensitizing effect to tazarotene, it is recommended that PUVA therapy be initiated at slightly lower doses than usual.[153] Topical tazarotene plus PUVA bath therapy is also clinically and statistically superior to vehicle plus PUVA bath therapy.[171]

The application of salicylic acid in petrolatum just before PUVA therapy is not recommended as it may hinder the penetration of UVA.[172] When calcipotriol is used with PUVA, it should not be applied within 2 hours of phototherapy.

TOPICAL AND BATH PSORALEN AND ULTRAVIOLET A FOR PSORIASIS

Application of 8-MOP in creams, ointments. or lotions followed by UVA irradiation is effective in clearing psoriasis, but may result in nonuniform distribution on the skin surface. This may induce unpredictable phototoxic erythema reactions and irregular patches of cosmetically unacceptable hyperpigmentation. Furthermore, the application of the medication is potentially labor intensive. For these reasons, topical psoralens are used most commonly in psoriasis for limited plaque psoriasis and palmoplantar disease.

PHOTOSENSITIVE PSORIASIS

Interestingly, UVA and UVB are both capable of triggering or aggravating psoriatic plaques in predisposed patients. This phenomenon appears to be linked to certain genetic traits, female gender and susceptibility to photosensitive disorders such as polymorphous light eruption. In predisposed individuals, there is a tendency toward creating a microenvironment that is inflammatory rather than immunosuppressive upon exposure to UVR, resulting in worsening of psoriatic disease.[173] However, even though there are anecdotal reports of developing polymorphous light eruption secondary to NB-UVB treatment for psoriasis, NB-UVB can still be a viable treatment option in these patients. The strategy is to temporarily discontinue phototherapy until the lesions resolve and to restart at a much lower NB-UVB dose. NB-UVB should be increased slowly, which allows for treatment of psoriatic plaques with simultaneous photohardening that leads to resolution of polymorphous light eruption.[174]

PHOTOTHERAPY OF ATOPIC DERMATITIS

NARROWBAND ULTRAVIOLET B

Studies evaluating NB-UVB as a treatment for severe atopic dermatitis have shown that it improves severity scores, reduces potent topical steroid use, and provides a long-term benefit for most patients.[175-178] Compared with bath PUVA, using half-body UVB versus UVA comparisons, NB-UVB and bath PUVA are both highly effective. Most patients, however, prefer NB-UVB. Relief of pruritus usually occurs in the first

2 weeks, prior to visible resolution of the cutaneous lesions.[179] Additionally, improvements can be maintained months after phototherapy is stopped. NB-UVB can also be used sequentially following cyclosporine, to avoid relapse of disease.[180]

There is little information regarding the use of NB-UVB in children, and long-term data on the safety of this therapy are still needed. However, those studies that have examined NB-UVB for atopic dermatitis and other skin diseases in children have found that it is well-tolerated and produces excellent responses with no serious side effects.[181-185] When side effects are mentioned, erythema is the most common[182]; other adverse reactions, such as herpes simplex reactivation, are rarely reported.[183] In some cases, UVA combined with NB-UVB appears to provide added benefit.[186]

Long-term studies in animal models evaluating the carcinogenic potential of tacrolimus (0.03% and 0.1%) and pimecrolimus 1% did not find an increase in the incidence of UV-induced skin tumor growth.[187] There are no studies evaluating the safety or efficacy of combined phototherapy with topical calcineurin inhibitors for atopic dermatitis in humans.

EXCIMER LASER AND ATOPIC DERMATITIS

The 308-nm xenon-chloride monochromatic excimer light has been evaluated in localized atopic dermatitis and has been shown to be efficacious in reducing its severity, and in diminishing its pruritus with lasting results.[70,188-190] In extensive atopic dermatitis, this treatment is impractical, but it is particularly useful for atopic dermatitis involving the hands,[70] and in situations in which there is an interest in limiting the use of topical steroids.

PSORALEN AND ULTRAVIOLET A

Oral PUVA is highly effective for the treatment of atopic dermatitis.[191-194] In contrast to psoriasis, the number of treatments required for clearance of atopic dermatitis may be relatively high. Additionally, a rebound effect may occur in a high percentage of patients if the phototherapy is not combined with other therapies or if maintenance therapy is not instituted.[191] Bath PUVA is also used for atopic dermatitis, primarily in Europe, and is a very effective treatment.[195-197]

ULTRAVIOLET A1

UVA1 phototherapy is a highly effective, nonsteroidal, therapeutic alternative for treatment of acute exacerbations of atopic dermatitis and is almost devoid of uncomfortable side effects.[57,103,105,198] Doses of UVA1 (60 to 130 J/cm^2 per day) over a 3-week period reduce the clinical severity of atopic dermatitis. However, effectiveness is short term and is followed by recurrence of symptoms in a majority of patients.[104,199] In one study, NB-UVB provided a greater therapeutic effect than UVA1 for chronic atopic dermatitis.[200]

PHOTOTHERAPY OF CUTANEOUS T-CELL LYMPHOMA

PSORALEN AND ULTRAVIOLET A

PUVA photochemotherapy has been a successful therapeutic option for cutaneous T-cell lymphoma (CTCL) since the 1970s'.[201,202] Complete clearing may be induced when malignant cells are confined to the epidermis and the superficial dermis, within the depth of UVA penetration. For the clearing phase, treatment schedules and dosimetry are essentially the same as for psoriasis. The treatment consists of 3 phases: a clearing phase, a maintenance phase, and monitoring off therapy. Maintenance therapy is not standardized; patients benefit most from individualized schedules.[203] Therapy is discontinued after a variable period of time and patients are monitored. Relapses tend to respond as well as initially when PUVA is resumed. Patients with tumor-stage CTCL (IIB or greater) exhibit a high rate of early recurrences, which require permanent maintenance treatment. In these cases, PUVA typically is combined with other modalities to produce complete responses. Prolonged remissions have been observed with combinations of PUVA and interferon-α2a[204] or low-dose interferon-α2b.[205] In later stages of CTCL, PUVA has been employed as a palliative treatment, reducing the tumor-cell burden and acting synergistically with other treatments.[202] For example, there has been success combining PUVA and oral bexarotene for the treatment of advanced CTCL (Sézary syndrome).[206]

Bathwater PUVA therapy with 8-MOP is a valuable phototherapeutic alternative, which can be considered for patients in whom systemic psoralen cannot be used. Excellent responses have been reported in patients with early stage mycosis fungoides[207] and in children.[208] There is also evidence of efficacy in patients with superficial folliculotropic mycosis fungoides.[209] Cream PUVA with 8-MOP as a form of targeted UV therapy can be considered in patients with high risk of skin cancer.[46]

NARROWBAND ULTRAVIOLET B

NB-UVB may be as effective as PUVA for early stage CTCL.[210-218] Some authors advocate starting with NB-UVB because of its more favorable safety and side-effect profile.[211] Clinical remissions are reported to last for 3[216] to 24.5[211] months; maintenance therapy tends to prolong remission.[217] NB-UVB also has been used successfully in conjunction with oral bexarotene.[219]

PHOTOTHERAPY OF VITILIGO

PUVA and NB-UVB are two of the leading treatments for vitiligo. NB-UVB decreases IL-17 and IL-22 levels that are usually elevated in vitiligo and also increases FoxP3-expressing cells, restoring the balance between Th17 and regulatory T cells.[220] It also appears to restore the balance of oxidant and antioxidants relieving oxidative stress that is considered to play a role in the pathogenesis of vitiligo.[221] When employed for vitiligo, NB-UVB is typically administered 3 times per week.[222] The earliest sign of response to therapy is perifollicular repigmentation. Cosmetically acceptable treatment success, defined as greater than or equal to 75% repigmentation, has been achieved in 12.5%[223] to more than 75%[224,225] of patients. Factors that predict how a patient will respond to NB-UVB include ethnic background, skin phototype, the areas treated,[224-230] and the type of vitiligo.[228] There does not appear to be an association between response to treatment and patients' sex, age, family history of vitiligo, or the extent of body surface involvement.[229-231] Patients who show early initial repigmentation are more likely to have a higher percentage of final repigmentation.[223,229] In individuals with Fitzpatrick skin types IV and V, vitiliginous areas have been noted to repigment slightly darker than the surrounding skin. This resolves after a few months, resulting in a cosmetically acceptable outcome.[222,229] Although data is somewhat limited, relapse rates may be anywhere from 25% to 84% after 1 year.[229,232,233] Those who relapse tend to respond to another course of phototherapy.

When NB-UVB is used in combination with topical tacrolimus 0.3% ointment, the therapeutic efficacy is higher than with NB-UVB alone.[234] This synergistic effect is mediated through upregulation of MMP-2 and MMP-9 resulting in enhanced melanocyte migration.[235] However, combination therapy is not effective in typical UV therapy–resistant sites such as the hands and feet.[236] Pseudocatalase cream has been used in conjunction with NB-UVB. Whether pseudocatalase increases the efficacy of NB-UVB is controversial.[237-239] In difficult-to-treat areas, laser dermabrasion in combination with topical steroids and NB-UVB twice weekly has been significantly more effective than just topical steroids and NB-UVB. Despite significant improvement in repigmentation rates, the procedure is poorly tolerated because of pain and there are risks of delayed wound healing and hypertrophic scarring.[240] A novel approach using afamelanotide, an analog of melanocyte-stimulating hormone, combined with NB-UVB has shown significant improvement compared to NB-UVB monotherapy especially in patients with Fitzpatrick skin types IV through VI.[236]

Targeted phototherapy with a 308-nm excimer laser also is reported to be effective in vitiligo and should be considered first-line therapy in localized vitiligo.[241-245] Sessions are performed 2 to 3 times weekly, with the ultimate rate of repigmentation dependent on the total number of sessions rather than the frequency.[246,247] The treatments are well-tolerated and side effects are minimal. Excimer laser achieved the same grade of repigmentation as NB-UVB, but at a lower total cumulative dose.[248] Because the laser is monochromatic, it can deliver higher energy exclusively to the affected areas while minimizing side effects. Similar to standard NB-UVB therapy, lesions on the face, neck, and trunk respond better than those on the extremities. The hands and feet have the least-favorable outcome.[241,244,249-252] Combining a topical antioxidant gel with the excimer laser appears to have higher efficacy in terms of repigmentation than excimer laser alone.[253] Monochromatic excimer light also is effective in patients with vitiligo, even if they have not previously responded to NB-UVB.[61]

Although PUVA was first used for vitiligo, it is used less often for that indication since the introduction of NB-UVB. Responses have been achieved in up to 70% of patients.[254] Combination therapy of PUVA and a medium-potency topical corticosteroid is 3 times more effective than either treatment alone.[255] In contrast to NB-UVB and PUVA, UVA1 does not cause repigmentation and only accentuates the difference in color between normal and vitiliginous areas by tanning the normal skin.

SCLEROTIC SKIN DISEASES

LOCALIZED AND SYSTEMIC SCLERODERMA

UVA1 has been reported to decrease lesional skin thickness, improve skin elasticity, reduce sclerotic plaques, and increase passive range of motion in localized scleroderma.[256-258] There have been varying opinions as to the best dose and treatment regimen.[259-261] In most studies, UVA1 has been administered at a dose of 60 to 130 J/cm^2 5 times per week, although lower doses (20 J/cm^2) also have been reported to be effective. When doses of 20 J/cm^2 and 70 J/cm^2 were compared, the higher dose caused greater improvement.[259] However, when 130 J/cm^2 was administered 3 times per week, the tanning response produced by the UVA1 treatments interfered with its ability to soften the sclerodermatous patches, implying that medium dose and less-frequent treatments would be more effective.[261] The recurrence after successful UVA1 treatment was dependent on the duration of morphea prior to treatment rather than morphea subtypes, Fitzpatrick skin type, or medium-to-high-dose regimens implying that a medium-high dose of UVA1 is adequate in terms of prevention of recurrence.[262]

The mechanism of action is at least partly through induction of MMP-1,[263] and downregulation transforming growth factor-β through the SMAD (Sma- and Mad-related protein) signaling pathway.[264-266] UVA1 downregulates human beta-defensin, IL-6, and IL-8, which correlates with clinical improvement.[267]

UVA1 also has been used to treat acrosclerosis in patients with systemic scleroderma.[268] Marked improvement was noted with softening of affected skin and increased finger movement. It also improved microstomia.[269] Oral and topical PUVA also have been used for this disease, with improvement in range of motion and contractures.[270] Oral PUVA has been used to treat disabling, extensive morphea in children.[271-274]

GRAFT-VERSUS-HOST DISEASE

In chronic graft-versus-host disease, NB-UVB has been employed as a second-line treatment in children[275] and adults[276] who are resistant to or have relapsed on standard immunosuppressive regimens. Oral PUVA,[277-281] topical PUVA,[282,283] and UVA1[284-286] also have been employed. Bath PUVA in combination with isotretinoin is another option for sclerodermoid graft-versus-host disease.[287] If phototherapy is to be employed for these patients, it is important to examine the patients regularly, as they already have an increased risk of skin cancer from their immunosuppressive therapies. There are anecdotal reports of successful treatment of sclerotic graft-versus-host disease with NB-UVB treatment.[288]

OTHER SCLEROTIC SKIN DISEASES

UVA1 has led to modest improvement in the degree of induration, and, at times, in mobility of the hands and legs in nephrogenic systemic fibrosis.[121,289] Total treatments have ranged from 22 treatments (with a cumulative dose of 1855 J/cm^2) to 50 treatments (3850 J/cm^2). There are also anecdotal reports of its use in scleredema, vulvar lichen sclerosis and stiff skin syndrome, as well as radiation-induced morphea.[60]

PRURITUS

UVB phototherapy is an option for the pruritus associated with chronic renal failure. Approximately 80% to 90% of patients improve within 2 to 5 weeks.[290-292] If symptoms recur, they commonly respond to retreatment with UVB. For this disorder, phototherapy works on a systemic level rather than locally, because BB-UVB exposure to one-half of the body improves pruritus in both the exposed and unexposed sites.[291] Some patients respond well to BB-UVB, but are less responsive to NB-UVB.[293]

Phototherapy is considered by some to be the most effective treatment for cholestatic pruritus.[294-296] UVB phototherapy also has been combined with cholestyramine.[297]

PUVA has resulted in improvement in aquagenic pruritus in several patients, but maintenance treatments may be required.[298-300]

Treatment with NB-UVB 3 times a week,[301] UVA in combination with UVB,[302] and PUVA[303-305] have been reported to improve the pruritus associated with polycythemia vera.

NB-UVB, BB-UVB, and PUVA have been used safely and effectively to treat eosinophilic folliculitis in HIV-positive patients.[306-310]

CHRONIC URTICARIA

NB-UVB should be considered in patients who have failed first-line antihistamine regimens. It appears to be effective and well-tolerated. BB-UVB has a higher relapse rate. The observed efficacy of NB-UVB may be partly from the greater penetration into the dermis and relatively larger systemic immunosuppressive effects of NB-UVB in comparison to BB-UVB. PUVA or UVA therapy shows some efficacy but results are inconsistent.[311]

PHOTODERMATOSES

NB-UVB[312-314] and oral PUVA[315,316] are useful methods for preventing outbreaks of moderate to severe polymorphous light eruption. "Hardening" is obtained by exposing the individual to low levels of phototherapy while, at the same time, placing them prophylactically on oral corticosteroids to prevent the rash. Proposed mechanisms by which phototherapy induces tolerance to sunlight include thickening of the stratum corneum, hyperpigmentation, and cutaneous immune modulation by normalizing UV-induced inflammatory cytokines such as IL-1β,[317] restoring impaired neutrophil chemotaxis,[318] increasing regulatory T cells,[319] and transiently decreasing Langerhans cells in the epidermis while increasing the mast cell recruitment into the papillary dermis.[320] Although NB-UVB is currently used more commonly than PUVA, PUVA has the advantage of a rapid and intense pigment induction at relatively low UVA doses that usually remain well below the threshold for eliciting an outbreak. Approximately 10% of patients will develop typical polymorphous light eruption lesions during the initial phase of PUVA, but these usually disappear with continued treatment. Phototherapy is typically initiated 1 month before the first anticipated intense sun exposure, such as a sunny midwinter vacation. Once "hardening" has been induced, it must be maintained by frequent exposure to ambient sunlight. Novel home UVB low-intensity phototherapy devices that can be used each day for 6 minutes have shown better acceptance by patients while providing the same efficacy as a BB-UVB hospital treatment.[321]

Lesions of solar urticaria also can be prevented with phototherapy. The regimen involves induction of tolerance by repeatedly exposing the patient to graded doses of the causative wavelengths.[322-324] Successful treatment has been achieved with repeated exposures to NB-UVB,[325] UVA, or PUVA.[322,324-327] PUVA may result in a response of greater duration. A condensed type of phototherapy called "rush hardening" also has been used.[328] In rush hardening patients are exposed to quarter- or half-body UVA irradiation at 50% of the determined minimal urticarial dose with hourly increases in body surface area irradiation and dose.[328] "Hardening"

or "desensitization" has been reported to occur in as few as 3 days. The most important parameter in rush hardening is to determine the minimal urticarial dose and action spectra immediately before starting therapy and initiating the treatment at a dose lower than the minimal urticarial dose to minimize exacerabations.[329] The disadvantage of this modality is that tolerance is lost quickly if the treatments are not continued every few days. For unexplained reasons, UVA1, which has effects on mast cells, is not particularly effective in preventing solar or other forms of urticaria.

Chronic actinic dermatitis and actinic prurigo are other photosensitive disorders that are reported to benefit from controlled, low doses of UV irradiation.[190,330,331] In contrast to polymorphous light eruption, an extended duration of treatment is often required for chronic actinic dermatitis.

OTHER DISEASES

LICHEN PLANUS

NB-UVB therapy has been used for recalcitrant lichen planus and is typically administered 3 times per week on nonconsecutive days. A complete response in 70% of patients has been reported after an average time of 10 weeks.[332-334] Improvement in pruritus can be expected before disappearance of skin lesions. Oral and topical PUVA[335] are other alternatives. In general, lichen planus tends to be more resistant to PUVA than psoriasis when treated with a similar schedule. A regimen of RePUVA may accelerate clearing, but has been reported to cause transient hyperpigmentation.[336] NB-UVB produces similar outcomes, but some have reported a better initial clinical response with PUVA.[337] Followup of patients who have cleared on PUVA shows that the disease reoccured at a higher frequency compared to non-PUVA group, raising the possibility that the treatment may prolong the disease.[335] Although exceedingly rare, PUVA has been reported to induce lichen planus[338] and lichen planus pemphigoides[339] in patients undergoing the therapy for other skin diseases. In a small series, the excimer laser has successfully treated erosive oral lichen planus.[340] However, the long-term effects of this form of radiant energy on the oral mucosa, which may also have been exposed to tobacco products, are unknown. Consequently, phototherapy for oral lichen planus should not be a first-line therapy for this form of the disease.

CHRONIC HAND ECZEMA

NB-UVB and local bath PUVA have been successful treatments for dyshidrotic eczema and chronic palmoplantar eczema.[341-343] Bath PUVA may be less effective in smokers with dyshidrotic eczema.[344] Oral PUVA is preferable for patients with hyperkeratotic eczema and bath PUVA is more beneficial for dyshidrotic eczema,[345] although oral PUVA also is effective for dyshidrotic eczema.[346]

Localized UVA1 has been used for dyshidrosis[347,348] and has the same efficacy when compared to cream PUVA for chronic vesicular dyshidrotic eczema.[347] Because the long-term effects of UVA1 are unknown, it has been recommended that courses of localized UVA1 phototherapy be performed no more than twice annually.

PITYRIASIS LICHENOIDES

NB-UVB and BB-UVB are safe and effective for both pityriasis lichenoides chronica[349,350] and pityriasis lichenoides et varioliformis acuta.[351] A complete response has been reported to occur with NB-UVB in 65% of pityriasis lichenoides et varioliformis acuta patients and a partial response in the rest.[351] NB-UVB also led to a complete response in more than 85% of pityriasis lichenoides chronica patients.

LYMPHOMATOID PAPULOSIS

Oral PUVA has been used for patients with lymphomatoid papulosis,[352,353] but relapse may occur upon cessation of therapy.[353] Bath PUVA is effective in lymphomatoid papulosis in children.[354,355] Some patients have also responded to targeted phototherapy with the 308-nm excimer laser.[356] UVA1 (60 J/cm^2) also has been employed,[357] but relapses are common.

TELANGIECTASIA MACULARIS ERUPTIVE PERSTANS

Oral PUVA is reserved for telangiectasia macularis eruptiva perstans patients with severe disease, because other therapies, such as laser treatment, may be safer long-term, and because the response is often temporary.[358-360]

URTICARIA PIGMENTOSA

UVA1 phototherapy ameliorates both the objective and subjective symptoms of urticaria pigmentosa in adult patients, and long-term remission can be achieved in many cases.[30,361,362] Although lesions may not respond completely with UVA1 therapy, the symptoms of pruritus are often relieved. Urinary histamine levels also decrease in response to UVA1. In some patients, systemic manifestations, such as diarrhea and migraine headaches, also have been reported to improve. In 1 patient with bone marrow infiltration, mast cell numbers decreased continuously after high-dose UVA1, which may have resulted from modulation of soluble cytokine production by UVA1-treated skin.[30] PUVA does not decrease mast cell numbers, which may explain its limited benefit in many patients.[363]

INDOLENT SYSTEMIC MASTOCYTOSIS

In a small case series, NB-UVB phototherapy resulted in complete and long-term remission of cutaneous lesions and pruritus after approximately 40 total treatments and a total median cumulative dose of 51.4 J/cm^2.[364]

Even though the number of treatments needed to achieve improvement in symptoms was lower with PUVA therapy, the average total exposure was higher with PUVA. In the case series, serum tryptase levels trended downward in patients receiving phototherapy and potentially may be used as a surrogate marker for response in some patients.[365]

GRANULOMA ANNULARE

Patients with widespread granuloma annulare treated with PUVA have had complete clearance of their disease.[366] Maintenance therapy may result in prolonged disease-free intervals. Bath and cream PUVA also is reported to be useful for granuloma annulare.[367-369] Although the mechanism of action of PUVA in granuloma annulare is unclear, selective elimination of pathogenic cells may be one explanation. UVA1 phototherapy provides good or excellent results in the majority of patients, but discontinuation of treatment is followed by early reoccurrence of disease.[370] There are anecdotal reports of NB-UVB successfully treating disseminated granuloma annulare.[371]

PERFORATING DISORDERS

There has been some success in treating perforating disorders with NB-UVB phototherapy.[372] There are anecdotal reports that PUVA also is effective.[373] Patients are treated 2 to 3 times weekly, with lesions and symptoms clearing after 10 to 15 treatments. The mechanism by which improvement occurs is unknown.

REFERENCES

1. Menter A, Korman NJ, Elmets CA, et al. Guidelines of care for the management of psoriasis and psoriatic arthritis: section 5. Guidelines of care for the treatment of psoriasis with phototherapy and photochemotherapy. *J Am Acad Dermatol.* 2010;62:114-135.
2. Taylor DK, Anstey AV, Coleman AJ, et al. Guidelines for dosimetry and calibration in ultraviolet radiation therapy: a report of a British Photodermatology Group workshop. *Br J Dermatol.* 2002;146:755-763.
3. Kochevar IE. Photobiology. Basic science. *Dermatol Clin.* 1986;4:171-179.
4. Yoon JH, Lee CS, O'Connor TR, et al. The DNA damage spectrum produced by simulated sunlight. *J Mol Biol.* 2000;299:681-693.
5. Gibbs NK, Tye J, Norval M. Recent advances in urocanic acid photochemistry, photobiology and photoimmunology. *Photochem Photobiol Sci.* 2008;7:655-667.
6. Landeck L, Jakasa I, Dapic I, et al. The effect of epidermal levels of urocanic acid on 25-hydroxyvitamin D synthesis and inflammatory mediators upon narrowband UVB irradiation. *Photodermatol Photoimmunol Photomed.* 2016;32:214-223.
7. Fritsche E, Schäfer C, Calles C, et al. Lightening up the UV response by identification of the arylhydrocarbon receptor as a cytoplasmatic target for ultraviolet B radiation. *Proc Natl Acad Sci U S A.* 2007; 104:8851-8856.
8. Heck DE, Vetrano AM, Mariano TM, et al. UVB light stimulates production of reactive oxygen species: unexpected role for catalase. *J Biol Chem.* 2003;278:22432-22436.
9. Freeman SE, Hacham H, Gange RW, et al. Wavelength dependence of pyrimidine dimer formation in DNA of human skin irradiated in situ with ultraviolet light. *Proc Natl Acad Sci U S A.* 1989;86:5605-5609.
10. Grether-Beck S, Felsner I, Brenden H, et al. Mitochondrial cytochrome c release mediates ceramide-induced activator protein 2 activation and gene expression in keratinocytes. *J Biol Chem.* 2003;278:47498-47507.
11. Xiang Y, Liu G, Yang L, et al. UVA-induced protection of skin through the induction of heme oxygenase-1. *Biosci Trends.* 2011;5:239-244.
12. Diffey BL, Kochevar IE. Basic principles of photobiology. In: Lim HW, Hönigsmann H, Hawk JLM, eds. *Photodermatology*. New York, NY: Informa Healthcare; 2007:15-27.
13. Averbeck D. Recent advances in psoralen phototoxicity mechanism. *Photochem Photobiol.* 1989;50: 859-882.
14. Krutmann J, Morita A, Elmets CA. Mechanisms of photo(chemo)therapy. In: Krutmann J, Hönigsmann H, Elmets CA, eds. *Dermatological Phototherapy and Photodiagnostic Methods*. 2nd ed. Berlin, Germany: Springer-Verlag; 2009:63-77.
15. Shreedhar V, Giese T, Sung VW, et al. A cytokine cascade including prostaglandin E2, IL-4, and IL-10 is responsible for UV-induced systemic immune suppression. *J Immunol*. 1998;160:3783-3789.
16. Pentland A, Needleman P. Modulation of keratinocyte proliferation in vitro by endogenous prostaglandin synthesis. *J Clin Invest.* 1986;77:246-261.
17. Pentland AP, Mahoney M, Jacobs SC, et al. Enhanced prostaglandin synthesis after ultraviolet injury is mediated by endogenous histamine stimulation. *J Clin Invest.* 1990;86:566-574.
18. Rodriguez-Burford C, Tu JH, Mercurio M, et al. Selective cyclooxygenase-2 inhibition produces heterogeneous erythema response to ultraviolet irradiation. *J Invest Dermatol.* 2005;125:1317.
19. Pilkington SM, Gibbs NK, Costello P, et al. Effect of oral eicosapentaenoic acid on epidermal Langerhans cell numbers and PGD2 production in UVR-exposed human skin: a randomised controlled study. *Exp Dermatol.* 2016;25(12):962-968.
20. Zhang Q, Yao Y, Konger RL, et al. UVB radiation-mediated inhibition of contact hypersensitivity reactions is dependent on the platelet-activating factor system. *J Invest Dermatol.* 2008;128:1780-1787.
21. Seiffert K, Granstein RD. Neuropeptides and neuroendocrine hormones in ultraviolet radiation-induced immunosuppression. *Methods.* 2002;28:97-103.
22. Zhang D, Chen Y, Chen L, et al. Ultraviolet irradiation promotes FOXP3 transcription via p53 in psoriasis. *Exp Dermatol.* 2016;25:513-518.
23. Buhl T, Schon MP. Peeking into immunoregulatory effects of phototherapy. *Exp Dermatol.* 2016;25:511-512.
24. Meulenbroeks C, van Weelden H, Schwartz C, et al. Basophil-derived amphiregulin is essential for UVB irradiation-induced immune suppression. *J Invest Dermatol.* 2015;135:222-228.

25. Zaiss DM, van Loosdregt J, Gorlani A, et al. Amphiregulin enhances regulatory T cell-suppressive function via the epidermal growth factor receptor. *Immunity*. 2013;38:275-284.
26. Bogaczewicz J, Malinowska K, Sysa-Jedrzejowska A, et al. Medium-dose ultraviolet A1 phototherapy and mRNA expression of TSLP, TARC, IL-5, and IL-13 in acute skin lesions in atopic dermatitis. *Int J Dermatol*. 2016;55:856-863.
27. Bogaczewicz J, Malinowska K, Sysa-Jedrzejowska A, et al. Medium-dose ultraviolet A1 phototherapy improves SCORAD index and increases mRNA expression of interleukin-4 without direct effect on human beta defensin-1, interleukin-10, and interleukin-31. *Int J Dermatol*. 2016;55:e380-e385.
28. Morita A, Werfel T, Stege H, et al. Evidence that singlet oxygen-induced human T helper cell apoptosis is the basic mechanism of ultraviolet-A radiation phototherapy. *J Exp Med*. 1997;186:1763-1768.
29. Ozawa M, Ferenczi K, Kikuchi T, et al. 312-nanometer ultraviolet B light (narrow-band UVB) induces apoptosis of T cells within psoriatic lesions. *J Exp Med*. 1999;189:711-718.
30. Stege H, Schopf E, Ruzicka T, et al. High-dose UVA1 for urticaria pigmentosa. *Lancet*. 1996;347:64.
31. Vella Briffa D, Eady R, James M, et al. Photochemotherapy (PUVA) in the treatment of urticaria pigmentosa. *Br J Dermatol*. 1983;109:67-75.
32. Scharffetter K, Wlaschek M, Hogg A, et al. UVA irradiation induces collagenase in human dermal fibroblasts in vitro and in vivo. *Arch Dermatol Res*. 1991;283:506-511.
33. Petersen MJ, Hansen C, Craig S. Ultraviolet A irradiation stimulates collagenase production in cultured human fibroblasts. *J Invest Dermatol*. 1992;99:440-444.
34. Wlaschek M, Heinen G, Poswig A, et al. UVA-induced autocrine stimulation of fibroblast-derived collagenase/MMP-1 by interrelated loops of interleukin-1 and interleukin-6. *Photochem Photobiol*. 1994;59:550-556.
35. Brenner M, Herzinger T, Berking C, et al. Phototherapy and photochemotherapy of sclerosing skin diseases. *Photodermatol Photoimmunol Photomed*. 2005;21:157-165.
36. Young AR. Damage from acute vs. chronic solar exposure. In: Giacomoni PU, ed. *Biophysical and Physiological Effects of Solar Radiation on Human Skin*. London, UK: RSC Publishing; 2007:3-23.
37. Brenner M, Hearing VJ. The protective role of melanin against UV damage in human skin. *Photochem Photobiol*. 2008;84:539-549.
38. Parrish JA, Jaenicke KF, Anderson RR. Erythema and melanogenesis action spectra of normal human skin. *Photochem Photobiol*. 1982;36:187-191.
39. Eller MS, Gilchrest BA. Tanning as part of the eukaryotic SOS response. *Pigment Cell Res*. 2000;13(suppl 8):94-97.
40. Gilchrest BA, Eller MS. DNA photodamage stimulates melanogenesis and other photoprotective responses. *J Investig Dermatol Symp Proc*. 1999;4:35-40.
41. Eller MS, Ostrom K, Gilchrest BA. DNA damage enhances melanogenesis. *Proc Natl Acad Sci U S A*. 1996;93:1087-1092.
42. Gilchrest BA, Zhai S, Eller MS, et al. Treatment of human melanocytes and S91 melanoma cells with the DNA repair enzyme T4 endonuclease V enhances melanogenesis after ultraviolet irradiation. *J Invest Dermatol*. 1993;101:666-672.
43. Passeron T, Ostovari N, Zakaria W, et al. Topical tacrolimus and the 308-nm excimer laser: a synergistic combination for the treatment of vitiligo. *Arch Dermatol*. 2004;140:1065-1069.
44. Abdel-Naser MB, Hann SK, Bystryn JC. Oral psoralen with UV-A therapy releases circulating growth factor(s) that stimulates cell proliferation. *Arch Dermatol*. 1997;133:1530-1533.
45. Saleh FY, Awad SS, Nasif GA, et al. Epithelial expression of cytokeratins 15 and 19 in vitiligo. *J Cosmet Dermatol*. 2016;15(4):312-317.
46. Reidel U, Bechstein S, Lange-Asschenfeldt B, et al. Treatment of localized mycosis fungoides with digital UV photochemotherapy. *Photodermatol Photoimmunol Photomed*. 2015;31:333-340.
47. Werfel T, Holiangu F, Niemann KH, et al. Digital ultraviolet therapy: a novel therapeutic approach for the targeted treatment of psoriasis vulgaris. *Br J Dermatol*. 2015;172:746-753.
48. van Weelden H, De La Faille HB, Young E, et al. A new development in UVB phototherapy of psoriasis. *Br J Dermatol*. 1988;119:11-19.
49. Perry HO, Soderstrom CW, Schulze RW. The Goeckerman treatment of psoriasis. *Arch Dermatol*. 1968;98:178-182.
50. Schneider LA, Hinrichs R, Scharffetter-Kochanek K. Phototherapy and photochemotherapy. *Clin Dermatol*. 2008;26:464-476.
51. Parrish JA, Jaenicke KF. Action spectrum for phototherapy of psoriasis. *J Invest Dermatol*. 1981;76:359-362.
52. Lynch M, Carroll F, Kavanagh A, et al. Comparison of a semiautomated hand-held device to test minimal erythema dose before narrowband ultraviolet B phototherapy with the conventional method using matched doses. *J Eur Acad Dermatol Venereol*. 2014;28:1696-1700.
53. Darne S, Stewart LC, Farr PM, et al. Investigation of cutaneous photoadaptation to narrowband ultraviolet B. *Br J Dermatol*. 2014;170:392-397.
54. Parrish JA, Fitzpatrick TB, Tanenbaum L, et al. Photochemotherapy of psoriasis with oral methoxsalen and longwave ultraviolet light. *N Engl J Med*. 1974;291:1207-1211.
55. Halpern SM, Anstey AV, Dawe RS, et al. Guidelines for topical PUVA: a report of a workshop of the British Photodermatology Group. *Br J Dermatol*. 2000;142:22-31.

55A. Pozo-Román T, González-López A, Velasco-Vaquero ME, et al. Psoralen cream plus ultraviolet A photochemotherapy (PUVA cream): our experience. *J Eur Acad Dermatol Venereol*. 2006 Feb;20(2):136-142. Available at https://www.ncbi.nlm.nih.gov/pubmed/16441619.

56. Mutzhas MF, Holzle E, Hofmann C, et al. A new apparatus with high radiation energy between 320-460 nm: physical description and dermatological applications. *J Invest Dermatol*. 1981;76:42-47.
57. Krutmann J, Czech W, Diepgen T, et al. High-dose UVA1 therapy in the treatment of patients with atopic dermatitis. *J Am Acad Dermatol*. 1992;26(2, pt 1):225-230.
58. Krutmann J, Morita A. Mechanisms of ultraviolet (UV) B and UVA phototherapy. *J Investig Dermatol Symp Proc*. 1999;4:70-72.

59. Dawe RS. Ultraviolet A1 phototherapy. *Br J Dermatol.* 2003;148:626-637.
60. Tuchinda C, Kerr HA, Taylor CR, et al. UVA1 phototherapy for cutaneous diseases: an experience of 92 cases in the United States. *Photodermatol Photoimmunol Photomed.* 2006;22:247-253.
61. Leone G, Iacovelli P, Paro Vidolin A, et al. Monochromatic excimer light 308 nm in the treatment of vitiligo: a pilot study. *J Eur Acad Dermatol Venereol.* 2003;17:531-537.
62. Nguyen T, Gattu S, Pugashetti R, et al. Practice of phototherapy in the treatment of moderate-to-severe psoriasis. *Curr Probl Dermatol.* 2009;38: 59-78.
63. Babino G, Giunta A, Esposito M, et al. UVA1 Laser in the treatment of vitiligo. *Photomed Laser Surg*. 2016;34:200-204.
64. Toll A, Velez-Gonzalez M, Gallardo F, et al. Treatment of localized persistent plaque psoriasis with incoherent narrowband ultraviolet B phototherapy. *J Dermatolog Treat*. 2005;16:165-168.
65. Lotti TM, Menchini G, Andreassi L. UV-B radiation microphototherapy. An elective treatment for segmental vitiligo. *J Eur Acad Dermatol Venereol.* 1999;13:102-108.
66. Zanardelli M, Kovacevic M, McCoy J, et al. Management of chronic pruritus with a UV filtering topical cream. *Dermatol Ther.* 2016;29:101-103.
67. Lee E, Koo J, Berger T. UVB phototherapy and skin cancer risk: a review of the literature. *Int J Dermatol.* 2005;44:355-360.
68. Weischer M, Blum A, Eberhard F, et al. No evidence for increased skin cancer risk in psoriasis patients treated with broadband or narrowband UVB phototherapy: a first retrospective study. *Acta Derm Venereol*. 2004;84:370-374.
69. Hearn RM, Kerr AC, Rahim KF, et al. Incidence of skin cancers in 3867 patients treated with narrowband ultraviolet B phototherapy. *Br J Dermatol.* 2008;159:931-935.
70. Aubin F, Vigan M, Puzenat E, et al. Evaluation of a novel 308-nm monochromatic excimer light delivery system in dermatology: a pilot study in different chronic localized dermatoses. *Br J Dermatol.* 2005;152:99-103.
71. Lim JL, Stern RS. High levels of ultraviolet B exposure increase the risk of non-melanoma skin cancer in psoralen and ultraviolet A-treated patients. *J Invest Dermatol.* 2005;124:505-513.
72. Stern RS, Laird N. The carcinogenic risk of treatments for severe psoriasis. *Cancer.* 1994;73:2759-2764.
73. Melski JW, Tanenbaum L, Parrish JA, et al. Oral methoxsalen photochemotherapy for the treatment of psoriasis: a cooperative clinical trial. 1977. *J Invest Dermatol.* 1989;92:153S; discussion 154S-156S.
74. Henseler T, Wolff K, Honigsmann H, et al. Oral 8-methoxypsoralen photochemotherapy of psoriasis. The European PUVA study: a cooperative study among 18 European centres. *Lancet*. 1981;1:853-857.
75. Honigsmann H. Psoralen photochemotherapy—mechanisms, drugs, toxicity. *Curr Probl Dermatol.* 1986: 15:52-66.
76. Basarab T, Millard TP, McGregor JM, et al. Atypical pigmented lesions following extensive PUVA therapy. *Clin Exp Dermatol.* 2000;25:135-137.
77. Rhodes AR, Harrist TJ, Momtaz TK. The PUVA-induced pigmented macule: a lentiginous proliferation of large, sometimes cytologically atypical, melanocytes. *J Am Acad Dermatol.* 1983;9:47-58.
78. Lassacher A, Worda M, Kaddu S, et al. T1799A BRAF mutation is common in PUVA lentigines. *J Invest Dermatol.* 2006;126:1915-1917.
79. Brose MS, Volpe P, Feldman M, et al. BRAF and RAS mutations in human lung cancer and melanoma. *Cancer Res.* 2002;62:6997-7000.
80. Gorden A, Osman I, Gai W, et al. Analysis of BRAF and N-RAS mutations in metastatic melanoma tissues. *Cancer Res.* 2003;63:3955-3957.
81. Pollock PM, Harper UL, Hansen KS, et al. High frequency of BRAF mutations in nevi. *Nat Genet.* 2003;33:19-20.
82. Poynter JN, Elder JT, Fullen DR, et al. BRAF and NRAS mutations in melanoma and melanocytic nevi. *Melanoma Res.* 2006;16:267-273.
83. Lever LR, Farr PM. Skin cancers or premalignant lesions occur in half of high-dose PUVA patients. *Br J Dermatol.* 1994;131:215-219.
84. Dunnick JK, Forbes PD, Eustis SL, et al. Tumors of the skin in the HRA/Skh mouse after treatment with 8-methoxypsoralen and UVA radiation. *Fundam Appl Toxicol.* 1991;16:92-102.
85. Stern RS, Liebman EJ, Vakeva L. Oral psoralen and ultraviolet-A light (PUVA) treatment of psoriasis and persistent risk of nonmelanoma skin cancer. PUVA Follow-up Study. *J Natl Cancer Inst.* 1998;90:1278-1284.
86. Marcil I, Stern RS. Squamous-cell cancer of the skin in patients given PUVA and ciclosporin: nested cohort crossover study. *Lancet.* 2001;358:1042-1045.
87. Nijsten TE, Stern RS. Oral retinoid use reduces cutaneous squamous cell carcinoma risk in patients with psoriasis treated with psoralen-UVA: a nested cohort study. *J Am Acad Dermatol.* 2003;49:644-650.
88. Stern RS. Genital tumors among men with psoriasis exposed to psoralens and ultraviolet A radiation (PUVA) and ultraviolet B radiation. The Photochemotherapy Follow-up Study. *N Engl J Med.* 1990;322:1093-1097.
89. Stern RS, Bagheri S, Nichols K. The persistent risk of genital tumors among men treated with psoralen plus ultraviolet A (PUVA) for psoriasis. *J Am Acad Dermatol.* 2002;47:33-39.
90. Abdulla FR, Breneman C, Adams B, et al. Standards for genital protection in phototherapy units. *J Am Acad Dermatol.* 2010;62:223-226.
91. Stern RS, Nichols KT, Vakeva LH. Malignant melanoma in patients treated for psoriasis with methoxsalen (psoralen) and ultraviolet A radiation (PUVA). The PUVA Follow-Up Study. *N Engl J Med.* 1997;336:1041-1045.
92. Lindelof B. Risk of melanoma with psoralen/ultraviolet A therapy for psoriasis. Do the known risks now outweigh the benefits? *Drug Saf.* 1999;20:289-297.
93. Stern RS. Lymphoma risk in psoriasis: results of the PUVA Follow-Up Study. *Arch Dermatol.* 2006;142:1132-1135.
94. Andley UP, Chylack LT Jr. Recent studies on photodamage to the eye with special reference to clinical phototherapeutic procedures. *Photodermatol Photoimmunol Photomed.* 1990;7:98-105.
95. Woo TY, Wong RC, Wong JM, et al. Lenticular psoralen photoproducts and cataracts of a PUVA-treated psoriatic patient. *Arch Dermatol.* 1985;121:1307-1308.
96. Boukes RJ, van Balen AT, Bruynzeel DP. A retrospective study of ocular findings in patients treated with PUVA. *Doc Ophthalmol.* 1985;59:11-19.

97. Calzavara-Pinton PG, Carlino A, Manfredi E, et al. Ocular side effects of PUVA-treated patients refusing eye sun protection. *Acta Derm Venereol Suppl (Stockh).* 1994;186:164-165.
98. Malanos D, Stern RS. Psoralen plus ultraviolet A does not increase the risk of cataracts: a 25-year prospective study. *J Am Acad Dermatol.* 2007;57:231-237.
99. Abdullah AN, Keczkes K. Cutaneous and ocular side-effects of PUVA photochemotherapy—a 10-year follow-up study. *Clin Exp Dermatol.* 1989;14:421-424.
100. Stern RS, Parrish JA, Fitzpatrick TB. Ocular findings in patients treated with PUVA. *J Invest Dermatol.* 1985;85:269-273.
101. Ronnerfalt L, Lydahl E, Wennersten G, et al. Ophthalmological study of patients undergoing long-term PUVA therapy. *Acta Derm Venereol.* 1982;62:501-505.
102. Glew WB, Nigra TP. Psoralens and ocular effects in humans. *Natl Cancer Inst Monogr.* 1984;66:235-239.
103. Krutmann J, Diepgen TL, Luger TA, et al. High-dose UVA1 therapy for atopic dermatitis: results of a multicenter trial. *J Am Acad Dermatol.* 1998;38:589-593.
104. Tzaneva S, Seeber A, Schwaiger M, et al. High-dose versus medium-dose UVA1 phototherapy for patients with severe generalized atopic dermatitis. *J Am Acad Dermatol.* 2001;45:503-507.
105. von Kobyletzki G, Pieck C, Hoffmann K, et al. Medium-dose UVA1 cold-light phototherapy in the treatment of severe atopic dermatitis. *J Am Acad Dermatol.* 1999;41:931-937.
106. Cavard C, Zider A, Vernet M, et al. In vivo activation by ultraviolet rays of the human immunodeficiency virus type 1 long terminal repeat. *J Clin Invest.* 1990;86:1369-1374.
107. Stein B, Kramer M, Rahmsdorf HJ, et al. UV-induced transcription from the human immunodeficiency virus type 1 (HIV-1) long terminal repeat and UV-induced secretion of an extracellular factor that induces HIV-1 transcription in nonirradiated cells. *J Virol.* 1989;63:4540-4544.
108. Yamagoe S, Kohda T, Oishi M. Poly(ADP-ribose) polymerase inhibitors suppress UV-induced human immunodeficiency virus type 1 gene expression at the posttranscriptional level. *Mol Cell Biol.* 1991;11:3522-3527.
109. Vogel J, Cepeda M, Tschachler E, et al. UV activation of human immunodeficiency virus gene expression in transgenic mice. *J Virol.* 1992;66:1-5.
110. Zmudzka BZ, Miller SA, Jacobs ME, et al. Medical UV exposures and HIV activation. *Photochem Photobiol.* 1996;64:246-253.
111. Breuer-McHam J, Simpson E, Dougherty I, et al. Activation of HIV in human skin by ultraviolet B radiation and its inhibition by NFkappaB blocking agents. *Photochem Photobiol.* 2001;74:805-810.
112. Breuer-McHam J, Marshall G, Adu-Oppong A, et al. Alterations in HIV expression in AIDS patients with psoriasis or pruritus treated with phototherapy. *J Am Acad Dermatol.* 1999;40:48-60.
113. Gelfand JM, Rudikoff D, Lebwohl M, et al. Effect of UV-B phototherapy on plasma HIV type 1 RNA viral level: a self-controlled prospective study. *Arch Dermatol.* 1998;134:940-945.
114. Akaraphanth R, Lim HW. HIV, UV and immunosuppression. *Photodermatol Photoimmunol Photomed.* 1999;15:28-31.
115. Menon K, Van Voorhees AS, Bebo BF Jr, et al. Psoriasis in patients with HIV infection: from the medical board of the National Psoriasis Foundation. *J Am Acad Dermatol.* 2010;62:291-299.
116. Juzeniene A, Stokke KT, Thune P, et al. Pilot study of folate status in healthy volunteers and in patients with psoriasis before and after UV exposure. *J Photochem Photobiol B.* 2010;101:111-116.
117. El-Saie LT, Rabie AR, Kamel MI, et al. Effect of narrowband ultraviolet B phototherapy on serum folic acid levels in patients with psoriasis. *Lasers Med Sci.* 2011;26:481-485.
118. Park KK, Murase JE. Narrowband UV-B phototherapy during pregnancy and folic acid depletion. *Arch Dermatol.* 2012;148:132-133.
119. Gloor M, Scherotzke A. Age dependence of ultraviolet light-induced erythema following narrow-band UVB exposure. *Photodermatol Photoimmunol Photomed.* 2002;18:121-126.
120. Powell JB, Gach JE. Phototherapy in the elderly. *Clin Exp Dermatol.* 2015;40:605-610.
121. Cowen EW, Nguyen JC, Miller DD, et al. Chronic phototoxicity and aggressive squamous cell carcinoma of the skin in children and adults during treatment with voriconazole. *J Am Acad Dermatol.* 2010;62:31-37.
122. Vanacker A, Fabre G, Van Dorpe J, et al. Aggressive cutaneous squamous cell carcinoma associated with prolonged voriconazole therapy in a renal transplant patient. *Am J Transplant.* 2008;8:877-880.
123. McCarthy KL, Playford EG, Looke DF, et al. Severe photosensitivity causing multifocal squamous cell carcinomas secondary to prolonged voriconazole therapy. *Clin Infect Dis.* 2007;44:e55-e56.
124. Fluhr JW, Gloor M. The antimicrobial effect of narrow-band UVB (313 nm) and UVA1 (345-440 nm) radiation in vitro. *Photodermatol Photoimmunol Photomed.* 1997;13:197-201.
125. Hruza L, Pentland A. Mechanisms of UV-induced inflammation. *J Invest Dermatol.* 1993;100:S35-S41.
126. Beissert S, Schwarz T. Role of immunomodulation in diseases responsive to phototherapy. *Methods.* 2002;28:138-144.
127. Walters IB, Ozawa M, Cardinale I, et al. Narrowband (312-nm) UV-B suppresses interferon gamma and interleukin (IL) 12 and increases IL-4 transcripts: differential regulation of cytokines at the single-cell level. *Arch Dermatol.* 2003;139:155-161.
128. Vahavihu K, Ala-Houhala M, Peric M, et al. Narrowband UVB treatment improves vitamin D balance and alters antimicrobial peptide expression in skin lesions of psoriasis and atopic dermatitis. *Br J Dermatol.* 2010;163(2):321-328.
129. Vahavihu K, Ylianttila L, Kautiainen H, et al. Narrowband ultraviolet B course improves vitamin D balance in women in winter. *Br J Dermatol.* 2010;162:848-853.
130. Zhu JW, Wu XJ, Lu ZF, et al. Role of VEGF receptors in normal and psoriatic human keratinocytes: evidence from irradiation with different UV sources. *PLoS One.* 2013;8:e55463.
131. Furuhashi T, Saito C, Torii K, et al. Photo(chemo) therapy reduces circulating Th17 cells and restores circulating regulatory T cells in psoriasis. *PLoS One.* 2013;8:e54895.
132. Gui J, Gober M, Yang X, et al. Therapeutic elimination of the type 1 interferon receptor for treating psoriatic skin inflammation. *J Invest Dermatol.* 2016;136:1990-2002.

133. Coimbra S, Oliveira H, Reis F, et al. C-reactive protein and leucocyte activation in psoriasis vulgaris according to severity and therapy. *J Eur Acad Dermatol Venereol*. 2010;24(7):789-796.
134. Metwally D, Sayed K, Abdel Hay R, et al. Reduction in tissue plasmin: a new mechanism of action of narrowband ultraviolet B in psoriasis. *Clin Exp Dermatol*. 2015;40:416-420.
135. Green C, Ferguson J, Lakshmipathi T, et al. 311 nm UVB phototherapy—an effective treatment for psoriasis. *Br J Dermatol*. 1988;119:691-696.
136. Stern RS, Armstrong RB, Anderson TF, et al. Effect of continued ultraviolet B phototherapy on the duration of remission of psoriasis: a randomized study. *J Am Acad Dermatol*. 1986;15:546-552.
137. Lebwohl M, Drake L, Menter A, et al. Consensus conference: acitretin in combination with UVB or PUVA in the treatment of psoriasis. *J Am Acad Dermatol*. 2001;45:544-553.
138. Iest J, Boer J. Combined treatment of psoriasis with acitretin and UVB phototherapy compared with acitretin alone and UVB alone. *Br J Dermatol*. 1989;120:665-670.
139. Green C, Lakshmipathi T, Johnson BE, et al. A comparison of the efficacy and relapse rates of narrowband UVB (TL-01) monotherapy vs. etretinate (re-TL-01) vs. etretinate-PUVA (re-PUVA) in the treatment of psoriasis patients. *Br J Dermatol*. 1992;127:5-9.
140. Lebwohl M. Acitretin in combination with UVB or PUVA. *J Am Acad Dermatol*. 1999;41: S22-S24.
141. Caliskan E, Tunca M, Açıkgöz G, et al. Narrow band ultraviolet-B versus Goeckerman therapy for psoriasis with and without acitretin: a retrospective study. *Indian J Dermatol Venereol Leprol*. 2015;81:584-587.
142. Asawanonda P, Nateetongrungsak Y. Methotrexate plus narrowband UVB phototherapy versus narrowband UVB phototherapy alone in the treatment of plaque-type psoriasis: a randomized, placebo-controlled study. *J Am Acad Dermatol*. 2006;54:1013-1018.
143. Kircik L, Bagel J, Korman N, et al. Utilization of narrow-band ultraviolet light B therapy and etanercept for the treatment of psoriasis (UNITE): efficacy, safety, and patient-reported outcomes. *J Drugs Dermatol*. 2008;7:245-253.
144. Bagel J. LCD plus NB-UVB reduces time to improvement of psoriasis vs. NB-UVB alone. *J Drugs Dermatol*. 2009;8:351-357.
145. Ashcroft DM, Li Wan Po A, Williams HC, et al. Combination regimens of topical calcipotriene in chronic plaque psoriasis: systematic review of efficacy and tolerability. *Arch Dermatol*. 2000;136:1536-1543.
146. Koo J. Calcipotriol/calcipotriene (Dovonex/Daivonex) in combination with phototherapy: a review. *J Am Acad Dermatol*. 1997;37(3, pt 2):S59-S61.
147. Kragballe K. Combination of topical calcipotriol (MC 903) and UVB radiation for psoriasis vulgaris. *Dermatologica*. 1990;181:211-214.
148. Bourke JF, Iqbal SJ, Hutchinson PE. The effects of UVB plus calcipotriol on systemic calcium homeostasis in patients with chronic plaque psoriasis. *Clin Exp Dermatol*. 1997;22:259-261.
149. Hecker D, Lebwohl M. Topical calcipotriene in combination with UVB phototherapy for psoriasis. *Int J Dermatol*. 1997;36:302-303.
150. Woo WK, McKenna KE. Combination TL01 ultraviolet B phototherapy and topical calcipotriol for psoriasis: a prospective randomized placebo-controlled clinical trial. *Br J Dermatol*. 2003;149, 146-150.
151. Youn JI, Park BS, Chung JH, et al. Photoprotective effect of calcipotriol upon skin photoreaction to UVA and UVB. *Photodermatol Photoimmunol Photomed*. 1997;13:109-114.
152. Koo JY, Lowe NJ, Lew-Kaya DA, et al. Tazarotene plus UVB phototherapy in the treatment of psoriasis. *J Am Acad Dermatol*. 2000;43(5, pt 1):821-828.
153. Hecker D, Worsley J, Yueh G, et al. Interactions between tazarotene and ultraviolet light. *J Am Acad Dermatol*. 1999;41:927-930.
154. Magliocco MA, Pandya K, Dombrovskiy V, et al. A randomized, double-blind, vehicle-controlled, bilateral comparison trial of bexarotene gel 1% versus vehicle gel in combination with narrowband UVB phototherapy for moderate to severe psoriasis vulgaris. *J Am Acad Dermatol*. 2006;54:115-118.
155. Lebwohl M, Martinez J, Weber P, et al. Effects of topical preparations on the erythemogenicity of UVB: implications for psoriasis phototherapy. *J Am Acad Dermatol*. 1995;32:469-471.
156. Hoffmann K, Kaspar K, Gambichler T, et al. Change in ultraviolet (UV) transmission following the application of Vaseline to non-irradiated and UVB-exposed split skin. *Br J Dermatol*. 2000;143:532-538.
157. Berne B, Blom I, Spangberg S. Enhanced response of psoriasis to UVB therapy after pretreatment with a lubricating base. A single-blind controlled study. *Acta Derm Venereol*. 1990;70:474-477.
157A. Kristensen B, Kristensen O. *Acta Derm Venereol*. 1991;71(1):37-40. Topical salicylic acid interferes with UVB therapy for psoriasis. Available at https://www.ncbi.nlm.nih.gov/pubmed/1676212.
158. Feldman SR, Mellen BG, Housman TS, et al. Efficacy of the 308-nm excimer laser for treatment of psoriasis: results of a multicenter study. *J Am Acad Dermatol*. 2002;46:900-906.
159. Vongthongsri R, Konschitzky R, Seeber A, et al. Randomized, double-blind comparison of 1 mg/L versus 5 mg/L methoxsalen bath-PUVA therapy for chronic plaque-type psoriasis. *J Am Acad Dermatol*. 2006;55:627-631.
160. Debbaneh MG, Levin E, Sanchez Rodriguez R, et al. Plaque-based sub-blistering dosimetry: reaching PASI-75 after two treatments with 308-nm excimer laser in a generalized psoriasis patient. *J Dermatolog Treat*. 2015;26:45-48.
161. Sivanesan SP, Gattu S, Hong J, et al. Randomized, double-blind, placebo-controlled evaluation of the efficacy of oral psoralen plus ultraviolet A for the treatment of plaque-type psoriasis using the Psoriasis Area Severity Index score (improvement of 75% or greater) at 12 weeks. *J Am Acad Dermatol*. 2009;61:793-798.
162. Yones SS, Palmer RA, Garibaldinos TT, et al. Randomized double-blind trial of the treatment of chronic plaque psoriasis: efficacy of psoralen-UV-A therapy vs narrowband UV-B therapy. *Arch Dermatol*. 2006;142:836-842.
163. Markham T, Rogers S, Collins P. Narrowband UV-B (TL-01) phototherapy vs oral 8-methoxypsoralen psoralen-UV-A for the treatment of chronic plaque psoriasis. *Arch Dermatol*. 2003;139:325-328.
164. Tanew A, Radakovic-Fijan S, Schemper M, et al. Narrowband UV-B phototherapy vs photochemotherapy in the treatment of chronic plaque-type

psoriasis: a paired comparison study. *Arch Dermatol.* 1999;135:519-524.
165. Van Weelden H, Baart de la Faille H, Young E, van der Leun JC. Comparison of narrow-band UV-B phototherapy and PUVA photochemotherapy in the treatment of psoriasis. *Acta Derm Venereol.* 1990;70:212-215.
166. Gordon PM, Diffey BL, Matthews JN, et al. A randomized comparison of narrow-band TL-01 phototherapy and PUVA photochemotherapy for psoriasis. *J Am Acad Dermatol.* 1999;41:728-732.
167. Ibbotson SH, Dawe RS, Dinkova-Kostova AT, et al. Glutathione S-transferase genotype is associated with sensitivity to psoralen-ultraviolet A photochemotherapy. *Br J Dermatol.* 2012;166:380-388.
168. Morison WL. Phototherapy and photochemotherapy. *Adv Dermatol.* 1992;7:255-270; discussion 271.
169. Honigsmann H, Wolff K. Results of therapy for psoriasis using retinoid and photochemotherapy (RePUVA). *Pharmacol Ther.* 1989;40:67-73.
170. Tzaneva S, Honigsmann H, Tanew A, et al. A comparison of psoralen plus ultraviolet A (PUVA) monotherapy, tacalcitol plus PUVA and tazarotene plus PUVA in patients with chronic plaque-type psoriasis. *Br J Dermatol.* 2002;147:748-753.
171. Behrens S, von Kobyletzki G, Gruss C, et al. PUVA-bath photochemotherapy (PUVA-soak therapy) of recalcitrant dermatoses of the palms and soles. *Photodermatol Photoimmunol Photomed.* 1999;15:47-51.
172. Birgin B, Fetil E, Ilknur T, et al. Effects of topical petrolatum and salicylic acid upon skin photoreaction to UVA. *Eur J Dermatol.* 2005;15:156-158.
173. Wolf P, Weger W, Patra V, et al. Desired response to phototherapy versus photo-aggravation in psoriasis: what makes the difference? *Exp Dermatol.* 2016;25(12):937-944.
174. Nakamura M, Bhutani T, Koo JY. Narrowband UVB-induced iatrogenic polymorphous light eruption: a case and suggestions to overcome this rare complication. *Dermatol Online J.* 2016;22(6).
175. George SA, Bilsland DJ, Johnson BE, et al. Narrow-band (TL-01) UVB air-conditioned phototherapy for chronic severe adult atopic dermatitis. *Br J Dermatol.* 1993; 128:49-56.
176. Grundmann-Kollmann M, Behrens S, Podda M, et al. Phototherapy for atopic eczema with narrow-band UVB. *J Am Acad Dermatol.* 1999;40:995-997.
177. Hudson-Peacock MJ, Diffey BL, Farr PM. Narrow-band UVB phototherapy for severe atopic dermatitis. *Br J Dermatol.* 1996;135:332.
178. Reynolds NJ, Franklin V, Gray JC, et al. Narrow-band ultraviolet B and broad-band ultraviolet A phototherapy in adult atopic eczema: a randomised controlled trial. *Lancet.* 2001;357:2012-2016.
179. Der-Petrossian M, Seeber A, Honigsmann H, et al. Half-side comparison study on the efficacy of 8-methoxypsoralen bath-PUVA versus narrow-band ultraviolet B phototherapy in patients with severe chronic atopic dermatitis. *Br J Dermatol.* 2000; 142:39-43.
180. Brazzelli V, Prestinari F, Chiesa MG, et al. Sequential treatment of severe atopic dermatitis with cyclosporin A and low-dose narrow-band UVB phototherapy. *Dermatology.* 2002;204:252-254.
181. Clayton TH, Clark SM, Turner D, et al. The treatment of severe atopic dermatitis in childhood with narrowband ultraviolet B phototherapy. *Clin Exp Dermatol.* 2007;32:28-33.
182. Ersoy-Evans S, Altaykan A, Sahin S, et al. Phototherapy in childhood. *Pediatr Dermatol.* 2008;25:599-605.
183. Jury CS, McHenry P, Burden AD, et al. Narrowband ultraviolet B (UVB) phototherapy in children. *Clin Exp Dermatol.* 2006;31:196-199.
184. Tay YK, Morelli JG, Weston WL. Experience with UVB phototherapy in children. *Pediatr Dermatol.* 1996;13:406-409.
185. Sidbury R, Davis DM, Cohen DE, et al. Guidelines of care for the management of atopic dermatitis: section 3. Management and treatment with phototherapy and systemic agents. *J Am Acad Dermatol.* 2014;71:327-349.
186. Pasic A, Ceović R, Lipozencić J, et al. Phototherapy in pediatric patients. *Pediatr Dermatol.* 2003;20: 71-77.
187. Lerche CM, Philipsen PA, Poulsen T, et al. Topical pimecrolimus and tacrolimus do not accelerate photocarcinogenesis in hairless mice after UVA or simulated solar radiation. *Exp Dermatol.* 2009;18:246-251.
188. Nistico SP, Saraceno R, Capriotti E, et al. Efficacy of monochromatic excimer light (308 nm) in the treatment of atopic dermatitis in adults and children. *Photomed Laser Surg.* 2008;26:14-18.
189. Baltás E, Csoma Z, Bodai L, et al. Treatment of atopic dermatitis with the xenon chloride excimer laser. *J Eur Acad Dermatol Venereol.* 2006;20:657-660.
190. Mavilia L, Mori M, Rossi R, et al. 308 nm monochromatic excimer light in dermatology: personal experience and review of the literature. *G Ital Dermatol Venereol.* 2008;143:329-337.
191. Atherton DJ, Carabott F, Glover MT, et al. The role of psoralen photochemotherapy (PUVA) in the treatment of severe atopic eczema in adolescents. *Br J Dermatol.* 1988;118:791-795.
192. Morison WL, Parrish J, Fitzpatrick TB. Oral psoralen photochemotherapy of atopic eczema. *Br J Dermatol.* 1978;98:25-30.
193. Uetsu N, Horio T. Treatment of persistent severe atopic dermatitis in 113 Japanese patients with oral psoralen photo-chemotherapy. *J Dermatol.* 2003;30:450-457.
194. Sheehan MP, Atherton DJ, Norris P, et al. Oral psoralen photochemotherapy in severe childhood atopic eczema: an update. *Br J Dermatol.* 1993;129:431-436.
195. de Kort WJ, van Weelden H. Bath psoralen-ultraviolet A therapy in atopic eczema. *J Eur Acad Dermatol Venereol.* 2000;14:172-174.
196. Ogawa H, Yoshiike T. Atopic dermatitis: studies of skin permeability and effectiveness of topical PUVA treatment. *Pediatr Dermatol.* 1992;9:383-385.
197. Yoshiike T, Sindhvananda J, Aikawa Y, et al. Topical psoralen photochemotherapy for atopic dermatitis: evaluation of two therapeutic regimens for inpatients and outpatients. *J Dermatol.* 1991;18: 201-205.
198. Kowalzick L, Kleinheinz A, Weichenthal M, et al. Low dose versus medium dose UV-A1 treatment in severe atopic eczema. *Acta Derm Venereol.* 1995;75: 43-45.
199. Abeck D, Schmidt T, Fesq H, et al. Long-term efficacy of medium-dose UVA1 phototherapy in atopic dermatitis. *J Am Acad Dermatol.* 2000;42:254-257.
200. Legat FJ, Hofer A, Brabek E, et al. Narrowband UV-B vs medium-dose UV-A1 phototherapy in chronic atopic dermatitis. *Arch Dermatol.* 2003;139:223-224.

201. Gilchrest BA, Parrish JA, Tanenbaum L, et al. Oral methoxsalen photochemotherapy of mycosis fungoides. *Cancer.* 1976;38:683-689.
202. Herrmann JJ, Roenigk HH Jr, Honigsmann H. Ultraviolet radiation for treatment of cutaneous T-cell lymphoma. *Hematol Oncol Clin North Am.* 1995;9:1077-1088.
203. Honigsmann H. Phototherapy for psoriasis. *Clin Exp Dermatol.* 2001;26:343-350.
204. Stadler R, Otte HG, Luger T, et al. Prospective randomized multicenter clinical trial on the use of interferon-2a plus acitretin versus interferon-2a plus PUVA in patients with cutaneous T-cell lymphoma stages I and II. *Blood.* 1998;92:3578-3581.
205. Rupoli S, Goteri G, Pulini S, et al. Long-term experience with low-dose interferon-alpha and PUVA in the management of early mycosis fungoides. *Eur J Haematol.* 2005;75:136-145.
206. McGinnis KS, Shapiro M, Vittorio CC, et al. Psoralen plus long-wave UV-A (PUVA) and bexarotene therapy: An effective and synergistic combined adjunct to therapy for patients with advanced cutaneous T-cell lymphoma. *Arch Dermatol.* 2003;139:771-775.
207. Weber F, Schmuth M, Sepp N, et al. Bath-water PUVA therapy with 8-methoxypsoralen in mycosis fungoides. *Acta Derm Venereol.* 2005;85:329-332.
208. Pabsch H, Rütten A, Von Stemm A, et al. Treatment of childhood mycosis fungoides with topical PUVA. *J Am Acad Dermatol.* 2002;47:557-561.
209. Pavlotsky F, Hodak E, Ben Amitay D, et al. Role of bath psoralen plus ultraviolet A in early-stage mycosis fungoides. *J Am Acad Dermatol.* 2014;71:536-541.
210. Ponte P, Serrao V, Apetato M. Efficacy of narrowband UVB vs. PUVA in patients with early-stage mycosis fungoides. *J Eur Acad Dermatol Venereol*. 2010;24(6):716-721.
211. Diederen PV, van Weelden H, Sanders CJ, et al. Narrowband UVB and psoralen-UVA in the treatment of early-stage mycosis fungoides: a retrospective study. *J Am Acad Dermatol.* 2003;48:215-219.
212. Gokdemir G, Barutcuoglu B, Sakiz D, et al. Narrowband UVB phototherapy for early-stage mycosis fungoides: evaluation of clinical and histopathological changes. *J Eur Acad Dermatol Venereol.* 2006;20:804-809.
213. Ahmad K, Rogers S, McNicholas PD, et al. Narrowband UVB and PUVA in the treatment of mycosis fungoides: a retrospective study. *Acta Derm Venereol.* 2007;87:413-417.
214. Ghodsi SZ, Hallaji Z, Balighi K, et al. Narrow-band UVB in the treatment of early stage mycosis fungoides: report of 16 patients. *Clin Exp Dermatol.* 2005;30:376-378.
215. Xiao T, Xia LX, Yang ZH, et al. Narrow-band ultraviolet B phototherapy for early stage mycosis fungoides. *Eur J Dermatol.* 2008;18:660-662.
216. Gathers RC, Scherschun L, Malick F, et al. Narrowband UVB phototherapy for early-stage mycosis fungoides. *J Am Acad Dermatol.* 2002;47:191-197.
217. Boztepe G, Sahin S, Ayhan M, et al. Narrowband ultraviolet B phototherapy to clear and maintain clearance in patients with mycosis fungoides. *J Am Acad Dermatol.* 2005;53:242-246.
218. Brazzelli V, Antoninetti M, Palazzini S, et al. Narrowband ultraviolet therapy in early-stage mycosis fungoides: study on 20 patients. *Photodermatol Photoimmunol Photomed.* 2007;23:229-233.
219. D'Acunto C, Gurioli C, Neri I. Plaque stage mycosis fungoides treated with bexarotene at low dosage and UVB-NB. *J Dermatolog Treat.* 2010;21(1):45-48.
220. Hegazy RA, Fawzy MM, Gawdat HI, et al. T helper 17 and Tregs: a novel proposed mechanism for NB-UVB in vitiligo. *Exp Dermatol.* 2014;23:283-286.
221. Karsli N, Akcali C, Ozgoztasi O, et al. Role of oxidative stress in the pathogenesis of vitiligo with special emphasis on the antioxidant action of narrowband ultraviolet B phototherapy. *J Int Med Res.* 2014;42:799-805.
222. Scherschun L, Kim JJ, Lim HW. Narrow-band ultraviolet B is a useful and well-tolerated treatment for vitiligo. *J Am Acad Dermatol.* 2001;44:999-1003.
223. Chen GY, Hsu MM, Tai HK, et al. Narrow-band UVB treatment of vitiligo in Chinese. *J Dermatol.* 2005;32:793-800.
224. Kanwar AJ, Dogra S, Parsad D, et al. Narrow-band UVB for the treatment of vitiligo: an emerging effective and well-tolerated therapy. *Int J Dermatol.* 2005;44:57-60.
225. Kanwar AJ, Dogra S. Narrow-band UVB for the treatment of generalized vitiligo in children. *Clin Exp Dermatol.* 2005;30:332-336.
226. Brazzelli V, Antoninetti M, Palazzini S, et al. Critical evaluation of the variants influencing the clinical response of vitiligo: study of 60 cases treated with ultraviolet B narrow-band phototherapy. *J Eur Acad Dermatol Venereol*. 2007;21:1369-1374.
227. Westerhof W, Nieuweboer-Krobotova L. Treatment of vitiligo with UV-B radiation vs topical psoralen plus UV-A. *Arch Dermatol.* 1997;133:1525-1528.
228. Anbar TS, Westerhof W, Abdel-Rahman AT, et al. Evaluation of the effects of NB-UVB in both segmental and non-segmental vitiligo affecting different body sites. *Photodermatol Photoimmunol Photomed.* 2006;22:157-163.
229. Nicolaidou E, Antoniou C, Stratigos AJ, et al. Efficacy, predictors of response, and long-term follow-up in patients with vitiligo treated with narrowband UVB phototherapy. *J Am Acad Dermatol.* 2007;56:274-278.
230. Hamzavi I, Jain H, McLean D, et al. Parametric modeling of narrowband UV-B phototherapy for vitiligo using a novel quantitative tool: the Vitiligo Area Scoring Index. *Arch Dermatol.* 2004;140:677-683.
231. Njoo MD, Bos JD, Westerhof W. Treatment of generalized vitiligo in children with narrow-band (TL-01) UVB radiation therapy. *J Am Acad Dermatol.* 2000;42:245-253.
232. Natta R, Somsak T, Wisuttida T, et al. Narrowband ultraviolet B radiation therapy for recalcitrant vitiligo in Asians. *J Am Acad Dermatol.* 2003;49:473-476.
233. Sitek JC, Loeb M, Ronnevig JR. Narrowband UVB therapy for vitiligo: does the repigmentation last? *J Eur Acad Dermatol Venereol.* 2007;21:891-896.
234. Nordal EJ, Guleng GE, Ronnevig JR. Treatment of vitiligo with narrowband-UVB (TL01) combined with tacrolimus ointment (0.1%) vs. placebo ointment, a randomized right/left double-blind comparative study. *J Eur Acad Dermatol Venereol.* 2011;25:1440-1443.
235. Lee KY, Jeon SY, Hong JW, et al. Endothelin-1 enhances the proliferation of normal human melanocytes in a paradoxical manner from the TNF-α-inhibited condition, but tacrolimus promotes exclusively the cellular migration without proliferation: a proposed action mechanism for combination

therapy of phototherapy and topical tacrolimus in vitiligo treatment. *J Eur Acad Dermatol Venereol.* 2013;27:609-616.
236. Dang YP, Li Q, Shi F, et al. Effect of topical calcineurin inhibitors as monotherapy or combined with phototherapy for vitiligo treatment: a meta-analysis. *Dermatol Ther.* 2016;29:126-133.
237. Schallreuter KU, Wood JM, Lemke KR, et al. Treatment of vitiligo with a topical application of pseudocatalase and calcium in combination with short-term UVB exposure: a case study on 33 patients. *Dermatology.* 1995;190:223-229.
238. Bakis-Petsoglou S, Le Guay JL, Wittal R. A randomized, double-blinded, placebo-controlled trial of pseudocatalase cream and narrowband ultraviolet B in the treatment of vitiligo. *Br J Dermatol.* 2009;161:910-917.
239. Schallreuter KU, Salem MA, Holtz S, et al. Basic evidence for epidermal H2O2/ONOO(-)-mediated oxidation/nitration in segmental vitiligo is supported by repigmentation of skin and eyelashes after reduction of epidermal H2O2 with topical NB-UVB-activated pseudocatalase PC-KUS. *FASEB J.* 2013;27:3113-3122.
240. Bayoumi W, Fontas E, Sillard L, et al. Effect of a preceding laser dermabrasion on the outcome of combined therapy with narrowband ultraviolet B and potent topical steroids for treating nonsegmental vitiligo in resistant localizations. *Br J Dermatol.* 2012;166:208-211.
241. Choi KH, Park JH, Ro YS. Treatment of Vitiligo with 308-nm xenon-chloride excimer laser: therapeutic efficacy of different initial doses according to treatment areas. *J Dermatol.* 2004;31:284-292.
242. Baltás E, Nagy P, Bónis B, et al. Repigmentation of localized vitiligo with the xenon chloride laser. *Br J Dermatol.* 2001;144:1266-1267.
243. Spencer JM, Nossa R, Ajmeri J. Treatment of vitiligo with the 308-nm excimer laser: a pilot study. *J Am Acad Dermatol.* 2002;46:727-731.
244. Taneja A, Trehan M, Taylor CR. 308-nm excimer laser for the treatment of localized vitiligo. *Int J Dermatol.* 2003;42:658-662.
245. Alhowaish AK, Dietrich N, Onder M, et al. Effectiveness of a 308-nm excimer laser in treatment of vitiligo: a review. *Lasers Med Sci.* 2013;28:1035-1041.
246. Passeron T, Ortonne JP. Use of the 308-nm excimer laser for psoriasis and vitiligo. *Clin Dermatol.* 2006;24:33-42.
247. Hofer A, Hassan AS, Legat FJ, et al. Optimal weekly frequency of 308-nm excimer laser treatment in vitiligo patients. *Br J Dermatol.* 2005;152:981-985.
248. Linthorst Homan MW, Spuls PI, Nieuweboer-Krobotova L, et al. A randomized comparison of excimer laser versus narrow-band ultraviolet B phototherapy after punch grafting in stable vitiligo patients. *J Eur Acad Dermatol Venereol.* 2012;26:690-695.
249. Ostovari N, Passeron T, Zakaria W, et al. Treatment of vitiligo by 308-nm excimer laser: an evaluation of variables affecting treatment response. *Lasers Surg Med.* 2004;35:152-156.
250. Esposito M, Soda R, Costanzo A, et al. Treatment of vitiligo with the 308 nm excimer laser. *Clin Exp Dermatol.* 2004;29:133-137.
251. Hofer A, Hassan AS, Legat FJ, et al. The efficacy of excimer laser (308 nm) for vitiligo at different body sites. *J Eur Acad Dermatol Venereol*. 2006;20:558-564.
252. Hadi S, Tinio P, Al-Ghaithi K, et al. Treatment of vitiligo using the 308-nm excimer laser. *Photomed Laser Surg*. 2006;24:354-357.
253. Soliman M, Samy NA, Abo Eittah M, et al. Comparative study between excimer light and topical antioxidant versus excimer light alone for treatment of vitiligo. *J Cosmet Laser Ther.* 2016;18:7-11.
254. Grimes PE, Minus HR, Chakrabarti SG, et al. Determination of optimal topical photochemotherapy for vitiligo. *J Am Acad Dermatol.* 1982;7:771-778.
255. Westerhof W, Nieuweboer-Krobotova L, Mulder PG, et al. Left-right comparison study of the combination of fluticasone propionate and UV-A vs. either fluticasone propionate or UV-A alone for the long-term treatment of vitiligo. *Arch Dermatol.* 1999;135:1061-1066.
256. Andres C, Kollmar A, Mempel M, et al. Successful ultraviolet A1 phototherapy in the treatment of localized scleroderma: a retrospective and prospective study. *Br J Dermatol.* 2010;162:445-447.
257. Kreuter A, Hyun J, Stücker M, et al. A randomized controlled study of low-dose UVA1, medium-dose UVA1, and narrowband UVB phototherapy in the treatment of localized scleroderma. *J Am Acad Dermatol.* 2006;54:440-447.
258. Kerscher M, Volkenandt M, Gruss C, et al. Low-dose UVA phototherapy for treatment of localized scleroderma. *J Am Acad Dermatol.* 1998;38:21-26.
259. Sator PG, Radakovic S, Schulmeister K, et al. Medium-dose is more effective than low-dose ultraviolet A1 phototherapy for localized scleroderma as shown by 20-MHz ultrasound assessment. *J Am Acad Dermatol.* 2009;60:786-791.
260. Morita A, Kobayashi K, Isomura I, et al. Ultraviolet A1 (340-400 nm) phototherapy for scleroderma in systemic sclerosis. *J Am Acad Dermatol.* 2000;43:670-674.
261. Wang F, Garza LA, Cho S, et al. Effect of increased pigmentation on the antifibrotic response of human skin to UV-A1 phototherapy. *Arch Dermatol.* 2008;144:851-858.
262. Vasquez R, Jabbar A, Khan F, et al. Recurrence of morphea after successful ultraviolet A1 phototherapy: a cohort study. *J Am Acad Dermatol.* 2014;70:481-488.
263. Gruss C, Reed JA, Altmeyer P, et al. Induction of interstitial collagenase (MMP-1) by UVA-1 phototherapy in morphea fibroblasts. *Lancet.* 1997;350:1295-1296.
264. Kreuter A, Hyun J, Skrygan M, et al. Ultraviolet A1 phototherapy decreases inhibitory SMAD7 gene expression in localized scleroderma. *Arch Dermatol Res.* 2006;298:265-272.
265. Gambichler T, Skrygan M, Tomi NS, et al. Significant downregulation of transforming growth factor-beta signal transducers in human skin following ultraviolet-A1 irradiation. *Br J Dermatol.* 2007;156:951-956.
266. Quan T, He T, Kang S, et al. Ultraviolet irradiation alters transforming growth factor beta/smad pathway in human skin in vivo. *J Invest Dermatol.* 2002;119:499-506.
267. Kreuter A, Hyun J, Skrygan M, et al. Ultraviolet A1-induced downregulation of human beta-defensins and interleukin-6 and interleukin-8 correlates with clinical improvement in localized scleroderma. *Br J Dermatol.* 2006;155:600-607.
268. von Kobyletzki G, Uhle A, Pieck C, et al. Acrosclerosis in patients with systemic sclerosis responds

to low-dose UV-A1 phototherapy. *Arch Dermatol.* 2000;136; 275-276.
269. Tewari A, Garibaldinos T, Lai-Cheong J, et al. Successful treatment of microstomia with UVA1 phototherapy in systemic sclerosis. *Photodermatol Photoimmunol Photomed.* 2011;27:113-114.
270. Kanekura T, Fukumaru S, Matsushita S, et al. Successful treatment of scleroderma with PUVA therapy. *J Dermatol.* 1996;23:455-459.
271. Scharffetter-Kochanek K, Goldermann R, Lehmann P, et al. PUVA therapy in disabling pansclerotic morphoea of children. *Br J Dermatol.* 1995;132:830-831.
272. Todd DJ, Askari A, Ektaish E. PUVA therapy for disabling pansclerotic morphoea of children. *Br J Dermatol.* 1998;138:201-202.
273. Morita A, Sakakibara S, Sakakibara N, et al. Successful treatment of systemic sclerosis with topical PUVA. *J Rheumatol.* 1995;22:2361-2365.
274. Grundmann-Kollmann M, Ochsendorf F, Zollner TM, et al. PUVA-cream photochemotherapy for the treatment of localized scleroderma. *J Am Acad Dermatol.* 2000;43:675-678.
275. Brazzelli V, Grasso V, Muzio F, et al. Narrowband ultraviolet B phototherapy in the treatment of cutaneous graft-versus-host disease in oncohaematological paediatric patients. *Br J Dermatol.* 2010; 162:404-409.
276. Grundmann-Kollmann M, Martin H, Ludwig R, et al. Narrowband UV-B phototherapy in the treatment of cutaneous graft versus host disease. *Transplantation.* 2002;74:1631-1634.
277. Vogelsang GB, Wolff D, Altomonte V, et al. Treatment of chronic graft-versus-host disease with ultraviolet irradiation and psoralen (PUVA). *Bone Marrow Transplant.* 1996;17:1061-1067.
278. Jampel RM, Farmer ER, Vogelsang GB, et al. PUVA therapy for chronic cutaneous graft-vs-host disease. *Arch Dermatol.* 1991;127:1673-1678.
279. Wiesmann A, Weller A, Lischka G, et al. Treatment of acute graft-versus-host disease with PUVA (psoralen and ultraviolet irradiation): results of a pilot study. *Bone Marrow Transplant.* 1999;23:151-155.
280. Eppinger T, Ehninger G, Steinert M, et al. 8-Methoxypsoralen and ultraviolet A therapy for cutaneous manifestations of graft-versus-host disease. *Transplantation.* 1990;50:807-811.
281. Atkinson K, Weller P, Ryman W, et al. PUVA therapy for drug-resistant graft-versus-host disease. *Bone Marrow Transplant.* 1986;1:227-236.
282. Hoffner MV, Carrizosa Esquivel A, Pulpillo Ruiz A, et al. Two cases of cutaneous chronic graft versus host disease in treatment with psoralen plus ultraviolet-A-bath photochemotherapy. *J Drugs Dermatol.* 2009; 8:1027-1029.
283. Leiter U, Kaskel P, Krähn G, et al. Psoralen plus ultraviolet-A-bath photochemotherapy as an adjunct treatment modality in cutaneous chronic graft versus host disease. *Photodermatol Photoimmunol Photomed.* 2002;18:183-190.
284. Calzavara Pinton P, Porta F, Izzi T, et al. Prospects for ultraviolet A1 phototherapy as a treatment for chronic cutaneous graft-versus-host disease. *Haematologica.* 2003;88:1169-1175.
285. Wetzig T, Sticherling M, Simon JC, et al. Medium dose long-wavelength ultraviolet A (UVA1) phototherapy for the treatment of acute and chronic graft-versus-host disease of the skin. *Bone Marrow Transplant.* 2005;35:515-519.
286. Ziemer M, Thiele JJ, Gruhn B, et al. Chronic cutaneous graft-versus-host disease in two children responds to UVA1 therapy: improvement of skin lesions, joint mobility, and quality of life. *J Am Acad Dermatol.* 2004;51:318-319.
287. Ghoreschi K, Thomas P, Penovici M, et al. PUVA-bath photochemotherapy and isotretinoin in sclerodermatous graft-versus-host disease. *Eur J Dermatol.* 2008;18:667-670.
288. Sorenson E, McAndrew R, Patel V, et al. Narrowband UV-B phototherapy for steroid-refractory sclerotic chronic cutaneous graft-vs-host disease. *JAMA Dermatol.* 2015;151:635-637.
289. Kreuter A, Gambichler T, Weiner SM, et al. Limited effects of UV-A1 phototherapy in 3 patients with nephrogenic systemic fibrosis. *Arch Dermatol.* 2008;144:1527-1529.
290. Gilchrest BA, Rowe JW, Brown RS, et al. Relief of uremic pruritus with ultraviolet phototherapy. *N Engl J Med.* 1977;297:136-138.
291. Gilchrest BA. Ultraviolet phototherapy of uremic pruritus. *Int J Dermatol.* 1979;18:741-748.
292. Simpson NB, Davison AM. Ultraviolet phototherapy for uraemic pruritus. *Lancet.* 1981;1:781.
293. Hsu MM, Yang CC. Uraemic pruritus responsive to broadband ultraviolet (UV) B therapy does not readily respond to narrowband UVB therapy. *Br J Dermatol.* 2003;149:888-889.
294. Hanid MA, Levi AJ. Phototherapy for pruritus in primary biliary cirrhosis. *Lancet.* 1980;2:530.
295. Perlstein SM. Phototherapy for primary biliary cirrhosis. *Arch Dermatol.* 1981;117:608.
296. Person JR. Ultraviolet A (UV-A) and cholestatic pruritus. *Arch Dermatol.* 1981;117:684.
297. Cerio R, Murphy GM, Sladen GE, et al. A combination of phototherapy and cholestyramine for the relief of pruritus in primary biliary cirrhosis. *Br J Dermatol.* 1987;116:265-267.
298. Holme SA, Anstey AV. Aquagenic pruritus responding to intermittent photochemotherapy. *Clin Exp Dermatol.* 2001;26:40-41.
299. Menage HD, Norris PG, Hawk JL, et al. The efficacy of psoralen photochemotherapy in the treatment of aquagenic pruritus. *Br J Dermatol.* 1993;129: 163-165.
300. Goodkin R, Bernhard JD. Repeated PUVA treatment of aquagenic pruritus. *Clin Exp Dermatol.* 2002;27: 164-165.
301. Baldo A, Sammarco E, Plaitano R, et al. Narrowband (TL-01) ultraviolet B phototherapy for pruritus in polycythaemia vera. *Br J Dermatol.* 2002;147:979-981.
302. Hernandez-Nunez A, Dauden E, Cordoba S, et al. Water-induced pruritus in haematologically controlled polycythaemia vera: response to phototherapy. *J Dermatolog Treat.* 2001;12:107-109.
303. Jeanmougin M, Rain JD, Najean Y. Efficacy of photochemotherapy on severe pruritus in polycythemia vera. *Ann Hematol.* 1996;73:91-93.
304. Swerlick RA. Photochemotherapy treatment of pruritus associated with polycythemia vera. *J Am Acad Dermatol.* 1985;13:675-677.
305. Morison WL, Nesbitt JA 3rd. Oral psoralen photochemotherapy (PUVA) for pruritus associated with polycythemia vera and myelofibrosis. *Am J Hematol.* 1993;42:409-410.
306. Kuwano Y, Watanabe R, Fujimoto M, et al. Treatment of HIV-associated eosinophilic pustular

folliculitis with narrow-band UVB. *Int J Dermatol.* 2006;45:1265-1267.
307. Misago N, Narisawa Y, Matsubara S, et al. HIV-associated eosinophilic pustular folliculitis: successful treatment of a Japanese patient with UVB phototherapy. *J Dermatol.* 1998;25:178-184.
308. Ho MH, Chong LY, Ho TT. HIV-associated eosinophilic folliculitis in a Chinese woman: a case report and a survey in Hong Kong. *Int J STD AIDS.* 1998;9:489-493.
309. Parker SR, Parker DC, McCall CO. Eosinophilic folliculitis in HIV-infected women: case series and review. *Am J Clin Dermatol.* 2006;7:193-200.
310. Ellis E, Scheinfeld N. Eosinophilic pustular folliculitis: a comprehensive review of treatment options. *Am J Clin Dermatol.* 2004;5:189-197.
311. Aydogan K, Karadogan SK, Tunali S, et al. Narrowband ultraviolet B (311 nm, TL01) phototherapy in chronic ordinary urticaria. *Int J Dermatol.* 2012;51:98-103.
312. Dummer R, Ivanova K, Scheidegger EP, et al. Clinical and therapeutic aspects of polymorphous light eruption. *Dermatology.* 2003;207:93-95.
313. Boonstra HE, van Weelden H, Toonstra J, et al. Polymorphous light eruption: a clinical, photobiologic, and follow-up study of 110 patients. *J Am Acad Dermatol.* 2000;42:199-207.
314. Bilsland D, George SA, Gibbs NK, et al. A comparison of narrow band phototherapy (TL-01) and photochemotherapy (PUVA) in the management of polymorphic light eruption. *Br J Dermatol.* 1993;129:708-712.
315. Murphy GM, Logan RA, Lovell CR, et al. Prophylactic PUVA and UVB therapy in polymorphic light eruption—a controlled trial. *Br J Dermatol.* 1987;116:531-538.
316. Gschnait F, Honigsmann H, Brenner W, et al. Induction of UV light tolerance by PUVA in patients with polymorphous light eruption. *Br J Dermatol.* 1978;99:293-295.
317. Wolf P, Gruber-Wackernagel A, Rinner B, et al. Phototherapeutic hardening modulates systemic cytokine levels in patients with polymorphic light eruption. *Photochem Photobiol Sci.* 2013;12:166-173.
318. Gruber-Wackernagel A, Heinemann A, Konya V, et al. Photohardening restores the impaired neutrophil responsiveness to chemoattractants leukotriene B4 and formyl-methionyl-leucyl-phenylalanin in patients with polymorphic light eruption. *Exp Dermatol.* 2011;20:473-476.
319. Schweintzger N, Gruber-Wackernagel A, Reginato E, et al. Levels and function of regulatory T cells in patients with polymorphic light eruption: relation to photohardening. *Br J Dermatol.* 2015;173:519-526.
320. Wolf P, Gruber-Wackernagel A, Bambach I, et al. Photohardening of polymorphic light eruption patients decreases baseline epidermal Langerhans cell density while increasing mast cell numbers in the papillary dermis. *Exp Dermatol.* 2014;23:428-430.
321. Franken SM, Genders RE, de Gruijl FR, et al. Skin hardening effect in patients with polymorphic light eruption: comparison of UVB hardening in hospital with a novel home UV-hardening device. *J Eur Acad Dermatol Venereol.* 2013;27:67-72.
322. Dawe RS, Ferguson J. Prolonged benefit following ultraviolet A phototherapy for solar urticaria. *Br J Dermatol.* 1997;137:144-148.
323. Ryckaert S, Roelandts R. Solar urticaria. A report of 25 cases and difficulties in phototesting. *Arch Dermatol.* 1998;134:71-74.
324. Ramsay CA. Solar urticaria treatment by inducing tolerance to artificial radiation and natural light. *Arch Dermatol.* 1977;113:1222-1225.
325. Calzavara-Pinton P, Zane C, Rossi M, et al. Narrowband ultraviolet B phototherapy is a suitable treatment option for solar urticaria. *J Am Acad Dermatol.* 2012;67:e5-e9.
326. Bernhard JD, Jaenicke K, Momtaz TK, et al. Ultraviolet A phototherapy in the prophylaxis of solar urticaria. *J Am Acad Dermatol.* 1984;10:29-33.
327. Parrish JA, Jaenicke KF, Morison WL, et al. Solar urticaria: treatment with PUVA and mediator inhibitors. *Br J Dermatol.* 1982;106:575-580.
328. Beissert S, Stander H, Schwarz T. UVA rush hardening for the treatment of solar urticaria. *J Am Acad Dermatol.* 2000;42:1030-1032.
329. Roelandts R. Diagnosis and treatment of solar urticaria. *Dermatol Ther.* 2003;16:52-56.
330. Crouch R, Foley P, Baker C. Actinic prurigo: a retrospective analysis of 21 cases referred to an Australian photobiology clinic. *Australas J Dermatol.* 2002;43:128-132.
331. Honigsmann H. Mechanisms of phototherapy and photochemotherapy for photodermatoses. *Dermatol Ther.* 2003;16:23-27.
332. Pavlotsky F, Nathansohn N, Kriger G, et al. Ultraviolet-B treatment for cutaneous lichen planus: our experience with 50 patients. *Photodermatol Photoimmunol Photomed.* 2008;24:83-86.
333. Taneja A, Taylor CR. Narrow-band UVB for lichen planus treatment. *Int J Dermatol.* 2002;41:282-283.
334. Saricaoglu H, Karadogan SK, Baskan EB, et al. Narrowband UVB therapy in the treatment of lichen planus. *Photodermatol Photoimmunol Photomed.* 2003;19:265-267.
335. Helander I, Jansen CT, Meurman L. Long-term efficacy of PUVA treatment in lichen planus: comparison of oral and external methoxsalen regimens. *Photodermatol.* 1987;4:265-268.
336. Carlin CS, Florell SR, Krueger GG. Induction of dramatic hyperpigmentation in a patient with generalized lichen planus treated with re-PUVA. *J Cutan Med Surg.* 2002;6:125-127.
337. Wackernagel A, Legat FJ, Hofer A, et al. Psoralen plus UVA vs. UVB-311 nm for the treatment of lichen planus. *Photodermatol Photoimmunol Photomed.* 2007;23:15-19.
338. Nanda S, Grover C, Reddy BS. PUVA-induced lichen planus. *J Dermatol.* 2003;30:151-153.
339. Kuramoto N, Kishimoto S, Shibagaki R, et al. PUVA-induced lichen planus pemphigoides. *Br J Dermatol.* 2000;142:509-512.
340. Kassem R, Yarom N, Scope A, et al. Treatment of erosive oral lichen planus with local ultraviolet B phototherapy. *J Am Acad Dermatol.* 2012;66:761-766.
341. Sezer E, Etikan I. Local narrowband UVB phototherapy vs. local PUVA in the treatment of chronic hand eczema. *Photodermatol Photoimmunol Photomed.* 2007;23:10-14.
342. Schempp CM, Muller H, Czech W, et al. Treatment of chronic palmoplantar eczema with local bath-PUVA therapy. *J Am Acad Dermatol.* 1997;36:733-737.
343. Behrens S, Grundmann-Kollmann M, Peter RU, et al. Combination treatment of psoriasis with

photochemotherapy and tazarotene gel, a receptor-selective topical retinoid. *Br J Dermatol.* 1999;141:177.
344. Douwes KE, Karrer S, Abels C, et al. Does smoking influence the efficacy of bath-PUVA therapy in chronic palmoplantar eczema? *Photodermatol Photoimmunol Photomed.* 2000;16:25-29.
345. Tzaneva S, Kittler H, Holzer G, et al. 5-Methoxypsoralen plus ultraviolet (UV) A is superior to medium-dose UVA1 in the treatment of severe atopic dermatitis: a randomized crossover trial. *Br J Dermatol.* 2010;162(3):655-660.
346. LeVine MJ, Parrish JA, Fitzpatrick TB. Oral methoxsalen photochemotherapy (PUVA) of dyshidrotic eczema. *Acta Derm Venereol.* 1981;61:570-571.
347. Petering H, Breuer C, Herbst R, et al. Comparison of localized high-dose UVA1 irradiation versus topical cream psoralen-UVA for treatment of chronic vesicular dyshidrotic eczema. *J Am Acad Dermatol.* 2004;50:68-72.
348. Schmidt T, Abeck D, Boeck K, et al. UVA1 irradiation is effective in treatment of chronic vesicular dyshidrotic hand eczema. *Acta Derm Venereol.* 1998;78:318-319.
349. Ersoy-Evans S, Hapa AA, Boztepe G, et al. Narrowband ultraviolet-B phototherapy in pityriasis lichenoides chronica. *J Dermatolog Treat.* 2009;20: 109-113.
350. Pavlotsky F, Baum S, Barzilai A, et al. UVB therapy of pityriasis lichenoides—our experience with 29 patients. *J Eur Acad Dermatol Venereol*. 2006;20:542-547.
351. Aydogan K, Saricaoglu H, Turan H. Narrowband UVB (311 nm, TL01) phototherapy for pityriasis lichenoides. *Photodermatol Photoimmunol Photomed.* 2008;24:128-133.
352. Lange-Wantzin G, Thomsen K, Hou-Jensen K. Lymphomatoid papulosis: a follow-up study. *Acta Derm Venereol.* 1984;64:46-51.
353. Thomsen K, Wantzin GL. Lymphomatoid papulosis. A follow-up study of 30 patients. *J Am Acad Dermatol.* 1987;17:632-636.
354. Hoetzenecker W, Guenova E, Hoetzenecker K, et al. Successful treatment of recalcitrant lymphomatoid papulosis in a child with PUVA-bath photochemotherapy. *Eur J Dermatol.* 2009;19:646-647.
355. Volkenandt M, Kerscher M, Sander C, et al. PUVA-bath photochemotherapy resulting in rapid clearance of lymphomatoid papulosis in a child. *Arch Dermatol.* 1995;131:1094.
356. Kontos AP, Kerr HA, Malick F, et al. 308-nm excimer laser for the treatment of lymphomatoid papulosis and stage IA mycosis fungoides. *Photodermatol Photoimmunol Photomed.* 2006;22:168-171.
357. Calzavara-Pinton P, Venturini M, Sala R. Medium-dose UVA1 therapy of lymphomatoid papulosis. *J Am Acad Dermatol.* 2005;52:530-532.
358. Sotiriou E, Apalla Z, Ioannides D. Telangiectasia macularis eruptive perstans successfully treated with PUVA therapy. *Photodermatol Photoimmunol Photomed.* 2010;26:46-47.
359. Martin LK, Romanelli P, Ahn YS, et al. Telangiectasia macularis eruptiva perstans with an associated myeloproliferative disorder. *Int J Dermatol.* 2004;43:922-924.
360. Metcalfe DD. The treatment of mastocytosis: an overview. *J Invest Dermatol.* 1991;96:S55-S56; discussion S56-S59, S60-S65.
361. Gobello T, Mazzanti C, Sordi D, et al. Medium- versus high-dose ultraviolet A1 therapy for urticaria pigmentosa: a pilot study. *J Am Acad Dermatol.* 2003;49:679-684.
362. Rombold S, Lobisch K, Katzer K, et al. Efficacy of UVA1 phototherapy in 230 patients with various skin diseases. *Photodermatol Photoimmunol Photomed.* 2008;24:19-23.
363. Kolde G, Frosch PJ, Czarnetzki BM. Response of cutaneous mast cells to PUVA in patients with urticaria pigmentosa: histomorphometric, ultrastructural, and biochemical investigations. *J Invest Dermatol.* 1984;83:175-178.
364. Brazzelli V, Grasso V, Manna G, et al. Indolent systemic mastocytosis treated with narrow-band UVB phototherapy: study of five cases. *J Eur Acad Dermatol Venereol*. 2012;26:465-469.
365. Brazzelli V, Grassi S, Merante S, et al. Narrow-band UVB phototherapy and psoralen-ultraviolet A photochemotherapy in the treatment of cutaneous mastocytosis: a study in 20 patients. *Photodermatol Photoimmunol Photomed.* 2016;32(5-6):238-246.
366. Kerker BJ, Huang CP, Morison WL. Photochemotherapy of generalized granuloma annulare. *Arch Dermatol.* 1990;126:359-361.
367. Szegedi A, Begany A, Hunyadi J. Successful treatment of generalized granuloma annulare with polyethylene sheet bath PUVA. *Acta Derm Venereol.* 1999;79:84-85.
368. Batchelor R, Clark S. Clearance of generalized papular umbilicated granuloma annulare in a child with bath PUVA therapy. *Pediatr Dermatol.* 2006;23:72-74.
369. Grundmann-Kollmann M, Ochsendorf FR, Zollner TM, et al. Cream psoralen plus ultraviolet A therapy for granuloma annulare. *Br J Dermatol.* 2001;144:996-999.
370. Schnopp C, Tzaneva S, Mempel M, et al. UVA1 phototherapy for disseminated granuloma annulare. *Photodermatol Photoimmunol Photomed.* 2005;21: 68-71.
371. Solano-Lopez G, Concha-Garzon MJ, de Argila D, et al. Successful treatment of disseminated granuloma annulare with narrowband UV-B phototherapy. *Actas Dermosifiliogr.* 2015;106:240-241.
372. Ohe S, Danno K, Sasaki H, et al. Treatment of acquired perforating dermatosis with narrowband ultraviolet B. *J Am Acad Dermatol.* 2004;50:892-894.
373. Serrano G, Aliaga A, Lorente M. Reactive perforating collagenosis responsive to PUVA. *Int J Dermatol.* 1988;27:118-119.
374. Krutmann J, Hönigsmann H, Elmets C, eds. *Dermatological Phototherapy and Photodiagnostic Methods*. 2nd ed. Berlin, Germany: Springer-Verlag; 2009.

Chapter 199 :: Photochemotherapy and Photodynamic Therapy

:: Herbert Hönigsmann, Rolf-Markus Szeimies, & Robert Knobler

AT-A-GLANCE

- Photochemotherapy (psoralen and ultraviolet A light [PUVA]) has been successfully used for more than 40 years. Its effectiveness has profoundly influenced dermatologic therapy in general, providing treatment for many diverse disorders besides psoriasis and vitiligo.
- PUVA can be combined with topical treatments and with some systemic agents (retinoids, methotrexate, and, perhaps, biologics) to enhance efficacy and to reduce the number of exposures.
- The most important adverse effects of oral PUVA consist of an increased risk of squamous cell carcinoma and a possible risk of melanoma. No such increased risk was found so far with bath-PUVA.
- Extracorporeal photochemotherapy (ECP) was introduced in the 1980s for the palliative treatment of erythrodermic cutaneous T-cell lymphoma.
- ECP appears to have a major impact in the treatment of graft-versus-host disease after allogeneic bone marrow transplantation where it allows progressive reduction or even discontinuation of the concomitant immunosuppressive therapy without an increase in graft-versus-host disease activity. Several other indications are under investigation.
- No serious side effects have been reported with ECP.
- Photodynamic therapy (PDT) for skin tumors started with the introduction of topical photosensitization by a porphyrin precursor (5-aminolevulinic acid or its methyl ester) that would avoid generalized light sensitivity over many weeks.
- Current experience with PDT of epithelial cancers and precancerous conditions suggests that actinic keratoses, Bowen disease, superficial and nodular basal cell carcinomas, and early squamous cell carcinomas can be treated curatively.
- Cosmetic outcomes following PDT are excellent; therefore, it is also used for rejuvenation purposes, frequently in combination with laser treatment.
- The only significant side effect of topical PDT is a stinging pain during and shortly after irradiation. With daylight-mediated PDT, pain is no longer an issue. PDT has neither mutagenic nor carcinogenic potential.

PHOTOCHEMOTHERAPY

Photochemotherapy with psoralens combines the use of oral or topical psoralens (P) and ultraviolet A radiation (UVA), termed *PUVA*. Psoralens are phototoxic compounds that enter cells and then absorb photons to produce photochemical reactions that alter the function of cellular constituents.[1] This interaction results in a beneficial therapeutic effect after repeated controlled phototoxic reactions. Psoralens can be administered orally or applied topically to the skin in the form of solutions, creams, or baths. This therapy is currently used in the treatment of several common and uncommon skin diseases.

HISTORICAL BACKGROUND

In the 1970s, it was shown that orally administered 8-methoxypsoralen (8-MOP) and subsequent irradiation with artificial UVA was a highly effective treatment for psoriasis.[2,3] Psoralen baths (soaking in a dilute psoralen solution) and subsequent UVA exposure (bath-PUVA), which originated in Scandinavia,[4] is also being used in many European institutions. The effectiveness of all variants of PUVA has been widely confirmed and has profoundly influenced dermatologic therapy, in general, providing treatment for numerous disorders in addition to psoriasis (Table 199-1). A major advance in phototherapy was the development of fluorescent bulbs that emitted narrowband UVB radiation at 311 to 313 nm in the mid-1980s. This narrow spectrum is slightly inferior in clearing psoriasis or mycosis fungoides. However, because it is easier to perform and possibly safer than PUVA, it is now more frequently used in many phototherapy centers. Narrowband UVB phototherapy is also beneficial for a variety of other dermatoses that were previously treated with PUVA. Nevertheless, PUVA has remained the mainstay for recalcitrant diseases.

PRINCIPLES OF PHOTOCHEMOTHERAPY

The rationale for PUVA therapy is to induce remissions of skin diseases by repeated, controlled phototoxic reactions. These reactions occur only when psoralens are photoactivated by UVA. Because of the penetration

TABLE 199-1
Phototherapy-Responsive Diseases

THERAPY OF DISEASE	PREVENTION OF DISEASE SYMPTOMS
▪ Psoriasis	▪ Polymorphous light eruption
▪ Palmoplantar pustulosis	▪ Hydroa vacciniforme[a]
▪ Mycosis fungoides (stages IA, IB)	▪ Solar urticaria
▪ Vitiligo	▪ Erythropoietic protoporphyria[a]
▪ Atopic dermatitis	▪ Chronic actinic dermatitis[a]
▪ Generalized lichen planus	▪ Polymorphous light eruption
▪ Urticaria pigmentosa	▪ Hydroa vacciniforme[a]
▪ Cutaneous graft-versus-host disease	▪ Solar urticaria
▪ Generalized granuloma annulare	▪ Erythropoietic protoporphyria[a]
▪ Pityriasis lichenoides*	▪ Chronic actinic dermatitis[a]
▪ Lymphomatoid papulosis[a]	
▪ Pityriasis rubra pilaris[a]	
▪ Localized scleroderma[a]	
▪ Psoriasis	
▪ Palmoplantar pustulosis	
▪ Mycosis fungoides (stages IA, IB)	
▪ Vitiligo	
▪ Atopic dermatitis	

[a]Experience limited to small number of patients.

characteristics of UVA, absorption of photons is confined to the skin. However, there is also some evidence that PUVA may exert systemic effects through circulating lymphocytes affected while transiting through the skin. Clinically, PUVA-induced phototoxic reactions are characterized by a delayed sunburn-like erythema and inflammation.

PSORALENS

Three psoralens are used in PUVA therapy. Methoxsalen or 8-methoxysporalen (8-MOP), obtained from the seeds of a plant called *Ammi majus*, is most widely used and the only psoralen available in the United States. Bergapten or 5-methoxypsoralen (5-MOP) and trioxsalen or 4,5′,8-trimethylpsoralen (TMP) are available in Europe and elsewhere.

PSORALEN PHOTOCHEMISTRY[5-7]

Psoralens intercalate between apposing DNA base pairs in the double helix in the absence of UV radiation. Absorption of photons in the UVA range results in the formation of a 3,4- or 4,5-cyclobutane addition product (adduct) with pyrimidine bases of native DNA. In the first step of this photochemical reaction, a monofunctional adduct with thymine or cytosine is formed. Some psoralens, including 8-MOP, TMP, and 5-MOP, can absorb a second photon, and this reaction leads to the formation of a bifunctional adduct with a 5,6-double bond of the pyrimidine base of the opposite strand, thus producing an interstrand crosslink of the double helix (Fig. 199-1). This intercalation of psoralens with epidermal DNA suppresses both DNA synthesis and cell division, and it was originally assumed that this was the therapeutic mechanism in psoriasis. However, crosslinking does not appear to be a prerequisite for the therapeutic effect,[7] and successful PUVA treatment of other skin diseases is unlikely to be directly caused by this molecular reaction; psoralens also react with RNA, proteins, and other cellular components, and indirectly modify proteins and lipids via singlet oxygen-mediated reactions or by generating free radicals.[7] Perhaps these mechanisms contribute to the effects of PUVA in diseases that are not hyperproliferative in nature.

The formation of mono- and bifunctional photoadducts in DNA results in the immediate inhibition of DNA synthesis. The interstrand crosslinks are believed to be largely responsible for eliciting skin photosensitization reactions of linear psoralens such as 8-MOP. Excessive production of these cyclobutane adducts causes cell death. Mutation and skin carcinogenesis also result from photoconjugation of psoralens to DNA because the cells surviving this DNA damage tend to repair it through an error-prone repair process.[7]

In Type II reactions (Chap. 17), reactive oxygen species ($^1O_2$, O_2, or OH) induce the oxidation of cellular lipoprotein membrane lipids and destruction of membrane-bound cytochrome P450. The membrane-damaging events activate the arachidonic acid metabolism pathway, which results in an increase of secondary oxidation products that contribute to the increased synthesis of eicosanoids. Furthermore, the reactive oxygen species can directly damage DNA by generating DNA strand breaks.[7]

MECHANISMS OF PHOTOCHEMOTHERAPY

Hypotheses about the mechanism of action in psoriasis are based on the known photoconjugation of psoralens to DNA with subsequent suppression of mitosis, DNA synthesis, and cell proliferation, expected to revert increased cell proliferation rates in psoriasis to normal. However, PUVA also alters the expression of cytokines and cytokine receptors, downregulates certain lymphocyte and antigen-presenting cell functions, influences adhesion molecule expression, and diminishes Langerhans cell numbers within the epidermis. In addition, PUVA affects immune effector cells such as lymphocytes or polymorphonuclear leukocytes. Because there is evidence that psoriasis is caused primarily by the action of blood-derived immunocytes, it is reasonable to speculate that PUVA therapy may act by affecting immune function through a direct phototoxic effect on lymphocytes in skin infiltrates. This is consistent with the observation that several other disorders that are not hyperproliferative in nature but immunomediated also respond well to PUVA. PUVA can revert pathologically altered patterns of keratinocyte differentiation and reduce the number of proliferating epidermal cells. Infiltrating lymphocytes are

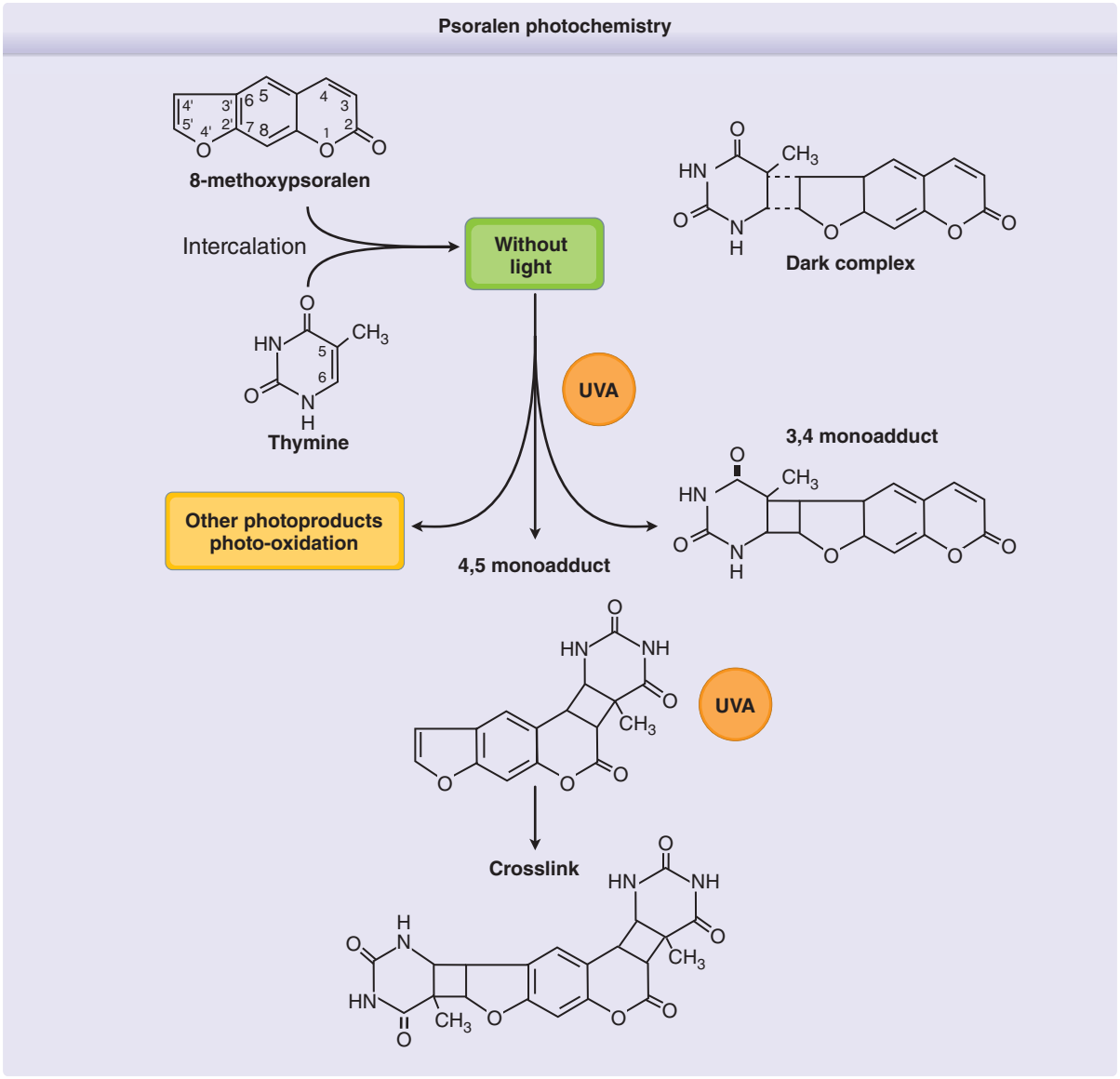

Figure 199-1 Psoralen photochemistry. Psoralens intercalate between apposing DNA base pairs forming a "dark complex." Absorption of ultraviolet A (UVA) photons leads to a 3,4- or 4,5-cyclobutane monoadduct with pyrimidine bases of native DNA. The absorption of a second photon results in a bifunctional adduct, producing an interstrand crosslink of the double helix.

strongly suppressed by PUVA, with variable effects on different T-cell subsets. Lymphocytes are far more likely to undergo apoptosis than keratinocytes[8] in response to PUVA, which may explain the high efficacy in cutaneous T-cell lymphoma (CTCL), as well as in inflammatory skin diseases including psoriasis that is now recognized to be in part T-cell mediated as well as hyperproliferative. Although much is known about pathways and mechanisms of psoralen photosensitization, the interactions and relative contributions to the clearing of a specific disease are not well understood.

Psoralens also stimulate melanogenesis. This involves the photoconjugation of psoralens to DNA in melanocytes, mitosis, and subsequent proliferation of melanocytes, an increased formation and melanization of melanosomes, an increased transfer of melanosomes to keratinocytes, and activation and increased synthesis of tyrosine mediated in part by stimulation of cAMP activity.

PHARMACOKINETICS

The important steps between the ingestion of a psoralen and its arrival at the site of action include absorption, first-pass effect, blood transportation, and tissue distribution. The absorption rate of a psoralen from the gut depends mainly on the physical characteristics of the preparation and the fat content of the concomitant food intake. Liquid preparations of 8-MOP and 5-MOP give higher and earlier peak serum levels than do crystalline formulations. In addition, peak serum levels are achieved by liquid preparations after a relatively reproducible time interval in all subjects, whereas wide time variability occurs with crystalline formulations. Before reaching the skin via the

circulation, psoralens are metabolized during passage through the liver. Plasma levels of 8-MOP administered orally at different doses show a strong nonlinearity, indicating a saturable first-pass effect. The unpredictable pharmacokinetic behavior is probably due to inter- and intraindividual variations of intestinal absorption, first-pass effect, blood distribution in the body, metabolism, and elimination of the drug.

Within the same individual, serum levels of 8-MOP correspond fairly well with skin reactivity, the peak of skin phototoxicity coinciding with peak serum levels. However, phototoxic responses to PUVA show large interindividual variations. Hence, measurement of serum psoralens is a research tool and not used to monitor clinical therapy.

The pharmacokinetics of 8-MOP after topical treatment depend on the method of application. 8-MOP topically applied as a 0.15% emulsion or solution leads to plasma levels comparable to those found with oral treatment if large areas of the body are treated. In contrast, plasma levels after bath-PUVA treatment of almost the total body surface are very low. Bathwater-delivered psoralens are readily absorbed in the skin but are promptly eliminated without cutaneous accumulation.[8]

ULTRAVIOLET A RADIATION

UVA sources commonly used for PUVA therapy are fluorescent lamps or high-pressure metal halide lamps. The typical fluorescent PUVA lamp has an emission peak at 352 nm and emits approximately 0.5% in the UVB range. UVA doses are given in Joules per centimeter-squared, usually measured with a photometer with a maximum sensitivity at 350 to 360 nm. Although the action spectrum of antipsoriatic activity and phototoxic erythema peaks at 335 nm, longer wavelengths have proved equally effective for clearing psoriasis if delivered in an adequate dose to obtain an equal erythemogenic response.[9]

PHOTOSENSITIVITY EFFECTS OF PHOTOCHEMOTHERAPY

PUVA treatment produces an inflammatory response that manifests as delayed phototoxic erythema, proportional to the dose of both drug and UVA and to the individual's sensitivity to phototoxic reactions. 8-MOP dose changes within individuals, over a narrow but clinically relevant range, appears to significantly alter the threshold for PUVA erythema, but not the rate of increase in erythema intensity with increasing UVA dose.[10] Importantly, the time course of PUVA erythema differs from sunburn or UVB erythema that appears after 4 to 6 hours and peaks 12 to 24 hours after exposure. PUVA erythema does not appear before 24 to 36 hours and peaks at 72 to 96 hours, or even later. Hence, daily PUVA treatments can result in unexpected severe delayed cumulative phototoxicity. PUVA erythema has a shallower dose-response curve than UVB erythema (by a factor of approximately 2), and this difference is maintained even at the point of maximum erythema.[11] Severe PUVA reactions may lead to blistering and to superficial skin necrosis. Overdoses of UVA are frequently followed by swelling, intense pruritus, and, sometimes, by a stinging sensation in the affected skin area, possibly as a consequence of damage of superficial nerve endings. Erythema is at present the only available parameter that allows an assessment of the magnitude of the PUVA reaction; thus, it represents an important criterion for dose adjustments.[9]

Pigmentation is the second important effect of PUVA. It may develop without clinically evident erythema, especially when oral 5-MOP or TMP is used; this is particularly important in the treatment of vitiligo and for the preventive therapy of certain photodermatoses. In unaffected skin, PUVA pigmentation is maximal approximately 7 days after a PUVA exposure and may last from several weeks to months. As with sun-induced pigmentation, the individual's ability to tan is genetically determined, but the dose-response curve is much steeper. A few PUVA exposures result in a much deeper tan than that produced by multiple exposures to solar radiation.

TREATMENT PROTOCOLS

TOPICAL TREATMENT

Application of 8-MOP in creams, ointments, or lotions followed by UVA irradiation is effective in clearing psoriasis but has several disadvantages. The nonuniform distribution on the skin surface induces unpredictable phototoxic erythema reactions and irregular patches of cosmetically unacceptable hyperpigmentation. Furthermore, if numerous lesions are present, the application is laborious and time consuming, and the treatment does not prevent the development of new active lesions in previously unaffected, untreated areas. Therefore, topical PUVA with psoralen creams, ointments, or lotions is now used only for limited plaque psoriasis and for palmoplantar disease.

BATH PHOTOCHEMOTHERAPY

The use of bathwater delivery of psoralens provides for a uniform drug distribution over the skin surface, very low psoralen plasma levels, and rapid elimination of free psoralens from the skin. Bathwater delivery of 8-MOP circumvents GI side effects and possible phototoxic hazards to the eyes because there is no systemic photosensitization. Skin psoralen levels are highly reproducible, and photosensitivity lasts no more than 2 hours. The higher incidence of unwanted burn reactions can be prevented by a lower starting dose (50% of the minimal phototoxic dose [MPD]) and a more cautious dosimetry in the initial treatment phase. A major drawback in many treatment facilities is the requirement for a bathtub. Originally, bath-PUVA was performed with TMP, but 8-MOP and 5-MOP are now being used as well. Bath-PUVA consists of 15 to 20 minutes of whole-body immersion in solutions of

0.5- to 5.0-mg 8-MOP per liter of bathwater. Irradiation needs to be performed immediately, as photosensitivity decreases rather rapidly. TMP is more phototoxic after topical application and is used at lower concentrations than 8-MOP. Minimal phototoxicity dose (MPD) determination for bath-PUVA must consider that the phototoxic threshold declines during the early treatment phase,[8] in contrast to oral PUVA. Guidelines for bath, local immersion, and other topical PUVA forms have been published by the British Photodermatology Group and are based, where possible, on the results of controlled studies, or otherwise on consensus.[12]

ORAL TREATMENT

In oral PUVA, 8-MOP is administered orally (0.6-0.8 mg/kg body weight) 1 to 3 hours before exposure, depending on the absorption characteristics of the particular drug brand. Liquid drug preparations are absorbed faster and yield higher and more reproducible serum levels than microcrystalline forms. For 5-MOP, the usual dosage is 1.2- to 1.8-mg/kg body weight.

The initial UVA doses are determined by either the patient's skin type[13-15] or by MPD testing.[9] The MPD is defined as the minimal dose of UVA that produces a barely perceptible, but well-defined, erythema when template areas of the skin are exposed to increasing doses of UVA. Erythema readings are performed 72 hours after testing, at which time the psoralen phototoxicity reaction usually reaches its peak. The MPD test should be performed on previously nonexposed skin (eg, buttocks). Although the MPD test is more time-consuming than phototyping, it allows for more accurate and higher UVA doses during initial treatment. Table 199-2 shows recommendations for dosimetry in bath and oral PUVA.

Repeated exposures are required to clear PUVA-responsive diseases, with gradual dose increments as pigmentation develops. Lower doses quite frequently result in failure of treatment except in those diseases in which induction of pigmentation is the desired objective. In most dermatoses amenable to PUVA, the frequency of treatments is reduced after satisfactory clearing of disease, and the last UVA dose is used as a maintenance dose, if maintenance treatment is planned. The duration of this maintenance phase and the frequency of treatments depend on the particular disease being treated and its propensity to relapse.

INDICATIONS FOR PHOTOCHEMOTHERAPY

PHOTOCHEMOTHERAPY FOR PSORIASIS

Basically, all types of psoriasis respond to PUVA (Figs. 199-2 and 199-3), although the management of erythrodermic or generalized pustular psoriasis is more difficult.[8] The effectiveness of oral PUVA in inducing and maintaining remission of psoriasis has been widely documented and confirmed by large-scale clinical trials (Figs. 199-2 and 199-3).

TABLE 199-2

Recommended Treatment Schedule for Photochemotherapy[a]

DETERMINATION OF MPD	READING	AFTER 96–120 H (BATH-PUVA) AFTER 72–96 H (ORAL PUVA)
Start of treatment	First therapeutic dose	30% of MPD (bath-PUVA) 50%-70% of MPD (oral PUVA)
Treatments 2 to 4 times weekly	No erythema, good response No erythema, no response Minimal erythema Persistent asymptomatic erythema Painful erythema (with or without blistering)	Increase once weekly by 30% Increase by 30% per session No increase No increase No treatment until symptoms subside
Resumption of treatment after missed sessions	After resolution of symptoms	Reduction of last dose by 50%; next increase by 10%

[a]Exact practices vary between the United States and Europe and among practitioners in specific locales, based on historical teaching and individual experiences.

MPD, minimal phototoxic dose; PUVA, psoralen and ultraviolet A light.

Administration: Three studies have compared bathwater delivery of 8-MOP with oral administration.[8] In 2 reports, initial doses were determined by skin typing, and treatments were given 2 to 3 times weekly. Dose increments were instituted with every treatment in one study, whereas smaller increments were given every third treatment in the other. In the third report, patients were treated according to the standard European regimen for oral PUVA, which is still in use (treatments 4 times weekly with an intermission on Wednesdays until clearing). This showed the lowest incidence of treatment failures and overdose phenomena, despite the potential burn risk of back-to-back PUVA treatments. Compared with oral 8-MOP, bath-PUVA showed equal clearing rates with fewer exposures.[8] The greater therapeutic efficacy could be because of a higher penetration of psoralens through the abnormal stratum corneum overlying psoriatic plaques, as compared with healthy perilesional skin where phototoxicity is monitored during the therapy. The incidences of erythema and pruritus were similar or lower compared with oral therapy. Systemic intolerance, such as nausea and vomiting, were not observed.

Oral 5-MOP–PUVA represents an alternative to oral 8-MOP–PUVA. Psoriatic lesions are cleared with a comparable number of treatments, but at the expense of significantly higher cumulative UVA doses. This difference may be due to the lower phototoxicity potential

Figure 199-2 Twenty-three-year-old patient with generalized psoriasis (seborrheic type). **A,** Before photochemotherapy treatment. **B,** After treatment. (From Wolff K, et al. Photochemotherapie bei Psoriasis. Klinische Erfahrungen bei 152 Patienten. *Dtsch Med Wochenschr*. 1975;100:2471, with permission.)

of 5-MOP and of its higher tanning activity. However, 5-MOP–PUVA therapy is not associated with nausea and vomiting and has a lower incidence of pruritus and severe phototoxic erythema.[8]

On complete clearing, patients are often assigned to maintenance therapy, during which the frequency of treatments is gradually reduced. The purpose of maintenance therapy is to achieve longer remission. Maintenance therapy in the original European regimen consisted of 1 month of twice-weekly treatments, with the last UVA dose used for clearing, followed by another month of once-weekly exposures. According to other recommendations,[16] maintenance treatment should be considered only on rapid relapses, because

Figure 199-3 Twenty-three-year-old patient with generalized psoriasis (plaque-type). **A,** Before photochemotherapy treatment. **B,** After treatment. (From Wolff K, Hönigsmann H. Clinical aspects of photochemotherapy. *Pharmacol Ther.* 1981;12:381, with permission.)

patients with a stable remission may be overtreated, and long-term risks of PUVA are related to the total cumulative phototoxic doses. In one recent left–right comparison study with psoriatics, PUVA maintenance treatment over 2 months did not increase the length of remission.[17] Thus, maintenance treatment should be given only in selected cases.

Erythrodermic and generalized pustular psoriasis (von Zumbusch type) respond to PUVA (Fig. 199-4), but the time required to induce remission is considerably longer, more treatments are needed, and higher failure rates are reported, compared with plaque or guttate varieties. Pustular eruptions of palms and soles are quite recalcitrant to treatment, regardless of whether they are true localized pustular psoriasis, nonpsoriatic palmoplantar pustulosis or pustular psoriasis, or pustular eczema. Oral PUVA alone can produce a slow but definite remission in many cases, but a considerable number of patients require adjunctive therapy for clearing. As mentioned above, the combination with topically applied 8-MOP can be beneficial, but bath-PUVA appears to be also quite effective in such cases.

PUVA alone can produce definite remissions in many patients with psoriasis, but a considerable number require additional therapies for clearing. Such combination therapy improves efficacy and may reduce side effects.

Combination Treatments: *Topical combinations:* Topical adjuvant therapies with glucocorticoids, anthralin, and tar preparations, and, more recently, with calcipotriol and tazarotene, have yielded good results. However, adjunctive topical therapy is unacceptable to some patients.

Methotrexate: A combination of PUVA and methotrexate can reduce the duration of treatment, number of exposures, and total UVA dose and is also effective in clearing patients unresponsive to PUVA or UVB alone.[18] This combination appears to be safe if used during the clearing phase only. However, if used for long-term treatment, PUVA and methotrexate may act synergistically in the development of skin cancers.[19]

Cyclosporine: Cyclosporine plus PUVA dramatically enhances skin carcinogenesis. This is in keeping with the observation of a greatly increased risk of cutaneous squamous cell carcinomas in patients with solid organ transplants maintained on this immunosuppressant. Thus, this combination should be definitely discouraged.[8,20-22]

Retinoids: The therapeutic efficacy of PUVA therapy is dramatically increased by daily oral retinoid (etretinate, acitretin, isotretinoin; 1 mg/kg) administration beginning 5 to 10 days before the initiation of PUVA, and continued throughout the clearing phase. This so-called *RePUVA* characteristically reduces the number of exposures by one-third and the total cumulative UVA dose by more than one-half. RePUVA also often clears "poor responders" who are not brought into complete remission by PUVA alone.[23]

The mechanism of the synergistic action of retinoids and PUVA is unknown, but may be a result of the accelerated desquamation that optimizes the optical properties of the skin and reduction of the inflammatory infiltrate. As an additional theoretic benefit, etretinate and other retinoids may protect against long-term carcinogenic effects of PUVA. In one study, patients with psoriasis treated with PUVA in combination with systemic retinoids showed a reduced risk of squamous cell

Figure 199-4 Eighteen-year-old patient with pustular psoriasis (von Zumbusch type). **A,** Before photochemotherapy treatment. **B,** After treatment. (From Hönigsmann H et al. Photochemotherapy for pustular psoriasis (von Zumbusch). *Br J Dermatol.* 1977;97:119, with permission. Copyright © 1977 John Wiley & Sons.)

carcinoma but not a significantly altered incidence of basal cell carcinoma (BCC).[24] Although retinoid toxicity is generally not a concern because the administration is limited to the clearing phase, the potential teratogenicity of retinoids represents a serious concern for women of childbearing age. In these patients, the use of isotretinoin is advisable because contraception is necessary for only 1 month after discontinuation of therapy, in contrast to etretinate and acitretin, which require 2 years of contraception because of their slower elimination.[8]

Biologics: The mechanism of action of biologic agents suggests that there may be additive effects in treating psoriasis with PUVA, but this remains to be further defined in clinical trials.[25,26] Presently, there are no long-term studies evaluating the safety and efficacy of the combination of any biologics with PUVA.

PUVA FOR CUTANEOUS T-CELL LYMPHOMA (CTCL, MYCOSIS FUNGOIDES)

Since the first promising results with PUVA in CTCL in 1976,[27] numerous investigators from the United States and Europe have confirmed the efficacy of PUVA for CTCL.[28] Treatment schedules and dosimetry are essentially the same as for psoriasis. The treatment consists of a clearing phase (Fig. 199-5), a maintenance phase consisting of 2 exposures per week for 1 month and 1 exposure per week for another month, and a followup phase without therapy. Remission should be confirmed by histologic examination of previously involved skin sites. After therapy is discontinued, the patient is monitored monthly and later bimonthly. If a relapse occurs, the patient is again subjected to a full PUVA course. Some investigators advocate permanent maintenance treatment consisting of treatments once monthly or every other month. However, the course of CTCL varies considerably from patient to patient, and clinical experience suggests that patients benefit most from individualized treatment schedules.[8]

Relapses often respond as well as the initial lesions when PUVA is resumed. Clinical remissions appear to be directly related to phototoxic destruction of the malignant lymphocytes that infiltrate the skin. Thus, complete clearing may be induced when the cells are confined to the epidermis and superficial dermis, the depth of effective UVA penetration into the skin.

Present knowledge indicates that PUVA is an excellent treatment option that may induce long-lasting disease-free intervals in CTCL if used in the early stages of the disease.[28] In later stages, PUVA may reduce the tumor cell burden and thus may act synergistically with other treatment. It improves the quality of life and may prolong survival when used in combination with more aggressive treatment modalities. Prolonged remissions were observed with combinations of PUVA with retinoids, bexarotene,[29,30] or interferon-α 2a.[31-33]

Patients with tumor-stage CTCL exhibit a high rate of early recurrences and, therefore, require indefinite maintenance treatment. PUVA causes complete tumor resolution only when used in combination with local x-ray treatment and/or systemic chemotherapy. Most followup studies have demonstrated that the great majority of patients with early disease can be kept in remission with or without maintenance therapy for several years, but tumor-stage patients (IIB) usually experience multiple recurrences despite aggressive combination therapies and eventually die within a few years.[28] Currently, no therapeutic regimen is known to alter the disease course of CTCL. Psoralen UV-A is an effective treatment for MF, inducing long-term

Figure 199-5 Forty-six-year-old patient with cutaneous T-cell lymphoma (mycosis fungoides) stage IB. **A,** Before photochemotherapy treatment. **B,** After treatment (clearing phase).

remissions and perhaps in some cases disease "cure." Thirty percent to 50% of patients remain disease free for 10 years, but late relapses occur.[34]

Successful treatment of erythrodermic CTCL (Sézary syndrome) has been reported with extracorporeal PUVA (photopheresis) (see section "Extracorporeal Photochemotherapy [Photopheresis]"). Possible long-term hazards related to frequent PUVA treatments are better justified for patients with CTCL, compared with patients with benign conditions.

PHOTOTHERAPY FOR ATOPIC DERMATITIS

Many patients with atopic eczema can benefit from PUVA therapy.[35] The treatment guidelines are the same as for psoriasis. However, the condition is more difficult to treat, and quite often a higher number of treatments are required to clear the eczema. There is a high and early recurrence rate, requiring frequent maintenance exposures. However, in a recent study, PUVA provided a better short- and long-term response than medium-dose UVA1 in patients with severe atopic eczema.[36] A combination of PUVA with topical glucocorticoids appears to be superior to PUVA alone in maintaining remissions. Because the average patient is young, long-term maintenance therapy is problematic; and combination of PUVA with topical immune modulators (tacrolimus, pimecrolimus), although effective, cannot be recommended until more data are available. The mechanism of action of PUVA in atopic eczema is unclear; current concepts support an alteration of lymphocytes in the dermal infiltrate.

PHOTOTHERAPY FOR LICHEN PLANUS

In generalized lichen planus, PUVA can provide an effective alternative to systemic glucocorticoid treatment, although it appears to be more resistant to PUVA than psoriasis when treated according to a similar schedule. More exposures and higher cumulative UVA doses are required for clearing, and not all patients respond satisfactorily. An exacerbation during PUVA treatment has been reported in a few patients. In patients who clear, relapses respond equally well when PUVA is resumed. Bath-PUVA can also clear lichen planus, and combined PUVA-etretinate regimen may be considered.[37]

PHOTOCHEMOTHERAPY FOR CUTANEOUS MASTOCYTOSIS

In cutaneous mastocytosis (urticaria pigmentosa), PUVA leads to a temporary involution of skin lesions[38] probably because of chronic degranulation of the mast cells. The treatment results in loss of Darier sign, relief of itching, and flattening and even complete disappearance of cutaneous papules and macules. Surprisingly, even systemic symptoms such as histamine-induced migraine and flushing improve gradually as treatment is continued.[38] In most patients, the manifestations of the disease recur several months after discontinuation of PUVA, but the recurrences respond as well as the original lesions.

Because treatment of cutaneous mastocytosis has been unrewarding with other modalities, the use of PUVA, although not curative, seems to be warranted in patients when the disease is causing severe distress.

PHOTOTHERAPY FOR MISCELLANEOUS DERMATOSES

Both acute and chronic pityriasis lichenoides[37] respond to PUVA, and favorable results have been reported for lymphomatoid papulosis.[39] However, the experience with these conditions is limited to a few anecdotal cases. In pityriasis rubra pilaris, the results are quite inconsistent. Some cases seem to respond well, others may flare, and some require combination treatment with retinoid or methotrexate therapy. Generalized granuloma annulare has been reported to clear completely, but long-term maintenance treatment was required to maintain remissions.[40] Regrowth of hair was noted in alopecia areata with either topical or systemic PUVA exposures localized to the alopecia areas. Followup studies of larger patient groups concluded that PUVA is generally not an effective treatment for alopecia areata.[41] The experience of the present authors has also not been encouraging. Localized scleroderma and pansclerotic morphea have been successfully treated with bath-PUVA and oral PUVA.[42,43]

PHOTOCHEMOTHERAPY FOR CHRONIC GRAFT-VERSUS-HOST DISEASE

Acute and chronic cutaneous graft-versus-host disease (GVHD) have become indications of increasing importance. Because of the clinical and histologic similarities of idiopathic lichen planus and lichenoid GVHD, PUVA treatment was evaluated for the latter.[44] PUVA cleared or improved this lichen planus–like eruption in patients who had not responded to conventional immunosuppressive therapy alone. PUVA can also improve acute GVHD,[45] although results of PUVA treatment for scleroderma-like variants of cutaneous GVHD are controversial. According to our own experience, the more circumscribed, localized forms appear to respond to PUVA with softening of the fibrotic, sclerotic connective tissue, but more widespread, disseminated lesions hardly respond.

Improvement of mucosal erosions followed by healing, observed during treatment of chronic lichenoid GVHD with PUVA, suggests that PUVA may exert both local and systemic effects, but this is not proven. There is no improvement of GVHD of other organs, such as the liver. The therapeutic regimen used for the treatment of chronic GVHD is basically the same as for psoriasis. UVA doses should not be increased too aggressively, to avoid erythema and possible (re)activation of GVHD.

In general, increase of the UVA dosage by 0.5 J/cm^2 at maximum after every second to fourth exposure is recommended. Patients are exposed to UVA radiation 3 to 4 times weekly. After clearing of skin lesions, the frequency of exposures is reduced.

Because there appears to be an overall increased risk of secondary malignancies for all bone marrow/peripheral stem cell recipients, patients should be examined on a regular basis for the development of cutaneous malignancies, independent of whether they have been treated with PUVA.

PHOTOCHEMOTHERAPY FOR VITILIGO

Vitiligo was the first disease treated with an ancient form of psoralen PUVA in India and Egypt. PUVA in its modern form stimulates melanogenesis, melanocyte proliferation, and migration, and *can* reconstitute the normal skin color in *many* vitiligo patients, *although the actual response rate has still not been defined*. However, it is less used now since narrowband UVB phototherapy has been shown to be an effective and possibly safer alternative for repigmentation of this condition.

To induce maximal repigmentation, patients need long-term therapy with 100 to 200 exposures given twice or thrice weekly. Approximately 70% of patients respond after 12 to 24 months (Fig. 199-6), defined as the development of perifollicular macules of repigmentation. If there is no response after 6 months or approximately 50 treatments (as defined as perifollicular macules of repigmentation), PUVA should be terminated. If treatment is discontinued, this newly acquired repigmentation may be lost. The permanency of PUVA-induced repigmentation in vitiligo is poorly documented. Some investigators have reported continuing pigment loss following PUVA, while others have reported the repigmentation to be long lasting.[46]

Figure 199-6 Twelve-year-old patient with generalized vitiligo of 4 years' duration. **A** and **C,** During the initial phases of photochemotherapy treatment. **B** and **D,** One month after treatment (8-methoxypsoralen + artificial ultraviolet A) with thrice-weekly exposures for 10 months.

Patient selection appears to be particularly important in vitiligo treatment. Lips, distal dorsal hands, tips of fingers and toes, areas of bony prominences, palms, soles, and nipples are very refractory to treatment, and patients with involvement limited to these areas should be excluded. Segmental vitiligo tends to show a variable response. Because of the different response in different body areas, total repigmentation is only rarely achieved, and some 30% of patients do not respond at all despite many months of therapy. Duration of the disease before PUVA therapy does not affect response rate.[46] It should be mentioned here that in a recent trial of nonsegmental vitiligo, narrowband-UVB therapy resulted in a better color match than oral PUVA.[47]

The mechanisms by which PUVA induces repigmentation in vitiligo skin are speculative. However, PUVA's known effect on a number of immunologic reactions suggests a suppression of the autoimmune stimulus for melanocyte destruction.

PHOTOCHEMOTHERAPY AS PREVENTION FOR PHOTODERMATOSES

Tolerance to sunlight can be induced in several photodermatoses by PUVA therapy.[48] In polymorphous light eruption, the most common photodermatosis, PUVA is the most effective preventive treatment.[49] In approximately 70% of patients with this condition, a 3- to 4-week PUVA course of 2 to 3 treatments per week suffices to suppress the disease on subsequent exposure to sunlight such as a holiday trip or the arrival of summer. The initial exposure and dose increments during therapy should be performed according to the guidelines outlined for psoriasis. PUVA has the advantage of a rapid and intense pigment induction at relatively low UVA doses that usually remain well below the threshold doses for eliciting the rash. Approximately 10% of patients develop typical lesions during the initial phase of PUVA, but these usually disappear when treatment is continued. The authors' treatment schedule consists of 3 to 4 treatments per week for 3 to 4 weeks in early spring. PUVA protects only temporarily, but subsequent sun exposures usually maintain protection and many patients remain protected for 2 to 3 months even after their pigmentation has faded.

The mechanism by which phototherapy induces tolerance to sunlight is not clear. Hyperpigmentation and thickening of the stratum corneum may be important factors, but other mechanisms, such as modulations of cutaneous immune function, also may be involved.[49]

There is also some experience with PUVA prophylaxis of other photodermatoses. In solar urticaria, PUVA therapy appears to be the most effective preventive treatment available and is certainly better than antihistamines. Tolerance to sunlight can be increased 10-fold or more after a single treatment course.[50] The suppressive effect may last throughout the summer if the patients have regular sunlight exposures, which seems to be necessary to maintain tolerance. Problems may arise during the first PUVA exposures, because, in some patients, the urticaria threshold dose is very low. In these cases, careful conditioning by stepwise UVA irradiation of single quadrants of the body surface a few hours before each PUVA treatment has proved useful. Treatments with PUVA are then given during the refractory period of presumed mast cell degranulation.

Successful PUVA therapy also has been reported in occasional cases of chronic actinic dermatitis and hydroa vacciniforme. Limited experience in patients with erythropoietic protoporphyria indicates that with a very cautious approach and in combination with beta-carotene, PUVA may increase light tolerance considerably.[51,52]

Extended treatment is usually not required in polymorphous light eruption but may be necessary in solar urticaria and chronic actinic dermatitis. There exist no ready-to-use schedules for these latter conditions, and PUVA is usually just one part of the management.[51]

PHOTOCHEMOTHERAPY IN HIV-INFECTED PATIENTS

The use of phototherapy and PUVA in HIV-infected patients with skin diseases is controversial. Both therapies can induce systemic immune suppression and may modify the immune status of the patient in a way that would worsen HIV disease.[53] Both UV radiation and psoralen photosensitization activate the HIV promoter, which could boost viral gene transcription and, eventually, virus production,[54] although available data and theoretic considerations indicate that UVB is more likely to be a hazard than PUVA in an HIV-infected population.[55,56] Nevertheless, oral PUVA treatment of psoriasis does not detectably accelerate progression of HIV disease or increase PUVA side effects, and hence PUVA is not considered contraindicated for HIV-positive patients with responsive skin diseases.[57]

SIDE EFFECTS AND TOXICITY OF PHOTOCHEMOTHERAPY

ACUTE SIDE EFFECTS

The side effects of PUVA include drug intolerance reactions as well as side effects of the combined action of psoralens plus UVA radiation (Table 199-3). Oral 8-MOP (0.6-0.8 mg/kg) has a high incidence of nausea (30% of patients) and vomiting (10% of patients), and this may occasionally require discontinuation of the treatment. The mechanism of this adverse effect is unknown. These side effects are more common with liquid preparations than with crystalline preparations, probably because of higher psoralen serum levels. With 5-MOP, nausea occurs rarely, even with doses of up to 1.8 mg/kg body weight.

Undesired acute effects of the combined action of psoralens and UVA include unexpectedly severe delayed erythema reactions. Severe burns with blistering can occur and may rarely require hospitalization.

TABLE 199-3
Side Effects and Toxicity of Photochemotherapy

Acute Side Effects	
Drug intolerance	Nausea, vomiting with oral MOP, but not with 5-MOP.
UVA overdosage	Can range from an increased delayed erythema reaction to severe burns with blistering. When large areas of skin are affected, systemic symptoms of excess phototoxicity, such as fever and general malaise, can occur.
Pruritus	Some patients experience persistent pruritus during photochemotherapy (PUVA) treatment, particularly after slight UVA overdosage.
Laboratory data	No significant abnormal findings in patients receiving PUVA over prolonged periods of time.
Potential Long-term Risks	
Chronic actinic damage	Chronic exposure to PUVA may produce changes in the skin that resemble photoaging. PUVA lentigines and generalized PUVA lentiginosis result from repeated and prolonged treatment and are commonly associated with high cumulative doses of UVA and a large number of treatments. So far, no increased risk of cutaneous melanoma associated with these lentigines has been recorded.
Carcinogenesis	The risk of squamous cell carcinoma, but not of basal cell carcinoma, is significantly increased in comparison with matched controls, and the magnitude of the increase appears to be dose-dependent. There is still uncertainty about PUVA being the sole factor—many of the affected patients had previous exposure to excessive sunlight and to treatments with carcinogenic potential, including arsenic, UVB, cyclosporine, and antimetabolite therapy. No increased risk was found so far with bath-PUVA.
Melanoma	Stern et al. reported from patients enrolled in the PUVA Follow-up Study (16-Center Study[69]) that, beginning 15 years after first exposure to PUVA, an increased risk of melanoma was observed. This risk was greater in patients exposed to high doses of PUVA and appeared to be increasing with the passage of time. The conclusions of this study have been questioned, and the authors now agree that the observed risk of melanoma does not represent an absolute contraindication to PUVA or that PUVA therapy should be abandoned. Rather, the risks of both melanoma and squamous cell carcinoma in PUVA should be weighed against the substantial efficacy of PUVA and the risks of other therapies.
Ophthalmologic effects	Several studies have shown no indication that psoralen-induced cataracts occur in patients undergoing long-term photochemotherapy, even in patients who neglected eye protection.

MOP, 8-methoxypsoralen; PUVA, psoralen and ultraviolet A light.

When large areas of skin are affected, systemic symptoms of excess phototoxicity, such as fever and general malaise, may occur. Nonsteroidal anti-inflammatory drugs and topical and systemic corticosteroids may be required to alleviate the symptoms but must be given early. Some patients experience persistent pruritus during PUVA treatment, particularly after slight UVA overdosage, and, in rare cases, a stinging pain may develop in circumscribed areas. The mechanism is unknown although a phototoxicity reaction affecting cutaneous nerves is postulated, and the symptoms are unresponsive to antihistamines. These complaints usually subside on continuation of treatment. Overdosage phenomena occur mostly in body areas not usually exposed to natural sunlight. Cautious dosimetry can minimize these side effects. The danger of overdosage is much less with 5-MOP than with 8-MOP.

Very rare side effects of PUVA include polymorphous light eruption-like rashes, acnelike eruptions, subungual hemorrhages caused by phototoxic reactions in the nail beds, and occasional hypertrichosis of the face. These disappear when treatment is discontinued. Single case reports note exacerbation of systemic lupus erythematosus and bullous pemphigoid during PUVA.

LABORATORY DATA

Analysis of laboratory data in several large-scale studies showed no significant abnormal findings in patients receiving PUVA over prolonged periods of time.[13,14,58] Serial laboratory examinations performed over a period of several years have not revealed any substantial evidence for impairment of hepatic function. Liver biopsies after 1 year of therapy did not reveal hepatotoxicity.[59] No evidence exists suggesting impairment of renal function.[13] Several large-scale studies have negated a suggested relation between PUVA therapy and the occurrence of antinuclear antibodies.[60]

POTENTIAL LONG-TERM RISKS OF PHOTOCHEMOTHERAPY

CHRONIC ACTINIC DAMAGE

Repeated photodamage to the skin can be expected to result in cumulative injury regardless of whether it is induced by sunlight, artificial UV radiation, or PUVA. Chronic exposure to PUVA may produce changes that resemble photoaging and that may compound the injury induced by sunlight.

PUVA lentigines and generalized PUVA lentiginosis result from repeated and prolonged treatment and are commonly associated with high cumulative doses of UVA and a large number of treatments.[14] The lentigines exhibit irregular borders and uneven pigmentation. No increased risk of cutaneous melanoma has been

associated with these lentigines, but the cosmetic effect may be quite disturbing.

CARCINOGENESIS

Cutaneous carcinogenicity is the major concern for long-term PUVA treatment associated with high cumulative UVA doses. PUVA is a photocarcinogen (Chap. 19). In laboratory animals, 8-MOP and 5-MOP have been unequivocally shown to induce skin cancer at levels of drug and UVA irradiation comparable to those used in PUVA therapy.[61,62] This risk is related to DNA damage, but PUVA-induced downregulation of immune responses may play an additional role. This risk must be assessed against the potential therapeutic benefit.

Long-term followup PUVA studies are confounded by the fact that patients, particularly those with severe psoriasis, are likely to have been exposed previously to other carcinogenic treatments, such as ionizing radiation, UVB therapy, methotrexate, tar, or arsenic, and accurate exposure data are often lacking.

In PUVA patients, the risk of squamous cell carcinoma, but not of BCC, is significantly increased in comparison with matched controls and the magnitude of the increase appears to be dose dependent.[19,62] However, there is uncertainty about PUVA being the sole factor—many of the affected patients had previous exposure to excessive sunlight and to treatments with carcinogenic potential, including arsenic, UVB, and antimetabolite therapy.[63] Particularly, high levels of UVB exposure appear to increase the risk of nonmelanoma skin cancer in PUVA-treated patients.[64] An increased risk of any skin cancer with oral PUVA has not been shown in the nonwhite population.[65] According to one study, the genitalia in men previously treated with tar and UVB appeared to be particularly susceptible to PUVA carcinogenesis,[66] but in a separate population the risk seemed not to be increased if only PUVA was used.[67] In a retrospective study from France comprising 5400 patients treated with PUVA between 1978 and 1998, no case of genital skin cancer was found, despite the fact that the genital area had not been protected.[68] This makes it unlikely that genital shielding is absolutely necessary.

Carcinogenicity of 5-MOP–UVA therapy in PUVA-treated patients is not documented, but 5-MOP has shown mutagenicity like 8-MOP in model systems.

Stern et al reported that of the cohort of 1380 patients enrolled in the 16-Center PUVA Follow-up Study, 23 patients have developed 26 invasive or in situ cutaneous melanomas over a period of roughly 25 years. Beginning 15 years after first exposure to PUVA, this constituted an increased risk of melanoma.[69,70] This risk was greater in patients exposed to high doses of PUVA and appeared to increase with the passage of time. Still, the authors conclude that the observed risk of melanoma does not represent an absolute contraindication to PUVA. Rather, the risks of both melanoma and squamous cell carcinoma in PUVA should be weighed against the substantial efficacy of PUVA and the risks of other therapies.[70,71] As well, no increased risk of melanoma has been observed so far in any large-scale study from Europe; and several other US studies did not show an increased risk of melanoma in patients treated with PUVA[72,73] Of note, PUVA's long-term risks have been subject to much greater scrutiny than the risks of other therapies advocated for severe psoriasis, such as methotrexate and, particularly, immunosuppressive therapies such as cyclosporine. These latter therapies greatly increase cancer risk in populations less likely to have substantial exposures to other known cutaneous carcinogens such as UVB than are patients with severe psoriasis. Early detection through careful, long-term followup and education of PUVA patients may reduce the long-term morbidity and mortality associated with this therapy, as can low cumulative dosage regimens.[74]

Studies of 944 Swedish and Finnish patients[75] and 158 Finnish patients[76] with psoriasis showing no association between cutaneous cancer and TMP or 8-MOP bath-PUVA, respectively, are also reassuring. Mathematic model studies indicate that the observed risk of squamous cell carcinoma is much higher with PUVA than with UVB,[77] but the carcinogenic risk of narrowband UVB in comparison with PUVA is unknown, and it will be crucial to monitor its long-term effects in psoriatics.

OPHTHALMOLOGIC EFFECTS

Data from animal studies indicate a risk of premature cataract formation due to PUVA, but clinical evaluation suggests no increase in lens opacities, even in patients who neglect careful eye protection during long-term PUVA.[78,79]

PATIENT SELECTION AND CONTRAINDICATIONS

In view of the potential short-term and long-term hazards of PUVA, the assignment of patients should be based on consideration of the risks and the benefit for the individual patient. If only a short-term course of therapy is planned, as, for example, in prevention of photodermatoses, the benefit very probably outweighs the risk. In the treatment of a malignant condition such as CTCL, long-term risks may be discounted because other treatment options bear even greater long-term risks. The major concerns relate to long-term treatment of psoriasis, by far the most common indication for PUVA. Careful patient selection is mandatory, bearing in mind that long-term risks of alternative therapies may simply be less well documented rather than less. Guidelines have been published.[15]

PUVA is not recommended during pregnancy, and women should be advised to use contraceptive measures while on PUVA. This precaution is only for reasons of absolute safety as there is no evidence that

8-MOP alone is teratogenic, and UVA does not penetrate through the abdominal and uterine walls. Further, a retrospective study in 256 deliveries among the cohort of the 16-Center PUVA Follow-up Study revealed no birth defects.[80] However, it should be emphasized that RePUVA bears the risk of retinoid teratogenicity.

Severe impairment of hepatic and renal functions is usually considered a contraindication to PUVA because metabolism and excretion of psoralens may be inadequate. PUVA is also contraindicated in patients with known light-aggravated or light-induced diseases such as lupus erythematosus, porphyria (but, as mentioned earlier, light tolerance can be induced by PUVA in erythropoietic protoporphyria), and xeroderma pigmentosum. Pemphigus vulgaris and bullous pemphigoid may be exacerbated by PUVA. Patients with chronic actinic damage and a history of skin cancers may be at higher risk for the development of new cancers. Previous arsenic intake and previous treatment with ionizing radiation also seem to increase the risk of nonmelanoma skin cancers. Immunosuppressed patients should probably not receive PUVA, although this is not yet clearly defined. As outlined earlier, PUVA can be used in HIV-positive patients. Cataracts and aphakia are not contraindications if adequate eye protection is employed.

CONCLUSIONS AND PERSPECTIVES

PUVA is a highly effective treatment for several dermatologic diseases. Although there exists comprehensive clinical experience documenting PUVA's short-term safety when used according to standardized methods, potential long-term sequelae are still being studied. Thus, treatment decisions should take into account whether other equally effective forms of therapy that carry a lower risk are available. Risk-versus-benefit varies with the disease being treated.

Severe widespread psoriasis is a devastating disease that may impair professional, social, and private life. After more than 3 decades of experience with PUVA for the treatment of psoriasis, it is evident that this therapy offers innumerable patients the chance to resume a normal life. For disabling psoriasis, the choice of therapies lies not between risk and safety but among modalities (methotrexate, cyclosporine, UVB, and biologics), none of which is absolutely safe.[71]

EXTRACORPOREAL PHOTOCHEMOTHERAPY (PHOTOPHERESIS)

Extracorporeal PUVA (ECP) was introduced in the 1980s for the palliative treatment of erythrodermic CTCL,[81] a disorder characterized by circulating malignant lymphocytes. Its efficacy was subsequently confirmed by several clinical trials and approved in 1988 by the U.S. Food and Drug Administration for this indication. At the International Consensus Conference on Staging and Treatment Recommendations for CTCL in 1994[82] and at the European Organization for Research and Treatment of Cancer Consensus Recommendations in 2006,[83] ECP was recommended as the first line of treatment for patients with erythrodermic CTCL.

Attempts to better characterize those CTCL patients likely to respond to ECP revealed a significant association between response and CD4:CD8 ratio. Patients with a ratio less than 10 are more likely to respond than patients with a ratio greater than 10. There is also a marginally significant association between response and lactic acid dehydrogenase (LDH) level, with patients whose LDH is not elevated at the start of treatment responding better than patients with an elevated LDH.[84]

Besides CTCL, ECP also plays an important role in the treatment of chronic GVHD after allogeneic bone marrow transplantation with excellent response rates. ECP also has been used in uncontrolled studies in several other autoimmune diseases including systemic sclerosis, acute allograft rejection among cardiac, lung, and renal transplant recipients[85-87] and Crohn disease, with some success.

TREATMENT METHOD

ECP originally involved the oral administration of 8-MOP followed by phlebotomy at the time of peak photosensitization passage of blood fractions from one arm vein through a photopheresis machine and back. A discontinuous flow cell separator harvests peripheral blood mononuclear cells (PBMCs) in a buffy coat collection and returns the red cell fraction to the patient without further treatment. The collection of PBMC is then exposed to 2.0 J/cm^2 of UVA using a photopheresis device that ensures exposure of individual PBMC in a thin film to the light source and then reinfused into the patient. More recently, 8-MOP is administered directly to the heparinized plasma and buffy coat fraction as it flows through a UVA exposure system, thereby avoiding 8-MOP-induced nausea and unintended phototoxicity with subsequent incidental sun exposure.[88] This treatment is customarily repeated on 2 successive days at 2- to 4-week intervals.

MECHANISM OF ACTION

The mode of action of ECP remains unknown. The PUVA exposures likely induce apoptosis of circulating malignant lymphocytes. However, it also has been shown that infusion of autologous haptenated cells in which apoptosis had been initiated by 8-MOP/UVA induces immunologic tolerance. This tolerance is likely

due primarily to regulatory T cells because transfer can be achieved in an animal model. Induction of regulatory T cells could also explain why ECP exerts a beneficial effect in a wide variety of immune-mediated diseases and why generalized immunosuppression does not occur with ECP.[89,90]

SIDE EFFECTS

No serious side effects have been reported with ECP. With oral ingestion of 8-MOP, transient nausea is not uncommon (as in oral PUVA therapy) and, rarely, episodes of hypotension and vasovagal reflex due to volume shifts during treatments have been noted. However, these events usually do not interfere with the treatment.

TREATMENT RESULTS

CUTANEOUS T-CELL LYMPHOMA

Erythrodermic CTCL (Sézary syndrome) was the first disease for which ECP was evaluated. A response occurs in up to 75% of the patients, with complete remissions in up to 25%. In Sézary syndrome patients who do not sufficiently respond to ECP alone, ongoing studies are evaluating possible synergistic effects with other treatments such as interferon-α, methotrexate, bexarotene, and total-skin electron-beam therapy.[91-94]

GRAFT-VERSUS-HOST DISEASE AND ALLOGRAFT REJECTION

ECP appears to have a major impact in the treatment of GVHD after allogeneic bone marrow transplantation.[95,96] In patients with either acute or chronic GVHD, ECP allows reduction or even discontinuation of immunosuppressive therapy without an increase in GVHD activity. More than 450 patients with chronic (even steroid-refractory cases), GVHD treated with ECP have been reported, with mean response rates of 63% (range 29%-100%). Responses were highest for those patients with cutaneous or mucous membrane involvement. Positive results also have been published for acute GVHD.[87,97] ECP is especially useful for patients affected by GVHD resistant to conventional treatment.

As mentioned above, ECP is effective in the treatment of acute allograft rejection among lung, cardiac, and renal transplant recipients. ECP is effective for patients resistant to conventional treatments, particularly if started early. Benefit is obtained without the complications typically encountered with immunosuppressive regimens used to control organ rejection.[98,99] Table 199-4 shows indications for photopheresis as currently approved by regulatory agencies.

TABLE 199-4
Indications for Photopheresis (as Seen by Regulatory Agencies in 2017)

Sufficient Evidence Available	
Erythrodermic cutaneous T-cell lymphoma	Chronic graft-versus-host disease
Acute graft-versus-host disease	Organ transplant rejection
Experimental and Investigational	
Scleroderma	Nephrogenic fibrosing dermopathy
Bullous dermatoses	Lichen planus
Crohn disease	Multiple sclerosis

PHOTODYNAMIC THERAPY

Photodynamic therapy (PDT) aims to destroy the desired target selectively, thereby minimizing damage to normal tissue. The photodynamic reaction consists of the excitation of photosensitizers (usually porphyrins) by visible light in the presence of oxygen, resulting in the generation of reactive oxygen species, particularly singlet oxygen. These reactive oxygen species mediate cellular and vascular effects, depending on the tissue localization of the photosensitizer, and results in a direct or indirect cytotoxic effect on the target cells.[100] In dermatology, PDT has been used effectively for precancerous and malignant conditions such as actinic keratosis, BCC, Bowen disease, and superficial squamous cell carcinoma, as well as for inflammatory and infectious dermatoses such as localized scleroderma, acne vulgaris, and leishmaniasis. A relatively new approach is the treatment of ageing skin with PDT (photochemorejuvenation).

PRINCIPLES OF PHOTODYNAMIC THERAPY

PHOTOSENSITIZERS

The ideal photosensitizer for PDT in dermatology should meet the following criteria: (1) chemical purity, (2) high singlet-oxygen quantum yield, (3) significant light absorption at wavelengths that penetrate the skin sufficiently deeply, (4) high tissue selectivity, and (5) efficacy after topical application.

Porfimer sodium (Photofrin), a systemically administered mixture of several hematoporphyrin derivative (HpD) ethers and esters, has a low selectivity for skin tumors, and leads to long-lasting photosensitivity; consequently, it is far from ideal for dermatologic use. In contrast, 5-aminolevulinic acid (ALA), an intermediate in heme biosynthesis or its methyl ester (MAL) leads to synthesis of photosensitizing protoporphyrin IX in the target tissue.[101] In this case, the concentration of the photosensitizer depends on the

metabolic status of the diseased tissue with photosensitization greatest in precancerous or malignant tissue. ALA in combination with blue light, ALA in combination with red light, and MAL in combination with red light are approved by the US Food and Drug Administration for the treatment of actinic keratoses. In Europe, New Zealand, Australia, and South America, ALA and MAL also have been registered for superficial and nodular BCCs, and MAL also for Bowen disease.

Most photosensitizers generate singlet oxygen with a quantum yield between 5% and 20%. A high quantum yield means that less sensitizer is required in the target tissue to induce sufficient PDT effects. The light absorption maxima of the current sensitizers are in the visible range (400-700 nm). In this range, light penetration in tissue is only up to 3 mm, limiting PDT to superficial tumors unless interstitial light propagation is used. A high selectivity for sensitizer accumulation in target tissue is necessary to avoid damage to surrounding normal tissue, and this is particularly important when larger areas are treated (eg, actinic keratoses). ALA and MAL show reasonably high selectivity after topical application, with the ratio of porphyrin induction in skin tumors to the surrounding tissue higher than 10:1,[102] likely due to a combination of enhanced ALA-MAL penetration through an abnormal stratum corneum and altered metabolism and accumulation within the premalignant or malignant cells.

LIGHT SOURCES AND DOSIMETRY

Light penetration into skin increases with longer wavelengths up to 1100 nm. Although porphyrins absorb maximally in the Soret band (400-410 nm, blue light), there are minor absorption peaks at longer visible light wavelengths. To increase depth of penetration while matching the absorption maxima of porphyrin photosensitizers, wavelengths around 630 nm are often used. Lasers are effective but they are quite expensive, require regular maintenance, and have a small treatment aperture. Hence, simpler incoherent light sources represent a valuable alternative. Fluorescent lamps or light-emitting diodes (LEDs) with appropriate red or blue light emission are commercially available and designed for treatment of large surface areas. Also, intense pulsed-light sources are used for dermatologic PDT. Dosimetry depends on the photosensitizer and light source used, as well as on the condition to be treated. For PDT of epithelial cancer, photosensitization must be sufficient to induce necrosis or apoptosis. With current incoherent light sources (lamps, LED), the treatment duration, apart from of ALA-MAL incubation time, is approximately 10 to 15 minutes. For treating inflammatory dermatoses, significantly lower doses suffice because the goal appears not to be cell death but rather sublethal damage or modulation of cellular functions.

A relatively new approach that is already registered in Europe, South America, Canada, and Australia is the combination of MAL application to AK lesions on the skin (face, scalp), followed by subsequent exposure to daylight for 120 min. This procedure is called daylight-mediated photodynamic therapy (DL-PDT).[103]

MECHANISM OF ACTION

PDT-induced effects are mediated by photo-oxidative reactions. During irradiation, the photosensitizer absorbs light (energy) and is converted to an excited (triplet) state. The energy can then be transferred to molecular oxygen (Type II photo-oxidative reaction), resulting in the generation of reactive oxygen species, mainly singlet oxygen. The biologic effects can be divided into primary cellular and secondary vascular damage. With HpD, early visible damage consists of cell membrane defects as a consequence of lipid peroxidation with consequent cell lysis. Depending on the intracellular localization of the photosensitizers, damage to subcellular structures, such as mitochondria, lysosomes, or endoplasmic reticulum, also occurs, whereas DNA is not a primary target. These direct effects probably play a key role in topical PDT, whereas vascular effects after systemic administration of photosensitizers appear to be the decisive event. These effects consist of vasoconstriction, blood stasis, and thrombosis of tumor vessels leading to tumor ischemia and subsequent necrosis.[104]

PHOTODYNAMIC THERAPY IN DERMATOLOGY

Table 199-5 lists current applications for PDT described in the literature. In contrast to other organs, the skin can be sensitized by either intravenous, topical, or intralesional routes of administration of the photosensitizer.

SYSTEMIC PHOTODYNAMIC THERAPY

PDT after systemic administration of HpD and porfimer sodium has been used for both skin cancers and inflammatory dermatoses. Standard therapeutic procedures do not yet exist.

Systemic Photodynamic Therapy for Oncologic Indications: Systemic PDT with porfimer sodium for Bowen disease is very effective,[105] but invasive squamous cell carcinomas respond less well, with recurrence rates of up to 50% within 6 months. Systemic PDT for BCCs, first used in 1981,[106] has been reported by Oseroff and coworkers[107] to give initial complete responses in 92.2% of 77 patients with sporadic BCC or nevoid BCC syndrome.[107] In these patients, the 5-year recurrence rate was 15%.

Benzoporphyrin-derivative monoacid ring A (verteporfin), registered for the ophthalmologic indication of age-related macular degeneration, is also under investigation for PDT of BCC and offers a duration

TABLE 199-5
Current Indications for Photodynamic Therapy

ONCOLOGIC	NONONCOLOGIC (ALL OFF-LABEL USES)

▪ Actinic keratosis[a#]
▪ Bowen disease[b]
▪ Actinic cheilitis[b]
▪ Superficial BCC[b]
▪ Nevoid BCC syndrome *(off-label use)*
▪ Keratoacanthoma *(off-label use)*
▪ Superficial SCC *(off-label use)*
▪ Kaposi sarcoma *(off-label use)*
▪ Cutaneous metastases *(off-label use)*
▪ Cutaneous T-cell lymphoma *(off-label use)*
	▪ Localized scleroderma
	▪ Human papillomavirus–associated dermatoses
	  ▪ Epidermodysplasia verruciformis
	  ▪ Verrucae vulgaris
	  ▪ Condylomata acuminata
	▪ Leishmaniasis
	▪ Acne vulgaris
	▪ Rosacea
	▪ Photochemorejuvenation of sun-damaged skin

[a]Approved in the Americas, European Union, Australia–New Zealand.
[b]Approved in the European Union, Australia–New Zealand, and Brazil.
[#]Approval for classical PDT with blue or red light (ALA, MAL) and daylight-mediated PDT (MAL).
BCC, basal cell carcinoma; SCC, squamous cell carcinoma.

Figure 199-7 Endogenous porphyrin fluorescence after topical application of 20% aminolevulinic acid formulation to a solid basal cell carcinoma. Twelve hours after aminolevulinic acid application, there was strong fluorescence of the tumor-bearing areas, and weak to no fluorescence of the surrounding dermis. Also visible is fluorescence in the overlying epidermis. (From Szeimies RM, Sassy T, Landthaler M. Penetration potency of topical applied & alpha-aminolevulinic acid for photodynamic therapy of basal cell carcinoma. *Photochem Photobiol.* 1994;59:73. Copyright © 1977 John Wiley & Sons.)

of cutaneous photosensitization of less than 72 hours, significantly shorter than that of porfimer sodium.[108]

Systemic Photodynamic Therapy for Nononcologic Indications: The use of PDT with HpD was reported for the treatment of psoriasis as early as 1937; better results were reported using red light instead of UVA,[109] and systemic PDT with verteporfin was also investigated in a Phase I study of 15 patients in whom clinical severity scores for psoriatic plaques improved after 5 weekly treatments.[110]

TOPICAL PHOTODYNAMIC THERAPY

Small hydrophilic molecules like ALA or MAL penetrate well into the skin, particularly if the stratum corneum is abnormal, as is the case in some epidermal tumors.[101] In addition, epidermal cells and the pilosebaceous unit synthesize porphyrins to a much greater extent than fibroblasts, myocytes, or endothelial cells[102]; epithelial tumors generally synthesize much higher amounts of protoporphyrin IX than the surrounding tissue and can therefore be destroyed without equivalent damage to healthy skin (Fig. 199-7).[101,111] Topical ALA-MAL-induced photosensitivity thus preferentially affects the target area. Systemic porphyrin induction is not observed after topical application.[112] The only significant side effect of topical ALA-MAL PDT is a stinging pain during and shortly after irradiation, proportional to the intensity of the phototoxicity reaction. In contrast to classical ALA/MAL PDT with red light, DL-PDT is not painful,[103] because of its different mode of action. With conventional PDT, PPIX formation is continuously induced during the incubation period (between 3 and 18 hours); PPIX therefore leaves the subcellular compartments of the cell and is excreted extracellularly to sustain cellular homeostasis. The consequence is photosensitization of free nerve endings in the epidermis. Upon illumination within the PDT procedure, direct ROS formation within and near those nerve fibers is responsible for the pain perception.[113,114] With DL-PDT, continuous illumination for 2 hours starts within 30 minutes following photosensitizer application. Newly formed PPIX then is still within the intracellular mitochondria of diseased keratinocytes (in the case of AK treatment) so that no PPIX or ROS reaches nerve fibers.[114]

Topical Photodynamic Therapy for Oncologic Indications[115-124]: The experience with treatment of epithelial cancers and precancerous conditions with PDT as of this writing suggests that actinic keratoses,[103,115,116] Bowen disease (Fig. 199-8),[117] superficial and nodular BCCs,[118-120] (tumor thickness less than 2 mm) are suitable for topical ALA/MAL-PDT. For this purpose, both photosensitizers are applied topically for variable incubation periods, with or without occlusion, followed by visible light exposure.

Actinic keratoses have been studied most extensively and respond to PDT as readily as to local cryotherapy or to broad-area 5-fluorouracil (Chap. 190) or imiquimod therapy (Chap. 192) administered over weeks to months. Topical application of a 20% ALA solution for

Figure 199-8 Bowen disease. **A,** Lesion located on the right lower leg. **B,** Twelve months after topical aminolevulinic acid–photodynamic therapy (10% aminolevulinic acid ointment, application for 4 hours, irradiation with argon-pumped dye laser [175 mW/cm^2; 180 J/cm^2]), clinically and histologically, there were no signs of tumor residue.

14 to 18 hours followed by irradiation with blue light (417 nm) for 1000 seconds (10 J/cm^2) clears more than 80% of actinic keratoses after 1 to 6 months,[116] and 90% complete clearance at 1 and 5 months was observed after one full face treatment using a 1- to 3-hour incubation period.[116] DL-PDT with MAL for mild to moderate AK is equally efficacious to conventional PDT with red LED light.[103,121] However, cutaneous metastases of malignant melanoma, pigmented BCC, and sclerodermiform variants of BCC respond poorly to ALA-PDT, probably because of insufficient porphyrin synthesis and/or penetration of light within the lesions.[111] Treatment efficacy is enhanced by repeated treatment sessions[121] or by lesion pretreatment with either fractionated ablative laser devices[122] (Er:YAG, CO_2) (Chap. 209) or microneedling.[122,123]

In superficial and nodular BCCs, 2 randomized phase-III studies have been reported so far comparing MAL-PDT with either surgery or cryotherapy. After an observation period of 60 months, MAL-PDT for superficial BCC showed a similar recurrence rate as cryotherapy (22% vs 20%). In nodular BCC, MAL-PDT was compared with simple excision; recurrence rates after 60 months were 14% and 4%, respectively. In both studies, the cosmetic outcome was considered superior for the PDT-treated groups.[118,119] Indeed, these and other reports[120,121] suggest that a major theoretical benefit of ALA/MAL-PDT is elimination of skin cancers without scarring, as well as prevention of such lesions in high-risk patients treated periodically with broad-area PDT.

CTCL (mycosis fungoides) also responded in 8 single case reports to ALA-MAL PDT after several treatment sessions. Controlled investigations are currently not available, and, as with PUVA treatment of single lesions, this treatment would not be expected to prevent the appearance of new lesions in other areas.[124]

Topical Photodynamic Therapy for Nononcologic Indications[125-141]: Few data are available regarding the treatment of inflammatory and proliferative skin conditions. These include psoriasis, localized scleroderma, human papilloma virus (HPV)–associated conditions, leishmaniasis, acne, and rosacea.

ALA/MAL-PDT is also effective for acne and rosacea, although optimal protocols have not been developed. In 2 separate studies,[134,135] 22 patients with mild to moderate acne on the back received 20% ALA cream under occlusion for 3 hours. The areas were then exposed to broadband (550-700 nm) or laser light (635 nm) using various protocols. The authors observed a significant reduction in inflammatory acne lesion counts compared with baseline that persisted at least 20 weeks in some patients.[134] One study found a reduction in sebaceous gland size and sebum secretion, as well as reduced fluorescence attributable to *Propionibacterium acnes*,[134] although the other did not.[135]

PDT with ALA or MAL also has been demonstrated to enhance the treatment of photodamaged skin with a variety of lasers and light sources (also Chaps. 209 and 210). Improvement of global appearance, fine lines, tactile skin roughness, mottled hyperpigmentation, and telangiectasias has been described.[138-145] Mode of action is based on the degradation of altered collagen and elastotic material and the formation of newly synthetized collagen directly underneath the epidermis.[142-144] The combination with daylight exposure also seems possible.[146]

PERSPECTIVES

The efficacy of PDT in the treatment of superficial neoplastic skin lesion, particularly actinic keratoses, Bowen disease, and superficial BCCs, has been sufficiently documented. PDT may also find a place in the treatment of selected patients with inflammatory dermatoses. Nonetheless, the limitations of both systemic and topical PDT have to be kept in mind. Crucial issues are the depth of the penetration of light, as well as of the sensitizer, into the skin, and inability to ensure complete eradication of malignancy by histologic criteria.

REFERENCES

1. Pathak MA, Fitzpatrick TB. The evolution of photochemotherapy with psoralens and UVA (PUVA): 2000 BC to 1992 AD. *J Photochem Photobiol B Biol.* 1992; 14(1-2):3-22.
2. Parrish JA, Fitzpatrick TB, Tanenbaum L, et al. Photochemotherapy of psoriasis with oral methoxsalen and long wave ultraviolet light. *N Engl J Med.* 1974; 291(23):1207-1211.
3. Wolff K, Fitzpatrick TB, Parrish JA, et al. Photochemotherapy for psoriasis with orally administered methoxsalen. *Arch Dermatol.* 1976;112(7):943-950.
4. Fischer T, Alsins J. Treatment of psoriasis with trioxsalen baths and dysprosium lamps. *Acta Derm Venereol.* 1976;56(5):383-390.
5. Dall'Acqua F. Principles of psoralen photosensitization. In: Hönigsmann H, Jori G, Young AR, eds. *The Fundamental Bases of Phototherapy*. Milano: OEMF; 1996:1-16.
6. Schmitt IM, et al. Photobiology of psoralens. In: Hönigsmann H, Jori G, Young AR, eds. *The Fundamental Bases of Phototherapy*. Milan: OEMF; 1996:17.
7. Averbeck D. Recent advances in psoralen phototoxicity mechanism. *Photochem Photobiol.* 1989;50(6):859-882.
8. Hönigsmann H. Phototherapy for psoriasis. *Clin Exp Dermatol.* 2001;26(4):343-350.
9. Wolff K, Gschnait F, Hönigsmann H, et al. Phototesting and dosimetry for photochemotherapy. *Br J Dermatol.* 1977;96(1):1.
10. Ibbotson SH, Dawe RS, Farr PM. The effect of methoxsalen dose on ultraviolet-A-induced erythema. *J Invest Dermatol.* 2001;116(5):813-815.
11. Ibbotson SH, Farr PM. The time-course of psoralen ultraviolet A (PUVA) erythema. *J Invest Dermatol.* 1999;113(3):346-350.
12. Halpern SM, Anstey AV, Dawe RS, et al. Guidelines for topical PUVA: a report of a workshop of the British photodermatology group. *Br J Dermatol.* 2000; 142(1):22-31.
13. Melski JW, Tanenbaum L, Parrish JA, et al. Oral methoxsalen photochemotherapy for the treatment of psoriasis: a cooperative clinical trial. *J Invest Dermatol.* 1977;68(6):328-335.
14. Henseler T, Wolff K, Hönigsmann H, et al. Oral 8-methoxypsoralen photochemotherapy of psoriasis. The European PUVA study: a cooperative study among 18 European centres. *Lancet.* 1981; 1(8225):853-857.
15. Menter A, Korman NJ, Elmets CA, et al. Guidelines of care for the management of psoriasis and psoriatic arthritis Section 5. Guidelines of care for the treatment of psoriasis with phototherapy and photochemotherapy. *J Am Acad Dermatol.* 2010;62(1): 114-135.
16. Anonymous. British Photodermatology Group guidelines for PUVA. *Br J Dermatol.* 1994;130(2):246-255.
17. Radakovic S, Seeber A, Hönigsmann H, et al. Failure of short-term psoralen and ultraviolet A light maintenance treatment to prevent early relapse in patients with chronic recurring plaque-type psoriasis. *Photodermatol Photoimmunol Photomed.* 2009;25(2):90-93.
18. Morison WL. Phototherapy and photochemotherapy. *Adv Dermatol.* 1992;7:255-270; discussion 271.
19. Stern RS, Laird N. Photochemotherapy follow-up study: the carcinogenic risks of treatments for severe psoriasis. *Cancer.* 1994;73(11):2759-2764.
20. Marcil I, Stern RS. Squamous-cell cancer of the skin in patients given PUVA and ciclosporin: nested cohort crossover study. *Lancet.* 2001;358(9287):1042.
21. Molin L, Larkö O. Cancer induction by immunosuppression in psoriasis after heavy PUVA treatment [letter]. *Acta Derm Venereol.* 1997;77(5):402.
22. van de Kerkhof PC, De Rooij MJ. Multiple squamous cell carcinomas in a psoriatic patient following high-dose photochemotherapy and cyclosporin treatment: response to long-term acitretin maintenance. *Br J Dermatol.* 1997;136(2):275-278.
23. Hönigsmann H, Wolff K. Results of therapy for psoriasis using retinoid and photochemotherapy (RePUVA). *Pharmacol Ther.* 1989;40:67.
24. Nijsten TEC, Stern RS. Oral retinoid use reduces cutaneous squamous cell carcinoma risk in patients with psoriasis treated with psoralen-UVA: a nested cohort study. *J Am Acad Dermatol.* 2003;49:644.
25. Ortonne JP, Khemis A, Koo JY, et al. An open-label study of alefacept plus ultraviolet B light as combination therapy for chronic plaque psoriasis. *J Eur Acad Dermatol Venereol.* 2005;19(5):556-563.
26. Lebwohl M. Combining the new biologic agents with our current psoriasis armamentarium. *J Am Acad Dermatol.* 2003;49(suppl 2):S118-S124.
27. Gilchrest BA, Parrish JA, Tanenbaum L, et al. Oral methoxsalen photochemotherapy of mycosis fungoides. *Cancer.* 1976;38(2):683-689.
28. Baron ED, Stevens SR. Phototherapy for cutaneous T-cell lymphoma. *Dermatol Ther.* 2003;16(4):303-310.
29. Zhang C, Duvic M. Retinoids: therapeutic applications and mechanisms of action in cutaneous T-cell lymphoma. *Dermatol Ther.* 2003;16(4):322-330.
30. Singh F, Lebwohl MG. Cutaneous T-cell lymphoma treatment using bexarotene and PUVA: a case series. *J Am Acad Dermatol.* 2004;51(4):570-573.
31. Tanew A, Hönigsmann H. Ultraviolet B and psoralen plus UVA phototherapy for cutaneous T-cell lymphoma. *Dermatol Ther.* 1997;4:38.
32. Stadler R, Otte HG, Luger T, et al. Prospective randomized multicenter clinical trial on the use of interferon-2a plus acitretin versus interferon-2a plus PUVA in patients with cutaneous T-cell lymphoma stages I and II. *Blood.* 1998;92(10):3578-3581.
33. Stadler R. Optimal combination with PUVA: rationale and clinical trial update. *Oncology (Williston Park).* 2007;2(suppl 1):29-32.
34. Querfeld C, Rosen ST, Kuzel TM. Long-term followup of patients with early-stage cutaneous T-cell lymphoma who achieved complete remission with psoralen plus UV-A monotherapy. *Arch Dermatol.* 2005;141(3):305-311.

35. Morison WL. *Phototherapy and Photochemotherapy of Skin Disease*. 2nd ed. New York, NY: Raven; 1991:148.
36. Tzaneva S, Kittler H, Holzer G, et al. 5-Methoxypsoralen plus ultraviolet (UV) A is superior to medium-dose UVA1 in the treatment of severe atopic dermatitis: a randomized crossover trial. *Br J Dermatol.* 2010; 162(3):655-660.
37. Honig B, Morison WL, Karp D. Photochemotherapy beyond psoriasis. *J Am Acad Dermatol.* 1994;31(5, pt 1): 775-790.
38. Christophers E, Hönigsmann H, Wolff K, et al. PUVA-treatment of urticaria pigmentosa. *Br J Dermatol.* 1978; 98(6):701-702.
39. Lange-Wantzin G, Thomsen K. PUVA-treatment in lymphomatoid papulosis. *Br J Dermatol.* 1982; 107(6):687-690.
40. Kerker BJ, Huang CP, Morison WL. Photochemotherapy of generalized granuloma annulare. *Arch Dermatol.* 1990;126(3):359-361.
41. Taylor CR, Hawk JLM. PUVA treatment of alopecia areata partialis, totalis and universalis: audit of 10 years' experience at St. John's Institute of Dermatology. *Br J Dermatol.* 1995;133(6):914-918.
42. Kerscher M, Volkenandt M, Meurer M, et al. Treatment of localised scleroderma with PUVA bath photochemotherapy. *Lancet.* 1994;343(8907):1233.
43. Scharfetter-Kochanek K, Goldermann R, Lehmann P, et al. PUVA therapy in disabling pansclerotic morphoea of children. *Br J Dermatol.* 1995;132(5):830-831.
44. Volc-Platzer B, Hönigsmann H, Hinterberger W, et al. Photochemotherapy improves chronic cutaneous graft-versus-host disease. *J Am Acad Dermatol.* 1990; 23(2, pt 1):220-228.
45. Kunz M, Wilhelm S, Freund M, et al. Treatment of severe erythrodermic acute graft-versus-host disease with photochemotherapy. *Br J Dermatol.* 2001; 144(4):901-902.
46. Kwok YK, Anstey AV, Hawk JL. Psoralen photochemotherapy (PUVA) is only moderately effective in widespread vitiligo: a 10-year retrospective study. *Clin Exp Dermatol.* 2002;27(2):104-110.
47. Yones SS, Palmer RA, Garibaldinos TM, et al. Randomized double blind trial of treatment of vitiligo. *Arch Dermatol.* 2007;143(5):578-584.
48. Hönigsmann H. Mechanisms of phototherapy and photochemotherapy for photodermatoses. *Dermatol Ther.* 2003;16(1):23-27.
49. Hönigsmann H. Polymorphous light eruption. *Photodermatol Photoimmunol Photomed.* 2008;24(3):155.
50. Roelandts R. Diagnosis and treatment of solar urticaria. *Dermatol Ther.* 2003;16(1):52-56.
51. Tanew A, Ferguson J. Phototherapy and photochemotherapy of the idiopathic photodermatoses. In: Krutmann J, Hönigsmann H, Elmets C, eds. *Dermatological Phototherapy and Photodiagnostic Methods.* 2nd ed. Berlin: Springer; 2009:119.
52. Roelandts R. Photo(chemo)therapy and general management of erythropoietic protoporphyria. *Dermatology.* 1995;190(4):330-331.
53. Ullrich SE. Does exposure to UV radiation induce a shift to a Th-2-like immune reaction? *Photochem Photobiol.* 1996;64(2):254-258.
54. Morrey JD, Bourn SM, Bunch TD, et al. In vivo activation of human immunodeficiency virus type 1 long terminal repeat by UV type A (UV-A) light plus psoralen and UV-B light in the skin of transgenic mice. *J Virol.* 1991;65(9):5045-5051.
55. Zmudzka BZ, Miller SA, Jacobs ME, et al. Medical UV exposures and HIV activation. *Photochem Photobiol.* 1996;64(2):246-253.
56. Morison WL. PUVA therapy is preferable to UVB phototherapy in the management of HIV-associated dermatoses. *Photochem Photobiol.* 1996;64(2):267-268.
57. Menon K, Van Voorhees AS, Bebo BF Jr, et al; for the National Psoriasis Foundation. Psoriasis in patients with HIV infection: from the medical board of the National Psoriasis Foundation. *J Am Acad Dermatol.* 2010;62(2):291-299.
58. Hönigsmann H. Psoralen photochemotherapy—mechanisms, drugs, toxicity. *Curr Probl Dermatol.* 1986;15:52-66.
59. Nyfors A, Dahl-Nyfors B, Hopwood D. Liver biopsies from patients with psoriasis related to photochemotherapy (PUVA): findings before and after 1 year of therapy in twelve patients. A blind study and review of literature on hepatotoxicity of PUVA. *J Am Acad Dermatol.* 1986;14(1):43-48.
60. Calzavara-Pinton PG, Franceschini F, Rastrelli M, et al. Antinuclear antibodies are not induced by PUVA treatment with uncomplicated psoriasis. *J Am Acad Dermatol.* 1994;30(6):955-958.
61. Dunnick JK, Forbes PD, Eustis SL, et al. Tumors of the skin in the HRA/Skh mouse after treatment with 8-methoxypsoralen and UVA radiation. *Fundam Appl Toxicol.* 1991;16(1):92-102.
62. Stern RS, Liebman EJ, Vakeva L. Oral psoralen and ultraviolet-A light (PUVA) treatment of psoriasis and persistent risk of nonmelanoma skin cancer. PUVA Follow-up Study. *J Natl Cancer Inst.* 1998;90(17): 1278.
63. Henseler T, Christophers E, Hönigsmann H, et al. Skin tumors in the European PUVA study. Eight year follow-up of 1643 patients treated with PUVA for psoriasis. *J Am Acad Dermatol.* 1987;16(1, pt 1): 108-116.
64. Lim JL, Stern RS. High levels of ultraviolet B exposure increase the risk of nonmelanoma skin cancer in psoralen and ultraviolet A-treated patients. *J Invest Dermatol.* 2005;124(3):505-513.
65. Murase JE, Lee EE, Koo J. Effect of ethnicity on the risk of developing nonmelanoma skin cancer following long-term PUVA therapy. *Int J Dermatol.* 2005; 44(12):1016-1021.
66. Stern RS; Members of the Photochemotherapy Follow-up Study. Genital tumors among men with psoriasis exposed to psoralens and ultraviolet A (PUVA) radiation and ultraviolet B radiation. *N Engl Med J.* 1990; 322(16):1093-1097.
67. Wolff K, Hönigsmann H. Genital carcinomas in psoriasis patients treated with photochemotherapy. *Lancet.* 1991;337(8738):439.
68. Aubin F, Puzenat E, Arveux P, et al. Genital squamous cell carcinoma in men treated by photochemotherapy. A cancer registry-based study from 1978 to 1998. *Br J Dermatol.* 2001;144(6):1204-1206.
69. Stern RS; The PUVA follow-up study. The risk of melanoma in association with long-term exposure to PUVA. *J Am Acad Dermatol.* 2001;44(5):755-761.
70. Stern RS, Nichols KT, Vakeva LH. Malignant melanoma in patients treated for psoriasis with methoxsalen (psoralen) and ultraviolet A radiation (PUVA). The PUVA follow-up study. *N Engl J Med.* 1997;336(15): 1041-1045.
71. Wolff K. Should PUVA be abandoned? [editorial]. *N Engl J Med.* 1997;336(15):1090-1091.

72. Forman AB, Roenigk HH Jr, Caro WA, et al. Long-term follow-up of skin cancer in the PUVA-48 cooperative study. *Arch Dermatol.* 1989;125(4):515-519.
73. Chuang TY, Heinrich LA, Schultz MD, et al. PUVA and skin cancer: a historical cohort study on 492 patients. *J Am Acad Dermatol.* 1992;26(2, pt 1):173-177.
74. Young AR. Photochemotherapy and skin carcinogenesis: a critical review. In: Hönigsmann H, Jori G, Young AR, eds. *The Fundamental Bases of Phototherapy*. Milan: OEMF; 1996:77.
75. Hannuksela-Svahn A, Sigurgeirsson B, Pukkala E, et al. Trioxsalen bath PUVA did not increase the risk of squamous cell skin carcinoma and cutaneous malignant melanoma in a joint analysis of 944 Swedish and Finnish patients with psoriasis. *Br J Dermatol.* 1999;141(3):497-501.
76. Hannuksela-Svahn A, Pukkala E, Koulu L, et al. Cancer incidence among Finnish psoriasis patients treated with 8-methoxypsoralen bath PUVA. *J Am Acad Dermatol.* 1999;40(5, pt 1):694-696.
77. Young AR. Carcinogenicity of UVB phototherapy assessed. *Lancet.* 1995;345(8962):1431-1432.
78. Stern RS. Ocular lens findings in patients treated with PUVA. Photochemotherapy follow-up study. *J Invest Dermatol.* 1994;103(4):534-538.
79. Malanos D, Stern RS. Psoralen plus ultraviolet A does not increase the risk of cataracts: a 25-year prospective study. *J Am Acad Dermatol.* 2007;57(2):231-237.
80. Stern RS, Lange R. Outcomes of pregnancies among women and partners of men with a history of exposure to methoxsalen photochemotherapy (PUVA) for the treatment of psoriasis. *Arch Dermatol.* 1991; 127(3):347-350.
81. Edelson R, Berger C, Gasparro F, et al. Treatment of cutaneous T-cell lymphoma. *N Engl J Med.* 1987; 316(6):297-303.
82. Demierre MF, Foss F, Koh H. Proceedings of the International Consensus Conference on cutaneous T-cell lymphoma (CTCL): treatment recommendations. *J Am Acad Dermatol.* 1997;36(3, pt 1):460-466.
83. Trautinger F, Eder J, Assaf C, et al. European Organisation for Research and Treatment of Cancer consensus recommendations for the treatment of mycosis fungoides/Sézary syndrome—update 2017. *Eur J Cancer.* 2017;77:57-74.
84. Knobler E, Warmuth I, Cocco C, et al. Extracorporeal photochemotherapy—the Columbia Presbyterian experience. *Photodermatol Photoimmunol Photomed.* 2002;18(5):232-237.
85. Scarisbrick J. Extracorporeal photopheresis: what is it and when should it be used? *Clin Exp Dermatol.* 2009;34(7):757-760.
86. Knobler R, Barr ML, Couriel DR, et al. Extracorporeal photopheresis: past, present, and future. *J Am Acad Dermatol.* 2009;61(4):652-665.
87. McKenna KE, Whittaker S, Rhodes LE, et al. Evidence-based practice of photopheresis 1987-2001: a report of a workshop of the British Photodermatology Group and the U.K. Skin Lymphoma Group. *Br J Dermatol.* 2006;154(1):7-20.
88. Knobler RM, Trautinger F, Graninger W, et al. Parenteral administration of 8-methoxypsoralen in photopheresis. *J Am Acad Dermatol.* 1993;28(4): 580-584.
89. Maeda A, Schwarz A, Kernebeck K, et al. Intravenous infusion of syngeneic apoptotic cells by photopheresis induces antigen-specific regulatory T-cells. *J Immunol.* 2005;174(10):5968-5976.
90. Maeda A, Schwarz A, Bullinger A, et al. Experimental extracorporeal photopheresis inhibits the sensitization and effector phases of contact hypersensitivity via two mechanisms: generation of IL-10 and induction of regulatory T cells. *J Immunol.* 2008;181(9):5956-5962.
91. Knobler R, Girardi M. Extracorporeal photochemoimmunotherapy in cutaneous T-cell lymphomas. *Ann N Y Acad Sci.* 2001;941:123-138.
92. Zic JA, Stricklin GP, Greer JP, et al. Long-term follow-up of patients with cutaneous T-cell lymphoma treated with extracorporeal photochemotherapy. *J Am Acad Dermatol.* 1996;35:935-945.
93. Gottlieb SL, Wolfe JT, Fox FE, et al. Treatment of cutaneous T-cell lymphoma with extracorporeal photopheresis monotherapy and in combination with recombinant interferon alfa: a 10-year experience at a single institution. *J Am Acad Dermatol.* 1996;35(6):946-957.
94. Shapiro M, Rook AH, Lehrer MS, et al. Novel multimodality biologic response modifier therapy, including bexarotene and long-wave ultraviolet A for a patient with refractory stage IVa cutaneous T-cell lymphoma. *J Am Acad Dermatol.* 2002;47(6):956-961.
95. Greinix HT, Volc-Platzer B, Rabitsch W, et al. Successful use of extracorporeal photochemotherapy in the treatment of severe acute and chronic graft-versus-host disease. *Blood.* 1998;92(9):3098-3104.
96. Foss FM, DiVenuti GM, Chin K, et al. Prospective study of extracorporeal photopheresis in steroid-refractory or steroid-resistant extensive chronic graft-versus-host disease: analysis of response and survival incorporating prognostic factors. *Bone Marrow Transplant.* 2005;35(12):1187-1193.
97. Greinix HT, Knobler RM, Worel N, et al. The effect of intensified extracorporeal photochemotherapy on long-term survival in patients with severe acute graft-versus-host disease. *Haematologica.* 2006;91(3): 405-408.
98. Dall'Amico R, Murer L. Extracorporeal photochemotherapy: a new therapeutic approach for allograft rejection. *Transfus Apher Sci.* 2002;26(3):197-204.
99. Kumlien G, Genberg H, Shanwell A, et al. Photopheresis for the treatment of refractory renal graft rejection. *Transplantation.* 2005;79(1):123-125.
100. Pass HI. Photodynamic therapy in oncology: mechanisms and clinical use. *J Natl Cancer Inst.* 1993; 85(6):443-456.
101. Kennedy JC, Pottier RH. Endogenous protoporphyrin IX, a clinically useful photosensitizer for photodynamic therapy. *J Photochem Photobiol B Biol.* 1992;14(4):275-292.
102. Fritsch C, Batz J, Bolsen K, et al. Ex vivo application of α-aminolevulinic acid induces high and specific porphyrin levels in human skin tumors: possible basis for selective photodynamic therapy. *Photochem Photobiol.* 1997;66(1):114-118.
103. Fitzmaurice S, Eisen DB. Daylight photodynamic therapy: what is known and what is yet to be determined. *Dermatol Surg.* 2016;42(3):286-295.
104. Penning LC, Dubbelman TM. Fundamentals of photodynamic therapy: cellular and biochemical aspects. *Anticancer Drugs.* 1994;5(2):139-146.
105. Jones CM, Mang T, Cooper M, et al. Photodynamic therapy in the treatment of Bowen's disease. *J Am Acad Dermatol.* 1992;27(6, pt 1):979-982.
106. Dougherty TJ. Photoradiation therapy for cutaneous and subcutaneous malignancies. *J Invest Dermatol.* 1981;77(1):122-124.

107. Oseroff AR, Blumenson LR, Wilson BD, et al. A dose ranging study, of photodynamic therapy with porfimer sodium (Photofrin®) for treatment of basal cell carcinoma. *Lasers Surg Med.* 2006;38(5):417-426.
108. Lui H, Anderson RR. Photodynamic therapy in dermatology. *Arch Dermatol.* 1992;128(12):1631-1636.
109. Weinstein GD, MeCullough JL, Nelson JS, et al. Low-dose photofrin II photodynamic therapy of psoriasis. *Clin Res.* 1991;39:509A.
110. Boehncke WH, Elshorst-Schmidt T, Kaufmann R. Systemic photodynamic therapy is a safe and effective treatment for psoriasis. *Arch Dermatol.* 2000; 136(2):271-272.
111. Szeimies RM, Sassy T, Landthaler M. Penetration potency of topical applied α-aminolevulinic acid for photodynamic therapy of basal cell carcinoma. *Photochem Photobiol.* 1994;59(1):73-76.
112. Fritsch C, Verwohlt B, Bolsen K, et al. Influence of topical photodynamic therapy with 5-aminolevulinic acid on porphyrin metabolism. *Arch Dermatol Res.* 1996; 288(9):517-521.
113. Warren CB, Karai LJ, Vidimos A, et al. Pain associated with aminolevulinic acid-photodynamic therapy of skin disease. *J Am Acad Dermatol.* 2009; 61(6):1033-1043.
114. Wang B, Shi L, Zhang YF, et al. Gain with no pain? Pain management in dermatological photodynamic therapy. *Br J Dermatol.* 2017;177(3):656-665.
115. Szeimies RM, Karrer S, Sauerwald A, et al. Topical photodynamic therapy with 5-aminolevulinic acid in the treatment of actinic keratoses: a first clinical study. *Dermatology.* 1996;192:246-251.
116. Jeffes EW, McCullough JL, Weinstein GD, et al. Photodynamic therapy of actinic keratosis with topical 5-aminolevulinic acid. *Arch Dermatol.* 1997; 133(6):727-732.
117. Morton CA, Whitehurst C, Moseley H, et al. Comparison of photodynamic therapy with cryotherapy in the treatment of Bowen's disease. *Br J Dermatol.* 1996;135(5):766-771.
118. Basset-Seguin N, Ibbotson SH, Emtestam L, et al. Topical methyl aminolaevulinate photodynamic therapy versus cryotherapy for superficial basal cell carcinoma: a 5 year randomized trial. *Eur J Dermatol.* 2008; 18(5):547-553.
119. Rhodes LE, de Rie M, Enström Y, et al. Photodynamic therapy using topical methyl aminolevulinate vs. surgery for nodular basal cell carcinoma: results of a multicenter randomized prospective trial. *Arch Dermatol.* 2004;140(1):17-23.
120. Szeimies RM, Ibbotson S, Murrell DF, et al. A clinical study comparing methyl aminolevulinate photodynamic therapy and surgery in small superficial basal cell carcinoma (8-20 mm), with a 12-month follow-up. *J Eur Acad Dermatol Venereol.* 2008; 22(11):1302-1311.
121. Morton C, Szeimies RM, Sidoroff A, et al. European Dermatology Forum Guidelines on topical photodynamic therapy. *Eur J Dermatol.* 2015;25(4):296-311.
122. Bay C, Lerche CM, Ferrick B, et al. Comparison of physical pretreatment regimens to enhance protoporphyrin IX uptake in photodynamic therapy: a randomized clinical trial. *JAMA Dermatol.* 2017;153(4):270-278.
123. Torezan L, Chaves Y, Niwa A, et al. A pilot split-face study comparing conventional methyl aminolevulinate-photodynamic therapy (PDT) with microneedling-assisted PDT on actinically damaged skin. *Dermatol Surg.* 2013;39(8):1197-1201.
124. Zane C, Venturini M, Sala R, et al. Photodynamic therapy with methylaminolevulinate as a valuable treatment option for unilesional cutaneous T-cell lymphoma. *Photodermatol Photoimmunol Photomed.* 2006;22(5):254-258.
125. Weinstein GD, McCullough JL, Jeffes EW. Photodynamic therapy (PDT) of psoriasis with topical delta aminolevulinic acid (ALA): a pilot dose ranging study. *Photodermatol Photoimmunol Photomed.* 1994; 10:92.
126. Radakovic-Fijan S, Blecha-Thalhammer U, Schleyer V, et al. Topical aminolaevulinic acid based photodynamic therapy as a treatment option for psoriasis? Results of a randomized, observer-blinded study. *Br J Dermatol.* 2005;152(2):279-283.
127. Schleyer V, Radakovic-Fijan S, Karrer S, et al. Disappointing results and low tolerability of photodynamic therapy with topical 5-aminolaevulinic acid in psoriasis. A randomized, double-blind phase I/II study. *J Eur Acad Dermatol Venereol.* 2006; 20(7):823-828.
128. Karrer S, Abels C, Landthaler M, et al. Topical photodynamic therapy for localized scleroderma. *Acta Dermatol Venereol.* 2000;80(1):26-27.
129. Karrer S, Bosserhoff AK, Weiderer P, et al. Keratinocyte-derived cytokines after photodynamic therapy and their paracrine induction of matrix metalloproteinases in fibroblasts. *Br J Dermatol.* 2004;151(4): 776-783.
130. Frank RG, Bos JD. Photodynamic therapy for condylomata acuminata with local application of 5-aminolevulinic acid. *Genitourin Med.* 1996;72(1):70-71.
131. Karrer S, Szeimies RM, Abels C, et al. Epidermodysplasia verruciformis treated using topical 5-aminolevulinic acid photodynamic therapy. *Br J Dermatol.* 1999; 140(5):935-938.
132. Stender IM, Na R, Fogh H, et al. Photodynamic therapy with 5-aminolaevulinic acid or placebo for recalcitrant foot and hand warts: randomized double-blind trial. *Lancet.* 2000;355(9208):963-966.
133. Asilian A, Davami M. Comparison between the efficacy of photodynamic therapy and topical paromomycin in the treatment of Old World cutaneous leishmaniasis: a placebo-controlled, randomized clinical trial. *Clin Exp Dermatol.* 2006;31(5):634-637.
134. Hongcharu W, Taylor CR, Chang Y, et al. Topical ALA-photodynamic therapy for the treatment of acne vulgaris. *J Invest Dermatol.* 2000;115(2):183-192.
135. Pollock B, Turner D, Stringer MR, et al. Topical aminolaevulinic acid-photodynamic therapy for the treatment of acne vulgaris: a study of clinical efficacy and mechanism of action. *Br J Dermatol.* 2004; 151(3):616-622.
136. Bhardwaj SS, Rohrer TE, Arndt K. Lasers and light therapy for acne vulgaris. *Semin Cutan Med Surg.* 2005; 24(2):107-112.
137. Nybaek H, Jemec GBE. Photodynamic therapy in the treatment of rosacea. *Dermatology.* 2005; 211(2):135-138.
138. Dover JS, Bhatia AC, Stewart B, et al. Topical 5-aminolevulinic acid combined with intense pulsed light in the treatment of photoaging. *Arch Dermatol.* 2005;141(10):1247-1252.
139. Gold MH, Bradshaw VL, Boring MM, et al. Split-face comparison of photodynamic therapy with 5-aminolevulinic acid and intense pulsed light versus intense pulsed light alone for photodamage. *Dermatol Surg.* 2006;32(6):795-801.

140. Ruiz-Rodriguez R, Sanz-Sanchez T, Cordoba S. Photodynamic photorejuvenation. *Dermatol Surg.* 2002; 28(8):742-744; discussion 744.
141. Touma DJ, Gilchrest BA. Topical photodynamic therapy: a new tool in cosmetic dermatology. *Semin Cutan Med Surg.* 2003;22(2):124-130.
142. Orringer JS, Hammerberg C, Hamilton T, et al. Molecular effects of photodynamic therapy for photoaging. *Arch Dermatol.* 2008;144(10):1296-1302.
143. Szeimies RM, Torezan L, Niwa A, et al. Clinical, histopathological and immunohistochemical assessment of human skin field cancerization before and after photodynamic therapy. *Br J Dermatol.* 2012; 167(1):150-159.
144. Kohl E, Torezan LA, Landthaler M, et al. Aesthetic effects of topical photodynamic therapy. *J Eur Acad Dermatol.* 2010;24(11):1261-1269.
145. Szeimies RM, Lischner S, Philipp-Dormston W, et al. Photodynamic therapy for skin rejuvenation: treatment options—results of a consensus conference of an expert group for aesthetic photodynamic therapy. *J Dtsch Dermatol Ges.* 2013;11(7):632-636.
146. Philipp-Dormston WG, Sanclemente G, Torezan L, et al. Daylight photodynamic therapy with MAL cream for large-scale photodamaged skin based on the concept of "actinic field damage": recommendations of an international expert group. *J Eur Acad Dermatol Venereol.* 2016;30(1):8-15.

Chapter 200 :: Radiotherapy

:: Roy H. Decker & Lynn D. Wilson

AT-A-GLANCE

- Radiotherapy is a collection of versatile treatment modalities that includes brachytherapy and external-beam radiation.
- The clinical effects of radiotherapy include acute and late skin changes:
  - Acute effects include an inflammatory reaction and desquamation.
  - Late effects include fibrotic changes and atrophy of skin adnexa.
  - Radiation-induced malignancy is a rare but serious side effect, which presents at a median of 10 years after treatment.
- Radiotherapy is indicated for selected benign, proliferative diseases after more conservative measures have failed.
- Radiotherapy is a valuable option for primary or adjuvant therapy for malignant skin disease.

The first documented use of radiation as a therapeutic treatment was for a cutaneous malignancy, in a patient with squamous cell cancer of the nose, in 1900. Over the next century, radiotherapy was widely used in the treatment of both malignant and benign disorders of the skin, in both adults and children. As the long-term consequences of radiotherapy became evident, particularly the risk of radiation-induced malignancy, its use in the treatment of benign diseases declined, particularly in children. Radiotherapy continues to have a small but important role in the management of benign proliferative diseases of the skin, but is more commonly used as a valuable adjunct or alternative to surgery for both premalignant and malignant lesions.

RADIATION MODALITIES

There are several choices for radiation modalities, some commonly available and others only in specialized centers. The selection is made on the basis of the anatomic location and size of the target, tumor biology, the nature of critical surrounding structures, and availability. In particular, with respect to the cutaneous targets, the depth of the lesion plays a large role in determining the optimal therapy.

High-energy photons, in the form of γ- or X-rays, are most commonly produced by a linear accelerator (LINAC) and are available in a spectrum of energies. Incident radiation deposits its energy as it passes through matter, becoming attenuated as a function of depth and the density of the tissue. Higher energy beams deliver increased doses at depth in tissue, and proportionally less at the surface (often referred to as "skin sparing"). Lower energy radiation deposits the dose primarily at the target surface, sparing deeper tissue. The most commonly available treatment energies in general oncology practice are in the megavoltage range (6 to 18 megavolts),[1] depositing their dose at a range practical for the treatment of internal targets in human tissue. Such beams were designed to relatively spare surface structures such as skin in the interest of delivering a higher dose to deeper target structures and sparing the skin from toxicity. This is in contrast to lower radiation energy beams in the kilovoltage range (commonly referred to as "superficial radiation therapy"), which are often more appropriate for cutaneous targets. Figure 200-1A shows the depth dose curves demonstrating the absorption of X-rays as a function of their energy.

Orthovoltage X-rays refer to lower-energy photons with maximum energy in the range of 125 to 400 kilovolts, often used in dermatologic applications because the dose at the skin surface is maximized. The dose is then rapidly attenuated as the beam penetrates deeper into soft tissue. Half of the incident energy is absorbed within the first few centimeters, and full dose is only delivered to a depth of a few millimeters. Consequently, the most appropriate use is for very superficial tumors. Importantly, lower doses continue to penetrate fairly deeply, so critical structures can still be exposed to a significant exit dose. Orthovoltage X-rays are produced by specialized treatment units that are far smaller than higher-energy machines. Because of their small size and the lower shielding requirements, they are much easier to install in medical offices or even in portable applications.

Grenz rays are even lower-energy X-rays in the range of 5 to 15 kilovolts, and therefore deposit their dose at shallower depths than orthovoltage. Historically, Grenz rays were used to treat superficial, benign skin disease. In these cases, the majority of the target processes occur within 1 mm of the skin surface. Grenz rays are no longer recommended as first-line therapy for routine treatment of benign cutaneous disease.

Charged particle therapy is also commonly used in cancer treatment, and includes both electrons, which are commonly available, and protons, which are available at select regional centers. Electrons are the product of the same linear accelerators used to produce megavoltage energy photons. Electron beams are commonly used in dermatologic applications because they deliver a high skin-surface dose and, unlike photons, the deposited dose rapidly falls to negligible values at depth in tissue. Different electron energies can be used to deliver therapeutic doses from 1 to 5 cm deep in tissue, and deeper tissues can be completely spared.

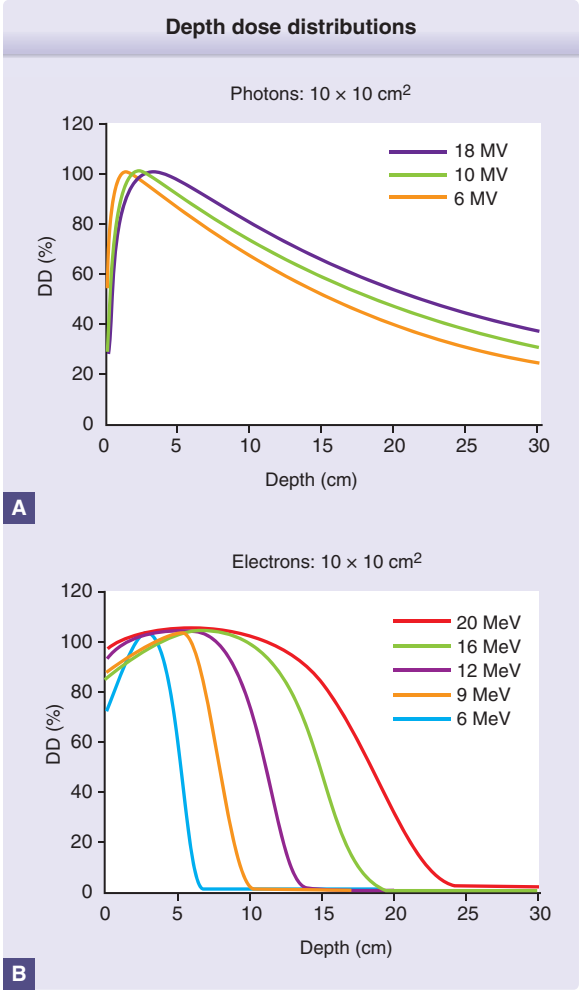

Figure 200-1 Depth dose distributions. **A,** The percent of the maximum radiation dose (DD) deposited at depth in tissue (in cm), as a function of the photon (X-ray) energy. As photon energy increases, the percent dose at superficial depth decreases, and the percent dose in deeper tissue increases. MV, megavolt. **B,** A similar relationship for electron therapy. In contrast to photons, the percent dose deposited at both superficial and deep tissue increases with electron energy. Note the difference in scale; electron energy is almost completely absorbed at shallower depths, compared to photons. MeV, million electron volts.

Figure 200-1B describes the depth dose characteristics of electrons.

Protons are charged particles that are the product of large and expensive cyclotrons or synchrotrons, and are available at a small number of specialized centers. Proton therapy is generally several times more expensive than photon or electron therapy, because of the very high capital outlay required to establish a center, although this cost is falling with the development of smaller treatment units. One consequence of a proton's relatively large mass is little side scatter during penetration of a proton beam. The dose is largely delivered within a few millimeters of the end of the particle range (the *Bragg peak*), rather than at shallower or deeper depths. By modulating the energy of the proton beam, radiation absorption can be more precisely delivered to deep tumor targets, with less incidental radiation of surrounding normal tissue. Like electrons, protons have a negligible exit dose, but unlike electrons, protons can be delivered to deep targets while sparing the overlying skin.

MODULATION OF EXTERNAL-BEAM RADIATION

Radiation treatment planning involves a complex set of decisions regarding the appropriate radiation modality, radiation energy, beam orientation, patient positioning, and the choice of treatment devices. The choice of device can help increase the radiation dose to targeted structures and block or reduce radiation exposure of normal tissue. "Bolus" is tissue-density material commonly used in radiation treatment of superficial skin malignancies. It can be custom designed in varying thicknesses and applied to the patient's skin during daily treatment. It serves several potential purposes: for higher-energy X-rays (eg, megavolt energy), or low-energy electrons, the surface dose is low compared to that in deeper tissue. By using the appropriate thickness of bolus, the skin dose can be raised to therapeutic levels (Fig. 200-2). Another function of bolus is to attenuate the incident beam to lower the dose that reaches deeper structures; for example, during treatment of a skin cancer on the

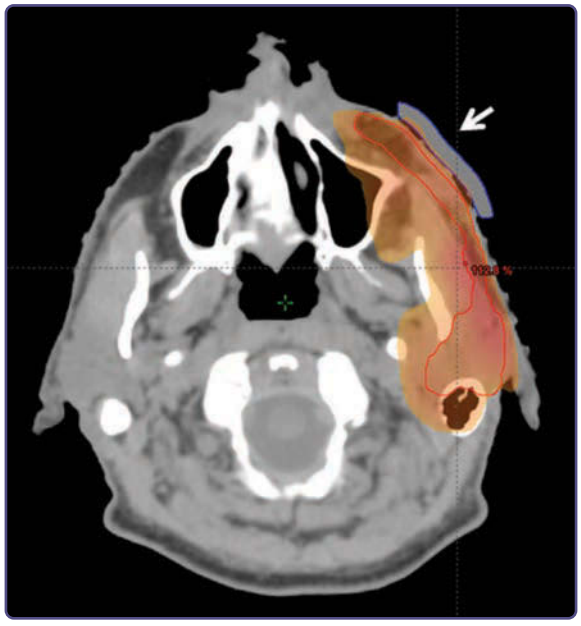

Figure 200-2 Bolus to increase the skin dose. A 61-year-old male underwent resection of a deeply invasive squamous cell carcinoma overlying the zygoma with involvement of parotid lymph nodes and facial nerve. The tumor bed was treated, along with the remaining parotid gland and course of the facial nerve, using megavoltage photons. A tissue-density bolus (*white arrow*) was placed over the tumor bed to increase the skin dose to 100% in that area.

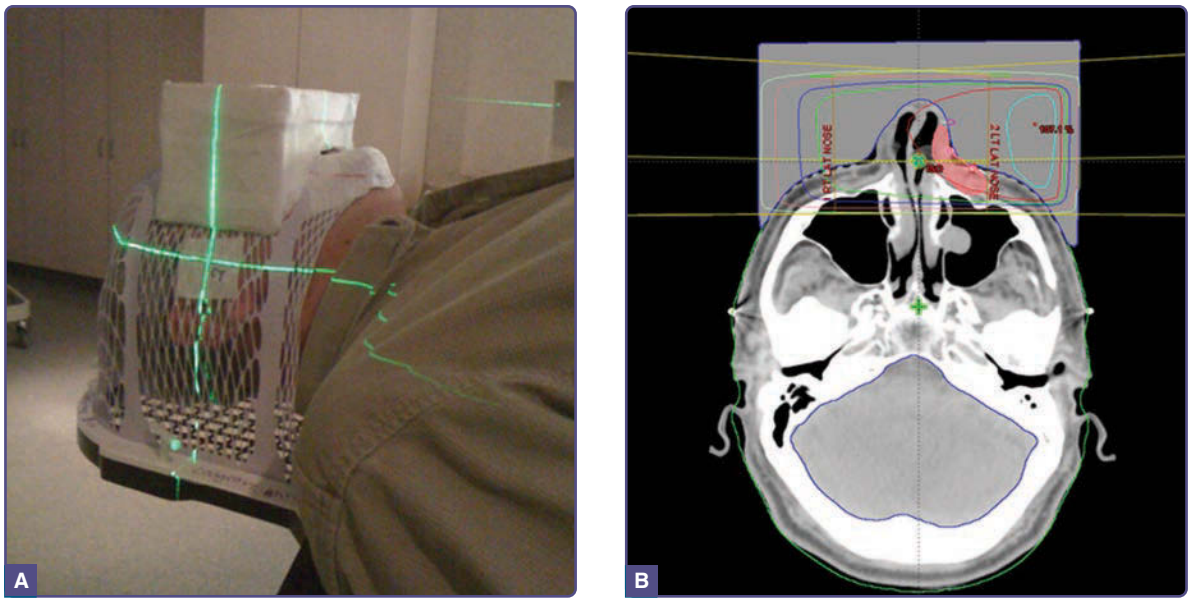

Figure 200-3 Bolus as a tissue compensator. A deeply invasive basal cell carcinoma was excised from the left nasal ala. **A,** The patient was immobilized for treatment in a thermoplastic mask. A rectangular, tissue-density box was constructed to overlay the nose and compensate for the irregular tissue contours in this area. **B,** The patient was treated with right and left lateral megavoltage photon beams, weighted left greater than right. The 100% isodose line (*red line*) covers the tumor bed (*red-shaded area*) with full dose at the skin surface and good dose homogeneity.

temple, the dose that reaches the underlying brain is decreased. Bolus material also can be used to compensate for complex topography and to smooth the dose distribution for treatment of the skin around the nose and ears (Fig. 200-3).

Beams can be shaped by a variety of devices depending on their energy. Megavoltage treatment beams may be shaped by custom-designed, 7-cm thick, lead alloy blocks to conform to the desired shape; most modern linear accelerators have a multileaf collimator (MLC), which contains sliding leaves of tungsten that conform to the desired treatment aperture. Electron-beam radiation is normally blocked with custom-made lead or lead alloy blocks. Orthovoltage radiation is blocked using much thinner custom lead shielding, typically placed on the patient's skin. Figure 200-4 shows an example of a custom blocking device for superficial radiation.

Traditionally, external-beam radiation beams are designed using blocks or static MLCs to conform to a target that is delineated clinically or using CT or other imaging. Multiple beams, beam angles, and energies are chosen to avoid specific normal structures, and the dose is calculated with iterative changes until an acceptable plan was generated. An "inverse planned" method is now increasingly used when the tumor target lies in proximity to a dose-limiting structure. Intensity-modulated radiation therapy incorporates individual radiation beams that are not static; the aperture changes during the treatment to finely adjust beam fluence. This requires a dynamic MLC, in which the leaves slide during beam-on time. During the pretreatment planning phase, the treating physician contours the target volume and those of the normal tissue organs at risk. Dose constraints for each contoured structure are chosen, and the physician, physicist, and dosimetry staff use dedicated treatment planning software algorithms to optimize the treatment plan. This is a time-intensive, expensive technique that can generate plans to treat complex-shaped tumor targets and spare adjacent, critical, normal tissue structures.

Figure 200-4 A custom lead shield that would be placed on the patient's face, with a cutout to allow orthovoltage treatment of a cutaneous malignancy of the left lower eyelid.

MECHANISM OF ACTION

The most common forms of radiotherapy used in clinical practice are X-rays and γ-rays. Both represent photon particles or electromagnetic waves that differ only in the method of their generation: γ-rays are emitted by nuclear reactions, whereas X-rays are emitted by energy transitions in orbital electrons. Ionizing radiation includes that part of the electromagnetic spectrum of sufficient energy to impart energy to target tissue by the ejection of orbital electrons. This is the primary means of energy absorption in human tissue following exposure to therapeutic radiation. As cells are largely composed of water, it is in water molecules that the majority of the ionization occurs, which results in the generation of short-lived free radicals such as hydroxyl radicals. Consequently, the effectiveness of radiation in tissue is dependent upon the availability of oxygen. This is clinically manifest in the reduced radiation response in hypoxic tissue, and is the reason that higher radiation doses are used in the postoperative setting when there is diminished microcirculation.

The primary mediator of cell death in response to ionizing radiation, in both tumor and normal tissue, is damage to DNA by indirect ionization by radiation-induced free radicals.[2] Indirect DNA damage is characteristic of sparsely ionizing radiation, including not only X-rays, but also commonly used charged particles such as electron and proton therapy. In contrast, densely-ionizing radiation (eg, neutrons, α particles) with a higher linear energy transfer deposit their energy densely along their incident tracks, and more commonly induce double-strand DNA breaks directly, without the intermediate ionization of cellular water.

The initial deposition of radiation energy in tissue and the resulting DNA damage occur within thousandths of a second of exposure. The biologic response to DNA damage includes modulation of cell death, differentiation, survival pathways, and activation of DNA repair. These biologic processes occur orders of magnitude more slowly than the initial DNA damage. The ultimate cellular response to radiation can be repair, senescence, differentiation, or cell death. Cell death may occur via apoptosis, a relatively rapid process, but more commonly occurs as mitotic cell death. Misrepair of double-strand DNA breaks generates chromosomal abnormalities, and cells die during failed mitosis, often several generations later.

DOSE AND FRACTIONATION SCHEDULE

The Systéme International d'Unites (SI) unit of radiation dose is the *gray* (Gy), which is defined as 1 joule (J) of energy absorbed per kilogram of tissue. An alternate unit of absorbed dose, largely replaced by the gray, is the rad (an acronym for *radiation absorbed dose*); 1 Gy is equal to 100 rads. Dose is specified to the target volume as defined by the treating radiation oncologist. Most epithelial malignancies are treated to a total dose in the range of 50 to 80 Gy; lymphoid malignancies typically respond to doses of 15 to 40 Gy. Select benign conditions can be treated with lower doses; hypertrophic scars and keloids are commonly prescribed doses in the range of 4 to 20 Gy.

Fractionation refers to the delivery of specified radiation dose in temporally separate treatments, and is recommended to both increase the efficacy of effects on target tissue and to allow normal irradiated tissue to repair radiation damage. Thus, the schedule of radiation fractionation can be used to both increase efficacy of the dose to the target and minimize radiation damage to normal tissue. Common fractionation schemes using conventional radiotherapy deliver treatments at intervals ranging from twice daily to once per week.

The effectiveness of radiation treatment is highly dependent upon the treatment schedule; both the total number of days over which the treatment is spread and the fraction size. The common daily fraction size is 1.8 to 2 Gy per day, given 5 days per week. Different fractionation schedules can be compared using a mathematical conversion to a biologically effective dose (BED), using a formula that accounts for the number of fractions, fraction size, and the DNA-repair characteristics of the target tissue. Commonly used dose-fractionation schedules for cutaneous malignancies include 60 Gy in 30 fractions, and 48 Gy in 12 fractions. The BED to the tumor is similar, but the dose of 48 Gy in 12 fractions would be expected to have more-severe acute and late side effects.

CLINICAL AND MOLECULAR ASPECTS OF RADIATION DERMATITIS

Skin changes after radiation exposure follow a predictable course dictated by radiation dose, timing, and the biology of the human inflammatory reaction.[3] The earliest reaction is erythema that may occur and resolve within hours, and is normally only evident after relatively high-dose exposure. The threshold dose is 2 Gy or greater skin dose, and is not normally noted after daily fractionated treatment of visceral organs with skin-sparing megavoltage radiation. This effect is noted in therapeutic courses aimed at cutaneous targets, where the skin receives full dose, or during treatment regimens that use large fraction sizes. Microscopically, there is a vasodilation and a transiently increased capillary permeability that results in mild erythema and edema at 2 to 24 hours following exposure. Prior to the adoption of SI units of radiation dose, skin erythema dose (SED) was used as a crude clinical measure of patient radiation exposure. This transient acute reaction is no longer commonly noted because of the increased use of high-energy, relatively skin-sparing radiation energies, and the increased use of lower fraction sizes. Acute, transient skin erythema is still reported following

interventional diagnostic and therapeutic procedures with prolonged fluoroscopy times.

The more sustained, common, and relevant reactions take place over a matter of weeks during and even shortly after fractionated radiation therapy. Acute radiation dermatitis progresses through characteristic stages of severity based on the accumulation of radiation-induced changes to dermal vasculature, appendageal structures, epidermal stem cells, and the activation of inflammatory pathways. Radiation dermatitis is a distinct adverse event graded by the National Cancer Institute's *Common Terminology Criteria for Adverse Events* (CTCAE). This scale is graded on severity, and primarily describes the acute reaction of skin exposed to therapeutic radiation. Chronic skin changes may occur months to years after exposure, and include a spectrum of changes characterized by fibrosis and atrophy. Table 200-1 summarizes the common acute and late adverse events attributable to radiation.

Grade 1 dermatitis first manifests as faint skin erythema within the treatment area. Erythema is seen in two contexts: first, there may be a transient vasodilation in the hours after a single fraction skin exposure of 2 Gy or higher. More commonly, erythema or hyperpigmentation develops over the first 2 to 3 weeks of fractionated radiation with accumulated exposure. Vasodilation and increasing vascular permeability occur early, and the resulting perivascular inflammation results in clinically characteristic erythema and edema. Moderate-to-brisk erythema is grade 2.

With continuing or higher-dose radiation exposure, damage to the basal cells in the epidermis may progress until this stem cell population is lost in localized areas, which results in dry desquamation (CTCAE grade 1). Further damage to the basal layer leads to more widespread desquamation, and the production of a fibrinous exudate resulting from increased arteriole permeability, loss of basement membrane integrity, and edema in the underlying dermis. This is characteristic of moist desquamation. The CTCAE differentiates moist desquamation based on whether it is patchy and localized to areas subject to trauma such as skin folds (grade 2), or confluent and present in a more widespread area (grade 3). Radiation damage to the underlying dermis may lead to ulceration, bleeding, and/or necrosis (grade 4). Skin adnexal cells are relatively radiosensitive and may not regenerate following exposure.

The process of epilation begins within days of radiation exposure. Sebaceous glands have similar sensitivity, and eccrine sweat glands become dysfunctional shortly afterward in a fractionated radiation treatment course. Histologically, these glandular structures demonstrate apoptosis, necrosis, and loss of normal mitotic activity. Chronically, there can be fibrotic replacement and loss of the supporting microvasculature. This leads to both acute and chronic hypohidrosis or anhidrosis.

Regeneration of areas of desquamation occurs through replacement of epidermal basal cells, either from islands of intact cells within the epidermis or by the migration of such cells from adjacent, uninvolved areas. Normal healing of the radiation wound becomes clinically evident approximately 2 weeks after exposure, consistent with the basal cell turnover time. Widespread confluent moist desquamation (grade 3), or more severe toxicity, such as necrosis of the epidermis or underlying dermis, may not undergo complete regeneration of the structural and adnexal elements. Instead, there can be prolonged inflammation, fibroblast activation, and collagen deposition. This fibrosis is often termed a consequential late effect, because it is a consequence of the severity of the acute reaction. It

TABLE 200-1
Commonly-Observed Adverse Events Attributable to Radiation

ADVERSE EVENT	GRADE 1	GRADE 2	GRADE 3	GRADE 4	GRADE 5
Radiation dermatitis	Faint erythema	Moderate-to-brisk erythema	Moist desquamation (other than skin folds and creases)	Skin necrosis	Death
	Dry desquamation	Patchy moist desquamation (mostly confined to skin folds and creases)	Bleeding induced by minor trauma or abrasion	Ulceration of full thickness of dermis	
		Moderate edema		Spontaneous bleeding	
Alopecia	Visible on close inspection	Hair loss ≥50% of normal	—	—	—
Atrophy	Associated with telangiectasia or pigmentation changes	Striae or adnexal structure loss	Ulceration	—	—
Induration or fibrosis	Mild, able to pinch skin	Moderate, able to slide skin but unable to pinch	Severe, unable to slide or pinch, limiting self-care	Generalized, impaired breathing or feeding	Death

is in contrast to the more common late fibrosis, which arises following the regeneration of relatively normal-appearing skin and can occur years after treatment.

Late radiation toxicity occurs months to years following exposure, following a period during which the skin may not exhibit significant abnormalities. The risk and severity of true late skin changes are a function of the irradiation dose and volume. A landmark study of normal tissue radiation tolerance determined that the risk of grade 4 or greater toxicity (ie, ulceration or necrosis) was 5% when 10 cm^2 of skin was treated to 70 Gy, or when 30 cm^2 was treated to 60 Gy.[4] Comorbid medical disease may exacerbate this risk; clinical risk factors associated with increased symptom severity include advanced patient age, diabetes, peripheral vascular disease, and tobacco use.[5] The concurrent administration of radiosensitizing drugs significantly increases the severity of acute radiation dermatitis and prolongs healing of the radiation wound. Collagen vascular diseases with a fibrotic cutaneous component (eg, scleroderma and systemic lupus erythematosus) are associated with a pronounced and often debilitating late subcutaneous fibrosis following radiation treatment.[6,7] Certain genetic syndromes, particularly inherited defects in DNA damage repair (eg, ataxia-telangiectasia), predispose to a severe, acute, and late radiation response in exposed normal tissue.

The late skin toxicity with the most functional consequence is subcutaneous fibrosis. Replacement of the subcutaneous adipose tissue with fibrous tissue leads to loss of normal range of motion, contraction, pain, and poor cosmesis. Even in cases where dermal and subcutaneous fibrosis is not clinically evident, there may be atrophy of skin adnexa. Hair follicles as well as sebaceous and sweat glands may be absent in previously-irradiated skin, because these are not regenerated during normal radiation wound repair. Loss of glandular elements leads to anhidrosis when extensive skin areas are irradiated, such as in total-skin electron therapy. The microvasculature of the dermis and subcutis may exhibit abnormal myointimal proliferation, leading to hypoperfusion. Tortuosity within small vessels and microthrombi result in visible telangiectasia. Irregular regeneration of the basal layer of the epidermis may be evident as dyspigmentation. Paradoxically, there may be a decrease in the population of resident skin fibroblasts in atrophic skin, resulting in loss of the normal collagen structure leading to impaired tissue remodeling, increased skin fragility, and poor wound healing.

The pathophysiologic mechanism of late changes, particularly fibrosis, in response to radiation is incompletely understood.[8,9] Transforming growth factor-beta (TGF-β) is a secreted protein that serves a complex regulatory role in normal tissue inflammation and remodeling by controlling proliferation, differentiation, and secretory function. TGF-β levels are increased within hours of radiation exposure, and this elevation has been correlated with late fibrotic changes. Abrogation of downstream mediator SMAD3 (Sma- and Mad-related protein 3), a proinflammatory signaling molecule induced in response to TGF-β, appears to protect tissue from late fibrotic changes after radiation exposure in laboratory models. TGF-β is a complex regulator of inflammation that increases fibroblast proliferation, differentiation, and activation, thereby increasing secretion of extracellular matrix components. TGF-β promotes its own secretion by fibroblasts in a self-amplifying cascade and decreases the production of matrix proteinases. Epithelial cell proliferation is diminished, and there is chemotaxis of mast cells and macrophages. The result is increasing production, processing, and deposition of collagen (fibrosis) and loss of epithelial reconstitution of normal tissue structure.

The initiating event in TGF-β activation in response to radiation is poorly understood. Latent TGF-β in the extracellular matrix may be activated by proteolytic enzymes that act in the presence of radiation-induced reactive oxygen species. Other potential sources of TGF-β include endothelial cells, fibroblasts, epithelial cells, and tissue macrophages, which may release TGF-β in direct response to radiation or as a generalized response to tissue damage.

RADIATION RECALL REACTIONS

Radiation recall is a phenomenon that was first described several decades ago. Radiation recall is a cutaneous reaction, in response to specific systemic agents, in the area of previous radiation exposure. The most commonly cited chemotherapeutic agents are anthracyclines, taxanes, and gemcitabine. Other systemic agents implicated in radiation recall reactions include standard chemotherapeutic agents, newer targeted therapeutics, and hormonal agents as well as nononcologic medications; Table 200-2 lists these agents based on case reports.

The clinical manifestations of radiation recall occur with the initial administration of the systemic agent—within minutes to days with IV drug, or days to weeks with oral medication. The timing of presentation may be related to the drug dose, and both the severity and timing of the reaction may be related to the prior radiation dose. The duration of the response may range from weeks to months. Interestingly, readministration of the same systemic agent does not consistently lead to recurrence of the phenomenon.[10]

Although a recall reaction can occur in any organ, skin is the most common site. It occurs in a well-demarcated area defined by the borders of the previous treatment field and can occur despite the lack of any clinically significant skin reaction during the previous radiation treatment. The clinical signs and symptoms mimic an acute radiation dermatitis, ranging from erythema to desquamation and necrosis. A localized maculopapular rash, characteristic of a hypersensitivity reaction, also has been described.

The pathogenesis of radiation recall is not well understood. An early hypothesis was that tissue stem cells remained depleted long after radiation, making the tissue more sensitive to cytotoxics. This does not explain,

TABLE 200-2
Radiation Recall Reactions

Agents implicated in inducing a radiation recall reaction include chemotherapy drugs, targeted and hormonal agents, and nononcologic medications.

- Chemotherapy
  - Arsenic trioxide
  - Bleomycin
  - Capecitabine
  - Cyclophosphamide
  - Cytarabine
  - Dacarbazine
  - Dactinomycin
  - Daunorubicin
  - Docetaxel
  - Doxorubicin
  - Epirubicin
  - Etoposide
  - Fluorouracil
  - Gemcitabine
  - Hydroxyurea
  - Idarubicin
  - Lomustine
  - Melphalan
  - Methotrexate
  - Paclitaxel
  - Vinblastine
- Targeted anticancer drugs
  - Bevacizumab
  - Pemetrexed
- Hormonal agents
  - Tamoxifen
- Nononcologic drugs
  - Gatifloxacin
  - Isoniazid
  - Levofloxacin
  - Simvastatin

however, radiation recall reactions elicited by noncytotoxics or, in some cases, the lack of a reaction to subsequent drug exposure. The clinicopathologic manifestations are best explained by a localized, acquired hypersensitivity reaction. Prior radiation therapy may alter the normal dermal immunologic response by changing basal and stimulated cytokine production. This is consistent with histologic findings of acute inflammation (eg, vasodilation, infiltration of inflammatory cell mediators) in affected tissue. Radiation recall dermatitis responds to treatment with topical or oral corticosteroids.

CLINICAL APPLICATIONS OF RADIATION

BENIGN DISEASE

The use of ionizing radiation for benign disease has decreased considerably, because of improvements in alternative therapy and an increasing awareness of the rare, but serious, side effects of radiotherapy.[11] Rare but serious side effects include fibrotic changes in the affected skin and, more significantly, a risk of secondary malignancy. It is estimated that the relative risk of malignancy following radiation treatment increases by 10% to 50%; the absolute risk, however, remains very low. These malignancies occur at a median of 10 years following treatment. The risk appears to be greater in younger patients, and in those patients whose treatment was targeted to anatomic areas at highest risk for malignancy (eg, breast or thyroid tissue). For this reason, radiotherapy should be (a) considered in benign disease only after other therapeutic options have been exhausted; (b) avoided when possible in children and young adults; and (c) delivered with attention to sparing radiation exposure to sensitive normal tissue.

Radiotherapy is effective for symptomatic treatment of several inflammatory dermatoses, including eczema, psoriasis, and lichen planus, at relatively low-dose exposures (ie, less than 10 Gy of fractionated treatment). Inflammatory dermatoses are rarely treated with radiation, given the number of other antiinflammatory options. Benign lymphoproliferative disorders are sensitive in a similar fashion, and disorders such as lymphomatoid papulosis, lymphoid hyperplasia, and lymphocytoma cutis have an excellent response to radiotherapy. These may be treated with radiation after other options have been exhausted, and are approached using lymphoma regimens. Other benign proliferative processes that can be treated with radiotherapy include keratoacanthomas and hemangiomas. Table 200-3 lists the diagnoses for which radiotherapy may be indicated.

A number of large series and one randomized trial have examined the efficacy of localized, low-dose irradiation for the prevention of recurrence of

TABLE 200-3
Cutaneous Indications for Primary or Adjuvant Radiotherapy[a]

Benign	Malignant
Eczema	Squamous carcinoma
Psoriasis	Basal cell carcinoma
Lichen planus	Melanoma
Benign lymphoid hyperplasia	Merkel cell carcinoma
Keratoacanthoma	Eccrine and apocrine carcinoma
Keloids/hypertrophic scars	Cutaneous T-cell and B-cell lymphomas
	Kaposi sarcoma
	Angiosarcoma
Premalignant	
Actinic keratoses	
Lentigo melanoma	
Bowen disease	
Erythroplasia of Queyrat	
Lymphocytoma cutis	

[a]Radiotherapy is not recommended as first-line therapy for all the listed indications, particularly the benign disorders.

hypertrophic scars or keloids following excision.[12-14] This should be undertaken after failure of more conservative therapies. The most common treatment regimen is to use kilovoltage X-rays or electrons to a total dose of 10 to 20 Gy delivered over several days. The treatment is usually initiated within 24 to 48 hours of excision. The recurrence risk after surgery and radiation is approximately 20% or less. The use of radiation without excision on existing keloids is not as effective.

MALIGNANT DISEASE

BASAL CELL CARCINOMA AND SQUAMOUS CELL CARCINOMA

Radiation has been used as primary treatment for basal and squamous cell carcinoma, as an alternative to excision, with local control rates of 90% or greater for small lesions.[15] There is concern for progressive late skin atrophy and necrosis decades after radiation, and for this reason surgical excision is usually thought to be a better option in younger patients (ie, those younger than age 55 years). The control rate for primary treatment is a function of tumor size and T stage. For small lesions, radiation is thought to offer local control that approximates the control seen with excision.

Radiation is also an effective adjuvant treatment, following excision or Mohs micrographic surgery. The clearest indication for adjuvant treatment is a positive surgical margin; other considerations include tumor depth greater than 4 mm in the case of squamous cell cancer or tumor size greater than 2 cm. Involvement of cartilage or bone is a strong predictor of local recurrence and consensus guidelines recommend adjuvant treatment. Perineural invasion correlates with both local and nodal recurrence following excision and is a relative indication for treatment.[16,17] Involvement of large, named nerves should prompt consideration of extension of the clinical target volume to include the proximal nerve tract. Other relative indications for treatment include poorly-differentiated tumors, adenosquamous subtype, and limitations imposed on excision by anatomic location. Patient factors include the presence of neurologic symptoms, implying underlying nerve involvement, and immunosuppressed host status. For squamous cell carcinoma, locally-advanced lesions may have a significant risk of nodal metastasis. In patients being treated adjuvantly or definitively for locally-advanced primaries with risk factors, draining lymphatics should be electively included.

Dose fractionation schemes represent a balance between patient convenience and the relative risk of poor cosmesis. A total of 60 to 66 Gy in 2-Gy fractions is appropriate for gross disease, with higher doses indicated for lesions larger than 2 to 4 cm. Published experience with relatively hypofractionated treatment has shown equivalent locoregional control after 45 to 50 Gy in 2.5-Gy fractions, or radiobiologically equivalent doses in fraction sizes of 3 or 4 Gy.

Tumors or postoperative areas that are at superficial depth may be treated with orthovoltage radiation to spare the deeper normal tissue. An alternative is electron therapy with the appropriate bolus to maximize the surface dose. When the target volume is deeper, then megavoltage X-rays, with appropriate bolus, may be required. Target structures such as lymph node basins or nerve tracts, in close proximity to critical normal structures, may require intensity-modulated radiation therapy.

MELANOMA

The role of radiotherapy in the management of localized melanoma has not been conclusively established. Radiotherapy is frequently used for palliation of unresectable lesions, and there is evidence that selected patients at increased risk of local or regional failure may reduce that risk with adjuvant radiation.[18] Risk factors predictive of local relapse after wide excision include tumor thickness greater than 4 mm, ulceration, satellitosis, positive surgical margins, mucosal origin, perineural invasion, and desmoplastic histology. Patients with positive lymph nodes at high risk of recurrence after node dissection may benefit from postoperative radiation directed at the nodal basin.[19,20]

Melanomas are frequently treated with hypofractionated radiation, with fraction sizes of 4 to 6 Gy (ie, 30 Gy in 5 fractions) using megavoltage X-rays. The recurrence risk for melanoma after radiation is significantly higher than that for squamous or basal cell carcinoma.

CUTANEOUS LYMPHOMAS

Cutaneous T-cell lymphomas include numerous subtypes, the most common of which are mycosis fungoides (MF) and anaplastic large-cell lymphoma. MF is exquisitely sensitive to radiotherapy and patients may present with localized or disseminated skin disease. Anaplastic large-cell lymphoma (CD30-positive) is also a common cutaneous T-cell lymphoma, but has a lower incidence than MF. The clinical presentation is also somewhat different, and these cells generally demonstrate a CD4-positive phenotype (which can be seen in MF), and also express cutaneous lymphocyte antigen. As opposed to MF, these cells are typically not epidermotropic and do stain positive for CD30. Lymphomatoid papulosis is also CD30 positive and may be associated with anaplastic large-cell lymphoma. Anaplastic lymphoma kinase is usually not overexpressed in patients suffering specifically from cutaneous lymphoma of the CD30-positive variety, though it may be expressed in patients with noncutaneous anaplastic large-cell lymphoma.

There are also a variety of subtypes of cutaneous B-cell lymphoma, but the most commonly encountered are diffuse large B-cell, marginal zone, and follicular center cell. Diffuse large B-cell lymphoma may express CD20 and CD79, and lesions involving the lower extremities may express BCL-2, BCL-6, and MUM-1.

Marginal zone lymphoma can be identified via expression of CD20 and CD79 and often BCL-2, but typically BCL-6 is not noted as a marker in this case. The follicular center cell variant may express CD20 and CD79, but expression of BCL-2 and MUM-1 is unusual.

Localized radiotherapy fields may be incorporated into the management of patients with limited disease, but in some cases, patients have extensive areas of skin which are involved and a total skin electron beam therapy (TSEBT) technique may be incorporated for adequate disease control.

Localized radiotherapy is typically provided using an electron technique and bolus material is applied to the skin in an effort to maintain an appropriate deposition of dose at the skin surface. Typically the 90% isodose curve is used to provide homogeneous coverage of the skin area in question and margins of 2 to 3 cm radially are incorporated into the treatment plan. Doses of 20 to 30 Gy in 2-Gy fractions are used. With this type of regimen for most cutaneous B-cell lymphomas, the complete response (CR) rate is greater than 95% with 5-year local control of approximately 75%.[21,22] Some patients may not be able to logistically receive daily therapy over several weeks, but are in need of palliation of lesions that are bleeding, uncomfortable, unsightly, or impairing function. Such patients may be candidates for an abbreviated regimen of 2 Gy × 2 for a total of 4 Gy, which has been found to provide excellent response rates with reasonable durability in selected patients with low-grade cutaneous B-cell lymphoma.[23]

TSEBT is significantly more complicated to provide and is typically used in patients suffering from extensive MF. TSEBT provides excellent response rates for patients with various levels of disease and also has been successful in patients with tumors of the skin, assuming that a supplemental boost is provided to the region involved by tumor. MF patches and plaques have an excellent response rate of 100% to TSEBT. The CR rate is variable and decreases with the degree of thickness associated with cutaneous lesions. Historically, the course of therapy is provided over approximately 8 to 10 weeks and, based on a Stanford technique, involves 36 fractions to the total skin using 6 fields with blocking of the eyes, hands, fingernails, and feet based on dosimetric parameters resulting from the individualized treatment program.[24] Newer data demonstrating excellent results with only 12 Gy have been published.[25] An advantage is that the course is much shorter and toxicities decreased compared with the 36-Gy regimen. The patient is treated in a variety of standing positions. Given its degree of complexity, TSEBT is best performed in centers that have a significant amount of experience with the technique. An important feature to be considered following response to TSEBT is a maintenance program, and such maintenance can be provided in a variety of forms. For MF patients with T1-level and T2-level disease, effective regimens, which have been documented in the literature, include the use of psoralen and ultraviolet A and mechlorethamine.

Both cutaneous T-cell and B-cell lymphomas are very sensitive to radiotherapy, and it is generally accepted that all lesions will respond and that localized cutaneous B-cell lymphoma lesions have a CR rate approaching 100%. Cutaneous T-cell lymphoma lesions have CR rates that are also excellent but are more dependent on extent of disease.

REFERENCES

1. Khan FM. *The Physics of Radiation Therapy*. 4th ed. Philadelphia, PA: Lippincott Williams & Wilkins; 2010.
2. Hall EJ, Giaccia AJ. *Radiobiology for the Radiologist*. 6th ed. Philadelphia, PA: Lippincott Williams & Wilkins; 2006:ix, 546.
3. Hymes SR, Strom EA, Fife C. Radiation dermatitis: clinical presentation, pathophysiology, and treatment 2006. *J Am Acad Dermatol*. 2006;54(1):28-46.
4. British Thoracic Society; Society of Cardiothoracic Surgeons of Great Britain and Ireland Working Party. BTS guidelines: guidelines on the selection of patients with lung cancer for surgery. *Thorax*. 2001;56(2):89-108.
5. Chon BH, Loeffler JS. The effect of nonmalignant systemic disease on tolerance to radiation therapy. *Oncologist*. 2002;7(2):136-143.
6. Holscher T, Bentzen SM, Baumann M. Influence of connective tissue diseases on the expression of radiation side effects: a systematic review. *Radiother Oncol*. 2006;78(2):123-130.
7. Lin A, Abu-Isa E, Griffith KA, et al. Toxicity of radiotherapy in patients with collagen vascular disease. *Cancer*. 2008;113(3):648-653.
8. Rodemann HP, Blaese MA. Responses of normal cells to ionizing radiation. *Semin Radiat Oncol*. 2007;17(2):81-88.
9. Lehnert S. *Biomolecular Action of Ionizing Radiation (Series in Medical Physics and Biomedical Engineering)*. New York, NY: Taylor & Francis; 2008.
10. Azria D, Magné N, Zouhair A, et al. Radiation recall: a well recognized but neglected phenomenon. *Cancer Treat Rev*. 2005;31(7):555-570.
11. Lahaniatis JE, Farzin F, Brady LW, et al. Radiation treatment for benign disease. A survey of current treatment programs. *Front Radiat Ther Oncol*. 2001;35:1-17.
12. Kovalic JJ, Perez CA. Radiation therapy following keloidectomy: a 20-year experience. *Int J Radiat Oncol Biol Phys*. 1989;17(1):77-80.
13. Lo TC, Seckel BR, Salzman FA, et al. Single-dose electron beam irradiation in treatment and prevention of keloids and hypertrophic scars. *Radiother Oncol*. 1990;19(3):267-272.
14. Sclafani AP, Gordon L, Chadha M, et al. Prevention of earlobe keloid recurrence with postoperative corticosteroid injections versus radiation therapy: a randomized, prospective study and review of the literature. *Dermatol Surg*. 1996;22(6):569-574.
15. Locke J, Karimpour S, Young G, et al. Radiotherapy for epithelial skin cancer. *Int J Radiat Oncol Biol Phys*. 2001;51(3):748-755.
16. McCord MW, Mendenhall WM, Parsons JT, et al. Skin cancer of the head and neck with clinical perineural invasion. *Int J Radiat Oncol Biol Phys*. 2000;47(1):89-93.
17. McCord MW, Mendenhall WM, Parsons JT, et al. Skin cancer of the head and neck with incidental microscopic perineural invasion. *Int J Radiat Oncol Biol Phys*. 1999;43(3):591-595.
18. Ballo MT, Ang KK. Radiotherapy for cutaneous malignant melanoma: rationale and indications. *Oncology (Williston Park)*. 2004;18(1):99-107.

19. Ballo MT, Ross MI, Cormier JN, et al. Combined-modality therapy for patients with regional nodal metastases from melanoma. *Int J Radiat Oncol Biol Phys*. 2006;64(1):106-113.
20. Gyorki DE, Ainslie J, Joon ML, et al. Concurrent adjuvant radiotherapy and interferon-alpha2b for resected high risk stage III melanoma—a retrospective single centre study. *Melanoma Res*. 2004;14(3):223-230.
21. Cotter GW, Baglan RJ, Wasserman TH, et al. Palliative radiation treatment of cutaneous mycosis fungoides—a dose response. *Int J Radiat Oncol Biol Phys*. 1983;9(10):1477-1480.
22. Wilson LD, Kacinski BM, Jones GW. Local superficial radiotherapy in the management of minimal stage IA cutaneous T-cell lymphoma (mycosis fungoides). *Int J Radiat Oncol Biol Phys*. 1998;40(1):109-115.
23. Neelis KJ, Schimmel EC, Vermeer MH, et al. Low-dose palliative radiotherapy for cutaneous B- and T-cell lymphomas. *Int J Radiat Oncol Biol Phys*. 2009;74(1):154-158.
24. Chen Z, Agostinelli AG, Wilson LD, et al. Matching the dosimetry characteristics of a dual-field Stanford technique to a customized single-field Stanford technique for total skin electron therapy. *Int J Radiat Oncol Biol Phys*. 2004;59(3):872-885.
25. Harrison C, Young J, Navi D, et al. Revisiting low-dose total skin electron beam therapy in mycosis fungoides. *Int J Radiat Oncol Biol Phys*. 2011;81:e651-e657.

Dermatologic Surgery PART 30

Chapter 201 :: Cutaneous Surgical Anatomy

:: Arif Aslam & Sumaira Z. Aasi

AT-A-GLANCE

- The superficial musculoaponeurotic system (SMAS) is a fibromuscular layer connecting the facial muscles. Incisions and undermining within the subcutaneous fat above SMAS will not result in damage to motor nerves.
- When planning reconstruction, the surgeon should consider cosmetic units, junctional lines, and resting skin tension lines to optimize the final aesthetic result.
- The three branches of the trigeminal nerve (cranial nerve V) provide sensory innervation to the face.
- The three main danger zones are areas where the temporal and marginal mandibular branches of the facial nerve and spinal accessory nerve lie superficial and can be easily injured. Damage to the temporal branch of the facial nerve may result in an ipsilateral eyebrow ptosis and obscuring of the superolateral visual field. The marginal mandibular branch of the facial nerve is vulnerable to damage along the inferior edge of the body of the mandible. Damage to the marginal mandibular branch of the facial nerve results in an asymmetrical smile. The spinal accessory nerve lies in the posterior triangle of the neck and may be identified by Erb's point.
- The rich vascular supply to the face from both the external and internal carotid ensures the reliable healing potential and viability of flaps and grafts in head and neck surgery.

INTRODUCTION TO CUTANEOUS SURGICAL ANATOMY

Factors such as the increasing incidence of skin cancer, the desire to maintain a youthful appearance in an aging population that is living longer, and the financial pressure to perform procedures in less invasive and more cost-effective ways have made surgery a cornerstone of the practice of dermatology. Knowledge of anatomy is critical for a number of reasons, including communicating precisely with colleagues, performing safe and efficient procedures, achieving aesthetic and functional reconstruction, understanding the lymphatic drainage, and anticipating metastatic spread of cutaneous malignancies. Because the vast majority of these procedures are performed on the head and neck, this chapter focuses on the anatomy of this critical region.

This chapter focuses on five important concepts in head and neck anatomy, which are

- The superficial musculoaponeurotic system (SMAS)
- Topography and cosmetic units
- Free margins
- Relaxed skin tension lines (RSTL)
- Facial motor nerves susceptible to damage during dermatologic surgery

THE SUPERFICIAL MUSCULOAPONEUROTIC SYSTEM

An important concept in understanding head and neck anatomy is the SMAS, a layer of superficial fascia that envelopes and links the facial expression muscles with each other and with the overlying skin.

It stretches over the cheeks between the temporalis and frontalis muscles above and the platysma muscle below. The SMAS also attaches to the orbicularis oculi muscles anteriorly and the trapezius muscle posteriorly and includes the fascia of the forehead and galea of the scalp.

Most of the superficial muscles of the scalp and face insert into the skin either directly through fibrous bands running in the subcutaneous tissue or indirectly by attachment to the SMAS, which in turn is attached to the skin. In the lateral areas of the face, the SMAS is organized and more visible but becomes less discrete medially. Because of its attachment to the skin superficially and muscles deep, the SMAS coordinates a wide range of facial expressions. In addition, the SMAS is an important landmark because most major arteries and nerves run within or deep to it. Dissection above the SMAS allows the dermatologic surgeon to safely avoid neurovascular structures.

TOPOGRAPHIC ANATOMY AND COSMETIC UNITS

Cosmetic units are zones of tissue that share cutaneous features such as color, texture, pilosebaceous quality, pore size, and degree of actinic exposure. These cosmetic units are demarcated by junction lines that can be discrete (eyebrows) or subtle (nasofacial sulcus). The forehead, temples, eyelids, nose, cheeks, upper and lower lips, chin, and ears represent the major cosmetic units of the face. Cosmetic units can also be further divided into subunits. Because of the tissue similarity, it is often best to reconstruct a surgical defect within a cosmetic unit or subunit or borrow tissue from nearby units. In addition, scar lines can be hidden easily in junction lines between the cosmetic units. Scars that cross cosmetic units are more noticeable and cosmetically less pleasing.

The more complex regions of the face that have multiple subunits include the nose, ears, and lips (Figs. 201-1 and 201-2).

Topographic anatomy and cosmetic units help localize areas of the face accurately for purposes of communication with colleagues and to perform the surgery itself. For instance, it is more helpful to describe a lesion on the face if it is said to be located on the "left nasal sidewall" versus left nose or "right triangular fossa" versus right ear. The subunits of the nose include the glabella (the area between the eyebrows), the root (the deep sulcus below the glabella and uppermost portion of the nose), the dorsum or bridge (the area overlying the nasal bone), lateral sidewalls (the sides of the nose), the nasal tip, the nasal ala (the nostril), the alar groove and nasolabial crease (the grooves that demarcate the alae superiorly from the lateral nasal sidewall and alae inferiorly from the lip, respectively), and the columella (the mobile linear structure separating the alae inferiorly) (see Fig. 201-1).

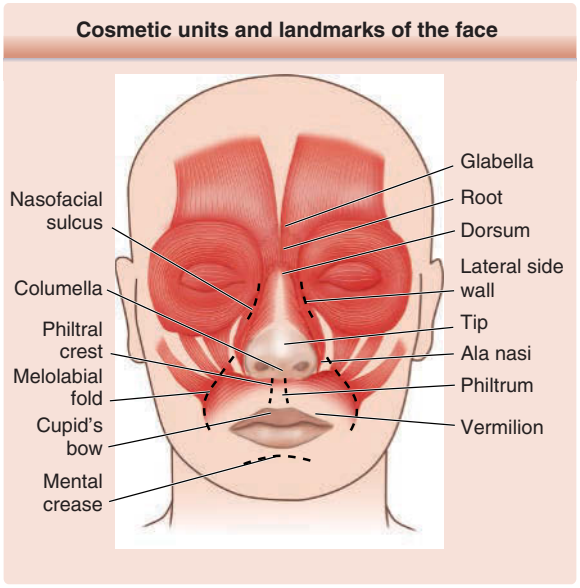

Figure 201-1 Cosmetic units and landmarks of the face.

The lateral surface of the ear is rimmed by the helix, a curved cartilaginous structure that begins at the crus just above the external auditory canal and continues around the ear to end at the fleshy lobule. The central concavity within which the external auditory meatus lies is the concha. The concha is divided by the crus of the helix into a superior portion; the cymba; and an inferior portion, the cavum. The posterior border of the concha is formed by another cartilaginous structure called the *antihelix*. Superiorly, the antihelix originates from two legs (*crus* is Latin for *leg*): (1) the

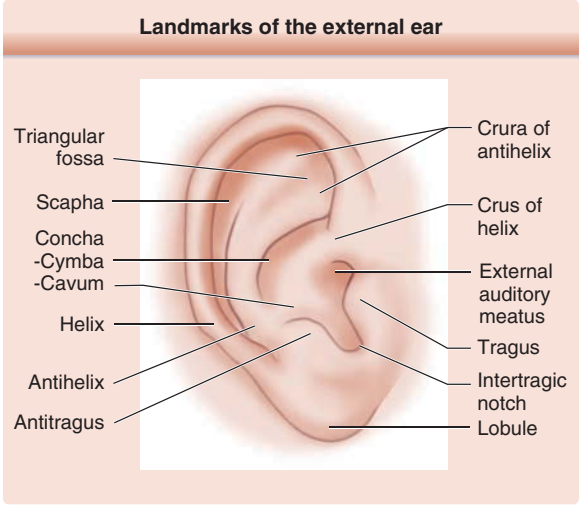

Figure 201-2 Landmarks of the external ear.

superior crus and (2) inferior crus. The region between the crura is referred to as the triangular fossa. The groove between the helix and antihelix is the scaphoid fossa. The triangulated cartilaginous structure just anterior to the auditory canal is called the *tragus*, and just posterior to this is the triangulated end of the antihelix, referred to as the *antitragus*. The inferior region between the tragus and antitragus is the intertragic notch (see Fig. 201-2).

The cutaneous upper lip has a concave depression in the center, called the *philtrum*, which is bounded by two ridges, the philtral crests. There is a prominent crease, the mental crease, which divides the cutaneous lower lip from the chin. The boundary between the red mucosal surface of the lips and the cutaneous surface is called the vermillion border. The raised contoured area of the inferior portion of the philtrum is a critical aesthetic landmark known as the *Cupid's bow* (see Fig. 201-1).

FREE MARGINS

A free margin is any anatomical structure that can be easily distorted when tension is placed on it. The eyelid margin, alar rim, lip vermillion, and helical rim are free margins. When these regions become distorted, the resulting asymmetry can cause cosmetic and functional concerns. An ectropion can result in epiphora, as well as conjunctival and corneal exposure leading to corneal scarring. An eclabium may result in altered speech, an asymmetrical smile, or drooling. The nasal ala does not have cartilage and is composed of fibrofatty tissue, thus making it quite vulnerable to distortion when tension is placed on it.

It is important for dermatologic surgeons to appreciate the tension vectors during wound closure to avoid free margin distortion.

RELAXED SKIN TENSION LINES

RSTLs are another characteristic of the face that help guide surgical reconstruction and allow the structural camouflage of scar lines. RSTLs are creases on the face that form over time because of factors such as loss of elastic tissue tone, lengthening of the collagenous fibrous septae that connect the dermis to the underlying facial muscles, development of excessive skin, gravity, and ultraviolet radiation exposure (see Fig. 201-3). RSTLs are most obvious on the face because unlike other muscles in the body that connect tendons and bones, facial muscles attach to the overlying skin. These lines can be induced by facial muscle movement in young people but inevitably become more pronounced with age. RSTLs usually run perpendicular to the underlying muscles. In most situations, the long axis of the excision should be placed parallel to the RSTL because they are often in the direction of the least tension for a scar. It is preferable to design flaps such that the majority of the scar lines fall within the RSTL.

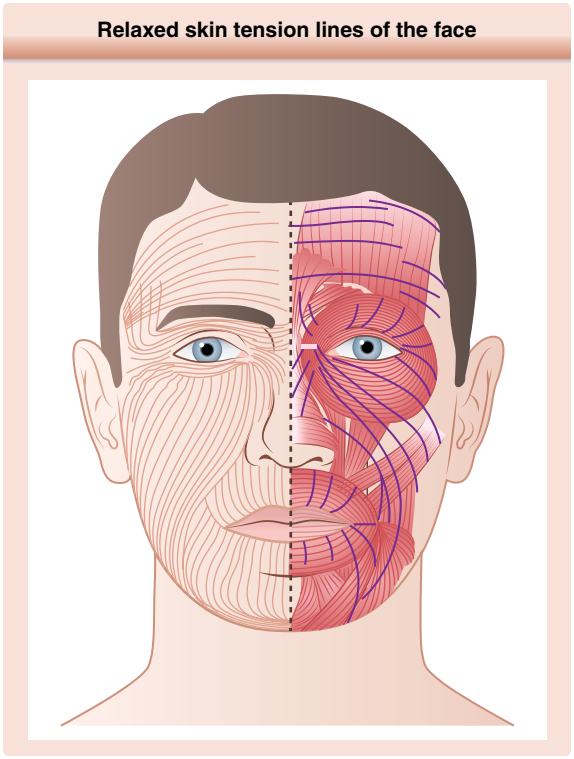

Figure 201-3 Relaxed skin tension lines of the face.

FACIAL MOTOR NERVES SUSCEPTIBLE TO DAMAGE DURING DERMATOLOGIC SURGERY

There are three main danger zones that are critical to understand while performing surgical procedures on the head and neck. Each of these zones involves a motor nerve and the muscles it innervates. These are the *temporal* and *marginal* mandibular branches of the facial nerve (cranial nerve VII) and the *spinal accessory nerve* (cranial nerve XI) (Table 201-1). These will be discussed in more detail below. It is important to confirm the baseline function of these nerves and muscles before performing a procedure in these areas so that it can be readily determined whether an injury occurred during surgery.

The facial nerve exits the skull through the stylomastoid foramen near the earlobe and immediately gives off the posterior auricular branch, which provides motor innervation to the occipital and posterior auricular muscles. It then enters the parotid gland at the midpoint of a line connecting the tragus with the angle of the mandible. Within the parotid gland, the facial nerve divides into the temporofacial and cervicofacial rami from which five branches arise. The well-known mnemonic "to Zanzibar by motor car" can be used to remember the five main branches: (1) temporal, (2) zygomatic, (3) buccal, (4) mandibular, and (5) cervical.

After leaving the parotid gland, the branches of the facial nerve lie deep to the SMAS and enter the

TABLE 201-1
Danger Zones of the Face

NERVE AT RISK	MUSCLE AFFECTED	LOCATION		DAMAGE
Temporal branch of the facial nerve	Frontalis, upper fibers of the orbicularis oculi, corrugator supercilii, anterior and superior auricular muscles	Facial nerve as it crosses the middle third of the zygomatic arch	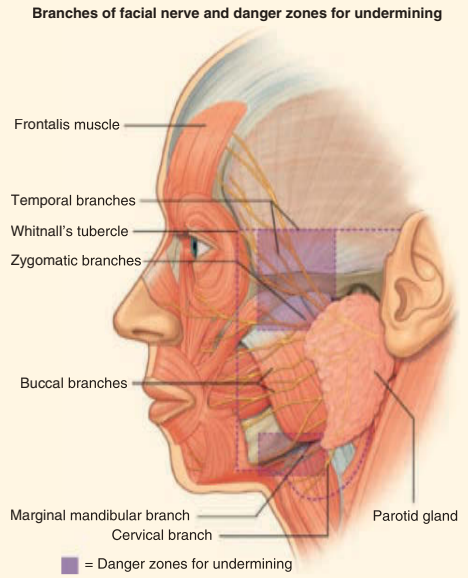	Flattening of forehead, diminished wrinkles, skin tension lines, eyebrow and eyelid ptosis, visual field disturbance
Marginal mandibular branch of the facial nerve	Depressor anguli oris, depressor labii inferioris, mentalis, part of orbicularis oris	Inferior border of the mandible, as the nerve crosses the angle of the mandible at the inferoanterior border of the masseter		Contralateral and upward pull on the mouth; ipsilateral side presents with lip droop
Spinal accessory nerve	Trapezius	Posterior triangle of the neck, from the midpoint of the posterior border of the sternocleidomastoid	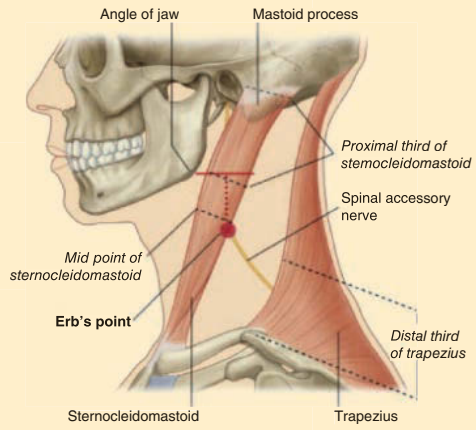	Paralysis of trapezius, winging of the scapula, shoulder drop, inability to shrug the shoulder, difficulty with arm abduction, chronic shoulder pain

Figures from Robinson JK, Hanke CW, Siegel DM, et al, eds. *Surgery of the Skin*, 3rd ed. St. Louis: Elsevier Saunders; 2015; with permission. Copyright © Elsevier.

muscles of facial expression from their deep surface. The branches of the facial nerve are therefore well protected during surgical procedures that are no deeper than fat. However, it is important to note that there can be minimal thickness of the fat layer at certain sites such as the temple and at other sites in older adult patients.

The two branches of the facial nerve most susceptible to injury during dermatologic surgery are the temporal branch as it crosses the zygomatic arch and the marginal mandibular branch along the inferior border of the mandible. The buccal and zygomatic branches form an interconnecting network across the midface, and although damage to these nerves may occur during surgical procedures, any injury is less debilitating than an injury to the temporal nerve because of the multiple rami in the buccal and zygomatic branches. Damage to the cervical branch is of minimal clinical importance because it innervates the platysma muscle, which also receives nerve fibers from the marginal mandibular nerve.

TEMPORAL BRANCH OF THE FACIAL NERVE

The temporal (or frontal) branch of the facial nerve innervates the frontalis, the upper fibers of the orbicularis oculi, the corrugator supercilii, and the anterior and superior auricular muscles. After emerging from the parotid gland, the nerve travels diagonally across the temple, where it lies between the superficial temporal fascia (a component of SMAS) and the deep temporal fascia. The temporal branch of the facial nerve divides into three to five rami as it crosses the middle third of the zygomatic arch. At this point, the nerve is most superficial and susceptible to damage and it is critical in this area to undermine just beneath the dermis in the superficial fat above the fascia. The approximate course of the temporal branch of the facial nerve can be projected on the skin by a line drawn from the earlobe to the lateral edge of the eyebrow and another line from the tragus to just above the and behind the highest forehead crease (Fig. 201-4).

Damage to the temporal branch of the facial nerve results in cosmetic and functional loss. Flattening of the forehead with diminished visibility of wrinkles and skin tension lines becomes easily noted. Over time, as the denervated muscle atrophies, patients develop eyebrow and eyelid ptosis, which may lead to visual field disturbance. A brow lift and blepharoplasty may be required to correct this problem.

MARGINAL MANDIBULAR NERVE

The marginal mandibular branch of the facial nerve exits the parotid gland at the angle of the jaw. It divides into two or more rami and travels anteriorly along the ramus of the mandible to supply the depressor anguli oris, the depressor labii inferioris, the mentalis, and part of the orbicularis oris. As it crosses the angle of the mandible at the inferoanterior border of the masseter, the marginal mandibular nerve is covered only by skin, subcutaneous fat, and fascia, which may be thin in this location, particularly in older adults. Damage to the marginal mandibular nerve results in contralateral and upward pull on the mouth while the affected ipsilateral side of the mouth is fixed in a grimace with a lip droop.

Danger zone for the temporal nerve

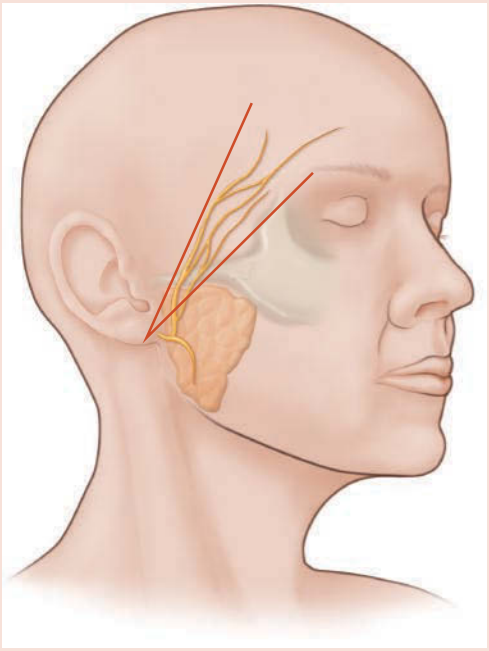

Figure 201-4 Danger zone for the temporal nerve.

SPINAL ACCESSORY NERVE

The posterior triangle of the neck is defined by the posterior border of the sternocleidomastoid, the anterior border of the trapezius, and the clavicle. The spinal accessory nerve enters the posterior triangle of the neck from under the posterior border of the sternocleidomastoid, roughly at its midpoint. It then crosses the floor of the posterior triangle, before leaving the posterior triangle under the trapezius. In the posterior triangle of the neck, the spinal accessory nerve occupies a relatively superficial location between the superficial and prevertebral layers of the deep cervical fascia.

One can anticipate the location of the spinal accessory nerve by drawing a line connecting the angle of the mandible with the mastoid process. A vertical line is then drawn from the midpoint of this line 6 cm inferiorly. The point at which this line intersects the

posterior border of the sternocleidomastoid muscle is Erb's point. This landmark indicates the location of several important sensory nerves, including the transverse cervical, lesser occipital, and great auricular nerves, but most important, the point at which the spinal accessory nerve emerges from behind the sternocleidomastoid.

Injury to the spinal accessory nerve leads to the paralysis of the trapezius with winging of the scapula, shoulder drop, inability to shrug the shoulder, difficulty with abducting the arm, and chronic shoulder pain.

SENSORY NERVES

The trigeminal nerve (cranial nerve V) provides the majority of the sensory innervation of the face (Figs. 201-5 and 201-6 and Table 201-2). It exits the skull via three foramina located bilaterally in the midpupillary line, the supraorbital, infraorbital, and mental foramina. The first branch, the ophthalmic nerve (V_1), has several branches that supply the innervation to the superior portion of the face: the supraorbital, supratrochlear, infratrochlear, external nasal, and lacrimal nerves. The supraorbital (lateral) and supratrochlear (medial) nerves supply the forehead and anterior scalp and are branches of the frontal nerve (the largest branch of the ophthalmic nerve). They exit from two

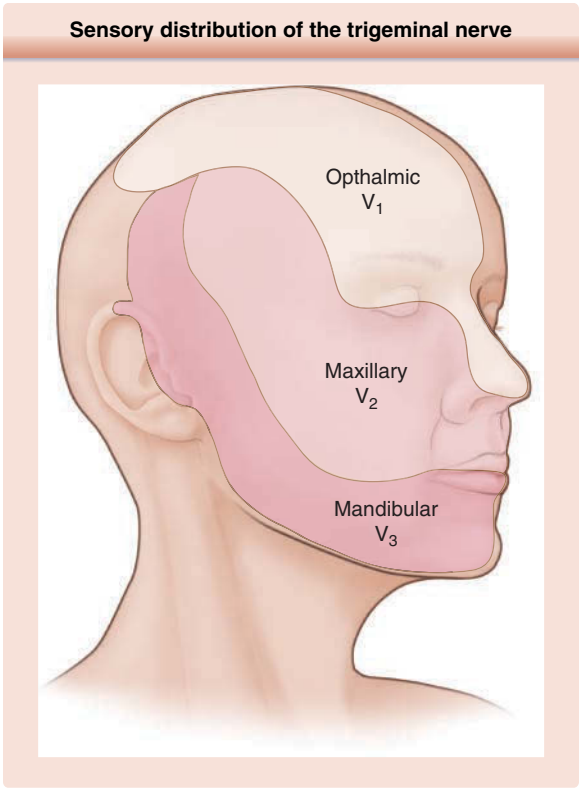

Figure 201-5 Sensory distribution of the trigeminal nerve.

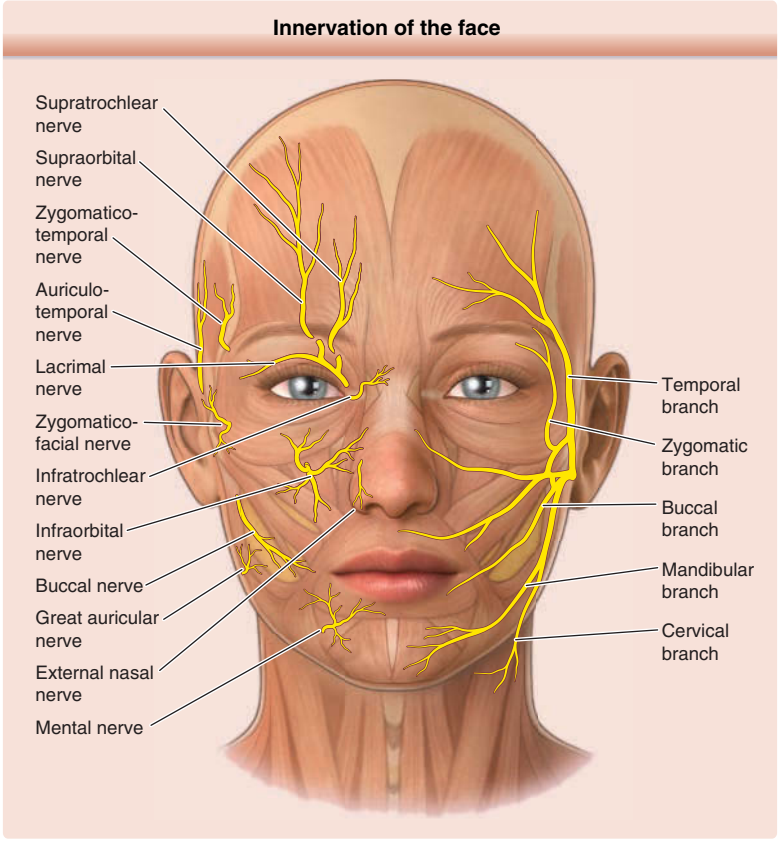

Figure 201-6 Nerves in the face. **A,** Sensory nerve supply to the skin of the face. **B,** Branches of the seventh cranial nerve to muscles of facial expression.

TABLE 201-2
Branches of the Trigeminal Nerve

BRANCH		AREA INNERVATED
V1 (Ophthalmic Nerve)		
Supraorbital (lateral) nerve		Forehead, anterior scalp
Supratrochlear (medial) nerve		Forehead, anterior scalp
Infratrochlear nerve (nasociliary)		Glabella, nasal root, nose bridge
External nasal nerve (dorsal nasal)		Anterior ethmoidal nerve, dorsal nose
Lacrimal nerve		Upper eyelid
V2 (Maxillary Nerve)		
Zygomatic nerve	Zygomaticofacial	Lateral canthus
	Zygomaticotemporal	Anterior temporal region
Infraorbital nerve		Eyelid, superior cheek
V3 (Mandibular Nerve)		
Auriculotemporal		Most of the temple, temporoparietal scalp, anterior ears, external ear canal, tympanic membrane
Buccal		Buccinators, buccal mucosa, gingiva
Mental		Lower lip, chin

notches along the orbital rim: (1) the supraorbital foramen or notch laterally and (2) the supratrochlear notch medially. The infratrochlear branch (of the nasociliary nerve) supplies the glabella, nasal root, and bridge. The external nasal branch (or the dorsal nasal nerve) is a branch of the anterior ethmoidal nerve of the nasociliary branch of V_1. The external nasal branch supplies the dorsal nose and provides the anatomical explanation of Hutchinson sign that can occur in some cases of herpes zoster of the ophthalmic nerve. Vesicles on the nasal tip indicate that the eye may be involved because the nasociliary branch of V_1 sends branches both to the nasal tip and the cornea. The lacrimal branch supplies sensation to the upper eyelid.

The second branch of the trigeminal nerve is the maxillary nerve (V_2). The maxillary nerve supplies sensation to the lateral nose, lower eyelid, superior cheek, and anterior temple. The maxillary nerve gives off two main branches that supply the skin of the face. The zygomatic branch of the maxillary nerve gives rise to the zygomaticofacial nerve, which exits the skull through the lateral zygomatic bone and supplies a small area of the lateral canthus. In addition, the zygomatic branch also gives rise to the zygomaticotemporal nerve, which exits the skull through the anterior temporal fossa and supplies skin of the anterior temporal region. The largest branch of the maxillary nerve is the infraorbital nerve that exits the skull through the infraorbital foramen of the maxilla. This supplies sensation to the eyelid and superior cheek.

The third branch of the trigeminal nerve is the mandibular nerve (V_3). Its branches provide sensory innervation to the lower lip, chin, mandibular and preauricular cheek, anterior ear, and central temporal scalp. The mandibular nerve gives off three major cutaneous branches: the (1) auriculotemporal, (2) buccal, and (3) mental nerves. The auriculotemporal nerve innervates most of the temple, the temporoparietal scalp, the anterior ears, parts of the external ear canal, and the tympanic membrane. The buccal nerve lies deep to the parotid gland and supplies the skin over the buccinators, the buccal mucosa, and the gingiva. The mental nerve exits through the mental foramen and is a continuation of the inferior alveolar nerve. The mental nerve supplies sensation to the lower lip and chin.

MUSCLES OF FACIAL EXPRESSION

The scalp has two muscles overlying it, the frontalis anteriorly and the occipitalis posteriorly. These muscles are joined by a thick fascia centrally over the scalp, the galea aponeurotica. The frontalis muscle also covers the forehead and elevates the eyebrows. The eyebrows move medially and downward with contraction of the corrugator supercilii muscles. The procerus lies between the supercilii muscles and draws the skin of the forehead inferiorly to create the horizontal creases at the root of the nose. The orbicularis oculi muscle surrounds the eye and consists of an orbital and palpebral portion. The orbicularis oculi muscle serves to close the eyes with the palpebral part with both reflexive and voluntary control and the orbital part with voluntary control. The central sphincter-like muscle around the mouth is the orbicularis oris. This muscle helps purse the lips to form certain sounds and whistle. The lip depressors are depressor anguli oris, depressor labii inferioris, and the mentalis. The lip elevators are the zygomaticus major, zygomatic minor, levator anguli oris, levator labii superioris, and levator superioris alaeque nasi. The risorius helps retract the corner of the mouth. The buccinators and masseter muscles help with mastication (Fig. 201-7).

VASCULAR ANATOMY

The blood supply of the face is almost entirely derived from branches of the external carotid artery (Fig. 201-8). Just posterior and medial to the angle of the mandible, the facial artery branches off the external carotid artery. The facial artery continues anteriorly and superiorly toward the angle of the mouth, giving off the inferior labial artery and superior labial arteries that supply the lips. The continuation of the facial artery in the nasofacial sulcus is called the *angular artery*. The angular artery continues superiorly to enter the orbit immediately over the medial canthal tendon, where it anastomoses with the ophthalmic artery, a branch of the internal carotid artery. After giving off the facial artery, the external carotid artery then passes deep to

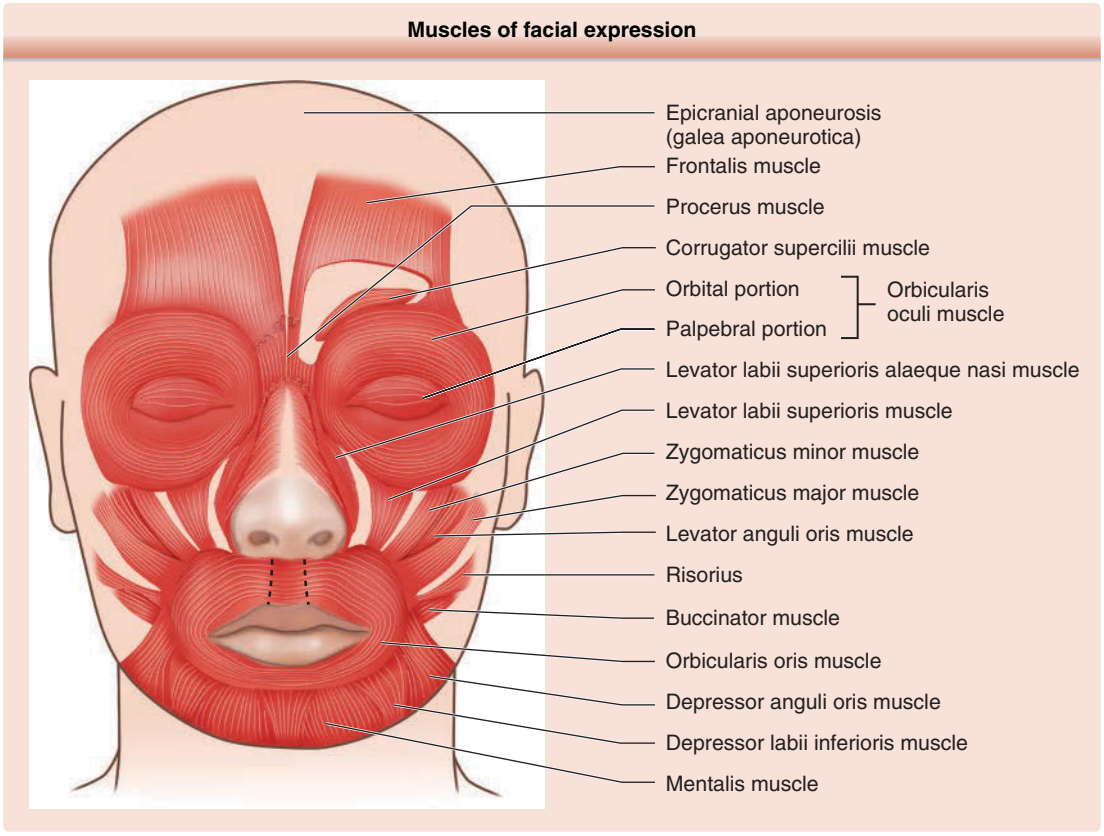

Figure 201-7 Muscles of facial expression.

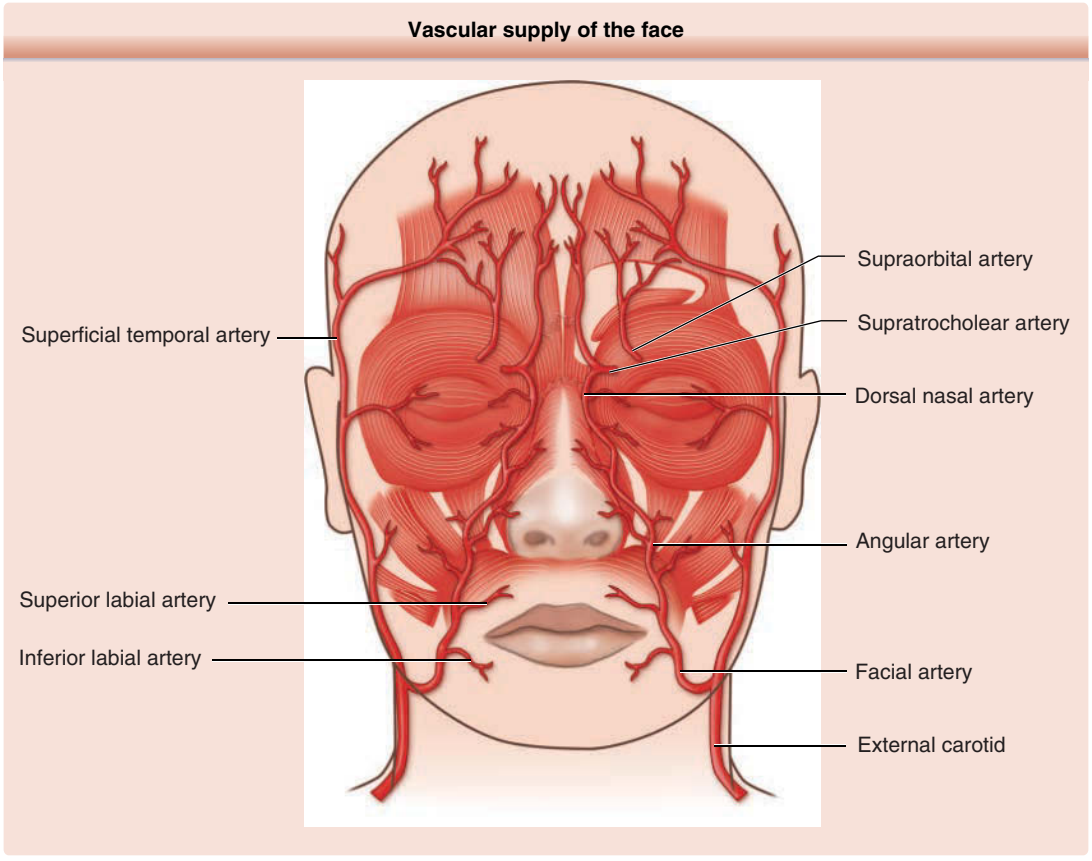

Figure 201-8 Vascular supply of the face.

the sternocleidomastoid muscle and enters the body of the parotid gland, where it gives off the posterior auricular artery that supplies the postauricular scalp, the maxillary artery, and the superficial temporal artery. The terminal branch of the maxillary artery exits the infraorbital foramen with the infraorbital nerve as the infraorbital artery to supply the lower eyelids and infraorbital cheek.

The terminal branches of the internal carotid artery are the ophthalmic artery branches, the supraorbital artery, and the supratrochlear artery. The supraorbital artery emerges from the supraorbital foramen, whereas the supratrochlear artery emerges more medially. The internal and external carotid systems join in two places: (1) where the supratrochlear branch and the dorsal nasal artery anastomose with the angular artery and (2) where the forehead branches of the supraorbital and supratrochlear arteries anastomose with branches of the superficial temporal artery.

The veins of the face are parallel and lie posterior to the arteries. Unlike the veins of the trunk and extremities, facial veins have no valves. This allows blood to flow in either direction. Thus, in the central face where there are anastomoses between branches of the ophthalmic vein and of the angular vein, infection has easy access to travel along the ophthalmic vein to the cavernous sinus. The angular vein also communicates with the deep facial vein and pterygoid plexus.

LYMPHATICS

The lymphatic vessels of the face generally drain from superficial to deep and medial to lateral and caudad. Although the general drainage patterns are described here, variations can occur. The posterior scalp drains to the postauricular and occipital nodes. The lateral and superior face, the forehead, and the lateral eyelids drain to the parotid nodes. The medial and inferior face, including the medial eyelids and lateral lips, drain to the submandibular nodes. The middle two-thirds of the lower lip and the chin drain to the submental nodes. These nodes can be optimally palpated by performing a bimanual examination with a gloved hand feeling through the floor of the mouth.

The lymph nodes of the head and neck eventually drain into a terminal series of nodes (deep cervical nodes) and finally into the lateral internal jugular chain.

ACKNOWLEDGMENTS

We acknowledge and are grateful to Brent Pennington, MD, coauthor of the previous edition of this chapter.

Chapter 202 :: Perioperative Considerations in Dermatologic Surgery

:: Noah Smith, Kelly B. Cha, & Christopher Bichakjian

AT-A-GLANCE

- Preoperative assessment includes a thorough medical and social history, and physical examination.
- The choice and route of anesthesia are determined by the nature and duration of the procedure, and by patient-dependent factors.
- Suture material and technique are selected based on the surgical procedure, anatomical location, and patient-related qualities of the wound.
- Proper perioperative care is essential to decrease risk of complications.

Dermatologists likely perform more cutaneous surgical procedures than any other medical or surgical specialty.[1] In addition to mastery of the technical aspects of a surgical procedure, the provider must also navigate a variety of perioperative considerations to maximize treatment efficacy and minimize complications. This chapter outlines the preoperative, operative, and postoperative considerations in dermatologic surgery.

PREOPERATIVE ASSESSMENT

Preoperative assessment is a critical component of ensuring a safe and successful surgical procedure. A detailed review of a patient's history, including past medical and surgical history, medications, allergies, and social history, should be conducted. This serves to identify and enable appropriate planning around factors that may contribute to increased potential for intraoperative and postoperative complications.

HISTORY AND PHYSICAL EXAMINATION

PAST MEDICAL AND SURGICAL HISTORY

Common conditions such as hypertension and diabetes may impact surgical outcome. Hypertension may increase the risk of bleeding both during and after surgery, while uncontrolled diabetes may result in delayed wound healing and increased risk of infection. Patients with inherited bleeding disorders may require administration of clotting factors.

Cardiac history, including valve replacement and history of joint replacement, may impact the decision to prescribe prophylactic antibiotics. The presence and proximity of implantable electronic devices, such as a pacemaker or defibrillator, may require a modification of the intraoperative approach to hemostasis to reduce risk of adversely affecting the function of such a device.

Antibiotic Prophylaxis: Antibiotics have an important role in the setting of dermatologic surgery. A wound infection following surgery may increase symptoms including pain, and can result in complications, including poor wound healing. The presence of skin microflora at baseline results in some level of bacterial contamination of a surgical wound following compromise of the epidermal barrier during surgery. Therefore, careful attention to maintaining as close to a sterile procedural field as possible during surgery is imperative to minimize the risk of postsurgical wound infection. Additional factors that may increase risk of infection include microbial pathogenicity, length of surgery, the presence of foreign material including suture or dead space, poor suturing or reconstructive technique, poor vascular supply, and host immunity.

As routine use of antibiotics may promote antibiotic resistance, the judicious use of antibiotics surrounding surgery is essential. Table 202-1 provides examples of clinical scenarios in which prophylactic antibiotics should be considered to prevent surgical site infection. The most common organism resulting in infection following cutaneous surgery is *Staphylococcus aureus*, and initiation of a first-generation cephalosporin (or clindamycin, if patient is penicillin or cephalosporin allergic) should be considered when indicated. Initiation of an antibiotic preoperatively or within 2 to 3 hours postoperatively is important in modifying infection risk as maximal protection against infection occurs when antibiotics are given prior to bacterial colonization of the wound.

A distinct indication for the use of prophylactic antibiotics in dermatologic surgery is the prevention of infection at a distant site as a result of an infected surgical wound or surgically-induced bacteremia. The 2 major concerns are infective endocarditis and prosthetic joint infection. According to the revised *Guidelines* of the American Heart Association, antimicrobial prophylaxis for the prevention of bacterial endocarditis is

TABLE 202-1
Risk Factors for Surgical Site Infection

- Inflamed or infected skin close to surgical site
- Flap reconstruction on the nose
- Wedge excision of the lip or ear
- Skin graft repair
- Mucosal, anogenital, or lower leg procedure site
- High-tension closure
- Multiple simultaneous procedures or prolonged procedure time
- Immunocompromised status

Adapted from Wright TI, Baddour LM, Berbari EF, et al. Antibiotic prophylaxis in dermatologic surgery: advisory statement 2008. *J Am Acad Dermatol*. 2008;59(3):464-73.

only indicated for patients with cardiac conditions that confer the highest risk of adverse outcome from infective endocarditis.[2] Table 202-2 lists the high-risk cardiac conditions for which antibiotic prophylaxis is suggested. However, there is no convincing evidence that antimicrobial prophylaxis provides significant benefit in terms of prevention of infective endocarditis, which is much more likely to result from random bacteremia associated with daily activities such as tooth brushing. Moreover, the risk of antibiotic-associated side effects may exceed the benefit, if any, from prophylactic therapy. The risk of infective endocarditis is generally considered to be the highest for dental procedures and is extrapolated to patients undergoing a surgical procedure of infected skin or skin structure.

In 2013, the American Dental Association (ADA) and American Academy of Orthopaedic Surgeons (AAOS) published a joint guideline on the prevention of orthopedic implant infections in patients undergoing dental procedures. The guideline states that there is no convincing evidence to support routine use of prophylactic antibiotics in patients with prosthetic joints who undergo dental procedures.[3] The conclusion is based on the observation that there is no convincing clinical or experimental evidence to suggest a link between bacteremia induced by a dental procedure and prosthetic joint infections. While the ADA/AAOS guideline also states that prophylactic antibiotics are not generally recommended for patients with prosthetic joints who are undergoing cystoscopy or GI endoscopies, no specific recommendations are made with regard to dermatologic procedures. However, given the low risk of bacteremia as a result of clean dermatologic procedures, it is reasonable to extrapolate from the ADA/AAOS guideline that the routine use of prophylactic antibiotics to prevent prosthetic joint infections is not recommended. However, this should be considered a general recommendation for healthy, immunocompetent patients, and the decision to prescribe prophylactic antibiotics must be made on an individual basis. Preoperative prophylactic antibiotics may be appropriate in select patients, including, but not limited to, patients with a history of previous prosthetic joint infection or individuals with high-risk comorbidities including immunosuppression.

TABLE 202-2
Cardiac Conditions Associated with the Highest Risk of Adverse Outcome from Endocarditis

- History of infective endocarditis
- Prosthetic heart valve or prosthetic material used for cardiac valve repair
- Congenital heart disease (CHD)
- Unrepaired cyanotic CHD, including palliative shunts and conduits
- Completely repaired congenital heart defect with prosthetic material or device, whether placed by surgery or by catheter intervention, during the first 6 months after the procedure
- Repaired CHD with residual defects at the site or adjacent to the site of a prosthetic patch or prosthetic device (which inhibit endothelialization)
- Cardiac transplantation recipients who develop cardiac valvulopathy

Adapted from Wilson W, Taubert KA, Gewitz M, et al. Prevention of infective endocarditis: guidelines from the American Heart Association: a guideline from the American Heart Association Rheumatic Fever, Endocarditis and Kawasaki Disease Committee, Council on Cardiovascular Disease in the Young, and the Council on Clinical Cardiology, Council on Cardiovascular Surgery and Anesthesia, and the Quality of Care and Outcomes Research Interdisciplinary Working Group. *J Am Dent Assoc*. 2007;138(6):739-45, 747-60.

For those patients who meet the criteria for endocarditis or prosthetic joint infection prophylaxis, administration of cephalexin (2 g by mouth for nonoral sites) or amoxicillin (2 g by mouth for oral sites) 1 hour prior to a cutaneous surgical procedure is considered adequate. Alternative regimens for individuals with a penicillin allergy include clindamycin 600 mg by mouth or azithromycin 500 mg by mouth, 1 hour prior to surgery.[2]

Known nasal carriers of methicillin-resistant *S. aureus* (MRSA) also can be considered for preoperative antibiotic therapy. MRSA has been observed in an increasing number of wounds, and a 4-fold increased risk of MRSA wound infection has been reported following a surgical procedure in nasal carriers of MRSA.[4] Treatment of the nasal vestibule with mupirocin 2% ointment prior to surgery may decrease risk of MRSA wound infection, although MRSA resistance to mupirocin ointment has been reported in up to 12% of individuals.[5,6]

Implantable Electronic Devices: The use of implantable electronic devices (IEDs) to manage various cardiac and neurologic disorders continues to expand. IEDs that may be encountered include cardiac and gastric pacemakers, implantable cardioverter defibrillators (ICDs), cochlear implants, and stimulators, including deep brain, vagal nerve, phrenic nerve, spinal cord, and bone. Electromagnetic interference (EMI) with the use of electrocautery during surgical procedures has been reported to result in malfunctioning of IEDs. The majority of outpatient cutaneous surgical procedures use an external, electrically powered energy source for hemostasis, whether in the form of electrocautery or electrosurgery. To select the appropriate method of hemostasis that minimizes EMI and maximizes patient safety, IED history must be elicited prior to the procedure.

Heat electrocautery functions by converting electrical energy into thermal energy at a metal tip, which produces hemostasis when directly contacting tissue.

Even though it is less effective than electrosurgery in hemostatic capability, electrocautery is the safest method of hemostasis in patients with IEDs with high risk of EMI as no electric current is passed to the patient. Additionally, an advantage of electrocautery is its ability to function in a wet environment.

Electrosurgery consists of a high-frequency alternating current through an unheated electrode. Current can be delivered either monopolarly, in which current is delivered to the surgical site through 1 electrode, or bipolarly, in which current is delivered to tissue between 2 adjacent electrodes. The use of monopolar electrosurgery without a grounding pad is a common method of obtaining hemostasis during office-based dermatologic procedures, as it is useful for both coagulation and dissection. Although generally safe, ungrounded, monopolar electrosurgery has the potential to cause EMI in a patient with an IED, as electrical current flows beyond the surgical site and disperses through the body. In contrast to monopolar electrosurgery, bipolar electrosurgery is useful only for coagulation and not dissection. As electrical current passes only across the tips of the bipolar instrument, there is minimal risk of EMI with bipolar electrocautery in a patient with an IED.

For patients with a pacemaker or ICD, heat electrocautery or bipolar electrosurgery are considered optimal methods of hemostasis given their minimal risk for EMI. Should a dermatologist proceed with ungrounded monopolar electrosurgery in a patient with an IED, the use of minimum power settings and short, intermittent, irregular bursts of less than 1 second are highly encouraged. An in vitro study conducted on pacemakers and ICDs with a hyfrecator used at settings typical of in-office dermatologic surgical procedures suggested that a hyfrecator can safely be used for dermatologic procedures outside a 5-cm device perimeter without causing EMI.[7] For a patient with a pacemaker or ICD on the left upper chest, the three-dimensional 5-cm perimeter would include the left upper back, left shoulder, and left aspect of the neck. Device interrogation should be performed after the procedure if any change of device function or settings is suspected.

For patients with a cochlear implant or a stimulator such as a deep brain, vagal nerve, phrenic nerve, spinal cord, or bone, referring to specific manufacturer recommendations regarding electrosurgery precautions is recommended when available. Electrosurgical instruments are capable of producing voltages that can result both in direct damage to a cochlear implant and in necrosis of vital cells of the basilar membrane of the cochlea, potentially rendering reimplantation ineffective. Generally, thermal electrocautery is preferred for cochlear implant or stimulator devices as it has the lowest associated risk of EMI if used at sufficient distance from the device.[8] For additional information on electrosurgery, see Chap. 206 ("Cryosurgery and Electrosurgery").

MEDICATIONS

A review of current prescription and nonprescription medications is important to identify medications that may contribute to intraoperative or postoperative complications as well as potential interactions if prescribing perioperative medications.

Anticoagulants: Anticoagulants are medications commonly prescribed to prevent thrombotic events in patients with atrial fibrillation, a history of stroke, or other predisposing conditions. When planning any type of surgical procedure, it is important to elicit the use of anticoagulant therapy, including warfarin, clopidogrel, aspirin, dipyridamole, and the novel oral anticoagulants such as dabigatran, rivaroxaban, and apixaban. Historically, anticoagulants were routinely discontinued prior to surgical procedures. However, recent studies focused on dermatologic surgery suggest that continuation of such medications, including novel oral anticoagulants, rarely results in significant adverse outcomes.[9] Most importantly, while bleeding complications are inconvenient and should be minimized, they do not outweigh the morbidity and mortality associated with thrombotic or embolic events, such as stroke or pulmonary embolism, which may result from discontinuation of anticoagulant therapy.[10] It has become standard practice to continue medically-indicated anticoagulants throughout the perioperative period, unless discontinuation is considered necessary because of a procedure-specific risk and directly cleared with the prescribing health care provider.

Elective nonprescription medications or supplements with antithrombotic properties for general or preventive health maintenance without the direct recommendation of a physician must also be considered in the perioperative setting. Examples include aspirin, nonsteroidal antiinflammatory drugs, and dietary or herbal supplements with antithrombotic properties, such as fish oil, garlic, ginger, *Ginkgo biloba*, ginseng, and vitamin E.[11] Alcohol also prolongs coagulation. Discontinuation of these substances 7 to 14 days prior to cutaneous surgery may be considered to decrease the risk of hemorrhagic complications. Table 202-3 lists several medications and supplements that inhibit platelet function.

TABLE 202-3
Medications That Inhibit Platelet Function

- Persantine
- Trental
- Sulfinpyrazone
- Clofibrate
- Salicylates
- Aspirin
- Sulfasalazine
- Vitamin E
- Plavix
- Herbs
  - *Ginkgo biloba*
  - Garlic
  - Feverfew
  - Ginger
  - Ginseng
  - Turmeric
- Nonsteroidal antiinflammatory drugs

Systemic Corticosteroids: Medical immunosuppression with systemic corticosteroids, particularly when used chronically in solid-organ transplant recipients or in patients with autoimmune disease, may result in delayed or poor surgical wound healing.[12]

ALLERGIES

Prior knowledge of a history of allergies to local anesthetics, including associated preservatives; other procedure-related allergens, such as topical antiseptics; and topical or oral antibiotics is important when selecting perioperative medications and surgical supplies. An allergy to latex mandates latex-free gloves and procedural products. Intolerance to adhesive tapes and bandages can be ameliorated by bandages with paper tape or by elastic compression dressings.

SOCIAL HISTORY

Alcohol: Chronic excessive alcohol consumption may result in increased bleeding risk through platelet dysfunction and reduced platelet count, in addition to coagulation abnormalities that can manifest in the setting of liver disease. The consumption of alcohol should preferably be limited for 7 to 14 days preoperatively and postoperatively.

Smoking and Nicotine: Smoking tobacco is associated with reduced tissue oxygenation and a prolonged effect on inflammatory and reparative cellular functions, resulting in impaired wound healing.[13] Smoking history is particularly relevant when considering a complex surgical reconstruction as smoking may increase the likelihood of flap or graft failure. Smoking cessation should be encouraged with all patients, for a minimum of 1 week preoperatively and postoperatively. Nicotine alone also is associated with impaired wound healing secondary to vasoconstriction.[14] This is important to note, as the use of electronic nicotine devices, or e-cigarettes, as an alternative to traditional cigarette smoking, is increasingly common. Discontinuation of e-cigarette use may be considered perioperatively.

Functional Status and Support System: A patient's mental status, mobility, ability to conduct activities of daily living, availability of transportation, and support system have critical practical implications related to a surgical procedure. Examples range from a patient's ability to reach a procedure site for routine cleaning and dressing changes to transportation for postoperative followup. Coordination of appropriate assistance may be warranted for debilitated patients who lack necessary resources in the postoperative period.

PREGNANCY

Special considerations are indicated when planning a surgical procedure in a pregnant patient. If a perioperative antibiotic is indicated, use pregnancy category B medications, which include β-lactam antibiotics (cephalosporins and penicillins) and azithromycin. Mupirocin ointment is also pregnancy category B. Notably, tetracyclines and sulfamethoxazole-trimethoprim are pregnancy category D and should be avoided. With regard to topical antiseptics, chlorhexidine is pregnancy category B. Hexachlorophene, a possible teratogen, and povidone-iodine, which carries a theoretical risk of impairing thyroid function if used extensively and long-term or as part of a procedure involving a low-birthweight neonate, are both pregnancy category C.[15] Isopropyl alcohol and ethyl alcohol have not been classified by the U.S. Food and Drug Administration, but are considered low risk as typically used during a routine dermatologic procedure. The majority of local anesthetics are pregnancy category C, with the exception of lidocaine, prilocaine, and etidocaine, which are pregnancy category B. The addition of epinephrine (pregnancy category C) to a local anesthetic has historically been avoided in pregnancy over concern for theoretical decreased uterine blood flow. While the effect on placental perfusion at the concentrations used in local anesthesia is unclear, epinephrine is generally considered safe when used judiciously and in relatively low volume.[16,17]

PHYSICAL EXAMINATION

Assessment of existing scars, including those from previous surgical procedures or at a body site similar to the planned procedure, is helpful in assessing a patient's propensity for scarring, particularly hypertrophic scarring and keloid formation. In such situations, it is reasonable to preoperatively discuss the concept of scar revision, including intralesional triamcinolone acetonide injection or ablative laser therapy, should a symptomatic or cosmetically-undesirable scar develop. The risk of hypertrophic scarring should specifically be discussed when performing surgery on anatomic sites with higher levels of tension and a predilection for hypertrophic scars, such as the upper trunk, shoulders, and upper arms. Identification of these features in existing scars can serve to educate a patient on expectations of future scarring in a personalized manner.

OPERATIVE CONSIDERATIONS AND PROCEDURE

INFORMED CONSENT

After a preoperative assessment has been completed and prior to performing a surgical procedure, a comprehensive informed consent that confirms the patient's identity, diagnosis, surgical site, planned procedure, and possible associated risks should be reviewed with

and signed by the patient. Specifically, 2 recognized patient identifiers, such as full legal name and birthdate, should be reviewed with the patient as a safeguard against performing the procedure on the wrong patient. Additionally, the surgical site should be outlined with a skin marker and agreed upon with the patient, with the assistance of one or two mirrors for visualization as needed, to minimize likelihood of wrong-site surgery. General surgical risks should be discussed, including pain and discomfort, bleeding, bruising, hematoma formation, wound infection, nerve damage, recurrence of the lesion, and the expectation of a scar.

VITAL SIGNS

Vital signs, specifically heart rate and blood pressure, should be measured prior to initiating and upon completion of a dermatologic procedure. Although hypertension may be observed secondary to anxiety surrounding a procedure, it is important to identify as uncontrolled hypertension may increase bleeding risk, both intraoperatively and postoperatively. Additionally, use of epinephrine may require further consideration in a patient with arrhythmia. For patients with severe hypertension or in whom untreated or unknown arrhythmia is identified, deferment of surgery until the condition can be evaluated and managed by an appropriate health care provider may be indicated.

LOCAL ANESTHESIA

Compared with general anesthesia, local anesthesia is effective, fast acting, low cost, and relatively simple to employ. The selection of the appropriate method and agent is based upon such factors as desired route of administration, rapidity of onset, and anticipated procedure length (Table 202-4). For dermatologic procedures, tissue infiltration is the most common route of administration of local anesthetic, and lidocaine, with its rapid onset of action and duration of 1 to 2 hours, is the most commonly used local anesthetic agent.

Local anesthetics function by impairing neuronal transmission of sensory input, including pain and heat. Specifically, the chemical structure of the anesthesia serves to block neuronal sodium channels, thereby inhibiting depolarization and impairing formation of an action potential across the nerve axon, resulting in an inability for signal to be relayed to the CNS. Smaller, unmyelinated C-type nerve fibers, which transmit heat and pain sensation, are blocked by local anesthetics more rapidly and effectively than larger, myelinated, Aδ-type nerve fibers, which transmit pressure sensation and innervate skeletal muscle fibers. Smaller volumes of local anesthetics therefore tend to block transmission of pain and heat stimuli, while preserving sensation of pressure and motor function. At higher volumes or with increased tissue infiltration, pressure sensation and motor function also may be impaired.

TABLE 202-4
Local Anesthetics

GENERIC NAME	PRIMARY USE	RELATIVE POTENCY	ONSET	DURATION[a] PLAIN	MAXIMUM[b] DOSE PLAIN (mg)	MAXIMUM[b] DOSE WITH EPINEPHRINE (mg)
Amides						
Bupivacaine	Infiltration	8	2 to 10 minutes	3 to 10 hours	175	250
Dibucaine	Topical	—	Rapid	Short	—	—
Etidocaine	Infiltration	6	3 to 5 minutes	3 to 10 hours	300	400
Lidocaine	Infiltration/topical	2	Rapid	1 to 2 hours	300	500 (3,850 dilute[c])
Mepivacaine	Infiltration	2	3 to 20 minutes	2 to 3 hours	300	400
Prilocaine	Infiltration	2	Rapid	2 to 4 hours	400	600
Prilocaine/lidocaine	Topical	—	30 to 120 minutes	Short	—	—
Esters						
Benzocaine	Topical	—	Rapid	Short	—	—
Chloroprocaine	Infiltration	1	Rapid	0.5 to 2 hours	600	—
Cocaine	Topical	—	2 to 10 minutes	1 to 3 hours	200	—
Procaine	Infiltration	1	Slow	1 to 1.5 hours	500	600
Proparacaine	Topical	—	Rapid	Short	—	—
Tetracaine	Infiltration	8	Slow	2 to 3 hours	20	—
Tetracaine	Topical	—	Rapid	Short	—	—

[a]In clinical practice, the duration of anesthesia appears to be less than stated above, especially for head and neck areas, and addition of epinephrine prolongs anesthesia by a factor of 2.

[b]Maximum doses are for a 70-kg person.

[c]Maximum safe dosage of tumescent lidocaine for 70-kg individual at 55 mg/kg.

The function of a local anesthetic is determined by its chemical structure. All local anesthetics are composed of three subunits: a lipophilic aromatic ring, a terminal amine group, and an intermediate linking chain that connects the hydrophobic and hydrophilic groups. Local anesthetics are characterized by the structure of this intermediate linking chain, which is either an amide or ester group.

Onset of action is related to the ionization constant (pK_a) of the anesthetic. The terminal amine group may exist in an uncharged, lipid soluble form or in a cationic, hydrophilic form. While the amine group is in the cationic, hydrophilic form to maintain its solubility in solution, the anesthetic penetrates the neuron when the amine group is in its uncharged, lipid soluble form. When the environmental pH is less than the pK_a, an increasing proportion of the amine group is in the cationic, hydrophilic form; when the environmental pH is greater than the pK_a, an increasing proportion of the amine group is in the uncharged, lipid soluble form. The pK_a of all local anesthetics is greater than the physiologic pH of 7.4, meaning that less than half of the amine groups in the anesthetic are in the lipid-soluble form, capable of penetrating the neuron when injected into tissue with a normal physiologic pH of 7.4. When injected into the acidic environment associated with inflamed tissues, even fewer of the amine groups are in the lipid soluble form, potentially explaining in part why inflamed or infected tissues are more difficult to anesthetize than normal-appearing skin. Buffering of an epinephrine-containing anesthetic solution, from the acidic pH at which it is often prepared to a pH closer to physiologic pH and the pKa of the anesthetic, may result in more rapid onset of action upon injection.

The lipid solubility of the lipophilic aromatic ring determines the potency of an anesthetic through its ability to diffuse through nerve sheaths and neural membranes of individual axons. The duration of action is proportional to the plasma protein binding properties of the anesthetic, as this correlates with affinity for binding within sodium channels, which corresponds to time of neural blockade.[18]

Amide anesthetics include lidocaine, prilocaine, bupivacaine, mepivacaine, and etidocaine. Amide anesthetics are metabolized by hepatic microsomal cytochrome P450 enzymes. Following dealkylation and hydrolysis in the liver, metabolites are ultimately excreted renally. An alternative to an amide anesthetic may be considered in patients with liver failure or in those taking medications such as propranolol, which may prolong the half-life of the anesthetic by inhibiting the activity of cytochrome P450 enzymes.

Ester anesthetics include procaine, benzocaine, tetracaine, and cocaine. Ester anesthetics are metabolized through hydrolysis by plasma pseudocholinesterases with subsequent renal excretion.

EPINEPHRINE

All local anesthetics are vasodilators, with the exception of cocaine, which is a vasoconstrictor. Even though local anesthetics afford the necessary blockade of pain sensation to allow for surgical procedures to be conducted, this vasodilatory effect results in increased intraoperative bleeding. By adding epinephrine to local anesthetics, typically at a concentration ranging between 1:100,000 and 1:500,000, the vasoconstrictive property of epinephrine is used to counteract the vasodilatory properties of local anesthetics and reduce intraoperative bleeding. The local vasoconstriction caused by epinephrine also serves to concentrate the anesthesia at the site of injection, resulting in increased duration and efficacy of anesthesia by up to 150% while reducing the potential for systemic absorption and toxicity.

As a potent α-adrenergic and β-adrenergic receptor agonist, the use of epinephrine as a component of local anesthetics has several contraindications. Its use is absolutely contraindicated in patients with pheochromocytoma or hyperthyroidism as it may result in hypertensive crisis. Relative contraindications include severe coronary artery disease, peripheral vascular disease, uncontrolled hypertension, acute angle glaucoma, and pregnancy, given the concern for decreased uterine blood flow. Epinephrine may also potentiate the effects of medications such as monoamine oxidase inhibitors, phenothiazines, and tricyclic antidepressants. Importantly, the use of epinephrine in patients taking medications of the β-adrenergic blocking (β-blocker) class may result in unopposed stimulation of α-adrenergic receptors, putting patients at risk of severe hypertension. Epinephrine should be used judiciously in patients taking such medications.

The use of epinephrine on distal anatomic regions with less-robust collateral circulation, such as the digits, nasal tip, and penis, has historically been cautioned against over concern that the vasoconstrictive properties of epinephrine could result in ischemia and tissue necrosis. More recently, ischemia and necrosis at distal anatomic sites have been attributed to use of excessive volume, resulting in a physical tamponade effect on the local vasculature. When used judiciously, a small volume of local anesthetic containing epinephrine can typically be used to safely anesthetize distal anatomic sites such as the digits, nasal tip, and penis. For patients with severe peripheral vascular disease, the use of an anesthetic without epinephrine or a lower concentration of epinephrine (1:500,000) may be warranted.

Systemic side effects associated with epinephrine are self limited and include feelings of anxiety and fear, tremor, heart palpitations, tachycardia, and hypertension. While exceedingly rare when used as part of conventional cutaneous surgery in an appropriate patient population, severe systemic side effects of excessive epinephrine dosing may include heart arrhythmias, cardiac arrest, and cerebrovascular hemorrhage.

TOPICAL ANESTHETICS

Topical administration of local anesthetic provides an alternative route to infiltration of tissue by injection. This may provide a suitable level of anesthesia for minor dermatologic procedures, such as shave biopsy, or when a significant skin surface area requires

anesthesia, such as prior to laser therapy. Topical anesthetics also may be considered when performing a procedure on an anxious patient, such as a child or patient with fear of needles. Sufficient penetration of the stratum corneum by the topical anesthetic, often requiring prolonged application time in combination with occlusion, is required for maximum efficacy.

Commonly used topical anesthetics include L-M-X (lidocaine hydrochloride) and EMLA (eutectic mixture of local anesthetics) creams. L-M-X cream consists of lidocaine delivered in a liposomal vehicle and is available in 4% (L-M-X4) or 5% (L-M-X5) concentrations. It is most effective when applied 30 minutes prior to a procedure; it may be occluded at the discretion of the provider and as tolerated by the patient. EMLA cream consists of a mixture of the amide anesthetics lidocaine and prilocaine, each at 2.5% concentration. EMLA is most effective when applied under occlusion 1 hour prior to a procedure with data suggesting equal efficacy to L-M-X cream applied 30 minutes prior to a procedure without occlusion. Both L-M-X and EMLA creams have been shown to be more effective than tetracaine 4% topical gel and a mixture of prilocaine and lidocaine in a liquid paraffin ointment vehicle. Importantly, prilocaine-containing topical preparations, including EMLA cream, have the potential to induce methemoglobinemia in infants and when applied to an impaired skin barrier, and should therefore be used with caution in such clinical scenarios. Allergic contact dermatitis to topical ester anesthetics such as benzocaine and tetracaine may occur.

Topical anesthetics are effective in providing anesthesia to mucosal membrane surfaces as they are readily absorbed in the absence of a stratum corneum. Tetracaine or proparacaine preparations may be used on the ocular surface prior to insertion of eye shields. Topical benzocaine and lidocaine are effective in anesthetizing oral mucosal surfaces prior to surgical procedures or to increase patient comfort while performing intraoral nerve blocks.

Cold may be used to offer transient anesthesia to diminish pain sensation as needed. A cryogen, such as ethyl chloride, may be delivered in a topical spray to a concentrated area of the skin prior to injection or nerve block. An ice cube or ice pack also may be held temporarily on a procedure site prior to needle insertion.

PERIPHERAL NERVE BLOCKAGE

When a cutaneous procedure involves a significant surface area of the skin, multiple injections to achieve a satisfactory level of anesthesia may be undesirable and lead to significant patient discomfort. Infiltration of a large volume of anesthetic at the procedure site may also distort anatomic structures while increasing the risk of anesthetic toxicity. In such a scenario, appropriate execution of a regional peripheral nerve block, based on comprehensive knowledge of regional anatomy, may be a useful tool when the anatomic region lies within a particular sensory nerve distribution. By injecting a small volume of anesthesia at the proximal aspect of a sensory nerve root, sensory anesthesia of the region supplied by that nerve can be effectively achieved. Caution is warranted as direct trauma to a nerve during blockage may result in neurapraxia, which may last 6 weeks or longer.

Nerve blockade is usually performed with a standard anesthetic such as lidocaine (1%) with epinephrine (1:100,000), using a 1-inch, small-diameter (30-gauge) needle. If extended effect is desired based upon the anticipated length of the procedure, a longer-acting anesthetic such as bupivacaine also may be used.

Nerve blockage in dermatologic surgery is particularly useful when performing procedures on the face or digits. Sensory input from the face is transmitted primarily via the trigeminal nerve (cranial nerve V), the branches of which are readily accessible for peripheral nerve blockage. Nerve blockade of the digits prior to digital or nail surgery allows for effective anesthesia with minimal volume, which is particularly important as injection of more than 1 mL around a digit may increase the risk for digital vascular tamponade with subsequent ischemia and necrosis.

Branches of the ophthalmic division (cranial nerve V1) of the trigeminal nerve include the supraorbital, supratrochlear, and infratrochlear nerves. The supraorbital nerve exits the skull via the supraorbital foramen, a bony prominence that is palpable at the orbital rim, just medial to the midpupillary line. The supratrochlear branch exits the skull approximately 1.5 cm medial to the supraorbital notch along the orbital rim. The infratrochlear nerve exits the skull just superior to the medial canthus. Nerve blockade of these 3 branches can be accomplished with a single injection and provides anesthesia to the ipsilateral forehead, frontal scalp, upper eyelid, medial canthus, and superior nasal sidewall and root. Blockade of these nerves is performed by inserting the needle 2 to 3 mm lateral to the supraorbital notch and advancing medially through the subcutaneous tissue to the medial canthus, followed by slow withdrawal of the needle while simultaneously injecting the medication along the path that the needle travels.

The maxillary division (cranial nerve V2) of the trigeminal nerve gives rise to several branches including the infraorbital nerve, which provides sensation to the ipsilateral lower eyelid, medial cheek, nasal ala, upper lip, and upper teeth. Nerve blockade of the infraorbital nerve with resulting anesthesia of these structures can be achieved using either a percutaneous or an intraoral approach. The infraorbital nerve exits the skull through the infraorbital foramen, which is located approximately 1 cm below the infraorbital rim along the midpupillary line. Percutaneous blockade of the infraorbital nerve is performed by inserting the needle perpendicularly into the skin at the infraorbital foramen and advancing the needle directly down to the maxillary bone, where the anesthetic is injected. The intraoral approach to infraorbital nerve blockade consists of palpating the sulcus just superior and lateral to the canine tooth, and inserting the needle at the superior portion of this sulcus. The needle should be advanced superiorly approximately 1 cm in the midpupillary line, where the anesthetic should be slowly

injected. The intraoral approach is typically less painful than the percutaneous one, and may be even better tolerated if a topical anesthetic such as lidocaine or benzocaine is applied to the oral mucosa prior to injection.

Branches of the mandibular division (cranial nerve V3) of the trigeminal nerve include the mental nerve, which supplies sensation to the ipsilateral lower lip and chin. The mental nerve exits the skull through the mental foramen, which is located along the mandible, just medial to the midpupillary line. The mental nerve is located opposite of the first bicuspid on the buccal mucosa of the lower lip, and can sometimes be visualized as a thin, white, glistening strand. Blockade of this nerve may be performed using an intraoral approach, with insertion of the needle at the inferior portion of the nerve along the buccal mucosa of the lower lip, just opposite the first bicuspid.

In addition to the above branches, there are other branches of the trigeminal nerve that are amenable to regional nerve blocks. These include the buccal, auriculotemporal, anterior ethmoidal (external nasal branches), and zygomaticotemporal nerves. A block of the greater auricular nerve off the cervical plexus provides anesthesia to the posterior auricle and angle of the mandible.

When performing digital or nail procedures, digital nerve blockade is readily possible based upon the longitudinal orientation of the digital sensory nerve along either lateral surface of the digit. A needle is inserted at the proximal aspect of the digit perpendicular to the lateral surface and advanced to the lateral aspect of the underlying digital bone. Injection of a small volume of anesthetic at this site can accomplish satisfactory anesthesia of the digit with minimal risk of tamponade effect.

SIDE EFFECTS

The most common side effect of local anesthetics is pain during administration, which is the result of acidity of the anesthetic preparation and injection technique. Epinephrine is more stable at an acidic pH, and premixed epinephrine-containing local anesthetics are typically prepared at an acidic pH between 3 and 5. The difference between the acidity of the solution and physiologic pH of 7.4 results in significant discomfort upon injection. Adjustment to a more basic pH closer to physiologic pH can be accomplished by addition of sodium bicarbonate to the solution, for example, 1 part 8.4% sodium bicarbonate mixed with 10 parts lidocaine. While this buffered solution causes less pain with injection, it should be noted that it increases the rate at which epinephrine degrades to approximately 25% per week. An alternative approach to preparing a more neutral solution is mixing epinephrine with the anesthetic at the time of the procedure.

Injection components including needle and syringe size, needle orientation to the skin, rate of tissue infiltration, and anatomic placement of anesthesia significantly impact the degree of discomfort experienced by the patient. Use of a small-diameter needle, such as 27-gauge or 30-gauge, is better tolerated with less pain during injection. Rapid injection of a large volume of anesthetic into tissue is also painful. Slow injection with a low-volume syringe, between 1 and 3 mL, allows for optimal control of the rate of tissue infiltration and minimization of pressure at the injection site. Insertion of the needle through a pore or at an orientation perpendicular to the skin may be better tolerated.[19] Injection of anesthesia at the subcutaneous layer is less painful than intradermal injection; however, intradermal injection results in more rapid onset and longer duration of action as compared to injection into the subcutaneous tissue. When anesthetizing a larger area, initiate anesthesia at the proximal aspect of the nerve distribution and insert subsequent needles within the anesthetized periphery to decrease overall pain. A nerve block could also be considered to provide regional anesthesia with fewer injections and lower volume of anesthesia. Additional techniques for lessening discomfort and anxiety of injection include cold or vibration at or near the site of needle insertion and distraction techniques ranging from social conversation to handheld devices with applications interesting to the patient.

Vasovagal reaction may occur during any portion of a dermatologic procedure. To decrease risk of vasovagal reaction, pain and anxiety should be minimized. The patient should be placed in a recumbent or Trendelenburg position prior to injection for local anesthesia and throughout the procedure. Signs and symptoms that herald vasovagal reaction include pallor, weakness, bradycardia, hypotension, nausea, and diaphoresis. Diaphoresis also may be observed in the settings of hypoglycemia or angina. Seizure can (rarely) occur in the context of a vasovagal reaction and is typically short lived. Should a vasovagal reaction occur, the patient should be placed in Trendelenburg position, which usually leads to resolution within minutes; standard surgical positioning in recumbent or Trendelenburg position facilitates this and mitigates the risk of adverse events such as falls. Cool compresses also can be soothing.

Allergic reactions to local anesthetics can occur. These are typically Type I, immunoglobulin E–mediated reactions that may manifest as angioedema, urticaria, bronchospasm, tachycardia, hypotension, and even cardiovascular collapse. Less commonly, Type IV, delayed hypersensitivity reactions presenting as allergic dermatitis may be observed. Allergy to ester anesthetics is far more common than to amide anesthetics, and typically occurs secondary to para-aminobenzoic acid (PABA), which is an intermediate metabolite of ester anesthetics. Importantly, cross-reactions to both injected and topical ester anesthetics can occur in individuals with allergies to para-phenylenediamine, sulfonamides, para-aminosalicylic acid, azo dyes, and PABA sunscreens.[20] Amide local anesthetics are not metabolized to a PABA derivate, and allergy to amide anesthetics is far less common. However, it is important to note that methylparaben, a preservative used in amide anesthetics, is structurally similar to PABA, and cross-reactivity to the aforementioned allergens may occur. Additionally,

metabisulfite, an antioxidant that is often added to epinephrine-containing local anesthetics as a stabilizer of epinephrine, may result in allergy and cross-react in individuals allergic to sulfites and bisulfites. Referral for allergy testing prior to surgery should be considered in patients who report a history or suspicion of allergy to local anesthetic or an associated preservative. In patients with documented or observed allergy to local anesthetics, alternative methods of local anesthesia for a simple dermatologic procedure include intradermal injection of diphenhydramine hydrochloride solution or bacteriostatic (0.9%) normal saline, although the efficacy of these methods is limited. Intradermal injection of diphenhydramine solution may result in classic antihistamine side effects, including significant drowsiness. The anesthetic effect of normal saline is likely related to a combination of tamponade effect on local nerves and a mild anesthetic effect of the preservative benzoyl alcohol.

Risk of anesthetic toxicity should be considered when performing large dermatologic procedures requiring significant volume of local anesthesia. Maximum dosage should be kept under 4.5 mg/kg of plain lidocaine without epinephrine, 7 mg/kg of lidocaine with 1:100,000 epinephrine, and for tumescent anesthesia, 55 mg/kg of 0.05% to 0.1% lidocaine with 1:1,000,000 epinephrine. Initial symptoms of anesthetic toxicity include circumoral and distal extremity numbness and tingling, tinnitus, lightheadedness, and nausea. More-severe manifestations of anesthetic toxicity that occur with increasing dose include CNS depression accompanied by hallucinations, seizures, and respiratory depression, followed by cardiovascular toxicity, including hypotension, arrhythmias, and cardiac arrest. Intraarterial and intravenous injection of local anesthetic results in increased serum levels of anesthetic and, therefore, increased risk of anesthesia toxicity. Drawing back on the syringe plunger after needle insertion and prior to infiltration of the anesthetic will reveal a flash of blood if the needle is within the lumen of a vessel, which warrants repositioning the needle. Of note, patients with liver disease are at increased risk of amide anesthetic toxicity secondary to reduced metabolism of amide anesthetic. Therefore, dose reduction of an amide local anesthetic or use of an ester anesthetic is recommended for a patient with liver disease undergoing an extensive dermatologic procedure requiring a significant volume of local anesthetic.

SKIN PREPARATION

Normal skin flora primarily consists of aerobic cocci, including *Streptococcus* and *Staphylococcus (aureus* and *epidermidis),* with *S. aureus* serving as the most common pathogen in cutaneous infection following dermatologic surgery. Other bacteria, including *Pseudomonas, Propionibacterium*, and micrococci, are commonly identified on the skin. *Pseudomonas* is a common pathogen related to infections of surgical sites involving cartilage, such as on the ear. An aseptic approach to cutaneous surgery involves preparation of the skin with an antiseptic solution to minimize the bacterial flora at the surgical site, followed by diligent surgical technique with a goal of minimizing microbial contamination of the surgical site during the procedure. However, as some bacteria reside in the pilosebaceous unit, complete sterilization of the skin with a topical antiseptic solution is not possible.

The area that is prepared with topical antiseptic should include the planned incision site with a wide margin of normal skin to provide an adequate surgical field for visualization, tissue handling, and path for suture material. Sterile towels or drapes should be placed at the edge of the prepared surgical field, and can be fixed in place with towel clamps, as needed. Every effort should be made to maintain patient positioning and orientation of the surgical field once the procedure is initiated to minimize the possibility of contamination of the surgical site. For nonglabrous surgical sites that require hair removal to optimally conduct a procedure, clipping hairs or using depilatory agents is favored over shaving. The use of a razor for hair removal prior to surgery may be associated with increased risk of surgical site infection, likely by causing microabrasions that serve as reservoirs for bacteria and promote infection.[21]

TOPICAL ANTISEPTICS

Characteristics that are considered when selecting an antiseptic include breadth of microbicidal or microbiostatic activity, rapidity of onset, duration of effect, potential for irritation, allergic sensitization, and toxicity including teratogenicity. Antiseptics commonly utilized in invasive skin procedures include iodophors, chlorhexidine, and isopropyl alcohol.

The most commonly used iodophor in cutaneous surgery is povidone-iodine. The mechanism of action through which iodophors act as antiseptics is through oxidation of microbial cell membranes by free iodine. Iodophors display broad antimicrobial activity against both Gram-positive and Gram-negative bacteria, fungi, mycobacteria, and viruses. The onset of action of povidone-iodine is usually within 1 to 3 minutes. The needle should be advanced superiorly approximately 1 cm in the midpupillary line, once the antiseptic has dried. The duration of microbicidal activity following application is on the order of hours, although contact with blood or serum results in attenuation and loss of microbicidal activity. Side effects include allergic contact dermatitis, irritant contact dermatitis, and risk of tissue necrosis in wounds with prolonged exposure to significant volume of iodophors.

Chlorhexidine, another commonly used topical antiseptic in cutaneous surgery, also disrupts cell membranes. It has broad antimicrobial activity including Gram-positive and Gram-negative coverage, with some antiviral coverage. It does not display suitable antimicrobial effect against fungi or mycobacteria. Advantages of chlorhexidine over povidone-iodine include an almost instant onset of action, sustained activity for many hours after application, additive effect with repeated applications, and superior decontamination of the skin with lower rates

of postoperative infection.[22] Potential side effects of chlorhexidine include keratitis or corneal ulceration, if direct contact with the cornea occurs, and cochlear and vestibular toxicity, if a perforation in the tympanic membrane allows chlorhexidine to reach the inner ear. These site-specific side effects limit the use of chlorhexidine on surgical sites near the ears and eyes. Additionally, tissue toxicity may occur as a side effect of prolonged exposure to chlorhexidine.

Isopropyl alcohol and ethyl alcohol are commonly used antiseptic agents for cutaneous procedures as they display broad antimicrobial activity against Gram-positive and Gram-negative bacteria, mycobacteria, viruses, and fungi, although to a lesser extent than iodophors or chlorhexidine. The mechanism of action is denaturation of microbial proteins. An advantage of isopropyl or ethyl alcohol is rapid onset of activity; however, this antimicrobial activity is not persistent. Additionally, as alcohols are highly flammable, they should be used with caution during procedures requiring electrosurgery.

Hexachlorophene is an antiseptic solution with excellent antimicrobial activity against Gram-positive bacteria; however, it possesses limited activity against Gram-negative bacteria and fungi. Additionally, hexachlorophene has neurotoxic properties and is readily absorbed through the skin, resulting in side effects in health care providers who frequently handle the medication and in infant patients. Importantly, hexachlorophene also may be teratogenic in individuals who frequently handle the antiseptic.

PATIENT POSITIONING

When positioning a patient for surgery, 4 aspects should be considered: (a) patient comfort; (b) accessibility and exposure of the surgical site; (c) tissue toxicity to surrounding tissue from the topical antiseptic; and (d) surgeon posture and comfort.

A position should be established that allows access and exposure of the intended surgical site and is comfortable for the patient to maintain throughout the duration of the procedure. This may be accomplished by a combination of table positioning and the use of arm rests and pillows of various shapes and sizes.

While cleansing with antiseptic, it is critically important to position the patient such that the risk of contact with vulnerable sites is minimized. If chlorhexidine is used on the head and neck region, contact with the eyes or external ear canal should be avoided.

Finally, the patient should ideally be positioned to optimize an ergonomic approach from the standpoint of the surgeon. Specifically, the table should be elevated to an appropriate height and the patient positioned such that the angles of back flexion and cervical neck flexion of the surgeon are both less than 15 degrees. Operating with a back flexion angle or cervical neck flexion angle greater than 15 degrees significantly increases long-term risk of disability associated with back and neck injury.

EQUIPMENT

Procedure room equipment typically consists of a mechanically-adjustable patient table, overhead adjustable procedure lights, hyfrecator, vital signs monitor, Mayo stand, waste receptacle for contaminated material, and suction device, as indicated.

Surgical tray setup, in terms of instruments and layout, may vary based upon factors including planned procedure and surgeon preference. However, it is important to maintain a consistent layout with regards to placement of surgical sharps in an attempt to minimize inadvertent injury and exposure to contaminated materials by the primary surgeon or other members of the surgical team.

Instruments that are commonly included as part of a basic excisional surgery tray are a curette; No. 3 or No. 7 scalpel handle with a blade; small forceps (eg, Bishop-Harmon) and/or smooth-toothed Adson forceps; delicate standard skin hook or double-prong skin hook; curved iris scissors; blunt-tipped undermining scissors; a hemostat; towel clamps; a needle holder; and suture scissors. Common blades are No. 15 and No. 10, with the No. 10 often used for large excisions on anatomic sites with a thicker dermis such as the back. Special procedures will require additional instruments, such as additional hemostats or skin hooks for larger procedures such as skin flaps, or a dermatome when a split-thickness skin graft is used during repair. Disposable material often included on a surgical tray includes suture, marking pen, gauze sponges, cotton tip applicator sticks, scratch pad for electrocautery tip, electrocautery hand piece and tip, surgical drapes, and foam or magnetic pad for discarded sharps, including blades and needles.

SURGICAL PROCEDURE

After the patient has provided informed consent for the procedure, the patient is properly positioned, and the surgery site is appropriately anesthetized and prepared, a final verification "time out" should be completed immediately prior to the skin incision. A "time out" consists of verbal confirmation of the correct patient, surgical procedure, surgical site, and when applicable, implanted devices. For additional information on surgical procedures, see Chap. 203, "Excisional Surgery and Repair, Flaps, and Grafts."

SUTURING

Repair of a surgical defect should maximize cosmetic and functional outcomes. For sutured repairs, the choice of appropriate suture material and the use of meticulous suturing technique are critical.

SUTURE MATERIALS

Selection of the proper suture material matches sutures with appropriate intrinsic characteristics to the anatomic location and anticipated tension of the planned repair. Table 202-5 summarizes the characteristics of suture material commonly used in dermatologic surgery.

Sutures are categorized most generally as absorbable and nonabsorbable, with an absorbable suture defined as losing half of its tensile strength within 2 months of placement. Absorbable sutures are typically used for approximation of the dermal and subcutaneous layers of the skin. They provide the key function of wound stabilization during the earliest period of scar formation, as a scar has only 5% to 10% of the original strength of the skin at 2 weeks postprocedure. Thus, the absorbable suture gradually loses its tensile strength as the scar gains intrinsic strength. Nonabsorbable sutures are most commonly used for external epidermal approximation, rather than significant structural support. They are typically removed within 1 to 2 weeks of the procedure.

Suture structure may be either monofilament or multifilament. Monofilament sutures are composed of a single, homogeneous strand, whereas multifilament sutures are composed of multiple identical strands that are arranged in a braided or twisted configuration. Monofilament sutures possess a low coefficient of friction, meaning that they pull through tissue with relative ease, and have low capillarity, resulting in both low tissue reactivity and low risk of infection. Monofilaments tend to have high memory, which describes the tendency of a suture to revert back to its original shape despite handling. As a result, a monofilament suture has lower knot security because of its tendency to unravel, and requires that additional knots be tied to minimize risk of wound dehiscence. Multifilament sutures tend to have low memory, resulting in increased knot security and requiring fewer ties. Multifilament sutures are structurally porous as a result of their braided or twisted configuration. This increased capillarity is associated with trapping of fluid and bacteria, thus increasing tissue reactivity and risk of infection.

Categorization of suture diameter is based upon the USP (United States Pharmacopeia) scale. For dermatologic surgery, suture size is typically between 3-0 and 6-0 (Table 202-6), with suture diameter being inversely related to the first digit of the USP designation. As tensile strength is directly related to the diameter of a suture, a USP 3-0 suture possesses a larger diameter

TABLE 202-5
Suture Materials

	TYPE	MEMORY	TISSUE REACTIVITY	KNOT STRENGTH	TENSILE STRENGTH HALF-LIFE
Nonabsorbable					
Cotton	Twisted	Low	Very high	—	—
Nylon	Monofilament	High	Low	Poor	—
Nylon	Braided	Low	Low	Fair	—
Polybutester	Monofilament	High	Low	Good	—
Polyester, uncoated	Braided	Low	Low	Very good	—
Polyester, coated	Braided	Low	Low	Good	—
Polypropylene	Monofilament	Very high	Very low	Poor	—
Silk	Braided/twisted	Very low	High	Excellent	—
Stainless steel	Monofilament/ braided/twisted	Very high	Very low	—	—
Absorbable					
Catgut, fast absorbing/ mild chromic	Twisted	Very high	High	Poor	2 days
Catgut	Twisted	Very high	High	Poor	4 days
Catgut, chromic	Twisted	Very high	High	Fair	1 wk
Polyglactin 910	Braided	Very low	Low	Good	2 wks
Polyglycolic acid	Braided	Very low	Low	Good	2 wks
Poliglecaprone 25	Monofilament	Low	Very low	Very good	1 wk
Polyglyconate	Monofilament	Low	Very low	Very good[a]	1 mo
Polydioxanone	Monofilament	High	Very low	Poor	1 mo

[a]For further reading on polyglyconate suture, see Fong ED, Bartlett AS, Malak S, Anderson IA. Tensile strength of surgical knots in abdominal wound closure. *ANZ J Surg.* 2008 Mar;78(3):164-6. doi: 10.1111/j.1445-2197.2007.04394.x.

Data from Melton JL, Hanke WC. Wound closure materials. In: Lask GP, Moy RI, eds. *Principles and Techniques of Cutaneous Surgery*. New York, NY: McGraw-Hill; 1996:77; Garrett AB. Wound closure materials. In: Wheel RG, ed. *Cutaneous Surgery*. Philadelphia, PA: WB Saunders; 1994:199; and Srivastava D, Taylor RS. Suturing technique and other closure materials. In: Robinson JK, Hanke CW, Siegel DM, et al, eds. *Surgery of the Skin*. 3rd ed. Philadelphia, PA: WB Saunders; 2015:193-213.

TABLE 202-6

Recommended Diameter and Time to Removal of Absorbable Suture According to Anatomical Site

ANATOMICAL SITE	RECOMMENDED SUTURE DIAMETER	LENGTH OF TIME PRIOR TO SUTURE REMOVAL
Eyelids	6-0	5 to 7 days
Face and ears	5-0	5 to 7 days
Neck	4-0, 5-0	7 days
Scalp	3-0, 4-0	7 to 14 days
Trunk and extremities	3-0, 4-0	10 to 14 days[a]

[a]High-tension sites or sites with poor wound healing may require sutures to remain in place longer.

and greater tensile strength than a 4-0 suture, and a 6-0 suture possesses a smaller diameter and lesser tensile strength than a 5-0 suture. The smallest suture diameter that provides adequate tensile strength for a repair should be selected. Typically, 5-0 sutures are used on anatomic sites of relatively low tension such as the face and ears; 6-0 suture may be used on or near sites of even less tension, such as the eyelid. Anatomic sites of higher tension, such as the trunk and scalp, typically require 4-0, and sometimes 3-0, suture. Depending on the dermal thickness and degree of photodamage of an individual's neck, 4-0 or 5-0 sutures are typically suitable. Dermatologic surgical procedures are generally best performed with needles intended for plastic or cosmetic surgery.

SUTURING TECHNIQUE

Appropriate suturing technique and careful suture placement are critical for maximizing cosmesis while minimizing complications. An ideal wound closure consists of meticulous wound edge approximation and eversion. As wound contraction normally occurs during healing, wound edge eversion at the time of closure promotes the development of a flat, smooth, cosmetically-appropriate scar. If the wound edge is not sufficiently everted during wound closure, wound contraction may increase the risk of a depressed or spread scar. An ideal wound closure also minimizes tension and dead space; maintains or restores anatomic contours with respect to cosmetic subunits; and avoids permanent suture track marks adjacent to the suture line, particularly in cosmetically sensitive areas.

Interrupted Sutures: Variants of interrupted sutures utilized in dermatologic surgery include the simple interrupted suture, the horizontal mattress suture, the half-buried horizontal mattress suture, and the vertical mattress suture.

Simple interrupted sutures are commonly used in dermatologic surgery as both buried and epidermal sutures. Properly placed, absorbable, buried, interrupted sutures are critical to a successful, layered wound closure. They reduce tension along the wound edges while providing necessary tensile support during the early stages of wound healing, minimizing risk of wound dehiscence. Eversion of the wound edges is best achieved by placing sutures in the deep dermis and subcutis in a heart-shaped configuration (Fig. 202-1), where the initial entry point of the needle

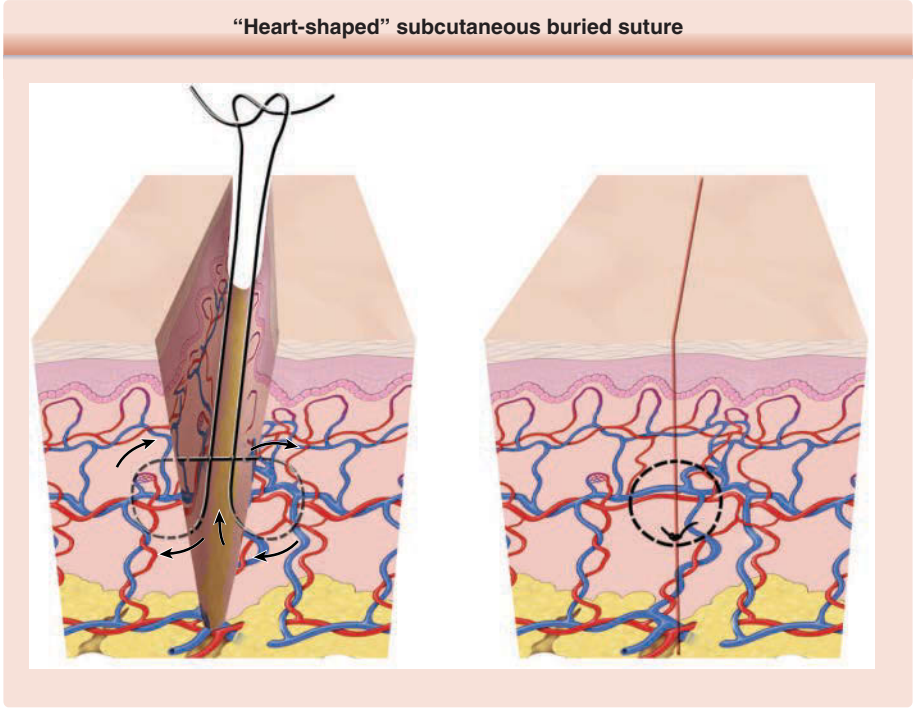

Figure 202-1 "Heart-shaped" subcutaneous buried suture.

on one side and the final exit point of the suture on the contralateral side are deepest relative to the skin surface. Placement of more superficial dermal sutures may be used as part of the layered wound closure of deeper wound defects to reduce dead space and further facilitate wound eversion.

Epidermal, nonabsorbable, simple interrupted sutures may be placed to precisely align the wound edges following cutaneous surgery. Although more time-consuming to place than a continuous, running suture, they may be considered in areas of high wound tension where wound dehiscence is a concern. Simple interrupted sutures allow for alternating sutures to be removed in stages over time, providing additional tensile support as needed to minimize risk of wound dehiscence. Interrupted sutures may also cause less edema and impaired microcirculation than a running suture, and may be considered when there is a concern for impaired wound healing. In the event that the placement of buried, dermal sutures results in uneven approximation of the epidermal edge with a "stepped" appearance, simple interrupted epidermal sutures can be used to evenly approximate the epidermal edge by placing the suture more superficially at the elevated epidermal edge and more deeply at the depressed epidermal edge.

The horizontal mattress suture (Fig. 202-2) may be used to reduce persistent tension along wound edges following placement of buried sutures. This technique also provides the added benefits of hemostasis and wound edge eversion, and may be utilized in cosmetically-sensitive areas. Horizontal mattress sutures also may be used as temporary bridging sutures as part of high-tension closures to offset tension and temporarily approximate wound edges, facilitating the ease with which subcutaneous or dermal sutures may be placed, after which time the bridging sutures may be removed. Alternatively, the bridging sutures may be left in place for several days to permit wound edge healing under reduced tension. The risk of wound-edge necrosis can be minimized by placing the suture at least a few millimeters from the wound edge. Affixing bolsters on either side of the wound edge can also reduce the risk of tissue necrosis.

The half-buried horizontal mattress suture, also referred to as a Gillies corner stitch or 3-point corner stitch, may be used in a variety of local flap closures, such as M-plasty, V-Y plasty, or rotation flaps, to approximate the flap tips to recipient wound corners. It may decrease flap tip necrosis by minimizing interference with the dermal vascular plexus of the flap tip.[23]

The vertical mattress suture (Fig. 202-3) can provide wound edge eversion, minimize dead space, and minimize tension. It acts as a combination of a buried dermal and interrupted epidermal suture. The initial entry and exit points of the suture are farther from the wound edge, followed by reentry and final exit points closer to the wound edge. The risk of tissue necrosis increases when the suture is placed under excessive tension. Care should be taken to remove the suture as soon as reasonable, as paired suture track mark scars may develop as this high-tension suture becomes embedded in the skin.

Running Sutures: Variants of a running suture include the simple running suture, the running locking suture, and the running subcuticular suture.

The simple, continuous running suture can be used to efficiently approximate wound edges of equal thickness under minimal tension. It is most useful when buried sutures were used to close the wound and eliminate dead space and tension. It allows for only 2 knots to be tied, thereby limiting the amount of suture material that rests against the skin and potentially minimizing the development of suture track mark scars. It is also useful in areas of thin skin, such as the eyelids, ears, neck, and scrotum, and to attach full-thickness or split-thickness skin grafts to the recipient wound edges. Fine adjustments along the suture line are more difficult to make with the simple running suture. When used on lax or thin skin, such as eyelid skin, the simple running suture may be more likely to pucker and cut into tissue. Avoidance

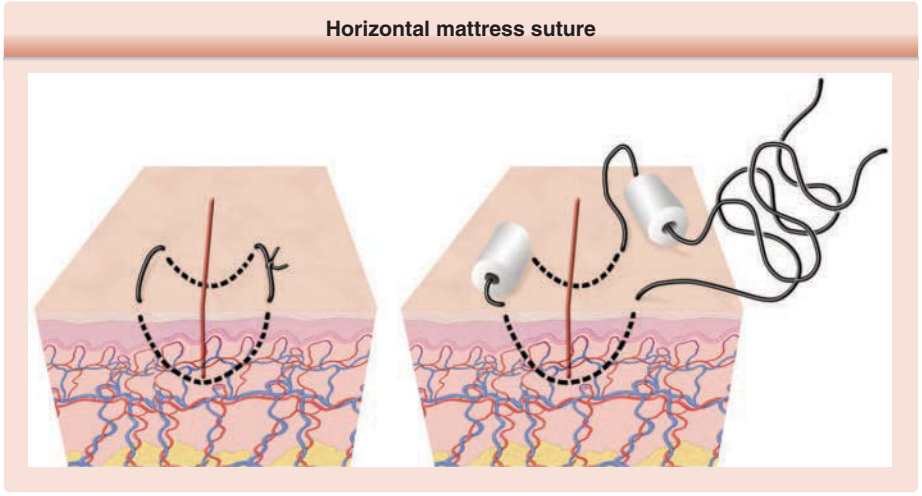

Figure 202-2 Horizontal mattress suture.

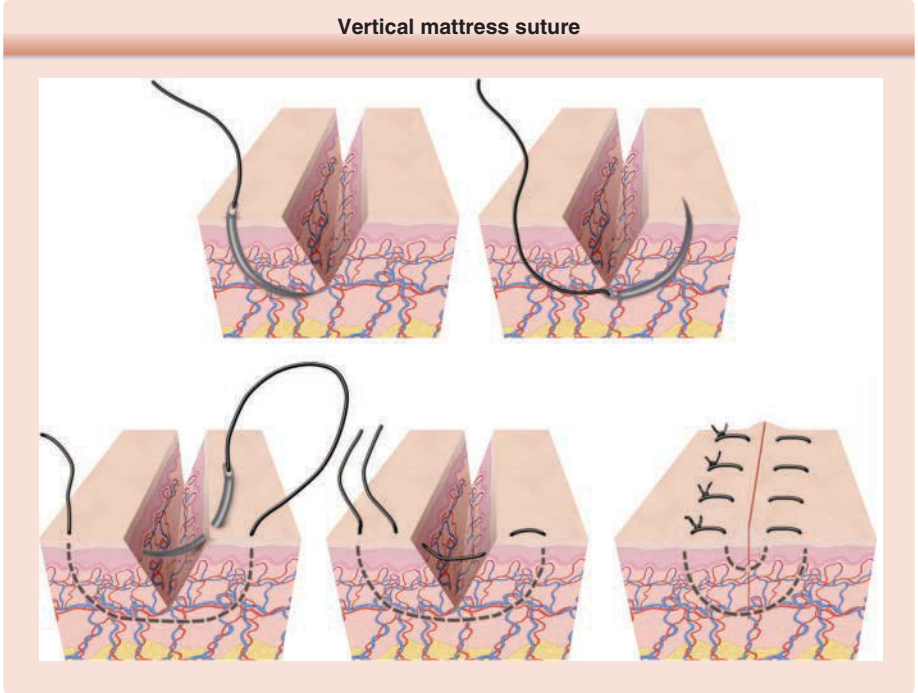

Figure 202-3 Vertical mattress suture.

of unnecessary tension when approximating wound edges and tying the end knots over small bolsters can reduce this risk.

The running locking suture may be useful when approximating wound edges of equal thickness under moderate tension and to aid in hemostasis of well-vascularized wounds such as on the scalp. It is a variant of the simple, continuous running suture in which the needle is passed through the previous loop prior to placing the next loop. It is best used at anatomic sites without a tendency for inversion. While the running locking suture is stronger than the simple running suture, there is an increased risk of wound-edge necrosis if the suture is placed too tightly or if significant postoperative wound swelling develops.

The running subcuticular suture is a buried running suture placed at the level of the superficial dermis that allows for wound edge approximation and decreases risk of suture track scarring in situations in which the suture will be left in place longer than typically recommended. It does not provide significant approximation of the wound edge, and is therefore best reserved for wound edges of relatively equal thickness that have already been closely approximated with deep, buried sutures. Either absorbable or nonabsorbable suture material may be used. Absorbable suture material, which should be monofilament and nonreactive, may be left in place until it is absorbed. Nonabsorbable suture, such as polypropylene, also may be used to minimize tissue reactivity and suture breakage within the wound. Nonabsorbable sutures will require removal at a future date; if left in place indefinitely to reduce scar stretching, a clear suture is best selected (Table 202-6).

STAPLE CLOSURE

Closure of a wound with staples rather than sutures can sometimes be considered, particularly for a long wound or a wound under very high tension. Advantages of staple closure include quick placement, high tensile strength of wound closure, easy removal with a surgical staple remover, minimal tissue reactivity, and potentially lower risk of infection of contaminated wounds compared to closure with sutures. A disadvantage is less precise wound edge approximation. A common site for staple closure of a surgical defect is on the scalp, where suturing may be technically more challenging if minimal hair removal around the surgical site is desired, and the suture line and potential track marks are hidden by the hair on the scalp. When more precise wound edge approximation is desired, closure should be performed with sutures.

HEALING BY SECOND INTENTION

Healing by second intention may be a reasonable, or even preferable, consideration for select surgical defects, based on the size, depth, and location of the defect as well as an individual patient's preferences, comorbidities, and postoperative activities. It is important to counsel the patient regarding the expected duration of the healing process and appearance of a granulating wound during that time. Wounds for which healing by second intention may be considered include relatively small and superficial defects on concave surfaces of the face including

the nasal root, the temple, the preauricular region, the fossae and conchal bowl of the ear, the posterior helix, and the postauricular sulcus. It is important to consider the site of a defect and nearby free margins, such as the eyelid, nasal ala, or lip, which may be adversely affected by wound contraction that occurs during healing by second intention. This allows for anticipation and avoidance of potential functional impairment such as ectropion or eclabium. Defects on the scalp and superficial wounds on the trunk and extremities also may be suitable for healing by second intention.

POSTOPERATIVE CONSIDERATIONS

IMMEDIATE POSTOPERATIVE CARE

Upon completion of a surgical procedure, a pressure bandage should be applied to the surgical site and left intact for 24 to 48 hours. An effective pressure dressing minimizes risk of postoperative bleeding and typically consists of petrolatum jelly applied directly to the wound, a nonadherent dressing, and a layer of cotton, all held under tension by surgical tape. Verbal and written instructions regarding home wound care, appropriate activity restrictions, and signs and symptoms of hemorrhage and wound infection should be reviewed with and provided to the patient prior to discharge, along with physician contact information should any questions or concerns arise. Patients treated for cutaneous malignancy should be counseled regarding recommended time frame for followup and skin surveillance.

After removal of the pressure dressing, the wound should be gently cleansed with mild soap and water once to twice daily, followed by reapplication of petrolatum jelly and a nonadherent dressing. An occluded wound reepithelializes and heals more rapidly than a dry wound, and petrolatum serves as an inert, nontoxic, nonirritating, and nonsensitizing occlusive wound dressing.[24] Petrolatum is generally preferred to topical antibiotic ointments, which are associated with a significant risk of allergic contact dermatitis. It has been demonstrated that topical antibiotics are not superior to petrolatum in preventing wound infection. The nonadherent dressing serves to immobilize the wound and reduce the chance of wound dehiscence. Cleansing with a dilute acetic acid (vinegar) solution can be considered for wounds at sites prone to *Pseudomonas* infection, such as the ear. Hydrogen peroxide can be used to debride significantly crusted wounds; however, prolonged use of hydrogen peroxide can result in tissue toxicity and impair wound healing. Alternative wound dressings such as gauze, films, hydrocolloids, hydrogels, and alginates may be considered for wounds with higher than typical levels of drainage.

FOLLOWUP

Recommended timing of nonabsorbable suture removal is based upon anatomic site and relative tension across a surgical defect. Leaving sutures in place for a longer period of time allows for increased wound healing, including reepithelialization, and lowers the risk of wound dehiscence. However, reepithelialization occurring around an epidermal suture may result in the development of permanent suture track marks adjacent to the suture line. Therefore, a balance must be struck between function and cosmesis. Sutures are removed more quickly from wounds in anatomic areas with abundant circulation and minimal tension, such as on the head and neck. Sutures on the face and ears should typically be removed in 5 to 7 days, on the eyelids in 5 to 7 days, on the neck in 7 days, and on the scalp in 7 to 14 days. On anatomic sites such as the trunk and extremities where tension is higher, increasing risk of dehiscence, sutures are typically left in place for 10 to 14 days. For particularly high-tension closures, such as on the lower legs, sutures may be left in place for up to 21 days after the procedure.

COMPLICATIONS

COMPLICATIONS IN THE IMMEDIATE POSTOPERATIVE PERIOD

Infection: Despite meticulous aseptic preparation and procedural technique, wound infection may occasionally occur. The most common culprits in cutaneous surgery include *Streptococcus pyogenes* and *S. aureus*. *Streptococcus* infection typically occurs within 24 to 48 hours of surgery, and presents clinically as tender, expanding erythema around the surgery site. *Staphylococcus* infection often appears as erythema and purulent drainage at 2 to 5 days following surgery. Treatment of wound infection with cephalexin 500 mg by mouth 3 to 4 times daily is often a first-line approach. Doxycycline 100 mg by mouth twice daily may be considered in the setting of penicillin allergy or MRSA infection. Wound culture should be considered for speciation and antibiotic sensitivity studies should a wound infection not respond to typical first-line antibiotic agents.[25]

Less commonly, wound infection by *Mycobacterium* species, including *Mycobacterium fortuitum* and *Mycobacterium chelonae*, may occur following cutaneous surgery. It typically presents weeks after the time of surgery as pyogenic abscess formation with local erythema, induration, and sinus formation. These infections may also display sporotrichoid spread suggestive of local lymphatic dissemination.

Contact Dermatitis: Wound dressing with an ointment such as petrolatum jelly is typically recommended following cutaneous surgery. Alternatively, antibiotic ointments such as neomycin or bacitracin are

Figure 202-4 Contact dermatitis to antibiotic ointment near skin flap.

sometimes used; however, allergic contact dermatitis to the antibiotic component of these ointments is not uncommon (Fig. 202-4).[26] Physical examination will reveal bright-red erythema, edema, or vesiculation in the general distribution of application. Pruritus is more common than pain. Contact dermatitis also may be observed secondary to topical antiseptics, such as iodinates and chlorhexidine, or adhesives in bandage materials, which may be allergic or irritant in etiology.

Pain: Postoperative pain following cutaneous surgery is typically minimal and well-controlled with measures to reduce swelling, such as minimizing physical activity and icing the wound, and acetaminophen as an analgesic. Rarely, more significant pain may be experienced when surgery involves larger areas or a complex repair. In such instances, a short course of analgesics may be considered. Acetaminophen alternating with ibuprofen has shown similar efficacy to acetaminophen with codeine for postoperative pain relief after dermatologic surgical procedures.[27]

Bleeding and Hematoma Formation: Bleeding in the postoperative period may occur despite best efforts to obtain meticulous hemostasis. Epinephrine used as a component of local anesthesia acts as a vasoconstrictor and provides temporary hemostatic effect during and immediately following the procedure. However, increased bleeding may occur after epinephrine is metabolized. When postoperative bleeding occurs, the patient should be instructed to apply firm, continuous pressure at the site of bleeding in an attempt to obtain hemostasis. For a wound healing by second intention, isolation and hyfrecation of the focus of bleeding may be all that is necessary to obtain hemostasis.

Ongoing bleeding beneath a sutured wound may result in formation of a hematoma (Fig. 202-5A). Management of a hematoma depends on the time of detection. When identified within 24 hours of surgery, management typically consists of removal of the sutures necessary to expose the source of bleeding (Fig. 202-5B), followed by efforts to obtain hemostasis, whether by hyfrecation or ligation of an identifiable vessel, and finally by resuturing of the wound (Fig. 202-5C). Final cosmesis is typically unaltered (Fig. 202-5D). If a patient presents with a hematoma more than 24 hours following surgery, aspiration of the hematoma using a large-bore needle may be attempted to reduce swelling and facilitate wound healing. If the hematoma recurs, suture removal may be required to obtain hemostasis. Narrow excision of the wound edges followed by resuturing will improve outcome.

Necrosis: Tissue necrosis may occur following a dermatologic procedure if there is inadequate blood supply at the procedure site. This most commonly occurs in the setting of a skin graft or flap repair (Fig. 202-6); it is less often observed in the setting of a primary closure, unless extremely tight epidermal approximating sutures are placed.

Intrinsic factors associated with the procedure itself that may impact wound healing and increase the risk of tissue necrosis include excessive wound tension, hematoma formation, and infection. Skin graft necrosis and failure may occur in the setting of excessive skin graft thickness, which may result in inadequate nutrient supply to the tissue, or inadvertent shearing forces or trauma to the graft. Partial or complete flap necrosis may occur due to incorrect flap design resulting in a pedicle of insufficient size to provide the required vascular supply, a flap that is too thin, excessive kinking of a flap, or excessive tension at the flap's leading edge, which may compromise its vascular supply.

Extrinsic factors that may contribute to the development of tissue necrosis in the postoperative period include impaired vascular or cardiac function, history of radiation to the involved skin, poorly-controlled diabetes, and smoking. As previously discussed, smoking tobacco and nicotine use may impair wound healing by causing vasoconstriction and decreasing vascular supply to the wound.

Dehiscence: Wound dehiscence may occur in the setting of primary wound closure under high tension, or if wound healing is complicated by infection or tissue necrosis. If dehiscence occurs within 24 hours of suture placement, resuturing of the wound may be performed without modification of the wound edge. However, if wound dehiscence occurs greater than 48 hours after initial wound closure, excision of approximately 1 mm of normal skin at the wound edge should be performed prior to resuturing the wound. If wound dehiscence occurs in the setting of infection or tissue necrosis, healing by second intention rather than resuturing the wound may be preferable. Leaving epidermal sutures in place for 2 to 3 weeks prior to suture removal may minimize the risk of wound dehiscence at anatomic sites of high wound tension, such as the back, and sites with relatively slow wound healing, such as the lower leg.

COMPLICATIONS IN THE DISTANT POSTOPERATIVE PERIOD

Milia or Keratinous Cysts: Milia cysts sometimes develop within or adjacent to a suture line

Figure 202-5 **A,** Swelling of right upper lip 2 hours after a skin flap procedure. **B,** Flap unsutured, exposing blood coagulated below. Arteriole bleeder found and tied off. **C,** Flap immediately resutured. **D,** Healed flap 3 months later.

following cutaneous surgery. They can be removed with needle incision and a comedone extractor. If a cystic lesion is not easily removed or recurs, biopsy should be considered to rule out skin cancer recurrence.

Suture Track Marks: Suture track marks can occur when suture material cuts into tissue because of tension or remains in place long enough to allow reepithelialization (Fig. 202-7A). Wound edge

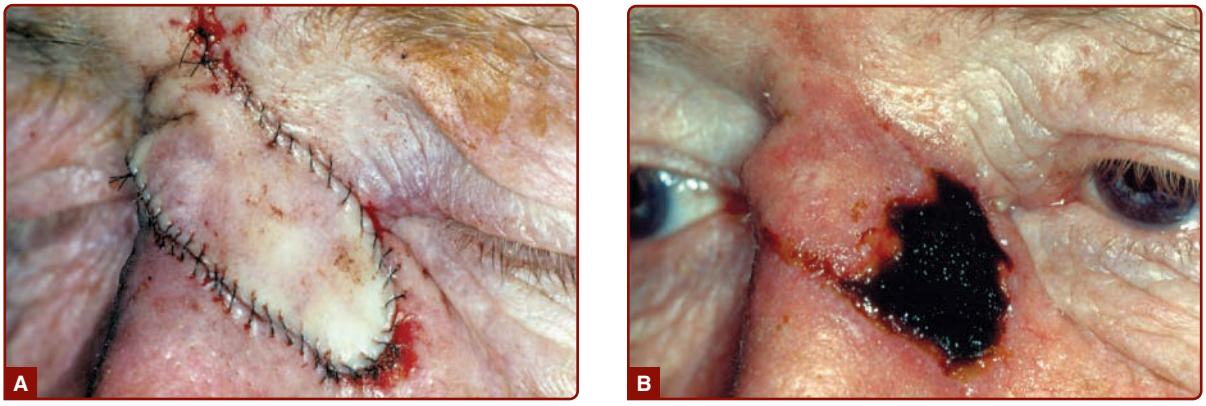

Figure 202-6 **A,** Flap from glabella to left dorsal nose. **B,** Necrosis in flap 1 week postoperatively.

approximation with polypropylene, which possesses plasticity after being stretched and reduces the risk of suture cutting into swollen tissue. The risk of track mark formation can be reduced by using an alternative suturing method such as a running suture, which evenly distributes tension along the wound length, or a running intradermal subcuticular suture. Dermabrasion can be used within 1 to 2 months of suture track formation to ameliorate the appearance (Fig. 202-7B and C).

Scar Formation: Scarring is an expected outcome that should be discussed with patients prior to any surgical procedure. Some scars require intervention to improve the cosmetic and functional outcome. These may include hypertrophic and keloid scars, depressed or furrow-like scars, and spread scars.

Hypertrophic scars are characterized by an elevated or thickened scar that is confined within the boundaries of the original defect (Fig. 202-8A). Anatomic sites with higher levels of tension, such as the upper trunk, shoulders, and upper arms, are more likely to develop hypertrophic scars. Keloid scars differ from hypertrophic scars in that they consist of expansile scar development with finger-like projections beyond the original wound boundaries (Fig. 202-9). Keloid scar formation is more common among patients with Fitzpatrick skin phototypes III to VI. Table 202-7 outlines key differences between hypertrophic and keloid scars. Hypertrophic and keloid scars may improve with intralesional triamcinolone acetonide injection, typically at a starting concentration of 10 mg/mL with dose increases up to 40 mg/mL as needed (Fig. 202-8B). Application of silicone gel or gel sheeting may result in reduced scar thickness and improvement in scar erythema; however, the available evidence is limited.[28] Additional treatment modalities with variable efficacy include surgical excision, intralesional 5-flourouracil or interferon-α, cryosurgery, radiotherapy, and laser therapy.[29,30]

Anatomic sites with an abundance of sebaceous glands, such as the nasal tip, are at increased risk of tissue tearing and separation at the wound edge,

Figure 202-7 **A,** Suture track marks around forehead scar. **B,** Dermabrasion of scar at 5 weeks after being sutured. **C,** Healed scar 2 months later. Suture track marks have disappeared.

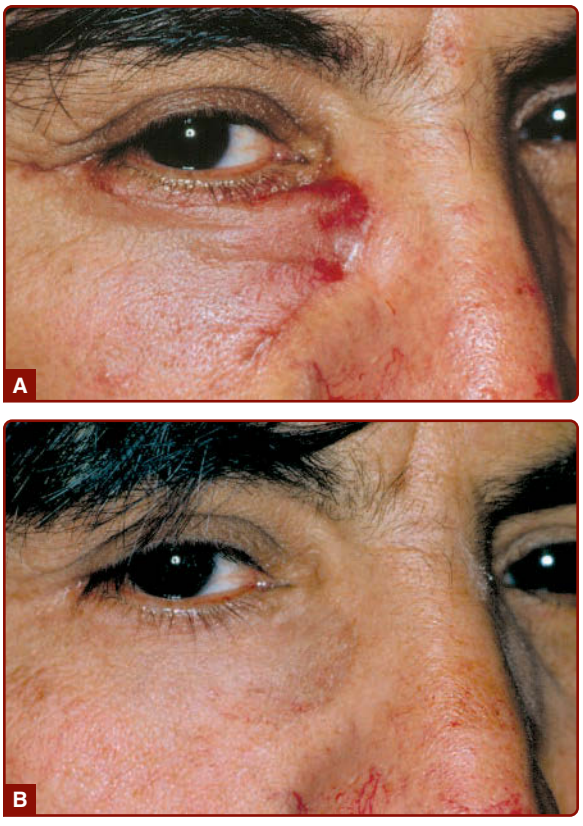

Figure 202-8 **A,** Hypertrophic flap on right nose and cheek. Treated with intralesional triamcinolone acetonide, 10 mg/mL. **B,** Flap 2 months later.

Figure 202-9 Keloid of earlobe and posterior auricular sulcus. Patient underwent an ear pinning procedure.

resulting in the development of a depressed or furrow-like scar. A depressed scar may be excised with undermining of the fresh wound edges and resutured with buried sutures and placement of vertical or horizontal mattress sutures. Sutures with a 5-0 USP designation or larger diameter should be used to appropriately evert the wound edges and minimize the risk of developing another depressed scar.

Spread, or widened, scars may occur when there is significant tension along a wound edge. Closure of wounds on anatomic sites of high tension, such as the scalp, upper trunk, shoulders, and upper arms, may predispose to spread scars.

TABLE 202-7
Comparison of Hypertrophic Scar and Keloid

	HYPERTROPHIC SCAR	KELOID
Incidence	Common	Uncommon
Race	All	Usually Fitzpatrick skin phototypes III to VI
Preceding injury	Yes	Sometimes
Location	Anywhere, especially perpendicular to maximal skin tension lines on the upper trunk, shoulders, and upper arms	Common at earlobes and trunk; rare on the central face
Growth	Within initial wound boundaries	Beyond initial wound boundaries
Improves with time	Typically	Typically not
Recurs with excision	Typically not	Typically

Buried Suture Extrusion ("Spitting Suture"): Buried, dissolvable sutures are not uncommonly observed to extrude through the sutured wound edge around 3 to 4 weeks following surgery, resulting in localized erythema, swelling, and sometimes sterile pustule formation. The partially-extruded suture material can be clipped at the wound edge, followed by gentle drainage of purulent material that may be present.

Erythema and Telangiectasia: Wound erythema is expected and generally improves within 3 to 12 months with appropriate photoprotection with broad-spectrum sunscreen or photoprotective barrier. Sun exposure may result in prolonged wound erythema or hyperpigmentation of a scar, particularly in individuals with darker skin types.

Telangiectasia formation adjacent to a sutured wound or associated with a flap or graft commonly occurs, perhaps more so in women secondary to estrogenic effects, and typically improves over time. If erythema or telangiectasia are cosmetically bothersome to the patient, a vascular laser, such as a 585-nm to 595-nm pulsed-dye laser or 532-nm potassium-titanyl-phosphate (KTP) laser, may be used to expedite the resolution of the erythema.

Hypopigmentation: Hypopigmentation of scars may occur as initial erythema gradually resolves. Hypopigmentation of skin grafts also may be observed. Scar hypopigmentation may be particularly noticeable if contrasted against a background of erythema in the setting of rosacea. If desired, laser treatment of erythema can soften the contrast and improve cosmesis.

Sensory Anesthesia: Sensory anesthesia at the site of cutaneous surgery is common, particularly following a flap or graft repair. It is typically self limited, often with complete resolution within 3 to 18 months, depending on the size and location of surgery. Notably, if one transects the supraorbital nerve while operating on the forehead, diminished or absent sensation to the central upper eyelid, ipsilateral forehead, and scalp may result. Additionally, if the greater auricular nerve is severed while operating at the Erb point on the lateral neck, potentially permanent anesthesia of the inferior aspect of the ipsilateral ear may result.

Motor Function Loss: Brief motor loss of facial muscles resulting from temporary anesthesia effects on superficial motor nerves, such as the temporal or marginal mandibular branches of the facial nerve, may be observed at the time of surgery, and should be discussed with the patient prior to performing a surgical procedure in these regions. Permanent motor loss may occur when nerve branches are transected during surgery. Diligent and careful surgical technique should be employed when operating in the region of the temporal or marginal mandibular branches of the facial nerve, as well as the spinal accessory nerve, to avoid this undesirable complication.

REFERENCES

1. Roenigk RK. Dermatologists perform more skin surgery than any other specialist: implications for health care policy, graduate and continuing medical education. *Dermatol Surg.* 2008;34(3):293-300.
2. Wilson W, Taubert KA, Gewitz M, et al. Prevention of infective endocarditis: guidelines from the American Heart Association: a guideline from the American Heart Association Rheumatic Fever, Endocarditis and Kawasaki Disease Committee, Council on Cardiovascular Disease in the Young, and the Council on Clinical Cardiology, Council on Cardiovascular Surgery and Anesthesia, and the Quality of Care and Outcomes Research Interdisciplinary Working Group. *J Am Dent Assoc.* 2007;138(6):739-745, 747-760.
3. Watters W 3rd, Rethman MP, Hanson NB, et al. Prevention of orthopaedic implant infection in patients undergoing dental procedures. *J Am Acad Orthop Surg.* 2013;21(3):180-189.
4. Safdar N, Bradley EA. The risk of infection after nasal colonization with *Staphylococcus aureus*. *Am J Med.* 2008; 121(4):310-315.
5. Jones JC, Rogers TJ, Brookmeyer P, et al. Mupirocin resistance in patients colonized with methicillin-resistant Staphylococcus aureus in a surgical intensive care unit. *Clin Infect Dis.* 2007;45(5):541-547.
6. Zoumalan RA, Rosenberg DB. Methicillin-resistant *Staphylococcus aureus*–positive surgical site infections in face-lift surgery. *Arch Facial Plast Surg.* 2008; 10(2):116-123.
7. Weyer C, Siegle RJ, Eng GG. Investigation of hyfrecators and their in vitro interference with implantable cardiac devices. *Dermatol Surg.* 2012;38(11):1843-1848.
8. Voutsalath MA, Bichakjian CK, Pelosi F, et al. Electrosurgery and implantable electronic devices: review and implications for office-based procedures. *Dermatol Surg.* 2011;37(7):889-899.
9. Chang TW, Arpey CJ, Baum CL, et al. Complications with new oral anticoagulants dabigatran and rivaroxaban in cutaneous surgery. *Dermatol Surg.* 2015;41(7):784-793.
10. Alam M, Goldberg LH. Serious adverse vascular events associated with perioperative interruption of antiplatelet and anticoagulant therapy. *Dermatol Surg.* 2002;28(11):992-998; discussion 998.
11. Chang LK, Whitaker DC. The impact of herbal medicines on dermatologic surgery. *Dermatol Surg.* 2001; 27(8):759-763.
12. Sbitany H, Xu X, Hansen SL, et al. The effects of immunosuppressive medications on outcomes in microvascular free tissue transfer. *Plast Reconstr Surg.* 2014;133(4):552e-558e.
13. Sorensen LT. Wound healing and infection in surgery: the pathophysiological impact of smoking, smoking cessation, and nicotine replacement therapy: a systematic review. *Ann Surg.* 2012;255(6):1069-1079.
14. Davies CS, Ismail A. Nicotine has deleterious effects on wound healing through increased vasoconstriction. *BMJ.* 2016;353:i2709.
15. Aitken J, Williams FL. A systematic review of thyroid dysfunction in preterm neonates exposed to topical iodine. *Arch Dis Child Fetal Neonatal Ed.* 2014; 99(1):F21-F28.
16. Richards KA, Stasko T. Dermatologic surgery and the pregnant patient. *Dermatol Surg.* 2002;28(3):248-256.
17. Sweeney SM, Maloney ME. Pregnancy and dermatologic surgery. *Dermatol Clin.* 2006;24(2):205-214, vi.
18. Becker DE, Reed KL. Essentials of local anesthetic pharmacology. *Anesth Prog.* 2006;53(3):98-108; quiz 109-110.
19. Martires KJ, Malbasa CL, Bordeaux JS. A randomized controlled crossover trial: lidocaine injected at a 90-degree angle causes less pain than lidocaine injected at a 45-degree angle. *J Am Acad Dermatol.* 2011;65(6):1231-1233.
20. LaBerge L, Pratt M, Fong B, et al. A 10-year review of *p*-phenylenediamine allergy and related para-amino compounds at the Ottawa Patch Test Clinic. *Dermatitis.* 2011;22(6):332-334.
21. Tanner J, Norrie P, Melen K. Preoperative hair removal to reduce surgical site infection. *Cochrane Database Syst Rev.* 2011(11):CD004122.
22. Darouiche RO, Wall MJ Jr, Itani KM, et al. Chlorhexidine-alcohol versus povidone-iodine for surgical-site antisepsis. *N Engl J Med.* 2010;362(1):18-26.
23. Kandel EF, Bennett RG. The effect of stitch type on flap tip blood flow. *J Am Acad Dermatol.* 2001;44(2):265-272.
24. Winter GD, Scales JT. Effect of air drying and dressings on the surface of a wound. *Nature.* 1963;197:91-92.
25. Hutcheson AC, Lang PG. Atypical mycobacterial infections following cutaneous surgery. *Dermatol Surg.* 2007;33(1):109-113.
26. Alavi A, Sibbald RG, Ladizinski B, et al. Wound-related allergic/irritant contact dermatitis. *Adv Skin Wound Care.* 2016;29(6):278-286.
27. Sniezek PJ, Brodland DG, Zitelli JA. A randomized controlled trial comparing acetaminophen, acetaminophen and ibuprofen, and acetaminophen and codeine for postoperative pain relief after Mohs surgery and cutaneous reconstruction. *Dermatol Surg.* 2011;37(7): 1007-1013.
28. O'Brien L, Jones DJ. Silicone gel sheeting for preventing and treating hypertrophic and keloid scars. *Cochrane Database Syst Rev.* 2013(9):CD003826.
29. Gold MH, Berman B, Clementoni MT, et al. Updated international clinical recommendations on scar management: part 1—evaluating the evidence. *Dermatol Surg.* 2014;40(8):817-824.
30. Gold MH, McGuire M, Mustoe TA, et al. Updated international clinical recommendations on scar management: part 2—algorithms for scar prevention and treatment. *Dermatol Surg.* 2014;40(8):825-831.

Chapter 203 :: Excisional Surgery and Repair, Flaps, and Grafts

:: Adele Haimovic, Jessica M. Sheehan, & Thomas E. Rohrer

AT-A-GLANCE

- Excisional surgery is one of the most common surgical procedures in dermatology.
- The goal of excisional surgery is to remove the lesion with appropriate margins and obtain the best cosmetic result.
- The planning and execution of dermatologic surgery procedures must balance risk and benefit and consider all options to achieve an optimal outcome. Wounds should be closed under minimal tension, with scars placed along cosmetic unit junctions or skin tension lines, contained within as few single cosmetic units as possible, without distorting critical anatomic structures and landmarks.
- The closure must preserve sensory and motor nerve function.
- An elliptical or fusiform excision is the fundamental procedure in dermatologic surgery and typically allows for a linear, side-to-side closure.
- Flap or graft repair may be considered when linear closure is not feasible.
- Flaps are commonly classified according to their primary movement as advancement, rotation, transposition, or interpolation.
- The 3 basic types of skin grafts are full-thickness, split-thickness, and composite.

BACKGROUND

The goal of any excisional surgery is to remove the lesion with appropriate margins and leave the least noticeable scar possible. To consistently attain aesthetically pleasing results, time must be taken long before the first incision to appropriately plan the procedure. Although excisional surgery is as much an art form as it is a science, there are many principles to keep in mind when planning the surgical excision and closure. Wounds should be closed under minimal tension, with scars placed along cosmetic unit junctions or skin tension lines, without distorting critical anatomic structures and landmarks (eyelid, eyebrow, nose, lip, hairline, etc). Biologically, the closure must be such that the mobilized skin and associated adnexal structures are viable, and there is maximal preservation of sensory and motor nerve function.

Knowledge of underlying anatomy is critical in both the design and execution of the excision (Chap. 201).

The planning and execution of dermatologic surgery procedures varies from case to case. A skilled surgeon evaluates the risks and benefits of various options in each patient and anticipates potential complications. The main risks of excisional surgery include pain and discomfort, bleeding, bruising, hematoma formation, nerve damage, wound infection, wound dehiscence, and undesirable scar or contracture. Key elements of dermatologic surgery procedures include proper patient selection and preparation; comprehension of risks and necessary precautions; obtaining effective local anesthesia; use of sterile or clean technique; informed procedure design and meticulous technique in performing the incision and repair; diligent postoperative wound care and patient education (Chap. 202).

EQUIPMENT

Prior to surgery, it is essential to have all the necessary instruments and equipment available and set up in an organized, accessible, and safe manner.

PROCEDURE ROOM

- Basic: mechanical table, powerful overhead procedure lights, electrocautery, vital signs monitor, Mayo stand (1 or 2), receptacle for contaminated waste, and a sharps container.
- Optional: depending on the location and scope of the procedure, suction may be needed.

SURGICAL TRAY

The specific instruments selected depend on the scope of the procedure and personal preference of the surgeon. It is helpful to set up the basic elements on the tray in the same layout each time. Consistency in placement of sharps prevents inadvertent injury with contaminated instruments to the surgeon or the assistant.

A basic excisional surgery tray (Fig. 203-1) contains:

- Instruments: curette, No. 3 or No. 7 Bard-Parker scalpel handle with a No. 15 or No. 10 blade or Beaver blade, small forceps (eg, Bishop-Harmon) and/or smooth-toothed Adson forceps, delicate standard

Figure 203-1 Surgical tray: a surgical tray should be equipped with high-quality delicate instruments. This tray has a scalpel, small skin hook, Bishop Harmon forceps, larger Adson forceps, 5-mm curette, curved iris scissors, blunt curved Metzenbaum scissors, delicate needle holder, suture scissors, gauze, and cotton-tipped applicators.

skin hook or double-prong skin hook, curved iris scissors, blunt-tipped undermining scissors, hemostat, towel clamps, needle holder, suture scissors. For larger procedures, such as flaps, additional hemostats or hooks may be needed. Special procedures will need other instruments added to this tray (eg, split-thickness skin grafts require a dermatome).

- Disposable material: marking pen, gauze sponges, cotton tip applicator sticks, scratch pad for electrocautery tip, electrocautery hand piece and tip, surgical drapes, foam or magnetic pad for discarded needles
- Suture: Proper suture selection is critical for optimal wound healing and aesthetic result (Chap. 202).

EXCISIONAL SURGERY

ELLIPTICAL EXCISION

Excisional surgery is one of the most frequently performed dermatologic surgery procedures. The elliptical or fusiform excision allows for a linear, side-to-side closure. The commonly referred to elliptical excision is actually fusiform in shape as the edges are pointed and not rounded as in a true ellipse.[1] Mastery of elliptical excision and closure is fundamental to more advanced procedures, including variations on the ellipse itself and planning and executing more complex flaps. An elliptical excision is indicated for the removal of small- to moderate-sized benign or malignant neoplasms as well as for excisional biopsy and scar revision.

PLANNING THE ELLIPSE

In planning the excision, the lesion to be excised must first be identified and confirmed by the patient. Using an appropriate marker, a circle is drawn around the lesion with the appropriate margins. The size of the surgical margin is dependent on the nature of the lesion.[2]

Once the margins of the lesion have been marked, the ellipse is planned. When planning a fusiform excision with linear closure, one must consider several factors, including the impact of the procedure on form and function. In addition to ensuring that an adequate reservoir of surrounding tissue or skin laxity is present, the surgeon must take great care to preserve free margins, minimize tension, and maintain skin contour.[3]

FREE MARGINS

Free margins, such as the eyelid margin, alar rim, and lip vermillion are of primary concern as they provide minimal to no opposition to the tension created from nearby tissue movement. Any distortion of a free margin will be aesthetically unacceptable and may even impact function. To prevent distortion, closures should be planned such that tension vectors are perpendicular to free margins.

RELAXED SKIN TENSION LINES

For optimal cosmetic results and maximum scar strength, the long axis of the fusiform excision should be oriented along relaxed skin tension lines.[4] Relaxed skin tension lines are generally perpendicular to the direction of the pull of the underlying muscle (Fig. 203-2). These lines should be identified while the

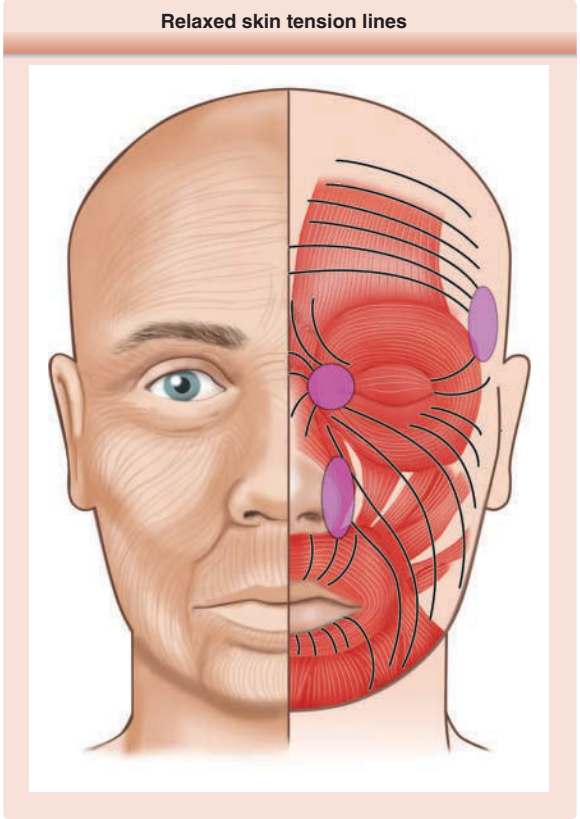

Figure 203-2 Relaxed skin tension lines. Relaxed skin tension lines generally form perpendicular to underlying muscles of facial expression. Closure lines heal better and with a thinner, less noticeable scar when placed in relaxed skin tension lines.

patient is sitting upright, and may be highlighted by asking the patient to make certain facial expressions. If the relaxed skin tension lines are not obvious, the direction of laxity may be identified by manipulating tissue manually. Relaxed skin tension lines rarely follow published diagrams, and closures should mimic the subtle arcs in the facial lines of expression.

COSMETIC UNITS

When possible, excisions should be restricted to one of the major cosmetic units. Within each cosmetic unit the skin shares a common color, thickness, texture, sebaceous quality and hair density. The major cosmetic units of the face include the forehead, periorbital area, nose, lips and perioral area, chin, and cheeks and can be further divided into smaller subunits (Fig. 203-3). Placing the incision line at the junction of the cosmetic units, or contour lines, also minimizes the appearance of the resultant scar as it will be hidden in a natural transition zone where the eye expects to see a change.[5]

When the elliptical excision and closure cannot include these conditions consideration must be given to other forms of repair such as flaps, grafts, partial purse sting closures, or healing by second intention.

The simple ellipse is based on an optimal length-to-width ratio of 3.5:1 to minimize the formation of redundant tissue at the apices, otherwise known as "dog-ears" or "standing tri-cones." The ratio may be increased to 4:1 or greater in locations with less tissue distensibility and in convex surfaces. Likewise, it may be decreased to 3:1 or less in concave surfaces or in areas where the tissue is more lax and a lower tendency to produce cones.[3] The apical angle between the 2 arciform incisions ranges from 37° to 74°, depending on the length-to-width ratio.[6] As the ratio becomes larger, the apical angle decreases; thus, for a ratio of 5:1, which may be needed for scalp surgery, the apical angle approaches 30° (Fig. 203-4). Standing cones will form if the sides of the closure are of unequal length, with redundant tissue developing on the longer side.

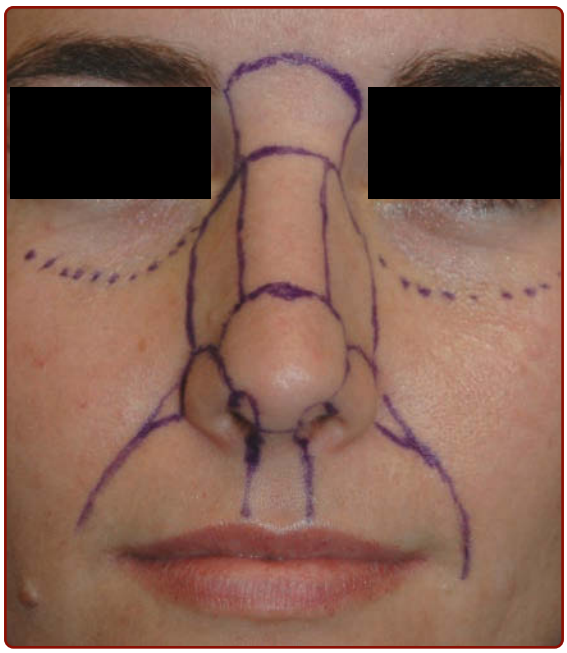

Figure 203-3 Cosmetic units. The face can be divided into many cosmetic units. The cosmetic units are differentiated from each other by alterations in skin texture, color, or contour. Incisions hide very well when placed in cosmetic unit junctions.

Figure 203-4 Acute apical angle. Certain areas such as the convex surface of an extremity or the nasal dorsum require a length-to-width ratio greater than 3:1.

It is important to note that as a wound is closed in a linear fashion, the length of the resultant scar will be longer than the distance between the 2 distal points drawn out in the preoperative design of the ellipse. The arc of the 2 sides of the closure that are brought together is necessarily longer than a straight line drawn between the distal points of the ellipse. Mathematically, with the angles used in excisional surgery, the arcs are roughly 20% longer than the straight line drawn down the middle of the ellipse. In most cases this becomes irrelevant as there is contraction along the long axis of a scar and the tissue around the closure distends and absorbs this small difference without any noticeable distortion. In areas such as the upper lip, however, this small difference may be enough to distort the lip margin inferiorly and be disfiguring. Lengthening the elliptical closure to bring it around the lip past the wet mucosal margin will often help hide this potential distortion.

TECHNIQUE

After the ellipse is planned and drawn, the field is anesthetized, prepped, draped, and the first incision is made using a scalpel (Fig. 203-5). In most instances, a No. 15 blade is used to score the epidermis or to cut through to the fat on the first pass; however, thick back skin may require the use of a No. 10 blade. The surgery begins with the point of the blade at the apex distal from the surgeon's position. As the incision progresses toward the arc of the ellipse, the belly of the blade is held perpendicular to the skin surface, preventing a beveled incision. As the opposite apex of the incision is

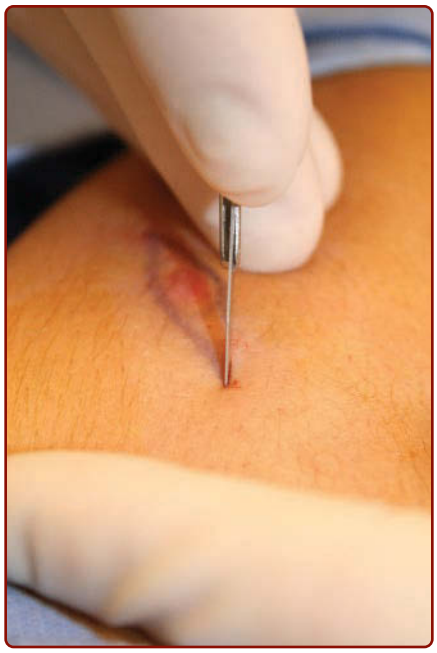

Figure 203-5 Incision. Incisions should be made 90° (perpendicular) to the skin surface and continued down through the dermis into the subcutaneous tissue.

approached, the blade rocks back up onto its tip, which allows the surgeon to clearly see the apex of the incision under the advancing hand. This prevents extending the incision beyond the planned apex. To prevent bunching of the tissue ahead of the pressure exerted by the blade, traction on the surrounding skin is held with the nondominant hand; in addition, an assistant may aid with traction. The depth of the excision is, again, dependent on the nature of the neoplasm being excised. When a side-to-side closure is planned, the depth of the incision must be full thickness into the superficial subcutaneous fat. The proximal apex of the ellipse is grasped gently with a toothed forceps or skin hooks to elevate the tissue. The base of the specimen is dissected in an even plane with a scalpel or scissors. The depth at the apices should be the same as the depth at the center; there is a tendency to remove the specimen with the depth at the apices more superficially. When the depth of the excision is not uniform, a more noticeable standing cone of tissue may surround the tips as the wound is closed.

CLOSURE

Undermining is performed to increase mobility of the surrounding tissue, aid in wound eversion, decrease tension on the wound edges, and diffuse scar contraction.[7] The subcutaneous tissue is undermined at the same level around all edges of the wound, including the apices, utilizing iris or blunt-tipped scissors. The tissue may be snipped or bluntly dissected by inserting the tip of the scissors and spreading. Electrosurgery is a common undermining technique performed in other surgical subspecialties. The plane of undermining will vary depending on body site but should be uniform in depth at all edges (Chap. 201). Knowledge of anatomy is extremely important and careful attention must be given to surrounding vital structures.

Although undermining is critical for dermatologic surgery, there are risks associated with extensive undermining. Such risks include but are not limited to inadvertent damage to structures such as nerves and vessels, vascular compromise for flaps, and the creation of large dead spaces with an increased chance for hematoma or seroma development.[8] Patients receiving anticoagulants or with reduced platelet number or function may benefit by limiting the extent of undermining as the risk of bleeding and hematoma formation is decreased.

Electrocoagulation or electrocautery is employed to attain meticulous hemostasis of the bed of the wound. A skin hook is used to gently elevate the wound edges to expose vessels injured during the excision or undermining. Blood that accumulates in the wound must be cleared with gauze or cotton swabs to allow for visualization of pinpoint bleeding and to allow for a relatively dry field. The cautery tip may be applied directly to the vessel until bleeding ceases. Alternatively, indirect coagulation is achieved using small forceps to grasp the vessel and applying the cautery tip to the forceps. Indirect cautery limits the residual thermal damage surrounding the cauterization and may speed wound healing and reduce the risk of infection. No matter which method is used, care should be taken to stop all significant bleeding while minimizing cautery char. Larger, more high-pressured arteries can require ligation with absorbable suture.

Suturing technique (Chap. 202) reduces and redistributes wound tension, everts the skin edge, eliminates dead space, and maintains or restores natural anatomic contours, while minimizing the formation of permanent suture marks on the skin surface. Most wounds are closed in 2 layers: (1) absorbable deep sutures and (2) nonabsorbable superficial sutures. Deeper wounds or those with significant dead space may benefit from a third, deep layer in the subcutaneous fat or fascia.

Ideally, the wound is closed by first placing the deep sutures using the rule of halves to minimize the formation of dog-ears (Fig. 203-6). The first suture is placed in the center of the wound. Each half of the remaining defect is closed in a similar manner, which is repeated until a suitable numbers of sutures have been placed. A wound gains only 7% of its final strength after 2 weeks.[9] As most skin sutures are removed within 1 to 2 weeks of placement, absorbable buried sutures are an important part of a layered wound closure.[10] Buried sutures typically dissolve over the course of months and provide support for the wound until epidermal tensile strength has increased sufficiently to prevent wound dehiscence.

Buried vertical-mattress sutures mechanically aid significantly in wound eversion and in doing so reduce or eliminate tension on the wound edge and produce thinner less noticeable scars (Fig. 203-7). This type of buried suture should be used in nearly all closures.

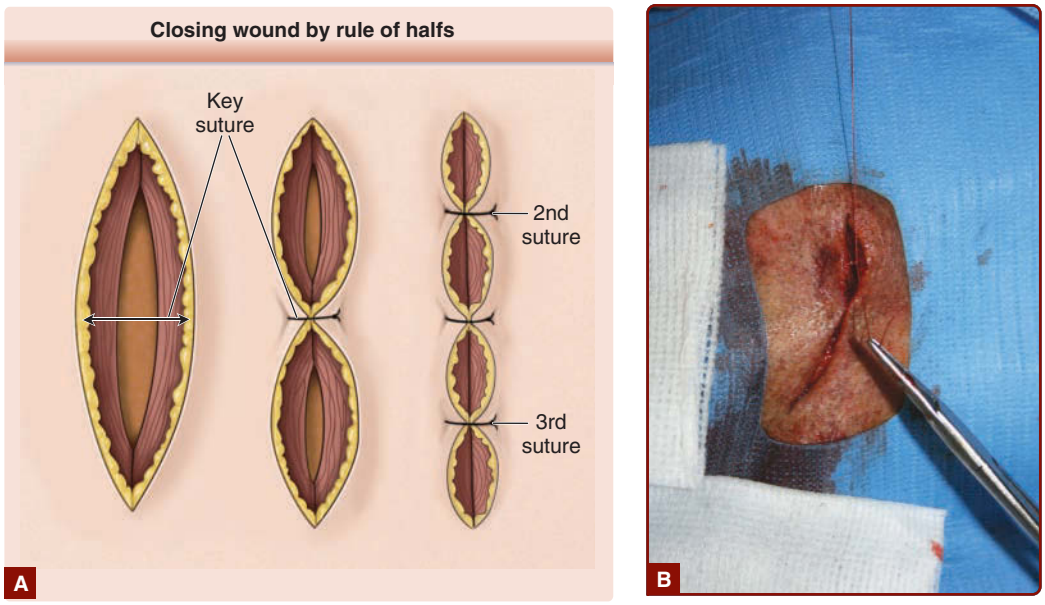

Figure 203-6 **A** and **B,** Closing wound by rule of halves. Sutures are placed at the midpoint of any open area of the defect.

Subcutaneous sutures help minimize or eliminate dead space and align deep structures such as skeletal muscle or fascia. They also can be used to anchor overlying tissue to underlying fixed structures, such as periosteum, to prevent distortion of free margins or maintain proper facial contour and function. This is exemplified by anchoring a melolabial flap to the maxillary periosteum. When tying a buried suture, it is important not only to keep both free ends of the suture on the same side of the loop created, but also to tie the suture in such a manner that draws the knot down on the same side so it will tuck up under the loop and not get hung up on it (Fig. 203-8). Buried sutures should align the wound edges such that they are perfectly approximated with good wound eversion before the placement of epidermal sutures.

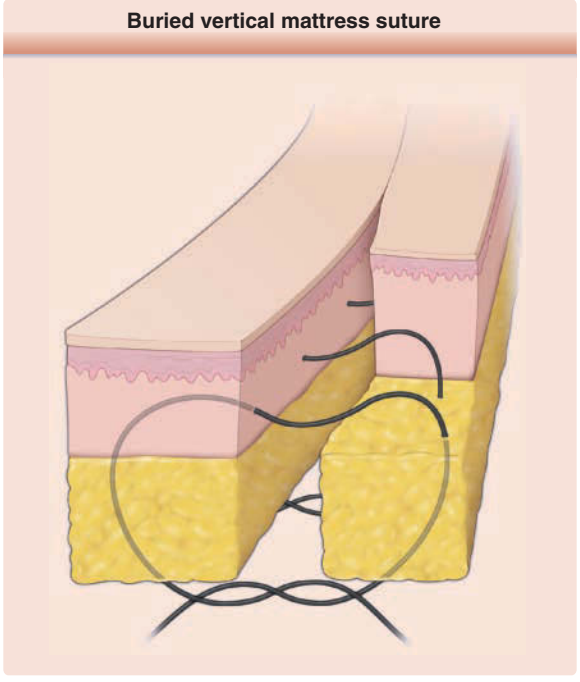

Figure 203-7 Buried vertical mattress suture. The buried vertical mattress suture gives excellent eversion to the wound edge and should be used for most if not all subcutaneous sutures.

Epidermal sutures are placed to approximate the margins of the skin edge. They should be evenly spaced and placed at roughly the same distance from the wound edge as the combined dermal–epidermal depth. Therefore, sutures placed on the eyelid will be much closer together than those placed on the thick skin of the back. Most practitioners use a running nonabsorbable minimally reactive monofilament suture, such as polypropylene or nylon, that requires subsequent removal.[11] Alternatives include running absorbable fast-acting gut,[12] absorbable or nonabsorbable running subcuticular sutures,[13] simple interrupted nonabsorbable sutures, and polymethylmethacrylate tissue glue. Simple interrupted sutures are more time-consuming to place and remove than a running suture. In settings where wound healing may be impaired due to the patient's advanced age or underlying disease, interrupted sutures may be preferred, as interrupted sutures may have, with all other factors being equal, greater tensile strength and less potential to pull through thin skin or impair microcirculation.[14]

SUTURE REMOVAL

The risk of crosshatch marks across the suture line can be minimized by removing the sutures within a week of placement, before the formation of epithelial suture tracks. On the face and ears, most skin sutures are removed within 5 to 7 days. Neck sutures should be

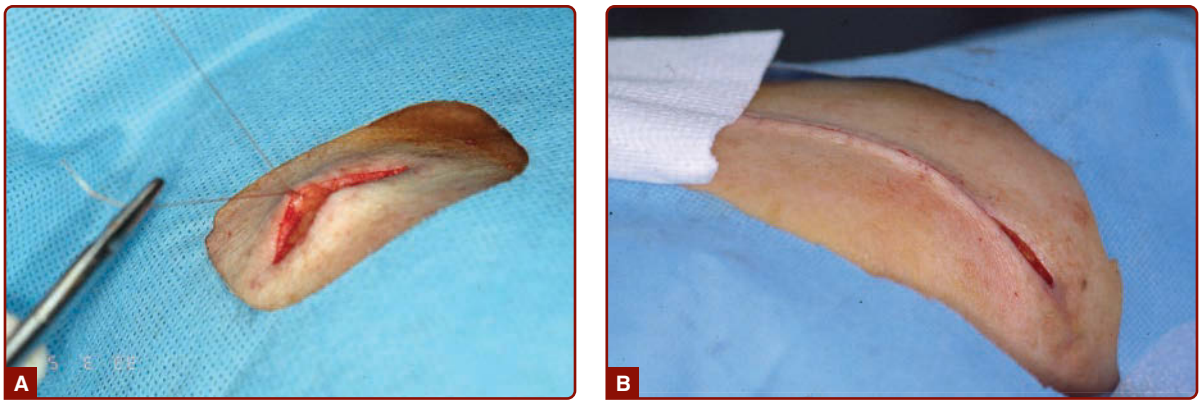

Figure 203-8 **A** and **B,** Tying deep sutures. When tying the knot, it is important to keep the 2 free ends on the same side of loop. The needle driver should be placed between the 2 free ends in the center of the wound. The loose end with the needle is then wrapped around the head of the needle driver and a knot is formed. Keeping the free ends on the same side of the loop will allow the knot to slip under the loop and draw the wound edges together. The wound should be together with skin edges nicely opposed and everted.

removed in 7 days and scalp sutures in 7 to 10 days. On the trunk and extremities, risk of wound dehiscence mandates that epidermal sutures may be left in place longer, typically 10 to 14 days, to provide additional support. In repairs under high tension or when dehiscence is likely, sutures may be left in place for 3 to 4 additional days. However, if sufficient buried sutures have been placed and the wound is well approximated at 7 to 10 days, epidermal sutures may be removed. The use of a running subcuticular suture for well-approximated wounds will prevent the formation of suture tracks and should be used in most cases that require sutures be left in for more than 7 days.

REVISION OF STANDING CONES OF TISSUE

Under certain circumstances, a circular excision may be performed when the orientation of the ellipse is difficult to anticipate. This may occur when the precise direction of relaxed skin tension lines and least tension is difficult to determine, when the length of the ellipse for an optimal outcome is unclear, or when alternative repairs may be considered, such as a local flap. Nonelliptical defects require revision of the cones or dog-ears. First, the wound is closed with a few centrally placed sutures; bilateral standing cones of excess tissue form on either side of the central closure. In addition, tissue redundancies may persist at one or both ends of a planned fusiform excision if the apical angle is too wide, if the sides are of unequal lengths, or on convex surfaces and the techniques for addressing these redundancies are similar under both clinical circumstances. Skillful repair of the redundant standing cones extend the incision line by removing an additional triangle of tissue at the tip (Fig. 203-9). The apex of the standing cone is lifted with forceps or a skin hook and manipulated to determine where to place the incision that releases the redundant tissue. The incision is made with a scalpel and the dog-ear is undermined. The free end of the cone is pulled over the incision and the remaining incision is made such that the resultant wound edges lie flat. The freed cone is termed a *Burow's triangle*. This technique results in a linear extension of the scar. Variations on the revision of tissue cones include a curved extension, an angled extension, and an M-plasty.

VARIATIONS OF THE ELLIPSE

RHOMBIC/TANGENT-TO-CIRCLE EXCISION

In a traditional fusiform excision, the lines connecting the 2 ends are curved. However, in a rhombic or tangent-to-circle excision, straight lines radiating in opposite directions connect the tips. This leads to the formation of 2 triangles that enclose the defect and form a rhombic shape. The advantages are simpler design, easier excision for the surgeon, and removal of less healthy tissue. The main disadvantage is notching or a gap can develop in the center of the defect where the 2 triangles peak.[1]

CURVED ELLIPSE

The classic fusiform excision creates a linear scar. At times, it is aesthetically preferable to create a curvilinear scar. The curvilinear repair is useful on the cheek and around the chin. The curved ellipse is created by intentionally designing it with one side longer than the other. The wound is closed by the rule of halves.

S-PLASTY

An S-shaped repair is useful on convex surfaces such as the extremities where a linear repair may result in persistent standing cones or indentations. The tension

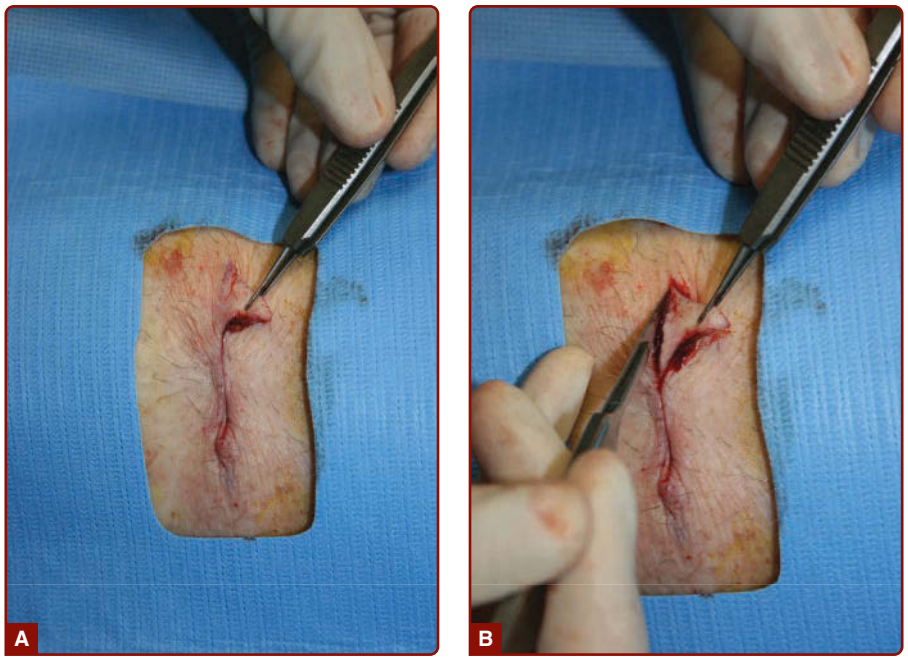

Figure 203-9 **A** and **B,** Standing cones. Redundant tissue may be removed by incising one side, draping the excess skin over the wound, and excising the resultant triangle.

vectors of a standard elliptical incision are perpendicular to the long axis of the ellipse. Because wounds contract along their long axis, designing the closure with an S-plasty displaces the tension over a greater length and a variety of angles (Fig. 203-10) and does not create a contracting in one direction with resulting indentation over a convex surface such as an extremity.

M-PLASTY

An M-plasty allows the length of a scar to be shortened. Rather than extending the end of an ellipse or removing a Burow's triangle, the redundant tissue may be excised inward, forming a M-shaped scar. The long axis of the incision is reduced by the length equivalent to the inverted triangle that makes the center of the M. This technique is useful for confining a scar to a single cosmetic unit or when an incision approaches a free margin. The scar may be camouflaged in locations where rhytides bifurcate, such as the crow's feet in the periorbital area or around the lips. It is important to advance the inverted triangle up into the rest of the ellipse to take full advantage of the scar-shortening effect. A half-buried horizontal mattress suture, also known as a tip stitch, may help prevent necrosis of the central tip.

PARTIAL CLOSURE

Partial closure is used when more extensive repairs are limited by lack of local tissue reservoirs or the patient's health or coagulation status. The wound is closed from the ends toward the center. When wound tension prevents further closure, the area remains open to heal by second intention. The final scar is usually linear and may resemble a spread scar in the middle. Alternatively, a purse-sting suture is placed around the wound and the tissue is drawn together circumferentially. The purse-string suture is closed just to the point of minimal tissue buckling. Additional guiding sutures may then be placed across the partially closed wound to attain better alignment and even further closure.

SERIAL EXCISION

In some cases, the length of an ellipse required to excise a lesion with a 3 or 4:1 ratio is too long for an acceptable cosmetic or functional outcome. In such instances, the lesion may be removed with a series of staged excisions. A partial excision is performed, ideally an ellipse that accommodates the full length of the lesion, with primary linear closure. During the following months, the surrounding tissue stretches and the tension in the area decreases. Additional excisions are performed in a similar manner, removing the remaining lesion as well as the scar or scars created from the first steps of the procedure. This is typically used to minimize the length of the final scar in large circumference neoplasms that are benign or low risk.

EXCISION WITHOUT CLOSURE

There are certain locations and situations where allowing a wound to heal by secondary intention is the preferred method of closure. Wounds in patients

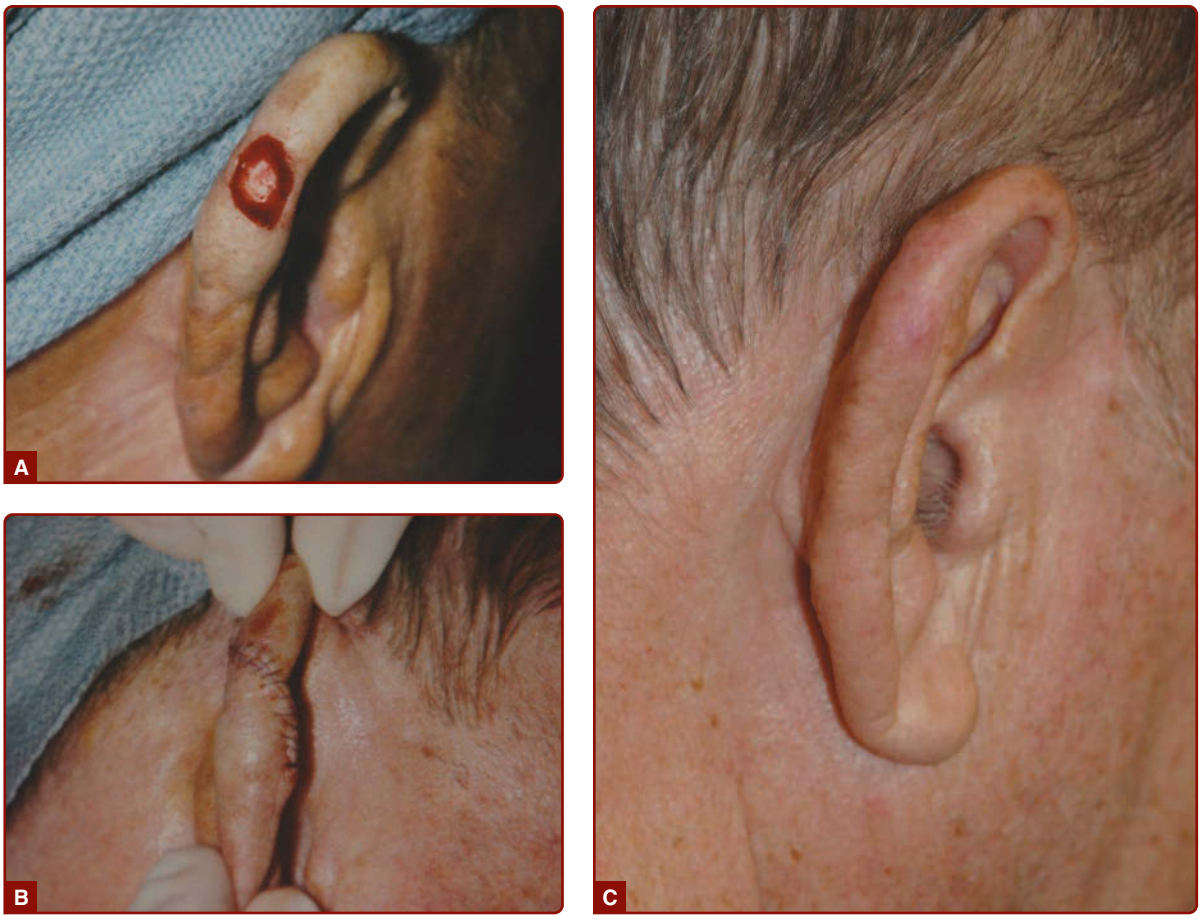

Figure 203-10 **A-C,** S-plasty closures are often used to give a wound a curvilinear line and to alter the tension vectors so they do not all pull along the long axis of the wound and cause noticeable contraction. The S-plasty is especially useful on convex surfaces where wound contraction may cause the scar to sink down and appear depressed.

who are poor surgical risks for reconstructive surgery, where there is relatively minimal tissue mobility (scalp, distal lower extremities), where there is a high risk of infection, or when the patient requests minimal down-time healing by secondary intention may be indicated.

Wounds located in concave areas such as the medial canthus, ear concha, alar crease (if small), temple region, and postauricular sulcus lend themselves well to healing by secondary intention.[15] Second intention wounds heal by both contraction and reepithelialization. First, a wound contracts to its maximum capacity, and then the remainder of the wound is filled in with scar tissue.[16] Contraction contributes to approximately 50% to 70% of the final wound closure and scar tissue fills out the remaining wound.[16] In general, increased wound contraction and decreased scar tissue will have a better cosmetic outcome; however, scar location, specifically contour of the lesion location, is the most important factor for cosmetic result.[15,16] Superficial wounds heal very well. Therefore, a very superficial wound, even on a convex surface such as the forehead or the nose, can potentially heal well. Because all wounds contract to some degree, it is important that there be no free margin along one side of the wound that can be elevated during wound contracture and cause distortion at the site. This may be encountered along the eyelid margins, ear margins, eyebrow, nasal ala, and lip vermillion border. These areas are almost always better managed with appropriate reconstructive surgery.

When a lesion is excised with the intention of allowing the wound to heal by secondary intention, appropriate margins should be included and the resulting defect will typically be circular in nature. The incision through the skin is beveled inward to provide exposure of the base of the wound. The depth need not reach the subcutaneous fat if the lesion can be removed satisfactorily by transecting the dermis.

Wounds that are allowed to granulate are more resistant to infection and do not form hematomas. In addition, the size of the final scar is kept to a minimum by negating the need to remove standing cones. These wounds, however, require more time to heal than those that are closed primarily and exhibit increased contracture. In some cases, there is an unpredictable cosmetic result. Employing a purse-string suture, a running suture that is placed circumferentially around

a wound and then pulled taut, can significantly decrease the circumference of a wound and abbreviate the healing time considerably.[17]

FLAPS

When simple primary closure cannot be done because a wound is too large, there is excessive tension, or an unacceptable functional or cosmetic result would ensue from a linear scar, a tissue-movement procedure, such as a flap or a graft, should be considered. A local skin flap is a portion of full-thickness skin and subcutaneous tissue transferred from an adjacent donor site into the surgical defect. The flap maintains its blood supply via a vascular pedicle that remains connected to the donor site.

Flaps may be categorized based on their blood supply. Axial pattern flaps depend on a named artery for their blood supply. In contrast, random pattern flaps, the most widely used in dermatologic surgery, are supported by the small arterioles and capillaries of the subdermal vascular plexus found in the mid-to-superficial fat. Therefore, undermining and flap mobilization must be done at or below this level to ensure adequate blood supply. If undermining occurs too superficially, the intradermal vasculature alone will often not be able to support a flap. In certain areas other than the face, the perfusion pressure of even the subdermal vascular plexus is often not sufficient to support a random pattern flap. Fortunately, the blood supply of the face is rich, estimated to be 10 times greater than necessary to support the skin's basic metabolic needs so it can support a wide variety of random pattern flaps.

The vascular perfusion pressure, that is, the force of blood flow through a vessel, is greatest at the proximal end of a vessel and decreases steadily as it travels more distal into the flap. To ensure flap survival, the perfusion pressure must be great enough to keep the distal capillaries of the flap open. If the pressure falls below a critical level, the capillaries close and insufficient blood is supplied to the distal end of the flap.

For years, it was believed that the viable length of a flap was directly proportional to the width of the pedicle. In 1970, Milton discovered that axial flaps in a pig model under the same conditions of blood supply survive only to a finite length regardless of width.[18] Daniel and Williams, as well as Stell, confirmed Milton's findings and concluded that there was an upper limit of flap length that cannot be increased by increasing the pedicle width.[19,20] The maximal flap length is determined by vascular supply, not simply pedicle width. The greater the perfusion pressure in the flap pedicle, the longer the flap can be without undergoing necrosis. In addition, the greater the perfusion pressure in the pedicle, the narrower the pedicle may be. Axial pattern flaps have the highest perfusion pressure at the base and therefore can support very narrow long flaps (generally greater than a 4:1 length-to-width ratio). Musculocutaneous flaps have the next greatest vascular perfusion pressure, followed by fasciocutaneous flaps, and finally random pattern flaps. Stell discovered that the greatest length of a viable axial flap was 60% greater than that of a random pattern flap. In general, random pattern flaps on the face should have a maximal length-to-width ratio of 3:1.[21] This is however only a rough guideline, and individual patient characteristics such as tobacco use, sebaceous nature of skin, prior radiation or surgical procedures, and precise location all affect vascular perfusion. To help ensure flap survival, the pedicle length-to-width ratios should not exceed 2:1 on the trunk and extremities.

The 2 movements involved in repairing a defect with a flap are the primary movement, which is the action of placing the flap into the defect and the secondary movement of tissue in the donor area, which closes the secondary defect and facilitates primary flap movement. Both movements are important in terms of distributing tension in the proper direction and over a larger area so as to minimize tension on the flap itself, which might compromise its survival.[22] Flaps are commonly classified according to their primary movement—advancement flaps, rotation flaps, transposition flaps, and interpolation flaps. This classification underplays the reality that many flaps have more than one primary movement, eg, a rotation flap usually has a component of advancement to fill the distal portion of a wound. Therefore, another way to classify flaps is by whether the primary movement is sliding, which displaces tissue redundancy at a site distant from the defect (advancement and rotation) or lifting, where a flap is moved over intact skin, reorienting wound tension (transposition and interpolation).

Flaps should only be placed over defects that are neoplasm free as it is difficult to detect tumor growth under a healthy flap and the neoplasm can continue to grow for an extended period of time before detection.

As with elliptical excisions, the flap should be planned paying attention to the concepts discussed above, such as free margins, skin laxity, relaxed skin tension lines, cosmetic units, and attention to function. The flap and possible resultant Burow's triangles should be drawn out with a marking pen while the patient is in an upright position. It is advisable to plan the flap prior to administering anesthesia, as the injected volume may distort the tissue and alter its movement.

Flap incisions should be made perpendicular to the skin, and the recipient wound edges should similarly be squared off. The thickness of the flap should be uniform and should approximate the thickness of the wound edge. The area around the flap should be widely undermined.

ADVANCEMENT FLAPS

The primary movement of an advancement flap is the one-dimensional sliding of tissue directly into a defect. In essence, incisions are made tangentially to the defect to free up neighboring tissue. With the wound edge acting as the free margin of the flap, the tissue is advanced into place, the key suture is placed at the advancing edge, and the tissue cones become apparent. Although

some adjacent tissue laxity may be tapped into with an advancement flap, the tension vectors of the closure remain the same and therefore the primary advantage of an advancement flap is the displacement of closure lines into more cosmetically acceptable locations. All advancement flaps are random-pattern flaps; they do not rely on a specific named vessel, but rather adequate tissue laxity, for survival.[23]

SINGLE ADVANCEMENT

The simplest example of a pure advancement flap is the *U-plasty*, whereby double, parallel incisions are made tangential to what is most often a round defect. The flap is undermined, advanced into the defect, and secured with sutures, creating a U-shaped scar (Fig 203-11). Redundant tissue cones may be sewn out using the rule of halves or removed as Burow's triangles at the base of the flap. Although the U-plasty is occasionally used to make the majority of lines in the repair of a forehead defect run in the horizontal direction with the natural skin tension lines, the fact that it does not alter tension vectors and does not significantly free tissue up limits its usefulness.

An *L-plasty* or A-to-L or O-to-L advancement is a single tangent flap where an incision is made at one end of a defect extending outward for some length, and the tissue mobilized is then advanced into the defect (Fig. 203-12). Tissue redundancy is created on the side of the defect opposite the flap incision and must be removed. Although this type of advancement flap may tap into some distant laxity, it is generally minimal. Advancement flaps also do not change the tension vectors of the closure. Advancement flaps spread the tension out over a longer distance and offer some of the closure line to be perpendicular to the vector of tension. O-to-L advancement flaps are particularly useful with defects where the limb of the flap may be incorporated into RSTLs or cosmetic unit junctions or where a linear closure may otherwise cross a free margin or cosmetic unit junction, as may be the case on the eyebrow, nose, or upper lip.

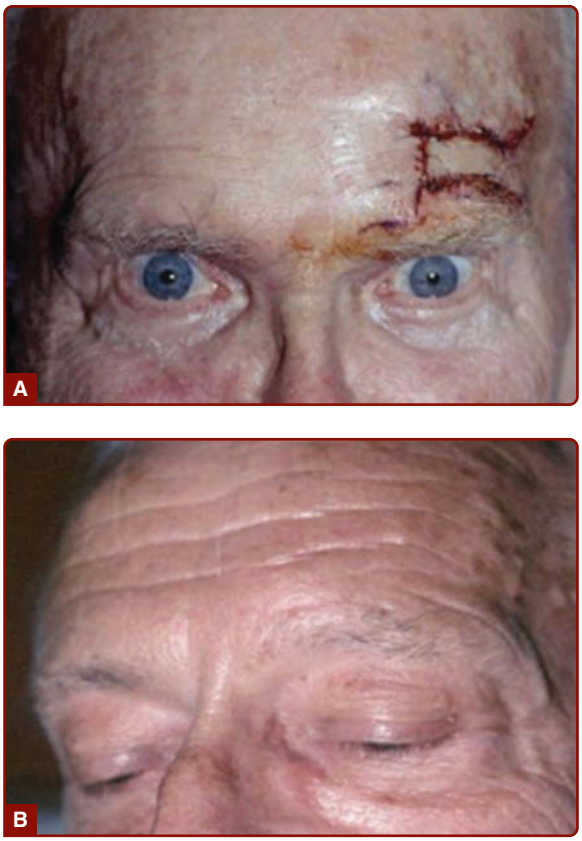

Figure 203-11 **A** and **B,** U-shaped advancement flap. Although advancement flaps do not necessarily change the vectors of tension of a closure, they do change the direction of the incisions and resultant scar line.

A larger single advancement flap is the *cheek advancement flap*, used to repair medium-to-large defects of the medial cheek and/or lateral nose (Fig. 203-13). The

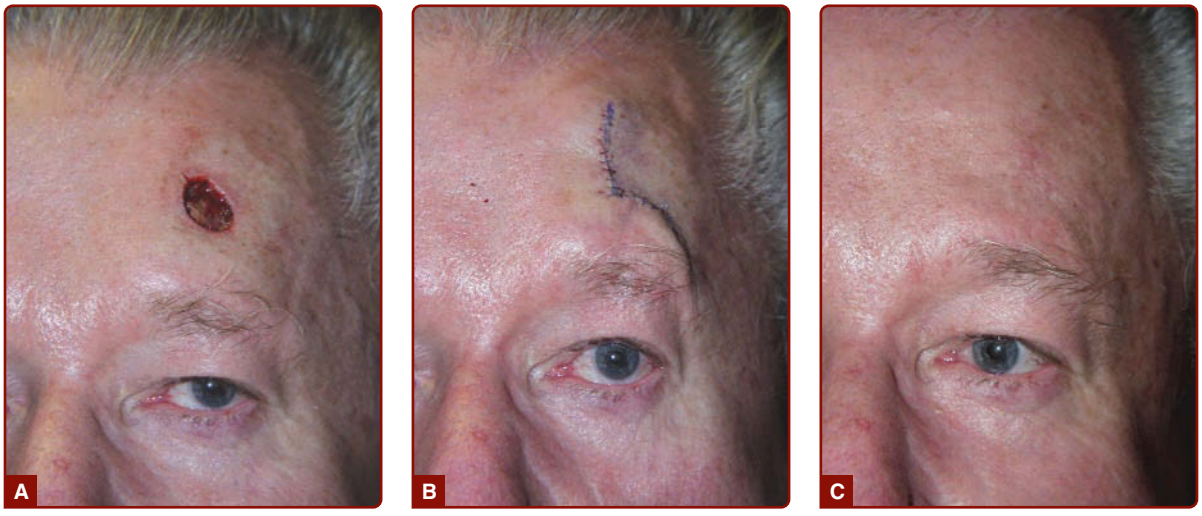

Figure 203-12 **A-C,** A to L advancement flap. Here, one line of the closure is drawn and incised perpendicular to the closure.

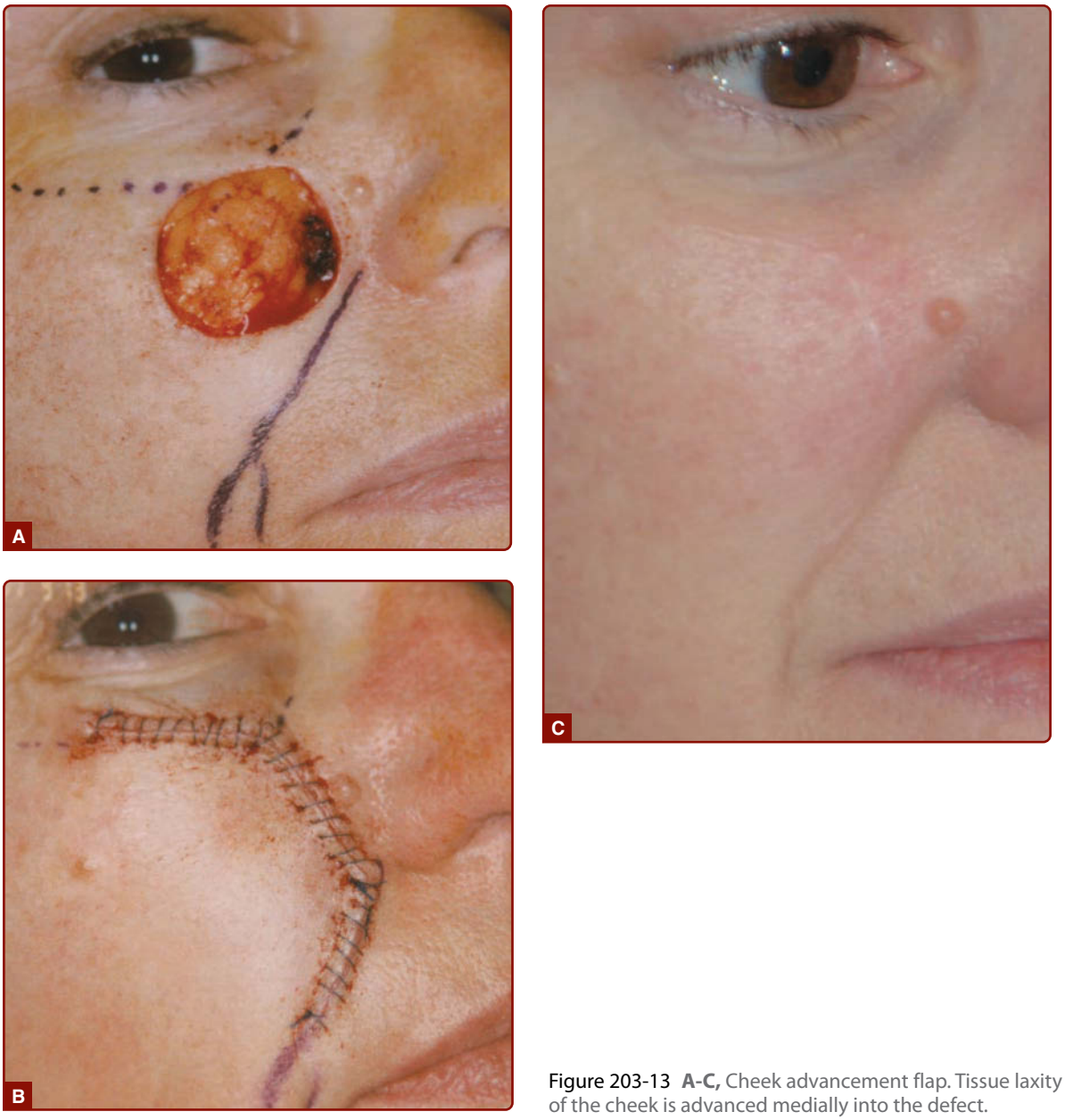

Figure 203-13 **A-C,** Cheek advancement flap. Tissue laxity of the cheek is advanced medially into the defect.

incision may be placed in the alar crease or nasolabial fold by removing tissue above and below the defect to allow the cheek to advance into the nasofacial sulcus. It is usually advantageous to tack the leading edge of a cheek advancement flap into periosteum at the nasal sidewall cheek junction, even if the defect is on the nasal sidewall. Tacking the flap to periosteum at the nasal sidewall cheek junction will take pressure off the leading edge and re-create the natural concave surface of the area and prevent unnatural webbing. When a defect involves both the cheek and the ala, a cheek advancement flap may be used to cover the defect on the cheek and a full-thickness skin graft may be used to repair the alar part of the defect (Fig. 203-14). This will keep the cosmetic units separate and place the scar lines along the cosmetic unit junctions.

Helical rim advancement flaps may be used to repair defects of the helix, utilizing the tissue laxity of the lobule. Traditionally, this flap was created with a through-and-through incision inferior to the defect along the scaphoid fossa, terminating in the lobule, and creating a narrow pedicle to be advanced (conceptually similar to the U-plasty). The survivability of this flap is proportional to the length-to-width ratio and could only be performed on inferior helical defects where this ratio will not exceed 3 to 4:1. A more popular modification of this flap is to use a single tangent incision along the scaphoid fossa, leaving the posterior auricular skin intact[24] (conceptually analogous to the L-plasty) (Fig. 203-15). This allows for the maintenance of a more reliable blood supply via the tissue inferiorly and posteriorly and permits the repair of defects more distant from the lobule.

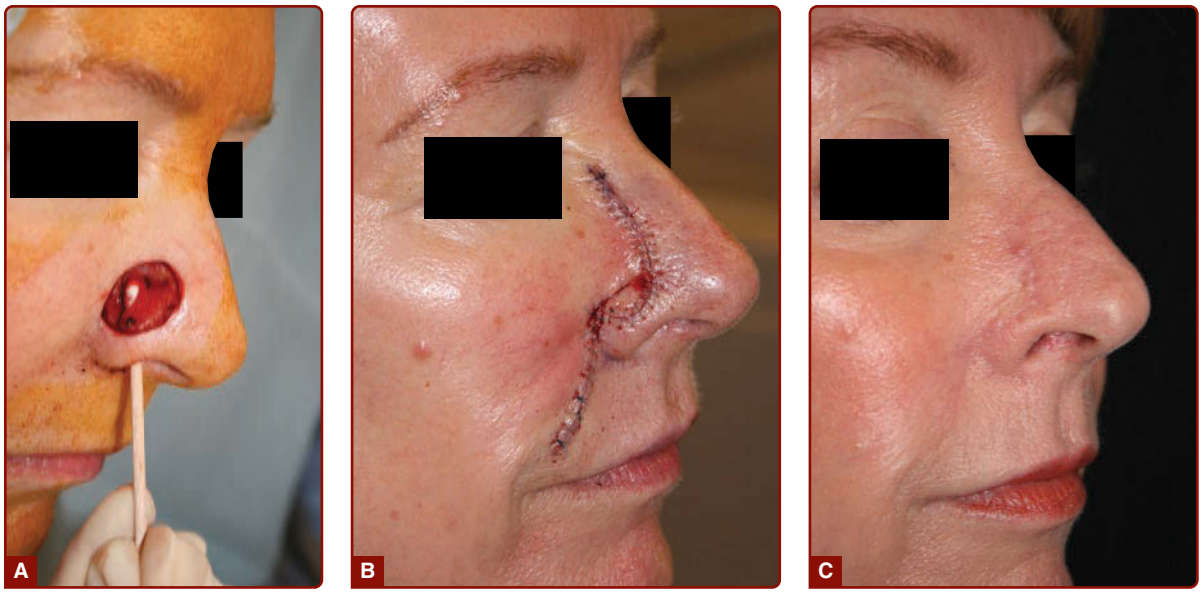

Figure 203-14 **A-C**, Cheek advancement flap with full-thickness skin graft. When the defect involves both the cheek and the ala, it is often best to utilize separate closures for each of the cosmetic units. Here a cheek advancement flap was used to close the part of the defect on the cheek, and a conchal bowl full-thickness skin graft was used to close the alar aspect of the defect.

It is important to have good eversion when closing this flap at the helical rim as forces of contraction during healing will tend to invert the wound edge and create an aesthetically unpleasant notch.

BILATERAL ADVANCEMENT

If 2 sets of parallel incisions are made symmetrically on both edges of the defect, a bilateral advancement flap, termed an *H-plasty*, has been created. This flap is essentially a bilateral U-plasty and is occasionally used on the forehead, eyebrow, glabella, and upper lip to hide incision lines along relaxed skin tension lines and cosmetic unit junctions.

Another commonly employed bilateral advancement flap is an O-to-T flap, also termed an A-to-T or a *T-plasty* (Fig. 203-16), analogous to a bilateral L-plasty. This flap is essentially a bilateral O to L flap. The standing cone is removed from one end of the defect, creating a triangle, or transforming an "O" into an "A." Single incisions extend from the base of this triangular defect, and the 2 sides of the triangle slide together along this baseline. This flap allows for redistribution of tension to 2 advancing edges. The T-plasty is best

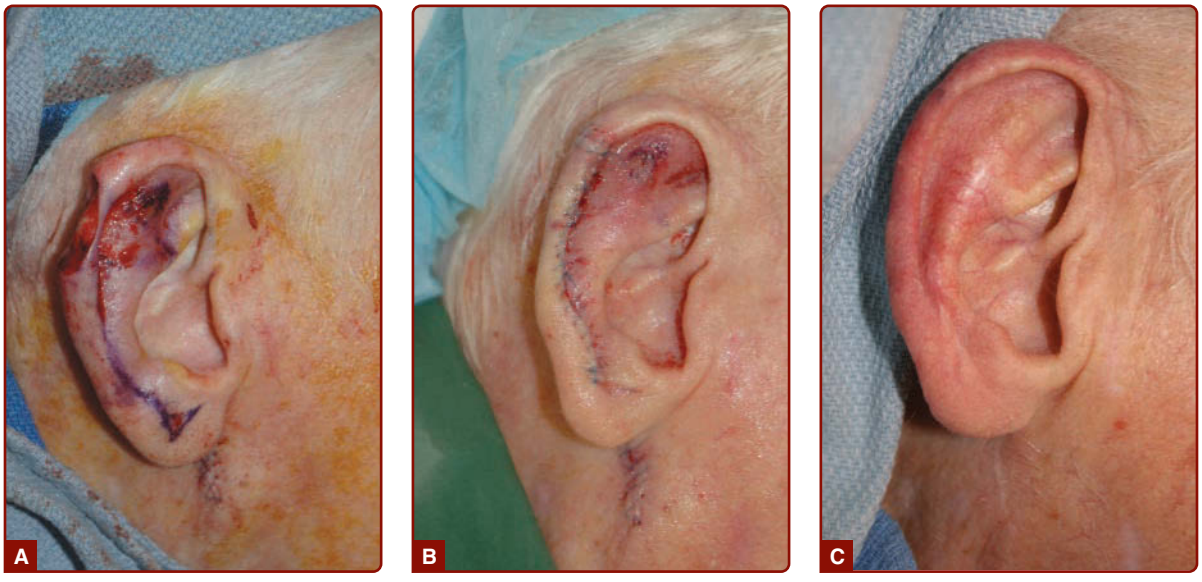

Figure 203-15 **A-C,** Helical rim advancement flap. An incision is made along the anterior helical rim down to the ear lobule. A "dog ear" is taken out on the posterior aspect of the ear. The helix is advanced superiorly to close the defect with everting sutures. This allows for consistent reconstruction of the helical rim.

Figure 203-16 **A** and **B,** This flap can be considered a bilateral O to L advancement flap.

performed with the broad base along a free margin or cosmetic unit junction (eg, lip, eyebrow).

CRESCENTIC ADVANCEMENT FLAP

The crescentic advancement flap utilizes the removal of a small crescent of tissue along an advancement flap to either better hide the scar line or increase the length of the line to prevent distortion. This flap is particularly useful for the repair of upper lip and perialar defects. The superior standing cone is removed in a crescentic shape around the ala such that the superior scar line is placed in the perinasal sulcus (Fig. 203-17).[25] For defects on the upper cutaneous lip, the inferior cone is removed along relaxed skin tension lines and extended through the vermilion border and around to the wet mucosa to prevent a downward distortion of the vermilion. A modification of the crescentic advancement includes the repair of a small, perialar defect of the medial cheek where both cones are removed around the ala, and the entire scar line is placed in the nasal sulcus, similar to the cheek advancement. Another modification includes incorporating a crescent along the vermilion border to an advancement flap closing a defect just superior to the vermilion border. Removing a crescent here increases the length of flap and helps minimize the differences in length between the flap and the total length of the closure (flap + defect). This will take some of the horizontal tension off the flap and minimize distortion of the lip and modiolus (Fig. 203-18).

V-TO-Y FLAP (FORMERLY REFERRED TO AS AN ISLAND PEDICLE FLAP)

A subcutaneous V-to-Y advancement flap may be considered as a variation of an advancement flap that has had all of its connections to the epidermis and dermis severed, maintaining its blood supply through a subcutaneous tissue pedicle (Fig. 203-19).[26] The flap is designed within cosmetic units when possible and, as with all repairs, it is optimal for the incision lines to run along cosmetic junctions. The V-to-Y flap is frequently used on nasal and perioral closures where free margins are at risk for distortion. The tension vectors of an island pedicle flap are primarily in the same direction as that of a primary closure; however, they are displaced distal to the wound (ie, superior to the nasal tip, superior or lateral to the vermilion border) and help avoid distortion of the area around the defect.

The V-to-Y flap is created by extending 2 nonparallel tangential incisions to meet at an approximate 30° angle, similar to when planning a Burow's triangle. The difference is that the incision lines stay parallel for a short distance before converging, creating a slightly larger triangle than would be created with a Burow's triangle. This extra length gives tissue that closely approximates the size of the defect and minimizes local distortion. The triangle may be designed larger or smaller depending on how much tension sharing is desired. The incisions are made just to the superficial subcutaneous tissue. The tip and sides of the flap are

Figure 203-17 **A-C,** Crescentic advancement flap. A crescent of tissue is removed around the lateral aspect of the ala and the cheek is advanced medially.

undermined widely extending outward from the flap in the subcutaneous plane. The triangular flap is also undermined slightly to help mobilize it. The flap is then advanced into the defect and sutured into place. For the flap to fit properly into a circular defect, either the corners of the flap must be trimmed or the defect squared off. The flap must be undermined with attention both to the mobility of the tissue and to the maintenance of a subcutaneous vascular pedicle. Although the initial design should have a broad pedicle, if

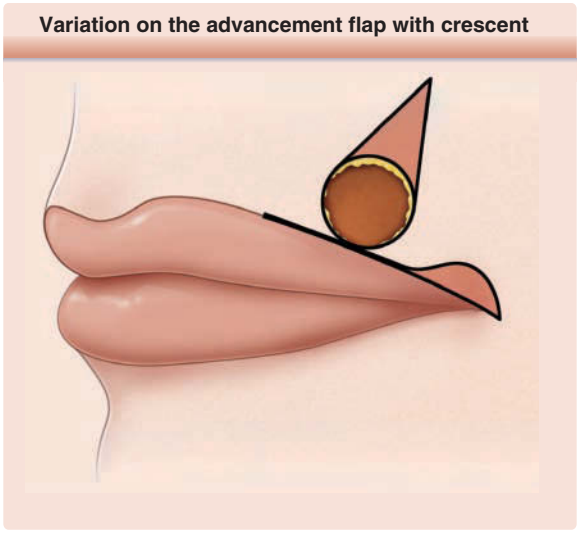

Figure 203-18 Variation on the advancement flap with crescent. Removing the crescent of tissue elongates the incision and compensates for the length mismatch of the incision versus the incision + defect.

mobility is limited the pedicle may be progressively diminished (particularly at the trailing tip of the flap).

When closing defects on the nasal dorsum and tip, a muscular flap is often created laterally on one or both sides. For this musculocutaneous island pedicle flap, undermining is performed both above and below the nasalis muscle. If there is not enough laxity to close the defect without upward tension on the nasal tip, the muscular flap is released horizontally at the superior and inferior edge to create a muscular sling that advances with the flap into place. The muscular attachment gives a robust blood supply to the flap and helps ensure its survival.

EAST–WEST FLAP

The east–west flap is an advancement flap used for small to medium-sized defects (up to 1.5 cm) of the lateral nasal supratip.[27] Two triangles are removed in the vertical axis. The superior one is adjacent to the defect and parallel to the long axis of the nose. The inferior triangle is midline, toward the columella. Removal of both triangles allows for an easy lateral sliding movement and closure (Fig. 203-20). This flap permits reconstruction without significant nasal distortion or excess tension,[27] and allows for excellent tissue match.

RINTALA FLAP

The Rintala flap is a superior based advancement flap for large defects on the nasal dorsum.[28] A rectangular flap from the nasal dorsum and glabella is elevated in the supraperiosteal plane and advanced downward to cover the defect. Burrows triangles are created proximal to the alar groove or on the forehead. Thorough undermining must be performed to avoid nasal tip elevation.[28]

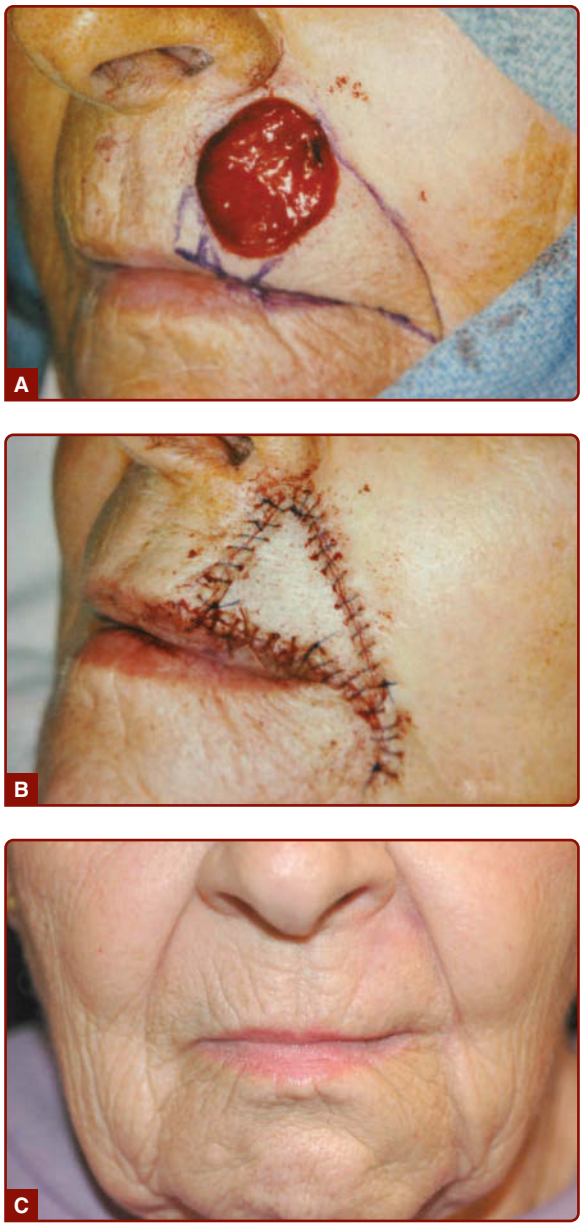

Figure 203-19 **A-C,** V to Y flap-A triangular shaped flap is incised through the dermis and advanced into the defect while a pedicle of tissue is left intact deep to the flap, which supplies a rich vascular network and aids in survival.

ROTATION FLAPS

In a rotation flap, skin moves into the defect by rotating around a pivot point (Fig. 203-21). This is classically used to close relatively large defects on the cheek, temple, or scalp. The design of the traditional rotation flap uses a curvilinear incision along an arc adjacent to the primary defect. Adjacent lax tissue is recruited while the closure tension is redirected in multiple directions away from the primary defect. The flap is designed with attention to its length and curvature.[29] Rotation flaps often require long incision lines, as a larger arc of the rotation vector allows closure with minimal tension on the flap's tip while simultaneously decreasing the width of the secondary defect. The ideal arc of a rotation flap extends up to 5 times the width of the defect and makes up approximately one-quarter of the circumference of a circle.

As the flap is raised and undermined, the adjacent tissue laxity allows the flap to rotate into the primary defect. The key stitch closes the primary defect and a burrows triangle usually forms at the base. The rotation flap has a large vascular pedicle and therefore has a lower risk of tissue necrosis. The stiffness about the pivot point may hinder the flap's movement,[29] and undermining the area of pivotal restraint improves flap mobility. If restraint of motion keeps the tip from moving into the distal defect, a back cut can increase tissue movement in areas of limited tissue laxity, such as the nose. However, caution must be taken as the back-cut may decrease the pedicle width, interfering with blood flow into the flap.

DORSAL NASAL ROTATION FLAP

Also known as the *Rieger flap*, this flap is employed to repair nasal defects involving the distal dorsum or tip.[30] The tissue reservoir of the nasal root and glabella allows for the movement of the dorsal nasal skin superior to the defect. A long, sweeping arc is created that extends into the nasofacial sulcus and terminates in the glabella. A back cut in the glabella improves the rotational mobility of this flap and is termed a *hatchet flap* (Fig. 203-22). If the arc of this flap is not long enough or there is too much tension on the leading edge of the flap, elevation of the nasal tip will result. Wide undermining at the level of the perichondrium is required.

BILATERAL ROTATION FLAP

At times, the size of the defect or the tension on the flap mandates a bilateral rotation flap, in which tissue is rotated into a defect from 2 opposite sides. The vectors of rotation may be mirror images of each other, recapitulating the premise of the A–T advancement flap. This may be utilized for large defects on the scalp and larger defects on the lower lip (Fig. 203-23). The vectors of movement also may be in opposition, creating an O-to-Z flap.

PERIOCULAR ROTATION FLAPS

Defects of the lower eyelid and infraorbital cheek are at high risk for ectropion. To prevent this complication, the tension must be parallel to the lid margin. Both the *Mustarde flap* and the modified *Tenzel flap* are rotation flaps that can help prevent ectropion. A Mustarde flap is useful for larger defects on the lower lid/periorbital cheek. The flap extends laterally from the defect, arches superiorly to the lateral canthus and temple and ends in the preauricular area. The flap is undermined

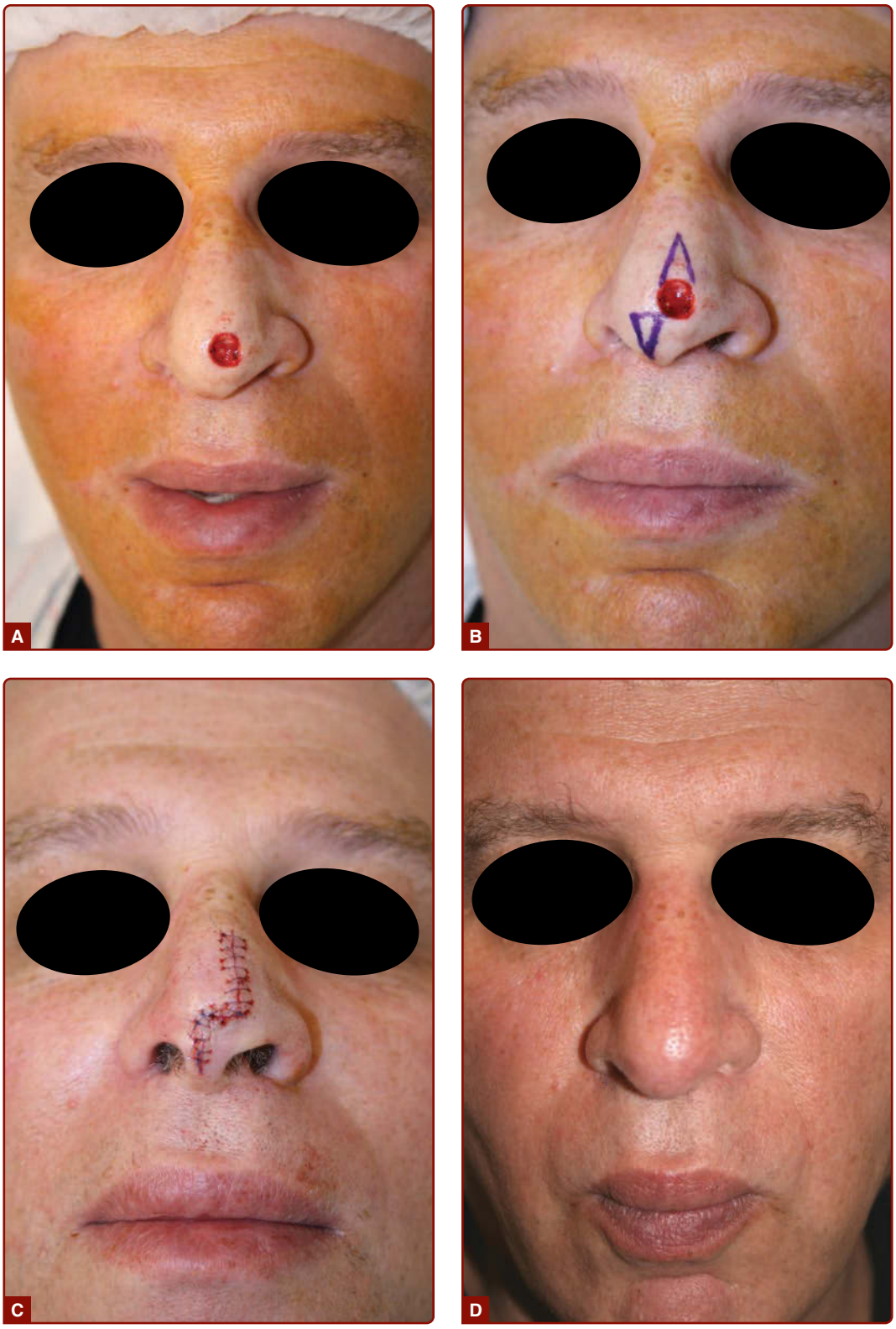

Figure 203-20 **A-D,** East–west flap. The east–west advancement flap is used for small to medium-sized defects on the nasal tip. It allows for excellent tissue match and minimal nasal distortion.

extensively and transposed over the defect. The Tenzel flap is a semicircular flap for a lower lid defect that rotates the skin and orbicularis muscle from the lateral canthal area. Additionally, the lateral canthal tendon is cut for increased tissue mobility. Both of these flaps must be anchored to the periosteum at the lateral orbital rim to help minimize downward tension on the eyelid and risk of ectropion.[31,32]

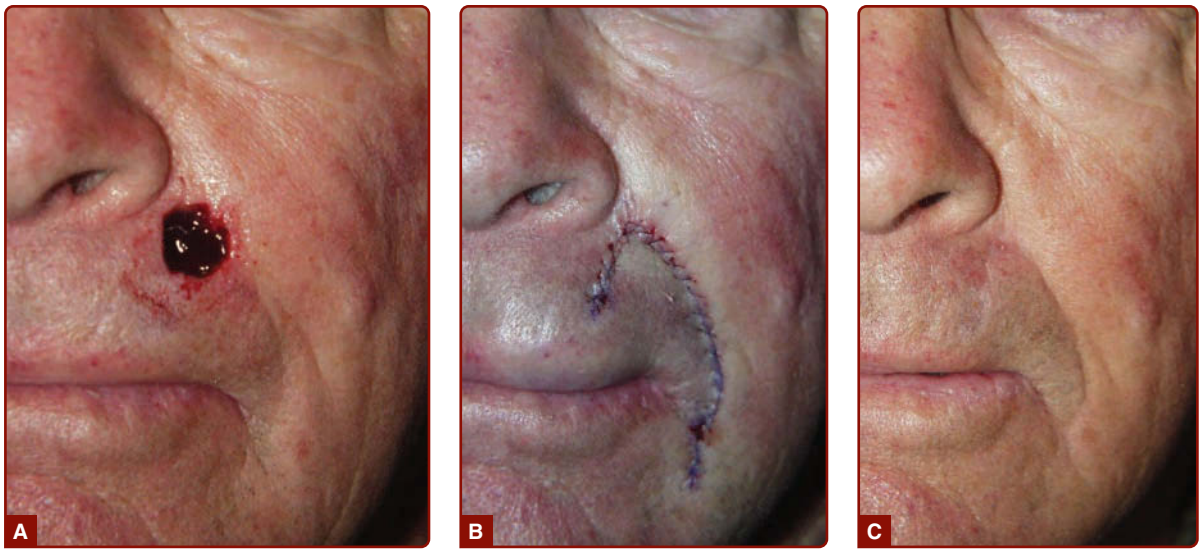

Figure 203-21 **A-C,** Rotation flap. An arcuate incision is made from one end of the defect and the flap is rotated into the defect. Rotation flaps help spread tension vectors out in multiple directions radiating from the arc.

SPIRAL FLAP

The Spiral flap has been shown to be effective for the reconstruction of small to medium-sized partial-thickness defects of the nasal ala and inferior nasal sidewall. It is a modified rotation flap with a 180° arc. The tip is advanced and rotated into the wound and sutured into the proximal aspect of the wound, the body of the flap follows creating a spiral (Fig. 203-24). With this flap, the cosmetic unit is preserved, there is no shortening of the nasal ala, and a standing cone does not form, therefore decreasing the risk of alar distortion.[33]

TRANSPOSITION FLAPS

A transposition flap is a random pattern flap, which borrows skin laxity from an adjacent area to fill a defect in an area with little or no skin laxity. In its travel from the donor site to the recipient site, the flap is lifted or "transposed" over a segment of intervening tissue. When the secondary defect is closed, the transposition flap pushes tissue into a defect rather than pulling it, as with the advancement and rotation flaps. While moving to the recipient site, the flap actually follows a rotational path and must be designed so it does not rotate too far and pull too tightly on its pedicle.

Transposition flaps have several advantages over other closures. Their primary function is to redistribute and redirect tension. This is useful in the closure of defects which would otherwise close under high tension or distort a nearby anatomical structure leading to functional or aesthetic impairment. Transposition flaps are usually smaller in overall size than advancement and rotation flaps. The resulting scars are geometric broken lines that may be less noticeable than longer linear closures in certain areas. This geometric broken line scar, however, may be thought of as a disadvantage as they are difficult to completely place along a relaxed skin tension line or cosmetic unit junction. One of the major advantages of transposition flaps is

Figure 203-22 **A-C,** Hatchet flap. The hatchet flap is a rotation flap with a cutback. The cutback gives the flap extra length and aids in its movement.

Figure 203-23 **A-C,** Bilateral rotation flap of the lip. Incisions are made bilaterally along the vermillion border and a redundant tricone of tissue is removed posteriorly into the wet mucosal lip. Both wings of the flap are rotated together and sutured with braided suture.

that they utilize adjacent skin and provide an excellent color and textural match.

The most common transposition flaps in cutaneous surgery include rhombic flaps (and their variations), bilobed flaps, and banner flaps such as the nasolabial flap. Knowledge of the tissue dynamics used in these 3 basic transposition flaps can be carried over to the planning and execution of the numerous variations of these flaps.

RHOMBIC FLAP

First described by Lindberg in 1963 is a single-lobed transposition flap. The classic rhombic flap was designed to create a secondary defect perpendicular to the primary defect.[34] When closed, it would not only provide tissue to the primary defect, but also redirect the tension vector by 90°. This allowed the primary defect to be closed under almost no wound edge tension. Subsequent modifications by DuFourmentel and Webster provide more tension sharing between the primary and secondary defects. These modifications are useful in situations where some laxity around the primary defect is available.[35]

The classic Lindberg rhombic flap is designed by conversion of the primary defect into a 4-sided parallelogram with each side of equal length and tip angles of 60° and 120°.[34] This rhombus forms the recipient site for the flap as well as the template on which to plan the flap incisions. In its classic configuration (Fig. 203-25), the incisions are designed by extending a line (line a–b) outward from one of the obtuse tips for a length equal to that of one side of the rhombus. From the free end of the extended line (point b), a second line (line b–c) is drawn. The tip angle in this configuration is 60°. The flap is lifted and transposed into place. The tension vector is redirected from that of closing the primary defect, to that of closing the new secondary defect created in the design of the flap. This allows the tension vector to be shifted and redirected by 90°.

There are 4 possible flap designs off of the short axis of any rhomboid defect (Fig. 203-26). Which of these 4 flap configurations is selected depends on several factors that affect the final outcome. These factors include adjacent anatomic structures, adjacent skin type, and where the scar line will be best hidden. Though the classic rhombic transposition flap can be designed and executed off of the long axis of the rhombus, there are 2 advantages to designing it off of the short axis of the defect. First, it keeps the flap as small as possible while filling the defect completely. Second, it minimizes the arc through which the flap must rotate to fit into the defect.

In designing the flap from the circular defect, the length of the line extended out from the defect should be drawn longer than the diameter of the circular defect. This will account for the fact that the diameter of the circular defect is shorter than the short axis of a rhombus drawn around the defect. A second line of the same length is drawn, keeping the tip angle at 60° to complete the flap. The triangle of tissue redundancy created by the rotation of the transposition flap is removed by trimming a Burow's triangle at the pivot point. The transposed tissue may be rounded to fit the circular defect, or the defect may be squared off to accommodate the angular flap. This choice can be made based on which option yields the best aesthetic result (Fig. 203-27).

As with any closure, understanding the tension forces is essential to the planning, execution, and outcome of the repair. There are 2 main tension forces associated with the classic rhombic flap. The first set of tension forces are realized during the approximation and closure of the secondary defect. The second set of tension forces are generated at the tip of the

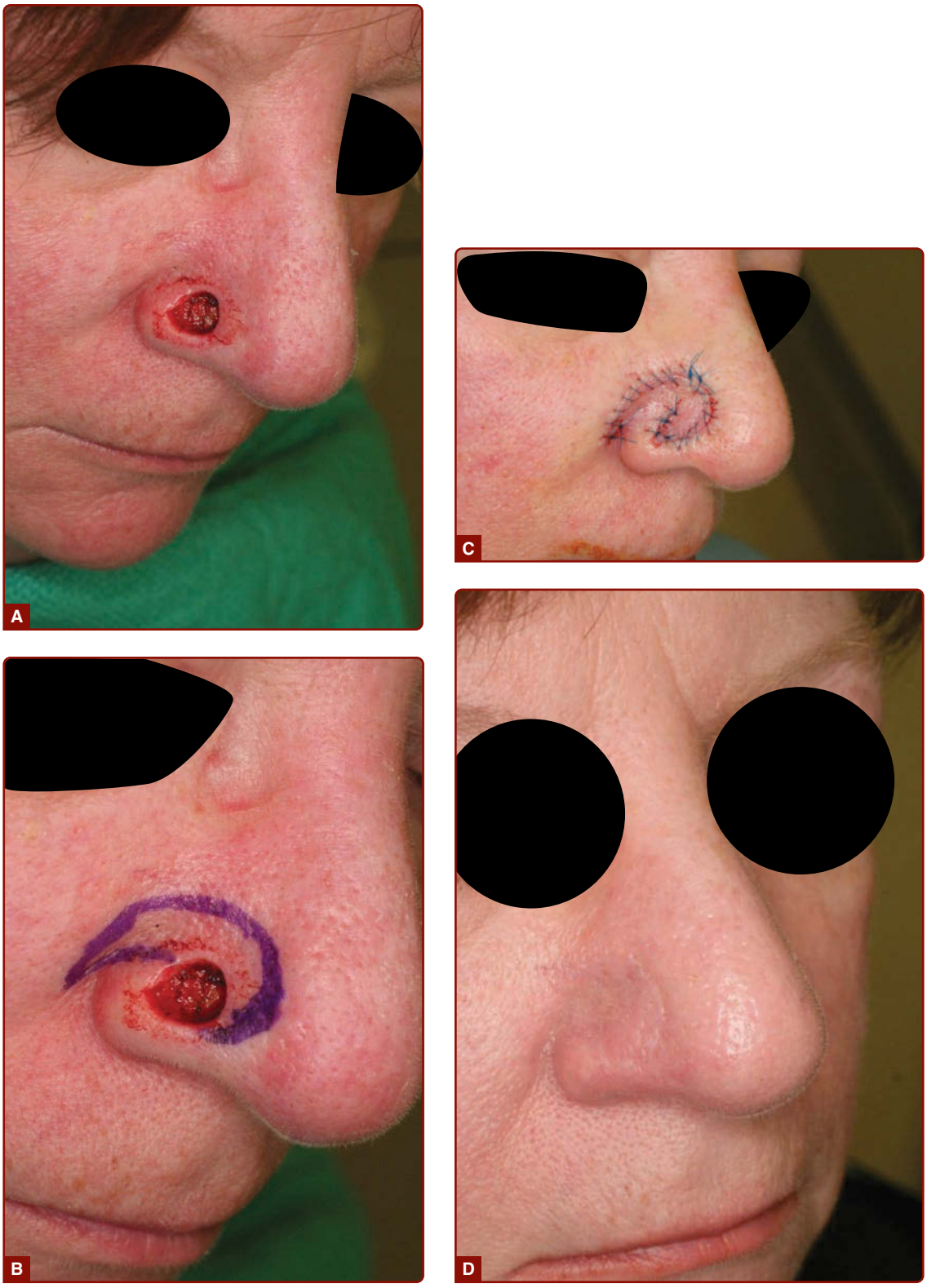

Figure 203-24 **A-D,** Spiral flap. The spiral flap is a modified rotation flap that can be used to repair defects of the nasal ala and alar groove. The flap is incised, undermined, and rotated into the wound with no alar distortion.

flap when moving it into the primary defect. These forces are due to the resistance to rotation at the flap's pedicle as well as shortening of the length of the flap during rotation into the recipient site. Dzubow describes these forces as pivotal restraint.[29] Securing the flap into the recipient site under high tension is not advised because it may lead to tip ischemia and necrosis. Two modifications in design can be utilized

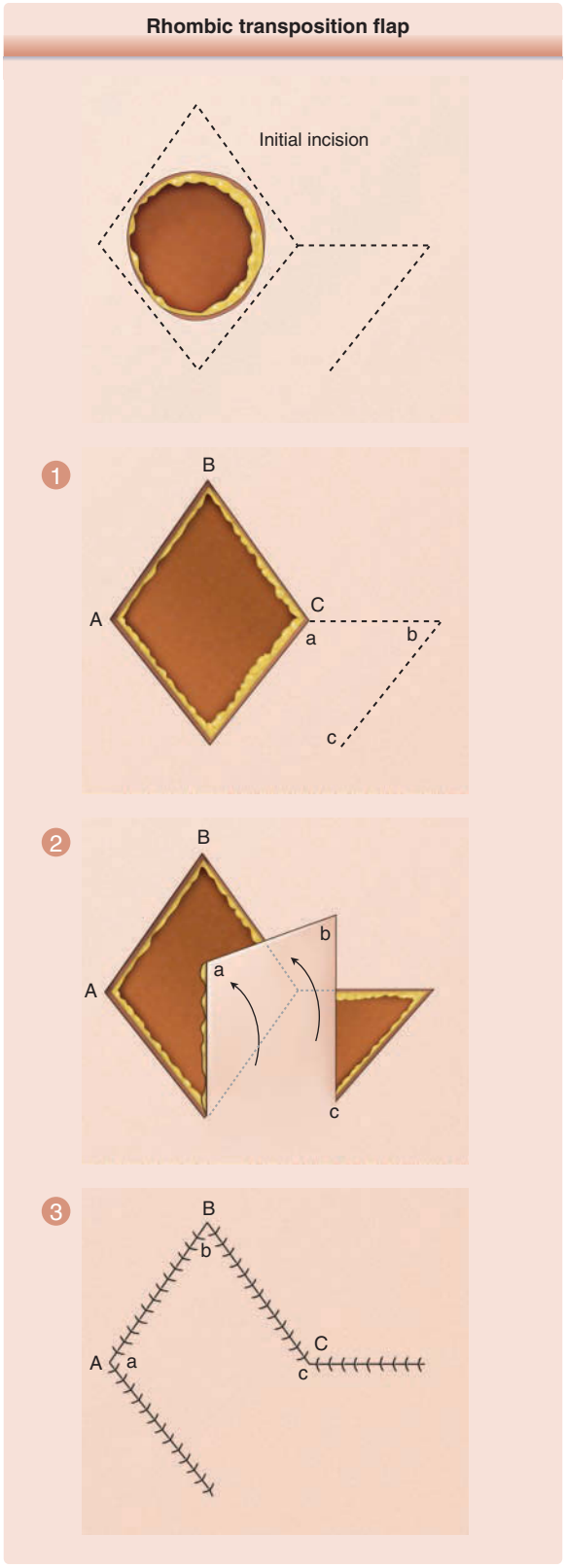

Figure 203-25 Rhombic transposition flap. Classic rhombic flaps alter the vectors of tension in a closure by 90° and leave a broken geometric scar shape. The tension is taken completely by the closure of the secondary defect as the flap is pushed into the primary defect.

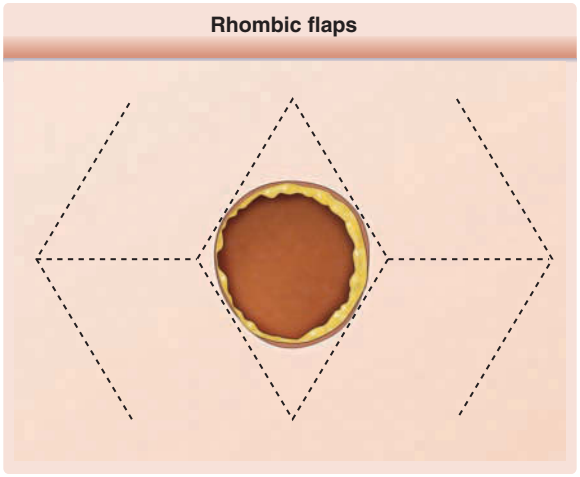

Figure 203-26 Rhombic flaps may be drawn in any of 4 directions off of the short axis of any rhomboid-shaped defect.

to assist in minimizing the shortening of the flap and subsequent tension at the flap tip.

- By lengthening both the leading edge and the secondary limb of the flap, the flap can be enlarged and lengthened. This lengthening can compensate for the shortening resulting from pivoting at the base, thus reducing tension at the tip when secured in the recipient defect.
- An alternate method to lengthen the flap is by designing the flap with a slightly more obtuse (greater than 120°) flap angle. Widely undermining around the flap also assists in the redistribution of tension vectors as well as redistribution of contractile forces during the healing phase.

The DuFourmentel Flap: The DuFourmentel flap modification differs from the classic rhombic transposition flap (Fig. 203-28) in that it utilizes a narrower flap tip angle and a shorter arc of rotation, allowing easier closure of the secondary defect, and some sharing of the tension between the primary and secondary defects. Given that there is generally some tissue laxity at the site of the surgical defect, the DuFourmentel modification is utilized by this author more than the classic rhombic flap.

As with the classic rhombic flap, it is designed by extending the first line from the short axis of the rhomboid defect. However, the angle at which the first line is extended differs from the classic rhombic flap in that it bisects the angle formed by the first line of the classic rhombic flap (which extends straight out from the short axis of the rhombic defect) and the line formed by extending one of the sides of the rhombus from the same corner of the rhombus. The length of the first line is equal to that of a side length of the rhombus. The second line originates from the free end of the first line, and is drawn parallel to the long axis of the rhombus. This second line's orientation results in a slightly widened pedicle, a decrease in the tip volume, and a decrease in the degree of rotation necessary to execute

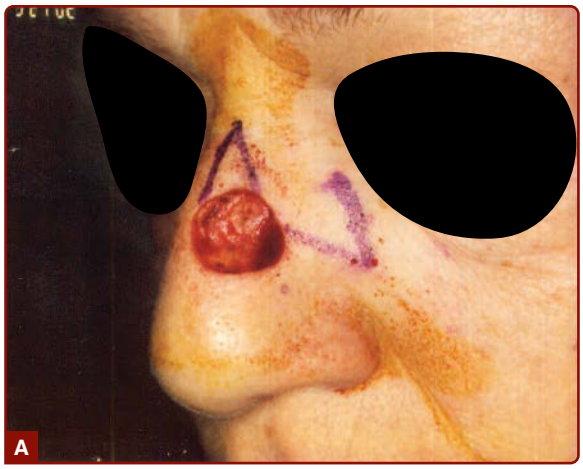

Figure 203-27 **A-C,** A modified rhombic flap allows for closure of circular defects. A standing cone is excised at the pivot point. The tissue is then transposed into the defect and the wound closure tension is redirected.

the flap. The tissue redundancy at the base of the leading edge of the flap can be removed by taking a slightly larger Burrow's triangle.

The 30°-Angle Webster Flap: The 30°-angle Webster modification of the classic rhombic flap utilizes a more acute angle than other rhombic

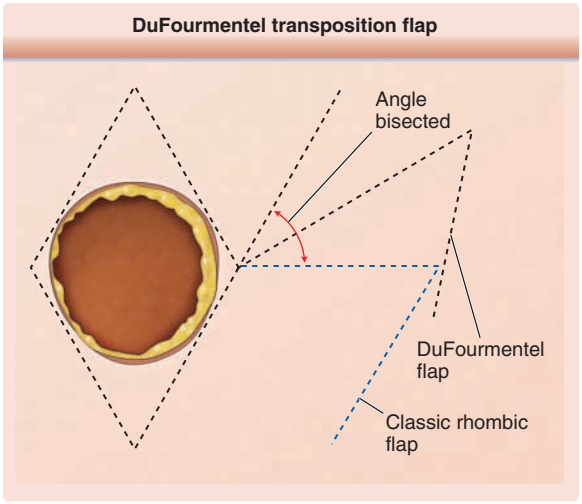

Figure 203-28 DuFourmentel transposition flap. The flap is designed with a narrower tip angle and a shorter arc of rotation. This allows easier closure of the secondary defect and allows some sharing of tension between the primary and secondary defects. The vectors of tension are altered by 45° not the full 90° seen in a classic rhombic flap.

transposition flaps, allowing for even greater tension sharing between the primary and secondary defects. A Webster 30°-angle flap is planned similarly to the DuFourmentel flap; however, its distal tip angle is designed to be 30° (Fig. 203-29). This gives the flap a slimmer design and narrower pedicle. The flap area is only 50% of the area of the primary defect; therefore, it only relieves half of the tension from the primary defect. This modification is used in situations where a fair amount of laxity exists in the horizontal axis of the rhombic shaped defect. Because this design places more tension on the primary defect, care must be taken not to close with too much lateral tension or distort adjacent anatomic structures.

Rhombic transposition flaps are very versatile and may be used to reconstruct a variety of defects. Transposition flaps are generally used when there is insufficient laxity in the immediate surrounding area of closure and/or the tension vectors need to be redirected. This is particularly important when repairing defects near free margins such as the eyelids and the nose. The most common areas they are employed include the nasal dorsum, nasal sidewall, medial and lateral canthus, lateral forehead, temple, cheek, perioral region, inferior chin, and the dorsal hand.

THE BANNER FLAP

Banner-type flaps are random-pattern finger-shaped cutaneous flaps that, like other transposition flaps, tap into adjacent skin to borrow laxity and fill a defect.[36] This flap is most commonly planned as a melolabial transposition to repair defects of the nasal ala or from the pre- or postauricular area to close defects on the ear. For an optimal cosmetic result, the scar is generally placed at the junction of 2 cosmetic units, providing

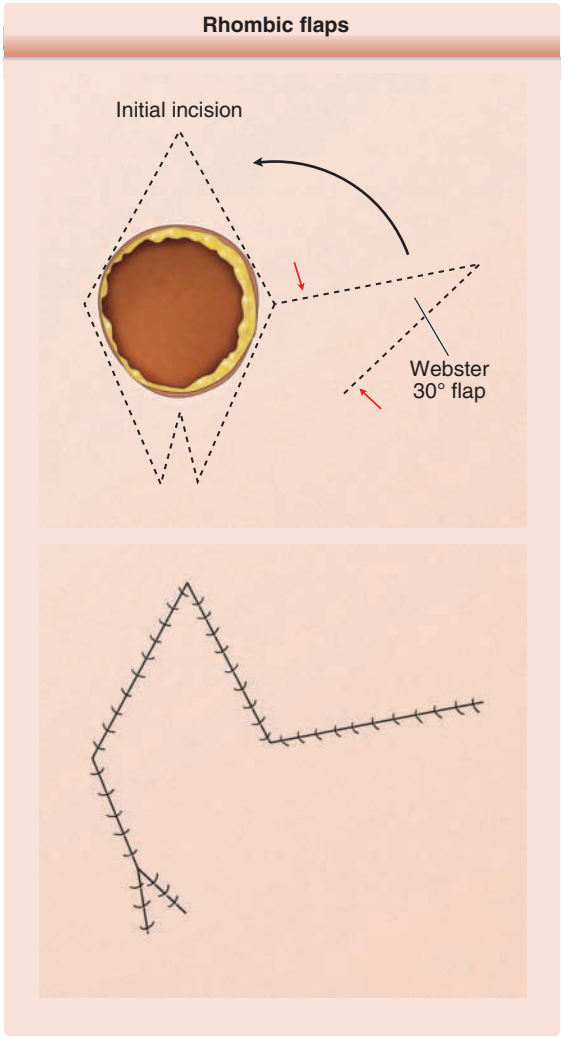

Figure 203-29 30° Webster flap. The angle of the rhombic flap is made even more acute, and more of the closure tension is shared with the primary defect.

excellent camouflage (in the nasolabial fold or preauricular sulcus) (Fig. 203-30).

The fundamental design of the banner flaps consists of a finger-shaped flap drawn with a width that is equal to the width of the defect and a length equal to the distance from the pivot point to the far edge of the defect. The flap is transposed and rotated in an arc around the pivot point to fill the defect. Because this is a long random-pattern flap with a narrow pedicle, the risk of vascular compromise may be high if the entire length of the flap is used and its pedicle originates from an area of minimal vascularity. To minimize risk of vascular compromise, the flap is typically designed to rotate through an angle of 60° to 120° instead of the originally described 180°. Additionally, when designing the backcut and removing the redundancy at the base of the flap, it should be designed in a direction away from the pedicle of the flap to avoid further narrowing of the pedicle, thereby maximizing flap viability. Typical locations for use of Banner-type flaps include the nasal ala, the superior helix of the ear, and the medial anterior ear.

BILOBED FLAP

The bilobed flap used today is a highly evolved transposition flap. The bilobed flap was first described by Esser in 1918. It became a workhorse flap only after the modifications described by Zitelli were published in 1989 (Fig. 203-31).[37] The design of the bilobed flap actually consists of 2 transposition flaps executed in succession, which follow the same direction of rotation over intervening tissues. The basic premise of this flap is to fill the defect with the primary lobe, while filling the secondary defect with the secondary lobe, leaving a triangle-shaped tertiary defect to be closed primarily. The key suture closes the tertiary defect. This series of transposition flaps allows the surgeon to further the reach of the flap, and borrow laxity from donor sites at

Figure 203-30 **A-C,** Banner transposition flap. A finger-shaped flap is incised and draped into the primary defect. These closure lines are generally placed along cosmetic unit junctions such as the preauricular sulcus.

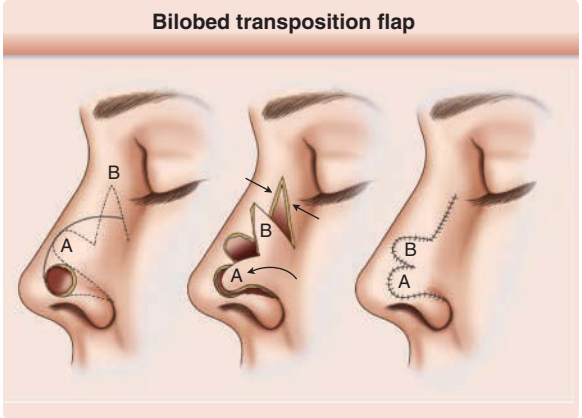

Figure 203-31 Bilobed transposition flap. The bilobed flap is designed with 2 adjacent transposition flaps elevated and rotated into position. The Zitelli modification (shown here) is designed placing the lobes over a 90° arc.

a greater distance from the defect while decreasing the arc of rotation of the pedicle.

The Zitelli modification of the bilobed flap is designed by placing the lobes over a 90° arc from the center of the defect, with the primary lobe rotating from a pivot point that is created by removing a Burow's triangle at one pole of the defect.[37] The width of the primary lobe should be equal to the width of the defect and should be long enough to just extend past the edge of the defect. The secondary lobe must be trimmed to match the secondary defect left by the transposition of the primary lobe.

As with the rhombic flap, the bilobed flap redirects the principal tension vector and takes advantage of tissue laxity of the donor site. This flap is predominantly used for small to medium-sized defects of the lower nose as the tension is redirected to a near vertical vector, preventing distortion of the alar rim (Fig. 203-32).

TRILOBE FLAP

This flap is very similar to the bilobed flap; however, it is able to use tissue that is further from the primary defect. The key suture closes the quaternary defect. In general, the primary lobe should be equal to the defect diameter, the secondary lobe should be 85% to 90% of the defect size, and the tertiary lobe should be 75% to 80% of the defect size. The trilobed flap is useful for defects on the distal tip of the nose and nasal ala.

Z-PLASTY

The Z-plasty is a transposition flap that improves the functional and cosmetic appearance of a scar by realigning a scar, camouflaging a scar, or most commonly increasing the scar length after contraction. The classic Z-plasty has 60° angles and will lengthen the scar by 75%. However, there are multiple variations based off of the classic Z-plasty. In a traditional Z-plasty there are 2 incisions of equal lengths, referred to as limbs, and 1 central incision. The limbs form 60° angles with the central incision. This leads to the formation of 2 triangular flaps that are transposed to redirect the tension vector and lengthen the central limb direction. This results in a new central incision that is perpendicular to the original central incision and ideally within relaxed skin tension lines.[38]

INTERPOLATION FLAPS

Interpolation flaps are more complex repairs that import pedicle-based tissue from a site distant to the defect. They are typically used on defects that are either too wide or too deep to reconstruct with local flaps or grafts. Many interpolation flaps may be classified as axial flaps if their vascular pedicle is based on a large, named artery. They are also commonly referred to as staged flaps as more than one stage is required to complete the repair. Interpolation flaps require careful planning, substantial time in executing, and significant, albeit temporary, disfigurement of the patient.

The first stage of an interpolation flap involves the design and creation of the flap, including repair of the secondary defect. The flap is designed around a substantial artery and therefore is able to support a larger mass of tissue than random flaps. Because the flap is used to repair defects distant from the donor site, the vascular pedicle must temporarily be left in place to ensure adequate blood supply. The distal end of the flap is thinned to match the depth of the defect and sutured in place. The area is bandaged and kept moist. The second stage generally takes place 2- to 3-weeks later, by which time the flap has established a local blood supply from the donor site. The pedicle is then divided from the donor site and the proximal portion of the flap is secured into the original defect. Because of granulation tissue formation, this portion of the flap may need to be thinned out subcutaneously to approximate the depth of the defect. The pedicle is also separated from the donor site, which will then require further steps for complete repair.

PARAMEDIAN FOREHEAD FLAP

The paramedian forehead flap is useful to repair large, deep nasal defects that may or may not require cartilage grafts. Tissue is mobilized from the forehead, based on one of the supratrochlear arteries, and transposed to repair large distal nasal defects with the pedicle remaining attached in the glabellar region (Fig. 203-33). The supratrochlear artery is located at the medial border of the eyebrow, approximately 1.5 to 2 cm from the midline.

The aesthetics of the repair are often improved when the defect is enlarged to include the total cosmetic subunit. The portion of the flap that will fill the defect is the superior portion closest to the hairline;

Figure 203-32 **A-E,** Execution of a medially based bilobed transposition flap. The tertiary defect is closed side to side, the secondary defect is filled with the second lobe of the flap, and the primary defect is filled with the first lobe of the flap. When used in this location, mobility and flap survival are improved when the flap is undermined below the nasalis muscle.

the width here should be equal to the widest portion of the defect, although the pedicle itself need be no wider than 1 to 1.5 cm. Its height must be equal to the distance from the base of the flap to the distal edge of the defect. In designing the flap, it is important that the vertical height of the forehead is able to accommodate the necessary length of the flap. The tissue is rotated approximately 180° around its pedicle and should be rotated medially as to minimize obscuration of the medial visual field of the ipsilateral eye; therefore, the flap will require less rotation if it is harvested from the forehead supplied by the supratrochlear artery contralateral to the defect.

The donor site is undermined and closed primarily as far superiorly as it will close. The distal aspect of the flap is debulked to the depth of the defect and secured at the distal margin with sutures. The proximal margin, by design, cannot be secured until the pedicle is divided. The donor site is repaired with a side-to-side closure, resulting in a long linear scar. The superior portion of the defect will be the widest, as it is here that the width of the defect must be accommodated,

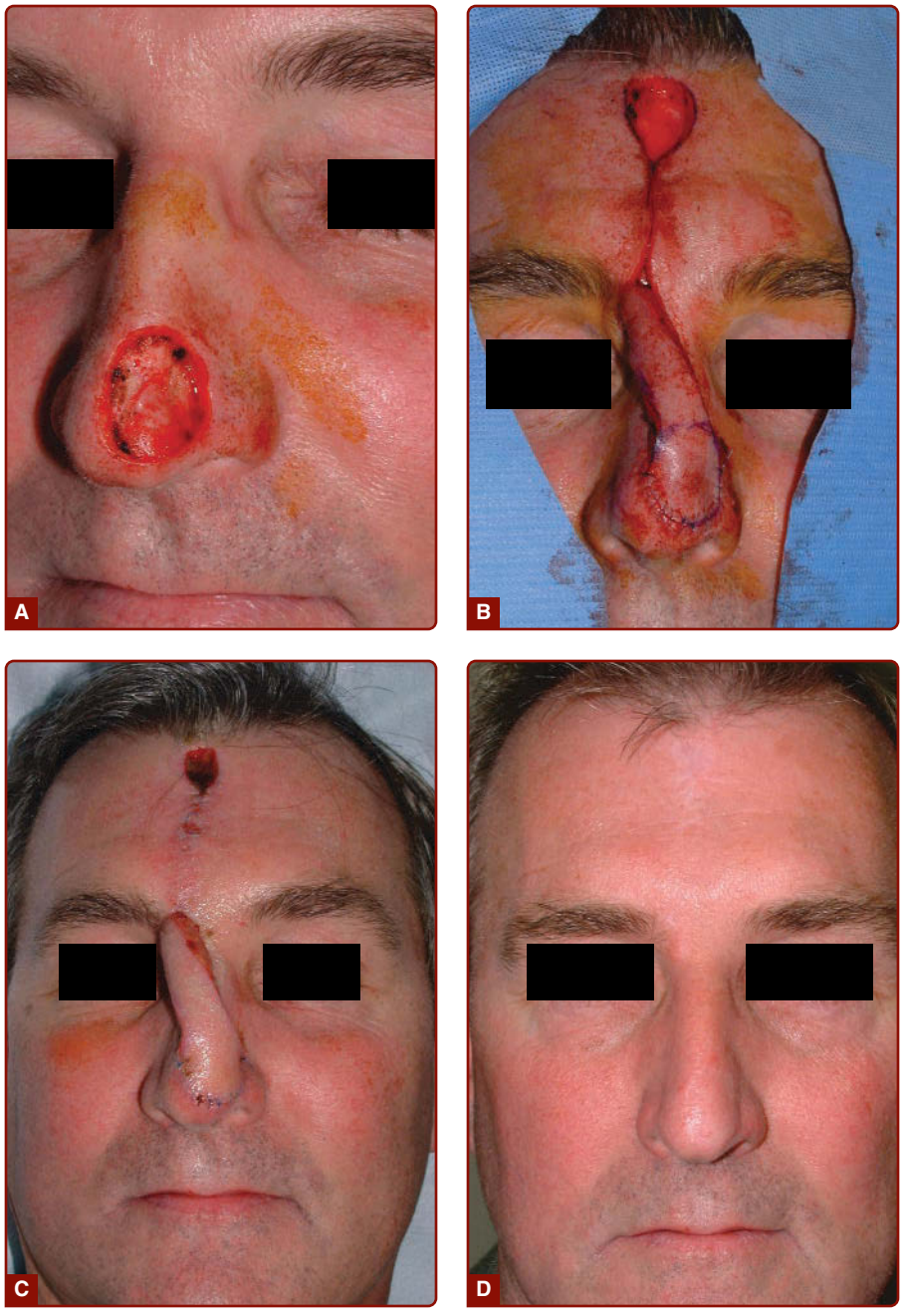

Figure 203-33 **A-D,** Paramedian forehead flap. For deep defects on the nose, a pedicled flap is created on the forehead based on the hearty vasculature of the supratrochlear arterial system and rotated down into place. The pedicle is divided and removed approximately 3 weeks after the inset of the flap (**C**).

and thus, generally this portion of the wound is too tight to be closed and is left to heal by secondary intention. The pedicle should be circumferentially wrapped with Vaseline or Xeroform gauze or Surgicel to prevent desiccation.

The second stage takes place 3 weeks subsequently. The pedicle is separated from the brow, the wound edges are freshened, and the donor defect is closed. After the pedicle is separated from the defect, the tissue is further debulked and trimmed, and the remaining edge is secured.

NASOLABIAL INTERPOLATION FLAP

This flap is used to repair complex defects of the ala, particularly in instances when cartilage grafting is also required to restore the structural integrity of the alar rim. The flap is harvested from the medial cheek and nasolabial fold and is based on branches of the angular artery (Fig. 203-34).

The aesthetics of the repair is often improved when the defect is enlarged to include the entire alar lobule. The flap is designed around a pedicle that will be

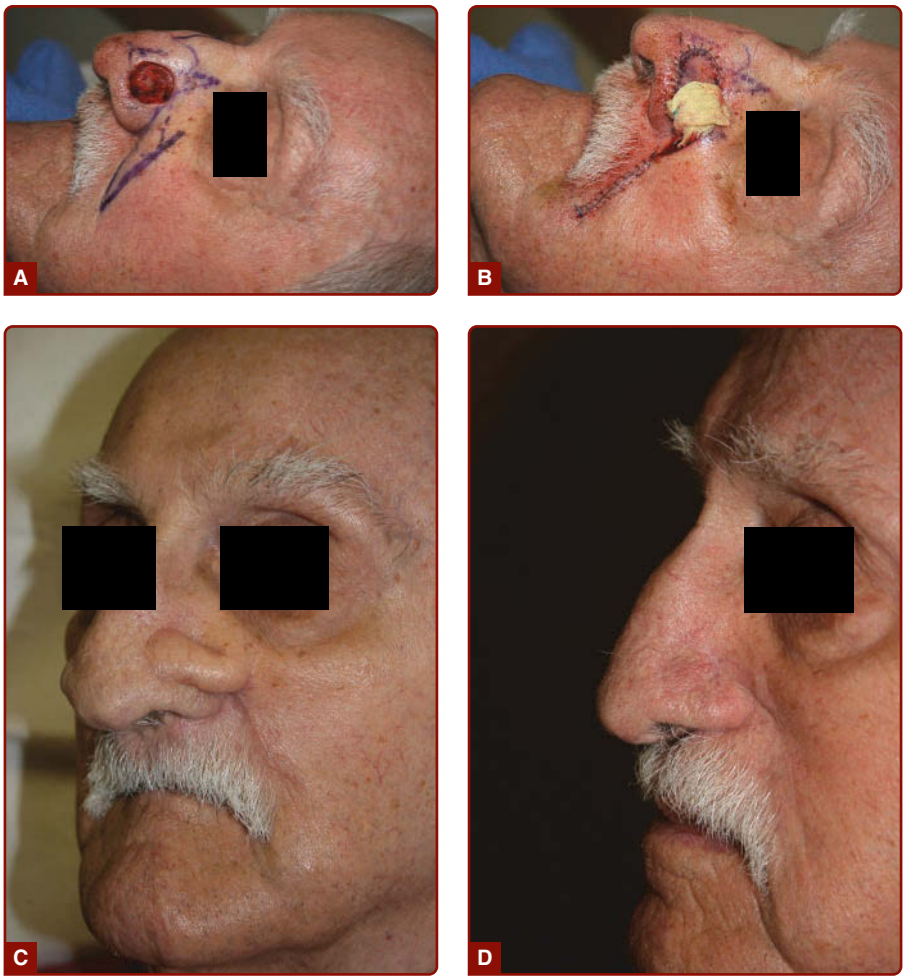

Figure 203-34 **A-D,** Nasolabial interpolation flap. The pedicle is created from excess skin lateral to the nasolabial fold and rotated into the defect. The pedicle is divided and removed approximately 3 weeks after the inset of the flap (c).

placed at the alar groove, extending as an ellipse that will be easily closed in the nasolabial fold. Through-and-through nasal defects will require the repair of the mucosa, and thus, the width of the flap must take this into account. This myocutaneous flap is dissected from the donor site, rotated downwardly, debulked and trimmed, and secured to the widely undermined defect.

As with the paramedian forehead flap, the pedicle may be wrapped with Vaseline or Xeroform gauze or Surgicel. Three weeks later, the pedicle is separated, the wound edges are freshened, and the donor defect is closed. After the pedicle is separated from the defect, the tissue is further debulked and trimmed, and the remaining edge is secured.

The reverse nasolabial flap, also known as a *Spear's flap*, is employed when the defect involves the entire ala. The motion of this flap is an upward rotation, opposite of the traditional nasolabial interpolation flap.

ABBÉ FLAP

The Abbé flap is also known as the *lip-switch flap* and is reserved for repair of large, deep defects, typically of the upper lip. It is particularly useful for defects that involve up to half of the lip without crossing the midline and those that penetrate into the muscularis. The Abbé flap is harvested from the ipsilateral lower lip and is based on the inferior labial artery. This artery is located deep to or within the orbicularis oris muscle and runs along the mucosal aspect of the vermillion border.[39]

The vermillion border and flap design must be properly marked out. The defect should be full thickness (including muscularis and oral mucosa) and may be enlarged to encompass the total cosmetic unit, which includes the ipsilateral upper cutaneous lip. The flap, also designed to be full-thickness to fill the enlarged defect, is rotated upon a vascular pedicle that makes up the lateral aspect of the flap. The inferior labial artery will be visualized as it is transected at the mobilized (medial) edge of the flap. The pedicle itself should be about 1 cm thick, containing the robust blood supply.

The donor site is undermined and closed first to facilitate the movement of the flap. It should be closed in layers as in the repair of a lip wedge resection: mucosa, muscularis, subcutaneous, then cutaneous. The flap is rotated superiorly and also inset with a layered closure.

Careful attention should be given to aligning the vermillion borders at the donor site and defect.

The pedicle of the Abbé flap should not be circumferentially wrapped, but kept moist with occlusive ointment. As with other interpolation flaps, the pedicle will remain in place for at least 3 weeks. During this time, the oral aperture will be significantly distorted, and the patient must be counseled. The pedicle is divided and the final repair takes place, again with careful attention to the placement of the vermillion borders.

RETROAURICULAR FLAP

The retroauricular flap is a 2-staged interpolation flap useful for large defects of the helix. Defects in this location typically involve the perichondrium and are not suitable for grafts. This flap is considered a random flap as it is not based on a large named artery. It is harvested from the richly vascularized skin of the postauricular scalp and is advanced over intervening intact skin to fill the helical defect; the pedicle remains attached to the posterior scalp (Fig. 203-35). The flap

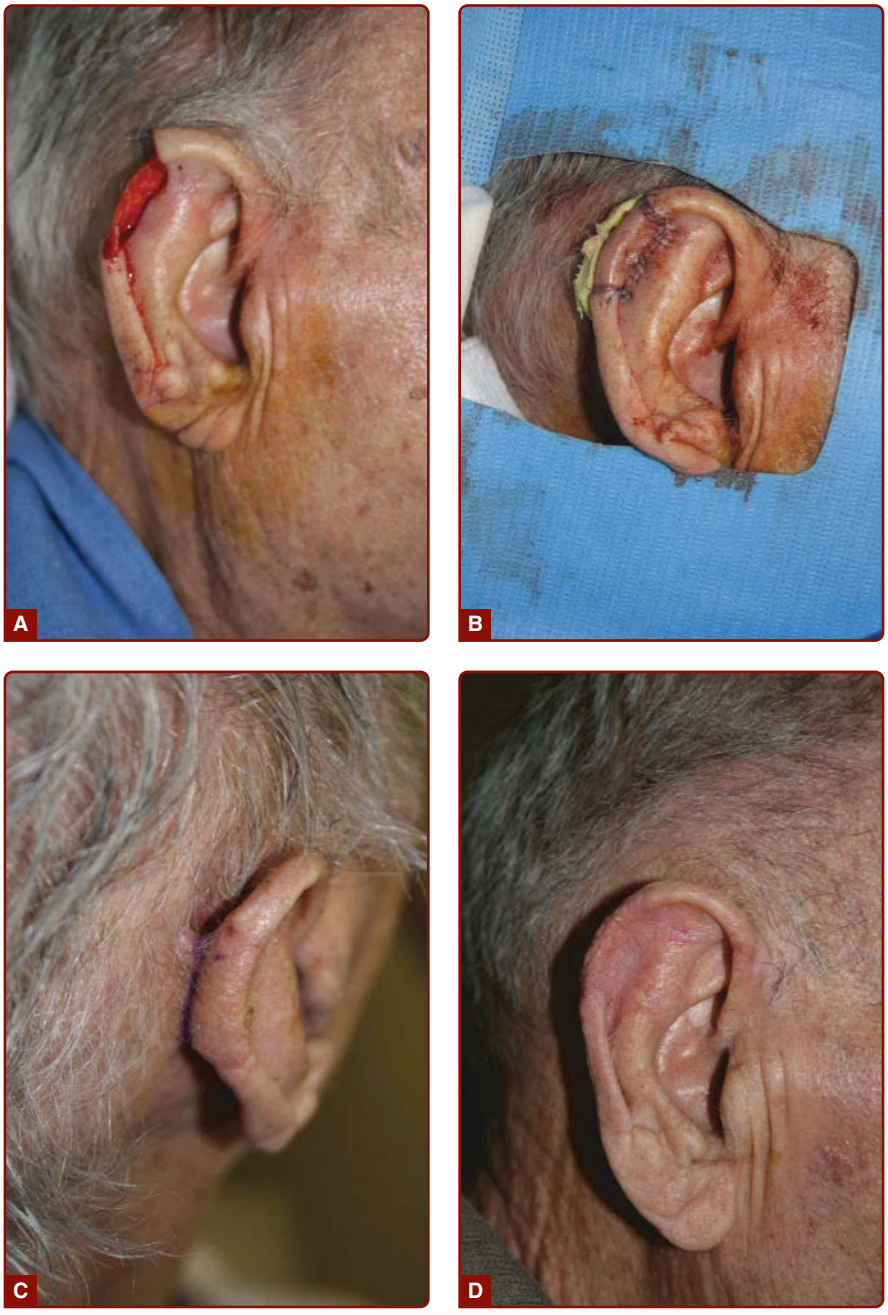

Figure 203-35 **A-D,** Retroauricular pedicle flap. A pedicled flap is developed posterior to the ear in a shape similar to the U-shaped advancement flap. The flap is advanced over the postauricular sulcus and over the auricular cartilage of the helix and sutured into place. The pedicle is divided and set back into place 3 weeks after the inset of the flap (**C**). The area surrounding the postauricular sulcus is allowed to heal in by second intention.

should be thinned to match the depth of the defect and carefully sewn into place. The pedicle is circumferentially dressed, and the patient is warned of likely postoperative bleeding and discomfort. The donor site is not repaired until pedicle take-down and often, because of its inconspicuous location, is allowed to heal secondarily.

GRAFTS

Skin grafts are transplanted skin from a donor to recipient site with the goal of closing a surgical defect or wound. They are typically used in reconstruction after removal of a cutaneous malignancy; however, they are also used in the treatment of chronic skin ulcerations, full-thickness burns, epidermolysis bullosa, and vitiligo. Grafts are completely detached from the donor site and receive all nutrients from the wound bed of the recipient site. The 3 basic types of skin grafts are full-thickness skin grafts (FTSG), split-thickness skin grafts (STSG), and composite grafts. FTSGs consist of epidermis with full-thickness dermis and preserved adnexa. STSGs consist of epidermis with partial-thickness dermis with loss of adnexa. Composite grafts are full-thickness skin grafts with cartilage attached to the graft.

Skin grafts are also categorized by their donor origin. These include autografts (donor = recipient), allografts (human to human), and xenografts (animal to human). Autografts are most commonly used in dermatology. Allografts and xenografts serve to protect and debride the wound and stimulate healing. They are commonly used for burn and chronic wounds.

Because the graft is completely separated from its blood source, it is essential for the transferred tissue to develop a new vascular supply from the recipient wound bed.

STAGES OF WOUND HEALING IN GRAFTS

- *Plasma Imbibition:* First 24 hours—plasmatic imbibition or ischemia: the graft affixes to the recipient bed via fibrinous material
- *Inosculation:* 48 to 72 hours—anastomosis and proliferation of preexisting vessels of the graft and recipient wound base
- *Revascularization:* 4 to 7 days—growth and proliferation of vessels from the base. Blood and lymphatic flow begin, leading to the reestablishment of full circulation.
- *Reinnervation:* 2 weeks to 1 year—sensory reinnervation occurs from the periphery to the center of the graft, and may never be fully restored.

Stress on the wound should be avoided to provide the best results. Overstimulation of the patient may lead to increased blood flow to graft site leading to fluid overload and disruption of vascularity. The patient should be advised not to undergo strenuous activity for at least 1 to 2 weeks. Mechanical shear forces, hematoma, seroma, or infection may prevent essential vascular growth and increase the rate of graft failure.

FULL-THICKNESS SKIN GRAFTS

FTSGs are useful for defects in which complex linear closures or a flap would not be suitable, where close monitoring of the site is advisable, and in certain areas where they provide optimal aesthetic reconstruction. When possible, FTSGs are chosen over STSGs because of their similarity in thickness and texture to surrounding skin and their relative lack of significant wound contraction. Because STSGs generally result in a depressed, hypopigmented, scar without normal epidermal texture, they are reserved for larger wounds that cannot be covered with FTSGs. When wounds are too deep for even an FTSG to cover without creating a depression (when the depth of the wound exceeds the thickness of a graft), secondary intention healing may be employed for a period of time to build the base of the wound up to the point where an FTSG would completely fill the defect.

FTSGs have essential nutrient requirements and, therefore, should not be placed at a site where the vascular supply is poor. FTSGs will not survive if transplanted directly over bone, cartilage, or tendon.

DETERMINING DONOR SITE

When planning your graft, there are many factors to be taken into consideration. The donor site should be well matched to the skin surrounding the defect in terms of thickness, texture, sun exposure, and adnexal structures.[40] Donor sites can be differentiated by thickness, for example, thin (eyelids, postauricular sulcus), medium thickness (preauricular, conchal, cervical), and thick (supraclavicular, clavicular, nasolabial fold, forehead). However, examining for tissue similarity, such as adnexal structures and sun exposure, is also pertinent.

Common sites for FTSGs for nasal defects include preauricular, postauricular, nasolabial fold, forehead, and conchal bowl skin. Preauricular skin can be used to repair most nasal defects, has similar sun exposure and skin quality, and heals with minimal scar visibility.[41,42] Conchal bowl grafts are particularly well matched for nasal tip and alar defects because of the similarity in texture and concentration of sebaceous glands (Fig. 203-36) as well as the ability to allow the donor site to heal by secondary intention.[43] Nasolabial fold and forehead skin offer excellent matches but leave secondary scars in more visible areas. Common donor sites for larger defects on the scalp and

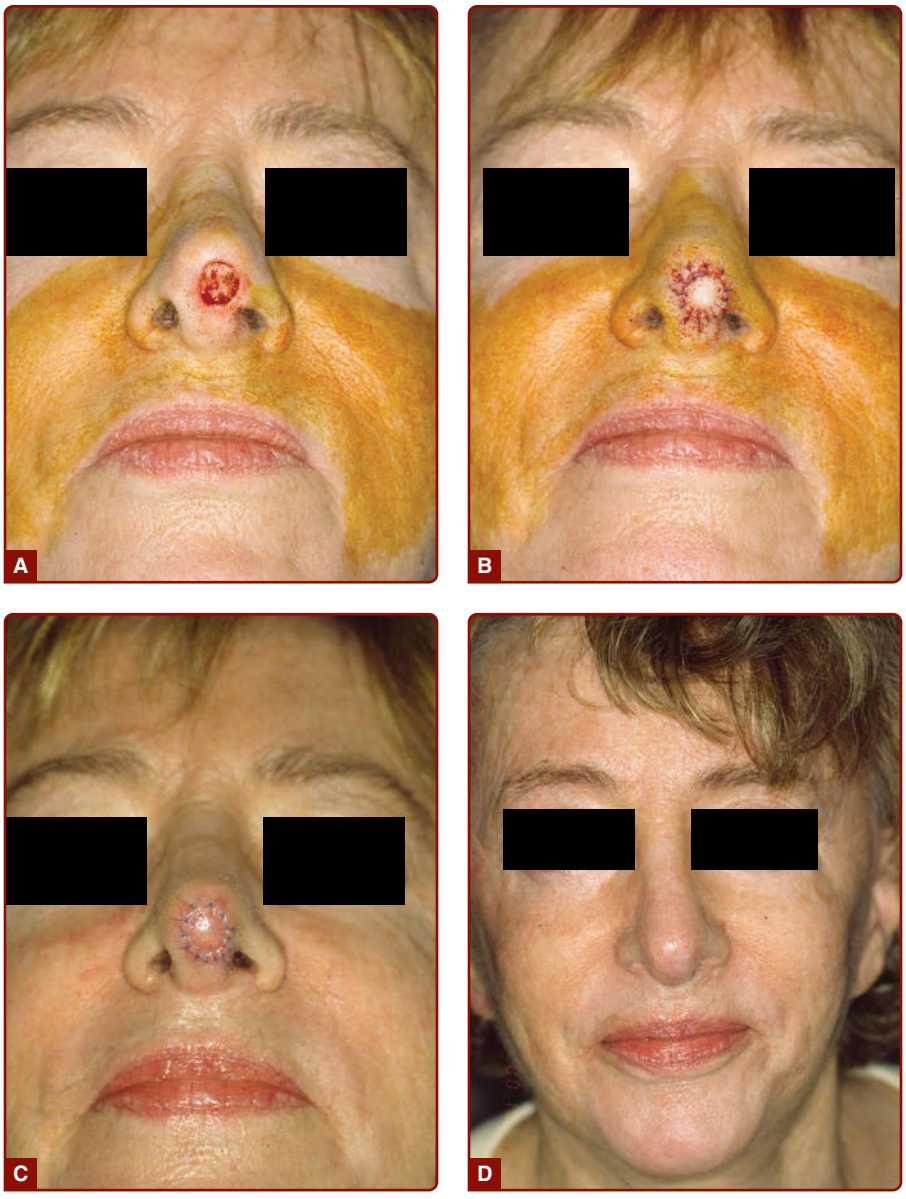

Figure 203-36 **A-D,** Conchal bowl full-thickness skin graft. The graft is harvested from the conchal bowl because, like the skin of the nasal tip and ala, the sebaceous density in the conchal bowl is high. The defect in the conchal bowl is allowed to heal by second intention.

forehead include the supraclavicular region, lateral neck, or inner arm.

HARVESTING

Once the donor site has been established, the graft is harvested. To ascertain the size and shape of the graft needed to fill a given defect, many surgeons will create a template using a nonstick dressing, pressing it against defect. The template is cut out and then traced with a marking pen onto the donor skin. Although some authors have recommended grafts be designed 10% to 20% larger than the defect to accommodate contraction of the graft skin once it is removed,[44] oversizing grafts can lead to unsightly pincushioning. For this reason, the authors size their grafts at or just under the size of the defect. If the donor site is to be closed primarily, an ellipse is planned around the designed graft (see section "Excisional Surgery").

Defatting the graft before securing it to the recipient bed is critical. The subcutaneous tissue is poorly vascularized and, therefore, hinders graft survival. Defatting can be performed with an iris scissors by trimming away the yellow fat to expose the shiny white dermis. If the area being repaired is uneven, thin areas of fat may be left on the graft to more closely approximate the natural contours. Alternatively, at times, it may be necessary to thin the dermis slightly to ensure similar thickness between graft and donor tissue. If this is the case, minimal thinning is recommended to avoid structural damage of adnexae. Once the graft has been prepared, it should be placed in the recipient bed as

soon as possible. The recipient bed should have good hemostasis without devitalizing the tissue with overuse of cautery.

Grafts generally need to be trimmed at the edges to ensure a perfect match to the donor site. Survival of the graft is also dependent on the surgical technique during placement. The graft must be manipulated and grasped gently.

Small-caliber nonabsorbable or fast-absorbing cat gut sutures are commonly used for FTSGs on the face. Insertion of sutures should be from graft to recipient tissue to minimize graft movement and best approximate wound edges. It is helpful to place the initial 4 sutures at intervals of approximately 90° from each other to ensure proper placement and to secure the graft. These are followed by interrupted sutures or, at times, running sutures to complete closure. When grafts are large or placed over concave areas, basting sutures help keep good graft to bed contact. This will stabilize the graft and minimize shearing forces. Several authors recommend the use of bolster dressings. Although bolster dressings may assist in prevention of hematomas and seromas, they also compromise vascularity and can increase the risk of necrosis.

For larger defects or those with exposed bone or cartilage at the periphery, a purse-string approach may be introduced. A purse-string suture is placed subdermally along the defect edges, then tightened to advance edges into the defect circumferentially. This technique helps protect exposed tissue as well as reduce the defect size, thereby allowing the surgeon to use a smaller graft.

Sutures should be removed in 1 week for grafts on the face. Healthy grafts are pink in color. Although a purple color indicates relative hypoxia, most grafts with this color will survive. A white color on the surface of a graft generally represents maceration and may do fine when no longer occluded. If the white color is full thickness, it may represent necrosis. Black grafts are necrotic. Gentle wound care without debridement is the best treatment for graft necrosis. The necrotic graft will act as a biologic wound dressing, promote dermal healing, and generally avoid contraction. Antibiotics should also be started to minimize the risk of infection.

BUROW'S/REGIONAL GRAFT

Burow's or regional grafts essentially use the Burow's triangle or dog-ear, often from a partial linear closure, to act as an FTSG (Fig. 203-37). This utilizes removed skin that might otherwise have been thrown away and eliminates the need for removing tissue from a separate donor site. Because these are often local grafts, the tissue match is generally excellent. Since a circular defect has a much larger surface area than a standard triangle taken in an elliptical closure, the triangle must be designed more like that of a V-to-Y advancement flap (island pedicle flap) with a wider and longer body.

SPLIT-THICKNESS SKIN GRAFTS

STSGs are composed of epidermis and partial dermis. Because these grafts are much thinner than FTSGs, they have a less rigorous demand for vascular support and have an increased survivability profile. Unfortunately, because they lack the full thickness of dermis and dermal appendageal structures, STSGs appear more like scar tissue than skin; they are depressed, hypopigmented, and have a shiny texture. They are used to cover large defects unable to be closed by other methods, to allow better wound bed surveillance, to line tubed pedicle flaps, or to resurface mucosa. STSGs are often harvested from the upper inner arm, thigh, or buttock. If small, STSGs may be harvested with a blade by hand. When they are larger, STSGs are harvested with a dermatome, which provides a more precise width and depth. Once the graft is obtained, it is placed in sterile saline on the meshing plate. Meshing is beneficial because it expands the donor tissue, allows wound exudate to drain preventing seroma and hematoma formation, and has been found to increase graft survival. Increased wound contraction and decreased cosmesis, however, are associated with meshing. After harvesting is complete, STSGs are placed over the defect and secured similarly to FTSG. For larger defects, surgical staples are often used to secure the graft.

STSG size can vary. They are categorized as thin (0.013-0.033 cm), medium (0.033-0.046 cm), or thick (0.046-0.076 cm). The amount of dermis present determines the chance of survival of the graft on a poor vascular bed. Generally, the thinner the graft, the higher the "take rate" but the poorer cosmesis. The donor site reepithelializes rapidly and relatively painlessly with the use of bio-occlusive dressings.

The main advantage of an STSG is that it survives even in locations with poor vascularization, such as over bone or cartilage. It also allows for early detection of tumor recurrence. Cosmetically, the final outcome of this graft is suboptimal with absent appendages, poor color match, and frequent wound contracture under the graft. For this reason, secondary intention healing and skin substitutes are often employed for defects once covered with STSGs. These methods avoid the wound care and generally unsightly appearance of the STSG harvest site.

PUNCH AND PINCH GRAFTS

A subset of STSGs includes punch and pinch grafts. These are useful for accelerating the healing phase of a chronic ulcer. Several grafts are harvested from a donor site and placed in the wound bed. Instruments used are a 4-mm punch for punch grafts or a scalpel (Weck knife) for pinch grafts. The rate of survival of these grafts is good if the site has meticulous postoperative care; however, the cosmetic outcome is suboptimal because of the variable thickness throughout the wound.

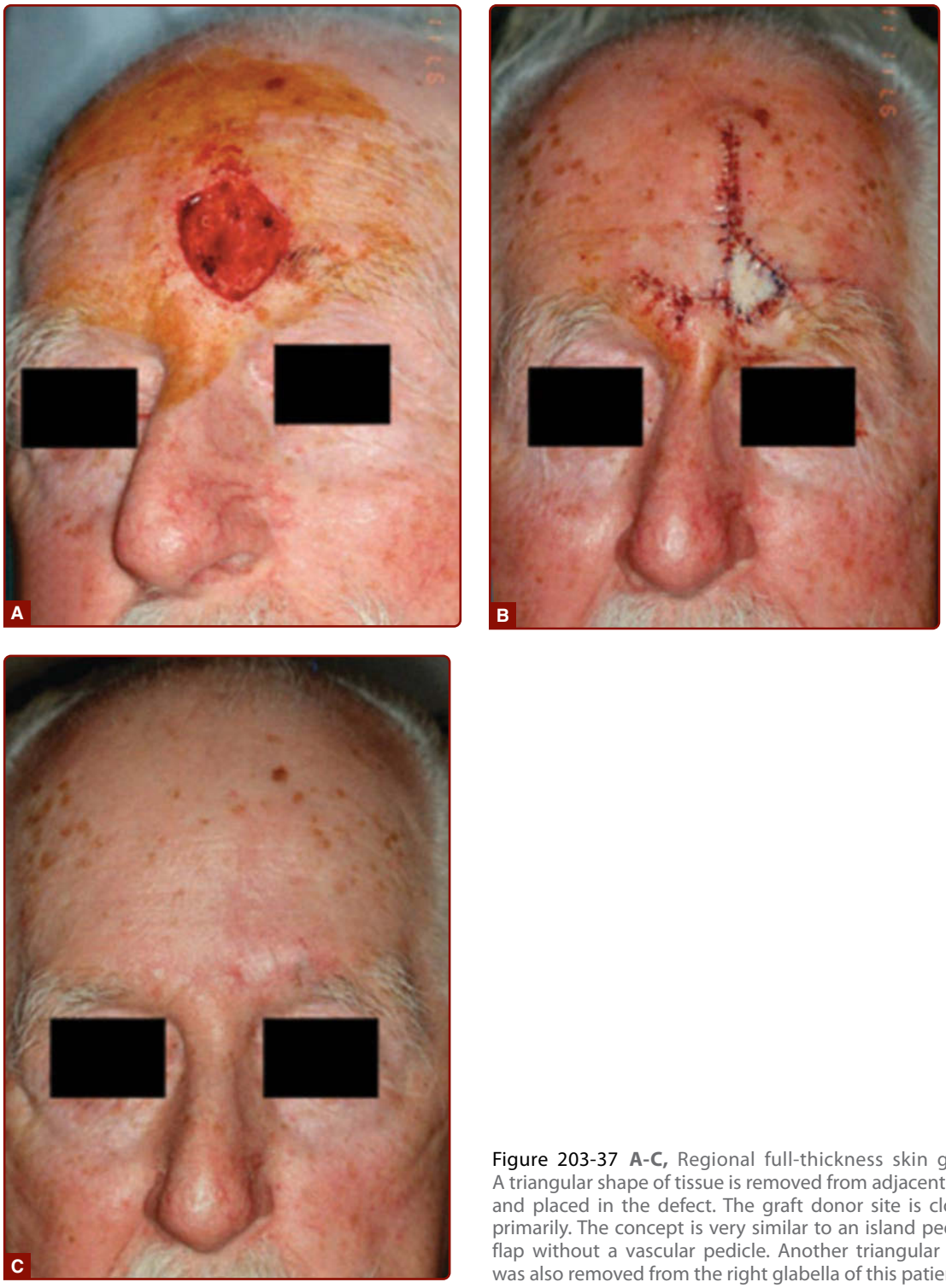

Figure 203-37 **A-C,** Regional full-thickness skin graft. A triangular shape of tissue is removed from adjacent skin and placed in the defect. The graft donor site is closed primarily. The concept is very similar to an island pedicle flap without a vascular pedicle. Another triangular area was also removed from the right glabella of this patient.

COMPOSITE GRAFTS

Composite grafts consist of 1 or more adjacent tissues, often involving a typical FTSG with underlying cartilage. Small full-thickness defects of the nasal ala and helical rim most commonly require such a graft. Donor sites for composite grafts frequently include the helix and conchal bowl. It is desirable to harvest the graft in a manner that allows the underlying cartilage to extend beyond overlying tissue. This extension allows for the cartilage to insert under the surrounding defect margins. Two small pockets are generally made across from each other at a level below the dermis in the recipient site to accommodate the cartilaginous wings on the composite graft. The cartilage may or may not

be sutured, and the remaining FTSG is sutured and secured as described earlier in this section. After being sutured into place, a composite graft with cartilage at its base receives its blood supply from its lateral margins only. Therefore, composite grafts should remain less than 2 cm^2, as a larger graft will not receive sufficient nutrients to allow its central portion to survive.[45] These grafts have the highest metabolic demand and therefore the highest rate of failure. Oral antibiotics against streptococcus and staphylococcus are recommended due to the high bacterial load of the nares. Pseudomonal coverage is often recommended for grafts performed on the ear.

FREE CARTILAGE GRAFTS

Free cartilage grafts consist of cartilage and perichondrium. They are commonly used to reconstruct defects on free margins such as the nasal tip, nasal ala, ear, and eyelid.[46] This type of graft assists in structural support (eg, prevent nasal valving) and retention of natural facial contours (eg, ala and helical rim). Elastic cartilage from the ear, versus hyaline cartilage from the nose, is the best for recontouring. A strip or disc of cartilage is usually harvested through an incision in the postauricular sulcus or conchal bowl. As is done with a composite graft, the strip of cartilage harvested is slightly longer than the size of the defect and the edges are inserted into pockets made under the dermis. The cartilage is sutured lightly into place with absorbable sutures. The site is then typically closed with a flap. Full-thickness skin grafts may be placed over very thin cartilage struts but as the size of the cartilage increases, the vascular supply to the graft becomes increasingly compromised and decreases graft survival. The addition of cartilage helps with structural support such as preventing collapse of the nasal valves, which results in disruption of air flow. It also helps retain the patient's original facial contours and prevents concavity and/or contraction of the repair.

SKIN SUBSTITUTES

Tissue that has been cultured or processed prior to grafting is known as a *skin substitute*. In addition to postsurgical wounds, they are being used for the treatment of burns and chronic ulcers to augment wound healing. There are 3 main types of skin substitutes: epidermal, dermal, and composite (combination of epidermal and dermal). They can be further categorized as autologous, allogenic, or xenogenic. Cost and shelf-life should be considered when using a skin substitute.[47]

Dermal xenografts, most commonly porcine xenografts, are frequently used in the dermatologic surgery. They are helpful for the repair of large defects, may decrease postoperative pain, and have a long shelf-life.[47] The dressings promote granulation and need minimum post-operative care, therefore are often helpful in elderly or debilitated patients. Dermal allogenic skin substitutes are developed from cadaver skin or neonatal foreskin-harvested allogenic fibroblasts. These are helpful in replacing the dermis in a defect, minimize wound contraction, and can be covered by an STSG. They can be helpful for the treatment of full thickness non-healing ulcers, fasciotomy wounds and other chronic wounds.

Autologous epidermal skin substitutes are derived by culturing the patient's own keratinocytes. These dressings are good for covering a wound and stimulating the healing process. Allogenic epidermal skin substitutes are keratinocytes from human foreskin or cadavers, they provide superficial and temporary coverage.

Composite skin substitutes, are bilayered, containing both epidermis and dermis and are made from allogenic neonatal foreskin-derived fibroblasts and keratinocytes and bovine collagen. They are useful for protection of large wounds where donor tissue is insufficient to cover.

POSTOPERATIVE CARE

Meticulous postoperative wound care is necessary to ensure an optimal outcome. Attention must be made to limit postoperative bleeding of all surgical wounds, particularly flaps and grafts, as hemorrhage or hematoma formation may jeopardize tissue survival and increase the risk of infection. Meticulous intraoperative hemostasis and good postoperative compression dressings are very important in minimizing postoperative bleeding. A pressure dressing should be applied and left intact for 24 to 48 hours. This dressing includes a layer of ointment applied directly to the wound, a nonstick bandage such as Telfa, gauze for pressure, and surgical tape. Finally, elastic dressing materials, such as Flexinet or Coban, may be helpful for wounds on the scalp or extremities.

For the aforementioned procedures, it is important that the wound be kept clean, moist, and covered until suture removal. This will eliminate desiccation and promote reepithelialization, reduce bacterial contamination, and aid in hemostasis. Verbal and written instructions regarding home wound care should be reviewed and then provided in writing to the patient. After removal of the pressure dressing, the wound should be cleaned once or twice daily with attention to gently removing any crust and debris that may form. This is followed by a layer of ointment. A bland, nonmedicated ointment such as petrolatum or aquaphor is preferred over topical antibiotic products such as neomycin. The use of these topical antibiotics following cutaneous surgery increases the risk of contact dermatitis[48] without imparting a significant reduction in infection rates.[49] The patient should be advised to limit activity for 1 to 2 weeks after surgery, particularly, movement that stretches or adds tension to the wound area and may result in wound dehiscence or a widened scar.

The signs and symptoms of hemorrhage and wound infection should be reviewed as early intervention can reduce serious complications. To better prepare patients, it is helpful to educate him or her about what to expect during normal wound healing. The patient should be provided with the physician's contact information and should be encouraged to call with any questions or concerns.

COMPLICATIONS OF DERMATOLOGIC SURGERY

Early complications of all forms of cutaneous surgery and closure are bleeding, pain, and infection. Bleeding typically occurs in the first 24 hours after surgery and must be addressed promptly. Low-flow ooze may be treated by compression. Patients should be instructed to apply direct pressure for at least 20 minutes without peeking to see if it is working. Frank arterial hemorrhage or large hematoma formation will require partial or complete suture removal, evacuation of clot, and exploration of the wound to allow visualization and closure of the bleeding vessel. Patients should be instructed to call if they see an enlarging mass below or around the wound.

Pain is usually manageable with nonnarcotic pain relievers such as acetaminophen. Acetaminophen may be administered at the time of surgery and continued for 24 hours to reduce the risk of postoperative discomfort. It is generally easier to get ahead of pain than it is to catch up to it. Patients should be instructed to avoid nonprescribed nonsteroidal anti-inflammatory medication for up to 48 hours postoperatively to reduce bruising and bleeding from platelet dysfunction. Although more severe pain may require the administration of prescription pain medication, it should be investigated to be sure more significant issues such as infection or hematoma are not occurring.

Signs of infection usually will occur within the first week after surgery and include increased pain, erythema, and heat around the wound, purulent and sometimes foul-smelling drainage, and fever. When wound infection is suspected, a culture must be obtained for pathogen identification and antibiotic susceptibility, and treatment with a broad-spectrum antibiotic should be initiated. Common pathogens on skin and mucosal surfaces are gram-positive cocci, notably staphylococci or, less commonly, streptococci. However, gram-negative aerobes and anaerobic bacteria contaminate skin in the groin/perineal areas. Gram-negative bacilli also may be cultured from ear and lower leg wounds, particularly in diabetic patients. Methicillin-resistant *Staphylococcus aureus* (MRSA) infections are increasing dramatically in frequency and should be vigilantly watched for.[50]

An expected consequence of surgery is the formation of a scar. Although the goal of reconstructive surgery is to minimize the appearance of the resultant scar, at times they may widen, or even become hypertrophic. With time, hypertrophic scars tend to flatten and soften. Their course may be hastened with the administration of intralesional steroids or 5-fluorouracil and a variety of fractional and vascular laser devices. In areas under tension and/or motion, such as the upper back and arms over the deltoids, scars may spread or become atrophic. Although scar spread may become less noticeable with time as the initial dark pink color fades, the width generally does not change significantly. Erythema and telangiectasia often form around scars during the healing phase and may persist for extended periods of time. Highly vascular areas (rosacea) and those under high tension are more likely to develop persistent erythema and telangiectasia. This can be effectively treated with lasers, such as the pulsed dye laser, KTP, or intense pulsed light.

Spitting sutures or suture granulomas from buried sutures may occur. Placing the buried dermal sutures in the appropriate plane will help minimize the occurrence. If the spitting suture becomes visible it may be trimmed out, but it is unadvisable to aggressively go after these as a scar may result.

In the case of a flap repair, additional complications may be encountered. In the early postoperative period, partial or complete flap necrosis may occur. This may be due to inadequate blood supply from the wound bed, which is more commonly encountered in smokers, or when an underlying hematoma is present. Flap design may also lead to vascular compromise and flap necrosis, as when the pedicle is too narrow to support the mass of the flap, when there is too much torque, or when there is too much tension at the flap's leading edge. Areas of partial necrosis will heal secondarily and may lead to a less appealing scar, which can be revised after wound healing is complete. Later in the postoperative period, a trapdoor deformity may occur in which the center of the flap becomes elevated and the suture line becomes depressed. It may resolve spontaneously over a period of 6–12 months. However, if the trapdoor effect or pin-cushioning persists, it may respond to intralesional steroids, 5 -fluorouracil, flap elevation with flap thinning, and/or fractional ablative lasers or dermabrasion. The risk of forming a trapdoor may be minimized with wide undermining around the primary defect, proper thinning and sizing of the flap, and the use of a sharp geometric shape for the flap (not rounded edges).

Complications of grafting include graft failure in the early postoperative period and results from inadequate nutrient supply to the tissue. This is often due to poor vascular health of the wound bed as encountered in smokers or diabetics, inadvertent shearing forces or trauma to the graft, hematoma or seroma formation, or infection. Later complications typically are attributed to the cosmetic appearance of the graft, usually related to mismatch of thickness, color, or texture. If the cosmetic result is unsatisfactory, fractional ablative or nonablative treatment or dermabrasion may be considered 6 to 12 weeks after graft placement. Contraction may be considerable, particularly with thinner grafts, which may result in the distortion of free margins.

MONITORING AND FOLLOWUP

If nonabsorbable epidermal sutures are placed, the patient should return for suture removal at the appointed time. If the defect has been left to heal secondarily, the wound should be checked in approximately 4 weeks. The surgical site should then again be evaluated 3 to 4 months postoperatively to ensure wound healing is progressing as expected. Patients who have been treated for malignancy should be counseled regarding proper followup for full skin examination to monitor for new or recurrent skin cancers.

ACKNOWLEDGMENTS

We would like to thank Melanie Kingsley, MD, for her help and contributions with earlier versions of this chapter.

REFERENCES

1. Goldberg LH, Alam M. Elliptical excisions: variations and the eccentric parallelogram. *Arch Dermatol*. 2004; 140:176-180.
2. Brodland DG, Zitelli JA. Surgical margins for excision of primary cutaneous squamous cell carcinoma. *J Am Acad Dermatol*. 1992;27:241-248.
3. Sobanko JF. Optimizing design and execution of linear reconstructions on the face. *Dermatol Surg*. 2015; 41(suppl 10):S216-S228.
4. Borgstrom S, Sandblom P. Suture technic and wound healing; an investigation based on animal experiments. *Ann Surg*. 1956;144:982-990.
5. Chow S, Bennett RG. Superficial head and neck anatomy for dermatologic surgery: critical concepts. *Dermatol Surg*. 2015;41(suppl 10):S169-S177.
6. Moody BR, McCarthy JE, Sengelmann RD. The apical angle: a mathematical analysis of the ellipse. *Dermatol Surg*. 2001;27:61-63.
7. Boyer JD, Zitelli JA, Brodland DG. Undermining in cutaneous surgery. *Dermatol Surg*. 2001;27:75-78.
8. Chen DL, Carlson EO, Fathi R, et al. Undermining and hemostasis. *Dermatol Surg*. 2015;41(suppl 10): S201-S215.
9. Harris DR. Healing of the surgical wound. I. Basic considerations. *J Am Acad Dermatol*. 1979;1:197-207.
10. Zitelli JA, Moy RL. Buried vertical mattress suture. *J Dermatol Surg Oncol*. 1989;15:17-19.
11. Wong NL. Review of continuous sutures in dermatologic surgery. *J Dermatol Surg Oncol*. 1993;19:923-931.
12. Guyuron B, Vaughan C. A comparison of absorbable and nonabsorbable suture materials for skin repair. *Plast Reconstr Surg*. 1992;89:234-236.
13. Alam M, Posten W, Martini MC, et al. Aesthetic and functional efficacy of subcuticular running epidermal closures of the trunk and extremity: a rater-blinded randomized control trial. *Arch Dermatol*. 2006; 142:1272-1278.
14. Speer DP. The influence of suture technique on early wound healing. *J Surg Res*. 1979;27:385-391.
15. Zitelli JA. Wound healing by secondary intention. A cosmetic appraisal. *J Am Acad Dermatol*. 1983;9: 407-415.
16. Mott KJ, Clark DP, Stelljes LS. Regional variation in wound contraction of Mohs surgery defects allowed to heal by second intention. *Dermatol Surg*. 2003; 29:712-722.
17. Lam TK, Lowe C, Johnson R, et al. Secondary intention healing and purse-string closures. *Dermatol Surg*. 2015; 41(suppl 10):S178-S186.
18. Milton SH. Pedicled skin-flaps: the fallacy of the length: width ratio. *Br J Surg*. 1970;57:502-508.
19. Daniel RK, Williams HB. The free transfer of skin flaps by microvascular anastomoses. An experimental study and a reappraisal. *Plast Reconstr Surg*. 1973;52: 16-31.
20. Stell PM. The pig as an experimental model for skin flap behaviour: a reappraisal of previous studies. *Br J Plast Surg*. 1977;30:1-8.
21. Heniford BW, Bailin PL, Marsico RE. Field guide to local flaps. *Dermatol Clin*. 1998;16:65-74.
22. Dzubow LM. Flap dynamics. *J Dermatol Surg Oncol*. 1991;17:116-130.
23. Kruter L, Rohrer T. Advancement flaps. *Dermatol Surg*. 2015;41(suppl 10):S239-S246.
24. Antia NH, Buch VI. Chondrocutaneous advancement flap for the marginal defect of the ear. *Plast Reconstr Surg*. 1967;39:472-477.
25. Mellette JR, Harrington AC. Applications of the crescentic advancement flap. *J Dermatol Surg Oncol*. 1991; 17:447-454.
26. Tomich JM, Wentzell JM, Grande DJ. Subcutaneous island pedicle flaps. *Arch Dermatol*. 1987;123: 514-518.
27. Goldberg LH, Alam M. Horizontal advancement flap for symmetric reconstruction of small to medium-sized cutaneous defects of the lateral nasal supratip. *J Am Acad Dermatol*. 2003;49:685-689.
28. Onishi K, Okada E, Hirata A. The Rintala flap: a versatile procedure for nasal reconstruction. *Am J Otolaryngol*. 2014;35:577-581.
29. Dzubow LM. The dynamics of flap movement: effect of pivotal restraint on flap rotation and transposition. *J Dermatol Surg Oncol*. 1987;13:1348-1353.
30. Rieger RA. A local flap for repair of the nasal tip. *Plast Reconstr Surg*. 1967;40:147-149.
31. Subramanian N. Reconstructions of eyelid defects. *Indian J Plast Surg*. 2011;44:5-13.
32. LoPiccolo MC. Rotation flaps—principles and locations. *Dermatol Surg*. 2015;41(suppl 10):S247-S254.
33. Humphreys TR. Use of the "spiral" flap for closure of small defects of the nasal ala. *Dermatol Surg*. 2001; 27:409-410.
34. Limberg AA. Design of local flaps. *Mod Trends Plast Surg*. 1966;2:38-61.
35. Bray DA. Clinical applications of the rhomboid flap. *Arch Otolaryngol*. 1983;109:37-42.
36. Masson JK, Mendelson BC. The banner flap. *Am J Surg*. 1977;134:419-423.
37. Zitelli JA. The bilobed flap for nasal reconstruction. *Arch Dermatol*. 1989;125:957-959.
38. Hove CR, Williams EF, Rodgers BJ. Z-plasty: a concise review. *Facial Plast Surg*. 2001;17:289-294.
39. Schulte DL, Sherris DA, Kasperbauer JL. The anatomical basis of the Abbé flap. *Laryngoscope*. 2001; 111:382-386.
40. Ratner D. Skin grafting. *Semin Cutan Med Surg*. 2003; 22:295-305.

41. Breach NM. Pre-auricular full-thickness skin grafts. *Br J Plast Surg*. 1978;31:124-126.
42. Corwin TR, Klein AW, Habal MB. The aesthetics of the preauricular graft in facial reconstruction. *Ann Plast Surg*. 1982;9:312-315.
43. Rohrer TE, Dzubow LM. Conchal bowl skin grafting in nasal tip reconstruction: clinical and histologic evaluation. *J Am Acad Dermatol*. 1995;33:476-481.
44. Hill TG. Contouring of donor skin in full-thickness skin grafting. *J Dermatol Surg Oncol*. 1987;13:883-888.
45. Konior RJ. Free composite grafts. *Otolaryngol Clin North Am*. 1994;27:81-90.
46. Adams C, Ratner D. Composite and free cartilage grafting. *Dermatol Clin*. 2005;23:129-140, vii.
47. Cronin H, Goldstein G. Biologic skin substitutes and their applications in dermatology. *Dermatol Surg*. 2013; 39:30-34.
48. Gette MT, Marks JG, Maloney ME. Frequency of postoperative allergic contact dermatitis to topical antibiotics. *Arch Dermatol*. 1992;128:365-367.
49. Smack DP, Harrington AC, Dunn C, et al. Infection and allergy incidence in ambulatory surgery patients using white petrolatum vs bacitracin ointment. A randomized controlled trial. *JAMA*. 1996;276:972-977.
50. Cruse PJ, Foord R. The epidemiology of wound infection. A 10-year prospective study of 62,939 wounds. *Surg Clin North Am*. 1980;60:27-40.

Chapter 204 :: Mohs Micrographic Surgery

:: Sean R. Christensen & David J. Leffell

AT-A-GLANCE

- Mohs micrographic surgery is a specialized form of skin cancer excision in which one physician functions as surgeon and pathologist, verifying surgical margins intraoperatively in successive stages.
- Mohs surgery achieves the highest cure rate and is the treatment of choice for basal cell and squamous cell carcinoma with high risk of recurrence or progression and for tumors in anatomic areas where tissue sparing is critical.
- Mohs surgery may also be used for treatment of melanoma in situ and other skin cancers in which pathologic margins can be verified on frozen sections.
- Mohs surgery optimizes functional and cosmetic outcomes after skin cancer removal, has a low rate of postoperative complications, and is highly cost-effective for appropriately selected tumors.

INTRODUCTION AND BACKGROUND

Complete surgical removal is the cornerstone of therapy for solid tumors. This is particularly true for nonmelanoma skin cancers, which have a low risk of metastasis. Complete surgical removal may be difficult to achieve, however, for skin cancers with extensive subclinical spread and for lesions adjacent to vital structures such as the eye. Staged excision or intraoperative pathologic examination of margin status have been used to help ensure adequate surgical margins, but these techniques are limited by logistical hurdles in coordination and communication between the surgeon and pathologist, the inability to precisely map areas of positive margins in three dimensional space, and the inherent limitation of standard pathologic specimen processing, which only examines a small, noncontiguous fraction of the surgical margin. In the 1930s and 1940s, Dr. Frederic Mohs developed a novel method of skin cancer excision using zinc chloride paste to chemically fix the tissue in situ on the patient followed by staged excision with rapid pathologic examination of the surgical margins by the operating physician.[1] The procedure was originally named *chemosurgery* because of the use of a chemical fixative (chemotherapy was not used). In his seminal report, Dr. Mohs reported an overall cure rate of 93% in 425 cases of nonmelanoma skin cancer, many of which were advanced lesions not amenable to standard surgical excision.

In the 1970s and 1980s, the use of chemical fixative was gradually replaced with frozen section analysis of unfixed (fresh) tissue, which allowed the procedure to be completed in hours rather than days. Application of the technique grew rapidly in subsequent years, as the superiority of the procedure over other forms of treatment was established in the peer-reviewed medical literature. Today, the technique known as Mohs micrographic surgery (MMS) is used for treatment of approximately one in five skin cancers in the United States.[2] It is the standard of care for basal cell carcinoma (BCC) and squamous cell carcinoma (SCC) with a high risk of recurrence or in sensitive anatomic locations or where clinical margins are difficult to ascertain. It is routinely indicated for treatment of other cutaneous malignancy as well. The inherent advantages of complete microscopic surgical margin analysis and precise tumor mapping allow for the highest possible cure rate while maximizing tissue preservation and optimizing cosmetic and functional outcomes. Additionally, because MMS is an office-based procedure, the high cost of hospital-based or ambulatory surgery center treatment is avoided, and patient satisfaction is enhanced.

OPERATIVE TECHNIQUE

The fundamental advantage of MMS is the microscopic analysis of the complete surgical margin, which cannot be accomplished with standard excision and pathologic processing. The thoroughness of the Mohs method is facilitated by the use of tangential, or beveled, excision. With standard excision, the skin is incised with the scalpel blade held perpendicular to the skin, creating a right angle between the peripheral and deep margin (Fig. 204-1A). Although this facilitates optimal wound closure, it prevents histopathologic analysis of the deep and peripheral margins in the same plane. In contrast, with the Mohs technique, incision of the skin is made at a 45-degree angle, creating a beveled, or sloping, surface to the excised specimen (Fig. 204-1B). After tissue is excised with a beveled edge, it is processed for histopathologic analysis with en face sections that are cut parallel to the surgical margin. This is another critical difference from standard excision, in which the excised specimen is most often sectioned perpendicular to the surgical margins in a "bread-loaf" fashion. Perpendicular sections allow for histopathologic examination of the central bulk of the tumor but cannot practically examine the entire surgical margin because each section only visualizes a few micrometers of margin length. Thousands of sections would be required to examine a few centimeters of surgical margin in its entirety, and thus representative sections are often examined at intervals of 1 to 2 mm. This results

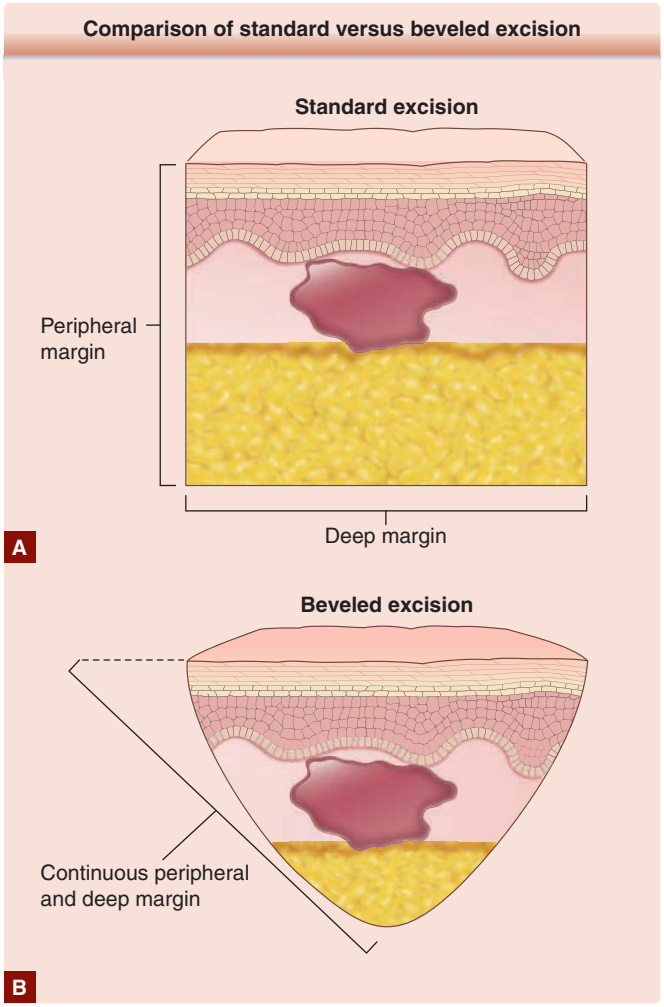

Figure 204-1 Comparison of standard versus beveled excision. **A,** With standard surgical excision, the incision is made perpendicular to the skin surface with a 90-degree angle between the peripheral and the deep margin. **B,** With beveled excision, the incision is made at a 45-degree angle with the skin surface, creating a continuous peripheral and deep margin on the same plane.

in examination of less than 1% to 3% of the length of the surgical margin. For many skin cancers with irregular subclinical extension, areas of malignancy may be missed on representative sections, resulting in false-negative margins and potential tumor recurrence (Fig. 204-2A). Beveled excision coupled with en face sections in Mohs surgery examines the entire deep and peripheral surgical margin in a single plane, permitting detection of focal areas of tumor extension as small as a few malignant cells (Fig. 204-2B). This difference is clinically relevant because perpendicular sections at intervals of 1 mm may miss up to 42% of irregular tumor extensions.[3]

MMS, like every surgical procedure, begins with a consultation between the surgeon and the patient. This allows the surgeon to confirm the pathologic diagnosis of skin cancer before surgery, examine the patient to evaluate tumor location and size, and assess for signs or symptoms of extensive subclinical extension such as paresthesia or motor nerve dysfunction. If there is uncertainty about the pathologic diagnosis (eg, from an inconclusive biopsy) or if malignant invasion of critical deep structures is suspected, further evaluation may be warranted before surgery. The patient must also be informed of the likely extent of the cancer, the implications for function and cosmesis, expectations for wound healing, and other associated risks and benefits of the procedure. After informed consent has been documented, the procedure can be scheduled or initiated.

Mohs surgery is almost universally performed as an office-based procedure under local anesthesia. Facility requirements include treatment rooms equipped to ensure patient comfort, optimal tissue excision, hemostasis, and reconstruction. The on-site histology laboratory for processing, sectioning, and staining the surgical specimens is a fundamental requirement of the Mohs technique. In addition to the surgeon, who also functions as the pathologist in reading intraoperative histopathology specimens, the procedure requires trained nursing staff and a histotechnician experienced in processing frozen sections. Because the procedure relies on accurate interpretation of histopathologic margin status, optimal histologic processing with robust quality control is essential.

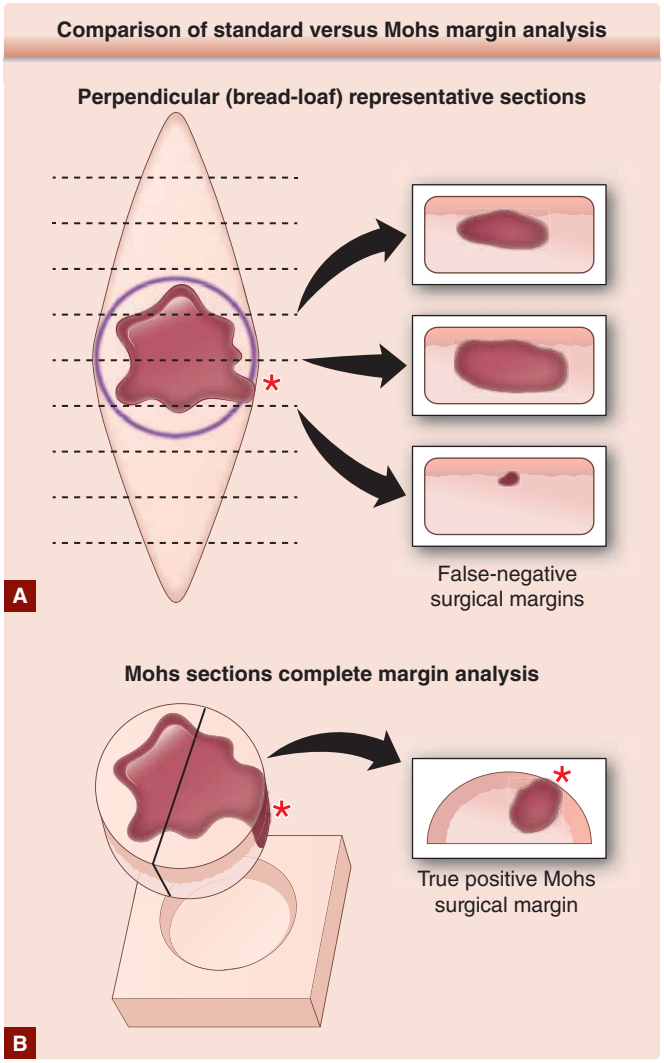

Figure 204-2 Complete margin analysis with Mohs surgical technique. **A,** With typical perpendicular or "bread-loaf" sections, representative cross sections, indicated by dashed lines, are examined at regular intervals along the excised tissue. Arrows indicate histopathologic visualization of tumor (red) with apparently clear margins in these sections. An irregular projection of tumor (*red asterisk*) at the margin is not detected in between these sections. **B,** In Mohs surgery, beveled excision specimens are examined with en face sections, permitting visualization of the entire deep and peripheral margin and identification of any tumor projections at the surgical margin (*red asterisk*). By definition, any tumor visible with en face sections is present at the surgical margin.

The Mohs procedure commences with accurate identification of the lesion to be treated (Fig. 204-3A) and confirmation of the site by the patient using a mirror. Photographic records from the time of the diagnostic biopsy may be extremely helpful in cases of patient uncertainty or when wound healing and the passage of time have obscured the precise location of the lesion. The patient is then positioned on the surgical table and the site is infiltrated with local anesthetic. The grossly visible tumor is debulked by curettage or blade if appropriate. The tendency of the semi-sharp curette to dislodge friable tumor aggregates while sparing normal skin helps to define the deep and lateral extent of the tumor. The skin lesion is then excised with a 1- to 2-mm margin around the curettage area, taking care to excise the tissue with a beveled edge at a level deep enough to ensure an adequate margin below the initial curettage (Fig. 204-3B). This may be at the intradermal, subcutaneous, muscular, or fascial layer, depending on the nature of the cancer and the anatomic site. Before removing the lesion, one or more score marks may be placed across the specimen and onto the surrounding skin to serve as anatomic markers for subsequent stages. Hemostasis is then obtained, a temporary bandage is placed over the wound, and the ambulatory patient waits in a comfortable waiting room while the specimens are processed for histopathologic examination.

The excised tissue from the first stage is transported by hand to the adjacent histology laboratory. The tissue is divided into appropriately sized specimens using the score marks made at the time of excision. The anatomic orientation relative to surrounding landmarks on the patient is preserved, each piece is marked with at

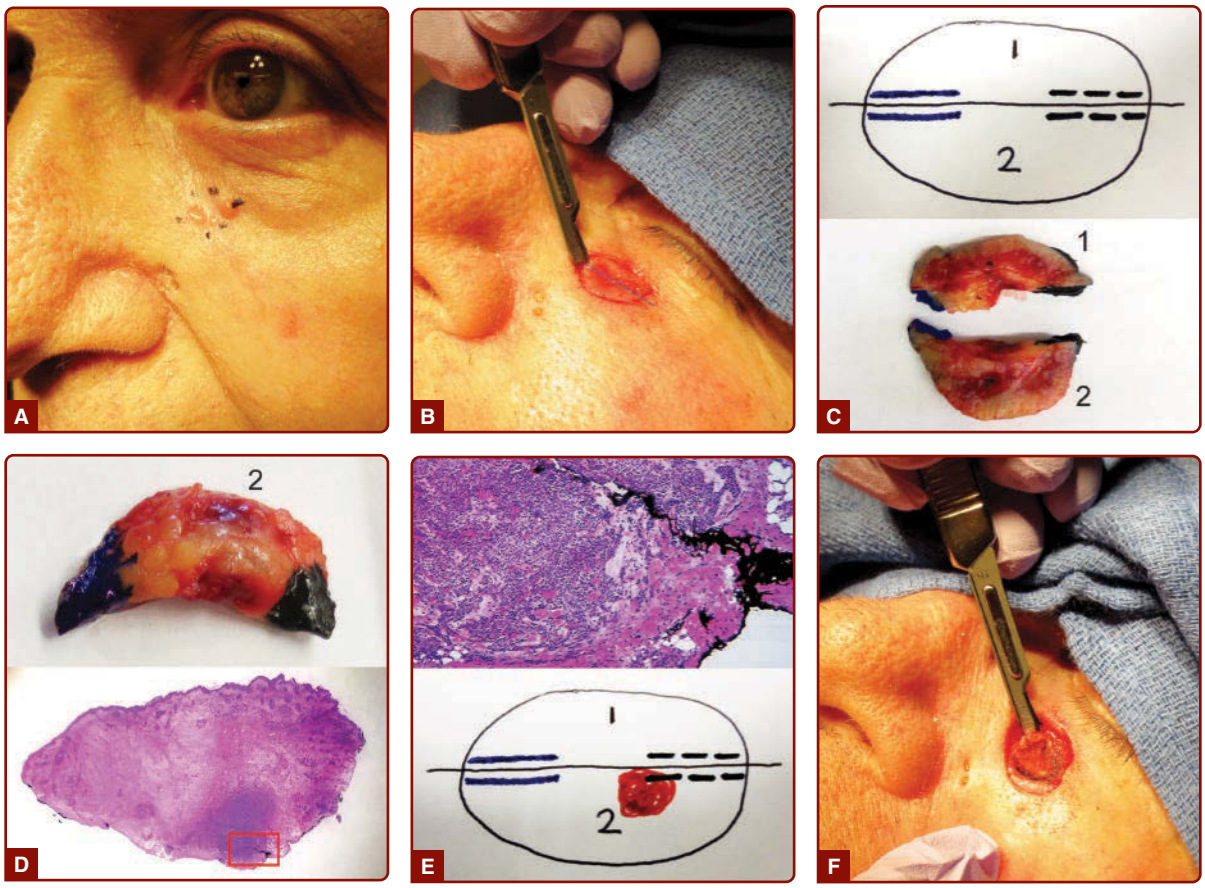

Figure 204-3 Mohs surgery procedure. **A,** A biopsy-confirmed basal cell carcinoma (BCC) is identified and marked on the left cheek overlying the inferior orbital rim. **B,** After curettage to remove gross carcinoma and define the clinical margins, the lesion is excised in the first stage with a narrow margin and a beveled edge, holding the scalpel at a 45-degree angle to the skin surface. A score mark (blue dashed line) is made on the excised specimen and extended onto the surrounding skin to preserve anatomic orientation. **C,** A map is drawn of the excised tissue (upper panel) and the specimen, shown with the epidermal surface facing up, is bisected along the score mark (lower panel). Indelible ink is used to mark the marginal surface blue on the left and black on the right. **D,** Piece 2 is shown flipped over with the deep marginal surface facing up, revealing the blue and black indelible ink (upper panel). Histopathologic sections are cut from the marginal surface and stained with hematoxylin and eosin (lower panel), revealing the epidermal peripheral margin and the subcutaneous deep margin in a single plane. The red box at the deep margin is shown at higher magnification in panel E. **E,** Higher magnification reveals persistent BCC at the deep margin near the black ink (upper panel). The area of carcinoma at the margins is marked on the map in red (lower panel). **F,** The area of residual carcinoma is excised in a second stage, again with a beveled edge to allow complete margin examination. This process is repeated until clear margins are obtained.

least two colors of indelible ink (to designate laterality or sidedness), and a "map" is drawn to represent the specimen and precisely locate any areas of positive margins (Fig. 204-3C). The tissue is frozen, mounted, and sectioned by the technician with en face sections such that the peripheral and deep margin are visualized on the histopathologic slides (Fig. 204-3D). The slides are then stained, often with standard hematoxylin and eosin stains. Inspection of the slides prepared in this fashion reveals the true surgical margin, and any areas of carcinoma that are noted represent tumor extension to the margin. If present, these areas of persistent malignancy in stage 1 are marked in their precise location on the map in relation to the inked edges (Fig. 204-3E).

If carcinoma is detected at the microscopically examined surgical margins, the patient is returned to the procedure room for ongoing staged excision. The fact that the Mohs surgeon functions as the pathologist in detecting and mapping any areas of positive surgical margins ensures the most focused and precise reexcision when subsequent stages are necessary. These subsequent stages are generally incised with a beveled edge to facilitate complete margin examination and may involve excision of epidermis and dermis from the peripheral margin; subcutis, muscle, fascia, or cartilage from the deep margin; or a combination of these depending on the location and extent of residual tumor (Fig. 204-3F). Subsequent stages are inked, mapped, processed, sectioned, and stained as described earlier, and the surgical margin is again examined microscopically by the surgeon. This iterative process continues until the surgical margins are free of carcinoma and a tumor-free plane has been achieved. When all surgical margins are clear, the patient is evaluated for consideration of immediate surgical repair or healing of the defect by second intent.

The staged nature of Mohs surgery allows optimal flexibility in surgical treatment. Because no a priori assumptions are made about required surgical margins, small lesions can be treated with a minimal surgical defect, and highly invasive lesions, even if not grossly evident, can be completely excised over multiple stages. In general, each stage takes 20 to 45 minutes to process in our laboratory; about half of patients achieve clear margins after a single stage, and approximately 90% are clear after two stages.[4] Skin cancers requiring four to six stages are uncommon. It is important to note that the Mohs technique does not examine the central portion of an excised tumor. In selected cases when additional information about histopathologic risk factors such as perineural invasion or poor differentiation is required, the frozen tissue can be thawed and submitted for standard perpendicular section processing through the bulk of the tumor. For the majority of BCCs and SCCs treated with Mohs surgery, this additional pathologic examination is not necessary.

INDICATIONS FOR MOHS SURGERY

BASAL CELL CARCINOMA

BCC is the most common human malignancy, with more than 2 million cases per year in the United States.[5] Although BCC rarely leads to metastasis or death, it can be highly destructive and result in significant morbidity and functional impairment. Given the disproportionate incidence of BCC on anatomically sensitive sites such as the nose, ears, and periocular skin, Mohs surgery has been performed for BCC more than any other skin cancer. Mohs surgery is particularly beneficial for facial BCC because of the tendency of this malignancy to exhibit subclinical extension (Fig. 204-4). Several risk factors have been identified to predict microscopic tumor extension beyond the grossly visible margin of the tumor, including poorly defined clinical margins; diameter greater than 2 cm; and location on the high-risk, or "H" zone of the face, encompassing the nose, eyelids, eyebrows, temples, lips, ear, and periauricular skin.[6-8] Histologic subtype of BCC is also a critical determinant of subclinical extension. Although most nodular BCC are completely excised with surgical margins of 4 mm, infiltrative and micronodular subtypes, when excised with the Mohs technique, were found to require surgical margins of 5 to 10 mm for complete clearance and were more likely to require excision of underlying muscle, cartilage, and periosteum.[9,10]

As it became clear that Mohs surgery could offer superior treatment outcomes for high-risk BCC, systematic studies of the procedure focused on this subgroup of tumors. Dr. Mohs himself published the largest series of cases of BCC of the eyelids: among 1124 primary BCC and 290 recurrent BCC with 5-year follow-up, the cure rates after Mohs surgery were an exceptional 99.4% and 92.4%, respectively.[11]

Figure 204-4 Basal cell carcinoma (BCC) subclinical extension. An apparently small BCC of the upper lip (**A**) was found to extend broadly over the cutaneous and mucosal lip and invade into the orbicularis oris muscle (**B**). Clear margins were obtained after three stages of Mohs surgery and the defect was repaired with a local skin flap.

Subsequent studies in thousands of patients have confirmed a long-term recurrence rate of 1% to 4% after Mohs surgery for primary BCC with high-risk features and a higher recurrence rate of 4% to 8% for recurrent BCC, which are likely to have greater subclinical invasion that could be masked by scarring from prior treatment.[12,13]

The durable cure rates obtained with Mohs surgery are superior to those obtained with standard excision as documented in several retrospective studies and one randomized clinical trial (Table 204-1). A pair of meta-analyses of published data on over ten thousand patients reported that Mohs surgery results in a recurrence rate that is three- to fourfold lower than standard excision,[14,15] and a more recent observational study confirmed that although standard excision provides a high rate of cure for cancers on low-risk anatomic locations, Mohs surgery affords at least as high of a cure rate when selectively used on tumors with high-risk features.[16] Yet interpretation of these studies is hampered by their retrospective nature and lack of appropriate controls. More recently, 10-year follow up data from a prospective, randomized trial has now provided high-level evidence that Mohs surgery is superior to standard excision for BCC at high risk of recurrence.[17] Both primary and recurrent BCC with high-risk features (>1-cm diameter and location on the H zone or with an infiltrative or micronodular histologic pattern) were found to have a more than twofold reduction in recurrence rate after Mohs surgery, although statistical significance was only reached for recurrent BCC. In contrast, small, primary BCC without aggressive histologic features on low-risk anatomic locations such as the trunk are unlikely to have significant benefit from the Mohs technique compared with other forms of surgical treatment.

SQUAMOUS CELL CARCINOMA

SCC is the second most common human malignancy, although recent evidence suggests that SCC incidence is increasing and may be approaching that of BCC.[5] Like BCC, SCC is effectively treated with Mohs surgery, facilitating identification and complete excision of irregular branches of subclinical tumor extension. Also like BCC, the differential efficacy of Mohs surgery over standard excision is most pronounced for tumors in the H zone of the face, and for tumors greater than 2 cm in diameter or with aggressive histologic features.[18] These tumors, as well as those recurring after previous treatment, exhibit an increased propensity for subclinical extension and an increased risk of incomplete excision in the absence of the complete margin assessment of Mohs surgery.[19] Particularly on the chronically sun-exposed scalp, SCC may exhibit an infiltrative histology with broad involvement of the fascia and periosteum that is not evident on examination of the skin surface (Fig. 204-5). Overall, the reported rates of recurrence of primary cutaneous SCC are up to 8.1% after standard excision and 3.1% after Mohs surgery.[20] The risk of recurrence for previously treated SCC is increased to 23.3% after standard excision and 10.0% after Mohs surgery.

Unlike BCC, SCC has a significant risk of regional and distant metastasis, particularly for certain subsets of SCC. Treatment is therefore focused not only on preventing local recurrence but on complete tumor extirpation to prevent metastasis. Four factors that appear most strongly associated with adverse outcomes in SCC are diameter greater than 2 cm, depth of invasion below the subcutaneous adipose, perineural invasion, and

TABLE 204-1
Recurrence of Basal Cell Carcinoma

REFERENCE	TYPE OF STUDY	BCC (*n*)	FOLLOW-UP PERIOD (yr)	LOCATION	RECURRENCE AFTER STANDARD EXCISION (%)	RECURRENCE AFTER MOHS SURGERY (%)	P VALUE
Primary Basal Cell Carcinoma							
van Loo et al[17] (2014)	Prospective randomized trial	397	10	Facial, high risk	12.2	4.4	0.1
Chren et al[16] (2013)	Retrospective observational	1127	5	Any[a]	3.5	2.1	> 0.1
Rowe et al[14] (1989a)	Meta-analysis	10,276	5	Any[b]	10.1	1.0	Not reported
Recurrent Basal Cell Carcinoma							
van Loo et al[17] (2014)	Prospective randomized trial	202	10	Facial, high risk	13.5	3.9	0.023
Rowe et al[15] (1989b)	Meta-analysis	3531	5	Any[c]	17.4	5.6	NR

[a]A total of 26% of excisions and 65% of Mohs were in high-risk anatomic sites (nose, eyelids, eyebrows, lips, temple, and ears and periauricular skin); 27% of all lesions were squamous cell carcinoma (SCC), not basal cell carcinoma (BCC).
[b]Data were derived from 12 separate reports; location was not reported (NR).
[c]Data were derived from 9 separate reports; location was not reported.

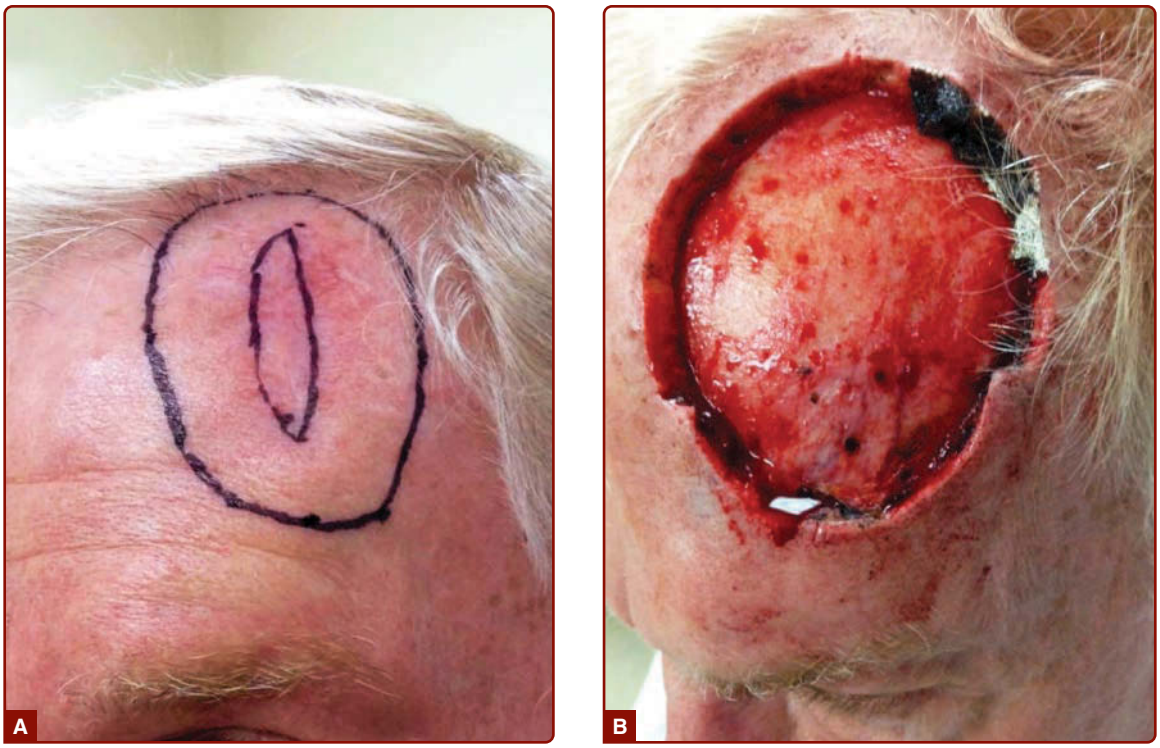

Figure 204-5 Squamous cell carcinoma (SCC) subclinical extension. SCC of the forehead and scalp with infiltrative histology and positive deep and lateral margins after initial excision and linear repair (**A**). A broad, 2-cm margin was excised as the initial stage of Mohs surgery (outer black line), but carcinoma was found infiltrating the fascia and periosteum at the surgical margins. Clear margins were obtained after the second stage of Mohs surgery. The defect measured 8.4 cm and extended to the exposed frontal bone (**B**); it was repaired with a delayed full-thickness skin graft.

poor histologic differentiation. In a large retrospective review, the presence of one of these factors increased local recurrence from 0.6% (no risk factors) to 5% (one risk factor) and 21% (two or three risk factors), and increased nodal metastasis from 0.1% (no risk factors) to 3% (one risk factor) and 21% (two or three risk factors).[21] Importantly, effective local control with Mohs surgery may decrease the risk of subsequent metastasis because SCC with perineural invasion was found to metastasize in 47% of cases after standard excision compared with 8.3% of cases after Mohs surgery.[20] Even with complete verification of the histopathologic margin status, however, SCC with perineural invasion or poor differentiation still presents a significant risk of local or regional recurrence. Adjuvant therapy such as radiation may be considered after Mohs surgery to decrease this risk, although high-quality evidence to support the benefit of this approach is lacking. Other risk factors for adverse outcomes of SCC that may benefit from Mohs surgery include host immunosuppression and location on the lip, ear, and temple. SCC arising on penile skin has also been reported to have a high rate of local and regional recurrence, and Mohs surgery is an effective treatment for penile SCC as well.[22]

SCC in situ can also be effectively treated with Mohs surgery. The reported cure rate for SCC in situ after Mohs surgery is 93.7%, which compares favorably with standard excision.[23] Although SCC in situ has been reported to progress to invasive SCC, the risk of progression in appropriately treated lesions appears to be very low. Moreover, a histopathologic study of depth of invasion of SCC in situ found that in 54 tumors, the maximum depth of invasion was only 0.82 mm.[24] Thus, with the exception of high risk lesions such as those within the H zone of the face or lesions with the clinical suggestion of invasive disease, other forms of treatment besides Mohs surgery should be considered for SCC in situ.

MELANOMA

Dr. Mohs first reported the use of margin-controlled excision for invasive melanoma in 1950 using the *chemosurgery* approach of in situ tissue fixation with zinc chloride, although this was not widely adopted.[25] The transition from in situ fixed tissue to fresh frozen tissue processing for Mohs surgery brought new controversy to the field because it was noted that artifacts introduced on frozen sections complicated the detection of intraepidermal melanocytes and decreased the sensitivity of melanoma detection.[26] The more recent development of immunohistochemical stains on frozen sections has brought the potential for more sensitive melanocyte detection and melanoma diagnosis at the microscopic margins but has not resolved the controversy.

Currently, Mohs surgery using immunohistochemical stains for melanoma antigen recognized by T cells

(MART-1) on rapidly processed frozen sections is the most common technique, although it is only used by a minority of Mohs surgeons, and its use is limited to melanoma in situ and superficially invasive melanoma (Breslow depth <1 mm) with a minimal risk of metastasis. The largest study to date on clinical outcomes with this technique reported a remarkably low 5-year local recurrence rate of less than 1% in more than 2000 melanomas; half of these cases were on the head and neck, 60% were in situ melanoma, and 30% were invasive with a Breslow depth of less than 1 mm.[27] Because of concerns about the accuracy of en face frozen sections for melanoma diagnosis and the potential for undetected invasive disease in unexamined tissue from the center of the tumor, other investigators have proposed staged excision with formalin-fixed sections or a combination of perpendicular (bread-loaf) and en face frozen sections during Mohs surgery, both of which can achieve high cure rates of greater than 95%.[28,29] Importantly, there has not yet been a direct comparison of Mohs surgery with standard wide excision for superficial melanoma in an appropriately matched cohort of patients, and additional study is required to determine the relative efficacy of these treatments. It is likely that some form of staged excision will provide significant benefit for patients with superficial melanoma on chronically sun-exposed skin because nearly 20% of these tumors will have subclinical extension beyond the recommended 5-mm margin of grossly uninvolved skin.[27] Ongoing investigation of the adaptation of the Mohs technique for melanoma treatment illustrates how technologic innovations in tissue processing and staining can be incorporated into surgical treatment, but how these innovations could improve outcomes remains to be determined.

OTHER SKIN CANCERS

Dermatofibrosarcoma protuberans (DFSP) is a rare cutaneous malignancy for which Mohs surgery may be particularly effective. DFSP is a slowly progressive tumor that rarely metastasizes but frequently has broad subclinical extension and a historically high recurrence rate after conventional excision. DFSP originates within the dermis or dermal–subcutaneous junction and frequently invades muscle or fascia, requiring accurate assessment of both peripheral and deep surgical margins (Fig. 204-6). The characteristic spindled cells of DFSP can be readily identified on frozen sections, and complete margin assessment with Mohs surgery facilitates identification of the irregular projections of the tumor that may be missed with standard perpendicular section processing. A meta-analysis of published studies on DFSP, none of which were randomized trials, found that whereas local recurrence after conventional excision was approximately 6%, this rate decreased to 1% after Mohs surgery.[30] For cases in which Mohs surgery is not practical, staged excision

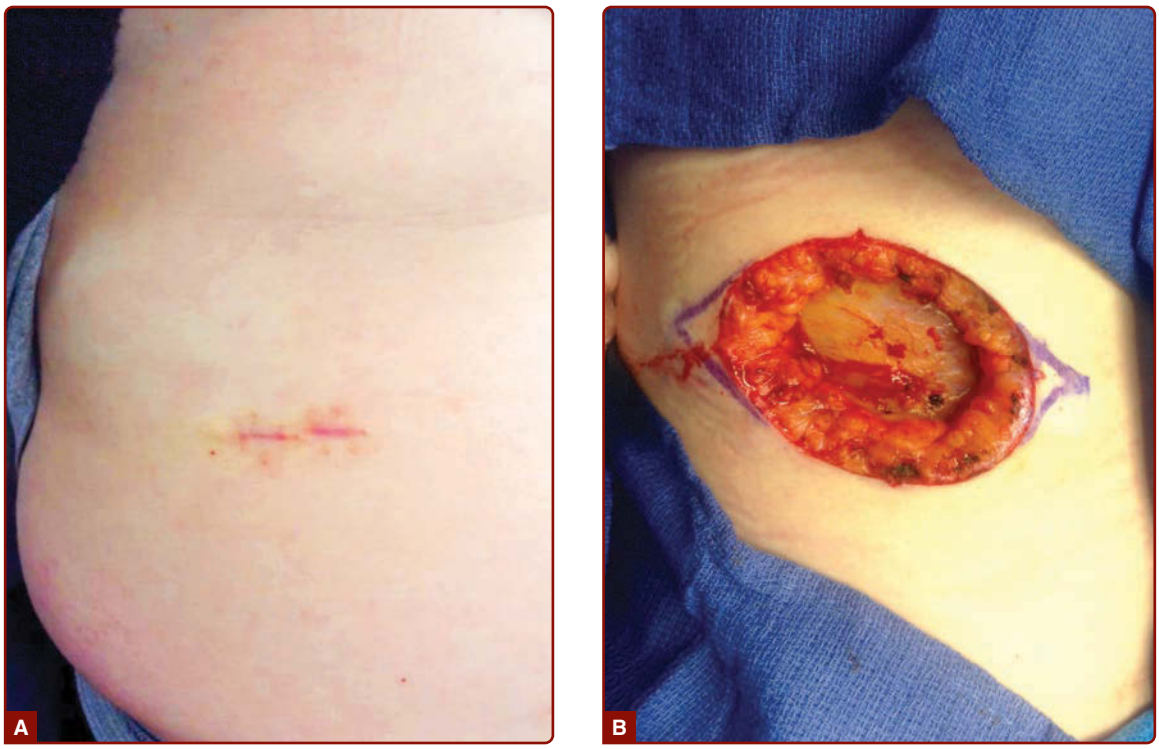

Figure 204-6 Dermatofibrosarcoma protuberans (DFSP). A subtle clinical lesion on the abdomen at the site of a biopsied DFSP (**A**) was found to extend over a broad area with penetration to the deep subcutis overlying the fascia of the abdominal wall musculature (**B**). Clear margins were obtained after three stages of Mohs surgery, and the defect was repaired with a linear closure.

with appropriate pathologic verification of clear margins can also be an effective treatment for DFSP.[31]

In principle, any solid cancer with contiguous growth (as opposed to discontiguous spread or satellite lesions) that can be identified on frozen histopathologic sections and is accessible from the external surface of the body can be treated with Mohs surgery. Mohs surgery is likely to provide the most therapeutic benefit for tumors with broad and unpredictable subclinical extension, such as microcystic adnexal carcinoma,[32] or tumors arising in anatomic locations for which tissue sparing is critical, such as sebaceous carcinoma of the eyelid or extramammary Paget disease (EMPD) of the genitalia. Although EMPD may be multifocal in some cases, a review of published observational studies found that Mohs surgery may result in a lower recurrence rate than standard excision.[33] Atypical fibroxanthoma is an uncommon spindle cell cancer of chronically sun-exposed skin with a behavior similar to high-risk cutaneous SCC that is effectively treated with Mohs surgery. The technique has also been used for treatment of adnexal carcinoma, apocrine and eccrine carcinoma, leiomyosarcoma, Merkel cell carcinoma, mucinous carcinoma, and other rare cutaneous malignancies.[34]

HEALING AND RECONSTRUCTION

Maximal conservation of normal, noncancerous tissue with Mohs surgery facilitates wound healing after tumor extirpation. With the use of in situ chemical fixation originally described by Dr. Mohs, immediate primary surgical repair was often not feasible because of the residual effects of the chemical fixative. Thus, nearly all of the 440 cases originally described by Dr. Mohs were allowed to heal by second intent, or granulation without surgical repair.[1] The continued use of second intent healing for defects after Mohs surgery, even after the transition to non–chemically fixed tissue, was a significant contribution to the surgical literature and established second intent healing as a viable option for selected wounds. Defects resulting from Mohs surgery may be particularly suited to healing without reconstruction because the procedure often creates wounds of shallow depth that may be conducive to second intent healing. This is in contrast to traditional surgical excision, which is routinely performed to the depth of the subcutaneous adipose or connective tissue. Other wounds with reliable functional and cosmetic results after second intent healing include wounds on thin skin such as the eyelid or ear and wounds on concave surfaces such as the medial canthus, anterior surface of the ear, and the temple (Fig. 204-7). Although Mohs surgical defects on convex surfaces such as the nasal tip, malar cheek, and central forehead can also heal with acceptable functional results, the resulting scars in these areas are more likely to be depressed and cosmetically conspicuous. In appropriately selected patients, healing of Mohs surgical defects by second intent results in patient satisfaction that is equivalent to primary surgical repair.[35]

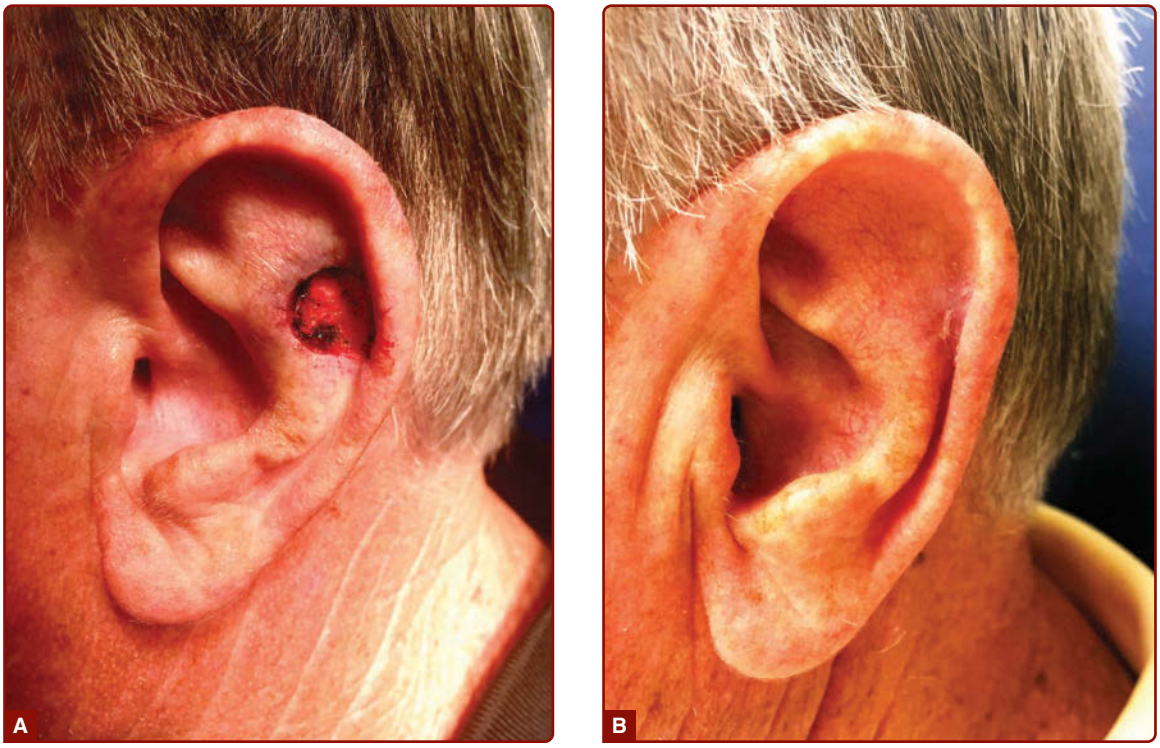

Figure 204-7 Healing by second intent. A 1.6-cm defect of the left scapha and antihelix after Mohs surgical extirpation of a basal cell carcinoma of the ear was allowed to heal by second intent (**A**). After 6 weeks, the wound is fully healed with an excellent cosmetic and functional result (**B**).

Figure 204-8 Local skin flap reconstruction. After two stages of Mohs surgery, the basal cell carcinoma shown in Fig. 204-3 was completely excised, leaving a 1.6-cm defect of the left cheek and lower eyelid (**A**). The defect was repaired with an advancement flap from the lateral lower eyelid and temple to avoid distortion of the free margin of the lower eyelid (**B**).

Pathologic verification of complete tumor extirpation after Mohs surgery also facilitates immediate surgical reconstruction because the Mohs technique provides the lowest possible risk of residual or recurrent cancer. As the use of frozen sections replaced in situ chemical fixation and Mohs surgery became the standard of care for anatomically sensitive areas such as the nose, lips, and eyelids, reconstruction with plastic and aesthetic surgical techniques has become an integral part of the technique. In fact, several advances in cutaneous reconstruction were described and popularized by Mohs surgeons, including the use of the buried vertical mattress suture, the modern bilobe transposition skin flap on the nose, and the use of cartilage grafts and multistaged interpolation flaps as office based-procedures under local anesthesia.[36-39] Immediate surgical repair with linear closure, skin grafts, or skin flaps from adjacent or interpolated tissue reservoirs is now used more often than second intent healing for Mohs surgical defects and permits optimal restoration of function and cosmesis in critical areas such as the eyelid and nose (Fig. 204-8).

RISKS AND COMPLICATIONS

Although no surgical procedure is without risk, Mohs surgery is a remarkably safe procedure with low complication rates. A multicenter prospective study of adverse events in 20,821 Mohs surgical procedures identified an overall adverse event rate of 0.72% and a serious adverse event rate of 0.02% (4 cases of 20,821).[40] The most common adverse events were infections (0.40% event rate), impaired wound healing including dehiscence and necrosis (0.14% event rate), and postoperative bleeding or hematoma (0.11% event rate). The four serious adverse events in this study were all infections requiring hospitalization, and no deaths or life-threatening cardiovascular complications were reported. Smaller studies have confirmed similarly low rates of complications (minor bleeding in 1.2% and infection in 0.9%) and reported mild postoperative pain scores (mean of 1.99 on a 0–10 scale of pain).[41] The use of local anesthetic rather than general anesthesia or conscious sedation, as well as the lack of significant volume shift or cardiovascular stress after cutaneous surgery likely contribute to the safety of the Mohs procedure.

The documented safety of office-based Mohs surgery allows the procedure to be performed with minimal risk on a wide range of patients, including octa- and nonagenarians and patients with comorbid conditions including stable cardiac disease. Nevertheless, preoperative evaluation to determine the relative risks and benefits of the procedure and to identify modifiable risk factors is critical. Patients with relatively indolent skin cancers who have limited life expectancy because of another terminal condition may not sufficiently benefit from the procedure to justify even small risks of complications. Patients on anticoagulant therapy such as aspirin, warfarin, or direct factor Xa inhibitors such as rivaroxaban or apixaban have a modestly increased risk of minor bleeding complications (1.7% vs 0.7% in one study[41]), but this is not a contraindication to Mohs surgery, and patients are generally advised to continue their prescribed anticoagulation therapy during and after surgery.

Antibiotic prophylaxis is generally not required before Mohs surgery, with a few notable exceptions. The American Heart Association and American College of Cardiology recommend prophylactic antibiotic therapy only for patients at highest risk of complications of infective endocarditis, including those with prosthetic heart valves, a prior history of infective endocarditis, cardiac transplant recipients with significant valvular disease, and patients with significant cyanotic congenital heart disease. Even in these high-risk patients, antibiotic prophylaxis is only recommended in cases with breach of the oral mucosa; surgical procedures on intact skin or gastrointestinal and genitourinary procedures are not clear indications for antibiotic prophylaxis.[42] Patients with total knee or hip replacements may be at increased risk of hematogenous total joint infection after Mohs surgery, and prophylaxis may be considered for these

patients as well. However, there is no evidence to support the use of antibiotic prophylaxis with routine surgical or dental procedures in these patients, and recent guidelines from the American Academy of Orthopedic Surgeons and the American Dental Association do not provide specific recommendations for prophylaxis after prosthetic joint replacement.[43] In general, Mohs surgeons use antibiotic prophylaxis sparingly and only in patients at highest risk for hematogenous or surgical site infections.

COST AND APPROPRIATE USE

Mohs surgery is widely used for treatment of nonmelanoma skin cancers and has been shown to be the most effective method of skin cancer eradication. The increasing use of Mohs surgery, however, has prompted concerns about the cost of this procedure relative to other surgical treatments. Cost analysis based on procedure codes and typical reimbursements indicates that the immediate cost of skin cancer treatment, including tumor removal, pathologic examination, and repair of the surgical defect, is approximately 25% greater for Mohs surgery than for standard surgical excision with permanent pathologic section analysis in the outpatient setting.[44] This cost differential is reversed, however, when immediate frozen section margin analysis is performed with non-Mohs surgical excision, raising the cost to nearly double that of Mohs surgery. Moreover, when Mohs surgery is limited to high-risk skin cancers or critical anatomic locations such as the H zone of the face, when the use of second intent healing instead of surgical repair is considered with selected Mohs surgery cases, and when the increased rate of recurrence is accounted for with standard surgical excision, the overall costs of Mohs surgery may be 20% to 30% less than standard excision.[45]

To ensure that Mohs surgery is reserved for clinical scenarios in which the procedure will be most cost-efficient and provide the greatest benefit over other forms of treatment, the American Academy of Dermatology, the American College of Mohs Surgery, the American Society for Dermatologic Surgery, and the American Society for Mohs Surgery jointly published appropriate use criteria (AUC) in 2012.[34] The appropriate use criteria define tumor-specific and patient-specific factors for which Mohs surgery is deemed to be either appropriate, uncertain, or inappropriate in most situations (Table 204-2). A central factor in the AUC is anatomic location, owing to the critical need for tissue sparing with Mohs surgery in certain locations as well as the increased risk of subclinical extension and recurrence of skin cancers in these areas. High-risk areas include the H zone of the face (eyelids, eyebrows, nose, lips, chin, ears and periauricular skin, and temples; Fig. 204-9), genitalia, hands, feet, ankles, and nipple and areola region. Medium-risk areas are the remainder of the face (cheeks, forehead, and jawline), scalp, neck, and pretibial surfaces. The trunk and the remainder of the extremities are considered low-risk areas. The AUC primarily focuses on specific clinical scenarios for BCC and SCC but also notes that Mohs surgery can be appropriate for melanoma in situ and other, more rare tumors. It is important to note that the AUC does not encompass all clinical scenarios nor does it imply that Mohs surgery is required for all tumors deemed appropriate. Individual clinical judgment must always be used to ensure optimal management of cutaneous malignancy, and the AUC are likely to be modified as further research and clinical experience can refine the recommendations.

TABLE 204-2
Mohs Surgery Appropriate Use Criteria[a]

DIAGNOSIS	RISK AREA[b]	CLINICAL DIAMETER (cm) <0.5	0.6–1	1.1–2	>2
Primary nodular BCC	High	A	A	A	A
	Medium	A	A	A	A
	Low	I	I	U	A
Primary aggressive BCC[c]	High	A	A	A	A
	Medium	A	A	A	A
	Low	U	A	A	A
Primary superficial BCC	High	A	A	A	A
	Medium	U	A	A	A
	Low	I	I	I	I
Recurrent BCC (not superficial)	Any	A	A	A	A
Recurrent superficial BCC	High	A	A	A	A
	Medium	A	A	A	A
	Low	I	I	I	I
Primary SCC without high-risk features[d]	High	A	A	A	A
	Medium	A	A	A	A
	Low	I	I	U	A
Primary SCC with high-risk features[d]	Any	A	A	A	A
Primary SCC in immunocompromised patient	High	A	A	A	A
	Medium	A	A	A	A
	Low	U	U	A	A
Recurrent SCC (invasive)	Any	A	A	A	A
Primary SCC in situ	High	A	A	A	A
	Medium	A	A	A	A
	Low	I	I	U	A

[a]The most common clinical scenarios are presented. Each scenario is scored as appropriate (A) or inappropriate (I) for Mohs surgery or uncertain (U).
[b]High-risk area: central face, eyelids, eyebrows, nose, lips, chin, ears and periauricular skin, temples, genitalia, hands, feet, ankles, and nipple and areola. Medium-risk area: cheeks, forehead, scalp, neck, jawline, and pretibial surface. Low-risk area: trunk and remainder of extremities.
[c]Aggressive basal cell carcinoma (BCC) includes pathologic subtypes of infiltrative, morpheaform or sclerosing, micronodular, and metatypical or keratotic or with perineural invasion.
[d]High risk features for squamous cell carcinoma (SCC) include poor differentiation, perineural or intravascular invasion, spindle cell or infiltrative features, Breslow depth >2 mm, and Clark level IV or greater.

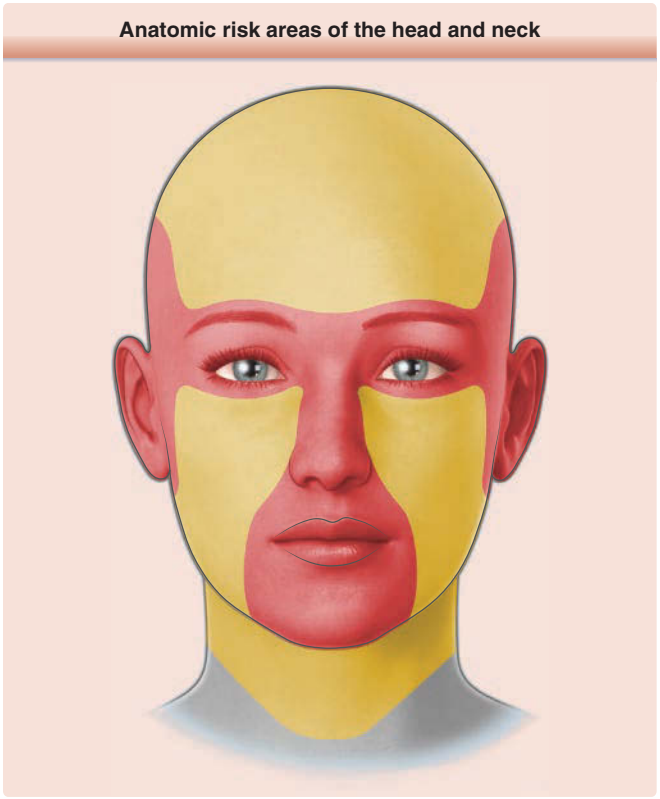

Figure 204-9 Mohs surgery appropriate use criteria anatomic risk areas of the head and neck. High-risk areas on the central face, eyelids, eyebrows, nose, lips, chin, ears, periauricular skin, and temples are shown in red. Medium-risk areas on the cheeks, forehead, scalp, neck and jawline are shown in yellow. Not shown are high-risk areas on the hands, feet, ankles, genitalia, and nipple and areola, as well as medium-risk areas on the pretibial surface.

CONCLUSIONS

Mohs surgery is a specialized form of skin cancer extirpation that relies on staged excision with immediate histopathologic examination of the entire deep and peripheral surgical margin. Mohs surgery is most often used to treat patients with BCCs and SCCs and has been shown to be superior to other forms of treatment for cancers at increased risk of recurrence. The versatility of the Mohs procedure allows for maximal tissue conservation while ensuring complete tumor removal and facilitates optimal wound healing, whether by immediate surgical reconstruction or by second intent. The procedure is the accepted standard of care for appropriately selected cancers as defined by the AUC. Ongoing investigation and technological advances will continue to refine the indications for Mohs surgery, which may include expanded use for superficial melanoma or other less common tumors.

REFERENCES

1. Mohs FE. Chemosurgery: a microscopically controlled method of cancer excision. *Arch Surg.* 1941;42(2):279-295.
2. Reeder VJ, Gustafson CJ, Mireku K, et al. Trends in Mohs surgery from 1995 to 2010: an analysis of nationally representative data. *Dermatol Surg.* 2015;41(3):397-403.
3. Kimyai-Asadi A, Katz T, Goldberg LH, et al. Margin involvement after the excision of melanoma in situ: the need for complete en face examination of the surgical margins. *Dermatol Surg.* 2007;33(12):1434-1439; discussion 1439-1441.
4. Donaldson MR, Coldiron BM. Mohs micrographic surgery utilization in the Medicare population, 2009. *Dermatol Surg.* 2012;38(9):1427-1434.
5. Rogers HW, Weinstock MA, Feldman SR, et al. Incidence estimate of nonmelanoma skin cancer (keratinocyte carcinomas) in the U.S. population, 2012. *JAMA Dermatol.* 2015;151(10):1081-1086.
6. Wolf DJ, Zitelli JA. Surgical margins for basal cell carcinoma. *Arch Dermatol.* 1987;123(3):340-344.
7. Batra RS, Kelley LC. Predictors of extensive subclinical spread in nonmelanoma skin cancer treated with Mohs micrographic surgery. *Arch Dermatol.* 2002;138(8):1043-1051.
8. Song SS, Goldenberg A, Ortiz A, et al. Nonmelanoma skin cancer with aggressive subclinical extension in immunosuppressed patients. *JAMA Dermatol.* 2016;152(6):683-690.
9. Hendrix JD Jr, Parlette HL. Duplicitous growth of infiltrative basal cell carcinoma: analysis of clinically undetected tumor extent in a paired case-control study. *Dermatol Surg.* 1996;22(6):535-539.
10. Hendrix JD Jr, Parlette HL. Micronodular basal cell carcinoma. A deceptive histologic subtype with frequent clinically undetected tumor extension. *Arch Dermatol.* 1996;132(3):295-298.
11. Mohs FE. Micrographic surgery for the microscopically controlled excision of eyelid cancers. *Arch Ophthalmol.* 1986;104(6):901-909.
12. Smeets NW, Kuijpers DI, Nelemans P, et al. Mohs' micrographic surgery for treatment of basal cell carcinoma of the face—results of a retrospective study and review of the literature. *Br J Dermatol.* 2004;151(1):141-147.

13. Leibovitch I, Huilgol SC, Selva D, et al. Basal cell carcinoma treated with Mohs surgery in Australia II. Outcome at 5-year follow-up. *J Am Acad Dermatol.* 2005;53(3):452-457.
14. Rowe DE, Carroll RJ, Day CL Jr. Long-term recurrence rates in previously untreated (primary) basal cell carcinoma: implications for patient follow-up. *J Dermatol Surg Oncol.* 1989;15(3):315-328.
15. Rowe DE, Carroll RJ, Day CL Jr. Mohs surgery is the treatment of choice for recurrent (previously treated) basal cell carcinoma. *J Dermatol Surg Oncol.* 1989;15(4):424-431.
16. Chren MM, Linos E, Torres JS, et al. Tumor recurrence 5 years after treatment of cutaneous basal cell carcinoma and squamous cell carcinoma. *J Invest Dermatol.* 2013;133(5):1188-1196.
17. van Loo E, Mosterd K, Krekels GA, et al. Surgical excision versus Mohs' micrographic surgery for basal cell carcinoma of the face: a randomised clinical trial with 10 year follow-up. *Eur J Cancer.* 2014;50(17):3011-3020.
18. Brodland DG, Zitelli JA. Surgical margins for excision of primary cutaneous squamous cell carcinoma. *J Am Acad Dermatol.* 1992;27(2 Pt 1):241-248.
19. Schell AE, Russell MA, Park SS. Suggested excisional margins for cutaneous malignant lesions based on Mohs micrographic surgery. *JAMA Facial Plast Surg.* 2013;15(5):337-343.
20. Rowe DE, Carroll RJ, Day CL Jr. Prognostic factors for local recurrence, metastasis, and survival rates in squamous cell carcinoma of the skin, ear, and lip. Implications for treatment modality selection. *J Am Acad Dermatol.* 1992;26(6):976-990.
21. Karia PS, Jambusaria-Pahlajani A, Harrington DP, et al. Evaluation of American Joint Committee on Cancer, International Union Against Cancer, and Brigham and Women's Hospital tumor staging for cutaneous squamous cell carcinoma. *J Clin Oncol.* 2014;32(4):327-334.
22. Machan M, Brodland D, Zitelli J. Penile squamous cell carcinoma: penis-preserving treatment with Mohs micrographic surgery. *Dermatol Surg.* 2016;42(8):936-944.
23. Hansen JP, Drake AL, Walling HW. Bowen's disease: a four-year retrospective review of epidemiology and treatment at a university center. *Dermatol Surg.* 2008;34(7):878-883.
24. Christensen SR, McNiff JM, Cool AJ, et al. Histopathologic assessment of depth of follicular invasion of squamous cell carcinoma (SCC) in situ (SCCis): Implications for treatment approach. *J Am Acad Dermatol.* 2016;74(2):356-362.
25. Mohs FE. Chemosurgical treatment of melanoma; a microscopically controlled method of excision. *Arch Derm Syphilol.* 1950;62(2):269-279.
26. Barlow RJ, White CR, Swanson NA. Mohs' micrographic surgery using frozen sections alone may be unsuitable for detecting single atypical melanocytes at the margins of melanoma in situ. *Br J Dermatol.* 2002;146(2):290-294.
27. Valentin-Nogueras SM, Brodland DG, Zitelli JA, et al. mohs micrographic surgery using MART-1 immunostain in the treatment of invasive melanoma and melanoma in situ. *Dermatol Surg.* 2016;42(6):733-744.
28. de Vries K, Greveling K, Prens LM, et al. Recurrence rate of lentigo maligna after micrographically controlled staged surgical excision. *Br J Dermatol.* 2016;174(3):588-593.
29. Etzkorn JR, Sobanko JF, Elenitsas R, et al. Low recurrence rates for in situ and invasive melanomas using Mohs micrographic surgery with melanoma antigen recognized by T cells 1 (MART-1) immunostaining: tissue processing methodology to optimize pathologic staging and margin assessment. *J Am Acad Dermatol.* 2015;72(5):840-850.
30. Foroozan M, Sei JF, Amini M, et al. Efficacy of Mohs micrographic surgery for the treatment of dermatofibrosarcoma protuberans: systematic review. *Arch Dermatol.* 2012;148(9):1055-1063.
31. Goldberg C, Hoang D, McRae M, et al. A strategy for the successful management of dermatofibrosarcoma protuberans. *Ann Plast Surg.* 2015;74(1):80-84.
32. Leibovitch I, Huilgol SC, Selva D, et al. Microcystic adnexal carcinoma: treatment with Mohs micrographic surgery. *J Am Acad Dermatol.* 2005;52(2):295-300.
33. Bae JM, Choi YY, Kim H, et al. Mohs micrographic surgery for extramammary Paget disease: a pooled analysis of individual patient data. *J Am Acad Dermatol.* 2013;68(4):632-637.
34. Ad Hoc Task F, Connolly SM, Baker DR, et al. AAD/ACMS/ASDSA/ASMS 2012 appropriate use criteria for Mohs micrographic surgery: a report of the American Academy of Dermatology, American College of Mohs Surgery, American Society for Dermatologic Surgery Association, and the American Society for Mohs Surgery. *J Am Acad Dermatol.* 2012;67(4):531-550.
35. Stebbins WG, Gusev J, Higgins HW 2nd, et al. Evaluation of patient satisfaction with second intention healing versus primary surgical closure. *J Am Acad Dermatol.* 2015;73(5):865-867;e861.
36. Zitelli JA, Moy RL. Buried vertical mattress suture. *J Dermatol Surg Oncol.* 1989;15(1):17-19.
37. Zitelli JA. The bilobed flap for nasal reconstruction. *Arch Dermatol.* 1989;125(7):957-959.
38. Sage RJ, Leach BC, Cook J. Antihelical cartilage grafts for reconstruction of mohs micrographic surgery defects. *Dermatol Surg.* 2012;38(12):1930-1937.
39. Jellinek NJ, Nguyen TH, Albertini JG. Paramedian forehead flap: advances, procedural nuances, and variations in technique. *Dermatol Surg.* 2014;40(Suppl 9):S30-S42.
40. Alam M, Ibrahim O, Nodzenski M, et al. Adverse events associated with mohs micrographic surgery: multicenter prospective cohort study of 20,821 cases at 23 centers. *JAMA Dermatol.* 2013;149(12):1378-1385.
41. Merritt BG, Lee NY, Brodland DG, et al. The safety of Mohs surgery: a prospective multicenter cohort study. *J Am Acad Dermatol.* 2012;67(6):1302-1309.
42. Nishimura RA, Otto CM, Bonow RO, et al. 2014 AHA/ACC guideline for the management of patients with valvular heart disease: a report of the American College of Cardiology/American Heart Association Task Force on Practice Guidelines. *J Am Coll Cardiol.* 2014;63(22):e57-e185.
43. Watters W 3rd, Rethman MP, Hanson NB, et al. Prevention of orthopaedic implant infection in patients undergoing dental procedures. *J Am Acad Orthop Surg.* 2013;21(3):180-189.
44. Rogers HW, Coldiron BM. A relative value unit-based cost comparison of treatment modalities for nonmelanoma skin cancer: effect of the loss of the Mohs multiple surgery reduction exemption. *J Am Acad Dermatol.* 2009;61(1):96-103.
45. Ravitskiy L, Brodland DG, Zitelli JA. Cost analysis: Mohs micrographic surgery. *Dermatol Surg.* 2012;38(4):585-594.

Chapter 205 :: Nail Surgery

:: Robert Baran & Olivier Cogrel

AT-A-GLANCE

- Nail surgery requires careful patient selection to prevent unnecessary complications.
- The technique used for anesthesia depends on the type of surgery. Distal digital block with ropivacaine 2 mg/mL is usually the best option.
- Partial nail avulsion allows the exploration and/or the treatment of a subungual lesion or the removal of a pathologic nail plate. Total nail plate avulsion should be discouraged to prevent nail bed shrinking and distal embedding.
- Nail biopsies are performed to determine the histopathologic features of a lesion or to clarify an uncertain clinical diagnosis.
- Lateral longitudinal biopsy is the best technique for inflammatory disorders or lateral longitudinal melanonychia.
- Punch biopsy less than 3 mm in the distal matrix does not produce serious dystrophy.
- Tangential shave excision is the best option for superficial matrix tumors such as wide longitudinal melanonychia or superficial epithelial benign tumors.

BACKGROUND

The main objectives of nail surgery are to aid diagnosis by biopsy, to treat infection, to alleviate pain, to remove local tumors, and to ensure the best cosmetic results in acquired and congenital abnormalities.

PERIOPERATIVE CONSIDERATIONS

PATIENT SELECTION

Providing the patient with an exact illustration of the operation is helpful to give the patient insight into the procedure and its expected outcome. A thorough discussion regarding postoperative morbidity is essential.

RISKS AND PRECAUTIONS

Preoperative photographs as well as any taken during surgery may be useful medicolegally. Careful history taking may reveal systemic disease such as diabetes mellitus, blood dyscrasia, vascular disease, vascular collagen disease (scleroderma), allergy, chronic pulmonary disease, or immune impairment. Any of these may at times be relative contraindications to surgery, may be associated with severe complications (infection, necrosis), or may call for alteration of the technique to be used. Surgery of the nail is not recommended in patients with high-risk conditions. A history of concurrent use of drugs may be relevant, because these drugs may affect anesthesia (eg, monoamine oxidase inhibitors or phenothiazines), prolong bleeding (eg, aspirin and anticoagulants), delay healing (eg, glucocorticoids), or have toxic effects on the nail apparatus (eg, retinoids). There may be a history of allergy to lidocaine or mepivacaine or to parabens contained in both as a preservative. A magnifying lens and dermoscopy are useful to observe the color, surface, and structure of the periungual tissue and to compare the unaffected contralateral digit. It may be necessary to probe to localize pain, to obtain a radiograph to rule out underlying bone involvement, or to ask for ultrasonography and MRI when a tumor is suspected. The basic requirements for nail surgery include a detailed knowledge of the anatomy and physiology of the nail apparatus on the part of the surgeon. Full aseptic conditions, regional block anesthesia, and local hemostasis are indispensable.

ANATOMY[1] (CHAP. 8)

The nail plate is the permanent product of the nail matrix. Its normal appearance and growth depend on the integrity of the perionychium and the bony phalanx (Fig. 205-1). The nail is a semihard horny plate covering the dorsal aspect of the tip of the digit. The nail is inserted proximally in an invagination that is practically parallel to the upper surface of the skin and laterally in the lateral nail grooves. This pocket-like invagination has a roof, the proximal nail fold, and a floor, the matrix from which the nail is derived. The matrix extends approximately 6 mm under the proximal nail fold, and its distal portion is only visible as the white semicircular lunula. The general shape of the matrix is a crescent, concave in its posteroinferior portion. The lateral horns of this crescent are more developed in the great toe and are located at the coronal plane of the bone. The ventral aspect of the proximal nail fold encompasses both a lower portion, which continues the matrix, and an upper portion (roughly three-quarters of its length), called the *eponychium* (Fig. 205-2). The germinal matrix forms the bulk of the nail plate. The proximal element forms the superficial third of the nail plate, whereas

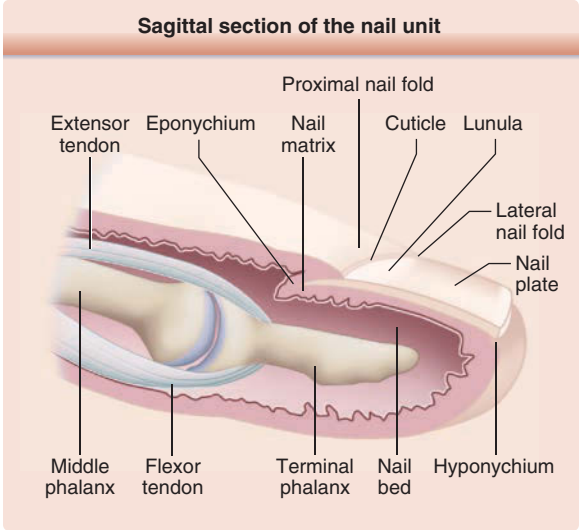

Figure 205-1 Sagittal section of the nail unit.

the distal element provides its inferior two-thirds. The ventral surface of the proximal nail fold adheres closely to the nail for a short distance and forms a gradually desquamating tissue, the cuticle, made of the stratum corneum of both the dorsal and the ventral sides of the proximal nail fold. The cuticle seals and protects the nail cul-de-sac. The nail plate is bordered by the proximal nail fold, which is continuous with the similarly structured lateral nail fold on each side. The nail bed extends from the lunula to the hyponychium. It has parallel, longitudinal rete ridges. In contrast to the matrix, the nail bed has a firm attachment to the nail plate. Colorless but translucent, this highly vascular connective tissue, containing glomus organs, transmits a pink color through the nail. Avulsion of the overlying nail plate denudes the nail bed. Distally, adjacent to the nail bed, lies the hyponychium, an extension of the volar epidermis under the nail plate, which marks the point at which the nail separates from the underlying tissue. The distal nail groove, which is convex anteriorly, separates the

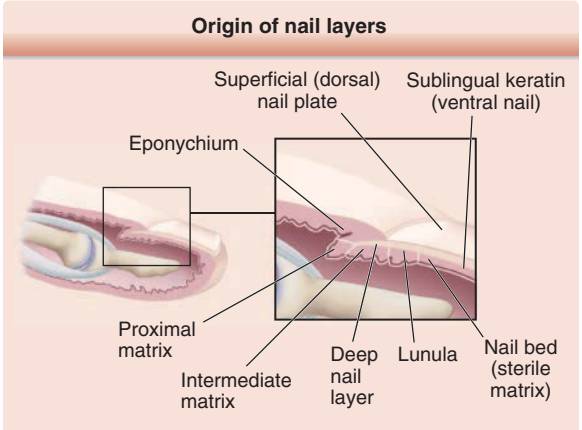

Figure 205-2 Origin of the nail layers. (Used with permission from P. Kechijian, MD.)

hyponychium from the fingertip. The circulation of the nail apparatus is supplied by 2 digital arteries that course along the digits and give off branches to the distal and proximal arches. The sensory nerves to the distal phalanx of the 3 middle fingers are derived from fine, oblique, dorsal branches of the volar collateral nerves. Longitudinal branches of the dorsal collateral nerves supply the terminal phalanx of the fifth digit and also the thumb. Among its multiple functions, the nail provides counterpressure to the pulp that is essential to the tactile sensation involving the fingers and to the prevention of hypertrophy of the nail bed.

INSTRUMENTS AND DRAPING

The instruments used in nail surgery are, in general, the same as those used in cutaneous surgery with the addition of the instruments listed in Table 205-1.

Draping is accomplished by means of a sterile surgical drape or a sterile glove on the involved hand. The tip of the glove is cut off on the finger that is to undergo surgery. The remaining open finger of the glove is then rolled back down the digit. This exsanguinates the digit and provides a tourniquet when it reaches the proximal part of the finger. Disinfection is extremely important to avoid contamination of the wound with consecutive infection. Isopropyl alcohol scrub and chlorhexidine have proven to be superior to povidone iodine washing.

ANESTHESIA

Local anesthesia should be administered while the patient is reclining or in a supine position. Lidocaine 1% or 2% is widely used because the incidence of allergy to this agent is very low as well as for its low cost. Buffered 2% lidocaine and ropivacaine are characterized by quick absorption and near instantaneous anesthesia. Applying Emla or LMD under occlusion 2 hours prior to the injection may lessen the pain especially in children. For anxious patients, administering a fast-acting benzodiazepine orally (midazolam, alprazolam or diazepam) 2 hours

TABLE 205-1
Instruments Required for Nail Surgery

- Nail elevators
- Single- or double-pronged skin hooks
- Double-action nail splitter (bone rongeur)
- Clippers, splitting scissors, English nail splitter
- Pointed scissors (Gradle scissors), curved iris scissors
- Small-nosed hemostats
- Disposable biopsy punches
- Penrose drains
- Luer-Lok syringe, 30-gauge needles

before anesthesia can considerably reduce the fear of the injection.[2] Ropivacaine 2 mg/mL is another agent that can be used and offers the advantage of a rapid onset and a long duration, usually between 8 and 12 hours. The use of local anesthesia in conjunction with epinephrine for surgery on digits is no longer contraindicated and offers the advantage of vasoconstriction and thus a less bloody surgical field. However, caution is warranted for patients with risk factors predisposing for local circulatory insufficiency. Buffering and warming the local anesthetic coupled with a slow rate of injection and small needle size, all drastically reduce the pain of injection. Buffering is accomplished with the use of 1 part 7.5% bicarbonate with 9 parts. Anesthetics are administered via a 30-gauge needle for fingernails or a 27-gauge needle for toenails on a Luer-Lock syringe using either a proximal digital block or, better, a distal digital block (wing block) procedure. Other techniques, such as median distal anesthesia or transthecal block, have not replaced the classic routes of anesthesia. Although emergencies related to minor surgery occur rarely, the ready availability of resuscitative equipment and expertise is essential.

PROXIMAL DIGITAL BLOCK

This is the more traditionally used block. Although less painful than the distal block procedure, the anesthesia takes 5 to 10 minutes to become established. The hand is laid down flat, with the fingers spread, so that 1 to 2 mL of anesthetic can be administered by a dorsal injection, with a thin needle inserted and directed tangentially to the sides of the bony phalanx at the base of the involved finger and as far as the lateral side of the flexor tendon (Fig. 205-3). A tourniquet effect may inadvertently be produced by injecting more than 5 mL of anesthetic and should be avoided. The absence of blood reflux in the syringe should be verified before injection if a nondental syringe is used. When the operation is strictly localized to a lateral region, a block limited to the nerves ipsilateral to the lesion suffices, as in the case of a partial distolateral nail avulsion.

DISTAL DIGITAL BLOCK

The distal digital block procedure is more painful than the proximal block procedure, but anesthesia occurs immediately. As such, it is our preferred method of anesthesia in the absence of a digital bacterial infection. For a distal digital block, the needle is inserted just behind the junction of the proximal nail fold and a lateral nail fold and a few 10ths of a milliliter of anesthetic is injected, which whitens the region. The injection is continued by aiming the needle toward the pad. One then returns to the initial area to inject the proximal fold transversely. Finally, at the junction of the proximal fold with the lateral fold on the opposite side, one proceeds as described earlier (Fig. 205-4). The anesthesia is almost immediate, and when the procedure is done correctly, injections rarely have to be extended to the distal area of the finger. Median distal administration is relatively simple and quick (Fig. 205-5). The needle is introduced at a 30° angle into the middle of the proximal nail fold and advanced distally into the underlying matrix. Anesthetic is injected slowly as the needle pierces first the nail plate, then the matrix, and finally the adjacent nail bed. The nail plate is soft and offers little resistance. Blanching confirms the delivery of anesthetic to the nail matrix and bed. Pain is brief and anesthesia nearly instantaneous. This method is suitable for most procedures performed on the proximal half of the nail unit. It is not suitable for matricectomy or complete nail avulsion.

TRANSTHECAL BLOCK

The flexor tendon sheath may be used as an avenue for introducing anesthetic to the core of the digit. Through centrifugal anesthetic diffusion all 4 digital nerves are anesthetized rapidly. This technique involves palmar percutaneous injection of 2 mL of lidocaine or ropivicaine into the potential space of the flexor tendon sheath at the level of the palmar flexion crease using a 3-mL syringe and a 25-gauge hypodermic needle. Postoperative pain may be more severe than with other techniques.

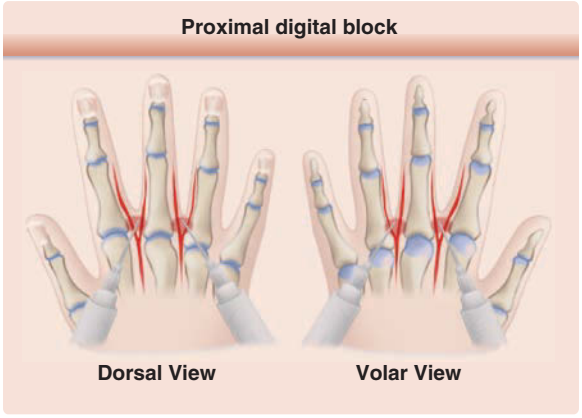

Figure 205-3 Proximal digital block.

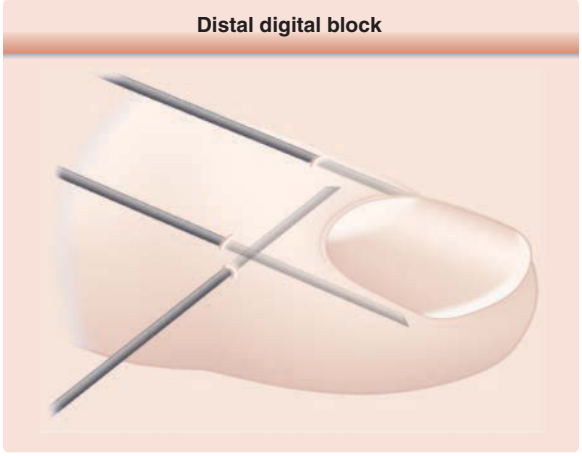

Figure 205-4 Distal digital block.

Figure 205-5 Median distal block.

REGIONAL BLOCKS AND GENERAL ANESTHESIA

These are used mainly in more extensive and painful surgeries or in circumstances under which it is useful to have anesthesia of more than 1 digit at the same time. For instance, it may be appropriate in the surgical treatment of numerous warts and in the infiltration of more than 1 finger with triamcinolone in the treatment of nail unit psoriasis. General anesthesia is also indicated for nail rotation of congenital malalignment of the big toe nail in children.

TOURNIQUETS

Most nail surgery procedures are undertaken with strict surgical ischemia to avoid bleeding and enable a correct visualization of the operative field. Use of the digital tourniquet is relatively safe and efficacious. For brief intraoperative hemostasis (eg, nail avulsion, punch biopsy of the nail bed), squeezing the sides of the digits is effective. If a prolonged bloodless field is required, a Penrose drain may be placed around the base of the digit and secured with a hemostatic clamp for use as a tourniquet. It is preferable not to leave it on for more than 15 to 20 minutes. The tourniquet application can be interrupted for a few minutes during longer procedures. Although it seems intuitive, it is essential to never forget the tourniquet on, as several cases of digital necrosis following forgotten tourniquet have been reported.[3]

To facilitate establishment of a bloodless field, the use of an exsanguinating tourniquet is recommended[1]

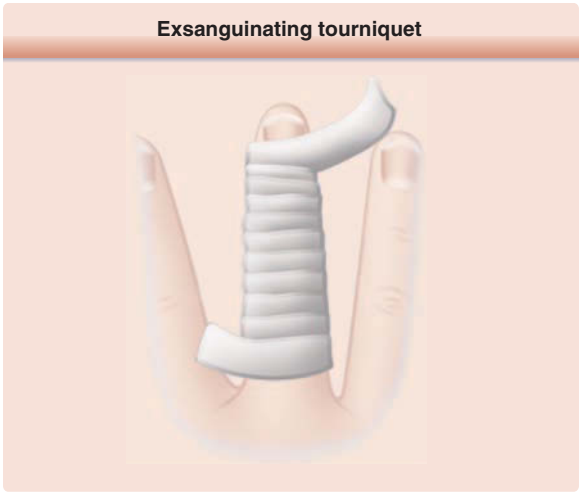

Figure 205-6 Exsanguinating tourniquet.

before anesthesia. A wide Penrose drain is wound tightly in loops that overlap in a distal to proximal fashion, with an exposed loose end left distally (Fig. 205-6). This "milks" the blood from the digit. The loose end is then grasped and the drain unwound, again from distal to proximal, until the nail unit is exposed with the final proximal loop. In the absence of contraindication, the addition of epinephrine to lidocaine, for example, may reduce the need for a tourniquet and produce better and longer pain control perioperatively.

DRESSING AND POSTOPERATIVE CARE

DRESSING

At the end of the operation, either the digit is cleansed with sterile 10% hydrogen peroxide solution and sprayed with a colorless disinfectant or an antiseptic with hemolytic action is applied. The nail area is then covered with an antiseptic or antibiotic ointment on gauze or pads. Dressing must be done in a way that takes into account oozing, pain, and sensitivity. A bulky dressing provides a cushion against local trauma. Compressive dressing is mandatory and must not be removed in the first 48 hours following the procedure. The compression must be applied to the distal part of the digit and not proximally to avoid a tourniquet effect. Then, the dressings should be changed every other day or daily if there is infection. Several layers of sterile gauze should be kept in place by Micropore (2.5-cm) tape placed first on the dorsal aspect of the finger or toe, then on the ventral aspect, and last on the lateral edges in a U shape (a circular dressing should never be applied in the first week). Finally, use of an X-span tube dressing or Surgitube will give the patient more freedom to use the hand, but care must be taken that dressings do not constrict

blood flow. During the first 48 hours, the arm must be kept in a sling. Stitches are removed after 7 to 12 days. When the feet are treated, daily chlorhexidine baths precede the care just described. For all operations involving the toes, the patient should wear an appropriate shoe or sandal after the dressing has been applied. The patient should be recumbent for 24 to 48 hours, with the foot elevated to 30°.

POSTOPERATIVE COMPLICATIONS

BLEEDING

Bleeding seen after the tourniquet is removed is not worrisome as the compressive dressing will stop it. In case of persistent bleeding, 35% aluminium chloride solution or an oxidized cellulose application (Gelfoam) should be applied. Alternatively, an extra injection of lidocaine + epinephrine bilaterally will stop the bleeding through compression of the vessels.

PAIN

Pain threshold varies based on the procedure and from patient to patient. CO_2 laser vaporization of warts and chemical matricectomy are the least painful procedures whereas larger excisions require the use of more potent postoperative painkillers. While the dressing is being put in place, the patient must be told what precautions to take. Providing a supply of moderately potent oral analgesics will help the patient feel in control of any pain. Elevating the extremity during the first 48 hours is advised to prevent swelling and decreases the experienced postoperative pain. Weak opioids can be prescribed in the presence of moderately perceived pain as well as nonsteroidal antiinflammatory drugs while strong opioids are restricted to intense pain. Pulsating pain beginning after 36 to 48 hours may indicate an infection, which should be treated according to the results of bacterial culture of the organism. Any bulky dressing that is blood stained after 24 hours should be changed.

DYSESTHESIA

Occurrence of postoperative long-term dysesthesia after nail surgery is well known. Complete or partial resolution may be noted after 6 to 12 months.

INFECTION

Prophylactic antibiotic treatment is mandatory for patients with prosthetic valve and in prevention of joint prosthesis infection. Peripheral vascular disease and young age (in childhood, the nail matrix is extremely fragile and behavior is less sanitary) are further indications. Tetanus toxoid for lesions of the toes should be discussed and advised especially in farmers, for example. If there are ragged surfaces to the nail, which makes thorough preoperative cleaning difficult, antibiotics may prevent wound infection. Postoperative infection may be caused by preoperative colonization or infection. Culture of preoperative swab specimens will indicate the best choice of drug after initial coverage with a broad-spectrum antibiotic. Attention to detail is important. Carelessness may result in serious infectious complications in the soft tissue and occasionally in bone. Routine or preoperative nail cleansing softens the nail plate and keeps contamination to a minimum. In the event of an infection, broad-spectrum antibiotics should be initiated.

ACQUIRED NAIL MALALIGNMENT[4]

Development of malalignment of the nail plate may result from lateral longitudinal biopsy in excess of the routine 3 mm.

RELAPSE

Relapse will depend on the nature of the lesion treated. Warts, ingrown nails, and myxoid cysts can be difficult to eradicate.

RESIDUAL DYSTROPHY

Residual dystrophies are not unusual when surgery involves the proximal area of the matrix. Nail spicules can be observed after lateral longitudinal excision, lateral matricectomies, or total removal of the nail apparatus.

UNPREDICTABLE COMPLICATIONS

- Necrosis can result from too tight stiches.
- Hypertrophic scars and keloids are rare.
- Implantation epidermoid cysts may occur in operation scars.
- Reflex sympathetic dystrophy now known as "Complex regional pain syndrome" Type I is rare. It presents with pain sensitive and motor disturbances along with autonomic and even soft tissue trophic changes.

NAIL AVULSION

A nail avulsion consists of separating the nail plate from its underlying attachments. It allows the exploration and/or the treatment of a subungual lesion or the removal of a pathologic nail plate. The nail is strongly adherent to its underlying bed and less adherent at the level of the distal matrix and the lateral nail folds. An avulsion is therefore easier to perform either a proximal or lateral approach. The

removal of the nail plate can be carried out using distal or proximal approaches. In both techniques, inserting the blunt instrument back and forth between the horny layer of the proximal nail fold and the nail plate loosens the proximal nail fold adherence. Anesthesia is mandatory except in case of preexisting onycholysis.

DISTAL APPROACH

In the more commonly used distal approach, a Freer septum elevator or a dental spatula is inserted between the nail plate and nail bed (Fig. 205-7A). The nail is separated from its nail-bed attachment using proximal force applied in anterior–posterior movements so as not to injure the longitudinal ridges of the nail bed. The detachment is completed by firmly pushing the instrument into the posterolateral corners of the nail plate. Then, one of the lateral edges is grasped with a sturdy hemostat, and extracted with an upward and circular movement to accomplish the removal of the nail plate.

PROXIMAL APPROACH

The advantage of a proximal approach for nail avulsion is to prevent an injury to the distal nail bed and hyponychium through the insertion of the Freer septum. The

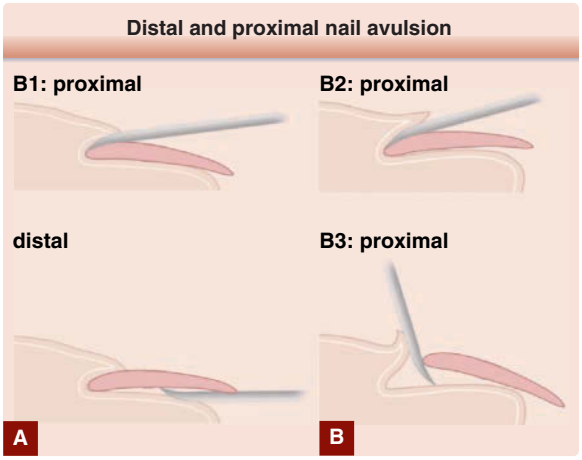

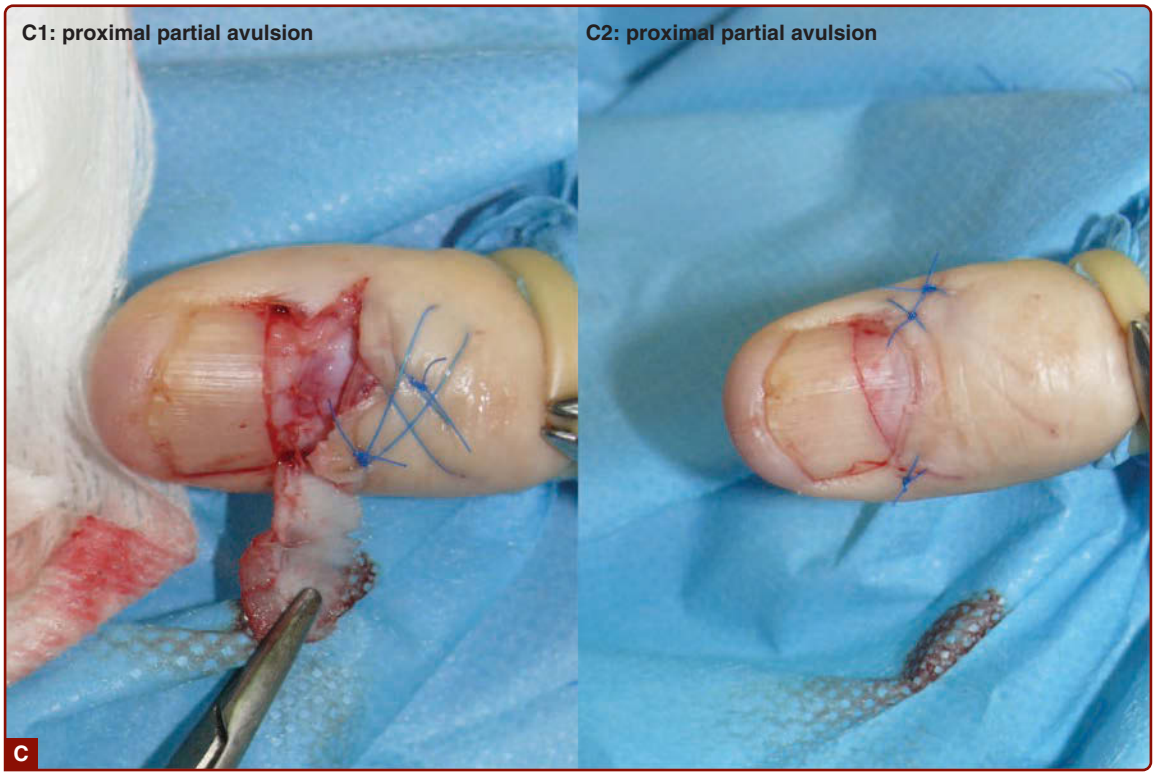

Figure 205-7 **A,** Distal nail avulsion. **B,** Proximal nail avulsion. **C,** Partial avulsions.

spatula is then used to reflect the proximal nail fold, and is delicately inserted under the base of the nail plate where adherence is normally weak (Fig. 205-7B). The instrument is advanced distally following the natural cleavage plane, and this operation is repeated on the entire width of the subungual region. After the last attachments are freed, the nail plate is easily pulled out.

Total surgical removal should be discouraged, however, because the distal nail bed may shrink and become dislocated dorsally. In addition, the loss of counterpressure produced by the removal of the nail plate allows expansion of the distal soft tissue, and the distal edge of the regrowing nail then embeds itself. In patients at high risk, nonsurgical removal of the nail plate should be considered when necessary. This can be accomplished by applying 40% urea paste directly to the nail after protecting the surrounding skin. Urea acts on the bond between nail keratin and diseased nail plate, sparing only the normal nail tissue.

PARTIAL NAIL AVULSION

The problems that can arise after total nail avulsion may be overcome by partially avulsing the nail. Partial distal avulsion requires only separation of the nail from the distal nail bed. This procedure can be performed under local anesthesia in selected patients, when, for instance, a fungal infection is of limited extent. An affected portion of the nail plate may be removed in one session, even when the disease has reached the deeper regions of the subungual tissue beneath the proximal nail fold. Commonly, an English anvil nail splitter or a double-action bone rongeur is used for this procedure. Partial surgical section of the lateral and/or medial segment of the nail plate may be sufficient for the treatment of distal lateral subungual onychomycosis (Fig. 205-7C). In the toe, this procedure leaves enough normal nail to counteract the upward forces exerted on the distal soft tissue when walking, and this will prevent the appearance of a distal nail wall. In proximal subungual onychomycosis, removal of the nonadjacent base of the nail plate, cut transversely, leaves the distal portion of the nail in place (Fig. 205-8), which decreases discomfort. Similarly, an acute paronychia that does not respond to appropriate antibiotics within 48 hours should be treated surgically by removing the base of the nail plate. Moreover, in cases of nail matrix procedures, a partial proximal avulsion prevents damaging the distal nail while allowing for an excellent visualization of the matrix and the cul-de-sac. The proximal nail plate is usually cut at its proximal third, lifted up, and always pulled back into its initial position at the end of the procedure.

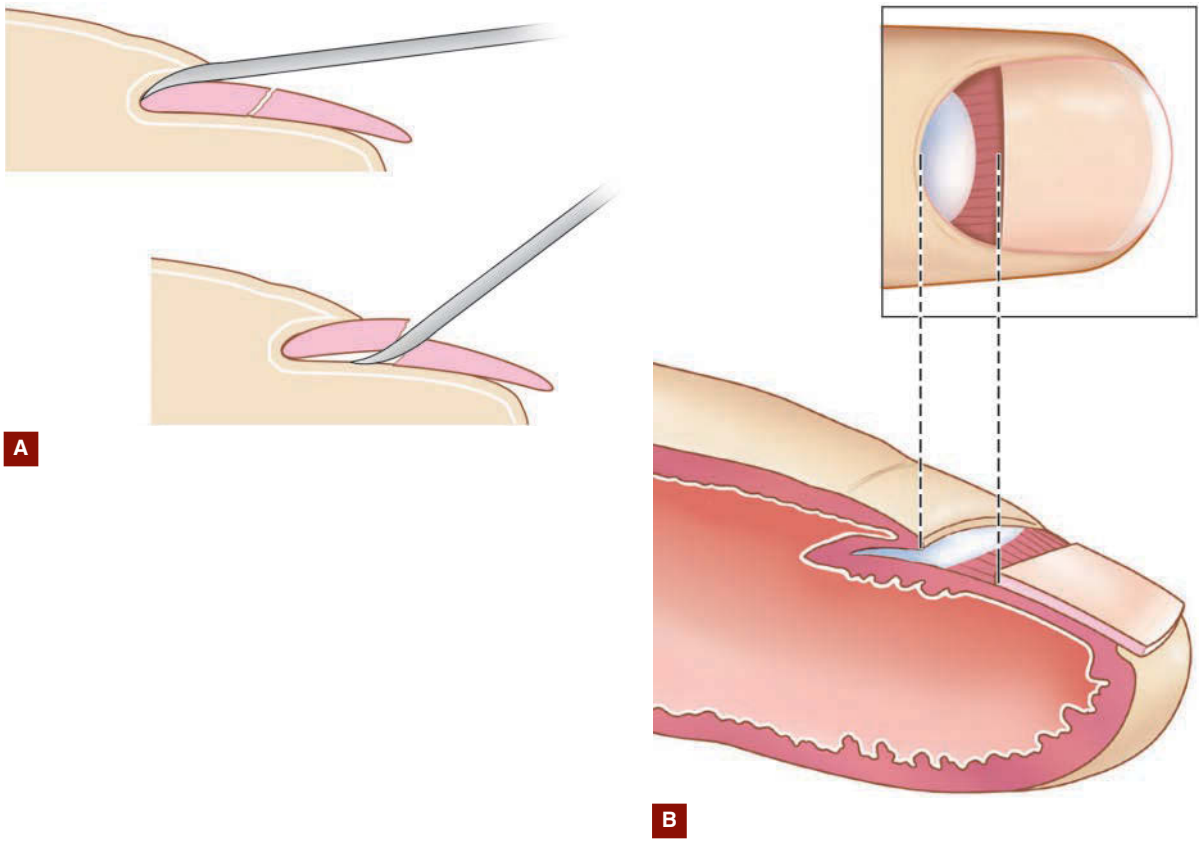

Figure 205-8 **A** and **B,** Technique of removal of the base of the nail plate.

TRAP DOOR NAIL AVULSION

This technique minimizes trauma in nail surgery when accessing the nail bed and matrix. Trap door nail plate avulsion entails separation of all periungual attachments except for that between the dorsum of the nail and the ventral aspect of the proximal nail fold. Both are then reflected en bloc in the manner of a trap door, utilizing the same oblique incisions normally made for reflection of the PNF alone. A partial medial trap door nail avulsion is also recommended for medial longitudinal excision.

NAIL BIOPSIES

Biopsies are performed to determine the histopathologic features of a lesion or to clarify an uncertain clinical diagnosis. Techniques depend on the location of the lesion.

LATERAL LONGITUDINAL BIOPSY OR LATERAL FUSIFORM EXCISION

It gives information of the entire nail organ and therefore represents the best technique for the diagnosis of inflammatory disorders as lichen planus or psoriasis when all the subunits of the nail apparatus are involved. Lateral longitudinal biopsy is also advised when longitudinal melanonychia[3] is located in the lateral part of the nail plate (Fig. 205-9). An elliptical incision may be made on either side of the nail plate and proximal nail fold. For the most part, the incisions parallel the lateral edge of the nail plate. Beginning in the lateral nail groove, the incisions should include a 3- to 4-mm nail segment reaching to the bone. (See Video 205-1 at mhprofessional.com/fitzderm9evideos) This ensures that a full-thickness fragment of the matrix with its lateral horn is obtained. Slightly curved iris scissors are useful for separating the tissue from the bone. Starting at the tip of the digit, one proceeds proximally while maintaining contact with the bony phalanx. Backstitches for the lateral nail folds avoid their flattening. It is helpful, especially for thick toenails, to soften the nail before the procedure by soaking it in warm water for 5 minutes.

Figure 205-9 Lateral longitudinal biopsy of longitudinal melanonychia located within the lateral third of the nail plate.

BIOPSY OF THE DISTAL NAIL MATRIX [5-7]

A 3-mm punch biopsy may be performed through the nail plate into the distal matrix. Three millimeters is the maximum size that does not produce serious dystrophy, although even biopsies of this size can cause such effects if carried out in the most proximal portion of the nail matrix. When a punch biopsy is used to sample longitudinal melanonychia of less than 3 mm in width, the circumferential incision is made around the origin of the band, through the nail plate (Fig. 205-10A). This area may be distal enough to be reached by pushing back the cuticle (Fig. 205-10B), but if it is more proximal, the proximal nail fold may have to be reflected using a posterolateral incision. The next step is to remove the proximal third of the nail plate (Figs. 205-10B and C), while leaving the cylinder of tissue containing the origin of the longitudinal melanonychia still in place. This technique allows the surgeon to inspect the surrounding nail matrix and bed with a magnifying lens to determine whether the pigment extends around the punch incision (Figs. 205-10C and D) and facilitates the removal of the cylinder of biopsy tissue with a Gradle scissors. (See Video 205-2 at mhprofessional.com/fitzderm9evideos.)

For transverse biopsy (Fig. 205-11), 2 small oblique incisions are made on each side of the proximal nail fold. The fold is then reflected to expose the matrix area. The proximal third of the nail plate is avulsed. Then, the lesion is removed by excising an elliptical or crescent-shaped wedge of tissue with the convex portion of the crescent paralleling the anterior border of the lunula. When longitudinal melanonychia lies within the midportion of the nail plate, the potential for postoperative dystrophy is great, and selection of the optimal biopsy method is difficult (Fig. 205-12) (Haneke's releasing flap technique derived from Schernberg's releasing flat method). It is important to establish the matrix origin (proximal or distal) of longitudinal melanonychia preoperatively, because the more proximal the origin, the greater the risk of nail dystrophy.[5] The origin of pigmentation may be determined by dermoscopy of the free edge of the nail.[8]

Tangential matrix biopsy (Fig. 205-13) for wide longitudinal melanonychia is a good option. Cutting, then reclining the proximal portion of the nail plate (1), after reflecting the proximal nail fold (2), the pigmented lesion is exposed. An incision is made around

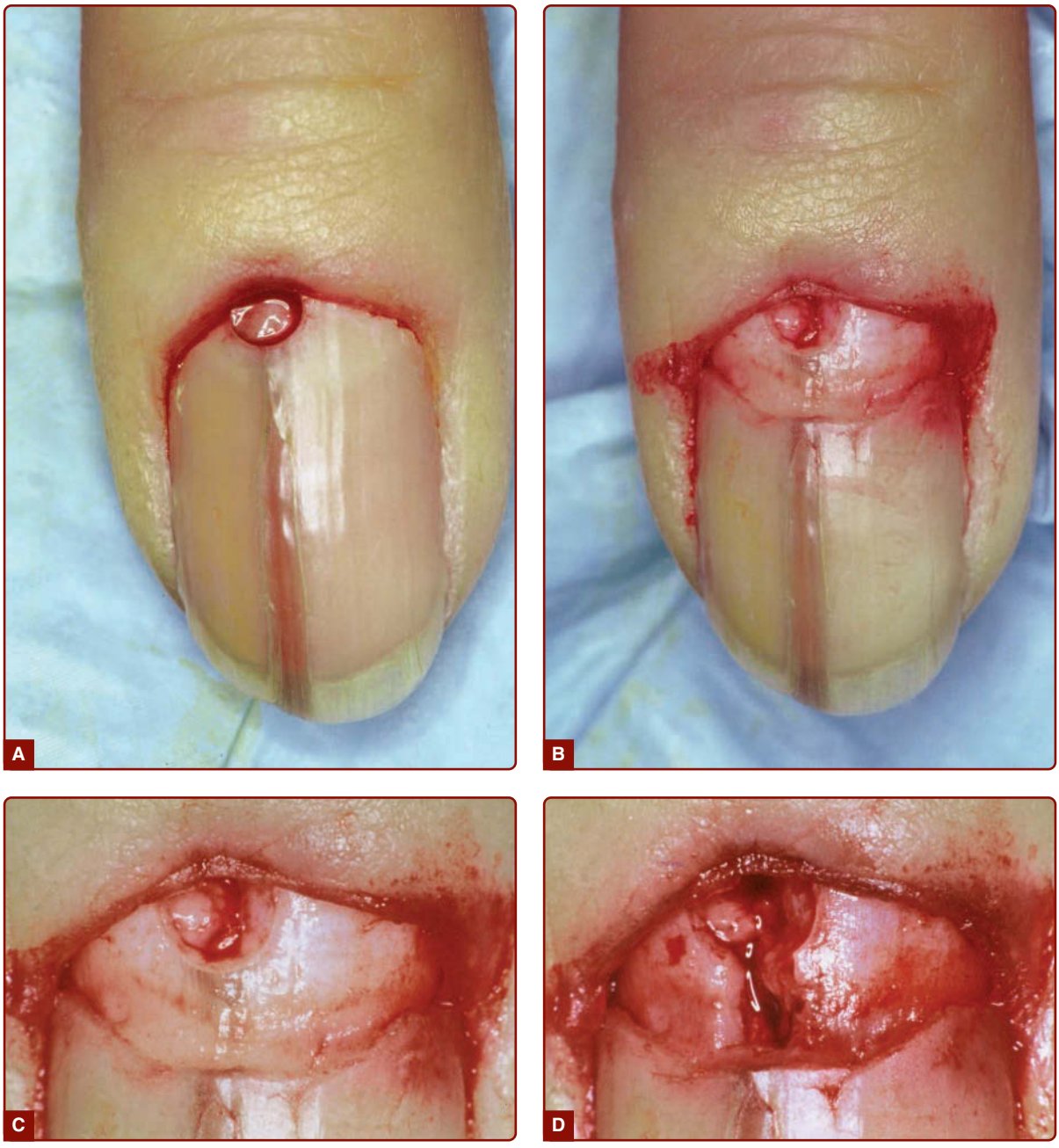

Figure 205-10 **A,** Punch biopsy of longitudinal melanonychia of width less than 3 mm. **B–D,** Removal of the base of the nail plate (**B**) to allow easy removal of the biopsied cylinder of matrix tissue (**C**), and pigment left distally (**D**).

the lesion, followed by its tangential removal. Finally, the proximal nail plate is replaced and the oblique incisions of the proximal nail fold are maintained by micropore. This technique is claimed to give the best cosmetic results.

NAIL BED BIOPSY

Biopsy (Fig. 205-14) may be useful in any pathologic condition involving the nail bed. Punch biopsy is done with a 3- or 4-mm-diameter punch, which is driven perpendicularly into the nail plate in a circular motion down to the bone. However, it is not always easy to extract the cylinder cut with an area this small. One useful technique is to perforate the nail plate with a 6-mm punch without injuring the underlying tissue (Fig. 205-14A). The covering nail is then detached by using the tip of the scalpel to remove the disk of nail, and the biopsy is performed easily by using the 4-mm punch to the bone. The tissue can then be released from its tether with fine scissors. It is advisable to replace the 6-mm disk of nail keratin, after cleaning with 10% hydrogen peroxide, to cover the hole. If the nail plate is thick, rotating grinders can

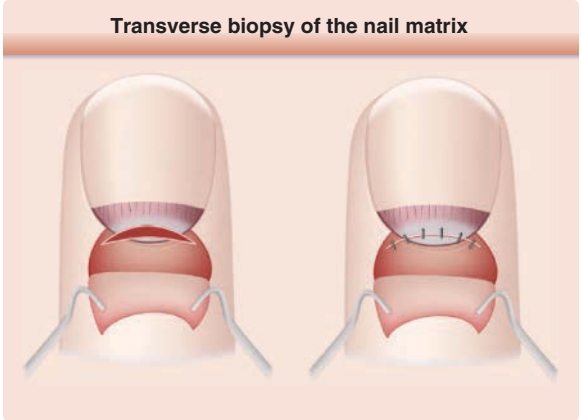

Figure 205-11 Transverse biopsy of the nail matrix.

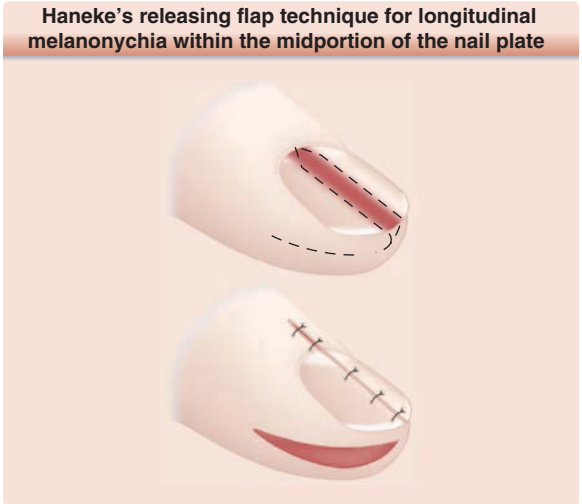

Figure 205-12 Haneke's releasing flap technique for longitudinal melanonychia within the midportion of the nail plate.

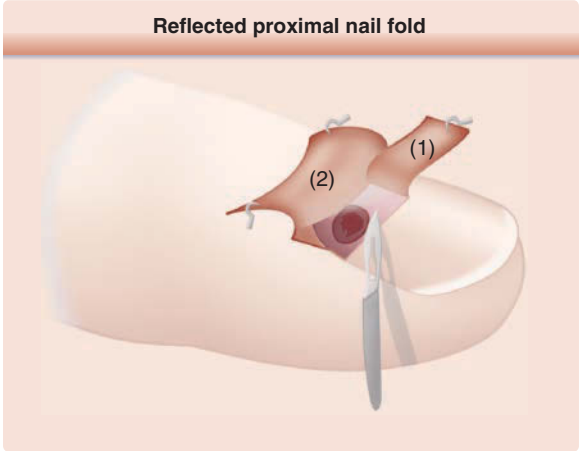

Figure 205-13 Reflected proximal nail fold and removal of the proximal portion of the nail plate exposing the pigmented lesion. Around the latter is made an incision followed by its tangential removal Haneke's matrix tangential biopsy technique.

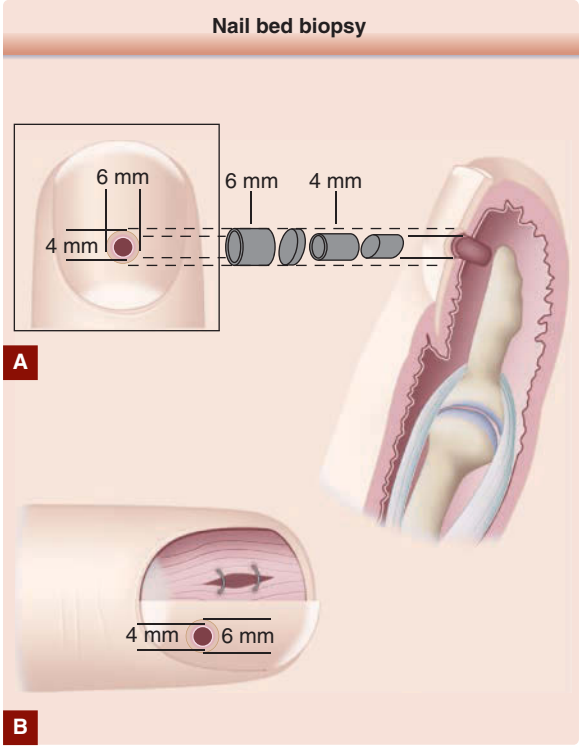

Figure 205-14 Nail bed biopsy. **A,** Punch biopsy. **B,** Fusiform biopsy.

be used to thin it down and facilitate the transungual biopsy.

PROXIMAL NAIL FOLD BIOPSY

A 2- to 3-mm punch may be used for biopsy of a tumor. A blister may be completely removed by shave biopsy using half a razor blade (Fig. 205-15). Excision of a 3-mm crescent-shaped tissue segment in the proximal region of the lateral nail folds may be helpful in the evaluation of collagen disease.

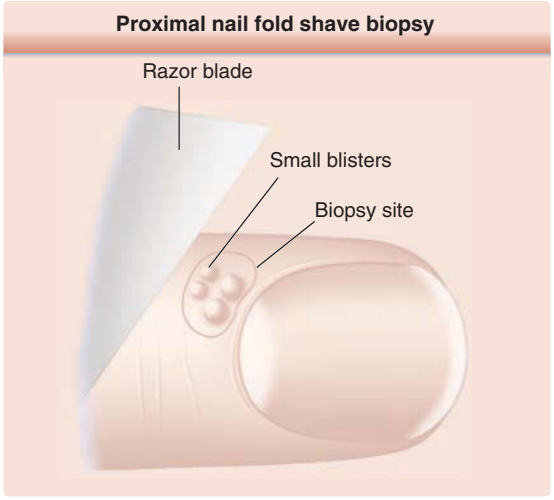

Figure 205-15 Proximal nail-fold shave biopsy.

APPLICATION TO THE DIFFERENT TISSUES OF THE NAIL APPARATUS

NAIL MATRIX PROCEDURES

When surgery involves the nail matrix, there are 3 primary approaches, including (1) a reduction in its width or (2) its length for removal of tumors, for instance, by using a cold steel procedure or (3) a 2- to 3-mm punch biopsy. In contrast to these 3 procedures, complete matricectomy, that is, ablation of the nail-forming tissue, is rarely performed because the nail is permanently lost (Fig. 205-16).

After reduction of the nail matrix width, one is left with a narrower nail and after reduction of the length, with a diminution in the thickness of the nail. Reduction of the matrix width is a useful and/or necessary procedure in the following major circumstances: need for lateral-longitudinal biopsy, lateral nail splitting, benign or malignant tumor in the lateral third of the nail apparatus, longitudinal melanonychia in a lateral location, ingrown nail, racquet nail. Destruction of lateral horn of the matrix can be performed surgically for lateral tumors or chemically with a solution of 88% phenol, 80% trichloroacetic acid, or 10% sodium hydroxide for nail splitting, ingrowing nail, or racquet nail (cf infra).

Reduction of the matrix length is necessary only in limited cases: to obtain a transverse elliptical biopsy specimen, to treat tumors that are 3 mm wide or larger, and to thin thick nails in patients with dystrophic congenital and/or hereditary disorders.

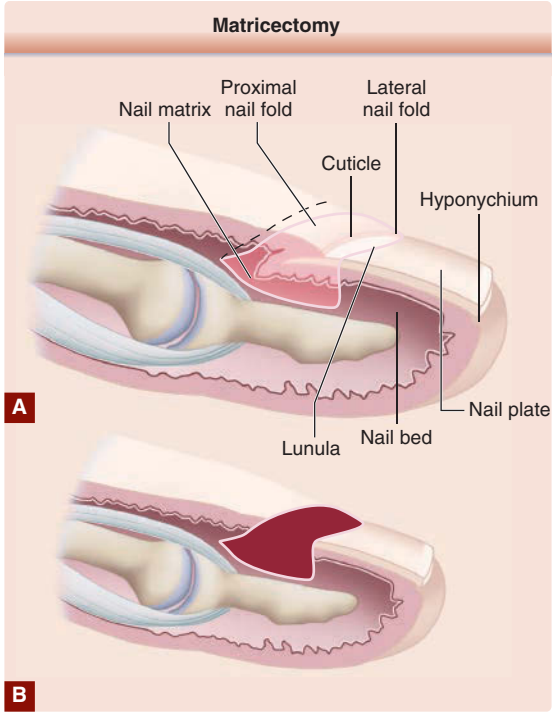

Figure 205-16 Matricectomy. **A,** Area of excision. **B,** Remaining defect.

NAIL MATRIX TUMORS

If the tumor is located within the lateral third of either portion of the nail, especially when it is close to the lateral margin, the best method is the technique recommended for lateral longitudinal nail biopsy, that is, the removal of the lateral portion of the nail with the defect. If the tumor is located in the middle region, the proximal nail fold is carefully freed from the underlying nail plate, obliquely incised at both sides, and reflected to expose the whole matrix area. For distal matrix tumors, excision is performed as a transverse biopsy except for very superficial epithelial tumors or wide longitudinal melanonychia that can be removed by tangential shave excision. (See Video 205-3 at mhprofessional.com/fitzderm9evideos.) For tumors located underneath the matrix, incision should be done parallel to the anterior border of the lunula.

If the tumor is located to the proximal nail matrix and too deep to allow a tangential excision, an alternative approach is the formation of a Schernberg nail bed–matrix flap with an L-shaped incision of the lateral aspect of the finger (Fig. 205-17). A technique slightly modified by E. Haneke.

NAIL ABLATION AND ISOLATED MATRICECTOMY

Nail ablation (Fig. 205-16A) is the definitive removal of the entire nail organ and matricectomy (Fig. 205-16B), the complete extirpation of the nail matrix, which results in permanent nail loss. The principle of nail ablation is the complete removal of the nail unit

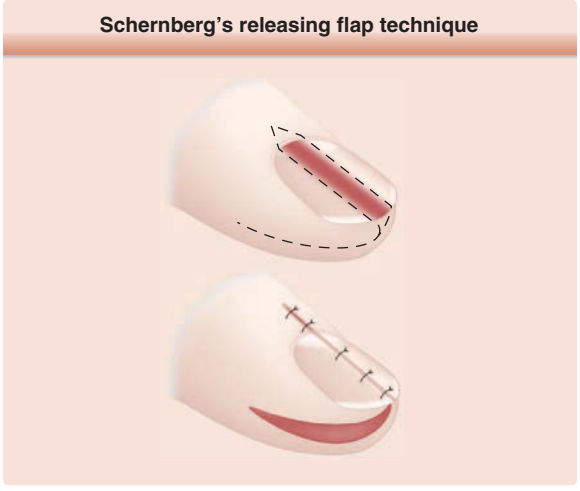

Figure 205-17 Schernberg's releasing flap method.

with hyponychium, nail bed, matrix, and lateral and proximal nail folds. Except for treatment of malignant tumors of the nail apparatus, nail ablation is rarely indicated. It may be necessary in the case of an excessively painful nail treated several times without success, but this should be an exception. Scalpel excision is strongly advocated whenever the surgical specimen needs histopathologic examination. If periungual pigmentation is associated with longitudinal melanonychia or if the latter is wider than 6 mm or the full thickness of the nail is pigmented, a large portion of the matrix would necessarily be involved. Under these circumstances, the underlying disease process is unlikely to be benign. The entire portion of the involved nail apparatus has to be excised en bloc.

The defect from nail ablation (Fig. 205-18B) may be covered with a free graft (split-thickness, full-thickness, reversed dermal graft), which usually takes on the bone in this particular location. A cross-finger flap is an alternative to a free graft. The use of the skin from the intermediate phalanx of a neighboring finger is more convenient for the patient than skin from the thenar area of the palm.

If only permanent nail matrix removal is necessary, the procedure is less extensive.

In cases in which pathologic examination of the removed tissue is unnecessary, phenol cautery, rather than scalpel excision, is the preferred technique for matricectomy. Most patients return to normal ambulation and activity as early as 1 day after the operation.

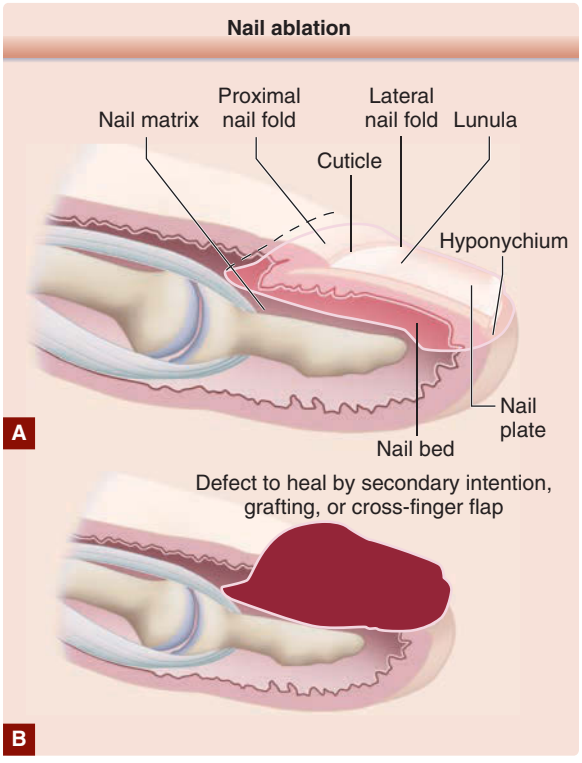

Figure 205-18 Nail ablation. **A,** Area of excision. **B,** Remaining defect.

NAIL-BED PROCEDURES

Nail-bed surgery is performed for biopsy, removal of tumors, and treatment of subungual hematoma or nail dystrophies such as onychogryphosis. If a larger nail bed fragment is needed, fusiform biopsy with a major longitudinal axis can be performed after partial avulsion of the lateral half of the nail (Fig. 205-14B; see Video 205-4 at mhprofessional.com/fitzderm9evideos) or after total avulsion if the fragment is central. After excision, the nail bed is undermined to facilitate reapproximation of both sides. The suture needle is used generously on these fragile subungual tissues. The wound is stitched with 6-0 resorbable thread. It is sometimes useful to make relaxing incisions at the most lateral margins of the nail bed.

SUBUNGUAL HEMATOMA

In cases of subungual hematoma, acute trauma with severe pain is always remembered by the patient. Depending on the site and intensity of the injury, the hematoma may be visible almost immediately or it may grow out from under the proximal nail fold within a few weeks.

When the hematoma is partial (less than 25% of the visible portion of the nail), it should be drained with a pointed scalpel or by hot paperclip cautery over the center of the dark spot (Fig. 205-19). This will produce relief from pain. Sometimes the nail sloughs as the new nail regenerates beneath the old one. Small hematomas may be included in the nail, but they cannot be degraded to hemosiderin, and results of the Prussian blue test will be negative. Therefore, to demonstrate the nature of the blackish pigment, scrapings are boiled in a small test tube with Hemostix, which gives a positive benzidine result. A hematoma involving more than 25% of the visible portion of the nail is a sign of significant nail bed injury. A radiograph is mandatory, because the phalanx may be fractured. The nail plate

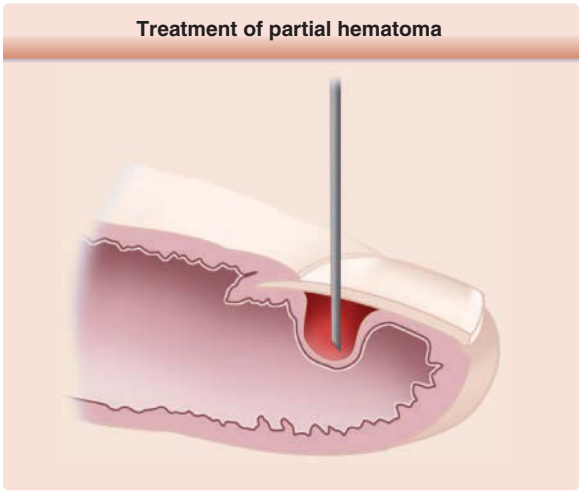

Figure 205-19 Treatment of partial hematoma.

is carefully removed and the hematoma evacuated. Traumatic nail bed laceration or wounds need a surgical approach to avoid delayed complications. Nail bed lacerations can be sutured after thorough cleaning with antiseptics, using 6-0 resorbable monofilament material. The avulsed nail plate should be put back to cover the wound and then kept in place by suturing to the lateral nail folds or the fingertip. Nail bed defects larger than 4 mm can be repaired using a split-thickness graft taken either from the nail bed of the same digit or from the nail bed of a great toe. The torn nail bed should be sutured with 6-0 resorbable thread, and large bites of tissue should be taken so that the suture material does not pull through when it is tied. The nail plate is cleaned, shortened, and slightly narrowed, and then replaced with sutures into the lateral nail folds. The stitches are left in for 2 weeks. Chronic hematomas are usually painless and are caused mainly by repeated microtrauma from either ill-fitting footwear or sporting activities. A notch is made with a scalpel blade at the distal and proximal border of the pigmented spot. Observation over a 3-week period will demonstrate whether the nail grows independently of the pigmentation or with it. However, chronic hematoma may resemble subungual melanoma and pose a distressing problem, and nonmigrating hematoma should be ruled out.

PROXIMAL NAIL FOLD PROCEDURES

RECALCITRANT CHRONIC PARONYCHIA

Presence of a foreign body (eg, hair) under the proximal nail fold is the main cause of recalcitrant chronic paronychia. The disorder manifests as a red swelling that is painless except when pressed, with secondary retraction of the paronychial tissue whose cuticle has disappeared and with recurrent episodes of acute paronychial inflammation.

For crescentic excision, a Freer septum elevator is inserted under the proximal nail fold to protect the matrix and extensor tendon. A No. 15 Bard-Parker blade is used to excise, en bloc, a crescent-shaped full-thickness skin segment, 4 mm at its greatest width that extends from one lateral nail fold to the other. Use of a beveled incision prevents accidental damage to the proximal nail matrix and the most proximal portion of the proximal nail fold, which is responsible for the normal shine of the nail plate (Fig. 205-20). In patients who experience repeated acute flares associated with chronic paronychia, additional removal of the base of the nail is useful.

The drawback of this technique is that the PNF is usually slightly retracted giving rise to a longer nail. This can be avoided by reclining the PNF in order to remove the fibrous under surface and suture it back to its original position.[9]

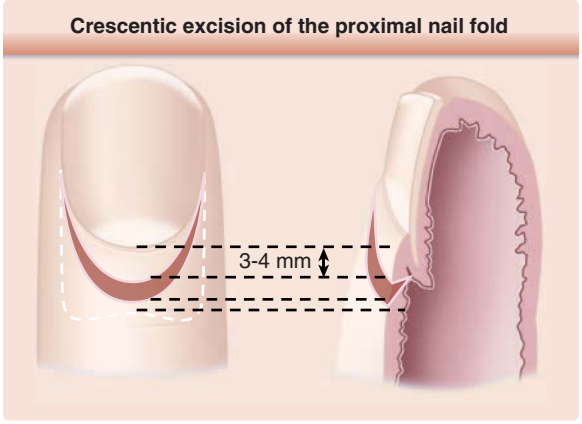

Figure 205-20 Crescentic excision of the proximal nail fold.

TUMORS OF THE PROXIMAL NAIL FOLD

Different techniques can be used to treat tumors of the proximal nail fold, depending on the nature of the tumor, its location, and the length of its long axis.

Crescentic excision is useful for small distal tumors. The crescent should not exceed 4 mm at its greatest width.

Tumors of the proximal nail fold that are situated in a median position and have a longitudinal axis longer than 4 to 5 mm can be excised with a wedge of proximal nail fold whose base is located at the free margin and whose apex points proximally (Fig. 205-21A). Two relaxing lateral incisions are then made in the proximal nail fold to allow suturing of the wedge-shaped defect after the undersurface of the proximal nail fold has been released from the nail plate (Fig. 205-21B).

The resulting symmetric narrow defects on both sides heal rapidly by secondary intention.

A small tumor on the lateral part of the proximal nail fold may be treated using a wedge-shaped excision

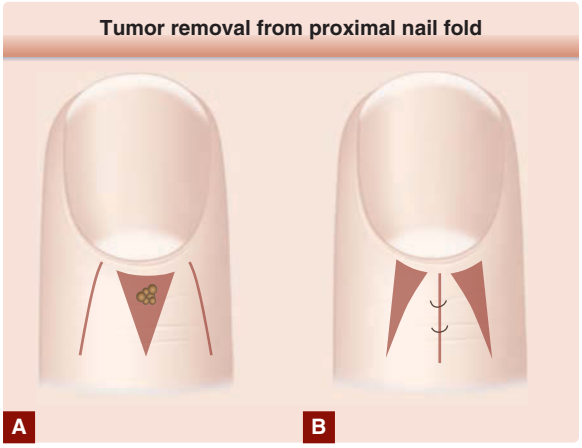

Figure 205-21 **A,** Tumor of the proximal nail fold situated in a median position. **B,** Suturing of the defect after relaxing lateral incisions are made and the proximal nail fold has been released from the nail plate.

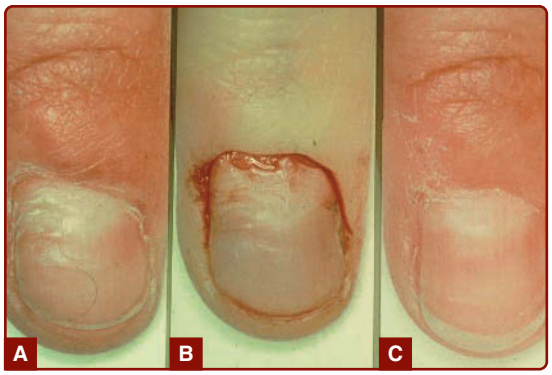

Figure 205-22 **A,** Irregular shape of the distal border of the proximal nail fold. **B,** Crescenting wedge-shaped excision of the proximal nailfold. **C,** Two months after healing.

(Fig. 205-22). Only one lateral relaxing incision is made at the opposite region of the proximal nail fold. To obtain better healing of the secondary defect, which is wider than in the procedure using 2 relaxing incisions, the surgery may be supplemented by making a relaxing crescent-shaped incision in the proximal nail fold.

A dorsal flap can be raised from the proximal nail fold by using 2 dorsolateral incisions and a horizontal one proximal to the cuticle. This gives complete exposure of subcutaneous tumors.

RECONSTRUCTION OF THE PROXIMAL NAIL FOLD

Reconstruction of the proximal nail fold may be necessary after any injury (accident, burn, avulsion caused by rapidly rotating belts and sanders, etc.). If the irregular tissue is excised, it is sometimes possible to recreate the distal curve of the proximal nail fold, which may produce a nearly perfect restoration. The proximal nail fold also may be restored by using 2 long, narrow, V-shaped transposition flaps from the lateral aspects of the terminal phalanx.

LATERAL NAIL FOLD PROCEDURES

A 2- to 4-mm punch can remove a tumor of the lateral nail fold (Fig. 205-23). Benign tumors may be removed by taking an elliptical wedge of tissue from the lateral nail fold and lateral nail wall. Malignant tumors, such as in Bowen disease, are treated by excision of the whole lateral nail fold or by Mohs micrographic surgery followed by healing by second intention.

INGROWN NAIL

Ingrown nail is a condition that occurs mainly in the great toe. It is created by impingement of the nail plate into the dermal tissue distally or into the distolateral

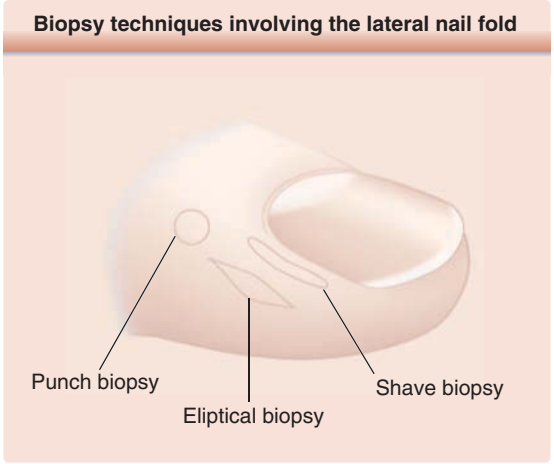

Figure 205-23 Biopsy techniques involving the lateral nail fold.

nail groove. Irrespective of the initial cause, the condition finally presents with a nail bed that is too narrow for its nail plate. Logical treatment is therefore aimed at correcting this disparity.

DISTAL TOENAIL EMBEDDING

Surgical avulsion or the loss of the toenail from trauma, such as tennis toe, may initiate the pathology. The distal subungual tissues released from the physiologic counterpressure of the nail plate become hypertrophic, and the newly formed nail plate abuts this distal wall. To treat the condition, a crescentic wedge-shaped excision is made around the distal phalanx (Fig. 205-24). The wedge should be 4 mm at its greatest width and must be dissected from the bone. The defect is closed with 5-0 monofilament sutures, which should be removed after 12 to 14 days.

Figure 205-24 Surgical treatment for distal nail embedding.

RETRONYCHIA

Retronychia represents proximal regrowth of the nail that occurs when the nail embeds backwards into the proximal nail fold. This condition involves usually big toenails but also, rarely, fingernails. There is a thickening of the proximal portion of the yellowish nail plate as well as a painful paronychia. There is an embedding of the nail into the proximal nail groove following an acute insulte of fingers or toes. There is a characteristic triade: disruption of the linear nail growth, subacute paronychia, with lifting at the rear of the nail due a double or triple-layered proximal nail plate associated with frequent xanthonychia. A longitudinal overcurvature may be seen. Proximal granulation tissue, inflammatory subungual exsudate and onycholysis are often observed.

Ultrasound shows the pathognomonic sign: the shortening of the distance between the proximal edge of the nail and the distal interphalangial joint. Surgical treatment consists of avulsing the nail showing superimposed layers of keratin (Fig. 205-25).[10,11]

JUVENILE (SUBCUTANEOUS) INGROWN NAILS

Juvenile or subcutaneous embedded nail is the most common type of ingrown nail. The nail is usually embedded medially, but both sides are often affected. In an effort to relieve the pain, the patient often tries to cut off the offending corner under the inflamed and swollen soft tissue. The remaining portion gives rise to a nail spicule piercing the epithelium of the lateral nail groove, which produces secondary infection and excessive granulation tissue.

Treatment at the early stage must be conservative but demands a high degree of patient compliance. The foot is soaked in warm water with povidone-iodine soap; then, under local anesthesia, the nail spicule is removed and a wisp of cotton wool is placed between the nail and the lateral nail groove. It should be moistened repeatedly with a disinfectant.

For definitive cure, surgical excision or, better, chemical suppression of the lateral horn of the nail matrix permanently narrows the nail. The lateral fifth of the nail plate is freed with a nail elevator from the proximal nail fold and the subungual tissues. It is then cut longitudinally with an English nail splitter or nail-splitting scissors and extracted using a sturdy hemostat. The lateral matrix horn is cauterized with a freshly made solution of liquefied phenol (88% solution) (Fig. 205-26). Above all, a bloodless field is needed, because blood inactivates phenol. Hemostasis is therefore accomplished with a tourniquet, and the blood is carefully cleaned from the space under the proximal nail fold using sterile gauze. The surrounding skin is protected with petroleum jelly. The phenol is rubbed onto the matrix epithelium for 30 seconds, 3 times with a cotton-tipped swab that is changed each time. Postoperative pain

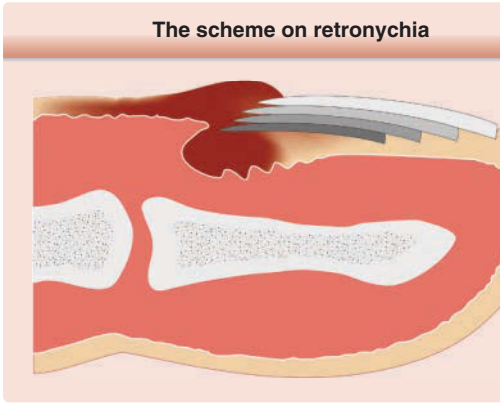

Figure 205-25 The scheme on retronychia.

Figure 205-26 **A,** Juvenile ingrown nail with excessive granulation tissue. **B,** Phenolization of the lateral matrix horn.

is minimal because phenol has a local anesthetic action and is antiseptic. The matrix epithelium is sloughed off, and oozing is usual for 2 to 6 weeks. Daily warm foot baths with povidone-iodine soap accelerate healing.

Besides phenol and 10% sodium hydroxide, 80% trichloracetic acid also has been performed for partial matricectomy. The wound almost always heals within 2 weeks without prolonged exudative discharge. Pain is mild but transient.

PINCER NAIL[12]

Overcurvature of the nails may affect the great toe alone or all the digits. This condition may be so painful that even contact with a bedsheet becomes unbearable.

When the condition is mild, the nail brace technique aims at correcting the inward distortion of the nail by maintaining continuous tension on the nail plate. A stainless steel wire brace is fitted to the nail plate. A series of adjustments adapted to the gradual decrease of curvature is made over a period of 6 months and results in a painless correction of the pincer nail. Because the underlying bone pathology remains untreated, however, relapse is usual. Therefore, the definitive cure—the use of phenol cautery on the lateral matrix horns—is undoubtedly the simplest effective treatment modality.

HYPERTROPHY OF THE LATERAL NAIL FOLD

Hypertrophic lateral nail folds are usually the result of long-standing ingrown nails. Inflammation may range from the subclinical to the severe. For treatment, approximately one-fifth of the nail digging into the lateral nail fold is removed. Then an elliptical wedge of tissue is taken from the lateral nail wall of the toe, down to the bone (Fig. 205-27). Suturing of the defect pulls the lateral nail fold away from the offending lateral nail edge. In severe cases, this procedure may be combined with phenol cautery of the lateral horn of the matrix. In contrast to adult-acquired hypertrophy of the lateral nail fold, congenital lateral hypertrophic lips disappear progressively and spontaneously within 12 months.

CONGENITAL MALALIGNMENT OF THE GREAT TOENAIL[13]

In congenital malalignment of the nail of the great toe, typically the nail is malaligned laterally, with transverse furrows on a thick brownish or greenish nail.

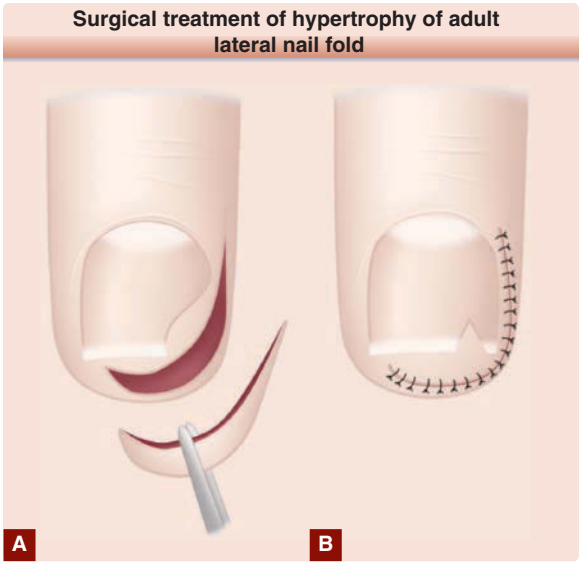

Figure 205-27 Surgical treatment of hypertrophy of adult lateral nail fold.

In 50% of cases, this condition corrects itself without therapy before the age of 10. If the appearance is extreme, surgery diminishes the risk of permanent dystrophy.

Treatment requires rotation of a bulky nail unit flap, including the entire nail, nail bed, and matrix (Fig. 205-28). This demands creation of an external Burow's triangle. An eccentric crescent-shaped excision is made to undermine the nail unit, with the maximum width located on the internal side of the foot, corresponding to the side to which the nail needs to be redirected. This crescent ends on each side 3 to 4 mm behind the most proximal part of the proximal nail fold. The nail bed and the matrix are then undermined and lifted until the fibers of the extensor tendon are visible on its bony insertion, and the dorsal expansion of the lateral ligament of the distal interphalangeal joint is cut.

Suturing the edges of the excised triangle together reduces the loss of cutaneous substance. The nail unit

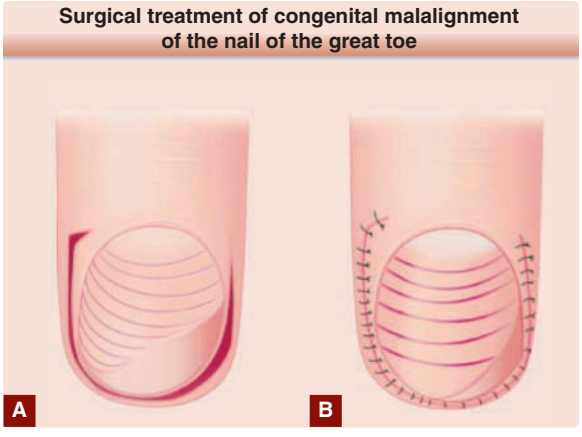

Figure 205-28 Surgical treatment of congenital malalignment of the nail of the great toe.

is rotated inwardly, because the maximum cutaneous resection is mostly distal and medial.

NONINVASIVE TREATMENT FOR INGROWN NAILS

Anchor taping, acrylic affixed gutter splint sculptered nail and others have obtained good results for treating ingrown nails, especially in children. Most ingrown nail cases are noninvasively cured by the combination of anchor-taping and acrylic affix gutter splint methods and do not require invasive surgery.[14]

REFERENCES

1. Fleckman P. Surgical anatomy of the nail unit. *Dermatol Surg*. 2001;27:257-260.
2. Jellinek N, Velez NF. Nail surgery: best way to obtain effective anesthesia. *Dermatol Clin*. 2015;33:265-271.
3. Durrant C, Townley WA, Ramkumar S, et al. Forgotten digital tourniquet: salvage of an ischaemic finger by application of medicinal leeches. *Ann R Coll Surg Engl*. 2006;88:462-464.
4. De Berker D, Baran R. Acquired malalignment: a complication of lateral longitudinal biopsy. *Acta Derm Venereol*. 1993;78:468-470.
5. Rich P. Nail biopsy: indications and methods. *Dermatol Surg*. 2001;27:229.
6. Baran R, Perrin C, Thomas L, et al. The melanocyte system of the nail and its disorders. In: Nordlung JJ, Boissy RE, Hearing VJ, et al., eds. *The Pigmentary System*. 2nd ed. Oxford: Blackwell; 2006:1057-1068.
7. Haneke E, Baran R. Longitudinal mélanonychie. *Dermatol Surg*. 2001;27:580.
8. Braun, Baran R, Saurat JH, et al. Surgical pearl: dermoscopy of the free edge of the nail determine the level of nail plate pigmentation and the location of its probable origin in the proximal or distal nail matrix. *J Am Acad Dermatol*. 2006;55:512-513.
9. Ferreira Vieira d'Almeida L, Papaiordanou F, Araujo Machado E, et al. Chronic paronychia treatment: Square flap technique. *JAAD*. 2016;75:398-403.
10. De Berker DAR, Richert B, Duhard E, et al. Retronychia: proximal ingrowing of the nail plate. *JAAD*. 2018;58:978-983.
11. Wortman X, Calderon P, Baran R. Finger retronychias detected early by 3D ultrasound examination. *JEADV*. 2012;2:254-256.
12. Baran R, Haneke E. Pincer nails. Definition and surgical treatment. *Dermatol Surg*. 2001;27:261-266.
13. Baran R, Haneke E. Etiology and treatment of nail malalignment. *Dermatol Surg*. 1998;24:719-721.
14. Arai H, Haneke E. Noninvasive treatment of ingrowing nails. In Baran R, Hadj-Rabia S, Silverman R. Pediatric nails disorders. *CRC Press*. 2017;263-274.

Chapter 206 :: Cryosurgery and Electrosurgery

:: Justin J. Vujevich & Leonard H. Goldberg

AT-A-GLANCE

- With a boiling point of –195.8 Celsius, liquid nitrogen is the cryogen of choice for treating benign and malignant neoplasms.
- Melanocytes and fibroblasts are the cells that are most and least sensitive to the destructive effects of cryosurgery.
- Tumors that require histopathology for diagnosis and recurrent nonmelanoma skin cancers are contraindications for treatment with cryosurgery.
- Several cryosurgery techniques exist to treat benign and malignant neoplasms.
- Electrosurgery can be categorized into electrofulguration, electrodessication, electrocoagulation, electrosection, electrocautery, and electrolysis (Table 206-4).
- Electrosurgical devices have a low risk of interfering with cardiac and non cardiac implanted electronic devices (IEDs).
- Perioperative and intraoperative safety considerations should be made when performing electrosurgery on patients with IEDs.
- Curettage and electrodessication is an acceptable definitive treatment for malignant tumors.

CRYOSURGERY

BACKGROUND

Cryosurgery refers to the use of extreme cold to destroy cells of abnormal or diseased tissue. The earliest use of a cold refrigerant in medicine is attributed to White, a New York dermatologist, in 1899.[1,2] Using a cotton-tipped applicator dipped into liquefied air, he successfully treated warts, nevi, and precancerous and cancerous lesions. In 1907, Whitehouse, another New York dermatologist, reported the use of the spray method in the cryosurgical treatment of skin cancers.[3]

Cryobiology refers to the study of the effects of subzero temperature on living systems. Tissue destruction from cryotherapy results from direct cell injury, vascular stasis, and the local inflammatory response.

Freezing cells convert water to ice (crystallization). Rapid freezing causes intracellular ice crystal formation with the disruption of electrolytes and pH changes, whereas slow freezing causes extracellular ice formation and less cell damage. Therefore, tissue effects and cell death are most readily achieved when tissue is frozen rapidly.[4]

During thawing, recrystallization occurs when ice crystals fuse to form large crystals that disrupt cell membranes. As the ice melts further, the extracellular environment becomes hypotonic, causing water to infuse into cells and cause cell lysis.[5] The longer the thawing time, the greater the damage to cells because of increased solute effect and greater recrystallization.

After freezing, stasis within the vasculature occurs. This loss of circulation and resultant anoxia is a major mechanism of injury from cryosurgery. As the tissue thaws at temperatures higher than 0°C (32°F), a brief hyperemic response ensues with resultant edema and inflammation.[5]

TARGETS OF CRYOSURGERY

Table 206-1 lists targets of cryosurgery with associated cell death temperatures. Melanocytes are the most sensitive to cryosurgery, with cell destruction at temperatures of –4°C to –7°C (24.8°F to 19.4°F).[6] As a result, depigmentation may occur, especially in darkly pigmented individuals. Keratinocytes require longer freezing to temperatures of –20°C to –30°C (–4°F to –22°F) until cell death and are more resistant to cooling effects. Fibroblasts are the most resistant to freezing and do not undergo cell death until –30°C to –35°C (–22°F to –31°F). A temperature of –50°C to –60°C (–58°F to –76°F) is needed for destruction of malignant lesions, whereas lesser degrees of freezing are needed for benign lesions.

CRYOGENS

Liquid nitrogen is the cryogen of choice in dermatology. It is easy to store in an insulated unit, easy to use, environmentally friendly, nonflammable, inexpensive, and, at –195.8°C (–320.4°F), has the lowest temperature of all the common cryogens, causing rapid freeze of treated tissue.

Other available cryogens include fluorinated hydrocarbons, solid carbon dioxide, and nitrous oxide (Table 206-2). Fluorinated hydrocarbons are used as topical sprays to provide temporary anesthesia before the removal of skin lesions and the administration of vaccinations. Cryogen spray cooling is also used to reduce the pain of laser surgery and eliminate overheating of the epidermis.[7]

TABLE 206-1
Tissue Target Cell Death Temperatures

CELL	TEMPERATURE (°C/°F)
Melanocytes	−4 to −7 (24.8 to 19.4)
Keratinocytes	−20 to −30 (−4 to −22)
Fibroblasts	−30 to −35 (−22 to −31)

PERIOPERATIVE CONSIDERATIONS

PATIENT SELECTION

Cryosurgery is one of several destruction modalities used for benign and malignant skin neoplasms. Several factors, including lesion type, size, depth, border, location, and patient skin type, should be considered when cryosurgery is a treatment choice.

ANATOMICAL SITE PRECAUTIONS

The cryosurgeon should be aware of certain anatomical locations where cryosurgery may lead to complications. Caution should be undertaken when treating lesions overlying nerves, such as the postauricular nerve on the neck or digital nerves on medial and lateral fingers and toes. Damage may result in regional paresthesia or motor dysfunction. In addition, cryosurgery at anatomical sites such as the eyelids, mucosa, nasal ala, and auditory canal, may result in scarring with retraction after treatment. As skin melanocytes are easily prone to destruction by freezing, the cryosurgeon should treat darkly-pigmented skin with caution as cryosurgery may result in hypopigmentation at treated sites.

TREATMENT CONTRAINDICATIONS

Absolute contraindications to cryosurgery include lesions that require histopathology for diagnosis and recurrent nonmelanoma skin cancers. Relative contraindications to cryosurgery include patients with cold urticaria, abnormal cold intolerance, cryoglobulinemia, or cryofibrinogenemia, or tumors with indistinct borders or darkly pigmented features (Table 206-3).

TABLE 206-2
Cryogens Used in Cryosurgery

AGENT	BOILING POINT (°C/°F)
Freon	−40.8/−41.4
Solid CO_2	−79.0/−110.2
Nitrous oxide	−89.5/−129.1
Liquid nitrogen	−195.8/−320.4

TABLE 206-3
Contraindications to Cryosurgery

- Lesions that require histopathology for diagnosis[a]
- Recurrent nonmelanoma skin cancers[a]
- Cold urticaria
- Abnormal cold tolerance
- Cryoglobulinemia
- Cryofibrinogenemia
- Tumors with indistinct borders or darkly pigmented features

[a]Absolute contraindication.

RISKS AND POTENTIAL COMPLICATIONS

Pain: In addition to pain during freezing, patients will experience some discomfort several hours post-treatment. Typically, pain is controlled with acetaminophen. Lesions such as periungual warts, digital lesions, or mucous membrane lesions may require stronger analgesics because of intense swelling and throbbing.

Bleeding: Patients on anticoagulant therapy should be warned of bruising resulting from tissue necrosis. If painful hemorrhagic bullae form, they may be drained with an 18-gauge needle inserted into the lateral blister skin. Care should be undertaken not to remove the surface of the bullae, as this tissue acts as a natural wound dressing.

Pigmentation Changes: Hypopigmentation or hyperpigmentation is the most disconcerting complication following cryosurgery. As shown in Table 206-1, pigmented cells are highly susceptible to freezing at temperatures of −4°C to −7°C (24.8°F to 19.4°F). Although pigmentation changes are usually transient, prolonged freezing for longer than 30 seconds may result in permanent pigment loss. Topical steroids, glycolic acids, retinoids, and hydroquinone may aid in reducing the incidence of hypopigmentation.

Nerve Damage: Treatment of lesions overlying nerves, such as the postauricular nerve on the neck or digital nerves on medial and lateral fingers and toes, may result in regional paresthesia or motor dysfunction. Digital neuropathy occurring after cryosurgery of digital warts has been reported.[8]

Scarring: Fibroblasts are the most resistant to freezing and do not undergo cell death until −30°C to −35°C (−22°F to −31°F). Therefore, most benign and premalignant lesions treated with cryotherapy heal with little scarring. Soft, contracted linear scars resulting from second intention may occur in malignancies treated with cryosurgery.

Alopecia: Freeze times longer than 20 seconds may result in alopecia. This is especially true when treating malignant lesions.

Insufflation of Soft Tissue: During freezing nitrogen gas may escape into perilesional skin,

producing crepitus. Pressure on the crepitated area will expel the gas. The use of a cone surrounding the biopsy site prevents crepitus from occurring.

ANESTHESIA

For the majority of patients, anesthesia is not necessary prior to a cryosurgical procedure. However, cryosurgery is painful, especially in children. For short cryosurgery treatment times, 1% lidocaine with 1:100,000 epinephrine may be locally injected prior to treatment. For longer cryosurgery treatment times, such as treatment of skin neoplasms (up to 30 seconds), local anesthesia is mandatory. Topical anesthesia can be applied approximately 1 hour prior to the procedure to minimize pain. A single-center, double-blinded, randomized, placebo-controlled, parallel-group trial comparing a cream containing 5% lidocaine and 5% prilocaine applied 1 hour prior to cryosurgery for warts, however, did not demonstrate a statistically significant difference in pain during the procedure.[9] For longer cryosurgery treatment times, such as treatment of skin neoplasms (up to 30 seconds), 1% lidocaine with 1:100,000 epinephrine can be locally injected prior to treatment.

PERIOPERATIVE CARE

Patients should be given simple verbal and written wound care instructions posttreatment. Edema, vesicles, bullae, and weeping should be expected from treated areas within 24 hours posttreatment. Treated sites may be rinsed with soap and water and patted dry with a towel daily. If actively weeping, the wound site may be bandaged.

Benign and premalignant lesion-treated sites heal typically in 1 to 2 weeks, with malignant lesion-treated sites requiring 3 to 4 weeks of healing. Clinically-suspicious actinic keratoses not responsive to cryosurgery should be biopsied to rule out invasive skin cancer.

CRYOSURGERY TECHNIQUES

There are several cryosurgical techniques that can be used in treating skin lesions. The open spray method is most frequently used. This method uses a handheld cryosurgical unit with fingertip trigger (Fig. 206-1). Patients may be seated or lying on an examination table at an angle. The canister should be held upright when treating the patient as tilting the canister sideways will result in the sudden release of a vapor from the canister. Spray tips with varying-sized apertures are attached to the unit, emitting a stream of liquid nitrogen toward the lesion from a distance of 1 to 2 cm.

Although freeze times vary for lesion types, an intermittent spray in a solid, circular, or paintbrush pattern is normally used. Longer spray times are required for thicker, keratotic lesions or malignant lesions; shorter times are required for thinner, atrophic, or benign lesions. The intermittent spray helps to localize treatment to the lesion with a small freeze halo, thus minimizing collateral normal tissue damage. This is particularly important when treating lesions around the orbital, nasal, auricular, genital, or periungual regions.

Figure 206-1 Actinic keratosis on forehead treated with liquid nitrogen.

As the lesion is treated, a lateral freeze spreads beyond the margins of the lesion. The measurement of the surface radius of the freeze is equal to the central depth of the freeze into the skin.[5] Temperature gradients exist within the freeze, with colder temperatures in the middle and warmer temperatures toward the periphery. In general, superficial lesions should have a clinical freeze margin of 2 to 3 mm, and malignant or deeper lesions should have a clinical freeze margin of 5 mm to ensure successful treatment.

The closed technique uses a copper cryoprobe that is attached to the cryosurgical unit. Once the metal probe is pressed against a lesion on the skin, the trigger of the unit is squeezed, and liquid nitrogen leaves the unit through a conduit line that maintains it in a closed system. This technique is useful for treating small, well-circumscribed lesions or lesions found in confined locations.

Similarly, a metal, cone-sized chamber can be attached to the cryosurgical unit and held in contact with the lesion. This allows liquid nitrogen spray to enter the cone and rapidly freeze the lesion. Another cone apparatus option includes holding an otoscope cover tip against the lesion with one hand while freezing with the cryosurgical unit held in the other hand. Treatment times using the cone method should be decreased because the final temperature at the orifice of the cone is obtained faster, when compared with an open spray.

If a cryospray unit is not available, the dipstick technique can be used. First, a small amount of liquid nitrogen is poured into a polystyrene cup or other insulated container. Cotton-tipped swabs are placed tip-down in the container and cooled. Using firm pressure, the cotton tips are placed against the lesion until a 2-mm to 3-mm halo forms around the treated lesion. This method treats lesions on the body where surrounding tissue must be spared, such as periorbital, mucosal, nail, and genital regions.

Alternatively, tissue forceps can be placed in the container and allowed to cool. This method is useful for treating filiform lesions such as verrucae and skin tags. The metal forceps cool rapidly, so insulated gloves should be worn while holding the forceps to prevent freeze injury to the practitioner's fingers.

Figure 206-2 Warts on hand treated with liquid nitrogen.

APPLICATIONS FOR COMMON BENIGN LESIONS

SEBORRHEIC KERATOSIS

The spray technique is an effective modality for treating this common lesion. Although longer freeze times of 10 to 15 seconds with a 1-mm to 2-mm halo are required for these raised growths, too aggressive freezing may result in scarring or hyperpigmentation. For cosmetic purposes and to prevent pigmentation changes, a lighter freeze followed by curettage may be preferential. Forewarn patients that a second treatment may be required, especially for thicker seborrheic keratoses.

VERRUCAE

Warts are a common problem, with a high prevalence in the population.[10] Although cryosurgery for warts has sustained a common practice in dermatology, varying techniques have been offered with regard to freezing method, number of freeze–thaw cycles, and frequency of treatment sessions. Cryosurgery using the spray technique is probably the most common method because of its quick, convenient use and ease of obtaining a freeze halo around the lesion (Fig. 206-2). The cotton-tip applicator technique is cheaper and may be less frightening to the patient, particularly if the patient is a child. Care must be undertaken not to cross-contaminate by reintroducing the cotton-tip applicator into a common flask.

Combination therapy with cryosurgery also has been advocated to treat verrucae. Berth-Jones and Huchinson[11] demonstrated a 52% cure rate at 3 months with the combination of cryotherapy, keratolytic wart paint, and paring. The authors also noted that paring the wart before cryotherapy improved the cure rates for plantar warts, but not hand warts.

SOLAR LENTIGO

As described in Table 206-1, pigmented cells are highly susceptible to freezing. Therefore, these lesions require a shorter freeze time of 3 to 5 seconds with minimal halo. For darker-skinned individuals, care must be taken not to induce hypopigmentation at treatment sites. Consequently, a test site in a cosmetically less noticeable region may be performed first before treating multiple lesions on sun-exposed areas. In addition, sunscreen with ultraviolet A and ultraviolet B protection should be advocated pretreatment and posttreatment.

KELOIDS AND HYPERTROPHIC SCARS

Treatment of keloids and hypertrophic scars is frequently unsatisfactory. Cryosurgery is a less common but effective means of treating these recalcitrant lesions. Freeze times of 30 seconds are required monthly until flattening is achieved. Zouboulis and colleagues reported a prospective study of 93 keloids and hypertrophic scars treated with 30-second freeze times over 1 to 3 sessions.[12] Improved responses were seen in patients treated with 3 or more sessions (79%), compared with subjects treated once or twice (33%).

DERMATOFIBROMA

Dermatofibroma treatment times may require cryosurgery up to 60 seconds because of the fibrotic nature of the lesion and the need to treat cells located in the deep dermis. Torre reported a series of 79 dermatofibromas treated with cryosurgery. Out of the 79 that were followed, 61 were no longer palpable post treatment.[13]

SEBACEOUS HYPERPLASIA

These benign lesions can be a cosmetic concern for patients. Freeze times of 5 to 10 seconds are required, using the cryoprobe technique with the probe applied directly into the central punctum of the lesion. Patients must be advised that retreatment is frequently necessary.

APPLICATIONS FOR PREMALIGNANT AND MALIGNANT LESIONS

Cryosurgery appears useful in well-defined lesions for situations where surgery is less favorable, either for technical or cosmetic reasons, or when the patient prefers this treatment option. The goal of cryosurgery is to cure the patient by destroying the lesion in a single treatment.

ACTINIC KERATOSIS

Cryosurgery is an effective modality for the treatment of actinic keratoses (AKs). The open spray technique, using a single freeze–thaw cycle of 8 to 10 seconds, is the treatment of choice. Hypertrophic AKs require longer freeze times, whereas atrophic AKs and AKs on thin-skinned regions require shorter freeze times. A 1-mm to 2-mm freeze margin around the lesion is adequate. For thicker lesions, pretreatment of emollients or curetting may shorten freezing times.

Although cryosurgery is widely used in dermatology for treatment of AKs, there are few well-designed studies assessing cure rates. Lubritz and Smolewski[14] treated 1018 AKs on 70 patients with cryosurgery with 20- to 45-second thaw times. At 1-year posttreatment, they reported a cure rate of 99%. Another prospective, multicenter study of 421 AKs larger than 5 mm in diameter on the face and scalp demonstrated a complete response of 39% with a 5-second freeze, 69% for a 5- to 20-second freeze, and 83% for a 20-second freeze.[15]

In patients with diffuse actinic damage, extensive cryosurgery, or cryopeeling, may be useful. Chiarello[16] reported cryopeeling was twice as effective as 5-fluorouracil in the reduction of actinic keratoses and the formation of squamous cell carcinomas at 1 and 3 years post-cryopeeling.

BOWEN DISEASE

Ahmed and colleagues[17] treated 26 Bowen disease patients using 3-mm clinical margins and spray technique with two 5- to 10-second freeze–thaw cycles. Two years after treatment, 50% of the treated lesions were still present at the same site. The average healing time was 46 days, with lesions on the lower leg taking longer to heal (90 days). Although the cure rate using cryosurgery for Bowen disease was low in this study, the authors did use a lower freeze time to minimize side effects postprocedure.

BASAL CELL CARCINOMA

Several studies have reported treating basal cell carcinomas (BCCs) with cryosurgery with cure rates ranging between 95% and 99%.[18-20] Although excellent cure rates have been claimed, few studies have demonstrated histologically that the BCC is no longer present posttreatment. Furthermore, there are no good studies comparing cryosurgery with other known treatment modalities, such as Mohs surgery, excision with clinical margins, and electrodesiccation and curettage.

Postsurgical cosmetic appearance is a concern to patients. Kokoszka and Scheinfeld[21] reported good cosmetic results in their review of the literature. Thissen and colleagues,[22] however, compared the cosmetic results of surgical excision compared with cryosurgery for BCCs of the head and neck and concluded that cosmetic results after excision are better than after cryosurgery.

SQUAMOUS CELL CARCINOMA

Similar cure rates to BCCs are evident when treating squamous cell carcinomas (SCCs) with cryosurgery. In a study of 563 primary SCCs, of which most were between 0.5 and 1.2 cm in diameter, Graham and Clark[23] reported a cure rate of 97.3%. Treatment technique with cryosurgery for SCCs is the same as for BCCs.

LENTIGO MALIGNA

With proper patient selection, cryosurgery can be an effective treatment option for lentigo maligna because of the sensitivity of melanocytes to cold. With the aid of a Wood lamp, a clinical margin of 5 mm is drawn around the visible borders of the lesion. The lesion is subsequently treated with a double freeze–thaw cycle of 30 to 60 seconds each cycle. Because atypical melanocytes may extend along the length of the hair follicles, treatment must freeze the tissue to this depth.

Stevenson and Ahmed[24] reviewed cure rates from more than 200 lentigo maligna patients treated with cryotherapy, with an overall recurrence rate of less than 9%. However, the recurrence rates in these studies ranged from 0% to 50%.

Advantages of cryotherapy for lentigo maligna include its efficiency and avoidance of large surgical scars. One major disadvantage of cryosurgery is the inability to assess whether the lesion has been completely destroyed. In addition, because no tissue is obtained for definitive confirmation of cancer removal, the chance exists that recurrent melanoma may develop and that it may be invasive. Overlying scars may conceal the cancer.

KAPOSI SARCOMA

Although not commonly used, Tappero and colleagues reported the treatment of Kaposi sarcoma using a double freeze–thaw cycle every 3 weeks.[25] An average of 3 treatments were required.

ELECTROSURGERY

Electrosurgery is a technique that uses the transmission of electricity to cut tissue, destroy tissue, and

TABLE 206-4
Modalities of Electrosurgery

	DAMPING	VOLTAGE & AMPERAGE	CURRENT	NUMBER OF TERMINALS	DESCRIPTION	CIRCUIT LOOP INVOLVES PATIENT
Electrofulguration	Damped sine wave	High-voltage, low-amperage	AC	Spark from monoterminal electrode to tissue through air; no direct contact	Least damaging modality; epidermis primarily affected	Yes
Electrodessication	Damped sine wave	High-voltage, low-amperage	AC	Direct contact from monoterminal electrode to tissue	Greater than electrofulguration, but damage is superficial	Yes
Electrocoagulation	Moderately damped sine wave	Low-voltage, high-amperage	AC	Direct contact from a biterminal node to tissue	Deeper tissue damage than electrofulguration and electrodessication; provides tissue coagulation	Yes
Electrosection	Undamped or slightly damped sine wave	Low-voltage, high-amperage	AC	Direct contact	Cuts tissue with minimal peripheral heat damage	Yes
Electrocautery		Low-voltage, high-amperage	DC	Heat is transferred from filament to tissue	Protein denaturation and coagulation	No[a]
Electrolysis		Low-voltage, low-amperage	DC	Negative electrode is applied to target tissue; acids are produced at the positive electrode	Tissue liquefaction (negative electrode); tissue coagulation (positive electrode)	Yes

[a]Therefore, this technique is useful for patients with pacemakers or in nonconductive tissues of the body.
AC, alternating current; DC, direct current.

cauterize vessels. Variations in current wavelength result in different biologic effects on tissue. For cutaneous procedures, electrosurgery can be categorized into 6 different treatment modalities: electrofulguration, electrodessication, electrocoagulation, electrosection, electrocautery, and electrolysis (Table 206-4).

MODALITIES OF ELECTROSURGERY

ELECTROFULGURATION

Electrofulguration uses a damped sine wave, high-voltage, low-amperage alternating current to generate a spark from a monoterminal electrode to the tissue via the air. There is no contact between the electrode and the tissue. This modality is the least tissue damaging of all of the high-frequency electrosurgery techniques, and results in rapid tissue healing. Most of the tissue damage is superficial, primarily involving the epidermis.

ELECTRODESSICATION

Electrodessication uses a damped sine wave, high-voltage, low-amperage alternating current to generate a current from direct contact of a monoterminal electrode to the tissue. Superficial tissue damage occurs as heat is transferred to tissue, causing cell death. The extent of tissue damage is directly related to electrode contact time with the skin. Although skin injury is greater with electrodessication compared to electrofulguration, most of the tissue damage remains superficial.

ELECTROCOAGULATION

Electrocoagulation uses a moderately damped sine wave, low-voltage, high-amperage alternating current to generate a current from direct contact of a biterminal electrode to the tissue. Tissue damage is deeper than with electrofulguration and electrodessication, providing tissue coagulation through the generation of heat in the tissue.

Another distinguishing feature of electrocoagulation is the involvement of the patient within the circuit. This allows the use of a lower voltage and higher amperage to generate more coagulation.

ELECTROSECTION

Electrosection uses an undamped or slightly damped sine wave, low-voltage, high-amperage alternating current to cut tissue with minimal peripheral heat damage. The "Bovie" knife incorporates a blended undamped and damped sine wave that provides both cutting and coagulation at the same time.

ELECTROCAUTERY

Electrocautery uses a heating filament tip connected to a low-voltage, high-amperage direct current, usually a battery. Heat is transferred from the filament to the target tissue, causing protein denaturation and tissue coagulation. There is no electric current transfer to the target tissue, and the patient is not part of the circuit loop.

Electrocautery is most used for patients with pacemakers or implantable cardiac defibrillators (ICDs) who are high-risk candidates for receiving electrosurgery. In addition, because patients are not part of the circuit loop, electrocautery is useful for nonconductive tissue areas of the body, such as the cartilage, bone, and nails.

ELECTROLYSIS

Electrolysis uses low-voltage, low-amperage direct current from a negative electrode to the positive electrode. The negative electrode is applied to the target tissue where electrons are released. The electrons interact with the tissue to produce sodium hydroxide and hydrogen gas resulting in tissue liquefaction. Acids are produced at the positive electrode resulting in tissue coagulation. The main use of electrolysis is for hair removal.

PERIOPERATIVE CONSIDERATIONS

PATIENT SELECTION

Patients commonly present for cutaneous surgery with either a cardiac pacemaker or an ICD. When taking preoperative history for surgery, patients should be asked if they have a device. Although technologic advances, such as titanium shielding, have provided safeguards against electromagnetic interference, electrosurgical devices may cause these cardiac devices to malfunction.

RISKS AND POTENTIAL COMPLICATIONS

Interference with Pacemakers/Implantable Cardiac Defibrillators: ICDs deliver an electrical response to an abnormal ventricular rhythm. Some ICDs have a combination of a pacemaker and defibrillator to respond to both bradycardia and tachycardia. Electromagnetic interferences from electrosurgical devices may mimic a cardiac arrhythmia and cause the unit to discharge. Alternatively, the ICD may also respond by inhibiting cardioversion or pacing.

Complications resulting from using electrosurgery for cutaneous surgery in patients with pacemakers or ICDs are uncommon. Matzke and colleagues published a 3-year retrospective review of 173 patients with pacemakers and 13 patients with ICDs who underwent dermatologic surgery and reported no documented complications from electrosurgery.[26] El-Gamal and colleagues reported a rate of 0.8 cases per 100 years of surgical practice from 166 completed surveys from members of the American College of Mohs Surgery and Cutaneous Oncology.[27] In this study, the types of interferences reported were skipped beats, reprogramming of a pacemaker, firing of an ICD, asystole, bradycardia, and depletion of pacemaker battery life. Weyer and colleagues[28] developed an ex vivo simulation device for assessing disruption of an implanted cardiac device. When electrosurgery was performed using normal (10W) and maximum (30W) power settings, the simulated devices only demonstrated interference at a distance of 1 cm with normal power settings and 3 cm at maximum power settings.

Safety and Recommendations for Patients with Implantable Cardiac Defibrillators: Recommendations have been published for the preoperative and intraoperative management of patients with pacemakers and ICDs during dermatologic surgery.[29-33] Patients should be asked when scheduling surgery if they have one of these devices. If present, a preoperative evaluation by the patient's cardiologist should be arranged before the surgical procedure. For management of patients with pacemakers or ICDs undergoing surgical procedures, consider the following recommendations.

- Obtain cardiology consultation to determine if any perioperative actions need to be planned.
- Provide continuous electrocardiography monitoring throughout the procedure.
- Have advanced cardiac life support staff and crash-cart equipment available.
- Consider the use of alternative means of hemostasis such as patient-applied manual pressure[34] or electrocautery.
- Place the dispersing electrode in a location that directs the current pathway away from the cardiac device.
- Use a bipolar forceps device to maintain the electrical circuit between the forceps tips.
- Use minimal power and short electrosurgical bursts of 5 seconds or less.
- Do not discharge the electrosurgical electrode on the skin directly over the pacemaker power source.

Patients may also present with noncardiac implanted electronic devices (IEDs) such as deep brain stimulators and cochlear implants. Noncardiac IEDs have a battery-powered pulse generator with electrodes that end in the targeted tissue. Risks and recommendations for noncardiac IEDs are similar to cardiac IEDs.[35] In some cases, the devices may be turned off, however, the clinical effects on the patient after turning off the device must be taken into consideration.

Burns: There are several situations in which burns may occur with electrosurgery. Thermal injury can

occur if there is inadequate contact between the patient and the dispersing electrode plate, when there is inadvertent contact between the dispersing electrode and the patient or surgeon, and if the patient or surgeon may "ground" himself or herself by touching a metal component of the table. Metal jewelry near the electrosurgical site should also be removed.

Fire: Electrosurgical current will ignite flammable substances like alcohol. When prepping the patient before electrosurgery, nonflammable disinfectants such as iodine or chlorhexidine should be used. If an alcohol-based disinfectant is used, the surgical area must be allowed to dry for at least 90 seconds prior to electrosurgery. In addition, electrosurgery should not be used near the presence of nasal cannulas, masks, or endotracheal anesthesia administering oxygen. Finally, care should be taken not to ignite paper surgical drapes in the surgical field.

Channeling: High-frequency electrosurgical current can be conducted along neurovascular bundles, causing pain and tissue damage distant to the local electrosurgical site. Using low-current settings or bipolar forceps may minimize this.

Infection and Mutagenicity: A plume of smoke is generated during electrosurgery. This traveling plume has been shown to contain carbonized tissue and blood, airborne particles, and various chemicals and gases. A review of the literature by Lewin and colleagues[36] reported that electrocautery produces a plume of smoke composed of at least 38 chemical contents, including hydrocarbons, phenols, nitriles, fatty acids, carbon monoxide, acrylonitrile, and hydrogen cyanide. In addition, smoke created from treating lesions such as warts may contain bacteria and viruses, such as human papillomavirus, which may transmit infection.[37]

No known long-term risk for neoplasia or infection is known. The Occupational Safety and Health Administration recommends that surgical smoke be removed and properly filtered by a smoke evacuation system as close to the surgical site as possible.[38] Furthermore, protective equipment, such as face shields and respiratory masks, should be worn during electrosurgery.

ANESTHESIA

During electrosurgery, local anesthesia such as lidocaine with epinephrine is required for patient's comfort.

PERIOPERATIVE CARE

For all treatment groups, wound areas should be covered with a pressure bandage consisting of a topical petroleum product directly on the wound, an overlying nonstick bandage, and firmly applied gauze with adhesive tape.

The pressure bandage is removed 24 to 48 hours posttreatment, and the wound site is cleaned with tap water or saline, gently rinsing over the wound. Petroleum jelly and bandage are changed daily after rinsing, for 3 to 4 weeks or until healed.

ELECTROSURGERY TECHNIQUES

EQUIPMENT

Electrosurgical equipment uses either direct or alternating current. In direct current, electrons flow in one direction, whereas in alternating current, electron flow reverses direction. With the exception of electrocautery or electrolysis, electrosurgical units used in dermatologic procedures have high-frequency alternating current.

Electrosurgical units can be *monopolar* or *bipolar,* referring to the number of tissue-containing tips at the end of a surgical electrode. Monopolar denotes 1 tip, and bipolar denotes 2 tips.

Monoterminal refers to the use of a treatment electrode without an indifferent or dispersing electrode. *Biterminal* refers to the use of both treatment and indifferent electrodes.

POSITIONING

Patients should be supine or prone on the examination table. The dispersing electrode (grounding pad) should be placed in a location that directs the current pathway away from the cardiac device (usually the right lower leg). If a pedal is used, it should be placed near the surgeon's feet.

ELECTROSURGERY APPLICATIONS

HEMOSTASIS

The most common application of electrosurgery is its use in maintaining hemostasis in the operative field. Different techniques of electrosurgery can be used based on the type of electrosurgical unit used during surgical procedures. Coagulation can be achieved using electrofulguration, electrodessication, or electrocoagulation by direct application of the electrode to the bleeding vessel. This provides conduction of heat to the vessel, resulting in tissue coagulation (Fig. 206-3).

Alternatively, vessels can be grasped by a forceps or hemostat, followed by application of the active electrode. When electrical current is placed against the metal instrument, heat is transferred from the electrode through the metal tip to the vessel. This technique is

Figure 206-3 Electrodessication of bleeding vessel during Mohs surgery.

best used when the surgical field cannot be visualized because of bleeding (Fig. 206-4).

ELECTROSURGERY OF BENIGN TUMORS

Electrodessication is an effective treatment modality for papular or plaque-like tumors of the epidermis, such as seborrheic keratoses, verrucae, dermatosis papulosis nigra, molluscum, or flat warts. First, the area around the lesion is anesthetized with lidocaine containing epinephrine. Then, the lesion is touched with the low-power electrode until a gray, superficial, charred layer involves the entire lesion. The charred tissue is removed from the treated lesion by wiping with a sterile gauze or curetting. The process is repeated until the lesion is removed at the level of the surrounding skin. This method results in minimal bleeding and scarring because just the epidermal components are removed.

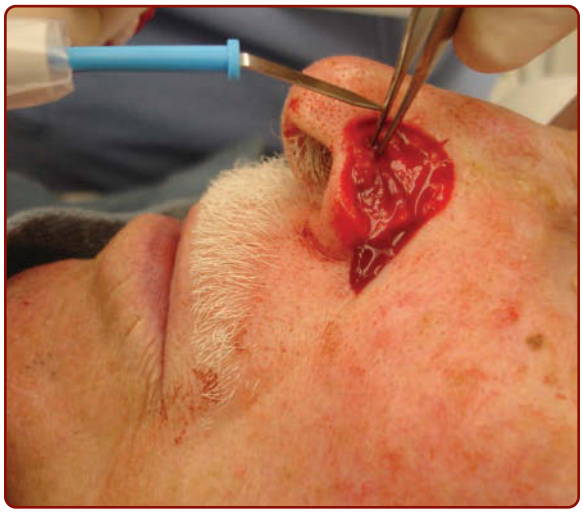

Figure 206-4 Electrocurrent applied to forceps to cauterize bleeding vessel during Mohs surgery.

CURETTAGE AND ELECTRODESSICATION OF MALIGNANT TUMORS

Curettage and electrodessication (C+D) is a commonly used treatment option for BCCs and SCCs. Certain tumor characteristics, however, should be present to ensure high cure rates and acceptable cosmetic outcome. Tumors should be primary; have distinct clinical borders; be located on sites of low recurrence, such as the trunk, extremities, or non-"H"-zone regions of the face; have a superficial or nodular histologic subtype; and have a diameter of less than 1 cm on the face and less than 2 cm on the trunk and extremities. In addition, C+D is a viable treatment option for patients with high morbidity cofactors that make surgical excision too risky, and for patients who cannot make regular followup visits.

Tumors not acceptable for C+D include those with indistinct borders, tumors on the "H"-zone of the face, tumors with an aggressive histologic pattern, tumors with high metastatic potential, and tumors that require histologic diagnosis. For patients with cardiac pacemakers or ICDs, electrocautery may be substituted for electrodessication.

The tumor outline should be marked, and lidocaine with epinephrine should be injected to provide adequate local anesthesia (Fig. 206-5). With firm counterpressure, the lesion is then curetted in a checkerboard pattern until the clinical appearance of the lesion is removed (Fig. 206-6). This is followed by electrodessication on high power of the base and periphery of the lesion (Fig. 206-7). This C+D procedure is repeated up to 2 more times until a resultant atrophic defect without clinical evidence of residual tumor is achieved. Some advocate the inclusion of a 2-mm to 4-mm rim of clinically normal skin during the C+D procedure, and individual variations of the protocol are established. If curettage of the BCC extends into subcutis, then an extensive invasion of a BCC has occurred, and excision should be performed.

The advantages of treatment with C+D include time efficiency, ease of surgical technique, and minimal posttreatment morbidity. Disadvantages of treating

Figure 206-5 Clinical outline of skin tumor before curettage and electrodessication.

Figure 206-6 Curettage of skin tumor during curettage and electrodessication procedure.

with C+D include nonconfirmation of histologic tumor clearance, practitioner-dependent efficacy, and potentially long (3- to 4-week) healing times via second intention healing. Furthermore, the cosmetic result may show hypopigmentation, atrophy, persistent erythema, and hypertrophic scarring.

OUTCOME ASSESSMENTS OF CURETTAGE AND ELECTRODESSICATION

The 5-year cure rates for C+D have been reported to be 74% to 100% for BCCs[39-49] and 96% to 100% for SCCs.[39] Although some authors have reported that 20% to 40% of tumors remain immediately following C+D, the 5-year cure rates demonstrate an additional factor may be contributing to the destruction of the treated malignancy. Some authors have speculated that the inflammatory response or a specific antitumor humoral response following electrosurgery may be responsible for the low recurrence rate.[50,51]

Figure 206-7 Electrodessication of skin tumor during curettage and electrodessication procedure.

C+D in combination with other topical treatments may have a synergistic effect in tumor clearance. In a double-blinded, placebo-controlled pilot study by Spencer,[52] 10 BCCs were treated with C+D and 10 patients were treated with C+D followed by 1 month of daily, topically-applied imiquimod cream. The author reported a substantially reduced frequency of residual BCC and improved cosmetic appearance in the C+D-imiquimod group compared with the C+D-alone group. Another study by Wu and colleagues[53] reported excellent efficacy and cosmetic results for nodular BCCs of the trunk and limbs treated with curettage (no electrodessication) followed by daily topical application of imiquimod cream for 6 to 10 weeks. In that study, 32 (94%) of 34 lesions demonstrated no residual histologic evidence of tumor.

REFERENCES

1. Mikhail GR. The application of chemosurgery in cancer. *Henry Ford Hosp Med J.* 1969;17:217-224.
2. White AC. Liquid air in medicine and surgery. *Med Rec.* 1899;56:109.
3. Whitehouse HH. Liquid air in dermatology: its indications and limitations. *JAMA.* 1907;49:371.
4. Mazur P. Freezing of living cells: mechanisms and implications. *Am J Physiol.* 1984;247:125-142.
5. Gage AA, Baust J. Mechanisms of tissue injury in cryosurgery. *Cryobiology.* 1998;37:171-186.
6. Gage AA, Meenaghan M. Sensitivity of pigmented mucosa and pigmented cells in skin due to freezing injury. *Cryobiology.* 1979;16:348-361.
7. Waldorf HA, Alster TS, McMillan K, et al. Effect of dynamic cooling on 585-nm pulse dye laser treatment of port-wine stain birthmarks. *Dermatol Surg.* 1997;24:657-662.
8. Nix TW Jr. Liquid nitrogen neuropathy. *Arch Dermatol.* 1965;92:185.
9. Gupta AK, Koren G, Shear NH. A double-blind, randomized, placebo-controlled trial of eutectic lidocaine/prilocaine cream 5% (EMLA) for analgesia prior to cryotherapy of warts in children and adults. *Pediatr Dermatol.* 1998;15:129-133.
10. Kilkenny M, Merlin K, Young R, et al. The prevalence of common skin conditions in Australian school students. *Br J Dermatol.* 1998;138(5):840-845.
11. Berth-Jones J, Hutchinson PE. Modern treatment of warts: cure rates at 3 and 6 months. *Br J Dermatol.* 1992;127:262-265.
12. Zouboulis CC, Blume U, Buttner P, et al. Outcomes of cryosurgery in keloids and hypertrophic scars. A prospective consecutive trial of case series. *Arch Dermatol.* 1993;129:1146-1151.
13. Torre D. Dermatological cryosurgery: a progress report. *Cutis* 1973;11:782.
14. Lubritz RR, Smolewski SA. Cryosurgery cure rate of actinic keratosis. *J Am Acad Dermatol.* 1982;7:631-632.
15. Thai KE, Fergin P, Freeman M, et al. A prospective study of the use of cryosurgery for the treatment of actinic keratoses. *Int J Dermatol.* 2004;43:687-692.

16. Chiarello SE. Cryopeeling (extensive cryosurgery) for treatment of actinic keratoses: an update and comparison. *Dermatol Surg.* 2000;26:728-732.
17. Ahmed I, Berth-Jones J, Charles-Holmes S, et al. Comparison of cryotherapy with curettage in the treatment of Bowen's disease: a prospective study. *Br J Dermatol.* 2000;143:759-766.
18. Kuflik EG, Gage AA. The five-year cure rate achieved by cryosurgery for skin cancer. *J Am Acad Dermatol.* 1991;24:1002-1004.
19. Torre D. Cryosurgery of basal cell carcinoma. *J Am Acad Dermatol.* 1986;15:917-929.
20. Kurlick EG. Cryosurgery for skin cancer: 30-year experience and cure rates. *Dermatol Surg.* 2004;30: 297-300.
21. Kokoszka A, Scheinfeld N. Evidence-based review of the use of cryosurgery in treatment of basal cell carcinoma. *Dermatol Surg.* 2004;29:566-571.
22. Thissen MR, Nieman FH, Ideler AH, et al. Cosmetic results of cryosurgery versus surgical excision for primary uncomplicated basal cell carcinomas of the head and neck. *Dermatol Surg.* 2000;26:759-764.
23. Graham G, Clark L. Statistical analysis in cryosurgery of skin cancer. *Clin Dermatol.* 1990;8:101-107.
24. Stevenson O, Ahmed I. Lentigo maligna: prognosis and treatment options. *Am J Clin Dermatol.* 2005;6:151-164.
25. Tappero JW, Berger TG, Kaplan LD, et al. Cryotherapy for cutaneous Kaposi's sarcoma associated with acquired immune deficiency syndrome: a phase II trial. *J Acquir Immune Defic Syndr.* 1991;4:839.
26. Matzke TJ, Christenson LJ, Christenson SD, et al. Pacemakers and implantable cardiac defibrillators in dermatologic surgery. *Dermatol Surg.* 2006;32:1155-1162.
27. El-Gamal HM, Dufresne RG Jr, Saddler K. Electrosurgery, pacemakers and ICDs: a survey of precautions and complications experienced by cutaneous surgeons. *Dermatol Surg.* 2001;27:385-390.
28. Weyer C, Siegle RJ, Eng GG. Investigation of hyfrecators and their in vitro interference with implantable cardiac devices. *Dermatol Surg.* 2012;38:1843-1848.
29. Krull KA, Pickard SD, Hall JC. Effects of electrosurgery on cardiac pacemakers. *J Dermatol Surg*. 1975;1:43-45.
30. Riordan AT, Gamache C, Fosko SW. Electrosurgery and cardiac devices. *J Am Acad Dermatol.* 1997;37:250-255.
31. Burke MC, Knight BP. Management of implantable pacemakers and defibrillators at the time of noncardiac surgery. *ACC Curr J Rev*. 2005;14:52-55.
32. LeVasseur JG, Kennard CD, Finley EM, et al. Dermatologic electrosurgery in patients with implantable cardioverter-defibrillators and pacemakers. *Dermatol Surg.* 1998;24:233-240.
33. Fader DJ, Johnson TM. Medical issues and emergencies in the dermatology office. *J Am Acad Dermatol.* 1997;36:1-16.
34. Behroozen DS, Petersen R, Goldberg LH. Surgical pearl: patient applied manual pressure for hemostasis. *J Am Acad Dermatol.* 2005;53:871-872.
35. Howe N, Cherpelis B. Obtaining rapid and effective hemostasis. Part II. Electrosurgery in patients with implantable cardiac devices. *J Am Acad Dermatol.* 2013;69:677-685.
36. Lewin JM, Brauer JA, Ostad A. Surgical smoke and the dermatologist. *J Am Acad Dermatol.* 2011;65:636-641.
37. Sawchuk WS, Weber PJ, Lowry DR, et al. Infectious papillomavirus in the vapor of warts treated with carbon dioxide laser or electrocoagulation: detection and protection. *J Am Acad Dermatol.* 1989;21:41-49.
38. Centers for Disease Control and Prevention (CDC). *Control of Smoke from Laser/Electric Surgical Procedures*. US Department of Health and Human Services (DHHS), National Institute for Occupational Safety and Health (NIOSH) Publication No. 96-128 (Hazard Controls 11). 1996. https://www.cdc.gov/niosh/docs/hazardcontrol/hc11.html.
39. Knox JM, Lyles TW, Shapiro EM, et al. Curettage and electrodessication in the treatment of skin cancer. *Arch Dermatol.* 1960;82:197-204.
40. Silverman MK, Kopf AW, Grin CM, et al. Recurrence rates of treated basal cell carcinomas. Part 2: curettage-electrodessication. *J Dermatol Surg Oncol.* 1991;17: 720-726.
41. Freeman RG, Knox JM, Heaton CL. The treatment of skin cancer. *Cancer.* 1964;17:535.
42. Tromovitch TA. Skin cancer: treatment by curettage and desiccation. *Calif Med.* 1965;103:107.
43. McCallum DI, Kinmont PC. Basal cell carcinoma: an analysis of cases seen at a combined clinic. *Br J Dermatol.* 1966;78:141.
44. Simpson JR. The treatment of rodent ulcers by curettage and cauterization. *Br J Dermatol.* 1966;78:147.
45. Knox JM, Freeman RG, Duncan WC, et al. Treatment of skin cancer. *South Med J.* 1967;60(3):241-246.
46. Shanoff LB, Spira M, Hardy SB. Basal cell carcinoma: a statistical approach to rational management. *Plast Reconstr Surg.* 1967;39:619.
47. Dubin N, Kopf AW. Multivariate risk score for recurrence of cutaneous basal cell carcinomas. *Arch Dermatol.* 1983;119:373.
48. Spiller WF, Spiller RF. Treatment of basal-cell carcinomas by a combination of curettage and cryosurgery. *J Dermatol Surg Oncol.* 1984;11:808.
49. Sweet RD. The treatment of basal cell carcinoma by curettage. *Br J Dermatol.* 1963;75:137.
50. Spencer JM, Tannenbaum A, Sloan L, et al. Does inflammation contribute to the eradication of basal cell carcinoma following curettage and electrodessication? *Dermatol Surg.* 1997;23:625-631.
51. Nouri K, Spencer JM, Taylor JR, et al. Does wound healing contribute to the eradication of basal cell carcinoma following curettage and electrodessication? *Dermatol Surg.* 1999;25:183-188.
52. Spencer JM. Pilot study of imiquimod 5% cream as adjunctive therapy to curettage and electrodessication for nodular basal cell carcinoma. *Dermatol Surg.* 2006;32:63-69.
53. Wu J, Oh C, Strutton G, et al. An open-label, pilot study examining the efficacy of curettage followed by imiquimod 5% cream for the treatment of primary nodular basal cell carcinoma. *Aust J Dermatol.* 2006;47:46-48.

This page intentionally left blank

Cosmetic Dermatology

PART 31

Chapter 207 :: Cosmeceuticals and Skin Care in Dermatology

:: Leslie Baumann

AT-A-GLANCE

- Dermatologists have the most training and scientific knowledge to understand cosmeceuticals and skin care products.
- Using a diagnostic skin typing system helps identify underlying skin issues and facilitates product matching and patient education.
- Cosmeceuticals and skin care products can be a source of a range of adverse reactions, including irritation and allergy; therefore, proper selection and patient compliance is critical for improved outcomes.

DERMATOLOGISTS ROUTINELY PROVIDE SKIN-CARE ADVICE

According to recent data, sales in the United States of skin-care cosmeceuticals approach $6.5 billion annually and international sales surpass $10 billion, with forecasts of steady continued growth.[1-3] A plethora of skin-care products are currently available to account for this substantial business volume. The vast variety of products, and the often exaggerated associated claims, is so complex that physicians and consumers are often confused about their indications and effectiveness. Dermatologists are uniquely positioned to decipher the product claims and supportive data (or lack thereof) and can guide their patients. They are trained in acne, rosacea, eczema, and many other skin concerns and therefore understand the underlying science of skin care, even if they choose not to sell skin-care products in their offices. Most dermatologists are too busy to spend time discussing skin care with patients. Using a diagnostic methodology to streamline the skin-care prescribing process and educate staff and patients is one approach. The methodology should include routine skin-care advice for facial skin as well as specific instructions for the treatment and healthy maintenance of body skin. Educating the patient on the proper use of sunscreen and medications, such as those for psoriasis, eczema, fungal infections, and wound healing, and how to use those medications in combination with cleansers and moisturizers improves patient compliance and outcomes. This chapter will focus on the issues that should be considered when developing a methodology to prescribe skin-care regimens to treat facial skin issues, but the concept can be easily extended to body skin.

IDENTIFYING FACIAL SKIN ISSUES

The process of properly diagnosing a patient's skin issues can be cumbersome and time consuming. One method is by assigning the skin a diagnosis such as acne, rosacea, melasma, contact/irritant dermatitis, eczema, psoriasis, or actinic keratosis and treating it accordingly. However, in many cases, the patient has more than one issue occurring concurrently. For example, many acne patients develop irritant dermatitis from acne medications. The focus here is caring for the skin from a phenotypic approach, which is a simplified way to discuss the various issues that need to be considered when prescribing the proper skin-care regimen. The phenotypic approach focuses on 4 main facial skin issues: skin hydration, inflammation, pigmentation, and skin aging risk factors.

SKIN HYDRATION

OILY VERSUS DRY

Xerosis, or "dry skin," is characterized by dull color (usually gray white), rough texture, and an elevated number of ridges, and may be associated with a sensation of tightness or itching.[4] Patients complain that their "skin is no longer radiant" because its rough surface is a poor reflector of light. Although the etiology of dry skin is multifactorial, the most significant factor in the development of xerosis is the role of the *stratum corneum (SC)* skin barrier and its capacity to retain water.

BILAYER LIPID MEMBRANE SKIN BARRIER

Rawlings et al. showed that patients with dry skin have a perturbation in the lipid bilayer of the SC.[5] The SC skin barrier is composed of a bilayer lipid membrane formed from 3 primary groups of compounds: (1) ceramides, (2) fatty acids, and (3) cholesterol. When present in the proper amount and ratio (1:1:1), these components help to protect the skin and keep it watertight (Figs. 207-1 and 207-2).[6] When the barrier is impaired, the skin develops an inability to retain water, which leads to dehydration if interventions to retard water evaporation are not implemented. Defects or deficiencies in this barrier layer of the skin cause a spike in water evaporation, known as transepidermal water loss (TEWL). TEWL leads to decreased water content in the SC and abnormal desquamation of corneocytes. Desmosomes remain intact at higher levels of the SC,[7] and desmoglein I levels remain elevated in the superficial SC of individuals with dry skin as compared to controls. This occurs because the enzymes necessary for desmosome digestion are impaired when the water level is insufficient, which spurs abnormal desquamation resulting in visible "clumps" of keratinocytes that leave the skin appearing rough and dry.[8] Recent studies suggest that both the initial cohesion and the ultimate desquamation of corneocytes from the SC surface may be orchestrated by localized changes in pH, which selectively activate different classes of extracellular proteases in a pH-dependent fashion.[9] For this reason, the pH of skin-care products should be taken into account when designing a skin-care regimen for a patient with dry skin. Impairment of the lipid bilayer of the SC can be engendered by various exogenous factors such as ultraviolet (UV) radiation, detergents, acetone, chlorine, and prolonged water immersion. Skin barrier impairment is often caused by an incorrect choice of skin cleansers and moisturizers or overzealous use of exfoliating methods. Although skin barrier function is the most important issue to consider when approaching dehydrated skin, there are other factors to take into account that affect the perception of skin hydration.



Figure 207-1 Brick-and-mortar structure of the epidermis. The pink bricks represent the keratinocytes and the blue represents the bilayer membrane layer.

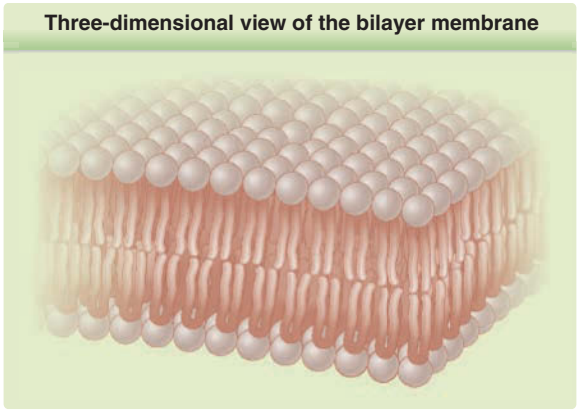

Figure 207-2 Three-dimensional view of the bilayer membrane.

SEBUM PRODUCTION

Sebum production plays a role in dry skin because it provides an occlusive layer on the surface of the skin that retards TEWL. When assessing the face for the presence of sebum, it is important to wait 20 minutes after the patient washes because that is how long it takes the sebaceous glands to generate enough sebum to be visualized and accurately measured on the skin's surface. The oily secretion of the sebaceous glands contains wax esters, sterol esters, cholesterol, di- and triglycerides, squalene,[10] and the antioxidant vitamin E and is thought to confer protection to the skin from environmental insults such as free radicals.[11] Lipids from modified sebaceous glands in the eye, called meibomian glands, help prevent dry eyes by hindering tear evaporation.[12,13] It is important to note that sebaceous gland–impoverished skin, such as the lips and the skin in prepubertal children, may be

at a higher risk for free radical and other environmental damage. Sebum production changes at different stages of life. It is well understood that an age-related change is seen in sebaceous gland activity, with levels typically low during childhood, rising in the mid- to late teens, and generally remaining stable for decades until trailing off in the seventh and eighth decades as endogenous androgen production declines.[14] Children between 2 and 9 years of age commonly display eczematous patches (pityriasis alba) on the face and trunk that disappear with the onset of sebaceous gland activation. The level of sebum production is influenced by diet, stress, hormone production, exercise, and genetics. In a study of 20 pairs each of identical and nonidentical like-sex twins, the identical twins exhibited essentially the same sebum excretion rates, with significantly divergent acne severity, whereas the nonidentical twins differed significantly according to both parameters, implying both the genetic influence of sebum and the mediation of exogenous factors in lesion development.[15]

The presence of sebum on the face does not exclude a skin barrier defect but often compensates for it. In fact, an adequate or increased amount of sebum production can mask a deficient skin barrier. This is the reason that some patients state that they have combination skin that is oily in the t-zone and dry along the sides of the face. In the case of this t-zone type of combination skin, the patient should be treated as an oily facial skin type because the barrier repair moisturizers will feel too heavy and cosmetically displeasing to them. However, they need to be treated with a barrier repair moisturizer in areas with few sebaceous glands such as the arms and legs.

NATURAL MOISTURIZING FACTOR

Natural moisturizing factor (NMF) provides intracellular hydration. It is derived from the breakdown of the protein filaggrin, which provides structural support and strength in the lower layers of the SC. It is broken down in the higher levels (stratum compactum) of the SC into free amino acids, including histidine, glutamine (glutamic acid), and arginine.[16] These osmotically active amino acids remain inside the keratinocyte and avidly bind to water. The pace at which filaggrin is broken down into NMF is thought to be regulated by aspartate protease (cathepsin), which initiates this cascade and determines the amount of NMF that is present.[17] Interestingly, this putative aspartate protease (cathepsin) is regulated by changes in external humidity. In other words, in low-humidity environments, the pace of NMF production increases. This acclimation process typically occurs over the course of several days,[18] and cannot yet be regulated artificially via products or procedures.

GLYCOSAMINOGLYCANS

Glycosaminoglycans (GAGs), such as heparan sulfate and hyaluronic acid, bind and hold water, providing skin hydration and structural integrity.[19] Although their role in skin hydration and aging is poorly understood, much research is ongoing to look at effects of aging on the characteristics of these and other important GAGs.[20] These GAGs are found in skin-care products that target dry and aged skin.

Hyaluronic Acid (HA): HA, which can bind 1000 times its weight in water, is a glycosaminoglycan found in the extracellular matrix and thought to give the skin its volume and plumpness. HA is produced mainly by fibroblasts and keratinocytes in the skin, and has an estimated turnover rate of 2 to 4.5 days in mammals.[21] HA is localized not only in the dermis but also in the epidermal intercellular spaces, especially the middle spinous layer, but not in the SC or stratum granulosum.[22] Aged skin, which is less plump than youthful skin, is characterized by decreased levels of HA. The exact contribution of HA in skin hydration is not clear. Studies have been conflicting about the penetration of HA into the skin on topical application,[23] but the size of the molecule plays an important role.[24] HA has been added to various drug formulations to increase drug delivery because it seems to play a role in enhancing penetration of other ingredients through a poorly understood mechanism.[25] Oral glucosamine supplements have been shown to increase production of HA in the skin and joints.[26,27]

Heparan Sulfate (HS): HS and heparan sulfate proteoglycans (HSPGs), such as syndecan, glypican, and perlecan, are the most common constituents of the cell surface and extracellular matrix, including the basement membrane. These glycans bind ligands at the cell surface and modulate key processes in the skin such as cell proliferation, migration, communication, and activation because of their capacity to bind, store, present, degrade, and amplify key secreted signaling molecules such as growth factors and cytokines. A decreased detection of endogenous HS and HSPGs in the skin has been linked to aging, resulting in deterioration of the mechanical properties of the dermis.[28] Increasing the amount of HS in the skin may provide an important target for skin rejuvenation by not only increasing the skin's ability to hold onto water but also restoring skin homeostasis. Endogenous HS is too large and highly polar to penetrate into skin when applied topically because it is rapidly degraded on the skin surface. Therefore, it serves primarily as a humectant, which brings water onto the surface of the skin. Studies are being conducted with an HS analog that has been shown to penetrate into skin to improve hydration and lower TEWL as well as improve wrinkles and even skin tone.[29]

AQUAPORIN-3

Aquaporin-3 (AQP3) is a member of a family of homologous aquaporin water channels that facilitate fluid transport. AQP3 is a member of a subclass of aquaporins called aquaglyceroporins, which transport not only water but also glycerol and possibly

other small solutes. Researchers have found that AQP3 is expressed at the plasma membrane of epidermal keratinocytes in human skin.[30] There is evidence for a high concentration of solutes (Na^+, K^+ and Cl^-) and a low concentration of water (13%-35%)[31] in the superficial SC, producing in the steady-state gradients of both solutes and water from the skin surface to the viable epidermal keratinocytes.[32,33] It has been proposed that AQP3 might facilitate transepidermal water permeability to protect the SC against desiccation by evaporative water loss from the skin surface and/or to dissipate water gradients in the epidermal keratinocyte cell layer.[30] A study looking at skin phenotype in transgenic mice lacking AQP3 showed significantly reduced water and glycerol permeability in AQP3 null mice proving that AQP3 is functional as a plasma membrane water/glycerol transporter in the epidermis.[34] Conductance measurements showed remarkably reduced SC water content in AQP3 null mice in most areas of the skin. However, epidermal cell water permeability is probably not a major determinant of SC hydration because water movement across AQP3 is markedly slow compared with other tissues.[35] Pharmacologic manipulation of AQP3 may be used in the future to treat skin disorders of excess and decreased hydration. At this time, the only cosmeceutical ingredients that have demonstrated a role in regulating AQP3 are Ajuga turkestanica[36] and glycerin.[37]

SKIN CARE FOR THE OILY–DRY PARAMETER

In the context of the oily–dry parameter, ideal skin is typically characterized by balanced sebum secretion, an intact SC with an unbroken barrier, sufficient levels of NMF and GAGs, and normal expression of AQP3. Skin-care products should be chosen with ingredients to meet these goals (Table 207-1).

Cleansers: The choice of cleanser is crucial because cleansers have a significant effect on the lipid contents of the skin, which affects skin barrier function. In the case of oily skin (excess sebum), a foaming cleanser that contains surfactants to remove the excess lipid is preferable. Oily skin types prefer the clean feeling that these give to the skin. For dry skin types, a nonfoaming cleanser such as an oil, cream, or milk cleanser is preferable. Choose nonfoaming cleansers that deposit fatty acids on the skin, thereby repairing the skin barrier. Good choices include stearic acid (a component of shea butter), which has straight nonpolar hydrophobic tails that stack closely together in the cell membrane giving optimal barrier repair. Linoleic acid, found in safflower oil, argan oil, and others, is also a good choice because of its antiinflammatory capabilities; however, its barrier repair properties are not as strong as those of stearic acid. Avoid oleic acid, found in olive oil, which can cause membrane disruption because its fatty acid hydrophobic tails project at an angle that disrupts the bilayer membrane's natural structure (Fig 207-3).[38] The pH of the cleanser also plays a role in skin barrier function. Soap cleansers that exhibit a high pH have been consistently shown to perturb the skin barrier. Dry skin types need a neutral or acidic cleanser while oily types that do not

TABLE 207-1

Types of Ingredients in Moisturizers for Topical Skin Care

Barrier Repair
- Ceramides
- Cholesterol
- Fatty acids
- MLE technology

Occlusives
- Oils
  - Argan
  - Safflower
  - Grape seed
  - Mineral
  - Jojoba
  - Flax seed
  - Lanolin
- Silicones
- Petrolatum
- Squalene
- Soybean oil
- Propylene glycol
- Wax
- Plastic wrap
- Fabrics or patches

Humectants
- α-Hydroxy acids
- Glycerin
- Heparan sulfate
- Hyaluronic acid
- Propylene glycol
- Sugars
- Urea

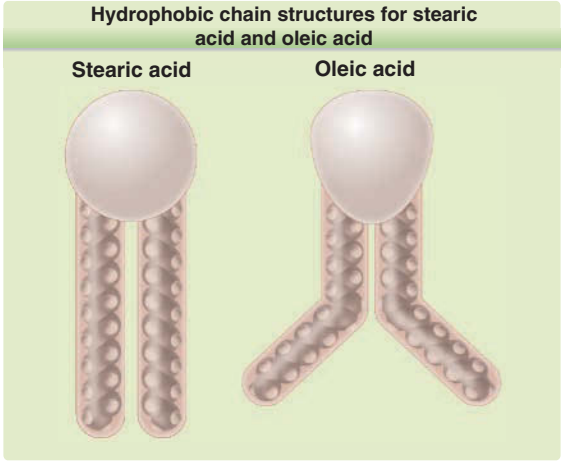

Figure 207-3 Stearic acid has straight hydrophobic "legs," whereas the hydrophobic chains of oleic acid stick out at an angle that precludes close packing of the membrane lipids.

exhibit a propensity for inflammation can tolerate a higher-pH soap-type cleanser. Cleansers are the most commonly used skin-care product, so their impact on oily and dry skin cannot be overemphasized.

Exfoliants: Exfoliants, which are often found in exfoliating cleansers, aid in desquamation of the superficial layer of the SC, leading to a smoother surface and greater light-reflecting abilities. Exfoliants can be mechanical as in the case of crushed shells, sugar or rice grains, aluminum particles, rotating brushes, or rough fabrics. These promote an immediate visual improvement of the skin but overuse can lead to barrier impairment. Hydroxy acids represent the family of chemical exfoliants.[39] α-Hydroxy acids such as lactic and glycolic acids have humectant properties, whereas β-hydroxy acids such as salicylic acid extract lipids from the skin and have drying properties. Exfoliants are often used by skin-care companies to show the immediate benefit of their product on the skin, but these benefits are short-lived and deceiving if the exfoliant products are not combined with barrier repair moisturizers.

Moisturizers: Moisturizers play an import role in treating dry and oily skin. Oily skin types make their own moisturizer because, by definition, they produce an adequate or excess amount of sebum to provide surface occlusion to help retard TEWL. The oily sensation that sebum causes on the skin may make people with oily skin types less likely to use sun protection because many sunscreen products are made with silicones and oil-soluble ingredients that render an oily feel. For this reason, very oily skin types should use a sunscreen in lieu of a moisturizer and slightly oily types should use a lighter lotion or serum-type moisturizer. The choice of cleanser will influence the need for a moisturizer. Oily types should avoid oils and heavy cream moisturizers and will likely prefer humectant-containing moisturizers such as those with hyaluronic acid and heparan sulfate analog. Dry skin types should all use a barrier repair moisturizer containing the proper ratio of ceramides, fatty acids, and cholesterol, which is 1:1:1.[40] Historically, ceramides have been derived from animals, but new technologies using a pseudoceramide formulated in a multilamellar emulsion (MLE) have been shown to mimic the skin's natural 3-dimensional barrier structure.[41] Only barrier repair moisturizers will help correct underlying defects in the skin so that skin health can improve; however, there are other classes of ingredients that are included in moisturizers as a temporary solution. These ingredients are popular because their effects are more rapidly observable than barrier repair ingredients, which may take 4 or more days to yield noticeable results.[42]

Emollients: Emollients are substances added to immediately soften and smooth the skin. They function by filling the spaces between desquamating corneocytes to create a smooth surface, which makes the skin reflect light better and impart immediate visible improvement.[43] Emollients provide increased cohesion that causes a flattening of the curled edges of the individual corneocytes.[4] This leads to a smoother surface with less friction and greater light refraction. Many emollients have barrier repair, humectant, and occlusive properties as well as smoothing emollient properties.

Occlusives: Occlusives, such as naturally occurring sebum and exogenously applied ingredients, often contain lipids and coat the surface of the skin. Plastic wrap, patches, and masks are examples of occlusion technologies used in skin-care regimens. The occlusive coating provides an emollient effect, helps increase penetration of previously applied ingredients, and decreases TEWL. Ingredients with the highest occlusive properties are petrolatum and oils. Petrolatum, for example, has a water vapor loss resistance 170 times that of olive oil.[44] However, petrolatum has a greasy feeling that may make agents containing it cosmetically unacceptable to many patients. Other commonly used occlusive ingredients include paraffin, squalene, dimethicone, soybean oil, grapeseed oil, propylene glycol, lanolin, and beeswax.[45] These agents are only effective while present on the skin; once removed, the TEWL returns to the previous level. Decreasing TEWL by more than 40% can lead to maceration and increased levels of bacteria; therefore, there is a limit to the amount of occlusive ingredients that can be used.[46]

Humectants: Humectants are ingredients with high water absorption capabilities that are able to attract water from the atmosphere. They are most effective when the atmospheric humidity is greater than 80%. Although humectants may draw water from the environment to help hydrate the skin, in low-humidity conditions they may absorb water from the deeper epidermis and dermis, leading to increased skin dryness.[47] For this reason, they are more effective when combined with occlusives. Humectants rapidly draw water into the skin, causing a slight swelling of the SC that gives the perception of smoother skin with fewer wrinkles. Examples of commonly used humectants include glycerin, sorbitol, sodium hyaluronate, urea, propylene glycol, α-hydroxy acids, and sugars. The effects of humectants are temporary, usually lasting less than 24 hours. However, the barrier repair properties of glycerin (also known as glycerol and glycerine) and its ability to traverse AQP3 channels give it longer-lasting effects than other humectants.[48]

Medications: Medications can affect skin type by changing sebum production rates or by perturbation of the skin barrier by disrupting lipid production. Oral ketoconazole,[49] oral spironolactone,[50] oral contraceptives, oral retinoids,[51] and injected botulinum toxin type A[52] have been shown to decrease sebum secretion. Statins and other cholesterol-lowering medications may increase the risk of dry skin but studies are conflicting.

SUMMARY OF SKIN CARE FOR DRY AND OILY SKIN TYPES

The basic care of dry and oily skin types begins with the choice of a cleanser and a moisturizer. At this time there are no skin-care ingredients known to increase NMF production and there are minimal data on ingredients that affect AQP3 function. Topical products have not been reliably shown to decrease sebum production. Humectants, occlusives, and exfoliants only offer temporary improvement. For this reason, oily skin types should be treated with a foaming cleanser and either a light moisturizer or no moisturizer at all. Dry skin types should be treated with lipid-sparing cleansers such as nonfoaming cleansers and barrier repair moisturizers. Humectant-, occlusive-, and exfoliant-containing cleansers and moisturizers can be added to the basic skin-care regimen to treat other issues such as pigmentation and wrinkles and to increase compliance by demonstrating a more rapid visible result on the skin.

SKIN SENSITIVITY

SENSITIVE VERSUS RESISTANT

Resistant skin is defined as skin that rarely exhibits signs of sensitivity, which include acne lesions, redness, itching, flushing, stinging, and urticaria. Sensitive skin, on the other hand, is characterized by frequent incidence of these characteristics of inflammation. There are 4 distinct variations of sensitive skin that should be considered independently when customizing a skin-care regimen. The 4 types of sensitive skin are (1) acne type (prone to developing acne lesions such as papules, pustules, comedones, and cysts); (2) rosacea type (featuring a tendency toward recurrent flushing, facial redness, and experiencing hot sensations); (3) stinging type (predilection to stinging or burning sensations); and (4) allergic type (more likely to exhibit erythema, pruritus, and skin flaking on contact with allergens and irritants). A review of 27,485 patient results from the Baumann Skin Type Indicator (BSTI) Questionnaire[53] taken by patients in 30+ different dermatology offices showed that 73% of patients who presented to these offices reported having sensitive skin (unpublished data). See Table 207-2 for the breakdown of sensitive subtypes in these patients. Each of these subtypes of sensitive skin can occur alone or in combination with other types of sensitive skin. Although all 4 types benefit from the addition of antiinflammatory ingredients,[54] each subtype has unique skin-care needs.

TABLE 207-2
The Subtype Breakdown of 27,485 Patients Seen by Dermatologists in 32 Practices in the USA (20,019 Patients Reported Sensitive Skin)[a]

	# PATIENTS	% PATIENTS
Acne	11,563	58%
Rosacea	9779	49%
Stinging	2970	15%
Allergic	10,990	55%
Acne and rosacea	4909	25%
Acne and stinging	1678	8%
Acne and allergic	5284	26%
Rosacea and stinging	1931	10%
Rosacea and allergic	4991	25%
Stinging and allergic	2135	11%

[a]Many patients exhibited more than 1 type of sensitive skin concurrently.

ACNE TYPE

Sensitive skin acne subtypes are characterized by recurring papules, pustules, comedones, and cysts and exhibit an increased amount of fluorescence from the porphyrins produced by *Propionibacterium acnes* bacteria when seen under various types of light. There are 3 primary factors in the pathogenesis of acne: (1) inflammation, (2) disordered keratinization, and (3) the presence of the bacteria *P. acnes*. In many acne cases, elevated sebum production is seen but this is not a requirement to develop acne. In fact, patients with dry skin and acne are more difficult to treat than those with oily skin and acne because many of the medications used to treat acne lead to dryness of the skin. Although acne has various causal pathways and contributing factors, the essential pathognomonic feature is abnormal keratinization of the SC with adherence of desquamated skin cells in the hair follicles. These skin cells combine with sebum and clog the follicle, creating a comedone. The bacteria *P. acnes* migrates into the hair follicle, causing a cascade of events including activation of Toll-like receptor 2. This stimulates the release of cytokines and other inflammatory factors that trigger the inflammatory response. Goals of treatment include lowering *P. acnes* levels, blocking inflammatory pathways, and normalizing keratinization. Skin-care regimens for acne take about 8 to 12 weeks to yield results, so patients should be educated about the delay to improve compliance. Camera imaging such as the Canfield Visa CA can be used to visualize the amount of *P. acnes* on the skin. This helps determine the amount of bacteria at baseline, tracks improvement, and encourages the patient to return for followup visits to check progress. Decreased bacterial counts are often seen in the camera before the acne lesions clear, showing the patient that progress is occurring. Regimens should be divided into treatment and maintenance programs. The treatment regimen should be implemented for the first 12 weeks, which is geared to speed healing of active lesions in addition to preventing new lesions. Use acne medications such as benzoyl peroxide, clindamycin, salicylic acid, and retinoids but they should be combined with nonfoaming cleansers and noncomedogenic

TABLE 207-3
Nonprescription Acne Treatments

- Normalize keratinization-
  - Hydroxy acids
  - Retinol
- Decrease *P. acnes*
  - Benzoyl peroxide
  - Silver
  - Blue light (415 nm)
  - Antimicrobials
- Antiinflammatories (see Table 207-4)

barrier repair ingredients in dry types. Acne treatment visits should be scheduled at weeks 4, 8, and 12 to improve compliance. Studies have shown that compliance improves around the time of the patient visit[55]; therefore, monthly visits are suggested until the acne medications are being tolerated and acne has significantly improved. After the acne has cleared, switch the patient to a retinoid-containing maintenance regimen geared to prevent recurrence (Table 207-3).

ROSACEA TYPE

Rosacea is characterized by facial redness and flushing that may include inflammatory papules and telangiectasias. Topical skin care for rosacea is primarily geared toward vasoconstrictive, antimicrobial, and antiinflammatory ingredients to decrease redness and prevent progression. Many types of antiinflammatory ingredients are found in skin-care products (Table 207-4). These should be combined with prescription medications and vascular laser (595 nm) treatments for maximal results. However, special thought needs to be given to what these types of patients should *not* use. Vigorous exfoliation should be avoided. Triggers such as cold and heat could contribute to this pathology if the patient uses extreme temperatures of water or has frequent facials that often include facial steaming.

TABLE 207-4
Antiinflammatory Ingredients

- Aloe vera
- Argan oil
- Arnica
- Bisabolol
- Caffeine
- Chamomile
- Colloidal oatmeal
- Cucumber
- Feverfew
- Green tea
- Hamamelis (witch hazel)
- Licorice extract

Niacinamide (also known as nicotinamide)

- Oxymethazoline
- Salicylic acid
- Zinc

The choice of cleansers, moisturizers, and sunscreens should include some form of antiinflammatory ingredient. If retinoids are to be used, they should be started slowly to avoid exacerbation of rosacea. Decreasing the dose and frequency by applying a low-strength retinoid on top of an antiinflammatory moisturizer every third night is often tolerated by rosacea patients. The dose and frequency can be increased as they adjust.

STINGING TYPE

Burning, stinging, or itching caused by application of a cosmetic or topical medicament without detectable visible or microscopic change is termed *sensory irritation*. The afferent limb of this reaction is carried by C nerve fibers that are present throughout the dermis and viable epidermis. The stinging occurs on the face within an hour of application in susceptible individuals. Patients with this subtype of sensitive skin do not have a higher incidence of atopy or dry skin, but do report frequent adverse reactions to cosmetics. Several tests such as the lactic acid stinging test have been devised to identify patients with the stinging propensity; however, there is no universally accepted test because different ingredients sting different people. Patients with rosacea and patients experiencing retinoid dermatitis often report stinging even with contact to only water. The stinging sensation is not necessarily associated with erythema as many patients feel stinging without experiencing redness or irritation.[56] Most often patients with the stinging subtype of sensitive skin feel stinging upon application of the following ingredients: α-hydroxy acids (particularly glycolic acid), benzoic acid, bronopol, cinnamic acid compounds, Dowicel 200, formaldehyde, lactic acid, propylene glycol, quaternary ammonium compounds, sodium lauryl sulfate, sorbic acid, urea, ascorbic acid, and witch hazel. Use of antiinflammatory ingredients may help lessen stinging but the best therapy is avoidance of products with stinging ingredients.

ALLERGIC/IRRITANT TYPE

The allergic/irritant subtype is more likely to develop a dermatitis upon exposure to various allergens and irritants. This subtype also has been called "status cosmeticus" by Fisher,[57] contact urticaria when a wheal and flare response occurs,[58] "cosmetic intolerance syndrome" when it occurs with cosmetics, and more commonly contact or irritant dermatitis. This subtype can be due to an increased immune response in the case of contact dermatitis or an impaired skin barrier that allows allergens and irritants to more easily enter the skin.[59] Various studies reveal that approximately 10% of patch-tested dermatologic patients are allergic to at least one ingredient common in cosmetic products.[60] Fragrances and preservatives are the most common allergens (Table 207-5). New emerging allergens include sorbitan, the preservatives methylisothiazolinone and sodium dehydroacetate, cetyl alcohol, bisabolol, peppermint, and the red pigment carmine.

TABLE 207-5

Frequently Identified Cosmetic Ingredients Causing Allergic Contact Dermatitis

- Benzyl alcohol
- Bisabolol
- Calendula (marigold)
- Cetyl alcohol
- Cinnamon
- Essential oils
- Fragrances
- Glyceryl thioglycolate
- Lanolin
- Niacinamide
- Paraphenylenediamine (PPD)
- Peppermint
- Preservatives
- Propylene glycol
- Sorbitan
- Sunscreens
- Toluene sulfonamide/formaldehyde resin
- Triclosan
- Vitamin E

The first step in treating these patients is to try and identify the allergen by patch testing or a detailed history. In some cases, a patient diary will reveal the culprit. The popularity of organic and natural ingredients has resulted in an increase in exposure to plant-derived allergens. Skin care should aim for avoidance of the allergen and fortification of the skin barrier with barrier repair ingredients. There are also cosmeceutical products that coat the skin to protect against nickel and other allergen contact.

CLEANSERS

Sensitive skin types are more prone to inflammation, so they should avoid extremes of temperature. Washing with tepid water is prudent. Avoiding exfoliants is particularly important including scrubs, facial cloths, and rotating brushes, which all can cause dermatographism, flushing, and other forms of inflammation in these susceptible types. In fact, friction has been associated with an increase in acne breakouts. Soothing cleansers that contain antiinflammatory ingredients are preferred. Hydroxy acid cleansers may irritate stinging and rosacea types but will help decrease *P. acnes* counts by lowering the pH and preventing and treating comedones in acne types. Salicylic acid is a good choice of hydroxy acids for acne skin types because it is lipophilic, able to enter the pilar unit, and exhibits the antiinflammatory properties of salicylates. Patients with the allergic/irritant subtype should avoid foaming cleansers that can disturb the skin barrier, facilitating entry of foreign substances into the skin.

MOISTURIZERS

Patients with acne are often hesitant about moisturizer use but at least one study has demonstrated improvement of acne with moisturizer use alone.[61] Moisturizers that do not contain comedogenic ingredients such as isopropyl myristate, isopropyl palmitate, and coconut oil (although not all forms of coconut extract are acnegenic) should be chosen. Patients with the rosacea type of sensitive skin do well with soothing antiinflammatory ingredients such as argan oil, chamomile, niacinamide, colloidal oatmeal, feverfew, licorice extract, green tea, and chamomile. These should be combined in the regimen with prescription rosacea medications such as azelaic acid, metronidazole, brimonidine, ivermectin, and oxymetazoline. Oxymetazoline and brimonidine have α-adrenoreceptor agonist activity that results in vasoconstriction, causing a rapid improvement in facial redness. Brimonidine has selective α_2 activity,[62] whereas oxymetazoline has effects on both α_1 and α_2 adrenergic receptors. Using these vasoconstrictive prescription products may improve compliance by showing rapid and noticeable results. Brimonidine has been associated with rebound redness, and therefore should be combined with other antiinflammatory ingredients. Oxymetazoline seems to confer some antiinflammatory benefits in addition to the vasoconstrictive effects.[63] If retinoids are used in rosacea-prone skin, they should be introduced slowly and in conjunction with antiinflammatory ingredients. Patients with stinging-type skin should avoid retinoids and ingredients with a low pH such as acids whereas patients with allergic- and irritant-prone skin should avoid known allergens and any harsh ingredients.

SUMMARY OF SKIN CARE FOR SENSITIVE SKIN TYPES

Treatment of sensitive skin depends upon the subtype. Many people have more than one type of sensitive skin. In that case, it is important to know which subtype is predominant. The allergic/irritant subtype is the most important because the treatment includes avoiding inciting factors. Use of a hypoallergenic skincare line is preferred in the case of this type of skin. Products should be added one at a time with a week in between each addition so that if the patient has a reaction, it is easier to identify the culprit. The second form of sensitive skin that trumps acne and stinging skin types is the rosacea type of skin. Patients who have inflammation and redness from rosacea need to have antiinflammatory ingredients added to their regimen and should be given about 4 weeks for the inflammation to calm down before adding any acne treatment ingredients. If the patient has concurrent stinging with the redness, in many cases the stinging will clear with the same antiinflammatory ingredients used for the rosacea regimens. Once the redness and stinging have improved and allergens have been identified, then the patient can be placed on an acne regimen with less risk of side effects. In summary, when treating sensitive skin with multiple subtypes, remove the allergens first, then add antiinflammatory ingredients, and

finally proceed with acne medications. The more subtypes of sensitive skin the patient has, the more closely they should be monitored. Acne patients may feel frustrated by the delay in resolution so it is important to explain the process to them. Addition of oral medications or blue light can hasten the process of acne treatment without compromising this stepwise routine. As with other skin issues, once the skin type has reverted to a resistant type, the patient can be placed on a maintenance regimen to keep the symptoms of the sensitive subtypes at bay.

SKIN PIGMENTATION

PIGMENTED VERSUS NONPIGMENTED

The third primary skin characterization parameter is based on the presence or absence of uneven skin tone caused by hyperpigmentation or dyschromia on the face. The dyschromia may be in the form of melasma, solar lentigines, or postinflammatory hyperpigmentation.

Skin pigment (melanin) is produced by melanocytes, which transfer the pigment via melanosomes to keratinocytes. Melanin is derived from the enzymatic breakdown of tyrosine by tyrosinase into 3,4-dihydroxyphenylalanine, which yields 2 forms of melanin (eumelanin and pheomelanin).[64] Four primary mechanisms can be employed to impede the development of skin pigmentation: sunscreen use and sun avoidance, inhibiting the tyrosinase enzyme, preventing melanosome transfer into keratinocytes by blocking the PAR-2 receptor, and increasing desquamation of the SC. Treatments work best if all of these 4 strategies are employed. Patient education is crucial because patient habits can greatly contribute to dyspigmentation, especially melasma. For example, stress, estrogen use, heat exposure, melatonin supplements, over exfoliation leading to skin inflammation, and lack of SPF use in cars and indoors can all contribute to melanocyte activation.

SUNSCREEN

Sunscreen should be a routine part of the skin regimen every morning even if the patient stays indoors. There are many new SPF formulations that block infrared and other forms of light that can worsen melasma. If the patient has oily skin, then the SPF can be used in lieu of a moisturizer. Acne-prone patients should be treated with a noncomedogenic sunscreen. Oral sun-protective supplements such as polypodium leukotomes and pycnogenols offer extra protection but should not be used as a replacement for sunscreen.

TYROSINASE INHIBITORS

Tyrosinase inhibitors block the production of melanin and include vitamin C, hydroquinone, kojic acid, arbutin, mulberry extract, and licorice extract (Table 207-6). Many authors recommend a "holiday" from tyrosinase inhibitors every 3 to 6 months to prevent tachyphylaxis although the need for this is anecdotal.[65,66] Ascorbic acid is a tyrosinase inhibitor that has a different structure than the others so it can be used during the holiday period. Hydroquinone is the most effective tyrosinase inhibitor but unfounded public concerns about hydroquinone safety[67] have popularized the use of similar derivatives such as kojic acid and arbutin. Hydroquinone has been found to be efficacious in combination with a retinoid and a steroid in the "Kligman formula" because retinoids and steroids such as fluocinolone inhibit tyrosinase. This triple combination agent combines hydroquinone with retinoids, which prevent the skin-thinning effects of steroids, and steroids that mitigate the inflammation from retinoids and hydroquinone.

TABLE 207-6
Cosmeceuticals to Reduce Skin Pigmentation

- Arbutin
- Hydroquinone
- Hydroxy acids
- Kojic acid
- Licorice extract
- Mulberry extract
- Niacinamide
- Pycnogenol
- Resorcinol
- Retinol
- Soy (with estrogenic components removed)
- Topical steroids
- Vitamin C (ascorbic acid)

PAR-2 BLOCKERS

Small proteins present in soy, such as soybean trypsin inhibitor and Bowman-Birk inhibitor, exhibit depigmenting activity and prevent UV-induced pigmentation both in vitro and in vivo.[68] These soy proteins inhibit the cleavage of the 7 transmembrane G-protein coupled receptor known as protease-activated receptor 2 (PAR-2). It is expressed in keratinocytes at intersection points with melanocytes and functions like a key opening a lock allowing the melanosomes to transfer from the melanocyte into the keratinocyte. Both soy and niacinamide, a derivative of vitamin B_3, have been shown to inhibit melanosome movement from melanocytes to keratinocytes.[69]

EXFOLIANTS

Removing the top layer of the SC induces the cell cycle to speed up, which hastens desquamation of melanosome-laden keratinocytes. The melanocytes cannot make the pigment fast enough to keep the keratinocytes full of melanosomes, so less pigmentation is seen at the cell surface. Exfoliants work much better

when combined with tyrosinase inhibitors and PAR-2 blocking agents in addition to sunscreen. Exfoliants can be mechanical such as microdermabrasion, scrubs, rotating brushes, or rough fabrics, or chemical such as hydroxy acids. Retinoids also serve the purpose of accelerating desquamation. These ingredients can be added into the skin-care regimen or applied as an in-office procedure to treat dyschromia. However, overuse or misuse can result in inflammation, which would stimulate the melanocytes to make more melanin and worsen the problem. For this reason, exfoliants should be used with extreme caution and patients should be educated about the harms of overexfoliating. Using exfoliating cleansers such as hydroxy acid cleansers is a low-risk way to add exfoliants into the skin-care regimen. In-office peels can be used but with caution and only by experienced users because peels can easily exacerbate melasma.

LIGNIN PEROXIDASE

Lignin peroxidase is an enzyme synthesized by the white-rot tree fungus *Phanerochaete chrysosporium* that breaks down lignin in decaying trees.[70] It is used in the paper industry to whiten wood pulp and was found to break down eumelanin, which has a similar structure to lignin.[71] In topical preparations, lignin peroxidase has been found to be effective for the improvement of skin pigmentation due to an excess of eumelanin. Lignin peroxidase is commercially available as a glycoprotein known as ligninase (or Melanozyme), which functions best at a pH of 2 to 4.5. It has been found to be nonirritating and safe for use in all of the sensitive skin subtypes. It can be used during the holiday period when tyrosinase inhibitors are discontinued to help prevent rebound of melasma during the maintenance period.

ANTIOXIDANTS

Antioxidants play multiple roles in the treatment and prevention of dyschromia. Their actions may include one or more of the following: chelating copper, neutralizing free radicals, and decreasing inflammation. Tyrosinase requires copper to function, and many antioxidants such as flavonoids chelate copper. Free radicals can incite inflammatory pathways leading to increased melanocyte activity. Many antioxidant ingredients such as argan oil and green tea have antiinflammatory activities independent of their antioxidant capabilities. Some antioxidants prevent UV-induced pigmentation by affecting the p53 pigmentation pathway through the rate-limiting step of p53 phosphorylation at site 15.[72] This phosphorylation step is blocked by the plant-derived antioxidant phloretin.[73] Ascorbic acid (vitamin C) is a unique antioxidant in that it also has tyrosinase-inhibiting properties separate from its antioxidant properties. Antioxidants are formulated in serums, sunscreens, and moisturizers.

SUMMARY OF SKIN CARE FOR PIGMENTED AND NONPIGMENTED SKIN TYPES

Nonpigmented types should use a daily sunscreen to preserve even skin tone. Pigmented skin types should be prescribed and educated on 2 forms of skin-care regimens: the treatment regimen and the maintenance regimen. Melasma studies show a 1- to 2-grade improvement at 12 to 16 weeks in most cases. For this reason, the treatment regimen should last 3 to 4 months and the patient should be warned that it may take several treatment cycles depending on (1) severity of melasma, (2) compliance with regimen, (3) sun avoidance, and (4) presence of other factors such as stress and estrogen use. Compliance is a major factor in achieving success. Monthly visits with photography and mexameter or other objective measurements at each visit can improve compliance. Patients should be counseled that changes in these measurements and in photos are not usually seen until 12 weeks to prevent discouragement, which usually occurs at the week 8 visit. The treatment cycle should consist of (1) daily broad-spectrum SPF; (2) twice-daily tyrosinase inhibitor; (3) nightly retinoid; (4) a PAR-2 blocking agent in either a sunscreen, serum, or moisturizer; and (5) an exfoliating cleanser. To save regimen steps and improve efficacy, the evening product can be a triple combination of retinoid, tyrosinase inhibitor, and a steroid such as the "Kligman formula." After 4 months, or on clearance of the pigmentation disorder, the regimen should be changed to a maintenance regimen. The maintenance regimen should not have tyrosinase inhibitors (with the exception of ascorbic acid) but should include (1) daily broad-spectrum SPF; (2) an antioxidant such as ascorbic acid; (3) a PAR-2 blocking agent in either a sunscreen, serum, or moisturizer; (4) lignin peroxidase; and (5) an exfoliating cleanser. The maintenance regimen will be used for at least 1 month or until pigmentation begins to return, at which time the treatment regimen will be resumed for another 4 months. The back-and-forth cycle will continue until the dyspigmentation clears. This may take 1 to 6 treatment cycles but clearing will occur in almost all cases if the patient is compliant with the regimen and lifestyle advice.

SKIN AGING

WRINKLE-PRONE SKIN VERSUS NON–WRINKLE-PRONE SKIN ("TIGHT")

Aging of the skin is a complex chain of events reflecting natural intrinsic and extrinsic processes. Intrinsic aging is a function of individual heredity and results

from the passage of time. This process is, of course, inevitable and beyond voluntary control. However, the largest percentage of skin aging is due to lifestyle factors such as sun exposure, tanning bed use, smoking, increased cortisol levels, increased blood sugar levels, lack of exercise, excessive use of drugs and alcohol, and poor diet. Use of daily sunscreen, retinoids, and other antiaging technologies can mitigate the risk of skin aging. Wrinkle-prone skin is found in patients over the age of 20 who do not use antiaging technologies to prevent wrinkles while also engaging in several deleterious lifestyle behaviors. There are many exaggerated claims about antiaging ingredient efficacy, but only a few have stood the test of scientific evaluation. Although many studies are ongoing, it is much too early for any technologies to manipulate gene expression and affect skin aging with one notable exception—retinoids. Retinoids, by definition, bind the retinoic acid receptor, which turns on and off various genes including the procollagen gene. The only antiaging technologies that have been proven in vivo to improve skin appearance with long-term use are daily sunscreen, hydroxy acids, ascorbic acid, and retinoids. Many other antiaging technologies are being studied that aim to improve the appearance of skin or slow aging by lengthening telomeres; neutralizing free radicals; affecting production of matrix metalloproteinases, growth factors, and cytokines; preventing glycation; increasing skin levels of hyaluronic acid, heparan sulfate, collagen, and elastin; preserving or improving mitochondrial or lysosome function; and upregulating sirtuin expression.[74] The focus here is on the technologies that have demonstrated efficacy and are more widely used by dermatologists and omits the overhyped and unproven technologies.

The dermatologic focus of antiaging skin care should be to prevent the formation of rhytides in the first place,[75] and to improve wrinkles and a thinning dermis once this occurs. Prevention of aging is difficult to prove but the goal is to halt the degradation of the main structural components of the skin—collagen, elastin, heparan sulfate, and HA—all of which are known to be diminished in aged skin. The treatment of aging skin, usually judged by visual analysis of wrinkles, is much easier to prove but harder to achieve without using deceptive measures such as photography and use of humectants that immediately plump the skin. For this reason, placebo-controlled trials are vital to substantiate wrinkle improvement claims. Ingredients that have data to substantiate claims of wrinkle *prevention* include sunscreens and retinoids. Ingredients that have plausible claims that they prevent skin aging include ascorbic acid, through its collagen-stimulating and antioxidant properties, and green tea because of its antioxidant and antiinflammatory properties. The only ingredients that have convincing peer-reviewed data about their *ability to improve wrinkles* are hydroxy acids, ascorbic acid, and retinoids. Ingredients that have qualities that suggest they improve skin aging but need more proof include growth factors such as transforming growth factor-β, epidermal-derived growth factor, hyaluronic acid, and heparan sulfate. Ingredients that have minimal to no published peer-reviewed scientific data on photoaging include stem cells, collagen, products to prevent or reverse glycation, and ingredients that claim to upregulate sirtuin or lengthen telomeres. It is important to note that an antiaging claim can be made on any product that contains sunscreen.

SUNSCREENS

UV exposure results in skin damage through several mechanisms including sunburn cell formation, creation of thymine dimers, collagenase production, and provoking an inflammatory response. Signaling through p53 following telomere disruption is also a common feature observed in aging as well as photodamage.[76] Although much remains to be learned about the mechanisms through which UV irradiation unleashes a chain of cascading health effects, photoaging, photocarcinogenesis, and photo-immunosuppression are well-known results of UV exposure.[77] Every antiaging regimen should consist of a daily SPF. The most important factor to consider when choosing a sunscreen is patient compliance. Oily types will not wear a heavy oil-based product, whereas acne-prone types often suspect their SPF as the cause of breakouts. Chemical sunscreen agents often precipitate allergic dermatitis in susceptible sensitive skin subtypes. Patients should be educated on the major points of sunscreen use because many do not use enough SPF and do not reapply it.

CLEANSERS

Cleansers prepare the skin by removing sweat, dirt, and debris that can decrease the penetration of skincare ingredients. Penetration of ingredients in their active form is a major issue for most antiaging products because the skin barrier prevents penetration of large and/or charged molecules. This barrier to penetration affects the efficacy of peptides, hyaluronic acid, growth factors, antioxidants, and many other ingredients. Cleansers can change the pH and other factors on the skin's surface that affect both penetration and the chemical structure and efficacy of the compounds that are placed on the skin after cleansing. For example, a low-pH cleanser such as a hydroxy acid will lower the skin's surface pH, increasing penetration of ascorbic acid, which penetrates more readily at a pH of 2 to 2.5.[78] A low pH would also improve the efficacy of lignin peroxide preparations and render the skin less hospitable for acne bacteria. Soap, on the other hand, increases the skin's pH.[79] The choice of an antiaging cleanser depends directly on skin hydration, presence of a sensitive subtype, and choice of therapeutic products to be used on the skin after cleansing.

MOISTURIZERS AND SERUMS

The main goal of antiaging skin care is to preserve and increase dermal levels of collagen, heparan sulfate, hyaluronic acid, and elastin. Of these, elastin is the most

elusive as no ingredients have been able to increase levels of mature functional elastin. To protect and/or encourage production of these components, antiaging serums and moisturizers should contain a retinoid at a minimum. Collagen synthesis has been shown to be increased through the use of retinoids.[80] Retinoids also have been demonstrated in animal models to increase production of HA[81] and have been shown in multiple studies to improve photoaged skin.[82-84] Not all patients, especially dry skin types and sensitive skin types with the rosacea subtype, can tolerate a retinoid. Retinoids penetrate easily into the skin and can incite a reaction known as retinoid dermatitis. Starting the patient accordingly on a regimen directed to barrier repair and/or decreasing inflammation for 4 weeks may increase patient tolerance of retinoids and prevent retinoid dermatitis. Retinoids should be started with a low dose and used sparingly. One suggested regimen is a pea-size amount of product applied over moisturizer every third night. The amount and frequency can be adjusted as the patient's dryness and inflammation improve. Oily and resistant skin types usually have no trouble tolerating retinoids.

Antioxidants are commonly used in antiaging regimens to neutralize free radicals that damage DNA and cell membranes leading to increased aging, and induce glycation that causes damage to collagen strands.[85] Free radicals can act directly on growth factor and cytokine receptors in keratinocytes and dermal cells, leading to skin inflammation. The direct effects of free radicals on the aging process are beginning to be understood. In 1998, investigators demonstrated that free radical activation of the mitogen-activated protein kinase pathways resulted in production of collagenase, which led to degradation of collagen.[86] Another study by Kang and colleagues on human skin supported this concept. They showed that when human skin was pretreated with the antioxidants genistein and *N*-acetyl cysteine, the UV induction of the cJun-driven enzyme collagenase was blocked.[87] Antioxidants may block the process of glycation, but more data are needed before this hypothesis is proven. Many antioxidants are available in skin-care products, including argan oil, vitamins C and E, ferulic acid, coenzyme Q_{10}, green tea, phloretin, pycnogenol, resveratrol, silymarin, and idebenone. Vitamin C is a particularly interesting antioxidant because it has the added ability to induce fibroblasts to produce collagen.[88]

Hydroxy acids have been shown in multiple studies to improve fine lines and skin texture.[89] Present in cleansers, moisturizers, masks, in-office peels, and several other modalities, they function by increasing desquamation of the SC cells, which stimulates the stem cells in the skin to begin to produce various important cell components including collagen and hyaluronic acid. Hydroxy acids must be formulated at the proper pH to be effective, with the most acidic versions causing the most exfoliation but with increased side effects. Hydroxy acids can affect the efficacy of other ingredients applied at the same time, so their order in the regimen should be carefully considered.

SUMMARY OF SKIN CARE FOR WRINKLE-PRONE SKIN TYPES

The goal of antiaging skin care is daily use of sunscreen, retinoids, and antioxidants combined with healthy lifestyle habits to minimize glycation, UV light exposure, and free radical production. Antioxidants should be obtained by a myriad of sources, including food, beverages, supplements, and topical products. There is no one best antioxidant, and studies support the fact that they work better in combination than alone.[90]

COMBINING THE 4 SKIN PARAMETERS TO ASSIGN A PHENOTYPE DIAGNOSIS

The 4 skin parameters can be combined to form 16 distinct skin phenotypes also known as Baumann Skin Types (Fig 207-4).[91-93] Diagnosing the skin type allows the dermatologist to more easily prescribe a skin-care regimen taking into account the issues discussed in this chapter. It is more efficient to use a methodology to preset customized skin-care regimens based on a skin type diagnosis than to develop a de novo skin-care regimen for each patient. In addition, this allows the physician to more easily track results and efficacy.

All facial skin, regardless of age or gender, can be assessed by evaluating the skin and assigning it to 4 different parameters by choosing one of the following: dry (D) or oily (O); sensitive (S) or resistant (R); pigmented (P) or nonpigmented (N); and wrinkle prone (W) or tight (T) [or non–wrinkle prone]. One of each of the 2 options is chosen, so for example, the facial skin would be considered dry (D) or oily (O).

Once the skin has been assigned one of each of the 4 parameters, these 4 parameters are combined and the skin is diagnosed as one of 16 distinct skin phenotypes. For example, an individual may exhibit dry, sensitive, pigmented, wrinkle-prone skin and be referred to as a DSPW skin type. This person would require significantly different skin-care products compared to someone with oily, sensitive, pigmented, and wrinkled skin (OSPW). In many cases, historical data are necessary to properly identify the skin phenotype. The Baumann Skin Type Indicator questionnaire was developed to speed the skin phenotype diagnostic process. It aids physicians in identifying a patient's skin type, factoring in sebum secretion, skin hydration, propensity for inflammation—such as acne and contact dermatitis—as well as uneven skin pigmentation on the face and habits that increase the risk for cutaneous aging and skin cancer.[53,94] The Baumann Skin Type Indicator is a 3- to 5-minute questionnaire that is administered in the waiting room prior to the patient consultation. It has been tested in all ethnicities and genders and in ages 14 and older to diagnose skin phenotype. Its use

Figure 207-4 Sixteen distinct Baumann skin types based on the designations Oily vs Dry; Sensitive vs Resistant; Pigmented vs Nonpigmented; and Wrinkled vs Tight. (The image herein is © Copyright 2016 MetaBeauty Inc. and is used with permission.)

has been validated in studies in white, Chinese, and Korean populations.[95]

Once the skin phenotype has been determined, certain extrinsic or intrinsic factors, such as a move to a different climate, a change in stress levels, pregnancy, menopause, aging, disease, and other stressors, can result in a skin type change. The Baumann Skin Type Indicator, a questionnaire developed to determine skin type, is helpful in assessing skin type initially and again after major life events.[96]

THE HEALTHIEST SKIN TYPE

The goal of a prescribed skin-care regimen is to improve the skin's appearance and health through proper lifestyle choices and daily use of topical and oral cosmeceuticals and medications. The healthiest skin type would manifest an adequate amount of sebum production to protect the skin from TEWL, free radicals, and allergens and irritants. This idealized healthy skin type would have a robust skin barrier, inflammatory pathways that are only activated when provoked, normalized melanocytic function to provide even skin tone, strong defenses against aging, and good lifestyle choices. This skin phenotype is ORNT or oily, resistant, nonpigmented, and tight. Although the baseline genetic Baumann Skin Type may exhibit various characteristics, consistent use of a proper regimen and therapeutic treatments can change the skin to the desirable characteristics of ORNT skin.

IDENTIFYING THE MOST EFFICACIOUS PRODUCTS

There is no one ingredient or product that is ideal for all skin types. Each skin type has individual needs that should be taken into account when choosing products and which ones to combine to maximize efficacy. There are other variables to consider when selecting a skin-care product for patients including the quality and choice of ingredients, product formulation, manufacturing, packaging, storage, and shipping. Counterfeit products have become a huge problem in the online retail world, so patients need guidance about what brands to use and where to purchase them. When

treatment regimens consisting of cosmeceuticals and/or medications do not work, patients will have poor outcomes, resulting in diminished trust that mars the physician–patient relationship.

CHOOSING INGREDIENTS

It is important to understand the characteristics of various ingredients and match formulations to a patient's skin type. Take into account which prescription medications will be combined in the regimen and how they will be affected by the cosmeceuticals. For example, hyaluronic acid–containing preparations may accelerate penetration of medications,[25] and the pro-oxidant activity of benzoyl peroxide can lessen the efficacy of other ingredients. The order of application and the combination of ingredients affects stability, efficacy, safety, and the chemical structure of the formulation, and there is really no such thing as an inactive ingredient (or excipient). Ingredients can modulate penetration, enhance the activity of other ingredients, or inactivate them depending on the order in which ingredients are used on the skin. For example, olive oil increases penetration of other ingredients because it has a high content of oleic acid, whereas safflower oil can reduce penetration by strengthening the skin barrier. It is imperative to know which ingredients work well together and which do not. The order in which ingredients are placed on the skin is also significant, because products can inactivate each other and affect absorption.

CHOOSING PRODUCTS

A brand-agnostic approach is recommended, choosing the best products from each brand and combining and testing them on various skin types to see which products and what combinations of products work best. The formulation recipe and the entire spectrum of production can affect efficacy. The "formulation recipe" refers to the order in which ingredients are added in the formulation process, the pH, the amount of each ingredient, the temperature at which the ingredient is added, and many other important factors that determine the final chemistry. Ingredients like vitamin C, green tea, and retinol are more expensive when formulated properly. Many "copycat" brands use the same ingredients, but they cannot use the patented recipe; therefore, the end product is qualitatively different.

How a product is made and packaged is pivotal. For example, retinol decomposes when exposed to light and air. If it is stirred in an open vat it loses its efficacy and therefore must be formulated in a closed system. The process of packaging the completed product is also important. The formulation can be exposed to air and light when the bottles, pumps, or jars are filled. A product may be formulated in one place and shipped to another location for final packaging—and many ingredients can lose their potency during transit. Once the product is filled and packaged, how it is stored and how long it is stored can also affect efficacy. Many sunscreens, antioxidants, and retinoids will lose efficacy when stored in high heat. This concern extends to how the products are stored in the warehouse, how they are shipped through the mail, how they are stored in the retail space, and where the patient stores the product once it is purchased. The container itself is also a significant consideration as air and light can enter tubes, affecting the efficacy of the formulation. Air and heat are the primary culprits for unstable ingredients such as retinoids and ascorbic acid; therefore, these should be packaged in amber bottles or airless pumps to minimize light and air exposure.

DESIGNING THE REGIMEN AND ORDER OF APPLICATION OF PRODUCTS

Once a doctor has identified a patient's skin type and properly matched products to her or his skin type, it is necessary to decide the order of the products. Table 207-7 gives an example of a basic structure of a skin-care regimen. The cleanser is the obvious first step in the morning and evening regimen to clear the skin of dirt and debris. The eye product is applied next to protect the thin skin from the third regimen step, which is the medication or treatment product. Examples include rosacea, acne, melasma, or seborrheic dermatitis medications. The fourth step is a moisturizer. In the morning, the fifth step is a sunscreen whereas in the evening the fifth step is a retinoid. The retinoid is applied last to limit penetration.

PATIENT EDUCATION

It is crucial to instruct the patient exactly *how* to apply the products. The order in which products are applied makes a difference. Ingredient interactions, ingredient

TABLE 207-7

A Typical Structure for a Skincare Regimen That Suits the Majority of Skin Types

MORNING	EVENING
Step 1: Cleanser	Step 1: Cleanser
Step 2: Eye product	Step 2: Eye product
Step 3: Treatment product or medication	Step 3: Treatment product or medication
Step 4: Moisturizer	Step 4: Moisturizer
Step 5: Sunscreen	Step 5: Retinoid

penetration times and cross reactions, and skin type factors such as the condition of the skin barrier, sebum production, thickness of the stratum corneum, and sun exposure and bathing habits should be considered. Providing a printed regimen with step-by-step instructions for morning and night can be beneficial to patients.

If possible, explain to patients the basis for each product selection because this can greatly enhance patient compliance and, thus, outcomes. Training your staff to facilitate this is a key component in patient education. Preprinted, web-based, or automatically emailed educational newsletters or fact sheets can be utilized, particularly in a busy practice. This information helps keep patients engaged and educates them about new technologies and products that are appropriate for their skin type.

ENCOURAGE COMPLIANCE

A followup visit after 1 month is recommended to check on patient progress. Studies have shown that routine followup improves compliance. In addition, any side effects can be mitigated. For example, a prescribed retinoid may have induced irritation, prompting the patient to stop using it. An imaging system in the office also can be useful as baseline, and followup photos help illustrate progress and encourage vigilance and compliance. The importance of a followup visit should be emphasized at the initial appointment. Ideally, visits should be every month until the skin condition has improved or the ideal ORNT skin type has been achieved.

CONCLUSION

Dermatologists have the scientific background and knowledge of skin pathology to develop and prescribe efficacious skin-care regimens. However, the many product choices and time pressure in the dermatology clinic make this process difficult. When patients choose the wrong skin-care products, they may experience less efficacy with prescription medications, so there is value in dermatologists taking the time to review every product that the patient places on their skin. Keeping the staff up-to-date on the latest technologies and implementing these in a busy medical practice is challenging. A standardized and scientific methodology using a diagnostic system to classify skin types can be used to facilitate the patient skin-care regimen prescribing process. This methodology should be easy to implement and speed patient consult times rather than slow them. Taking time to train the staff and providing educational handouts for patients can streamline the process and make it more effective, resulting in improved patient outcomes. Incorporating staff training and patient education is mandatory to improve patient compliance. Using monthly followup appointments and analyses such as photography and instrumentation to show progress to patients keeps them interested and motivated to improve the health of their skin.

REFERENCES

1. http://www.ibisworld.com/industry/cosmeceutical-skincare-production.html. Accessed August 6, 2016.
2. http://www.freedoniagroup.com/Cosmeceuticals.html. Accessed August 6, 2016.
3. http://www.wdrb.com/story/32522329/surge-in-sales-of-physician-dispensed-cosmeceuticals-expected-as-demand-for-skincare-products-among-aged-people-rises-reports-tmr. Accessed August 6, 2016.
4. Chernosky ME. Clinical aspects of dry skin. *J Soc Cosmet Chem*. 1976;27:365-376.
5. Rawlings AV, Hope J, Rogers J, et al. Skin dryness—what is it? *J Invest Dermatol*. 1993;100:510.
6. Bouwstra JA, Dubbelaar FE, Gooris GS, et al. The lipid organization in the skin barrier. *Acta Derm Venereol Suppl (Stockh)*. 2000;208:23-30.
7. Wildnauer RH, Bothwell JW, Douglass AB. Stratum corneum biomechanical properties. I. Influence of relative humidity on normal and extracted human stratum corneum. *J Invest Dermatol*. 1971;56(1):72-78.
8. Orth D. Appa Y. Glycerine: a natural ingredient for moisturizing skin. In: Loden M, Maibach H, eds. *Dry Skin and Moisturizers*. Boca Raton, FL: CRC Press; 2000:214.
9. Ekholm IE, Brattsand M, Egelrud T. Stratum corneum tryptic enzyme in normal epidermis: a missing link in the desquamation process? *J Invest Dermatol*. 2000; 114(1):56-63.
10. Thiboutot D. Regulation of human sebaceous glands. *J Invest Dermatol*. 2004;123(1):1-12.
11. Clarys P, Barel A. Quantitative evaluation of skin surface lipids. *Clin Dermatol*. 1995;13(4):307-321.
12. Mathers WD, Lane JA. Meibomian gland lipids, evaporation, and tear film stability. *Adv Exp Med Biol*. 1998;438:349-360.
13. Tiffany JM. The role of meibomian secretion in the tears. *Trans Ophthalmol Soc UK*. 1985;104(pt 4):396-401.
14. Pochi PE, Strauss JS, Downing DT. Age-related changes in sebaceous gland activity. *J Invest Dermatol*. 1979;73(1):108-111.
15. Walton S, Wyatt EH, Cunliffe WJ. Genetic control of sebum excretion and acne—a twin study. *Br J Dermatol*. 1988;118(3):393-396.
16. Elias PM. The epidermal permeability barrier: from the early days at Harvard to emerging concepts. *J Invest Dermatol*. 2004;122(2):xxxvi-xxxix.
17. Scott IR, Harding CR. Filaggrin breakdown to water binding compounds during development of the rat stratum corneum is controlled by the water activity of the environment. *Dev Biol (Basel)*. 1986;115(1):84-92.
18. Sato J, Denda M, Chang S, et al. Abrupt decreases in environmental humidity induce abnormalities in permeability barrier homeostasis. *J Invest Dermatol*. 2002;119(4):900-904.
19. Gallo RL, Trowbridge J. Proteoglycans and glycosaminoglycans of skin. In: Freedberg IM, Eisen AZ, Wolff K, et al, eds. *Fitzpatrick's Dermatology in General Medicine*. 6th ed. New York, NY: McGraw-Hill; 2003:210-216.
20. Lee DH, Oh JH, Chung JH. Glycosaminoglycan and proteoglycan in skin aging. *J Dermatol Sci*. 2016;83(3): 174-181.

21. Tammi R, Säämänen AM, Maibach HI, et al. Degradation of newly synthesized high molecular mass hyaluronan in the epidermal and dermal compartments of human skin in organ culture. *J Invest Dermatol*. 1991;97(1):126-130.
22. Sakai S, Yasuda R, Sayo T, et al. Hyaluronan exists in the normal stratum corneum. *J Invest Dermatol*. 2000;114(6):1184-1187.
23. Brown TJ, Alcorn D, Fraser JR. Absorption of hyaluronan applied to the surface of intact skin. *J Invest Dermatol*. 1999;113(5):740-746.
24. Rieger M. Hyaluronic acid in cosmetics. *Cosm Toil*. 1998;113(3):35-42.
25. Brown MB, Jones SA. Hyaluronic acid: a unique topical vehicle for the localized delivery of drugs to the skin. *J Eur Acad Dermatol Venereol*. 2005;19(3):308-318.
26. Baumann L. Skin ageing and its treatment. *J Pathol*. 2007;211(2):241-251.
27. Murad H, Tabibian MP. The effect of an oral supplement containing glucosamine, amino acids, minerals, and antioxidants on cutaneous aging: a preliminary study. *J Dermatolog Treat*. 2001;12(1):47-51.
28. Maquart F-X, Brézillon S, Wegrowski Y. Proteoglycans in skin aging. In: Farage MA, Miller KW, Maibach HI, eds. *Textbook of Aging Skin*. Berlin: Springer-Verlag; 2010:109.
29. Gallo RL, Bucay VW, Shamban AT, et al. The potential role of topically applied heparin sulfate in the treatment of photodamage. *J Drugs Dermatol*. 2015;14(7):669-674.
30. Sougrat R, Morand M, Gondran C, et al. Functional expression of AQP3 in human skin epidermis and reconstructed epidermis. *J Invest Dermatol*. 2002; 118(4):678-685.
31. Takenouchi M, Suzuki H, Tagami H. Hydration characteristics of pathologic stratum corneum—evaluation of bound water. *J Invest Dermatol*. 1986;87(5):574-576.
32. Warner RR, Bush RD, Ruebusch NA. Corneocytes undergo systematic changes in element concentrations across the human inner stratum corneum. *J Invest Dermatol*. 1995;104(4):530-536.
33. Warner RR, Myers MC, Taylor DA. Electron probe analysis of human skin: element concentration profiles. *J Invest Dermatol*. 1988;90(1):78-85.
34. Ma T, Hara M, Sougrat R, et al. Impaired stratum corneum hydration in mice lacking epidermal water channel aquaporin-3. *J Biol Chem*. 2002;277(19):17147-17153.
35. Yang B, Verkman AS. Water and glycerol permeabilities of aquaporins 1-5 and MIP determined quantitatively by expression of epitope-tagged constructs in Xenopus oocytes. *J Biol Chem*. 1997;272(26):16140-16146.
36. Dumas M, Gondran C, Barre P, et al. Effect of an *Ajuga turkestanica* extract on aquaporin 3 expression, water flux, differentiation and barrier parameters of the human epidermis. *Eur J Dermatol*. 2002;12(6):XXV-XXVI.
37. Hara M, Verkman AS. Glycerol replacement corrects defective skin hydration, elasticity, and barrier function in aquaporin-3-deficient mice. *Proc Natl Acad Sci U S A*. 2003;100(12):7360-7365.
38. Naik A, Pechtold LARM, Potts RO, et al. Mechanism of oleic acid-induced skin penetration enhancement in vivo in humans. *J Control Release*. 1995;37(3):299-306.
39. Kim TH, Choi EH, Kang YC, et al. The effects of topical alpha-hydroxyacids on the normal skin barrier of hairless mice. *Br J Dermatol*. 2001;144(2):267-273.
40. Zettersten EM, Ghadially R, Feingold KR, et al. Optimal ratios of topical stratum corneum lipids improve barrier recovery in chronologically aged skin. *J Am Acad Dermatol*. 1997;37(3, pt 1):403-408.
41. Park BD, Youm JK, Jeong SK, et al. The characterization of molecular organization of multilamellar emulsions containing pseudoceramide and type III synthetic ceramide. *J Invest Dermatol*. 2003;121(4):794-801.
42. Lodén M, Bárány E. Skin-identical lipids versus petrolatum in the treatment of tape-stripped and detergent-perturbed human skin. *Acta Derm Venereol* 2000;80(6):412-415.
43. Draelos Z. Moisturizers. *Atlas of Cosmetic Dermatology*. New York, NY: Churchill Livingstone; 2000:85.
44. Spruit D. The interference of some substances with the water vapour loss of human skin. *Dermatologica*. 1971;142(2):89-92.
45. Draelos Z. Moisturizers. *Atlas of Cosmetic Dermatology*. New York, NY: Churchill Livingstone; 2000:83.
46. Wehr RF, Krochmal L. Considerations in selecting a moisturizer. *Cutis*. 1987;39(6):512-515.
47. Idson B. Dry skin: moisturizing and emolliency. *Cosmet Toiletr*. 1992;107:69.
48. Fluhr JW, Gloor M, Lehmann L, et al. Glycerol accelerates recovery of barrier function in vivo. *Acta Derm Venereol*. 1999;79(6):418-421.
49. De Pedrini P, Rapisarda R, Spano G. The effect of ketoconazole on sebum secretion in patients suffering from acne and seborrhoea. *Int J Tissue React*. 1988; 10(2):111-113.
50. Goodfellow A, Alaghband-Zadeh J, Carter G, et al. Oral spironolactone improves acne vulgaris and reduces sebum excretion. *Br J Dermatol*. 1984;111(2): 209-214.
51. Goldstein JA, Socha-Szott A, Thomsen RJ, et al. Comparative effect of isotretinoin and etretinate on acne and sebaceous gland secretion. *J Am Acad Dermatol*. 1982;6(4, pt 2, suppl):760-765.
52. Rose AE, Goldberg DJ. Safety and efficacy of intradermal injection of botulinum toxin for the treatment of oily skin. *Dermatol Surg*. 2013;39(3, pt 1):443-448.
53. Baumann L. Understanding and treating various skin types: the Baumann Skin Type Indicator. *Dermatol Clin*. 2008:26(3):359-373.
54. Baumann L. Anti-inflammatory agents. In: Baumann L, ed. *Cosmeceuticals and Cosmetic Ingredients*. New York, NY: McGraw-Hill; 2015:227-228.
55. Feldman SR, Camacho FT, Krejci-Manwaring J, et al. Adherence to topical therapy increases around the time of office visits. *J Am Acad Dermatol*. 2007;57(1): 81-83.
56. Basketter DA, Griffiths HA. A study of the relationship between susceptibility to skin stinging and skin irritation. *Contact Dermatitis*. 1993;29(4):185-188.
57. Fisher AA. "Status cosmeticus": a cosmetic intolerance syndrome. *Cutis*. 1990;46(2):109-110.
58. Amin S, Maibach HI. Immunologic contact urticaria definition. In: Amin S, Lahti A, Maibach HI, eds. *Contact Urticaria Syndrome*. Boca Raton, FL: CRC Press; 1997:11.
59. Jovanovic M, Poljacki M, Duran V, et al. Contact allergy to Compositae plants in patients with atopic dermatitis. *Med Pregl*. 2004;57(5-6):209-218.
60. Orton DI, Wilkinson JD. Cosmetic allergy: incidence, diagnosis, and management. *Am J Clin Dermatol*. 2004;5(5):327-337.
61. Chularojanamontri L, Tuchinda P, Kulthanan K, et al. Moisturizers for acne: what are their constituents? *J Clin Aesthet Dermatol*. 2014;7(5):36-44.
62. Piwnica D, Rosignoli C, de Ménonville ST, et al. Vasoconstriction and anti-inflammatory properties of the selective α-adrenergic receptor agonist brimonidine. *J Dermatol Sci*. 2014;75(1):49-54.

63. Tuettenberg A, Koelsch S, Knop J, et al. Oxymetazoline modulates proinflammatory cytokines and the T-cell stimulatory capacity of dendritic cells. *Exp Dermatol* 2007;16(3):171-178.
64. Freedberg IM, Eisen AZ, Wolff K, et al, eds. *Fitzpatrick's Dermatology in General Medicine*. 5th ed. New York, NY: McGraw-Hill; 1999:996.
65. Woolery-Lloyd H, Kammer JN. Treatment of hyperpigmentation. *Semin Cutan Med Surg*. 2011;30(3):171-175.
66. Sofen B, Prado G, Emer J. Melasma and post inflammatory hyperpigmentation: management update and expert opinion. *Skin Ther Lett*. 2016;21(1):1-7.
67. Levitt J. The safety of hydroquinone: a dermatologist's response to the 2006 Federal Register. *J Am Acad Dermatol*. 2007;57(5):854-872.
68. Paine C, Sharlow E, Liebel F, et al. An alternative approach to depigmentation by soybean extracts via inhibition of the PAR-2 pathway. *J Invest Dermatol*. 2001;116(4):587-595.
69. Hakozaki T, Minwalla L, Zhuang J, et al. The effect of niacinamide on reducing cutaneous pigmentation and suppression of melanosome transfer. *Br J Dermatol*. 2002;147(1):20-31.
70. Baumann L. Lignin peroxidase. In: Baumann L, ed. *Cosmeceuticals and Cosmetic Ingredients*. New York, NY: McGraw-Hill; 2015:123-124.
71. Woo S, Cho J, Lee B, et al. Decolorization of melanin by lignin peroxidase from *Phanerochaete chrysosporium*. *Biotechnol Bioprocess Eng*. 2004;9:256-260.
72. Cui R, Widlund HR, Feige E, et al. Central role of p53 in the suntan response and pathologic hyperpigmentation. *Cell*. 2007;128(5):853-864.
73. Oresajo C, Stephens T, Hino PD, et al. Protective effects of a topical antioxidant mixture containing vitamin C, ferulic acid, and phloretin against ultraviolet-induced photodamage in human skin. *J Cosmet Dermatol*. 2008;7(4):290-297.
74. Baumann L. Overview of aging. In: Baumann L, ed. *Cosmeceuticals and Cosmetic Ingredients*. New York, NY: McGraw-Hill; 2015:317-321.
75. Baumann L. How to prevent photoaging? *J Invest Dermatol*. 2005;125(4):xii-xiii.
76. Kosmadaki MG, Gilchrest BA. The role of telomeres in skin aging/photoaging. *Micron*. 2004;35(3):155-159.
77. Marrot L, Belaïdi JP, Meunier JR. Importance of UVA photoprotection as shown by genotoxic related endpoints: DNA damage and p53 status. *Mutat Res*. 2005;571(1-2):175-184.
78. Pinnell SR, Yang H, Omar M, et al. Topical L-ascorbic acid: percutaneous absorption studies. *Dermatol Surg*. 2001;27(2):137-142.
79. Ananthapadmanabhan KP, Moore DJ, Subramanyan K, et al. Cleansing without compromise: the impact of cleansers on the skin barrier and the technology of mild cleansing. *Dermatol Ther (Heidelb)*. 2004; 17(suppl 1):16-25.
80. Varani J, Warner RL, Gharaee-Kermani M, et al. Vitamin A antagonizes decreased cell growth and elevated collagen-degrading matrix metalloproteinases and stimulates collagen accumulation in naturally aged human skin. *J Invest Dermatol*. 2000;114(3):480-486.
81. Margelin D, Medaisko C, Lombard D, et al. Hyaluronic acid and dermatan sulfate are selectively stimulated by retinoic acid in irradiated and nonirradiated hairless mouse skin. *J Invest Dermatol*. 1996;106(3):505-509.
82. Weiss JS, Ellis CN, Headington JT, et al. Topical tretinoin improves photoaged skin. A double-blind vehicle-controlled study. *JAMA*. 1988;259(4):527-532.
83. Kafi R, Kwak HS, Schumacher WE, et al. Improvement of naturally aged skin with vitamin A (retinol). *Arch Dermatol*. 2007;143(5):606-612.
84. Cho S, Lowe L, Hamilton TA, et al. Long-term treatment of photoaged human skin with topical retinoic acid improves epidermal cell atypia and thickens the collagen band in papillary dermis. *J Am Acad Dermatol*. 2005;53(5):769-774.
85. Baumann L. Antioxidants. In: Baumann L, ed. *Cosmeceuticals and Cosmetic Ingredients*. New York, NY: McGraw-Hill; 2015:135-136.
86. Fisher GJ, Talwar TS, Lin JY, et al. Retinoic acid inhibits induction of c-Jun protein by ultraviolet irradiation that occurs subsequent to activation of mitogen-activated protein kinase pathways in human skin in vivo. *J Clin Invest*. 1998;101(6):1432-1440.
87. Kang S, Chung JH, Lee JH, et al. Topical *N*-acetyl cysteine and genistein prevent ultraviolet-light-induced signaling that leads to photoaging in human skin in vivo. *J Invest Dermatol*. 2003;120(5):835-841.
88. Nusgens BV, Humbert P, Rougier A, et al. Topically applied vitamin C enhances the mRNA level of collagens I and III, their processing enzymes and tissue inhibitor of matrix metalloproteinase 1 in the human dermis. *J Invest Dermatol*. 2001;116(6):853-859.
89. Ditre CM, Griffin TD, Murphy GF, et al. Effects of alpha-hydroxy acids on photoaged skin: a pilot clinical, histologic, and ultrastructural study. *J Am Acad Dermatol*. 1996;34(2, pt 1):187-195.
90. Lin JY, Selim MA, Shea CR, et al. UV photoprotection by combination topical antioxidants vitamin C and vitamin E. *J Am Acad Dermatol*. 2003;48(6):866-874.
91. Baumann L. Cosmetics and skin care in dermatology. In: Wolff K, ed. *Fitzpatrick's Dermatology in General Medicine*. 7th ed. New York, NY: McGraw-Hill; 2008: 2357-2364.
92. Baumann L. The Baumann skin typing system. In: Farage MA, Miller KW, Maibach HI, eds. *Textbook of Aging Skin*. Berlin, Germany: Springer-Verlag; 2010: 929-944.
93. Baumann L. The importance of skin type: the Baumann skin type system. In: Baumann L, ed. *Cosmeceuticals and Cosmetic Ingredients*. New York, NY: McGraw-Hill; 2015:1-4.
94. Baumann L, Penfield R, Clarke J, et al. A validated questionnaire for quantifying skin oiliness. *J Cosmet Dermatol Sci Appl*. 2014;4(2):78-84.
95. Baumann L. Validation of a questionnaire to diagnose the Baumann skin type in all ethnicities and in various geographic locations. *J Cosmet Dermatol Sci Appl*. 2016;6(1):34-40.
96. Baumann L. *The Skin Type Solution*. New York, NY: Bantam Dell; 2006.

Chapter 208 :: Fundamentals of Laser and Light-Based Treatments

:: Omer Ibrahim & Jeffrey S. Dover

AT-A-GLANCE

- Lasers and flashlamps harness the power of light to precisely treat a myriad of cutaneous disorders and conditions.
- Laser light is monochromatic, coherent, and collimated; whereas, intense pulsed light (IPL) is polychromatic, broadband, and divergent.
- Upon light's impact with skin, several tissue interactions occur including reflection, transmission, scattering, and absorption.
- Laser parameters such as fluence, pulse duration, wavelength, and spot size can be adjusted to safely deliver energy to the skin to achieve desired therapeutic effects.
- In general, within the visible spectrum longer-wavelength light penetrates more deeply.
- Laser and light delivered though a larger spot size penetrates more deeply into tissue and is scattered less than with smaller spot sizes.
- Selective photothermolysis allows lasers and light sources to target specific chromophores in the skin to achieve certain effects while minimizing injury to surrounding structures.
- Fractional photothermolysis creates evenly distributed zones of microthermal injury in skin to produce columns of injury in the epidermis and dermis, leaving intervening columns of unaltered skin, thereby decreasing healing time and minimizing adverse effects.
- Knowledge of the potentially hazardous effects of lasers and flashlamps, and implementation of safety measures, are essential to maintain a safe environment for the practitioner, staff, and patient.

INTRODUCTION

Light is a fundamental form of energy that is harnessed in the form of lasers and pulsed light sources that has countless applications in modern medicine. In 1900, Max Planck described that light is released, transferred, and absorbed in specific amounts of energy called quanta.[1] In 1917, Einstein published "The Quantum Theory of Radiation" in which he suggested that most atoms exist in a ground-energy state, and upon absorbing energy are converted to higher energy levels. When these excited atoms return to their ground state, they release energy as photons or electromagnetic waves. Einstein also discovered that when a photon of a specific wavelength collides with an excited atom, 2 photons are released concurrently with equal frequencies, a phenomenon otherwise known as "stimulated emission."[2,3]

Laser is an acronym for *light amplification by the stimulated emission of radiation*. Theodore Maiman created the first laser in 1960 by using an energy source to energize solid ruby crystals.[4] Since this seminal discovery, the variety and applications of lasers in medicine has expanded dramatically over the ensuing decades. Because of its accessibility, the skin was the object of many of the early experiments that sought to harness this powerful modality, and as a result over the years lasers have revolutionized the treatment of numerous cutaneous disorders.

LASER PRINCIPLES

In its simplest form, a laser device creates energy in the form of a beam of light that interacts with its target tissue. Light and other forms of electromagnetic radiation are composed of photons that travel at a constant velocity, or speed of light (c = 2.998 × 10^8 m/s) in a vacuum.[5] The major properties of radiation are wavelength λ and frequency ν, which are correlated: $c = \lambda \cdot \nu$. The energy of a photon is proportional to its frequency, such that the energy of radiation increases with increasing frequency (and decreasing wavelength). Visible light represents a relatively small portion of the electromagnetic spectrum, ranging from 390 nm (violet) to 700 nm (red), and can be seen by the human eye.[5] Most lasers used in dermatology fall within the visible-light range and the near infrared spectrum (Table 208-1).

Natural light and spontaneously emitted light such as that from a light bulb are created as a result of excited atoms that emit photons at different times, in any direction and usually with different wavelengths. This electromagnetic radiation is incoherent, divergent and spectrally broadband. In contrast, lasers are fundamentally different. All laser devices are composed of an energy source and an optical resonator. The energy source is what is used to bring atoms and electrons to an excited energy state, and can take the form of an electrical current, flashlamp, or even another laser.[6] The resonator is composed of a medium enclosed within a tube that contains 2 parallel mirrors, one of which is completely opaque and the other is partially transmissible. The medium can be a solid, liquid, liquid crystal, or gas. The medium determines the resultant wavelength and properties of the laser. The energy source drives the electrons in the medium to an excited

TABLE 208-1
Commonly Used Dermatologic Lasers

LASER	WAVELENGTH	TARGET	EFFECT IN TARGET	MODE (PULSE DURATION)	APPLICATIONS
Excimer	308 nm	DNA, proteins	Photochemical reactions	Pulsed (μs)	Comparable to narrow-band UVB[311]
Argon	488/514 nm	Vascular lesions	Semiselective coagulation	Pulsed (ms)	Telangiectases, spider nevi, venous lakes
		Tissue	Coagulation		Syringoma, xanthelasma, epidermal nevi
Frequency-doubled Nd:YAG (KTP)	532 nm	Vascular lesions	Selective coagulation	Pulsed (ms)	Telangiectases, spider nevi, venous lakes
Frequency doubled Nd:YAG	532 nm	Pigmented lesions and tattoos	Selective and fast heating (explosion)	Pulsed (ns, ps)	Ephelides, lentigines, tattoos (red)
Flashlamp pumped pulsed dye	585-600 nm	Vascular lesions	Selective coagulation	Pulsed (ms)	Port-wine stains, telangiectases, rosacea, spider nevi
		Tissue			Scars, keloids, warts, photoaging
Ruby	694 nm	Pigmented lesions and tattoos	Selective and fast heating (explosion)	Pulsed (ns, ps)	Benign melanin-containing lesions, tattoos (black, blue, green), dermal melanocytoses
Alexandrite	755 nm	Vascular lesions	Selective coagulation	Pulsed (ms)	Large vessels (leg veins, hypertrophic port-wine stains)
		Tissue			Hair removal
		Pigmented lesions and tattoos	Selective and fast heating (explosion)	Pulsed (ns, ps)	Benign melanin-containing lesions, tattoos (black, blue, green) Dermal melanocytoses
Diode	810 nm	Vascular lesions	Selective coagulation	Pulsed (ms)	Large vessels (leg veins, hypertrophic port-wine stains)
		Tissue			Hair removal
Nd:YAG	1064 nm	Vascular lesions	Unspecific coagulation	Continuous wave (cw)	Vascular malformations, tumors
		Vascular lesions	Selective coagulation	Pulsed (ms)	Large vessels (leg veins, hypertrophic port-wine stains)
		Tissue			Hair removal
		Pigmented lesions	Selective and fast heating (explosion)	Pulsed (ns, ps)	Benign melanin-containing lesions, tattoos (black, blue, green), dermal melanocytoses
Erbium glass	1540 nm	Tissue	Selective coagulation (nonablative)	Pulsed (ms)	Skin remodeling, photoaging
Diode	1450-1550 nm	Tissue	Selective coagulation	Pulsed (ms)	Skin remodeling, photoaging
Thulium	1927 nm	Tissue	Selective coagulation (nonablative)	Pulsed (ms)	Skin remodeling, photoaging
Er:YAG	2940 nm	Tissue	Selective and fast heating (ablation)	Pulsed (ms)	Skin resurfacing, epidermal ablation
CO_2	10,600 nm	Tissue	Nonspecific coagulation (vaporization)	Continuous wave (cw)	Vaporization of tissue
			Selective and fast heating ablation	Pulsed (ms)	Skin resurfacing, epidermal ablation

CO_2, carbon dioxide; Er:YAG, erbium-doped yttrium aluminum garnet; KTP, potassium titanyl phosphate; Nd:YAG, neodymium-doped yttrium aluminum garnet; UVB, ultraviolet B.

state. After excitation, or "pumping," the atoms or molecules return from the excited to the ground state and thereby emit photons with a specific wavelength λ_L that is determined by the energy difference ΔE of the excited and the ground state with

$$\Delta E = hc/\lambda_L$$

The combination of such identical transitions and photons with the same wavelength λ_L in a confined volume (laser medium) allows another process to occur: the stimulated emission of photons, as described by Albert Einstein[2] (Fig. 208-1). If an electron in an excited state encounters another photon of the same energy, it releases another photon of the same wavelength (Fig. 208-2). Therefore, one photon stimulates the next atom or molecule to emit a photon. The resulting 2 photons stimulate the next 2 atoms or molecules, and that results in 4 photons and so on. The photons move back and forth between the parallel mirrors, colliding with and exciting other atoms in the process. This chain reaction does not change the energy of photons but increases their number exponentially. Once the number of excited atoms outweighs the number of atoms in the ground state, this is referred to as inversion. Ultimately, the photons that are traveling in a perfectly parallel direction exit the resonator through the partially transmissible mirror at the distal end of the resonator as a laser beam (Fig. 208-3).

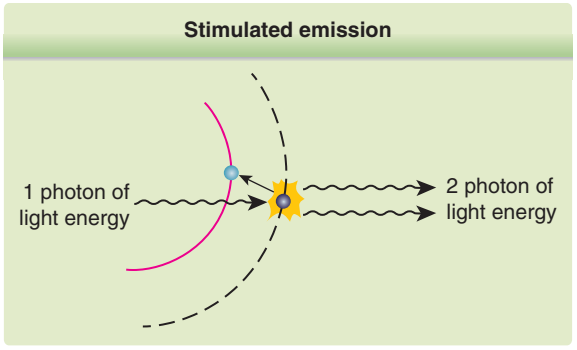

Figure 208-2 When an excited atom collides with a photon of light of the same wavelength that it has previously absorbed, it returns to its resting state and emits 2 photons of light energy of the same wavelength traveling coherently and in parallel direction. This is referred to as stimulated emission. (Used with permission from Dover JS, Arndt KA. *Illustrated Cutaneous Laser Surgery: A Practitioner's Guide*. Norwalk, CT: Appleton & Lange; 1990. Copyright © McGraw-Hill Education.)

The resulting beam possesses a number of unique traits that distinguishes it from natural or incandescent light; lasers emit light that is monochromatic, coherent, and collimated (Fig. 208-4).[5] The monochromatic nature of laser describes its temporal coherence: laser light is composed of a single wavelength, as opposed to natural

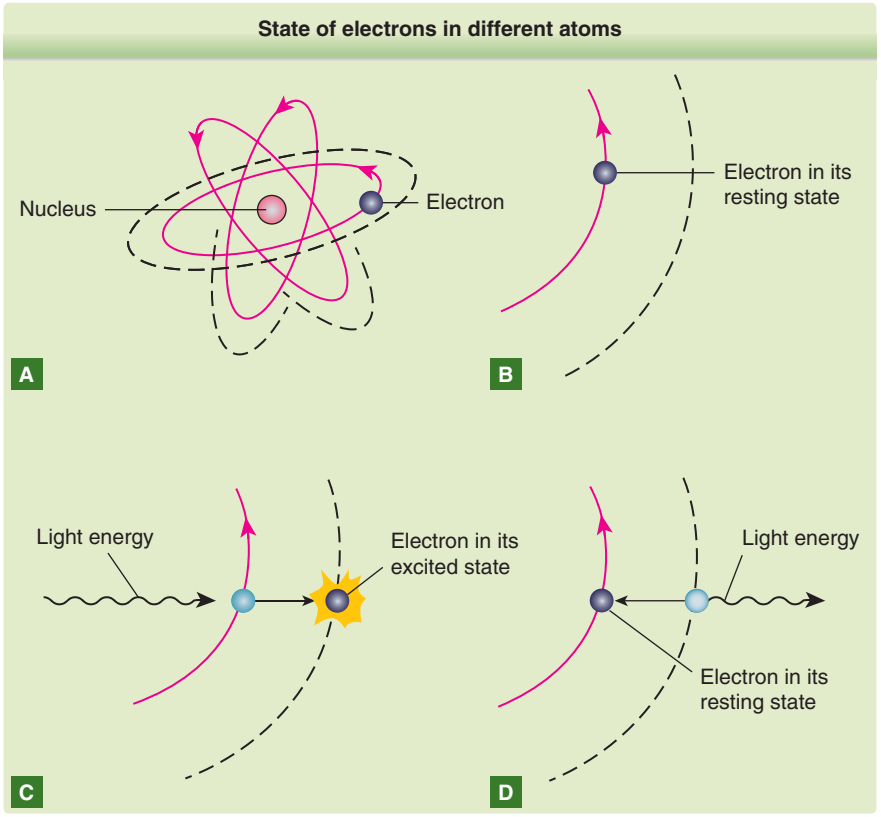

Figure 208-1 **A, B,** A diagram of an atom with its electron in its resting state. **C,** Upon absorption of light energy, the atom's electron transitions from its resting state to its excited state. **D,** When the electron returns to its resting state, energy is released as electromagnetic radiation (light), a process otherwise referred to as spontaneous emission. (Used with permission from Dover JS, Arndt KA. *Illustrated Cutaneous Laser Surgery: A Practitioner's Guide*. Norwalk, CT: Appleton & Lange; 1990. Copyright © McGraw-Hill Education.)

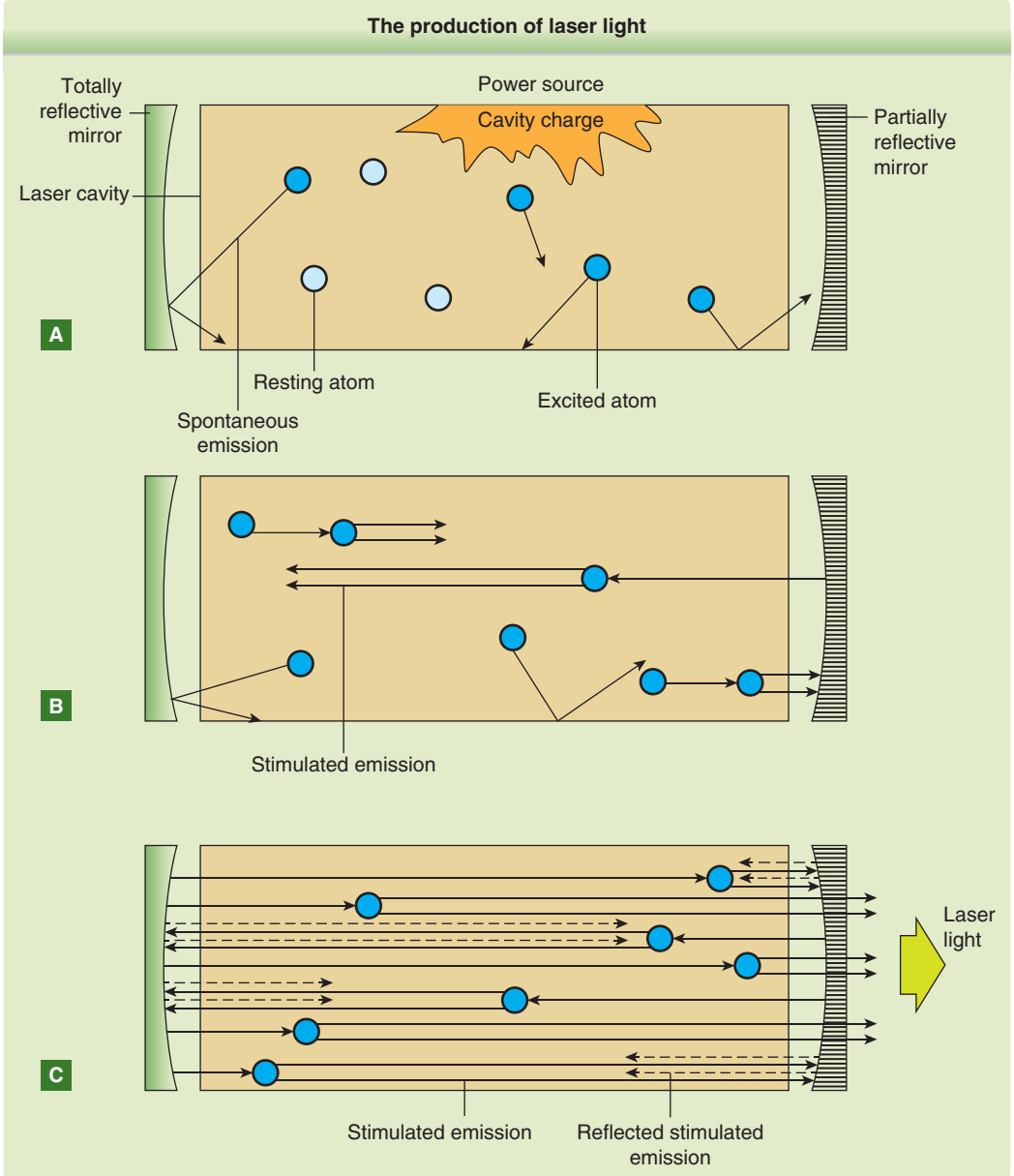

Figure 208-3 The production of laser light: **A,** The charge in the cavity pumps the electrons to an excited state. **B,** Emitted photons of light energy collide with excited atoms and produce stimulated emission. **C,** The light reflects back and forth within the cavity, promoting further stimulated emission and amplifying the process. Finally, a small portion of the laser light passes through the partially transmissible mirror as a laser beam. (Used with permission from Dover JS, Arndt KA. *Illustrated Cutaneous Laser Surgery: A Practitioner's Guide*. Norwalk, CT: Appleton & Lange; 1990. Copyright © McGraw-Hill Education.)

or incandescent light that emits light across the entire visible spectrum. This property of laser light is important therapeutically as it allows for the selective absorption of the laser by specific chromophores (light-absorbing compounds). Laser light is also coherent, in that the waves are in phase in space and time. The crests and troughs of the light wave are synchronous and therefore the laser beam exhibits minimal divergence, allowing the beam to travel larger distances without substantial loss of intensity. Finally, laser light is collimated, in that all the photons are parallel to each other. Collimation not only allows the light to travel long distances with minimal distortion and dispersion, but also allows the dense packing of energy into a relatively small volume of light.

The temporal behavior of the laser emission depends on the temporal behavior of the excitation of the atoms or molecules. That is, when the energy supply to the laser medium is continuous, the emission of the laser is considered continuous-wave emission. Continuous-wave lasers produce a continuous beam of laser light with little or no variation in power output over time. Shutters may be opened or closed to either permit or obstruct the laser beam from exiting the device. Shutters can be set to open for a few milliseconds to several seconds, depending on the treatment goal.

When the energy supply of the laser is limited to a certain time interval by gas discharge or flashlamp, this is referred to as pulsed excitation, and the laser

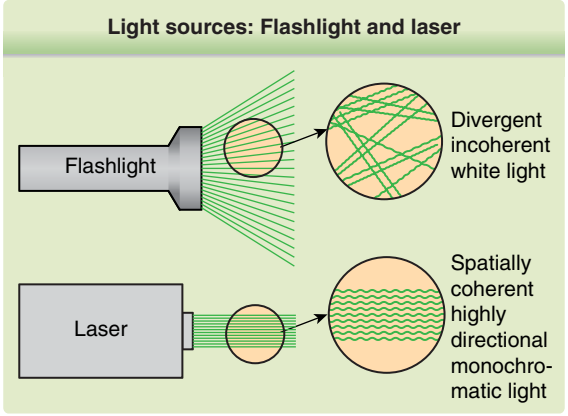

Figure 208-4 An ordinary light source such as a flashlight produces light that is divergent, coherent, and polychromatic (above), whereas a laser emits light that is spatially collimated, coherent, and monochromatic. (Used with permission from Dover JS, Arndt KA. *Illustrated Cutaneous Laser Surgery: A Practitioner's Guide*. Norwalk, CT: Appleton & Lange; 1990. Copyright © McGraw-Hill Education.)

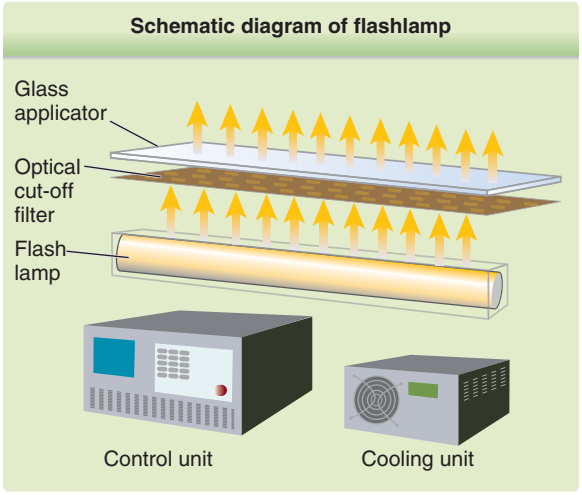

Figure 208-5 The flashlamp of intense pulsed light (IPL) emits radiation that is filtered by a cut-off filter. The control unit operates radiant exposure and pulse duration.

emits pulses accordingly. These laser pulse durations can vary from microseconds to milliseconds, and the energy within the pulse of a pulsed beam is not constant; it builds, peaks, and then tapers within a very short time. The peak power outputs of pulsed lasers are often greater than the maximum output of continuous-wave lasers by up to 100-fold.

To achieve very short pulse durations in the nanosecond or picosecond range, the resonator is additionally equipped with an optical polarizer and a nonlinear crystal. The polarizer sets the linear polarization of the laser beam that passes through the crystal. However, if an appropriate electrical voltage is applied to the crystal, the polarization of the photons is changed inside the crystal and subsequently blocked by the optical polarizer. This prevents photons from running back and forth inside the resonator (oscillation), which hampers light amplification and which is equivalent to a low circuit quality of the resonator. In such a case, the stimulated emission is minimized and the pumping of the laser medium produces a maximum number of excited atoms or molecules in the laser medium. When this maximum number is achieved, the electrical voltage of the crystal is switched off within nanoseconds and the photons can easily pass the crystal, which is equivalent to a high circuit quality of the resonator. Now, the laser oscillation immediately starts and the light amplification yields a very high number of photons per time unit because of the high number of excited atoms or molecules in the laser medium. The outcome of this circuit quality switch (Q-switch) is a very intense laser pulse with pulse durations in the range of nanoseconds to picoseconds.

INTENSE PULSED LIGHT PRINCIPLES

Intense pulsed light (IPL) devices are not lasers, but rather contain a flashlamp that produces noncoherent light of a broad spectrum of wavelengths that can be tuned and set to different wavelengths, fluences, and pulse durations.[7] IPL technology delivers noncoherent light from about 420 nm to the far-infrared spectrum around 1200 nm (Fig. 208-5). Different cutoff filters and separate handpieces are used to "tune" the broad spectrum of light to certain desired wavelengths to target specific chromophores and to tailor the treatment to specific skin types. The filter cuts off emitted light, allowing only wavelengths longer than a certain threshold value to pass through. For example, a 560-nm filter is used to treat vascular lesions, allowing wavelengths longer than 560 nm to pass through, corresponding to the vascular absorption peak of 585 to 595 nm.[7] Longer-wavelength cutoff filters may be used to treat pigment in darker individuals. In addition, adjustments of the fluence, pulse duration, and cooling system can be made on the device to optimize treatment.

BASIC PARAMETERS OF OPTICAL RADIATION

The main parameters of optical radiation are wavelength, optical power, intensity, the exposure time and radiant exposure or fluence. The unit for energy is Joule (J); optical power Watt (W); intensity (W/cm^2); radiant exposure (J/cm^2); the exposure time second (s); and the area of irradiation on the skin surface (cm^2). After being transported through a glass fiber or articulated arm, laser radiation is usually applied as a circular spot to the skin surface by means of a lens in a holder. The spot size and the energy of the laser beam determine the radiant exposure (J/cm^2). The IPL applicator directly contacts the skin through an ultrasonic gel. Thus, the radiant exposure of IPL emission is determined by the size of the applicator and the energy of radiation (J/cm^2).

To achieve various therapeutic objectives, exposure times ranging from picoseconds to seconds are employed. Continuous wave lasers use exposure times

in the range of fractions of a second to seconds, correlating to the length of time the switch is activated. In most medical treatments, individual laser or light pulses are used. The exposure time is predefined by the pulse duration of a single laser or IPL pulse. In the case of pulsed radiation, the exposure time is equivalent either to a single pulse or to a train of single pulses. The broad range of pulse durations implies a broad range of intensities and applications.

The most frequently modified parameter in laser treatments is the radiant exposure or fluence. It is the product of light intensity and exposure time. When taking the total range of medical treatments into account, the radiant exposure varies from about 1 to 400 J/cm^2 for pulsed radiation. This range can be exceeded for continuous-wave applications.

LASER ENERGY DELIVERY

ARTICULATED ARMS

The delivery of laser energy from the optical resonator to the tissue is accomplished through several methods. First, the incorporation of articulated arms into laser systems have facilitated the delivery of energy from the laser cavity to the desired location. Energy is transferred through a series of hollow, interconnected tubes with reflecting mirrors at each connection.[8] Each mirror reflects the desired wavelength of laser such that collimation and coherence are preserved. The energy beam is then focused through a lens in the attached handpiece. Although more recently designed lasers have articulated arms that are less bulky and rigid, the arms can still be cumbersome and difficult to navigate through extremely flexible and spatially constrained situations. Despite their inherent rigidity, articulated arms remain the mainstay in CO_2 lasers, as CO_2 cannot be transmitted through fiber optics.[8]

FIBER OPTICS

Fiber optics are fine flexible fibers most commonly composed of quartz that also have revolutionized the transmission of laser energy to tissue. Most visible and some invisible continuous-wave laser light can be transmitted through fiber optics. Unlike articulated arms, fiber optics fibers are flexible, but also associated with some loss of energy and coherence, thereby limiting the ability to focus the beam.[8] In addition, fiber optic extensions require extra care and precaution as overstretching the handpiece away from the laser console may result in fiber breakage and further loss of energy and coherence.

MICROMANIPULATORS

Micromanipulators can be used to couple articulated arms and fiber optics through a microscope, allowing precise movement of the laser across tissue. This technology is mainly used by gynecologists to treat cervical lesions and by otolaryngologists for laryngeal and inner ear surgery.

FIBER LASERS

Fiber laser technology is the latest advent in laser engineering that has paved the way for more precise, highly reliable, and highly flexible lasing capabilities.[9-12] As discussed, in the traditional design of a laser, stimulated emission and laser beam generation occur within the resonator, and the articulated arm or fiber optic tube transmits the beam to the handpiece. Depending on the system, the beam may undergo loss of energy and coherence. In contrast, fiber lasers have harnessed the ability to generate a highly efficient and highly precise laser beam within the transmitting fiber tube itself. Fiber lasers are composed of glass tubes doped with rare-earth elements such as erbium (1550 nm) or thulium (1927 nm). A power source, most commonly a diode, provides the initial pumping of atoms within the cavity. The photons then travel through the metal-doped tube eventually coalescing into a monochromatic, coherent, and collimated beam of energy once they reach the distal handpiece.[9-12] Fiber lasers can be relatively compact and adaptable as a result of the bendability and flexibility of their fibers, and they can provide highly reliable, highly precise, efficient outputs of energy.

LASER–TISSUE INTERACTIONS

When laser light reaches tissue a number of different responses may occur. The light beam may undergo reflection, transmission, absorption, and scatter (Fig. 208-6).[8] The fundamental effect of the laser light depends on the absorption of the light beam. Absorption is described as the conversion of laser energy to heat when its photons strike the target chromophore. Reflection occurs when the laser beam strikes the surface at an oblique angle and a portion of the beam bounces off the surface in a different direction. Because of the inherent reflective property of the stratum corneum, even laser beams perfectly perpendicular to the skin undergo about 5% reflectance.[5] Reflection of the beam, even with perfect operator technique, necessitates the use of safety goggles. Scattering of laser occurs when the light passes through the stratum corneum, but deviates once in the tissue due to contact with small molecules in the skin. This process is more likely to occur with shorter wavelengths. The size of the scattering objects ranges from a few nanometers (small cell organelles, cell membranes) to a few microns (large cell organelles, cells, collagen fibers) to hundreds of microns (hair follicle, sweat glands). Scattering of the beam changes the focus of the laser and increases the spatial distribution of the light within tissue, thereby increasing the effective irradiated area.

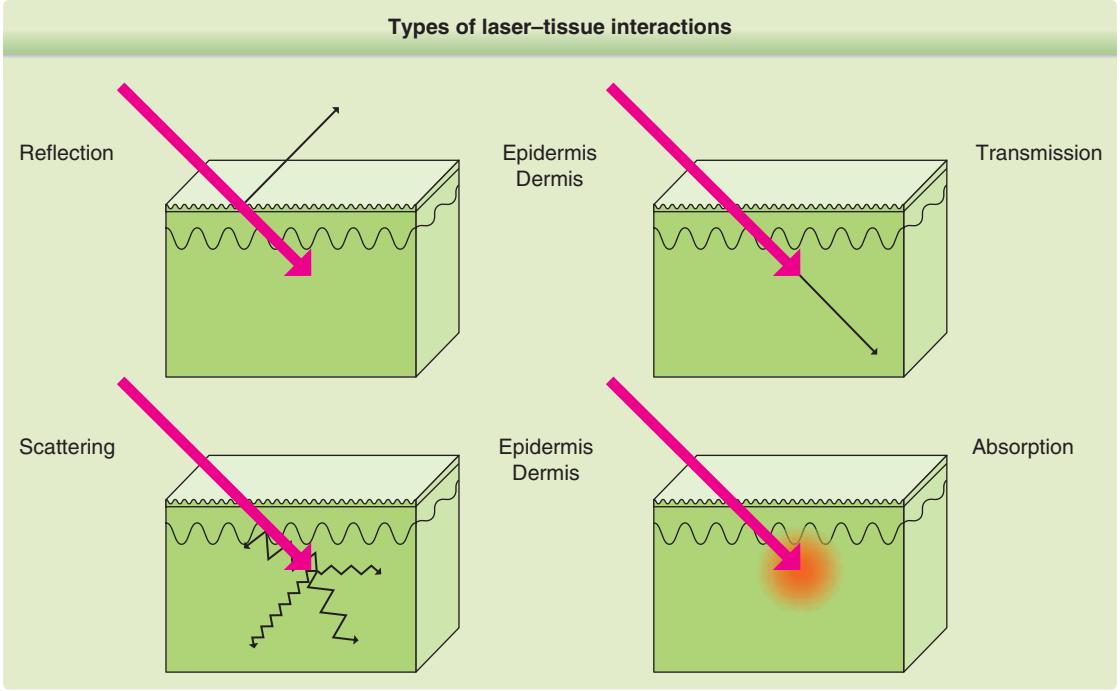

Figure 208-6 Types of laser–tissue interactions: Reflection, transmission, scattering, and absorption. (Used with permission from Franck P, Henderson PW, Rothaus KO. Basics of Lasers: History, Physics, and Clinical Applications. *Clin Plast Surg*. 2016;43[3]:505-513. Copyright © Elsevier.)

Finally, transmission of the laser occurs when the beam is not absorbed by the target chromophore and is conducted to deeper structures. This is more likely to occur with longer wavelengths and larger spot sizes.[5] For example, ultraviolet B radiation (around 300 nm) penetrates skin up to only a few tenths of a millimeter, whereas infrared radiation achieves a penetration depth of up to a few millimeters. However, the increase in penetration depth with increasing wavelength reverses for wavelengths longer than about 1100 nm because radiation is increasingly absorbed by water in skin.

For monochromatic lasers, photons of a single wavelength are absorbed according to the absorption coefficient of the respective chromophores (absorbing targets in the skin) at this wavelength (Fig. 208-7). The absorption of broadband radiation of IPL is more complex given the polychromatic nature of the light. Photons of different wavelengths are absorbed by different chromophores, thereby necessitating the use of cut-off filters when specific effects or actions are required of the IPL system (Fig. 208-8).

When laser or IPL light is absorbed by a chromophore, several types of interactions ensue: chemical (photochemical), mechanical (photoacoustic or photodisruptive), or thermal.[5] An example of a photochemical effect is the use of low-level laser therapy in the treatment of hair loss, in which photons are presumed to be absorbed by mitochondria and activate the cellular respiratory chain to induce hair growth.[13] Photoacoustic effects can be exemplified by the use of nanosecond or picosecond lasers in the treatment of pigmented lesions and tattoos: high-energy photons absorbed by pigment generate acoustic waves within the particles leading to their break up.[14]

Photothermal effects, the mechanism on which most lasers rely, describe the transformation of light energy into heat when absorbed by a chromophore, causing direct damage to adjacent cells, tissues, and structures. The neodymium-doped yttrium aluminum garnet (Nd:YAG) laser (1064 nm frequency doubled to 532 nm) and pulsed dye lasers (585–600 nm) preferentially interact with oxyhemoglobin. Radiation of ruby lasers (694 nm), alexandrite lasers (755 nm), and diode lasers (around 810 nm) are less well absorbed by oxyhemoglobin and more suitable for pigmented chromophores in benign pigmented lesions and for hair removal. Radiation of the Nd:YAG laser (1064 nm) is minimally absorbed by all skin chromophores. Nevertheless, at high radiant exposures, this laser can be used for nonspecific coagulation of tissue as a continuous wave, or for pigmented or vascular lesions as a short or long pulse. Infrared lasers such as the erbium-doped yttrium aluminum garnet (Er:YAG) and carbon dioxide (CO_2) lasers interact solely with water heating up tissue for vaporization or ablation. These ablative lasers induce thermal damage to the epidermis and dermis to stimulate neocollagenesis, tissue rejuvenation, and skin tightening. In contrast, nonablative lasers (1440, 1540, 1550, 1565, and 1927 nm) target dermal tissue to induce bulk heating of dermal collagen and avoid damage to the epidermis. Ablative and nonablative laser principles are discussed in further detail later.

Unlike photochemical effects such as low-level laser therapy, which occurs at very low energy levels, photothermal reactions necessitate relatively high energy

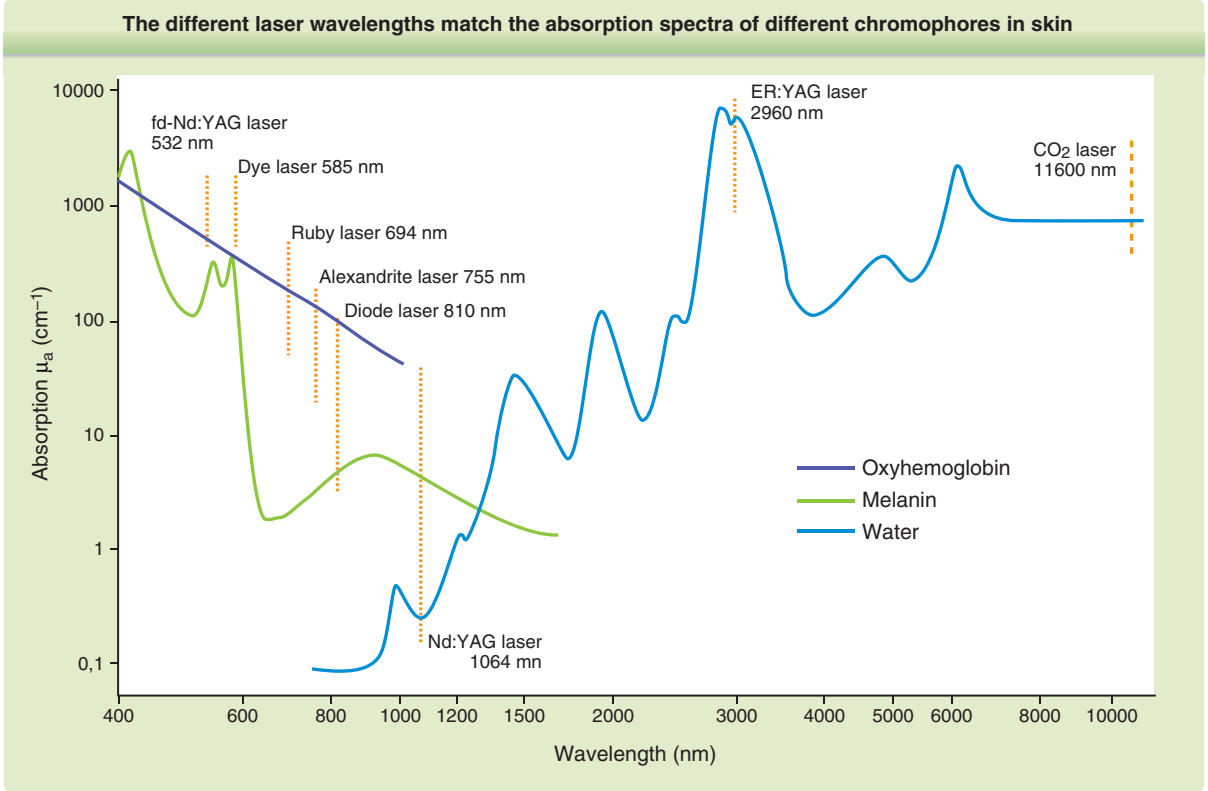

Figure 208-7 The different laser wavelengths match the absorption spectra of different chromophores in skin.

levels. After being absorbed by the target chromophore (eg, oxyhemoglobin in a blood vessel), the energy of the photons causes an increase in temperature inside the target. Concurrently, some heat flows to the tissue adjacent to the target, thereby limiting the temperature increase to a maximum value.[15]

At low intensities and long exposure times (pulse duration), laser or IPL radiation causes moderate temperature increases. At temperatures below 50°C, reversible thermal damage, local vasodilation, and inflammatory cascade activation are produced.[16] At temperatures between 50°C and 100°C, tissue and its proteins undergo irreversible coagulation or denaturation (Fig. 208-9). Reaching temperatures in this range even for as short as 1 millisecond results in coagulative necrosis of tissue. The extent of thermal damage depends on wavelength, intensity, and duration of exposure.[15]

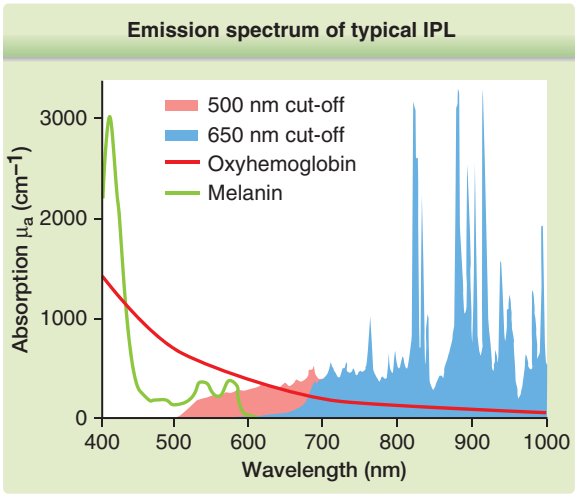

Figure 208-8 The emission spectrum of a typical intense pulsed light (IPL) is broad. Filters with a 500-nm cut-off provide an overlap with the absorption of oxyhemoglobin; filters with a 650-nm cut-off provide an overlap with the absorption of melanin.

At temperatures greater than 100°C, tissue vaporization occurs, generating plume containing water vapor and tissue components (Fig. 208-9).[16] The use of short CO_2 laser pulses heats up tissue very quickly, leading to rapid vaporization. This effect causes precise small holes with minimal thermal damage of the adjacent tissue. With sufficiently high energy levels at temperatures greater than 100°C, steam can be formed deep within tissue cavities. This can lead to explosion and mechanical damage to tissue. The Nd:YAG laser penetrates deeply into tissue and can generate these deep-seated steam cavities, leading to tissue explosion and eventual ulceration. Because the total energy of the laser pulse is limited, ablation and explosion can be restricted to a very small volume. Such high intensities at short pulse durations are accomplished only with lasers and not with IPL.

As a general rule, the higher the intensity (W/cm^2) and the shorter the pulse duration, the higher the maximum temperature inside the targeted volume. By changing the intensity and pulse duration parameters, the temperature can be modulated to achieve coagulation,

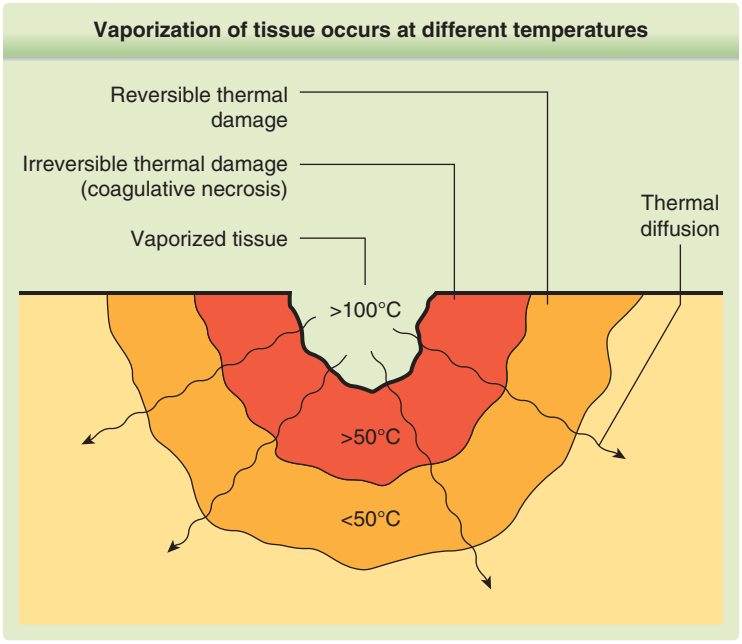

Figure 208-9 At temperatures greater than 100°C, vaporization of tissue occurs. At temperatures between 50°C and 100°C, irreversible thermal coagulation occurs. At temperatures below 50°C, tissue undergoes reversible thermal damage. (Used with permission from Dover JS, Arndt KA. *Illustrated Cutaneous Laser Surgery: A Practitioner's Guide*. Norwalk, CT: Appleton & Lange; 1990. Copyright © McGraw-Hill Education.)

vaporization, or explosion of a specific target in skin. The total amount of energy is proportional to both the power and the pulse duration, where E (Joules) = P (watts) × t (seconds).[8] Therefore, to maintain a constant energy output, a decrease in power requires an increase in pulse duration. However, the tissue effects can be vastly different. For example, using higher power and shorter pulse duration results in more tissue vaporization and less surrounding coagulative necrosis, while lower power and longer pulse widths results in less vaporization and more coagulative necrosis at the edge of the vaporized tissue (Fig. 208-10).

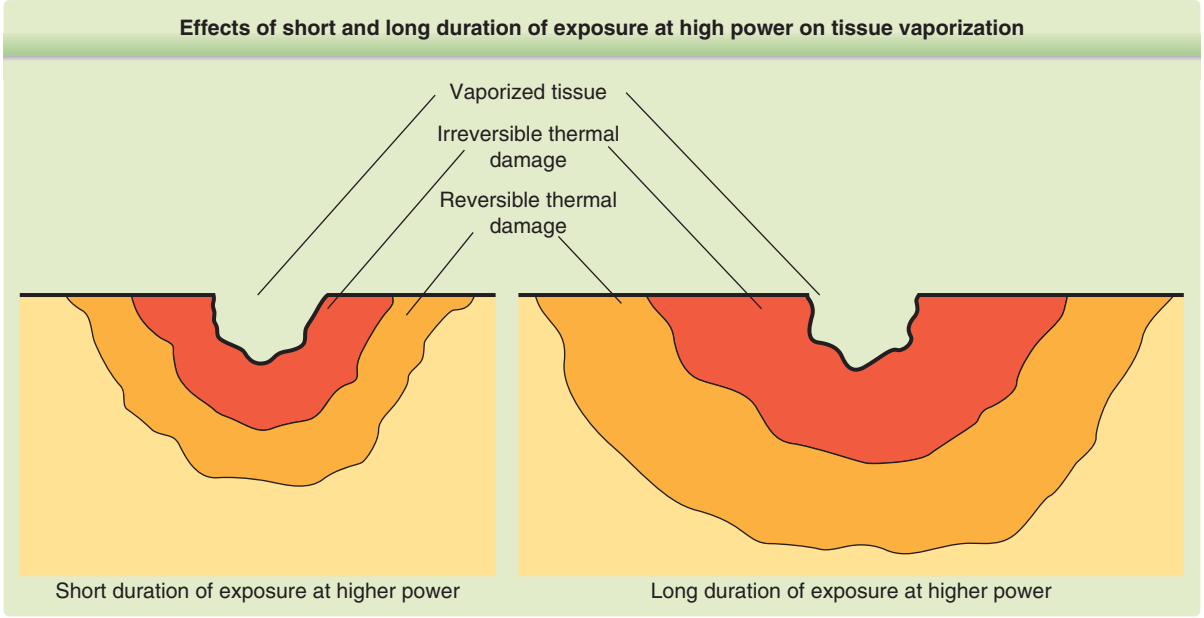

Figure 208-10 A high power with shorter pulse duration results in more tissue vaporization and less surrounding coagulative necrosis, while a high or a relatively lower power and longer pulse width results in less vaporization and more coagulative necrosis at the edge of the vaporized tissue. (Used with permission from Dover JS, Arndt KA. *Illustrated Cutaneous Laser Surgery: A Practitioner's Guide*. Norwalk, CT: Appleton & Lange; 1990. Copyright © McGraw-Hill Education.)

SELECTIVE PHOTOTHERMOLYSIS

In the 1980s, Anderson and Parrish described the model of selective photothermolysis that revolutionized how lasers can be used to safely treat specific ailments of the skin.[17] Using a 577-nm wavelength for vessels and 351-nm wavelength for pigment, they demonstrated that by selecting a wavelength that can be delivered to a specific chromophore with a pulse duration or exposure time shorter than the thermal relaxation time, the damage to the peripheral tissue would be minimized. The thermal relaxation time is defined as the time needed for the irradiated tissue to cool down to half of its heated temperature.[18] The keys to this theory are twofold: laser light must be absorbed by the target by selecting a wavelength absorbed by the chromophore in the target, and the correct pulse duration is essential for spatial confinement of heat in the target.

The pulse duration should be comparable to the thermal relaxation time (t_R), which mainly depends on the diameter of the target (D)

$$t_R = \rho c/(16k) \times D^2$$

where ρ, c, k are thermal parameters of the target. The thermal relaxation time is roughly proportional to the square of the mean diameter of the target. Therefore, the larger the chromophore, the longer the required pulse duration, and the greater the overall heating.

WAVELENGTH

The major chromophores in skin in order of depth of location are water, melanin, and hemoglobin. The CO_2 laser (10,600-nm) is absorbed by tissue water, limiting penetration into skin to less than 0.1 mm.[19] The beam can be delivered with a large spot size and low power density or focused with great power density. The CO_2 laser can be used to vaporize and cut tissue while coagulating blood vessels. The Er:YAG laser (2940 nm) is also preferentially absorbed by water. Argon-ion lasers (488 and 514 nm), KTP lasers (532nm), and pulsed dye lasers (585-595 nm) may be absorbed by both hemoglobin and melanin. Ruby lasers (694 nm) are absorbed mainly by melanin pigment although a small amount of hemoglobin absorption also occurs. Alexandrite lasers (755 nm) are preferentially absorbed by melanin, and therefore useful for pigmented lesions and hair. As mentioned earlier, although there is no specific chromophore for the Nd:YAG laser (1064 nm), this wavelength is absorbed, albeit less than with other visible wavelengths, by hemoglobin and melanin and at higher fluences it can be used to treat pigmented or vascular lesions.

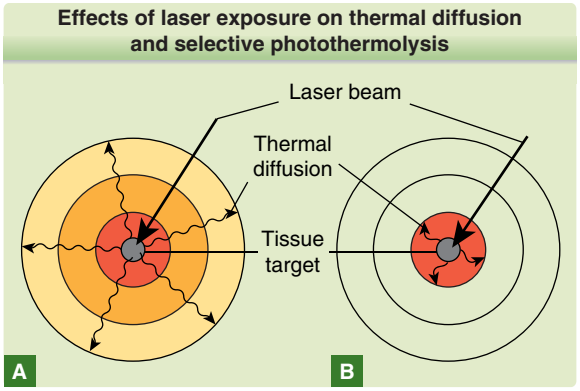

Figure 208-11 **A,** Longer laser exposure time results in increased thermal diffusion out of the target and damage to adjacent structures. **B,** Collateral thermal injury can be reduced by choosing a wavelength that is specifically absorbed by the target chromophore and by maintaining a pulse duration that is shorter than the thermal relaxation (cooling) time of the target. This is referred to as selective photothermolysis. (Used with permission from Dover JS, Arndt KA. *Illustrated Cutaneous Laser Surgery: A Practitioner's Guide*. Norwalk, CT: Appleton & Lange; 1990. Copyright © McGraw-Hill Education.)

PULSE DURATION

The pulse duration determines the size of target that will be selectively damaged. Coagulation of small blood vessels with diameters of 50–150 µm require pulse durations in the millisecond range.[20-22] Initially, only the temperature in the vessel increases, coagulating the vessel. Because of the temperature increase, however, heat begins to diffuse to the adjacent dermis. At this point, the radiation pulse should be terminated to achieve selective vessel destruction. Pulse durations longer than the thermal relaxation time result in excessive heat flow to the dermis, which may cause unnecessary adverse reactions (Fig. 208-11). The same range of pulse durations is applied for the treatment of large vessels such as leg veins.[23]

The pulse duration necessary to effectively treat pigment in hair, epidermal and dermal melanocytic lesions, and tattoos depends on the size (and therefore the thermal relaxation time) of the target chromophore (Table 208-2). Hair follicles are 0.02 to 0.2 millimeters

TABLE 208-2
Target Chromophores, Size, and Pulse Duration

TARGET	APPROXIMATE SIZE OF TARGET	PULSE DURATION
blood vessels	50-150 µm	ms
Hair follicles	0.02-0.2 µm	10-50 ms
Melanocytes	7 µm	ms to ns
Melanosomes	1.5 µm	ns to ps
Tattoo pigment particles	100 nm (0.1 µm)	ns to ps

in diameter and are targeted by pulses in the range of 10 to 50 milliseconds.[24] Melanocytes are a few µm in diameter (average 7 µm) and require pulse widths ranging from milliseconds to nanoseconds. Melanosome diameter ranges from 1 to 1.5 µm and can be targeted by nanosecond and picosecond pulses.[25] Tattoo pigment particles are on average 100 nanometers (0.1 µm) in diameter and are targeted by nanosecond and picosecond pulses.[26]

FRACTIONAL PHOTOTHERMOLYSIS: ABLATIVE VS NONABLATIVE FRACTIONATION

In the late 1980s and 1990s, ablative lasers (CO_2 and erbium) gained rapid popularity for the treatment of facial photodamage and skin laxity. Although the results were dramatic, so were the potential side effects. Prolonged recovery times and the potential for serious adverse effects were its ultimate downfall, and the nonablative lasers of the time fell short of the dramatic results that ablative ones offered. In response to these dilemmas, the concept of fractional photothermolysis emerged.[27] Fractional photothermolysis creates spatially distributed columns of microthermal injury within the treatment area, called microscopic treatment zones (MTZs). These are generated in the skin by focused laser irradiation. There is enough energy in each column of MTZ to induce thermal heating or ablation without spread to adjacent tissue. Fractional irradiation allows relatively deeper penetration of the laser beam into the dermis, causing controlled denaturation, transepidermal elimination of the coagulated debris, and reactive collagen remodeling, while maintaining the integrity of the epidermis, shortening healing times, and decreasing side effects.[19]

Fractional photothermolysis can be performed in either ablative (CO_2 and erbium) or nonablative (1440, 1540, 1550, 1565, and 1927 nm) mode. In ablative fractionation, there is controlled vaporization of thin columns of both epidermis and dermis alike. In nonablative fractionation, the heating is concentrated within the dermis, leaving the epidermis relatively or absolutely spared.[27,28] The theory is that intense heating of columns within the dermis with intervening normal skin can induce enough protein denaturation and collagen remodeling and synthesis. Overall, nonablative fractional lasers allow for higher levels of intense heat within the dermis, and therefore better results, in comparison to the older nonfractionated, nonablative lasers that merely created a homogenous layer of dermal heat.[27] As expected, nonablative fractional photothermolysis is much better tolerated, with fewer side effects and shorter healing time. However, results may not be as impressive as ablative fractional resurfacing. Fractional photothermolysis can be used to treat a myriad of dermatologic conditions including photoaging, acne scarring, traumatic scarring, skin laxity, and dyschromias.[28] Fractionation has also helped pave the way for laser-assisted topical drug delivery.[29-32]

SKIN COOLING

Laser and light therapy requires the delivery of high radiant exposure to targets within the dermis or the dermal–epidermal junction, while minimizing injury to the epidermis. To reach these targets, photons must traverse the epidermis, which can itself absorb radiation. In addition, the buildup of heat within the dermis can diffuse to epidermal structures causing unintended damage. To circumvent unwanted injury, skin cooling systems have been developed to protect the epidermis while delivering sufficient heat to the dermis.[33]

Cooling can be achieved before, during, or after treatment, referred to as precooling, parallel cooling, and postcooling.[33] There are 2 types of cooling methods: contact cooling, sometimes known as bulk cooling, and noncontact cooling (Table 208-3). Contact cooling can be active or passive. Active contact cooling employs copper or sapphire tips integrated into the laser handpiece, and passive contact cooling involves the use of ice or cold aqueous gels. In contact cooling, heat is transferred from the warm skin to the cooling agent. In passive cooling, heat is transferred through diffusion from the cutaneous surface to the ice or gel. In active cooling, the tip actively removes heat by thermoelectric elements or flowing liquid cooling agents.[33] Noncontact cooling can be achieved with cryogen spray or forced cold air. The first device used for spray cooling was liquid nitrogen spray held at a certain distance from skin during laser treatment. This technique was operator-dependent, imprecise, and came with risks of cryonecrosis. The development of the dynamic cooling device (DCD) integrated within the laser system has revolutionized epidermal cooling.[34-36] The inbuilt software allows the user to set specific DCD spray and delay settings. The device sprays the cryogen, usually the nontoxic 1,1,1,2-tetrafluoroethane, at –15°C immediately before the application of the laser. The DCD allows for uniform, precise, and reproducible cooling with every laser pulse.[33] Forced cold air (Zimmer Cryo; Zimmer Medizin Systems, Irvine, CA) can deliver cooling before, during, and after laser application without interfering with the laser beam.

TABLE 208-3
Cooling Methods in Cutaneous Laser Surgery

CONTACT COOLING	NONCONTACT COOLING
Active (copper, sapphire tips)	Cryogen spray (liquid nitrogen)
Passive (ice)	Pulsed cryogen spray (dynamic cooling device)
Passive (aqueous gels)	Forced refrigerated air (Zimmer Cryo, Zimmer Medizin Systems, Irvine, CA)

The device minimizes pain and unwanted thermal injury during laser and light treatment.

LASER SAFETY

The use of lasers and intense pulsed light sources requires knowledge and application of many safety measures to reduce the risk of temporary or permanent tissue damage (Table 208-4). The organizations that regulate laser operations are the International Electrotechnical Commission (IEC), the American National Standards Institute (ANSI), the Center for Devices and Radiological Health (CDRH) of the US FDA, the Department of Labor's Occupational Safety and Health Administration (OSHA), and the Council of Radiation Control Program Directors (CRCPD).[37] The ANSI Z136.3 is a regulatory document that provides guidance for the safe use of lasers in medicine. These regulations are implied, and compliance is mandated by the individual institution or organization.[38] Prior to any laser or light-based procedure, possible side effects should be discussed with the patient in detail, to protect the patient and provider alike.

SKIN SAFETY

Radiation of any wavelength can pose a risk to any human tissue, and in particular the eyes and skin.[39,40] Cutaneous injuries are the most common complications of dermatologic laser surgery and the most common cause of laser-related litigation.[41] In one study, laser hair removal was the most frequently implicated procedure in lawsuits, likely as a result of the high number of procedures done per year. The second most commonly litigated procedure was rejuvenation, including fully ablative carbon dioxide resurfacing, ablative and nonablative fractional resurfacing, and intense pulsed light treatments.[41] Reported cutaneous injuries included burns, scars, and pigmentary changes.

TABLE 208-4
Principles of Laser Safety

- Set patient realistic expectations
- Discuss, in-detail, the procedure and possible side effects
- Select correct device for target chromophore and patient skin type
- Lower fluences, longer pulse durations, longer wavelengths, higher cutoff filters decrease risk in darker skin types
- Precooling, cooling during procedure, postprocedural cooling
- When using radiofrequency energy, avoid patients with implantable devices or pacemakers
- Lowest risk lasers are vascular, pigment-specific, and nonablative types
- Ablative lasers are higher risk, with greater chances of infection and scarring
- Appropriate eye protection is essential; eye protection is device-specific
- When used for tissue vaporization, plumes must be evacuated to avoid infectious material

Avoidance of cutaneous injuries requires appropriate laser selection and realistic expectations. Selecting the correct laser/light device demands careful consideration of the target chromophore as well as the patient's natural skin color, while keeping in mind that more aggressive treatment to achieve results may increase the risk of pigmentary alteration, burns, and scars. Lower fluences, longer pulse durations, and longer wavelengths or higher cutoff filters decrease the risk of injury to darker skin types. Appropriate pre-cooling, cooling during the procedure, and post-procedural cooling all provide additional epidermal protection.[38] When using devices that employ radiofrequency energy and may have less deleterious effects on the epidermis, patients with implantable devices or pacemakers should be avoided and caution should be taken in areas with tattoos or overlying metal implants, hardware, and braces.[42]

Overall, the risk of cutaneous injuries is lower with pigment-specific, vascular, and nonablative lasers. Ablative lasers lead to epidermal and dermal destruction, albeit controlled, that increases the risk of infection and scarring.[38] Fractionally ablative lasers have minimized this risk significantly.

EYE SAFETY

Ocular injuries arise from direct or indirect (reflected) laser light, and 70% of ocular injuries result from inappropriate or lack of use of eye protection. Types of ocular injuries are wavelength-specific, and severity is dependent on energy level, beam size, and exposure time.[38] Radiation between 380 and 1400 nm is transmitted by the eye and absorbed by the retina.[43] The refractive media of the eye gathers and focuses this spectrum onto the retina and increases the irradiance by a factor of more than 10,000 above the irradiance at the cornea.[43] Thus, even a small amount of energy from low-power lasers can still inflict significant damage on the retina. Photons of wavelengths shorter than 380 nm are absorbed by organic molecules in the cornea, thereby causing injury or cataract formation. Light of wavelengths longer than 1000 to 1400 nm is readily absorbed by water, does not penetrate deeply, and therefore may cause corneal injury, even ablation or vaporization, by a thermal process.[43]

The pulse duration and energy level determine the type of ocular injury: thermal, mechanical, or photochemical. Thermal damage occurs when energy is absorbed by the chromophore, such as melanin in the retina, at a pulse ranging from microseconds to seconds. Heat is generated faster than it can be dissipated, thereby denaturing proteins resulting in cell death and tissue necrosis. Mechanical injury is caused when energy is rapidly absorbed at pulse durations ranging from picoseconds to nanoseconds. A rapid absorption of energy and therefore rapid increase in temperature strips electrons from atoms, disintegrating tissue to a pool of ions and electrons, or plasma. Concomitant vaporization of water results in a compressive pressure

pulse, or explosion, that disrupts surrounding tissue. Photochemical damage results from energy at relatively lower levels and longer pulse durations, more than a few seconds. The slow delivery of energy does not deliver enough heat to induce thermal damage. However, single photons can break molecular bonds in nucleic acids and proteins. Retinal cells can recover from this type of damage over a period of weeks, but over a certain threshold damage can be irreversible.[43]

In response to visible light, the macula activates the blink reflex within 150 to 250 milliseconds. Additionally, the "aversion response," or turning away of the head from the light source, is another natural defense mechanism against harmful visible radiation. However, these reflexes are not rapid enough to protect from most laser systems, which possess pulse durations shorter than 250 milliseconds. Also, the aversion response to radiation at the retinal periphery can lead to an instinctive turning of the head towards the light source and result in further damage.[44] Furthermore, injuries from lasers of invisible, longer wavelength radiation such as the Nd:YAG and carbon dioxide lasers can occur entirely unnoticed.

Complete protection from laser injury requires adequate knowledge of the properties and mode of employment of the instrument in use. The universal safety precaution in place to prevent eye injuries is the use of proper eyewear. Safety goggles are composed of filters that either reflect or absorb specific wavelengths of light, while allowing sufficient light of other wavelengths to be transmitted. Laser goggles are rated by optical density (OD) at various wavelengths, and an OD of at least 4 is considered safe. The important parameters of the radiation sources are wavelength, pulse duration, intensity, and radiant exposure. These parameters of a laser or IPL system determine the characteristics of the safety goggles. Each laser or IPL requires special safety goggles that are labeled for their use, including wavelength range of protection, laser mode, and scale number of protection. The manufacturer of lasers or IPL must provide sufficient information about the appropriate safety goggles, which can be found in the handbook of each laser or IPL device. The main limitation of these devices is the reluctance of personnel to wear them. It is also important to pair the correct eyewear with the correct corresponding laser device, and in the age of multiwavelength lasers, the laser operator must remember to switch goggles if need be when switching from wavelength to wavelength.

MAINTAINING LASER SAFETY

When employing a medical laser, it is mandatory to appoint a laser safety officer (LSO). This person possesses the authority to draft, maintain, and enforce the laser safety guidelines and controls to ensure the proper employment of lasers in the medical setting. The LSO administers the overall laser safety program where the duties include items such as confirming the classification of lasers and ensuring that the proper control measures are in place, approving substitute controls and conducting medical surveillance. The LSO should receive detailed training, including laser fundamentals, laser bioeffects, exposure limits, classifications, control measures (including area controls, eye wear, barriers, etc), and medical surveillance requirements.

To maintain the safety of all persons in the vicinity of a laser or light device, safety checklists can be used. In a controlled environment such as a dermatology clinic, updated checklists and compliant personnel can significantly reduce adverse events and morbidity by ensuring adherence to crucial checkpoints such as confirming eyewear placement and proper setup of the laser.[45] Checklists can be of 2 forms, depending on the complexity of the task. READ-DO checklists demand that users perform each step as they check them off. DO-CONFIRM checklists require that users perform the tasks from memory but then pause to make sure all facets of the checklist were met prior to treatment. Safety checklists are able to make potentially risky procedures safer and less error prone.

ACKNOWLEDGMENTS

We extend our sincerest gratitude to Michael Landthaler, Wolfgang Bäumler, and Ulrich Hohenleutner for their indispensable work "Lasers and Flashlamps in Dermatology" in *Fitzpatrick's Dermatology*, 8th edition.

REFERENCES

1. Dicke RH. Coherence in spontaneous radiation processes. *Phys Rev*. 1954;93:99-110.
2. Einstein A. Zur Quantentheorie der Strahlung. *Phys Zeitschrift*. 1917;18:121-128.
3. Azadgoli B, Baker RY. Laser applications in surgery. *Ann Transl Med*. 2016;4(23):452.
4. Maiman TH. Stimulated optical radiation in ruby. *Nature*. 1960;187:493-494.
5. Franck P, Henderson PW, Rothaus KO. Basics of lasers: history, physics, and clinical applications. *Clin Plast Surg*. 2016;43(3):505-513.
6. De Felice E. Shedding light: laser physics and mechanism of action. *Phlebology*. 2010;25(1):11-28.
7. Raulin C, Greve B, Grema H. IPL technology: a review. *Lasers Surg Med*. 2003;32(2):78-87.
8. Dover JS, Arndt KA. *Illustrated Cutaneous Laser Surgery: A Practitioner's Guide*. Norwalk, CT: Appleton & Lange; 1990.
9. Rahman Z, Alam M, Dover JS. Fractional Laser treatment for pigmentation and texture improvement. *Skin Therapy Lett*. 2006;11(9):7-11.
10. Wanner M, Tanzi EL, Alster TS. Fractional photothermolysis: treatment of facial and nonfacial cutaneous photodamage with a 1,550-nm erbium-doped fiber laser. *Dermatol Surg*. 2007;33(1):23-28.
11. Chiu RJ, Kridel RW. Fractionated photothermolysis: the Fraxel 1550-nm glass fiber laser treatment. *Facial Plast Surg Clin North Am*. 2007;15(2):229-237, vii.

12. Thongsima S, Zurakowski D, Manstein D. Histological comparison of two different fractional photothermolysis devices operating at 1,550 nm. *Lasers Surg Med*. 2010;42(1):32-37.
13. Gupta AK, Foley KA. A critical assessment of the evidence for low-level laser therapy in the treatment of hair loss. *Dermatol Surg*. 2017;43(2):188-197.
14. Ho DD, London R, Zimmerman GB, et al. Laser-tattoo removal—a study of the mechanism and the optimal treatment strategy via computer simulations. *Lasers Surg Med*. 2002;30(5):389-397.
15. Bogdan Allemann I, Kaufman J. Laser principles. *Curr Probl Dermatol*. 2011;42:7-23.
16. Herd RM. Basic laser principles. *Dermatol Clin*. 1997; 15:355-372.
17. Anderson RR, Parish JA. Selective photothermolysis: precise microsurgery by selective absorption of pulsed radiation. *Science*. 1983;220:524-527.
18. Goldman L, Wilson RG, Hornby P, et al. Radiation from Q-switched ruby laser: effect of repeated impacts of power output of 10 megawatts on a tattoo of man. *J Invest Dermatol*. 1964;44:69-71.
19. Borges J, Manela-Azulay M, Cuzzi T. Photoaging and the clinical utility of fractional laser. *Clin Cosmet Investig Dermatol*. 2016;9:107-114.
20. Brightman LA, Geronemus RG, Reddy KK. Laser treatment of port-wine stains. *Clin Cosmet Investig Dermatol*. 2015;8:27-33.
21. Morton LM, Smith KC, Dover JS, et al. Treatment of purpura with lasers and light sources. *J Drugs Dermatol*. 2013;12(11):1219-1222.
22. Franca K, Chacon A, Ledon J, et al. Lasers for cutaneous congenital vascular lesions: a comprehensive overview and update. *Lasers Med Sci*. 2013;28(4):1197-1204.
23. Meesters AA, Pitassi LH, Campos V, et al. Transcutaneous laser treatment of leg veins. *Lasers Med Sci*. 2014;29(2):481-492.
24. Zandi S, Lui H. Long-term removal of unwanted hair using light. *Dermatol Clin*. 2013;31(1):179-191.
25. Thong HY, Jee SH, Sun CC, et al. The patterns of melanosome distribution in keratinocytes of human skin as one determining factor of skin colour. *Br J Dermatol*. 2003;149(3):498-505.
26. Hogsberg T, Loeschner K, Lof D, et al. Tattoo inks in general usage contain nanoparticles. *Br J Dermatol*. 2011;165(6):1210-1218.
27. Manstein D, Herron GS, Sink RK, et al. Fractional photothermolysis: a new concept for cutaneous remodeling using microscopic patterns of thermal injury. *Lasers Surg Med*. 2004;34(5):426-438.
28. Saedi N, Jalian HR, Petelin A, et al. Fractionation: past, present, future. *Semin Cutan Med Surg*. 2012;31(2): 105-109.
29. Waibel JS, Wulkan AJ, Shumaker PR. Treatment of hypertrophic scars using laser and laser assisted corticosteroid delivery. *Lasers Surg Med*. 2013;45(3):135-140.
30. Rkein A, Ozog D, Waibel JS. Treatment of atrophic scars with fractionated CO_2 laser facilitating delivery of topically applied poly-L-lactic acid. *Dermatol Surg*. 2014;40(6):624-631.
31. Waibel JS, Mi QS, Ozog D, et al. Laser-assisted delivery of vitamin C, vitamin E, and ferulic acid formula serum decreases fractional laser postoperative recovery by increased beta fibroblast growth factor expression. *Lasers Surg Med*. 2016;48(3):238-244.
32. Haak CS, Hannibal J, Paasch U, et al. Laser-induced thermal coagulation enhances skin uptake of topically applied compounds. *Lasers Surg Med*. 2017;49(6): 582-591.
33. Das A, Sarda A, De A. Cooling devices in laser therapy. *J Cutan Aesthet Surg*. 2016;9(4):215-219.
34. Waldorf HA, Alster TS, McMillan K, et al. Effect of dynamic cooling on 585-nm pulsed dye laser treatment of port-wine stain birthmarks. *Dermatol Surg*. 1997;23:657-662.
35. Anvari B, Milner TE, Tanenbaum BS, et al. A comparative study of human skin thermal response to sapphire contact and cryogen spray cooling. *IEEE Trans Biomed Eng*. 1998;45:934-941.
36. Nahm WK, Tsoukas MM, Falanga V, et al. Preliminary study of fine changes in the duration of dynamic cooling during 755-nm laser hair removal on pain and epidermal damage in patients with skin types III-V. *Lasers Surg Med*. 2002;31:247-251.
37. US Department of Labor, Occupational Safety and Health Administration website. OSHA Technical Manual, Section III, Chapter 6. https://www.osha.gov/dts/osta/otm/otm_iii/otm_iii_6.html. Accessed February 9, 2017.
38. Lolis M, Dunbar SW, Goldberg DJ, et al. Patient safety in procedural dermatology: part II. Safety related to cosmetic procedures. *J Am Acad Dermatol*. 2015;73(1): 15-24; quiz 25-26.
39. Goldman L. Progress in laser safety in biomedical installations. *Arch Environ Health*. 1970;20(2):193-196.
40. Powell CH, Goldman L. Recommendations of the Laser Safety Conference. *Arch Environ Health*. 1969; 18(3):448-452.
41. Jalian HR, Jalian CA, Avram MM. Common causes of injury and legal action in laser surgery. *JAMA Dermatol*. 2013;149(2):188-193.
42. Rongsaard N, Rummaneethorn P. Comparison of a fractional bipolar radiofrequency device and a fractional erbium-doped glass 1,550-nm device for the treatment of atrophic acne scars: a randomized split-face clinical study. *Dermatol Surg*. 2014;40(1):14-21.
43. Barkana Y, Belkin M. Laser eye injuries. *Surv Ophthalmol*. 2000;44(6):459-478.
44. Boldrey EE, Little HL, Flocks M, et al. Retinal injury due to industrial laser burns. *Ophthalmology*. 1981;88(2): 101-107.
45. Hamilton HK, Dover JS. Using checklists to minimize complications from laser/light procedures. *Dermatol Surg*. 2014;40(11):1173-1174.

Chapter 209 :: Laser Skin Resurfacing: Cosmetic and Medical Applications

:: Bridget E. McIlwee & Tina S. Alster

AT-A-GLANCE

- Several ablative and nonablative laser technologies are available for the treatment of cosmetic concerns including photodamage, rhytides, and scarring.
- Fractional laser technology has increased clinical applications and reduced postoperative recovery and side-effect profiles of laser skin resurfacing.
- Individual patient characteristics and expectations, as well as the risks and benefits inherent to each treatment modality, should be considered prior to laser selection.

AN OVERVIEW

Years of damaging ultraviolet light exposure manifests clinically with skin dyspigmentation, roughened surface texture, and variable degrees of wrinkling and laxity. Other imperfections, such as scars from trauma, past surgical procedures, or acne, also affect the appearance of the skin. Histologically, the effects of aging and trauma are usually limited to the epidermis and upper papillary dermis, levels that are easily targeted by a variety of ablative and nonablative lasers.

The selection of lasers available to treat cutaneous photodamage, textural irregularities, and cosmetic imperfections continues to grow. Progress over the past few decades has led to a great increase in the number of laser skin resurfacing procedures with options that cater to a diverse patient population. The spectrum ranges from fully ablative resurfacing with pulsed and scanned carbon dioxide (CO_2) and erbium:yttrium aluminum garnet (Er:YAG) lasers, to newer nonablative and fractional laser devices.[1-3] Determining the most appropriate laser system requires consideration of the severity of the photodamage, scarring, or other imperfection to be treated, the expertise of the dermatologic surgeon, and the expectations and lifestyle of the individual patient. Thorough preoperative patient evaluation and preparation, intraoperative technical expertise, and close postoperative care and followup are all essential to optimizing clinical outcomes while preventing and minimizing the risk of complications.

ABLATIVE LASER RESURFACING

The mechanism of action of either the CO_2 or Er:YAG system for laser skin resurfacing (LSR) involves the absorption of infrared wavelengths by water-containing tissue. Treatment with these laser systems causes tissue vaporization and dermal collagen denaturation, which results in tissue contraction and subsequent stimulation of neocollagenesis.[4,5] Ablative LSR treatment thus causes removal of the entirety of the epidermis and a portion of the dermis.[6]

Ablative laser wounds induce a cascade of physiologic healing responses, ultimately leading to cutaneous remodeling and the desirable aesthetic results of laser resurfacing. After ablative LSR, it is thought that progenitor cells dwelling within the pilosebaceous units play a key role in repopulating the epidermis as well as recruiting other cells to the area to aid in various wound-healing processes. For this reason, the use of ablative LSR is not advocated on nonfacial skin as the relative paucity of pilosebaceous units in such areas hampers postoperative healing and may lead to increased risk of adverse events.[7]

Tissue ablation results in significant postoperative recovery for patients with serosanguinous discharge and crusting during the 7- to 10-day reepithelialization process. The risk of complications is highest during the reepithelialization stage when infection, erythema, and swelling can lead to permanent skin dyspigmentation and scarring if left unattended.[8]

For many years, the pulsed ablative CO_2 laser was considered the gold standard in skin resurfacing. Developed in the mid-1990s, a variety of pulsed and scanned CO_2 laser systems were used for LSR that demonstrated excellent efficacy for the treatment of rhytides, photodamage, and scars.[1-3] The subsequent development of pulsed and scanned Er:YAG lasers, as well as combination CO_2 and Er:YAG laser systems, were also highly effective for skin resurfacing and resulted in reduced damage to normal tissue surrounding treatment areas.[1-3,9,10]

NONABLATIVE LASER RESURFACING

Despite the clinical advantages of advanced ablative lasers, the prolonged postoperative recovery and potential complications associated with their use eventually led to a decrease in their popularity.[8,11,12] Nonablative laser devices were subsequently introduced with the goal of stimulating dermal neocollagenesis without inducing epidermal injury or requiring significant postoperative recovery. Although demonstrable changes in dermal collagen could be achieved with nonablative laser skin treatment and the postoperative management was favorable with few side effects, clinical improvement was modest and multiple treatments were necessary to obtain satisfactory results.[13]

A continued desire for superior clinical results while maintaining a manageable recovery and side-effect profile gave rise to a number of ablative laser devices that adhere to the concept of fractional photothermolysis.

FRACTIONAL PHOTOTHERMOLYSIS AND FRACTIONAL RESURFACING

A novel concept in skin treatment, termed *fractional photothermolysis*, was described and developed by Manstein and colleagues in 2004.[14] Fractional photothermolysis involves the creation of laser-induced small thermal injuries or microscopic treatment zones (MTZs) in water-containing skin with sparing of normal healing skin around each MTZ. The intact, nontreated skin forms bridges between the MTZs, thereby leading to more rapid healing.

The process of cutaneous healing after fractional photothermolysis differs in several ways from the healing required after fully ablative laser techniques. First, histologic evaluation of skin immediately after fractional laser irradiation reveals thermal injury sharply confined to the MTZ, which extends from the epidermis to the mid-dermis. Because the undamaged, intact epidermal tissue between MTZs contains viable transient amplifying cells capable of rapid reepithelialization, healing after fractional laser ablation progresses quite rapidly. The degenerated, necrotic dermal and epidermal debris from the MTZ is incorporated into columns and then eliminated transepidermally. This production of microscopic epidermal necrotic debris appears to be unique to the process of fractional photothermolysis.[14] Microscopic epidermal necrotic debris are naturally exfoliated within days of treatment.

Ablative lasers that adhere to the concept of fractional photothermolysis for ablative fractional resurfacing (AFR) include CO_2, Er:YAG, and erbium:yttrium scandium gallium garnet (Er:YSGG) lasers. The pedicles of thermally induced coagulation produced by these systems extend to far greater dermal depths than those delivered by nonablative devices. AFR thereby induces greater tissue contraction and neocollagenesis than nonablative lasers while leading to rapid reepithelialization and a more favorable side-effect profile than fully ablative lasers.[3,15,16] Because of the less-invasive nature of AFR, nonfacial areas, such as the neck, chest, and dorsal hands, can be more safely treated.[17,18] The technical characteristics of AFR reduce recovery time, postoperative discomfort, and complications associated with traditional multipass ablative LSR.[15]

EQUIPMENT

Table 209-1 identifies the available skin resurfacing lasers and light-based devices.

ABLATIVE LASERS

CARBON DIOXIDE

The first system developed for ablative cutaneous laser resurfacing was the CO_2 laser, which was approved by the U.S. Food and Drug Administration in 1996. The 10,600-nm wavelength emitted by CO_2 lasers is absorbed by water-containing tissue. Because of their efficacy in ameliorating severe photodamage, rhytides, and laxity, CO_2 lasers remain the gold standard in ablative LSR.[13] The earliest systems were continuous-wave CO_2 lasers, which were highly effective for gross lesional destruction; however, these systems could not reliably ablate fine layers of tissue because of their prolonged tissue-dwell times and unacceptably high rates of scarring and dyspigmentation.[19] With the subsequent development of high-energy pulsed CO_2 lasers, higher energy densities could be applied with exposure times shorter than the thermal relaxation time of water-containing tissue, thereby lowering the risk of injury to surrounding, nontargeted tissue.[4,5]

TABLE 209-1
Skin Resurfacing Lasers and Light-Based Devices

LASER TYPE	MEDIUM	WAVELENGTH
Ablative pulsed/scanned	CO_2	10,600 nm
	Er:YAG	2940 nm
	CO_2/Er:YAG	10,600/2940 nm
Nonablative	IPL	500-1200 nm
	Nd:YAG	1064 nm, 1320 nm
	Diode	980 nm, 1450 nm
	Er:Glass	1540 nm
Fractionated (ablative)	CO_2	10,600 nm
	Er:YAG	2940 nm
	Er:YSGG	2790 nm
Fractionated (nonablative)	Erbium fiber	1550 nm
	Thulium	1927 nm

CO_2, carbon dioxide; Er:YAG, erbium:yttrium aluminum garnet; Er:YSGG, erbium:yttrium scandium gallium garnet; IPL, intense pulsed light; Nd:YAG, neodymium:yttrium aluminum garnet.

The initial laser systems (Ultrapulse, SilkTouch) emitted either individual pulses (ranging from 600 microseconds to 1 millisecond [msec]) or microprocessor-directed scans that limited tissue dwell-time to less than 1 msec. The peak fluences (4 to 5 J/cm^2) delivered per pulse or scan vaporized water-containing tissue to a depth of 20 to 60 µm with a zone of thermal damage ranging from 20 to 150 µm, depending on the number of laser passes delivered.[4-6,20,21]

ERBIUM:YTTRIUM ALUMINUM GARNET

Er:YAG lasers emit 2940 nm light with a much higher water absorption coefficient (12,800 cm^{-1}) than CO_2 lasers (800 cm^{-1}), thereby rendering Er:YAG laser energy 12 to 18 times more efficiently absorbed by water-containing tissue than is CO_2 laser energy.[22,23] At typical treatment parameters, the Er:YAG laser ablates 2 to 4 µm of tissue per J/cm^2 and produces narrow zones of thermal necrosis (20 to 50 µm).[22-24] Its short pulse duration (mean: 250 microseconds) decreases thermal diffusion (with less-effective hemostasis and increased intraoperative bleeding), and along with its shallow dermal penetration, often hampers deeper dermal treatment and significant collagen contraction.[10] The major disadvantage of short-pulsed Er:YAG laser treatment (reduced thermal tissue effect) leads to a significant advantage: a shorter postoperative recovery.[25] Technologic advancements led to the subsequent development of modulated Er:YAG lasers systems that emit a combination of short and long coagulative pulses to achieve deeper tissue ablation depths and coagulative zones of thermal injury (comparable to CO_2) to improve hemostasis and increase collagen remodeling.[26-29]

HYBRIDS

More recently, Er:YAG-CO_2 hybrid laser systems have been devised to simultaneously deliver both ablative Er:YAG and coagulative CO_2 laser pulses. The Er:YAG component of these hybrid lasers generates fluences as high as 28 J/cm^2 with a 350-microsecond pulse duration; hemostasis is concomitantly provided by the CO_2 component (programmed to deliver 1-msec to 100-msec pulses at 1 to 10 W of power). Depending on the treatment parameters used, these hybrid systems produce significant zones of thermal necrosis (50 µm) with measurable increases in posttreatment collagen thickness.[1]

NONABLATIVE LASERS

Most of the nonablative systems emit light in the infrared portion of the electromagnetic spectrum, including the intense pulsed light (500 to 1200 nm), neodymium:yttrium aluminum garnet (Nd:YAG) (1064 and 1320 nm), diode (980 and 1450 nm), and Er:Glass (1540 nm) lasers. These nonablative laser systems target dermal water, which leads to collagen heating and subsequent dermal remodeling, but without production of an external wound because of concomitant application of epidermal cooling that prevents tissue vaporization.

Because nonablative lasers have limited thermal tissue effect, treatments are commonly delivered in a series of 3 or more monthly sessions to produce mild clinical results.

FRACTIONAL LASERS

Since the introduction, in 2004, of the first fractional laser using the concept of fractional photothermolysis, a wide range of fractional ablative and nonablative lasers has become available. The mid-infrared wavelengths of these fractional systems target water-containing tissue to produce skin photocoagulation at depths of 200 to 500 µm with spacing between each microthermal zone of 200 to 300 µm.[30] Compared to fully ablative LSR, only 15% to 25% of treated skin is ablated during a typical fractional photothermolysis treatment. Differences in depth of ablation and coagulation, variation in available spot size and shape, application of energy (stamped vs rolling), and ergonomics of the laser handpiece distinguish one fractional device from another, but few differences in overall clinical improvement have been demonstrated.[2,3]

INDICATIONS AND CONTRAINDICATIONS FOR LASER SKIN RESURFACING

INDICATIONS

Pulsed, scanned, and fractional lasers have been used to successfully treat photodamaged skin, atrophic scars, and a variety of epidermal and dermal lesions (Figs. 209-1 to 209-3; Table 209-2).[1-3,9,16,31] Pulsed and scanned CO_2 lasers typically demonstrate 50% to 80% improvement of facial rhytides and acne scars after 1 skin resurfacing treatment.[9,21] The clinical results are longstanding and have been shown to improve for 18 months after treatment.[32] Although Er:YAG LSR also leads to substantive (>50%) improvement of photodamaged skin and scars, the modulated (variable pulsed Er:YAG) and hybrid (Er:YAG-CO_2) systems more closely mirror the clinical results obtained with CO_2 laser.[13,29] Similar clinical results can be obtained with the ablative fractionated lasers, but often more than one laser treatment is necessary.[2,3] Moderate to severe acne scarring in patients with a wide range of skin phototypes (I to V) shows significant (50% to 75%) clinical improvement in scar depth after 2 or 3 fractional CO_2 laser treatments.[33] Quantitative image analysis of nonacne atrophic traumatic or surgical

Figure 209-1 Facial photodamage and rhytides before (**A**) and several months after (**B**) ablative CO_2 laser skin resurfacing.

scars 6 months after fractional CO_2 laser treatments demonstrated clinical and volumetric improvement with mean reduction of scar volume and depth by 38% (traumatic scars) and 36% (surgical scars).[34]

One of the biggest advantages of fractional laser treatment is its ability to be safely and effectively applied to nonfacial as well as physiologically impaired skin with fewer pilosebaceous glands (eg, burn scars). As such, fractionated lasers can be used for a much wider range of skin conditions, including extensive body scars and photodamaged skin on the arms and legs.[3] In addition, fractionated lasers have shown usefulness

Figure 209-2 Facial photodamage and rhytides before (**A**) and 6 months after (**B**) fractional ablative CO_2 laser skin resurfacing.

Figure 209-3 Atrophic scars before (**A**) and 6 months after (**B**) fractional ablative CO_2 laser skin resurfacing.

TABLE 209-2
Lesions and Conditions Amenable to Laser Skin Resurfacing

- Actinic damage
  - Actinic cheilitis
  - Actinic keratoses
  - Facial rhytides (superficial and deep)
  - Superficial dyschromia (lentigines, melasma)
  - Superficial nonmelanoma skin cancer (squamous or basal cell carcinomas)
- Atrophic scars (acne, surgical, traumatic)
- Epidermal lesions
  - Seborrheic keratosis
  - Epidermal nevi
  - Verrucae
- Benign hyperplasias/neoplasms
  - Adnexal tumors (syringomas, angiofibromas)
  - Lymphangioma
  - rhinophyma
  - Sebaceous hyperplasia
  - Xanthomas, xanthelasma
- Miscellaneous dermatologic conditions
  - Balanitis xerotica obliterans
  - Chondrodermatitis nodularis helicis
  - Colloid milia
  - Eruptive hair cysts
  - Hailey-Hailey disease
  - Keratoderma
  - Lichen sclerosus
  - Onychodystrophy
  - Porokeratosis

in improving CO_2 laser–induced hypopigmentation, residua from infantile hemangioma, and topical drug delivery.[2,18]

PATIENT SELECTION

The ideal patient for cutaneous laser resurfacing has a fair complexion (Fitzpatrick skin phototype I or II) with photodamaged or scarred facial skin. Patients with darker skin tones (phototypes III to VI) are best treated with fractionated systems because of their lower postoperative dyspigmentation profile.[15] Importantly, the patient should have realistic expectations of the treatment process and the anticipated clinical results. Adequate preoperative patient evaluation and education are essential to optimize the clinical outcomes (Table 209-3). Because ablative LSR can be complicated by a prolonged postoperative recovery, pigmentary alteration, or an unexpected side effect, proper patient selection is paramount. The patient's emotional ability to tolerate an extended convalescence is an important factor in determining the most appropriate choice of laser for treatment.

Although CO_2 or modulated Er:YAG ablative LSR produces the most dramatic clinical results, some patients may be unable to tolerate the intensive recovery periods required. Ablative LSR postoperative recovery involves 7 to 10 days of intense wound healing during the reepithelialization process, followed by intense erythema for several additional weeks. For patients who are unable to commit to an extended recovery process, nonablative or fractional LSR may be a more appropriate choice. After AFR, intense erythema and serosanguinous drainage are evident for 2 to 3 days, followed by complete reepithelialization and diminution of erythema by day 6 or 7. Nonablative lasers typically produce mild erythema and edema, which spontaneously resolve within 24 hours. In contrast to ablative systems, nonablative and fractionated lasers can be safely applied to nonfacial areas because there is no epidermal disruption and, thus, areas with a

TABLE 209-3
Laser Skin Resurfacing: Patient Selection, Risks, and Precautions

- Are the lesions amenable to laser skin resurfacing?
  - All suspicious (malignant) lesions require biopsy before treatment.
- Has the patient *ever* had the areas treated before?
  - Laser skin resurfacing can unmask hypopigmentation or fibrosis produced by prior dermabrasion, cryosurgery, or phenol peels.
  - Patients with prior lower blepharoplasties using an external approach are at greater risk of ectropion formation after infraorbital ablative skin resurfacing.
- What is the patient's skin phototype?
  - After laser skin resurfacing, patients with lighter skin tones (skin phototype I or II) have a lower incidence of postoperative hyperpigmentation than patients with darker skin tones.
- Does the patient have a history of herpes labialis?
  - Prophylactic antiviral medication for patients undergoing perioral laser skin resurfacing is advised because reactivation and/or dissemination of prior herpes simplex virus infection can occur.
  - Laser-deepithelialized skin is particularly susceptible to primary inoculation by herpes simplex virus.
- Does the patient have evidence of inflammation (acne, psoriasis, eczema) or infection?
  - Avoidance of treatment in patients with active skin inflammation will reduce the risk of prolonged postoperative healing and disseminated infection.
- Does the patient have an immunologic deficiency or autoimmune disease?
  - Intact immunologic function and collagen repair mechanisms are necessary to optimize the tissue healing response during the recovery period.
- Is the patient taking any medications that are contraindicated?
  - Oral retinoids (eg, isotretinoin) have been shown to have a detrimental effect on wound healing and collagenesis leading many practitioners to delay treatment for 6 months after retinoid discontinuation; however, recent research has revealed no greater risk of postoperative hypertrophic scar formation with concomitant ingestion of oral retinoids and laser skin resurfacing.
- Does the patient have a tendency to form hypertrophic scars or keloids?
  - Patients with a propensity to scar abnormally will be at greater risk of scar formation after laser skin resurfacing, independent of laser selectivity and operator expertise.
- Does the patient have realistic expectations of the procedure and will the patient adhere to postoperative instructions?
  - Those who cannot physically or emotionally tolerate the postoperative recovery period should be dissuaded from pursuing ablative laser skin resurfacing procedures.

relative paucity of pilosebaceous glands necessary for reepithelialization (such as the neck and anterior chest) can be safely treated.

CONTRAINDICATIONS

When considering a patient for LSR, there are several contraindications of which the physician must be cognizant. First and foremost, patients must be counseled adequately such that their expectations are in line with the clinical results that can be reasonably expected from the LSR procedure.

Active skin infections—whether bacterial, viral, or fungal—are absolute contraindications to laser resurfacing procedures. Furthermore, as ablated skin heals from progenitor cells contained within the pilosebaceous units, patients with adnexal abnormalities may have significant issues with postoperative wound healing, and should not undergo ablative LSR. This subset of patients includes those who have previously undergone therapeutic skin irradiation which often compromises local adnexa.

As isotretinoin and other systemic retinoids affect the function of sebaceous units, the issue of pursuing ablative LSR in patients who have received isotretinoin therapy remains controversial. Although many experts in the field of laser surgery advocate a washout period of at least 6 months,[8,11-13] newer published research demonstrates normal reepithelialization and lack of scar formation in patients undergoing ablative LSR while on concomitant isotretinoin therapy.[35]

Patients who have a history of keloid or hypertrophic scar formation should be carefully counseled and considered, as these types of scars can potentially result from LSR. Patients with a history of extensive electrolysis or aggressive chemical peels and/or dermabrasion may have cutaneous adnexal structures that are damaged or absent, leading to impaired postoperative healing and unfavorable results. Patients with a history of skin grafts and previous ablative laser resurfacing procedures also fall into this category. Certainly, patients who have had prior treatments can undergo LSR, but laser parameters might need adjustments based on the observed intraoperative laser-tissue interaction.

Darker-skinned patients (skin phototypes III to VI) should be informed regarding the risk of hypopigmentation or hyperpigmentation after ablative LSR that may be permanent in some cases. In these patients, it may be prudent to perform a spot test on an inconspicuous area (eg, an area of the face normally obscured by the patient's hair). If no dyspigmentation is observed in the area several weeks to months after application, full-face treatment may be more comfortably pursued.

If a patient has a history of herpes labialis [herpes simplex virus (HSV)], the prophylactic antiviral regimen may be modified with earlier initiation of treatment and/or extension of the typical 7-day posttreatment course.[36]

PROCEDURE AND TECHNIQUE

PREOPERATIVE CARE

Currently, no consensus has been reached regarding the most appropriate preoperative medical regimen for LSR patients. The use of topical retinoic acid compounds, hydroquinone bleaching agents, or α-hydroxy acids for several weeks before cutaneous resurfacing has been touted by some as a means of speeding recovery and decreasing the incidence of postinflammatory hyperpigmentation; others, however, have reported that these regimens do little to affect, in particular, postoperative pigmentation.[37] Although topical tretinoin accelerates postoperative reepithelialization after dermabrasion and deep chemical peels, laser-induced wounds are intrinsically different from those created by other destructive methods, and, thus, laser skin penetration and postoperative healing are not typically affected by topical tretinoin application.[36]

Because of the moist, deepithelialized state of ablative laser-resurfaced skin and the potential for bacterial contamination and overgrowth, many laser surgeons advocate oral antibiotic prophylaxis. This practice remains controversial, particularly as a controlled study demonstrated no significant change in post-LSR infection rates with prophylactic antibiotic use.[38]

In contrast, given the susceptibility of LSR-treated skin to viral infection, antiviral prophylaxis is recommended for all ablative LSR patients regardless of prior HSV history. Oral prophylaxis is often started on the day of, or prior to, treatment and continues until reepithelialization is complete (7 to 10 days).[36]

ANESTHESIA

Most LSR procedures are delivered in outpatient office settings or ambulatory surgery facilities. Topical lidocaine cream or other anesthetic preparations are often applied for an hour prior to treatment in order enhance tissue hydration and anesthetic penetration prior to laser irradiation.[39] Regional nerve blockade and IV sedation may be used to provide more complete anxiolysis, amnesia, and sedation during ablative LSR procedures.[40]

PROCEDURE

SAFETY PRECAUTIONS

Standard protective health equipment and precautions should be observed. All patients, physicians, and staff in the room during LSR must wear appropriate protective eyewear throughout the entirety of the procedure. Furthermore, a smoke evacuator should be used to

protect patient and staff from inhalation of the ablative laser plume as it may contain both carcinogens and infectious particles. If the patient has been anesthetized with IV sedation and oxygen is in use, additional precautions must be taken to prevent combustion of the oxygen or other flammable substances by high-powered laser energy.

TECHNIQUE

After appropriate informed consent is obtained, eye protection is in place, and anesthesia or sedation is employed, laser treatment can begin. Ablative LSR is typically advised for the entire face to avoid postoperative discrepancy between treated and untreated skin in adjacent cosmetic units. Conversely, nonablative and fractional laser treatment can be performed on separate facial and nonfacial cosmetic units without fear of prolonged healing and mismatched skin. Regardless of laser system used, meticulous laser technique with nonoverlapping scans will minimize excessive thermal damage to skin during treatment. Additional laser passes are delivered perpendicular to previous passes until the desired clinical effect has been achieved. Optimal laser settings vary depending upon the laser system employed and the severity of the condition being treated.

Carbon Dioxide Ablative Laser Skin Resurfacing: The objective of ablative LSR is to vaporize unwanted skin lesions as deep as the papillary dermis. Limiting the depth of penetration decreases the risk of scarring and permanent pigmentary alteration. When choosing treatment parameters, several factors should be considered, including site to be resurfaced, the skin phototype of the patient, and previous skin treatments administered.[7,36] Anatomic location can guide selection of treatment parameters; for example, thinner skin (eg, periorbital) requires fewer laser passes than thicker facial skin, and laser resurfacing of nonfacial skin (eg, neck, chest) should be avoided because of the relative paucity of pilosebaceous units in these areas.[7,36]

The depth of ablation (usually restricted to the epidermis and upper papillary dermis) correlates directly with the number of passes performed.[41] "Stacking" laser pulses by treating an area with multiple passes in rapid succession or by using a high-overlap setting on a scanning device leads to excessive thermal injury with increased risk of scarring and should, thus, be avoided.[8,42] After several overlapped laser passes, an ablative plateau is reached, tissue ablation becomes less effective, and tissue heating (eg, thermal damage) is greatly increased.[42] To reduce the risk of excessive thermal injury during multipass LSR procedures, partially desiccated tissue should be removed manually with wet gauze after each pass to expose the underlying dermis to subsequent laser passes.[42]

In an attempt to address many of the difficulties associated with multipass CO_2 LSR, refinements in surgical technique have been developed. A minimally-traumatic single-pass CO_2 LSR procedure has been described that results in faster postoperative reepithelialization and an improved side-effect profile as compared to the multipass technique.[43] During this single-pass protocol, partially desiccated tissue is not removed (as is standard during multipass procedures); rather, the lased skin is left intact to serve as a biologic wound dressing. Additional laser passes can then be applied focally to areas of more extensive photodamage in order to limit unnecessary thermal and mechanical trauma to less-involved skin. Numerous reports have substantiated the improved side-effect profile of this less-aggressive protocol.[44-46]

Er:YAG Ablative Laser Skin Resurfacing: The short-pulsed Er:YAG laser fluences used most often range from 5 to 15 J/cm^2 depending on the degree of photodamage and anatomic location. Because of an improved absorption coefficient—10 times greater than CO_2 lasers—thermal energy conveyed during Er:YAG procedures is confined to the targeted tissue with minimal collateral thermal damage. Very little thermal tissue necrosis is produced with each pass of the short-pulsed Er:YAG laser, making manual removal of desiccated tissue between passes often unnecessary; however, it takes 3 to 4 times as many Er:YAG passes to achieve similar depths of penetration as the CO_2 laser at typical treatment parameters.[7] Treatment of deep dermal lesions or areas of the face with extensive photodamage may require up to 9 or 10 passes of the short-pulsed Er:YAG laser, whereas the CO_2 laser would affect similar levels of tissue ablation in only 2 or 3 passes.[7,10] Modified Er:YAG laser systems provide improved hemostasis and visualization of the treatment area, as well as enhanced collagen contraction because of the added thermal effects on the tissue.[13] As such, modified and hybrid systems are generally delivered as single treatments with clinical outcomes similar to pulsed or scanned CO_2 lasers.

Ablative Fractional Skin Resurfacing: Fractional CO_2 laser systems typically involve delivery of 70 to 100 mJ energies with 20% to 30% coverage to achieve depths of penetration of 200 to 1600 µm. Treatment of periocular skin (thinner) and neck skin (fewer pilosebaceous units) require a decrease in both energy and coverage density. Although clinical results and, thus, patient satisfaction may improve with the use of higher fluences, higher treatment energies increase the risk of adverse events such as pain, erythema, and postoperative dyspigmentation.[47] Ablative fractional lasers generally require only 1 treatment to achieve patient satisfaction. However, reappraisal of photodamage, rhytides, or scarring can be performed 6 to 12 months postoperatively to assess if additional treatments are clinically warranted.

Nonablative Laser Skin Resurfacing: Significant improvement of facial and nonfacial rhytides, scars, and dyspigmentation has been demonstrated using a wide range of different nonablative laser systems. Treatments are typically delivered in a series of 3 or more monthly sessions with clinical improvement averaging 30% to 50%. By increasing the

energy delivered, greater depth of dermal penetration (and tissue effect) is achieved. Similarly, increasing the density (or area of coverage) also serves to increase clinical effect without significantly altering postoperative recovery. In general, nonablative laser skin treatment of facial skin has shown superior results to nonfacial (eg, neck, chest, dorsal hand) skin; however, good clinical outcomes have been achieved in a variety of conditions and treatment areas (including traumatic scars and abdominal striae). Clinical assessment scores corresponding to 50% to 75% improvement or more are typically reported after a series of 3 or more treatments on facial rhytides.[48] Similarly, atrophic acne scars have shown remarkable improvement (50% and higher) after a treatment series using either a 1550-nm erbium-doped fiber laser or a number of other fractionated diode and Nd:YAG lasers (1410 nm to 1540 nm).[49-51] Additionally, nonablative fractionated lasers have been used with success to improve the appearance of large pores and hypertrophic scars from a variety of causes.[52-54]

POSTOPERATIVE CARE AND PATIENT INSTRUCTIONS

Proper wound care during the immediate postoperative period is vital to the successful recovery of laser-resurfaced skin. Partial-thickness cutaneous wounds heal more efficiently and with a reduced risk of scarring when maintained in a moist environment. The presence of a dry crust or scab impedes keratinocyte migration. Although there is consensus among laser surgeons on this principle, disagreement exists regarding the optimal dressing for the laser-ablated wound. Either an open or a closed wound dressing may be prescribed. The "open" dressing technique involves frequent application of thick healing ointment to the deepithelialized skin surface, whereas the "closed" technique calls for the placement of occlusive or semiocclusive dressings directly on the lased skin. Although the open technique facilitates wound visualization, the closed technique requires less patient involvement and may also decrease postoperative pain. Increased patient comfort, decreased erythema and edema, increased rate of reepithelialization, and decreased requirement for patient effort in wound care are among other advantages of closed wound dressings, but their use involves additional expense and a higher infection risk.[55]

In addition to wound care, postoperative ice pack application and the administration of antiinflammatory medications should be prescribed. Pain medication during the first few postoperative days is particularly important for patients undergoing fully ablative LSR. Comparatively, although pinpoint bleeding, serosanguinous drainage, and edema can be significant during the first 24 to 36 hours after AFR, minimal (if any) discomfort is present.

OUTCOMES ASSESSMENT

There are many clinical and histologic benefits of cutaneous laser resurfacing. The greatest advantages associated with CO_2 LSR are excellent tissue contraction, hemostasis, prolonged neocollagenesis, and collagen remodeling. Histologic examination of CO_2 laser-treated skin demonstrates replacement of epidermal cellular atypia and dysplasia with normal, healthy epidermal cells from adjacent follicular adnexal structures.[20] The most profound effects occur in the papillary dermis, where coagulation of disorganized masses of actinically-induced elastotic material are replaced with normal compact collagen bundles arranged in parallel to the skin's surface.[56] Immediately after CO_2 laser treatment, a normal inflammatory response is initiated with granulation tissue formation, neovascularization, and increased recruitment of macrophages and fibroblasts.[56]

After ablative CO_2 LSR, most studies have shown at least a 50% improvement over baseline skin tone and wrinkle severity.[3,6,7] Persistent collagen shrinkage and dermal remodeling are responsible for much of the continued clinical benefits observed after treatment and are influenced by several factors.[28,57] Thermal effects of laser skin irradiation result in collagen fiber contraction through disruption of interpeptide bonds at temperatures ranging from 55°C to 62°C (131°F to 143.6°F). This results in a conformational change of collagen's basic triple-helical structure, thereby shortening the molecule to approximately one-third of its normal length.[58] These laser-remodeled collagen fibers may act as the contracted scaffold for neocollagenesis. Fibroblasts that migrate into laser wounds after resurfacing may upregulate the expression of immune-modulating factors that serve to further enhance collagen shrinkage and ongoing neocollagenesis.[59]

Investigators have compared collagen tightening induced by the CO_2 laser to that induced by the CO_2–Er:YAG hybrid laser system.[60] Intraoperative contraction of approximately 43% was produced after three passes of the CO_2 laser, compared to 12% contraction after Er:YAG irradiation. At 4 weeks, however, the CO_2 laser-treated and Er:YAG laser-treated sites were contracted to the same degree. This highlights the different mechanisms of physiologic tissue tightening observed after various laser treatments. Immediate thermal-induced collagen tightening is the predominant response seen after CO_2 irradiation, whereas modulated Er:YAG laser resurfacing induces slow and progressive rather than immediate collagen tightening.[60-62]

Significant clinical improvement of rhytides and atrophic scars following fractional ablative LSR has been demonstrated in several published studies.[18,33,34,59] Moderate to marked (50% to 75%) improvement is typical, with better results obtained when higher energies and density coverage are implemented. Not surprisingly, the use of more-aggressive laser parameters tends to yield better clinical outcomes, but also longer postoperative recovery.[18]

SIDE EFFECTS AND COMPLICATIONS

Side effects associated with LSR vary and are related to the expertise of the operator, the anatomic location treated, the skin phototype of the patient, underlying skin conditions, the aggressiveness of the laser procedure, postoperative wound care, and several other variables (Table 209-4).

When most ablative LSR techniques are compared (single-pass CO_2 vs multipass, long-pulsed Er:YAG), postoperative healing times and complication profiles are comparable, even in patients with darker skin phototypes.[45] In a retrospective review and analysis of 100 consecutively-treated patients, investigators found that average time to reepithelialization was 5.5 days with single-pass CO_2 and 5.1 days with long-pulsed Er:YAG laser resurfacing.[46]

COMMON POSTOPERATIVE REACTIONS

Erythema and edema are expected in the immediate postoperative period and are not considered adverse events. The duration, incidence, and severity of erythema can vary between and among different CO_2 and Er:YAG systems.[11,12] The degree of erythema correlates directly with the depth of ablation and the number of laser passes performed.[7] In an extended evaluation of 50 patients, postoperative erythema averaged 4.5 weeks in duration after single-pass CO_2 laser treatment and 3.6 weeks after long-pulsed Er:YAG laser treatment.[46] A split-face comparison of pulsed CO_2 and variable-pulsed Er:YAG LSR revealed decreased erythema and edema with faster healing on the Er:YAG laser-treated facial half as compared to CO_2.[46]

TABLE 209-4

Side Effects and Complications of Ablative and Nonablative Laser Skin Resurfacing

Expected
- Erythema
- Edema
- Pruritus

Mild
- Prolonged erythema
- Milia
- Acne
- Allergic or irritant contact dermatitis

Moderate
- Infection (bacterial. viral, fungal)
- Transient hyperpigmentation

Severe
- Permanent hypopigmentation
- Hypertrophic scarring
- Ectropion

While postoperative erythema also may be aggravated by underlying rosacea or dermatitis, most erythema will resolve spontaneously. Application of topical ascorbic acid after reepithelialization may serve to decrease the degree of cutaneous inflammation.[62] Light-emitting diode photomodulation also has been shown to improve postlaser erythema and to help patients recover more quickly post-LSR.[63] Potentially irritating topicals, such as retinoic acid derivatives, glycolic acid, fragrance-containing or chemical-containing cosmetics, and chemical sunscreens should be strictly avoided in the early postoperative period until substantial reepithelialization has occurred.

MINOR SIDE EFFECTS

Mild side effects of ablative LSR include milia formation and worsening of acne which may be exacerbated by the postoperative use of occlusive dressings and ointments. Milia and acne usually resolve spontaneously as healing progresses and the application of thick emollient creams and occlusive dressings ceases. For acne flares that do not respond to topical preparations, oral antibiotics may be prescribed.

Contact dermatitis, either irritant or allergic, can develop in response to various topical medications, soaps, and moisturizers used postoperatively. Most of these reactions are irritant in nature, due in part to the decreased barrier function of newly resurfaced skin.[64]

Hyperpigmentation is one of the more common side effects of ablative LSR and occurs to some degree in all treated patients with darker skin tones.[7,11,15,65] The hyperpigmentation is generally transient, but resolution can be hastened by the postoperative use of a variety of topical agents, including hydroquinone as well as retinoic, azelaic, kojic, and glycolic acids. Daily sunscreen use is also important to prevent further skin darkening during the healing process.

Hypopigmentation is often not observed for several months postoperatively. Estimates vary, but postoperative hypopigmentation may occur in upwards of 10% to 20% of patients after ablative LSR.[66] Its incidence is markedly reduced with use of fractionated lasers. Hypopigmentation is of particular concern because it is often refractory to treatment and may be permanent. The use of an excimer laser or topical photochemotherapy to stimulate repigmentation has proven successful in some patients.[66,67] Others report improvement of hypopigmentation after the use of a non-AFR laser.[68]

MODERATE SIDE EFFECTS

The most common infection following ablative laser resurfacing is reactivation of labial HSV infection, most likely encouraged by thermal tissue injury and epidermal disruption.[11,15] After CO_2 LSR, approximately 7% of all patients develop a localized or disseminated form of HSV infection.[11,15,65] Evidence of HSV infection

typically presents within the first postoperative week and, because of the denuded condition of newly lased skin, can present as erosions without intact vesicles. Even with appropriate antiviral prophylaxis, it is possible for a herpetic outbreak to occur. To prevent dissemination or scarring, HSV infection should be treated aggressively.[7] Oral antiviral agents such as acyclovir, famciclovir, and valacyclovir are effective against HSV infection, although IV therapy may be required in severe (disseminated) cases. Because many patients may be unaware of their HSV status and because laser-ablated skin is susceptible to inadvertent exposure to HSV, most practitioners advocate the use of oral prophylaxis during the postoperative period until reepithelialization is complete (7 to 10 days).[8]

Other postoperative wound infections associated with ablative LSR include *Staphylococcus* and *Pseudomonas* infections as well as cutaneous candidiasis. All postoperative infections should be treated aggressively with the appropriate systemic antibiotic or antifungal agent.[55]

There have been rare reports of koebnerization of lesions (psoriasis, keratoacanthomas) after ablative LSR.[69] It is, thus, imperative to perform a full skin examination and obtain a complete medical and family history to determine whether a predilection for this undesirable side effect is present.

SEVERE COMPLICATIONS

The most severe complications associated with ablative cutaneous laser resurfacing are hypertrophic scarring and the formation of ectropion.[11,12] While the risk of scarring is low, inadvertent pulse stacking or scan overlapping and incomplete removal of desiccated tissue between laser passes can cause excessive thermal injury leading to fibrosis. Ablative laser resurfacing of skin with absent, poorly functioning, or decreased pilosebaceous units (eyelids, neck, chest) can also increase the likelihood of hypertrophic scar formation.

Postoperatively, focal areas of bright erythema with associated pruritus, particularly along the mandible, may signal impending scar formation.[15] Potent topical corticosteroid preparations should be applied to these areas to decrease the inflammatory response. Pulsed-dye laser treatment can be used to improve the appearance and symptoms of such scars.[70]

Ectropion of the lower eyelid is rarely seen after periorbital LSR; however, if encountered, it often requires surgical correction. Ectropion is more likely to occur in patients who have had previous lower blepharoplasty or other surgical manipulation of the periorbital region. Preoperative examination is essential to determine eyelid laxity and skin elasticity. If the infraorbital skin does not return briskly to its normal resting position after a manual downward pull ("snap test"), then ablative laser resurfacing near the lower eyelid margin should be avoided. In general, lower fluences and fewer laser passes should be used in the periorbital area to decrease the risk of fibrosis and lid eversion.

SIDE EFFECTS OF ABLATIVE FRACTIONAL LASER SKIN RESURFACING

The main advantages of ablative fractional lasers—as compared to fully ablative LSR techniques—are their excellent side-effect profiles and low incidence of complications.[15] Postoperative recovery is quicker and more predictable after AFR treatment, with pinpoint bleeding and serosanguinous discharge resolving within 24 to 48 hours. Intense erythema and crusting are typically seen for 3 to 6 days postoperatively. Moderate erythema lasts days to weeks, standing in sharp contrast to the months of erythema often experienced after traditional ablative LSR. Post-AFR erythema may be slower to resolve in patients with skin phototype I or II and in those who received more-aggressive treatments. Even with fractional resurfacing, particular care must be taken when treating anatomic sites with a relative paucity of pilosebaceous units such as the eyelids, neck, and chest. Excessive thermal injury in these areas can result in subsequent hypertrophic scarring. With proper technique, however, excellent clinical results can be achieved, accompanied by a quicker convalescence as compared to traditional ablative LSR and a much lower risk of scarring and dyspigmentation.

NEW AND FUTURE DEVELOPMENTS USING ABLATIVE LASERS

Ablative fractional lasers create microscopic vertical holes through the epidermis. In addition to stimulating the physiologic effects responsible for antiaging results, these microscopic holes can serve as channels through which topically applied drugs can gain access to the dermis.[71] Initial histologic studies have shown that the microthermal zones created by ablative fractional lasers penetrate to depths of at least 300 µm and diameters of 100 µm. The ability of a variety of different drugs, including topical methyl 5-aminolevulic acid, 5-aminolevulinic acid, lidocaine, platelet-rich plasma, autologous cells, corticosteroids, and ascorbic acid, to penetrate skin using laser-assisted delivery systems has been studied.[72] Dermal penetration of each of these drugs has uniformly been increased when applied to ablative fractional laser–treated skin. Because physicochemical properties of a particular drug greatly influence its ability to permeate tissues (even after stratum corneum penetration), the number, size, and depth of laser-induced channels affect drug delivery. AFR-assisted drug delivery promises to be an important dermatologic therapy in the future and numerous investigations are being conducted to evaluate appropriate drug-specific channel density and depth parameters for a wide variety of topical medications. In addition, fractional ablative lasers combined with

other laser technology have been shown to amplify clinical results and shorten recovery times in the treatment of pigmented lesions and tattoos.[73] Clinical trials are underway to elucidate the safety and effectiveness of these and other combination treatments using ablative and fractional laser technology.

REFERENCES

1. Alexiades-Armenakas M, Dover JS, Arndt KA. The spectrum of laser skin resurfacing: nonablative, fractional, and ablative laser resurfacing. *J Am Acad Dermatol.* 2008;58:719-737.
2. Brightman LA, Brauer JA, Anolik R, et al. Ablative and fractional ablative lasers. *Dermatol Clin.* 2009;27:479-489.
3. Aslam A, Alster TS. Evolution of laser skin resurfacing: from scanning to fractional technology. *Dermatol Surg.* 2014;40:1163-1172.
4. Walsh JT, Flotte TJ, Anderson RR, et al. Pulsed CO_2 laser tissue ablation: effect of tissue type and pulse duration on thermal damage. *Lasers Surg Med.* 1988;8:108-118.
5. Walsh JT, Deutsch TF. Pulsed CO_2 laser tissue ablation: measurement of the ablation rate. *Lasers Surg Med.* 1988;8:264-275.
6. Ross EV, McKinlay JR, Anderson RR. Why does carbon dioxide resurfacing work? *Arch Dermatol.* 1999;135:444-454.
7. Alster TS. Cutaneous resurfacing with CO_2 and erbium:YAG lasers: preoperative, intraoperative, and postoperative considerations. *Plast Reconstr Surg,* 1999;103:619-632.
8. Treatment of complications of laser skin resurfacing. *Arch Facial Plast Surg*. 2000 Oct-Dec;2(4):279-84.
9. Alster TS, Lupton JR. An overview of cutaneous laser resurfacing. *Clin Plast Surg.* 2001;28:37-52.
10. Alster TS, Lupton JR. Erbium:YAG cutaneous laser resurfacing. *Dermatol Clin.* 2001;19:453-466.
11. Nanni CA, Alster TS. Complications of carbon dioxide laser resurfacing: an evaluation of 500 patients. *Dermatol Surg.* 1998;24:315-320.
12. Alster TS, Doshi S. Ablative and non-ablative laser skin resurfacing. In Burgess C (ed). *Cosmetic Dermatology*. Heidelberg: Springer-Verlag, 2005: 111-126.
13. Alster TS, Tanzi EL. Laser skin resurfacing: ablative and nonablative. In: Robinson J, Sengelman R, Siegel DM, et al, eds. *Surgery of the Skin*. Philadelphia, PA: Elsevier; 2005:611-624.
14. Manstein D, Herron GS, Sink RK, et al. Fractional photothermolysis: a new concept for cutaneous remodeling using microscopic patterns of thermal injury. *Lasers Surg Med.* 2004;34:426-438.
15. Metelitsa AI, Alster TS. Fractionated laser skin resurfacing treatment complications: a review. *Dermatol Surg.* 2010;36:299-306.
16. MacGregor JL, Alster TS. Fractional resurfacing lasers: ablative and non-ablative. In: Nouri K, ed. *Dermatologic Surgery: Step by Step*. Oxford, England UK: Blackwell; 2013: 349-358.
17. Tierney EP, Kouba DJ, Hanke CW. Review of fractional photothermolysis: treatment indications and efficacy. *Dermatol Surg.* 2009;5:1445-1461.
18. Hunzeker CM, Weiss ET, Geronemus RG. Fractionated CO_2 laser resurfacing: our experience with more than 2000 treatments. *Aesthet Surg J*. 2009;29:317-322.
19. Lanzafame RJ, Naim JO, Rogers DW, et al. Comparisons of continuous-wave, chop wave, and superpulsed laser wounds. *Lasers Surg Med.* 1988;8:119-124.
20. Alster TS, Kauvar ANB, Geronemus RG. Histology of high-energy pulsed CO_2 laser resurfacing. *Semin Cutan Med Surg.* 1996;15:189-193.
21. Alster TS, Nanni CA, Williams CM. Comparison of four carbon dioxide resurfacing lasers: a clinical and histopathologic evaluation. *Dermatol Surg.* 1999;25:153-159.
22. Hibst R, Kaufmann R. Effects of laser parameters on pulsed ErYAG laser ablation. *Lasers Med Sci.* 1991;6:391-397.
23. Hohenleutner U, Hohenleutner S, Baumler W, et al. Fast and effective skin ablation with an Er:YAG laser: determination of ablation rates and thermal damage zones. *Lasers Surg Med.* 1997;20:242-247.
24. Alster TS. Clinical and histologic evaluation of six erbium:YAG lasers for cutaneous resurfacing. *Lasers Surg Med.* 1999;24:87-92.
25. Tanzi EL, Alster TS. Side effects and complications of variable-pulsed erbium:yttrium-aluminum-garnet laser skin resurfacing: extended experience with 50 patients. *Plast Reconstr Surg.* 2003;111:1524-1529.
26. Pozner JM, Goldberg DJ. Histologic effect of a variable pulsed Er:YAG laser. *Dermatol Surg.* 2000;26:733-736.
27. Ross EV, McKinlay JR, Sajben FP, et al. Use of a novel erbium laser in a Yucatan minipig: a study of residual thermal damage (RTD), ablation, and wound healing as a function of pulse duration. *Lasers Surg Med.* 1999;26:15-17.
28. Fitzpatrick RE, Rostan EF, Marchell N. Collagen tightening induced by carbon dioxide laser versus erbium:YAG laser. *Lasers Surg Med.* 2000;27:395-403.
29. Rostan EF, Fitzpatrick RE, Goldman MP. Laser resurfacing with a long pulse erbium:YAG laser compared to the 950 ms pulsed CO_2 laser. *Lasers Surg Med.* 2001;29:136-141.
30. Waibel J, Beer K, Narurkar V, et al. Preliminary observations on fractional ablative resurfacing devices: clinical impressions. *J Drugs Dermatol.* 2009;8:481-485.
31. Hruza GJ. Laser treatment of epidermal and dermal lesions. *Dermatol Clin.* 2002;20:147-164.
32. Walia S, Alster TS. Prolonged clinical and histologic effects from CO_2 laser resurfacing of atrophic acne scars. *Dermatol Surg.* 1999;25:926-930.
33. Walgrave SE, Ortiz AE, MacFalls HT, et al. Evaluation of a novel fractional resurfacing device for treatment of acne scarring. *Lasers Surg Med.* 2009;41:122-127.
34. Weiss ET, Chapas A, Brightman L, et al. Successful treatment of atrophic postoperative and traumatic scarring with carbon dioxide ablative fractional resurfacing: quantitative volumetric scar improvement. *Arch Dermatol.* 2010;146:133-140.
35. Alster TS, Khoury R. Treatment of laser complications. *Facial Plast Surg.* 2009;25:316-323.
36. Alster TS. Preoperative preparation for CO_2 laser resurfacing. In: Coleman WP, Lawrence N, eds. *Skin Resurfacing*. Baltimore, MD: Williams & Wilkins; 1998:171-179.
37. Alster TS, Tanzi EL. Complications in laser and light surgery. In: Goldberg DB, ed. *Laser Skin Surgery.* Vol. 2. Philadelphia, PA: Elsevier;2005:103-118.
38. Walia S, Alster TS. Cutaneous CO_2 laser resurfacing infection rate with and without prophylactic antibiotics. *Dermatol Surg.* 1999;25:857-861.
39. Kilmer SL, Chotzen V, Zelickson BD, et al. Full-face laser resurfacing using a supplemented topical anesthesia protocol. *Arch Dermatol.* 2003;139:1279-1283.

40. Bing J, McAuliffe MS, Lupton JR. Regional anesthesia with monitored anesthesia care for dermatologic laser surgery. *Dermatol Clin.* 2002;20:123-134.
41. Ruback BW, Schroenrock LD. Histological and clinical evaluation of facial resurfacing using a carbon dioxide laser with the computer pattern generator. *Arch Otolaryngol Head Neck Surg.* 1997;123:929-934.
42. Fitzpatrick RE, Smith SR, Sriprachya-anunt S. Depth of vaporization and the effect of pulse stacking with a high-energy, pulsed carbon dioxide laser. *J Am Acad Dermatol.* 1999;40:615-622.
43. David L, Ruiz-Esparza J. Fast healing after laser skin resurfacing: the minimal mechanical trauma technique. *Dermatol Surg.* 1997;23:359-361.
44. Ruiz-Esparza J, Barba Gomez JM. Long-term effects of one general pass laser resurfacing: a look at dermal tightening and skin quality. *Dermatol Surg.* 1999;25:169-174.
45. Alster TS, Hirsch RJ. Single-pass CO_2 laser skin resurfacing of light and dark skin: extended experience with 52 patients. *J Cosmet Laser Ther.* 2003;5:39-42.
46. Tanzi EL, Alster TS. Single-pass carbon dioxide versus multiple-pass Er:YAG laser skin resurfacing: a comparison of postoperative wound healing and side-effect rates. *Dermatol Surg.* 2003;29:80-84.
47. Kono T, Chan HH, Groff WF, et al. Prospective direct comparison study of fractional resurfacing using different fluences and densities for skin rejuvenation in Asians. *Lasers Surg Med.* 2007;39:311-314.
48. Wanner M, Tanzi EL, Alster TS. Fractional photothermolysis: treatment of facial and non-facial cutaneous photodamage with a 1,550 nm erbium-doped fiber laser. *Dermatol Surg.* 2007;33:23-28.
49. Alster TS, Tanzi EL, Lazarus M. The use of fractional laser photothermolysis for the treatment of atrophic scars. *Dermatol Surg.* 2007;33:295-299.
50. Hu S, Chen MC, Lee MC, et al. Fractional resurfacing for the treatment of atrophic facial acne scars in Asian skin. *Dermatol Surg.* 2009;35:826-832.
51. Chan NP, Ho SG, Yeung CK, et al. The use of non-ablative fractional resurfacing in Asian acne scar patients. *Lasers Surg Med.* 2010;42:710-715.
52. Kunishige JH, Katz TM, Goldberg LH, et al. Fractional photothermolysis for treatment of surgical scars. *Dermatol Surg.* 2010;36:538-541.
53. Waibel J, Wulkan AJ, Lupo M, et al. Treatment of burn scars with the 1,550 nm nonablative fractional erbium laser. *Lasers Surg Med.* 2012;44:441-446.
54. Saedi N, Petrell K, Arndt K, et al. Evaluating facial pores and skin texture after low-energy nonablative fractional 1440-nm laser treatments. *J Am Acad Dermatol.* 2013;68:113-118.
55. Sriprachya-anunt S, Fitzpatrick RE, Goldman MP, et al. Infections complicating pulsed carbon dioxide laser resurfacing for photo-aged facial skin. *Dermatol Surg.* 1997;23:527-536.
56. Ratner D, Viron A, Puvion-Dutilleul F, et al. Pilot ultrastructural evaluation of human preauricular skin before and after high-energy pulsed carbon dioxide laser treatment. *Arch Dermatol.* 1998;134:582-587.
57. Ross E, Naseef G, Skrobal M, et al. In vivo dermal collagen shrinkage and remodeling following CO_2 laser resurfacing. *Lasers Surg Med.* 1996;18:38-43.
58. Flor PJ, Spurr OK. Melting equilibrium for collagen fibers under stress: elasticity in the amorphous state. *J Am Chem Soc.* 1960;83:1308.
59. Alster TS. On: increased smooth muscle actin, factor XIIIa, and vimentin-positive cells in the papillary dermis of carbon dioxide laser-debrided porcine skin. *Dermatol Surg.* 1998;24:155.
60. Ross VE, Miller C, Meehan K, et al. One-pass CO_2 versus multiple-pass Er:YAG laser resurfacing in the treatment of rhytides: a comparison side-by-side study of pulsed CO_2 and Er:YAG lasers. *Dermatol Surg.* 2001;27:709-715.
61. Zachary CB. Modulating the Er:YAG laser. *Lasers Surg Med.* 2002;26:223-226.
62. Alster TS, West TB. Effect of topical vitamin C on postoperative carbon dioxide resurfacing erythema. *Dermatol Surg.* 1998;24:331-334.
63. Alster TS, Wanitphakdeedecha R. Improvement of post-fractional laser erythema with light-emitting diode photomodulation. *Dermatol Surg.* 2009;35:813-815.
64. Fisher AA. Lasers and allergic contact dermatitis to topical antibiotics, with particular reference to bacitracin. *Cutis.* 1996;58:252-254.
65. Manuskiatti W, Fitzpatrick RE, Goldman MP. Long-term effectiveness and side effects of carbon dioxide laser resurfacing for photoaged facial skin. *J Am Acad Dermatol.* 1999;40:401-411.
66. Friedman PM, Geronemus RG. Use of the 308-nm excimer laser for postresurfacing leukoderma. *Arch Dermatol.* 2001;137:824-825.
67. Grimes PE, Bhawan J, Kim J, et al. Laser resurfacing-induced hypopigmentation: histologic alteration and repigmentation with topical photochemotherapy. *Dermatol Surg.* 2001;27:515-520.
68. Glaich AS, Rahman Z, Goldberg LH, et al. Fractional resurfacing for the treatment of hypopigmented scars: a pilot study. *Dermatol Surg.* 2007;33:289-294.
69. Mamelak AJ, Goldberg LH, Marquez D, et al. Eruptive keratoacanthomas on the legs after fractional photothermolysis: report of two cases. *Dermatol Surg.* 2009;35:513-518.
70. Alster TS, Nanni CA. Pulsed-dye laser treatment of hypertrophic burn scars. *Plast Reconstr Surg,* 1998;102:2190-2195.
71. Haedersdal M, Erlendsson AM, Paasch U, et al. Translational medicine in the field of ablative fractional laser (AFXL)-assisted drug delivery: a critical review from basics to current clinical status. *J Am Acad Dermatol.* 2016;74:981-1004.
72. Bloom BS, Brauer JA, Geronemus RG. Ablative fractional resurfacing in topical drug delivery: an update and outlook. *Dermatol Surg.* 2013;39:839-848.
73. Weiss ET, Geronemus RG. Combining fractional resurfacing and Q-switched ruby laser for tattoo removal. *Dermatol Surg.* 2011;37:97-99.

Chapter 210 :: Nonablative Laser and Light-Based Therapy: Cosmetic and Medical Indications

:: Jeffrey S. Orringer

AT-A-GLANCE

- Nonablative treatments produce no clinical wounds.
- Nonablative procedures are associated with minimal social downtime and a low risk of complications.
- Several visible light and infrared wavelengths may be used for nonablative applications.
- Nonablative devices may be used for a variety of conditions including benign pigmented lesions, vascular lesions, hair removal, tattoo removal, scarring, and wrinkles.

BACKGROUND

Much of modern laser therapy is based on the principle of selective photothermolysis, first detailed by Anderson and Parrish in 1983.[1] In short, this principle states that with the use of a wavelength of light that is preferentially absorbed by a cutaneous target applied over an appropriate pulse duration, a skin structure may be selectively destroyed if adequate energy is delivered. This principle opened the door to a revolution in laser and light-based therapy for a wide variety of both medical and cosmetic applications.

Laser and light-based therapy may be categorized as nonablative when a biologic change is produced without the creation of a clinically relevant wound. Thus, as opposed to ablative laser techniques, nonablative treatments tend to necessitate minimal postprocedure wound care and are associated with a highly favorable risk profile. Although nonablative devices in general may produce results that are sometimes less dramatic than ablative techniques for some indications, they are the clear treatment of choice for a number of aesthetic and medical conditions. For some indications, serial nonablative procedures may produce results that approach or even surpass those that may be obtained from more invasive procedures.

Nonablative lasers may be further categorized as those utilizing visible light or infrared light. In addition, light-based devices that involve a broad band of wavelengths are often referred to as intense pulsed light (IPL) systems. Other energy-based devices that are used in a nonablative fashion such as radiofrequency devices and focused ultrasound systems may also have a variety of aesthetically oriented applications, and these will be reviewed in greater detail elsewhere in the text (Chap. 211). Another increasingly critical subcategory of energy-based systems is that of fractionated or fractional devices. Based on the principle of fractional photothermolysis first reported by Manstein and colleagues in 2004, a fractionated application of laser energy involves numerous microscopically small laser beams applied to the skin with sparing of a percentage of intervening skin surface area.[2] The resulting columns of thermally altered tissue are called microscopic treatment zones (MTZs).[3] These MTZs form the basis of clinical changes while the intervening untreated skin facilitates relatively rapid healing. In this way, patient safety is enhanced while social downtime is minimized.

PERIOPERATIVE CONSIDERATIONS

PATIENT SELECTION

There has been a significant trend in aesthetic medicine toward treatments that produce clear results but minimize interruptions in patients' lives. Nonablative laser therapy is generally associated with the need for rather brief social downtime, but patients must be counseled about the expected healing process. With nonablative treatments for many conditions such as certain vascular lesions and benign pigmented lesions, results are often dramatic and fairly rapid in onset. Alternatively, achieving optimal outcomes for some other indications such as acne scarring and rhytides may require serial procedures and results may be more subtle and develop very gradually. Thus, ideal patients for nonablative laser therapy are those who are willing and able to handle the resulting brief social downtime and who are willing to accept potentially more subtle results for some conditions. Potential candidates for nonablative treatments are generally attracted to the very favorable risk profile of many such procedures.

Patients of any age are reasonable candidates for some forms of nonablative laser therapy, while in other cases, elderly patients or those with severe photodamage may not be ideal patients. For example, nonablative laser resurfacing may produce results that are too subtle for a patient with deep rhytides and profound skin laxity to appreciate a meaningful clinical difference. Patients of either gender are likely to respond to

nonablative treatments, and men are now increasingly among those seeking noninvasive laser therapy and other aesthetic procedures.[4]

Particular care must be taken when performing some forms of nonablative laser and light-based procedures on patients with darker skin tones due to an increased risk of postinflammatory dyspigmentation. Although many infrared lasers are essentially "color blind" and may be safely used for patients of any Fitzpatrick skin type, the use of some shorter-wavelength visible-light devices must be undertaken only with great care in patients with more pigmented skin using lower fluences and often with the use of perioperative topical therapies such as hydroquinone. In such cases, initial treatment of small test areas is recommended.

RISKS AND POTENTIAL COMPLICATIONS

Nonablative therapies have become extremely popular in part because of the very low risk of complications associated with the proper use of these devices.[5] However, it is vital to recall that these procedures may, in fact, produce significant complications and a detailed and thorough knowledge of skin optics and cutaneous physiology is necessary to mitigate against these risks.[6-8] Patients must be counseled that infection, scarring, and temporary or even permanent skin discoloration may result from these procedures. In fact, a survey from the American Society for Dermatologic Surgery notes that some nonablative procedures such as laser hair removal result in significant numbers of complications annually—particularly when performed by nonphysicians.[9]

Although many nonablative procedures may create no apparent surface changes in the skin, others may produce some degree of crusting requiring topical therapy such as emollients. Other potential complications include ocular injuries which may be prevented with the use of wavelength-appropriate eyewear and patient safety goggles or corneal shields. Localized tissue reactions such as edema and erythema are associated with many nonablative treatments.

SAFETY

A detailed knowledge of laser safety regulations and procedures is required to optimize the safety of not only patients but also clinical personnel. Basic safety precautions demand the use of wavelength-specific eye protection and the posting of device-specific warning signs on the treatment room door. All windows must be appropriately covered and smoke evacuators used when there are concerns about the formation of a laser plume. Reflective surfaces adjacent to the treatment site should be covered and care must be taken to avoid circumstances that increase the risk of an electrical fire. Many institutions have specific laser privileging processes and policies regarding the potential delegation of any laser treatment. Device-specific in-service training of laser support personnel is required. All safety measures taken should ideally be in accordance with the American National Standards Institute (ANSI) guidelines that describe best practice laser safety methods in health care facilities.

ANESTHESIA

Although media descriptions of various nonablative procedures may suggest that such treatments are virtually painless, pain of variable intensity is often associated with nonablative therapy.[10] Many nonablative procedures may be tolerated without the use of anesthetic techniques whereas others may require a variety of interventions such as the use of topical anesthetic creams, ice applications, forced chilled air, local anesthesia, oral or injectable analgesics, and/or regional nerve blocks. There is great variability in patient tolerance for these treatments, and it is critical to work with each patient to understand his or her needs and expectations to optimize patient comfort. The latter is a critical part of patient satisfaction.

PERIOPERATIVE CARE

Most nonablative laser procedures do not require a specific perioperative topical regimen, but patients with darker Fitzpatrick skin types may be treated with hydroquinone or other agents intended to minimize the risk of postinflammatory dyspigmentation. Commonly, patients are asked to apply petrolatum to treated skin to facilitate healing after laser therapy, particularly when surface changes such as crusting occur. Although the use of antibacterial antibiotics is usually not required, patients with a strong history of herpes simplex may benefit from prophylactic perioperative antiviral medications in some cases. Because many nonablative laser procedures generate significant erythema and edema, topical application of ice and elevation of treated body sites are often advised.

TYPES OF DEVICES

VISIBLE AND INFRARED LASERS AND INTENSE PULSED LIGHT

There is a wide variety of laser systems available for dermatologic uses. Although many lasers, such as the argon, copper vapor, and krypton lasers, are of primarily historical significance in dermatology, others are widely used for a number of applications. The flashlamp-pumped pulsed dye laser, now most

commonly used at a wavelength of 595 nm, remains the gold standard device for several applications including the treatment of port-wine stains and a variety of benign vascular conditions that are of significant cosmetic concern to patients. The 532-nm-wavelength potassium titanyl phosphate (KTP) laser is commonly used to treat vascular conditions such as discrete telangiectases and facial hypervascularity. The long-pulsed 1064-nm-wavelength neodymium yttrium-aluminum-garnet (Nd:YAG) laser is commonly used for facial vessels, "spider veins" of the legs, and hair removal, whereas diode lasers (810 nm) are one of the more commonly used systems for hair removal. Another commonly used wavelength, 755 nm, is used by a variety of long-pulsed alexandrite laser systems, with common applications including the treatment of vascular lesions and hair removal. The ruby (694-nm) laser was the first laser used for dermatologic applications, and this wavelength is still employed by some systems in the treatment of both pigment-related and vascular conditions. Carbon dioxide (10,600 nm) and erbium:YAG (2940 nm) lasers are most frequently used for resurfacing applications, but these are considered ablative devices for most applications. However, several other infrared laser systems have been used for nonablative dermal remodeling including both fractionated and nonfractionated systems. Examples of nonfractionated devices include the 1320-nm-wavelength novel Nd:YAG laser, the 1450-nm-wavelength diode laser, and the 1540-nm-wavelength erbium-doped phosphate glass laser. Fractionated nonablative devices include the 1550-nm-wavelength erbium-doped fiber laser as well as a variety of other systems using several other wavelengths (1440, 1540, and 1927 nm, for example). The excimer laser (308-nm) is an ultraviolet light source sometimes used to treat conditions such as psoriasis and vitiligo. Some of the laser wavelengths noted above may be used in Q-switched mode with brief nanosecond-range pulse durations (and more recently with even shorter picosecond pulse durations) to treat pigmented lesions such as lentigines and tattoos. Finally, there are multiple systems available that produce a broad band of visible and infrared light. Although these devices are not truly lasers, such IPL systems have overlapping applications in the treatment of such conditions as vascular lesions, pigmentation, and unwanted hair. These IPL systems usually generate a band of light with wavelengths ranging from about 500 to 1200 nm. Filters are used with these systems to narrow the spectrum of light applied to the skin and to, thereby, more specifically target certain skin chromophores.

The advent of various cooling techniques that are intended to protect the epidermis has, in some cases, allowed for the safe and effective use of higher fluences.[11-13] The most common cooling techniques involve a dynamic cryogen spray, direct contact cooling such as with the use of a chilled sapphire tip, or bulk cooling with the use of a forced cold air chiller unit. By chilling the surface of the skin, the epidermis is cooled even as dermal structures are targeted and complications such as blistering and crusting are often avoided.

RADIOFREQUENCY AND ULTRASOUND SYSTEMS

Several commercially available devices use radiofrequency energy and focused ultrasound waves to create cutaneous changes. In most cases, these systems are used to heat the dermis and and/or subcutaneous structures in a nonablative fashion. Applications include skin tightening, decreasing adipose tissue, and skin rejuvenation via dermal remodeling. These devices and procedures will be reviewed in greater detail in Chap. 211, "Noninvasive Body Contouring."

APPLICATIONS

TREATMENT OF VASCULAR LESIONS

Numerous cosmetic and medical vascular conditions are responsive to nonablative laser therapy. Efficacious devices use wavelengths near peaks in the absorption spectrum for oxygenated hemoglobin. Selective targeting of hemoglobin results in thermal damage to blood vessels within the treated lesions, including coagulation of vessel walls.

PORT-WINE STAINS

Port-wine stains (PWSs) or capillary vascular malformations are relatively common, generally congenital lesions that usually present as pink or red patches at birth (Fig. 210-1). Over a period of years, PWSs grow in proportion to the patient and, because of progressive ectasia of the vessels, may gradually darken such that many are dark red or purple in color by adulthood. Many such lesions also become hypertrophic and may develop discrete vascular papules within them that are a potential source of bleeding.[14] In rare cases, PWSs may be acquired during adolescence or adulthood and their development may be related to trauma to the affected skin.[15,16] In other instances, PWSs may be associated with multisystem conditions such as Sturge-Weber syndrome or Klippel-Trenaunay syndrome (Chap. 147). PWSs may be functionally, psychosocially, and aesthetically impactful, and laser therapy is the treatment of choice for the vast majority of capillary vascular malformations.

A number of continuous-wave lasers such as the argon laser were initially applied to the treatment of PWSs, but complications such as scarring and dyspigmentation due to bulk heating limited their use.[17] With the introduction of pulsed laser systems in the 1980s, the flashlamp-pumped pulsed dye laser (PDL) emerged as the gold standard treatment for PWSs. PDL systems involve a high-power flashlamp whose energy excites organic rhodamine dye. This leads to the production of yellow light of a specific wavelength.

Figure 210-1 Capillary vascular malformation (port-wine stain) of the central face, before (**A**) and after (**B**) serial pulsed dye laser therapy.

Earlier systems used 585-nm-wavelength laser light, whereas more recent PDLs have used a wavelength of 595 nm, thought to be preferable in the treatment of PWSs because of the comparatively increased tissue penetration of the longer wavelength. Relatively short pulse durations (0.45-1.5 msec) are generally used in the treatment of PWSs.[18] This leads to purpura that lasts for approximately 1 to 2 weeks post-treatment. The advent of dynamic cryogen spray cooling to protect the epidermis has allowed for the use of higher fluences, potentially leading to more pronounced results and a decreased risk of complications. A series of treatments, sometimes with progressively higher fluences, is generally required for optimal results. Although only a small minority of PWSs respond completely to laser therapy, the vast majority (more than 85% of patients) demonstrate significant improvement with lightening of at least 50% or better.[18] Some degree of clinical recurrence is fairly common as residual vessels undergo gradual dilation in accordance with the natural history of these lesions.[19] Periodic laser therapy may thus be required to maintain improvements achieved with the initial treatment series.

Other devices including KTP lasers, Nd:YAG lasers, combined PDL/Nd:YAG lasers, and IPL systems also have been employed in the treatment of PWSs with varying results. The long-pulsed alexandrite (755-nm) laser and the long-pulsed Nd:YAG (1064-nm) laser have proven useful in treating the exophytic papules that may develop within PWSs. The latter tend to produce less purpura than do PDL systems, but the use of the Nd:YAG laser in the treatment of PWSs has been associated with a relatively increased risk of scarring as compared to the PDL.[20]

The anatomic location of the PWS and its size may impact final clinical results with laser therapy.[21] In general, facial lesions clear more easily at the lateral aspects of the face whereas central facial PWSs of the cheeks and upper lip tend to be more resistant. Larger lesions of the extremities, and in particular of the legs, may be less treatment responsive than those of the trunk or head and neck.[21,22] In addition, smaller lesions tend to clear with laser therapy more completely than do larger PWSs. Some advocate early treatment starting before one year of age, although positive results may be achieved at any age.[22-25]

HEMANGIOMAS

Infantile hemangiomas (IHs) are common benign vascular tumors that generally appear in the first month of life and tend to initially present as a circumscribed erythematous telangiectatic plaque (Chap. 118).[26] These benign proliferations of endothelial tissue undergo a period of growth lasting several months before stabilizing in appearance and then eventually gradually involuting over a period of years.[27] Although many IHs do not require active intervention, others are associated with complications such as bleeding, ulceration, infection, and impingement on vital structures. Such lesions may be treated with a variety of topical or systemic medications and/or laser therapy. The ability of transcutaneous lasers to improve deeper hemangiomas is limited, but PDL treatments do speed re-epithelialization of ulcerated IHs and may halt the growth of some superficial lesions.[26,28] Because of the potential for side effects from the laser therapy itself, treatment should be considered carefully given the natural history of IHs and the expectation of spontaneous involution over time.

Following maximal involution of IHs, about 50% of patients have no trace of the lesion remaining whereas many others are left with residual fibrofatty tissue and telangiectases.[29] PDL treatments (or those using other vascular devices such as IPL or the KTP laser) are quite effective at improving the residual superficial hypervascularity. Fibrofatty tissue has traditionally been treated with surgical excision, but fractionated laser resurfacing has more recently been used to address this issue with promising results.[30]

TELANGIECTASES, ANGIOMAS, VENOUS LAKES

Particularly among patients with lighter skin tones, prominent facial telangiectases are a very common reason for which patients seek cosmetic intervention (Fig. 210-2). Whether based on photodamage, rosacea, autoimmune disorders, or other causes, telangiectasia may be aesthetically problematic. Individual vessels are efficiently treated with KTP and Nd:YAG lasers, usually without resulting purpura. For broad areas of hypervascularity in the setting of photodamage or rosacea, the pulsed dye laser is often highly effective. Newer systems with programmable extended pulse durations (≥6 msec) generally allow for purpura-free treatments. Multiple passes and/or pulse stacking techniques may sometimes be used to enhance efficacy.[31,32] Hypervascular poikiloderma of Civatte may similarly respond well to PDL treatments. IPL treatments are a commonly used and effective alternative for the treatment of facial redness.

A variety of other common benign vascular lesions may be effectively addressed with nonablative laser therapy. Angiomas and venous lakes in particular are common aesthetic issues that are handled nicely with pulsed dye, KTP, or Nd:YAG laser treatments. Typically, only 1 or 2 treatment sessions result in the complete resolution of these lesions. Although surgery or endovenous techniques are generally required for true varicose veins of the legs, smaller prominent vessels may be effectively treated transcutaneously with a variety of systems including the Nd:YAG, alexandrite, diode (940-nm), and pulsed dye lasers. See Chap. 212 for more information on the treatment of leg veins.

Figure 210-2 Telangiectatic vessels of the nose, before (**A**) and after (**B**) potassium titanyl phosphate (KTP) laser therapy.

TREATMENT OF PIGMENTED LESIONS

Treatment of benign pigmented lesions is frequently performed with Q-switched (QS) lasers of a variety of wavelengths.[33] Care must be taken to appropriately diagnose pigmented lesions to avoid the inadvertent treatment of premalignant or malignant lesions. Laser therapy may lighten the color of such lesions and thereby potentially impede the diagnosis of a pigmented malignancy. Only lesions felt to have no increased risk of malignant degeneration should be treated with laser therapy.[34,35]

LENTIGINES AND SEBORRHEIC KERATOSES

Lentigines are among the most common reasons for patients to seek a cosmetic dermatology consultation. These lesions may be effectively treated with QS-alexandrite, QS-ruby, and frequency doubled (532-nm)

QS-Nd:YAG lasers. The latter may more frequently cause some purpura in association with the treatment, but all of these devices are quite effective. Immediately following QS laser treatment, a white frosting of the epidermis transiently appears at the treatment sites. This represents intraepidermal water vapor and the whitening effect fades within several minutes. Facial lesions ultimately typically become a bit darker and scaly or develop superficial crusting for approximately 5 days postprocedure, whereas those located on the trunk or extremities may require longer periods (often 1-2 weeks) for healing. IPL is another potentially efficacious treatment for lentigines, although results with this modality are sometimes more gradual and require multiple treatments. Thin seborrheic keratoses also respond nicely to QS laser therapy, with the advantage over cryotherapy of a significantly decreased risk of hypopigmentation and a more predictably favorable outcome.

CAFÉ-AU-LAIT MACULES AND BECKER NEVI

QS lasers using various wavelengths (532, 694, 755, and 1064 nm) are potentially effective for café-au-lait macules and for Becker nevi (Fig. 210-3). The latter respond less consistently. Both types of lesions should initially be treated with test spots of various wavelength lasers to determine which, if any, is most likely to provide a positive outcome. Recurrence of these lesions is possible even after apparent clinical resolution. Even if the pigment within a Becker nevus is only partially responsive to QS laser therapy, the density of hair often seen within these lesions may be reduced with laser hair removal. Hair reduction may provide a significant cosmetic benefit when hypertrichosis is a striking feature.[36]

Figure 210-3 Café-au-lait macule of the right upper lip, before (**A**) and after (**B**) Q-switched alexandrite laser therapy.

NEVUS OF OTA AND NEVUS OF ITO

Nevi of Ota and Ito are more commonly seen among Asian patients, with the former located on the face and the latter seen on the neck. These melanocytic lesions are benign but may be aesthetically disfiguring. Given the depth of pigmentation in nevi of Ota and Ito, relatively deeper-penetrating laser wavelengths are generally used. The QS ruby, alexandrite, and Nd:YAG lasers all may be effective for these lesions.[37] Multiple treatments are usually required for maximal correction.

MELASMA

This common but poorly understood condition is often resistant to QS laser and IPL treatments. More recently, nonablative fractionated laser therapy used with conservative energy levels has been performed for this condition with somewhat more encouraging yet variable results.[38,39] New protocols using low-fluence QS 1064-nm-wavelength Nd:YAG lasers are being developed and studied for the treatment of melasma.[40,41] Mainstays of treatment continue to include topical therapies and avoidance of factors including ultraviolet light that tend to exacerbate melasma.

HAIR REMOVAL

Laser hair removal has become among the most commonly performed cosmetic procedures. Lasers or light-based devices work to remove hair by injuring the follicular unit following absorption of energy by its melanin-containing structures. Thermal damage to the follicle ensues, thus preventing new hair growth. There is some controversy as to the exact mechanism(s) of action of laser hair removal in that various authors have proposed the need to destroy cells of the hair bulge and/or the hair bulb to achieve long-term hair removal.[42,43]

Although most patients seek photoepilation for cosmetic reasons, others undergo laser hair removal for medical reasons such as pseudofolliculitis barbae. Patients with excessive hair growth, in particular those with signs of an endocrinopathy, should be evaluated by an endocrinologist. Regardless of the etiology or patient motivation for hair removal, treatment is not effective for white or blond hair because the lack of eumelanin content in such hair does not facilitate adequate absorption of laser energy. Similarly, thick or coarse hair is generally easier to remove than fine

hair because there is simply less target chromophore in the more wispy hair seen among some patients. The use of longer-wavelength devices such as the 1064-nm Nd:YAG laser has allowed patients with darker skin tones to be candidates for safe and effective laser hair removal.[44,45] The relatively less pronounced absorption of longer wavelengths by epidermal melanin content decreases the chances of complications such as dyspigmentation, yet the energy is still absorbed well enough by deeper pigment-containing structures in the hair follicle to allow for adequate efficacy.[46] In addition, the use of longer pulse durations in laser hair removal for patients with darker skin tends to heat skin structures more slowly and thus further decreases the risks of hypopigmentation and/or hyperpigmentation. For all patients undergoing laser hair removal, strict perioperative sun precautions are necessary to avoid dyspigmentation. Patients must also be instructed to avoid alternative hair removal treatments such as waxing, threading, and plucking that actually remove the target chromophore and render photoepilation ineffective. Shaving unwanted hair is acceptable and, in fact, is routinely performed prior to treatment to allow maximal penetration of laser energy without significant absorption at the surface of the skin. This may help avoid burns due to singeing of surface hair.

Laser or IPL-based hair removal is generally performed as a series of treatments and there is often the need for some degree of maintenance therapy even when long-term hair reduction is achieved. Direct comparative studies seem to indicate that the long-pulsed alexandrite (755-nm) and diode (810-nm) lasers are among the most effective devices for this indication.[46] However, excellent results also have been demonstrated for both the Nd:YAG (1064-nm) laser and several IPL systems. Most devices used for photoepilation include a cooling system to minimize epidermal damage and decrease the potential for complications. Patients can usually expect erythema and perifollicular edema following each treatment, but the need for significant social downtime is uncommon with this procedure. One complication of photoepilation that may be unique to laser hair removal is paradoxical new hair growth in the area surrounding the treatment site.[47] This is more commonly seen in patients of Fitzpatrick types III or IV skin, with new hair formation tending to occur at the margins of treated skin—especially on the face or neck.

TATTOO REMOVAL

The incidence of tattoo acquisition is on the rise and with this trend there is also a growing demand for tattoo removal. In addition to decorative tattoos, other types of tattoos such as embedded graphite pencil material, old radiation markers, gunpowder from explosives, and other material such as gravel from biking or motor vehicle accidents may sometimes be effectively removed with laser therapy. Traditional methods of tattoo removal such as excision and dermabrasion are fraught with the potential for significant scarring. However, in more recent years, QS lasers of various wavelengths have been used to selectively target specific ink colors and thereby lighten or remove tattoos (Fig. 210-4).[48,49] Working via photoacoustic and photomechanical effects, QS devices force exogenous tattoo material within lysosomes to be expelled into the extracellular space. Altered ink particles are then taken up by the lymphatic system. With respect to the principle of selective photothermolysis (Chap. 208), the nanosecond-range pulse durations of QS lasers match nicely with the tiny subcellular ink particles that comprise most tattoos, making for efficient clearance of the ink. More recently, promising results also have been demonstrated with the treatment of tattoos using lasers with pulse widths in the picosecond range.[50,51]

Figure 210-4 Decorative tattoo, before (**A**) and after (**B**) serial Q-switched Nd:YAG laser therapy.

Although there is some variability based on the specific mixture of inks in a given tattoo, in general, black and dark blue ink is addressed well with the QS Nd:YAG (1064-nm) laser, the QS alexandrite (755-nm) laser, or the QS ruby (694-nm) laser. Blue and green inks may be challenging to remove in some cases, but excellent results have been reported with the use of the QS alexandrite and QS ruby lasers as well as the newer picosecond-based devices. Red ink may respond well to the frequency-doubled QS Nd:YAG (532 nm) laser while purple and orange colors are often successfully treated with either the 532-nm- or the 755-nm-wavelength devices. Yellow ink may be difficult to eliminate, but it may respond the QS 532-nm laser.

TABLE 210-1
Nonablative Laser Treatment for Common Dermatologic Indications

	PREFERRED LASERS	POSTTREATMENT EFFECTS AND SPECIAL CONSIDERATIONS
Vascular Lesions		
Port-wine stains	PDL (595 nm) KTP (532 nm) Alexandrite[a] (755 nm) Nd:YAG[a] (1064 nm)	PDL: purpura 1-2 wk posttreatment Nd:YAG: less purpura; slightly increased risk of scarring
Infantile hemangiomas[b]	PDL (595 nm) IPL KTP (532 nm)	PDL can speed re-epithelialization of ulcerated IH
Telangiectases, angiomas, venous lakes	KTP (532 nm) Nd:YAG (1064 nm) PDL (595 nm)	Purpura may occur Multiple passes and/or pulse stacking with the PDL or KTP laser may enhance efficacy
Pigmented Lesions		
Lentigines and seborrheic keratoses	QS alexandrite (755 nm) QS ruby (694 nm) QS frequency-doubled Nd:YAG (532 nm) IPL	Transient white frosting of the epidermis Lesions may darken with superficial crusting ~5 days postprocedure (facial lesions) or 1-2 wk (truncal lesions). Frequency-doubled Nd:YAG: purpura may occur IPL: more gradual improvement with more treatments required
Café-au-lait macules, Becker nevi	QS frequency-doubled Nd: YAG (532 nm) QS ruby (694 nm) QS alexandrite (755 nm) QS Nd: YAG (1064 nm)	Lesions may recur Becker nevi: laser hair removal also may be considered
Nevus of Ota, Nevus of Ito	QS ruby (694 nm) QS alexandrite (755 nm) QS Nd:YAG (1064 nm)	Multiple treatments needed
Melasma	QS Nd:YAG (1064 nm)	Use at low fluences only for melasma Topical therapies are still the mainstay of treatment
Hair Removal		
	Nd:YAG laser (1064 nm) IPL Alexandrite (755 nm) Diode (800-810 nm)	Erythema and perifollicular edema following each treatment Multiple sessions needed Nd:YAG: Safer and effective for darker skin types IPL: Gradual hair reduction but maintenance therapy needed
Tattoo Removal		
Black/dark blue	QS Nd:YAG (1064 nm) QS alexandrite (755 nm) QS ruby (694 nm)	Edema Blistering Crusting Pinpoint bleeding Multiple sessions needed
Blue and green	QS alexandrite (755 nm) QS ruby (694 nm)	
Red ink	QS frequency-doubled Nd:YAG (532 nm)	
Purple and orange	QS frequency-doubled Nd:YAG (532 nm) Alexandrite (755 nm)	
Yellow	QS frequency-doubled Nd:YAG (532 nm)	
Treatment of Textural Changes[c]		
Striae rubra; hypervascular scars	PDL	

[a]Effective for exophytic lesions in port-wine stains.
[b]Laser treatment options covered more extensively in Chap. 118.
[c]Textural changes are further addressed in Chap. 209.
IPL, intense pulsed light; KTP, potassium titanyl phosphate; Nd:YAG, neodymium-doped yttrium aluminum garnet; PDL, pulsed dye laser; QS, Q-switched.

Treatments may be painful and often require topical or local anesthetics, although some patients tolerate treatments without anesthesia. Edema, blistering, crusting, and pinpoint bleeding are all rather common after laser-mediated tattoo removal, requiring topical applications of petrolatum to speed healing. In many cases, numerous treatment sessions may be necessary to maximally lighten a tattoo, and some colors (yellow, light green, etc) may be particularly resistant. Recently, the so-called R20 treatment method has been proposed. This involves multiple treatment passes performed on the same day but separated by several minutes.[52] Preliminary results imply the potential to decrease the time to tattoo clearance by minimizing the required number of treatment sessions, although practical matters of clinic flow may limit the use of this method in some practices. Initial reports of the use of picosecond lasers to treat tattoos also suggest that clearance may be achieved in fewer treatments for some ink colors.[50] In predicting the outcome of laser treatment of a tattoo, patients may be counseled that large, newer, multicolored professionally placed tattoos are the most difficult to adequately eliminate. Alternatively, small, older, amateur tattoos of a single color tend to respond best.

In addition to standard concerns about complications such as hypopigmentation or scarring, laser treatment of tattoos may also result in a few potential side effects that are unique to this procedure. Some inks may undergo an oxidization reaction when laser energy is applied, resulting in an immediate darkening effect that may or may not respond to additional treatments with alternative devices and wavelengths.[53] Inks containing titanium dioxide (often white or pink colors) are particularly susceptible to this phenomenon. When treating colors of tattoo ink that are known to be at a higher risk for this problem, small test areas should initially be treated and assessed. Some patients may develop an allergic response to the ink within their own tattoo. When this occurs, QS laser treatment of the tattoo is generally to be avoided to mitigate against the possibility of creating a wider spread localized or even systemic allergic reaction.[54] When signs of an allergic response (pruritus, induration, erythema) within a tattoo are noted, patients are often counseled to have the offending ink excised or otherwise treated. Finally, patients who have received systemic gold therapy are at risk for developing localized chrysiasis when treated with a QS laser. A blue-gray discoloration of the skin develops at the sites of laser therapy due to structural alterations in dermal gold deposits.[55]

TREATMENT OF TEXTURE (RHYTIDES, STRIAE, AND SCARS)

Laser treatment of textural changes in the skin is primarily accomplished with the use of ablative or nonablative resurfacing devices, often applied in a fractional manner.[56] This issue is extensively addressed in Chap. 209, "Laser Resurfacing: Cosmetic and Medical Applications." Briefly, by targeting water as the chromophore, both ablative and nonablative systems have been shown to induce dermal remodeling and neocollagenesis that lead to improvements in the quality and texture of skin.[57-59] In addition to devices that are designed to specifically produce alterations in the dermal matrix and collagen, some vascular-specific lasers may also play a role in the treatment of erythematous striae (striae rubra) and hypervascular scars. Pulsed dye lasers are frequently used to target the telangiectatic vessels within scar tissue and stretch marks.[60] Serial treatment is often required for optimal results and, in the case of hypertrophic scars, laser therapy may be combined with intralesional injections of corticosteroids or 5-fluorouracil.

CONCLUSIONS

Nonablative laser therapy provides physicians with an array of tools to treat myriad conditions that are of medical and aesthetic concern to patients (Table 210-1). Advancements in laser design and therapeutic strategies are making laser therapy increasingly effective and safe, but optimal use of these devices requires extensive training and experience. Although highly effective for many indications, even nonablative laser procedures may produce significant complications whose occurrence may be mitigated against by the use of meticulous technique and an extensive knowledge of laser–tissue interactions. The evolution of laser therapy promises to facilitate the treatment of an ever-increasing number of cutaneous problems.

REFERENCES

1. Anderson RR, Parrish JA. Selective photothermolysis: precise microsurgery by selective absorption of pulsed radiation. *Science*. 1983;220(4596):524-527.
2. Manstein D, Herron GS, Sink RK, et al. Fractional photothermolysis: a new concept for cutaneous remodeling using microscopic patterns of thermal injury. *Lasers Surg Med*. 2004;34(5):426-438.
3. Laubach HJ, Tannous Z, Anderson RR, et al. Skin responses to fractional photothermolysis. *Lasers Surg Med*. 2006;38(2):142-149.
4. Rossi AM. Men's aesthetic dermatology. *Semin Cutan Med Surg*. 2014;33(4):188-197.
5. Alam M, Kakar R, Nodzenski M, et al. Multicenter prospective cohort study of the incidence of adverse events associated with cosmetic dermatologic procedures: lasers, energy devices, and injectable neurotoxins and fillers. *JAMA Dermatol*. 2015;151(3):271-277.
6. Graber EM, Tanzi EL, Alster TS. Side effects and complications of fractional laser photothermolysis: experience with 961 treatments. *Dermatol Surg*. 2008;34(3):301-305; discussion 305-307.
7. Hirsch R. Iatrogenic laser complications. *Clin Dermatol*. 2011;29(6):691-695.

8. Setyadi HG, Jacobs AA, Markus RF. Infectious complications after nonablative fractional resurfacing treatment. *Dermatol Surg*. 2008;34(11):1595-1598.
9. Brody HJ, Geronemus RG, Farris PK. Beauty versus medicine: the nonphysician practice of dermatologic surgery. *Dermatol Surg*. 2003;29(4):319-324.
10. Orringer JS, Kovarik HY, Chubb H, et al. A gender-based comparison of pain tolerance during pulsed dye laser therapy. *J Cosmet Laser Ther*. 2014;16(5):253-257.
11. Kao B, Kelly KM, Aguilar G, et al. Evaluation of cryogen spray cooling exposure on in vitro model human skin. *Lasers Surg Med*. 2004;34(2):146-154.
12. Klavuhn KG, Green D. Importance of cutaneous cooling during photothermal epilation: theoretical and practical considerations. *Lasers Surg Med*. 2002;31(2):97-105.
13. Svaasand LO, Randeberg LL, Aguilar G, et al. Cooling efficiency of cryogen spray during laser therapy of skin. *Lasers Surg Med*. 2003;32(2):137-142.
14. Cantatore JL, Kriegel DA. Laser surgery: an approach to the pediatric patient. *J Am Acad Dermatol*. 2004;50(2):165-184; quiz 185-188.
15. Adams BB, Lucky AW. Acquired port-wine stains and antecedent trauma: case report and review of the literature. *Arch Dermatol*. 2000;136(7):897-899.
16. Smoller BR, Rosen S. Port-wine stains. A disease of altered neural modulation of blood vessels? *Arch Dermatol*. 1986;122(2):177-179.
17. Stratigos AJ, Dover JS. Overview of lasers and their properties. *Dermatol Ther*. 2000;13:2-16.
18. Reyes BA, Geronemus R. Treatment of port-wine stains during childhood with the flashlamp-pumped pulsed dye laser. *J Am Acad Dermatol*. 1990;23(6, pt 1): 1142-1148.
19. Nelson JS, Geronemus RG. Redarkening of port-wine stains 10 years after laser treatment. *N Engl J Med*. 2007;356(26):2745-2746; author reply 2746.
20. Willey A, Anderson RR, Azpiazu JL, et al. Complications of laser dermatologic surgery. *Lasers Surg Med*. 2006;38(1):1-15.
21. Renfro L, Geronemus RG. Anatomical differences of port-wine stains in response to treatment with the pulsed dye laser. *Arch Dermatol*. 1993;129(2):182-188.
22. Morelli JG, Weston WL, Huff JC, et al. Initial lesion size as a predictive factor in determining the response of port-wine stains in children treated with the pulsed dye laser. *Arch Pediatr Adolesc Med*. 1995;149(10):1142-1144.
23. Ashinoff R, Geronemus RG. Flashlamp-pumped pulsed dye laser for port-wine stains in infancy: earlier versus later treatment. *J Am Acad Dermatol*. 1991;24(3):467-472.
24. Mariwalla K, Dover JS. The use of lasers in the pediatric population. *Skin Ther Lett*. 2005;10(8):7-9.
25. van der Horst CM, Koster PH, de Borgie CA, et al. Effect of the timing of treatment of port-wine stains with the flash-lamp-pumped pulsed-dye laser. *N Engl J Med*. 1998;338(15):1028-1033.
26. Ashinoff R, Geronemus RG. Failure of the flashlamp-pumped pulsed dye laser to prevent progression to deep hemangioma. *Pediatr Dermatol*. 1993;10(1):77-80.
27. Drolet BA, Esterly NB, Frieden IJ. Hemangiomas in children. *N Engl J Med*. 1999;341(3):173-181.
28. David LR, Malek MM, Argenta LC. Efficacy of pulse dye laser therapy for the treatment of ulcerated haemangiomas: a review of 78 patients. *Br J Plast Surg*. 2003;56(4):317-327.
29. Bruckner AL, Frieden IJ. Hemangiomas of infancy. *J Am Acad Dermatol*. 2003;48(4):477-493; quiz 494-496.
30. Laubach HJ, Anderson RR, Luger T, et al. Fractional photothermolysis for involuted infantile hemangioma. *Arch Dermatol*. 2009;145(7):748-750.
31. Rohrer TE, Chatrath V, Iyengar V. Does pulse stacking improve the results of treatment with variable-pulse pulsed-dye lasers? *Dermatol Surg*. 2004;30(2, pt 1): 163-167; discussion 167.
32. Tanghetti EA, Sherr EA, Alvarado SL. Multipass treatment of photodamage using the pulse dye laser. *Dermatol Surg*. 2003;29(7):686-690; discussion 690-691.
33. Saedi N, Green JB, Dover JS, et al. The evolution of quality-switched lasers. *J Drugs Dermatol*. 2012;11(11):1296-1299.
34. Jones CE, Nouri K. Laser treatment for pigmented lesions: a review. *J Cosmet Dermatol*. 2006;5(1):9-13.
35. Polder KD, Landau JM, Vergilis-Kalner IJ, et al. Laser eradication of pigmented lesions: a review. *Dermatol Surg*. 2011;37(5):572-595.
36. Lapidoth M, Adatto M, Cohen S, et al. Hypertrichosis in Becker's nevus: effective low-fluence laser hair removal. *Lasers Med Sci*. 2014;29(1):191-193.
37. Chan HH, Kono T. Nevus of Ota: clinical aspects and management. *Skinmed*. 2003;2(2):89-96; quiz 87-88.
38. Halachmi S, Haedersdal M, Lapidoth M. Melasma and laser treatment: an evidenced-based analysis. *Lasers Med Sci*. 2014;29(2):589-598.
39. Rivas S, Pandya AG. Treatment of melasma with topical agents, peels and lasers: an evidence-based review. *Am J Clin Dermatol*. 2013;14(5):359-376.
40. Alsaad SM, Ross EV, Mishra V, et al. A split face study to document the safety and efficacy of clearance of melasma with a 5 ns q switched Nd YAG laser versus a 50 ns q switched Nd YAG laser. *Lasers Surg Med*. 2014;46(10):736-740.
41. Kauvar AN. Successful treatment of melasma using a combination of microdermabrasion and Q-switched Nd:YAG lasers. *Lasers Surg Med*. 2012;44(2):117-124.
42. Grossman MC, Dierickx C, Farinelli W, et al. Damage to hair follicles by normal-mode ruby laser pulses. *J Am Acad Dermatol*. 1996;35(6):889-894.
43. Orringer JS, Hammerberg C, Lowe L, et al. The effects of laser-mediated hair removal on immunohistochemical staining properties of hair follicles. *J Am Acad Dermatol*. 2006;55(3):402-407.
44. Ismail SA. Long-pulsed Nd:YAG laser vs. intense pulsed light for hair removal in dark skin: a randomized controlled trial. *Br J Dermatol*. 2012;166(2):317-321.
45. Rao K, Sankar TK. Long-pulsed Nd:YAG laser-assisted hair removal in Fitzpatrick skin types IV-VI. *Lasers Med Sci*. 2011;26(5):623-626.
46. Bouzari N, Tabatabai H, Abbasi Z, et al. Laser hair removal: comparison of long-pulsed Nd:YAG, long-pulsed alexandrite, and long-pulsed diode lasers. *Dermatol Surg*. 2004;30(4, pt 1):498-502.
47. Alajlan A, Shapiro J, Rivers JK, et al. Paradoxical hypertrichosis after laser epilation. *J Am Acad Dermatol*. 2005;53(1):85-88.
48. Choudhary S, Elsaie ML, Leiva A, et al. Lasers for tattoo removal: a review. *Lasers Med Sci*. 2010; 25(5):619-627.
49. Kilmer SL, Anderson RR. Clinical use of the Q-switched ruby and the Q-switched Nd:YAG (1064 nm and 532 nm) lasers for treatment of tattoos. *J Dermatol Surg Oncol*. 1993;19(4):330-338.
50. Brauer JA, Reddy KK, Anolik R, et al. Successful and rapid treatment of blue and green tattoo pigment with a novel picosecond laser. *Arch Dermatol*. 2012;148(7):820-823.

51. Saedi N, Metelitsa A, Petrell K, et al. Treatment of tattoos with a picosecond alexandrite laser: a prospective trial. *Arch Dermatol*. 2012;148(12):1360-1363.
52. Kossida T, Rigopoulos D, Katsambas A, et al. Optimal tattoo removal in a single laser session based on the method of repeated exposures. *J Am Acad Dermatol*. 2012;66(2):271-277.
53. Anderson RR, Geronemus R, Kilmer SL, et al. Cosmetic tattoo ink darkening. A complication of Q-switched and pulsed-laser treatment. *Arch Dermatol*. 1993;129(8):1010-1014.
54. Bernstein EF. A widespread allergic reaction to black tattoo ink caused by laser treatment. *Lasers Surg Med*. 2015;47(2):180-182.
55. Trotter MJ, Tron VA, Hollingdale J, et al. Localized chrysiasis induced by laser therapy. *Arch Dermatol*. 1995;131(12):1411-1414.
56. Alexiades-Armenakas MR, Dover JS, Arndt KA. The spectrum of laser skin resurfacing: nonablative, fractional, and ablative laser resurfacing. *J Am Acad Dermatol*. 2008;58(5):719-737; quiz 738-740.
57. Orringer JS, Kang S, Johnson TM, et al. Connective tissue remodeling induced by carbon dioxide laser resurfacing of photodamaged human skin. *Arch Dermatol*. 2004;140(11):1326-1332.
58. Orringer JS, Rittie L, Baker D, et al. Molecular mechanisms of nonablative fractionated laser resurfacing. *Br J Dermatol*. 2010;163(4):757-768.
59. Orringer JS, Voorhees JJ, Hamilton T, et al. Dermal matrix remodeling after nonablative laser therapy. *J Am Acad Dermatol*. 2005;53(5):775-782.
60. Alster TS. Improvement of erythematous and hypertrophic scars by the 585-nm flashlamp-pumped pulsed dye laser. *Ann Plast Surg*. 1994;32(2):186-190.

Chapter 211 :: Noninvasive Body Contouring

:: Murad Alam

AT-A-GLANCE

- Noninvasive body contouring includes skin tightening, fat reduction, and cellulite treatment.
- Noninvasive body-contouring treatments are associated with minimal intraoperative risk, postoperative discomfort, and recovery time, but overall effectiveness may be less than for more invasive procedures.
- Improvement in body contouring may be maximized when noninvasive modalities are repeated or used in combination.

BACKGROUND

WHAT IS NONINVASIVE BODY CONTOURING?

In dermatology, body contouring is defined in contradistinction to more superficial skin remodeling. Change in the fine skin texture is thus not considered amenable to treatment by body-contouring methods. On the other hand, body contouring can correct change in skin elevation, shape, and drape associated with full-thickness dermal aging or injury, as well as such change secondary to alteration in the morphology or size of the subcutaneous layer.

Whether a method of body contouring is classified as noninvasive or invasive is predicated on the degree of manual or device-based macroscopic injury to the skin that use of this method entails. This can be a subtle determination. Noninvasive body contouring may be defined by exclusion as typically not requiring scalpel incision or excision, manual dissection of the skin tissue planes, or insertion of devices (eg, suction cannulas, drains, sutures) that are of sufficient size and bore to elicit scarring upon healing. In general, noninvasive procedures are associated with less postoperative discomfort and briefer recovery, requiring minimal time away from work and social activities.

MAJOR TYPES OF NONINVASIVE BODY CONTOURING

Noninvasive body contouring is a rapidly evolving field. As such, the nosology of clinical conditions requiring body contouring remains fluid and subject to change. Currently, the 3 widely recognized therapeutic subtypes of noninvasive body contouring are skin tightening, fat reduction, and cellulite treatment. As is obvious, these treatments are designed to address excess or sagging skin (skin tightening), pockets of unwanted fat (fat reduction), and dimpling of the thighs and buttocks (cellulite treatment). There may be overlap. That is, noninvasive body-contouring modalities used to target a particular condition may favorably impact other skin contour problems at the same anatomic site, albeit to a lesser extent.

PHYSICIAN AND PATIENT PREFERENCE FOR NONINVASIVE BODY CONTOURING

Physicians and patients both have reasons for preferring noninvasive body contouring to invasive contouring procedures. Patients may perceive noninvasive interventions as less "frightening," or safer, and also less drastic or vain than surgery. Those who wish to avoid even the smallest visible scars, or to minimize postoperative downtime, also may be attracted to noninvasive options.

From a physician's standpoint, noninvasive body contouring offers the promise of fewer complications to manage. It is also less time intensive from a provider standpoint, as in some cases much of the work is accomplished by devices that are positioned or injected over the treatment area rather than by direct physician manipulation. Finally, more patients are good candidates for noninvasive body-contouring approaches, which are routinely used to correct minor conditions for which an invasive procedure may be excessive or not indicated.

TYPES OF BODY CONTOURING

SKIN TIGHTENING[1-14]

INDICATIONS AND PATIENT SELECTION

Noninvasive skin tightening is most appropriate for patients with mild to moderate skin laxity without severe sagging. In patients with Fitzpatrick skin types I to III, this usually correlates to ages in the

25 to 55 years range. Focal facial anatomic areas that are responsive to noninvasive tightening include the forehead and brows, the midface, and the neck and jowls. Off the head and neck, skin can be tightened on the upper arms, décolletage area, abdomen, knees, and other areas. Patients appropriate for this procedure expect the possibility of modest improvement, but clearly understand that complete resolution, a so-called home-run, is unlikely except in selected cases of mild skin laxity.

Some types of cosmetic complaints will not resolve with skin tightening. Crepe-like skin with fine superficial textural change will generally not respond. Pigmentary abnormalities must be addressed by vascular or pigment devices, not skin-tightening devices. Extremely saggy skin, with underlying loss of substructure and fat-pad integrity, will not return to its youthful contour after noninvasive tightening. Patients with severe photodamage or severe sagging who would like the gold standard treatment are typically dissuaded from receiving skin tightening. For such concerns, nonablative or ablative resurfacing procedures with or without excisional lifting approaches, such as rhytidectomy, brow lift, or blepharoplasty, may be more successful.

TYPES OF DEVICES AND TECHNOLOGIES

Several distinct technologies have been adapted for skin tightening. These include light-based devices, notably infrared lasers and light sources. Additionally, radiofrequency devices, including monopolar and bipolar devices, as well as more exotic configurations, are in widespread use. Recently, there has been a proliferation of insertional needle and injectable radiofrequency skin tightening devices that skirt the boundary between noninvasive and minimally invasive. High-frequency ultrasound is also commonly used for skin tightening. Devices that have other primary indications, but secondarily induce skin tightening, include ablative resurfacing devices, particularly carbon dioxide laser, as well as insertional infrared laser-tipped devices used in laser lipolysis.

MODES OF ACTION

Fully noninvasive skin tightening spares the epidermis and superficial dermis, and directs energy into the deep dermis and subcutis. This energy, which can be infrared light, radiofrequency, or ultrasound, heats the skin. Precisely directed heat injury results in numerous small volumetric zones of thermal necrosis. The immediate mechanisms of shrinkage include collagen contraction resulting from collagen denaturation, and shrinkage of the fibrous septae of the fat lobules, which compresses the subcutis (Fig. 211-1). It has been suggested that heat-induced shrinkage may also effect superficial muscular aponeurotic system shrinkage, in a manner akin to surgical plication in a facelift, but this is highly speculative and unproven. Longer-term, over a period of 30 to 90 days, neocollagenesis may result in additional skin tightening.

Based on experience with the index device for noninvasive skin tightening, a monopolar radiofrequency[1,2,9-12] device introduced in 2002, several treatment paradigms have been adopted across devices. First, to avoid the risk of skin burns or localized fat atrophy manifesting as configurated skin depressions, several to many lower-energy passes rather than 1 to 2 high-energy passes are typically performed. Second, to maximize effectiveness, zones of thermal necrosis are placed close together, very densely. As many focal necrosis zones as feasible are created in each plane of the dermis, with 2 to 3 such planes not being uncommon. The objective is to maximize the cumulative volumetric injury because this is believed to coincide with the degree of tissue tightening. Of course, some skin must be spared between zones of thermal injury so as to allow prompt, reliable, and scarless wound healing.

Ultrasound[3,4,6,14] is useful for skin tightening because it is a form of energy that can be configured to penetrate arbitrarily deeply into the skin without causing injury to overlying structures. As such, ultrasound for skin tightening can be readily configured to create zones of thermal necrosis at several different levels in the dermis (Fig. 211-2).

Insertional radiofrequency needles[5] penetrate into the skin, with an array of fine microneedles delivering heat to an adjustable depth of less than 1 mm to several millimeters. In this manner, insertional hot needles can achieve many of the same benefits of microfocused ultrasound. Insulated needles may be used to propagate heat just from the needle tips; noninsulated needles leak heat along their whole length, thus potentially causing more tightening at the cost of more of a visible epidermal and superficial dermal injury.

Carbon dioxide (10,600 nm) laser[7,13] ablates the epidermis and partial thickness dermis. Immediate tissue tightening is seen as a result of collagen denaturation. Laser lipolysis operates under the skin surface, as a fine laser fiber encased in a protective metal sleeve is introduced via a skin puncture into the subcutis. The hot laser tip, traditionally an Nd:YAG (neodymium:yttrium aluminum garnet) laser, protrudes from the sheath and is moved back and forth under the dermis to induce heat-related contraction. A handheld temperature gun can be held over the skin by an assistant to ensure that the peak temperature adjacent to the laser tip does not exceed the 40°C to 42°C (100°F to 107.6°F) at which full-thickness injury or burn can occur. In this manner, laser lipolysis can augment liposuction, which reduces fat but does not tighten skin. Similar radiofrequency wands can be used for skin tightening at multiple sites on the body.

AVOIDING AND MANAGING COMPLICATIONS

Noninvasive skin tightening is generally very safe, with anticipated mild sequelae. Expected posttreatment tissue effects are erythema and edema, lasting



Figure 211-1 Immediate collagen denaturation and contraction (**A**), as well as thermally-mediated shrinkage of the fibrous septae of the subcutaneous fat (**B**), are among the mechanisms of noninvasive skin tightening.

from several hours to 1 to 2 days. Intraoperative discomfort can be managed with topical anesthesia or, in some cases, with oral benzodiazepines and analgesics. Because treatment paradigms have moved away from very-high-energy passes, burns and fat atrophy have become rare. Repeated treatment of the same size can very rarely result in heat stacking culminating in white, wheal-like skin plaques, which resolve with time and topical steroids. Scars and pigmentary change are exceedingly rare.

Radiofrequency needling may result in punctate marks on the skin, which resolve over 1 to 2 days. Pinpoint bleeding may also occur with some devices. Rare indented scarring has been reported.

Carbon dioxide laser is routinely associated with more protracted downtime: 1 week for fractional resurfacing and 2 to 3 weeks for traditional full-face resurfacing. Persistent erythema, edema, crust, and serous drainage is common, particularly after full-face resurfacing. Overtreatment and heat stacking with

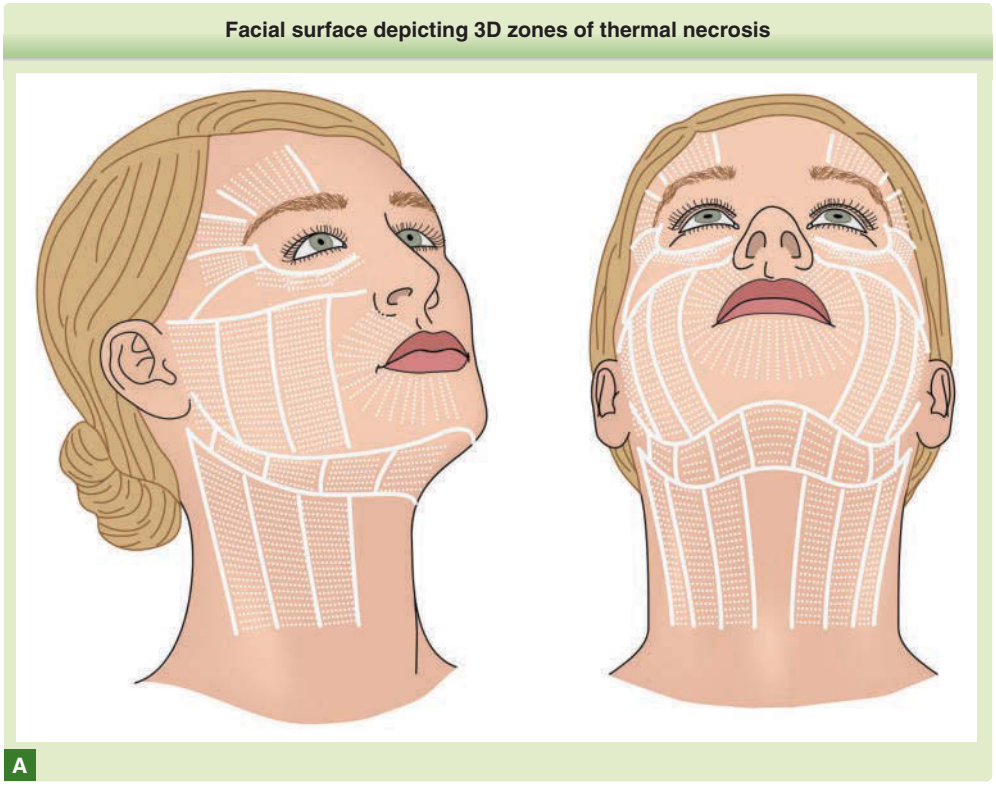

Figure 211-2 Noninvasive skin tightening proceeds by creating minute 3-dimensional zones of thermal necrosis in the dermis, with skin tightening the sum of immediate contraction and collagen remodeling over the ensuing months. Over time, these zones of thermal necrosis are placed ever more densely across the face (**A**) and in multiple planes in the skin (**B**), as demonstrated in these schematics of the facial surface and dermal cross section, respectively.

carbon dioxide laser can result in significant adverse events, notably hypopigmentation that does not resolve and scarring.

Laser lipolysis is usually uncomplicated, requiring only healing of the entry sites, which may also have been used for liposuction. Burns, including those associated with full-thickness tears in the skin, can occur if the laser tip is held subdermally at one anatomic location for too long. Overtreatment can also result in seromas, which must be drained promptly. Radiofrequency wands comparable in effect to lipolysis lasers have been optimized for skin tightening, with built-in temperature monitoring that can help prevent burns.

ADAPTING TREATMENTS FOR ANATOMIC AREAS, SKIN TYPES, AND DEGREE OF RESPONSE[15]

A certain minimum density of zones of thermal necrosis is required to elicit the best result. As such, patients with larger faces or bodies may require more total treatment spots or lines. Pain response is subjective and also varies across individuals. Even though noninvasive skin-tightening procedures are always performed with the patient awake, some patients may require anxiolytics or analgesics. There is a very low treatment-associated risk of pigmentary abnormality in

patients with darker-pigmented skin; consequently, treatment regimens are not usually adjusted for skin type. Greater care is taken when treating off the head and neck. On truncal and extremity sites, posttreatment healing is slower, and handpieces are adapted to be larger and to deliver energy deeper, as the dermis is thicker.

Depending on treatment response, repeat treatments may be indicated. If a patient is among the minority who experience no or very minimal response, additional treatments may be deferred as they may be similarly futile. Should the patient be willing to try again and incur further costs, then despite the heightened risk of failure, it is reasonable to proceed. More commonly, an observable benefit is obtained after the first treatment. In this case, a patient may receive additional treatments to improve upon this outcome. The average number of treatments per course varies by device and technology, from as few as 1 or 2, to as many as 4 to 6 or more. In some cases, it may be prudent to wait for 2 or 3 months before retreating to allow new collagen to form, as these newly laid-down fibers may be relatively more amenable to subsequent energy-mediated contraction.

Carbon dioxide laser, laser lipolysis, and radiofrequency wand tightening are often single procedures, as their longer-associated postoperative downtime is counterbalanced by greater effectiveness. Carbon dioxide procedures, and to a lesser extent insertional radiofrequency needles, should be used with some caution in patients with darker-pigmented skin so as to minimize the risk of hyperpigmentation. Indeed, the risk of such pigmentation in darker skin types is almost 100% with carbon dioxide laser. Laser lipolysis and subdermal radiofrequency wand tightening are less concerning in darker skin types because they deliver energy under the skin and do not directly injure the epidermis and papillary dermis.

EXPECTED OUTCOMES

After treatment of the forehead and upper face, 1 to 2 mm of brow elevation is commonly seen at 60 to 90 days (Fig. 211-3). Treatments on the lower face may result in modestly more defined jawline or neck contour with slightly reduced skin excess. Midface treatments may result in more subtle skin tightening.

Off the face, outcomes are even more variable. Successful skin tightening on the abdomen, upper and lower knees, décolletage area, and upper arms has been reported. Treatment parameters are modified for these indications.

The degree of tightening or wrinkle reduction is generally modest. Patients with significant skin excess may be better served by a surgical tightening or skin-reduction

Figure 211-3 Noninvasive skin tightening was first quantitatively demonstrated for brow elevation, which is relatively easier to measure given the availability of anatomic landmarks. More recently, skin tightening has been used on the lower face, neck, and other parts of the body. (From Alam M, White LE, Martin N, et al. Ultrasound tightening of facial and neck skin: a rater-blinded prospective cohort study. *J Am Acad Dermatol*. 2010;62(2):262-69, Fig. 5, with permission.)

procedure, or by a minimally-invasive form of skin tightening like carbon dioxide laser, laser lipolysis, or subdermal wand radiofrequency. Alternatively, such patients should be prepared to undergo numerically more treatments of energy-based noninvasive skin tightening for an incrementally greater degree of improvement.

NONINVASIVE AND MINIMALLY INVASIVE FAT REDUCTION[16-31]

INDICATIONS AND PATIENT SELECTION

Noninvasive fat reduction is most appropriate for treatment of small pockets of excess fat resistant to diet and exercise. Treatments with energy-based modalities may result in permanent reduction of such pockets. Early data with cryolipolysis showed that so-called love handles, or protrusions of abdominal fat on either side of the flanks, were particularly responsive to treatment (Fig. 211-4). More recent experience has confirmed that even large subcutaneous collections of abdominal and truncal fat will remit with noninvasive fat reduction, although many serial treatments may be needed.

Noninvasive fat reduction does not reduce excess skin, and may worsen the appearance of skin folds if a substantial quantity of fat is removed because normal skin elasticity is insufficient to retract the skin adequately. For example, after fat-reduction treatment, patients seeking correction of sagging upper arms may observe even more hanging skin. When faced with the risk of exacerbating excess skin, physicians consulting with patients requesting fat reduction should explain the risks. Ideally, susceptible patients should be prepared to undergo, if necessary, a subsequent skin-reduction procedure, such as an elliptical excision to resect upper arm skin. Thermal fat-reduction methods may be slightly more effective in shrinking skin, but the aforementioned constraints still apply.

Fat-reduction treatments do not smooth the appearance of cellulite. Cellulite, or dimpling of the thighs and buttocks, is discussed further in the next section.

TYPES OF DEVICES AND TECHNOLOGIES

Fat reduction can be accomplished with physical modalities, including radiofrequency energy, therapeutic ultrasound, and cryolipolysis. In the United States, cryolipolysis was the first widely used noninvasive treatment for fat, and is the most used and best described approach for this indication. Minimally-invasive approaches include injection

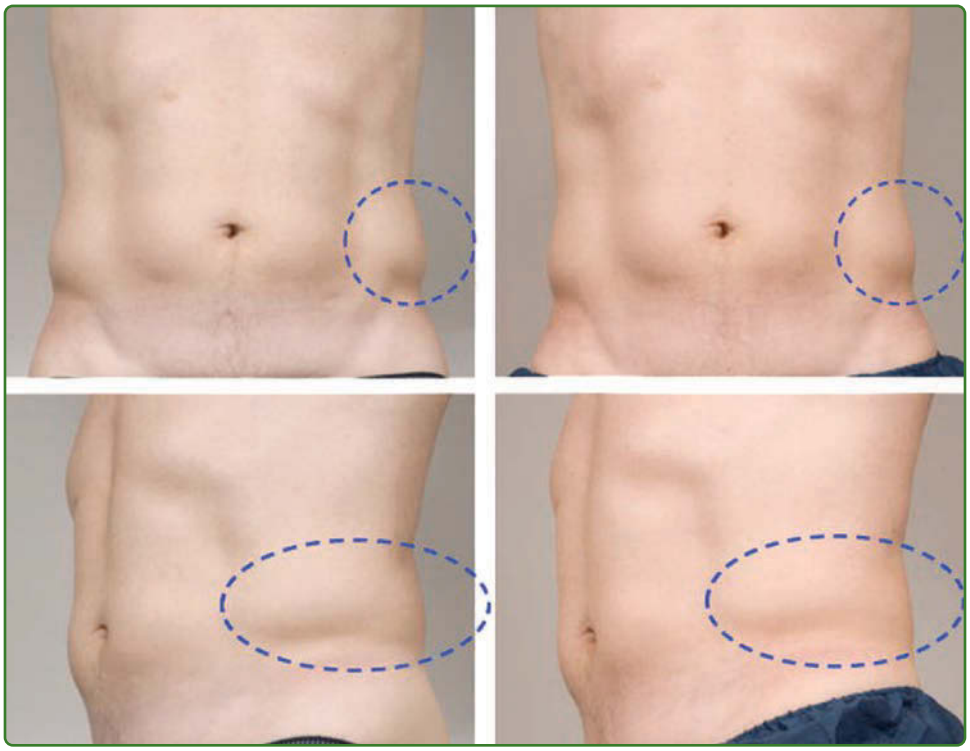

Figure 211-4 Fat reduction by cryolipolysis was first demonstrated to reduce the small fat pockets in the "love handles," as shown in this figure. Noninvasive fat-reduction methods have since been also used to treat larger areas of subcutaneous fat and fat accumulations in the submental area on the neck, using modified handpieces and repeated treatments. (Reprinted by permission from Springer: Coleman SR, Sachdeva K, Egbert BM, et al. Clinical efficacy of noninvasive cryolipolysis and its effects on peripheral nerves. *Aesth Plast Surg*. 2009;33(4):482-488, Fig. 1. Copyright © 2009.)

chemical adipocytolysis and laser lipolysis. Tumescent liposuction, which accesses fat through tiny apertures that reepithelialize without sutures into barely visible punctate scars also may be considered a form of minimally-invasive fat reduction, but it is incorrectly often considered more invasive than it is. Liposuction is discussed in depth elsewhere in this text.

MODES OF ACTION

The different technologies for noninvasive and minimally-invasive fat reduction span a range of modes of action. As a group, the energy-based modalities[16-21] are more similar than different. Radiofrequency and ultrasound energy targeting fat are configured to direct energy deeper and more diffusely than necessary for tightening skin. Ultrasound fat reduction devices can be further subdivided into thermal and mechanical types. Thermal ultrasound heats adipocytes, as does radiofrequency used for fat destruction, and mechanical ultrasound breaks fat cells apart by propagating an acoustic shock wave.

Cryolipolysis[22-25] is predicated on the mechanism of popsicle panniculitis (Fig. 211-5). Fat is destroyed by freezing while the overlying dermis and epidermis are spared (Fig. 211-6B).

Chemical adipocytolysis[26-29] employs deoxycholate, a detergent, to emulsify fat cells. It is currently only U.S. Food and Drug Administration (FDA) approved for submental fat reduction (Fig. 211-6A). Laser lipolysis,[30,31] discussed in depth in the previous section on skin tightening, can also melt fat by direct heat injury.

In all cases of noninvasive and minimally invasive fat reduction, fat cells are lysed, with the constituent fatty acids then resorbed into the systemic circulation. For modalities that have proceeded through the FDA premarket approval process, the FDA has requested data regarding blood lipid levels following treatments. Such analyses have shown the absence of a cotemporaneous sharp elevation in lipid levels. This may be attributable to the small quantity of fat cells lysed per treatment, the high intrinsic biologic clearance capacity for fatty acids, or the slow rate at which the products of adipocytolysis are mobilized over many hours to days.

AVOIDING AND MANAGING COMPLICATIONS

Like nonsurgical skin tightening, noninvasive and minimally-invasive fat reduction are safe procedures. Intraoperative tenderness can be managed with oral anxiolytics and analgesics. Tenderness requiring medication is less common with cryolipolysis, as the associated cold sensation inherent to the procedure results in intraoperative pain relief after a few minutes. With heat and shockwave–based modalities, treatment over bony prominences, surgical scars, or hernias is avoided to prevent injury to these structures.

After each treatment of cryolipolysis, local paresthesia and numbness are expected to persist for several weeks before gradually resolving completely. There are extremely rare reports of cryolipolysis actually stimulating fat growth, which then can be corrected by liposuction; these episodes are idiosyncratic and cannot be planned for, predicted, or actively circumvented.

Fat-reduction treatments can result in asymmetry. Similarly, they can result in too much fat being removed, which can lead to a skeletonized, unattractive appearance. The risk of both these outcomes is minimized by carefully mapping the distribution of pretreatment fat. Pinching the fat to be treated can provide the operator with information regarding the quantity and relative distribution of fat. Treatment intensity, duration, and frequency can then be adjusted to meet specific patient needs, and to correct preexisting asymmetries.

It is preferred that patients be at or above their normal weight before a fat reduction treatment regimen. If they diet to a level below their baseline weight prior to treatment, they will likely eventually regain weight after treatment. This new gain may manifest in unexpected areas, as treated pockets of fat will be depleted of adipocytes and less able to accommodate future weight gain.

Chemical injection adipocytolysis routinely results in extreme posttreatment edema. Patients receiving such treatment to the submental area may have a "bull frog"–like double-chin and underneck swelling for several days. This can be tender and warm. Injections are best avoided over the course of the marginal mandibular nerve. In a small proportion of cases, chemical injection adipocytolysis results in temporary marginal mandibular nerve dysfunction and palsy, but this resolves completely over several weeks.

Laser lipolysis can result in burns and seromas. These are discussed further in the section on skin tightening.

ADAPTING TREATMENTS FOR ANATOMIC AREAS AND SKIN TYPES

Noninvasive and minimally invasive fat reduction modalities can be safely and effectively applied at a wide range of anatomic sites. Common treatment areas include the neck and submental area, upper arms, upper and lower abdomen, flanks and love handles, thighs, and knees. The feasibility of treatments at a particular site can be limited by the size and shape of available handpieces. For instance, in recent years, specialized cryolipolysis handpieces have been developed to conform to the submental area, thighs, and other areas.

One to several noninvasive or minimally-invasive fat reduction treatments may be needed to reach the desired outcome. Multiple treatments are the norm.

Fat reduction without surgery is appropriate for patients of all Fitzpatrick skin types. Pigmentary abnormality typically does not occur at a higher rate in darker-skinned patients.

EXPECTED OUTCOMES

Fat-reduction treatments can result in partial or complete permanent resolution of small pockets of excess

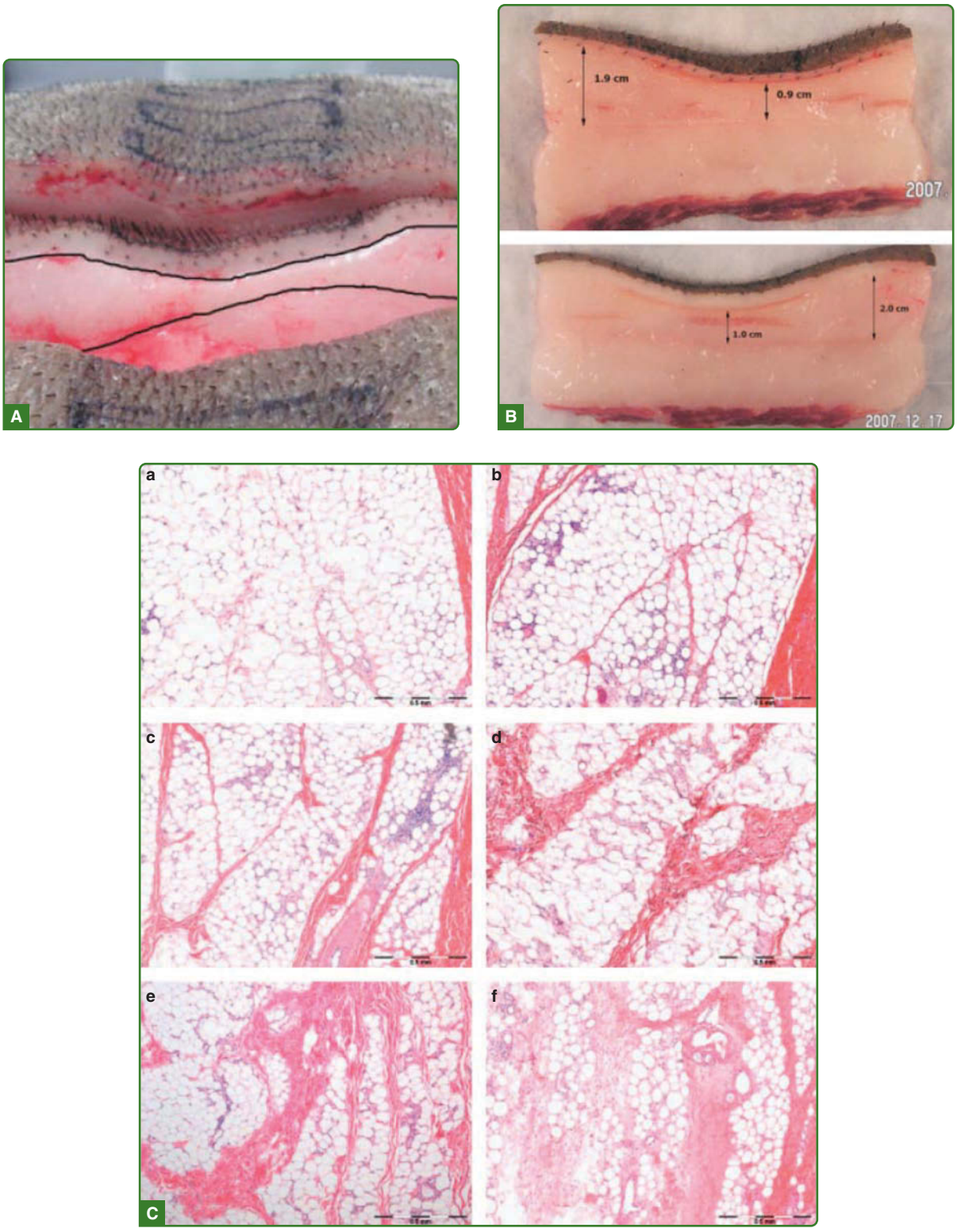

Figure 211-5 Fat shrinkage secondary to cryolipolysis creates a band of cold-mediated injury in the deep subcutis, with this causing shrinkage of the fat layer, in vivo (**A**) and ex vivo (**B**), as shown in this porcine model. Concurrently, there is an inflammatory reaction (**C**) that is easily seen from day 3 (*top left*) to day 90 (*bottom right*). (From Zelickson B, Egbert BM, Preciado J, et al. Cryolipolysis for noninvasive fat cell destruction: initial results from a pig model. *Dermatol Surg*. 2009;35(10):1462-70, Figs. 4, 6, and 8, with permission. © 2009 by the American Society for Dermatologic Surgery, Inc. Published by Wiley Periodicals, Inc.)

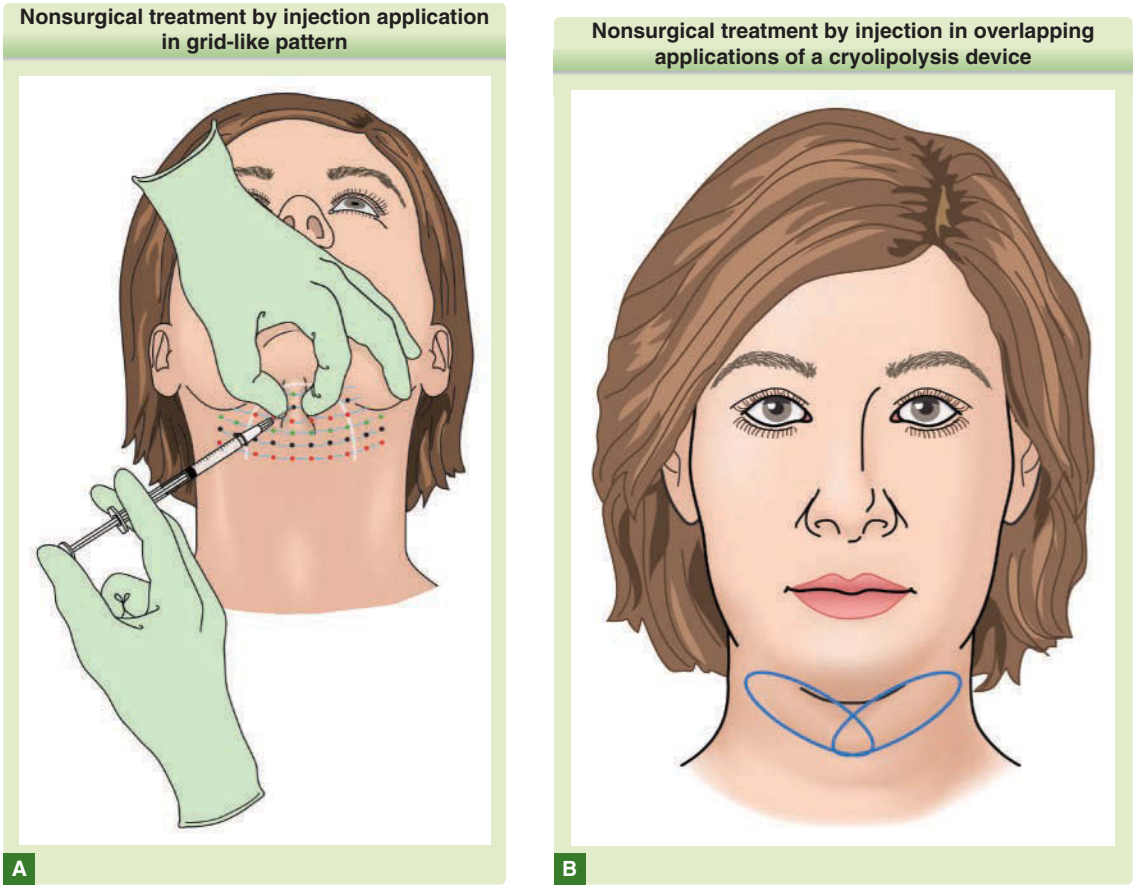

Figure 211-6 Nonsurgical treatment of submental fat can be accomplished by injection of deoxycholate in a grid-like pattern (**A**), or by 2 overlapping applications of a cryolipolysis device (**B**). The marginal mandibular nerve is avoided in both cases.

subcutaneous fat that is diet and exercise resistant. Visceral fat, which can be associated with health risks, is not reduced. Patients should be aware that fat-reduction treatments will not tighten skin or erase cellulite, and may even worsen loose skin in older patients.

Repeated treatments with noninvasive modalities can eliminate larger reservoirs of fat for patients willing to tolerate many consecutive treatments as well as the attendant financial cost. Given the intervals between treatments, treatments of large accumulations of fat may require many months or even years to complete. A more efficient one-time procedure like liposuction may be a reasonable alternative. Needless to say, and as discussed before, regardless of the modality used, successful fat removal does not preclude future weight gain, including fat accumulation at untreated anatomic sites.

CELLULITE REMOVAL[32-40]

INDICATIONS AND PATIENT SELECTION

Cellulite was historically a popular rather than a technical term, but is now also in common usage in clinical and research medicine, and serves both functions. Simply, cellulite is skin dimpling of the buttocks and upper thighs (Fig. 211-7). It is more common in women, and may worsen with aging. There is no strong association between overall body weight and cellulite, which is seen frequently in non-overweight individuals.

Cellulite removal technologies are best suited for patients with localized dimpling of the affected areas. Widespread skin rippling, deep creases, and severe excess fat of the upper thighs and buttocks are not corrected with current therapies for cellulite. Younger people tend to respond better, as they often do not suffer from the concurrent issues of skin excess and skin sagging.

It is unclear why cellulite is more common in women than in men (Fig. 211-8). One hypothesis, borne of anatomic studies, is that men have fascial bands in the affected area comprised of crisscrossed rather than parallel fibers. Presumably, these bands are more impermeable to fat herniation, and hence dimpling, than the parallel bands in most women. Whatever the cause, cellulite is markedly more common in women, who also tend to be more bothered by it, and more likely to seek treatment.

Patients seeking cellulite treatment should understand that this will not prevent the formation of new

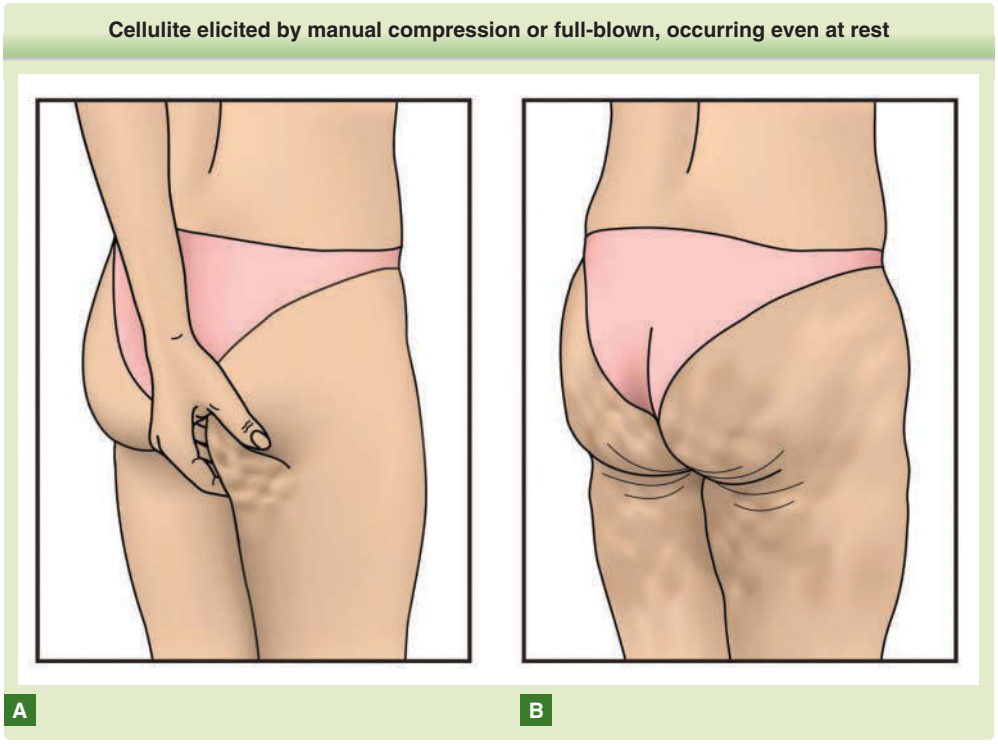

Figure 211-7 Cellulite is the dimpling of the skin on the thighs and buttocks, and can be incipient, elicited by manual compression (**A**) or full-blown, occurring even at rest (**B**).

cellulite dimples in the future. Some dimples may not respond at all, and cellulite treatment will not result in fat reduction or a buttock or thigh lift. Multiple treatments may be necessary. A physical exercise regimen also may be recommended as adjunctive therapy. The ideal patient is a 20- to 50-year-old woman of normal weight with a few localized areas of cellulite, mostly on the buttock.

TYPES OF DEVICES AND TECHNOLOGIES

There are several specific therapies for cellulite. Many of these are predicated on the concept of subcision, pioneered for treatment of acne scars by the late Norman Orentreich, a pioneering New York dermatologist who also discovered the scientific basis for

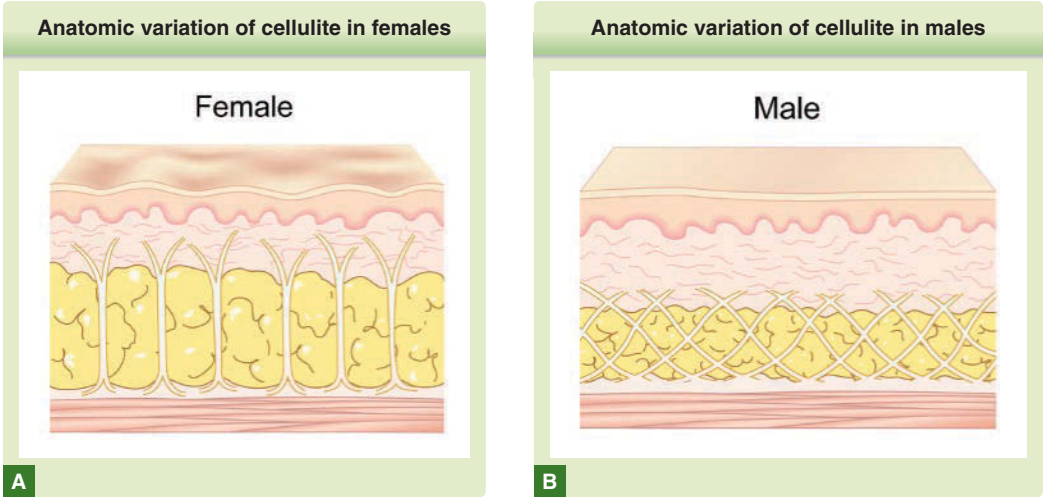

Figure 211-8 Cellulite is believed to be potentiated by anatomic variation, particularly by the parallel fascial bands more characteristic in women (**A**). The fascial bands more typical in men, which are believed to be a more crisscross pattern (**B**), may be more resistant to subcutaneous fat herniation.

hair transplantation. Hypodermic needles, lasers, and mechanical devices have been used to correct cellulite. Temporary improvement in the appearance of cellulite can be obtained by noninvasive light and massage devices. Nondevice interventions include physical exercise, but weight loss is less helpful.

MODES OF ACTION

Subcision entails inserting a metal implement with a sharp end through the skin, and then moving it back and forth subdermally in a fanning motion to sever fascial bands and release fibrous attachments around pockets of subcutaneous fat depression or herniation (Fig. 211-9A). This results in elevation of the depressed area by mechanical release. Trauma associated with the procedure can secondarily induce collagen remodeling as well as capillary leaks that culminate in fibrotic plugs that further elevate the depressed area.

Subcision with a hypodermic needle similar to that used for acne scar subcision was shown to be effective for cellulite by Doris Hexsel, a Brazilian dermatologist. Limiting factors were routine bleeding and bruising, and risk of hematoma.

To make subcision[32-36] for cellulite better tolerated, specific devices have been developed. These aim to minimize disfiguring bleeding and bruising, and to reduce the sensitivity of the procedure to minor differences in operator technique. An insertional Nd:YAG laser device with a hot tip has been used to separate fascial bands and melt fat, while cauterizing small vessels to reduce bleeding. More recently, a device has been developed to mechanically elevate and hold the dermal–subcutaneous junction in place, after which standardized cold needles separate the fascia using a fanning motion. Remaining in the same plane mitigates the risk of injuring peripheral vessels. Device-based subcision for cellulite uses injection of dilute local anesthesia, so-called tumescent anesthesia, to protect skin structures by inflating the skin layers and inducing preoperative vasoconstriction.

Noninvasive laser and light devices, often with multiple heads, have been used to treat cellulite. The FDA guidance for these devices notes that they[37-40] may temporarily improve the appearance of cellulite. The primary mode of action appears to be the induction of edema, which camouflages cellulite dimples. There also may be some degree of mechanical disruption of the cellulite, but this is speculative and has not been definitely shown.

Weight loss does not improve cellulite, which is a condition of the superficial subcutis and not of the deeper fat. Liposuction, by reducing superficial fat, can exacerbate cellulite, although in most cases liposuction is performed to avoid superficial suctioning and therefore has no net effect on cellulite. Physical exercise can improve cellulite by increasing muscle mass. Muscle growth increases the size of the compartment under the fat, pressing the fascia against the subcutis and dermis, and thus flattening cellulite.

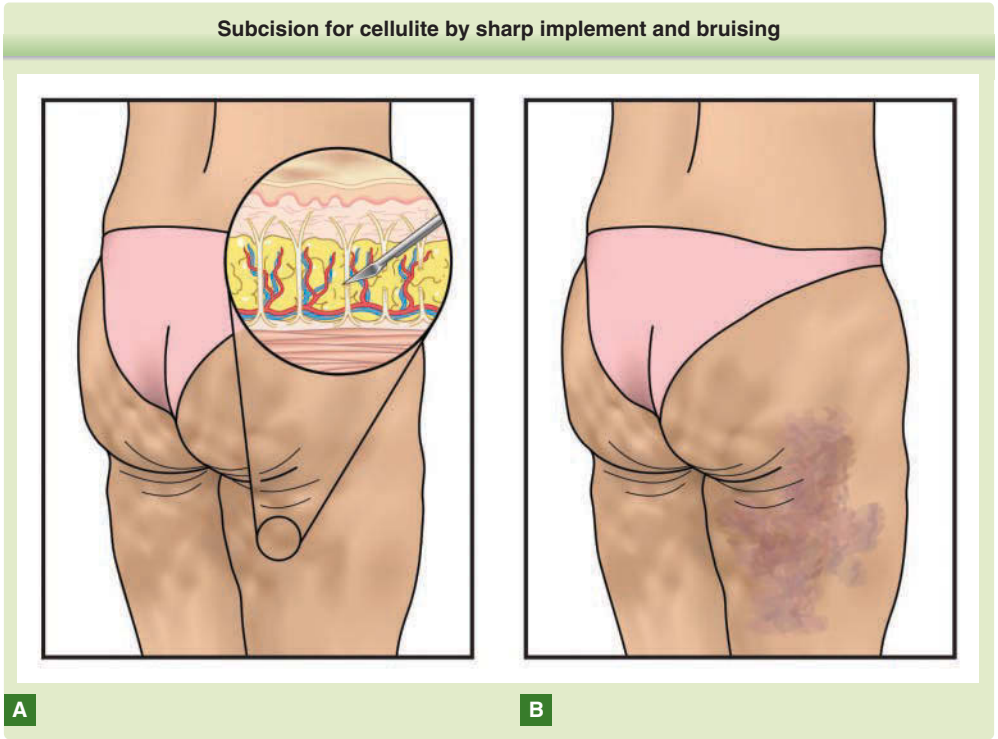

Figure 211-9 Subcision for cellulite entails release of skin dimpling by using a sharp implement in a rasping, fanning motion under the dermis to sever restrictive subcutaneous fibrous septae and fascial bands (**A**). Preoperative infiltration of tumescent anesthesia can mitigate bruising (**B**). More modern device-based variants of this technique are less operator-dependent and less likely to cause pain or bruising.

AVOIDING AND MANAGING COMPLICATIONS

Bruising is the common, annoying but not serious complication of subcision-based techniques for cellulite reduction. Apart from being tender and impeding social activities in which the affected skin is exposed, bruising can be troublesome, if it resolves with persistent hyperpigmentation. This is more common in patients with darker-pigmented skin, who also may be left with dark marks caused at the point of needle or device insertions.

Bruising in cellulite treatment can be minimized. Sharp injury to small vessels that results in bleeding and bruising can be reduced by employing devices that either cauterize or stabilize the skin tissue during the procedure (Fig. 211-9B). Allowing tumescent anesthesia to set for approximately 30 minutes or longer before the procedure ensures adequate vasoconstriction.

Hematomas and seromas have been reported infrequently and appear to be relatively more likely after application of hot-tipped laser treatments that may induce copious focal trauma. If such fluid accumulation occurs, it needs to be decompressed by syringe extraction or surgical drainage. A preventive strategy is limiting the number of dimples treated at one time in a given contiguous anatomic area.

Like bleeding and bruising, discomfort during the procedure can be managed by application of tumescent anesthesia. Such anesthesia also inflates the skin mechanically, reducing the risk of inadvertent injury to deeper structures and vessels.

ADAPTING TREATMENTS FOR ANATOMIC AREAS AND SKIN TYPES

In general, subcision-based treatments for cellulite are safe for all skin types. Patients with Fitzpatrick skin Type IV and higher may develop hyperpigmentation at the site of ecchymoses or entry sites. Buttock dimpling appears more amenable to treatment than cellulite of the thighs.

EXPECTED OUTCOMES

Treatment of cellulite can result in improvement of small skin dimples of the buttocks and thighs. Several treatments are typically required, and not all dimples will resolve. Better demarcated round dimples will improve more than larger, irregular ones, and buttock dimples may respond better than thigh dimples.

Postoperative bruising and pinpricks at the site of insertion sites may be visible and tender for several days to 2 weeks. Hyperpigmentation in localized patches is possible, but uncommon, and is a greater risk in darker-skinned patients.

Current treatments do not reduce the future risk of developing more cellulite. Physical exercise and stable, normal weight levels may improve cellulite, or at least slow its exacerbation.

MEANS OF OPTIMIZATION

REPEAT THERAPIES

Treatments for skin tightening, fat reduction, and cellulite removal are often performed repeatedly for best effect. The likely number of treatments is dependent on the degree of the problem to be corrected, a discussion with the patient regarding their preference, and practical constraints, like the time required, patient tolerance of discomfort,[41] and aggregate cost. There is increasing evidence that performing many treatments for skin tightening or fat reduction can result in marked and continuous improvement. Treatments are frequently spaced 1 to 3 months apart to allow for wound healing and collagen remodeling prior to retreatment.

COMBINATION THERAPIES

In some cases, improvement may be maximized by using different modalities in combination for the same indication. For instance, several different technologies may be used for fat reduction for optimal effect. Different molecular mechanisms associated with these treatments may augment the cumulative improvement. Again, this requires planning, discussion with the patient, and communication of reasonable expectations.

SUMMARY

Noninvasive body-contouring methods, including skin tightening, fat reduction, and cellulite removal, are emerging technologies. Adverse events are minimal and posttreatment recovery time is brief. Younger to middle-aged adult patients with limited overall skin laxity and sagging are the best candidates. Effectiveness continues to improve and is further enhanced by repeat and combination treatments. Even though some single-intervention invasive surgical procedures for similar indications may be as, or even more, effective, patients are increasingly averse to the risk, scarring, and sense of invasiveness associated with these.

REFERENCES

1. Beasley KL, Weiss RA. Radiofrequency in cosmetic dermatology. *Dermatol Clin.* 2014;32(1):79-90.
2. Weiss RA. Noninvasive radio frequency for skin tightening and body contouring. *Semin Cutan Med Surg.* 2013;32(1):9-17.
3. MacGregor JL, Tanzi EL. Microfocused ultrasound for skin tightening. *Semin Cutan Med Surg.* 2013;32(1):18-25.

4. Minkis K, Alam M. Ultrasound skin tightening. *Dermatol Clin.* 2014;32(1):71-77.
5. Tanaka Y. Long-term three-dimensional volumetric assessment of skin tightening using a sharply tapered non-insulated microneedle radiofrequency applicator with novel fractionated pulse mode in Asians. *Lasers Surg Med.* 2015;47(8):626-633.
6. Gold MH, Sensing W, Biron J. Use of micro-focused ultrasound with visualization to lift and tighten lax knee skin (1.). *J Cosmet Laser Ther.* 2014;16(5):225-229.
7. Dainichi T, Kawaguchi A, Ueda S, et al. Skin tightening effect using fractional laser treatment: I. A randomized half-side pilot study on faces of patients with acne. *Dermatol Surg.* 2010;36(1):66-70.
8. Goldberg DJ, Hussain M, Fazeli A, et al. Treatment of skin laxity of the lower face and neck in older individuals with a broad-spectrum infrared light device. *J Cosmet Laser Ther.* 2007;9(1):35-40.
9. Alam M, Levy R, Pajvani U, et al. Safety of radiofrequency treatment over human skin previously injected with medium-term injectable soft-tissue augmentation materials: a controlled pilot trial. *Lasers Surg Med.* 2006;38(3):205-210.
10. Nahm WK, Su TT, Rotunda AM, et al. Objective changes in brow position, superior palpebral crease, peak angle of the eyebrow, and jowl surface area after volumetric radiofrequency treatments to half of the face. *Dermatol Surg.* 2004;30(6):922-928; discussion 928.
11. Vega JM, Bucay VW, Mayoral FA. Prospective, multicenter study to determine the safety and efficacy of a unique radiofrequency device for moderate to severe hand wrinkles. *J Drugs Dermatol.* 2013;12(1):24-26.
12. Carruthers J, Fabi S, Weiss R. Monopolar radiofrequency for skin tightening: our experience and a review of the literature. *Dermatol Surg.* 2014;40(suppl 12):S168-S173.
13. Ortiz AE, Goldman MP, Fitzpatrick RE. Ablative CO_2 lasers for skin tightening: traditional versus fractional. *Dermatol Surg.* 2014;40(suppl 12):S147-S151.
14. Alam M, White LE, Martin N, et al. Ultrasound tightening of facial and neck skin: a rater-blinded prospective cohort study. *J Am Acad Dermatol.* 2010;62(2):262-269.
15. Alam M. What devices to use or not use in skin of color. *Semin Cutan Med Surg.* 2016;35(4):218-222.
16. Robinson DM, Kaminer MS, Baumann L, et al. High-intensity focused ultrasound for the reduction of subcutaneous adipose tissue using multiple treatment techniques. *Dermatol Surg.* 2014;40(6):641-651.
17. Adatto MA, Adatto-Neilson RM, Morren G. Reduction in adipose tissue volume using a new high-power radiofrequency technology combined with infrared light and mechanical manipulation for body contouring. *Lasers Med Sci.* 2014;29(5):1627-1631.
18. Adatto MA, Adatto-Neilson R, Novak P, et al. Body shaping with acoustic wave therapy AWT(®)/EPAT(®): randomized, controlled study on 14 subjects. *J Cosmet Laser Ther.* 2011;13(6):291-296.
19. Jewell ML, Baxter RA, Cox SE, et al. Randomized sham-controlled trial to evaluate the safety and effectiveness of a high-intensity focused ultrasound device for noninvasive body sculpting. *Plast Reconstr Surg.* 2011;128(1):253-262.
20. Nassar AH, Dorizas AS, Shafai A, et al. A randomized, controlled clinical study to investigate the safety and efficacy of acoustic wave therapy in body contouring. *Dermatol Surg.* 2015;41(3):366-370.
21. Saedi N, Kaminer M. New waves for fat reduction: high-intensity focused ultrasound. *Semin Cutan Med Surg.* 2013;32(1):26-30.
22. Zelickson BD, Burns AJ, Kilmer SL. Cryolipolysis for safe and effective inner thigh fat reduction. *Lasers Surg Med.* 2015;47(2):120-127.
23. Munavalli GS, Panchaprateep R. Cryolipolysis for targeted fat reduction and improved appearance of the enlarged male breast. *Dermatol Surg.* 2015;41(9):1043-1051.
24. Garibyan L, Cornelissen L, Sipprell W, et al. Transient alterations of cutaneous sensory nerve function by noninvasive cryolipolysis. *J Invest Dermatol.* 2015;135(11):2623-2631.
25. Wanitphakdeedecha R, Sathaworawong A, Manuskiatti W. The efficacy of cryolipolysis treatment on arms and inner thighs. *Lasers Med Sci.* 2015;30(8):2165-2169.
26. Jones DH, Carruthers J, Joseph JH, et al. REFINE-1, a multicenter, randomized, double-blind, placebo-controlled, phase 3 trial with ATX-101, an injectable drug for submental fat reduction. *Dermatol Surg.* 2016;42(1):38-49.
27. Ascher B, Hoffmann K, Walker P, et al. Efficacy, patient-reported outcomes and safety profile of ATX-101 (deoxycholic acid), an injectable drug for the reduction of unwanted submental fat: results from a phase III, randomized, placebo-controlled study. *J Eur Acad Dermatol Venereol.* 2014;28(12):1707-1715.
28. Salti G, Ghersetich I, Tantussi F, et al. Phosphatidylcholine and sodium deoxycholate in the treatment of localized fat: a double-blind, randomized study. *Dermatol Surg.* 2008;34(1):60-66; discussion 66.
29. Rotunda AM, Weiss SR, Rivkin LS. Randomized double-blind clinical trial of subcutaneously injected deoxycholate versus a phosphatidylcholine-deoxycholate combination for the reduction of submental fat. *Dermatol Surg.* 2009;35(5):792-803.
30. Leclère FM, Moreno-Moraga J, Mordon S, et al. Laser-assisted lipolysis for cankle remodelling: a prospective study in 30 patients. *Lasers Med Sci.* 2014;29(1):131-136.
31. Alexiades-Armenakas M. Combination laser-assisted liposuction and minimally invasive skin tightening with temperature feedback for treatment of the submentum and neck. *Dermatol Surg.* 2012;38(6):871-881.
32. Green JB, Cohen JL, Kaufman J, et al. Therapeutic approaches to cellulite. *Semin Cutan Med Surg.* 2015;34(3):140-143.
33. Zerini I, Sisti A, Cuomo R, et al. Cellulite treatment: a comprehensive literature review. *J Cosmet Dermatol.* 2015;14(3):224-240.
34. Luebberding S, Krueger N, Sadick NS. Cellulite: an evidence-based review. *Am J Clin Dermatol.* 2015;16(4):243-256.
35. Hexsel DM, Mazzuco R. Subcision: a treatment for cellulite. *Int J Dermatol.* 2000;39(7):539-544.
36. Kaminer MS, Coleman WP 3rd, Weiss RA, et al. Multicenter pivotal study of vacuum-assisted precise tissue release for the treatment of cellulite. *Dermatol Surg.* 2015;41(3):336-347.
37. Russe-Wilflingseder K, Russe E, Vester JC, et al. Placebo controlled, prospectively randomized, double-blinded study for the investigation of the effectiveness and safety of the acoustic wave therapy (AWT(®)) for cellulite treatment. *J Cosmet Laser Ther.* 2013;15(3):155-162.

38. Hexsel D, Siega C, Schilling-Souza J, et al. Noninvasive treatment of cellulite utilizing an expedited treatment protocol with a dual wavelength laser-suction and massage device. *J Cosmet Laser Ther.* 2013;15(2):65-69.
39. Truitt A, Elkeeb L, Ortiz A, et al. Evaluation of a long pulsed 1064-nm Nd:YAG laser for improvement in appearance of cellulite. *J Cosmet Laser Ther.* 2012;14(3):139-144.
40. Mlosek RK, Woźniak W, Malinowska S, et al. The effectiveness of anticellulite treatment using tripolar radiofrequency monitored by classic and high-frequency ultrasound. *J Eur Acad Dermatol Venereol.* 2012;26(6):696-703.
41. Kakar R, Ibrahim O, Disphanurat W, et al. Pain in naïve and non-naïve subjects undergoing nonablative skin tightening dermatologic procedures: a nested randomized control trial. *Dermatol Surg.* 2014;40(4):398-404.

Chapter 212 :: Treatment of Varicose Veins and Telangiectatic Lower-Extremity Vessels

:: Daniel P. Friedmann, Vineet Mishra, & Jeffrey T. S. Hsu

AT-A-GLANCE

- Reverse venous flow (reflux) is exceedingly common in the general population.
- Age, pregnancy, body mass, and a family history of varicose leg veins all increase the incidence of venous reflux in patients.
- Duplex ultrasound examination can rapidly, effectively, and reproducibly map the superficial venous pathways of the lower extremities and identify sources of reflux in a noninvasive fashion.
- Sclerotherapy is the gold standard treatment for spider veins, although lasers may play an important adjuvant or alternative role.
- Varicose veins are often treated with a combination of endovenous ablation and sclerotherapy or phlebectomy, depending on their underlying cause.

Abnormal lower-extremity veins, from unsightly telangiectasias ("spider veins") to symptomatic varicose veins, affect millions of people worldwide. Although telangiectasias and reticular veins are often considered solely a cosmetic nuisance, they are, like varicose veins, an early manifestation of chronic venous disease (CVD) and may foreshadow the development of advanced CVD, termed chronic venous insufficiency (CVI). Signs and symptoms of CVI have high socioeconomic costs, including reduced quality of life and millions of work days lost per year, in the United States and Western Europe.[1,2]

While telangiectasias and reticular veins may be treated with sclerotherapy or long-pulsed vascular lasers, varicose veins require sclerotherapy (typically with the aid of duplex ultrasound guidance), ambulatory phlebectomy, or endovenous thermal ablation. Successful treatment of lower-extremity venous disease is predicated on the fundamental understanding of venous anatomy, physiology, and patterns of insufficiency; methods of diagnosing venous disease; uses and actions of sclerosing solutions; and the proper use of posttreatment compression.

VENOUS ANATOMY AND PHYSIOLOGY

The venous system of the lower extremities is an intricate, variable network of vessels divided into 3 compartments (superficial, deep, and perforating) that allow for outflow of blood back to the heart and local tissue drainage and thermoregulation (Fig. 212-1). One-way valves are present in veins of all 3 systems, ensuring unidirectional blood flow against gravity, toward the heart.

DEEP VENOUS SYSTEM

The veins of the deep venous compartment lie beneath muscular (aka deep aponeurotic) fascia and act as a conduit for approximately 90% of venous return from the leg. Deep venous blood flow is regulated by the physiologic alternate contraction–relaxation of the calf flexor–extensor skeletal muscles that act as a peristaltic pump. During calf muscle contraction, rising pressure in the deep compartment (up to 250 mm Hg) propels blood through the deep system in a proximal direction with an ejection fraction of 65%.[3] This and the fact that these high pressures close valves of deep and perforating veins prevent retrograde blood flow.

The deep vein system begins in the foot, where the digital and metatarsal veins drain into the deep plantar venous arch or pedal vein, which, in turn, drain into the posterior and anterior tibial veins at the ankle. The tibial veins and peroneal vein actually contribute little to the calf muscle pump. Instead, it is the large, spiral-shaped gastrocnemius and sural veins that are critical members of the calf muscle pump, directly emptying venous sinuses within the belly of calf muscles. The confluence of these multiple calf veins forms the popliteal vein at or immediately below the knee. The small saphenous vein (SSV) may drain into the popliteal vein at this point, forming the saphenopopliteal junction. The deep femoral regularly communicates with the popliteal vein as well, either directly (38% of cases) or via a tributary (48% of cases).[3]

The popliteal vein becomes the femoral vein at the upper margin of the popliteal fossa and courses through the adductor canal in the middle third of anteromedial thigh.[4] Approximately 9 cm distal to the inguinal ligament, the femoral vein joins the deep femoral vein, creating the common femoral vein.[5] The common femoral vein has multiple veins that drain into it immediately below the inguinal ligament; the most important of these is the great saphenous vein

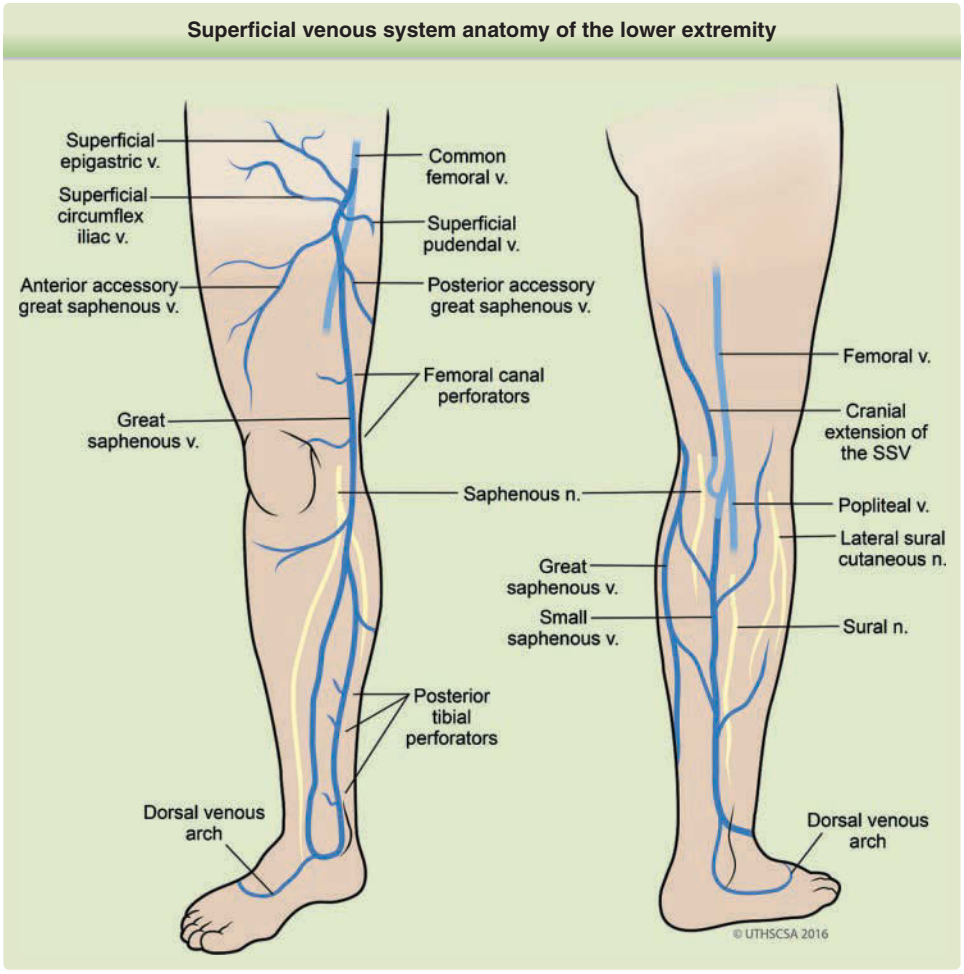

Figure 212-1 Superficial and (pertinent) deep venous system anatomy of the lower extremity. n, Nerve; SSV, small saphenous vein; v, vein. (Reproduced with permission from UT Health Science Center at San Antonio. © UTHSCSA.)

(GSV), forming the saphenofemoral junction (SFJ). The common femoral vein ultimately becomes the external iliac vein at the level of the inguinal ligament.

SUPERFICIAL VENOUS SYSTEM

The cutaneous microcirculation and subcutaneous saphenous truncal veins (and associated veins) comprise the superficial venous network. A network of subdermal reticular veins runs parallel to the skin surface, helping to drain dermal and subcutaneous tissue.

The GSV and SSV are circumscribed by a thin saphenous sheath, which merges with muscular fascia to form the saphenous compartment (Fig. 212-2).[4] Accessory veins are saphenous-like and ascend parallel with saphenous veins, while tributary veins are tortuous and varicose in nature; do not course with saphenous veins; and are a conduit between the saphenous system and reticular vein network. Unlike the GSV and SSV, which are found entirely within the saphenous compartment, accessory and tributary veins lie outside of (ie, superficial to) the saphenous compartment within subcutaneous tissue. The primary exception to this rule is the anterior accessory of the GSV, which can course anterior to the GSV within its own layer of hyperechoic fascia in the proximal thigh.[5] Nevertheless, the GSV may penetrate the saphenous fascia

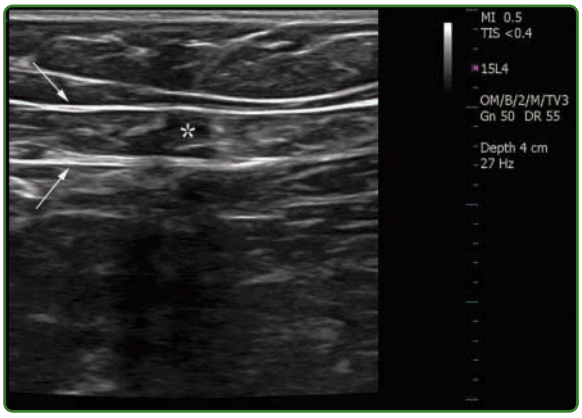

Figure 212-2 Thigh segment of the great saphenous vein (*asterisk*) within the saphenous compartment (*arrows*).

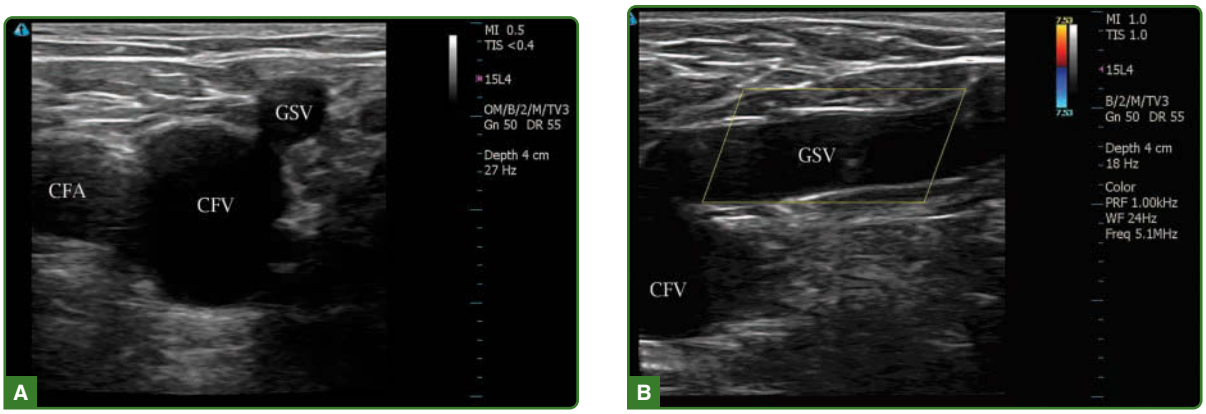

Figure 212-3 The saphenofemoral junction in transverse (**A**) and longitudinal (**B**) views. Note the "Mickey Mouse sign" produced by the relationship of the 3 vessels in transverse view (**A**). CFA, common femoral artery; CFV, common femoral vein; GSV, great saphenous vein.

at the level of the mid or distal thigh, becoming more superficial. True duplication of the GSV is present in the thigh in 8% of cases, and in the calf in 25% of cases, with both vessels lying within the saphenous sheath; unlike the GSV, the SSV is rarely duplicated.[3,6]

The GSV originates in the dorsal foot from the dorsal venous arch and internal marginal vein. It courses anterior to the medial malleolus, ascends the medial calf within the triangle formed by the tibia and medial gastrocnemius, and continues in the anteromedial thigh. Anatomical variations of the GSV and its tributary and accessory veins in the knee and thigh are common.[7,8] The GSV terminates at the SFJ approximately 3 cm inferior to the inguinal ligament (and 3 to 4 cm inferior and lateral to the pubic tubercle), at the level of the groin skin crease (Fig. 212-3).[9,10] The SFJ extends from the termination of the GSV to its preterminal valve and is bound proximally by the suprasaphenic and distally by the infrasaphenic valves of the common femoral vein.[5] Multiple tributaries (Table 212-1) drain into the GSV at the SFJ, with the majority of these doing so within the SFJ between the terminal valve (1 to 2 mm from GSV termination) and preterminal valve (2 to 5 cm distal to the terminal valve) (Fig. 212-4).[11] The preterminal valve ensures that reflux into these tributaries does not occur when the terminal valve is closed.[5]

The saphenous nerve lies anteriorly to the GSV within the saphenous compartment from the medial foot to 2 to 3 cm distal and medial to the tibial tuberosity, supplying cutaneous sensation to the medial aspects of the leg, ankle, and foot. It can run intimately with the vein more than 80% of the time in the distal third of the leg (often with the nerve perineum histologically attached to the vein adventitia) and nearly 60% of the time in the middle third of the leg.[12]

The SSV originates in the lateral foot from the dorsal venous arch, coursing posterior to the lateral malleolus and between gastrocnemius muscles in the posterior calf. SSV termination, however, is variable. Sixty percent of the time it drains into the popliteal vein at the saphenopopliteal junction within 5 cm of the popliteal skin crease, with junctional anatomy analogous to that of the SFJ.[10] One-third of the time it drains into the popliteal vein above the knee joint, and below the knee joint in the remaining 5% to 10%.[6] Yet, it may also terminate above the popliteal fossa in another deep vein or thigh GSV, communicate with the popliteal vein but terminate in the thigh GSV, or terminate below the popliteal fossa in another deep vein or leg GSV. When it terminates at the saphenopopliteal junction, the proximal segment of the SSV may actually pierce and lie deep to the deep fascia in order to reach the popliteal fossa, the only significant exception among vessels of the superficial venous system. A proximal

TABLE 212-1
Major Great Saphenous Vein Tributary Veins

LOCATION	NAME	COURSE/FUNCTION
Saphenofemoral junction	Superficial circumflex iliac vein	Drains blood from the groin
	Superficial epigastric vein	Drains blood from abdominal wall
	Superficial/external pudendal vein	Drains blood from the pelvis
	AAGSV	Courses anterolateral to the GSV, aligned over the femoral artery/vein in the proximal thigh
	PAGSV	Courses posterior to the GSV; rarer than the AAGSV
Proximal thigh	Anterior thigh circumflex vein	Ascends obliquely in the anterior thigh, draining into GSV or AAGSV
	Posterior thigh circumflex vein	Ascends obliquely in the posterior thigh, draining into GSV or PAGSV. May originate in SSV or its thigh extension
Leg	Posterior arch vein	Below the knee segment of the PAGSV

AAGSV, anterior accessory of the great saphenous vein; GSV, great saphenous vein; PAGSV, posterior accessory of the great saphenous vein.

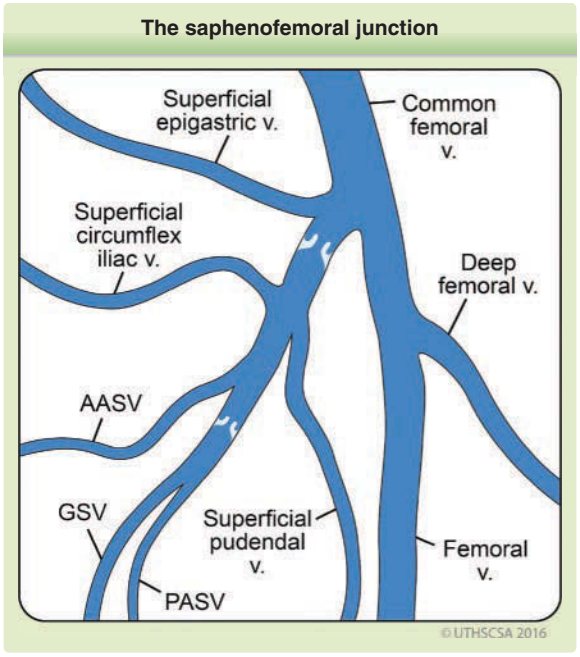

Figure 212-4 The saphenofemoral junction (SFJ). The great saphenous vein (GSV) drains into the common femoral vein at the SFJ, immediately below the inguinal ligament. Numerous tributaries drain into the GSV, primarily between the terminal valve and preterminal valve. AAGSV, anterior accessory of the great saphenous vein; PAGSV, posterior accessory of the great saphenous vein; v, vein. (Reproduced with permission from UT Health Science Center at San Antonio. © UTHSCSA.)

SSV segment deep to the deep fascia cannot become grossly incompetent.

A cranial extension of the SSV may continue into the thigh. If it communicates with the GSV in the medial thigh via the posterior thigh circumflex vein, it is often referred to as the *Giacomini vein*. This intersaphenous communicating vein may be significantly more common in patients with combined GSV and SSV incompetence. The sural nerve lies just lateral to the SSV within the saphenous compartment primarily in the distal third of the leg (but may do so as far up as the apex of the calf), after which it travels below the muscular fascia.[3,13] The SSV may also travel in close proximity to the tibial nerve in the popliteal fossa before its termination in the popliteal vein.[14] The tibial nerve provides motor to medial and lateral plantar muscles, while the sural nerve provides cutaneous sensation to the posterolateral leg and lateral foot.

The subdermic lateral venous system of the lateral thigh is often considered the third primary territory of the superficial venous system. It represents the remnant of the embryonic vena marginalis lateralis and is a high-risk area for vein development. A popliteal fossa vein (aka posterior fossa vein) also may be found ascending the upper calf and posterior knee in up to 3% of patients, piercing the deep fascia and emptying into the popliteal vein at a separate junction.[11] Its presence may correlate with a higher propensity for incompetence of the GSV, its tributaries, and adjacent perforating veins.[15]

PERFORATING VENOUS SYSTEM

Perforating veins course through the deep fascia to connect the superficial and deep systems.[16] Perforating veins of the ankle, leg, knee, and thigh direct flow in a *superficial to deep* direction. During calf muscle pump contraction, perforator valves close, preventing flow into the superficial system; when calf muscle relaxation occurs, deep venous pressure is reduced and perforator valves open, resuming flow into the deep system.[3,17] Valvular insufficiency in these veins can thereby lead to outward flow (or sometimes bidirectional flow) into lower pressure saphenous or reticular veins and is frequently associated with reflux in the superficial system.[3,18] Perforating veins of the foot are the exception, normally directing flow toward superficial veins.

Although perforating veins are highly variable in arrangement, connection, size, and distribution, they are best grouped on the basis of their topography.[4] The 4 clinically important locations for perforators are the thigh, knee fold, and upper medial and lower medial leg.[17] Table 212-2 lists these and other perforators. The number and size of competent and the number of incompetent perforating veins correlate directly with the severity of CVD.[18]

EPIDEMIOLOGY AND PREDISPOSING FACTORS

A number of epidemiologic studies provide information regarding telangiectatic and varicose lower-extremity veins and predisposing factors associated with their development. The Edinburgh Vein Study found that in a random sample of 1566 people 16 to 64 years of age, 1316 people (84%) had telangiectasias (88% of women and 79% of men).[19] Of these, 92% of the telangiectasias were graded as mild in severity and were primarily located in the posteromedial aspects of the thigh, popliteal fossa, and proximal calf. Subjects with telangiectasias were significantly more likely to be female (89.7%), more advanced in age (mean: 56.6 vs 34.4 years; $p < 0.001$), and have had a history of pregnancy. Advancing grade of telangiectasia was significantly associated with the presence and severity of varicose veins and increasing incompetence in proximal and distal GSV segments ($p < 0.001$), but not the SSV.[20]

The prevalence of superficial and deep venous reflux increases with age.[21] While segmental venous reflux may be found in superficial and deep veins in subjects without varicosities, the presence of superficial and combined superficial and deep reflux correlate with varicose vein severity.[22] A study of GSV reflux in women with varicose veins also demonstrated progression from segmental to multisegmental reflux over time.[23]

The Edinburgh Vein Study reported rates of GSV incompetence above and below the knee of 2.9% and 7.2% in patients without evidence of CVD, 28.0%

TABLE 212-2
Major Perforating Veins of the Lower Extremity

LOCATION	SUBLOCATION	NAME	CONNECTION/ROLE
Thigh	Medial thigh	Perforators of the femoral canal (formerly known as the Dodd or Hunterian perforators)	GSV to the proximal popliteal vein in the distal thigh or the femoral vein in the mid thigh
		Inguinal perforators	GSV to the femoral vein in the proximal thigh
	Posterior thigh	Posteromedial and posterolateral thigh, sciatic, and pudendal perforators	
	Other areas	Anterior and lateral thigh perforators	
Knee	Popliteal fossa	Popliteal fossa perforator	SSV to the popliteal vein
	Other areas	Medial knee, lateral knee, suprapatellar, and infrapatellar perforators	
Leg	Medial leg	Paratibial perforators (formerly known as the Boyd perforator)	GSV to the posterior tibial veins in the upper third of the medial leg
		Posterior tibial perforators (formerly known as Cockett perforators)	Posterior accessory GSV of the leg (*posterior arch vein*) to the posterior tibial veins in the mid-to-distal third of the medial leg
	Posterior leg	Medial and lateral gastrocnemius perforators	SSV to the gastrocnemius vein
		Intergemellar perforators	SSV to the soleal vein
		Para-Achillean perforators	SSV to fibular veins
	Other areas	Anterior leg perforators	GSV to anterior tibial vein
		Lateral leg perforators	

GSV, great saphenous vein; SSV, small saphenous vein.

and 35.8% in those with varicosities but no signs of CVI, and 51.7% to 55.6% and 44.4% to 68.9% in those with CVI. SSV incompetence prevalence rates in those same categories were 1.7%, 10.8%, and 10.3% to 11.1%, respectively.[24] SSV prevalence rates approaching 30% (alone or in combination with other areas of reflux) have been reported and are likely subject to referral bias.[25,26] The presence of SSV reflux also has been positively correlated with an increased incidence of concurrent deep (popliteal greater than femoral) venous reflux.[6,25]

Long-term followup (mean: 13.4 years) showed disease progression in 193 (57.8%) of 334 patients with varicose veins or CVI at baseline.[27] Risk factors for progression included having both varicose veins and CVI at baseline (63.6% vs 40% with only varicose veins; $p = 0.002$); history of deep vein thrombosis (DVT; 4 times as likely); and family history of varicose veins (nearly twice as likely). In patients with only varicose veins at baseline, disease progression increased with age ($p = 0.04$), with patients older than age 55 years being almost 4 times as likely as those 18 to 34 years old. Family history of varicose veins and overweight/obesity also significantly increased the risk of CVI development twofold. Although men were more likely to have saphenous varicose veins at baseline (39.7% vs 32.2%), the incidence of varicose veins and CVI was not significantly different between genders, increasing proportionately with age.[28,29] Garcia-Gimeno and colleagues,[30] however, found that female gender also increased the frequency (by 1.3 times) of more-severe CVI. Although prolonged standing, dietary intake, and smoking have been postulated to be risk factors for developing varicose veins, evidence is lacking.[31]

Subjects with baseline superficial venous reflux were at twofold risk of ipsilateral clinical progression, with the rate of progression increasing by 1.7 times per refluxing venous segment, 2.6 times with combined superficial and deep reflux, and nearly 5 times with the presence of SSV reflux.[27] Of 306 patients free from reflux at baseline, the incidence of developing reflux over this same followup time was 12.7% (annual incidence of 0.9%). Reflux developed most commonly in the GSV, particularly the lower third of the thigh (8.1% incidence).[32]

A study of 5187 Italian patients demonstrated a 77.3% prevalence of CVD.[33] Men had significantly higher rates of saphenous varicose veins than women (27.4% vs 19.5%; $p < 0.0001$). The rate of saphenous vein incompetence increased rapidly with advancing age, with venous reflux found in 53% of patients older than age 50 years and saphenous varicose veins being 5.9 times more likely than in younger subjects. The prevalence of lower-extremity veins and venous incompetence were significantly higher in subjects with a positive family history of venous disease.

Like in the Edinburgh Vein Study, men demonstrated lower rates of telangiectasias than women (33.4% vs 69.9%), with women being 4 times more likely than men to develop telangiectasia if nulliparous and 5.5 times more likely after having 1 or more children.[34] Women with more than 3 children demonstrated a greater prevalence than nulliparous females with regard to telangiectasias (75.7% vs 63.4%; $p < 0.0001$), saphenous varicose veins (35.5% vs 12.0%; $p < 0.0001$), and nonsaphenous varicose veins (50.5% vs 19.6%; $p < 0.0001$).

A history of hormone replacement therapy was significantly more likely in patients with telangiectasias than with no lower-extremity veins in the Edinburgh Vein Study. Interestingly, women without clinically evident leg veins were more likely to have used oral contraceptives than those with telangiectasias

(84.4% vs 44.0%; $p < 0.001$). A study of 3590 women by Jukkola and colleagues[35] confirmed that advanced age and higher parity are associated with varicose veins, but found that hormone replacement therapy or oral contraceptive use does not increase their risk.

The most frequent presenting symptom of CVD in the Italian vein study was tired, heavy legs.[33] Tingling, heat sensation, pain, and swelling were also common. Apart from tingling, all were more common in women compared to men but not necessarily age related. Multiparity significantly increased the prevalence and onset of these subjective symptoms in female subjects.

VENOUS PATHOPHYSIOLOGY

Dysfunction of either the superficial, deep, or perforating venous system can create widespread venous hypertension, leading to the abnormal dilation, tortuosity, and dysfunction of superficial veins. Increased deep venous pressure can also result from arteriovenous malformations, pelvic masses, obesity, or sources of intraabdominal pressure.[36] Other potential contributing factors for venous hypertension include combined venous outflow obstruction (DVT or thrombophlebitis) and reflux, calf muscle pump failure, or congenital absence of valves.[37]

The venous system of the lower extremity relies on the interdependent functionality of valves, vein walls, and flow hemodynamics. Disruption of one of these components interferes with the integrity of the others, creating a positive feedback loop that eventuates in pathologic retrograde flow (referred to as reflux), prolonged venous hypertension, and varicose vein formation. Although primary valvular incompetence (disruption or loss) was once thought to be the inciting event for this disease process, recent evidence demonstrates that vein wall alterations precede valvular damage and insufficiency and are thus the primary event.[38] Recent studies suggest that given the frequent occurrence of normal saphenous veins in patients with varicose veins, varicose disease may progressively extend in an antegrade fashion, with a centripetal progression from saphenous tributaries associated with varicose veins toward saphenous veins.[39]

Varicose veins demonstrate significant structural and biochemical defects in cellular and extracellular connective tissue matrix components of all layers of the vein wall, altering venous tone and weakening its structure.[37,38] These include increased collagen, decreased elastin, increased tissue inhibitor of metalloproteinases activity, increased or decreased matrix metalloproteinase activity, and elevated transforming growth factor-β1 and fibroblast growth factor-β, promoting a state of extracellular connective tissue matrix accumulation.[40] These abnormalities are thought to be a product of hemodynamic stresses (eg, hypoxia, mechanical stretch, and low shear stress) and subsequent inflammatory cascades brought on by prolonged venous hypertension and stasis.[41,42]

Valvular incompetence is often multicentric, developing simultaneously in discontinuous venous segments. The hormone-induced and volume-induced venous distensibility and elevated deep venous pressures generated by pregnancy can produce valvular incompetence. Vein diameter and valve closure time of the common femoral vein, femoral vein, popliteal vein, GSV, and SSV significantly increase from the second to the end of the third trimester of pregnancy in primigravid women ($p = 0.001$), reverting to baseline in most cases within 3 months of delivery.[43] Primary valvular insufficiency resulting from degenerative disease with age or thrombophlebitis associated with DVT can affect any venous system.

HISTORY AND EXAMINATION

A thorough history and physical examination is essential to understand the nature of venous insufficiency in a given patient. Past or present signs and symptoms of CVD should be noted, ranging from subjective and nonspecific (eg, discomfort, aching, cramps, fatigue, and heaviness) to objective (eg, edema, dermatitis, pigmentation, and ulceration). A family history of large varicose veins denotes a greater likelihood of truncal varicosities, even when presenting with telangiectasias alone.[44] Symptoms of pelvic congestion syndrome (pelvic pain, aching or heaviness, and dyspareunia) should be ruled out in premenopausal women with varicose veins. Exacerbation of signs and symptoms with menstrual periods should also be documented.

Table 212-3 lists the relative and absolute contraindications to treatment of the superficial venous system. Although treatment of varicose veins is contraindicated

TABLE 212-3
Contraindications to Treatment of Lower Extremity Veins

RELATIVE CONTRAINDICATIONS[a]	ABSOLUTE CONTRAINDICATIONS
History of SVT, DVT or hypercoagulability	Acute SVT, DVT, or hypercoagulability
Mild PAD	Advanced PAD
Breastfeeding	Pregnancy (1st and 2nd trimester)
Diabetes	Concurrent general anesthesia
Obesity	Immobilized state
Inability to tolerate compression	Prior anaphylaxis to a proposed sclerosing agent
History of lower-extremity trauma	Infection localized to the treatment area or severe generalized infection

[a]Relative contraindications may require evaluation with duplex ultrasound or therapeutic control prior to treatment.

DVT, deep venous thrombosis; PAD, peripheral artery disease; SVT, superficial venous thrombosis.

during the first and second trimesters of pregnancy, extremely painful or bleeding varicose veins may be safely treated in the third trimester by endovenous ablation. Treatment is typically postponed, however, as varicosities and telangiectasias may resolve spontaneously within 1 to 6 months postpartum. A history of migraines or a known congenital heart defect should be noted and included in informed consent for sclerotherapy.

Physical examination involves inspection of the entire affected lower extremity in a 360-degree rotation. Telangiectasias ("spider veins") are red to dark blue vessels measuring 1 mm or less in diameter, while reticular veins are deeper, larger (1 to 3 mm), and exhibit a blue or greenish hue. Varicose veins measure 4 mm or larger and are bulging, dilated, and tortuous in nature.[36] Although varicose veins and other cutaneous signs of venous insufficiency are best evaluated with the patient in a standing position; reticular veins are most easily visible when lying prone or supine. The use of transillumination is also helpful in detailing the relationship and extent of reticular veins to telangiectasias. Palpation along saphenous vein distributions helps rule out early varicose veins that are not yet visible. Cutaneous hallmarks of CVD typically appear on the lower leg and medial malleolus and include edema, stasis dermatitis, hemosiderin pigmentation, lipodermatosclerosis, and cutaneous ulceration.[40] The clinical-etiologic-anatomic-pathophysiologic (CEAP) classification system is a descriptive tool that may aid in diagnosis and severity assessment (Table 212-4).[45]

Patients with superficial venous disease limited to scattered telangiectasias and reticular veins without evidence of CVI or associated varicose veins on visual examination do not require further workup. Preoperative duplex ultrasonography (DUS) is not typically required for these aesthetic concerns. However, DUS may still have value in localizing reflux in incompetent subcutaneous reticular veins or underlying perforating veins associated with extensive, treatment-resistant thigh telangiectasias.[46-48] Previous venous surgery also warrants DUS before performing additional treatment.

Asymptomatic or symptomatic varicose veins in a saphenous system distribution, such as the mid or distal thigh, anteromedial calf, extending distally from the popliteal fossa, or extending into the groin require diagnostic evaluation with DUS to evaluate for primary sources of retrograde flow.[10,49] It also may be useful in patients without visible varicosities who have signs and symptoms of venous hypertension suggestive of saphenous vein incompetence, as well as for identifying nonsaphenous sources of reflux caused by incompetent perforators.[50]

DUS remains the gold standard diagnostic study because of its noninvasive, reliable, and cost-effective venous imaging, providing far greater diagnostic accuracy than continuous-wave Doppler ultrasound.[49] Progressive improvements in the ease-of-use and portability of DUS devices have allowed them to largely supersede the use of more invasive, limited, and outdated diagnostic options, such as venography and plethysmography. Current DUS devices can superimpose Doppler information on areas of blood flow within a grayscale B-mode (time-delay) image as a graduated color scale (red and blue) based on direction and speed. Detection of physiologic reflux is best evaluated with the patient standing upright or in 45-degree reverse Trendelenburg position (tilted-table technique). The deep vein system is first evaluated to rule out obstruction. Failure to fully compress a vein with downward pressure along with the presence of intraluminal echogenicity is highly suspicious for thrombus. The superficial venous system is then evaluated for obstruction and reflux. Manual compression at the apex of the calf increases antegrade blood flow that should cease almost immediately upon release. Valsalva maneuver may additionally be used to elicit reflux at the SFJ. Reflux times greater than 500 msec are considered to be abnormal (Fig. 212-5). Mean and maximal vein diameter should also be documented.[51]

TABLE 212-4
Clinical-Etiologic-Anatomic-Pathophysiologic (CEAP) Classification Tool

Clinical class	C0	No signs of venous disease
	C1	Telangiectasias or reticular veins
	C2	Varicose veins
	C3	Edema of venous origin
	C4a	Hemosiderin pigmentation or eczematous changes
	C4b	Lipodermatosclerosis or atrophie blanche
	C5	Healed venous ulcer
	C6	Active venous ulcer
Etiology	Ec	Congenital
	Ep	Primary
	Es	Secondary
	En	No venous cause identified
Anatomic Distribution	As	Superficial veins
	Ap	Perforating veins
	Ad	Deep veins
	An	No venous location identified
Pathophysiology	Pr	Reflux
	Po	Obstruction
	Pr,o	Reflux and obstruction
	Pn	No venous pathophysiology identifiable

SCLEROTHERAPY

Derived from the Greek word for *hard*, the term *sclerotherapy* describes the introduction of a foreign substance into the lumen of a vessel, causing endothelial damage (endosclerosis) and transient vasospasm with subsequent fibrotic occlusion and eventual obliteration.[52] The fitting term *endovascular chemoablation* also has been proposed. Sclerotherapy remains an excellent primary treatment option for cutaneous veins

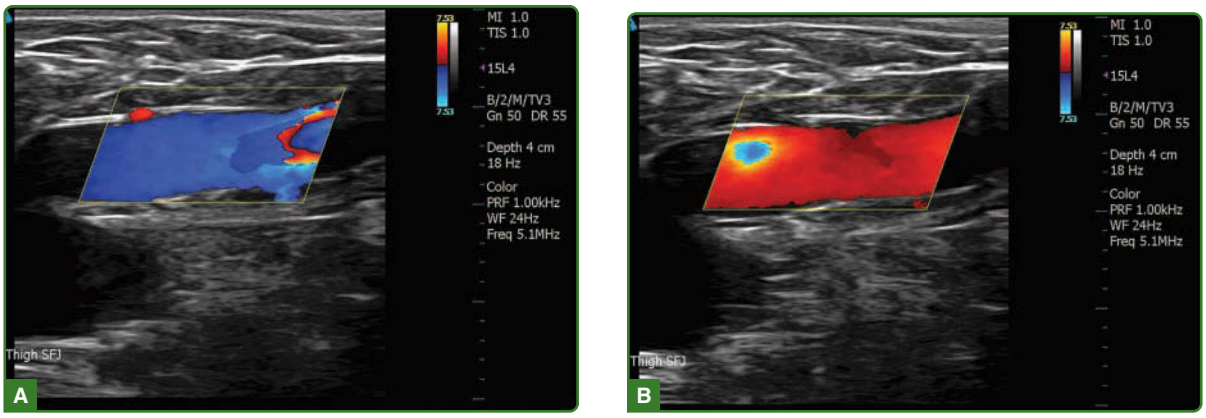

Figure 212-5 Duplex ultrasound examination of the saphenofemoral junction. **A,** Manual compression at the apex of the calf increases antegrade blood flow in the saphenofemoral junction. Blood flow should cease almost immediately upon release. **B,** Retrograde blood flow (reflux) time greater than 500 msec is abnormal. Blue and red colors represent bidirectional flow relative to a stationary duplex ultrasound transducer.

of all sizes and adjuvant therapy to endovenous procedures for saphenous veins and ambulatory phlebectomy for saphenous tributaries and varicose veins.[53]

HISTORICAL ASPECTS

Although sclerotherapy was first attempted in 1682, when Zollikofer of St. Gallen, Switzerland, injected an acid intravenously to produce a thrombus, the foundations of modern sclerotherapy began in the early 20th century. Scharff (1910) first reported venous thrombosis and sclerosis from the use of mercuric chloride for the intravenous treatment of syphilis.[54] Linser confirmed these findings and began using 20% hypertonic saline (HS) in 1921. Biegeleisen reported the first treatment of telangiectasias in the 1930s using sodium morrhuate. Although McAusland first popularized sclerotherapy in the United States in 1939, it was not until a safe synthetic sclerosing agent, sodium tetradecyl sulfate (STS), was developed in 1946 that sclerotherapy began to be seriously studied in the country. Renewed interest in sclerotherapy developed in the 1970s, with Duffy promoting the use of polidocanol (POL) and HS as safe and effective sclerosing solutions among dermatologists in the 1980s. The double-syringe technique developed by Tessari in 2000 increased the popularity of foam sclerotherapy worldwide.[55]

Another key to the success and acceptance of sclerotherapy was the addition of elastic compression, whose ease of use and popularity were facilitated by the discovery of a vulcanization process for increasing the elasticity and durability of rubber followed by the creation of synthetic, latex-free elastomers in the mid-19th century.[56]

SCLEROSING AGENTS

The ideal sclerosing agent would be selective against damaged endothelium (ie, abnormal blood vessels) with minimal to no reversible damage to surrounding tissue, be painless to inject, and have no adverse events.[57] Unfortunately, an ideal sclerosing agent does not yet exist. Currently available sclerosing agents are classified into 3 groups based on chemical structure and mechanism of action: detergent, hyperosmotic (hypertonic), and chemical (irritant).[58] A 2011 Cochrane review demonstrated that the available evidence does not suggest superior efficacy or subject satisfaction for any one sclerosing agent class for the treatment of lower extremity telangiectasias.[59] Table 212-5 describes the relative complications for each sclerosing agent.

TABLE 212-5
Complications by Sclerosing Agent

SCLEROSING AGENT	PAIN WITH INJECTION	PIGMENTATION	NECROSIS	ALLERGIC REACTIONS
Polidocanol	0	+/++	+	+
Sodium tetradecyl sulfate	+	++	+	+
Glycerin	+	0	0	0
Chromated glycerin	++	0	0	+
Hypertonic saline	+++	+	+++	0
Hypertonic saline/dextrose	++	+	+	0

0, none; +, minimal; ++, moderate; +++, significant/severe.

DETERGENT SCLEROSING AGENTS

Detergent sclerosing agents are long-chain fatty acids that aggregate into micelles, interfering with endothelial cell surface lipids and proteins.[60] By decreasing endothelial cell surface tension, they cause plaques of endothelial desquamation within seconds of injection. The ability to be foamed gives detergent solutions a noted advantage over the other sclerosant groups. Foaming increases the potency of detergents twofold to fourfold by mechanically displacing blood and maximizing endothelial contact.[57]

POL (Asclera, Merz North America, Inc., Raleigh, NC; Aethoxysklerol, Chemische Fabrik Kreussler & Co., Wiesbaden, Germany) is composed of hydroxypolyethoxydodecane dissolved in distilled water with a 5% ethanol stabilizer that was originally developed as an anesthetic, but was subsequently found to sclerose small-diameter vessels after intradermal injection.[57] POL gained popularity worldwide for treating smaller-diameter dermal vessels because of its painless intravascular injection and extremely low incidence of cutaneous necrosis with extravasation. The U.S. Food and Drug Administration (FDA) has approved POL for sclerosis of uncomplicated veins whose diameter is less than 1 mm (0.5% solution) and for those whose diameter is from 1 to 3 mm (1% solution). Decades of combined experience with POL inside and outside the United States has confirmed its safety and efficacy as a sclerosing agent.[61,62]

STS (Sotradecol, Mylan Institutional LLC, Canonsburg, PA; Fibrovein, STD Pharmaceuticals, Hereford, United Kingdom) is an anionic surfactant that is FDA approved for uncomplicated varicose veins of the lower extremities in 1% and 3% concentrations. In repeated studies, both POL and STS have been found to be largely equivalent in terms of efficacy.[63] Like with POL, the risk of postsclerotherapy hyperpigmentation (PSH) with STS is directly proportional to concentration injected, and a relatively high incidence of PSH has been reported at inappropriately high doses (1% STS).[64] However, a study by Goldman and colleagues showed that STS and POL injected at equivalent concentrations had no significant difference in PSH.[63,65] Cutaneous necrosis risk with STS is low with concentrations less than 1%, but increases significantly at higher concentrations.

Sodium morrhuate is a 5% solution of the salts of saturated and unsaturated fatty acids in cod liver oil, although approximately 10% of its fatty acid composition is unknown. Sodium morrhuate should not be used for cutaneous sclerotherapy given the significant potential for cutaneous necrosis and the highest risk of anaphylaxis among sclerosing agents.

Ethanolamine oleate is a synthetic sclerosing agent for varicose veins that, like sodium morrhuate, should not be used for cutaneous sclerotherapy. Also like sodium morrhuate, ethanolamine oleate was exempted from FDA approval because of its common use prior to FDA safety requirements. Ethanolamine oleate is associated with anaphylaxis, cutaneous necrosis, pulmonary toxicity, and nonspecific red blood cell (RBC) hemolysis.[58]

HYPEROSMOTIC SCLEROSING AGENTS

This class of off-label sclerosing agents produces endothelial cell surface protein denaturation by means of concentration-dependent osmotic dehydration leading to fibrin deposition and thrombus formation. Although hyperosmotic sclerosing agents have been used off label for telangiectasias, they have numerous disadvantages, including rapid dilution in blood, transient pain and muscle cramping from extravascular diffusion or extravasation, and nonspecific collateral damage of RBCs and perivascular tissue. Appropriately so, their usage has steadily declined with the growing worldwide popularity of synthetic detergents with far superior side-effect profiles.[66]

Hypertonic saline, wrought with shortcomings and FDA approved only as an abortifacient, is still commonly used in the United States in concentrations from 10% to 30% to treat telangiectasias (most often 23.4% or diluted to 11.7% for smaller telangiectasias). The only advantages of HS are its low cost and lack of allergenicity when unadulterated. Given the significant pain associated with the intravascular injection of HS, lidocaine is often added to the solution, potentially increasing the risk of allergic reaction. HS 23.4% carries the highest risk of cutaneous necrosis from injection-site extravasation, particularly when injecting very close to the skin surface. Injection of hyaluronidase into sites of extravasation may significantly reduce the incidence of cutaneous necrosis with HS.[67]

HS and dextrose (Sclerodex, Omega Laboratories Ltd, Montreal, Canada) is a viscous mixture of 10% HS and 25% dextrose in propylene glycol and phenethyl alcohol. The decreased osmolarity of HS in HS and dextrose produces less pain and muscle cramping, and an ulceration risk less than that of 23.4% HS. Allergic reactions have been reported, potentially because of the phenethyl alcohol component of the solution. Given its relatively weak sclerosant properties, it is best reserved for the treatment of small telangiectasias.

Glycerin (50% to 100%, but most often 72%) is a weak hyperosmotic sclerosing agent that is an excellent treatment option for telangiectasias given its exceedingly rare risks of PSH, telangiectatic matting, and cutaneous necrosis.[68] Its high viscosity and transient pain with injection are both reduced with the addition of lidocaine.[69] Although no allergic reactions have been reported with glycerin, the addition of lidocaine may theoretically increase this risk. Epinephrine is often added to glycerin as well, increasing vasospasm and potentially enhancing efficacy. Glycerin is used off label in the United States, but is FDA approved for relief of intracranial pressure resulting from acute glaucoma or cerebral edema. The volume injected per session should not exceed 10 mL, as larger amounts may induce transient hematuria from ureteral colic or hemoglobinuria from RBC hemolysis. Glycerin is best avoided in diabetic patients because of the risk of iatrogenic secondary hyperglycemia.

CHEMICAL SCLEROSING AGENTS

Chemical irritant sclerosing agents lead to dissolution of intimal intracellular bonds and subsequent endothelial dysfunction and death.[57] The resulting exposed subendothelial connective tissue and elastic lamina also triggers thrombus formation. Like hyperosmotic sclerosing agents, their off-label therapeutic effects are limited by rapid dilution in blood and inactivation by blood proteins. Polyiodinated iodine is a strong chemical sclerosant that is rarely used because of a high risk of cutaneous necrosis with perivascular injection. Ethanol is also rarely used for dermatologic indications, being reserved for arteriovenous malformations and other high-flow vascular abnormalities.

Chromated glycerin (72% solution) possesses combined osmotic and chemical mechanisms of action. The addition of a chromium alum to glycerin increases its sclerosing power, which may impart a greater risk of PSH; it prevents hematuria and ureteral colic. Unfortunately, chromated glycerin has no FDA label and therefore has poor availability in the United States.

SCLEROTHERAPY TECHNIQUE

Despite 150 years of sclerotherapy, there is still no absolute, irrefutable technique to achieve flawless results. No quote is more fitting than that of Henry Faxon, an assistant in surgery at Harvard Medical School in 1933, who, upon thorough review of cases performed at the peripheral circulatory clinic of the Massachusetts General Hospital, stated:

> "We feel from our three and one-half years' experience that the surgeon who believes that there is nothing more required than a syringe, some solution, and a patient to effect permanent obliteration of varicose veins, still has much to learn."[70]

Nevertheless, there are basic principles and guidelines that experienced practitioners should follow to optimize efficacy and mitigate adverse events. First, treatment should proceed from points of highest to lowest pressure reflux, progressing from the largest varicosities to telangiectasias in stepwise fashion. Patients with saphenous vein reflux must have their saphenous disease addressed prior to sclerotherapy for saphenous tributaries and varicose veins. Likewise, sclerotherapy for reticular veins and telangiectasias should proceed only after varicose veins and larger sources of reflux have been addressed (Fig. 212-6).

Injection of telangiectasias is simultaneously performed with injection of reticular veins, with the goal of maximizing treatment efficacy and reducing the number of treatments necessary for complete clearance.[71] Weiss and Weiss[46] showed an association between telangiectasias and the presence of reflux in adjacent reticular veins on the lateral thighs. When no clear feeder vessel is visualized, transillumination with a light-emitting diode (Veinlite, Translite LLC, Sugar Land, TX) or fiber optic device (Sam's Light, Wagner Medical, Middlebourne, WV) may help identify a "feeding" reticular vein. When no associated reticular vein is present, then the point at which the telangiectasias begin to branch out or arborize is the ideal site at which to begin injecting. The use of a magnified cross-polarized light device (Syris Scientific, LLC, Grey, ME) can dramatically improve visualization of fine telangiectasias.

The patient should be positioned lying flat, either supine or prone, depending on the area of the lower extremities being treated. The goal of treatment is to inject intravascularly with minimal pressure, so as to minimize extravasation and prevent vessel rupture.[72] As injection pressure is inversely proportional to the square of the syringe piston radius, the smaller the vein, the larger the syringe that should be used. Therefore, although a 3-mL syringe can be used for reticular veins, telangiectasias are best treated with a 5- to 6-mL syringe.[71] Both types of veins should be treated with a 30-gauge half-inch needle. Given that telangiectasias are extremely superficial (subepidermal), bending the needle to an angle of 10 to 30 degrees with the bevel up, placed on the skin so that the needle is parallel to the skin surface, facilitates treatment. The syringe should be held between the index and middle fingers, with the thumb on the plunger, while the fourth and fifth fingers support the practitioner's hand against the patient's lower extremity in a fixed position to stabilize the hand. The practitioner's nondominant hand or the hands of an assistant can simultaneously be used to stretch the skin in the treatment area (Fig. 212-7).

Venous diameter is the critical factor for determining which sclerosing agent class and concentration is most appropriate for treatment (Table 212-6). The lowest sufficient concentration should always be used.[73] Vessel diameter also predicts treatment success. Vessels with a diameter of 0.3 mm or less are likely to require multiple treatments, while those with a diameter of 0.5 mm or more may require only a single treatment. The volume of sclerosing agent injected per site should be limited to 1 mL and is typically 0.5 mL or less. Although a conservative limit for total liquid sclerosant volume is approximately 10 mL, significantly larger volumes can be used safely over large areas as long as the volume per injection remains small. Treatment intervals vary, but allowing 3 months for maximal clearance following a sclerotherapy session, helps minimize the number of retreatments (Figs. 212-8 and 212-9). When ineffective sclerosis is evident at followup, the concentration of sclerosing agent, *not* the volume per site, ought to be increased.

FOAM SCLEROTHERAPY

Foam sclerotherapy with detergent sclerosing agents has become a standard treatment of veins larger than

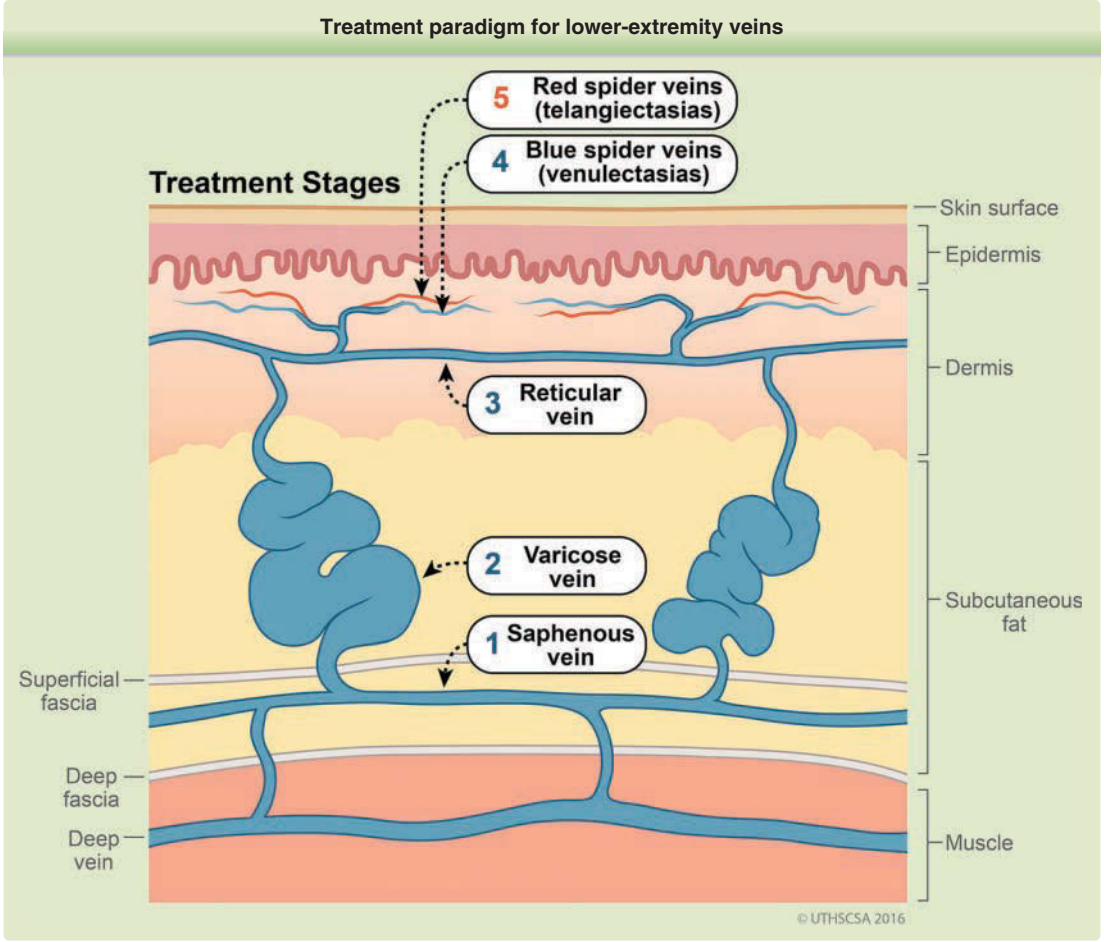

Figure 212-6 Treatment paradigm for lower extremity veins. Treatment is best approached sequentially. The largest, highest-pressure sources of reflux (eg, saphenous veins) should be treated first, with the smallest, lowest-pressure vessels (eg, venulectasias and telangiectasias) treated last. (Reproduced with permission from UT Health Science Center at San Antonio. © UTHSCSA.)

1 mm.[74] Foam microbubbles mechanically displace blood within targeted veins, maximizing endothelial contact time, decreasing sclerosing agent dilution, and increasing detergent potency at least twofold.[75] Foam sclerotherapy can thereby enhance treatment efficacy and reduce the overall number of sessions for complete clearance.[76] This method also enables the use of lower sclerosing agent concentrations and

Figure 212-7 Proper sclerotherapy injection technique.

TABLE 212-6

Sclerosing Agent Class and Concentration by Vessel Size

VESSEL SIZE	APPROPRIATE SCLEROSING AGENT CONCENTRATION
<1 mm (spider veins)	▪ 0.1% to 0.25% STS liquid ▪ 0.25% to 0.5% POL liquid ▪ 72% Glycerin mixed 2:1 with 1% lidocaine ± epinephrine

1 to 3 mm (reticular veins)	▪ Small (1 to 2 mm)
	  ▪ 0.25% STS foam or 0.5% STS liquid
	  ▪ 0.5% POL foam or 1% POL liquid
	▪ Large (3 mm)
	  ▪ 0.5% STS foam
	  ▪ 1% POL foam

>3 mm (varicose veins, incompetent saphenous tributary veins)	▪ 1% POL foam ▪ 0.5% to 1% STS foam
>5 mm (incompetent saphenous veins or their tributaries)	▪ 3% POL foam ▪ 1% to 3% STS foam

POL, polidocanol; STS, sodium tetradecyl sulfate.

Figure 212-8 Before (*left*) and 3 months after (*right*) 2 sessions of sclerotherapy performed 3 months apart. Sodium tetradecyl sulfate foam 0.25% and glycerin 72% were used for reticular veins and telangiectasias, respectively.

volumes, decreasing potential adverse events and risks of systemic toxicity. An additional advantage of foam is its echogenicity, making it easily visualized on duplex ultrasound. Use of foam sclerotherapy, however, should be approached cautiously in vessels smaller than 1 mm because of an increased risk of vessel rupture and associated pigmentation and matting.[77]

Agitating a detergent sclerosing agent with a gas, most commonly air, produces a foam. The most commonly used techniques for foam sclerotherapy are the Tessari (double-syringe with 3-way stopcock) and modified Tessari (double-syringe with Luer-to-Luer connector) methods.[78] In either method, 1 sterile syringe is filled with room air, while the other is filled with a detergent sclerosing agent, with an optimal liquid-to-gas dilution ratio of 1:4. The contents of the syringes are quickly shifted back and forth approximately 10 to 20 times; the turbulent flow generates homogeneous foam (Fig. 212-10). The foamed solution should be used immediately (injected via the 3-mL syringe) because it degrades within 60 to 90 seconds. Commercially prepared POL microfoam has a smaller, narrower bubble size distribution and slower degradation rate, which may enhance results, compared to physician-compounded POL foam.[79]

POSTSCLEROTHERAPY COMPRESSION

There are multiple reasons why compression following sclerotherapy enhances results and mitigates adverse events. First and foremost, compression promotes sclerophlebitis and eliminates thrombophlebitis (Fig. 212-11).[80] Decreasing the extent of thrombus formation in treated veins may significantly decrease the risk of recanalization, PSH, and even telangiectatic matting. Compression also can augment the direct apposition of treated vein walls, leading to more effective intraluminal fibrosis. It also likely serves a role in enhancing the function of the calf muscle pump and decreasing the extent and duration of bruising and edema posttreatment.[81]

Figure 212-9 Before (*left*) and 3 months after (*right*) 2 sessions of sclerotherapy performed 3 months apart. Sodium tetradecyl sulfate 0.25% foam and glycerin 72% were used for reticular veins and telangiectasias, respectively.

Figure 212-10 Double-syringe system with Luer-to-Luer connector for foaming a detergent sclerosing agent with room air (1:4 liquid-to-gas ratio).

As graduated elastic compression stockings should cover the entire treated area, thigh-high stockings are most commonly prescribed postsclerotherapy.[82] The class and duration of compression following sclerotherapy remains a point of contention between practitioners.[58] Although 7 days is superior to 3 days of compression, compression for 3 days leads to significantly greater improvement and fewer adverse events than no compression at all.

SIDE EFFECTS AND COMPLICATIONS

PHYSICAL URTICARIA

Physical urticaria localized to sites of injection may occur transiently following treatment with any

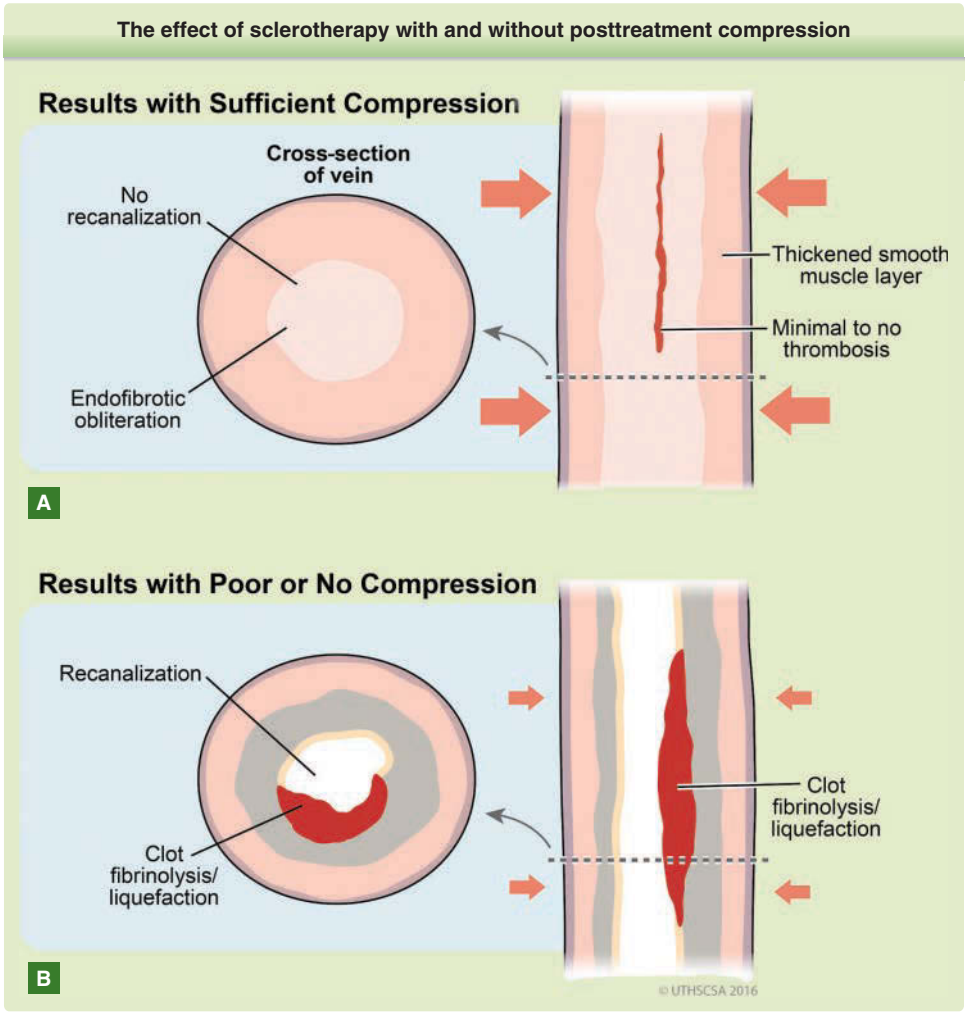

Figure 212-11 The effect of sclerotherapy with and without posttreatment compression. **A,** Proper compression promotes endofibrosis, leading to complete venous occlusion. **B,** Poor to no compression enables thrombosis, which impedes endofibrosis and results in recanalization. (Reproduced with permission from UT Health Science Center at San Antonio. © UTHSCSA.)

Figure 212-12 Physical urticaria within minutes of injecting 0.25% sodium tetradecyl sulfate for reticular veins.

sclerosing agent, even HS (Fig. 212-12).[83] Their appearance is likely a consequence of endothelial irritation and histamine release from perivascular mast cells. The intensity of urticaria may increase with greater sclerosing agent concentrations or repeat treatment sessions.

COAGULUM

Coagulum formation is not uncommon following sclerotherapy and represents focal thrombus formation resulting from incomplete occlusion of the vascular lumen during treatment. These thrombi incite a subacute perivenulitis with RBC extravasation. Coagula present clinically as mildly tender indurated dermal or subcutaneous nodules (depending on what type of vein was treated) that may persist for months. It is best to evacuate coagula at approximately 2 weeks postsclerotherapy using a 21- to 25-gauge needle and bimanual expression (Fig. 212-13).[84]

POSTSCLEROTHERAPY HYPERPIGMENTATION

PSH is defined as the temporary appearance of linear pigmentation along the course of a treated vein of any size (Fig. 212-14). It is initially related to perivascular hemosiderin deposition from the superficial dermal extravasation of RBCs secondary to dilation or rupture of treated vessels; however, over time, the hemosiderin may be replaced by melanin.[85] The incidence of pigmentation is directly related to the type and concentration of sclerosing agent, as well as to the diameter of treated vessel.[86] Table 212-7 lists the factors that increase the risk of PSH.[87,88] Weak sclerosing agents, such as glycerin and chromated glycerin, have the lowest risk of PSH. Vessels with diameters smaller than 1 mm also rarely (if ever) develop PSH.[86]

Pigmentation clears spontaneously in 70% of patients within 6 months but rarely persists for longer than a year.[86] Nanosecond or picosecond Q-switched lasers (694-nm ruby, 755-nm alexandrite, or 1064-nm Nd:YAG [neodymium:yttrium aluminum garnet]) are often effective for clearing PSH, although low fluences should be used in darker-skinned patients to avoid causing hypopigmentation or worsening hyperpigmentation.[89,90] Picosecond 532-nm frequency-doubled Nd:YAG laser treatment may be useful for PSH, but only in very light-skinned patients.

TELANGIECTATIC MATTING

Telangiectatic matting is the blush-like, grouped appearance of fine (<0.2 mm) red telangiectasias replacing or adjacent to an area of prior sclerotherapy or surgical vein ligation. Angiogenic and inflammatory pathophysiologic mechanisms have been implicated.[88] Inflammatory-mediated endothelial injury from sclerosing agents can lead to the release of mast cell heparin, whose affinity for endothelial growth factors can trigger microvascular proliferation via capillary endothelial cell proliferation and angiogenesis. Excess inflammation and thrombus formation with sclerotherapy may create a hypermetabolic state that incites reactive blood vessel growth. Angiogenesis also may be a direct response to targeted vessel closure produced by sclerotherapy. Dilation of existing subclinical blood vessels is thought to play a combinatory or alternative role.[88]

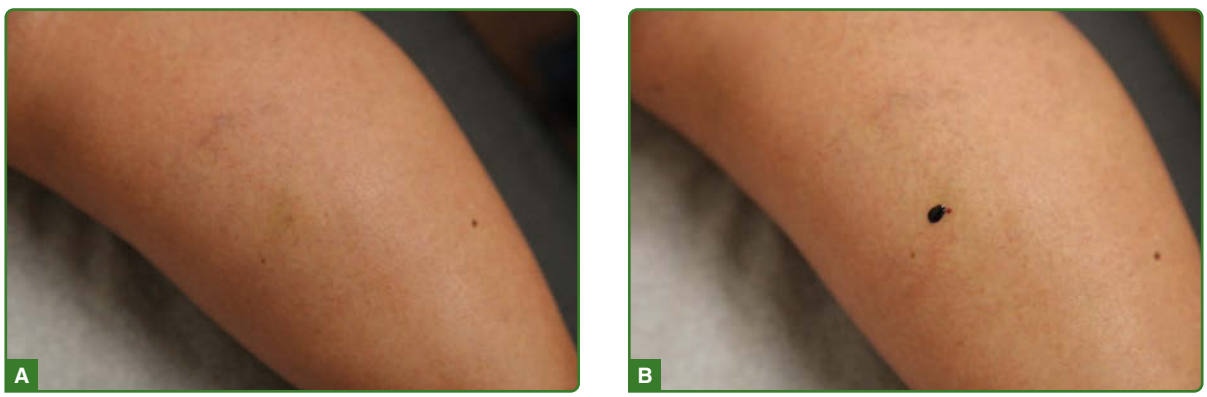

Figure 212-13 **A,** Postsclerotherapy coagulum 2 weeks after sclerotherapy. **B,** Evacuation of coagulum (thrombectomy) following puncture with a 25-gauge needle and bimanual compression.

Figure 212-14 Before (*left*) and 6 months after (*right*) 1320-nm endovenous laser ablation of the thigh segment of the great saphenous vein with sclerotherapy for the associated medial knee and anteromedial leg varicose veins using 0.5% sodium tetradecyl sulfate foam. Note the mild residual postsclerotherapy hyperpigmentation at followup.

Although the most common area for telangiectatic matting is the medial thigh, it may also appear in the medial ankle and medial or lateral calf.[88] Predisposing factors include obesity, a family history of leg veins, a prolonged history of telangiectasias, hyperestrogenic states, such as pregnancy, and use of oral contraceptives or hormonal therapy.[91] As the incidence of telangiectatic matting may be proportional to the degree of inflammation and thrombus formation, weak sclerosing agents are thought unlikely to cause telangiectatic matting.

A retrospective study of more than 2100 patients reported a telangiectatic matting incidence of 16% in patients treated with HS and POL.[91] Spontaneous resolution usually occurs within 3 to 12 months of onset, with 70% to 80% of cases resolving within the first 6 months.[86,88] Telangiectatic matting can be treated with a weak hypertonic sclerosing agent or 585-nm to 595-nm pulsed-dye laser.[92] The treatment of any residual feeding reticular veins may also quicken its resolution.

TABLE 212-7

Risk Factors for Postsclerotherapy Hyperpigmentation

Patient-related	Skin Type V or VI (hemosiderin and inflammatory cascade may stimulate cutaneous melanocytes)
	Periprocedural minocycline use (perivascular deposition of iron complexes or hemosiderin and minocycline moieties)
	Increased vessel fragility (decreased capillary strength) 2 days after ovulation and 3 to 5 days before menstruation
Procedure-related	Excessive sclerosing agent concentrations (lead to excessive inflammation) and injection pressures (cause vessel rupture and extravasation)
	Lack of graduated compression
	Excessive ecchymosis
	Untreated coagulum

CUTANEOUS NECROSIS/ ULCERATION

Cutaneous ulceration may occur with any sclerosing agent. However, the risk from perivenous dermal extravasation of detergent (POL, STS) or weak hypertonic (glycerin, chromated glycerin) sclerosing agents is very unlikely with typical product concentrations and small injection volumes. If extravasation occurs, one should stop injecting and massage the dermal bleb to minimize prolonged blanching of the area.

Cutaneous necrosis may also occur by a number of other mechanisms.[93] Rapid or large-volume injection into a telangiectasia associated with an arteriole by means of an arteriovenous anastomosis can produce

Figure 212-15 Superficial venous thrombophlebitis 2 weeks postsclerotherapy. Signs and symptoms resolved with graduated compression and nonsteroidal antiinflammatory medications.

localized ulceration.[94] Reactive arterial vasospasm can occur from puncture of a nearby artery without injection of sclerosing agent, leading to a porcelain-white injection site that progresses to hemorrhagic bulla formation. Prolonged nongraduated compression greater than 30 to 40 mm Hg can also induce tissue anoxia.

SUPERFICIAL VENOUS THROMBOPHLEBITIS

In contrast, to a coagulum, which is a focal and mildly tender lesion resulting from proper sclerotherapy, superficial venous thrombophlebitis (SVT) presents clinically as a markedly tender, indurated, linear erythematous cord (Fig. 212-15). Signs of symptoms of SVT may develop even weeks posttreatment. The incidence of SVT postsclerotherapy is variable and was recently found to be 4.7% in a large-scale review of foam sclerotherapy for varicose veins.[95] However, a subsequent survey of 1605 French patients only found 2 occurrences of SVT that were caused by foam POL or STS.[62] Treatment consists of leg elevation, compression, and nonsteroidal antiinflammatory drugs. Extension of superficial thrombophlebitis into the deep venous system is extremely rare.

DEEP VENOUS THROMBOSIS (DVT)

DVT following sclerotherapy is relatively rare (incidence < 1%) and may be a result of sclerosing agent migration into the deep venous system resulting from excessive injection volumes (>1 mL) at a single site and from the use of foam sclerotherapy.[58,62] Patients with preexisting hypercoagulable states, difficulty mobilizing, or undergoing a concomitant surgical procedure are likely to be at higher risk. Pulmonary emboli, however, are extremely rare. Suspicion for DVT or pulmonary emboli should prompt duplex ultrasound imaging and referral for possible anticoagulation.[58] Transient, self-limited chest tightness, shortness of breath, or coughing may occur in a minority of patients immediately following treatment with foam sclerotherapy and should not be confused with pulmonary emboli.

INTRAARTERIAL INJECTION

This dreaded medical emergency is, fortunately, extremely rare. Intraarterial injection of a sclerosing agent produces a sludge embolus from denatured endothelial cells and blood that obstructs microcirculation, leading to secondary thrombosis and necrosis.[96] Consequently, the extent of cutaneous necrosis is related to the amount of sclerosing agent injected. Highest-risk areas for intraarterial injection are the popliteal fossa, dorsal foot, and medial malleolus.

Warning signs immediately following injection usually include a continuous intense burning pain (far beyond normal) and bone-white cutaneous blanching in an arterial pattern. Progression to a sharply-demarcated area of cyanosis within minutes is typical. This may eventuate in wide areas of skin necrosis and damage to underlying subcutaneous tissue and muscle. Rarely, cutaneous signs and symptoms following arterial injection may not be seen for up to 24 hours; these cases may be from leakage of sclerosant into the arterial circulation via an arteriovenous anastomosis.[93]

Treatment involves the immediate initiation of a vasodilatory protocol (massage, aspirin, warm compresses, and oxygen); flushing the inadvertently injected artery with normal saline or heparin; and vascular surgery consultation for intravenous anticoagulation with heparin. Infiltration with 1% to 3% procaine is recommended to inactivate STS, if used.

NEUROLOGIC SYMPTOMS

Rare reports of headaches and visual disturbances, and exceedingly rare accounts of transient ischemic attack and stroke, have been described postsclerotherapy and are associated with the presence of a patent foramen ovale or a history of migraine with aura.[97] Although they may more commonly occur with injection of foam, they also have been reported with liquid sclerotherapy and in patients without patent foramen ovale.[98] Given the latter and the fact that asymptomatic patients can demonstrate cerebrovascular microemboli, other factors, including endothelin release from damaged endothelial cells and genetic susceptibility, may play a role.[99]

MINIMALLY-INVASIVE SURGICAL APPROACHES FOR VARICOSE VEINS

The Swiss surgeon Rima was the first to recognize the critical role of saphenofemoral reflux in the pathogenesis of varicose veins in the late 18th century. Although he performed the first high ligation

of the GSV, Trendelenburg advanced the procedure in 1890.[100,101] Saphenous stripping was developed by Mayo in 1904 and advanced during the early 20th century.

However, the postoperative morbidity, potential for scarring, and need for general or epidural anesthesia associated with traditional surgical management established the need for minimally-invasive methods of treating saphenous reflux. In March 1999, the first endovenous radiofrequency ablation (RFA) device was cleared by the FDA.[102] Endovenous laser ablation (EVLA) followed soon thereafter.[103] Dermatologic surgeons were instrumental in developing these endovenous techniques.

ENDOVENOUS ABLATION/ OCCLUSION TECHNIQUES

Endovenous ablation has largely replaced traditional surgical management in industrialized countries such as the United States and England, given the decreased morbidity, more rapid recovery, and improved cosmetic outcomes with RFA and EVLA compared to surgical methods.[104,105] Postoperative pain, wound infection, and hematoma formation are also particularly far less common.[106] Endovenous techniques have likewise been found to improve patient quality of life, while significantly decreasing patient and societal costs of managing venous disease relative to surgery.[107] Large-scale reviews have found no significant long-term differences in primary failure, recurrence, or neovascularization rates between RFA, EVLA, and surgical intervention.[106,108,109]

Endovenous therapy is typically performed *prior* to addressing superficial varicosities, reticular veins, or telangiectasias, as part of a proximal to distal (highest to lowest pressure) treatment approach. The radiofrequency catheter or laser fiber are introduced into the target vein under duplex ultrasound guidance and then advanced to 2 to 3 cm from the SFJ or saphenopopliteal junction termination (Fig. 212-16A). Dilute lidocaine is infiltrated into the perivenous saphenous compartment immediately prior to treatment, which acts as a heat sink, physically distances the vein from surrounding tissue, and induces circumferential apposition of the vein wall onto the catheter or fiber (Fig. 212-16B). Tumescent anesthesia with this procedure reduces postoperative pain and allows for immediate ambulation postprocedure, mitigating the risk for DVT.[110]

Energy is delivered to the target saphenous vessel as the catheter or fiber is slowly withdrawn from the patient (see Fig. 212-16C). Thermal damage causes destruction of the intima and collagen denaturation of the media within the vein wall, leading to fibrotic vascular occlusion.[111,112]

RADIOFREQUENCY

The efficacy for radiofrequency elimination of reflux is 90% at 2 years and 80% at 5 years.[108] The RFA catheter comes in direct contact with the vessel wall and produces resistive heating (impedance) by means of a high-frequency, electrode-mediated alternating current. As impedance decreases with increasing tissue coagulation, the amount of heat that can be generated is inherently limited.

LASER

Irreversible thermal damage of the inner vein wall, a requirement for permanent vessel occlusion by EVLA,

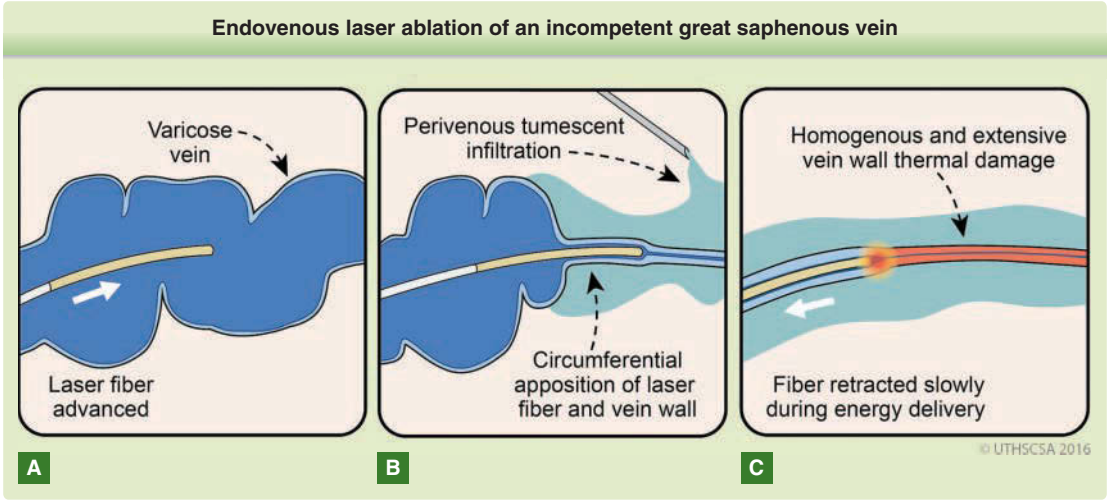

Figure 212-16 Endovenous laser ablation of an incompetent great saphenous vein (GSV). **A,** The GSV is accessed under duplex ultrasound and a laser fiber is advanced to 2 to 3 cm from the saphenofemoral junction. **B,** Dilute lidocaine solution is infiltrated into the perivenous space (ie, the saphenous compartment) under ultrasound guidance. **C,** Transmural thermal damage is produced as the fiber is retracted at a fixed pull-back speed. (Reproduced with permission from UT Health Science Center at San Antonio. © UTHSCSA.)

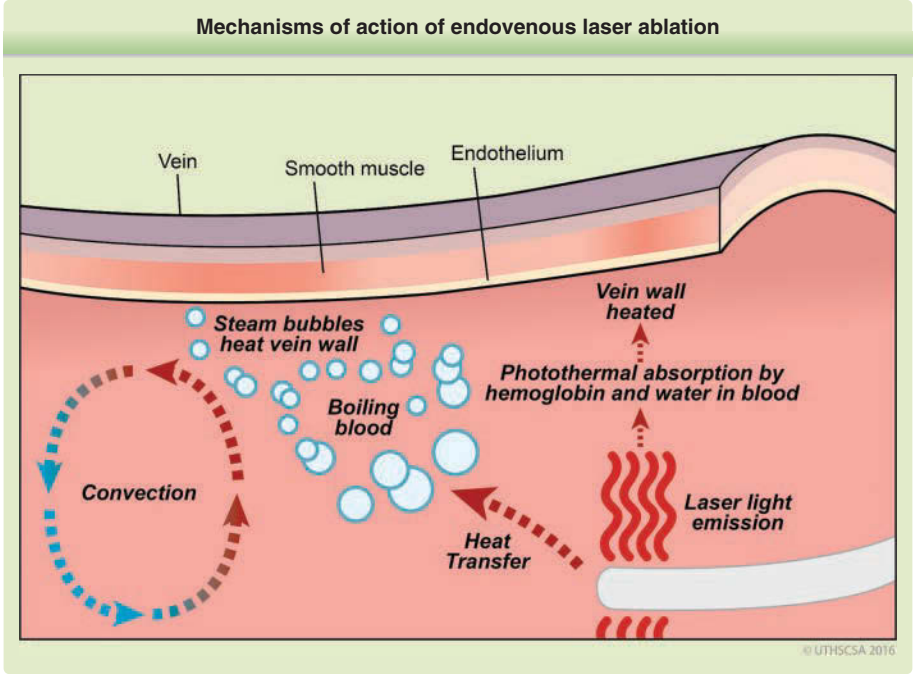

Figure 212-17 Mechanisms of action of endovenous laser ablation. Vessel injury is produced from the heating of residual blood immediately surrounding the laser fiber, leading to secondary damage of the vessel wall. Residual blood heating occurs as a result of (a) heat transfer from a hot fiber tip and (b) photothermal absorption of hemoglobin and water. Both may lead to steam bubble formation. (Reproduced with permission from UT Health Science Center at San Antonio. © UTHSCSA.)

can be achieved by a number of devices and wavelengths. It was originally assumed that intravascular coagulation occurs by selective photothermolysis of either hemoglobin in RBCs of intraluminal blood using shorter wavelengths (810, 940, 980, and 1064 nm) *or* water in the vein wall using longer wavelengths (1320, 1470, 1500 nm, and higher).[113,114] However, recent mathematical models show that irreversible thermal damage of the inner vein wall is *not* dependent on competitive direct photothermal absorption by hemoglobin or water.[115,116] Instead, thermal damage is primarily achieved by the combined effects of heat transfer through a small residual layer of intraluminal blood from an extremely hot layer coating the fiber tip and photothermal absorption by both chromophores within that blood layer (Fig. 212-17).[115] Both mechanisms may act on the wall via steam bubble diffusion as well.[116,117]

Limiting the amount of residual intraluminal blood thereby decreases the distance for heat transfer to the vein wall and enhances efficacy. This is achieved by reducing vein diameter during treatment with Trendelenburg positioning and perivenous tumescent fluid infiltration.[118] The extent of thermal injury to the vessel wall is also strongly dependent on the amount and duration of heat exposure, which is a factor of both laser power (energy delivered over time) and the rate of fiber pullback.

Despite having a fundamentally identical mechanism of action, newer EVLA devices with longer wavelengths produce less postoperative pain and potentially have greater efficacy than their older counterparts with shorter wavelengths. However, this may simply be a factor of the pulsed-wave energy delivery, decreased power,[119,120] faster pullback velocity,[121] and protected fiber tip design[122] that are now the standard with longer wavelength device treatments.[113,123] Regardless of the device, long-term closure rates with EVLA match, if not exceed, those of RFA. Typical results of EVLA combined with foam sclerotherapy or ambulatory phlebectomy are shown in Figs. 212-14 and 212-18, respectively. Both subjects were treated with a 1320-nm device using 12 W, 50 Hz, and a 2 mm/sec pull-back speed.

AMBULATORY PHLEBECTOMY

The first documented case of surgical removal of varicose veins, described by Plutarch, was performed on the Roman Consul Gaius Marius (157-186 BC) without anesthesia. The field advanced slowly in Ancient Rome and Greece, with Celsus (25 BC-30 AD) detailing primitive stripping and cauterization, contemporaries Antyllus and Galen (second century AD) describing ligation and vein removal with hooks, and Paulus of Aegina (660 AD) performing ligation and stripping.[100] Modern-day ambulatory phlebectomy originated with Swiss dermatologist

Figure 212-18 Before (*left*) and 1 year after (*right*) 1320-nm endovenous laser ablation of the thigh segment of the great saphenous vein (GSV), combined with ultrasound-guided foam sclerotherapy for the below-the-knee segment of the GSV and anterior accessory GSV (1% sodium tetradecyl sulfate) and ambulatory phlebectomy of associated anteromedial thigh and medial leg varicose veins.

Robert Muller in the late 1960s and was refined and popularized worldwide by Ramelet, Ricci, Georgiev, and Goldman.[101]

Ambulatory phlebectomy is an outpatient procedure to remove varicose veins through tiny incisions and small hooks using only local anesthesia (Fig. 212-19).[124,125] Ambulatory phlebectomy is often combined with endovenous ablation techniques for treatment of the SFJ or saphenopopliteal junction and sclerotherapy for treatment of associated reticular networks and telangiectasias. Varicose veins or saphenous tributaries that are resistant to foam sclerotherapy are also particularly suitable for ambulatory phlebectomy. Compared to sclerotherapy for varicose veins, ambulatory phlebectomy may have a lower risk of SVT, DVT, PSH, and cutaneous necrosis.[126]

LASER AND LIGHT SOURCES

Although sclerotherapy remains the gold standard for superficial, small-caliber vessels of the lower extremities, laser devices may be a valuable alternative or adjunct treatment option. Patients with vessels with diameters too small to cannulate with a 30-gauge needle, a history of needle phobia, or an unwillingness to wear graduated compression stockings may all benefit from laser therapy.[127]

Selective thermal damage of a pigmented cutaneous chromophore can be achieved by delivering a wavelength within its absorption spectrum at an appropriate fluence and pulse duration.[128] The primary chromophore of cutaneous blood vessels is intravascular oxyhemoglobin, with some influence

Figure 212-19 Before (*left*) and 1 year following (*right*) a single session of ambulatory phlebectomy.

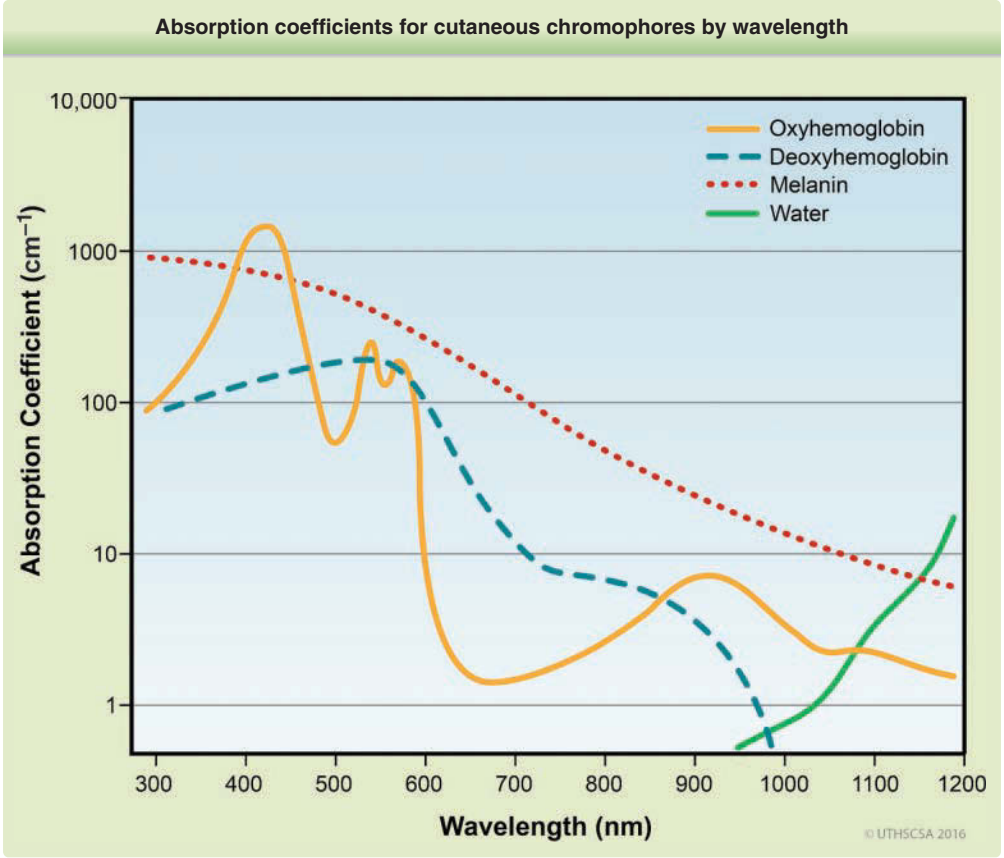

Figure 212-20 Absorption coefficients for cutaneous chromophores by wavelength. (Reproduced with permission from UT Health Science Center at San Antonio. © UTHSCSA.)

from deoxyhemoglobin as well. Oxyhemoglobin has 3 absorption peaks at 418, 540, and 575 to 580 nm, while deoxyhemoglobin peaks at 550 to 560 nm (Fig. 212-20). Current pulsed-dye laser (585 to 595 nm) and frequency-doubled Nd:YAG (532 nm) devices match these absorption peaks and can effectively target telangiectasias (Fig. 212-21).[129] Intense pulsed light devices (515 to 1200 nm) also can be used for photothermal sclerosis of telangiectasias.[130,131]

Near-infrared wavelengths at 800 to 1100 nm match a small, yet broad peak for oxyhemoglobin.[132] Devices emitting 810 and 940 nm have been shown to improve lower-extremity veins.[133,134] Long-pulsed Nd:YAG devices (1064 nm) allow for thermocoagulation of larger, deeply situated vessels (eg, reticular veins) up to 3.7 mm in depth.[135] The minimal melanin absorption of 1064 nm energy makes this wavelength ideal for darker or suntanned skin types. However, laser therapy for reticular veins must be performed with care because of the treatment-related pain, high rates of recurrence with incomplete treatment, and the risk of blistering or ulceration from improper technique.

Figure 212-21 Before (*left*) and 1 month following (*right*) a single treatment of 585- to 595-nm pulsed-dye laser for isolated telangiectasias of the medial malleolus.

REFERENCES

1. Rabe E, Pannier F. Societal costs of chronic venous disease in CEAP C4, C5, C6 disease. *Phlebology.* 2010;25(suppl 1):64-67.
2. Onida S, Davies AH. Predicted burden of venous disease. *Phlebology.* 2016;31(1)(suppl):74-79.
3. Meissner MH. Lower extremity venous anatomy. *Semin Intervent Radiol.* 2005;22(3):147-156.
4. Caggiati A, Bergan JJ, Gloviczki P, et al. Nomenclature of the veins of the lower limbs: an international interdisciplinary consensus statement. *J Vasc Surg.* 2002;36(2):416-422.
5. Caggiati A, Bergan JJ, Gloviczki P, et al. Nomenclature of the veins of the lower limb: extensions, refinements, and clinical application. *J Vasc Surg.* 2005;41(4):719-724.
6. O'Donnell TF, Iafrati MD. The small saphenous vein and other "neglected" veins of the popliteal fossa: a review. *Phlebology.* 2007;22(4):148-155.
7. Ricci S, Cavezzi A. Echo-anatomy of long saphenous vein in the knee region: proposal for a classification in five anatomical patterns. *Phlebology.* 2002;16(3):111-116.
8. Ricci S, Caggiati A. Echoanatomical patterns of the long saphenous vein in patients with primary varices and in healthy subjects. *Phlebology.* 1999;14(2):54-58.
9. Gillespie D, Glass C. Importance of ultrasound evaluation in the diagnosis of venous insufficiency: guidelines and techniques. *Semin Vasc Surg.* 2010;23(2):85-89.
10. Oguzkurt L. Ultrasonographic anatomy of the lower extremity superficial veins. *Diagn Interv Radiol.* 2012;18(4):423-430.
11. Cavezzi A, Labropoulos N, Partsch H, et al. Duplex ultrasound investigation of the veins in chronic venous disease of the lower limbs—UIP consensus document. Part II. Anatomy. *Eur J Vasc Endovasc Surg.* 2006;31(3):288-299.
12. Murakami G, Negishi N, Tanaka K, et al. Anatomical relationship between saphenous vein and cutaneous nerves. *Okajimas Folia Anat Jpn*. 1994;71(1):21-33.
13. Ricci S, Moro L, Antonelli Incalzi R. Ultrasound imaging of the sural nerve: ultrasound anatomy and rationale for investigation. *Eur J Vasc Endovasc Surg.* 2010;39(5):636-641.
14. Tuveri M, Borsezio V, Argiolas R, et al. Ultrasonographic venous anatomy at the popliteal fossa in relation to tibial nerve course in normal and varicose limbs. *Chir Ital*. 2009;61(2):171-177.
15. Delis KT, Knaggs AL, Hobbs JT, et al. The nonsaphenous vein of the popliteal fossa: prevalence, patterns of reflux, hemodynamic quantification, and clinical significance. *J Vasc Surg Venous Lymphat Disord*. 2006;44(3):611-619.
16. Mozes G, Gloviczki P. New discoveries in anatomy and new terminology of leg veins: clinical implications. *Vasc Endovascular Surg.* 2004;38(4):367-374.
17. van Neer PA, Veraart JC, Neumann HA. Venae perforantes: a clinical review. *Dermatol Surg.* 2003;29(9):931-942.
18. Labropoulos N, Mansour MA, Kang SS, et al. New insights into perforator vein incompetence. *Eur J Vasc Endovasc Surg.* 1999;18(3):228-234.
19. Ruckley CV, Evans CJ, Allan PL, et al. Telangiectasia in the Edinburgh Vein Study: epidemiology and association with trunk varices and symptoms. *Eur J Vasc Endovasc Surg.* 2008;36(6):719-724.
20. Ruckley CV, Allan PL, Evans CJ, et al. Telangiectasia and venous reflux in the Edinburgh Vein Study. *Phlebology.* 2012;27(6):297-302.
21. Evans CJ, Allan PL, Lee AJ, et al. Prevalence of venous reflux in the general population on duplex scanning: the Edinburgh vein study. *J Vasc Surg.* 1998;28(5):767-776.
22. Allan PL, Bradbury AW, Evans CJ, et al. Patterns of reflux and severity of varicose veins in the general population—Edinburgh Vein Study. *Eur J Vasc Endovasc Surg.* 2000;20(5):470-477.
23. Engelhorn CA, Manetti R, Baviera MM, et al. Progression of reflux patterns in saphenous veins of women with chronic venous valvular insufficiency. *Phlebology.* 2012;27(1):25-32.
24. Ruckley CV, Evans CJ, Allan PL, et al. Chronic venous insufficiency: clinical and duplex correlations. The Edinburgh Vein Study of venous disorders in the general population. *J Vasc Surg.* 2002;36(3):520-525.
25. Lin JC, Iafrati MD, O'Donnell TF, et al. Correlation of duplex ultrasound scanning-derived valve closure time and clinical classification in patients with small saphenous vein reflux: Is lesser saphenous vein truly lesser? *J Vasc Surg.* 2004;39(5):1053-1058.
26. Myers KA, Ziegenbein RW, Zeng GH, et al. Duplex ultrasonography scanning for chronic venous disease: patterns of venous reflux. *J Vasc Surg.* 1995;21(4):605-612.
27. Lee AJ, Robertson LA, Boghossian SM, et al. Progression of varicose veins and chronic venous insufficiency in the general population in the Edinburgh Vein Study. *J Vasc Surg Venous Lymphat Disord*. 2015;3(1):18-26.
28. Evans CJ, Fowkes FG, Ruckley CV, et al. Prevalence of varicose veins and chronic venous insufficiency in men and women in the general population: Edinburgh Vein Study. *J Epidemiol Community Health.* 1999;53(3):149-153.
29. Robertson L, Lee AJ, Evans CJ, et al. Incidence of chronic venous disease in the Edinburgh Vein Study. *J Vasc Surg Venous Lymphat Disord*. 2013;1(1):59-67.
30. García-Gimeno M, Rodríguez-Camarero S, Tagarro-Villalba S, et al. Reflux patterns and risk factors of primary varicose veins' clinical severity. *Phlebology.* 2013;28(3):153-161.
31. Robertson L, Evans C, Fowkes FG. Epidemiology of chronic venous disease. *Phlebology.* 2008;23(3):103-111.
32. Robertson LA, Evans CJ, Lee AJ, et al. Incidence and risk factors for venous reflux in the general population: Edinburgh Vein Study. *Eur J Vasc Endovasc Surg.* 2014;48(2):208-214.
33. Chiesa R, Marone EM, Limoni C, et al. Chronic venous insufficiency in Italy: the 24-cities cohort study. *Eur J Vasc Endovasc Surg.* 2005;30(4):422-429.
34. Chiesa R, Marone EM, Limoni C, et al. Demographic factors and their relationship with the presence of CVI signs in Italy: the 24-cities cohort study. *Eur J Vasc Endovasc Surg.* 2005;30(6):674-680.
35. Jukkola TM, Mäkivaara LA, Luukkaala T, et al. The effects of parity, oral contraceptive use and hormone replacement therapy on the incidence of varicose veins. *J Obstet Gynaecol.* 2006;26(5):448-451.
36. Goldman MP, Weiss RA, Bergan JJ. Diagnosis and treatment of varicose veins: a review. *J Am Acad Dermatol.* 1994;31(3):393-413.
37. Naoum JJ, Hunter GC. Pathogenesis of varicose veins and implications for clinical management. *Vascular.* 2007;15(5):242-249.

38. Lim CS, Davies AH. Pathogenesis of primary varicose veins. *Br J Surg*. 2009;96(11):1231-1242.
39. Pittaluga P, Chastanet S. Saphenous vein preservation: is the new gold standard? In: Becquemin JP, Alimi YS, eds. *Updates and Controversies in Vascular Surgery*. Turin, Italy: Minerva Medica; 2007:392-399.
40. Bergan JJ, Schmid-Schönbein GW, Smith PD, et al. Chronic venous disease. *N Engl J Med*. 2006;355(5):488-498.
41. Naoum JJ, Hunter GC, Woodside KJ, et al. Current advances in the pathogenesis of varicose veins. *J Surg Res*. 2007;141(2):311-316.
42. Bergan JJ, Pascarella L, Schmid-Schönbein GW. Pathogenesis of primary chronic venous disease: insights from animal models of venous hypertension. *J Vasc Surg Venous Lymphat Disord*. 2008;47(1):183-192.
43. Asbeutah AM, Al-Azemi M, Al-Sarhan S, et al. Changes in the diameter and valve closure time of leg veins in primigravida women during pregnancy. *J Vasc Surg Venous Lymphat Disord*. 2015;3(2):147-153.
44. Sadick NS. Predisposing factors of varicose and telangiectatic leg veins. *J Dermatol Surg Oncol*. 1992;18(10):883-886.
45. Rabe E, Pannier F. Clinical, aetiological, anatomical and pathological classification (CEAP): gold standard and limits. *Phlebology*. 2012;27(suppl 1):114-118.
46. Weiss RA, Weiss MA. Doppler ultrasound findings in reticular veins of the thigh subdermic lateral venous system and implications for sclerotherapy. *J Dermatol Surg Oncol*. 1993;19(10):947-951.
47. Weiss RA, Weiss MA. Continuous wave venous Doppler examination for pretreatment diagnosis of varicose and telangiectatic veins. *Dermatol Surg*. 1995;21(1):58-62.
48. Schuller-Petrović S, Pavlović MD, Schuller S, et al. Telangiectasias resistant to sclerotherapy are commonly connected to a perforating vessel. *Phlebology*. 2013;28(6):320-323.
49. Khilnani NM, Min RJ. Duplex ultrasound for superficial venous insufficiency. *Tech Vasc Interv Radiol*. 2003;6(3):111-115.
50. Malgor RD, Labropoulos N. Diagnosis and follow-up of varicose veins with duplex ultrasound: how and why? *Phlebology*. 2012;27(suppl 1):10-15.
51. Coleridge-Smith P, Labropoulos N, Partsch H, et al. Duplex ultrasound investigation of the veins in chronic venous disease of the lower limbs—UIP consensus document. Part I. Basic principles. *Eur J Vasc Endovasc Surg*. 2006;31(1):83-92.
52. Duffy DM. Cosmetic applications of sclerotherapy. *G Ital Dermatol Venereol*. 2012;147(1):45-63.
53. Friedmann DP, Liolios AM, Goldman MP. An update on the treatment of lower extremity veins. *Curr Dermatol Rep*. 2014;3(2):113-121.
54. Hach W. How sublimate of mercury for syphilis led to sclerotherapy for varicose veins. *Phlebologie*. 2013; 42(4):213-218.
55. Wollmann J. The history of sclerosing foams. *Dermatol Surg*. 2004;30(5):694-703.
56. Partsch H. Use of compression therapy. In: Goldman MP, Guex JJ, Weiss RA, eds. *Sclerotherapy: Treatment of Varicose and Telangiectatic Leg Veins*. 5th ed. Philadelphia, PA: Saunders Elsevier; 2011:123-155.
57. Duffy DM. Sclerosants: a comparative review. *Dermatol Surg*. 2010;36(suppl 2):1010-1025.
58. Weiss MA, Hsu JT, Neuhaus I, et al. Consensus for sclerotherapy. *Dermatol Surg*. 2014;40(12): 1309-1318.
59. Schwartz L, Maxwell H. Sclerotherapy for lower limb telangiectasias. *Cochrane Database Syst Rev*. 2011;12:CD008826.
60. Parsi K. Interaction of detergent sclerosants with cell membranes. *Phlebology*. 2015;30(5):306-315.
61. Rabe E, Pannier F. Sclerotherapy of varicose veins with polidocanol based on the guidelines of the German Society of Phlebology. *Dermatol Surg*. 2010;36(suppl 2): 968-975.
62. Guex J, Schliephake DE, Otto J, et al. The French polidocanol study on long-term side effects: a survey covering 3,357 patient years. *Dermatol Surg*. 2010;36(suppl 2):993-1003.
63. Goldman MP. Treatment of varicose and telangiectatic leg veins: double-blind prospective comparative trial between aethoxyskerol and sotradecol. *Dermatol Surg*. 2002;28(1):52-55.
64. Rabe E, Schliephake D, Otto J, et al. Sclerotherapy of telangiectases and reticular veins: a double-blind, randomized, comparative clinical trial of polidocanol, sodium tetradecyl sulphate and isotonic saline (EASI study). *Phlebology*. 2010;25(3):124-131.
65. Rao J, Wildemore JK, Goldman MP. Double-blind prospective comparative trial between foamed and liquid polidocanol and sodium tetradecyl sulfate in the treatment of varicose and telangiectatic leg veins. *Dermatol Surg*. 2005;31(6):631-635.
66. Dietzek CL. Sclerotherapy: introduction to solutions and techniques. *Perspect Vasc Surg Endovasc Ther*. 2007;19(3):317-324.
67. Zimmet SE. The prevention of cutaneous necrosis following extravasation of hypertonic saline and sodium tetradecyl sulfate. *J Dermatol Surg Oncol*. 1993;19(7):641-646.
68. Ghaznavi AM, Nakamura M, Tepper D. An analysis of 72% chromated glycerin used for sclerotherapy: sterility, potency, and cost after extended shelf life. *Dermatol Surg*. 2015;41(1):121-125.
69. Friedmann DP. Commentary on an analysis of 72% chromated glycerin used for sclerotherapy. *Dermatol Surg*. 2015;41(2):277-278.
70. Clinical methods for sclerotherapy of varicose veins. In: Goldman MP, Guex JJ, Weiss RA, eds. *Sclerotherapy: Treatment of Varicose and Telangiectatic Leg Veins*. 5th ed. Philadelphia, PA: Saunders Elsevier; 2011:238-281.
71. Goldman MP. My sclerotherapy technique for telangiectasia and reticular veins. *Dermatol Surg*. 2010;36(suppl 2):1040-1045.
72. Mann MW. Sclerotherapy: it is back and better. *Clin Plast Surg*. 2011;38(3):475-487, vii.
73. Sadick NS. Choosing the appropriate sclerosing concentration for vessel diameter. *Dermatol Surg*. 2010;36(suppl 2):976-981.
74. Alder G, Lees T. Foam sclerotherapy. *Phlebology*. 2015;30(2)(suppl):18-23.
75. Bergan J. Sclerotherapy: a truly minimally invasive technique. *Perspect Vasc Surg Endovasc Ther*. 2008;20(1):70-72.
76. Uncu H. Sclerotherapy: a study comparing polidocanol in foam and liquid form. *Phlebology*. 2010; 25(1):44-49.
77. Stücker M, Kobus S, Altmeyer P, et al. Review of published information on foam sclerotherapy. *Dermatol Surg*. 2010;36(suppl 2):983-992.
78. Cavezzi A, Tessari L. Foam sclerotherapy techniques: different gases and methods of preparation, catheter versus direct injection. *Phlebology*. 2009;24(6):247-251.

79. Carugo D, Ankrett DN, Zhao X, et al. Benefits of polidocanol endovenous microfoam (Varithena®) compared with physician-compounded foams. *Phlebology.* 2016;31(4):283-295.
80. Goldman MP. Compression in the treatment of leg telangiectasia: theoretical considerations. *J Dermatol Surg Oncol.* 1989;15(2):184-188.
81. Weiss RA, Sadick NS, Goldman MP, et al. Post-sclerotherapy compression: controlled comparative study of duration of compression and its effects on clinical outcome. *Dermatol Surg.* 1999;25(2):105-108.
82. Goldman MP. How to utilize compression after sclerotherapy. *Dermatol Surg.* 2002;28(9):860-862.
83. Guex JJ. Complications and side-effects of foam sclerotherapy. *Phlebology.* 2009;24(6):270-274.
84. Scultetus AH, Villavicencio JL, Kao T, et al. Microthrombectomy reduces postsclerotherapy pigmentation: multicenter randomized trial. *J Vasc Surg.* 2003;38(5):896-903.
85. Goldman MP, Kaplan RP, Duffy DM. Postsclerotherapy hyperpigmentation: a histologic evaluation. *J Dermatol Surg Oncol.* 1987;13(5):547-550.
86. Weiss RA, Weiss MA. Incidence of side effects in the treatment of telangiectasias by compression sclerotherapy: hypertonic saline vs. polidocanol. *J Dermatol Surg Oncol.* 1990;16(9):800-804.
87. Clemetson CA, Blair L, Brown AB. Capillary strength and the menstrual cycle. *Ann N Y Acad Sci.* 1962; 93:279-299.
88. Goldman MP, Sadick NS, Weiss RA. Cutaneous necrosis, telangiectatic matting, and hyperpigmentation following sclerotherapy. Etiology, prevention, and treatment. *Dermatol Surg.* 1995;21(1):19-29.
89. Tafazzoli A, Rostan EF, Goldman MP. Q-switched ruby laser treatment for postsclerotherapy hyperpigmentation. *Dermatol Surg.* 2000;26(7):653-656.
90. Moore M, Mishra V, Friedmann DP, et al. Minocycline-induced postsclerotherapy pigmentation successfully treated with a picosecond alexandrite laser. *Dermatol Surg.* 2016;42(1):133-134.
91. Davis LT, Duffy DM. Determination of incidence and risk factors for postsclerotherapy telangiectatic matting of the lower extremity: a retrospective analysis. *J Dermatol Surg Oncol.* 1990;16(4):327-330.
92. Cavezzi A, Parsi K. Complications of foam sclerotherapy. *Phlebology.* 2012;27(suppl 1):46-51.
93. Bergan JJ, Weiss RA, Goldman MP. Extensive tissue necrosis following high-concentration sclerotherapy for varicose veins. *Dermatol Surg.* 2000;26(6):535-541.
94. Bihari I, Magyar E. Reasons for ulceration after injection treatment of telangiectasia. *Dermatol Surg.* 2001;27(2):133-136.
95. Jia X, Mowatt G, Burr JM, et al. Systematic review of foam sclerotherapy for varicose veins. *Br J Surg.* 2007;94(8):925-936.
96. Parsi K, Hannaford P. Intra-arterial injection of sclerosants: report of three cases treated with systemic steroids. *Phlebology.* 2016;31(4):241-250.
97. Rush JE, Wright DD. More on microembolism and foam sclerotherapy. *N Engl J Med.* 2008;359(6):656-657.
98. Gillet JL. Neurological complications of foam sclerotherapy: fears and reality. *Phlebology.* 2011;26(7): 277-279.
99. Duffy DM. Prevention of excessive endothelin-1 release in sclerotherapy: in vitro and in vivo studies. *Dermatol Surg.* 2014;40(12):1306-1308.
100. Introduction. In: Goldman MP, Guex JJ, Weiss RA, eds. *Sclerotherapy: Treatment of Varicose and Telangiectatic Leg Veins*. 5th ed. Philadelphia, PA: Saunders Elsevier; 2011:ix-xiv.
101. Caggiati A, Allegra C. Historical introduction. In: Bergan JJ, Bunke-Paquette N, eds. *The Vein Book*. 2nd ed. Oxford, UK: Oxford University Press; 2014:1-14.
102. Goldman MP. Closure of the greater saphenous vein with endoluminal radiofrequency thermal heating of the vein wall in combination with ambulatory phlebectomy: preliminary 6-month follow-up. *Dermatol Surg.* 2000;26(5):452-456.
103. Weiss RA. Comparison of endovenous radiofrequency versus 810 nm diode laser occlusion of large veins in an animal model. *Dermatol Surg.* 2002;28(1):56-61.
104. Brown K, Moore CJ. Update on the treatment of saphenous reflux: laser, RFA or foam? *Perspect Vasc Surg Endovasc Ther.* 2010;21(4):226-231.
105. Nesbitt C, Eifell RK, Coyne P, et al. Endovenous ablation (radiofrequency and laser) and foam sclerotherapy versus conventional surgery for great saphenous vein varices. *Cochrane Database Syst Rev.* 2011;10:CD005624.
106. Siribumrungwong B, Noorit P, Wilasrusmee C, et al. A systematic review and meta-analysis of randomised controlled trials comparing endovenous ablation and surgical intervention in patients with varicose vein. *Eur J Vasc Endovasc Surg.* 2012;44(2):214-223.
107. Kelleher D, Lane TR, Franklin IJ, et al. Socio-economic impact of endovenous thermal ablation techniques. *Lasers Med Sci.* 2014;29(2):493-499.
108. Merchant RF, Pichot O. Long-term outcomes of endovenous radiofrequency obliteration of saphenous reflux as a treatment for superficial venous insufficiency. *J Vasc Surg.* 2005;42(3):502-509.
109. Miyazaki K, Nishibe T, Sata F, et al. Long-term results of treatments for varicose veins due to greater saphenous vein insufficiency. *Int Angiol.* 2005;24(3):282-286.
110. Memetoğlu ME, Kurtcan S, Kalkan A, et al. Combination technique of tumescent anesthesia during endovenous laser therapy of saphenous vein insufficiency. *Interact Cardiovasc Thorac Surg.* 2010;11(6):774-777.
111. Navarro L, Min RJ, Boné C. Endovenous laser: a new minimally invasive method of treatment for varicose veins—preliminary observations using an 810 nm diode laser. *Dermatol Surg.* 2001;27(2):117-122.
112. Manfrini S, Gasbarro V, Danielsson G, et al. Endovenous management of saphenous vein reflux. Endovenous Reflux Management Study Group. *J Vasc Surg.* 2000;32(2):330-342.
113. Weiss RA, Weiss MA, Eimpunth S, et al. Comparative outcomes of different endovenous thermal ablation systems on great and small saphenous vein insufficiency: long-term results. *Lasers Surg Med.* 2015;47(2):156-160.
114. Lee JM, Jung IM, Chung JK. Clinical and duplex-sonographic outcomes of 1,320-nm endovenous laser treatment for saphenous vein incompetence. *Dermatol Surg.* 2012;38(10):1704-1709.
115. Poluektova AA, Malskat WS, van Gemert MJ, et al. Some controversies in endovenous laser ablation of varicose veins addressed by optical-thermal mathematical modeling. *Lasers Med Sci.* 2014;29(2):441-452.
116. van Ruijven PW, Poluektova AA, van Gemert MJ, et al. Optical-thermal mathematical model for endovenous laser ablation of varicose veins. *Lasers Med Sci.* 2014;29(2):431-439.

117. Proebstle TM, Sandhofer M, Kargl A, et al. Thermal damage of the inner vein wall during endovenous laser treatment: key role of energy absorption by intravascular blood. *Dermatol Surg.* 2002;28(7):596-600.
118. Vuylsteke ME, Martinelli T, Van Dorpe J, et al. Endovenous laser ablation: the role of intraluminal blood. *Eur J Vasc Endovasc Surg.* 2011;42(1):120-126.
119. Proebstle TM, Moehler T, Gül D, et al. Endovenous treatment of the great saphenous vein using a 1,320 nm Nd:YAG laser causes fewer side effects than using a 940 nm diode laser. *Dermatol Surg.* 2005;31(12):1678-1683.
120. Vuylsteke M, De Bo T, Dompe G, et al. Endovenous laser treatment: is there a clinical difference between using a 1500 nm and a 980 nm diode laser? A multicenter randomised clinical trial. *Int Angiol.* 2011;30(4):327-334.
121. Kabnick LS. Outcome of different endovenous laser wavelengths for great saphenous vein ablation. *J Vasc Surg.* 2006;43(1):88.e1-88.e7.
122. Doganci S, Demirkilic U. Comparison of 980 nm laser and bare-tip fibre with 1470 nm laser and radial fibre in the treatment of great saphenous vein varicosities: a prospective randomised clinical trial. *Eur J Vasc Endovasc Surg.* 2010;40(2):254-259.
123. Malskat WS, Poluektova AA, van der Geld CW, et al. Endovenous laser ablation (EVLA): a review of mechanisms, modeling outcomes, and issues for debate. *Lasers Med Sci.* 2014;29(2):393-403.
124. Ramelet AA. Müller phlebectomy. A new phlebectomy hook. *J Dermatol Surg Oncol.* 1991;17(10):814-816.
125. Smith SR, Goldman MP. Tumescent anesthesia in ambulatory phlebectomy. *Dermatol Surg.* 1998; 24(4):453-456.
126. Ramelet AA. Complications of ambulatory phlebectomy. *Dermatol Surg.* 1997;23(10):947-954.
127. Meesters AA, Pitassi LH, Campos V, et al. Transcutaneous laser treatment of leg veins. *Lasers Med Sci.* 2014;29(2):481-492.
128. Anderson RR, Parrish JA. Selective photothermolysis: precise microsurgery by selective absorption of pulsed radiation. *Science.* 1983;220(4596):524-527.
129. McCoppin HH, Hovenic WW, Wheeland RG. Laser treatment of superficial leg veins: a review. *Dermatol Surg.* 2011;37(6):729-741.
130. Goldman MP, Eckhouse S. Photothermal sclerosis of leg veins. ESC Medical Systems, LTD Photoderm VL Cooperative Study Group. *Dermatol Surg.* 1996; 22(4):323-330.
131. Fodor L, Ramon Y, Fodor A, et al. A side-by-side prospective study of intense pulsed light and Nd:YAG laser treatment for vascular lesions. *Ann Plast Surg.* 2006;56(2):164-170.
132. Ross EV, Domankevitz Y. Laser treatment of leg veins: physical mechanisms and theoretical considerations. *Lasers Surg Med.* 2005;36(2):105-116.
133. Klein A, Bäumler W, Koller M, et al. Indocyanine green-augmented diode laser therapy of telangiectatic leg veins: a randomized controlled proof-of-concept trial. *Lasers Surg Med.* 2012;44(5):369-376.
134. Kaudewitz P, Klövekorn W, Rother W. Treatment of leg vein telangiectases: 1-year results with a new 940 nm diode laser. *Dermatol Surg.* 2002;28(11):1031-1034.
135. Kunishige JH, Goldberg LH, Friedman PM. Laser therapy for leg veins. *Clin Dermatol.* 2007;25(5): 454-461.

Chapter 213 :: Chemical Peels and Dermabrasion

:: Gary Monheit & Bailey Tayebi

AT-A-GLANCE

- Chemexfoliation agents are broadly classified into superficial, medium, and deep peeling agents according to their depth of penetration and histologic injury.
- Preoperative evaluation of skin type, degree of photoaging, and underlying skin disorders is critical in safeguarding against potential complications.
- Appropriate patient selection and choice of procedure are critical to success.
- Keratocoagulation, evidenced by a white frosting of the skin, is generally regarded as the desired clinical end point of chemical peeling with trichloroacetic acid.
- Mechanical resurfacing, which includes microdermabrasion, manual dermasanding, and motorized dermabrasion, is an effective method for treatment of scars.
- Infection, prolonged erythema, pigmentary alterations, and scarring are potential complications of resurfacing procedures.

BACKGROUND

Resurfacing procedures, including chemical, mechanical, and laser resurfacing, wound the skin in a controlled and predictable manner so as to promote the growth of new skin with improved texture and quality. The art of chemical peeling dates back to ancient Egyptian times when the use of animal oils, salt, and lactic acid in sour milk were used to cosmetically enhance the appearance of skin. Mechanical exfoliation was first described in Greek and Roman literature using compounds containing mustard, sulfur, and limestone. In the mid-1800s, Viennese dermatologist Ferdinand Hebra used various peeling agents to treat pigmentary abnormalities. These early exfoliative agents included tinctures of iodine and lead, croton oil, cantharides, and various acids, including sulfuric, acetic, hydrochloric, and nitric acids. Tilbury Fox first introduced phenol to the topical dermatology arena in 1871. A decade later, P. G. Unna reported on the use of salicylic acid, resorcinol, phenol, and trichloroacetic acid (TCA) as peeling agents. Over the next century, several physicians worked to modify peeling agent formulations, combinations, and procedures. In the 1980s, Samuel Stegman identified the depth of injury associated with various peeling agents, which enabled later categorization into superficial, medium, and deep chemical peels. Today, chemexfoliation, or chemical peeling, involves the application of a chemical exfoliant aimed to wound and subsequently regenerate the epidermis and/or dermis to remove superficial skin lesions, improve pigmentary abnormalities and photodamage, and address textural concerns (Table 213-1).[1]

PERIOPERATIVE CONSIDERATIONS

The perioperative evaluation is a critical component of every chemical resurfacing procedure. The physician should seek a thorough understanding of patient treatment goals, expectations, and allotted down time prior to initiation of the procedure. The physician should also assess the patient's level of compliance and need for preprocedural and/or postprocedural adjuvant treatments.[2] Patients should be instructed to avoid depilatory procedures, such as waxing and shaving, prior to the procedure, as well as ultraviolet light exposure before and after the date of the chemical peel. Lastly, preoperative photographs should be taken to serve as a benchmark with which to grade clinical results.

INDICATIONS

Chemexfoliation indications can be classified into pigmentary (eg, postinflammatory hyperpigmentation, melasma), photoinduced (eg, actinic keratoses), and textural abnormalities (eg, epidermal growths, rhytides, scarring, acne vulgaris).[2]

PATIENT SELECTION

The perioperative evaluation should assess the patient's skin type, degree of photoaging, and whether or not the patient has underlying skin disorders. When evaluating skin type, it is useful to classify patients according to their Fitzpatrick skin phototype (SPT). In general, darker skin types (SPT IV to SPT VI) have an increased risk of pigmentary alterations following chemical peels. While superficial peels tend to be well tolerated by all skin types, deep peels are commonly avoided in patients with SPT IV to SPT VI skin because of the higher risks of postprocedural pigmentary change and scarring (Table 213-2).[2-4]

The patient's degree of photodamage assists the physician in electing the appropriate rejuvenation procedure necessary to achieve clinically significant results.

TABLE 213-1
Resurfacing Procedures

	PEELING	DERMABRASION	LASER
Superficial	Glycolic Jessner solution Salicylic acid	Microdermabrasion	–
Medium depth	Jessner solution + 35% trichloroacetic acid	Manual dermasanding	Erbium laser
Deep	Baker phenol peel	Mechanical dermabrasion	CO_2 laser

The Glogau system, which classifies patients into categories I through IV based on whether the patient has mild, moderate, advanced, or severe photodamage, is a useful categorization tool for this purpose. In general, both category I and category II photodamage will improve with more superficial peeling agents (Fig. 213-1). Category III will respond to medium-depth peels, while category IV will require deep peeling agents possibly in combination with mechanical and/or laser resurfacing procedures[3] (Fig. 213-2).

Lastly, inquiring about a patient's underlying skin disorders allows the physician to safeguard against potentially-devastating complications such as infection and scarring. The physician should inquire about a history of atopy, rosacea, isotretinoin therapy, poor wound healing, connective tissue disease, and hypertrophic or keloid scar formation as chemical resurfacing may be contraindicated in these patients.[4] Additionally, a history of recurrent infections, including bacterial, fungal, and viral, should be elicited in the preoperative consultation. A patient with recurrent herpes simplex virus should be prophylactically treated with an antiviral agent prior to the procedure. Common pretreatment regimens include acyclovir 400 mg thrice daily and valacyclovir 500 mg twice daily starting on the day of the peel and continued until reepithelialization has occurred (Table 213-3).[3,5]

TABLE 213-2
Fitzpatrick Skin Phototypes and Peel Indications

SKIN PHOTOTYPE	SKIN REACTION	PEEL		
		SUPERFICIAL	MEDIUM	DEEP
I	Always burn, never tan	+	+	–
II	Always burn, sometimes tan	+	+	–
III	Sometimes burn, always tan	+	+	–
IV	Never burn, always tan	+	+	±
V	Moderate pigmented skin	+	±	–
VI	Darkly pigmented skin	+	±	–

–, no; +, yes; ±, either.

SIDE EFFECTS

The perioperative consultation is also an appropriate time to review the risks and benefits of chemical peeling. Expected intraoperative side effects include stinging, burning, and/or itching. In the immediate postoperative period, erythema, edema, and desquamation may be experienced.[2]

PERIOPERATIVE PREPARATIONS

Chemical peeling agents can penetrate to predictable histologic depths; however, the physician can augment this depth with the use of certain preoperative preparations.[6-8] Topical pretreatment with retinoic, glycolic, or lactic acid alone, or in combination, will increase the absorption of the wounding agent and promote a more even penetration of the peel. Pretreatment should begin 2 to 4 weeks before the procedure and be discontinued approximately 2 to 3 days prior to the peel date.[2,6] Pretreatment with a topical retinoid may also speed the healing process (Table 213-4).[4]

Topical medications such as 2% to 5% hydroquinone may be applied to the skin preoperatively and postoperatively to minimize the risk of postinflammatory hyperpigmentation. Pretreatment should be considered in patients with SPT III to SPT VI, and in those treated for problems of hyperpigmentation.[6] Application of hydroquinone, in addition to a ultraviolet A/ultraviolet B protective sunscreen (sun protection factor 30 or higher), should be initiated 2 to 4 weeks prior to the date of the peel and resumed once reepithelialization has occurred postoperatively. As a rule, patients prone to dyschromias should adhere to a policy of strict sun avoidance in the perioperative period.

PROCEDURAL TECHNIQUE

Following informed consent, instruct the patient to remove any makeup with a gentle facial cleanser. The patient is then placed in the supine position on the operating table with the head elevated to a 30-degree angle.[9] This position minimizes the risk of solution inadvertently dripping toward the eyes and allows the physician to visualize the complete treatment area.

In general, more superficial chemical peels do not require sedation or other forms of anesthesia. Medium and deep peeling agents, however, are associated with significantly more operative discomfort and may

Figure 213-1 Glogau photoaging types I and II. Indications for superficial peeling.

Figure 213-2 Glogau photoaging types III and IV. Indications for medium and deep chemical peeling.

TABLE 213-3
Contraindications to Medium and Deep Peels

RELATIVE CONTRAINDICATIONS	ABSOLUTE CONTRAINDICATIONS
Active skin disease	Open wounds, excoriations
Recent facial surgery	Isotretinoin within last 6 months
History of facial keloids	Pregnancy
History of postinflammatory hyperpigmentation	Unrealistic expectations
Radiation to head and neck	Poor patient–physician relationship
Active skin infection ▪ Bacterial ▪ Viral	

require sedative and pain medications and/or local nerve blocks. Such blocks commonly include anesthetizing the supraorbital, infraorbital, temporal, and mental nerves.[9]

Once the patient has been positioned and the appropriate level of anesthesia has been undertaken, the skin is vigorously cleansed and degreased. A variety of cleansing agents may be used for this purpose including hexachlorophene, acetone, rubbing alcohol, chlorhexidine, or some combination of these agents.[3,6,7,9] An even application can be achieved with a 4-inch × 4-inch gauze. The skin should then be rinsed and dried prior to application of the chemexfoliant.

TABLE 213-4
Preoperative and Postoperative Care for Chemical Peels

Preparation (Weeks to Days Before Peel)
- Topical pretreatment with a retinoid, glycolic or lactic acid solution (begin 2 to 4 weeks prior, discontinue 2 to 3 days before peel date)
- Consider topical 2% to 5% hydroquinone preoperatively and postoperatively, if postinflammatory hyperpigmentation is a concern (2 to 4 weeks prior)
- Sun avoidance, especially in individuals at risk for dyschromias
- Consider pretreatment with acyclovir 400 mg thrice daily or valacyclovir 500 mg twice daily on the day of peel and until reepithelialization

Preprocedural Care (Immediately Prior to Peel)
- Cleanse skin with gentle facial cleanser
- Position patient with head up at a 30-degree angle
- Consider sedative/pain medications or local nerve blocks for medium to deep peels
- Degrease skin with acetone, hexachlorophene, rubbing alcohol, or chlorhexidine
- Rinse and dry skin prior to application of chemexfoliant

Postprocedural Care
- Cleanse skin up to 4 times/day
- Dilute 0.25% acetic acid (1 tbsp vinegar in 1 pint water) as cleansing agent
- Pat dry, apply bland emollient
- Daily sunscreen use
- Avoidance of excessive sun exposure

This cleansing regimen will remove all oil and debris and promote even penetration of the wounding agent while minimizing the risk of a spotty or ineffective peel.

For medium-depth peeling, an absorbing agent may be applied to the skin to increase the effectiveness or penetration depth of the peeling agent. In 1986, Brody and Hailey applied solid carbon dioxide (CO_2) in combination with acetone prior to application of 35% TCA to disrupt the epidermal barrier and achieve a more even peel at a greater histologic depth.[3] Later, in 1989, Monheit described a similar technique using Jessner solution prior to application of 35% TCA. Acting as an absorbing agent, Jessner solution removes the stratum corneum allowing for deeper penetration of TCA. Coleman similarly demonstrated greater wounding depths with use of 70% glycolic acid prior to application of 35% TCA.[3,9] Use of absorbing agents such as these offers improved safety, minimizes the risk of pigmentary alterations and scarring, and creates clinical results comparable to a deep 50% TCA peel.

The peeling agent is then applied. This is commonly done with cotton-tipped applicators or 4-inch × 4-inch/2-inch × 2-inch gauze. The face is peeled sequentially by anatomic location starting on the forehead, followed by the temples, cheeks, and finally the lips and eyelids.[3] Feathering of the solution into the hairline, brows, and jawline helps to conceal lines of demarcation between peeled and nonpeeled areas.[9] Alternatively, a superficial peeling agent may be applied to such areas as neck and décolleté to assist in blending treated and untreated cosmetic units. Special care is taken to protect the eyes during a chemical peel. A semidry applicator should be used to carry the solution within 2 to 3 mm of the lid margin. Furthermore, tears are wicked away with a dry cotton-tipped applicator to prevent peel solution from traveling to the puncta and eye via capillary action.[9] Should peel solution inadvertently enter the eye, initiate aggressive irrigation with normal saline flushes immediately.

During the procedure, the physician is able to ensure even application of the peeling agent by the demonstration of even frosting. Frosting is representative of underlying keratocoagulation, or denaturation of epidermal keratin proteins.[9] Although true frosting does not occur with each and every peeling agent, frosting is generally regarded as the desired end point. Level I frosting is defined as erythema with blotchy or spotty frosting. This is often seen with light chemical peels. Level II frosting is commonly seen in medium-depth chemical peels and is achieved when a white coating is evident with a slight erythematous background showing through. Level III frosting is attained when a solid white enamel-like frosting is demonstrated on the skin. This is seen in deeper chemical peels and is indicative of peel penetration into the papillary dermis.[3]

Immediately following the procedure, cool saline compresses are applied for 5 to 10 minutes. This is for comfort as the reaction is complete after frosting. Only glycolic acid peels require neutralization. A bland emollient as well as a broad-spectrum sunscreen are then gently massaged into the skin.

CHEMICAL RESURFACING PROCEDURES

Chemical peeling involves the application of a chemical agent that wounds the epidermis and/or dermis and stimulates collagen remodeling and new epidermal growth, thus achieving a cosmetic benefit. The degree of penetration, destruction, and inflammation determines the level of peeling.[3] Superficial peeling agents remove the stratum corneum and wound the epidermis.[8,9] Destruction of the entire epidermis defines a full superficial peel. Medium-depth peels penetrate through the papillary dermis to the upper reticular dermis.[3,8] Deep peeling agents wound a greater portion of the reticular dermis resulting in production of new collagen and ground substances (Fig. 213-3).[3,8,9]

SUPERFICIAL CHEMICAL PEELING

Superficial chemical peels are indicated for acne, particularly comedonal acne, enlarged pores, postinflammatory hyperpigmentation, melasma, mild photodamage, and fine textural concerns.[2,4,10] Superficial exfoliants include 10% to 20% TCA (20% to 35% TCA achieves a complete epidermal peel), Jessner solution (14% salicylic acid, 14% lactic acid, and 14% resorcinol in ethanol), resorcinol, salicylic acid, and α-hydroxy acids such as glycolic acid.[2,6] Superficial peeling agents disrupt corneocyte adhesion and lead to regeneration of a thickened epidermis, normalization of the basal cell layer, and dispersal of melanin. Superficial agents may also enact dermal change including increased dermal collagen and improved quality of elastic fibers.[11,12] Complete recovery is expected in 2 to 4 days (Fig. 213-4).[4,6]

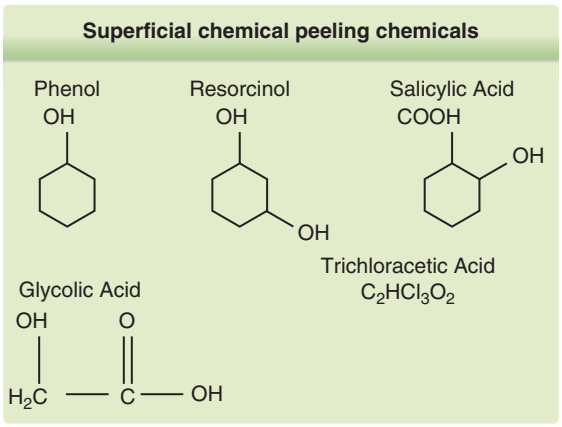

Figure 213-4 Superficial chemical peeling chemicals.

Salicylic acid is a naturally occurring β-hydroxy acid derived from the bark of the willow tree. It is regarded as a safe peel in all skin types for the treatment of acne, melasma, and postinflammatory hyperpigmentation. As described by Grimes, salicylic acid exhibits a lipophilic nature that allows for effective dissolution of the stratum corneum as well as comedolysis.[13] Therefore,

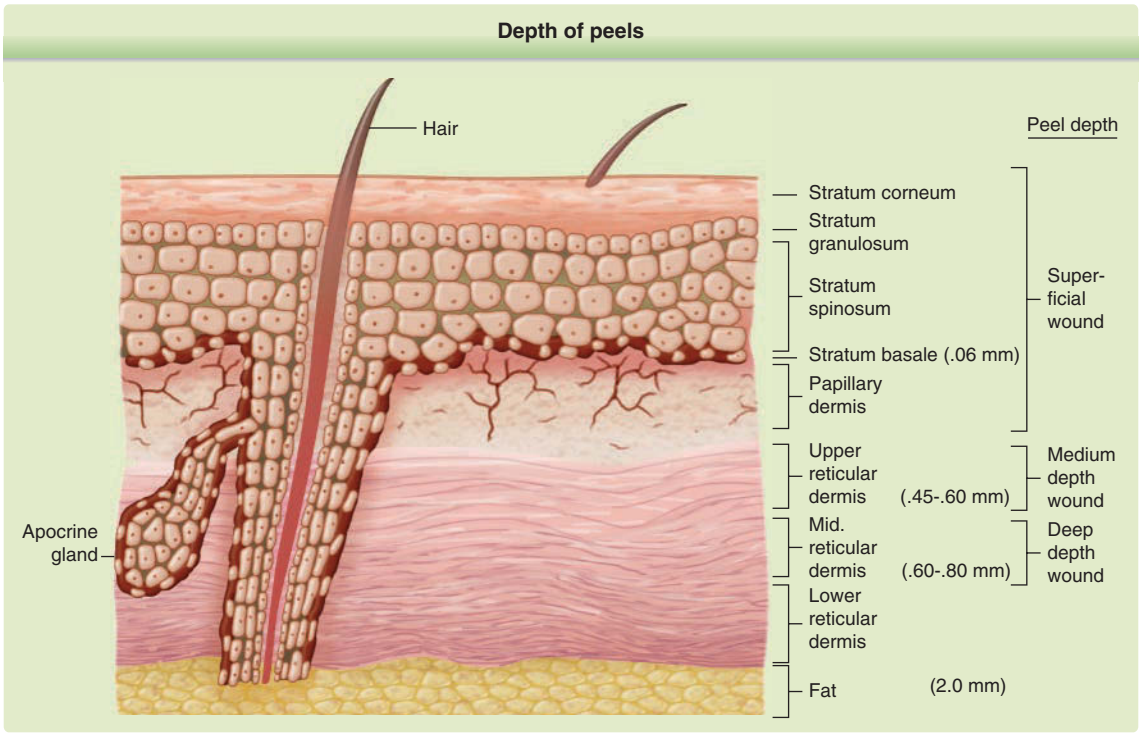

Figure 213-3 Depth of peels.

Figure 213-5 Salicylic acid peel for acne. **A,** Pretreatment. **B,** Perifollicular frosting. **C,** After 3 treatments.

salicylic acid proves beneficial in the treatment of comedonal and papular/pustular acne.[2,4,13,14] A split-face study by Meguid and colleagues reported that treatment of inflammatory acne lesions with the use of 30% salicylic acid was superior to treatment using 25% TCA, although an improvement in total lesions, including both comedonal and inflammatory, occurred in 95% of patients on the salicylic acid–treated side (Fig. 213-5).[14] Salicylic acid peels are also effective in the treatment of dyschromias. In a pilot study by Grimes, 88% of patients with SPT V and SPT VI demonstrated improvement in dyschromias, with 4% hydroquinone pretreatment followed by a graduated series of 20% and 30% salicylic acid peels.[10] Salicylic acid is a preferential peeling agent for dyschromia as it is the least inflammatory of peeling agents. It has the least risk of producing postinflammatory hyperpigmentation (Fig. 213-6).

α-Hydroxy acids include glycolic acid along with several other naturally, occurring, nontoxic agents such as lactic, citric, malic, and tartaric acid.[2,6] Glycolic acid concentrations of 10% to 70% are frequently used in the treatment of acne, dyschromias, and mild signs of photoaging, and are safe in most skin types. Unlike other superficial peeling agents, the action of glycolic acid is time dependent and must be neutralized with normal saline, water, or sodium bicarbonate. α-Hydroxy acids wound the skin via loss of keratinocyte cohesion within the epidermis. Peels using 70% glycolic acid can also result in increased fibroblast proliferation, collagen and elastic fiber formation, and melanin dispersion.[2,15]

MEDIUM-DEPTH CHEMICAL PEELING

Medium-depth chemical peels are indicated for the treatment of mild to moderate photoaging, pigmentary disorders, lentigines, epidermal growths, rhytides, and actinic keratoses.[9] Peeling agents include 45% to 60% TCA as well as combination peels such as Jessner solution with 35% TCA (Monheit peel), 70% glycolic acid with 35% TCA (Coleman peel), and solid CO_2 with 35% TCA (Brody peel).[3,6,9] Fifty percent TCA is not used any longer because of the risk of scar from deeper penetration of the agent in the dermis. Combination peels are the preferred medium-depth peels because of their lower risk of postprocedural dyschromias and scarring.[3,9] Histologically, medium-depth chemical peels are associated with diminished solar elastosis, fibroblast proliferation, increased collagen formation, and reorganization of elastic fibers (see Fig. 213-3; Table 213-5).[8,12]

TCA is a crystalline inorganic compound that results in keratocoagulation, or protein denaturation, and resultant cell death, as indicated by a white frosting on the skin. Effects of this self-neutralizing peeling agent are cumulative with each application penetrating deeper than the last. TCA may be relatively quantitated with utilization of 1 to 4 cotton-tipped applicators. Loose or wrinkled skin should be stretched to achieve an even application of the solution and prevent pooling of the solution in folds. A level II to level III frosting is generally complete within 30 seconds to 2 minutes of TCA application; however, thicker epidermal growths may require additional applications.[2,9] Moreover, areas of poor frosting may require careful reapplication of the peeling agent.[3] At the completion of the peel, cool

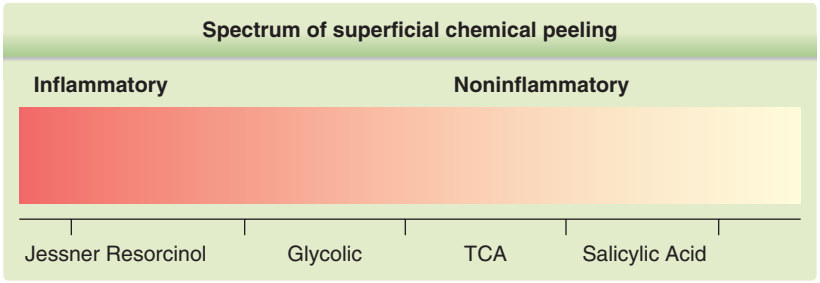

Figure 213-6 Spectrum of superficial chemical peeling. TCA, trichloroacetic acid.

saline compresses are placed on the skin. A bland emollient and sunscreen are then applied. Expected side effects include erythema, edema, and desquamation. Edema of the eyelids may be severe enough that it closes the lids. As the skin heals, erythema intensifies as desquamation comes to an end within 3 to 4 days. New skin is evident within 6 to 7 days, and healing is complete within 7 to 10 days. At this point, the erythema is reminiscent of a sunburn and is expected to resolve within 3 to 4 weeks.[9] TCA should be used cautiously in SPT IV to SPT VI. One should never "overcoat" TCA once the frosting is complete as accumulated TCA will produce a deeper peel (Fig. 213-7).

DEEP CHEMICAL PEELING

Deep chemical peels are indicated for deep rhytides and severe photoaging (Glogau categories III and IV) and include peeling agents such as Baker phenol.[9] The phenol is diluted to a concentration of 45% to 55% with croton oil, hexachlorophene, and water, and is referred to as the Baker-Gordon phenol peel. Two variations, an occluded and unoccluded, exist in clinical practice. In the occluded phenol peel, zinc oxide tape is placed over the skin after the peeling solution has been applied so as to increase absorption. The unoccluded method, described by McCollough, requires application of higher volumes of peeling solution; however, depth of penetration is diminished as compared to the occluded technique. Both variations of the Baker-Gordon phenol peel possess inherent risks and require monitoring and IV fluid administration because of potential cardiac, renal, and hepatic toxicities.[3,16,17] Baker-Gordon deep chemical peeling is a more aggressive procedure with inherent risks, but is the most permanent skin rejuvenation of all resurfacing procedures.

TABLE 213-5
Medium-Depth Wounding

- Trichloroacetic acid (TCA) 50%
- Liquified phenol USP (U.S. Pharmacopoeia) 88%
- Solid carbon dioxide + TCA 35% to 50%
- Jessner solution + TCA

High concentrations of TCA are used in the treatment of atrophic scars in a procedure known as TCA chemical reconstruction of skin scars (TCA CROSS). In this procedure, first described by Lee and colleagues, TCA is applied with a sharp-tipped wooden applicator pressed firmly against the base of the scar until a white frost is apparent. Because high concentrations (70% to 100%) of TCA penetrate to the deep dermis, histologic remodeling also occurs at this level. Such remodeling consists of dermal expansion with increased collagen proliferation that results in elevation of depressed, atrophic scars.[18,19] Agarwal and colleagues reported successful use of 70% TCA applied with standard TCA CROSS technique in the treatment of boxcar, rolling, and ice pick scars in SPT IV and SPT V. In this study, postinflammatory hyperpigmentation was reported but improved with time and use of "depigmenting" creams; formation of keloids, persistent erythema, and reactivation of herpes simplex virus were not seen.[19]

Medium-depth and deep peeling agents result in significant inflammation and wounding within the deep reticular dermis and heal with 4 characteristic stages, including inflammation, coagulation, reepithelialization, and fibroplasia. Inflammation and coagulation occur within hours of application of the peeling agent. Reepithelialization then begins on day 3 and continues through days 10 to 14. Fibroplasia is the last stage of the healing process and persists for 3 to 4 months. This stage includes neoangiogenesis and collagen proliferation.[3] In a histologic and biochemical analysis by Butler and colleagues, reorganization of dermal collagen and elastic fiber networks was prominently seen following 50% TCA and phenol peels.[12] These dermal changes allow for the improvement in rhytides and other signs of photoaging seen clinically following deep chemical peels.

POSTOPERATIVE CARE

Following a chemical peel, patients are instructed to cleanse the skin up to 4 times daily to prevent infection and debride the necrotic exfoliation. Dilute 0.25% acetic acid (1 tablespoon vinegar in 1 pint water) is a commonly recommended cleansing agent because of its antibacterial action against *Pseudomonas* and other Gram-negative bacterial organisms.[3,5,9] After cleansing, the skin is patted dry and a bland emollient is applied.

Figure 213-7 Levels of frosting. **A,** Level I: erythema with streaky frosting—superficial epidermal. **B,** Level II: white frosting with visible erythema—full-thickness epidermal. **C,** Level III: white enamel frosting—epidermal or dermal.

COMPLICATIONS

Complications can occur either intraoperatively or postoperatively.[3] Intraoperative complications include, but are not limited to, incorrect peel concentrations, use of expired products, accidental solution misplacement, and failure to properly neutralize the peel solution. Such errors may be prevented with care taken to check concentrations and dates of expiration. As removal of intact peeling agent crystals from the storage bottle may lead to higher concentrations placed on the skin, the physician should pour the peeling solution into a secondary container prior to initiation of the procedure. Furthermore, solution should never be passed over the face or allowed to actively drip onto the skin. Neutralizing solutions should be identified properly (eg, sodium bicarbonate for glycolic acid peels) and kept at the patient's bedside for quick placement following completion of the peel.

Postoperative complications include infection (bacterial, viral, fungal), prolonged erythema, pruritus, pigmentary alterations, contact dermatitis, milia/acne, exacerbation of an underlying skin disease, and scarring.[3,9] Frequent postoperative visits and early recognition of complications are critical, especially for medium and deep chemical peels in which risks of scarring are inherently higher. Delayed wound healing and persistent erythema are signs that skin is not healing normally and are indicative of scarring potential. Delayed healing is evident with the appearance of friable, stellate erosions on the skin at the time reepithelialization is expected. As erosions may be indicative of infectious etiologies, all such wounds should be cultured. Erosions should be treated with artificial wound dressings and topical or systemic corticosteroids.[5] Persistent erythema is defined as erythema lasting longer than 3 to 5 days for a superficial peel, 15 to 30 days for a medium-depth peel, and 60 to 90 days for a deep chemical peel.[3] Etiologies include underlying skin disorders such as rosacea and atopy, contact dermatitis or sensitivity to the peeling agent, and aggressive peeling techniques.[20] Persistent erythema should be treated promptly with topical and/or systemic corticosteroids (Fig. 213-8).[3,5,20]

Postinflammatory hyperpigmentation and other pigmentary dyschromias are more common in SPT IV to SPT VI with medium and deep chemical peels presenting a greater risk than superficial peels. Hyperpigmentation is also more common

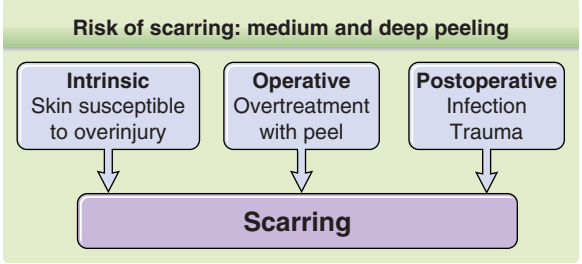

Figure 213-8 Risk of scarring: medium and deep peeling.

in individuals on hormonal therapies including oral contraceptive pills and photosensitizing medications.[5] In general, superficial peels should be elected in individuals with darker skin types. The physician may recommend treatment with hydroquinone, with or without a retinoid, in the perioperative period to minimize risks of hyperpigmentation.[2,4,5] Hypopigmentation, on the other hand, can be a complication associated with phenol peels. The resulting coloration of the skin is comparable to the natural appearance of sun-protected sites, such as the axillae and postauricular skin, and is directly proportional to the amount of phenol applied.[5] Deeper penetration can efface the papillary dermis creating a much lighter appearance with an "alabaster" texture.

MECHANICAL RESURFACING PROCEDURES

MICRODERMABRASION

Developed by Marini and Lo Brutto in 1985, microdermabrasion is a closed-system mechanical resurfacing procedure using abrasive aluminum oxide crystals to ablate the superficial epidermis.[21-23] The machine operates by discharging crystals onto the skin from a compression source. Crystals wound the superficial epidermis, removing keratinocytes and sebum, and are then returned to a waste container via vacuum suction. The ablative strength of the procedure is dependent on the strength of the vacuum and contact time with the skin. Depth of injury and clinical results are generally comparable to that of superficial chemical peels. Histologic investigation by Freedman and colleagues demonstrated return of a "basket-weave" stratum corneum, thickening of the epidermis and dermis, and increased collagen and elastic fibers following a series of microdermabrasion treatments.[24]

Microdermabrasion is regarded as a safe procedure in most skin types. The procedure is well tolerated and does not require anesthesia. Indications include enlarged pores, fine rhytides, mild photodamage, and acne scarring. Multiple treatments are usually necessary to achieve appreciable clinical results. Side effects are minimal and short-lived including erythema, petechiae/purpura, and tenderness. Complications such as persistent erythema, telangiectases, and postinflammatory hyperpigmentation are uncommon; however, microdermabrasion is best avoided in patients with underlying rosacea, and aggressive technique should be discouraged in patients with SPT V and SPT VI. Rare complications to the technician involve inhalation of the crystals and include pulmonary fibrosis and foreign-body granuloma, which are a result of the aluminum oxide crystals used in the procedure. To minimize such risks, eye protection and masks should be worn by the operators.[23,25]

TABLE 213-6
Manual vs Motorized Dermabrasion

MANUAL DERMABRASION	MOTORIZED DERMABRASION
▪ Minimal cost of equipment, no maintenance, disposable ▪ No aerosolization of blood and infectious particles ▪ Difficult to perform in concavities (alar groove, nasolabial fold) ▪ Longer procedure time ▪ Depending on material used, risk for granuloma formation if inadequate postprocedural cleaning	▪ High cost of machine; gas sterilization of burrs and fraises required; face shields, draping required ▪ Aerosolization of blood and infectious particles ▪ Specialized burr shapes provide ease of use in smaller units or concavities ▪ Shorter procedure time ▪ No risk for granuloma formation

Data from Gillard M, Wang T, Boyd C. Conventional diamond fraise vs manual spot dermabrasion with drywall sanding screen for scars from skin cancer surgery. *JAMA Dermatol*. 2002;138(8):1035-39.

MANUAL DERMASANDING

Manual dermabrasion (Table 213-6), or dermasanding, uses sterile sandpaper of varying grades to ablate the epidermis and portions of the dermis. Two hundred or 400 grit-grade sandpaper wrapped around gauze or a cotton-tipped applicator is used to abrade the skin until punctate bleeding is evident. This cost- and time-effective procedure is frequently elected for the treatment of surgical scars. A split-scar study by Poulos and colleagues reported improvement in the appearance of surgical scars, particularly that of scar color and elevation, following manual dermabrasion performed 6 to 8 weeks postoperatively.[26] It is important to rinse the abraded skin thoroughly to remove the silica-carbide crystals as they can become imbedded in the skin and create granulomas or tattoos (Fig. 213-9).

MOTORIZED DERMABRASION

Motorized dermabrasion (see Table 213-6) is a mechanical resurfacing technique in which handheld devices using burrs of varying degrees of coarseness are used to remove layers of the epidermis and/or dermis.[25] Biopsies of dermabraded skin demonstrate normalization of the rete ridge pattern, increased type I collagen, and increased elastic fibers.[27,28]

Motorized dermabrasion is indicated for moderate to severe photodamage, including textural changes, rhinophyma, and scar revision. Patients with SPT IV to SPT VI should be treated cautiously because of the potential for postprocedural pigmentary alterations. To minimize such risks, pretreatment and posttreatment with a topical retinoid or hydroquinone may be elected.

Manual dermasanding used in conjunction with medium-depth chemical peel

Sterile sandpaper dipped in water
- rolled around 2-in × 2-in gauze
- or 3 mL syringe
- or dental roll

Figure 213-9 Manual dermasanding can be used in conjunction with medium-depth chemical peel to provide selective deeper resurfacing.

Prior to the procedure, the treatment area is injected with local anesthesia. Regional nerve blocks also may be done to improve patient comfort. For larger treatment areas, sedative medications and/or general anesthesia may be required. The physician and assistants should wear gowns and eye protection because of aerosolization of skin particles and blood during the procedure.

The proper burr should then be selected for the treatment area and desired clinical result. Commonly-used burrs include diamond fraises and wire brushes. The physician is able to control the depth of destruction by means of the amount of pressure applied and the selected speed of the dermabrader. Punctate bleeding is indicative of wounding to the level of the papillary dermis while more confluent bleeding is seen with wounding to the level of the reticular dermis. To minimize the risk of adverse events including scarring, treatment should never extend below the mid-reticular dermis (Fig. 213-10).

At the conclusion of the procedure, cool saline-soaked gauze is applied to the skin followed by application of a bland emollient. The patient is instructed to cleanse the treated skin with 0.25% acetic acid daily and keep the affected skin moist with a bland emollient until reepithelialization has occurred at approximately 7 to 10 days. Ultraviolet radiation should be strictly avoided and broad-spectrum sunscreens should be applied daily. Healing generally occurs in 2 to 4 weeks and postprocedural erythema is expected to resolve in 1 to 2 months.[25]

Surgical landmarks

Papillary dermis/capillary loops
- ➢ Small red dots-fraise
- ➢ Corn rows of bleeding-brush

Upper reticular dermis
- ➢ Large red dots-fraise
- ➢ White parallel lines in collagen-brush

Mid-deep reticular dermis
- ➢ Yellow globules-sebaceous glands
- ➢ Frayed collagen bundles

Figure 213-10 Surgical landmarks.

CONCLUSIONS

Chemical and mechanical resurfacing procedures serve as effective treatments for a multitude of pigmentary, textural, and photodamage-related concerns. A vast variety of procedures exist, each targeting a specific depth of wounding and repair and each with its own inherent risks and benefits. It is prudent for the physician to have a broad knowledge base regarding these procedures so as to ensure treatment success and safeguard against untoward complications. Likewise, the proper selection of patients and choice of procedure are critical. With appropriate usage, resurfacing procedures can be a gratifying part of dermatologic practice.

REFERENCES

1. Brody HJ, Monheit GD, Resnik SS, et al. A history of chemical peeling. *Dermatol Surg.* 2000;26:405-409.
2. Salam A, Dadzie OE, Galadari H. Chemical peeling in ethnic skin: an update. *Br J Dermatol.* 2013;169:82-90.
3. Monheit GD. Chemical peels. *Skin Therapy Lett.* 2004;9(2):6-11.
4. Berson DS, Cohen JL, Rendon MI, et al. Clinical role and application of superficial chemical peels in today's practice. *J Drugs Dermatol.* 2009;8(9):803-811.
5. Brody HJ. Complications of chemical resurfacing. *Dermatol Clin.* 2001;19(3):427-438.
6. Coleman WP III, Brody HJ. Advances in chemical peeling. *Dermatol Clin.* 1997;15(1):19-26.
7. Brody HJ. Trichloroacetic acid application in chemical peeling. *Oper Tech Plast Reconstr Surg*. 1995;2(2): 127-128. https://www.sciencedirect.com/science/article/pii/S1071094905800071
8. Nelson BR, Fader DJ, Gillard M, et al. Pilot histologic and ultrastructural study of the effects of medium-depth chemical facial peels on dermal collagen in patients with actinically damaged skin. *J Am Acad Dermatol.* 1995;32(3):472-478.
9. Monheit GD. The Jessner's + TCA peel: a medium-depth chemical peel. *J Dermatol Surg Oncol.* 1989;15(9): 945-950.
10. Grimes PE. The safety and efficacy of salicylic acid peels in darker racial-ethnic groups. *Dermatol Surg.* 1999;25(1):18-22.
11. Ditre CM, Griffin TD, Murphy GF, et al. Effects of α-hydroxy acids on photoaged skin: a pilot clinical, histological, and ultrastructural study. *J Am Acad Dermatol.* 1996;34:187-195.
12. Butler PE, Gonzalez S, Randolph MA, et al. Quantitative and qualitative effects of chemical peeling on photoaged skin: an experimental study. *Plast Reconstr Surg.* 2001;107:222-228.
13. Grimes PE. The safety and efficacy of salicylic acid chemical peels in darker racial-ethnic groups. *Dermatol Surg.* 1999;25:18.
14. Abdel Meguid AM, Elaziz Ahmed Attallah DA, Omar H. Trichloroacetic acid versus salicylic acid in the treatment of acne vulgaris in dark-skinned patients. *Dermatol Surg.* 2015;41:1398-1404.
15. Kubiak M, Mucha P, Debowska R, et al. Evaluation of 70% glycolic peels versus 15% trichloroacetic peels for the treatment of photodamaged facial skin in aging women. *Dermatol Surg.* 2014;40:883-891.
16. Alt TH. Occluded Baker-Gordon chemical peel: review and update. *J Dermatol Surg Oncol.* 1989;15(9):980-993.
17. Landau M. Cardiac complications in deep chemical peels. *Dermatol Surg.* 2007;33:190-193.
18. Lee JB, Chung WG, Kwahck H, et al. Focal treatment of acne scars with trichloroacetic acid: chemical reconstruction of skin scars method. *Dermatol Surg.* 2002:28:1017-1021.
19. Agarwal N, Gupta LK, Khare AK, et al. Therapeutic response of 70% trichloroacetic acid CROSS in atrophic acne scars. *Dermatol Surg.* 2015;41:597-604.
20. Maloney BP, Millman B, Monheit G, et al. The etiology of prolonged erythema after chemical peel. *Dermatol Surg.* 1998;24:337-341.
21. Tsai R, Wang C, Chan H. Aluminum oxide crystal microdermabrasion: a new technique for treating facial scarring. *Dermatol Surg.* 1995;21:539-542.
22. Bhalla M, Thami GP. Microdermabrasion: reappraisal and brief review of literature. *Dermatol Surg.* 2006;32: 809-814.
23. Shim EK, Barnette D, Hughes K, et al. Microdermabrasion: a clinical and histopathologic study. *Dermatol Surg.* 2001;27:524-530.
24. Freedman BM, Rueda-Pedraza E, Waddell SP. The epidermal and dermal changes associated with microdermabrasion. *Dermatol Surg.* 2001;27:1031-1034.
25. Kim EK, Hovsepian RV, Mathew P, et al. Dermabrasion. *Clin Plast Surg.* 2011;38:391-395.
26. Poulos E, Taylor C, Solish N. Effectiveness of dermasanding (manual dermabrasion) on the appearance of surgical scars: a prospective, randomized, blinded study. *J Am Acad Dermatol.* 2003;48:897-900.
27. Benedetto AV, Griffin TD, Benedetto EA, et al. Dermabrasion: therapy and prophylaxis of the photoaged face. *J Am Acad Dermatol.* 1992;27(3):439-447.
28. Nelson BR, Metz RD, Majmudar G, et al. A comparison of wire brush and diamond fraise superficial dermabrasion for photoaged skin. *J Am Acad Dermatol.* 1996;34(2):235-243.

Chapter 214 :: Liposuction Using Tumescent Local Anesthesia

:: C. William Hanke, Cheryl J. Gustafson, William G. Stebbins, & Aimee L. Leonard

AT-A-GLANCE

- Liposuction is one of the most commonly performed cosmetic procedures practiced by dermatologic surgeons.
- The tumescent technique of local anesthesia is one of the most important innovations in liposuction surgery.[1]
- Liposuction performed with tumescent local anesthesia allows for the removal of large volumes of fat safely and effectively.
- Liposuction is characterized by unparalleled safety, rapid patient recovery, and low postoperative morbidity.
- Importantly, liposuction is very safe to perform in the office setting, the preferred venue for the procedure when carried out by dermatologic surgeons.

PATIENT SELECTION

Liposuction should be regarded not as a method of weight reduction or an alternative to diet and exercise, but as a body-contouring procedure. The ideal candidate is a healthy patient near his or her ideal body weight who has disproportionate, localized adipose deposits resistant to diet and exercise. Liposuction should be avoided in patients with unrealistic treatment goals and those with emotional or psychological instability (ie, presence of an eating disorder or body dysmorphic disorder). A comprehensive preoperative consultation that includes a screening questionnaire is used to identify patients who are appropriate candidates. During the consultation, the risks, goals, anticipated results, and expected postoperative course are discussed.

PREOPERATIVE EVALUATION

Table 214-1 outlines preoperative preparation. Taking a thorough medical history will screen for patients who may be poor surgical candidates for liposuction (see the section "Risks and Precautions"). Patients at risk for complications should receive medical clearance before surgery.[2,3] A careful review of all medications is essential. All anticoagulant medications, including vitamins and herbal supplements, should be discontinued 2 weeks before surgery. Use of medically-necessary anticoagulant therapy is a contraindication for tumescent liposuction. Medications that are metabolized by the hepatic cytochrome P450 3A4 enzyme system should be identified. These medications may interfere with the hepatic metabolism of lidocaine, which leads to the potential for toxicity. They should be discontinued or tapered off 2 weeks before surgery if permitted by the prescribing physician. For patients who are unable to interrupt therapy, a lower maximum dose of lidocaine may be used (ie, less than 35 mg/kg).

Preoperative laboratory testing includes complete blood count with differential and platelet count, prothrombin time, partial thromboplastin time, and chemistry panel (including liver function tests); serologic testing for HIV and hepatitides B and C viruses; and, for females, a serum pregnancy test.[2] An electrocardiogram may be considered when the patient is older than the age of 60 years or when indicated based on the patient's history or a review of systems.

RISKS AND PRECAUTIONS

Table 214-2 identifies the risks of liposuction and the precautions that should be taken.

PATIENT POSITIONING

Proper patient positioning is essential for safe and effective removal of adipose tissue. Specific positioning maneuvers differ by anatomic target site and are used to avoid important anatomic structures and optimize cannula access to fatty deposits.

EQUIPMENT

Liposuction requires the following equipment (Figs. 214-1 and 214-2):

- Tumescent local anesthetic solution
- Infiltration needles and/or cannulas
- Intravenous or peristaltic pump tubing
- Infiltration pump
- Liposuction cannulas (manual and/or powered)
- Aspiration tubing
- Aspiration pump with aspirate receptacles
- Monitoring device and emergency equipment

TABLE 214-1
Preoperative Preparation

- Drug intake review:
  - Discontinue all anticoagulant medications and nonprescription supplements that may augment bleeding (at least 2 weeks prior to procedure)
  - Discontinue all medications that may interfere with lidocaine metabolism (drugs metabolized through cytochrome P450 3A4) at least 2 weeks prior to procedure
- Preoperative laboratory testing:
  - Complete blood count with differential and platelet count
  - Prothrombin time
  - Partial thromboplastin time
  - Chemistry panel with liver function tests
  - Serologic testing for HIV, hepatitides B and C
  - Serum pregnancy test for females
  - Electrocardiogram if >60 years of age, or otherwise indicated

ANESTHESIA

Lidocaine is the preferred anesthetic for tumescent liposuction.[2] The maximum dose reported to be safe is 55 mg/kg.[4] Normal saline (0.9% sodium chloride) is typically used as a vehicle. Sodium bicarbonate is used to buffer the solution, and epinephrine is added to augment hemostasis and slow the absorption of lidocaine. Table 214-3 outlines the compositions of tumescent lidocaine solutions of 0.05%, 0.075%, and 0.1%. Using the highest concentration liposuction solution (0.1% lidocaine) provides better analgesia and is useful in treating small or sensitive areas. In comparison, the lower concentrations (0.075% and 0.05% lidocaine) provide adequate anesthesia and are used when treating large or multiple areas. Accurate recordkeeping of tumescent anesthetic solution preparation and administration is critical to avoid lidocaine toxicity.

TABLE 214-2
Risks and Precautions for Liposuction

- Contraindications to liposuction
  - Severe cardiovascular disease
  - Severe coagulation disorders, including hemophilia
  - Pregnancy
- Conditions that put patients at risk for complications
  - History of bleeding diathesis, thrombophlebitis, or emboli (fat or thrombotic)
  - History of infectious disease (including hepatitis and HIV infection)
  - Poor wound healing
  - Diabetes mellitus
  - Immunosuppression
  - Prior extensive abdominal surgery
  - Hepatic disease
  - Renal disease
  - Morbid obesity
  - Underlying systemic disease with functional limitations
  - Use of anticoagulant medications, vitamins, or herbal supplements
  - Use of medications metabolized by cytochrome P450 3A4 enzyme system

Figure 214-1 A selection of liposuction cannulas, including hand cannulas (*left*) and powered cannulas (*right*). (Used with permission from C. William Hanke, MD.)

TECHNIQUE

With the patient standing, the target areas for treatment as well as entry sites for cannula insertion are outlined with a permanent marker. The patient is brought to the procedure table and undergoes sterile preparation. Entry sites are anesthetized locally using 1% lidocaine with 1:100,000 epinephrine. These sites are then incised with a No. 11 blade. A blunt-tipped infiltration cannula or 21-gauge needle is inserted, and tumescent anesthesia fluid is delivered to the subcutaneous space. Rates of infiltration and amounts of fluid delivered vary depending on target area and patient tolerance.

Liposuction aspiration cannulas vary in diameter, tip style, and tip configuration. One innovation is powered liposuction using a motorized cannula. In general, larger cannulas with tapered tips and multiple distal

Figure 214-2 Liposuction equipment including (*from top to bottom*) tumescent anesthetic solution, infiltration pump and tubing, aspirate receptacles, and aspiration pump. (Used with permission from C. William Hanke, MD.)

TABLE 214-3
Tumescent Liposuction Solutions

	0.1%	0.075%	0.05%
Sodium chloride 0.9%	1000 mL	1000 mL	1000 mL
Lidocaine 1%	100 mL	75 mL	50 mL
Epinephrine 1:1000	1 mL	1 mL	1 mL
Sodium bicarbonate 8.4%	10 mL	10 mL	10 mL

apertures allow easier fat removal but also increase tissue injury. The choice of cannula depends on anatomic site as well as surgeon preference and experience. The cannula is inserted into entry sites with the tip apertures facing downward, away from the dermis. Tunneling with the cannula is performed in linear, even strokes with the surgeon's dominant hand; the nondominant hand, or "smart hand," controls the cannula tip position at all times. The majority of suctioning should be aimed parallel to the axis of lymphatic drainage to minimize tissue trauma. Uneven or overly aggressive suctioning can lead to contour irregularities and should be avoided. End points can be measured as the time spent in a given area, the amount of fat suctioned, patient discomfort, and assessment of the target area by palpation. The transition from yellow adipocyte-rich aspirate into fat-sparse serosanguineous tumescent fluid is an additional end point. Comparative suctioned aspirate volumes and vital signs are also recorded throughout the procedure.

OUTCOMES ASSESSMENT

Several studies support the excellent safety profile and high rates of patient satisfaction observed with tumescent liposuction. A 1995 survey of dermatologic surgeons who performed tumescent liposuction on 15,336 patients found no fatalities or serious complications. There were no adverse events that necessitated hospitalization.[5] In 2002, Housman and colleagues reported a serious adverse event rate of 0.68 per 1000 cases in a survey of 267 dermatologic surgeons who performed 66,570 liposuction procedures; no deaths were reported.[6] In a prospective study involving 688 liposuction patients, Hanke and colleagues found a major complication rate of only 0.14% and a minor complication rate of 0.57%. Eighty-four percent of patients reported high levels of satisfaction with the procedure (Figs. 214-3 and 214-4).[7]

COMPLICATIONS

The majority of medical and surgical complications from tumescent liposuction, such as bleeding, hematoma, infection, and lidocaine toxicity, can be avoided by comprehensive perioperative patient evaluation and adherence to published guidelines of care. Aesthetic complications, such as surface irregularities, persistent edema, and suboptimal target area fat reduction, can be minimized by proper patient selection, patient education, and good technique. Dermatologic surgeons performing liposuction should be knowledgeable about the prevention and management of all potential intraoperative and postoperative complications.

Figure 214-3 Liposuction of the neck, preoperative. (Used with permission from C. William Hanke, MD.)

PATIENT INSTRUCTIONS

Anticipated sequelae of tumescent liposuction include copious drainage from cannula entry sites, ecchymoses, edema, soreness, postural dizziness, and temporary dysesthesia. Proper education and instructions regarding diet, activity, and use of compression garments prepare the patient for the postoperative period. The patient must be discharged to the care of a family member or friend. The patient is encouraged to ambulate and avoid immobilization. Heavy exercise and hot baths and showers should be avoided.

MONITORING AND FOLLOWUP

A series of followup visits is scheduled to assist the patient through the immediate postoperative period and to assess the long-term surgical outcome. Postoperative healing from liposuction is characterized by a protracted period of edema resolution followed by subsequent skin contracture, which leads to a delayed

Figure 214-4 Liposuction of the neck, postoperative. (Used with permission from C. William Hanke, MD.)

final treatment result. Taking preoperative and postoperative photographs and weight measurements is essential to address patient concerns and assess treatment response. Patients are encouraged to wait at least 6 months before judging the final cosmetic result. The performance of touchup procedures in a treated area should be deferred for at least 1 year.

OTHER USES

In addition to being an aesthetic procedure, tumescent local anesthesia is being used for symptomatic breast reduction and lipedema.

Excess, heavy breast tissue can have a significant impact on various aspects of one's quality of life. From a physical perspective, women with heavy, large breasts often experience chronic neck, back, and/or shoulder pain, as well as discomfort from bra straps. Also, the bulky breast tissue can impair one's physical mobility. For instance, many women with bulky breasts report difficulty exercising because of the weight and volume of their breast tissue. Additionally, the enlarged breast size can make it challenging to find appropriate-fitting athletic gear. As a result, their desire and ability to exercise regularly are often reduced, which not only impacts their physical well-being, but also their emotional and psychological well-being.

Likewise, women with large breasts often have difficulty finding clothing that properly fits as their chest circumference may be outof proportion to other body measurements. As a result, these women often wear larger clothing sizes to compensate for the enlarged breast tissue. Hence, these patients may report self-consciousness, embarrassment, and/or depressive symptoms related to their heavy, enlarged breast tissue. Therefore, it is important for health care providers to be aware of the impact that enlarged, heavy breasts can have on the patient's quality of life, including physical, emotional, and psychological.

Excision is one of the most common methods of breast reduction. Usually this procedure is done under general anesthesia. Common complications from excision include postoperative pain, scarring, necrosis of the nipple–areolar complex, and prolonged healing. Habbema and colleagues evaluated the use of liposuction with tumescent local anesthesia for breast reduction in 151 women. The average volume reduction was 415 mL per breast (41% of the preoperative volume). In addition to reducing breast volume, tumescent liposuction significantly reduced breast ptosis. Prior to liposuction, the average preoperative value of breast sagging was 6.5 cm. At 6 weeks postliposuction, the average value for ptosis was 3.6 cm.[8]

Of the 151 patients, all but 1 (0.7%) were mostly (21.8%) or very (77.5%) satisfied with the results of tumescent liposuction. None of the patients requested or required a secondary "touchup" procedure. Breast reduction had a significant impact on patients' quality of life, as many experienced improvement or complete resolution of chronic shoulder, neck, or back pain. Additionally, patients reported fewer physical restrictions when exercising. Many of the women also reported the ability to wear more attractive, well-fitting clothing. Overall, most patients experienced improvement in their self-confidence following the procedure. In conclusion, Habbema and colleagues found tumescent liposuction to be an effective, safe, and minimally invasive procedure for breast reduction in women.

Men with enlarged breasts from excess fat (pseudogynecomastia) and/or hypertrophic ductal and stromal tissue (gynecomastia) are good candidates for tumescent liposuction. In a published study, 38 male patients (ages 23 to 64 years) with enlarged breast tissue underwent liposuction using tumescent local anesthesia.[9] A single entry site was made in each axillary fossa to allow insertion of the microcannula. In addition to removing undesired excess adipose tissue, excess ductal and stromal tissue were effectively removed using this minimally-invasive procedure. There were no early postoperative complications, such as infection, hematoma, or seroma. From an aesthetic perspective, there were no treatment-induced asymmetries or contour deformities. Additionally, patients were very satisfied with the final outcome as none required open excision or skin-reduction procedures. Overall, tumescent liposuction was found to be a safe and effective procedure for gynecomastia.

Lipedema is a chronic, painful disorder of subcutaneous adipose tissue and lymphatics. It clinically manifests as symmetrical fatty swelling of the bilateral waist, hips, and legs (Fig. 214-5). Unlike the "normal" fatty

Figure 214-5 Female patient with significant lipedema. Note the significant bilateral fatty swelling of the lower extremities that ends at the level of the ankles. (Used with permission from C. William Hanke, MD.)

tissue of obesity, the adipose tissue in lipedema cannot be reduced with diet and exercise; consequently, liposuction using tumescent local anesthesia is being used in the management of lipedema. In a German study by Rapprich and colleagues, 25 lipedema patients underwent tumescent liposuction of the lower extremities. The average reduction in leg volume was 6.9%. Leg pain was significantly reduced from an average score of 7.2 preprocedure to 2.1 postprocedure. Patients also reported a significant improvement in quality of life (8.7 to 3.6).[10]

REFERENCES

1. Klein JA. The tumescent technique for liposuction surgery. *Am J Cosmet Surg*. 1987;4:263. Available at http://journals.sagepub.com/doi/10.1177/074880688700400403.
2. Hanke CW, Sattler G. *Liposuction*. Philadelphia, PA: Elsevier; 2005.
3. Svedman KJ, Coldiron B, Coleman WP 3rd, et al. ASDS guidelines of care for tumescent liposuction. *Dermatol Surg*. 2006;32(5):709-716.
4. Ostad A, Kageyama N, Moy RL. Tumescent anesthesia with a lidocaine dose of 55 mg/kg is safe for liposuction. *Dermatol Surg*. 1996;22(11):921-927.
5. Hanke CW, Bernstein G, Bullock S. Safety of tumescent liposuction in 15,336 patients. National survey results. *Dermatol Surg*. 1995;21(5):459-462.
6. Housman TS, Lawrence N, Mellen BG, et al. The safety of liposuction: results of a national survey. *Dermatol Surg*. 2002;28(11):971-978.
7. Hanke CW, Cox SE, Kuznets N, et al. Tumescent liposuction report performance measurement initiative: national survey results. *Dermatol Surg*. 2004;30(7):967-977.
8. Habbema L. Breast reduction using liposuction with tumescent local anesthesia and powered cannulas. *Dermatol Surg*. 2009;35(1):41-50; discussion 50-52.
9. Boni R. Tumescent power liposuction in the treatment of the enlarged male breast. *Dermatology*. 2006;213(2):140-143.
10. Rapprich S, Dingler A, Podda M. Liposuction is an effective treatment for lipedema—results of a study with 25 patients. *J Dtsch Dematol Ges*. 2011;9(1):33-40.

Chapter 215 :: Soft-Tissue Augmentation

:: Lisa M. Donofrio & Dana L. Ellis

AT-A-GLANCE

- Soft-tissue fillers are used for multiple cosmetic and therapeutic indications.
- A wide variety of injectable soft-tissue fillers are available for clinical use, including biodegradable products such as hyaluronic acid, collagen, calcium hydroxylapatite, and poly-L-lactic acid; products that remain indefinitely in tissue, such as polymethylmethacrylate microspheres, hydrogel polymers, and silicone; and viable autologous fat.
- Adequate clinician training in the use of these agents is essential for the prevention of adverse events.

As we age, lines, grooves, and creases become more apparent. Superficial rhytides are largely caused by solar damage, characterized by the loss of collagen at the epidermal–dermal junction and an increased elastosis in the reticular dermis. Repetitive facial movement over the years produces pronounced rhytides in the most active areas of the face, such as the forehead, glabella, periorbital and perioral areas, and nasolabial folds. Rhytides tend to appear deeper in the nasolabial and melolabial creases with the compounding feature of soft-tissue atrophy.[1]

Facial rejuvenation comes in many forms; its primary stake being replacement of soft-tissue volume by an assortment of augmentation techniques. Two major categories are subcutaneous volumizers and dermal fillers. Although subcutaneous volumizers tend to provide more long-lasting results, with improvements in dermal fillers over the past several years, these products have become increasingly popular and are now widely used. When deciding which technique(s) to use in the correction of facial soft-tissue atrophy, an accurate diagnosis of the level(s) of volume loss must be made. In younger patients, dermal fillers may be adequate for treatment, while in a more advanced aging face, a combination of the two above categories may be necessary to obtain optimal results. [1]

METHOD AND TECHNIQUE

Dermal filler use began in the mid 1980s and has since become the cornerstone of facial filling in the office setting.[1] There are several dermal fillers approved for use in the United States (Table 215-1). Soft-tissue fillers (Table 215-2) are either injected through a sharp needle or blunt cannula. The level of injection into the skin and the length of the needle chosen depend on the type of filler injected, the properties of the filler, the area injected, and the desired result. Threading is a technique in which the needle is inserted into the skin and the filler is deposited in a linear fashion along the track of the needle as it is being withdrawn. Fanning is a type of threading in which, instead of inserting the needle into a new area each time, the needle is just withdrawn so that a new track can be made radially adjacent to the last. In the "push-ahead" technique, an injection is made in an anterograde direction, so that the injectable material flows from the tip of the needle and hydrodissects the tissues as it flows. This technique is often used in areas where bruising is more likely to occur along the needle track, such as the upper lid and brow. In the depot method of injection, small "pearls" of material are deposited serially, usually along a fold or deep by bone. Crosshatching is an approach used to diffusely cover an area with the injected material. In this method, linear threads are lined up in succession and a second series of rows is then layered at right angles to the first. Some of the more viscous fillers on the U.S. market are injected in a deep subcutaneous bolus through a blunt cannula or large-bore needle. Figure 215-1 illustrates the different injection techniques. Whichever technique is chosen, care should be taken in highly vascular areas to avoid intravascular injection of filling material. With each injection, the plunger of the syringe should be drawn back to check for blood flow, and if it is found, the needle should be withdrawn and repositioned.

COLLAGENS

Once considered the "gold standard" of dermal fillers, collagens (bovine, human, and porcine) are no longer available on the U.S. market.

NONABSORBABLE (PERMANENT) MATERIALS

One collagen-containing product worth mentioning is polymethylmethacrylate (PMMA microspheres). PMMA is a nonbiodegradable, biocompatible, synthetic polymer that is often used in other medical devices, such as bone cement and intraocular lenses.[1] PMMA beads are minuscule, round, smooth particles that are not absorbed by the body. When used as a soft-tissue filler, these beads are suspended in a gel-like solution that contains cow (bovine) collagen and are injected into the face. A few months after it is injected, the collagen gel breaks down and natural collagen fills

TABLE 215-1
U.S. Food and Drug Administration–Approved and Available Dermal Fillers

TRADE NAME	MATERIAL
Restylane Silk	Hyaluronic acid with lidocaine
ArteFill (no longer available)	Polymethylmethacrylate beads, collagen, lidocaine
Bellafill	Polymethylmethacrylate beads, collagen, lidocaine
Fibrel (no longer available)	Collagen
Sculptra	Poly-L-lactic acid
Sculptra Aesthetic	Poly-L-lactic acid
Restylane Injectable Gel	Hyaluronic acid
Restylane-L Injectable Gel	Hyaluronic acid with lidocaine
Restylane Lyft with Lidocaine	Hyaluronic acid with lidocaine
CosmoDerm 1 Human-Based Collagen (no longer available)	Collagen
Captique Injectable Gel	Hyaluronic acid
Prevelle Silk	Hyaluronic acid with lidocaine
Hylaform	Modified hyaluronic acid (avian source)
Belotero Balance	Hyaluronic acid
Zyplast (no longer available)	Collagen
Evolence Collagen Filler (no longer available)	Collagen
Radiesse	Hydroxylapatite
Elevess	Hyaluronic acid with lidocaine
Juvederm	Hyaluronic acid
Juvederm Voluma XC	Hyaluronic acid with lidocaine
Zyderm Collagen Implant (no longer available)	Collagen
Revanesse Versa	Hyaluronic acid
Juvederm Vollure XC	Hyaluronic acid
Juverderm Volbella XC	Hyaluronic acid with lidocaine
Restylane Refyne	Sodium hyluronate
Restylane Defyne	Sodium hyluronate

out the residual space. This dermal filler is considered semipermanent, and is most often used to treat medium-to-deep rhytides and folds, particularly the nasolabial creases. It is also used by some to fill pitted scars and to augment the lips.

HYALURONIC ACIDS

PATIENT SELECTION

Hyaluronic acid–derived fillers are a good choice for patients who desire a long period of correction or more volume enhancement. They are currently approved for augmentation of the nasolabial folds, mid cheeks, and lips, but other common areas of treatment include the labiomental crease and periorbital areas. Patients often feel that the hyaluronic acid fillers are softer and more natural in appearance than the collagens were, but they need to be warned about the risk of increased erythema, edema, and bruising associated with these products.

FORMULATIONS

Hyaluronic acid is a polysaccharide and a normal extracellular component of most mammalian tissues including the dermis. Hyaluronic acid polymers offer superb biocompatibility and provide the same structural and mechanical properties of normal subcutaneous tissue. Injectable U.S. Food and Drug Administration (FDA)-approved forms include non–animal-derived stabilized hyaluronic acid products made through a bacterial fermentation process and an avian-derived version isolated from cocks' combs. Brands of injectable hyaluronic acids differ not only in their derivation but also in their concentration of hyaluronic acid per milliliter of product, type of crosslinking or stabilizing agents, viscosity, and particle size. In its native form, hyaluronic acid has a short life span. However, crosslinking increases its longevity. As the proportion and degree of crosslinking increases, the gel becomes more and more like a solid, is more resistant to degradation by enzymes and free radicals, and as such, tends to persist longer in tissue. Injection of crosslinked hyaluronic acid into the deep dermis also has been shown to increase de novo collagen synthesis by fibroblast stretching, resulting in even longer-lasting correction.[1] Some hyaluronic acid products exist as biphasic gels containing both crosslinked and uncrosslinked particles, and some as monophasic gels containing only crosslinked particles. The biphasic non–animal-derived stabilized hyaluronic acid products are made en bloc initially and then passed through a sieve to create particles ranging in size from 10,000 per mL to 100,000 per mL with a hyaluronic acid concentration of 20 mg/mL. The smaller particle size permits injection through smaller-gauge needles into finer wrinkles and the larger particle size is best for volumetric filling. The small amount of non-crosslinked hyaluronic acid allows for smooth flow with low injection pressures. Monophasic hyaluronic acid gels are produced by varying the amount of high- and low-molecular weight hyaluronic acid, producing a hydrogenous gel. The monophasic product is available in 2 formulations, one containing 24 mg/mL of hyaluronic acid and one containing 30 mg/mL of hyaluronic acid. The crosslinking agent used in both the monophasic and biphasic products is BDDE (1,4-butanediol diglycidyl ether). The avian-derived hyaluronic acid, contains 6 mg/mL of hyaluronic acid highly crosslinked with divinyl sulfide. The hydrophilic nature of hyaluronic acid allows it to create larger volumes relative to its mass. This property makes hyaluronic acid fillers especially useful for soft-tissue augmentation. The hyaluronic acid fillers

TABLE 215-2
Clinical Features of Soft-Tissue Fillers

FILLER	USES	TYPE	PLACEMENT	COMPLICATIONS	LONGEVITY
Hyaluronic acid	Treatment of medium-to-deep folds, lips, acne scars, periorbital hollows, facial contouring	Non–animal-derived stabilized hyaluronic acid	Mid-to-deep dermis or superficial subcutis	Allergic reaction or inflammation, blue discoloration, misplacement, lumps	6 to 12 months
Calcium hydroxylapatite	Treatment of deep folds, nipple reconstruction, nasal reconstruction, jawline, malar augmentation	Calcium hydroxylapatite	Deep dermis to superficial subcutis	Nodules (especially in lips and periorbitally), misplacement with demarcation of product	6 to 18 months
Poly-L-lactic acid	Treatment of HIV lipoatrophy, nasolabial fold, cheek, and temple hollows	Poly-L-lactic acid	Superficial subcutis	Visible and palpable papules	2 years or longer
Autologous fat	Pan-facial filling, especially periorbital area	Autologous fat	Subcutaneous tissue	Bumps, vascular occlusive events with injudicious placement	5 years or longer
Silicone	Treatment of scars, HIV lipoatrophy, lips, deep folds	Silicone oil	Deep dermis	Delayed granuloma formation, migration	—

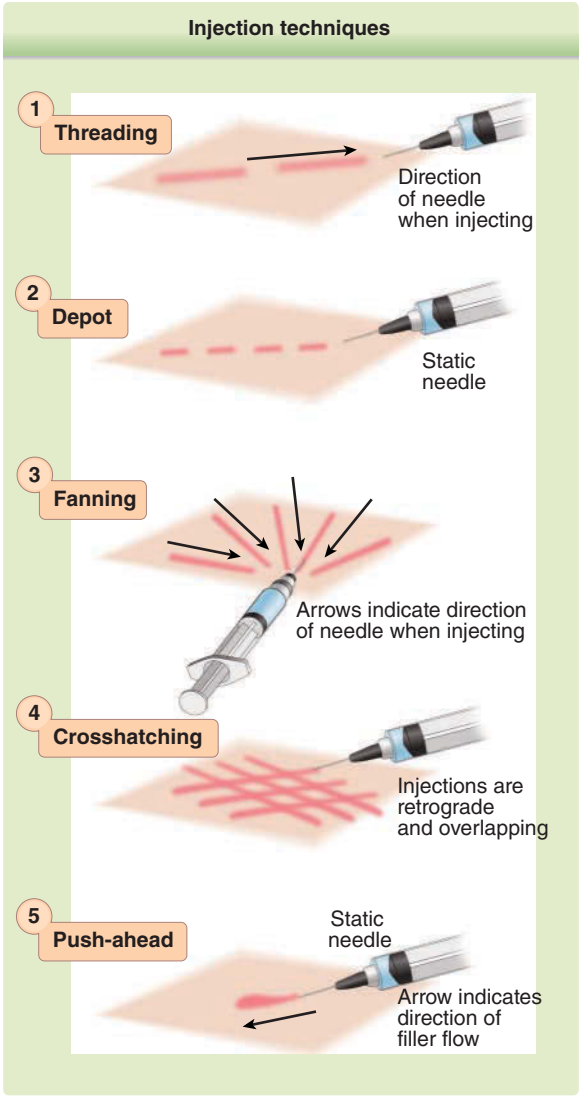

Figure 215-1 Injection techniques.

have an excellent tolerability profile and can be used without the need for skin testing.[1]

ANESTHESIA

As a consequence of their high viscosity, hyaluronic acid products can cause significant discomfort on injection so most hyaluronic acids on the market are combined with lidocaine. As such, it is often beneficial to inject antegrade (in addition to retrograde), as placement of the lidocaine-containing product ahead of the needle tip, can help decrease the associated pain. Topical anesthetic also can be applied before injection. This usually results in adequate anesthesia for periorbital, nasolabial fold, and labiomental crease injections; however, if lips or perioral rhytides are being treated, an ancillary local infiltration of 1% lidocaine or segmental nerve block may be indicated.

TECHNIQUE

Hyaluronic acids should be injected with the patient in a position that elicits the defect or creases to be treated and offers ease of injection to the operator. This is best accomplished by reclining the patient to a 45-degree angle. All the hyaluronic acid products come with a needle in the gauge of choice for ease of injection and preservation of the physical properties of the gel. However, because of their viscoelastic properties, the hyaluronic acids can often be injected through needles tailored to the area or level of injection. For instance, a 32-gauge needle allows for more precise injection of vertical lip rhytides and a 1.5-inch needle may facilitate injection into distal sites. Hyaluronic acids are injected in most areas via threading, depot, or fanning. They

Figure 215-2 Thirty-five-year-old woman before (**A**) and after (**B**) infiltration of Restylane into the nasolabial folds.

are particularly amenable to crosshatching in areas where a greater density of augmentation is desired. In particular, when hyaluronic acid is injected into the nasolabial fold it is important to span the width of the fold with a serial threading technique and then crosshatch at right angles. This gives structural integrity to the fold and prevents the undesirable result of merely moving the fold medially (Fig. 215-2). In addition, it is often necessary to "suspend" the fold by augmenting the cheek. This is usually done with a deep bolus injection of a high density hyaluronic acid. The labiomental crease can be injected similarly to the nasolabial fold, again blending the product so as not to move the fold medially. Lip injections are made using a depot or threading technique, either along the vermilion border, in the body of the lip, or in a combination of both. Perhaps one of the most exciting off-label applications of hyaluronic acids is the correction of tear trough deformity or suborbital hollows. Injections are made either under the orbicularis oculi muscle near the orbital bone or subdermally above the muscle. Intramuscular injections are to be avoided as the movement in this area increases the risk of lumping of the product. A depot method of injection in which very small amounts of hyaluronic acid are deposited on each pass is preferred, but threading also can be helpful to ensure even blending into neighboring areas. The push-ahead technique is preferred for the sub-brow area. After injection, the periorbital area should be vigorously massaged to disperse the product and minimize aggregation of gel particles. Although periorbital injection of hyaluronic acid results in high levels of patient satisfaction, it is an advanced injection method best left to those with the greatest injecting experience.

POSTPROCEDURE INSTRUCTIONS

The application of ice immediately after the procedure and periodically throughout the day is recommended after the injection of hyaluronic acid. Patients are instructed to avoid manipulation of the treated area and extremes of temperature for the first 48 hours after injection. If the lips were treated in a patient with a history of cold sores, then an antiviral medication should be administered prophylactically on the day of the procedure. Patients are instructed to return to the office if they experience any problem such as redness, purulence, or nodule formation.

UNIQUE COMPLICATIONS

Common side effects of dermal fillers include bleeding or bruising during and following the procedure. Patients should expect some degree of pain during injections. As recommended above, the application of ice to the injection sites can decrease these symptoms. Most additional complications result from improper application of the product. Placement of this clear gel too superficially results in a blue discoloration, known as the Tyndall effect. This occurs as superficial injection allows for more water binding in the dermis, which selectively reflects the blue wavelength of light, making it appear darker than the surrounding skin. Placement of too large an aliquot can result in a noninflammatory bump. Most ill-placed hyaluronic acid can be removed by incising with a 20-gauge needle and expressing the material. An important characteristic of the hyaluronic acid products is their ability to break down with the use of an enzyme known as hyaluronidase. This enzyme breaks the crosslinks by hydrolysis of the glucosamine and glucuronic acid moiety. A few hyaluronidase products are commercially available in the United States in 200 units/mL and 150 units/mL vials. Approximately 15 to 20 units of hyaluronidase can be injected directly into a pea-sized volume of hyaluronic acid, leading to its degradation within minutes to hours.

Hyaluronic acid products also contain small amounts of impurities that can cause hypersensitivity reactions; true allergic reactions, however, are exceedingly rare. Patients can react to sterile bacterial proteins or avian

proteins by forming sterile abscesses or granulomatous inflammatory nodules. It has been shown that these nodules, which appear clinically to be granulomas, may in fact be small foci of infection. Treatment with an antistaphylococcal antibiotic is the initial treatment of choice. If no resolution occurs, dilute intralesional corticosteroids can be administered, or hyaluronidase can be injected to cause rapid dissolution of the product.[2] It is also important to be aware that excess water absorption by many of the hyaluronic acid fillers can cause immediate swelling that will often decrease over days.

LONGEVITY

In general, the longevity of augmentation is greater for the more highly crosslinked or stabilized forms and is also directly proportional to filler viscosity and particle size. Naturally occurring hyaluronic acid is metabolized by lymphatic clearance and is eventually degraded in the liver to carbon dioxide and water. Hyaluronic acid–based products are broken down via isovolemic degradation; they maintain a constant volume throughout their degradation because of their ability to bind water. This property makes possible a very long-lasting product.

BIODEGRADABLE MICROPARTICLE INJECTABLE IMPLANTS

POLY-L-LACTIC ACID

PATIENT SELECTION

Poly-L-lactic acid (PLLA) was approved by the FDA in 2004 for correction of HIV-related facial atrophy and is also approved for the cosmetic correction of shallow-to-deep contour deficiencies. Currently in the United States, PLLA is well known as a no-downtime, long-lasting filler with a wide range of applications. PLLA's uniqueness lies in the fact that it is not a direct filling agent but rather a biostimulatory agent, eliciting tissue thickening over the course of many months and many treatment sessions. It is, therefore, the ideal filler for someone desiring a gradual, subtle change. Because PLLA works by initiating a foreign-body tissue response, it is not suited for patients taking immunosuppressive or antiinflammatory drugs, and it appears to work most efficiently in younger patients with robust immune responses. PLLA can be used for volume enhancement in the nasolabial fold, labiomental crease, chin, jawline, buccal hollows, and temples. Some practitioners have found it efficacious for filling for the dorsum of aging hands, however there is a moderate risk of nodule formation in this area. It is not recommended for use in the lips and should be used with care in the periorbital area.

FORMULATION

PLLA is supplied as a vial (367.5 mg) of freeze-dried powder of synthetic L-polymer of polylactic acid (from the α-hydroxy acid family), sodium carboxymethylcellulose, and mannitol. Injection of PLLA on repeated occasions presumably initiates an immune response that eventually leads to fibroblast activation and collagen deposition. High-level ultrasonographic images taken before and after a series of treatments in study patients confirms the presence of a zone of dermal thickening, but the exact mechanism is unknown.

ANESTHESIA

PLLA must be reconstituted at least 2 hours in advance of use; however, current standard of care is reconstitution at least 8 hours before treatment to fully suspend and hydrate the microparticles of PLLA. The package insert recommends reconstitution with 3 to 5 mL of sterile water, but the consensus of physicians currently using the product is to reconstitute with a minimum of 5 mL of diluent. It is possible to reconstitute the product in advance with 4 mL or more of sterile water and immediately before injection to add 1 mL of 1% lidocaine to the bottle. This tempers the pain on injection. In addition, patients may want to apply a topical anesthetic containing either 4% lidocaine or 20% tetracaine in advance of treatment.

TECHNIQUE

Because of the diffuse panfacial nature of PLLA injections, it is helpful to inject the patient in a supine position. PLLA is injected through a 25- to 26-gauge needle. Because of the risk of particle clumping, the bottle must be agitated frequently throughout the course of treatment. The operator must maintain maximum control over injection amounts, so drawing the material up into 1-mL syringes is highly recommended. The injection technique used when infiltrating PLLA is diffuse crosshatching and threading. Depot deposition of product is not recommended. The principle is to inject PLLA into areas that will eventually display a direct impact from local volume change or affect neighboring areas by filling and suspending tissues upstream. Lower-face injections are performed diffusely over a wide surface area and involve the placement of 0.1-mL linear threads of solution 2 mm apart. The recommended technique is to inject across folds to distend them, rather than filling them directly. No attempt at volumetric correction is made during treatment; rather, the intent is to place the PLLA solution diffusely. The level of injection in the lower face (cheek, nasolabial fold, jawline, labiomental crease, chin) is subdermal (Fig. 215-3). In the upper face (temples and periorbital area) treatment is via diffuse threading of 0.05 mL of PLLA solution under or close to periosteum. No more than 0.5 mL total should be distributed in this fashion. If clogging of the needle occurs, it should be withdrawn and either changed or cleared before proceeding. Many practitioners have found that

Figure 215-3 Thirty-nine-year-old woman before (**A**) and 4 months after (**B**) the last of 2 Sculptra treatments to the lower face.

the use of long needles (1.5 inches) better facilitates even dispersion of the product.

POSTPROCEDURE INSTRUCTIONS

Immediately after injection, treated areas must be vigorously massaged to distribute the suspension evenly into the tissues. No blebs of material should be palpable. When the practitioner is satisfied that this is the case, the massage may then be continued in a gentler manner by an assistant for the next 5 minutes. Ice is then applied to the face for 20 minutes. The patient may then apply makeup and resume normal activities. The patient should massage the areas of injection for 5 minutes, 5 times a day for 5 days. Because minimal augmentation is achieved in each session, patients are instructed to return at 6-week intervals for additional treatments. The motto "treat, wait, assess" is an important one to follow when using PLLA. Resultant augmentation can take 4 months or longer to occur, so patience is necessary to avoid overcorrection. For the average patient with cosmetic concerns, between 3 and 6 treatments will be required for ample augmentation to occur. For patients with severe lipoatrophy, a minimum of 6 sessions will be required, often with injection of 2 vials per session.

UNIQUE COMPLICATIONS

Superficial injection of PLLA most often results in visible papule formation.

Reconstitution with inadequate amounts of fluid may also increase this risk. Delayed formation of subcutaneous papules has been reported in the literature. These papules although palpable are most often nonvisible, asymptomatic, and noninflammatory, and require no treatment. If they are of concern to the patient, an attempt can be made to break apart the papules by injecting sterile water into them or by teasing them apart with a 27-gauge needle. Results of an 8-year injectable filler safety study found evidence to support a decreased risk of nodules with increasing dilutions.[3] Rarely, large visible nodules can be seen as a late-onset side effect. Intralesional cortisone may be of help since they are often inflammatory or granulomatous in nature. Surgical removal is also an option for large unresponsive or deforming nodules.

LONGEVITY

The results from PLLA infiltration are thought to last 2 years or longer, with gradual resorption and breakdown of the product to lactic acid over the course of 2 to 3 years.

CALCIUM HYDROXYLAPATITE

PATIENT SELECTION

Patients requiring augmentation of the nasolabial folds, labiomental crease, mandibular ramus, cheeks, or prejowl sulcus, or those with age-related atrophy of the dorsal hands are candidates for treatment with calcium hydroxylapatite (CaHA). CaHA also has been used with success in the correction of atrophic acne scars, in the recontouring of nasal defects, and in nipple reconstruction after failed nipple areolar reconstruction. Because of the risk of nodule formation, CaHA is not recommended for lip augmentation and should be used judiciously in the periorbital area.

FORMULATION

Originally approved for use by the FDA as a radiographic marker and for the correction of oral and

maxillofacial defects and the treatment of vocal cord insufficiency, CaHA has since gained approval for treatment of the nasolabial folds and dorsal hands. All other areas mentioned above are common off-label uses. The microspheres of CaHA, once injected into the deep dermis, form a scaffold to support the growth of autologous collagen so there is overlap with this product as not only a temporary filler, but also as a biostimulatory agent. CaHA contains smooth spheres of 30% CaHA between 25 and 45 microns and 70% carboxymethylcellulose gel suspension, which serves to hold the microspheres in place until it is resorbed and neocollagenesis takes place.[1] CaHA contains no animal or human tissues, so allergy testing is not indicated. This filler is unique in that the standard syringe volume is 1.5 mL of material, making it the largest packaged syringe by volume.[1]

ANESTHESIA AND TECHNIQUE

Injection of CaHA is quite uncomfortable, so it is almost always necessary to anesthetize the area first with 1% lidocaine. For facial injections, a current popular practice is to mix 0.2 mL of 1% lidocaine with the CaHA via a female–female adapter. This not only provides adequate anesthesia, but also thins the product to allow for smoother injection. Because of its viscosity, CaHA must be injected through a 27- to 28-gauge needle. Placing the patient supine or at 45 degrees, a threading technique is used, with infiltration staying at the dermal–subcutaneous junction in the area of the nasolabial fold and at the deep fat or supraperiosteal region in the areas of the cheek and mandible. CaHA appears to work best if patients undergo retreatment or touchup at 3 months. For injections to the dorsal hands, the patient should be placed in a comfortable position with the hands faced prone on a flat surface. The FDA approved method of injecting CaHA in the hands, involves using 1.3 mL of the CaHA-injectable implant mixed with 0.2 mL of 2% lidocaine HCl. Using a 27-gauge needle, several 0.2- to 0.5-mL aliquots are injected subdermally in the space bound laterally between the first and fifth metacarpals, proximally by the dorsal wrist crease, and distally by the metacarpophalangeal joints. This is followed by gentle massaging of the injected areas to blend the product evenly across the dorsal hand. The number of injection points is left to the discretion of the treating physician, based on the amount of correction needed. No more than 3 mL of the CaHA implant is to be injected per hand. Some clinicians prefer to use cannulas for CaHA injection in the dorsal hands using either a bolus or threading technique.

POSTPROCEDURE INSTRUCTIONS

There can be marked swelling and bruising after the injection of CaHA, so posttreatment icing is recommended. Many physicians advocate immediate postinjection massage but others believe that continued massage is unwarranted.

UNIQUE COMPLICATIONS

CaHA is not a mucopolysaccharide and therefore does not rely on water binding for its persisting clinical effect and it does not carry the risk of producing the Tyndall effect in the skin. However, if CaHA is injected too superficially or at appropriate levels in thin skin, its opacity can be seen. Because it contains microspheres of CaHA and collagen forms around these particles, these physical properties can lead to more palpability in the soft subcutaneous tissues. The majority of complications with CaHA (nodules) are seen in the lips, but it is possible for nodules lasting 1 to 2 years to occur anywhere the substance is injected. These nodules are supposedly noninflammatory, and often the material can be extruded from a puncture incision. Persistent nodules may have to be surgically removed. Demarcation of product is especially evident in the periorbital area, as is prolonged erythema.

LONGEVITY

In a 12-month, multicenter prospective randomized split face trial comparing CaHA to non–animal-derived stabilized hyaluronic acid in the nasolabial folds, CaHA was found to provide significantly greater correction at all time points. In practice, though, longevity appears variable, with effects lasting anywhere between 6 and 18 months.[4]

AUTOLOGOUS FAT TRANSFER

PATIENT SELECTION

Autologous fat transfer (AFT) is a practical option for patients who desire a more dramatic global change in facial appearance. Recent anatomic research suggests that facial fat is delineated in discreet fat compartments that change morphologically over time.[5] Therefore, using fat as a filler is done with the intent of restoring the youthful architecture to these fat compartments. This provides broader rejuvenation to the aging face affected by volume loss. Fat is a versatile filler, effective in the periorbital area as well as the lips. Because it is autologous, it is the filler of choice for patients with collagen vascular disease or proven allergic reactions to collagens or hyaluronic acids. AFT is a more involved surgical procedure than the injection of the other fillers previously discussed. There are a subset of patients in whom AFT is not indicated. These patients include those with very low body fat, such as long distance runners, the elderly, and those with HIV-associated lipodystrophy, patients on concomitant anticoagulant treatment, and those who are of poor health.

TECHNIQUE

PREPARATION AND ANESTHESIA

For 2 weeks before the initial AFT procedure, the patient must stop taking all nonsteroidal antiinflammatory drugs, vitamin E, ω-3 fatty acid supplements, and ginkgo, ginger, or ginseng supplements. The patient is instructed to begin therapy with an appropriate antistaphylococcal antibiotic starting the day before the procedure. On the day of the procedure, the donor fat site and the face are both washed with an antibacterial soap. The physician then delineates the area to be suctioned with a marking pen. Every attempt should be made to choose a donor site that benefits a patient aesthetically. The outer thighs and hips in women and the flanks in men are usually good sites for fat harvesting.

In preparation for fat transfer, a pattern is drawn on the face delineating the areas in which fat is to be placed and highlighting any scars or baseline asymmetry. The patient is then placed on a sterile, draped operating table and the areas requiring fat suctioning are infiltrated with dilute local anesthesia until turgid (tumescent technique; Table 215-3; see Chap. 214).

It takes at least 20 minutes for the epinephrine in the tumescent fluid to achieve hemostasis. The face is then anesthetized diffusely with dilute 0.5% lidocaine with epinephrine 1:200,000, and segmental nerve blocks are established where appropriate. For safety, the total lidocaine dose in the tumescent fluid should not exceed 35 mg/kg of body weight.

FAT HARVESTING

Suctioning of the fat used for transplantation should be done by hand with an open-tipped harvesting cannula attached to a 10-mL syringe. After a hole is made with a 1.5-mm punch or No. 11 blade, the cannula is inserted into the deep fat and moved back and forth while the plunger on the syringe is retracted. Fat collection usually occurs quite rapidly and, due to the vasoconstrictive properties of the tumescent fluid, is nearly bloodless. After fat extraction, the syringes may be placed into a centrifuge and spun at 3400 revolutions per minute for 20 seconds or left to stand for 20 minutes to allow separation of the hydrophilic tumescent fluid from the lipophilic fat. The infranate of tumescent fluid should then be decanted before the fatty layer is transferred to 1-mL syringes in preparation for injection into the face. Any supranate of ruptured fat cells (triglycerides and free fatty acids) should be discarded.

TABLE 215-3

Tumescent Anesthesia Solution

- 1 L Normal saline
- 50 mg Lidocaine
- 0.5 to 1 mg Epinephrine
- 12.5 mEq Sodium bicarbonate

FAT TRANSFER

All AFT to the face is performed with the patient fully supine using an 18-gauge or smaller blunt cannula for infiltration. Incision sites can be made with an 18-gauge needle, a NoKor needle (Becton, Dickinson and Co., USA), or the tip of a No. 11 blade scalpel. Fat is infiltrated in a retrograde manner; that is, fat is injected only as the cannula is withdrawn. Injection is in small aliquots of 0.1 mL or less using a threading or depot method. Placement of fat always starts closest to bone when possible and then proceeds up through muscle and into subcutaneous fat. Fat is deposited in a crosshatched three-dimensional lattice and thus imparts structure as well as augmentation to the tissues. All areas of the face should be addressed to achieve filling both laterally and anteriorly. The goal is to advance tissues forward and elevate them away from the bone, fill in areas of shadow, and restore youthful contours.

POSTPROCEDURE INSTRUCTIONS

Immediately after the procedure and on-and-off for the next 2 days, ice should be applied to the face. The area suctioned is dressed with absorbent pads, and a snug garment is applied. Incision sites on the body and face are left unsutured. The patient is instructed not to submerge the body in water until all incisions are healed (approximately 1 week). Antibiotics must be continued for 6 days after the initial procedure. Intramuscular triamcinolone may be given to reduce postoperative edema.

UNIQUE COMPLICATIONS

Postoperative edema and ecchymoses are common and last for approximately 2 weeks. Undercorrection with a gradual decrease in augmentation is common and usually represents a decline in edema rather than absorption of the fat. For this reason, fat transfer should never be recommended as a one-time procedure, but rather as a series of treatments with cumulative augmentation and long-term results. Small, persistent lumps can occur that represent either fat cysts or accumulation of fat. They can be treated, usually to resolution, with intralesional injection of triamcinolone (2 to 4 mg/mL). If a larger fat lump is present, the best option is to feather it into the surrounding tissues with an infiltration cannula. Irregularities can also occur at the harvest site, but operator experience and judicious removal of fat makes this a highly unlikely event. Rarely, infections, such as atypical mycobacteria, can be seen and should be in the differential diagnosis for any nodules occurring up to 1 year following AFT.

Figure 215-4 Fifty-five-year-old woman before (**A**) and 20 months after (**B**) full-face fat transfer treatment series.

LONGEVITY

Many authors using a standardized, multilevel microinjection technique have published photodocumentation of long-term followup demonstrating persistence of autologous fat (Fig. 215-4).[6] When AFT is done with proper technique, the results are permanent. Successful grafting really depends on the precise performance of four important aspects: collecting, processing, injecting and protecting.

INJECTABLE SILICONE

PATIENT SELECTION

Injectable silicone is categorically a permanent filler with a wide range of applications. It appears to provide permanent, cosmetically superior augmentation for treatment of HIV lipoatrophy, plantar defects, and scars. Historically, silicone injection has been associated with disfiguring tissue distortions and migration of product. These side effects can almost always be traced to the use of large-volume injections or non–medical-grade silicone. Because of the controversial nature of silicone augmentation, patient selection for cosmetic indications is complex, and use of the procedure should be reserved for those physicians who have extensive experience in the injection of silicone as a filler and who understand the concepts outlined in the "Technique" section.

Patients with a known history of autoimmune disease, and those with chronic or active infections should be excluded from treatment.

FORMULATION

Injectable silicone has both inspired a loyal following and provoked vehement opposition. There is no approved silicone for soft-tissue skin augmentation. However, off-label uses of ophthalmologic preparations of silicone have been adapted for use, especially in the treatment of HIV-associated lipoatrophy and other clinical conditions of facial volume loss. One formulation, PMS-350, has European approval for treatment of glabellar lines, nasolabial folds, perioral lines, lip augmentation, and scarring disorders. Silicone oil varies in chemical structure, physical properties, purity, sterility, and biocompatibility. Medical-grade silicone oil contains long polymers of dimethylsiloxanes.[7] It is noncarcinogenic and does not appear to be associated with arthritic disease in mice. Viscosity of silicone oil is measured in centistokes (cs), which is a unit of kinematic viscosity. After injection, silicone is encapsulated in collagenous fibrous tissue, so that final augmentation is a result of both volume of injected silicone and host tissue response.

ANESTHESIA

Currently available forms of silicone do not contain an anesthetic solution, because such small volumes are injected on each visit an ancillary anesthesia is not often required. If desired, a topical anesthetic agent containing 4% lidocaine or 20% tetracaine may be applied before the procedure.

TECHNIQUE

Improper technique in the injection of silicone oil will almost always guarantee permanent adverse sequelae. Consequently, it is absolutely necessary that a physician considering its use apprentice with an experienced practitioner. Silicone (1000 cs) is highly viscous and must be injected through either a 26-gauge needle on a 1-mL

syringe or a 30-gauge needle on a 0.3-mL syringe. Use of a microinjection technique is paramount to success with silicone, so large-bore needles are never to be used. The microdroplet injection technique involves injecting 0.01 mL of silicone oil, with the needle bevel down, into the deep dermis in a depot fashion at 1- to 3-mm intervals. Note that 100 droplets are therefore required to empty a 1-mL syringe. Except in the treatment of HIV cheek atrophy, it is rare to use more than 0.3 mL total per injection session. Treated areas are always undercorrected, and patients are instructed to return for multiple injection sessions at monthly intervals until full augmentation occurs.

POSTPROCEDURE INSTRUCTIONS

There is very little postoperative discomfort, edema, or ecchymosis after microinjection with liquid silicone. Ice may be applied if needed to lessen the risk of postinjection ecchymosis. Patients may apply makeup and pursue their daily activities as usual after injection.

UNIQUE COMPLICATIONS

Most authorities on silicone use agree that the incidence of serious complications after the proper use of medical-grade silicone is very low. In an FDA-authorized study involving 1400 patients over a 20-year period, 2 patients experienced serious side effects: one case involved migration of silicone after treatment with large volumes, and the second involved inflammation and necrosis in a patient with concomitant Weber-Christian disease and rheumatoid arthritis. Local granulomatous nodularities can occur many years after the cessation of treatment and are usually preceded by a systemic infection. Treatment regimens for granulomas include intralesional or systemic steroids, minocycline, topical imiquimod and, if necessary, surgical excision.[8]

LONGEVITY

The augmentation derived from liquid silicone injection is permanent. Many authors have published reports of long-term studies, some with 30-year followup, showing persistence of improvement. Patients receiving liquid silicone injections will continue to age, and, for this reason, additional augmentation may be required should neighboring areas of age-related atrophy develop.

COMPLICATIONS ASSOCIATED WITH THE USE OF ALL FILLERS

Vascular occlusion is perhaps the most devastating complication associated with the use of all fillers. This can manifest as local necrosis, CNS infarction, or blindness. Blindness and middle cerebral artery infarction have been described most often after fat transfer, but vascular occlusion with ensuing sequelae has occurred after the use of collagen and hyaluronic acid fillers as well. In theory, the central occlusive events have occurred from high-pressure injections with retrograde flow into arterioles that connect with the internal carotid system. It is, therefore, of utmost importance to keep the needle or cannula moving during withdrawal while depositing filler and to exert as little pressure as possible on the syringe. For similar reasons, when fat transfer is performed, only blunt cannulas should be used for infiltration.

Other complications common to the use of all fillers include ecchymosis, edema, extrusion or drifting of the filling substance, foreign-body reactions, pigmentary alteration, injection site scarring, overcorrection, undercorrection, misplacement, and infection.

REFERENCES

1. Newman J. Review of soft tissue augmentation in the face. *Clin Cosmet Investing Dermatol*. 2009;2:141-150.
2. Lowe NJ, Maxwell CA, Patnaik R. Adverse reactions to dermal fillers: review. *Dermatol Surg*. 2005;31:1616.
3. Rossner F, Rossner M, Hartmann V, et al. Decrease of reported adverse events to injectable polylactic acid after recommending an increased dilution: 8-year results from the injectable filler safety study. *J Cosmet Dermatol*. 2009;8:14-18.
4. Moers-Carpi MM, Tefet JO. Calcium hydroxylapatite versus nonanimal stabilized hyaluronic acid for the correction of the nasolabial folds: a 12 month, multicenter, prospective, randomized, controlled, split-face trial. *Dermatol Surg*. 2009;34:210-221.
5. Rohrich RJ, Pessa JE. The fat compartments of the face: anatomy and clinical implications for cosmetic surgery. *Plast Reconstr Surg*. 2007;119:2219-2227.
6. Donofrio LM. Panfacial volume restoration with fat. *Dermatol Surg*. 2005;31:1496.
7. Narins RS, Beer K. Liquid injectable silicone: a review of its history, immunology, technical considerations, complications and potential. *Plast Reconstr Surg*. 2006;118:77-84.
8. Duffy DM. Liquid silicone for soft tissue augmentation. *Dermatol Surg*. 2005;31:1530.

Chapter 216 :: Botulinum Toxin

:: Richard G. Glogau

COMMERCIAL MARKET

When Drs. Jean and Alastair Carruthers made the critical leap from ophthalmologist Dr. Alan Scott's seminal use of botulinum as an alternative to strabismus surgery to the cosmetic use of the toxin to treat the glabellar frown lines, no one could have predicted the explosive growth of this agent in the commercial market.[1] On April 15, 2002, the US Food and Drug Administration (FDA) approved Allergan, Inc.'s Botox Cosmetic* (botulinum toxin type A) for "temporary improvement in the appearance of moderate-to-severe glabellar lines in adult men and women 65 or younger." This was the first elective cosmetic indication for which any commercially available botulinum toxin in the US market had been approved.

The toxin had previously been approved and was marketed as Botox® for the treatment of strabismus, blepharospasm, and cervical dystonia but existing off-label cosmetic use of the toxin had already propelled annual sales to $250 million per year by 2002. With FDA recognition of the cosmetic indication, sales of both Botox® and Botox Cosmetic® surpassed $1 billion per year by the end of 2009. The last half of 2015 and first half of 2016 produced $2.6 billion in sales. Analysts anticipate a $3 billion annual market for Botox® and Botox Cosmetic® in 2017-2018.

Allergan's product in the US market has equaled the brand name equity of Pfizer's product Viagra® (sildenafil citrate). "Botox" is now part of the daily vernacular, used to refer to a class of biologic neurotoxins in much the same way as the well-known trademarks Coke® and Kleenex® are used to refer to carbonated beverages and facial tissue. The clinical utility of the neurotoxin is so widely known today that the word *Botox* has become a generic term in the public mind for all agents used in cosmetic neurotoxin therapy, although the term is properly reserved for Allergan's trademarked commercial version of the type A neurotoxin complex.

In April 2009, the FDA approved a third commercial neurotoxin, a serotype A product, Dysport® (Ipsen [UK]/Medicis [US]) to join Allergan's Botox®/Botox Cosmetic® and a previously approved serotype B product, Myobloc® (Solstice Neurosciences [US]). In July 2011, the FDA approved a fourth commercial neurotoxin for the US market, a serotype A product, Xeomin® (Merz Pharma GmbH [Germany]). To emphasize the noninterchangeability of these biologic toxins, the FDA in August 2009 required the manufacturers to adopt new drug names: onabotulinumtoxinA (Botox®/Botox Cosmetic®), abobotulinumtoxin A (Dysport®), rimabotulinum toxin B (Myobloc®), and incobotulinum toxin A (Xeomin®).

Another serotype A toxin in development in 2011, at the time the last edition was written, was called PurTox® (Mentor [US]). This toxin is purportedly a "naked" toxin, that is, without complexing proteins, and probably with a molecular weight similar to that of Xeomin®. Johnson & Johnson acquired Mentor in 2009 and decided in 2014 to walk away from the neurotoxin portion of their investment represented by PurTox®. The development of this toxin is apparently at an end, all production having ceased, and with some of the intellectual property reportedly having been sold off. The $16-million manufacturing facility that Mentor had built in Madison, Wisconsin, was deemed redundant by Johnson & Johnson and was donated to a private–public research foundation based at University of Wisconsin.

In 2014, Allergan spent $65 million (with potential milestone bonuses of another $180 million) to acquire worldwide licensing rights (exclusive of Korea) for the neurotoxin products produced by Medy-Tox [Korea], which are marketed outside the United States under the names Meditoxin® or Neuronox®. The Medy-Tox product is produced in liquid form. Some clinicians have suggested that the liquid formulation may provide a stable, prefilled syringe as a convenience for those practitioners who would like to avoid the required dilution of the lyophilized forms of botulinum toxin such as Botox Cosmetic® and Dysport®. Others speculate that Allergan simply made this licensure agreement to stave future competition for Botox® in the US commercial space.

Korea has been the center of another commercial botulinum toxin product, Botulax®, which was released in Korea and Japan in 2010. It has been used for blepharospasm and glabellar lines. It is an A-type toxin that has a molecular weight of about 900 kDa, similar to Allergan's product, with the accessory complexing protein structure wrapped around the central 150-kDa core toxin like Botox®. Botulax® is made by Hugel Pharma and is made from the Clostridium strain CBFC26.

The American company ALPHAEON (Irvine, CA) acquired Evolus, Inc (Santa Barbara, CA) in 2013 and, as a result of that acquisition, entered into licensure agreement with Daewoong Pharmaceutical (Seoul, Korea) to develop a 900-kDa A toxin for the US and other international markets. This toxin is named Evosyal® and has been known as either DWP-450 or Nabota® in the Korean markets. Evosyal® has completed Phase II and III trials in the US and is awaiting FDA approval.

*It is the editors' policy not to use trade names in this book. However, in certain instances, the editors had to depart from this policy to avoid confusion.

Another serotype of A toxin in use outside of the United States (Asia, South America) is Hengli®/ Prosigne® (Lanzhou [China]). The hurdles to entry into the US market, particularly given the FDA's rigorous manufacturing standards, may ultimately forestall entry of the Chinese product into the US market. At the time of this writing, there are no particular plans reportedly afoot to bring Hengli® into the US market.

RECENT DEVELOPMENTS

An A-type toxin manufactured by Revance Therapeutics (Newark, CA), daxibotulinumtoxinA, was initially formulated as a topical gel (RT001™) and then as formula for injection (RT002™). Although early Phase II trials showed promise for the topical formulation in the treatment of hyperhidrosis and crow's feet, in June 2016, the company announced that the RT001 phase 3 trial for crow's feet had failed to meet its primary endpoints and that future efforts would center on the phase 3 trials of the injectable RT002 for glabellar lines and Phase II trials for cervical dystonia. Earlier, Phase II trials of the RT002 injectable suggested a statistically significant increase in duration of action that would merit confirmation studies in phase 3.

In January 2016, Allergan announced the purchase of Anterios, Inc, a biopharmaceutical firm that purported to have a proprietary technology that permits delivery of neurotoxins through the skin. The transport system, called NDS™, was apparently developed with intellectual property from the University of Massachusetts, and involves surrounding the target molecule with nano-particles that permit movement of the molecule across the skin barriers. The topical A-type toxin, ANT-1207, has completed Phase II clinical trials in lateral canthal lines, acne, and hyperhidrosis in March 2016, but results were unpublished at the time of this writing. An additional formulation of A-type toxin in liquid form, AI-09, is in preclinical development as an injectable form of the A toxin.

PHARMACOLOGY

TOXIN STRUCTURE

Botulinum neurotoxins are currently categorized into 7 distinct serotypes: A, B, C1, D, E, F, and G.[2] The molecules vary in their biosynthesis, size, cellular sites of action, binding kinetics, duration of effect, and stability. The serotypes currently commercially available, serotypes A and B, are derived from different strains of *Clostridium botulinum*. They both have 150-kDa dichain polypeptides with a heavy chain and light chain linked by disulfide bonds. During biosynthesis, the molecules of A and B can be surrounded by proteins to form a neurotoxin complex, ranging from 500 to 900 kDa (Fig. 216-1). Xeomin® (incobotulinumtoxin A) consists of the 150-kDa dichain without accessory proteins.

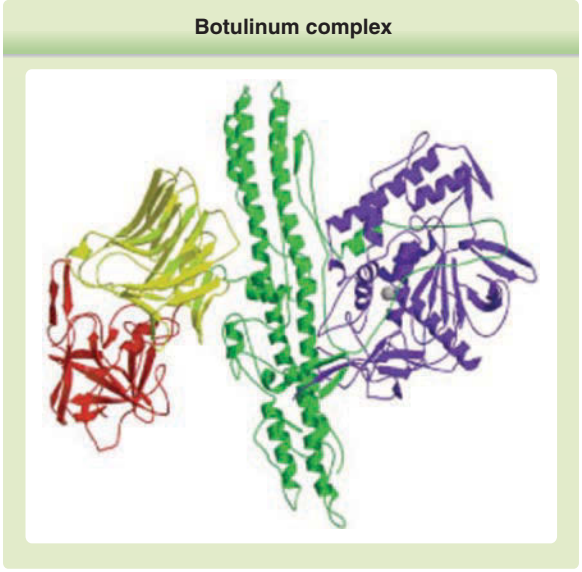

Figure 216-1 Schematic of the botulinum complex showing the binding domain with the N-terminus (*yellow*) and the C-terminus (*red*), together with the translocation domain (*green*) and the light chain (*blue*). (Used with permission from Turton K, Chaddock JA, Acharya KR. Botulinum and tetanus neurotoxins: structure, function and therapeutic utility. *Trends Biochem Sci*. 2002;27:554. Copyright © Elsevier.)

MECHANISM OF ACTION

The toxin enters the nerves by binding to surface protein receptors and undergoing endocytosis into internalized vesicles. The light chain is released into the nerve cytosol, and the SNARE (soluble *N*-ethylmaleimide-sensitive factor attachment protein receptor) protein complex is cleaved to inhibit exocytosis of the neurotransmitters such as acetylcholine (Fig. 216-2). Type A toxin cleaves SNAP-25 (synaptosome-associated protein of 25 kDa), whereas type B cleaves VAMP (vesicle-associated membrane protein), also called *synaptobrevin* (Fig. 216-3). These proteins are necessary for the release of acetylcholine from vesicles within the cytoplasm of the motor nerve endings. The binding characteristics of each serotype dictate the locus of action on the intracellular SNARE protein complex (Table 216-1).

The end result is a chemodenervation of the cholinergic neurons, either motor nerves or autonomic nerves, leading to localized absence of skeletal muscle activity or autonomic control of target organs such as the eccrine sweat glands. The way in which the nerves escape the effect of the neurotoxin is partially understood.[3] The chemodenervated nerve endings develop collateral sprouting near the primary terminus of the nerve. These sprouts eventually make proximate contact with the targets, either muscle or gland, and begin to overcome the loss of neurotransmitter at the end organ synaptic junctions.

Once these sprouts have reestablished chemical contact with their targets, muscles resume activity and glands begin to secrete. Simultaneously, the original

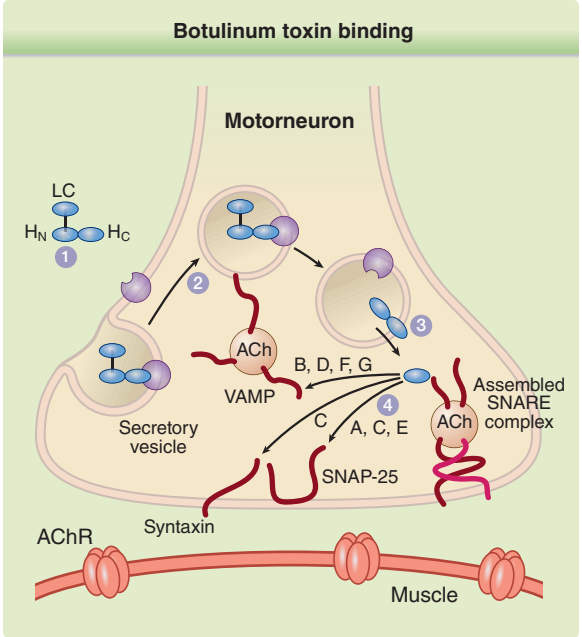

Figure 216-2 The heavy-chain domain of the botulinum neurotoxin complex binds to the plasma membrane receptor (1), and the complex is internalized (2). The light-chain fragment is then released into the cytoplasm (3), where it cleaves the SNARE (soluble *N*-ethylmaleimide-sensitive factor attachment protein receptor) protein complex at a site determined by the neurotoxin serotype (4). This disruption of the SNARE complex prevents exocytosis of acetylcholine (ACh) into the synaptic space of the neuromuscular junction n. A through G, neurotoxin serotypes; AChR, acetylcholine receptor; LC, light chain; H_C, heavy chain C-terminus; H_N, heavy chain N-terminus; SNAP-25, synaptosome-associated protein of 25 kDa; VAMP, vesicle-associated membrane protein. (Used with permission from Turton K, Chaddock JA, Acharya KR. Botulinum and tetanus neurotoxins: Structure, function and therapeutic utility. *Trends Biochem Sci*. 2002;27:555. Copyright © Elsevier.)

chemodenervated terminal nerve ending begins to degrade the blocked SNARE proteins and develop new proteins to resume the chemical exocytosis of acetylcholine. While these repairs are under way, and while the original terminal nerve ending reacquires communication with the target organ, the collateral sprouts begin to slowly resorb until anatomically nothing is left but the original terminal ending with restored junctional activity.

Four commercially available preparations of botulinum neurotoxin were on the market in the United States and Europe in late 2016, and one was pending approval (Table 216-2). All but one are serotype botulinum toxin A, and one is a serotype botulinum toxin B. The products differ in their methods of manufacture, commercial form, and biologic profiles. Various other toxins are available outside of the US or are in current development. These are summarized, compared, and contrasted in Table 216-3.

The units by which these products are described are not interchangeable because of the nature of the assays used to determine their potency. The mouse assays used differ in the diluents used and are not comparable. There is no such thing as a standard neurotoxin unit; hence, there is no "International Unit" for neurotoxin. Thus, there is no way of standardizing neurotoxin units to compare serotype A products to each other, let alone to other serotype B products.

Although the molecule complexes are unique, similar uses are based on clinical observations. For example, in the glabellar frown line pivotal trials, 20 units of Botox® or Xeomin® and 50 units of Dysport® were used.[4] Botox® is generally diluted with either 1.0, 2.0, or 2.5 mL of saline per 100 units, producing concentrations of either 10 units per 0.1 mL, 5 units per 0.1 mL, or 4 units per 0.1 mL, respectively. Xeomin® is diluted with 2.5 mL per 100-unit vial. Allergan's pivotal trial used the 4 unit per 0.1 mL dilution.

Dysport® is usually diluted with 1.5 mL of saline per 300-unit vial producing a concentration of 10 units in 0.05 mL as used in the pivotal trial. Notice that the Dysport® pivotal trial used injection volumes that were half those used in the Allergan trial: 0.05 mL (10 U) per injection point (Dysport®) versus 0.1 mL (4 U) per injection site (Botox®). It is unclear whether such differences in volume may contribute to behavioral differences between the 2 products in terms of diffusion and persistence. At some point, a larger volume might increase diffusion but probably decrease persistence since less drug would saturate the receptors in a given area.

The use of sterile saline with preservative (benzyl alcohol) as a diluent appears to lessen the sting of injection with Botox® and Dysport®. Myobloc®, the B serotype, causes more discomfort on injection because of its low pH, but it is stable in liquid form at room temperature for many months.

In addition to the drug name changes, which the FDA required of the manufacturers in 2009, the agency instituted a Risk Evaluation and Mitigation Strategy (REMS), and a boxed warning for these products that warned of the possibility of spread distant from the injection site with potentially life-threatening consequences. Emphasizing the noninterchangeability of these commercial products, the FDA wished to minimize the possibility of medication errors as well as draw attention to the need for tailoring specific doses of each toxin product to specific situations.

IMMUNOLOGY

The possibility of antibody-mediated resistance appears to be largely theoretical. Original Botox® batch No. 79-11, widely used in ophthalmology and neurology for years, produced rare cases of nonresponse in the treatment of torticollis and blepharospasm. Newer batches introduced in 1997, No. 91223US and No. BCB2024, have significantly less protein load. Although cases of primary nonresponse may be rarely encountered, immunologic resistance to Botox® and Botox Cosmetic® does not appear to be clinically relevant in dermatology, even at the dosages used to treat

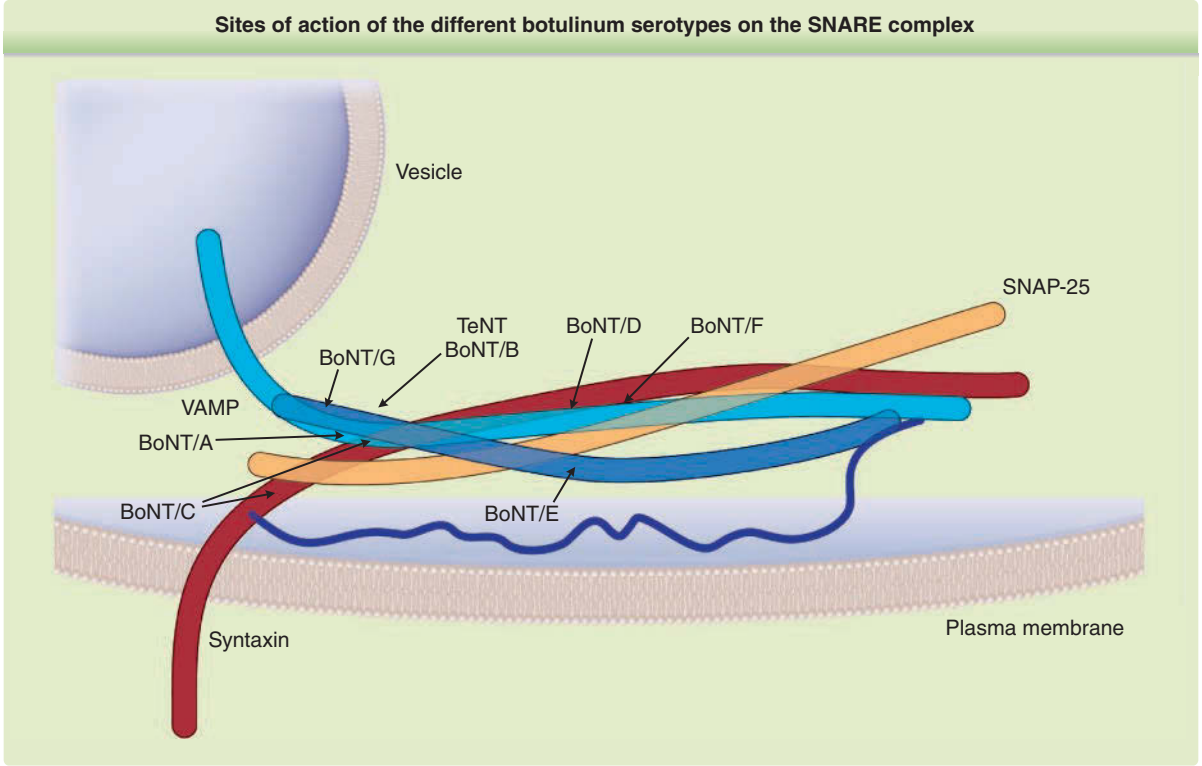

Figure 216-3 Schematic representation showing the sites of action of the different botulinum serotypes on the intracellular protein complex known as the SNARE (soluble *N*-ethylmaleimide-sensitive factor attachment protein receptor) proteins responsible for exocytosis of acetylcholine from the nerve. Botulinum A serotype cleaves SNAP-25 (synaptosome-associated protein of 25 kDa). Other serotypes impact VAMP (vesicle-associated membrane protein), synaptobrevin, or syntaxin. BoNT/A through BoNT/G, botulinum neurotoxin serotypes A through G; TeNT, tetanus neurotoxin.

hyperhidrosis, which can average 400 units per treatment session. In addition, the treatment interval does not appear to be a significant factor in clinical resistance for the newer batches and at the smaller dosages used in cosmetic facial treatment, although exposure to the toxin at increasingly shorter intervals may theoretically be associated with development of neutralizing antibodies. In clinical practice, the reality of induced resistance on the basis of development of neutralizing antibodies is extremely rare, a fact bolstered by the difficulty in trying to purposefully induce resistance to the toxin through repeated vaccination.

TABLE 216-1

Binding Sites in the Snare Protein Complex of the 7 Known Botulinum Toxin Serotypes

SEROTYPE	INTRACELLULAR PROTEIN
A	SNAP-25
B	VAMP/synaptobrevin
C1	SNAP-25 and syntaxin
D	VAMP/synaptobrevin
E	SNAP-25
F	VAMP/synaptobrevin
G	VAMP/synaptobrevin

SNAP-25, synaptosome-associated protein of 25 kDa; SNARE, soluble *N*-ethylmaleimide-sensitive factor attachment protein receptor; VAMP, vesicle-associated membrane protein.

INDICATIONS

Botulinum toxin is used in cosmetic dermatology primarily for the treatment of dynamic expression lines in the upper third of the face (the glabellar brow furrow, horizontal frontalis forehead lines, periocular rhytides aka crow's feet) and for the treatment of axillary hyperhidrosis. Less common and therapeutically more challenging indications are platysmal banding in the neck, perioral rhytides, marionette lines at the corners of the mouth from the action of the depressor anguli oris, shaping the lower face with masseter volume reduction, postsurgical synkinesis in the lower face, and palmar/plantar and forehead/scalp hyperhidrosis.

TREATMENT

GLABELLAR LINES (BROW FURROWS)

A firm understanding of the underlying facial anatomy is the sine qua non of successful aesthetic therapy with botulinum toxin. Depending on the muscle

TABLE 216-2
Comparison of the Properties of the Commercially Available Forms of Botulinum Toxin in Current Medical Use in the United States (4) and Pending (1)

PROPRIETARY NAME	BOTOX® BOTOX® COSMETIC	DYSPORT®	XEOMIN®	MYOBLOC®	RT001 TOPICAL RT002 INJECTABLE
Non-proprietary Name (FDA)	Onabotulinum-toxin A	Abobotulinumtoxin A	Incobotulinumtoxin A	Rimabotulinumtoxin B	Daxibotulinumtoxin A
First approval	1989 (US) 2002 (US)	1991 (UK)	2010 (US)	2000 (US)	Pending
Manufacturer	Allergan (US)	Ipsen (UK)	Merz (Germany)	Solstice Neurosciences (US)	Revance Therapeutics (US)
Commercial US	Yes	Yes	Pending US	Yes	Pending US
Serotype	A	A	A	B	A
Strain	Hall (Allergan)	Hall	Hall	Bean	Hall
Process	Crystallization	Chromatography	Chromatography	Chromatography	Chromatography
Excipients	HSA (500 µg) Sodium chloride	HSA (125 µg) Lactose	HSA (1 mg/vial) Sucrose (5 mg/vial)	HSA (500 µg/mL) Sodium succinate Sodium chloride	HSA
Receptor/Target	SV2/SNAP-25	SV2/SNAP-25	SV2/SNAP-25	Syt II/VAMP	SV2/SNAP-25
Complex molecular weight uniformity	~900 kDa homogeneous	~500 kDa heterogeneous	~150 kDa	~700 kDa homogeneous	~150 kDa
Stabilization Solubilization pH	Vacuum dried Normal saline ~ 7	Lyophilization Normal saline ~ 7	Vacuum dried Normal saline ~ 7.4	Solution N/A 5.6	Lyophilization Normal saline ~ 7
Package (units per vial)	100, 200	300, 500	100	2500/5000/10,000	50
Neurotoxin protein per vial (ng/vial)	~5 (100-U vial)	4.35 (500-U vial)	0.6 (100-U vial)	25/50/100	1 (100-U vial)

mass present and the degree of atrophy from prior treatment, 20 to 35 units of Botox® or Xeomin® or 50 to 75 units of Dysport® may be placed in 5 separate injection points to treat the corrugators and procerus muscle in the average brow (Fig. 216-4). A 30-gauge, 31-gauge, or even 32-gauge needle and a tuberculin or diabetic syringe are used to minimize the trauma of the intramuscular injections. The corrugator injections are placed (1) just at or above the medial brow and (2) in or just medial to the midpupillary line, at least 1 cm above the bony orbital rim (see Fig. 216-4). The fifth injection is placed in the procerus at the midline at a point just above the horizontal creases created in the glabella at the bridge of the nose. Figure 216-5 shows the results of the procedure.

Based on earlier experience with ophthalmologic periocular injections for treatment of muscle spasms, patients have been instructed to remain upright for 2 to 3 hours to limit the incidence of eyelid ptosis, which occurs with diffusion of the toxin down into the levator muscles of the lid (Fig. 216-6). With operator experience, the incidence of ptosis after injection of the brow should be less than 2%.

Temporary stimulation of Müller muscle in the lid can be achieved with 0.5% apraclonidine or 2.5% phenylephrine eyedrops or even naphazoline hydrochloride 0.025%/pheniramine maleate 0.3% eyedrops (Naphcon A® available over the counter) (see Fig. 216-6). These will produce 2 to 3 mm of elevation of the lash margin, and administration may be repeated at intervals of 4 to 6 hours as needed until the distant diffusion effect of the botulinum toxin on the levator muscle disappears, usually in 2 to 3 weeks.

HORIZONTAL FOREHEAD LINES

The frontalis is treated at the horizontal equator of the forehead or above to avoid inactivation of the lower third of the frontalis muscle, which is responsible for suspension and movement of the eyebrows (see Figs. 216-4 and 216-7). Twelve to 20 units of Botox® or 20 to 50 units of Dysport® are placed in 4 or 5 divided doses equidistantly along the forehead equator. If too large a dose is applied or injection sites are placed too low, brow ptosis and loss of brow arch are produced, which leads to an unpleasant, heavy sensation in the brow as well as an aesthetically unattractive appearance in females.

Unlike in the treatment of eyelid ptosis, there is no comparable adrenergic agent available to reverse brow ptosis induced by botulinum, and the patient

TABLE 216-3

Comparison of the Properties of Some Commercial Forms of Botulinum Toxin in Use Outside the United States or Pending US Approval

PROPRIETARY NAME	PURTOX®	MEDITOXIN® NEURONOX®	DWP-450, EVOSYAL®, NABOTA®	BOTULAX®	HENGLI®/ PROSIGNE®	ANT-1207 TOPICAL AI-09 INJECTABLE
Non-proprietary Name (FDA)	Not named	Licensed to Allergan Outside Korea	Outside US only	Outside US only	Outside US only	In trials US
First approval	No approval	2006 (Korea)	2013 (Korea)	2010 (Korea, Japan)	1993 (China)	Pending US
Manufacturer	Mentor (J&J) (US)	Medy-Tox (Korea)	Daewoong Pharma (Korea), Alphaeon (US), Evolus, Inc. (US)	Hugel Pharma (Korea)	Lanzhou (China)	Anterios (US) Acquired by Allergan 2016
Commercial US	No approval	No	Pending	No	No	Pending
Serotype	A	A	A	A	A	A
Strain	Hall	Hall	Hall	Clostridium CBFC26	Hall	Hall
Process	Chromatography	Chromatography	Chromatography	Chromatography	Crystallization	Chromatography
Excipients	HSA Trehalose	HSA (500 µg) Sodium chloride	HSA (500 µg) Sodium chloride	HSA (500 µg) Sodium chloride	Porcine gelatin 5 mg Dextran 25 mg Sucrose 25 mg	Unpublished; Proprietary NDS technology
Receptor/target	SV2/SNAP-25	SV2/SNAP-25	SV2/SNAP-25	SV2/SNAP-25	SV2/SNAP-25	SV2/SNAP-25
Complex molecular weight uniformity	~150 kDa	~150 kDa	? ~150 kDa	900 kDa	~500 kDa heterogeneous	? 150 kDa
Stabilization Solubilization pH	Lyophilization Normal saline ~7	Lyophilization	Lyophilization	Freeze Dried 6.5 ± 0.5	Lyophilization	Liquid
Package (units per vial)	100	50/100	100	50/100/200	100	Unpublished
Neurotoxin protein per vial (ng/vial)	1 (100-U vial)	?	?	<2.5 / <5.0 / <10	?	Unpublished

must wait several weeks for the effect to wear off. In a patient who has never received botulinum toxin before, it is wise to separate the glabellar area from the forehead area and to wait a couple of weeks between treating the two to avoid the possibility of overtreatment and brow ptosis. Many patients find even the smallest drop in brow position very bothersome, and great care should be taken to avoid this complication of aesthetic treatment.

LATERAL CANTHAL LINES (CROW'S FEET)

The rhytides at the corners of the eye respond favorably to injections of toxin; however, patients frequently confuse true crow's feet rhytides with the dynamic expression lines that appear across the malar eminence laterally in conjunction with smiling and contraction of the zygomaticus muscles. Toxin may successfully ameliorate true crow's feet, which radiate directly from the lateral canthus and are associated with contraction of the orbicularis oculi muscles by themselves. But the "smile lines" that appear over the malar eminence often lie in wait for the unwary injector. Placing toxin at or below the malar eminence in an attempt to weaken these lines may lead to paralysis of the zygomaticus muscles and a drooping corner of the mouth that cannot spontaneously be raised, so that the patient may acquire a poststroke appearance.

To safely approach crow's feet, the toxin is usually placed at 1 to 3 injection points approximately 1 cm lateral to the lateral canthus. Some practitioners place all of the drug at one point, and others distribute the dose evenly among 3 points. Typical doses range from 10 to 18 units of Botox® or 25 to 30 units of Dysport® depending on the estimate of muscle mass and activity.

Great care must be taken to make the injections into the skin only, raising wheals or blebs that can be gently massaged down. Intramuscular injection in this area will reliably produce unwanted bruising because of the rich venous plexus underlying the skin in this region. The toxin will readily diffuse from the blebs into the underlying orbicularis muscle, relaxing

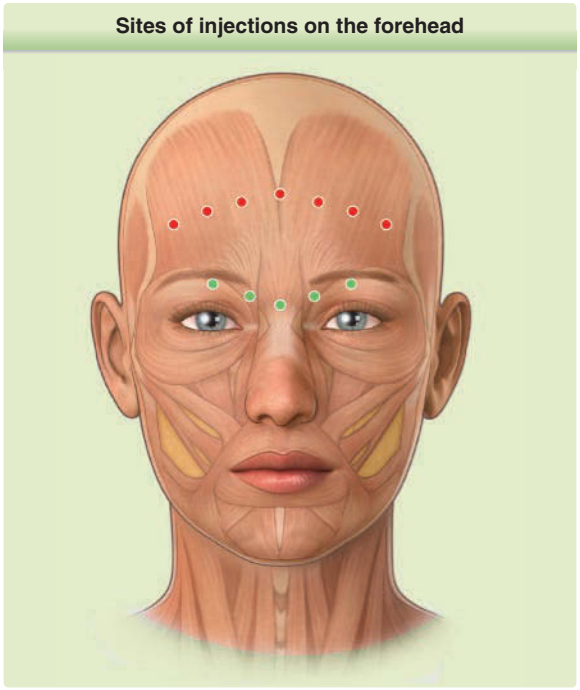

Figure 216-4 Sites of injections on the forehead. The corrugator and procerus muscles are weakened by carefully positioning 5 injections of botulinum toxin of 5 units each (Botox®) (*green circles*). If Dysport® is used, 10 units would be placed in the 3 central injection points but the lateral corrugator injection points (represented by the red circles) are a little medial and slightly higher than the lateral injection points used for Botox,® in most cases, according to Ascher.[15] Forceful knitting of the brow is prevented. To weaken the frontalis muscle, injections are placed in 5 or more divided doses along the forehead equator (*red circles*).

Figure 216-5 Before botulinum toxin treatment of the corrugator and procerus muscles (*upper panel*) and 1 week after treatment (*lower panel*).

the grip on the overlying skin and smoothing out the wrinkles. As previously mentioned, care must be taken to avoid injecting too low down onto the malar eminence, where diffusion may affect the zygomaticus major muscle and disrupt the symmetrical movement of the corner of the mouth in smiling.

The patient being treated for crow's feet should have good lower eyelid tarsal tone to avoid the appearance of senile ectropion from too much laxity of the lower eyelid. Pretreatment of the crow's feet area is very useful as an adjunctive technique before laser resurfacing. It prevents the problem of rhytides being readily re-formed by repeated squinting during the postoperative healing period, in which case the resurfacing may give rise to more noticeable lines than existed before the resurfacing.

COMBINATION THERAPY

As clinical experience accumulated with these commercial botulinum toxin products, experts in soft-tissue augmentation soon recognized that a synergy exists between soft-tissue fillers and neurotoxins.[5] Concomitant with the rise in the use of botulinum neurotoxin for cosmetic applications, the marketplace for soft-tissue augmentation expanded with the introduction of injectable hyaluronic acid gels (Chap. 215). These agents provided the first new directions in cosmetic therapy since the introduction of solubilized bovine collagen in the mid-1970s. The ability to control both muscles of expression and their secondary lines and folds, and to repair age-related volume changes in subcutaneous tissue has revolutionized minimally invasive cosmetic techniques.

Many patients have eagerly embraced simultaneous treatment with both fillers and botulinum toxin to achieve a natural look and forego more traditional incisional surgery.[6] As an example, patients frequently combine treatment of the upper third of the face (glabellar frown lines, horizontal forehead lines, and crow's feet) with volume restoration of the lower and middle face (lip enhancement, filling of nasolabial fold and marionette lines, chin and cheek augmentation) (Chap. 215).

HYPERHIDROSIS

Focal axillary hyperhidrosis is successfully treated with botulinum toxin by using Minor starch-iodine test to map out the extent of surface area in the axillary vault

Figure 216-6 Patient who developed ptosis of the right upper eyelid due to diffusion of the botulinum toxin from the area above the midbrow down into the levator muscle of the upper eyelid. The lower photograph shows the patient approximately 1 minute after instillation of 2 drops of apraclonidine 0.5% ophthalmic solution into the right eye. Direct adrenergic stimulation of Müller muscle occurs, which lifts the lid temporarily. The drops may be administered every 4 hours as needed. The botulinum-induced ptosis resolves spontaneously, usually in 3 weeks or less.

Figure 216-7 The upper half of the frontalis muscle is weakened by injecting 4 or 5 sites equidistantly along the equator of the forehead with a total of 16 to 20 units of Botox® or 30 to 50 units of Dysport®. Patient is shown before treatment (*upper panel*) and 1 week after treatment (*lower panel*).

that is affected. Anesthesia may be achieved with a eutectic mixture of local anesthetics but is usually not needed because of the relative insensitivity of the axillary skin. Doses of 2.5 to 4.0 units of Botox® are placed every 1 to 2 cm as intradermal injections in axillary skin. Reliable anhidrosis is produced within 72 hours and will last for 8 to 12 months with doses of 50 to 100 units of Botox® per axilla (Fig. 216-8). The duration of effect appears to be dose related, and doses of up to 200 units (Dysport®) per axilla have been reported to produce dryness for up to 29 months.[7] Aside from insignificant bruising from the needle trauma, there are no apparent side effects. Compensatory hyperhidrosis is not a clinically significant side effect, probably because of the relatively small surface area of the axillary vaults in contrast to the much larger surface areas affected by the surgical interruption of the nerves that occurs with endoscopic cervical sympathectomy, where compensatory hyperhidrosis is a real concern in up to a third of patients treated.

Palmar hyperhidrosis (Fig. 216-9) is more challenging to treat because of (1) the more limited diffusion of the toxin in palmar skin, (2) the pain on injection, and (3) the generally predictable incidence of temporary weakness in the hand. Anesthesia is achieved with regional wrist blocks of the median, ulnar, and radial nerves using lidocaine 1% to 2% without epinephrine. Approximately, 100 to 150 units of Botox® are needed to treat a single palm, divided into 50 to 60 intradermal injections of 2 to 3 units each. Onset of anhidrosis peaks in 5 to 7 days and is accompanied by minor weakness of the intrinsic muscles of the hand, which makes tasks requiring strength and stability (eg, pushing a button through a buttonhole) difficult to perform. The weakness usually subsides within 3 weeks, whereas the anhidrosis persists for several months. There is wider variation in response to palmar treatment than to axillary treatment, with anhidrosis lasting from 4 to 12 months, which probably reflects the technical difficulties in achieving even dispersion of the toxin through the palmar skin.

SIDE EFFECTS AND COMPLICATIONS

Minor needle trauma and bruising on injection with a 30-gauge needle are insignificant short-term complications of botulinum toxin injection, and use of a smaller-gauge needle (31 gauge or 32 gauge) will minimize needle trauma. Minor discomfort can be made more tolerable in some patients by pretreating the injection site areas with topical anesthetic and using sterile saline with preservative as a diluent, which greatly reduces the sensation of injection.

Figure 216-8 Minor starch-iodine test is used to demonstrate the area of axillary sweating (*top panel*). The pattern of intradermal botulinum toxin injections is shown with the starch-iodine material in place to highlight the injection points (*middle panel*). One week later, the treated axilla shows a negative result on the starch-iodine test (*bottom panel*).

The more problematic complications to consider are eyelid ptosis, which can occur after injections in the glabellar brow (see Fig. 216-6); brow ptosis from overzealous treatment of the frontalis muscle; transient lid edema from periocular injections; headaches after injections anywhere in the upper third of the face; and palmar weakness after injections for hyperhidrosis.

Antibody-mediated resistance appears to be an exceedingly rare event and of little clinical consequence in cosmetic dermatologic uses of botulinum toxin. Although millions of doses have been given as of this writing, there is no well-documented evidence of the development of immunologic resistance in patients treated with cosmetic doses. Resistance continues to be observed in patients treated for cervical dystonia, albeit at much lower rates than in the early years, probably because of the lower protein content of current formulations.

Eyelid ptosis is thought to be best avoided by carefully placing the midbrow injections at a minimal distance of 1 cm from the superior orbital rim, keeping the injection rate slow and gentle, and having the patient avoid prone positions and sleeping for 2 hours after injection.

Restricting injections to the upper two-thirds of the frontalis and reducing doses to the minimum necessary to produce the desired clinical effect may minimize brow ptosis. Unopposed muscle groups may trigger headaches as a rebound phenomenon after facial injections of botulinum toxin, but their etiology is unclear. Usually nonsteroidal anti-inflammatory agents are sufficient to treat them, unless the patient experiences migraines, in which case the patient's usual migraine medication will be required.

In hyperhidrosis, palmar weakness is a predictable consequence of injecting the palms. It is transient and dealt with by clear preinjection counseling. There is no similar effect of any clinical significance in either the axillae or the feet.

Figure 216-9 Hands showing response to Minor starch-iodine test. The left hand was not treated. The right hand received 100 units of intradermal Botox® 1 week before the photograph was taken.

COSMETIC USES "OFF-LABEL"

At the present time, the only FDA-approved indications for cosmetic botulinum toxin are the glabellar frown lines and the lateral canthal lines or crow's feet. But clinicians have described a variety of different anatomic locations that can benefit from carefully dosed botulinum toxin. These include the horizontal lines on the forehead (frontalis muscle),[8,9] the vertical rhytides of the upper lip (orbicularis),[10,11] the rhytides from nasalis muscles ("bunny lines"),[12] the melomental folds at the corners of the mouth (depressor anguli oris),[13,14] the deep mental crease on the chin and pebbly or peau d'orange chin (mentalis),[15] hypertrophy of the masseters (squared lower face),[16,17] and horizontal neck lines and bow-string bands of the neck (platysma).[18,19] The techniques and doses for these indications have been widely discussed, but few have been systematically studied.

SUMMARY

The development of botulinum toxin treatment has brought great creativity and capability to cosmetic dermatologic therapy. Further evolution will occur as new serotypes come to market and greater therapeutic synergies evolve as developers of soft-tissue augmentation systems strive to achieve similar effect and elegance. The high degree of efficacy and safety in the use of botulinum toxins in cosmetic dermatology has produced a great level of satisfaction in patients and physicians alike.

REFERENCES

1. Carruthers JD, Carruthers, JA. The evolution of botulinum neurotoxin type A for cosmetic applications. *J Cosmet Laser Ther*. 2007;9:186.
2. Aoki KR. Pharmacology and immunology of botulinum toxin serotypes. *J Neurol*. 2001;248(suppl 1):3-10.
3. Meunier FA, Lisk G, Sesardic D, et al. Dynamics of motor nerve terminal remodeling unveiled using SNARE-cleaving botulinum toxins: the extent and duration are dictated by the sites of SNAP-25 truncation. *Mol Cell Neurosci*. 2003;22(4):454-466.
4. Carruthers A, Carruthers J, Coleman WP 3rd, et al. Multicenter, randomized, phase III study of a single dose of incobotulinumtoxinA, free from complexing proteins, in the treatment of glabellar frown lines. *Dermatol Surg*. 2013;39(4):551-558.
5. Carruthers JD, Glogau RG, Blitzer A; Facial Aesthetics Consensus Group F. Advances in facial rejuvenation: botulinum toxin type a, hyaluronic acid dermal fillers, and combination therapies—Consensus recommendations. *Plast Reconstr Surg*. 2008;121(5)(suppl): 5S-30S; quiz 31S-36S.
6. Molina B, David M, Jain R, et al. Patient satisfaction and efficacy of full-facial rejuvenation using a combination of botulinum toxin type A and hyaluronic acid filler. *Dermatol Surg*. 2015;41(suppl 1):S325-S332.
7. Glogau RG. Hyperhidrosis and botulinum toxin A: patient selection and techniques. *Clin Dermatol*. 2004; 22(1):45-52.
8. Carruthers A, Carruthers J. Botulinum treatment of forehead wrinkles. *Plast Reconstr Surg*. 2006;117(4):1354; author reply 1355.
9. Steinsapir KD, Rootman D, Wulc A, et al. Cosmetic microdroplet botulinum toxin A forehead lift: a new treatment paradigm. *Ophthal Plast Reconstr Surg*. 2015; 31(4):263-268.
10. Barton FE Jr, Carruthers J, Coleman S, et al. The role of toxins and fillers in perioral rejuvenation. *Aesthet Surg J*. 2007;27(6):632-640.
11. Semchyshyn N, Sengelmann RD. Botulinum toxin A treatment of perioral rhytides. *Dermatol Surg*. 2003; 29(5):490-495; discussion 495.
12. Tamura BM, Odo MY, Chang B, et al. Treatment of nasal wrinkles with botulinum toxin. *Dermatol Surg*. 2005; 31(3):271-275.
13. Braz AV, Louvain D, Mukamal LV. Combined treatment with botulinum toxin and hyaluronic acid to correct unsightly lateral-chin depression. *An Bras Dermatol*. 2013;88(1):138-140.
14. Choi YJ, Kim JS, Gil YC, et al. Anatomical considerations regarding the location and boundary of the depressor anguli oris muscle with reference to botulinum toxin injection. *Plast Reconstr Surg*. 2014;134(5):917-921.
15. Papel ID, Capone RB. Botulinum toxin A for mentalis muscle dysfunction. *Arch Facial Plast Surg*. 2001; 3(4):268-269.
16. Ahn J, Horn C, Blitzer A. Botulinum toxin for masseter reduction in Asian patients. *Arch Facial Plast Surg*. 2004; 6(3):188-191.
17. Chang CS, Kang GC. Achieving ideal lower face aesthetic contours: combination of tridimensional fat grafting to the chin with masseter botulinum toxin injection. *Aesthet Surg J*. 2016;36(10):1093-1100.
18. Brandt FS, Boker A. Botulinum toxin for the treatment of neck lines and neck bands. *Dermatol Clin*. 2004; 22(2):159-166.
19. Kane MA. Nonsurgical treatment of platysma bands with injection of botulinum toxin a revisited. *Plast Reconstr Surg*. 2003;112(5)(suppl):125S-126S.

Chapter 217 :: Hair Transplantation

:: Robin H. Unger & Walter P. Unger

AT-A-GLANCE

- Most patients undergoing surgical procedures for hair loss have either male pattern baldness (MPB) or female pattern hair loss (FPHL).
- Surgical techniques used to treat hair loss include hair transplantation, alopecia reduction, and transposition flaps. The latter 2 techniques are rarely used currently.
- Follicular units (FUs) are the building blocks of modern hair transplantation (follicular unit transplanting [FUT]).
- The 2 main methods of donor harvest are strip harvesting and follicular unit excision (FUE). The latter may be achieved using a variety of techniques and devices.
- Minoxidil or finasteride may arrest or partially reverse MPB and FPHL, so a trial of treatment is often appropriate prior to surgery, or concurrent with surgery.
- Additional innovations of potential benefit include bio-enhanced storage solutions and platelet-rich plasma (PRP)

BACKGROUND

Hamilton and Norwood described the degrees of severity of male pattern baldness (MPB) from a mild Type I to a severe Type VII[1-3] (Fig. 217-1). Fortunately, a large majority of male patients do **not** progress past Types VI: Norwood found that at age 79 only 11% of men have Type VII MPB (Table 217-1), and Unger found that among 328 men older than 65 only 13.7% have Type VII MPB[4] (Table 217-2). Thus, if one treats all or most patients as if they will develop Type VI MPB, one is being reasonably cautious. Exceptions are individuals with earlier than usual onset of significant degrees of MPB or Diffuse Unpatterned Alopecia especially if there is a family history of Type VII MPB, in which case it is wiser to plan on an evolution to Type VII MPB.

Ludwig described 3 degrees of female pattern hair loss (FPHL),[5] whereas Olsen developed a distinct classification system based on her observation of a "Christmas-tree" pattern of hair loss[6] (Fig. 217-3). According to Hamilton's study, 79% of postpubertal females develop at least a mild Hamilton/Norwood pattern of hair loss.[2] Most female patients do not have a sufficiently large and/or high-density donor area to surgically treat all of the eventually affected alopecic areas. For this reason, some practitioners believe that women are "rarely" candidates for hair restoration surgery (HRS)—a view promulgated by the media and therefore shared by the general public! However, in the authors' experience, and in a survey of experts, the opposite appears to be the case.[7] A less than optimal donor/recipient ratio does not preclude surgery but does require a treatment plan that focuses on cosmetically strategic areas. In women, this most often corresponds to the frontal area and the part-line, which is usually a 5-mm-wide anteroposterior corridor (Fig. 217-2). The thickened hair in these areas can then be styled in a way that camouflages untreated areas. When this is done, the cosmetic improvement is significant, and patient satisfaction is high.[8]

In men, the transplantation of areas of MPB should be conceptualized as consisting of 4 areas: (1) a frontal area extending from the proposed hairline to a coronal line drawn perpendicularly between the tragus of each ear; (2) a midscalp area extending from the posterior border of the frontal area to a point where the caudal scalp changes its orientation from parallel to the ground to more or less vertical; (3) a vertex area that consists of the remainder of the alopecic regions; and finally (4) evolving areas of alopecia adjacent to the aforementioned 3 major areas, which on close inspection contain hair that appears likely to be temporary. Commonly, each transplant session treats one of the 3 major areas, plus adjacent evolving areas. Occasionally, the treatment of evolving areas of hair loss is deferred to a later session to transplant a larger proportion of already existing more obvious areas of hair loss. In such cases, sufficient numbers of grafts must be left in reserve to permit the future treatment of these areas, unless an "isolated frontal forelock" is the ultimate goal.

In Unger's study of 328 males older than 65 years, he delineated an area within the zone of rim hair that contained 8 or more hairs per 4-mm circle.[4] He referred to this as the "safe" donor area; later to the "safest" donor area (SDA). For most patients, the equivalent of 3 to 5 strips, each of which is 10 mm, can be excised from the SDA during their lifetime. Each of those strips produces 1500 to 2750 follicular units (FUs) (Fig. 217-3), depending on the density of the donor hair. Current methods of follicular unit excision (FUE) allow slight expansion upon Unger SDA, although *not* as extensively as some practitioners are claiming.

PATIENT SELECTION

During the initial consultation, surgeons must clarify whether the hair loss is temporary or responsive to medical treatment. Dermoscopy may be a very useful method to evaluate the underlying etiology of hair loss.[9] A comprehensive discussion of this subject is available elsewhere in this textbook. Provided

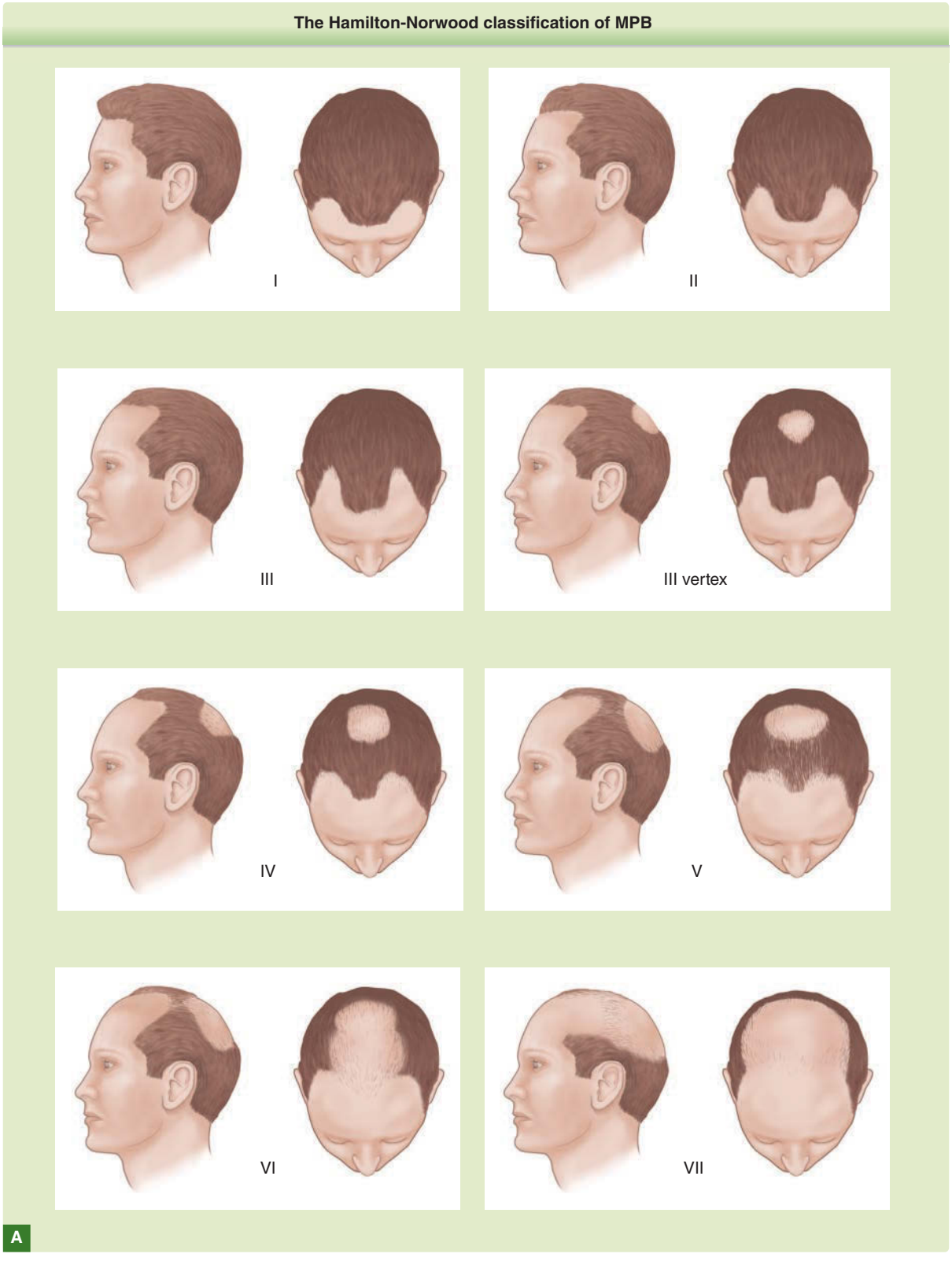

Figure 217-1 **A,** The Hamilton-Norwood classification of MPB. **B,** The Norwood classification for Type A variant MPB. **C,** Ludwig pattern of hair loss in females.

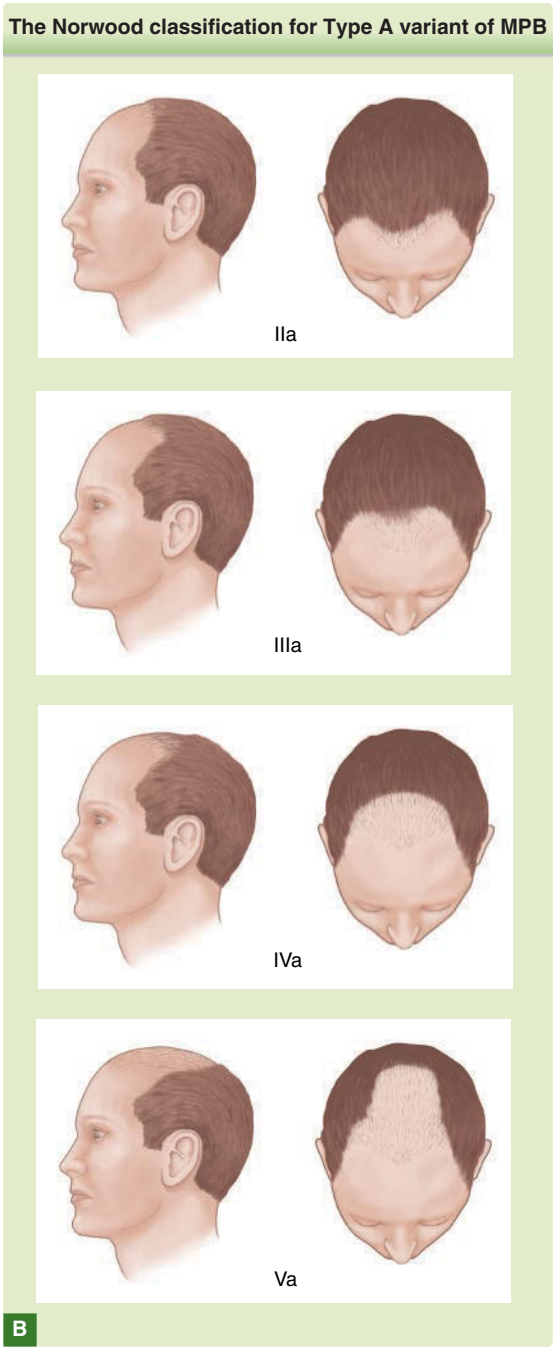

Figure 217-1 (*continued*)

this is not the case, the first step in the surgical evaluation of a patient is to assess the current and anticipated future size of the donor and recipient areas. An accurate assessment of the donor/recipient ratio depends on professional experience, the family history of patterned hair loss, and most importantly the patient's age. The second step is to evaluate hair characteristics. Table 217-3 lists the hair characteristics of the best hair transplant candidates. Not all of these characteristics are necessary for a satisfactory result, but each one improves the final cosmetic appearance.

The authors do not follow any strict rules on patient selection with respect to the stage of hair loss, age, or gender. For example, in regard to the stage of hair loss, it is important to note that the recipient area does not need to be completely alopecic to successfully operate. In fact, there are important advantages to transplanting at an earlier stage of MPB, although treating such areas demands a high degree of skill. Many surgeons have resorted to shaving the recipient areas for ease of surgery; the authors do not find this necessary and it certainly helps patients to seamlessly resume regular life shortly after surgery. Similarly, there are no definite age requirements, although younger patients, especially those under the age of 25, should have more conservative treatment plans. As part of this planning, such patients are encouraged to use medical treatment to delay or partially reverse the progression of MPB. In addition, surgeons should leave enough hair in the SDA to permit at least 1 future surgery in the event of unexpected areas of hair loss.

With respect to gender, it is worth mentioning again that women are more often than generally thought acceptable candidates for hair restoration surgery, despite the strong disagreement of a few surgeons. In an effort to discern the consensus opinion, the authors informally polled a group of leading experts in the field. From among this group, a majority (13 of 22) felt that more than 50% of women had enough donor hair to permit *at least* 1 transplant. In the authors' opinion, the percentage is even higher provided that the patient's expectations are commensurate with what is realistically possible given their anticipated eventual donor/recipient ratio and hair characteristics. A strategically planned surgery, with a focus on transplanting the frontal zone and part-line, usually produces a cosmetically significant improvement, and typically leaves female patients very satisfied.[10]

Although hair transplantation surgery is predominantly used to treat patients with MPB or FPHL, it also can be used to correct surgical scars, (Fig. 217-4), treat congenital areas of hair loss such as temporal triangular alopecia, and change hairlines. With appropriate care, it has also successfully improved areas of cicatricial alopecia such as end-stage central centrifugal cicatricial alopecia or areas of alopecia resultant from radiation therapy. Although predominantly used for the scalp, hair transplantation also can be performed on other sites such as the eyebrows and beard area in select cases.

TABLE 217-1
Hamilton Study of Incidence of MPB (Norwood-Hamilton Scale) by Age

	AGE (y)						
	18–29	30–39	40–49	50–59	60–69	70–79	≥80
Type I	110 (60%)	60 (36%)	55 (33%)	45 (28%)	29 (19%)	18 (17%)	12 (16%)
Type II	52 (28%)	43 (26%)	38 (22%)	32 (20%)	24 (16%)	20 (19%)	11 (14%)
Type III	14 (6%)	30 (18%) (3V)[a]	37 (20%) (15V)[a]	34 (23%) (15V)[a]	22 (15%) (10V)[a]	16 (16%) (7V)[a]	12 (16%) (8V)[a]
Type IV	4 (3%)	16 (10%)	15 (10%)	21 (9%)	17 (12%)	13 (13%)	9 (12%)
Type V	3 (2%)	10 (6%)	13 (8%)	15 (10%)	22 (15%)	13 (13%)	9 (12%)
Type VI	2 (1%)	4 (3%)	7 (4%)	10 (7%)	19 (13%)	11 (11%)	10 (13%)
Type VII	0	2 (1%)	5 (3%)	4 (3%)	16 (10%)	11 (11%)	14 (17%)
Total	185 (100%)	165 (100%)	165 (100%)	156 (100%)	149 (100%)	102 (100%)	77 (100%)

[a]Numbers in parentheses under Type III represent Type III Vertex individuals.

RISKS AND PRECAUTIONS

Before proceeding with surgery, the patient's physician is contacted to discuss any areas of major medical concern. Basic instruments and supplies needed for surgery are listed in Table 217-4. For safety, the operating room should be equipped with the medications and equipment needed for basic monitoring and advanced life support. Although rarely necessary, the authors prefer operating with an anesthetist or anesthesiologist when patients have significant underlying health risks, including serious cardiovascular conditions, certain respiratory problems, and seizure disorders. Table 217-5 presents a list of significant (but rare) potential intraoperative complications.

Whenever possible, the patient should also be free of all medications that may negatively influence bleeding or healing properties. This includes blood thinners such as acetyl salicylic acid, nonsteroidal anti-inflammatory medications, and natural supplements that may create bleeding problems such as garlic, and Ginkgo biloba. Patients are also encouraged to stop alcohol consumption 10 days before surgery as this may prolong bleeding time.

PATIENT POSITIONING

When removing the donor strip, the authors' patients are placed in a prone position, with their head in a "doughnut" ("prone") pillow that allows them to breathe comfortably. During the creation of the recipient sites and the insertion of the grafts, patients remain in a semisupine position except when working on the inferior portion of the vertex, in which case a prone position facilitates the work of both the surgeon and technicians.

TABLE 217-2
Unger Study of Incidence of MPB (Norwood-Hamilton Scale) in Men Older Than 65

	AGE (years)			
TYPE	65–69	70–74	75–79	80+
I	2 (3.6%)	5 (6.2%)	4 (5.5%)	2 (1.7%)
II	9 (16.4%)	7 (8.6%)	7 (9.6%)	12 (10.1%)
III	4 (7.3%)	15 (18.5%)	18 (24.7%)	11 (9.2%)
IV	10 (18.2%)	16 (19.8%)	8 (11.0%)	10 (8.4%)
V	6 (10.9%)	7 (8.6%)	10 (13.7%)	16 (13.4%)
VI	13 (23.6%)	19 (23.5%)	16 (21.9%)	37 (31.1%)
VII	11 (20.0%)	12 (14.8%)	10 (13.7%)	31 (26.1%)
Total	55 (100%)	81 (100%)	73 (100%)	119 (100%)

Note:

- In age group 65–69, if one excludes Type I and II, 33 of the remaining 44 (75%) have Types III–VI (83.3% Norwood);
- In age group 70–74, if one excludes Type I and II, 57 of the remaining 69 (82.6%) have Types III–VI (82.8% Norwood);
- In age group 75–79, if one excludes Type I and II, 52 of the remaining 62 (83.9%) have Types III–VI;
- In age group 80+, if one excludes Type I and II, 74 of the remaining 105 (70.5%) have Types III–VI (74.0% Norwood).

Figure 217-2 **A,** A 54-year-old female patient with significant hair loss in the hairline and temple regions. **B**, The same patient 2½ years after a session of 1248 FUs and 264 DFUs. The frontal view shows the effect that can be achieved for the overall appearance.

RECIPIENT AREA DESIGN[11]

On the morning of the surgery, a grease pencil is used to outline the treatment area. The frontal recipient area is designed by drawing the proposed hairline.



Figure 217-3 A relatively small number of single hairs emerge from the scalp. Most often, hairs grow in small groupings of 2 to 5, as shown in the above photo. These groupings are referred to as *follicular units*.

TABLE 217-3
Ideal Hair Characteristics

- High-density hair in the safe donor area
- A mixture of fine and coarse hair
- Minimal contrast between the skin and the hair color
- Wave or curl

The midline, anteriormost point of the hairline should be as superior as acceptable to the patient, but nearly always lies within the area in which the vertical forehead changes into the essentially horizontal caudal scalp.

The lateral borders are determined by outlining the supratemporal "humps"—semihemispheric areas containing only temporary hair and that are in the superior temporal areas (with the exception of those with existing Type VII MPB). Some of this area may or may not have initially persisting original hair but, regardless, should sooner (or later) usually be transplanted. The lateral ends of the proposed hairline are then joined to the supratemporal humps with a slight flare, to produce a rounded corner that creates a natural shape, but that usually leaves patients with a mature-looking hairline that includes frontotemporal recessions. In some patients, the anterior border of temporal hair is significantly receded, and it may need to be re-created at the same time as the anterior supratemporal humps are being transplanted. The posterior border of the frontal area is completed with an arc that helps create a natural pattern of hair loss in the event that the patient decides not to transplant any further posteriorly, or does not have sufficient donor hair to do so. When transplanting the midscalp, the posterior aspects of the supratemporal humps are included, and the posterior border of the transplant is similarly finished in an arc. For the vertex area, either the entire region or its anticipated eventual periphery can be transplanted, depending on the available donor supply and patient goals.

For less experienced surgeons, it may be useful to consider using a premade grid template with 1-cm^2 boxes to estimate the surface area of the target treatment area and use this to determine the number of grafts necessary to cover the proposed treatment area. This will also help the surgeon determine the ideal, achievable graft density.

DONOR AREA DETERMINATION

Choosing the optimal location and width of the donor strip is one of the most important decisions made during hair transplanting. For the first surgery, the authors typically choose a donor area that lies in the middle of the densest zone of the fringe hair, and extends into the temporal region in males, but ends posterior to the ears in females. This location is the

Figure 217-4 Transplanting hair to alopecic areas after a facelift procedure showing before (**A** and **C**) and after (**B** and **D**) photos.

most logical, because hair is progressively lost from the superior and inferior borders of the fringe hair in MPB, and hence this position provides the greatest degree of likelihood that transplanted hair is permanent. Each subsequent harvest includes any scar from prior session(s), as well as donor hair immediately superior and inferior to it. This results in the presence of only 1 scar, regardless of the number of sessions carried out (Fig. 217-5). To determine the location of the densest zone, it is sometimes helpful to wet the hair to determine the superior and inferior margins of current areas that are already thinning somewhat. Another useful adjunct that can be employed is a hand-held densitometer. This allows the practitioner to more objectively quantify the patient's donor density and estimate the total number of grafts that can be safely obtained from the donor area and help in the surgical planning. Once the donor area is identified, hair in a 10- to 18-mm-wide zone is clipped to approximately 2-mm length and cleansed with alcohol- and typically an iodine-based antiseptic. FUE harvest may be taken from a slightly expanded SDA, but the surgeon still needs to be wary of going too far outside of it. Subsequent harvests will result in the small punctuate scars becoming more numerous and closer together; thus, the surgeon needs to be particularly careful with choosing extraction sites location and density during the first and any subsequent harvesting in the same areas. To limit this problem, some FUE surgeons recommend "splitting individual multi-hair FU in vivo" with the punch being utilized; this technique has not yet been shown to produce good hair survival in both the recipient and donor areas.

DONOR SITE EXCISION[12]

Strip harvesting and follicular unit excision are currently the 2 main methods being used by hair restoration surgeons for the purpose of donor harvest (Fig. 217-6). In recent years, there has been a rising tide of hair restoration surgeons who are promoting the "superiority" and benefits of FUE. FUE in our opinion, however, remains optimally indicated in only a select group of patients, whereas strip harvesting remains a method that still has significant and more long-term proven benefits. In particular, the frequent promotion of FUE as

TABLE 217-4
Instruments and Supplies Needed in Hair Transplantation

INSTRUMENTS AND SUPPLIES	STRIP HARVESTING	FUE
Preoperative Surgical Planning and Setup		
▪ Aluminum rat tail comb	✓	✓
▪ Curved Metzenbaum scissors	✓	✓
▪ China marker grease pencil	✓	✓
▪ Prone pillow	✓	✓
Anaesthesia		
▪ Syringes (various sizes)	✓	✓
▪ Short-acting local anaesthesia (eg, lidocaine)	✓	✓
▪ Long-acting local anaesthesia (eg, bupivacaine)	✓	✓
▪ Epinephrine (1 in 100,000 dilution)	✓	✓
Harvesting Follicular Units		
▪ Double-bladed cutting knife handle	✓	
▪ No. 10 scalpel blade	✓	
▪ No. 15 scalpel blade	✓	
▪ Small curved surgical scissors	✓	
▪ Small straight Iris scissors	✓	
▪ Hyfrecator	✓	
▪ Smoke evacuation system	✓	
▪ Needle driver	✓	
▪ Suture material	✓	
▪ Toothed curved forceps	✓	
▪ Straight Adson forceps	✓	
▪ Stainless steel bowls	✓	✓
▪ FUE extraction devices (eg, manual punch, motorized device, robotic system)		✓
▪ Aid to Extraction instrument for FUE		✓
Processing and Storage of Follicular Units		
▪ Stereoscopic microscope with under-lighting	✓	✓
▪ Clear plastic cutting boards	✓	✓
▪ Double-sided razor blades	✓	✓
▪ Razor blade holder	✓	✓
▪ Divided Petri dishes	✓	✓
▪ Holding solution (eg, hypothermasol)	✓	✓
▪ Electric chilling device or ice packs	✓	✓
Recipient Site Creation		
▪ Hypodermic needles (18G, 19G, and 20G)	✓	✓
▪ Cut to size blades	✓	✓
Graft Insertion		
▪ No. 5 planting jeweler's forceps	✓	✓
▪ No. 2 jeweler's forceps	✓	✓
▪ Ring graft storage	✓	✓
▪ Implanters (used either as sharp implanter or for loading into premade sites)	✓	✓
▪ Magnifying loupes	✓	✓
Other Consumables		
▪ Gauze	✓	✓
▪ Telfa pads	✓	✓
▪ Kerlix dressing	✓	✓
▪ Povidone-iodine solution	✓	✓
▪ Hydrogen peroxide solution	✓	✓

TABLE 217-5
Major Intraoperative Risks

- Lidocaine toxicity
- Respiratory depression secondary to sedatives or narcotics
- Excessive intraoperative bleeding

"minimal incision surgery" is completely unwarranted (Table 217-6). Notwithstanding the preceding, it is the authors' opinion that all good hair restoration practices should include surgeons skilled in both techniques, and be able to offer both option to patients, after taking into account patient long-term donor/recipient area ratios, hair characteristics, and lifestyle.

Figure 217-5 The hair was clipped short in the donor area before the surgery. The narrow scar that can be seen in this photo is the only scar he is going to have as we typically excise any scar from a prior surgery as part of the subsequent donor strips. Scars are usually 0.2 to 1.5 mm wide regardless of the number of strips that have been excised. We believe that this is mainly because we nearly always try to choose strip widths that create wounds that that will close with what we call "minus 1" (-1) to minus 2 (-2) tension, that is, we believe we could have taken a strip that was 1.0 to 2.0 mm wider than what was actually excised.

Figure 217-6 FUE. **A,** The donor area is shown after suturing. **B**, The donor area shows the sites of extraction during FUE. **C,** At 6 months after surgery, the scars are not visible and the overall appearance of the donor is not different from before the FUE. **D,** Fully healed donor strip.

TABLE 217-6
FUE "Minimal Incision Surgery"?

	DONOR AREA	
	FUE punch (2000 0.9 mm diameter)	STRIP (24-cm strip length)
Total incision length	$2\pi r \times 2000$ sites 2000 (0.9 mm) diameter $(2 \times 3.14 \times 0.45) \times 2000$ = 565.2 cm	24 cm × 2 (sides) = 48 cm
Area of scar	$\pi r^2 \times 2000$ $(3.14)\ (0.45^2) \times 2000 = 12.72\ cm^2$	24 cm × 0.1 cm (at most) $= 2.4\ cm^2$

Typical strip harvesting produces a far smaller total incision length and total area of scar than does typical FUE when a 1 mm diameter punch is used for the latter. (If a 0.9-mm punch or 0.8-mm punch was used, the total incision lengths and area of scars would be, respectively, 565.2 cm and 12.71 cm^2 for the 0.9-mm punch and 502.4 cm and 10.048 cm^2 for the 0.8-mm punch). Yet FUE is often promoted as "minimal incision surgery"?!!

STRIP HARVESTING

Strip harvesting (also called the unified tissue harvest technique) is the most commonly employed method by the majority of hair restoration surgeons for donor harvest. This has been the mainstay for donor harvesting following the old punch graft harvesting methods, and has allowed large numbers of grafts to be taken from the densest region of the "safest donor area" while retaining a single linear scar that is typically unnoticeable when carried out by good hair restoration surgeons.

ANESTHESIA

Oral sedatives (eg, diazepam and lorazepam) are given to the patient approximately half an hour prior to commencing the surgery. In some patients who may have additional anxiety and have difficulty tolerating a prolonged procedure, an anesthetist or anesthesiologist can be employed to facilitate surgery with conscious sedation.

Once the donor area is identified and clipped, the surgeon proceeds with administering local anesthesia, usually 1% or 2% lidocaine with 1 in 100,000 epinephrine along the inferior and lateral edges of the clipped donor area. Subsequently, longer-acting anesthesia such as bupivacaine is administered before the initial lidocaine becomes ineffective.

STRIP REMOVAL

Effectiveness of the anesthetic block is verified directly prior to strip harvesting. Scalp laxity is clinically assessed to determine the appropriate width of the donor strip, which in the authors' practice is typically 8 to 15 mm wide and is usually wider in the middle section and narrower toward the temporal regions. A prudent decision is to take a *slightly* narrower strip than the examination suggests is possible, thus permitting a margin of error that will minimize the possibility of a high-tension donor closure, and hence production of a wider than optimal scar.

Immediately prior to donor tissue excision, the donor area is tumesced with 10 to 40 mL of normal saline. This increases tissue turgor, thereby minimizing bleeding, but also limiting distortion of the follicle that might otherwise result in FU transection. The authors typically use a single-blade scalpel to cut donor tissue parallel to the exit angle of the hair. Occasionally, if the follicles are particularly long, the superficial epidermis is scored and blunt dissection may be used to increase the depth of incision. The incision begins and ends approximately 2 cm lateral to the ends of the clipped donor area. To reduce the likelihood of "dog ears" forming, the 2 ends are tapered to a 30° angle using a No. 15 scalpel. The depth of the incision can vary significantly. In the first surgery, the blades are placed in high subcutaneous fat, to minimize underlying neurovascular damage. In subsequent surgeries, where fibrous scar tissue has formed deep to the original donor site, the depth of the incision may be increased to permit its removal. This is important because scar tissue is avascular, space occupying, and tethers the edges of the wound, thereby increasing donor closing tension and interfering with wound healing. At the same time, care is observed to prevent the creation of a depression in the tissue.

Importantly, the entire strip is removed in 3 sections, each sutured before reassessing scalp laxity in the remaining unharvested section(s). This provides greater control of bleeding and a more accurate guide to the optimal width of the next section of the strip to be excised. Vessels with exuberant bleeding are cauterized using a unipolar hyfrecator. The wound sections are closed either with a single-layer running suture or with a bi-layered closure. The bi-layered closure is typically employed if the authors feel that there is greater than optimal closing tension or if there is hyperlaxity in the scalp. In practice, the authors use an absorbable No. 3.0 PDS II suture for their subcutaneous interrupted sutures, and a No. 2.0 to 4.0 Prolene or Supramid for the superficial closing suture. Other surgeons sometimes close the donor site with staples, but at this point, the authors prefer sutures for greater precision in wound edge approximation, and a more comfortable postoperative patient experience.

Occasionally, the authors will employ a "trichophytic closure" to minimize scar visibility in individuals who have previously (and rarely) healed with a wider than usual scar or in patients who wear their hair very short and who have a strong contrast in the color of their skin and hair. In such instances, a very thin slice of the epidermis (<1 mm from the edge) on the inferior wound edge is removed prior to donor closure, using either

curved scissors or a bent razor blade. This creates a purposeful controlled transection of the upper portion of hair follicles, and when the 2 edges of the wound are apposed, most of these transected follicles will lie under the line of closure. If properly done, these hairs then grow *through* the middle of the donor scar, thus reducing the noticeability of scar tissue. The potential disadvantages of a trichophytic closure include temporary folliculitis, an alteration in the direction of hair growing through the scar, and a change in the density of hair follicles within the scar that could be more visible than a thin scar in patients who wear very short hair. It should also be avoided in patients with tighter than average scalps as it results in a minimal increase in wound tension (if the same width strip is taken).

FOLLICULAR UNIT EXCISION

FUE is an alternative method of donor harvesting and as mentioned earlier is widely gaining popularity among hair restoration surgeons and patients for a variety of reasons; in fact, many young surgeons use only this method of harvesting. Using this technique, each individual FU is harvested directly from the scalp, rather than from a strip of donor tissue.[13,14] FUs are excised using a small, sharp cylindrical punch (generally 0.8-1.2 mm in diameter), which superficially incises the skin around each FU. The FU can then be carefully removed with forceps and gentle traction. The donor wounds are left to heal by secondary intention over the course of 7 to 10 days, finally leaving multiple small white scars over the harvested area.

On the one hand, this technique offers distinct advantages. Most importantly, it does not leave a linear scar. The resultant punctate scars are minimally noticeable, even with the hair closely cropped (Fig. 217-7). Thus, this is a useful procedure for individuals who want to wear exceptionally short hairstyles, those who have a tendency to heal with wider scars, and patients with a strong dislike or fear of linear scars. It is also an excellent technique to provide additional grafts after strip harvest surgery is for variable reasons no longer a good option. On the other hand, FUE is associated with important disadvantages. Chief among them, if a patient is destined to develop greater than Type V MPB, and therefore will need more than 6000 transplanted FUs; many of these grafts would need to be harvested from areas outside the boundaries of the SDA (Fig. 217-7). This is because in most patients FUE involves the extraction of every third or fourth FU (depending on patient ages, donor hair density, caliber, color contrast with the skin, etc.), and therefore the donor area would have to be 3 to 4 times as large as the donor area required for strip harvesting and would necessitate extension beyond the SDA. The hair within many of these FUs is therefore less likely to be permanent and may ultimately disappear in the future. Also, as the fringe hair beyond the SDA is progressively lost and/or miniaturized, the small hypopigmented scars from the FUE harvest may become exposed. In a worse-case scenario, overharvesting could result in a moth-eaten appearance that is difficult to rectify.

Equally important to consider are the transection rates during graft harvesting. Most hair restoration surgeons who practice both strip harvesting and FUE still find that transection rates are higher for FUE than for strip excision. Although improvement in FUE instrumentation has led to a significant decrease in FUE transection rates compared to its early days, there is still skepticism regarding equivalent transection rates in FUE reported by some practitioners.

Figure 217-7 **A,** This is an intraoperative photo of a patient who had a linear scar from prior conventional strip harvesting, and who was undergoing FUE with the intention of placing grafts within the linear scar, and in areas of alopecia. The FUE was carried out by another surgeon. The round holes are the sites of FU extraction. The superimposed rectangle outlines the safe donor area (SDA). Many of the FUE sites were outside of the SDA, and the hair in these harvested grafts will likely be lost with time as MPB progresses. **B,** A photo taken 9 months postoperatively demonstrates the most important, immediately recognizable advantage of FUE, namely, the ability for the patient to cut the donor area to any length without visible scarring. The previous linear scar has been effectively concealed with grafting.

In FUE, each FU is at risk of transection when it is extracted blindly from the scalp. In contrast, in strip harvesting, only grafts at the edges of the strip are vulnerable, because other FUs are prepared with magnified, direct visualization (see below). Also, the FU grafts obtained through FUE tend to be more skeletonized with less surrounding supportive tissue. Contrast this with the grafts that are created from strip harvesting, which tend to have more protective tissue surrounding each follicle (Fig. 217-8). This is believed to lend greater protection to the FU and is likely to contribute to higher survival rates and hence better growth from strip harvest surgeries. The use of implanters, which minimize handling of grafts, may help minimize the trauma associated with implanting FUE grafts and improve their survival. As of this writing, there are very few survival studies to assess the growth of FUE grafts, and the few that have been completed indicate lower survival.[15]

FUE also may be suggested on occasion as a first surgery in the occasional young patient who wants to preserve the option of stopping hair transplants and switching to a short "buzzed look." The authors most often recommend FUE be used to complement strip harvesting, not to replace it, except in select patients for whom the benefits outweigh the drawbacks. In particular, FUE may be helpful in thinning the bushy temple regions in some patients and it can be utilized to obtain FU for placement into linear scars produced by strip harvesting. This is desirable when the scar is wider than average or when no further strip harvesting is planned. Such an approach combines the main advantage of strip harvesting—the maximization of the number of permanent hairs that can be harvested via the strip method—with the main advantage of FUE, the lack of a linear scar. For this purpose, we recommend that patients with a poorer prognosis (ie, MPB Type VI or VII) start with sessions using strip harvesting followed by FUE. This will maximize the number of available permanent hairs for harvesting over the patient's lifetime. In some situations, a combination approach with both a strip harvest and FUE also can be carried out on the same day in select patients. This approach is employed when the patient has had previous surgeries that have resulted in a tight, limited donor area due to underlying scarring, as performing FUE around the strip harvest scar can theoretically help in increasing the laxity of the scalp. Additional points of comparison between FUE and strip harvesting are outlined in Table 217-7.

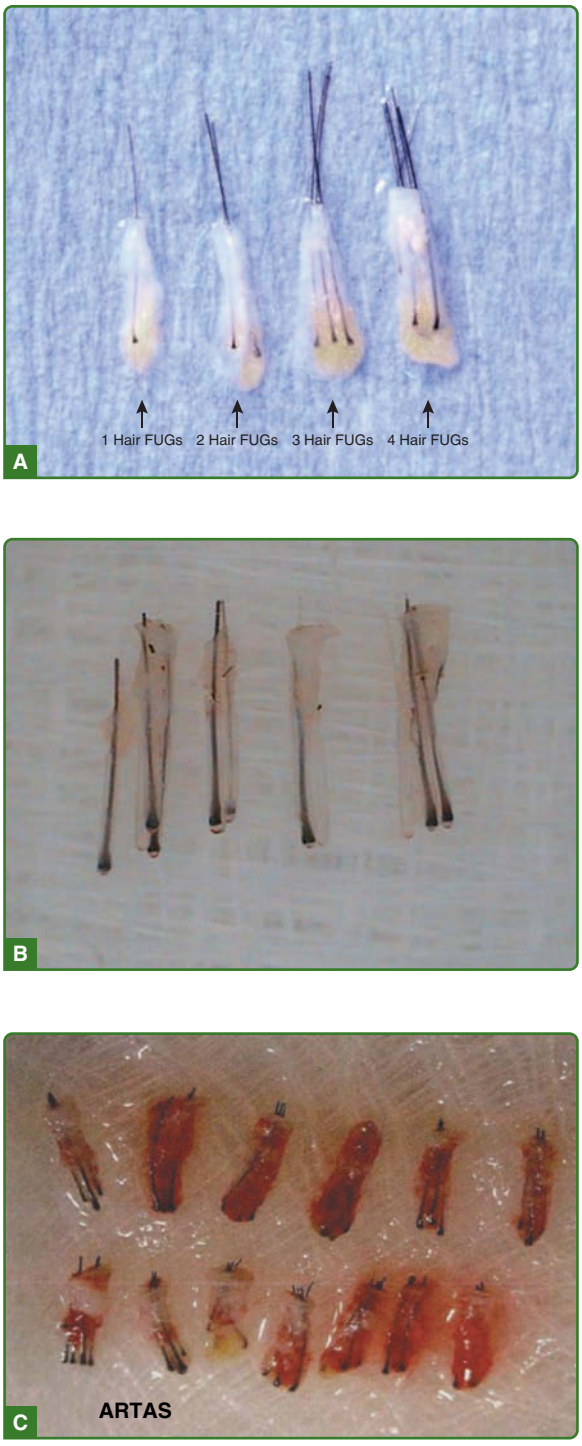

Figure 217-8 Comparison of grafts obtained through 3 different techniques. **A,** Grafts are harvested using the strip method. The grafts are trimmed into a " tear drop " shape preserving the appendages and leaving enough fat tissue to protect the follicle. **B,** Grafts are harvested by FUE using a motorized punch. Grafts are skeletonized and "naked," losing their accompanying appendages and devoid of fat tissue for added protection. Note also that there is a more than desired amount of epidermis that needs to be trimmed, which makes the grafts more skeletonized. **C,** Grafts harvested by FUE using the ARTAS robot.

ANESTHESIA

Just like in strip harvesting, oral sedation is given on the morning of the surgery and local anesthesia is employed by way of a ring block around the determined harvest area once this area is shaved and cleansed with usually povidone iodine.

TABLE 217-7
Advantages And Disadvantages Of Follicular Unit Extraction

Advantages
- Reduced postoperative pain
- Fairly rapid donor healing
- Fewer limits on postoperative activity, which is beneficial for patients who need a quick return to activity
- No suturing required
- Absence of linear scar
- Ideal for patients who prefer to wear their hair short (<2 mm)
- Ability to selectively choose FUs according to desired size or texture
- Ability to utilize body hair in patients with insufficient scalp donor hair
- Ideal for donor scar repair
- Requires a smaller team of technicians

Disadvantages
- Difficult to obtain large numbers of grafts without exceeding the limits of the safe donor area
- Higher follicular transection rates
- Skeletonized grafts with potentially lower survival rates due to increased vulnerability and trauma during placing
- More difficult postoperative camouflage because hair needs to be shaved short for harvesting of significant number of grafts
- Longer operative times
- Scarring of donor area makes subsequent FUE sessions more challenging and limited

INSTRUMENTATION AND ROBOTICS

FUE is a surgeon (and his or her surgical team) AND instrument dependent procedure and there are an increasing number of devices that are being developed to increase both efficiency as well as accuracy of the method. A range of instruments have been developed and marketed, from simple manual FUE punches to motorized FUE devices (with a variety of distinguishing features ranging from whether a sharp or dull tip is employed, to whether the device uses a rotatory head or an oscillatory head) and entire robotic systems.[16] The most important properties of the instrument chosen include the amount of surrounding tissue left intact around the grafts, the rate of transection, the size of the resultant punctuate scars, and flexibility in tissue characteristics. It is difficult to find a good objective overview of the benefits and drawbacks of each instrument but, fortunately, as with all innovations, the field continues to evolve.[17]

BODY FUE

Body to scalp FUE can be used if the patient has insufficient donor hair in the scalp. The highest growth rates have been observed in hairs harvested from the beard and chest areas. However, the hair in these areas have different growth rates than from scalp and also has a different curl and caliber/coarseness. Hence, it is not recommended for transplantation into the hairline area, which is more visible and should be created using fine scalp hair. However, the body hair can be mixed posterior to transplanted scalp hair to lend increased density, or to camouflage scars.

GRAFT PREPARATION

STRIP HARVESTING

The preparation of grafts from a strip harvest is accomplished using either stereoscopic microscopes or magnifying loupes or glasses. After removal of a donor strip, the first step is "slivering" the donor strip, in which slices, one FU wide, are carefully produced from the strip, much like cutting a loaf of bread into individual slices. These "slivers," composed of 4 to 10 FUs, are then further divided into individual FUs. FUs naturally occur in clusters of 1 to 4 hairs, with the average white FU containing an average of 2.3 hairs (other races usually have lower hair density, and hairs/FUs as well as different hair characteristics described elsewhere in this chapter). Occasionally, 2 very closely spaced FUs are combined into an individual "follicular family" (FF) small enough to fit into a typical FU recipient site. Compared with larger multi-FU grafts, FUs and FFs are far more susceptible to injury during graft preparation, storage, and insertion.[18] Therefore, technicians must have thorough and prolonged training, excellent manual dexterity, and ongoing supervision.

The ideal FU has most of its epidermis removed and is tear shaped, with the tapered end near the epidermis and the bulkier end in the subcutaneous tissue (Fig. 217-8A). This results in an FU wherein the dermal and subcutaneous tissue remains surrounding the follicle isthmus, hair bulge, and dermal papilla. The donor tissue is kept moist at all times, and prepared FUs are stored in a sectioned Petri dish filled with a storage solution.[19] It is important to ensure that the grafts remain cool throughout the procedure; hence the Petri dish constantly rests on icepacks or an electric chilling device. Within the sectioned dish, FUs are distributed into labeled compartments depending on the number and caliber of hairs. In this way, the individuals planting grafts can immediately find the type of graft that they need for a particular recipient site. Hairs that are partially transected are not discarded, provided that the distal two-thirds or proximal half is intact. They are, however, placed in less cosmetically important regions, because hair growth from these grafts is unpredictable.

FOLLICULAR UNIT EXCISION

As individual units are harvested directly from the donor area, processing of the grafts typically involves primarily removing damaged follicles from partially

transected FUs, as well as segregating the FU according to number of hair follicles.

GRAFT STORAGE

Today, hair transplantation surgery is largely a full-day procedure as larger sessions involving thousands of small grafts have replaced the smaller older sessions involving far fewer and larger grafts. As such, it is important to ensure graft viability by storing them in the best possible way once they are out of the body. The technical team must ensure that the grafts remain moist and chilled from the point of harvesting to the point of graft insertion. Survival of transplanted grafts has been found to decrease over the length of time that they are out of the body, with negative factors being ischemia-induced hypoxemia, adenosine triphosphate (ATP) depletion, and ischemia-reperfusion injury. There are various types of storage media being developed, and practitioners are increasingly using hypothermic tissue–holding solutions (eg, HypoThermosol) to replace intravenous fluids (eg, lactated Ringer). Some practitioners also add liposomal ATP to the holding solution as ATP depletion has been found to negatively influence graft survivability.[20]

RECIPIENT SITE CREATION[22]

Recipient sites are created using hypodermic needles or small blades cut to match the size of grafts. Prior to the creation of recipient sites, local anesthesia typically using 1% lidocaine with 1 in 100,000 epinephrine, is administered as a ring block surrounding the area to be treated. As necessary subsequently, a 1 in 50,000 epinephrine solution or normal saline is injected intermittently and superficially into the recipient area to provide better hemostasis. Such infiltration offers the additional advantage of spreading any existing recipient area hairs farther apart, thus minimizing the risk of injury when making incisions. Furthermore, as the solutions dissipate, the recipient sites move closer together, which ultimately produces higher hair density.

The authors stress that all incisions should be made at the same angle and direction as any persisting terminal or vellus hairs (Fig. 217-9). Much of the art of hair

Figure 217-9 Transplanting hair to areas with preexisting hair. **A** and **C** show the areas with preexisting hair before the surgery and the result after transplanting as shown in **B** and **D**.

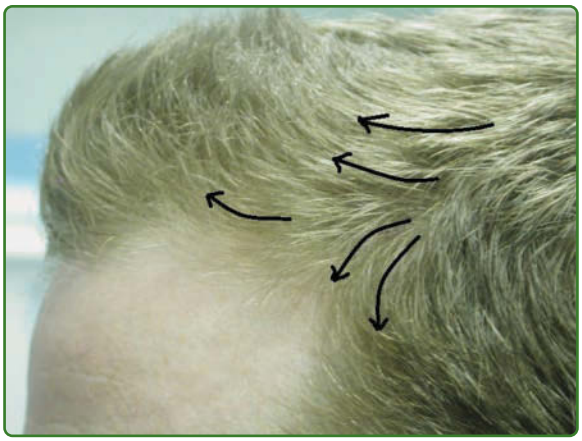

Figure 217-10 Although various directions and angles of hairs in different areas have been described, none of these generalities apply to all patients. Hair directions and angles can change dramatically in relatively small areas. The surgeon should follow what he or she observes rather than any general rule concerning hair angle and direction.

transplanting resides in the ability of the surgeon to do this, as both angle and direction vary considerably from patient to patient, and between different areas of the scalp. If one fails to do this, the resultant appearance will be unnatural and preexisting hair in the recipient area can be lethally damaged. Therefore, recipient site creation should be done slowly and carefully to ensure accurate angling and direction (Fig. 217-10). Typically, it will take between 1½ and 2½ hours to make 2000 to 2500 sites, depending on the density of preexisting hair in the recipient area and the amount of bleeding.

Recipient sites also can be created in either a perpendicular (coronal) or parallel (sagittal) fashion, relative to the hair direction and angle. The authors typically make most sites in a sagittal fashion and create coronal sites in temporal areas and in eyebrows, where it is ideal and natural to have the transplanted hairs lie flat.

GRAFT DENSITY

If hair survival is high, a density of 20 to 30 FUs/cm^2 produces very good cosmetic results while preserving donor hair for future areas; consequently, this is the density that the authors prefer (Fig. 217-11). Higher-density grafting is limited to small cosmetically strategic areas of the recipient area, including an oval area in the anterior midline of the frontal area. Greater density in this particular area gives an impression of higher density across the entire frontal area. The authors believe that it is a significant mistake to create an overly dense hairline, which is not natural, and that better results can be achieved by creating a higher-density area behind the anterior hairline. The hairline should also be created with macro- and micro-irregularities to create a natural appearance and not a too straight and dense line that does not occur in nature.

Figure 217-11 **A,** Before. Objective was more hair but subtle enough to increase likelihood of not being noticed by others. **B,** 12 months after 1 session at 15 to 20 cm^2.

A second reason for grafting at 20 to 30 FUs/cm^2 is that most studies on hair survival have demonstrated a tendency for unacceptable decreases in hair survival at higher FU densities, especially when the total incision length exceeds 3.0 cm/cm^2.[21-23] In part, this is because of increased competition for a limited blood supply and also may be because higher densities require smaller recipient sites and, therefore, more graft handling. Although hair survival at high FU densities has improved substantially in the last few years, good cosmetic results can be achieved with 20 to 30 FUs/cm^2 (Fig. 217-12), and thus higher densities are reserved for individuals with small areas of alopecia and publicly visible professions. For other individuals, especially younger patients with uncertain long-term donor/recipient ratios, it is often an inappropriate use of a limited resource. The authors believe that it is important to create a natural appearance with maximal cosmetic improvement using the minimum number of hairs to meet the patient's density objectives (Fig. 217-13). This approach will allow the hair restoration surgeon to treat more of the alopecic areas that will develop

Figure 217-12 **A, B,** and **C,** A patient before treatment (**A** and **B**) and 9 months after the second of 2 transplants (C)—the first to the frontal area and the second to the midscalp area with a total of 3864 FUs and a relatively low density of approximately 20 to 30 FUs/cm^2. **D,** A frontal view of the same patient taken at the same time as **C**. Note that the hair appears thicker in this view than in **C**.

over the patient's lifetime, rather than depleting the patient's finite number of donor grafts by overcommitting to a higher density than is required.

With regard to "mega-sessions" of 3000 to 5000 FUs, it should be pointed out that the average recipient site is 1 mm long, and while 1 mm seems quite small, the *total* length of a 3000-, 4000-, or 5000-graft session is respectively 9.99, 13.33, and 16.67 ft. Obviously, the larger the area treated, the more worrisome any given number of incisions and the resulting vascular damage. It seems reasonable to be cautious about creating 10 to 16 ft of incisions on the scalp until high hair survival rates in such sessions have been confirmed.

To determine the optimal size of the recipient site, several grafts containing varying numbers of hairs are tested in different sized incisions. The needle or blade size is adjusted accordingly. In general, the hair restoration surgeon should try to create the smallest recipient sites into which the grafts can be easily placed as this minimizes vascular disruption. Typically, 1-hair FU and fine 2-hair FU fit into sites made with 20-G needles, higher caliber 2-hair FUs fit into 19G sites, and 3- and 4-hair FUs fit into sites made with 18-G needles. On the other hand, the ideal graft fit is one that is "snug," and not made too small and tight to require significant handling during insertion. Though a mixture of 1, 2, and 3 or more hairs is used in all areas, in general, sites for 1 or 2 fine-haired FUs are created in the hairline zone, and sites for 2 or 3 coarse-haired FUs are created in areas that need greater hair density.

GRAFT INSERTION

After the recipient sites have been created, the surgeon reviews with their assistants the locations where the various sized FUs should be placed. Usually, 2 or 3 technicians work on a single patient simultaneously. Prior to graft insertion, platelet-rich plasma (PRP) and ACell is injected into the recipient sites and a small amount of the mixture is reserved for bathing grafts in before their placement. A group of grafts is removed from the fluid-filled wells of the Petri dish, placed in a "ring" filled with PRP and ACell on the finger, and from there placed in its recipient site. In this way, grafts are kept constantly moist. The skilled technician minimizes trauma to the follicles by handling only the subcutaneous tissue along the base of the graft rather

Figure 217-13 The "Christmas tree" pattern of hair loss as described by Olsen. Before surgery and after 1 surgery in a patient with a limited donor density. Concentrating grafts along the part-line and frontal block created an excellent cosmetic improvement.

than the grafts themselves. The long axis of each incision tells the technician the direction in which the graft should be inserted, and the graft typically slides in easily at the angle with which the site was made with 1 or 2 swift movements. The recipient area is kept clean by regularly spraying a mixture of saline (90%) and peroxide (10%), and the grafts are left slightly elevated to help in identifying sites that have not yet been filled. At the end of the procedure, grafts are repositioned to the level of the epidermis, or left slightly elevated, but never below the skin surface as this can cause pitting, or depressions, in the perifollicular skin.

HAIR IMPLANTERS

In some countries, for example Korea, the use of hair implanters has largely replaced the forceps technique of placing grafts. When used properly, hair implanters enhance graft viability by minimizing mechanical trauma to the follicle because the graft is pulled into the device by grasping its hair(s) and the crucial hair bulge and dermal papilla are not touched while loading the implanters as well as during implantation. Furthermore, some implantation devices enable the surgeon to simultaneously place the grafts into the sites as they are being made by the implanter, thus reducing the overall time for the procedure.

Because FUE grafts are both more skeletonized and vulnerable to trauma, some practitioners believe that using hair implanters in FUE cases has a significant advantage since the implanters not only fit more easily into the hollow needle of the implanter than into the skin, but their use also concurrently minimizes graft trauma during handling. Some physicians also find greater success rates when using implanters in Asian patients than in patients of other races. This could be because, as noted earlier, the Asian hair shaft diameter is generally greater than in whites and straighter, making it easier to properly load into the implanter. Implanters will likely develop further and become more important for all types of hair in the near future.

REPAIR SURGERY

The appearance of the recipient area of patients who have easily visible, unnatural grafting from prior surgeries, in particular from multi–follicular unit (MFU) grafting, can be greatly improved with modern hair transplanting techniques, primarily by placing FUs anterior and peripheral to these larger grafts.[24] If FUs with too many hairs or too coarse hairs have been inappropriately placed

in the hairline zone, these can be dealt with similarly, by surrounding them with properly selected FUs. For larger grafts, the excision of all or a portion of any larger grafts also may be useful in minimizing "plugginess," while providing additional hair that can be transplanted elsewhere in the recipient area (Figs. 217-14 and 217-15). For patients in whom poor planning resulted in the unnatural placement of grafts, for example, a hairline that is too far anteriorly, the grafts can be excised either individually or by employing an "en bloc" excision.

In the donor area, multiple rows of scarring can often be reduced by excising a strip of tissue that contains 2 rows of scar tissue and an intervening zone of hair-bearing skin. This converts 2 scars into a single scar, while providing additional hair for use in the recipient area. It is important, however, that the removed strip is not so wide as to prevent a tension free closure. Alternatively, donor scarring can be improved by transplanting FUs, often obtained via FUE, into abnormally wide scars.

Figure 217-14 **A,** This 39-year-old patient had an "FUT" procedure carried out by another physician 3 years before this photograph was taken. A number of errors have been made. These included a failure to transplant into evolving areas of hair loss, and the placement of grafts that contained too many hairs, or too coarse a texture, in the hairline zone. The black crayon outlines the area that we proposed to treat. **B,** The patient returned 9 months after his first repair consisting of 1973 FUs. A new hairline had been created using finely textured 1- and 2-haired grafts. The rest of the frontal area was repaired by surrounding prior grafts with FUs, and by extending the transplant into adjacent areas of evolving hair loss. A third session, this time to the midscalp, was carried out 2 months after this photo was taken.

Figure 217-15 **A,** This patient had a procedure done by another surgeon using round grafts. The grafts contained too many hairs, and too many coarse hairs are seen especially in the hair line zone. Another hair transplant procedure was done using the strip method to correct the hairline and add density to the scalp extending the treatment to areas of possible future loss. **B,** The patient is seen after 1 year showing refined hairline and increased density of hair and coverage of the scalp.

SIDE EFFECTS AND COMPLICATIONS

The potential side effects and complications of hair restoration surgery are listed in Table 217-8.[25] Below we elaborate on a few of them:

1. Edema: Severe postoperative edema is unusual, but can be unsightly if it occurs in the frontal region, or interfere with healing if it occurs in the donor area. The risk is minimized by prescribing perioperative corticosteroids, by proper postoperative patient positioning, and by using ice compresses adjacent to but not on the actual operative sites.
2. Infection: Although rare, infection can present as early folliculitis in the recipient area, or more seriously wound dehiscence in the donor area. A number of measures such as prophylactic perioperative antibiotics reduce the risk of superficial surgical site infection.

TABLE 217-8
Side Effects and Complications

Side Effects
- Minor bleeding
- Scalp hypoesthesia
- Edema
- Crusting
- Pruritus
- Postoperative telogen effluvium

Medical Complications
- Wound Infection
- Wound dehiscence
- Neuralgia and neuromas
- Arteriovenous fistulas
- Central recipient area necrosis
- Folliculitis

Aesthetic Complications
- Visible scarring
- Hypertrophic and keloid scarring
- Unnatural appearance
- Poor density

3. Bleeding: Minor donor area bleeding can occur in the first few days postoperatively. Usually this resolves with firmly applied pressure, but rarely extra suturing is required.
4. Donor area scarring: In the authors' office, significant attention is given to measures that minimize the likelihood of wide donor scarring: the wound is closed with the absolute minimum of tension; postoperative edema is minimized through the aforementioned measures; and postoperative care is meticulous. Although this prevents wide scars in most patients, intrinsic poor wound-healing characteristics and severe scarring from old surgeries can result in wider than average scars. In such situations, grafts harvested from FUE can be transplanted into the scar, or alternatively trichophytic closures or double-layer suturing can be carried out during subsequent strip excisions.
5. Poor density: This may reflect poor hair survival, suboptimal graft distribution, or poor postoperative care. This problem is probably entirely avoidable.
6. Postoperative effluvium: This problem may occur in hair-bearing areas in the recipient or donor areas. It is presumably due to the interruption of blood supply and is always temporary. Approximately 10% to 20% of male patients and 50% of females experience some degree of postoperative effluvium.

PATIENT FOLLOWUP

In the authors' practice, all patients are seen the day after surgery for bandage removal. The hair and scalp are thoroughly washed and the occasional dislodged graft can be adjusted. Postoperative instructions are also reviewed at this point and a clean cap is used to cover the surgical area before sending the patient home. Unless contraindicated, the patients in our practice are also given a tapering course of oral corticosteroids to minimize postoperative swelling.

All patients are seen 8 to 12 days postoperatively to check the surgical area and remove sutures. A followup appointment is also generally booked for 4 to 6 weeks postoperatively to check that healing is progressing along the normal course and again at 9 to 12 months to assess the surgical results and determine any need for further treatment.

ALOPECIA REDUCTION

Alopecia reduction, or scalp reduction, is defined as the excision of an area of alopecia or future alopecia.[26] In the past, the technique was used in conjunction with hair transplantation as a means of reducing the size of the prospective recipient area, and thus conserving grafts for cosmetically vital areas of the scalp. Unfortunately, the technique is technically demanding, and the high frequency of medical and aesthetic complications, in inexperienced hands, led to the procedure falling out of favor. Currently, the technique is used to repair aesthetically unsatisfactory hair transplanting, to excise areas of cicatricial alopecia, or for hairline advancement.

Despite the cosmetic improvement offered by the procedure, alopecia reduction is rarely used and it does come with its own set of complications. These include postoperative bleeding, infection, nerve damage, persistent hair thinning or loss in the fringe areas, disorientation of hair direction, stretch back, and poor scars which can all be minimized if the procedure is done properly.

CONCLUSION

The evolution of hair transplanting, over the last 10 to 15 years, has resulted in a remarkable increase in the number of patients who are candidates for the procedure and an even more impressive improvement in the naturalness of the results. Unfortunately, these new techniques also require far more skill and patience from not only the surgeon but also their surgical team. Additionally, hair restoration surgeons are not miracle workers, and individuals must be educated as to what they can realistically expect from hair transplanting. When this is done, the reward is nearly always a satisfied and grateful patient.

ACKNOWLEDGMENTS

We would like to acknowledge Dr Mark A. Unger, who contributed to the version of this chapter that was included in the previous edition.

REFERENCES

1. Unger W, Shapiro R. Commentary on Russell Knudsen's effect of medical therapy on surgical planning. In: Unger WP, Shapiro R, eds. *Hair Transplantation*. 4th ed. New York, NY: Marcel Dekker; 2004:148-151.
2. Hamilton JB. Patterned loss of hair in men: types and incidence. *Ann N Y Acad Sci*. 1951;53(3):708-728.
3. Norwood OT. Classification and incidence of male pattern baldness. In: Norwood OT, Sheill R, eds. *Hair Transplant Surgery*. 2nd ed. Springfield, IL: Charles C. Thomas; 1984:3-14.
4. Unger WP, Cole J. Donor harvesting. In: Unger WP, Shapiro R, eds. *Hair Transplantation*. 4th ed. New York, NY: Marcel Dekker; 2004:301-334.
5. Ludwig E. Classification of the types of androgenetic alopecia (common baldness) occurring in the female sex. *Br J Dermatol*. 1977;97(3):247-254.
6. Olsen EA. Female pattern hair loss: clinical features and potential hormonal factors. *J Am Acad Dermatol*. 2001;4(3)(suppl 1):S70-S80.
7. Unger WP, Unger RH. Hair transplanting: an important but often forgotten treatment for female pattern hair loss. *J Am Acad Dermatol*. 2003;49(5):853-860.
8. Unger RH. Female Hair Restoration. *Facial Plast Surg Clin North Am*. 2013;21(3):407-441.
9. Tosti A. *Dermoscopy of the Hair and Scalp Disorders With Clinical and Pathological Correlations*. London: Informa Healthcare; 2007.
10. Unger WP. Unger's technique for anesthesia. In: Unger WP, Shapiro R, eds. *Hair Transplantation*. 4th ed. New York, NY: Marcel Dekker; 2004:250-254.
11. Unger WP. Planning and organizing the recipient area. In: Unger WP, Shapiro R, Unger RH, et al, eds. *Hair Transplantation*. 5th ed. New York, NY: Informa USA; 2011:106-152.
12. Devroye JM. An overview of the donor area. In: Unger WP, Shapiro R, Unger RH, et al, eds. *Hair Transplantation*. 5th ed. New York, NY: Informa USA; 2011:247-261.
13. Rassman WR, Bernstein R, McLellan R, et al. Follicular unit extraction: minimally invasive surgery for hair transplantation. *Dermatol Surg*. 2002;28(8):720-728.
14. Harris J. Conventional FUE. In: Unger WP, Shapiro R, Unger RH, et al, eds. *Hair Transplantation*. 5th ed. New York, NY: Informa USA; 2011:291-295.
15. Beehner ML. FUE vs FUT-MD: Study of 1,780 follicles in four patients. *Hair Transplant Forum Intl*. 2016; 26(4):160-161.
16. Rose PT, Nusbaum B. Robotic hair restoration. *Dermatol Clin*. 2014;32(1):97-107.
17. Devroye J. Powered FU. Extraction with the Short-Arc-Oscillation Flat Punch FUE System (SFFS). *Hair Transplant Forum Intl*. 2016;26(4):129, 134-136.
18. Beehner M. Comparison of survival of FU grafts trimmed chubby, medium, and skeletonized. *Hair Transplant Forum Intl*. 2010;20(1):6.
19. Cooley J. Ischemia reperfusion injury and graft storage solutions. *Hair Transplant Forum Intl*. 2009;13(4):121.
20. Cooley J. Bio-enhanced hair restoration. *Hair Transplant Forum Intl*. 2014;24(4).
21. Unger WP, Shapiro R. The hairline. In: Unger WP, Shapiro R, Unger RH, et al, eds. *Hair Transplantation*. 5th ed. New York, NY: Informa USA; 2011:372-372.
22. Mayer M, Keene S, Perez-Meza D. Follicular unit density and hair yield. Paper presented at: Annual Meeting of the International Society of Hair Restoration Surgery, Sydney, Australia; October 2005.
23. Beehner M. Studying the effect of FU planting density on hair survival. *Hair Transplant Forum Intl*. 2006; 16(1):247-248.
24. Vogel JE. Correction of cosmetic problems secondary to hair transplanting. In: Unger WP, Shapiro R, Unger RH, et al, eds. *Hair Transplantation*. 5th ed. New York, NY: Informa USA; 2011:473-478.
25. Cooley J. Complications of hair transplantation. In: Unger WP, Shapiro R, eds. *Hair Transplantation*. 4th ed. New York, NY: Marcel Dekker; 2004:568-573.
26. Marzola M. Alopecia reductions. In: Unger WP, Shapiro R, Unger RH, et al, eds. *Hair Transplantation*. 5th ed. New York, NY: Informa USA; 2011:483-489.

This page intentionally left blank

INDEX

Tables, figures, and boxes are indicated by an italic *t*, *f*, and *b*, respectively, following the page number.

1,25(OHD), 2307
2-Bromo-2-nitropropane-1,3-diol, allergic contact dermatitis from, 404
2-Nitroso-1-naphthol-4-sulfonic acid test, for cobalt, 403
2 × 2 tables, sensitivity and specificity, 46, 46*f*
3′ splice site, 292
3′UTR, 292
5-Fluorocytosine, for amebas, 3248
5-Fluorouracil (5-FU)
  for Bowen disease, 1871, 1871*t*
  for Darier disease, 884, 884*t*
  for extramammary Paget's disease, 1941
  pellagra from, 2214
  phototoxicity, 1658*t*, 1661–1662
5-Fluorouracil (5-FU), topical
  for actinic keratosis, 1864, 1864*t*, 1865–1866, 1865*t*
  for basal cell carcinoma, 1889
    prevention, with basal cell nevus syndrome, 1896
  for basal cell nevus syndrome, 1896
  for extramammary Paget's disease, 1941
5-Hydroxytryptamine reuptake inhibitors. *See also specific types*
  hyperhidrosis from, 1465
5-Methoxypsoralen (5-MOP), 3665, 3666–3667
  bathwater delivery, 3667–3668
5′ splice site, 292
5′UTR, 292
6,4-pyrimidine pyrimidone photoproducts, UV radiation damage, 275–276, 275*f*–277*f*
6-Mercaptopurine, pellagra from, 2214
8-Methoxypsoralen (8-MOP), 3664, 3665, 3666–3667. *See also* Photochemotherapy; Psoralen and ultraviolet A (PUVA)
  bathwater delivery, 3667–3668
  oral, 3668, 3668*t*
  topical, 3667
9-*cis*-retinoic acid. *See* Alitretinoin
13-*cis*-retinoic acid. *See* Isotretinoin
14α-demethylase, 3443
16S rRNA
  gene, 254, 258
  microbiome sequencing, 254
18S rRNA
  gene, 254, 258
  microbiome sequencing, 254
28S rRNA gene, 254, 258
30°-angle Webster flap, 3746, 3747*f*
45 XO, 299*t*
47 XXY, 299*t*, 303
47 XYY, 299*t*
48 XXYY, 299*t*
49 XXXXY, 299*t*

A

AAGAB, punctate palmoplantar keratoderma type I, 844
Abacavir, 3506–3507, 3509*t*
  severe cutaneous adverse reactions, 195, 195*f*
Abatacept
  for juvenile idiopathic arthritis, 1155
  for psoriatic arthritis, 1136*t*, 1137
  for rheumatoid arthritis, 1152
  for vasculitis, 2557
Abbé flap, 3751–3752
ABCA12, 211
  congenital ichthyosiform erythroderma, 791*f*
  Harlequin ichthyosis, 779*t*
ABCB4, intrahepatic cholestasis of pregnancy, 1770
ABCB6, dyschromatosis universalis hereditaria, 1325, 1327*t*, 1386
ABCB11, intrahepatic cholestasis of pregnancy, 1770
ABCC6, pseudoxanthoma elasticum, 1232, 2309
ABCC9, osteochondrodysplasia with hypertrichosis, 1564
ABCC11, bromhidrosis, 1469
ABCDE, melanoma, 1983, 1992, 1992*t*
Aberrant somatic hypermutation, 2098
ABHD5, Chanarin-Dorman syndrome, 803, 804*f*
ABL1, 3558
Ablative fractional resurfacing (AFR), 3835
  equipment, 3835*t*, 3836
    CO_2 laser, 3835
    Er:YAG laser, 3835
  technique, 3840
Ablative laser resurfacing, 3834. *See also* Laser, ablative
  equipment
    CO_2 laser, 3834, 3835–3836
    Er:YAG laser, 3834, 3835
    hybrid lasers, 3836
Abscess, 2395*t*
  CA-MRSA, 2725
  cutaneous, 2395*t*
  dental, nummular eczema, 386
  Munro microabscesses, 24
  nodular lymphocyte collections, 26
  S. aureus, 2724–2725, 2725*f*
  staphylococcal, 2724–2725, 2725*f*
Absorption bases, 3373*t*, 3374
Absorption factors, topical therapy
  application
    frequency, 3371
    quantity, 3371
  occlusion, 3371
  particle size, 3372
  rate, 3364
  rubbing or massaging, 3371–3372
  stratum corneum, 3370–3371, 3370*f*–3371*f*
ABT-510, antiangiogenesis, 3604*t*
Abuse, child. *See* Child abuse; Sexual abuse, child
Abuse, domestic, 1717–1724. *See also* Domestic abuse
Abuse, physical, 1717–1724
  at-a-glance, 1717*b*
  clinical course and prognosis, 1723–1724
  clinical features, 1718–1720
    distribution, 1719–1720, 1719*f*–1720*f*
    location, 1718–1719, 1718*f*
    morphology, 1718
  diagnosis, 1721–1722
  differential diagnosis, 1723, 1723*t*, 1724*t*
  epidemiology, 1717
  etiology and pathogenesis, 1720–1721, 1721*t*
  imaging, 1722
    fractures, 1722
    head injury, 1723
    visceral trauma, 1723
  laboratory testing, 1722
  management, 1724, 1724*t*
Acanthamoeba
  keratitis, 3248
  opportunistic infections, 3247–3248
Acanthaster planci, 3352
Acantholysis, 23, 23*f*
  dyskeratosis, 23, 23*f*
  pemphigus, 916–917, 918*f*, 921, 921*f*
Acantholytic disorders of skin, 877–892. *See also specific disorders*
  acrokeratosis verruciformis of Hopf, 884–885, 885*f*
  at-a-glance, 877*b*
  Darier disease, 877–884
  differentiating, 892*f*
  Grover disease, 890–892, 890*f*
  Hailey-Hailey disease, 886–890
Acantholytic epidermolysis bullosa simplex, 1017
Acantholytic squamous cell carcinoma, 1910, 1910*f*
Acanthoma fissuratum, 1806
Acanthosis
  condyloma acuminatum, 31, 31*f*
  epidermal cells, 21, 21*f*
  psoriasis, 24
  seborrheic keratosis, 31, 31*f*
  verruca plana, 31
  verruca vulgaris, 30, 30*f*
Acanthosis nigricans, 2441–2443
  acromegaly, 2519
  at-a-glance, 2441*b*
  clinical course and prognosis, 2447
  clinical features, 2441–2443, 2442*t*, 2447*f*, 2495, 2495*f*
    hypermelanosis, 1362–1363, 1362*f*

Acanthosis nigricans (*Cont.*):
Cushing syndrome, 2513
with diabetes mellitus, 2494–2496, 2495*f*
diagnosis, 2443, 2447
differential diagnosis, 2447
epidemiology, 2441, 2494–2495
etiology and pathogenesis, 2443, 2495–2496
historical perspective, 2441
management, 2447, 2496
Acaricides. *See also specific types*
for Lyme disease prevention, 3300–3301
Acarina, 3325*f*, 3328–3330. *See also specific types*
mites, 3329
ticks, 3329–3330, 3329*f*
Accutane, for lupus erythematosus, 1054*t*
ACE, allergic contact dermatitis, 192
ACE inhibitor–induced angioedema, 695, 699
ACE inhibitors. *See* Angiotensin-converting enzyme (ACE) inhibitors
Acetic acid
for green nail syndrome, 2795
for *P. aeruginosa*
folliculitis and hot-foot syndrome, 2796
otitis externa and perichondritis, 2796
Acetylcholine (Ach)
eccrine sweat gland, 80
sweat secretion, 82, 83*f*
Acid. *See also specific acids*
burn, 1683
Acid (LSD), 1711
Acitretin. *See also* Retinoid(s), oral
chemical structure, 3397, 3397*f*
for lichen planus, 544
for lupus erythematosus, 1054*t*
metabolism and pharmacokinetics, 3399
for psoriasis, 484*t*, 492
with HIV, 3122
Acitretin, oral
adverse effects, 3402, 3402*t*
for Darier disease, 884, 884*t*
for discoid lupus erythematosus, cicatricial alopecia, 1527
for ichthyosis, 783
indications and contraindications, 3400
for lichen nitidus, 558, 558*t*
for lichen planus, 546
for palmoplantar keratodermas, inherited, 821
for pityriasis rubra pilaris, 503
Acne
acute febrile ulcerative, 1449, 1450*f*
adolescents, 1757–1758
androgen-related, 2517
with endocrinology abnormalities
congenital adrenal hyperplasia, 1451–1452
polycystic ovarian syndrome, 1451
infantile, 1448, 1449*f*, 1732, 1733*f*
Mallorca, 1453, 1621, 1623*f*
microbiome, skin, 257, 257*t*
mid-childhood, 1448
neonatal, 1448, 1449*f*
from occupational exposures, 446
PAPA, PASH, and PAPASH syndromes, 1450
SAPHO syndrome, 1450
with solid facial edema, 1451
steroid, 1714
variants, 1448–1452 (*See also specific types*)
Acne aestivalis, 1453
Acne conglobata, 1448–1449
Acne excoriée, 1451
Acne excoriée des jeunes filles, 1451
Acne fulminans, 1449, 1450*f*
from isotretinoin, 1449–1450
Acneiform eruptions, 1452–1455. *See also specific types*
acne aestivalis, 1453
Apert syndrome, 1454
chloracne, 1452–1453
cytotoxic agents, 3482
drug-induced, 750*t*, 751, 752*f*, 1452, 1452*t*
EGFR inhibitor associated, 1452
glucocorticoids, 3390–3391
gram-negative folliculitis, 1453
occupational acne, 1452–1453
perioral dermatitis, 1454–1455, 1454*f*
pseudoacne of the nasal crease, 1454, 1454*f*
radiation acne, 1453
steroid folliculitis, 1452
tropical acne, 1453
Acne keloidalis, 2723
Acne keloidalis nuchae, 1530–1531, 1530*f*
Acne mechanica, 1451
Acne necrotiva, 1531
Acne rosacea. *See* Rosacea
Acne type sensitive skin, 3808–3809, 3808*t*, 3809*t*
Acne varioliformis, 1531
Acne vulgaris, 1391–1401
at-a-glance, 1391*b*
clinical course and prognosis, 1401
clinical features, 1392–1394
complications, 1392–1394, 1396*f*
cutaneous, 1392, 1393*f*–1395*f*
history, 1392
noncutaneous, 1392
diagnosis
laboratory testing, 1399–1400
pathology, 1400
differential diagnosis, 1400–1401, 1400*t*
epidemiology, 1391–1392
etiology and pathogenesis, 1394–1399, 1396*f*–1397*f*
Morbihan disease, 1451
Propionibacterium acnes, 1394–1395, 1398–1399
Acne vulgaris management, 1400*t*, 1401–1412
algorithm, 1401*t*
diet, 1409
isotretinoin, 1407–1409
local, 1402–1404
cleansing, 1402
topical, 1402–1404, 1402*t*–1403*t*
azelaic acid, 1403*t*, 1404
benzoyl peroxide, 1403*t*, 1404
dapsone, 1403*t*, 1404
erythromycin and clindamycin, 1403*t*, 1404
resorcinol, 1404
retinoids, 1402–1404, 1402*t*
salicylic acid, 1404
sodium sulfacetamide, 1403*t*, 1404
sulfur, 1404
nonprescription, 3808–3809, 3809*t*
in pregnancy, 1411–1412, 1412*t*
procedures, 1409–1411
chemical peels, 1410
corticosteroids, intralesional, 1409
dermabrasion, 1411
fillers, 1411
microneedling, 1411
phototherapy, 1410–1411
subcision, 1409
surgery, 1409
regimens and timing, 1401
systemic, 1404–1407
antibiotics and antibacterials, 1404–1406
bacterial resistance, 1405–1406
cephalexin, 1405
clindamycin and dapsone, 1405
macrolides, 1405
tetracyclines, 1404–1405
trimethoprim-sulfamethoxazole, 1405
hormonal, 1406–1407
antiandrogens, 1406–1407
glucocorticoids, 1406
gonadotropin-releasing hormone agonists, 1406
oral contraceptives, 1406, 1406*t*
Acoustic neuromas, 2154
Acquired bilateral nevus of Ota-like macules (ABNOM), 1357*t*, 1374–1375, 1375*f*
Acquired digital fibrokeratoma, 2483
Acquired elastosis perforans serpiginosa (AEPS), 1203–1209, 1204*t*. *See also* Acquired perforating disorders (APD)
Acquired generalized lipodystrophy, 1297*f*, 1301
Acquired idiopathic facial pigmentation, 1370–1371
Acquired idiopathic generalized anhidrosis (AIGA), 1466
Acquired immunodeficiency syndrome (AIDS). *See* Human immunodeficiency virus (HIV)/AIDS
Acquired partial lipodystrophy, 1297*f*, 1300, 1300*f*
Acquired patterned hypermelanosis, 1372
flagellate mushroom dermatitis, 1372
phytophotodermatitis, 1372
Acquired perforating collagenosis (APC), 1203–1209, 1204*t*. *See also* Acquired perforating disorders (APD)
Acquired perforating disorders (APD), 1203–1209. *See also specific types*
associations, 1205, 1207*t*
at-a-glance, 1203*b*
clinical course and prognosis, 1208
clinical features, 1203–1205, 1204*f*–1205*f*
cutaneous manifestations, 2438
definition and classification, 1203
with diabetes mellitus, 2502
diagnosis
histopathology, 1206–1207, 1206*f*–1207*f*
laboratory tests, 1207
differential diagnosis, 1207–1208, 1208*t*
etiology and pathogenesis, 1205–1206
management, 1208–1209, 1208*t*
secondary, 1203, 1204*t*
synonyms, 1203, 1204*t*
Acquired zinc deficiency (AZD), 2224
Acral Darier disease, 884–885, 885*f*
Acral digital fibrokeratoma, 2483
Acral distribution, 11
Acral erythema, from cytotoxic agents, 3483–3484, 3484*f*, 3484*t*
Acral hyperpigmented macules, 1372
Acral lentiginous melanoma (ALM), 1984*f*–1985*f*, 1986. *See also* Melanoma
Acral melanocytes, 332
Acral melanoma, 332
nail, 1606–1608, 1607*f*–1608*f*, 1608*t*
Acral peeling skin syndrome, 1015*t*, 1017
Acral pseudolymphomatous angiokeratoma of childhood (APACHE), 2122–2123, 2123*f*
Acral scleroderma, pterygium inversum, 1573
Acrivastine. *See also* Antihistamines, H_1
dosing regimens, 3454–3455, 3454*t*
Acrochordons, 1736
acanthosis nigricans, 2495, 2495*f*
acromegaly, 2519
Acrodermatitis chronica atrophicans (ACA), 3290–3292, 3291*f*, 3294*t*
Acrodermatitis continua of Hallopeau, 463
Acrodermatitis continua suppurativa of Hallopeau, nail involvement, 1580, 1580*f*

Acrodermatitis enteropathica (AE)
nail changes, 1597, 1597*f*
zinc deficiency, 2221*b*, 2224–2226, 2225*f*, 2225*t*
Acro-dermato-ungual-lacrimal-tooth (ADULT) syndrome, 2378, 2381–2382
Acrofacial vitiligo, 1331. *See also* Vitiligo
Acrokeratoelastoidosis of Costa, 844–847, 844*f*, 846*t*
Acrokeratosis paraneoplastica of Bazex, 2442*t*, 2451–2453, 2451*f*–2452*f*
pili torti, 1541*t*
Acrokeratosis verruciformis, cellular defect, 781*t*
Acrokeratosis verruciformis of Hopf (AKV), 884–885, 885*f*
Acroleic meningocele, 2166–2167, 2167*f*
Acromegaly, 2518–2519, 2518*f*, 2519*t*, 2520*f*
hirsutism, 1556*t*, 1559, 2519
Acromelanosis progressiva, 1377–1378
Acticoat, for burn wound care, 1686*t*, 1687
Actinic cheilitis, 1859, 1860*f*
Actinic dermatitis, chronic, 1639–1643
at-a-glance, 1639*b*
clinical course and prognosis, 1642
clinical features, 1640–1641, 1640*f*–1641*f*
complications, 1642
differential diagnosis, 1642*t*
epidemiology, 1639
etiology and pathogenesis, 1639–1640
laboratory tests
blood, 1641–1642
histology, 1641
patch and photopatch, 1642
phototesting, 1642
from photosensitivity, 1661, 1661*f*
prevention, 1643
treatment, 1643
Actinic elastosis, 283
keratoacanthoma, 32
pathology, 28, 29*f*
rosacea, 1427, 1434
squamous cell carcinoma, invasive, 32
Actinic granuloma, 566
Actinic keratoses (AK), 1857–1867
at-a-glance, 1857*b*
clinical course and prognosis, 1863
invasive squamous cell carcinoma progression, 317, 1857, 1862*f*, 1863, 1902
regression, 1863
clinical features, 1858–1860
actinic cheilitis, 1859, 1860*f*
classification, 1859–1860, 1860*t*
cutaneous horn, 6*t*, 1859, 1860*f*
dyskeratosis, 22
erythematous AK, 1858, 1858*f*
field cancerization, 1858, 1859*f*
hypertrophic AK, 1859, 1859*f*
spreading pigmented AK, 1858, 1858*f*
subtypes, 1858–1859, 1858*f*–1860*f*
diagnosis, 1861
dermoscopy, 1861
histopathology, 1861, 1863*f*
differential diagnosis, 1863
epidemiology, 1857–1858
etiology and pathogenesis, 1861, 1862*f*
cytotoxic agents, 3484
p53, DNA cell repair, 281
p53, UV mutations, 276
historical perspective, 1857
prevention
nicotinamide, 1867
retinoids, 1867
sunscreens, 1867
treatment, 1864–1867
cryosurgery, 3795
field-targeted therapies, 1865–1866, 1865*t*
imiquimod, 3595
lesion-targeted therapies, 1864–1865, 1864*t*
Actinic lentigo. *See* Solar lentigo
Actinic lichen nitidus, 555–556
Actinic lichen planus, 531*t*, 532–533
Actinic prurigo, 1628–1632
at-a-glance, 1628*b*
clinical course and prognosis, 1631–1632
clinical features, 1628–1629, 1629*f*
complications, 1629
definition, 1628
diagnosis, 1630, 1630*f*
diagnostic algorithm, 1630, 1631*f*
differential diagnosis, 1630–1631, 1631*t*
epidemiology, 1628
etiology and pathogenesis, 1629–1630
historical perspective, 1628
management, 1632, 1632*f*
prevention, 1632
risk factors, 1630
Actinic reticuloid, 1639, 2119–2120, 2120*f*
Actinic reticuloid syndrome, 1639–1643. *See also* Actinic dermatitis, chronic
Actinomadura madurae actinomycetoma, 2884–2890, 2886*f*, 2888*f*. *See also* Actinomycetoma
Actinomadura pelletieri actinomycetoma, 2884–2890. *See also* Actinomycetoma
Actinomyces, 2876
Actinomycetoma, 2884–2890, 2969
at-a-glance, 2884*b*
clinical features
cutaneous, 2885–2886, 2885*f*–2887*f*
noncutaneous, 2886
definitions, 2885
diagnosis, 2877*t*
imaging, 2888–2889
laboratory tests, 2877*t*, 2887–2888, 2887*f*–2888*f*
pathology, 2888, 2888*f*
differential diagnosis, 2889, 2889*t*
epidemiology, 2885
etiology and pathogenesis, 2886–2887
historical perspective, 2885
management, 2889–2890
Actinomycosis, 2876–2880
at-a-glance, 2876*b*
clinical features
cutaneous, 2877–2878, 2877*f*–2878*f*
noncutaneous, 2878
definition, 2876
diagnosis, 2877*t*, 2879–2880
differential diagnosis, 2880, 2880*t*
epidemiology, 2876–2877
etiology and pathogenesis, 2879
historical perspective, 2876
management, 2880
opportunistic infection, 2985
Activate apoptosis cascade, 2098
Activins, in wound healing, 2704*t*
Acute contact dermatitis (ACD), 439, 442*t*
Acute cutaneous lupus erythematosus (ACLE), 1038, 1038*t*. *See also* Lupus erythematosus (LE)
classification, 1038, 1038*t*
clinical course and prognosis, 1052
clinical features, 1041–1042, 1041*f*
diagnosis
histopathology, 1050–1051, 1050*f*
immunohistology, 1051–1052
epidemiology, 1038–1039
management, initial, 1054, 1054*t*
Acute febrile neutrophilic dermatosis. *See* Sweet syndrome
Acute febrile ulcerative acne, 1449, 1450*f*
Acute generalized exanthematous pustulosis (AGEP)
CCR6, 183
from drugs, clinical features, 749, 751, 752*f*, 752*t*
immunologic responses, 194–195, 195*f*
Acute hemorrhagic edema of infancy, 2530*t*, 2531
Acute hepatic porphyrias (AHP), 2249–2252
at-a-glance, 2249*b*
clinical features, 2250
diagnosis, 2251
enzyme deficiencies, 2236*f*, 2250
etiology and pathogenesis, 2250
precipitating factors
drugs and exogenous chemicals, 2250, 2251*t*
endocrine factors, 2250–2251
nutrition, 2251
pregnancy, 2251
prevalence and inheritance, 2235*t*, 2250
therapy, 2251–2252
carbohydrate loading, 2252
Acute intermittent porphyria (AIP), 2235*t*, 2237*t*, 2249–2252
Acute irritant contact dermatitis, 439, 441–443, 442*t*, 443*t*
Acute rheumatic fever (ARF), 1158–1160, 1160*t*
at-a-glance, 1158*b*
clinical features, 1158–1160
cutaneous, 1159–1160, 1159*f*, 1159*t*
general, 1158–1159
noncutaneous, 1160
diagnosis, 1159*t*, 1160
epidemiology, 1158
treatment, 1160
Acute rheumatic fever (RF), 770
Acute stress gastritis, burns, 1681
Acute telogen effluvium, 1507, 1508*t*
Acute tuberculous ulcer, 2867, 2867*f*, 2867*t*
ACVRL1 (ALK1)
fibrodysplasia ossificans progressiva, 2312
hereditary hemorrhagic telangiectasia 2, 2640*t*, 2662
Acyclovir, 3493–3496
for adamantiades–Behçet disease, 2575*t*
dosing regimens, 3494–3495, 3495*t*
for herpes simplex virus, 3029–3031, 3030*t*–3032*t*, 3493–3496
with HIV, 3117
for herpesvirus simiae, 3341
for herpes zoster
immunocompetent, 3053, 3053*t*
immunocompromised, 3053–3054, 3053*t*
indications, 3493–3494
for infectious mononucleosis, Epstein-Barr virus, 3002
mechanism of action, 3493, 3494*f*
pharmacokinetics, 3493
for pityriasis rosea, 524
side effects and precautions, 3496, 3496*t*
thymidine kinase and, 524
for varicella-zoster virus, 3051
with HIV, prophylactic, 3118
immunocompetent children, 3051–3052, 3052*t*
immunocompromised, 3052, 3052*t*
ophthalmic zoster, immunocompetent, 3053, 3053*t*
Acylceramide, 211–212, 213, 214*f*, 215*f*
Adalimumab, 169, 175, 3536*f*, 3537–3538, 3549*t*
granuloma annulare from, 567
for hidradenitis suppurativa, 1490
for lupus erythematosus, 1057
for psoriasis, 469*f*, 487*t*, 493–494
for psoriatic arthritis, 980*t*, 981, 1136*t*, 1137
for pyoderma gangrenosum, 614*t*
for rheumatoid arthritis, 1152
for SAPHO syndrome, 1450
for sarcoidosis, 581*t*, 582

ADAM10, reticulate acropigmentation of Kitamura, 1326, 1327*t,* 1355
Adamantiades–Behçet disease, 2567–2576
  at-a-glance, 2567*b*
  clinical course and prognosis, 2573–2574
  clinical features, 2569–2573
    mucocutaneous lesions, 2569–2570, 2570*f*–2572*f*
    systemic lesions, 2570–2573
  diagnosis
    criteria, international, 2573, 2573*t*
    histopathology, 2572*f,* 2573
    pathergy test, 2571*f,* 2573
    radiologic findings, 2573
  differential diagnosis, 2574*t*
  epidemiology, 2567
  etiology and pathogenesis, 2567–2569
    epigenetics, 2569
    genetics and immunogenetics, 2567–2568
    immunologic mechanisms
      autoimmune, 2568–2569
      cytokine mediators, 2569
      endothelial cells, 2569
      heat shock proteins, 2569
    infectious precipitants, 2568
  historical aspects, 2567
  prevention, 2575
  treatment, 2574–2575, 2574*t*–2576*t*
Adamson fringe, 94
ADAMTS2, dermatosparaxis Ehlers-Danlos syndrome, 1213*t*
ADAMTS3, Hennekam lymphedema-lymphangiectasia, 2640*t*
Adapalene
  for acne vulgaris, 1402–1404, 1402*t*
  chemical structure, 3397, 3397*f*
  for Darier disease, 884, 884*t*
  for Fox-Fordyce disease, 1477
  indications and contraindications, 3399
Adaptive immune system, 132, 132*t,* 143–145. *See also specific components*
  cells, 143, 144*f*
  cellular constituents, 132*t,* 135–137
    dendritic cells, 134–135, 135*t,* 136*f*
    T lymphocytes, 133*f,* 136–137, 136*f*–137*f*
      irritant dermatitis, 414
  responses, 144–145, 145*f*
    rosacea, 1430
    vitamin D, 153
ADAR1, dyschromatosis symmetrica hereditaria, 1324, 1327*t*
Addison disease, 2513–2515
  clinical features, 2513–2514, 2513*t,* 2514*f*
    hypermelanosis, 1361–1362, 2514, 2514*f*
    melanonychia, 1570
  diagnosis and laboratory tests, 2514–2515
  etiology and pathogenesis, 2514
Adefovir, adverse effects, 3512
Adenoid cystic carcinoma, 1836–1837, 1837*f*
Adenoid squamous cell carcinoma, 1910, 1910*f*
Adenolipoma, 2173
Adenoma
  hidradenoma, 1822–1823, 1823*f*
  hidradenoma papilliferum, 1835–1836, 1835*f*
  nipple, 1836
  sebaceous, 33, 1822*t,* 1849–1850, 1850*f*
  spiradenoma, 1822*t,* 1826–1827, 1826*f*
  syringocystadenoma papilliferum, 1833–1834, 1834*f*
  toxic, 2504 (*See also* Hyperthyroidism)
  trichoadenoma, 1848
  tubular, 1834–1835
Adenosine synthase A (AdsA), 2727
ADGRE2, vibratory urticaria and angioedema, 690, 693
Adherence
  extracellular adherence protein, 2727
  fungal infections, superficial, 2928
  topical therapy, 3363–3364
Adherens junctions, keratinocytes, 64
Adhesion molecule receptors, eosinophil expression, 656
Adipocytes (adipose cells), 55, 1251
Adipocytolysis, chemical, fat reduction, 3863, 3865*f*
Adipose, development, 53–55
Adiposopathy, 2286
Adjuvanted glycoprotein E subunit zoster vaccine (RZV), 3057–3058, 3058*t*
Adnexal structures, 26. *See also specific types*
  development, 56–58, 57*f*
  hidradenitis suppurativa, 1483
Adnexal tumors, pathology, 33–34
  sebaceous tumors, 33–34
  syringoma, 33
  trichoblastoma, 33
  trichoepithelioma, 33, 33*f*
Adolescent dermatology, 1756–1758. *See also specific disorders*
  acne, 1757–1758
  axillary hyperhidrosis, 1758
  confidentiality, 1757
  evaluation techniques, 1757
  indoor tanning, 1758
Adoptive T-cell therapy (ACT), for melanoma, 2006
  unresectable metastatic disease, 2006
ADRA2A, familial partial lipodystrophy, 1298
Adrenal gland disorders, 2512–2515
  Addison disease, 2513–2515
  at-a-glance, 2512*b*
  Cushing syndrome, 2512–2513, 2512*t*
Adrenal tumors, hirsutism from, 1556*t,* 1559
Adrenergic blockers, on sweating, 84–85
Adrenergic urticaria, 685
Adrenocorticotropic hormone (ACTH), Cushing syndrome, 2512
Adriamycin, for cutaneous lymphoma with HIV, 3121
Adult acne. *See* Rosacea
Adulterants, drug abuse, 1712
Adult-onset Still disease (AOSD), 1155–1158, 1160*t*
  at-a-glance, 1155*b*
  clinical course and prognosis, 1158
  clinical features
    complications, 1156–1157
    cutaneous, 1155*f,* 1156, 1156*t*
    general, 1155–1156, 1155*f*
    noncutaneous, 1156
  diagnosis, 1157, 1157*t*
  differential diagnosis, 1156*t,* 1158
  epidemiology, 1155
Adult progeria. *See* Werner syndrome (WS)
Adult T-cell leukemia (ATL), 3125–3127
Adult xanthogranuloma, 2034
Advanced glycation end products (AGEs)
  diabetes mellitus, 2494
  diabetic thick skin, 2496
Advancement flaps, 3734–3740
  bilateral, 3737–3738, 3738*f*
    H-plasty, 3737
    T-plasty, 3737–3738, 3738*f*
  crescentic, 3738, 3739*f*
  east–west, 3739, 3741*f*
  movement and key suture, 3734
  Rintala, 3739
  single, 3735–3737, 3735*f*
    cheek, 3735–3736, 3736*f*–3737*f*
    helical rim, 3736–3737, 3737*f*
    L-plasty, 3735, 3735*f*
  tension vectors, 3735
  V-to-Y, 3738–3739, 3740*f*
Aeromonas hydrophila, 2829*t,* 2843–2844
Aerosols, 3373*t,* 3376. *See also specific types*
Aethoxysclerol injections, for telangiectasia with rosacea, 1439
Afamelanotide
  for protoporphyrias, 2249
  for solar urticaria, 1653
  for vitiligo, 1345–1346
Afatinib, acneiform eruptions from, 1452
Afatinib dimaleate, 3559*t,* 3570–3571, 3570*f*
  for non–small-cell lung cancer, 3566
A fibers, pruritus, 353, 354*f*
African tick bite fever (ATBF), 3314–3315
  clinical and laboratory findings, 3314
  diagnosis and differential diagnosis, 3315, 3316*t*
  epidemiology and vectors, 3309*t,* 3315
  etiology and pathogenesis, 3306
  treatment and prognosis, 3309*t,* 3315, 3316*t*
African trypanosomiasis, 3238–3240, 3238*f*–3239*f,* 3239*t*
Agammaglobulinemia, 2394–2396
Aggressive house spider, 3327–3328
Aggressive systemic mastocytosis (ASM), 711*t,* 712, 714–715. *See also* Mastocytosis
Aging, skin, 1779–1788, 3812–3814
  appendages, 1783–1784
    hair, 1783–1784
    nails, 1784
  bullous pemphigoid, 1788
  cellular senescence, 1765
  dermatoses, geriatric, 1784–1786
    benign skin lesions, 1784–1785, 1784*f*–1785*f*
    malignant skin lesions, 1785–1786
    pruritus, 1786
    xerosis, 1786
  dermis, 1783, 1784*t*
  drug eruptions, 1788
  epidermis, 1782–1783, 1783*t*
  extrinsic, 1780–1782, 1781*t*
  glands and nerves, 1784
  infections, 1786–1788
    bacterial, 1787
    fungal, 1787
    parasitic, 1787
    viral, 1787–1788
  intrinsic, 1780, 1780*f,* 1781*f,* 1781*t*
    photoaging, 282–284, 282*f*–283*f,* 283*t*
  oxidative stress, 1765–1766, 1779–1780, 1780*f,* 1780*t*
  photoprotected *vs.* photoexposed, 1765, 1780*f*
  phototherapy safety, 3645
  senile purpura, 1788
  skin care
    cleansers, 3813
    moisturizers and serums, 3813
    sunscreens, 3813
  telogen effluvium, 1509
  tobacco use, 1713
  ulcers, 1788
  wrinkle-prone *vs.* non–wrinkle-prone skin, 3812–3814
Agminated lentigines, 1967–1970, 1969*f,* 1970*t*
agouti, 2504
Agouti-related protein *(AgRP),* 2503, 2504
AGPAT2, 55
  congenital generalized lipodystrophy, 1296, 1297*f*
Agrin, 241
AgRP, 2503, 2504
Agyria, slate-gray pigmentation, 1658
Aicardi-Goutières syndrome, 1040
AIDS. *See* Human immunodeficiency virus (HIV)/AIDS
AIDS phobia, 1701
AIF-1, systemic sclerosis, 1093
AIRE, chronic mucocutaneous candidiasis, 2399
Air hammers, Raynaud phenomena, 2616
Air pollution, on skin aging, 1781

Airway assessment, burn injuries, 1684
Ajellomyces capsulatus, 2975
AKT, seborrheic keratoses, 1800, 1800*t*
AKT2, familial partial lipodystrophy, 1297–1298
AKT3, macrocephaly–capillary malformation, 2640*t*, 2642
AKT inhibitors. *See also specific types*
  for melanoma, 3586
Alagille syndrome, 2288–2289
Alarmins, 222, 222*t*, 420
  eosinophil-derived neurotoxin, 654
Albendazole
  for cutaneous larva migrans, 3265*t*, 3266
  for enterobiasis, 3265*t*, 3267
  for strongyloidiasis, 3272
Albinism
  ocular, 1310*t*, 1314–1315
  oculocutaneous, 1309–1314 (*See also* Oculocutaneous albinism (OCA))
Albright hereditary osteodystrophy (AHO), 2312
Albright sign, 2511
Alcohol use and abuse
  acute hepatic porphyrias, 2250
  cutaneous manifestations, 1713
  flushing, 1438*t*
  porphyria cutanea tarda, 1713, 2239
  preoperative examination, 3709
  rosacea and, 1713
    fibrosis and glandular hyperplasia, 1433*f*
    flushing and erythema, 1422, 1427, 1432f
    as trigger, 1427, 1427*t*, 1429
    TRP channels, 1428*f*
ALDH3A2, Sjögren-Larsson syndrome, 807–808, 807*f*
ALDH18A1, cutis laxa, 1238, 1240
Aldosterone, on sweat duct NaCl reabsorption, 83
Alefacept, 3543, 3550*t*
Alemtuzumab
  for adamantiades–Behçet disease, 2576*t*
  for cutaneous T-cell lymphomas, 2093*t*, 2094–2095
  on eosinophils, 658
  for hypereosinophilic syndromes, 665
Alendronate, for hyperimmunoglobulinemia E syndrome, 2415
Alezzandrini syndrome, vitiligo, segmental variant, 1334
Alirocumab, for dyslipidemia, 2287
Alitretinoin. *See also* Retinoid(s), oral
  chemical structure, 3395, 3396*f*, 3397, 3397*f*
  for irritant dermatitis, hand, 424
  metabolism and pharmacokinetics, 3398–3399
  structure, 3395, 3396*f*
Alitretinoin, oral
  adverse effects, 3402, 3402*t*
  for Darier disease, 884, 884*t*
  indications and contraindications, 3400
  for palmoplantar keratodermas, inherited, 821
Alitretinoin, topical
  adverse effects, 3402
  for Kaposi sarcoma, 3120
ALK1. See ACVRL1 (ALK1)
Alkali, burn, 1683
Allantoin, for epidermolysis bullosa, 1028, 1028*f*
Allelic heterogeneity, 295
Allergen immunotherapy, for atopic dermatitis, 380
Allergic contact dermatitis (ACD), 395–409
  acute, nail changes, 1582–1583
  age, 395–396
  from antibiotics, topical, 404–405
  at-a-glance, 395*b*
  clinical course and prognosis, 408–409
  clinical features, cutaneous, 396–397
  from corticosteroids, 3391
  dendritic cells, dermal, 193*f*, 194
  diagnosis, 398–405
    auto transfer, 400
    diagnostic algorithm, 398
    supportive studies, 398
  diagnosis, allergen-specific, 403–405
    antibiotics, topical, 404–405
    bacitracin, 404–405
    cement, cobalt marker, 404
    chromium, 404
    cobalt, 403
    formaldehyde, 404
    formaldehyde nonreleasers, 404
    formaldehyde releasers, 404
    fragrances, 404
    gold, 404
    hair products, 405, 405*t*
    leather, cobalt marker, 404
    metals, 403–404
    neomycin, 404
    nickel, 403
    para-phenylenediamine, 405
    preservatives, 404
    rubber and latex, 405
    steroids, topical, 405, 406*t*
  diagnosis, topographic, 398–402, 399*f*
    airborne, 400
    axillae, 399*f*, 401
    ectopic, 400
    eyelids, 400
    face, 399*f*, 400
    hands and feet, 399*f*, 401
    lips, 400–401, 401*f*
    mucous membranes, 401–402
    neck, 399*f*, 401
    scalp, 399*f*, 400
    scattered generalized, 402
    systemic, 402, 402*t*, 403*t*
    torso, 399*f*, 401
  differential diagnosis, 408, 409*t*
  drugs reactivating, 402, 403*t*
  epidemiology, 395–396
  erythema multiforme-like, 396–397, 396*t*
  etiology and pathogenesis, 397–398
    elicitation phase, 397–398
    sensitization phase, 397
  gender, 396
  gene polymorphisms, 192
  hypersensitivity phases, 193, 193*f*
  immunologic responses, 192–194, 193*f*
  from irritant dermatitis, 421
  vs. irritant dermatitis, 415, 416*t*
  Langerhans cells, 194
  lichenoid, 396*t*, 397
  lymphomatoid, 396*t*, 397
  management, 409
  noneczematous variants, 396, 396*t*
  nummular eczema, 385, 386
  occupational, 439, 444
    patch testing, 450
    skin prick testing and contact urticaria, 450, 451*f*
  patch-testing mechanics, 405–408 (*See also* Patch-testing mechanics)
  pigmented, 396*t*, 397
  purpuric, 396*t*, 397
  race/ethnicity, 396
  risk factors, 452
  rodent models
    hypersensitivities, 193
    phases and pathophysiology, 193–194, 193*f*
  susceptibility and familial predisposition, 192
  from topical therapy, 3377
Allergic contact dermatitis syndrome, 402, 402*t*
Allergic contact diaper dermatitis, 1741, 1741*t*
Allergic/irritant type sensitive skin, 3808*t*, 3809–3810, 3810*t*
Allergic reactions. *See also* Angioedema; Drug reactions; Urticaria; *specific types*
  allergic urticaria, anaphylaxis from, 687
  eosinophils, 27, 27*f*
  immune responses, chemokine receptors, 181
  to local anesthetics, 3713–3714
Allergic rhinitis, filaggrin mutations, 216
Allergic salute, 1454
Allergies. *See also specific types*
  eosinophils, 653
  preoperative examination, 3709
Allicin, for adamantiades–Behçet disease, 2576*t*
Allodermanyssus sanguineus, 3309*t*, 3315. *See also* Rickettsialpox
Allogeneic bone marrow transplantation, for epidermolysis bullosa, 1028
Allogeneic stem cell transplantation. *See* Stem cell transplantation (SCT)
Allograft, 3753
  rejection
    eosinophils, 653
    extracorporeal photochemotherapy for, 3678
Allopurinol
  for gout, 2315–2316
  for gouty panniculitis, 1283*b*
  granuloma annulare from, 566
  for leishmaniasis, 3236
  palisaded neutrophilic and granulomatous dermatitis from, 1148
All-*trans*-retinoic acid (ATRA). *See* Tretinoin
All-*trans*-retinol. *See also* Vitamin A (retinol)
  oxidation, 3397
  structure, 3395, 3396*f*
Allylamines, 3436–3441, 3438*t*–3439*t*
  mechanism of action, 3436
  naftifine, 3436–3437, 3438*t*
  terbinafine, 3437–3441, 3438*t*, 3439*t*, 3441*t*
Aloe vera, for frostbite, 1669
Alopecia. *See also* Baldness; *specific types*
  after cryosurgery, 3792
  cicatricial, 1524–1533 (*See also* Cicatricial alopecias)
  from cytotoxic agents, 3481–3482, 3482*f*, 3483*t*
  psoriasis, scalp, 464
  from psychological and emotional distress, 89
  from radiotherapy, 3691*t*
  subtypes, 1524, 1525*f*
Alopecia areata (AA), 1517–1522
  animal models, 199–200
  associated disorders, 1517, 1518*t*, 1584
  at-a-glance, 1517*b*, 1583
  clinical features, 1517, 1518*f*, 1583
    nail changes, 1583–1584, 1584*f*
  complications, 1519
  diagnosis, 1518–1519, 1518*f*, 1584
  differential diagnosis, 1519, 1519*t*, 1584
  etiology and pathogenesis, 199, 1517–1518, 1583
    global transcriptional profiling, 200
    HLA haplotype inheritance, 303, 304*t*
    single nucleotide polymorphisms, 200
  immunologic responses, 199–201, 200*f*
  infants, 1753
  patchy, 199
  pathology, 1519
  phenotypic variants, 199
  prognosis and clinical course, 1519, 1584
  totalis, 199

Alopecia areata (AA) (*Cont.*):
treatment, 1519–1522, 1584
algorithm, 1520*f*
anthralin, 1521
conservative management, 1519
corticosteroids
intralesional, 1520
systemic, 1521
topical, 1520
cyclosporine, 1522
hair transplantation, 3931–3948 (*See also* Hair transplantation)
immunotherapy, topical, 1521
Janus kinase inhibitors, 1522
minoxidil, topical, 1521
photo(chemo)therapy, 1521–1522
platelet-rich plasma, 1520
prostaglandin analogs, 1521
PUVA, 3672
universalis, 199
Alopecia areata incognita, 1514
Alopecia areata universalis, 1517, 1518*f*
Alopecia mucinosa, 1529, 2081–2082, 2082*f*, 2082*t*
Alopecia neoplastica, 2461
ALOX3E, collodion baby, 787
ALOX12B
collodion baby, 787
congenital ichthyosiform erythroderma, 790*f*, 793
ALOXE3, congenital ichthyosiform erythroderma, 790*f*, 793
5α-Reductase inhibitors. *See also specific types*
for hyperandrogenism, 2518
Alpha-hydroxy acids, 3618, 3619*t*
Alphavirus mosquito-borne diseases, 3136*t*, 3141–3143
at-a-glance, 3141*t*
Chikungunya, 3136*t*, 3141–3142, 3142*f*
fundamentals, 3141
Mayaro, 3136*t*, 3142–3143
O'nyong-nyong, 3136*t*, 3142–3143
Ross River, 3136*t*, 3142–3143
Sindbis group, 3136*t*, 3142–3143
α_1-Antichymotrypsin, Rosai-Dorfman disease, 2031
α_1-Antitrypsin, Rosai-Dorfman disease, 2031
α6β1 integrin, epidermolysis bullosa, 1012–1013
α6β4 Integrin, epidermolysis bullosa, 1012–1013
α-Adrenergic blockers. *See also specific types*
for Raynaud phenomena, 2622
α-Antitrypsin, 1267, 1268
α-Antitrypsin panniculitis, 1253*t*, 1266–1269
at-a-glance, 1266*b*–1267*b*
clinical course and prognosis, 1269
clinical features, 1267–1268, 1267*f*–1268*f*
diagnosis, 1268–1269, 1268*f*
differential diagnosis, 1269, 1269*t*
epidemiology, 1267
etiology and pathogenesis, 1268
management, 1269
α-Fetoprotein, ataxia-telangiectasia, 2409
α-Galactosidase A, Fabry disease, 2292, 2293*f*
α-Hydroxy acids. *See also* Glycolic acid chemical peels, 3899*f*, 3900
α-Linoleic acid, 2203
α-Melanocyte stimulation hormone (α-MSH), 342, 342*f*–343*f*
seborrheic dermatitis, 433
Alport syndrome, collagen IV mutations, 240
Alprostadil, for Raynaud phenomena, 2621*t*
Aluminum acetate, 3613*t*, 3617
for seborrheic otitis externa, 435
Aluminum chloride, 3616
for pitted keratolysis, 2741
Aluminum chloride hexahydrate, for hyperhidrosis
in Fabry disease, 2302
primary focal, 1462
Aluminum compounds, 3616
Aluminum hydroxide, for pseudoxanthoma elasticum, 1233
Aluminum salts, 3613*t*, 3617
Aluminum sulfate, 3613*t*, 3617
Alveolar rhabdomyosarcoma (ARMS), 2144
AMAC-1, non–Langerhans cell histiocytosis, 2030
Amalgams, lichenoid contact dermatitis, 538
Amblyomma americanum, 3308*f*, 3309*t*, 3310*t*, 3320, 3329
Amblyomma cajennense, 3309*t*
Ambras syndrome, 1563–1564
Ambrisentan, for pulmonary artery hypertension in systemic sclerosis, 1101
Amebas, 3247–3248
Amebiasis, 3246–3247, 3247*f*
American dog tick, 3307, 3308*f*, 3309*t*, 3310*t*, 3320, 3329. *See also* Ticks
American trypanosomiasis, 3240–3242, 3241*f*
American wood tick, 3307, 3308*f*, 3309*t*, 3329
Amide anesthetics, local, 3710*t*, 3711
Amikacin
for actinomycetoma, 2889
for *Nocardia* and nocardiosis, 2884, 2971
Amino acids, sweat, 82
Aminoglycosides
for ataxia-telangiectasia, 2409
lichenoid contact dermatitis, 538
topical, 3420*t*, 3421 (*See also* Gentamicin; Neomycin)
δ-Aminolevulinate deficiency porphyria (ADP), 2235*t*, 2237*t*, 2249–2252
5-Aminolevulinic acid (5-ALA), photodynamic therapy, 274–275, 3678–3681. *See also* Photodynamic therapy (PDT)
δ-Aminolevulinic acid 1 (ALA), 2234
δ-Aminolevulinic acid synthase (ALAS), 2234, 2236*f*
δ-Aminolevulinic acid synthase 1 (ALAS1), 2235, 2236*f*
δ-Aminolevulinic acid synthase 2 (ALAS2), 2236*f*
Aminoquinoline antimalarial agents. *See also specific types*
for lupus erythematosus, 1054, 1054*t*, 1055–1056
5-Aminosalicylic acid, for adamantiades–Behçet disease, 2574*t*
Amiodarone
hypermelanosis, 1365, 1367*f*
phototoxicity, 1662
blue-gray pigmentation, 1658, 1661*f*
Amish brittle hair syndrome. *See* Trichothiodystrophy (TTD)
Amlodipine
granuloma annulare from, 567
photodistributed telangiectasia, 1661
for Raynaud phenomena, 2620–2621, 2621*t*
Ammonia, sweat, 82
Ammonium bituminosulfonate, 3611
Amorolfine, 3438*t*, 3447
for onychomycosis, 3447
topical, for fungal infections
nail, 1595
superficial, 2935*t*
for vulvovaginal candidiasis, 3447
Amoxicillin
for actinomycosis, 2880
for human bites, 3338–3339
for Lyme borreliosis, 769, 773*t*, 3299, 3300*t*
for *N. brasiliensis* actinomycetoma, 2889
for skin and soft-tissue infections, dosing, 3410*t*
Amoxicillin-clavulanate
for cat scratches, deep, 3338
for nocardiosis, 2884
for *Pasteurella multocida,* 3339
for skin and soft-tissue infections, dosing, 3410*t*
Amoxicillin-clavulanic acid
for *Burkholderia pseudomallei,* 2846
for cat bite, 2837
for dog bite, 2837
for group A *Streptococcus*
impetigo and ecthyma, 2739, 2739*t*
recurrent infections, 2739, 2739*t*
for *Pasteurella multocida,* 2837
for rat-bite fever, 2839
for staphylococcal impetigo, ecthyma, and folliculitis, 2730, 2731*t*
Amphetamines, 1711. *See also specific types*
Amphiregulin, 3540
Amphotericin B
for blastomycosis, 2979
for chromoblastomycosis, 2972
for chronic mucocutaneous candidiasis, 2401
for coccidioidomycosis, 2980
for cryptococcosis, 2984
with HIV, 3115
for histoplasmosis, African, 2977
for leishmaniasis, 3236, 3237*t*
for *Penicillium marneffei,* with HIV, 3115
Raynaud phenomena from, 2616
for rhinosporidiosis, 3244
for *Talaromyces marneffei,* 2982
Amphotericin B, IV
for histoplasmosis, African, 2977
for paracoccidioidomycosis, 2981
for sporotrichosis, 2968
Ampicillin
for erysipeloid, 2847
for infective endocarditis, 2818
for listeriosis, 2841
for *Neisseria meningitidis,* 2787
Ampicillin rash, 2999–3000, 2999*f*
Ampicillin-tazobactam, for pyomyositis, 2778
Amputation neuroma, 2147*t*–2148*t*, 2150–2151, 2150*t*
AMSTAR, 44
Amyloidosis, 2258–2270
amyloid diseases, 2258–2259, 2259*t*
amyloid fibril protein nomenclature, 2258, 2259*t*
anosacral, 2264
at-a-glance, 2258*b*
definition, 2258
friction, 2264
histologic criteria, 2258, 2259*t*
localized, 2262
nail changes, 1597, 1598*f*
notalgia paresthetica, 2264
pathogenesis, 2259, 2260*f*
systemic, 2442*t*, 2458
towel-associated, 2264
treatment strategies, 2269–2270
Amyloidosis, cutaneous, 1383, 2262–2267, 2262*t*
amyloid adjacent to tumors, 2265
amyloidosis cutis dyschromica, 2266, 2266*f*
biphasic cutaneous amyloidosis, 2262*t*, 2263
cutis laxa in familial amyloid, mutant gelsolin, 2265
diagnostic approach, 2267–2269
biochemistry, 2269
initial evaluation, 2267, 2267*t*
laboratory, 2267–2268, 2267*t*
pathology, 2268–2269, 2268*f*
differential diagnosis, 2267*t*
epidemiology, 2266–2267
genetics and pruritus, 2266–2267
injection-site amyloidosis, 2265–2266
lichen amyloidoses, 2262*t*, 2263, 2264*f*
localized, variant forms, 2264
macular, 2262–2263, 2262*t*, 2263*f*

nodular, 2263*f*, 2264–2265, 2265*f*
transthyretin, 2265, 2265*f*
treatment strategies, 2269–2270
Amyloidosis, systemic, 2259–2262
epidemiology, 2261–2262
paraneoplastic, 2458
AL, 2458
primary, 2458
secondary, 2458
skin disease in, 2260–2261, 2261*f*
treatment strategies, 2269
Amyloidosis cutis dyschromica, 2266, 2266*f*
Anabolic steroids, 1714
Anagen, 92, 93*f*, 95, 97
release
delayed, 1511
immediate, 1511
short, 1511
Anakinra, 3533, 3548*t*
for adamantiades–Behçet disease, 2576*t*
for cryopyrin-associated periodic syndromes, 625
for deficiency of the IL-1 receptor antagonist, 628
for Erdheim–Chester disease, 2038
for hyperimmunoglobulinemia D with periodic fever syndrome/mevalonate kinase deficiency, 635
for juvenile idiopathic arthritis, 1155
for Majeed syndrome, 644
for otulipenia/OTULIN-related autoinflammatory syndrome, 638
for pyogenic arthritis, pyoderma gangrenosum, and acne syndrome, 643
for rheumatoid arthritis, 1152–1153
for SAPHO syndrome, 645
for Schnitzler syndrome, 627
for TNF receptor-associated periodic syndrome, 637
Anal cancer, with HIV, 3120–3121
Anal dysplasia, 1871*t*, 1873*b*–1874*b*
Analgesics, topical. *See also specific types*
capsaicin, 3610
eutectic mixture of local anesthetics cream, 3611, 3712
lidocaine, 3611
Anal intraepithelial neoplasia (AIN), 1871*t*, 1873*b*–1874*b*
Anal lichen planus, 535, 535*f*
Anal squamous intraepithelial neoplasia, 1871*t*, 1873*b*–1874*b*
Analytic studies. *See also specific disorders and types*
experimental, 42–43, 42*f*
levels of evidence, 44
observational, 42*f*, 43–44
quality reporting, 44
Anaphylaxis. *See also specific types and causes*
definition, 687
exercise-induced, 699
urticaria, 687, 690
wheals or angioedema, 684
Anaplasma phagocytophilum, 3296, 3299, 3320, 3321*f*
Borrelia burgdorferi coinfection, 3295
Anaplasmoses, 3320–3322. *See also* Human granulocytic anaplasmosis (HGA)
Anaplastic large cell lymphoma
cutaneous, 2085–2086, 2086*f*
radiotherapy for, 3693*t*, 3694
Anaplastic lymphoma kinase (ALK), cutaneous anaplastic large cell lymphoma, 2085
Anaplastic rhabdomyosarcoma, 2144
Anatomy, cutaneous
arterioles, 117, 118*f*
cutaneous nerve, in pruritus, 352*f*
facial, surgical, 3697–3703 (*See also* Facial anatomy, cutaneous surgical)
genital, female, older child, 1754, 1755*f*
glands, 70
hair follicle, 92–95
melanocytes, 268*f*, 328–330
nail, 106–107, 108*f*
nervous system, 311*f*, 351–352
reactive units, 19, 21*f*
sebaceous glands, 70–71, 71*f*
sensory nerves, facial, 3702–3703, 3702*f*, 3703*t*
sweat glands, eccrine, 78–79, 79*f*
vascular
blood vascular system, 116
face, 3703–3705, 3704*f*
venous, 3871–3874, 3872*f*
wound healing, 2700, 2701*f*
Anchoring fibrils, 246, 246*f*
basement membrane, 239, 239*f*
epidermolysis bullosa, inherited, 1011, 1012*f*, 1013
Anchoring filaments, 242*f*, 245
epidermolysis bullosa, inherited, 1011, 1012–1013, 1012*f*
Ancient schwannoma, 2155
ANCR, 67
epidermal differentiation, 66, 67, 67*f*
Ancylostoma braziliense, 3252*t*
exposure and symptom onset interval, 3259, 3260*t*
exposure history, 3254
lesions
migratory, 3255–3256, 3255*t*, 3256*f*
papular and macular, 3257, 3258*t*
progression and duration, 3259, 3260*t*
urticaria and pruritus, 3258–3259, 3258*t*
Ancylostoma caninum, 3252*t*
exposure and symptom onset interval, 3259, 3260*t*
lesions
migratory skin, 3255–3256, 3255*t*, 3256*f*
papular and macular, 3257, 3258*t*
progression and duration, 3259, 3260*t*
urticaria and pruritus, 3258–3259, 3258*t*
Ancylostoma duodenale, 3252*t*
exposure and symptom onset interval, 3259, 3260*t*
lesions
migratory skin, 3255*t*
papular and macular, 3257, 3258*t*
progression and duration, 3259, 3260*t*
urticaria and pruritus, 3258–3259, 3258*t*
Androgen(s). *See also specific types*
excess, 2516–2518, 2517*f*, 2517*t*
sebaceous glands, 76–77
Androgenetic alopecia (AGA), 1495–1505, 2516–2517
at-a-glance, 1495*b*
clinical course and prognosis, 1502–1504
clinical features, 1496–1497
female pattern
Christmas tree, 1497, 1498*f*
Ludwig type, 1496, 1497*f*–1498*f*
male pattern, Hamilton-Norwood type, 1496, 1496*f*–1497*f*
definition, 1495
diagnosis, 1498–1501
algorithm, 1501, 1501*f*
automatic digitalized system, for hair density and anagen/telogen hairs, 1500
biopsy, 1500
clinical examination, 1496*f*–1498*f*, 1499–1500
dermoscopy, 1500
global photography, 1500
laboratory testing, 1500–1501
patient history, 1498–1499, 1499*f*
phototrichogram/trichoscan, 1500
trichogram, 1500
differential diagnosis, 1502, 1502*t*
diffuse alopecia areata, 1502, 1502*t*, 1503*f*
ectodermal dysplasia, 1502
frontal fibrosing alopecia, 1502, 1502*t*, 1503*f*
hypotrichosis simplex, 1502
telogen effluvium, 1502, 1502*t*, 1503*f*
traction alopecia, 1502, 1502*t*, 1503*f*
epidemiology, 1495
etiology and pathogenesis, 1497–1498
men, 1497–1498
risk factors, 1497
women, 1498
management, 1504–1505
counseling, 1505
hair replacement, nonpermanent, 1505
laser therapy, low-level, 1505
medications, 1504
screening, 1505
surgery, 1504–1505
Androgen modulation therapy, for hidradenitis suppurativa, 1490
Anemia. *See also specific types*
iron-deficiency, 2223
pernicious, 2206*t*, 2217–2218
Anesthesia
general, in children, 1756
local, 3710–3714, 3710*t* (*See also specific techniques*)
cryosurgery, 3793
electrosurgery, 3798
peripheral nerve blockage, 3712–3713
Anesthetics, local. *See also specific types*
alkalinizing, 1755
amide, 3710*t*, 3711
chemical structure and function, 3711
child administration, 1755
epinephrine, 3711
ester, 3710*t*, 3711
lipid solubility, 3711
mechanism of action, 3710
onset of action, 3711
peripheral nerve blockage, 3712–3713
for pruritus, 358
side effects, 3713–3714
topical, 3711–3712
Anetoderma, 1193–1195
associated conditions, 1194, 1194*t*
at-a-glance, 1193*b*
clinical features, 1193–1194, 1194*f*
differential diagnosis, 1195, 1195*t*
epidemiology, 1193*b*
Jadassohn-Pellizzari types, 1193
pathogenesis, 1193*b*
pathology, 1194, 1195*f*
Schweninger-Buzzi types, 1193
treatment, 1195
Anetoderma of prematurity, 1746
ANF469, brittle cornea syndrome, 1213*t*, 1217*t*
Angel kiss, 1734
Angelman syndrome, genomic imprinting, 300
Angel's kiss, *vs.* capillary malformations, 2638
Angioblastic T-cell lymphoma, granuloma annulare from, 567
Angioblastoma of Nakagawa, 2059*b*, 2061–2062, 2061*f*
Angioblasts, 27–28, 58
Angiocentric pattern, 25–26, 26*f*
Angioedema, 684–704, 749, 2395*t*. *See also* Hereditary angioedema (HAE); *specific types*
at-a-glance, 684*b*
bradykinin-induced, 685, 694, 694*f*, 695, 696, 701
cholinergic, 686*f*, 690
chronic spontaneous urticaria with, 685
clinical course and prognosis, 701
clinical features
cutaneous, 685, 686*f*
noncutaneous, 685–687

Angioedema (*Cont.*):
definition, 684
diagnosis, 695–701
ACE inhibitor induced, 699
acquired, 698–699
algorithm, 691, 696*f*
autoinflammatory syndrome, 699
control status, 699
disease severity, 699
hereditary, 698
history taking, 695–696
subtypes, 698–699
diagnostic tests, 688*t*
differential diagnosis, 701
epidemiology, 685
etiology and pathogenesis, 693, 694, 694*f*
autoimmune mechanism, 692
factors inducing or aggravating
ACE inhibitors, 695, 699
aspirin and NSAIDs, 694
contrast media, 695
historical perspective, 684
management, 701–704
interventions, 701–702
medications, 702–703
neutrophils, 27
prevention and screening, 703–704
reactions and systemic disease symptoms
anaphylaxis, 690
Darier sign, 690
hereditary angioedema, 690
wheal, from skin test, 690
spontaneous urticaria with, 688
types, 687–688
urticarial vasculitis with, 691
vibratory, 690
ADGRE2, 690, 693
diagnosis, 688*t*, 698
underlying disorders, 693, 694
wheals, 689*t*
wheals, 689*t*
Angiogenesis, blood vessel
dermal, 125–127, 126*f*, 127*f*
embryogenesis, 126, 126*f*
healthy, 125
inflammation, tissue injury, or tumor growth, 125
tumor, 128–129, 128*f*
vascular endothelial growth factor, 125
Angiokeratoma, 2299–2300, 2300*t*. *See also specific types*
Angiokeratoma circumscriptum, 2300*t*, 2655
Angiokeratoma of Fordyce, 2300*t*
Angiokeratoma of Mibelli, 2300*t*
Angiokeratoma of the vulva, 2300*t*
Angioleiomyoma, 2130–2138, 2131*t*–2132*t*
clinical course and prognosis, 2138
clinical features, 2136
differential diagnosis, 2136–2137
etiology and pathogenesis, 2130, 2134*f*
histopathology, 2136, 2137*f*
management, 2138
Angiolipoma, 2178–2179, 2178*f*–2179*f*
Angiolymphoid hyperplasia, nodular lymphocyte collections, 26
Angiolymphoid hyperplasia with eosinophilia (ALHE), 667–669, 2124–2125, 2125*f*
clinical course, prognosis, and management, 669, 669*f*
clinical features, 667
diagnosis, 668
differential diagnosis, 668–669, 668*t*, 669*t*
eosinophils, 27, 27*f*
etiology and pathogenesis, 667
Angioma, 2636. *See also* Vascular malformations
laser therapy for, 3850, 3853*t*
senile, 1785, 1785*f*
Angiopoietin 1 (ANGPT1), 127*f*
Angiosarcoma
in elderly, 1785–1786, 1786*f*
pathology, 37, 37*f*
Angiotensin-converting enzyme (ACE) inhibitors
angioedema from, 695, 699
interstitial granulomatous drug reaction from, 1149
psoriasis exacerbation by, 479
for Raynaud phenomena, 2621*t*, 2622
for scleroderma renal crisis, 1102
Angiotensin I, 120
Angiotensin II, 120
Angiotensin-receptor blockers. *See also specific types*
for proteinuria in Fabry disease, 2303
Angle of Lovibond, 1596
Angular artery, 3703, 3704*f*
Anhidrosis, 1460*t*, 1463–1467
acquired idiopathic generalized, 1466
clinical course, prognosis, and management, 1467
clinical features, 1459, 1465, 1465*f*
congenital insensitivity to pain with anhidrosis, 1466
diagnosis, 1466–1467, 1467*f*
Fabry disease, 1466
hypohidrotic ectodermal dysplasia, 1465–1466
miliaria, 1466, 1466*f*
Sjögren syndrome, 1174
Anifrolumab, for lupus erythematosus, 1057
Animal bites, aquatic, 3344–3358. *See also* Aquatic organism bites and stings; *specific types*
Animal bites, land, 3338–3344. *See also* Plague; Rat-bite fever; Tularemia; *specific types*
at-a-glance, 3338*b*
bacterial infection
Capnocytophaga canimorsus, 3339
cat scratch disease, 2797–2805, 3340 (*See also* Cat scratch disease (CSD))
Pasteurella multocida, 3339
Porphyromonas spp., 3339
Staphylococcus intermedius, 3339
epidemiology, 3338
pathogenesis and treatment, 3338, 3339*t*
snakebites, 3341–3344
viral infection
herpesvirus simiae, 3341
rabies, 3340–3341
Animal models of carcinogenesis, human skin cancer, 321–323
basal cell carcinoma, 321–322
chemically induced, rodents, 322–323
squamous cell carcinoma, 321
Anitihelix, 3698, 3698*f*
Ankle-brachial index (ABI), obstructive peripheral arterial disease, 2671, 2672*f*
Ankyloblepharon-ectodermal defects-clefting (AEC), p63-related, 2378, 2381–2382
Ankyloblepharon filiforme adnatum (AFA), 2379–2380, 2379*f*
Ankylosing spondylitis, cutaneous necrotizing venulitis with, 2529
Annular elastolytic giant cell granuloma, 566
Annular epidermolytic ichthyosis, 798, 798*f*
Annular lichen planus, 530, 531*f*, 531*t*
Annular shape (configuration), 9, 10*f*
Anogenital intraepithelial neoplasia and cancer (AGIN), 3096*t*, 3103–3104, 3104*f*
Anogenital warts, 3096*t*, 3099*t*, 3102–3103, 3103*f*
Anonychia, 1568
lichen planus, 535
Anopheles mosquito, 3242, 3242*f*
Anoplura, 3325*f*
Anosacral amyloidosis, 2264
ANT-1207, 3922
Antacids. *See also specific types*
lupus erythematosus from, 1041*t*
mycophenolate mofetil interactions, 3519
Anterior cervical hypertrichosis, 1564
Anthracyclines, 3465*f*, 3480–3481. *See also* Doxorubicin; Pegylated liposomal doxorubicin (PLD); *specific types*
Anthralin (dithranol)
for alopecia areata, 1521
for psoriasis, 489
Anthrax, 2827–2830, 2828*f*
at-a-glance, 2827*b*
clinical course and prognosis, 2828–2830
clinical features, 2827–2828, 2828*f*
etiology and epidemiology, 2827, 2829*t*
occupational, 448
prevention, 2830
treatment, 2828
Anthrenus scrophuliae, 3331
Anthropophilic, 2926, 2926*t*, 2927*t*
Antiandrogens. *See also specific types*
for acne vulgaris, 1406–1407
for hirsutism, 1561–1563, 1562*t*
Antiangiogenic agents, 3590–3604. *See also specific types*
at-a-glance, 3590*b*
becaplermin, 3590–3592
bevacizumab, 3592
bortezomib, 3592–3593
cetuximab, 3593
corticosteroids, 3593
direct *vs.* indirect, 3590, 3590*b*
erlotinib, 3593–3594
everolimus, 2456, 2489, 3527–3529, 3594
experimental, 3603, 3604*t*
historical perspective, 3590
imiquimod, 3594–3595
interferon-α2B, 3595–3597, 3596*t*
mechanisms of action, 3590, 3591*f*
panitumumab, 3597
pegaptanib, 3597
propranolol, 3598–3599, 3598*f*
ranibizumab, 3599
sirolimus, 3599–3600
sorafenib, 3600
sunitinib, 3600–3601
temsirolimus, 3601
thalidomide, 3601–3603, 3602*t*
trastuzumab, 3603
Antibiotics, 9, 10*f*
erythema nodosum from, 1256
lupus erythematosus from, 1041*t*
prophylaxis, preoperative, 3706–3707, 3707*t*
Antibiotics, systemic, 3407–3419
at-a-glance, 3407*b*
background, 3407
cephalosporins, 3409–3413
clindamycin, 3414–3415
daptomycin, 3419
dosing regimens, 3410*t*
ertapenem, 3419
fluoroquinolones, 3416–3417
lipoglycopeptides, 3418
macrolides, 3415–3416
oxazolidinones, 3418
penicillins, 3407–3409
quinupristin/dalfopristin, 3419
recommended, by organism, 3408*t*
side effects and precautions, 3411*t*–3412*t*
tetracyclines, 3413–3414
tigecycline, 3419
trimethoprim-sulfamethoxazole, 3417–3418
vancomycin, 3418

Antibiotics, topical, 3419–3421. *See also specific types*
allergic contact dermatitis from, 404–405
aminoglycosides, 3420*t*, 3421
bacitracin, 3420*t*, 3421
background, 3407
clindamycin, 3419, 3420*t*
fusidic acid, 3420*t*, 3421
mupirocin, 3420, 3420*t*
polymyxin B, 3420*t*, 3421
retapamulin, 3420*t*, 3421
silver sulfadiazine, 3420*t*, 3421
Antibody deficiency disorders, genetic, 2394–2398
agammaglobulinemia, 2394–2396
common variable immunodeficiency, 2396–2398, 2398*f*
immunoglobulin A deficiency, 2398*b*
Anti-CD38 monoclonal antibodies, for systemic amyloids, 2269
Anti-CD52. *See* Alemtuzumab
Anticitrullinated protein antibodies (ACPAs), rheumatoid arthritis, 1151–1152
Anticoagulant-induced skin necrosis, 757, 757*f*
Anticoagulants. *See also specific types*
for malignant atrophic papulosis, 2634, 2634*t*
preoperative examination, 3708, 3708*t*
for Raynaud phenomena, 2623
Anticonvulsants. *See also specific types*
lupus erythematosus from, 1041*t*
nodular pseudolymphoma from, 2116, 2116*f*
pseudolymphoma from, 756
Anti-CR4 (mogamulizumab), 2095–2096, 3543–3544, 3550*t*
Antidepressants. *See also specific types*
pellagra from, 2214
for pruritus, 358
Antiepileptics. *See also specific types*
lupus erythematosus from, 1041*t* (*See also specific types*)
Antiepiligrim cicatricial pemphigoid. *See* Mucous membrane pemphigoid (MMP)
Antifolate medications, 2216
Antifungal drugs, 3436–3449. *See also specific types*
allylamines, 3436–3441, 3438*t*–3439*t*
mechanism of action, 3436
naftifine, 3436–3437, 3438*t*
terbinafine, 3437–3441, 3438*t*, 3439*t*, 3441*t*
amorolfine, 3438*t*, 3447
at-a-glance, 3436*b*
azoles, 3438*t*–3440*t*, 3441–3445
imidazoles, 3438*t*, 3443–3445
clotrimazole, 3438*t*, 3443
econazole, 3438*t*
efinaconazole, 3438*t*, 3444–3445
ketoconazole, 3438*t*, 3443–3444
luliconazole, 3444
miconazole, 3438*t*, 3444
oxiconazole, 3438*t*
sertaconazole, 3438*t*, 3444
mechanism of action, 3443
triazoles, 3438*t*–3440*t*, 3445–3446
benzylamines, butenafine, 3438*t*, 3441
ciclopirox, 3438*t*, 3446–3447
combination therapy, 3449
drug–drug interactions, 3442*t*–3443*t*
fundamentals, 3436
griseofulvin, 3440*t*, 3441*t*, 3448
lupus erythematosus from, 1041*t*
mechanism of action, 3437*f*
new carrier vehicles and formulations, 3448–3449
polyenes, nystatin, 3438*t*, 3446
for seborrheic dermatitis, 434
tavaborole, 3438*t*, 3447–3448
triazoles, 3442*t*
fluconazole, 3439*t*, 3441*t*, 3442*t*, 3445
itraconazole, 3439*t*, 3441*t*, 3442*t*, 3445–3446
types, 3436
Antigen-presenting cells, 181–182, 182*f*
type IV hypersensitivity reactions, 397
Antigens. *See also specific disorders*
type IV hypersensitivity reactions, 397
Antihistamines, 3451–3459. *See also specific types*
at-a-glance, 3451*b*
for eosinophilic folliculitis with HIV, 3123
for erythema annulare centrifugum, 773*t*
for erythema annulare centrifugum, itching in, 767
for Fox-Fordyce disease, 1477
for graft-versus-host disease, 2333
histamine, 3451
ketotifen, 3459
lupus erythematosus from, 1041*t*
for nighttime itch, sedating
in lichen simplex chronicus, 391
in nummular eczema, 388
in prurigo nodularis, 391
for pemphigoid gestationis, 1767
for pigmented purpuric dermatoses, 2595
for pruritus, 358
tricyclic antidepressants, 3459
for urticaria, second-generation nonsedating, 702
for Wells syndrome, 667
Antihistamines, H_1, 3451–3457
in breastfeeding, 3457
in children, 3456
for cutaneous necrotizing venulitis, 2537
dosing regimens, 3454–3455, 3454*t*–3455*t*
drug interactions, 3456
in elderly, 3456
first- *vs.* second-generation, 3451
historical perspective, 3451
indications, 3453–3454, 3453*t*
for mastocytosis, 719, 719*t*
mechanism of action, 3451–3452, 3452*f*, 3452*t*
pharmacokinetics
first generation, 3452–3453
second generation, 3453
pregnancy, 3456–3457
risks and precautions, 3455–3456, 3455*t*
for solar urticaria, 1653, 1654*f*
Antihistamines, H_2, 3457–3459
in children, 3459
dosing regimens, 3458*t*
drug interactions, 3458–3459
in elderly, 3459
indications, 3457, 3457*t*
initiation of therapy, 3457–3458
for mastocytosis, 719, 719*t*
mechanism of action, 3457
pharmacokinetics, 3457
pregnancy, 3459
risks and precautions, 3458, 3458*t*
for urticaria, 702
Antihypertensives. *See also specific types*
lupus erythematosus from, 1041*t*
Anti-IgE autoantibody (IgG), type I hypersensitivity, 691, 691*f*
Antiinflammatory therapy, topical. *See also specific types*
for atopic dermatitis
calcineurin inhibitors, 378
coal tar preparations, 378
corticosteroids, 377
crisaborole, 378
emollients, 376–377
coal tar, 3611
crisaborole, 3611
shale oil, 3611
wood tar, 3611
Anti-La/SS-B
lupus erythematosus, 1048, 1050
Sjögren syndrome, 1170
Antimalarials. *See also* Chloroquine; Hydroxychloroquine; *specific types*
for α-antitrypsin panniculitis, 1269
for dermatomyositis, 1077
for lichen planus
cutaneous, 544
oral, 546
for lupus erythematosus, 1054*t*, 1055–1056
for lupus panniculitis, 1275
side effects, 1056
psoriasis exacerbation, 479
retinopathy, 1055
Anti–melanoma differentiation–associated gene 5 (anti-*MDA5*), dermatomyositis, 1068, 1073
Anti–MI-2, dermatomyositis, 1070*t*
Antimicrobial agents, topical, 3611–3614, 3612*t*–3613*t*. *See also specific types*
azelaic acid, 3613*t*, 3614
benzoyl peroxide, 3613*t*, 3614
chlorhexidine, 3611, 3612*t*
clioquinol, 3612*t*, 3613–3614
dyes
brilliant green, 3611, 3612*t*
gentian violet, 3611, 3612*t*
hydrogen peroxide, 3612*t*, 3613
metronidazole, 3612*t*, 3614
mupirocin, 3613*t*, 3614
povidone-iodine, 3612*t*, 3613
retapamulin, 3613*t*, 3614
Antimicrobial barrier, skin, 220–223
properties, 220–222, 222*t*
proteins
cell production, 222, 223*f*
functions, 223
skin surface, 222, 222*t*
Antimicrobial peptides (AMPs), 174–175
Antimony, for leishmaniasis, 3236, 3236*t*
Antineutrophil cytoplasmic antibodies (ANCA)
cutaneous necrotizing venulitis, 2529, 2534–2535
cytoplasmic, 2535
perinuclear, 2529, 2535
vasculitis, 2541, 2548
pulmonary and cutaneous manifestations, 2428–2430
Antinuclear antibody (ANA)
lupus erythematosus, 1048–1049
vasculitis, 2548
Anti–nuclear matrix protein 2 (NXP2), dermatomyositis, 1070*t*
Antioxidants. *See also specific types*
for aging skin, 3814
for dyschromia, 3812
porphyria cutanea tarda, 2240
for Raynaud phenomena, 2623
Antioxidant systems, skin, 1779, 1780*t*
Antiparasitic agents, topical, 3614–3616, 3615*t*. *See also specific types*
crotamiton, 3614, 3615*t*
ivermectin, 3615, 3615*t*
lindane, 3614–3615, 3615t
malathion, 3615, 3615*t*
permethrin, 3615–3616, 3615*t*
pyrethrins, synergized, 3615*t*, 3616
spinosad, 3615*t*, 3616
Antiperspirants
aluminum compounds, 3616
glycopyrrolate, 3616
iontophoresis, 3616
Antiphospholipid antibody syndrome, livedo racemosa, 2684

Antiproliferative agents, 3463–3471. *See also specific types*
  at-a-glance, 3463*b*
  chemical structures, 3465*f*
  hydroxyurea, 3465*f*, 3469–3471
  methotrexate, 3463–3469, 3465*f*
Antipruritic agents, topical. *See also specific types*
  diphenhydramine, 3617*t*
  doxepin, 3616, 3617*t*
  menthol, 3617, 3617*t*
  phenol, 3617, 3617*t*
  pramoxine hydrochloride, 3617, 3617*t*
Antiretroviral therapy (ART), 3503–3508. *See also specific types*
  adverse effects, 3505
  available drugs, 3503, 3503*t*
  drug interactions, 3506
  entry inhibitor, 3506
  fundamentals, 3503
  fusion inhibitor, 3506
  for HIV-associated eosinophilic pustular folliculitis, 671
  initiation, 3504
  integrase strand transfer inhibitors, 3508, 3509*t*
  mechanisms of action, 3503–3504
  nonnucleoside reverse transcriptase inhibitors, 3507–3508, 3509*t*
  nucleoside and nucleotide reverse transcriptase inhibitors, 3506–3507, 3509*t*
  prevention
    postexposure prophylaxis, 3505, 3505*t*
    preexposure prophylaxis, 3504–3505, 3505*t*
  protease inhibitors, 3508, 3509*t*
  regimens, 3504, 3504*t*
Anti-Ro antibody, cutaneous necrotizing venulitis, 2529
Anti-Ro/SS-A
  lupus erythematosus, 1048, 1050
  Sjögren syndrome, 1170
Antiseptics, topical, 3714–3715. *See also specific types*
  chlorhexidine, 3714–3715
  ethyl alcohol, 3715
  hexachlorophene, 3715
  isopropyl alcohol, 3715
  povidone-iodine, 3714
Anti–small ubiquitin-like modifier activating enzyme (SAE), dermatomyositis, 1070*t*
Anti-TGF-β, for systemic sclerosis, 1098
Antithymocyte globulin, for cytophagic histiocytic panniculitis, 1278
Anti-TNF-α. *See* Infliximab
Antitragus, 3698*f*, 3699
Anti–transcriptional intermediary factor (TIF1)-γ, dermatomyositis, 1070*t*
Anti–tRNA synthetase, dermatomyositis, 1070*t*
Antivenom, for crotaline snake bites, 3343
Antiviral drugs, 3493–3513. *See also specific types*
  at-a-glance, 3493*b*
  for cytomegalovirus infections, 3499–3501
    cidofovir, 3501, 3501*t*
    foscarnet, 3500–3501, 3500*t*
    ganciclovir and valganciclovir, 3499–3500, 3500*t*
  for herpesvirus infections, 3493–3499
    acyclovir, 3493–3496, 3495*t*
    famciclovir and penciclovir, 3494*f*, 3497–3498, 3498*t*
    mechanisms of action, 3494*f*
    trifluridine, 3498–3499, 3499*t*
    valacyclovir, 3496–3497, 3497*t*
  for HIV infection, 3503–3508 (*See also* Antiretroviral therapy (ART))
  interferons, 3502–3503, 3502*t*
  investigational drugs, 3509–3513, 3509*t*
    for hepatitis B, 3512
    for hepatitis C, 3509–3512
    for other viral infections, 3512–3513
  pregnancy categories, 3496*t*
Antoni A areas, 38
  schwannoma, 2155, 2155*f*, 2156*f*
Antoni B areas, 38
  schwannoma, 2155, 2155*f*
Ant stings, 3333–3334
AP1S3, PPPP, 479
AP3B1, Hermansky-Pudlak syndrome, 1316*t*
AP3D1, Hermansky-Pudlak syndrome, 1316*t*
APECED (autoimmune polyendocrinopathy, candidiasis, and ectodermal dystrophy), chronic mucocutaneous candidiasis, 2399–2401, 2400*t*, 2401*f*
Apert syndrome, acneiform eruptions, 1454
Apidae, 3333–3334
APJ, 28
Aplasia cutis congenita (ACC), 1737–1738, 1738*f*
Aplastic anemia, from dapsone, 3429
ApoB100 mutations, 2288
ApoB lipoprotein pheresis, for hypercholesterolemia, 2288
Apocrine adenocarcinoma, 1837–1838
  primary cutaneous cribriform carcinoma, 1838
Apocrine appendage tumors, 1820, 1821*t*, 1831–1838, 1831*t*. *See also* Appendage tumors, apocrine; *specific types*
Apocrine glands
  development, 27
  neonates, 1728
Apocrine miliaria, 1475–1478. *See also* Fox-Fordyce disease
Apocrine mixed tumor, 1832–1833, 1833*f*
Apocrine sweat glands, 71*t*, 83–85
Apolipoprotein, synthesis, 2280
Apolipoprotein E (apoE), 2273
Apoptosis, 278–279, 281
  receptors, eosinophil expression, 656
  signaling cascades, 280–281, 280*f*
Apparent leukonychia, 1568, 1569*t*, 1570*f*
Appendageal carcinoma, with HIV, 3121
Appendages. *See also specific types*
  aging, 1783–1784
    hair, 1783–1784
    nails, 1784
  development, 49, 52*t*
  as skin barrier, 3367
Appendage tumors, 1820–1853. *See also specific types*
  at-a-glance, 1820*b*
  classification, 1820, 1821*t*
  clinical presentation, 1820
  genetic syndromes, 1820, 1822*t*
  histopathology, 1820–1822
Appendage tumors, apocrine, 1820, 1821*t*, 1831–1838, 1831*t*
  benign, 1831–1836
    apocrine mixed tumor, 1832–1833, 1833*f*
    hidradenoma papilliferum, 1835–1836, 1835*f*
    hidrocystoma, 1822*t*, 1831–1832, 1832*f*
    nipple adenoma, 1836
    syringocystadenoma papilliferum, 1833–1834, 1834*f*
    tubular adenoma, 1834–1835
  malignant, 1836–1838
    adenoid cystic carcinoma, 1836–1837, 1837*f*
    apocrine adenocarcinoma, 1837–1838
    mucinous carcinoma, 1838
    primary cutaneous cribriform carcinoma, 1838
Appendage tumors, eccrine, 1820, 1821*t*, 1822–1830
  benign, 1822–1827, 1822*t*
    cylindroma, 1822*t*, 1825–1826, 1825*f*
    hidradenoma, 1822–1823, 1823*f*
    poroma, 1823–1825, 1824*f*
    spiradenoma, 1822*t*, 1826–1827, 1826*f*
    syringoma, 1827, 1827*f*
  malignant, 1827–1830
    cylindrocarcinoma/spiradenocarcinoma, 1822*t*, 1829
    digital papillary adenocarcinoma, 1829–1830
    hidradenocarcinoma, 1827–1828
    microcystic adnexal carcinoma, 1830, 1830*f*
    porocarcinoma, 1828–1829, 1828*t*
Appendage tumors, follicular, 1838–1849
  biphasic, follicular germinative and stromal cells, 1839*t*
    trichoblastoma, 1840–1841, 1840*f*
    trichoepithelioma, 1822*t*, 1841–1842, 1842*f*
  germinative cells, basal cell carcinoma, 1839
  hair follicle and its germinative cells, 1838
  infundibular, 1839*t*
    dilated pore (of Winer), 1849
    trichoadenoma, 1848
  matrical, 1839*t*
    pilomatrical carcinoma, 1844–1845
    pilomatricoma, 1822*t*, 1843–1844, 1844*f*
  mesenchymal, trichodiscoma/fibrofolliculoma, 1822*t*, 1839*t*, 1843–1844, 1843*f*
  outer root sheath differentiation neoplasms
    bulb/stem, trichilemmoma, 1822*t*, 1839*t*, 1845–1846, 1846*f*
    isthmic, 1839*t*
      pilar sheath acanthoma, 1847
      proliferating pilar tumor, 1822*t*, 1847–1848, 1848*f*
      tumor of follicular infundibulum, 1846–1847
  pan-follicular, trichofolliculoma, 1839, 1839*f*, 1839*t*
Appendage tumors, sebaceous, 1822*t*, 1839*t*, 1849–1853, 1849*t*
  benign
    sebaceoma/sebaceous epithelioma, 1822*t*, 1850–1851, 1851*f*, 1852*t*
    sebaceous adenoma, 1822*t*, 1849–1850, 1850*f*
  malignant, sebaceous carcinoma, 1822*t*, 1851–1853, 1852*f*, 1852*t*
Apple-jelly sign, 9*f*, 12*t*
Application, on topical therapy absorption
  frequency, 3371
  quantity, 3371
Apremilast
  for adamantiades–Behçet disease, 2575*t*
  for Behçet disease, 2557
  for pityriasis rubra pilaris, 503
  for plaque psoriasis, 176
  for psoriasis, 176, 486*t*, 492
  for psoriatic arthritis, 176, 980–981, 980*t*, 1136*t*, 1137
AQP5, palmoplantar keratoderma Bothnia type, 825
Aquagenic palmoplantar keratoderma, 2430
Aquagenic urticaria, 690. *See also* Urticaria
  clinical features, 685, 686*f*
  diagnosis, 698
  diagnostic tests, 688*t*
Aquagenic wrinkling of palms, pulmonary and cutaneous manifestations, 2430
Aquaporin-3 (AQP3), 3805–3806
Aquatic organism bites and stings, 3344–3359. *See also specific types*
  Cnidaria, 3344–3350

echinoderms, 3350–3352
fish bites, 3358–3359, 3358*f*
marine worms, 3352–3355
mollusks, 3355–3356, 3355*f*
seal bite, 3344
sponges, dermatitis, 3350, 3350*f*
venomous fish spines, 3356–3358
catfish, 3357
prevention, 3357
scorpionfish, 3357, 3357*f*
stingrays, 3356, 3356*f*
symptoms, 3357
treatment, 3358
weeverfish, 3357
Arachnida, 3324–3330
Acarina, 3325*f*, 3328–3330
mites, 3329 (*See also* Mite(s))
ticks, 3329–3330, 3329*f*
Aranae, 3324–3328
prevention, 3334–3335
Scorpiones, 3328
Aranae, 3324–3328
Latrodectus, 3324–3326, 3326*f*
Loxosceles, 3326–3327, 3326*f*–3327*f*
tarantulas, 3328
Tegenaria agrestis, 3327–3328
ARC, cellular defect, 781*t*
ARCI with hypertrichosis, cellular defect, 782*t*
Arc lamps, phototherapy, 3639
Arcuate shape, 10
Areolar glands, 70. *See also* Sebaceous glands
Argasidae, 3329
Argatroban, for rheumatoid vasculitis, 1151
L-Arginine, for Raynaud phenomena, 2621, 2621*t*
Argyll Robertson pupil, ocular syphilis, 3157
Argyria, 1365
gray to blue nail matrix, 1569
ARID1A, cutaneous T-cell lymphomas, 2075
Aripiprazole
for delusions of parasitosis, 1696, 1697*t*
for dermatitis artefacta, 1703
Arizona recluse spider, 3327
Armadillo family proteins, desmosomal, 233
plakoglobin, 233, 237
plakophilins, 233, 237
ARPC3, 905
ARSE, chondrodysplasia punctata X-linked recessive, 778*t*, 805
Arsenic
basal cell carcinoma from, 1895
nail changes, 1598
phototherapy safety with exposure to, 3645
Arsenical keratoses (ArKs), 1879–1880, 1880*f*
Artemis, severe combined immunodeficiency, 2405–2406
Arteries, face, 3703–3705, 3704*f*
Arterioles, dermal, 49
anatomy, 117, 118*f*
deep vascular plexus, 116, 117*f*
superficial vascular plexus, 116, 117*f*
Arteriovenous malformations (AVMs), 2636, 2637*t*, 2638*f*, 2658–2663. *See also* Vascular malformations; *specific types*
at-a-glance, 2658*b*
clinical course and prognosis, 2662–2663
clinical features, 2659–2661
complications, 2661
cutaneous, 2638*f*, 2659–2660, 2660*f*–2661*f*
noncutaneous, 2661
diagnosis, 2662
differential diagnosis, 2662, 2662*t*
epidemiology, 2659
etiology and pathogenesis, 2661–2662
genetic, 2640*t*
management, 2663
nidus, 2658–2659
syndromic disorders
Bonnet-Dechaume-Blanc syndrome, 2659
Cobb syndrome, 2659
hereditary hemorrhagic telangiectasia, 2659
Parkes Weber syndrome, 2659
phosphatase and tensin homolog hamartoma tumor syndrome, 1360, 2152, 2640*t*, 2659
Wyburn-Mason syndrome, 2659
Arteritis
cannabis, 1712
giant cell, 2541, 2554, 2555*f* (*See also* Vasculitis)
necrotizing
Kawasaki disease, 2584
systemic, 2539–2558 (*See also* Vasculitis)
Takayasu, 2540, 2554
temporal, 1256, 2541, 2554, 2555*f*
Arthralgias, dermatomyositis, 1070
Arthritis
acute rheumatic fever, 1159*t*
dermatomyositis, 1070
granulomatous dermatitis, interstitial, 27
juvenile idiopathic, 1153–1155, 1154*f*, 1160*t*
psoriatic arthritis with, 972*f*, 1128
Arthrochalasia Ehlers-Danlos syndrome (aEDS), 1216*t*
Arthroconidia, 2926*t*
Arthropod bites and stings, 3324–3335
Arachnida, 3324–3330
at-a-glance, 3324*b*
Chilopoda, Centipedes, 3330
differential diagnosis, 3324, 3326*t*
Diplopoda, millipedes, 3330
histopathology, 3324
Insecta, 3330–3334
persistent nodular reactions, 2115–2116, 2115*f*
pictorial key, 3324, 3325*f*
prevention, 3334–3335
treatment principles, 3324, 3325*t*
Articulated arms, laser energy delivery, 3825
Asboe-Hansen sign, 12*t*
Ascaris lumbricoides, 3252*t*, 3253, 3254
biliary disease, 3261
exposure and symptom onset interval, 3259, 3260*t*
granulomatous hepatitis, 3261
Loeffler syndrome, 3260–3261
progression and duration, 3259, 3260*t*
urticaria and pruritus, 3258–3259, 3258*t*
Ascorbate, for Ehlers-Danlos syndromes, 1223
Ascorbic acid. *See* Vitamin C (ascorbic acid)
L-Ascorbic acid/glycolytic acid, for striae, 1197
Ash-leaf spots, tuberous sclerosis complex, 2480, 2481*f*
ASIP, 342
ASIP, 344
ASK2, dedifferentiated liposarcoma, 2189
Asp caterpillar, 3334, 3334*f*
Aspergillus, 2984–2985
with HIV, 3114
Aspirin
for cercarial dermatitis, 3354
for cryofibrinogenemia, 2609
for kaposiform hemangioendothelioma, 2063
for Kawasaki disease, 2587, 2587*t*
for malignant atrophic papulosis, 2634, 2634*t*
for mastocytosis, 719
for necrobiosis lipoidica, 2501
for Raynaud phenomena, 2621*t*, 2623
for rheumatoid vasculitis, 1153
for Still disease, adult-onset, 1158
urticaria from, 694–695, 694*t*
Aspirin asthma, 694
Assassin bug, 3240, 3332
Assessment, preoperative, 3706–3709. *See also specific procedures*
history and physical examination, 3706–3709 (*See also* History and physical examination)
Association, 41. *See also specific disorders*
causal, 41
measures, 45–46, 45*t*
Astaxanthin, oral photoprotection, 3630
Asteatos eczema, 444
Asteatotic dermatitis, 444
Astemizole, for pruritus in lichen nitidus, 558, 558*t*
Asthma
aspirin, 694
Charcot-Leyden crystal protein, 651*f*, 652
with eczema, filaggrin mutations, 216
Astringents, 3613*t*, 3617–3618. *See also specific types*
aluminum salts, 3613*t*, 3617
potassium permanganate, 3613*t*, 3617–3618
silver nitrate, 3613*t*, 3618
Asymmetric periflexural exanthem of childhood, 3013–3015, 3014*t*, 3015*t*
ATAC-seq, 293
Ataxia telangiectasia (AT), 2407–2409, 2407*f*–2408*f*, 2445*t*
clinical features, 2344*t*
genome instability, spontaneous, 2342
mechanisms, 2345*t*
Atazanavir, 3508, 3509*t*
Atazanavir-cobicistat, 3508, 3509*t*
Atelephalangia with anonychia, 1568
Atheromatous embolism, 2675–2679
at-a-glance, 2675*b*
clinical course and prognosis, 2678–2679
clinical features
complications, 2677
cutaneous, 2676–2677, 2676*t*, 2677*f*
history, 2676
related physical findings, 2677
diagnosis, 2677–2678
differential diagnosis, 2678, 2678*t*
epidemiology, 2676
etiology and pathogenesis, 2676
management, 2679
prevention, 2679
Atkins Diet, for dermatitis herpetiformis, 1007
AT-like disorder (ATLD), 2344*t*, 2345*t*
ATM (ataxia-telangiectasia mutated)
ataxia-telangiectasia, 2407*b*
blastic plasmacytoid dendritic cell neoplasm, 2102
A-to-L flap, 3735, 3735*f*
Atopic dermatitis (AD), 363–373
at-a-glance, 363*b*
atopic march, 196, 196*f*
attention-deficit hyperactivity disorder, 366
B cells, 149
chemokines, 182–183
clinical course and prognosis, 373
clinical features, 364–368
cutaneous, 364, 365*f*–366*f*, 366*t*
nail changes, 1582
noncutaneous
atopic comorbidities, 365–366
psychosocial impact, 366
complications
bacterial infection, 366–367
exfoliative dermatitis, 368
fungal infection, 367
hand dermatitis, 368
ocular, 367–368
viral infection, 367, 367*f*
Corynebacterium, 197
definition and nomenclature, 363–364

Atopic dermatitis (AD) (*Cont.*):
diagnosis, supportive studies
imaging, 371–372
laboratory testing, 371
pathology, 371, 372*t*
diagnostic criteria, 364
differential diagnosis, 372–373, 373*t*
epidemiology, 364, 416
etiology and pathogenesis, 196–197, 196*f*, 368–371, 420
cytokine-driven skin inflammation, 369–370
epithelial differentiation complex, immune effects, 370
genetics, 368–369
immunopathology, 369
overview, 368
pruritus basis, 370–371
skin barrier function, decreased, 368
filaggrin mutations, 420
immunologic responses, 195–197, 196*f*
inflammatory responses, to common organisms, 421, 421*f*
itching, eosinophils in, 656
lesion distribution, age and, 364, 365*f*, 366*f*
microbiome, skin, 257, 257*t*
neonatal, 1739
nummular lesions, 385
pathophysiology, genetics, 301
prevention, 381
Staphylococcus aureus, 197
superantigens, 2767
Atopic dermatitis (AD) management, 373–381
dupilumab, 176, 197
education as intervention, 373–374, 375*t*
hospitalization, 378
overview, 373, 374*f*
phototherapy, 378, 3646*t*, 3648–3649
excimer laser, 3649
narrowband UVB, 3648–3649
PUVA, 3649, 3672
ultraviolet A1, 3649
pruritus, 376
systemic therapy, 378–381
allergen immunotherapy, 380
antimetabolites, 379–380
Chinese herbal medications, 380
cyclosporine, 379
dupilumab, 379
extracorporeal photopheresis, 380
glucocorticoids, 379
initiation, decision, 378–379
interferon-γ, 380
omalizumab, 380
probiotics, 380
vitamin D, oral, 380–381
topical therapy
antiinflammatory
calcineurin inhibitors, 378
coal tar preparations, 378
corticosteroids, 377
crisaborole, 378
emollients, 376–377
trigger identification and elimination, 374–376
allergens, 375
emotional stressors, 375
general considerations, 374–375
infectious agents, 375–376
Atopic eczema, filaggrin mutations, 216
Atopic eruption of pregnancy (AEP), 1768*t*, 1775–1777
clinical course and prognosis, 1776
clinical features, 1775, 1776*f*–1777*f*
diagnosis and differential diagnosis, 1775
epidemiology, 1775
etiology and pathogenesis, 1775
management, 1776
risk factors, 1775
Atopic keratoconjunctivitis, 368
Atopic-like dermatitis, 2395*t*
Atopic march, 196, 196*f*
Atopiform dermatitis, 364
ATP2A2, 879, 880, 885, 887
ATP2C1, 886, 887–888
ATP6V0A2, cutis laxa, 1239
ATP6V1A, cutis laxa, 1239
ATP7A
cutis laxa, 1240
Menkes syndrome, 1540
ATP8B1 (FIC1), intrahepatic cholestasis of pregnancy, 1770
At-risk population, 45
Atrophic disorders of skin, 1193–1200. *See also specific types*
anetoderma, 1193–1195
idiopathic atrophoderma of Pasini and Pierini, 1198–1199, 1198*f*
middermal elastolysis, 1195–1197, 1196*f*
striae, 1197
Atrophic gastritis, dermatitis herpetiformis, 1003
Atrophic lichen planus, 531, 531*t*
Atrophie blanche, 2530*t*, 2532, 2532*f*
Atrophoborrelioses, cutaneous, 3292, 3294*t*
Atrophoderma of Pasini-Pierini, hypermelanosis, 1383
Atrophoderma vermiculatum (AV), 869–872, 869*t*, 870*f*, 871*f*, 872*t*, 1199, 1199*f*
Atrophy, 6
from corticosteroids, 21, 3390
epidermal cells, 21, 22*f*
from radiotherapy, 3691*t*
Attagenus megatoma, 3331
Attention-deficit hyperactivity disorder (ADHD), atopic dermatitis, 366
Attributable risk, 45, 45*t*
Atypical fibroxanthoma, 36–37
Atypical intradermal smooth muscle neoplasms (AISMN), 2138–2141. *See also* Leiomyosarcoma
Atypical lipomatous tumor, 2186–2188, 2186*f*–2188*f*
Atypical mycobacteria, 2870–2874. *See also* Mycobacteria other than *M. Tuberculosis* (MOTT) skin diseases
Atypical nevus, 1944
Augmentation. *See also specific types*
intravenous, α-AT protein, for α-antitrypsin panniculitis, 1269
soft-tissue, 3911–3920
Auriculotemporal nerve, 3702*f*, 3703, 3703*t*
Auspitz sign, 12*t*
parapsoriasis, 509
psoriasis, 458, 459*f*
Australian blue-ringed octopus, 3355–3356, 3355*f*
Autacoids. *See also specific types*
inflammation, 124
Autism spectrum disorder (ASD), 1758–1760
background, 1758–1759
dermatology, 1759–1760
genodermatoses, 1759, 1759*t*
skin findings, 1759, 1759*t*
treatment, 1760*t*
Autoantibodies. *See also specific types*
dermatomyositis, clinical associations, 1068, 1070*t*
laminin-332, 962, 964
plakin, paraneoplastic pemphigus, 937, 938*f*, 938*t*
Sjögren syndrome, 1172–1173
systemic sclerosis, 1089, 1090*t*, 1094, 1095*t*
Autoeczematization (id) response, 2767
Autografts, 3753
Autoimmune blistering diseases. *See also specific diseases*
classification, 201
diagnosis, histology, 201
eosinophils, 659
immunologic responses, 201–203
management
glucocorticoids, systemic, 202
rituximab, 202
Autoimmune bullous diseases (ABDs). *See also specific types*
etiology and pathogenesis, 982
nail changes, 1586–1587, 1586*f*
Autoimmune connective tissue disease
cardiovascular and cutaneous manifestations, 2427
pulmonary and cutaneous manifestations, 2430
Autoimmune diseases. *See also specific types*
chronic spontaneous urticaria, 687
dermatitis herpetiformis, 1004
lichen planus and, 540
vitiligo, 1335
Autoimmune neutrophilic dermatoses syndrome, 1149, 1149*f*
Autoimmune polyendocrinopathy, candidiasis, and ectodermal dystrophy (APECED), 2399–2401, 2400*t*, 2401*f*
Autoimmune progesterone dermatitis, 2515
Autoimmune thyroid diseases, chronic spontaneous urticaria, 687
Autoimmune urticaria, 687, 691, 691*f*, 692
Autoinflammatory disorders, 621–645, 622*t*. *See also specific disorders*
at-a-glance, 621*b*
Blau syndrome/early-onset sarcoidosis, 640–641, 641*f*
CARD14-mediated pustular psoriasis, 629–631, 632*f*
chronic atypical neutrophilic dermatosis with lipodystrophy and elevated temperature syndrome/proteasome-associated autoinflammatory syndrome, 639–640
clinical presentation, 621
cryopyrin-associated periodic syndromes, 621–625, 623*t*, 624*f*
deficiency of the IL-1 receptor antagonist, 627–628, 628*f*
deficiency of the IL-36 receptor antagonist, 628–629, 630*f*
familial Mediterranean fever, 595, 631–633, 633*f*
haploinsufficiency of A20, 637–638, 637*f*
hyperimmunoglobulinemia D with periodic fever syndrome/mevalonate kinase deficiency, 634–635, 635*f*
IL-1 mediated, 622*t*
IL-36 mediated, 622*t*
Majeed syndrome, 643–644
monogenic, 621*b*
otulipenia/OTULIN-related autoinflammatory syndrome, 638
psoriasis 2, 629–631, 632*f*
pyogenic arthritis, pyoderma gangrenosum, and acne syndrome, 642–643, 642*f*
SAPHO syndrome, 644–645, 645*f*
Schnitzler syndrome, 625–627, 626*f*
TNF receptor-associated periodic syndrome, 635–637, 636*f*
Autoinflammatory lipodystrophy syndrome, 1299
Autoinflammatory syndrome
cryopyrin associated periodical syndrome, 699
Schnitzler syndrome, 699
Autologous fat transfer (AFT), 3913*t*, 3917–3918, 3918*t*, 3919*f*

Autologous peripheral blood stem cell transplantation, for scleromyxedema, 1168
Automatic digitalized system for hair density and anagen/telogen hairs, 1500
Automeris io, 3334
Autonomic nerves, 354–355
Autonomic nervous system, rosacea, 1430, 1432*f*
Autosomal dominant ARVC, plakophilin mutations, 237
Autosomal dominant inheritance and disorders, 295–296, 295*t*, 296*f*
Autosomal dominant striate palmoplantar keratoderma, 237
Autosomal recessive congenital ichthyosis (ARCI), 778, 779*t*, 781*t*
  genes, 779*t*–780*t*, 782*t*, 787–788
  with hypotrichosis, 782*t*
  TGM1, 787, 788, 788*f*
Autosomal recessive inheritance and disorders, 296, 296*f*, 296*t*
Auto transfer, allergic contact dermatitis, 400
Avascular necrosis, from glucocorticoids, 3386
Avobenzone, 3625–3626, 3626*t*, 3628
Axillary hyperhidrosis, adolescents, 1758
Azapropazone, for adamantiades–Behçet disease, 2575*t*
Azathioprine, 3471–3474
  for actinic dermatitis prevention, 1643
  for actinic prurigo, 1632
  for adamantiades–Behçet disease, 2575, 2575*t*
  for atopic dermatitis, 380
  for bullous pemphigoid, 952, 952*t*
  chemical structure, 3465*f*
  complications
    anaphylaxis, 3473
    carcinogenesis, 3473–3474
    GI, 3473
    hematologic, 3473
    hepatic, 3473
    infections, 3473
    mutagenicity and teratogenicity, 3474
  for connective tissue disease–associated panniculitis, 1283*b*
  for cryofibrinogenemia, 2609
  for cryoglobulinemia II and III, HCV, 2607
  for dermatomyositis, 1078
  dosing regimen, 3472, 3472*t*
  drug interactions, 3474
  for erythema gyratum repens, 2455
  for erythema multiforme, 730
  for graft-versus-host disease
    chronic, 2334
    oral, 2335
  indications, 3471–3472, 3471*t*
  initiating therapy, 3472
  for lichen planus, 544–545
  for lupus erythematosus, 1054, 1054*t*, 1057
  mechanism of action, 3471
  monitoring therapy, 3472, 3472*t*
  for mucous membrane pemphigoid, 966*t*, 967
  pellagra from, 2214
  for pemphigus, 924
  pharmacokinetics, 3471
  photocarcinogenesis, 1905
  for pyoderma gangrenosum, 614*t*
  for reactive arthritis, 1142
  risks and precautions, 3473, 3473*t*
  for Still disease, adult-onset, 1158
    reactive phagocytic syndrome in, 1158
  thiopurine methyltransferase conversion, 924
  for vasculitis, 2557
Azelaic acid
  for acne vulgaris, 1403*t*, 1404
  antimicrobial actions, 3613*t*, 3614
  as bleaching agent, 3618
  for melasma, 2242
  for perioral dermatitis, 1455
  for rosacea, 1439
Azelastine, 3454–3455, 3454*t*. *See also* Antihistamines, H_1
  for mastocytosis, 719, 719*t*
Azithromycin. *See also* Macrolides
  for African tick bite fever, 3309*t*
  for bacillary angiomatosis, 2806
  for cat scratch disease, 2805
  for chancroid, 3189–3190, 3190*t*
  for granuloma inguinale, 3205, 3206*t*
  for Mediterranean spotted fever, 3309*t*
  for pityriasis lichenoides, 515, 515*t*
  for *Salmonella* enteric fever, 2808
  for skin and soft-tissue infections, dosing, 3410*t*
  topical, for perioral dermatitis, 1455
  for trench fever, 2805
  for typhus
    endemic, 3310*t*
    epidemic, 3310*t*
  for verruga peruana, 2806
Azithromycin, oral/sytemic
  for acne vulgaris, 1405
  for chlamydia, 3217, 3217*t*
  for leishmaniasis, 3236
  for lymphogranuloma venereum, 3198, 3198*t*
  for mycoplasmas, genital, 3214, 3214*t*
  for rosacea, 1439
  for yaws, 3181
Azoles, 3438*t*–3440*t*, 3441–3445. *See also specific types*
  imidazoles, 3438*t*, 3443–3445
    clotrimazole, 3438*t*, 3443
    econazole, 3438*t*
    efinaconazole, 3438*t*, 3444–3445
    ketoconazole, 3438*t*, 3443–3444
    luliconazole, 3444
    miconazole, 3438*t*, 3444
    oxiconazole, 3438*t*
    sertaconazole, 3438*t*, 3444
  mechanism of action, 3443
  triazoles, 3438*t*–3440*t*, 3445–3446
Azula, 3173–3177
Aβ sensory fibers, 353
Aδ sensory fibers, 353, 354*f*

B

B3GALT6, spondylodysplastic Ehlers-Danlos syndrome, 1213*t*, 1217*t*
B4GALT7, spondylodysplastic Ehlers-Danlos syndrome, 1213*t*, 1217*t*
Babesia microti
  Borrelia burgdorferi coinfection, 3295
  Ixodes transmission, 3320
Bacillary angiomatosis (BA)
  bacteriology, 2797, 2797*t*
  clinical course and prognosis, 2805
  clinical features
    complications, 2802
    cutaneous, 2799*t*, 2800, 2801*f*
    noncutaneous, 2799*t*, 2801–2802
  diagnosis
    imaging, 2804
    laboratory, 2799*t*, 2804
    pathology, 2804, 2804*f*
  differential diagnosis, 2804, 2805*t*
  epidemiology, 2798
  etiology and pathogenesis, 2803–2804
  with HIV, advanced, 3114
  management, 2806
Bacille Calmette-Guérin (BCG)
  attenuated, 2859 (*See also* Tuberculosis (TB))
  immunization
    granuloma annulare from, 566
    sequelae, 2867–2868
Bacillus anthracis, 2827–2830
  at-a-glance, 2827*b*
  clinical course and prognosis, 2828–2830
  clinical features, 2827–2828, 2828*f*
  etiology and epidemiology, 2827, 2829*t*
  occupational, 448
  prevention, 2830
  treatment, 2828
Bacillus oleronius, rosacea, 1427, 1428*f*–1429*f*, 1429
Bacitracin, topical, 3420*t*, 3421
  allergic contact dermatitis from, 404–405
  for burn wound care, 1686*t*, 1687
Bacteremia, *Pseudomonas aeruginosa*
  diagnosis, 2794
  etiology and pathogenesis, 2793–2794
  management, 2796
Bacteria. *See also specific types*
  molecular structure, 254
  skin microbiome
    dermatologic disorders, 257, 257*t*
    sequencing methods, 254
Bacterial vaginosis (BV), 3217–3219, 3218*f*
BAFF (B-cell activating factor), Sjögren syndrome, 1171
Baker-Gordon phenol peel, 3901
Baker phenol, chemical peels, 3901
Balamuthia, 3247–3248
Balamuthia mandillaris, 3247–3248
Balanced translocation, 300
Balanitis, 983, 983*f*, 2958–2959
Baldness. *See also* Alopecia; *specific types*
  Christmas-tree pattern, 3931, 3946*f*
  classification, female-pattern, 3931, 3933*f*
    Christmas-tree pattern, 3931, 3946*f*
  classification, male-pattern, 3931, 3932*f*
    Hamilton-Norwood, 3931, 3932*f*
      incidence, men >65, 3931, 3934*t*
      incidence by age, 3931, 3934*t*
    Ludwig, 3931, 3933*f*
    Norwood, 3931, 3933*f*
Balloon cell nevus, 1955
Balsam of Peru
  allergic contact dermatitis from, 404
  dyshidrosiform hand eczema from, 400, 402
Bamboo hair. *See* Trichorrhexis invaginata
Band-Aid disease, 2064
BANK1, graft-versus-host disease, 2322
Bannayan-Riley-Ruvalcaba syndrome, 1360
  lipoma, 2172, 2173*t*
Banner flap, 3746–3747, 3747*f*
BAP1, Spitz nevus, 1964–1965
Baricitinib
  for alopecia areata, 1522
  for rheumatoid arthritis, 1152
Barnyard pox, 3081. *See also Parapoxvirus*
Barracuda attacks, 3358
Barraquer-Simons syndrome, 1297*f*, 1300, 1300*f*
Barrier, skin, 206–226, 3367–3368. *See also* Skin barrier
Barrier cream, 424, 425
Bartonella, 2796–2806
  at-a-glance, 2796*b*–2797*b*
  clinical course and prognosis, 2804–2805
  clinical features, cutaneous
    bacillary angiomatosis, 2799*t*, 2800, 2801*f*
    Carrion disease, 2799*t*, 2800, 2801*f*
    cat scratch disease, 2798, 2799*t*, 2800*f*
    complications, 2802
    trench fever, 2799*t*, 2800
  clinical features, noncutaneous
    bacillary angiomatosis, 2799*t*, 2801–2802
    Carrion disease, 2799*t*, 2802
    cat scratch disease, 2799*t*, 2800–2801
    trench fever, 2799*t*, 2801

Bartonella (*Cont.*):
diagnosis
laboratory, 2799*t*, 2804–2805
pathology, 2804, 2804*f*
differential diagnosis, 2804, 2805*t*
epidemiology
bacillary angiomatosis, 2798
Carrion disease, 2798
cat scratch disease, 2797
trench fever, 2798
etiology and pathogenesis, 2803–2804
infective endocarditis, 2817
introduction and bacteriology, 2797, 2797*t*
management, 2805–2806
Bartonella henselae, 3114. *See also* Bacillary angiomatosis (BA)
cat scratch disease, 3340
Bartonella quintana, 3114. *See also* Bacillary angiomatosis (BA)
Bart-Pumphrey syndrome (BPS), 829–832, 845*t*
Bart syndrome, 1022
Basal cell carcinoma (BCC), 1839, 1884–1891
at-a-glance, 1884*b*
carcinogenesis, 310–314
animal models, 321–322
general principles, 310–313, 312*f*
genetics, 313–314
clinical and histologic manifestations, 1885
nail, 1605
diagnosis, 1885–1886, 1886*t*
epidemiology, 1884
prevalence, 310
etiology and pathogenesis, 1884
hedgehog signaling pathway, 1884, 1885*f*, 1885*t*
lupus vulgaris, 2866
molecular basis, 311*f*, 314
PUVA, 315
genetics, 314
hedgehog pathway, 3572, 3573*f*
mutations, 1884, 1885*t*
pathology, 32–33, 32*f*, 2284
subtypes
basosquamous carcinoma, 1887–1888
fibroepithelioma of Pinkus, 1888
morpheaform, 1886*t*, 1887, 1887*f*
nodular, 1886, 1886*t*, 1887*f*
pigmented, 1886, 1886*t*
superficial, 1886–1887, 1886*t*, 1887*f*
treatment, 1888–1891
algorithm, 1888*f*
course and prognosis, 1891
cryosurgery, 1889–1890, 3795
curettage and electrodessication, 1889, 3799–3800, 3799*f*–3800*f*
outcome assessments, 3800
excision, standard, 1889
general, 1888
hedgehog inhibitors, 1890
imiquimod, 3595
locally advanced BCC, 1890
metastatic BCC, 1890
Mohs micrographic surgery, 1888–1889, 3765–3766, 3765*f*, 3766*t*
nonsurgical, indications, 1888, 1888*t*
perineural invasion, 1890
photodynamic therapy, 1889–1890, 3679–3680
radiation therapy, 1890, 3693*t*, 3694
topical, 1889
Basal cell nevus syndrome (BCNS), 314, 1891–1897, 2444*t*
clinical features, 1892–1894
cutaneous lesions, 1892–1893, 1893*f*
jaw cysts, 1894, 1895*f*
long limbs, 1894, 1894*f*
skeletal and radiographic findings, 1894*f*
tissue overgrowth and large body size, 1893–1894, 1894*f*
complications, prognosis, and clinical course, 1896, 1896*t*
diagnosis, 1894–1895, 1895*t*, 1896*t*
differential diagnosis, 1895
epidemiology, 1891
etiology and pathogenesis
genetic abormality, 1891–1892
PTCH1 function, 1892
PTCH1 protein function, 1885*f*
Sonic Hedgehog pathway mutations, 1892
treatment, 1896–1897
Basal lamina, 23
Basal progenitor cells, epidermis, 63–64, 63*f*, 64*t*, 65*t*
BASC (*BRCA1*-associated genome surveillance complex), 2346
Basement membranes, 207, 210*f*, 232, 238–243
biochemical composition, 240
components
epidermal-specific, 234*f*, 242–243, 243*f*
ubiquitous, 240–242, 240*t*, 242*t*
collagen IV, 240, 241*f*
collagen XVIII, 241
fibulins, 241, 241*f*, 242
laminins, 240–241, 241*f*, 242*t*
nidogens, 240, 241
proteoglycans, 241–242
syndecans, 242
disease targets, 244*t*
structure and function, 238, 238*t*
ultrastructure, 238–240, 239*f*
Bases
absorption, 3373*t*, 3374
hydrocarbon, 3373*t*, 3374
oleaginous, 3374
water-soluble, 3373*t*, 3374–3375
Basic fibroblast growth factor, 3542
Basidiobolomycosis, 2967*t*, 2973
Basidiobolus haptosporus, 2973
Basidiobolus ranarum, 2973
Basiliximab, for paraneoplastic pemphigus, 941*t*, 942
Basophils, 133, 154*t*, 156
activators, 695
secretory granules, 154*t*
Basosquamous carcinoma, 1887–1888. *See also* Basal cell carcinoma
Bateman purpura, 1788
Bathing suit ichthyosis, 781*t*, 788
Baumann Skin Type Indicator (BSTI) Questionnaire, 3808
Bazex-Dupré-Christol syndrome, 1200
trichoepithelioma, 1822*t*, 1841
Bazex syndrome, 2442*t*, 2451–2453, 2451*f*–2452*f*
pili torti, 1541*t*
Bc12, primary cutaneous diffuse large B-cell lymphoma, 2100
B cell(s), 143, 148–149
graft-versus-host disease, 2322
rosacea, 1430
systemic sclerosis, 1094
B-cell activating factor (BAFF). *See also* B-lymphocyte stimulator (BLys)
graft-versus-host disease, 2322
for lupus erythematosus, 1057
B-cell lymphoma
B. burgdorferi, 3292–3293
dermal metastases, 2462
dermatitis herpetiformis, 2459
extranodal marginal zone, 2097, 2097*t*, 2099–2100, 2099*t*
with HIV, 3114
B-cell lymphoproliferative disease, *B. burgdorferi*, 3292–3293, 3292*f*–3293*f*
B-cell pseudolymphoma, cutaneous, 2110–2111, 2111*t*
Bcl6, primary cutaneous diffuse large B-cell lymphoma, 2100
BCR, chronic myelogenous leukemia, 3558
BCR-ABL1, 3558–3559
BCR-ABL inhibitors, 3558–3565. *See also* Tyrosine kinase inhibitors (TKIs), small-molecule
BCX7653, for hereditary angioedema, 694*f*, 702
BDCA-2/CD303, blastic plasmacytoid dendritic cell neoplasm, 2102
"Beard area" hemangioma, 2048–2049
Beare syndrome, pili torti, 1541*t*
Beau lines, 1574, 1575*f*, 1575*t*
Becaplermin, 3590–3592
Becker epidermal nevus syndrome, 1812
Becker hamartoma (melanosis), 1375–1376, 1375*f*
Becker nevi, 1375–1376, 1375*f*
hypertrichosis, 1565
Q-switched laser for, 3851, 3853*t*
smooth muscle hamartoma, 2141
Beckwith-Wiedemann syndrome, 2446*t*
Bedbug, 3325*f*, 3331–3332, 3332*f*
Bednar tumor, 2159
Bee stings, 3333–3334
Beetles, 3331
Behçet disease
apremilast for, 2557
HLA haplotype inheritance, 303, 304*t*
Beighton scale, 1219, 1220*t*
Bejel, 3182–3184, 3183*f*, 3184*t*
Belimumab, for lupus erythematosus, 1057
Belinostat, 3559*t*, 3578–3579, 3578*f*
Bell palsy
herpes simplex virus, 3026–3027
varicella-zoster virus, 3026–3027
Bendamustine, for primary cutaneous diffuse large B-cell lymphoma, 2101
Benign cephalic histiocytosis, 2034
Benign epithelial tumors, 1799–1812. *See also specific types*
acanthoma fissuratum, 1806
chondrodermatitis nodularis helicis, 1805, 1806*f*
clear cell acanthoma, 1804, 1805*f*
cysts of epidermal origin, 1812–1817 (*See also* Cysts, of epidermal origin)
epidermal nevus, 1806–1812 (*See also* Nevus, epidermal)
lichen striatus, 1802–1804, 1803*f*
seborrheic keratosis, 1785, 1785*f*, 1799–1802
warty dyskeratoma, 1806
Benign intravascular proliferation of lymphocytes, 2125–2126, 2126*f*
Benign lymphocytic infiltrates, 3293
Benign migratory glossitis. *See* Geographic tongue
Benign neonatal cephalic pustulosis, 1732, 1733*f*
Benign nerve sheath neoplasms, 2154–2162. *See also specific types*
nerve sheath myxoma, 2160–2161, 2160*f*
neurofibroma, 2150*t*, 2157–2160
perineuroma, 2150*t*, 2161, 2162*f*
schwannomas, 2150*t*, 2154–2157
Benign nerve sheath tumors (neuromas), 2150–2154
mucosal neuromas and MEN2B, 2152–2154
palisaded encapsulated neuroma, 2147*t*–2148*t*, 2150*t*, 2151–2152, 2152*f*–2153*f*
rudimentary polydactyly, 2151, 2151*f*
traumatic neuroma, 2147*t*–2148*t*, 2150–2151, 2150*t*
Benign Triton tumor, 2131*t*–2132*t*, 2146, 2146*f*
Benign tumors. *See also specific types*
electrosurgery of, 3799
vs. malignant, 30

neonatal, 1742–1744
infantile digital fibroma, 1743
infantile myofibromatosis, 1742–1743
Benralizumab, on eosinophils, 658
Benzathine penicillin
for acute rheumatic fever, 1160
for bejel, 3184
for pinta, 3177
Benzathine penicillin G
for group A *Streptococcus* impetigo and ecthyma, 2739, 2739*t*
for skin and soft-tissue infections, dosing, 3410*t*
for syphilis, 3160*t*, 3166
Benznidazole, for Chagas disease, 3241
Benzocaine, 1761*t*, 3710*t*
Benzodiazepines
abuse, 1711
for hyperhidrosis, stress-induced, 1463
Benzoic acid, for oral photoprotection, 3630
Benzophenones, 3625–3626, 3626*t*, 3627, 3628
Benzothiazinones, 2890
for actinomycetoma, 2890
Benzoyl peroxide, 3613*t*, 3614
for acne vulgaris, 1403*t*, 1404
for atopic eruption of pregnancy, 1777
for erythrasma, 2743
for pitted keratolysis, 2741
for trichobacteriosis, 2744
Benzoyl peroxide, for seborrheic dermatitis, 435
Benzyl alcohol, for lice, 3281*t*, 3284
Benzylamines, 3438*t*, 3441
Berardinelli-Seip syndrome, 55, 1295, 1296–1297, 1297*f*, 1298*t*
Bergapten, 3665
Beriberi, 2206*t*, 2212
Berry bugs, 3278, 3278*t*
Beryllium granulomas, 27
Beryllium lymphocyte proliferation test (Be-LPT), 451
Besnier prurigo, 388
Beta-blockers
for hyperhidrosis, stress-induced, 1463
for infantile hemangiomas
systemic, 2055–2057, 2057*f*
topical, 2056–2057
interstitial granulomatous drug reaction from, 1149
for Marfan syndrome, 1229
nail changes from, 1599
psoriasis exacerbation by, 479
Raynaud phenomena from, 2616
for rosacea, persistent erythema, 1438
Beta-carotene
for oral photoprotection, 3630
for protoporphyrias, 2249
Betacellulin, 3540
Betamethasone, for adamantiades–Behçet disease, 2574, 2574*t*
Betamethasone valerate, for lupus erythematosus, 1055
β_1 Integrins, 247–248
epidermal basal cells, 62
β-Catenin, 50
hair follicles, 90*f*, 91
β-Defensin, 223*f*
β-Defensin 1, 75, 222, 222*t*
β-Defensin 2, 75, 222, 222*t*
β-Defensin 3, 222, 222*t*
β-Hemolytic *Streptococcus*, cutaneous necrotizing venulitis, 2529
β-Hydroxy-β-methylglutaryl-coenzyme A (HMG-CoA), pityriasis lichenoides, 513
β-Hydroxy-β-methylglutaryl-coenzyme A (HMG-CoA) reductase, 2280
Betel, 1713
Bethanechol, hyperhidrosis from, 1466
Bevacizumab, 3592
for pseudoxanthoma elasticum, 1233
Bexarotene. *See also* Retinoid(s), oral
adverse effects
oral agents, 3402, 3402*t*
topical agents, 3402
for cutaneous T-cell lymphoma, 3399, 3400
metabolism and pharmacokinetics, 3399
topical
chemical structure, 3397, 3397*f*
indications and contraindications, 3399
for mycosis fungoides, 2090
Bias, 41
information, 41
selection, 41
Bicalutamide, for hirsutism, 1561, 1562*t*, 1563
BIDS, trichothiodystrophy, 1539*t*
Biett collarette, 3150, 3150*f*
Bifonazole, for seborrheic dermatitis, 435
Biglycan, dermal cell-matrix adhesion, 247
Bilateral advancement flaps, 3737–3738, 3738*f*
H-plasty, 3737
T-plasty, 3737–3738, 3738*f*
Bilateral cellulitis, 2748
Bilateral rotation flap, 3740, 3742*f*
Bilateral symmetric distribution, 12
Bilayered living cellular construct (BLCC), 2710, 2711*t*
Bilayered living skin equivalent, for diabetic ulcers, 2498–2499
Bilayer lipid membrane skin barrier, 3804, 3804*f*
Bile acid transporters, for pruritus, 360
Biliary cirrhosis, primary
cutaneous manifestations, 2433
lichen planus and, 539
Bilobed flap, 3747–3748, 3748*f*, 3749*f*
Bimatoprost, for alopecia areata, 1521
Bimekizumab, for psoriatic arthritis, 1137
Bioburden, microbial, 255
Bio-enhanced storage solutions, for hair transplantation, 3931*b*
Biofilm formation, wound healing, 2708, 2709*f*
Bioflavonoid, for pigmented purpuric dermatoses, 2596
Biologic agents. *See also specific types*
on antigen-presenting cells, 139
for lupus erythematosus, 1057
lupus erythematosus from, 1041*t*
on pathologic tissue response, 139
photochemotherapy with, 3671
for vasculitis, 2557
Biologically effective dose (BED), 3690
Biologic exposure, occupational, 448–450
background, 448
bacterial
anthrax, 448
brucellosis, 449
erysipeloid, 448–449
fish tank granuloma, 448
pitted keratolysis, 449
Staphylococcus, 448
Streptococcus, 448
tularemia, 449
fungal, 449
viral
bloodborne pathogens, 450
herpes simplex virus, 449
human papillomavirus, 450
orf, 449
pseudocowpox, 449–450, 3066*t*, 3081–3083, 3082*f*, 3083*t*
Biologic neurotoxins, 3921. *See also* Botulinum toxin
Biologic response modifiers. *See also specific types*
for erythroderma, in primary cutaneous T-cell lymphomas, 2093, 2093*t*
for mycosis fungoides, 2080
Biomonitoring, occupational skin diseases, 451
Biopsy. *See also specific sites, types, and disorders*
infants, pitfalls, 1750, 1751*t*
site, choosing, 18
submissions, 18–19
type, choosing, 18, 19*t*
Biotin, 2207*t*, 2220
deficiency, 2220–2221, 2220*t*
Biotinidase deficiency, 2220, 2220*t*
neonates and children, 1740
Biphasic cutaneous amyloidosis, 2262*t*, 2263
Biphasic (epithelial-mesenchymal) neoplasms of follicular germinative and follicular stromal cells, 1839*t*
desmoplastic trichoepithelioma, 1841–1842
trichoblastoma, 1840–1841, 1840*f*
trichoepithelioma, 1822*t*, 1841–1842, 1842*f*
Bipolar electrosurgical unit, 3798
Birbeck granules, Langerhans cell histiocytosis, 2020, 2026, 2027*f*
Birthmarks, 1732–1734, 1751–1752
common, 1733*t*
epidemiology, 1732–1733
epidermal nevus, 1734
nevus depigmentosus, 1752
nevus sebaceus, 1734
pigmentary
café-au-lait macules, 1733
congenital melanocytic nevi, 1733
dermal melanocytosis, 1733
nevus anemicus, 1734, 1734*t*
nevus depigmentosus, 1734, 1734*t*
pigmentary mosaicism, 1733–1734, 1752, 1752*f*
vascular
infantile hemangioma, 1734
nevus simplex, 1734
vascular malformations, 1734
Birt-Hogg-Dubé syndrome, 2444*t*
appendage tumors, 1820, 1822*t*
trichodiscoma/fibrofolliculoma, 1822*t*, 1843
Bisphosphonates
for pseudoxanthoma elasticum, 1233
for SAPHO syndrome, 645
bone pain, 1450
Biterminal electrode, 3798
Bites and stings. *See also specific types*
aquatic organisms, 3344–3358 (*See also* Aquatic organism bites and stings)
arthropod, 3324–3335
cellulitis from, 2748
fish, 3358–3359, 3358*f*
human
cellulitis, 2748
treatment, 3338–3339
land animals, 3338–3344 (*See also* Animal bites, land)
leech, 3353
octopus, 3355–3356, 3355*f*
seal, 3344
shark, 3358
stork, 1734, 2638
Biting midges, 3325*f*, 3330–3331
Bitot spots, vitamin A deficiency, 2205
Björnstad syndrome, pili torti, 1541*t*
B-K moles, 1944, 1990
Black carpet beetle, 3331
Black color, 8*t*
Black flies, 3325*f*, 3330–3331
Black-legged tick, 3287, 3296, 3308*f*, 3311*t*, 3329. *See also* Ticks
Black measles. *See* Rocky Mountain Spotted Fever (RMSF)
Black piedra, 2935*t*–2936*t*, 2940, 2940*t*
Black salve, 3611
Black sea nettle, 3344, 3345*f*
Black tar heroin, 1710

Black widow spider *(Latrodectus),* 3326*t*
L. bishopi, 3324–3326, 3326*f*
L. geometricus, 3324–3326, 3326*f*
L. hesperus, 3324–3326, 3326*f*
L. mactans, 3324–3326, 3326*f*
L. various, 3324–3326, 3326*f*
Blaschkoid distribution, 11
epidermal nevus, 1806, 1807*t*
graft-versus-host disease, 2326, 2326*f*
lichen striatus, 559, 559*f*
Blaschkoid lichen planus, 530–531, 531*f,* 531*t*
Blaschko linear acquired inflammatory skin eruption (BLAISE). *See* Lichen striatus
Blaschko lines, 1803, 1803*f*
chromosomal and functional mosaicisms, 302, 302*f*
epidermal nevus, 1803*f,* 1806
lichen striatus, 559, 1803, 1803*f*
Blastic plasmacytoid dendritic cell neoplasm (BPDCN), 2102, 2102*f*
Blastomyces dermatitides, 2977–2979, 2978*f*
Blastomycosis, 2977–2979, 2978*f*
keloidal, 2967*t,* 2972–2973
South American, 2980–2981, 2981*f*
Blastula, 52
Blau syndrome (BS)/early-onset sarcoidosis (EOS), 640–641, 641*f*
Bleach baths
for hidradenitis suppurativa, 1487
for staphylococcal nares and skin decolonization, 2731*t,* 2732
Bleaching agents, topical. *See also specific types*
azelaic acid, 3618
hydroquinone, 3618
monobenzyl ether of hydroquinone, 3618
tretinoin, 3618
Bleeding
after cryosurgery, 3792
after nail surgery, 3778
gastrointestinal, cutaneous manifestations, 2433
postoperative, 3721, 3722*f*
splinter hemorrhages
infective endocarditis, 1596
nails, 1571–1572, 1573*f*
Bleomycin
hypermelanosis, 1365
intralesional
for HPV warts with HIV, 3118
for Kaposi sarcoma, 3120
for linear porokeratosis with squamous cell carcinoma, 905–906
nail changes from, 1599
Raynaud phenomena from, 2616, 3486
sclerotic dermal reactions from, 3486
systemic sclerosis and, 1093
Blepharitis
seborrheic, 428 (*See also* Seborrheic dermatitis)
staphylococcal, 2723
Blepharoconjunctivitis
herpes simplex virus, 3026
from isotretinoin, 3402
Blepharophyma, rosacea, 1421*f,* 1422
BLIMP-1, sebaceous gland development, 72, 73*f*
Blindness, river, 3261
Blister beetles, 3331
Blistering (blisters), 13*t,* 14. *See also specific diseases*
autoimmune diseases, eosinophils, 659
classification, 22, 22*t*
friction, 418
hemorrhagic, mastocytosis, 713, 713*f*
junctional, bullous pemphigoid, 23, 24f
paraneoplastic pemphigus, 936–937, 936*f*
pathology, 23
dermolytic blistering, 24
junctional blistering, 23–24
subepidermal
bullous pemphigoid, 24f, 25 (*See also* Bullous pemphigoid (BP))
pathology, 24f, 25
pathophysiology, 947, 948*f*–949*f*
sucking, 1732
Blitz nevi, 1959
BLK, Kawasaki disease, 2584
BLM, Bloom syndrome, 1361, 2344, 2362
BLNK, agammaglobulinemia, 2396
BLOC153, Hermansky-Pudlak syndrome, 1316*t*
BLOC complexes, 339, 339*f*
Bloch-Sulzberger syndrome. *See* Incontinentia pigmenti (IP)
Blood flow, skin
determinants, 120
diabetes type 1, 122
heat stress protection, 225–226, 225*f*
normal, 121
Blood products. *See also specific types*
urticaria from, 695
Blood vessel angiogenesis
dermal, 125–127, 126*f,* 127*f*
embryogenesis, 126, 126*f*
healthy, 125
inflammation, tissue injury, or tumor growth, 125
tumor, 128–129, 128*f*
vascular endothelial growth factor, 125
Blood vessels. *See specific types*
Bloom syndrome (BS), 1361, 2361–2362, 2445*t*
BLM mutations, RecQ family, 2344
clinical course, prognosis, and management, 2362
clinical features, 2343*t,* 2361, 2361*f*
diagnosis, 2362
differential diagnosis, 2343*t,* 2362
epidemiology, 2361
etiology and pathogenesis, 2362
genome instability, spontaneous, 2342
mechanisms, 2345*t*
squamous cell carcinoma, 1904*t*
Blueberry muffin syndrome, 1744, 3004–3007, 3006*t. See also* Human cytomegalovirus (HCMV)
Blue bottle, 3345
Blue-gray color, 8*t*
Blue light, for acne vulgaris, 1410
Blue nails, 1569, 1569*t*
Wilson disease, 1597
Blue nevus, 1957–1961
at-a-glance, 1957*b*
clinical course and prognosis, 1961
clinical features, 1957–1959
complications, 1959
cutaneous, 1957–1959, 1958*f*
related physical conditions, 1959
sites, 1957–1958
Tyndall effect, 1957
diagnosis, 1959–1961
pathology, 1959–1961, 1960*f*
special tests, 1961
differential diagnosis, 1961*t*
epidemiology, 1957
etiology and pathogenesis, 1959
phakomatosis pigmentovascularis, 1959
prevention and counseling, 1961
risk factors, 1959
treatment, 1961
Blue rubber bleb nevus syndrome (BRBN), 2646–2653, 2647*f,* 2648*t*. *See also* Venous anomalies
venous anomalies, 2647, 2647*f*
B lymphocytes. *See* B cell(s)
B-lymphocyte stimulator (BLys). *See also* B-cell activating factor (BAFF)
for lupus erythematosus, 1057
BMP (bone morphogenic protein), 50
hair development, 27
Boceprevir, for hepatitis C virus, 3511
Bockhart impetigo, 2722–2723
Body cavity–based lymphomas, 172
Body contouring, 3857
Body contouring, noninvasive, 3857–3868. *See also specific types*
at-a-glance, 3857*b*
cellulite removal, 3865–3868
classification, 3857
definition, 3857
fat reduction, noninvasive and minimally invasive, 3862–3865, 3862*f,* 3865*f*
optimization therapies
combination, 3868
repeat, 3868
preference, physician and patient, 3857
skin tightening, 3857–3862
subtypes, therapeutic, 3857
Body dysmorphic disorder (BDD), 1698–1699
Body-focused repetitive behavior disorders, 1701
Body lice, 3282–3283, 3282*t*
Body mass index (BMI), obesity, 2502
Body odor, 1469
bromhidrosis, 1469–1471, 1470*t*
Body surface area (BSA), 3371
Boils. *See* Furuncles (boils)
Bolus (radiotherapy), 3688–3689, 3688*f*–3689*f*
Bombidae, 3333–3334
Bone, acute ectopic formation, 1681
Bone marrow transplantation (BMT)
for epidermolysis bullosa, 1028
for extranodal natural killer/T-cell lymphoma, nasal type, 2087
for Langerhans cell histiocytosis, 2029
for Wiskott-Aldrich syndrome, 2404
Bone morphogenetic proteins (BMPs), 247
hair follicles, 90*f,* 91, 92
Bone pain
from retinoids, 3403
in SAPHO syndrome, bisphosphonates for, 1450
Bonita, scombroid fish poisoning, 3359
Bonnet-Dechaume-Blanc syndrome, 2659. *See also* Arteriovenous malformations (AVMs)
Borderline-borderline leprosy
clinical features, 2897–2898, 2899*f*
histopathology, 2907, 2909*f*
Borderline-lepromatous leprosy
clinical features, 2899, 2899*f*
histopathology, 2907, 2909*f*
Borderline-tuberculoid leprosy
clinical features, 2897, 2898*f*
histopathology, 2907, 2908*f*
Borrelia
B-cell pseudolymphoma, 2110*t,* 2111–2112, 2112*f*
fasciitis, 3292
lymphocytoma, 3292–3293, 3292*f*–3293*f*
T-cell pseudolymphoma, 2121
Borrelia afzelii, Ixodes transmission, 3320
Borrelia burgdorferi, 3287–3288, 3288*f,* 3295–3296. *See also* Lyme borreliosis
Anaplasma phagocytophilum coinfection, 3295
Babesia microti coinfection, 3295
direct detection, 3296–3297
erythema migrans, 767–769
extranodal marginal zone lymphoma, 2099–2100
primary cutaneous marginal zone lymphoma, 2097
Borrelia garinii, Ixodes transmission, 3320
Borrelia microti, 3296
Borrelia miyamotoi, 3296
Bortezomib, 3592–3593
Bosentan
for pulmonary artery hypertension in digital vasculopathy, 1100, 1100*t,* 1101
for Raynaud phenomena, 2621*t,* 2622

Bosutinib, 3559*t*, 3563–3564, 3563*f*
Botox. *See* Botulinum toxin
Botryomycosis
  diagnosis, 2877*t*
  staphylococcal, 2725, 2725*f*
Botulax, 3921
Botulinum neurotoxin (BoNT), for Raynaud phenomena, 2623
Botulinum toxin, 3921–3930
  ANT-1207, 3922
  commercial market, 3921–3922
  cosmetic uses, "off-label," 3930
  daxibotulinumtoxinA, 3922
  forms, current medical use
    outside U.S. or pending, 3926*t*
    U.S. or pending, 3925*t*
  historical perspective, 3921
  indications, 3924
  NDS transport system, 3922
  pharmacology, 3922–3923
    immunology, 3923–3924
    mechanism of action, 3922–3923, 3923*f*, 3924*t*–3926*t*
    toxin structure, 3922, 3922*f*
  for pitted keratolysis, 2741
  recent developments, 3922
  side effects and complications, 3928–3929
  treatment with, 3924–3928
    combination therapy, 3927
    glabellar lines, 3924–3925, 3927*f*–3928*f*
    horizontal forehead lines, 3925–3926, 3927*f*–3928*f*
    hyperhidrosis, 3927–3928, 3929*f*
    lateral canthal lines, 3926–3927
Botulinum toxin type A (BTA). *See also* Botulinum toxin
  for Hailey-Hailey disease, 890
  injections
    for hidradenitis suppurativa, 1491
    for hyperhidrosis
      in Fabry disease, 2302
      primary focal, 1462
Boutonneuse fever. *See* Mediterranean spotted fever (MSF)
Bovine papular stomatitis virus, 3066*t*, 3081
Bowel-associated dermatosis-arthritis syndrome, 2436
Bowen disease (BD), 32, 1867–1871. *See also* Squamous cell carcinoma (SCC) in situ
  at-a-glance, 1867*b*
  clinical course and prognosis, 1870
  clinical features, 1868–1869, 1868*f*
  diagnosis, 1869
  differential diagnosis
    clinical, 1869*t*, 1870
    histopathologic, 1870, 1870*t*
  epidemiology, 1868
  erythronychia, 1568
  etiology and pathogenesis, 1869
  genital, 1871*t*, 1874*b*
  historical perspective, 1868
  melanonychia, 1570
  mitochondrial DNA mutations, 300
  nail, 1605, 1605*f*
  treatment, 1870–1871, 1871*t*
    cryosurgery, 3795
    photodynamic therapy, 3671*f*, 3679–3681, 3680*t*
Bowenoid papulosis (BP), 1871–1872, 1871*t*, 1872*f*, 3103–3104, 3104*f*
Box jellyfish, 3346–3347, 3347*f*
BP180 (collagen XVII), 243–244, 244*f*
  bullous pemphigoid, 202, 944, 946, 949*t*, 950*f*
  inherited epidermolysis bullosa, 1012–1013
  junctional epidermolysis bullosa, 1020
  mucous membrane pemphigoid, 963, 964
BP230
  bullous pemphigoid, 944, 946–947, 950*f*
  deficiency, epidermolysis bullosa simplex, 1012, 1015*t*, 1017, 1018
BPAG1. *See* BP180
BPAG2. *See* BP230
Brachmann-de Lange syndrome, hypertrichosis, 1564
Brachyonychia, 1568
Bradykinin-induced angioedema, 685, 695
  C1 inhibitor, 694, 694*f*
  diagnostic algorithm, 696
  imaging, 701
BRAF, 3580, 3581*f*
  Erdheim–Chester disease, 2038
  in melanoma, 3579–3580
BRAF
  cardiofaciocutaneous syndrome, 871
  common acquired melanocytic nevi, 1953
  congenital melanocytic nevi, 1946
  dysplastic melanocytic nevi, 1975
  eruptive nevi, 1953
  melanoma, target therapies, 2007–2009, 2008*f*
  Spitz nevus, 1964
  V600E mutation, 3579
    Langerhans cell histiocytosis, 2020, 2021, 2022*f*
    syringocystadenoma papilliferum, 1834
  V600K mutation, 3579
BRAF inhibitors. *See also specific types*
  for Erdheim–Chester disease, 2038
  keratoacanthoma from, 32
BRAF/MEK inhibitions, for melanoma, 2007–2009, 2008*f*
Bragg peak, 3688
Branchial cleft anomalies, neonatal, 1736
Branchial (cleft) cyst, 1816
  neonatal, 1736
Braun-Falco-Marghescu syndrome, 1200
BRCA1, Fanconi anemia, 2365
BRCA2, Fanconi anemia, 2365
Breast cancer, MCP-1, 184
Breast reduction, tumescent local anesthesia liposuction, 3909
B-regulatory cells (Bregs), 149
Brentuximab vedotin, 3546, 3547*f*, 3551*t*
  for cutaneous anaplastic large cell lymphoma, 2086
  for cutaneous T-cell lymphomas, 2093*t*, 2095
BRESEK (BRESHECK) syndrome, 873
Breslow index (melanoma), 1998
Brilliant green, 3611, 3612*t*
Brill-Zinsser disease, 3318–3319. *See also* Typhus, epidemic (louse-borne)
Brimonidine, for rosacea
  flushing and transient erythema, 1439
  persistent erythema, 1438
Brincidofovir (CMX001), for smallpox, 3072
Bristleworm dermatitis, 3352–3553, 3352*f*
Brittle cornea syndrome, 1217*t*. *See also* Ehlers-Danlos syndromes
Brittle nails, 1575–1576, 1576*f*, 1576*t*
Brivudin, for varicella-zoster virus, 3051
Broadband ultraviolet A (UVA), for morphea, 1114*f*, 1115, 1115*t*
Broadband ultraviolet B (BB-UVB)
  devices and therapy, 3640–3641, 3640*t*–3641*t*
  for psoriasis, 3646–3647, 3647*f*
Brodalumab, 3535, 3536*f*, 3548*t*
  for psoriasis, 176, 469*f*
Brody peel, 3900
Bromelain, for pityriasis lichenoides, 515, 515*t*
Bromhidrosis, 1469–1471, 1470*t*
Bromine, chemical burns, 441–442, 443*t*
2-Bromo-2-nitropropane-1,3-diol (bronopol), allergic contact dermatitis from, 404
Bromosis, delusion of, 1696
Bronopol, allergic contact dermatitis from, 404
Brooke-Spiegler syndrome
  appendage tumors, 1820, 1822*t*
  cylindroma, 1822*t*, 1825, 1828
  spiradenocarcinoma, 1822*t*, 1828
  spiradenoma, 1822*t*, 1826
  trichoepithelioma, 1822*t*, 1841
Brow furrows, botulinum toxin for, 3924–3925, 3927*f*–3928*f*
Brown adipose disease (BAT), subcutaneous fat necrosis of newborn, 1279
Brown color, 7, 8*t*
Brown recluse spider, 3326–3327, 3326*f*–3327*f*
Brown-tailed moth, 3334
Brown-Vialetto-Van Laere syndrome, riboflavin transport, 2213
Brown widow, 3324–3326, 3326*f*
Brucella, infective endocarditis, 2817
Brucellosis, 2829*t*, 2833–2835
  occupational, 449
Brugia malayi, 3252*t*, 3268, 3268*f*
  exposure and symptom onset interval, 3259, 3260*t*
  limb edema, 3259
  management, 3265*t*
  progression and duration, 3259, 3260*t*
  subcutaneous nodules and masses, 3257, 3257*t*
Brugia timori, 3252*t*, 3268, 3268*f*
  exposure and symptom onset interval, 3259, 3260*t*
  limb edema, 3259
  management, 3265*t*
  progression and duration, 3259, 3260*t*
Brünauer-Fohs-Siemens syndrome, 838, 846*t*
Bruton disease, 2394–2396
Bruton hypogammaglobulinemia–developed progressive vaccinia, 3076, 3076*f*
BSCL2, congenital generalized lipodystrophy, 1296, 1297
Bubo, chancroid, 3187, 3188*f*
Buccal nerve, 3702*f*, 3703, 3703*t*
Buccinator muscle, 3703, 3704*f*
Buckley syndrome, 2413–2415, 2413*f*–2414*f*, 2413*t*
Budesonide, steroid allergen testing, 405, 406*t*
Buerger disease, 2679–2682. *See also* Thromboangiitis obliterans (TAO)
Buffalo hump, Cushing syndrome, 2513
Bulbous peg, 90*f*, 91–92
Bulb/stem outer root sheath differentiation neoplasms, trichilemmoma, 1822*t*, 1839*t*, 1845–1846, 1846*f*
Bulla, 4*t*, 5, 5*f*, 6*f*. *See also specific types and disorders*
Bullosis diabeticorum, 2502, 2502*t*
Bullous congenital ichthyosiform erythroderma. *See* Epidermolytic ichthyosis
Bullous dermolysis of the newborn, 1021
Bullous diseases of hemolysis, 2438
Bullous disorders, paraneoplastic. *See also specific types*
  bullous pemphigoid, 2442*t*, 2459
  dermatitis herpetiformis, 2443*t*, 2459
  paraneoplastic pemphigus, 934–942, 2442*t*, 2458
Bullous disorders of dialysis, 2438
Bullous epidermolysis, nail changes, 1601, 1601*f*
Bullous eruptions, drug-related, 750*t*, 752–753, 752*t*
  bullous pemphigoid, 753
  linear immunoglobulin A disease, 752, 753
  pemphigus, 753
  pseudoporphyria, 752–753

Bullous eruptions, drug-related (*Cont.*):
Stevens-Johnson syndrome, 753
toxic epidermal necrolysis, 753
Bullous impetigo
clinical features, 2758, 2758*f*–2759*f*
diagnosis and differential diagnosis, 2761
etiology and pathogenesis, 2758
nail changes, 1591–1592, 1592*f*
S. aureus, 2721–2722, 2722*f*
treatment and prognosis, 2761
Bullous pemphigoid (BP), 761*t*, 944–952
at-a-glance, 944*b*
autoantigens, 201–202
BP180, 202, 944, 946, 949*t*, 950*f*
BP230, 944, 946–947, 950*f*
clinical course and prognosis, 951–952
clinical features, 944–946
complications, 946
cutaneous, 944–946, 945*f*
in elderly, 1788
noncutaneous, 946
urticarial phase, 17*f*
diagnosis, 948–951
immunofluorescence, 950–951, 950*f*
pathology, 948–950, 950*f*
differential diagnosis, 951, 951*t*
drug-induced, 753
eosinophils, 659
epidemiology, 944
etiology and pathogenesis, 946–948
antigens, 946–947
autoantibodies, 201–202
COL17, 202
immunopathology, 946
junctional blistering, 23, 24f
subepidermal blistering, 24f, 25, 947, 948*f*–949*f*
historical perspective, 944
immunologic responses, 201–202
management, medications, 952, 952*t*
paraneoplastic, 2442*t*, 2459
risk factors, 948
Bullous pyoderma gangrenosum, 606–607, 606*f*. *See also* Pyoderma gangrenosum (PG)
Bullous varicella, 2722
Bupivacaine, 3710*t*
for venomous fish spines, 3358
Burden of disease, 40
Buried suture extrusion, postoperative, 3724
Buried vertical mattress suture, 3729–3730, 3730*f*
Burkholderia mallei, 2829*t*, 2835–2837
Burkholderia pseudomallei, 2829*t*, 2844–2846
Burkitt lymphoma, with HIV, 3114
Burns, 1679–1690
at-a-glance, 1679*b*
chemical, 441–443, 443*t*
clinical features, 1679–1681
4th-degree burn, 1681
full-thickness burn (3rd degree), 1680–1681, 1680*t*, 1681*f*
partial-thickness burn (2nd degree), 1679–1680, 1680*f*, 1680*t*
percent total body surface area, 1681
superficial burn (1st degree), 1679, 1680*f*, 1680*t*
complications, 1681
diagnosis, 1684–1686
airway assessment, 1684
burn assessment, 1684
fluid resuscitation, 1684–1686, 1685*t*
rule of nines, 1685, 1685*f*
wound care assessment, 1686–1687, 1686*t*
epidemiology, 1679
etiology and pathogenesis, 1682–1684
burn pathophysiology, 1682
chemical burn, 1683
electrical burn, 1682–1683
flame burn, 1682
scald burn, 1682
Stevens-Johnson syndrome, 1683–1684
toxic epidermal necrolysis, 1683–1684
management, 1687–1690
essentials, 1687*t*
infection, 1688–1689
outpatient care, 1687–1688
pain, 1688
Parkland Formula, 1685–1686, 1685*t*
pruritus, 1689
scar, 1689–1690
triage, 1687
vaccination, 1688
wound care, 1686–1687, 1686*t*
nonaccidental, 1720, 1723*t* (*See also* Abuse, physical)
Burow's graft, 3755, 3756*f*
Burow's triangle, 3731
Buruli ulcer disease, 2871, 2872*f*, 2872*t*
Buschke-Ollendorff syndrome, 1241–1242
Butcher's warts, 3098
Butenafine, 3438*t*, 3441
for candidiasis, 3441
for dermatophyte infections, 3441
for fungal infections, superficial, 2935*t*
for pityriasis versicolor, 3441
Butterflies, 3334, 3334*f*
Butterfly rash, lupus erythematosus, 1038, 1039*t*, 1041, 1042*f*
Butterfly sign, neurotic excoriation, 1700
Buttonhole sign, 12*t*
Butyl methoxydibenzoylmethane, 3625–3626, 3626*t*, 3628
B virus, 3341
Bystander effect, 276
Bywater lesions, 1150, 1150*f*

C

C1-INH, for hereditary angioedema, 694*f*, 702, 2420
C1 inhibitor, in bradykinin production in angioedema, 685, 694, 694*f*, 695
C1R, periodontal Ehlers-Danlos syndrome, 1213*t*, 1218*t*
C1S, periodontal Ehlers-Danlos syndrome, 1213*t*, 1218*t*
C2
deficiency, cutaneous necrotizing venulitis, 2533
dermatitis herpetiformis, 1006
C3
acrokeratosis paraneoplastica of Bazex, 2452
chronic bullous disease of childhood, 993
linear immunoglobulin A dermatosis, 993
relapsing polychondritis, 1188
C4 deficiency, cutaneous necrotizing venulitis, 2533
C7Orf11, trichothiodystrophy, 1539
C9orf92, myolipoma, 2184
C10orf11, oculocutaneous albinism type 7, 1310*t*, 1313
C11orf95-NKL2 fusion gene, chondroid lipoma, 2183
C13orf31, leprosy, 2902
C68, non-Langerhans cell histiocytosis, 2027*t*, 2029*b*
Cadherins, desmosomal, 233, 234–237, 234*f*–235*f*
desmocollin 2, 236*t*, 237
desmocollin 3, 236*t*, 237
desmoglein 1, 235, 236*t*
congenital defects, 208*t*, 215
desmoglein 2, 236, 236*t*
desmoglein 3, 236, 236*t*
pemphigus, 202
desmoglein 4, 236, 236*t*
expression patterns, 234–235, 234*f*
isoforms, 234–235, 234*f*
pemphigus autoantigens, 235, 235*f*
Cadmium, nail changes, 1598
Café-au-lait macules (CALMs), 1376–1377, 1377*f*
infants, 1752
neonatal, 1733
Café-au-lait syndromes, familial, 1360–1361
Bloom syndrome, 1361
Legius syndrome, 1360, 2473
McCune-Albright syndrome, 302, 1361
neurofibromatosis type 1, 1361
Silver-Russell syndrome, 1361
Watson syndrome, 1361
Calabar swelling, loiasis, 3259, 3268, 3268*f*
eyelid, 3262
Calcification disorders, 2307–2312, 2308*t*. *See also specific types*
aberrant calcification, 2308, 2308*t*
dystrophic, 2308–2310, 2308*t*, 2309*f*
iatrogenic, 2308*t*, 2311–2312
idiopathic, 2308*t*, 2311
metastatic, 2308*t*, 2310–2311, 2310*f*
Calcific uremic arteriolopathy. *See* Calciphylaxis
Calcifying epithelioma of Malherbe, 1822*t*, 1843–1844, 1844*f*
Calcineurin inhibitors (CNIs), 3519–3527. *See also specific types*
cyclosporine, 3520–3524
for dermatomyositis, 1078
on eosinophils, 658
historical perspective, 3519–3520
for nummular eczema, 388
pimecrolimus, 3526–3527
for pityriasis lichenoides, 515, 515*t*
for pruritus, 358
for psoriasis, 490
for systemic sclerosis, skin hardening in, 1100*t*, 1101
tacrolimus, 3524–3526
Calcineurin inhibitors (CNIs), oral/systemic
for dermatomyositis, 1078
for graft-versus-host disease, 2335
Calcineurin inhibitors (CNIs), topical. *See also specific types*
for actinic dermatitis prevention, 1643
for actinic prurigo, 1632, 1632*f*
for amyloidosis, cutaneous, 2270
for atopic dermatitis, 378
for dermatomyositis, 1078
for eosinophilic pustular folliculitis, 671
for Fox-Fordyce disease, 1477
for graft-versus-host disease, 2333
for Hailey-Hailey disease, 889
for keratosis pilaris atrophicans, 872
for lichen planopilaris, 546
for lichen planus
cutaneous, 543–544
oral, 545
for lichen sclerosus, 1121
for lichen striatus, 560–561
for lupus erythematosus, 1054*t*, 1055
for mucous membrane pemphigoid, 966, 966*t*
for pityriasis rubra pilaris, 503
for psoriasis, 482*t*, 490
for seborrheic dermatitis, 434–435
for vitiligo, 1340
Calcinosis
dermatomyositis, 1067, 1078
metastatic, 2308*t*, 2310–2311, 2310*f*, 2509
chronic renal failure and calciphylaxis, 2310–2311, 2310*f*, 2509–2510, 2511*f*
Calcinosis cutis, 2307, 2308*t*, 2509
from IV calcium chloride and calcium gluconate, 2311–2312
Thibierge-Weissenbach syndrome, 1090

Calciphylaxis, 2310–2311, 2310*f*, 2438
  clinical features, 7*f*
  thyroid disease, 2509–2510, 2511*f*
Calcipotriene (calcipotriol), 3619
  for inflammatory linear verrucous epidermal nevus, 1809
  for morphea, 1114*f*, 1115, 1115*t*
  for palmoplantar keratodermas, inherited, 821
  for prurigo nodularis, 392
  for psoriasis, 482*t*, 488, 3122
Calcitonin, intranasal, 2307
  granuloma annulare from, 566
Calcitonin gene-related peptide (CGRP), prurigo nodularis, 389
Calcitriol. *See* Vitamin D (calcitriol)
Calcium, 2307
  regulatory hormones, 2307
  supplemental, for mastocytosis, 719*t*, 720
Calcium channel blockers (CCBs). *See also specific types*
  interstitial granulomatous drug reaction from, 1149
  for lupus panniculitis, 1275
  photodistributed telangiectasia, 1661
  for Raynaud phenomena, 2620–2621, 2621*t*
Calcium chloride, IV, calcinosis cutis from, 2311–2312
Calcium disorders, 2307–2312. *See also* Calcification disorders
  aberrant calcification, 2308, 2308*t*
  at-a-glance, 2307*b*
Calcium dobesilate
  antiangiogenesis, 3604*t*
  for pigmented purpuric dermatoses, 2596
Calcium gluconate, IV, calcinosis cutis from, 2311–2312
Calcium hydroxyapatite, 3913*t*, 3916–3917
Calcium hydroxylapatite (CaHA), soft-tissue filler, 3913*t*, 3916–3917
Calcium sulfate, 3617
Calf muscle pump, 2689–2690, 2690*f*
California Moray eel, 3358–3359, 3358*f*
Calymmatobacterium granulomatis, 3204
Campath, eosinophils, 656
cAMP/CREB, hidradenoma, 1823
Canakinumab, 3533, 3548*t*
  for adamantiades–Behçet disease, 2576*t*
  for cryopyrin-associated periodic syndromes, 625
  for familial Mediterranean fever, 633
  for hyperimmunoglobulinemia D with periodic fever syndrome/mevalonate kinase deficiency, 635
  for Majeed syndrome, 644
  for Schnitzler syndrome, 627
  for Still disease, adult-onset, 1158
  for TNF receptor-associated periodic syndrome, 637
Cancer, skin. *See also* Tumor, skin; *specific types*
  amyloid adjacent to tumors, 2265
  chemokines, 183–185, 185*f*
  in elderly, 1785
  granuloma annulare, 567
  hallmarks, 310–311, 312*f*
  heterogeneity
    intertumor, 313
    intratumor, 312
  with HIV, malignant, 3119–3121
    at-a-glance, 3119*b*
    cutaneous lymphomas, 3121
    HPV-induced dysplasia and squamous carcinoma, 3120–3121
    Kaposi sarcoma, 3119–3120, 3119*f*, 3120*t*
    melanoma, 3121
    Merkel cell carcinoma and appendageal carcinoma, 3121
    smooth muscle tumors, pediatric, 3121
  nail tumors, 1602–1608 (*See also* Nail, tumors)
  polymorphic light eruption, 1617–1618
  prevalence, 310
  prevention, 323
    sunscreen, 3628
  from PUVA, 3644–3645
  stem cells, 312–313, 312*f*
  treatment, 323
  vasculature
    angiogenesis and vasculogenesis, 125–127, 126*f*, 127*f*
    tumor angiogenesis, 128–129, 128*f*
    wound healing, 127–128, 128*f*
Cancer-immunity-cycle, 2004
Cancrum oris, 2226–2228, 2227*f*, 2228*t*
Candida
  cutaneous infection, 2395*t*
  cutaneous necrotizing venulitis, 2530
  diaper dermatitis, 1741, 1741*t*
  with HIV, 3115–3116
    nail infections, 3116
  infective endocarditis, 2817
Candida albicans
  disseminated, IV drug use, 1708–1709
  in elderly, 1787
  paronychia, 2725
Candida antigen, intralesional
  for HPV with HIV, 3118
  for molluscum contagiosum virus, 3090
Candida endophthalmitis, IV drug use, 1709
Candidiasis, 2952–2959
  at-a-glance, 2952*b*
  chronic mucocutaneous, 2399–2401, 2400*t*, 2401*f*
  clinical course and prognosis, 2957
  clinical features, 2952–2956
    complications, 2996
    cutaneous, 2952–2955, 2953*f*–2955*f*
    noncutaneous, 2955–2956
  diagnosis, 2956–2957, 2956*f*–2957*f*
  differential diagnosis, 2957*t*
  epidemiology, 2952
  etiology and pathogenesis, 2956
    genetic mutations, 2929
  management, 2957, 2958*t*
    chronic mucocutaneous candidiasis, 2959
    cutaneous, 2957–2958
    disseminated candidiasis, 2959
    oral, 2958
    paronychia and onychomycosis, 2958
    vulvovaginitis and balanitis, 2958–2959
  opportunistic infections, 2984
  risk factors, 2956
Cannabis, 1711–1712
Cannabis arteritis, 1712
Cannabis sativa, 1711–1712
Canthal lines, lateral, botulinum toxin for, 3926–3927
Cantharidin, 3619–3620
  for molluscum contagiosum, 3089–3090
    with HIV, 3116
Cantú syndrome, 1564
Capecitabine, lichenoid photosensitive eruption, 1661
Capillaries, dermal, 117, 118*f*
Capillary malformations, 2636, 2637–2646, 2637*t*, 2638*f*. *See also* Vascular malformations; *specific types*
  at-a-glance, 2637*b*
  clinical course and prognosis, 2643–2644, 2644*f*, 3848
  clinical features, 2639–2641, 2639*t*, 3848
    complications, 2641, 2644*f*
    cutaneous, 2639–2640, 2642*f*–2643*f*
    noncutaneous, 2641
  diagnosis, 2642–2643, 2645*f*
  differential diagnosis, 2646*t*
  epidemiology, 2638, 3848
  etiology and pathogenesis, 2641–2642
    genetic, 2640*t*
  inherited, 2638
  management, 2644, 2645*f*
    laser therapy, nonablative, 3848–3849, 3849*f*, 3853*t*
  prevention, 2645
  syndromic disorders
    diffuse capillary malformation with overgrowth, 2639, 2640, 2642*f*
    macrocephaly–capillary malformation, 2639
    phakomatosis pigmentovascularis, 2639, 2641*f*
    Sturge-Weber syndrome, 2639, 2642*f*
Capnocytophaga canimorsus, 3339
Capsaicin, 3610
  for amyloidosis, cutaneous, 2270
  for prurigo nodularis, 392
Captopril, drug-induced pemphigus, 915
Caput succedaneum, 1730
Carate, 3173–3177
Carbamates, allergic contact dermatitis from, 405
Carbamazepine, Stevens-Johnson syndrome, 304, 304*t*
Carbapenems. *See also specific types*
  for *Burkholderia pseudomallei*, 2846
  for *Chromobacterium violaceum*, 2849
  contraindications, 2890
  for *Nocardia* actinomycetoma, 2889
  systemic, 3419
Carbapenem-vancomycin, for pyomyositis, 2778
Carbaryl, for lice, 3281–3282, 3281*t*
Carbocysteine, for pulmonary fibrosis in systemic sclerosis, 1101
Carbohydrate loading, for acute hepatic porphyrias, 2252
Carbol-fuchsin, for green nail syndrome, 2795
Carbon dioxide (CO_2), solid
  chemical peels, 3898
    medium-depth, 3900, 3901*t*
  cryogenesis, 3791, 3792*t*
  dermabrasion, 3898
Carbon monoxide
  from fire, 1681
  from tobacco use, 1714
Carboplatin, for Merkel cell carcinoma, 1931
Carboxylase deficiency, neonates, 1740
Carbuncles. *See also specific disorders*
  definition, 2724
  staphylococcal, 2724, 2725*f*
Carcinogenesis. *See also specific carcinogens and cancers*
  in elderly, 1785
  genome instability, spontaneous, 2342 (*See also* DNA repair; Genome instability disorders)
  mutator phenotype, 2342
  PUVA, 3644–3645
Carcinogenesis, human skin cancer
  animal models, 321–323
  etiology, 315–321
    chemical, 320, 320*t*
    ionizing radiation, 320
    photocarcinogesis, 315–317 (*See also* Photocarcinogenesis)
    viral, 318–320
      general features, 318–319, 319*t*
      human papillomaviruses, 319, 319*t*
      human polyomaviruses, 319–320
    wounds, chronic, 320–321
  treatment, 323

Carcinogenesis, skin and, 310–324
at-a-glance, 310*b*
cutaneous, 310–315
general principles, 310–313, 311*f*, 312*f*
genetics
basal cell carcinoma, 314
general concepts, 313
squamous cell carcinoma, 314–315
Carcinoid syndrome
hypermelanosis, 1362
pellagra, 2214
Carcinomas. *See also specific types*
basal cell, 1839, 1884–1891
Merkel cell, 1920–1932
sebaceous, 34, 1822*t*, 1851–1853, 1852*f*, 1852*t*
squamous cell, 1901–1916
CARD9, chronic mucocutaneous candidiasis, 2399, 2929
CARD11, 314
CARD14
CARD14-mediated pustular psoriasis, 622*t*, 629–631
pityriasis rubra pilaris, 502, 503
PPPP, 479
psoriasis, 199, 478
psoriasis 2, 622*t*
CARD14-mediated pustular psoriasis (CAMPS)/psoriasis 2 (PSORS2), 629–631, 632*f*
CARD15. See NOD2 (CARD15)
Cardiac sarcoidosis, 576
Cardiac-valvular Ehlers-Danlos syndromes (cvEDS), 1214*t*, 1221. *See also* Ehlers-Danlos syndromes
Cardiofaciocutaneous syndrome, cutis laxa, 1237*t*
Cardiovascular system disorders
cutaneous manifestations, 2425–2427
autoimmune connective tissue disease, 2427
earlobe crease, 2425
endocarditis, 2425
erythroderma, 2427
inherited connective tissue disease, 2425–2427
psoriasis, 2425
systemic lupus erythematosus, 2427
systemic sclerosis, 2427
prophylaxis, preoperative, 3706–3707, 3707*t*
skin manifestations, 2395*t*–2396*t*, 2425–2427
Carditis. *See also* Endocarditis; Infective endocarditis (IE)
acute rheumatic fever, 1159*t*, 1160
Carney complex, 1359, 2444*t*
Carney complex/LAMB syndrome, blue nevus, 1959, 1961
Carney syndrome, lentigo simplex, 1968
Carotenemia, 2204*b*, 2208–2209
Carotenoderma, 2204*b*, 2208–2209
Carotenoids, oral photoprotection, 3630
Carotid artery, external, 3703–3705, 3704*f*
Carpal tunnel syndrome, Raynaud phenomena, 2615
Carpet beetles, 3331
Carpet tack sign, 12*t*
Carrion disease
bacteriology, 2797, 2797*t*
clinical course and prognosis, 2805
clinical features
complications, 2802
cutaneous, 2799*t*, 2800, 2801*f*
noncutaneous, 2799*t*, 2802
diagnosis
laboratory, 2799*t*, 2804–2805
pathology, 2804
differential diagnosis, 2804, 2805*t*
epidemiology, 2798
etiology and pathogenesis, 2803–2804
management, 2806
Cartilage–hair syndrome, 2402*b*
Carvajal syndrome, 842–843, 846*t*
woolly hair, 1545
Carvedilol, for rosacea, 1438
Casal's necklace, 2215
Case-control study, 44
Caseous necrosis, 27
Case reports, 44
Case series, 44
CASP, Kawasaki disease, 2584
CASP8, 314
Caspase 14 deficiency, 217
Castellani (carbol-fuchsin), for green nail syndrome, 2795
Castleman disease, 2125
paraneoplastic pemphigus, 2*f*, 934, 935
Castor bean tick, 3329
Catagen, 93*f*, 95, 97–98
Cataracts, atopic dermatitis, 368
Cat bites, 3338–3340
bacterial infections
Pasteurella multocida, 2829*t*, 2837–2838, 3339
Porphyromonas spp., 3339
cellulitis, 2748
pathogenesis and treatment, 3338, 3339*t*
Catechins, oral photoprotection, 3630
Caterpillars, 3334, 3334*f*
Catfish, 3356
Cathelicidin (LL-37), 222, 222*t*
functions, 223
rosacea, 1428*f*–1429*f*, 1429
sebaceous gland expression, 75
Cathepsin K
relapsing polychondritis, 1189
UVA on, 283
Cathepsin L, relapsing polychondritis, 1189
Cat scratch disease (CSD), 2797–2805, 3340
bacteriology, 2797, 2797*t*
clinical course and prognosis, 2804–2805
clinical features
complications, 2802
cutaneous, 2798, 2799*t*, 2800*f*
noncutaneous, 2799*t*, 2800–2801
diagnosis
laboratory, 2799*t*, 2804
pathology, 2804, 2804*f*
differential diagnosis, 2804, 2805*t*
epidemiology, 2797
etiology and pathogenesis, 2803–2804
management, 2805
Causal association, 41
CAV, congenital generalized lipodystrophy, 1296
CAV1, Wiedemann-Rautenstrauch syndrome, 1299
Caveolin 1, 1296
CAVIN1, congenital generalized lipodystrophy, 1296–1297
Cavum, 3698, 3698*f*
CBc12, extranodal marginal zone lymphoma, 2099
CC11, eosinophils, 657–658
CC24, eosinophils, 657
CC26, eosinophils, 657
CC-5013 (Relimid), 3601
CCBE1, Hennekam lymphedema-lymphangiectasia, 2640*t*, 2657
CC chemokine, eosinophils, 657
CC chemokine ligand 11, 172
CC cytokines, eosinophil activation, 657–658
CCDC122, leprosy, 2902
CCL2
systemic sclerosis, 1093
wound healing, 2708
CCL3, eosinophils, 655
CCL5
eosinophils, 655
systemic sclerosis, 1093
CCL11, 156
atopic dermatitis, 183
eosinophils, 655
CCL17, 160*t*
immune surveillance, 122, 122*f*
psoriasis, 183
CCL18, atopic dermatitis, 183
CCL20, 160*t*
psoriasis, 183
CCL27, 160*t*
immune surveillance, 122–123
CCND1, chondroid lipoma, 2183
CCR1, 181
CCR2, 181
CCR3, eosinophils, 657
CCR4, 147, 3543
atopic dermatitis, 182–183
cutaneous T-cell lymphomas, 2076*f*
immune surveillance, 122, 122*f*
tissue resident effector T cells, 147
CCR5, 181, 182
CCR6, acute generalized exanthematous pustulosis, 183
CCR7, 180–181, 180*f*, 182
cancer, 185, 185*f*
CCR7/L-selectin (CD62L), recirculating memory T cells, 147
CCR10, 147
atopic dermatitis, 182–183
cancer, 185, 185*f*
immune surveillance, 122, 122*f*
CD1a, 135, 149
Langerhans cell histiocytosis, 2019, 2021, 2022*f*, 2026, 2026*t*, 2027*f*, 2027*t*
Langerhans cells, 151, 152
CD1a+
pityriasis lichenoides, 513
type IV hypersensitivity reactions, 397
CD1d, sebaceous gland expression, 75
CD1 gene family, 149, 151
CD1-restricted T-cells, 149–151
CD2, Langerhans cell histiocytosis, 2027*t*
CD2BP1, PAPA syndrome, 608
CD3
Sézary syndrome, 2083
Sweet syndrome, 595
CD4
blastic plasmacytoid dendritic cell neoplasm, 2102
nevus lipomatosis superficialis, 2175
systemic sclerosis, 1094
T helper cells, lichen planus, 527–528
CD4+
dermatosis, 595
lichen nitidus, 557
parapsoriasis, 509
pityriasis lichenoides, 513
primary cutaneous CD4+ small and medium T-cell lymphoproliferative disorder, 2087–2088
relapsing polychondritis, 1188
seborrheic dermatitis, 432
Sézary syndrome, 2083
small/medium T-cell lymphoproliferative disorder, 2114, 2114*f*
T cells, 136, 145
T helper cells, 303
CD7, parapsoriasis, 509
CD7+/CD62L+, 136–137, 137*f*
CD8
herpes simplex virus, 3027
Kawasaki disease, 2584
Merkel cell carcinoma, 1929
T-cytotoxic (CD8-Tc) cells, lichen planus, 527–528
CD8+
pityriasis lichenoides, 513
seborrheic dermatitis, 432
T cells, 134, 136, 145
vitiligo, 1335

CD8+ T-cell pseudolymphoma in immunodeficiency, 2120–2121
CD10, primary cutaneous follicular center lymphoma, 2099
CD11b
cutaneous necrotizing venulitis, 2534
dermatitis herpetiformis, 1004
eosinophils, 658
juvenile xanthogranuloma, 2032
Langerhans cell histiocytosis, 2027*t*
CD11b/CD18 (Mac-1)-dependent cellular adhesion, 657
CD11c
eosinophils, 658
juvenile xanthogranuloma, 2032
Langerhans cell histiocytosis, 2027*t*
CD13, Langerhans cell histiocytosis, 2027*t*
CD14
eosinophils, 656
lichen nitidus, 557
protein-energy malnutrition, 2203
sebaceous gland expression, 75
CD16, eosinophils, 655–656, 658
CD19
primary cutaneous follicular center lymphoma, 2099
systemic sclerosis, 1093
CD20
extranodal marginal zone lymphoma, 2099
primary cutaneous diffuse large B-cell lymphoma, 2100
primary cutaneous follicular center lymphoma, 2099
CD22, systemic sclerosis, 1093
CD25, 170, 3543
CD28, cutaneous T-cell lymphomas, 2075, 2076*f*
CD30, 3546
eosinophils, 656
CD30+
lymphoproliferative disorders, nodular lymphocytic infiltrates, 27
pityriasis lichenoides, 513, 514
CD30L, 3546
CD30+ T-cell pseudolymphoma, 2114, 2115*f*
CD31+
infantile hemangiomas, 2052, 2053
tufted angioma, 2062
CD31, dedifferentiated liposarcoma, 2190
CD32, eosinophils, 655–656
CD34
hibernoma, 2186
lipoblastoma/lipoblastomatosis, 2177
pleomorphic liposarcoma, 2193
spindle-cell lipoma and pleomorphic lipoma, 2181*f*–2182*f*, 2182
trichodiscoma/fibrofolliculoma, 1822*t*, 1843
CD34+
dermatofibrosarcoma protuberans, 2182
infantile hemangiomas, 2052, 2053
solitary fibrous tumor, 2182
CD35, eosinophils, 655
CD36, juvenile xanthogranuloma, 2032
CD40
hyperimmunoglobulin M syndrome, 2402
Kawasaki disease, 2584
CD40 ligand
CD40L, T follicular helper cells, 146
CD154, 168
CD44, eosinophils, 658
CD45
eosinophils, 656
multicentric reticulohistiocytosis, 2038
CD45RA+, 136, 137*f*, 180
CD45RO+, 136, 137*f*
CD46, epidermal basal cells, 62
CD50, eosinophils, 656
CD52, eosinophils, 656
CD54, eosinophils, 656, 658
CD56, blastic plasmacytoid dendritic cell neoplasm, 2102
CD58, 3543
CD62L, eosinophils, 656
CD62L-/CCR7+, 136, 137*f*
CD66c, Langerhans cell histiocytosis, 2027*t*
CD68
benign cephalic histiocytosis, 2034
generalized eruptive histiocytoma, 2035
hereditary progressive mucinous histiocytosis, 2039
juvenile xanthogranuloma, 2032
Langerhans cell histiocytosis, 2027*t*
lichen nitidus, 557
multicentric reticulohistiocytosis, 2038
non–Langerhans cell histiocytosis, 2030
papular xanthoma, 2035
progressive nodular histiocytosis, 2040
Rosai-Dorfman disease, 2031
CD69
eosinophils, 656, 658
tissue resident effector T cells, 147
CD69+, 136, 137*f*
CD79a
extranodal marginal zone lymphoma, 2099
primary cutaneous diffuse large B-cell lymphoma, 2100
primary cutaneous follicular center lymphoma, 2099
CD86, systemic sclerosis, 1093
CD95, eosinophils, 656
CD99, inflammation, 124
CD103+, 136, 137*f*
CD103, tissue resident effector T cells, 147
CD116, eosinophils, 656
CD123
blastic plasmacytoid dendritic cell neoplasm, 2102
eosinophils, 656
CD125, eosinophils, 656
CD131, 172
CD133+, infantile hemangiomas, 2051–2052
CD138, extranodal marginal zone lymphoma, 2099
CD141, 135
CD141+, 135
CD141+, type IV hypersensitivity reactions, 397
CD151, 243, 243*f*
CD158k/KIR3DL2, Sézary syndrome, 2083
CD162, eosinophils, 656
CD162 (PSGL-1), eosinophils, 657
CD163
cytophagic histiocytic panniculitis, 1276
juvenile xanthogranuloma, 2032
non–Langerhans cell histiocytosis, 2030
progressive nodular histiocytosis, 2040
Rosai-Dorfman disease, 2031
Sweet syndrome, 595
CD207 (langerin), 151
Langerhans cell histiocytosis, 2021, 2022*f*, 2026, 2027*t*
CD247, graft-versus-host disease, 2322
CD300LF, Langerhans cell histiocytosis, 2027*t*
CDAGS syndrome, 902*t*, 904
CDK4
atypical lipomatous tumors, 2174, 2182, 2187
dedifferentiated liposarcoma, 2190
genetic counseling, 305
lipoma, 2174
melanoma, 1990, 1991
pleomorphic liposarcoma, 2193
CDK6, dysplastic melanocytic nevi, 1975
CDKN1B, blastic plasmacytoid dendritic cell neoplasm, 2102
CDKN2A, 314
actinic keratosis, 1861
blastic plasmacytoid dendritic cell neoplasm, 2102
dysplastic melanocytic nevi, 1975
genetic counseling, 305
melanoma, 1990–1991, 1991*f*
myxoid liposarcoma, 2192
primary cutaneous diffuse large B-cell lymphoma, 2100–2101
CDKN2A-CDK4-TP53 pathway mutations, melanoma, 1990–1991, 1991*f*
CDKN2A-CDKN2B, cutaneous T-cell lymphomas, 2075, 2076, 2076*f*
CDPX2, 1200
CDSN, peeling skin syndromes, 803
C/EBP, epidermal differentiation, 66, 67*f*
CEDNIK, cellular defect, 781*t*
Cefaclor, serum sickness–like reactions from, 751, 752*t*
Cefazolin
for group A Streptococcus lymphangitis, 2739, 2739*t*
for skin and soft-tissue infections, dosing, 3410*t*
for *Staphylococcus* necrotizing fasciitis, 2775, 2776*t*
Cefdinir, for skin and soft-tissue infection, 3410*t*
Cefepime, for *P. aeruginosa*
bacteremia and ecthyma gangrenosum, 2796
otitis externa, malignant, 2796
Cefotaxime
for *H. influenzae* facial cellulitis, 2810
for *Neisseria meningitidis*, 2787
photodistributed telangiectasia, 1661
Cefotaxime plus clindamycin, for necrotizing fasciitis, 2775, 2776*t*
Cefotaxime plus metronidazole, for necrotizing fasciitis, 2775, 2776*t*
Cefprozil, for skin and soft-tissue infection, 3410*t*
Ceftaroline, for MRSA skin and soft tissue infections, complicated, 2731*t*, 2732
Ceftazidime
for *Burkholderia pseudomallei*, 2846
for *P. aeruginosa*
bacteremia and ecthyma gangrenosum, 2796
otitis externa, malignant, 2796
for *Vibrio vulnificus*, 2843
Ceftazidime-avibactam, for *P. aeruginosa* bacteremia and ecthyma gangrenosum, 2796
Ceftolozane-tazobactam, for *P. aeruginosa* bacteremia and ecthyma gangrenosum, 2796
Ceftriaxone
for cat scratches, deep, 3338
for chancroid, 3189–3190, 3190*t*
for erysipeloid, 2847–2848
for gonorrhea prophylaxis, in newborns, 3210, 3210*t*
for *H. influenzae* facial cellulitis, 2810
for infective endocarditis, 2818
for Lyme borreliosis, 3299, 3300*t*
for *Neisseria meningitidis*, 2787–2788
for nocardiosis, 2884
for Oroya fever, 2806
for *Salmonella* enteric fever, 2808
Cefuroxime, for Lyme borreliosis, 769, 773*t*, 3299, 3300*t*
Cefuroxime axetil, for Lyme borreliosis, 3299, 3300*t*
Celecoxib, for basal cell carcinoma prevention, with basal cell nevus syndrome, 1896
Celiac disease
chronic spontaneous urticaria, 687
dermatitis herpetiformis, 1003, 1004
Cell–basement membrane adhesion, 232
Cell–cell adhesion, 232

Cell death temperatures, cryosurgery, 3791, 3792*t*
Cell killing disorders, 2409–2419. *See also* Phagocytosis and cell killing disorders
Cell-mediated immune responses, chemokine receptors, 181
Cell types
  skin
    central developmental signaling pathways, 50
    epidermis pathology, 19–20
    formed during development, 49–50
  skin tumors, 30
Cellular deficiencies, genetic, 2399–2402
  cartilage–hair syndrome, 2402*b*
  chronic mucocutaneous candidiasis, 2399–2401, 2400*t*, 2401*f*
Cellular dermal matrix, 2711, 2711*t*
Cellular retinoic acid binding protein (CRABP) II, 3397, 3398*t*
Cellular retinol binding protein (CRBP), 3397, 3398*t*
Cellular schwannoma, 2155
Cellular senescence, in aging, 1765
Cellulite, 3865–3866, 3866*f*
Cellulite removal, noninvasive body contouring, 3865–3868
  adaptations, anatomic area and skin type, 3868
  complications, 3867*f*, 3868
  devices and technologies, 3866–3867
  indications and patient selection, 3865–3866, 3866*f*
  modes of action, 3867, 3867*f*
  outcomes, expected, 3868
Cellulitis, 2746–2754. *See also specific types*
  at-a-glance, 2746*b*
  bilateral, 2748
  clinical course and prognosis, 2752
  clinical features
    clinical variants, 2747–2748
    complications, 2747, 2747*f*
    cutaneous, 2746–2747, 2747*f*
    noncutaneous, 2747
  definitions, 2746
  diagnosis, 2750–2751, 2751*t*
  differential diagnosis, 2751–2752, 2751*t*, 2752*f*
  in elderly, 1787
  eosinophilic, 654
  epidemiology, 2746
  etiology and pathogenesis, 2748–2749
    microbiology, 2749, 2749*t*
  Haemophilus influenzae, 2809–2810
  historical perspective, 2746
  management, 2752–2754
    adjunctive treatments, 2754
    antibiotics
      duration, 2754
      for nonpurulent cellulitis, 2753–2754, 2753*t*
      for purulent cellulitis, 2753*t*, 2754, 2754*t*
      for recurrent cellulitis, 2753*t*, 2754
    prevention, 2754
    prophylaxis, antibiotic, 2754
  orbital, 2748
  periorbital, 2748
  preseptal, 2748
  purulent, 2748
  risk factors, 2750
Cement (cobalt marker), allergic contact dermatitis from, 404
Centipedes, 3330
Central centrifugal cicatricial alopecia (CCCA), 1528, 1528*f*
Central memory T cells (T_{CM}), 147, 148*f*, 2072
  cutaneous T-cell lymphomas, 2072, 2073, 2074
Central nervous system heterotopia
  cutaneous ganglioneuroma, 2167
  ganglion cell tumor, 2167
  meningeal heterotopia, 2166–2167, 2167*f*
  myxopapillary ependymoma, 2167
  neuroglial heterotopia, 2166
Centrofacial lentiginosis, 1360
  lentigo simplex, 1968
Centromere, 291, 291*f*
Cephalexin
  for acne vulgaris, 1405
  for group A *Streptococcus* impetigo and ecthyma, 2739, 2739*t*
  for skin and soft-tissue infections, dosing, 3410*t*
  for staphylococcal impetigo, ecthyma, and folliculitis, 2730, 2731*t*
Cephalohematoma, 1730
Cephalosporins. *See also specific types*
  for *Aeromonas hydrophila*, 2844
  for dissecting folliculitis, 1530
  first-generation, for trench fever, 2806
  for *S. aureus*, in folliculitis decalvans, 1529
  third-generation
    for erysipeloid, 2847–2848
    for *H. influenzae* facial cellulitis, 2810
Cephalosporins, systemic, 3409–3413
  dosing regimen, 3411*t*, 3412
  indications and contraindications, 3412, 3413*t*
  pharmacology and mechanism of action
    metabolism, absorption, and distribution, 3412
    structure, 3409–3412
  side effects and precautions, 3411*t*, 3412–3413
  for skin and soft-tissue infection, 3410*t*
Ceramides, 213, 215*f*
Ceratopogonidae, 3325*f*, 3330–3331
Cercarial dermatitis, 3252*t*, 3253–3254, 3265*t*, 3269–3271, 3270*f*, 3353–3354, 3353*f*
Cerebro-oculo-facial-skeletal (COFS) syndrome, 2342, 2346*f*, 2355
  gene mutations, 2344, 2350
Cerebrotendinous xanthoma, 2277
Certolizumab
  for psoriatic arthritis, 469*f*, 494, 980*t*, 981, 1136*t*, 1137
  for rheumatoid arthritis, 1152
Cervical necrotizing fasciitis, 2772
Cestodes, 3251, 3252*t*. *See also specific types*
  exposure and symptom onset interval, 3259, 3260*t*
  progression and duration, 3259, 3260*t*
Cetirizine. *See also* Antihistamines, H_1
  dosing regimens, 3454–3455, 3455*t*
  for mastocytosis, 719, 719*t*
  for pruritus, in lichen nitidus, 558, 558*t*
Cetuximab, 3541, 3550*t*, 3559*t*, 3565, 3567, 3593
  acneiform eruptions from, 1452
C fibers, 353
  pruritus, 353, 354*f*
CGI-58, Chanarin–Dorfman syndrome, 780*t*
Chagas disease, 3240–3242, 3241*f*
Chagoma, 3240
Chainsaws, Raynaud phenomena, 2616
Chalk, 1711
Chanarin–Dorfman syndrome, 780*t*, 803–804, 804*f*
  cellular defect, 781*t*
  CGI-58, 780*t*
  congenital, 1740
  genes
    ABHD5, 803, 804*f*
    PNPLA2, 803
Chancre
  syphilis
    chancre redux, 3149
    edema indurativum, 3149
    Hunterian, 3148
  tuberculous, 2861–2863, 2863*f*, 2863*t*
Chancre immunity, 3161
Chancroid, 3186–3190
  at-a-glance, 3186*b*
  clinical features, 3186–3188, 3187*f*, 3188*t*
  complications, 3189, 3189*t*
  diagnosis, 3188–3189
  differential diagnosis, 3188, 3189*t*
  epidemiology, 3186
  HIV, 3190
  prevention, 3190
  prognosis and clinical course, 3189
  treatment, 3189–3190, 3190*t*
Chaperone-based enzyme enhancement therapy, for Fabry disease, 2303
Chapping, 415, 419*f*
Charcoal, oral
  for congenital erythropoietic porphyria, 2244
  for hepatoerythropoietic porphyria, 2243
Charcot-Leyden crystal protein, 651*f*, 652
Charged particle therapy, 3687–3688, 3688*f*
Chaulmoogra oil, for leprosy, 2916
Chédiak-Higashi syndrome (CHS), 1318–1319, 2415–2418, 2445t
  at-a-glance, 1318*b*, 2415*b*
  characteristics, 2416*t*
  clinical course, prognosis, and management, 1319, 2418
  clinical features, 1318, 2416, 2417*f*
  diagnosis, 1309, 2416*f*, 2417
  differential diagnosis, 1319, 2417–2418
  epidemiology, 2416
  etiology and pathogenesis, 1318–1319, 2416–2417
  squamous cell carcinoma, 1904*t*
Cheek advancement flap, 3735–3736, 3736*f*–3737*f*
Cheilosis, riboflavin deficiency, 2213, 2213*f*
Cheiroarthropathy, 2496–2497, 2496*f*
Chelating agents, 3377
Chemical adipocytolysis, fat reduction, 3863, 3865*f*
Chemical peels, 3895–3903. *See also specific types*
  for acne vulgaris, 1410
  for actinic keratosis, 1866
  at-a-glance, 3895*b*
  chemical resurfacing procedures, 3899–3903 (*See also* Chemical resurfacing procedures)
  complications, 3902–3903
  historical perspective, 3895
  for melasma, 1381, 2242
  perioperative considerations
    contraindications, 3897, 3898*t*
    indications, 3895
    patient selection, 3895–3896, 3896*t*, 3897*f*
    preparations, 3896, 3898*t*
    side effects, 3896
  technique, procedural, 3896–3898
Chemical penetration enhancers, 3376
Chemical resurfacing procedures, 3899–3903
  chemicals, 3899, 3899*f*–3900*f*
  complications, 3902–3903, 3902*f*
  deep, 3901
  fundamentals, 3899
  medium-depth, 3900–3901, 3901*t*, 3902*f*
  postoperative care, 3901
  superficial, 3899–3900, 3899*f*, 3901*f*
Chemicals. *See also specific types*
  acne from, 446
  burns, 441–443, 443*t*, 1683
  carcinogenesis, 320, 320*t*
    rodent models, 322–323
  injuries, dyskeratosis, 22
Chemical sclerosing agents, 3880
Chemokine(s), 160*t*, 176–182. *See also specific types*
  definition, 159, 3543

dendritic cell trafficking, skin to regional lymph nodes, 181–182, 182*f*
in disease, 182–186
atopic dermatitis, 182–183
cancer, 183–185, 185*f*
infectious diseases, 185–186
psoriasis, 183, 184*f*
eosinophils
CC, 657
tissue trafficking, 650*f*, 656–657
functions, 176–177
inflammation, 124, 124*f*
leukocytes
recruitment, multistep model, 179–180, 180*f*
trafficking, cutaneous, 179
macrophage-derived, adipocyte lipolysis, 1251
mast cell granules, 154, 154*t*
melanoma, secretion, 184
neutrophil release, 155
signal transduction, 168*f*, 177–179, 178*t*, 179*f*
structure, 177
T-cell migration, 180–181, 180*f*
wound healing, 2708
Chemokine receptors, 177–179, 178*t*, 179*f*
antimicrobial proteins on, 223
Chemotactic factors, 132
receptors, eosinophil expression, 655
Chemotaxis inhibitory protein of *S. aureus* (CHIPS), 2727
Chemotherapy drugs. *See also specific types*
drug reactions, 757–759, 758*t*
for Langerhans cell histiocytosis, 2029, 2029*t*
lupus erythematosus from, 1041*t*
Chemotherapy-induced syringosquamous metaplasia (CISM), 3483
Chewer's mucosa, 1713
Chigger fever, 3306, 3319–3320
Chiggers, 3278, 3278*t*
Chigoe flea, 3333, 3333*f*
Chikungunya, 1369, 3141–3142, 3142*f*
Chilblain lupus erythematosus, 1047–1048, 1047*f*
of nails, 1587–1588, 1587*f*
Chilblains, 1673–1674, 1674*f*
Child abuse, 1762–1763
clinical course and prognosis, 1723–1724
clinical features, 1718–1719, 1718*f*
location, 1718–1719, 1718*f*
morphology, 1718
diagnosis, 1721
differential diagnosis, 1723, 1723*t*, 1724*t*
epidemiology, 1717
etiology and pathogenesis, 1720–1721, 1720*f*
imaging
fractures, 1722
head injury, 1723
visceral trauma, 1723
laboratory testing and imaging, 1722
management, 1724, 1724*t*
sexual (*See* Sexual abuse, child)
Child dermatology. *See* Pediatric and adolescent dermatology
Childhood-onset dermatitis. *See* Atopic dermatitis (AD)
Child neglect, 1762–1763
CHILD syndrome, 804–805, 804*f*
cellular defect, 781*t*
genes
EBP, 778*t*, 805
NSDHL, 208*t*, 213, 215*f*, 778*t*
SC4MOL, 208*t*, 213, 215*f*
verruciform xanthoma, 2276
Chilopoda, 3330
Chimeric autoantigen receptor (CAAR) T cells, autoimmune blistering disease, 203
Chironex fleckeri, 3346–3347, 3347*f*
Chlamydia, 3214–3217
clinical course and prognosis, 3217
clinical features, 3215
diagnosis, 3216, 3216*f*
differential diagnosis, 3216*t*
epidemiology, 3215
etiology and pathogenesis, 3215–3216
fundamentals, 3214
management, 3217, 3217*t*
prevention and screening, 3217
sarcoidosis, 577
Chlamydia trachomatis, 3215–3216, 3216*f*
lymphogranuloma venereum, 3193–3194, 3196–3197
Chloracne, 1452–1453
Chlorambucil, 3478–3480
for adamantiades–Behçet disease, 2576*t*
for African tick bite fever, 3309*t*, 3315
chemical structure, 3465*f*
complications, 3479–3480
for cryofibrinogenemia, 2609
for cryoglobulinemia II and III, HCV, 2607
dosing regimen, 3479
drug interactions, 3480
for erythrasma, 2743
for extranodal marginal zone lymphoma, 2100
indications, 3478–3479, 3479*t*
initiating therapy, 3479
mechanism of action, 3478
for Mediterranean spotted fever, 3309*t*, 3315
monitoring therapy, 3479, 3479*t*
pharmacokinetics, 3478
risks and precautions, 3479, 3479*t*
Chloramphenicol
for actinomycosis, 2880
for *Chromobacterium violaceum*, 2849
for *Neisseria meningitidis*, 2787–2788
pellagra from, 2214
for Rocky Mountain spotted fever, 3309*t*, 3312
for typhus
endemic, 3310*t*
epidemic, 3310*t*
Chloramphenicol-β lactam, for Oroya fever, 2806
Chlorasma (melasma), 1379–1381, 1380*f*, 1765, 1766*f*
Chlorhexidine (gluconate), 3611, 3612*t*, 3714–3715
soap, for staphylococcal nares and skin decolonization, 2731*t*, 2732
Chlorinated hydrocarbons, occupational acne from, 1452–1453
Chlormadinone acetate, for androgenetic alopecia, 1504
Chlormethine, for mycosis fungoides, 2090
Chloronychia, 1568–1569, 1569*t*, 1571*f*
Chloroprocaine, 3710*t*
Chloroquine
for amebiasis, 3247
for dermatomyositis, 1077
hypermelanosis from, 1365
for lichen planus, 544
for lupus erythematosus, 1054*t*
Chloroquine diphosphate, for lupus erythematosus, 1054*t*, 1056
Chlorpheniramine. *See also* Antihistamines, H_1
dosing regimens, 3454–3455, 3454*t*
Chlorpromazine
hypermelanosis from, 1365
phototoxicity, 1662
blue-gray pigmentation, 1658, 1661*f*
on riboflavin transport, 2213
Cholecalciferol. *See* Vitamin D_3 (cholecalciferol)
Cholestasis of pregnancy. *See* Intrahepatic cholestasis of pregnancy (ICP)
Cholestatic jaundice of pregnancy. *See* Intrahepatic cholestasis of pregnancy (ICP)
Cholestatic pruritus, cutaneous manifestations, 2431
Cholesterol
biosynthesis, 213, 215*f*
dietary, 2280
epidermis, 212–213
synthesis, 2279*f*, 2280–2281
Cholesterol transporter, 2280
Cholesteryl ester transfer protein (CETP), 2280, 2281
Cholestyramine
mycophenolate mofetil interactions, 3519
for protoporphyric hepatopathy, 2249
Cholinergic angioedema, 686*f*, 690
Cholinergic dermographism, 689
Cholinergic pruritus, 690
Cholinergic urticaria, 686*f*, 690. *See also* Urticaria
anaphylaxis from, 687
clinical features, 685, 686*f*
diagnosis, 688*t*, 698
pathogenesis, sweat antigens, 691–692
risk factors, 695
Chondrodermatitis nodularis helicis (CNH), 1805, 1806*f*
Chondrodysplasia punctata, 778*t*, 805–806
rhizomelic, 805
X-linked dominant, 778*t*, 806, 1200
X-linked recessive, 778*t*, 805–806
Chondrodysplasia punctata X-linked recessive (CDPX), 778*t*, 805
ARSE, 778*t*, 805
Chondroid lipoma, 2182–2183, 2183*f*
Chondroitin sulfate, dermal cell-matrix adhesion, 247
Chondrolipoma, 2173, 2173*f*
Chorea, acute rheumatic fever, 1159*t*, 1160
Christmas tree pattern
hair loss, 1497, 1498*f*, 3931, 3946*f*
pityriasis rosea, 518, 520, 520*f*, 521*f*
Chromated glycerin, 3879*t*, 3880
Chromatin conformation capture (3C), 293
Chromatin modification, 3575
Chromatin remodelers, 67, 67*f*
Chromhidrosis, 1471–1473, 1472*f*, 1472*t*
Chromium, allergic contact dermatitis from, 404
Chromobacterium violaceum, 2849
Chromoblastomycosis, 2966*t*, 2971–2972, 2971*f*–2972*f*
Chromomycosis, 2966*t*, 2971–2972, 2971*f*–2972*f*
Chromonychia, 1568–1570, 1569*t*
apparent leukonychia, 1568, 1569*t*, 1570*f*
blue nails, 1569, 1569*t*
chloronychia, 1568–1569, 1569*t*, 1571*f*
erythronychia, 1568, 1569*t*, 1570*f*–1571*f*
leukonychia, diffuse, 1568, 1570*f*
leukonychia punctata, 1568, 1569*f*
melanonychia, 1569–1570, 1569*t*, 1572*f*
pseudoleukonychia, 1568, 1569*t*, 1570*f*
Chromophores, 267–268, 268*f*
photodermatoses, 273
photo-immunosuppression, 271–272
Chromosomal band, cytogenetic, 290, 291*f*
Chromosomal disorders, 297–300, 298*t*–299*t*. *See also specific types*
Chromosomal maps, 290, 291*f*
Chromosomal mosaicism, 302
Chromosome, structure, 290–292, 291*f*
Chromosome 4, short arm deletion, 298*t*
Chromosome 5, short arm deletion, 299*t*
Chromosome 18, long arm deletion, 299*t*
Chronic actinic dermatitis (CAD), 1639–1643. *See also* Actinic dermatitis, chronic
Chronically sun-damaged (CSD) melanoma, 278

Chronic atypical neutrophilic dermatosis with lipodystrophy and elevated temperature syndrome (CANDLE)/proteasome-associated autoinflammatory syndrome (PRAAS), 639–640
Chronic bullous disease of childhood (CBDC), 992–999
  at-a-glance, 992*b*
  clinical features
    cutaneous, 995, 996*f*
    mucosal, 995
  definition and overview, 992
  differential diagnosis, 998
  disease associations, 997
  epidemiology, 992–993
  etiology and pathogenesis, 993–994, 993*t*, 994*t*
  treatment and prognosis, 994*t*, 998–999, 998*t*
Chronic cutaneous lupus erythematosus (CCLE), 1038, 1038*t*. *See also* Lupus erythematosus (LE)
  classification, 1038, 1038*t*
  clinical course and prognosis, 1053
  clinical features, 1044–1048
    chilblain lupus erythematosus, 1047–1048, 1047*f*
    cicatricial alopecia, 1526–1527, 1526*f*
    classic discoid lupus erythematosus, 1044–1045, 1044*f*–1046*f*
    hypertrophic discoid lupus erythematosus, 1046
    lupus erythematosus profundus/lupus erythematosus panniculitis, 1047, 1047*f*
    lupus erythematosus tumidus, 1048, 1048*f*
    mucosal discoid lupus erythematosus, 1046–1047
    other variants, 1048
  diagnosis
    histopathology, 1050*f*, 1051
    immunohistology, 1052
  epidemiology, 1039
  tobacco use on, 1714
Chronic diffuse telogen hair loss (CDTE), 1507–1508, 1508*f*, 1508*t*
Chronic eosinophilic leukemia. *See* Myeloproliferative hypereosinophilic syndrome
Chronic granulomatous disease (CGD), 2409–2412
Chronic infantile neurologic cutaneous and articular syndrome (CINCA), 621–625, 623*t*. *See also* Cryopyrin-associated periodic syndromes
Chronic kidney disease (CKD), with acquired perforating disorders, 1205
Chronic leukocytoclastic vasculitis. *See* Granuloma faciale
Chronic lymphocytic leukemia (CLL)
  lymphocytic cuffing of venules, 27
  paraneoplastic pemphigus, 2*f*, 934
Chronic mucocutaneous candidiasis (CMC), 2399–2401, 2400*t*, 2401*f*. *See also* Candidiasis
  genetic mutations, 2929
  management, 2959
Chronic myelogenous leukemia (CML)
  BCR, 3558
  imatinib mesylate for, 658
Chronic papular onchodermatitis, hypermelanosis from, 1369
Chronic radiation keratoses, 1881*b*
Chronic recurrent multifocal osteomyelitis (CRMO), Majeed syndrome, 643–644
Chronic renal failure, metastatic calcification, 2310–2311, 2310*f*
Chronic scar keratoses, 1881*b*
Chronic spontaneous urticaria (CSU), 684–704. *See also* Urticaria
  clinical features, 685, 687*f*
  complications
    autoimmune thyroid diseases, 687
    other autoimmune diseases, 687
  diagnosis
    disease severity, 699
    laboratory testing, 696
    quality of life, 699
    tests, 688*t*
  epidemiology, 685
  etiology and pathogenesis
    organ disorders, other, 694
    other factors, 694, 694*t*
    risk factors, 695
    stress and fatigue, 694
  evaluation
    disease severity, 688*t*, 699
    quality of life, 699
  management
    counseling, 703
    interventions, 694*t*, 701–702
    medications, 702–703
    treatment algorithm, 703, 703*f*
  pathogenesis
    autoimmune mechanism, 691*f*, 692
    coagulation system, 693
    pseudoallergy, 692
Chronic telogen effluvium, 1508, 1508*f*, 1508*t*
Chronic urticaria, 687, 688, 688*t*
Chronic venous disease (CVD), 2686–2693
  at-a-glance, 2686*b*–2687*b*
  clinical course and prognosis, 2690
  clinical features, 2687–2689
    atrophie blanche, 2688, 2688*f*
    complications, 2688–2689
    cutaneous lesions, 2687–2688, 2687*f*–2690*f*
    lipodermatosclerosis, 2687*f*, 2688
    stasis dermatitis, 2687–2688, 2687*f*
    venous ulceration, 2688, 2688*f*–2689*f*
  diagnosis, 2690, 2690*f*
  differential diagnosis, 2674*t*, 2689*t*, 2690
  epidemiology, 2687
  etiology and pathogenesis, 2689–2690, 2690*f*
  management, 2690–2691, 2691*t*
  prevention, 2691–2692
  signs and symptoms, 2687*t*
  telangiectasias and reticular veins, 3871
  on ulcers in elderly, 1788
Chronic venous insufficiency (CVI). *See* Chronic venous disease (CVD)
Chrysaora achylos, 3344, 3345*f*
Chrysaora quinquecirrha, 3344
CHST8, peeling skin syndromes, 794–804
CHST14, musculocontractural Ehlers-Danlos syndrome, 1213*t*
CHSTA, peeling skin syndromes, 803
Churg-Strauss vasculitis, cocaine abuse, 1709
Chylomicrons, 2280
  type I hyperlipidemias, 2281
Cicatricial alopecias, 1524–1533
  at-a-glance, 1524*b*
  subtypes, 1524, 1525*f*
Cicatricial alopecias, primary, 1524–1531
  classification, 1524, 1526*t*
  clinical features, 1524
  diagnosis, 1524–1525
  differential diagnosis, 1531, 1531*t*
  epidemiology, 1524
  etiology and pathogenesis, 1524
  lymphocytic, 1526–1529, 1526*t*
    alopecia mucinosa, 1529
    central centrifugal cicatricial alopecia, 1528, 1528*f*
    chronic cutaneous lupus erythematosus, 1526–1527, 1526*f*
    frontal fibrosing alopecia, 1527–1528, 1527*f*
    keratosis follicularis spinulosa decalvans, 1529
    lichen planopilaris, 1527–1528, 1527*f*
    pseudopelade of Brocq, classic, 1528
  mixed, 1526*t*, 1530–1531
    acne keloidalis nuchae, 1530–1531, 1530*f*
    acne necrotiva, 1531
    erosive pustular dermatosis, 1531
  neutrophilic, 1526*t*, 1529–1530
    dissecting folliculitis, 1530, 1530*f*
    folliculitis decalvans, 1529–1530, 1529*f*
  prognosis and clinical course, 1525–1526
  treatment, 1526
Cicatricial alopecias, secondary, 1524, 1531–1533
  clinical features, 1531
  differential diagnosis, 1533*t*
  etiology and pathogenesis, 1531, 1532*t*
  prognosis and clinical course, 1531
  tinea capitis, 1531–1532, 2941–2944 (*See also* Tinea capitis)
  traumatic hair loss, 1532–1533
    injuries, 1532–1533
    pressure alopecia, 1533
    traction alopecia, 1533, 1533*f*
    trichotillomania, 1533, 1533*f*, 1697*t*, 1699–1700
  treatment, 1531
Ciclopirox, 3438*t*, 3446–3447
  for candidiasis, cutaneous, 3447
  for dermatophytoses, 3447
  for fungal infections
    nail, lacquer, 1595, 1596*t*
    superficial, 2935*t*
  for onychomycosis, 3447
  for seborrheic dermatitis, 435
    scalp, 3447
  for tinea versicolor, 3447
CIDEC, familial partial lipodystrophy, 1299
Cidofovir, 3501, 3501*t*
  for human cytomegalovirus, 3006–3007
Cidofovir, topical
  for epidermodysplasia verruciformis, with HIV, 3118
  for molluscum contagiosum, 3090
    with HIV, 3116
Ciguatera toxin, 3359
Cilostazol
  for peripheral arterial disease, 2674*t*, 2675
  for thromboangiitis obliterans, 2681
Cimetidine. *See also* Antihistamines, H_2
  dapsone interactions, 3425, 3425*t*
  dosing regimens, 3458*t*
  for hyperimmunoglobulinemia E syndrome, 2415
  for mastocytosis, 719, 719*t*
  for molluscum contagiosum virus, 3090
Cimex lectularius, 3325*f*, 3331–3332, 3332*f*
Cimicidae, 3325*f*, 3331–3332, 3332*f*
Cinnabar, pseudolymphoma from, 2117
Cinnamic acid, oral photoprotection, 3630
Ciprofloxacin. *See also* Fluoroquinolones
  for African tick bite fever, 3309*t*, 3315
  for chancroid, 3189–3190, 3190*t*
  for erysipeloid, 2847–2848
  for granuloma inguinale, 3205, 3206*t*
  for green nail syndrome, 2795
  for *Klebsiella rhinoscleromatis* rhinoscleroma, 2809
  for Mediterranean spotted fever, 3309*t*, 3315
  for *Nocardia* actinomycetoma, 2889
  for Oroya fever, 2806

for *P. aeruginosa*
folliculitis and hot-foot syndrome, 2796
nail, 1593
otitis externa, 2796
malignant, 2796
perichondritis, 2796
pediatrics, 1762
for *Salmonella* enteric fever, 2808
for skin and soft-tissue infections, dosing, 3410*t*
for verruga peruana, 2806
Circinate balanitis, reactive arthritis with, 983, 983*f*, 1139, 1139*f*–1140*f*
Circumscribed morphea, 1107, 1107*t*
Cisplatin
for extramammary Paget's disease, 1941
for Merkel cell carcinoma, 1931
Raynaud phenomena from, 2616, 3486
Cisplatin with gemcitabine, Raynaud phenomena from, 3486
Citric acid, keratolytic actions, 3618, 3619*t*
CK15, trichodiscoma/fibrofolliculoma, 1822*t*, 1843
c-Kit, 335
c-kit, mastocytosis, 717, 749–750
C-KIT inhibition, for melanoma, 2009
CLA, 147, 180, 2762
immune surveillance, 122, 122*f*
inflammation, acute *vs.* chronic, 125
tissue resident effector T cells, 147
Cladophialophora carrionii, 2966*t*, 2971–2972, 2971*f*–2972*f*
Cladribine, for Langerhans cell histiocytosis, 2029
CLA-E, immune surveillance, 123
Clam digger's itch, 3353–3354, 3353*f*
Clarithromycin. *See also* Macrolides
for African tick bite fever, 3309*t*, 3315
for bacillary angiomatosis, 2806
for erythrasma, 2743
for Mediterranean spotted fever, 3309*t*, 3315
for rosacea, 1439
for skin and soft-tissue infections, dosing, 3410*t*
Classical Ehlers-Danlos syndrome (cEDS). *See also* Ehlers-Danlos syndromes
clinical features, 1212, 1213*t*, 1218–1221, 1219*f*, 1220*f*, 1220*t*
diagnostic criteria, 1214*t*
inheritance and gene defects, 1213*t*
Classical-like Ehlers-Danlos syndrome (clEDS). *See also* Ehlers-Danlos syndromes
clinical features, 1213*t*, 1221
definition, 1221
diagnostic criteria, 1214*t*
inheritance and gene defects, 1213*t*
with propensity for arterial rupture/vascular like cEDS, 1221
Classic discoid lupus erythematosus, 1044–1045, 1044*f*–1046*f*
Class I cytokine receptor family, 169–170
Class II cytokine receptor family ligands, 173–175
IL-10, "antiinflammatory" cytokine, 174
IL-10–related cytokines, novel, 174–175
IL-19, IL-20, IL-22, IL-24, and IL-26, 174–175
interferons, JAK/STAT pathway signaling prototypes, 173–174
Claudin, 65
Claudin 1, 65, 220
mutation, neonatal ichthyosis, 65
Clavi syphilitica, 3150, 3151*f*
Clavulanate, for actinomycosis, 2880
Clazakizumab, for rheumatoid arthritis, 1152
CLC-2, inflammation, 124
CLDN1, neonatal ichthyosis-sclerosing cholangitis syndrome, 780*t*
Cleansers, skin, 3806–3807, 3806*f*
for aging skin, 3813
for sensitive skin, 3810
Clear cell acanthoma, 1804, 1805*f*
ClearLight, for acne vulgaris, 1410
Cleft palate, EEC syndrome, 2381
Clidae, 3325*f*, 3330–3331
Climatic therapy, for psoriasis, 491
Clindamycin
for acne vulgaris, 1405
for actinomycosis, 2880
for bites, human and monkey, 3339
for clostridial gas gangrene, 2780
for group A *Streptococcus*
impetigo and ecthyma, 2739, 2739*t*
lymphangitis, 2739, 2739*t*
recurrent infections, 2739, 2739*t*
for MRSA
impetigo, ecthyma, and folliculitis, 2730, 2731*t*
skin and soft tissue infections, complicated, 2731*t*, 2732
for *Nocardia* actinomycetoma, 2889
for skin and soft-tissue infections, dosing, 3410*t*
for *Staphylococcus*
furuncles, carbuncles, and abscesses, 2731*t*, 2732
impetigo, ecthyma, and folliculitis, 2730, 2731*t*
necrotizing fasciitis, 2775, 2776*t*
for toxoplasmosis, 3249
Clindamycin, systemic, 3414–3415
for acne vulgaris, 1405
for dissecting folliculitis, 1530
dosing regimen, 3410*t*, 3414
indications and contraindications, 3414, 3414*t*, 3415*t*
pharmacology and mechanism of action, 3414
for *S. aureus*, in folliculitis decalvans, 1530
side effects and precautions, 3412*t*, 3415
Clindamycin, topical, 3419, 3420*t*
for acne keloidalis nuchae, 1530
for acne vulgaris, 1402*t*, 1403*t*, 1404
for bacterial vaginosis, 3219*t*
for erythrasma, 2743
for Fox-Fordyce disease, 1477–1478
for hidradenitis suppurativa, 1490
for perioral dermatitis, 1455
for pitted keratolysis, 2741
for rosacea, 1439
for trichobacteriosis, 2744
Clindamycin plus penicillin
for clostridial gas gangrene, 2780
for *Clostridium* necrotizing fasciitis, 2775, 2776*t*
Clinical-Etiologic-Anatomic-Pathophysiologic (CEAP) classification tool, 3877, 3877*t*
Clinically amyopathic dermatomyositis (CADM), 1061–1062, 1062*f*
Clinical trials, 40, 42–43
Clioquinol, 3612*t*, 3613–3614
topical, pediatric toxicity, 1761*t*
Clobetasol
oral, for graft-versus-host disease, 2335
steroid allergen testing, 405, 406*t*
topical
for lichen planopilaris, 547
for sarcoidosis, 580–581
Clobetasol propionate, topical
for actinic dermatitis prevention, 1643
for bullous pemphigoid, 952, 952*t*
for graft-versus-host disease, genital, 2335
for lichen sclerosus, 1121, 1122
for lupus erythematosus, 1055
Clofarabine, for Langerhans cell histiocytosis, 2029
Clofazimine
for erythema dyschromicum perstans, 1385
for leprosy, 2916–2917, 2917*t*
for lupus erythematosus, 1057
for Morbihan disease, 1451
for *N. brasiliensis* actinomycetoma, 2889
for Sweet syndrome, 601*t*, 602
Clomipramine, for hair pulling disorder, 1697*t*, 1700
Clonal dermatitis, 508, 508*f*, 2122
Clonal dynamics, mutation burden and, 317, 318*f*
Clonal seborrheic keratosis, 1802, 1802*f*
Clonidine, for hyperhidrosis, prime focal, 1463
Clopidogrel
for malignant atrophic papulosis, 2634, 2634*t*
for thromboangiitis obliterans, 2681
Closed technique, cryosurgery, 3793
Clostridium
crepitant cellulitis, 2775
gas gangrene, 2779–2780
IV drug use, 1708
Clostridium botulinum, 3922
IV drug use, 1708
Clostridium difficile colitis, microbiome studies, 259–260
Clostridium tetani, IV drug use, 1708
Clothing
occupational skin disease prevention, 452–453
photoprotection, 3630
Clotrimazole, 3438*t*, 3443
for candidiasis, superficial, 3443
for dermatophytosis, superficial, 3443
for seborrheic dermatitis, 435
Clotrimoxazole
for fungal infections, superficial, 2935*t*
for toxoplasmosis, 3249
Clouston syndrome, 832–833, 845*t*, 2377–2378, 2377*f*
CLOVES syndrome
gene mutations and lymphatic malformations, 2640*t*
lipoma, 2173*t*
lymphatic anomalies, 2653–2654, 2653*f*
VEGF-C, 2640*t*
Cloxacillin, for dissecting folliculitis, 1530
Clubbing, cor pulmonale, 1596, 1596*f*
Club drugs, 1711
CMH (C mechano-heat sensitive), 353, 354*f*
C_{MIA} (C-mechanoinsensitive afferences), 353, 354*f*
Cnidaria, 3344–3350, 3345*f*–3347*f*
classes and identification, 3344
corals, 3349–3350, 3349*f*
jellyfish, 3344–3348
nematocysts, 3344, 3345*f*
Portuguese man-of-war, 3344–3346, 3346*f*
sea anemone dermatitis, 3348–3349, 3349*f*
Coagulation factor XIIIa, 117
Coagulation system, 118–119, 119*f*
urticaria and angioedema, 693
Coagulum, after sclerotherapy, 3884, 3884*f*
Coal miners, systemic sclerosis, 1093
Coal tar, 3611
crude, phototoxicity, 1658*t*, 1662
photosensitization, 274
preparations/derivatives
for atopic dermatitis, 378
occupational acne from, 1452–1453
for psoriasis, 489–490
Cobalamin. *See* Vitamin B_{12} (cobalamin)
Cobalt
allergic contact dermatitis from, 403
punctate purpura of cobalt, 406–407

Cobalt chloride, punctate purpura of cobalt, 406–407
Cobb syndrome, 2659. *See also* Arteriovenous malformations (AVMs)
Cobimetinib, 3559*t*, 3585, 3585*f*
Cocaine, 1709–1710, 1710*f*, 3710*t*
Coccal infections, nail changes, 1591–1592, 1592*f*
Coccidioidal granuloma, 2979–2980, 2980*f*
Coccidioides immitis, 2979–2980, 2980*f*
Coccidioides posadasii, 2979–2980, 2980*f*
Coccidioidomycosis, 2979–2980, 2980*f*
Cochlear implant, preoperative examination, 3708
Cockayne syndrome (CS), 2355–2357
  at-a-glance, 2355*b*
  chemical phenotypes, 2342, 2346*f*
  clinical course and prognosis, 2357
  clinical features, 2343*t*, 2355
  diagnosis, 2355–2356, 2356*f*
  differential diagnosis, 2356–2357
  DNA repair defects, 279, 2342
  epidemiology, 2355
  etiology and pathogenesis, 2355
  gene mutations, 2355
  management, 2357
  mechanisms, 2345*t*
Cockayne-Touraine of dominant dystrophic epidermolysis bullosa, 1021, 1021*f*, 1029*t*
Codeine, 1714
Coenurosis, 3252*t*
  exposure and symptom onset interval, 3259, 3260*t*
  progression and duration, 3259, 3260*t*
COFS (cerebro-oculo-facial-skeletal) syndrome, 2342, 2346*f*, 2355
  gene mutations, 2344, 2350
Cognitive behavioral therapy (CBT), for body dysmorphic disorder, 1699
Cohort, 42
Cohort study, 43
COL1A1, Ehlers-Danlos syndrome
  arthrochalasia, 1213*t*
  vascular, 1213*t*
COL1A2, Ehlers-Danlos syndrome
  arthrochalasia, 1213*t*
  cardiac-valvular, 1213*t*
COL3A1, Ehlers-Danlos syndrome
  hypermobility, 1213*t*
  vascular, 1213*t*, 1222–1223
COL5A1, classical Ehlers-Danlos syndrome, 1213*t*, 1222
COL5A2, classical Ehlers-Danlos syndrome, 1213*t*, 1222
COL7A1, 292, 314
  dystrophic epidermolysis bullosa, 246, 1015*t*, 1023–1024
  gene inhibition therapy, 307
  squamous cell carcinoma, 1903
COL12A1, myopathic Ehlers-Danlos syndrome, 1213*t*, 1218*t*
COL14A1, punctate palmoplantar keratoderma type I, 844
COL17. *See* BP180
COL17A1
  junctional epidermolysis bullosa
    generalized intermediate, 1015*t*
    localized, 1015*t*, 1020
  revertant mosaicism, 303
Colchicine
  for adamantiades–Behçet disease, 2575, 2575*t*
  for α-antitrypsin panniculitis, 1269
  for Behçet-related erythema nodosum, 1259
  for cryofibrinogenemia, 2609
  for cryoglobulinemia II and III, non-HCV, 2607
  for epidermolysis bullosa acquisita, 978, 979*t*
  for familial Mediterranean fever, 633
  for gout, 2315
  for gouty panniculitis, 1283*b*
  for haploinsufficiency of A20, 638
  for palisaded neutrophilic and granulomatous dermatitis, 1148
  for pigmented purpuric dermatoses, 2596
  for relapsing polychondritis, 1190
  for Sweet syndrome, 601*t*, 602
Cold cholinergic urticaria, 690
Cold contact urticaria, 689, 697
Cold-dependent dermographism, 689
Cold erythema, 1675
Cold injuries, 1666–1676
  acrocyanosis, 1672–1673, 1672*f*
  at-a-glance, 1666*b*
  classification, 1667, 1667*t*
  cold panniculitis, 1675–1676
  cold urticaria, 1674–1675, 1675*f*
  cooled skin, reticulate, 1667, 1667*f*
  dampness and, nonfreezing, 1672, 1672*f*
  frostbite, 1667–1670, 1668*f*–1669*f*, 1669*t*
  frostnip, 1668, 1668*f*
  iatrogenic, 1670, 1670*f*
  pernio, 1673–1674, 1674*f*
  physiologic response, 1666–1667, 1667*f*
  polymorphous cold eruption, 1675
  prevalence, 1666
  prolonged exposure, Raynaud phenomena, 2616
  self-inflicted, 1670–1671, 1671*f*
  thermoregulation, 1666
  winter xerosis, 1672, 1672*f*
Cold panniculitis, 1254*t*, 1280–1282, 1282*t*, 1675–1676
Cold urticaria, 689, 1674–1675, 1675*f*. *See also* Urticaria
  diagnostic tests, 688*t*
  pathogenesis, autoimmune mechanism, 691*f*, 692
  underlying disorders, 693
Cole disease, 846*t*, 847
Coleman peel, 3900
Coleoptera, 3331
Colistin, for *P. aeruginosa* bacteremia and ecthyma gangrenosum, 2796
Collagen
  denaturation and contraction, skin tightening, 3858, 3859*f*
  dermal cell-matrix adhesion, 247
  phototherapy on, 3638
Collagen IV, 240, 241*f*
Collagen-vascular disease, paraneoplastic, 2442*t*. *See also specific types*
  dermatomyositis, 2442*t*, 2453
  progressive systemic sclerosis, 2442*t*, 2453
Collagen VII, anchoring fibrils, 1013
Collagen XVII. *See* BP180
Collagen XVIII, 241, 247
Collagen XVII mutation, epidermolysis bullosa, 243, 244*t*
Collision lesions, 1802
Collodion, 3375
Collodion, flexible, 3375
Collodion baby, 786–787, 786*f*, 787*t*, 1739–1740
  ALOX3E, 787
  ALOX12B, 787
  TGM1, 787
Collodion ichthyosis, self-improving, 781*t*
Collodion membrane diseases, 787*t*
Color, 7–9, 8*t*
  black, 8*t*
  blue-gray, 8*t*
  brown, 7, 8*t*
  green, 8*t*
  orange, 8*t*
  pink or salmon, 8*t*
  plum, 8*t*
  red, 7–9, 8*t*, 9*f*
  red-brown, 8*t*
  violet to lilac, 8*t*
  white, 8*t*
  yellow, 8*t*
Color film developers, lichenoid contact dermatitis, 538
Columella, 3698, 3698*f*
Combined antibody and T-cell deficiency, 2402–2409
  ataxia-telangiectasia, 2407–2409, 2407*f*–2408*f*
  ectodermal dysplasia with immunodeficiency, 2406–2407, 2407*f*
  hyperimmunoglobulin M syndrome, 2402*b*
  severe combined immunodeficiency, 2404–2406, 2405*t*
  Wiskott-Aldrich syndrome, 2402–2404, 2403*f*
Combined nevus, 1955
Commensals, 2719
  infection (*See* Superficial cutaneous infections and pyodermas; *specific types*)
Common acquired melanocytic nevi, 1951–1957. *See also* Melanocytic nevi, common acquired
Common carpet beetle, 3331
Common variable immunodeficiency (CVID), 2396–2398, 2398*f*
Community-acquired methicillin-resistant *Staphylococcus aureus* (CA-MRSA)
  abscesses, 2725
  epidemiology, skin and soft tissue infections, 2720–2721
  management, 2731*t*, 2732
Companion layer (hair follicle), 93*f*, 94, 94*t*
Comparative biology, 207*t*
  skin barrier, 207, 208*t*, 209*f*
Comparative effectiveness, 42
Comparative efficacy studies, 43
Complement deficiency disorders, genetic, 2419–2420
  at-a-glance, 2419*b*
  clinical manifestations, 2420*t*
  cutaneous necrotizing venulitis, 2530*t*, 2533
  hereditary angioedema, 2419–2420, 2420*t*
Complement receptors, eosinophil expression, 655
Complete lymph node dissection (CLND), for melanoma, 1995, 2000–2001
Composite grafts, 3756–3757
Composite hemangioendothelioma, 2064
Compound heterozygote, 296
Compounding medications, 3621
Compression therapy
  hosiery, for Fabry disease, 2302
  for lipodermatosclerosis, 1264
  postsclerotherapy, 3882–3883, 3883*f*
  for venomous snakebites, 3342–3343
Concha, 3698, 3698*f*
Conchal bowl grafts, 3753, 3754*f*
Condyloma acuminatum
  imiquimod for, 3595
  pathology, 31, 31*f*
Condyloma lata, 3152, 3152*f*. *See also* Syphilis
Cones, standing, revision of, 3731, 3732*f*
Cone-sized chamber, cryosurgery, 3793
Cone snail envenomations, 3355
Confidentiality, adolescents, 1757
Configuration, 9–12. *See also* Shape and configuration
Confounding, 41
Congenital adrenal hyperplasia (CAH)
  acne with, 1451–1452
  androgen excess, 2516–2517
  hirsutism, 1556*t*, 1559

Congenital auricular fistula, 1817
Congenital dyserythropoietic anemia (CDA), Majeed syndrome, 643–644
Congenital eccrine angiomatous hamartoma, 2059*b*, 2065
Congenital erythropoietic porphyria (CEP), 2235*t*, 2237t, 2243–2244, 2244*f*
Congenital generalized hypertrichosis, 1564
Congenital generalized lipodystrophy (CGL), 1295, 1296–1297, 1297*f*, 1298*t*
Congenital hemangiomas, 2043*t*, 2059–2060, 2059*b*, 2060*f*–2061*f*
Congenital hypertrichosis lanuginosa (CHL), 1563–1564
Congenital ichthyosiform erythroderma (CIE)
  cellular defect, 781*t*
  clinical course, prognosis, and management, 794
  clinical features, 788–789, 790*f*
  etiology and pathogenesis, 790*f*, 791*f*, 793
    ABAC12, 791*f*
    ALOX12B, 790*f*, 793
    ALOXE3, 790*f*, 793
    TGM1, 788*f*–789*f*, 792
Congenital ichthyosis, 1745
Congenital insensitivity to pain with anhidrosis (CIPA), 1466
Congenital leukemia, 1744
Congenital malalignment of big toenail, 1592*f*, 1602
  surgery for, 3789–3790, 3789*f*
Congenital melanocytic nevi (CMN), 1733, 1944–1949
  at-a-glance, 1944*b*
  clinical course and prognosis, 1948
  clinical features, 1944–1946, 1945*f*
    complications, 1945–1946
    cutaneous, 1945
    related physical conditions, 1945
  diagnosis, 1947–1948
    imaging, 1948
    pathology, 1947–1948, 1947*f*
  differential diagnosis, 1948, 1948*t*
  epidemiology, 1944
  etiology and pathogenesis, 1946–1947, 1946*f*
  prevention and counseling, 1949
  risk factors, 1946, 1946*f*
  treatment, 1948
Congenital midline hamartoma, 2131*t*–2132*t*, 2145–2146
Congenital muscular dystrophy, laminin mutations, 241
Congenital onychodysplasia of index finger (COIF), 1568
Congenital onychodysplasia of Iso-Kikucho (COIF), 1568
Congenital reticulated ichthyosiform erythroderma, 781*t*, 798–799, 799*f*
Congenital rubella syndrome, 2992, 2993
Congenital smooth muscle hamartoma (CSMH), 1743–1744
Conidiobolomycosis, 2967*t*, 2973
Conidiobolus coronatus, 2973
Conjunctival lichen planus, 535
Conjunctivitis, erythema multiforme, 726, 727*f*
Connective tissue disease–associated panniculitis, 1283*b*
Connective tissue diseases
  autoimmune
    cardiovascular and cutaneous manifestations, 2427
    pulmonary and cutaneous manifestations, 2430
  cutaneous necrotizing venulitis with, 2529
  dystrophic calcification, 2308–2309, 2309*f*
  genetic disorders, 1212–1247 (*See also specific disorders*)
    Buschke-Ollendorff syndrome, 1241–1242
    cutis laxa, 1233–1241
    Ehlers-Danlos syndromes, 1212–1225
    lipoid proteinosis, 1242–1247
    Marfan syndrome, 1225–1229
    pseudoxanthoma elasticum, 1229–1233
  inherited, cardiovascular and cutaneous manifestations, 2425–2427
  Raynaud phenomena, 2614, 2615
Connexin-associated palmoplantar keratodermas, 829–832
Connexin disorders, 800–802
  cellular defects
    erythrokeratodermia variabilis et progressiva, 781*t*
    keratitis-ichthyosis deafness syndrome, 781*t*
  clinical course, prognosis, and management
    erythrokeratodermia variabilis et progressiva, 802
    keratitis-ichthyosis-deafness syndrome, 802
  clinical features, 800, 801*f*, 807*f*
    erythrokeratodermia variabilis et progressiva, 800, 801*f*
    keratitis-ichthyosis deafness syndrome, 800–801, 802*f*, 845*t*
  erythrokeratodermia variabilis et progressiva, 777*t*
  etiology and pathogenesis, 801–802
    erythrokeratodermia variabilis et progressiva, 801
    keratitis-ichthyosis-deafness syndrome, 801–802
  genes, 800
Conradi-Hünermann-Happle syndrome, 778*t*, 805–806, 1200
  cellular defect, 781*t*
  EBP, 778*t*, 806
Conradi-Hünerman syndrome
  X-linked dominant disorder, 296–297, 296*t*
  X-linked dominant inheritance, 296–297
CONSORT, 43, 44
Contact dermatitis. *See also specific types*
  lichenoid, 538
  methylisothalizoline, 1756*f*
  postoperative, 3720–3721, 3721*f*
  systemic, 402, 402*t*, 403*t*
  toxic, nail changes, 1582–1583
Contact urticaria (CU), 444–446, 690. *See also* Urticaria
  clinical features, 685, 686*f*
  diagnosis, 698
    algorithm, 451*f*
    tests, 688*t*
  diagnostic tests, 688*t*
  immunologic, 445–446, 445*t*
    from topical therapy, 3378
  nonimmunologic, 445, 445*t*
  radioallergosorbent testing, 450–451
  skin prick testing, 450
  of uncertain mechanism, 446
Contour resection, for capillary malformations, 2644
Contrast media, urticaria from, 695
Conus geographicus, 3355, 3355*f*
Conus magus, 3355, 3355*f*
Cooks syndrome, 1568
Cooling, skin, laser and light-based treatments, 3830–3831, 3830*t*, 3848
Copper, 2221
  Menkes disease and, 2221–2222, 2221*b*, 2222*t*
Copperhead snake, 3342, 3342*f*
Coproporphyrin III, for acne vulgaris, 1410
Corals, 3349–3350, 3349*f*
  cuts from, 3350
Coral snakes, 3342–3344, 3343*t*
Cornelia de Lange syndrome, hypertrichosis, 1564
Corneocyte, 107, 107*f*, 209, 211*f*, 212*f*
  3D shape, 213*f*, 220, 221*f*
  lipid envelope formation, 208*t*, 211, 214*f*
Corneodesmosin, 238
  congenital defects, 208*t*, 215
Corneodesmosomes, 208*t*, 209, 210*f*, 212*f*, 213–214
Cornification diseases. *See* Ichthyoses; *specific types*
Cornified cell envelope formation, 208*t*, 211, 214*f*
Cornu cutaneum, 1859, 1860*f*
Corona veneris, 3150
Cor pulmonale, clubbing, 1596, 1596*f*
Corrugator supercilii muscles, 3703, 3704*f*
Cortex, hair follicle, 93*f*, 94, 94*t*
Corticosteroids. *See also* Glucocorticoids; *specific types*
  antiangiogenic, 3593
  cellular effects, 3382–3383
  for connective tissue disease–associated panniculitis, 1283*b*
  for cryoglobulinemia II and III, HCV, 2607
  for drug eruptions with HIV, 3111
  for hemophagocytic lymphohistiocytosis, 2032
  for hypereosinophilic syndromes, 663
  for lichen planus, 544
  for psoriasis, with HIV, 3122
  for Schnitzler syndrome, 627
  for Still disease, adult-onset, 1158
Corticosteroids, intraarticular
  for central centrifugal cicatricial alopecia, 1528
  for gout, 2315
  for juvenile idiopathic arthritis, 1155
  for reactive arthritis, 1142
  for SAPHO syndrome, 645
Corticosteroids, intralesional
  for acne necrotica, 1531
  for acne vulgaris, 1409
  for adamantiades–Behçet disease, genital ulcers and skin lesions, 2574–2575, 2574*t*
  for alopecia areata, 1520
  for burn scars, 1690
  for cutaneous macular and papular amyloidosis, 2270
  for extranodal marginal zone lymphoma, 2100
  for frontal fibrosing alopecia, 547
  for granuloma annulare, 569, 569*t*
  for infantile hemangiomas, 2058
  for keratosis follicularis spinulosa decalvans, 1529
  for lichen planopilaris, 547
  for lichen planus
    cutaneous, 544
    oral, 545
  for lichen simplex chronicus, 391
  for lichen striatus, 561
  for nail lichen planus, 547
  for palisaded neutrophilic and granulomatous dermatitis, 1148
  for pigmented purpuric dermatoses, 2595–2596
  for prurigo nodularis, 391
  for Rosai-Dorfman disease, 2031
Corticosteroids, systemic (oral/IV)
  for adamantiades–Behçet disease, genital ulcers and skin lesions, 2575, 2576*t*
  for alopecia areata, 1521
  for alopecia mucinosa, 1529
  atrophy from, 21, 3390
  for Blau syndrome/early-onset sarcoidosis, 641
  for cellulitis and erysipelas, 2754
  for chemotherapy extravasation, 3486

Corticosteroids, systemic (oral/IV) (*Cont.*):
for chronic atypical neutrophilic dermatosis with lipodystrophy and elevated temperature syndrome/proteasome-associated autoinflammatory syndrome, 640
for cytophagic histiocytic panniculitis, 1278
for dermatomyositis, 1077
for epidermal necrolysis, 744
for erythema annulare centrifugum, 767
for erythema elevatum diutinum, 2566
for erythema multiforme, 730
for erythema nodosum leprosum, 2917
for gout, 2315
for graft-versus-host disease
acute, 2332
chronic, 2334
for Hailey-Hailey disease, 890
for infantile hemangiomas, 2057–2058
for infectious mononucleosis, Epstein-Barr virus, 3002, 3002*t*
for intercellular IgA dermatosis, 989
for kaposiform hemangioendothelioma, 2063
for leprosy, 2917
for lichen nitidus, 558, 558*t*
for lichen planopilaris, 546–547
for lichen planus, 545–546
for lichen planus pigmentosus, 1386
for lupus panniculitis, 1275
lymphocyte-rich infiltrate from, simulating lymphoma, 2115*f*
for macrophage activation syndrome, 1155
for morphea, 1114*f*, 1115–1116, 1115*t*
for multicentric reticulohistiocytosis, 2038
for nummular eczema, 388
for otulipenia/OTULIN-related autoinflammatory syndrome, 638
for palisaded neutrophilic and granulomatous dermatitis, 1148
for paraneoplastic pemphigus, 941*t*, 942
for pemphigus, 922–923
perioral dermatitis from, 1754, 1754*f*
for phototoxicity, 1662
preoperative examination, 3709
for pyogenic arthritis, pyoderma gangrenosum, and acne syndrome, 643
for reactive arthritis, 1142
for reactive phagocytic syndrome, in adult-onset Still disease, 1158
for relapsing polychondritis, 1190
for SAPHO syndrome, 645
for seborrheic dermatitis with HIV, 3122
for subcorneal pustular dermatosis, 619, 619*t*
for subcutaneous panniculitis-like T-cell lymphoma, 2086
for Sweet syndrome, 601, 601*t*, 2457
for systemic sclerosis, pulmonary fibrosis, 1101
for systemic sclerosis, skin hardening, 1100*t*, 1101
for tufted angioma, 2062
for urticaria, 702
Corticosteroids, topical
for acne necrotica, 1531
for actinic dermatitis prevention, 1643
for actinic prurigo, 1632, 1632*f*
for adamantiades–Behçet disease, genital ulcers and skin lesions, 2574, 2574*t*
for allergic contact dermatitis, 409
allergic contact dermatitis from, 405, 406*t*
for alopecia areata, 1520
for atopic dermatitis, 377
for atopic eruption of pregnancy, 1777
atrophy from, 21, 3390
for bullous pemphigoid, 952, 952*t*
for central centrifugal cicatricial alopecia, 1528
for chemotherapy extravasation, 3486
for cicatricial alopecia
discoid lupus erythematosus, 1527
lichen planopilaris, 1527
for cutaneous macular and papular amyloidosis, 2270
for cutaneous T-cell lymphomas, 2092–2093
for Darier disease, 884, 884*t*
for dermatomyositis, 1077
for eosinophilic folliculitis with HIV, 3123
for epidermolysis bullosa, 1028
for erosive pustular dermatosis, 1531
for erythema annulare centrifugum, 767, 773*t*
for erythema gyratum repens, 772, 773*t*, 2454
for extranodal marginal zone lymphoma, 2100
for Fox-Fordyce disease, 1477
for graft-versus-host disease
chronic, 2333
oral, 2335
for granuloma annulare, 569, 569*t*
for granuloma faciale, 675, 675*t*
for Hailey-Hailey disease, 889
hypothalamic–pituitary–adrenal axis suppression from, 3378
for incontinentia pigmenti, 1352
for inflammatory linear verrucous epidermal nevus, 1809
for irritant dermatitis, 424
for keratosis follicularis spinulosa decalvans, 1529
for keratosis pilaris, 869
for keratosis pilaris atrophicans, 872
for Langerhans cell histiocytosis, 2028
for lichen nitidus, 558, 558*t*
for lichen planopilaris, 546
for lichen planus
cutaneous, 543
oral, 545
for lichen planus pigmentosus, 1386
for lichen sclerosus, 1121, 1122
for lichen simplex chronicus, 391
for lichen striatus, 560–561
for linear and whorled nevoid hypermelanosis, 1352
for lupus panniculitis, 1275
lymphocyte-rich infiltrate from, simulating lymphoma, 2115*f*
for melasma, 2242
for mucous membrane pemphigoid, 966, 966*t*
for mycosis fungoides, 2090
for nail lichen planus, 547
for necrobiosis lipoidica, 2501
for nevus comedonicus, 1811
for nummular eczema, 388
for papular pruritic eruption with HIV, 3123
for papuloerythroderma of Ofuji, 672
for parapsoriasis, 510
for pemphigoid gestationis, 1767
for pemphigus, 922–923
for perioral dermatitis, 1455
for phototoxicity, 1662
for pigmented purpuric dermatoses, 2595
for pityriasis lichenoides, 515, 515*t*
for pityriasis rubra pilaris, 503
for polymorphic eruption of pregnancy, 1775
for prurigo nodularis, 391
for psoriasis, 482t, 488, 489*f*
for reactive arthritis, 1142
for sarcoidosis, 580–581
for seborrheic dermatitis, 434
with HIV, 3122–3123
for systemic sclerosis, skin hardening, 1100*t*, 1101
for tufted angioma, 2062
for vitiligo, 1340
Cortisol
mechanism of action, 3382
naturally occurring, 3382 (*See also* Glucocorticoids)
Corynebacterium
atopic dermatitis, 197
bromhidrosis, 1469
microbiome, skin, 256, 257*t*
pitted keratolysis, 449, 2741
trichobacteriosis, 2743–2744, 2743*f*
Corynebacterium diphtheriae, 2829*t*, 2851–2853
Corynebacterium minutissimum, erythrasma, 2741–2743, 2742*f*
Corynebacterium pseudotuberculosis, 2853
Corynebacterium ulcerans, 2853
Cosmeceuticals and skin care, 3803–3817. *See also specific topics*
aging, skin, 3812–3814
at-a-glance, 3803*b*
healthiest skin type, 3815
hydration, skin, 3804–3808
identifying facial skin issues, 3803
most efficacious products, identifying, 3815–3817, 3816*t*
compliance, encouraging, 3817
ingredient choice, 3816
patient education, 3816–3817
product choice, 3816
regimen and order of application, 3816, 3816*t*
phenotype diagnosis, 3814–3815, 3815*f*
pigmentation, skin, 3811–3812
sensitivity, skin, 3808–3811
skin-care advice, 3803
Cosmetic units, 3698, 3698*f*
Costello syndrome, cutis laxa, 1237*t*
Cotrimoxazole. *See* Trimethoprim-sulfamethoxazole (TMP-SMX)
Coumarin, on vitamin K, 2211
Cowden disease, 2444*t*
Cowden syndrome
appendage tumors, 1820, 1822*t*
lipoma, 2173*t*
trichilemmoma, 1822*t*, 1845
Cowhage, pruritus, 356
Cowpox virus, 3065, 3066*t*
Coxiella, infective endocarditis, 2817
Coxsackie A6–associated atypical hand-foot-mouth disease (HFMD), 3012–3013, 3012*f*–3013*f*, 3013*t*, 3015*t*
Coxsackie virus, atopic dermatitis, 367
CPOX, hereditary coproporphyria, 2235*t*, 2250
Crab lice, 3281*t*, 3283–3284, 3283*f*–3284*f*, 3284*t*
Cradle cap, 428, 429*f*
Crandall syndrome, pili torti, 1541*t*
Craniofacial necrotizing fasciitis, 2772
Crank, 1711
Craquelé scale, 6*t*
Crash diet, telogen effluvium from, 1509, 1509*f*
CRBN, thalidomide binding, 3601
Creams, 3373*t*, 3374
CREBBP, 314
Crepitus, after cryosurgery, 3793
Crescendo allergic pattern, 407
Crescendo phenomenon, 441
Crescentic advancement flap, 3738, 3739*f*
CREST syndrome, dystrophic calcification, 2308–2309, 2309*f*
Cribriform basaloid lobules, trichoepithelioma, 33, 33*f*
Crisaborole, 3611
for atopic dermatitis, 378
CRISPR/Cas9 (clustered regularly interspaced short palindromic repeats), 307
Critical ischemia, Raynaud phenomena management, 2624–2625
Crohn disease

hidradenitis suppurativa, 1484
linear IgA dermatosis, 997
Cromolyn sodium, for mastocytosis, 718*t*, 719
Cronkhite-Canada syndrome (CCS), 1382–1383, 2434*t*, 2436
Crosshatching, 3911, 3913*f*
Cross-presentation, 135, 138
dendritic cells, 152
Langerhans cells, 152–153
Cross-sectional studies, 44
Crotalidae polyvalent immune FAB (FabAV), 3343–3344
Crotaline snake bites, 3342–3344, 3343*t*
Crotamiton, 3614, 3615*t*
Crown of Venus, 3150
Crow's feet, botulinum toxin for, 3926–3927
CRTC1
hidradenocarcinoma, 1828
hidradenoma, 1823
Crus of antihelix, 3698–3699, 3698*f*
Crust, 5*f*, 6, 7*f*
Cryobiology, 3791
Cryodestruction, liquid nitrogen, 1670, 1670*f*
Cryofibrinogenemia, 2607–2609, 2608*t*
Cryofibrinogens, 2599, 2608
in cold urticaria, 693
Cryofiltration, for cryoglobulinemia type I, 2606
Cryogens, 3791, 3792*t*
Cryoglobulin(s), 2599, 2600*f*
cold urticaria, 693
cutaneous necrotizing venulitis, 2529
type I, 2599, 2601*t*
type II, 2599–2600, 2601*t*
type II-III, 2600, 2601*t*
type III, 2599–2600, 2601*t*
vasculitis, 2548–2549
Cryoglobulinemia, 2599–2607
at-a-glance, 2599*b*
classification, 2599–2600, 2601*t*
clinical course and prognosis, 2604–2605
clinical features
cutaneous, 2600–2601, 2601*f*–2602*f*
noncutaneous
Meltzer triad, 2602
musculoskeletal, 2602
neurologic, 2602
pulmonary, 2602–2603
renal, 2602
complications, 2605–2606
definitions, 2599, 2600*f*
diagnosis, 2603–2604, 2604*t*
differential diagnosis, 2604, 2605*t*
epidemiology, 2600
etiology and pathogenesis, 2603
historical perspective, 2599
management
type I, 2606
type II and III, HCV-associated, 2606
type II and III, non-HCV, 2607
Sjögren syndrome and, 2603
Cryoglobulinemic vasculitis, 2541
Cryolipolysis, fat reduction, 3862–3863, 3864*f*–3865*f*
Cryopeeling, for actinic keratosis, 1866
Cryopreserved placental membrane, 2711, 2711*t*
Cryoproteins, in cold urticaria, 693
Cryopyrin-associated periodic syndromes (CAPS), 621–625, 689
at-a-glance, 621*b*
clinical characteristics, 623, 623*t*
clinical course and prognosis, 625
clinical features, 623–624, 624*f*
diagnosis, 624–625, 624*f*, 699
differential diagnosis, 625
epidemiology, 623
etiology and pathogenesis, 623
management, 625
NLRP3 (CIASI), 622*t*, 623, 689, 699
pathology, 700
Cryosurgery, 3791–3795
for actinic keratosis, 1864, 1864*t*
for basal cell carcinoma, 1889
for benign lesions
dermatofibroma, 3794
keloids and hypertrophic scars, 3794
sebaceous hyperplasia, 3794
seborrheic keratosis, 3794
solar lentigo, 3792*t*, 3794
verrucae, 3794, 3794*f*
cryogens, 3791, 3792*t*
for granuloma faciale, 675, 675*t*
historical perspective, 3791
mechanisms, 3791
perioperative considerations, 3792–3793
anatomical site precautions, 3792
anesthesia, 3793
care, 3793
contraindications, 3792, 3792*t*
patient selection, 3792
risks and complications, 3792–3793
for premalignant and malignant lesions
actinic keratosis, 3795
basal cell carcinoma, 3795
Bowen disease, 3795
Kaposi sarcoma, 3795
lentigo maligna, 3795
squamous cell carcinoma, 3795
techniques
closed, 3793
dipstick, 3794
metal, cone-sized chamber, 3793
open spray method, 3793, 3793*f*
tissue forceps technique, 3794
tissue targets and cell death temperatures, 3791, 3792*t*
Cryotherapy
for angiolymphoid hyperplasia with eosinophilia, 669
for hidradenitis suppurativa, 1491
for HPV warts, nail, 1591
for oral hairy leukoplakia, with HIV, 3114
for prurigo nodularis, 392
for pyogenic granula, 2064
for scars, hypertrophic, 1690
for seborrheic keratosis, 1802
thermal radiation and hypermelanosis from, 1365
for warts, 3100
Cryptic leishmaniasis, 3234
Cryptococcosis, 2982–2984, 2983*f*
Cryptococcus gattii, 2982–2984, 2983*f*
with HIV, 3114–3115, 3115*f*
Cryptococcus neoformans, 2982–2984, 2983*f*
with HIV, 3114–3115, 3115*f*
Cryptosporidiosis, 3244–3245
Cryptosporidium, 3244–3245
Cryptosporidium hominis, 3244
Cryptosporidium parvum, 3244
Crystal, 1711
CSA (ERCC8), Cockayne syndrome, 2355
CSB (ERCC6), Cockayne syndrome, 2355
CSCL8
eosinophils, 655
psoriasis, 470*f*
CSCL9, psoriasis, 470*f*
CSCL10, psoriasis, 470*f*
CSTA, peeling skin syndromes, 803
CTACK, immune surveillance, 122–123
CTACK/CCL27, 181
CTCF, eosinophils, 2075
Ctenocephalides felis, 3310*t*, 3318
CTLA-4, systemic sclerosis, 1093
CTNNB1, pilomatricoma, 1844
CTSC, Papillon-Lefèvre syndrome, 835
Cubomedusae, 3346–3347, 3347*f*
Cullen sign, 2434
Cumulative irritant contact dermatitis, 443, 444*f*
Cunninghamella bertholletiae, 2984, 2985*f*
Cupid's bow, 3698*f*, 3699
Curcumin (diferuloylmethane)
antiangiogenesis, 3604*t*
for systemic amyloids, 2269
Curettage and electrodessication (C&D)
of basal cell carcinoma, 1889, 3799–3800, 3799*f*–3800*f*
outcome assessments, 3800
of malignant tumors, 3799–3800, 3799*f*–3800*f*
outcome assessments, 3800
of squamous cell carcinoma, 3799–3800, 3799*f*–3800*f*
outcome assessments, 3800
Curling ulcer, burns, 1681
Curth-Macklin ichthyosis, 65*t*
Curved ellipse, 3731
Cushing disease, 2513
Cushing syndrome, 2512–2513
clinical features, 2512–2513
hirsutism, 1556*t*, 1559, 2512
hypermelanosis, 1362, 2513
hypertrichosis, 2512
diagnosis and laboratory tests, 2513
epidemiology, etiology, and pathogenesis, 2513
management, 2513
Cutaneous amyloidosis, 1383
Cutaneous anaplastic large cell lymphoma, 2085–2086, 2086*f*
Cutaneous B-cell lymphomas, radiotherapy for, 3693*t*, 3694–3695
Cutaneous B-cell pseudolymphoma, 2110–2111, 2111*t*
Cutaneous CD4+ small/medium T-cell lymphoproliferative disorder, 2114, 2114*f*
Cutaneous epithelial neoplasms, eosinophils, 659
Cutaneous ganglioneuroma, 2167
Cutaneous granulomas, 2395*t*
Cutaneous horn, 6*t*, 1859, 1860*f*
Cutaneous inflammatory pseudotumor, 2124
Cutaneous larva migrans (CLM), 3251
clinical features, serpiginous, 10
migratory skin lesions, 3255–3256, 3255*t*, 3256*f*
papular and macular lesions, 3257, 3258*t*
syndrome, 3264–3266, 3265*t*, 3266*f*
Cutaneous leukocytoclastic angiitis, 2552–2553. *See also* Vasculitis
Cutaneous lupus erythematosus (CLE), 1038, 1038*t*. *See also* Lupus erythematosus (LE)
Cutaneous Lupus Erythematosus Disease Area and Severity Index (CLASI), 1053
Cutaneous lymphocyte antigen (CLA). *See* CLA
Cutaneous lymphoid hyperplasia, nodular lymphocytic infiltrates, 27
Cutaneous lymphoma, 2072–2102
classification, 2072, 2073*f*, 2073*t*
epidemiology, 2072
with HIV, 3121
precursor neoplasms, blastic plasmacytoid dendritic cell neoplasm, 2102, 2102*f*
Cutaneous lymphoma, primary cutaneous B-cell lymphomas, 2097–2102, 2097*t*
etiology, 2097
extranodal marginal zone lymphoma, 2097, 2097*t*, 2099–2100, 2099*t*
intravascular cutaneous B-cell lymphoma, 2101
pathogenesis, 2098
primary cutaneous diffuse large B-cell lymphoma
leg type, 2080–2101, 2097*t*, 2099*t*, 2100*f*
other, 2101

Cutaneous lymphoma, primary cutaneous B-cell lymphomas (*Cont.*):
primary cutaneous follicular center lymphoma, 2097, 2097*t*, 2098–2099, 2098*f*, 2099*t*
primary cutaneous marginal zone lymphoma, 2097, 2097*t*, 2099–2100, 2099*t*
staging, 2101
treatment principles, 2099*t*, 2101–2102
Cutaneous lymphoma, primary cutaneous T-cell lymphomas, 2072–2097
endogenous factors, 2073, 2073*f*
etiology, 2073
exogenous factors, 2074
fundamentals, 2072
mycosis fungoides, 2077–2081
definition, 2077
differential diagnosis, 2079, 2081*t*
histopathology, 2079, 2080*f*–2081*f*, 2081*t*
treatment and prognosis, 2079–2081
mycosis fungoides, clinical findings
hypopigmented mycosis fungoides, 2079, 2079*t*
other symptoms, 2078
skin signs, 2077–2078, 2077*f*–2079*f*
mycosis fungoides variants, 2081–2083, 2082*t*
folliculotropic mycosis fungoides, 2081–2082, 2082*f*, 2082*t*
granulomatous slack skin, 2082*t*, 2083, 2083*f*
pagetoid reticulosis, 2082, 2082*t*, 2083*f*
pathogenesis, 2074–2076, 2076*f*
primary cutaneous CD30+ lymphoproliferative disorders, 2084–2087
cutaneous anaplastic large cell lymphoma, 2085–2086, 2086*f*
extranodal natural killer/T-cell lymphoma, nasal type, 2087, 2087*f*
lymphomatoid papulosis, 2084–2085, 2084*f*–2085*f*
subcutaneous panniculitis-like T-cell lymphoma, 2086
provisional entities of cutaneous T-cell lymphoma, 2087–2089
cutaneous γδ T-cell lymphoma, 2088
definition, 2087
primary cutaneous acral CD8+ T-cell lymphoproliferation, 2088–2089
primary cutaneous aggressive epidermotropic CD8+ cytotoxic T-cell lymphoma, 2088
primary cutaneous CD4+ small and medium T-cell lymphoproliferative disorder, 2087–2088
Sézary syndrome, 2083–2084
clinical findings, 2073, 2082*t*
definition, 2073
laboratory findings, 2073
treatment and prognosis, 2073, 2082*t*
staging, 2081*t*, 2089, 2089*t*
treatment principles, 2089–2097
algorithms, 2091*t*–2092*t*
allogeneic stem cell transplantation, 2096–2097
chemotherapy, single-agent
gemcitabine, 2096
pegylated liposomal doxorubicin, 2096
pralatrexate, 2096
electron beam therapy, local and total skin, 2090–2092
erythroderma, 2093, 2093*t*
fundamentals, 2089–2090, 2090*t*
imiquimod and resiquimod, 2090
interferon-α therapy, 2092, 2093*t*, 2094, 3539–3540
maintenance and topical steroids, 2092–2093
monoclonal antibodies, targeted, 2094–2096
alemtuzumab, 2093*t*, 2094–2095
brentuximab vedotin, 2093*t*, 2095, 3546, 3547*f*, 3551*t*
mogamulizumab, 2095–2096
multidisciplinary team, 2090
mycosis fungoides, 2090
photochemotherapy, extracorporeal, 2092, 2093*t*, 2094
prognostic factors, 2090
retinoid therapy, 2093–2094, 2093*t*
staging system, international TNM, 2089, 2090*t*
surrogate markers, 2090
Cutaneous mastocytosis (CM), 711, 711*t*. *See also* Mastocytosis
neonatal, 1744
PUVA for, 3672
Cutaneous meningioma, 2166–2167, 2167*f*
Cutaneous metastases, 2460–2462, 2461*f*. *See also specific cancers*
Cutaneous myiasis, fly larva, 3331, 3331*f*
Cutaneous necrotizing venulitis (CNV), 2527–2537
associated chronic disorders, 2529
at-a-glance, 2527*b*
classification, 2527, 2528*t*
clinical features, 2528–2529, 2528*f*
diagnosis
histopathology, 2535–2536, 2536*f*
laboratory testing, 2535, 2535*t*
differential diagnosis, 2536*t*
epidemiology, 2528
etiology and pathogenesis, 2533–2535
historical perspective, 2527
idiopathic disorders, 2530–2533, 2530*t*
acute hemorrhagic edema of infancy, 2530*t*, 2531
eosinophilic vasculitis, 2530*t*, 2533
erythema elevatum diutinum, 2530*t*, 2531
genetic complement deficiencies, 2530*t*, 2533
idiopathic, 2533
immunoglobulin A vasculitis, 2530–2531, 2530*t*
livedoid vasculopathy, 2530*t*, 2532–2533, 2532*f*
nodular vasculitis, 2530*t*, 2532, 2532*f*
Sneddon syndrome, 2530*t*, 2533
urticarial venulitis, 2530*t*, 2531, 2531*f*
infections and drugs, precipitating, 2529–2530, 2530*t*
management, 2536–2537, 2537*t*
Cutaneous paraneoplastic disorders/syndromes, 2441–2462. *See also* Paraneoplastic syndromes, cutaneous; *specific types*
bullous disorders, paraneoplastic pemphigus, 934–942
dermal proliferative disorders
multicentric reticulohistiocytosis, 2036–2038, 2037*f*
necrobiotic xanthogranuloma, 2038–2039
hyperkeratotic dermatoses, 2441–2453, 2442*t* (*See also* Hyperkeratotic dermatoses)
reactive erythemas, erythema gyratum repens, 771–772, 772*f*, 773*t*
Cutaneous pathergy, Sweet syndrome, 590–591
Cutaneous photobiology. *See* Photobiology, cutaneous; *specific disorders*
Cutaneous plasmacytosis, 2124
Cutaneous polyarteritis nodosa, 17*f*
Cutaneous pseudolymphomas, 2108–2126. *See also* Pseudolymphomas (PSLs), cutaneous
Cutaneous rheumatoid vasculitis, 1150, 1150*f*
Cutaneous surgical anatomy, face, 3697–3703. *See also* Facial anatomy, cutaneous surgical
Cutaneous T cell–attracting chemokine (CTACK, CCL17, CCL27)
atopic dermatitis, 370
immune surveillance, 122, 122*f*
Cutaneous T-cell lymphoma (CTCL)
addressins, 125
dermatitis herpetiformis, 2459
erythrodermic (*See* Sézary syndrome)
management
phototherapy, 3646*t*, 3649
PUVA, 3666, 3671–3672, 3671*f*
radiotherapy, 3693*t*, 3694
primary, 3399
bexarotene for, 3399
central memory T cells, 2072, 2073, 2074
effector memory T cells, 2072, 2073, 2074
migratory memory T cells, 2072, 2074
superantigenic toxins, 2768
Cutaneous T-cell pseudolymphoma, 2113–2114, 2113*f*, 2114*f*
Cutaneous vasculature. *See* Vasculature, cutaneous
Cutaneous γδ T-cell lymphoma, 2088
Cutaneovisceral angiomatosis with thrombocytopenia, 2059*b*, 2064
Cutibacterium acnes, skin microbiome, 256–257, 257*t*, 258
Cuticle, hair follicle, 93*f*, 94, 94*t*
Cuticular border, 79
Cutis laxa, 1233–1241
acquired, 1241
at-a-glance, 1233*b*–1234*b*
clinical features, 1234, 1238–1239
ARCL2, 1236*t*, 1238
ARCL2, conserved oligomeric Golgi, 1236*t*
ARCL2A, 1235*t*, 1238, 3939
ARCL2B, 1236*t*, 1238
ARCL type 2, 1235*t*, 1238
ARCL type 3a, 1236*t*, 1238, 1240
ARCL type 3b, 1236*t*, 1240
autosomal dominant, 1234, 1235*t*
autosomal recessive, 1234, 1235*t*
cardiofaciocutaneous syndrome, 1237*t*
Costello syndrome, 1237*t*
gerodermia osteodysplastica, 1237*t*, 1238–1239
MACS/RIN2, 1237*t*, 1239–1240
metabolic, 1234, 1235*t*
ARCL1B, 1234
ARCL1C, 1234, 1235*t*
Noonan syndrome, 1237*t*
skin, 1234
transaldolase deficiency, 1237*t*
X-linked, 1234, 1235*t*
differential diagnosis, 1240–1241
epidemiology, 1234
etiology and pathogenesis, 1239–1240
intracellular trafficking defects, 1239–1240
metabolism defects, 1240
in familial amyloid, gelsolin mutation, 2265
fibulin mutations, 242
laboratory investigation, 1240
subtypes and associated defects, 1234, 1235*t*–1238*t*
treatment, 1241
Cutis marmorata, neonatal, 1732
Cutis marmorata telangiectatica congenita, 1746, 1746*f*

Cutting agents (drug abuse), 1712, 1712*f*
Cutting oils, occupational acne from, 1452–1453
Cw*14, paraneoplastic pemphigus, 935
CX47, four-limb lymphedema, Klippel-Trenaunay syndrome, 2640*t*
CXC10
  pityriasis rosea, 522
  Sweet syndrome, 596
  wound healing, 2708
CXCL5, inflammation, 125
CXCL8, 160*t*
  inflammation, 124
  systemic sclerosis, 1093
CXCL9
  leprosy, 2905, 2905*f*
  morphea, 1111
CXCL10
  leprosy, 2905
  morphea, 1111
  vitiligo, 1335
CXCL10–CXCR3, halo nevi, 1953
CXCL13, eosinophils, 655
CXCL14, 182
CXCR1, 180
  psoriasis, 183
CXCR2, 180
  psoriasis, 183
  systemic sclerosis, 1093
CXCR3, 181
CXCR4
  cancer, 185, 185*f*
  WHIM syndrome, 2415
Cyanea capillata, 3344, 3345*f*–3346*f*
Cyanide toxicity, fires, 1681
Cyclobutane pyrimidine dimers (CPDs), UV radiation damage, 275–276, 275*f*–277*f*, 315–317, 316*f*, 317*f*
Cyclooxygenase (COX)-2, inflammation, 123–124, 123*f*
Cyclopamine, 1890
Cyclophosphamide, 3476–3478
  for amyloidosis, cutaneous, 2270
  chemical structure, 3465*f*
  complications
    carcinogenicity, 3478
    cardiac/pulmonary toxicity, 3478
    cutaneous, 3478
    genitourinary, 3477–3478
    GI, 3477
    hematologic, 3477
    infectious disease, 3478
    mutagenicity and teratogenicity, 3478
  for cryoglobulinemia II and III, HCV, 2607
  for cytophagic histiocytic panniculitis, 1278
  dosing regimen, 3476
  drug interactions, 3478
  hypermelanosis, 1365
  indications, 3476
  initiation, therapy, 3476–3477
  for lupus erythematosus, 1054
  mechanism of action, 3476
  monitoring therapy, 3477, 3477*t*
  for mucous membrane pemphigoid, 966*t*, 967
  for multicentric reticulohistiocytosis, 2038
  for paraneoplastic pemphigus, 941*t*, 942
  for pemphigus, 925
  pharmacokinetics, 3476
  for primary cutaneous diffuse large B-cell lymphoma, 2101
  for relapsing polychondritis, 1190
  for rheumatoid vasculitis, 1153
  risks and precautions, 3477, 3477*t*
  for sarcoidosis, 581*t*
  for Still disease, adult-onset, 1158
    reactive phagocytic syndrome in, 1158
  for systemic sclerosis, 1098
  for systemic sclerosis, pulmonary fibrosis, 1101
  for vasculitis, 2557
Cyclophosphamide, hydroxydaunorubicin, vincristine, and prednisone (CHOP)
  for cutaneous anaplastic large cell lymphoma, 2086
  for cutaneous lymphoma with HIV, 3121
Cyclosporin A
  for adamantiades–Behçet disease, 2574*t*, 2576*t*
  for epidermal necrolysis, 744
  for epidermolysis bullosa acquisita, 978, 979*t*
  for psoriasis, 469*f*, 484*t*, 492
  for vasculitis, 2557
Cyclosporine, 3475, 3520–3524. *See also* Calcineurin inhibitors (CNIs)
  for actinic dermatitis prevention, 1643
  for actinic prurigo, 1632
  for alopecia areata, 1522
  for atopic dermatitis, 379
  for central centrifugal cicatricial alopecia, 1528
  contraindications, 3521–3522
  for cytophagic histiocytic panniculitis, 1278
  dosing regimen, 3522, 3522*t*
  drug interactions, 3521, 3521*t*, 3523, 3524
  on eosinophils, 658
  for graft-versus-host disease
    acute, 2332
    oral, 2335
  for hemophagocytic lymphohistiocytosis, 2032
  for hyperimmunoglobulinemia E syndrome, 2415
  indications, 3521
  for Kimura disease, 669
  for lichen nitidus, 558, 558*t*
  for lichen planopilaris, 547
  for lichen planus
    cutaneous, 545
    oral, 546
  for lupus erythematosus, 1057
  lymphocyte-rich infiltrate from, simulating lymphoma, 2115*f*
  for macrophage activation syndrome, 1155
  mechanism of action, 3520–3521, 3520*f*
  monitoring, therapeutic, 3522, 3522*f*
  mycophenolate mofetil interactions, 3519
  for nummular eczema, 388
  for papuloerythroderma of Ofuji, 672
  for paraneoplastic pemphigus, 941*t*, 942
  patch testing and, 408
  pharmacology, 3521
  photochemotherapy with, 3670
  for pityriasis lichenoides, 515, 515*t*
  for psoriasis, 198, 469*f*
    with HIV, 3122
  for pustular psoriasis of pregnancy, 1772
  for pyoderma gangrenosum, 613, 614*t*
  for reactive arthritis, 1142
  side effects, 3521*t*, 3522–3523
    serious, 3523–3524, 3524*t*
  for solar urticaria, 1653, 1654*f*
  for Still disease, adult-onset, 1158
    reactive phagocytic syndrome in, 1158
  for Sweet syndrome, 601*t*, 602
  for urticaria, 702
  vaccination, 3524
  for Wells syndrome, 667
CYLD
  cylindroma, 1825
  trichoepithelioma, 1841
Cylindrocarcinoma/spiradenocarcinoma, 1822*t*, 1829
Cylindroma, 1822*t*, 1825–1826, 1825*f*
Cymba, 3698, 3698*f*
CYP21A2, congenital adrenal hyperplasia, 2516
Cyproheptadine. *See also* Antihistamines, H_1
  dosing regimens, 3454–3455, 3454*t*
Cyproterone, for acne vulgaris, 1406
Cyproterone acetate
  for acne vulgaris, 1407
  for androgenetic alopecia, 1504
  for hirsutism, 1561, 1562*t*
  for hyperandrogenism, 2518
Cysteine, for protoporphyrias, 2249
Cystic chromomycosis, 2967*t*, 2972
Cysticercosis, 3252*t*
  exposure and symptom onset interval, 3259, 3260*t*
  progression and duration, 3259, 3260*t*
Cystic fibrosis transmembrane regulator (CFTR) protein, typhoidal *Salmonella*, 2807
Cystic hygroma. *See* Lymphatic anomalies
Cysts, of epidermal origin, 1812–1817
  at-a-glance, 1812*b*
  branchial cyst, 1816
  dermoid cyst, 1816
  epidermoid cyst, 1813–1814, 1813*f*
  milia, 1814–1815, 1815*f*
  preauricular cyst, 1817
  steatocystoma, 1815–1816, 1815*f*
  trichilemmal cyst, 1814, 1814*f*
Cytarabine, for Langerhans cell histiocytosis, 2029
Cytochrome P450 enzymes (CYPs)
  heme synthesis, 2235
  porphyria cutanea tarda, 2239
Cytokine(s), 160*t*, 3531. *See also specific types*
  atopic dermatitis, 369–370
  B-cell response, 148
  definition, 159
  dendritic cells, 152
  eosinophil, 649, 650*f*, 652, 655
  eosinophil activation, 657
  functions, 159
  keratinocyte, 160
  macrophage-derived, adipocyte lipolysis, 1251
  from mast cell granules, 154, 154*t*
  recombinant, 3539–3540
    interferons, 3539–3540, 3549*t*
    interleukin 2, 3539, 3549*t*
  Sweet syndrome, 595–596
  T-cells producing, 145–146
  therapeutic targeting, 159
Cytokine(s), Th17 axis, 173, 3534–3537, 3536*f*. *See also specific types*
  IL-12, 3535–3536
    ustekinumab, 3536, 3536*f*, 3548*t*
  IL-17A antagonists, 3534–3535, 3536*f*, 3548*t*
    brodalumab, 3535, 3536*f*, 3548*t*
    ixekizumab, 3535, 3536*f*, 3548*t*
    secukinumab, 3534–3535, 3548*t*
  IL-22, 3535
  IL-23, 3536–3537
  IL-23 antagonists
    guselkumab, 3536*f*, 3537, 3549*t*
    risankizumab, 3536*f*, 3537, 3549*t*
    tildrakizumab, 3536*f*, 3537, 3549*t*
Cytokine antagonists, 159
Cytokine biology, 159–175, 160*t*
  activities, range, 160
  classification, 160
    structural, 161
  cutaneous biology, 161, 163*t*
  nomenclature, 159–160
  pleiotropism and redundancy, 159–160, 161
  receptor binding, 161
  signal transduction pathways, 161–175 (*See also* Cytokine signal transduction pathways)

Cytokine biology (*Cont.*):
T cell–derived, 160–161, 161*f*
therapeutic implications, 175–176
Cytokine receptors. *See also specific types*
binding, 161
classification, major families, 161, 162*t*
eosinophil expression, 656
Cytokine signal transduction pathways, 161–175
class II cytokine receptor family ligands, 173–175
IL-10, "antiinflammatory" cytokine, 174
IL-10–related cytokines, novel, 174–175
IL-19, IL-20, IL-22, IL-24, and IL-26, 174–175
interferons, JAK/STAT pathway signaling prototypes, 173–174
cytokines with receptors that include γ_C chain, 170–171
IL-2 and IL-15, 170–171
IL-4 and IL-13, 161*f*, 163*t*, 171
IL-7 and thymic stromal lymphopoietin, 171
IL-9 and IL-21, 171
cytokines with receptors using glycoprotein 130, 172
cytokines with receptors using IL-3 receptor β chain, 171–172
fundamentals, 161–162, 162*t*
hematopoietin receptor family class I, ligands, 169–170
IL-1 family, 163*t*, 165–168, 165*f*, 166*f*
IL-2, 163*t*
IL-4, 163*t*
IL-5, 163*t*
IL-6, 161*f*, 163*t*
IL-10, 163*t*
IL-12, 163*t*, 173
IL-13, 163*t*
IL-17, 163*t*, 169, 170*f*
IL-22, 163*t*
IL-23, 161*f*, 163*t*, 173
IL-25, 163*t*
IL-26, 163*t*
IL-27, 163*t*
IL-31, 163*t*
IL-35, 163*t*, 173
JAK/STAT pathway, 162–165, 165*f*
nuclear factor κB, 162, 164*f*
inhibitor, 162
T helper 1 and T helper 17 responses, cytokines regulating, 173
transforming growth factor-β family and receptors, 175
tumor necrosis factor, 168–169, 168*f*
Cytomegalovirus (CMV) infections
antiviral drugs for, 3499–3501 (*See also specific types*)
cidofovir, 3501, 3501*t*
foscarnet, 3500–3501, 3500*t*
ganciclovir and valganciclovir, 3499–3500, 3500*t*
chemokines, 185–186
human, 3004–3007, 3015*t* (*See also* Human cytomegalovirus (HCMV))
Cytophagic histiocytic panniculitis (SHP), 1253*t*, 1275–1278
at-a-glance, 1275*b*
clinical course and prognosis, 1277
clinical features, 1275–1276, 1276*f*
diagnosis, 1276–1277, 1277*f*
differential diagnosis, 1277, 1277*t*
epidemiology, 1275
etiology and pathogenesis, 1276
management, 1277–1278
Cytoplasmic ANCAs (cANCAs), cutaneous necrotizing venulitis, 2535
Cytosine arabinoside, for lupus erythematosus, 1057
Cytotoxic agents, 3476–3487. *See also specific types*
anthracyclines, 3465*f*, 3480–3481
chlorambucil, 3465*f*, 3478–3480
cyclophosphamide, 3465*f*, 3476–3478
mucocutaneous reactions, 3481–3487
acneiform eruption, 3482
acral erythema, 3483–3484, 3484*f*, 3484*t*
actinic keratoses, inflammation of, 3484
alopecia, 3481–3482, 3482*f*, 3483*t*
hyperpigmentation
cutaneous, 3484–3485, 3484*f*, 3485*t*
mucosal, 3487
local injury, 3486, 3486*f*
mucositis/stomatitis, 3486–3487, 3487*f*, 3487*t*
nail pigmentation, 3483
nail plate dystrophy, 3482–3483, 3482*f*, 3482*t*
neutrophilic eccrine hidradenitis, 3483, 3483*f*, 3483*t*
photosensitivity, 3485, 3485*t*
radiation enhancement reactions, 3486
radiation recall reaction, 3485, 3485*f*, 3485*t*
Raynaud phenomena, 3486
sclerotic dermal reactions, 3486
syringosquamous metaplasia, 3483
Cytotoxic T cells
fixed drug eruption, 194
graft-versus-host disease, 2321
Stevens-Johnson syndrome, 194, 195*f*
toxic epidermal necrolysis, 194, 195*f*
type IV hypersensitivity reactions, 397
Cytoxan, for epidermolysis bullosa acquisita, 979*t*

D

D816V, mastocytosis, 750
DAB389–Il-2, 3543, 3550*t*
Dabrafenib, 3559*t*, 3582–3583, 3583*f*
keratoacanthoma from, 32
for melanoma, 2007–2009, 2008f
on squamous cell carcinoma, 315
on squamous cell carcinoma risk, 1906
Dabska tumor, 2064
Dacarbazine (DTIC), for melanoma, 2009
Daclatasvir, for hepatitis C, 3512
Daclizumab
for adamantiades–Behçet disease, 2575*t*
for paraneoplastic pemphigus, 941*t*, 942
Dactylitis
psoriatic arthritis with, 973*f*, 1128–1129, 1129*f*
reactive arthritis with, 984, 1140
Dakin solution, for epidermolysis bullosa, 1026
Dalbavancin, systemic, 3418
Danger-associated molecular patterns (DAMPs), allergic contact dermatitis, 193
Dapsone, 3423–3429
for acne fulminans, 1449
for acne vulgaris, 1403*t*, 1404, 1405
for actinomycetomas, 2971
for adamantiades–Behçet disease, 2575, 2575*t*
adverse reactions, 3426–3429, 3427*t*
hemolysis, 3426–3427, 3427*t*
liver, 3427, 3427*t*
methemoglobinemia, 3427, 3427*t*
monitoring, 2890
other, 3427, 3427*t*
serious
agranulocytosis, 3428
aplastic anemia, 3429
dapsone hypersensitivity syndrome, 3428
hemolysis and methemoglobinemia, 3428
skin, 3427, 3427*t*
for α-antitrypsin panniculitis, 1269
at-a-glance, 3423*b*
for bullous pemphigoid, 952, 952*t*
chemical structure, 3424, 3424*f*
for chronic bullous disease of childhood, 994*t*, 998*t*, 999
for cutaneous necrotizing venulitis, 2537
for cutis laxa, 1241
for dermatitis herpetiformis, 1006
dosages, 3426
for drug-induced linear IgA dermatosis, 998*t*
drug interactions, 3425, 3425*t*
for epidermolysis bullosa acquisita, 978, 979*t*
for erythema dyschromicum perstans, 1385
for erythema elevatum diutinum, 2565
for granuloma faciale, 675, 675*t*
historical perspective, 3423
hypersensitivity syndrome, 194
indications, medical
antiinflammatory action, 3426, 3426*t*
antimicrobial action, 3425–3426, 3426*t*
initiating therapy, 3429
for intercellular IgA dermatosis, 989
for leprosy, 2916–2917, 2917*t*
for linear IgA dermatosis, 994*t*, 995, 998*t*, 999
for lupus erythematosus, 1054*t*, 1056
mechanism of action
antiinflammatory, 3423–3424
bacteriostatic antibiotic, 3423
monitoring therapy, 3429, 3429*t*
for mucous membrane pemphigoid, 966*t*, 967
for *N. brasiliensis* actinomycetoma, 2889
overdose, treating, 3429
for palisaded neutrophilic and granulomatous dermatitis, 1148
for pemphigus, 925
pharmacology, 3424–3425
for prurigo pigmentosa, 1374
for pyoderma gangrenosum, 614*t*
for relapsing polychondritis, 1190
for rosacea
facial lymphedema, 1442
phymata, 1440
for subcorneal pustular dermatosis, 619, 619*t*
for Sweet syndrome, 601*t*, 602
topical, 3426
for urticaria, 702
for Wells syndrome, 667
Dapsone hypersensitivity syndrome, 3428
Daptomycin, 3419
for group A *Streptococcus* lymphangitis, 2739, 2739*t*
for MRSA skin and soft tissue infections, 2731*t*, 2732
Darier disease (DD), 877–884, 892*f*
acantholysis and dyskeratosis, 23, 23*f*
at-a-glance, 877*b*
autosomal dominant disorder, 295, 295*t*
clinical course and prognosis, 884
clinical features, 877–880
clinical variants, 879, 879*f*
complications, 880, 880*f*
cutaneous, 877–879, 878*f*
dyskeratosis, 22
erythronychia, 1568
gonadal mosaicism, 302
noncutaneous, 879
red lines, 1568, 1571*f*
related physical findings, 879–880
segmental disease, 879
differential diagnosis, 883–884, 883*t*
epidemiology, 877
etiology and pathogenesis, 880–883, 881*f*
cellular defect, 781*t*
histopathology, 883, 883*f*

management
genetic counseling, 884
medications, 884, 884*t*
Darier keratinocytes, 881
Darier-Roussy sarcoid, 574
Darier sign, 12*t*
mastocytosis, 713
cutaneous, neonatal, 1744
wheals, 684
pseudo-, 12*t*
urticaria, 690
Darunavir, 3508, 3509*t*
Darunavir-cobicistat, 3508, 3509*t*
Dasatinib, 3559*t*, 3562–3563, 3562*f*
for mastocytosis, 720
DaxibotulinumtoxinA (RT001/RT002), 3922
DCT015, 3600
D-dimer, in chronic spontaneous urticaria, 693
Death domain, 168, 168*f*
"Death receptors," eosinophil-expressed, 656
De Barsy syndrome, 1236*t*, 1240
Deck-chair sign, 2078
papuloerythroderma of Ofuji, 672
Decorin, dermal cell-matrix adhesion, 247
Decrescendo irritant pattern, 407
Decrescendo phenomenon, 441
Dectin-1, chronic mucocutaneous candidiasis, 2929
Dedifferentiated liposarcoma, 2188–2191, 2189*f*–2190*f*
at-a-glance, 2188*b*
clinical course, prognosis, and treatment, 2190–2191
clinical features, 2189
differential diagnosis, 2190
epidemiology, 2189
etiology and pathogenesis, 2189
histologic features, 2189–2190, 2189*f*–2190*f*
Deep morphea, 1108, 1110*f*
Deep vascular plexus (DVP), 116–117, 117*f*
Deep venous system, 3871–3872, 3872*f*
Deep venous thrombosis (DVT), after sclerotherapy, 3886
Deer flies, 3325*f*, 3330–3331
Deer tick, 3287, 3296, 3308*f*, 3311*t*, 3329. *See also* Ticks
DEET (*N*,*N*-diethyl-3-methylbenzamide), 3334–3335
for leishmaniasis prevention, 3237
for Lyme disease prevention, 3300–3301
pediatric toxicity, 1761*t*
Deferoxamine, for hemochromatosis, 1364
Deficiency of the IL-1 receptor antagonist (DIRA), 627–628, 628*f*
Deficiency of the IL-36 receptor antagonist, 628–629, 630*f*
Degos disease, 2630–2634. *See also* Malignant atrophic papulosis (Degos disease)
Degos disease–like lesions, 2632
Dehiscence, wound, postoperative, 3721
Dehydrated human amnion/chorion membrane, 2711, 2711*t*
Dehydroemetine, for amebiasis, 3247
Dehydroepiandrosterone (DHEA)
hyperandrogenism, 2517–2518
neonatal acne, 1448
Dehydroepiandrosterone sulfate (DHEAS)
acne with congenital adrenal hyperplasia, 1451–1452
hyperandrogenism, 2517–2518, 2517*t*
sebaceous glands, 76–77
Delavirdine, 3507–3508, 3509*t*
Delayed cold urticaria, 689
Delayed dermographism, 689
Delayed pressure urticaria (DPU), 685, 690. *See also* Urticaria
clinical features, cutaneous, 685
diagnosis, 698
diagnostic tests, 688*t*
Deletions, 294*f*, 295, 300
Delusional skin disorders, 1693–1697
at-a-glance, 1693*b*
delusions of parasitosis, 1694–1696, 1695*t*, 1696*t*
other, 1696
Delusion of bromosis, 1696
Delusions of parasitosis (infestations), 1694–1696, 1695*t*, 1696*t*
Demarcation, 9
Dementia paralytica, 3157
14α-Demethylase, 3443
Demodex brevis, 3278, 3278*t*
Demodex folliculorum
periorificial dermatitis, 1455
rosacea and rhinophyma, 1420, 1420*f*, 1425*f*, 1427, 1428*f*–1429*f*, 1429, 1430, 1433*f*
Demodex folliculorum hominis, 3278, 3278*t*
Demographic urticaria, 686*f*, 688–689, 688*t*, 697. *See also* Urticaria
Dendritic cell(s) (DCs), 134–136, 135*t*, 136*f*, 143, 151–153
allergic contact dermatitis, 193*f*, 194
functions, 151
with innate immune functions, 134–135, 134*t*
Langerhans cells, 152–153, 152*t*
myeloid, 151–152, 152*t*
perivascular, skin, 117
plasmacytoid, 152, 152*t*
psoriasis, 466, 469, 470*f*, 479
trafficking from skin to regional lymph nodes, chemokines, 181–182, 182*f*
Dendritic cell neurofibroma with pseudorosettes, 2159, 2159*f*
Dendrocytes, resident dermal, 117
Dengue virus, 3135–3137, 3136*t*, 3137*f*
Denileukin diftitox (DAB389–Il-2), 3543, 3550*t*
Dental abscess, nummular eczema, 386
Dental pitting, tuberous sclerosis complex, 2483, 2484*f*
Dental restorations, lichenoid contact dermatitis, 538
denV T4 endonuclease, for xeroderma pigmentosum, 2354
Depigmentation therapy, for vitiligo, 1342
Depot method, 3911, 3913*f*
Depressor anguli oris muscle, 3703, 3704*f*
Depressor labi inferioris muscle, 3703, 3704*f*
Depth dose distributions, 3687, 3688*f*
Dermabrasion, 3903–3905, 3903*t*, 3904*f*
for acne vulgaris, 1411
for actinic keratosis, 1866
for follicular atrophodermas, 1200
historical perspective, 3895
manual, 3903, 3903*t*, 3904*f*
microdermabrasion, 3903
motorized, 3903, 3903*t*, 3904*f*
for rosacea, 1423, 1442*t*
Dermacentor andersoni, 3307, 3308*f*, 3309*t*, 3329
Dermacentor-borne necrosis erythema and lymphadenopathy, 3315
Dermacentor variabilis, 3307, 3308*f*, 3309*t*, 3310*t*, 3320, 3329. *See also* Ticks
Dermal cell-matrix adhesion, 246–248
cell-matrix interactions and cellular functions, 247–248
extracellular matrix, 246–247
Dermal connective tissue, genetic disorders. *See* Connective tissue diseases, genetic disorders; *specific disorders*
Dermal dendritic cells. *See* Dendritic cell(s) (DCs)
Dermal deposition, paraneoplastic, 2442*t*. *See also specific types*
amyloidosis, systemic, 2442*t*, 2458
scerlomyxedema, 2442*t*, 2458
Dermal-epidermal basement membrane zone, inherited epidermolysis bullosa, 1011, 1012*f*
Dermal-epidermal cohesion disturbances, 23–24, 24*f*
Dermal-epidermal junction
anatomy and function, 23
cohesion disturbances, 23–24, 24*f*
neonates, 1728
pathology, 23
Dermal melanocyte hamartoma, 1357*t*, 1358, 1958
Dermal melanocytosis, neonatal, 1733
Dermal papilla, 90*f*, 94–95
Dermal "plus" reaction pattern, 14, 14*t*
Dermal proliferative disorders, 2442*t*
multicentric reticulohistiocytosis, 2442*t*, 2457
necrobiotic xanthogranuloma, 2442*t*, 2457–2458
Dermal reaction pattern, 15, 15*t*
Dermal regeneration matrix, 2711, 2711*t*
Dermasanding, 3903, 3903*t*, 3904*f*
Dermatan sulfate, dermal cell-matrix adhesion, 247
Dermatiaceous, 2926*t*
Dermatite polymorphe prurigineuse, 1002
Dermatitis. *See also specific types*
barrier destruction, 414, 415*t*
clonal, 508, 508*f*
definition, 414
lichenoid, 25, 25f, 539
parapsoriasis and, 506–507, 508*f*
spongiotic, 24, 24f
Dermatitis artefacta, 1702–1703
Dermatitis herpetiformis (DH), 1002–1008, 2443*t*, 2459
clinical course and prognosis, 1007
clinical features
cutaneous, 1002, 1003*f*, 2434
noncutaneous
autoimmune diseases, 1004
bone loss, 1004
gastrointestinal, 1003
malignancy, 1003–1004
neurologic disease, 1004
diagnosis, laboratory
direct immunofluorescence, 1005–1006, 1005*f*
pathology, 1006–1007, 1006*f*
serum studies, 1006
differential diagnosis, 1007, 1007*t*
epidemiology, 1002
etiology and pathogenesis, 1004–1005
HLA haplotype inheritance, 303, 304*t*
iodides, 1005
linear IgA dermatosis, 992, 994–995
thyroid disease, 1004
historical perspective, 1002
management
elemental and other diets, 1008
gluten-free diet, 1007–1008
sulfones, 1007
pathology, blistering
dermolytic, 24
subepidermal, 25
Dermatofibroma
cryosurgery for, 3794
pathology, 36, 36*f*
Dermatofibrosarcoma protuberans (DFSP)
imatinib on, 3558
Mohs micrographic surgery for, 3768–3769, 3768*f*
pathology, 36, 37*f*
Dermatographism, 12*t*
Dermatomal distribution, 11
Dermatomes, 351
Dermatomyositis (DM), 1061–1078
autoantibodies, clinical associations, 1068, 1070*t*
clinical course and prognosis, 1074–1075

Dermatomyositis (DM) (*Cont.*):
clinical features, cutaneous, 1062–1068, 2430
alopecia, 1068
calcinosis, 1067
characteristic, 1063
distribution, skin changes, 1063, 1064*f*
DM rash, 1061–1062, 1062*f*
Gottron papules (sign), 9*f*, 1063–1064, 1064*f*–1065*f*
heliotrope sign, 1063, 1063*f*
history and triggers, 1062–1063
Holster sign, 1064–1065, 1065*f*
interface/lichenoid changes, 25
mechanic's hands, 1065, 1065*f*
nail changes, 1587–1588
ovoid palatal patch, 1066, 1066*f*
palmar reticular pattern, 1066, 1067*f*
panniculitis, 1068
photodistribution, 1064
poikiloderma, 1067, 1067*f*
psoriasis, overlapping features, 1068
scalp, 1063, 1063*f*
shawl sign, 1063, 1066*f*
Sontheimer's diagnostic criteria, 1064, 1064*t*
ulceration, 1065–1066, 1065*f*
vasculopathy, 1065, 1066*f*
V-neck sign, 1063, 1064*f*
clinical features, cutaneous"red on white", 1067, 1067*f*
clinical features, extracutaneous, 1068–1071
cardiovascular, 1070–1071
gastrointestinal, 1070
joint, 1070
malignancy, internal, 1071
muscle, 1069–1070
pulmonary, 2430
interstitial lung disease, 1065, 1068, 2430
pulmonary arterial hypertension, 1068–1069
clinically amyopathic, 1061–1062, 1062*f*
connective tissue disease–associated panniculitis with, 1283*b*
definitions, 1061–1062
diagnosis, 1072–1074
fundamentals, 1072
helpful skin findings, 1072
laboratory
anti-MDA5, 1068, 1073
autoantibodies, 1073
EMG studies, 1073
MRI, 1073–1074
muscle enzymes, 1073
muscle disease, 1072
syndromic presentations, 1072–1073
differential diagnosis, 1075*t*
epidemiology, 1062
etiology and pathogenesis, 1071–1072
drugs, 756
genetics, 1071–1072
management, 1076–1078
for calcinosis, 1078
cancer screening, 1076
monitoring
cardiovascular, 1076–1077
muscle, 1076
pulmonary, 1076
physical medicine and rehabilitation, 1078
principles, 1076
ruxolitinib, 176
systemic therapy, 1077–1078
tofacitinib, 176
topical therapy, 1077
treatment ladder, 1077, 1077*t*
paraneoplastic, 2442*t*, 2453
pathology, 1074–1075
muscle histopathology, 1074
skin histopathology, 1074, 1074*f*
perivascular lymphocytic infiltrates, 27
Dermatomyotome, 52
Dermatopathia pigmentosa reticularis, 1354
Dermatopathology laboratory, 19
Dermatophilus congolensis, pitted keratolysis, 2741
Dermatophytes, 2925, 2926. *See also specific types*
atopic dermatitis, 376
in elderly, 1787
habits and hosts, 2927*t*
IV drug use, 1708–1709
Dermatophytes, diagnosis, 2929–2933
colony and microscopic morphology
Epidermophyton floccosum, 2931*t*
Microsporum audouinii, 2931*t*
Microsporum canis, 2931*t*
Microsporum gypseum, 2931*t*
Trichophyton interdigitale, 2932*t*
Trichophyton rubrum, 2932*t*
Trichophyton schoenleinii, 2932*t*
Trichophyton tonsurans, 2932*t*
Trichophyton verrucosum, 2932*t*
Trichophyton violaceum, 2932*t*
culture, 2929*t*, 2930–2931, 2931*t*–2933*t*
histopathology, 2933
laboratory identification methods, 2929*t*
microconidia and macroconidia
Epidermophyton, 2931, 2931*t*
Microsporum, 2931, 2931*t*
Trichophyton, 2931, 2931*t*
microscopic, 2930, 2930*f*
Trichophyton nutritional growth requirements, 2931, 2933*t*
Wood lamp fluorescence, 2933, 2933*t*
Dermatophyte test medium, 2929*t*
Dermatophytic folliculitis, 2724
Dermatophytoses, 2943–2949. *See also specific types*
clinical features, 17*f*, 2940–2941
dermatophytid reaction, 2937
epidemiology, 2940
etiology and pathogenesis, 2940–2941
management, 2934*t*–2936*t*
onychomycosis, 2937–2940 (*See also* Onychomycosis)
piedra, 2940, 2940*t*
tinea barbae, 2940–2941, 2941*f*, 2941*t*
tinea capitis, 2941–2944, 2942*f*–2943*f*, 2943*t*
tinea corporis, 2944–2945, 2944*f*, 2945*t*
tinea cruris, 2945–2946, 2945*f*, 2946*t*
tinea favosa, 2929*t*, 2931*t*–2932*t*, 2946–2947, 2946*f*
tinea nigra, 2947–2948, 2947*f*, 2948*t*
tinea pedis and tinea manuum, 2938*t*, 2948–2949, 2948*f*–2949*f*, 2949*t*
Dermatoses, 992, 993*f*
geriatric, 1784–1786
benign skin lesions, 1784–1785, 1784*f*–1785*f*
malignant skin lesions, 1785–1786
pruritus, 1786
xerosis, 1786
on photoexposed sites, 1643–1644, 1643*f*, 1643*t*
patient approach, 1644–1647
clinical features and distribution, 1644, 1645*f*
laboratory studies, 1644–1646, 1646*t*
photopatch testing, 1647
phototesting, 1646–1647
pregnancy, with fetal risk, 1765–1773
intrahepatic cholestasis of pregnancy, 1767–1771, 1768*t*
pemphigoid gestationis, 1766–1767, 1768*t*, 1769*f*
pustular psoriasis of pregnancy, 1768*t*, 1771–1773, 1772*f*, 1772*t*
pregnancy, without fetal risk
atopic eruption of pregnancy, 1768*t*, 1775–1777, 1776*f*–1777*f*
polymorphic eruption of pregnancy, 1768*t*, 1773–1775, 1773*f*–1774*f*, 1775*t*
Dermatosis papulosis nigra, 1801, 1802*f*
electrosugery for, 3799
Dermatosparaxis Ehlers-Danlos syndromes (dEDS), 1216*t*
Dermis, 49*b*, 50, 51*f*. *See also* Skin
aging on, 1783, 1784*t*
development, 52*t*
Dermographism, 688–689, 697. *See also* Urticaria
cholinergic, 689
cold-dependent, 689
delayed, 689
mastocytosis, 713
symptomatic, 686*f*, 688–689 (*See also* Urticaria)
diagnosis, 697
diagnostic tests, 688*t*
urticaria, 685, 686*f*
Dermoid cyst, 1816
neonatal, 1735
Dermolytic blistering, 24
Dermomalacia, vitamin A deficiency, 2205
Dermoscopy
actinic keratoses, 1861
androgenetic alopecia, 1500
dysplastic melanocytic nevi, 1976
melanoma, 1992, 1992*t*
telogen effluvium, 1513, 1513*f*
De Sanctis-Cacchione syndrome, 2349, 2350. *See also* Xeroderma pigmentosum (XP)
Descriptive measures, 45
Descriptive studies, 42*f*, 44
Desert recluse spider, 3326–3327
Desert rheumatism, 2979–2980, 2980*f*
Desipramine, blue-gray pigmentation from, with sun exposure, 1658, 1661*f*
Desloratadine. *See also* Antihistamines, H_1
dosing regimens, 3454–3455, 3455*t*
Desmocollin, 3–4
Desmocollin 1, 236–237, 236*t*
Desmocollin 2, 236*t*, 237
Desmocollin 3, 236*t*, 237
Desmoglein 1, 235, 236*t*
congenital defects, 208*t*, 215
Desmoglein 2, 236, 236*t*
Desmoglein 3, 236, 236*t*
pemphigus, 202
Desmoglein 4, 236, 236*t*
Desmoglein compensation, pemphigus, 917, 918*f*
Desmoplakin, 233, 237
Desmoplastic melanoma (DM), 1985*f*, 1986. *See also* Melanoma
Desmoplastic squamous cell carcinoma, 1910, 1910*f*–1911*f*
Desmoplastic trichoepithelioma, 33, 1841–1842
Desmosomal proteins, 233–238
cadherins, 233, 234–237, 234*f*–235*f* (*See also* Cadherins, desmosomal)
categories, 233
corneodesmosin, 238
desmoplakin, 233, 237
envoplakin, 237–238
periplakin, 237–238
plakins, 233
plakoglobin, 233, 237
plakophilins, 233, 237
Desmosomes, 22, 212*f*, 232. *See also* Corneodesmosomes
definition, 214
keratin filaments, 64
ultrastructure, 232–233, 234*f*
Desoximethasone, allergic safety, 405
Desquamative scale, 6*t*
Detergents, irritant dermatitis from, 420, 420*f*
Detergent sclerosing agents, 3879

Developers, film, lichenoid contact dermatitis, 538
Developmental abnormalities, neonatal skin, 1734–1738
  aplasia cutis congenita, 1737–1738, 1738*f*
  branchial cleft anomalies, 1736
  dermoid cysts, 1735
  encephalocele, 1736
  human tail, 1736
  hypertrichosis, 1736, 1737*f*
  lumbosacral midline, assessment, 1735, 1736*f*
  meningocele, 1735
  midline nasal and facial lesions, 1735
  minor anomalies, 1735, 1735*f*
  myelomeningocele, 1735
  nasal glioma, 1735, 1737*f*, 2166
  thyroglossal duct cyst, 1736
  urachal cysts and polyps, 1737
Developmental biology, skin, 49–60
  adnexal development, 56–58, 57*f*
  at-a-glance, 49*b*
  cutaneous nerve development, 56
  embryonic development, summary, 50–52, 52*t*
  epidermis differentiation, 53, 54*f*
  hematopoietic cells, 59
  melanocyte differentiation, 56
  mesenchyme/fibroblast and adipose development, 53–55
  mosaicism, 59
  neural crest and somite development, 52–53
  skin cell types
    central developmental signaling pathways, 50
    formed during development, 49–50
  structures, skin, 50, 51*f*
  vasculature, 58–59
Dexamethasone
  for adamantiades–Behçet disease, 2574, 2574*t*
  for systemic amyloids, 2269
Diabetes mellitus (DM), 2493–2504, 3543
  associated disorders, 2494–2500
    acanthosis nigricans, 2494–2496, 2495*f*
    acquired perforating disorders, 1205
    diabetic thick skin, 2496
    eruptive xanthomas, 2497, 2497*f*
    foot care, general, 2499–2500, 2500*t*
    infections, cutaneous, 2497–2498, 2498*t*
    joint mobility, limited, 2496, 2496*f*
    lipemia retinalis, 2497
    obesity and metabolic syndrome, 2283, 2502–2504, 2504*t*
    scleredema diabeticorum, 2497
    scleroderma-like syndrome, 2496–2497
    unknown pathogenesis, 2500–2502
      acquired perforating disorders, 2502
      bullosis diabeticorum, 2502, 2502*t*
      diabetic dermopathy, 2501–2502, 2501*f*
      granuloma annulare, 567, 2501
      necrobiosis lipoidica, 2500–2501, 2500*f*
  at-a-glance, 2493*b*
  clinical features, 2493, 2494*t*
    advanced glycation end products, 2494, 2496
    hypermelanosis, 1362
    thick skin, 2496
  epidemiology, 2493
  etiology and pathogenesis, 2493–2494
    immune dysfunction, 2498
  microbiome, skin, 257, 257*t*
  prevention, exercise, 2285
  type 1
    blood flow, skin, 122
    chronic spontaneous urticaria, 687
    dermatitis herpetiformis, 1004
  ulcers, 2498–2500, 2498*f*, 2499*f*, 2500*t*
    clinical features, 2498, 2498*f*
    epidemiology, 2498
    etiology and pathogenesis, 2498
    management, 2498–2499, 2499*f*
    prevention, 2499–2500, 2500*t*
Diabetic dermopathy, 2501–2502, 2501*f*
Diacerin, for epidermolysis bullosa, 1028, 1028*f*
Diagnosis, dermatologic. *See also specific diseases*
  art and science, 1
  skin phenotype, 3814–3815, 3815*f*
Diagnostic signs, cutaneous, 12
  apple-jelly sign, 9*f*, 12*t*
  Asboe-Hansen sign, 12*t*
  Auspitz sign, 12*t*
  buttonhole sign, 12*t*
  carpet tack sign, 12*t*
  Darier sign, 12*t*
  dermatographism, 12*t*
  Fitzpatrick sign, 12*t*
  Nikolsky sign, 12*t*
  pseudo-Darier sign, 12*t*
Dialectical behavior therapy, for dermatitis artefacta with borderline personality disorder, 1703
Dialkyl thioureas, allergic contact dermatitis from, 405
Dialysis patients, porphyria cutanea tarda, 2438
Diaminodiphenyl sulfone. *See* Dapsone
Diaper dermatitis, 1741–1743, 1741*t*, 1753
  allergic contact, 1741, 1741*t*
  candidal, 1741, 1741*t*
  dermatoses not etiologically related to diapers, 1742
  granuloma gluteale infantum, 1742
  irritant, 1741, 1741*t*
  Jacquet erosive dermatitis, 1741–1742
  Langerhans cell histiocytosis, 1741*t*, 1742, 1743*f*
  napkin psoriasis, 1741*t*, 1742, 1742*f*
  pseudoverrucous papules and nodules, 1741, 1742*f*
  seborrheic dermatitis, 1741*t*, 1742
  treatment, 1742, 1743*t*
Diaper rash, 418. *See also* Irritant dermatitis
Diazolidinyl urea, allergic contact dermatitis from, 404
Diazone, for dermatitis herpetiformis, 1006
Dibucaine, 3710*t*
Dichloroacetic acid, 3620
Diclofenac, granuloma annulare from, 566
Diclofenac-Na, for actinic keratosis, 1864*t*, 1865–1866, 1865*t*
Dicloxacillin
  for chronic bullous disease of childhood, 994*t*, 999
  for skin and soft-tissue infections, dosing, 3410*t*
  for staphylococcal impetigo, ecthyma, and folliculitis, 2730, 2731*t*
Didanosine, 3506–3507, 3509*t*
Diet
  for acne vulgaris, 1409
  cholesterol in, 2280
  for dermatitis herpetiformis, 1007–1008
    Atkins, 1007
    elemental, 1007
    gluten-free, 1006–1007, 2459
  glucocorticoids and, 3384
  for lipodystrophy, low-fat, 1304
  nickel in, dyshidrosiform hand eczema from, 402
  telogen effluvium from, 1509, 1509*f*
  for xanthomas and lipoprotein disorders, 2286
Diethylcarbamazepine (DEC)
  for *Brugia*, 3265*t*
  for filariasis, 3265*t*
  for loiasis, 3265*t*
  for *Mansonella streptocerca*, 3265*t*
  for *Wuchereria bancrofti*, 3265*t*
Differentiation syndrome
  definition, 593
  Sweet syndrome with, 593
Diffuse alopecia areata, 1502, 1502*t*, 1503*f*
Diffuse capillary malformation with overgrowth (DCMO), 2639, 2640, 2642*f*
Diffuse cutaneous leishmaniasis (DCL), 3232, 3232*f*
Diffuse cutaneous sclerosis, B cells, 149
Diffuse idiopathic skeletal hyperostosis (DISH) syndrome, from retinoids, 3403
Diffuse inherited palmoplantar keratodermas with extracutaneous features
  dominant inheritance, 828–834
    Bart-Pumphrey syndrome, 829–832, 845*t*
    connexin-associated palmoplantar keratodermas, 829–832
    hidrotic ectodermal dysplasia, 832–833, 845*t*
    Huriez syndrome, 824*f*, 833–834, 845*t*
    keratitis–ichthyosis–deafness syndrome, 829–832, 830*f*, 845*t*
    keratoderma–congenital alopecia syndrome, 832, 845*t*
    Olmsted syndrome, 828–829, 845*t*
    palmoplantar keratoderma with deafness, 829–832, 845*t*, 846*t*
    Vohwinkel syndrome, 781*t*, 783*f*, 824*f*, 829–832, 836, 845*t*, 846*t*
  mitochondrial inheritance, palmoplantar keratoderma with deafness, 836
  recessive inheritance, 834–836
    Naxos disease, 781*t*, 835–836, 845*t*
    palmoplantar hyperkeratosis with squamous cell carcinoma of skin and sex reversal syndrome, 836, 845*t*
    Papillon-Lefèvre syndrome, 782*t*, 834–835, 834*f*, 845*t*
Diffuse mastocytosis (DM), 710–720, 712*f*, 713*f*, 749–759. *See also* Mastocytosis
Diffuse neonatal hemangiomatosis, 2049–2050, 2050*f*
Diffuse nonepidermolytic palmoplantar keratoderma (NEPPK), Unna-Thost palmoplantar keratoderma, 823
Diffuse palmoplantar keratodermas without extracutaneous features
  dominant inheritance, 821–825
    epidermolytic palmoplantar keratoderma, 781*t*, 821–823, 822*f*, 845*t*
    Greither syndrome, 823–824, 845*t*
    loricrin keratoderma, 824–825, 824*f*, 845*t*
    palmoplantar keratoderma Bothnia type, 825, 845*t*
    Unna-Thost palmoplantar keratoderma, 823, 845*t*
  recessive inheritance, 825–828
    mal de Meleda, 781*t*, 825–827, 826*f*, 845*t*
    Nagashima-type palmoplantar keratoderma, 827–828, 845*t*
Diffuse pattern, 26, 26*f*
Diffusion
  Fick's laws, 3364
  laws of, 3364
DiGeorge syndrome, 1740
Digital fibroma, infantile, 1743
Digital neuropathy, after cryosurgery, 3792
Digital papillary adenocarcinoma, 1829–1830
Digit regeneration, nail epithelium in, 111–113, 112*f*
5α-Dihydrotestosterone (DHT), 2518
  sebaceous glands, 76

Dilated pore (of Winer), 1849
Diloxanide furoate, for amebiasis, 3247
Diltiazem
  phototoxicity
    blue-gray pigmentation, 1658
    photodistributed telangiectasia, 1661
  for Raynaud phenomena, 2621, 2621*t*
Diluents, drug abuse, 1712, 1712*f*
Dimethylgloxime test, for nickel, 403
Dimethyl sulfoxide (DMSO)
  for chemotherapy extravasation, 3486
  for cutaneous amyloidosis, 2270
  for lipoid proteinosis, 1247
Dimple sign, 12*t*
Dinitrochlorobenzene, 3620
Diphenhydramine, 3617*t*. *See also* Antihistamines, H_1
  dosing regimens, 3454–3455, 3454*t*
  for pruritus, in lichen nitidus, 558, 558*t*
Diphenylcyclopropenone, 3620
  for alopecia areata, 1521
Diphtheria, 2829*t*, 2851–2853
  antitoxin, 2853
  pertussis, and tetanus (DPT) vaccine, 2853
Diplopoda, 3330
  millipedes, 3330
Dipstick technique, cryosurgery, 3794
Diptera, 3325*f*, 3330–3331, 3331*f*
Dipyridamole
  for malignant atrophic papulosis, 2634, 2634*t*
  for necrobiosis lipoidica, 2501
Direct-acting antivirals (DAAs), for hepatitis C virus, 3510
  first-generation, 3511
  second-generation, 3511–3512
Direct immunofluorescence. *See* Immunofluorescence, direct
Direct salt-split skin immunofluorescence, epidermolysis bullosa acquisita, 977, 977*f*
Direct tumor involvement of skin
  cutaneous metastases, 2460–2462, 2461*f*
  leukemia and lymphoma cutis, 2462
  Paget's and extramammary Paget's diseases, 2462
Dirofilaria spp., 3252*t*
  exposure and symptom onset interval, 3259, 3260*t*
  migration, through eye, 3261
  progression and duration, 3259, 3260*t*
  pulmonary nodules, 3261
  subcutaneous nodules and masses, 3257, 3257*t*
Discoid eczema, 385–388. *See also* Nummular eczema
Discoid lupus erythematosus (DLE)
  cicatricial alopecia, 1526–1527, 1526*f*
  classic, 1044–1045, 1044*f*–1046*f*
  hyperkeratotic, 1046
  hypertrophic, 1046
  Koebner phenomenon, 1045
  lichenoid, 1048
  mucosal, 1046–1047
  verrucous, 1046
Discoid shape, 9–10, 10*f*
Disease-modifying antirheumatic drugs (DMARDs). *See also* Azathioprine; Leflunomide; Methotrexate; Sulfasalazine; *specific types*
  for psoriatic arthritis, 1135, 1136*t*
  for reactive arthritis, 1142
Dishpan hands, 415
Disodium cromoglycate, for mastocytosis, 718*t*, 719
Dissecting folliculitis, 1530, 1530*f*
Disseminated gonococcal infection (DGI), 3209–3210
Disseminated intravascular coagulation (DIC), 2822–2824
  clinical course and prognosis, 2824
  clinical features, 2822–2823, 2822*f*–2823*f*
  definition and historical perspective, 2822, 2822*t*
  diagnosis, 2823
  differential diagnosis, 2823–2824
  epidemiology, 2822
  etiology and pathogenesis, 2823
  management, 2824
  prevention, 2824
Disseminated pruriginous angiodermatitis, 2591*t*, 2592
Disseminated superficial actinic porokeratosis (DSAP), 901–902, 902*t*, 903*f*, 906*t*
Disseminated superficial porokeratosis (DSP), 902, 902*t*, 906*t*
Disseminated superficial porokeratosis of immunosuppression, 902–903, 906*t*
Disseminated xanthosiderohistiocytosis, 2036
Distal toenail embedding surgery, 3787, 3787*f*
Distribution, multiple lesions, 11–12
  acral, 11
  bilateral symmetric, 12
  Blaschkoid, 11
    epidermal nevus, 1806, 1807*t*
    graft-versus-host disease, 2326, 2326*f*
    lichen striatus, 559, 559*f*
  dermatomal/zosteriform, 11
  extensor, 11
  flexor, 11
  follicular, 11
  generalized, 12
  intertriginous, 11
  localized, 12
  lymphangitic and sporotrichoid, 11
  seborrheic, 11
  sun exposed/photodistributed, 11
  sun protected, 11
  truncal, 11
  universal, 12
Dithranol, for psoriasis, 489
DKC1, dyskeratosis congenita, 1353, 2367
DLX3, tricho-dento-osseous syndrome, 2389
DMDM hydantoin, allergic contact dermatitis from, 404
DM rash, 1061–1062, 1062*f*
DNA damage. *See also specific disorders and genes*
  responses, 275*f*, 278–281, 279*f*–280*f*
  UV radiation, photocarcinogenesis, 275–278, 275*f*–277*f*
DNA hypermethylation, 304
  melanoma, 304
DNA methylation, 304
  epidermis differentiation regulation, 66, 67*f*
DNA mutations. *See also specific types*
  UV radiation, photocarcinogenesis, 275–278, 275*f*–277*f*
DNA photoproducts, 315–316, 316*f*
DNA repair, 275*f*, 278–281, 279*f*–280*f*
  nucleotide excision repair (*See* Nucleotide excision repair (NER))
  photocarcinogenesis, 275*f*, 278–281, 279*f*–280*f*
DNA repair disorders, 2347–2361. *See also specific disorders*
  at-a-glance, 2342*b*
  carcinogenesis, 311
  chemical phenotypes, 2342, 2346*f*
  Cockayne syndrome, 2343*t*, 2355–2357, 2356*f*
  genome instability, spontaneous, 2342
  hereditary nonpolyposis colon cancer/Muire-Torre syndrome, 2343*t*
  mechanisms, 2342, 2345*t*
  molecular defects, 2342, 2346*t*
  nucleotide excision repair, impaired, 2342
  trichothiodystrophy, 2343*t*, 2357–2361
  xeroderma pigmentosum, 2342, 2343*t*, 2347–2354
  XP-CS complex, 2343*t*, 2344, 2345*t*, 2357
  XP/DDT, 2343*t*
DNase-hypersensitivity regions 1 & 2, dermatitis herpetiformis, 1005
DNMT1, 66, 67*f*
DNNMT3A, cutaneous T-cell lymphomas, 2075
DNNT3A, cutaneous T-cell lymphomas, 2075
Docetaxel, sclerotic dermal reactions from, 3486
DOCK8, hyperimmunoglobulinemia E syndrome, 2414, 2414*f*
Docosanol, for recurrent herpes labialis, 3030, 3030*t*
Dog bites, 3338–3340, 3338*b*
  bacterial infections
    Capnocytophaga canimorsus, 3339
    Pasteurella multocida, 2829*t*, 2837–2838, 3339
    Porphyromonas spp., 3339
    Staphylococcus intermedius, 3339
  cellulitis, 2748
  pathogenesis and treatment, 3338, 3339*t*
  viral infection, rabies, 3340–3341
Dog tick, American, 3307, 3308*f*, 3309*t*, 3310*t*, 3320, 3329
Dolutegravir, 3508, 3509*t*
Domestic abuse, 1717–1724
  clinical course and prognosis, 1723
  clinical features, 1717–1720, 1719*f*–1720*f*
  diagnosis, 1722
  differential diagnosis, 1723, 1723*t*, 1724*t*
  epidemiology, 1717
  etiology and pathogenesis, 1721
  imaging
    fractures, 1722
    head injury, 1723
    visceral trauma, 1723
  laboratory testing and imaging, 1722
  management, 1724, 1724*t*
Dominant dystrophic epidermolysis bullosa (DDEB), 1020–1021
  Cockayne-Touraine, 1021, 1021*f*, 1029*t*
  Pasini subtype, 1021, 1029*t*
Domperidone, for esophageal symptoms in systemic sclerosis, 1102
Donovan bodies, granuloma inguinale, 3204, 3204*f*
Donovanosis, 3202–3206. *See also* Granuloma inguinale (GI)
Dopachrome tautomerase (DCT), melanogenesis, 337–339
Doppler imaging, Raynaud phenomena, 2618
Dorsal nasal artery, 3704*f*, 3705
Dorsal nasal rotation flap, 3740, 3742*f*
Dorsum (nose), 3698, 3698*f*
Dory flop, 3148
Dose-response relationship, occupational exposures, 453
Double nail, 1568, 1569*f*
Douglas-fir tussock moth, 3334
Dowling-Degos disease (DDD), 65*t*, 781*t*, 1326–1327, 1327*t*
Dowling-Meara disease, 1015–1016, 1015*f*, 1029*t*
Doxepin, 3616, 3617*t*
  for Fox-Fordyce disease, 1477
  for lichen simplex chronicus and prurigo nodularis, nighttime itch, 391
  for mastocytosis, 719, 719*t*
  for neurotic excoriation, 1697*t*, 1700
Doxorubicin, 3480–3481
  chemical structure, 3465*f*
  extravasation injury from, 3486, 3486*f*
  hypermelanosis from, 1365

Doxycycline. *See also* Tetracyclines
for acne vulgaris, 1405
for actinomycosis, 2880
for African tick bite fever, 3309*t*, 3315
for α-antitrypsin panniculitis, 1269
for anthrax, 2828
for bacillary angiomatosis, 2806
with HIV, 3114
for Brill-Zinsser disease, 3319
for brucellosis, 2835
for cat scratch disease, 2805
for chlamydia, 3217, 3217*t*
for ehrlichioses, 3310*t*, 3322
for filariasis, 3265*t*
for granuloma inguinale, 3205, 3206*t*
for human granulocytic anaplasmosis, 3311*t*, 3322
for human monocytic ehrlichiosis, 3310*t*, 3322
lichenoid photosensitive eruption from, 1661
for lichen planopilaris, 547
for Lyme borreliosis, 769, 773*t*, 3299, 3300*t*
for lymphogranuloma venereum, 3198, 3198*t*
for *Mansonella perstans*, 3265*t*
for Mediterranean spotted fever, 3309*t*, 3315
for MRSA impetigo, ecthyma, and folliculitis, 2730, 2731*t*
for mycoplasmas, genital, 3214
phototoxicity, 1662
for plague, 2833
for prurigo pigmentosa, 1374
for rickettsialpox, 3309*t*, 3318
for Rocky Mountain spotted fever, 3309*t*, 3312
for rosacea, 1439
for SAPHO syndrome, 645
for skin and soft-tissue infections, dosing, 3410*t*
for staphylococcal furuncles, carbuncles, and abscesses, 2731*t*, 2732
for syphilis, 3160*t*, 3166
for systemic amyloids, 2269
for trench fever, 2805
for typhus
endemic, 3310*t*
epidemic, 3310*t*, 3319
for *Vibrio vulnificus*, 2843
for yaws, 3181
Doxycycline-ciprofloxacin, for *Aeromonas hydrophila* necrotizing fasciitis, 2775, 2776*t*
Doxycycline plus cefotaxime, for *Vibrio vulnificus* necrotizing fasciitis, 2775, 2776*t*
Doxycycline plus ceftriaxone, for necrotizing fasciitis
Aeromonas hydrophila, 2775, 2776*t*
Vibrio vulnificus, 2775, 2776*t*
Doxycycline-prednisolone, for rosacea, facial lymphedema, 1442
Doxycycline-rifampicin, for cat scratch disease, 2805
D-penicillamine, for adult-onset Still disease, 1158
DPP/BMP, 89, 90*f*
DQB1*0503, pemphigus, 917
Dracunculus medinensis, 3252*t*
migratory skin lesions, 3255*t*, 3256–3257, 3256*f*
subcutaneous nodules and masses, 3257, 3257*t*
DRB1*0402, pemphigus, 917
DRB*03, paraneoplastic pemphigus, 935
Dressing
after nail surgery, 3777–3778
wound, 2709, 2710*t*
Drospirenone
for acne vulgaris, 1406
for androgenetic alopecia, 1504
Drospirenone + ethinyl estradiol, for acne vulgaris, 1406, 1406*t*
Drug(s). *See also specific types and topics*
pediatrics and adolescents
drug labeling, 1760–1761
systemic
antimicrobials, 1762
dosages, 1761–1762
glucocorticoids, 1762
topical, 1761, 1761*t*
preoperative examination, 3708–3709
Drug abuse, 1705–1714. *See also specific types*
clinical features, 1706–1714, 1706*t*
alcohol, 1713
amphetamines, other, 1711
anabolic steroids, 1714
betel, 1713
cannabis, 1711–1712
club drugs, 1711
cocaine, 1709–1710, 1710*f*, 3710*t*
cutting agents, 1712, 1712*f*
γ-hydroxybutyrate, 1711
hallucinogens, 1711
heroin, 1710–1711, 1711*f*
inhalant abuse, 1709
IV drug use, 1706–1709, 1707*f*
krokodil, 1713
MDMA, 1711
methamphetamine, 1711
methylphenidate, 1711
opiates, prescription, 1714
psilocybin, 1711
sedatives, 1711
tobacco, 1713–1714
definition, 1705
diagnosis, 1706
epidemiology, 1705
etiology and pathogenesis, 1705–1706
historical perspective, 1705
management, 1714
noncutaneous issues, 1714
Drug delivery, cutaneous
absorption rate, 3364
therapeutic efficacy, 3364
Drug–drug interactions. *See also specific types*
cutaneous reactions, 760
Drug eruptions
cocaine abuse, 1709
in elderly, 1788
erythema multiforme, 727–728, 727*f*
lymphocytic cuffing of venules, 27
Drug hypersensitivity syndrome, 750, 750*f*–751*f*, 750*t*, 752*t*
Drug-induced acne, 1452, 1452*t*
Drug-induced hypersensitivity syndrome (DiHS)
genetic predisposition, 194
HHV-6, 3008
immunologic abnormalities after, 195
immunologic responses, 194–195, 195*f*
T cells, 194–195
Drug-induced lichen planus, 531*t*, 536–538, 537*f*, 537*t*
Drug-induced linear IgA dermatosis, 998, 998*t*
vs. classical linear IgA dermatosis, 992, 993*t*
cutaneous manifestations, 995–996
disease associations, 997
immunoreactants and circulating antibodies, 993, 993*t*
mucosal involvement, 996
treatment and prognosis, 994*t*, 998–999, 998*t*
Drug-induced pemphigus, 914–915
Drug-induced phototoxic dermatitis, photobiology, 273
Drug-induced vasculitis, 2553, 2553*f*
Drug injection sites, cutaneous pseudolymphoma at, 2116–2117, 2117*f*
Drug labeling, pediatrics and adolescents, 1760–1761
Drug reactions. *See also specific types*
eosinophils, 27, 27*f*
immune reconstitution inflammatory syndrome, HIV, 3109
immunologic responses, 194–195, 195*f*
nail, 1598–1599
Drug reactions, cutaneous, 749–762
at-a-glance, 749*b*
clinical course and prognosis, 761–762
clinical features, 749–759
anticoagulant-induced skin necrosis, 757, 757*f*
bullous eruptions, 750*t*, 752–753, 752*t*
bullous pemphigoid, 753
linear immunoglobulin A disease, 752, 753
pemphigus, 753
pseudoporphyria, 752–753
Stevens-Johnson syndrome, 753
toxic epidermal necrolysis, 753
chemotherapy agents, newer, 10*t*, 757
cutaneous pseudolymphoma, 756, 2116, 2116*f*
dermatomyositis, 756
exanthematous eruptions, 749–750, 750*f*–751*f*, 750*t*
fixed drug eruptions, 753–754, 754*f*
hyperpigmentation, 754, 755*t*
lichenoid
eruptions, 754–756
interface/lichenoid changes, 25
lupus, 752*t*, 756
morphologic approach, 749
neutrophilic eccrine hidradenitis, 757–759, 758*t*
purpuric reactions, 756–757
pustular and acneiform eruptions, 750*t*, 751, 752*f*
urticarial eruptions, 750–751, 750*t*
diagnosis, 760–761
differential diagnosis, 761*t*
epidemiology, 749
etiology, 759
immunologic, 759–760, 759*t*
management, 762
pathogenesis, 759–760, 759*t*
prevention, 762
severe, premonitory signs, 760–761, 760*t*
Drug-related baboon syndrome, 402
Drug-related disorders. *See also specific types*
cutaneous necrotizing venulitis, 2529–2530
cutaneous pseudolymphoma, 756, 2116, 2116*f*
granuloma annulare, 566–567
palpable purpura, 2530
pigmented purpuric dermatoses, 2594, 2594*t*
Raynaud phenomena, 2615, 2615*t*, 2616
telogen effluvium, 1510–1511, 1510*t*, 1511*f*
Drug-related eosinophilia with systemic symptoms (DRESS)
genetic predisposition, 194
immunologic abnormalities after, 195
immunologic responses, 194–195, 195*f*
T cells, 194–195
Dry gangrene, 1669, 1669*f*
Dry skin. *See* Xerosis; *specific disorders*
DSAP1, 902, 905
Dsc1, 233–235, 234*f*, 236–237
Dsc2, 233–235, 234*f*, 237
Dsc3, 233–235, 234*f*, 237
DSE, musculocontractural Ehlers-Danlos syndrome, 1213*t*

Dsg1, 233, 234*f*, 235
DSG1, striate palmoplantar keratoderma, 836, 837
Dsg2, 233–234, 234*f*, 236
Dsg3, 64
Dsg4, 233–234, 234*f*, 236
Dsg nonassembly depletion hypothesis, 917
DSP
  acantholytic epidermolysis bullosa simplex, 1015*t*
  Carvajal syndrome, 843
  striate palmoplantar keratoderma, 836, 837
DST, 294
DST-e, BP230 deficiency epidermolysis bullosa simplex, 1015*t*, 1018
DTNBP1, Hermansky-Pudlak syndrome, 1316*t*
DuFourmentel flap, 3745–3746, 3746*f*
Dunnigan type lipodystrophy, 1295, 1296*t*, 1297, 1297*f*, 1303*f*, 1304
Dupilumab, 3545–3546, 3545*f*, 3551*t*
  for atopic dermatitis, 176, 197, 379, 3545–3546, 3545*f*
Dupuytren contracture, alcohol abuse, 1713
Duration (disease), 45
Dust mite, house, 3278, 3278*t*
Dutaseride
  for frontal fibrosing alopecia, 547
  for hirsutism, 1563
Dyes
  brilliant green, 3611, 3612*t*
  gentian violet, 3611, 3612*t*
Dynamic cooling device (DCD), 3830–3831
Dysbetalipoproteinemia, 2281–2282
Dyschromatosis symmetrica hereditaria (DSH), 1324–1325, 1324*f*, 1327*t*
Dyschromatosis universalis hereditaria (DUH), 1325, 1327*t*
  hyperpigmentation, 1386
Dyshidrosiform hand eczema
  from balsam of Peru, 400, 402
  from nickel, 402
Dyskeratosis
  acantholysis and, 23, 23*f*
  epidermal cells, 21–22
  Merkel cell polyomavirus, 319
Dyskeratosis congenita (DKC), 1353, 2344*t*, 2345*t*, 2366–2367, 2446*t*
  squamous cell carcinoma, 1904*t*
Dyskeratosis follicularis, Darier, 1568, 1571*f*
Dyslipidemia. *See also* Lipoprotein disorders
  drugs in, 2283
  epidemiology, 2274
  Fredrickson-Levy-Lees, 2288*t*
  granuloma annulare, 567
  hepatic causes, 2282–2283
  historical perspective, 2273–2274
  lichen planus and, 540, 541
  type V, 2282
Dysplastic melanocytic nevi, 1973–1977
  at-a-glance, 1973*b*
  clinical course and prognosis, 1976–1977
  clinical features, 1973–1974, 1974*f*–1975*f*
  diagnosis, 1975–1976, 1976*f*
  differential diagnosis, 1976*t*
  epidemiology, 1973
  etiology and pathogenesis, 1975
  prevention, 1977
  treatment, 1977
Dysplastic nevus, 1944. *See also* Dysplastic melanocytic nevi; *specific types*
Dysplastic nevus spilus, 1950
Dysplastic nevus syndrome, 1990, 2446*t*
Dysport, 3921, 3923. *See also* Botulinum toxin
Dystrophic calcification, 2308–2310, 2308*t*, 2309*f*
  connective tissue diseases, 2308–2309, 2309*f*
  cutaneous neoplasms, 2309–2310
  Ehlers-Danlos syndrome, 2309
  infections, 2310
  other, 2310
  panniculitis, 2309
  pilomatricomas, 2309
  porphyria cutanea tarda, 2309
  pseudoxanthoma elasticum, 2309
Dystrophic dominant epidermolysis bullosa (DDEB), gene inhibition therapy, 307
Dystrophic epidermolysis bullosa (DEB), 1020–1024, 1029*t*
  dominant, 1020–1021
  generalized autosomal dominant dystrophic epidermolysis bullosa, 1021
  localized autosomal dominant dystrophic epidermolysis bullosa, 1021, 1021*f*, 1029*t*
  nail changes, 1601
  recessive, 1020, 1021–1023, 1022*f*–1023*f*
  squamous cell carcinoma, 1904*t*

E

Ear landmarks, external, 3698–3699, 3698*f*
Earlobe crease, cardiovascular disease, 2425
Early latent syphilis, 3154
Early-onset sarcoidosis (EOS), 640–641, 641*f*
Ear pits, 1817
East–west flap, 3739, 3741*f*
Ebastine, 3454–3455, 3455*t*. *See also* Antihistamines, H_1
EBI3, 173
EBP
  CHILD syndrome, 778*t*, 805
  X-linked dominant chondrodysplasia punctata, 778*t*, 806
E-cadherin, 150*f*
Ecallantide, for hereditary angioedema, 694*f*, 702
Eccrine appendage tumors, 1820, 1821*t*, 1822–1830. *See also* Appendage tumors, eccrine; *specific types*
Eccrine duct, sweat gland, 79, 79*f*
Eccrine glands, neonates, 1728
Eccrine nevus, hyperhidrosis with, 1464
Eccrine sweat glands, 71*t*, 78–83. *See also* Sweat glands, eccrine
Eccrine sweat glands, disorders, 1459–1467. *See also specific types*
  anhidrosis, 1460*t*, 1463–1467
  classification, 1460*t*
  hyperhidrosis
    primary focal, 1459–1463, 1460*t*
    secondary, 1460*t*, 1463–1465, 1464*f*
Echinocandins, for chronic mucocutaneous candidiasis, 2401
Echinococcus
  biliary disease, 3261
  exposure and symptom onset interval, 3259, 3260*t*
  liver masses, 3261
  progression and duration, 3259, 3260*t*
  subcutaneous nodules and masses, 3257, 3257*t*
Echinococcus granulosis, 3252*t*, 3254
Echinococcus multilocularis, 3252*t*, 3254
Echinoderms, 3350–3352
  sea cucumbers, 3352
  sea urchins, 3350–3351, 3351*f*–3352*f*
  starfish, 3352
ECM1, 293
  lipoid proteinosis, 1245
Econazole, 3438*t*
  for fungal infections, 2935*t*
Ecstasy (MDMA), 1711
Ecstasy, liquid, 1711
Ecthyma, staphylococcal, 2722, 2723*f*
Ecthyma contagiosum, occupational exposure, 449
Ecthyma gangrenosum, 2722
  Pseudomonas aeruginosa, 2722
    diagnosis, 2794
    etiology and pathogenesis, 2793–2794
    management, 2796
Ectoderm, 52
  neural crest development, 52
Ectodermal dysplasias, 1502, 2372–2391
  at-a-glance, 2372*b*
  Bazex-Dupré-Christol syndrome, 1200
  classification, 2372
  diagnostic algorithm, 2372, 2373*f*
  EEC syndrome, 2381
  focal dermal hypoplasia, 2384–2386, 2385*f*
  hidrotic ectodermal dysplasia, 2377–2378, 2377*f*
  hypohidrotic ectodermal dysplasia, 2373–2377 (*See also* Hypohidrotic ectodermal dysplasia (HED))
  incontinentia pigmenti, 2386–2388
  nail changes, 1600–1601, 1600*f*
  neonatal presentation, 1745
  oculo-dento-digital dysplasia, 2389–2390
  P63-related ectodermal dysplasia syndromes, 2378–2381, 2381–2382
  tooth and nail syndrome, 2388–2389, 2388*f*
  tricho-dento-osseous syndrome, 2389
  tricho-rhino-phalangeal syndrome, 2390–2391, 2390*f*
  WNT10A disorders, 2382–2384, 2383*f*
Ectodermal-dysplasia-skin fragility syndrome, plakophilin mutations, 237
Ectodermal dysplasia with immunodeficiency, 2406–2407, 2407*f*
Ectodermosis pluriorificialis, 724
Ectodysplasin (EDA), 90f, 91
  recombinant, for hypohidrotic ectodermal dysplasia, 2377
Ectodysplasin signal transduction pathway, 2375*f*
Ectoenzymes, endothelial cell, on platelet activation, 119
Ectopic bone formation, acute, 1681
Ectothrix, 2926*t*
  tinea capitis, 1531–1532
Ectothrix hair, 2930, 2930*f*
Ectrodactyly, EEC syndrome, 2381, 2382*f*
Eculizumab, for malignant atrophic papulosis, 2634, 2634*t*
Eczema. *See also specific types*
  asteatos, 444
  atopic, filaggrin mutations, 216
  discoid, 385–388 (*See also* Nummular eczema)
  hand
    chronic, phototherapy for, 3652
    dyshidrosiform
      from balsam of Peru, 400, 402
      from nickel, 402
  nail changes, 1581–1583, 1582*f*
  nonatopic, 364
  nummular, 385–388
Eczema coxsackium, 367, 3012, 3013*f*
Eczema craquelé, 444
  in elderly, 1786, 1786*f*
Eczema herpeticum, 3025–3026, 3025*f*, 3032*t*
  viral, with atopic dermatitis, 367, 367*f*
Eczematid-like purpura of Doucas and Kapetanakis, 2591–2592, 2591*t*
Eczematous reaction pattern, 13–14, 13*t*
Eczema vaccinatum, 3075–3076, 3076*f*
ED-1, hypohidrotic ectodermal dysplasia, 1465–1466
EDA, 90*f*, 91
EDA1, hypohidrotic ectodermal dysplasia, 2375–2376
Edar, 89
EDAR, 50, 90*f*, 91
  hypohidrotic ectodermal dysplasia, 2376
  receptor, 50

EDARADD, hypohidrotic ectodermal dysplasia, 2376
Edema. *See also* Lymphedema; *specific types and disorders*
  definition, 2693
  eosinophils, 660
  solid facial, acne with, 1451
Edema indurivatum, 3149
EDN3, Waardenburg syndrome, 1322*t*, 1323
Ednrb, 335
EDNRB, Waardenburg syndrome, 1322*t*, 1323
EEC syndrome, 2381, 2382*f*
Efalizumab, granuloma annulare from, 567
Efavirenz, 3507–3508, 3509*t*
Effect estimates, 45, 45*t*
Effectiveness, 42
  comparative, 42
  vs. efficacy, 43, 43*t*
Effector, type IV hypersensitivity reactions, 397
Effector memory T cells (T_{EM}), 147, 148*f*
  cutaneous T-cell lymphomas, 2072, 2073, 2074
Efficacy, 41–42
  vs. effectiveness, 43, 43*t*
Efficacy studies
  comparative, 43
  initial, 43
Eficonazole, for onychomycosis, 3444
Efinaconazole, 3438*t*, 3444–3445
  for nail infections, fungal, 1595, 1596*t*
Eflornithine
  for African trypanosomiasis, 3239–3240, 3239*t*
  for hirsutism, 1561
EGF, hair follicles, 97
EGFR, 315, 3541
  porocarcinoma, 1828
EGFR inhibitor(s). *See also specific types*
  acneiform eruptions from, 1452
EGFR inhibitor associated eruption, 1452
Ehlers-Danlos syndromes (EDS), 1212–1225
  at-a-glance, 1212*b*
  classification, 2*t*
  clinical features, 1212–1222, 1213*t*
    cardiac valvular subtype, 1214*t*, 1221
    classical, 1212, 1213*t*, 1218–1221, 1219*f*, 1220*f*, 1220*t*
    classical-like Ehlers-Danlos syndrome, 1213*t*, 1221
    hypermobility type, 1213*t*, 1222
    osteogenesis imperfecta EDS overlap syndrome, 1221
    vascular type, 1214*t*, 1221, 1221*f*
  collagen pathology, 28
  diagnostic criteria
    arthrochalasia, 1216*t*
    brittle cornea syndrome, 1217*t*
    cardiac-valvular, 1214*t*
    classical, 1214*t*
    classical-like, 1214*t*
    dermatosparaxis, 1216*t*
    hypermobile, 1215*t*
    kyphoscoliotic, 1216*t*
    musculocontractural, 1218*t*
    myopathic, 1218*t*
    periodontal, 1218*t*
    spondyloplastic, 1217*t*
    vascular, 1214*t*
  differential diagnosis, 1223
  dystrophic calcification, 2309
  epidemiology, 1212
  etiology and pathogenesis, 1222–1223
    classical, 1222
    vascular, 1222–1223
  laboratory investigation
    histopathology, 1223
    molecular testing, subtypes, 1223
  pregnancy, 1225
  prevention and treatment, 1223–1225
Ehrlichia chaffeensis, 3310*t*, 3320
Ehrlichioses, 3320–3322
  diagnosis and differential diagnosis, 3315*t*, 3316*t*, 3321–3322, 3321*f*
  epidemiology and vectors, 3310*t*–3311*t*, 3320
  etiology and pathogenesis, 3306, 3308*f*, 3320
  pathology, 3321
  prevention, 3322
  treatment and prognosis, 3310*t*–3311*t*, 3316*t*, 3322
Eikenella corrodens, IV drug use skin and soft tissue infections, 1708
Eisenmenger complex, clubbing, 1596, 1596*f*
Ekbom syndrome, lipoma, 2173*t*
Elastic fibers, basement membrane, 239
Elastin, dermal cell-matrix adhesion, 247
Elastolysis, generalized, 1233–1241. *See also* Cutis laxa
Elastosis perforans serpiginosa, 1230
Elbasvir, for hepatitis C virus, 3512
Elder abuse
  clinical course and prognosis, 1723
  clinical features, 1717–1720, 1719*f*–1720*f*
  diagnosis, 1721–1722
  differential diagnosis, 1723, 1723*t*, 1724*t*
  epidemiology, 1717
  etiology and pathogenesis, 1721, 1721*t*
  imaging
    fractures, 1722
    head injury, 1723
    visceral trauma, 1723
  laboratory testing and imaging, 1722
  management, 1724, 1724*t*
Elderly. *See* Aging; *specific disorders*
Elective lymph node dissection (ELND), for melanoma, 2000–2001
Electrical burn, 1682–1683
Electrocautery, 3796*t*, 3797
  bipolar, with implantable electronic device or pacemaker, 3797
  heat, with implantable electronic devices, 3797
  for rosacea, 1442*t*, 1443
Electrochemotherapy (ECT), for melanoma, 2002–2003
Electrocoagulation, 3796, 3796*t*
Electrodessication, 3796, 3796*t*. *See also* Curettage and electrodessication (C&D)
  for benign tumors, 3799
  for dermatosis papulosis nigra, 3799
  for flat warts, 3799
  for sarcoidosis, 582
  for seborrheic keratosis, 1802, 3799
Electrofulguration, 3796, 3796*t*
Electrofulguration and curettage, for molluscum contagiosum with HIV, 3116
Electrolysis, 3796*t*, 3797
  for hirsutism, 1563
  for hypertrichosis, 1565
Electromagnetic interference, preoperative examination, 3707
Electromagnetic radiation, 3820
  divisions and wavelengths, 265–267, 266*f*, 266*t*
  skin interaction, 267–268, 267*f*–268*f*
Electron beam therapy (EBT)
  for cutaneous T-cell lymphomas
    local and total skin, 2090–2092
    primary, 2090–2092
  total skin (*See* Total skin electron beam therapy (TSEBT))
Electroneuromyography, for leprosy, 2911
Electrosection, 3796, 3796*t*
Electrosurgery, 3795–3800. *See also specific types and applications*
  electrocautery, 3796*t*, 3797
  electrocoagulation, 3796, 3796*t*
  electrodessication, 3796, 3796*t*
  electrofulguration, 3796, 3796*t*
  electrolysis, 3796*t*, 3797
  electrosection, 3796, 3796*t*
  for hemostasis, 3798–3799, 3799*f*
  with implantable electronic devices, 3797
  for malignant tumors, curettage and electrodessication, 3799–3800, 3799*f*–3800*f*
    outcome assessments, 3800
  perioperative considerations
    anesthesia, 3798
    patient selection, 3797
    perioperative care, 3798
    risks and complications, 3797–3798
  techniques
    equipment, 3798
    patient positioning, 3798
Elejalde disease, squamous cell carcinoma, 1904*t*
Elemental diets, for dermatitis herpetiformis, 1007
Elephantine psoriasis, 459
Elicitation phase, type IV hypersensitivity reaction, 397–398
Elliptical excision, 3727–3731
  closure, 3729–3730, 3730*f*–3731*f*
  cosmetic units, 3728, 3728*f*
  ellipse variations, 3731–3732
    curved ellipse, 3731
    M-plasty, 3732
    partial closure, 3732
    rhombic/tangent-to-circle excision, 3731
    serial excision, 3732
    S-plasty, 3731–3732, 3733*f*
  free margins, 3727
  planning, 3727
  relaxed skin tension lines, 3727–3728, 3727*f*
  suture removal, 3730–3731
  technique, 3728–3729, 3729*f*
Elvitegravir, 3508, 3509*t*
Emberger syndrome, 2694
Embolization, superselective, for arteriovenous malformations, 2663
Embryology, hair follicle, 89–90
Embryonal rhabdomyosarcoma (ERMS), 2144
Embryonic development, skin, 50–52, 52*t*
EMLA. *See* Eutectic mixture of local anesthetics (EMLA) cream
Emollients, 3374, 3807
  for atopic dermatitis, 376–377
  bland
    for keratosis pilaris, 869
    for psoriasis, 490
  for Darier disease, 884, 884*t*
  for irritant dermatitis, 424
  for palmoplantar keratodermas, inherited, 821
  for parapsoriasis, 510
  for seborrheic dermatitis, 434
Emotional sweating, 80
Emtricitabine, 3506–3507, 3509*t*
Emulsions
  oil-in-water, 3373*t*, 3374
  water-in-oil, 3373*t*, 3374
en, 89, 90*f*
Enalapril, for Raynaud phenomena, 2621*t*, 2622
Encephalitis, herpes simplex virus, 3027
Encephalocele, neonatal, 1736
Encorafenib, on squamous cell carcinoma, 315
Endemic pemphigus foliaceus, 910, 911*t*, 913
Endemic typhus. *See* Typhus, endemic (murine or flea-borne)

Endocarditis, 2425
  cutaneous manifestations, 2425
  infective, 2815–2818 (*See also* Infective endocarditis (IE))
  IV drug use, cutaneous signs, 1709
  Libman-Sacks, systemic lupus erythematosus, 2427
  risk, history and physical examination, 3706–3707, 3707*t*
  splinter hemorrhages, 1596
Endocrine system, topical therapy on, 3378
Endocrinopathies
  hirsutism from, 1559
  hypermelanosis, 1361–1362, 1361–1363
    acanthosis nigricans, 1362–1363, 1362*f*, 2441–2443, 2494–2496, 2495*f* (*See also* Acanthosis nigricans)
    Addison disease, 1361–1362, 2514, 2514*f*
    carcinoid syndrome, 1362
    Cushing syndrome, 1362, 2513
    diabetes, 1362
    hyperthyroidism, 1362
    maturational dyschromia, 1363, 1363*f*
    Nelson syndrome, 1362
    pheochromocytoma, 1362
Endoderm, 52
Endopeptidases, 354
Endoscopic thoracic sympathectomy, for severe palmar hyperhidrosis, 1462–1463
Endothelial-activating cytokines, eosinophil tissue trafficking, 650*f*, 656–657
Endothelial cells (ECs), dermal
  blood fluidity, 118
  cutaneous vasculature, 116, 117, 118*f*
  hemostasis, 118–119, 119*f*
  inflammation
    acute, 124, 124*f*
    acute *vs.* chronic, 124*f*, 125
    chronic, 125
  perfusion, 120, 121*f*
  permselectivity, 119–120, 120*f*
  wound healing, 2701–2704, 2701*f*, 2702*f*
Endothrix, 2926*t*
Endothrix hair, 2930, 2930*f*
Endovascular chemoablation, 3877. *See also* Sclerotherapy
Enfuvirtide, 3506
ENG, hereditary hemorrhagic telangiectasia 1, 2640*t*, 2662
Enhancers, 293
Enoxaparin, for lichen nitidus, 558, 558*t*
ENPP1, Cole disease, 847
Entamoeba histolytica, 3246
Entecavir
  adverse effects, 3512
  for hepatitis B virus, 3512
Enteric fever, *Salmonella*, 2806–2808
Enterobiasis, 3266–3267
  exposure and symptom onset interval, 3259, 3260*t*
  management, 3265*t*
  progression and duration, 3259, 3260*t*
  urticaria and pruritus, 3258–3259, 3258*t*
Enterobius vermicularis
  exposure and symptom onset interval, 3259, 3260*t*
  management, 3265*t*
  progression and duration, 3259, 3260*t*
  urticaria and pruritus, 3258–3259, 3258*t*
Enterotoxins, 2727
Enteroviruses, 3010–3013. *See also specific types*
  hand-foot-mouth disease, 3010–3011, 3011*f*, 3015*t*
    Coxsackie A6–associated atypical, 3012–3013, 3012*f*–3013*f*, 3013*t*, 3015*t*
  nail changes, 1591, 1591*f*
Enthesitis
  juvenile idiopathic arthritis, 1154
  psoriatic arthritis, 973*f*–974*f*, 1129, 1129*f*
  reactive arthritis, 984, 984*f*, 1140, 1140*f*
Entomophthoromycosis, 2967*t*, 2973
Entry inhibitor, 3506
Envoplakin, 211, 237–238
Enzyme replacement therapy (ERT), for Fabry disease, 2303
Eosinophil(s), 132–133, 154*t*, 156, 649–658, 1377
  activation, 657–658
  allograft rejection, 653
  biologic functions, 652
  constituents and activities, 654–655
    cytokines, 649, 650*f*, 652, 655
    eosinophil cationic protein, 651*f*, 652, 654
    eosinophil-derived neurotoxin, 651*f*, 652, 654
    eosinophil granule proteins, 651*f*, 652, 654
    eosinophil peroxidase, 651*f*, 652, 654
    lipid mediators, 651f, 655
    major basic protein, 651*f*, 652, 654
  in cutaneous diseases, 659–675, 659*t* (*See also specific diseases*)
    angiolymphoid hyperplasia with eosinophilia, 667–669
    at-a-glance, 659*b*
    clinical reaction patterns with eosinophils, 659*t*
      eosinophilia-myalgia syndrome, 675
      eosinophilic fasciitis, 675
    eosinophilic pustular folliculitis, 670–671, 670*f*, 671*t*
    fundamentals, 659–660
    granuloma faciale, 673–675
    hypereosinophilic syndromes, 660–665
    Kimura disease, 667*t*, 668, 669–670
    papuloerythroderma of Ofuji, 671–672
    Wells syndrome, 665–667
  in disease, 653
  eosinophilic factors–cytokines–intracellular signaling interactions, 2*f*, 649–651
  factors working together, 656
  in immune function, 652–653
  inflammatory reactions, 27, 27f
  myelosuppressive drugs on, 658
  ontogeny and development, 254*f*, 649
  pharmacologic manipulation, 658
  secretory granules, 154*t*
  surface expression, 655–656
    adhesion molecule receptors, 656
    apoptosis, receptors in, 656
    chemotactic factor and complement receptors, 655
    cytokine receptors, 656
    immunoglobulin gene superfamily membrane receptors, 655–656
  tissue trafficking, 650*f*, 656–657
    chemokines, 650*f*, 656–657
    endothelial-activating cytokines, 650*f*, 656–657
    eosinophil-activating cytokines, 650*f*, 656–657
  ultrastructure and granule content, 651–652, 651*f*
Eosinophil-activating cytokines, eosinophil tissue trafficking, 650*f*, 656–657
Eosinophil-associated disease, 658. *See also specific types*
Eosinophil cationic protein (ECP), 651*f*, 652, 654
Eosinophil-derived neurotoxin (EDN), 651*f*, 652, 654
Eosinophil granule proteins, 651*f*, 652, 654
Eosinophilia, 652
  helminthic infections, 3263, 3263*t*
  tumor prognosis, favorable, 653
Eosinophilia-myalgia syndrome, 656, 675
Eosinophilic cellulitis, 27, 27*f*, 654
Eosinophilic endomyocardial disease, 660*t*, 661
Eosinophilic fasciitis, 675, 1110, 3292
  eosinophils, 656
  Lyme disease, 3292
Eosinophilic folliculitis (EF)
  with HIV
    phototherapy for, 3123
    well-controlled, 3123–3124, 3123*f*
  infantile, 2395*t*
Eosinophilic gastroenteritis, Charcot-Leyden crystal protein, 651*f*, 652
Eosinophilic granuloma, Langerhans cell histiocytosis, 2019, 2020*t*
Eosinophilic granulomatosis with polyangiitis, 660, 2551–2552. *See also* Hypereosinophilic syndromes (HES); Vasculitis
Eosinophilic leukemia, chronic. *See* Myeloproliferative hypereosinophilic syndrome
Eosinophilic panniculitis, 659
Eosinophilic pustular folliculitis (EPF), 670–671, 670*f*, 671*t*
Eosinophilic vasculitis, 2530*t*, 2533
Eosinophil peroxidase (EPO), 651*f*, 652, 654
Eotaxin, 172
Eotaxin/CCL11, atopic dermatitis, 183
Ependymoma, myxopapillary, 2167
EPHB4
  arteriovenous malformations, 2662
  capillary malformations, 2640*t*, 2642
  Sturge-Weber syndrome, 2640*t*
Ephelis, 1970–1971
  sun-induced (*See* Solar lentigo)
Ephrin B2, 28
Epicatechin, oral photoprotection, 3630
Epicatechingallate, oral photoprotection, 3630
Epidemic typhus. *See* Typhus, epidemic (louse-borne)
Epidemiology, 40–47. *See also specific disorders and topics*
  basic concepts, 40–42
  definition, 40
  measures, 45–47
    association, 45–46, 45*t*
    descriptive, 45
    patient-reported outcome, 46–47, 46*t*
    test characteristics, 46, 46*f*
  studies, 40
  study designs, 42–44, 42*f*
    analytic studies
      experimental, 42–43, 42*f*
      observational, 42*f*, 43–44
    descriptive studies, 42*f*, 44
    meta-analysis, 44
Epidermal adhesion, 232–238
  at-a-glance, 232*b*
  desmosomal proteins, 233–238 (*See also* Desmosomal proteins)
  desmosome ultrastructure, 232–233, 233*f*
Epidermal barrier, neonates, 1728
Epidermal cysts, 1812–1817. *See also* Cysts, of epidermal origin; *specific types*
Epidermal–dermal adhesion, 238–246
  anchoring fibrils, 246, 246*f*
  anchoring filaments, 245
  basement membranes, 232, 238–243, 238*t* (*See also* Basement membranes)
  epithelial lamina densa, 245–246
  hemidesmosomes, 243–245, 244*f*, 244*t*
  integrin α3β1, 245
  kindlin-1, 245
  laminins, 242*f*
Epidermal differentiation complex (EDC), 65
  atopic dermatitis, 368
Epidermal growth factor (EGF), 3540
  angiogenesis, 126*f*, 127
  ligands and antagonists

adverse effects, 3541–3542
cetuximab, 3541, 3550*t*
clinical use, 3541–3542, 3550*t*
panitumumab, 3541, 3550*t*
recombinant human EGF, 3541
wound healing, 2704*t*, 2706
Epidermal growth factor receptor (EGFR), 3565
drug development, 3565
family, 3540–3542, 3541*f*
ligands and antagonists, 3541–3542
signaling
drug interruption, 3565
in non–small-cell lung cancer, 3565
Epidermal growth factor receptor (EGFR) inhibitors, 3565–3572
afatinib dimaleate, 3559*t*, 3570–3571, 3570*f*
at-a-glance, 3565*b*
background, 3565–3566, 3566*f*
cetuximab, 3559*t*, 3567
erlotinib hydrochloride, 3559*t*, 3569–3570, 3569*f*
gefitinib, 3559*t*, 3568–3569, 3568*f*
osimertinib, 3559*t*, 3571–3572, 3571*f*
panitumumab, 3559*t*, 3568
Epidermal melanin unit, 330–331
Epidermal necrolysis, 733–745. *See also* Stevens-Johnson syndrome (SJS); Toxic epidermal necrolysis (TEN)
at-a-glance, 733*b*
clinical features, 736–738, 736*f*
cutaneous lesions, 736, 737*f*–738*f*
history, 736
mucous membrane, 736–737, 739*f*
systemic involvement, 737–738
complications and sequelae, 740–742, 741*f*, 741*t*
definition, 733, 734*t*
differential diagnosis, 739–740, 740*t*
epidemiology, 733, 734*t*
etiology, 733–735, 734*t*
histopathology, 738*f*, 739, 740*f*
historical perspective, 733
laboratory values, 738
pathogenesis, 735–736
prevention, 744–745
prognosis and clinical course, 734*t*, 742, 742*f*
treatment, 742–744, 743*t*
Epidermal nevus, 1806–1812. *See also* Nevus, epidermal
infants, 1752
neonatal, 1734
Epidermal nevus syndrome, 1811–1812, 1812*t*
Epidermal transglutaminase (eTG), dermatitis herpetiformis, 934, 1002, 1004–1005, 1006
Epidermis
aging on, 1782–1783, 1783*t*
barrier function, 143, 156
basic structure, 207, 210*f*
comparative biology, 207, 207*t*, 208*t*, 209*f*
development, 52*t*
differentiation, 53, 54*f*, 778
neonates, 1727–1728
replication, 20
structure, 49*b*, 50, 51*f*
basic, 207, 210*f*
Epidermis, cell pathology
cohesion disturbances, 22–23, 22*f*–23*f*
acantholysis, 23, 23*f*
blisters, 22, 22*t* (*See also* Blistering (blisters))
dyskeratosis, 23, 23*f*
pathology, 23–24, 24*f*
spongiosis, 22, 22*f*
differentiation disturbances, 21–22
hyperproliferation, seborrheic dermatitis, 433
kinetic disturbances, 21, 21*f*, 22*f*
Epidermis, differentiation, 63–68
at-a-glance, 62*b*
basal cells, 63–64, 63*f*, 64*t*, 65*t*
granular cells, 64–65
keratin-based, inherited bullous diseases, 64, 65*t*
keratin family and sites of expression, 64, 64*t*
regulation, epigenetic regulators, 66–67, 67*f*
chromatin remodelers, 67
DNA methylation, 66
histone modifications, 66, 67*f*
posttranscriptional regulation, 67
regulation, transcriptional regulators, 66
spinous cells, 64
stratum corneum, 66
structural markers, 63–64, 63*f*
Epidermis, growth
at-a-glance, 62*b*
proliferation, 63
stem cell niche, 62–63
stem cells, 62
Epidermis, pathology, 19–23
acantholysis, 23, 23*f*
acanthosis, 21, 21*f*
atrophy, 21, 22*f*
cell types, 19–20
dyskeratosis, 23, 23*f*
epidermal cell
cohesion disturbances, 22–23, 22*f*–23*f*
differentiation disturbances, 21–22
kinetic disturbances, 21, 21*f*, 22*f*
spongiosis, 22, 22*f*
Epidermodysplasia verruciformis (EV), 1871*t*, 1872–1873, 3100–3102, 3101*t*
at-a-glance, 1872*b*
clinical course, prognosis, and management, 1873, 3102
clinical features, 1873, 1873*f*, 3100–3101, 3101*f*
diagnosis and histology, 3102, 3102*f*
epidemiology, 1873
etiology and pathogenesis, 1873, 3096*t*, 3101
with HIV, 3118, 3118*f*
invasive cancer in, 3100, 3101*f*
squamous cell carcinoma, 1904*t*
treatment, 1873
Epidermodysplasia verruciformis (EV)–like syndromes, 3096*t*, 3100–3102, 3102*f*
Epidermoid cyst, 1813–1814, 1813*f*
Epidermolysis bullosa (EB)
dystrophic, *COL7A1*, 246
pathology
acantholysis, 23, 23*f*
blistering
dermolytic, 24
junctional, 23–24, 24f
collagen XVII mutation, 243, 244*t*
keratins, 64, 65*t*
squamous cell carcinoma, 1904*t*
Epidermolysis bullosa (EB), inherited, 1011–1030, 1029*t*. *See also specific types*
classification, 1013, 1014*f*, 1015*t*, 1029*t*
clinical features, 1013–1024, 1029*t*
dystrophic epidermolysis bullosa, 1020–1024
epidermolysis bullosa simplex, 1015–1018
junctional epidermolysis bullosa, 1018–1020
Kindler syndrome, 1024
diagnosis, 1022*f*, 1024–1025
prenatal, 305
differential diagnosis, 1025*t*
etiology and pathogenesis, 1011–1013
anchoring fibrils, 1011, 1012*f*, 1013
anchoring filaments, 1011, 1012–1013, 1012*f*
dermal-epidermal basement membrane zone, 1011, 1012*f*
hemidesmosomes, 1011, 1012, 1012*f*
keratin filaments, 1011–1012, 1012*f*
gene replacement therapy, 307
genetic counseling, 1025
historical perspective, 1011
neonatal presentation, 1745
treatment, 1025–1030
allogeneic cell therapies, 1028
antiinflammatory therapies, 1027–1028, 1028*f*
autologous cell therapies, 1030
extracutaneous
eye lesions, 1027
gastrointestinal, 1026–1027
nutrition, anemia, and cardiovascular disease, 1027
oropharyngeal lesions, 1027
psychology, 1027
infection, 1026
supportive skin care, 1026
surgical, 1026
tumors, 1026
Epidermolysis bullosa acquisita, 971–979
at-a-glance, 971*b*
blistering, subepidermal, 25
clinical features, 972–973, 973*f*
clinical presentations
Brunsting–Perry pemphigoid–like, 974*f*, 975
bullous pemphigoid–like, 974, 974*f*–975*f*
classic, 973–974, 973*f*–974*f*
immunoglobulin A bullous dermatosis–like, 975
incidence, 975, 976*f*
mucous membrane pemphigoid–like, 974*f*, 975
complications, 978
diagnosis, 978, 978*t*
differential diagnosis, 977–978, 978*t*
epidemiology, 971
etiology and pathogenesis, 246, 971–972
inflammatory, subepidermal blistering, 25
laboratory tests
direct immunofluorescence, 976, 976*f*
direct salt-split skin immunofluorescence, 977, 977*f*
enzyme-linked immunosorbent assay, 977
histopathology, 976
immunoelectron microscopy, 976–977
indirect salt-split skin immunofluorescence, 977
Western immunoblotting, 977
physical findings, related, 975–976
treatment, 978–979, 979*t*
Epidermolysis bullosa hereditaria dystrophica, nail changes, 1601, 1601*f*
Epidermolysis bullosa simplex (EBS), 65*t*, 1015–1018, 1029*t*
acantholytic epidermolysis bullosa simplex, 1017
acral peeling skin syndrome, 1015*t*, 1017
BP230 deficiency, 1012, 1015*t*, 1017
cellular defect, 781*t*
epidermolysis bullosa simplex of Ogna, 1016
epidermolysis bullosa simplex superficialis, 1017
epidermolysis bullosa simplex with mottled pigmentation, 1017
epidermolysis bullosa simplex with muscular dystrophy, 1016–1017
exophilin-5 deficiency, 1015*t*, 1017
generalized intermediate epidermolysis bullosa simplex, 1016, 1016*f*, 1029*t*
generalized severe epidermolysis bullosa simplex, 1015–1016, 1015*f*, 1029*t*
Koebner type, 1016, 1016*f*, 1029*t*

Epidermolysis bullosa simplex (EBS) (*Cont.*):
localized epidermolysis bullosa simplex, 1016, 1016*f*, 1029*t*
molecular pathology, 1017–1018
nail changes, 1601
plakophilin deficiency, 1017
short inhibitory RNA, 307
Weber-Cockayne type, 1016, 1016*f*, 1029*t*
Epidermolysis bullosa simplex of Ogna, 1016
Epidermolysis bullosa simplex superficialis, 1017
Epidermolysis bullosa simplex with limb girdle muscular dystrophy, 65*t*
Epidermolysis bullosa simplex with mottled pigmentation, 65*t*, 1017
Epidermolysis bullosa simplex with muscular dystrophy, 1016–1017
Epidermolysis bullosa simplex with progressive muscular dystrophy, plectin mutations, 245
Epidermolysis hyperkeratosis, 65*t*, 305
Epidermolytic ichthyosis, 777*t*
annular, 798, 798*f*
Blaschko's lines mosaicism, 302
cellular defect, 781*t*
clinical features, 781*t*, 795–796, 795*f*–798*f*
etiology and pathogenesis, 799
genes, 781*t*
KRT1, 777*t*
KRT10 and *KRT1*, 777*t*, 799
superficial, 777*t*
clinical features, 796–798, 797*f*
KRT2, 777*t*
Epidermolytic keratosis palmaris et plantaris, nail changes, 1601, 1601*f*
Epidermolytic palmoplantar keratoderma (EPPK), 781*t*, 821–823, 822*f*, 845*t*
Epidermophyton
diagnosis, microconidia and macroconidia, 2931, 2931*t*
tinea capitis, 1531
Epidermophyton floccosum, 2931*t*
Epifix, 2711
Epigallocatechin-3-gallate
oral photoprotection, 3630
for systemic amyloids, 2269
Epigen, 3540
Epigenetic mosaicism, 303
Epigenetics, 304–305
epidermis differentiation, 66–67, 67*f*
Epinephrine
in local anesthetics, 3711
for mastocytosis, syringes, 720
tumescent local anesthesia liposuction, 3907, 3908*t*
Epiregulin, 3540
Episodic angioedema with eosinophils, 654
Epithelial growth factor receptor (EGFR) agents. *See also specific types*
cetuximab, 3593
erlotinib, 3593
panitumumab, 3597
Epithelial lamina densa, 245–246
Epithelial-mesenchymal neoplasms of follicular germinative and follicular stromal cells, 1839*t*
desmoplastic trichoepithelioma, 1841–1842
trichoblastoma, 1840–1841, 1840*f*
trichoepithelioma, 1822*t*, 1841–1842, 1842*f*
Epithelial placode, 90–91, 90*f*
Epithelial precancerous lesions, 1857–1881. *See also specific types*
actinic keratoses, 1857–1867
arsenical keratoses, 1879–1880, 1880*f*
Bowen disease, 1867–1871 (*See also* Bowen disease)
chronic radiation keratoses, 1881*b*
chronic scar keratoses, 1881*b*
hydrocarbon keratoses, 1880*b*–1881*b*
oral cavity, potentially malignant disorders, 1876–1879
definition and terminology, 1876
erythroplakia, 1878–1879, 1879*t*
leukoplakia, 1876–1878, 1877*f*, 1878*t*
thermal keratoses, 1880*b*
viral-associated, 1871–1875, 1871*t*
anogenital tract, lower, 1871*t*, 1873–1875
anal intraepithelial neoplasia, 1871*t*, 1873*b*–1874*b*
penile intraepithelial neoplasia, 1871*t*, 1876*f*, 1975*b*
perianal intraepithelial neoplasia, 1871*t*, 1874*b*
vulvar intraepithelial neoplasia, 1871*t*, 1874*b*–1875*b*
Bowenoid papulosis, 1871–1872, 1871*t*, 1872*f*
epidermodysplasia verruciformis, 1871*t*, 1872–1873, 1873*f*
HPV with, 1871, 1871*t*
Epithelioid cells, 27
Epithelioid hemangioma, 27, 27*f*, 667–669, 2043*t*
Epithelioid perineuroma, 2161
Epithelioid schwannoma, 2155
Epithelioma, sebaceous, 33–34
Epithelioma cuniculatum, 1908
Eponychium, 106, 107*f*, 3774, 3775*f*
Epratuzumab, for Sjögren syndrome, 1181
ε-aminocaproic acid, for urticaria, 702
Epstein-Barr virus (EBV), 2998–3002, 3015*t*
at-a-glance, 2998*b*
clinical course and prognosis, 3001–3002
clinical features, 2999–3001
ampicillin rash, 2999–3000, 2999*f*
genital ulcers, non-sexually related acute, 3000, 3000*f*
hydroa vacciniforme–like lymphoproliferative disease, 3001
infectious mononucleosis, 2999–3000, 2999*f*
lymphomatoid granulomatosis, 3001
nasal-type extranodal natural killer/T cell lymphoma, 3000
neoplastic conditions, 3000–3001, 3000*t*
other nonneoplastic association, 3000
diagnosis, 3001
differential diagnosis, 3002*t*
epidemiology, 2998
etiology and pathogenesis, 2998–2999
Gianotti-Crosti syndrome with, 3000
for hemophagocytic lymphohistiocytosis, 2032
with HIV, advanced, 3113–3114
hydroa vacciniforme and, 1635, 1637
management, 3002
Sjögren syndrome, 1172
Epstein-Barr virus (EBV)-associated natural killer (NK)/T-cell lymphoma, 2074
Epstein pearls, 1731, 1814
Equestrian (cold) panniculitis, 1254*t*, 1280–1282, 1282*t*
ERAP1, psoriasis, 479
ErbB1, 3565. *See also* Epidermal growth factor receptor (EGFR)
ErbB2 (HER2/neu), 336, 3565
ErbB3 (HER3), 3565
ErbB4 (HER2), 3565
ERCC2, 295
trichothiodystrophy, 780*t*, 808
ERCC3, trichothiodystrophy, 780*t*, 807
Erdheim–Chester disease, 2038
ERG, dedifferentiated liposarcoma, 2190
Ergosterol, 3436, 3437*f*
ERK
Langerhans cell histiocytosis, 2021, 2022*f*
squamous cell carcinoma, 315
Erlotinib, 3593–3594
acneiform eruptions from, 1452
for non–small-cell lung cancer, 3566
Erlotinib hydrochloride, 3559*t*, 3569–3570, 3569*f*
Erosive and ulcerative lichen planus, 532, 532*f*
Erosive pustular dermatosis, 1531
Ertapenem, systemic, 3419
for necrotizing fasciitis, 2775, 2776*t*
Eruptive histiocytoma, 2034
Eruptive nevi, 1953
Eruptive pseudoangiomatosis, 3013, 3015*t*
Eruptive xanthomas, 2274–2275, 2275*f*
with diabetes mellitus, 2497, 2497*f*
pathology, 2284
Erysipelas, 2746–2754
at-a-glance, 2746*b*
clinical course and prognosis, 2752
clinical features, 2747–2748
definitions, 2746
diagnosis, 2750–2751, 2751*t*
differential diagnosis, 2751–2752, 2751*t*, 2752*f*
in elderly, 1787
epidemiology, 2746
etiology and pathogenesis, 2748–2749, 2749*t*
historical perspective, 2746
management, 2752–2754, 2753*t*, 2754*t*
prevention, 2754
risk factors, 2750
Erysipeloid, 2829*t*, 2846–2848, 2847*f*
occupational, 448–449
Erysipelothrix rhusiopathiae, occupational exposure, 448–449
Erythema, 8–9, 8*t*, 16, 16*t*. *See also specific disorders; specific types and disorders*
acral, from cytotoxic agents, 3483–3484, 3484*f*, 3484*t*
cold, 1675
figurate, 16, 16*t*
morbilliform, 16
persistent, differential diagnosis, 1438*t*
postoperative, 3724
reactive, 2454–2456
erythema gyratum repens, 771–772, 772*f*, 773*t*, 2442*t*, 2454–2455, 2454*f*
necrolytic migratory erythema, 2455–2456, 2455*f*
targetoid, 16, 16*t*
urticarial, 7*f*, 16, 16*t*
Erythema ab igne, hypermelanosis, 1373, 1373*f*
Erythema annulare centrifugum, 765–767, 766*f*–767*f*, 773*t*
Erythema arthriticum epidemicum, 2838–2839
Erythema contusiformis, 1255
Erythema dyschromicum perstans (EDP), 1384–1385, 1384*f*
Erythema elevatum diutinum (EED), 2530*t*, 2531, 2562–2566
associated conditions, 2563–2564, 2564*t*
at-a-glance, 2562*b*
clinical features, 2562, 2563*f*
diagnosis, 2564, 2564*f*, 2565*t*
differential diagnosis, 2564–2565, 2565*t*
epidemiology, 2562
historical perspectives, 2562
management, 2565–2566
pathogenesis, 2562–2563
Erythema gyratum repens, 771–772, 772*f*, 773*t*
paraneoplastic, 2442*t*, 2454–2455, 2454*f*
Erythema induratum and nodular vasculitis (EI/NV), 1252*t*, 1259–1262
at-a-glance, 1259*b*
clinical course and prognosis, 1261
clinical features, 1259, 1260*f*

diagnosis, 1260–1261, 1261*f*
differential diagnosis, 1261, 1261*t*
epidemiology, 1259
etiology and pathogenesis, 1259–1260
management, 1261–1262
Mycobacterium tuberculosis, 1252*t,* 1259–1261, 2532
Erythema induratum of Bazin, 2869
Erythema infectiosum, 2994–2998, 3015*t*. *See also* Parvovirus B19
Erythema marginatum (rheumaticum), 769–771, 770*f,* 773*t*
acute rheumatic fever, 1159, 1159*f,* 1159*t*
Erythema migrans, 767–769, 768*f,* 773*t,* 3288–3290, 3289*f*–3291*f,* 3290*t,* 3294*t*. *See also* Lyme borreliosis
Erythema multiforme (EM), 723–731
at-a-glance, 723*b*
clinical features, 724–727
cervical lymphadenopathy and genital erosions, 726
complications, 726–727
cutaneous, 724–726, 725*f*–726*f*
fever, 726
history, 724
mouth erosion, 726
noncutaneous, 726, 726*f*–727*f*
course and prognosis, 730
definitions and classification, 723–724
diagnosis, 728–730
approach, 728, 729*f*
etiology, underlying, 729–730
histopathology, 728–729, 729*f*
laboratory studies, 728
differential diagnosis, 730, 731*t*
epidemiology, 724
etiology and pathogenesis, 727–728, 727*f,* 727*t*
interface/lichenoid changes, 25
management, 730
prevention, 730
Erythema multiforme-like allergic contact dermatitis, 396–397, 396*t*
Erythema necrotisans. *See also* Leprosy
clinical course and prognosis, 2915, 2915*f*
clinical features, 2915, 2915*f*
histopathology, 2910–2911
Erythema nodosum, 1252*t,* 1255–1259
at-a-glance, 1255*b*
clinical course and prognosis, 1258
clinical features, 1255, 1256*f*
diagnosis, 1256–1257, 1258*f*
differential diagnosis, 1257, 1258*t*
epidemiology, 1255
etiology and pathogenesis, 1256, 1257*t*
helminthic infections, 3259
management, 1258–1259
sarcoidosis, 575
single-agent, 1255
subcutaneous fat inflammation, 29, 29*f*
Erythema nodosum leprosum (ENL), 2529. *See also* Leprosy
clinical course and prognosis, 2914–2915, 2914*t,* 2915*f*
histopathology, type 2 reaction, 2909–2910, 2912*f*
leprosy, 2904, 2905*f*
Erythematous actinic keratosis, 1858, 1858*f*
Erythema toxicum neonatorum, 1731, 1731*f*
Erythoxylum coca, 1709
Erythrasma, 2741–2743, 2742*f*
Erythroderma. *See also specific disorders*
cardiovascular disease, 2427
neonatal, 1739–1740
Erythrodermic psoriasis, 461, 462*f*
PUVA for, 3670
Erythrokeratodermia variabilis et progressiva (EKVP), 777*t,* 800–802
cellular defect, 781*t*
clinical course, prognosis, and management, 802
clinical features, 800, 801*f*
etiology and pathogenesis, 801
genes
GJA1, 801, 801*f*
GJB3, 801, 801*f*
GJB4, 801, 801*f*
Erythroleukoplakia, 1878
Erythromelalgia, 2684–2686, 2685*f,* 2686*t*
SCN9A, 122, 2685
Erythromelanosis follicularis faciei et colli (EFFC), 867
Erythromycin. *See also* Macrolides
for actinomycosis, 2880
for acute rheumatic fever, 1160
for bacillary angiomatosis, 2806
with HIV, 3114
for bullous pemphigoid, 952, 952*t*
for cat scratch disease, 2805
for chronic bullous disease of childhood, 994*t,* 999
for diphtheria, 2853
for gonorrhea prophylaxis, in newborns, 3210, 3210*t*
for granuloma inguinale, 3205, 3206*t*
for group A *Streptococcus* impetigo and ecthyma, 2739, 2739*t*
for listeriosis, 2841
for pityriasis lichenoides, 515, 515*t*
for pityriasis rosea, 524
for staphylococcal impetigo, ecthyma, and folliculitis, 2730, 2731*t*
for trench fever, 2805
for verruga peruana, 2806
Erythromycin, oral/systemic
for acne vulgaris, 1405
for chlamydia, 3217, 3217*t*
for dissecting folliculitis, 1530
for lymphogranuloma venereum, 3198, 3198*t*
for *S. aureus,* in folliculitis decalvans, 1529
for yaws, 3181
Erythromycin, topical
for acne vulgaris, 1403*t,* 1404
for erythrasma, 2743
for hidradenitis suppurativa, 1490
for perioral dermatitis, 1455
for pitted keratolysis, 2741
for rosacea, 1439
for *S. aureus,* in folliculitis decalvans, 1530
for trichobacteriosis, 2744
Erythromycin base. *See also* Macrolides, systemic
for chancroid, 3189–3190, 3190*t*
for skin and soft-tissue infections, dosing, 3410*t*
Erythronychia, 1568, 1569*t,* 1570*f*–1571*f*
Erythroplakia (erythroplasia), 1878–1879, 1879*t*
Erythroplasia of Queyrat (EQ), 1871*t,* 1875*b,* 1876*f*
Erythropoietic protoporphyria (EPP), 2235*t,* 2237t, 2245–2249. *See also* Protoporphyrias
hypertrichosis from, 1565
photoprotection for, 3632, 3632*t*
Erythrose peribuccal of Brocq, 1383
Erythrose pigmenta faciei, 1383
Erythrose pigmentosa peribuccalis, 1383
Escitalopram, photodistributed telangiectasia, 1661
E-selectin, 180
cutaneous necrotizing venulitis, 2534
dermatitis herpetiformis, 1005
eosinophils, 657
inflammation
acute, 124, 124*f*
chronic, 124*f,* 125
leprosy, 2904, 2905*f*
from mast cell granules, 154, 154*t*
Esophageal disorders, cutaneous manifestations, 2434
Esophageal lichen planus, 534
Essential fatty acids (EFAs), 2203–2204, 2204*t*
deficiency, neonates, 1740
Ester anesthetics, local, 3710*t,* 3711. *See also specific types*
Estrogen(s)
acute hepatic porphyrias, 2250–2251
cutaneous manifestations, 2515–2516, 2515*f*
dermatitis, 2242, 2515
porphyria cutanea tarda, 2239–2240
skin aging and, 1782, 1782*t*
thermoregulation and hot flushes, 121–122
Estrogen replacement therapy, 2515
for graft-versus-host disease, genital, 2335
for porphyria, 2242
Etanercept, 169, 175, 3536*f,* 3537, 3549*t*
for adamantiades–Behçet disease, 2575*t*
for epidermal necrolysis, 744
for graft-versus-host disease, 2333
granuloma annulare from, 567
for hyperimmunoglobulinemia D with periodic fever syndrome/mevalonate kinase deficiency, 635
for IBD-related erythema nodosum, 1259
for lupus erythematosus, 1057
for Majeed syndrome, 644
for psoriasis, 469*f,* 487*t,* 493–494
for psoriatic arthritis, 1136*t,* 1137
for pyoderma gangrenosum, 614*t*
for pyogenic arthritis, pyoderma gangrenosum, and acne syndrome, 643
for rheumatoid arthritis, 1152
for TNF receptor-associated periodic syndrome, 637
Ethambutol, for tuberculosis, 2862*t*–2863*t*
Ethanolamine oleate, 3879
Ethyl alcohol, 3715
Ethyl alcohol with formalin, biopsy specimen, 19
Ethylenediamine dihydrochloride, allergic contact dermatitis from, systemic reactivation, 402, 403t
Etidocaine, 3710*t*
Etidronate, for pseudoxanthoma elasticum, 1233
Etoposide
for cytophagic histiocytic panniculitis, 1278
for hemophagocytic lymphohistiocytosis, 2032
for Merkel cell carcinoma, 1931
for reactive phagocytic syndrome, in adult-onset Still disease, 1158
Etravirine, 3507–3508, 3509*t*
Etretinate. *See also* Retinoid(s), oral
lymphocyte-rich infiltrate from, simulating lymphoma, 2115*f*
metabolism and pharmacokinetics, 3399
for papuloerythroderma of Ofuji, 672
Eumelanin, 330
structure and function, 336
synthesis, 337, 338*f*
Eumelanogenesis, 337, 338*f*
Eumelanosomes, 330
Eumycetoma, 2877*t,* 2966*t,* 2969–2971, 2969*f,* 2970*t*
Euphorbia peplus, 1866
Euproctis chrysorrhoea, 3334
Eutectic mixture of local anesthetics (EMLA) cream, 3611, 3712
for child procedures, 1755

Euxyl K400, allergic contact dermatitis from, 404
Evaluation techniques
  adolescents, 1757
  in children, 1754, 1754*f*
  infants, 1750, 1751*f*, 1751*t*
EVER1, epidermodysplasia verruciformis, 1873, 3101
EVER2, epidermodysplasia verruciformis, 1873, 3101
Everolimus, 3527–3529, 3594
  for necrolytic migratory erythema, 2456
  for tuberous sclerosis complex, 2489
Evidence, levels of, 44
Evidence/strength ratings, category, 1488*t*
Evolocumab, for dyslipidemia, 2287
EV-plane warts, 1873, 1873*f*
Ewing sarcoma, 2164
EWSR1-DDIT3 fusion, myxoid liposarcoma, 2191
Examination. *See* Physical examination
Exanthem. *See also specific disorders and types*
  definition, 12
  viral, lymphocytic cuffing of venules, 27
Exanthematic pustular psoriasis, 462
Exanthematous eruptions, drug-induced, 749–750, 750*f*–751*f*, 750*t*
Exanthematous viral diseases, 2989–3015. *See also* Viral diseases, exanthematous; *specific diseases*
Exanthem subitum, 3015*t*
  HHV-6, 3007–3008
  HHV-7, 3009
Excimer laser. *See* Laser, excimer
Excisional surgery and repair, 3726–3734, 3731–3732. *See also specific types*
  at-a-glance, 3726*b*
  complications, 3758
  elliptical excision, 3727–3731
    ellipse variations, 3731–3732
  equipment, 3726–3727, 3727*f*
  excision without closure, 3732–3734
  goal, 3726
  monitoring and follow-up, 3759
  planning and execution, case-by-case, 3726
  postoperative care, 3757–3758
  revision, of standing cones of tissue, 3731, 3732*f*
Exercise
  for Ehlers-Danlos syndromes, 1223
  for intermittent claudication, 2674, 2674*t*
  for xanthomas and lipoprotein disorders, 2285
Exercise-induced anaphylaxis, 699
Exfoliants, 3807. *See also specific types and therapies*
  for skin pigmentation, 3811–3812
Exfoliative dermatitis, atopic dermatitis, 368
Exfoliative scale, 6*t*
Exfoliative toxin diseases, 2757–2761
  clinical features, 2758–2761
    generalized forms, 2759–2760, 2759*f*–2760*f*
    intermediate forms, 2760–2761
    localized forms, 2758, 2758*f*–2759*f*
  diagnosis and differential diagnosis, 2761
  etiology and pathogenesis, 2758
  treatment and prognosis, 2761
Exfoliative toxins, 2758
Exogen, 93*f*, 98
  definition, 1511
  modulated, 1511
Exons, 291
Exophiala jeanselmei, phaeohypomycosis, 2966*t*, 2972
Exophilin-5 deficiency, epidermolysis bullosa simplex, 1015*t*, 1017
Experimental studies, 40, 42–43, 42*f*
EXPH5, epidermolysis bullosa simplex, 1015*t*, 1017, 1018
Explanatory studies, 42
  vs. pragmatic trials, 43, 43*t*
Expressivity, genotype, 295
Exsiccation eczematoid irritant contact dermatitis, 444
EXT1, tricho-rhino-phalangeal syndrome, 2391
Extensor distribution, 11
External-beam radiotherapy
  modulation, 3688–3689, 3688*f*
  for mycosis fungoides, 2090
External carotid artery, 3703–3705, 3704*f*
External ear, landmarks, 3698–3699, 3698*f*
External nasal nerve, 3702*f*, 3703, 3703*t*
Extracellular adherence protein (EaP), 2727
Extracellular matrix
  dermis, 246–247
  inflammatory pathology, 28–29, 29f
  pathology, 28–29, 29f
Extracellular signal-regulated kinase (ERK), 3580
Extracellular signal-regulated kinase (ERK) inhibitors, 3586
Extracorporeal photochemotherapy (ECP), 3677–3678
  for allograft rejection, 3678
  at-a-glance, 3664*b*
  for cutaneous T-cell lymphomas, 2092, 2093*t*, 2094
  for ephelides, 1377
  for epidermolysis bullosa acquisita, 978
  for graft-versus-host disease, 3678, 3678*t*
  historical perspective, 3677
  for hypereosinophilic syndromes, 665
  mechanism of action, 3677–3678
  for Sézary syndrome, 3678, 3678*t*
  side effects, 3678
  treatment method, 3677
  uses, 3677
Extracorporeal photopheresis (ECP)
  for atopic dermatitis, 380
  for graft-versus-host disease
    acute, 2332–2333
    chronic, 2334
  for pityriasis rubra pilaris, 504
Extracutaneous melanocytes, 332
Extramammary Paget's disease (EMPG), 1934–1941. *See also* Paget's disease
  clinical course and prognosis, 1939
  clinical features, 1934–1935, 1935*f*
  definition, 2004
  diagnosis, 1937, 1937*t*
  differential diagnosis, 1936*t*
  direct tumor involvement of skin, 2462
  epidemiology, 1934
  etiology and pathogenesis, 1935–1936
  historical perspective, 1934
  immunohistochemistry markers, 1937–1938, 1938*t*
  management, 1940–1941, 1940*f*
  mitochondrial DNA mutations, 300
  Mohs micrographic surgery for, 3769
Extranodal marginal zone (B-cell) lymphoma (EMZL), 2097, 2097*t*, 2099–2100, 2099*t*
Extranodal natural killer/T-cell lymphoma, nasal type, 2087, 2087*f*
Extravasation, chemotherapy, local injury, 3486, 3486*f*
Extrinsic skin aging, 1780–1782, 1781*t*
Eyes
  disease, psoriatic arthritis with, 974*f*–975*f*, 1129–1130
  openers, 1711
  tuberous sclerosis complex, 2485
Ezetimibe, on LDL-C, 2286

F

F1P1L1-PDGFRA mutation, hypereosinophilic syndromes, 661–663, 664*f*
FabAV, 3343–3344
Fabry disease, 2292–2303
  anhidrosis, 1466
  at-a-glance, 2292*b*
  clinical features, 2293–2298, 2300*t*
    angiokeratoma, 2293, 2293*f*–2295*f*
    angiomas and telangiectases, 2293*f*, 2295
    disease severity and, 2295
    facial features, 2296, 2297*f*
    histopathology, 2293–2295, 2296*f*
    lower-limb edema and lymphedema, 2297, 2297*f*
    Raynaud phenomena, 2298
    sweating abnormalities, 2297–2298
  diagnosis, 2296*f*, 2299
  differential diagnosis, 2299–2300, 2300*t*
    angiokeratoma corporis diffusum, 2300, 2301*t*
    angiokeratomas, 2299–2300, 2300*t*
  epidemiology, 2292
  etiology and pathogenesis, 2292, 2293*f*
  genetic counseling, 2303
  natural history, 2292, 2293*f*
  noncutaneous findings, 2293*f*, 2298*t*
    cardiac, 2299
    cerebrovascular, 2299
    gastrointestinal, 2299
    neurologic, 2298
    other, 2299
    renal, 2299
    sensory organ, 2298–2299
  prognosis and clinical course, 2300
  treatment, 2300–2303
    chaperone-based enzyme enhancement therapy, 2303
    enzyme replacement therapy, 2303
    multidisciplinary, 2300–2302, 2302*t*
    symptomatic
      organ system therapies, 2302–2303
      skin-directed therapies, 2302
  X-linked recessive disorder, 297, 297*t*
Facial Afro-Caribbean eruption (FACE), 1454
Facial anatomy, cutaneous surgical, 3697–3703
  at-a-glance, 3697*b*
  cosmetic units, 3698–3699, 3698*f*
  facial expression muscles, 3703, 3704*f*
  facial motor nerves, danger zones, 3699–3702, 3700*t*
    facial nerve, marginal mandibular branch, 3699, 3700*t*, 3701
    facial nerve, temporal branch, 3699, 3700*t*, 3701, 3701*f*
    spinal accessory nerve, 3699, 3700*t*, 3701–3702
  free margins, 3699
  importance, 3697
  lymphatics, 3703, 3704*f*
  relaxed skin tension lines, 3699, 3699*f*
  sensory nerves, 3702–3703, 3702*f*, 3703*t*
  superficial musculoaponeurotic system, 3698
  topographic anatomy, 3698–3699, 3698*f*
  vascular anatomy, face, 3703–3705, 3704*f*
Facial artery, 3703, 3704*f*
Facial expression, muscles, 3703, 3704*f*
Facial melanosis and pigmented contact dermatitis, 1381–1382, 1382*f*
Facial motor nerves, danger zones, 3699–3702, 3700*t*
  facial nerve
    marginal mandibular branch, 3699, 3700*t*, 3701
    temporal branch, 3, 3700*t*, 3701, 3701*f*
  spinal accessory nerve, 3699, 3700*t*, 3701–3702
Facial rejuvenation, 3911
Factitial and traumatic panniculitis, 1254*t*, 1282*b*, 1282*f*
Factitial dermatitis, 1702–1703

Factitious disorders, 1702–1703
Factor IX, 119
Factor IXa, 119
Factor X, 119
Factor Xa, 119
Factor XIIIa
  juvenile xanthogranuloma, 2032
  xanthoma disseminatum, 2036
FALDH (ALDH10, ALDH3A2), Sjögren-Larsson syndrome, 779*t*, 781*t*
False negative, 46, 46*f*
False positive, 46, 46*f*
Famciclovir, 3497–3498
  dosing regimens, 3498, 3498*t*
  for herpes simplex virus, 3029–3031, 3030*t*–3032*t*
  for herpes zoster
    immunocompetent, 3053, 3053*t*
    immunocompromised, 3053*t*, 3054
    ophthalmic zoster, immunocompetent, 3053, 3053*t*
  indications, 3497–3498
  mechanism of action, 3494*f*, 3497
  pharmacokinetics, 3497
  side effects and precautions, 3498
  for varicella-zoster virus, 3051
    with HIV, 3118
    immunocompetent
      adolescents and adults, 3052, 3052*t*
      children, 3052, 3052*t*
    immunocompromised, 3052, 3052*t*
Familial adenomatous polyposis, 2436
Familial atypical multiple mole-melanoma syndrome, 1990, 2446*t*
Familial benign pemphigus, acantholysis, 23, 23*f*
Familial café-au-lait syndromes. *See also specific types*
  Bloom syndrome, 1361, 2342, 2343*t*, 2345*t*, 2361–2362, 2445*t*
  Legius syndrome, 1360, 2473
  McCune-Albright syndrome, 302, 1361
  neurofibromatosis type 1, 1361
  Silver-Russell syndrome, 1361
  Watson syndrome, 1361
Familial cold autoinflammatory syndrome (FCAS), 621–625, 623*t*. *See also* Cryopyrin-associated periodic syndromes
Familial cold urticaria, 1675
Familial cold urticaria syndrome, 689
Familial combined hyperlipidemia, 2281
Familial dysautonomia (FD), hyperhidrosis, 1464
Familial Hibernian fever, 636
Familial hypercholesterolemia, type IIa hyperlipidemias, 2281
Familial hypertriglyceridemia, 2282
Familial hypoalphalipoproteinemia, 2282
Familial lentiginosis syndromes, 1358–1360. *See also specific types*
  Bannayan-Riley-Ruvalcaba syndrome, 1360, 2172, 2173*t*
  Carney complex, 1359, 2444*t*
  centrofacial lentiginosis, 1360, 1968
  characteristics, 1358
  LEOPARD syndrome, 1359, 1360*f*, 1968
  Peutz-Jeghers syndrome, 1359, 1359*f*, 1968, 2434*t*, 2436, 2445*t*
Familial Mediterranean fever (FMF), 631–633, 633*f*
  Sweet syndrome, 595
Familial partial lipodystrophy (FPL), 1295, 1297–1298, 1297*f*
Familial progressive hyperpigmentation with or without hypopigmentation, hyperpigmentation, 1387
Familial wool hair, 1545
Famine fever, 3318–3319. *See also* Typhus, epidemic (louse-borne)
Famotidine. *See also* Antihistamines, H_2
  dosing regimens, 3458*t*
  for mastocytosis, 719, 719*t*
FANC, Fanconi anemia, 2365
FANCA-N, squamous cell carcinoma, 1904
FANCD1 (BRCA2), Fanconi anemia, 2365
Fanconi anemia (FA), 2364–2366, 2445*t*
  clinical features, 2344*t*, 2364–2365, 2365*f*
  diagnosis and differential diagnosis, 2344*t*, 2365–2366
  epidemiology, 2364
  etiology and pathogenesis, 2365
  genome instability, spontaneous, 2342
  mechanisms, 2345*t*
  squamous cell carcinoma, 1904*t*
Fanning, 3911, 3913*f*
Fantasy, 1711
FAS, cutaneous T-cell lymphomas, 2075, 2076*f*
Fasciitis
  eosinophilic, 675, 1110, 3292
  necrotizing, 2770–2775 (*See also* Necrotizing fasciitis)
Fascin
  Langerhans cell histiocytosis, 2027*t*
  progressive nodular histiocytosis, 2040
  Rosai-Dorfman disease, 2031
Fasciola hepatica, 3252*t*
  biliary disease, 3261
  exposure and symptom onset interval, 3259, 3260*t*
  exposure history, 3254
  hepatitis, 3261
  hepatomegaly, 3261
  life cycle, 3253
  migration, through eye, 3261
  migratory skin lesions, 3255*t*, 3256
  progression and duration, 3259, 3260*t*
Fas ligand (FasL), 168
Fat
  grafting, for burn scars, 1690
  reduction, noninvasive and minimally invasive, 3862–3865
    adaptations, anatomic area and skin type, 3863
    complications, 3863
    devices and technologies, 3862–3863
    indications and patient selection, 3862, 3862*f*
    modes of action, 3863, 3864*f*–3865*f*
    outcomes, expected, 3863–3865
  sick, 2286
  subcutaneous, inflammatory reactions, 29–30, 29*f*
  transfer, autologous, 3913*t*, 3917–3918, 3918*t*, 3919*f*
FAT, 314
FAT4, Hennekam lymphedema-lymphangiectasia, 2640*t*
FATP4 (SCL27), ichthyosis prematurity syndrome, 779*t*, 806
Fat-soluble vitamins, 2204–2211, 2204*b*, 2280. *See also* Vitamin(s), fat-soluble
Fatty acids, essential (EFAs), 2203–2204, 2204*t*
Faun tail, 1564–1565, 1736
Favre-Racouchot syndrome, 1453
Favus, 2926*t*
FBN1, Marfan syndrome, 1227
FCGR2A, Kawasaki disease, 2584
FcγRI, eosinophils, 655–656
FcγRII (CD32), eosinophils, 655–656
FcγRIII, eosinophils, 655–656, 658
FcεRI
  type I hypersensitivity, 691–692, 691*f*
  urticaria, 695
FDFR1, hypereosinophilic syndromes, 662
FDPS, porokeratosis, 902*t*
Febrile ulceronecrotic Mucha–Habermann disease (FUMHD), 511, 512*f*
FECH, erythropoietic protoporphyria, 2235*t*, 2236*f*, 2246
Felodipine
  photodistributed telangiectasia, 1661
  for Raynaud phenomena, 2620–2621, 2621*t*
Felon, staphylococcal, 2725, 2726*f*
Felty syndrome ulcers, rheumatoid arthritis, 1150–1151, 1150*f*
Female genital anatomy, older child, 1754, 1755*f*
Female pattern androgenetic alopecia
  Christmas tree pattern, 1497, 1498*f*
  Ludwig type, 1496, 1497*f*
  Sinclair scale, 1496, 1497*f*
Female pattern hair loss (FPHL), telogen effluvium, 1513–1514
Femoral vein, 3871–3872, 3872*f*
Ferguson-Smith syndrome, squamous cell carcinoma, 1904*t*
FERMT3, leukocyte adhesion deficiencies, 2412*b*
Ferrochelatase (FECH), 2235, 2236*f*
Fexofenadine. *See also* Antihistamines, H_1
  dosing regimens, 3454–3455, 3455*t*
  for mastocytosis, 719, 719*t*
  for pruritus
    in lichen nitidus, 558, 558*t*
    in lichen simplex chronicus, 391
    in prurigo nodularis, 391
Fgf, 89, 90*f*
FGF, hair development, 27
Fgf5, 97
FGF23, tumoral calcinosis, 2311
FGFR3
  benign lichenoid keratoses, 1973
  keratinocytic epidermal nevus, 1808
  seborrheic keratoses, 1800, 1800*t*
  solar lentigo, 1971
FH, leiomyoma, 2130, 2131*t*, 2135, 2136
Fialophora verrucosa, 2966*t*, 2971–2972, 2971*f*–2972*f*
Fiberglass dermatitis, 417
Fiber lasers, 3825
Fiber optics, laser energy delivery, 3825
Fibrates, on triglycerides, 2286
Fibrillin, Marfan syndrome, 1227
Fibrillopathies/fibrillinopathies, 1227
Fibrin degradation products (FDPs), in chronic spontaneous urticaria, 693
Fibrinogen, inflammation, 124
Fibrinoid necrosis, 27
Fibroblast, 49, 1163
  development, 53–55
  heterogeneity, 55
  papillary, 55
  reticular, 55
  wound healing, 2701*f*–2703*f*, 2703
Fibroblast disorders, 1163, 1165*t*. *See also specific types*
  scleredema, 1163–1166, 1164*t*
  scleromyxedema, 1164*t*, 1166–1168, 2442*t*, 2444–2446
Fibroblast growth factor (FGF), 3542
  wound healing, 2704*t*, 2707
Fibroblast growth factor 1 (FGF-1), angiogenesis, 126*f*, 127
Fibroblast growth factor 2 (FGF-2)
  angiogenesis, 126*f*, 127
  tumor angiogenesis, 128, 128*f*
  wound healing, 128, 128*f*
Fibroblast growth factor 5 (FGF-5), hair follicles, 89, 90*f*, 97
Fibrodysplasia ossificans progressiva, 2312
Fibroepithelioma of Pinkus (FEP), 1888. *See also* Basal cell carcinoma
Fibrofolliculoma, 1822*t*, 1839*t*, 1842–1843, 1843*f*
Fibrohistiocytic tumors, pathology
  atypical fibroxanthoma, 36–37
  dermatofibroma, 36, 36*f*
  dermatofibrosarcoma protuberans, 36, 37*f*
Fibrolipomatous hamartoma of nerve, 2175, 2175*f*

Fibronectin (FN)
  inflammation, 124
  wound healing, 2703
Fibropathy, 1163
Fibrosis. *See also specific disorders*
  eosinophil-induced, 656
  hepatic, 3261
  nephrogenic systemic, 1163, 1165*t*, 1168, 3651
  oral submucous, betel, 1713
  from radiotherapy, 3691*t*
  rosacea, 1432, 1433*f*
  systemic sclerosis, 1092*f*, 1095
    pulmonary, 1101
Fibrous dermis, 28–29, 29f
Fibrous hamartoma of infancy, 1743
Fibroxanthoma, atypical, 36–37
Fibula nolitangere, 3350, 3350*f*
Fibulins, 242
Fick's laws, 3364
Fiddle-back spiders, 3326–3327, 3326*f*–3327*f*
Fiddler's neck, 1451
Field cancerization, 1858, 1859*f*
Field-targeted photodynamic therapy, for actinic keratosis, 1866
Fiessinger–Leroy syndrome. *See* Reactive arthritis
Fifth disease, 2994–2998, 3015*t*. *See also* Parvovirus B19
Figurate erythemas, 16, 16*t*
  lymphocytic cuffing of venules, 27
Filaggrin
  atopic dermatitis, 420
  degradation, 216–217, 216*f*
  function, 783
  gene mutations, 216
    atopic dermatitis, 196, 420
    disease associated with, 216
  granular cells, 64
  haploinsufficiency, 208*t*, 217
  ichthyosis vulgaris, 777*t*, 783
  keratin cytoskeleton, 216–217, 216*f*
  natural moisturizing factors, 208*t*, 217
  stratum corneum, 216
Filariasis, 3267–3269. *See also specific types*
  classification and types, 3252*t*, 3267
  clinical features
    cutaneous
      loiasis, 3252*t*, 3256*f*, 3268, 3268*f*
      mansonelliasis, 3252*t*, 3268–3269
      onchocercosis, 3252*t*, 3269
    lymphatic, 3268, 3268*f*
  diagnosis, 3269
  epidemiology, 3267–3268
  exposure and symptom onset interval, 3259, 3260*t*
  management, 3265*t*, 3269
  progression and duration, 3259, 3260*t*
  pulmonary nodules, 3261
  urticaria and pruritus, 3258–3259, 3258*t*
  vector, 3254
Filgotinib, for lupus erythematosus, 1058
Filiform warts, 3098, 3098*f*
Fillers
  for acne vulgaris, 1411
  dermal, 3911, 3912*t*
    for acne vulgaris, 1411
  inflammatory reactions, 29
Film developers, lichenoid contact dermatitis, 538
Filobasidiella bacillispora, 2982
Filobasidiella neoformans, 2982
Finasteride
  for androgenetic alopecia, 1504
  for female pattern hair loss, 3931*b*
  for frontal fibrosing alopecia, 547
  for hirsutism, 1562*t*, 1563
  for hyperandrogenism, 2518
  for male pattern baldness, 3931*b*
Finger systolic pressure, Raynaud phenomena, 2618
Finger-tip unit (FTU), 3371
FIP1L1-PDGFRA
  hypereosinophilic syndromes, 661–662
  myeloproliferative hypereosinophilic syndrome, 658
Fire ants, 3333
Fire corals, 3349–3350, 3349*f*
Fish bites, 3358–3359, 3358*f*
Fish-handler's disease, 448–449
Fish oils, 2203
Fish spines, venomous, 3356–3358
  catfish, 3357
  prevention, 3357
  scorpionfish, 3357, 3357*f*
  stingrays, 3356, 3356*f*
  symptoms, 3357
  treatment, 3358
  weeverfish, 3357
Fish tank granuloma, 2871, 2873*f*, 2873*t*
Fissure, 6–7
Fitzpatrick (dimple) sign, 12*t*
Fitzpatrick skin phototype, chemical peels and dermabrasion, 3895, 3896*t*
5-Amino-levulinic acid (5-ALA), photodynamic therapy, 274–275
5α-reductase inhibitors, for hyperandrogenism, 2518
Fixed drug eruptions (FDEs), 753–754, 754*f*
  cytotoxic T cells, 194
  hypermelanosis, 1365, 1367*f*
  hypermelanosis from, 1383
Fixed drug reaction
  clinical features, 4*f*
  interface/lichenoid changes, 25
FK-506. *See* Tacrolimus
FKBP14, kyphoscoliotic Ehlers-Danlos syndrome, 1213*t*, 1216*t*
Flagellate mushroom dermatitis, 1372
Flag sign, kwashiorkor, 2202, 2202*f*. *See also* Protein-energy malnutrition (PEM)
Flame burn, 1682
Flame figures, Wells syndrome, 666, 666*f*
Flap surgery, 3734–3753
  advancement flaps, 3734–3740
    bilateral, 3737–3738, 3738*f*
      H-plasty, 3737
      T-plasty, 3737–3738, 3738*f*
    crescentic, 3738, 3739*f*
    east–west, 3739, 3741*f*
    movement and key suture, 3734
    Rintala, 3739
    single, 3735–3737, 3735*f*
      cheek, 3735–3736, 3736*f*–3737*f*
      helical rim, 3736–3737, 3737*f*
      L-plasty, 3735, 3735*f*
    tension vectors, 3735
    V-to-Y, 3738–3739, 3740*f*
  complications, 3758
  equipment, 3726–3727, 3727*f*
  indications, 3734
  interpolation flaps, 3748–3753
    Abbé, 3751–3752
    classification and use, 3748
    nasolabial, 3750–3751, 3751*f*
    paramedian forehead, 3748–3750, 3750*f*
    retroauricular, 3752–3753
    steps, 3748
  length, viable, 3734
  monitoring and follow-up, 3759
  movements, 3734
  planning, 3734
  postoperative care, 3757–3758
  rotation flaps, 3740–3742
    bilateral, 3740, 3742*f*
    dorsal nasal, 3740, 3742*f*
    fundamentals, 3740, 3742*f*
    hatchet, 3740, 3742*f*
    Mustarde, 3740–3741
    periocular, 3740–3741
    spiral, 3742, 3744*f*
    Tenzel, 3740–3741
  transposition flaps, 3742–3748
    advantages, 3742–3753
    banner, 3746–3747, 3747*f*
    bilobed, 3747–3748, 3748*f*, 3749*f*
    definition and use, 3742
    rhombic, 3743–3745, 3745*f*–3746*f*
      30°-angle Webster, 3746, 3747*f*
      DuFourmentel, 3745–3746, 3746*f*
    trilobe, 3748
    Z-plasty, 3748
  types, 3734
  vascular perfusion pressure and flap survival, 3734
Flashlamp-pumped pulsed-dye laser. *See* Laser, pulsed-dye (PDL)
Flat primary lesions
  macule, 4, 4*f*, 4*t*
  patch, 4, 4*f*, 4*t*
Flat warts, electrodessication for, 3799
Flatworms, 3251, 3252*t*
Flavin-adenine dinucleotide (FAD), 2213
Flavin mononucleotide (FMN), 2213
Flaviviridae, 3135
Flavivirus mosquito-borne diseases, 3135–3141, 3136*t*. *See also specific types*
  at-a-glance, 3135*b*
  dengue virus, 3135–3137, 3136*t*, 3137*f*
  West Nile virus, 3136*t*, 3139–3141, 3140*f*
  yellow fever virus, 3136*t*, 3139
  Zika virus, 3136*t*, 3137–3139, 3138*f*
Flavonoids, oral photoprotection, 3630
FLCN, trichodiscoma/fibrofolliculoma, 1822*t*, 1843
Fleas, 3325*f*, 3332–3333, 3332*f*–3333*f*
Flexible collodions, 3375
Flexor distribution, 11
Flexural accentuation, irritant dermatitis, 418–419, 419*f*
FLG, 292, 868
  ichthyoses, 783
  ichthyosis vulgaris, 777*t*, 783
  semidominant disorder, 296
FLG1, atopic dermatitis, 369
Flies (Diptera), 3325*f*, 3330–3331, 3331*f*
  black, 3325*f*, 3330–3331
  deer, 3325*f*, 3330–3331
  horse, 3325*f*, 3330–3331
  tsetse, 3325*f*, 3330–3331
    African trypanosomiasis, 3238, 3238*f*, 3240
Flucloxacillin
  for chronic bullous disease of childhood, 994*t*, 999
  for chronic mucocutaneous candidiasis, 2401
Fluconazole, 3439*t*, 3441*t*, 3442*t*, 3445
  for amebas, 3248
  for *Candida*/candidiasis, 3445
  for coccidioidomycosis, 2980
  for cryptococcal meningitis, 3445
  for cryptococcosis, 2984
  for fungal infections
    nail, 1596
    superficial, 2935*t*
  for *Malassezia*, 2963, 2963*t*
  for onychomycosis, 3445
  for pityriasis versicolor, 3445
  for seborrheic dermatitis, 435
  for tinea, 3445
  for tinea capitis, 1532
Flucytosine
  for chromoblastomycosis, 2972
  for cryptococcosis, 2984
    with HIV, 3115
Fluegelzellen cells, 94
Fluid-filled lesions
  pustule, 4*t*, 5, 6*f*
  vesicle and bulla, 4*t*, 5, 5*f*, 6*f*

Fluid resuscitation, for burn injuries, 1684–1686, 1685*t*
Flukes, 3251, 3252*t*. *See also specific types*
  biliary disease, 3261
  exposure and symptom onset interval, 3259, 3260*t*
  progression and duration, 3259, 3260*t*
Fluocinonide, for graft-versus-host disease
  genital, 2335
  oral, 2335
Fluorescein, phototoxicity, 1658*t*
Fluorescence, 268
Fluorescent lamps, phototherapy, 3639–3641
Fluoroquinolones
  for anthrax, weaponized, 2828
  for *Chromobacterium violaceum*, 2849
  nail changes, 1599
  for *P. aeruginosa* bacteremia and ecthyma gangrenosum, 2796
  for *Pasteurella multocida*, 3339
  systemic, 3416–3417
    dosing regimen, 3410*t*, 3417
    indications and contraindications, 3416*t*, 3417, 3417*t*
    pharmacology and mechanism of action, 3416, 3416*t*
    side effects and precautions, 3411*t*, 3417
  for trench fever, 2806
5-Fluorouracil (5-FU)
  for Bowen disease, 1871, 1871*t*
  for Darier disease, 884, 884*t*
  for extramammary Paget's disease, 1941
  pellagra from, 2214
  phototoxicity, 1658*t*, 1661–1662
5-Fluorouracil (5-FU), topical
  for actinic keratosis, 1864, 1864*t*, 1865–1866, 1865*t*
  for basal cell carcinoma, 1889
    prevention, with basal cell nevus syndrome, 1896
  for basal cell nevus syndrome, 1896
  for extramammary Paget's disease, 1941
Fluoxetine
  for hair pulling disorder, 1697*t*, 1700
  for neurotic excoriation, 1697*t*, 1700
  for Raynaud phenomena, 2621*t*, 2622
Flurandrenolide, for lupus erythematosus, 1055
Flushing
  causes and differential diagnoses, 1438*t*
  forms, observations differentiating, 1438*t*
Flutamide
  for acne vulgaris, 1407
  for androgenetic alopecia, 1504
  for hirsutism, 1561, 1562*t*, 1563
  for hyperandrogenism, 2518
Fluvoxamine, for neurotic excoriation, 1697*t*, 1700
Foam cells, 2284, 2284*f*
Foams, 3373*t*, 3375–3376
Foam sclerotherapy, 3880–3882, 3883*f*
Focal adhesion kinase (pp^{125}FAK), 248
Focal dermal hypoplasia, 55, 2384–2386, 2385*f*. *See also* Goltz syndrome
  functional mosaicism, 303
  X-linked dominant disorder, 296–297, 296*t*
  X-linked dominant inheritance, 296–297
Focal idiopathic hyperhidrosis, adolescents, 1758
Focal inherited palmoplantar keratoderma with extracutaneous features
  dominant inheritance, 838–841
    Howel-Evans syndrome, 834*f*, 841, 846*t*
    pachyonychia congenita, 838–841, 839*f*, 840*t*, 846*t*
  recessive inheritance, 841–843
    Carvajal syndrome, 842–843, 846*t*
    Richner-Hanhart syndrome, 841–842, 846*t*
Focal inherited palmoplantar keratoderma without extracutaneous features, dominant inheritance, 836–838
  hereditary keratosis palmoplantaris variant of Wachters, 838, 846*t*
  striate palmoplantar keratoderma, 837–838, 837*f*, 846*t*
Focal vitiligo, 1331. *See also* Vitiligo
Fogo selvagem, 910, 911*t*, 913
Folate. *See* Vitamin B_9 (folate)
Folded luggage sign, 2078
Folic acid deficiency, hypermelanosis, 1363
Follicular appendage tumors, 1838–1849. *See also* Appendage tumors, follicular; *specific types*
Follicular atrophoderma, 1199–1200
  associated syndromes, 1200
  atrophoderma vermiculatum, 1199
  Bazex-Dupré-Christol syndrome, 1200
  Conradi-Hünermann-Happle syndrome, 1200
  keratosis pilaris atrophicans, 1064, 1199–1200
  therapy, 1200
Follicular distribution, 11
Follicular germinative cell neoplasm, basal cell carcinoma, 1839
Follicular helper T cells (TfH), 146, 146*f*, 160
Follicular impetigo, 2722–2723
Follicular lichen planus, 531*t*, 532
  scalp, 533–534, 533*f*
Follicular melanocytes, 331
Follicular mesenchymal differentiation neoplasms, trichodiscoma/fibrofolliculoma, 1822*t*, 1839*t*, 1842–1843, 1843*f*
Follicular mucinosis, 2081–2082, 2082*f*, 2082*t*
Follicular occlusion, hidradenitis suppurativa, 1483
Follicular penetration, 3367, 3371*f*
Follicular rupture, nodular lymphocyte collections, 26
Follicular scale, 6*t*
Follicular unit (FU), for hair transplantation, 3931, 3935*f*
Follicular unit excision (FUE), 3931, 3936–3943, 3940*f*
  advantages and disadvantages, 3942*t*
  for donor site excision, 3940–3942, 3940*f*
  for graft preparations, 3942–3943
  "minimal incision surgery," 3941*t*
Folliculitis. *See also specific types*
  dermatophytic, 2724
  dissecting, 1530, 1530*f*
  eosinophilic pustular, 670–671, 670*f*, 671*t*
  hair follicle, 26
  Malassezia, 2960, 2960*f*–2961*f*
  Pseudomonas aeruginosa
    clinical features, 2724, 2790, 2791*t*, 2792*f*
    diagnosis, 2794
    etiology and pathogenesis, 2793
    management, 2796
  staphylococcal, 2722–2724, 2723*f*–2724*f*, 2723*t*, 2730, 2731*t*
Folliculitis decalvans (FD), 1529–1530, 1529*f*
Folliculitis keloidalis, 2723
Folliculitis mechanica, 1451
Folliculitis spinulosa decalvans, 872
Folliculitis ulerythematosa reticulata, 870
Folliculotropic mycosis fungoides, 2081–2082, 2082*f*, 2082*t*
Fomite (lice), 3279
Fonsecaea compactum, 2966*t*, 2971–2972, 2971*f*–2972*f*
Fonsecaea pedrosoi, 2966*t*, 2971–2972, 2971*f*–2972*f*
Food allergies
  filaggrin mutations, 216
  gastric dysmotility, eosinophils in, 656
  irritant dermatitis from, mouth, 421–422, 422*f*
Food-dependent exercise-induced urticaria (FDEIA), 695, 699
Fordyce spots, 70, 72*f*
Forehead lines, horizontal, botulinum toxin for, 3925–3926, 3927*f*–3928*f*
Formaldehyde, 3620
  allergic contact dermatitis from, 404
    formaldehyde nonreleasers, 404
    formaldehyde releasers, 404
Formalin, biopsy specimen, 18–19
Formication, cocaine abuse, 1709–1710
Formicidae, 3333–3334
Formulations
  skin surface, 3366–3367
  topical, 3372–3377, 3373*t* (*See also* Topical formulations)
Fosamprenavir, 3508, 3509*t*
Foscarnet, 3500–3501, 3500*t*
  for human cytomegalovirus, 3006–3007
  for varicella-zoster virus, 3051
Fosfomycin, for actinomycetoma, 2889
Four-helix bundle proteins, 161
Fournier gangrene, 2772–2773
14α-demethylase, 3443
FOXC2
  Klippel-Trenaunay syndrome, 2640*t*
  lymphedema distichiasis, 2640*t*, 2656, 2695
FoxD3 (Forkhead Box D3), 334*f*, 335
Fox-Fordyce disease, 1475–1478
  clinical course and prognosis, 1477
  clinical features, 1475, 1476*f*
  diagnosis, 1476
  differential diagnosis, 1477, 1477*t*
  epidemiology, 1475
  etiology and pathogenesis, 1475–1476
  histopathology, 1476–1477, 1476*f*
  management, 1477–1478, 1477*t*
  pathophysiology, 1476
FOXO1, sebaceous glands, 77
FOXP1, primary cutaneous diffuse large B-cell lymphoma, 2100
FOXP3
  cutaneous T-cell lymphomas, 2075
  IPEX syndrome, 146
Fox P3 expression, UVB on, 3638
Fractional photothermolysis, 3830, 3835
  for acne scars, 1411
  historical perspective, 3846
Fractional resurfacing, 3835
Fractional thermolysis, for burn scars, 1690
Fractionation schedule, radiotherapy, 3690
Fractures, physical abuse, 1722
Fragile X syndrome, 299*t*
Fragility breaks, 297
Fragrance mix I/II, allergic contact dermatitis from, 404
Fragrances, allergic contact dermatitis from, 404
Francisella tularensis, 449, 2829*t*, 2830–2832, 2831*f*, 3320. *See also* Tularemia
Frank sign, 2425
Fray color, 8*t*
Freckle, 1970–1971
  sun-induced (*See* Solar lentigo)
Fredrickson-Levy-Lees dyslipidemias, 2273, 2282, 2288*t*
Free cartilage grafts, 3757
Free fatty acid synthesis, skin, 213, 215*f*
Free margins, 3699
  elliptical excision, 3727
Freon, cryogen, 3791, 3792*t*
Friction, irritant dermatitis, 418
Friction blisters, 418
Friction melanosis (amyloidosis), 1365, 2264
Frontal fibrosing alopecia (FFA), 533–534, 533*f*, 1502, 1502*t*, 1503*f*, 1527–1528, 1527*f*
Frontalis muscle, 3703, 3704*f*
Frontal nerve, 3702–3703
Frostbite, 1666, 1667–1670, 1668*f*–1669*f*, 1669*t*
  blister, 1668–1669
  deep superficial, 1668, 1668*f*

Frostbite (*Cont.*):
dry gangrene, 1669, 1669*f*
pathophysiology, 1667
prevention and prognostic signs, 1669, 1669*t*
sequelae, 1669–1670
superficial, 1668, 1668*f*
treatment, 1669
Fuchs syndrome, 724
Fucidic acid, for *S. aureus* in folliculitis decalvans, 1530
Full-thickness skin grafts (FTSGs), 3753–3755
Burow's/regional, 3755, 3756*f*
conchal bowl, 3753, 3754*f*
donor site, determining, 3753–3754, 3754*f*
harvesting, 3754–3755
uses, 3753
Fulvene-5, antiangiogenesis, 3604*t*
Fumaric acid esters (FAEs)
for necrobiosis lipoidica, 2501
for pityriasis rubra pilaris, 503
for psoriasis, 484*t*, 492
Functional mosaicism, 302–303
Functional status, preoperative examination, 3709
Fungal infections. *See also specific types*
atopic dermatitis, 367
disseminated, with HIV, 3114
in elderly, 1787
granulomas, 27
IV drug use, 1708–1709
nail, 1593–1596 (*See also* Onychomycosis)
neonatal, 1738*t*, 1739
occupational exposure, 449
Fungal infections, deep, 2965–2985
classification, 2965
mycoses (*See also* Mycoses)
subcutaneous, 2965–2973, 2966*t*–2967*t*
systemic, 2973–2985
Fungal infections, superficial, 2925–2949
at-a-glance, 2925*b*
clinical course and prognosis, 2933
dermatophytes, 2925, 2926
habits and hosts, 2927*t*
dermatophytoses, 2943–2949 (*See also* Dermatophytoses)
diagnosis, 2929–2933
colony and microscopic morphology
Epidermophyton floccosum, 2931*t*
Microsporum audouinii, 2931*t*
Microsporum canis, 2931*t*
Microsporum gypseum, 2931*t*
Trichophyton interdigitale, 2932*t*
Trichophyton rubrum, 2932*t*
Trichophyton schoenleinii, 2932*t*
Trichophyton tonsurans, 2932*t*
Trichophyton verrucosum, 2932*t*
Trichophyton violaceum, 2932*t*
culture, 2929*t*, 2930–2931, 2931*t*–2933*t*
histopathology, 2933
laboratory identification methods, 2929*t*
microconidia and macroconidia
Epidermophyton, 2931, 2931*t*
Microsporum, 2931, 2931*t*
Trichophyton, 2931, 2931*t*
microscopic, 2930, 2930*f*
Trichophyton nutritional growth requirements, 2931, 2933*t*
Wood lamp fluorescence, 2933, 2933*t*
epidemiology, 2926–2927
management, 2933, 2934*t*–2936*t*
mycoses, 2925, 2926*t*
pathogenesis, 2927–2929
adherence, 2928
genetics, 2929
host response, 2928–2929
invasion, 2928
taxonomy
anthropophilic, 2926, 2926*t*, 2927*t*
genotypical *vs.* classical, 2925–2926
geophilic, 2926, 2926*t*, 2927*t*
zoophilic, 2926, 2926*t*, 2927*t*
terminology, 2926*t*
Fungi
clinical importance, 254
skin microbiome, sequencing methods, 254
Furocoumarins, phototoxicity, 1658*t*, 1662
Furuncles (boils). *See also specific disorders*
definition, 2724
staphylococcal, 2724, 2724*f*
Fusarium, 2984–2985
FUS-DDIT2 fusion, myxoid liposarcoma, 2191
Fusidic acid, topical, 3420*t*, 3421
for erythrasma, 2743
for group A *Streptococcus* impetigo, 2739, 2739*t*
for pitted keratolysis, 2741
for *S. aureus*, in folliculitis decalvans, 1530
for staphylococcal impetigo, 2730, 2731*t*
Fusiform biopsy, nail-bed, 3783*f*, 3785
Fusion inhibitor, 3506

G

Gal7, in cutaneous amyloidosis, 2266–2267
Galactocatechin, oral photoprotection, 3630
Galectin-10, 651*f*, 652
Gallic acid, oral photoprotection, 3630
Galli-Galli disease, 781*t*, 1354
GALNT3, tumoral calcinosis, 2311
Gambian trypanosomiasis, 3238–3240, 3239*t*
γ-benzene hexachloride, 3614–3615, 3615t
γ-catenin, 237
gene mutation, mast cell granules, 154, 154*t*
γC chain, cytokines with receptors including, 170–171
IL-2 and IL-15, 170–171
IL-4 and IL-13, 161*f*, 163*t*, 171
IL-7 and thymic stromal lymphopoietin, 171
γ-hydroxybutyrate, 1711
γδ T cells, 150*f*, 151, 220
juvenile idiopathic arthritis, 1154
receptor, 145
Ganciclovir, 3499–3500, 3500*t*
for HHV-6 prevention, 3009
for human cytomegalovirus, 3006–3007
for human cytomegalovirus prevention, 3007
Ganglion cell tumor, 2167
Ganglioneuroma, cutaneous, 2167
Gangrene, dry, 1669, 1669*f*
Gangrenous cellulitis, 2775–2777, 2776*t*
Gardner disease, 2444*t*
Gardnerella vaginalis bacterial vaginosis, 3218
Gardner syndrome, 2434*t*, 2436
lipoma, 2172, 2173*t*
pilomatricoma, 1822*t*, 1844
Garments, photoprotection
clothing, 3630
UV protection factor, 3630–3631
Gas discharge lamps, phototherapy, 3639
Gas gangrene, 2775, 2779–2780
Gastric antral vascular ectasia, systemic sclerosis, 1091
Gastric carcinoma, eosinophils and prognosis, 653
Gastrin-releasing peptide receptor (GRPR), 355
Gastritis
acute stress, burns, 1681
atrophic, dermatitis herpetiformis, 1003
Gastroesophageal reflux, systemic sclerosis, 1091
Gastrointestinal system disorders, skin manifestations, 2403*t*–2404*t*, 2433–2436
bleeding, 2433
bowel-associated dermatosis-arthritis syndrome, 2436
dermatitis herpetiformis, 2434
eosinophils, 652
esophageal, 2434
gastrointestinal bleeding, 2433
inflammatory bowel disease, 2436
Kaposi sarcoma, 2434
malabsorption, 2433–2434
polyposis syndromes, 2436
Gastrula, 52
GATA-1, congenital erythropoietic porphyria, 2235*t*
GATA-2, Emberger syndrome, 2640*t*, 2657, 2694
GATA-3
mycosis fungoides and Sézary syndrome, 2075
T helper 2 cells, 145
Gaucher disease, cellular defect, 781*t*
GBN1, Wiedemann-Rautenstrauch syndrome, 1299
GDF2, hereditary hemorrhagic telangiectasia 23, 2640*t*
Gefitinib, 3559*t*, 3568–3569, 3568*f*
acneiform eruptions from, 1452
for non–small-cell lung cancer, 3566
Gel nails, treatment effects, 1578
Gels, 3373*t*, 3375
Gelsolin, cutis laxa in familial amyloid, 2265
Gemcitabine
for blastic plasmacytoid dendritic cell neoplasm, 2102
for cutaneous T-cell lymphomas, 2096
Gemfibrozil, psoriasis, 479
Gemifloxacin. *See* Fluoroquinolones
Gender
affirmation/transition, 1793*t*
dysphoria, 1793, 1793*t*
expression, 1793*t*
identity, 1792–1793, 1793*t*
Gene(s). *See also specific genes and disorders*
disease, finding, 293–294
mutations, 294–295, 294*f* (*See also* Mutations, gene; *specific types*)
polymorphisms, 294–295, 294*f* (*See also specific types*)
protein-encoding, 291–292, 291*f*
structure, 290–292, 291*f*
Gene inhibition therapy, 306–307
Generalized arterial calcification of infancy (GACI), 1232, 1233
Generalized atrophic benign epidermolysis bullosa (GABEB), 1020
Generalized atrophic epidermolysis bullosa mitis, 1019
Generalized autosomal dominant dystrophic epidermolysis bullosa, 1021
Generalized distribution, 12
Generalized elastolysis, 1233–1241. *See also* Cutis laxa
Generalized eruptive histiocytoma (GEH), 2035, 2036*f*
Generalized eruptive histiocytoma (GEH) of childhood, 2034
Generalized eruptive histiocytosis, 2034
Generalized intermediate epidermolysis bullosa simplex, 1016, 1016*f*, 1029*t*
Generalized intermediate junctional epidermolysis bullosa, 1018–1019, 1019*f*, 1029*t*
Generalized lymphatic anomaly (GLA), 2654
Generalized morphea, 1107, 1107*t*, 1108*f*–1109*f*
Generalized pustular psoriasis (GPP), 461–462, 463*f*
familial, epidemiology, 628

Generalized pustular psoriasis of von Zumbusch, nail involvement, 1580
Generalized severe epidermolysis bullosa simplex, 1015–1016, 1015*f*, 1029*t*
Generalized severe junctional epidermolysis bullosa, 1016*f*, 1018, 1029*t*
Generalized type ichthyosis, 777*t*
General paresis of the insane, 3157
Gene replacement therapy, 307
Gene silencing, DNA hypermethylation, 304
Gene therapy and editing, 294
Genetic counseling, 305
Genetic databases, 290, 290*t*
Genetic (locus) heterogeneity, 295
Genetic immunodeficiency diseases, 2394–2420. *See also specific types*
  antibody deficiency disorders, genetic, 2394–2398
  cellular deficiencies, 2399–2402
  clinical features, 2394, 2396*t*, 2397*f*
  combined antibody and T-cell deficiency, 2402–2409
  complement deficiency disorders, 2419–2420
  overview, 2394, 2395*t*
  phagocytosis and cell killing disorders, genetic, 2409–2419
Genetic linkage, 293
Genetics, skin and, 289–308
  at-a-glance, 289*b*
  chromosomal disorders, 297–300, 298*t*–299*t*
  chromosome and gene structure, 290–292, 291*f*
  complex disease genetics, 300–301
  disease genes, finding, 293–294
  epigenetics, 304–305
  gene expression, 292–293
  gene mutations and polymorphisms, 294–295, 294*f* (*See also specific types*)
  gene therapy and editing, 306–308
  genetic and genomic databases, 290, 290*t*
  genetic counseling, 305
  genome-wide association studies, 301
  histocompatibility antigen disease association, 303–304, 304*t*
  human genome, 289–290
  Human Genome Project, 289
  Mendelian disorders, 295–297, 295*t*–297*t*, 296*f*–297*f*
  mitochondrial disorders, 300
  mosaicism, 301–303, 302*f*
  precision medicine, 308
  prenatal diagnosis, 305–306, 306*f*
Genistein, oral photoprotection, 3630
Genital anatomy, older female child, 1754, 1755*f*
Genital Bowen disease (GBD), 1871*t*, 1874*b*, 1875*b*, 1876*f*
Genital leiomyoma, 2130–2138, 2131*t*–2132*t*. *See also* Leiomyoma, genital
Genital lichen planus, male, 535
Genital mycoplasmas, 3212–3214, 3212*f*
Genital warts, differential diagnosis, 3099*t*
Genodermatoses, 289
  autism spectrum disorder, 1759, 1759*t*
  nail, 1599–1602
    bullous epidermolysis group, 1601, 1601*f*
    congenital malalignment of big toenail, 1592*f*, 1602
    cornification diseases, 1601, 1601*f*
    dyskeratosis congenita, 1601
    ectodermal dysplasias, 1600–1601, 1600*f*
    nail-patella syndrome, 1601
    pachyonychia congenita, 1599–1600, 1600*f*
  neonatal
    anetoderma of prematurity, 1746
    congenital ichthyosis, 1745
    cutis marmorata telangiectatica congenita, 1746, 1746*f*
    ectodermal dysplasia, 1745
    epidermolysis bullosa, 1745
    incontinentia pigmenti, 1745
    sclerema neonatorum, 1746
    subcutaneous fat necrosis of the newborn, 1745, 1746*f*
  with palmoplantar keratodermas, inherited, 817, 818, 818*t*, 819*f*
Genome, human, 289–290
  gene expression, 292–293
Genome instability disorders, 2361–2367
  at-a-glance, 2342*b*
  ataxia telangiectasia, 2342, 2344*t*
  AT-like disorder, 2344*t*
  BASC defects, 2346
  Bloom syndrome, 1361, 2342, 2343*t*, 2345*t*, 2361–2362, 2445*t*
  clinical features, 2343*t*–2344*t*
  dyskeratosis congenita, 2344*t*, 2366–2367, 2446*t*
  Fanconi anemia, 2342, 2344*t*, 2364–2366, 2365*f*
  helicases and RecQ family, 2344
  mechanisms, 2342, 2345*t*
  Nijmegen breakage syndrome, 2344*t*
  Rothmund-Thomson syndrome, 2344*t*
  Seckel syndrome, 2344*t*
  spontaneous genome instability, 2342
  telomeres, 2344–2346
  Werner syndrome, 2343*t*, 2362–2363
Genome stability, 2342
Genome-wide association studies (GWAS), 301
Genomic databases, 290, 290*t*
Genomic imprinting, 300
Genomics studies, skin microbiome
  bacterial communities, 256–257, 257*t*, 259*f*
  design, 255–256, 255*f*
  fungal communities, 257–258, 259*f*
  sequencing methods, 254–255
  viral communities, 258–259
Genotype
  expressivity, 295
  nonpenetrant, 295
Gentamicin
  for bacillary angiomatosis, 2806
  for brucellosis, 2835
  for *Chromobacterium violaceum*, 2849
  for granuloma inguinale, 3205
  for infective endocarditis, 2818
  for *Nocardia* actinomycetoma, 2889
  for trench fever, 2805
  for tularemia, 2831
Gentamicin, topical, 3420*t*, 3421
  for green nail syndrome, 2795
  for Hailey-Hailey disease, 889
  for *Pseudomonas aeruginosa*
    folliculitis and hot-foot syndrome, 2796
    nail, 1593
Gentian violet
  antiangiogenesis, 3604*t*
  topical, 3611, 3612*t*
    for fungal infections, superficial, 2936*t*
    for green nail syndrome, 2795
    for oral hairy leukoplakia, with HIV, 3114
Geographic shape, 10
Geographic tongue, psoriasis, 464–465
Geophilic, 2926, 2926*t*, 2927*t*
Germ hair, primary, 90–91, 90*f*
Germinativum, 52
Gerodermia osteodysplastica, 1237*t*, 1238–1239
Gevokizumab, for adamantiades–Behçet disease, 2576*t*
GGCX, pseudoxanthoma elasticum, 1232
Ghrelin
  growth hormone release, 2518
  receptor, 2504, 2518*f*
Giacomini vein, 3874
Gianotti-Crosti syndrome (GCS), 3002–3004
  at-a-glance, 3002*b*
  clinical course and prognosis, 3004
  clinical features, 3003, 3003*f*
  diagnosis, 3003
  differential diagnosis, 3003*t*
  with Epstein-Barr virus, 3000, 3002–3004, 3003*f*, 3015*t*
  etiology and pathogenesis, 3002–3003
  management, 3004
Giant cell arteritis (GCA), 2541, 2554, 2555*f*. *See also* Vasculitis
Giant cellulitis-like Sweet syndrome, 591, 591*f*
Giant condyloma acuminatum Buschke-Löwenstein, 1908
Giardia duodenalis, 3245–3246, 3245*f*
Giardia intestinalis, 3245–3246, 3245*f*
Giardia lamblia, 3245–3246, 3245*f*
Giardiasis, 3245–3246, 3245*f*
Gingival fibromatosis with hypertrichosis, 1564
GJA1
  erythrokeratodermia variabilis et progressiva, 801, 801*f*
  hidrotic ectodermal dysplasia, 832–833
  oculo-dento-digital dysplasia, 2390
  palmoplantar keratoderma-congenital alopecia syndrome, 832
GJB2
  Bart-Pumphrey syndrome, 828–829
  keratitis-ichthyosis-deafness syndrome, 777*t*, 802, 802*f*
  KID syndrome, 828–829
  palmoplantar keratoderma with deafness syndrome, 828–829
  Vohwinkel syndrome, 828–829
GJB3
  erythrokeratodermia variabilis et progressiva, 801, 801*f*
  ichthyosis, generalized type, 777*t*
GJB4
  erythrokeratodermia variabilis et progressiva, 801, 801*f*
  ichthyosis, generalized type, 777*t*
  progressive symmetric erythrokeratoderma, 777*t*
GJB6
  hidrotic ectodermal dysplasia, 832–833
  KID syndrome, 829
GJC2, four-limb lymphedema, Klippel-Trenaunay syndrome, 2640*t*
GLA, Fabry disease, 2292
Glabella, 3698, 3698*f*
Glabellar lines, botulinum toxin for, 3924–3925, 3927*f*–3928*f*
Glanders, 2829*t*, 2835–2837
Glands, skin, 70–84. *See also specific types*
  anatomy, 70
  diseases, 70, 71*t*
  in elderly, 1784
  functions and classification, 70
  holocrine, 70
  merocrine, 70, 84
  sebaceous glands, 70–77
  sebum, 70
  sweat gland diseases
    apocrine, 71*t*
    eccrine, 71*t*
  sweat glands, 78–85
Glass, 1711
  photoprotection
    in buildings and cars, 3631
    sunglasses, 3631–3632
Glassy membrane, 95
Gleich syndrome, 661. *See also* Hypereosinophilic syndromes (HES)
  eosinophils, 654

Gli1, 95
Glioma, neonatal nasal, 1735, 1737*f*, 2166
Glogau system, 3896, 3897*f*
GLOMULIN, glomuvenous malformation, 2640*t*, 2650
Glomus tumor, 1604, 1604*f*
Glomuvenous malformations (GVMs), 2646–2653, 2648*t*, 2649*f*. *See also* Venous anomalies
Glossina morsitans, 3238
Glossinidae, 3325*f*, 3330–3331
  African trypanosomiasis, 3238, 3238*f*, 3240
Glossitis
  benign migratory (*See* Geographic tongue)
  vitamin B_6 deficiency, 2216
Glossitis areata migrans. *See* Geographic tongue
Gloves
  allergies to
    irritant dermatitis, 420, 420*t*, 423*t*
    latex, contact urticaria, 445–446, 445*t*
  dermatitis from (*See also* Irritant dermatitis)
    differential diagnosis, 423–424, 423*t*
    irritant avoidance, 424–425
  protective
    irritant avoidance, 424–425
    occupational skin disease, 452–453
    wet work, 424
Glucagonoma syndrome, necrolytic migratory erythema, 2455–2456, 2455*f*
Glucocorticoids, 3382–3392. *See also* Corticosteroids; Prednisone; *specific types*
  acneiform eruptions from, 3390–3391
  for acne vulgaris, 1406
  for eosinophil-associated disease, 658
  for filariasis, 3265*t*
  for hirsutism
    congenital adrenal hyperplasia, 1561, 1562*t*
    polycystic ovarian syndrome, 1561, 1562*t*
  for hypereosinophilic syndromes, with imatinib, 663
  intramuscular, 3383
  for rheumatoid arthritis, 1152
  tachyphylaxis from, 3389–3390
Glucocorticoids, intralesional, 3383
  for acne conglobata, 1449
  for acute febrile ulcerative acne, 1449
  for angiolymphoid hyperplasia with eosinophilia, 669
  for lupus erythematosus, 1055
Glucocorticoids, systemic, 3382–3388. *See also specific types*
  for acne conglobata, 1449
  for acne fulminans, 1449
  for acne vulgaris, 1406
  adrenal suppression from, 3385
  adverse effects, 3385–3388, 3386*t*
    avascular necrosis, 3386–3387
    cardiovascular disease, 3387
    gastrointestinal, 3387
    hypothalamic–pituitary–adrenal axis suppression, 3387
    lactation and pregnancy, 3387
    osteoporosis, 3386
    pediatrics, 3387–3388
    psychiatric, 3387
    steroid withdrawal syndrome, 3387
  for angiolymphoid hyperplasia with eosinophilia, 669
  at-a-glance, 3382*b*
  for atopic dermatitis, 379
  for autoimmune blistering diseases, 202
  cellular effects, 3382–3383
  for cryofibrinogenemia, 2609
  dosing regimen, 3383
  for hyperimmunoglobulinemia D with periodic fever syndrome/mevalonate kinase deficiency, 635
  indications, 3383, 3383*t*
  initiating therapy
    drug choice and equivalencies, 3384, 3384*t*
    evaluation, pre-treatment, 3384
    fundamentals, 3383–3384
  IV, 3383
  for juvenile idiopathic arthritis, 1155
  for Kimura disease, 669
  for Langerhans cell histiocytosis, 2028
  for lupus erythematosus, 1054, 1057
  for mastocytosis, 719–720, 719*t*
  for Morbihan disease, 1451
  for mucous membrane pemphigoid, 966*t*, 967
  pediatrics and adolescents, 1762
  for pemphigus, 922–923
  pharmacology and mechanism of action, 3382–3383
  for pyoderma gangrenosum, 613, 614*t*
  for seborrheic dermatitis, 435
  side effects and precautions
    adrenal suppression, 3385
    diet, 3384
    immunizations, 3385
    infections, 3384–3385
    preventive measures, 3385*t*
  for vasculitis, 2557
  for Wells syndrome, 667
Glucocorticoids, topical, 3388–3391
  adverse effects, 3390–3392
    acneiform reactions, 3391
    allergic reactions and cross-reactivity, 3391–3392, 3391*t*
    atrophic changes, 3390–3392
    infection development, 3391
    other cutaneous, 3391
    systemic, 3391
  at-a-glance, 3387*b*
  continuing use, 3390, 3390*t*
  dosing regimen, 3390
  for eosinophilic pustular folliculitis, 671
  indications
    general, 3389
    geriatric, 3389
    pediatric, 3389
    pregnancy, 3389–3390
    responsiveness, of dermatoses, 3389*t*
  initiating, 3390, 3390*t*
  for lupus erythematosus, 1054*t*, 1055
  for mastocytosis, 718*t*, 719
  mechanism of action
    antiproliferative, 3388
    pharmacokinetics, 3389
    vasoconstriction, 3388
  potency ranking, 3388*t*
  for pyoderma gangrenosum, 613, 614*t*
  for sea bather's eruption, 3354, 3355*t*
  side effects and precautions, 3390
Glucuronic acid, keratolytic actions, 3618, 3619*t*
GLUT1
  infantile hemangiomas, 2051
  perineurioma, 2161
Glutaraldehyde, 3620
Gluten, dermatitis herpetiformis, 1004
Gluten-free diet
  for dermatitis herpetiformis, 1006–1007
    cancer prophylaxis, 2459
  low-fat, for lipodystrophy, 1304
Gluten-sensitive enteropathy
  dermatitis herpetiformis, 1003, 1004, 1007
  linear IgA dermatosis, 996–997
Glycerin, 3878*t*, 3880
  chromated, 3878*t*, 3880
Glycolic acid
  for actinic keratosis, 1866
  chemical peels, 3899*f*, 3900
    superficial, 3901*f*
  keratolytic actions, 3618, 3619*t*
  for striae, 1197
Glycopeptides. *See* Vancomycin
Glycoprotein 130, cytokines with receptors using, 172
Glycopyrrolate, 3616
  for hyperhidrosis
    primary focal, 1462
    prime focal, 1463
Glycopyrrolate sodium, for hyperhidrosis in Fabry disease, 2302
Glycosaminoglycans (GAGs), 3805
  dermal cell-matrix adhesion, 247
  heparan sulfate, 3805
  hyaluronic acid, 3805
Glycyrrhiza inflata extract, for seborrheic dermatitis, 435–436
GM-CSF, 172
GNA11
  blue nevus, 1959
  phakomatosis pigmentovascularis, 2640*t*, 2642
  rapidly involuting congenital hemangioma, 2060
GNAQ
  blue nevus, 1959
  capillary malformations, 2640*t*, 2642
  phakomatosis pigmentovascularis, 2640*t*
  rapidly involuting congenital hemangioma, 2060
Gnathophyma, rosacea, 1421*f*, 1422
Gnathostoma spinigerum, 3252*t*
  conjunctivitis, 3261
  exposure and symptom onset interval, 3259, 3260*t*
  exposure history, 3254
  migration, through eye, 3261
  migratory skin lesions, 3255*t*, 3256
  progression and duration, 3259, 3260*t*
  subcutaneous nodules and masses, 3257, 3257*t*
Goiter, from thyroid disease, 2504. *See also* Thyroid disease
Gold
  allergic contact dermatitis from, 404, 419*f*
    patch testing, 408, 408*f*
  lichen planus from, 538
  for lupus erythematosus, 1054*t*, 1057
  for Still disease, adult-onset, 1158
Goldenhar-Gorlin syndrome, lipoma, 2173*t*
Gold miners, systemic sclerosis and, 1093
Golimumab
  for psoriatic arthritis, 469*f*, 494, 980*t*, 981, 1136*t*, 1137
  for rheumatoid arthritis, 1152
Goltz-Gorlin syndrome, 2384–2386, 2385*f*
  hidrocystoma, 1822*t*, 1832
Goltz syndrome, 55, 2384–2386, 2385*f*
  functional mosaicism, 303
  pili torti, 1541*t*
  trichorrhexis nodosa, 1538*t*
  X-linked dominant inheritance, 296–297
Gomm-Button disease, 587
Gonadal mosaicism, 301
Gonadotropin-releasing hormone (GnRH) agonists. *See also specific types*
  for acne vulgaris, 1406
Gonorrhea, 3207–3212
  at-a-glance, 3207*b*
  clinical course and prognosis, 3211
  clinical features, complications, 3210
  clinical features, cutaneous
    disseminated disease, 3209
    men, 3208, 3208*f*–3209*f*
    proctitis, 3209
    women, 3208
  clinical features, noncutaneous
    disseminated disease, 3209–3210
    newborns and children, 3210, 3210*t*
    pelvic inflammatory disease, 3209
    pharyngitis, 3209

diagnosis, laboratory, 3210–3211
epidemiology, 3207–3208
etiology and pathogenesis, 3210
historical perspective, 3207
Neisseria gonorrhoeae and gonococci, 3207, 3208*f*
prevention, newborns and children, 3210, 3210*t*
screening recommendations, 3212
treatment
contraindications, 3212
disseminated disease, 3211–3212, 3212*t*
localized, uncomplicated disease, 3211, 3211*t*
in neonates, 3211, 3212*t*
sexual partners, 3212
Gonosomal mosaicism, 301
Goodpasture syndrome, collagen IV mutations, 240
Goose bumps, 92
Gorham-Stout syndrome, 2654
Gorlin syndrome. *See* Basal cell nevus syndrome
Gottron papules, 9*f*
dermatomyositis, 1061, 1062*f*, 1066
Gottron sign, dermatomyositis, 1061, 1062*f*, 1066
Gout, 2313–2316
clinical manifestations, 2314, 2314*f*–2315*f*
epidemiology, 2313
laboratory presentation and pathology, 2314*f*–2315*f*, 2315
pathogenesis and classification, 2313–2314, 2314*t*
treatment, 2315–2316
Gouty panniculitis, 1283*b*
GPR143, ocular albinism, 1310*t*, 1315
G protein–coupled receptor (GPCR), 354
chemokine signal transduction, 168*f*, 177–178, 179*f*
G-protein signaling, chemokine signal transduction, 168*f*, 177–178, 179*f*
GRADE scale, 44
Grafix, 2711
Graft (skin), 2710
Graft preparation, 3942–3943
follicular unit excision, 3942–3943
graft storage, 3943
strip harvesting, 3941*f*, 3942
Graft surgery, 3753–3757
allografts, 3753
autografts, 3753
complications, 3758
composite grafts, 3756–3757
equipment, 3726–3727, 3727*f*
free cartilage grafts, 3757
full-thickness skin grafts, 3753–3755
Burow's/regional graft, 3755, 3756*f*
conchal bowl grafts, 3753, 3754*f*
donor site, determining, 3753–3754, 3754*f*
harvesting, 3754–3755
uses, 3753
monitoring and follow-up, 3759
postoperative care, 3757–3758
skin substitutes, 3757
split-thickness skin grafts, 3755
punch and pinch grafts, 3755
for vitiligo, 1343, 1344*f*
for vitiligo, 1343
types and uses, 3753
wound healing, graft stages, 3753
xenografts, 3753
Graft-versus-host disease (GVHD), 2320–2335, 2395*t*
at-a-glance, 2320*b*
classification, 2323, 2323*f*
clinical features, 2322–2330
cutaneous, 2323–2328
acute disease, 2323–2325, 2324*f*, 2325*t*
Blaschkoid, 2326, 2326*f*
chronic disease, 2325–2328, 2325*t*, 2326*f*–2327*f*
erythematous-dusky macules/papules to morbilliform exanthem, 2323–2324, 2324*f*
erythroderma and bulla, 2324–2325, 2324*f*
"lichenoid" or "sclerodermoid," 2325–2326
lichen planus-like, 2325–2326, 2326*f*
morphea-like, 2326, 2326*f*
nails, 2328
poikiloderma, 2325–2326, 2326*f*
sclerosis, 2325, 2326–2328, 2327*f*
subcutaneous fat and fascia, 2327*f*, 2328
histopathology, 2328–2330, 2330*f*
history, 2322–2323
interface/lichenoid changes, 25
lichenoid, 539
organ system, 2325*t*
physical, related, 2323, 2325*t*, 2329*t*, 2330*f*
signs and symptoms, NIH Consensus, 2328, 2329*t*
staging, 2325*t*
complications, 2331–2332
diagnosis
laboratory tests, 2330–2331
special tests and imaging, 2331
differential diagnosis, 2331, 2331*t*
epidemiology, 2320–2321, 2321*t*
etiology and pathogenesis, 2321–2322, 2321*t*
HLA mismatch, 2320
transfusion, 2322–2323
lichen planus, 527, 528 (*See also* Lichen planus)
prevention, 2332
prognosis and clinical course, 2332
risk factors, 2320, 2321*t*
severe combined immunodeficiency, 2404–2405
treatment, 2332–2335
acute, 2332–2333
chronic, 2333–2335, 2335*t*
extracorporeal photochemotherapy, 3678, 3678*t*
oral and vulvovaginal disease, chronic, 2335
phototherapy, 3646*t*, 3651
chronic disease, 2333
PUVA, 3672–3673
supportive care, 2335
Graham-Little-Piccardi-Lasseur syndrome (GLPLS)
follicular lichen planus, 532
scalp, 533–534, 533*f*
lichen planopilaris, 1527–1528, 1527*f*
Grains, 2876, 2877*t*, 2879
mycetoma, 2969, 2970*f*, 2970*t*
Gram-negative bacteria, 2782
Gram-negative coccal and bacillary infections, 2782–2810. *See also specific types*
Bartonella, 2796–2806
Haemophilus influenzae cellulitis, 2809–2810
Klebsiella rhinoscleromatis, 2808–2809, 2809*f*
Neisseria meningitidis, 2782–2788
Pseudomonas aeruginosa, 2789–2796
Salmonella enteric fever, 2806–2808
Gram-negative folliculitis, acneiform eruptions from, 1453
Gram-negative rosacea, 1425. *See also* Rosacea
Gram-positive bacteria, 2782
Gram-positive infections with toxin production, 2757–2768. *See also specific types*
at-a-glance, 2757*b*
epidemiology
risk factors, 2757
toxins and diseases, 2758*t*
exfoliative toxin diseases, 2757–2761
clinical features, 2758–2761
generalized forms, 2759–2760, 2759*f*–2760*f*
intermediate forms, 2760–2761
localized forms, 2758, 2758*f*–2759*f*
diagnosis and differential diagnosis, 2761
etiology and pathogenesis, 2758
treatment and prognosis, 2761
superantigenic toxin diseases, 2761–2768
atopic dermatitis, 2767
autoeczematization response, 2767
classification, 2762
cutaneous T-cell lymphoma, 2768
etiology and pathogenesis, 2761–2762, 2761*f*
psoriasis, 2767
recalcitrant erythematous desquamating disorder, 2764
scarlet fever, 2764–2766, 2765*f*
differential diagnosis, 2766
staphylococcal, 2766
streptococcal, 2765–2766
treatment and prognosis, 2766
toxic shock syndrome, 2762–2764
clinical features, staphylococcal, 2762–2763, 2762*f*, 2763*t*
clinical features, streptococcal, 2763
differential diagnosis, 2763–2764, 2764*t*
treatment and prognosis, 2764
toxin-mediated erythema, 2766–2767
Gram stain, 2782
Grand Canyon recluse spider, 3327
Granular cells, 64–65
Granular cell tumor (GCT), 2147*t*–2148*t*, 2150*t*, 2165–2166, 2165*f*
Granular layer, 52
Granular parakeratosis, infantile, 1753
Granules, cytoplasmic, eosinophils, 651*f*, 652
Granulocyte, 132, 154–157, 154*t*
basophils, 154*t*, 156
eosinophils, 154*t*, 156
keratinocytes, 154*t*, 156–157
neutrophils, 145*f*, 154–156, 154*t*
secretory granules, 154, 154*t*
Granulocyte colony-stimulating factor (G-CSF)
erythema nodosum, 1256
neutrophil generation, 155
Sweet syndrome, 593, 596
Granulocyte-macrophage colony-stimulating factor (GM-CSF)
eosinophils, 655, 656, 657
development, 649, 650*f*
for leishmaniasis, 3236
Sweet syndrome, 596
for tuberculosis, 2861
type IV hypersensitivity reactions, 397
vasculitis from, 2553, 2553*f*
wound healing, 2704*t*, 2707
Granuloma, pathology
infectious, 27
inflammatory reactions, 27, 28*f*
mycotic, 27
Granuloma annulare (GA), 564–570
at-a-glance, 564*b*
clinical course and prognosis, 570
clinical features, 10*f*, 564–566
cutaneous
generalized, 564–565, 565*f*
localized, 564, 565*f*
patch, 566
perforating, 565–566, 566*f*
subcutaneous, 565
history, 564
noncutaneous, 566
with diabetes mellitus, 2501

Granuloma annulare (GA) (*Cont.*):
differential diagnosis, 569*t*
epidemiology, 564
etiology and pathogenesis
pathogenic mechanisms, 567
predisposing events
bites and stings, 566
drugs, 566–567
infections and immunizations, 566
other, 566
sun exposure, 566
trauma, 566
systemic disorders
diabetes mellitus, 567
dyslipidemia, 567
malignancy, 567
thyroid disease, 567
laboratory tests
general, 567
histopathology, 567–568, 568*f*
special, 568–569
pathology
granulomatous reactions, 27
inflammatory reactions, 27, 28*f*
thyroid disease, 567
treatment, 569–570, 569*t*
photochemotherapy, 3672
phototherapy, 3653
Granuloma faciale, 673–675, 673*f*–674*f*, 674*t*
Granuloma fissuratum, 1806
Granuloma gluteale infantum, 1742
Granuloma inguinale (GI), 3202–3206
at-a-glance, 3202*b*
clinical course and prognosis, 3205
clinical features, 3202–3204, 3203*f*
diagnosis, 3204, 3204*f*
differential diagnosis, 3204, 3205*t*
epidemiology, 3202
etiology and pathogenesis, 3204
historical perspective, 3202
management, 3205, 3206*t*
transmission, mode, 3202
Granulomatosis with polyangiitis, 2550–2551, 2551*f*, 2552*f*. *See also* Vasculitis
epidemiology, 2540
Granulomatous dermatoses, 1148–1149. *See also* Rheumatoid arthritis (RA)
Granulomatous pigmented purpura, 2593
Granulomatous reactions, inflammatory, 27–28, 28*f*
Granulomatous rosacea, 1424, 1434. *See also* Rosacea
Granulomatous slack skin, 2082*t*, 2083, 2083*f*
Granulysin, 151
Granzyme B, 151
Grape seed extract, oral photoprotection, 3630
Graves disease, 2504–2509. *See also* Hyperthyroidism
Gray, 3690
Grazoprevir, for hepatitis C virus, 3512
Great saphenous vein (GSV), 3872–3874, 3872*f*–3874*f*, 3873*t*
Great toenail, congenital malalignment, 1592*f*, 1602
surgery for, 3789–3790, 3789*f*
Green color, 8*t*
Green nail, 1568–1569, 1569*t*, 1571*f*
Green nail syndrome, *Pseudomonas aeruginosa*
clinical features, 2790, 2791*t*, 2792*f*
diagnosis, 2794
etiology and pathogenesis, 2793
management, 2795
Greither syndrome, 823–824, 845*t*
Grenz rays, 3687
Grenz zone, pseudolymphomatous folliculitis, 2115
Greying, hair, 101
Grey Turner sign, 2434
GRHL3, 66, 67, 67*f*
epidermal differentiation, 66, 67, 67*f*
Griscelli syndrome (GS), 1317–1318, 2418–2419, 2419*f*, 2445*t*
characteristics, 2416*t*
clinical features, 2417*f*, 2418
epidemiology, 2418
etiology and pathogenesis, 340, 2418–2419, 2419*f*
prognosis, clinical course, and treatment, 2419
squamous cell carcinoma, 1904*t*
Griseofulvin, 3440*t*, 3441*t*, 3448
for fungal infections, superficial, 2935*t*
for *Microsporum* tinea capitis, 3448
for mycetomas, 2971
pediatrics, 1762
for pigmented purpuric dermatoses, 2596
for tinea capitis, 1532
in children, 3438
for Wells syndrome, 667
Gritty scale, 6*t*
Grocott methenamine silver (GMS) histopathology, dermatophytes, 2929*t*
Grönblad-Strandberg syndrome, 1229–1233. *See also* Pseudoxanthoma elasticum
Groove sign, eosinophilic fasciitis, 675
Grotthuß–Draper law, 267
Group A *Streptococcus* (GAS), 2733. *See also Streptococcus*
acute rheumatic fever, 1160
scarlet fever, 2764–2766
skin infections, 2733–2740 (*See also Streptococcus*)
Group A β-hemolytic *Streptococcus*
cellulitis and erysipelas, 2749, 2749*t*
erythema marginatum, 769–771, 770*f*
Grouped shape, 11
Grover disease, 890–892, 890*f*
Growing pains, 1222
Growth factors, 3540–3543. *See also specific types*
epidermal growth factor, ligands and antagonists, 3541–3542, 3550*t*
epidermal growth factor receptor, 3540–3542, 3541*f*
human skin homeostasis and diseases, 3540–3541, 3541*f*
fibroblast growth factors, 3542
insulin-like growth factor/insulin, 3542–3543
recombinant, 3539–3540
Growth hormone (GH), 2518, 2518*f*
deficiency, 2519–2521
ghrelin receptors on, 2504, 2518*f*
Growth hormone (GH) disorders, 2518–2521
acromegaly, 2518–2519, 2518*f*, 2519*t*, 2520*f*
at-a-glance, 2518*b*
growth hormone deficiency, 2519–2521
panhypopituitarism, 2519–2521, 2520*t*, 2521*f*
Growth hormone releasing hormone (GHRH), 2518, 2518*f*
GTF2E2, trichothiodystrophy, 2360
GTF2H5, trichothiodystrophy, 780*t*, 807
GUMBY/FAM105B, otulipenia/ORAS, 622*t*, 638
Gumma, syphilis, 3155–3156, 3155*f*–3156*f*
Günther disease, 2235*t*, 2237t, 2243–2244, 2244*f*. *See also* Erythropoietic protoporphyria
Guselkumab, 3537, 3549*t*
IL-23 antagonist action, 1137, 3536*f*, 3537, 3549*t*
mechanism of action, 139
for psoriatic arthritis, 469*f*, 981, 1137
Gustatory sweating, 1463–1464, 1464*f*
Guttate (eruptive) psoriasis, 459–460, 460*f*
Streptococcus, throat, 479
Gymnothorax mordax, 3358–3359, 3358*f*
Gypsy moth caterpillar, 3334

H

H_1 antihistamines. *See* Antihistamines, H_1
H_2 antihistamines. *See* Antihistamines, H_2
Haber syndrome, 1355
Habit tic, 1598, 1599*f*
HACEK organisms, infective endocarditis, 2817
Haemaphysalis leporispalustris, 3309*t*
Haemophilus ducreyi
chancroid, 3186–3190 (*See also* Chancroid)
epidemiology, 3186
Haemophilus influenzae
cellulitis, 2809–2810
cutaneous necrotizing venulitis, 2530
Type B, cellulitis and erysipelas, 2749
Hageman factor XII, coagulation and wound healing, 2701
Hailey-Hailey disease, 886–890, 892*f*
autosomal dominant disorder, 295, 295*t*
cellular defect, 781*t*
clinical course and prognosis, 888
clinical features, 886–887, 886*t*
complications, 887
cutaneous, 886–887, 886*f*, 887*f*
noncutaneous, 887
papular acantholytic dyskeratosis, 886–887
segmental disease, 886
differential diagnosis, 888, 888*t*
epidemiology, 886
etiology and pathogenesis, 887–888
gonadal mosaicism, 302
histopathology, 888, 888*f*
leukonychia, 1568, 1571*f*
management, 889–890, 889*t*
Haim-Munk syndrome, 834–835
Hair. *See also specific disorders*
aging on, 1783–1784
appearance, telogen effluvium, 1512
curled, 92
curvature, 92
development, 25–27, 57*f*
evolution and function, 89
psoriasis, 464
types, 92, 92*t*
HAIR-AN, hirsutism from, 1556*t*, 1558–1559
Hair breakage disorders, 1537–1543
monilethrix, 1543, 1543*f*, 1543*t*, 1550*t*
pili torti, 1540–1541, 1540*f*, 1541*f*, 1541*t*, 1549*t*
trichorrhexis invaginata, 1542–1543, 1542*f*, 1550*t*
trichorrhexis nodosa, 1537–1538, 1538*f*, 1538*t*, 1549*t*
trichoschisis, 1539–1540, 1539*f*, 1549*t*
trichothiodystrophy, 1539–1540, 1539*f*, 1539*t*, 1549*t*
Hair bud, 90*f*, 91–92
Hair collar sign, 1738
Hair follicle, 1838
biology, 89–92
at-a-glance, 89*b*
bulbous peg, 90*f*, 91–92
embryology, 89–90
epithelial placode and primary germ hair, 90–91, 90*f*
evolution and function, 89
mature, 92
cycle, 95–98
anagen, 93*f*, 95, 97
catagen, 93*f*, 95, 97–98
stem cells, 93*f*, 96, 96*f*
telogen and exogen, 93*f*, 95, 98
development, 56–58, 57*f*
germinative cells, 1838
inflammatory processes, 26
neonates, 1728
penetration pathways across, 3368
Hair follicle anatomy, 92–95
hair types, 92, 92*t*
microscopic, 93–95, 93*f*, 94*t*

dermal papilla, 90*f*, 94–95
hair shaft, 94, 94*t*
inner root sheath, 93*f*, 94, 94*t*
innervation, 95
outer root sheath, 93, 93*f*
perifollicular sheath, 95
Hair implanters, 3946
Hair loss. *See also* Alopecia; Baldness
count, telogen effluvium, 1512
infants, 1752–1753
alopecia areata, 1753
nevus sebaceus, 1752, 1752*f*
occipital alopecia, 1752
telogen effluvium, 1752
tinea capitis, 1753
triangular temporal alopecia, 1752
trichotillomania, 1753, 1753*f*
Hair pigmentation, 98–101
greying, 101
hair cycle–dependent melanocyte changes, 100, 100*f*
melanocytes
development, 98, 99*f*, 100*f*
pigment-producing, 99–100
stem cells, 98–99
molecular control, 101
Hair products, allergic contact dermatitis from, 405, 405*t*
Hair pulling disorder, 1533, 1533*f*, 1697*t*, 1699–1700
Hair pull test, telogen effluvium, 1512
Hair removal, nonablative laser therapy for, 3851–3852, 3853*t*
Hair replacement, nonpermanent, for androgenetic alopecia, 1505
Hair shaft, 93*f*, 94, 94*t*
Hair shaft disorders, 1537–1551
at-a-glance, 1537*b*
hair breakage, 1537–1543
monilethrix, 1543, 1543*f*, 1543*t*, 1550*t*
pili torti, 1540–1541, 1540*f*, 1541*f*, 1541*t*, 1549*t*
trichorrhexis invaginata, 1542–1543, 1542*f*, 1550*t*
trichorrhexis nodosa, 1537–1538, 1538*f*, 1538*t*, 1549*t*
trichoschisis, 1539–1540, 1539*f*, 1549*t*
trichothiodystrophy, 1539–1540, 1539*f*, 1539*t*, 1549*t*
other, 1547–1548
loose anagen syndrome, 1547, 1547*t*, 1551*t*
pili annulati, 1548, 1551*t*
summary, 1549*t*–1551*t*
unruly hair, 1543–1547
hypotrichosis, 1546–1547, 1546*t*, 1550*t*
Marie-Unna hereditary hypotrichosis, 1544–1545, 1545*t*, 1550*t*
uncombable hair syndrome, 1543–1544, 1544*f*, 1544*t*, 1550*t*
woolly hair, 1545–1546, 1545*f*, 1546*t*, 1550*t*
Hair transplantation, 3931–3948
for alopecia reduction, 3948
at-a-glance, 3931*b*
for cicatricial alopecia, 1526
classification
female-pattern, 3931, 3933*f*
male-pattern, 3931, 3932*f*
Ludwig, 3931, 3933*f*
Norwood, 3931, 3933*f*
male-pattern, Hamilton-Norwood, 3931, 3932*f*
incidence, men >65, 3931, 3934*t*
incidence by age, 3931, 3934*t*
donor area determination, 3935–3936, 3938*f*
donor site excision, 3936–3942
follicular unit excision, 3931, 3940–3942, 3940*f*, 3942*t*
"minimal incision surgery," 3937, 3939*t*
strip harvesting, 3939
strip removal, 3939–3940
follicular unit, 3931, 3935*f*
graft insertion, 3945–3946
hair implanters, 3946
graft preparation, 3942–3943
follicular unit excision, 3942–3943
graft storage, 3943
strip harvesting, 3941*f*, 3942
historical perspective, 3931
instruments and supplies, 3934, 3937*t*
"minimal incision surgery," 3939*t*
patient follow-up, 3948
patient positioning, 3934
patient selection, 3931–3933, 3936*f*
recipient area design, 3935
recipient site creation, 3943–3945, 3943*f*
graft density, 3944–3945, 3944*f*–3945*f*
repair surgery, 3946–3947, 3947*f*
risks and precautions, 3934, 3937*t*
safest donor area, 3931, 3944*f*
side effects and complications, 3947–3948, 3948*t*
Hairy pinna, 1564
Hairy polythelia, 1564
Half-and-half nails, renal insufficiency, 1597, 1597*f*
Hallopeau-Siemens, 1020, 1022–1023, 1022*f*–1023*f*, 1029*t*
Hallucinogens, 1711
Hallux nail, 1592*f*, 1602
surgery for, 3789–3790, 3789*f*
Hallux valgus interphalangeus, 1602
Halogen rosacea, 1425. *See also* Rosacea
Halo nevi
clinical features, 1952–1953, 1952*f*
pathology, 1955
HAM-56
Rosai-Dorfman disease, 2031
xanthoma disseminatum, 2036
Hamartin, tuberous sclerosis complex, 2485
Hamartoma
Becker, 1375–1376, 1375*f*
congenital eccrine angiomatous, 2059*b*, 2065
congenital midline, 2131*t*–2132*t*, 2145–2146
of cutaneous adnexa and mesenchyme, 2146
dermal melanocyte, 1357*t*, 1358, 1958
fibrolipomatous hamartoma of nerve, 2175, 2175*f*
meningeal, 2166–2167, 2167*f*
multiple hamartoma syndrome (*See* Cowden syndrome)
neonatal, 1742–1744
congenital smooth muscle hamartoma, 1743–1744
fibrous hamartoma of infancy, 1743
nevus sebaceus, 1734
neuromuscular, 2131*t*–2132*t*, 2146, 2146*f*
PTEN hamartoma tumor syndrome, 1360, 2152, 2640*t*, 2659
rhabdomyomatous mesenchymal, 2131*t*–2132*t*, 2145–2146
smooth muscle, 2131*t*–2132*t*, 2141–2143 (*See also* Smooth muscle hamartoma)
Hamilton-Norwood type androgenetic alopecia, 1496, 1496*f*–1497*f*
HANAC, collagen IV mutations, 240
Hand dermatitis. *See also* Irritant dermatitis
atopic dermatitis, 368
definition, 414–415
Hand eczema
chronic, phototherapy for, 3652
dyshidrosiform
from balsam of Peru, 400, 402
from nickel, 402
Hand-foot-mouth disease (HFMD), 3010–3011, 3011*f*, 3015*t*
Coxsackie A6–associated atypical, 3012–3013, 3012*f*–3013*f*, 3013*t*, 3015*t*
differential diagnosis, 3013*t*
nail changes, 1591, 1591*f*
Hand-Schüller-Christian (HSC) disease, Langerhans cell histiocytosis, 2019–2020, 2020*t*
Hanifin-Rajka criteria, atopic dermatitis, 364
Hapalochlaena maculosa, 3355*f*, 3356
Haploinsufficiency, 295
Haploinsufficiency of A20 (HA20), 637–638, 637*f*
Haptens, 397
Hardeners, nail, treatment effects, 1578
Hardening, skin. *See also specific disorders*
actinic prurigo, 1632*f*
irritant dermatitis, 424
polymorphic light eruption, photohardening for, 1623–1624
systemic sclerosis, 1100*t*, 1101
Harlequin color change, 1732
Harlequin ichthyosis, 208*t*, 211
cellular defect, 781*t*
clinical course, prognosis, and management, 794–795
clinical features, 789–791, 791*f*
diagnosis, 793–794
genes, 779*t*
ABCA12, 779*t*, 791*f*, 793
Hartnup disease, pellagra, 2214
Harvest mites, 3278, 3278*t*
Hashimoto-Pritzker disease, Langerhans cell histiocytosis, 2019, 2020*t*
Hashimoto thyroiditis, 2504–2509. *See also* Hypothyroidism
Hatchet flap, 3740, 3742*f*
Haverhill fever, 2838–2839
Hawaiian fire sponge, 3350
Haxthausen disease, 1254*t*, 1280–1282, 1282*t*, 1675–1676
Hay–Wells syndrome, 2379–2381, 2379*f*
Hazard identification, occupational exposures, 453
Hazard ratio, 45, 45*t*
Head injury, physical abuse, 1723
Head lice, 3279–3282
Healing by second intention, 3719–3720
Health services research, 40
"Heart-shaped" subcutaneous buried suture, 3717–3718, 3717*f*
Heat rash
infants, 1753
neonates, 1731
Heat stress protection
sweating, 225
vasculature and blood flow, 225–226, 225*f*
Heat urticaria. *See also* Urticaria
diagnosis, 697–698
diagnostic tests, 688*t*
urticaria, 686*f*, 689
Hedgehog inhibitors, basal cell carcinoma treatment, 1890
Hedgehog (HH) signaling pathway, 3572, 3573*f*
basal cell carcinoma, 1890
basal cell nevus syndrome, 1891
epidermal proliferation, 63
PTCH1, 311*f*, 314
Helical rim advancement flap, 3736–3737, 3737*f*
Helicase
in nucleotide-excision repair, 2344
RecQ family, 2344
Helicobacter pylori
eosinophils, 652
extranodal marginal zone lymphoma, gastric, 2097
Heliotrope sign, dermatomyositis, 1061, 1062*f*, 1063
Helix, 3698, 3698*f*

Heller median canaliform dystrophy, of thumb nails, 1598, 1598*f*
Helminthic infections, 3251–3272, 3252*t*. *See also specific types*
at-a-glance, 3251*b*
Charcot-Leyden crystal protein, 651*f*, 652
clinical features, 3254–3262
complications, 3262
cutaneous, 3255–3259
edema, localized, 3259
erythema nodosum, 3259
exposure and symptom onset interval, 3259, 3260*t*
migratory skin lesions, 3255–3257, 3255*t*, 3256*f*
papular and macular lesions, 3257–3258, 3258*t*
petechiae, 3259
progression and duration, 3259, 3260*t*
skin textures or pigmentation changes, 3259
subcutaneous nodules and masses, 3257, 3257*t*
ulcers, 3259
urticaria and pruritus, 3258–3259, 3258*t*
vesicles or bullae, 3259
noncutaneous, 3260–3262
gastrointestinal disease, 3261
lymphadenopathy, 3262
neurologic disease, 3261
ocular disease, 3261–3262
other symptoms, 3262
pulmonary disease, 3260–3261
patient approach
dermatologic history, 3255
general medical history, 3255
travel and residence, 3254
cutaneous larva migrans syndrome, 3264–3266, 3265*t*, 3266*f*
diagnosis, 3262–3264
laboratory testing, 3263, 3263*t*
radiologic, 3264
supportive studies, 3262–3263
Dracunculus medinensis, 3252*t*, 3255*t*, 3256–3257, 3256*f*
enterobiasis, 3265*t*, 3266–3267
epidemiology, 3251
etiology and pathogenesis, 3262
Fasciola hepatica, 3252*t*, 3253, 3254, 3255*t*, 3256
filariasis, 3252*t*, 3265*t*, 3267–3269, 3268*f*
Gnathostoma spinigerum, 3252*t*, 3254, 3255*t*, 3256
immigrants and refugees, 3251–3253, 3253*f*
life cycle and transmission, 3253–3254
management, 3264, 3266*t* (*See also specific infections*)
nematodes, 3251, 3252*t*
Paragonimus westermani, 3252*t*, 3255*t*, 3256
schistosomal infections, 3252*t*, 3253–3254, 3265*t*, 3269–3271, 3270*f*
Spirometra mansonoides, 3252*t*, 3255*t*, 3256
strongyloidiasis, 3252*t*, 3253, 3254, 3255*t*, 3256*f*, 3265*t*, 3271–3272, 3271*f*
travelers, 3251
Helper innate lymphoid cells, 134
Helper T cells. *See* T cell(s), helper
Hemangioma, 2636. *See also* Vascular malformations; *specific types*
"beard area," 2048–2049
definition and specificity, 2042
hepatic, 2050, 2050*f*
infantile, 1734, 2042–2059, 2043*t*, 3849 (*See also* Infantile hemangiomas (IH))
lobular capillary (*See* Pyogenic granuloma (PG))
LUMBAR syndrome, 2045, 2048, 2048*f*
multifocal, 2049–2050, 2050*f*
PELVIS, 2048
periocular, 2048, 2049*f*
PHACE, 2044–2045, 2045*f*, 2047–2048, 2047*t*, 3598–3599, 3598*f*
propranolol for, 3598–3599, 3598*f*
SACRAL, 2048
verrucous, 2649
Hematin, 2235
Hematoma
cephalohematoma, 1730
postoperative, 3721, 3722*f*
subungual, 1570–1571, 1572*f*
surgery for, 3785–3786, 3785*f*
Hematopoietic cells, development, 59
Hematopoietic stem cell transplantation (HCT)
allogeneic, 2320
for congenital erythropoietic porphyria, 2244
graft-versus-host disease from, 2320 (*See also* Graft-versus-host disease)
pretransplantation regimens, 2320
prevalence, 2320
for severe combined immunodeficiency, 2404*b*, 2406
syngeneic, 2320
Hematopoietin receptor family class I, ligands, 169–170
Heme. *See also specific porphyrias*
synthesis and functions, 2234–2235, 2236*f*
Hemerocampa pseudotsugata, 3334
Hemidesmosomes, 23, 232, 239, 239*f*, 243–245
CD151, 243, 243*f*
collagen XVII, 243–244, 244*f*
disease targets, 244*t*
epidermolysis bullosa, inherited, 1011, 1012, 1012*f*
keratin filaments, 64
Hemin, 2234–2235
for acute hepatic porphyrias, 2252
for protoporphyric hepatopathy, 2249
Hemiptera, 3325*f*
Cimicidae, 3325*f*, 3331–3332, 3332*f*
Reduviidae, 3332
Hemochromatosis, 2223
cutaneous manifestations, 2431–2432
hypermelanosis, 1364
Hemodialysis, for epidermal necrolysis, 744
Hemolysis
bullous diseases of, 2438
from dapsone, 3426–3427, 3427*t*, 3428
Hemophagocytic lymphohistiocytosis (HLH), 2032
cytophagic histiocytic panniculitis with, 1275–1276
macrophage activation syndrome, juvenile idiopathic arthritis, 1154
Hemorrhagic diseases of newborn (HDN), vitamin K deficiency, 2204*b*, 2211
Hemostasis
cutaneous vasculature, 118–119, 119*f*
electrosurgery for, 3798–3799, 3799*f*
Hengli, 3922
Henle layer, 93*f*, 94, 94*t*
Heparan sulfate (HS), 3805
anticoagulant, 119
dermal cell-matrix adhesion, 247
Heparan sulfate proteoglycans (HSPGs), 3805
Heparin
for lipoid proteinosis, 1247
for malignant atrophic papulosis, 2634, 2634*t*
telogen effluvium from, 1510*t*, 1511, 1511*f*
Heparin-binding (HB)-EGF6, 3398*t*
Heparin-binding EGF-like factor, 3540
Hepatic hemangioma, 2050, 2050*f*
Hepatic sarcoidosis, 576–577
Hepatitis, cutaneous manifestations, 2433
Hepatitis B virus (HBV)
cutaneous manifestations, 2433, 2433*t*
cutaneous necrotizing venulitis, 2529
erythema induratum and nodular vasculitis, 1260
granuloma annulare, 566
investigational drugs for, 3509*t*, 3512
occupational exposure, 450
polyarteritis nodosa, 2541
Hepatitis C virus (HCV)
cryoglobuline vasculitis, 2541
cutaneous manifestations, 2433, 2433*t*
cutaneous necrotizing venulitis, 2529
cutaneous T-cell lymphomas, 2097
direct-acting antivirals for, 3510
first-generation, 3511
second-generation, 3511–3512
epidemiology, 3509
erythema induratum and nodular vasculitis, 1260
granuloma annulare, 566
investigational drugs for, 3509–3512, 3509*t*
lichen planus and, 539–540, 541
life cycle, 3510
occupational exposure, 450
PEG-IFNα and ribavirin combination therapy, 3510–3511
porphyria cutanea tarda, 2240
Sjögren syndrome, 1172
structure and genotypes, 3509–3510
Hepatobiliary system disorders, skin manifestations, 2401*t*, 2430–2433
cholestatic pruritus, 2431
hemochromatosis, 2431–2432
hepatitis, 2433
hormone-induced skin changes, 2431
jaundice, 2431
nail changes, 2431
other signs, 2431
pigmentary changes, 2431
primary biliary cirrhosis, 539, 2433
vascular lesions, 2430–2431
Wilson disease, 2433
Hepatocyte growth factor (HGF), angiogenesis, 127
Hepatoerythropoietic porphyria (HEP), 2235*t*, 2237t, 2243
HER2/neu
hidradenocarcinoma, 1828
sebaceous carcinoma, 1822*t*, 1852
Herald patch, pityriasis rosea, 518, 519, 519*f*, 520*f*, 522
Hereditary and sensory autonomic neuropathy (HSAN) type III, 1464
Hereditary angioedema (HAE), 691, 698, 2419–2420, 2420*t*. *See also* Angioedema
C1 inhibitors, 694*f*
clinical features, 685, 686*f*, 698
diagnosis, 698
diagnostic algorithm, 691, 696*f*
differential diagnosis, 697*t*
prevention and screening, 703–704
urticaria, 690
Hereditary coproporphyria (HCP), 2235*t*, 2237*t*, 2249–2252
hypertrichosis from, 1565
Hereditary disorders of genome instability and DNA repair, 2342–2367. *See also specific disorders*
at-a-glance, 2342*b*
chemical phenotypes, 2342, 2346*f*
DNA repair disorders, 2342, 2346*t*, 2347–2361
genome instability disorders, 2361–2367
genome stability, 2342
malignant transformation, 2342
mechanisms, 2342, 2345*t*
molecular defects, 2342, 2346*t*

mutations and phenotypes, 2342–2344
nucleotide excision repair, impaired, 2342
Hereditary gelsolin amyloidosis (AGel amyloidosis), 1241
Hereditary hemorrhagic telangiectasia (HHT), arteriovenous malformations, 2659. *See also* Arteriovenous malformations (AVMs)
Hereditary hypotrichosis simplex (HHS), 1546–1547, 1546*t*, 1550*t*
Hereditary keratosis palmoplantaris variant of Wachters, 838, 846*t*
Hereditary leiomyomatosis and renal cell carcinoma, 2135, 2135*t*, 2445*t*
Hereditary nonpolyposis colon cancer (HNPCC)/Muire-Torre syndrome (MTS), 2343*t*, 2344, 2345*t*
Hereditary progressive mucinous histiocytosis, 2039–2040, 2039*f*
Hereditary wool hair, 1545
Herlitz junctional epidermolysis bullosa, 1016*f*, 1018, 1029*t*
prenatal diagnosis, 305
Hermansky-Pudlak syndrome (HDS), 339, 1315–1317, 1316*t*
at-a-glance, 1315*b*
clinical course, prognosis, and management, 1317
clinical features, 1311*f*, 1316
diagnosis, 1317
differential diagnosis, 1317
epidemiology, 1315–1316
etiology and pathogenesis, 1316–1317
squamous cell carcinoma, 1904*t*
types, 1316, 1316*t*
Hermodice carunculata, 3352, 3352*f*
Heroin, 1710–1711, 1711*f*
Herpes gestationis, 1766–1767, 1768*t*, 1769*f*
Herpes gladiatorum, 3024, 3025*f*, 3032*t*
Herpes incognito, 2118
Herpes labialis, 3022–3023, 3022*f*
herpes simplex viruses, 258
Herpes rugbiorum, 3024, 3032*t*
Herpes simplex virus (HSV), 3021–3033
at-a-glance, 3021*b*
atopic dermatitis, 376
clinical course and prognosis, 3029
clinical features, 3022–3027
complications, 3027
cutaneous
abdomen, 3024, 3024*f*
athletes, 3024, 3025*f*
eczema herpeticum, 3025–3026, 3025*f*
genital, 3023–3024, 3023*f*–3024*f*
herpetic whitlow, 3024, 3025*f*
neonatal, 3025*f*, 3026
orofacial, 3022–3023, 3022*f*
recurrent, 3026
erythema multiforme, 727–730
prevention, 730
nail changes, 1589–1590, 1589*f*
noncutaneous
neurologic, 3026–3027
ocular, 3026
diagnosis
laboratory testing, 3027–3028, 3027*t*
pathology, 3028, 3028*f*
differential diagnosis, 3028–3029, 3029*t*
in elderly, 1787
epidemiology, 3021–3022
herpes labialis, 258
with HIV, 3117, 3117*f*
management, 3029–3033
counseling, 3029
medications, 3029–3032
antiviral resistance, 3032–3033
disseminated, 3032*t*
eczema herpeticum, 3032*t*
genital, 3031*t*
herpes gladiatorum, 3032*t*
neonatal, 3032*t*
orofacial herpes, 3029–3030, 3030*t*
whitlow, 3032*t*
neonatal, 1738–1739, 1739*f*, 3022*t*, 3025*f*, 3026, 3032*t*
occupational exposure, 449
prevention, 3033
risk factors, 3027
types, 3021
Herpes vegetans, with HIV, 3117, 3117*f*
Herpesvirus infections, antiviral drugs for, 3493–3499. *See also specific types*
acyclovir, 3493–3496, 3495*t*
famciclovir and penciclovir, 3494*f*, 3497–3498, 3498*t*
mechanisms of action, 3494*f*
trifluridine, 3498–3499, 3499*t*
valacyclovir, 3496–3497, 3497*t*
Herpesvirus simiae (B virus), 3341
Herpes zoster, 3035–3058
at-a-glance, 3035*b*
clinical features, 3041–3047
chronic disseminated, immunocompromised, 3046, 3047*f*
complications, 3042, 3045–3047, 3045*t*, 3046, 3047*f*
cranial nerve involvement, 3042, 3044*f*–3045*f*
nail changes, 1590, 1590*f*
pain, 3042
prodrome and zoster sine herpete, 3041–3042
pruritus, 3042
Ramsay-Hunt syndrome, 3042, 3045*f*
rash, 3042, 3043*f*–3045*f*
diagnosis, 3048–3051
clinical, 3043*f*–3045*f*, 3048–3049, 3049*f*
laboratory, 3049–3051, 3050*f*
differential diagnosis, 3049*t*
in elderly, 1787
epidemiology, 3036–3039, 3037*f*–3038*f*
etiology and pathogenesis, 3047–3048
fundamentals, 3035
historical perspective, 3035–3036
management, 3051, 3053–3054
analgesics, 3054
antiinflammatory therapy, 3054
antiviral agents, 3051
immunocompetent, 3053, 3053*t*
immunocompromised, 3053–3054, 3053*t*
human diploid cell rabies vaccine, 3340–3341
postherpetic neuralgia, 3038*f*, 3054
topical, 3053
pain pathogenesis, 3048
prevention, 3056–3058, 3058*t*
adjuvanted glycoprotein E subunit zoster vaccine, 3057–3058, 3058*t*
human diploid cell rabies vaccine, 3340–3341
live attenuated zoster vaccine, 3056–3057
vaccine, with HIV, 3118
Herpetic gingivostomatitis, 3022, 3022*f*
Herpetic whitlow, 3024, 3025*f*, 3393*t*
Herpetiform shape, 11
Hes1, epidermal differentiation, 66, 67*f*
Heterogeneity
allelic, 295
cancer
intertumor, 313
intratumor, 312
genetic, 295
Heteronuclear RNA, 292
Heteroplasmy, 300
Heterotransfer, allergic contact dermatitis, 400
Heterozygote, compound, 296
Hexachlorobenzene, porphyria cutanea tarda from, 2240
Hexachlorocyclohexane, 3614–3615, 3615*t*
Hexachlorophene, 3715
HFE, porphyria cutanea tarda, 2239
hHb1, monilethrix, 1543
hHb3, monilethrix, 1543
hHb6, monilethrix, 1543
HHF35, xanthoma disseminatum, 2036
hh/ptc, 89
HHV8-associated diseases, 172
Hibernoma, 2185–2186, 2185*f*
Hidradenitis suppurativa (HS), 1480–1491
clinical course and prognosis, 1487
clinical features, 1480, 1481*f*–1482*f*
comorbidities and associated diseases, 1484
complications, 1480–1482
local, 1481, 1482*f*
quality of life, 1480
squamous cell carcinoma, 1482, 1482*f*
systemic, 1481
diagnosis, 1484–1487
algorithm, 1486*f*
clinical criteria, 1484, 1484*t*, 1485*f*
clinical phenotypes, 1485
histopathology, 1486–1487
imaging, 1485
laboratory testing, 1485
severity and Hurley staging, 1484–1485, 1486*t*
differential diagnosis, 1484, 1485*t*
epidemiology, 1480
etiology and pathogenesis, 1482–1484
adnexal structures, 1483
androgens, 1483
bacteria, 1484
follicular occlusion, 1483
genetics, 1483
immune dysregulation, 1483–1484
multifactorial, 1482
obesity, 1483
smoking, 1483
management, 1487–1491
algorithm, 1489*f*
evidence/strength ratings, 1488*t*
category, 1488*t*
lifestyle modifications and home remedies, 1487–1489
medical therapy
antibiotics, 1489–1490
biologics, 1490
hormonal, 1490
immunosuppressants, 1490
metformin, 1490
retinoids, 1490
mental health, 1491
pain management, 1491
surgical therapy
botulin toxin A, intralesional, 1491
cryotherapy, 1491
excisional, 1490
laser, 1490–1491
radiotherapy, 1491
tobacco use on, 1714
Hidradenocarcinoma, 1827–1828
Hidradenoma, 1822–1823, 1823*f*
Hidradenoma papilliferum, 1835–1836, 1835*f*
Hidrocystoma, 1822*t*, 1831–1832, 1832*f*
Hidrotic ectodermal dysplasia (HED), 832–833, 845*t*, 2377–2378, 2377*f*
High-density lipoprotein (HDL), 2273–2274
epidemiology, 2274
synthesis and metabolism, 2280–2281
Highland moccasin, 3342, 3342*f*
Highly active retroviral therapy–induced lipodystrophy in HIV-infected patients, 1297*f*, 1301, 1302*f*, 3111, 3112, 3113*f*

"High pruritus," heroin, 1710
Hill, Sir Bradford, 41
Hirsutism, 1555–1563
  acromegaly, 1556*t*, 1559, 2519
  androgen excess, women, 2517
  at-a-glance, 1555*b*
  causes, 1556, 1556*t*
    associated
      acromegaly, 1556*t*, 1559
      adrenal tumors, 1556*t*, 1559
      congenital adrenal hyperplasia, nonclassic, 1556*t*, 1559
      Cushing syndrome, 1556*t*, 1559, 2512
      endocrinopathies, 1559
      HAIR-AN, 1556*t*, 1558–1559
      hyperprolactinemia, 1556*t*, 1559
      idiopathic hirsutism, 1556*t*, 1558, 1558*f*
      ovarian tumors, 1559
      polycystic ovary syndrome, 1556*t*, 1558, 1558*f*
      pregnancy, 1556*t*, 1559
      SAHA syndrome, 1556*t*, 1559
  clinical findings and diagnosis, 1556–1558, 1557*t*
  epidemiology, 1555
  evaluation, 1556*t*, 1559–1561, 1560*f*
  pathogenesis, 1555–1556
  psychological and emotional distress, 89
  treatment, 1561–1563, 1562*t*
    androgen suppression, 1561–1563, 1562*t*
    electrolysis and lasers, 1563
Histamine, 3451
  effects, 3451
  mast cell granules, 153–154, 154*t*
  pruritus, 356
Histamine receptors, 3451
Histiocyte, granulomatous reaction, 27–28, 28*f*
Histiocytoid Sweet syndrome, 591
Histiocytosis
  at-a-glance, 2018*b*
  classification, 2018, 2019*t*
  rheumatoid arthritis
    intralymphatic, 1151
    intravascular, 1151
Histiocytosis, Langerhans cell, 2019–2029. *See also* Langerhans cell histiocytosis
Histiocytosis, non–Langerhans cell, 2029–2040
  adult xanthogranuloma, 2034
  at-a-glance, 2029*b*
  benign cephalic histiocytosis, 2034
  classification, 2019*t*, 2029
  Erdheim–Chester disease, 2038
  etiology and pathogenesis, 2029–2030
  generalized eruptive histiocytoma, 2035, 2036*f*
  generalized eruptive histiocytoma of childhood, 2034
  hemophagocytic lymphohistiocytosis, 2032
  hereditary progressive mucinous histiocytosis, 2039–2040, 2039*f*
  juvenile xanthogranuloma, 2032–2034, 2033*f*, 2034*t*
  marker expression, 2027*t*, 2030
  multicentric reticulohistiocytosis, 2036–2038, 2037*f*
  necrobiotic xanthogranuloma, 2038–2039, 2442*t*, 2457–2458
  papular xanthoma, 2034–2035
  progressive nodular histiocytosis, 2040
  Rosai-Dorfman disease, 2031–2032, 2031*f*
  xanthoma disseminatum, 2035–2036, 2036*f*, 2037*f*
Histiocytosis X, 2020
Histochemical stains, 19, 20*t*, 21*t*
Histocompatibility antigen disease association, 303–304, 304*t*
Histologic mycosis fungoides simulators, 2118–2122. *See also under* Pseudolymphomas (PSLs), cutaneous
Histone
  acetylation regulation, 3575–3576, 3576*f*
  modifications, 3575
    epidermis differentiation regulation, 66, 67*f*
Histone acetyltransferases, 3576, 3576*f*
Histone deacetylase inhibitors, 3575–3580
  at-a-glance, 3575*b*
  background, 3575–3576, 3576*f*
  belinostat, 3578–3579, 3578*f*
  panobinostat, 3579–3580, 3579*f*
  romidepsin, 3577–3578, 3577*f*
  vorinostat, 3576–3577, 3576*f*
Histone deacetylases (HDACs), 3576, 3576*f*
Histoplasma capsulatum var. *capsulatum*, 2975–2976, 2976*f*–2977*f*. *See also* Histoplasmosis, small-form (classic)
  with HIV, 3115, 3115*f*
Histoplasma capsulatum var. *duboisii*
  with HIV, 3115, 3115*f*
  large-form, 2977
  small-form, 2975–2976, 2977*f*
Histoplasma farciminosum, 2975
Histoplasmosis
  African, 2977
  large-form, 2977
  small-form (classic), 2975–2976, 2976*f*–2977*f*
    primary cutaneous, 2975
    progressive disseminated
      acute, 2975, 2976*f*
      chronic, 2975
    pulmonary
      acute, 2975
      chronic, 2975
Histoplasmosis capsulati, 2975–2976, 2976*f*–2977*f*
Histoplasmosis duboisii, 2977
History and physical examination, 3706–3709. *See also specific disorders*
  allergies, 3709
  antibiotic prophylaxis, 3706–3707, 3707*t*
  anticoagulants, 3708, 3708*t*
  cardiac conditions and endocarditis risk, 3706–3707, 3707*t*
  corticosteroids, systemic, 3709
  history, 1–2
    taking, 2*t*
  implantable electronic devices, 3707–3708
  medications, 3708–3709
  past medical and surgical history, 3706–3708
  physical examination, 3709
  pregnancy, 3709
  social history
    alcohol, 3709
    functional status and support systems, 3709
    smoking and nicotine, 3709
  surgical site infections, risk factors, 3706, 3707*t*
HIV. *See* Human immunodeficiency virus (HIV)/AIDS
HLA-A25, cutaneous necrotizing venulitis, 2533
HLA-B8
  chronic bullous disease of childhood, 993
  dermatitis herpetiformis, 1005
HLA-B18, cutaneous necrotizing venulitis, 2533
HLA-B27
  juvenile idiopathic arthritis, 1154
  psoriatic arthritis, 30, 976, 1131, 1131*f*
  reactive arthritis, 984, 1140
HLA-B*1502, 304
HLA class I molecules, drug reactions, 760
HLA class II molecules, drug reactions, 760
HLA-Cw6, psoriasis, 471, 477, 477*f*
HLA-DPA-1, graft-versus-host disease, 2322
HLA-DQ2
  chronic bullous disease of childhood, 993
  dermatitis herpetiformis, 1005
HLA-DQ8, dermatitis herpetiformis, 1005
HLA DQA*0501, Sjögren syndrome, 1170
HLA-DQB1*03, cutaneous T-cell lymphomas, 2073, 2073*f*
HLA DQB1*0201, Sjögren syndrome, 1170
*HLADQB1*0301*, mucous membrane pemphigoid, 962
HLA-DQB1*0604/0605, systemic sclerosis, 1093
HLA-DQw2, dermatitis herpetiformis, 1005
HLA-DR
  cutaneous necrotizing venulitis, 2534
  eosinophils, 658
  multicentric reticulohistiocytosis, 2038
HLA-DR2, cutaneous necrotizing venulitis, 2533
HLA-DR3
  chronic bullous disease of childhood, 993
  relapsing polychondritis, 1188
HLA-DR4
  actinic prurigo, 1629–1630
  chronic spontaneous urticaria, 695
  pemphigus, 917
HLA-DRB1, rheumatoid arthritis, 1152
HLA-DRB1*03-positive leukocyte antigen, erythema nodosum, 1256
HLA-DRB1*11
  cutaneous T-cell lymphomas, 2073, 2073*f*
  juvenile idiopathic arthritis, 1154
HLA-DRB1*1302, systemic sclerosis, 1093
HLA-DR-DQ, leprosy, 2902
HLA-SRB1*0301, systemic sclerosis, 1093
HMGA2, myolipoma, 2184
Hobo spider, 3327–3328
Hodgkin disease (lymphoma)
  granuloma annulare from, 567
  ichthyosis, acquired, 809, 2448
  nodular sclerosing, eosinophils and prognosis, 653
Holocarboxylase synthetase defect, 2220, 2220*t*
Holocrine glands, 70
Holocrine secretion, 73–74
Holothurin, 3352
Homing, skin, T cells, 146–147
Homozygote, 296
Honokiol, antiangiogenesis, 3604*t*
Hookworm, 3252*t*, 3255*t*
  abdominal pain, 3261
  exposure and symptom onset interval, 3259, 3260*t*
  Loeffler syndrome, 3260–3261
  papular and macular lesions, 3257, 3258*t*
  progression and duration, 3259, 3260*t*
  urticaria and pruritus, 3258–3259, 3258*t*
Horizontal forehead lines, botulinum toxin for, 3925–3926, 3927*f*–3928*f*
Horizontal mattress suture, 3718, 3718*f*
Hormone-induced skin changes, 2431
Hormone replacement therapy
  estrogen, 2515
    for graft-versus-host disease, genital, 2335
    for porphyria, 2242
  for telangiectasia, 3875–3876
Hormone response elements, retinoid receptors, 3395
Horn cysts, trichoepithelioma, 33
Horse antithymocyte globulin, for graft-versus-host disease, 2332
Horse flies, 3325*f*, 3330–3331
Horse rider's pernio, 1254*t*, 1280–1282, 1282*t*
Hospital-acquired methicillin-resistant *Staphylococcus aureus* (HA-MRSA), 2721

Hot flushes, estrogen and thermoregulation, 121–122
Hot-foot syndrome, *Pseudomonas aeruginosa*
  clinical features, 2790, 2791*t*, 2792*f*
  diagnosis, 2794
  etiology and pathogenesis, 2793
  management, 2796
"Hot tub" folliculitis, 2724. *See also* Folliculitis, *Pseudomonas aeruginosa*
House dust mite, 3278, 3278*t*
Howel-Evans syndrome, 834*f*, 841, 846*t*, 2444*t*
hox, 89
HOX (homebox), 50
H-plasty, 3737
HPLH1, hemophagocytic lymphohistiocytosis, 2032
HPS1, Hermansky-Pudlak syndrome, 1316, 1316*t*
HPS2, Hermansky-Pudlak syndrome, 1316–1317, 1316*t*
HPS3, Hermansky-Pudlak syndrome, 1316*t*, 1317
HPS4, Hermansky-Pudlak syndrome, 1316, 1316*t*
HPS5, Hermansky-Pudlak syndrome, 1316*t*, 1317
HPS6, Hermansky-Pudlak syndrome, 1316*t*, 1317
HPS7, Hermansky-Pudlak syndrome, 1316*t*, 1317
HPS8, Hermansky-Pudlak syndrome, 1316*t*, 1317
HPS9, Hermansky-Pudlak syndrome, 1316*t*, 1317
HPS10, Hermansky-Pudlak syndrome, 1316–1317, 1316*t*
Hr, 323
Hras, 314
HRAS, 314–315
  keratinocytic epidermal nevus, 1808
  nevus sebaceus, 1809
  nevus spilus, 1950
  porocarcinoma, 1828
  seborrheic keratoses, 1800, 1800*t*
  Spitz nevus, 1964
  syringocystadenoma papilliferum, 1834
  trichilemmoma, 1845
HS (hypertonic saline), 3878, 3878*t*, 3879
HS (hypertonic saline) and dextrose, 3878, 3878*t*, 3879
Huffer rash, 1670, 1671*f*
Human bites
  cellulitis, 2748
  treatment, 3338–3339
Human cytomegalovirus (HCMV), 3004–3007, 3015*t*
  at-a-glance, 3004*b*
  clinical course and prognosis, 3006
  clinical features
    congenital HCMV, 3004
    in immunocompetent, 3005
    in immunocompromised, 3005
    perinatal HCMV, 3004–3005
  complications, 3006
  diagnosis, 3005–3006, 3006*f*
  differential diagnosis, 3006*t*
  epidemiology, 3004
  management, 3006–3007
Human diploid cell rabies vaccine (HDRV), 566, 3340–3341
Human genome. *See* Genome, human
Human Genome Project, 289
Human granulocytic anaplasmosis (HGA), 3320–3322
  clinical and laboratory findings, 3312*t*, 3320–3322
  diagnosis and differential diagnosis, 3315*t*, 3321–3322, 3321*f*
  epidemiology and vectors, 3311*t*, 3320, 3321*f*
  etiology and pathogenesis, 3320
  pathology, 3321
  prevention, 3322
  treatment and prognosis, 3311*t*, 3316*t*, 3322
Human herpesvirus 4 (HHV-4), 2998–3002, 3015*t*. *See also* Epstein-Barr virus (EBV)
Human herpesvirus 6 (HHV-6), 3007–3009, 3008*f*, 3015*t*. *See also specific disorders*
  clinical course and prognosis, 3008–3009
  clinical features
    drug-induced hypersensitivity syndrome, 3008 (*see also* Drug-induced hypersensitivity syndrome (DiHS))
    exanthem subitum, 3007–3008, 3008*f*, 3015*t*
    pityriasis rosea, 518, 521–522 (*see also* Pityriasis rosea)
    Rosai-Dorfman disease, 3008 (*see also* Rosai-Dorfman disease (RDD))
  diagnosis, 3008
  epidemiology, 3007
  etiology and pathogenesis, 3007
  management, 3009
  prevention, 3009
Human herpesvirus 7 (HHV-7), 3009–3010
  clinical course and prognosis, 3010
  clinical features
    exanthem subitum, 3009, 3015*t*
    lichen planus, 3009
    pityriasis rosea, 518, 521–522, 524, 3009
  diagnosis, 3009–3010
  differential diagnosis, 3010*t*
  epidemiology, 3009
  etiology and pathogenesis, 3009
  management, 3010
Human herpesvirus 8 (HHV-8), mycosis fungoides, 508
Human immunodeficiency virus 1 (HIV-1), chemokines, 186
Human immunodeficiency virus (HIV)/AIDS, 3107–3113
  acute infection, 3108
  acute retroviral syndrome, 3108
  at-a-glance, 3107*b*
  CD4 T-cell counts, 3108, 3108*t*
  chancroid and, 3190
  clinical course, prognosis, and management, 3108–3109
  clinical features, 3107–3108
  defining illnesses, 3108, 3109*t*
  diagnosis, 3108, 3108*t*
  epidemiology, 3107
  etiology and pathogenesis, 3107
  leishmaniasis coinfection, 3225, 3226*f*
  leprosy with, 2915–2916
  lichenoid reaction with, 534
  life cycle stages, 3503
  medications and their effects, 3109–3112
    antiretroviral therapy, 3109, 3110*t* (*See also* Antiretroviral therapy (ART))
    at-a-glance, 3109*b*
    clinical course, prognosis, and management, 3111–3112
    clinical features, 3109–3111, 3111*f*–3113*f*
    diagnosis and differential diagnosis, 3111
    epidemiology, 3109
    etiology and pathogenesis, 3111
    highly active retroviral therapy–induced lipodystrophy in HIV-infected patients, 1297*f*, 1301, 1302*f*, 3111, 3112, 3113*f*
  melanonychia, 1570
  mucocutaneous infections, 3113–3124
    at-a-glance, 3113*b*
    cutaneous malignancy, 3119–3121
      at-a-glance, 3119*b*
      cutaneous lymphomas, 3121
      HPV-induced dysplasia and squamous carcinoma, 3120–3121
      Kaposi sarcoma, 3119–3120, 3119*f*, 3120*t*
      melanoma, 3121
      Merkel cell carcinoma and appendageal carcinoma, 3121
      smooth muscle tumors, pediatric, 3121
    immune reconstitution inflammatory syndrome, 3124, 3124*t*
    drug reactions, 3109
    infections, well-controlled HIV, 3117–3119
      herpes simplex virus 1/2, 3117, 3117*f*
      human papillomavirus, 3118, 3118*f*
      staphylococcal, 3117
      syphilis, 3118–3119
      varicella-zoster virus, 3117–3118
    inflammatory conditions, 3121–3123
      at-a-glance, 3121*b*
      eosinophilic folliculitis, 3123–3124, 3123*f*
      papular pruritic eruption, 3123, 3123*f*
      psoriasis, 3121–3122
      seborrheic dermatitis, 3122–3123, 3122*f*
    mycoses, invasive, 2973–2975, 2974*t*
    opportunistic infections, advanced HIV, 3113–3116
      bacillary angiomatosis, 3114
      leishmaniasis, atypical, 3116
      molluscum contagiosum, severe, 3116, 3116*f*
      mycobacterial, 3114
      mycoses, invasive, 3114–3115, 3115*f*
      mycoses, superficial, 3115–3116, 3116*f*
      oral hairy leukoplakia and other Epstein-Barr virus disease, 3113–3114
      scabies, 3116
  occupational exposure, 450
  photochemotherapy with, 3674
  phototherapy safety, 3645
  porphyria cutanea tarda, 2240
  recalcitrant erythematous desquamating disorder, 2764
  seborrheic dermatitis, 431, 431*f*
  Sjögren syndrome, 1172
  syphilis and, 3159
Human leukocyte antigen (HLA), 303. *See also* HLA
  chronic bullous disease of childhood, 993
  disease association, 303–304, 304*t*
  paraneoplastic pemphigus, 935
  serotypes, Sweet syndrome, 595
Human leukocyte antigen D-related (HLA-DR)
  parapsoriasis, 509
  pityriasis lichenoides, 513
Human Microbiome Project, 254
Human monocytic ehrlichiosis (HME), 3320–3322
  clinical and laboratory findings, 3312*t*, 3320–3322
  diagnosis and differential diagnosis, 3315*t*, 3316*t*, 3321–3322, 3321*f*
  epidemiology and vectors, 3310*t*, 3320, 3321*f*
  etiology and pathogenesis, 3320
  pathology, 3321
  prevention, 3322
  treatment and prognosis, 3310*t*, 3316*t*, 3322
Human papillomavirus (HPV), 3095–3104
  anal intraepithelial neoplasia, 1871*t*, 1873*b*–1874*b*
  at-a-glance, 3095*b*
  carcinogenesis, 319, 319*t*
  cocaine abuse, 1709

Human papillomavirus (HPV) (*Cont.*):
diseases caused by, 3095, 3096*t*
epidemiology, 3096–3097
high-risk and low-risk types, 3095
with HIV
dysplasia, 3120–3121
well-controlled, 3118, 3118*f*
mucosal and peri-mucosal infections, 3102–3104
anogenital intraepithelial neoplasia and cancer, 3096*t*, 3103–3104, 3104*f*
anogenital warts, 3096*t*, 3099*t*, 3102–3103, 3103*f*
oral warts, 3096*t*, 3103, 3104*f*
squamous cell carcinoma, oral and oropharyngeal, 3096*t*, 3104
nail changes, 1590–1591, 1590*f*
occupational exposure, 450
seborrheic keratoses, 1800
skin infections, 3097–3102 (*See also specific types*)
cutaneous warts, 3096*t*, 3097–3100, 3097*f*–3099*f*, 3099*t*, 3101*t*
epidermodysplasia verruciformis, 3096*t*, 3100–3102, 3101*f*, 3101*t*
epidermodysplasia verruciformis–like syndromes, 3096*t*, 3100–3102, 3101*t*, 3102*f*
squamous cell carcinoma, 3096*t*, 3102
on squamous cell carcinoma risk, 1906
verruca vulgaris, 30–31, 30*f*, 258, 3099*f*
with viral-associated epithelial precancerous lesions, 1871, 1871*t*
virology, 3095, 3096*f*
Human polyomaviruses (PyV), carcinogenesis, 319–320, 319*t*
Human tail, 1736
Human T-cell lymphotropic virus 1 (HTLV-1), leprosy with, 2915–2916
Human T-cell lymphotropic virus 1 (HTLV-1)-associated T-cell leukemia/lymphoma, 2074
Human T-lymphotropic virus (HTLV), mucocutaneous manifestations, 3125–3127
adult T-cell leukemia and, 3125–3127
at-a-glance, 3125*b*
clinical course, prognosis, and management, 3126–3127
clinical features, 3125, 3126*f*
diagnosis, 3125
differential diagnosis, 3126
epidemiology, 3125
Humectants, 3807
Hunterian chancre, 3148
Hunting reaction of Lewis, 1666
Huriez syndrome, 824*f*, 833–834, 845*t*
Hutchinson Gilford progeria, 283, 1299
Hutchinson sign
external nasal branch, 3703
ophthalmic zoster, 3042
Huxley layer, 93*f*, 94, 94*t*
Hyaline, 95
Hyalohyphomycotic cysts, 2972
Hyaluronic acid (HA), 3805
for aphthous oral ulcers, in adamantiades–Behçet disease, 2574, 2574*t*
dermal cell-matrix adhesion, 247
soft-tissue filler, 3912–3915, 3913*t*, 3914*f*
Hyaluronidase, for chemotherapy extravasation, 3486
Hydration, skin, 3804–3808
aquaporin-3, 3805–3806
bilayer lipid membrane skin barrier, 3804, 3804*f*
glycosaminoglycans, 3805
natural moisturizing factor, 3805
oily *vs.* dry, 3804–3808
sebum production, 3804–3805
skin care for, 3806–3807
stratum corneum, 3804
xerosis, 3804
Hydroa vacciniforme (HV), 1634–1637
at-a-glance, 1634*b*
clinical course and prognosis, 1637
clinical features, 1634–1635, 1635*f*
definition, 1634
diagnosis, 1635–1636, 1636*f*
diagnostic algorithm, 1636, 1636*f*
differential diagnosis, 1636–1637, 1636*t*
epidemiology, 1634
etiology and pathogenesis, 1635
historical perspective, 1634
management, 1637
prevention, 1637
Hydroa vacciniforme–like lymphoproliferative disease (HVLL), Epstein-Barr virus, 3001
Hydrocarbon bases, 3373*t*, 3374
Hydrocarbon keratoses, 1880*b*–1881*b*
Hydrochloride salt, heroin abuse, 1710
Hydrochlorothiazide, phototoxicity, 1662
Hydrocodone abuse, 1714
Hydrocortisone, 3382. *See also* Glucocorticoids
mechanism of action, 3382
pediatric toxicity, 1761*t*
percutaneous absorption, 3370, 3370*f*
Hydrocortisone-17-butyrate, steroid allergen testing, 405, 406*t*
Hydrofluoric acid
burn, 1683
chemical burns, 441–442, 443*t*
Hydrogen peroxide, 3612*t*, 3613
Hydroquinone, 3618
for melasma, 1381, 2242
for postinflammatory hyperpigmentation, 1379
for slate-gray pigmentation, phototoxicity, 1662–1663
Hydroxy acids, for aging skin, 3814
Hydroxybutyrate
abuse, 1711
for frontal fibrosing alopecia, 547
Hydroxychloroquine
for central centrifugal cicatricial alopecia, 1528
for dermatomyositis, 1077
for discoid lupus erythematosus, cicatricial alopecia, 1526
for erythema nodosum, 1259
for lichen planopilaris, 546
for lichen planus
cutaneous, 544
oral, 546
for lupus erythematosus, 1054, 1054*t*
for lupus panniculitis, 1275
for morphea, 1116
for nail lichen planus, 547
with pentoxifylline, for lipodermatosclerosis, 1264
for porphyria cutanea tarda, 2242
for rheumatoid vasculitis, 1153
for rosacea, facial lymphedema, 1442
for Still disease, adult-onset, 1158
for urticaria, 702
Hydroxychloroquine sulfate, for cutaneous necrotizing venulitis, 2537
Hydroxychloroquine sulfate, for lupus erythematosus, 1054*t*, 1055–1056
Hydroxydaunorubicin, for primary cutaneous diffuse large B-cell lymphoma, 2101
Hydroxymethylbilane (HMB)
congenital erythropoietic porphyria, 2244
porphyrias, 2234
Hydroxyurea, 3469–3471
chemical structure, 3465*f*
complications, 3470–3471
for congenital erythropoietic porphyria, 2244
dosing regimen, 3470
drug interactions, 3471
on eosinophils, 658
indications, 3469–3470, 3469*t*
initiating therapy, 3470
mechanism of action, 3469
monitoring therapy, 3470, 3470*t*
pharmacokinetics, 3469
for psoriasis, 485*t*, 493
with HIV, 3122
risks and precautions, 3470, 3470*t*
Hydroxyzine. *See also* Antihistamines, H_1
dosing regimens, 3454–3455, 3454*t*
for nighttime itch, in lichen simplex chronicus and prurigo nodularis, 391
Hymenoptera, 3333–3334
Hyperandrogenism, 2516–2518, 2517*f*, 2517*t*
Hypercalcemia
differential diagnosis, 2509*f*
parathyroid disease, 2509–2512 (*See also* Parathyroid disease)
Hypercholesterolemia, familial, 2281
Hypereosinophilic syndromes (HES), 660–665
at-a-glance, 660*b*
classification, 664*f*
clinical course, prognosis, and management, 663–665, 664*f*
clinical features, 660–661, 660*t*
diagnosis, 660*t*, 662–663, 662*t*
differential diagnosis, 663, 663*t*
eosinophil-induced fibrosis, 656
etiology and pathogenesis, 661–662
Gleich syndrome, 654, 661
imatinib mesylate for, 658
mucocutaneous manifestations, 660–661, 661*f*, 661*t*
Hyperextensibility, skin
Ehlers-Danlos syndromes, 1212, 1218, 1219*f* (*See also* Ehlers-Danlos syndromes)
Remvig criteria, 1212, 1219*t*
Hypergammaglobulinemic purpura, cutaneous necrotizing venulitis with, 2529
Hyperglucagonemia, necrolytic migratory erythema, 2455–2456, 2455*f*
Hyperhidrosis
axillary, adolescents, 1758
botulinum toxin for, 3927–3928, 3929*f*
clinical presentation, 1459
epidemiology, 1459
paroxysmal localized, 1464
primary focal (essential), 1459–1463, 1460*t*
clinical course, prognosis, and management, 1461–1463, 1462*t*
clinical features, 1461, 1461*t*
diagnosis and disease severity, 1461, 1461*f*, 1461*t*
etiology and pathogenesis, 1461
secondary, 1460*t*, 1463–1465, 1464*f*
clinical course, prognosis, and management, 1465
clinical features, 1463
diagnosis, 1465
etiology and pathogenesis, generalized, 1464–1466
medications and toxins, 1465
pathogenesis, 1464
Riley-Day syndrome, 1464
etiology and pathogenesis, localized with cutaneous disorders, 1464
eccrine nevus, 1464
gustatory sweating, 1463–1464, 1464*f*
paroxysmal localized hyperhidrosis, 1464
Hyper IGE syndrome, 197
Hyperimmunoglobulinemia D with periodic fever syndrome (HIDS)/mevalonate kinase deficiency (MKD), 634–635, 635*f*

Hyperimmunoglobulin E recurrent infection syndrome, 2413–2415, 2413*f*–2414*f*, 2413*t*
Hyperimmunoglobulin E syndrome, 1740, 2413–2415, 2413*f*–2414*f*, 2413*t*
Hyperimmunoglobulin M syndrome, 2402*b*
Hyperkeratosis. *See also specific disorders*
  condyloma acuminatum, 31, 31*f*
  definition, 776
  epidermolysis hyperkeratosis, 65*t*, 305
  ichthyoses, 776
  linear epidermolytic hyperkeratosis, 302
  palmoplantar hyperkeratosis with squamous cell carcinoma of skin and sex reversal syndrome, 836, 845*t*
  seborrheic keratosis, 31, 31*f* (*See also* Seborrheic keratoses (SK))
  subungual, 1572–1573, 1574*f*
  verruca planta, 31
Hyperkeratotic dermatoses, 2441–2453, 2442*t*. *See also specific disorders*
  acanthosis nigricans, 2441–2443, 2442*t*, 2447, 2495, 2495*f*
  acrokeratosis paraneoplastica of Bazex, 1541*t*, 2442*t*, 2451–2453, 2451*f*–2452*f*
  ichthyosis, acquired, 2442*t*, 2447–2448
  Leser-Trélat sign, 2442*t*, 2449–2451, 2460*f*
  pityriasis rotunda, 2442*t*, 2448
  tripe palms, 2442*t*, 2448–2449, 2448*f*
Hyperkeratotic discoid lupus erythematosus, 1046
Hyperkeratotic scale, 6*t*
Hyperlipidemia
  from retinoids, 3403
  secondary, acquired, 2281–2282
  type I, 2281, 2282
  type IIa, 2281
  type IIb, 2281, 2282
  type III, 2281–2282, 2288
  type IV, 2281, 2282
Hypermelanosis, acquired, 1361–1387. *See also* Melanoma; *specific types*
  acquired patterned, 1372
    flagellate mushroom dermatitis, 1372
    phytophotodermatitis, 1372
  acromelanosis progressiva, 1377–1378
  atrophoderma of Pasini-Pierini, 1383
  café-au-lait macules, 1376–1377, 1377*f*
  Cronkhite-Canada syndrome, 1382–1383
  cutaneous amyloidosis, 1383
  drugs, 1365–1367
    clinical course and prognosis, 1367
    clinical features, 1365, 1367*f*
    diagnosis, 1366–1367
    etiology and pathogenesis, 1366
    management, 1367
    medications, 1365*t*, 1367*f*
    prevalence, 1365
  endocrinopathies, 1361–1363
    acanthosis nigricans, 1362–1363, 1362*f*
    Addison disease, 1361–1362, 2514, 2514*f*
    carcinoid syndrome, 1362
    Cushing syndrome, 1362, 2513
    diabetes, 1362
    hyperthyroidism, 1362
    maturational dyschromia, 1363, 1363*f*
    Nelson syndrome, 1362
    pheochromocytoma, 1362
  ephelides, 1377
  erythema ab igne, 1373, 1373*f*
  erythema dyschromicum perstans, 1384–1385, 1384*f*
  erythrose peribuccal of Brocq, 1383
  fixed drug eruptions, 1365, 1367*f*, 1383
  idiopathic eruptive macular hyperpigmentation, 1386
  infections
    chikungunya, 1369
    chronic papular onchodermatitis, 1369
    pintids, 1369
  lichen planus pigmentosus, 1385–1386, 1385*f*
  melasma, 1379–1381, 1380*f*
  metabolic conditions
    hemochromatosis, 1364
    porphyria cutanea tarda, 1364
  mixed hypomelanosis and hypermelanosis, 1386–1387
    dyschromatosis hereditaria universalis, 1386
    familial progressive hyperpigmentation with or without hypopigmentation, 1387
    reticulate acropigmentation of Dohi, 1387
    vagabond leukemia, 1387
  nevus of Becker, 1375–1376, 1375*f*
  nevus of Hori, 1357*t*, 1374–1375, 1375*f*
  nutritional conditions, 1363–1364
    folic acid deficiency, 1363
    kwashiorkor, 1363
    pellagra, 1363–1364
    vitamin B_{12} deficiency, 1363
  ochronosis, 1368
  partial unilateral lentiginosis, 1381
  physical causes
    friction melanosis, 1365
    ionizing radiation, 1364–1365
    thermal radiation, 1365
    UV radiation and pigmentation, 1364
  physiologic hyperpigmentation
    acquired idiopathic facial pigmentation, 1370–1371
    acral hyperpigmented macules, 1372
    longitudinal melanonychia, 1372
    mucosal melanosis, 1371–1372, 1371*f*
    periorbital pigmentation, 1371, 1371*f*
    pigmentary demarcation lines, 1369–1371, 1370*f*
  postinflammatory hyperpigmentation, 1378–1379, 1379*f*, 1379*t*
  prurigo pigmentosa, 1373–1374, 1374*f*
  Riehl melanosis, 1381–1382, 1382*f*
  systemic sclerosis, 1368
  toxins and medications, 1365–1367
    clinical course and prognosis, 1367
    clinical features, 1365, 1367*f*
    diagnosis, 1366–1367
    etiology and pathogenesis, 1366
    management, 1367
    medications, 1365*t*, 1367*f*
    prevalence, 1365
  tumoral conditions
    mast cell disorders, 1364
    melanoma, 1364
Hypermelanosis, congenital, 1351–1361. *See also specific types*
  Bannayan-Riley-Ruvalcaba syndrome, 1360, 2172, 2173*t*
  Carney complex, 1359, 2444*t*
  centrofacial lentiginosis, 1360, 1968
  dermal melanocyte hamartoma, 1357*t*, 1358
  dermatopathia pigmentosa reticularis, 1354
  dyskeratosis congenita, 1353
  familial café-au-lait syndromes, 1360–1361
    Bloom syndrome, 1361
    Legius syndrome, 1360, 2473
    McCune-Albright syndrome, 302, 1361
    neurofibromatosis type 1, 1361
    Silver-Russell syndrome, 1361
    Watson syndrome, 1361
  familial lentiginosis syndromes, 1358–1360
  Galli-Galli disease, 1354
  Haber syndrome, 1355
  incontinentia pigmenti, 1351–1352
  LEOPARD syndrome, 1359, 1360*f*, 1968
  linear and whorled nevoid hypermelanosis, 1351
  Mongolian spots, 1356–1358, 1357*t*, 1358*f*
  Naegeli-Franceschetti-Jadassohn syndrome, 1353–1354
  nevus of Ito, 1356, 1357*f*, 1357*t*, 3851, 3853*t*
  nevus of Ota, 1355–1356, 1356*f*, 1357*t*, 3851, 3853*t*
  Peutz-Jeghers syndrome, 1359, 1359*f*, 1968, 2434*t*, 2436, 2445*t*
  reticulate acropigmentation of Kitamura, 1325–1326, 1327*t*, 1355
Hypermobility Ehlers-Danlos syndromes (hEDS). *See also* Ehlers-Danlos syndromes
  clinical features, 1213*t*, 1222
  diagnostic criteria, 1215*t*
  inheritance and gene defect, 1213*t*
Hyperosmotic sclerosing agents, 3879
Hyperparathyroidism, 2509–2512
  at-a-glance, 2509*b*
  calciphylaxis, 2509–2510, 2511*f*
  clinical features, 2509–2511, 2509*t*, 2510*f*
  diagnosis and laboratory tests, 2512
  differential diagnosis, hypercalcemia, 2509*f*
  epidemiology, 2509
  etiology and pathogenesis, 2511–2512
  management, 2510*t*, 2512
  patient approach, 2509, 2510*t*
Hyperpigmentation. *See also* Melanocytes; Pigmentation; *specific disorders*
  after chemical peels, 3902–3903
  after cryosurgery, 3792
  clinical features, 329*t*
  drugs and cytotoxic agents, 754, 755*t*
    cutaneous, 3484–3485, 3484*f*, 3485*t*
    IV drug use, 1707, 1707*f*
    mucosal, 3487
    nail, 754, 755*t*
  gene mutations, 266*t*, 328, 329*t*
  hyperthyroidism, 2509
  postsclerotherapy, 3884, 3885*f*, 3885*t*
Hyperprolactinemia, hirsutism from, 1556*t*, 1559
Hypersensitivity angiitis/vasculitis, 2527
Hypersensitivity reactions. *See also* Angioedema; Urticaria; *specific types*
  adamantiades–Behçet disease, 2571*f*, 2573
  vaccinia virus, 3075, 3075*f*
Hypersensitivity syndrome reaction (HSR), 750, 750*f*–751*f*, 750*t*, 752*t*
Hypertension, venous, on wound healing, 2712
Hyperthyroidism
  at-a-glance, 2504*b*
  clinical features, 2505–2506, 2505*f*, 2505*t*, 2506*t*
    hyperpigmentation, 2509
    thyroid acropachy, 2506, 2509
    thyroid dermopathy, 2505–2506, 2505*f*
    urticaria, 2506
  congenital, 2504–2505
  diagnosis and laboratory tests, 2508
  epidemiology, 2504–2505
  etiology and pathogenesis, 2507–2508, 2508*t*
  hypermelanosis, 1362
  management, 2509
  skin manifestations, 2407*t*, 2439
Hypertonic saline (HS), 3878, 3878*t*, 3879
Hypertonic saline (HS) and dextrose, 3878, 3878*t*, 3879
Hypertrichosis, 1563–1565
  acquired, other forms, 1564*t*, 1565
  at-a-glance, 1563*b*
  congenital
    forms, 1563–1564, 1564*t*
    localized, 1564–1565, 1564*t*
  definition, 1563
  etiology, 1564*t*
  neonatal, 1736, 1737*f*

Hypertrichosis (*Cont.*):
from porphyrias, 1565
psychological and emotional distress, 89
treatment, 1565
Hypertrichosis cubiti, 1564
Hypertrichosis lanuginosa acquisita, paraneoplastic, 2443*t*, 2459–2460, 2459*f*
from glucocorticoids, 3391
Hypertriglyceridemia
familial, 2282
type I hyperlipidemias, 2281
Hypertrophic actinic keratosis, 1859, 1859*f*
Hypertrophic discoid lupus erythematosus, 1046
Hypertrophic lichen planus, 531, 531*t*, 532*f*
Hypertrophic scar. *See also specific types*
postoperative, 3723–3724, 3723*f*, 3724*t*
treatment, cryosurgery, 3794
Hyperuricemia, gout, 2313, 2314*t*
Hypervitaminosis D, metastatic calcification, 2311
Hyphae, 2926*t*
Hypochondriacal syndrome, 1701
Hypocomplementemic urticarial vasculitis syndrome (HUVS), 692, 2531
Hypodense, 658
Hypodermis, 49*b*, 50, 51*f*
Hypodermitis sclerodermiformis (lipodermatosclerosis), 1252*t*, 1262–1264, 1262*f*–1263*f*, 1264*t*
Hypohidrosis, Sjögren syndrome, 1174
Hypohidrotic ectodermal dysplasia (HED), 1465–1466, 2373–2377
at-a-glance, 2373*b*
clinical course and prognosis, 2376–2377
clinical features, 2373–2375, 2374*f*–2375*f*
diagnosis, 2376
differential diagnosis, 2376, 2376*t*
epidemiology, 2373
etiology and pathogenesis, 2375–2376, 2375*f*
forms, 2373
historical perspectives, 2373
management, 2376–2377
X-linked recessive disorder, 297, 297*t*
Hypomelanization, kwashiorkor, 2202, 2202*f*
Hypomelanosis of Ito, chromosomal mosaicism, 302
Hypomelanotic blue nevus, 1958
Hyponychia, 1568
Hyponychium, 107, 107*f*, 3775, 3775*f*
Hypoparathyroidism, 2509–2512
at-a-glance, 2509*b*
clinical features, 2509–2511, 2509*t*
diagnosis and laboratory tests, 2512
epidemiology, 2509
etiology and pathogenesis, 2511–2512
management, 2511*t*, 2512
patient approach, 2509, 2511*t*
Hypopigmentation
after cryosurgery, 3792
from glucocorticoids, 3391
postoperative, 3724
Hypopigmentation disorders. *See also* Melanocytes; Pigmentation; *specific types*
clinical features, 329*t*
gene mutations, 266*t*, 328, 329*t*
Hypopigmented mycosis fungoides, 2079, 2079*t*
Hypothalamic–pituitary–adrenal axis suppression, corticosteroid, 3378, 3387
Hypothalamus, sweating, 79–80
Hypothermia, subcutaneous fat necrosis of newborn, 1279
Hypothyroidism
at-a-glance, 2504*b*
from bexarotene, for cutaneous T-cell lymphoma, 3403
clinical features, 2506*t*, 2507, 2507*t*
congenital, 2504
diagnosis and laboratory tests, 2508
epidemiology, 2504–2505
etiology and pathogenesis, 2507–2508, 2508*t*
management, 2509
skin manifestations, 2407*t*, 2439
Hypotrichosis, 1546–1547, 1546*t*
Hypotrichosis simplex, 1502
Hypoxia, subcutaneous fat necrosis of newborn, 1279

I

Iatrogenic calcification, 2308*t*, 2311–2312
IBIDS, trichothiodystrophy, 1539*t*
Icatibant, for hereditary angioedema, 694*f*, 702
Ice, 1711
Ichthammol, 3611
Ichthyoacanthotoxicosis, 3356
Ichthyol, 3611
Ichthyoses, 775–809. *See also specific types*
at-a-glance, 775*b*
classification and nomenclature, 775–776
clinical features, 776
hyperkeratosis, 776
nail changes, 1601
scale, 775
Curth-Macklin, 65*t*
etiology and pathogenesis, 778, 783
etymology and terminology, 775
genetics, 776
cellular defect, inheritance and gene/protein, 781*t*
FLG, 777*t*, 783
SPINK5, 778
historical perspective, 775
ichthyosis vulgaris, 6*f*, 295, 295*t*, 777*t*, 783–785, 784*f*
peeling skin disorders, 803
resources, 809
therapeutic approaches, common, 782–783
in children, 782–783
for sweating, decreased, 783
Ichthyoses, acquired, 809, 2442*t*, 2447–2448
fundamentals, 809
Hodgkin disease, 809, 2448
hyperkeratotic dermatoses, 2442*t*, 2447–2448
pityriasis rotunda, 809
reticulated papillomatosis of Gougerot and Carteaud, 809
Ichthyoses, autosomal dominant, 777*t*
epidermolytic ichthyosis, 777*t*
generalized type, 777*t*
keratitis-ichthyosis-deafness syndrome, 777*t*
localized type, 777*t*
progressive symmetric erythrokeratoderma, 777*t*
superficial epidermolytic ichthyosis, 777*t*
Ichthyoses, autosomal recessive congenital (ARCI), 778, 779*t*–780*t*, 787–795
ARCI/CIE, 779*t*, 781*t*
with hypotrichosis, 782*t*
ARCI/LI, 779*t*, 781*t*
cellular defects, 781*t*
Chanarin–Dorfman syndrome, 780*t*, 781*t*
classification and mutations, 787–788
clinical course, prognosis, and management, 794
clinical features, 788–792
bathing suit ichthyosis, 788
congenital ichthyosiform erythroderma, 788–789, 788*t*, 790*f*
harlequin ichthyosis, 779*t*, 789–791, 791*f*
lamellar ichthyosis, 788, 788*f*, 788*t*
TGM1 mutation, 788, 788*f*–789*f*
Netherton syndrome, 779*t*, 791, 792*f*–793*f*, 794*f*
diagnosis, 793–794
etiology and pathogenesis, 793
congenital ichthyosiform erythroderma, 790*f*, 791*f*, 793
ALOX12B, 790*f*, 793
ALOXE3, 790*f*, 793
TGM1, 788*f*–789*f*, 793
harlequin ichthyosis, *ABCA12*, 791*f*, 793
lamellar ichthyosis, 793
harlequin ichthyosis, 779*t*
multiple sulfatase deficiency, 780*t*, 806
neonatal ichthyosis-sclerosing cholangitis syndrome, 780*t*
Netherton syndrome, 779*t*
terminology, 787
Ichthyoses, autosomal semidominant, 777*t*
Ichthyoses, congenital, 1740, 1745
collodion baby and newborn presentations, 786–787
Ichthyoses, connexin disorders, 800–802
cellular defects
erythrokeratodermia variabilis et progressiva, 781*t*
keratitis-ichthyosis deafness syndrome, 781*t*
clinical course, prognosis, and management
erythrokeratodermia variabilis et progressiva, 802
keratitis-ichthyosis-deafness syndrome, 802
clinical features, 800, 801*f*, 807*f*
erythrokeratodermia variabilis et progressiva, 800, 801*f*
keratitis-ichthyosis deafness syndrome, 802*f*, 845*t*
erythrokeratodermia variabilis et progressiva, 777*t*
etiology and pathogenesis, 801–802
erythrokeratodermia variabilis et progressiva, 801
keratitis-ichthyosis-deafness syndrome, 801–802
genes, 800
Ichthyoses, keratinopathic, 795–800
clinical course, prognosis, and management, 800
clinical features, 795–799
annular epidermolytic ichthyosis, 798, 798*f*
epidermolytic ichthyosis, 781*t*, 795–796, 795*f*–798*f*
ichthyosis with confetti, 798–799, 799*f*
linear ichthyosiform erythroderma, 796
superficial epidermolytic ichthyosis, 777*t*, 796–798, 797*f*
diagnosis, 800
etiology and pathogenesis, 799–800
epidermolytic ichthyosis, 799
ichthyosis with confetti, 799–800
Ichthyoses, syndromic, 803–809
Chanarin-Dorman syndrome, 780*t*, 781*t*, 803–804, 804*f*
CHILD syndrome, 804–805, 804*f*
chondrodysplasia punctata, 778*t*, 805–806
rhizomelic chondrodysplasia punctata, 805
X-linked dominant, 778*t*, 805–806, 1200
X-linked recessive, 778*t*, 805
ichthyosis follicularis, alopecia, and photophobia syndrome, 782*t*, 806, 869*t*, 872–873
ichthyosis prematurity syndrome, 779*t*, 781*t*, 806
multiple sulfatase deficiency, 780*t*, 806
Refsum disease, 780*t*, 806–807

Sjögren–Larsson syndrome, 779*t*, 781*t*, 807–808, 807*f*
trichothiodystrophy, 780*t*
Ichthyoses, X-linked inheritance, 778*t*, 2446*t*
CHILD syndrome, 778*t*
X-linked recessive ichthyosis, 297, 297*t*, 778*t*, 785–786, 785*f*
Ichthyosiform scale, 6*t*
Ichthyosis bullosa of Siemens, 781*t*
Ichthyosis bullosa of Siemens palmoplantar keratodermas, 65*t*
Ichthyosis follicularis, alopecia, and photophobia syndrome (IFAP), 782*t*, 806, 869*t*, 872–873
MBTPS2, 869*t*, 873*t*
Ichthyosis hystrix, 65*t*
Ichthyosis linearis circumflexa (ILC), 791, 792*f*
cellular defect, 782*t*
Ichthyosis prematurity syndrome, 776, 779*t*
cellular defect, 781*t*
FATP4 (SCL27), 779*t*, 806
Ichthyosis variegata, 781*t*
Ichthyosis vulgaris, 777*t*, 783–785, 784*f*
autosomal semidominant, 295, 295*t*, 777*t*
cellular defect, 781*t*
clinical course, prognosis, and management, 784–785
clinical features, 6*f*
differential diagnosis, 783
filaggrin and *FLG*, 777*t*, 783
genetics, *FLG*, 783
vs. xerosis, 783
Ichthyosis with confetti, 781*t*, 798–799, 799*f*
clinical features, 798–799, 799*f*
KRT10 and *KRT1*, 777*t*, 799–800
Ichthyosis with sclerosing cholangitis, 781*t*
Icterus gravidarum. *See* Intrahepatic cholestasis of pregnancy (ICP)
IDH1, Maffucci syndrome, 2640*t*, 2651
IDH2
blastic plasmacytoid dendritic cell neoplasm, 2102
Maffucci syndrome, 2640*t*, 2651
Idiopathic atrophoderma of Pasini and Pierini, 1198–1199, 1198*f*
Idiopathic calcification, 2308*t*, 2311
Idiopathic eruptive macular hyperpigmentation, 1386
Idiopathic focal hyperhidrosis, adolescents, 1758
Idiopathic follicular mucinosis, 2082
Idiopathic jaundice of pregnancy. *See* Intrahepatic cholestasis of pregnancy (ICP)
Idiopathic urticaria. *See* Spontaneous urticaria
IFIH1, psoriasis, 478
IFNG, psoriasis, 478
IFN-α-dependent molecule MxA, blastic plasmacytoid dendritic cell neoplasm, 2102
IgA pemphigus, 202, 981–990. *See also* Intercellular immunoglobulin A dermatosis
SPD-type, 617, 981
Iguana bites, *Serratia marcescens*, 3340
IKBKG, 297
hypohidrotic ectodermal dysplasia, 2376
incontinentia pigmenti, 1320, 1352, 1745, 2387
IL. *See* Interleukin
IL1RN, 3533
deficiency of the IL-1 receptor antagonist, 622*t*, 627, 3533
IL-1 Trap, for cryopyrin-associated periodic syndromes, 625
IL12B, psoriasis, 478
IL16, 192
allergic contact dermatitis, 192
IL23A, psoriasis, 478
IL-23–IL-17 signaling, psoriasis, 478
IL23R
psoriasis, 199, 478
psoriatic arthritis, 1131
IL36R, PPPP, 479
IL36RN, 3533, 3534
deficiency of the IL-36 receptor antagonist, 622*t*, 628–629
psoriasis, 199
Iloprost
for Raynaud crisis, 2624
for Raynaud phenomena, 2621–2622, 2621*t*
for systemic sclerosis, pulmonary artery hypertension, 1101
Imatinib mesylate, 3559–3561, 3559*t*
adverse effects, 3561
anticancer mechanisms, 3558
for chronic myelogenous leukemia, 658
on dermatofibrosarcoma protuberans, 3558
dosing regimen, 3561, 3561*t*
drug interactions, 3561
on eosinophils, 658
for graft-versus-host disease, 2334
for hypereosinophilic syndromes, 658, 663
for Kimura disease, 670
for mastocytosis, 720
for melanoma, 2009
pharmacology and mechanism of action, 3559, 3560*f*
for plexiform neurofibromas, 2477
for Rosai-Dorfman disease, 2032
Imidazoles, 3438*t*, 3443–3445. *See also specific types*
clotrimazole, 3438*t*, 3443
econazole, 3438*t*
efinaconazole, 3438*t*, 3444–3445
ketoconazole, 3438*t*, 3443–3444
for leishmaniasis, 3237*t*
luliconazole, 3444
for *Malassezia*, 2963, 2963*t*
miconazole, 3438*t*, 3444
oxiconazole, 3438*t*
sertaconazole, 3438*t*, 3444
Imidazolidnyl urea, allergic contact dermatitis from, 404
Imidazoquinoline. *See* Imiquimod
IMiDs, 3601
Imipenem
for erysipeloid, 2847–2848
for *Nocardia*, 2971
actinomycetoma, 2889
nocardiosis, 2884
Imipenem-cilastatin
for actinomycosis, 2880
for necrotizing fasciitis, 2775, 2776*t*
Imiquimod, 174, 3594–3595, 3620
for actinic keratosis, 1864*t*, 1865*t*, 1866, 3595
for condyloma acuminata, 3595
for cutaneous T-cell lymphomas, 2090
for HPV warts, nail, 1591
for HPV with HIV, 3118
for infantile hemangiomas, 2058
for molluscum contagiosum, 3090
with HIV, 3116
psoriasis exacerbation by, 479
for superficial basal cell carcinoma, 3595
Imiquimod, topical
for basal cell carcinoma, 1889
for epidermodysplasia verruciformis, 1873
with HIV, 3118
for extramammary Paget's disease, 1941
for Kaposi sarcoma, 3120
for Langerhans cell histiocytosis, 2028
for leishmaniasis, 3236
Immediate contact reactions, 434*t*, 444–446
Immediate telogen release, 98
Immune cells. *See also specific types*
development, 50
Immune checkpoint blockers. *See also* Ipilimumab; Nivolumab; Pembrolizumab
immune-related adverse events from, 2006, 2006*t*
for melanoma, 2001–2002, 2005–2006, 2005*f*, 2006*t*, 2007*f*, 2009
side effects, treatment algorithm, 2006, 2007*f*
Immune dysregulation. *See also specific disorders*
hidradenitis suppurativa, 1483–1484
IPEX, 146
Immune protection factor, sunscreen, 3625
Immune reconstitution inflammatory syndrome (IRIS)
with HIV/AIDS, 3124, 3124*t*
drug reactions, 3109
histoplasmosis, African, 2977
leprosy, 2915–2916
middermal elastolysis, 1196
Immune responses
adaptive, 144–145, 145*f*
rosacea, 1430
innate, 144–145, 145*f*
Immune surveillance, cutaneous vasculature, 122–123, 122*f*
Immune system, cutaneous, 143–157, 144*f*
allergic contact dermatitis, 397–398
function, eosinophils in, 652–653
phototherapy on, 3637–3638
skin-associated lymphoid tissue, 122, 506
Immune system, cutaneous, cellular components
at-a-glance, 143*b*
B cells, 143, 148–149
dendritic cells, 143, 144*f*, 146*f*, 148*f*, 151–153, 152*t*
functions, 151
Langerhans cells, 152–153, 152*t*
myeloid, 151–152, 152*t*
plasmacytoid, 152, 152*t*
granulocytes, 154–157, 154*t*
basophils, 154*t*, 156
eosinophils, 154*t*, 156, 652–653
keratinocytes, 154*t*, 156–157
neutrophils, 145*f*, 154–156, 154*t*
innate and adaptive immune system, 143–145
cells, 143, 144*f*
immune responses, 144–145, 145*f*
macrophages, 143, 153, 153*t*
mast cells, 153–154
natural killer cells, 151
T cells (*See* T cell(s))
Immune system, cutaneous, soluble mediators, 159–186
at-a-glance, 159*b*
chemokines, 159, 160*t*, 176–182 (*See also* Chemokine(s))
chemokines, in disease, 182–186
atopic dermatitis, 182–183
cancer, 183–185, 185*f*
infectious diseases, 185–186
psoriasis, 183, 184*f*
concept, 159, 160*t*
cytokine biology, 159–175, 160*t* (*See also* Cytokine biology)
therapeutic implications, 175–176
therapeutic implications and applications, 186
Immune system, UV radiation on, 270–275
immunostimulation, 270–271
immunosuppression, 271–272, 271*f*
photobiology
photodermatoses, 273
phototherapy, 273–275

Immune system, UV radiation on (*Cont.*):
proinflammatory and antiinflammatory, 270
skin phototypes, 272, 272*t*
sunburning, 272
tanning, 272–273, 272*f*
Immunization. *See* Vaccines (vaccination)
Immunobiologics, 3531–3551, 3548*t*–3551*t*. *See also specific types*
alefacept, 3543, 3550*t*
at-a-glance, 3531*b*
brentuximab vedotin, 3546, 3547*f*, 3551*t*
cytokines, Th17 axis, 3534–3537
definition, 3531
denileukin diftitox, 3543, 3550*t*
dupilumab, 3545–3546, 3545*f*, 3551*t*
growth factors, 3540–3543
interleukin 1, 3531–3533
interleukin 18, 3533
interleukin 33, 3533–3534
interleukin 36, 3534
mogamulizumab, 2095–2096, 3543–3544, 3550*t*
recombinant cytokines and growth factors, 3539–3540
rituximab, 3544–3545, 3550*t*
tocilizumab, 3546–3547, 3551*t*
tumor necrosis factor-α, 3536*f*, 3537–3538, 3549*t*
Immunodeficiency. *See also specific types*
CD8+ T-cell pseudolymphoma in, 2120–2121
common variable, 2396–2398, 2398*f*
ectodermal dysplasia with, 2406–2407, 2407*f*
neonatal erythroderma, 1739
neonatal syndromes, 1740
primary, patterns and differential diagnosis, 2394, 2396*t*
severe combined, 2404–2406, 2405*t*
Immunodeficiency diseases, genetic, 2394–2420
antibody deficiency disorders, 2394–2398
agammaglobulinemia, 2394–2396
common variable immunodeficiency, 2396–2398, 2398*f*
immunoglobulin A deficiency, 2398*b*
cellular deficiencies, 2399–2402
cartilage–hair syndrome, 2402*b*
chronic mucocutaneous candidiasis, 2399–2401, 2400*t*, 2401*f*
clinical features, 2394
combined antibody and T-cell deficiency, 2402–2409
ataxia-telangiectasia, 2407–2409, 2407*f*–2408*f*
ectodermal dysplasia with immunodeficiency, 2406–2407, 2407*f*
hyperimmunoglobulin M syndrome, 2402*b*
severe combined immunodeficiency, 2404–2406, 2405*t*
Wiskott-Aldrich syndrome, 2402–2404, 2403*f*
complement deficiency disorders, 2419–2420
at-a-glance, 2419*b*
clinical manifestations, 2420*t*
hereditary angioedema, 2419–2420, 2420*t*
manifestations, 2394, 2395*t*
patterns and differential diagnosis, 2394, 2396*t*, 2397*f*
phagocytosis and cell killing disorders, 2409–2419
chronic granulomatous disease, 2409–2412
hyperimmunoglobulinemia E syndrome, 2413–2415, 2413*f*–2414*f*, 2413*t*
leukocyte adhesion deficiencies, 2412*b*
other, 2409, 2410*t*
silvery hair syndromes, 2415–2419, 2416*t*
Chédiak-Higashi syndrome, 2415–2418, 2416*t*
Griscelli syndrome, 2416*t*, 2418–2419, 2419*f*
WHIM syndrome, 2415
Immunofluorescence, direct
biopsy specimen, 19
dermatitis herpetiformis, 1005–1006, 1005*f*
epidermolysis bullosa acquisita, 976, 976*f*
salt-split skin, 977, 977*f*
linear immunoglobulin A dermatosis, 992, 993*f*
lupus erythematosus, 1051, 1051*f*
pemphigus, 911*t*, 919
Immunofluorescence, indirect
pemphigus, 911*t*, 919–920
salt-split skin, epidermolysis bullosa acquisita, 977
Immunoglobulin (Ig)
gene superfamily membrane receptors, eosinophil expression, 655–656
superfamily, eosinophils, 656
Immunoglobulin A (IgA)
deficiency, 2398*b*
dermatitis herpetiformis, skin deposits, 1004–1006, 1005*f*
Kawasaki disease, 2584
linear band
chronic bullous disease of childhood, 993–994, 993*t*
linear IgA dermatosis, 993–994, 993*t*
seborrheic dermatitis, 432
subcorneal pustular dermatosis, 617–619
vasculitis, 2530–2531, 2530*t*
Immunoglobulin D (IgD), primary cutaneous diffuse large B-cell lymphoma, 2100
Immunoglobulin E (IgE), 134
mast cell expression, 153
nummular eczema, 386
type I hypersensitivity, 691, 691*f*
Immunoglobulin E (IgE) receptors (FcεRI)
type I hypersensitivity, 691–692, 691*f*
urticaria, 695
Immunoglobulin G (IgG)
acrokeratosis paraneoplastica of Bazex, 2452
seborrheic dermatitis, 432
Immunoglobulin G_4 (IgG_4), extranodal marginal zone lymphoma, 2097
Immunoglobulin G γ (IgG-γ) paraproteinemia, scleromyxedema, 1166–1167
Immunoglobulin M (IgM)
acrokeratosis paraneoplastica of Bazex, 2452
primary cutaneous diffuse large B-cell lymphoma, 2100
Immunohistochemical stains, 19, 20*t*, 21*t*
Immunological structure, skin, 130–139
adaptive component, 132, 132*t*
at-a-glance, 130*b*
constituents, 132–137
cellular, adaptive, 132*t*, 135–137
dendritic cells, 135–136, 135*t*, 136*f*
T lymphocytes, 133*f*, 136–137, 136*f*–137*f*
cellular, innate, 132–134, 132*t*
dendritic cells with innate immune functions, 134–135, 134*t*
granulocytes, mast cells, 132–134
innate lymphocytes, 132–134
macrophages, 134
molecular, receptors and effectors, 132, 133*f*, 134*t*
historical perspectives, 130–131, 131*f*
homeostatic conditions, 137–138
innate component, 132, 132*t*, 133*f*
pathologic conditions, 133*f*, 138–139, 138*t*
post scriptum, 139
Immunologic contact urticaria, 445–446, 445*t*
from topical therapy, 3378
Immunologic diseases, basic principles, 192–203
allergic contact dermatitis, 192–194, 193*f*
alopecia areata, 199–201, 200*f*
at-a-glance, 192*b*
atopic dermatitis, 195–197, 196*f*
autoimmune blistering diseases, 201–203
bullous pemphigoid, 201–202
pemphigus, 201–202
pemphigus foliaceous, 201
pemphigus vulgaris, 201
drug reactions, 194–195, 195*f*
future directions, 203
psoriasis, 197–199
skin barrier
homeostasis, 192
leukocytes and commensal microbes, 192
skin immune responses, 192
Immunologic drug reactions, 759, 759*t*
Immunostimulation
DNA pathway, 1040
UV radiation, 270–271
Immunosuppression
photo-, 271–272, 271*f*
UV radiation, 271–272, 271*f*
Immunosuppressive and immunomodulatory drugs, 3517–3529. *See also specific types*
at-a-glance, 3517*b*
calcineurin inhibitors, 3519–3527
characteristics, 3517
historical perspective, 3517
for irritant dermatitis, 424
lupus erythematosus from, 752*t*, 756, 1041*t*
mycophenolate mofetil, 3517–3519, 3518*f*, 3518*t*
patch testing and, 408
for pemphigus, 923–924
shortcomings, 3517
Immunosuppressive/antiinflammatory agents, 3471–3476. *See also specific types*
azathioprine, 3465*f*, 3471–3474
cyclosporine, 3475
mycophenolate mofetil, 3465*f*, 3475
mycophenolic acid, 3465*f*, 3475
tacrolimus, 3475–3476
thalidomide, 3476
thioguanine, 3465*f*, 3474–3475, 3474*t*–3475*t*
Impetiginization, 2722
Impetigo
follicular, 2722–2723
S. aureus, 2721–2722, 2721*f*–2722*f*, 2730, 2731*t*
Impetigo herpetiformis, 1768*t*, 1771–1773, 1772*f*, 1772*t*
Implantable cardioverter defibrillators (ICDs)
electrosurgery
interference, 3797
safety and recommendations, 3797
preoperative examination, 3707–3708
Implantable electronic device (IED), preoperative examination, 3707–3708
Implanters, hair, 3946
Inborn errors of metabolism, 2234
Incandescent lamps, phototherapy, 3639
Incidence, 45
Incobotulintoxin A, 3921, 3922. *See also* Botulinum toxin
Incontinentia pigmenti (IP), 1319–1321, 1351–1352, 2386–2388

at-a-glance, 1319*b*, 2386
clinical course and prognosis, 1321, 1352, 2388
clinical features, 1319–1320, 1319*f*–1320*f*, 1351–1352, 1352*f*, 2386, 2387*f*
diagnosis, 1320–1321, 1352, 2387
differential diagnosis, 1321, 2387
epidemiology, 2386
etiology and pathogenesis, 1320, 1352, 2386–2387
management, 1321, 1352, 2388
neonatal presentation, 1745
X-linked dominant disorder, 296–297, 296*t*
IncRNA, epidermis differentiation, 67
Indeterminate leprosy, 2896, 2896*f*
clinical features, 2896, 2896*f*
histopathology, 2907, 2907*f*
Indinavir, 3508, 3509*t*
nail changes, 1599
Indirect salt-split skin immunofluorescence, epidermolysis bullosa acquisita, 977
Indolent systemic mastocytosis (ISM), 710–720, 711*t*, 712*f*. *See also* Mastocytosis
Indomethacin
for adamantiades–Behçet disease, 2576*t*
for gout, 2315
for Sweet syndrome, 601*t*, 602
Indoor tanning, adolescents, 1758
Indoximod, for melanoma, 2009, 2010*t*
Induced pluripotent stem cell (IPSC), 28
Inducible skin-associated lymphoid tissue, allergic contact dermatitis, 397–398
Inducible urticaria, 687, 688*t*
disease severity, 688*t*, 699
pathogenesis, immune mechanism, 692
Infant. *See also* Newborn
neonates, 1727
preterm, skin, 224
Infant dermatology, 1750–1753. *See also specific disorders*
biopsy pitfalls, 1750, 1751*t*
birthmarks, 1732–1734, 1751–1752 (*See also* Birthmarks)
diaper region
diaper dermatitis, 1753
infantile granular parakeratosis, 1753
infantile perineal protrusion, 1753
miliaria rubra, 1753
evaluation techniques, 1750, 1751*f*, 1751*t*
hair loss, 1752–1753
alopecia areata, 1753
nevus sebaceus, 1752, 1752*f*
occipital alopecia, 1752
telogen effluvium, 1752
tinea capitis, 1753
triangular temporal alopecia, 1752
trichotillomania, 1753, 1753*f*
Infantile acne, 1448, 1449*f*, 1732, 1733*f*
Infantile digital fibroma, 1743
Infantile granular parakeratosis, 1753
Infantile hemangiomas (IH), 1734, 2042–2059, 2043*t*, 3849
at-a-glance, 2042*b*
classification, ISSVA, 2042, 2043–2044, 2043*t*
indeterminate, 2045, 2045*f*
localized, 2044, 2045*f*
minimal or abortive growth, 2043, 2044*f*
segmental, 2044–2045, 2045*f*
segmental with PHACE, 2045, 2045*f*
clinical features
cutaneous, 3849
growth characteristics, classification, 2043–2046, 2044*f*–2045*f*
growth characteristics, involution, 2043, 2044*f*
growth characteristics, proliferation, 2042, 2044*f*
history, 2042, 2043*t*
noncutaneous and complications, 2045–2046, 2046*t*
diagnosis
algorithm, 2052*f*
imaging, 2053
laboratory, thyroid function tests, 2053
pathology, 2053
supportive studies, 2052–2053
differential diagnosis, 2054*t*–2055*t*
epidemiology, 2042
etiology and pathogenesis, 2051–2052, 2051*f*
management, 2053–2059
interventions, 2053–2055, 2055*f*
medications, 2055–2058
beta blockers, 2055–2057, 2057*f*
corticosteroids, 2057–2058
imiquimod, 2058
interferon-α, 2058
vincristine, 2058
procedures
laser, 2058, 3849–3850, 3853*t*
surgical, 2042–2228
screening, 2059
segmental
facial segments, 2046, 2046*f*
syndromes with, 2046–2050
"beard area," 2048–2049
hepatic, 2050, 2050*f*
LUMBAR syndrome, 2045, 2048, 2048*f*
multifocal, 2049–2050, 2050*f*
PELVIS, 2048
periocular, 2048, 2049*f*
PHACE, 2044–2045, 2045*f*, 2047–2048, 2047*t*
SACRAL, 2048
ulceration, 2050–2051, 2050*f*, 2050*t*
Infantile myofibromatosis, 1742–1743
Infantile nodular leprosy, 2896, 2897*f*
Infantile papular acrodermatitis, 3002–3004. *See also* Gianotti-Crosti syndrome (GCS)
Infantile perineal (pyramidal) protrusion, 1753
Infantile seborrheic dermatitis, 428, 429*f*
Infectins, chemokines, 185–186
Infection-induced panniculitis, 1252*t*, 1264–1266
Infectious mononucleosis, Epstein-Barr virus, 2999–3000, 2999*f*. *See also* Epstein-Barr virus (EBV)
Infective endocarditis (IE), 2815–2818
clinical course and prognosis, 2817–2818
clinical features, 2815–2816, 2816*f*, 2816*t*
cutaneous manifestations, 2425
cutaneous necrotizing venulitis, 2530
definition and historical perspective, 2815
diagnosis, 2817
differential diagnosis, 2817, 2817*t*
epidemiology, 2815
etiology and pathogenesis, 2816–2817
gonococcal, 3209–3210
management, 2818
prevention/screening, 2818
risk, preoperative examination, 3706–3707, 3707*t*
splinter hemorrhages, 1596
Infiltration pattern, skin tumor, 30
Inflammasome, 165, 166*f*, 623
rosacea, 1429–1430
Inflammatory bowel disease (IBD)
cutaneous manifestations, 2436
erythema nodosum from, 1256
from isotretinoin, 3403
psoriatic arthritis with, 1130–1131
pustular eruption of IBD, 607
pyoderma gangrenosum, 607–608 (*See also* Pyoderma gangrenosum (PG))
Inflammatory disorders. *See also specific disorders*
as cutaneous pseudolymphoma, 2121–2122
with HIV, 3121–3123
immune system, 138–139
neonatal, 1739
Inflammatory linear verrucous epidermal nevus (ILVEN), 464, 1802*t*, 1807–1809, 1808*f*
vs. keratinocytic epidermal nevus, 1808–1809
Inflammatory nail disorders, 1578–1588. *See also specific types*
alopecia areata, 1583–1584, 1584*f*
autoimmune bullous diseases, 1586–1587, 1586*f*
eczema, 1581–1583, 1582*f*
lichen planus of nails, 1584–1586, 1585*f*
psoriasis, 1578–1581 (*See also* Psoriasis, nail)
so-called connective tissue diseases, 1587–1588, 1587*f*
vasculitis and vasculopathies, 1588, 1588*f*
Inflammatory pseudotumor, 2124
cutaneous, 2124
Inflammatory reactions, skin lesion pathology, 19–30
fat, subcutaneous, 29–30, 29*f*
fibrous dermis and extracellular matrix, 28–29, 29*f*
reticular dermis, 25–28 (*See also* Reticular dermis)
superficial reactive unit, 19–25, 21f (*See also* Superficial reactive unit)
Infliximab, 169, 175, 3536*f*, 3538, 3549*t*
for adamantiades–Behçet disease, 2576*t*
for epidermolysis bullosa acquisita, 978, 979*t*
for Erdheim–Chester disease, 2038
for graft-versus-host disease, 2333
granuloma annulare from, 567
for hidradenitis suppurativa, 1490
for hypereosinophilic syndromes, 665
for IBD-related erythema nodosum, 1259
for lupus erythematosus, 1057
for lupus panniculitis, 1275
for psoriasis, 198, 469*f*, 487*t*, 493–494
for psoriatic arthritis, 980*t*, 981, 1136*t*, 1137
for pustular psoriasis of pregnancy, 1772
for pyoderma gangrenosum, 614*t*
for relapsing polychondritis, 1190
for rheumatoid arthritis, 1152
for SAPHO syndrome, 1450
for sarcoidosis, 582
Information bias, 41
Informed consent, preoperative, 3709–3710
Infraorbital nerve, 3702*f*, 3703, 3703*t*
Infrared radiation, cutaneous responses, 284
Infratrochlear nerve, 3702–3703, 3702*f*, 3703*t*
Infundibular differentiation, neoplasms with, 1839*t*
dilated pore (of Winer), 1849
trichoadenoma, 1848
Ingenol mebutate, for actinic keratosis, 1864*t*, 1865, 1865*t*, 1866
Ingrowing nail, 1576, 1577*f*
noninvasive treatment, 3790
surgery for, 3788–3789
congenital malalignment of great toenail, 3789–3790, 3789*f*
distal toenail embedding, 3787, 3787*f*
hypertrophy of lateral nail fold, 378, 3789*f*
juvenile ingrown nails, 3788–3789, 3788*f*
pincer nail, 3789
retronychia, 3788
Inhalant abuse, 1709
frostbite from, 1670, 1671*f*
Inherited connective tissue disease. *See* Connective tissue disease, inherited
Inherited epidermolysis bullosa. *See* Epidermolysis bullosa, inherited

Inherited palmoplantar keratodermas (PPKs). *See* Palmoplantar keratodermas (PPKs), inherited
Initial efficacy studies, 43
Injection-site amyloidosis, 2265–2266
Ink4a, 323
INK4α, melanoma, 1991
Innate cells, 143, 144*f*
Innate immune system, 143–145, 145*f*
  cellular constituents, 132–137, 132*t*
    cells, 143, 144*f*
    dendritic cells with innate immune functions, 134–135, 134*t*
    granulocytes, mast cells, 132–134
    innate lymphocytes, 134
    macrophages, 134
  responses, 144–145, 145*f*
  sebaceous glands, 75
Innate lymphocytes, 134
Innate lymphoid cells (ILCs), 149, 150*f*
  helper, 134
  psoriasis, 468, 469*f*
Inner root sheath (hair follicle), 93*f*, 94, 94*t*
Inoculation, 3753. *See also* Vaccines (vaccination)
INPP5A, 315
Insecta, 3330–3334
  Coleoptera, 3331
  Diptera, 3325*f*, 3330–3331, 3331*f*
  Hemiptera, 3325*f*
    Cimicidae, 3325*f*, 3331–3332, 3332*f*
    Reduviidae, 3332
  Hymenoptera, 3333–3334
  irritant dermatitis from, 417
  Lepidoptera, 3334, 3334*f*
  Siphonaptera, 3325*f*, 3332–3333, 3332*f*–3333*f*
Insect bite, eosinophilic, 27, 27*f*, 654
Insecticide, topical, for body lice, 3283
Insertional radiofrequency needles, skin tightening, 3848, 3858, 3859
Insertions, 294*f*, 295
Instruments, surgical, 3715. *See also specific surgeries*
  nail surgery, 3775, 3775*t*
Insufflation, soft tissue, after cryosurgery, 3792–3793
Insulin, 3543
Insulin-like growth factor-1 (IGF1), 3542
  diabetes mellitus, 2494, 2495
  growth hormone effects, 2518, 2518*f*
Insulin-like growth factor-2 (IGF2), 3542
Insulin-like growth factor (IGF)/insulin, 3542–3543
Insulin receptor (IR), 3542, 3543
INTEGRA Dermal Regeneration Template, 2711, 2711*t*
Integrase strand transfer inhibitors (INSTIs), 3508, 3509*t*
Integrins, 179
  eosinophils, 656
  functions, 247–248
  wound healing, 2704
Integrin α3β1, 245
Integrin α6β4, 245
Integument, 192, 207*t*
Intense pulsed light (IPL)
  devices, 3824, 3824*f*, 3846, 3847–3848
  filters, 3848
  for hair removal, 3852, 3853*t*
  for hirsutism, 1561
  for lentigines and seborrheic keratoses, 3850–3851, 3853*t*
  for melasma, 1381, 3850, 3851, 3853*t*
  optical radiation principles, 3824–3825
  for Peutz-Jeghers syndrome, 1359
  for port-wine stains, 3849
  principles, 3824, 3824*f*
  for rosacea, 1438, 1442*t*, 1443
    persistent erythema, 1438, 1442*t*
    tissue interactions, 3826–3828, 3827*f*–3828*f*
  varicose vein surgery, 3890, 3890*f*
Intensity-modulated radiation therapy, 3689
Intercellular adhesion molecule (ICAM)-1
  eosinophils, 656, 657
  inflammation
    acute, 124, 124*f*
    acute *vs.* chronic, 125
    chronic, 125
Intercellular adhesion molecule (ICAM)-3, eosinophils, 656
Intercellular immunoglobulin A dermatosis (IAD), 202, 981–990
  associated diseases, 985
  at-a-glance, 981*b*
  autoantigens, 982
  classification and nomenclature, 981, 982*t*
  clinical course and prognosis, 989
  clinical features, 982–985, 983*t*
    intraepidermal neutrophilic dermatosis–type, 983–984, 983*t*, 984*f*
    pemphigus foliaceus–type, 983*t*, 984, 985*f*
    pemphigus vegetans–type, 983*t*, 984, 984*f*
    pemphigus vulgaris–type, 983*t*, 984, 985*f*
    subcorneal pustular dermatosis–type, 983, 983*f*, 983*t*
    undetermined-type, 983*t*, 984–985
  definition, 981
  diagnosis, 985–989
    complementary DNA transfection method, 988, 988*f*
    enzyme-linked immunosorbent assays, 988–989
    histopathology, 985–986, 985*f*–986*f*
    immunoblotting, 988, 988*f*
    immunofluorescence
      direct, 986–987, 986*f*
      indirect, 987, 987*f*
  differential diagnosis, 589, 589*t*, 989, 989*t*
  epidemiology, 981–982
  etiology and pathogenesis, 982
  historical perspective, 981
  perspectives, 990
  prognosis and clinical course, 589
  subtypes, 981
  treatment, 589, 589*t*, 989–990
    corticosteroids and immunosuppressive agents, 989–990
    dapsone and other sulfones, 989
    other, 990
Intercellular penetration, 3367
Interface reaction, 25, 25*f*
Interferon (IFN), 3502–3503
  dosing regimens, 3502, 3502*t*
  for HPV warts with HIV, 3118
  indications, 3502
  JAK/STAT pathway signaling prototypes, 173–174
  mechanisms of action, 3502, 3595–3596
  for necrolytic migratory erythema, 2456
  for papuloerythroderma of Ofuji, 672
  pegylated (*See* Pegylated interferon)
  pharmacokinetics, 3502
  Raynaud phenomena from, 2616
  side effects and precautions, 3502–3503
  signaling, psoriasis, 478
  type I (IFN-α & IFN-β), 173 (*See also* Interferon-alpha (IFN-α); Interferon-beta (IFN-β))
    biologics targeting, 1057
    lupus erythematosus, 1040
    signaling, lupus erythematosus, 1039*t*, 1040
    Sjögren syndrome, 1171
  viral diseases treated with, 3502
Interferon (IFN), recombinant, 3539–3540, 3549*t*. *See also* Pegylated interferon
  interferon-alpha, 3539–3540, 3549*t*
  interferon-alpha 2a, 3539, 3549*t*
  interferon-alpha 2b, 3539, 3549*t*
Interferon (IFN)-alfacon-1, for hepatitis C, 3502, 3502*t*
Interferon-alpha (IFN-α), 134, 163*t*, 173–174, 3539–3540, 3549*t*
  for adamantiades–Behçet disease, 2575, 2575*t*, 2576*t*
  for angiolymphoid hyperplasia with eosinophilia, 669
  for cutaneous T-cell lymphomas, 2092, 2093*t*, 2094, 3539–3540
  on eosinophils, 658
  for epidermodysplasia verruciformis, with HIV, 3118
  for Erdheim–Chester disease, 2038
  for extranodal marginal zone lymphoma, 2100
  for hypereosinophilic syndromes, 663–665
  for infantile hemangiomas, 2058
  in lupus erythematosus, 1040
  for melanoma, 2001
  for molluscum contagiosum virus, 3090
  for mycosis fungoides, 2080
  for primary cutaneous CD4+ small and medium T-cell lymphoproliferative disorder, 2088
  for primary cutaneous follicular center lymphoma, 2099
  psoriasis exacerbation by, 479
  recombinant, 3539–3540, 3549*t*
  in Sjögren syndrome, 1171
  for viral infections, 3502
  for Wells syndrome, 667
  for xeroderma pigmentosum, 2354
Interferon-alpha 2a (IFN-α2a), 3539, 3539*t*
  for adamantiades–Behçet disease, 2575, 2575*t*
  in linear IgA dermatosis, 997
  in morphea, 1111
  recombinant, 3539, 3549*t*
Interferon-alpha 2b (IFN-α2b), 3539, 3539*t*, 3595–3597, 3596*t*
  for condyloma acuminata, 3502, 3502*t*
  for Kaposi sarcoma, 3502, 3502*t*
  mechanism of action, 3595–3596
  recombinant, 3539, 3549*t*
Interferon-beta (IFN-β), 134, 163*t*, 173–174
  in dermatomyositis, 1071
  in lupus erythematosus, 1040
  for molluscum contagiosum virus, 3090
  for viral infections, 3502
Interferon-gamma (IFN-γ), 134, 163*t*, 173–174, 3540
  for atopic dermatitis, 380
  in dermatitis herpetiformis, 1004
  on eosinophils, 658
  in erythema nodosum, 1256
  four-helix bundle protein, 161
  in histiocytosis, non–Langerhans cell, 2029
  in inflammation, 124
  for leishmaniasis, 3236
  in leprosy, 2904, 2905, 2905*f*
  in lichen planus, 528
  in morphea, 1111
  for mycosis fungoides, 2080
  in pityriasis rosea, 522
  in psoriasis, 466, 469*f*, 479
  in sarcoidosis, 577, 577*f*
  in seborrheic dermatitis, 432
  in Sweet syndrome, 596
  T helper 1 cells, 145
  tissue effector T cells, 147
  for tuberculosis, 2861
  in vitiligo, 1335
Interferon-gamma 1b (IFN-γ1b), 3540
Interferon-inducible protein 10 (CXC10)
  pityriasis rosea, 522

Sweet syndrome, 596
wound healing, 2708
Interferonopathies, 1040
Interferon regulatory factor-5 variants, systemic sclerosis and, 1094
Interfollicular melanocyte, 330
Interleukin, recombinant. *See also specific types*
IL-2, 3539, 3549*t*
Interleukin 1 (IL-1), 3531–3533
autoinflammatory disorders, 621*b*, 622*t*
family, 160*t*, 163*t*, 165–168, 165*f*, 166*f*, 3531, 3532*f*
histiocytosis, non–Langerhans cell, 2029, 2030
inflammation, 124
psoriasis, 470*f*
signaling pathway, 3531, 3532*f*
Sweet syndrome, 595
type IV hypersensitivity reactions, 397
wound healing, 2704*t*, 2707–2708
Interleukin 1 (IL-1) antagonists, 3533, 3548*t*. *See also specific types*
anakinra, 3533, 3548*t*
for Blau syndrome/early-onset sarcoidosis, 641
canakinumab, 3533, 3548*t*
for cryopyrin-associated periodic syndromes, 625
deficiency, 3533
for deficiency of the IL-36 receptor antagonist, 629
for familial Mediterranean fever, 633
for macrophage activation syndrome, 1155
rilonacept, 3533, 3548*t*
Interleukin 1 receptor (IL-1R), 167
IL1RN, 3533
deficiency of the IL-1 receptor antagonist, 622*t*, 627, 3533
Interleukin 1 receptor 1 (IL-1R1), 167, 3531
Interleukin 1 receptor 2 (IL-1R2), 167, 3531
Interleukin 1 receptor antagonists (IL-1Ra), 160*t*, 167
deficiency of, 627–628, 628*f*
for haploinsufficiency of A20, 638
histiocytosis, non–Langerhans cell, 2030
for otulipenia/OTULIN-related autoinflammatory syndrome, 638
Interleukin 1α (IL-1α), 160*t*, 3531
inflammation, 124
seborrheic dermatitis, 432
systemic sclerosis, 1093
Interleukin 1β (IL-1β), 150*f*, 165–167, 3531
inflammation, 124
leprosy, 2905, 2905*f*
sarcoidosis, 577, 577*f*
S. aureus skin infections, 2727
seborrheic dermatitis, 432
systemic sclerosis, 1093
Interleukin 2 (IL-2), 163*t*, 170–171, 3539, 3549*t*
central memory T cells, 147
cutaneous T-cell lymphomas, 2075
dermatitis herpetiformis, 1004
erythema nodosum, 1256
for hemophagocytic lymphohistiocytosis, 2032
leprosy, 2905, 2905*f*
lichen planus, 528
for melanoma
high dose, 2007
intralesional, 2002, 2003*f*
recombinant, 3539, 3549*t*
sarcoidosis, 577, 577*f*
Sweet syndrome, 596
systemic sclerosis, 1093, 1094
T helper 1 cells, 145
for tuberculosis, 2861
Interleukin 2 receptor (IL-2R), 170
Interleukin 2 receptor α (IL-2Rα), 170–171
Interleukin 2 receptor β_c (IL-2Rβ_c), 170
Interleukin 3 (IL-3)
eosinophils, 655, 656, 657
development, 649, 650*f*
mast cell maturation, 153
Interleukin-3 receptor β (IL-3Rβ, CD131), 171–172
Interleukin 4 (IL-4), 163*t*, 171, 657
dermatitis herpetiformis, 1004
eosinophils, 657
on helper T-cells, 161*f*
histiocytosis, non–Langerhans cell, 2030
inflammation, 124
lichen planus, 528
mycosis fungoides and Sézary syndrome, 2075
seborrheic dermatitis, 432
systemic sclerosis, 1094
T follicular helper cells, 146
T helper 2 cells, 145, 147
T-helper cell 17, 161
tissue effector T cells, 147
Interleukin 5 (IL-5), 163*t*, 171–172
eosinophils, 156, 655, 656, 657
development, 649, 650*f*
mycosis fungoides and Sézary syndrome, 2075
T helper 2 cells, 145
Interleukin 6 (IL-6), 160*t*, 163*t*, 172, 3546
Castleman tumors, 935
graft-versus-host disease, 2321
on helper T-cells, 161*f*
histiocytosis, non–Langerhans cell, 2030
leprosy, 2904, 2905*f*
panniculitis, 1251
paraneoplastic pemphigus, 935
Sweet syndrome, 596
T-helper cell 17, 161
wound healing, 2704*t*, 2708
Interleukin 6 receptor (IL-6R), 3546–3547
Interleukin 7 (IL-7), 171
cutaneous T-cell lymphomas, 2075
Interleukin 8 (IL-8). *See also* CXCL8
dermatitis herpetiformis, 1005
erythema nodosum, 1256
panniculitis, 1251
Sweet syndrome, 595, 596
type IV hypersensitivity reactions, 397
Interleukin 9 (IL-9), 171
T helper 9 cells, 146
Interleukin 10 (IL-10), 160, 163*t*, 174–175
as "antiinflammatory" cytokine, 174
anti-inflammatory effect, 149
graft-versus-host disease, 2322
histiocytosis, non–Langerhans cell, 2030
leprosy, 2904, 2905, 2905*f*
lichen planus, 528
phototherapy on, 3637
systemic sclerosis, 1093, 1094
Interleukin 10 (IL-10)–related cytokines, novel, 174–175
Interleukin 12 (IL-12), 150*f*, 161, 163*t*, 173, 3535–3536
antiangiogenesis, 3604*t*
on helper T-cells, 161*f*
morphea, 1111
psoriasis, 468, 469*f*, 470*f*
sarcoidosis, 577, 577*f*
seborrheic dermatitis, 432
for tuberculosis, 2861
ustekinumab, 3536, 3536*f*, 3548*t*
Interleukin 12 (IL-12) antagonist. *See* Ustekinumab
Interleukin 13 (IL-13), 163*t*, 171, 657
eosinophils, 657
histiocytosis, non–Langerhans cell, 2030
inflammation, 124
mycosis fungoides and Sézary syndrome, 2075, 2076
systemic sclerosis, 1093, 1094
T helper 2 cells, 145
Interleukin 15 (IL-15), 150*f*, 170–171
cutaneous T-cell lymphomas, 2075
leprosy, 2904
Interleukin 15 receptor (IL-15R), 170
Interleukin 15 receptor α (IL-15Rα), 170
Interleukin 17 (IL-17), 137, 163*t*, 169, 170*f*
chronic mucocutaneous candidiasis, 2399, 2929
deficiency (*See also* Job syndrome)
S. aureus skin and soft tissue infections risk, 2726
graft-versus-host disease, 2321
inflammation, 124
leprosy, 2904, .2905*f*
pityriasis rosea, 522
in psoriasis, 176, 198, 199, 468, 469*f*, 470*f*
S. aureus skin infections, 2727
Sweet syndrome, 595
systemic sclerosis, 1094
T-helper cell 17 production, 160
tissue effector T cells, 147
Interleukin 17A (IL-17A)
immunochemistry, 3534
leprosy, 2905, 2905*f*
mutations, 3534
proinflammatory effects, 3534
sources, skin cells, 3534
T helper 17 cells, 146
vasoconstriction, 120
Interleukin 17A (IL-17A) antagonists, 3534–3535, 3536*f*, 3548*t*. *See also specific types*
brodalumab, 3535, 3536*f*, 3548*t*
ixekizumab, 3535, 3536*f*, 3548*t*
secukinumab, 3534–3535, 3536*f*, 3548*t*
Interleukin 17F (IL-17F), T helper 17 cells, 146
Interleukin 17 (IL-17) inhibitors. *See also* Ixekizumab; Secukinumab
for deficiency of the IL-36 receptor antagonist, 629
for psoriatic arthritis, 980*t*, 981
Interleukin 17 (IL-17) receptors, chronic mucocutaneous candidiasis, 2399
Interleukin 18 (IL-18), 160*t*, 167, 3533
type IV hypersensitivity reactions, 397
Interleukin 18 binding protein (IL-18BP), 167, 3533
Interleukin 18 receptor (IL-18R), 167, 3533
Interleukin 19 (IL-19), 174–175
Interleukin 20 (IL-20), 174–175
Interleukin 21 (IL-21), 171
graft-versus-host disease, 2321
T follicular helper cells, 146
T helper 17 cells, 146
T helper cells, 161*f*
Interleukin 22 (IL-22), 163*t*, 174–175
psoriasis, 468, 469*f*
T helper 17 cells, 146
Interleukin 23 (IL-23), 150*f*, 163*t*, 173, 3536–3537
on helper T-cells, 161*f*
psoriasis, 198, 466–468, 469*f*, 470*f*
T-helper cell 17, 161
Interleukin 23 (IL-23) antagonists. *See also* Ustekinumab
guselkumab, 3536*f*, 3537, 3549*t*
for psoriasis, 494
risankizumab, 3536*f*, 3537, 3549*t*
tildrakizumab, 3536*f*, 3537, 3549*t*
Interleukin 24 (IL-24), 174–175
Interleukin 25 (IL-25), 150*f*, 163*t*
Interleukin 26 (IL-26), 163*t*, 174–175
Interleukin 27 (IL-27), 163*t*, 173
Interleukin 31 (IL-31), 163*t*, 172
prurigo nodularis, 389
Interleukin 31 receptor A (IL-31RA), 172
in cutaneous amyloidosis, 2266
Interleukin 33 (IL-33), 150*f*, 3533–3534
atopic dermatitis, 369–370
Interleukin 35 (IL-35), 163*t*, 173

Interleukin 36 (IL-36), 3532*f*, 3534
  autoinflammatory disorders, 622*t*
  psoriasis, 469–471, 469*f*, 470*f*
Interleukin 36 (IL-36), recombinant, for deficiency of the IL-36 receptor antagonist, 629
Interleukin 36 receptor antagonist (IL-36RA), 3532*f*, 3534
  deficiency of, 628–629, 630*f*
Intermediate-density lipoprotein (IDL), 2280
Intermediate leprosy, 2907, 2907*f*
Internal organ disorders, skin manifestations, 2425–2439. *See also* Organ disorders, internal, skin manifestations; *specific organs*
Internal transcribed spacer (ITS) regions, microbiome sequencing, 254
Interpolation flaps, 3748–3753
  Abbé, 3751–3752
  classification and use, 3748
  nasolabial, 3750–3751, 3751*f*
  paramedian forehead, 3748–3750, 3750*f*
  retroauricular, 3752–3753
  steps, 3748
Interrupted sutures, 3717–3718, 3717*f*–3719*f*
Interstitial granulomatous dermatitis (IGD), 1148–1149. *See also* Rheumatoid arthritis (RA)
Interstitial granulomatous drug reaction (IGDR), 1148–1149. *See also* Rheumatoid arthritis (RA)
Interstitial lung disease (ILD)
  dermatomyositis, 1062, 1065, 1068, 2430
  rheumatoid arthritis, 2430
  systemic sclerosis, 2430
Intertriginous distribution, 11
Intertumor heterogeneity, 313
Intervention, 41
Intracellular penetration, 3367, 3371*f*
Intradermal lipoma, 2173, 2174*f*
Intraepidermal neutrophilic (IEN) dermatosis–type intercellular IgA dermatosis, 983–984, 983*t*, 984*f*
Intrahepatic cholestasis of pregnancy (ICP), 1767–1771, 1768*t*
  clinical course and prognosis, 1771
  clinical features, 1770
  diagnosis, 1770
  differential diagnosis, 1770–1771
  epidemiology, 1765, 1770
  etiology and pathogenesis, 1770
  historical perspective and terminology, 1770
  management, 1771
Intralymphatic histiocytosis, rheumatoid arthritis, 1151
Intramuscular lipoma, 2173, 2174*f*
Intratumor heterogeneity, 312
Intravascular cutaneous B-cell lymphoma, 2101
Intravascular histiocytosis, rheumatoid arthritis, 1151
Intravenous augmentation therapy, α-AT protein, for α-antitrypsin panniculitis, 1269
Intravenous (IV) drug use, cutaneous signs, 1706–1709
  endocarditis, 1709
  hyperpigmentation, 1707, 1707*f*
  panniculitis, 1707
  skin and soft-tissue infections, 1707–1709, 1708*f*
  skin popping scars, 1706*t*, 1707
  track marks, 1706–1707, 1706*t*, 1707*f*
Intravenous immunoglobulin (IVIG)
  for chronic bullous disease of childhood, 994*t*, 999
  for connective tissue disease–associated panniculitis, 1283*b*
  for cytophagic histiocytic panniculitis, 1278
  for dermatomyositis, 1078
  for epidermal necrolysis, 744
  for epidermolysis bullosa acquisita, 978, 979*t*
  for hemophagocytic lymphohistiocytosis, 2032
  for hyperimmunoglobulinemia E syndrome, 2415
  for Kawasaki disease, 2587, 2587*t*
  for malignant atrophic papulosis, 2634, 2634*t*
  for mucous membrane pemphigoid, 966*t*, 967
  for paraneoplastic pemphigus, 941*t*
  for pemphigus, 924–925
  for pyoderma gangrenosum, 614*t*
  for solar urticaria, 1653
  for Still disease, adult-onset, 1158
    reactive phagocytic syndrome in, 1158
  for toxic shock syndrome, 2764
  for transient aplastic crisis, 2998
  for urticaria, 702
Intrinsic skin aging, 1780, 1780*f*, 1781*f*, 1781*t*
  photoaging, 1779, 1780, 1781–1782
Introns, 291
  splicing out, 292
Invariant natural killer cells (iNK cells), 150*f*, 151
Inverse lichen planus, 536
Inverse planned method, 3689, 3689*f*
Inverse psoriasis, 461, 461*f*
Inverted follicular keratosis, 31
Involucrin, 211
Iodinated compounds, topical, 3612*t*, 3613–3614
Iodinated contrast media (ICM), urticaria from, 695
Iodine
  chemical burns, 441–442, 443*t*
  deficiency, hypothyroidism, 2507
Iodophors, 3612*t*, 3613–3614
Iodoquinol
  for amebiasis, 3247
  pediatric toxicity, 1761*t*
Io moth, 3334
Ionizing radiation (IR)
  carcinogenesis, 320
  hypermelanosis from, 1364–1365
  occupational exposure, 447–448, 448*f*
  radiation acne from, 1453
Iontophoresis, 3376, 3616
  for hyperhidrosis
    in Fabry disease, 2302
    palmar-plantar, 1462
IPEX (immune dysregulation, polyendocrinopathy,enteropathy, and X-linked) syndrome, 146
Ipilimumab
  immune-related adverse events from, 2006, 2006*t*
  lichen planus from, 537
  for melanoma, 1990*f*, 2001–2002, 2005–2006, 2005*f*, 2006*t*, 2007*f*
    plus vemurafenib, 2009
  side effects, treatment algorithm, 2006, 2007*f*
iPLEDGE program, 1796, 3403
Ipramine, blue-gray pigmentation from, with sun exposure, 1658, 1661*f*
Ipranavir, 3508, 3509*t*
IR3535, for Lyme disease prevention, 3301
Irbesartan, for Marfan syndrome, 1229
IRF4, 344
IRF4-MUM1, primary cutaneous diffuse large B-cell lymphoma, 2100
iRhom2, Howel-Evans syndrome, 841
Iritis, herpes simplex virus, 3026
Iron, 2223
  hypermelanosis from, 1365, 1367*f*
  for protoporphyrias, 2249
Iron deficiency, 2223, 2223*t*
  telogen effluvium from, 1510
Iron-deficiency anemia, 2223
Iron excess, 2224
Irrgang-Kaposi syndrome, 1253*t*, 1272–1275. *See also* Lupus panniculitis
Irritant contact dermatitis (ICD), 439–444
  vs. acute contact dermatitis, 439, 442*t*
  background, 439, 443*f*
  clinical features, 439–444
    acute ICD and chemical burns, 441–443, 443*t*
    asteatotic dermatitis, 444
    cumulative ICD, 443, 444*f*
    irritant reaction CD, 442
    pustular and acneiform ICD, 444
    subjective ICD, 444
    traumatic ICD, 444
  risk factors, 452
  topical therapy, subjective or sensory, 3377
  from topical therapy, 3377
Irritant dermatitis, 414–426
  acute, self-diagnosis, 414
  vs. allergic contact dermatitis, 415, 416*t*
  at-a-glance, 414*b*
  barrier destruction, 414, 415*t*
  clinical course and prognosis, hardening, 424
  clinical features, 418–420
    cutaneous, 418–419, 418*f*–419*f*
    flexural accentuation, 418–419, 419*f*
    noncutaneous, 420
  complications, 421–422
    allergic contact dermatitis, 421
    food allergy, 421–422, 422*f*
    immune response, to less-potent allergens or microbiome, 421, 421*f*
    prevention, 425
  definitions, 414–415
  diagnosis, 422–423
    algorithm, 422–423, 423*t*
    imaging, 422
    patch testing, 422
    pathology, 422, 422*f*
    transepidermal water loss, 422
  differential diagnosis, 423–424, 423*t*
  epidemiology, 415–418
    atopic dermatitis, 416
    climate, 415–416
    gender, 416
    nonoccupational, 417–418, 418*t*
    occupational, 416–417, 417*t*
    rubbing or stretching, 418
    specific exposures, 416–418, 417*t*
  etiology
    atopic dermatitis, 420
    wet work, detergents, and gloves, 420, 420*t*, 423*t*
  historical perspective, 415
  management, 424–426
    counseling, 424
    gloves, 424–425
    medications, 424
    prework products, topical, 424, 425
    treatment algorithm, 425
  pathogenesis
    allergic sensitization potential, 420–421
    danger signals, 420
    epidermal insult, 420
  prevention, 425
  screening, 425–426
  T cells, adaptive immunity, 414
Irritant diaper dermatitis, 1741, 1741*t*
Irritant reaction contact dermatitis, 442
Irritated seborrheic keratosis, 1802
Irsoglandine, for adamantiades–Behçet disease, 2576*t*
Isethionate, for amebas, 3248

Island pedicle flap, 3738–3739, 3740*f*
Isoflavones, oral photoprotection, 3630
Iso-Kikucho syndrome, 1568
Isolated limb perfusion (ILP), for melanoma, satellite or in-transit metastases, 2004
Isolated split hand–split foot malformation, isolated, 2378, 2381–2382
Isomorphic response. *See* Koebner phenomenon
Isoniazid
  for lichen nitidus, 558, 558*t*
  for *N. brasiliensis* actinomycetoma, 2889
  for tuberculosis, 2862*t*–2863*t*
  for tuberculosis verrucosa cutis, 2861
Isopropyl alcohol, 3715
Isotopic response, Sweet syndrome, 590
Isotretinoin. *See also* Retinoid(s), oral
  for acne conglobata, 1449
  acne fulminans from, 1449–1450
  for acne vulgaris, 1407–1409
  chemical structure, 3395, 3396*f*, 3397, 3397*f*
  for hyperimmunoglobulinemia E syndrome, 2415
  for Langerhans cell histiocytosis, 2028
  metabolism and pharmacokinetics, 3398–3399
  for Morbihan disease, 1451
  for rosacea
    facial lymphedema, 1442
    phymata, 1439–1440
  sebaceous glands, 77
  structure, 3395, 3396*f*
Isotretinoin, oral
  for acne necrotica, 1531
  for acne vulgaris, 1407–1409
  adverse effects, 3402, 3402*t*
  for alopecia mucinosa, 1529
  for Darier disease, 884, 884*t*
  for discoid lupus erythematosus, cicatricial alopecia, 1527
  for dissecting folliculitis, 1530
  for eosinophilic folliculitis with HIV, 3123
  for erosive pustular dermatosis, 1531
  for follicular atrophodermas, 1200
  for hidradenitis suppurativa, 1490
  for ichthyosis, 782
  indications and contraindications, 3400
  for lichen planus pigmentosus, 1386
  for pityriasis rubra pilaris, 503
Isotretinoin, topical
  for Darier disease, 884, 884*t*
  for rosacea, 1439
Isthmic outer root sheath differentiation neoplasms, 1839*t*
  pilar sheath acanthoma, 1847
  proliferating pilar tumor, 1822*t*, 1847–1848, 1848*f*
  tumor of follicular infundibulum, 1846–1847
Itching purpura, 2591*t*, 2592
ITGA3, junctional epidermolysis bullosa with respiratory and renal involvement, 1015*t*, 1020
ITGA6, junctional epidermolysis bullosa with pyloric atresia, 1015*t*
ITGA9, fetal chylothorax, Klippel-Trenaunay syndrome, 2640*t*
ITGB2, leukocyte adhesion deficiencies, 2412*b*
ITGB4, junctional epidermolysis bullosa with pyloric atresia, 1015*t*
ITPKC, Kawasaki disease, 2584
Itraconazole, 3439*t*, 3441*t*, 3442*t*, 3445–3446
  for blastomycosis, 2979
  for *Candida*, 3446
  for chromoblastomycosis, 2972
  for chronic mucocutaneous candidiasis, 2401
  for *Cladophialophora carrionii*, 2972
  for coccidioidomycosis, 2980
  for cryptococcosis, 2984
  for lichen nitidus, 558, 558*t*
  for *Madurella mycetomatis* infection, 2971
  for *Malassezia*, 2963, 2963*t*
  for mucormycosis, subcutaneous, 2973
  for onychomycosis, nondermatophyte, 3446
  for paracoccidioidomycosis, 2981
  for *Penicillium marneffei*, with HIV, 3115
  for pityriasis versicolor, 3446
  for seborrheic dermatitis, 435
  for sporotrichosis, 2968
  for *Talaromyces marneffei*, 2982
  for tinea capitis, 1532, 3446
  for tinea corporis, pedis, cruris, and manum, 3446
Itraconazole, oral
  for eosinophilic folliculitis with HIV, 3123
  for fungal infections, superficial, 2935*t*
  for histoplasmosis, African, 2977
  for nail infections, 1595–1596, 1596*t*
Ivermectin, 3615, 3615*t*
  for cutaneous larva migrans, 3265*t*, 3266
  for lice, 3281, 3281*t*, 3284
  for *Mansonella ozzardi*, 3265*t*
  for *Onchocerca volvulus*, 3265*t*
  for scabies, with HIV, 3116
  for strongyloidiasis, 3265*t*, 3272
Ivermectin, oral
  for body lice, 3283
  for perioral dermatitis, 1455
Ivermectin, topical
  for lice, 3281*t*, 3284
  for perioral dermatitis, 1455
  for rosacea, 1439
Ixekizumab, 3535, 3536*f*, 3548*t*
  for plaque psoriasis, 176, 469*f*
  for psoriasis, 176, 198, 469*f*, 487*t*, 494
  for psoriatic arthritis, 469*f*, 980*t*, 981, 1136*t*, 1137
Ixodes, 3320
  erythema migrans, 767–769
Ixodes pacificus, 3308*f*, 3310*t*, 3311*t*, 3329
Ixodes persulcatus, 3296
Ixodes ricinus, 3296, 3311*t*
Ixodes scapularis, 3287, 3296, 3308*f*, 3311*t*, 3329
Ixodidae, 3329

J

Jacquet erosive dermatitis, 1741–1742
JAK inhibitors
  for lichen planus, 543
  for lupus erythematosus, 1058
  for vitiligo, 1345
JAK-STAT inhibitors. *See also* Ruxolitinib; Tofacitinib
  for graft-versus-host disease, 2334
JAK-STAT pathway, 162–165, 165*f*, 3595
  signaling, interferons as prototypes, 173–174
JAK-STAT3 pathway, cutaneous anaplastic large cell lymphoma, 2085
JAK1, eosinophil development, 649
JAK2, eosinophil development, 649–651
JAK2-STAT mutations
  cutaneous T-cell lymphomas, 2075–2076, 2076*f*
  lupus erythematosus, 1058
JAK2-STAT5 pathway, eosinophils, 254
  development, 651
JAK3 activation, cutaneous T-cell lymphomas, 2075, 2076*f*
Janeway lesion, infective endocarditis, 1709, 2425, 2815–2816, 2816*f*
Janus kinase inhibitors. *See also* Tofacitinib; *specific types*
  for alopecia areata, 1522
Janus kinase–signal transducers and activators of transcription. *See* JAK-STAT
Japanese spotted fever, 3315
Jarisch-Herxheimer reaction, 3298–3299
  from penicillin with HIV, 3119
  syphilis treatment, 3167
Jaundice
  alcohol abuse, 1713
  hepatobiliary disease, 2431
Jellyfish sting, 3344–3348
  clinical features, 10*f*
  cubomedusae, 3346–3347, 3347*f*
  nematocysts, 3344, 3345*f*
  Portuguese man-of-war, 3344–3346, 3346*f*
  prevention, 3347, 3348*t*
  sea nettles, 3344, 3345*f*–3346*f*
  treatment, 3347–3348, 3348*f*, 3348*t*
Jenner, Edward, 130
Jessner-Kanof, 3293
Jessner solution, for chemical peels
  for actinic keratosis, 1866
  medium-depth, 3900, 3901*t*
  superficial, 3899, 3899*f*, 3901*f*
Jigger, 3333, 3333*f*
Job syndrome, 197, 2413–2415, 2413*f*–2414*f*, 2413*t*
  S. aureus skin and soft tissue infections risk, 2726
Joenen tumors, 2482–2483, 2483*f*
Joint mobility
  hypermobility, Beighton scale, 1219, 1220*t*
  limited, with diabetes mellitus, 2496, 2496*f*
JUN, dedifferentiated liposarcoma, 2189
Junctional blistering, 23–24
Junctional epidermolysis bullosa (JEB), 1018–1020, 1029*t*
  generalized intermediate junctional epidermolysis bullosa, 1018–1019, 1019*f*, 1029*t*
  generalized severe junctional epidermolysis bullosa, 1016*f*, 1018, 1029*t*
  histopathology, 1018
  junctional epidermolysis bullosa with pyloric atresia, 1019, 1029*t*
  junctional epidermolysis bullosa with respiratory and renal involvement, 1019
  laminin 332, 245
  laminin mutations, 241
  laryngo-onycho-cutaneous syndrome, 1020
  localized junctional epidermolysis bullosa, 1019, 1029*t*
  molecular pathology, 1020, 1020*f*
  nail changes, 1601
  non-Herlitz junctional epidermolysis bullosa, 1020, 1020*f*
  prenatal diagnosis, 306
  squamous cell carcinoma, 1904*t*
Junctional epidermolysis bullosa, autosomal recessive, 296, 296*t*
Junctional epidermolysis bullosa gravis, 1016*f*, 1018
Junctional epidermolysis bullosa mitis, 1018–1019, 1019*f*, 1029*t*
Junctional epidermolysis bullosa with pyloric atresia, 1019, 1029*t*
Junctional epidermolysis bullosa with respiratory and renal involvement, 1019
Junction zone, 23
"Junk" DNA, 289
JUP
  acantholytic epidermolysis bullosa simplex, 1015*t*
  Naxos disease, 835
  plakophilin deficiency epidermolysis bullosa simplex, 1015*t*

Juvenile idiopathic arthritis (JIA), 1153–1155, 1154*f*, 1160*t*
Juvenile ingrown nails, 3788–3789, 3788*f*
Juvenile Still disease, 1153–1155, 1154*f*, 1160*t*
Juvenile xanthogranuloma (JXG), 2032–2034, 2033*f*, 2034*t*

K

K6HF, loose anagen syndrome, 1547
Kallikreins
  corneodesmosome degradation, 214
  LEKTI binding, 210*f*, 215
  rosacea, 1428*f*–1429*f*, 1429
  synthesis, 214
Kallman syndrome, 300
  X-linked, with X-linked recessive ichthyosis, 786
Kamino bodies, Spitz nevus, 35, 35*f*
Kanamycin, for actinomycetoma, 2889
KANK2, 836
Kaposi hemangioendothelioma (KHE), 2059*b*, 2062–2063, 2062*f*
Kaposi sarcoma (KS), 172
  chemokines, 185–186
  clinical features, 9*f*, 2434
  cryosurgery for, 3795
  in elderly, 1786
  with HIV, 3119–3120, 3119*f*, 3120*t*
  viral carcinogenesis, 318, 319*t*
Kaposi varicelliform eruption, 3024, 3025*f*
κ-opioid receptor agonists, for uremic pruritus, 360
κ-opioids, 355
Karyotype, 297
Kasabach-Merritt phenomenon (KMP), 2062, 2062*f*
  Kaposi-form hemangioendothelioma, 2062, 2062*f*
  tufted angioma, 2061
Katayama fever, 3258*t*, 3261, 3262, 3263, 3270. *See also* Schistosomal infections (*Schistosoma* spp.)
Kathon CG, allergic contact dermatitis from, 404
Kava dermopathy, 809
Kawasaki disease, 2580–2587
  at-a-glance, 2580*b*
  clinical course and prognosis, 2586–2587
  clinical features, 2581–2583
    complications, 2583, 2583*f*
    cutaneous, 2581, 2581*f*–2582*f*
    noncutaneous, 2581–2582, 2582*f*–2583*f*, 2583*t*
  diagnosis, 2584–2586, 2585*t*
  differential diagnosis, 2586, 2586*t*
  epidemiology, 2540, 2580–2581
  etiology and pathogenesis, 2583–2584
  heart disease from, 2580
  historical perspective, 2580
  management, 2587, 2587*t*
  risk factors, 2584
KCNJ8, osteochondrodysplasia with hypertrichosis, 1564
Keloidal blastomycosis, 2967*t*, 2972–2973
Keloids
  cryosurgery for, 3794
  postoperative, 3723–3724, 3724*f*, 3724*t*
Kelvin's tetrakaidecahedron, 207*t*, 220, 221*f*
Keratan sulfate, dermal cell-matrix adhesion, 247
Keratin, 50
  basal progenitor cells, epidermis, 63–64
  cytoskeleton, filaggrin and, 216–217, 216*f*
  family and sites of expression, 64, 64*t*
  filaments, inherited epidermolysis bullosa, 1011–1012, 1012*f*
  inherited bullous diseases of, 64, 65*t*
  promoters, 293
Keratin 1, 63*f*, 64*t*
Keratin 5, 63, 63*f*
Keratin 6, 3397, 3398*t*
Keratin 10, 63*f*, 64*t*
Keratin 71, 89
Keratin-associated protein, genes, 290–291, 291*f*
Keratinization, 20, 22
Keratinocyte, 30, 50, 51*f*, 154*t*, 156–157
  adherens junctions, 64
  adhesion, laminin 332, 245
  antimicrobial proteins from, 222, 223*f*
  cytokines, 160
  development, 49
  epidermis, 19
  inflammation and wound healing, 2701*f*–2703*f*, 2703, 2704–2705
  innervation, 351–352
  melanosome
    trafficking and degradation, 341–342
    transfer to, 340, 340*f*–341*f*
  phototherapy on, 3638
  psoriasis, 471, 479
  shape, for skin barrier homeostasis, 207*t*, 213*f*, 220, 221*f*
  squamous cell carcinoma, invasive, 32, 32*f*
  stratum granulosum, 211
  structure, 64
  transmembrane proteins, 232
  wound healing, 2705
Keratinocyte growth factor (KGF), 95, 340
Keratinocytic epidermal nevus, 1806–1809, 1812*t*
  at-a-glance, 1806*b*–1807*b*
  clinical course and prognosis, 1809
  clinical features, 1807, 1807*f*–1808*f*
  diagnosis, 1808
  differential diagnosis, 1808–1809
  epidemiology, 1807
  etiology and pathogenesis, 1807–1808
  histopathology, 1808, 1808*f*
  nevus unius lateris, 1807, 1808*f*
  treatment, 1809
Keratinocytic tumors, pathology, 30–32
  basal cell carcinoma, 32–33, 32*f*
  condyloma acuminatum, 31, 31*f*
  keratoacanthoma, 32
  seborrheic keratosis, 31, 31*f*
  squamous cell carcinoma, 31–32, 31*f*
    invasive, 32, 32*f*
  verruca plana, 31
  verruca vulgaris, 30–31, 30*f*
Keratinopathic ichthyoses, 795–800. *See also* Ichthyoses, keratinopathic
Keratinous cysts, postoperative, 3721–3722
Keratitis
  Acanthamoeba, 3248
  onchocerciasis, 3261
  stromal, HSV, 3026
Keratitis-ichthyosis-deafness (KID) syndrome, 777*t*, 829–832, 830*f*, 845*t*
  cellular defects, 781*t*
  clinical course, prognosis, and management, 802
  clinical features, 800–801, 802*f*, 845*t*
  congenital, 1740
  etiology and pathogenesis, 801–802
  GJB2, 777*t*, 802, 802*f*, 845*t*
  proliferating pilar tumor, 1822*t*, 1848*f*
Keratinization, trichilemmal, 93
Keratoacanthoma (KA), 32. *See also* Squamous cell carcinoma (SCC)
  associated syndromes, 1904*t*
    Muir-Torre syndrome, 32, 1904*t*, 1908
  clinical presentation, 1908, 1908*f*
    solar elastosis, 32
  etiology and pathogenesis, 1904*t*
    BRAF inhibitors, 32
    dabrafenib, 32
    drugs, 1906
    precursor lesions, 1902
    sorafenib, 32
    UVA and UVB, 1902–1903
    vemurafenib, 32
    viral infection, 1906
  histopathology, 1911, 1911*f*
  pathology, 32
  Smith-Ferguson syndrome, 314
  squamous cell carcinoma and, 1902, 1904*t* (*See also* Squamous cell carcinoma (SCC))
Keratocoagulation, 3898, 3900
Keratoconjunctivitis, herpes simplex virus, 3026
Keratoconjunctivitis sicca, Sjögren syndrome, 1174, 1179
Keratoconus, 368
Keratoderma (Carnissa), cellular defect, 781*t*
Keratoderma blenorrhagicum, reactive arthritis with, 983, 984*f*, 1140, 1140*f*
Keratoderma–congenital alopecia syndrome (PPKCA), 832, 845*t*
  Stevanovic type, 832
  Wallis type, 832
Keratohyalin granules, 64, 216, 216*f*
Keratolytic agents. *See also specific types*
  alpha-hydroxy acids, 3618, 3619*t*
  calcipotriene, 3619
  for ichthyosis, 782
    keratinopathic, 800
  for keratosis pilaris, 869
  for keratosis pilaris atrophicans, 872
  lactic acid, 3619, 3619*t*
  for nevus comedonicus, 1811
  for palmoplantar keratodermas, inherited, 821
  for pityriasis rubra pilaris, 503
  propylene glycol, 3618–3619, 3619*t*
  for reticulated papillomatosis of Gougerot and Carteaud, 809
  salicylic acid, 3619, 3619*t*
  for seborrheic dermatitis, 434
  urea, 3619, 3619*t*
Keratomalacia, vitamin A deficiency, 2205, 2205*f*
Keratoses
  actinic, 1857–1867 (*See also* Actinic keratoses (AK))
  chronic radiation, 1881*b*
  chronic scar, 1881*b*
  hydrocarbon, 1880*b*–1881*b*
  inverted follicular, 31
  lichenoid, 539
  thermal, 1880*b*
Keratosis follicularis amiantacea, 429–430, 431*f*
Keratosis follicularis rubra, 867–869, 868*f*, 869*t*
Keratosis follicularis spinulosa decalvans (KFSD), 869*t*, 870, 872–873, 873*f*, 1529
Keratosis lichenoides chronica (KLC), 539
Keratosis pilaris (KP), 867–869, 868*f*, 869*t*
Keratosis pilaris atrophicans (KPA), 869–872, 870*f*, 871*f*, 872*t*, 1067*f*, 1199–1200, 1199*f*
Keratosis pilaris atrophicans faciei (KPAF), 869–872
Keratosis pilaris rubra (KPR), 867–869, 868*f*, 869*t*
Keratosis pilaris rubra atrophicans faciei, 869–872, 869*t*, 870*f*, 872*t*, 1529
Keratotic scale, 6*t*
Keshan disease, 2222
Keshin–Beck disease, 2222
Ketoconazole, 3438*t*, 3443–3444
  for dermatophytosis, 3443
  for hirsutism, 1562*t*
  for *Madurella mycetomatis* infection, 2971
  for mucormycosis, subcutaneous, 2973
  for seborrheic dermatitis, 435, 3443
  for tinea capitis, 1532
Ketoconazole, topical
  for fungal infections, superficial, 2936*t*

for *Malassezia*, 2963, 2963*t*
for *Malassezia furfur* seborrheic dermatitis with HIV, 3122
for seborrheic dermatitis with HIV, 3122–3123
Ketotifen
antihistaminic activity, 3459
for mastocytosis, 719, 719*t*
for Morbihan disease, 1451
Kidneys
systemic sclerosis, 1091
transplantation, for acute hepatic porphyrias, 2252
tuberous sclerosis complex, 2484–2485
KIF11, Klippel-Trenaunay syndrome, 2640*t*, 2657
KiM1P
papular xanthoma, 2035
xanthoma disseminatum, 2036
Kimura disease, 667*t*, 668, 669–670
angiolymphoid hyperplasia with eosinophilia and, 2124–2125, 2125*f*
at-a-glance, 667*b*
differential diagnosis, 668, 668*f*, 669*t*
management, 669–670
Kinase genes, Spitz nevus, 1964
KIND1, Kindler syndromes, 1015*t*, 1024
Kindler syndrome, 1024
autosomal recessive disorder, 296, 296*t*
Kindlin-1, 245, 1024
Kinetochore, 291
Kissing, psoriasis, 125, 126*f*
Kissing bugs, 3240, 3332
KIT
blastic plasmacytoid dendritic cell neoplasm, 2102
melanoma, 2009
piebaldism, 1321
KIT, BCR-ABL, and PDGFR inhibitors, 3558–3565. *See also* Tyrosine kinase inhibitors (TKIs), small-molecule
KIT, mastocytosis, 749–750
Kitamura reticular acropigmentation, 1325–1326, 1327*t*, 1355
KITLG, 344
familial progressive hyperpigmentation with or without hypopigmentation, 1387
KIT ligand, mast cell maturation, 153
Klebsiella granulomatis, 3204
Klebsiella pneumoniae subsp. *rhinoscleromatis*, 2808–2809, 2809*f*
Klebsiella rhinoscleromatis rhinoscleroma, 2808–2809, 2809*f*
Klf4, 66, 67, 67*f*
epidermal differentiation, 66, 67*f*
KLF4, 479
Kligman's formula, 3811
for melasma, 1381, 2242
for postinflammatory hyperpigmentation, 1379
KLIK genodermatosis, cellular defect, 782*t*
Klinefelter syndrome, 297, 303
Klippel-Trenaunay syndrome, 2640*t*, 2653
KLOTHO, tumoral calcinosis, 2311
KMT2C, 314
KMT2D, 314
KNSTRN, 314
Knuckling, condyloma acuminatum, 31, 31*f*
Koch phenomenon, tuberculosis, 2859–2860
Koch's postulates, 253
Koebner phenomenon, 725
acquired perforating disorders, 1204*t*
discoid lupus erythematosus, 1045
lichen nitidus, 554, 555*f*
lichen planus, 530, 530*f*
linear IgA dermatosis and, 995
linear lesion, 10
linear shape, 10
positive patch test, psoriasis or lichen planus, 408
psoriasis, 138, 458–459, 459*f*
erythrodermic, 461
generalized pustular, 462
xanthomas, 2275
Koebner reaction, 167–168
Koilocytes
condyloma acuminatum, 31, 31*f*
verruca planta, 31
verruca vulgaris, 30, 30*f*
Koilonychia, iron deficiency, 2223
Koplik spots, measles, 2990, 2990*f*
KP1, xanthoma disseminatum, 2036
K-ras
actinic keratosis, 1861
neurofibromatosis, 2471
KRAS
arteriovenous malformations, brain, 2640*t*, 2662
blastic plasmacytoid dendritic cell neoplasm, 2102
cardiofaciocutaneous syndrome, 871
nevus sebaceus, 1809
Noonan syndrome, 871
seborrheic keratoses, 1800
Krause corpuscles, 351–352
Krokodil, 1713
KRT1
epidermolytic ichthyosis, 777*t*, 799
epidermolytic palmoplantar keratoderma, 822
Greither syndrome, 824
hereditary keratosis palmoplantaris variant of Wachters, 838
ichthyosis with confetti, 777*t*
keratinocytic epidermal nevus, 1808
striate palmoplantar keratoderma, 836, 837
Unna-Thost palmoplantar keratoderma, 823
KRT2, superficial epidermolytic ichthyosis, 777*t*
KRT5
dermatopathia pigmentosa reticularis, 1354
Dowling-Degos disease, 1326–1327, 1327*t*, 1354
generalized severe epidermolysis bullosa simplex, 1015*t*
KRT6A, pachyonychia congenita, 838–840, 840*t*
KRT6B, pachyonychia congenita, 838–840, 840*t*
KRT6C
hereditary keratosis palmoplantaris variant of Wachters, 838
pachyonychia congenita, 838–840, 840*t*
Unna-Thost palmoplantar keratoderma, 823
KRT9, epidermolytic palmoplantar keratoderma, 822
KRT10
epidermolytic ichthyosis, 777*t*, 799
ichthyosis with confetti, 777*t*, 799
keratinocytic epidermal nevus, 1808
KRT14, 291, 291*f*
generalized intermediate epidermolysis bullosa simplex, 1015*t*
generalized severe epidermolysis bullosa simplex, 1015*t*
localized epidermolysis bullosa simplex, 1015*t*
Naegeli-Franceschetti-Jadassohn syndrome, 1353
KRT17, pachyonychia congenita, 838–840, 840*t*
KRT81, monilethrix, 1543
KRT83, monilethrix, 1543
KRT86, monilethrix, 1543
Kwashiorkor, 2199*b*, 2200–2203, 2202*t*. *See also* Protein-energy malnutrition (PEM)
hypermelanosis, 1363
Kyphoscoliotic Ehlers-Danlos syndromes (KEDS), 1216*t*
Kyrie disease (KD), 1203–1209, 1204*t*. *See also* Acquired perforating disorders (APD)
cutaneous manifestations, 2438
Kytococcus sedentarius, pitted keratolysis, 2741

L

L914F
mucocutaneous venous malformations, 2650
venous malformations, 2650
Label-retaining cells (LRCs), 108–109
slow-cycling, 108
Labial arteries, 3703, 3704*f*
Laboratory Risk Indicator for Necrotizing Fasciitis (LRINEC), 2773, 2773*t*
Lacazia loboi, 2973
Lactate, sweat, 81
Lactation, glucocorticoids, 3387
Lactic acid, 3619, 3619*t*
keratolytic actions, 3618, 3619*t*
topical, for pityriasis rotunda, 2448
Lactobacillus rhamnosus strain GG, for atopic dermatitis prevention, 380
Lagophthalmos, leprosy, 2900, 2900*f*, 2901
LAMA3
generalized intermediate junctional epidermolysis bullosa, 1015*t*
generalized severe junctional epidermolysis bullosa, 1015*t*
junctional epidermolysis bullosa, 1015*t*, 1020
junctional epidermolysis bullosa inversa, 1015*t*
laryngo-onycho-cutaneous syndrome, 1015*t*
localized junctional epidermolysis bullosa, 1015*t*
LAMAC2
generalized intermediate junctional epidermolysis bullosa, 1015*t*
generalized severe junctional epidermolysis bullosa, 1015*t*
junctional epidermolysis bullosa inversa, 1015*t*
localized junctional epidermolysis bullosa, 1015*t*
LAMB3, 303
generalized intermediate junctional epidermolysis bullosa, 1015*t*
generalized severe junctional epidermolysis bullosa, 1015*t*
junctional epidermolysis bullosa, 1015*t*, 1020
junctional epidermolysis bullosa inversa, 1015*t*
localized junctional epidermolysis bullosa, 1015*t*
LAMB syndrome, blue nevus, 1959, 1961
Lamellar body, 211, 212*f*, 214
Lamellar fibroplasia, dysplastic nevi, 34, 34*f*
Lamellar ichthyosis (LI). *See also* Autosomal recessive congenital ichthyosis
autosomal recessive, 296, 296*t*
cellular defect, 781*t*
clinical course, prognosis, and management, 794
clinical features, 787–788, 788*f*, 788*t*
etiology and pathogenesis, 792
gene replacement therapy, 307
TGM1, 788, 788*f*, 788*f*–789*f*
Lamellar scale, 6*t*
Lamin-311, epidermolysis bullosa, inherited, 1013
Lamin-332, epidermolysis bullosa, inherited, 1013
Lamin-332 genetic graft, for epidermolysis bullosa, 1030

Lamina densa, 238, 239, 239*f*
Lamina lucida, 238, 239, 239*f*
Lamina propria, eosinophils, 652
Laminin, 240–241, 241*f*, 242*f*, 242*t*
  anchoring filaments, 245
  mutations, junctional epidermolysis bullosa, 241
Laminin 332
  autoantibodies, 962, 964
  junctional epidermolysis bullosa, 245, 1020
  keratinocyte adhesion, 245
Lamivudine, 3506–3507, 3509*t*
Lamps, phototherapy
  arc, 3639
  fluorescent, 3639–3641
  gas discharge, 3639
  incandescent, 3639
Lanadelumab, for hereditary angioedema, 694*f*, 702
Langerhans cell(s), 30, 149–153, 152*t*
  activation and actions, 219*f*, 220
  allergic contact dermatitis, 194
  development, 49
  epidermis, 19, 20
  lichen nitidus, 554, 557
  type IV hypersensitivity reactions, 397–398
Langerhans cell histiocytosis, 2019–2029. *See also* Histiocytosis, Langerhans cell
  at-a-glance, 2019*b*
  classification, 2018, 2019, 2019*t*, 2020*t*
    new, 2019*t*, 2021
    traditional, 2019, 2020*t*
  clinical course and prognosis, 2027–2028
  clinical features, 2021–2025
    classification, 2021, 2022*f*–2023*f*
  clinical features, cutaneous, 2021–2023, 2023*f*–2024*f*
  clinical features, noncutaneous, 2023–2025
    bone and bone marrow, 2023, 2024
    central nervous system, 2023, 2025
    endocrinopathies, 2025
    gastrointestinal system, 2025
    liver and spleen, 2023, 2024
    lungs, 2023, 2024–2025
    lymph nodes, 2023, 2024
  diagnosis, 2025–2026
    histopathology, 2025–2026, 2026*f*–2027*f*, 2027*t*
    history, 2025
    laboratory testing and imaging, 2025, 2025*t*, 2026*t*
    marker expression, 2026, 2027*t*
    physical examination, 2025
  diaper area, 1741*t*, 1742, 1743*f*
  differential diagnosis, 2027, 2028*t*
  eosinophils, 659
  epidemiology, 2020–2021
  etiology and pathogenesis, 2021
  historical perspective, 2019–2020
  management, 2028–2029, 2029*t*
  neonatal, 1744
Langerin (CD207), 135, 151
Lanosterol demethylase enzyme, 3443
Lanreotide, for necrolytic migratory erythema, 2456
Lanugo hair, 92, 92*t*
Lapatinib, acneiform eruptions from, 1452
LARC, cancer cell secretion, 184
Large-plaque parapsoriasis (LPP), 505–511, 506*f*–507*f*, 509*f*. *See also* Parapsoriasis
Large simple studies, 43
L-arginine, for Raynaud phenomena, 2621, 2621*t*
Laryngo-onycho-cutaneous syndrome, 1020
Laser, ablative
  for actinic keratosis, 1864*t*, 1865
  for Bowen disease, 1871, 1871*t*
  hybrid, 3836
  for seborrheic keratosis, 1802
Laser, alexandrite
  for hirsutism, 1563
  long-pulsed, 3848
  Q-switched, for café-au-lait spots, 1377, 2476, 3848, 3851, 3851*f*, 3853*t*
Laser, carbon dioxide (CO_2), 3834, 3835–3836, 3848. *See also* Laser skin resurfacing (LSR)
  ablative fractional resurfacing, 3835
  ablative laser resurfacing, 3834
  for actinic keratosis, 1865
  for arsenical keratoses, 1880
  for benign cephalic histiocytosis, 2034
  for burn scars, 1690
  equipment, 3835–3836, 3835*t*
  for erythroplakia, 1879
  for follicular atrophoderma, 1200
  for generalized eruptive histiocytoma, 2035
  for generalized eruptive histiocytoma of childhood, 2034
  for hidradenitis suppurativa, 1491
  for HPV warts
    with HIV, 3118
    nail, 1591
  for lymphatic anomalies, 2658, 2658*f*
  for neurofibromas, 2477
  for papular xanthoma, 2035
  for pyogenic granula, 2064
  for rosacea, 1439, 1442*t*, 1443
  skin tightening, 3858, 3860
  for striae, 1197
  technique, 3840
Laser, copper vapor, for café-au-lait spots, 2476
Laser, erbium-doped
  fiber, 3848
  phosphate glass, 3848
Laser, Er:YAG, 3834, 3835, 3848. *See also* Laser skin resurfacing (LSR)
  ablative fractional resurfacing, 3835
  ablative laser resurfacing, 3834
  for actinic keratosis, 1865
  for arsenical keratoses, 1880
  equipment, 3835–3836, 3835*t*
  for melasma, 1381, 3851, 3853*t*
  for rosacea, 1439, 1442*t*, 1443
  technique, 3840
Laser, excimer, 3848
  for atopic dermatitis, 3649
  for prurigo nodularis, 392
  for psoriasis, 483*t*, 491, 3647, 3649
  for vitiligo, 3650
Laser, fractional, 2283, 3846. *See also* Laser skin resurfacing (LSR)
  equipment, 3835*t*, 3836
  photothermolysis, 3830, 3835
  technique, 3840
Laser, Nd:YAG, 3848
  for Fabry disease, 2302
  for hair removal, 3851–3852, 3853*t*
  for hidradenitis suppurativa, 1491
  for hirsutism, 1563
  for lymphatic anomalies, 2658
  for nail infections, fungal, 1596, 1596*t*
  for partial unilateral lentiginosis, 1381
  Q-switched
    for café-au-lait spots, 2476, 3848, 3850
    for tattoo removal, 3852–3854, 3852*f*, 3853*t*
  for varicose veins, 3890, 3890*f*
Laser, nonablative, 3846–3854
  at-a-glance, 3846*b*
  definition and applications, 3846
  devices
    lasers, 3846, 3847–3848
    radiofrequency and ultrasound, 3848
  for hair removal, 3851–3852, 3853*t*
  historical perspective, 3846
  perioperative considerations
    anesthesia, 3847
    patient selection, 3846–3847
    perioperative care, 3847
    risks and potential complications, 3847
    safety, 3847
  for pigmented lesions, 3850–3851, 3853*t*
    Becker nevi, 3851, 3853*t*
    café-au-lait macules, 3851, 3851*f*, 3853*t*
    lentigines and seborrheic keratoses, 3850–3851, 3853*t*
    melasma, 1381, 3851, 3853*t*
    nevus of Ito, 3851, 3853*t*
    nevus of Ota, 1356, 3851, 3853*t*
    Q-switched, 3848, 3850
  for tattoo removal, 3852–3854, 3852*f*, 3853*t*
  for texture, 3853*t*, 3854
  for vascular lesions, 3848–3850, 3853*t*
    angiomas, 3850, 3853*t*
    hemangiomas, infantile, 2058, 3849–3850, 3853*t*
    port-wine stains, 3848–3849, 3849*f*, 3853*t*
    telangiectases, 3850, 3850*f*, 3853*t*
    venous lakes, 3850, 3853*t*
Laser, picosecond
  for medication-induced pigmentation, 1367
  for nevus of Hori, 1375
  for nevus of Ota, 1356
  for postinflammatory hyperpigmentation, 1379
Laser, potassium titanyl phosphate (KTP), 3848
Laser, pulsed-dye (PDL), 3848
  for acne scars, 1411
  for angiomas, 3850, 3853*t*
    tufted, 2062
  for burn scars, 1690
  for capillary malformations, 2644, 3848–3849
  for Fabry disease, 2302
  as gold standard, 3848
  for granuloma faciale, 675, 675*t*
  for HPV warts, nail, 1591
  for infantile hemangiomas, 2058, 3849–3850, 3853*t*
  for keratosis pilaris atrophicans, 872
  for multicentric reticulohistiocytosis, 2038
  for port-wine stains, 2644, 3848–3849, 3849*f*, 3853*t*
  for pyogenic granula, 2064
  for rosacea, 1442*t*
  for striae, 1197
  for varicose veins, 3890, 3890*f*
Laser, quality-switched (QS)
  for Becker nevi, 3851, 3853*t*
  for café-au-lait macules, 1377, 2476, 3848, 3850, 3851, 3851*f*, 3853*t*
  for erythema ab igne, 1373
  for medication-induced pigmentation, 1367
  for nevus of Hori, 1375
  for nevus of Ito, 3851, 3853*t*
  for nevus of Ota, 1356, 3851, 3853*t*
  for partial unilateral lentiginosis, 1381
  for Peutz-Jeghers syndrome, 1359
  for pigmented lesions, 2476, 3848, 3850
  for postinflammatory hyperpigmentation, 1379
  for Riehl melanosis, 1382
Laser, ruby, 3848
Laser photocoagulation, for pseudoxanthoma elasticum, 1233
Laser safety officer (LSO), 3832
Laser skin resurfacing (LSR), 3834–3844
  ablative, 3834
  at-a-glance, 3834*b*
  contraindications, 3838–3839
  developments, new and future ablative, 3843–3844
  equipment
    ablative

carbon dioxide, 3835–3836, 3835*t*
Er:YAG, 3835–3836, 3835*t*
hybrids, 3836
fractional, 3835*t*, 3836
nonablative, 3836
fractional photothermolysis, 1411, 3835
fractional resurfacing, 3835
indications, 3836–3838, 3837*f*, 3838*t*
laser selection, 3834
nonablative, 3835
outcomes assessment, 3841
patient selection, 3838–3839, 3838*t*
procedure and technique, 3839–3841
anesthesia, 3839
postoperative care and patient instructions, 3839
preoperative care, 3839
safety precautions, 3839–3840
technique
CO_2 ablative laser, 3840
Er:YAG ablative laser, 3840
fractional ablative laser, 3840
nonablative, 3840–3841
side effects and complications
ablative fractional LSR, 3843
common postop reactions, 3842
minor, 3842
moderate, 3842–3843
overview, 3842, 3842*t*
severe, 3843
Laser therapy, 3820–3832. *See also specific types*
for acne scars, 1411
for acne vulgaris, 1410
for androgenetic alopecia, 1505
for angiolymphoid hyperplasia with eosinophilia, 669
at-a-glance, 3820*b*
definition, 3820
dermatologic, available, 3821, 3821*t*
energy delivery
articulated arms, 3825
fiber lasers, 3825
fiber optics, 3825
micromanipulators, 3825
fractional photothermolysis, 3830, 3835
fractionated, 3848 (*See also specific types*)
for granuloma faciale, 675, 675*t*
for hereditary progressive mucinous histiocytosis, 2040
for hidradenitis suppurativa, 1490–1491
for hirsutism, 1563
historical perspective, 3820
for hypertrichosis, 1565
for infantile hemangiomas, 2058, 3849–3850, 3853*t*
lasers, available dermatologic, 3821, 3821*t*
laser–tissue interactions, 3825–3828, 3826*f*–3828*f*
for Mongolian spots, 1358
nonfractionated, 3848 (*See also specific types*)
photothermolysis, selective, 3829–3830
principles, 3820–3824, 3822*f*–3824*f*
safety, 3831, 3831*t*
for rosacea, 1439, 1442*t*, 1443
flushing and transient erythema, 1439, 1442*t*
persistent erythema, 1438, 1442*t*
phymata, 1440
ruby, 3848
safety, 3831–3832
eye, 3831–3832
maintaining, 3832
skin, 3831
skin cooling, 3830–3831, 3830*t*, 3848
varicose vein surgery, 3889–3890, 3890*f*
Laser toning
for melasma, 1381
for Riehl melanosis, 1382
Latanoprost, for alopecia areata, 1521
Late benign syphilis, 3155
Late latent syphilis, 3154
Latent syphilis, 3154
Latent tumor growth factor-β-binding proteins (LTBPs), 247
Lateral border recycling compartment, 124
Lateral canthal lines, botulinum toxin for, 3926–3927
Lateral sidewalls (nose), 3698, 3698*f*
Latex allergy
allergic contact dermatitis, 405
urticaria
contact, latex gloves, 445–446, 445*t*
IgE-mediated, 695
Latrodectus, 3324–3326, 3326*f*
Latrodectus bishopi, 3324–3326, 3326*f*
Latrodectus geometricus, 3324–3326, 3326*f*
Latrodectus hesperus, 3324–3326, 3326*f*
Latrodectus mactans, 3324–3326, 3326*f*
Latrodectus various, 3324–3326, 3326*f*
Laugier-Hunziker-Baran syndrome, melanonychia, 1570
Laugier-Hunziker syndrome, 1372
lentigo simplex, 1968
Law of Colles, 3161
Lawrence syndrome, 1297*f*, 1301
LCE3B, psoriasis, 479
LCE3C, psoriasis, 479
LDL receptor adaptor protein 1 (LDLRAP1), 2281
Leather (cobalt marker), allergic contact dermatitis from, 404
Ledipasvir and sofosbuvir (Harvoni), for hepatitis C virus, 3512
Leech
bites, 3353
therapy, cutaneous pseudolymphoma from, 2116, 2116*f*
Leflunomide
for juvenile idiopathic arthritis, 1155
for psoriatic arthritis, 979, 980, 980*t*, 1135, 1136*t*, 1137
for rheumatoid arthritis, 1152
for sarcoidosis, 581*t*
Legius syndrome, 1360, 2473
Leg ulcers, differential diagnosis, 2672, 2674*t*
Leiner disease, 428–429. *See also* Seborrheic dermatitis
Leiomyoma, 2130–2138, 2131*t*–2132*t*
angioleiomyoma, 2131*t*–2132*t*
clinical course and prognosis, 2138
clinical features, 2135–2136, 2136*f*
differential diagnosis, 2136–2137
epidemiology, 2130
etiology and pathogenesis, 2130–2135
angioleiomyoma, 2130, 2134*f*
FH mutation, 2130, 2131*t*, 2135, 2136
genital, 2130, 2134*f*
hereditary leiomyomatosis and renal cell carcinoma, 2135, 2135*t*
multiple cutaneous and uterine leiomyomatosis, 2130, 2135
nipple and areola, 2130, 2135*f*
piloleiomomas, 2130, 2134*f*
histopathology, 2136, 2136*f*–2137*f*
management, 2138
pathology, 38–39, 38*f*
pilar, 2131*t*–2132*t*
symplastic, 2136
Leiomyoma, genital, 2130–2138, 2131*t*–2132*t*
clinical course and prognosis, 2138
clinical features, 2136
differential diagnosis, 2136–2137
etiology and pathogenesis, 2130, 2134*f*, 2135
histopathology, 2136
management, 2138
Leiomyoma cutis, 2130, 2134–2138. *See also* Leiomyoma
Leiomyosarcoma, 39, 39*f*, 2131*t*–2132*t*, 2138–2141
at-a-glance, 2138*b*
clinical course and prognosis, 2141
clinical features, 2138–2139, 2139*f*
differential diagnosis, 2140–2141
epidemiology, 2138
etiology and pathogenesis, 2138
histopathology, 2139–2140, 2140*f*
with HIV, 3114
management, 2141
Mohs micrographic surgery, 2141
pathology, 39, 39*f*
Leishman-Donovan bodies, 3234
Leishmania, 3225, 3226*t*, 3227*f*
HIV sensitivity, 3116
host, 3225–3226, 3226*t*
Leishmaniasis, 3223–3238, 3224*t*
at-a-glance, 3223*t*
clinical features, 3228–3234
complex lesions, 3236–3237
cryptic, 3234
cutaneous, B cells, 149
cutaneous, localized, 3228–3232, 3228*t*, 3229*f*–3231*f*
chronic, 3231, 3231*f*
complications, 3231
diffuse, 3232, 3232*f*
leishmaniasis recidivans, 3231
reactivation, 3231
disease forms and causative species, 3228*t*
granulomas, infectious, 27
with HIV, advanced, 3116
leishmanid, 3233–3234
mucocutaneous, 3232, 3233*f*
post–kala-azar dermal, 3228, 3228*t*, 3233, 3234*f*, 3235
visceral, 3232–3233
viscerotropic, 3233
diagnosis
culture, 3235
histology, 3234–3235, 3235*f*
impression smear, 3234
molecular analysis, 3235
Montenegro skin test, 3235
techniques with limited value, 3235
visceral leishmaniasis, 3235
differential diagnosis, 3235, 3236*t*
epidemiology, 3223–3225
cutaneous, 3224, 3224*f*
HIV coinfection, 3225, 3226*f*
mucocutaneous, 3224
visceral, 3224, 3225*f*
etiology, 3225–3227
insect vector, 3226*t*, 3227
parasite and life cycle, 3225, 3226*t*, 3227*f*
reservoir host, 3225–3226, 3226*t*
pathogenesis
host-related factors, 3228
parasite-related factors, 3227–3228
prevention, 3237–3238
treatment, 3235–3237
choice, 3236, 3236*t*
local therapy, 3236, 3236*t*
systemic therapy, 3236, 3237*t*
vaccine, 3237–3238
Leishmaniasis recidivans, 3231
Leishmanid, 3233–3234
Leishmanin, 3235
Leishmanization, 3237–3238
LEKTI, 210*f*, 215
atopic dermatitis, 369
kallikrein binding, 210*f*, 215
Nagashima-type palmoplantar keratoderma, 828
Netherton syndrome, 793
trichorrhexis invaginata, 1542
LEKTI-2, Nagashima-type palmoplantar keratoderma, 828
LEMD3 (MAN1), Buschke-Ollendorff syndrome, 1242

Lennert lymphoma, granuloma annulare from, 567
Lentigines
  agminated, 1967–1970, 1969*f*, 1970*t*
  laser therapy for, 3850–3851, 3853*t*
  partial unilateral, 1967–1970, 1969*f*, 1970*t*
  PUVA, 1970, 1971*f*
  unilateral, 1967–1970, 1969*f*, 1970*t*
Lentiginosis, 1967–1970. *See also* Lentigo simplex
Lentiginous mosaicism, 1967–1970, 1969*f*, 1970*t*
Lentigo maligna (LM), 1985–1986
  cryosurgery for, 3795
Lentigo maligna melanoma (LMM), 1984*f*, 1985–1986. *See also* Melanoma
Lentigo senilis. *See* Solar lentigo
Lentigo simplex, 1967–1970
  at-a-glance, 1967*b*–1968*b*
  clinical features
    clinical features, 1969
    cutaneous, 1968, 1968*f*–1969f
    related physical findings, 1969
  clinical presentation, 1970
  diagnosis, 1969
  differential diagnosis, 1970*t*
  epidemiology, 1968
  etiology and pathogenesis, 1969
  prevention, 1970
  treatment, 1970
Lentinula edodes, flagellate mushroom dermatitis, 1372
Leonine facies, leprosy, 2897, 2898*f*
LEOPARD syndrome, 1359, 1360*f*
  lentigo simplex, 1968
Lepidoptera, 3334, 3334*f*
Lepidopterism, 3334
Lepra reactions, 2914, 2914*t*
Lepromatous leprosy. *See also* Leprosy
  CD1a-restricted T-cell responses, 149
  clinical features, 2896–2897, 2896*f*–2898*f*
    histoid Wade, 2897, 2898*f*
    infiltration, 2897, 2898*f*
    Lucio leprosy, 2897
  histopathology, 2907, 2910*f*
    histoid Wade, 2907, 2910*f*
Leprosy, 2892–2919
  at-a-glance, 2892*b*
  clinical course and prognosis, 2914–2916, 2914*t*, 2915*f*
    erythema nodosum leprosum, 2914–2915, 2914*t*, 2915*f*
    with HIV/HTLV, immune reconstitution inflammatory syndrome, 2915–2916
    lepra reactions, 2914, 2914*t*
    Lucio phenomenon, 2915, 2915*f*
    reversal reaction, 2914, 2915*f*, 2915*t*
  clinical features, 2896–2901
    anesthesia, lesion, 2898
    blood capillary dilation, 2899
    borderline-borderline, 2897–2898, 2899*f*
    borderline-lepromatous, 2899, 2899*f*
    borderline-tuberculoid, 2897, 2898*f*
    clinical spectrum, 2896, 2896*f*
    complications, 2900–2901, 2901*f*
    cutaneous, 2896–2900, 2896*f*–2899*f*
    fixed claws and bone resorption, 2901, 2901*f*
    granulomas, infectious, 27
    granulysin, 151
    indeterminate leprosy, 2896, 2896*f*
    infantile nodular leprosy, 2896, 2897*f*
    iodine-starch or alizarin red sweating assessment, 2899
    leonine facies, 2897, 2898*f*
    lepromatous leprosy, 2896–2897, 2896*f*, 2897*f*–2898*f*
      histoid Wade, 2897, 2898*f*
      infiltration, 2897, 2898*f*
      Lucio leprosy, 2897
    noncutaneous, 2900, 2900*f*
    pain sensitivity testing, 2899
    paresthesia, 2898–2899
    plasma cells, 149
    tactile sensitivity testing, 2899–2900
    thermal testing, 2899
    tuberculoid leprosy, 2896, 2896*f*, 2897*f*
    ulcers, hands and feet, 2901, 2901*f*
  definition, 2892, 2893
  diagnosis, 2905–2913
    algorithm, 2913*f*
    electroneuromyography, 2911
    histopathology, 2906–2911, 2907*f*–2912*f*
      borderline-borderline leprosy, 2907, 2909*f*
      borderline-lepromatous leprosy, 2907, 2909*f*
      borderline-tuberculoid leprosy, 2907, 2908*f*
      erythema nodosum leprosum, 2909–2910, 2912*f*
      globi (rafts), 2907, 2911*f*
      indeterminate leprosy, 2907, 2907*f*
      lepromatous leprosy, 2907, 2910*f*
      lepromatous leprosy, histoid Wade, 2907, 2910*f*
      Lucio phenomenon, 2910–2911
      reversal reactions, 2908–2909, 2911*f*
      tuberculoid leprosy, 2907, 2908*f*
    imaging, 2911
    laboratory testing, 2905–2906, 2906*f*
  differential diagnosis, 2914*t*
  epidemiology, 2893–2896, 2894*f*–2895*f*
    in children <15 yr, 2893, 2895*f*
    new cases
      detection rates, 2893, 2894*f*
      with grade 2 disability at diagnosis, 2893, 2895*f*
    prevalence, global, 2893, 2894*f*
  genome conservation, worldwide, 2893
  historical perspectives, 2892–2893
  immunology, 2904–2905, 2905*f*
  management, 2916–2919
    counseling, 2918
    medications, 2916–2918, 2916*f*, 2917*t*
    prevention/screening, 2918, 2919*f*
    procedures, 2918
    treatment algorithm, 2919*f*
  pathophysiology, 2903–2905, 2903*f*, 2905*f*
  primary neural, 2900
  risk factors, 2901–2902
Leptin, 2503
Leptospira interrogans, 2829*t*, 2849–2850
Leptospirosis, 2829*t*, 2849–2851
Leptotrombidium, 3319
Leptotrombidium deliense, 3319
Lesbian, gay, bisexual, and transgender (LGBT) person care, 1792–1796
  approaches to care, 1796–1797
  at-a-glance, 1792*b*
  definition, 1792
  men who have sex with men, 1793–1794, 1794*t*–1795*t*
  terminology and demographics, 1792–1793, 1793*t*
  transgender persons, 1794–1796
    fundamentals, 1794
    transgender men, 1795–1796
    transgender women, 1796
  women who have sex with women, 1794
Leser-Trélat sign, 2442*t*, 2449–2451, 2460*f*
Lesinurad, for gout, 2316
Lesions, skin. *See also specific types and disorders*
  benign, in elderly, 1784–1785, 1784*f*–1785*f*
  pathology, 18–39 (*See also* Pathology, skin lesions)
Lethal functional epidermolysis bullosa, 1016*f*, 1018
Letterer-Siwe disease, Langerhans cell histiocytosis, 2020, 2020*t*
Leukemia
  congenital, 1744
  erythema nodosum from, 1256
  neurofibromatoses, 2474
Leukemia cutis, 2462
  Sweet syndrome with, 593
Leukocyte adhesion deficiencies, 2412*b*
Leukocytes
  cutaneous trafficking, chemokines, 179
  inflammation and wound healing, 2702
  recruitment, multistep model, 179–180, 180*f*
  skin, 192
Leukocytic vasculitis, angiocentric pattern, 26
Leukocytoclastic vasculitis, nail changes, 1588
Leukoderma acquisitum centrifugum, 1952–1953, 1952*f*
Leukokeratosis nicotinica palati, 1714
Leukonychia
  apparent, 1568, 1569*t*, 1570*f*
  cytotoxic agents, 3483
  diffuse, 1568, 1570*f*
Leukonychia punctata, 1568, 1569*f*
Leukopigmentary nevus, 1952–1953, 1952*f*
Leukoplakia, 1876–1878, 1877*f*, 1878*t*
Leukotriene inhibitors. *See also specific types*
  erythema nodosum from, 1256
Leuprolide, for acne vulgaris, 1406
Leuprolide acetate, for hirsutism, 1561, 1562*t*
Levamisole, 1710, 1710*f*
  for erythema multiforme, 730
Levamisole-induced necrosis syndrome (LINES), 1710, 1710*f*
Levator anguli oris muscle, 3703, 3704*f*
Levator labii superioris muscle, 3703, 3704*f*
Levator superioris alaeque nasi muscle, 3703, 3704*f*
Levels of evidence, 44
Levocetirizine. *See also* Antihistamines, H_1
  dosing regimens, 3454–3455, 3455*t*
Levofloxacin. *See also* Fluoroquinolones
  for chlamydia, 3217*t*
  for *P. aeruginosa*, nail, 1593
  for skin and soft-tissue infections, dosing, 3410*t*
LGBT person care, 1792–1796. *See also* Lesbian, gay, bisexual, and transgender (LGBT) person care
Libman-Sacks endocarditis, systemic lupus erythematosus, 2427
Lice, 3278–3284
  body, 3282–3283, 3282*t*
  crab, 3281*t*, 3283–3284, 3283*f*–3284*f*, 3284*t*
  fomite, 3278
  head, 3279–3282 (*See also* Pediculosis capitis)
  nit, 3280, 3280*f*
  species, 3278
Lichen amyloidoses, 2262*t*, 2263, 2264*f*
  of auricular concha hyperpigmentation of the bowl of the area, 2264
Lichen aureus, 2591*t*, 2592, 2592*f*
Lichenification, 6, 7*f*
Lichen nitidus, 554–558
  actinic, 555–556
  at-a-glance, 554*b*
  clinical features, 5*f*, 554–556, 555*f*–556*f*, 555*t*
  differential diagnosis, 557*t*
  epidemiology, 554
  etiology and pathogenesis, 554
  vs. lichen planus, 555*t*
  pathology, 556–557, 557*f*

prognosis, 557
rare forms, 556*t*
treatment, 558, 558*t*
Lichenoid contact dermatitis, 538
allergic, 396*t*, 397
Lichenoid dermatitis, 539
pathology, 25, 25f
Lichenoid discoid lupus erythematosus, 1048
Lichenoid eruptions, drug-induced, 25, 754–756
Lichenoid graft-versus-host disease, 539
Lichenoid keratosis, 539
Lichenoid variant of paraneoplastic pemphigus, 937
Lichen planopilaris (LPP), 531*t*, 533–534, 1527–1528, 1527*f*
clinical course and prognosis, 543
Graham-Little-Epicardial-Lasseur syndrome, 1527–1528, 1527*f*
management, 546–547
skin-directed therapies, 546
systemic, 544, 546–547
pathology, 541–542
scalp, 532, 533, 533*f*
thyroid dysfunction with, 540, 541
Lichen planus, 527–547
at-a-glance, 527*b*
clinical course and prognosis, 543
clinical features, 529–539
clinical variants, configuration
annular, 530, 531*f*, 531*t*
linear, Blaschkoid, and zosteriform, 530–531, 531*f*, 531*t*
clinical variants, morphology
actinic, 531*t*, 532–533
atrophic, 531, 531*t*
erosive and ulcerative, 532, 532*f*
follicular, 531*t*, 532
hypertrophic, 531, 531*t*, 532*f*
pigmentosus, 531*t*, 532, 533*f*
vesiculobullous, 531–532, 532*f*
clinical variants, site of involvement, 533–536
inverse lichen planus, 536
mucosal lichen planus, 531*f*, 531*t*, 534–535, 534*f*, 535*f*
nails, 531*t*, 535–536, 536*f*
palmoplantar, 531*t*, 532*f*, 536, 536*f*
scalp, 533–534, 533*f*
clinical variants, special forms, 536–539
drug-induced, 531*t*, 536–538, 537*f*, 537*t*, 754, 755*t*
keratosis lichenoides chronica, 539
lichenoid dermatitis, 539
lichenoid graft-versus-host disease, 539
lichenoid keratosis, 539
lichen planus–lupus erythematosus overlap, 531*t*, 538, 538*f*
lichen planus pemphigoides, 531*t*, 538–539, 538*f*
cutaneous, 529–530, 529*f*–530*f*
erythronychia, 1568
interface/lichenoid changes, 25, 25f
Koebner phenomenon, 530, 530*f*
malignant transformation, 540, 540*f*
onycholysis, 1572, 1573*f*
diagnosis, 540–543
clinical, 540
supportive studies, 540–543
laboratory testing, 540–541, 541*t*
pathology, 541–543, 541*f*–542*f*
differential diagnosis, 543, 543*t*
epidemiology, 529
HHV-7, 3009
historical perspective, 527
vs. lichen nitidus, 555*t*
pathogenesis, 527–529
antigen recognition, 527–528
genetic and epigenetic regulations, 529
keratinocyte apoptosis, 528
lymphocyte activation, 528
resolution, 528–529
related findings, 539–540, 539*t*
treatment, 543–547
frontal fibrosing alopecia, 547
lichen planopilaris, 546–547
nail lichen planus, 547
phototherapy, 3652
PUVA, 3672
treatment, cutaneous lichen planus, 543–545
phototherapy, 3652
skin-directed therapies
calcineurin inhibitors, topical, 543–544
corticosteroids, intralesional, 544
corticosteroids, topical, 543
phototherapy, 544
systemic therapies
acitretin, 544
antimalarials, 544
corticosteroids, 544
cyclosporine, 545
fundamentals, 544
methotrexate, 544
metronidazole, 544
mycophenolate mofetil and azathioprine, 544–545
other, 545
sulfasalazine, 544
treatment, oral lichen planus
skin-directed therapies
calcineurin inhibitors, topical, 545
corticosteroids, intralesional, 545
corticosteroids, topical, 545
retinoids, 545
systemic therapies
antimalarials, 546
corticosteroids, oral, 545–546
cyclosporine, 546
mycophenolate mofetil, 546
other, 546
retinoids, oral, 546
Lichen planus follicularis tumidus, 532
Lichen planus–like eruptions, drug-induced, 754–755, 755*t*
Lichen planus–lupus erythematosus overlap, 531*t*, 538, 538*f*
Lichen planus of nails, 531*t*, 535–536, 536*f*, 1584–1586, 1585*f*
Lichen planus of the scalp, 533–534, 533*f*
Lichen planus pemphigoides, 531*t*, 538–539, 538*f*, 945
Lichen planus pigmentosus, 531*t*, 532, 533*f*, 1385–1386, 1385*f*
Lichen planus pigmentosus inversus, 536
Lichen purpurus (aureus), 2591*t*, 2592, 2592*f*
Lichen ruber planus, vasculature changes, 125
Lichen sclerosus (LS), 1116–1122
at-a-glance, 1116*b*
clinical course and prognosis, 1120–1121
clinical features, 1117–1119
definition, 1116
diagnosis, 1119–1120, 1120*f*, 1121*t*
differential diagnosis, 1120, 1120*f*, 1121*t*
epidemiology, 1116–1117
etiology and pathogenesis, 1119
management, 1121–1122
adjunctive, 1122
extragenital, 1122
maintenance, 1122
male genital, 1122
phototherapy and systemic, 1121–1122
topical, 1121
morphea, overlying, 1106, 1107*f*
prevention, 1122
Lichen sclerosus et atrophicus
lichen planus and, 540
Lyme disease, 3292
Lichen scrofulosorum, 2868–2869, 2869*t*
Lichen simplex chronicus (LSC), 388–392
clinical features, 7*f*, 389–390, 389*f*
complications, 390–391
differential diagnosis, 390*t*
epidemiology, 388
etiology and pathogenesis, 388–389
laboratory tests, 390
prognosis and clinical course, 391
special tests, 390
treatment, 391–392, 391*f*
Lichen striatus, 558–561, 1802–1804, 1803*f*
at-a-glance, 558*b*, 1802*b*
Blaschko lines, 1803, 1803*f*
clinical features, 5*f*, 559, 559*f*–560*f*, 1803
differential diagnosis, 560, 561*t*, 1804
etiology and pathogenesis, 559, 1803
histopathology, 1804
historical perspective, 559
pathology, 559, 560*f*
prognosis and treatment, 560–561
treatment, 1804
Lichtheimia, 2984, 2985*f*
Licochalcone, for seborrheic dermatitis, 435–436
Lidocaine, 3611, 3710*t*
for adamantiades–Behçet disease, 2574, 2574*t*
for cryosurgery, 3793
pediatric, 1761
for rosacea, flushing and transient erythema pain, 1439
for rosacea, persistent erythema pain, 1438
for sea urchin injury, 3351
for tumescent local anesthesia liposuction, 3907, 3908*t*
for venomous fish spines, 3358
Lidocaine hydrochloride (L-M-X), 3712
Lidocaine with epinephrine
cryosurgery, 3793
for sea urchin injury, 3351
for venomous fish spines, 3358
Lifetime prevalence, 45
Light, natural and spontaneously emitted, 3820
Light, visible, 3820
radiation, cutaneous responses, 284
Light-based therapy. *See also* Intense pulsed light (IPL); *specific types*
at-a-glance, 3820*b*
historical perspective, 3820
nonablative, 3846–3854
at-a-glance, 3846*b*
definition and applications, 3846
devices, intense pulsed light, 3846, 3847–3848
historical perspective, 3846
perioperative considerations
anesthesia, 3847
patient selection, 3846–3847
perioperative care, 3847
risks and potential complications, 3847
safety, 3847
for port-wine stains, 3849
skin cooling, 3830–3831, 3830*t*, 3848
Lightening agents, 1379*t*
Lignin peroxidase, for skin pigmentation, 3812
Lilac color, 8*t*
Limb girdle muscular dystrophy, epidermolysis bullosa simplex with, 65*t*
Limb–mammary syndrome, 2378, 2381–2382
Lincosamides. *See* Clindamycin
Lindane, 3614–3615, 3615t
for lice, 3281*t*, 3284
pediatric toxicity, 1761*t*

Linea nigra, 1765, 1766*f*
Linear and whorled nevoid hypermelanosis, 1351
Linear chronic lupus erythematosus, 1048
Linear configuration, 10
Linear epidermal nevi. *See* Keratinocytic epidermal nevus
Linear epidermolytic hyperkeratosis type, Blaschko's lines mosaicism, 302
Linear ichthyosiform erythroderma, 796
Linear immunoglobulin A (linear IgA) dermatosis, 761*t*, 992–999
  at-a-glance, 992*b*
  clinical features, 6*f*
    cutaneous, 994–996, 995*f*–996*f*
    disease associations, 996–997
    mucosal, 995
  definition and overview, 992
  diagnosis
    direct immunofluorescence, 992, 993*f*
    histopathology, 997–998, 997*f*
  differential diagnosis, 998, 998*t*
  drug-induced, 752, 753
    vs. classical, 992, 993*t*
  epidemiology, 992–993
  etiology and pathogenesis, 993–994, 993*t*, 994*t*
  treatment and prognosis, 994*t*, 998–999, 998*t*
Linear immunoglobulin A disease
  blistering, subepidermal, 25
  drug-induced, 753
Linear lichen planus, 530–531, 531*f*, 531*t*
Linear morphea, 1107–1108, 1107*t*, 1109*f*
Linear porokeratosis, 903, 903*f*, 906*t*
Linear psoriasis, 464
Linear verrucous epidermal nevi. *See* Keratinocytic epidermal nevus
Linezolid
  for actinomycosis, 2880
  adverse effects, 2890
  for group A *Streptococcus* lymphangitis, 2739, 2739*t*
  for MRSA skin and soft tissue infections, complicated, 2731*t*, 2732
  for *N. brasiliensis* actinomycetoma, 2889–2890
  for nocardiosis, 2884
  for staphylococcal furuncles, carbuncles, and abscesses, 2731*t*, 2732
  systemic, 3418
Linoleic acid, 2203, 3806
Lion's mane, 3344, 3345*f*–3346*f*
LIPE, lipodystrophy, 1299
Lipedema, tumescent local anesthesia liposuction for, 3909–3910, 3909*f*
Lipemia retinalis, with diabetes mellitus, 2497
Lipid(s)
  metabolism, 2278–2281, 2279*f*
  sebaceous gland, 73, 74, 74*f*
Lipid bodies, eosinophil, 256
Lipid disorders. *See* Lipoprotein disorders
Lipid droplets (LDs), sebaceous glands, 70, 72*f*
Lipid lamellae, 207, 209, 210*f*, 211*f*, 212*f*
  intercorneocyte formation, 208*t*, 211–212, 214*f*
Lipid-lowering agents. *See also specific types*
  interstitial granulomatous drug reaction from, 1149
Lipid mediators
  eosinophils, 651f, 655, 657
  mast cell granules, 154, 154*t*
Lipoblastoma/lipoblastomatosis, 2176–2178, 2177*f*
Lipodermatosclerosis, 1252*t*, 1262–1264, 1262*f*–1263*f*, 1264*t*
  in elderly, 1788
Lipodystrophy, 1295–1305
  acquired, 1299–1302
    generalized, 1297*f*, 1301
    localized, 1302
    partial, 1297*f*, 1300, 1300*f*
  at-a-glance, 1295*b*
  classification, 1295, 1296*t*
  clinical course and prognosis, 1304
  diagnosis, 1302–1304
    cutaneous, 1302–1303, 1303*f*
    history, 1302
    laboratory testing, 1303–1304
    special tests and imaging, 1304
  differential diagnosis, 1304
  Dunnigan type, 1295, 1296*t*, 1297, 1297*f*, 1303*f*, 1304
  epidemiology, 1295
  genetic, 1295–1299, 1296*t*
    congenital generalized, 1296–1297, 1297*f*, 1298*t*
    familial partial, 1295, 1297–1298, 1297*f*
    mandibuloacral dysplasia-associated, 1295, 1298–1299
    other types, 1299
  management, 1304–1305
  syndromes, 55
    highly active retroviral therapy-induced lipodystrophy in HIV-infected patients, 1297*f*, 1301, 1302*f*, 3111, 3112, 3113*f*
Lipofuscin, chromhidrosis, 1471
Lipogenic neoplasms, 2172–2194
  angiolipoma, 2178–2179, 2178*f*–2179*f*
  at-a-glance, 2172*b*
  atypical lipomatous tumor, 2186–2188, 2186*f*–2188*f*
  chondroid lipoma, 2182–2183, 2183*f*
  dedifferentiated liposarcoma, 2188–2191, 2189*f*–2190*f*
  hibernoma, 2185–2186, 2185*f*
  lipoblastoma/lipoblastomatosis, 2176–2178, 2177*f*
  lipoma, 2172–2174
  lipomatosis, 2174–2175
    of nerve, 2175, 2175*f*
  myolipoma, 2184–2185, 2184*f*
  myxoid liposarcoma, 2191–2192, 2192*f*
  nevus lipomatosis superficialis, 2176, 2176*f*
  pleomorphic lipoma, 2179–2182, 2181*f*
  pleomorphic liposarcoma, 2193–2194, 2193*f*–2194*f*
  spindle-cell lipoma, 2179–2182, 2180*f*–2182*f*
  well-differentiated liposarcoma, 2186–2188
Lipoglycopeptides, systemic, 3418. *See also* Dalbavancin, systemic; Oritavancin, systemic; Telavancin
Lipohypertrophy, from antiretroviral therapy, 3111, 3113*f*
Lipoid proteinosis (LP), 1242–1247
  at-a-glance, 1242*b*–1243*b*
  clinical features
    cutaneous lesions, 1243–1244, 1244*f*
    patient approach, 1243, 1243*f*
    physical findings, related, 1244–1245, 1245*f*
  diagnosis
    CT, brain, 1246
    histopathology, 1246
    laboratory investigation, 1245–1246, 1246*f*
  differential diagnosis, 1246*t*
  epidemiology, 1243
  etiology and pathogenesis, 1245
  prevention, 1247
  prognosis and clinical course, 1246–1247
  treatment, 1247
Lipoleiomyosarcoma, 2187
Lipoma, 2172–2174
  adenolipoma, 2173
  chondrolipoma, 2173, 2173*f*
  intradermal, 2173, 2174*f*
  intramuscular, 2173, 2174*f*
  mitochondrial DNA mutations, 300
Lipomatosis, 2174–2175
  of nerve, 2175, 2175*f*
Liponyssoides sanguineus, 3309*t*, 3315. *See also* Rickettsialpox
Lipopolysaccharidoses (MPS), hypertrichosis, 1564
Lipoprotein disorders, 2273–2289. *See also* Xanthoma(s); *specific types*
  at-a-glance, 2273*b*
  definition, 2273
  diagnosis, 2283–2285
    imaging, 2285
    pathology, 2282*f*, 2284–2285
    supportive studies and laboratory testing, 2283–2284
  epidemiology, 2274
  etiology and pathogenesis
    primary, 2281–2282
    secondary, 2282–2283
  Fredrickson-Levy-Lees dyslipidemias, 2288*t*
  historical perspective, 2273–2274
  lipoprotein synthesis, 2279*f*, 2280–2281
  management, 2285–2289
    counseling and screening, 2288–2289
    lifestyle interventions, 2285–2286
    medications, 2286–2287
    procedures, 2417–2418, 2418*t*
  pathogenesis, lipid metabolism, 2278–2281, 2279*f*
Lipoprotein lipase (LPL), 2280
Lipoprotein receptor-related protein (LRP) receptor, 2280
Liposomes
  definition, 3376
  transdermal delivery systems, 3376
Liposuction
  on cellulite, 3867
  tumescent, 3863
  tumescent local anesthesia, 3906–3910
    anesthesia, 3907, 3908*t*
    at-a-glance, 3906*b*
    breast reduction, 3909
    complications, 3908
    equipment, 3906, 3907*f*
    lipedema, 3909–3910, 3909*f*
    monitoring and follow-up, 3908–3909
    outcomes assessment, 3908, 3908*f*
    patient positioning, 3906
    patient selection, 3906
    preoperative evaluation, 3906, 3907*t*
    risks and precautions, 3906, 3907*t*
    technique, 3907–3908
Liquid cryosurgery, 1670, 1670*f*
Liquid ecstasy, 1711
Liquid nitrogen
  cryodestruction, 1670, 1670*f*
  cryogen, 3791, 3792*t*
  cryosurgery, for actinic keratosis, 1864, 1864*t*, 1866
Liquid topical drugs, 3373*t*, 3375–3376. *See also specific types*
  foams, 3373*t*, 3375–3376
  shake lotions, 3373*t*, 3375
  solutions, 3373*t*, 3375
  suspensions, 3373*t*, 3375
Liquid X, 1711
Lisch nodules, neurofibromatoses, 2469, 2469*f*
Listeriosis *(Listeria monocytogenes)*, 2829*t*, 2840–2841
Lithium
  psoriasis exacerbation by, 479
  for seborrheic dermatitis, 435
Live attenuated Oka VZV zoster vaccines (ZVL), for herpes zoster, 3056–3057
Livedoid vasculopathy, 2530*t*, 2532–2533, 2532*f*
  nail changes, 1588, 1588*f*

Livedo racemosa, 10*f*, 2682–2684, 2682*t*
antiphospholipid antibody syndrome, 2684
at-a-glance, 2682*b*
clinical features, 2682–2683, 2682*t*, 2683*f*
diagnosis, 2683–2684
differential diagnosis, 2684, 2684*t*
epidemiology, 2682
etiology and pathogenesis, 2683
management, 2684
Livedo reticularis, 2682–2684, 2682*t*
at-a-glance, 2682*b*
clinical features, 2682–2683, 2682*t*, 2683*f*
diagnosis, 2683–2684
differential diagnosis, 2684, 2684*t*
epidemiology, 2682
etiology and pathogenesis, 2683
management, 2684
polyarteritis nodosa, 2553, 2554*f*
Liver spot. *See* Solar lentigo
Liver transplantation
for acute hepatic porphyrias, 2252
for protoporphyric hepatopathy, 2249
Liver X receptors (LXRs), sebaceous glands, 76*t*, 77
Living skin equivalent, for diabetic ulcers, 2498–2499
LMNA
familial partial lipodystrophy, 1297
lipodystrophy, 1295, 1299
mandibuloacral dysplasia-associated lipodystrophy, 1295, 1299
L-M-X (lidocaine hydrochloride), 3712
LMXB1, nail-patella syndrome, 1601
Lobo disease, 2967*t*, 2972–2973
Lobomycosis, 2967*t*, 2972–2973
Lobular capillary hemangioma. *See* Pyogenic granuloma (PG)
Lobular panniculitis, 29–30
Localized autosomal dominant dystrophic epidermolysis bullosa, 1021, 1021*f*, 1029*t*
Localized distribution, 12
Localized epidermolysis bullosa simplex, 1016, 1016*f*, 1029*t*
Localized hypertrophic neuropathy, 2161
Localized junctional epidermolysis bullosa, 1019, 1029*t*
Localized lipodystrophy, 1302
Localized recessive dystrophic epidermolysis bullosa, 1020, 1021–1023, 1022*f*–1023*f*, 1029*t*
Localized scleroderma cutaneous assessment tool (LoSCAT), 1112
Localized scleroderma damage index (LoSD), 1112
Localized scleroderma severity index (LoSSI), 1112
Localized type, 777*t*
Locus heterogeneity, 295
Loeffler syndrome, 3260–3261
Loeys-Dietz syndrome, 1200
Logistic regression, 45
Loiasis *(Loa loa)*, 3252*t*, 3259, 3268, 3268*f*
edema, localized, 3259
exposure and symptom onset interval, 3259, 3260*t*
eyelid swelling, 3262
management, 3265*t*
migration, through eye, 3261
migratory skin lesions, 3255*t*, 3256*f*
ocular disease, 3261
progression and duration, 3259, 3260*t*
subcutaneous nodules and masses, 3257, 3257*t*
urticaria and pruritus, 3258–3259, 3258*t*
Lomitapide, for hypercholesterolemia, 2287
Lone Star tick, 3308*f*, 3309*t*, 3310*t*, 3320, 3329
Longitudinal grooves, nail, 1575, 1576*f*
Longitudinal melanonychia (LM), 1372, 1605–1606, 1606*f*–1607*f*
differential diagnosis, 1606*t*
Loose anagen syndrome (LAS), 1547, 1547*t*, 1551*t*
Lopinavir/ritonavir boosting, 3508, 3509*t*
LOR
loricrin keratoderma, 824
progressive symmetric erythrokeratoderma, 777*t*
Loratadine. *See also* Antihistamines, H_1
dosing regimens, 3454–3455, 3455*t*
for mastocytosis, 719, 719*t*
for pruritus, in lichen nitidus, 558, 558*t*
Loricrin keratoderma (LK), 824–825, 824*f*, 845*t*
Loricrin, 64, 211
defects, 208*t*, 211
Losartan
for epidermolysis bullosa, 2743
for Marfan syndrome, 1229
for Raynaud phenomena, 2621*t*, 2622
Lotions, 3373*t*, 3375. *See also specific types*
shake, 3373*t*, 3375
Louis-Bar syndrome, 2407–2409, 2407*f*–2408*f*
Low-density lipoprotein (LDL), 2273–2274
epidemiology, 2274
synthesis and metabolism, 2280–2281
Low-fat diet, for lipodystrophy, 1304
Low-molecular-weight heparin (LMWH)
for lymphatic anomalies, 2657
for Raynaud phenomena, 2623
for venous anomalies, 2652
Loxosceles, 3326–3327, 3326*f*–3327*f*
Loxosceles arizonica, 3327
Loxosceles deserta, 3326–3327
Loxosceles kaiba, 3327
Loxosceles reclusa, 3326–3327, 3326*f*–3327*f*
Loxosceles rufescens, 3326–3327
LPIN2, Majeed syndrome, 622*t*, 623
L-plasty, 3735, 3735*f*
LR1G1, epidermal basal cells, 62
LRP1, keratosis pilaris atrophicans, 871
LSD, 1711
L-selectin, 180, 180*f*
eosinophils, 656
inflammation, acute *vs.* chronic, 125
LST, Hermansky-Pudlak syndrome, 1316*t*
Lucio phenomenon, leprosy. *See also* Leprosy
clinical course and prognosis, 2915, 2915*f*
clinical features, 2897, 2915, 2915*f*
histopathology, 2910–2911
Luliconazole, 3444
for tinea cruris, corporis, and pedis, 3444
LUMBAR syndrome, 2045, 2048, 2048*f*
Lumbosacral midline, neonatal assessment, 1735, 1736*f*
Luminous transmittance, 3631
Lund & Browder chart, 1685, 1685*f*
Lungs, tuberous sclerosis complex, 2485
Lunula, 107, 107*f*
Lupoid rosacea, 1424. *See also* Rosacea
Lupoid sycosis, 2723
Lupus, cutaneous, B cells, 149
Lupus band test, nonlesional, 1052
Lupus erythematosus (LE), 1037–1058. *See also* Systemic lupus erythematosus (SLE)
acute cutaneous, 1038, 1038*t*
at-a-glance, 1037*b*
bullous, subepidermal blistering, 25
chronic cutaneous, 1038, 1038*t*
classification, 1037–1038, 1038*t*–1039*t*
clinical course and prognosis, 1052–1053
acute, 1052
chronic, 1053
outcome measures, 1053
subacute, 1052
clinical features, 5*f*, 1041–1048
acute, 1041–1042, 1041*f*
bullous, 5*f*
chronic, 1044–1048
chilblain lupus erythematosus, 1047–1048, 1047*f*
classic discoid lupus erythematosus, 1044–1045, 1044*f*–1046*f*
hypertrophic discoid lupus erythematosus, 1046
lupus erythematosus profundus/lupus erythematosus panniculitis, 1047, 1047*f*
lupus erythematosus tumidus, 1048, 1048*f*
mucosal discoid lupus erythematosus, 1046–1047
other variants, 1048
lupus erythematosus nonspecific skin disease, 1048
nail changes, 1587–1588, 1587*f*
noncutaneous, 1040*t*, 1048
subacute, 1042–1044, 1043*f*
cutaneous, 1038, 1038*t*
definition and overview, 1037
dermatitis herpetiformis, 1004
diagnosis, 1048–1052
approach, 1049*f*
histopathology
acute, 1050–1051, 1050*f*
chronic, 1050*f*, 1051
general findings, 1050
subacute, 1050*f*, 1051
immunohistology, 1051–1052
acute, 1051
chronic, 1052
general findings, 1051
subacute, 1052
laboratory testing, 1048–1050
differential diagnosis, 1052, 1053*t*
drug-induced, 752*t*, 756, 1041, 1041*t*
epidemiology, 1038–1039
etiology and pathogenesis, 1040–1041
environmental factors, 1040–1041
immunologic factors, 1040
interface/lichenoid changes, 25
management, 1053–1058
general principles, 1054–1055
initial, 1053–1054, 1054*t*
Law of Lupus, 1054*t*
local therapy
calcineurin inhibitors, topical, 1055
glucocorticoids, intralesional, 1055
glucocorticoids, topical, 1055
sun protection, 1055
surgical and cosmetic therapy, 1058
systemic therapy
antimalarial-refractory, immunosuppressive, 1057–1058
antimalarial-refractory, nonimmunosuppressive, 1056–1057
antimalarials, 1055–1056
therapeutic options, 1054*t*
treatment algorithm, 1058
nomenclature and classifications, 1037–1038, 1038*t*–1040*t*
overview, 1040*t*
perieccrine inflammation, 26
perivascular lymphocytic infiltrates, 27
prevention, 1058
photoprotection, 3632, 3632*t*
subacute cutaneous, 1038, 1038*t*
drug-induced, 752*t*, 756
tobacco use on, 1714
UV radiation on, 271
Lupus erythematosus edematous, 1048
Lupus erythematosus hypertrophicus et profundus, 1046, 1048
Lupus erythematosus panniculitis. *See* Lupus panniculitis
Lupus erythematosus profundus, 1047, 1047*f*
Lupus erythematosus telangiectaticus, 1048
Lupus erythematosus tumidus, 1048, 1048*f*
Lupus erythematosus vermiculatus, 1048

Lupus panniculitis, 1047, 1047*f*, 1253*t*, 1272–1275
  at-a-glance, 1272*b*
  clinical course and prognosis, 1274
  clinical features, 1273, 1273*f*
  diagnosis, 1274
  differential diagnosis, 1274, 1274*t*
  epidemiology, 1272–1273
  etiology and pathogenesis, 1273–1274
  management, 1275
Lupus pernio, sarcoidosis, 573–574, 574*f*–575*f*
Lupus planus, 1046
Lupus profundus, 1253*t*, 1272–1275. *See also* Lupus panniculitis
Lupus verrucosus, 2863–2864, 2864*f*, 2864*t*
Lupus vulgaris (LV), 2858, 2864–2866, 2865*f*–2866*f*, 2865*t*
Luteinizing hormone (LH), neonatal acne, 1448
LXRs, sebaceous glands, 76*t*, 77
Lycopene, oral photoprotection, 3630
Lymantria dispar, 3334
Lyme borreliosis, 3287–3301
  at-a-glance, 3287*b*
  clinical features, 3288–3295
    complications, 3295
  clinical features, cutaneous
    early, erythema migrans, 767–769, 3288–3290, 3289*f*–3291*f*, 3290*t*, 3294*t*
    late, 3290–3293, 3294*t*
      acrodermatitis chronica atrophicans, 3290–3292, 3291*f*, 3294*t*
      cutaneous atrophoborrelioses, 3292, 3294*t*
      cutaneous lymphoborrelioses, 3292–3293, 3292*f*–3293*f*, 3294*t*
      cutaneous scleroborrelioses, 3292, 3294*t*
      other lesions, 3293, 3294*t*
  clinical features, noncutaneous, 3293–3295, 3294*t*
    cardiac, 3294
    in children, 3295
    musculoskeletal, 3294–3295, 3294*t*
    nervous system, 3293, 3294*t*
    ophthalmic, 3295
    other, 3295
    perinatal, 3295
  diagnosis, 3296–3297
    approach, 3298*f*
    direct detection, *B. burgdorferi*, 3296–3297
    serologic, 3297
  differential diagnosis, 3298, 3299*t*
  epidemiology, 3287–3288, 3288*f*
  historical perspective, 3287
  management, 3298–3299, 3300*t*
  pathogenesis, 3295–3296
  prevention, 3299–3301
  risk factors, 3295
  vaccine, 3301
Lyme disease. *See* Lyme borreliosis
Lymphadenosis benigna cutis solitaria, *Borrelia*, 3293
Lymphangiectasia, 2697
Lymphangioma circumscriptum. *See* Lymphatic anomalies
Lymphangitic distribution, 11
Lymphatic anomalies, 2637*t*, 2653–2658. *See also* Vascular malformations; *specific types*
  at-a-glance, 2653*b*
  classification, 2653
  clinical course and prognosis, 2657
  clinical features
    complications, 2654*f*, 2655, 2656*f*
    cutaneous, 2638*f*, 2653–2654, 2654*f*–2655*f*
    noncutaneous, 2655
  diagnosis, 2645*f*, 2657
  differential diagnosis, 2657*t*
  epidemiology, 2653
  etiology and pathogenesis, 2655–2657
    genetic, 2640*t*
  management, 2657–2658, 2658*f*
  syndromic disorders
    CLOVES syndrome, 2653–2654, 2653*f*
    generalized lymphatic anomaly, 2654
    Gorham-Stout syndrome, 2654
    Klippel-Trenaunay syndrome, 2653
Lymphatic filariasis, 3268, 3268*f*
Lymphatics, facial, 3703, 3704*f*
Lymphedema, 2693–2697, 2693*b*
  at-a-glance, 2693*b*
  congenital, lymphatic anomalies, 2655
  definition, 2693
  localized areas, 2697
  lymphatic anomalies, 2655
  primary, 2693–2695, 2693*f*
    Emberger syndrome, 2694
    epidemiology, 2693–2694
    lymphedema-distichiasis, 2694–2695
    Milroy syndrome, 2655, 2694
  secondary, 2693, 2695–2697
    clinical course and prognosis, 2696
    clinical features, 2693, 2694*f*, 2695, 2695*t*
    diagnosis, 2695–2696
    differential diagnosis, 2696, 2696*t*
    epidemiology, 2693, 2695
    management, 2696–2697, 2696*t*
  verrucous skin changes, 2694*f*
Lymphedema-distichiasis, 2694–2695
Lymph nodes
  head and neck, 3705
  nodal nevi, 1966–1967, 1967*t*
Lymphadenosis cutis, 2110*t*, 2111–2112, 2112*f*
Lymphoborrelioses, cutaneous, 3292–3293, 3292*f*–3293*f*, 3294*t*
Lymphocyte(s)
  benign intravascular proliferation, 2125–2126, 2126*f*
  beryllium lymphocyte proliferation test, 451
  infiltrates
    benign, 3293
    disorders with, 2117–2118, 2122–2125
    drug-related, 2115*f*, 2118
    inflammatory reactions, 26–27
  innate, 134
  psoriasis, 466–468, 469*f*, 470*f*
Lymphocyte infiltration of the skin (LIS), Jessner-Kanof, 2122
Lymphocytic hypereosinophilic syndromes, 660–665. *See also* Hypereosinophilic syndromes (HES)
Lymphocytic primary cicatricial alopecias, 1526–1529, 1526*f*–1528*f*, 1526*t*
  alopecia mucinosa, 1529
  central centrifugal cicatricial alopecia, 1528, 1528*f*
  chronic cutaneous lupus erythematosus, 1526–1527, 1526*f*
  frontal fibrosing alopecia, 1527–1528, 1527*f*
  keratosis follicularis spinulosa decalvans, 869*t*, 870, 872–873, 873*f*, 1529
  lichen planopilaris, 1527–1528, 1527*f*
  pseudopelade of Brocq, classic, 1528
Lymphocytoma, borrelial, 3292–3293, 3292*f*–3293*f*
Lymphocytoma cutis, 2110*t*, 2111–2112, 2112*f*
  nodular lymphocytic infiltrates, 27
Lymphoepithelial Kazal-type-related inhibitor. *See* LEKTI
Lymphogranuloma venereum, 3193–3198
  at-a-glance, 3193*b*
  Chlamydia trachomatis, 3193–3194, 3196–3197
  clinical course and prognosis, 3198
  clinical features, 3194–3196
    extragenital-anal inoculation, 3196
    ocular autoinoculation, 3196
    oropharyngeal infection, 3196
    primary stage, 3194, 3194*f*
    secondary stage, 3194–3195, 3195*f*
    tertiary stage, 3195–3196
  complications, 3198
  diagnosis
    histopathologic examination, 3197
    laboratory tests, 3196–3197
    procedures, 3197
  differential diagnosis, 3197–3198, 3197*t*, 3198*f*
  epidemiology, 3193
  etiology and pathogenesis, 3193–3194
  prevention, 3198–3199
  treatment, 3198, 3198*t*
Lymphoid hyperplasia, nodular lymphoid collections, 26
Lymphoma
  body cavity–based, 172
  cutaneous, 2072–2102 (*See also* Cutaneous lymphoma)
    with HIV, 3121
  dermatitis herpetiformis, 2459
  erythema nodosum from, 1256
  management, in Sjögren syndrome, 1181
  from PUVA, 3645
Lymphoma cutis, 5*f*, 2462
Lymphomatoid allergic contact dermatitis, 396*t*, 397
Lymphomatoid contact dermatitis (LCD), 2118–2119, 2118*f*
Lymphomatoid drug reaction, 2118*f*, 2119
Lymphomatoid granulomatosis, Epstein-Barr virus, 3001
Lymphomatoid papulosis, 505, 2084–2085, 2084*f*–2085*f*
  management
    photochemotherapy, 3672
    phototherapy, 3652
  nodular lymphocytic infiltrates, 27
  pityriasis lichenoides and, 513
Lymphoplasmacytic plaque (LPP), 2123–2124, 2123*f*–2124*f*
Lymphopoietin, thymic stromal, eosinophils and, 653
Lymphoproliferative disorders. *See also* *specific types*
  eosinophils, 659
Lymphotoxin α (LT-α), 168
Lymphotoxin β (LT-β), 168
Lymph vessels, 50
Lynch syndrome, 1849, 2344
Lyonization, 297
Lysergic acid diethylamide (LSD, acid), 1711
LYST, Chédiak-Higashi syndrome, 1318–1319, 2415–2417
Lysyl oxidase, collagen crosslinking, 2221
Lytta vesicatoria, 3331

M

M1 macrophages, 153, 153*t*
M2 macrophages, 153, 153*t*
Macaques, herpesvirus simiae (B virus), 3341
Mackerel, scombroid fish poisoning, 3359
Macrocephaly–capillary malformation (M-CM), 2639
Macroconidia, 2926*t*
Macrofibrils, 94
Macroglossia, 2261, 2261*f*
Macrolides, systemic, 3415–3416. *See also* *specific types*
  dosing regimen, 3410*t*, 3416
  indications and contraindications, 3415, 3415*t*, 3416*t*
  pharmacology and mechanism of action, 3410*t*, 3415
  side effects and precautions, 3412*t*, 3416
Macronutrients, 2200–2204, 2226–2228

essential fatty acids, 2203–2204, 2204*t*
protein-energy malnutrition, 2200–2203
Macrophage(s), 134
graft-versus-host disease, 2322
inflammation and wound healing, 2701*f*, 2702, 2702*f*
non-Langerhans cell histiocytosis
alternative activated (Mϕ2), 2029, 2030
classically activated (Mϕ1), 2029–2030
psoriasis, 479
resident skin, 117
Macrophage activation syndrome (MAS), juvenile idiopathic arthritis, 1154
Macrophage chemoattractant protein-1 (CCL2), in wound healing, 2708
Macrophage migration inhibitory factor, erythema nodosum, 1256
MACS/RIN2 syndrome, 1237*t*, 1239–1240
Macular amyloidoses, 2262–2263, 2262*t*, 2263*f*
Macular reaction pattern, 14*t*, 15
Macule, 4, 4*f*, 4*t*
Maculopapular eruptions
drug-induced, 749
maculopapular rash of SLE (*See* Acute cutaneous lupus erythematosus (ACLE))
Madelung disease
alcohol abuse, 1713
lipomatosis, 2174
Madura foot, 2966*t*, 2969–2971, 2969*f*–2970*f*, 2970*t*
Madurella mycetomatis, 2966*t*, 2969–2971
Maduromycosis, 2966*t*, 2969–2971, 2969*f*–2970*f*, 2970*t*
Maffucci syndrome, 2446*t*, 2646–2653, 2647f. *See also* Venous anomalies
venous anomalies, 2647, 2647*f*
Majeed syndrome, 643–644
Majocchi granuloma, 2944, 2945*f*
Majocchi purpura, 2590, 2591*t*, 2592*f*
Major basic protein (MBP)-1, 651*f*, 652, 654
Major basic protein (MBP)-2, 651*f*, 652, 654
Major histocompatibility complex (MHC)
class I molecules, 134, 303
superantigens, 2761–2762, 2761*f*
class II molecules, 303
genes, psoriasis, 471, 471*f*, 477–478, 477*f*
Malabsorption, gut, 2433–2434
Malalignment of great toenail, congenital, 1592*f*, 1602
surgery for, 3789–3790, 3789*f*
Malaria, 3241–3242, 3242*f*
Malar rash, lupus erythematosus, 1038, 1039*t*, 1041, 1042*f*
Malassezia, 2959–2963
at-a-glance, 2959*b*
benign neonatal cephalic pustulosis, 1732, 1733*f*
blepharitis, seborrheic dermatitis, 428
clinical course and prognosis, 2962–2963
clinical features, 2959–2960, 2960*f*–2961*f*
diagnosis, 2960–2962, 2962*f*
differential diagnosis, 2962, 2962*t*
etiology and pathogenesis, 2960
folliculitis
in elderly, 1787
with HIV, 3116
seborrheic dermatitis, 428, 432, 433
with HIV, 3116
management, 2963, 2963*t*
microbiome, skin, 258, 259*f*
risk factors, 2960
seborrheic dermatitis, 432–433
Malassezia furfur, atopic dermatitis, 367
Malassezia globosa, MGL_1304 from, in cholinergic urticaria, 690, 692
Malassezia sympodialis
atopic dermatitis, 367
irritant dermatitis, 421, 421*f*
neonatal acne, 1448
Malathion, 3615, 3615*t*
for lice, 3281, 3281*t*, 3284
Mal de Meleda, 781*t*, 825–827, 826*f*, 845*t*
keratoderma, 781*t*
Mal de pinto, 3173–3177
Male-lethal type Bloch-Sulzberger syndrome. *See* Incontinentia pigmenti (IP)
Male pattern androgenetic alopecia, Hamilton-Norwood type, 1496, 1496*f*–1497*f*
Malignancy
vs. benignancy, skin tumors, 30
dermatomyositis, 1071
from topical therapy, 3377, 3378
Malignant atrophic papulosis (Degos disease), 2630–2634
approach, 2631*f*
at-a-glance, 2630*b*
clinical features, 2630–2632
cutaneous and ocular lesions, 2631–2632, 2631*f*–2632*f*
benign Degos, 2632
classic Degos, 2632
Degos disease–like lesions (secondary Degos), 2632
history, 2630–2631
complications, 2633
diagnosis, 2633
differential diagnosis, 2633, 2633*t*
epidemiology, 2630
etiology and pathogenesis, 2630
laboratory tests
histopathology, 2632–2633, 2632*f*–2633*f*
other, 2633
prognosis and clinical course, 2633–2634
treatment, 2634, 2634*t*
Malignant nerve sheath tumors, 2163–2164, 2163*f*
Malignant nerve tumors, 2163–2164, 2163*f*
Malignant peripheral nerve sheath tumor (MPNST), 2147*t*–2148*t*, 2150*t*, 2163–2164, 2163*f*
neurofibromatoses, 2474
Malignant schwannoma, 2163–2164, 2163*f*
Malignant skin lesions, in elderly, 1785–1786
Malignant transformation, 2342
Malignant tumors of nerve, 2163–2164, 2163*f*
malignant nerve sheath tumors, 2163–2164, 2163*f*
Mallorca acne, 1453, 1621, 1623*f*
Malnutrition
protein-energy, 2200–2203 (*See also* Protein-energy malnutrition (PEM))
telogen effluvium from, 1509, 1509*f*
MAML2
hidradenocarcinoma, 1828
hidradenoma, 1823
Mammalian target of rapamycin (mTOR) inhibitors, 3527–3529. *See also specific types*
dosing regimen, 3528
drug interactions, 3528
on eosinophils, 658
everolimus, 2456, 2489, 3527–3529, 3594
indications and contraindications, 3528
mechanism of action, 3527, 3527*f*
monitoring, therapeutic, 3528
pharmacology, 3528
side effects and precautions, 3528–3529, 3528*t*
sirolimus, 3599–3600 (*See also* Sirolimus (rapamycin))
on squamous cell carcinoma risk, posttransplantation, 1905
temsirolimus, 3601
for tuberous sclerosis complex, 2489–2490
Mammalian tolloid, 1013
Mammary Paget's disease (MPD), 1934–1941
clinical course and prognosis, 1938–1939
clinical features, 1934–1935, 1935*f*
definition, 2004
diagnosis, 1936–1937
differential diagnosis, 1936*t*
epidemiology, 1934
etiology and pathogenesis, 1935–1936
historical perspective, 1934
immunohistochemistry markers, 1937–1938, 1938*t*
management, 1939–1940, 1939*f*
Mandibular hypoplasia, deafness, progeroid features-associated lipodystrophy, 1299
Mandibular nerve, 3702*f*, 3703, 3703*t*
marginal, 3699–3702, 3700*t*
Mandibuloacral dysplasia-associated lipodystrophy (MAD), 1295, 1298–1299
Manganese, 2223
Manhattan plot, 301
Manifestation threshold, 443
Mansonella ozzardi
exposure and symptom onset interval, 3259, 3260*t*
progression and duration, 3259, 3260*t*
urticaria and pruritus, 3258–3259, 3258*t*
Mansonella perstans, 3252*t*, 3268–3269
exposure and symptom onset interval, 3259, 3260*t*
eyelid swelling, 3262
hypo- or hyperpigmentation, 3259
progression and duration, 3259, 3260*t*
subcutaneous nodules and masses, 3257, 3257*t*
urticaria and pruritus, 3258–3259, 3258*t*
Mansonella streptocerca, 3252*t*, 3268–3269
exposure and symptom onset interval, 3259, 3260*t*
hypo- or hyperpigmentation, 3259
management, 3265*t*
progression and duration, 3259, 3260*t*
urticaria and pruritus, 3258–3259, 3258*t*
Mansonelliasis, 3252*t*, 3268–3269
exposure and symptom onset interval, 3259, 3260*t*
hypo- or hyperpigmentation, 3259
lichenification, 3259
progression and duration, 3259, 3260*t*
urticaria and pruritus, 3258–3259, 3258*t*
Manual dermabrasion, 3903, 3903*t*, 3904*f*
MAP2K1 (MEK)
arteriovenous malformations, extracranial, 2640*t*, 2662
cardiofaciocutaneous syndrome, 871
Langerhans cell histiocytosis, 2021, 2022*f*
MAP2K2, cardiofaciocutaneous syndrome, 871
MAP3K3, verrucous venous malformation, 2640*t*, 2650
MAPK, 3558, 3560*f*
MAPK inhibitors, 3580–3585. *See also* Mitogen-activated protein kinase (MAPK) inhibitors
MAPK pathway, 3580, 3581*f*, 3586
pemphigus, 917
Marasmic kwashiorkor, 2200
Marasmus, 2199*b*, 2200–2203, 2201*f*, 2201*t*. *See also* Protein-energy malnutrition (PEM)
Maraviroc, 3506
Marfanoid habitus, 1225–1226, 1225*f*
Marfan syndrome, 1225–1229
at-a-glance, 1225*b*
clinical features, 1225–1226, 1225*f*
differential diagnosis, 1227, 1228*t*–1229*t*
epidemiology, 1225
etiology and pathogenesis, 1226–1227
laboratory investigation, 1227
neonatal, 1226

Marfan syndrome (*Cont.*):
pediatric patients, 1226
treatment, 1227–1229
Marginal mandibular nerve, 3699, 3700*t*, 3701
Marginal zone lymphoma
extranodal, 2097, 2097*t*, 2099–2100, 2099*t*
primary cutaneous, 2097, 2097*t*, 2099–2100, 2099*t*
vs. cutaneous B-cell pseudolymphoma, 2110, 2111*t*
radiotherapy for, 3695
Margins, free, 3699
Marie-Unna hereditary hypotrichosis (MUHH), 1544–1545, 1545*t*, 1550*t*
Marijuana, 1711–1712
Marimastat, for arteriovenous malformations, 2663
Marine-based necrotizing soft-tissue infections, 2776–2777, 2776*t*
Marine dermatitis, 3354, 3354*f*, 3354*t*, 3355*t*
Marine worms, 3352–3355
bristleworm dermatitis, 3352–3353, 3352*f*
cercarial dermatitis, 3252*t*, 3253–3254, 3265*t*, 3269–3271, 3270*f*
leech bites, 3353
sea bather's eruption, 3354, 3354*f*, 3354*t*, 3355*t*
Marjolin ulcer, 320–321
Marseille fever. *See* Mediterranean spotted fever (MSF)
Marshall syndrome, 1241
Mary Jane, 1711–1712
Mask of pregnancy, 2515–2516, 2515*f*
Mas-related GPCRs (Mrgprs), pruritus, 355–356
Massaging, on skin absorption, 3371–3372
Masseter muscle, 3703
Mast cell activation disorder, 717
Mast cell activators, 695
Mast cell disorders
differential diagnosis, 716–717, 718*t*
hypermelanosis, 1364
Mast cell leukemia (MCL), 711*t*, 712
Mast cell mediators, mastocytosis, 712*t*, 713
Mast cells, 133–134, 153–154, 710
phototherapy on, 3638
secretory granules, 153–154, 154*t*
skin, 117
type I hypersensitivity, 691, 691*f*
urticaria, 684
Mastocytosis, 710–720
at-a-glance, 710*b*
clinical features, 711–715
classification, 711–712, 711*t*, 712*f*, 712*t*
cutaneous lesions, 712–713, 712*f*–714*f*
Darier sign, 684
diarrhea and malabsorption, 714
exercise, heat, and local trauma on, 714
mast cell mediator–related symptoms, 712*t*, 713
musculoskeletal pain and skeletal lesions, 715
neuropsychiatric, 715
pregnancy, 715
skin and GI symptoms, 713–714
splenomegaly, 714–715
cutaneous, 711, 711*t*
neonatal, 1744
diagnostic algorithm, 716, 717*f*
differential diagnosis, 716–717, 718*t*
epidemiology, 710
laboratory tests, 712*t*, 715–716, 715*f*, 716*f*
pathogenesis, 710–711, 711*t*
prognosis, 717–718
treatment, 718–720, 718*t*, 719*t*
cutaneous, 718–720, 718*t*
PUVA, 3672
noncutaneous, 718–720, 719*t*
phototherapy, indolent systemic disease, 3652–3653
Matchbox sign, 1694
Matrical differentiation neoplasms, 1839*t*
pilomatrical carcinoma, 1844–1845
pilomatricoma, 1822*t*, 1843–1844, 1844*f*
Matricectomy, 3784–3785, 3784*f*
Matriptase, 214
congenital defects, 215
Matrix, nail, 107–108, 108*f*, 3774, 3775*f*
Matrix lentigo, melanonychia, 1606, 1607*f*
Matrix melanoma, pigmented, 1606, 1607*f*
Matrix metalloproteinase (MMP), in wound healing, 2703, 2704–2705, 2706*t*
Matrix metalloproteinase (MMP)-3
relapsing polychondritis, 1189
wound healing, 2703–2705, 2706*t*
Matrix metalloproteinase (MMP)-8, relapsing polychondritis, 1189
Matrix metalloproteinase (MMP)-9, relapsing polychondritis, 1189
Matrix nevus, melanonychia, 1606, 1607*f*
Maturational dyschromia, 1363, 1363*f*
Maxillary nerve, 3702*f*, 3703, 3703*t*
Mayaro virus (MAYV), 3136*t*, 3142–3143
MBTPS2
ichthyosis follicularis, alopecia, and photophobia syndrome, 806, 873*t*
Olmsted syndrome, 829
MC1R, 15–17, 342*f*–344*f*, 2503
melanoma, 343–344
melanomagenesis, 343–344
signaling, 342–343, 342*f*–343*f*
UV-induced tanning, 343, 344*f*
MC1R, 344
genetic counseling, 305
MC3R, 2503–2504
MC4R, 2503
MCC-HI, Merkel cell carcinoma, 1925, 1925*f*
MCC-LO, Merkel cell carcinoma, 1925, 1925*f*
McCune-Albright syndrome, 1361
Blaschko's lines mosaicism, 302
MCP-1, breast cancer, 184
MCR-1, ephelides, 1377
MDM2
atypical lipomatous tumor, 2174
dedifferentiated liposarcoma, 2190, 2190*f*
lipoma, 2174
pleomorphic liposarcoma, 2193
MDMA (ecstasy), 1711
MDMA, atypical lipomatous tumors, 2182, 2187
Measles, 2989–2992, 2990*f*, 3015*t*
at-a-glance, 2989*b*
clinical course and prognosis, 2991
clinical features, 2990
diagnosis, 2990–2991
differential diagnosis, 2991*t*
epidemiology, 2989*b*
etiology and pathogenesis, 2989
Koplik spots, 2990, 2990*f*
management, 2991, 2991*t*
prevention, 2989, 2991–2992
Measles immunoglobulin, for measles postexposure prophylaxis, 2991
Measles mumps rubella and varicella (MMR and varicella) vaccine, 2994
Measles mumps rubella (MMR) vaccine, 2992, 2994
Mebendazole, for enterobiasis, 3265*t*, 3267
MECA-79, acute *vs.* chronic inflammation, 124*f*, 125
Mechanical exposure, occupational, 446–447
Mechanical resurfacing procedures, 3903–3904, 3903*t*, 3904*f*
manual dermabrasion, 3903, 3903*t*, 3904*f*
microdermabrasion, 3903
motorized dermabrasion, 3903–3904, 3903*t*, 3904*f*
Mechanical stress protection, skin, 224
Mechanical urticaria, 686*f*, 688–689, 688*t*, 697. *See also* Urticaria
diagnosis, 688*t*, 697
MECT1, hidradenoma, 1823
MECT1-MAML2 fusion
hidradenocarcinoma, 1828
hidradenoma, 1822
Mediterranean recluse spider, 3326–3327
Mediterranean spotted fever (MSF), 3314–3315
clinical and laboratory findings, 3314, 3317*f*
diagnosis and differential diagnosis, 3315, 3315*t*, 3316*t*
epidemiology and vectors, 3309*t*, 3314
etiology and pathogenesis, 3306
treatment and prognosis, 3309*t*, 3315, 3316*t*
Medulla, hair follicle, 93*f*, 94, 94*t*
Mees lines, cytotoxic agents, 3483
MEFV, familial Mediterranean fever, 622*t*, 631
Megalopyge opercularis, 3334, 3334*f*
Meglumine antimoniate, for leishmaniasis, 3236, 3237*t*
Meibomian glands, 70. *See also* Sebaceous glands
Meissner corpuscles, 351–352
in elderly, 1784
MEK
Langerhans cell histiocytosis activation, 2021, 2022*f*
neurofibromatosis, 2471
MEK, melanoma, target therapies, 2007–2009, 2008*f*
MEK inhibitors, for melanoma, 3580, 3586
Melanin, 336–342, 3811
structure and function, 336–337
eumelanin, 336
pheomelanin, 336–337
synthesis, 337–342
eumelanogenesis, 337, 338*f*
melanosome, 337
biogenesis and trafficking, 338–339, 339*f*
structure, 337–338
trafficking and degradation, 341–342
transfer to keratinocytes, 340, 340*f*–341*f*
tyrosinase, 337
TYRP1, 337–339, 338*f*
TYRP2/dopachrome tautomerase, 337
tanning, 272–273
Melanoacanthoma, 1801
Melanocortin 1 receptor (MC1R), 2503–2504
Melanocortin 3 receptor (MC3R), 2503–2504
Melanocortin 4 receptor (MC4R), 2503
Melanocyte keratinocyte transplantation, for vitiligo, 1343–1345, 1344*f*
Melanocytes, 30, 328–345, 3811
anatomy, 268*f*, 328
at-a-glance, 328*b*
development, 49
differentiation, 56
distribution, 330–332
acral, 332
epidermal melanin unit, 330–331
extracutaneous, 332
follicular, 331
interfollicular, 330
epidermis, 19, 20
formation, migration, and survival, 332–336, 333–336
c-Kit, 335
Ednrb, 335
FoxD3, 334*f*, 335
growth signaling, 335–336
melanocyte motility and migration, Rac1, 336
MITF, 333–334, 334*f*

neuregulin/ErbB2/ErbB3, 336
PAX3, 334*f*, 335
SOX2, 334*f*
SOX10, 334*f*, 335
transcription factors, 333–335
Wnt/β-catenin, 335–336
hair
development, 98, 99*f*, 100*f*
hair cycle–dependent changes, 100, 100*f*
pigment-producing, 99–100
stem cells, 98–99
histology, 328–330
melanin, 336–342 (*See also* Melanin)
neural crest differentiation and migration, 332–333, 333*f*
numbers, 328
phototherapy on, 3638–3639
regulators and mutations, 266*t*, 328
stem cells, 331
ultrastructure, 330, 331*f*
Melanocyte type 1 receptor (MC-1R), 101
Melanocytic bridging, dysplastic nevi, 34, 34*f*
Melanocytic nevi, 1944–1977
blue nevus, 1957–1961 (*See also* Blue nevus)
congenital, 1944–1949
definition, 1944
dysplastic, 1944, 1973–1977 (*See also* Dysplastic melanocytic nevi)
fundamentals, 1944
lentigo simplex, 1967–1970 (*See also* Lentigo simplex)
melanoma from, 1990
nevus spilus, 1949–1951, 1949*f*, 1950*t*
nodal nevi, 1966–1967, 1967*t*
pathogenesis, 1944
pathology
common, 34, 34*f*
dysplastic, 34, 34*f*
Spitz, 34–35, 35*f*
pigmented spindle cell nevus, 1961–1963, 1962*f*–1963*f*, 1963*t*
pregnancy changes, 1765
solar lentigo, 1970–1973 (*See also* Solar lentigo)
Spitz nevus, 35, 358*f*, 1963–1966
Melanocytic nevi, common acquired, 1951–1957
at-a-glance, 1951*b*
balloon cell nevus, 1955
clinical course and prognosis, 1956–1957
clinical features, 1951–1953
complications, 1953
cutaneous, 1951–1953, 1952*f*
related physical conditions, 1953
combined nevus, 1955
compound type, 1954, 1955*f*
dermal type, 1954–1955, 1955*f*
diagnosis, 1954–1956
pathology, 1954–1956, 1954*f*–1955*f*
special tests, 1956
differential diagnosis, 1956*t*
epidemiology, 1951
etiology and pathogenesis, 1953–1954
junctional type, 1954, 1955*f*
prevention and counseling, 1957
recurrent melanocytic nevus, 1955
risk factors, 1953
treatment, 1957
Melanocytosis, neonatal, 1733
Melanoma, 1982–2000
acral, 332
at-a-glance, 1982*b*
clinical course, 1996–1998
AJCC classification, 1997–1998, 1997*t*, 1998*t*
metastatic melanoma of unknown primary, 1997
stage I and II, 1996
stage III, 1996, 1996*f*, 1997*t*
stage IV, 1996–1997, 1996*f*
TNM classifications, 1996, 1997*t*
clinical features, 1983–1989
complications, 1988–1989
clinical features, cutaneous, 1983–1988
acral lentiginous melanoma, 1984*f*–1985*f*, 1986
desmoplastic melanoma, 1985*f*, 1986
hypermelanosis, 1364
lentigo maligna, 1985–1986
lentigo maligna melanoma, 1984*f*, 1985–1986
mucosal melanoma, 1986–1988, 1987*f*
nevoid melanoma, 1988
nodular melanoma, 1983–1985, 1984*f*
spitzoid melanoma, 1988
subungual melanoma, 1985*f*, 1986, 1986*t*
superficial spreading melanoma, 1983, 1984*f*–1985*f*
clinical features, noncutaneous, 1988
uveal melanomas, 1988
definition, 1982
diagnosis, 1991–1995
algorithm, 1995*f*
dermoscopy, 1992, 1992*t*
early detection, 1991
histology, 1985*f*, 1992–1994, 1993*f*
laboratory testing, 1994
physical examination and ABCDE checklist, 1992, 1992*t*
regional skin and lymph node ultrasound, 1994
sentinel lymph node biopsy, 1994–1995, 2000–2001
tomography, 1994
diagnostic algorithm, 1995*f*
differential diagnosis, 1995*t*
epidemiology, 1982–1983, 1983*f*
etiology and pathogenesis, 1989–1991
CDKN2A-CDK4-TP53 pathway mutations, 1990–1991, 1991*f*
chemokine secretion, 184
DNA hypermethylation, 304
family history, 1990
MC1R, 343–344
melanocytic nevi, 1990
pathology, 35
PUVA, 3644
skin phenotype, 1990
sun damage, 278
sun exposure, 1989–1990
telomere maintenance gene mutations, 1991
follow-up, 2011
growth phases
radial, 35
vertical, 35
historical perspective, 1982
with HIV, 3121
MECA-79, 125
mitochondrial DNA mutations, 300
mortality, 310
pathology, 35–36, 35*f*
desmoplastic vertical growth phase, 36
malignant, 35, 35*f*
nodular, 35
radial growth phase, 35
superficial spreading, 35
vertical growth phase, 35–36
desmoplastic, 36
pathophysiology, 3580, 3581*f*
prevention, 2011
sunscreen, 3628
prognostic factors, 1998–2000
distant metastases, 2000
gender and age, 1998
primary melanoma
angiolymphatic invasion, 1999
microscopic satellites, 1997*t*, 1998*t*, 1999
mitotic rate, 1997*t*, 1998*t*, 1999
tumor infiltrating lymphocytes, 1984*f*, 1999
tumor thickness, 1998
ulceration, 1997*t*, 1998–1999
regional metastases, 1999
regression, 1984*f*, 2004
screening, 2011
ungual, 1606–1608, 1607*f*–1608*f*, 1608*t*
Melanoma in situ, 35
Melanoma management, 2000–2011
adjuvant, 2001–2002
immune checkpoint blockers, 2001–2002
interferon-α, 2001
radiotherapy, 2002
AKT inhibitors, 3586
future directions, 2000*t*, 2009–2011, 2010*t*
local hepatic therapy, for uveal melanoma with liver metastases, 2004
MEK inhibitors, 3580, 3586
radiotherapy, 3693*t*, 3694
satellite or in-transit metastases, 2002–2004
electrochemotherapy, 2002–2003
IL-2, intralesional, 2002, 2003*f*
isolated limb perfusion, 2004
talimogene laherparepvec, 2002
surgical
Mohs micrographic surgery, 3767–3768
primary melanoma, 2000
regional metastases, 2000–2001
macroscopic nodal disease, 2001
microscopic nodal disease, 2000–2001
treatment algorithm, 2010*f*
unresectable metastatic disease, 2004–2009
immunotherapies, 2004–2007
adoptive T-cell therapy, 2006
fundamentals, 1984*f*, 2004–2005
IL-2, high dose, 2007
immune checkpoint blockade, 2005–2006, 2005*f*, 2006*t*, 2007*f*
surgery and radiotherapy, 2004
targeted therapies, 2007–2009
BRAF/MEK inhibitions, 2007–2009, 2008*f*
chemotherapies, 2009
c-KIT inhibition, 2009
fundamentals, 2007
Melanonychia, 1569–1570, 1569*t*, 1572*f*, 1605–1608
benign, 1605–1606, 1606*f*–1607*f*
ungual melanoma, 1606–1608, 1607*f*–1608*f*, 1608*t*
Melanophilin (Mlph), 340, 340*f*
Melanosis, oral, tobacco use, 1714
Melanosis perioralis et peribuccalis, 1383
Melanosome, 337
biogenesis and trafficking, 338–339, 339*f*
structure, 337–338
trafficking and degradation, within keratinocyte, 341–342
transfer to keratinocytes, 340, 340*f*–341*f*
Melanotic macule, 1967–1970. *See also* Lentigo simplex
Melanotic schwannoma, 2155–2157
Melarsoprol, for African trypanosomiasis, 3239–3240, 3239*t*
Melasma, 1379–1381, 1380*f*, 1765, 1766*f*, 2515–2516, 2515*f*
Melatonin, for sarcoidosis, 581*t*
Meleney gangrene, 2772
Melioidosis, 2829*t*, 2844–2846
Melkerson-Rosenthal syndrome, rosacea, 1451
Melphalan
reticulate scleroderma from, 3486
for scleromyxedema, 1168
for systemic amyloids, 2269

Meltzer triad, 2602
Memory T cells, 117, 180–181
  central, 147, 148*f*, 2072
    cutaneous T-cell lymphomas, 2072, 2073, 2074
  effector, 147, 148*f*
    cutaneous T-cell lymphomas, 2072, 2073, 2074
  long-term residence, 117
  migratory, 2072, 2074
    cutaneous T-cell lymphomas, 2072, 2074
  recirculating, 147
  resident, 147, 148*f*
MEN1, hyperparathyroidism, 2509
Mendelian disorders, 295–297, 295*t*–297*t*, 296*f*–297*f*. *See also specific types*
Meningeal hamartoma, 2166–2167, 2167*f*
Meningeal heterotopia, 2166–2167, 2167*f*
Meningitis
  cryptococcal, 3445
  gonococcal, 3209–3210
Meningitis belt, 2783
Meningocele, 1735
  acroleic, 2166–2167, 2167*f*
  rudimentary, 2166–2167, 2167*f*
Meningococcal disease. *See Neisseria meningitidis*
Meningococcal vaccines, 2788, 2788*t*
Menkes disease
  copper and, 2221–2222, 2221*b*, 2222*t*
  cutis laxa, 1234
Menkes syndrome
  ATP7A, 1540
  pili torti, 1540, 1541*t*
  trichorrhexis nodosa, 1538*t*
  X-linked recessive disorder, 297, 297*t*
Mental crease, 3698*f*, 3699
Mentalis muscle, 3703, 3704*f*
Mental nerve, 3702*f*, 3703, 3703*t*
Menthol, 3617, 3617*t*
  for pruritus, 358
Men who have sex with men (MSM), 1793–1794, 1794*t*–1795*t*
Mepivacaine, 3710*t*
  for adamantiades–Behçet disease, 2574, 2574*t*
Mepolizumab
  on eosinophils, 658
  for hypereosinophilic syndromes, 665
  for vasculitis, 2557
MER2-2 negative patients, 245
Mercaptobenzothiazole, allergic contact dermatitis from, 405
Mercury, lichenoid contact dermatitis from, 538
Merkel cell, 30
  development, 50, 56
  epidermis, 19, 20
Merkel cell carcinoma (MCC), 1920–1932
  at-a-glance, 1920*b*
  clinical course and prognosis, 1921–1922
  clinical presentation, 1921*t*
    cutaneous, 1921, 1921*t*, 1922*f*
    noncutaneous, 1921
  diagnosis, 1925–1929
    hematoxylin and eosin stain, 1925–1926
    histopathology, 1925–1926, 1925*f*
    immunohistochemical stains
      CAM5.2 antibodies, 1926, 1926*t*
      cytokeratin-7, 1926, 1926*t*
      cytokeratin-20, 1926, 1926*t*
      Merkel cell polyomavirus oncoprotein, 1926, 1926*t*
      thyroid transcription factor-1, 1926, 1926*t*
  differential diagnosis, 1921*t*
  epidemiology, 1920–1921
  etiology and pathogenesis, 1922–1925
    age >65 years, 1922–1923, 1923*f*
    in elderly, 1785
    immune suppression, 1923
    Merkel cell polyomavirus, 258, 319, 319*t*, 1923–1925, 1924*f*, 1925*f*
    risk factors, 1922–1923
    sun exposure, 1923, 1923*f*
    viral carcinogenesis, 318, 319*t*
  historical perspective, 1920
  HIV with, 3121
  management, 1929–1932
    chemotherapy, 1931–1932
    immune therapy, 1930–1931
    optimal treatment, 1931*f*, 1932
    radiation therapy, 1929–1930, 1930*f*
    surgery
      draining node bed, 1929
      primary site, 1929
  staging and prognosis, 1926–1929
    AJCC, 1926–1927, 1927*t*
    prognostic findings, histology
      CD8 infiltration, 1929
      lymphovascular invasion, 1928
      Merkel cell polymavirus oncoprotein expression, 1929
      p63, 1929
      tumor growth pattern, 1928
    radiologic imaging, 1928
    sentinel lymph node biopsy, 1927–1928, 1928*f*
  surveillance, 1932
Merkel cell polyomavirus (MCPyV), 258, 319, 319*t*, 1923–1925, 1924*f*, 1925*f*
  oncoprotein, 1926, 1926*t*
  oncoprotein expression, 1929
Merocrine glands, 70, 84
Meroisodisomy, 300
Meropenem
  for necrotizing fasciitis, 2775, 2776*t*
  for *Nocardia* actinomycetoma, 2889
Mesenchymal stem cell infusion, for graft-versus-host disease, 2333
Mesenchyme, development, 53–55
Mesoderm, 52
Messenger RNA, 292
MET, blastic plasmacytoid dendritic cell neoplasm, 2102
Meta-analysis, 44
Metabolic syndrome, 2283
  definition, 2502, 2502*t*
  lichen planus and, 540
  obesity and diabetes mellitus, 2283, 2502–2504, 2504*t*
  polycystic ovarian syndrome, 2516
Metabolism. *See also specific substances*
  defects, cutis laxa, 1240
  inborn errors of, 2234
  lipids, 2278–2281, 2279*f*
  skin, 3368–3369
    on topical therapy, 3369
Metal(s)
  allergic contact dermatitis from, 403–404
  cutaneous pseudolymphoma from, 2117, 2117*f*
  fragments, burning, 443*t*
Metalloproteinase-2, Sweet syndrome, 595
Metalloproteinase-9, Sweet syndrome, 595
Metaphyseal chondrodysplasia, McKusick type, 2402*b*
Metastases. *See also specific types*
  chemokines, 184–185, 185*f*
  cutaneous, 2460–2462, 2461*f* (*See also specific cancers*)
Metastatic calcification (calcinosis), 2308*t*, 2310–2311, 2310*f*, 2509
  chronic renal failure and calciphylaxis, 2310–2311, 2310*f*, 2509–2510, 2511*f*
  hypervitaminosis D, 2311
  milk–alkali syndrome, 2311
  tumoral calcinosis, 2311
Metastatic melanoma of unknown primary (MUP), 1997
Metformin
  for acanthosis nigricans, 2496
  for hidradenitis suppurativa, 1490
  for hirsutism, 1562*t*
Meth, 1711
Methamphetamine, 1711
Methemoglobinemia, from dapsone, 3427, 3427*t*, 3428
Methicillin-resistant *Staphylococcus aureus* (MRSA), 2720. *See also* Community-acquired methicillin-resistant *Staphylococcus aureus* (CA-MRSA); Hospital-acquired methicillin-resistant *Staphylococcus aureus* (HA-MRSA)
  atopic dermatitis, 366–367, 376
  cellulitis and erysipelas, 2746
  diagnosis, 2728, 2729*f*
  in elderly, 1787
  with HIV, 3117
  nasal carriers, preoperative prophylaxis, 3707
  nummular eczema, 386
Methotrexate (MTX), 3463–3469
  for actinic dermatitis prevention, 1643
  for adamantiades–Behçet disease, 2576*t*
  for atopic dermatitis, 379–380
  for Blau syndrome/early-onset sarcoidosis, 641
  for bullous pemphigoid, 952, 952*t*
  chemical structure, 3465*f*
  complications
    anaphylaxis, 3468
    carcinogenicity, 3468
    GI, 3467–3468
    hematologic, 3467
    hepatic, 3468
    mucosal and cutaneous, 3468
    mutagenicity and teratogenicity, 3468
    opportunistic infections, 3468
    pulmonary, 3468
  for connective tissue disease–associated panniculitis, 1283*b*
  for cutaneous anaplastic large cell lymphoma, 2086
  cutaneous reactions, 1148 (*See also* Rheumatoid arthritis (RA))
  for dermatomyositis, 1077
  dosing regimen, 3464–3465
  drug interactions, 3469, 3469*t*
  folate and folinic acid supplementation, 3468–3469
  for graft-versus-host disease, 2332
  for hemophagocytic lymphohistiocytosis, 2032
  historical perspective, 3463
  indications, 3464
  initiating therapy, 3465–3466
  for juvenile idiopathic arthritis, 1155
  laboratory monitoring, 3466, 3466*t*
  for Langerhans cell histiocytosis, 2028
  for lichen planopilaris, 547
  for lichen planus, 544
  for lupus erythematosus, 1054*t*, 1057
  for lymphomatoid papulosis, 2084–2085
  mechanism of action, 3463–3464, 3465*f*
  monitoring therapy, 3466–3467, 3466*t*, 3467*t*
  for morphea, 1114*f*, 1115–1116, 1115*t*
  for multicentric reticulohistiocytosis, 2038
  for nummular eczema, 388
  overdose, 3469
  for pemphigus, 924
  pharmacokinetics, 3464
  photochemotherapy with, 3670
  for pigmented purpuric dermatoses, 2596
  for pityriasis lichenoides, 515, 515*t*
  for psoriasis, 484*t*, 491–492
    with HIV, 3122
  for psoriatic arthritis, 979–980, 980*t*, 1135, 1136*t*
  for pyoderma gangrenosum, 613, 614*t*
  for reactive arthritis, 1142

for relapsing polychondritis, 1190
for rheumatoid arthritis, 1152
risks and precautions, 3465, 3466*t*, 3467
for SAPHO syndrome, 1450
for Still disease, adult-onset, 1158
reactive phagocytic syndrome in, 1158
for systemic sclerosis, skin hardening in, 1101
for urticaria, 702
for vasculitis, 2557
Methyl aminolevulinic acid (MAL), photodynamic therapy, 275
Methylbenzethonium chloride, for leishmaniasis, 3236, 3236*t*
Methylchloroisothiazolinone/methylisothiazolinone (MCI/MI), allergic contact dermatitis from, 404
Methyldibromoglutaronitrile/phenoxyethanol (MDGN/PE), allergic contact dermatitis from, 404
Methylenedioxymethamphetamine (MDMA), 1711
Methyl ester 5-aminolevulinic acid (MAL), in photodynamic therapy, 3678–3681. *See also* Photodynamic therapy (PDT)
Methylisothiazolinone, contact dermatitis, 1756*f*
Methylphenidate, 1711
Methylprednisolone. *See also* Corticosteroids
for adamantiades–Behçet disease, 2575*t*
genital ulcers and skin lesions, 2575, 2575*t*
Methylprednisolone, IV pulse
for morphea, 1114*f*, 1115–1116, 1115*t*
for pemphigus, 925
for pyoderma gangrenosum, 613, 614*t*
Methylprednisolone sodium succinate, for Sweet syndrome, 601, 601*t*
Metoclopramide, for GI symptoms in Fabry disease, 2303
Metreleptin, for lipodystrophy, 1305
Metronidazole, 3612*t*, 3614
for amebiasis, 3247
for clostridial gas gangrene, 2780
for giardiasis, 3246
for lichen planus, 544
for seborrheic dermatitis, 435
for trichomoniasis, 3243
Metronidazole, systemic
for bacterial vaginosis, 3219*t*
for rosacea, 1439
Metronidazole, topical
for bacterial vaginosis, 3219*t*
for hidradenitis suppurativa, 1490
for perioral dermatitis, 1455
for rosacea, 1439
Metrophyma, rosacea, 1421*f*, 1422
Mevalonate kinase deficiency (MKD), 634–635, 635*f*
Meyerson phenomenon, 1802
Meyerson's nevus, 1953*f*
MGL_1304, in cholinergic urticaria, 690, 692
MIC2
Ewing sarcoma, 2164
primitive neuroectodermal tumor, 2164
Micaceous scale, 6*t*
Michelin tire baby syndrome, 2141, 2143
Michel medium, 19
Miconazole, 3438*t*, 3444
for candidiasis, cutaneous, 3444
for fungal infections, superficial, 2936*t*
for pitted keratolysis, 2741
for seborrheic dermatitis, 435
for tinea cruris, corporis, and pedis, 3444
Microarrays, 293
Microbial bioburden, 255
Microbiome, 254
definition, 253
immune response to, 421, 421*f*
Microbiome, skin, 253–260
at-a-glance, 253*b*
Clostridium difficile colitis, 259–260
composition, 256–259
topographic challenges, 256
studies
bacterial dermatologic disorders, 257, 257*t*
from culturing to genomics, 253–254
design, 255–256, 255*f*
genomics studies
bacterial, 256–257, 257*t*, 259*f*
fungal, 257–258, 259*f*
viral, 258–259
sequencing methods, 254–255
Microciona prolifera, 3350
Micrococcus sedentarius. *See Kytococcus sedentarius*
Microconidia, 2926*t*
Microcystic adnexal carcinoma, 1830, 1830*f*
Microdermabrasion, 3376, 3903
Microfibril-associated glycoproteins (MAGPs), 247
Microfibrils
basement membrane, 239
dermal cell-matrix adhesion, 247
Microgranules, eosinophil, 256
Micromanipulators, 3825
Microneedling
for acne vulgaris, 1411
for striae, 1197
Micronodular basal cell cardinoma, 1886
Micronutrients, 2204–2226. *See also specific types*
minerals, 2221–2226
noma, 2226–2228, 2227*f*, 2228*t*
vitamins
fat-soluble, 2204–2211, 2204*b*, 2280
water-soluble, 2211–2221
Micronychia, 1568
Microscopic polyangiitis (MPA), 2527, 2550, 2550*f*. *See also* Vasculitis
Microscopic treatment zones (MTZs), 3830, 3846
fractional photothermolysis, 3835
Microspheres, 3374
Microsponges, 3374
Microsporum, 2931, 2931*t*
Microsporum audouinii, 2931*t*
Microsporum canis, 1531, 2926, 2931*t*
Microsporum gypseum, 2926, 2931*t*
Microtubule-associated protein (MAP), 248
Mid-childhood acne, 1448
Middermal elastolysis (MDE), 1195–1197, 1196*f*
Midline nasal and facial lesions, neonatal, 1735
Midostaurin, for mastocytosis, 720
Miescher granulomas, erythema nodosum, 1257–1258
MIF, systemic sclerosis, 1093
Migalastat, for Fabry disease, 2303
Migratory memory T cells (T_{MM}), 2072, 2074
cutaneous T-cell lymphomas, 2072, 2074
Migratory skin lesions, 3255–3257, 3255*t*, 3256*f*. *See also* Helminthic infections
Mikulicz cells, *Klebsiella rhinoscleromatis* rhinoscleroma, 2808–2809
Mikulicz syndrome, sarcoid, 575
Milia, 1730–1731, 1814–1815, 1815*f*
eruptive, 1814–1815
neonatal, 1730–1731
postoperative, 3721–3722
Miliaria, 1466, 1466*f*
Miliaria crystallina, 1731–1732
Miliaria pustulosa, 1466
Miliaria rubra
infants, 1753
neonates, 1731
Miliary osteoma cutis of the face, 2313
Milk–alkali syndrome, metastatic calcification, 2311
Milker's nodule, 449–450, 3066*t*, 3081–3083, 3082*f*, 3083*t*
Millepora alcicornis, 3349–3350, 3349*f*
Millipedes, 3330
Milroy syndrome, 2655, 2694
Miltefosine, for leishmaniasis, 3237*t*
Minerals, 2221–2226. *See also specific minerals*
at-a-glance, 2221*b*
copper, 2221
Menkes disease and, 2221–2222, 2221*b*, 2222*t*
iron, 2223
deficiency, 2223, 2223*t*
excess, 2224
manganese, 2223
selenium, 2222
deficiency, 2222
excess, 2222–2223
zinc, 2221*b*, 2224
deficiency, 2221*b*, 2224–2226, 2225*f*, 2225*t*
toxicity, 2226
Miniaturized hair, 92*t*
Minimal erythema dose (MED), 3624, 3640–3641
Minimycetoma, 2886
Minocycline. *See also* Tetracyclines
for acne vulgaris, 1405
for alopecia mucinosa, 1529
blue-gray pigmentation from, with sun exposure, 1658, 1661*f*
for dissecting folliculitis, 1530
hypermelanosis from, 1365, 1367*f*
for MRSA impetigo, ecthyma, and folliculitis, 2730, 2731*t*
for nocardiosis, 2884
for pigmented purpuric dermatoses, 2596
for pityriasis lichenoides, 515, 515*t*
for prurigo pigmentosa, 1374
for pyoderma gangrenosum, 614*t*
for reticulated papillomatosis of Gougerot and Carteaud, 809
for rosacea
facial lymphedema, 1442
papules and pustules, 1439
for *S. aureus*, in folliculitis decalvans, 1529
for skin and soft-tissue infections, dosing, 3410*t*
for staphylococcal furuncles, carbuncles, and abscesses, 2731*t*, 2732
for Wells syndrome, 667
Minoxidil, topical
for alopecia areata, 1521
for androgenetic alopecia, 1504
for female pattern hair loss, 3931*b*
for frontal fibrosing alopecia, 1528
hypertrichosis from, 1565, 1565*f*
for male pattern baldness, 3931*b*
for telogen effluvium, 1514
Mipomersen, for hypercholesterolemia, 2287
miRNA, epidermis differentiation, 67
miRNA-22, cutaneous T-cell lymphomas, 2075, 2076*f*
Missense mutations, 295
Mite(s), 3329. *See also specific types*
Demodex folliculorum
periorificial dermatitis, 1455
rosacea and rhinophyma, 1420, 1420*f*, 1425*f*, 1427, 1428*f*–1429*f*, 1429, 1430, 1433*f*
Demodex folliculorum hominis, 3278, 3278*t*
harvest, 3278, 3278*t*
house dust, 3278, 3278*t*
scrub-itch, 3278, 3278*t*
Mite-bite associated spotted fevers, 3315–3318. *See also* Rickettsialpox
MITF, 332, 333–334, 334*f*, 343, 343*f*
solar lentigo, 1971
MITF
Tietz syndrome, 1323
Waardenburg syndrome, 1322*t*, 1323

Mitochondrial disorders, 300
Mitochondrial DNA mutations, 300
Mitogen-activated extracellular signal-regulated kinase (MEK). *See also* MEK
  Langerhans cell histiocytosis activation, 2021, 2022*f*
  neurofibromatosis, 2471
Mitogen-activated extracellular signal-regulated kinase (MEK) inhibitors, for melanoma, 3586
Mitogen-activated protein kinase (MAPK), 3558, 3560*f*
Mitogen-activated protein kinase (MAPK) inhibitors, 3580–3585
  at-a-glance, 3580*b*
  background, 3580–3581, 3581*f*
  cobimetinib, 3585, 3585*f*
  dabrafenib, 3582–3583, 3583*f*
  trametinib, 3584, 3584*f*
  vemurafenib, 3581–3582, 3581*f*
Mitogen-activated protein kinase (MAPK) pathway. *See* MAPK pathway
Mitotic activity, skin tumors, 30
Mixed connective tissue disease (MCTD)
  cutaneous necrotizing venulitis with, 2529
  SSc overlap syndromes, 1087, 1089*t*
Mixed hypomelanosis and hypermelanosis, 1386–1387
  dyschromatosis hereditaria universalis, 1386
  familial progressive hyperpigmentation with or without hypopigmentation, 1387
  reticulate acropigmentation of Dohi, 1387
  vagabond leukemia, 1387
Mixed morphea, 1107*t*, 1108
Mixed primary cicatricial alopecias, 1526*t*, 1530–1531
  acne keloidalis nuchae, 1530–1531, 1530*f*
  acne necrotiva, 1531
  erosive pustular dermatosis, 1531
Mixed pseudolymphoma, 2113–2114, 2113*f*, 2114*f*
Mixed tumor of the pilosebaceous–apocrine complex, 1832–1833, 1833*f*
Mixed vitiligo, 1332, 1332*f*. *See also* Vitiligo
Mizolastine. *See also* Antihistamines, H_1
  dosing, 3454–3455, 3455*t*
MK2 (MAPK activated protein kinase 2), pemphigus, 917
MLH1
  DNA mismatch repair gene, 304
  sebaceous adenomas, 1822*t*, 1849
MLPH
  Griscelli syndrome, 1317–1318
  Hermansky-Pudlak syndrome, 1316*t*
MNK, Menkes disease, 2221
Modulated exogen (provisional), 1511
Mogamulizumab (anti-CR4), 3543–3544, 3550*t*
  for cutaneous T-cell lymphomas, 2095–2096
Mohs micrographic surgery (MMS), 3761–3772
  appropriate use criteria, 3771, 3771*t*, 3772*f*
  at-a-glance, 3761*b*
  cost, 3771
  healing and reconstruction, 3769–3770, 3769*f*–3770*f*
  historical perspective, 3761
  indications, 3765–3769
    basal cell carcinoma, 1888–1889, 3765–3766, 3765*f*, 3766*t*
    dermatofibrosarcoma protuberans, 3768–3769, 3768*f*
    extramammary Paget's disease, 3769
    leiomyosarcoma, 2141
    melanoma, 3767–3768
    solid cancers, other, 3769
    squamous cell carcinoma, 3766–3767, 3767*f*
  operative technique, 3761–3765
    complete margin analysis, 3762, 3763*f*
    pre-surgery consultation, 3762
    stages, 3763–3765, 3764*f*
    standard *vs.* beveled incision, 3761–3762, 3762*f*
    surgical setting, 3762
  risks and complications, 3770–3771
  summary, 3772
Moisturizers, skin, 3806*t*, 3807
  for aging skin, 3813–3814
  ingredients, 3806*t*
  for sensitive skin, 3810
Moisturizing factors, natural
  filaggrin degradation and, 208*t*, 217
  newborn skin, 223, 224*t*
Molecular targeted therapies, 3558–3586, 3559*t*. *See also specific types*
  AKT inhibitors, for melanoma, 3586
  epidermal growth factor receptor inhibitors, 3565–3572
  histone deacetylase inhibitors, 3575–3580
  KIT, BCR-ABL, and PDGFR inhibitors, 3558–3565 (*See also* Tyrosine kinase inhibitors (TKIs), small-molecule)
  MEK inhibitors, for melanoma, 3580, 3586
  mitogen-activated protein kinase inhibitors, 3580–3585
  smoothened inhibitors, 3572–3575
Molluscipoxvirus, 3067*t*
Molluscum contagiosum virus, 3067*t*, 3086–3090
  at-a-glance, 3086*b*
  clinical course and prognosis, 3089
  clinical features
    complications, 3087–3088, 3087*f*
    cutaneous, 3087, 3087*f*
    noncutaneous, 3087
  diagnosis, 3088–3089, 3089*f*
  differential diagnosis, 3089, 3089*t*
  epidemiology, 3086–3087
  etiology and pathogenesis, 3088
  with HIV, advanced, 3116, 3116*f*
  management, 3089–3090
  prevention/screening, 3090
  risk factors, 3088
Molluscum fibrosum pendulum, tuberous sclerosis complex, 2483, 2484*f*
Mollusks
  cone snail envenomations, 3355, 3355*f*
  octopus bites, 3355–3356, 3355*f*
Mometasone, for lichen sclerosus, 1121
Mometasone furoate, for lichen sclerosus, 1121, 1122
Mongolian spots, 1356–1358, 1357*t*, 1358*f*, 1958–1959
  neonatal, 1733
Monilethrix, 1543, 1543*f*, 1543*t*, 1550*t*
Monkeypox virus, 3066*t*, 3078–3081
  at-a-glance, 3078*b*
  clinical course and prognosis, 3080–3081
  clinical features
    complications, 3079
    cutaneous, 3078, 3079*f*
    noncutaneous, 3078, 3080*f*
    prodrome, 3078
  diagnosis, 3080, 3080*f*
  differential diagnosis, 3071*t*, 3080
  epidemiology, 3078
  etiology and pathogenesis, 3079–3080
  management, 3081
  prevention, 3081
Monkeys, herpesvirus simiae (B virus), 3341
Monobenzyl ether of hydroquinone, 3618
Monochloroacetic acid, 3620
Monoclonal antibodies, targeted. *See also specific types*
  for cutaneous T-cell lymphomas, 2093*t*, 2094–2096
  EGFR blocking, 3565
Monocyte chemoattractant protein 1 (MCP-1), inflammation, 124
Monocyte chemoattractant protein 3 (MCP-3), inflammation, 124*f*, 125
Monocyte chemotactic protein-1, panniculitis, 1251, 1268
Monocytes, wound healing, 2701*f*, 2702, 2702*f*
Mononucleosis, infectious, Epstein-Barr virus, 2999–3000, 2999*f*. *See also* Epstein-Barr virus (EBV)
Monopolar electrosurgical unit, 3798
Monorecidive syphilis, 3149
Monoterminal electrode, 3798
Montelukast, for itch
  in lichen simplex chronicus, 391
  in prurigo nodularis, 391
Montenegro skin test, 3235
Montgomery glands, 70. *See also* Sebaceous glands
Moon facies, 2513
MOR1D, 355
Moray eel, 3358–3359, 3358*f*
Morbihan disease, 1425–1426, 1426*f*. *See also* Rosacea
  acne vulgaris, 1451
Morbilliform eruptions
  drug-induced, 749
  with HIV, 3109
Morbilliform erythemas, 16
Morgellons disease, 1694–1696, 1695*t*, 1696*t*
Morgellons psychodermatology, 1693, 1695*t*
Morphea, 1106–1116
  at-a-glance, 1106*b*
  classification, 1106, 1107*t*
  clinical course and prognosis, 1112
  clinical features, 1106–1110
    complications, 1110
  clinical features, cutaneous, 1106–1110
    circumscribed morphea, 1107, 1107*t*
    deep morphea, 1108, 1110*f*
    eosinophilic fasciitis, 675, 1110, 3292
    generalized morphea, 1107, 1107*t*, 1108*f*–1109*f*
    linear morphea, 1107–1108, 1107*t*, 1109*f*
    mixed morphea, 1107*t*, 1108
    stages, cutaneous lesions, 1106, 1108*f*
  clinical features, noncutaneous, 1110
  diagnosis, 1111–1112, 1111*f*
  differential diagnosis, 1107*t*, 1112
  epidemiology, 1106
  etiology and pathogenesis, 1110–1111
  inflammatory reactions, 28
  lichen sclerosus overlying, 1106, 1107*f*
  Lyme disease, 3292
  management, 1112–1116, 1113*f*
    adjunctive therapy, 1116
    algorithm, 1113*f*–1114*f*, 1115
    antimicrobials, 1116
    evidence, lack of, 1116
    immunomodulators
      methotrexate, with/without corticosteroids, 1114*f*, 1115–1116, 1115*t*
      mycophenolate mofetil, 1115*t*, 1116
      other, 1115*t*, 1116
    overview, 1112
    patient evaluation, 1113–1115
    phototherapy, 1114*f*, 1115, 1115*t*
    vitamin D derivative, 1114*f*, 1115, 1115*t*
  pansclerotic, 1107*t*, 1110
Morpheaform (sclerosing infiltrative) basal cell carcinoma, 1886*t*, 1887, 1887*f*. *See also* Basal cell carcinoma
Morphea profunda, 1108, 1110*f*
Morphine abuse, 1714
Morphology, 3–12. *See also specific lesions and disorders*

color, 7–9, 8*t*
brown, 7, 8*t*
red, 7–9, 8*t*, 9*f*
diagnostic signs, cutaneous, 12*t*
distribution, multiple lesions, 11–12 (*See also* Distribution, multiple lesions)
historical perspectives, 3–4
reaction pattern, 4 (*See also* Reaction pattern)
shape and configuration, 9–12 (*See also* Shape and configuration)
terms, variation and ambiguity, 4
Morphology, primary
flat (nonpalpable) primary lesions
macule, 4, 4*f*, 4*t*
patch, 4, 4*f*, 4*t*
fluid-filled lesions
pustule, 4*t*, 5, 6*f*
vesicle and bulla, 4*t*, 5, 5*f*, 6*f*
fundamentals, 4, 4*t*
raised (palpable) primary lesions
nodule, 4*t*, 5, 5*f*
papule, 4, 4*t*, 5*f*
plaque, 4*t*, 5, 5*f*
Morphology, secondary change
atrophy, 6
crust, 5*f*, 6, 7*f*
fissure, 6–7
lichenification, 6, 7*f*
scale, 6, 6*t*
Morula, 52
Mosaicism, 59, 301–303, 302*f*
chromosomal, 302
hypomelanosis of Ito, 302
epigenetic, 303
functional, 302–303
47 XXY, 303
Blaschko lines, 302, 302*f*
focal dermal hypoplasia, 303
Goltz syndrome, 303
Klinefelter syndrome, 303
X-linked recessive hypohidrotic ectodermal dysplasia, 303
genetic, 301–303, 302*f*
neurofibromatoses, 302
gonadal, 301
Darier disease, 302
Hailey-Hailey disease, 302
superficial actinic porokeratosis, 302
gonosomal, 301
lentiginous, 1967–1970, 1969*f*, 1970*t*
pigmentary, 1351, 1733–1734, 1752, 1752*f*
neonatal, 1733–1734, 1752, 1752*f*
revertant, 303, 303*f*
COL17A1, 303
non-Herlitz junctional epidermolysis bullosa, 303
segmental, 302
somatic, 301
tuberous sclerosis, 302
Mosaic localized NF-1, 2472, 2473*f*
Mosaic neurofibromatosis type 1, 2472, 2473*f*
Mosaic warts, 3098, 3098*f*
Mosquito-borne viral diseases, 3135–3143. *See also specific types*
alphavirus, 3136*t*, 3141–3143
at-a-glance, 3141*t*
Chikungunya, 3136*t*, 3141–3142, 3142*f*
fundamentals, 3141
Mayaro, 3136*t*, 3142–3143
O'nyong-nyong, 3136*t*, 3142–3143
Ross River, 3136*t*, 3142–3143
Sindbis group, 3136*t*, 3142–3143
at-a-glance, 3135*b*
definitions, 3135
flavivirus, 3135–3141, 3136*t*
dengue virus, 3135–3137, 3136*t*, 3137*f*
West Nile virus, 3136*t*, 3139–3141, 3140*f*
yellow fever virus, 3136*t*, 3139
Zika virus, 3136*t*, 3137–3139, 3138*f*
historical perspective, 3135
Mosquitoes, 3325*f*, 3330–3331
Moth-eaten, syphilis, 3150, 3151*f*
Moths, 3334, 3334*f*
Motor function loss, postoperative, 3724
Motorized dermabrasion, 3903–3904, 3903*t*, 3904*f*
Motor nerves, facial, danger zones, 3699–3702, 3700*t*
Mottling, neonatal, 1732
Moxifloxacin. *See also* Fluoroquinolones
for mycoplasmas, genital, 3214, 3214*t*
for *Nocardia*, 2971
actinomycetoma, 2889
M-plasty, 3732
MPLKIP, trichothiodystrophy, 808, 1539
MS-1 antigen. *See* Stabilin-1
MS-1-HMWP. *See* Stabilin-1
MSH2, sebaceous adenomas, 1822*t*, 1849
MSH6, sebaceous adenomas, 1822*t*, 1849
MSX1, tooth and nail syndrome, 2388
mTORCI signaling, tuberous sclerosis complex, 2485
mTOR inhibitors. *See* Mammalian target of rapamycin (mTOR) inhibitors; *specific types*
MTOR pathway signaling, squamous cell carcinoma, 315
MTTS1, palmoplantar keratoderma with deafness, 836
Mucinous carcinoma, 1838
Muckle-Wells syndrome (MWS), 621–625, 623*t*, 624*f*. *See also* Cryopyrin-associated periodic syndromes
cold urticaria, 1675
Mucocutaneous candidiasis, chronic, 2399–2401, 2400*t*, 2401*f*
Mucocutaneous venous malformations (VMCMs), 2646–2653, 2648*t*. *See also* Venous anomalies
Mucor, 2984, 2985*f*
Mucormycosis, 2984, 2985*f*
subcutaneous, 2967*t*, 2973
Mucosal-associated invariant T (MAIT) cells, 150*f*, 151
psoriasis, 468
Mucosal discoid lupus erythematosus, 1046–1047
Mucosal lichen planus, 530*f*, 531*t*, 534–535, 534*f*–535*f*
Mucosal melanoma, 1986–1988, 1987*f*. *See also* Melanoma
Mucosal melanosis, 1371–1372, 1371*f*
Mucosal neuromas, 2152–2154
Mucosal vitiligo, 1331, 1332*f*. *See also* Vitiligo
Mucositis, from cytotoxic agents, 3486–3487, 3487*t*
Mucous membrane pemphigoid (MMP), 960–967
at-a-glance, 960*b*
clinical course and prognosis, 965
clinical features, 960–962
complications, 962, 963*t*
cutaneous, 960–962, 961f–962f
noncutaneous, 962
definition, 960
diagnosis, 964–965
differential diagnosis, 965, 965*t*
epidemiology, 960
historical perspectives, 960
management, 965–967, 966*t*
local care, 966–967
systemic, 967
risk factors, 962–964, 963*f*, 963*t*
Muehrcke lines, 1568, 1570*f*
hypoalbuminemia, 1597
Muir-Torre syndrome, 2444*t*
appendage tumors, 1820, 1822*t*
keratoacanthoma, 32
sebaceoma/sebaceous epithelioma, 1850
sebaceous adenomas, 1822*t*, 1849
sebaceous carcinoma, 1822*t*, 1852
sebaceous tumors, 33
squamous cell carcinoma, 1904*t*
Muir-Torre syndrome (MTS), gene mutations, 2344
Multicentric reticulohistiocytosis (MRH), 2036–2038, 2037*f*
paraneoplastic, 2442*t*, 2457
Multifocal hemangioma, 2049–2050, 2050*f*
Multifocal infantile hemangioma with or without extracutaneous disease, 2049–2050, 2050*f*
Multifocal lymphangioendotheliomatosis (MLT), 2049–2050, 2050*f*, 2059*b*, 2064
Multifocal venous malformations (MVM), 2646–2653. *See also* Venous malformations
Multileaf collimator (MLC), 3689
Multilineage colony-stimulating factor, 172
Multiple carboxylase deficiency, 2220, 2220*t*
trichorrhexis nodosa, 1538*t*
Multiple cutaneous and uterine leiomyomatosis, 2130, 2135
Multiple endocrine neoplasia (MEN)
MEN I syndrome, 2444*t*
MEN IIa syndrome, 2444*t*
MEN IIb syndrome, 2152–2154
MEN IIb/III syndrome, 2444*t*
Multiple hamartoma syndrome. *See* Cowden syndrome
Multiple myeloma, amyloidosis, transthyretin, 2458
Multiple self-healing squamous epithelioma, 1904*t*
Multiple sulfatase deficiency, 780*t*, 806
SUMF1, 780*t*, 806
Multistep model of leukocyte recruitment, 179–180, 180*f*
Munchausen syndrome, factitial and traumatic panniculitis, 1254*t*, 1282*b*, 1282*f*
Munro microabscesses, psoriasis, 24
Mupirocin, topical, 3420, 3420*t*, 3613*t*, 3614
for bullous impetigo, 2761
for group A *Streptococcus* impetigo, 2739, 2739*t*
for *Staphylococcus*
impetigo, 2730, 2731*t*
nares and skin decolonization, 2731*t*, 2732
S. aureus, in folliculitis decalvans, 1530
staphylococcal scalded skin syndrome, 2761
Mural cells, 116
Muscular dystrophy, epidermolysis bullosa simplex with, 1016–1017
Muscular proliferations, cutaneous, 2133*f*. *See also* Smooth muscle tumors
Musculocontractural Ehlers-Danlos syndromes (mcEDS), 1218*t*. *See also* Ehlers-Danlos syndromes
Mushroom
dermatitis, flagellate, 1372
psilocybin, 1711
Mus musculus, 3309*t*
rickettsialpox reservoir, 3315 (*See also* Rickettsialpox)
Mustarde flap, 3740–3741
Mutagenicity, electrosurgery, 3798
Mutations, gene, 294–295, 294*f*. *See also specific genes and disorders*
definition, 295
detection techniques, 293–294
insertions or deletions, 294*f*, 295
missense, 295
mitochondrial DNA, 300
mutation burden, clonal dynamics, 317, 318*f*
nonsense, 295
silent, 294
splice site mutations, 295

Mutator phenotype, 2342
Mutilating keratoderma with ichthyosis, 824–825, 824*f*, 845*t*
μ-opioids, 355
MVD, porokeratosis, 902*t*
MVK
  hyperimmunoglobulinemia D with periodic fever syndrome, 622*t*, 634
  mevalonate kinase deficiency, 622*t*, 634
  porokeratosis, 902*t*, 904–905
Myasthenia gravis, pemphigus with, 915
MYB, cylindroma, 1825
MYB-NFIB
  adenoid cystic carcinoma, 1836
  cylindroma, 1825
Myc, primary cutaneous diffuse large B-cell lymphoma, 2100
MYC, squamous cell carcinoma, 315
Mycetoma, 2966*t*, 2969–2971, 2969*f*–2970*f*, 2970*t*
  grains, 2969, 2970*f*, 2970*t*
Mycobacterial infections. *See also specific types*
  granulomas, infectious, 27
  with HIV, advanced, 3114
  postoperative infection, 3720
  sarcoidosis, 577, 578
Mycobacteria other than *M. tuberculosis* (MOTT) skin diseases, 2870–2874
  at-a-glance, 2870*b*
  epidemiology, 2858, 2859
  etiology and pathogenesis, 2870, 2871*f*
  historical perspectives, 2870
  identification, 2870–2871
  M. abscessus, 2874
  M. chelonae, 2874
  M. fortuitum, 2874
  M. genavense, 2874
  M. haemophilum, 2874
  M. kansasii, 2871–2873, 2873*t*
  M. marinum, 2871, 2873*f*, 2873*t*
  M. scrofulaceum, 2873–2874
  M. szulgai, 2874
  M. ulcerans, 2871, 2872*f*, 2872*t*
  Mycobacterium-avium intracellulare, 2514, 2859, 2874, 3114
  organ involvement, 2870, 2870*t*
  treatment, 2871, 2872*t*
Mycobacterium abscessus, 2874
Mycobacterium-avium intracellulare, 2874
  adrenal insufficiency, 2514
  with HIV/AIDS, 2859, 3114
Mycobacterium balnei, 2871, 2873*f*, 2873*t*
Mycobacterium bovis. *See also* Tuberculosis (TB)
  with HIV, 3114
  skin diseases, 2861–2867
    lupus vulgaris, 2858, 2864–2866, 2865*f*–2866*f*, 2865*t*
    orificial tuberculosis, 2867, 2867*f*, 2867*t*
    primary inoculation, 2861–2863, 2863*f*, 2863*t*
    scrofuloderma, 2858, 2859*f*, 2866–2867, 2866*f*, 2867*t*
    tuberculous verrucosa cutis, 2863–2864, 2864*f*, 2864*t*
Mycobacterium chelonae, 2874
  postoperative infection, 3720
Mycobacterium fortuitum, 2874
  postoperative infection, 3720
Mycobacterium genavense, 2874
Mycobacterium haemophilum, 2874
Mycobacterium kansasii, 2871–2873, 2873*t*
  with AIDS, 2859
Mycobacterium leprae, 2892, 2901–2905, 2903*f*. *See also* Leprosy
  cutaneous necrotizing venulitis, 2529
  laboratory testing, 2906
Mycobacterium lepromatosis, 2897
Mycobacterium marinum, 2871, 2873*f*, 2873*t*
  fish tank granuloma, 448
Mycobacterium monacense, erythema induratum, 1260
Mycobacterium scrofulaceum, 2873–2874
Mycobacterium szulgai, 2874
Mycobacterium tuberculosis, 2858–2861, 2859. *See also* Tuberculosis (TB)
  CD1a-restricted T-cell responses, 149
  granulomas, infectious, 27
  with HIV, 3114
  skin diseases, 2861–2867
    erythema induratum and nodular vasculitis, 1252*t*, 1259–1262, 2532
    lupus vulgaris, 2858, 2864–2866, 2865*f*–2866*f*, 2865*t*
    orificial tuberculosis, 2867, 2867*f*, 2867*t*
    primary inoculation, 2861–2863, 2863*f*, 2863*t*
    scrofuloderma, 2858, 2859*f*, 2866–2867, 2866*f*, 2867*t*
    tuberculous verrucosa cutis, 2863–2864, 2864*f*, 2864*t*
Mycobacterium ulcerans, 2871, 2872*f*, 2872*t*
Mycophenolate mofetil (MMF), 3465*f*, 3475, 3517–3519
  for actinic dermatitis prevention, 1643
  adverse effects, serious, 3519, 3519*t*
  for atopic dermatitis, 380
  for bullous pemphigoid, 952, 952*t*
  for central centrifugal cicatricial alopecia, 1528
  chemical structure, 3465*f*
  for chronic bullous disease of childhood, 994*t*, 998*t*, 999
  for connective tissue disease–associated panniculitis, 1283*b*
  for dermatomyositis, 1077–1078
  dosing regimen, 3518, 3518*t*
  drug interactions, 3519
  for erythema induratum and nodular vasculitis, 1262
  for erythema multiforme, 730
  for graft-versus-host disease
    acute, 2332–2333
    chronic, 2334
  indications and contraindications, 3518
  for lichen planopilaris, 547
  for lichen planus
    cutaneous, 544–545
    oral, 546
  for linear IgA dermatosis, 999
  for lupus erythematosus, 1054*t*, 1057
  monitoring, therapeutic, 3518–3519
  for morphea, 1115*t*, 1116
  for mucous membrane pemphigoid, 966*t*, 967
  organ transplantation formula, 3517, 3518*f*
  for paraneoplastic pemphigus, 941*t*, 942
  for pemphigus, 924
  pharmacology and mechanism of action, 3517–3518
  pregnancy, 3519
  for psoriasis, 485*t*, 493
  for pyoderma gangrenosum, 614*t*
  for systemic sclerosis, 1098
  for systemic sclerosis, pulmonary fibrosis, 1101
  vaccinations, 3519
  for vasculitis, 2557
Mycophenolic acid (MPA), 3465*f*, 3475, 3517–3519, 3518*f*
Mycoplasma
  definition, 3212, 3212*f*
  genital, 3212–3214, 3212*f*
Mycoplasma curtisii bacterial vaginosis, 3218
Mycoplasma genitalium, 3212–3214, 3212*f*
Mycoplasma hominis
  bacterial vaginosis, 3218
  genital, 3212–3214, 3212*f*
Mycoplasma pneumoniae, erythema multiforme, 723–724, 726, 727, 729. *See also* Erythema multiforme (EM)
Mycoplasma pneumoniae-induced rash and mucositis (MIRM), 723
Mycoses, 2925, 2926*t*. *See also* Fungal infections, superficial; *specific types*
  invasive, with advanced HIV, 3114–3115, 3115*f*
  subcutaneous, 2965–2973, 2966*t*–2967*t*
    at-a-glance, 2965*b*
    chromoblastomycosis, 2966*t*, 2971–2972, 2971*f*–2972*f*
    lobomycosis, 2967*t*, 2972–2973
    mycetoma, 2966*t*, 2969–2971, 2969*f*–2970*f*, 2970*t*
    phaeohyphomycosis, 2967*t*, 2972
    rhinosporidiosis, 2967*t*, 2973, 3244
    sporotrichosis, 2965, 2966*t*, 2968–2969, 2968*f*
    subcutaneous mucormycosis, 2967*t*, 2973
  superficial
    with HIV, advanced, 3115–3116, 3116*f*
    prevalence, 3436
  systemic, 2973–2985
    at-a-glance, 2973*b*
    blastomycosis, 2977–2979, 2978*f*
    coccidioidomycosis, 2979–2980, 2980*f*
    cryptococcosis, 2982–2984, 2983*f*
    histoplasmosis, 2975–2977
      African, 2977
      small-form, 2975–2976, 2976*f*–2977*f*
    opportunistic
      vs. endemic, 2974–2975
      nocardiosis, 2985
      underlying predisposition, 2973–2974, 2974*t*, 3114–3115, 3115*f*
    opportunistic, cutaneous aspects, 2984
      actinomycosis, 2985
      Aspergillus, 2984–2985
      candidiasis, systemic, 2984
      Fusarium, 2984–2985
      mucormycosis, 2984, 2985*f*
      Scedosporium, 2984–2985
      Trichosporon, 2984–2985
    paracoccidioidomycosis, 2980–2981, 2981*f*
    respiratory, endemic, 2974
    route of infection and dissemination, 2974, 2974*f*
    Talaromyces marneffei, 2982
    varieties, 2973
Mycosis fungoides (MF), 2077–2081
  clinical features
    hypopigmented mycosis fungoides, 2079, 2079*t*
    other symptoms, 2078
    skin signs, 2077–2078, 2077*f*–2079*f*
  definition, 2077
  diagnosis, early, 2081*t*
  differential diagnosis, 2079, 2081*t*
  granuloma annulare from, 567
  histopathology, 2079, 2080*f*–2081*f*, 2081*t*
  human herpesvirus-8, 508
  vs. nodular T-cell pseudolymphomas, 2114
  parapsoriasis and, 506–507, 508*f*
  PUVA for, 3666, 3671–3672, 3671*f*
  simulators, histologic, 2118–2122 (*See also under* Pseudolymphomas (PSLs), cutaneous)
  staging, 2081*t*, 2089, 2089*t*
  tissue resident memory T cells, 147
  treatment and prognosis, 2079–2081
    early stage, 2090
    radiotherapy, 3693*t*, 3694
    treatment algorithms, 2091*t*-2092*t*
  variants, 2081–2083, 2082*t*

folliculotropic mycosis fungoides, 2081–2082, 2082*f*, 2082*t*
granulomatous slack skin, 2082*t*, 2083, 2083*f*
pagetoid reticulosis, 2082, 2082*t*, 2083*f*
Mycotic granulomas, 27
Myeloid cells, psoriasis, 468–471, 470*f*
Myeloid dendritic cells, 151–152, 152*t*
Myelokathexis, chemokines, 186
Myelomeningocele, 1735
Myeloperoxidase, Sweet syndrome, 595
Myeloproliferative hypereosinophilic syndromes, 660–665. *See also* Hypereosinophilic syndromes (HES)
on eosinophils, 658
MYO5A
Griscelli syndrome, 1317–1318, 2418–2419, 2418*f*
Hermansky-Pudlak syndrome, 1316*t*
Myobloc, 3921, 3923. *See also* Botulinum toxin
Myocarditis
Still disease, adult-onset, 1157
systemic lupus erythematosus, 2427
Myoclonus epilepsy and ragged-red fibers syndrome, lipoma, 2173*t*
Myofascial release, for Ehlers-Danlos syndromes, 1223
Myofibroblasts, remodeling and wound healing, 2701*f*, 2702*f*, 2705
Myofibromatosis, infantile, 1742–1743
Myolipoma, 2184–2185, 2184*f*
Myonecrosis, 2777–2780
clostridial gas gangrene, 2779–2780
pyomyositis, 2777–2778, 2777*t*, 2778*t*
Myopathic Ehlers-Danlos syndromes (mEDS), 1218*t*. *See also* Ehlers-Danlos syndromes
Myosin Va (MyoVa), 340, 340*f*
Myositis, SSc overlap syndromes, 1087
Myrmecia, 3098
Myroxylon pereirae. *See* Balsam of Peru
Myxedema, hypothyroidism, 2507
Myxoid liposarcoma, 2191–2192, 2192*f*
Myxoid pseudocyst, 1604, 1604*f*
Myxopapillary ependymoma, 2167

N

Na^+, sweat duct reabsorption, 82–83, 83*f*
N-acetylcysteine, for Raynaud phenomena, 2623
N-acetyltransferase-1, 3369
NaCl, sweat duct reabsorption, 82–83, 83*f*
NADPH oxidase, chronic granulomatous disease, 2411
Naegeli-Franceschetti-Jadassohn syndrome, 1353–1354
Naegleria, 3247–3248
Naegleria fowleri, 3247–3248
Nafcillin
for group A *Streptococcus* lymphangitis, 2739, 2739*t*
for skin and soft-tissue infections, dosing, 3410*t*
for *Staphylococcus* necrotizing fasciitis, 2775, 2776*t*
for toxic shock syndrome, 2764
Naftifine, 3436–3437, 3438*t*
for *Candida*, interdigital, 3437
for tinea pedis, cruris, corporis, and versicolor, interdigital, 3437
Nagashima-type palmoplantar keratoderma, 827–828, 845*t*
Nagayama spots, exanthem subitum, 3008
Nail, 106–114. *See also* Ungual; *specific topics*
ablation, 3784–3785, 3785*f*
aging on, 1784
anatomy and function, 106–107, 108*f*
artificial, treatment effects, 1578
at-a-glance, 106*b*
biting, 1701
cuticle, 107, 107*f*
development, 27
digit regeneration, epithelium in, 111–113, 112*f*
growth and differentiation, 107–108
hyperpigmentation
cytotoxic agents, 3483
drug-induced, 754, 755*t*
lichen planus, 531*t*, 535–536, 536*f*
malalignment, after nail surgery, 3778
overcurvature, 1577–1578, 1578*f*
picking, 1701
psoriasis, 464, 464*t*, 465*f*
Nail avulsion, surgical, 3778–3781
distal approach, 3779, 3779*f*
for nail infections, fungal, 1595
partial, 3780, 3780*f*
proximal approach, 3779–3780, 3779*f*
trap door, 3781
uses, 3778
Nail bed, 107, 107*f*, 3775, 3775*f*
biopsy, fusiform, 3783*f*, 3785
surgery, 3785–3786
fusiform, 3783*f*, 3785
hematoma, subungual, 3785–3786, 3785*f*
indications, 3785
Nail biopsies
lateral longitudinal
of distal nail matrix, 3781–3782, 3782*f*–3783*f*
fundamentals, 3781, 3781*f*
nail bed, 3782–3783, 3783*f*
proximal nail fold longitudinal, 3782
Nail disorders, 1568–1608. *See also specific types*
drug reactions, 1598–1599
general disease, 1596–1598
amyloidosis, 1597, 1598*f*
arsenic, 1598
cadmium, 1598
cardiovascular and pulmonary, 1596, 1596*f*–1597*f*
hepatobiliary, 2431
intestinal and hepatic, 1597, 1597*f*
intoxications, 1598
psychological, 1598, 1598*f*
renal system, 2437
urogenital, 1597, 1597*f*
vitamin A toxicity, 1598
genodermatoses, 1599–1602 (*See also* Genodermatoses, nail)
nail signs and nail-specific conditions, 1568–1578
tumors, 1602–1608
Nail fold, 3774–3775, 3775*f*
biopsy, proximal longitudinal, 3783
capillaroscopy, Raynaud phenomena, 2618, 2618*f*
procedures
hypertrophy of lateral nail fold, 3789, 3789*f*
lateral, 3787, 3787*f*
proximal, 3786–3787
paronychia, recalcitrant chronic, 3786, 3786*f*
reconstruction, 3787
tumors, 3786–3787, 3786*f*–3787*f*
tumors, surgery for, 3786–3787, 3786*f*–3787*f*
Nail infectious disorders, 1588–1596. *See also specific types*
at-a-glance, 1588*b*–1589*b*
bacterial, 1591–1593
coccal, 1591–1592, 1592*f*
Pseudomonas, 1592–1593, 1592*f*
fungal, 1593–1596 (*See also* Onychomycosis)
clinical course, prognosis, and management, 1595–1596, 1596*t*
clinical features, 1593–1594, 1593*f*–1594*f*
diagnosis, 1595
differential diagnosis, 1595
disease associations, 1595
etiology and pathogenesis, 1594–1595
facts, 1593, 1593*t*
viral, 1589–1591
enterovirus, 1591, 1591*f*
herpes simplex virus, 1589–1590, 1589*f*
herpes zoster, 1590, 1590*f*
human papillomavirus, 1590–1591, 1590*f*
varicella virus, 1590
Nail inflammatory disorders, 1578–1588. *See also specific types*
alopecia areata, 1583–1584, 1584*f*
autoimmune bullous diseases, 1586–1587, 1586*f*
eczema, 1581–1583, 1582*f*
lichen planus of nails, 1584–1586, 1585*f*
psoriasis, 1578–1581 (*See also* Psoriasis, nail)
so-called connective tissue diseases, 1587–1588, 1587*f*
vasculitis and vasculopathies, 1588, 1588*f*
Nail matrix
procedures, 3784, 3784*f*
tumors, 3784–3785, 3784*f*–3785*f*
matricectomy, isolated, 3784–3785, 3784*f*
nail ablation, 3784–3785, 3785*f*
Schernberg's releasing flap methods, 3784, 3784*f*
Nail-patella syndrome, nail changes, 1601
Nail plate (NP), 107, 107*f*, 108*f*, 3774–3775, 3775*f*
dystrophy, from cytotoxic agents, 3482–3483, 3482*f*, 3482*t*
Nail proximal fold (NPF), 106–107, 107*f*, 108*f*
Nail signs and specific conditions, 1568–1578
anonychia, 1568
Beau lines, 1574, 1575*f*, 1575*t*
brachyonychia, 1568
brittle nails, 1575–1576, 1576*f*, 1576*t*
chromonychia, 1568–1570, 1569*t*
apparent leukonychia, 1568, 1569*t*, 1570*f*
blue nails, 1569, 1569*t*
chloronychia, 1568–1569, 1569*t*, 1571*f*
erythronychia, 1568, 1569*t*, 1570*f*–1571*f*
leukonychia, diffuse, 1568, 1570*f*
leukonychia punctata, 1568, 1569*f*
melanonychia, 1569–1570, 1569*t*, 1572*f*
pseudoleukonychia, 1568, 1569*t*, 1570*f*
double nail, 1568, 1569*f*
hyponychia, 1568
ingrown nails, 1576, 1577*f*
longitudinal grooves, 1575, 1576*f*
micronychia, 1568
onychogryphosis, 1573, 1574*f*
onycholysis, 1572, 1573*f*
onycholysis semilunaris, 1572, 1573*f*
onychomadesis, 1574, 1575*f*, 1575*t*
onychorrhexis, 1575, 1576*f*
onychoschizia, 1575–1576, 1576*f*
pincer nails, 1577–1578, 1578*f*
pitting, 1574, 1575*f*, 1575*t*
pterygium, 1573, 1574*f*
pterygium inversum, 1573, 1574*f*
racket nail, 1568
retronychia, 1576–1577, 1577*f*
splinter hemorrhages, 1571–1572, 1573*f*
subungual hematoma, 1570–1571, 1572*f*
subungual hyperkeratosis, 1572–1573, 1574*f*
trachyonychia, 1574–1575, 1575*f*, 1575*t*
treatment effects, 1578

Nail stem cell pools, 108–111
fundamentals, 108–109
rapidly cycling unipotent nail stem cells, 110–111, 110*f*
slow-cycling bifunctional nail proximal fold stem cells, 109, 110*f*
Nail surgery, 3774–3789
at-a-glance, 3774*b*
dressing, 3777–3778
ingrown nail, 3787–3789
congenital malalignment of great toenail, 3789–3790, 3789*f*
distal toenail embedding, 3787, 3787*f*
hypertrophy of lateral nail fold, 3789, 3789*f*
juvenile ingrown nails, 3788–3789, 3788*f*
pincer nail, 3789
retronychia, 3788
nail avulsion, 3778–3781
distal approach, 3779, 3779*f*
partial, 3780, 3780*f*
proximal approach, 3779–3780, 3779*f*
trap door, 3781
uses, 3778
nail-bed procedures, 3785–3786
fusiform biopsy, 3783*f*, 3785
hematoma, subungual, 3785–3786, 3785*f*
indications, 3785
nail biopsies
lateral longitudinal of distal nail matrix, 3781–3782, 3782*f*–3783*f*
fundamentals, 3781, 3781*f*
nail bed, 3782–3783, 3783*f*
proximal nail fold longitudinal, 3783
nail fold procedures, 3786–3787 (*See also* Nail fold, procedures)
nail matrix
procedures, 3784, 3784*f*
tumors, 3784–3785, 3784*f*–3785*f*
objectives, 3774
perioperative considerations, 3774–3777
anatomy, 3774–3775, 3775*f*
anesthesia, 3775–3777
distal digital block, 3776, 3776*f*–3777*f*
general anesthesia, 3777
proximal digital block, 3776, 3776*f*
regional blocks, 3777
transthecal block, 3776
instruments and draping, 3775, 3775*t*
patient selection, 3774
risks and precautions, 3774
tourniquets, 3777, 3777*f*
postoperative complications
bleeding, 3778
dysesthesia, 3778
infections, 3778
nail malalignment, acquired, 3778
pain, 3778
relapse, 3778
residual dystrophy, 3778
unpredictable, 3778
Nail tumors, 1602–1608
benign, epithelial and fibroepithelial, 1602–1605
glomus tumor, 1604, 1604*f*
myxoid pseudocyst, 1604, 1604*f*
onychocytic matricoma, 1602, 1603*f*
onychomatricoma, 1603, 1603*f*
onychopapilloma, 1603, 1603*f*
subungual exostosis, 1605, 1605*f*
subungual filamentous tumors, 1603
subungual osteochondroma, 1605
ungual fibrokeratoma, 1603–1604, 1603*f*
malignant, 1605
basal cell carcinoma, 1605
Bowen disease, 1605, 1605*f*
onycholemmal carcinoma, 1605
squamous cell carcinoma, 1605, 1605*f*
melanonychia, 1605–1608
benign, 1605–1606, 1606*f*–1607*f*
ungual melanoma, 1606–1608, 1607*f*–1608*f*, 1608*t*
Nail unit
anatomy, 3774–3775, 3775*f*
layers, origin, 3774–3775, 3775*f*
Nalidixic acid, 3416
Naltrexone, for prurigo nodularis, 392
Nanoparticles, inorganic, 3628
Napkin psoriasis, 461*f*, 464, 1741*t*, 1742, 1742*f*
Naproxen
for acute rheumatic fever, joint manifestations, 1160
hyperhidrosis from, 1465
phototoxicity, pseudoporphyria from, 1658, 1661, 1661*f*
Narrowband ultraviolet B (NB-UVB). *See* Ultraviolet B (UVB) phototherapy, narrowband
Nasal ala, 3698, 3698*f*
Nasal crease
allergic salute, 1454
pseudoacne of nasal crease, 1454, 1454*f*
Nasal glioma, 2166
neonatal, 1735, 1737*f*
Nasal-type extranodal natural killer/T cell lymphoma (ENK/T), Epstein-Barr virus, 3000
Nasolabial interpolation flap, 3750–3751, 3751*f*
Natriuretic polypeptide B (Nppb), 355
Natural gene therapy, 303, 303*f*
Natural history of disease, 40. *See also specific disorders*
Natural killer (NK) cells, 134, 151
psoriasis, 468
Natural moisturizing factor (NMF), 65, 3805
Naxos disease (ND), 781*t*, 835–836, 845*t*
cellular defect, 781*t*
plakoglobin mutations, 237
woolly hair, 1545
NCSTN
hidradenitis suppurativa, 1483
PASH syndrome, 1484
NDS, 3922
Necator americanus, 3252*t*
exposure and symptom onset interval, 3259, 3260*t*
migratory skin lesions, 3255*t*
papular and macular lesions, 3257, 3258*t*
progression and duration, 3259, 3260*t*
urticaria and pruritus, 3258–3259, 3258*t*
Necitumumab, acneiform eruptions from, 1452
Necrobiosis, 27
Necrobiosis lipoidica, with diabetes mellitus, 2500–2501, 2500*f*
clinical features, 9*f*, 2500–2501, 2500*f*
epidemiology and pathogenesis, 2501
granulomatous reactions, 27
historical perspectives and terminology, 2500
management, 2501
Necrobiotic xanthogranuloma, 2038–2039, 2284
paraneoplastic, 2442*t*, 2457–2458
Necrolytic migratory erythema, paraneoplastic, 2442*t*, 2455–2456, 2455*f*
Necrosis
after sclerotherapy, 3885–3886
anticoagulant-induced, 757, 757*f*
postoperative, 3721, 3722*f*
Necrotizing arteritis
Kawasaki disease, 2584
systemic, 2539–2558 (*See also* Vasculitis)
Necrotizing cellulitis, 2775–2777, 2776*t*
Necrotizing erysipelas, 2770. *See also* Necrotizing fasciitis
Necrotizing fasciitis, 2770–2775
clinical course and prognosis, 2774–2775, 2774*t*
clinical features
cutaneous, 2771
noncutaneous, 2771–2772
diagnosis, 2773–2774, 2773*t*
differential diagnosis, 2774, 2774*t*
in elderly, 1787
epidemiology, 2770
etiology, microbiology, and pathogenesis, 2770–2771, 2771*t*
historical perspectives, 2770
IV drug use, 1708, 1708*f*
management, 2775, 2776*t*
subtypes
anatomic, 2772–2773
cervical and craniofacial, 2772
Fournier gangrene, 2772–2773
microbiologic, 2772, 2772*t*
Necrotizing granulomatous vasculitis, cocaine abuse, 1709
Necrotizing soft-tissue infections, 2772, 2775–2777, 2776*t*
marine-based, 2776, 2776*t*
Necrotizing Sweet syndrome, 591
Necrotizing ulcerative stomatitis, 2226–2228, 2227*f*, 2228*t*
Necrotizing vasculitis, 2529–2530
Necrotizing venulitis, cutaneous, 2527–2537. *See also* Cutaneous necrotizing venulitis (CNV)
Needles
insertional radiofrequency, skin tightening, 3848, 3858, 3859
microneedling
for acne, 1411
for striae, 1197
Negative predictive value, 46, 46*f*
Neisseria gonorrhoeae, 3207, 3210–3211. *See also* Gonorrhea
cutaneous necrotizing venulitis, 2529
Neisseria meningitidis, 2782–2788
at-a-glance, 2782*b*
clinical course and prognosis, 2787
clinical features
complications, 2785
cutaneous, 2783–2784, 2784*f*
noncutaneous, 2784–2785, 2784*f*
diagnosis, 2786
differential diagnosis, 2786, 2787*t*
epidemiology, 2783
etiology and pathogenesis, 2785
risk factors, 2785–2786
introduction and bacteriology, 2782–2783
management
chemoprophylaxis, 2788
early, 2787
medications, 2787–2788
procedures, 2788
vaccination, 2788, 2788*t*
necrotizing venulitis, cutaneous, 2529
NEK9 kinase, nevus comedonicus, 1811
Nekam diseases, 539
Nelfinavir, 3508, 3509*t*
Nelson syndrome, 2513
hypermelanosis, 1362
Nematodes, 3251, 3252*t*. *See also specific types*
exposure and symptom onset interval, 3259, 3260*t*
progression and duration, 3259, 3260*t*
urticaria and pruritus, 3258–3259, 3258*t*
NEMO
for ectodermal dysplasia with immunodeficiency, 2406
incontinentia pigmenti, 1745, 2387
Neohaematopinus sciuropteri, 3310*t*
Neomycin, topical, 3420*t*, 3421
allergic contact dermatitis from, 404
Neonatal acne, 1448, 1449*f*
Neonatal dermatology, 1727–1746. *See also specific topics*

at-a-glance, 1727*b*
developmental abnormalities, 1734–1738 (*See also* Developmental abnormalities, neonatal skin)
diaper dermatitis, 1741–1742, 1741*t*
diseases, 1730–1734 (*See also specific types*)
birthmarks, 1732–1734
transient dermatoses of neonate, 1730–1732
erythroderma, 1739–1740
examination techniques, 1729–1730
genodermatoses
neonatal presentation, 1745
other, 1745–1746
hamartomas and benign tumors, 1742–1744
infections, 1738–1739, 1738*t*
fungal, 1739
herpes simplex virus, 1738–1739, 1739*f*
viral, congenital, 1738, 1738*t*
neonatal period, 1727
neoplastic proliferative disorders, 1744
seborrheic dermatitis, 1740
skin
physiology, 1727–1728
prematurity, 1728–1729
skin care, 1729
Neonatal herpes, 3022*t*, 3025*f*, 3026
Neonatal ichthyosis-sclerosing cholangitis syndrome, 780*t*
Neonatal-onset multisystem inflammatory disease (NOMID), 621–625, 623*t*. *See also* Cryopyrin-associated periodic syndromes
Neonatal pemphigus, 914
Neonate
full-term infants, 1727
neonatal period, 1727
preterm infants, 1727
skin care, 1729
Neoplasms. *See also specific types*
with bulb/stem outer root sheath differentiation, trichilemmoma, 1822*t*, 1839*t*, 1845–1846, 1846*f*
follicular germinative cells, basal cell carcinoma, 1839
with follicular mesenchymal differentiation, trichodiscoma/fibrofolliculoma, 1822*t*, 1839*t*, 1842–1843, 1843*f*
with isthmic outer root sheath differentiation, 1839*t*
pilar sheath acanthoma, 1847
proliferating pilar tumor, 1822*t*, 1847–1848, 1848*f*
tumor of follicular infundibulum, 1846–1847
with matrical differentiation, 1839*t*
pilomatrical carcinoma, 1844–1845
pilomatricoma, 1822*t*, 1843–1844, 1844*f*
with pan-follicular differentiation, trichofolliculoma, 1839, 1839*f*, 1839*t*
Neoplastic disorders, neonatal, 1744
Neoplastic disorders, skin lesion pathology, 30–39
adnexal tumors, 33–34
sebaceous tumors, 33–34
syringoma, 33
trichoblastoma, 33
trichoepithelioma, 33, 33*f*
assessment, skin tumors
benignancy *vs.* malignancy, determination, 30
cell types, 30
melanocytic lesions, 34–36 (*See also* Melanocytic nevi)
melanoma, 35–36, 35*f*
melanoma, desmoplastic vertical growth phase, 36
melanoma, malignant, 35, 35*f*
melanoma, superficial spreading, 35
melanoma, vertical growth phase, 35–36
melanoma in situ, 35
nevi, common, 34, 34*f*
nevi, dysplastic, 34, 34*f*
nevi, Spitz, 34–35, 35*f*
tumors of dermal origin, 36–37
tumors of dermal origin, fibrohistiocytic tumors
atypical fibroxanthoma, 36–37
dermatofibroma, 36, 36*f*
dermatofibrosarcoma protuberans, 36, 37*f*
tumors of epidermal origin, 30–33
tumors of epidermal origin, keratinocytic, 30–33
basal cell carcinoma, 32–33, 32*f*
condyloma acuminatum, 31, 31*f*
keratoacanthoma, 32
seborrheic keratosis, 31, 31*f*
squamous cell carcinoma, 31–32, 31*f*
invasive, 32, 32*f*
verruca plana, 31
verruca vulgaris, 30–31, 30*f*, 258, 3099*f*
tumors of neural origin
neurofibroma, 38, 38*f*
schwannomas, 38
tumors of smooth muscle origin
leiomyoma, 38–39, 38*f*, 2130, 2134–2138
leiomyosarcoma, 39, 39*f*, 2131*t*–2132*t*, 2138–2141
tumors of vascular origin
angiosarcoma, 37, 37*f*
pyogenic granuloma, 37, 37*f*
Neoprene, allergic contact dermatitis from, 405
Nephrogenic systemic fibrosis, 1163, 1165*t*, 1168
pathophysiology, 1163
phototherapy for, 3651
Nerve growth factor, prurigo nodularis, 389
Nerve root compression, Raynaud phenomena, 2615
Nerves
autonomic, 354–355
blockage, peripheral, 3712–3713
cutaneous
development, 56
in elderly, 1784
facial motor, danger zones, 3699–3702, 3700*t*
facial nerve
marginal mandibular branch, 3699, 3700*t*, 3701
temporal branch, 3699, 3700*t*, 3701, 3701*f*
spinal accessory nerve, 3699, 3700*t*, 3701–3702
hair follicle, 95
sensory
efferent function, 353–354
functional subgroups, 352–353
Nerve sheath myxoma, 2147*t*–2148*t*, 2160–2161, 2160*f*
Nerve sheath tumors
benign, 2150–2154, 2154–2162 (*See also specific types*)
mucosal neuromas and MEN2B, 2152–2154
nerve sheath myxoma, 2160–2161, 2160*f*
neurofibroma, 2147*t*–2148*t*, 2150*t*, 2157–2160
palisaded encapsulated neuroma, 2147*t*–2148*t*, 2150*t*, 2151–2152, 2152*f*–2153*f*
perineurioma, 2150*t*, 2161, 2162*f*
rudimentary polydactyly, 2151, 2151*f*
schwannomas, 2150*t*, 2154–2157
traumatic neuroma, 2147*t*–2148*t*, 2150–2151, 2150*t*
malignant peripheral, 2147*t*–2148*t*, 2150*t*
neurofibromatoses, 2474
peripheral, 2146–2150, 2147*t*–2148*t* (*See also* Peripheral nerve sheath tumors)
Nerve tumors
malignant, 2163–2164, 2163*f*
primitive neuroectodermal tumor, 2150*t*, 2164–2165
Nervous system, cutaneous, 351–355
anatomy, 311*f*, 351–352
autonomic nerves, 354–355
pruritus, cutaneous C and A fibers, 353, 354*f*
sensory nerves, 352–354
in skin diseases, 357
spinal cord, 355
Netherton syndrome, 779*t*
allergies, 217
bamboo hair, 1542–1543, 1542*f*, 1550*t*
cellular defect, 782*t*
clinical course, prognosis, and management, 795
clinical features, 792*f*–793*f*, 794*f*
congenital, 1740
diagnosis, 793–794
drug treatment, pediatric, 1761
etiology and pathogenesis, 793
gene mutations, 196–197
Leiner disease and, 429
LEKTI, 793
matriptase defects, 215
neonatal erythroderma, 1739
SPINK5, 197, 778, 779*t*, 782, 782*t*, 792*f*, 793
trichorrhexis invaginata, 791, 793*f*
trichorrhexis nodosa, 1538*t*
Netrin-4, allergic contact dermatitis, 192
Nettle, stinging, 684
Neural crest development, 52–53
Neuraminidase inhibitors, 3512–3513
Neuregulin/ErbB2/ErbB3, 336
Neurilem(m)omas, 38, 2150*t*, 2154–2157. *See also* Schwannomas
Neurinomas, 2150*t*, 2154–2157. *See also* Schwannomas
Neurobiology, skin, 351–360
at-a-glance, 351*b*
cutaneous nervous system, 351–355 (*See also* Nervous system, cutaneous)
nervous system in skin diseases, 357
perspectives, 360
pruritus, 355–357, 356*t* (*See also* Pruritus)
Neuroblastoma, neonatal, 1744
Neurocysticercosis, 3261
Neurofibroma, 2150*t*, 2157–2160
clinical course and prognosis, 2159
clinical features, 2157, 2158*f*
diffuse, 2157, 2158*f*
localized, 2157
pigmented, 2157, 2158*f*
plexiform, 2157
definition, 2154*b*
dendritic cell neurofibroma with pseudorosettes, 2159, 2159*f*
differential diagnosis, 2159
epidemiology, 2157
etiology and pathogenesis, 2157
histopathology, 2158–2159, 2158*f*–2159*f*
management, 2159–2160
pathology, 38, 38*f*
plexiform, 2150*t*, 2154, 2154*b*, 2157, 2467, 2468*f*, 2477
Neurofibromatoses (NF), 2445*t*, 2465–2477
at-a-glance, 2465*t*
autosomal dominant disorder, 295, 295*t*
clinical course and prognosis, 2473–2476
cancer, 2474–2475
leukemia, 2474
malignant peripheral nerve sheath tumors, 2474
other tumors, 2475
pheochromocytoma, 2474

Neurofibromatoses (NF), clinical course and prognosis (*Cont.*):
intelligence and learning disabilities, 2475–2476
radiographic evaluation, 2473–2474
skeletal complications, 2474, 2474*f*
unidentified bright objects, 2475, 2476*f*
vasculopathy, 2475
clinical features, 2465–2469, 2466*f*, 2466*t*
café-au-lait spots, 2465, 2466*f*
discrete neurofibromas, 2465–2467, 2466*f*–2467*f*
intertriginous freckling, 2465, 2466*f*
Lisch nodules, 2469, 2469*f*
optic pathway tumors, 2467–2469, 2469*f*
osseous lesions, distinctive, 2469, 2469*f*, 2470*f*
plexiform neurofibromas, 2467, 2468*f*
diagnosis, 2471
differential diagnosis, 2471–2473, 2471*t*
Legius syndrome, 1360, 2473
mosaic, type 1, 2472, 2473*f*
neurofibromatosis type 1–Noonan syndrome, 2472–2473
neurofibromatosis type 2, 2471–2472, 2472*f*, 2472*t*
schwannomatosis, 2473
etiology and pathogenesis
epidemiology, 2470
molecular biology, 2470–2471
genetics, 2470
mosaicism, 302
management
café-au-lait spots, 2476, 3851, 3851*f*, 3853*t*
discrete cutaneous neurofibromas, 2476–2477
general, 2476
optic pathway tumors, 2476, 2477
plexiform neurofibromas, 2477
Neurofibromatosis type 1 (NF1), 1361
Neurofibromatosis type 1–Noonan syndrome, 2472–2473
Neurofibromatosis type 2 (NF2), 2445*t*, 2471–2472, 2472*f*, 2472*t*
Neurofibromin, 2470–2471
Neurofibromin 1, in melanoma, 3581
Neurofibrosarcoma, 2163–2164, 2163*f*
Neurogenic sarcoma, 2163–2164, 2163*f*
Neuroglial heterotopia, 2166
Neurokinin-1 receptor (SP receptor, NK1R), 355
Neurolem(m)omas, 2150*t*, 2154–2157. *See also* Schwannomas
Neuroma, 2150–2154
mucosal neuromas and MEN2B, 2152–2154
palisaded encapsulated, 2147*t*–2148*t*, 2150*t*, 2151–2152, 2152*f*–2153*f*
rudimentary polydactyly, 2151, 2151*f*
traumatic, 2147*t*–2148*t*, 2150–2151, 2150*t*
Neuromuscular choristoma, 2131*t*–2132*t*, 2146, 2146*f*
Neuromuscular hamartoma, 2131*t*–2132*t*, 2146, 2146*f*
Neuropeptides, 354. *See also specific types*
Neurosarcoidosis, 576
Neurosarcoma, 2163–2164, 2163*f*
Neuro-Sweet disease, 592
Neurosyphilis, 3157
Neurothekeoma, 2159
Neurotic excoriation, 1697*t*, 1700–1701, 1700*f*
Neutral lipid storage disease. *See* Chanarin–Dorfman syndrome
Neutrophil extracellular traps (NETs), 155*f*, 156
Trousseau syndrome, 2460
vasculitis, 2541
Neutrophilic dermatoses, 1149, 1149*f*, 2442*t*. *See also* Rheumatoid arthritis (RA); *specific types*
Majeed syndrome, 643–644
pyoderma gangrenosum, 2442*t*, 2457
Sweet syndrome, 2442*t*, 2456–2457
Neutrophilic dermatosis of dorsal hands, Sweet syndrome, 591
Neutrophilic eccrine hidradenitis
from cytotoxic agents, 3483, 3483*f*, 3483*t*
drug-induced, 757–759, 758*t*
perieccrine inflammation, 26
Neutrophilic primary cicatricial alopecias, 1526*t*, 1529–1530
dissecting folliculitis, 1530, 1530*f*
folliculitis decalvans, 1529–1530, 1529*f*
Neutrophils, 27, 132–133, 145*f*, 154–156, 154*t*
inflammation and wound healing, 2701*f*, 2702, 2702*f*
inflammatory reactions, 27
secretory granules, 154*t*
Nevirapine, 3507–3508, 3509*t*
Nevoid basal cell carcinoma syndrome. *See* Basal cell nevus syndrome
Nevoid melanoma, 1988. *See also* Melanoma
Nevoid telangiectasia, alcohol abuse, 1713
Nevomelanocytes, 1944
common acquired melanocytic nevi, 1954–1955
multinucleated, 1955
Nevus. *See also specific types*
atypical, 1944
dysplastic, 1944
epidermal, 1806–1812
Blaschkoid distribution, 1806, 1807*t*
Blaschko lines, 1803*f*, 1806
epidermal nevus syndrome, 1811–1812, 1812*t*
fundamentals, 1806
infants, 1752
keratinocytic, 1806–1809 (*See also* Keratinocytic epidermal nevus)
neonatal, 1734
nevus comedonicus, 1810–1811, 1811*f*, 1812*t*
nevus sebaceus, 1809–1810, 1809*f*–1810*f*, 1810*t*, 1812*t*
variants and syndrome, 1812*t*
maturation, 34
melanocytic, 1944–1977 (*See also* Melanocytic nevi)
pathology
common, 34, 34*f*
dysplastic, 34, 34*f*
Nevus anemicus
differential diagnosis, 1339–1340, 1339*t*
neonatal, 1734, 1734*t*
Nevus comedonicus, 1810–1811, 1811*f*, 1812*t*
Nevus depigmentosus, 1752
differential diagnosis, 1338*t*, 1339
neonatal, 1734, 1734*t*
Nevus flammeus neonatorum, 2641*f*
vs. capillary malformations, 2638
Nevus fuscoceruleus acromiodeltoideus, 1356, 1357*f*, 1357*t*
Nevus fuscoceruleus ophthalmomaxillaris, 1356, 1357*f*, 1357*t*
Nevus lipomatosis superficialis, 2176, 2176*f*
Nevus of Becker, 1375–1376, 1375*f*
hypertrichosis, 1565
Q-switched laser for, 3851, 3853*t*
smooth muscle hamartoma, 2141
Nevus of Hori, 1357*t*, 1374–1375, 1375*f*
Nevus of Ita, 1958–1959
Nevus of Ito, 1356, 1357*f*, 1357*t*
Q-switched laser for, 3851, 3853*t*
Nevus of Ota, 1355–1356, 1356*f*, 1357*t*, 1958–1959
Q-switcher laser for, 1356, 3851, 3853*t*
Nevus sebaceus, 1809–1810, 1809*f*–1810*f*, 1810*t*, 1812*t*
infants, 1752, 1752*f*
neonatal, 1734
Nevus sebaceus syndrome, 1734
Nevus simplex
vs. capillary malformations, 2638
neonatal, 1734
Nevus spilus, 1949–1951, 1949*f*, 1950*t*
Nevus spilus-type congenital melanocytic nevus, 1950
Nevus unius lateris, 1807, 1808*f*
Newborn
bullous dermolysis of, 1021
collodion baby and ichthyoses, 786–787
gonorrhea prophylaxis, 3210, 3210*t*
hemorrhagic diseases of, 2204*b*, 2211
moisturizing factors, natural, 223, 224*t*
pseudoverrucous papules and nodules, 1741, 1742*f*
skin, epidermal barrier, 223–224, 224*t*
subcutaneous fat necrosis of, 1254*t*, 1278–1280, 1279*f*, 1280*t*, 1745, 1746*f*
transepidermal water loss, 223–224, 224*t*
Newborn effluvium, 1508–1509
Next-generation sequencing (NGS), 294
NF1
neurofibromatosis, 2470
neurofibromatosis type 1, 1361
Nf1, neurofibromatosis, 2471
NF2, schwannomas, 2154, 2155
NFKBIA, psoriasis, 478
NFKBIZ, psoriasis, 478, 479
NF-κB, 162, 164*f*, 3592
bortezomib on, 3592
for ectodermal dysplasia with immunodeficiency, 2406
leprosy, 2904
psoriasis, 470*f*, 478
NFκB2, cutaneous T-cell lymphomas, 2075, 2076*f*
NF-κB inhibitor, 162
NF-κB signal transduction pathway, 162, 164*f*
inhibitor, 162
Niacin. *See* Vitamin B_3 (niacin)
Niacinamide
photoprotection, oral, 3629
for squamous cell carcinoma prevention, 1915
Nicardipine, for Raynaud phenomena, 2620–2621, 2621*t*
Niche, epidermal stem cell, 62–63
Nickel, dietary, dyshidrosiform hand eczema from, 402
Nickel allergy, 138
contact dermatitis, 403
gene polymorphisms, 192–193
Nickels and dimes, syphilis, 3150–3151, 3151*f*
Nicolau-Balus syndrome, 1200
Nicotiana, 1713
Nicotinamide
for actinic keratosis prevention, 1867
for bullous pemphigoid, 952, 952*t*
photoprotection, oral, 3629
Nicotinamide-adenine dinucleotide (NAD), 2214
Nicotinamide-adenine dinucleotide phosphate (NADP), 2214
Nicotine stomatitis, 1714
Nicotine use. *See* Smoking and nicotine use
Nidogens, 240, 241
Niemann-Pick C-like protein 1 transporter, 2280
Nifedipine
photodistributed telangiectasia, 1661
for Raynaud phenomena, 2620–2621, 2621*t*
Nifurtimox
for African trypanosomiasis, 3239–3240, 3239*t*
for Chagas disease, 3241
Nijmegen breakage syndrome (NBS)
clinical features, 2344*t*
mechanisms, 2345*t*

Nikolsky sign, 12*t*
  bullous impetigo, *S. aureus*, 2721–2722, 2722*f*
  epidermal necrolysis, 736, 738*f*
  exfoliative toxins, 2758
  pemphigus, 912, 917
  staphylococcal scalded skin syndrome, 2759–2760, 2759*f*
Nilotinib, 3559*t*, 3561–3562, 3561*f*
  for mastocytosis, 720
  for melanoma, 2009
NIPBL, Cornelia de Lange syndrome, 1564
Nipple adenoma, 1836
Nit (lice), 3280, 3280*f*
Nitazoxanide
  for giardiasis, 3246
  for yellow fever virus, 3139
Nitric oxide
  endothelial cell, on platelet activation, 119, 119*f*
  for Raynaud phenomena, 2621
Nitric oxide synthase-3 (NOS-3), 120
Nitrogen, liquid
  cryodestruction, 1670, 1670*f*
  cryogen, 3791, 3792*t*
  cryosurgery, for actinic keratosis, 1864, 1864*t*, 1866
Nitrogen mustard, topical
  for cutaneous T-cell lymphomas, 2092–2093
  for Langerhans cell histiocytosis, 2028
2-Nitroso-1-naphthol-4-sulfonic acid test, for cobalt, 403
Nitrous oxide, cryogen, 3791, 3792*t*
Nivolumab
  immune-related adverse events from, 2006, 2006*t*
  lichen planus from, 537
  for melanoma, 2002, 2005–2006, 2005*f*, 2006*t*, 2007*f*, 2010*f*
  side effects, treatment algorithm, 2006, 2007*f*
Nizatidine. *See also* Antihistamines, H_2
  dosing regimens, 3458*t*
  for mastocytosis, 719, 719*t*
NK1R, for pruritus, 360
NLRP3 (CIASI)
  chronic infantile neurologic cutaneous and articular syndrome, 623
  cold urticaria, 693
  cryopyrin-associated periodic syndrome, 622*t*, 623, 689, 699
  familial cold autoinflammatory syndrome, 622*t*, 623
  Muckle-Wells syndrome, 622*t*, 623
  neonatal onset multisystem inflammatory disease, 622*t*, 623
  Schnitzler syndrome, 622*t*, 626
Nocardia, 2876
  actinomycetoma, 2884–2890, 2886*f*–2887*f* (*See also* Actinomycetoma)
  mycetomas, 2966*t*, 2969–2971
Nocardia brasiliensis actinomycetoma, 2884–2890, 2886*f*–2887*f*. *See also* Actinomycetoma
Nocardiosis, 2880–2884
  at-a-glance, 2880*b*
  clinical course, prognosis, and management, 2884
  clinical features
    cutaneous, 2881–2882, 2882*f*
    noncutaneous, 2882
  definitions, 2881
  diagnosis, 2877*t*, 2883
  differential diagnosis, 2883, 2884*t*
  epidemiology, 2881
  etiology and pathogenesis, 2882–2883
  historical perspective, 2881
  opportunistic infection, 2985
  prevention, 2884
NOD2 (CARD15)
  Blau syndrome, 622*t*, 640
  early-onset sarcoidosis, 622*t*, 640
  graft-versus-host disease, 2322
  leprosy, 2902
Nodal nevi, 1966–1967, 1967*t*
Nodular amyloidosis, 2263*f*, 2264–2265, 2265*f*
Nodular basal cell carcinoma, 1886, 1886*t*, 1887*f*. *See also* Basal cell carcinoma
Nodular melanoma (NM), 1983–1985, 1984*f*. *See also* Melanoma
Nodular pattern, 26, 26*f*
Nodular prurigo of Hyde, 388
Nodular pseudolymphoma, 2109–2118
  arthropod bite reactions, persistent nodular, 2115–2116, 2115*f*
  Borrelia-associated B-cell pseudolymphoma, 2110*t*, 2111–2112, 2112*f*
  CD30+ T-cell pseudolymphoma, 2114, 2115*f*
  classification, 2109
  cutaneous B-cell pseudolymphoma, 2110–2111, 2111*t*
  cutaneous T-cell and mixed pseudolymphoma, 2113–2114, 2113*f*, 2114*f*
  drug and vaccine injection sites, 2116–2117, 2117*f*
  from drugs, 2116, 2116*f*
  infections with lymphocyte-rich infiltrates simulating lymphoma, 2115*f*, 2117–2118
  from leech therapy, 2116, 2116*f*
  prevention, 2110
  pseudolymphomatous folliculitis, 2114–2115, 2115*f*
  scabies, nodular, 2115–2116
  tattoos or metals, 2117, 2117*f*
  treatment, 2110, 2110*t*
Nodular vasculitis, 1252*t*, 1259–1262, 2530*t*, 2532, 2532*f*. *See also* Erythema induratum and nodular vasculitis (EI/NV)
Nodule, 4*t*, 5, 5*f*
  eosinophilia, rheumatism, dermatitis, and swelling, 654
  rheumatoid, 1146–1148, 1147*f*, 1148*t* (*See also* Rheumatoid arthritis (RA))
  subcutaneous, acute rheumatic fever, 1159–1160, 1159*t*
Nodulosis
  accelerated, 1148
  rheumatoid, 1146–1148, 1147*f*, 1148*t*
Noggin, 90*f*, 91
Noma, 2226–2228, 2227*f*, 2228*t*
Nonablative laser skin resurfacing, 3835
  equipment, 3836
  technique, 3840–3841
Nonabsorbable materials, 3911–3912
Nonatopic eczema, 364
Nonbullous congenital ichthyosiform erythroderma (NCIE), 787–788, 788*t*. *See also* Autosomal recessive congenital ichthyosis
Non-epidermolytic palmoplantar keratoderma, cellular defect, 781*t*
Non-Herlitz junctional epidermolysis bullosa, 1018–1019, 1019*f*, 1020, 1020*f*, 1029*t*
  revertant mosaicism, 303
Non-Hodgkin lymphoma (NHL)
  amyloidosis, transthyretin, 2458
  dermatitis herpetiformis, 1003–1004, 2459
  granuloma annulare from, 567
  paraneoplastic pemphigus, 2*f*, 934
Nonimmunologic contact urticaria (NICU), 445, 445*t*
Noninvasive body contouring, 3857–3868. *See also* Body contouring, noninvasive
Noninvoluting congenital hemangioma (NICH), 2059–2060, 2059*b*, 2060*f*
Nonionizing radiation, occupational exposure, 447–448, 448*f*
Nonlethal junctional epidermolysis bullosa, 1018–1019, 1019*f*, 1029*t*
Nonnucleoside reverse transcriptase inhibitors (NNRTIs), 3507–3508, 3509*t*
Nonpalpable primary lesions
  macule, 4, 4*f*, 4*t*
  patch, 4, 4*f*, 4*t*
Nonpenetrant, 295
Nonsense mutations, 295
Non–small-cell lung cancer (NSCLC), EGFR signaling, 3565
Nonsteroidal antiinflammatory drugs (NSAIDs). *See also specific types*
  for cellulitis and erysipelas, 2754
  for cryoglobulinemia II and III, non-HCV, 2607
  for cutaneous necrotizing venulitis, 2537
  for eosinophilic pustular folliculitis, 671
  erythema nodosum from, 1256
  for gout, 2315
  for hyperimmunoglobulinemia D with periodic fever syndrome/mevalonate kinase deficiency, 635
  for infectious mononucleosis, Epstein-Barr virus, 3002, 3002*t*
  for juvenile idiopathic arthritis, 1155
  lupus erythematosus from, 1041*t*
  for Majeed syndrome, 644
  for palisaded neutrophilic and granulomatous dermatitis, 1148
  psoriasis exacerbation by, 479
  for reactive arthritis, 1142
  for relapsing polychondritis, 1190
  for rosacea, persistent erythema pain, 1438
  for SAPHO syndrome, 645, 1450
  for Schnitzler syndrome, 627
  for Still disease, adult-onset, 1158
  for TNF receptor-associated periodic syndrome, 637
  urticaria from, 694–695, 694*t*
Noonan syndrome, cutis laxa, 1237*t*
Norethindrone acetate + ethinyl estradiol, for acne vulgaris, 1406, 1406*t*
Norfloxacin, for Oroya fever, 2806
Norgestimate + ethinyl estradiol, for acne vulgaris, 1406, 1406*t*
Normolipidemic xanthomas, 2283
North American blastomycosis, 2977–2979, 2978*f*
Northern black widow spider, 3324–3326, 3326*f*
Northern copperhead, 3342, 3342*f*
NOS2, psoriasis, 479
Notalgia paresthetica amyloidosis, 2264
Notch
  epidermal differentiation, 66, 67*f*
  epidermal proliferation, 63
Notch, 323
NOTCH, 314
Notch 1, actinic keratosis, 1861, 1862*f*
Notch pathway, hair follicles, 90*f*, 91, 92
Notch receptor, 50
Notch signaling, 66
NPra, 355
NRAS
  blastic plasmacytoid dendritic cell neoplasm, 2102
  congenital melanocytic nevi, 1946
  syringocystadenoma papilliferum, 1834
NSDHL, CHILD syndrome, 208*t*, 213, 215*f*, 778*t*
NTRK1, congenital insensitivity to pain with anhidrosis, 1466
Nuclear factor of IL-6, 172
Nuclear factor κB (NF-κB). *See* NF-κB

Nucleoside and nucleotide reverse transcriptase inhibitors (NRTIs), 3506–3507, 3509*t*
  for hepatitis B virus, 3512
Nucleosome, 3575
Nucleotide-binding oligomerization domain-containing protein 2 (NOD2), *S. aureus* skin infections, 2727
Nucleotide excision repair (NER), 279–280, 279*f*, 316*f*
  gene mutations, XP variant defects, 2344
  helicase genes and disorders, 2344
  impaired, 2342
  MC1R signaling, 343–344
Nummular dermatitis, 10*f*
Nummular eczema, 385–388
  alcohol abuse, 1713
  at-a-glance, 385*b*
  clinical features, 386–387, 386*f*–387*f*
    nail changes, 1582–1583
  complications, 388
  diagnosis
    laboratory tests, 387
    special tests, 387, 387*f*
  differential diagnosis, 387, 387*t*
  epidemiology, 385
  etiology and pathogenesis, 385–386
  historical perspective, 385
  prognosis and clinical course, 388
  treatment, 388
Nummular shape, 9–10, 10*f*
Nutritional disease, cutaneous changes, 2199–2228. *See also specific topics*
  at-a-glance, 2199*b*
  hypermelanosis, 1363–1364
    folic acid deficiency, 1363
    kwashiorkor, 1363
    pellagra, 1363–1364
    vitamin B_{12} deficiency, 1363
  kwashiorkor, 1363, 2199*b*
  macronutrients, 2200–2204, 2226–2228
    essential fatty acids, 2203–2204, 2204*t*
    protein-energy malnutrition, 2200–2203
  marasmus, 2199*b*
  micronutrients, 2204–2226
    minerals, 2221–2226
    noma, 2226–2228, 2227*f*, 2228*t*
    vitamins
      fat-soluble, 2204–2211, 2204*b*, 2280
      water-soluble, 2211–2221
  refeeding syndrome, 2199*b*
Nyctalopia, zinc deficiency, 2224
Nystatin, 3438*t*, 3446
  for candidiasis, 3446

O

Oatmeal baths
  for cercarial dermatitis, 3354
  for sea bather's eruption, 3354
Obesity
  clinical features, 2503, 2503*t*
  cutaneous disorders with, 2502, 2502*t*
    hidradenitis suppurativa, 1483
    psoriasis, 479
  definition and calculation, 2502
  diabetes mellitus, 2283
    metabolic syndrome and, 2502–2504, 2504*t*
  epidemiology, 2502–2503
  etiology and pathogenesis, 2503–2504
  management, 2504
Observational studies, 42*f*, 43–44
Obsessive-compulsive and related disorders, 1698–1701
  body dysmorphic disorder, 1698–1699
  body-focused repetitive behavior disorders, 1701
  hair pulling disorder, 1697*t*, 1699–1700
  neurotic excoriation, 1697*t*, 1700–1701, 1700*f*
Obstetric cholestasis. *See* Intrahepatic cholestasis of pregnancy (ICP)
OCA2, 344
  genetic counseling, 305
  oculocutaneous albinism type 2, 1310*t*, 1312
Occipital alopecia, infants, 1752
Occipital horn syndrome, 1234
Occlusion, on skin absorption, 3371
Occlusive junction, 207, 207*t*, 209*f*
Occlusives, 3807
Occult spinal dysraphism, 1735
Occupational acne, 1452–1453
Occupational contact dermatitis (OCD), 439–444
  allergic contact dermatitis, 439, 444
  contact urticaria and immediate contact reactions
    contact urticaria of uncertain mechanism, 446
    diagnostic algorithm, 451*f*
    immunologic contact urticaria, 445–446, 445*t*
    nonimmunologic contact urticaria, 445, 445*t*
    radioallergosorbent testing, 450–451
    skin prick testing, 450
  irritant contact dermatitis, 439–444 (*See also* Irritant contact dermatitis (ICD))
  occupations at risk, 442*t*
Occupational skin diseases (OSDs), 438–453. *See also specific types*
  at-a-glance, 438*b*
  background, 438
  common, 438, 440*t*
  contact urticaria and immediate contact reactions, 444–446, 445*t*
  diagnosis
    beryllium lymphocyte proliferation test, 451
    biomonitoring, 451
    other, 451
    patch testing and allergic contact dermatitis, 450
    radioallergosorbent testing and contact urticaria, 450–451
    skin prick testing and contact urticaria, 450, 450*f*
  disease spectrum, 439, 440*t*
  epidemiology, 439, 441*f*
  exposure, 446–450
    biologic, 448–450 (*See also* Biologic exposure, occupational)
    chemical, acne, 446
    classification, 438
    mechanical, 446–447
    physical
      ionizing and nonionizing radiation, 447–448, 448*f*
      thermal stress, 447
  health risk assessment
    dose-response relationship, 453
    exposure assessment, 453
    hazard identification, 453
    risk characterization, 453
  historical perspective, 438
  management and hierarchy of controls, 452, 452*f*
  occupational contact dermatitis, 439–444
  risk factors, 452–453
OCEBM scale, 44
Ochronosis, 1368
Octopus bites, 3355–3356, 3355*f*
Octreotide
  for necrolytic migratory erythema, 2456
  for pancreatic panniculitis, 1272
Ocular albinism (OA), 1310*t*, 1314–1315
Ocular rosacea. *See also* Rosacea
  clinical features, 1424, 1424*f*
  diagnosis, 1434
  differential diagnosis, 1436, 1436*t*
  management, 1442, 1443*t*
Ocular sarcoidosis, 576, 576*f*
Ocular syphilis, 3157
Oculocutaneous albinism (OCA), 1309–1314
  at-a-glance, 1309*b*
  clinical course, prognosis, and management, 1314
  clinical features, 1310–1312
    OCA type 1, 1310, 1311*f*
    OCA type 2, 1310–1311
    OCA type 3, 1311
    OCA type 4, 1311–1312, 1311*f*
    OCA type 5, 1312
    OCA type 6, 1312
    OCA type 7, 1312
  diagnosis, 1313–1314
  differential diagnosis, 1314
  etiology and pathogenesis, 1312–1313
    OCA type 1, 1312
    OCA type 2, 1312–1313
    OCA type 3, 1313
    OCA type 4, 1313
    OCA type 5, 1313
    OCA type 6, 1313
    OCA type 7, 1313
  prevalence, 1309
  squamous cell carcinoma, 1903, 1904*t*
  types, 1309, 1309*t*
Oculo-dento-digital dysplasia (ODDD), 2389–2390
Oculodentodigital dysplasia (ODDD), 832
Oculo-orogenital syndrome
  vitamin B_2 deficiency, 2214
  vitamin B_6 deficiency, 2216
Odds ratio, 45
Odocileus virginianus, 3320
Odonto-onycho-dermal dysplasia (OODD), 2382–2384, 2383*f*
Odor, body, 1469
  bromhidrosis, 1469–1471, 1470*t*
Ofloxacin. *See also* Fluoroquinolones
  for chlamydia, 3217*t*
  for nocardiosis, 2884
  for *Salmonella* enteric fever, 2808
Oil dermatitis, 416–417
Oil drop sign (oil spotting), psoriasis, 464, 464*t*
  nail, 1580
Oil-in-water emulsions, 3373*t*, 3374
Ointments, 3373*t*, 3374–3375
  absorption bases, 3373*t*, 3374
  hydrocarbon bases, 3373*t*, 3374
  microspheres, 3375
  oil-in-water emulsions, 3373*t*, 3374
  water-in-oil emulsions, 3373*t*, 3374
  water-soluble bases, 3373*t*, 3374–3375
Olanzapine
  for delusions of parasitosis, 1696, 1697*t*
  for dermatitis artefacta, 1703
Oleaginous bases, 3374
Oleic acid (olive oil), 3806, 3806*f*
Olfactory reference syndrome, 1696
Olmsted syndrome, 828–829, 845*t*
Olsen scale hair loss, 1497, 1498*f*
Omalizumab
  for atopic dermatitis, 197, 380
  for autoimmune urticaria, 691, 691*f*
  for bullous pemphigoid, 952, 952*t*
  efficacy, by disease, 197
  for mastocytosis, 719, 719*t*
  for solar urticaria, 1653, 1654*f*
  for urticaria, 691*f*, 692, 702
Ombitasvir-paritaprevir-ritonavir and dasabuvir (Viekira Pak), for hepatitis C virus, 3512
Omega-3-fatty acids, on triglycerides, 2287

Omenn syndrome, 1740
severe combined immunodeficiency, 2405–2406
Omeprazole
dapsone interactions, 3425, 3425*t*
erythema nodosum from, 1256
OMIM 301845, 1200
OMIM 302960, 1200
Omphalomesenteric duct cyst, 1737
Onchocerciasis *(Onchocerca volvulus)*, 3252*t*, 3269
depigmentation, 3259
exposure and symptom onset interval, 3259, 3260*t*
exposure history, 3254
ichthyosis, 3259
keratitis, 3261
lichenification, 3259
life cycle and transmission, 3253, 3253*f*
management, 3265*t*
ocular disease, 3261
papular and macular lesions, 3258, 3258*t*
progression and duration, 3259, 3260*t*
retinitis, 3261
subcutaneous nodules and masses, 3257, 3257*t*
Onchocytes, 107, 107*f*
Onchodermatitis, 3261
Oncogenes, 313
Online Mendelian Inheritance in Man (OMIM), 290
Onychocytic matricoma, 1602, 1603*f*
Onychodaknomania, 1598
Onychodystrophy, psoriasis, 464
Onychogryphosis, 1573, 1574*f*
Onycholemmal carcinoma, 1605
Onycholysis, 1572, 1573*f*
Onycholysis semilunaris, 1572, 1573*f*
Onychomadesis, 1574, 1575*f*, 1575*t*
Onychomatricoma, 1603, 1603*f*
Onychomycosis, 1593–1596, 2937–2940. *See also specific types*
clinical course, prognosis, and management, 1595–1596, 1596*t*
clinical features, 1593–1594, 1593*f*–1594*f*
distolateral subungual type, 2937, 2938*f*
other, 2937
proximal subungual type, 2937, 2938*f*
white superficial type, 2937, 2938*f*
diagnosis, 1595, 2929*t*, 2931*t*–2932*t*, 2939
differential diagnosis, 1581*t*, 1595, 2939, 2939*t*
disease associations, 1595
epidemiology, 2937
etiology and pathogenesis, 1594–1595, 2938–2939
facts, 1593, 1593*t*
management, 2934*t*
candidiasis, 2958
mechanical, 2939–2940
systemic, 2934*t*, 2939
topical, 2935*t*–2936*t*, 2939
subtypes, 2938*t*
Onychopapilloma, 1603, 1603*f*
erythronychia, 4*f*, 1568
Onychophagia, 1598, 1598*f*, 1701
Onychorrhexis, 1575, 1576*f*
lichen planus, 535
Onychoschizia, 1575–1576, 1576*f*
lichen planus, 535
Onychoteiromania, 1598
Onychotemnomania, 1598
Onychotillomania, 1598, 1599*f*, 1701
O'nyong-nyong, 3136*t*, 3142–3143
Open spray method, 3793, 3793*f*
Operative considerations and procedure, 3709–3720. *See also specific surgeries*
anesthesia, local, 3710–3714, 3710*t* (*See also* Anesthetics, local)
antiseptics, topical, 3714–3715
equipment, 3715
informed consent, 3709–3710
patient positioning, 3715
skin preparation, 3714–3715
surgical procedure, 3715
suturing, 3715–3720 (*See also* Suturing)
Ophthalmic nerve, 3702, 3702*f*
Ophthalmic zoster, 3042, 3044*f*–3045*f*, 3046
Ophthalmoganglionar complex, 3240
Opiate abuse, prescription, 1714
Opioids, hyperhidrosis from, 1465
Opportunistic infections, with advanced HIV, 3113–3116
bacillary angiomatosis, 3114
leishmaniasis, atypical, 3116
molluscum contagiosum, severe, 3116, 3116*f*
mycobacterial, 3114
mycoses
invasive, 3114–3115, 3115*f*
superficial, 3115–3116, 3116*f*
oral hairy leukoplakia and other Epstein-Barr virus disease, 3113–3114
Optical density (OD), laser goggles, 3832
Optical radiation, principles, 3824–3825
Optic pathway tumors (OPTs), 2467–2469, 2469*f*, 2476, 2477
ORAI1, Kawasaki disease, 2584
Oral allergy syndrome (OAS), contact urticaria, 690, 695
Oral cavity, potentially malignant disorders, 1876–1879
definition and terminology, 1876
erythroplakia, 1878–1879, 1879*t*
leukoplakia, 1876–1878, 1877*f*, 1878*t*
Oral contraceptives
for acne vulgaris, 1406, 1406*t*
erythema nodosum from, 1256
for hirsutism, 1561, 1562*t*
for hyperandrogenism, 2518
mycophenolate mofetil interactions, 3519
Oral hairy leukoplakia, with advanced HIV, 3113–3114
Oral lichenoid reactions (OLRs), 534, 535*f*
Oral squamous cell carcinoma, 1907–1908
HPV, 3096*t*, 3104
Oral submucous fibrosis, betel, 1713
Oral warts, 3096*t*, 3103, 3104*f*
Orange color, 8*t*
Orbicularis oculi muscle, 3703, 3704*f*
Orbicularis oris muscle, 3703, 3704*f*
Orbital cellulitis, 2748
Orchopeas howardi, 3310*t*
Orf virus, 3066*t*, 3083–3086
at-a-glance, 3083*b*
clinical course and prognosis, 3086
clinical features
complications, 3084–3085, 3085*f*
cutaneous, 3084, 3084*f*–3085*f*, 3084*t*
noncutaneous, 3084
diagnosis, 3085–3086, 3086*f*
differential diagnosis, 3086
epidemiology, 3083–3084
etiology and pathogenesis, 3085
sheep and transmission, 3083
management, 3086
occupational exposure, 449
prevention, 3086
risk factors, 3085
Organ disorders, internal, skin manifestations, 2425–2439. *See also specific organs*
cardiovascular system, 2395*t*–2396*t*, 2425–2427
gastrointestinal system, 2403*t*–2404*t*, 2433–2436
hepatobiliary system, 2401*t*, 2430–2433
pulmonary system, 2397*t*–2398*t*, 2428–2430
renal system, 2406*t*, 2436–2439
thyroid, 2407*t*, 2439
Organogenesis, 52
Organoid nevus, infants, 1752, 1752*f*
Organ transplantation. *See also specific organs*
mycophenolate mofetil for, 3517, 3518*f*
mycoses after, 2974, 2974*f*, 2974*t*
phototherapy safety, 3645
squamous cell carcinoma prevention after, immunosuppressive regimen change, 1916
Orientia tsutsugamushi, 3319–3320
Orificial tuberculosis, 2867, 2867*f*, 2867*t*
Oritavancin, systemic, 3418
Oropharyngeal squamous cell carcinoma, HPV, 3096*t*, 3104
Oroya fever
bacteriology, 2797, 2797*t*
clinical course and prognosis, 2805
clinical features
complications, 2802
cutaneous, 2799*t*, 2800, 2801*f*
noncutaneous, 2799*t*, 2802
diagnosis
laboratory, 2799*t*, 2804–2805
pathology, 2804
differential diagnosis, 2804, 2805*t*
epidemiology, 2798
etiology and pathogenesis, 2803–2804
management, 2806
Orthopoxvirus, 3065–3081. *See also specific types*
cowpox virus, 3065, 3066*t*, 3073, 3083
diagnosis, real-time PCR, 3070
monkeypox virus, 3066*t*, 3078–3081
smallpox, 3065–3073, 3066*t*
clinical features
cutaneous, 3067–3068, 3068*f*
prodrome, 3067
epidemiology, 3067
vaccinia virus, 3066*t*
small pox vaccination and, 3066*t*, 3073–3078
Orthovoltage X-rays, 3687
Oseltamivir, 3512–3513
Osimertinib (AZD9291), 3559*t*, 3571–3572, 3571*f*
acneiform eruptions from, 1452
Osler nodes, infective endocarditis, 2425, 2815, 2816
IV drug use, 1709
Osmidrosis, 1469
OSMR, in cutaneous amyloidosis, 2266
Osseous lesions, neurofibromatoses, 2469, 2469*f*, 2470*f*
Ossification, primary, 2312–2313
aberrant ossification, 2308
Albright hereditary osteodystrophy, 2312
fibrodysplasia ossificans progressiva, 2312
platelike osteoma cutis, 2312
progressive osseous heteroplasia, 2312–2313, 2313*f*
Osteochondrodysplasia with hypertrichosis, 1564
Osteogenesis imperfecta EDS overlap syndrome, 1221
Osteoporosis, from glucocorticoids, 3386
Ostraceous psoriasis, 459
Ostraceous scale, 6*t*
Otic lichen planus, 535
Otitis externa, *Pseudomonas aeruginosa*, 2790, 2791*t*
clinical features, 2790, 2791*t*, 2793
diagnosis, 2794
etiology and pathogenesis, 2793
management, 2796
O-to-L flap, 3735, 3735*f*
OTULIN, 622*t*, 638
Otulipenia/OTULIN-related autoinflammatory syndrome (ORAS), 638
Outcome, 40

Outer root sheath, 93, 93*f*, 94*t*
Outer root sheath differentiation neoplasms
bulb/stem, trichilemmoma, 1822*t*, 1839*t*, 1845–1846, 1846*f*
isthmic, 1839*t*
pilar sheath acanthoma, 1847
proliferating pilar tumor, 1822*t*, 1847–1848, 1848*f*
tumor of follicular infundibulum, 1846–1847
Outside-in-signaling, cell–matrix, 247–248
Ovarian tumors, hirsutism from, 1559
Overlying plexiform neurofibromas with spinal dysraphism, hypertrichosis, 1564–1565
Oxacillin
for skin and soft-tissue infections, dosing, 3410*t*
for *Staphylococcus intermedius*, 3339
for *Staphylococcus* necrotizing fasciitis, 2775, 2776*t*
Oxazolidinones, systemic, 3418. *See also* Linezolid; Tedizolid, systemic
Oxiconazole, 3438*t*
Oxidative DNA damage, UV radiation, 276–278, 277*f*
Oxidative stress, aging and, 1765–1766, 1779–1780, 1780*f*, 1780*t*
Oxpentifylline
for adamantiades–Behçet disease, 2576*t*
for frostbite, 1669
Oxybenzone, 3625–3626, 3626*t*, 3627, 3628
Oxybutazone, for erythema nodosum, 1259
Oxybutynin, for hyperhidrosis, 1463
Oxycodone abuse, 1714
Oxymetazoline, for rosacea, 1439
Oxytetracycline, for rosacea, 1439
Ozone (layer), 3623
on skin aging, 1781
UVC filtering, 265–266

P

p8, trichothiodystrophy, 1539
P13K/AKT pathway, 3543
p16
atypical lipomatous tumor, 2174
dedifferentiated liposarcoma, 2190, 2190*f*
lipoblastoma/lipoblastomatosis, 2178
p16, actinic keratosis, 1861
p53. See also TP53
actinic keratosis, 1861, 1862*f*
DNA cell repair, cutaneous squamous cell carcinoma, 281
myxoid liposarcoma, 2192
plexiform neurofibromas, 2467
squamous cell carcinoma and keratoacanthoma, 1906–1907
UV mutations, 376
p63, 50, 66, 67*f*
Merkel cell carcinoma, 1929
P63-related ectodermal dysplasia syndromes, 2378–2381, 2381–2382
at-a-glance, 2378*b*
EEC syndrome, 2381, 2382*f*
etiology and pathogenesis, 2381–2382
Hay–Wells/Rapp–Hodgkin syndrome, 2379–2381, 2379*f*, 2380*f*
mutations, 2378
PABA (*para*-aminobenzoic acid), 3624
Pacemaker, preoperative examination, 3708
Pachyonychia congenita, 838–841, 846*t*
cellular defect, 781*t*
clinical features, 838–839, 839*f*, 840*t*
nail changes, 1599–1600, 1600*f*
etiology and pathogenesis, 839–840
pathology, 840
treatment, 840–841
Pacinian corpuscles, 351
in elderly, 1784
PADI3, uncombable hair syndrome, 1544
Paederus, 3331
Pagetoid reticulosis, 2082, 2082*t*, 2083*f*
Paget's disease, 1934–1941
at-a-glance, 1934*b*
clinical course and prognosis, 1938–1939
clinical features
cutaneous, 1934–1935, 1935*f*
history, 1934
noncutaneous, 1935
definitions and types, 1934
diagnosis
extramammary, 1937, 1937*t*
immunohistochemistry markers, 1937–1938, 1938*t*
mammary, 1936–1937
pathology, 1937–1938, 1937*f*, 1938*f*
differential diagnosis, 1936*t*
direct tumor involvement of skin, 2462
epidemiology, 1934
etiology and pathogenesis
extramammary, 1936
mammary, 1935–1936
historical perspective, 1934
management
extramammary, 1940–1941, 1940*f*
mammary, 1939–1940, 1939*f*
Paget's disease of the breast, 1934–1941. *See also* Paget's disease
PAHX, Refsum disease, 780*t*, 806
Pain
abdominal, hookworm, 3261
after cryosurgery, 3792
after nail surgery, 3778
bone
from retinoids, 3403
in SAPHO syndrome, bisphosphonates for, 1450
congenital insensitivity to, with anhidrosis, 1466
growing, 1222
herpes zoster, 3042, 3048
leprosy, 2899
postherpetic neuralgia, 3048
postoperative, 3721
Pain management
burns, 1688
hidradenitis suppurativa, 1491
Palisaded encapsulated neuroma (PEN), 2147*t*–2148*t*, 2150*t*, 2151–2152, 2152*f*–2153*f*
Palisaded neutrophilic granulomatous dermatitis (PNGD), 1148–1149. *See also* Rheumatoid arthritis (RA)
Palisading granulomas, inflammatory reactions, 27, 28*f*
Palmar erythema, alcohol abuse, 1713
Palmar pustular psoriasis of Barber-Königsbeck, nail involvement, 1580, 1580*f*
Palmoplantar hyperkeratosis with squamous cell carcinoma of skin and sex reversal syndrome, 836, 845*t*
Palmoplantar keratoderma Bothnia type, 825, 845*t*
Palmoplantar keratodermas (PPKs), inherited, 816–847, 845*t*–846*t*
acquired conditions, 818, 821*t*
at-a-glance, 816*b*–817*b*
classification, 817
diagnosis, 818, 820*f*
differential diagnosis, 818–820, 818*t*, 821*t*
diffuse inherited palmoplantar keratodermas with extracutaneous features, dominant inheritance, 828–834
Bart-Pumphrey syndrome, 829–832, 845*t*
connexin-associated palmoplantar keratodermas, 829–832
hidrotic ectodermal dysplasia, 832–833, 845*t*
Huriez syndrome, 824*f*, 833–834, 845*t*
keratitis–ichthyosis–deafness syndrome, 829–832, 830*f*, 845*t*
keratoderma–congenital alopecia syndrome, 832, 845*t*
Olmsted syndrome, 828–829, 845*t*
palmoplantar keratoderma with deafness, 781*t*, 783*f*, 824*f*, 829–832, 836, 845*t*, 846*t*
Vohwinkel syndrome, 781*t*, 783*f*, 824*f*, 829–832, 836, 845*t*, 846*t*
diffuse inherited palmoplantar keratodermas with extracutaneous features, mitochondrial inheritance, palmoplantar keratoderma with deafness, 836
diffuse inherited palmoplantar keratodermas with extracutaneous features, recessive inheritance, 834–836
Naxos disease, 781*t*, 835–836, 845*t*
palmoplantar hyperkeratosis with squamous cell carcinoma of skin and sex reversal syndrome, 836, 845*t*
Papillon-Lefèvre syndrome, 782*t*, 834–835, 834*f*, 845*t*
diffuse palmoplantar keratodermas without extracutaneous features, dominant inheritance, 821–825
epidermolytic palmoplantar keratoderma, 781*t*, 821–823, 822*f*, 845*t*
Greither syndrome, 823–824, 845*t*
loricrin keratoderma, 824–825, 824*f*, 845*t*
palmoplantar keratoderma Bothnia type, 825, 845*t*
Unna-Thost palmoplantar keratoderma, 823, 845*t*
diffuse palmoplantar keratodermas without extracutaneous features, recessive inheritance, 825–828
mal de Meleda, 781*t*, 825–827, 826*f*, 845*t*
Nagashima-type palmoplantar keratoderma, 827–828, 845*t*
epidemiology, 817–818
focal inherited palmoplantar keratoderma with extracutaneous features, dominant inheritance, 838–841
Howel-Evans syndrome, 834*f*, 841, 846*t*
pachyonychia congenita, 838–841, 839*f*, 840*t*, 846*t*
focal inherited palmoplantar keratoderma with extracutaneous features, recessive inheritance, 841–843
Carvajal syndrome, 842–843, 846*t*
Richner-Hanhart syndrome, 841–842, 846*t*
focal inherited palmoplantar keratoderma without extracutaneous features, dominant inheritance, 836–838
hereditary keratosis palmoplantaris variant of Wachters, 838, 846*t*
striate palmoplantar keratoderma, 837–838, 837*f*, 846*t*
genodermatoses with, 817, 818, 818*t*, 819*f*
morphological patterns, 817
punctate inherited palmoplantar keratoderma with extracutaneous features, dominant inheritance, Cole disease, 846*t*, 847
punctate inherited palmoplantar keratoderma without extracutaneous features, dominant inheritance, 843–847
type I, 843–844, 843*f*, 846*t*
type II, 844, 846*t*
type III, 844–847, 844*f*, 846*t*
terminology, 817
therapeutic approaches, common, 820–821
retinoids, oral, 821
surgery, 821

Palmoplantar keratodermas (PPKs) with deafness, 781*t*, 783*f*, 824*f*, 829–832, 836, 845*t*, 846*t*
Palmoplantar lichen planus, 531*t*, 532*f*, 536, 536*f*
Palmoplantar pustular psoriasis (PPPP)
  management, 494
  treatment, 494
Palmoplantar pustulosis (PPP), 462–463
Palpable arciforme migratory erythema (PAME), 2122
Palpable primary lesions
  nodule, 4*t*, 5, 5*f*
  papule, 4, 4*t*, 5*f*
  plaque, 4*t*, 5, 5*f*
Palpable purpura
  cocaine abuse, 1709
  cutaneous necrotizing venulitis, 2528, 2528*f*
  drug-induced vasculitis, 757
  drug reactions, 2530
Pancreatic panniculitis, 1253*t*, 1270–1272, 1270*f*–1271*f*, 1271*t*
Pancrelipase, for GI symptoms in Fabry disease, 2303
Pan-follicular differentiation neoplasms, trichofolliculoma, 1839, 1839*f*, 1839*t*
Panhypopituitarism, 2519–2521, 2520*t*, 2521*f*
Panitumumab, 3541, 3550*t*, 3565, 3568, 3597
  acneiform eruptions from, 1452
  molecular target and indications, 3559*t*
Panniculitis, 1251–1255. *See also specific types*
  α-antitrypsin, 1253*t*, 1266–1269
  cold, 1254*t*, 1280–1282, 1282*t*, 1675–1676
  connective tissue disease-associated, 1283*b*
  cytophagic histiocytic, 1253*t*, 1275–1278
  definition, 1251
  with dermatomyositis, 1253*t*
  dystrophic calcification, 2309
  eosinophilic, 659
  factitial and traumatic, 1254*t*, 1282*b*, 1282*f*
  gouty, 1283*b*
  infection-induced, 1252*t*, 1264–1266
  IV drug use, 1707
  lupus, 1253*t*, 1272–1275
  pancreatic, 1253*t*, 1270–1272, 1270*f*–1271*f*, 1271*t*
  pathology
    infectious, 30
    inflammatory reactions
      lobular, 29–30
      septal, 29, 29*f*
      traumatic, 30
  pathophysiology, 1251
  poststeroid, 1283*b*–1284*b*
  septal *vs.* lobular, 1255*t*, 1256
  subcutaneous, Sweet syndrome, 591
  types, 1252*t*–1254*t*
Panobinostat, 3559*t*, 3579–3580, 3579*f*
Pansclerotic morphea, PUVA for, 3672
PAPASH syndrome, 608, 1450
  hidradenitis suppurativa, 1484
PAPA syndrome, 608, 613, 1450
Papilla, dermal, 90*f*, 94–95
Papillary fibroblasts, 55
Papillary intralymphatic angioendothelioma (PILA), 2064
Papillary mesenchymal bodies, trichoepithelioma, 33, 33*f*
Papillomatosis
  psoriasis, 24
  seborrheic keratosis, 31 (*See also* Seborrheic keratoses (SK))
  verruca vulgaris, 30, 30*f*
Papillomaviruses, 3095, 3096*f*. *See also* Human papillomavirus (HPV)
Papillon-Lefèvre keratoderma, 782*t*
Papillon-Lefèvre syndrome (PLS), 782*t*, 834–835, 834*f*, 845*t*
Papular acrodermatitis of childhood, 3002–3004. *See also* Gianotti-Crosti syndrome (GCS)
Papular pruritic eruption (PPE), with well-controlled HIV, 3123, 3123*f*
Papular pseudolymphoma, 2123
Papular purpuric gloves-and-socks syndrome, 2996, 3015*t*
Papular xanthoma, 2034–2035
Papules, 4, 4*t*, 5*f*
  differential diagnosis, 1439*t*
Papuloerythroderma of Ofuji, 671–672, 672*f*, 2121, 2121*f*
  deck-chair sign, 672
  eosinophils, 671–672
Papulonecrotic tuberculid, 2869, 2869*f*, 2869*t*
Papulosquamous reaction pattern, 12*t*, 13
PAR-2 blockers, 3811
Parabens, 3377
Paracoccidioidal granuloma, 2980–2981, 2981*f*
Paracoccidioides brasiliensis, 2980–2981, 2981*f*
Paracoccidioidomycosis, 2980–2981, 2981*f*
Paradental diseases. *See also specific types*
  nummular eczema, 386
Paradoxical psoriasis, 3538
Paraffin waxing, for systemic sclerosis, 1102
Paragonimus westermani, 3252*t*
  exposure and symptom onset interval, 3259, 3260*t*
  migratory skin lesions, 3255*t*, 3256
  neurologic disease, 3261
  progression and duration, 3259, 3260*t*
  pulmonary nodules, 3261
  subcutaneous nodules and masses, 3257, 3257*t*
Parakeratosis, 21
  infantile granular, 1753
  psoriasis, 21, 24
  spongiotic dermatitis, 24
  squamous cell carcinoma in situ, 32
  verruca vulgaris, 31
Paramedian forehead flap, 3748–3750, 3750*f*
Paramenthane-3,8-diol (PMD), for Lyme disease prevention, 3301
Paraneoplastic pemphigus (PNP), 202, 934–942, 2443*t*, 2458. *See also specific types*
  at-a-glance, 934*b*
  clinical features, 935–937
    defining, 935*t*
    history, cutaneous lesions, 935–937, 936*f*
    related, 937
  diagnosis and differential diagnosis, 940, 940*f*, 941*t*
  epidemiology, 934
  etiology and pathogenesis, 934–935, 935*f*
  laboratory tests, 937–940
    antigens, target, 938, 939*t*
    histopathology, 938–939, 939*f*, 939*t*
    immunopathology, 939*f*, 940
    PNP antiplakin autoantibodies, 937, 938*f*
    special, 940
  lichenoid variant, 937
  lymphoproliferative disorder, underlying, 934
  prevention, 942
  prognosis and clinical course, 941
  treatment, 941–942, 941*t*
  tumors associated with, 934, 935*f*
Paraneoplastic syndromes, 2441
Paraneoplastic syndromes, cutaneous, 2441–2462, 2442*t*–2443*t*
  bullous, 2443*t*
  bullous disorders
    bullous pemphigoid, 2442*t*, 2459
    dermatitis herpetiformis, 2443*t*, 2459
    paraneoplastic pemphigus, 2443*t*, 2458
  collagen-vascular disease, 2442*t*
    dermatomyositis, 2453
    progressive systemic sclerosis, 2453
    dermal deposition, 2442*t*
    amyloidosis, systemic, 2442*t*, 2458
    scleromyxedema, 2442*t*, 2458
  dermal proliferative disorders, 2442*t*
    multicentric reticulohistiocytosis, 2442*t*, 2457
    necrobiotic xanthogranuloma, 2442*t*, 2457–2458
  direct tumor involvement of skin
    cutaneous metastases, 2460–2462, 2461*f*
    leukemia and lymphoma cutis, 2462
    Paget's and extramammary Paget's diseases, 2462
  fundamentals, 2441
  genetic syndromes involving skin and/or mucous membranes and associated with malignancy, 2444*t*–2446*t*, 2460
  hyperkeratotic dermatoses, 2441–2453, 2442*t*
  hypertrichosis lanuginosa acquisita, 2443*t*, 2459–2460, 2459*f*
  neutrophilic dermatoses, 2442*t*
    pyoderma gangrenosum, 2442*t*, 2457
    Sweet syndrome, 2442*t*, 2456–2457
  paraneoplastic syndromes, 2441
  reactive erythemas, 2442*t*, 2454–2456
    erythema gyratum repens, 2442*t*, 2454–2455, 2454*f*
    necrolytic migratory erythema, 2442*t*, 2455–2456, 2455*f*
  Trousseau syndrome, 2443*t*, 2460
Paraneoplastic vasculitis, 2529
Para-phenylenediamine (PPD), allergic contact dermatitis from, 405, 405*t*
Parapoxvirus, 3066*t*, 3081–3086
  bovine papular stomatitis virus, 3066*t*, 3081
  lymphocyte-rich infiltrate from, simulating lymphoma, 2115*f*, 2118
  Orf virus, 3066*t*, 3083–3086 (*See also* Orf virus)
  pseudocowpox, 449–450, 3066*t*, 3081–3083, 3082*f*, 3083*t*
Parapsoriasis, 505–511
  at-a-glance, 505*b*
  classification, 505, 506*t*
  clinical course and prognosis, 510–511
  clinical features
    complications, 506
    cutaneous, 505–506, 506*f*–507*f*, 506*t*
  diagnosis, 508–509, 508*t*
  differential diagnosis, 509–510, 510*t*
  epidemiology, 505
  etiology and pathogenesis, 506–508, 508*f*
  historical perspective, 505
  pathology, 509, 509*f*
  poikiloderma, 505, 506*t*
Parapsoriasis en plaques, 505–511. *See also* Parapsoriasis
Parastomal pyoderma gangrenosum, 607. *See also* Pyoderma gangrenosum (PG)
Parathyroid disease, 2509–2512
  at-a-glance, 2509*b*
  calciphylaxis, 2509–2510, 2511*f*
  clinical features, 2509–2511, 2509*t*, 2510*f*
  diagnosis and laboratory tests, 2512
  differential diagnosis, hypercalcemia, 2509*f*
  epidemiology, 2509
  etiology and pathogenesis, 2511–2512
  management, 2510*t*, 2511*t*, 2512
  patient approach, 2509, 2510*t*, 2511*t*
Parathyroid hormone (PTH), 2307
  in parathyroid disease, 2511–2512
Parathyroid hormone-related peptide (PTHrP), 2511
Parathyroid hormone-related peptide (PTHrP) receptor, 2511
Parkes Weber syndrome, 2659. *See also* Arteriovenous malformations (AVMs)

Parkinsonism, seborrheic dermatitis, 433
Parkland Formula, for burns, 1685–1686, 1685*t*
Paromomycin
  for amebiasis, 3247
  for cryptosporidiosis, 3245
  for leishmaniasis
    systemic, 3236
    topical, 3236, 3236*t*
Paromomycin sulfate, for leishmaniasis, 3237*t*
Paronychia
  candidiasis, 2958
  recalcitrant chronic, 3786, 3786*f*
  staphylococcal, 2725, 2726*f*
Paronychia congenita (PC), short inhibitory RNA, 307–308
Paroxetine, for neurotic excoriation, 1697*t*, 1700
Paroxysmal localized hyperhidrosis, 1464
Parry-Romberg syndrome, 3292
Partial closure, 3732
Partially involuting congenital hemangioma, 2060, 2061*f*
Partial nail avulsion, 3780, 3780*f*
Partial unilateral lentiginosis (PUL), 1381, 1967–1970, 1969*f*, 1970*t*
Particle size, on absorption, 3372
Parvovirus B19, 2994–2998, 3015*t*
  at-a-glance, 2994*b*
  clinical course and prognosis, 2996
  clinical features
    in adults, 2995*f*, 2996
    in children, 2995, 2995*f*
    papular purpuric gloves-and-socks syndrome, 2996, 3015*t*
  complications
    chronic B19, 2997
    fetal B19, 2997
    other, 2997
    transient aplastic crisis, 2997
  diagnosis, 2996
  differential diagnosis, 2997*t*
  epidemiology, 2994
  etiology and pathogenesis, 2995
  prevention, 2998
  treatment, 2997–2998, 2998*t*
PASH syndrome, 1450
  hidradenitis suppurativa, 1484
Pasini subtype, dominant dystrophic epidermolysis bullosa, 1021, 1029*t*
Pasireotide, for necrolytic migratory erythema, 2456
Pastes, drug, 3373*t*, 3375
Pasteurella, 2829*t*
  cellulitis and erysipelas, 2749, 2749*t*
Pasteurella multocida, 2829*t*, 2837–2838, 3339
Patch, 4, 4*f*, 4*t*
PATCHED1. *See also PTCH1*
  basal cell nevus syndrome, 1891
Patch testing
  allergic contact dermatitis, 405–408
    occupational, 450
  in children, 7*f*, 1756
  irritant dermatitis, 422
Patch-testing mechanics, 405–408
  allergen selection and placement, 405–406
  clinical relevance, assigning, 407
  complications, 407–408, 408*f*
  failure, complications from, 408
  grading and interpreting, 406–407, 407*f*
  systemic immunosuppressive agents, 408
Pathergy, cutaneous, Sweet syndrome, 590–591
Pathergy test, adamantiades–Behçet disease, 2571*f*, 2573
Pathologische Anatomie Leiden-endothelial (PAL-E) antigen, 117
Pathology, skin lesions, 18–39. *See also specific disorders*
  at-a-glance, 18*b*
  biopsy
    site, choosing, 18
    submissions, 18–19
    type, choosing, 18, 19*t*
  histopathology, immunohistochemical and histochemical stains, 19, 20*t*, 21*t*
  inflammatory reactions, 19–30
  neoplastic disorders, 30–39
Patient approach, 1–3. *See also specific disorders*
  history, 1–2, 2*t*
  physical examination
    conditions, ideal, 2–3
    scope, 2, 3*t*
    technique, 3
    tools, 3
Patient-oriented research, 40
Patient positioning, operative, 3715
Patient-reported outcome measures (PROMs), 46–47, 46*t*
Patterned dyschromatosis, neonatal, 1733–1734
Pattern recognition receptors (PRRs), 1251
PAX3, 334*f*, 335
  Waardenburg syndrome, 1322*t*, 1323
PAX3-FOXO1A, rhabdomyosarcoma, 2131*t*, 2144, 2145
PAX5, primary cutaneous diffuse large B-cell lymphoma, 2100
PAX7-FOXO1A, rhabdomyosarcoma, 2131*t*, 2144, 2145
PBGD/HMBS, acute hepatic porphyrias, 2235*t*, 2250
PBIDS, trichothiodystrophy, 1539*t*
PCSK9 inhibitors, for dyslipidemia, 2287
PCSK9 mutations, 2288
PCWH, 1323
PCYT1A, lipodystrophy, 1299
PDGFR inhibitors, 3558–3565. *See also* Tyrosine kinase inhibitors (TKIs), small-molecule
PD-L1, Langerhans cell histiocytosis, 2021
Peanut exposure, early age, on peanut allergies, 381
Peau d'orange
  scleredema, 1164, 1165*f*
  scleredema diabeticorum, 2497
Pediatric and adolescent dermatology, 1750–1763. *See also specific disorders*
  adolescents, 1756–1758 (*See also* Adolescent dermatology)
  at-a-glance, 1750*b*
  autism spectrum disorder, 1758–1760, 1758*t*, 1759*t* (*See also* Autism spectrum disorder (ASD))
  child abuse and neglect, 1762–1763
  children, 1754–1756
    evaluation, 1754, 1754*f*
    general anesthesia and sedation, 1756
    genital anatomy, female, 1754, 1755*f*
    patch testing, 7*f*, 1756
    procedures, performing, 1754–1756, 1755*f*, 1755*t*
  helpful tips, 1751*t*
  infants, 1750–1753 (*See also* Infant dermatology; Neonatal dermatology)
  medications
    drug labeling, 1760–1761
    systemic
      antimicrobials, 1762
      dosages, 1761–1762
      glucocorticoids, 1762
    topical, 1761, 1761*t*
  phototherapy safety, 3645
Pedicellariae, 3350, 3351*f*
Pediculicides, for lice, 3281–3282, 3281*t*, 3284
Pediculosis, 3278–3284
  in elderly, 1787
  lice species, 3278
Pediculosis capitis, 3279–3282
  at-a-glance, 3279*b*
  clinical features, 3280, 3280*f*
  complications, 3280
  differential diagnosis, 3280*t*
  epidemiology, 3279
  etiology and pathogenesis, 3279–3280, 3279*f*
  treatment, 3280–3282, 3281*t*
Pediculosis corporis, 3282–3283, 3282*t*
Pediculosis pubis, 3281*t*, 3283–3284, 3283*f*–3284*f*, 3284*t*
Pediculus humanus capitis, 3278
Pediculus humanus humanus, 3278
Pediculus humanus var. *corporis*, 3310*t*, 3318
Peeling skin syndromes, 803
  cellular defect, 781*t*
  genes
    CDSN, 803
    CHST8, 794–804
    CHSTA, 803
    CSTA, 803
    SERPINB8, 803
    TGM5, 803
Peels, chemical, 3895–3905. *See also* Chemical peels
PEG 4000, 3374
Pegaptanib, 3597
Pegylated interferon-α (PEG-IFNα), 3539, 3549*t*
  for hepatitis B virus, 3512
    with hepatitis D virus coinfection, 3512
  for hepatitis C virus, 3510–3511
  and ribavirin combination therapy, for hepatitis C virus, 3510–3511
Pegylated interferon-α-2a (PEG-IFNα-2a)
  for condyloma acuminata, 3502, 3502*t*
  for hepatitis B, chronic, 3502, 3502*t*
  for hepatitis C, chronic, 3502, 3502*t*
Pegylated interferon-α-2b (PEG-IFNα-2b)
  for condyloma acuminata, 3502, 3502*t*
  for cryoglobulinemia II and III, HCV
    mild to moderate, 2606
    severe, 2607
  for hepatitis B, chronic, 3502, 3502*t*
  for hepatitis C, chronic, 3502, 3502*t*
Pegylated liposomal doxorubicin (PLD), 3480–3481
  chemical structure, 3480–3481
  for cutaneous T-cell lymphomas, 2096
Pellagra, 2206*t*, 2214–2215, 2215*f*, 2215*t*
  hypermelanosis, 1363–1364
Pellino-1, allergic contact dermatitis, 192
Peltier effect, 1675
Pelvic inflammatory disease (PID), *Neisseria gonorrhoeae*, 3209
PELVIS, 2048
Pembrolizumab
  immune-related adverse events from, 2006, 2006*t*
  lichen planus from, 537
  for melanoma, 2002, 2005, 2005*f*, 2009, 2010*f*
  for Merkel cell carcinoma, 1931
  side effects, treatment algorithm, 2006, 2007*f*
Pemphigoid
  cell-poor variant, subepidermal blistering, 25
  keratinocyte transmembrane proteins, 232
  mucous membrane, 960–967
  pathology, eosinophils, 27, 27*f*
Pemphigoid (herpes) gestationis (PG), 1766–1767, 1768*t*, 1769*f*
Pemphigus, 761*t*, 909–925. *See also specific types*
  at-a-glance, 909*b*
  clinical course and prognosis, 922
  clinical features, 912–915
    drug-induced pemphigus, 914–915
    immunologic responses, 201–202

keratinocyte transmembrane proteins, 232
myasthenia gravis with, 915
neonatal pemphigus, 914
other associated diseases, 915
pemphigus foliaceus
cutaneous, 911*t*, 913, 914*f*
endemic, 910, 911*t*, 913
pemphigus erythematosus, 911*t*, 914
pemphigus vegetans, 911*t*
pemphigus vulgaris
cutaneous, 909, 910*t*, 911*t*, 912–913, 912*f*–913*f*
mucous membrane lesions, 12*f*, 911*t*, 912*f*, 913
thymoma with, 915
definitions, 909
diagnosis, 919–922
laboratory testing
enzyme-linked immunosorbent assay, 911*t*, 920–921, 920*f*
immunofluorescence, 911*t*, 919–920, 920*f*
pathology, 911*t*, 920–921, 921*f*
differential diagnosis and nosology, 909, 910*t*, 911*t*
epidemiology
age of onset, 912
incidence, prevalence, and sex ratio, 910
etiology and pathogenesis, 915–919
acantholysis pathophysiology, 916–917
autoantibodies, 201–202
desmoglein 3, 202
desmoglein compensation, 917, 918*f*
desmosomal cadherin autoantigens, 235, 235*f*
drugs, 753
electron microscopy, 916
genetics, immune response, 917–919
HLA haplotype inheritance, 303, 304*t*
pemphigus autoantigens, 915–916
familial benign, acantholysis, 23, 23*f*
historical perspective, 909
management, 922–925
corticosteroids, 922–923
cyclophosphamide, 925
dapsone, 925
future strategies, 927
intravenous immunoglobulin, 924–925
methylprednisolone, pulse IV, 925
oral immunosuppressive agents, 923–924
azathioprine, 924
methotrexate, 924
mycophenolate mofetil, 924
plasmapheresis, 925
rituximab, 923
paraneoplastic, 934–942, 2458
subtypes and variants, 909, 911*t*
with thymoma, 202
Pemphigus erythematosus, 911*t*, 914
Pemphigus foliaceus
clinical features, 911*t*
cutaneous, 911*t*, 913, 914*f*
endemic, 910, 911*t*, 913
histopathology, 921–922, 921*f*
immunologic responses, 201
pathophysiology, desmoglein 3, 202
Pemphigus foliaceus (PF)–type intercellular IgA dermatosis, 983*t*, 984, 985*f*
Pemphigus group, acantholysis, 23, 23*f*
Pemphigus neonatorum, 2721–2722, 2722*f*
Pemphigus vegetans (PVeg), 911*t*
Pemphigus vegetans (PVeg)–type intercellular IgA dermatosis, 983*t*, 984, 984*f*
Pemphigus vulgaris (PV), 909
clinical features
cutaneous, 909, 910*t*, 911*t*, 912–913, 912*f*–913*f*
mucous membrane lesions, 12*f*, 912*f*, 913
histopathology, 911*t*, 921, 921*f*
immunologic responses, 201
Pemphigus vulgaris (PV)–type intercellular IgA dermatosis, 983*t*, 984, 985*f*
Penciclovir, 3497–3498
dosing regimens, 3498, 3498*t*
for herpes simplex virus, 3029–3031, 3030*t*
indications, 3497–3498
mechanism of action, 3494*f*, 3497
pharmacokinetics, 3497
side effects and precautions, 3498
for varicella-zoster virus, 3051
Penetration enhancers
chemical, 3376
physical, 3376
Penetration pathways, 3371*f*
follicular, 3367, 3371*f*
hair follicles, 3368, 3371*f*
intercellular, 3367
intracellular, 3367, 3371*f*
stratum corneum, 3367–3368, 3371*f*
Penicillamine
for group A *Streptococcus* lymphangitis, 2739, 2739*t*
pemphigus from, 915
for yaws, 3181
D-Penicillamine, for adult-onset Still disease, 1158
Penicillin. *See also specific types*
for *Aeromonas hydrophila*, 2844
for anthrax, 2828
for bejel, 3184
for bites, human and monkey, 3339
for diphtheria, 2853
for erysipeloid, 2847
historical perspective, 2720
for listeriosis, 2841
for *Pasteurella multocida*, 2837, 3339
for rat-bite fever, *S. moniliformis*, 2839
severe cutaneous adverse reactions, 195, 195*f*
for *Streptococcus iniae*, 2849
for syphilis, with HIV, 3118–3119
systemic, 3407–3409
dosing regimen, 3409, 3410*t*
indications and contraindications, 3409, 3409*t*
pharmacology and mechanism of action
metabolism, absorption, and distribution, 3409
structure, 3407–3409
side effects and precautions, 3409, 3411*t*
for trench fever, 2806
Penicillin G
for anthrax, weaponized, 2828
for infective endocarditis, 2818
for *Neisseria meningitidis*, 2787
for skin and soft-tissue infections, dosing, 3410*t*
Penicillin plus clindamycin, for *Streptococcus* necrotizing fasciitis, 2775, 2776*t*
Penicillin plus gentamicin, for *Nocardia* actinomycetoma, 2889
Penicillin VK
for acute rheumatic fever, 1160
for group A *Streptococcus* impetigo and ecthyma, 2739, 2739*t*
Penicilliosis, 2982
Penicilliosis marneffei, 2982
Penicillium marneffei, with HIV, 3115
Penile intraepithelial neoplasia (PIN), 1871*t*, 1875*b*, 1876*f*
Penile lichen planus, 531*f*, 535
Pentamidine
for African trypanosomiasis, 3239–3240, 3239*t*
for amebas, opportunistic, 3248
for leishmaniasis, 3237*t*
Pentatrichomonas hominis, 3243
Pentoxifylline
for adamantiades–Behçet disease, 2576*t*
for cryofibrinogenemia, 2609
for erythema induratum and nodular vasculitis, 1262
for erythema nodosum leprosum, 2918
for leishmaniasis, 3236, 3237*t*
for lipodermatosclerosis, 1264
with hydroxychloroquine, 1264
for papular pruritic eruption with HIV, 3123
for peripheral arterial disease, 2674*t*, 2675
for Raynaud phenomena, 2621*t*, 2623
for sarcoidosis, 581*t*, 582
for thromboangiitis obliterans, 2681
Pentoxifylline, for pigmented purpuric dermatoses, 2596
Peptide receptor radionuclide therapy, for necrolytic migratory erythema, 2456
Peramivir, 3512–3513
Percutaneous absorption. *See also specific agents*
through stratum corneum, 210*f*, 217–218, 218*f*
toxicity, 3378
Perforating disorders
acquired, 1203–1209, 2438 (*See also* Acquired perforating disorders (APD))
phototherapy for, 3653
Perforating folliculitis (PF), 1203–1209, 1204*t*. *See also* Acquired perforating disorders (APD)
Perforating venous system, 3874, 3875*t*
Perforin gene, hemophagocytic lymphohistiocytosis, 2032
Perfusion
endothelial cells, 120, 121*f*
isolated limb, for melanoma metastases, 2004
vascular perfusion pressure, 3734
flap survival, 3734
vasculature, cutaneous, 120, 121*f*
Periadnexal (perifollicular) pattern, 26, 26*f*
Perianal intraepithelial neoplasia (PaIN), 1871*t*, 1874*b*
Pericarditis
systemic lupus erythematosus, 2427
systemic sclerosis, 2427
Perichondritis, *Pseudomonas aeruginosa*
clinical features, 2790, 2791*t*, 2793
diagnosis, 2794
management, 2796
Pericytes (PCs), 116, 117, 118*f*
Perieccrine inflammation, 26
Perifollicular sheath, 95
Perifolliculitis capitis, 2723
Perilipin (PLIN) family, sebaceous plants, 77
Perineural invasion, basal cell carcinoma, 1890
Perineural malignant peripheral nerve sheath tumor, 2494
Perineurioma, 2147*t*–2148*t*, 2150*t*, 2161, 2162*f*
Perinevoid leukoderma, 1952–1953, 1952*f*
Perinevoid vitiligo, 1952–1953, 1952*f*
Perinuclear ANCAs (pANCAs), cutaneous necrotizing venulitis, 2529, 2535
Periocular hemangioma, 2048, 2049*f*
Periocular rotation flaps, 3740–3741
Periodic acid-Schiff (PAS) histopathology, dermatophytes, 2929*t*
Periodontal Ehlers-Danlos syndrome (pEDS), 1213*t*, 1218*t*. *See also* Ehlers-Danlos syndromes
Perionychotillomania, 1598, 1599*f*
Perioperative considerations, 3706–3724
at-a-glance, 3706*b*
history and physical examination, 3706–3709 (*See also* History and physical examination)

Perioperative considerations (*Cont.*):
operative considerations and procedure, 3709–3720
anesthesia, local, 3710–3714, 3710*t* (*See also* Anesthetics, local)
antiseptics, topical, 3714–3715
equipment, 3715
informed consent, 3709–3710
patient positioning, 3715
skin preparation, 3714–3715
surgical procedure, 3715
suturing, 3715–3720 (*See also* Suturing)
vital signs, 3710
postoperative, 3720–3724 (*See also* Postoperative considerations)
preoperative assessment, 3706–3709
Perioral (periorificial) dermatitis, 1454–1455, 1454*f*
in children, 1754, 1754*f*
Periorbital cellulitis, 2748
Periorbital pigmentation, 1371, 1371*f*
Periorificial granulomatous dermatitis, 1454, 1454*f*
Peripheral arterial disease (PAD), obstructive, 2669–2675
at-a-glance, 2669*b*
clinical course and prognosis, 2673–2674
clinical features, 2669–2671
acute limb ischemia, 2669, 2670*t*
complications, 2671
cutaneous, 2669–2670, 2670*f*, 2670*t*
noncutaneous, 2670
diagnosis, 2671, 2672*f*, 2673*f*
differential diagnosis, 2672–2673, 2673*t*–2674*t*
epidemiology, 2669
etiology and pathogenesis, 2671
management, 2674–2675, 2674*t*
prevention, 2675
Peripheral blood stem cell transplantation, for scleromyxedema, 1168
Peripheral nerve blockage, regional, 3712–3713
Peripheral nerve sheath tumors, 2146–2150, 2147*t*–2148*t*
diagnosis, 2149*f*
fundamentals, 2146
malignant, 2147*t*–2148*t*, 2150*t*
neurofibromatoses, 2474
malignant transformation, 2146
nerve sheath constituents, 2146
neurofibromatosis 1, 2146
Peripheral venous disease. *See* Chronic venous disease (CVD)
Periplakin, 211, 237–238
Periporitis staphylogenes, 2723
Perivascular extravasation unit, 117
Perlecan, 241, 241*f*, 243*f*
dermal cell-matrix adhesion, 247
Permanent materials, 3911–3912
Permethrins, 3615–3616, 3615*t*
for eosinophilic folliculitis with HIV, 3123
for lice, 3281*t*, 3284
for rosacea, 1439
Permselectivity, 119–120, 120*f*
Pernicious anemia, 2206*t*, 2217–2218
Pernio (perniosis), 1673–1674, 1674*f*
perieccrine inflammation, 26
Peromyscus leucopus, 3320
Peroxisomal biogenesis disorder complementation group 11, 805
Peroxisome-proliferator-activated receptors (PPARs)
fibrates on, 2286
PPARβ/δ, 73*f*, 76*t*, 77
PPARγ, 73*f*, 76*t*, 77
sebaceous glands, 76*t*, 77
Persistent acantholytic dermatosis, 882*t*, 890–892, 890*f*, 891*f*, 891*t*, 892*f*
Persistent edema of rosacea, 1425–1426, 1426*f*
Persistent pigment darkening (PPD) method, 3625
Personal protective equipment (PPE), occupational skin disease prevention, 452–453
Pertuzumab, acneiform eruptions from, 1452
Petechiae, 4*f*
Peto studies, 43
Peutz-Jeghers syndrome, 1359, 1359*f*, 2434*t*, 2436, 2445*t*
lentigo simplex, 1968
PEX-7, Refsum disease, 780*t*, 806
PGD2, 150*f*
pH
skin, 1728
skin cleanser, 3806–3807
PHACE (posterior fossa brain malformations, hemangiomas of the face, arterial anomalies, cardiac anomalies, and eye abnormalities), 2047–2048, 2047*t*
propranolol on, 3598–3599, 3598*f*
screening, 2059
segmental infantile hemangioma with, 2044–2045, 2045*f*
Phaeohyphomycosis, 2967*t*, 2972
Phaeomycotic cyst, 2967*t*, 2972
Phagocytosis and cell killing disorders, genetic, 2409–2419
chronic granulomatous disease, 2409–2412
hyperimmunoglobulinemia E syndrome, 2413–2415, 2413*f*–2414*f*, 2413*t*
leukocyte adhesion deficiencies, 2412*b*
other, 2409, 2410*t*
silvery hair syndromes, 2415–2419, 2416*t*
Chédiak-Higashi syndrome, 2415–2418, 2416*t*
Griscelli syndrome, 2416*t*, 2418–2419, 2419*f*
WHIM syndrome, 2410*t*, 2415
Phakomatosis pigmentovascularis (PPV), 2639, 2641*f*
blue nevus, 1959
Phakomatosis spilorosea, nevus spilus, 1950
Pharyngitis, *Neisseria gonorrhoeae*, 3209
Phase I studies, 42
Phase II studies, 43
Phase III studies, 43
Phase IV studies, 43
Phenol, 3617, 3617*t*
Baker, 3901
Baker-Gordon, 3901
chemical peels
deep, 3901
medium-depth, 3901*t*
superficial, 3899, 3899*f*
for molluscum contagiosum virus, 3089
toxicity, 1683
Phenolic acids, oral photoprotection, 3630
Phenolic compounds, chemical burns, 441–442, 443*t*
Pheomelanin, 336–337
Phenothiazines, hypermelanosis from, 1365
Phenotype, skin
diagnosis, four skin parameters combined, 3814–3815, 3815*f*
melanoma, 1990
psoriatic arthritis with, 972*t*, 1128
Phenoxymethylpenicillin. *See* Penicillin VK
Phentolamine, for Raynaud crisis, 2624
Phenytoin
nodular pseudolymphoma from, 2116, 2116*f*
pellagra from, 2214
Pheochromocytoma
hypermelanosis, 1362
neurofibromatoses, 2474
Pheomelanin, 337, 338*f*
Pheromones, 1469
Philadelphia chromosome, 3558
Philtrum, 3698*f*, 3699
Phlebotomine sandfly, leishmaniasis vector, 3225, 3226*t*, 3227
Phlebotomy
for hemochromatosis, 1364
for porphyria cutanea tarda, 2242
Phonophoresis, 3376
Phosphatase and tensin homolog hamartoma tumor syndrome (PHTS), arteriovenous malformations, 1360, 2152, 2640*t*, 2659. *See also* Arteriovenous malformations (AVMs)
Phosphodiesterase (PDE) inhibitors, for Raynaud phenomena, 2621, 2621*t*
Phosphodiesterase 4 (PD4), 176
Phospholipase-β3 (PLCβ3), 353
Photoaging, 282–284, 282*f*–283*f*, 283*t*, 1779, 1780, 1781–1782
Photoallergens, 1657
systemic, 1660*t*, 1663
topical, 1660*t*, 1663
Photoallergic dermatitis, photobiology, 273
Photoallergy
clinical features, 1658*t*, 1663
definition, 1657
differential diagnosis, 1664
histopathology, 1663
management, 1663
pathophysiology, 1663
patient evaluation, 1663–1664
photoallergens, 1657
systemic, 1660*t*, 1663
topical, 1660*t*, 1663
prevalence, 1657
sensitizing agents, topical, 1658*t*
ultraviolet filters, 3627
Photobiology, cutaneous, 265–285
at-a-glance, 265*b*
cutaneous responses
to infrared radiation, 284
to UV radiation, 268–284 (*See also* Ultraviolet (UV) radiation, cutaneous responses)
to visible light radiation, 284
photophysics, photochemistry, and, 267–268, 267*f*–268*f*
sources, UV and visible radiation
artificial, 267
sunlight, 265–267, 266*f*, 266*t*
Photocarcinogenesis, 275–284, 315–317
actinic keratoses to squamous cell carcinoma, 317, 1857, 1862*f*, 1863, 1902
DNA damage, 275–278
cyclobutane pyrimidine dimers, 275–276, 275*f*–277*f*, 315–317, 316*f*, 317*f*
oxidative, 276–278, 277*f*
photocarcinogenesis, 275–278, 275*f*–277*f*
pyrimidine dimers, 275–278, 277*f*
pyrimidine pyrimidone photoproducts, 275–276, 275*f*–277*f*
mutation burden and clonal dynamics, 317, 318*f*
photoaging, 282–284, 282*f*–283*f*, 283*t*
UV radiation
sunlight, 315
wavelengths causing, 281–282
UV radiation-induced DNA damage and repair, 275–281, 275*f*–277*f*, 279*f*–280*f*, 315–317
DNA photoproducts, 315–316, 316*f*
mutations, 316–317, 318*f*
Photochemistry, 267–268, 267*f*–268*f*
Photochemotherapy, 274, 3664–3677. *See also* Psoralen and ultraviolet A (PUVA)
for alopecia areata, 1521–1522

at-a-glance, 3664*b*
conclusions and perspectives, 3677
historical perspective, 3664
in HIV-infected patients, 3674
indications
granuloma annulare, 3672
lymphomatoid papulosis, 3672
pityriasis rubra pilaris, 3672
psoriasis, 3668–3671, 3669*f*, 3670*f*
indications, for PUVA
alopecia areata, 3672
atopic dermatitis, 3649, 3672
cutaneous mastocytosis, 3672
cutaneous T-cell lymphoma, 3666, 3671–3672, 3671*f*
graft-versus-host disease, 3672–3673
lichen planus, 3672
pansclerotic morphea, 3672
photodermatoses prevention, 3674
pityriasis lichenoides, 3672
scleroderma, localized, 3672
vitiligo, 3673–3674, 3673*f*
for Langerhans cell histiocytosis, 2028
long-term risks, potential
actinic damage, chronic, 3675–3676
carcinogenesis, 3676
ophthalmologic, 3676
nail changes, 1599
patient selection and contraindications, 3676–3677
principles, 3664–3667
mechanisms, 3665–3666
pharmacokinetics, 3666–3667
photosensitivity effects, 3667
psoralen photochemistry, 3665, 3666*f*
responsive diseases, 3664, 3665*t*
ultraviolet A radiation, 3667
psoralens, 3665, 3666*f*
side effects and toxicity
acute, 3674–3675, 3675*t*
laboratory data, 3675
treatment protocols
bath photochemotherapy, 3667–3668
oral, 3668, 3668*t*
topical, 3667
Photodermatoses. *See also specific types*
diagnosis, 273
photobiology, 273
phototherapy for, 3651–3652
prevention, PUVA for, 3674
Photodistribution, 11
irritant dermatitis, multifactorial, 424
Sweet syndrome, 591
telangiectasia, 1661
Photodynamic therapy (PDT), 274–275, 3678–3682. *See also specific types*
for acne vulgaris, 1410
for actinic keratosis, 1864*t*, 1865
field-targeted, 1866
at-a-glance, 3664*b*
for basal cell carcinoma, 1889–1890
for Bowen disease, 1871, 1871*t*
efficacy and perspectives, 3682
for extramammary Paget's disease, 1941
for HPV warts with HIV, 3118
indications, 3680*t*
for leishmaniasis, 3236
for pigmented purpuric dermatoses, 2596
for pityriasis lichenoides, 515, 515*t*
principles
light sources and dosimetry, 3679
mechanism of action, 3679
photosensitizers, 3678–3679
systemic
for non-oncology indications, 3680, 3680*t*
for oncology indications, 3679–3680, 3680*t*
topical, 3680–3682
mechanisms, 3680, 3680*f*
for non-oncology indications, 3680*t*, 3681
for oncology indications, 3671*f*, 3680–3681, 3680*t*
Photoepilation, 3851–3852, 3853*t*
Photoexacerbated dermatitis, 1643–1644, 1643*f*, 1643*t*
Photoexposed sites, approach to dermatosis on, 1644–1647
clinical features and distribution, 1644, 1645*f*
laboratory studies, 1644–1646, 1646*t*
photopatch testing, 1647
phototesting, 1646–1647
Photoexposure. *See also* Sun exposure
accelerated skin changes, 1661
on skin aging, 1765, 1780*f*
Photography, global, androgenetic alopecia, 1500
Photohardening, for polymorphic light eruption, 1623–1624
Photo-immunosuppression, 271, 271*f*
Photons, 3820
stimulated emission, 3822, 3822*f*
Photoonycholysis, 1658, 1660*f*
Photopatch testing, 1642, 1647
Photophoresis. *See* Extracorporeal photochemotherapy (ECP)
Photophysics, 267–268, 267*f*–268*f*
Photo-phytodermatitis, 273
Photopneumatic device, for acne vulgaris, 1410–1411
Photoproduct, 267–268, 268*f*
for lichen planus pigmentosus, 1386
for phototoxicity prevention, 1662
Photoprotection, 3623–3632
for actinic dermatitis prevention, 1643
for acute hepatic porphyrias, 2251
at-a-glance, 3623*b*
for ataxia-telangiectasia, 2409
for congenital erythropoietic porphyria, 2244
for dermatomyositis, 1077
for DNA repair disorders, 2353–2354
for dysplastic melanocytic nevi prevention, 1977
for erythropoietic protoporphyria, 2249, 3632
for erythrose peribuccal of Brocq, 1383
garments
clothing, 3630
UV protection factor, 3630–3631
glass
buildings and cars, 3631
sunglasses, 3631
for lichen planus pigmentosus, 1386
for lupus erythematosus, 1055, 3632
for medication-induced pigmentation, 1367
for melasma, 1380
minimal erythema dose, 3624
for ochronosis, 1367
for photosensitive skin diseases, 3632, 3632*t*
for polymorphic light eruption, 1621
for postinflammatory hyperpigmentation, 1379
for Riehl melanosis, 1382
on skin aging, 1765, 1780*f*
for squamous cell carcinoma prevention, 1915
sunscreen, 3623–3629 (*See also* Sunscreen)
UV, 224–225
UVA, assessment, 3625
for xeroderma pigmentosa, 3632
for X-linked protoporphyria, 2235*t*
Photoprotection, oral
adverse effects, 3629
astaxanthin, 3630
beta-carotene, 3630
carotenoids, 3630
definition and use, 3629
flavonoids, 3630
ingredients, active, 3629, 3629*t*
lycopene, 3630
nicotinamide, 3629
nonpolyphenols, 3630
phenolic acids, 3630
polyphenols, 3629–3630
resveratrol, 3630
vitamin C, 3629
vitamin E, 3629
Photorejuvenation, 1866
Photosensitive lupus dermatitis. *See* Acute cutaneous lupus erythematosus (ACLE)
Photosensitivity, 1657–1664, 3632. *See also specific types*
at-a-glance, 1657*b*
from cytotoxic agents, 3485, 3485*t*
differential diagnosis, 1664
patient evaluation, 1663–1664
persistence and evolution to chronic actinic dermatitis, 1661, 1661*f*
photoallergy, 1663
phototoxicity, 1657–1663
prevalence, 1657
Sweet syndrome, 596
Photosensitivity dermatitis, 1639–1643. *See also* Actinic dermatitis, chronic
Photosensitization, coal tar, 274
Photosensitized reaction, 267–268, 267*f*–268*f*
Photosensitizers, 1640
photodynamic therapy, 274–275
Photostability, ultraviolet filters, 3627, 3627*f*
Phototherapy, 3635–3653. *See also specific types*
for acne vulgaris, 1410–1411
for acquired perforating disorder, 1209
at-a-glance, 3635*b*
for atopic dermatitis, 378, 3646*t*, 3648–3649
for cutaneous T-cell lymphoma, 3646*t*, 3649
for eosinophilic folliculitis with HIV, 3123
for graft-versus-host disease, 2333
for granuloma annulare, 3653
for hand eczema, chronic, 3652
for lichen planus, 3652
cutaneous, 544
for lymphomatoid papulosis, 3652
for mastocytosis, indolent systemic, 3652–3653
mechanisms, 3635–3639, 3637*f*
on collagen, 3638
on immune system, 3637–3638
on keratinocytes, 3638
on mast cells, 3638
on melanocytes, 3638–3639
for papuloerythroderma of Ofuji, 672
for perforating disorders, 3653
photobiology, 273–275
for photodermatoses, 3651–3652
phototoxic reactions, avoidance and management, 3642, 3642*t*
for pityriasis lichenoides, 515, 515*t*, 3652
prevalence, 1657
for pruritus, 3651
for psoriasis, 273–274, 483*t*, 490–491, 3645–3648, 3646*t*, 3647*f*
climatic therapy, 491
excimer laser, 483*t*, 491, 3649
history, 490
with HIV, 3122
mechanism of action, 490
psoralen and ultraviolet A light, 483*t*, 491
ultraviolet B light, 483*t*, 490
ultraviolet radiation, 271

Phototherapy (*Cont.*):
safety, 3643–3645
arsenic exposure, 3645
in children, 3645
in elderly, 3645
with HIV, 3645
photosensitizing medications, avoiding, 3645
in pregnancy, 3645
transplantation patients, 3645
ultraviolet A1, 3645
ultraviolet B, 3643
for sclerotic skin diseases
graft-versus-host disease, 3646*t*, 3651
nephrogenic systemic fibrosis, 3651
other, 3651
scleroderma, localized and systemic, 3646*t*, 3650–3651
targeted, 3643
for telangiectasia macularis eruptive perstans, 3652
ultraviolet A1, 3642–3643
for urticaria, chronic, 3651
for urticaria pigmentosa, 3652
for vitiligo, 3646*t*, 3650
Phototherapy devices, 3639–3643
arc or gas discharge lamps, 3639
basic principles, 3639–3640
digital, 3639
fluorescent lamps, 3639–3641
fundamentals, 3639
incandescent lamps, 3639
minimal erythema dose, 3640–3641
phototoxic reactions, avoidance and management, 3642, 3642*t*
psoralen and ultraviolet A, 3641–3642, 3641*t*, 3642*t*
targeted phototherapy, 3643
treated area size, 3640
ultraviolet A1, 3642–3643
ultraviolet B
broadband, 3640–3641, 3641*t*
narrowband, 3640–3641, 3640*t*
wavelength, 3640
Photothermolysis
fractional, 3830, 3835
for acne scars, 1411
historical perspective, 3846
selective, 3829–3830
pulse duration, 3829–3830, 3829*f*, 3829*t*
wavelength, 3829
Phototoxicity, 1657–1663
acute, 1657–1658, 1660*f*
clinical features, 1657–1661, 1658*t*
accelerated photo-induced changes, 1661
acute phototoxicity, 1657–1658, 1660*f*
chronic effects, 1661
lichenoid photosensitive eruption, 1661
photodistributed telangiectasia, 1661
photoonycholysis, 1658, 1660*f*
photosensitivity persistence and evolution to chronic actinic dermatitis, 1661, 1661*f*
pseudoporphyria, 1658, 1661, 1661*f*
slate-gray pigmentation, 1658, 1661*f*
definition, 1657
differential diagnosis, 1664
histopathology, 1658*t*, 1662
lichenoid photosensitive eruption, 1661
management, 1662–1663
pathophysiology, 1662
patient evaluation, 1663–1664
phototoxic agents
systemic, 1659*t*, 1662
topical, 1658*t*, 1661–1662
prevalence, 1657
Phototrichogram
androgenetic alopecia, 1500
telogen effluvium, 1512–1513
Phototypes, skin, 272, 272*t*
Phrynoderma (toad skin), vitamin A deficiency, 2205, 2205*f*
Phthiriasis palpebrarum, 3284, 3284*f*
Phthirus pubis, 3278
Phycomycosis, 2984, 2985*f*
subcutaneous, 2967*t*, 2973
Phylloquinone, 2211
Phyma
differential diagnosis, 1437*t*
rosacea, 1420–1422, 1421*f*, 1432, 1433*f*, 1434
Physalia physalis, 3344–3346, 3346*f*
Physalis utriculus, 3345
Physical abuse, 1717–1724. *See also* Abuse, physical
Physical examination
conditions, ideal, 2–3
neonatal skin, 1729–1730
preoperative, 3709
scope, 2, 3*t*
technique, 3
tools, 3
Physical exposure, occupational, 447–448
ionizing and nonionizing radiation, 447–448, 448*f*
thermal stress, 447
Physical penetration enhancers, 3376
Physical stress barrier, skin, 224–226, 225*f*
heat stress protection
sweating, 225
vasculature and blood flow, 225–226, 225*f*
mechanical stress protection, 224
UV stress protection, 224–225
Physical urticaria. *See also* Urticaria
after sclerotherapy, 3883–3884, 3884*f*
clinical features, cutaneous, 685
Physiologic hyperpigmentation, 1369–1372
acquired idiopathic facial pigmentation, 1370–1371
acral hyperpigmented macules, 1372
longitudinal melanonychia, 1372
mucosal melanosis, 1371–1372, 1371*f*
periorbital pigmentation, 1371, 1371*f*
pigmentary demarcation lines, 1369–1371, 1370*f*
Phytanic acid deficiency, Refsum disease, 806
Phytonadione. *See* Vitamin K (phytonadione)
Phytophotodermatitis, 1372
PI3K/AKT/PTEN, epidermal proliferation, 63
Picaridin, for Lyme disease prevention, 3301
Pick me ups, 1711
Piebaldism, 1321–1322
Piedra, 2935*t*–2936*t*, 2940, 2940*t*
Pigmentary demarcation lines (PDLs), 1369–1371, 1370*f*
Pigmentary mosaicism, 1351, 1733–1734, 1752, 1752*f*
neonatal, 1733–1734
Pigmentation, 328–345. *See also* Hyperpigmentation; Hypopigmentation; *specific disorders*
at-a-glance, 328*b*
gene mutations, 266*t*, 328
hepatobiliary disease, 2431
melanocytes, 328–342 (*See also* Melanin; Melanocytes)
variation, regulation of, 342–344
genes, other, 344
MC1R
in melanomagenesis, 343–344
signaling, 342–343, 342*f*–343*f*
in tanning, 343, 344*f*
MSH-MC1R-MITF pathway, 342–344
Pigmentation, hair, 98–101
hair cycle–dependent melanocyte changes, 100, 100*f*
melanocyte development, 98, 99*f*, 100*f*
melanocyte stem cells, 98–99
molecular control, 101
pigment-producing melanocytes, 99–100
Pigmentation, skin, 3811–3812
antioxidants, 3812
cosmeceuticals reducing, 3811, 3811*t*
exfoliants, 3811–3812
lignin peroxidase, 3812
PAR-2 blockers, 3811
pigmented *vs.* nonpigmented, 3811–3812
sunscreen, 3811
tyrosinase inhibitors, 3811
Pigmented allergic contact dermatitis, 396*t*, 397
Pigmented basal cell carcinoma, 1886, 1886*t*. *See also* Basal cell carcinoma
Pigmented epithelioid melanocytoma, 1959
Pigmented purpuric dermatoses (PPDs), 2590–2596, 2593
at-a-glance, 2590*b*
clinical course and prognosis, 2595
clinical features, 2590–2593
eczematid-like purpura of Doucas and Kapetanakis, 2591–2592, 2591*t*
granulomatous pigmented purpura, 2593
itching purpura, 2591*t*, 2592
lichen aureus, 2591*t*, 2592, 2592*f*
pigmented purpuric dermatosis/mycosis fungoides overlap, 2593
pigmented purpuric lichenoid dermatosis of Gougerot and Blum, 2591, 2591*t*, 2592*f*
progressive pigmentary dermatosis, 2590, 2591*t*
purpura annularis telangiectodes, 2590, 2591*t*, 2592*f*
unilateral linear capillaritis, 2593
diagnosis
laboratory testing, 2594
pathology, 2595, 2595*f*
differential diagnosis, 2596*t*
epidemiology, 2590, 2591*t*
etiology and pathogenesis, 2593–2594, 2594*t*
drugs, 2594, 2594*t*
other causes, 2594, 2594*t*
management, 2595–2596
Pigmented purpuric dermatosis/mycosis fungoides overlap, 2593
Pigmented purpuric eruptions. *See* Pigmented purpuric dermatoses (PPDs)
Pigmented purpuric lichenoid dermatosis of Gougerot and Blum, 2591, 2591*t*, 2592*f*
Pigmented schwannoma, 2155–2157
Pigmented spindle cell nevus (PSCN), 1961–1963, 1962*f*–1963*f*, 1963*t*
Pigmentokeratotica, nevus spilus, 1950
PIK3CA
benign lichenoid keratoses, 1973
hidradenoma papilliferum, 1835
keratinocytic epidermal nevus, 1808
lymphatic malformation, 2640*t*
macrocephaly–capillary malformation, 2640*t*, 2642
seborrheic keratoses, 1800, 1800*t*
solar lentigo, 1971
venous malformations, 2650
PIK3R2
macrocephaly–capillary malformation, 2640*t*, 2642
venous malformation, 2640*t*
PIK31, SHORT syndrome, 1299
Pilar cyst, 1814, 1814*f*
Pilar leiomyoma, 2131*t*–2132*t*
clinical course and prognosis, 2138
clinical features, 2135, 2136*f*
differential diagnosis, 2136–2137

etiology and pathogenesis, 2130
histopathology, 2136, 2136*f*, 2137*f*
management, 2138
Pilar sheath acanthoma, 1847
Pili annulati, 1548, 1551*t*
Pili torti, 1540–1541, 1540*f*, 1541*f*, 1541*t*, 1549*t*
Pili trianguli et canaliculi, 1543–1544, 1544*f*, 1544*t*
Pilocarpine, hyperhidrosis from, 1466
Pilomatrical carcinoma, 1844–1845
Pilomatricoma (pilomatrixoma), 1822*t*, 1843–1844, 1844*f*
dystrophic calcification, 2309
Pilosebaceous unit, 70, 71*f*
Pimecrolimus, 3526–3527. *See also* Calcineurin inhibitors (CNIs)
dosing regimen, 3522*t*, 3526
drug interactions, 3527
on eosinophils, 658
indications and contraindications, 3526
for nummular eczema, 388
pharmacology and mechanism of action, 3520*f*, 3526
for psoriasis, 482*t*, 490
for seborrheic dermatitis, 434–435
side effects and precautions, 3526–3527, 3527*t*
Pimecrolimus, topical
for actinic dermatitis prevention, 1643
for Fox-Fordyce disease, 1477
for lichen striatus, 560–561, 1804
for lupus erythematosus, 1055
for perioral dermatitis, 1455
for pigmented purpuric dermatoses, 2595
Pimozide
for delusions of parasitosis, 1696, 1697*t*
for dermatitis artefacta, 1703
Pincer nail, 1577–1578, 1578*f*
surgery for, 3789
Pinch grafts, 3755
Pineapple extract. *See* Bromelain
Pine tar, 3611
Pink color, 8*t*
Pinta, 3173–3177
at-a-glance, 3173*b*
clinical course and prognosis, 3177
clinical features
complications, 3176
cutaneous, 3174–3175, 3175*f*–3176*f*
noncutaneous, 3175
definition, 3173
diagnosis
laboratory testing, 3176
pathology, 3176–3177
differential diagnosis, 3177*t*
epidemiology, 3174
etiology and pathogenesis, 3176
historical perspective, 3173–3174
management, 3177
Pintids, hypermelanosis from, 1369
Pinworms, 3265*t*, 3266–3267
Piperacillin-tazobactam
for *P. aeruginosa*
bacteremia and ecthyma gangrenosum, 2796
otitis externa, malignant, 2796
for pyomyositis, 2778
Piperacillin-tazobactam plus vancomycin, for necrotizing fasciitis, 2775, 2776*t*
Pirfenidone, 2477
Pitted keratolysis, 2740–2741, 2741*f*
occupational, 449
Pitting, 1574, 1575*f*, 1575*t*
Pit vipers, 3342, 3342*f*
Pityriasiform scale, 6*t*
Pityriasis amiantacea, 429–430, 431*f*. *See also* Seborrheic dermatitis
Pityriasis lichenoides, 511–515
at-a-glance, 511*b*
clinical course and prognosis, 515
clinical features
complications, 512
cutaneous, 511–512, 511*f*–512*f*
diagnosis and pathology, 513–514, 513*f*–514*f*
differential diagnosis, 514, 514*t*
epidemiology, 511
etiology and pathogenesis, 512–513
lymphomatoid papulosis and, 513
management, 515, 515*t*
phototherapy, 515, 515*t*, 3652
PUVA, 3672
Pityriasis lichenoides chronica (PLC), 505, 511–515. *See also* Pityriasis lichenoides
Pityriasis lichenoides et varioliformes acuta (PLEVA), 505, 511–515
Pityriasis lichenoides with ulceronecrosis and hyperthermia (PLUH), 511, 512*f*
Pityriasis rosea, 518–524
at-a-glance, 518*b*
clinical course and prognosis, 524
clinical features, 518–521
Christmas tree pattern, 518, 520, 520*f*, 521*f*
complications, 521
cutaneous, 519–520, 519*f*–521*f*
herald patch, 518, 519, 519*f*, 520*f*, 522
history, 518–519
polycyclic eruption, 11*f*
diagnosis, 522–523
laboratory tests, 522
pathology, 522–523, 522*f*–523*f*
differential diagnosis, 523, 523*t*
epidemiology, 518
etiology and pathogenesis, 521–522
HHV-6, 518, 521–522
HHV-7, 3009
historical perspective, 518
management, 524
Pityriasis rotunda, 809, 2442*t*, 2448
Pityriasis rubra pilaris (PRP), 498–503
at-a-glance, 498*b*
classification and clinical features, 498–502, 499*t*
associations, 501–502
type I, 498, 499*f*–501*f*, 499*t*
type II, 498, 499*t*
type III, 498, 499*t*, 501*f*
type IV, 498–500, 499*t*, 502*f*
type V, 499*t*, 500
type VI, 501
clinical course and prognosis, 502–503
diagnosis, 502
differential diagnosis, 502*t*, 869*t*
epidemiology, 498
etiology and pathogenesis, 502, 502*f*
management
systemic, 503–504, 503*t*
topical, 503, 503*t*
photochemotherapy for, 3672
Pityriasis versicolor
Malassezia, 2959, 2960*f*–2961*f* (*See also Malassezia*)
seborrheic dermatitis, 432
Pityrosporum. See Malassezia
Pityrosporum blepharitis, 428
Pityrosporum folliculitis
in elderly, 1787
with HIV, 3116
seborrheic dermatitis, 428, 432, 433
Pityrosporum ovale, in elderly, 1787
PKD1, tuberous sclerosis complex, 2485
PKP1, plakophilin deficiency epidermolysis bullosa simplex, 1015*t*
PLAG1
apocrine mixed tumor, 1832
lipoblastoma/lipoblastomatosis, 2177
Plague, 2829*t*, 2832–2833
Plakin
autoantibodies, paraneoplastic pemphigus, 937, 938*f*, 938*t*
desmosomal, 233
Plakoglobin, 237
gene mutation, mast cell granules, 154, 154*t*
Plakophilin, 233, 237
mutations and disease, 237
autosomal dominant ARVC, 237
ectodermal-dysplasia-skin fragility syndrome, 237
epidermolysis bullosa simplex, 1017
Plane warts, 31, 3098, 3098*f*, 3099*t*
Plane xanthomas, 2275–2276, 2278*f*, 2282–2283
Planing, surgical. *See* Dermabrasion
Plants, irritant dermatitis from, 417
Plaque, 4*t*, 5, 5*f*
Plaquenil, for graft-versus-host disease, 2334
Plaques fauchée en prairie, 3151, 3152*f*
Plaque-type psoriasis, 458–459, 458*f*–460*f*
Plasmacytoid dendritic cells (PDCs), 152, 152*t*
lupus erythematosus, 1040
Plasmacytosis, cutaneous, 2124
Plasma exchange
for cryoglobulinemia type I, 2606
for protoporphyric hepatopathy, 2249
for vasculitis, 2557
Plasma imbibition, 3753
Plasmalemmal vesicle protein (PV)-1, 117
Plasmapheresis
for cryofibrinogenemia, 2609
for epidermal necrolysis, 744
for epidermolysis bullosa acquisita, 978
for hypercholesterolemia, 2288
for pancreatic panniculitis, 1272
for paraneoplastic pemphigus, 941*t*, 942
for pemphigus, 925
for urticaria, 702
Plasmodium falciparum, 3242
Plasmodium vivax, 3242
Platelet-derived growth factor (PDGF), 3590
angioblast development, 28
angiogenesis, 127*f*
graft-versus-host disease, 2322
tumor angiogenesis, 128, 128*f*
wound healing, 128, 128*f*, 2704*t*, 2707
Platelet-derived growth factor (PDGF), recombinant, for diabetic ulcers, 2498–2499
Platelet endothelial cell adhesion molecule (PECAM)-1, inflammation, 124
Platelet-rich plasma (PRP)
for alopecia areata, 1520
for frontal fibrosing alopecia, 1528
for hair transplantation, 3931*b*
Platelets, in wound healing, 2701, 2701*f*, 2702*f*
Platelike osteoma cutis, 2312
Platyhelminths, 3251, 3252*t*
PLCG1, cutaneous T-cell lymphomas, 2075
PLCG2, cold urticaria, 689
PLDN, Hermansky-Pudlak syndrome, 1316*t*
PLEC1
epidermolysis bullosa simplex of Ogna, 1015*t*
epidermolysis bullosa simplex with muscular dystrophy, 1015*t*
junctional epidermolysis bullosa with pyloric atresia, 1015*t*
Plectin, 243, 243*f*
epidermolysis bullosa, inherited, 1012
epidermolysis bullosa simplex with progressive muscular dystrophy, 245
Pleomorphic lipoma, 2179–2182, 2181*f*
at-a-glance, 2179*b*
clinical course, prognosis, and treatment, 2182

Pleomorphic lipoma (*Cont.*):
clinical features, 2179
differential diagnosis, 2182
epidemiology, 2179
etiology and pathogenesis, 2180
histologic features, 2180–2182, 2181*f*
Pleomorphic liposarcoma, 2193–2194, 2193*f*–2194*f*
Pleomorphic rhabdomyosarcoma, 2144
Plethysmography, Raynaud phenomena, 2618
Plexiform neurofibroma, 2150*t*, 2154, 2154*b*, 2157, 2467, 2468*f*, 2477
Plexiform schwannoma, 2154, 2155, 2156*f*. *See also* Schwannomas
PLIN1, familial partial lipodystrophy, 1298
PLIN2, sebaceous glands, 77
PLOD1, kyphoscoliotic Ehlers-Danlos syndrome, 1213*t*, 1216*t*
Plucked chicken skin, 1230
Plum color, 8*t*
PMS2, sebaceous adenomas, 1822*t*, 1849
PMVK, porokeratosis, 902*t*, 904
PNPLA2, Chanarin-Dorman syndrome, 803
Podofilox, 3620
Podophyllin, for oral hairy leukoplakia with HIV, 3114
Podophyllotoxin, topical
for HPV warts with HIV, 3118
for molluscum contagiosum virus, 3090
POEMS syndrome, Castleman disease, 2125
POFUT1, Dowling-Degos disease, 1327, 1327*t*
POGLUT1, Dowling-Degos disease, 1327, 1327*t*
Poikiloderma
dermatomyositis, 1067, 1067*f*
differential diagnosis, 506*t*
parapsoriasis, 505, 506*t*
Poikiloderma atrophicans vasculare, 505, 506*t*
Point prevalence, 45
Poison bun sponge, 3350, 3350*f*
Poisoning. *See also* Bites and stings
seafood, 3359
Poison ivy/oak, allergic contact dermatitis from, 396
Poison sumac, allergic contact dermatitis from, 396
POL, 3878, 3878*t*, 3879
POLD1, mandibular hypoplasia, deafness, progeroid features-associated lipodystrophy, 1299
POLH, xeroderma pigmentosum, XP-variant, 2351
Polidocanol (POL), 3878, 3878*t*, 3879
for pruritus, 358
for rosacea, persistent erythema pain, 1438
Poliovirus receptor, inflammation, 124
POLR3A, Wiedemann-Rautenstrauch syndrome, 1299
Polyarteritis nodosa (PAN), 2541, 2553, 2554*f*. *See also* Vasculitis
Poly-A tail, 292
Polycyclic configuration, 11, 11*f*
Polycystic ovarian syndrome (PCOS)
acanthosis nigricans, 2495
acne with, 1451
androgen excess, 2516–2517
hirsutism from, 1556*t*, 1558, 1558*f*
metabolic syndrome, 2516
Polydactyly, rudimentary, 2151, 2151*f*
Polyenes, 3438*t*, 3446
Poly-L-lactic acid (PLLA), 3913*t*, 3915–3916, 3916*f*
soft-tissue filler, 3913*t*, 3915–3916, 3916*f*
Polymethylmethacrylate (PMMA microspheres), 3911–3913
Polymorphic eruption of pregnancy (PEP), 1768*t*, 1773–1775
clinical course and prognosis, 1774–1775
clinical features, 1773–1774, 1773*f*–1774*f*
diagnosis, 1774
differential diagnosis, 1775*t*
epidemiology, 1773
etiology and pathogenesis, 1774
management, 1775
risk factors, 1774
Polymorphic light eruption (PMLE), 1611–1624
at-a-glance, 1611*b*
clinical course and prognosis, 1621
clinical features, 1612–1615
complications, 1613–1615
cutaneous, 1612, 1612*f*–1618*f*
insect bite, 1612, 1617*f*
juvenile spring eruption, 1612, 1617*f*
macular, 1612, 1612*f*
maculopapular, 1612, 1613*f*
noncutaneous, 1612
papular, 1612, 1614*f*
papulovesicular, 1612, 1615*f*
pinpoint, 1612, 1617*f*
plaque type, 1612, 1616*f*
purpura solaris, 1612, 1618*f*
wavebands, 1612
definition, 1611
diagnosis, 1618*t*, 1619–1621
algorithm, 1620–1621, 1622*f*
criteria, 1619*t*
laboratory testing, 1619
pathology, 1619, 1619*f*
patient history, 1619
phototesting and photoprovocation, 1619–1620, 1620*f*
differential diagnosis, 1621, 1621*t*, 1622*f*, 1623*f*
epidemiology, 1611–1612
etiology and pathogenesis, 1615–1618
antimicrobial peptides, 1618
genetics, 1618
hormonal factors, 1618
immunologic, 1615–1618
carcinogenesis and, 1617–1618
photoantigens, possible, 1616–1617
historical perspective, 1611
hydroa vacciniforme and, 1635
management, 1621–1624
experimental approaches, 1624
medications, 1621–1623
photohardening, 1623–1624
prevention/prophylaxis, 1621
severe cases, 1624
Polymorphisms, gene, 294–295, 294*f*. *See also specific types*
Polymorphous cold eruption, 1675
Polymorphous light eruption, 273
Polymyositis/dermatomyositis, cutaneous necrotizing venulitis with, 2529
Polymyxin B
for *P. aeruginosa*, nail, 1593
topical, 3420*t*, 3421
Polyphenols, oral photoprotection, 3629–3630
Polypoid seborrheic keratosis, 1801
Polyposis syndromes, 2436
Polyurethane, allergic contact dermatitis from, 405
Ponatinib, 3559*t*, 3564–3565, 3564*f*
Popliteal vein, 3871, 3872*f*
Popping scars, skin, 1706*t*, 1707
Popsicle panniculitis, 1675
PORC, Goltz syndrome, 55
PORCN, focal dermal hypoplasia, 2384
Porifera, dermatitis from, 3350, 3350*f*
Porocarcinoma, 1828–1829, 1828*t*
Porokeratosis, 901–906
at-a-glance, 901*b*
clinical features, 901–904
CDAGS syndrome, 902*t*, 904
disseminated superficial actinic porokeratosis, 901–902, 902*t*, 903*f*, 906*t*
disseminated superficial porokeratosis, 902, 902*t*, 906*t*
disseminated superficial porokeratosis of immunosuppression, 902–903, 906*t*
linear porokeratosis, 903, 903*f*, 906*t*
porokeratosis of Mibelli, 901, 902*f*, 902*t*, 906*t*
porokeratosis palmaris et plantaris disseminata, 902*t*, 904, 904*f*, 906*t*
punctate porokeratosis, 904, 906*t*
course and prognosis, 906
differential diagnosis, 905, 905*t*
epidemiology, 901
etiology and pathogenesis, 904–905
histopathology, 905, 905*f*
subtypes summarized, 906*t*
treatment, 905–906, 906*t*
Porokeratosis of Mibelli (PM), 901, 902*f*, 902*t*, 906*t*
Porokeratosis palmaris et plantaris disseminata, 902*t*, 904, 904*f*, 906*t*
Porokeratosis punctata palmaris et plantaris, 904, 904*f*, 906*t*
Poroma, 1823–1825, 1824*f*
Porphobilinogen (PBG), 2234
Porphyria(s), 2234–2252. *See also specific types*
acute, 2234, 2235*t*
biochemical abnormalities and differentiating measurements, 2234, 2237*t*
cutaneous, 2234, 2235*t*
heme synthesis and functions, 2235, 2236*f*
historical perspective, 2234
hypertrichosis from, 1565
mutated enzymes, inheritance, and classification, 2234, 2235*t*
photobiology, 273
Porphyria cutanea tarda (PCT), 2235–2243, 2235*t*
at-a-glance, 2235*b*
biochemical abnormalities and differentiating measurements, 2234, 2237*t*
clinical features, 2237–2238, 2238*f*–2239*f*
blistering, 24, 2237
subepidermal, 25
hypermelanosis, 1364, 2237, 2238*f*
hypertrichosis, 1565, 2237, 2238*f*
pseudoscleroderma, 2237
diagnosis, 2241
dystrophic calcification, 2309
epidemiology, 2235*b*
etiology and pathogenesis, 2240–2241, 2240*f*
susceptibility factors, 2238–2240
alcohol, 1713, 2239
antioxidants, 2240
chemical exposure, 2240
dialysis patients, 2438
drugs, 2240
estrogens, 2239–2240
hepatitis C, 2240
HIV, 2240
identification, 2241–2242
iron and hemochromatosis gene mutations, 2239
smoking and cytochrome P450 enzymes, 2239
UROD mutations, 2235*t*, 2236*f*, 2237–2241, 2240*f*
therapy, 2242
Porphyrins
for acne vulgaris, 1410
in photodynamic therapy, 3678–3681, 3678*f* (*See also* Photodynamic therapy (PDT))
Porphyromonas spp., 3339
Porrigo amiantacea, 429–430, 431*f*
Portuguese man-of-war, 3344–3346, 3346*f*

Port-wine stains. *See* Capillary malformations
Posaconazole
  for chronic mucocutaneous candidiasis, 2401
  for histoplasmosis, African, 2977
  for sporotrichosis, 2968
Positive predictive value, 46, 46*f*
Postcapillary venules, 117
Postexposure prophylaxis (PEP), HIV, 3505, 3505*t*
Postherpetic neuralgia (PHN), 1787, 3037*f*–3038*f*, 3045–3046
  management, 3038*f*, 3054
  pain pathogenesis, 3048
Postinflammatory hyperpigmentation (PIH)
  hypermelanosis, 1378–1379, 1379*f*, 1379*t*
  lichen striatus, 560
  patch testing, 408
Postinflammatory hypopigmentation, patch testing, 407–408
Post–kala-azar dermal leishmaniasis (PKDL), 3228, 3228*t*, 3233, 3234*f*, 3235
Postmarketing studies, 43
Postoperative considerations, 3720–3724
  complications, distant
    buried suture extrusion, 3724
    erythema and telangiectasia, 3724
    hypopigmentation, 3724
    milia or keratinous cysts, 3721–3722
    motor function loss, 3724
    scar formation, 3722*f*, 3723–3724, 3723*f*–3724*f*, 3724*t*
    sensory anesthesia, 3724
    suture track marks, 3722–3723, 3723*f*
  complications, immediate
    bleeding and hematoma, 3721, 3722*f*
    contact dermatitis, 3720–3721, 3721*f*
    dehiscence, 3721
    infection, 3720
    necrosis, 3721, 3722*f*
    pain, 3721
  follow-up, 3720
  immediate care, 3720
Postoperative pyoderma gangrenosum, 607. *See also* Pyoderma gangrenosum (PG)
Postphlebitic syndrome, 2690
Poststeroid panniculitis, 1283*b*–1284*b*
Postterm infants, skin, 1728, 1728*f*
Pot, 1711–1712
POT1, melanoma, 1990, 1991
Potassium chromate, allergic contact dermatitis from, 404
Potassium hydroxide (KOH)
  candidiasis, 2956, 2957*f*
  dermatophyte identification, 2929*t*
  Malassezia, 2960, 2962*f*
  for molluscum contagiosum virus, 3089
  scale examination, for fungi, 2930, 2930*f*
Potassium iodide
  side effects, 602
  for sporotrichosis, 2968–2969
  for Sweet syndrome, 601*t*, 602
Potassium permanganate, 3613*t*, 3617–3618
Pott, Percivall, 320
Poultices, 3373*t*, 3374
Povidone-iodine, 3612*t*, 3613, 3714
  for fungal infections, superficial, 2936*t*
  pediatric, 1761
Powders, 3373–3374, 3373*t*
Pox virus, 3065–3090, 3066*t*–3067*t*. *See also specific types*
  at-a-glance, 3065*b*
  Molluscipoxvirus, 3067*t*, 3086–3090
  Orthopoxvirus, 3065–3081, 3066*t*
  Parapoxvirus, 3066*t*, 3081–3086
  Yatapoxvirus, 3067*t*
PPARG, familial partial lipodystrophy, 1295, 1297
PPARβ/δ, 73*f*, 76*t*, 77
PPARγ, 73*f*, 76*t*, 77
PPK varians, 838, 846*t*
PPK with deafness (Vohwinkel syndrome), 781*t*, 783*f*, 824*f*, 829–832, 836, 845*t*, 846*t*
PPOX, variegate coproporphyria, 2235*t*, 2250
Prader-Willi syndrome, genomic imprinting, 300
Pragmatic studies, 42
Pragmatic trials, 43
Pralatrexate, for cutaneous T-cell lymphomas, 2096
Pramiconazole, for seborrheic dermatitis, 435
Pramoxine hydrochloride, 3617, 3617*t*
Praziquantel
  for perioral dermatitis, 1455
  for schistosomiasis, 3265*t*
Prazosin, for Raynaud phenomena, 2621*t*, 2622
PRDM1, sebaceous gland development, 72, 73*f*
PRDM5, brittle cornea syndrome, 1213*t*, 1217*t*
Preauricular cyst, 1817
Precancerous lesions, epithelial, 1857–1881. *See also* Epithelial precancerous lesions; *specific types*
PRECIS, 43
Precision medicine, 308
Precursor B-cell lymphoblastic lymphoma, dermal metastases, 2462
Precursor neoplasms, blastic plasmacytoid dendritic cell neoplasm, 1202*f*, 2102
Precursor proopiomelanocortin (POMC), 342, 342*f*
Prednisolone, oral/systemic
  for acne fulminans, 1449
  for adamantiades–Behçet disease, genital ulcers and skin lesions, 2575, 2575*t*, 2576*t*
  for cellulitis and erysipelas, with antibiotics, 2754
  for discoid lupus erythematosus, cicatricial alopecia, 1526
  for erythema elevatum diutinum, 2566
  for graft-versus-host disease, 2335
  for infantile hemangiomas, 2057–2058
  for Kawasaki disease, 2587
  for Langerhans cell histiocytosis, 2029, 2029*t*
  for lupus erythematosus, 1057
  for papuloerythroderma of Ofuji, 672
  for polymorphic light eruption, 1623
  for Rosai-Dorfman disease, 2031
Prednisone, 3383. *See also* Glucocorticoids
  for chronic bullous disease of childhood, 994*t*, 998*t*
  for immune reconstitution inflammatory syndrome, HIV, 3124
  for linear IgA dermatosis, 998*t*, 999
  for paraneoplastic pemphigus, 941*t*, 942
  for pityriasis lichenoides, 515, 515*t*
  for Wells syndrome, 667
Prednisone, oral
  for allergic contact dermatitis, 409
  for cryoglobulinemia II and III, non-HCV, 2607
  for mucous membrane pemphigoid, 966*t*, 967
  patch testing and, 408
  for pemphigus, 922–923
  for polymorphic light eruption, 1621–1623
  for pyoderma gangrenosum, 613, 614*t*
Prednisone, systemic
  for bullous pemphigoid, 952, 952*t*
  for cryofibrinogenemia, 2609
  for dermatomyositis, 1077
  for epidermolysis bullosa acquisita, 978, 979*t*
  for erythema nodosum leprosum, 2917
  for infantile hemangiomas, 2057–2058
  for lupus erythematosus, 1054*t*, 1057
  for morphea, 1114*f*, 1115–1116, 1115*t*
  for Sweet syndrome, 601, 601*t*
Preexposure prophylaxis (PrEP), HIV, 3504–3505, 3505*t*
Pregnancy
  acute intermittent porphyria, 2250–2251
  glucocorticoids, 3387
  hirsutism, 1556*t*, 1559
  melanonychia, 1570
  phototherapy safety, 3645
  preoperative examination, 3709
  sunscreen, 3627–3628
  telogen effluvium from, 1509
Pregnancy, skin changes and diseases, 1765–1777
  common, 1765, 1766*f*, 1766*t*
  dermatoses, with fetal risk, 1765–1773
    intrahepatic cholestasis of pregnancy, 1767–1771, 1768*t*
    pemphigoid gestationis, 1766–1767, 1768*t*, 1769*f*
    pustular psoriasis of pregnancy, 1768*t*, 1771–1773, 1772*f*, 1772*t*
  dermatoses, without fetal risk, 1773–1777
    atopic eruption of pregnancy, 1768*t*, 1775–1777, 1776*f*–1777*f*
    polymorphic eruption of pregnancy, 1768*t*, 1773–1775, 1773*f*–1774*f*, 1775*t*
  linea nigra, 1765, 1766*f*
  melasma, 1765, 1766*f*
  pruritus, 1765
  striae gravidarum, 1765, 1767*f*
Preimplantation genetic haplotyping, 306
Premature infant skin, 224
Premature termination codon mutation, 292
Prenatal diagnosis, genetics, 289, 305–306, 306*f*
Preseptal cellulitis, 2748
Preservatives
  allergic contact dermatitis from, 404
  topical therapy, 3377
Pressure alopecia, 1533
Preterm (premature) infants, 1727
Pretibial myxedema, 2505, 2505*f*. *See also* Hyperthyroidism
  inflammatory pathology, 28
Prevalence, 45
Prework cream, 424, 425
Prilocaine, 3710*t*
  cryosurgery, 3793
Prilocaine/lidocaine, 3710*t*
Primary biliary cirrhosis
  cutaneous manifestations, 2433
  lichen planus and, 539
Primary cutaneous acral CD8+ T-cell lymphoproliferation, 2088–2089
Primary cutaneous aggressive epidermotropic CD8+ cytotoxic T-cell lymphoma, 2088
Primary cutaneous B-cell lymphomas, 2097–2102. *See also under* Cutaneous lymphoma
Primary cutaneous CD4+ small and medium T-cell lymphoproliferative disorder, 2087–2088
Primary cutaneous CD30+ lymphoproliferative disorders, 2084–2087
  cutaneous anaplastic large cell lymphoma, 2085–2086, 2086*f*
  extranodal natural killer/T-cell lymphoma, nasal type, 2087, 2087*f*
  lymphomatoid papulosis, 2084–2085, 2084*f*–2085*f*
  subcutaneous panniculitis-like T-cell lymphoma, 2086

Primary cutaneous cribriform carcinoma, 1838
Primary cutaneous diffuse large B-cell lymphoma (PCLBCL)
  leg type, 2080–2101, 2097*t*, 2099*t*, 2100*f*
  other, 2101
Primary cutaneous follicular center lymphoma (PCFCL), 2097, 2097*t*, 2098–2099, 2098*f*, 2099*t*
  vs. cutaneous B-cell pseudolymphoma, 2110–2111, 2111*t*
Primary cutaneous marginal zone lymphoma (PCMZL), 2097, 2097*t*, 2099–2100, 2099*t*
  vs. cutaneous B-cell pseudolymphoma, 2110, 2111*t*
Primary cutaneous T-cell lymphomas (CTCL), 2072–2097, 3399. *See also under* Cutaneous lymphoma
  bexarotene for, 3399, 3400
Primary germ hair, 90–91, 90*f*
Primary immunodeficiency syndrome-associated dermatitis, skin microbiome, 257, 257*t*
Primary vasculitis of the CNS, 2554
Primitive neuroectodermal tumor (PNET), 2150*t*, 2164–2165
PRISMA, 44
Prison fever, 3318–3319. *See also* Typhus, epidemic (louse-borne)
PRKAR1A, Carney complex, 1359
PRKCQ, cutaneous T-cell lymphomas, 2075
Proanthocyanidins, oral photoprotection, 3630
Probenecid
  dapsone interactions, 3425, 3425*t*
  for gouty panniculitis, 1283*b*
Probiotics, for atopic dermatitis, 380
Procaine, 3710*t*
  for venomous fish spines, 3358
Procedure room, 3726
Procerus muscle, 3703, 3704*f*
Processionary caterpillars, 3334
Proctitis, *Neisseria gonorrhoeae*, 3209
Profilaggrin, 64–65, 216, 783
Progeria, adult. *See* Werner syndrome (WS)
Progerin, 283
Progesterone
  acute hepatic porphyrias, 2250
  cutaneous manifestations, 2515–2516
Programmed cell death. *See* Apoptosis
Progressive nodular histiocytosis, 2040
Progressive osseous heteroplasia (POH), 2312–2313, 2313*f*
Progressive pigmentary dermatosis, 2590, 2591*t*
Progressive symmetric erythrokeratoderma, 777*t*
Progressive systemic sclerosis, 2442*t*, 2453
  paraneoplastic, 2442*t*, 2453
Proliferating pilar tumor, 1822*t*, 1847–1848, 1848*f*
Proliferation, epidermal, 63
Proliferative disorders, dermal. *See also specific types*
  multicentric reticulohistiocytosis, 2036–2038, 2037*f*, 2442*t*, 2457
  necrobiotic xanthogranuloma, 2038–2039, 2442*t*, 2457–2458
  neonatal, 1744
Promethazine, for papular pruritic eruption with HIV, 3123
PROMIS, 46–47
Promoters, 292
Proopiomelanocortin (POMC), 2503–2504
  ACTH and Cushing syndrome, 2512
Proopiomelanocortin (POMC)–MC-1R pathway, 101
Proparacaine, 3710*t*
Propionibacterium. *See Cutibacterium*
Propionibacterium acnes, 3808
  acne vulgaris, 1394–1395, 1398–1399
  sarcoidosis, 577
Propofol, Raynaud phenomena from, 2616
Propranolol
  antiangiogenic actions, 3598–3599, 3598*f*
  for hemangioma, 3598–3599, 3598*f*
  for hyperhidrosis, stress-induced, 1463
  for infantile hemangiomas, 2055–2056, 2057*f*
  for Marfan syndrome, 1229
  for tufted angioma, 2062
Proprotein convertase subtilisin/kexin type 0 (PCKSK9), 2281
Propylene glycol, 3618–3619, 3619*t*
  for ichthyosis, 782
  for *Malassezia*, 2963, 2963*t*
  for palmoplantar keratodermas, inherited, 821
  for seborrheic dermatitis, 435
Prosector's wart, 2863–2864, 2864*f*, 2864*t*
Prosigne, 3922
Prospective study, 43
Prostacyclin
  endothelial cell, on platelets, 119, 119*f*
  for systemic sclerosis
    digital vasculopathy in, 1100
    pulmonary artery hypertension in, 1101
Prostaglandin analogs. *See also specific types*
  for alopecia areata, 1521
Prostaglandin H synthase 2. *See* Cyclooxygenase (COX)-2
Prostaglandin inhibitors. *See also* Naproxen
  hyperhidrosis from, 1465
Prostaglandins
  for Raynaud crisis, 2624
  for Raynaud phenomena, 2621, 2621*t*
Prostanoid, for thromboangiitis obliterans, 2681
Prosthetic joint infections, preoperative prophylaxis, 3707
Protease(s)
  rosacea, 1428*f*–1429*f*, 1429
  sweat, 82
Protease-activated receptor-2 (PAR2), 340, 356
Protease-activated receptor-4 (PAR4), 356
Protease inhibitors (PIs), 3508, 3509*t*
Proteasome-associated autoinflammatory syndrome (PRAAS), 639–640
Proteasome inhibitors. *See also specific types*
  bortezomib, 3592–3593
  for systemic amyloids, 2269
Protein A, *S. aureus*, 2727
Protein C concentrate, for *N. meningitidis* with purpura fulminans, 2788
Protein-energy malnutrition (PEM), 2200–2203
  clinical features, 2201, 2201*f*–2202*f*
  differential diagnosis, 2203*t*
  epidemiology, 2200–2201
  laboratory testing, 2202–2203
  treatment, 2203
Protein-replacement (augmentation) therapy, for α-antitrypsin panniculitis, 1269
Proteoglycans, 241–242
  dermal cell-matrix adhesion, 247
  wound healing, 2704
Prothrombin, in wound healing, 2701
Prothrombin fragment 1+2 (PF_{1+2}), in chronic spontaneous urticaria, 693
Proton pump inhibitors (PPIs). *See also specific types*
  for mastocytosis, 719, 719*t*
  mycophenolate mofetil interactions, 3519
  for systemic sclerosis, esophageal symptoms, 1101–1102
Proton therapy, 3688
Proto-oncogenes, 313
Protoporphyrias, 2235*t*, 2237t, 2245–2249
  at-a-glance, 2245*b*
  clinical features, 2247–2248, 2247*f*–2248*f*, 2247*t*
  diagnosis, 2248–2249
  epidemiology, 2246
  erythropoietic protoporphyria, 2235*t*
  etiology and pathogenesis, 2246
  therapy, 2249
  X-linked, 2235*t*
Provisional entities of cutaneous T-cell lymphoma, 2087–2089
  cutaneous γδ T-cell lymphoma, 2088
  definition, 2087
  primary cutaneous acral CD8+ T-cell lymphoproliferation, 2088–2089
  primary cutaneous aggressive epidermotropic CD8+ cytotoxic T-cell lymphoma, 2088
  primary cutaneous CD4+ small and medium T-cell lymphoproliferative disorder, 2087–2088
Proximal subungual onychomycosis, with HIV, 3115
Pruriceptors, 353
Prurigo aestivalis. *See* Polymorphic light eruption (PMLE)
Prurigo gravidarum. *See* Intrahepatic cholestasis of pregnancy (ICP)
Prurigo nodularis (PN), 388–392
  clinical features, 389–390, 390*f*
  complications, 390–391
  differential diagnosis, 391*t*
  epidemiology, 388
  etiology and pathogenesis, 388–389
  laboratory tests, 390
  prognosis and clinical course, 391
  special tests, 390
  treatment, 391–392, 391*f*
Prurigo nodules, alcohol abuse, 1713
Prurigo pigmentosa, 1373–1374, 1374*f*
Pruritic dermatoses, Merkel cell polyomavirus, 319
Pruritic urticarial papules and plaques of pregnancy, 1768*t*, 1773–1775, 1773*f*–1774*f*, 1775*t*
Pruritus, 357–360. *See also specific types*
  alcohol abuse, 1713
  atopic dermatitis, 370–371, 376
  autonomic nerves, 354–355
  basis, 370–371
  C and A fibers, cutaneous, 353, 354*f*
  cholestatic, 2431
  cholinergic, 690
  classification and clinical manifestations, 357–358, 358*f*
  cutaneous nerve anatomy, 351–352, 352*f*
  in elderly, 1786
  "high" (heroin), 1710
  management
    approach, 358–360, 359*f*
    burns, 1689
    new drugs, 360
    phototherapy, 3651
  neurobiology, 355–357, 356*t*
  pregnancy, 1765
  renal, 2436
  sensory nerves
    efferent function, 353–354
    functional subgroups, 352–353
  spinal cord, 355
Pruritus gravidarum. *See* Intrahepatic cholestasis of pregnancy (ICP)
PsAPASH, hidradenitis suppurativa, 1484
P-selectin
  eosinophils, 657
  inflammation, 124, 124*f*
  leprosy, 2904
P-selectin glycoprotein ligand-1 (PSGL-1, CD162), eosinophils, 656

PSEN1, hidradenitis suppurativa, 1483
PSEN2, hidradenitis suppurativa, 1483
PSENEN, hidradenitis suppurativa, 1483
Pseudoacne of the nasal crease, 1454, 1454*f*
Pseudoacromegalic face, Fabry disease, 2296, 2297*f*
Pseudoallergy, 692
Pseudoaneurysms, IV drug use, 1709
Pseudocellulitis, 2750
Pseudochromhidrosis, 1472, 1472*t*
Pseudocowpox, 449–450, 3066*t*, 3081–3083, 3082*f*, 3083*t*
Pseudo-Cushing syndrome, 2513
Pseudo-Darier sign, 12*t*
  congenital smooth muscle hamartoma, 1743–1744
  smooth muscle hamartoma, 2141
Pseudodominant phenotype/disorder, 296
Pseudoeccrine chromhidrosis, 1472, 1472*t*
Pseudofolliculitis barbae, 2723, 2724*f*
Pseudoglucagonoma syndrome, 2455
Pseudo horn cysts, seborrheic keratosis, 31, 31*f*
Pseudohypoparathyroidism, 2511
Pseudojaundice, hypothyroidism, 2507
Pseudolepromatous leishmaniasis, 3232, 3232*f*
Pseudoleukonychia, 1568, 1569*t*, 1570*f*
Pseudolymphomas (PSLs), cutaneous, 2108–2126
  from anticonvulsants, 756
  benign intravascular proliferation of lymphocytes, 2125–2126, 2126*f*
  classification, 2108, 2109*t*
  course, 2109
  cutaneous T-cell, 2113–2114, 2113*f*, 2114*f*
  definition, 2108
  diagnostic approach, 2108–2109
  drug-induced, 756
  etiology, 2108, 2109*t*
  histologic mycosis fungoides simulators, 2118–2122
    actinic reticuloid, 2119–2120, 2120*f*
    Borrelia-associated T-cell pseudolymphoma, 2121
    CD8+ T-cell pseudolymphoma in immunodeficiency, 2120–2121
    clonal dermatitis, 508, 508*f*, 2122
    inflammatory disorders as, 2121–2122
    lymphocyte infiltration of the skin Jessner-Kanof, 2122
    lymphomatoid contact dermatitis, 2118–2119, 2118*f*
    lymphomatoid drug reaction, 2119, 2119*f*
    palpable arciforme migratory erythema, 2122
    papuloerythroderma Ofuji, 671–672, 672*f*, 2121, 2121*f*
    T-cell clones in inflammatory skin diseases, detection, 2122
  historical aspects and terminology, 2108, 2109*t*
  lymphocyte-rich infiltrates, other disorders with, 2122–2125
    acral pseudolymphomatous angiokeratoma, 2122–2123, 2123*f*
    angiolymphoid hyperplasia with eosinophilia, 2124–2125, 2125*f*
    Castleman disease, 2125
    cutaneous inflammatory pseudotumor, 2124
    cutaneous plasmacytosis, 2124
    lymphoplasmacytic plaque, 2123–2124, 2123*f*–2124*f*
  nodular lymphocyte collections, 26
  nodular pseudolymphoma, 2109–2118
    arthropod bite reactions, persistent nodular, 2115–2116, 2115*f*
    Borrelia-associated B-cell pseudolymphoma, 2110*t*, 2111–2112, 2112*f*
    CD30+ T-cell pseudolymphoma, 2114, 2115*f*
    classification, 2109
    cutaneous B-cell pseudolymphoma, 2110–2111, 2111*t*
    cutaneous T-cell and mixed pseudolymphoma, 2113–2114, 2113*f*, 2114*f*
    drug and vaccine injection sites, 2116–2117, 2117*f*
    from drugs, 756, 2116, 2116*f*
    infections with lymphocyte-rich infiltrates simulating lymphoma, 2115*f*, 2117–2118
    from leech therapy, 2116, 2116*f*
    prevention, 2110
    pseudolymphomatous folliculitis, 2114–2115, 2115*f*
    scabies, nodular, 2115–2116
    tattoos or metals, 2117, 2117*f*
    treatment, 2110, 2110*t*
Pseudolymphomatous folliculitis, 2114–2115, 2115*f*
Pseudomonas
  cellulitis, 2749
    in elderly, 1787
  cutaneous necrotizing venulitis, 2530
  erysipelas, 2749
Pseudomonas aeruginosa, 2789–2796
  at-a-glance, 2789*b*
  chloronychia, 1568–1569, 1569*t*, 1571*f*
  clinical course and prognosis, 2795
  clinical features, 2790–2793
    cutaneous
      bacteremia and ecthyma gangrenosum, 2783*f*, 2790–2792, 2791*t*
      external otitis and perichondritis, 2790, 2791*t*, 2793
      folliculitis and hot-foot syndrome, 2790, 2791*t*, 2792*f*
      green nail syndrome and toe web infection, 2790, 2791*t*, 2792*f*
    noncutaneous, 2792–2793
  diagnosis
    bacteremia and ecthyma gangrenosum, 2794
    external otitis and perichondritis, 2794
    folliculitis and hot-foot syndrome, 2794
    green nail syndrome and toe web infection, 2794
  differential diagnosis, 2794, 2795*t*
  ecthyma gangrenosum, 2722
  epidemiology, 2789–2790
  epidermolysis bullosa, 1026
  etiology and pathogenesis
    bacteremia and ecthyma gangrenosum, 2793–2794
    external otitis, 2793
    folliculitis and hot-foot syndrome, 2793
    green nail syndrome and toe web infection, 2793
  "hot tub" folliculitis, 2724
  introduction and bacteriology, 2789
  management
    bacteremia and ecthyma gangrenosum, 2796
    external otitis and perichondritis, 2796
    folliculitis and hot-foot syndrome, 2796
    general, 2795
    green nail syndrome and toe web infection, 2795
  nail changes, 1592–1593, 1592*f*
  prevention, 2796
Pseudopelade of Brocq (PPB), 534, 1528
Pseudoporphyria, 761*t*
  dialysis patients, 2438
  drug-induced, 752–753
  phototoxicity, 1658, 1661, 1661*f*
Pseudopseudohypoparathyroidism, 2312
Pseudorheumatoid nodulosis, 1148
Pseudoscleroderma, 2237
Pseudotail, 1736
Pseudoverrucous papules and nodules, newborn, 1741, 1742*f*
Pseudoxanthoma elasticum (PXE), 1229–1233
  at-a-glance, 1229*b*–1230*b*
  clinical features, 1230–1231, 1230*f*
  differential diagnosis, 1231*t*, 1233
  dystrophic calcification, 2309
  epidemiology, 1230
  etiology and pathogenesis, 1232
  generalized arterial calcification of infancy, 1232, 1233
  laboratory investigation, 1232, 1232*f*, 1232*t*
  pathology, 28
  prevention and treatment, 1233
Psilocybin, 1711
PSMA6, psoriasis, 479
PSMB8
  autoinflammatory lipodystrophy syndrome, 1299
  CANDLE, 622*t*, 629
  PRAAS, 622*t*, 629
Psoralen(s), 3665, 3666*f*
  5-methoxypsoralen, 3665–3668
  8-methoxypsoralen, 3664–3668, 3668*t*
  bathwater delivery, 3667–3668
  photochemistry, 3665, 3666*f*
  photochemotherapy, 274, 3665
  phototoxicity, 1657–1658
  for SAPHO syndrome, 645
  topical, 3667
  4,5′,8-trimethylpsoralen, 3665
Psoralen and ultraviolet A (PUVA). *See also* Photochemotherapy
  acne aestivalis from, 1453
  for actinic prurigo, 1632
  for alopecia areata, 1521–1522
  for atopic dermatitis, 3649, 3672
  on basal cell cancer risk, 315
  with biologics, 3670
  for cutaneous anaplastic large cell lymphoma, 2086
  for cutaneous T-cell lymphoma, 2092–2093, 3649
  with cyclosporine, 3670
  effects, 3636*f*, 3637–3638
  generalized eruptive histiocytoma, 2035
  for graft-versus-host disease, 2334
  granuloma annulare from, 566
  on immune system, 3638
  for lichen nitidus, 558, 558*t*
  lupus erythematosus from, 1041*t*
  for lymphomatoid papulosis, 2085
  for mastocytosis, 718*t*, 720
  melanoma from, 1989
  with methotrexate, 3670
  for morphea, 1114*f*, 1115, 1115*t*
  for mycosis fungoides, 2090
  onycholysis from, 1658, 1660*f*
  for papuloerythroderma of Ofuji, 2121
  for parapsoriasis, 511
  photochemotherapy devices, 3641–3642, 3641*t*, 3642*t*
  phototoxicity
    long-term therapy, 1661
    reactions from, 3642, 3642*t*
  for pigmented purpuric dermatoses, 2596
  for pityriasis rubra pilaris, 503
  for primary cutaneous CD4+ small and medium T-cell lymphoproliferative disorder, 2088
  for prurigo nodularis, 392
  for psoriasis, 483*t*, 491, 3647–3648
    topical and bath PUVA, 3648
  with retinoids, 3670–3671

Psoralen and ultraviolet A (PUVA) (*Cont.*):
safety, 3644–3645
actinic damage, 3644
acute side effects, 3644
carcinogenesis, 3644–3645
ophthalmologic effects, 3645
for scleredema, 1166
on squamous cell cancer risk, 315
for systemic sclerosis, skin hardening in, 1100*t*, 1101
UVA in, 3667
for vitiligo, 1341, 1341*f*, 3650
Psoriasiform scale, 6*t*
Psoriasin (S100A7), 137, 222, 222*t*
Psoriasis, 457–482
alcohol abuse, 1713
at-a-glance, 457*b*
cardiovascular disease, 2425
chemokines, 183, 184*f*
clinical features, 5*f*, 7*f*, 458–466
complications
cardiovascular morbidity, 465
psychosocial, 465–466
elephantine psoriasis, 459
clinical features, cutaneous, 458–464
Auspitz sign, 458, 459*f*
erythrodermic psoriasis, 461, 462*f*
guttate psoriasis, 459–460, 460*f*
hair and sebaceous glands, 464
inverse psoriasis, 461, 461*f*
Koebner phenomenon, 138, 458–459, 459*f*
linear psoriasis, 464
nail changes, 464, 464*t*, 465*f*
napkin psoriasis, 461*f*, 464
plaque-type psoriasis, 458–459, 458*f*–460*f*
pustular psoriasis, 461–463, 463*f*
sebopsoriasis, 463–464
small plaque psoriasis, 461
Woronoff ring, 459, 460*f*
clinical features, noncutaneous, 464–465
geographic tongue, 464–465
psoriatic arthritis, 465
congenital, 1739
definition, 457
dermatomyositis, overlapping features, 1068
diagnosis, 479–481
algorithm, 480*f*
laboratory testing, 479–481
pathology, 479
differential diagnosis, 481, 481*t*
epidemiology
age of onset, 457–458
genetic, 458
prevalence, 457
etiology and pathogenesis, 199, 466–471
histopathology, 466, 468*f*
immunopathogenesis, 466–471
lesion development, 466, 467*f*, 468*f*
LL37 reactions, 199
single nucleotide polymorphisms, 199
genetics, 471–479, 471*f*, 472*t*–476*t*
MHC genes, 471, 471*f*, 477–478, 477*f*
non-MHC genes, 471*f*, 472*t*–476*t*, 478–479
dendritic cell and macrophage function, 479
IL-23–IL-17 signaling, 478
interferon signaling, 478
keratinocyte responses, 479
NF-κB signaling, 478
historical perspective, 457
with HIV, 3121–3122
HLA haplotype inheritance, 303, 304*t*
IL-17, 176, 198, 199
IL-23, 198
immunologic responses, 197–199
immunopathogenesis
keratinocytes, 471
lymphocytes, 466–468, 469*f*, 470*f*
myeloid cells, 468–471, 470*f*
infantile, 1739
kissing, 125, 126*f*
lymphocytes, 198
microbiome, skin, 257, 257*t*
napkin, 461*f*, 464, 1741*t*, 1742, 1742*f*
natural history, 481–482
onycholysis, 1572, 1573*f*
ostraceous psoriasis, 459
paradoxical, 3538
pathology, 24, 25f
acanthosis, 24
papillomatosis, 24
parakeratosis, 21, 24
pustular, 6*f* (*See also* Pustular psoriasis)
risk factors, other
drugs, 479
infections, 479
obesity, 479
smoking, 479
rupioid, 459
superantigens, 2767
T helper 17 cells, 146
TNF-α, 198
tobacco use on, 1714
vasculature changes, 125, 126*f*
Psoriasis, nail, 197, 464, 464*t*, 465*f*, 1578–1581
at-a-glance, 1578*b*
clinical features, 1579–1580, 1579*f*–1580*f*
course, 1581
diagnosis, 1581
differential diagnosis, 1581*t*
disease associations, 1581
etiology and pathogenesis, 1578
treatment, 1581
Psoriasis 2 (PSORS2), 629–631, 632*f*
Psoriasis management, 482–494
biologic, 198–199, 487*t*, 493–494
adalimumab, 469*f*, 487*t*, 493–494
brodalumab, 176, 469*f*
etanercept, 469*f*, 487*t*, 493–494
IL-23 antagonists, 494
infliximab, 198, 469*f*, 487*t*, 493–494
ixekizumab, 176, 198, 469*f*, 487*t*, 494
secukinumab, 176, 198, 469*f*, 487*t*, 494
TNF-α antagonists, 469*f*, 487*t*, 493–494
ustekinumab, 464, 469*f*, 487*t*, 494
combination treatments, 494
general considerations, 480*f*, 482–488, 482*t*–487*t*
palmoplantar pustular psoriasis, 494
photochemotherapy, 3668–3671
administration, 3668–3670
combination treatments, 3670–3671
effectiveness, 3668, 3669*f*, 3670*f*
phototherapy, 273–274, 483*t*, 490–491, 3645–3648, 3646*t*, 3647*f* (*See also* Phototherapy, for psoriasis)
climatic therapy, 491
excimer laser, 483*t*, 491, 3649
history, 490
with HIV, 3122
mechanism of action, 490
photosensitive psoriasis, 3648
PUVA, 483*t*, 491, 3647–3648
topical and bath, 3648
ultraviolet B, 483*t*, 490
broadband and narrowband, 3646–3647, 3647*f*
UV radiation, 271
pregnancy, 488*t*
systemic, oral, 484*t*–486*t*, 491–493
acitretin, 484*t*, 492
apremilast, 176, 486*t*, 492
cyclosporin A, 469*f*, 484*t*, 492
cyclosporine, 198
fumaric acid esters, 484*t*, 492
hydroxyurea, 485*t*, 493
methotrexate, 484*t*, 491–492
mycophenolate mofetil, 485*t*, 493
steroids, 493
sulfasalazine, 485*t*, 493
6-thioguanine, 485*t*, 493
tofacitinib, 176, 486*t*, 492
targeted phototherapy, 3647
topical, 482*t*, 488–490
anthralin, 489
bland emollients, 490
calcineurin inhibitors, 482*t*, 490
coal tar, 489–490
corticosteroids, 482*t*, 488, 489*f*
salicylic acid, 490
tazarotene, 482*t*, 490
vitamin D_3 and analogues, 482*t*, 488, 3122
women of childbearing potential, 488*t*
Psoriasis vulgaris, 458*f*, 459
Psoriatic arthritis (PsA), 197, 465, 1127–1138
at-a-glance, 1127*b*
clinical course and prognosis, 978, 1134
clinical features, 1127–1131
cutaneous, 972*f*, 1127–1128
medical risk factors and comorbidities, 1131
nail involvement, 1580
noncutaneous, 1128–1131
arthritis, 972*f*, 1128
dactylitis, 973*f*, 1128–1129, 1129*f*
enthesitis, 973*f*–974*f*, 1129, 1129*f*
eye disease, 974*f*–975*f*, 1129–1130, 1130*f*–1131*f*
inflammatory bowel disease, 1130–1131
phenotypes, 972*t*, 1128
spondyloarthritis, 974*f*, 1129
diagnosis
classification, CASPAR, 977*t*, 1128*t*, 1133
early, 1132
differential diagnosis, 978*f*, 1133, 1134*f*
epidemiology, 1127
etiology and pathogenesis
genetics, 1131–1132
pathogenesis, 1132
risk factors, 1132
management, 978–981, 1134–1137
adalimumab, 980*t*, 981
algorithm, 981, 982*f*, 1137
apremilast, 980–981, 980*t*
certolizumab, 469*f*, 493, 980*t*, 981
Core Domain Set, 978–979, 979*f*, 1134, 1135*f*
golimumab, 469*f*, 494, 980*t*, 981
guselkumab, 469*f*, 981, 1137
infliximab, 980*t*, 981
ixekizumab, 469*f*, 980*t*, 981
leflunomide, 979, 980, 980*t*
methotrexate, 979–980, 980*t*
new molecules, 1137
recommendations, 1135–1137, 1136*t*
risankizumab, 469*f*, 981
secukinumab, 469*f*, 980*t*, 981
sulfasalazine, 979, 980, 980*t*
tildrakizumab, 469*f*, 981
tofacitinib, 981
ustekinumab, 980*t*, 981
prevention/screening, 976–977, 977*t*, 981–982, 1137–1138
with pustulosis palmaris et plantaris, 463
Psoriatic arthritis and PASH (PsAPASH), hidradenitis suppurativa, 1484
Psoriatic arthropathy, HLA haplotype inheritance, 303, 304*t*
PSORS2, psoriasis, 478
PSTPIP1
PAPA syndrome, 608, 622*t*, 642, 1450
PASH syndrome, 1484
Psychodermatology
categorization, 1694*t*
delusional skin disorders, 1693–1697
at-a-glance, 1693*b*

delusions of parasitosis, 1694–1696, 1695*t*, 1696*t*
other, 1696
factitious disorders, dermatitis artefacta, 1702–1703
Morgellons, 1693, 1695*t*
nail changes, 1598, 1598*f*–1599*f*
obsessive-compulsive and related disorders, 1698–1701
AIDS phobia, 1701
at-a-glance, 1698*b*
body dysmorphic disorder, 1698–1699
body-focused repetitive behavior disorders, 1701
hair pulling disorder, 1697*t*, 1699–1700
hypochondriacal syndrome, 1701
neurotic excoriation, 1697*t*, 1700–1701, 1700*f*
onychophagia and onychotillomania, 1701
psychopharmacologic agents, 1697*t*
stress, telogen effluvium from, 1510
Psychogenic excoriation, 1697*t*, 1700–1701, 1700*f*
Psychogenic pseudoeffluvium, 1514
PTCH
rhabdomyoma, 2131*t*, 2143
syringocystadenoma papilliferum, 1834
PTCH1, 314, 3572, 3573*f*
basal cell carcinoma, 1884, 1885*t*
basal cell nevus syndrome, 1885*f*, 1891
trichoepithelioma, 1841
PTEN
arteriovenous malformations, 2659, 2662
Bannayan-Riley-Ruvalcaba syndrome, 1360
mucocutaneous neuromas, 2152
PTEN hamartoma tumor syndrome, 1360, 2152, 2640*t*, 2659
squamous cell carcinoma, 1903–1904
PTEN hamartoma tumor syndrome, 1360, 2152, 2640*t*, 2659
p-tert butyl-phenol formaldehyde resin, allergic contact dermatitis from, 404
Pterygium, 1573, 1574*f*
lichen planus, 535–536
Pterygium inversum, 1573, 1574*f*
PTPN11
LEOPARD syndrome, 1359
Noonan syndrome, 871
ulerythema ophryogenes, 871
PTPN14, lymphedema–choanal atresia, Klippel-Trenaunay syndrome, 2640*t*
PTPN22
psoriatic arthritis, 1131
systemic sclerosis, 1093
PTRF, congenital generalized lipodystrophy, 1296
Pubic lice. *See* Crab lice
Public health. *See also specific disorders and topics*
basic concepts, 40–42
definition, 40
epidemiology, 40–47 (*See also* Epidemiology)
Puffy hand syndrome, 1710–1711, 1711*f*
Pulmonary artery hypertension (PAH)
dermatomyositis, 1068–1069
systemic sclerosis, 1090–1091, 1100
Pulmonary sarcoidosis, 576
Pulmonary system disorders, skin manifestations, 2397*t*–2398*t*, 2428–2430
antineutrophilic cytoplasmic antibody–associated vasculitis, 2428–2430
aquagenic wrinkling of palms, 2430
autoimmune connective tissue disease, 2430
infectious diseases, 2430
sarcoidosis, 2428
yellow nail syndrome, 2430
Pulsed-dye laser (PDL). *See* Laser, pulsed-dye (PDL)
Pulsed light, intense (IPL). *See* Intense pulsed light (IPL)
Punch graft, 3755
for vitiligo, 1343, 1344*f*
Punctate inherited palmoplantar keratoderma with extracutaneous features, dominant inheritance, Cole disease, 846*t*, 847
Punctate inherited palmoplantar keratoderma without extracutaneous features, dominant inheritance, 843–847
punctate palmoplantar keratoderma
type I, 843–844, 843*f*, 846*t*
type II, 844, 846*t*
type III, 844–847, 844*f*, 846*t*
Punctate porokeratosis, 904, 906*t*
Punctate purpura of cobalt, 407
Purpura annularis telangiectodes, 2590, 2591*t*, 2592*f*
Purpura solaris, 1612, 1618*f*
Purpuric allergic contact dermatitis, 396*t*, 397
Purpuric reaction
drug-induced, 756–757
pattern, 7*f*, 16, 16*t*
PurTox, 3921
Purulent cellulitis, 2748
Push-ahead technique, 3911, 3913*f*
Puss caterpillar, 3334, 3334*f*
Pustular and acneiform eruptions, drug-induced, 750*t*, 751, 752*f*
Pustular and acneiform irritant contact dermatitis, 444
Pustular dermatosis, Sweet syndrome, 591
Pustular eruption of IBD, 607. *See also* Pyoderma gangrenosum (PG)
Pustular eruption of ulcerative colitis, Sweet syndrome, 591
Pustular psoriasis, 461–463, 463*f*
acrodermatitis continua of Hallopeau, 463
annular, 462
exanthematic, 462
generalized, 461–462, 463*f*
nail involvement, 1580
of pregnancy, 1768*t*, 1771–1773, 1772*f*, 1772*t*
pustulosis palmaris et plantaris, 462–463
PUVA for, 3670
Pustular pyoderma gangrenosum, 607. *See also* Pyoderma gangrenosum (PG)
Pustules, 4*t*, 5, 6*f*
differential diagnosis, 1439*t*
Pustulosis palmaris et plantaris (PPPP), 462–463
with psoriatic arthritis, 463
treatment, 494
PUVA lentigines, 1970, 1971*f*
PUVA lentigo, 1970–1973. *See also* Solar lentigo
PYCR1, cutis laxa, 1240
PYCR2, cutis laxa, 1240
Pyemotes herfsi, 3278, 3278*t*
Pyemotes tritici, 3278, 3278*t*
Pyemotes ventricosus, 3278, 3278*t*
Pyoderma faciale-O'Leary, 1424–1425. *See also* Rosacea
Pyoderma gangrenosum (PG), 605–615
agammaglobulinemia, 2394
at-a-glance, 605*b*
clinical features, 606–607
bullous pyoderma gangrenosum, 606–607, 606*f*
complications, 607
cutaneous, 606–607, 606*f*
noncutaneous, 607
parastomal, 607
postoperative, 607
pustular, 607
ulcerative, 606, 606*f*
vegetative, 606*f*, 607
definitions, 605
diagnosis
algorithm, 609
histopathology and infectious stains/cultures, 609–610
laboratory testing, 610
other, 610
vascular studies, 610
differential diagnosis, 610, 612*t*
epidemiology and disease associations, 605–606
etiology and pathogenesis, 607–609
associated diseases, 607–608
genetics, 608–609
hormones, 609
inflammatory mediators, 608
neutrophil activity, aberrant, 608
management, 610–614
approach, 610–611, 611*f*
counseling, 614
medications, 611–613, 614*t*
procedures, 613
for unresponsive disease, 613
wound care, 613
paraneoplastic, 2442*t*, 2457
pathology
neutrophils, 27
nodular lymphocyte collections, 26
prevention/screening, 614–615
rheumatoid arthritis, 1150–1151, 1150*f*
Pyogenic arthritis, pyoderma gangrenosum, and acne (PAPA) syndrome, 642–643, 642*f*
Pyogenic granuloma (PG), 2043*t*, 2059*b*, 2063–2064, 2063*f*
pathology, 37, 37*f*
Pyomyositis, 2777–2778, 2777*t*, 2778*t*
Pyrantel pamoate, for enterobiasis, 3265*t*, 3267
Pyrazinamide, for tuberculosis, 2862*t*–2863*t*
Pyrethrins, synergized, 3615*t*, 3616
Pyridostigmine, hyperhidrosis from, 1466
Pyridoxine. *See* Vitamin B_6 (pyridoxine)
Pyrimethamine, for toxoplasmosis, 3249
Pyrimidine dimers, UV radiation, 275–278, 277*f*
Pyrimidine pyrimidone photoproducts, UV radiation, 275–276, 275*f*–277*f*
6,4-Pyrimidine pyrimidone photoproducts, UV radiation damage, 275–276, 275*f*–277*f*
Pyrithione zinc shampoo, for *Malassezia*, 2963, 2963*t*
Pyrogenic toxic superantigens, 2727
Pyrrolidone carboxylic acid, 65
Pyruvic acid, keratolytic actions, 3618, 3619*t*

Q

Quality of life (QoL), patient-reported outcome measures, 46–47, 46*t*
Quality reporting, 44
Quality-switched lasers. *See* Laser, quality-switched (QS)
QuantiFERON-TB Gold (QFT-G) test, 2860
Quaternium-15, allergic contact dermatitis from, 404
Quinacrine
for lupus erythematosus, 1054*t*, 1056
for lupus panniculitis, 1275
Quinapril, for Raynaud phenomena, 2621*t*, 2622
Quinidine, granuloma annulare from, 566
Quinolone, pediatrics, 1762
Quinupristin/dalfopristin, systemic, 3419
for MRSA skin and soft tissue infections, complicated, 2731*t*, 2732
QUORUM, 44

R

R20 treatment, 3854
R915C, venous malformations, 2650
R1141X, pseudoxanthoma elasticum, 1232
Rab27A, 340, 340*f*
RAB27A
  Griscelli syndrome, 1317–1318, 2418–2419, 2419*f*
  Hermansky-Pudlak syndrome, 1316*t*
Rabies, 3340–3341
Rabies immune globulin (RIF), 3340–3341
Rac1, 336
Rac2, leukocyte adhesion deficiencies, 2412*b*
Racket nail, 1568
Rad, 3690
Radiation
  electromagnetic, 3820
  ionizing, 265
  nonionizing, 265
  occupational exposure, 447–448, 448*f*
  optical, principles, 3824–3825
  solar, 265–267, 266*f,* 266*t*
  types, 265, 266, 266*f,* 266*t*
Radiation acne, 1453
Radiation dermatitis, 3690–3692, 3691*t*
Radiation enhancement reactions, 3486
Radiation keratoses, chronic, 1881*b*
Radiation recall reaction, 3485, 3485*f,* 3485*t,* 3692–3693, 3693*t*
Radiation therapy, superficial, 3688, 3872–3874
  great saphenous vein, 3872–3874, 3872*f*–3874*f,* 3873*t*
  saphenofemoral junction, 3873, 3873*f*–3874*f,* 3873*t*
  saphenous nerve, 3873
  small saphenous vein, 3872–3874, 3872*f,* 3873
Radioallergosorbent testing, contact urticaria, 450–451
Radiofrequency needles, insertional, skin tightening, 3848, 3858, 3859
Radiofrequency systems, 3848
  fat reduction, 3848, 3862, 3863
Radiotherapy, 3687–3695. *See also specific types and disorders*
  adverse effects
    alopecia, 3691*t*
    atrophy, 3691*t*
    induration or fibrosis, 3691*t*
    radiation dermatitis, 3690–3692, 3691*t*
    radiation recall reactions, 3692–3693
  at-a-glance, 3687*b*
  for basal cell carcinoma, 1890
  bolus, 3688–3689, 3688*f*–3689*f*
  clinical applications, 3693–3696
    benign disease, 3693–3694, 3693*t*
    extranodal marginal zone lymphoma, 2100
    Kimura disease, 669
    malignant disease
      basal cell carcinoma, 3693*t,* 3694
      cutaneous B-cell lymphomas, 3693*t,* 3694–3695
      cutaneous T-cell lymphomas, 3693*t,* 3694
      marginal zone lymphomas, 3695
      melanoma, 3693*t,* 3694
      squamous cell carcinoma, 3693*t,* 3694
    primary cutaneous CD4+ small and medium T-cell lymphoproliferative disorder, 2088
    primary cutaneous follicular center lymphoma, 2099
  custom lead/alloy shield, 3689, 3689*f*
  dose, biologically effective, 3690
  dose and fractionation schedule, 3690
  external-beam radiation, modulation, 3688–3689, 3688*f*
  for extramammary Paget's disease, 1941
  for hidradenitis suppurativa, 1491
  intensity-modulated radiation therapy, 3689
  mechanism of action, 3690
  for melanoma, 2002, 3693*t,* 3694
  for Merkel cell carcinoma, 1929–1930, 1930*f*
  radiation modalities
    charged particle therapy, 3687–3688, 3688*f*
    depth dose distributions, 3687, 3688*f*
    Grenz rays, 3687
    orthovoltage X-rays, 3687
    proton therapy, 3688
    selection, 3687
    skin sparing, 3687
    treatment energies, 3687
  superficial, 3688
RAF1
  LEOPARD syndrome, 1359
  Noonan syndrome, 871
RAG-1, Omenn syndrome, 1740
RAG-2, Omenn syndrome, 1740
Raised (palpable) primary lesions
  nodule, 4*t,* 5, 5*f*
  papule, 4, 4*t,* 5*f*
  plaque, 4*t,* 5, 5*f*
Raltegravir, 3508, 3509*t*
Ramsay-Hunt syndrome, 3042, 3044*f*–3045*f*
Randomized clinical trials
  efficacy, 41–42
  pragmatic, 43
Ranibizumab, 3599
Ranitidine. *See also* Antihistamines, H_2
  dosing regimens, 3458*t*
  for mastocytosis, 719, 719*t*
RANTES, erythema nodosum, 1256
Rapamycin. *See* Sirolimus (rapamycin)
Rapidly cycling unipotent nail stem cells, 110–111, 110*f*
Rapidly involuting congenital hemangioma (RICH), 2059–2060, 2059*b,* 2060*f*
Rapp-Hodgkin syndrome, 2379–2381, 2379*f,* 2380*f*
  pili torti, 1541*t*
RAS
  benign lichenoid keratoses, 1973
  melanoma, 3580
  plexiform neurofibromas, 2467
  squamous cell carcinoma and keratoacanthoma, 1907
Ras, neurofibromatosis, 2470–2471
RASA1
  arteriovenous malformations, 2662
  capillary malformations, 2640*t,* 2642
Ras-guanosine triphosphatase–extracellular signal-regulated kinase, eosinophil signaling, 651
Ras-MAPK pathway
  eosinophil signaling, 651
  epidermal proliferation, 63
RAS-RAF-MEK-ERK pathway. *See* MAPK pathway
Rat-bite fever, 2829*t,* 2838–2839
Rattlesnake, timber, 3342, 3342*f*
Raynaud crisis, 2624–2625
Raynaud phenomena (RP), 2613–2625
  associations
    connective tissues diseases, 2615
    medications and toxins, 2615*t,* 2616
    neurologic disorders, 2615
    occupational, 2615–2616
    other, 2616
  at-a-glance, 2613*b*
  Cannabis arteritis, 1712
  clinical course and prognosis, 2619–2620
  clinical features, 2613–2615
    blood pressure and arterial filling, 2614
    cutaneous, 2614, 2614*f*
    history, 2613–2614
    neurologic, 2614–2615
  cocaine abuse, 1709
  from cytotoxic agents, 3486
  diagnosis
    criteria and algorithm, 2617, 2617*t*
    Doppler imaging, 2618
    finger systolic pressure, 2618
    laboratory studies, 2617
    nailfold capillaroscopy, 2618, 2618*f*
    plethysmography, 2618
    thermal imaging, 2618
  differential diagnosis, 2618–2619, 2618*t*
  epidemiology, 2613
  etiology and pathogenesis
    intravascular, 2617
    neural, 2616–2617
    other, 2617
    vascular, 2616
  management, 2620–2625
    algorithm, 2625*f*
    behavioral modification, 2620, 2620f
    critical ischemia, 2624–2625
    pharmacologic, 2620–2623
      anticoagulants and thrombolytics, 2623
      antioxidants, 2623
      aspirin and antiplatelet therapies, 2621*t,* 2623
      nitric oxide, 2621, 2621*t*
      pentoxifylline, 2621*t,* 2623
      phosphodiesterase inhibitors, 2621, 2621*t*
      vasoconstriction inhibitors, 2621*t,* 2622
      vasodilators, 2620–2622, 2621*t*
    procedural
      botulinum neurotoxin, 2623
      surgical debridement and amputation, 2624
      sympathectomy, 2623–2624
      vascular reconstruction, 2624
    ulcer care, 2624
  occupational, 2615–2616
  primary and secondary, 2613
  pterygium inversum, 1573
  rheumatoid vasculitis, 1151
  systemic sclerosis, 1086, 1087, 1088*f,* 1095–1096, 1096*t*
  thermoregulatory reflex, 122
  triggers, 2613
  vasospastic attacks, 122
RB1, blastic plasmacytoid dendritic cell neoplasm, 2102
Rb-1 expression, loss
  nevus lipomatosis superficialis, 2175
  spindle-cell lipoma and pleomorphic lipoma, 2182, 2182*f*
Reaction patterns, 4, 12–17. *See also specific types*
  definition and fundamentals, 12–13
  dermal, 15, 15*t*
  eosinophil involvement
    eosinophilia-myalgia syndrome, 675
    eosinophilic fasciitis, 675, 1110, 3292
  with surface change
    dermal "plus," 14, 14*t*
    eczematous, 13–14, 13*t*
    papulosquamous, 12*t,* 13
    vesiculobullous, 13*t,* 14
  without surface change
    dermal, 15, 15*t*
    erythemas, 16, 16*t*
      figurate, 16, 16*t*
      morbilliform, 16
      targetoid, 16, 16*t*
      urticarial, 7*f,* 16, 16*t*
    macular, 14*t,* 15
    purpuric, 15–16, 16*t,* 17*f*
    subcutaneous, 15, 15*t*
Reactive arthritis (ReA), 1138–1142
  at-a-glance, 1138*b*
  with circinate balanitis, 983, 983*f,* 1139, 1139*f*–1140*f*

clinical features, 983*f*–984*f*, 1139–1140
cutaneous, 1139–1140
nail involvement, 1580, 1580*f*
noncutaneous, 983*f*–984*f*, 1140
with dactylitis, 984, 1140
definition and nomenclature, 1139
diagnosis, 1141
differential diagnosis, 1141
with enthesitis, 984, 984*f*, 1140, 1140*f*
epidemiology, 1139
genetics, 1140–1141
HLA-B27, 984, 1140
HLA haplotype inheritance, 304*t*
with keratoderma blenorrhagicum, 983, 984*f*, 1140, 1140*f*
prognosis, 1142
risk factors, 1141
treatment, 1142
Reactive erythemas, paraneoplastic, 2442*t*, 2454–2456. *See also specific types*
erythema gyratum repens, 771–772, 772*f*, 773*t*, 2442*t*, 2454–2455, 2454*f*
necrolytic migratory erythema, 2442*t*, 2455–2456, 2455*f*
Reactive granulomatous dermatitis, 1148–1149. *See also* Rheumatoid arthritis (RA)
Reactive hemophagocytic syndrome, adult-onset Still disease, 1156
Reactive oxygen species (ROS)
allergic contact dermatitis, 193
UV radiation, 276–278, 277*f*, 315
Reactive perforating collagenosis, 1203–1205
Reactive units, skin, anatomy, 19, 21*f*
Real-time PCR (RT-PCR), orthopoxviruses, 3070
Rebamipide, for adamantiades–Behçet disease, 2575*t*
Recalcitrant erythematous desquamating disorder (REDD), 2764
Receptor activator of NF-κB ligand (RANKL), 168
Receptor-activity-modifying proteins (RAMPS), 178
Recessive dystrophic epidermolysis bullosa (RDEB), 314, 1020, 1021–1023, 1022*f*–1023*f*, 1029*t*
squamous cell carcinoma, 1903, 1904*t*
Recessive dystrophic epidermolysis bullosa (RDEB) mitis, 1020, 1021–1023, 1022*f*–1023*f*, 1029*t*
Rechallenge, type IV hypersensitivity reaction, 397
Reciprocal translocation, 300
Recluse spiders, 3326–3327, 3326*f*–3327*f*
Recombinant human platelet-derived growth factor BB (becaplermin), 3590–3592. *See also* Becaplermin
RecQ helicases, 2344
Bloom syndrome, 1361, 2344, 2362
RECQL4 (RecQ family)
Rothmund-Thomson syndrome, 2344, 2364
squamous cell carcinoma, 1904
Recurrent jaundice of pregnancy. *See* Intrahepatic cholestasis of pregnancy (ICP)
Recurrent melanocytic nevus, 1955
Recurrent toxin-mediated perineal erythema, 2766–2767
Red blood cell transfusions, for protoporphyric hepatopathy, 2249
Red-brown color, 8*t*
Red bugs, 3278, 3278*t*
Red color, 7–9, 8*t*, 9*f*. *See also* Erythema
Red-legged widow, 3324–3326, 3326*f*
Red light, for acne vulgaris, 1410
Red sponge, 3350
Red tattoo dye, pseudolymphoma from, 2117
Reduviidae (kissing/assassin bug), 3240, 3332
Trypanosoma cruzi vectors, 3332
Reed nevus, 1961–1963, 1962*f*–1963*f*, 1963*t*
Reed syndrome, 2134, 2136, 2445*t*
Refeeding, protein-energy malnutrition, 2203
Refeeding syndrome, 2199*b*
Reflex sympathetic dystrophy, Raynaud phenomena, 2615
Reflux, venous, 3871, 3876
Refsum disease, 780*t*, 806–807
cellular defect, 781*t*
PAHX, 780*t*, 806
PEX-7, 780*t*, 806
phytanic acid deficiency, 806
Refugees, helminthic infections, 3251–3253, 3253*f*
Regeneration matrix, dermal, 2711, 2711*t*
Regenerative maturation (keratinocytes), 471
Regional graft, 3755, 3756*f*
Regulatory T cells (Tregs), 160
graft-versus-host disease, 2321–2322
psoriasis, 146, 146*f*, 468, 469*f*
Reinnervation, grafts, 3753
Reiter syndrome. *See* Reactive arthritis
Relapsing polychondritis (RP), 1186–1190
at-a-glance, 1186
clinical course and prognosis, 1189–1190
clinical features
cutaneous, 1186, 1187*f*–1188*f*
noncutaneous, 1186–1187, 1188*f*
diagnosis, 1189, 1189*t*
differential diagnosis, 1190*t*
epidemiology, 1186
etiology and pathogenesis, 1188–1189
management, 1190
Relapsing Polychondritis Activity Index (RPDAI), 1190
Relative risk, 45
Relaxed skin tension lines (RSTLs), 3699, 3699*f*
elliptical excision, 3727–3728, 3727*f*
Renal crisis, scleroderma, 1086, 1087, 1091, 1102, 1102*t*
Renal insufficiency, half-and-half nails, 1597, 1597*f*
Renal pruritus, 2436
Renal sarcoidosis, 576
Renal system disorders, skin manifestations, 2406*t*, 2436–2439
acquired perforating dermatoses, 2438
bullous diseases of hemolysis, 2438
calciphylaxis, 2438, 2509–2510, 2511*f*
nail changes, 2437
renal pruritus, 2436
Replicative senescence, 1765–1766
Reporter genes, 293
RePUVA, 3670
lymphocyte-rich infiltrate from, simulating lymphoma, 2115*f*, 2118
Reserpine, for frostbite, 1669
Reservoir, skin surface, 3366
Resident memory (T_{RM}) cells, 147, 148*f*
Resins, formaldehyde-containing, allergic contact dermatitis from, 404
Resiquimod, 174
for cutaneous T-cell lymphomas, primary, 2090
Resistant skin, 3808
Reslizumab, for hypereosinophilic syndromes, 665
Resonator (laser), 3820
Resorcinol
for acne vulgaris, 1404
chemical peel, superficial, 3899, 3899*f*, 3901*f*
for hidradenitis suppurativa, 1487
Resorption, topical therapy, 3369–3370
Resveratrol, oral photoprotection, 3630
Retapamulin, topical, 3420*t*, 3421–3422, 3613*t*, 3614
for group A *Streptococcus* impetigo, 2739, 2739*t*
for staphylococcal impetigo, 2730, 2731*t*
Reticular configuration, 10, 10*f*
Reticular dermis pathology, inflammatory reactions, 25–28
fibrous dermis and extracellular matrix, 28–29, 29f
infiltrate composition, 26–28
eosinophils, 27, 27*f*
granulomatous reactions, 27–28, 28*f*
lymphocytes, 26–27
neutrophils, 27
pattern evaluation, 25–26
angiocentric, 25–26, 26*f*
nodular, 26, 26*f*
periadnexal, 26, 26*f*
Reticular fibroblast, 55
Reticular perineurioma, 2161
Reticular pigmented anomaly of the flexures, 1354
Reticulate acropigmentation of Dohi, 1324–1325, 1324*f*
hyperpigmentation, 1387
Reticulate acropigmentation of Kitamura (RAK), 1325–1326, 1326*f*, 1327*t*, 1355
Reticulated papillomatosis of Gougerot and Carteaud, 809
Reticulated seborrheic keratosis, 1801, 1801*f*
Reticulate pigment disorders, 1324–1327
at-a-glance, 1324*b*
Dowling-Degos disease, 65*t*, 781*t*, 1326–1327, 1327*t*
dyschromatosis symmetrica hereditaria, 1324–1325, 1324*f*, 1327*t*
dyschromatosis universalis hereditaria, 1325, 1327*t*
reticulate acropigmentation of Kitamura, 1325–1326, 1326*f*, 1327*t*, 1355
Reticulate scleroderma, from melphalan, 3486
Retiform configuration, 10, 10*f*
Retiform hemangioendothelioma, 2064
Retiform perineurioma, 2161
Retinal photocoagulation, for incontinentia pigmenti, 2387
Retinoic acid 4-hydroxylase (CYP26), 3397–3398, 3398*t*, 3403–3404
Retinoic acid metabolism blocking agents (RAMBAs), 3398
Retinoic acid receptors (RARs), 3395, 3397
sebaceous glands, 76*t*, 77
Retinoic acid–responsive element (RARE), 3397
Retinoid(s), 3395–3404. *See also specific types*
for acanthosis nigricans, 2447, 2496
for acne vulgaris, 1402–1404, 1402*t*
for acrokeratosis paraneoplastica of Bazex, 2453
for aging skin, 3814
at-a-glance, 3395*b*
for cutaneous T-cell lymphomas, 2093–2094, 2093*t*
dosing regimen, 3400–3401
oral, 3401, 3401*t*
topical, 3400–3401, 3401*t*
drug interactions, 3404
for hidradenitis suppurativa, 1490
historical perspective, 3395
indications and contraindications, 3399–3400
oral, 3400
topical, 3399–3400
monitoring therapy, 3403–3404
for mycosis fungoides, 2080
early stage, 2090
nail changes, 1599

Retinoid(s) (*Cont.*):
pharmacology and mechanism of action, 3395–3399
genes, target, 3397, 3398*f*, 3398*t*
metabolism, 3397–3399
all-*trans*-retinoic acid, hydroxylation, 3397–3398
oral retinoids, acitretin and etretinate, 3399
oral retinoids, bexarotene, 3399
oral retinoids, isotretinoin and other first-generation, 3398–3399
retinol, esterification and oxidation, 3397
receptors, 3397, 3398*f*
structure
generation, 3397, 3397*f*
nomenclature, 3395–3397, 3396*f*
photochemotherapy with, 3670–3671
phototoxicity, 1658*t*, 1662
for pityriasis lichenoides, 515, 515*t*
for pityriasis rotunda, 2448
PUVA with, 3670–3671
sebaceous glands, 77
side effects
oral retinoids, 3402–3403, 3402*t*
topical retinoids, 3402
on skin pigmentation, 3812
synthetic, 3397, 3397*f* (*See also specific types*)
for tripe palms, 2449
Retinoid(s), oral/systemic. *See also* Acitretin; Bexarotene; Etretinate; Isotretinoin
for actinic keratosis prevention, 1867
for arsenical keratoses, 1880
for basal cell nevus syndrome, 1896
for congenital ichthyosiform erythroderma, 794
for Darier-White disease, 3400
dosing regimen, 3401, 3401*t*
for epidermodysplasia verruciformis, with HIV, 3118 (*See also specific types*)
for harlequin ichthyosis, 794
for ichthyosis, 3400
lamellar, 794
indications and contraindications, 3400
for keratosis follicularis spinulosa decalvans, 1529
for lichen nitidus, 558, 558*t*
for lichen planus, 545, 546
metabolism and pharmacokinetics, 3398–3399
acitretin and etretinate, 3399
bexarotene, 3399
isotretinoin and other first-generation, 3398–3399
for palmoplantar keratodermas, inherited, 821
for pityriasis rubra pilaris, 503
for porokeratosis, 906
side effects, 3402–3403, 3402*t*
teratogenesis, 3402
Retinoid(s), topical
for actinic keratosis prevention, 1867
for arsenical keratoses, 1880
for basal cell carcinoma prevention, 1896
for Darier disease, 884, 884*t*
dosing regimen, 3400–3401, 3401*t*
for epidermodysplasia verruciformis, 1873
for erythema ab igne, 1373
for ichthyosis, 783
keratinopathic, 800
indications and contraindications, 3399–3400
for inflammatory linear verrucous epidermal nevus, 1809
for keratosis pilaris, 869
for keratosis pilaris atrophicans, 872
for melasma, 2242
for nevus comedonicus, 1811
side effects, 3402
Retinoid dermatitis, 3402
chemical peels and dermabrasion, 3896, 3897*t*
flexural, 419, 419*f*
Retinoid receptors, 3397, 3398*f*
target sequences, 3395
Retinoid X receptor (RXR), 3395, 3397
Refsum disease, 806
Retinol. *See* Vitamin A (retinol)
Retinyl esters, 3395, 3396*f*
Retroauricular flap, 3752–3753
Retronychia, 1576–1577, 1577*f*
surgery for, 3788
Retroperitoneal sarcoma, paraneoplastic pemphigus, 2*f*, 934
Retrospective study, 44
Revascularization, grafts, 3753
Reversal reaction, leprosy, 2905, 2905*f*. *See also* Leprosy
clinical course and prognosis, 2914, 2914*t*, 2915*f*
histopathology, 2908–2909, 2911*f*
Reverse venous flow (reflux), 3871
Revertant mosaicism, 303, 303*f*
Revision surgery, standing cones of tissue, 3731, 3732*f*
RFN113A, trichothiodystrophy, 808
Rhabdomyoma, 2131*t*–2132*t*, 2143–2144, 2144*f*
Rhabdomyomatous mesenchymal hamartoma, 2131*t*–2132*t*, 2145–2146
Rhabdomyosarcoma (RMS), 2131*t*–2132*t*, 2144–2145, 2145*f*
Rhagades, congenital syphales, 3158, 3158*f*
RHBDF2, Howel-Evans syndrome, 841
Rheumatic fever (RF)
acute, 770, 1158–1160, 1159*t*, 1160*t* (*See also* Acute rheumatic fever (ARF))
erythema marginatum, 769–771, 770*f*
generalized eruptive histiocytoma of childhood, 2034
Rheumatoid arthritis (RA), 1146–1153, 1160*t*
at-a-glance, 1146*b*
clinical course and prognosis, 1152–1153
clinical features
cutaneous, 1146–1151, 2430
chronic spontaneous urticaria, 687
granulomatous dermatoses, 1148–1149
methotrexate-related cutaneous reactions, 1148
neutrophilic dermatoses, 1149, 1149*f*
other skin, 1151
rheumatoid nodules and nodulosis, 1146–1148, 1147*f*, 1148*t*
cutaneous, vascular
cutaneous necrotizing venulitis, 2529
intravascular or intralymphatic histiocytosis, 1151
pyoderma gangrenosum and Felty syndrome ulcers, 1150–1151, 1150*f*
rheumatoid vasculitis, 1149–1150, 1150*f*
general, 1146
noncutaneous, 1151, 1151*t*
articular, 1151
interstitial lung disease, 2430
pulmonary, 2430
definitions and classification, 1146, 1147*t*
diagnosis, 1147*t*, 1152
differential diagnosis, rheumatoid nodules, 1148, 1148*t*
epidemiology, 1146
etiology and pathogenesis, 1151–1152
Rheumatoid factor (RF), vasculitis, 2548
Rheumatoid nodules and nodulosis, 27, 1146–1148, 1147*f*, 1148*t*. *See also* Rheumatoid arthritis (RA)
Rheumatoid vasculitis, 1149–1150, 1150*f*
Rhino-entomophthoromycosis, 2967*t*, 2973
Rhinophyma
differential diagnosis, 1437*t*
rosacea, 1419, 1420–1422, 1421*f*, 1432, 1433*f*, 1434
Rhinoscleroma, 2808–2809, 2809*f*
Rhinosporidiosis, 2967*t*, 2973, 3244
Rhinosporidium seeberi, 2973, 3244
Rhipicephalus sanguineus, 1195*f*, 3307, 3308*f*, 3309*t*, 3314
Rhizomelic chondrodysplasia punctata (RCDP), 805
Rhizopus microsporus, 2984, 2985*f*
Rhizopus rhizopodiformis, 2984, 2985*f*
RHOA, cutaneous T-cell lymphomas, 2075
Rhodesian trypanosomiasis, 3238–3240, 3239*f*, 3239*t*
Rhodococcus equi, 2853
Rho kinase inhibitors, for Raynaud phenomena, 2622
Rhombic flap, 3743–3746, 3745*f*–3746*f*
30°-angle Webster, 3746, 3747*f*
DuFourmentel, 3745–3746, 3746*f*
Rhombic/tangent-to-circle excision, 3731
Rho-TTF, primary cutaneous diffuse large B-cell lymphoma, 2100
Rhytides, laser therapy for, 3853*t*, 3854
Ribavirin
for cryoglobulinemia II and III, HCV
mild to moderate, 2606
severe, 2607
for epidermodysplasia verruciformis, with HIV, 3118
for hepatitis C virus, 3511
for measles, 2991
for respiratory syncytial virus, 3513
Riboflavin. *See* Vitamin B_2 (riboflavin)
Ribonuclease (RNase) 2. *See* Eosinophil-derived neurotoxin (EDN)
Ribozymes, 292
Richner-Hanhart syndrome, 841–842, 846*t*
Rickets, 2206*t*, 2209–2211, 2210*t*
Rickettsia, 3306–3318. *See also* Spotted fever group; *specific disorders*
cutaneous necrotizing venulitis, 2530
etiology and pathogenesis, 3306
taxonomic reclassification, 3306
Rickettsia africae, 3314
Rickettsia akari, 3309*t*, 3315
Rickettsia conorii, 3309*t*, 3314
Rickettsia felis, 3310*t*, 3318
Rickettsia japonica, 3315
Rickettsialpox, 3315–3318
clinical and laboratory findings, 3315–3317, 3317*f*
diagnosis and differential diagnosis, 3315*t*, 3317
epidemiology and vectors, 3309*t*, 3315
etiology and pathogenesis, 3306
pathology, 3317
treatment and prognosis, 3309*t*, 3316*t*, 3318
Rickettsia prowazekii, 3310*t*, 3318
Rickettsia raoultii, 3315
Rickettsia rickettsii
Rocky Mountain Spotted Fever, 3307, 3309*t*, 3316*t* (*See also* Rocky Mountain Spotted Fever (RMSF))
surface proteins, 3306
tick transmission, 3320
Rickettsia slovaca, 3315
Rickettsia typhi, 3310*t*, 3318
Rieger flap, 3740, 3742*f*
Riehl melanosis, 1381–1382, 1382*f*
Rifabutin, for ehrlichioses/anaplasmosis, 3316*t*

Rifampicin
for bacillary angiomatosis, 2806
for cat scratch disease, 2805
dapsone interactions, 3425, 3425*t*
for leprosy, 2916–2917, 2917*t*
for verruga peruana, 2806
Rifampicin-gentamicin, for cat scratch disease, 2805
Rifampin
for actinomycetomas, 2971
for dissecting folliculitis, 1530
for ehrlichioses, 3310*t*, 3322
for hidradenitis suppurativa, 1490
for human granulocytic anaplasmosis, 3310*t*, 3322
for human monocytic ehrlichiosis, 3310*t*, 3322
for *N. brasiliensis* actinomycetoma, 2889
for rickettsial diseases, 3316*t*
for *S. aureus*, in folliculitis decalvans, 1529–1530
for staphylococcal nares and skin decolonization, 2731*t*, 2732
for tuberculosis, 2862*t*–2863*t*
Rifamycin, for bacillary angiomatosis, 2806
Rifapentine, for tuberculosis, 2862*t*–2863*t*
Riley-Day syndrome, hyperhidrosis, 1464
Rilonacept, 3533, 3548*t*
for cryopyrin-associated periodic syndromes, 625
Rilpivirine, 3507–3508, 3509*t*
Rintala flap, 3739
RIPK2, leprosy, 2902
Risankizumab, 3536*f*, 3537, 3549*t*
mechanism of action, 139
for psoriatic arthritis, 469*f*, 981
Risk characterization, occupational exposures, 453
Risk difference, 45, 45*t*
Risk factor, 41. *See also specific disorders*
Risk ratio, 45
Risorius muscle, 3703, 3704*f*
Risperidone
for delusions of parasitosis, 1696, 1697*t*
for dermatitis artefacta, 1703
Ritonavir boosting, 3508, 3509*t*
Ritter disease, 2721–2722, 2722*f*, 2759
Rituximab, 3544–3545, 3550*t*
for autoimmune blistering diseases, 202
for bullous pemphigoid, 952, 952*t*
for cryoglobulinemia II and III
HCV, 2607
non-HCV, 2607
for dermatomyositis, 1078
for epidermolysis bullosa acquisita, 978–979, 979*t*
for extranodal marginal zone lymphoma, 2100
fundamentals, 3544
for graft-versus-host disease, 2334
indications, 3544
initiating therapy and monitoring, 3544–3545
for juvenile idiopathic arthritis, 1155
for lupus panniculitis, 1275
for mucous membrane pemphigoid, 966*t*, 967
for non-Hodgkin B-cell lymphomas, 3544
for paraneoplastic pemphigus, 941*t*, 942
for pemphigus, 923, 3544
primary cutaneous diffuse large B-cell lymphoma, 2101
reactions, 3544
for rheumatoid arthritis, 1152, 3544
risks, precautions, and complications, 3545
for Sjögren syndrome, 1181
for Still disease, adult-onset, 1158
for systemic sclerosis, 1098
for vasculitis, 2557
Rituximab, cyclophosphamide, hydroxydaunorubicin, vincristine, and prednisolone (R-CHOP), primary cutaneous diffuse large B-cell lymphoma, 2101
River blindness, 3261
Rivet guns, Raynaud phenomena, 2616
RNA
heteronuclear, 292
messenger, 292
short inhibitory, 307
RNA polymerase, 292
RNase 3. *See* Eosinophil cationic protein (ECP)
RNase 7, 222, 222*t*
RNA sequencing, 293
Rocky Mountain Spotted Fever (RMSF), 3307–3314. *See also Rickettsia rickettsii*
clinical and laboratory findings, 3307, 3312*t*, 3313*f*–3314*f*
cutaneous necrotizing venulitis, 2530
diagnosis, 3307, 3315*t*, 3316*t*
differential diagnosis, 3307, 3315*t*, 3316*t*
epidemiology and vectors, 3307, 3308*f*, 3309*t*
etiology and pathogenesis, 3306
pathology, 3307, 3314*f*
prevention, 3312
treatment and prognosis, 3309*t*, 3312, 3316*t*
Rodnan Skin Score, systemic sclerosis, 1089, 1096
Romaña sign, 3240
Rombo syndrome, 1200
trichoepithelioma, 1822*t*, 1841
Romidepsin, 3559*t*, 3577–3578, 3577*f*
Ronchese syndrome, pili torti, 1541*t*
Rontalizumab, for lupus erythematosus, 1057
Root (nose), 3698, 3698*f*
RORγt, for psoriatic arthritis, 1137
Rosacea, 1419–1443
alcohol and, 1713
fibrosis and glandular hyperplasia, 1433*f*
flushing and erythema, 1422, 1427, 1432f
mistinterpretation, 1419, 1420
as trigger, 1427, 1427*t*, 1429
TRP channels, 1428*f*
at-a-glance, 1419*b*
clinical features, 1419–1426
blushing, 1422
erythema, persistent, 1420, 1420*f*
flushing and transient erythema, 1422
gram-negative rosacea, 1425
halogen rosacea, 1425
lupoid or granulomatous rosacea, 1424
ocular rosacea, 1424, 1424*f*
papules and pustules, 1423–1424, 1423*f*
persistent edema of rosacea, 1425–1426, 1426*f*
phymata, 1420–1422, 1421*f*
rhinophyma, 1420
rosacea conglobate, 1424, 1424*f*
rosacea fulminans, 1424–1425
steroid rosacea, 1425, 1425*f*
telangiectasia, 1422–1423, 1423*f*
diagnosis, 1434–1436
classification, 1434–1435, 1435*t*
histopathology, 1434
severity grading, 1436, 1436*t*
tools, 1435, 1435*t*
differential diagnosis, 1436, 1437*t*–1439*t*
erythema, persistent, 1438*t*
flushing, 1438*t*
most prominent, 1437*t*
papules and pustules, 1439*t*
rhinophyma, 1437*t*
telangiectasias, 1438*t*
epidemiology and disease burden, 1419
etiology and pathogenesis, 1426–1427
comorbidities and mechanisms, 1426
environmental triggers, 1426–1427
genetics and mechanisms, 1426
etymology, 1419
management, 1436–1443
do's and dont's, 1441*t*
maintenance therapy, 1442
off-label, first- and second-line, 1436–1442, 1440*f*–1441*f*
for erythema, persistent, 1438, 1442*t*
for facial lymphedema, 1442
for flushing and transient erythema, 1427*t*, 1439, 1442*t*
for ocular rosacea, 1442, 1443*t*
for papules and pustules, 1439
for phymata, 1439–1440
for telangiectasia, 1439
pathomechanism-based, 1436–1438, 1441*f*
phenotype-driven algorithm, 1436, 1440*f*
physical methods, 1442*t*, 1443
skin care, 1436, 1441*t*
surgical, 1442*t*, 1443
symptom manifestation–dependent, 1440*f*
trigger avoidance, 1436, 1441*t*
mechanisms of disease, 1427–1434, 1428*f*–1429*f*
gastrointestinal tract, 1434
immune responses, 1428*f*–1429*f*, 1429–1430
adaptive immunity imbalance, 1430
inflammasome, 1429–1430
skin barrier dysfunction, 1429
toll-like receptors, proteases, and cathelicidin, 1429
neurovascular dysregulation and neuroinflammation, 1430, 1431*f*, 1432*f*
phymatous changes, fibrosis, and glandular hyperplasia, 1432, 1433*f*
proinflammatory mediators, 1427–1429, 1428*f*–1429*f*
telangiectasia, 1434
Melkerson-Rosenthal syndrome, 1451
trigger factors, environmental, 1420, 1420*f*, 1422, 1424, 1426–1427, 1427*t*, 1428*f*–1429*f*
heat, noxious cold, 1427, 1428*f*–1429*f*
microorganisms, 1427, 1428*f*–1429*f*
UV radiation, 1420, 1423, 1423*f*, 1427, 1428*f*–1429*f*
Rosacea conglobate, 1424, 1424*f*. *See also* Rosacea
Rosacea fulminans, 1424–1425, 1434, 1439*t*
Rosacea type sensitive skin, 3808*t*, 3809, 3809*t*
Rosai-Dorfman disease (RDD), 2031–2032, 2031*f*, 3008
Rose bengal, phototoxicity, 1658*t*
Roseola infantum, 3007–3009, 3008*f*, 3015*t*. *See also* Human herpesvirus 6 (HHV-6)
Roseola syphilitica, 3150, 3150*f*
Rose spots, *Salmonella* enteric fever, 2807
Ross River virus (RRV), 3136*t*, 3142–3143
Rotation flaps, 3740–3742
bilateral, 3740, 3742*f*
dorsal nasal, 3740, 3742*f*
fundamentals, 3740, 3742*f*
hatchet, 3740, 3742*f*
Mustarde, 3740–3741
periocular, 3740–3741
spiral, 3742, 3744*f*
Tenzel, 3740–3741

Rothmund-Thomson syndrome (RTS), 2363–2364, 2445*t*
  clinical course, prognosis, and management, 2364
  clinical features, 2344*t*, 2363–2364
  diagnosis and differential diagnosis, 2344*t*, 2364
  epidemiology, 2363
  etiology and pathogenesis, 2344, 2364
  mechanisms, 2345*t*
  RECQL4 gene mutations, RecQ family, 2344
  squamous cell carcinoma, 1904*t*
Rough nails. *See* Trachyonychia
Round shape, 9–10, 10*f*
Roundworms, 3251, 3252*t*. *See also specific types*
  exposure and symptom onset interval, 3259, 3260*t*
  progression and duration, 3259, 3260*t*
  urticaria and pruritus, 3258–3259, 3258*t*
Rove beetles, 3331
RSPO1, palmoplantar hyperkeratosis with squamous cell carcinoma of skin and sex reversal syndrome, 836
R-spondin 2, 89
RT001/RT002, 3922
RT5, epidermolysis bullosa simplex
  generalized intermediate, 1015*t*
  localized, 1015*t*
Rubber, allergic contact dermatitis from, 405
Rubbing, on skin absorption, 3371–3372
Rubella, 2992–2994, 3015*t*
  at-a-glance, 2992*b*
  clinical course and prognosis, 2993–2994
  clinical features, 2992–2993
  congenital rubella syndrome, 2992, 2993
  diagnosis, 2993
  differential diagnosis, 2993*t*
  epidemiology, 2992
  etiology and pathogenesis, 2992
  management, 2994
  prevention, 2994
Rubella vaccine, 2994
Rubeola, 2989–2992, 3015*t*. *See also* Measles
Rubinstein-Taybi syndrome, pilomatricoma, 1822*t*, 1844
Rudimentary meningocele, 2166–2167, 2167*f*
Rudimentary polydactyly, 2151, 2151*f*
Ruffini corpuscles, 351
Rule of halves, wound closure, 3729, 3730*f*
Rule of nines, 1685, 1685*f*
Runaround (nail), 1591, 1592*f*
Running sutures, 3718–3719
RUNX2, CDAGS syndrome, 902*t*
Rupoid psoriasis, 459
Russell bodies, 3234
Rutoside, for pigmented purpuric dermatoses, 2596
Ruxolitinib
  for alopecia areata, 1522
  for atopic dermatitis, 197
  for dermatomyositis, 176
  for graft-versus-host disease, 2334
  for lupus erythematosus, 1058

S

S-100
  dedifferentiated liposarcoma, 2190
  hibernoma, 2186
  lipoblastoma/lipoblastomatosis, 2177
S100B
  hereditary progressive mucinous histiocytosis, 2039
  Langerhans cell histiocytosis, 2021, 2026, 2027*t*
  Rosai-Dorfman disease, 2031, 2031*f*
Sabinas syndrome, trichothiodystrophy, 1539*t*
Sabouraud dextrose agar (SDA), dermatophyte isolation, 2930–2931
Sacroiliitis, psoriatic arthritis with, 974*f*, 1129
Saddleback moth, 3334
Safest donor area (SDA), hair transplantation, 3931, 3944*f*
Sagartia, 3349
SAHA syndrome, hirsutism from, 1556*t*, 1559
Saksenaea vasiformis, 2984, 2985*f*
Salicylic acid, 3619, 3619*t*, 3620
  chemical peels, superficial, 3899–3900, 3899*f*–3900*f*, 3901*f*
  for HPV warts, nail, 1591
Salicylic acid, topical
  for acne vulgaris, 1404
  for actinic keratosis, 1864, 1864*t*, 1865–1866, 1865*t*
  for palmoplantar keratodermas, inherited, 821
  pediatric, 1761
  for pityriasis rotunda, 2448
  for psoriasis, 490
  for warts, 3099
Saline, topical, pediatric, 1761
Salivary glands, Sjögren syndrome, 1172
Salivary gland scintigraphy (SGS), 1178–1179
Salmon color, 8*t*
Salmonella
  bacteriology, 2806
  enteric fever, 2806–2808
Salmonella paratyphi, 2807
Salmonella typhi, 2806–2807
Salmon patch, 1734
  vs. capillary malformations, 2638
  psoriasis, 464, 464*t*
Salt-and-ice challenge, 1670–1671, 1671*f*
Salt-split skin immunofluorescence, epidermolysis bullosa acquisita
  direct, 977, 977*f*
  indirect, 977
Sand flea, 3333, 3333*f*
Sand fly, leishmaniasis vector, 3225, 3226*t*, 3227
Sandlis, 3325*f*, 3330–3331
Sanger sequencing, 254
San Joaquin Valley Fever, 2979–2980, 2980*f*
Saphenofemoral junction (SFJ), 3873, 3873*f*–3874*f*, 3873*t*
Saphenous nerve, 3872*f*, 3873
SAPHO syndrome, 644–645, 645*f*, 1450
Sappinia, 3247–3248
Saquinavir, 3508, 3509*t*
Sarcoidal granulomas
  characteristics, 27
  inflammatory reactions, 27, 28*f*
Sarcoidosis, 572–583
  at-a-glance, 572*b*
  clinical course and prognosis, 579–580
  clinical features, 9*f*, 572–577, 573*t*
  clinical features, cutaneous nonspecific
    erythema nodosum, 575
    other, 575–576
  clinical features, cutaneous specific, 572–575
    additional, 575, 575*f*
    alopecia, 575
    great mimicker, 1–2
    hypopigmented areas, 574–575, 575*f*
    lupus pernio, 573–574, 574*f*–575*f*
    mucous membrane, 575
    papules and plaques, 573, 573*f*–574*f*
    scar sarcoid, 574, 575*f*
    subcutaneous nodules, 574
  clinical features, nail findings, 575
  clinical features, noncutaneous
    cardiac, 576
    hepatic, 576–577
    neurosarcoidosis, 576
    ocular, 576, 576*f*
    other organs, 577
    pulmonary, 576
    renal, 576
  diagnosis, 578, 578*t*
  diagnostic algorithm, 579, 579*f*
  differential diagnosis, 580, 580*t*
  early-onset, 640–641, 641*f*
  epidemiology, 572
  erythema nodosum from, 1256
  etiology and pathogenesis, 577
  historical perspective, 572
  imaging, 578–579
  laboratory testing, 578
  management, 580–583
    antimalarials, 581*t*, 582
    CLEAR antibiotic regimen, 581*t*, 582
    corticosteroids, systemic, 581, 581*t*
    cyclophosphamide, 581*t*, 582
    electrodessication and laser therapy, 582
    hydroxychloroquine and chloroquine, 581*t*, 582
    methotrexate, 581–582, 581*t*
    minocycline and doxycycline, 581*t*, 582
    other agents, 581*t*, 582
    phototherapy and photodynamic therapy, 581*t*, 582
    prevention and screening, 582
    skin therapy, 580–581
    tetracyclines, 581*t*, 582
    TNF antagonists, 581*t*, 582
    treatment algorithm, 583*f*
  pathology, 579, 579*f*
  pulmonary and cutaneous manifestations, 2428
  risk factors, 577–578
Sarcoptes scabiei, HIV hypersensitivity, 3116
Sarilumab, for rheumatoid arthritis, 1152
SART3, 905
SATB2, dedifferentiated liposarcoma, 2190
SAVI, 1040
SC4MOL, CHILD syndrome, 208*t*, 213, 215*f*
Scabies, 3274–3278
  at-a-glance, 3274*b*
  clinical features, 3274–3276, 3275*f*–3276*f*
  complications, 3276
  differential diagnosis, 3276*t*
  in elderly, 1787
  epidemiology, 3274, 3275*f*
  etiology and pathogenesis, 3274
  with HIV, 3116
  nodular, 2115–2116
  pathology, eosinophils, 27, 27*f*
  prevention, 3277–3278
  treatment, 3276–3277, 3277*t*
Scald burn, 1682
Scale, 6, 6*t*
  ichthyosis, 775 (*See also* Ichthyoses)
Scaphoid fossa, 3699
Scar (scarring)
  after chemical peels, 3902, 3902*f*
  after cryosurgery, 3792
  dermal injury producing, 414
  formation, postoperative, 3723–3724, 3723*f*–3724*f*, 3724*t*
  keratoses, chronic, 1881*b*
  laser therapy for, 3853*t*, 3854
  management, burns, 1689–1690
  rejuvenation, 1689
  sarcoid, 574, 575*f*
Scarlatiniform variant, 2760–2761
Scarlet fever, 2764–2766, 2765*f*
  differential diagnosis, 2766
  staphylococcal, 2766
  streptococcal, 2765–2766
  treatment and prognosis, 2766
Scattered configuration, 11
Scatter factor (SF), angiogenesis, 127
Scedosporium, 2984–2985
Scedosporium apiospermum, 2966*t*, 2969–2971
Schamberg disease, 2590, 2591*t*
Schamberg's pigmented purpuric dermatosis, 26
Schamroth sign, 1596

Schernberg's releasing flap method, 3784, 3784*f*
Schimmelpenning, nevus sebaceus, 1734
Schistosomal infections (*Schistosoma* spp.), 3252*t*
  clinical features, 3270, 3270*f*
  diagnosis, 3270
  differential diagnosis, 3270
  epidemiology, 3269–3270
  exposure and symptom onset interval, 3259, 3260*t*
  granulomatous hepatitis, 3261
  hepatic fibrosis, 3261
  life cycle, 3253–3254
  management, 3265*t*, 3270
  ocular disease, 3261–3262
  papular and macular lesions, 3257, 3258*t*
  progression and duration, 3259, 3260*t*
  verrucous lesions, 3259
Schistosome dermatitis, 3252*t*, 3253–3254, 3265*t*, 3269–3271, 3270*f*, 3353–3354, 3353*f*
Schizotrypanides, 3240
Schnitzler syndrome, 625–627, 626*f*, 2531
  diagnosis, 699
  pathology, 700
Schöpf-Schulz-Passarge syndrome (SSPS), 2382–2384, 2383*f*
  hidrocystoma, 1822*t*, 1832
Schulman syndrome, 675, 1110
  eosinophils, 656
  Lyme disease, 3292
Schwann cells, peripheral nerve sheath tumors, 2146
Schwannomas, 2150*t*, 2154–2157
  clinical course and prognosis, 2157
  clinical features, 2154, 2154*f*
  definition, 2154*b*
  differential diagnosis, 2157
  epidemiology, 2154
  epithelioid, 2155
  etiology and pathogenesis, 2154
  histopathology, 2155–2157, 2155*f*–2156*f*
  management, 2157
  melanotic, 2155–2157
  multiple, 2154–2155
  pathology, 38
  plexiform, 2154, 2155, 2156*f*
Schwannomatosis, 2473
Scleredema, 1163–1166, 1164*t*
  at-a-glance, 1163*b*
  clinical features, 1164, 1165*f*
  epidemiology, 1163–1164
  histopathology, 1164, 1165*f*
  historical perspective, 1163
  pathogenesis, 1164
  pathophysiology, 1163
  prognosis and course, 1166
  treatment, 1166
Scleredema diabeticorum, 2497
Sclerema neonatorum, 1746
Scleroborrelioses, cutaneous, 3292, 3294*t*
Scleroderma. *See* Systemic sclerosis (SSc)
Scleroderma-like syndrome, 2496–2497
Scleroderma renal crisis (SRC), 1086, 1087, 1091, 1102, 1102*t*
Scleromyxedema, 1164*t*, 1166–1168
  at-a-glance, 1166*b*
  clinical features, 1166–1167, 1167*f*
  epidemiology, 1166
  histopathology, 1167–1168, 1167*f*
  paraneoplastic, 2442*t*, 2444–2446
  pathogenesis, 1166
  pathophysiology, 1163
  prognosis and clinical course, 1168
  treatment, 1168
Sclerosing disorders, 1163, 1190. *See also specific types*
  scleredema, 1163–1166
  scleromyxedema, 1166–1168
Sclerosing infiltrative basal cell carcinoma, 1886*t*, 1887, 1887*f*. *See also* Basal cell carcinoma
Sclerosing perineurioma, 2161
Sclerosis. *See also specific types*
  from cytotoxic agents, 3486
  diffuse cutaneous, B cells, 149
  systemic, 1086–1102, 1094*f*, 1096*t*, 1097*f* (*See also* Systemic sclerosis (SSc))
Sclerotherapy, 3877–3886
  definition and etymology, 3877
  foam sclerotherapy, 3880–3882, 3883*f*
  historical perspective, 3878
  percutaneous intralesional, for venous anomalies, 2652
  postsclerotherapy compression, 3882–3883, 3883*f*
  sclerosing agents, 3878–3880
    chemical, 3880
    classification, 3878
    complications, 3878, 3878*t*
    detergent, 3879
    hyperosmotic, 3879
    for lymphatic anomalies, 2658
  side effects and complications, 3883–3886
    coagulum, 3884, 3884*f*
    deep venous thrombosis, 3886
    hyperpigmentation, 3884, 3885*f*, 3885*t*
    intraarterial injection, 3886
    necrosis/ulceration, cutaneous, 3885–3886
    neurologic symptoms, 3886
    physical urticaria, 3883–3884, 3884*f*
    superficial venous thrombophlebitis, 3886, 3886*f*
    telangiectatic matting, 3884–3885
  technique, 3880, 3881*f*–3882*f*, 3881*t*
Sclerotic skin diseases, phototherapy for
  graft-versus-host disease, 3646*t*, 3651
  nephrogenic systemic fibrosis, 3651
  other, 3651
  scleroderma, 3646*t*, 3650–3651
SCN9A, erythromelalgia, 122, 2685
Scolopendra, 3330
Scombroid food poisoning, 3359
Scorpaena plumieri, 3357
Scorpiones (scorpions), 3328
Scorpionfish, 3357, 3357*f*
SCORTEN, 761
Scrofuloderma, 2858, 2859*f*, 2866–2867, 2866*f*, 2867*t*
Scrub-itch mites, 3278, 3278*t*
Scrum pox, 3024, 3032*t*
Scurvy, 2206*t*, 2218–2219, 2219*f*, 2219*t*
Sea anemone dermatitis, 3348–3349, 3349*f*
Sea bather's eruption (SE), 3354, 3354*f*, 3354*t*, 3355*t*
Sea cucumbers, 3352
Seafood ingestion, 3359
Seafood poisoning, 3359
Seal bite, 3344
Seal finger, 2829*t*, 2839–2840, 3344
Sea lice infestation, 3354–3355, 3354*f*, 3354*t*
Sea nettles stings, 3344, 3345*f*–3346*f*
Sea urchins, 3350–3351, 3351*f*–3352*f*
Sea wasp, 3346–3347, 3347*f*
Sebaceous duct, 70, 71*f*
Sebaceous follicles, 70–71
Sebaceous glands, 70–77
  anatomy
    histology, 70, 71*f*–72*f*
    location, 70–71, 71*f*
  at-a-glance, 70*b*
  development, 27, 57*f*
  diseases, 71*t*
  embryogenesis and morphogenesis, 71–73, 72*f*–73*f*
  Fordyce spots, 70, 72*f*
  hyperplasia
    cryosurgery for, 3794
    neonatal, 1731, 1731*f*
  lipid droplets, 70, 72*f*
  neonates, 1728
    hyperplasia, 1731, 1731*f*
  physiology
    holocrine secretion, 73–74
    innate immunity, 75
    sebum
      function, 74, 75*t*
      lipid composition, 74, 74*f*
  psoriasis, 464
  size and sebum production, regulation, 75–78
    androgens, 76–77
    cells and lipids, formation and discharge, 77
    FOXO1, 77
    hormone receptors, 76*t*
    LXRs, 76*t*, 77
    peroxisome-proliferator-activated receptors, 76*t*, 77
    retinoids, 77
    sebocytes, stem-like characteristics, 75
    structural proteins, 77
Sebaceous tumors
  adenomas, 33, 1822*t*
  adnexal, pathology, 33–34
  carcinomas, 34, 1822*t*
  classification, 33
  epitheliomas, 33–34
  pathology, 33–34
Sebocytes, 70, 71*f*
  stem-like characteristics, 75
Sebopsoriasis, 463–464
Seborrheic dermatitis, 428–436
  alcohol abuse, 1713
  at-a-glance, 428*b*
  clinical course and prognosis, 434
  clinical features
    general, 415*f*, 428, 429*f*–431*f*
    Leiner disease, 428–429
    pityriasis amiantacea, 417*f*, 429–430, 431*f*
  diagnosis, 433, 434*t*
  diaper area, 1741*t*, 1742
  differential diagnosis, 434, 434*t*, 435*t*
  epidemiology, 428
  etiology and pathogenesis, 431–433
    epidermal hyperproliferation, 433
    immune response and inflammation, 432
    lipid and host susceptibility factors, 432–433
    microbial effects, 432
    neurotransmitter abnormalities, 433
    other factors, 433
  with HIV/AIDS, 431, 3116
    well-controlled, 3122–3123, 3122*f*
  infantile, 428, 429*f*
  management, 434–436
  neonatal, 1739, 1740
  Pityrosporum folliculitis/blepharitis, 428
Seborrheic distribution, 11
Seborrheic keratoses (SK), 1799–1802
  acanthosis, 31, 31*f*
  at-a-glance, 1799*b*
  clinical features, 1799–1800, 1800*f*
  clinicopathologic variants, 1800–1801
    common, 1800*f*–1801*f*, 1801
    dermatosis papulosa nigra, 1801, 1802*f*
    melanoacanthoma, 1801
    polypoid, 1801
    reticulated, 1801, 1801*f*
    stucco keratosis, 1801
  in elderly, 1785, 1785*f*
  epidemiology, 1799
  etiology and pathogenesis, 1800, 1800*t*
  histologic variants
    clonal, 1802, 1802*f*
    irritated, 1802
    malignant transformation or collision lesions, 1802

Seborrheic keratoses (SK) (*Cont.*):
pathology, 31, 31*f*
treatment, 1802
cryosurgery, 3794
electrodessication, 3799
laser
ablative, 1802
nonablative, 3850–3851, 3853*t*
Seborrheic scale, 6*t*
Sebum, 70, 71*f*, 73
apocrine sweat gland, 83
function, 74, 75*t*
lipid composition, 74, 74*f*
neonate production, 1728
production, skin, 3804–3805
Seckel syndrome
clinical features, 2344*t*
mechanisms, 2345*t*
Secondary germ, hair follicles, 96
Second intention, healing by, 3719–3720
Secretory coil, 78, 79*f*
Secretory granules. *See also specific types*
granulocytes, 154, 154*t*
mast cells, 153–154, 154*t*
Secretory vessels. *See also specific types*
eosinophil, 256
Secukinumab, 3534–3535, 3548*t*
for adamantiades–Behçet disease, 2575*t*
for plaque psoriasis, 176, 3534
for psoriasis, 176, 198, 469*f*, 487*t*, 494
for psoriatic arthritis, 469*f*, 980*t*, 981, 1136*t*, 1137
Sedatives, abuse, 1711
Segmental hyalinizing vasculitis, 2530*t*, 2532, 2532*f*
Segmental infantile hemangiomas
classification, 2044–2045, 2045*f*
with PHACE, 2045, 2045*f*
facial segments, 2046, 2046*f*
syndromes with, 2046–2050
"beard area" hemangiomas, 2048–2049
hepatic hemangiomas, 2050, 2050*f*
LUMBAR syndrome, 2045, 2048, 2048*f*
multifocal hemangiomas, 2049–2050, 2050*f*
PELVIS, 2048
periocular hemangiomas, 2048, 2049*f*
PHACE, 2044–2045, 2045*f*, 2047–2048, 2047*t*
SACRAL, 2048
Segmental lentiginosis, 1967–1970, 1969*f*, 1970*t*
Segmental mosaicism, 302
Segmental neurofibromatoses, 2472, 2473*f*
Segmental pigmented purpura, 2593
Segmental variant, vitiligo. *See* Vitiligo, segmental variant
Selectins, 179–180
inflammation, 124
Selection bias, 41
Selective photothermolysis, 3829–3830
pulse duration, 3829–3830, 3829*f*, 3829*t*
wavelength, 3829
Selective serotonin reuptake inhibitors (SSRIs). *See also specific types*
for body dysmorphic disorder, 1697*t*, 1698–1699
for dermatitis artefacta, 1703
for hair pulling disorder, 1697*t*, 1700
for neurotic excoriation, 1697*t*, 1700
for Raynaud phenomena, 2622
Selenium, 2222
deficiency, 2222
excess, 2222–2223
Selenium sulfide
for fungal infections, superficial, 2936*t*
shampoo, for *Malassezia*, 2963, 2963*t*
Self-improving collodion ichthyosis, cellular defect, 781*t*
SE-like superantigens, 2727
Semidominant phenotype/disorder, 296
Senear-Usher syndrome, 914
Senescence, replicative, 1765–1766
Senile angiomas, 1785, 1785*f*
Senile lentigo. *See* Solar lentigo
Senile purpura, 1788
Sensitive skin, variations, 3808
Sensitivity, skin, 3808–3811
acne type, 3808–3809, 3808*t*, 3809*t*
allergic/irritant type, 3808*t*, 3809–3810, 3810*t*
cleansers, 3810
moisturizers, 3810
rosacea type, 3808*t*, 3809, 3809*t*
sensitive *vs.* resistant, 3808–3810
skin care for, 3810–3811
stinging type, 3808*t*, 3809
Sensitivity, statistical
2 x 2 tables, 46, 46*f*
definition, 46
Sensitization phase, type IV hypersensitivity reaction, 397
Sensory anesthesia, postoperative, 3724
Sensory irritation, 3809
Sensory nerves, cutaneous, 49
development, 56
efferent function, 353–354
face, 3702–3703, 3702*f*, 3703*t*
facial surgical anatomy, 3702–3703, 3702*f*, 3703*t*
functional subgroups, 352–353
vasoconstriction, 355
Sentinel lymph node biopsy (SLNB)
melanoma, 1994–1995, 2000–2001
Merkel cell carcinoma, 1927–1928, 1928*f*
squamous cell carcinoma, 1912
Sepsis and septic shock, 2818–2822
clinical course and prognosis, 2821
clinical features
complications, 2820
cutaneous, 2818–2820, 2819*f*
noncutaneous, 2820
definition, 594
diagnosis, 2820–2821
differential diagnosis, 2821, 2821*t*
epidemiology, 2818
etiology and pathogenesis, 2820
management, 2821–2822
prevention, 2822
Septa, 29
Septal panniculitis, inflammatory reactions, 29, 29*f*
Septicemia. *See* Sepsis and septic shock
Sequencing
methods, 254–255
microbiome, skin, 253
SERCA, Darier disease, 880–883, 881*f*
SERCA2, Darier disease, 881–883
SERCA2b, Darier disease, 882
Serial excision, 3732
Serotonin reuptake inhibitors, hyperhidrosis from, 1465
Serpiginous configuration, 10, 10*f*
SERPIN7, Nagashima-type palmoplantar keratoderma, 827
SERPINB7, Nagashima-type palmoplantar keratoderma, 827–828
SERPINB8, peeling skin syndromes, 803
Serratia marcescens, 3340
Sertaconazole, 3438*t*, 3444
for dermatomycoses, 3444
for tinea pedis, 3444
Sertraline, for hair pulling disorder, 1697*t*, 1700
Serum amyloid P-component (SAP), 2258
Serum angiotensin-converting enzyme (SACE), sarcoidosis, 578
Serums, for aging skin, 3813–3814
Serum sickness, 130
urticaria from, 695
Serum sickness–like reactions, 750*t*, 751, 752*t*
Seventh cranial nerve, facial branches, 3702, 3702*f*, 3703*t*
Severe combined immunodeficiency (SCID), 2404–2406, 2405*t*
graft-versus-host disease, 2404–2405
hematopoietic stem cell transplantation for, 2404*b*, 2406
neonates, 1740
Severe cutaneous adverse reactions (SCARs). *See also specific types*
drugs causing, 195
genetic predisposition, 194
immunologic responses, 194–195, 195*f*
TCR repertoire model, 195
Severe recessive dystrophic epidermolysis bullosa, 1020, 1022–1023, 1022*f*–1023*f*, 1029*t*
Severe sepsis. *See* Sepsis and septic shock
Severe syndrome. *See* Sepsis and septic shock
Sex (gender), 1793*t*
Sexual abuse, child
clinical features, 1719
conditions mistaken for, 1724*t*
diagnosis, 1721
etiology and pathogenesis, 1720–1721, 1720*f*
laboratory testing, 1722
prevalence, 1718
Sexual behavior, 1792–1793, 1793*t*
Sexually transmitted diseases (STDs). *See also specific types*
telogen effluvium from, 1510
Sexual orientation, 1792–1793, 1793*t*
Sézary syndrome, 2083–2084
central memory T cells, 147
clinical features, 2073, 2082*t*
definition, 2073
laboratory findings, 2073
staging, 2081*t*, 2089, 2089*t*
treatment and prognosis, 2073, 2082*t*
eosinophils, 653
extracorporeal photochemotherapy, 3678, 3678*t*
treatment algorithms, 2091*t*-2092*t*
Shaft, hair. *See* Hair shaft
Shagreen patch, tuberous sclerosis complex, 2482, 2482*f*–2483*f*, 2487
Shake lotions, 3373*t*, 3375
Shale oil, 3611
Shape and configuration, 9–12
annular, 9, 10*f*
arcuate, 10
geographic, 10
grouped/herpetiform, 11
linear, 10
polycyclic, 11, 11*f*
reticular, retiform, 10, 10*f*
round/nummular/discoid, 9–10, 10*f*
scattered, 11
serpiginous, 10, 10*f*
stellate, 7*f*, 10
targetoid, 10, 11*f*
whorled, 10
Shark bites, 3358
Shea butter, stearic acid, 3806, 3806*t*
Sheep tick, 3329
Shellac-like scale, 6*t*
Shh
hair development, 27
ligands, 50
Shingrix, 3057–3058, 3058*t*
Ship fever, 3318–3319. *See also* Typhus, epidemic (louse-borne)
SHOC2, loose anagen syndrome, 1547
Short anagen syndrome, 1511
Short inhibitory RNA (siRNA), 307–308
SHORT syndrome, 1299
Shotgun metagenomic sequencing, 254–255
Shulman syndrome, 3292
Sialometry, 1178

Sibine stimulate, 3334
Sick fat, 2286
Sidewalls, lateral (nose), 3698, 3698*f*
Siemens syndrome, 838, 846*t*
Sifalimumab, for lupus erythematosus, 1057
Siglec-8, eosinophils, 656
Signal transduction pathways
  chemokine, 168*f*, 177–179, 178*t*, 179*f*
  cytokine, 161–175
Signature mutation
  definition, 316
  UV, 316, 317*f*
Sildenafil
  for pulmonary artery hypertension in digital vasculopathy, 1100, 1101
  for Raynaud phenomena, 2621, 2621*t*
Silent mutations, 294
Silica
  dust, systemic sclerosis and, 1093
  granulomas, 27
Silicone
  injectable, 3913*t*, 3919–3920
  soft-tissue filler, 3913*t*, 3919–3920
Silicon ointments, 3374
Silicosis, systemic sclerosis and, 1093
Silvadene nitrate, for burn wound care, 1686–1687, 1686*t*
Silver, lichenoid contact dermatitis, 538
Silver nitrate, 3613*t*, 3618
  for burn wound care, 1686*t*, 1687
  for gonorrhea prophylaxis in newborns, 3210
  jet-black nail, 1568, 1572*f*
  for molluscum contagiosum virus, 3089
Silver-Russell syndrome (SRS), 1361
Silver sulfadiazine, topical, 3420*t*, 3421
  for pyoderma gangrenosum, 613
Silvery hair syndromes, 2415–2419, 2416*t*. *See also specific types*
  Chédiak-Higashi syndrome, 2415–2418, 2416*t*
  Griscelli syndrome, 2416*t*, 2418–2419, 2419*f*
Simple lentigo, 1967–1970. *See also* Lentigo simplex
Simprevir, for hepatitis C virus, 3511–3512
Simuliidae, 3325*f*, 3330–3331
Sinclair scale, female pattern hair loss, 1496, 1497*f*
Sindbis group viruses, 3136*t*, 3142–3143
Sinecatechins, 3621
Single advancement flap, 3735–3737, 3735*f*
  cheek, 3735–3736, 3736*f*–3737*f*
  helical rim, 3736–3737, 3737*f*
  L-plasty, 3735, 3735*f*
Single-cell necrosis, basal cell carcinoma, 32
Single nucleotide polymorphism (SNP), 294
Single nucleotide polymorphism (SNP) chip arrays, 293
Singlet state, 267–268, 268*f*
Sinus histiocytosis with massive lymphadenopathy, 2031–2032, 2031*f*
Siphonaptera, 3325*f*, 3332–3333, 3332*f*–3333*f*
Sirolimus (rapamycin), 3599–3600
  on eosinophils, 658
  for graft-versus-host disease, 2334, 2335
  for kaposiform hemangioendothelioma, 2063
  for lymphatic anomalies, 2657–2658
  for multifocal lymphangioendotheliomatosis with thrombocytopenia, 2064
  on squamous cell carcinoma risk, posttransplantation, 1905
  for tuberous sclerosis complex, 2485, 2489
  for venous anomalies, 2652
Sirukumab, for rheumatoid arthritis, 1152
Sitosterolemia, 2278
Sixth disease, 3007–3009, 3008*f*, 3015*t*. *See also* Human herpesvirus 6 (HHV-6)
Sjögren–Larsson syndrome (SLS), 779*t*, 781*t*, 807–808, 807*f*
  ALDH3A2, 807
  congenital, 1740
  FALDH, 779*t*, 781*t*
Sjögren syndrome, 1170–1181, 1171*f*
  at-a-glance, 1170*b*
  chronic spontaneous urticaria, 687
  clinical course and prognosis, 1180
  clinical features, 1173–1177
    exocrine gland, 1173–1174
      anhidrosis/hypohidrosis, 1174
      cutaneous xerosis, 1174
      eyelid dermatitis, 1174
      keratoconjunctivitis sicca, 1174, 1179
      upper respiratory tract dryness, 1174
      xerostomia, 1173, 1173*f*, 1174
    extraglandular, cutaneous, 1174–1176, 1174*t*
      annular erythema, 1175–1176, 1175*f*
      cutaneous vasculitis, 1174–1175
      erythema nodosum, 1176
      hypergammaglobulinemic purpura, 1174, 1175*f*
      necrotizing vasculitis, 1175
      palpable purpura, 1175
      Raynaud phenomena, 1176, 1176*f*
      urticarial vasculitis, 1175
    extraglandular, noncutaneous, 1176–1177
      fatigue and fibromyalgia, 1176
      lymphoid/lymphoproliferative, 1177
      musculoskeletal, 1176
      pregnancy, 1177
      thyroid, 1176
      visceral, 1177
  cryoglobulinemia, 2603
  cutaneous necrotizing venulitis with, 2529
  dermatitis herpetiformis, 1004
  diagnosis, 1177–1180
    classification criteria, 1177–1178, 1178*t*
    histopathology, 1179–1180, 1179*f*
    laboratory testing, 1179
    ocular dryness, 1179
    oral dryness
      salivary gland scintigraphy, 1178–1179
      sialometry, 1178
  epidemiology, 1170
  etiology and pathogenesis, 1170–1173
    autoantibodies, 1172–1173
    environmental, 1172
    glandular epithelium, 1172
    immunogenetic, 1170–1171
    innate and adaptive immunity, 1171
  fundamentals, 2*f*, 1170
  nodular amyloidosis, 2264
  treatment
    of dry eyes, 1180–1181, 1180*t*
    of dry mouth, 1180, 1180*t*
    of extraglandular manifestations, 1181
    molecular target therapy, 1181
  vasculitis with, 2552
SKCM, Merkel cell carcinoma, 1925, 1925*f*
Skin, neonatal
  physiology, 1727–1728
  postterm, 1728, 1728*f*
  preterm, 1728–1729
Skin aging, 1779–1788. *See also* Aging, skin
Skin and soft-tissue infections (SSTIs). *See also specific types*
  IV drug use
    etiologic organisms, 1708
    functions, 192
    skin popping, 1707
Skin-associated lymphoid tissue (SALT), 122, 506
  allergic contact dermatitis, 397–398
Skin barrier, 206–226, 3367–3368
  antimicrobial, 220–223
    properties, 220–222, 222*t*
    proteins
      cell production, 222, 223*f*
      functions, 223
      skin surface, 222, 222*t*
  appendages, 3367
  at-a-glance, 206*b*
  atopic dermatitis, 368
  bilayer lipid membrane, 3804, 3804*f*
  comparative biology, 207, 208*t*, 209*f*
  destruction, dermatitis, 414, 415*t*
  epidermis, 207, 210*f*
  function, 130
    inter- and intraindividual variation, 3368
    pathologic processes on, 3370
  homeostasis, 192
  newborn, epidermal barrier, 223–224, 224*t*
  penetration pathways, 3367–3368
    hair follicles, 3368
    intercellular, follicular, and intracellular, 3367, 3371*f*
    stratum corneum, 3367–3368, 3371*f*
  physical stress, 224–226, 225*f*
    heat stress protection
      sweating, 225
      vasculature and blood flow, 225–226, 225*f*
    mechanical stress protection, 224
    UV stress protection, 224–225
  stratum corneum, 207–218, 3367, 3371*f* (*See also* Stratum corneum)
  structure, basic, 207, 209*f*
  tight junctions, 208*t*, 210*f*, 218*f*, 219–220, 219*f* (*See also* Tight junctions)
Skin care. *See also specific topics*
  advice, 3803
  aging skin, 3812–3814
  cleansers, 3806–3807, 3806*f*
  emollients, 3807
  exfoliants, 3807
  facial skin issues, identifying, 3803
  healthiest skin type, 3815
  humectants, 3807
  medications, 3807
  moisturizers, 3806*t*, 3807
  most efficacious products, identifying, 3815–3817, 3816*t*
    compliance, encouraging, 3817
    ingredient choice, 3816
    patient education, 3816–3817
    product choice, 3816
    regimen and order of application, 3816, 3816*t*
  neonatal, 1729
  occlusives, 3807
  for oily-dry skin, 3806–3808
  phenotype diagnosis, 3814–3815, 3815*f*
  for pigmentation, 3811–3812, 3811*t*
  for sensitive skin, 3810–3811
    cleansers, 3810
    moisturizers, 3810
  summary, 3808
Skin cell types. *See* Cell types, skin
Skin cooling, laser and light-based treatments, 3830–3831, 3830*t*, 3848
Skin erythema dose (SED), 3690–3691
Skin glands, 70–84. *See also* Glands, skin; *specific types*
Skin hardening. *See* Hardening, skin
Skin homing, T cells, 146–147
Skin immune system. *See* Immune system, skin
Skin planing, surgical. *See* Dermabrasion
Skin popping scars, 1706*t*, 1707
Skin preparation, operative, 3714–3715
  antiseptics, topical, 3714–3715
Skin prick testing (SPT), contact urticaria, 450, 451*f*
Skin sparing radiotherapy, 3687
Skin substitutes, 3757
  acellular products, 2711, 2711*t*
  cellular products, 2710–2711, 2711*t*

Skin surface, 3364–3367
applications, 3364–3366
formulations, 3366–3367
parameters affecting drugs in, 3364, 3366*t*
reservoir, 3366
Skin tightening, noninvasive, 3857–3862
adaptations, anatomic area, skin type, and degree of response, 3860–3861
complications, 3858–3860
devices and technologies, 3858
indications and patient selection, 3857–3858
modes of action, 3858, 3859*f*–3860*f*
outcomes, expected, 3861–3862, 3861*f*
Skin tumor. *See* Tumor, skin; *specific types*
SL1122-37, 3600
Slac-2a/melanophilin, Griscelli syndrome, 2419, 2419*f*
Slate-gray pigmentation, phototoxicity, 1658, 1661*f*
SLC17A9, porokeratosis, 902*t*
SLC24A5, 344
oculocutaneous albinism type 6, 1310*t*, 1313
SLC35C1, leukocyte adhesion deficiencies, 2412*b*
SLC39A4, 2224
SLC39A8, 2223
SLC39A13, spondylodysplastic Ehlers-Danlos syndrome, 1213*t*, 1217*t*
SLC45A2, 344
oculocutaneous albinism type 4, 1310*t*, 1313
Sleeping sickness, 3238–3240, 3238*f*–3239*f*, 3239*t*
SLE rash. *See* Acute cutaneous lupus erythematosus (ACLE)
Slow-cycling bifunctional nail proximal fold stem cells, 109, 110*f*
Slow-cycling label retaining cells, 108
SLURP, mal de Meleda, 826–827
SMAARCB1, schwannomas, 2155
SMAD3, radiation dermatitis, 3691*t*
SMAD4, hereditary hemorrhagic telangiectasia 23, 2640*t*
Small-molecule tyrosine kinase inhibitors, 3558–3565. *See also specific types*
acneiform eruptions from, 1452
at-a-glance, 3558*b*
background, 3558–3559, 3560*f*
bosutinib, 3559*t*, 3563–3564, 3563*f*
dasatinib, 3559*t*, 3562–3563, 3562*f*
imatinib mesylate, 3559–3561, 3559*t*
nilotinib, 3559*t*, 3561–3562
ponatinib, 3559*t*, 3564–3565, 3564*f*
Small-plaque parapsoriasis (SPP), 505–511, 507*f*, 510*f*. *See also* Parapsoriasis
Small plaque psoriasis, 461
Smallpox (variola virus), 3065–3073, 3066*t*
atopic dermatitis, 367
clinical course and prognosis, 3072
clinical features
complications, 3069
cutaneous, 3067–3069, 3068*f*–3069*f*
flat smallpox, 3068
hemorrhagic smallpox, 3069
modified smallpox, 3068
noncutaneous, 3069
prodrome, 3067
variola sine eruption, 3069
diagnosis, 3070–3071
differential diagnosis, 3071–3072, 3071*t*
epidemiology, 3067
etiology and pathogenesis, 3069–3070, 3069*f*
historical perspective, 3065–3067
management, 3072
prevention, 3072–3073, 3072*t*
Small vessel disease of myocardium, systemic sclerosis, 2427
Small vessel vasculitis, angiocentric pattern, 26
Smith-Ferguson syndrome, 314
SMO, 3572, 3573*f*
basal cell carcinoma, 1884, 1885*t*
Smoke plume, electrosurgery, mutagenicity, 3798
Smoker's palate, 1714
Smoking and nicotine use
acute hepatic porphyrias, 2250
cutaneous manifestations, 1714
hidradenitis suppurativa, 1483
porphyria cutanea tarda, 2239
preoperative examination, 3709
psoriasis exacerbation by, 479
rheumatoid vasculitis, 1149–1150
Smoking cessation
for hidradenitis suppurativa, 1487
for thromboangiitis obliterans, 2682
for xanthomas and lipoprotein disorders, 2285
Smoothened inhibitors, 3572–3575
at-a-glance, 3572*b*
background, 3572, 3573*f*
sonidegib, 3574–3575, 3574*f*
vismodegib, 3572–3574, 3572*f*
Smooth muscle cells (SMCs), cutaneous vasculature, 116, 117
Smooth muscle hamartoma, 2131*t*–2132*t*, 2141–2143
at-a-glance, 2141*b*
clinical course and prognosis, 2143
clinical features, 2141–2142, 2142*f*
congenital, 1743–1744
differential diagnosis, 2142–2143
epidemiology, 2141
etiology and pathogenesis, 2141
histopathology, 2142, 2142*f*
management, 2143
Smooth muscle tumors, 2130–2143, 2131*t*–2132*t*. *See also specific types*
diagnosis, 2133*f*
leiomyoma, 2130, 2134–2138
leiomyosarcoma, 39, 39*f*, 2131*t*–2132*t*, 2138–2141
pediatric, with HIV, 3121
smooth muscle hamartoma, 2131*t*–2132*t*, 2141–2143
SNA12
piebaldism, 1321
Waardenburg syndrome, 1322*t*, 1323
Snakebites, 3341–3344
clinical presentation, 3342
coral snakes, 3342
epidemiology, 3341–3342
identification, 3342, 3343*f*
Northern copperhead, 3342, 3342*f*
pit vipers, 3342, 3342*f*
timber rattlesnake, 3342, 3342*f*
toxicity, 3342, 3342*f*
treatment, 3342–3344, 3343*t*
SNARE protein complex, botulinum toxin, 3922–3923, 3923*f*–3924*f*, 3924*t*
Sneddon syndrome, 2530*t*, 2533
Sneddon-Wilkinson disease, 617–619. *See also* Subcorneal pustular dermatosis
Snorter's warts, 1709
So-called connective tissue diseases, 1587–1588, 1587*f*
Social history, preoperative examination
alcohol, 3709
functional status and support systems, 3709
smoking and nicotine, 3709
Sodium bicarbonate, tumescent local anesthesia liposuction, 3907, 3908*t*
Sodium chloride
topical, pediatric, 1761
tumescent local anesthesia liposuction, 3907, 3908*t*
Sodium hypochlorite, for green nail syndrome, 2795
Sodium morrhuate, 3879
Sodium nitroprusside, for Raynaud phenomena, 2621, 2621*t*
Sodium stibogluconate, for leishmaniasis, 3236, 3237*t*
Sodium sulfacetamide
for acne vulgaris, 1403*t*, 1404
for perioral dermatitis, 1455
for rosacea, 1439
Sodium tetradecyl sulfate (STS), 3878, 3878*t*, 3879
Sofosbuvir, for hepatitis C virus, 3512
Sofosbuvir and veltpatasvir (Epclusa), for hepatitis C virus, 3512
Soft-tissue augmentation, 3911–3920
at-a-glance, 3911*b*
autologous fat transfer, 3913*t*, 3917–3918, 3918*t*, 3919*f*
biodegradable microparticle injectable implants, 3915–3917
calcium hydroxyapatite, 3913*t*, 3916–3917
poly-L-lactic acid, 3913*t*, 3915–3916, 3916*f*
collagens, 3911–3912
complications, 3920
facial rejuvenation, 3911
hyaluronic acid, 3912–3915, 3913*t*, 3914*f*
method and technique
fillers, dermal, 3911, 3912*t*
injection, 3911, 3913*f*
nonabsorbable materials, 3911–3912
silicone, injectable, 3913*t*, 3919–3920
Solar elastosis
keratoacanthoma, 32
pathology, 28, 29*f*
rosacea, 1427, 1434
squamous cell carcinoma, invasive, 32
Solar erythema, 272
sunburn reaction, dyskeratosis, 22
Solar lentigo, 1970–1973
at-a-glance, 1970*b*
clinical features, 1970–1971, 1971*f*–1972*f*
cryosurgery for, 3792*t*, 3794
diagnosis, 1971–1972
in elderly, 1784–1785, 1784*f*
epidemiology, 1970
etiology and pathogenesis, 1971
Solar purpura, 1612, 1618*f*
Solar radiation, wavelengths, 265–267, 266*f*, 266*t*
carcinogenic, 281–282
Solar urticaria (SolU), 273, 1650–1655. *See also* Urticaria
at-a-glance, 1650*b*
clinical course and prognosis, 1652
clinical features, 1650, 1651*f*
definition, 1650
diagnosis, 698, 1651–1652, 1652*f*
algorithm, 1653*f*
tests, 688*t*
differential diagnosis, 1654*t*
epidemiology, 1650
etiology and pathogenesis, 1651
historical perspective, 1650
management, 1652–1655
counseling, 1655
medications, 1653
monitoring, 1655
procedures, 1653–1655
treatment algorithm, 1654*f*
trigger avoidance, 1652
pathogenesis, autoimmune mechanism, 691*f*, 692

risk factors, 1651
underlying disorders, 693
urticaria, 690, 693
Solenopsis invicta, 3333
Solitary papular angiokeratoma, 2300*t*
Soluble mediators, cutaneous immune system, 159–186, 160*t*
at-a-glance, 159*b*
chemokines, 160*t*, 176–182 (*See also* Chemokine(s))
chemokines, in disease, 182–186
atopic dermatitis, 182–183
cancer, 183–185, 185*f*
infectious diseases, 185–186
psoriasis, 183, 184*f*
concept, 159, 160*t*
cytokine biology, 159–175, 160*t* (*See also* Cytokine biology)
therapeutic implications, 175–176
therapeutic implications and applications, 186
Solutions, topical, 3373*t*, 3375. *See also specific types*
Somatic mosaicism, 301
Somatogenesis, 52
Somatostatin, 355
growth hormone release, 2518, 2518*f*
Somatostatin analogs, for necrolytic migratory erythema, 2456
Somite development, 53
Sonic hedgehog (Shh) signaling pathway
basal cell carcinoma, 1884, 1885*f*, 1892
hair follicles, 90*f*, 91–92
sebaceous glands, 71, 72*f*
Sonidegib, 3559*t*, 3574–3575, 3574*f*
for basal cell carcinoma, 1890
Sonophoresis, 3376
Sorafenib, 3600
keratoacanthoma from, 32
for melanoma, 2007
on squamous cell carcinoma risk, 1906
SORT scale, 44
SOS1, Noonan syndrome, 871
South American blastomycosis, 2980–2981, 2981*f*
Southern black widow spider, 3324–3326, 3326*f*
Southern tick-associated rash illness (STARI), 3298
SOX2, 315, 334*f*
SOX9, sebaceous gland development, 72, 73*f*
SOX10, 334*f*, 335
Waardenburg syndrome, 1322*t*, 1323
SOX18, Klippel-Trenaunay syndrome, 2640*t*, 2657
Spaek finger, 3344
Spanish fly, 3331
Sparganosis, 3252*t*
conjunctivitis, 3261
migratory skin lesions, 3255*t*, 3256
SPD-type IgA pemphigus, 617, 981
Special site nevi, 1956
Specificity
2 x 2 tables, 46, 46*f*
definition, 46
Specimen sign, 1694
Speckled lentiginous nevus, 1949–1951, 1949*f*, 1950*t*
Speed, 1711
Spheroids, 2309
Spherules, 2309
Spherulin vaccine, for coccidioidomycosis, 2980
Sphingolipids, Darier disease, 882
Spider angiomata, alcohol abuse, 1713
Spider veins. *See* Telangiectasia
Spina bifida, myelomeningocele, 1735
Spinal accessory nerve, 3699, 3700*t*, 3701–3702
Spinal cord, 355
Spinal dysraphism, occult, 1735
Spindle-cell hemangioendothelioma, 2059*b*, 2063
Spindle-cell hemangioma, 2043*t*, 2059*b*, 2063
Spindle-cell lipoma, 2179–2182
at-a-glance, 2179*b*
clinical course, prognosis, and treatment, 2182
clinical features, 2179
differential diagnosis, 2182
epidemiology, 2179
etiology and pathogenesis, 2180
histologic features, 2180–2182, 2180*f*–2182*f*
Spindle-cell squamous cell carcinoma, 1910, 1910*f*
SPINK5
atopic dermatitis, 369
Netherton syndrome, 197, 778, 779*t*, 782, 782*t*, 792*f*, 793
trichorrhexis invaginata, 1542
Spinosad, 3615*t*, 3616
for lice, 3281*t*, 3284
Spinous cells, 64
Spiradenoma, 1822*t*, 1826–1827, 1826*f*
Spiral flap, 3742, 3744*f*
Spirillum minus, 2829*t*, 2838–2839
Spirometra mansonoides, 3252*t*
exposure and symptom onset interval, 3259, 3260*t*
migratory skin lesions, 3255*t*, 3256
progression and duration, 3259, 3260*t*
subcutaneous nodules and masses, 3257, 3257*t*
Spironolactone
for acne vulgaris, 1406–1407
for androgenetic alopecia, 1504
for hidradenitis suppurativa, 1490
for hirsutism, 1561–1563, 1562*t*
for hyperandrogenism, 2518
Spitz nevus, 1963–1966
at-a-glance, 1963*b*
clinical course and prognosis, 35, 1965–1966
clinical features, 1964, 1964*f*
diagnosis, 1965, 1965*f*
Kamino bodies, 35, 35*f*, 1965
differential diagnosis, 1966*t*
epidemiology, 1963–1964
etiology and pathogenesis, 1964–1965
pathology, 34–35, 35*f*
prevention, 1966
treatment, 1966
Spitzoid melanoma, 1988. *See also* Melanoma
S-plasty, 3731–3732, 3733*f*
Splendore-Hoeppli phenomenon, 2973
Splice acceptor site, 292
Splice donor site, 292
Splice site mutations, 295
Splinter hemorrhages
bacterial endocarditis, 1596
nails, 1571–1572, 1573*f*
Split hand–split foot malformation, isolated, 2378, 2381–2382
Split-thickness skin grafts (STSGs), 3755
punch and pinch grafts, 3755
for vitiligo, 1343
"Splitting suture," postoperative, 3724
Spondyloarthritis, psoriatic arthritis with, 974*f*, 1129
Spondyloplastic Ehlers-Danlos syndromes (spEDS), 1217*t*. *See also* Ehlers-Danlos syndromes
Sponge fisherman's disease, 3349
Sponges, dermatitis from, 3350, 3350*f*
Spongiform pustules, psoriasis, 24
Spongin, 3350
Spongiosis, 22, 22*f*
Spongiotic dermatitis, 24, 24f
Spontaneous urticaria, 687*f*, 688, 688*t*
angioedema with, 688
diagnosis, 697, 697*t*
diagnostic tests, 688*t*
Sporothrix brasiliensis, 2965, 2966*t*, 2968–2969
Sporothrix globosa, 2965, 2966*t*, 2968–2969
Sporothrix luriei, 2965, 2966*t*, 2968–2969
Sporothrix mexicana, 2965, 2966*t*, 2968–2969
Sporothrix schenckii, 449, 2965, 2966*t*, 2968–2969
Sporotrichoid distribution, 11
Sporotrichosis, 2965, 2966*t*, 2968–2969, 2968*f*
occupational exposure, 449
Spotted fever group, 3306–3318. *See also specific infections*
African tick bite fever, 3314–3315
at-a-glance, 3306*b*
clinical and diagnostic findings, 3312*t*
diagnosis and differential diagnosis, 3315*t*, 3316*t*
epidemiology and vectors, 3309*t*–3311*t*
etiology and pathogenesis, 3306
infection mechanisms, 3306
Mediterranean spotted fever, 3314–3315
rickettsialpox, 3315–3318
Rocky Mountain Spotted Fever, 3307–3314
taxonomic reclassification, 3306
tick-bite associated, 3314–3315
treatment and prognosis, 3309*t*–3311*t*, 3316*t*
SPP1, pseudoxanthoma elasticum, 1232
Spreading pigmented actinic keratosis, 1858, 1858*f*
SPRED1, Legius syndrome, 1360, 2465, 2470
Spun glass hair, 1543–1544, 1544*f*, 1544*t*
Squamous cell carcinoma (SCC), 1901–1916
anogenital, 3096*t*
at-a-glance, 1901*b*
carcinogenesis, 310–315
animal models, 321
general principles, 310–313, 311*f*, 312*f*
genetics, 313–315
clinical presentation, 1907–1908
classical presentation, 1907, 1907*f*
lower lip, 1908, 1908*f*
oral, 1907–1908
verrucous, 1908
differential diagnosis, 1908
dyskeratosis, 22
dystrophic epidermolysis bullosa, 1021
epidemiology and demographics
age, 1902
geographic factors, 1902
incidence, 1901
morbidity and mortality, 1901–1902
race, 1902
sex, 1902
ERK pathway signaling, 315
etiology and pathogenesis, 1902–1907
associated syndromes and genes, 1903–1904, 1904*t*
molecular aspects
p53 *(TP53)*, 1906–1907
RAS, 1907
precursor lesions, 1902
PUVA, 315
risk factors, 1902–1906, 1905*t*
carcinogens, 1904
chronic inflammation and skin injury, 1906
drugs, 1905–1906
genetic predisposition, 1903–1904, 1904*t*
immunosuppression, 1904–1905
UV radiation, 1902–1903
viral infection, 1906
vemurafenib, in melanoma patients, 315
viral carcinogenesis, 318
xeroderma pigmentosum, 314

Squamous cell carcinoma (SCC) (*Cont.*):
genes and mutations, 314–315
CDKN2A, 314
EGFR, 315
FAT, 314
HRAS, 314–315
INPP5A, 315
KMT2C, 314
KMT2D, 314
KNSTRN, 314
molecular drivers and, 314–315
mutation burden and clonal dynamics, 317, 318*f*
MYC, 315
NOTCH, 314
p53, DNA cell repair, 281
p53, UV mutations, 276
TP53, 314, 315
hidradenitis suppurativa, 1482, 1482*f*
histopathology, 1908–1911
basic features, 1909, 1909*f*
diagnosis, 1910, 1910*t*
general considerations, 1908–1909
grading, 1911
variants
acantholytic SCC, 1910, 1910*f*
desmoplastic SCC, 1910, 1910*f*–1911*f*
keratoacanthoma, 1911, 1911*f*
spindle-cell SCC, 1910, 1910*f*
verrucous SCC, 1910, 1910*f*
HIV with, 3120–3121
HPV and, 3096*t*, 3102
oral and oropharyngeal SCC, 3096*t*, 3104
invasive, from actinic keratoses, 317, 1857, 1862*f*, 1863, 1902
of lower lip, 1908, 1908*f*
from lupus vulgaris, 2866
management, 1912–1913
chemotherapy, 1913
cryosurgery, 3795
curettage and electrodessication, 3799–3800, 3799*f*–3800*f*
outcome assessments, 3800
lymph node dissection and sentinel lymph node biopsy, elective prophylactic, 1912
Mohs micrographic surgery, 3766–3767, 3767*f*
radiotherapy, 1912, 3693*t*, 3694
surgery, 1912
systemic, locally advanced and metastatic SCC, 1913
targeted therapy, 1913
topical therapy, 1912
mTOR pathway signaling, 315
nail, 1605, 1605*f*
parakeratosis, 21
pathology, 31–32, 31*f*
invasive SCC, 32, 32*f*
prevalence, 310
prevention, 1915–1916
niacinamide chemoprevention, 1915
precursor lesion treatment, 1915
solid organ transplant recipients, immunosuppressive regimen change, 1916
sun protection, 1915
vitamin A chemoprevention, 1915
prognosis, 1913–1915
aftercare, 1914
fundamentals, 1913
high-risk lesions and prognostic risk factors, 1913–1914
local recurrence, 1913, 1914*t*
metastasis, 1913, 1914*t*
secondary skin cancer, 1914–1915
PUVA on risk of, 315
recessive dystrophic epidermolysis bullosa, 314
staging, 1911, 1912*t*
in ulcerative oral lichen planus, 532
Squamous cell carcinoma (SCC) in situ, 31–32, 31*f*, 32*f*. *See also* Bowen disease
Squaric acid dibutyl ester, 3620
Squid topical drugs, shake lotions, 3373*t*, 3375
SSc overlap syndromes, 1087, 1089*f*, 1089*t*
mixed connective tissue disease, 1087, 1089*t*
myositis, intense, 1087
other, 1087
SSc sine scleroderma, 1087
SSH1, 905
ST2, 3533–3534
Stabilin-1, 117
generalized eruptive histiocytoma, 2035
hereditary progressive mucinous histiocytosis, 2039
histiocytosis, non–Langerhans cell, 2030
juvenile xanthogranuloma, 2032
non-Langerhans cell histiocytosis, 2027*t*, 2029*b*
Rosai-Dorfman disease, 2031, 2031*f*
xanthoma disseminatum, 2036, 2037*f*
Stabilizers, 3377
Stable anchoring contacts, 1013
Stains, 19, 20*t*, 21*t*
Standing cones, revision surgery for, 3731, 3732*f*
Stanozolol
for cryofibrinogenemia, 2609
for lipodermatosclerosis, 1264
Staphopain (ScpA), 2727
Staphylococcal enterotoxin A (SEA), recalcitrant erythematous desquamating disorder, 2764
Staphylococcal enterotoxin B (SEB)
recalcitrant erythematous desquamating disorder, 2764
staphylococcal scarlet fever, 2764
toxic shock syndrome, 2762
Staphylococcal enterotoxin C (SEC), toxic shock syndrome, 2762
Staphylococcal nuclease (Nuc), 2727
Staphylococcal scalded skin syndrome (SSSS), 2758
acantholysis, 23, 23*f*
clinical features, 2759–2760, 2759*f*–2760*f*
diagnosis and differential diagnosis, 2761
etiology and pathogenesis, 2758
neonates, 1740
treatment and prognosis, 2761
Staphylococcal skin infections, 2719–2733
at-a-glance, 2719*b*
classification, 2720
clinical features, 2721–2725
complications, 2725
cutaneous, 2721–2725
abscesses, 2724–2725, 2725*f*
botryomycosis, 2725, 2725*f*
carbuncles, 2724, 2725*f*
ecthyma, 2722, 2723*f*
folliculitis, 2722–2724, 2723*f*–2724*f*, 2723*t*
furuncles, 2724, 2724*f*
impetigo, 2721–2722, 2721*f*–2722*f*
paronychia, 2725, 2726*f*
whitlow, 2725, 2726*f*
noncutaneous, 2725
coagulase-negative and -positive, 2720
diagnosis, 2728, 2729*f*
differential diagnosis, 2730*t*
epidemiology, 2720–2721
etiology and pathogenesis, 2726–2728
exfoliative toxins, 2727
immunity, 2727–2728
risk factors, 2726
virulence factors, toxins, and superantigens, 2726–2727
management, 2728–2733, 2731*t*
algorithm, 2729*f*
antibiotic-resistant strains, 2728–2730
clinical course and prognosis, 2728
impetigo, ecthyma, and folliculitis, 2730, 2731*t*
prevention and screening, 2732–2733
skin and soft tissue infections and syndromes, 2720–2721, 2720*t*
Staphylococcal superantigen-like 5 (SSL5), 2727
Staphylococcal superantigen-like 11 (SSL11), 2727
Staphylococcus
with HIV, 3117
occupational exposure, 448
scarlet fever, 2766
toxic shock syndrome, 2762–2763, 2762*f*, 2763*t*
in toxin-mediated disease, 2757 (*See also* Gram-positive infections with toxin production)
Staphylococcus aureus. *See also* Methicillin-resistant *Staphylococcus aureus* (MRSA)
atopic dermatitis, 197, 366–367, 375
bullous impetigo, 2758, 2758*f*–2759*f*, 2761
cellulitis and erysipelas, 2749, 2749*t*
clinical course and prognosis, 2728
clinical features, 2721–2725
complications, 2725
cutaneous, 2721–2725
abscesses, 2724–2725, 2725*f*
botryomycosis, 2725, 2725*f*
ecthyma, 2722, 2723*f*
folliculitis, 2722–2724, 2723*f*–2724*f*, 2723*t*
impetigo, 2721–2722, 2721*f*–2722*f*
paronychia, 2725, 2726*f*
whitlow, 2725, 2726*f*
noncutaneous, 2725
cutaneous necrotizing venulitis, 2529
cutaneous T-cell lymphomas, 2074
diagnosis, 2728, 2729*f*
differential diagnosis, 2730*t*
epidemiology, 2720–2721, 2720*t*
epidermolysis bullosa, 1026
EPO binding, 654
etiology and pathogenesis, 2726–2728
with HIV, 3117
infective endocarditis, 2816–2817
irritant dermatitis, 421
IV drug use skin and soft tissue infections, 1708
management, 2728–2733, 2731*t* (*See also under* Staphylococcal skin infections)
algorithm, 2729*f*
microbiome, skin, 256–257, 257*t*, 258
nummular eczema, 386
occupational exposure, 448
patch testing infection, 408
with pityriasis amiantacea, 430
postoperative infection, 3720
preoperative prophylaxis, 3706–3707
prevention and screening, 2732–2733
pyomyositis, 2777–2778, 2777*t*, 2778*t*
skin and soft tissue infections and syndromes, 2720–2721, 2720*t*
superantigens, 2727
superficial cutaneous infections and pyodermas, 2719–2733 (*See also* Staphylococcal skin infections)
surgical site infections, 2748
toxin-mediated erythema, 2766–2767
toxins and diseases, 2758*t*
Staphylococcus epidermidis
epidemiology, 2720
microbiome, skin, 256–257, 257*t*, 258
Staphylococcus intermedius, 3339
Staphyloxanthin, 2727

Staple closure, 3719
Starch baths
for cercarial dermatitis, 3354
for sea bather's eruption, 3354
Starch granuloma, 1712
Starfish, 3352
Starvation, 2200–2203. *See also* Protein-energy malnutrition (PEM)
Stasis dermatitis, 418
STAT, 163
STAT1, herpes simplex encephalitis, 3027
STAT3
atopic dermatitis, 197
cutaneous T-cell lymphomas, 2075–2076, 2076*f*
hyperimmunoglobulinemia E syndrome, 2414
hyperimmunoglobulin E syndrome, 1740
STAT5 activation, cutaneous T-cell lymphomas, 2075, 2076*f*
STAT5B, cutaneous T-cell lymphomas, 2075
STAT6, solitary fibrous tumor, 2182
Statins, on LDL-C, 2286
Stavudine, 3506–3507, 3509*t*
Stearic acid, 3806, 3806*t*
Steatocystoma, 1815–1816, 1815*f*
Steinberg sign, Marfan syndrome, 1226
Stein-Leventhal syndrome. *See* Polycystic ovarian syndrome (PCOS)
Stellate configuration, 7*f,* 10
Stem cell factor (SCF), mast cell maturation, 153
Stem cells
cancer, 312–313, 312*f*
dynamics and potency, 113
epidermis, 62
niche, 62–63
hair follicle, 93*f,* 96, 96*f*
melanocyte, hair, 98–99
Stem cells, nail
digit regeneration, 111–113, 112*f*
fundamentals, 108–109
homeostasis and regeneration, 108–111
rapidly cycling unipotent nail stem cells, 110–111, 110*f*
slow-cycling bifunctional nail proximal fold stem cells, 109, 110*f*
Stem cell therapy, for wound healing, 2712
Stem cell transplantation (SCT)
allogeneic, for epidermolysis bullosa, 1028
autologous peripheral blood, for scleromyxedema, 1168
for cutaneous T-cell lymphomas, 2096–2097
for ectodermal dysplasia with immunodeficiency, 2407
hematopoietic (*See* Hematopoietic stem cell transplantation (HCT))
for systemic sclerosis, 1098, 1100*t*
for Wiskott-Aldrich syndrome, 2404
Steroid(s). *See also* Corticosteroids; Glucocorticoids; *specific types*
anabolic, 1714
for psoriasis, 493
resistance, eosinophil-associated disease, 658
Steroid acne, 1714
Steroid folliculitis, 1452
Steroid rosacea, 1425, 1425*f*. *See also* Rosacea
Steroid withdrawal syndrome, 3387
Stevens-Johnson syndrome (SJS), 733–745, 761*t*. *See also* Drug reactions, cutaneous
at-a-glance, 733*b*
with burn injury, 1683–1684
carbamazepine-induced, HLA haplotype inheritance, 304, 304*t*
clinical course and prognosis, 734*t*, 742, 742*f,* 761–762
clinical features, 11*f,* 736–738, 736*f,* 753
cutaneous lesions, 736, 737*f*–738*f*
history, 736
mucous membrane, 736–737, 739*f*
systemic involvement, 737–738
complications and sequelae, 740–742, 741*f,* 741*t*
cytotoxic T cells, 194, 195*f*
definition, 733, 734*t*
differential diagnosis, 739–740, 740*t*
epidemiology, 733, 734*t,* 749
etiology, 733–735, 734*t*
genetic predisposition, 194
histopathology, 738*f,* 739, 740*f*
historical perspective, 733
with HIV, 3111–3112
immunologic drug reactions, 759–760, 759*t*
immunologic responses, 194–195, 195*f*
laboratory values, 738
management, 742–744, 743*t,* 762
pathogenesis, 735–736
prevention, 744–745, 762
Still disease
adult-onset, 1155–1158, 1160*t* (*See also* Adult-onset Still disease (AOSD))
juvenile, 1153–1155, 1154*f,* 1160*t*
Stimulator, preoperative examination, 3708
Stinging nettle, 684
Stinging type sensitive skin, 3808*t,* 3809
Stingrays, 3356, 3356*f*
STK11, Peutz-Jeghers syndrome, 1359
Stockings, compression, for lipodermatosclerosis, 1264
Stokes Law, 268
Stomatitis
from cytotoxic agents, 3467*f,* 3486–3487, 3487*t*
nicotine, 1714
paraneoplastic pemphigus, 935–936, 936*f*
Stomatitis gangrenosa, 2226–2228, 2227*f,* 2228*t*
Stonefish stings, 3357
Stop codon, 292
Storiform pigmented neurofibroma, 2159
Stork bite, 1734, 2638
Stratum basale, 207, 210*f*
Stratum corneum, 66, 207–218, 210*f,* 3367
absorption factors, 3370–3371, 3370*f*–3371*f*
corneocyte lipid envelope formation, 208*t,* 211, 214*f*
corneodesmosomes, 208*t,* 209, 210*f,* 212*f,* 213–214
cornified cell envelope formation, 208*t,* 211, 214*f*
dry skin, 3804
filaggrin degradation and natural moisturizing factors, 208*t,* 217
function, 207
intercorneocyte lipid lamellae formation, 208*t,* 211–212, 214*f*
in utero development, 224
keratin cytoskeleton and filaggrin, 216–217, 216*f*
lipid composition, 208*t,* 212–213, 215*f*
multidomain structure, 217, 218*f*
neonates, 1728
penetration pathways across, 3367–3368, 3371*f*
percutaneous absorption through, 210*f,* 217–218, 218*f*
skin barrier, 207–218, 3367
structure, basic, 209, 211*f*–213*f*
Stratum granulosum, 207, 210*f*
Stratum spinosum, 207, 210*f*
Streptobacillus moniliformis, 2829*t,* 2838–2839
Streptococcal pyrogenic exotoxin A (SPEA), 2763
staphylococcal scarlet fever, 2764
Streptococcal pyrogenic exotoxin B (SPEB), 2763
Streptococcus
cutaneous necrotizing venulitis, 2529
in elderly, 1787
group A, 2733
acute rheumatic fever from, 1160
scarlet fever, 2764–2766
skin infections, 2733–2740
group A β-hemolytic
cellulitis and erysipelas, 2749, 2749*t*
erythema marginatum, 769–771, 770*f*
occupational exposure, 448
pharyngitis, acute rheumatic fever from, 1158
scarlet fever, 2764–2766, 2765*f*
skin and soft tissue infections, IV drug use, 1708
throat, guttate psoriasis, 479
toxic shock syndrome, 2763
toxin-mediated disease, 2757 (*See also* Gram-positive infections with toxin production)
toxin-mediated erythema, 2766–2767
Streptococcus iniae, 2829*t,* 2848–2849
Streptococcus pyogenes
bullous impetigo, 2758, 2758*f*–2759*f,* 2761
cellulitis and erysipelas, 2749, 2749*t*
epidermolysis bullosa, 1026
IV drug use skin and soft tissue infections, 1708
postoperative infection, 3720
toxins and diseases, 2758*t*
Streptococcus skin infections, 2733–2740
at-a-glance, 2733*b*
classification, 2733
clinical course and prognosis, 2738
clinical features, 2734–2736
complications, 2736
cutaneous, 2734–2735, 2735*f*
noncutaneous, 2735–2736
diagnosis, 2729*f,* 2737–2738
differential diagnosis, 2738, 2738*t*
epidemiology, 2734
etiology and pathogenesis, 2736–2737
historical perspective, 2733
immunity, 2737
infections and toxin syndromes, 2733*t*
management, 2739–2740, 2739*t*
Streptodornase, for cryofibrinogenemia, 2609
Streptogramin antibiotics. *See* Quinupristin/dalfopristin
Streptokinase, for cryofibrinogenemia, 2609
Streptomyces somaliensis actinomycetoma, 2884–2890, 2966*t,* 2969–2971. *See also* Actinomycetoma
Streptomycin
for actinomycetoma, 2889, 2971
for brucellosis, 2835
for *N. brasiliensis* actinomycetoma, 2889
for plague, 2833
for tularemia, 2831
for verruga peruana, 2806
Stress
gastritis, acute, burns, 1681
psychological, telogen effluvium from, 1510
reduction
for Fox-Fordyce disease, 1477
for hidradenitis suppurativa, 1487
urticaria, 694
Stress barrier, skin, 224–226, 225*f*. *See also* Physical stress barrier, skin
Stretch marks, pregnancy, 1765, 1767*f*
Striae, 1197
laser therapy for, 3853*t,* 3854
Striae distensae (pregnancy), 1765, 1767*f*
Striae gravidarum, 1765, 1767*f*
Striated muscle tumors, 2131*t*–2132*t,* 2133*f,* 2143–2146
neuromuscular hamartoma, 2131*t*–2132*t,* 2146, 2146*f*
rhabdomyoma, 2131*t*–2132*t,* 2143–2144, 2144*f*

Striated muscle tumors (*Cont.*):
rhabdomyomatous mesenchymal hamartoma, 2131*t*–2132*t*, 2145–2146
rhabdomyosarcoma, 2131*t*–2132*t*, 2144–2145, 2145*f*
Striate palmoplantar keratoderma, 837–838, 837*f*, 846*t*
Strip harvesting
donor site excision, 3939
graft preparation, 3941*f*, 3942
STROBE, 44
Stromal keratitis, herpes simplex virus, 3026
Strongyloidiasis *(Strongyloides stercoralis, S. fuelleborni)*, 3252*t*
abdominal pain, 3261
clinical features, 3255*t*, 3271, 3271*f*
complications, 3271–3272
diagnosis, 3272
epidemiology, 3271
exposure and symptom onset interval, 3259, 3260*t*
life cycle, 3253
Loeffler syndrome, 3260–3261
management, 3255*t*, 3265*t*, 3272
migratory skin lesions, 3254, 3255*t*, 3256*f*
neurologic disease, 3261
progression and duration, 3259, 3260*t*
Structures, skin, 50, 51*f*
STS, 3878, 3878*t*, 3879
STS, X-linked recessive ichthyosis, 778*t*, 785, 785*f*
Stucco keratosis, 1801
Study designs, epidemiology, 42–44, 42*f*
analytic studies
experimental, 42–43, 42*f*
observational, 42*f*, 43–44
descriptive studies, 42*f*, 44
meta-analysis, 44
Sturge-Weber syndrome, capillary malformations, 2639, 2642*f*
STX11, hemophagocytic lymphohistiocytosis, 2032
STXBP2, hemophagocytic lymphohistiocytosis, 2032
Subacute cutaneous lupus erythematosus (SCLE)
classification, 1038, 1038*t*
clinical course and prognosis, 1052
clinical features, 1042–1044, 1043*f*
diagnosis
histopathology, 1050*f*, 1051
immunohistology, 1052
drug-induced, 752*t*, 756
epidemiology, 1039
tobacco use on, 1714
Subacute sclerosing panencephalitis, from measles, 2991
Subcision
for acne vulgaris, 1409
cellulite removal, 3867, 3867*f*
Subcorneal pustular dermatosis (SPD), 617–619
at-a-glance, 617*b*
clinical course and prognosis, 619
clinical features, 588*f*, 617–618, 618*f*
differential diagnosis, 619, 619*t*
epidemiology, 617
etiology and pathogenesis, 617
histopathology, 588*f*, 618–619, 618*f*
SPD-type, 617–619, 981
treatment, 619, 619*t*
Subcorneal pustular dermatosis (SPD)–type intercellular IgA dermatosis, 983, 983*f*, 983*t*
Subcutaneous fat necrosis of newborn, 1254*t*, 1278–1280, 1279*f*, 1280*t*, 1745, 1746*f*
Subcutaneous ingrown nails, 3788–3789, 3788*f*
Subcutaneous lupus erythematosus, 1253*t*, 1272–1275. *See also* Lupus panniculitis
Subcutaneous mucormycosis, 2967*t*, 2973
Subcutaneous mycoses, 2965–2973, 2966*t*–2967*t*. *See also* Mycoses, subcutaneous
Subcutaneous nodules, sarcoidosis, 574
Subcutaneous panniculitis-like T-cell lymphoma (SPTCL), 1274*t*, 1276, 2086
cytophagic histiocytic panniculitis, 1276, 1278
lupus panniculitis, 1276
Subcutaneous phycomycosis, 2967*t*, 2973
Subcutaneous reaction pattern, 15, 15*t*
Subcutaneous tissue disorders, 1251–1284. *See also specific types*
α-antitrypsin panniculitis, 1253*t*, 1266–1269
cold panniculitis, 1254*t*, 1280–1282, 1282*t*
connective tissue disease–associated panniculitis, 1283*b*
cytophagic histiocytic panniculitis, 1253*t*, 1275–1278
erythema induratum and nodular vasculitis, 1252*t*, 1259–1262
erythema nodosum, 1252*t*, 1255–1259
factitial and traumatic panniculitis, 1254*t*, 1282*b*, 1282*f*
gouty panniculitis, 1283*b*
infection-induced panniculitis, 1252*t*, 1264–1266
lipodermatosclerosis, 1252*t*, 1262–1264, 1262*f*–1263*f*, 1264*t*
lupus panniculitis, 1253*t*, 1272–1275
pancreatic panniculitis, 1253*t*, 1270–1272, 1270*f*–1271*f*, 1271*t*
panniculitis, 1251–1255, 1252*t*–1254*t*
panniculitis with dermatomyositis, 1253*t*
poststeroid panniculitis, 1283*b*–1284*b*
subcutaneous fat necrosis of newborn, 1254*t*, 1278–1280, 1279*f*, 1280*t*, 1745, 1746*f*
Subepidermal blistering, 24f, 25, 947, 948*f*–949*f*. *See also* Bullous pemphigoid (BP)
Suberanilohydroxamic acid. *See* Vorinostat
Subjective irritant contact dermatitis, 444
Substance P
chromhidrosis, 1471
prurigo nodularis, 389
Substrate deprivation, for Fabry disease, 2303
Subungual exostosis, 1605, 1605*f*
Subungual filamentous tumors, 1603
Subungual hematoma, 1570–1571, 1572*f*
surgery, 3785–3786, 3785*f*
Subungual hyperkeratosis, 1572–1573, 1574*f*
Subungual melanoma, 1985*f*, 1986, 1986*t*. *See also* Melanoma
Subungual osteochondroma, 1605
Sucking blisters, 1732
Sucralfate suspension, for adamantiades–Behçet disease, 2574*t*
Sudomotor axon reflex tests, 122
erythromelalgia, 122
Sudoriparous angioma, 2059*b*, 2065
SUFU, basal cell carcinoma, 1884, 1885*t*
Sulfacetamide, for periorificial dermatitis, 1455
Sulfadiazine
for amebas, opportunistic, 3248
for glanders, 2836
for nocardiosis, 2884
for toxoplasmosis, 3249
Sulfamylon cream, for burn wound care, 1686*t*, 1687
Sulfapyridine
for bullous pemphigoid, 952, 952*t*
for chronic bullous disease of childhood, 994*t*, 998*t*, 999
for dermatitis herpetiformis, 1006
for erythema elevatum diutinum, 2565
for linear IgA dermatosis, 998*t*, 999
Sulfasalazine
for adamantiades–Behçet disease, 2576*t*
for lichen planus, 544
for psoriasis, 485*t*, 493
for psoriatic arthritis, 979, 980, 980*t*, 1135, 1136*t*
Raynaud phenomena from, 2616
for reactive arthritis, 1142
for rheumatoid arthritis, 1152
for SAPHO syndrome, 1450
for Still disease, adult-onset, 1158
Sulfisoxazole, for nocardiosis, 2884
Sulfonamides
for nocardiosis, 2884
pellagra from, 2214
Sulfones
for bullous pemphigoid, 952, 952*t*
for dermatitis herpetiformis, 1006
for erythema elevatum diutinum, 2565
for intercellular IgA dermatosis, 989
for leprosy, 2916
Sulfoxone (diazone), for dermatitis herpetiformis, 1006
Sulfur, topical
for acne vulgaris, 1404
for rosacea, 1439
for seborrheic dermatitis, 435
SUMF1, multiple sulfatase deficiency, 780*t*, 806
Summer prurigo, 1628–1632. *See also* Actinic prurigo
Summertime lichenoid actinic eruption, 555–556
Sun avoidance. *See* Photoprotection
Sunblock, 3625
Sunburn, 272
dyskeratosis, 22
Sunburn cells, 22
Sun exposed distribution, 11
Sun exposure. *See also* Photoexposure; Photoprotection
granuloma annulare, 566
melanoma, 1989–1990
middermal elastolysis, 1195
Sunglasses, 3631–3632
Sun-induced freckle. *See* Solar lentigo
Sunitinib, 3600–3601
for necrolytic migratory erythema, 2456
Sunlight, divisions and wavelengths, 266–267, 266*f*, 266*t*
Sun protected distribution, 11
Sun protection. *See* Photoprotection
Sun protection factor (SPF), 3624–3625, 3624*f*
Sunscreen, 3623–3629
for actinic keratosis prevention, 1867
for aging skin, 3813
in children, 3627
controversies
inorganic nanoparticles, 3628
nonmelanoma skin cancer and melanoma, 3628
systemic, potential, 3628
vitamin D, 3628–3629
history, 3624
immune protection factor, 3625
for pigmentation, 3811
in pregnancy, 3627–3628
sun protection factor, 3624–3625, 3624*f*
uses, 3623–3624
UVA protection, assessment, 3625
UV filters, 3625–3627, 3626*t*, 3627*f*
UV for erythema *vs.* damage, 3624
Superantigenic toxin diseases, 2761–2768
atopic dermatitis, 2767
autoeczematization response, 2767
classification, 2762
cutaneous T-cell lymphoma, 2768
etiology and pathogenesis, 2761–2762, 2761*f*
psoriasis, 2767

recalcitrant erythematous desquamating disorder, 2764
scarlet fever, 2764–2766, 2765*f*
toxic shock syndrome, 2762–2764, 2762*f*, 2763*t*, 2764*t*
toxin-mediated erythema, 2766–2767
Superantigens, 2761–2762, 2761*f*
Superficial actinic porokeratosis, gonadal mosaicism, 302
Superficial basal cell carcinoma, 1886–1887, 1886*t*, 1887*f*. *See also* Basal cell carcinoma
Superficial benign smooth muscle tumor, 2130, 2134–2138. *See also* Leiomyoma
Superficial cutaneous infections and pyodermas, 2719–2744. *See also specific types*
commensals, 2719
erythrasma, 2741–2743, 2742*f*
historical perspective, 2720
pitted keratolysis, 2740–2741, 2741*f*
staphylococcal skin infections, 2719–2733
streptococcal skin infections, 2733–2740
trichobacteriosis, 2743–2744, 2743*f*
Superficial epidermolytic ichthyosis, 777*t*
clinical features, 796–798, 797*f*
KRT2, 777*t*
Superficial leiomyoma, 2130, 2134–2138. *See also* Leiomyoma
Superficial leiomyosarcoma, 39, 39*f*, 2131*t*–2132*t*, 2138–2141. *See also* Leiomyosarcoma
Superficial musculoaponeurotic system (SMAS), 3698
Superficial pemphigus. *See* Pemphigus foliaceus
Superficial pyoderma gangrenosum, 606*f*, 607. *See also* Pyoderma gangrenosum (PG)
Superficial reactive unit, 19–25, 21f
anatomy, 19, 21*f*
pathological reactions, entire unit, 24–25
interface and lichenoid dermatitis, 25, 25f
psoriasis, 24, 25f
spongiotic dermatitis, 24, 24f
subepidermal blistering processes, 24f, 25
pathology, dermal–epidermal junction, cohesion disturbances, 23–24, 24*f*
pathology, epidermis, 19–23
acantholysis, 23, 23*f*
acanthosis, 21, 21*f*
atrophy, 21, 22*f*
cell types, 19–20
dyskeratosis, 23, 23*f*
epidermal cell cohesion disturbances, 22–23, 22*f*–23*f*
epidermal cell differentiation disturbances, 21–22
epidermal cell kinetic disturbances, 21, 21*f*, 22*f*
spongiosis, 22, 22*f*
Superficial spreading melanoma (SSM), 1983, 1984*f*–1985*f*. *See also* Melanoma
Superficial vascular plexus (SVP), 116, 117*f*
Superficial venous system, 3872–3874, 3872*f*–3874*f*, 3873*t*
Superficial venous thrombophlebitis (SVT), after sclerotherapy, 3886, 3886*f*
Supernumerary digits, 1735, 1735*f*
Supersaturated potassium iodide solution (SSKI)
for erythema induratum and nodular vasculitis, 1262
for erythema nodosum, 1259
Superselective embolization, for arteriovenous malformations, 2663
Support systems, preoperative examination, 3709
Supraorbital artery, 3704*f*, 3705
Supraorbital nerve, 3702–3703, 3702*f*, 3703*t*
Supratrochlear artery, 3704*f*, 3705
Supratrochlear nerve, 3702–3703, 3702*f*, 3703*t*
Suramin, for African trypanosomiasis, 3239–3240, 3239*t*
Surface, skin, 3364–3367
formulations, 3366–3367
parameters affecting drugs in, 3364, 3366*t*
reservoir, 3366
surface applications, 3364–3366
Surgery. *See also* Perioperative considerations; Postoperative considerations; *specific types*
at-a-glance, 3726*b*
telogen effluvium from, 1509
Surgical anatomy, cutaneous facial, 3697–3703. *See also* Facial anatomy, cutaneous surgical
Surgical site infections (SSTIs), 2748, 3706, 3707*t*. *See also specific types*
Surgical skin planing. *See* Dermabrasion
Surgical tray, 3726–3727, 3727*f*
Surviving Sepsis Campaign, 2821
Suspensions, topical, 3373*t*, 3375
Sutton nevus, 1952–1953, 1952*f*
Suture track marks, postoperative, 3722–3723, 3723*f*
Suturing, 3715–3720
healing by second intention, 3719–3720
materials, 3716–3717, 3716*t*
purpose, 3715
staple closure, 3719
suture diameter and time to removal, 3716–3717, 3717*t*
technique, 3717–3719
interrupted sutures, 3717–3718, 3717*f*–3719*f*
running sutures, 3718–3719
Sweat
ammonia and amino acids, 82
composition, 81–82, 82*f*
inorganic ions, 81, 82*f*
lactate, 81
proteins and proteases, 82
secretion mechanisms, 82, 83*f*
urea, 81–82
Sweat gland disorders, eccrine, 1459–1467. *See also specific types*
anhidrosis, 1460*t*, 1463–1467
classification, 1460*t*
hyperhidrosis
primary focal, 1459–1463, 1460*t*
secondary, 1461–1463
Sweat glands, 78–85
apocrine, 83–85
diseases, 71*t*
at-a-glance, 78*b*
development, 27
eccrine, 78–83
acetylcholine, 80
anatomy and function, 78–79, 79*f*
development, 78
diseases, 70, 71*t*
ductal reabsorption, 82–83, 83*f*
eccrine myoepithelium, pharmacology and function, 81
emotional sweating, 80
energy metabolism, 81
innervation, 1459
neural control, 79–80
pharmacology and sweating rate, 80–81, 81*f*
Sweating
eccrine
neonates, 1728
regulation, 1459
in elderly, 1784
emotional, 80
gustatory, 1463–1464, 1464*f*
heat stress protection, 225
neural control, 79–80
periodicity, 81
rate, 80–81, 81*f*
Sweet syndrome, 587–602
associated conditions, 593, 594*t*, 595*t*
at-a-glance, 587*b*
clinical course and prognosis, 601
clinical features, 589–593, 589*t*
complications, 593
history, 589
clinical features, cutaneous, 589–591
cutaneous pathergy and isotopic response, 590–591
giant cellulitis-like variant, 591, 591*f*
histiocytoid variant, 591
lesion morphology, 589–590, 590*f*
necrotizing variant, 591
neutrophilic dermatosis, dorsal hands, 591
panniculitis, subcutaneous, 591
pustular dermatosis, 591
clinical features, noncutaneous, 591–593, 592*t*
bone, 591, 592*t*
cardiac, 592, 592*t*
central nervous system, 592, 592*t*
ocular, 592, 592*t*
oral, 592, 592*t*
organs, 591, 592*t*
otic, 592–593, 592*t*
spleen, 592*t*, 593
definition, 587
diagnosis, 596–599
classical *vs.* drug-induced criteria, 588*t*
diagnostic criteria, 588*t*, 596–597
drug-induced, 588*t*, 597, 597*f*
malignancy-associated, 597
supportive studies, 597–599
imaging, 599
laboratory testing, 597–598
pathology, 598–599, 598*f*, 599*f*
differential diagnosis, 599–601
clinical, 599–600, 600*t*
histological, 600–601, 600*t*
drug-induced, 587, 588*t*, 597, 597*f*
epidemiology, 587, 588*t*
etiology, 593–594
associated diseases, 593, 594*t*
conditions and drugs, 593, 595*t*
leukemia cutis, concurrent, 593
systemic inflammatory response syndrome, 593–594
historical perspective, 587
malignancy workup, 602
management
antibiotics, 602
first-line, 601–602, 601*t*
other agents, 602
second-line, 601*t*, 602
paraneoplastic, 587*b*, 593, 601, 2442*t*, 2456–2457
pathology
neutrophils, 27
nodular lymphocyte collections, 26
pathogenesis, 594–596
animal models, 594–595
bacterial, viral, or tumor antigens, 595
cytokines, 595–596
familial Mediterranean fever, 595
human leukocyte antigen serotypes, 595
immunohistochemical studies, 596
photosensitivity, 596
Swimmer's ear, *Pseudomonas aeruginosa*, 2790, 2791*t*
Swimmer's itch, 3252*t*
clinical features, 3270, 3270*f*
diagnosis, 3270–3271
differential diagnosis, 3270

Swimmer's itch (*Cont.*):
epidemiology, 3269–3270
life cycle and helminth transmission, 3253–3254
management, 3265*t*, 3271
Swimming pool granuloma, 2871, 2873*f*, 2873*t*
Sybert palmoplantar keratosis, 823–824
Sycosis barbae, staphylococcal, 2723, 2723*f*
Symmetrical circumscribed allotrichia, 1545
Symmetrical drug-related intertrigonous and flexural exanthema (SDRIFE), 402, 402*t*
Symmetry
bilateral symmetric distribution, 12
skin tumors, 30
Symplastic leiomyoma, 2136
Symptomatic dermographism, 686*f*, 688–689. *See also* Urticaria
diagnosis, 697
diagnostic tests, 688*t*
Synanceja, 3357
Synaptobrevin, 80
Syndecans, 242
dermal cell-matrix adhesion, 247
Synergistic necrotizing cellulitis, 2772
Synovitis
inflammatory, rheumatoid arthritis, 1151
SAPHO syndrome, 644–645, 645*f*
Syphilids, 3150
Syphilis, 3145–3168
at-a-glance, 3145*b*
chancres
chancre redux, 3149
edema indurivatum, 3149
extragenital, 3149, 3149*f*
genital, 3148*f*–3149*f*, 3149
Hunterian, 3148
clinical course and prognosis, 3166
clinical features, 3147–3159
condyloma lata, 3152, 3152*f*
dory flop, 3148
exposure and incubation, 3147–3148
granulomas, infectious, 27
gumma, 3155–3156, 3155*f*–3156*f*
latent syphilis, 3154
neurosyphilis, 3157
ocular, 3157
plasma cells, 149
primary syphilis
cutaneous, 3148–3149, 3148*f*–3149*f*
noncutaneous, 3149
secondary syphilis
cutaneous, 3150–3153, 3150*f*–3153*f*
definition, 3149
interface/lichenoid changes, 25
maculopapular rash, 3153, 3154*t*
noncutaneous, 3153
stages, 3147, 3147*t*
tertiary syphilis
cutaneous, 3155–3156, 3155*f*–3156*f*
differential diagnosis, 3156*t*
noncutaneous, 3156
congenital, 1740, 3157–3158, 3158*f*–3159*f*
definitions, 3145
diagnosis, 3161–3166
direct detection, *T. pallidum*
darkfield microscopy, 3161, 3161*f*
direct fluorescence antibody test, 3161
molecular tests, 3162
histopathologic examination, 3162
serology, 3162–3166
congenital syphilis, 3166
nontreponemal serologic tests, 3162–3164, 3163*f*, 3164*t*
rapid serologic tests, 3166
reverse sequence algorithm, 3164–3165, 3165*f*
tests, sensitivity and specificity, 3162, 3162*t*
treponemal serologic tests, 3163*f*, 3164
differential diagnosis, 3149*t*
epidemiology, 3146–3147
etiology and pathogenesis, 3159–3161
historical perspective, 3145–3146
HIV with, 3118–3119, 3159, 3160*t*
management, 3160*t*, 3166–3168
CDC recommendations, 3160*t*, 3166
complications, 3167
disease reporting, 3167–3168
follow-up, clinical and serologic, 3166–3167
persons exposed to syphilis, 3167–3168
prevention and screening, 3168
treatment complications, 3167
monorecidive, 3149
Syphiloderms, 3150
Syringocystadenoma papilliferum, 1833–1834, 1834*f*
Syringoma, 33, 1827, 1827*f*
Syringosquamous metaplasia (CSM), from cytotoxic agents, 3483
Syringotropic mycosis fungoides, perieccrine inflammation, 26
Systemic amyloidosis
inflammatory pathology, 29
nail changes, 1597, 1598*f*
Systemic cold urticaria, 689
Systemic contact dermatitis (SCD), 402, 402*t*, 403*t*
Systemic inflammatory response syndrome, Sweet syndrome with, 593–594
Systemic lupus erythematosus (SLE). *See also* Lupus erythematosus (LE)
bullous, 246
cardiovascular and cutaneous manifestations, 2427
chronic spontaneous urticaria, 687
cutaneous necrotizing venulitis with, 2529
drug-induced, 752*t*, 756, 1041, 1041*t*
Libman-Sacks endocarditis, 2427
myocarditis, 2427
pericarditis, 2427
pulmonary and cutaneous manifestations, 2430
vasculitis with, 2552
Systemic mastocytosis (SM), 710–720. *See also* Mastocytosis
Systemic mastocytosis with associated clonal hematologic non–mast-cell-lineage disease (SM-ADNMD), 710–720, 711*t*
Systemic mycoses, 2973–2985. *See also* Mycoses, systemic
Systemic necrotizing arteritis, 2539–2558. *See also* Vasculitis
Systemic polyangiitis, 2527
Systemic sclerosis (SSc), 1086–1102, 1094
at-a-glance, 1086*b*
cardiovascular and cutaneous manifestations, 2427
classification and subsets, 1086–1089
autoantibodies, 1089, 1090*t*
diffuse, 1087, 1088*f*
early, 1087
frequency and timing, 1089
general, 1086–1087
genetics, 1089
limited, 1087, 1088*f*
SSc overlap syndromes, 1087, 1089*f*, 1089*t*
mixed connective tissue disease, 1087, 1089*t*
myositis, intense, 1087
other, 1087
SSc sine scleroderma, 1087
clinical course and prognosis, 1098
clinical features
cardiopulmonary, 1090–1091
cardiovascular, 2427
myocardium small vessel disease, 2427
pericarditis, 2427
cutaneous, 2427, 2430
general, 1086
GI, 1091
involvement, frequency, 1099, 1099*t*
kidney, 1091
nail changes, 1587–1588
organ, 1089–1091
pulmonary, 2430
skin, 1088*f*, 1090–1092, 1091*f*
vasculopathy, 1088*f*, 1089–1090
digital, 1090
cocaine abuse, 1709
cutaneous necrotizing venulitis with, 2529
definition, 1086
diagnosis, 1095–1097
cardiopulmonary, 1096–1097, 1096*t*
GI, 1096*t*, 1097
kidney, 1096*t*, 1097
Raynaud phenomena, 1086, 1087, 1088*f*, 1095–1096, 1096*t*
skin sclerosis and Rodnan Skin Score, 1087, 1089, 1094*f*, 1096, 1096*t*, 1097*f*
differential diagnosis, 1097–1098, 1098*t*
epidemiology, 1086
etiology and pathogenesis, 1092–1095
environmental factors, 1093
fibrosis, 1092*f*, 1095
genetic factors, 1093
histopathology, 1093–1094, 1094*f*
immune events, 1094–1095, 1095*t*
major facets, 1092–1093, 1092*f*
vasculopathy, 1094
hypermelanosis, 1368
inflammatory reactions, 28
interstitial lung disease, 2430
management, 1098–1102
algorithm, 1100*f*
cardiopulmonary, 1101
digital vasculopathy and complications, 1099–1100, 1099*t*
disease-modifying treatment, 1098–1099, 1099*t*
GI, 1101–1102
other supportive measures, 1102
phototherapy, 3646*t*, 3650–3651
localized sclerosis, 3646*t*, 3650–3651
PUVA, 3672
scleroderma renal crisis, 1102, 1102*t*
skin, 1099*t*, 1101

T

T790M mutation, 3566
T1105N–T1106P, blue rubber bleb nevus syndrome, 2650
Tabanidae, 3325*f*, 3330–3331
Tabes dorsalis, 3157
TACI, common variable immunodeficiency, 2396*b*
Tacrolimus, 3475–3476, 3524–3526. *See also* Calcineurin inhibitors (CNIs)
for adamantiades–Behçet disease, 2576*t*
contraindications, 3525
for cytophagic histiocytic panniculitis, 1278
for Darier disease, 884
dosing regimen, 3522*t*, 3525
drug interactions, 3521*t*, 3526
on eosinophils, 658
for graft-versus-host disease, 2332, 2335
indications, 3524–3525
for lichen simplex chronicus, 391
monitoring, therapeutic, 3525
for nummular eczema, 388

for palisaded neutrophilic and granulomatous dermatitis, 1148
pharmacology and mechanism of action, 3520*f*, 3524
for pityriasis lichenoides, 515, 515*t*
for porokeratosis, 905
for prurigo nodularis, 391
for seborrheic dermatitis, 434–435
side effects and precautions, 3525
serious, 3526
for urticaria, 702
Tacrolimus, topical
for actinic dermatitis prevention, 1643
for angiolymphoid hyperplasia with eosinophilia, 669
for chronic bullous disease of childhood, 994*t*, 998*t*, 999
for eosinophilic pustular folliculitis, 671
for frontal fibrosing alopecia, 1528
for graft-versus-host disease
genital, 2335
oral, 2335
for Hailey-Hailey disease, 889
for incontinentia pigmenti, 1352
for Langerhans cell histiocytosis, 2028
for lichen nitidus, 558, 558*t*
for lichen planus pigmentosus, 1386
for lichen striatus, 560–561, 1804
for linear and whorled nevoid hypermelanosis, 1352
for morphea, 1116
for mucous membrane pemphigoid, 966, 966*t*
for Netherton syndrome, 795
pediatric toxicity, 1761*t*
for perioral dermatitis, 1455
for psoriasis, 482*t*, 490
Tadalafil
for pulmonary artery hypertension in digital vasculopathy, 1100, 1101
for Raynaud phenomena, 2621, 2621*t*
Taenia multiceps, 3252*t*
exposure and symptom onset interval, 3259, 3260*t*
neurologic disease, 3261
progression and duration, 3259, 3260*t*
subcutaneous nodules and masses, 3257, 3257*t*
Taenia solium, 3252*t*
exposure and symptom onset interval, 3259, 3260*t*
neurologic disease, 3261
progression and duration, 3259, 3260*t*
subcutaneous nodules and masses, 3257, 3257*t*
Taiga tick, 3329
Takayasu arteritis, 2540, 2554. *See also* Vasculitis
Talaromyces marneffei, 2974, 2982
Talc granuloma, 1712, 1712*f*
TALENS (transcription activator-like effector nucleases), 307
Talimogene laherparepvec (T-VEC), for melanoma, 2002
Tanning, 272–273, 272*f*
indoor, adolescents, 1758
skin phototypes, 272, 272*t*
UV-induced, MC1R pathway, 343, 344*f*
Tapeworms, 3251, 3252*t*. *See also specific types*
exposure and symptom onset interval, 3259, 3260*t*
progression and duration, 3259, 3260*t*
Tar acne, 1453
Tarantula, 3328, 3328*f*
TARC, immune surveillance, 122, 122*f*
Targeted phototherapy, 3643
Targeted therapies, molecular, 3558–3586. *See also* Molecular targeted therapies; *specific therapies*
Targetoid erythemas, 16, 16*t*
Targetoid hemosiderotic hemangioma, 2064
Targetoid shape, 10, 11*f*
Tar preparations
for nummular eczema, 388
for parapsoriasis, 510
Tarsal glands, 70. *See also* Sebaceous glands
TAT, Richner-Hanhart syndrome, 842
Tattoos
inflammatory reactions, 29, 29*f*
pseudolymphoma from, 2117, 2117*f*
removal
nonablative laser therapy, 3852–3854, 3852*f*, 3853*t*
R20 treatment, 3854
Tavaborole, 3438*t*, 3447–3448
for nail infections, fungal, 1595, 1596*t*
for onychomycosis, 3448
Taxanes, nail changes, 1599
Tay syndrome, trichothiodystrophy, 1539*t*
Tazarotene, topical, 3397
for acne vulgaris, 1402*t*, 1404
for Darier disease, 884, 884*t*
indications and contraindications, 3399
for palmoplantar keratodermas, inherited, 821
for psoriasis, 482*t*, 490
Tazobactam, for actinomycosis, 2880
Tc1, psoriasis, 466, 468, 469*f*, 470*f*
Tc17, psoriasis, 468, 469*f*, 470*f*
Tc22, psoriasis, 468, 469*f*
T cell(s), 133*f*, 136–137, 136*f*–137*f*, 143, 145–147. *See also specific types*
adaptive immunity, irritant dermatitis, 414
CAAR, 203
CD4+, 136, 145
CD8+, 134, 136, 145
vitiligo, 1335
cytotoxic
fixed drug eruption, 194
graft-versus-host disease, 2321
Stevens-Johnson syndrome, 194, 195*f*
toxic epidermal necrolysis, 194, 195*f*
type IV hypersensitivity reactions, 397
γδ, 150*f*, 151, 220
juvenile idiopathic arthritis, 1154
receptor, 145
hyperplasia, *Borrelia*, 3292–3293, 3292*f*–3293*f*
immune surveillance, 122–123, 122*f*
memory
central, 147, 148*f*
effector, 147, 148*f*
long-term residence, 117
migratory, 2072, 2074
recirculating, 147
resident, 147, 148*f*
migration, chemokine-mediated, 180–181, 180*f*
perivascular, noninflamed skin, 117
phototherapy on, 3637
psoriasis, 466
regulatory, 160
graft-versus-host disease, 2321–2322
psoriasis, 146, 146*f*, 468, 469*f*
relapsing polychondritis, 1189
rosacea, 1430
skin-associated lymphoid tissue, 506
skin homing, 146–147
systemic sclerosis, 1094
type IV hypersensitivity reactions, 397–398
unconventional, innate, and innate-like, 149–151, 150*f*
innate lymphoid cells, 149, 150*f*
invariant natural killer cells, 150*f*, 151
mucosal-associated invariant T cells, 150*f*, 151
unconventional and innate-like T cells, 149–151, 150*f*
vitiligo, 1335
T cell(s), helper. *See* Th...
T follicular helper, 146, 146*f*, 160
type I, Sweet syndrome, 596
type IV hypersensitivity reactions, 397
T cell clones in inflammatory skin diseases, detection, 2122
T-cell–driven skin diseases, 138, 138*t*
T-cell leukemia/lymphoma
blastic plasmacytoid dendritic cell neoplasm, 2102
cutaneous (*See* Cutaneous T-cell lymphoma (CTCL))
granuloma annulare from, 567
T-cell lymphoproliferative disorders, parapsoriasis, 507
T-cell pseudolymphoma, cutaneous, 2113–2114, 2113*f*, 2114*f*
TCHH, uncombable hair syndrome, 1544
TCR repertoire model, severe cutaneous adverse reactions, 195
T cytotoxic 1. *See* Tc1
Tea tree oil, for seborrheic dermatitis, 436
Tecovirimat, for smallpox, 3072
Tedania ignis, 3350
Tedizolid, systemic, 3418
Tegenaria agrestis, 3327–3328
TEK, mucocutaneous venous malformations, 2650
Telangiectasia. *See also specific types*
alcohol abuse, 1713
differential diagnosis, 1438*t*
hormone replacement therapy, 3875–3876
laser therapy for, 3850, 3850*f*, 3853*t*
nevoid, alcohol abuse, 1713
photodistributed, 1661
postoperative, 3724
rosacea, 1422–1423, 1423*f*, 1434
treatment, lower-extremity vessels, 3871–3894 (*See also* Varicose veins and telangiectatic lower-extremity vessels treatment)
Telangiectasia macularis eruptiva perstans
mastocytosis, 713, 714*f*
phototherapy for, 3652
Telangiectatic matting, 3884–3885
Telaprevir, for hepatitis C virus, 3511
Telavancin, 3418
for group A *Streptococcus* lymphangitis, 2739, 2739*t*
for MRSA skin and soft tissue infections, 2731*t*, 2732
Telbivudine, adverse effects, 3512
Telogen, 93*f*, 95, 98
club hairs, 1512, 1512*f*
Telogen effluvium, 98, 1502, 1502*t*, 1503*f*, 1507–1514
from acitretin *vs.* isotretinoin, 3402
at-a-glance, 1507*b*
clinical course, prognosis, and management, 1514, 1514*f*
clinical features, 1507, 1508*t*
acute telogen effluvium, 1507, 1508*t*
chronic diffuse telogen hair loss, 1507–1508, 1508*f*, 1508*t*
chronic telogen effluvium, 1508, 1508*f*, 1508*t*
diagnosis
hair appearance, 1512
hair loss count, 1512
hair pull test, 1512
histology, 1513
laboratory examination, 1513
medical history and physical examination, 1513
phototrichogram and trichoscan, 1512–1513
trichogram, 1512
trichoscopy, 1513, 1513*f*

Telogen effluvium (*Cont.*):
differential diagnosis
alopecia areata incognita, 1514
female pattern hair loss, 1513–1514
psychogenic pseudoeffluvium, 1514
epidemiology, 1507
etiology, 1508–1511, 1508*t*
aging, 1509
drugs, 1510–1511, 1510*t*, 1511*f*
febrile illness, 1509
iron deficiency, 1510
malnutrition, 1509, 1509*f*
misc., 1511
newborn effluvium, 1508–1509
pregnancy, 1509
psychological stress, 1510
sexually transmitted diseases, 1510
surgery, 1509
systemic disease, 1510
thyroid disease, 1509
weight loss, 1509, 1509*f*
zinc deficiency, 1510
historical perspective, 1507
infants, 1752
pathogenesis
delayed anagen release, 1511
delayed telogen release, 1511
immediate anagen release, 1511
immediate telogen release, 1511
modulated exogen, 1511
short anagen, 1511
thyroid disease, 1509
trichogram, 1512
Telogen release
delayed, 1511
immediate, 1511
Telomeres, 290, 291*f*
genome instability disorders, 2344–2346
dyskeratosis congenita, 2367
maintenance gene mutations, melanoma, 1991
oxidative stress on, 1765, 1780*f*
Temozolomide (TMZ), for melanoma, 2009
Temperature
body, preoptic hypothalamus, 79
cell death, cryosurgery, 3791, 3792*t*
Temporal arteritis, 1256, 2541, 2554, 2555*f*
Temporal branch, facial nerve, 3699, 3700*t*, 3701, 3701*f*
Temsirolimus, 3601
Tendinous xanthomas, 2275, 2277*f*, 2281, 2284
Tenofovir
adverse effects, 3512
for hepatitis B virus, 3512
Tenofovir disoproxil fumarate, 3506–3507, 3509*t*
Tenosynovitis
definition, 3209–3210
gonococcal, 3210
Tension vectors, advancement flaps, 3735
Tenzel flap, 3740–3741
Terbinafine, 3437–3441
for chromoblastomycosis, 2972
for chronic mucocutaneous candidiasis, 2401
for *Cladophialophora carrionii*, 2972
for dermatophytosis, 3437–3438
dosages and formulations
systemic, 3439*t*, 3440
topical, 3438*t*, 3440
drug–drug interactions, 3440–3441, 3442*t*
indications, 3437–3440
mechanism of action, 3437
for mycetomas, 2971
pharmacokinetics, 3437
for seborrheic dermatitis, 435
side effects, 3440, 3441*t*
for sporotrichosis, 2968
for tinea capitis, 1532
in children, 3438
for *Trichophyton mentagrophytes*, 3438
for *Trichophyton rubrum*, 3438
Terbinafine, oral
for fungal infections
nail, 1595, 1596*t*
superficial, 2935*t*
for onychomycosis, with HIV, 3116
pediatrics, 1762
Terbinafine, topical, for fungal infections, 2936*t*
TERC, dyskeratosis congenita, 2367
Terminal hair, 92, 92*t*
Terry nails, 1713
alcohol abuse, 1713
liver disease, 1597
TERT, melanoma, 1990, 1991
p-Tert butyl-phenol formaldehyde resin, allergic contact dermatitis from, 404
Testosterone, sebaceous glands, 76
Tetanus toxoid vaccine
for burns, 1688
for venomous fish spines, 3358
Tetracaine, 3710*t*
Tetracyclines. *See also specific types*
for acne vulgaris, 1404–1405
for actinomycosis, 2880
for African tick bite fever, 3309*t*, 3315
for bullous pemphigoid, 952, 952*t*
for ehrlichiosis, human monocytic, 3310*t*
for erythrasma, 2743
fixed drug eruptions, 753–754, 754*f*
for human granulocytic anaplasmosis, 3311*t*
for *Klebsiella rhinoscleromatis* rhinoscleroma, 2809
for Mediterranean spotted fever, 3309*t*, 3315
nail changes from, 1599
for *N. brasiliensis* actinomycetoma, 2889
for *Pasteurella multocida*, 3339
pediatrics, 1762
for pityriasis lichenoides, 515, 515*t*
in pregnancy, 3316*t*
for prurigo pigmentosa, 1374
for rickettsial diseases, 3316*t*
for rickettsialpox, 3318
for Rocky Mountain spotted fever, 3309*t*, 3312, 3316*t*
for seal finger, 2840
Tetracyclines, oral/systemic, 3413–3414
for acne conglobata, 1449
for acne keloidalis nuchae, 1530
for central centrifugal cicatricial alopecia, 1528
for dissecting folliculitis, 1530
dosing regimen, 3410*t*, 3414
for hidradenitis suppurativa, 1490
indications and contraindications, 3413–3414, 3413*t*, 3414*t*
pharmacology and mechanism of action, 3413
side effects and precautions, 3411*t*, 3414
for yaws, 3181
Δ9-Tetrahydrocannabinol (THC), 1712
Tetrahydrofolate. *See* Vitamin B_9 (folate)
Tetrakaidecahedron, Kelvin's, 207*t*, 220, 221*f*
2,3,7,8-Tetrachlorodibenzo-*p*-dioxide (TCDD, dioxin), porphyria cutanea tarda from, 2240
Texture, skin, laser therapy for, 3853*t*, 3854
T follicular helper cells (T_{FH}), 146, 146*f*, 160
TGFBR2, Marfan syndrome, 1227
TGM1
autosomal recessive congenital ichthyosis, 787–788, 788*f*
collodion baby, 787
TGM3, uncombable hair syndrome, 1544
TGM5, peeling skin syndromes, 803
acral, 1015*t*, 1017, 1018
Th1, 145, 146*f*, 160, 161*f*
cutaneous T-cell lymphomas, 2075
inflammation, 124
leprosy, 2904
psoriasis, 466, 470*f*
responses
contact sensitization, atopic dermatitis, 420
cytokines regulating, 173
graft-versus-host disease, 2321
rosacea, 1430
S. aureus skin infections, 2728
Sweet syndrome, 596
vasculitis, 2541
Th1-associated cytokines, morphea, 1111
Th2, 145–146, 146*f*, 160, 161*f*
atopic dermatitis, 370
cutaneous T-cell lymphomas, 2075
inflammation, 124
lichen nitidus, 554
mycosis fungoides and Sézary syndrome, 2075
responses
contact sensitization, atopic dermatitis, 420
dermatophytoses, 2928
graft-versus-host disease, 2321, 2322
systemic sclerosis, 1094
Th9, 146, 146*f*, 160
Th17, 146, 146*f*, 160, 161
chronic mucocutaneous candidiasis, 2399
cutaneous T-cell lymphomas, 2075
graft-versus-host disease, 2321
hyperimmunoglobulinemia E syndrome, 2414
leprosy, 2904, 2905*f*
psoriasis, 183, 460*f*, 468, 469*f*
responses, cytokines regulating, 173
rosacea, 1430
S. aureus skin infections, 2727–2728
vasculitis, 2541
Th17 axis cytokines, 3534–3537
IL-12, 3535–3536
ustekinumab, 3536, 3536*f*, 3548*t*
IL-17A antagonists, 3534–3535, 3536*f*, 3548*t*
brodalumab, 3535, 3536*f*, 3548*t*
ixekizumab, 3535, 3536*f*, 3548*t*
secukinumab, 3534–3535, 3548*t*
IL-22, 3535
IL-23, 3536–3537
IL-23 antagonists
guselkumab, 3536*f*, 3537, 3549*t*
risankizumab, 3536*f*, 3537, 3549*t*
tildrakizumab, 3536*f*, 3537, 3549*t*
Th22, 160
leprosy, 2904
psoriasis, 468, 469*f*
Thalidomide, 3476, 3601–3603, 3602*t*
for actinic prurigo, 1632, 1632*f*
for adamantiades–Behçet disease, 2575*t*, 2576*t*
for aphthous stomatitis, recurrent, 3602*t*
for arteriovenous malformations, 2663
for Behçet syndrome, 3602*t*
CRBN binding, 3601
for erythema multiforme, 730
for erythema nodosum leprosum, 3602*t*
severe reaction, 3602*t*
for graft-versus-host disease, 2334, 3592, 3602*t*
granuloma annulare from, 567
for Langerhans cell histiocytosis, 2028
for leprosy, 2917
for lupus erythematosus, 1054*t*, 1056–1057, 3602, 3602*t*
for pyoderma gangrenosum, 614*t*
for sarcoidosis, 581*t*, 582
for Still disease, adult-onset, 1158
Thalidomide analogs, for systemic amyloids, 2269
Thaumetopoea, 3334

THC, 1712
T helper cells. *See* Th...
Thermal imaging (thermography), Raynaud phenomena, 2618
Thermal keratoses, 1880*b*
Thermal radiation, hypermelanosis from, 1365
Thermal stress, 447
Thermolysis. *See also* Photothermolysis
  fractional, for burn scars, 1690
  for hyperhidrosis, 1462
Thermoregulation, 1666
  cutaneous vasculature, 121–122, 121*t*
  nonglabrous and glabrous skin, 121, 121*t*
Thiabendazole, for cutaneous larva migrans, 3265*t*, 3266
Thiamine. *See* Vitamin B_1 (thiamine)
Thiamine pyrophosphate, 2212
Thiazolidinediones, for lipodystrophy, 1305
Thibierge-Weissenbach syndrome, calcinosis cutis near joints, 1090
Thickening agents, 3377
Thimerosal, allergic contact dermatitis from, 402, 403t
Thioguanine, 3474–3475
  chemical structure, 3465*f*
  complications, 3475
  dosing regimen, 3474
  drug interactions, 3475
  indications, 3474, 3474*t*
  initiating therapy, 3474
  mechanism of action, 3474
  monitoring therapy, 3474, 3475*t*
  pharmacokinetics, 3474
  risks and precautions, 3475, 3475*t*
6-Thioguanine, for psoriasis, 485*t*, 493
Thiol-containing foods, pemphigus, 915
Thiopurine methyltransferase (TPMT), 924
Thiuram, allergic contact dermatitis from, 405
  systemic reactivation, 402, 403t
Threading, 3911, 3913*f*
Three-compartment model, 3364–3368, 3365*f*, 3366*t*
  skin barrier, 3367–3368
    appendages, 3367
    function, inter- and intraindividual variation, 3368
    penetration pathways, 3367–3368, 3371*f*
    stratum corneum, 3367, 3371*f*
  skin surface, 3364–3367
    formulations, 3366–3367
    parameters affecting drugs in, 3364, 3366*t*
    reservoir, 3366
    surface applications, 3364–3366
  topical drug delivery, 3364–3368, 3365*f*, 3366*t*
  viable tissue, 3368
Thrombin
  inflammation, 124
  on platelet activation, 119
Thromboangiitis obliterans (TAO), 2679–2682
  at-a-glance, 2679*b*
  clinical features, 2680, 2680*f*
  diagnosis, 2680, 2681*f*
  differential diagnosis, 2681*t*
  epidemiology, 2679
  etiology and pathogenesis, 2680
    cocaine abuse, 1709
    tobacco use, 1714, 2680
  management, 2681–2682, 2681*t*
  prevention, 2682
Thrombocytopenia, cutaneovisceral angiomatosis with, 2059*b*, 2064
Thrombocytopenic purpura, congenital, 3004–3007, 3004*f*, 3006*t*. *See also* Human cytomegalovirus (HCMV)
Thrombomodulin, 119
Thrombotic thrombocytopenic purpura, adult-onset Still disease, 1156
Thrombus formation, 117, 119*f*
Thymic stromal lymphopoietin (TSLP), 150*f*, 171
  atopic dermatitis, 369–370
  eosinophils, 156
  pruritus, 356, 356*t*
Thymic stromal lymphopoietin receptor chain (TSLPR), 171
Thymic stromal lymphopoietin (TSLP), 163*t*
Thymidine kinase, acyclovir and, 524
Thymoma
  paraneoplastic pemphigus, 2*f*, 934
  pemphigus with, 202, 915
Thymus and activation-regulated chemokine (CCL27), immune surveillance, 122–123
Thyroglossal duct cyst, 1736
Thyroid acropachy, 2506, 2509
Thyroid dermopathy, 2505–2506, 2505*f*. *See also* Hyperthyroidism
  inflammatory pathology, 28
Thyroid disease, 2504–2509
  at-a-glance, 2504*b*
  clinical features
    hyperthyroidism, 2505–2506, 2505*f*, 2505*t*
    hypothyroidism, 2507, 2507*t*
  dermatitis herpetiformis, 1004
  diagnosis and laboratory tests, 2508
  epidemiology, 2504–2505
  etiology and pathogenesis, 2507–2508, 2508*t*
  granuloma annulare, 567
  management, 2509
  skin manifestations, 2407*t*, 2439
  telogen effluvium from, 1509
Thyroid hormone
  medical conditions on, 2508, 2508*t*
  medications on, 2508, 2508*t*
TIBOLA/DEBONEL, 3315
Tick-borne lymphadenopathy, 3315
Ticks, 3329–3330, 3329*f*. *See also specific types*
  classification, 3329
  clinical features, 3329
  management, 3329–3330
Ticlopidine, for kaposiform hemangioendothelioma, 2063
TIE2
  blue rubber bleb nevus, 2640*t*, 2650–2651
  mucocutaneous venous malformation, 2640*t*
  multifocal venous malformations, 2650
  venous malformations, 2640*t*, 2650
Tietz syndrome, 332, 1323
Tigecycline, 3419
  for actinomycosis, 2880
Tightening, skin, noninvasive, 3857–3862
  adaptations, anatomic area, skin type, and degree of response, 3860–3861
  complications, 3858–3860
  devices and technologies, 3858
  indications and patient selection, 3857–3858
  modes of action, 3858, 3859*f*–3860*f*
  outcomes, expected, 3861–3862, 3861*f*
Tight junctions, 207, 210*f*
  function, 208*t*, 210*f*, 218*f*, 219–220
  granular cells, 65
  intraepidermal immune-mediated cell interactions, 219*f*, 220
  keratinocyte shape, skin barrier homeostasis, 207*t*, 213*f*, 220, 221*f*
  structure, 218*f*, 219
Tigroid leukodystrophy, 2355
Tildrakizumab, 3536*f*, 3537, 3549*t*
  mechanism of action, 139
  for psoriatic arthritis, 469*f*, 981
Timber rattlesnake, 3342, 3342*f*
Timolol, for infantile hemangiomas, 2056–2057
TINCR, 67
  epidermal differentiation, 66, 67, 67*f*
Tincture, 3375
Tinea amiantacea, 429–430, 431*f*
Tinea asbestina, 429–430, 431*f*
Tinea barbae
  clinical features, 2938*t*, 2940–2941
  diagnosis, 2929*t*, 2931*t*–2932*t*, 2941
  differential diagnosis, 2941, 2941*t*
  epidemiology, 2940
  etiology and pathogenesis, 2941
  management, 2934*t*–2936*t*, 2941
  subtypes and common causes, 2938*t*
Tinea capitis, 2941–2944
  cicatricial alopecia, 1531–1532
  clinical features, 2938*t*, 2942, 2942*f*–2943*f*
    "black dot," 2942, 2942*f*
    inflammatory type, 2942, 2943*f*
    noninflammatory type, 2933*t*, 2942, 2942*f*
  diagnosis, 2929*t*, 2938*t*, 2942–2943
  differential diagnosis, 2943, 2943*t*
  epidemiology, 2941–2942
  favus, 1532
  infants, 1753
  management, 2934*t*–2936*t*, 2943–2944
Tinea corporis, 2944–2945
  clinical features, 2944, 2944*f*–2945*f*
  diagnosis, 2929*t*, 2931*t*–2932*t*, 2945
  differential diagnosis, 2945, 2945*t*
  epidemiology, 2944
  etiology and pathogenesis, 2944–2945
  management, 2934*t*–2936*t*, 2945
Tinea cruris
  clinical features, 2945–2946, 2945*f*
  diagnosis, 2929*t*, 2946
  differential diagnosis, 2946, 2946*t*
  epidemiology, 2945
  etiology and pathogenesis, 2946
  management, 2934*t*–2936*t*, 2946
Tinea favosa, 2946–2947
  clinical features, 2946, 2946*f*
  diagnosis, 2929*t*, 2931*t*–2932*t*, 2947
  differential diagnosis, 2939*t*, 2947
  epidemiology, 2946
  etiology and pathogenesis, 2946
  management, 2934*t*–2936*t*, 2947
Tinea manuum, 2948–2949
  clinical features, 2949, 2949*f*
  diagnosis, 2929*t*, 2931*t*–2932*t*, 2949
  epidemiology, 2948
  etiology and pathogenesis, 2949
  management, 2934*t*–2936*t*, 2949
Tinea nigra, 2947–2948
  clinical features, 2947, 2947*f*
  diagnosis, 2947
  differential diagnosis, 2947, 2948*t*
  epidemiology, 2947
  etiology and pathogenesis, 2947
  management, 2934*t*–2936*t*, 2947–2948
Tinea pedis, 2948–2949
  clinical features
    acute ulcerative type, 2949
    chronic hyperkeratotic type, 2948, 2948*f*
    interdigital type, 2948, 2948*f*
    vesicular id reaction, 2949
    vesiculobullous type, 2948–2949, 2948*f*
  diagnosis, 2929*t*, 2931*t*–2932*t*, 2949
  differential diagnosis, 2949, 2949*t*
  in elderly, 1787
  epidemiology, 2948
  etiology and pathogenesis, 2949
  management, 2934*t*–2936*t*, 2949
Tinea unguium, 2937
Tinidazole
  for bacterial vaginosis, 3219*t*
  for giardiasis, 3246
  for trichomoniasis, 3243
Tioconazole, for fungal infections, 2936*t*

Tip-DCs, 152
Tissue factor pathway inhibitor, 119
Tissue freezing, cold injuries, 1666–1667
Tissue inhibitors of metalloproteinases (TIMPs), in wound healing, 2703
Tissue trafficking, eosinophils in, 650*f*, 656–657
  chemokines, 650*f*, 656–657
  endothelial-activating cytokines, 650*f*, 656–657
  eosinophil-activating cytokines, 650*f*, 656–657
Titanium dioxide, 3625–3627, 3625*t*, 3628
Tixocortol pivalate, steroid allergen testing, 405, 406*t*
TLR-1, leprosy, 2902, 2904
TLR-2
  leprosy, 2902, 2904
  rosacea, 1428*f*–1429*f*, 1429
TLR-4, leprosy, 2902, 2904
T lymphocytes. *See* T cell(s)
TMC6, epidermodysplasia verruciformis, 1873
TMC8, epidermodysplasia verruciformis, 1873
TNF, graft-versus-host disease, 2322
TNF2, chronic bullous disease of childhood, 993
TNFA, allergic contact dermatitis, 192
TNFAIP3, 192
  cutaneous T-cell lymphomas, 2075
  haploinsufficiency of A20, 622*t*, 627
  psoriasis, 478
  psoriatic arthritis, 1131
  Sjögren syndrome, 1171
TNF-α converting enzyme (TACE), 168
TNF-related apoptosis-inducing ligand (TRAIL), 168
TNFRSF1A, TNF receptor-associated periodic syndrome, 622*t*, 636
TNFSF15
  leprosy, 2902
  psoriasis, 478
TNIP1, psoriasis, 478
TNXB, 1221
  classical-like Ehlers-Danlos syndrome, 1213*t*
  hypermobility Ehlers-Danlos syndrome, 1213*t*
Tobacco use. *See* Smoking and nicotine use
Tobramycin, for *P. aeruginosa* folliculitis and hot-foot syndrome, 2796
Tocilizumab, 3546–3547, 3551*t*
  for juvenile idiopathic arthritis, 1155
  for multicentric reticulohistiocytosis, 2038
  for rheumatoid arthritis, 1152
  for Still disease, adult-onset, 1158
  for vasculitis, 2557
Tocopherol. *See* Vitamin E (tocopherol)
Dα-Tocopheryl polyethylene glycol-1000 succinate (TPGS), 2210
Toenail embedding, surgery for, 3787, 3787*f*
Toe web infection, *Pseudomonas aeruginosa*
  clinical features, 2790, 2791*t*, 2792*f*
  diagnosis, 2794
  etiology and pathogenesis, 2793
  management, 2795
Tofacitinib, 176
  for atopic dermatitis, 197
  for graft-versus-host disease, 2334
  for lupus erythematosus, 1058
  for psoriasis, 176, 486*t*, 492
  for psoriatic arthritis, 981, 1136*t*, 1137
  for rheumatoid arthritis, 1152
Tofacitinib citrate, for alopecia areata, 1522
Toll-like receptor (TLR), 165*f*, 1251
  antimicrobial proteins on, 223
  dermatophytoses, 2928–2929
  functions, 134, 134*t*
  IL-1 receptor, 165*f*
  leprosy, 2902, 2904
  mutations, on infection, 2929
  nuclear factor κB signal transduction pathway, 162, 164*f*
  pruritus, 355
  rosacea, 1428*f*–1429*f*, 1429
Toll-like receptor 1 (TLR1), invasive fungal disease, 2929
Toll-like receptor 2 (TLR2)
  dermatophytoses, 2929
  S. aureus skin infections, 2727
  sebaceous gland expression, 75
Toll-like receptor 4 (TLR4)
  fungal disease, invasive, 2929
  sebaceous gland expression, 75
Toll-like receptor 6 (TLR6), dermatophytoses, 2929
Toll-like receptor 7 (TLR7), 134, 134*t*, 3594
Toll-like receptor 9 (TLR9), 134, 134*t*
Toll-like receptor (TLR) antagonists. *See* Imiquimod; Resiquimod
Tolnaftate, for fungal infections, superficial, 2936*t*
Toluene sulfonamide formaldehyde resin, allergic contact dermatitis from, 404
Tooth and nail syndrome, 2388–2389, 2388*f*
Topical formulations, 3372–3377, 3373*t*. *See also specific types*
  aerosols, 3373*t*, 3376
  liposomes, transdermal delivery systems, 3376
  liquids, 3373*t*, 3375–3376
    foams, 3373*t*, 3375–3376
    shake lotions, 3373*t*, 3375
    solutions, 3373*t*, 3375
    suspensions, 3373*t*, 3375
  ointments, 3373*t*, 3374–3375
    absorption bases, 3373*t*, 3374
    hydrocarbon bases, 3373*t*, 3374
    oil-in-water emulsions, 3373*t*, 3374
    water-in-oil emulsions, 3373*t*, 3374
    water-soluble bases, 3373*t*, 3374–3375
  pastes, 3373*t*, 3375
  penetration enhancers
    chemical, 3376
    physical, 3376
  poultices, 3373*t*, 3374
  powders, 3373–3374, 3373*t*
  stabilizers, 3377
  thickening agents, 3377
Topical medications, 3610–3621. *See also specific types*
  analgesics
    capsaicin, 3610
    eutectic mixture of local anesthetics cream, 3611, 3712
    lidocaine, 3611
  antiinflammatory agents
    coal tar, 3611
    crisaborole, 3611
    shale oil, 3611
    wood tar, 3611
  antimicrobial agents, 3611–3614, 3612*t*–3613*t*
    azelaic acid, 3613*t*, 3614
    benzoyl peroxide, 3613*t*, 3614
    chlorhexidine, 3611, 3612*t*
    clioquinol, 3612*t*, 3613–3614
    dyes
      brilliant green, 3611, 3612*t*
      gentian violet, 3611, 3612*t*
    hydrogen peroxide, 3612*t*, 3613
    metronidazole, 3612*t*, 3614
    mupirocin, 3613*t*, 3614
    povidone-iodine, 3612*t*, 3613
    retapamulin, 3613*t*, 3614
  antiparasitic agents, 3614–3616, 3615*t*
    crotamiton, 3614, 3615*t*
    ivermectin, 3615, 3615*t*
    lindane, 3614–3615, 3615t
    malathion, 3615, 3615*t*
    permethrin, 3615–3616, 3615*t*
    pyrethrins, synergized, 3615*t*, 3616
    spinosad, 3615*t*, 3616
  antiperspirants
    aluminum compounds, 3616
    glycopyrrolate, 3616
    iontophoresis, 3616
  antipruritic agents
    diphenhydramine, 3617*t*
    doxepin, 3616, 3617*t*
    menthol, 3617, 3617*t*
    phenol, 3617, 3617*t*
    pramoxine hydrochloride, 3617, 3617*t*
  astringents
    aluminum salts, 3613*t*, 3617
    potassium permanganate, 3613*t*, 3617–3618
    silver nitrate, 3613*t*, 3618
  at-a-glance, 3610*b*
  bleaching agents
    azelaic acid, 3618
    hydroquinone, 3618
    monobenzyl ether of hydroquinone, 3618
    tretinoin, 3618
  compounding medications, 3621
  keratolytic agents
    α-hydroxy acids, 3618, 3619*t*
    calcipotriene, 3619
    lactic acid, 3619, 3619*t*
    propylene glycol, 3618–3619, 3619*t*
    salicylic acid, 3619, 3619*t*
    urea, 3619, 3619*t*
  wart therapies
    cantharidin, 3619–3620
    dichloroacetic acid, 3620
    dinitrochlorobenzene, 3620
    diphenylcyclopropenone, 3620
    formaldehyde, 3620
    glutaraldehyde, 3620
    imiquimod, 3620
    monochloroacetic acid, 3620
    podofilox, 3620
    salicylic acid, 3620
    sinecatechins, 3621
    squaric acid dibutyl ester, 3620
    trichloroacetic acid, 3620
Topical therapy, 3363–3379. *See also specific types*
  absorption factors, other
    application frequency, 3371
    application quantity, 3371
    occlusion, 3371
    particle size, 3372
    rubbing or massaging, 3371–3372
    stratum corneum, 3370–3371, 3370*f*–3371*f*
  adherence, 3363–3364
  at-a-glance, 3363*b*
  cutaneous drug delivery
    absorption rate, 3364
    therapeutic efficacy, 3364
  diffusion
    Fick's laws, 3364
    laws of, 3364
  formulations, 3372–3377, 3373*t* (*See also* Topical formulations)
  key steps, 3363
  resorption, 3369–3370
  side effects and precautions
    local, 3377–3378
      allergic contact dermatitis, 3377
      fundamentals, 3377
      irritant contact dermatitis, 3377
      malignancies, 3377
      other, 3378
      subjective or sensory irritant contact dermatitis, 3377
    systemic, 3378–3379
      endocrine system, 3378
      fundamentals, 3378

immunologic contact urticaria, 3378
malignancies, 3378
transdermal drugs, 3378–3379
skin metabolism, 3368–3369
three-compartment model, 3364–3368, 3365*f*, 3366*t*
skin barrier, 3367–3368
appendages, 3367
inter- and intraindividual variation, 3368
pathologic processes on, 3370
penetration pathways, 3367–3368, 3371*f*
stratum corneum, 3367, 3371*f*
skin surface, 3364–3367
formulations, 3366–3367
parameters affecting drugs in, 3364, 3366*t*
reservoir, 3366
surface applications, 3364–3366
viable tissue, 3368
vehicle, 3372, 3372*t*
Topiramate
granuloma annulare from, 566
on sweat duct function, 83
Topographic anatomy, face, 3698–3699, 3698*f*
TORC1
hidradenocarcinoma, 1828
hidradenoma, 1823
Tosylamide, allergic contact dermatitis from, 404
Total skin electron beam therapy (TSEBT), 3695
for cutaneous lymphoma, primary, 2090–2092
for cutaneous T-cell lymphomas, 2092–2093
for mycosis fungoides, 2090
Tourniquets
exsanguinating, 3777, 3777*f*
nail surgery, 3777, 3777*f*
Towel-associated amyloidosis, 2264
TOX, cutaneous T-cell lymphomas, 2079
Toxic adenoma, 2504. *See also* Hyperthyroidism
Toxic epidermal necrolysis (TEN), 733–745, 761*t*. *See also* Drug reactions, cutaneous
at-a-glance, 733*b*
with burn injury, 1683–1684
carbamazepine-induced, HLA haplotype inheritance, 304*t*
clinical course and prognosis, 761–762
clinical features, 736–738, 736*f*, 753
cutaneous lesions, 736, 737*f*–738*f*
history, 736
mucous membrane, 736–737, 739*f*
systemic involvement, 737–738
complications and sequelae, 740–742, 741*f*, 741*t*
cytotoxic T cells, 194, 195*f*
definition, 733, 734*t*
differential diagnosis, 739–740, 740*t*
epidemiology, 733, 734*t*, 749
etiology, 733–735, 734*t*
genetic predisposition, 194
histopathology, 738*f*, 739, 740*f*
historical perspective, 733
with HIV, 3109, 3111–3112, 3111*f*
immunologic drug reactions, 759–760, 759*t*
immunologic responses, 194–195, 195*f*
laboratory values, 738
management, 742–744, 743*t*, 762
pathogenesis, 735–736
prevention, 744–745, 762
prognosis and clinical course, 734*t*, 742, 742*f*
Toxic multinodular goiter, 2504–2509. *See also* Hyperthyroidism
Toxic oil syndrome, eosinophils, 656
Toxic shock syndrome (TSS), 2762–2764
clinical features
staphylococcal, 2762–2763, 2762*f*, 2763*t*
streptococcal, 2763
differential diagnosis, 2763–2764, 2764*t*
superantigens, 2762
treatment and prognosis, 2764
Toxic shock syndrome toxin-1 (TSST-1), 2727
Toxin-mediated erythema, 2766–2767
Toxocara canis, 3252*t*, 3261
exposure and symptom onset interval, 3259, 3260*t*
hepatomegaly, 3261
neurologic disease, 3261
ocular disease, 3261–3262
progression and duration, 3259, 3260*t*
Toxocara cati, 3252*t*
exposure and symptom onset interval, 3259, 3260*t*
hepatomegaly, 3261
neurologic disease, 3261
ocular disease, 3261–3262
progression and duration, 3259, 3260*t*
Toxoplasma gondii, 3248, 3249*t*
Toxoplasmosis, 3248–3249, 3249*t*
TP53, 314, 315. *See also p53*
basal cell carcinoma, 1884, 1885*t*
blastic plasmacytoid dendritic cell neoplasm, 2102
cutaneous T-cell lymphomas, 2075
keratoacanthoma, 1906–1907
mutation burden and clonal dynamics, 317, 318*f*
squamous cell carcinoma, 1904, 1906–1907
TP63, 315
TPCN, 344
TPCN2, 344
T-plasty, 3737–3738, 3738*f*
Trachyonychia, 1574–1575, 1575*f*, 1575*t*
lichen planus, 536
nail changes, 1582
Track marks, IV drug use, 1706–1707, 1706*t*, 1707*f*
Traction alopecia, 1502, 1502*t*, 1503*f*, 1533, 1533*f*
TRAF3IP2
chronic mucocutaneous candidiasis, 2399
psoriasis, 478, 479
Tragus, 3698*f*, 3699
Trametinib, 3559*t*, 3584, 3584*f*
Tranexamic acid
for melasma, 1381
for Riehl melanosis, 1382
for urticaria, 702
Transaldolase deficiency, cutis laxa, 1237*t*
Transcellular micropathway, 3370
Transcortin, 3382
Transdermal delivery systems
liposomes, 3376
side effects and precautions, systemic, 3378–3379
Transepidermal water loss (TEWL), 207*t*, 3804
irritant dermatitis, 422
neonatal skin, 1728
postterm infants, 1728, 1728*f*
prematurity, 1728–1729
newborn skin, 223–224, 224*t*
rosacea, 1429
Transforming growth factor-α (TGF-α), 160*t*, 3540
hair follicles, 92
wound healing, 2704*t*, 2708
Transforming growth factor-β (TGF-β), 160*t*
angioblast development, 28
angiogenesis, 126*f*, 127
family, 175
radiation dermatitis, 3691*t*
tumor angiogenesis, 128–129, 128*f*
wound healing, 128, 128*f*, 2704*t*, 2706–2707
Transforming growth factor-β1 (TGF-β1)
hair follicles, 98
on helper T-cells, 161*f*
Transforming growth factor-β R1 (TGF-βR1), heterozygous germline inactivation, 314
Transforming growth factor-β (TGF-β) receptors, 175
Transfusion-associated graft-versus-host disease (TA-GVHD), 2322–2323
Transgender persons, 1794–1796
definition, 1793*t*
fundamentals, 1794
transgender men, 1795–1796
transgender women, 1796
Transglutaminase 1, 211
defects, 208*t*, 211
Transgrediens et progrediens palmoplantar keratoderma, 823–824
Transient acantholytic dermatosis, 882*t*, 890–892, 890*f*, 891*f*, 891*t*
differentiating, 892*f*
Transient aplastic crisis, parvovirus B19, 2997
Transient dermatoses of neonate, 1730–1732
benign neonatal cephalic pustulosis, 1732, 1733*f*
caput succedaneum, 1730
cephalohematoma, 1730
differential diagnosis, 1730*t*
erythema toxicum neonatorum, 1731, 1731*f*
harlequin color change, 1732
infantile acne, 1448, 1449*f*, 1732, 1733*f*
milia, 1730–1731
miliaria crystallina, 1731–1732
miliaria rubra, 1731
mottling and cutis marmorata, 1732
sebaceous gland hyperplasia, 1731, 1731*f*
sucking blisters, 1732
transient neonatal pustular melanosis, 1731, 1732*f*
Transient neonatal pustular melanosis, 1731, 1732*f*
Transient receptor potential (TRP)
ion channels, rosacea, 1427, 1427*t*, 1428*f*–1429*f*, 1429, 1430
pruritus, 355
Transient receptor potential of the vanilloid 1 (TRPV1), 353
prurigo nodularis, 389
pruritus, 355, 357
skin diseases, 357
Translocation. *See also specific types and substances*
balanced, 300
reciprocal, 300
Transplantation
bone marrow
allogeneic, for epidermolysis bullosa, 1028
for extranodal natural killer/T-cell lymphoma, nasal type, 2087
for Langerhans cell histiocytosis, 2029
for Wiskott-Aldrich syndrome, 2404
hair, 3931–3948 (*See also* Hair transplantation)
hematopoietic stem cell
allogeneic, 2320
for congenital erythropoietic porphyria, 2244
graft-versus-host disease from, 2320 (*See also* Graft-versus-host disease)
pretransplantation regimens, 2320
prevalence, 2320
for severe combined immunodeficiency, 2404*b*, 2406
syngeneic, 2320
melanocyte keratinocyte, for vitiligo, 1343–1345, 1344*f*

Transplantation (*Cont.*):
stem cell
allogeneic, for epidermolysis bullosa, 1028
autologous peripheral blood, for scleromyxedema, 1168
for cutaneous T-cell lymphomas, 2096–2097
for ectodermal dysplasia with immunodeficiency, 2407
hematopoietic (*See* Hematopoietic stem cell transplantation (HCT))
for systemic sclerosis, early diffuse cutaneous, 1098, 1100*t*
for Wiskott-Aldrich syndrome, 2404
Transplantation, solid organ
kidney, for acute hepatic porphyrias, 2252
liver
for acute hepatic porphyrias, 2252
for protoporphyric hepatopathy, 2249
mycophenolate mofetil for, 3517, 3518*f*
mycoses after, 2974, 2974*f*, 2974*t*
phototherapy safety, 3645
squamous cell carcinoma prevention after, immunosuppressive regimen change, 1916
Transposition flaps, 3742–3748
advantages, 3742–3753
banner, 3746–3747, 3747*f*
bilobed, 3747–3748, 3748*f*, 3749*f*
definition and use, 3742
rhombic, 3743–3746, 3745*f*–3746*f*
30°-angle Webster, 3746, 3747*f*
DuFourmentel, 3745–3746, 3746*f*
trilobe, 3748
Z-plasty, 3748
Transthyretin amyloidosis (ATTR), 2259–2260, 2265, 2265*f*
non-Hodgkin lymphoma, 2458
Transverse nasal crease
allergic salute, 1454
pseudoacne of nasal crease, 1454, 1454*f*
Trap door nail avulsion, 3781
Trastuzumab, 3603
Traumatic irritant contact dermatitis, 444
Traumatic neuroma, 2147*t*–2148*t*, 2150–2151, 2150*t*
Traumatic panniculitis, inflammatory reactions, 30
T regulatory cells (Tregs), 160
graft-versus-host disease, 2321–2322
psoriasis, 146, 146*f*, 468, 469*f*
Trematodes, 3251, 3252*t*. *See also specific types*
exposure and symptom onset interval, 3259, 3260*t*
progression and duration, 3259, 3260*t*
Trench fever
bacteriology, 2797, 2797*t*
clinical course and prognosis, 2805
clinical features
complications, 2802
cutaneous, 2799*t*, 2800
noncutaneous, 2799*t*, 2801
diagnosis, laboratory, 2799*t*, 2804
differential diagnosis, 2804, 2805*t*
epidemiology, 2798
etiology and pathogenesis, 2803–2804
management, 2805–2806
Treponema carateum, 3173–3174
Treponema pallidum, 3146–3147. *See also* Syphilis
Treponema pallidum ssp. *endemicum*, 3183. *See also* Yaws
Treponema pallidum ssp. *pertenue*, 3180. *See also* Yaws
Treponematoses
endemic (nonvenereal), 3173–3184 (*See also specific types*)
bejel, 3182–3184, 3183*f*, 3184*t*
classification, 3173
epidemiology, 3173
pinta, 3173–3177
yaws, 3177–3182
venereal (*See* Syphilis)
Treprostinil, for malignant atrophic papulosis, 2634, 2634*t*
Tretinoin, 3397, 3618
for acne vulgaris, 1402–1404, 1402*t*
hydroxylation, 3397–3398
structure, 3395, 3396*f*
Tretinoin, topical
adverse effects, 3402
for Darier disease, 884, 884*t*
for Fox-Fordyce disease, 1477
for hidradenitis suppurativa, 1490
indications and contraindications, 3399
for lichen planus, oral, 545
for rosacea, 1439
for striae, 1197
Triamcinolone, intradermal/intralesional
for acne vulgaris, 1409
for adamantiades–Behçet disease, genital ulcers and skin lesions, 2574–2575, 2574*t*
for ataxia-telangiectasia, 2409
for Fox-Fordyce disease, 1477
for hidradenitis suppurativa, 1490
for sarcoidosis, 581
Triamcinolone, topical
for adamantiades–Behçet disease, genital ulcers and skin lesions, 2574, 2574*t*
for graft-versus-host disease, oral, 2335
Triamcinolone acetonide, intralesional
for acne keloidalis nuchae, 1530
for alopecia areata, 1520
for cicatricial alopecia
discoid lupus erythematosus, 1526–1527
frontal fibrosing alopecia, 5
lichen planopilaris, 1527
for hidradenitis suppurativa, 1490
for lichen simplex chronicus, 391
for lupus erythematosus, 1055
for prurigo nodularis, 391
for *S. aureus*, in folliculitis decalvans, 1530
Triamcinolone hexacetonide, for alopecia areata, 1520
Triangular fossa, 3698*f*, 3699
Triangular temporal alopecia, infants, 1752
Triatomine bugs, 3240, 3241*f*
Triazoles, 3438*t*–3440*t*, 3442*t*, 3445–3446
fluconazole, 3439*t*, 3441*t*, 3442*t*, 3445
itraconazole, 3439*t*, 3441*t*, 3442*t*, 3445–3446
for onychomycosis, with HIV, 3116
Trichilemmal cyst, 1814, 1814*f*
Trichilemmal keratinization, 93
Trichilemmoma, 1822*t*, 1839*t*, 1845–1846, 1846*f*
Trichinella spiralis, 3252*t*
exposure and symptom onset interval, 3259, 3260*t*
progression and duration, 3259, 3260*t*
Trichloroacetic acid (TCA), 3620
for actinic keratosis, 1866
for Bowen disease, 1871, 1871*t*
chemical peels, 3898
deep, 3901
medium-depth, 3900–3901, 3901*t*
superficial, 3899, 3899*f*, 3901*f*
for molluscum contagiosum virus, 3089
Trichoadenoma, 1848
Trichobacteriosis, 2743–2744, 2743*f*
Trichoblastic fibroma, 33
Trichoblastoma, 33, 1840–1841, 1840*f*
Tricho-dento-osseous (TDO) syndrome, 2389
Trichodiscoma/fibrofolliculoma, 1822*t*, 1839*t*, 1842–1843, 1843*f*
Trichodysplasia spinulosa (TS), 869*t*, 873–875, 874*f*
Trichodysplasia spinulosa-associated polyomavirus (TSPyV), 874
Merkel cell polyomavirus, 319
Trichoepithelioma, 1822*t*, 1841–1842, 1842*f*
desmoplastic, 33
pathology, 33, 33*f*
Trichofolliculoma, 1839, 1839*f*, 1839*t*
Trichogram
androgenetic alopecia, 1500
telogen effluvium, 1512
Trichohepatoenteric syndrome (THE), trichorrhexis nodosa, 1538*t*
Trichomonas tenax, 3243
Trichomonas vaginalis, 3243
Trichomoniasis, 3243
Trichomycosis, 2743–2744, 2743*f*
Trichophyton
microconidia and macroconidia, 2931, 2931*t*
nutritional growth requirements, 2931, 2933*t*
Trichophyton interdigitale, 2926, 2932*t*
Trichophyton mentagrophytes, occupational exposure, 449
Trichophyton rubrum
colony and microscopic morphology, 2932*t*
with HIV, 3116, 3116*f*
Trichophyton schoenleinii, 2932*t*
Trichophyton tonsurans
colony and microscopic morphology, 2932*t*
tinea capitis, 1531–1532
Trichophyton verrucosum
colony and microscopic morphology, 2932*t*
occupational exposure, 449
Trichophyton violaceum, 2932*t*
Tricho-rhino-phalangeal syndrome (TRPS), 2390–2391, 2390*f*
Trichorrhexis invaginata, 1542–1543, 1542*f*, 1550*t*
Netherton syndrome, 791, 793*f*
Trichorrhexis nodosa (TN), 1537–1538, 1538*f*, 1538*t*, 1549*t*
Trichoscan, 1500
androgenetic alopecia, 1500
telogen effluvium, 1512–1513
Trichoschisis, 1539–1540, 1539*f*, 1549*t*
Trichoscopy, telogen effluvium, 1513, 1513*f*
Trichosporon, 2984–2985
Trichothiodystrophy (TTD), 1539–1540, 1539*f*, 1539*t*, 1549*t*, 2357–2361
at-a-glance, 2357*b*
chemical phenotypes, 2342, 2346*f*
clinical course and prognosis, 2360
clinical features, 2343*t*, 2358*f*, 2359–2360, 2359*t*
BIDS, 1539*t*
IBIDS, 808, 1539*t*
PBIDS, 808, 1539*t*
definitions, 2343*t*, 2357, 2358*f*
diagnosis, 2358*f*, 2359*t*, 2360
DNA repair defects, 279, 808, 2343*t*, 2357–2361
nucleotide excision repair, 2342
epidemiology, 2359
etiology and pathogenesis, 1539, 2360
genes
C7Orf11, 1539
ERCC2, 780*t*, 808
ERCC3, 780*t*, 808
GTF2E2, 2360
GTF2H5, 780*t*, 808
MPLKIP, 808, 1539
p8, 1539
RFN113A, 808
TTDA (GTF2H5), 1539, 2360
TTDN1, 780*t*, 1539
XPB (ERCC3), 1539, 2360
XPD (ERCC2), 1539, 2360

hair breakage, 808, 1539–1540, 1539*f*, 1539*t*, 1549*t*
historical perspective, 2358–2359
ichthyosis, autosomal recessive congenital, 780*t*, 781*t*, 808–809, 808*f*
management, 2360–2361
mechanisms, 2345*t*
photosensitivity, 808, 1541*t*
Sabinas syndrome, 1539*t*
Tay syndrome, 1539*t*
trichorrhexis nodosa, 1538*t*
Trichotillomania, 1533, 1533*f*, 1697*t*, 1699–1700
infants, 1753, 1753*f*
Tricyclic antidepressants (TCAs). *See also specific types*
antihistaminic activity, 3459
for hair pulling disorder, 1697*t*, 1700
hyperhidrosis from, 1466
for nighttime itch, in lichen simplex chronicus and prurigo nodularis, 391, 1697*t*, 1700
on riboflavin transport, 2213
Trifluridine, 3498–3499
dosing regimens, 3499, 3499*t*
indications, 3498–3499
mechanism of action and pharmacokinetics, 3498
side effects and precautions, 3499
Trigeminal nerve, 3702–3703, 3702*f*, 3703*t*
herpes zoster, 3042, 3044*f*–3045*f*
Triglyceridemia, from retinoids, 3403
Trilobe flap, 3748
Trimethoprim, dapsone interactions, 3425, 3425*t*
Trimethoprim-sulfamethoxazole (TMP-SMX)
for acne vulgaris, 1405
for actinomycetomas, 2971
for *Burkholderia pseudomallei*, 2846
for granuloma inguinale, 3205, 3206*t*
for listeriosis, 2841
phototoxicity, 1657, 1660*f*
for plague, 2833
for *S. aureus*, in folliculitis decalvans, 1529
Trimethoprim-sulfamethoxazole (TMP-SMX), systemic, 3417–3418
adverse effects, 2890
for cat scratch disease, 2805
for chronic bullous disease of childhood, 994*t*
for human T-lymphotropic virus, 3126
for *Klebsiella rhinoscleromatis* rhinoscleroma, 2809
for linear IgA dermatosis, 999
for MRSA impetigo, ecthyma, and folliculitis, 2730, 2731*t*
for *N. brasiliensis* actinomycetoma, 2889
for nocardiosis, 2884
for Oroya fever, 2806
for *Pasteurella multocida*, 3339
for staphylococcal furuncles, carbuncles, and abscesses, 2731*t*, 2732
for trench fever, 2806
4,5′,8-Trimethylpsoralen (TMP), 3665
Trioxsalen, 3665
Tripelennamine. *See also* Antihistamines, H_1
dosing regimens, 3454–3455, 3454*t*
with pentazocine, 1711
Tripe palms, 2442*t*, 2448–2449, 2448*f*, 2495
Triple antibiotic, allergic contact dermatitis from, 404
Triplet state, 267–268, 268*f*
Tris-nitromethane, allergic contact dermatitis from, 404
Trisodium phosphonoformate (foscarnet), 3500–3501, 3500*t*
Trisomy 12, 298*t*
Trisomy 13, 298*t*
Trisomy 18, 298*t*
Trisomy 21, clubbing, 1596, 1596*f*
Trombicula, 3278, 3278*t*
Trombiculidae, 3278, 3278*t*
Tropical acne, 1453
Trousseau syndrome, paraneoplastic, 2443*t*, 2460
Trp53, 323
TRP ankyrin type 1 (TRPA1), rosacea, 1427, 1427*t*, 1428*f*–1429*f*, 1430
TRPS1, tricho-rhino-phalangeal syndrome, 2391
TRPV1, prurigo nodularis, 389
TRPV3
Olmsted syndrome, 828–829
palmoplantar keratoderma Bothnia type, 825
TRP vanilloid type 1 (TRPV1), rosacea, 1427, 1427*t*, 1428*f*–1429*f*, 1430
TRP vanilloid type 2 (TRPV2), rosacea, 1427*t*, 1430
TRP vanilloid type 3 (TRPV3), rosacea, 1430
TRP vanilloid type 4 (TRPV4), rosacea, 1427*t*, 1428*f*–1429*f*, 1430
True negative, 46, 46*f*
True positive, 46, 46*f*
T.R.U.E. Test, 405–408
allergen selection and placement, 405–406
clinical relevance, assigning, 407
complications, 407–408, 408*f*
failure, complications from, 408
grading and interpreting, 406–407, 407*f*
systemic immunosuppressive agents, 408
Truncal distribution, 11
Trypanosoma brucei, 3238
Trypanosoma brucei gambiense, 3238
Trypanosoma brucei rhodesiense, 3238
Trypanosoma cruzi, 3240
Reduviidae vectors, 3332
Trypanosomiasis
African, 3238–3240, 3238*f*–3239*f*, 3239*t*
American, 3240–3242, 3241*f*
Trypomastigotes, 3238
Ts and blues, 1711
TSC1, tuberous sclerosis complex, 2485, 2488
TSC2, tuberous sclerosis complex, 2485, 2488
TSC-associated neuropsychiatric disorders (TAND), 2480, 2487
Tsetse flies, 3325*f*, 3330–3331
African trypanosomiasis, 3238, 3238*f*, 3240
TSS toxin-1 (TSST-1), 2762
recalcitrant erythematous desquamating disorder, 2764
Tsutsugamushi fever, 3306, 3319–3320
TTDA (GTF2H5), trichothiodystrophy, 1539, 2360
TTDN1, trichothiodystrophy, 780*t*, 1539
Tuberculids, 2868–2870, 2868*t*
erythema nodosum, 2870 (*See also* Erythema nodosum)
lichen scrofulosorum, 2868–2869, 2869*t*
nodular vasculitis/erythema induratum of Bazin, 2869 (*See also* Nodular vasculitis)
papulonecrotic tuberculid, 2869, 2869*f*, 2869*t*
Tuberculin reaction, 2859–2860
Tuberculin skin tests, granuloma annulare from, 566
Tuberculoid leprosy
clinical features, 2896, 2896*f*, 2897*f*
histopathology, 2907, 2908*f*
Tuberculosis (TB), 2858–2861. *See also Mycobacterium tuberculosis; specific types*
at-a-glance, 2858*b*
classification, cutaneous TB, 2859*t*
diagnosis
histopathology, 2860
polymerase chain reaction, 2860
QuantiFERON-TB Goldtest, 2860
tuberculin reaction, 2859–2860
epidemiology, 2858–2859, 2859*t*
etiology and pathogenesis
host, 2859
Mycobacterium, 2859
route of infection, 2859, 2860*f*
extensively drug resistant, 2861
in HIV-positive, 2858
prevalence, worldwide, 2858
treatment, cutaneous TB, 2861, 2862*t*–2863*t*
cytokines, 2861
skin, special considerations, 2861
Tuberculosis colliquativa cutis, 2858, 2859*f*, 2866–2867, 2866*f*, 2867*t*
Tuberculosis luposa, 2858, 2864–2866, 2865*f*–2866*f*, 2865*t*
Tuberculosis ulcerosa cutis et mucosae, 2867, 2867*f*, 2867*t*
Tuberculous chancre, 2861–2863, 2863*f*, 2863*t*
Tuberculous primary complex, 2861–2863, 2863*f*, 2863*t*
Tuberculous ulcer. *See also specific types*
acute, 2867, 2867*f*, 2867*t*
Tuberculous verrucosa cutis, 2863–2864, 2864*f*, 2864*t*
Tuberin (TSC2), tuberous sclerosis complex, 2485
Tuberoeruptive xanthomas, 2275, 2275*f*–2278*f*, 2282
Tuberous sclerosis, 2445*t*
autosomal dominant disorder, 295, 295*t*
genetics, mosaicism, 302
gonadal mosaicism, 302
Tuberous sclerosis complex (TSC), 2480–2491
at-a-glance, 2480*b*
clinical course and prognosis, 2489
clinical features, 2480–2485
clinical features, cutaneous, 2480–2484
dental pitting, 2483, 2484*f*
facial angiofibromas, 2480–2482, 2481*f*–2482*f*
fibrous cephalic plaque, 2482, 2482*f*
folliculocystic and collagen hamartomas, 2483
hypomelanotic macules, 2480, 2481*f*
intraoral fibromas, 2483–2484, 2484*f*
miliary fibromas, 2483
molluscum fibrosum pendulum, 2483, 2484*f*
shagreen patch, 2482, 2482*f*–2483*f*, 2487
ungual fibromas, 2480, 2482–2483, 2483*f*
clinical features, noncutaneous
brain, 2484
complications, 2485
eyes, 2485
heart, 2484
kidneys, 2484–2485
lungs, 2485
other organs, 2485
diagnosis, 2485–2488, 2487*t*
algorithm, 2488, 2488*f*
clinical criteria, 2487*t*
genetic criterion, 2485–2486, 2487*t*
imaging and laboratory testing, 2487–2488
molecular diagnosis, 2488
pathology, 2486–2487, 2487*f*
differential diagnosis, 2489, 2489*t*
etiology and pathogenesis, 2485, 2486*f*
management
counseling, 2490
medications, 2489–2490
procedures, 2490
risk factors, 2485
screening, 2490–2491
surveillance, 2490
Tuberous xanthomas, 2275, 2275*f*, 2283, 2284
Tubular adenoma, 1834–1835
Tubulovesicular structures, eosinophil, 256

Tufted angioma (TA), 2059*b*, 2061–2062, 2061*f*
Tularemia, 449, 2829*t*, 2830–2832
  at-a-glance, 2830*b*
  clinical course and prognosis, 2831–2832
  clinical features, 2830–2831, 2831*f*
  differential diagnosis, 2831
  etiology and epidemiology, 2830
  occupational exposure, 449
  prevention, 2832
  tick transmission, 3320
  treatment, 2829*t*, 2831
Tumescent liposuction
  fat reduction, 3863
  local anesthesia, 3906–3910 (*See also* Liposuction, tumescent local anesthesia)
Tumor, skin. *See also* Cancer, skin
  assessment (*See also specific types*)
    benignancy *vs.* malignancy, determination, 30
    cell types, 30
    cytology, 30
  direct tumor involvement of skin
    cutaneous metastases, 2460–2462, 2461*f*
    leukemia and lymphoma cutis, 2462
    Paget's and extramammary Paget's diseases, 2462
  infiltration pattern, 30
  mitotic activity, 30
Tumoral calcinosis (TC), 2311
Tumor infiltrating lymphocytes (TILs), melanoma, 1984*f*, 1999
Tumor-initiating cells, 312–313, 312*f*
Tumor necrosis factor (TNF), 168–169, 168*f*
  inflammation, chronic, 124–125
Tumor necrosis factor-α (TNF-α), 163*t*, 168–169, 3536*f*, 3537–3538, 3549*t*. *See also* Etanercept
  adipocyte lipolysis, 1251
  blockade, 175
  from dendritic cells, 152
  eosinophils, 657
  erythema nodosum, 1256
  fundamentals, 3537
  for haploinsufficiency of A20, 638
  histiocytosis, non–Langerhans cell, 2030
  infections, 3538
  inflammation, 124
  leprosy, 2904, 2905, 2905*f*
  malignancy, 3538
  mast cell granules, 154, 154*t*
  for otulipenia/OTULIN-related autoinflammatory syndrome, 638
  paradoxical psoriasis, 3538
  psoriasis, 171*f*, 198
  for SAPHO syndrome, 645
  sarcoidosis, 577, 577*f*
  seborrheic dermatitis, 432
  Sweet syndrome, 595
  systemic sclerosis, 1093
  T helper 1 cells, 145
  T helper 9 cells, 146
  type IV hypersensitivity reactions, 397
  vasoconstriction, 120
Tumor necrosis factor-α (TNF-α) antagonists, 175
  adalimumab, 3536*f*, 3537–3538, 3549*t*
  etanercept, 3536*f*, 3537, 3549*t*
  infliximab, 3536*f*, 3538, 3549*t*
  for psoriasis, 469*f*, 487*t*, 493–494
  rheumatoid neutrophilic dermatosis, 1149
  for sarcoidosis, 581*t*, 582
Tumor necrosis factor-α (TNF-α) antibody, 169
Tumor necrosis factor-α (TNF-α) converting enzyme (TACE), 168
Tumor necrosis factor-β (TNF-β), 168
  histiocytosis, non–Langerhans cell, 2030
Tumor necrosis factor (TNF) inhibitors. *See also specific types*
  for epidermal necrolysis, 744
  for juvenile idiopathic arthritis, 1155
  for multicentric reticulohistiocytosis, 2038
  palisaded neutrophilic and granulomatous dermatitis from, 1148
  for pityriasis rubra pilaris, 504
  for reactive phagocytic syndrome, in adult-onset Still disease, 1158
  rheumatoid vasculitis from, 1151
  for Sjögren syndrome, 1181
Tumor necrosis factor receptor 1 (TNFR1), 168, 169*f*
Tumor necrosis factor receptor 2 (TNFR2), 168
Tumor necrosis factor receptor-associated periodic syndrome (TRAPS), 635–637, 636*f*
Tumor of follicular infundibulum, 1846–1847
Tumors of dermal origin, pathology
  fibrohistiocytic tumors
    atypical fibroxanthoma, 36–37
    dermatofibroma, 36, 36*f*
    dermatofibrosarcoma protuberans, 36, 37*f*
  fundamentals, 36
Tumors of epidermal origin, pathology, 30–33
  keratinocytic tumors, 30–32
    basal cell carcinoma, 32–33, 32*f*
    condyloma acuminatum, 31, 31*f*
    keratoacanthoma, 32
    seborrheic keratosis, 31, 31*f*
    squamous cell carcinoma, 31–32, 31*f*
    squamous cell carcinoma, invasive, 32, 32*f*
    verruca plana, 31
    verruca vulgaris, 30–31, 30*f*, 258, 3099*f*
Tumors of neural origin, pathology
  neurofibroma, 38, 38*f*
  schwannomas, 38
Tumors of smooth muscle origin, pathology
  leiomyoma, 38–39, 38*f*
  leiomyosarcoma, 39, 39*f*
Tumors of vascular origin, pathology
  angiosarcoma, 37, 37*f*
  pyogenic granuloma, 37, 37*f*
Tumor suppressor genes, 313
  neurofibromatosis, 2470
Tuna, scombroid fish poisoning, 3359
Tungiasis, 3333, 3333*f*
Tungidae, 3333, 3333*f*
Turmeric root poultice, for hidradenitis suppurativa, 1487
Turner syndrome, common acquired melanocytic nevi, 1953–1954
Tuzun syndrome, 1200
2-nail dystrophy, 535, 536*f*
2 x 2 tables, sensitivity and specificity, 46, 46*f*
Two feet–one hand syndrome, 25*f*
TYK2
  dermatomyositis, 1072
  herpes simplex encephalitis, 3027
  hyperimmunoglobulinemia E syndrome, 2414
  psoriasis, 478
Tyndall effect, 7
  blue nevi, 1957
Type 1 reaction, leprosy, 2905, 2905*f*
Type I hypersensitivity, urticaria and angioedema, 691–692, 691*f*
Type III interferon, 173
Type IV hypersensitization, 397
  allergic contact dermatitis, 396
  elicitation phase, 397–398
  leprosy, 2905, 2905*f*
  sensitization phase, 397
Typhoid fever, 2806–2808
Typhoid fever vaccine, 2808
Typhus, 3318–3322
  ehrlichioses, 3320–3322
  endemic (murine or flea-borne), 3318
    clinical and laboratory findings, 3318
    diagnosis and differential diagnosis, 3315*t*, 3316*t*, 3318
    epidemiology and vectors, 3310*t*, 3318
    etiology and pathogenesis, 3306
    treatment and prognosis, 3310*t*, 3316*t*, 3318
  epidemic (louse-borne), 3318–3319
    clinical and laboratory findings, 3319
    diagnosis and differential diagnosis, 3315*t*, 3319
    epidemiology and vectors, 3308–3319, 3310*t*
    etiology and pathogenesis, 3306
    prevention, 3319
    treatment and prognosis, 3310*t*, 3316*t*, 3319
  etiology and pathogenesis, 3306
  infection mechanisms, 3306
  scrub, 3306, 3319–3320
TYR, 344
  oculocutaneous albinism type 1, 1310*t*, 1312
  squamous cell carcinoma, 1903
Tyrosinase
  melanin biosynthesis, 2221
  melanogenesis, 337
Tyrosinase inhibitors, 3811
Tyrosine kinase, 3558
  drug development, 3558
  for Kimura disease, 670
  small-molecular-weight compounds inhibiting, 3565
Tyrosine kinase inhibitors (TKIs), 3565–3566
  for mastocytosis, 720
  Raynaud phenomena from, 2616
  small-molecule, 3558–3565
    acneiform eruptions from, 1452
    at-a-glance, 3558*b*
    background, 3558–3559, 3560*f*
    bosutinib, 3559*t*, 3563–3564, 3563*f*
    dasatinib, 3559*t*, 3562–3563, 3562*f*
    imatinib mesylate, 3559–3561, 3559*t*
    nilotinib, 3559*t*, 3561–3562
    ponatinib, 3559*t*, 3564–3565, 3564*f*
Tyrosine kinase receptor 1 (Tie), vascular remodeling and stabilization, 127
Tyrosine kinase receptor 2 (Tie), vascular remodeling and stabilization, 127
Tyrosinemia II, cellular defect, 781*t*
TYRP1, 344
  melanogenesis, 337–339, 338*f*
  oculocutaneous albinism type 3, 1310*t*, 1313
TYRP2, melanogenesis, 337, 338*f*
Tyson glands, 70. *See also* Sebaceous glands
Tzanck smear, herpes simplex virus, 3028, 3028*f*

U

U2HR, Marie Unna hereditary hypotrichosis, 1545
Ulcer. *See also specific types and disorders*
  after sclerotherapy, 3885–3886
  aging, 1788
  Buruli ulcer disease, 2871, 2872*f*, 2872*t*
  Curling, burns, 1681
  dermatomyositis, 1065–1066, 1065*f*
  diabetic, 2498–2500, 2498*f*, 2499*f*, 2500*t* (*See also under* Diabetes mellitus (DM))
  in elderly, 1788
  Felty syndrome, 1150–1151, 1150*f*
  foot, differential diagnosis, 2672, 2673*t*
  genital (*See also specific types*)
    Epstein-Barr virus, 3000, 3000*f*
  helminthic infections, 3259
  infantile hemangiomas, 2050–2051, 2050*f*, 2050*t*

leg, differential diagnosis, 2672, 2674*t*
leprosy, 2901, 2901*f*
Marjolin, 320–321
melanoma, 1997*t*, 1998–1999
Raynaud phenomena, 2624
from sclerotherapy, 3885–3886
tuberculous, acute, 2867, 2867*f*, 2867*t*
venous, 2688, 2688*f*–2689*f* (*See also* Chronic venous disease (CVD))
in elderly, 1788
Ulcerative colitis
hidradenitis suppurativa, 1484
linear IgA dermatosis, 997
pustular eruption, Sweet syndrome, 591
Ulcerative pyoderma gangrenosum, 606, 606*f*. *See also* Pyoderma gangrenosum (PG)
Ulcus durum, 3148
Ulerythema ophryogenes (UO), 869–872, 869*t*, 870*f*, 872*t*, 1529
Ultrasound therapy, 3848
fat reduction, 3848, 3862
for lipodermatosclerosis, 1264
skin tightening, 3848, 3858, 3860*f*
Ultraviolet A (UVA), 3623
actinic prurigo, 1629
keratoacanthoma, 1902–1903
penetration depth, 3635, 3637*f*
polymorphic light eruption, 1612
squamous cell carcinoma, 1902–1903
Ultraviolet A (UVA) phototherapy
broadband, for morphea, 1114*f*, 1115, 1115*t*
effects, 3636*f*, 3637
for eosinophilic pustular folliculitis, 671
for lichen nitidus, 558, 558*t*
lupus erythematosus from, 1041*t*
for parapsoriasis, 511
in photochemotherapy, 3667
for pityriasis lichenoides, 515, 515*t*
for prurigo nodularis, 392
for SAPHO syndrome, 645
for systemic sclerosis, skin hardening in, 1100*t*, 1101
Ultraviolet A1 (UVA1) phototherapy, 3642–3643
for atopic dermatitis, 3649
for graft-versus-host disease, 2333–2334
for lichen sclerosus, 1122
for morphea, 1114*f*, 1115, 1115*t*
safety, 3645
for scleredema, 1166
Ultraviolet B (UVB), 3623
actinic prurigo, 1629
basal cell carcinoma, 1884
keratoacanthoma, 1902–1903
penetration depth, 3635, 3637*f*
polymorphic light eruption, 1612
squamous cell carcinoma, 1902–1903
Ultraviolet B (UVB) phototherapy
for acne vulgaris, 1410
for alopecia areata, 1521
for atopic eruption of pregnancy, 1777
broadband, 3640–3641, 3641*t*
for psoriasis, 3646–3647, 3647*f*
for cutaneous T-cell lymphoma, 2092
dyskeratosis, 22
effects, 3635–3637, 3636*f*
for eosinophilic pustular folliculitis, 671
for Langerhans cell histiocytosis, 2028
for lichen nitidus, 558, 558*t*
for lichen planus, 544
for mycosis fungoides, 2090
narrowband, 3640–3641, 3640*t*
for actinic prurigo, 1632
for atopic dermatitis, 3648–3649
for cutaneous T-cell lymphoma, 3649
devices, 3640–3641, 3640*t*
for morphea, 1114*f*, 1115, 1115*t*
for psoriasis, 3646–3647, 3647*f*
for pustular psoriasis of pregnancy, 1772
for vitiligo, 1341–1342, 3650
for nummular eczema, 388
for parapsoriasis, 510
for pigmented purpuric dermatoses, 2596
for pityriasis lichenoides, 515, 515*t*
for pityriasis rosea, 524
for prurigo nodularis, 392
for psoriasis, 483*t*, 490
safety, 3643
for seborrheic dermatitis, 436
for urticaria, 702
for vitiligo, 1342
Ultraviolet (UV) filters, 3625–3627, 3626*t*
history, 3624
immune protection, 3625
photoallergy, 3627
photostability, 3627, 3627*f*
sun protection factor, 3624–3625, 3624*f*
systemic influence, potential, 3628
UV protection, assessment, 3625
Ultraviolet (UV) light
avoidance (*See* Photoprotection)
photoaging damage, 282–284, 282*f*–283*f*, 283*t*
photoexacerbated dermatitis from, 1643–1644, 1643*f*, 1643*t*
psoriasis from, 458
Ultraviolet radiation (UVR)
basal cell carcinoma from, 1884
common acquired melanocytic nevi from, 1953, 1957
damage
reactive oxygen species, 276–278, 277*f*, 315
6,4-pyrimidine pyrimidone photoproducts, 275–276, 275*f*–277*f*
dysplastic melanocytic nevi from, 1975
exposure prevention, for melanoma prevention, 2011
lupus erythematosus from, 1041
photocarcinogenesis, 275–284
DNA damage and repair, 315–317
DNA photoproducts, 315–316, 316*f*
mutations, 316–317, 318*f*
sunlight, 315
phototherapy devices and lamps, 3639–3640 (*See also* Phototherapy devices)
physical stress barrier, 224–225
pigmentation and hypermelanosis from, 1364
for psoriasis, 271
radiation acne from, 1453
signature mutation, 316, 317*f*
skin cancer from, rodent models, 323
solar lentigo from, 1971
wavelengths, photocarcinogenesis, 281–282
Ultraviolet radiation (UVR), cutaneous responses, 268–284
immune system, 270–275
immunostimulation, 270–271
immunosuppression, 271–272, 271*f*
photodermatoses, photobiology, 273
phototherapy, photobiology, 273–275
proinflammatory and antiinflammatory, 270
skin phototypes, 272, 272*t*
sunburning, 272
tanning, 272–273, 272*f*
photocarcinogenesis, 275–284 (*See also* Photocarcinogenesis)
vitamin D photobiology, 268–270
production, biochemical pathway, 269–270, 270*f*
UVA *vs.* UVB, 269*t*
vitamin D functions, 268–269
UNC13D, hemophagocytic lymphohistiocytosis, 2032
UNC-93B, herpes simplex encephalitis, 3027
Uncombable hair syndrome, 1543–1544, 1544*f*, 1544*t*, 1550*t*
Unconventional, innate, and innate-like t cell(s), 149–151, 150*f*
innate lymphoid cells, 149, 150*f*
invariant natural killer cells, 150*f*, 151
mucosal-associated invariant T cells, 150*f*, 151
unconventional and innate-like T cells, 149–151, 150*f*
Unconventional and innate-like T cells, 149–151, 150*f*
Undetermined-type intercellular IgA dermatosis, 983*t*, 984–985
Undifferentiated rhabdomyosarcoma, 2144
Ungual fibrokeratoma, 1603–1604, 1603*f*
Ungual fibromas, tuberous sclerosis complex, 2480, 2482–2483, 2483*f*
Ungual lichen planus, melanonychia, 1570
Ungual melanoma, 1606–1608, 1607*f*–1608*f*, 1608*t*
Unidentified bright objects (UBOs), neurofibromatoses, 2475, 2476*f*
Unified tissue harvest technique, 3939
Unifocal Langerhans cell histiocytosis, 2019, 2020*t*
Unilateral laterothoracic exanthem (ULE), 3013–3015, 3014*t*, 3015*t*
Unilateral lentigines, 1967–1970, 1969*f*, 1970*t*
Unilateral linear capillaritis, 2593
Uniparental disomy, 300
Uniparental heterodisomy, 300
Uniparental isodisomy, 300
Universal distribution, 12
Unmasking IRIS, 3124
Unna boot, for chronic venous disease, 2691–2692, 2692*f*
Unna nevus, 2638, 2641*f*. *See also* Capillary malformations
Unna-Thost palmoplantar keratoderma, 823, 845*t*
Unruly hair, 1543–1547
hypotrichosis, 1546–1547, 1546*t*
Marie-Unna hereditary hypotrichosis, 1544–1545, 1545*t*, 1550*t*
uncombable hair syndrome, 1543–1544, 1544*f*, 1544*t*, 1550*t*
woolly hair, 1545–1546, 1545*f*, 1546*t*, 1550*t*
Untranslated regions (UTR), 292
Upadacitinib, for psoriatic arthritis, 1137
Uppers, 1711
Urachal cysts and polyps, neonatal, 1737
Urban-Rifkin-Davis syndrome, 1234, 1235*t*
Urea, 3619, 3619*t*
for pruritus, 358
sweat, 81–82
Ureaplasma, genital, 3212–3214
Uric acid–lowering therapy, for gout, 2315
Uricases, for gout, 2316
Urocanic acid, 65
UROD
hepatoerythropoietic porphyria, 2235*t*, 2243
porphyria cutanea tarda, 2235*t*, 2236*f*, 2237–2241, 2240*f*
Uroporphomethene, porphyria cutanea tarda, 2240, 2240f
Uroporphyrinogen decarboxylase (UROD), porphyria cutanea tarda, 2235*t*, 2236*f*, 2237–2241
Uroporphyrinogen III synthase (UROS), congenital erythropoietic porphyria, 2235*t*, 2244
UROS, congenital erythropoietic porphyria, 2235*t*, 2244
Ursodeoxycholic acid (UDCA)
intrahepatic cholestasis of pregnancy, 1771
for protoporphyric hepatopathy, 2249
Urtica dioica, 684
Urticaria, 684–704. *See also specific types*
aquagenic, 690
at-a-glance, 684*b*
cholinergic, 686*f*, 690

Urticaria (*Cont.*):
chronic, 688
clinical course and prognosis, 701
clinical features
cutaneous, 685, 686*f*–687*f*
noncutaneous, 685–687
cold, 689, 1674–1675, 1675*f*
diagnostic tests, 688*t*
pathogenesis, autoimmune mechanism, 691*f*, 692
underlying disorders, 693
complications
autoimmune thyroid diseases, 687
other autoimmune diseases, 687
contact, 690
definition, 684
delayed pressure, 690
diagnosis, 695–701
algorithm, 695, 696*f*, 701
aquagenic urticaria, 698
autoinflammatory syndrome, 699
cholinergic urticaria, 698
cold contact urticaria, 697
contact urticaria, 698
delayed pressure urticaria, 698
diagnostic tests, 688*t*
evaluation
control status, 699
disease severity, 688*t*, 699
quality of life, 699
heat urticaria, 697–698
history taking, 695–696
imaging, 701
laboratory testing, 696–697
pathology, 700–701, 700*f*
spontaneous urticaria, 697, 697*t*
symptomatic dermographism, 688*t*, 697
urticarial vasculitis, 698
vibratory urticaria and angioedema, 698
diagnostic tests, 688*t*
differential diagnosis, 697*t*, 701
eosinophils and, 654
epidemiology, 685
etiology and pathogenesis, 691–695
aspirin and other NSAIDs, 694–695, 694*t*
autoimmune mechanism, 691, 692
blood products, 695
coagulation system, 693
contrast media, 695
infections, 693
neurologic mechanism, 693
other factors, 694–695, 694*t*
other mast cell and basophil activators, 695
pseudoallergy, 692
risk factors, 695
serum sickness, 695
stress and fatigue, 694
type I hypersensitivity, 691–692, 691*f*
food-dependent exercise-induced, 695, 699
heat, 686*f*, 689
historical perspective, 684
hyperthyroidism, 2506
management, 701–704
in children, 703
counseling, 703
interventions, 694*t*, 701–702
medications, 702–703
phototherapy, 3651
in pregnancy and lactation, 703
prevention and screening, 703–704
treatment algorithm, 703, 703*f*
pathophysiology, mast cells, 684
physical, after sclerotherapy, 3883–3884, 3884*f*
reactions and systemic disease symptoms
anaphylaxis, 690
Darier sign, 690
hereditary angioedema, 690
wheal, from skin test, 690
solar (*See* Solar urticaria (SolU))
spontaneous, 687*f*, 688, 688*t*
subtypes, 687–691
symptomatic dermographism, 686*f*, 688–689
urticarial vasculitis, 690–691
vibratory, 690
diagnosis, 698
underlying disorders, 693
wheal characteristics, 689*t*
Urticaria Control Test (UCT), 699
Urticaria factitia, 686*f*, 688–689, 688*t*, 697. *See also* Urticaria
Urticarial eruptions, drug-induced, 750–751, 750*t*
Urticarial erythemas, 7*f*, 16, 16*t*
Urticarial multiforme, 727
Urticarial vasculitis (venulitis), 690–691, 2530*t*, 2531, 2531*f*
angioedema with, 691
clinical features, cutaneous, 685
diagnosis, 698
hypocomplementemic urticarial vasculitis syndrome, 692
pathology, 700*f*, 701
Urticaria pigmentosa (UP)
management
phototherapy, 3652
PUVA, 3672
mastocytosis, 710–720, 711*f*, 715*f* (*See also* Mastocytosis)
Urushiol, 396
Ustekinumab, 175, 3536, 3536*f*, 3548*t*
for adamantiades–Behçet disease, 2576*t*
for CARD14-mediated pustular psoriasis/psoriasis 2, 631
for hidradenitis suppurativa, 1490
for pityriasis rubra pilaris, 504
for psoriasis, 464, 469*f*, 487*t*
for psoriatic arthritis, 980*t*, 981, 1136*t*, 1137
for pyoderma gangrenosum, 614*t*
Uveal melanomas, 1988. *See also* Melanoma
Uveitis, psoriatic arthritis with, 1130, 1130*f*–1131*f*
UV protection factor (UPF), 3630–3631

V

V560G, mastocytosis, 750
V600E mutation, BRAF, 3579
V600K mutation, BRAF, 3579
Vaccines (vaccination)
Bacille Calmette-Guérin
granuloma annulare from, 566
sequelae, 2867–2868
for burns, 1688
with cyclosporine treatment, 3524
diphtheria, pertussis, and tetanus (DPT), 2853
glucocorticoid use with, 3385
granuloma annulare from, 566
herpes simplex virus, 3033
herpes zoster
adjuvanted glycoprotein E subunit zoster vaccine, 3057–3058, 3058*t*
with HIV, 3118
live attenuated Oka VZV zoster, 3056–3057
live attenuated zoster vaccine, 3056–3057
human diploid cell rabies, 3340–3341
injection sites, cutaneous pseudolymphoma at, 2116–2117, 2117*f*
leishmaniasis, 3237–3238
Lyme borreliosis, 3301
measles, 2989, 2991–2992
postexposure prophylaxis, 2991
measles mumps rubella (MMR), 2992, 2994
measles mumps rubella and varicella (MMR and varicella), 2994
meningococcal, 2788, 2788*t*
monkeypox, 3081, 3081*t*
with mycophenolate mofetil treatment, 3519
Neisseria meningitidis, 2788, 2788*t*
rubella, 2994
smallpox, 3072–3078, 3072*t*, 3073*b*
spherulin, for coccidioidomycosis, 2980
tetanus toxoid, for burns, 1688
typhoid fever, 2808
vaccinia virus
monkeypox, 3081, 3081*t*
small pox and, 3066*t*, 3073–3078
varicella-zoster virus, 3054–3055
Vaccinia necrosum (gangrenosa), 3076, 3076*f*
Vaccinia virus, 3066*t*, 3073
monkeypox vaccination and, 3081, 3081*t*
Vaccinia virus, small pox vaccination and, 3072–3078
at-a-glance, 3073*b*
clinical course and prognosis, 3077–3078
clinical features
cutaneous, 3073–3074, 3074*f*
noncutaneous, 3074
complications, cutaneous, 3074–3076, 3075*f*–3076*f*
accidental vaccinia, 3074–3075, 3075*f*
Bruton hypogammaglobulinemia–developed progressive vaccinia, 3076, 3076*f*
eczema vaccinatum, 3075–3076, 3076*f*
erythema multiforme, 3075, 3075*f*
fetal/congenita vaccinia, 3075, 3076*f*
generalized, nonspecific, immune-mediated, 3075, 3075*f*
hypersensitivity reactions, 3075, 3076*f*
vaccinia necrosum, 3076, 3076*f*
complications, noncutaneous, 3076
diagnosis, 3077
effectiveness, 3072
epidemiology, 3073
etiology and pathogenesis, 3076–3077, 3077*f*
indications and contraindications, 3072*t*
postexposure protection, 3073
prevention, 3078
stockpiles, government, 3072–3073
Vagabond leukemia, 1387
Vaginal lichen planus, 535
Valacyclovir, 3496–3497
dosing regimens, 3496–3497, 3497*t*
for herpes simplex virus, 3029–3031, 3030*t*–3032*t*
with HIV, 3117
for herpes zoster
immunocompetent, 3053, 3053*t*
immunocompromised, 3053*t*, 3054
for human cytomegalovirus, 3006–3007
prevention, in immunocompromised, 3007
indications, 3496
mechanism of action and pharmacokinetics, 3494*f*, 3496
for ophthalmic zoster, 3053, 3053*t*
side effects and precautions, 3497
for varicella-zoster virus, 3051
with HIV, 3118
immunocompetent
adolescents and adults, 3052, 3052*t*
children, 3052, 3052*t*
immunocompromised, 3052, 3052*t*
Valganciclovir, 3499–3500, 3500*t*
for human CMV prevention in immunocompromised, 3007
Valley fever, 2979–2980, 2980*f*
Vancomycin, systemic, 3418
for dog bites, 3339
for group A *Streptococcus* lymphangitis, 2739, 2739*t*
for infective endocarditis, 2818
linear IgA dermatosis from, 995, 997

for MRSA skin and soft tissue infections, complicated, 2731*t*, 2732
for pyomyositis, 2778
for *Staphylococcus* necrotizing fasciitis, 2775, 2776*t*
for toxic shock syndrome, 2764
Vancomycin/clindamycin, for toxic shock syndrome, 2764
Vanishing bone disease, 2654. *See also* Lymphatic anomalies
Vaping, marijuana, 1712
Varicella, diagnosis and differential diagnosis, 3040*f*, 3048, 3049*t*
Varicella-zoster virus (VZV), 3035–3058
at-a-glance, 3035*b*
clinical features, 3039–3041, 3040*f*
nail changes, 1590
diagnosis, 3040*f*, 3048–3051, 3049
clinical, 3040*f*, 3048
laboratory, 3049–3051, 3050*f*
differential diagnosis, 3049*t*
in elderly, 1787
epidemiology, 3036
etiology and pathogenesis, 3046–3047
fundamentals, 3035
historical perspective, 3035–3036
with HIV, 3117–3118
management, 3051–3053
antiviral therapy, 3051
immunocompetent, adolescents and adults, 3052, 3052*t*
immunocompetent, children, 3051–3052, 3052*t*
immunocompromised, 3052–3053, 3052*t*
topical therapy, 3051
prevention, 3054–3056
infection control, 3055–3056
postexposure prophylaxis, 3055
vaccine, 3054–3055
Varicose veins and telangiectatic lower-extremity vessels treatment, 3871–3890
at-a-glance, 3871*b*
Clinical-Etiologic-Anatomic-Pathophysiologic classification tool, 3877, 3877*t*
contraindications, 3876–3877, 3876*t*
epidemiology and predisposing factors, 3874–3876
history and examination, 3876–3877, 3876*t*
minimally invasive surgery, varicose veins, 3886–3890
ambulatory phlebectomy, 3888–3889, 3889*f*
endovenous ablation/occlusion techniques
applications and technique, 3887, 3887*f*
great saphenous vein, incompetent, 3887, 3887*f*
laser, 3850, 3850*f*, 3853*t*, 3887–3888, 3888*f*–3889*f*
radiofrequency, 3848, 3887
historical perspective, 3886–3887
laser and light sources, 3889–3890, 3890*f*
sclerotherapy, 3877–3886 (*See also* Sclerotherapy)
venous anatomy and physiology, 3871–3874, 3872*f* (*See also* Venous anatomy and physiology)
venous pathophysiology, 3876
Variegate porphyria (VP), 2234, 2235*t*, 2237*t*, 2249–2252
hypertrichosis from, 1565
Variola sine eruption, 3069
Variolation, 3065
Variola virus. *See* Smallpox (variola virus)
Varnish, nail, treatment effects, 1578
Vascular anatomy, face, 3703–3705, 3704*f*
Vascular cellular adhesion molecule (VCAM), eosinophils, 656, 657
Vascular cellular adhesion molecule 1 (VCAM-1)
cutaneous necrotizing venulitis, 2534
inflammation
acute, 124, 124*f*
acute *vs.* chronic, 125
chronic, 125
Vascular Ehlers-Danlos syndrome (vEDS)
clinical features, 1213*t*, 1221, 1221*f*
diagnostic criteria, 1214*t*
etiology and pathogenesis, 1222–1223
inheritance and gene defect, 1213*t*
Vascular endothelial growth factor (VEGF)
angiogenesis, 125, 126*f*, 127
leprosy, 2905, 2905*f*
lichen ruber planus, 125
mast cell granules, 154, 154*t*
pityriasis rosea, 522
Sweet syndrome, 595
tumor angiogenesis, 128, 128*f*
wound healing, 128, 128*f*, 2704*t*, 2707
Vascular endothelial growth factor (VEGF) agents
bevacizumab, 3592
pegaptanib, 3597
ranibizumab, 3599
Vascular lesions, cutaneous manifestations, 2430–2431
Vascular malformations, 2636–2663. *See also specific types*
arteriovenous malformations, 2636, 2637*t*, 2638*f*, 2658–2663
at-a-glance, 2636*b*
classification, 2636, 2637*t*
clinical features, 2636
definition, 2636
diagnosis, 2637
epidemiology, 2636
etiology and pathogenesis, 2637, 2639*t*
genetic, 2640*t*
management, 2637
neonatal, 1734
Vascular perfusion pressure, 3734
flap survival, 3734
Vascular remodeling, 126
Vascular tumors, 2042–2065. *See also specific types*
congenital eccrine angiomatous hamartoma, 2059*b*, 2065
hemangioendothelioma
composite, 2064
Kaposi, 2059*b*, 2062–2063, 2062*f*
retiform, 2064
hemangioma
congenital, 2043*t*, 2059–2060, 2059*b*, 2060*f*–2061*f*
infantile, 2042–2059 (*See also* Infantile hemangiomas (IH))
spindle-cell, 2059*b*, 2063
targetoid hemosiderotic, 2064
Kasabach-Merritt phenomenon, 2062, 2062*f*
multifocal lymphangioendotheliomatosis, 2059*b*, 2064
papillary intralymphatic angioendothelioma, 2064
pyogenic granuloma, 2059*b*, 2063–2064, 2063*f*
tufted angioma, 2059*b*, 2061–2062, 2061*f*
Vasculature, cutaneous, 116–129. *See also specific vessels*
anatomy, blood vascular system, 116
at-a-glance, 116*b*
development, 58–59
embryogenesis, 126, 126*f*
heat stress protection, 225–226, 225*f*
inflammation
acute, 123–124, 123*f*, 124*f*
acute *vs.* chronic, 125
chronic, 124–125, 124*f*
lichen ruber planus, 125
properties and functions, 117–123, 119*t*
hemostasis, 118–119, 119*f*
immune surveillance, 122–123, 122*f*
perfusion, 120, 121*f*
permselectivity, 119–120, 120*f*
thermoregulation, 121–122, 121*t*
psoriasis, 125, 126*f*
structure and organization, 116–117, 117*f*
wound healing and cancer, 125–129
angiogenesis and vasculogenesis, 125–127, 126*f*, 127*f*
tumor angiogenesis, 128–129, 128*f*
wound healing, 127–128, 128*f*
Vasculitis. *See also specific types*
Behçet disease (*See* Adamantiades–Behçet disease)
cocaine abuse, 1709
cryoglobulinemic (*See* Cryofibrinogenemia; Cryoglobulinemia)
cutaneous rheumatoid, 1150, 1150*f*
drug-induced, 756–757
IgA vasculitis (*See* Cutaneous necrotizing venulitis (CNV))
Kawasaki disease (*See* Kawasaki disease)
nail changes, 1588, 1588*f*
necrotizing, 2529–2530
neutrophils, 27
paraneoplastic, 2529
rheumatoid, 1149–1150
urticarial, 690–691
diagnosis, 698
hypocomplementemic urticarial vasculitis syndrome, 692
pathology, 700*f*, 701
Vasculitis, cutaneous, 2539–2558
at-a-glance, 2539*b*
classification, 2539–2540, 2540*f*
clinical course and prognosis, 2554–2555
clinical features
cutaneous, 2540–2541, 2546*f*, 2550*f*–2554*f*
noncutaneous, 2541, 2542*t*–2543t
cutaneous leukocytoclastic angiitis, 2552–2553
definition, 2539
diagnosis, 2541–2550
algorithm, 2541–2543, 2544*f*
audiology testing, 2550
biopsy
other, 2547
skin, 2545–2547, 2546*f*
drug abuse screening, 2549
electromyography, 2550
errors, common, 2558
imaging
angiography, 2549–2550
chest, 2549
sinus, 2549–2550
infectious disease exposures, 2545
laboratory testing, 2547–2549
acute phase reactants, 2548
antineutrophil cytoplasmic antibodies, 2548
antinuclear antibodies, 2548
autoimmune serologies, 2548
complement, 2549
complete blood count, 2547–2548
infectious diseases, 2549
liver function, 2547
paraproteins and cryoglobulins, 2548–2549
renal function, 2547
rheumatoid factor, 2548
medical history, 2545
nerve conduction studies, 2550
physical examination, 2545
systems review, 2542*t*–2543*t*, 2543
toxin exposures, 2545

Vasculitis, cutaneous (*Cont.*):
drug-induced, 2553, 2553*f*
epidemiology, 2540
etiology and pathogenesis, 2541
giant cell arteritis, 2554, 2555*f*
granulomatosis with polyangiitis, 2550–2551, 2551*f*, 2552*f*
eosinophilic, 2551–2552
malignancy-associated, 2552
management, 2555–2558
biologic agents, 2557
emergencies, medical, 2558
errors, common, 2558
general approach, 2555–2557, 2556*f*
glucocorticoids, 2557
immunosuppressive agents, other, 2557
other, 2557
systemic vasculitis, 2557
microscopic polyangiitis, 2550, 2550*f*
polyarteritis nodosa, 2553, 2554*f*
primary, of CNS, 2554
signs, symptoms, and disease processes, 2542*t*–2543*t*
with Sjögren syndrome, 2552
with systemic lupus erythematosus, 2552
systemic vasculitides, 2539
Takayasu arteritis, 2554
Vasculogenesis, 125–127, 126*f*, 127*f*
Vasculopathy. *See also specific types*
digital, systemic sclerosis, 1090, 1091*f*, 1099–1100, 1099*t*
livedoid, 2530*t*, 2532–2533, 2532*f*
nail changes, 1588, 1588*f*
neurofibromatoses, 2475
systemic sclerosis, 1088*f*, 1089–1090, 1094, 1099–1100, 1099*t*
Vasoconstriction
cold, 1666
from glucocorticoids, 3388
reflex cutaneous, 355
sensory nerves, 355
thermoregulation, 121
Vasoconstriction inhibitors. *See also specific types*
for Raynaud phenomena, 2621*t*, 2622
Vasodilation, thermoregulation, 121
Vasodilators. *See also specific types*
for Raynaud phenomena, 2620–2622, 2621*t*
Vegetative pyoderma gangrenosum, 606*f*, 607. *See also* Pyoderma gangrenosum (PG)
VEGF3, 2655–2656
Milroy syndrome, 2655, 2694
VEGF-C
CLOVES, 2640*t*
Nonne-Milroy lymphedema, 2640*t*
VEGFR3, Nonne-Milroy lymphedema, 2640*t*
Vehicle, topical therapy, 3372, 3372*t*
Veil cells, 117
Veins, cutaneous. *See also specific veins*
anastomoses, 117
face, 3704*f*, 3705
Vellus hair, 92, 92*t*
Vemurafenib, 3559*t*, 3581–3582, 3581*f*
erythema nodosum from, 1256
granuloma annulare from, 567
keratoacanthoma from, 32
for melanoma, 2007–2009, 2008f
phototoxicity, 1662
plus ipilimumab, for melanoma, 2009
squamous cell carcinoma from, 1906
in melanoma patients, 315
Venlafaxine, photodistributed telangiectasia, 1661
Venomous fish spines, 3356–3358
catfish, 3357
prevention, 3357
scorpionfish, 3357, 3357*f*
stingrays, 3356, 3356*f*
symptoms, 3357
treatment, 3358
weeverfish, 3357
Venous anatomy and physiology, 3871–3874. *See also specific veins*
deep venous system, 3871–3872, 3872*f*
perforating venous system, 3874, 3875*t*
superficial venous system, 3872–3874, 3872*f*–3874*f*, 3873*t*
Venous anomalies, 2646–2653. *See also specific types*
at-a-glance, 2646*b*
cerebral developmental, 2652
clinical course and prognosis, 2652
clinical features, 2647–2651, 2648*t*
complications, 2648*f*–2649*f*, 2650
cutaneous, 2647–2649, 2648*f*–2649*f*, 2648*t*
noncutaneous, 2649–2650
definition, 2646
diagnosis, 2647*f*, 2651
differential diagnosis, 2651, 2651*t*
epidemiology, 2646
etiology and pathogenesis, 2650–2651
locations, 2646
management, 2652–2653
syndromic disorders
blue rubber bleb nevus syndrome, 2647, 2647*f*
Maffucci syndrome, 2647, 2647*f*
verrucous venous malformation, 2649, 2649*f*
Venous compression, for venomous snakebites, 3342–3343
Venous hypertension, on wound healing, 2712
Venous insufficiency, on ulcers in elderly, 1788
Venous lakes, laser therapy for, 3850, 3853*t*
Venous leg ulcers, healing. *See* Wound healing
Venous-lymphatic constriction bandage, for jellyfish sting, 3347–3348
Venous malformations, 2636, 2637*t*, 2638*f*. *See also* Vascular malformations
capillary, 2636, 2637–2646, 2637*t*, 2638*f*
etiology and pathogenesis, genetic, 2640*t*
lymphatic anomalies, 2637*t*, 2638*f*, 2653–2658
venous anomalies, 2646–2653
Venous pathophysiology, 3876
Venous thromboembolism (VTE), Trousseau syndrome, 2443*t*, 2460
Venous ulcers. *See* Chronic venous disease (CVD)
Venules, dermal, 49
deep vascular plexus, 116–117, 117*f*
postcapillary, 117
superficial vascular plexus, 116, 117*f*
Veratrum californicum, 1890
Vermilion border, 3698*f*, 3699
Vernix caseosa, 224, 1728
neonatal skin protection, 1728
Verocay body, 38
schwannoma, 2155, 2155*f*
Verrucae. *See* Warts (verrucae)
Verruca plana, 31, 3098, 3098*f*
Verruca vulgaris, 30–31, 30*f*, 258, 3099*f*
Verruciform xanthoma, 2276
Verrucous carcinoma, oral, tobacco use, 1714
Verrucous discoid lupus erythematosus, 1046
Verrucous squamous cell carcinoma, 1908, 1910, 1910*f*
Verrucous venous malformation (VVM), 2649
Verrucous xanthomas, 2284–2285
Verruga peruana, 2797–2806
bacteriology, 2797, 2797*t*
clinical course and prognosis, 2805
clinical features
complications, 2802
cutaneous, 2799*t*, 2800, 2801*f*
noncutaneous, 2799*t*, 2802
diagnosis
laboratory, 2799*t*, 2804–2805
pathology, 2804
differential diagnosis, 2804, 2805*t*
epidemiology, 2798
etiology and pathogenesis, 2803–2804
management, 2806
Vertical mattress suture, 3718, 3719*f*
Very-low-density lipoprotein (VLDL), 2273
synthesis, 2280
Vesicants, extravasation injury, 3486, 3486*f*
Vesicles, 4*t*, 5, 5*f*, 6*f*, 13*t*, 14
Vesicular systems, 3376
Vesiculobullous lichen planus, 531–532, 532*f*
Vesiculobullous reaction pattern, 13*t*, 14
Vessels, blood. *See specific types*
VH1-46 B-cells, pemphigus, 919
Vibratory angioedema, 690
ADGRE2, 690, 693
diagnosis, 688*t*, 698
underlying disorders, 693, 694
wheals, 689*t*
Vibratory tools, Raynaud phenomena, 2616
Vibratory urticaria, 690, 698
Vibrio carchariae, 3358
Vibrio cholerae, 2843
Vibrio parahaemolyticus, 2843
Vibrio vulnificus, 2829*t*, 2841–2843, 2842*f*
necrotizing soft-tissue infections, 2775–2777, 2776*t*
Viekira Pak, for hepatitis C virus, 3512
Vimentin
juvenile xanthogranuloma, 2032
progressive nodular histiocytosis, 2040
xanthoma disseminatum, 2036
Vinblastine
for Kaposi sarcoma, 3120
for Langerhans cell histiocytosis, 2029, 2029*t*
Raynaud phenomena from, 2616
Vinca alkaloids. *See also specific types*
extravasation injury, 3486
Vincristine
for cutaneous lymphoma with HIV, 3121
for hemophagocytic lymphohistiocytosis, 2032
for infantile hemangiomas, 2058
for Kaposi sarcoma, 3120
Raynaud phenomena from, 3486
Vinegar baths, for *P. aeruginosa*, nail, 1592
Vinyl chloride manufacturing, Raynaud phenomena, 2616
Violet color, 8*t*
Viral-associated epithelial precancerous lesions, 1871–1875, 1871*t*
anogenital tract, lower, 1871*t*, 1873–1875
anal intraepithelial neoplasia, 1871*t*, 1873*b*–1874*b*
penile intraepithelial neoplasia, 1871*t*, 1876*f*, 1975*b*
perianal intraepithelial neoplasia, 1871*t*, 1874*b*
vulvar intraepithelial neoplasia, 1871*t*, 1874*b*–1875*b*
Bowenoid papulosis, 1871–1872, 1871*t*, 1872*f*
epidermodysplasia verruciformis, 1871*t*, 1872–1873, 1873*f*
Viral carcinogenesis, 318–320
general features, 318–319, 319*t*
human papillomaviruses, 319, 319*t*
human polyomaviruses, 319–320
Viral diseases. *See also specific types*
acantholysis, 23, 23*f*
atopic dermatitis, 367, 367*f*
congenital, 1738

in elderly, 1787–1788
nail, 1589–1591
enterovirus, 1591, 1591*f*
herpes simplex virus, 1589–1590, 1589*f*
herpes zoster, 1590, 1590*f*
human papillomavirus, 1590–1591, 1590*f*
varicella virus, 1590
Viral diseases, exanthematous, 2989–3015, 3015*t*. *See also specific diseases*
enteroviruses, 3010–3013
hand-foot-mouth disease, 3010–3011, 3011*f*, 3015*t*
Coxsackie A6–associated atypical, 3012–3013, 3012*f*–3013*f*, 3013*t*, 3015*t*
Epstein-Barr virus, 2998–3002, 3015*t*
eruptive pseudoangiomatosis, 3013, 3015*t*
erythema infectiosum, 2994–2998, 3015*t*
Gianotti-Crosti syndrome, 3002–3004, 3015*t*
human cytomegalovirus, 3004–3007, 3015*t*
human herpesvirus 6, 3007–3009, 3008*f*, 3015*t*
human herpesvirus 7, 3009–3010, 3010*t*
measles, 2989–2992, 3015*t*
papular purpuric gloves-and-socks syndrome, 3015*t*
parvovirus B10, 2994–2998
rubella, 2992–2994, 3015*t*
unilateral laterothoracic exanthem, 3013–3015, 3014*t*, 3015*t*
Viral diseases, mosquito-borne, 3135–3143. *See also specific types*
alphavirus, 3136*t*, 3141–3143
at-a-glance, 3141*t*
Chikungunya, 3136*t*, 3141–3142, 3142*f*
fundamentals, 3141
Mayaro, 3136*t*, 3142–3143
O'nyong-nyong, 3136*t*, 3142–3143
Ross River, 3136*t*, 3142–3143
Sindbis group, 3136*t*, 3142–3143
at-a-glance, 3135*b*
definitions, 3135
flavivirus, 3135–3141, 3136*t*
dengue virus, 3135–3137, 3136*t*, 3137*f*
West Nile virus, 3136*t*, 3139–3141, 3140*f*
yellow fever virus, 3136*t*, 3139
Zika virus, 3136*t*, 3137–3139, 3138*f*
historical perspective, 3135
Virchow triad, 2460
Viruses, skin microbiome, sequencing methods, 254
Viscerotropic leishmaniasis, 3233
Visible light, 3820
radiation, cutaneous responses, 284
Vismodegib, 3559*t*, 3572–3574, 3572*f*
for basal cell carcinoma, 1890
prevention, with basal cell nevus syndrome, 1896
squamous cell carcinoma from, 315
for xeroderma pigmentosum, 2354
Vital signs, operative, 3710
Vitamin(s)
fat-soluble, 2204–2211, 2204*b*, 2280 (*See also specific vitamins*)
water-soluble, 2211–2221, 2211*b* (*See also specific vitamins*)
Vitamin A (retinol), 2204, 2207*t*
deficiency, 2204–2206, 2205*f*, 2205*t*, 2206*t*
for erythema gyratum repens, 2454
esterification and oxidation, 3397
for lichen planus pigmentosus, 1386
for measles, 2991
nail changes, 1598
for squamous cell carcinoma prevention, 1915
toxicity, 2206–2208, 2208*t*
Vitamin A (retinol) analogues, for psoriasis, 482*t*, 488, 3122
Vitamin B_1 (thiamine), 2207*t*, 2212
deficiency (beriberi), 2206*t*, 2212
Vitamin B_2 (riboflavin), 2207*t*, 2212–2213
deficiency, 2213–2214, 2213*f*, 2213*t*
Vitamin B_3
niacin
neonatal, 2211*b*
for pellagra, 1364
nicotinamide, for actinic keratosis prevention, 1867
Vitamin B_3 (niacin), 2207*t*, 2214
deficiency, 2206*t*, 2214–2215, 2215*f*, 2215*t*
photoprotection, oral, 3629
on triglycerides, 2287
Vitamin B_6 (pyridoxine), 2207*t*, 2215–2216
deficiency, 2206, 2206*t*
Vitamin B_9 (folate), 2207*t*, 2216
Vitamin B_{12} (cobalamin), 2207*t*, 2216–2217
deficiency, 2206*t*, 2217–2218
hypermelanosis, 1363
melanonychia, 1570
Vitamin C (ascorbic acid), 2207*t*, 2211*b*, 2218
deficiency, 2206*t*, 2218–2219, 2219*f*, 2219*t*
for hyperimmunoglobulinemia E syndrome, 2415
photoprotection, oral, 3629
for pigmented purpuric dermatoses, 2596
for pseudoxanthoma elasticum, 1233
Vitamin D (calcitriol), 268–270, 2207*t*, 2209
adaptive immune response, 153
for atopic dermatitis, 380–381
biochemical pathway, synthesis, 269–270, 270*f*
deficiency, 269, 2206*t*, 2209–2211, 2210*t*
derivative, for morphea, 1114*f*, 1115, 1115*t*
excess ingestion, metastatic calcification and nephrolithiasis, 2311
functions, 268–269
for mastocytosis, 719*t*, 720
photoprotection, 3629
rosacea, 1429
sources, 269
sunscreen, 3628–3629
UVA *vs.* UVB, 269*t*
for xeroderma pigmentosum, 2354
Vitamin D analogs
for erythema annulare centrifugum, 767, 773*t*
for psoriasis, with HIV, 3122
Vitamin D_3 (cholecalciferol), 2307
for psoriasis, 482*t*, 488, 3122
Vitamin D_3 analogs
for pityriasis rubra pilaris, 503
for psoriasis, 482*t*, 488, 3122
Vitamin E (tocopherol), 2207*t*, 2211
for protoporphyric hepatopathy, 2249
for pseudoxanthoma elasticum, 1233
sebum, 74
Vitamin K (phytonadione), 2207*t*, 2211
deficiency, 2206*t*, 2211–2212
deficiency, hemorrhagic diseases of newborn, 2204*b*, 2211
Vitiligo, 1330–1346
at-a-glance, 1330*b*
clinical course and prognosis, 1340
clinical features, 1331–1334
acrofacial vitiligo, 1331
associations, 1334
complications, 1334
distribution, 1331, 1331*f*
focal vitiligo, 1331
mixed vitiligo, 1332, 1332*f*
mucosal vitiligo, 1331, 1332*f*
presentation patterns, 1331–1332
segmental variant, 1331–1332, 1332*f*
vitiligo universalis, 1331
definition, 1330
dermatitis herpetiformis, 1004
diagnosis
clinical examination, 1336–1337, 1337*f*
histology, 1337
laboratory testing, 1337
differential diagnosis, 1337–1340, 1338*t*, 1339*f*–1340*f*
disease activity, clinical markers, 1332–1334, 1333*f*
confetti-like depigmentation, 1333, 1333*f*
inflammatory vitiligo, 1333, 1333*f*
Koebner phenomenon, 1332, 1333*f*, 1334
K-VSCOR score, 1334
trichrome vitiligo, 1332–1333, 1333*f*
VIDA score, 1334
epidemiology, 1330–1331
etiology and pathogenesis, 1334–1336
convergence theory, 1335
hypotheses, competing, 1334–1335
risk factors, 1336
segmental variant, 1335–1336
T cells and cytokines, autoimmunity, 1335
historical perspective, 1330
HLA haplotype inheritance, 303
management, 1340–1346
combination therapies, 1342
cosmetics, 1342
depigmentation therapy, 1342
emerging therapies, 1345–1346
nontraditional, 1342–1343
phototherapy, 1341–1342, 3646*t*, 3650
psoralen and ultraviolet A, 1341
ultraviolet B, narrowband, 1341–1342, 1341*f*
ultraviolet B, targeted, 1342
psychological interventions, 1342
surgical, 1343–1345, 1343*f*, 1344*f*
topical therapies, 1340–1341
treatment algorithm
segmental vitiligo, 1345, 1346*f*
vitiligo, 1345, 1345*f*
PUVA for, 3673–3674, 3673*f*
segmental variant
Alezzandrini syndrome, 1334
clinical course and prognosis, 1340
clinical features, 1331–1332, 1332*f*
demographics, patient, 1330
diagnosis, 1336–1337
differential diagnosis, 1337, 1338*t*, 1339–1340
etiology and pathogenesis, 1335–1336
management, 1342, 1343, 1343*f*
algorithm, 1345, 1346*f*
Vitiligo universalis, 1331
Vitreous membrane, 95
VLA-4, eosinophils, 657
Vogt-Koyanagi-Harada syndrome (VKHS), 332, 1334
Vohwinkel, 781*t*, 783*f*, 824*f*, 829–832, 836, 845*t*, 846*t*
Vohwinkel syndrome (VS), 781*t*, *783f*, 824*f*, 829–832, 836, 845*t*, 846*t*
Camisa type, 824–825, 824*f*, 845*t*
Volar pad development, 27
von Recklinghausen disease, 1361
von Zumbush-type generalized pustular psoriasis, 461–462, 463*f*
Voriconazole
for blastomycosis, 2979
for chronic mucocutaneous candidiasis, 2401
for histoplasmosis, African, 2977
for *Madurella mycetomatis* infection, 2971
for paracoccidioidomycosis, 2981
phototoxicity, 1661, 1662
for sporotrichosis, 2968
Vorinostat, 3559*t*, 3576–3577, 3576*f*
Vörner-Unna-Thost type Naxos disease, 1545
V-to-Y flap, 3738–3739, 3740*f*

Vulvar intraepithelial neoplasia (VIN), 1871*t*, 1874*b*–1875*b*
Vulvar lichen planus, 535
Vulvovaginal gingival syndrome, 535
Vulvovaginitis, candidiasis, 2958–2959
V-Y advancement, burn scars, 1690

W

Waardenburg syndrome (WS), 1322–1323
  clinical course, prognosis, and management, 1323
  clinical features, 1322–1323, 1323*f*
  diagnosis, 1323, 1323*t*
  etiology and pathogenesis, 1323
    melanocytes, 332
  subtypes, 1322, 1322*t*
Waldenström macroglobulinemia, paraneoplastic pemphigus, 2*f*, 934
Walker-Murdoch sign, Marfan syndrome, 1226
Walt Disney dwarfism, 1237*t*, 1238–1239
Wangiella dermatitidis
  chromoblastomycosis, 2966*t*, 2971–2972, 2971*f*–2972*f*
  phaeohypomycosis, 2966*t*, 2972
Warfarin, telogen effluvium from, 1510*t*, 1511, 1511*f*
Warts (verrucae), 3096*t*, 3097–3100. *See also* Verruca
  anogenital, 3096*t*, 3099*t*, 3102–3103, 3103*f*
  butcher's, 3098
  clinical course and prognosis, 3099, 3100*f*
  clinical features, 3097–3098, 3097*f*–3098*f*
  cutaneous, 3096*t*
  diagnosis and pathology, 3097*f*, 3098–3099, 3099*f*
  differential diagnosis, 3099*t*
  etiology and pathogenesis, 3098
  EV-plane, 1873, 1873*f*
  filiform, 3098, 3098*f*
  flat, electrodessication for, 3799
  genital, 3099*t*
    differential diagnosis, 3099*t*
  HPV
    anogenital, 3096*t*, 3099*t*, 3102–3103, 3103*f*
    cutaneous, 3096*t*, 3097–3100, 3097*f*–3099*f*, 3099*t*, 3101*t*
    with HIV, 3118
    nail, 1591
    oral, 3096*t*, 3103, 3104*f*
  mosaic, 3098, 3098*f*
  oral, 3096*t*, 3103, 3104*f*
  plane, 31, 3098, 3098*f*, 3099*t*
  prosector's, 2863–2864, 2864*f*, 2864*t*
  snorter's, 1709
  syndromes, 3099, 3100*t*
  treatment, 3099–3100, 3101*t*
    cryosurgery, 3794, 3794*f*
    electrodessication, 3799
    topical (*See also specific types*)
      cantharidin, 3619–3620
      dichloroacetic acid, 3620
      dinitrochlorobenzene, 3620
      diphenylcyclopropenone, 3620
      formaldehyde, 3620
      glutaraldehyde, 3620
      imiquimod, 3620
      monochloroacetic acid, 3620
      podofilox, 3620
      salicylic acid, 3620
      sinecatechins, 3621
      squaric acid dibutyl ester, 3620
      trichloroacetic acid, 3620
  verruca plana, 31, 3098, 3098*f*
  verruca vulgaris, 30–31, 30*f*, 258, 3099*f*
Warty dyskeratoma, 1714, 1806
Warty tuberculosis, 2863–2864, 2864*f*, 2864*t*
WASP, Wiskott-Aldrich syndrome, 2402–2404
Wasp stings, 3333–3334
Waterborne infections, 3359, 3359*t*
Waterhouse-Friderichsen syndrome, Addison disease, 2514
Water-in-oil emulsions, 3373*t*, 3374
Water loss
  claudin-1, 220
  transepidermal (*See* Transepidermal water loss (TEWL))
Water-soluble bases, 3373*t*, 3374–3375
Water-soluble vitamins, 2211–2221, 2211*b*. *See also* Vitamin(s), water-soluble
Watson syndrome, 1361
Wavelength
  phototherapy devices, 3640
  selective photothermolysis, 3829
  solar radiation, 266–267, 266*f*, 266*t*
    carcinogenic, 281–282
Weed, 1711–1712
Weeverfish, 3357
Wegener's granulomatosis, 2550–2551, 2551*f*, 2552*f*
Weibel-Palade body, 118*f*, 124
Weight loss/management
  crash diet, telogen effluvium from, 1509, 1509*f*
  for hidradenitis suppurativa, 1487
  for xanthomas and lipoprotein disorders, 2286
Well-differentiated liposarcoma, 2186–2188
Wells syndrome, 665–667
  at-a-glance, 665*b*
  clinical course, prognosis, and management, 667
  clinical features, 665–666, 665*f*
  diagnosis and associated conditions, 666, 666*f*, 666*t*
  differential diagnosis, 666–667, 667*t*
  eosinophils, 27, 27*f*, 654
  etiology and pathogenesis, 666
Werner syndrome (WS), 2362–2363, 2446*t*
  clinical course, prognosis, and management, 2363, 2366
  clinical features, 2343*t*, 2362–2363
  diagnosis and differential diagnosis, 2343*t*, 2363
  epidemiology, 2362
  etiology and pathogenesis, 2344, 2363
  mechanisms, 2345*t*
  squamous cell carcinoma, 1904*t*
Wernicke encephalopathy, thiamine deficiency, 2212
Westerhof syndrome, 1387
Western black-legged tick, 3308*f*, 3310*t*, 3311*t*, 3329
Western black widow, 3324–3326, 3326*f*
West Indian bristleworm, 3352–3353, 3352*f*
West Nile virus, 3136*t*, 3139–3141, 3140*f*
Wet wipes, child contact dermatitis, 1756, 1756*f*
Wet work
  gloves for, 424
  irritant dermatitis, 420, 420*f*
wg/wnt/catenin, 89, 90*f*
Wheals. *See also* Urticaria
  anaphylaxis, 684
  skin test, 690
  urticaria, 689*t*
WHIM syndrome, 2410*t*, 2415
  chemokines, 186
White color, 8*t*
White frosting, 3898, 3900
White phosphorus burn, 441–442, 443*t*, 1683
White piedra, 2935*t*–2936*t*, 2940, 2940*t*
White sponge nevus, cellular defect, 781*t*
Whitlow
  herpetic, 3024, 3025*f*, 3393*t*
  staphylococcal, 2725, 2726*f*
Whorled configuration, 10
Wickham striae, 6*t*
  lichen planus, 529–530, 529*f*
Widow spiders, 3324–3326, 3326*f*
  black widow, 3326*t*
  brown widow, 3324–3326, 3326*f*
  Northern black widow, 3324–3326, 3326*f*
  red-legged widow, 3324–3326, 3326*f*
  Southern black widow, 3324–3326, 3326*f*
  Western black widow, 3324–3326, 3326*f*
Wiedemann-Rautenstrauch syndrome, 1299
Wilms tumor, macrocephaly–capillary malformation, 2639
Wilson disease
  blue nails, 1597
  cutaneous manifestations, 2433
Wing cells, 94
Winter dermatitis, 444
Winter xerosis, 1672, 1672*f*
Wiskott-Aldrich syndrome (WAS), 2402–2404, 2403*f*, 2446*t*
  X-linked recessive, 297, 297*t*
Witkop syndrome, 2388–2389, 2388*f*
Wnt (wingless)
  epidermal proliferation, 63
  ligands, 50
  signaling pathway, sebaceous glands, 71, 72*f*
WNT10A, disorders, 2382–2384, 2383*f*
Wnt/β-catenin, 335–336
WNT/β-catenin pathway, 90*f*, 91
Wolf's isotopic response, 590
Women who have sex with women (WSW), 1794
Wood lamp fluorescence, dermatophytes diagnosis, 2933, 2933*t*
Wood tar, 3611
Wood tick, American, 3307, 3308*f*, 3309*t*, 3329
Woolly hair, 1545–1546, 1545*f*, 1546*t*, 1550*t*
  trichorrhexis nodosa, 1538*t*
Woolly hair nevus, 1545
Woronoff ring, 459, 460*f*
  psoriasis, 459, 460*f*
Wound, chronic, carcinogenesis, 320–321
Wound healing, 127–128, 128*f*
  at-a-glance, 2700*b*
  primary, 2700
    delayed, 2700
  secondary intention, 2700
  skin anatomy in, 2700, 2701*f*
  skin grafts, 3753
  tertiary intention, 2700
Wound healing, clinical issues, 2708–2713
  age-related changes, 2712
  chronic wounds and impaired healing, 2712
  skin grafts, 2710
  skin substitutes
    acellular products, 2711, 2711*t*
    cellular products, 2710–2711, 2711*t*
  standards of care, basic, 2712–2713
  stem cell therapy, 2712
  wound bed preparation
    biofilm formation, 2708, 2709*f*
    dressings, 2709, 2710*t*
    epithelial edge tissue, 2709
    infection/inflammation and antiseptics, 2708, 2709*t*
    moisture balance, 2708–2709
    tissue debridement, 2708, 2708*t*
  wound closure, predicting, 2713
Wound healing, mechanisms, 2700–2708
  fetal healing, 2705
  growth factors and cytokines, 2704*t*, 2706–2708
    chemokines, 2708
    epidermal growth factor, 2704*t*, 2706
    fibroblast growth factor, 2704*t*, 2707

granulocyte-macrophage colony-stimulating factor, 2704*t*, 2707
matrix metalloproteinases, 2706*t*
platelet-derived growth factor, 2704*t*, 2707
proinflammatory cytokines, 2707–2708
transforming growth factor-β, 2704*t*, 2706–2707
vascular endothelial growth factor, 2704*t*, 2707
phases, 2700–2705, 2701*f*
coagulation, 2701–2702, 2701*f*, 2702*f*
inflammation, 2701*f*, 2702, 2702*f*
abnormal, 2703
proliferation, 2701*f*–2703*f*, 2703–2705
remodeling, 2701*f*, 2702*f*, 2705
Wrinkle-prone *vs.* non–wrinkle-prone skin, 3812–3814
WRN (RecQ helicase)
lipodystrophy with Wermer syndrome, 1299
squamous cell carcinoma, 1904
Werner syndrome, 2344, 2363
Wuchereria bancrofti, 3252*t*, 3268, 3268*f*
exposure and symptom onset interval, 3259, 3260*t*
exposure history, 3254
limb edema, 3259
management, 3265*t*
progression and duration, 3259, 3260*t*
subcutaneous nodules and masses, 3257, 3257*t*
Wyburn-Mason syndrome, 2659

X

Xanthelasma, 2283
Xanthelasmoidal mastocytosis, 713
Xanthine oxidase inhibitors, for gout, 2315–2316
Xanthogranuloma
adult, 2034
juvenile, 2032–2034, 2033*f*, 2034*t*
necrobiotic, 2038–2039
paraneoplastic, 2442*t*, 2457–2458
Xanthoma(s), 2273–2289
at-a-glance, 2273*b*
cells, inflammatory reaction patterns, 27–28, 28*f*
cerebrotendinous, 2277
clinical features, 2274–2278
complications, 2278
cutaneous, 2274–2276, 2275*f*–2278*f*
noncutaneous, 2276–2278
definitions, 2273
diagnosis, 2283–2285
imaging, 2285
pathology, 2282*f*, 2284–2285
supportive studies and laboratory testing, 2283–2284
differential diagnosis, 2285, 2285*t*
epidemiology, 2274
eruptive, 2274–2275, 2275*f*
etiologies and risk factors, 2281–2283
normolipidemic xanthomas, 2283
primary dyslipidemias, 2281–2282
secondary dyslipidemias, 2282–2283
Fredrickson-Levy-Lees dyslipidemias, 2288*t*
historical perspective, 2273–2274
management, 2285–2289
counseling and screening, 2288–2289
lifestyle interventions
diet, 2286
exercise, 2285
smoking, 2285
weight management, 2286
medications
adjuvant, ezetimibe, 2286
adjuvant, fibrates, 2286
future options, 2287
lomitapide, 2287
mipomersen, 2287
niacin, 2287
omega-3-fatty acids, 2287
PCSK9 inhibitors, 2287
secondary dyslipidemias, 2287
statins, 2286
procedures
ApoB lipoprotein pheresis and plasmapheresis, 2288
biopsy, 2287, 2288*t*
surgery, laser therapy, and cryotherapy, 2287
papular, 2034–2035
pathogenesis, 2278–2281, 2279*f*
plane, 2275–2276, 2278*f*, 2282–2283
tendinous, 2275, 2277*f*, 2281
tuberoeruptive, 2275, 2275*f*–2278*f*, 2282
tuberous, 2275, 2275*f*, 2283
verruciform, 2276
Xanthoma disseminatum, 2035–2036, 2036*f*, 2037*f*, 2276–2277, 2278
Xanthomatous reaction patterns, 27–28, 28*f*
Xenografts, 3753
Xenopsylla cheopis, 3310*t*, 3318
Xeomin, 3921, 3922, 3923. *See also* Botulinum toxin
Xeroderma pigmentosum (XP), 314, 2347–2354, 2446*t*
at-a-glance, 2342*b*
autosomal recessive disorder, 296, 296*t*
chemical phenotypes, 2342, 2346*f*
clinical course and prognosis, 2353
clinical features, 2342, 2343*t*
cutaneous
cancer, 2348, 2350*f*
skin, 2348, 2349*f*
noncutaneous
cancers, internal, 2350
eyes, 2347–2349, 2348*f*
neurologic, 2349
diagnosis, laboratory testing
cellular hypersensitivity, 2351
chromosome abnormalities, 2351–2352
DNA repair, 2352
DNA sequence analysis, 2352–2353
drug and chemical hypersensitivity, 2352
prenatal diagnosis, 2353
differential diagnosis, 2353
DNA repair defects, 279–280
epidemiology, 2347
etiology and pathogenesis
complementation groups, 2346*f*, 2346*t*, 2350
A, 2346*t*, 2350
B, 2350, 2351*f*
C, 2350
D, 2350
E, 2350–2351
F, 2351
G, 2351, 2351*f*–2352*f*
xeroderma pigmentosum variant, 2351
nucleotide excision repair, impaired, 2342
parents, 2351
genome instability, DNA-damaging agents, 2342
historical perspective, 2347
management
cancer, 2354
general, 2353
hearing loss, 2354
heterozygotes, 2354
medications, 2354
patient support groups, 2354
sun protection, 2353–2354
mechanisms, 2345*t*
photoprotection for, 3632, 3632*t*
photosensitivity, 271
squamous cell carcinoma, 1903, 1904*t*
variants, 2350, 2351
XPD(ERCC2), 2344
Xeroderma pigmentosum–Cockayne syndrome complex (XP-CS), 2343*t*, 2344, 2345*t*, 2357
Xeroform, for burn wound care, 1686*t*, 1687
Xerosis, 3804. *See also specific disorders*
in elderly, 1786, 1786*f*
vs. ichthyosis vulgaris, 783
winter, 1672, 1672*f*
Xerotic scale, 6*t*
X-linked agammaglobulinemia (XLA), agammaglobulinemia, 2396
X-linked dominant chondrodysplasia punctata (CDPX2), 778*t*, 805–806, 1200
cellular defect, 781*t*
EBP, 778*t*, 806
X-linked dominant inheritance and disorders, 296–297, 296*t*, 297*f*. *See also specific types*
X-linked dominant protoporphyria, 296–297, 296*t*
X-linked ichthyosis, 300, 2446*t*
cellular defect, 781*t*
recessive, 297, 297*t*
X-linked protoporphyria (XLP), 2235*t*, 2237t, 2245–2249. *See also* Protoporphyrias
X-linked recessive hypohidrotic ectodermal dysplasia, 303
X-linked recessive ichthyosis (XLI), 297, 297*t*, 778*t*, 785–786
clinical course, prognosis, and management, 786
clinical features, 785, 785*f*
diagnosis, 786
etiology and pathogenesis, 785–786
STS, 778*t*, 785*f*, 786
with X-linked Kallman syndrome, 786
X-linked recessive inheritance and disorders, 296–297, 297*f*, 297*t*. *See also specific types*
XP, xeroderma pigmentosum variant, 2350, 2351
XP-A, 2346*t*, 2350
XPA-G, squamous cell carcinoma, 1903
XPA-V, squamous cell carcinoma, 1903
XP-B, 2350, 2351*f*
on helicases, 2344
trichothiodystrophy, 1539, 2360
xeroderma pigmentosum, 2350
XP-C, 2350
XP-CS, 2343*t*, 2344, 2345*t*, 2357
XP-D, 2350
chemical phenotypes, 2342, 2346*f*
COFS syndrome, 2344, 2350
on helicases, 2344
trichothiodystrophy, 1539, 2360
xeroderma pigmentosum, 2344, 2350
XP-DDT, 2343*t*
XP-E, 2350–2351
XP-F, 2351
XP-G, 2351, 2351*f*
XP-TTD
chemical phenotypes, 2342, 2346*f*
gene mutations, 2344
mechanisms, 2345*t*
XP variants, 2350, 2351
squamous cell carcinoma, 1904*t*
XRCC1, dysplastic melanocytic nevi, 1975
XXY genotype, 297

Y

Yap, epidermal proliferation, 63
Yatapoxvirus, 3067*t*
Yaws, 3177–3182

Yaws (*Cont.*):
at-a-glance, 3177*b*
clinical course and prognosis, 3181
clinical features, 3178–3180
cutaneous, 3178–3179, 3178*f*–3179*f*
noncutaneous, 3179–3180
definition, 3177
diagnosis
imaging, 3180, 3181*f*
laboratory testing, 3180
pathology, 3180
differential diagnosis, 3181*t*
epidemiology, 3178
etiology and pathogenesis, 3180
historical perspective, 3177–3178
management
medications, 3181
prevention and screening, 3182
Yearly prevalence, 45
Yeast infections, 2952–2963. *See also specific types*
candidiasis, 2952–2959
Malassezia, 2959–2963
Yellow color, 8*t*
Yellow fever virus, 3136*t*, 3139
Yellow nail syndrome (YNS), 1596–1597, 1597*f*, 2430
Yersinia enterocolitica, Sweet syndrome with, 595
Yersinia pestis, 2829*t*, 2832–2833

Z

ZC3H12C, psoriasis, 479
ZEB1, cutaneous T-cell lymphomas, 2075
Zidovudine, 3506–3507, 3509*t*
hypermelanosis from, 1365
Zika virus, 3136*t*, 3137–3139, 3138*f*
Zinc, 2221*b*, 2224
deficiency, 2224–2226, 2225*f*, 2225*t*
telogen effluvium from, 1510
toxicity, 2226
Zinc gluconate, for hidradenitis suppurativa, 1487–1489
Zinc oxide, 3625–3627, 3625*t*, 3628
for lichen sclerosus, 1122
Zinc pyrithione
for fungal infections, superficial, 2936*t*
for seborrheic dermatitis, 435
Zinc sulfate, for leishmaniasis, 3237*t*
Zinsser-Cole-Engman syndrome, 2344*t*, 2345*t*, 2366–2367, 2446*t*
squamous cell carcinoma, 1904*t*
Ziploc sign, 1694
Zirconium granulomas, 27
ZMPSTE24, mandibuloacral dysplasia-associated lipodystrophy, 1299
ZMPSTEA24, lipodystrophy, 1295
ZNF750, 66, 67*f*
epidermal differentiation, 66, 67*f*
Zone of coagulation, 1681, 1681*f*
Zone of hyperemia, 1681, 1681*f*
Zone of stasis, 1681, 1681*f*
Zoophilic, 2926, 2926*t*, 2927*t*
Zosteriform distribution, 11
Zosteriform lentiginous nevus, 1949–1951, 1949*f*, 1950*t*
Zosteriform lichen planus, 530–531
Zoster sine herpete, 3042
Z-plasty, 3748
burn scar rejuvenation, 1689–1690
Zygomatic nerve, 3702*f*, 3703, 3703*t*
Zygomatus major muscle, 3703, 3704*f*
Zygomatus minor muscle, 3703, 3704*f*
Zygomycosis, 2984, 2985*f*
subcutaneous, 2967*t*, 2973